# CHAPMAN'S ORTHOPAEDIC SURGERY

MICHAEL W. CHAPMAN

*Third Edition*

SECTION EDITORS
ROBERT M. SZABO
RICHARD MARDER
KELLY G. VINCE
ROGER A. MANN
JOSEPH M. LANE
ROBERT F. McLAIN
GEORGE RAB

*Volume 1*

# Chapman's Orthopaedic Surgery

## CONTENTS


*Dedication*

*Section Editors*

*Contributing Authors*

*Preface to the Third Edition*

*Preface to the First Edition*

*Acknowledgments*

Color Plates

Volume 1: Principles, Fractures
Volume 2: Hand, Sports
Volume 3: Sports, Arthroplasty, Foot, Skeletal Disorders
Volume 4: Spine, Pediatrics

# VOLUME 1

## SECTION I
## SURGICAL PRINCIPLES AND TECHNIQUES
*Michael W. Chapman*

1. Surgical Approaches to the Upper Extremity
*William L. Green*

2. Surgical Approaches to the Acetabulum and Pelvis
*Joel M. Matta*

3. Surgical Approaches to the Lower Extremity
*Marc F. Swiontkowski and Patricia A. Post*

4. Imaging Modalities in Orthopaedics
*Adam Greenspan*

5. Preoperative Planning and Perioperative Management
*David J. Hak and James A. Goulet*

6. Instrumentation and Implants
*Michael W. Chapman*

7. Anesthesia and Pain Management
*Dennis L. Fung*

8. Soft-Tissue Management
*Thomas P. Whetzel and Thomas R. Stevenson*

9. Bone Grafting, Bone Graft Substitutes, and Growth Factors
*Michael W. Chapman and Juan J. Rodrigo*

## SECTION II
## FRACTURES, DISLOCATIONS, NONUNIONS, AND MALUNIONS
*Michael W. Chapman*

### *General*

10. Fracture Healing and Closed Treatment of Fractures and Dislocations
*Michael W. Chapman*

11. Principles of Internal and External Fixation
*Michael W. Chapman*

12. Open Fractures
*Michael W. Chapman*

13. Compartment Syndromes
*R. Scott Meyer and Scott J. Mubarak*

14. Management of Polytrauma
*Lawrence B. Bone*

### *Upper Extremity*

15. Fractures and Dislocations of the Shoulder Girdle and Humerus
*Christopher G. Finkemeier and Robert R. Slater, Jr.*

16. Fractures and Dislocations of the Elbow and Forearm
*Michael W. Chapman*

### *Pelvis and Femur*

17. Fractures and Dislocations of the Pelvic Ring
*Dana C. Mears and Sridhar M. Durbhakula*

18. Fractures of the Acetabulum, Hip Dislocations, and Femoral Head Fractures
*Steven A. Olson and Joel M. Matta*

19. Fractures of the Hip and Proximal Femur
*Michael W. Chapman*

20. Diaphyseal Fractures of the Femur
*Michael W. Chapman*

21. Supracondylar and Articular Fractures of the Distal Femur
*Roby D. Mize*

### *Patella and Tibia*


**22. Patellar Fractures**
*Timothy J. Bray*

**23. Fractures of the Tibial Plateau**
*Kenneth A. Egol and Kenneth J. Koval*

**24. Fractures of the Shafts of the Tibia and Fibula**
*Michael W. Chapman*

**25. Ankle Fractures and Dislocations Including Pylon Fractures**
*Robert H. Leland and Jeffrey W. Mast*


### *Malunions and Nonunions*


**26. Principles of Treatment of Nonunions and Malunions**
*Michael W. Chapman*

**27. Nonunions and Malunions of the Upper Extremity**
*Michael W. Chapman*

**28. Nonunions and Malunions of the Pelvis**
*Ross K. Leighton*

**29. Nonunions and Malunions of the Hip**
*Michael W. Chapman*

**30. Nonunions and Malunions of the Femoral Shaft and Patella**
*Michael W. Chapman*

**31. Nonunions and Malunions of the Tibia**
*James A. Goulet and David J. Hak*

**32. Management of Fractures, Nonunions, and Malunions with Ilizarov Techniques**
*Stuart A. Green, James Aronson, Dror Paley, Kevin D. Tetsworth, and J. Charles Taylor*


# VOLUME 2

## SECTION III
## THE HAND
*Robert M. Szabo*

### *Microvascular Surgery*


**33. Management of Vascular Disorders in the Upper Extremity**
*Peter J. Evans, David S. Ruch, Beth Paterson Smith, and L. Andrew Koman*

**34. Replantation**
*James R. Urbaniak*

**35. Free Tissue Transfer**
*Lior Heller, Reynaldo L. Aponte, and L. Scott Levin*

**36. Vascularized Bone Grafts**
*Kimberly K. Mezera and Andrew J. Weiland*


### *General Principles and Anatomy*


**37. Principles of Hand Surgery and Surgical Approaches to the Hand and Wrist**
*Michelle Gerwin Carlson, Robert M. Szabo, and Paul R. Lipscomb*


### *Trauma*


**38. Fingertip and Nail Bed Injuries**
*Barry M. Katzman and David J. Bozentka*

**39. Dislocations and Ligamentous Injuries of the Digits**
*Donald H. Lee and Robert J. Neviaser*

**40. Fractures of the Metacarpals and Phalanges**
*Jesse B. Jupiter and David A. Alessandro*

**41. Dislocations of the Carpus**
*James H. Dobyns and Richard Berger*

**42. Fractures of the Carpal Bones**
*Martin A. Posner*

**43. The Distal Radioulnar Joint**
*Robert R. Slater, Jr.*

**44. Fractures of the Distal Radius**
*Robert M. Szabo*

**45. Gunshot, Crush, Injection, and Frostbite Injuries of the Hand**
*Beth A. Purdy and Robert Lee Wilson*

**46. Amputations of the Hand**
*Terry R. Light*


### *Conditions of Tendons*


**47. Principles of Tendon Repair**
*Paul R. Manske*

**48. Flexor Tendon Injuries**
*John S. Gould and Beth G. Nicholson*

**49. Extensor Tendon Injuries**
*James S. Thompson and Clayton A. Peimer*

**50. Stenosing Tenosynovitis and Epicondylitis**
*Mark E. Pruzansky*


### *Conditions of Nerves*

**51. Principles of Nerve Repair**
*Robert M. Szabo*

**52. Compression Neuropathies of the Upper Extremity**
*Mark N. Halikis, Julio Taleisnik, and Robert M. Szabo*

**53. Neuromas**
*Alan E. Freeland*

**54. Principles for Restoration of Muscle Balance after Forearm and Hand Paralysis**
*Paul W. Brand and Anne Hollister*

**55. Radial Nerve Palsy**
*Larry K. Chidgey and Robert M. Szabo*

**56. Median Nerve Palsy**
*Steven M. Green*

**57. Ulnar Nerve Paralysis**
*Paul W. Brand and Anne Hollister*

**58. Tendon Transfers in Combined Nerve Palsies of the Forearm and Hand**
*George E. Omer, Jr. and William F. Blair*

**59. Neurologic Conditions about the Shoulder**
*Robert M. Szabo*

**60. Brachial Plexus Injuries**
*Hanno Millesi*

**61. Surgery of the Thoracic Outlet**
*Robert D. Leffert*

### *Reconstructive Procedures*

**62. Dupuytren's Disease**
*John D. Lubahn*

**63. Intrinsic Muscle Contractures**
*Clayton A. Peimer*

**64. Burn Contractures**
*Peter J. Stern and Kevin P. Yakuboff*

**65. Management of Volkmann's Contracture**
*Richard H. Gelberman and Michael J. Botte*

**66. Surgical Treatment of the Upper Extremity in Cerebral Palsy**
*Gary A. Miller and F. William Bora, Jr.*

**67. Management of Upper Extremity Dysfunction Following Stroke or Brain Injury**
*Mary Ann E. Keenan and Patrick J. McDaid*

**68. Reconstruction of the Upper Extremity in Tetraplegia**
*Michelle A. James*

**69. Congenital Hand Malformations**
*Michelle A. James*

**70. Management of the Arthritic Hand**
*David R. Steinberg*

**71. Arthroplasty of the Hand**
*Jennifer Moriatis Wolf and Arnold-Peter C. Weiss*

**72. Arthrodesis of the Hand and Wrist**
*Edward Akelman, Michael T. LeGeyt, and Dina Hulsizer Galvin*

**73. Infections of the Hand**
*Robert M. Szabo and Carl F. Palumbo*

**74. Tumors of the Hand**
*Clayton A. Peimer and James S. Thompson*

**75. Arthroscopic Surgery of the Wrist**
*Louis M. Adler and A. Lee Osterman*

## SECTION IV
## SPORTS MEDICINE
*Richard A. Marder*

### *Shoulder*

**76. Biomechanics and Functional Anatomy of the Shoulder**
*Jacquelin Perry*

**77. Shoulder Arthroscopy**
*John P. Meehan*

**78. Chronic and Acute Injuries of the Acromioclavicular and Sternoclavicular Joints**
*Michael A. Wirth and Charles A. Rockwood, Jr.*

**79. Disorders of the Rotator Cuff**
*Richard A. Marder*

**80. Shoulder Instability**
*Deryk G. Jones and Jon J. P. Warner*

### *Elbow*

**81. Instability and Tendon Disorders of the Elbow**
*Ronald E. Glousman*

**82. Arthroscopic Treatment of the Elbow**
*Laura A. Timmerman*

### *Knee*

**83. Anatomy and Biomechanics of the Knee**
*Robert J. Johnson and Bruce Beynnon*

84. Principles of Arthroscopy of the Knee
*David B. Coward*

85. Meniscus Tears
*Joseph C. Milne and Richard A. Marder*

86. Chondral Injuries
*John R. Raskind and Juan J. Rodrigo*

87. Patellofemoral Joint Disorders
*Alan C. Merchant*

88. Tendinopathies about the Knee
*Eric A. Heiden*

# VOLUME 3

## SECTION IV
## SPORTS MEDICINE
*Richard A. Marder*

### *Knee*

89. Isolated Anterior Cruciate Ligament Injury
*James D. Ferrari and Bernard R. Bach, Jr.*

90. Isolated Posterior Cruciate Ligament Injury and Posterolateral Laxity
*Leslie J. Bisson and William G. Clancy, Jr.*

91. Dislocations and Multiple Ligamentous Injuries of the Knee
*Richard A. Marder and Jan P. Ertl*

92. Complications of Knee Surgery
*John R. Raskind*

### *Ankle*

93. Arthroscopy of the Ankle
*Richard D. Ferkel and Steven J. McGrath*

94. Tendon Lacerations and Other Tendon Disorders about the Ankle
*George Lian*

95. Ankle Ligament Injuries
*Richard A. Marder*

### *General*

96. Stress Fractures
*Richard A. Marder*

97. Adolescent Sports Injuries
*Letha Y. Griffin and Xavier A. Duralde*

98. Use of Lasers in Orthopaedic Surgery
*Kenneth B. Trauner*

## SECTION V
## JOINT RECONSTRUCTION, ARTHRITIS, AND ARTHROPLASTY
*Kelly G. Vince*

### *General*

99. Management of the Arthritic Joint
*Juan J. Rodrigo and M. Eric Gershwin*

100. Design and Performance of Joint Replacements
*Peter S. Walker*

### *Upper Extremity*

101. Primary Arthroplasty of the Shoulder
*Robert G. Marx and Edward V. Craig*

102. Arthroplasty and Arthrodesis of the Elbow
*Graham J. W. King*

103. Failed Shoulder Arthroplasty: Revision and Arthrodesis
*Guido Marra, Ken Yamaguchi, and Evan Flatow*

### *Lower Extremity*

104. Osteotomies About the Hip—Adults
*Roland J. Barr and Richard F. Santore*

105. Primary Total Hip Arthroplasty
*Daniel J. Berry*

106. Failed Hip Arthroplasty: Revision and Arthrodesis
*Paramjeet S. Gill and Wayne G. Paprosky*

107. Osteotomies of the Knee for Osteoarthritis
*James C. Karageannes and Russell E. Windsor*

108. Primary Total Knee Arthroplasty
*Dennis W. Burke and Hugh O'Flynn*

109. Revision Knee Arthroplasty and Arthrodesis of the Knee
*Kelly G. Vince*

## SECTION VI
## THE FOOT
*Roger A. Mann*

110. Fractures of the Hindfoot

*Timothy J. Bray*

**111. Fractures and Dislocations of the Midfoot and Forefoot**
*Linda Ferris*

**112. Hallux Valgus**
*Roger A. Mann and Jeffrey A. Mann*

**113. Lesser Toe Disorders**
*Mark S. Mizel*

**114. Peripheral Nerve Lesions of the Foot and Ankle**
*Martin G. Mankey*

**115. Arthrodeses of the Foot and Ankle**
*Roger A. Mann and Jeffrey A. Mann*

**116. Diabetic Foot Care**
*Jason H. Calhoun and Jon T. Mader*

**117. Rheumatoid Arthritis of the Foot**
*Michael J. Coughlin*

**118. Tendon Disorders of the Foot and Ankle**
*Mark M. Casillas and Roger A. Mann*

**119. Miscellaneous Disorders of the Foot**
*Loretta B. Chou*

## SECTION VII
## NEOPLASTIC, INFECTIOUS, NEUROLOGIC AND OTHER SKELETAL DISORDERS
*Joseph M. Lane*

### *Amputations*

**120. Amputations of the Lower Extremity**
*Walther H. O. Bohne and Jan Paul Ertl*

**121. Amputations of the Upper Extremity**
*Edward A. Athanasian*

**122. Principles of Amputee Prosthetics**
*Patricia G. Rossbach, Michael A. Joyce, Eric Schaffer, and Joseph M. Lane*

### *Other Disorders*

**123. Orthopaedic Management of Lower Extremity Dysfunction Following Stroke or Brain Injury**
*Mary Ann E. Keenan and Guy Alan Lee*

**124. Heterotopic Ossification and Charcot Neuroarthropathy**
*Gary Shapiro and Mathias Bostrom*

**125. Osteonecrosis**
*Marvin E. Steinberg and Michael A. Mont*

### *Tumors and Tumor-Like Conditions*

**126. Principles of Limb Salvage Surgery**
*Steven Gitelis, Martin Malawer, Douglas MacDonald, and Gordon Derman*

**127. Benign Bone Tumors**
*Carol D. Morris, Francis Y. Lee, and Mark C. Gebhardt*

**128. Malignant Bone Tumors**
*Kristy L. Weber and Franklin H. Sim*

**129. Soft-Tissue Sarcomas and Benign Soft-Tissue Tumors of the Extremities**
*Terrance D. Peabody and Michael A. Simon*

**130. Metastatic Bone Disease**
*Frank J. Frassica, Deborah A. Frassica, Steven A. Lietman, Edward F. McCarthy, and James F. Wenz*

**131. Metabolic Bone Disease**
*William F. Flynn, Joseph M. Lane, and Charles N. Cornell*

### *Infection and Hemophilia*

**132. Principles of Treatment of Infection and Antimicrobial Therapy**
*Ashkan Lahiji and John L. Esterhai, Jr.*

**133. Management of Acute and Chronic Osteomyelitis**
*Michael J. Patzakis*

**134. Management of Pyarthrosis**
*Stuart B. Goodman, Loretta B. Chou and David J. Schurman*

**135. Management of Infected Implants**
*Kevin L. Garvin, Matthew A. Mormino and Theresa M. McKillip*

**136. Orthopaedic Management of Hemophilic Arthropathy**
*James V. Luck, Jr., Judith C. Lin, Carol K. Kasper, and Laurence J. Logan*

# VOLUME 4

## SECTION VIII
## THE SPINE
*Robert F. McLain*

### *Principles and Anatomy*

**137. Biomechanics of Spinal Instrumentation**
*Christian M. Puttlitz, Vijay K. Goel, and Robert F. McLain*

**138. Surgical Approaches to the Spine**
*Robert G. Watkins*

### *Trauma*

139. Upper Cervical Spine Fractures and Instability
*Claude Gelinas and Alan M. Levine*

140. Fractures and Dislocations of the Cervical Spine from C3 to C7
*Michael J. Goebel, Charles Carroll, IV, and Paul C. McAfee*

141. Thoracolumbar Fractures: Evaluation, Classification, and Initial Management
*Robert F. McLain and Daniel R. Benson*

142. Operative Treatment of Thoracic and Thoracolumbar Fractures
*Robert F. McLain and Daniel R. Benson*

### *Disc Injury and Degeneration*

143. Cervical Disc Disease
*Louis G. Jenis and Howard S. An*

144. Lumbar Disc Herniation
*Dan M. Spengler*

145. Degenerative Disc Disease
*Eeric Truumees and Harry N. Herkowitz*

146. Anterior Lumbar Interbody Fusion
*Thomas A. Zdeblick*

147. Spinal Stenosis
*Gordon R. Bell*

148. Failed and Revision Cervical Spine Surgery
*Eeric Truumees and Robert F. McLain*

149. Management of the Patient with Failed Low-Back Surgery
*William C. Lauerman and Sam W. Wiesel*

### *Tumors and Infections*

150. Pyogenic and Granulomatous Infections of the Spine
*Munish C. Gupta and Daniel R. Benson*

151. Tumors and Infections of the Cervical Spine
*Kamshad Raiszadeh and Behrooz A. Akbarnia*

152. Tumors of the Spine
*Robert F. McLain*

### *Rheumatoid Disease*

153. Surgery of the Spine in Ankylosing Spondylitis
*Edward H. Simmons*

154. Rheumatoid Arthritis of the Cervical Spine
*Robert A. Hart and Charles R. Clark*

### *Spinal Deformity*

155. Anterior Approach to Scoliosis
*Jesse Butler and Michael F. Schafer*

156. Posterior Surgery for Scoliosis
*Howard A. King*

157. Spinal Surgery for Myelomeningocele
*Thomas E. Kuivila*

158. Spinal Surgery in Congenital Syndromes
*Paul D. Sponseller*

159. Surgical Treatment of Adult Scoliosis
*Robert F. McLain and Isador Lieberman*

160. Surgical Management of Degenerative Scoliosis
*Serena S. Hu and David S. Bradford*

161. Surgery for Kyphosis Deformity
*Jack K. Mayfield*

162. Spondylolisthesis
*John D. Miles and Robert W. Gaines, Jr.*

163. Revision and Salvage after Surgery for Spinal Deformity
*Robert F. McLain*

## SECTION IX
## PEDIATRIC DISORDERS
*George T. Rab*

164. Operative Treatment of Children's Fractures and Injuries of the Physes
*George T. Rab*

165. Congenital Shoulder and Elbow Malformations and Deformities
*Michelle A. James and Karen D. Heiden*

166. Surgery for Developmental Dysplasia of the Hip
*George T. Rab*

167. Congenital Deformities of the Foot
*George T. Rab and Peter B. Salamon*

168. Surgical Management of Torsional Deformities of the Lower Extremities
*Vincent S. Mosca and Lynn T. Staheli*

169. Angular Deformities of the Lower Extremities in Children
*George H. Thompson*

170. Leg-Length Discrepancy in Children
*Kent A. Vincent and Colin I. Moseley*

171. Pediatric Applications of Circular and Unilateral External Fixation
*Deborah F. Stanitski*

**172. Slipped Capital Femoral Epiphysis**
*Randall T. Loder*

**173. Legg-Calvé-Perthes Disease**
*John A. Herring*

**174. Congenital Lower Limb Deficiency**
*William L. Oppenheim, Hugh G. Watts, Robert M. Bernstein, and Yoshio Setoguchi*

**175. Principles of Amputation in Children**
*George T. Rab*

**176. Bone and Joint Infections in Children**
*Paul P. Griffin*

**177. Surgery for Cerebral Palsy**
*Lawrence A. Rinsky*

**178. Muscle and Nerve Disorders in Children**
*William G. Mackenzie and J. Richard Bowen*

**179. The Orthopaedic Management of Myelodysplasia and Spina Bifida**
*Nigel S. Broughton and Malcolm B. Menelaus*

**180. Bone Dysplasias, Metabolic Bone Diseases, and Generalized Syndromes**
*Lori A. Karol*

To

Our teachers on whose shoulders the contributors to the third edition and I stand.
Our patients who inspired us to write this book so that they will receive the finest of care.
Our students, residents, fellows, and colleagues whose questions and guidance provided the guideposts for the text.

And

To my wife, Elizabeth (Betty) Casady Chapman, whose patience and support endures,
and to my parents, William P. and Ethel B. Chapman, whose skills in parenting induced the discipline
necessary to take on the monumental task of writing and editing this book.

**Michael W. Chapman, M.D.**

# CHAPTER 1

# SURGICAL APPROACHES TO THE UPPER EXTREMITY

*William L. Green*

**W. L. Green:** Department of Orthopaedic Surgery, University of California, San Francisco, California, 94118.

Shoulder
- Sternoclavicular Approach
- Acromioclavicular Approach
- Henry's Anterior Approach
- Leslie and Ryan's Anterior Axillary Approach
- Henry's Anterior Strap Approach
- Lateral Deltoid Splitting Exposure
- Posterior Exposure

Humerus
- Henry's Anterolateral Exposure
- Henry's Posterior Exposure
- Medial Exposure

Elbow
- Lateral Exposure
- Henry's Anterolateral Exposure
- Medial Exposure
- Anteromedial Exposure
- Bryan and Morrey's Posterolateral Exposure
- Chapman's Comprehensive Posterior Approach
- Posterior Transolecranon Exposure
- Henry's Posterior Interosseous Nerve Exposure

Forearm
- Anterior Exposure of the Distal two Thirds of the Radius
- Ulnar Shaft Exposure
- Posterior Exposure of the Radius
- McConnell's Median and Ulnar Nerve Exposure

Chapter References

Surgery injures tissues. Proper planning and thorough understanding of the surgical exposure, however, can minimize tissue injury and expedite the procedure. Proper exposure protects the important neurovascular structures by providing direct observation or enabling total avoidance. The surgical exposures described in this chapter allow excellent exposure of the upper extremities.

Hemostasis is mandatory. Because most procedures in the upper extremity are done under tourniquet control, a cut vessel requires immediate coagulation or ligation. Otherwise, it retracts, goes into spasm, and may later start bleeding. Never purposely cut a cutaneous nerve. Every severed nerve forms a neuroma, and every neuroma can become exquisitely tender. Always strive for a cosmetically acceptable scar using, if possible, subcuticular sutures with Steri-strips.

## SHOULDER

### STERNOCLAVICULAR APPROACH

Exposure of the sternoclavicular joint (SC) is rarely necessary. Infection, arthritis, or posterior dislocation of this joint may necessitate an open procedure.

- Make an incision along the medial 4 cm of the clavicle and curve it gently, inferiorly over the SC joint. This joint is at a 45° inclination, so incise the capsule from superior medial to inferior lateral.
- If resecting the medial clavicle, remove 1.5 cm of bone, staying medial to the costoclavicular ligament.
- For a posterior dislocation, release of the sternocleidomastoid muscle origin superiorly may improve the exposure. Be very careful of the vital structures posterior to the SC joint (i.e., right innominate artery, left common carotid artery, subclavian vein, and lung tissue).

### ACROMIOCLAVICULAR APPROACH

Exposure of the acromioclavicular joint (AC) may be necessary for arthritis, dislocation, or intra-articular fracture.

- Make a 6–7 cm, anterior to posterior saber incision just medial to the AC joint. Incise the trapezius and deltoid fascia, and elevate off the clavicle as needed.
- Cut the capsule perpendicular to the joint and reflect it anteriorly and posteriorly to expose the joint. It is important to reattach this capsule to close the space created if the distal clavicle has been resected.
- If repair or reconstruction of the coracoclavicular ligaments is required, extend the exposure inferiorly to expose the coracoid process. This is best done by splitting the deltoid or utilizing the deltopectoral interval (Fig. 1.1).

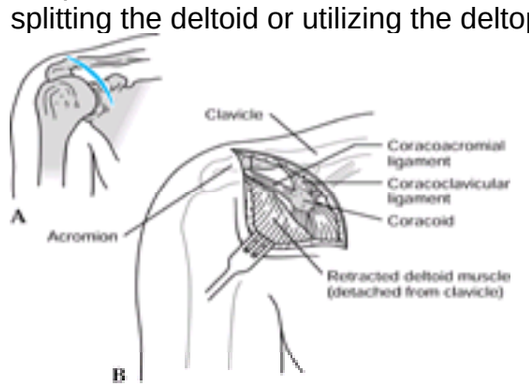


***Figure 1.1.*** Exposure of the acromioclavicular joint and coracoid process.

### HENRY'S ANTERIOR APPROACH

Henry's anterior approach (3) is used to treat recurrent anterior shoulder dislocations, fractures of the proximal humerus, rotator cuff repairs or reconstructions, and anterior shoulder arthrotomies and arthroplasties (Fig. 1.2).

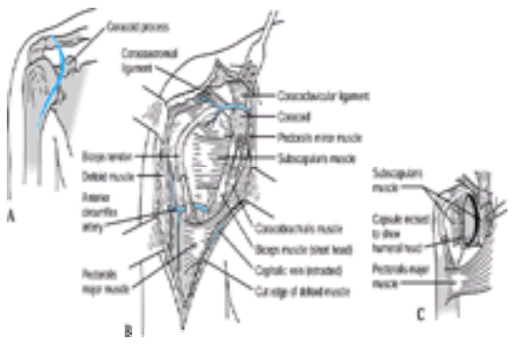

***Figure 1.2.*** Henry's anterior approach.

- Position the patient in a semi-sitting position (40° off the horizontal) with a rolled towel under the ipsilateral scapula. The shoulder should be freely mobile. A Mayo stand, padded with a pillow, next to the operating room table facilitates resting the shoulder in abduction and external rotation. Drape the arm free. Overwrap the stockinet on the hand and forearm to facilitate control of the arm.
- Locate the deltopectoral groove. In an obese patient, this groove is located by internal and external rotation of the shoulder. Start the incision at the clavicle just medial to the coracoid, and extend it distally along the deltopectoral groove to the deltoid insertion for approximately 15 cm.
- Develop skin flaps to expose the deep fascia. Open the fascia over the deltopectoral groove with blunt scissors, looking for the cephalic vein. This vein serves as an important landmark for identifying the avascular interval between the deltoid and pectoralis major muscles. Bluntly develop this interval, and retract the deltoid laterally and the pectoralis major medially. The vein can be ligated or retracted with the deltoid.
- In the proximal wound, incise the clavipectoral fascia arising over the coracoacromial ligament, and identify and coagulate the underlying acromial branch of the thoracoacromial artery. The anterior circumflex vessels lie in the middle of the wound, just superior to the pectoralis major muscle; they may need to be isolated, clamped, and coagulated.
- Retracting the coracobrachialis and short head of the biceps medially with a broad retractor protects the axillary neurovascular bundle. Detachment of the anterior deltoid muscle from the clavicle should be avoided if at all possible, because it usually weakens the anterior deltoid. If detachment is necessary, carefully elevate a flap of tendon superiorly and inferiorly off the clavicle for resuturing the deltoid, or detach the deltoid by removing a small wafer of bone and reattaching it with drill holes later. For extensive proximal humerus procedures, detach the deltoid insertion off its tubercle distally and reflect the deltoid superiorly. This provides excellent exposure. Repair of the deltoid is simplified by suturing it to the origin of the brachialis with interrupted figure-eight sutures.
- If better exposure of the rotator cuff is necessary, resection of the coracoacromial ligament and an anterior acromioplasty as described by Neer (7) facilitates exposure. The anterior joint capsule can be exposed by releasing the subscapularis tendon. This is facilitated by passing a curved hemostat from distal to proximal in the interval between the tendon and the anterior joint capsule, exiting between the subscapularis and the supraspinatus. Because the tendon and capsule blend together near the humeral insertion of the tendon, cut it 2.5 cm medial to its humeral insertion. After the tendon is released, tag it with a nonabsorbable suture to ensure easy identification when it is reattached.
- If exposure of the axillary neurovascular structures is necessary, incise and reflect medially the humeral insertion of the pectoralis major. Identify the loose fascia overlying the short head of the biceps and coracobrachialis. Incise this fascia medially over the coracobrachialis muscle 3.5 cm distal to the coracoid to avoid cutting its innervation from the musculocutaneous nerve. Develop the interval medial to the biceps and coracobrachialis muscles, and reflect these muscles laterally to expose the neurovascular bundle.
- Wider exposure is possible if the muscle origins from the coracoid are transected. If more proximal exposure is needed, it may be necessary to transect the origin of the pectoralis minor muscle. A more comprehensive exposure for total shoulder arthroplasties is described in the article by Neer et al. (9). In such cases, release the origins of the coracobrachialis and the short head of the biceps from the tip of the coracoid, leaving a cuff on the tip of the coracoid for repair. Leave the pectoralis minor intact. Retraction medially must be gentle to avoid injury to the musculocutaneous nerve.

### LESLIE AND RYAN'S ANTERIOR AXILLARY APPROACH

Leslie and Ryan's anterior axillary approach (Fig. 1.3) (5) is useful for exposing the anterior shoulder for recurrent shoulder dislocations if a more cosmetically acceptable scar is desired (4). The exposure, however, may be restricted in a patient with well-developed musculature.

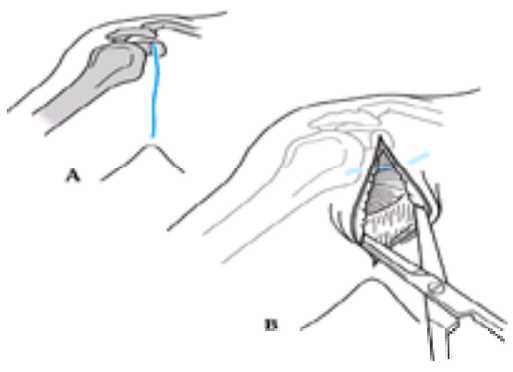

***Figure 1.3.*** Leslie and Ryan's axillary exposure.

- With the patient's arm at his side, identify the superior aspect of the anterior axillary fold. From this point, make an incision 7 cm inferiorly into the axilla. Because the skin and subcutaneous tissue are quite mobile in this area, extensive undermining above the deep fascia is possible for exposure of the deltopectoral groove.
- The rest of the surgical exposure is as described previously in the section on Henry's Anterior Approach. Exposure can be facilitated by extending the skin incision proximally to the tip of the coracoid. This approach is identical to Henry's anterior approach, with the exception of the limited skin incision.

### HENRY'S ANTERIOR STRAP APPROACH

Henry's anterior strap approach is useful for exposing the rotator cuff.

- Start the incision over the acromioclavicular joint, and extend it 8 cm inferiorly along the anterior deltoid, just lateral to the deltopectoral groove.
- After mobilizing skin flaps, identify the clavicular attachment of the deltoid. Detach only as much of the deltoid as necessary for exposure, using the technique as described under Henry's Anterior Approach.
- Incise the underlying subacromial bursa to expose the rotator cuff. Internal and external rotation of the shoulder help to further visualize the anterior and posterior portions of the cuff.

### LATERAL DELTOID SPLITTING EXPOSURE

The lateral deltoid splitting exposure is used for limited exposure of the rotator cuff and subacromial bursa (Fig. 1.4).

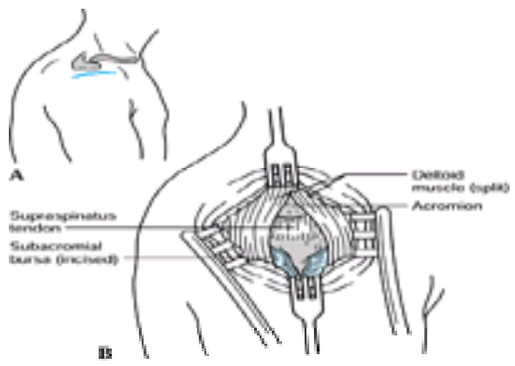


***Figure 1.4.*** Lateral deltoid splitting exposure.

- Make a transverse incision approximately 6 cm long, starting 2.5 cm inferior to the lateral tip of the acromion. This gives a more cosmetic scar than a vertical incision.
- Undermine the skin flaps, and bluntly incise the deltoid muscle parallel to its fibers from the tip of the acromion superiorly to 4 cm inferiorly. Branches of the axillary nerve course transversely, approximately 5 cm inferior to the tip of the acromion; avoid cutting them.
- Expose the subacromial bursa in the floor of this exposure. Incise the bursa and expose the underlying rotator cuff. Rotation and abduction of the shoulder exposes most of the rotator cuff in the operative field. Additional exposure of the rotator cuff is facilitated by detaching the lateral one third of the deltoid from the acromion and performing an anterior acromioplasty. Refer to Henry's Anterior Approach for a complete description.

**POSTERIOR EXPOSURE**

Exposure of the posterior shoulder joint may be necessary for posterior shoulder instability, dislocation, glenoid osteotomy, or soft tissue tumor. Two posterior surgical exposures may be used. The posterior inverted U approach described by Abbott and Lucas (1) detaches the deltoid from the scapular spine, and the other exposure splits the deltoid parallel to its fibers.

***Abbot and Lucas Inverted* U *Approach***

The posterior inverted U approach (Fig. 1.5) is based on the relatively avascular plane between the posterior and middle heads of the deltoid muscle.

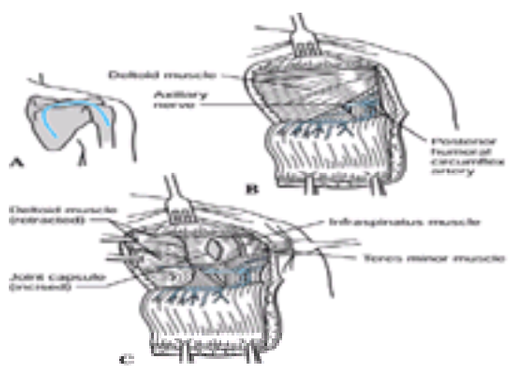


***Figure 1.5.*** Abbott and Lucas inverted U approach.

- Begin the incision parallel to the medial border of the posterior deltoid muscle and extend 5 cm superiorly to the spine of the scapula. Continue along the subcutaneous border of the spine to the acromion laterally.
- Extend the incision inferiorly 7.5 cm to the humeral head along the posterior and middle deltoid interval. By blunt dissection, medially expose the posterior border of the deltoid, and laterally expose the interval between the posterior and middle deltoid fibers.
- Free the deltoid origin by subperiosteal dissection from the scapular spine and reflect the skin and muscle flap inferiorly, exposing the infraspinatus and the teres minor muscles and the quadrangular space.
- The capsule can now be exposed by splitting the interval between the infraspinatus and the teres minor muscle medial to the conjoined tendon (sometimes this interval is difficult to find initially). Better exposure can be gained by detaching 1 cm of the infraspinatus tendon insertion and reflecting it superiorly. The suprascapular nerve innervates this muscle below the scapular spine, so be careful with its retraction.

***Deltoid Splitting Approach***

The deltoid splitting approach (Fig. 1.6) theoretically prevents possible weakening of the deltoid.

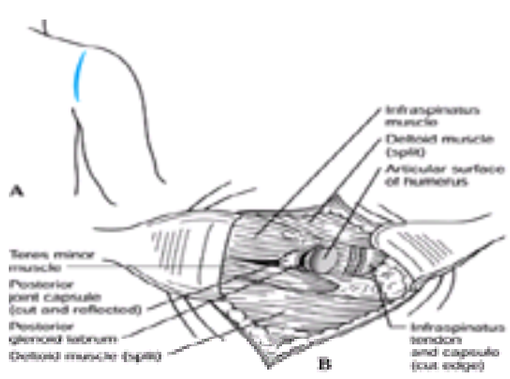


***Figure 1.6.*** Posterior exposure.

- Locate the posterior glenohumeral joint by rotating the shoulder. The “soft spot” superior to the posterior axillary line helps to identify the joint. Start a vertical incision superiorly at the spine of the scapula and extend it inferiorly 6–7 cm, parallel to the posterior axillary line. Undermine the skin flaps medially and laterally.
- Bluntly split the deltoid parallel to its fibers to expose the infraspinatus and teres minor portions of the rotator cuff. The axillary nerve passes through the quadrangular space beneath the teres minor to innervate the deltoid. In the posterior deltoid, therefore, this nerve is located more inferiorly than in the lateral deltoid.
- Develop the muscle interval between the infraspinatus and the teres minor. This interval is located medial to the conjoined insertions at the humeral neck. Avoid dissecting into the infraspinatus muscle to protect its innervation from the suprascapular nerve.
- Detach part of the infraspinatus tendon off of the joint capsule, leaving a stump of tendon for later reattachment. Retraction of the infraspinatus superiorly and the teres minor inferiorly exposes the posterior joint capsule. Greater exposure can be obtained by detaching more of the infraspinatus or part of the teres minor. Avoid excessive retraction of the teres minor to prevent traction injury to the axillary nerve.

## HUMERUS

### HENRY'S ANTEROLATERAL EXPOSURE

- Identify the interval between the biceps and the brachialis by grasping and moving the mobile biceps muscle medially (Fig. 1.7). Incise the skin just lateral to the border of the biceps 8 cm proximal to the elbow flexion crease, and continue distally, crossing the elbow flexion crease if needed. This exposure is extensile and can be carried to the shoulder as needed using the deltopectoral interval.

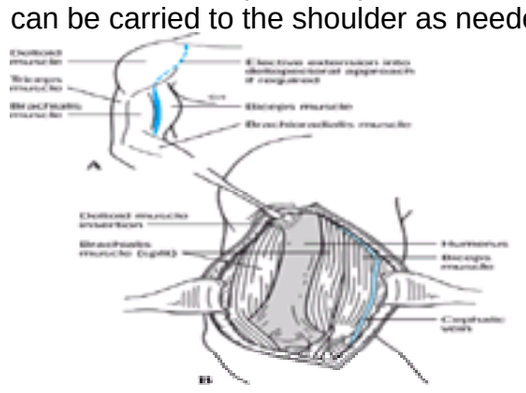

***Figure 1.7.*** Henry's anterolateral exposure.

- While protecting the cephalic vein, retract the biceps medially to expose the brachialis covering the distal anterior one half of the humerus. The shaft of the humerus is exposed by blunt dissection through the brachialis muscle in an oblique direction from proximal lateral to distal anterior. Do not sever the cutaneous branches of the musculocutaneous nerve crossing over the brachialis muscle distally. The radial nerve can be identified, if necessary, by splitting the brachialis muscle 1 cm distal and posterolateral to the deltoid insertion. Otherwise, the radial nerve is protected by the brachialis muscle reflected laterally.
- Wider exposure of the humerus can be achieved by flexing the elbow, which relaxes these muscles. If more proximal exposure is needed, refer to Henry's anterior shoulder approach described previously. If more distal exposure is required, refer to Henry's anterior elbow exposure described later in this chapter.
- In nonunions, full exposure of the radial nerve may be necessary before safe exposure of the bone is possible. In this case, undermine the skin anteriorly and posteriorly over the distal arm. Identify the interval between the brachialis and brachioradialis. This interval can be difficult to find. The fibers of the two muscles have slightly different degrees of coarseness and different directions, which the surgeon can detect visually. Split bluntly into the most distal portion of this interval; a Metzenbaum scissors is useful. Approximately 1–2.5 cm deep into the interval, identify the radial nerve and follow it proximally into the spiral groove or until you are proximal to the fracture and the nerve is freed from all scar tissue and callus.

### HENRY'S POSTERIOR EXPOSURE

- To perform Henry's posterior exposure (Fig. 1.8, Fig. 1.9), place the patient prone on the operating table with the upper extremity on an arm board or on a padded gynecologic knee support. The lateral decubitus position with the arm supported on bolsters also works well. Identify the long head of the triceps, which is mobile and posteromedial. Using this as a landmark, make an incision (Fig. 1.8) 3 cm inferior to the acromion, extending distally along the lateral edge of this muscle to the olecranon if necessary. Develop the skin and subcutaneous flaps to expose the long and lateral heads of the triceps.

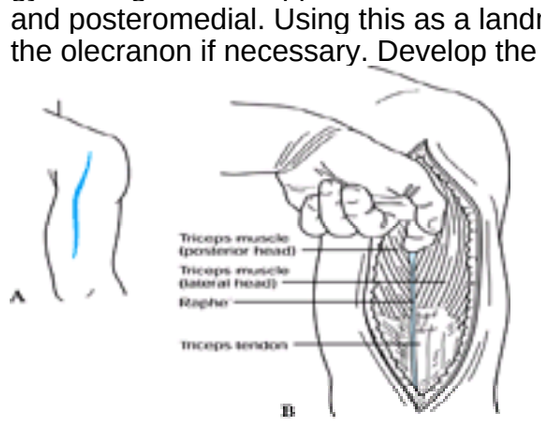


***Figure 1.8.*** Henry's posterior exposure (posterior and lateral heads of triceps exposure).

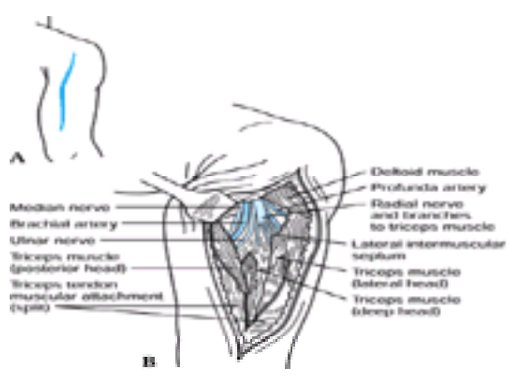


***Figure 1.9.*** Henry's posterior exposure (deep head of triceps exposure).

- Digitally develop the proximal interval between these two heads of the triceps. Lift the seam from the underlying tissue and split it distally. The distal one half of this seam requires sharp dissection along the septum between the long and the lateral heads. Splitting the seam (Fig. 1.9) exposes the deep head of the triceps, with the neurovascular bundles located proximally.
- Notice the relation of the radial nerve and its branches to the three heads of the triceps. While protecting the median nerve, ulnar nerve, and brachial artery medially, and the radial nerve and profunda artery laterally, the deep head of the triceps can be safely split to expose the posterior shaft of the humerus (Fig. 1.10). Confirm that branches of the radial nerve are identified and protected before splitting the deep head. The radial nerve may be further visualized distally by splitting the lateral intermuscular septum. To expose the radial nerve more proximally requires incising the tendinous insertion of the teres major and latissimus dorsi.

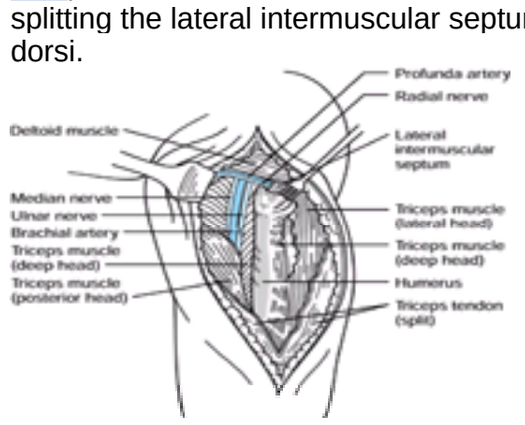


***Figure 1.10.*** Henry's posterior humeral shaft exposure.

### MEDIAL EXPOSURE

The medial approach is used to explore the median and ulnar nerves and brachial artery (Fig. 1.11).

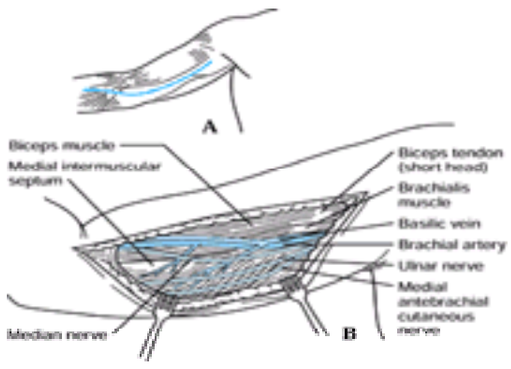


***Figure 1.11.*** Medial exposure.

- Identify the medial border of the mobile biceps muscle. Start the incision proximally from the anterior axillary fold to the level of the elbow flexion crease distally, following the border of the biceps. If more distal exposure is needed, refer to the anteromedial elbow exposure. Protect the branches of the medial antecubital cutaneous nerve in the subcutaneous tissue.
- Starting proximally, incise the deep fascia to expose the brachial artery, the basilic vein, and the median and ulnar nerves. The artery, vein, and median nerve course distally, staying anterior to the medial intermuscular septum to enter the antecubital fossa. The ulnar nerve penetrates the intermuscular septum at the midpoint of the upper arm, entering the posterior compartment of the upper arm. To expose the ulnar nerve distally, incise this septum.

## ELBOW

### LATERAL EXPOSURE

The lateral exposure is useful for exposing the radial head and elbow joint for removal of loose bodies and synovectomy (Fig. 1.12).

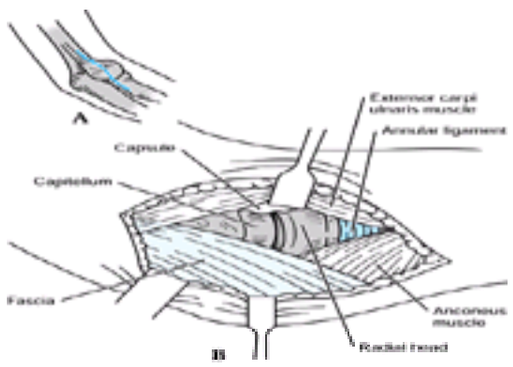


***Figure 1.12.*** Lateral exposure.

- Pronate the forearm and flex the elbow 90° on an arm board. Identify the lateral epicondylar ridge and the radial head by rotating the forearm. Make a gentle curvilinear incision along the lateral epicondylar ridge 3–4 cm proximal to the joint line and extending 3–4 cm distal to the joint along the interval between the extensor carpi ulnaris and the anconeus overlying the radial head.
- Proximally, reflect the triceps posteriorly. Reflect the extensor carpi radialis longus and the brachioradialis anteriorly. This dissection can be subperiosteal, or a wafer of bone may be taken with the extensor carpi radialis longus origin.
- The radial nerve passes anteriorly between the brachialis and the brachioradialis and therefore is protected with this proximal exposure. Distally, sharply incise the interval between the extensor carpi ulnaris and anconeus to expose the underlying joint capsule. Incise the joint capsule from the lateral epicondyle to the annular ligament of the radial head. Do not extend the incision distal to the annular ligament, because this can sever the posterior interosseous nerve, which crosses anterolaterally across the radial neck through the supinator muscle. Pronation of the forearm helps to place this nerve anterior to the operative field. A smaller incision may be used if only the radial head is to be exposed. Wider exposure for synovectomy or other procedures is accomplished by detaching the common exterior origin and the joint capsule from the humerus.

### HENRY'S ANTEROLATERAL EXPOSURE

Henry's anterolateral exposure is useful for exposing the radial nerve and the arch of Frohse, lesions of the proximal radius, and the radial tuberosity for bicipital tendon ruptures (Fig. 1.13) (2).

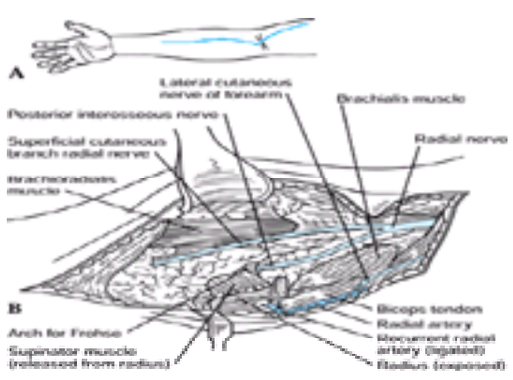


***Figure 1.13.*** Henry's anterolateral exposure.

- Position the arm with the elbow extended and the forearm supinated. Start the incision along the lateral border of the biceps proximally, cross the elbow flexion crease in a curvilinear fashion, and extend the incision distally along the medial border of the brachioradialis. The length of the incision depends on the operative needs. If exposure of the anterior distal humerus is needed, refer to Henry's anterolateral humeral surgical exposure described previously.
- Identify and preserve the lateral cutaneous nerve of the forearm proximally in the interval between the biceps and brachialis muscles. Identify the biceps tendon and the lacertus fibrosis.
- For better exposure, incise the lacertus fibrosis, flex the elbow, and pronate the forearm. Bluntly develop the interval between the brachioradialis laterally and the

pronator teres medially to expose the radial artery.
- Identify and ligate the recurrent radial vessels located by sliding a finger distally along the lateral edge of the bicipital tendon. Do not cut the radial artery.
- After these vessels are ligated, the brachioradialis can be retracted laterally to expose the radial nerve exiting the upper arm between the brachialis and brachioradialis. The superficial cutaneous radial nerves pass distally into the forearm under the covering of the brachioradialis muscle. The posterior interosseous nerve penetrates the supinator muscle under the arch of Frohse.
- To expose the proximal radius, reflect the origin of the supinator off the radius just lateral to the radial tuberosity. A small bursa identifies this interval. Identification of the radial tuberosity is facilitated by pronating and supinating the forearm while palpating over the bicipital tendon. Do not incise through the supinator muscle, because this action can cut a branch of the posterior interosseous nerve.

**MEDIAL EXPOSURE**

Use the medial exposure to expose the ulnar nerve or medial elbow joint (Fig. 1.14).

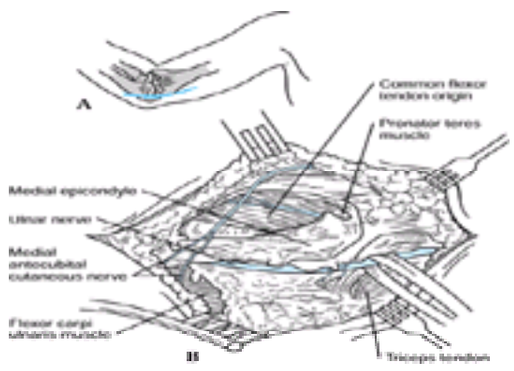


***Figure 1.14.*** Medial exposure.

- Place the elbow on an arm board with the shoulder externally rotated and the elbow flexed 90°. Identify the medial epicondyle. Start the incision approximately 4 cm proximal to the epicondyle, and extend the incision 4 cm distally along the flexor carpi ulnaris.
- Bluntly dissect the subcutaneous tissue and identify the branches of the medial antebrachial cutaneous nerves.
- After these nerves are protected and the deep fascia over the flexor-pronator muscles is exposed, palpate for the ulnar nerve proximal to the ulnar groove. Expose this nerve by incising its overlying fascia.
- If the nerve is to be transposed anteriorly, several principles apply:
  1. The medial intermuscular septum must be incised to prevent proximal tethering of the transposed nerve.
  2. The thick ligament over the ulnar groove must be incised.
  3. The fascia over the flexor carpi ulnaris must be incised to prevent distal tethering of the nerve.
  4. The ulnar muscular branches of the flexor carpi ulnaris may need to be exposed to facilitate the transfer.
  5. Pass a 0.6 cm Penrose drain around the nerve for retraction.
  6. Protect the accompanying small vessels to the ulnar nerve, if at all possible, to prevent ischemic damage to the nerve.

- To expose the medial aspect of the elbow joint, define the interval between the brachialis and pronator teres anteriorly and protect the ulnar nerve posteriorly. Osteotomize the medial epicondyle with its attached flexor pronator muscles and retract it distally. Be careful not to retract it too vigorously, to prevent median nerve injury. The joint capsule and medial collateral ligament complex can be incised to expose the joint. The osteotomized bone may be reattached with sutures or preferably with a 3–4 mm A-O cancellous screw through a hole drilled before the osteotomy. During closure, do not suture the deep fascia of the forearm, to prevent an iatrogenic compartment syndrome.

**ANTEROMEDIAL EXPOSURE**

The anteromedial exposure is useful for exposing the brachial artery, median nerve, and bicipital tendon (Fig. 1.15).

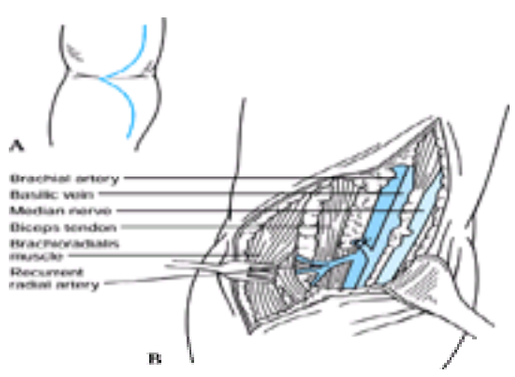


***Figure 1.15.*** Anteromedial exposure.

- Place the arm with the elbow extended and the forearm supinated. Start the incision proximally along the medial border of the biceps, zigzag along the elbow flexion crease, and extend it distally along the pronator teres. The length of the incision depends on the operative needs. If more proximal exposure is needed, refer to the medial humeral exposure.
- Identify the basilic vein and branches of the medial antebrachial cutaneous nerve in the subcutaneous tissue. Incise the deep fascia proximally to expose the median nerve and brachial artery.
- Trace these structures distally to the level of the elbow flexion crease, where they dive under the lacertus fibrosis. While protecting these structures, incise this fibrotic band.
- Bluntly develop the interval between the brachioradialis and the pronator teres to expose the radial and ulnar arteries and the median nerve. If more distal exposure of these nerves is needed, refer to McConnell's exposure of the median and ulnar nerves of the forearm described later in this chapter.

**BRYAN AND MORREY'S POSTEROLATERAL EXPOSURE**

The posterolateral exposure of Bryan and Morrey (6) is useful for previous elbow dislocations, arthroplasty, and repair of comminuted interarticular fracture of the distal humerus. It avoids an olecranon osteotomy by preserving the continuity of the triceps mechanism.

- Position the patient in a supine position with a rolled towel under the scapula. A sterile tourniquet may be utilized. Make a posterior incision lateral to the olecranon 9 cm proximal to the olecranon tip, extending it 9 cm distal to the tip.
- Create a triceps and ulnar periosteal flap in continuity by incising the lateral border of the triceps and extending it distally 6 cm along the ulnar shaft.
- By careful subperiosteal dissection, reflect the triceps tendon and its periosteal attachment in continuity toward the lateral side, preserving the ulnar collateral ligament.
- The radial head can be exposed by including the anconeus in the subperiosteal dissection. The ulnar nerve is protected by the soft tissues. Exposure and transfer is usually not necessary unless it is at risk. Now the entire posterior elbow joint is exposed (Fig. 1.16). Further exposure for arthroplasty can be obtained by releasing the joint capsule.

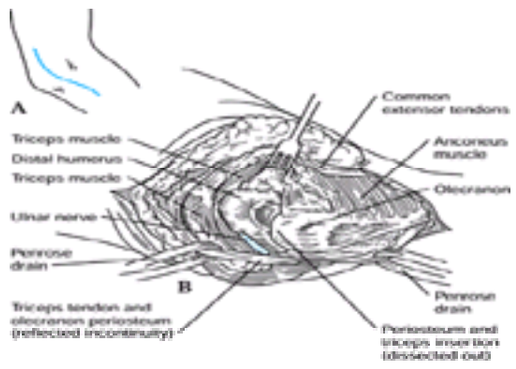


***Figure 1.16.*** Posterolateral exposure.

**CHAPMAN'S COMPREHENSIVE POSTERIOR APPROACH**

The Chapman comprehensive posterior approach was developed for the open reduction and internal fixation of intraarticular fractures of the distal humerus. It has also proven useful for reconstructive surgery, including complete posterior and anterior release for arthrofibrosis of the elbow. It avoids olecranon osteotomy with its potential complications and provides better exposure.

- Position the patient in the lateral decubitus position with the operated elbow supported on a well-padded gynecologic knee support and flexed to 90°. Be certain that the forearm is not obstructed, as further flexion to 110° is necessary for full exposure of the articular surface.
- Make a longitudinal midline posterior incision as long as necessary, staying slightly to one side of the olecranon; full exposure requires an incision at least 20 cm in length. Incise directly down to the deep fascia. Creation of flaps is not necessary unless transfer of the ulnar nerve is planned.
- If transfer of the ulnar nerve is necessary, do it now, placing the nerve in a subcutaneous tunnel.
- Split the triceps muscle in the midline, beginning proximally and extending distally to the olecranon. Split the joint capsule as well.
- Elevate the extensor and flexor forearm muscles off the shaft of the proximal ulna with a sharp elevator, beginning about 4 cm distally and working proximally to the tip of the olecranon.
- Using a #15 blade, reflect the triceps insertion, medially and laterally, off the olecranon in continuity with the forearm muscles, maintaining the integrity of the retinaculum and periosteum. Take the joint capsule in continuity with these flaps (Fig. 1.17).

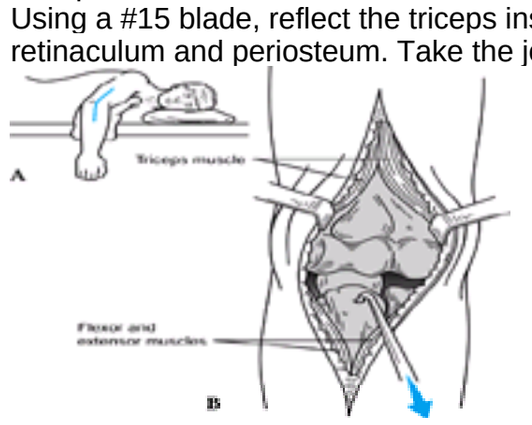


***Figure 1.17.*** Chapman's comprehensive posterior approach.

- With meticulous subperiosteal dissection, reflect the lateral triceps and the forearm muscle extensor origins in continuity, laterally, staying on bone and including the joint capsule until the tip of the lateral epicondyle is reached. Perform the same maneuver medially, avoiding injury to the ulnar nerve, which in most cases can be left undisturbed in its sulcus. Include the joint capsule in this dissection, preserving its continuity with the overlying musculocutaneous structures.
- For complete exposure, flex the elbow to 110° and distract the olecranon with a bone hook to expose the distal third of the humerus and its entire articular surface. With further release, it is possible to isolate and excise the anterior capsule if needed.

Closure of a single layer of capsule, muscle, and fascia, using interrupted figure-eight sutures, allows early mobilization of the elbow joint.

**POSTERIOR TRANSOLECRANON EXPOSURE**

The posterior transolecranon exposure is excellent for exposing a comminuted intra-articular distal humeral fracture (Fig. 1.18), although it does have the disadvantage of the olecranon osteotomy.

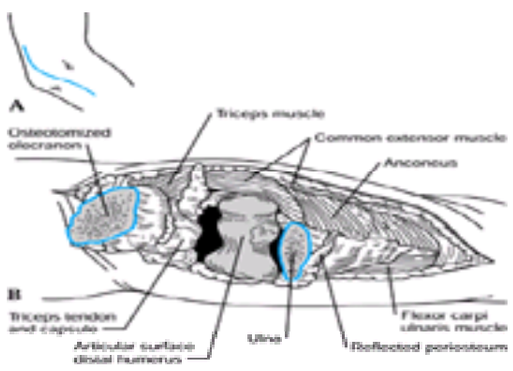


***Figure 1.18.*** Posterior transolecranon exposure.

- Place the patient supine with her arm across her chest. The skin incision is the same as that previously described for the posterolateral approach to the elbow. Incise the deep fascia to expose the triceps tendon and proximal olecranon. Identify and protect the ulnar nerve medially.
- Make a 1 cm linear incision through the triceps tendon to expose the tip of the olecranon. Predrill and tap the olecranon for two fixation screws. Expose the medial and lateral borders of the proximal 3 cm of the olecranon, protecting the ulnar nerve. Before cutting the olecranon with a small oscillating saw, score the bone at the proposed osteotomy site to ensure proper alignment during reattachment. Cut the bone 2 cm from its tip. Use either a transverse osteotomy, as illustrated, or a chevron osteotomy, which may help with a more accurate reattachment. Use an osteotome to cut the subchondral bone.
- Reflect the triceps proximally with its attached olecranon. Release the remaining medial and lateral soft-tissue attachments as necessary to facilitate proper exposure of the distal intra-articular humerus.
- Perform closure by realigning the olecranon fragment and securing it with two cancellous lag screws and washers. An alternative method is to add a tension band wire.

**HENRY'S POSTERIOR INTEROSSEOUS NERVE EXPOSURE**

- With the forearm pronated, palpate the posterior border of the mobile wad to identify the interval between the extensor carpi radialis brevis and the extensor digitorum communis (Fig. 1.19). Start an incision proximally, at the radiocapitellar joint line, and extend it 6 cm distally along this interval.

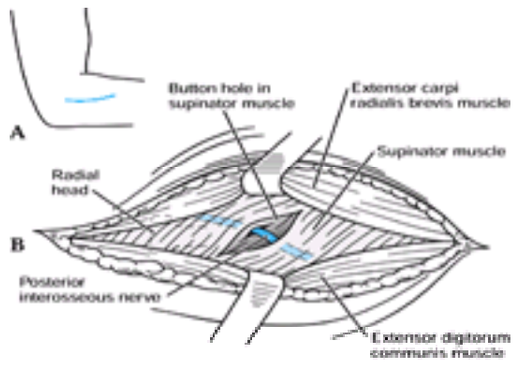


***Figure 1.19.*** Henry's posterior interosseous nerve exposure.

- Develop skin flaps and incise the deep fascia. Distally, the interval between these muscles is easily separated and, once identified, can be split with scissors from distal to proximal to expose the underlying supinator muscle. Avoid cutting into the supinator muscle during this step.
- Bluntly dissect along the muscle fibers of the supinator 3 cm distal to the radial head to expose the posterior interosseous nerve. Rotation of the forearm at this time facilitates locating this nerve.
- If exposure of the proximal radius is needed, incorporate this incision with the lateral exposure of the elbow (Fig. 1.12). After the posterior interosseous nerve is safely identified, the supinator muscle can be reflected from the ulna to expose the proximal radius.

## FOREARM

### ANTERIOR EXPOSURE OF THE DISTAL TWO THIRDS OF THE RADIUS

To expose the proximal one third of the radius, refer to Henry's anterolateral elbow exposure described previously and to Thompson's approach described later in this chapter. In its distal third, the anterior radius is flat and can accommodate a plate better than the convex posterior surface (Fig. 1.20).

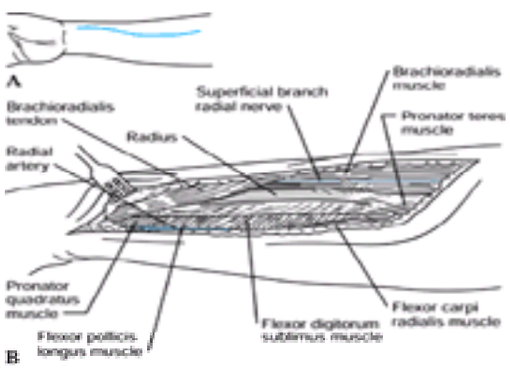


***Figure 1.20.*** Anterior exposure of the distal two thirds of radius.

- With the forearm supinated, start a curvilinear incision 4–5 cm distal to the elbow flexion crease along the medial border of the brachioradialis muscle, and extend it inferiorly toward the radial styloid. The length of the incision depends on the exposure needed.
- Incise the deep fascia, and distally develop the interval between the brachioradialis and the flexor carpi radialis to expose the medial border of the radius. Protect the radial artery, which runs in this interval, and ligate its branches if needed.
- The superficial cutaneous branch of the radial nerve travels under the brachioradialis muscle in the proximal two thirds of the forearm and must be identified and protected. Expose the radius distally by reflecting the pronator quadratus and the flexor pollicis longus subperiosteally.
- For more proximal exposure subperiosteally, dissect the flexor digitorum sublimis and pronator teres off the radius. Forearm pronation facilitates proximal exposure of the pronator teres attachment.

### ULNAR SHAFT EXPOSURE

- The ulnar shaft approach is facilitated by flexing the elbow and laying the arm across the patient's chest (Fig. 1.21). Identify the subcutaneous border of the ulna by palpation. Make a skin incision just volar to this border. The length of the incision depends on the surgical needs.

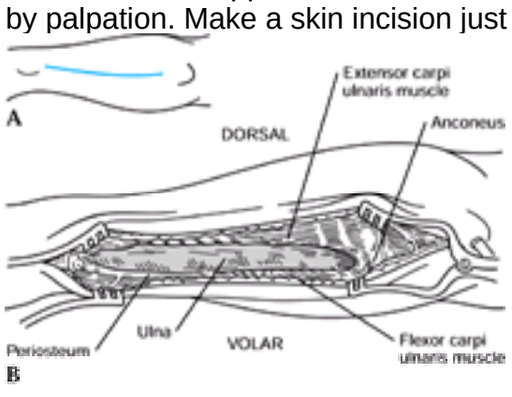


***Figure 1.21.*** Ulnar shaft exposure.

- Incise the deep fascia, and distally expose the ulnar shaft by incising the periosteum between the flexor carpi ulnaris and the extensor carpi ulnaris.
- Subperiosteally, reflect the flexor carpi ulnaris or extensor carpi ulnaris for volar or dorsal exposure, respectively. To expose the shaft proximally, continue the subperiosteal dissection between the flexor carpi ulnaris medially and the anconeus laterally.
- Identify and protect the ulnar nerve if the proximal ulna (olecranon) is exposed. In the distal exposure, the ulnar nerve is safely protected if the flexor carpi ulnaris is subperiosteally reflected.

### POSTERIOR EXPOSURE OF THE RADIUS

To expose the proximal one third of the posterior radius, refer to Henry's exposure of the posterior interosseous nerve described previously and to Thompson's extended exposure described later in this section (Fig. 1.22).

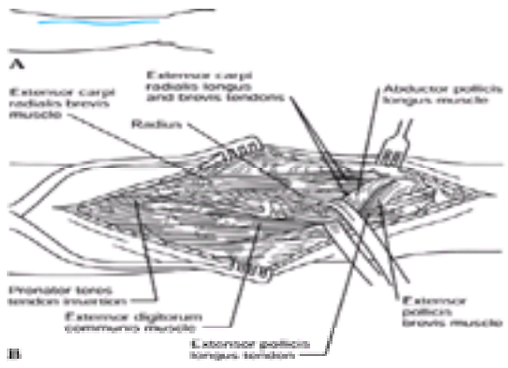


***Figure 1.22.*** Posterior exposure of the distal two thirds of the radius.

- With the forearm pronated, palpate for the posterior border of the mobile wad to identify the interval between the extensor carpi radialis brevis and the extensor digitorum communis. Proximally start a curvilinear incision in this interval 5 cm distal to the radiocapitellar joint, and extend it distally to the wrist joint midway between the radial styloid and Lister's tubercle. The length of the incision depends on the surgical needs.
- Incise the deep fascia, and proximally identify and develop the muscle interval between the extensor carpi radialis brevis and the extensor digitorum communis to expose the radial shaft. In the middle one third of this exposure, the abductor pollicis longus and the extensor pollicis brevis cross the radial shaft obliquely toward the distal radial border of the radius. These muscles are left intact but mobilized so they can be retracted proximally and distally as needed.
- To expose the distal radius, dissect between the extensor carpi radialis brevis and the extensor pollicis longus. The posterior interosseous nerve is not encountered with this approach if the supinator muscle is not exposed and the radial shaft is approached as described. For more proximal dissection, it is essential to identify and protect the posterior interosseous nerve.
- In 1918, Thompson (10) described extensions of this exposure, including exposure of the entire radius and exposure of the posterior interosseous nerve if needed. Follow the line of separation between the extensor digitorum communis and the extensor carpi radialis brevis muscles up to the lateral epicondyle of the humerus if needed. This fully exposes the supinator muscle. Detaching the origins of these muscles from the lateral epicondyle allows even wider exposure. By supinating the radius, the junction of the supinator origin and the biceps tendon can be visualized.
- Carefully dissect the supinator off the radius, staying against bone. Expose only as much radius as necessary. Avoid over-retraction, because a stretch injury to the posterior interosseous nerve can result, particularly where it is tethered by the motor branches to the extensor digitorum communis. To expose the posterior interosseous nerve, identify it proximal to the supinator, and trace it into the body of the supinator.

### McCONNELL'S MEDIAN AND ULNAR NERVE EXPOSURE

- Place the forearm supinated on an arm board. Proximally, start the incision near the medial epicondyle and extend it distally in a lazy-**S** fashion to the radial border of the pisiform (2) (Fig. 1.23). The length of the incision depends on the surgical needs. Protect the medial antebrachial cutaneous nerves in the proximal forearm.

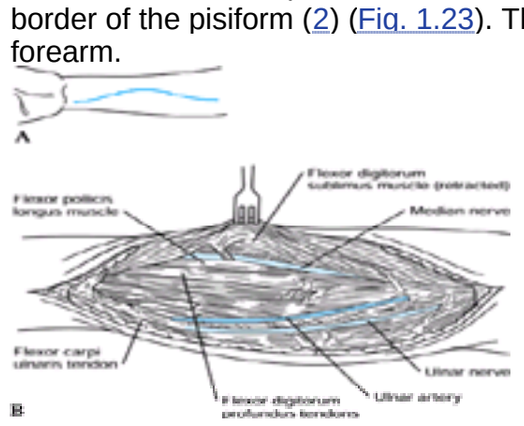


***Figure 1.23.*** McConnell's median and ulnar nerve exposure.

- Distally, expose the ulnar artery and nerve by incising the deep fascia along the radial border of the flexor carpi ulnaris. Retracting the flexor carpi ulnaris ulnarly and the flexor digitorum sublimis radially allows the ulnar artery and nerve to be visualized and followed proximally. Flexion of the wrist helps to relax these tendons.
- The artery and nerve run parallel until the proximal one third of the forearm, where the artery courses toward the antecubital fossa and the ulnar nerve continues under the flexor carpi ulnaris to the ulnar groove. Protect the branches of the ulnar nerve innervating the flexor carpi ulnaris and part of the flexor digitorum profundus in the proximal forearm.
- Distally, identify the median nerve as the flexor digitorum sublimis is reflected radially. Follow the median nerve proximally as it lies between the sublimis and profundus muscles. Halfway up the forearm, the median nerve is bound to the intermediate tendinous portion of the sublimis muscle. Because the nerve is on the radial side of this juncture, incising along its ulnar border further exposes the nerve.
- To expose the median nerve more proximally, identify and develop the interval between the pronator teres and the flexor carpi radialis. Just inferior and deep to the pronator teres lies the median nerve. Sometimes the arch of the sublimis covers the nerve at this level, but dissecting through this portion of the sublimis exposes the nerve.

### CHAPTER REFERENCES

Each reference is categorized according to the following scheme: *, classic article; #, review article; !, basic research article; and +, clinical results/outcome study.


* 1. Abbott LC, Lucas DB. The Tripartite Deltoid and Its Surgical Significance in Exposure of the Scapulohumeral Joint. *Ann Surg* 1952;136:392.

\# 2. Crenshaw AH. Surgical Approaches. In: Edmonson AS, Crenshaw AH, eds. *Campbell's Operative Orthopaedics,* 6th ed. St. Louis: Mosby, 1980:81.

* 3. Henry AK. The Upper Limb and Neck. In: Henry AK, ed. *Extensile Exposures*, 2nd ed. Baltimore: Williams & Wilkins, 1957:15.

\# 4. Hoppenfeld S, deBoer P. *Surgical Exposures in Orthopaedics.* Philadelphia: JB Lippincott, 1984:1.

* 5. Leslie JT, Ryan TJ. The Anterior Axillary Incision to Approach the Shoulder Joint. *J Bone Joint Surg Am* 1962;44:1193.

\+ 6. Morrey BF, Bryan AS, Dobyns JH, Linscheid R. Total Elbow Arthroplasty. *J Bone Joint Surg Am* 1981;63:1050.

\# 7. Morrey BF. Surgical Exposures of the Elbow. In: Morrey BF, ed. *The Elbow and Its Disorders*, 2nd ed. Philadelphia: WB Saunders, 1993:3.

* 8. Neer CS II. Anterior Acromioplasty for the Chronic Impingement Syndrome in the Shoulder. *J Bone Joint Surg Am* 1972;54:41.

* 9. Neer CS II, Watson KC, Stanton FJ. Recent Experience in Total Shoulder Replacement. *J Bone Joint Surg Am* 1982;64:3319.

* 10. Thompson JE. Anatomical Methods of Approach in Operating on the Long Bones of the Extremities. *Ann Surg* 1918;68:309.

# CHAPTER 2

# SURGICAL APPROACHES TO THE ACETABULUM AND PELVIS

*Joel M. Matta*

**J. M. Matta:** University of Southern California School of Medicine, Los Angeles, California 90089.

Approaches to the Acetabulum
Operative Techniques
Approaches to the Pelvic Ring
Operative Techniques
Chapter References

## APPROACHES TO THE ACETABULUM

Fracture classification as well as specific fracture pattern determine the surgical approach to the acetabulum. The vast majority of fractures can be reduced and fixed through a single surgical approach.

The important preoperative question is whether or not the fracture can be reduced through the chosen approach. Fixation is less of a determining factor inasmuch as all three approaches—ilioinguinal (II), Kocher-Langenbeck (KL), and extended iliofemoral (EIF)—give access for fixation of both the anterior and posterior columns. I prefer to operate on the Tasserit (Judet) surgical table, placing patients prone for the KL, supine for the II, and lateral for the EIF approaches. If the surgeon chooses to operate on a standard table, particularly without traction, the reduction can usually also be performed. In that case, however, the need for either two approaches or the EIF may arise more often, and my recommendations for surgical approach (Table 2.1) may not apply. The KL and II approaches are preferable to the EIF approach because the EIF involves more muscle stripping from the outside of the bone. As a result, the period of rehabilitation is longer and the incidence of heterotopic ossification is higher. If the reduction and fixation are not judged to be possible through either the KL or II alone, however, choose the EIF.

| |
|---|
| ***Indications for Kocher-Langenbeck approach*** |
| Associated posterior column and posterior wall fractures |
| Posterior wall fractures |
| Posterior column fractures |
| Transverse fractures |
| Associated transverse and posterior wall fractures |
| T-shaped fractures |
| ***Indications for ilioinguinal approach*** |
| Anterior wall fracture |
| Anterior column fracture |
| Associated anterior and posterior hemitransverse fractures |
| Both-column fractures |
| ***Indications for extended iliofemoral approach*** |
| T-shaped fractures |
| Both-column fractures |
| Associated transverse and posterior wall fractures |
| Old fractures |

***Table 2.1. Acetabulum Fractures: Indications for the Various Operative Approaches***

In some instances, the surgeon may initially choose the KL or II approaches, but during surgery he may find that completion of the reduction is impossible. In these cases, complete the reduction and fixation for the exposed column of the acetabulum, taking care not to place fixation into unreduced fracture lines. Close the wound and turn the patient from prone to supine or vice versa to perform a subsequent II or KL approach.

I do not advocate placing the patient in the so-called floppy lateral position to perform simultaneous II and KL approaches. Dispensing with the Tasserit table and placing the patient in the floppy lateral position limits the effectiveness of either the II or KL approach and makes the need for a second approach more likely. With the patient in the floppy position, it is also difficult to maintain adhesion of surgical drapes, and sterility is thereby compromised. Second surgical approaches should rarely be needed if the surgeon does appropriate preoperative planning (3,4).

In exceptional cases, for example certain T-shaped fractures, it may be desirable to plan for the KL and II surgical approaches to be performed successively in preference to the EIF. First, position the patient prone, then supine, or vice versa.

## OPERATIVE TECHNIQUES

### *Ilioinguinal (II) Approach*

After finding existing approaches to the anterior acetabulum to be inadequate, Emile Letournel (2) returned to the historic Paris anatomy institute, the Fer à Moulin, where he developed the II approach. The innovation of the approach was that in opening the inguinal canal at its roof and floor for access to the pelvis, it would nonetheless be possible to obtain a sound repair of the soft tissues at the completion of the procedure. This elegant approach remains the standard for access to the anterior column and internal aspects of the innominate bone. Through this approach, the interior of the joint can be visualized through displaced fracture lines (intraoperative visualization with the image intensifier can be helpful as well), but it is not visible after completion of the reduction. The reduction is inferred by the reduction of the inner aspect of the innominate bone.

- Place a Foley catheter in the bladder before positioning the patient.
- Position the patient supine, usually on a fracture table—the Tasserit (Judet) table is preferable. Support the pelvis with a narrow sacral support to facilitate the necessary access around the iliac crest; a broad flat table top inhibits access. Place the hip in about 20° of flexion to relax the iliopsoas and facilitate access to the internal iliac fossa and true pelvis.
- Start the incision in the midline of the abdomen, 2 cm proximal to the symphysis pubis. Direct the incision laterally toward the anterior superior iliac spine, and follow the iliac crest about two thirds of the way posteriorly to or beyond the most lateral convexity of the crest (Fig. 2.1).

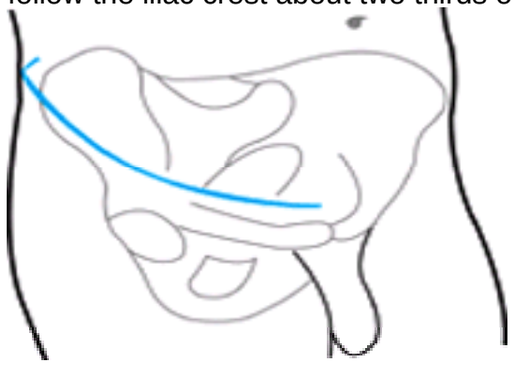

***Figure 2.1.*** Skin incision for the II approach.

- Sharply incise the periosteum over the iliac crest, and release the attachment of the abdominal muscles and the iliacus from the iliac crest. Using a periosteal elevator, expose the internal iliac fossa as far posteriorly and medially as the anterior SI joint and the pelvic brim. Be careful to avoid injuring the internal femoral cutaneous nerve to the thigh (discussed below).
- The first abdominal layer encountered is the aponeurosis of the external oblique and the external rectus abdominis sheath in the most medial portion of the incision. Incise this layer in line with the skin incision.
- Reflect the aponeurosis of the external oblique and the external rectus sheath distally as a single layer; the inguinal canal is thereby unroofed (Fig. 2.2).

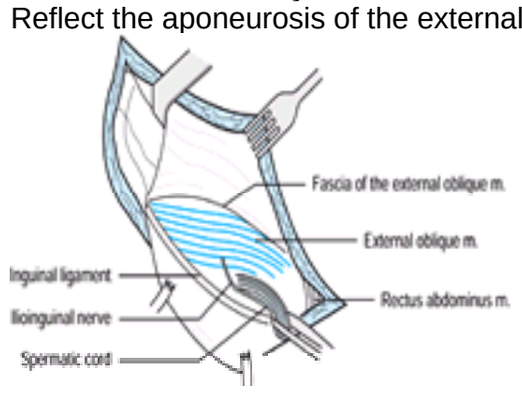


***Figure 2.2.*** Unroofing of the inguinal canal.

- Identify the ilioinguinal nerve and spermatic cord or round ligament. Pass a finger bluntly around the spermatic cord, and pass a Penrose drain around the spermatic cord and ilioinguinal nerve together.
- Detach the common origin of the internal oblique and transverse abdominis from the inguinal ligament by sharply incising along the ligament and splitting it. Leave about 1 mm of the inguinal ligament with the muscle origin. Detach the transversalis fascia from the inguinal ligament by splitting a small portion of the ligament with the transversalis fascia.
- Medial to this split, transect the conjoined tendon of the internal oblique and transverse abdominis and a portion of the rectus tendon near the body of the pubis (Fig. 2.3). The medial portion of this dissection gives access to the retropubic space of Retzius.

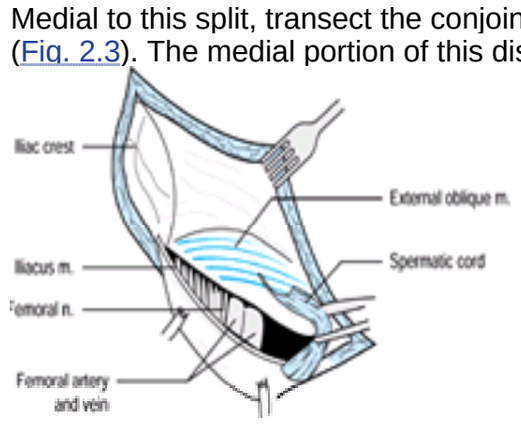


***Figure 2.3.*** Detachment of the abdominal muscles and fascia from the inguinal ligament.

- Perform the incision along the inguinal ligament, with care to avoid injuring the structures immediately underlying it, which include the external iliac vessels and their accompanying lymphatics, the femoral nerve, and the lateral cutaneous nerve of the thigh.
- Beneath the inguinal ligament lie two lacunae that contain the structures passing under it. Laterally is the lacuna musculorum, and medially is the lacuna vasorum (Fig. 2.4). The two lacunae are separated by the iliopectineal fascia, which runs obliquely from the anterior iliac crest to the pectineal eminence and the pelvic brim. The iliopsoas and the femoral and lateral cutaneous nerves of the thigh are found in the lacuna musculorum. The femoral vessels and their surrounding lymphatics are found in the lacuna vasorum. The lateral cutaneous nerve of the thigh is found at a variable distance from the anterior superior spine, from just adjacent to it to 3 cm medially. It is usually found immediately after incision along the inguinal ligament. The femoral nerve is more posterior and medial within the iliopsoas sheath and intimately is associated with the iliopsoas muscle.

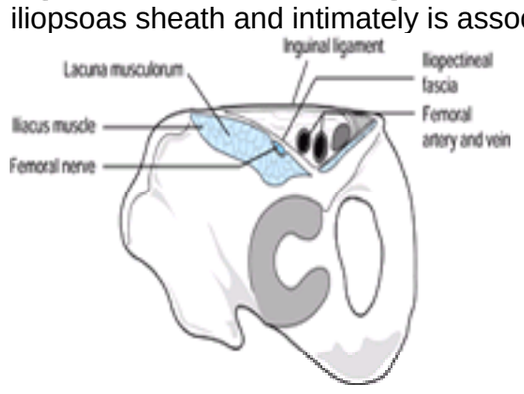


***Figure 2.4.*** Oblique section of the lacuna musculorum and lacuna vasorum at the level of the inguinal ligament.

- Incise the iliopectineal fascia, which divides the false pelvis from the true pelvis, to gain access to the true pelvis and its quadrilateral surface. Incise it at the level of the inguinal ligament in a posterior and medial direction to the pectineal eminence, and then detach it proximally from the pelvic brim. Before dividing this fascia, fully isolate it by carefully dissecting the external iliac or femoral vessels with the surrounding lymphatics off the medial aspect of the fascia. Dissect the iliopsoas and femoral nerve off the lateral aspect. Retract these structures medially and laterally away from the fascia, and sharply incise the fascia to the pectineal eminence. Cut the fascia proximally along the pelvic brim in a proximal and posterior direction until the anterior SI joint is palpable (Fig. 2.5*A*, Fig. 2.5*B* and Fig. 2.5*C*). The fascia attachment may be combined at the pectineal eminence with the psoas minor tendon attachment. If the psoas minor tendon attachment is present, it appears as a very dense section of the fascia and should be transected.

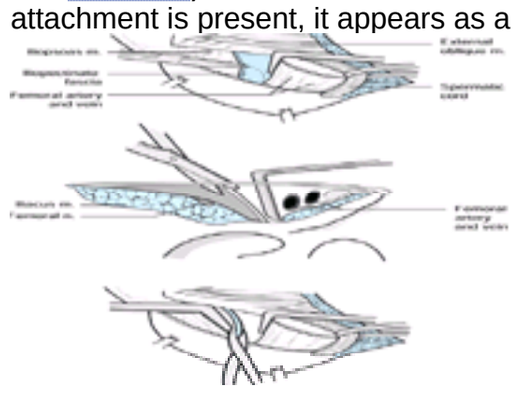

***Figure 2.5.*** **A:** Division of the iliopectineal fascia to the pectineal eminence. **B:** Oblique section dividing the fascia. **C:** Proximal division of the fascia from the pelvic brim.

- Pass a second Penrose drain around the iliopsoas and femoral nerve together. Passing a finger posteriorly to the external iliac vessels into the retropubic space medially, check for the possibilities of a retropubic anastomosis or anomalous origin to the obturator artery (corona mortis) from the external iliac. If this anomalous artery is present, it should be palpable on the posterior aspect of the superior pubic ramus. Visualize this area to check for the anastomosis. If present, sacrifice this anastomosis by cauterizing it or ligating it. Place a Penrose drain around the iliac vessels and their surrounding lymphatics as a unit. Do not

dissect the vessels individually. Individual dissection injures the lymphatics and produces postoperative lymphedema of the extremity.

- Further expose the bone and the fracture lines by periosteal elevation along the superior pubis ramus and pelvic brim. Use a periosteal elevator over the pelvic brim to clear the obturator internus muscle from the quadrilateral surface, and approach the posterior column. In doing so, approach the sciatic notch carefully, because it is easy to injure the superior gluteal vessels or branches of the internal iliac vein. The obturator nerve can easily be seen as it runs parallel and medial to the quadrilateral surface and enters the obturator canal at the superolateral aspect of the obturator foramen. The exposure is now complete. Perform the operation through the various windows surrounded by the structures crossing the inguinal ligament.
- The first window (Fig. 2.6) gives access to the internal iliac fossa, the anterior SI joint, and the proximal pelvic brim. Retraction can be performed with lever retractors placed on the anterior SI joint and the pelvic brim.

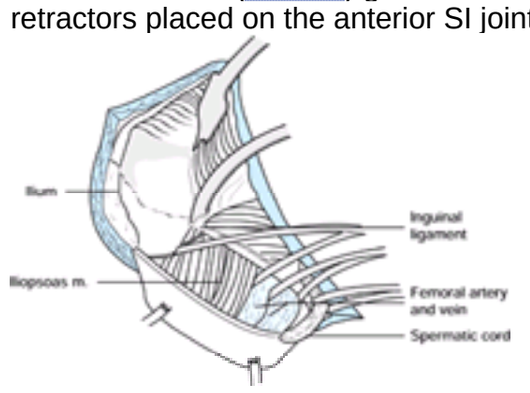


***Figure 2.6.*** The first window of the II approach.

- The second window (Fig. 2.7), which is accessed by retracting the iliopsoas and femoral nerve laterally and the external iliac vessels medially, gives access to the pelvic brim from the anterior SI joint beyond the pec-tineal eminence. It also gives access to the quadrilateral surface for reduction of posterior column fractures. The iliopsoas can be retracted fairly vigorously laterally without danger of injury to the femoral nerve. Take care with medial retraction of the external iliac vessels; this is usually done with a ribbon retractor, with its tip placed against the quadrilateral surface. After retraction of the vessels, check the pulse repeatedly to be certain that too great a force has not been applied.

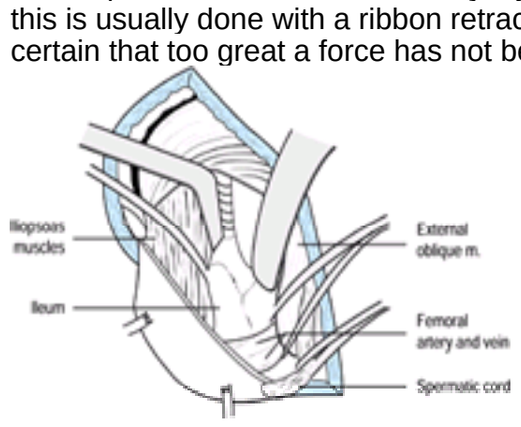


***Figure 2.7.*** The second window of the II approach.

- The third window lies medial to the vessels and gives access to the superior pubic ramus and the symphysis pubis as well as the quadrilateral surface (Fig. 2.8). The spermatic cord may be retracted medially or laterally.

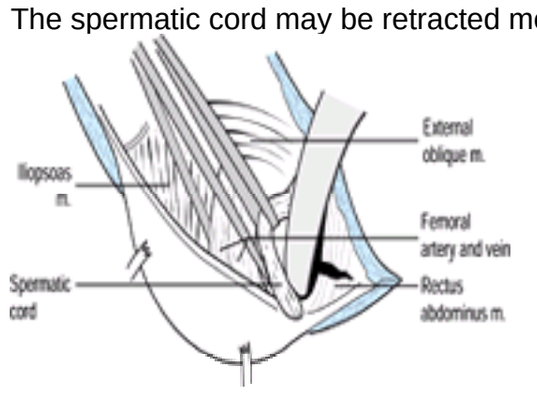


***Figure 2.8.*** Access to the retropubic space and symphysis through the third window.

- It is often desirable to obtain access to the external aspect of the ileum to manipulate the anterior column segment for placing bone-holding forceps around the bone. Gain access by releasing the inguinal ligament and sartorius from their origins on the anterior superior spine. Elevate the tensor fascia lata and gluteus minimus muscles from the anterior iliac wing as necessary. Detachment of rectus origin and anterior hip capsule has been described for the purpose of visualizing the articular surface following reduction, but I believe that this procedure is unwise because it can easily devascularize fracture fragments of the anterior column or wall.
- At the completion of the procedure, place a suction drain in the space of Retzius. Also drain the internal iliac fossa and true pelvis adjacent to the quadrilateral surface. If the lateral ilium has been exposed, drain it as well.
- If the sartorius and inguinal ligament have been released from the anterosuperior spine, reattach them using suture through drill holes in the bone. Then reattach the abdominal fascia to the fascia lata along the iliac crest. For the repair along the iliac crest, draw the abdominal muscles anteriorly and distally, because attachment of the abdominals in too proximal a position along the crest prevents a satisfactory closure along the inguinal ligament.

### *Kocher-Langenbeck (KL) Approach*

The KL approach is the primary approach to the posterior column of the acetabulum. It affords excellent exposure of the retroacetabular surface, the greater and lesser sciatic notch, the ischial tuberosity, and the inferior portion of the iliac wing. The anterior column can often be reduced and stabilized by manipulation through the greater sciatic notch or by intraarticular manipulation through the acetabulum.

- Position the patient prone and on the Tasserit or other suitable table. Keep the knee flexed at least 60° and the hip extended during the operation to prevent tension on the sciatic nerve.

## HINTS AND TRICKS

### *Ilioinguinal Approach*

- Place a suture as a marker in the abdominal muscles at the anterior superior spine when they are taken down. Placing this suture back in position is a helpful guide to closure, ensuring proper tension on the abdominal muscles.
- Then reattach the common origin of the internal oblique and transverse abdominis to the inguinal ligament and the transversalis fascia to the inguinal ligament.
- Then repair the conjoined tendon and tendon of the rectus abdominis. Faulty repair of the transversalis fascia can produce an inguinal hernia.
- Reapproximate the aponeurosis of the external oblique, then close the subcutaneous tissues and skin.

- Start the incision about 5 cm lateral to the posterosuperior spine, and extend it anteriorly and distally to the tip of the greater trochanter and then distally along the axis of the femur to approximately the midportion of the thigh (Fig. 2.9).

***Figure 2.9.*** Skin incision for the KL approach.

- Split the gluteal fascia in line with the fibers of the gluteus maximus, and split the fascia lata over the femur. Incise the trochanteric bursa, and bluntly split the fibers of the gluteus maximus. Halt the splitting of the gluteus maximus when the neurovascular bundle of the inferior gluteal nerve is reached as it crosses through the muscle fibers (Fig. 2.10). It is possible to continue with the splitting if additional exposure is needed, but the superior portion of the gluteus maximus will be denervated. Transect the tendon of the gluteus maximus at its femoral insertion. Beware of the large bleeder in this area.

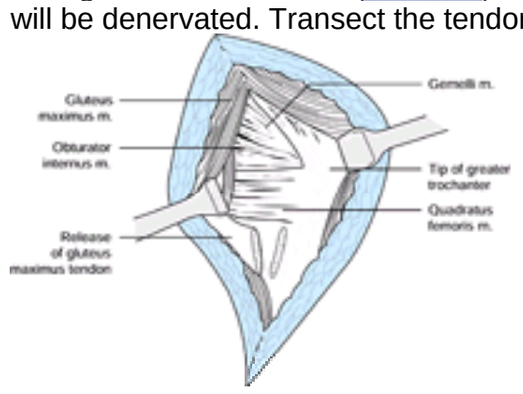


***Figure 2.10.*** Splitting of the gluteus maximus muscle.

- It is useful to locate the sciatic nerve as it crosses the posterior aspect of the quadratus femoris. Follow the nerve proximally to where it disappears beneath the piriformis muscle. To follow the nerve to this point, it is necessary to clamp and cauterize a small vascular pedicle that crosses posteriorly and laterally to the nerve. Transection of this pedicle allows more nerve mobility and better posterior column exposure.
- Locate the tendon of the piriformis muscle, tag it with suture, and transect it at its trochanteric insertion. Reflect it posteriorly to expose the greater sciatic notch. Identify the tendon of the obturator internus, which is paralleled by the two gemelli superiorly and inferiorly. Tag these structures with suture, and transect them at the trochanteric insertion. Reflection of the obturator internus and the two gemelli from the retroacetabular surface is an essential part of the exposure that is often missed. This tendon leads to the lesser sciatic notch and the bursa of the obturator internus, where the tendon passes through the lesser notch. As the tendon with its accompanying gemelli are reflected posteriorly and medially, the inferior portion of the retroacetabular surface and superior pole of the ischial tuberosity are clearly exposed.
- With a periosteal elevator, clear the retroacetabular surface and the superior pole of the ischial tuberosity. Use subperiosteal elevation on the inferior aspect of the iliac wing and anteriorly superior to the hip capsule to expose this area. In the area of the greater sciatic notch, avoid damaging the superior gluteal vessels or nerve with the elevator. An elevator may also be placed in the greater sciatic notch to clear the periosteum and obturator internus origin from the quadrilateral surface. This technique allows assessment of the fracture reduction by palpation of the quadrilateral surface as far anteriorly as the pelvic brim.
- A Hohmann retractor with its tip driven into the bone may be placed on the inferior iliac wing for retraction of the abductors, but do not retract too proximally in this area; a stretch injury of the superior gluteal nerve could result. Cobra retractors or a specialized sciatic nerve retractor are normally placed with its tip in the greater or lesser sciatic notch, but be careful not to stretch the sciatic nerve (Fig. 2.11). If more anterior access to the inferior wing is necessary, the gluteus medius tendon may be partially or completely transected at its insertion, or a trochanteric osteotomy can be performed.

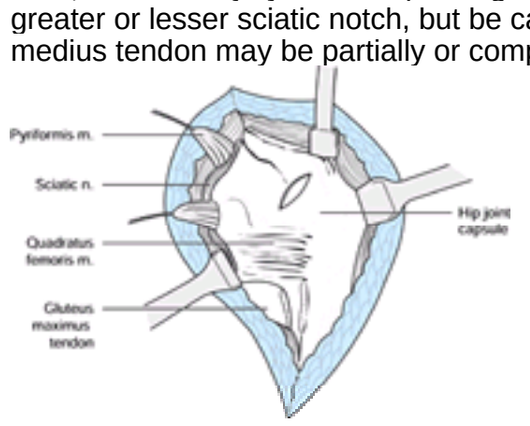


***Figure 2.11.*** Completed exposure of the retroacetabular surface.

- At the completion of the operation, place suction drains to drain the greater sciatic notch and inferior iliac wing area. Reattach the tendons of the piriformis and obturator internus muscles to the trochanter. Repair of these muscles provides a soft-tissue barrier between the sciatic nerve and internal fixation plate on the posterior column. Repair the maximus tendon, and close the fascia and skin.
- Leave suction drains in place for approximately 48 hours. Mobilize the hip and begin gait training when the patient is comfortable.

### *Extended Iliofemoral (EIF) Approach*

Emile Letournel developed the EIF approach to provide simultaneous access to both columns of the acetabulum. It is primarily an approach to the external aspect of the innominate bone, giving access to the entire external aspect of the iliac wing, the entire retroacetabular surface, and the posterior column, including the ischial tuberosity (Table 2.1). The internal aspect of the bone may also be exposed, with exposure of the distal portion of the internal iliac fossa to the anterior SI joint and the anterior column distally to the pectineal eminence. This exposure follows a logical neurovascular interval, reflecting muscles innervated by the superior and inferior gluteal nerves posteriorly and laterally and muscles innervated by the femoral nerve medially. Exposure of the posterior column is equal to that which can be obtained through the KL approach. The anterior column exposure, however, is less extensive than the II approach provides.

- Place the patient in the lateral position, preferably on the Tasserit table.
- Start the incision at the posterior superior iliac spine, and carry it anteriorly along the crest to the anterior superior spine and then anterolaterally down the thigh.
- Sharply incise the periosteum over the iliac crest, and release the fascia lata from the crest. Subperiosteally dissect the gluteal muscles and the tensor fascia lata from the lateral aspect of the iliac wing (Fig. 2.12).

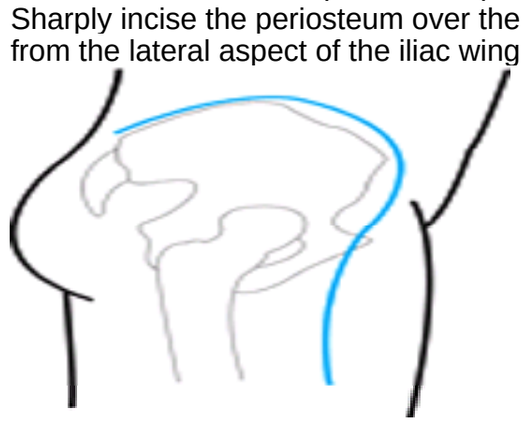

***Figure 2.12.*** Skin incision for the EIF approach.

- The incision in the deep fascia proceeds from the anterior superior spine in a distal and slightly more lateral direction. Split the fascia lata overlying the tensor fascia lata muscle to a point approximately halfway down the thigh or until the distal extent of the tensor fascia lata muscle is reached. Reflect the tensor fascia lata muscle posteriorly from its medial fascial compartment.
- Longitudinally split this medial fascia to expose the rectus femoris muscle. Medial retraction of the rectus exposes another layer of fascia and aponeurotic fibers directly posterior to it. Split this fascia and associated aponeurosis longitudinally. Clamp and ligate the internal femoral circumflex vessels, which are found immediately beneath this fascia (Fig. 2.13).

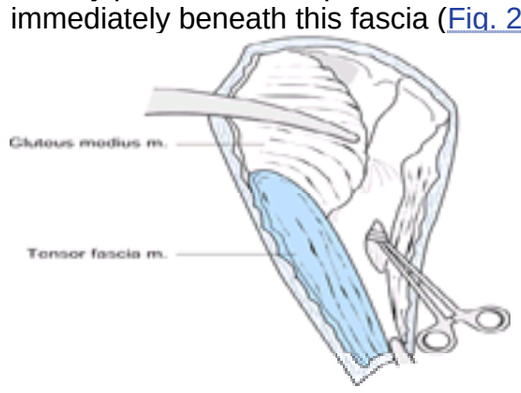


***Figure 2.13.*** Exposure of the lateral femoral circumflex vessels.

- Opening this fascial plane exposes the vastus lateralis and anterior portion of the trochanter with the insertion of the gluteus minimus. Tag the portion of the trochanter with the insertion of the gluteus minimus. Tag the tendon of the gluteus minimus with a suture and transect it in its midsubstance, leaving a 1 cm stump with the trochanter and another 1 cm with the origin. It is also necessary to dissect sharply the gluteus minimus insertion from the superior hip capsule and continue elevation of the gluteal muscles until the greater sciatic notch is exposed.
- Identify the gluteus medius tendon at its insertion on the lateral aspect of the greater trochanter, and transect it in its midsubstance, leaving a 1 cm stump on the trochanter. Tag the tendon on the muscle side with multiple sutures to facilitate identification and repair (Fig. 2.14). Alternatively, after transecting the gluteus minimus tendon in the usual fashion, perform an osteotomy of the greater trochanter to detach the gluteus medius insertion.

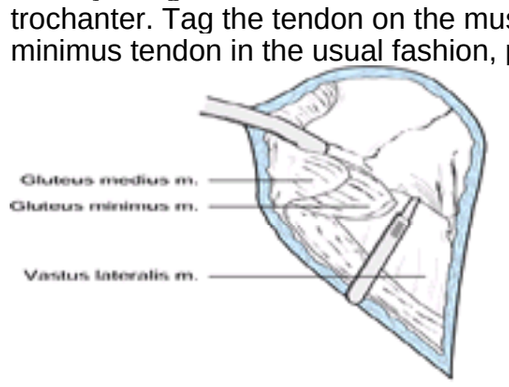


***Figure 2.14.*** Transection of the gluteus minimus and gluteus medius tendons.

- Identify the piriformis tendon at its insertion on the superior aspect of the trochanter. Tag it with suture and transect it near its insertion to further expose the greater sciatic notch. Tag the tendon of the obturator internus and the two gemelli with a single suture, and transect them near the trochanter. Reflection of this tendon and the two gemelli from the retroacetabular surface exposes the lesser sciatic notch and the bursa of the obturator internus, where the tendon slides in the lesser sciatic notch from inside the pelvis.
- Use subperiosteal dissection as necessary to expose the bone surface and fracture lines. Subperiosteal dissection along the posterior border of the greater sciatic notch gives access to the quadrilateral surface and helps protect the superior gluteal vessels and nerve, as they now fall away from the bone in a posterior and medial direction.
- Excise the reflected head of the rectus femoris muscle from the superior hip capsule to expose more of the anterior column. A capsulotomy may be performed at the level of the rim of the acetabulum to expose the internal aspect of the joint. Distraction of the femoral head aids this exposure (Fig. 2.15).

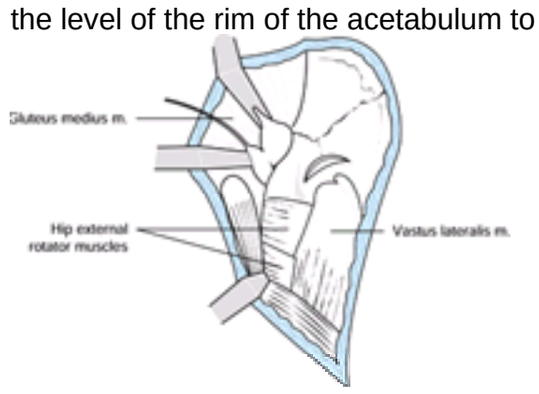


***Figure 2.15.*** Completed exposure of the external aspect of the bone.

- The internal iliac fossa may be exposed by detachment of the abdominal muscles from the iliac crest, and by detachment of the sartorius and inguinal ligament from the anterior superior spine. Dissection may be carried out posteriorly and medially to the anterior SI joint and the pelvic brim.
- Transection of the direct head of the rectus femoris at its bony origin completes the maximum access to the anterior column (Fig. 2.16). Exposure beyond the pelvic brim allows access around the bone, which is particularly useful for callus excision during surgery on old fractures.

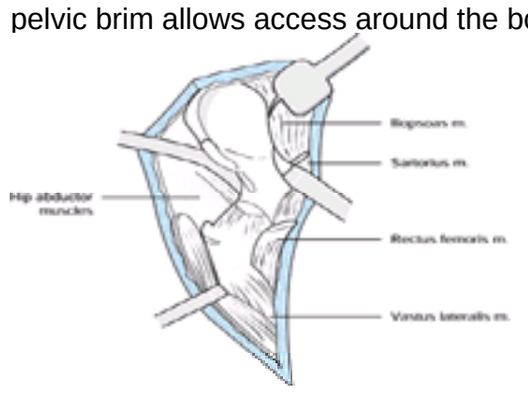


***Figure 2.16.*** Exposure of the internal iliac fossa.

- With exposure of both sides of the iliac wing, there is a danger of devascularizing large segments of the anterior column. Carefully preserve vascular muscle pedicles to the bone to maintain vascularity. In the case of a high anterior column fracture that takes the anterior border of the iliac wing, it is wise to preserve its attachments to the anterior hip capsule and rectus femoris and, if possible, to additional muscle pedicles.
- Take care with dissection around the greater sciatic notch. Injury to the superior gluteal vessels or nerve in this area could compromise the blood and nerve

supply to the large abductor muscle flap. Place a wet sponge over the muscles to prevent desiccation during the operation.

- At the completion of the operation, place suction drains along the course of the rectus femoris and vastus lateralis muscles to drain the external iliac fossa and greater sciatic notch. If the internal aspect of the bone has been exposed, drain it as well. Reattachment of the rectus femoris and sartorius origins is facilitated by placement of a suture through a drill hole in the bone. Reattach the tendons of the piriformis and obturator internus muscles to the trochanter with suture. Repair the tendons of the gluteus medius and minimus musles at the trochanteric insertion with multiple sutures. Reapproximate the fascia lata to the abdominal fascia at the iliac crest, and close the fascia lata anterolaterally over the thigh.
- Keep the suction drains in place for about 48 hours after surgery. During the initial postoperative period, use an abduction pillow while the patient is in bed. Start passive mobilization of the hip within a few days but avoid passive abduction. Begin gait training when the patient's symptoms allow.

## APPROACHES TO THE PELVIC RING

- To approach the pelvic ring, position the patient on a radiolucent table, with the sacrum centered over a radiolucent area at least 1.5 m in length. This positioning allows angulation of the image intensifier to facilitate assessment of the reduction and to guide fixation.
- Place the patient supine for the approach to the symphysis or anterior SI joint or prone for the approach to the posterior pelvic ring. When both anterior and posterior reduction and fixation are required, position the patient prone for the posterior approach and subsequently turn the patient supine.

### OPERATIVE TECHNIQUES

#### *Approach to the Symphysis Pubis*

- Position the patient supine on the operating table.
- Insert a Foley catheter in the bladder before the operation.
- Make either a transverse incision 2 cm proximal to the symphysis pubis or a vertical midline incision (Fig. 2.17). The transverse incision gives a more cosmetic result, whereas the vertical incision can be extended for intraabdominal access in the case of multiple injuries.

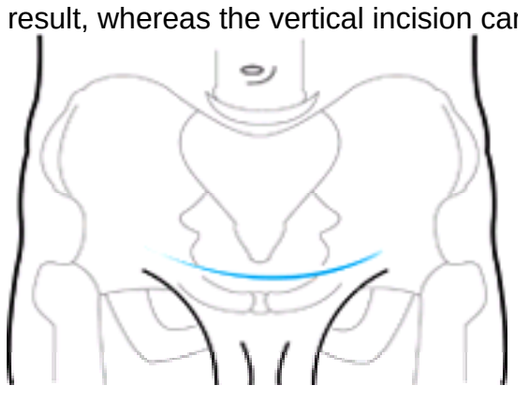

***Figure 2.17.*** Skin incision for the approach to the symphysis pubis.

**HINTS AND TRICKS**

Positioning the patient laterally for combined simultaneous anterior and posterior approaches typically does not save time and introduces significant problems: access to the bone becomes more awkward (especially anterior), the image intensifier is more difficult to use, and sterility is compromised. In some cases, it is preferable to approach the anterior and posterior lesions simultaneously through the II approach with the patient supine. In other cases, the skin incision may appear as the II but the deep dissection is done as for the approach to the symphysis and the approach to the anterior SI joint.

- In either case, locate the two heads of the rectus abdominis. In the acute symphysis diastasis, one of the heads of the rectus is commonly torn from its bony attachment. Separate the two heads of the rectus abdominis from each other by a vertical incision along the linea alba (Fig. 2.18). Identify the pyramidalis muscle just proximal to the symphysis: Split it vertically along the line of the linea alba. Directly beneath the abdominal wall lie the preperitoneal fat proximally and the bladder distally. In an acute injury, the bladder falls away from the posterior surface of the symphysis, although it may adhere to the bone in an old injury. If the bladder adheres to the bone, free the bladder carefully with a periosteal elevator along the posterior aspect of the bone to avoid injury to it.

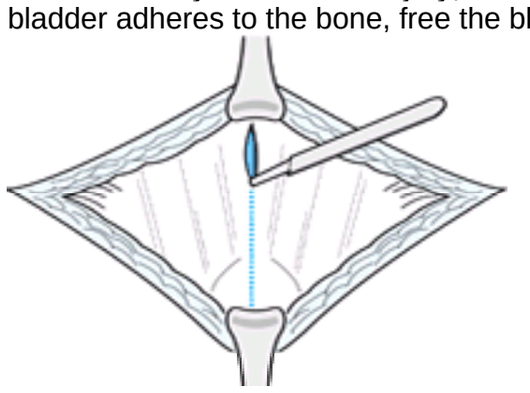

***Figure 2.18.*** Incision along the linea alba.

- Leave the two heads of the rectus abdominis attached to the anterior and outer aspect of the symphysis, although the posterior portion of their insertion may be freed somewhat by sharp dissection along the superior aspect of the symphysis and superior pubic ramus. A long proximal split of the linea alba enhances exposure.
- Place the point of a narrow Hohmann retractor over the superior pubic ramus on each side of the symphysis, and retract the two heads of the rectus laterally (Fig. 2.19). Use a large malleable retractor in the space of Retzius to retract the bladder posteriorly. Periosteal elevation along the superior part of the symphysis and the superior ramus completes the exposure necessary for reduction and plate application.

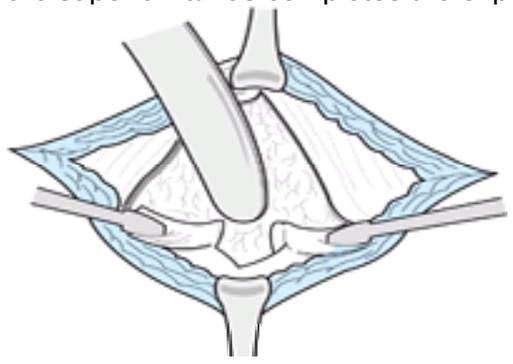

***Figure 2.19.*** Retraction of the two heads of the rectus abdominis.

- The superior pubic ramus can also be approached through this interval without transecting the rectus abdominis if reduction and fixation of the ramus are indicated.
- Identify the obturator nerve and artery, which lie posterior to the most lateral portion of the superior pubic ramus.
- It is also possible to continue with proximal exposure of the pelvic brim and posterior exposure of the quadrilateral surface, as is done with the Stoppa approach (1).
- If the fixation of the superior ramus is planned or contemplated, it is advisable to prep the skin over the iliac crest to allow extension of the incision to the II

approach in case it is necessary to extend a plate into the internal iliac fossa.
- At the completion of surgery, place a suction drain in the retropubic space. Closure is normally simple, with approximation of the two heads of rectus abdominis along the linea alba and closure of the subcutaneous tissues and skin.

### *Approach to the Posterior Ring*

A single incision can be used to approach fractures of the sacrum, dislocations of the SI joint, or fracture dislocations of the SI joint.

- Position the patient prone on a fully radiolucent table, if available.
- Make a vertical incision 2 cm lateral to the posterosuperior spine. Start the incision 5 cm lateral to the iliac crest, and end it 5 cm distal to the superior border of the greater sciatic notch (Fig. 2.20).

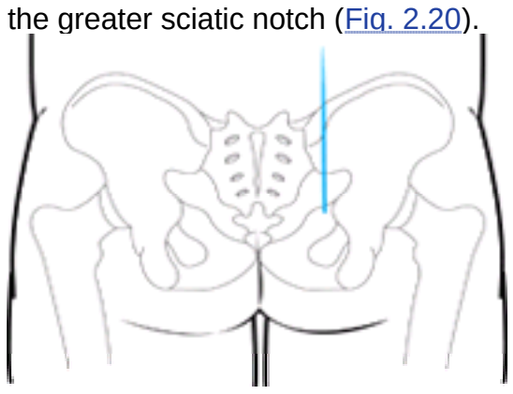

***Figure 2.20.*** Skin incision for the approach to the posterior pelvic ring.

- Locate the very thin fascia overlying the gluteus maximus, just beneath the subcutaneous tissue. Elevate the subcutaneous tissue off the gluteal fascia medially to expose the point of origin of the gluteus maximus from the posterior crest of the ilium and from the posterior aspect of the sacrum more distally.
- Reflect the gluteus maximus from its point of origin along the posterior ilium, and reflect it from the sacrum. Immediately beneath the portion of the maximus that overlies the sacrum is the fascia that overlies the multifidus muscles of the spine. Reflect the maximus off this fascia (Fig. 2.21).

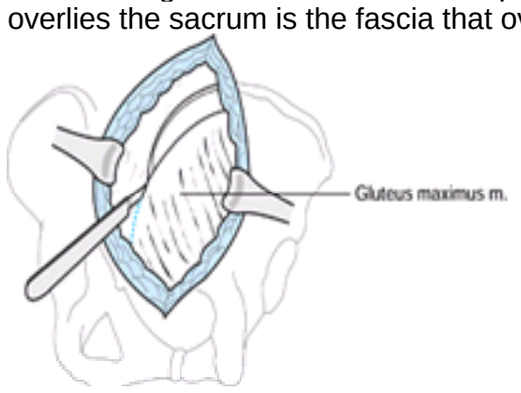


***Figure 2.21.*** Reflection of the gluteus maximus muscle from the posterior crest and multifidus fascia.

- Also reflect a portion of the medius and minimus laterally from the iliac wing to expose the posteroexternal aspect of the wing. Take care to not injure the superior gluteal vessels and nerve as the gluteal muscles are reflected from the wing immediately superior to the greater sciatic notch.
- Exposure of the greater sciatic notch is necessary for reduction of the SI joint. It allows the surgeon to pass a finger through the notch to palpate the anterior SI joint or to palpate a sacral fracture on the anterior portion of the sacrum. It also permits assessment of the position of the neural foramina and positions of fractures around the neural foramina. As you detach the gluteal muscles from the posterior crest and sciatic notch area, also detach the piriformis muscle from its origin at the greater notch.
- If the sacrum is fractured, it is necessary to expose the fracture line as it traverses the posterior sacral lamina. Elevate the multifidus muscles from the posterior aspect of the sacrum in a lateral to medial direction starting at the lateral edge of the sacrum. Small nerve branches that exit through the posterior sacral foramina supply some sensation to the skin overlying the sacrum and additionally innervate the multifidus muscles. It is usually possible to preserve them, even when the sacral foramina are exposed posteriorly; if they must be sacrificed, the resulting disability is negligible (Fig. 2.22).

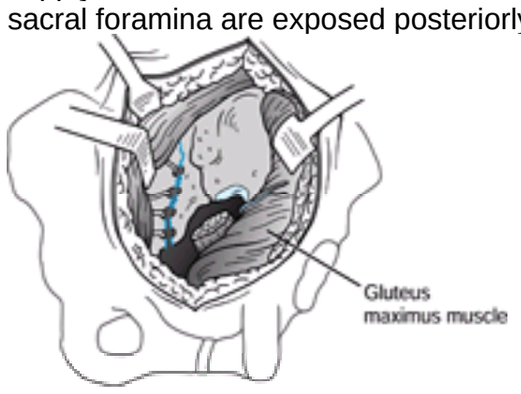


***Figure 2.22.*** Completed exposure of the posterior ilium, SI joint, and sacral lamina.

- Although palpation is not necessary in most cases, it is possible to obtain access for palpation of the internal iliac fossa and anterior aspect of the superior SI joint by releasing the erector spinaea muscles and abdominal muscles from the superior portion of the crest and by placing a finger over the top of the crest into the internal iliac fossa.
- At the completion of the operation, drain the lateral ilium. Drain the greater sciatic notch; if the internal iliac fossa has been exposed, drain it as well. Closure is simple: Reapproximate the gluteal fascia to the fascia overlying the multifidus and erector spinae muscles.

For bilateral posterior lesions that require both reduction and fixation, I recommend bilateral simultaneous approaches.

### *Approach to the Anterior SI Joint*

In some cases, anterior exposure of the SI joint may be desirable.

- Position the patient supine.
- Start the incision in line with the II approach, about 5 cm medial and distal to the anterosuperior spine, and proceed posteriorly along the iliac crest about two thirds of the way along the crest.
- Sharply incise the periosteum over the iliac crest. Release the abdominal muscles from the crest by subperiosteal dissection. Incise the aponeurosis of the external oblique muscle in line with the skin incision and reflect it distally.
- Split the lateral portion of the inguinal ligament to detach the lateral portion of the origin of the internal oblique and transversus abdominis muscles. Split the inguinal ligament with care to avoid transecting the lateral cutaneus nerve of the thigh.
- Elevate the iliacus from the internal iliac fossa medially to the SI joint and as far distally as the pelvic brim. It is necessary to dissect subperiosteally along the anterior aspect of the sacral ala, but take care to avoid too vigorous medial dissection. The L-5 nerve root, which crosses the anterior sacral ala, can suffer stretch injury from vigorous retraction exposure. Visualize the anterior SI joint for reduction. Facilitate exposure by the use of deep, straight-tipped, broad retractors or sharp-tipped Hohmann retractors whose tips can be driven into the anterior sacrum.

### *Approach to the Iliac Wing*

For isolated fractures of the iliac wing, proceed as follows.

- Position the patient lateral or supine.
- Incise the skin over and parallel to the iliac crest.
- Cut the periosteum sharply along the superior aspect of the crest. From this point, expose the external or internal aspect of the wing by elevating the gluteal muscles, the iliacus, or both, as necessary, for reduction and fixation.

### *Exposure of the Ischium, by Michael W. Chapman*

Isolated exposure of the ischium, although rarely required, is most commonly used for debridement of osteomyelitis due to an overlying decubitus ulcer. It is also used occasionally for biopsy.

- Position the patient supine on a regular operating table and place the legs in the lithotomy position using obstetric leg holders.
- Prepare and drape the perineum; use adhesive plastic drapes to exclude the anus from the field.
- Make a vertical incision as long as necessary for the exposure, directly over the ischium but somewhat lateral; 7.5 to 10 cm. (3 to 4 inches) usually suffice.
- Dissect directly down to the ischium. Exposure is usually facilitated by using an electric cautery knife to reflect the muscle origins directly off the bone.
- Avoid injury to vital structures by staying on bone. Remember that the pudendal nerve runs in Alcock's canal on the medial aspect of the ischium.
- If good hemostasis is obtained, then layered closure without a drain is possible. Infected wounds are often packed open.

## CHAPTER REFERENCES

Each reference is categorized according to the following scheme: *, classic article; #, review article; !, basic research article; and +, clinical results/outcome study.


+ 1. Cole JD, Bolhofner BR. Acetabular Fracture Fixation Via a Modified Stoppa Limited Intrapelvic Approach. Description of Operative Technique and Preliminary Treatment Results. *Clin Orthop* 1994;305:112.

* 2. Letournel E. *Fractures of the Acetabulum.* New York: Springer-Verlag, 1981.

+ 3. Matta JM. Fractures of the Acetabulum: Accuracy of Reduction and Clinical Results in Patients Managed Operatively Within Three Weeks After the Injury. *J Bone Joint Surg Am* 1996;78:1632.

+ 4. Matta JM. *Surgical Approaches to Fracture of the Acetabulum and Pelvis.* Joel M. Matta, M.D. Inc., Los Angeles, 1989.

# CHAPTER 3

# SURGICAL APPROACHES TO THE LOWER EXTREMITY

*Marc F. Swiontkowski and Patricia A. Post*

**M. F. Swiontkowski:** Department of Orthopaedic Surgery, University of Minnesota Medical School, Minneapolis, Minnesota, 55455.
**P. A. Post:** Department of Orthopaedics and Rehabilitation, Vanderbilt University, Nashville, TN, 37232.

Hip
- Anterior Approaches
- Posterior Approaches
- Thigh—Femoral Shaft

Knee
- Anterior Approaches
- Posterolateral Approaches

Tibia and Fibula
- Proximal Anterior Approach for Medial or Lateral Deep Exposure
- Henry's Exposure of the Peroneal Nerve and Proximal Fibula
- Tibial Shaft: Anterior Approach
- Tibial Shaft: Posteromedial Approach
- Tibia and Fibula Shafts: Posterolateral Approach of Harmon

Ankle
- Exposures for Ankle Fractures

Foot
- Skin Incisions
- Tarsus
- Calcaneus
- Metatarsals
- Metatarsophalangeal Joints
- Interphalangeal Joints

Chapter References

## HIP

### ANTERIOR APPROACHES

#### *Hardinge Approach*

The Hardinge approach is a direct lateral approach to the hip described by Kevin Hardinge in 1982 (1) for total hip arthroplasty, based on a modification of the original description of this approach by McFarland and Osborne (4). Hardinge described its use with the patient supine; however, most surgeons today use the lateral/decubitus position because it provides better access for two surgeons standing on opposite sides of the table. It also allows for increased mobility of the operated extremity (Fig. 3.1).The advantage of the supine position is that it makes orientation of the components easier and facilitates comparison of leg lengths for correction of discrepancy.

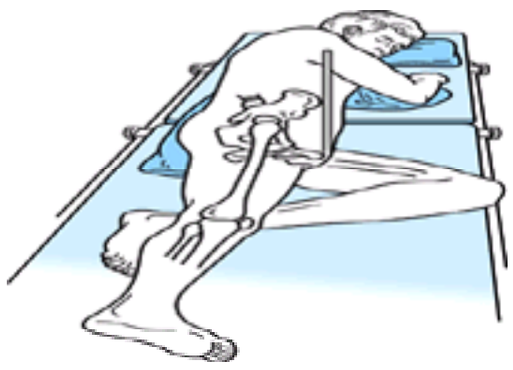

***Figure 3.1.*** With the patient in the lateral decubitus position, notice that anterior superior iliac spines are vertically aligned.

The Hardinge approach is useful for hemiarthroplasty for femoral neck fracture, as well as for total hip arthroplasty. It allows the surgeon direct visualization of the acetabulum and excellent access to the entire circumference. It avoids morbidity from osteotomy of the greater trochanter and maintains the continuity of the abductor mechanism. Because the posterior portion of the gluteus medius muscle, with its thick tendon, is left intact, early rehabilitation is possible. Partial weight bearing with crutches is usually possible immediately after surgery.

- Begin the skin incision about 3–4 inches (7 to 10 cm) distal to the prominence of the greater trochanter in the midportion of the lateral aspect of the thigh, directly over the femur. Extend it in line with the femur over the prominence of the trochanter, inclining about 20° posteriorly in the proximal one-third of the wound. The total incision length is usually 8–10 inches (20 to 25 cm); in obese or muscular patients, a longer incision is necessary (Fig. 3.2).

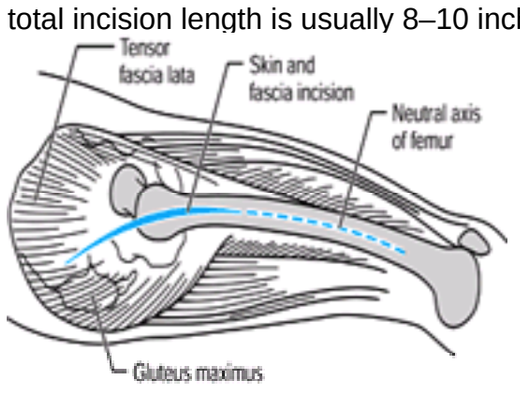


***Figure 3.2.*** Make the initial incision in line with the neutral axis of the femur.

- Incise sharply down to the deep fascia with minimal undermining of the subcutaneous tissue. Divide the gluteal fascia and iliotibial band in line with the skin incision. Retract the tensor fascia lata anteriorly, separating it from its conjoined origin with the gluteus medius. Avoid injury to the superior gluteal nerve and artery by dissecting this interval with a relatively blunt instrument. We prefer a large-key periosteal elevator (Fig. 3.3).

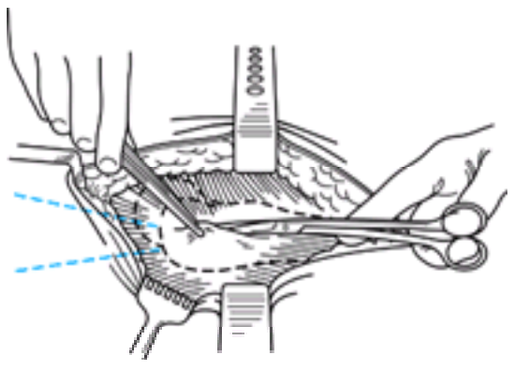

***Figure 3.3.*** Charnley initial incision retractor in place.

- At the trochanteric ridge formed by the origin of the vastus lateralis, at the mid-lateral point of the greater trochanter, use an electrocautery knife set on “cutting” to incise the gluteus medius longitudinally, extending distalward through the vastus lateralis, curving slightly anteriorly. Control bleeding from the transverse branch of the lateral circumflex artery in the vastus lateralis origin. Reflect the gluteus medius insertion and vastus lateralis muscles in continuity anteriorly off the greater trochanter, taking care to stay on bone to maintain the maximum thickness of tendon. Do not cut across the muscle fibers of the gluteus medius proximally; split them in line with the incision with a large-key periosteal elevator. Do not split proximally more than 5 cm above the trochanter to avoid injury to the superior gluteal nerve (Fig. 3.4).

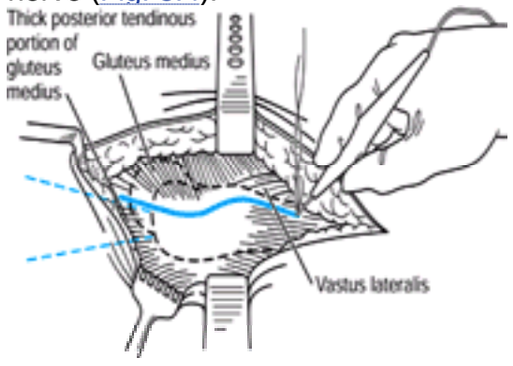


***Figure 3.4.*** Anterior insertion of the gluteus medius is mobilized.

- Retract the gluteus medius; in the supine position, adduct the thigh to facilitate exposure of the gluteus minimus, which is reflected off the hip joint capsule superiorly. In his original description, Hardinge incises the capsule, does not excise it, and repairs it following arthroplasty. To permit adequate access to the acetabulum for noncemented cups, we prefer to isolate the hip joint capsule, placing a cobra retractor anteroinferiorly and superoposteriorly to expose the capsule. We then excise the anterior two thirds of the capsule intact (Fig. 3.5).

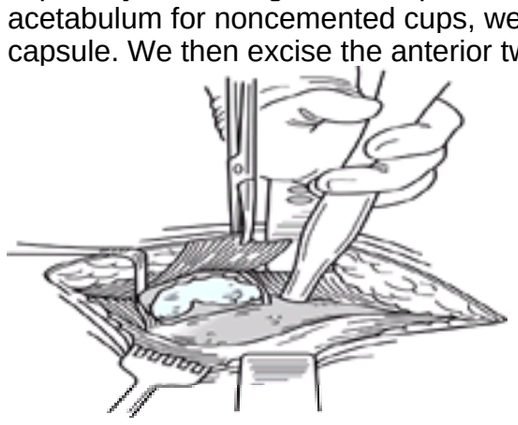

***Figure 3.5.*** Expose the capsule.

- Dislocate the hip by flexing and adducting it while levering the femoral head out of the acetabulum, cutting the ligamentum teres. When using the lateral decubitus position, drop the leg off the edge of the table into a sterile pocket formed from a large drape sheet. Transect the femoral neck with an oscillating saw (Fig. 3.6*A*).

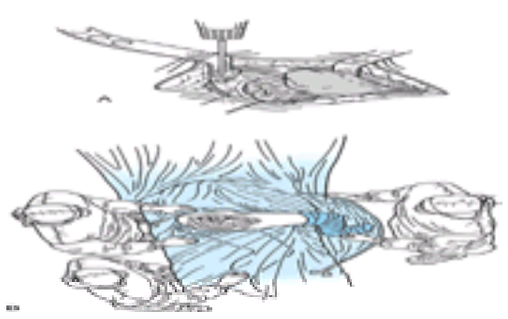

***Figure 3.6.*** **A:** Superior retractor is held in place by $^{1}/_{8}$ in. Steinmann pins or drill bits. **B:** Place the tibia in a pouch positioned vertical to the floor.

- This position gives ideal exposure of the femur for insertion of a prosthesis. Protect the insertion of the posterior portion of the gluteus medius during preparation of the femur with appropriate retractors, which also elevate the trochanter to provide better exposure (Fig. 3.6*B*).
- When preparing and inserting the acetabulum, keep the leg on the operating table in line with the torso, using specially designed or sharp-tipped Hohmann retractors to facilitate exposure of the acetabulum.
- For repair of the gluteus medius, place a series of heavy (we prefer #5 Tevdek) sutures through the bone of the greater trochanter. Then direct the suture in a horizontal mattress fashion through the tendinous portion of the gluteus medius, securing it firmly to bone. Make these holes and place the sutures prior to insertion of the prosthesis using an awl, drill-point, or towel-clip. Next, repair the longitudinal split in the gluteus medius and vastus lateralis with #1 sutures. Close the split in the deep fascia and iliotibial band in a similar fashion (Fig. 3.7).

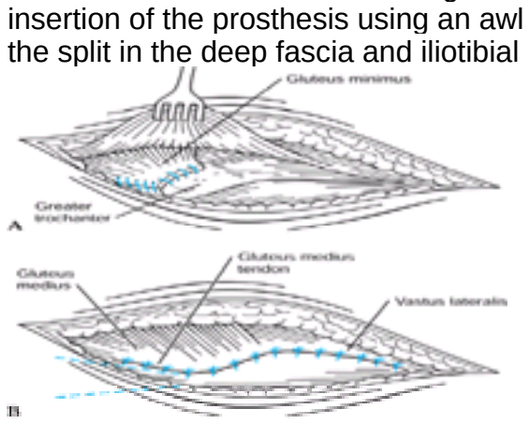


***Figure 3.7.*** **A:** Reattachment of the gluteus minimus. **B:** Suturing of the gluteus medius and vastus lateralis.

### *Smith-Petersen Approach*

Refer to Chapter 2 for the extended iliofemoral approach.

### *Watson-Jones Approach*

The Watson-Jones anterior approach to the hip joint, femoral neck, and proximal femur is useful for capsular incisions, reduction of femoral neck fractures, upper femoral osteotomies, and internal fixation of proximal femoral fractures. One advantage of this approach is that it exposes the femoral neck, thereby allowing the surgeon to accurately identify femoral anteversion.

- At a point 2–3 cm posterior to the anterosuperior iliac spine, begin the incision directed toward the midportion of the greater trochanter (Fig. 3.8*A*). Then angle the incision into a straight lateral orientation and proceed distally 10–15 cm.

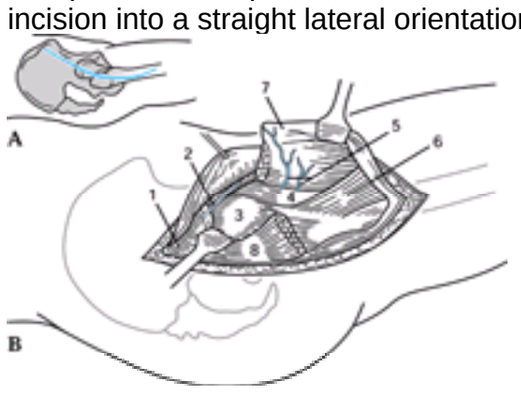


***Figure 3.8.*** Watson-Jones anterolateral approach to the hip. **A:** Skin incision. **B:** The vastus lateralis is retracted anteriorly, as is the tensor fascia, exposing the anterior hip capsule. *1*, Gluteus medius; *2*, nerve to tensor fasciae latae; *3*, hip joint capsule; *4*, iliopsoas; *5*, lateral circumflex femoral vessels; *6*, vastus intermedius; *7*, vastus lateralis (reflected); *8*, greater trochanter. (From Schlumpf R. Proximal Femur: Lateral Approach. In: Rüedi T, von Hochstetter AHC, Schlumpf R, eds. *Surgical Approaches for Internal Fixation.* Berlin: Springer-Verlag, 1984:115–121.)

- Identify the interval between the gluteus medius and tensor fascia lata, best done at a point halfway between the anterosuperior iliac spine and the greater trochanter.
- Place a pointed retractor posterior to the tensor fascia lata with the point on the anterior rim of the acetabulum. With posteriorly directed retraction of the gluteus medius, expose the hip capsule (Fig. 3.1*B*). Chapman (personal communication, 1993) facilitates this exposure by first splitting the fascia lata distally. As the dissection is carried proximally, the interval between the bellies of the tensor fascia lata and gluteus medius muscles becomes more obvious. Thus it is easier to identify the superior gluteal artery and nerve and avoid wandering in the wrong interval.
- Incise the hip capsule in line with the femoral neck in its midportion. To gain greater exposure to the femoral neck and head, extend the capsular incision perpendicular to the plane of the initial incision by dissecting the capsule off the intertrochanteric ridge superiorly and inferiorly.
- For greater exposure of the proximal femoral shaft, detach the vastus lateralis from the vastus tubercle portion of the anterior intertrochanteric line. From this point distally, split the vastus longitudinally or retract it anteriorly, and detach it from the insertion on the most proximal portion of the linea aspera to gain access to the femoral shaft.
- For wider exposure to the intracapsular femur, detach the anterior fibers of the gluteus medius from the anterior one half of the tendinous insertion on the greater trochanter, leaving a cuff of tendon on the trochanter for later repair.

### *Harris Approach*

Joint reconstructive procedures that require wide exposure of the femoral neck and acetabulum call for the Harris anterolateral approach to the hip joint. This approach is useful in that the hip can be dislocated anteriorly or posteriorly.

- Place the patient in the lateral position with the unaffected hip facing down. Bean bags, kidney rests, or “hip positioners” attached to the operating table help to maintain the true lateral position. Abduct the affected limb 60° and keep the hip extended and the knee flexed. A Mayo stand with a pillow and sterile cover relieves the assistants of considerable burden in maintaining this position.
- Make a lazy U–shaped skin incision beginning 5 cm posterior and 2 cm proximal to the anterosuperior iliac spine. Curve the incision distally toward the posterior greater trochanter (Fig. 3.9*A*), and extend it distally and slightly anteriorly for a distance of 15 cm.

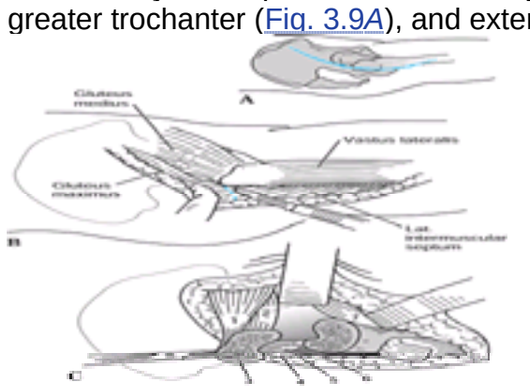


***Figure 3.9.*** Harris anteriolateral approach to the hip. **A:** Skin incision. **B:** The anterior aspect of the gluteus maximus insertion on the iliotibial tract is incised 1.5 cm posteriorly to allow greater exposure of the posterior aspect of the greater trochanter. **C:** The trochanter is osteotomized, exposing the external rotators and hip capsule. *1*, Gluteus medius; *2*, gluteus minimus; *3*, greater trochanter (osteotomized); *4*, piriformis; *5*, obturator internus; *6*, obturator externus; *7*, iliopsoas. (From Rosenthal S. Surgical Approaches. In: Crenshaw AH, ed. *Campbell's Operative Orthopaedics,* 6th ed. St. Louis: CV Mosby, 1980:70.)

- Working distally to proximally, divide the iliotibial band in line with its fibers. At the level of the trochanter, direct the fascia lata incision 1 cm anterior to the insertion of the gluteus medius on the greater trochanter, and continue the incision of this layer anteriorly in line with the incision.
- To provide posterior exposure, make an oblique incision in the deep surface of the posteriorly reflected fascia lata and into the substance of the gluteus medius for a distance of 5 cm (Fig. 3.9*B*). Place a pointed Hohmann retractor on the anterior acetabulum to retract the anterior part of the tensor fascia lata and iliotibial band anteriorly.
- Sharply dissect the origin of the vastus lateralis from the vastus tubercle portion of the intertrochanteric line. Isolate the abductors from the joint capsule anteriorly by blunt dissection.
- Elevate the periosteum from the proximal femur transverse to the long axis of the femur at a distance of 3–3.5 cm from the tip of the trochanter. At this point, before osteotomizing the greater trochanter, the surgeon may choose to predrill or measure holes for later osteotomy screw or wire fixation. Direct the osteotomy superiorly and medially toward a point 5 mm lateral to the superior hip capsular attachment on the femoral neck (Fig. 3.9*C*).
- Free the superior part of the joint capsule from the abductors. By virtue of the posterior fascia lata and gluteus medius incision, posterior exposure is now possible. Divide the piriformis and external rotators at their femoral insertions. For arthroplasties, excise the posterior and anterior capsule, as necessary.
- Place a narrow Hohmann or Bennett retractor deep to the rectus femoris on the anteroinferior iliac spine to improve visualization anteriorly. To expose the iliopsoas tendon, flex the hip and rotate it externally. This tendon can be divided and sutured to a remnant of intact anterior capsule if desired to correct a flexion contracture. The hip can be dislocated anteriorly to gain access to the entire femoral head and neck by placing the greater trochanter into the acetabulum. For exposure of the acetabulum, retract the greater trochanter superiorly and dislocate the femoral head posteriorly. Maintain the abducted position of the limb for trochanteric reattachment and wound closure.

## POSTERIOR APPROACHES

### *Moore Approach*

The Moore or “Southern” exposure provides excellent access to the posterior femoral neck for bone graft procedures, posterior drainage of septic joints, or reconstructive procedures of the proximal femur.

- Place the patient in the lateral position with the unaffected side facing down. Bean bags, kidney rests, or “hip positioners” attached to the operating table are excellent adjuncts for maintaining the true lateral position. Alternatively, the procedure can be done with the patient prone. The prone position may be recommended for certain femoral neck bone grafting procedures.
- Begin the incision 10 cm distal to the posterosuperior iliac spine, and extend it laterally and distally in line with the gluteal fibers (Fig. 3.10*A*) to the posterior margin of the greater trochanter. Then carry the incision distally for a distance of 15–20 cm in line with the femoral shaft.

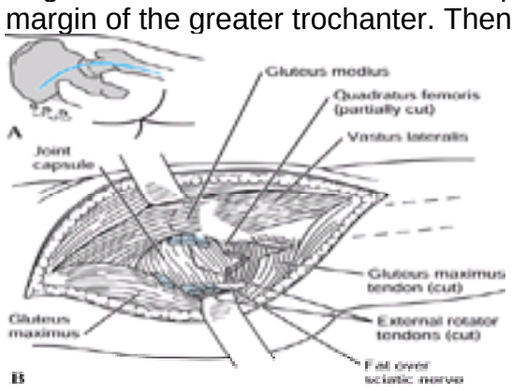


***Figure 3.10.*** Moore posterior approach to the hip. **A:** Skin incision. **B:** Detachment and retraction of the external rotators; incision of the hip capsule. (From Thomas HA. The Hip. In: Hoppenfeld S, deBoer P, eds. *Surgical Exposures in Orthopaedics: The Anatomic Approach.* Philadelphia: JB Lippincott, 1984:342.)

- Divide the thick fascia lata distally and the thin gluteal fascia proximally in line with the skin incision. Divide the deep fibers of the gluteal musculature bluntly using a finger-spreading technique, preserving the branches of the superior gluteal nerve and vessels in the proximal dissection. Partially divide the distal insertion of the fibers of the gluteal musculature from their femoral insertion to allow distal retraction. Retract in a plane perpendicular to the gluteal split, and expose the greater trochanter.
- Identify the sciatic nerve in the medial portion of the wound and carefully protect it. Divide the external rotators and the tendon of the piriformis at their femoral insertions, and retract them medially, forming a protective sling over the sciatic nerve (Fig. 3.10*B*). Expose the posterior part of the hip capsule, and incise along the axis of the femoral neck. For exposure of the femoral neck, dissect the distal insertion of the capsule from the posterior intertrochanteric ridge. Protect the medial femoral circumflex artery inferiorly; it supplies the femoral head in its terminal branch, the lateral epiphyseal artery. For procedures that require hip dislocation, flex the hip to 90°, keeping the knee flexed, and externally rotate the thigh.

### *Ludloff Medial Approach*

The Ludloff medial approach is most useful for open reduction of congenitally dislocated hips; for resection of small, primary, benign bone tumors in the region of the lesser trochanter; and for obturator neurectomies.

- Position the patient supine, with the affected hip flexed, abducted, and externally rotated. This position brings the lesser trochanter closer to the skin surface.
- Make a longitudinal incision on the medial thigh, starting 3 cm distal to the pubic tubercle in line with the adductor longus, which is easily palpable (Fig. 3.11*A*). Develop the plane between the adductor longus and brevis muscles anteriorly and the adductor magnus and gracilis muscles posteriorly. The posterior branch of the obturator nerve is visible on the belly of the adductor magnus; protect it unless it is to be cut to relieve muscular spasticity. The anterior branch lies on the anterior surface of the adductor brevis and is protected by retraction of this muscle. The lesser trochanter is visible in the base of the wound (Fig. 3.11*B*). Isolate the iliopsoas tendon with blunt dissection. It is then easily transected, allowing greater exposure of the medial hip capsule.

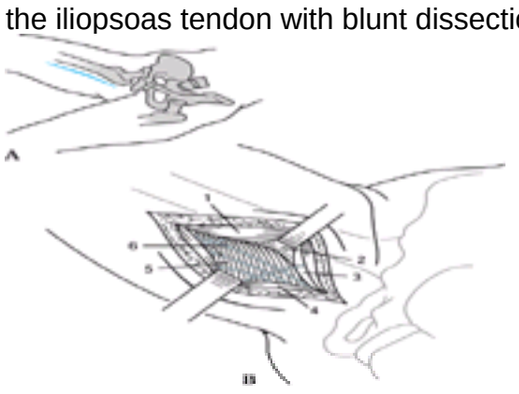

***Figure 3.11.*** Ludloff medial approach to the hip. **A:** Skin incision; patient positioning. **B:** The adductor longus is retracted anteriorly, exposing the lesser trochanter, inferior hip capsule, and posterior branches of the obturator nerve. *1*, Adductor longus; *2*, lesser trochanter; *3*, adductor brevis; *4*, gracilis; *5*, adductor magnus; *6*, obturator nerve, posterior branch. (From Thomas HA. In: Hoppenfeld S, deBoer P, eds. *Surgical Exposures in Orthopaedics: The Anatomic Approach.* Philadelphia: JB Lippincott, 1984:349, 351.)

- Open the capsule in line with the inferior capsular attachment, and extend the capsular incision in a perpendicular orientation; this favors visualization of the acetabulum and femoral head.

## THIGH—FEMORAL SHAFT

### *Lateral Approach*

The lateral or posterolateral approach to the femur is useful for tumor resection or internal fixation of shaft fractures. It is the preferred approach to the femoral shaft for most situations.

- Position the patient in the lateral or the supine position.Elevate the hindquarter 30° to 45° with a pad under the buttock.
- Make an incision of the necessary length along a line between the greater trochanter and the lateral femoral condyle (Fig. 3.12*A*). Divide the superficial and deep fascia in line with the incision.

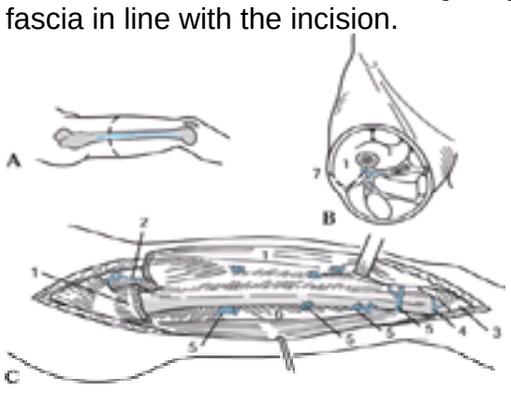

***Figure 3.12.*** Lateral approach to the femoral shaft. **A:** Skin incision and level of cross section. **B:** Plane of dissection shown in cross section. **C:** The vastus lateralis has been mobilized anteriorly and the perforating vessels ligated, exposing the entire femoral shaft. *1*, Vastus lateralis; *2*, lateral circumflex femoral vessels; *3*, joint capsule (knee); *4*, lateral superior genicular artery; *5*, perforating arteries, posterior vastus branches; *6*, lateral intermuscular septum; *7*, incision. (From Schlumpf R. Femoral Shaft: Lateral Approach. In: Rüedi T, von Hochstetter AHC, Schlumpf R, eds. *Surgical Approaches for Internal Fixation.* Berlin:

Springer-Verlag, 1984:125-127.)

- For the preferred posterolateral approach, retract the vastus lateralis anteriorly, and dissect the muscle off the lateral intermuscular septum where it attaches to the linea aspera of the femur (Fig. 3.12*B*). Make the incision 2–3 cm more posterior to help with this part of the exposure.
- Carefully identify, ligate, and divide the perforating branches of the profunda femoris in the middle third of the femoral shaft (Fig. 3.12*C*). If the surgeon inadvertently transects at the level of the septum, these vessels can retract to the medial side of the septum, producing impressive hemorrhage.
- For the lateral approach, divide the vastus lateralis and intermedius in line with the incision. As in the posterolateral approach, identify and ligate the perforating branches of the profunda femoris with the descending branch of the lateral femoral circumflex artery in the proximal third of the femoral shaft, and the superolateral geniculate artery in the distal third.

### *Anterolateral Approach*

The anterolateral approach to the femoral shaft is useful if poor skin or violation of muscle compartments by tumor render the posterolateral or lateral approaches impossible. It is not the exposure of choice for most conditions, because postoperative quadriceps adhesions can result, particularly if the knee cannot be mobilized immediately after surgery. Combined with an anterolateral approach to the knee joint, it becomes a versatile and wide exposure for T-type intra-articular fractures of the distal femur. Meticulous layered closure and immediate mobilization of the knee joint prevents loss of motion due to quadriceps adhesions. M. W. Chapman, the editor of this book, prefers this approach for comminuted intra-articular fractures of the distal femur (personal communication, 1999).

- Make a skin incision along the line between the anterosuperior iliac spine and the lateral border of the quadriceps tendon as it inserts into the patella. Incise the superficial and deep fascia in line with the incision, and develop the interval between the rectus femoris medially and the vastus lateralis laterally (Fig. 3.13*A*). This interval is easily identified proximally.

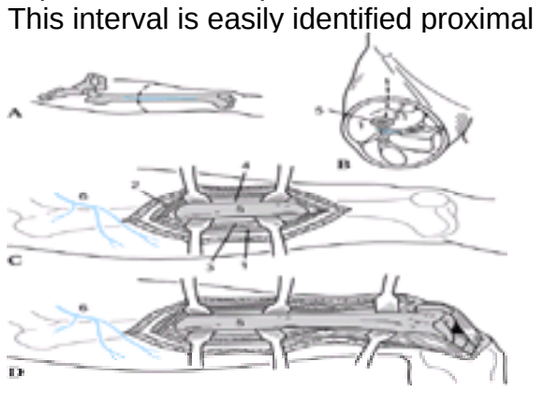

***Figure 3.13.*** Anterolateral approach to the femoral shaft. **A:** Skin incision and level of cross section. **B:** Plane of dissection between the rectus femoris and vastus lateralis through the vastus intermedius. (From Schlumpf R. Distal Femur: Lateral Approach. In: Rüedi T, von Hochstetter AHC, Schlumpf R, eds. *Surgical Approaches for Internal Fixation.* Berlin: Springer-Verlag, 1984:132-135.) **C:** Retraction of the vastus intermedius and rectus femoris anteriorly and vastus lateralis inferiorly exposes the entire femoral shaft. **D:** The dissection can be carried out distally to expose the articular surface of the distal femur and knee joint. *1*, Vastus lateralis; *2*, rectus femoris; *3*, vastus intermedius; *4*, periosteum; *5*, femur; *6*, lateral circumflex femoral artery. (From Thomas HA. The Femur. In: Hoppenfeld S, deBoer P, eds. *Surgical Exposures in Orthopaedics: The Anatomic Approach.* Philadelphia: JB Lippincott, 1984:372.)

- Divide the thinnest and midline portion of the vastus intermedius in line with its fibers, and expose the femur by subperiosteal dissection (Fig. 3.13*B*). The exposure is best limited to the distal two thirds of the femoral shaft, because proximally the innervation to the vastus lateralis limits exposure.
- If it is desirable to expose the articular condyles and knee, carry the incision through a lateral parapatellar approach to the knee. The patella can be dislocated medially (Fig. 3.13*C*, Fig. 3.13*D*).

### *Posterior Approach*

The posterior approach, as originally described, is useful only for the middle three fifths of the femoral shaft. It is probably indicated only for treatment of tumors and exploration of the sciatic nerve. It can be extended into Henry's exposure of the sciatic nerve to provide a comprehensive extensile approach to the posterior thigh.

- Position the patient prone on the operating table, using appropriate bolsters to allow free abdominal and chest movement. Align the incision with the femur from 5 cm distal to the gluteal fold to 10 cm proximal to the popliteal crease (Fig. 3.14*A*). Incise the superficial and deep fascia in line with the skin incision, avoiding the posterior femoral cutaneous nerve.

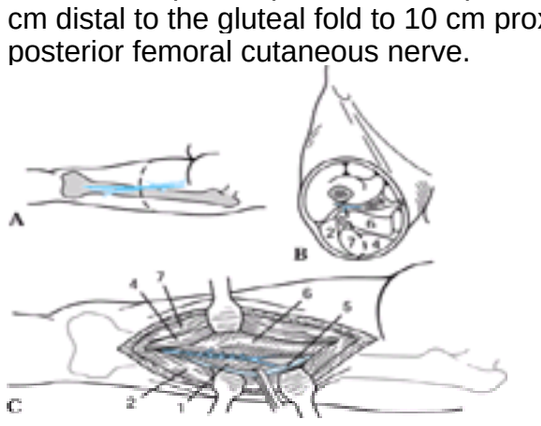

***Figure 3.14.*** Posterior approach to the femoral shaft. **A:** Skin incision and level of cross section. **B:** Plane of dissection between the semimembranosus and adductor magnus and the semitendinosus. (From Schlumpf R. Femoral Shaft: Lateral Approach. In: Rüedi T, von Hochstetter AHC, Schlumpf R, eds. *Surgical Approaches for Internal Fixation.* Berlin: Springer-Verlag, 1984:124.) **C:** Lateral retraction of the sciatic nerve. *1*, Biceps femoris, short head; *2*, biceps femoris, long head; *3*, linea aspera; *4*, semimembranosus; *5*, sciatic nerve; *6*, adductor magnus; *7*, semitendinosus. (From Thomas HA. The Femur. In: Hoppenfeld S, deBoer P, eds. *Surgical Exposures in Orthopaedics: The Anatomic Approach.* Philadelphia: JB Lippincott, 1984:376.)

- Identify the interval between the biceps femoris and the vastus lateralis. In the proximal part of the dissection, detach the short head of the biceps femoris sharply from the linea aspera. Then reflect it medially (Fig. 3.14*B*) to expose the femoral shaft.
- In the distal half of the wound, retract the long head of the biceps laterally to expose the sciatic nerve (Fig. 3.14*C*). Gently retract the sciatic nerve laterally to expose the femur. Take the adductor magnus and biceps femoris off the linea aspera sharply. For sciatic nerve explorations, begin the deep dissection in this distal half of the wound.

### *Medial Approach*

The medial approach is useful primarily for repair of the femoral artery; usually such arterial injuries are associated with fractures. It is also occasionally useful for medial internal fixation of fractures or osteotomies.

- With the patient supine and the hip flexed and externally rotated, position the knee in flexion. Begin the incision at the mid thigh and extend it distally to 5 cm distal to the adductor tubercle (Fig. 3.15*A*). Carefully incise the superficial fascia and the deep fascia, which is quite thin in this region; at the same time, avoid the saphenous vein and nerve, which are superficial.

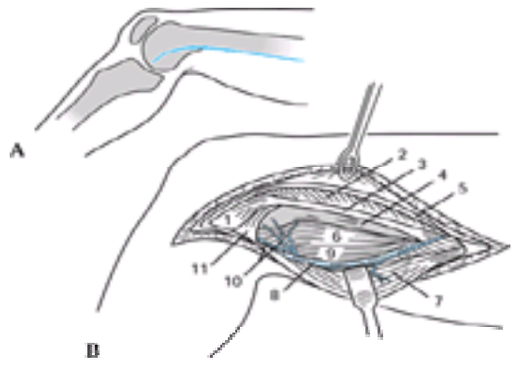

***Figure 3.15.*** Medial approach to the distal femur. **A:** Skin incision. **B:** The intramuscular septum falls posteriorly with the knee in flexion. Mobilize it anteriorly or take it down and reattach it to gain exposure to the midline of the distal femur. *1*, Medial condyle, femur; *2*, vastus medialis muscle; *3*, adductor tendon; *4*, femoral shaft; *5*, deep fascia; *6*, intramuscular septum; *7*, sartorius; *8*, saphenous nerve and superior geniculate artery; *9*, biceps femoris muscle; *10*, popliteal vessels; *11*, gastrocnemius muscle. (From Stead Z. Medial Route Extended to Femoropopliteal Trunks to the Shaft. In: Henry AK, ed. *Extensile Exposure,* 2nd ed. Edinburgh: Churchill Livingstone, 1973:216.)

- Distally identify the anterior edge of the sartorius, which falls posteriorly with progressive knee flexion. The adductor tendon is visible. Mobilize it anteriorly or take it down and reattach it to gain exposure to the midline of the distal femur.
- Incise its fascia with care posteriorly (Fig. 3.15*B*). Posterior to the adductor, the popliteal vessels and, more deeply, the tibial branch of the sciatic nerve are visible. Position internal fixation plates anteriorly to the adductor tubercle after performing subperiosteal dissection, taking care to avoid violating the joint capsule.

#### *Henry's Exposure of the Sciatic Nerve*

Henry (4) described a combination of approaches that allow the sciatic nerve to be explored from its extrapelvic origin to the popliteal fossae (2).

- Position the patient prone and outline the “question mark” incision (Fig. 3.16*A*). Avoid injury to the posterior cutaneous nerve of the thigh as it exits from beneath the gluteus maximus and runs distally down the thigh. After incising the deep gluteal fascia, develop the interval between the gluteus medius and maximus.

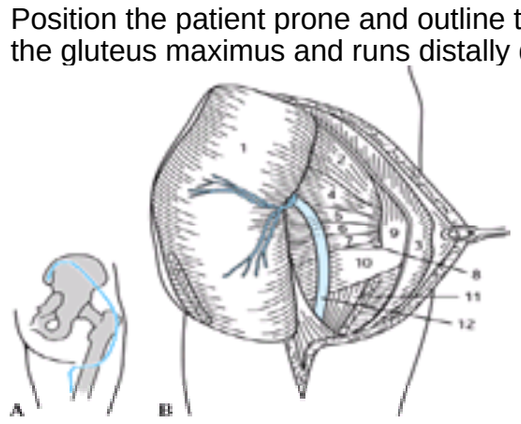

***Figure 3.16.*** Henry's exposure of the sciatic nerve. **A:** Skin incision. **B:** Mobilization of the gluteal mass medially on its neurovascular bundle to expose the sciatic nerve. *1*, Gluteus maximus; *2*, gluteus medius; *3*, iliotibial tract; *4*, piriformis; *5*, gemellus superior; *6*, obturator internus; *7*, gemellus inferior; *8*, obturator externus; *9*, greater trochanter; *10*, quadratus femoris; *11*, adductor magnus; *12*, sciatic nerve. (From Stead Z. Structures Under the Gluteal Lid. In: Henry AK, ed. *Extensile Exposure,* 2nd ed. Edinburgh: Churchill Livingstone, 1973:189.)

- Cut the gluteus maximus free from its insertion into the femur, and fold the entire gluteus maximus flap back medially on its neurovascular bundle. The sciatic nerve, proximally exposed, is easily traced to the superior margin of the long head of the biceps femoris, where it passes deeply to this muscle (Fig. 3.16*B*). From this point distally, the entire exposure is as previously described for the posterior approach.

## KNEE

### ANTERIOR APPROACHES

#### *Anteromedial Approach*

The anteromedial approach allows adequate exposure of the knee joint for most intraarticular problems. The list includes meniscectomy (total or partial), removal of loose bodies, stabilization of osteochondral fractures, ligament or meniscal repair, drainage procedures, ligament reconstructions, fixation or excision of patella fractures, and synovectomy. The anteromedial deep dissection can be combined with a straight anterior skin incision (Fig. 3.17) for more extensive exposure for these conditions and for total knee replacement. Use it whenever possible, because it gives the best possible route for reexploration, whenever repeat procedures may be required or when later reconstructive procedures are anticipated.

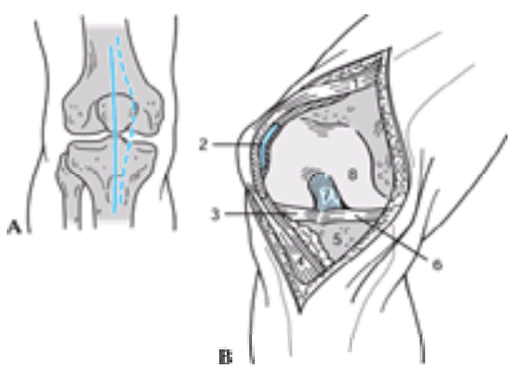

***Figure 3.17.*** Anterior and anteromedial exposure to the knee. **A:** Skin incisions; anterior (*solid line*), anteromedial (*dotted line*). **B:** The deep exposure for the two approaches is the same. *1*, Quadriceps tendon; *2*, articular surface, patella; *3*, lateral meniscus; *4*, patellar ligament; *5*, medial tibial plateau; *6*, medial meniscus; *7*, anterior cruciate ligament; *8*, medial femoral condyle. (From Thomas HA. The Knee. In: Hoppenfeld S, deBoer P, eds. *Surgical Exposures in Orthopaedics: The Anatomic Approach.* Philadelphia: JB Lippincott, 1984:376.)

- For the anterior incision, make a straight incision midline extending 10 cm above the patella to 3 cm below the tibial tubercle (Fig. 3.17*A*). For the anteromedial incision, begin on the medial side of the quadriceps tendon, 5–7 cm above the patella. Curve the incision around the superomedial border of the patella, then distally to the medial side of the tibial tubercle. Preserve the infrapatellar branches of the saphenous nerve whenever possible.
- The deep dissection is identical for both procedures (Fig. 3.17*B*). Divide the vastus medialis muscle from the quadriceps tendon on the medial side, leaving a 5 mm cuff of tendon on the muscle side. Extend the quadriceps tendon split proximally to the extent of the skin incision. Divide the capsule and synovium together, 5 mm lateral to the medial border of the patella.
- Carry this deep dissection down to the medial side of the tibial tubercle. Flex the knee, completely divide the synovium in line with the capsular incision, and dislocate the patella laterally (Fig. 3.17*B*) to expose the notch of the femur, revealing the anterior cruciate and medial meniscus. Carefully preserve the patellar tendon insertion if the patella is to be inverted for joint replacement procedures. Subperiosteal dissection of the medial one half of the tendon at the joint line will

decrease the tension in the tendon during this maneuver.

### *Anterolateral Approach*

The anterolateral approach does not yield as complete exposure to all joint structures as do the anteromedial and the anterior approaches. It is useful for exposure of the anterior two thirds of the lateral meniscus, for isolated lateral compartment reconstructive procedures, and for internal fixation of lateral tibial plateau or femoral condyle fractures, particularly if combined with anterolateral exposure of the femoral shaft.

- With the knee in slight flexion, begin the incision 10 cm proximal to the patella in line with the insertion of the vastus lateralis on the quadriceps tendon (Fig. 3.18*A*). Curve the incision gently at the lateral patellar border, and extend it distally to the level of the tibial tubercle lateral to it. The deep capsular incision is 5 mm lateral to the insertion of the vastus lateralis on the quadriceps tendon.

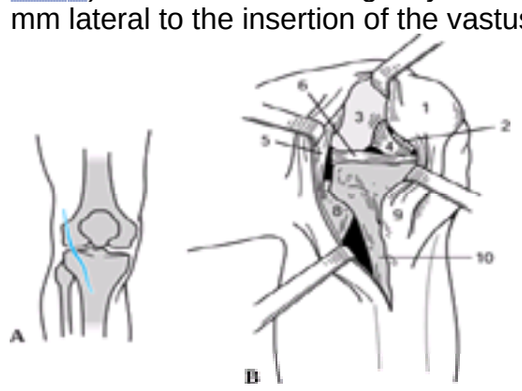


***Figure 3.18.*** Anterolateral approach to the knee. **A:** Skin incision. **B:** Medial subluxion of the patella exposes the anterior cruciate and lateral meniscus. *1*, Patella; *2*, posterior cruciate ligament; *3*, lateral femoral condyle; *4*, anterior cruciate ligament; *5*, fibular collateral ligament; *6*, lateral meniscus; *7*, transverse ligament; *8*, fibular head; *9*, tibial tuberosity; *10*, lateral tibial surface. (From McConnell J. Surgical Approaches. In: Edmonson AS, Crenshaw AH, eds. *Campbell's Operative Orthopaedics,* 6th ed, vol 1. St. Louis: CV Mosby, 1980:44.)

- Incise the synovium in the same plane, and sublux the patella medially to expose the anterior cruciate and lateral meniscus (Fig. 3.18*B*). The patella cannot be inverted medially because of the strong medial orientation of the quadriceps attachments.

## POSTEROLATERAL APPROACHES

### *Henderson Approach (3)*

The posterolateral approach to the knee is most frequently used for lateral extraarticular ligament reconstructions or in combination with an anteromedial approach for an intraarticular reconstruction. It is also useful for exposure of the posterior half of the lateral meniscus and for explorations of the common peroneal nerve and its branches.

- With the knee flexed 90°, make a gently curved 15 cm incision (*dotted line* in Fig. 3.19*A*) just anterior to the biceps femoris tendon and fibular head to expose the fascia lata. Keep the position of the common peroneal nerve (Fig. 3.19*B*) in mind constantly.

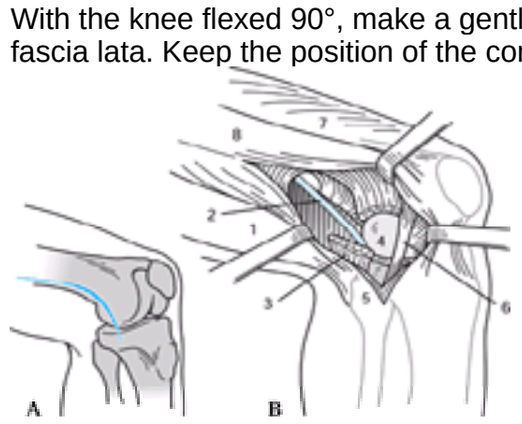


***Figure 3.19.*** Henderson's posterolateral approach to the knee. **A:** Skin incision can be extended proximally (*dotted line*) for exposure of the fascia lata. **B:** Exposure of the common peroneal nerve and fibular collateral ligament. *1*, Biceps femoris; *2*, common peroneal nerve; *3*, lateral head of gastrocnemius (cut); *4*, lateral femoral condyle; *5*, fibular head; *6*, fibular collateral ligament; *7*, vastus lateralis; *8*, iliotibial band.

- Proximally, follow the anterior surface of the lateral intramuscular septum back to the linea aspera. At this point, the nerve is just posterior to the dissection.
- Expose the lateral femoral condyle and fibular collateral ligament origin in the midportion of the wound. The lateral head of the gastrocnemius muscle is evident posteriorly and protects the nerve at that level. The posterior half of the lateral meniscus is visible posterior to the fibular collateral ligament with the popliteus tendon coming up from posteroinferior to the posterior-midmeniscus region (Fig. 3.19*B*). This tendon may be retracted posteriorly as the capsule and synovium are opened through a longitudinal incision above the menisci.

### *Bruser Approach*

The Bruser approach permits good exposure of the entire lateral meniscus. Resection of the meniscus does not require release of the fibular collateral ligament.

- Position and drape the patient to allow full flexion; more than 100° of flexion is helpful. Make the incision parallel to the lateral meniscus, beginning anteriorly at the lateral border of the patellar tendon (Fig. 3.20*A*). Its posterior limit is at a line between the fibular head and lateral femoral condyle. Divide the subcutaneous tissue in line with the incision, and divide the iliotibial band in line with its fibers.

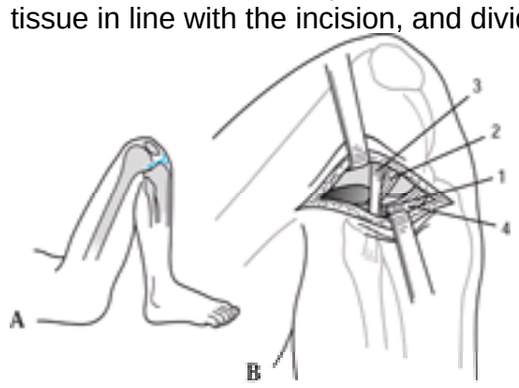


***Figure 3.20.*** Bruser's posterolateral approach to the knee. **A:** Line of skin incision parallel to the lateral meniscus located halfway between the patella and tibial tubercle (*arrow*). **B:** Division of the iliotibial band. *1*, Iliotibial band; *2*, popliteal tendon; *3*, fibular collateral ligament; *4*, torn lateral meniscus. (From McConnell J. Surgical Approaches. In: Edmonson AS, Crenshaw AH, eds. *Campbell's Operative Orthopaedics,* 6th ed, vol. 1. St. Louis: CV Mosby, 1980:47.)

- The knee must be flexed during this part of the dissection to prevent transection of the iliotibial band. Divide the iliotibial band along the lines of its fibers to Gurde's tubercle, expose the fibula, collateral ligament, and the torn lateral meniscus central to it. The relaxed fibular collateral ligament must be protected posteriorly when this incision is made (Fig. 3.20*B*). The inferolateral geniculate artery should be ligated, because it lies at the posterolateral corner of the meniscus. Incise the synovium, allowing complete exposure of the meniscus.

### *Posteromedial Approach*

The posteromedial approach described by Henderson (2) is useful for exposure of the posteromedial corner of the knee joint for posterior meniscal horn resections, posteromedial corner reconstructions, or repair or reconstruction of the posterior cruciate ligament.

- Position the patient supine with the hip in external rotation and the knee flexed 90°.
- Make a 10 cm incision from the adductor tubercle along the course of the tibial collateral ligament and anterior to the pes anserine tendons (Fig. 3.21*A*).

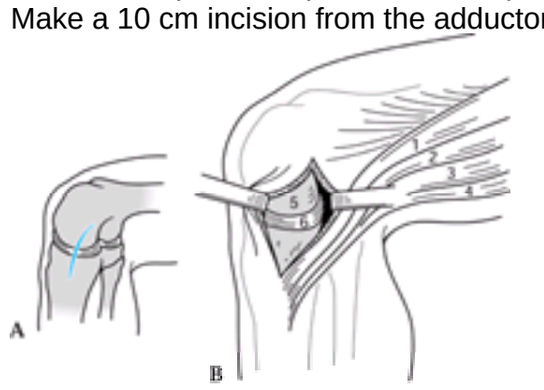


***Figure 3.21.*** Henderson's posteromedial approach to the knee. **A:** Skin incision. **B:** The deep dissection is carried out anterior to the pes anserine tendons. *1*, Sartorius; *2*, gracilis; *3*, semimembranosus; *4*, semitendinosus; *5*, medial femoral condyle; *6*, medial meniscus. (From Thomas HA. In: Hoppenfeld S, deBoer P, eds. *Surgical Exposures in Orthopaedics: The Anatomic Approach.* Philadelphia: JB Lippincott, 1984:400, 415.)

- Incise the oblique portion of the tibial collateral ligament in line with the tendons, and also incise the capsule below (Fig. 3.21*B*). This incision exposes the medial meniscus and allows access to the posteromedial compartment. For capsular and posterior cruciate reconstructions, it is necessary to develop the interval between the capsule and the pes anserine tendons and semimembranosus.
- Retract the hamstrings and medial head of the gastrocnemius muscle posteriorly. For wider exposure, take down the origin of the medial head of the gastrocnemius.

### *Posterior Approach*

The posterior approach to the knee is rarely needed, but it provides invaluable exposure of the posterior neurovascular structures and joint capsule. Indications for its use include exposure of the popliteal neurovascular structures, posterior cruciate ligament repairs, release of posterior knee contractures, and resection of popliteal masses.

- Position the patient prone. Initiate an S-shaped incision (Fig. 3.22*A*) with the superior arm lateral and the transverse portion at the level of the posterior crease (orient the incision transversely along the flexion crease and direct it superolaterally and inferomedially). Carefully incise the popliteal fascia in the midline.

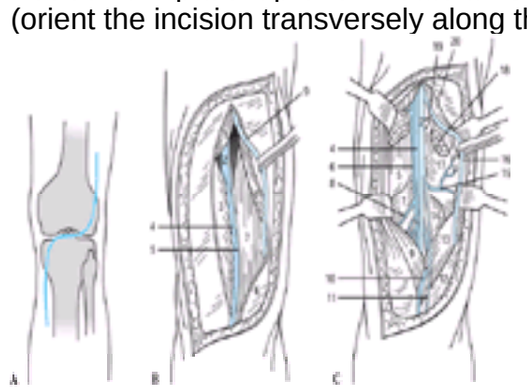

***Figure 3.22.*** Posterior approach to the knee. **A:** Skin incision. **B:** A linear split of the deep fascia. *1*, Semimembranosus; *2*, popliteal vein; *3*, medial head of gastrocnemius; *4*, small saphenous vein; *5*, medial sural cutaneous nerve; *6*, popliteal fascia; *7*, lateral head of gastrocnemius; *8*, biceps femoris; *9*, common peroneal nerve. **C:** Sectioning of the gastrocnemius heads. *1*, Semimembranosus; *2*, tibial nerve; *3*, medial head of gastrocnemius; *4*, popliteal vein; *5*, posterior joint capsule; *6*, popliteal artery; *7*, oblique popliteal ligament; *8*, medial inferior genicular artery; *9*, medial head of gastrocnemius; *10*, small saphenous vein; *11*, medial sural cutaneous nerve; *12*, fascia; *13*, lateral head of gastrocnemius; *14*, plantaris; *15*, lateral inferior genicular artery; *16*, common peroneal nerve; *17*, arcuate ligament; *18*, lateral head of gastrocnemius; *19*, plantaris; *20*, biceps femoris. (From Thomas HA. The Knee. In: Hoppenfeld S, deBoer P, eds. *Surgical Exposures in Orthopaedics: The Anatomic Approach.* Philadelphia: JB Lippincott, 1984:431.)

- linear split of the deep fascia exposes the common peroneal nerve, the popliteal vein, and two heads of the gastrocnemius. Identify the sural nerve as it rests in the midline in the distal portion of the wound, and trace it proximally until it leads you to the tibial component of the sciatic nerve (Fig. 3.22*B*).
- Identify the common peroneal nerve from proximal to distal as it runs along the posterior border of the biceps femoris. The popliteal vein lies over the tibial nerve at the level of the gastrocnemius muscle heads. The popliteal artery lies deep and medial to the tibial nerve. There are five geniculate arteries that limit retraction of the artery. One of the branches may have to be ligated, depending on the direction that the dissection needs to take.
- To reach the posteromedial or posterolateral corners of the joint section, the medial head or lateral head of the gastrocnemius muscle can be sectioned, leaving a tendinous cuff to repair (Fig. 3.22*C*). In this way, the entire posterior capsule (popliteal artery, tibial nerve, and deep capsular structures) in its medial and lateral extent can be exposed. The capsule must be opened transversely to expose the posterior cruciate ligament in the midline.

## TIBIA AND FIBULA

### PROXIMAL ANTERIOR APPROACH FOR MEDIAL OR LATERAL DEEP EXPOSURE

We highly recommend the straight anterior approach for reduction of medial or lateral tibial plateau fractures, or for resection of tumors or infectious processes involving this region of the tibia.

- With the knee gently flexed, make the distal half of the straight anterior approach to the knee joint, beginning at the superior pole of the patella. After incising the subcutaneous tissue in line with the incision, subcutaneously dissect in the lateral or medial direction (or both), with the knee flexed to 90° (Fig. 3.23).

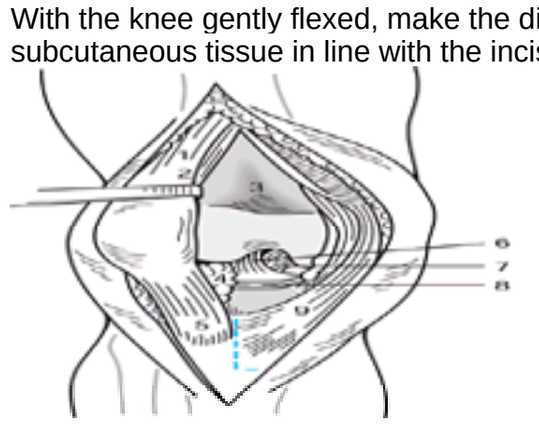

***Figure 3.23.*** Anterior approach to the proximal tibial shaft. The skin incision of the anterior approach to the knee (see Fig. 3.17) can be extended distally to expose the proximal tibia. The pes anserine tendons can be released subperiosteally (*dotted line*) to expose the medial tibial condyle. *1*, Quadriceps tendon; *2*, quadriceps femoris, vastus medialis; *3*, suprapatellar recess; *4*, infrapatellar fatty body of Hoffa; *5*, tibial tuberosity; *6*, anterior cruciate ligament; *7*, posterior cruciate ligament; *8*, anterior horn, medial meniscus; *9*, pes anserinus. (From Schlumpf R. Knee Joint and Proximal Tibia: Lateral Parapatellar Approach. In:

Rüedi T, von Hochstetter AHC, Schlumpf R, eds. *Surgical Approaches for Internal Fixation.* Berlin: Springer-Verlag, 1984:151.)

- To gain exposure medially, elevate the pes anserine insertion and superficial portion of the medial collateral ligament subperiosteally. Divide the meniscotibial ligament (i.e., the deep portion of the medial collateral ligament) beneath the meniscus, allowing visualization of the tibial joint surface. Leave enough tissue attached to the tibia to allow reattachment of the meniscus.
- To gain exposure laterally, open the joint capsule lateral to the patellar tendon. Elevate the musculature of the anterior compartment subperiosteally posterior to the level of the fibular collateral ligament. Elevate Gurde's tubercle with an osteotome or reflect the iliotibial band insertion to allow more complete exposure for application of plates to the proximal lateral tibia. Examine the joint surface by incising the meniscotibial attachments of the anterior half of the lateral meniscus.

**HENRY'S EXPOSURE OF THE PERONEAL NERVE AND PROXIMAL FIBULA**

Henry (4) described a complete exposure of the fibula that, in its proximal half, allows complete exposure of the peroneal nerve.

- Position the patient laterally with the affected limb up. Make the skin incision in line with the fibula distally (to trace the superficial branch of the peroneal nerve) and biceps femoris proximally, curving posteriorly at the joint line at an angle of 45° (Fig. 3.24*A*).

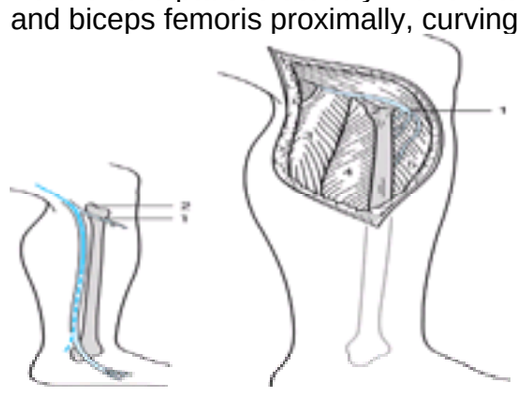

***Figure 3.24.*** Henry's exposure of the peroneal nerve and proximal fibula. **A:** Skin incision. *1*, Common peroneal nerve; *2*, head of fibula. **B:** The peroneal muscles have been divided transversely and retracted anteriorly to expose the motor divisions of the deep peroneal nerve proximally. *1*, Common peroneal nerve (lat. popliteal); *2*, head of fibula; *3*, gastrocnemius; *4*, soleus; *5*, peroneus longus. (From Stead Z. In: Henry AK, ed. *Extensile Exposure,* 2nd ed. Edinburgh: Churchill Livingstone, 1973:293, 295.)

- Identify the common peroneal nerve where it lies deep to the biceps tendon in the proximal portion of the wound. Handle the nerve gently in a rubber sling for retraction. Divide the deep fascia in line with the nerve, developing a plane of division between the soleus and peroneal muscles. A thin extension of the peroneus longus origin must be divided at the fibular neck (Fig. 3.24*B*). The nerve is now freed as it curves anteriorly, dividing into muscular branches. Elevate the peroneal muscles subperiosteally to expose the upper one half of the fibula.

**TIBIAL SHAFT: ANTERIOR APPROACH**

The entire shaft of the tibia can be exposed by the anterior route for osteotomies, internal fixation of fractures or nonunions, excision of bone tumors, or drainage of infectious processes.

- Position the patient supine with a pad under the affected hip to gain slight internal rotation of the leg. Make the incision 10–15 cm lateral and parallel to the crest of the tibia (Fig. 3.25). Distally, incise along the medial border of the anterior tibial tendon to allow intraarticular exposure, if required. Reflect the skin and periosteum as a single layer for a medial exposure. Alternatively, lateral subperiosteal dissection allows retraction of the anterior compartment musculature. Avoid complete soft-tissue elevation medially and laterally because of the effect on bone blood supply with this radical exposure.

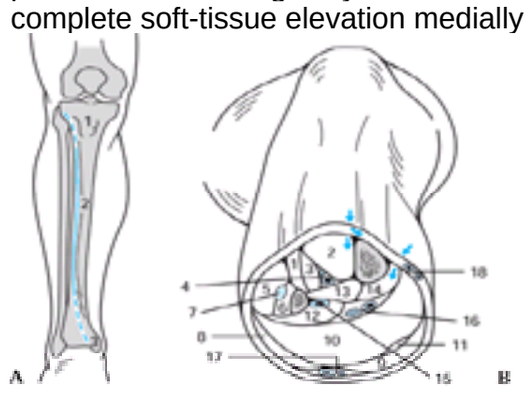

***Figure 3.25.*** Anterior approach to the tibial shaft. **A:** Skin incision, just lateral to the tibial crest can be extended proximally and distally to expose the entire shaft (*dotted lines*). *1*, Tibial tuberosity; *2*, anterior border; *3*, medial malleolus. **B:** A cross section of the mid calf reveals the plane of dissection to the lateral surface of the tibia and medially to the fascia of the deep posterior compartment (*arrows*). *1*, Extensor digitorum; *2*, tibialis anterior; *3*, extensor hallucis longus; *4*, deep peroneal nerve, anterior tibial vessels; *5*, peroneus longus; *6*, peroneus brevis; *7*, superficial peroneal nerve; *8*, lateral head, gastrocnemius; *9*, medial head, gastrocnemius; *10*, soleus; *11*, plantaris; *12*, flexor hallucis longus; *13*, tibialis posterior; *14*, flexor digitorum longus; *15*, peroneal artery; *16*, tibial nerve with posterior tibial vessel; *17*, sural nerve with small saphenous vein; *18*, saphenous nerve with great saphenous vein. (From Schlumpf R. Tibial Shaft: Anterior Approach. In: Rüedi T, von Hochstetter AHC, Schlumpf R, eds. *Surgical Approaches for Internal Fixation.* Berlin: Springer-Verlag, 1984:155, 156.)

**TIBIAL SHAFT: POSTEROMEDIAL APPROACH**

In cases of fracture, nonunion, malunion, bone tumor, or infection associated with poor anterior skin coverage, elect a posteromedial approach to the tibial shaft, particularly for the proximal third. The two-incision method of compartment release also calls for a posteromedial approach for release of the deep posterior compartment.

- Position the patient supine. Flex the affected hip and rotate it externally with the knee flexed. Make the incision in line with the tibia 1–2 cm posterior to the posterior border of the tibia (Fig. 3.26*A*). Protect the saphenous vein and nerve as the subcutaneous tissue is incised in line with the skin incision.

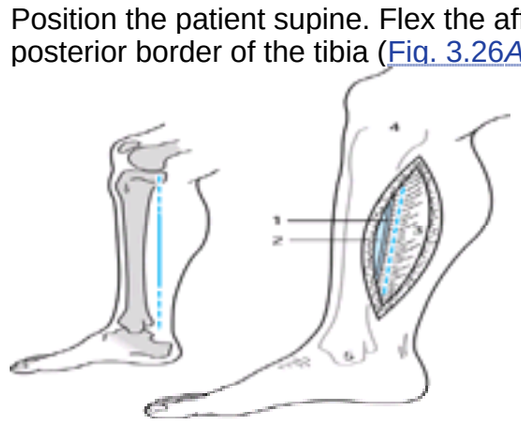

***Figure 3.26.*** Posteromedial approach to the tibial shaft. **A:** Skin incision. **B:** The deep dissection exposing the fascia. *1*, Saphenous nerve; *2*, great saphenous vein; *3*, crural fascia (superficial); *4*, medial condyle, tibia; *5*, medial malleolus. (From Schlumpf R. Tibial Shaft: Posteromedial Approach. In: Rüedi T, von Hochstetter AHC, Schlumpf R, eds. *Surgical Approaches for Internal Fixation.* Berlin: Springer-Verlag, 1984:159, 161.)

- Divide the superficial compartment fascia 5 mm posterior to the posterior border of the tibia. Carry out the deep dissection exposing the fascia of the lower leg posterior to the saphenous nerve and vein. Divide the deep fascia posterior to the border of the tibia in line with the fibers of the flexor hallucis longus proximally, flexor digitorum longus in the mid tibia, and posterior tibialis distally (Fig. 3.26*B*). Retract the muscles posteriorly, exposing the tibia for the required procedure.

**TIBIA AND FIBULA SHAFTS: POSTEROLATERAL APPROACH OF HARMON (2)**

The posterior exposure allows access to the middle two thirds of the tibia and is also useful when the anterior and anteromedial aspects of the leg have poor soft-tissue coverage. It is the classic exposure for bone grafting of tibial nonunions.

- Position the patient prone or on his side with the affected leg up. Make the skin incision (Fig. 3.27*A*) longitudinally along the lateral border of the gastrocnemius (Fig. 3.27*B*). The deep plane is between the peroneal musculature (laterally) and the superficial and deep posterior compartment musculature (medially), exposing the intraosseous membrane.

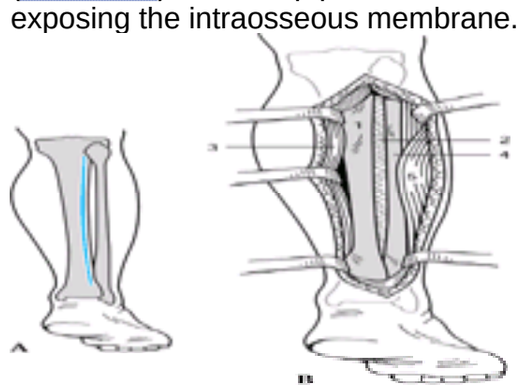

***Figure 3.27.*** Harmon posterolateral approach to the tibial shaft. **A:** Skin incision. **B:** The deep plane is between the peroneal musculature and the superficial and deep posterior compartment musculature. *1*, Tibia; *2*, interosseous membrane; *3*, soleus and gastrocnemius; *4*, fibula; *5*, peroneal muscles. (From Edmonson AS, Crenshaw AH, eds. *Campbell's Operative Orthopaedics,* 6th ed, vol 1. St. Louis: CV Mosby, 1980:39.)

- Develop the plane between the triceps surae posteriorly and peroneal muscles anteriorly, exposing the posterior surface of the fibula. Elevate the flexor hallucis longus portion of the posterior tibial muscle that originates from the intraosseous septum, and strip the muscle medially off the posterior surface of the tibia. Take care in the proximal one third of the wound to avoid the peroneal artery and vein. The posterior tibial artery and nerve lie between the flexor hallucis longus and the posterior tibial muscle and are not easily seen; avoid medial retraction at any place other than the subperiosteal level.
- With careful subperiosteal dissection, expose the posterior surface of the middle two thirds of the tibia. In nonunions for which this approach is most commonly used, callus, scar, and loss of the interosseous membrane can make exposure in the region of the nonunion difficult. To facilitate exposure, use a long incision. Expose the interosseous membrane and posterior tibia first in areas of undisturbed anatomy proximally and distally to the fracture. Once you have established the proper plane of dissection, it is fairly easy to expose the nonunion. As you pass medial to the peroneal muscles and follow the fibula to the interosseous membrane, the line of dissection is more or less directly anterior. To avoid perforating the membrane, use a large-key or Cobb elevator to develop the exposure. In compartment syndrome where compartment fasciotomy is required, swelling and hematoma can obscure the fascial septae dividing the anterior, lateral, and posterior compartments. In this situation, develop the skin and subcutaneous tissue flaps for 2.5–3 cm anteriorly and posteriorly. In the midportion of the wound, make a transverse incision through the deep fascia. Identification of the longitudinally running fascial divisions between the compartments is then easy.

## ANKLE

### *Anterior Approach*

The anterior approach to the ankle is useful for many techniques of ankle arthrodesis, internal fixation of distal tibia (i.e., intraarticular) fractures, joint debridement and removal of loose bodies, synovectomy, drainage of septic joints, and joint replacement arthroplasty. Through this approach, both malleoli and the whole articular surface of the distal tibia can be exposed.

- Position the patient supine with a folded sheet under the hip of the affected side in order to internally rotate the limb. Make a longitudinal 15 cm incision midway between the lateral and medial malleoli, beginning 10 cm proximal to the joint line (Fig. 3.28*A*). Identify and protect the terminal branches of the superficial peroneal nerve. Incise the deep fascia of the leg in line with the skin incision. Identify the interval between the extensor hallucis longus and the extensor digitorum longus. Protect the anterior tibial artery and the deep peroneal nerve, which are just medial to the extensor hallucis tendon.

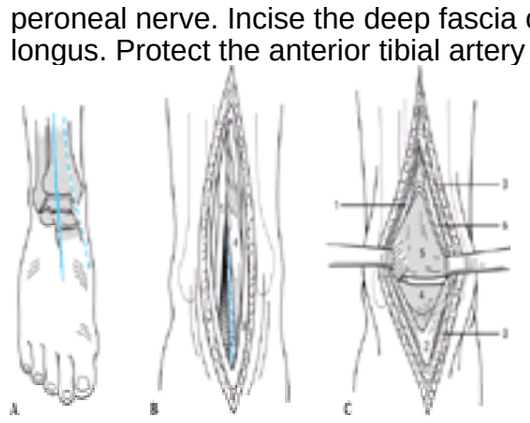

***Figure 3.28.*** Anterior approach to the ankle. **A:** Skin incision. **B:** Division of the extensor retinaculum exposes the extensor hallucis and extensor digitorum tendons. *1*, Extensor digitorum longus; *2*, deep peroneal nerve and anterior tibial artery (neurovascular bundle); *3*, extensor retinaculum; *4*, extensor hallucis longus. **C:** Division of the joint capsule exposes the joint. *1*, Extensor digitorum longus; *2*, joint capsule of ankle; *3*, extensor retinaculum; *4*, dome of talus; *5*, distal tibia; *6*, extensor hallucis longus. (From Thomas HA. The Ankle and Foot. In: Hoppenfeld S, deBoer P, eds. *Surgical Exposures in Orthopaedics: The Anatomic Approach.* Philadelphia: JB Lippincott, 1984:472, 473.)

- Retract the tendon of the extensor hallucis medially, taking the neurovascular bundle with it, and the extensor digitorum longus laterally (Fig. 3.28*B*). Distally, at the level of the ankle joint, the neurovascular bundle crosses the ankle joint behind the extensor hallucis tendon. Mobilize it carefully as the joint is exposed.
- The capsule is visible beneath the tendons and can be longitudinally incised or dissected off the distal tibia as the procedure requires (Fig. 3.28*C*).

### *Anteromedial Approach*

We recommend the anteromedial approach to the ankle for internal fixation of intraarticular fractures of the distal tibia and medial malleolus. It is an extensile continuation of the anterior approach to the tibial shaft (Fig. 3.25).

- Following the course of the tibialis anterior tendon, curve the incision medially toward the tip of the medial malleolus, beginning 5 cm above the ankle joint (Fig. 3.29). Identify the saphenous vein and nerve. Divide the ankle capsule anterior to the deltoid ligament. Deeply develop the interval between the tibialis anterior tendon and the medial malleolus. Retract the tendon laterally, and open the joint by longitudinal incision and subperiosteal dissection.

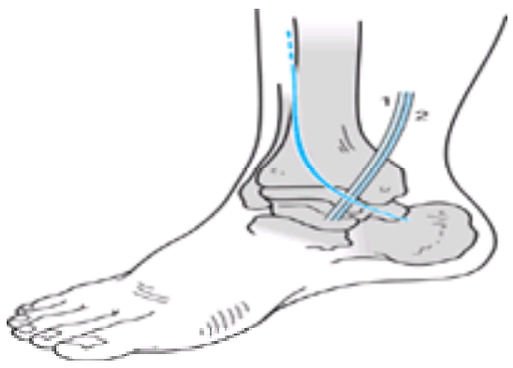

***Figure 3.29.*** Anteromedial approach to the ankle. *1*, Saphenous nerve; *2*, saphenous vein. (From Schlumpf R. Medial Malleolus and Distal Tibia. In: Rüedi T, von Hochstetter AHC, Schlumpf R, eds. *Surgical Approaches for Internal Fixation.* Berlin: Springer-Verlag, 1984:167.)

### *Anterolateral Approach*

The anterolateral approach extended distally allows exposure of the joints of the hind foot and the ankle joint. It is useful for ankle arthrodesis, triple arthrodesis, and talectomy.

- Make a 15 cm incision centered over the distal tibiofibular joint, beginning 5 cm proximal to the ankle joint (Fig. 3.30*A*). Curve the incision anteriorly, crossing the ankle joint 2 cm medial to the tip of the lateral malleolus and extending onto the dorsum of the foot 2 cm medial to the base of the fifth metatarsal. The incision crosses the distal tibiofibular joint and angles anteriorly over the cuboid. Identify and protect the branches of the superficial peroneal nerve and the saphenous vein.

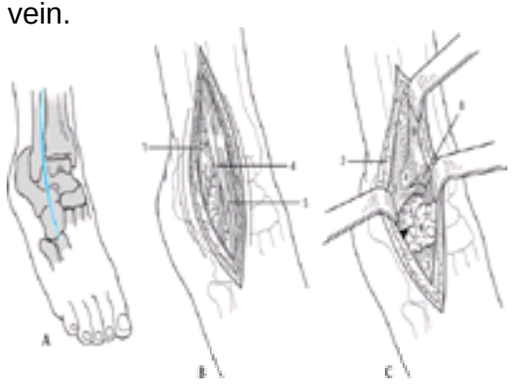

***Figure 3.30.*** Anterolateral approach to the ankle. **A:** Skin incision. **B:** Deep dissection exposes the sinus tarsi distally. *1*, Extensor retinaculum; *2*, anterior inferior tibiofibular ligament; *3*, sinus tarsi fat pad; *4*, peroneus tertius tendon; *5*, extensor digitorum longus tendons. **C:** Retraction of the tendons exposes the anterior ligament complex of the ankle. *1*, Interosseous membrane; *2*, extensor retinaculum; *3*, distal fibula; *4*, anterior inferior tibiofibular ligament; *5*, anterior talofibular ligament; *6*, sinus tarsi fat pad; *7*, extensor digitorum brevis; *8*, joint capsule of ankle; *9*, distal tibia. (From Thomas HA. The Ankle and Foot. In: Hoppenfeld S, deBoer P, eds. *Surgical Exposures in Orthopaedics: The Anatomic Approach.* Philadelphia: JB Lippincott, 1984:497.)

- Develop the interval between the major peroneal muscles laterally and the extensor muscles anteriorly. The deep dissection is conducted between the extensor tendons and the peroneal tendons, exposing the sinus tarsi distally (Fig. 3.30*B*).
- Retract the extensor tendons medially to expose the ankle capsule (Fig. 3.30*C*). The origin of the extensor digitorum brevis can be elevated off the calcaneus to expose the calcaneocuboid and talonavicular joints and the fat within the sinus tarsi.

### *Posterior Approach*

The posterior approach is useful for tendon lengthenings, release of the posterior capsule of the ankle, and exposure of posterior malleolus fractures.

- The skin incision is based on the medial border of the triceps surae tendon. Make a 10 cm longitudinal incision along the posterolateral border of the tendo calcaneus to its insertion on the calcaneus (Fig. 3.31*A*). Protect the terminal branches of the sural nerve laterally. Retract the tendo calcaneus medially (Fig. 3.31*B*). Lengthening of the tendon can be performed if the procedure requires it. Divide the areolar tissue anterior to the tendon, and enter the space between the flexor hallucis longus tendon medially and the peroneal tendons laterally.

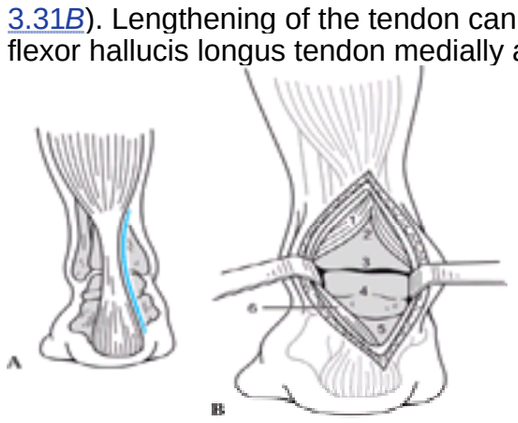

***Figure 3.31.*** Posterior approach to the ankle. **A:** Skin incision. **B:** Deep dissection. *1*, Flexor hallucis longus; *2*, tibia; *3*, ankle joint; *4*, talus; *5*, subtalar joint; *6*, Achilles tendon. (From Stead Z. Exposing the Back of the Distal End of the Tibia. In: Henry AK, ed. *Extensile Exposure,* 2nd ed. Edinburgh: Churchill Livingstone, 1973:270-271.)

- Deep dissection carries the triceps surae tendon and neurovascular bundle medially. Sharply dissect the lateral fibers of the flexor hallucis muscle belly from the posterior fibular border, and develop this interval, exposing the distal tibia, posterior ankle joint, and posterior talus (Fig. 3.31*B*). The retracted flexor hallucis longus protects the medial neurovascular structures.

### *Posteromedial Approach*

The posteromedial approach is indicated for clubfoot release, exploration of the neurovascular structures, exposure of posterior malleolus fractures, and tendon lengthenings or transfers.

- Position the patient supine in the figure-four position, with the affected ankle resting on the opposite thigh.
- Make a 10 cm longitudinal incision along the posterior tibial tendon, midway between the medial malleolus and the tendo calcaneus (Fig. 3.32*A*). Incise the deep fascia in line with the skin incision (Fig. 3.32*B*). Division of the superficial retinaculum exposes the posterior tibial, flexor digitorum, and flexor hallucis tendons and the posterior tibial artery and nerve.

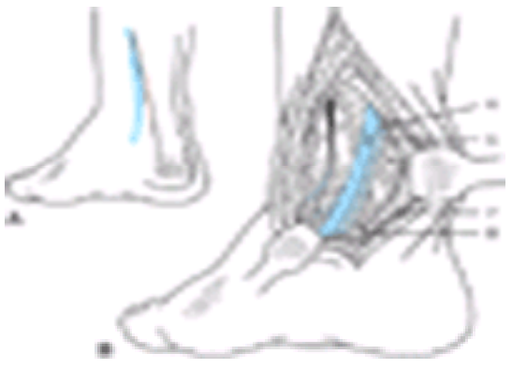

***Figure 3.32.*** Posteromedial approach to the ankle. **A:** Skin incision. **B:** Division of the superficial retinaculum. *1*, Tibialis posterior; *2*, flexor digitorum longus; *3*, posterior tibial artery; *4*, posterior tibial vein; *5*, posterior tibial nerve; *6*, flexor hallucis longus; *7*, fascia over deep flexor compartment; *8*, fibrous pulley over flexor hallucis longus (opened). (From Thomas HA. The Ankle and Foot. In: Hoppenfeld S, deBoer P, eds. *Surgical Exposures in Orthopaedics: The Anatomic Approach.* Philadelphia: JB Lippincott, 1984:485, 486.)

- Retract the tendon of the flexor hallucis longus medially after dissecting its lateral fibers off the fibula, protecting the nerve and artery, and exposing the distal posteromedial corner of the tibia with the ankle joint capsule.

***Posterolateral Approach***

The posterolateral approach is useful for visualization of posterior malleolus fractures, posterior capsulotomy, posterior subtalar facet arthrodesis, and tendon lengthenings and transfers.

- Position the patient prone. Make a longitudinal 10 cm incision halfway between the posterior border of the lateral malleolus and the lateral border of the Achilles tendon (Fig. 3.33*A*). The lateral border of the triceps surae tendon is a landmark for the incision. Protect the terminal branch of the sural nerve. The peroneus brevis consists of a muscle belly in this region, and the peroneus longus is tendinous. Incise the peroneal retinaculum to allow easy repair.

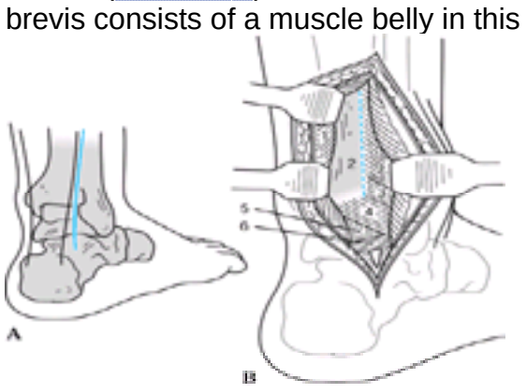

***Figure 3.33.*** Posterolateral approach to the ankle. **A:** Skin incision. **B:** The tendon is retracted medially and the peroneal tendons laterally. *1*, Flexor hallucis longus (detached); *2*, posterior tibia (incise periosteum); *3*, posterior inferior tibiofibular ligament; *4*, transverse tibiofibular ligament; *5*, posterior joint capsule of ankle; *6*, posterior talofibular ligament. (From Thomas HA. The Ankle and Foot. In: Hoppenfeld S, deBoer P, eds. *Surgical Exposures in Orthopaedics: The Anatomic Approach.* Philadelphia: JB Lippincott, 1984:489, 491, 517.)

- Detach the lateral fibers of the flexor hallucis longus where they arise from the fibula. Retract this muscle medially, exposing the posterolateral ligament complex (Fig. 3.33*B*). Longitudinal subperiosteal dissection exposes the distal tibia, and a linear capsular incision exposes the joint.

**EXPOSURES FOR ANKLE FRACTURES**

For simple fractures of the malleoli, straight longitudinal skin incisions directly over the malleoli (rather than curved incisions) permit direct access, are extensile, and have low morbidity (Fig. 3.34).

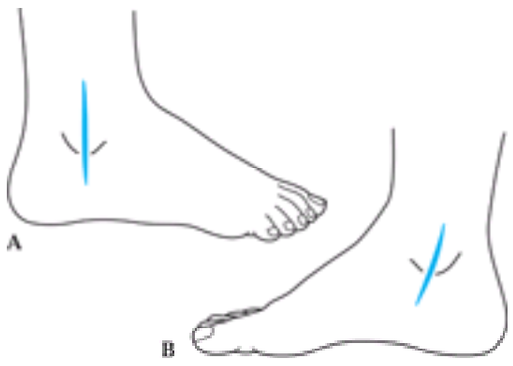

***Figure 3.34.*** Medial and lateral approaches to the ankle. **A:** Lateral approach. The skin, subcutaneous tissue, and periosteum is incised in line with the distal fibula. **B:** Medial approach. The incision is placed centrally in the midportion of the medial malleolus. The skin, subcutaneous tissue, and periosteum dissection is in line with the incision. Care must be taken not to divide the saphenous vein.

## FOOT

**SKIN INCISIONS**

In general, skin incisions in the foot should be longitudinal and extensile. They should give optimal exposure to the area required and have the possibility of extension to the proximal or distal joint. Preserve cutaneous nerves and veins if it is technically possible to do so.

**TARSUS**

***Anterior Approach***

The more distal extension of the anterior approach to the ankle joint allows good exposure of the talonavicular joint, naviculocuneiform joint, and the first metatarsal–cuneiform joint. Preserve the dorsal veins and gain direct exposure of the joints of the mid foot between the tendons of the extensor digitorum. More distal exposure and deep dissection exposes the bases of the metatarsals.

- Beginning proximally, make the anterior incision (Fig. 3.35) in line with the lateral aspect of the second metatarsal, and continue it distally. Retract the deep peroneal nerve and dorsalis pedis artery medially with the extensor hallucis longus and tibialis anterior tendons, exposing the dorsal capsular structures of these joints.

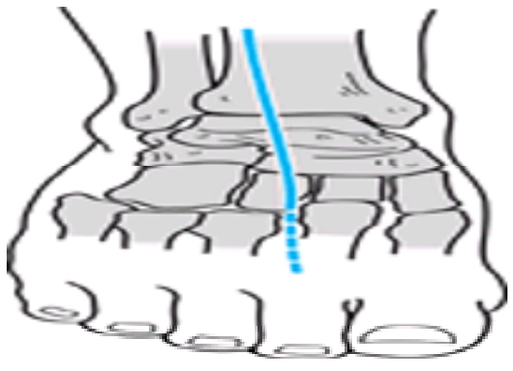

***Figure 3.35.*** Anterior approach to the tarsus. This exposure is the distal extension of the anterior approach to the ankle (see Fig. 3.28). (From Thomas HA. The Ankle and Foot. In: Hoppenfeld S, deBoer P, eds. *Surgical Exposures in Orthopaedics: The Anatomic Approach.* Philadelphia: JB Lippincott, 1984:472, 513.)

- Incise the capsule of the involved joint longitudinally and dissect subperiosteally to expose the joint(s) for arthrodesis or open reduction of articular surfaces.

***Lateral Kocher Approach***

The lateral Kocher approach yields combined exposure of the ankle, midtarsal, and subtalar joints (Fig. 3.36).

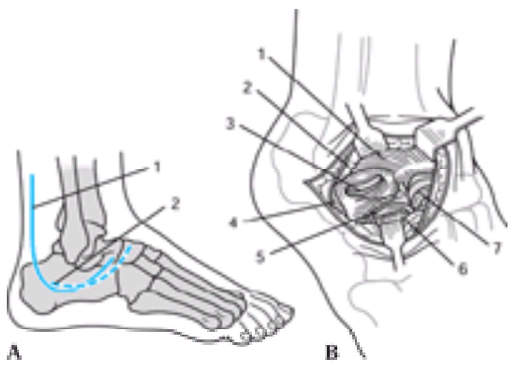


***Figure 3.36.*** Lateral approaches to the tarsus: Kocher and Ollier. **A:** Skin incisions. *1*, Skin incision, Kocher approach; *2*, skin incision, Ollier approach. (From Stead Z. Exposure of the Distal Two-Thirds of the Anterior Neurovascular Bundle. In: Henry AK, ed. *Extensile Exposure,* 2nd ed. Edinburgh: Churchill Livingstone, 1973:277.) **B:** Deep dissection of the Ollier approach consists of detaching the extensor digitorum brevis and retracting distally exposing the midtarsus. The deep exposure of the Kocher approach is similar in its distal arm but yields better access to the subtalar joint because of its proximal arm. *1*, Anterior talofibular ligament; *2*, sinus tarsi fat pad; *3*, posterior talocalcaneal joint; *4*, peronei; *5*, calcaneocuboid joint; *6*, extensor digitorum brevis; *7*, talonavicular joint. (From Thomas HA. The Ankle and Foot. In: Hoppenfeld S, deBoer P, eds. *Surgical Exposures in Orthopaedics: The Anatomic Approach.* Philadelphia: JB Lippincott, 1984:503.)

- Begin the incision as far proximally as indicated, and proceed longitudinally 2 cm posterior to the fibula. Gently curve the incision anteriorly at the distal flare of the fibula, and reach the midpoint of the bone 2.5 cm distal to the tip (Fig. 3.36*A*). Curve the incision 110° anteriorly in the direction of the talonavicular joint. Incise the peroneal fascia, and retract the tendons posteriorly, protecting the sural nerve.
- Divide the talocalcaneal ligament to expose the subtalar joint capsule (Fig. 3.36*B*). If possible, avoid dividing the peroneal tendons because of the risk of scarring within the sheath; if necessary, use a step-cut technique. The calcaneonavicular joint capsule can be visualized by dissection further distally, following the peroneus brevis tendon.
- To visualize the articular surface of the tibia, divide the anterior talofibular ligament and sublux the talus by varus stress. Divide the capsule and synovium anterior to the fibula, revealing the articular surfaces of the ankle.

***Lateral Ollier Approach***

The lateral Ollier approach provides excellent exposure of the talonavicular joint, calcaneocuboid joint, and lateral subtalar joint. It provides an excellent cosmetic result because of the abundance of soft tissue in the area.

- Begin the incision 3 cm posterior to the calcaneocuboid joint (Fig. 3.36*A*). Follow the skin lines in an anteromedial direction, and end the incision over the dorsal aspect of the talonavicular joint. Do not undermine the skin flaps.
- Detach the origin of the extensor digitorum brevis, and retract it distally (Fig. 3.36*B*). If possible, preserve the fat within the sinus tarsi to maintain the contour of the foot and improve soft-tissue coverage. Medially, retract the extensor tendons to expose the talonavicular joint. Laterally, retract the peroneal tendons to fully expose the calcaneocuboid joint and the posterior facet of the subtalar joint. The joint capsules can be sharply dissected free in line with the joint surfaces to expose the joints as necessary.

***Lateral Gatellier and Chastung Approach***

Open reduction of large posterolateral distal tibial fractures in the setting of a trimalleolar ankle fracture calls for the lateral Gatellier and Chastung approach. This method can also be used for anterolateral osteochondral fractures.

- Make the incision along the fibula, beginning 15 cm proximally from the tip (Fig. 3.37*A*). Curve the incision anteriorly along the pathway of the peroneal tendons at the tip of the fibula. Expose the fibula subperiosteally. Incise the periosteal tendon sheath, allowing the tendons to sublux anteriorly, and turn the fibula distally through the fracture.

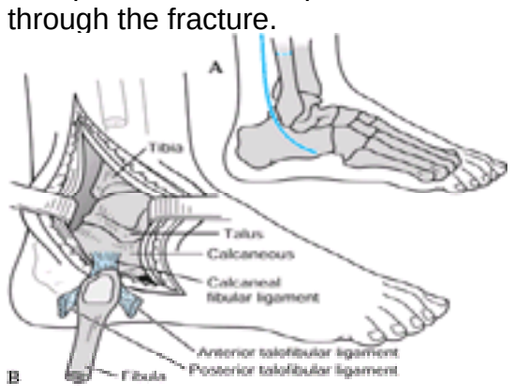


***Figure 3.37.*** Lateral approach to the tarsus of Gatellier and Chastung. **A:** Skin incision and level of fibular osteotomy. **B:** The fibula has been osteotomized and reflected, based on the calcaneofibular ligament. Sectioning of the anterior and posterior talofibular ligaments exposes the ankle joint. (From Stead Z. Exposure of the Fibula and Nerves Related to It. In: Henry AK, ed. *Extensile Exposure,* 2nd ed. Edinburgh: Churchill Livingstone, 1973:293.)

- Alternatively, make an osteotomy 7–10 cm from the fibular tip to allow this same maneuver. The calcaneofibular and talofibular ligaments serve as the hinge for the fibula to allow complete exposure of the distal tibia and ankle joint (Fig. 3.37*B*). Fix the fracture or osteotomy of the fibula anatomically and rigidly, and carefully reconstruct the peroneal tendon sheath. The disadvantage of this approach is devascularization of the distal tibia.

## CALCANEUS

### *Medial Approach*

The medial approach is occasionally indicated for open reduction of the calcaneus and for management of bone tumors.

- Make the incision from an anterior position located 3 cm anterior and 4 cm inferior to the tip of the medial malleolus. Extend the incision in a straight line to the medial border of the Achilles tendon. Divide the deep fascia in line with the incision, and similarly divide the fat deep to this layer.
- Retract the abductor hallucis inferiorly, and expose the body of the calcaneus subperiosteally. Divide the plan tar aponeurosis and strip the muscle origins inferiorly to expose the plantar surface. Whenever possible, minimize the dissection of the specialized plantar tissues because of the highly specialized septa that originate in the body of the calcaneus.

### *Lateral Approach*

The lateral exposure allows excellent observation of the subtalar joint for isolated subtalar arthrodesis or open reduction of this joint.

- Begin the incision at the lateral border of the tendo calcaneus at its insertion (Fig. 3.38). Extend the incision obliquely to a point 4 cm distal to the lateral tip of the malleolus. Protect the terminal branch of the sural nerve posteriorly.

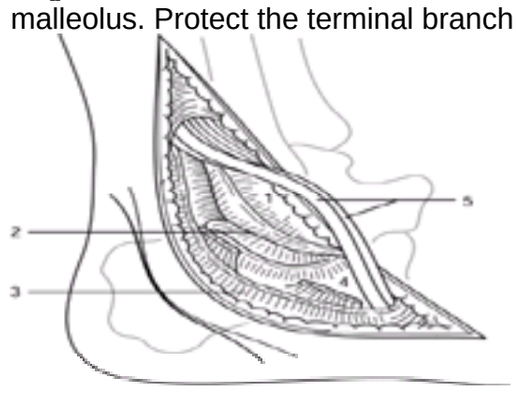

***Figure 3.38.*** Lateral approach to the calcaneus. The skin incision is essentially that of Figure 3.36, extended 2 cm distally. The peroneal tendon sheath is opened, and the tendons are subluxed anteriorly to expose the subtalar joint. *1*, Lateral malleolus; *2*, posterior talocalcaneal joint; *3*, peroneal fascia; *4*, peroneal tubercle; *5*, peroneal tendons. (From Thomas HA. The Ankle and Foot. In: Hoppenfeld S, deBoer P, eds. *Surgical Exposures in Orthopaedics: The Anatomic Approach.* Philadelphia: JB Lippincott, 1984:506.)

- Expose the peroneal tendons, and retract superiorly to expose the bone and subtalar joint. In extreme circumstances, the tendons can be sectioned and resutured. Handle the fragile skin and soft tissues carefully in cases of trauma to lessen the relatively high risk of wound complications after this exposure.

Benirschke popularized a “hockey-stick” approach for internal fixation of fractures of the calcaneus because it allows better exposure of the posterior calcaneus (personal communication, 1988). It is essentially a lateral approach, but the skin incision parallels the Achilles tendon as far as 1–2.5 cm above the weight-bearing surface of the foot, where it then turns anteriorly, parallel to the plantar aspect of the heel (Fig. 3.39). Carry the incision to the calcaneocuboid joint, and develop the proximal flap at a subperiosteal level. The sural nerve and peroneal tendons are maintained within this thick flap. Do not make the corner too short. Avoid excessive fixed retraction to prevent slough of the corner of the flap.

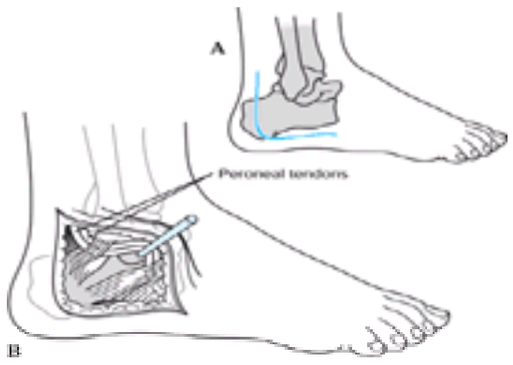


***Figure 3.39.*** Lateral approach to the calcaneus for open reduction and internal fixation (ORIF), as popularized by Benirschke. **A:** The skin incision is more vertical and posteriorly placed than the standard lateral approach (see Fig. 3.38). This enables full exposure of the calcaneal tuberosity. The incision is curved anteriorly at the inferior border of the calcaneus. **B:** The flap is elevated and includes the skin and subcutaneous fat, the calcaneal fibular ligament and perineal tendon sheaths. Kirschner wires can be placed in the talus to retract the flap.

“U” Approach

The “U” approach can be used for radical clubfoot releases and exposure of the entire subtalar joint for arthrodesis.

- Position the patient prone. Connect the posterior two thirds of the medial and lateral approaches at the level of the insertion of the tendo calcaneus. To expose the subtalar joint completely, step-cut to lengthen the tendo calcaneus. Carefully preserve the sural nerve during this exposure. Expose the body of the calcaneus medially and laterally by subperiosteal dissection.

### *Split Heel Approach*

The only indication for the split heel approach of Gaenslen is osteomyelitis of the calcaneus.

- Position the patient prone. Make a longitudinal incision in the middle of the heel (Fig. 3.40*A*).

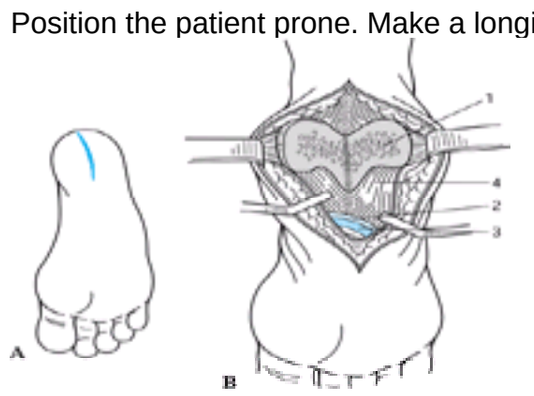


***Figure 3.40.*** Gaenslen's split heel approach to the calcaneus. **A:** Skin incision. **B:** The specialized fibrofatty tissue of the heel pad has been divided in line with the incision. The tuber of the calcaneus and the plantar fascia has been divided and the plantar neurovascular bundle protected distally. *1*, Calcaneus; *2*, plantar nerve; *3*, plantar artery; *4*, plantar fascia. (From Edmonson AS, Crenshaw AH, eds. *Campbell's Operative Orthopaedics,* 6th ed, vol 2. St. Louis: CV Mosby,

1980:1317.)

- Split the tuber of the calcaneus 2–3 cm; make certain that the skin incision is long enough to allow the split. Divide the plantar aponeurosis from the plantar surface of the calcaneus at the level of the abductor digiti quinti (Fig. 3.40*B*).
- Protect the lateral plantar artery and nerve and retract them medially in the distal portion of the wound. Divide the quadratus plantae longitudinally with sharp dissection and split the calcaneus longitudinally with a sharp osteotome. Spread the two halves to allow complete resection of necrotic bone. Preserve the cortical shell as much as possible.

## METATARSALS

### *Dorsal Approach*

The metatarsal shafts are best exposed through longitudinal incisions on the medial side of the foot over the first metatarsal, on the lateral side of the foot over the fifth, or through the second-to-third or third-to-fourth metatarsal intervals. For multiple metatarsal fractures, the middle three bones can be reached through the two intervals. If feasible, preserve veins along with minor cutaneous nerve branches. Retract the extensor tendons medially or laterally, and directly expose the bone.

### *Plantar Approach*

The plantar approach is advisable for direct exposure of the individual neurovascular bundles. Use the dorsal approach for metatarsal bony problems because of the multiple layers of flexor tendons. The intervals for the incisions are the same as the dorsal incisions. Incise the deep fascia in line with the skin, and retract the flexor tendons medially or laterally as indicated. The neurovascular bundles lie among the flexor digitorum brevis, abductor hallucis, abductor digiti quinti, and the long flexor tendons.

## METATARSOPHALANGEAL JOINTS

### *Dorsal Approach*

- Approach the second through fifth metatarsophalangeal joints through dorsal incisions lateral to the extensor tendons (Fig. 3.41). In the case of the fifth meta tarsophalangeal joint, make the incision on the medial side of the extensor tendon.

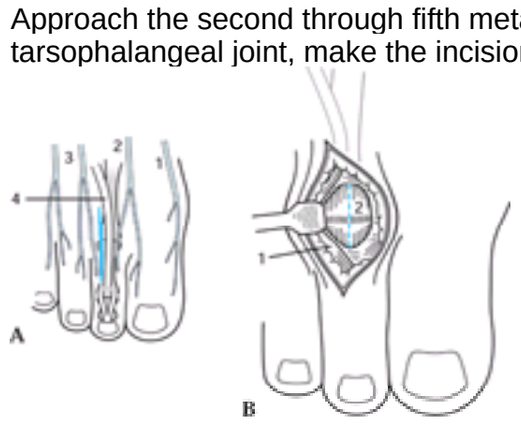


***Figure 3.41.*** Dorsal approach to the metatarsophalangeal joints. **A:** Skin incision outlined lateral to the extensor complex. *1*, Saphenous nerve; *2*, deep peroneal nerve; *3*, branches of superficial and peroneal nerves; *4*, extensor digitorum longus. **B:** The extensor tendon can be retracted laterally, exposing the metatarsophalangeal joint. For exposure of the metatarsal shafts, the incisions are carried more proximally, the dorsal veins preserved whenever possible, and the tendons retracted medially or laterally. *1*, Extensor digitorum longus tendon; *2*, joint capsule. (From Thomas HA. The Ankle and Foot. In: Hoppenfeld S, deBoer P, eds. *Surgical Exposures in Orthopaedics: The Anatomic Approach.* Philadelphia: JB Lippincott, 1984:525.)

- Retract the tendons, and open the joint capsule by a longitudinal incision.
- For resection of common digital (Morton's) neuromas, make a longitudinal incision over the dorsum of the web space of concern. Dissect deeply, taking care to identify and retract the extensor tendons and superficial sensory nerves. Identify the digital nerves and trace them proximally to the common digital nerve.

### *Plantar Approach*

Some surgeons prefer a plantar, more direct approach to the common digital nerves. A plantar approach is indicated as well in cases of metatarsophalangeal joint sepsis. Make longitudinal incisions between the metatarsal heads. The neurovascular bundles are located deep to the long flexor tendons, which must be retracted to expose the metatarsophalangeal joints to the side of least resistance. Although earlier teaching indicated that plantar scars are painful, well-placed ones usually are not.

### *First Metatarsal Head Exposure*

Approach the first metatarsophalangeal joint best through a 4 cm dorsomedial incision. Protect the dorsal digital nerve, and turn the joint capsule back on a distally based flap for reconstructive bunion procedures.

## INTERPHALANGEAL JOINTS

Approach the toe interphalangeal joints dorsally with straight linear incisions by retracting the extensor mechanism to one side. Carefully repair the extensor mechanism. The interphalangeal joints can also be exposed by mid-lateral incisions, carefully retracting the neurovascular bundles plantarward. In general, we do not recommend a plantar incision, because the stout flexor tendons and neurovascular bundles are problems from this approach.

## CHAPTER REFERENCES

Each reference is categorized according to the following scheme: *, classic article; #, review article; !, basic research article; and +, clinical results/outcome study.


* 1. Hardinge K. The Direct Lateral Approach to the Hip. *J Bone Joint Surg Br* 1982;64:17.

* 2. Harmon PH. A Simplified Approach to the Posterior Tibia for Bone Grafting and Fibular Transference. *J Bone Joint Surg Br* 1945;27A:496.

* 3. Henderson MS. Posterolateral Incision for the Removal of Loose Bodies from the Posterior Compartment of the Knee Joint. *Surg Gynecol Obstet* 1921;33:698.

* 4. Henry AK. *Extensile Exposure,* 2nd ed. Edinburgh: Churchhill Livingstone, 1973.

* 5. McFarland B, Osborne G. Approach to the Hip: A Suggested Improvement on Kocher's Method. *J Bone Joint Surg Br* 1954;36:364.

# CHAPTER 4

# IMAGING MODALITIES IN ORTHOPAEDICS

*Adam Greenspan*

**A. Greenspan:** Department of Orthopaedics, University of California–Davis, Sacramento, California, 95817.

Conventional Radiography
Standard Projections
Special Projections
Magnification Radiography
Stress Views
Scanogram
Fluoroscopy and Videotaping
Digital Radiography
Conventional Tomography
Computed Tomography
Arthrography
Tenography and Bursography
Angiography
Myelography
Discography
Ultrasound
Skeletal Scintigraphy
Single Photon Emission Computed Tomography
Magnetic Resonance Imaging
Trauma
Tumors
Chapter References

Continued progress in radiology and the introduction of new imaging modalities have significantly improved our capabilities for diagnosing orthopaedic conditions. Although conventional radiography remains the primary diagnostic tool, ancillary techniques are used to characterize the abnormality more accurately, to predict possible complications, and to monitor postoperative recovery. The newer imaging modalities, however, are expensive (e.g., magnetic resonance imaging, or MRI), may expose the patient to radiation (e.g., computed tomography, or CT), and are frequently employed unnecessarily or inappropriately.

This chapter sets forth the principles and limitations of current imaging modalities, and sets guidelines for choosing particular modalities. Time and cost considerations should discourage redundant studies. The surgeon familiar with these techniques can confidently order the least number of tests necessary to dictate a course of therapy.

Radiologists and orthopaedic surgeons are frequently concerned about which modality they should use for a particular problem. Although there are numerous algorithms for evaluating various problems at different anatomic sites, the answer cannot always be succinctly stated (22). The choice of techniques for imaging bone and soft-tissue abnormalities is dictated by the clinical presentation, equipment availability, expertise, cost, and restrictions referable to individual patients. For example, allergy to ionic or nonionic iodinated contrast agents may preclude the use of arthrography; the presence of a pacemaker may preclude the use of MRI; and physiologic states such as pregnancy may preclude the use of ionized radiation, favoring instead sonography.

No matter which ancillary technique is used, a plain film must be available for comparison. The choice of imaging technique is usually dictated by the type of suspected abnormality. If osteonecrosis is suspected, for example, and the radiographs are normal, the physician should proceed immediately to MRI examination, the most sensitive modality. It can detect necrotic changes in bone long before plain films, tomography, CT, or scintigraphy can provide positive evidence.

In evaluation of internal derangement of the knee, obtain plain films first; if the abnormality is not obvious, proceed with MRI, because this modality provides an exquisite contrast resolution of the bone marrow, articular cartilage, ligaments, menisci, and soft tissues. In evaluating rotator cuff abnormalities, particularly partial or complete tears, arthrography and MRI are currently the most effective procedures. Although ultrasound can also detect rotator cuff tears, because of its low sensitivity (68%) and low specificity (75% to 84%) it is seldom used as the definitive diagnostic procedure (9,36,60). Figure 4.1 depicts the gamut of standard and special radiographic projections and various ancillary imaging techniques currently available for evaluating injury of the shoulder girdle.



***Figure 4.1.*** Standard, special, and ancillary imaging techniques used to evaluate injury to the shoulder girdle.

In evaluating wrist pain, start with conventional radiographs and trispiral tomography before proceeding to arthrotomography or CT-arthrography. In this case, MRI is a less desirable technique, because it is less sensitive and specific than CT-arthrotomography in detecting abnormalities of the triangular fibrocartilage and various intercarpal ligaments, particularly if three-compartment injection is used (40,41). If one suspects carpal tunnel syndrome, however, MRI is preferred because it provides inherent high-contrast differences among muscles, tendons, and ligaments. Similarly, if osteonecrosis of the carpal bones is suspected and the plain films are normal, MRI is the preferred method. In evaluating fractures and fracture healing of carpal bones, trispiral tomography is still the procedure of choice because it gives a high degree of spatial resolution.

In evaluating bone tumors, conventional radiography and tomography are still the gold standard for diagnostic purposes. To evaluate intraosseous and soft-tissue extension of tumor, however, use CT or the more accurate MRI. In evaluating results of treatment of malignant tumors by radiotherapy and chemotherapy, dynamic MRI using gadolinium diethylenetriamine penta-acetic acid (Gd-DTPA) for contrast enhancement is much superior to scintigraphy, CT, or even plain MRI.

Figure 4.2 depicts an algorithm helpful in evaluating bone lesions discovered on standard radiographs. Notice that the proper order for employing various imaging modalities depends on two factors: whether the plain film findings are diagnostic for any particular tumor, and the lesion's uptake of a tracer on the bone scan. Scintigraphy plays a crucial role in dictating the use of different techniques. The use of CT or MRI may depend on the features found on conventional radiographs. If there is no evidence of soft-tissue extension, CT is superior to MRI for detecting subtle cortical erosions and periosteal reaction, and it provides an excellent means to determine the intraosseous extension of the tumor. If, however, the radiographs suggest cortical destruction and a soft-tissue mass, MRI is the preferred modality because it provides exquisite soft-tissue contrast and can determine the extraosseous extension of the tumor better than CT can.

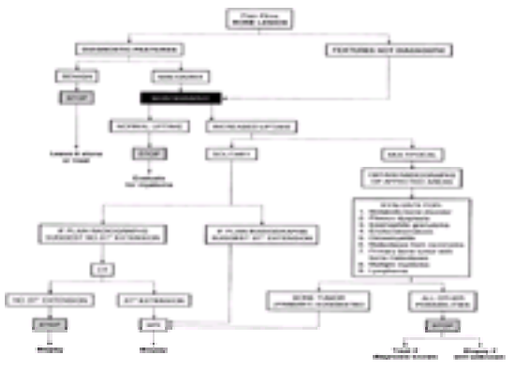

***Figure 4.2.*** Algorithmic evaluation of bone lesion discovered on the standard radiographs. **ST*, soft tissue.

## CONVENTIONAL RADIOGRAPHY

### STANDARD PROJECTIONS

The most important modality for the evaluation of bone and joint disorders, particularly traumatic conditions, is conventional radiography. Obtain at least two views of the involved bone at 90° angles to each other, with each view including the two joints adjacent to the injured bone; this decreases the risk of missing an associated fracture, subluxation, or dislocation at a site remote from the apparent primary injury. In children, it is frequently necessary to obtain a radiograph of the normal, unaffected limb for comparison. The standard films usually comprise the anteroposterior and lateral views; occasionally, oblique and special views are necessary, particularly in the evaluation of fractures of complex structures, such as the elbow, wrist, ankle, and pelvis. A weight-bearing view may be of value for dynamic evaluation of the joint space during weight bearing.

Special projections may be required to demonstrate abnormalities of the bone or joint to further advantage.

### SPECIAL PROJECTIONS

#### *Grashey Projection of the Shoulder*

In imaging the shoulder, Grashey projection permits the glenoid to be seen in profile. To obtain this view, place the patient in a 40° posterior oblique position with the central beam directed toward the glenohumeral joint. The film in this projection shows the glenoid in true profile, and the glenohumeral joint space is clearly visible. This is particularly effective in demonstrating suspected posterior dislocation (4).

#### *West Point View of the Shoulder*

If the patient is unable to abduct the arm and cannot be positioned for a conventional axillary view, the West Point view may be similarly effective. To obtain this view, position the patient prone on the radiographic table, and place a pillow under the affected shoulder to raise it about 8 cm. Position the film cassette against the superior aspect of the shoulder. Angle the radiographic tube toward the axilla at 25° to the patient's midline and 25° to the table's surface. On the film in this projection, the relationship of the humeral head and the glenoid can be evaluated as well as it can be evaluated on the axillary view, but the anteroinferior glenoid rim, which is seen tangentially, is better visualized.

#### *Angled View of the Acromioclavicular Joint*

To evaluate the acromioclavicular articulation, use a special low-kilovoltage technique with the central beam directed 15° cephalad toward the clavicle. Reduce exposure factors to about 33% to 50% of those used in obtaining the standard anteroposterior view of the shoulder. The film in this projection shows the acromial end of the clavicle, acromion, and acromioclavicular joint (4).

#### *Y-Projection of the Shoulder Girdle*

The Y-projection, also known as the trans-scapular view, is very effective for evaluation of the scapula. Have the patient stand erect, with the injured side against the raised radiographic table. Rotate the trunk about 20° from the table to allow separation of the two shoulders. Slightly abducted the arm on the injured side and flex the elbow, with the hand resting on the ipsilateral hip. Direct the central beam toward the medial border of the protruding scapula. The film in this projection provides a true lateral view of the scapula as well as an oblique view of the proximal humerus.

#### *Radial Head–Capitellum View of the Elbow*

The radial head–capitellum view is used to evaluate the elbow joint. It is a variant of the lateral projection that overcomes the major limitation of the standard lateral view by projecting the radial head ventrad, free of overlap by the coronoid process (Fig. 4.3). It has proved to be a particularly effective technique to demonstrate the capitellum, the coronoid process, and the humeroradial and humeroulnar articulations (32).

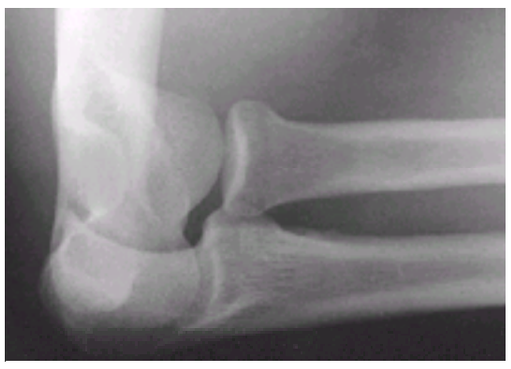

***Figure 4.3.*** A special 45° angle view of the elbow projects the radial head ventrad, free of the overlap of coronoid process. The capitellum is also well demonstrated.

#### *Norgaard View of the Hands*

The Norgaard view, a semisupinated oblique view of the hand and the wrist (i.e., the “allstate” or ball-catcher's view) effectively demonstrates the radial aspects of the metacarpal heads and the base of the proximal phalanges in the hand and the triquetrum and pisiform bones in the wrist (10).

#### *Merchant View of the Patella*

In the knee joint, the special axial projection of the patella known as the Merchant view is helpful in evaluating the patellofemoral joint. This view is particularly effective in detecting subtle subluxations of the patella (46).

For this view, position the patient supine on the radiographic table, with the knee flexed about 45° at the table's edge. A device keeping the knee at this angle also

holds the film cassette. Direct the central beam caudally through the patella at a 60° angle from the vertical. On the film in this projection, the articular facets of the patella and femur are well demonstrated.

***Lauren View of the Patella***

For the Lauren view, position the patient as for the Merchant view, but direct the central beam cephalad through the patella.

***Harris-Beath View and Broden View of the Ankle***

Evaluation of the ankle frequently necessitates special projections to demonstrate the details of the subtalar joint. To demonstrate the posterior and middle facets of this joint, use the posterior tangential view (i.e., the Harris-Beath). To demonstrate the posterior facet, talofibular joint, and tibiofibular syndesmosis, use the Broden view (Fig. 4.4) (4).

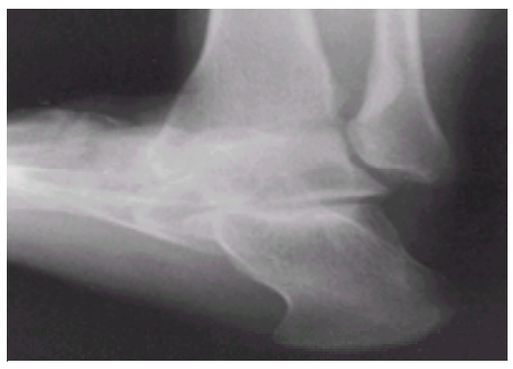

***Figure 4.4.*** A special view of the ankle obtained at 30° cephalad angulation (Broden view) demonstrates the posterior facet of the subtalar joint, talofibular joint, tibiofibular syndesmosis, and sustentaculum tali.

***Fuchs View of the Odontoid***

I recommend the Fuchs view for the demonstration of the odontoid process if its upper half is not clearly shown on the open-mouth view (4). For this view, position the patient supine on the radiographic table, with the neck hyperextended. Direct the central beam vertically to the neck just below the tip of the chin. The radiograph obtained in this projection clearly reveals the odontoid, especially its upper half.

## MAGNIFICATION RADIOGRAPHY

Magnification radiography is occasionally used to enhance the bony details not well delineated on the standard radiographic projections. This technique involves a special screen–film system and geometric enlargement that yields magnified images of the bones and joints with increased sharpness and bony detail (28). The technique is particularly effective for demonstrating early changes in some arthritides and metabolic disorders. It may be useful for demonstrating subtle fracture lines not seen on routine projections.

## STRESS VIEWS

Stress views are important in the evaluation of ligamentous tears and joint stability. In the hand, obtain abduction-stress film of the thumb if gamekeeper's thumb, resulting from disruption of the ulnar collateral ligament of the first metacarpophalangeal joint, is suspected. In the lower extremity, the stress views of the knee and ankle joints are frequently obtained. Evaluation of knee instability due to ligament injuries may require this technique in cases of suspected tear of the medial collateral ligament, and less frequently for evaluating insufficiency of the anterior and posterior cruciate ligaments.

To obtain a stress film of the knee joint for evaluation of the medial collateral ligament, position the patient supine with the knee flexed about 15° to 20°. With the thigh fixed, apply pressure against the medial aspect of the leg below the knee, forcing the knee into valgus. The films thus obtained show the anteroposterior projection. To obtain a stress film of the knee joint for evaluation of the anterior cruciate ligament, position the patient on his side, with the knee flexed 90°. Apply pressure against the posterior aspect of the upper leg (anterior-drawer stress). The films show the lateral projection.

Evaluation of ankle ligaments also requires stress radiography. Inversion (adduction) (Fig. 4.5) and anterior-drawer stress films are most frequently obtained; only rarely is an eversion (abduction) stress examination required. To obtain an inversion stress film of the ankle joint, position the patient supine with the lower leg fixed, and apply pressure on the lateral aspect of the foot, adducting the heel and forcing the foot into varus position. For anterior-drawer stress examination, position the patienton her side with the lower leg fixed, and apply posterior stress to the heel. The films show the lateral projection.

***Figure 4.5.*** The anteroposterior view of the ankle after application of inversion stress shows widening of the lateral compartment of the ankle joint, indicating a tear of the lateral collateral ligament.

## SCANOGRAM

Scanogram is the most widely used method for measurement of limb lengths. This technique requires a slit-beam diaphragm with a 1.5 mm opening attached to the radiographic tube, and a long film cassette. The radiographic tube can move in the long axis of the radiographic table. During the exposure, the tube traverses the whole length of the film, scanning the entire extremity. This technique allows the x-ray beam to intersect the bone ends perpendicularly, and limb lengths can be compared (4,52). A modified technique may be used with three separate exposures over the hip joints, knees, and ankles if a motorized radiographic tube is not available. In this technique, an opaque tape measure is placed longitudinally down the center of the radiographic table (4).

Occasionally, a so-called orthoroentgenogram is indicated. For this technique, position the patient supine with the lower limbs on a 3-ft-long cassette and a long ruler at one side. Make a single exposure, centered at the knees and including the entire length of both limbs and the ruler.

## FLUOROSCOPY AND VIDEOTAPING

Fluoroscopy is a fundamental diagnostic tool for many radiologic procedures, including arthrography, tenography, bursography, arteriography, and percutaneous bone

or soft-tissue biopsy. Fluoroscopy combined with videotaping is useful in the evaluation of the kinematics of joints. Because it delivers a high dose of radiation, it is used only occasionally (e.g., in evaluating joint movement and detecting transient subluxation). It occasionally is used in follow-up examination of the healing process after fractures to evaluate the degree of bone union. Fluoroscopy is still used in conjunction with myelography if it is important

- to observe the movement of the contrast column in the subarachnoid space,
- to check proper placement of the needle and monitor the flow of contrast medium,
- to assess intraoperatively the reduction of a fracture or the placement of hardware.

## DIGITAL RADIOGRAPHY

Digital (computed) radiography is the process of digital image acquisition using an x-ray detector. The detector comprises a photostimulable phosphor imaging plate and image reader/writer that processes the latent image information for laser printing on film. A major advantage of computed radiography over conventional film and screen radiography is that, once acquired, the digital image data are readily manipulated to produce alternative renderings. In addition, energy subtraction imaging may be acquired: Two images, acquired either sequentially or simultaneously with different filtration, are used to reconstruct a soft tissue–only image or a bone-only image.

Digital subtraction radiography uses a video processor and a digital disk added to a fluoroscopy imaging system to provide on-line viewing of subtraction images (23). This technique is most widely used to evaluate the vascular system; it is occasionally used in conjunction with arthrography. Use of high-performance video cameras with low-noise characteristics allows a single video frame of precontrast and postcontrast images to be used for subtraction. Spatial resolution can be maximized using a combination of geometric magnification, electric magnification, and a small anode-to-target distance. The subtraction technique removes surrounding anatomic structures and isolates the opacified vessel or joint, making it more conspicuous.

Use nonvascular digital radiography to evaluate bone abnormalities and, in conjunction with contrast injection (i.e., digital arthrography), to evaluate subtle abnormalities of the joints, such as tears of the lunate-triquetral ligament or the abnormalities of the triangular fibrocartilage in the wrist (Fig. 4.6). Use it also to evaluate the stability of a prosthesis. Digital radiography offers improved image quality, contrast sensitivity, and exposure latitude. It is also an efficient mode in which to store, retrieve, and transmit radiographic image data. Digital images can be displayed on film or on a monitor. A significant advantage of image digitization is its ability to produce data with low noise and a wide dynamic range. Image digitization is suitable for window-level analysis in a manner comparable to that employed in a CT scanner (56).

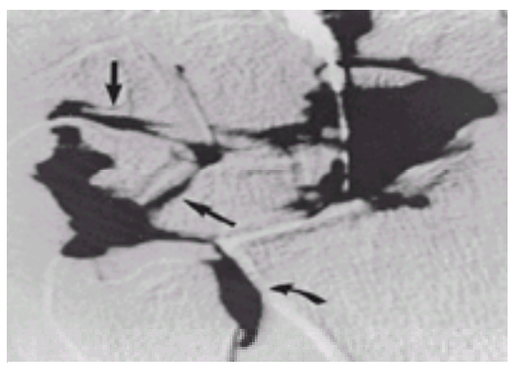

***Figure 4.6.*** Digital subtraction wrist arthrogram demonstrates a leak of contrast into the proximal intercarpal articulation (*arrows*) through the perforation in the lunate-triquetral ligament. Notice a leak of contrast into the distal radioulnar joint (*curved arrow*), indicating a tear of the triangular fibrocartilage complex. (Courtesy of BJ Manaster, MD, Salt Lake City, UT.)

Choose digital subtraction angiography (DSA), the most frequently used variant of digital radiography, to evaluate trauma and tumors of the bone and soft tissue, and to view the vascular system. In trauma to the extremity, DSA is effectively used to evaluate arterial occlusion, pseudoaneurysms, arteriovenous fistulas, and transection of the arteries (30). The advantage of DSA over conventional film techniques is the rapidity of the study with the ability to obtain multiple repeated projections. Bone subtraction is useful in clearly delineating the vascular structures. In evaluating bone and soft-tissue tumors, DSA is an effective tool for mapping tumor vascularity.

## CONVENTIONAL TOMOGRAPHY

Tomography is body-section radiography that enhances visualization of lesions too small to be seen on conventional radiographs. It is also effective for demonstrating anatomic detail that is obscured by overlying structures. It employs continuous motion of the radiographic tube and film cassette in opposite directions throughout exposure, with the fulcrum of the motion located in the plane of interest. The technique blurs structures above and below the area being examined, thereby sharply outlining the object to be studied on a single plane of focus. The newly developed tomographic units can better localize the image and can detect lesions as small as 1 mm in diameter.

The simplest tomographic movement is linear, with the radiographic tube and film cassette moving on a straight line in opposite directions. This linear movement has little application in the study of bones because it creates streaks that often interfere with radiologic interpretation. Resolution of the plane of focus, much clearer if there is uniform blurring of undesired structures, requires a multidirectional movement, as in zonography or circular tomography. In this type of tomography, the radiographic tube makes one circular motion at a preset angle of inclination. More complex multidirectional hypocycloidal or trispiral movements increase the distance of excursion of the tube and create a varying angle of projection of the x-ray beam during exposure. These complex movements are advantageous because they produce even greater blurring outside the field of interest and yield the sharpest focal plane images.

Trispiral tomography is superior to conventional radiographs in the visualization of subtle fractures (35). It is helpful for delineating the extent of the fracture line (Fig. 4.7), evaluating the healing process, and evaluating nonunions (51). It is also useful in evaluating tumor and tumorlike lesions (e.g., the nidus of an osteoid osteoma, a calcific matrix in an enchondroma or chondrosarcoma). Small cystic and sclerotic lesions and subtle erosions are well demonstrated. Tomograms are better interpreted with plain radiographs for comparison.

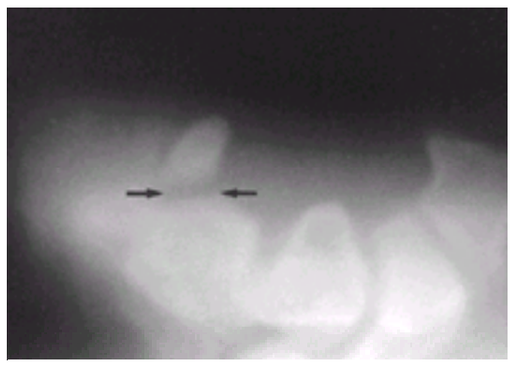

***Figure 4.7.*** Trispiral tomography obtained in the carpal tunnel projection demonstrates a fracture of the hook of the hamate (*arrows*).

## COMPUTED TOMOGRAPHY

Computed tomography is an indispensable modality in the evaluation of many traumatic conditions and various bone and soft-tissue tumors because of its cross-sectional imaging capability. In trauma, CT is extremely useful because of its abilities to define the presence and extent of fracture or dislocation, to evaluate such intra-articular abnormalities as damage to the articular cartilage or presence of noncalcified and calcified osteocartilaginous bodies, and to evaluate adjacent soft

tissues. CT is important in the detection of small bony fragments displaced into the joints after trauma, in the detection of the small displaced fragments of the fractured vertebral body (Fig. 4.8), and in the assessment of concomitant injury to the cord or thecal sac (14).

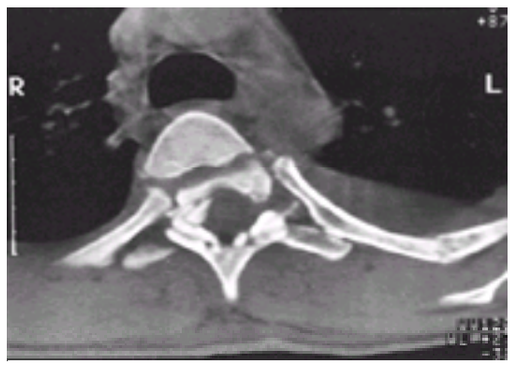


***Figure 4.8.*** CT section through the level of T3 accurately demonstrates the comminuted fracture of the vertebral body and laminae. Notice small bony fragment encroaching on the spinal cord.

Advantages of CT over conventional radiography are its ability to provide excellent contrast resolution, accurate measurement of the tissue attenuation coefficient, and direct transaxial images. Another advantage is its ability to image the bone in coronal, sagittal, and oblique planes, using reformation technique. This multiplanar reconstruction is particularly helpful in evaluating vertebral alignment (Fig. 4.9), demonstrating horizontally oriented fractures of the vertebral body, and evaluating complex fractures of the pelvis or calcaneus, abnormalities of the sacrum and sacroiliac joints, sternum, sternoclavicular joints, temporomandibular joints, and wrist.



***Figure 4.9.*** Sagittal CT reconstructed image effectively shows the flexion tear-drop fracture of C5. Malalignment of the vertebral bodies and narrowing of the spinal canal are well demonstrated.

Modern CT scanners employ collimated fan beams directed only at the tissue layer under investigation. Recently developed spiral (helical) scanning permits three-dimensional reconstruction for analysis of regions with complex anatomy, such as the face, pelvis, vertebral column, wrist, foot, and ankle (Fig. 4.10) (11,27,42). The CT data may be used to create three-dimensional plastic models of the area of interest, which can facilitate operative planning and allow rehearsal of complex reconstructive procedures.

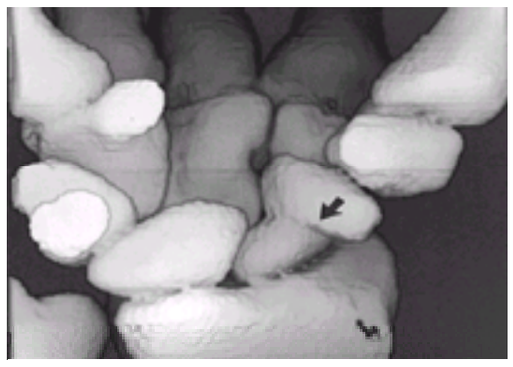

***Figure 4.10.*** Three-dimensional CT reconstruction of the wrist demonstrates a nonunited fracture of the scaphoid (*arrow*) complicated by osteonecrosis of the proximal fragment.

Although CT by itself is rarely helpful in making a specific diagnosis of bone and soft-tissue tumors, it can provide a precise evaluation of the extent of the bone lesion and may demonstrate a break through the cortex and the involvement of surrounding soft tissues (Fig. 4.11). Moreover, CT is helpful for delineating a tumor in bones having complex anatomic structures, such as the scapula, pelvis, and sacrum, which may be difficult to image fully with conventional radiographic techniques or even conventional tomography. CT examination is crucial in determining the extent and spread of a tumor in the bone and surrounding soft tissues if limb salvage is contemplated, allowing a safe margin of resection to be planned. It is also useful for monitoring the results of treatment and evaluating recurrence of resected tumor.

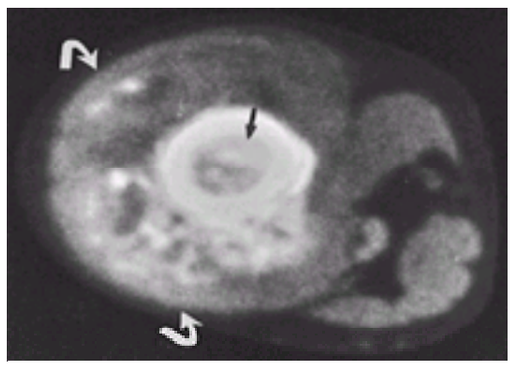

***Figure 4.11.*** CT section through the proximal thigh of a patient with osteosarcoma of the femur. The tumor involves the bone marrow (*arrow*) and is breaking through the cortex, producing a large soft-tissue mass (*curved arrows*).

Computed tomography is an important modality for successful aspiration or biopsy of bone or soft-tissue lesions because it provides visual guidance for precise

placement of biopsy needles within the lesion.

The ability of CT to measure the attenuation coefficients of each pixel provides a basis for accurate quantitative bone mineral analysis in cancellous and cortical bone (8,26). Evaluation of bone mass measurement underscores continuing progress in our understanding of bone metabolism and provides valuable insight into improvement of evaluation and treatment of osteoporosis and other metabolic bone disorders (55).

Disadvantages of CT include the so-called average volume effect, which results from insufficient resolution to describe inhomogeneities of the tissue. Because of this, the Hounsfield's units represent average values of the different components of the tissue. This effect becomes particularly important if normal and pathologic processes interface within a section under investigation.

Another disadvantage of CT is poor tissue characterization. Despite the ability of CT to discriminate some density differences, a simple analysis of attenuation values does not permit precise histologic characterization. Moreover, if the patient moves at all, the result is artifacts that degrade the image quality. Similarly, metal (e.g., prosthesis, rods, screws) produces significant artifacts. Finally, the radiation dose may occasionally be high, particularly if contiguous and overlapping sections are obtained during an examination.

## ARTHROGRAPHY

Arthrography is the introduction of a contrast agent into the joint space. *Positive* contrast describes iodide solution, and *negative* contrast refers to air. Despite the evolution of newer diagnostic imaging modalities, such as CT and MRI, arthrography has retained its importance in daily radiologic practice (25). Arthrography is technically simple, and interpretation is much easier than interpretation of ultrasound, CT, or MRI (33). Although virtually every joint can be injected with contrast, arthrography is most frequently performed in the shoulder, wrist, ankle, and elbow.

It is important to obtain preliminary films before any arthrographic procedure, because contrast may obscure some joint abnormalities (e.g., osteochondral body) that can be easily detected on the plain film. Arthrography is particularly effective in demonstrating rotator cuff tear (Fig. 4.12) and adhesive capsulitis in the shoulder, osteochondritis dissecans, osteochondral bodies, and subtle abnormalities of the articular cartilage in the elbow joint. In the wrist, it is still a very effective procedure for evaluating abnormalities of the triangular fibrocartilage complex (53). The introduction of three-compartment injection techniques combined with digital technique and postarthrographic CT examination has made this modality almost always the procedure of choice in evaluating a painful wrist (40).

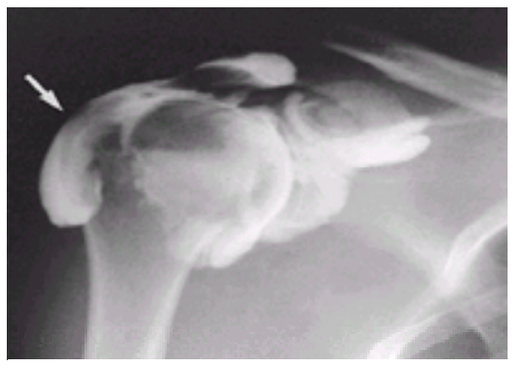

***Figure 4.12.*** After injection of contrast agent into the shoulder joint, there is opacification of the subacromial-subdeltoid bursae complex (*arrow*), indicating a rotator cuff tear.

Although arthrography of the knee has been almost completely replaced by MRI, it still may be used to demonstrate injuries to the soft-tissue structures, such as the joint capsule, menisci, and various ligaments (Fig. 4.13). It also provides important information on the status of the articular cartilage, particularly if the surgeon suspects subtle chondral or osteochondral fracture or requires confirmation of osteochondral bodies (e.g., osteochondritis dissecans).

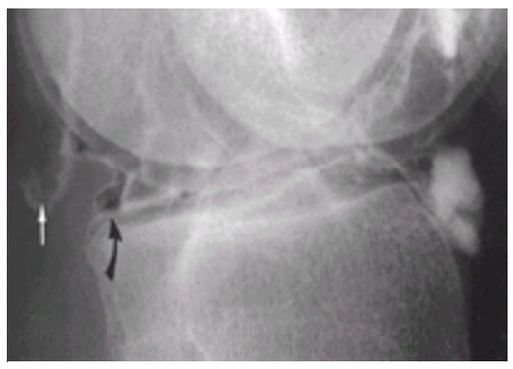

***Figure 4.13.*** Double-contrast arthrogram of the knee demonstrates a bucket-handle tear of the posterior horn of medial meniscus (*curved arrow*) and a popliteal cyst (*straight arrow*).

In the examination of any joint, arthrography can be combined with tomography (i.e., arthrotomography), with CT (i.e., arthro-CT), or with digitization of an image (i.e., digital subtraction arthrography) to provide additional information (Fig. 4.6) (43).

There are relatively few absolute contraindications to arthrography. Even hypersensitivity to iodine is only a relative contraindication, because a single contrast study using only air can be performed.

## TENOGRAPHY AND BURSOGRAPHY

Contrast material is occasionally injected into the tendon sheath to evaluate the integrity of a tendon, in a procedure known as a tenogram. CT and MRI have superseded this procedure, but it is still used, mainly to evaluate traumatic or inflammatory condition of tendons of the lower extremity, such as peroneus longus and brevis (Fig. 4.14), tibialis anterior and posterior, and flexor digitorum longus, and to outline the synovial sheaths within the carpal tunnel in the upper extremity.

***Figure 4.14.*** Tenogram demonstrates irregular accumulation of the contrast in the proximal portion of the sheath of the peroneus brevis tendon (*arrow*), indicating

tenosynovitis. Notice the normal appearance of the tendon of the peroneus longus (*open arrow*).

Bursography involves the injection of contrast agent into bursae. This procedure has mostly been abandoned, and only occasionally the subacromial-subdeltoid bursae complex is directly injected with contrast agent to demonstrate partial tears of the rotator cuff.

## ANGIOGRAPHY

In arteriography, contrast agent is injected into the arteries and films are obtained, usually in a rapid sequence. In venography, contrast is injected into the veins. The technique is used most frequently to detect vascular trauma.

In evaluating tumors, arteriography is used mainly to map bone lesions, to demonstrate the vascularity of the lesion, and to assess the extent of disease (Fig. 4.15). It is also used to demonstrate the vascular supply of a tumor and to locate vessels suitable for preoperative intraarterial chemotherapy. It is useful in demonstrating the area suitable for open biopsy, because most vascular parts of a tumor contain the most aggressive component of the lesion. Occasionally, arteriography can be used to demonstrate abnormal tumor vessels, corroborating findings with plain film radiography and tomography. Arteriography is often extremely helpful in planning limb-salvage procedures by demonstrating the regional vascular anatomy and permitting a plan to be drawn for the resection procedure. It is sometimes used to outline the major vessels before resection of a benign tumor. It can be combined with an interventional procedure, such as embolization of hypervascular tumors, before surgery. It also plays a major role in assessing the effectiveness of chemotherapy in the treatment of malignant bone and soft-tissue tumors.

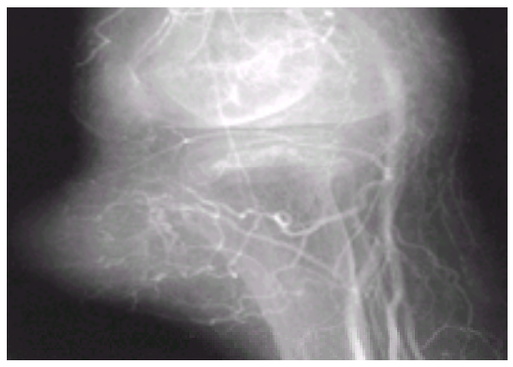

***Figure 4.15.*** Femoral arteriogram demonstrates feeding vessels and vascularity of a large paratibial liposarcoma.

## MYELOGRAPHY

During myelography, water-soluble contrast agents are injected into the subarachnoid space, mixing freely with the cerebral spinal fluid to produce a column of opacified fluid with a higher specific gravity than the clear fluid. Tilting the patient allows the opacified fluid to run up or down the thecal sac under the influence of gravity. The puncture usually is done in the lumbar area, at L2–L3 or L3–L4 levels. For examination of the cervical area, a C1–C2 puncture is performed. Myelographic examination has been almost completely replaced by high-resolution CT and high-quality MRI.

## DISCOGRAPHY

Discography is an injection of contrast material into the nucleus pulposus. Although many surgeons have abandoned the use of this controversial procedure, under tightly restricted indications and immaculate technique a discogram can yield valuable information (29,59). Discography is a valuable aid for determining the source of a patient's low-back pain. It is not a pure imaging technique, because the symptoms produced during the test (e.g., pain during the injection) are considered to have even greater diagnostic value than the radiographs obtained (66). Always combine it with CT examination (Fig. 4.16). According to the official position statement on discography by the Executive Committee of the North American Spine Society in 1988, this procedure “is indicated in the evaluation of patients with unremitting spinal pain, with or without extremity pain, of greater than 4 months duration, when the pain has been unresponsive to all appropriate methods of conservative therapy” (21). According to the same statement, before discography is performed, the patient should have undergone investigation with other modalities (e.g., CT, MRI, myelography), and surgical correction of the patient's problem should be anticipated.

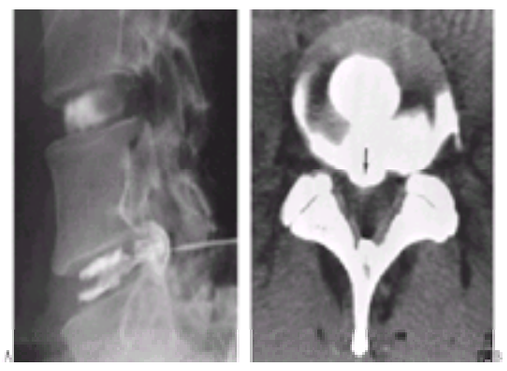

***Figure 4.16.*** **A:** Discogram demonstrates herniation of the nucleus pulposus at the L4–L5 level. Normal disc is outlined at the L3–L4 interspace. **B:** CT scan at the L4–L5 level after discography confirms the posterior central disc herniation (*arrow*).

## ULTRASOUND

Ultrasound is a safe, noninvasive modality that relies on the interaction of propagated sound waves with tissue interfaces in the body. Whenever the directed pulsing of sound waves encounters an interface between tissues of different acoustic impedance, reflection or refraction occurs, which is then recorded with a sensitive transducer and converted into images. An advantage of this technique is that, because it does not use ionized radiation, it is safe to use on pregnant women and infants. Modern probe technology, development of real-time imaging, and color Doppler imaging have extended to some degree the use of ultrasound in orthopaedic radiology. Higher-frequency transducers of 7.5 and 10 MHz have excellent spatial resolution and are ideal for imaging of the appendicular skeleton. Some applications of ultrasound in orthopaedics include evaluation of the rotator cuff and injured tendons (e.g., Achilles tendon) (7,24,60,64). Ultrasound is occasionally used during surgery to assess reduction of spinal fractures (65). It is also used to image soft-tissue tumors (e.g., hemangioma) (15).

The most effective application, however, is in evaluation of the infant hip. In this case, ultrasound has become the imaging modality of choice, because of the hip's cartilaginous composition, ultrasound's real-time capability for studying motion and stress, the absence of ionizing radiation, and the relative cost effectiveness. The newest development in this area is the introduction of three-dimensional ultrasound for evaluation of developmental dysplasia of the hip. Three-dimensional sonography provides functional utility in the evaluation of the joint in the added sagittal plane (section image) and craniocaudal projection (revolving spatial image). This technique permits excellent demonstration of the femoral head–ace-tabulum relationship and femoral head containment.

Sonography has been applied to certain areas in rheumatic disorders, in particular to differentiation of popliteal fossa masses (e.g., aneurysm, Baker's cyst, hypertrophied synovium). More recent ultrasound techniques such as Doppler ultrasound or colorflow imaging, which expresses motion from moving red blood cells in color, have found limited applications in orthopaedic radiology. This modality is used mainly to detect arterial narrowing and venous thrombosis. Also, there have been

a limited number of reports regarding the use of this technology in measuring tumor vascularity within soft tissue masses.

## SKELETAL SCINTIGRAPHY

One of the major advantages of skeletal scintigraphy (i.e., radionuclide bone scan) over all other imaging techniques is its ability to image the entire skeleton at once. A bone scan can confirm the presence of the disease, demonstrate the distribution of a lesion (Fig. 4.17), and help to evaluate the activity of a pathologic process. Indications for skeletal scintigraphy include traumatic conditions, tumors (primary and metastatic), arthritides, infections, and metabolic bone disease. The detected abnormality may consist of decreased uptake of bone-seeking radiopharmaceutical (e.g., early stage of osteonecrosis) or increased uptake (e.g., fracture, neoplasm, focus of osteomyelitis). Some structures under normal conditions may show increased activity (e.g., sacroiliac joints or normal growth plates).

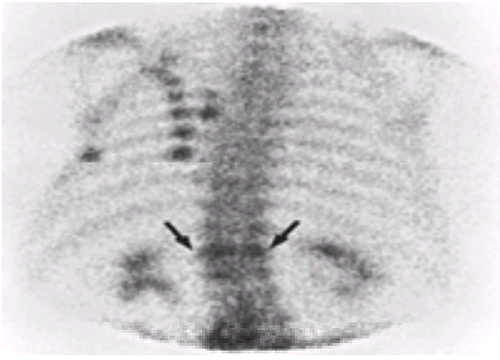

***Figure 4.17.*** Bone scan obtained after injection of 15 mCi of technetium-99m methylene diphosphonate demonstrates increased uptake of the radiopharmaceutical at the site of multiple rib fractures. The increased uptake at the level of L1 is secondary to the compression fracture of the vertebral body (*arrows*).

Scintigraphy is a sensitive imaging modality, but it lacks specificity. It is impossible to differentiate between various processes that can cause increased uptake. Occasionally, however, the bone scan may yield very specific information and even suggest the diagnosis, as in multiple myeloma or osteoid osteoma. In the search for myeloma, scintigraphy is helpful for differentiating bony metastases. In most cases of myeloma, there is no significant increase in the uptake of the radiopharmaceutical; in skeletal metastases, however, invariably the uptake of the tracer is significantly elevated. In osteoid osteoma, there is a typical appearance of the bone scan that demonstrates a “double-density sign.” There is more increased uptake in the center, due to the nidus, and less increased uptake at the periphery, related to the reactive sclerosis surrounding the nidus.

Radionuclide bone scan is an indicator of mineral turnover; because there is usually an enhanced deposition of bone-seeking radiopharmaceuticals in areas of bone undergoing change and repair, a bone scan is useful in localizing tumors and tumor-like lesions in the skeleton. This is particularly helpful in fibrous dysplasia, eosinophilic granuloma, or metastatic cancer, in which more than one lesion develop. It also plays an important role in localizing small lesions, such as osteoid osteoma, which may not always be seen on the plain film studies. In most instances, radionuclide bone scan cannot differentiate benign lesions from malignant tumors, because both conditions have an increased blood flow with resultant increased isotope deposition and increased osteoblastic activity. It may, however, permit differentiation of benign lesions, such as bone islands, that usually do not absorb the radioactive isotope.

In traumatic conditions, scintigraphy is extremely helpful in the early diagnosis of stress fractures, which may not be seen on conventional radiographs or tomographic studies. It also has value in diagnosing fractures of the scaphoid or the femoral neck in elderly patients if the routine radiographic examinations appear normal (13,39).

In metabolic bone disorders, bone scintigraphy is helpful in establishing the extent of skeletal involvement in Paget's disease and assessing the response to treatment. Although it is of no use in the evaluation of patients with generalized osteoporosis, it may occasionally be helpful in differentiating osteoporosis from osteomalacia and in differentiating multiple vertebral fractures resulting from osteoporosis from those occurring in metastatic carcinoma.

Skeletal scintigraphy is frequently used to evaluate infections. In particular, $^{99m}$technetium–methylene diphosphonate ($^{99m}$Tc-MDP) and $^{111}$indium ($^{111}$In) are highly sensitive in detecting early and occult osteomyelitis (2). For detecting recurrent active infection in patients with chronic osteomyelitis, $^{111}$In-labeled leukocytes appear to be the tracer of choice. It must be stressed, however, that $^{111}$In-labeled leukocytes accumulate in active bone marrow, and this tendency limits their sensitivity for the detection of chronic osteomyelitis. To improve the diagnostic ability of this technique, some advocate a study that combines $^{99m}$Tc-sulfur colloid bone marrow with $^{111}$In-labeled leukocytes. In chronic osteomyelitis, imaging with $^{67}$gallium ($^{67}$Ga) citrate is more accurate in detecting the response or lack of response to treatment than $^{99m}$Tc-phosphate bone imaging. A three-phase technique can be effectively used to differentiate soft-tissue infection (cellulitis) and osseous infection (osteomyelitis).

In neoplastic conditions, the detection of skeletal metastasis is probably the most common indication for skeletal scintigraphy. It also is frequently used to determine the extent of a lesion or the presence of skip lesions or intraosseous metastases. It is not the method of choice to determine the extent of the lesion in the bone. Scintigraphy alone cannot diagnose the type of the tumor, but it may be useful in detecting and localizing some primary tumors and multifocal lesions (e.g., multicentric osteosarcoma).

$^{99m}$Tc-MDP scans are used primarily to determine whether a lesion is monostotic or polyostotic, information essential in the staging of a bone tumor. Although the degree of abnormal uptake may be related to the aggressiveness of the lesion, this finding does not correlate well with histologic grade. Gallium-67 may be taken up in a soft-tissue sarcoma and may help to differentiate a sarcoma from a benign soft-tissue lesion.

Although a bone scan may be useful in demonstrating the extent of the primary malignant tumor in bone, it is not as accurate as CT or MRI. It may be useful in the detection of local recurrence of tumor and occasionally may indicate the response or lack of response to radiotherapy or chemotherapy.

In the evaluation of arthritides, a bone scan can demonstrate the distribution of the lesion in the skeleton; this method has completely replaced the previously used radiographic joint survey. Scintigraphy can determine the distribution of arthritic changes in large and small joints and in areas usually not detected by standard radiography, such as the sternomanubrial and temporomandibular joints (38).

Several bone-seeking tracers are available for scintigraphic imaging (44).

**Diphosphonates** Gamma-emitting agents have been developed for diagnostic radionuclide imaging. The radiopharmaceuticals currently in use in bone scanning include the organic diphosphonates, ethylene diphosphonates, methylene diphosphonates (MDP), and methane hydroxydiphosphonates, all labeled with $^{99m}$Tc, a pure gamma-ray emitter with a 6-hour half-life. MDP is more frequently used, particularly in adults, typically in a dose that provides 15 mCi of $^{99m}$Tc radiation. After intravenous injection of the radiopharmaceutical, approximately 50% of the dose localizes in bone. The remainder circulates freely in the body and eventually is excreted by the kidneys.

A gamma camera is used in a procedure known as three-phase isotope bone scan. The first phase, the radionuclide angiogram, is the first minute after injection, when the serial images demonstrate the radioactive tracer in the major blood vessels. In the second phase, the blood-pool scan, which lasts from 1 to 3 minutes after injection, isotope is detected in the vascular system and in the extracellular space in the soft tissues before being taken up by bone. The third phase, or static bone scan, usually occurs 2 to 3 hours after injection and discloses the presence of radiopharmaceutical in the bone. This phase may be divided into two stages. In the first stage, the isotope diffuses passively through the bone capillaries. In the second stage, the radionuclide is concentrated in bone. The most intense localization occurs in the first and second phases in areas with increased blood flow and in the third phase in areas with increased osteogenic activity, increased calcium metabolism, and active bone turnover.

**Gallium-67** $^{67}$Ga-citrate is frequently used to diagnose infectious processes in bone and joints. The sensitivity of $^{67}$Ga for abscess detection varies from 58% to 100% and specificity from 75% to 99%. The images are usually obtained 6 and 24 hours after the injection of 5 mCi of this radiopharmaceutical. These images have been shown to be extremely accurate in monitoring response to therapy of chronic osteomyelitis and infectious arthritis. The changing activity of $^{67}$Ga uptake parallels the patient's clinical course in septic arthritis more closely than the images obtained after injection of $^{99m}$Tc-diphosphonate. A gallium scan is also used to differentiate sarcomas from benign soft-tissue lesions.

**Indium** Controversy still exists regarding diagnostic advantage of $^{111}$In oxine-labeled leukocytes over other bone-seeking radiopharmaceuticals for detecting inflammatory abnormalities in the skeletal system (45). Because $^{111}$In-labeled leukocytes are not usually incorporated into areas of increased bone turnover, indium imaging presumably reflects inflammatory activity only, and early experience has shown it to be specific in the detection of abscesses or acute infectious processes, including osteomyelitis and septic arthritis. The sensitivity varies from 75% to 90%, and specificity is approximately 91% (57). False-negative results often occurred for patients with chronic infections in which there was reduced inflow of circulating leukocytes. False-positive results were seen for patients who had an inflammatory process without infection (e.g., rheumatoid arthritis mistaken for septic arthritis).

**Nanocolloid** In Europe, very small particles of $^{99m}$Tc-colloid of human serum albumin were tried as a bone marrow imaging agent. About 86% of these particles are 30 nm or smaller, and the remainder are between 30 and 80 nm. When this “nanocolloid” is used for detection of osteomyelitis in the extremities, it has a sensitivity equal to that of $^{111}$In-leukocytes.

## SINGLE PHOTON EMISSION COMPUTED TOMOGRAPHY

Pathologic processes produce significantly different, characteristic, nonuniform distribution of administered radiopharmaceutical tracers. Imaging the distributions yields information about the functional status of bony tissues. A perfect image of such an object would be an exact, three-dimensional replica of the distribution of activity within the area of interest (6). This goal has been partially achieved through the tomoscanner and dual Anger-type scintillation cameras operated in the conjugate counting mode, or single photon emission computed tomography (SPECT).

The recent development of single photon emission tomography (SPET) and SPECT has tremendously increased diagnostic precision in evaluating bone and joint abnormalities. The efficiency of instrumentation for SPECT is improving with multiple crystal detectors, fan beam and cone beam collimators, detection of a greater fraction of photons, and improved algorithms. Compared with planar images, SPECT provides increased contrast resolution, using a tomographic mode that eliminates the noise from tissue outside the plane of imaging; in this regard, it is similar to conventional tomography. It provides quantitative and qualitative information on the uptake of bone-seeking radiopharmaceuticals.

## MAGNETIC RESONANCE IMAGING

Magnetic resonance imaging is based on the reemission of an absorbed radiofrequency signal while the patient is in a strong magnetic field (31). An external magnetic field is usually generated by a magnet with field strengths of 0.2 to 1.5 tesla. The system includes a magnet, radiofrequency coils (transmitter and receiver), gradient coils, and a computer display unit with digital storage facilities.

The ability of MR to image body parts depends on the intrinsic spin of atomic nuclei with an odd number of protons or neutrons (e.g., hydrogen), which generates a magnetic moment. Nuclei of tissues placed within the main magnetic field tend to align along the direction of that field. Application of radiofrequency (rf) pulses induces resonance of particular sets of nuclei. The required frequency of the pulse is determined by the strength of the magnetic field and the nucleus under investigation. The energy absorbed during the transition from the induced high-energy state to the normal low-energy state is released; this can be recorded as an electrical signal, which provides the data from which digital images are derived (58).

Two relaxation times, T1 and T2, are employed. The T1 relaxation time is a term used to describe the return of protons to equilibrium after application and removal of the rf pulse. T2 relaxation time is a term used to describe the associated loss of coherence or phase between individual protons immediately after the application of rf pulse. A variety of rf pulse sequences can be used to enhance the differences in tissue relaxation times T1 and T2, providing the necessary image contrast.

The most commonly used sequences are partial saturation recovery, inversion recovery, and fast scan technique. Inversion recovery sequences can be combined with multiplanar imaging to shorten scan time. Spin echo short pulse repetition (TR £ 0.5 sec) and short echo delay (TE £ 40 msec) sequences (or T1) provide good anatomic detail. Long TR (³1.5 sec) and long TE (³³90 msec) pulse sequences (or T2) provide good contrast, sufficient for evaluation of pathologic processes. With a short inversion time in the range of 100 to 150 msec, the effects of prolonged T1 and T2 relaxation times are cumulative, and the signal from fat is suppressed. This technique is short time inversion recovery (STIR), and it has been useful for evaluating bone tumors (3).

Fast imaging techniques have become increasingly popular because they provide advantages compared with much slower spin echo imaging. In particular, gradient recalled echo (GRE) pulse sequences using variable flip angles (5° to 90°) have gained rapid acceptance in orthopaedic radiology because they represent the most effective means of performing fast MR imaging.

Several different types of GRE methods in clinical use, each of which relies on using a reduced flip angle to enhance the signal with short TR. These techniques are known by a variety of acronyms such as FLASH (fast low-angle shot), FISP (fast imaging with steady procession), GRASS (gradient-recalled acquisition), and MPGR (multiplanar gradient recalled).

In most examinations, obtain at least two planes (axial and coronal or sagittal); for many injuries, all three planes are necessary. For adequate MR imaging, surface coils are necessary because they provide improved spatial resolution. Most surface coils are designed specifically for different areas of the body, such as knee, shoulder, wrist, and temporomandibular joints.

The musculoskeletal system is ideally suited for evaluation by MRI because different tissues display different signal intensity on T1- and T2-weighted images. The images displayed may have a high, intermediate, or low signal intensity. High signal intensity of fat planes and differences in signal intensity of various structures allow separation of the different tissue components. Fat, bone marrow, and hematoma display relatively high signal intensity on T1- and T2-weighted images; cortical bone, air, ligaments, tendons, and fibrocartilage display low signal intensity on T1- and T2-weighted images; muscle, nerves, and hyaline cartilage display intermediate signal intensity on T1- and T2-weighted images. Most tumors display low to intermediate signal intensity on T1-weighted images, and high signal intensity on T2-weighted images.

The use of MRI in orthopaedic radiology is confined primarily to trauma and tumors.

### TRAUMA

Magnetic resonance imaging evaluation of trauma to the knee, particularly meniscal and ligamentous abnormalities, has high negative predictive value (16). This test can be used to screen patients before surgery and avoid unnecessary arthroscopies. Some types of meniscal tears may be difficult to detect, such as bucket-handle tears, tears of the free edge, and peripheral detachments. Medial and lateral collateral ligaments, anterior and posterior cruciate ligaments, and tendons around the knee joint are well visualized on MRI (5). Abnormalities of these structures can be diagnosed with high accuracy (37). Osteochondral fractures and lesions of osteochondritis dissecans can also be effectively imaged (Fig. 4.18). In the shoulder, impingement syndrome and most complete and incomplete rotator cuff tears can be accurately diagnosed (Fig. 4.19).

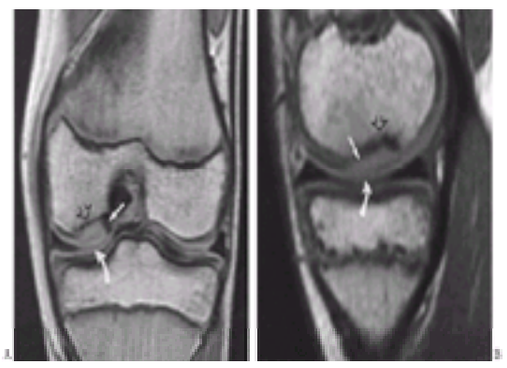

***Figure 4.18.*** Coronal (**A**) and sagittal (**B**) MR images of the knee demonstrate a necrotic segment of bone (*arrow*), separated from the medial femoral condyle by a low-signal-intensity band, representing a sclerotic margin of reactive tissue at the interface between necrotic and viable bone (*open arrow*). The articular cartilage is intact (*curved arrow*), indicating an *in situ* lesion of osteochondritis dissecans.

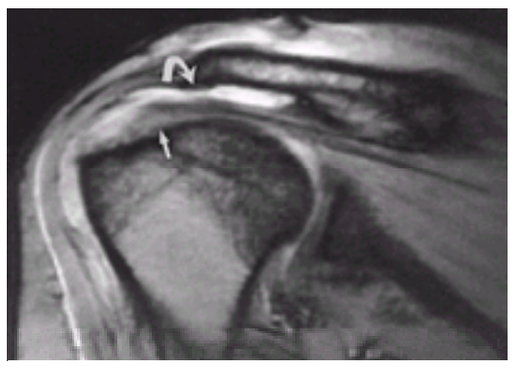

***Figure 4.19.*** Oblique coronal MR image of the shoulder (multiplanar gradient, TR = 500, TE = 20, flip angle = 30°) demonstrates a complete tear of the supraspinatus tendon (*arrow*). Areas of high signal intensity (*curved arrow*) represent accumulation of fluid in the subacromial–subdeltoid bursae complex.

Much more difficult to diagnose is a tear of the cartilaginous labrum. Traumatic lesions of the tendons, such as biceps tendon rupture, can easily be diagnosed with this technique. MRI effectively delineates traumatic joint effusions and hematomas, as well as the changes of osteonecrosis at various sites (Fig. 4.20) (47). This modality can detect the early changes of osteonecrosis, even when conventional radiography, tomography, and radionuclide bone scan are normal (12). MRI of the ankle and foot has been used in diagnosing tendon ruptures and posttraumatic osteonecrosis of the talus. In the wrist and hand, MRI has been successfully used in the early diagnosis of posttraumatic osteonecrosis of the scaphoid. Nevertheless, it is not the technique of choice for evaluating abnormalities of triangular fibrocartilage complex, for which arthrography is preferred, particularly with the combination of CT and digital imaging.

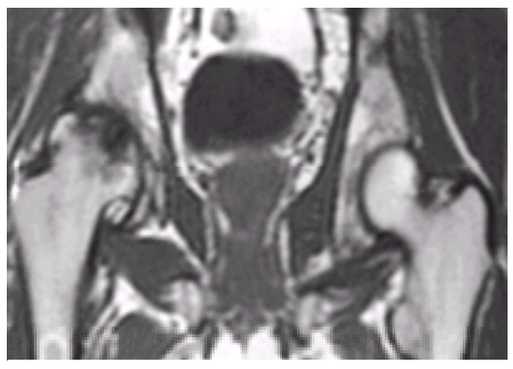

***Figure 4.20.*** Coronal MR image of the pelvis (spin echo, TR = 600, TE = 20) demonstrates advanced osteonecrosis of the right femoral head.

Magnetic resonance arthrography (MRA) has become popular in recent years. The diagnostic accuracy of this technique may exceed that of conventional MRI. It better demonstrates the intra-articular structures because they can be separated by capsular distention. Such distention can be achieved with intra-articular injection of contrast material such as diluted gadopentate dimeglumine (gadolinium diethylenetriamine penta-acetic acid, or Gd-DTPA) or saline. The generated images are very similar to those obtained of the joint with preexisting joint fluid (joint effusion). In clinical practice, MRA is used predominantly in the evaluation of shoulder abnormalities, such as internal derangement, glenohumeral joint instability, rotator cuff disorders, or articular cartilage and cartilaginous labrum abnormalities. Indirect MRA is a procedure in which, prior to the MRI examination of the joint, an intravenous injection of gadolinium is given. Like direct MRA, this technique may improve detection of rotator cuff tears, labral pathology, and adhesive capsulitis.

Magnetic resonance angiography can help the physician visualize blood vessels. Unlike conventional contrast angiography, it does not demonstrate the blood volume itself, but rather it depicts a *property* of blood flow. One of its advantages lies in fact that after a three-dimensional MR angiography data set is collected, the physician may choose any number of viewing directions. This feature also eliminates vascular overlapping.

Numerous pulse sequences have been proposed to produce angiographic contrast. Some rely on the rapid inflow of relaxed blood into the region in which the stationary tissue is saturated. These methods are time-of-flight (TOF) or flow-related enhancement (FRE). Others, which rely on the velocity-dependent change of phase of moving blood in the presence of a magnetic field gradient, are the phase-contrast methods. Some methods involve the subtraction of flow-dephased images from flow-compensated images. The application of MR angiography in orthopedic radiology includes evaluation of the vascular structures in patients with trauma to the extremities, and in assessment of vascularity of musculoskeletal neoplasms.

The greatest use of MRI is in trauma of the spine, the spinal cord, the thecal sac, and nerve roots, and in the evaluation of disc herniation (34). MRI is also useful in evaluating spinal ligament injury. Demonstration of the relationship of vertebral fragments to the spinal cord with direct sagittal imaging is extremely helpful, particularly in the cervical and thoracic areas.

**TUMORS**

Magnetic resonance imaging is indispensable in evaluating bone and soft-tissue tumors. Particularly in the evaluation of soft-tissue masses, MR offers distinct advantages over CT. Tissue planes surrounding the lesion can be more adequately visualized, and neurovascular involvement can be evaluated without the use of intravenous contrast (62).

A number of pulse sequences can be used to evaluate musculoskeletal tumors. These include spin-echo (SE) sequences, inversion recovery (IR) sequences, STIR sequences, GRE sequences, and fast T2 or fat-suppression T2-weighted sequences. SE sequences are the most effective for identification and staging of most skeletal tumors. The signal intensity for normal tissues is predictable using these sequences. On T1-weighted images, fat and bone marrow have a high signal intensity that changes to intermediate intensity on T2 weighting. Muscles have intermediate signal intensity on both T1 and T2 sequences. Cortical bone and fibrocartilage have low signal on both sequences. Fluid has intermediate signal on T1-weighted and high signal intensity on T2-weighted images (Table 4.1). Most bone tumors have increased T1 and T2 relaxation times compared with normal tissue and therefore are imaged as areas of low or intermediate signal intensity on T1-weighted SE sequences and high signal intensity on T2-weighted sequences.

| | *Image* | |
|---|---|---|
| *Tissue* | *T1-weighted* | *T2-weighted* |
| Hematoma | High | High |
| Fat, fatty marrow | High | Intermediate |
| Muscle, nerves, hyaline cartilage | Intermediate | Intermediate |
| Cortical bone, tendons, ligaments, fibrocartilage, scar tissue, air | Low | Low |
| Hyaline cartilage | Intermediate | Intermediate |
| Red (hematopoietic) marrow | Low | Intermediate |
| Fluid | Intermediate | High |
| Tumors (generally) | Intermediate-to-low | High |
| Lipoma | High | Intermediate |
| Hemangioma | Intermediate (slightly higher than muscle) | High |

***Table 4.1. MRI Signal Intensities of Various Tissues***

Magnetic resonance imaging is crucial in evaluating intra- and extraosseous extensions of tumors (1,48,62). It can determine soft-tissue invasion by a tumor with great accuracy (Fig. 4.21). MRI in many instances is superior to CT, particularly in the coronal plane, in delineating the extraosseous and intramedullary extent of the tumor and its relationship to surrounding structures. Showing sharper demarcation between normal and abnormal tissue than CT, especially in evaluating the extremities, MRI reliably identifies the spatial boundaries of tumor masses, encasement and displacement of major neurovascular bundles, and the extent of joint involvement. T1-weighted spin echo images enhance tumor contrast with bone, bone marrow, and fatty tissue (Fig. 4.22*A*), and T2-weighted spin echo images enhance tumor contrast with muscle and accentuate peritumoral edema (Fig. 4.22*B*). Axial and coronal images have been employed in determining the extent of soft-tissue invasion in relation to important vascular structures. Compared with CT, MR images do not clearly depict or allow characterization of calcification in the tumor matrix; large amounts of calcification or ossification are occasionally undetectable. Moreover, MRI has shown itself less satisfactory than CT, and even less satisfactory than plain films and tomography, in demonstrating cortical destruction and periosteal reaction.

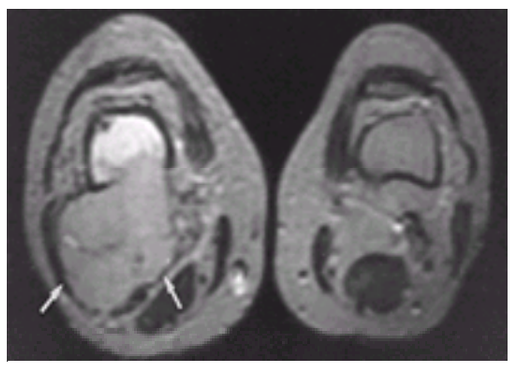

***Figure 4.21.*** On the MR axial image (T2-weighting), the involvement of the bone marrow is demonstrated by high signal intensity of the tumor (Ewing's sarcoma). The soft-tissue extension of the tumor displaying intermediate signal intensity is well demonstrated (*arrows*).

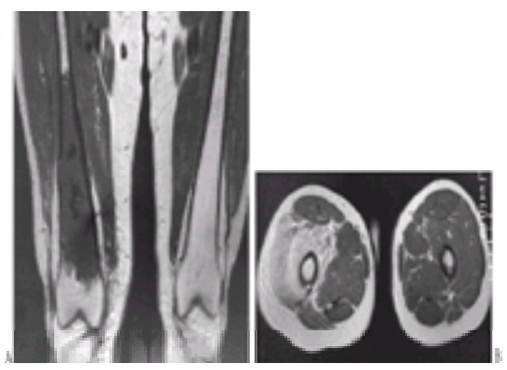

***Figure 4.22.*** **A:** T1-weighted coronal MR image demonstrates good contrast between the tumor in the right femur (dedifferentiated chondrosarcoma), which displays low signal intensity, and normal bone marrow, which displays high signal intensity. **B:** T2-weighted axial MR image of the same patient enhances the contrast between tumor, displaying high or intermediate signal intensity, and normal muscles, displaying low signal intensity.

Several investigators stressed the advantage of contrast enhancement of MR images using intravenous injection of Gd-DTPA. Enhancement was found to give better delineation of the tumor in richly vascularized parts, in compressed tissue immediately surrounding the tumor, and in atrophic but richly vascularized muscle (50). The contrast studies also improved the differentiation of necrotic tissue from viable areas in various malignant tumors (18).

According to recent investigations, MRI may have an additional application in evaluating tumor response to irradiation and chemotherapy and in evaluating local recurrence (54). Although static MRI was of little value for assessment of response to the treatment, dynamic MR imaging using Gd-DTPA had a higher degree of accuracy (85.7%) and was superior to scintigraphy, particularly in patients who were receiving intra-arterial chemotherapy (19,20). The latest observation suggests that MR spectroscopy may also be useful in evaluating patients undergoing chemotherapy (17,61).

Magnetic resonance imaging is usually not suitable for establishing the precise nature of a bone tumor, and too much faith has been placed in MRI as a method for differentiating benign from malignant lesions (63). Trials using combined $^{1}$H MRI (proton imaging) and $^{31}$P MR spectroscopy failed to differentiate most benign lesions from malignant tumors (49). Despite the use of various criteria, the application of MRI to tissue diagnosis has rarely brought satisfactory results, because the small number of protons in calcified structures renders MRI less useful in evaluation of bone lesions (1). The physician can miss valuable evidence related to the production of the tumor matrix using this modality, because it is unsatisfactory for demonstrating small calcified structures. Moreover, MRI has been an imaging modality of low specificity. T1 and T2 measurements are generally of limited value for histologic characterization of musculoskeletal tumors.

Quantitative determination of relaxation times has not proved to be clinically valuable in identifying tumor types, although it has proved to be an important technique in the staging of osteosarcoma or chondrosarcoma (63). T2-weighted images are a crucial factor in delineating extraosseous extension of tumor and peritumoral edema and assessing the involvement of major neurovascular bundles. Necrotic areas change from low-intensity signal in the T1-weighted image to a very bright, intense signal in the T2-weighted images and can be differentiated from viable, solid tumor tissue.

Although MRI cannot predict the histology of bone tumors, it is a useful tool for differentiating round cell tumors and metastases from stress fractures and medullary infarcts in symptomatic patients with normal radiographs. It can occasionally differentiate benign from pathologic fractures (3,63).

Magnetic resonance imaging also has disadvantages, which include the contraindications of scanning patients with cardiac pacemakers or cerebral aneurysm clips, and those who are claustrophobic. The presence of metallic objects, such as ferromagnetic surgical clips, causes focal loss of the signal with or without distortion of image. Metallic objects create “holes” in the image, but ferromagnetic objects cause more distortion (48). MRI still lacks high resolution for evaluating osseous anatomy and fractures compared with CT and conventional tomography. As in CT, an average volume effect may be observed in MR images, rendering occasional pitfalls in the interpretation. Motion artifacts can be eliminated using fast imaging techniques.

## CHAPTER REFERENCES

Each reference is categorized according to the following scheme: *, classic article; #, review article; !, basic research article; and +, clinical results/outcome study.


! 1. Aisen AN, Martel W, Braunstein EM, et al. MRI and CT Evaluation of Primary Bone and Soft Tissue Tumors. Am J Radiol 1986;46:749.

! 2. Al Sheikh W, Sfakianakis GN, Mnaymneh W, et al. Subacute and Chronic Bone Infections: Diagnosis Using In-111, Ga-67, and Tc99m MDP Bone Scintigraphy and Radiography. *Radiology* 1985;55:501.

# 3. Baker LL, Goodman SB, Perkash I, et al. Benign versus Pathologic Compression Fractures of Vertebral Bodies: Assessment with Conventional Spin-Echo, Chemical-Shift, and STIR MR Imaging. *Radiology* 1990;74:495.

* 4. Ballinger PW. *Merrill's Atlas of Radiographic Positions and Radiologic Procedures,* 6th ed, vol. 1. St. Louis: CV Mosby, 1986.

* 5. Bassett LW, Grover JS, Seeger LL. Magnetic Resonance Imaging of Knee Trauma. *Skeletal Radiol* 1990;19:401.

* 6. Beck RN. Radionuclide Imaging Principles. In: Taveras JM, Ferrucci JT, eds. *Radiology—Diagnosis, Imaging, Intervention,* vol. 1. Philadelphia: JB Lippincott, 1990:Chap. 19.

+ 7. Berman L, Klenerman L. Ultrasound Screening for Hip Abnormalities: Preliminary Findings in 1001 Neonates. *Br Med J* 1986;293:719.

! 8. Borders J, Kerr E, Sartoris DJ, et al. Quantitative Dual-energy Radiographic Absorptiometry of the Lumbar Spine: In Vivo Comparison with Dual-photon Absorptiometry. *Radiology* 1989;170:129.

# 9. Brandt TD, Cardone BW, Grant TH, et al. Rotator Cuff Sonography: A Reassessment. *Radiology* 1989;173:323.

* 10. Brower AC. *Arthritis in Black and White.* Philadelphia: WB Saunders, 1988.

# 11. Burk DL, Mears DC, Kennedy WH, et al. Three-Dimensional Computed Tomography of Acetabular Fractures. *Radiology* 1985;155:183.

* 12. Coleman BG, Kressel HY, Dalinka MK, et al. Radiographically Negative Avascular Necrosis: Detection with MR Imaging. *Radiology* 1988;168:525.

+ 13. Colhoun EN, Johnson SR, Fairclough JA. Bone Scanning for Hip Fracture in Patients with Osteoarthritis: Brief Report. *J Bone Joint Surg Br* 1987;69:848.

# 14. Dalinka MK, Boorstein JM, Zlatkin MB. Computed Tomography of Musculoskeletal Trauma. *Radiol Clin North Am* 1989;27:933.

# 15. Derchi LE, Balconi G, DeFlaviis L, et al. Sonographic Appearance of Hemangiomas of Skeletal Muscle. *J Ultrasound Med* 1989;8:263.

# 16. Deutsch AL, Mink JH. Magnetic Resonance Imaging of Musculoskeletal Injuries. *Radiol Clin North Am* 1989;27:983.

! 17. Dewhirst MW, Sostman HD, Leopold KA, et al. Soft-Tissue Sarcomas: MR Imaging and MR Spectroscopy for Prognosis and Therapy Monitoring. *Radiology* 1990;174:847.

# 18. Erlemann R, Reiser MF, Peters PE, et al. Musculoskeletal Neoplasms: Static and Dynamic Gd-DTPA-Enhanced MR Imaging. *Radiology* 1989;171:767.

! 19. Erlemann R, Sciuk J, Bosse A, et al. Response of Osteosarcoma and Ewing Sarcoma to Preoperative Chemotherapy: Assessment with Dynamic and Static MR Imaging and Skeletal Scintigraphy. *Radiology* 1990;175:791.

! 20. Erlemann R, Vasallo P, Bongartz G, et al. Musculoskeletal Neoplasms: Fast Low-Angle Shot MR Imaging with and without Gd-DTPA. *Radiology* 1990;176:489.

* 21. The Executive Committee of the North American Spine Society: Position Statement on Diskography. *Spine* 1988;13:1343.

* 22. Ferrucci JT. Imaging Algorithms for Radiologic Diagnosis. In: Taveras JM, Ferrucci JT, eds. *Radiology—Diagnosis, Imaging, Intervention,* vol. 1. Philadelphia: Lippincott, 1990:Chap. 36.

# 23. Foley WD, Wilson CR. Digital Orthopedic Radiography: Vascular and Non-Vascular. In: Galasko CSB, Isherwood I, eds. *Imaging Techniques in Orthopedics.* London: Springer-Verlag, 1989:145.

# 24. Fornage BD. Achilles Tendon: US Examination. *Radiology* 1986;159:759.

* 25. Freiberger RH, Pavlov H. Knee Arthrography. *Radiology* 1988;166:489.

! 26. Genant HK, Boyd DP. Quantitative Bone Mineral Analysis Using Dual Energy Computed Tomography. *Invest Radiol* 1977;12:545.

# 27. Genant HK, Cann CE, Chafetz NI, Helms CA. Advances in Computed Tomography of the Musculo-skeletal System. *Radiol Clin North Am* 19:645:1981.

* 28. Genant HK, Resnick D. Magnification Radiography. In: Resnick D, ed. *Bone and Joint Imaging.* Philadelphia: WB Saunders, 1989:85.

# 29. Gibson MJ, Buckley J, Mawhinney R, et al. Magnetic Resonance Imaging and Discography in the Diagnosis of Disc Degeneration. *J Bone Joint Surg Br* 1986;68:369.

# 30. Goodman PC, Jeffrey RB Jr, Brant-Zawadzki M. Digital Subtraction Angiography in Extremity Trauma. *Radiology* 1984;153:61.

* 31. Greenfield GB. *Radiology of Bone Diseases,* 5th ed. Philadelphia: JB Lippincott, 1990:12.

! 32. Greenspan A, Norman A. The Radial Head-Capitellum View: Useful Technique in Elbow Trauma. *Am J Roetgenol* 1982;138:1186.

# 33. Gundry CR, Schils JP, Resnick D, Sartoris DJ. Arthrography of the Post-Traumatic Knee, Shoulder, and Wrist. Current Status and Future Trends. *Radiol Clin North Am* 1989;27:957.

# 34. Haughton VM. MR Imaging of the Spine. *Radiology* 1988;166:297.

# 35. Ho C, Sartoris DJ, Resnick D. Conventional Tomography in Musculoskeletal Trauma. *Radiol Clin North Am* 1989;27:929.

! 36. Hodler J, Fretz CJ, Terrier F, Gerber C. Rotator Cuff Tears: Correlation of Sonographic and Surgical Findings. *Radiology* 1988;169:791.

# 37. Holt G, Helms CA, Steinbach L, et al. Magnetic Resonance Imaging of the Shoulder: Rationale and Current Applications. *Skeletal Radiol* 1990;19:5.

# 38. Jones MM, Moore WH, Brewer EJ, et al. Radionuclide Bone/Joint Imaging in Children with Rheumatic Complaints. *Skeletal Radiol* 1988;17:1.

+ 39. King JB, Turnbull TJ. An Early Method of Confirming Scaphoid Fracture. *J Bone Joint Surg Br* 1981;63:287.

* 40. Levinsohn EM, Palmer AK, Coren AB, Zinberg E. Wrist Arthrography: The Value of the Three Compartment Injection Technique. *Skeletal Radiol* 1987;16:539.

* 41. Levinsohn EM. Imaging of the Wrist. *Radiol Clin North Am* 1990;28:905.

* 42. Magid D, Fishman EK. Imaging of Musculoskeletal Trauma in Three Dimensions. *Radiol Clin North Am* 1989;27:945.

# 43. Manaster B. Digital Arthrography of the Wrist. *Am J Roentgenol* 1986;147:563.

# 44. McAfee JG. Update on Radiopharmaceuticals for Medical Imaging. *Radiology* 1989;171:593.

# 45. McAfee JG, Samin A. Indium-111 Labelled Leukocytes: A Review of Problems in Image Interpretation. *Radiology* 1985;155:221.

* 46. Merchant AC, Mercer RL, Jacobson RH, Cool CR. Roentgenographic Analysis of Patello-Femoral Congruence. *J Bone Joint Surg Am* 1974;56:1391.

! 47. Mitchell DG, Rao VM, Dalinka MK, et al. Femoral Head Avascular Necrosis: Correlation of MR Imaging, Radiographic Staging, Radionuclide Imaging, and Clinical Findings. *Radiology* 1987;162:709.

* 48. Murphy WA. Magnetic Resonance Imaging. In: Resnick D, ed. *Bone and Joint Imaging.* Philadelphia: WB Saunders, 1989:120.

! 49. Negendank WG, Crowley MG, Ryan JR, et al. Bone and Soft-Tissue Lesions: Diagnosis with Combined H-1 MR Imaging and P-31 MR Spectroscopy. *Radiology* 1989;173:181.

! 50. Pettersson H, Eliasson J, Egund N, et al. Gadolinium-DTPA Enhancement of Soft Tissue Tumors in Magnetic Resonance Imaging—Preliminary Clinical Experience in Five Patients. *Skeletal Radiol* 1988;17:319.

# 51. Posner MA, Greenspan A. Trispiral Tomography for the Evaluation of Wrist Problems. *J Hand Surg* 1988;13A:175.

* 52. Pugh DG, Winkler TN. Scanography of Leg-Length Measurement: An Easy Satisfactory Method. *Radiology* 1966;87:130.

# 53. Reinus WR, Hardy DC, Totty WG, Gilula LA. Arthrographic Evaluation of the Carpal Triangular Fibrocartilage Complex. *J Hand Surg* 1987;12A:495.

! 54. Reuther G, Mutschler W. Detection of Local Recurrent Disease in Musculoskeletal Tumors: Magnetic Resonance Imaging versus Computed Tomography. *Skeletal Radiol* 1990;19:85.

# 55. Sartoris DJ, Resnick D. Current and Innovative Methods for Noninvasive Bone Densitometry. *Radiol Clin North Am* 1990;28:257.

# 56. Sartoris DJ, Sommer FG. Digital Film Processing: Applications to the Musculo-skeletal System. *Skeletal Radiol.* 1984;11:274.

# 57. Schauwecker DS. Osteomyelitis: Diagnosis with In-111-Labeled Leukocytes. *Radiology* 1989;171:141.

* 58. Schmalbrock P, Beltran J. Principles of Magnetic Resonance Imaging. In: Beltran J, ed. *MRI Musculoskeletal System.* Philadelphia: JB Lippincott, 1990.

# 59. Shapiro R. Current Status of Lumbar discography. [Letter] *Radiology* 1986;159:815.

# 60. Soble MG, Kaye AD, Guay RC. Rotator Cuff Tear: Clinical Experience with Sonographic Detection. *Radiology* 1989;173:319.

! 61. Sostman HD, Charles HC, Rockwell S, et al. Soft-Tissue Sarcomas: Detection of Metabolic Heterogeneity with P-31 MR Spectroscopy. *Radiology* 1990;176:837.

# 62. Steinbach L. MRI of Musculoskeletal Tumors. *Contemp Diagn Radiol* 1989;12:1.

# 63. Sundaram M, McLeod RA. MR Imaging of Tumor and Tumorlike Lesions of Bones and Soft Tissues. *Am J Roentgenol* 1990;155:817.

# 64. Suzuki S, Awaya G, Wakita S, et al. Diagnosis by Ultrasound of Congenital Dislocation of the Hip Joint. *Clin Orthop* 1987;217:171.

+ 65. Vincent KA, Benson DR, McGahan JP. Intraoperative Ultrasonography for Reduction of Thoracolumbar Burst Fractures. *Spine* 1989;14:387.

# 66. Weinstein J, Claverie W, Gibson S. The Pain of Discography. *Spine* 1988;13:1344.

# CHAPTER 5

# PREOPERATIVE PLANNING AND PERIOPERATIVE MANAGEMENT

*David J. Hak and James A. Goulet*

**D. J. Hak and J. A. Goulet:** Section of Orthopaedic Surgery, University of Michigan, Ann Arbor, Michigan, 48109.

Rationale for Preoperative Planning
Perioperative Medical Management
- Cardiac Disease
- Pulmonary Disease
- Renal Disease
- Liver Disease
- Diabetes Mellitus
- Rheumatic Disease
- Human Immunodeficiency Virus
- Nutrition
- Effects of Substance Abuse
- Other Drugs

Blood Transfusions
- Packed Red Blood Cells
- Plasma and Its Derivatives
- Platelets
- Complications of Blood Transfusion
- Transfusion-Transmitted Disease
- Methods to Minimize Use of Homologous Blood Transfusions

Preoperative Surgical Planning
- Techniques for Creating Preoperative Drawings
- Osteotomy
- Total Joint Arthroplasty
- Computerized Planning Techniques

Intraoperative Surgical Management
- The Surgeon's Attitude and Conduct
- Choice of Anesthesia
- Antibiotics
- Positioning the Patient
- The Tourniquet
- Skin Preparation
- Draping
- Skin Incision and Soft-tissue Technique
- Surgical Technique on Bone
- Wound Drainage
- Wound Irrigation and Closure
- Dressings

Surgeon's Safety
- Hepatitis B Virus
- Hepatitis C
- Human Immunodeficiency Virus

Postoperative Patient Care
- Venous Thromboembolism Prophylaxis

Chapter References

## RATIONALE FOR PREOPERATIVE PLANNING

Success of surgery is increasingly being measured by the patient's satisfaction and functional outcome. Not only must the procedure be performed technically well, but also all the associated factors, from preoperative evaluation to postoperative therapy and follow-up, must be efficient and well coordinated.

Preoperative preparation includes careful evaluation of the patient's medical and social situation to minimize the risks of perioperative complications and problems. Preoperative clearance may require consultation with a medical specialist or anesthesiologist. It may be necessary to coordinate autologous blood donations. Additionally, it may be necessary to make discharge plans, which could involve home care or transfer to a rehabilitation or skilled nursing facility.

Preoperative patient education is on the rise as the frequency and duration of inpatient hospitalization decline. Patient education prepares patient and family for the anticipated surgery and the postoperative recovery period. Patients' understanding of their role in this process is important to a successful outcome.

Increasing demands on their time require surgeons to perform efficiently without sacrificing quality. With preoperative planning, the surgeon thinks through the operation ahead of time, which allows the operation to run more smoothly and quickly and provides important time-management benefits.

Additionally, increasing technological complexity demands increased preoperative preparation. For example, there are now a multitude of implants available for surgeons to choose from. Preoperative preparation enables the surgeon to select the optimal implant for a given patient and become familiar with its use, and to be sure that all necessary equipment is available for the procedure. Being well prepared includes having backup plans to handle any contingencies that might arise.

## PERIOPERATIVE MEDICAL MANAGEMENT

Over the course of an orthopaedist's career, some complications are inevitable and nonpreventable (37). Careful perioperative management can help minimize their occurrence, thus increasing the patient's chances for a successful outcome. It can also provide a solid medical-legal defense should any serious complication arise.

For both elective and emergent procedures, medical consultation may be necessary to manage chronic medical conditions that may be exacerbated by surgery. Orthopaedists can anticipate treating a larger proportion of elderly patients, many of whom have multiple chronic medical problems and decreased functional reserves.

Findings from the patient's medical history dictate the need for further testing and consultation. Using a list (Table 5.1) can help ensure that all possible conditions are covered. Written questionnaires, some of which can be computer coded, are also available. If written forms are used to collect medical data, review them carefully with the patient to ensure that the history is accurate and complete. Make certain that the patient understands the terminology; for example, a patient who has had several “heart attacks” may answer no to questions about myocardial infarctions because he is unfamiliar with the form's medical terminology.

| | |
|---|---|
| 1. | What is the nature of the current orthopaedic disease or injury? What were the risk factors for the disease or illness? If there was an injury, what were the dynamics of the injury, and where did the injuring forces occur? |
| 2. | Current medications |
| 3. | Allergies |
| 4. | History of smoking |
| 5. | History of intravenous or recreational drug abuse |
| 6. | History of blood transfusion or transfusion reaction |
| 7. | Previous surgery and history of complications |
| 8. | Hypertension |
| 9. | Diabetes |
| 10. | Cancer |
| 11. | Genetic disorder |
| 12. | Lung disease (e.g., tuberculosis, asthma, emphysema, shortness of breath, dyspnea on exertion, wheezing, number of pillows the patient sleeps on) |
| 13. | Cardiac disease (e.g., previous myocardial infarction, chest pain, arrhythmias, history of congestive heart failure) |
| 14. | Endocrine disease (e.g., postmenopausal, history of steroid use, history of adrenal insufficiency) |
| 15. | Hematologic disease (e.g., factor deficiency, prolonged bleeding, history of deep venous thrombosis, history of thromboembolic disease) |
| 16. | Liver disease (e.g., history of cirrhosis, hepatitis) |
| 17. | Genitourinary disease (e.g., history of renal calculi, infection, or insufficiency) |
| 18. | Neurologic disease (e.g., history of neurologic disorder, any specific central or peripheral nerve deficiency) |
| 19. | Vascular disease (e.g., history of cerebrovascular event, peripheral vascular disease) |

Adapted from Cardenas AD, Shindell R, E: Comparative Planning for Elective Surgery, ed. Clinical Orthopaedics, 2nd ed. Philadelphia: Lippincott, 1993.

***Table 5.1. Outline for Review of Current and Past Medical History***

Preoperative laboratory tests serve to evaluate existing medical conditions, to screen for asymptomatic conditions, and to identify patients who are at increased risk of adverse postoperative outcomes (152). Performing standard testing (e.g., electrocardiogram, chest x-ray, blood chemistries) on all preoperative patients has been shown to be not only unnecessarily costly, but also of limited benefit in identifying patients with potential medical problems. Instead, current practice calls for individualized evaluation and presurgical testing based on each patient's medical history, family history, age, and physical examination (Table 5.2) (72,90). Although the value of routine screening tests in predicting postoperative complications has also been shown to be extremely low (72), abnormalities in electrocardiograms, chest x-rays, and nutritional status have been shown to be associated with postoperative complications in a general surgical population (152). Velanovich found a strong association between postsurgical complications and the American Society of Anesthesiologists' classification used to assess patients' anesthetic risk (Table 5.3) (152).

| Patient status | Hemoglobin | PTT/PT | PLT | UA | K+ | BUN/Creat | Glucose | CXR | EKG | Additional tests |
|---|---|---|---|---|---|---|---|---|---|---|
| Age | | | | | | | | | | |
| <1 mo | X | — | — | — | — | — | — | — | — | — |
| >60 yr | Female only | — | — | — | — | — | — | — | — | — |
| 60–69 yr | Female only | — | — | — | — | — | — | — | Male: >40 yr Female: >50 yr | — |
| 69 yr | X | — | — | — | — | X | X | X | X | — |
| Females with blood loss | X | — | — | X | — | — | — | — | — | — |
| Associated conditions | | | | | | | | | | |
| Cardiovascular disease | X | — | — | — | — | X | — | X | X | ? Stress test |
| Pulmonary disease | X | — | — | — | — | — | — | X | — | ABG/CXR/EKG |
| Smoker (>10 pack-yr) | X | — | — | — | — | — | — | X | X | ABG/CXR/EKG |
| Hepatic disease | — | X | — | — | — | — | — | — | — | GGT |
| Renal disease | X | — | — | — | X | X | — | — | — | — |
| Diabetes | — | — | — | — | X | X | X | — | X | — |
| Bleeding disorder | — | X | X | — | — | — | — | — | — | — |
| Malignancy | X | — | — | — | — | — | — | X | — | — |
| Morbid obesity | X | — | — | — | — | — | — | — | X | Weight/PFT/CXR/EKG |
| Medications | | | | | | | | | | |
| Anticoagulant | X | X | — | — | — | — | — | — | — | — |
| Digoxin | — | — | — | — | X | X | — | — | X | — |
| Diuretic | — | — | — | — | X | X | — | — | — | — |
| Corticosteroid | — | — | — | — | X | — | X | — | — | — |

PTT/PT, prothrombin time and partial prothrombin time; UA, type and screen; PLT, platelet count; BUN/Creat, blood urea nitrogen and creatinine; CXR, chest x-ray; EKG, electrocardiogram; PFT, pulmonary function tests; ABG, arterial blood gas; AST, aspartate aminotransferase.

A stress test (including exercise tolerance test, dipyridamole thallium scintigraphy, or dobutamine echocardiography) and PFT/CXR/EKG should be individualized to the patients and procedure planned.

Reprinted with permission from Mathias JM, Bulbulia JS. "Routine" Preoperative Studies: Which Studies is Which Patients? Arch Intern Med 150:1689–1693, 1990.

***Table 5.2. Recommended Preoperative Testing for Elective Surgery***

| | |
|---|---|
| ASA I | Healthy individual with no systemic disease who is undergoing elective surgery |
| ASA II | Individual with one-system, well-controlled disease, which does not affect daily life |
| ASA III | Individual with multiple-system or well-controlled major system disease, which limits daily activity |
| ASA IV | Individual with severe, incapacitating disease, which is poorly controlled or end-stage |
| ASA V | Individual who is in imminent danger of death and is not expected to live through the next 24 hours |

Reproduced with permission from Velanovich V. The Value of Routine Preoperative Laboratory Testing in Predicting Postoperative Complications: A Multivariate Analysis. *Surgery* 1991;109(3):236.

***Table 5.3. The American Society of Anesthesiologists' Clinical Classification System***

## CARDIAC DISEASE

Cardiac disease, highly prevalent among many orthopaedic patient populations, has a significant impact on perioperative morbidity and mortality. Question patients specifically about chest pain and shortness of breath on moderate exertion, in addition to any history of myocardial infarction. Physical examination findings that may suggest congestive heart failure include jugular venous distention, rales, or an S3 gallop.

Goldman developed a multifactorial risk index to stratify patients into low, medium, and high risk for cardiac complications (52,53) (Table 5.4 and Table 5.5). Patients with unstable angina, severe aortic stenosis, or a 6-month history of myocardial infarction are at highest surgical risk. Medical evaluation of patients with cardiac disease may call for preoperative echocardiograms and stress tests, which usually require advance scheduling.

| Criteria | Points* |
|---|---|
| History: | |
| Age over 70 years | 5 |
| Myocardial infarction in the past 6 months | 10 |
| Physical examination: | |
| S3 gallop or jugular venous distention | 11 |
| Important valvular aortic stenosis† | 3 |
| Electrocardiogram: | |
| Rhythm other than sinus or premature atrial contractions on last preoperative electrocardiogram | 7 |
| >5 premature ventricular contractions/min documented at any time before operation | 7 |
| General status: | |
| Electrolyte abnormalities (potassium <3.0 mmol/L, HCO2 < 20 mmol/L, renal insufficiency (blood urea nitrogen >50 mg/dL, creatinine >3 mg/dL), abnormal arterial blood gases (PO2 < 60 mm Hg, PCO2 > 50 mm Hg), abnormal liver status (elevated aspartate transaminase or physical signs of chronic liver disease), or any condition that causes the patient to be chronically bedridden | 3 |
| Operation: | |
| Intraperitoneal, intrathoracic, or aortic site of surgery | 3 |
| Emergency operation | 4 |

* Surgical risk from lowest to highest may be classified as I (0–3 points), II (4–12 points), III (13–26 points), IV (>26 points).

Reproduced with permission from Goldman L, Caldera DL, Nussbaum SR, et al. Multifactorial Index of Cardiac Risk in Noncardiac Surgical Procedures. *N Engl J Med* 1977;297:845–850.

***Table 5.4. Calculation of Multifactorial Cardiac Risk Index***

| Class | Point total | No or only minor complication (N = 943) | Life-threatening complication* (N = 39) | Cardiac deaths (N = 19) |
|---|---|---|---|---|
| I (N = 537) | 0–5 | 532 (99%) | 4 (0.7%) | 1 (0.2%) |
| II (N = 316) | 6–12 | 295 (93%) | 16 (5%) | 5 (2%) |
| III (N = 130) | 12–25 | 112 (86%) | 15 (11%) | 3 (2%) |
| IV (N = 18) | ≥26 | 4 (22%) | 4 (22%) | 10 (56%) |

* Documented intraoperative or postoperative myocardial infarction, pulmonary edema, or ventricular tachycardia without progression to cardiac death.
Reproduced with permission from Goldman L, Caldera DL, Nussbaum SR, et al. Multifactorial Index of Cardiac Risk in Noncardiac Surgical Procedures. *N Engl J Med* 1977;297(16):845.

***Table 5.5. Cardiac Risk Index***

Mild to moderate hypertension per se has not been shown to increase surgical risk, but it may be associated with other risk factors, such as cardiac disease, that can contribute to perioperative complications. Patients can continue to take most antihypertension medications during the perioperative period. Carefully monitor the volume status and electrolyte balance of patients taking diuretics.

**PULMONARY DISEASE**

Evaluate the pulmonary function of patients who smoke, those who are morbidly obese, and those with asthma and chronic pulmonary disease (99). Patients with significant hypercapnia (elevated $CO_2$) and an $FeV_1$ (forced expiratory volume in 1 sec) of less than 1 liter are at greatest risk of pulmonary complications (6). Evaluation of postoperative arterial blood gas (ABG) results can be difficult in these patients when there is a question of possible pulmonary embolism. A baseline preoperative ABG is helpful if patients become symptomatic after surgery.

A patient's pulmonary function can be improved if she stops smoking in the weeks preceding surgery. Preoperative instruction in coughing and deep breathing exercises is also helpful. Use of narcotic analgesics, which can depress the respiratory system, should be minimized when possible to decrease postoperative pulmonary complications. The use of continuous epidural anesthesia may be beneficial for patients with pulmonary disease undergoing lower extremity surgery.

Atelectasis due to decreased pulmonary inspiratory volumes, common in the postsurgical patient, may result in significant problems for patients with underlying pulmonary disease. Use incentive spirometry, and administer inhaled bronchodilating agents as soon as any sign of bronchospasm develops.

Management of asthmatic patients often requires the use of bronchodilators and inhaled corticosteroids. In some cases, intravenous corticosteroids may also be indicated. Guidelines have been set for the preoperative medication of asthmatic patients based on the severity of their disease (Table 5.6) (71).

| Severity of asthma | Outpatient treatment | Perioperative medications |
|---|---|---|
| Mild | Bronchodilators; no history of corticosteroid usage | Prednisone, 1 mg/kg per day to maximum of 60 mg for 3–7 d preoperatively<br>Hydrocortisone sodium succinate, 100 mg IV every 8 h perioperatively |
| Moderate | Bronchodilators; intermittent inhaled or systemic corticosteroids now or in the past | Prednisone, 1 mg/kg per day to maximum of 60 mg for 3–7 d preoperatively<br>Hydrocortisone sodium succinate, 100 mg IV every 8 h perioperatively |
| Severe | Bronchodilators; inhaled corticosteroids; systemic corticosteroid dependency now or in the past | Prednisone, 1 mg/kg per day to maximum of 60 mg for 3–7 d preoperatively<br>Hydrocortisone sodium succinate, 100 mg IV every 8 h perioperatively |

Assumes good control of asthma with outpatient treatment.
IV, intravenously.
Reprinted with permission from Kaplan CS, Yarnold PR, Grossman LC. Low Complication Rate of Corticosteroid-Treated Asthmatics Undergoing Surgical Procedures. *Arch Intern Med* 1993;153:1379.

***Table 5.6. Recommended Preoperative Medication for Surgery in Asthmatic Patients, Stratified by Asthma Severity***

**RENAL DISEASE**

Patients with chronic renal insufficiency and end-stage renal disease are at increased risk for perioperative complications (75). Volume status, blood pressure, and electrolyte abnormalities must be carefully managed. These patients are at risk for developing hyperkalemia leading to cardiac arrhythmias. Patients with end-stage renal disease may have uremic platelet dysfunction leading to increased bleeding and a higher risk of infection. Dosages of medications excreted by the kidneys need to be adjusted in these patients. Avoid the use of nephrotoxic medications, which might cause further renal damage.

Acute renal failure may occur in any patient who becomes severely volume depleted and hypotensive. The postsurgical risk is particularly great in patients with limited reserve, such as the elderly and those with diabetes, congestive heart failure, or preexisting renal disease. Rhabdomyolysis leading to acute renal failure is a risk in trauma patients who sustain a significant crush injury or extremity ischemia. Laboratory findings include myoglobin in the urine and elevated skeletal muscle creatine kinase. Treatment includes alkalinization of the urine with sodium bicarbonate, intravenous furosemide (Lasix), and intravenous mannitol. Carefully monitor electrolytes because these patients may become hyperkalemic.

**LIVER DISEASE**

The risk of perioperative complications and death in patients with liver disease increases with the severity of their disease. Patients who have evidence of hepatic decompensation (hypoalbuminemia, coagulopathy, ascites, encephalopathy) are at the greatest risk. In patients with cirrhosis, the risk correlates with Child's classification. Elective surgery is contraindicated in patients with decompensated cirrhosis (Child's class C), acute alcoholic hepatitis, and acute viral hepatitis. Patients with chronic hepatitis without evidence of cirrhosis or hepatic decompensation generally do not have an increased complication risk (42).

Consider preoperative evaluation of the coagulation system in patients with liver disease, since they may also have impaired hemostasis. Closely monitor the fluid status, electrolyte balance, and blood pressure of these patients, and avoid using potentially hepatotoxic medications. Disturbances in hepatic function may lead to prolonged action of anesthetic agents that are metabolized in the liver. Sedatives, narcotic analgesics, and intravenous induction agents should be used with caution, as they may cause a prolonged depression of consciousness and precipitate hepatic encephalopathy if used in standard doses. Resistance to curare-like neuromuscular blocking agents may require large dosages for effectiveness, leading to problems with anesthetic reversal after surgery.

**DIABETES MELLITUS**

Patients with diabetes mellitus often have coexisting cardiac, renal, and neurologic disease (45). A patient may have severe cardiac disease with a history of silent myocardial infarctions without being aware of it. Patients with diabetes mellitus also have increased risk for postoperative infections and problems with wound healing. Most experts recommend that surgery be done on diabetic patients early in the day to simplify insulin administration and glucose monitoring (64).

Patients who take oral hypoglycemics to control their diabetes are usually managed after surgery with fingerstick glucose levels every 6 hours and a sliding-scale insulin dosage for blood sugars greater than 250 mg/dl. It may be necessary to hold long-acting oral hypoglycemics preoperatively to decrease the risk of hypoglycemia.

Insulin-dependent patients with type I juvenile onset diabetes must be carefully monitored after surgery for development of ketoacidosis. Type I diabetics require both insulin and glucose while fasting. Provide intravenous fluids containing dextrose while they are fasting and either sliding-scale subcutaneous or continuous intravenous insulin. Patients with type II adult onset diabetes are not at risk for ketoacidosis. They may be managed by either sliding-scale subcutaneous or continuous intravenous

insulin (45). While many treatment regimens have been suggested for insulin-dependent patients, on the morning of surgery we generally hold the patient's regular insulin and give one half of the usual dose of long-acting insulin, while administering an intravenous infusion of 5% dextrose.

## RHEUMATIC DISEASE

Patients with rheumatoid arthritis who have been treated with steroids may require supplemental steroid doses for stress during the perioperative period. Patients who have been treated with steroids for a year prior to surgery may have suppression of the hypothalamic-pituitary-adrenal axis. Normally, the adrenal glands respond to surgical stress by producing additional corticosteroids, equivalent to 300–400 mg of hydrocortisone per day, for the first 2 days after surgery. Patients whose adrenal response is suppressed are unable to produce the necessary corticosteroids; without supplementation, they may develop an adrenal crisis.

Patients who take daily doses of prednisone of 7.5 mg or more can be assumed to have adrenal suppression and require perioperative steroids. These patients should receive hydrocortisone hemisuccinate, 100 mg intravenously every 6–8 hours, beginning preoperatively and continuing for 72 hours after surgery. Other patients who may be at risk include those who have been on higher doses of prednisone (20 mg daily) at some point during the year before surgery, and even some patients who take chronic daily doses of less than 7.5 mg. These patients should undergo a cosintropin (synthetic adrenocorticotropic hormone) stimulation test to measure their adrenal response. If a patient's serum cortisol level rises above 20 mg/dl at 1 hour after injection of 25 units of cosintropin, then the adrenal axis is not suppressed, and perioperative steroid supplementation is not required (6) .

Patients with rheumatoid arthritis may also develop severe disease of the cervical spine. Obtain lateral flexion and extension radiographs of the cervical spine to rule out instability, which could result in neurologic injury during intubation or operative positioning.

## HUMAN IMMUNODEFICIENCY VIRUS

Advances in the medical management of human immunodeficiency virus (HIV) have extended the length of time before infected patients advance to acquired immunodeficiency syndrome (AIDS). It is expected that an increasing number of asymptomatic HIV-positive patients will require orthopaedic surgical procedures. Issues concerning the risk of transmission to the surgeon are addressed later in this chapter (see the section on Surgeon's Safety).

In the late 1980s and early 1990s, some surgeons expressed concern that the suppressive effect of anesthesia and surgical trauma on cellular immunity could be detrimental to the immunologic competence of patients with HIV infection. Initial concerns about potential disease progression as a result of surgery were based mainly on emotional preconceptions and anecdotal misconceptions (129).

A more substantial concern has been the potential for an increased postoperative infection rate in HIV-positive patients. In general, the risk of postoperative infection in patients with HIV who have not advanced to AIDS is not higher than that in the general population (88). The risk of surgical complications increases with the progression of disease. Factors reported to have the greatest correlation with outcome risk are a history of opportunistic infection, a CD4 level less than 200, a serum albumin less than 25 g/l, and cutaneous anergy (88). In a review of orthopaedic surgery in the HIV-positive patient, Luck (88) provides a surgical-risk rating system (Table 5.7). Attempts to correlate surgical outcome with CD4 lymphocyte counts alone has provided conflicting results; it is now generally accepted that CD4 counts alone are not a predictor of poor surgical outcome.

| *Status* | *Points* |
|---|---|
| CD4 cell level | |
| ≥500 | 0 |
| 200–500 | 1 |
| <200 | 2 |
| <100 | 3 |
| Anergy | |
| 1 test | 1 |
| 2 tests | 2 |
| Platelets | |
| ≤60,000 | 1 |
| Absolute PMNs | |
| ≤1000 | 1 |
| Serum albumen | |
| ≤25 g/l | 1 |
| AIDS-defining condition | |
| Opportunistic infection | 1 |
| Neoplasm | 2 |

Total points:
0 points = risk of postoperative complication for orthopaedic procedures about the same as general population
1 point = slight increased risk of postoperative complication
2—3 points = moderate increased risk of postoperative complication
4 or more points = higher risk of postoperative complication
Reproduced with permission from Luck JV. Orthopaedic Surgery on the HIV-positive Patient: Complications and Outcome. Instr Course Lect 1994;43:343.

***Table 5.7. Surgical Risk-rating System for HIV-positive Patients***

The rate of early postoperative infection and wound healing complications has been reported to be increased in patients with AIDS, but it is generally not increased in patients who are HIV positive without AIDS. In hemophilic patients, the incidence of late infection of prosthetic joints has been reported to be increased in patients who are also HIV positive, especially when their CD4 count is less than 200 (119,148). The incidence of late prosthetic joint infections in patients with hemophilia was higher than in the general population prior to the HIV pandemic. The infection risk may be even higher in the HIV-positive hemophilic patient, but current studies have not shown a statistically significant increase. At this time, there are no data to show that this risk applies to the HIV-positive nonhemophilic patient with a prosthetic joint (88a).

Several interventions may improve the medical status of patients with advanced-stage AIDS who must undergo surgery. Patients who have an unacceptably low white blood cell count (absolute polymorphonuclear leukocyte count < 1,000) may be treated with granulocyte-stimulating factor. Measles, mumps, and rubella vaccine should be updated 2 weeks before surgery in patients who are anergic (88). Many of the medications used to suppress HIV and to provide prophylaxis against AIDS-related opportunistic infections suppress bone-marrow function (88). As a result, AIDS patients may have chronic anemia that may benefit from treatment with erythropoietin (62). Patients with thrombocytopenia (platelet count < 60,000) should receive a platelet transfusion immediately before surgery.

## NUTRITION

Protein and calorie malnutrition has a significant effect on the healing of wounds and fractures, as well as on immunocompetence (138). Protein-calorie malnutrition is associated with depression of multiple aspects of the immune system response, including decreases in polymorphonuclear phagocytosis and bactericidal activity, circulating opsonins, complement levels, cell-mediated immunity, lymphocyte blastogenic responses to mitogen, number of T lymphocytes, function of T-helper cells, new antibody synthesis, and secretory IgA levels (1).

Many severely malnourished patients require emergent surgical intervention; they will likely benefit from increased postoperative nutritional support. Trauma and elective surgery both markedly increase a malnourished individual's nutritional needs.

## EFFECTS OF SUBSTANCE ABUSE

### *Tobacco*

Smoking adversely affects pulmonary function. Cessation of smoking before surgery may improve a patient's pulmonary function.

Recent studies have also demonstrated the deleterious effect of smoking on bone healing (80,120). In addition, nicotine is suspected of increasing the risk of postoperative wound infections. Studies have recommended that tobacco use be discontinued from a half day to a week prior to surgery, and for at least a week after surgery, to minimize nicotine's adverse effects on wound healing (80).

### *Alcohol*

A large percentage of traumatic injuries occur as a result of alcohol abuse, and the problem extends to patients in all communities. While it may be easy to identify the inebriated trauma patient, it may be far more difficult to identify alcohol abuse in a businessperson seeking a routine total joint arthroplasty. Approximately 10% of chronic alcoholics who abruptly discontinue drinking may develop significant alcohol withdrawal, possibly associated with a hyperkinetic state, hallucinations, and seizures. Consider treating all patients with suspected alcohol abuse with benzodiazepines, thiamine, and multivitamins. Advanced liver disease in chronic alcoholics may lead to bleeding disorders. Obtain a prothrombin time to screen for coagulation disorders, a platelet count to rule out thrombocytopenia, and a bleeding time to rule

out platelet dysfunction.

### OTHER DRUGS

Cocaine abuse has become increasingly prevalent. Withdrawal from cocaine is not medically dangerous; the half-life of cocaine is approximately 90 min, allowing most surgery to be delayed until after the period of acute intoxication. Cocaine abuse has been associated with several cardiac complications, and chronic abuse may accelerate coronary atherosclerosis, interstitial myocardial fibrosis, and congestive heart failure. Chronic abuse may also lead to recurrent pneumonia, pulmonary barotrauma, diffuse alveolar hemorrhage, and asthma (140).

Opioid dependence may result from both prescribed and illicit drug use. Patients with chronic preoperative pain may have developed dependence on opioids, a class of drugs that includes heroin, morphine, codeine, oxycodone, and meperidine. Withdrawal symptoms may develop as the patient's postoperative analgesia is reduced. To make the diagnosis of opioid dependence, the physician must observe at least three signs and symptoms of opioid withdrawal (Table 5.8). Treatment of opioid withdrawal may require methadone, a long-acting opioid, from which the patient may be weaned in an outpatient drug dependency program. Clonipine 0.1–0.3 mg may also be helpful in reducing the signs of opioid withdrawal, especially in patients with hypertension (140).

Dysphoric mood
Nausea or vomiting
Muscle aches
Lacrimation or rhinorrhea
Pupillary dilation, piloerection, or sweating
Diarrhea
Yawning
Fever
Insomnia

With permission from American Psychiatric Association. *Diagnostic and Statistical Manual of Mental Disorders*, 4th ed. Washington, DC: American Psychiatric Association, 1994.

***Table 5.8. Signs and Symptoms in Opioid Withdrawal***

The abuse of benzodiazepines (lorazepam, alprazolam, oxazepam, diazepam, and chlordiazepoxide) is extremely common and may lead to physiologic dependence and withdrawal. Signs and symptoms of withdrawal may include lethargy, ataxia, irritability, dysphoria, fatigue, tremor, and, rarely, seizure. Place patients who develop withdrawal symptoms on a longer-acting benzodiazepine (diazepam, chlordiazepoxide), which can be slowly tapered over 6–12 weeks. Propranolol, 20 mg every 6 hours, can be used for the treatment of hypertension, tachycardia, and anxiety that may occur during benzodiazepine withdrawal (140).

## BLOOD TRANSFUSIONS

The use of blood transfusions in orthopaedic surgery has become the focus of intense interest largely in response to concerns about posttransfusion disease and its consequences. Transfusion of donated blood can be minimized through the use of predonation autologous blood and through perioperative blood salvage (8).

The Joint Committee on Hospital Accreditation now requires an audit of the appropriateness of all transfusions as part of its hospital accreditation process. Failure to obtain informed consent and inappropriate or unnecessary transfusion have even become the focus for plaintiff's attorneys in cases of posttransfusion AIDS. The patient's physician, not the blood bank, has been the target of litigation in these cases (96).

Orthopaedic surgeons are frequently confronted with emergency or elective cases involving large amounts of blood loss. As the physicians responsible for prescribing transfusions, they must therefore be thoroughly familiar with the indications for specific blood components as well as the dangers of blood product transfusion.

Blood component therapy (using the individual components of fractionated whole blood) is based on the concept that patients are best treated by administration of only the specific blood product they require. The use of pooled blood products from multiple donors has been reduced to minimize the risk of disease transmission.

### PACKED RED BLOOD CELLS

Packed red blood cells (PRBC) are prepared by removing most of the plasma from a donor unit of whole blood. A unit of PRBC contains the same amount of hemoglobin as a unit of whole blood, but its hematocrit, depending on the preservative solution, is at least doubled (to 70%). Transfusion of PRBC rather than whole blood allows the recipient to receive the equivalent number of red cells without unnecessary expansion of the plasma volume. The use of PRBC allows blood banks to use supernatant cells and plasma to prepare other components. Neither whole blood nor PRBC is sterilized, so any plasma-or cell-associated organisms not detected by donor screening may be transmitted to the recipient by transfusion of these products.

Transfusion with PRBC is indicated when tissue oxygen delivery, particularly delivery to vital organs, is inadequate. A threshold for transfusion based on a given hemoglobin level cannot be set, since oxygen delivery depends on several factors, including hemoglobin level, inspired oxygen concentration, cardiac output, and pulmonary gas exchange. Increased cardiac output in a young, healthy patient may easily compensate for a low hemoglobin level, but an older patient with cardiac disease or one who is taking beta-blocker medication may be unable to increase cardiac output and will require transfusion.

Factors to consider when deciding whether a patient requires a PRBC transfusion include the patient's physiologic state, underlying medical condition, ability to compensate for diminished oxygen-carrying capacity, oxygen requirements of vital organs, and ongoing and anticipated blood loss (5).

### PLASMA AND ITS DERIVATIVES

A single unit of fresh frozen plasma (FFP) contains the plasma separated from one unit of whole blood obtained from a single donor. It contains normal plasma levels of labile (factors V and VIII) and stable clotting factors, albumin, and gamma globulin. ABO compatibility testing is mandatory for all recipients, and Rh compatibility testing is recommended for women of child-bearing age, as the small number of red cells that may be present in an Rh-positive unit could sensitize the Rh-negative patient. FFP is indicated for patients with plasma coagulation factor deficiencies, including those who are undergoing a massive transfusion and those with a heritable coagulation factor deficiency or coagulopathy secondary to severe liver disease. FFP is also indicated when immediate correction of anticoagulation due to warfarin is required, for replacement transfusion in plasmapheresis, for immunodeficient patients, and for patients with thrombotic thrombocytopenic purpura. The approximate volume of each unit of FFP is 200–175 cc. Larger-volume jumbo units, approximately 400–600 cc, are obtained from a single donor using apheresis. FFP should be administered immediately after thawing, with the dose guided by coagulation testing. The maximal effect of FFP declines within 2 to 4 hours after administration.

In 1998, the U.S. Food and Drug Administration licensed solvent/detergent plasma. This component is prepared from pools of 2,500 donor units, and it is treated with a solvent, tri-(*N*-butyl) phosphate, and a detergent, triton X-100, to inactivate lipid-enveloped viruses, including hepatitis B, hepatitis C, and HIV. Its drawbacks relate to the pooling process, which increases patient exposure to non-lipid-enveloped viruses such as hepatitis A and parvovirus B19. Solvent/detergent plasma is indicated for the rapid reversal of warfarin anticoagulation and therapeutic plasma exchange for microangiopathic hemolytic anemia. Its approximate volume is 200 cc and it must be used within 24 hours of thawing.

Cryoprecipitate is prepared by collecting the precipitate that forms during slow thawing of FFP at refrigerator temperature. It contains fibrinogen, fibronectin, and factor VIII. One unit of cryoprecipitate contains approximately 10 ml of plasma and an average of 200 mg of fibrinogen, or 80–120 units of factor VIII activity. Cryoprecipitate is especially useful as a source of fibrinogen in consumptive coagulopathies. It is also indicated for the treatment of patients with hypofibrinogenemia and those with mild hemophilia A. Patients with severe classic hemophilia are treated with factor VIII concentrate. In view of the changing availability of stored coagulation products and the increased risk associated with the administration of some of these products, we recommend consultation with a hematologist for the treatment of any complex coagulopathy.

### PLATELETS

Platelets are supplied either as single-donation units or in packs that contain a pool of platelets from about six to ten donors. Administration of pooled platelets poses a greater infection risk than does that of single-donor units. Pooled platelets are more readily available, however, since they are easily obtained as a component of whole blood donations. A more complex apheresis process must be used to obtain a sufficient quantity of platelets from a single donor.

Platelets must be stored in special containers that permit oxygen exchange, and they must be preserved at room temperature with constant agitation. Properly stored, they can be used for up to 5 days after collection. Platelet concentrates should be typed for ABO, and because they are contaminated with red cells they should be tested for the Rh antigen. One unit of platelets separated from a single unit of whole blood contains at least $5.5\times10^{10}$ platelets and usually raises the platelet count of a 70 kg patient by about $7{,}500\times10^{9}$ platelets per liter. The increase in posttransfusion platelet count may be far less than anticipated for a variety of reasons, including fever, splenomegaly, rapid hemorrhage, disseminated intravascular coagulation, and refractoriness due to formation of anti-HLA antibodies. It must be appreciated that the best test for platelet effectiveness is cessation of bleeding.

Platelet transfusion is indicated for bleeding that results from thrombocytopenia. Massive transfusion—at least 20 units of blood in a 24-hour interval—may result in generalized oozing, with platelet counts lower than $80\times10^{9}$/liter, suggesting the need for platelet transfusion. The administration of platelets in this setting should be based on documented platelet counts. Do not administer platelets prophylactically except in the setting of preoperative platelet deficiency—a platelet count of less than $10\times10^{9}$/liter. Patients who are actively bleeding, whose bleeding time is greater than twice normal, and whose platelet count is less than $50\times10^{9}$/liter should receive platelets. The preoperative platelet count of a surgical candidate should be at least $60–80\times10^{9}$/liter.

## COMPLICATIONS OF BLOOD TRANSFUSION

Although significant strides have been made to ensure a safe blood supply, the recognition of new transfusion-related complications, and the inability to totally eradicate previously recognized complications, reaffirms the admonition that blood should be transfused only when absolutely necessary (11). Most of the complications associated with transfusion of blood and blood products are related to an immune response to incompatible units, to an adverse physiologic response to transfusion, or to infectious disease transmission (Table 5.9).

| Risk | Prevalence |
|---|---|
| Transfusion reaction | 5%[a] |
| Fatal hemolytic | <1:1,000,000[b] |
| Nonfatal hemolytic | 1:25,000[c] |
| Fever or urticaria | 1–3:100[a] |
| Transmission of disease | |
| HIV-1 | 1:200,000–1:800,000[b] |
| Hepatitis B | 1:200,000[d] |
| Hepatitis C | 1:100,000[e] |
| Immunomodulation | |
| Infection | 20% to 25% increase postoperatively[f] |

[a] As reported in the study by Aubuchon JP, et al. *Increasing the Safety of Blood Transfusion*. Washington, DC: American Red Cross, 1992.
[b] As reported in the study by the Centers for Disease Control. Mortality Attributable to HIV Infection/AIDS—United States, 1981–1990. *JAMA*, 1991;265:848.
[c] As reported in the study by Dodd RY. The Risk of Transfusion-Transmitted Infections (editorial). *N Engl J Med*, 1992;327:419.
[d] As reported in Gross JB Jr. Clinicians' Guide to Hepatitis C. *Mayo Clin Proc* 1998;73:143-155.
[e] As reported in the study by Fernandez MC, et al. Blood Transfusion and Postoperative Infection in Orthopedic Patients. *Transfusion* 1992;32:318.
Adapted with permission from Lance ML, Healy WL. Blood Transfusion in Orthopaedic Operations: Current Concepts Review. *J Bone Joint Surg* 1998;78A(8):1268.

***Table 5.9. Estimated Risk of Allogenic Blood Transfusion***

Safe transfusion practice requires strict policies with meticulous guidelines for patient identification, blood collection and labeling, pretransfusion testing, and transfusion administration and monitoring. These policies are necessary to decrease the risk of human error; a fatal transfusion reaction can occur from administration of an improperly labeled specimen, confusion of specimens in the laboratory, or transfusion of blood to the wrong patient.

### *Nonhemolytic Transfusion Reactions*

The most frequent adverse reactions associated with blood transfusions are nonhemolytic transfusion reactions, which occur in as many as 2% to 5% of all transfusions (11). Although they may cause discomfort to the transfusion recipient, these reactions are usually not serious. Febrile reactions, the most common of these complications, most often result from the recipient's antibody response to leukocyte antigens in the donor blood. Chills, fever, headache, myalgia, nausea, and, occasionally, severe rigors may occur during the transfusion or up to several hours after it has been completed. Treatment of febrile reactions is supportive and rarely requires cessation of the transfusion. Approximately 15% of patients who have such a reaction will react similarly with future transfusions. Leukocyte-removal filters diminish the likelihood of febrile reactions, but use of such filters is expensive and retards blood flow. For these reasons, they should be reserved for those patients who have had at least two adverse reactions.

Most allergic reactions to transfusion are mild, consisting only of slight urticaria. Like febrile reactions, they usually occur toward the end of the transfusion of erythrocytes. Allergic transfusion reactions, thought to be related to the presence of foreign protein in the transfused blood, can cause urticaria associated with itching, shaking chills, fever, and erythema. The more serious findings of laryngeal edema and bronchospasm (anaphylaxis) fortunately are much less frequent, occurring in less than 1% of such reactions (34). For most patients, treatment is supportive and the reaction may be anticipated to subside spontaneously within several hours of the transfusion. The risk of an allergic response is increased for individuals with hay fever, atopy, or asthma. These patients may benefit from pretreatment with diphenhydramine HCl or possibly with hydrocortisone. Patients who have previously had multiple severe allergic reactions to transfusions are at high risk of developing further such reactions. These reactions may be ameliorated by using washed components.

### *Hemolytic Transfusion Reactions—Acute and Delayed*

Hemolytic transfusion reactions are uncommon, but the high morbidity and mortality rates associated with them mandates a thorough knowledge of their manifestations and treatment. Estimates of the risk of hemolytic transfusion reactions range from 1:4,000 to 1:25,000 (83,100,115). Of the fatal reactions, nearly half have arisen from administrative and clerical errors, including mislabeled samples and incorrect patient identification. Hemolytic transfusion reactions occur with small quantities of transfused erythrocytes, usually less than 50 cc (10). The classic signs and symptoms include chills, fever, chest pain, and flank pain. Less commonly, patients experience nausea, hemoglobinuria, shock, and a subjective sensation of impending death.

General anesthesia masks many of the classic signs and symptoms. In that situation, the patient's only manifestation may be the oozing that occurs because of the consumption of clotting factors. The consequences of hemolytic transfusion reactions are serious and may be fatal, arising mainly from the effects of intravascular hemolysis on the renal and coagulation systems. Immediately stop the transfusion and return the unused blood and a sample of the patient's own blood to the blood bank for recrossmatching.

Of greatest importance is immediate determination of the presence of hemoglobinemia. Visually compare the postreaction serum with the pretransfusion specimen in the blood bank. Verify that the identity of the unit and the requisition correspond to the patient, confirming that the patient has received the intended unit of blood. Perform a direct antiglobulin test on the patient's red cells. Other tests indicated when hemolytic reaction is strongly suspected include retyping the transfused blood, and obtaining serum bilirubin and urinary urobilinogen. Hemoglobin concentration, platelet count, partial thromboplastin time, serum fibrinogen level, and serum potassium levels may be necessary in patients with overt hemolysis. If hyperkalemia due to hemolysis is suspected, an electrocardiogram will confirm the diagnosis before the clinical laboratory determination.

Management of the patient with an immediate acute hemolytic reaction initially involves hydration with generous administration of fluids and diuretics. Monitor urinary output with an indwelling catheter and maintain output at 75–100 ml/hour. Use intravenous fluids and pressors, if necessary, to prevent hypotension, thereby ensuring an adequate renal blood flow. If there is no diuresis, indicating renal failure, cease attempts at hydration. Intravenous furosemide may be necessary to maintain adequate renal perfusion. Contact consulting services immediately; consider transferring the patient to an intensive care unit.

Delayed hemolytic transfusion reactions are less dramatic events than acute hemolytic transfusion reactions. A delayed reaction is characterized by initial survival of transfused erythrocytes, followed by hemolysis within 1 to 7 days (116,139). The reaction results from an anamnestic response of an antibody that was formed after a previous sensitizing event, but that is no longer detectable in pretransfusion testing. The patient usually manifests only anemia, or no increase in hemoglobin in response to the transfusion, but he may also have chills, fever, and jaundice. Renal failure is extremely rare.

Delayed hemolytic transfusion reactions may occur more often than acute reactions and may frequently be missed. In one series, one third of the patients with delayed

hemolytic transfusion reactions were asymptomatic and were diagnosed only when a second transfusion was ordered (100). If you are considering returning to surgery a postoperative patient in whom there is continued occult blood loss from a traumatic or surgical source, first rule out delayed hemolytic transfusion reaction as a possibility. Unnecessary surgery can be avoided if the diagnosis of delayed hemolytic transfusion reaction is made.

### *Complications of Massive Transfusion*

Significant problems may arise when large amounts of blood are transfused. The term *massive transfusion* refers to transfusion of more than 10 units of blood in a 24-hour period. Hemostatic defects, hypothermia, and metabolic abnormalities have been reported in association with the transfusion of such volumes of blood. Anticipating these problems and taking appropriate measures to treat or prevent their development can be life saving.

Abnormal bleeding associated with massive transfusion may result from dilutional thrombocytopenia, disseminated intravascular coagulation, low levels of factors V and VIII, or the occurrence of a hemolytic transfusion reaction. Dilutional thrombocytopenia is the most likely cause of a hemorrhagic diathesis in a patient who has received a massive transfusion, since the transfused stored blood lacks functional platelets. Patients who manifest acute thrombocytopenia develop a hemorrhagic diathesis at a much higher platelet count than do patients with chronic thrombocytopenia, and a platelet count of $100\times10^9$/l or less is a reasonably accurate guide to predicting a bleeding problem from dilutional thrombocytopenia.

Other coagulation factor deficiencies that may occur with massive transfusions include deficiencies of factors V and VIII. These factors gradually decrease to 15% and 50% of normal, respectively, after 21 days of storage (97), and they are therefore in lower concentrations in stored blood than in fresh blood or plasma. Hemostasis is unaffected even though levels of factors V and VIII are reduced to as low as 10%–20% of normal; therefore, their deficit is an unlikely primary cause of bleeding during massive blood transfusion. Nevertheless, these deficiencies may intensify bleeding from other causes (98). Disseminated intravascular coagulation is fairly uncommon and is associated with a high rate of mortality. Discussion of this entity is beyond the scope of this chapter.

The possibility of a hemolytic transfusion reaction must be considered when a hemorrhagic diathesis develops following blood transfusion. A massive transfusion may demand such speed in blood processing that the risk of human error increases significantly.

Rapid infusion of large volumes of unwarmed blood, which has been stored at 4°C, can cause rapid lowering of the core body temperature by as much as 10–15°. Hypothermia causes shivering, which increases oxygen consumption dramatically and may increase ventricular irritability and even induce cardiac arrest if the hypothermia is profound. Blood may be warmed toward body temperature, but it should not be warmed above 37°C. Warming must be done with a special device that warms the blood during its passage through the transfusion set. The warming system must be equipped with a visible thermometer and, ideally, with a warning system to prevent overheating. Blood will hemolyze if heated above 45°C.

A number of metabolic abnormalities, such as acidosis, hyperkalemia, and reduction in the level of ionized calcium, have also been associated with the transfusion of massive volumes of stored blood. Monitor patients closely for these problems and try to prevent them by appropriate treatment.

### *Effect of Allogenic Transfusions on the Immune System*

Several studies have highlighted the potential adverse effects on the immune system of large homologous blood transfusions. The concern is an increased risk of postoperative infections following allogeneic blood transfusions (36,40,79,101). Other investigators have questioned how large an effect, if any, allogeneic blood transfusions have on the postoperative infection rate (151).

Concerns have also been raised about the potential of blood transfusions to impair the immunosuppressive response, decreasing the patient's ability to combat cancer recurrence or metastatic disease. In one study of 155 patients with nonmetastatic osteosarcoma treated with amputation and adjuvant chemotherapy, perioperative blood transfusion was associated with a significant decrease in disease-free state and overall decreased survival (27).

## TRANSFUSION-TRANSMITTED DISEASE

The potential for disease transmission has been substantially reduced through donor education, medical and social history review, exclusion of anonymous donors, and improved serologic screening methods. Despite these improvements, risk of disease transmission remains a concern with any blood transfusion. The greatest threat to the safety of the blood supply is blood donation by seronegative donors who are infectious but who have not yet undergone seroconversion (131).

Although new techniques of testing, such as direct viral detection tests, will improve the safety of the blood supply, it remains unlikely that any test or combination of tests will ever decrease the risk for disease transmission to zero (131).

### *Hepatitis B Virus*

Screening blood donors for hepatitis B virus (HBV) surface antigen (HBsAg) has greatly reduced the incidence of transfusion-related hepatitis B. Infection risk is estimated to range from 1 in 200,000 transfusions to 1 in 800,000 (83). Ten percent of patients infected with HBV develop chronic hepatitis, and less than 1% develop fulminant hepatitis. Acute HBV infection is self-limited in approximately 90% of cases.

### *Hepatitis C Virus*

Hepatitis C (known previously as non-A, non-B hepatitis) is a serious health threat. It is estimated that as many as 4 million Americans (1.5% of the population) are infected with HCV. While acute HBV infection is self-limited in 90% to 95% of cases, 85% of patients with acute hepatitis C develop chronic infection (58). Chronic HCV infection can lead to cirrhosis, liver failure, and hepatocellular carcinoma. In the United States, HCV accounts for approximately 20% of cases of acute hepatitis, 70% of chronic hepatitis, and 30% of end-stage liver disease (66). HCV infection is the disease that most often necessitates liver transplantation. Approximately 10,000 people die each year from HCV infection, and the number is expected to triple in the next 10–20 years.

The natural history of HCV infection has not been fully characterized. The clinical course of HCV infection is variable, with fewer than 20% of patients developing symptoms of infection. Since most infections are asymptomatic, patients do not know that they are infected. Chronic HCV infection is typically a very slow process in which symptoms may not be noted for decades after infection. One investigator estimates that cirrhosis occurs in at least 20% of patients within 20 years of infection (103). The risk of hepatocellular carcinoma increases after the development of cirrhosis, with a reported 5-year risk of 7% and a 10-year risk of 14% (39).

Although viewed as less threatening by patients, transmission of HBV and HCV has occurred far more often than transmission of HIV. Patients who received blood transfusions prior to the introduction of screening tests for HCV in 1990 are at risk for having contracted chronic HCV infection. Widespread testing and educational efforts have been launched to identify this group of patients who are at risk. Patients who received blood transfusions prior to July 1992, when more sensitive screening tests were introduced, should be tested for exposure to hepatitis C virus. A nationwide “targeted look-back” has begun in the United States, in an attempt to find patients who received blood from donors who subsequently tested positive for hepatitis C. The risk of HCV infection prior to implementation of anti-HCV testing in mid 1990 was conservatively estimated at 1% per unit of transfused blood. These estimates predict that during that time, 40,000 people acquired HCV infection yearly from blood transfusions (3). With the current screening methods, the risk of HCV transmission is about 0.001% per unit of blood transfused (58).

### *Human Immunodeficiency Virus*

Before HIV antibody screening of blood began in 1985, the risk of receiving a seropositive unit of a blood component was approximately 0.04% (2). By November 1995, the number of cases of transfusion-associated cases of AIDS diagnosed and reported in the United States was 7,700 (24). Many previously asymptomatic patients continue to be diagnosed each year from transfusions administered prior to 1986.

After the introduction of HIV antibody screening, however, the number of transfusion-associated AIDS cases that have occurred from screened transfusions fell to less than 20 cases per year from 1986 to 1991 (132). Concern over potential transmission of the HIV virus has resulted in new laws requiring consent for blood transfusion, alterations in transfusion policies, and use of alternative techniques to avoid homologous blood transfusion.

Several mechanisms to minimize the risk of transfusion-associated AIDS are in place. Elimination of the “high-risk” blood donor through questioning or through self-exclusion has proven partially effective. As a result, the prevalence of HIV-positive donors was reduced by nearly two thirds from 1985 to 1987 (113). A second and more effective adjunctive mechanism was the implementation of anti-HIV testing (153). Used for screening since 1985, this test is more than 99% sensitive. All positive results detected by repeated enzyme immunoassay must be confirmed by western blot testing. Since the advent of screening methods, the risk of transfusion-transmitted HIV infection has been estimated to be 1 in 493,000 (95% confidence interval, 202,000 to 2,778,000) (131)—about one-fifth the risk of HCV

transmission by blood transfusion.

Because of the time period that exists between the onset of the infection and the development of detectable antibodies, there remains a small risk of HIV transmission from screened blood donors. Refinements in the screening assays have narrowed this period to approximately 22 days (131). The polymerase chain reaction technique can be used to identify viral nucleic DNA or RNA before an antibody response develops and may further reduce the risk of disease transmission (154).

The advent of AIDS greatly increased interest in directed donation programs, in the use of autologous blood, and in avoidance of blood transfusion unless specifically indicated. Patients with hemophilia are far more likely to have developed transfusion-associated AIDS than any other patient group in a typical orthopaedic surgery practice. Previously, factor VIII and factor IX concentrate used in the treatment of hemophilia was derived in commercial lots from 10,000 to 30,000 donors, resulting in an extremely high risk of disease transmission. The risk of new HIV infection in these patients is directly related to the volume of clotting factor and blood component used, and it has decreased markedly since the introduction of heat-treated concentrates prepared from plasma screened for HIV antibody. Development of factor VIII concentrate derived from recombinant techniques has significantly reduced the risk of transfusion-associated AIDS in this patient population.

### *Other Transmissible Infectious Agents*

Transmission of another human retrovirus, HTLV-I, has also been reported as a result of blood transfusion. HTLV-I infection has been associated with adult T + -cell leukemia and HTLV-I–associated myelopathy (HAM), also termed tropical spastic paraparesis (127). The incubation period between infection and manifestations of these diseases can be extremely long. This retrovirus is most common on the island of Kyushu, Japan, and in parts of the Caribbean basin. Only a small percentage of the population in the United States is believed to be HTLV-I seropositive (approximately 0.025% of donors tested). Nevertheless, blood-donor screening for antibody to HTLV-I was initiated in 1989 due to these disease associations (20). Seroconversion for antibody to HTLV-I is reported to have occurred in one patient, who developed an associated myelopathy following multiple trauma and subsequent transfusion with many units of banked blood products. The report of this seroconversion underscores the potential value of screening blood donors for antibody to this virus (32).

Cytomegalovirus (CMV) may be the most common viral agent transmitted via blood transfusion, although it is likely that many of the cases of posttransfusion CMV infection are due to reactivation of existing infection—possibly because of immunosuppression in the patient—rather than to primary infection (156). The prevalence of CMV infection, endemic in the United States, increases with age, so that as many as 70% of blood donors over age 60 are infected by CMV. Posttransfusion CMV infection is not known to be a significant clinical problem in the immunocompetent transfusion recipient, and blood is not routinely tested for this agent.

Current indications for blood products that are from donors with a negative test for IgG anti-CMV include AIDS patients who are CMV-seronegative, CMV-negative bone marrow transplantation recipients, and solid-organ transplant recipients who receive organs from CMV -seronegative donors (146). Since CMV is carried in the transfused leukocyte, leukocyte-removal filters can be used to further reduce the risk of transfusion-transmitted CMV to these patients. Concern also exists over the possible transmission of prions, which cause spongiform encephalopathies such as variant Creutzfeldt-Jakob disease, in which there is rapidly progressive dementia and motor dysfunction (22). In March 1997, the World Health Organization concluded that there has been no proven or even probable transmission of Creutzfeldt-Jakob disease through blood products (13).

Although, theoretically, a large number of other infectious diseases could be transmitted by blood transfusion, few pose clinical problems. Blood donor testing and the use of screening to exclude donors who have been exposed to malaria, syphilis, toxoplasmosis, yersiniosis, salmonellosis, typhus, trypanosomiasis, herpesvirus infections, brucellosis, Colorado tick fever, leishmaniasis, Epstein-Barr virus, and filariasis minimize the potential risk of transmission of such diseases through donated blood.

## METHODS TO MINIMIZE USE OF HOMOLOGOUS BLOOD TRANSFUSIONS

The risk of infection and death associated with blood transfusion cannot be completely eliminated, even with the best screening methods. The goal of reducing the risks associated with transfusions, therefore, is directly related to reducing the number of transfusions required by surgical patients. The methods available for minimizing blood transfusions include meticulous hemostasis in the operative field, hypotensive anesthesia, hemodilution, use of prebanked autologous blood, intraoperative and postoperative blood salvage, and acceptance of a lower hematocrit “transfusion trigger.” Concern about transmission of human immunodeficiency virus has heightened interest in these methods for orthopaedic surgeons and their patients and has made blood conservation an important part of every surgeon's practice.

### *Minimizing Intraoperative Blood Loss*

Intraoperative blood loss can be minimized by both the surgeon and the anesthesiologist. The most effective way to reduce the need for blood transfusion is to control the amount of blood lost during surgery. Methods under the surgeon's control include careful operative exposure through avascular tissue planes; good hemostasis using an electrocautery and ligatures; short operating time; and the judicious use of collagen pads, thrombin powder, sterile bone wax, and tourniquets (83).

### *Hypotensive Anesthesia*

Multiple studies have shown that using hypotensive anesthesia can effectively reduce intraoperative blood loss in orthopaedic surgical patients, particularly during spine surgery and total hip arthroplasty surgery (91,105). A series of 24 Jehovah's Witness patients had a 30% reduction in intraoperative blood loss with the use of hypotensive anesthesia, compared with the blood loss for the previous arthroplasty on their contralateral hip under normotensive anesthesia (105). Nelson et al. recommend the combined use of narcotic and inhalant anesthesias to achieve the goal of a stable hypotensive level throughout the surgical procedure. They further recommend positioning the patient to reduce engorgement of blood vessels at the surgical site, adhering closely to the use of local measures to minimize blood loss (107). These recommendations deserve close attention.

### *Hemodilution*

Another technique that has been shown to decrease the need for homologous blood transfusion is hemodilution. Whole blood collected from the patient immediately before surgery is simultaneously replaced with colloid or crystalloid to maintain a constant circulating blood volume. Since the blood lost during surgery is diluted and has a lower hematocrit, fewer red cells are lost. The whole blood that was collected preoperatively is transfused after the major blood loss has ceased, or before then if necessary because of hypoxemia, hypotension, or tachycardia. The hemodilution technique has been recommended for any elective surgery procedure in which a 1,000 cc blood loss is anticipated (108).

### *Autologous Blood Donation*

Procuring predeposit autologous blood is a safe and simple procedure (10,149,161). After a patient is determined to be medically eligible for autologous transfusion and informed consent has been obtained, blood is collected and stored. During the donation period, place patients on oral iron supplementation. The rate of donation of blood is limited primarily by the donor's ability to regenerate and maintain an adequate red-blood-cell mass. Multiple serial autologous donations may be obtained as long as the donor's hemoglobin level is at least 11 g/dl, or the hematocrit is at least 33%. These levels are considerably lower than those required for voluntary homologous donation.

As many as 10 units of blood have been stored preoperatively using this method (42). Current studies are evaluating the role of erythropoietin to increase erythropoiesis in patients undergoing autologous blood donation (see below). The only requirement in addition to those of standard blood banking techniques is special identification and segregation of the donor's blood to ensure that it is appropriately and safely redirected to the donor.

### *Intraoperative Blood Salvage and Reinfusion*

Intraoperative blood salvage was initially associated with serious risks, including disseminated intravascular coagulation, fatal air embolism, hemoglobinemia, and hemolytic nephrotoxicity (16,78). Recent improvements in the design of the autotransfusing device have eliminated many of the problems that had been associated with intraoperative autologous transfusion. Intraoperatively, lost blood is suctioned into an enclosed system in which the blood cells are separated from the debris and serum through a centrifugation process. The autologous red cells are washed, suspended in a saline solution, and then reinfused. As much as 50%–60% of the shed red blood cells may be salvaged by this technique.

Mean transfusion requirements are significantly less when intraoperative autologous transfusion is used than when it is not used, and the combined use of preoperatively deposited and intraoperatively collected autologous blood can often eliminate the need for homologous transfusion (57). The technique has been shown to be effective in orthopaedic patients undergoing spine surgery, revision total joint arthroplasty, and acetabular fracture surgery (31,57,159). Indications for its use include patients in whom the estimated intrasurgical blood loss is expected to be more than 900–1,500 cc (44,150). Potential complications of this technique include

cell hemolysis and air embolism (150).

### *Postoperative Blood Salvage and Reinfusion*

Postoperative salvage has also been shown to be safe and effective for both adults and children (9,17,43,61,73). Postoperative salvage consists of reinfusing unwashed, filtered salvaged blood from surgical drains during the early postoperative period (first 4–6 hours) when drainage is at its greatest. Unwashed shed blood is deficient in coagulation factors and platelets and may contain free hemoglobin and fibrin degradation products from hemolysis and lysis of clots, in addition to fat particles, bone fragments, methylmethacrylate monomer, and vasoactive mediators.

These may cause adverse effects such as hypotension and hyperthermia when the shed blood is reinfused. Postoperative autologous transfusion with unwashed shed blood should be limited to two units, and reinfusion should occur within 6 hours after the start of the collection (83). Relative contraindications for the postoperative salvage of shed blood include tumor and infection (83).

### *Lowering the "Transfusion Trigger"*

Several years ago, most physicians regarded a perioperative hemoglobin level of 10 g/dl as an indication for transfusion (141). The physiologic basis for this value was not well proven. A better appreciation of the risks associated with the administration of blood products, however, has brought about the need to reevaluate the "transfusion trigger" for perioperative blood administration. Studies have demonstrated that patients can safely undergo anesthesia and surgery with preoperative values as low as 8 g/dl (142). Some patients with chronic anemia, such as those with chronic renal failure, tolerate hemoglobin levels less that 7 g/dl (102).

When deciding the threshold below which transfusion should be performed, consider the physiologic parameters unique to the individual patient rather than arbitrary hemoglobin or hematocrit levels. The decision to transfuse should take into account the duration of the anemia, the intravascular volume, the extent of the operation, the probability of massive blood loss, and the presence of coexisting medical morbidity, such as impaired pulmonary function, inadequate cardiac output, myocardial ischemia, or cerebrovascular or peripheral vascular disease (102).

Monitoring with intraarterial lines, pulmonary artery catheters, and continuous electrocardiography, as well as frequent sampling for hemoglobin levels, has proven beneficial in determining when to transfuse (84). Instead of scheduling invasive monitoring for every patient, Nelson et al. (107) have recommended dividing patients into high-risk and low-risk categories on the basis of clinical judgment. They suggest monitoring hypovolemia in low-risk patients by following routine vital signs. It may be successfully managed with the infusion of crystalloid solutions if the hemoglobin is above a level of approximately 7 g/dl or the hematocrit is above 20%.

In this scheme, patients in the high-risk category require not only more invasive monitoring but also, as a rule, higher hemoglobin and hematocrit levels than do low-risk patients. In these high-risk patients, the relationship between anemia and signs such as tachycardia, tachypnea, and low mixed venous oxygen saturation should be evaluated more rigorously, and transfusion of PRBC is recommended until the physiologic signs of anemia are reversed (107).

### *Erythropoietin*

Natural erythropoietin is secreted by the kidney in response to hypoxemia and hemorrhagic stress. It binds to receptors in the bone marrow, stimulating the production of red blood cells (83). Recombinant human erythropoietin has a wide variety of potential clinical applications. It is approved for the treatment of anemia due to several conditions, including chronic renal failure and malignancy, and in HIV-positive patients undergoing treatment with zidovudine. Its potential uses in orthopaedic surgery are currently being explored (19).

One possible role for erythropoietin in orthopaedics is as an adjunct during preoperative autologous blood donations for elective surgery (55). Often, the number of units that can be donated is limited as the patient becomes anemic. Some orthopaedic patients also have medical conditions resulting in mild chronic anemia. Many patients' preoperative hematocrits are lowered following autologous donation, and 10% to 20% still require allogeneic blood transfusions (54). Anemia (a hematocrit of 39% or less) at the time of the first autologous donation is reported to be the most important indicator that a patient will require allogeneic blood transfusions in addition to autologous units (56).

Recombinant human erythropoietin has been shown to be of no clinical benefit in patients without preexisting anemia (hematocrit > 39%) undergoing preoperative autologous blood donation, as these patients were able to stimulate sufficient erythropoiesis through their endogenous erythropoietin response (54). In patients undergoing autologous blood donations who have preexisting anemia, the role of recombinant human erythropoietin remains controversial. Recombinant human erythropoietin has been shown to be effective in decreasing the need for allogeneic blood transfusions in hip arthroplasty patients who did not donate autologous blood (21,38).

### *Directed Donor Blood*

More and more patients are requesting donor-designated blood transfusions, or directed donations, as an alternative to standard homologous blood transfusions. This transfusion practice, unlike autologous blood transfusion, is controversial. There is no evidence to suggest that it is any safer than homologous blood transfusion, and under some circumstances (e.g., graft-versus-host disease in surgical patients who have received blood from first-degree relatives), it may be extremely deleterious (51,65,109,147). In addition, there is concern that individuals asked to donate for family members may feel compelled to violate the usual voluntary self-exclusion criteria. Our blood bank provides directed donor service for patients who desire it solely for reasons of public relations rather than for any medical reason.

## PREOPERATIVE SURGICAL PLANNING

The value of surgical planning has been well described, and its importance has grown as surgery has become more technically complex. Surgeons who think through the operative procedure in advance can easily alter the sequence of steps to provide the optimal outcome, a luxury not often available in the middle of surgery. Preoperative surgical plans have most commonly been used for complex acute and reconstructive trauma, osteotomies, total joint arthroplasty, and other technically challenging procedures (92). The benefits of preoperative planning can also be applied to simple, straightforward cases.

Planning should include making both a drawing of the planned procedure and a written series of steps and reminders. Mast et al. have described the "surgical tactic" as an outline of sequential steps used in the operating room that will bring about the desired end result (93). While a well-thought-out preoperative plan is not a guarantee of success, it may reduce the potential for intraoperative error and allow the operation to proceed smoothly from step to step. It is important to share these plans with the anesthesiologist and operating room staff, so that they will be able to anticipate all the needs of both surgeon and patient.

In setting forth the steps of the operation, advance planning helps ensure that all necessary equipment is requested and available, and that all support personnel have been brought on board. As the steps are planned, the required equipment is listed.

Several techniques have been described for creating preoperative drawings:

Using the direct overlay technique
Using a reverse tracing of the uninjured or unaffected side
Using the anatomic knee joint axis or mechanical axis of the limb

No single technique is superior: different methods may be better suited for different situations. In some cases, a combination of methods may be used to obtain the best possible preoperative plan.

A number of items are required to make preoperative drawings:

Good-quality anteroposterior (AP) and lateral radiographs of the injured or affected extremity or joint
Good-quality AP and lateral radiographs of the contralateral uninjured or unaffected extremity or joint
Tracing paper or clear overexposed x-ray film
Colored pens or pencils
A light box
Implant templates

The AO (Arbeitsgemeinschaft für Osteosynthesefragen) preoperative planning kits, which include templates for all the AO fracture implants, are an excellent resource

for planning operative fracture care. The textbook *Planning and Reduction Technique in Fracture Surgery* by Mast, Jakob, and Ganz (93) provides numerous case examples with preoperative plans and surgical techniques for fracture reduction and fixation. Obtaining adequate, good-quality x-ray films is a major hurdle in preoperative planning in trauma patients. Radiographs obtained without overlying plaster splints are best for imaging individual fracture fragments. Traction views are frequently beneficial in correcting overlap or malrotation of fragments. Traction views may be especially helpful in the supracondylar femur and distal humerus fractures, where muscle pull often malrotates the distal fragments.

Radiographs vary in their magnification depending on the body habitus of the patient and the length of the beam from the cassette. The amount of magnification can vary from 6% to 36% with a 40-inch exposure distance, and from 3% to 17.5% with a 72-inch exposure distance (144). Most templates are magnified by 10% to 15% to account for the radiographic magnification. Special radiographic magnification markers can be applied to the skin at the level of the bone to determine the individual magnification, but this degree of accuracy may not always be necessary. Exact measurements can also be obtained from computed tomography.

In cases where an angular deformity is present, the greatest deformity usually exists in a plane other than either the AP or the lateral view. Mathematical formulas can be used to determine the maximal deformity (117,123). A properly planned oblique osteotomy can provide multiplanar correction of a malunion (69,125,128). Plain radiographs also do not account for rotational deformities that may be present. Rotational deformities may be evaluated by physical examination, and if necessary more precise evaluation can be obtained by axial computed tomography (CT) scans. (See Chapter 32 for more details.)

## TECHNIQUES FOR CREATING PREOPERATIVE DRAWINGS

### *Direct Overlay Technique*

The direct overlay technique is best employed in the case of fractures involving the shaft of relatively straight bones. Follow these steps for a simple fracture:

- Obtain a radiograph of the fracture (Fig. 5.1*A*).

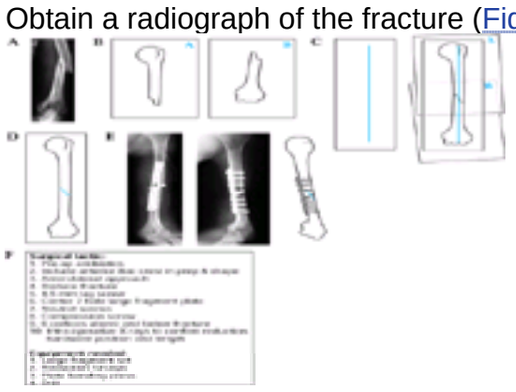

***Figure 5.1.*** Preoperative planning for humeral shaft fracture using the direct overlay method. **A:** Radiograph of fracture. **B:** Tracings of each fracture. **C:** Reduction of the fracture. **D:** Tracing of the “reduced” fracture. **E:** Addition of appropriate screws and plates. **F:** The surgical tactic.

- On separate pages, trace the proximal fragment, the distal fragments, and any intervening comminution or butterfly fragments (Fig. 5.1*B*).
- Draw a vertical line on a separate piece of paper.
- “Reduce” the proximal and distal fragments by aligning their long axes with the vertical line (Fig. 5.1*C*).
- “Reduce” any comminution or butterfly fragments into a best-fit position.
- Make a final composite drawing of the reduced fracture (Fig. 5.1*D*).
- Using selected templates, trace the appropriate fixation implant (Fig. 5.1*E*).
- Write out the surgical tactic, listing all sequential steps required to achieve the planned result (Fig. 5.1*F*).

Rather than using separate sheets of paper for each fragment, simple fracture patterns may be drawn onto a single sheet of tracing paper by rotating the paper into correct alignment as each fragment is drawn. Alternatively, cut out the individual fracture fragments, creating a jigsaw puzzle of fracture fragments.

Occasionally, individual fracture fragments will not fit into place—when the fragment is malrotated and its radiographic projection does not match either the true AP or lateral view. In these cases, make an approximation of the size and shape of the fracture fragments, which may sometimes be inferred from the space left over after other fragments are drawn in their “reduced” positions.

### *Reverse Tracing of the Opposite Extremity*

To use a reverse image of the uninjured or unaffected extremity as a template for planned reconstruction, follow these steps (Fig. 5.2):

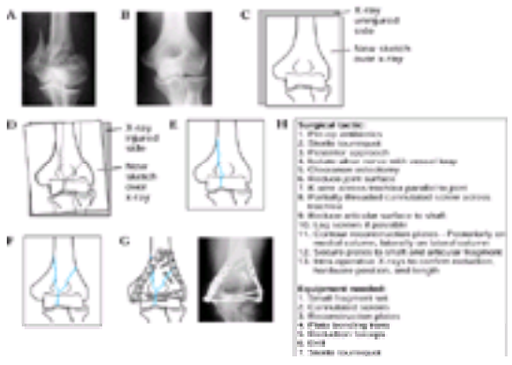

***Figure 5.2.*** Preoperative planning for supracondylar elbow fracture using the reverse image method. **A:** Radiograph of the fractured supracondylar humerus with intracondylar extension. **B:** Reversed radiograph of the uninjured side. **C:** Traced outline of reversed radiograph. **D,E:** Individual fracture lines. **F:** The final drawing. **G:** Addition of appropriate screws and plates. **H:** The surgical tactic.

- Obtain radiographs of the injured and uninjured extremities (Fig. 5.2*A*, Fig. 5.2*B*).
- Reverse the radiograph of the uninjured or unaffected extremity and trace its outline (Fig. 5.2*B*, Fig. 5.2*C*).
- Place the tracing over the radiograph of the injured or affected extremity, and align the shafts or articular surfaces (align whichever appear more similar).
- Trace the fracture lines, adjusting the paper until all major fracture lines have been traced (Fig. 5.2*D*, Fig. 5.2*E* and Fig. 5.2*F*).
- Using selected templates, trace the appropriate fixation implant (Fig. 5.2*G*).
- Write out the surgical tactic, listing all sequential steps required to achieve the planned result (Fig. 5.2*H*).

### *Knee Joint or Limb Axis Model*

An understanding of the normal axis of the knee joint or the mechanical and anatomic axes of the lower limb may be utilized to create a preoperative plan (Fig. 5.3).

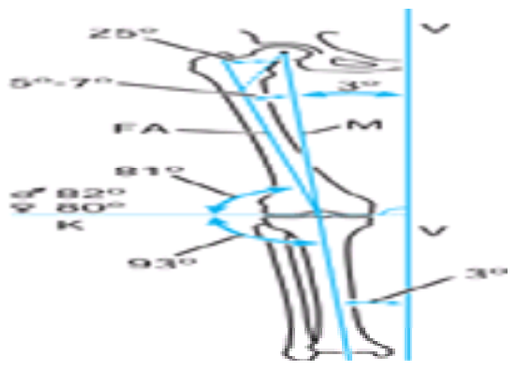


***Figure 5.3.*** Normal anatomic and mechanical axis relationships of the lower extremity. The mechanical axis (*M*) goes from the center of the femoral head to the center of the ankle. The angle between the mechanical axis and the anatomic axis of the femur (*FA*) is normally between 5° and 7°. The axis of the knee joint (K) is perpendicular to the vertical axis of the body (V). (Redrawn with permission from Müller ME. Intertrochanteric Osteotomy: Indication, Preoperative Planning, Technique. In: Schatzker J, ed. *The Intertrochanteric Osteotomy.* Berlin, Springer-Verlag, 1984.)

Use the knee joint axis template (Fig. 5.4*B*) to do preoperative planning for fractures involving the distal femur or proximal tibia. This template provides not only the normal axis lines of the knee joint but also the anatomic axes of the femoral and tibial shafts (Fig. 5.4).

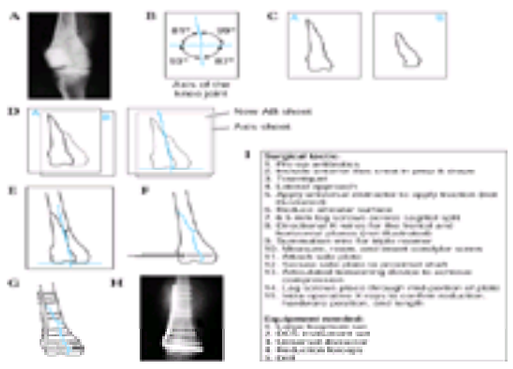

***Figure 5.4.*** Preoperative planning for supracondylar femur fracture using the joint axis template. **A:** Radiograph of fracture. **B:** Knee joint axis template. **C:** Tracing of individual fracture fragments. **D:** Reduction of the two most distal fracture fragments. **E:** Reduction of the metaphyseal and shaft component. **F:** Use a template to draw initial fixation of the intercondylar split; show insertion of the two 5.5 mm cancellous screws. Insert a guidewire parallel to the anterior femoral condyles and distal femoral condyles. After reaming, insert the dynamic condylar lag screw (DCS). **G,H:** Use templates to draw in side plate and screws of the appropriate length. Indicate the use of the articulated tensioning device if necessary to aid the reduction and achieve interfragmentary compression. **I:** The surgical tactic.

- Obtain a radiograph of the fracture (Fig. 5.4*A*).
- Trace each of the fracture fragments on an individual sheet of paper (Fig. 5.4*C*).
- “Reduce” and align the articular fracture fragments along the horizontal axis of the knee joint template (Fig. 5.4*D*).
- “Reduce” the metaphyseal and diaphyseal fragments with the articular fragments, aligning the diaphyseal fragment along the shaft axis line (Fig. 5.4*E*).
- Using selected templates, trace the appropriate fixation implant (Fig. 5.4*F*, Fig. 5.4*G*).
- Write out the surgical tactic, listing all sequential steps required to achieve the planned result (Fig. 5.4*I*).

### OSTEOTOMY

Blount highlighted the importance of careful preoperative planning for osteotomies, stating that, “Nowhere in surgery is preoperative meditation and careful planning of more value” (18). Numerous different types of osteotomies have been developed, which are described in Chapter 26, Chapter 27, Chapter 28, Chapter 29, Chapter 30, Chapter 31 and Chapter 32 and Chapter 104. Careful planning of an osteotomy may permit multiple simultaneous corrections, including length, rotation, angulation, and displacement. An understanding of the normal mechanical axis and the anatomic axis of the lower limb is an essential part of any planned osteotomy of the lower limb (Fig. 5.3). Standing long-cassette radiographs may be necessary to plan the degree of correction required.

An osteotomy must be carefully planned and its steps sequentially executed. When a blade plate is required, the preoperative plan must identify the location where the cortical window for the seating chisel will be placed, and its direction and depth. Because it is difficult to control small proximal or distal fragments, in many cases the path for the blade is best cut before you make any of the osteotomy cuts. The osteotomy becomes the final step prior to the planned fixation. Intraoperatively, confirm restoration of alignment with fluoroscopy, using an electrocautery cord as a radiopaque “plumb” line. Center one end of the cord over the femoral head and the other over the ankle joint, reproducing the new mechanical axis. Then visualize the location where the mechanical axis (electrocautery cord) crosses the knee joint and compare it with the preoperative plans.

Kirschner (K-) wires inserted proximal and distal to the planned osteotomy site can also serve as markers for rotational or angular corrections. If a blade plate is to be used, K-wires may also be used as alignment guides for placement of the seating chisel. You can also score the cortical bone to judge rotational corrections. Figure 5.4 is an example of this technique applied to the distal femur.

### TOTAL JOINT ARTHROPLASTY

Most manufacturers can supply clear acetate templates of arthroplasty implants for preoperative planning. For total hip arthroplasty, these templates allow the surgeon to plan the size and position for the implants. Variables that should be considered include the location of the hip center, the neck cut, the implant position, and the anticipated implant neck length. Different implants provide varying amounts of femoral offset, a factor that may influence abductor muscle function. Further details of preoperative planning for total joint arthroplasty are provided in Chapter 101, Chapter 102 and Chapter 103, Chapter 105, Chapter 106, Chapter 108 and Chapter 109.

### COMPUTERIZED PLANNING TECHNIQUES

Computer programs have also been developed to assist in the preoperative planning of osteotomies and total joint replacement. These systems require digitization of the radiographs. Once all the data have been acquired, they offer the benefit of allowing the surgeon to easily try different degrees of correction (143). In some cases, three-dimensional CT may be helpful to better visualize certain deformities or complex fractures (74). Reconstruction models can also be made from CT data to assist in the planning of extremely complex correction involving deformed bones or joints (112). (See Chapter 17.)

## INTRAOPERATIVE SURGICAL MANAGEMENT*

Good results from surgery are achieved with intelligent and informed decision making, appropriate indications for surgery, complete preoperative planning, technically precise surgery, gentle soft-tissue technique, and a well-designed and well-executed postoperative rehabilitation program. Good results from a surgery depend on many seemingly insignificant aspects of surgical technique that lead to precision and efficiency and minimize complications.

### THE SURGEON'S ATTITUDE AND CONDUCT

Good preoperative planning permits surgeons to approach the operation with an attitude of confidence and with the assurance that they will be able to handle any contingencies or unexpected complications. Establish a businesslike attitude in the operating room. Lighthearted conversation and background music in the operating room are appropriate in some circumstances but must not distract from the conduct of the surgery. Distractions slow down the operating team and may lead to

inadvertent breaks in surgical technique and other errors.

Treat all personnel with respect. Public verbal abuse of operating room staff because of perceived deficiencies is inappropriate and unproductive. The operating team will perform most effectively and most efficiently if you maintain a calm and dignified demeanor throughout the case and if the procedure is approached in a methodical and logical fashion.

Sharing the preoperative plan with operating room personnel before the surgery is always beneficial. You are ultimately responsible for the availability and condition of instruments and implants. Although this responsibility is customarily delegated to the nursing staff, in whole or in part, it is prudent to review with the scrub nurse the instrument and implant setup immediately before the case. It is helpful to talk through the planned surgery quickly with the operating team before the surgical preparation to be certain that everybody understands what is planned, all instruments are present and functional, and appropriate implants are available.

## CHOICE OF ANESTHESIA

The choice of anesthesia is usually left to the anesthesiologist, who bases the decision on the requirements of the surgery, patient safety, and patient desires (see Chapter 7). It is important, however, for you to advise the anesthesiologist on the requirements for the operation to be performed. In the upper extremity, regional or local anesthesia frequently is used. General anesthesia is used when the operation is too long for regional or local anesthesia or when extremely delicate surgery, such as neurovascular anastomosis, requires the patient to be very still.

The same applies to surgery of the lower extremity; however, regional anesthesia by blocking multiple peripheral nerves is used infrequently because multiple blocks are required and usually do not provide sufficient anesthesia for the use of a tourniquet. If there is no contraindication, epidural anesthesia works extremely well for lower extremity surgery, particularly when performed in an ambulatory surgery unit, because the anesthetic does not have the residual effects of general anesthesia. Epidural anesthesia may also be used in conjunction with general anesthesia. The pain relief provided by the epidural permits a “lighter” general anesthesia and is useful postoperatively for pain management. Epidural anesthesia may be combined with hypotensive anesthesia in appropriately selected patients, resulting in less blood loss, fewer transfusions, and a decreased rate of deep vein thrombosis (86,134). Plan for the prophylaxis of perioperative deep venous thrombosis before selecting epidural anesthesia, to avoid the risk of the patient's developing an epidural hematoma when low-molecular-weight heparin is being concurrently administered (68,162). Spinal anesthesia is equally effective but can not be readministered easily if the surgical procedure takes longer than estimated. It can provide a higher level of anesthesia, but the risk of complications such as headaches is slightly increased.

When major blood loss is expected—such as in hip reconstructive surgery, pelvic surgery, and spine surgery—hypotensive anesthesia, when not contraindicated, is extremely useful to minimize it. Use of hypotensive anesthesia requires a careful preoperative workup of the patient; therefore, it is important to consult with the anesthesiologist early.

## ANTIBIOTICS

The use of prophylactic antibiotics in clean orthopaedic surgery remains controversial. In our hospital and in most institutions in North America, prophylactic antibiotics are used when wound exposure time is expected to be more than 2 hours, or when major orthopaedic implants will be used. The antibiotic used most commonly for prophylaxis in orthopaedic surgery is cefazolin (104).

Cefazolin is an inexpensive first-generation cephalosporin that provides broad-spectrum gram-positive coverage; it has a high peak serum level and a long half-life. We generally give 1 g cefazolin sodium intravenously with the preoperative medications, although some authors recommend an initial dose of 2 g to achieve a higher antibiotic level in bone (157). If you plan to use a tourniquet, administer the antibiotic at least 5 minutes before it is inflated (12).

If vancomycin is required in the potentially allergic patient, infuse it slowly over at least 1 hour to avoid anaphylactoid reactions that can occur from rapid infusion. When there is a question of possible infection, hold preoperative antibiotics until intraoperative cultures are obtained. For operative procedures of longer duration, administer an additional intraoperative dose of antibiotics at approximately 4 hours.

Depending on the nature of the operative procedure, continue antibiotics postoperatively, at 1 g every 8 hours for 24 hours; then discontinue. Some surgeons prefer to administer prophylactic antibiotics for a longer period of time, but there is no concrete evidence showing that longer duration is beneficial (106). Other antibiotics may be required if there has been major prior surgery, previous infection, or contamination. When the wound is large or has been exposed for more than 2 hours, we thoroughly irrigate it with a low-pressure mechanical irrigator with sterile normal saline, followed by bacitracin solution, 25,000 units per liter of saline.

Antibiotics also may be added to the methylmethacrylate in total joint surgery. Methylmethacrylate beads impregnated with antibiotics have been advocated to treat open fractures and bone infections. These applications are discussed in more detail in Chapter 12, Chapter 105, Chapter 106, Chapter 132, Chapter 133, and Chapter 135.

As important as the use of prophylactic antibiotics is the operating room environment (104). The majority of postoperative wound infections are caused by airborne contamination. The second most common source of organisms is the patient, and the third is the surgical team. An operating room of modern design with positive-pressure air flow is important. Maintain good discipline in the operating room to minimize unnecessary conversation, traffic, and movement. In particular, personnel moving in and out of the operating room must avoid traveling directly through the doors leading into the adjacent hallways; when possible, they should pass through the substerile room that is present in most surgical suites.

For orthopaedic surgery, we recommend that all operating room personnel wear hoods to cover exposed hair. Masks must direct air flow from the mouth and nose, away from the operative field. All operating personnel must wear freshly laundered surgical scrub suits, which include pants that are secured at the ankle to minimize fallout. Wear double surgical gloves or similar coverage during the drape and surgical procedures. Some surgeons recommend replacing outer gloves following draping. After draping, one pair of gloves is satisfactory for strictly soft-tissue surgery when implants are not used, although most orthopaedic surgeons routinely double-glove. Gowns must be impervious to water and must cover the back.

For major surgical procedures lasting longer than 2 hours and involving implants or large surgical exposures, a special low-bacteria environment using either horizontal or vertical laminar air flow or ultraviolet lamps may be preferable. If horizontal laminar air flow is used, take care, especially in total knee arthroplasty, not to impede the air flow onto the operative field. Turbulent or impeded air flow may actually increase the rate of contamination.

## POSITIONING THE PATIENT

The four most common positions for surgery are the supine, prone, and right and left lateral decubitus positions. Specialized positions are used for surgery to the cervical spine, shoulder, and low back (see specific chapters). The orthopaedic table is used to position patients for internal fixation of hip fractures, femur fractures, fractures of the tibia, and other special situations.

Positioning is the responsibility of the anesthesiologist and the surgeon. Particularly when the patient will undergo a prolonged procedure, take care to avoid putting pressure on neurovascular structures, muscle compartments, and bony prominences. Position the patient to allow free expansion of the thoracic cavity and movement of the diaphragm. Place gel or foam pads in areas of high pressure concentration to avoid injury to the skin.

### *Supine Position*

- Place the patient on her back on a well-padded, standard operating table, and insert pads under the occiput and heels. For lower extremity surgery, place upper extremities on padded arm boards and gently secure them. Avoid placing tension on the brachial plexus and axillary artery by abducting the arms no higher than 90°, and preferably no more than 60°. Insert disposable foam elbow pads under the elbows.
- When access to the thorax or shoulders is necessary, use sheets to tuck the arms alongside the trunk on the operating table. For upper extremity surgery or other surgery not involving the lower extremities, place a pillow under the calves to keep the knees and hips slightly flexed. Place disposable foam pads on the heels. Avoid crossing the legs.

### *Prone Position*

- Place the patient prone. Position bolsters alongside the ventral thorax and abdomen to permit expansion of the thorax and downward movement of the diaphragm. Make the bolsters by rolling blankets and taping them into rolls approximately 4 inches in diameter. The bolsters contact the anterior shoulder, avoiding the axilla, and end slightly below the anterosuperior iliac spine. Avoid placing pressure on the lateral femoral cutaneous nerve just medial to the

anterosuperior iliac spine.

- Place pads beneath both knees. Place a pillow transversely under both legs to elevate the feet off the mattress and to protect the legs. For the upper extremities, the same rules for positioning in the supine position apply in the prone position. Specialized frames, positions, and devices are used for spine surgery in the prone position.

### *Lateral Decubitus Position*

- Place the patient in the lateral decubitus position. Stabilize the trunk with a bean bag or appropriately positioned kidney rests placed beneath the mattress. Provide additional support for small patients, using folded sheets or towels. Position kidney rests to support the patient at the pelvis, unless they will interfere with the surgical approach.
- To avoid placing pressure on the shoulder and axillary neurovascular bundle on the downside, place a lateral chest roll made with a rolled bath towel or a cloth-covered liter saline bag transversely supporting the thorax just below the axilla. Unless surgery is to be performed on the upper extremities, gain additional stability by placing upper extremities on an airplane splint secured to the operating table. It is necessary to use elbow pads and appropriate padding to protect the extremities.
- If the lower extremities are not involved in the operative procedure, place a blanket beneath the lower leg for padding and a pillow between the legs to cushion them. Place blankets over the upper thigh and secure them with the strap from the operating table to further stabilize the patient. Carefully pad above and below the peroneal nerve on the lower leg to avoid placing pressure on it.
- If the surgery involves the upper leg, such as in total hip arthroplasty, surround the lower leg with layers of sheets. Build the sheets up to the level of the upper leg to provide a smooth platform for the surgery and to protect the lower leg. Do not tape across the chest wall; taping may produce excessive downward pressure and interfere with respiration.

### *Supine Position on the Orthopaedic Table*

Positioning of the patient on the orthopaedic table varies considerably according to the table type and the operative procedure. The general principles of positioning a patient for surgery of an intertrochanteric hip fracture, however, apply in most cases.

- Place the patient in the supine position on the padded table top, using the general principles already described for a regular table. Use a radiolucent perineal post; pad it, and position it to one side of the genitalia.
- Place the lower extremity designated for surgery into traction on a foot piece (Fig. 5.5). If the manufacturer has not provided a special foot holder, use appropriate padding and proper wrap to protect the soft tissues and heel, particularly in elderly patients. Secure the foot to prevent intrasurgical loss of traction.



***Figure 5.5.*** **A:** Supine position on the Chick-Langren Orthopaedic table for internal fixation of a right hip fracture. **B:** Positioning for internal fixation of a right hip using bilateral lower extremity traction. We prefer this position to that shown in (**A**), because it stabilizes the pelvis better and permits more effective traction for reduction of the fracture. (Courtesy of Chick Orthopaedic, Chick Medical Products, Greenwood, SC.)

- Place the other lower extremity in the lithotomy position in a leg holder and abduct it to allow clearance for the C-arm fluoroscope. We have found it most effective to place the healthy leg in traction as well. Be careful when placing patients in the lithotomy position to avoid placing excess pressure on the popliteal fossa. Limit the length of time in this position to avoid complications of compartment syndrome (35,137).
- Use bilateral traction to centralize the pelvis on the perineal post and avoid pelvic rotation. Bilateral traction permits more effective fracture reduction that can be better maintained. It also facilitates radiography. Bilateral traction presents problems only when a patient has a hip adduction contracture. Abduction to 45° is usually necessary for positioning of the C-arm fluoroscope. Occasionally, in very comminuted intertrochanteric or subtrochanteric fractures, it is necessary to support the shaft of the femur or provide an upward push on the trochanters. Some operating tables have attachments for this purpose.
- Alternatively, place a well-padded crutch beneath the point at which upward pressure is desired and push it into place. The rubber foot of the crutch prevents it from shifting, and the oblique position of the crutch usually prevents it from interfering with the swing of the C-arm. Position the C-arm fluoroscope so that it swings freely from the AP to the lateral position without impinging on the patient. Test the swing before draping the patient.

### *Lateral Decubitus Position on the Orthopaedic Table*

The general precautions for lateral decubitus positioning described previously apply when the orthopaedic table is used.

- The torso has a tendency to roll into the supine position. To prevent this, gently lock the elbow into full extension and secure the forearm to an airplane splint with broad adhesive tape (Fig. 5.6). Protect the ulnar nerve. Use a vertical pelvic post with a well-padded perineal post positioned so that the patient's anterosuperior iliac spine lies adjacent to and slightly above the pelvic post. This position stabilizes the pelvis and permits adequate flexion of the hip.



***Figure 5.6.*** **A:** Posterior view of a patient in the lateral decubitus position for closed intramedullary nailing of the right femur. If the right upper extremity is secured to the arm board with the elbow in extension, the torso is stable and the cross-body strap is not necessary. The affected limb is in skeletal traction with a pin in the proximal tibia. If a large-threaded Steinmann pin is used, the auxiliary foot support is not necessary in most cases. The unaffected limb rests on a well-padded foot board. Extend the board proximal to the knee to avoid injury to the common peroneal nerve, pad the leg, and secure the leg to the board with muslin or 3-inch tape. **B:** On this frontal view, note that the pelvic post is positioned just caudal to the anterosuperior iliac spines (it is behind the C-arm). The perineal post can be used to support a short proximal fragment. With a stout Steinmann pin in the tibia, the foot support is not necessary. (Courtesy of Chick Orthopaedic, Chick Medical Products, Greenwood, SC.)

- Secure the uppermost lower extremity that is designated for surgery (usually for closed intramedullary nailing) using tibial pin skeletal traction to the tibial pin-holding device on the orthopaedic table. Not all orthopaedic tables provide this extremely useful device.
- Before placing the patient in the lateral position, insert a large-threaded Steinmann pin transversely through the tibia at or slightly below the tibial tubercle (in adults). Pad the skin around the pin with sterile dressings, and secure it to the traction device.
- Place the extremity in traction, and position it as necessary for the procedure. Secure the downside lower extremity to a well-padded leg board that attaches to the orthopaedic table. Securely wrap the extremity to the leg board, which must extend proximal to the knee. Take care to avoid pressure on the peroneal nerve. Additional details on the position used for closed intramedullary nailing of the femur are provided in Chapter 11 and Chapter 20.

## THE TOURNIQUET

Use of a tourniquet greatly facilitates extremity surgery; it provides a bloodless field, which is essential for most surgery of the hand and foot. There are, however, potential dangers associated with the use of the tourniquet, and you must be familiar with its proper use. Use a constant-pressure-regulated tourniquet that is inflated with nitrogen. We apply it only to the upper arm and proximal thigh (finger and toe tourniquets fashioned from Penrose drains are described in the chapters on hand surgery). Even with modern, reliable pneumatic tourniquets, it is possible to apply excessive pressure. Use a calibration gauge to check the accuracy of tourniquet pressure readings before each use.

Tourniquets are available in various lengths and widths for various sizes of extremities. The pressure pattern produced by a tourniquet is cone shaped, diminishing in width as the depth of the extremity is reached. Therefore, wide tourniquets are necessary for large extremities; do not use narrow tourniquets on large limbs (60).

### *Securing the Tourniquet*

In obese people, the tourniquet tends to migrate distally as it is inflated; in certain procedures in the distal arm and thigh, therefore, it is necessary to secure the tourniquet in a proximal position to allow adequate room for the surgery.

- Place three strips of 2-inch tape on the anterior, lateral, and posterior surfaces of the upper thigh or upper arm. After the tourniquet is in place, fold them upward over the tourniquet and secure them with circumferential tape around the tourniquet (Fig. 5.7).

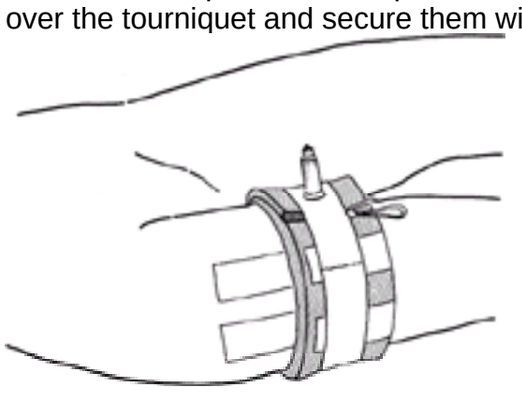

***Figure 5.7.*** Tourniquet in place on the upper thigh, wrapped and secured to the thigh to prevent tourniquet migration.

- Before applying the tourniquet, pad the extremity with several smoothly applied layers of soft cast-padding material to prevent wrinkling and pinching of the skin as the tourniquet inflates. Apply the tourniquet snugly, and tie it securely. Improper application may result in “unwrapping” of the tourniquet during the surgery, and the result can be soft-tissue or neurovascular injury.
- Failure of the tourniquet during surgery is a great inconvenience and in some cases also a significant interference. Check all components of the tourniquet system before use. Keep prep solutions and chemicals away from the tourniquet and padding materials. Before preparing the skin, cover the tourniquet with an adhesive plastic towel drape. Sterile disposable tourniquets are available for application after a sterile field is established.
- In most cases, exsanguinate the limb before inflating the tourniquet by wrapping the limb with an Esmarch or rubber bandage from distal to proximal. Esmarch bandages, once used as tourniquets, are no longer recommended because their pressure cannot be monitored, and damage to neurovascular structures can occur.
- Do not exsanguinate the limb if infection or tumor is present.
- Appropriate tourniquet inflation pressure is just enough to prevent arterial blood flow into the limb—no higher. This pressure depends on the age of the patient, the status of the vasculature, the blood pressure, and the size of the extremity (135). Reid, Camp, and Jacob (122) recommend a pressure of 50–75 mm Hg above systolic blood pressure (i.e., 135 to 225 mm Hg) in the upper extremity. Pressures of 100–150 mm Hg over systolic blood pressure (i.e., 175 to 305 mm Hg) are usually necessary in the lower extremity. Inflate tourniquets quickly to prevent venostasis, which may fill the venous tree before occlusion of arterial blood flow.

### *Precautions*

The length of tourniquet ischemia that can be tolerated by the limb without residual effects varies considerably from patient to patient and depends on the condition of the limb and the pathology being treated. In general, tourniquet times should not exceed 2 hours and are best kept at 1½ hours or less. In many procedures, it is possible to complete the exposure and obtain good control of potential bleeding vessels within 1–1½ hours of tourniquet time. At that point, the tourniquet often can be deflated and not require reinflation for the remainder of the procedure.

Total tourniquet time of more than 2 hours almost always results in some temporary posttourniquet problems. The most common complaints are partial anesthesia and tingling, and hypersensitivity in the limb for 1 to 2 days following surgery. Rarely, muscle weakness accompanies these symptoms. With tourniquet times of 2 hours or less, true palsies almost never occur; if they do, they are usually the result of pressure on a peripheral nerve, rather than ischemic changes from tourniquet use.

Repeated inflation of the tourniquet is possible but not advisable. Do this only when the tourniquet is absolutely essential and when the advantages justify the risks. If the tourniquet is in place for 1 hour, deflate it for at least 20 minutes to restore normal oxygenation, pH, and chemistry of the limb. Tourniquet time may be extended to 3 hours if the tourniquet is deflated for at least 20 minutes at the end of each hour. Deflation for 20 minutes every hour, however, usually interferes with the operative procedure, so it is wiser to proceed with the tourniquet for 2 hours and then discontinue its use. When the tourniquet is deflated, it sometimes causes a venous-tourniquet effect and must be removed from the limb during the operative procedure.

Once the tourniquet is released, ensure that perfusion to the extremity has been restored, especially when more than a single operative procedure is involved. In such cases, a tourniquet could potentially remain inflated and in place long beyond the accepted limits. It is also critically important to identify adequate peripheral pulses when vascular damage could potentially occur, such as during a total knee replacement. Diagnosis of the vascular injury while the patient is still in the operating room may save hours.

## SKIN PREPARATION

Ask patients to clip and clean the nails of the affected limb before surgery, and to remove nail polish. Warn them to avoid activities for 3 weeks before surgery that could cause minor scratches and abrasions to the affected extremity. For clean individuals, special bathing before surgery is not necessary. Shaving in advance of the actual time of the surgery is contraindicated because of the risk of accidental nicking of the skin. Razor cuts more than a few hours old may harbor bacteria. Shaving and prepping in most hospitals are performed in the operating room immediately before the surgery, preferably in a preoperative preparation room to avoid contaminating the operating suite with hair. If shaving must be done in the operating room, do it wet to avoid aerosolizing hair, which may contaminate the surgical instruments. Because shaving increases bacterial production from sweat and sebaceous glands, shave only the immediate area of the surgical incision. It is usually not necessary to shave the entire extremity.

The technique, methods, and solutions used in the preparation of the skin for surgery are variable and remain controversial. The most commonly used skin-preparation solutions are halogen agents that contain organic iodides such as povidone-iodine soap and solution. Most surgeons prefer to defat the skin and remove loose skin debris with a 5- to 10-minute scrub with soap using sterile sponges and gloves.

- Begin the scrub at the incision site and move in a centrifugal fashion outwardly until the appropriate area has been prepared. For extremity surgery, prepare the entire extremity, from the tips of the fingers or toes to the tourniquet.
- Take care to avoid dripping excessive soap or solution, which can cause burns of sensitive mucosal membranes, onto the genitalia. Also avoid dripping it onto the operating table. If you use alcohol, take extreme care to prevent it from pooling beneath the operative field and posing a fire hazard during use of electrocautery.
- Wash and dry the limb or surgical site with sterile towels. Then apply povidone-iodine solution either from a prepackaged spray bottle, which is safest from the standpoint of contamination, or with sponge sticks, working from the site outward. Let this solution dry in place, because its antibacterial action continues for a substantial period of time during the surgery. If the patient has a history of sensitivity to iodine, other choices are chlorhexidine gluconate and hexachlorophene [such as pHisoHex (Sanofi Winthrop, New York)].

## DRAPING

To avoid contamination of the limb during draping, lay the extremity on a sterile sheet or have an assistant support it using sterile gloves or towels. This maneuver is exceedingly difficult with heavy extremities that are unstable because of fractures. Take care to avoid contamination, particularly proximally.

There are many different satisfactory draping routines. We present general guidelines for satisfactory draping and three typical draping routines: one for the upper or lower extremity, one for the shoulder, and one for the hip. They use the standard sheets available in an average general surgery pack without specialized split and extremity sheets as well.

Although it is possible for one person to drape a patient satisfactorily, ideal technique requires three people. One assistant supports the extremity and maintains its sterility as it is being draped, and the other two obtain the draping materials from the back table and deploy them. Perform draping after the scrub nurse, surgeon, and assistant are fully gloved and gowned. Drape with double gloves, because inadvertent contamination can occur. Strip off the outer set of gloves after the drape and put on a new second set for the procedure.

### *Upper or Lower Extremity Draping*

- Place a cover sheet over the end of the table to protect the surgeon and assistants from accidentally contaminating their gowns by brushing against the nonsterile operating table. Roll a double-layered tubular stocking or waterproof cover over the extremity (Fig. 5.8). Use a folded, sterile towel to cover the tourniquet. Secure it snugly around the thigh or the arm just distal to the tourniquet with one or two towel clips.

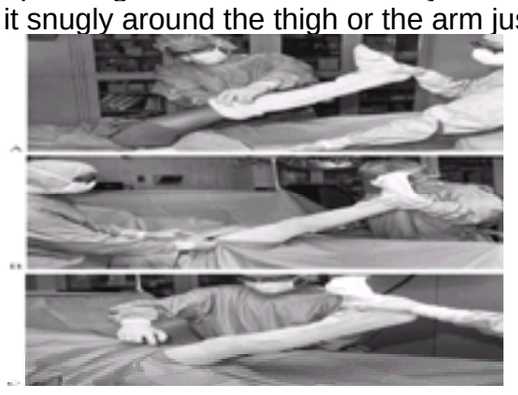

***Figure 5.8.*** **A:** Draping the lower and upper extremity with two cover sheets, sterile towel, and tubular stockinet. **B:** Placement of cuffed sheets. **C:** Extremity extended through the hole of a laparotomy sheet. (Courtesy of David Templeman, M.D.)

- Roll the stockinet into place, up to or over the tourniquet, to prevent accidental contamination of sterile gloves and gown. In addition, if incisions are carried far proximally, the towel prevents accidental exposure of unprepared skin. Place a second half-sheet with the proximal end folded downward 6 inches beneath the extremity, taking care not to contaminate the folded edge. Lay the limb down on this sheet. Place a second half-sheet with its distal edge folded double for a distance of approximately 1 foot over the proximal portion of the limb, matching the folded edge of the underlying half-sheet. Secure these two sheets snugly together and to the rolled stockinet with four towel clips (Fig. 5.8*B*).
- Next, place the limb through the hole in a large laparotomy or extremity sheet. If a laparotomy sheet is used, secure it snugly around the limb with two towel clips just below the previously applied two half-sheets. Leave no exposed underlying half-sheets (Fig. 5.8*C*).

We strongly recommend that draping be done only with disposable paper sheets. This draping routine—the equivalent of more than four standard cloth sheets plus a waterproof layer—provides optimal protection against contamination. When the drape is completed, incise the stockinet with a pair of scissors and fold it back to expose an adequate area for the surgery. We cover the skin with a povidone-impregnated adhesive plastic sheet. If you do not wish to use plastic incision drapes, suture or staple skin towels to the skin after the incision is made. If a povidone-impregnated adhesive plastic skin drape is used, defat the skin with alcohol before applying the drape to ensure optimal adhesion. Adhesive drapes that remain in place provide nearly ideal protection from the surrounding skin.

Loose plastic skin drapes increase the risk of contamination. If the plastic drape loosens during the procedure, we recommend removing and replacing it with standard skin towel drapes. Carry the preparation and drape up to the tourniquet, so that the entire limb is available if necessary.

### *Upper Extremity and Shoulder Drape*

The basic principles already outlined apply to the use of the upper extremity drape.

- For surgery on the upper extremity distal to the shoulder, drape as for the lower extremity; use a hand table if desired.
- For shoulder surgery, carry the skin preparation well up on to the neck and anterior and posterior chest wall. Cover the torso and legs with a water-impervious barrier sheet.
- Roll a tubular stockinet to the elbow. Secure a sheet into the axilla and across the chest. Cover the proximal extent of the shoulder with a second sheet posteriorly and a third anteriorly, which meet on the lateral neck. Secure these drapes with an adhesive drape and then pass the limb through an extremity or laparotomy sheet, and secure it with staples and another adhesive drape (Fig. 5.9).

***Figure 5.9.*** This shoulder drape is completed. Note that the sheets are attached high on the neck and wide on the chest wall to provide full exposure.

### *Hip Drape*

Perform the drape for surgery of the hip in the lateral decubitus position in nearly an identical manner. Modify as necessary to be certain that the perineum is draped out of the operative field to provide freedom of movement of the limb, which is necessary for hip arthroplasty. Do not use a tourniquet.

- Position the initial barrier sheet. Roll a tubular or water-impervious stockinet over the extremity to the mid thigh. Bring the first half-sheet into position, and secure it with staples to the medial surface of the thigh, approximately 8 inches distal to the perineum. Bring it carefully proximal along the anterior and posterior aspects of the thigh and onto the torso.
- Secure this drape to the skin with large skin staples. Towel clips can be used as well, but they tear through paper drapes and interfere with radiography. Carry both the skin preparation and drape well proximally onto the rib cage.
- Put the second sheet in place, and use skin staples to secure it at the uppermost margin of the operative field, proximal to the iliac crest. Fold the lower sheet into the groin. Further secure these sheets with application of a povidone-impregnated adhesive plastic drape (Fig. 5.10*A*).

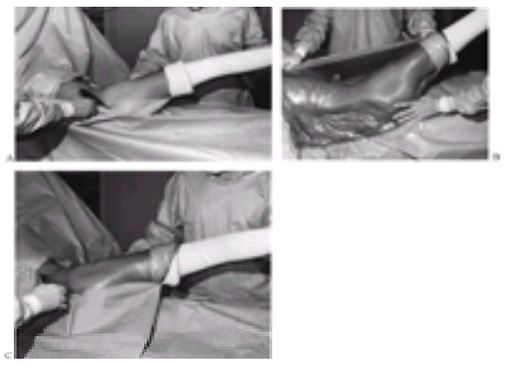

***Figure 5.10.*** **A:** Draping in the lateral decubitus position for hip surgery. **B:** Exposed skin is covered with a large povidone-impregnated plastic drape. **C:** The extremity is brought through the hole in a laparotomy sheet.

- Place the extremity through the hole in a laparotomy sheet, and secure it to the medial thigh in the same location as the previous sheets. Enlarge the hole in the drape with a pair of scissors; bring it proximally over the extremity, and secure it to the patient with skin staples. Secure this drape with a large povidone-impregnated plastic sheet. With this draping arrangement, a number of impervious layers are placed around the operative site. The limb is free to move because the sheets are not brought directly into the groin, and the groin is well draped out of the field (Fig. 5.10*B*). We have found this fairly lightweight drape suitable for all reconstructive surgery around the hip and pelvis. Some surgeons prefer to add additional impervious layers, particularly if prolonged surgery involving considerable blood loss is expected. Special draping sets using combinations of adhesive-backed U-drapes work very well also, but are usually somewhat expensive.
- Bring the extremity through the holes in a laparotomy sheet cut to fit the exposure desired (Fig. 5.10*C*). Staple it in place and secure it with a second plastic drape. This method avoids draping into the groin and gives ample sheet in the groin area for movement of the extremity.

***Draping for Intramedullary and Hip Nailing***

Draping for intramedullary nailing and hip nailing on the orthopaedic fracture table is similar to that just described for the hip. Square off the operative site with sterile sheets secured to the skin with staples and an adhesive drape (Fig. 5.11*A*). Place the final drape, a laparotomy sheet, on the hip. The extremity is not draped free. Appropriate draping in both procedures allows the C-arm to move beneath the drapes, preserving the sterile field (Fig. 5.11*B*). With the C-arm in the lateral position, place the drapes so that they hang 2 inches or so off the floor. Note that the entire hip and thigh are available for the operative procedure. Drape only the C-arm receiving head; do not drape the arm itself. Draping hinders movement and nearly always results in contamination. For hip fractures, a vertical adherent clear plastic drape works very well when full access to the extremity is not necessary.

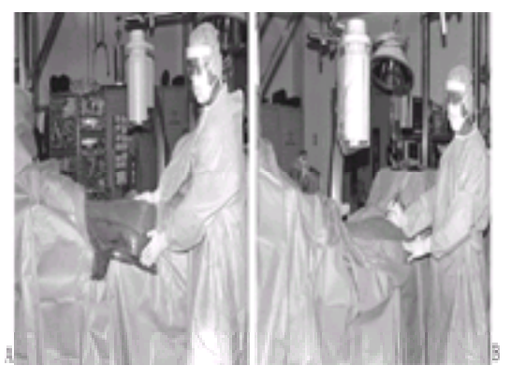

***Figure 5.11.*** **A:** Drape for intramedullary nailing of the femur. **B:** Lateral decubitus position on a fracture table.

For intramedullary nailing of the tibia, similar principles apply (Fig. 5.12). First cover the vertical posts and other table parts that might be contacted during surgery. Place a large drape sheet above the knee and secure it circumferentially with staples. Apply a similar drape around the ankle. Leave enough room for distal cross-screw insertion. Then create a “mesenteric” drape with a laparotomy sheet. Secure it with an adhesive plastic skin drape. The entire leg is left free, and the mesentery covers the C-arm in the lateral position.

***Figure 5.12.*** Drape for intramedullary nailing of the tibia on a fracture table.

**SKIN INCISION AND SOFT-TISSUE TECHNIQUE**

Gentle, atraumatic, rapid, soft-tissue surgical technique with good hemostasis is essential for good results. Straight skin incisions generally provide the best exposure, the least risk of skin necrosis, and the best cosmetic results. Incisions can be longitudinal between the joints and over the extensor surface of joints. Over the flexor surface of joints, incisions must be transverse. When it is necessary to extend incisions that cross the flexor surface of joints, make curvilinear ones. In the torso, follow Langer's lines (see Chapter 1, Chapter 2 and Chapter 3). Hoppenfeld and deBoer's text, *Surgical Exposures in Orthopaedics*, provides numerous detailed drawings and descriptions of various surgical approaches as well (67).

Make skin incisions with a fresh scalpel blade and never with a pair of scissors or cutting current. For easy closure and best cosmetic results, make incisions at right angles to the skin. It is often difficult in orthopaedic procedures when dealing with very irregular surfaces to make such incisions. Take care to remain at right angles to the skin even as the incision curves across the surface of the limb.

After you have made the initial cut, continue dissection with a sharp knife. Avoid blunt spreading with scissors or electrocautery, which adds to soft-tissue damage. In certain areas where subcutaneous and muscle hemorrhage is a particular problem, as in the spine, electrocautery is used more frequently with minimal morbidity. Rapid, precise dissection with the scalpel where tissues must be cut, and blunt dissection with the finger or an elevator where tissue planes can be split bluntly, is the most atraumatic and rapid technique. Dissection with the scalpel, particularly in the region of important neurovascular bundles, requires precise knowledge of anatomy. Neurovascular bundles can be safely dissected out with a #15 blade if the surgeon knows the anatomy and works from proximal to distal to avoid cutting into the axillae of nerve and vascular branches. The good surgeon treading in an anatomic region that she visits infrequently will greatly improve her surgical technique by thoroughly reviewing the anatomy and surgical approach before surgery.

In the lateral approach to the hip, it is common practice to use a curved Mayo scissors to split the fascia lata and expose the posterior border of the tensor fascia lata muscle, but this is totally unnecessary. The surgeon wastes time in switching from the knife to the scissors and back again. Most scissors are too dull and result in slow, traumatic surgery. The knife is precise and quick. In certain situations, the spread-and-cut technique with scissors is permissible. It must be recognized, however, that using the scissors for spreading and cutting is usually slow and traumatic. It is most effective in dissecting out neurovascular structures where heavy scarring is present, and in finding the digital neurovascular bundles in the hand and foot.

Even if a tourniquet is in place, obtain hemostasis layer by layer as the dissection proceeds. Isolate small vessels, clamp with the tip of a forceps, and coagulate. Ligate larger vessels with an appropriate-size suture. Major arteries and veins in the proximal portions of the limb generally require double ligature, usually with a suture ligature in the arteries, using appropriate-size, nonabsorbable suture material. In the subcutaneous fat, it is sometimes quicker to control hemorrhage with light pressure from a sponge or laparotomy tape and then touch the bleeding points with the electrocautery.

**HINTS AND TRICKS**

- Prolonged and overvigorous retraction is damaging. Use self-retaining retractors sparingly and with minimal pressure.
- Retract only tissues that need to be retracted, and avoid the skin edges.
- Broad blades or tines cause less injury than narrow ones.
- Do not use self-retaining retractors on neurovascular bundles. Hand-held retractors can also cause nerve injury if used with excessive force.
- Be certain to place the retractors in the correct position, and avoid placing pressure on sensitive structures.
- Advise the assistant to be diligent in maintaining the proper position and pressure.

Handle tissues with toothed forceps rather than with clamps. Be careful not to crush the tissue with the forceps; instead, use only one tine of the forceps to retract the tissue (Fig. 5.13*A*). During suturing, for example, rather than pinching the tissue, it is better to pass the needle between the tines of the forceps, which are used to support the tissues (Fig. 5.13*B*). This technique avoids skin trauma and places the forceps in an ideal position to grasp the end of the suture needle.

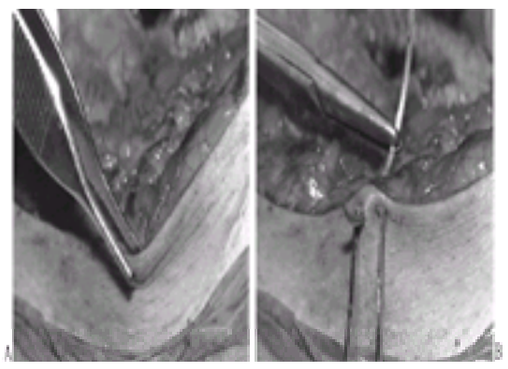

***Figure 5.13.*** Forceps technique.

For the most part, retraction is used more than necessary. Do not use it unless you have to. Do not repeatedly handle tendons or neurovascular bundles. When necessary, place neurovascular bundles in an appropriate-size Penrose drain loop, which is then used for gentle retraction. Surgical exposures that exploit the intervals between muscles are less traumatic than those that split muscles. Minimize wound exposure to limit contamination and keep tissues moist. Cover the portions of the wound not in the active surgical field with saline-moistened sponges. In some instances, particularly in prolonged procedures where a portion of the wound is not being used, it may be appropriate to use temporary retaining sutures to hold the tissues approximated, or staples in the skin. When a second wound is necessary, such in as bone-grafting procedures, close the ancillary incisions as soon as possible rather than leaving the wound open until you close the main wound.

After prolonged surgery, irrigate and debride the wound as in an open fracture before closure. Excise all damaged and nonviable muscle. Copiously irrigate with sterile saline using a mechanical pulsatile lavage-type irrigator.

**SURGICAL TECHNIQUE ON BONE**

When handling bone, preserve its vascular supply and avoid exposing it to excessive heat, which is necrogenic. To preserve vascular supply, expose only the portion of the bone absolutely essential to the operation. In the mid diaphysis, the periosteum and contiguous muscle envelope supply little blood to the cortex; therefore, subperiosteal dissection is permissible. Preserve the nutrient artery, perforating vessels, and ligament and tendon insertions, if possible. Bone fragments with only minimal muscle attachments are probably devascularized, but if they are anatomically and securely fixed they may become revascularized.

Necrosis of bone during orthopaedic procedures usually results from overheating of the bone by cutting and drilling instruments, especially if they are dull and run at excessive speeds. Keep all cutting and drilling tools sharp, and cool them with saline during use. Replace drill points and saw blades frequently. Sharp hand instruments are essential for precise, skillful, and rapid carpentry of bone. Avoid stress-risers in bone, which may later lead to pathologic fracture. Holes or windows in bone, particularly in the mid diaphysis, are significant stress-risers. Holes smaller than 5 mm in diameter present few problems, but holes more than 10 mm in diameter, or more than 30% of the diameter of the bone, lower the strength of bone, particularly in torsion. Make windows as smooth and round as possible. Terminate cuts in bone at a drill hole to dissipate the stress-riser effect.

Hemostasis in bone, particularly cancellous bone, can be a problem. We prefer bone wax for hemostasis. Soften the wax by kneading it, and apply it to the bleeding area with the finger protected by a laparotomy tape. Remove all excess wax.

**WOUND DRAINAGE**

Because orthopaedic surgery frequently leaves large, bleeding bone surfaces, suction-drainage is frequently utilized, although some authors question the necessity of routine drainage (14,30,82,124). Many drains and methods are available. Take care when placing suction drains directly on raw, bleeding bone surfaces or in intramedullary canals to avoid exsanguination. Pass the trocar through the soft tissues at an angle. This technique may better allow the drainage tract, which exits the various fascial barriers at separate locations, to seal. It prevents the development of a persistent draining tract. Direct connection to wall suction is generally contraindicated because of the risk of excessive bleeding. Commercially available, self-activated suction reservoirs are safest. On occasion, it may be prudent to delay activation of suction until several hours after the completion of surgery to allow formation of a clot on bone surfaces.

Inadvertent suturing of drains is easily preventable. After inserting and cutting the drain at the appropriate length (Fig. 5.14*A*), pull the drain back into the wound so that the cut end remains visible during wound closure (Fig. 5.14*B*). Close the entire wound or fascia with the exception of the part nearest the exposed cut end of the drain (Fig. 5.14*C*), then advance the drain to the premarked point, making sure that the drain is free. Then close the remaining wound. If a drain is inadvertently sewn in, postoperative removal may be possible; attach a 5-pound weight to break the offending suture. Inspect all drains upon removal to ensure that breakage has not occurred.

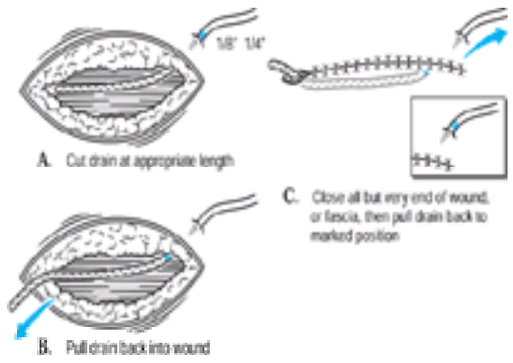


***Figure 5.14.*** Technique to ensure drain is not inadvertently sewn into the wound.

To avoid accidental removal of drains when applying dressings and moving the patient from the operating table, suture the drain to the skin or carefully tape it to the extremity. In addition to providing egress for blood and serum, drains provide a route for organisms to enter the wound. Remove drains as soon as bleeding and drainage from the wound have ceased, in most cases by 48 hours after surgery. To avoid contaminating the wound, do not irrigate plugged drains. Use large enough drains to prevent plugging by clots.

**WOUND IRRIGATION AND CLOSURE**

Minimize the risk of infection by routine irrigation of wounds before closure. In small wounds for which exposure time has been short, bulb or syringe-type irrigation is adequate. When wounds have been exposed for more than 1 hour and involve large surface areas, copious irrigation with a mechanical pulsatile lavage irrigator is recommended. The addition of antibiotics or sterile castile soap to the irrigation solution may be helpful in removing surface bacteria (7,34). Other authors have reported detrimental effects of aggressive pulsatile lavage on the soft tissues and early fracture healing (33,89).

Wound closures must be anatomic, atraumatic, and generally watertight. Use the smallest possible suture that provides adequate strength. In orthopaedics, running sutures for closure are generally contraindicated, because use of the limb may result in failure of these sutures and wound dehiscence. Interrupted sutures provide a stronger closure and allow fine adjustment of tension to avoid tissue necrosis.

We use nonabsorbable, synthetic, braided sutures, size 0 or larger, for the repair of ligaments, tendon insertions (except in the hand and foot and in children, where smaller or different types of sutures may be indicated), fascia, and fibrous joint capsules. Braided sutures are easier to handle and are less likely to slip than monofilament. Use monofilament sutures when the risk of infection is high, because they are associated with a lower rate of infection than braided sutures.

In a typical orthopaedic closure, such as a lateral hip wound, we use a size 0 polyglactin suture for repair of the quadriceps origin using figure-eight sutures. Figure-eight sutures are helpful when tension is high or sutures tend to pull through the tissues. Close the deep fascia of the thigh with 0 or 2-0 interrupted sutures. Close the subcutaneous tissues with inverted, interrupted, 3-0 polyglactin sutures. When cosmetic issues are not of great concern and speed is important, we close the skin with staples. We generally remove staples 7 to 14 days postoperatively and replace them with skin tapes. Interrupted sutures, preferably using a monofilament synthetic, nonabsorbable material, are an alternative to staples. Avoid strangulation of the subdermal vascular plexus by approximating the skin edges without tension.

We do not recommend the use of retention sutures in extremity wounds. Place sutures at right angles to the skin and 3–4 mm from the edge. Simple, interrupted sutures are best. We avoid mattress sutures, if possible, because they devascularize skin edges more than simple sutures. The suture described by Allgöwer et al. is useful where the viability of the skin is marginal (Fig. 5.15). The subcuticular stitch is placed on the most precarious side of the wound. Use Gillie's suture on the corners of flaps. For most skin closures, we prefer a running subcuticular suture of either 3-0 or 4-0 absorbable polyglactin, and in some cases nylon or proline, which is later removed. Augment this closure with skin tapes placed so that there is no tension. When significant postoperative swelling is expected, do not use skin tapes. Avoid benzoin adhesive under skin tapes because of the risk of allergic reaction.

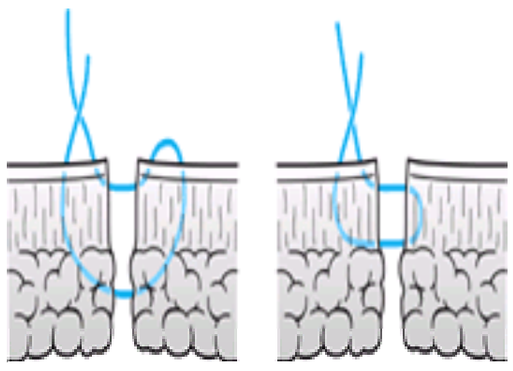

***Figure 5.15.*** Allgöwer stitch for closing skin with marginal vascular supply. (Redrawn with permission from Müeller ME, Allgöwer M, Schneider R, Willenegger H. *Manual of Internal Fixation.* New York: Springer-Verlag, 1979.)

**DRESSINGS**

For surgery of the extremities, we use a supportive dressing that we call a Robert Jones dressing. Place a sterile, nonadhesive dressing on the wound. Do not use nonabsorbent dressings, which do not allow passage of blood and serum, because accumulation of blood and serum around the incision can cause inflammation. We prefer gauze impregnated with 3% bismuth tribromophenate (Xeroform) in a petrolatum blend, with some of the petrolatum scraped off. Over the gauze, place sterile gauze sponges followed by abdominal pads, depending on the amount of postoperative blood and fluid expected from the wound. Encase the entire extremity in bulk, sterile cotton that is rolled to produce a snug dressing approximately 2–3 inches thick.

Overwrap with 4- or 6-inch wide cast padding followed by plaster splints to maintain the limb in the desired position. Finally, overwrap with a bias-cut stockinet. This dressing removes fluids from the operative site by capillary action. It provides firm support to the limb to *limit* swelling, yet there is ample volume to *permit* swelling of the limb without pressure or neurovascular compromise. The outer hard dressing positions the limb appropriately.

A Robert Jones dressing cannot be used for the proximal thigh, hip, trunk, or shoulder. In these locations, hold the gauze sponges and abdominal pads in place with tape or a burn stocking. Use tape with care in orthopaedics, because considerable postoperative swelling often occurs. Strong adhesive tape, such as paper tape, applied tightly may shear the skin and cause blisters. Dress patients who have a history of tape sensitivity with hypoallergenic tape or no tape at all. An elastic bandage (Ace-wrap) applied in spica fashion around hip incisions holds the dressing in place and also provides gentle compression.

It is important not to place splints against rubberized pillows, as the heat generated as the plaster sets may be severe enough to cause a superficial skin burn. Splints should initially remain uncovered and elevated on cloth blankets or towels until the heat is dispersed.

Immediately after the conclusion of the procedure, the surgical team can elevate the limb, position any necessary traction devices, or reapply thromboembolic stockings or sequential compression devices. Delay can be minimized if the surgical team performs these tasks rather than waiting for written postoperative orders to be followed. Additionally, the surgeon can then be sure that the appropriate devices and position are used.

## SURGEON'S SAFETY

A surgeon's concern about personal safety can be an emotional issue. Inadvertent percutaneous self-injury may be anxiety provoking, especially if the patient is

perceived to be in a high-risk category or known to be infected with a transmissible disease. Having accurate information about the potential for disease transmission is the most effective way to minimize anxiety.

The AIDS epidemic has focused an increased awareness on the safety of the surgical team, especially for orthopaedic surgeons, who are frequently exposed to sharp bone fragments and use power tools that aerosolize particles. The actual risk of AIDS transmission is low; the risk of transmission of other infectious diseases, namely hepatitis B and C, is much greater. While adequate prophylaxis to hepatitis B may be obtained through vaccination, the operating team must take precautions to minimize their risk of contracting hepatitis C and other infectious organisms. Universal precautions have been developed to minimize the surgical team's risk of intraoperative infection exposure (47).

**HEPATITIS B VIRUS**

The development of an effective vaccine has made hepatitis B (HBV) a preventable disease. Because of the high risk of percutaneous injury, all operating room personnel should receive hepatitis B vaccine. HBV is much more contagious than other viruses; the risk of transmission of infection has been estimated to be 30% following a single percutaneous exposure to blood from a patient whose HBV disease is in the most infectious period (136).

Development of an effective vaccine against hepatitis B has effected a dramatic decrease in the transmission of HBV to health care workers through blood exposure. In 1993, an estimated 1,450 health care workers became infected with HBV though exposure to blood and body fluids, a 90% decrease from the number infected in 1985. Between 5% and 10% of those infected with HBV develop chronic hepatitis and are at risk for developing cirrhosis and hepatocellular carcinoma. An estimated 100 to 200 health care workers have died annually during the 1990s as a result of complications related to chronic HBV infection (25). Among the orthopaedic surgeons surveyed at the 1991 meeting of the American Academy of Orthopaedic Surgeons, 67% had received the hepatitis B vaccination. The incidence of vaccination was inversely proportional to the age of the surgeon. Ninety percent of surgeons between 20 and 29 years old had been vaccinated, while only 35% of surgeons 60 years or older had been vaccinated. Thirteen percent of individuals showed evidence of infection with HBV and less than 1% showed infection with hepatitis C. The prevalence of both infections increased with age. Only 3% of those in their third decade of life were infected with HBV, while 27% of surgeons 60 years or older showed serologic evidence of HBV infection (133).

Antibodies to HBV decline with time after vaccination. Up to 60% of those vaccinated lose detectable antibodies over 12 year (25). Despite declining antibody levels, vaccine-induced immunity continues to protect against clinical HBV disease (59). Further periodic serologic testing is not currently recommended once adequate antibody response has been confirmed following primary vaccination (25).

**HEPATITIS C**

Hepatitis C (HCV), a serious health threat affecting a large percentage of the population, is a potential risk for practicing orthopaedic surgeons since no effective vaccine exists. The risk of infection from needle sticks in HCV is intermediate between that of HIV and HBV (103). The risk to health care workers from a random needle stick has been estimated to be about 0.1% (58). Several studies have reported that the risk of seroconversion in health care workers sustaining a percutaneous exposure to blood from anti-HCV-positive patients ranges from 0% to 6% (41,77,81). There appears to be a higher risk from hollow-bore needle sticks than from the more common suture needle sticks or the other sharp objects surgeons are exposed to. In one study, four seroconversions were seen following 331 hollow-bore needle sticks, while no seroconversions were reported following 105 injuries with suture needles or other sharp objects (118).

It is recommended that health care workers exposed to hepatitis C be tested after exposure and again 6–9 months later to detect hepatitis C antibodies (48). If hepatitis C infection is diagnosed, liver function studies should be performed to evaluate for chronic hepatitis.

In the past, treatment with immune globulin was recommended following exposure to non-A, non-B hepatitis (now known as hepatitis C). The immune globulin, which came from pooled plasma (some from donors infected with HCV), was felt to confer passive immunity. Since 1992, however, patients who are hepatitis C positive have been excluded as plasma donors. Current data do not support the use of immune globulin for prophylaxis against hepatitis C.

Alpha interferon has been shown to be effective in the short term in the treatment of chronic HCV infection. Treatment is recommended for patients who are at greatest risk of progression to end-stage cirrhosis. This group includes patients with a persistently elevated alanine aminotransferase, presence of HCV RNA in the blood, and a liver biopsy showing either portal or bridging fibrosis and at least a moderate degree of inflammation and necrosis (103). Combination of the antiviral medication ribavirin with alpha interferon has shown promise in early studies (121).

**HUMAN IMMUNODEFICIENCY VIRUS**

The risk of HIV transmission from an infected patient to an orthopaedic surgeon is unknown. While the risk of seroconversion after a single percutaneous exposure may be low, great concern remains about the cumulative risk to orthopaedic surgeons, who often sustain numerous percutaneous injuries over the course of a lifetime. The cumulative risk has been estimated to be as high as l% to 4% (160).

While no one knows the exact risk, this figure may represent an overestimate for several reasons. The risk of HIV transmission is affected by the degree of viremia in the patient, the volume of the exposure, and the seroprevalence in the patient population, which varies greatly by geographical region. An estimated 5% to 10% of acute trauma patients in certain urban areas may be HIV positive (88). It is believed that the greatest risk of transmission is from a percutaneous injury, and that aerosolized particles, mucous membrane exposure, and exposure to intact skin present a low risk of disease transmission. Percutaneous injury with a hollow-bore needle is believed more likely to result in HIV transmission than injury by a solid suture needle, which is more commonly the experience of orthopaedic surgeons (46).

Virus transmission has not been documented with a solid-core suture needle injury. Needle type, size, and depth of penetration have been shown to be independent predictors for the volume of blood transferred in a percutaneous needle stick. The volume of blood transmitted is reduced by at least 50% when the needle passes through a glove made of any kind of material (94). The probability of transmission of infections may be more associated with the patient's viral titer than with the amount of the inoculum (114). Prospective studies of health care workers have estimated that the average risk of HIV transmission after a percutaneous exposure to HIV-infected blood is approximately 0.3% (95% confidence interval, 0.2% to 0.5%) (15).

As of June 1997, the Centers for Disease Control and Prevention had received 52 reports of documented U.S. health care workers who had seroconversion following occupational HIV exposure. Possible occupational HIV transmission has been reported in 114 cases in which the health care worker had no other known risk factor but there was no specific documented exposure (26). A seroprevalence survey involving 48% of the orthopaedic surgeons attending the 1991 annual meeting of the American Academy of Orthopaedic Surgeons found only two HIV-positive individuals (0.06%), and both of these surgeons reported additional nonoccupational risk factors (23).

A brief window of time exists after primary HIV infection before systemic infection occurs. During this time, postexposure antiretroviral intervention may modify viral replication. The U.S. Public Health Service has established recommendations for postexposure prophylaxis based on the risk of infection following the exposure and the infectivity of the exposure source (26) (Fig. 5.16). These recommendations are likely to continue to evolve as new retroviral agents or combination of agents are introduced and as HIV strains develop drug resistance. The risks of toxicity and side effects from prophylaxis will need to be continually weighed against the relatively low risk of disease transmission following an occupational exposure.



***Figure 5.16.*** Determining the need for HIV postexposure prophylaxis (PEP) after an occupational exposure[a]. (Reprinted with permission from Centers for Disease Control. Public Health Service Guidelines for the Management of Health Care Worker Exposure to HIV and Recommendations for Postexposure Prophylaxis. *MMWR*

In one study, 74% of surgeons' documented exposures to blood during surgery were potentially preventable by the use of additional barrier precautions, such as face shields and fluid-resistant gowns (111). Although there have been no documented cases of transmission, the possibility has been raised that HIV could be transmitted via aerosolized particles produced by power tools (70). Use face shields to prevent this kind of contamination (76) and splash shields to minimize the spread of the aerosolized fluids from mechanical pulsatile lavage. Double gloving, initially popularized in total joint arthroplasty as a way of minimizing the risk of the surgeon's contaminating the patient (95), has become important in protecting the surgeon. Latex glove perforation occurs frequently. The use of double gloves has been shown to be effective in minimizing the risk of perforation. Double gloving may result in a 60% to 80% decrease in inner glove perforation and visible blood contamination (49). Some authorities recommend inspecting and routinely changing latex gloves at least every 2 hours during long-duration procedures (87,126). One author has recommended that gloves be changed at least every 25 minutes (114). Cloth, Kevlar, and stainless-steel-reinforced gloves provide additional protection from perforation (63,87,126,145). Despite the use of these reinforced protective gloves, perforation of the inner gloves nevertheless occurs and may go unrecognized. Fluid sensors have been developed to alert surgeons when a glove has been penetrated.

Use fluid-impervious gowns during surgeries in which the gown may become saturated with blood or fluid. The use of a self-contained air exchange system may also offer protection, but the benefits it confers may be outweighed by communication difficulties it causes that could lead to accidental injury (28). Alternatively, an impervious urology apron worn under the surgical gown effectively prevents contamination of the trunk and lower extremities (49). Knee-length rubber boots or impervious shoe covers are recommended for cases in which the potential for blood loss is significant, or during arthroscopy.

The American Academy of Orthopaedic Surgeons (AAOS) has recommended changing surgical methods to reduce the risk of injury: Be aware and cautious, use pop-off needles, avoid having more than one person suture at a time, announce the passage of sharp instruments and pass them in a kidney basin or other device. Take care to avoid digital palpation of fracture sites or sharp bone surfaces. Cover pins and wires with protective caps. Periodically inspect gloves and gowns (4).

In the event of a percutaneous exposure, the AAOS recommends the following procedure (4):

- Wash the affected area immediately.
- Bleed the wound.
- Apply 70% isopropyl alcohol on the wound directly.
- Report the incident.

## POSTOPERATIVE PATIENT CARE

Postoperative care varies tremendously depending on the operation performed and the condition of the patient. Several general principles apply to the majority of patients, however. Elevate limbs postoperatively to improve venous and lymphatic return, but not so high that arterial input is compromised. In general, the ideal level is where the most distal portion of the extremity is 10 cm above the heart. Elevation on pillows is usually more comfortable for the patient and less hazardous than slings. Immobilize only joints that must be immobilized. Unless contraindicated, all mobile parts must be moved after surgery, either by active, active-assistive, or passive exercises.

Early mobilization of patients into a chair at bedside, to the toilet, and subsequently for ambulation is important. With today's surgical techniques, enforced bed rest after surgery is unusual. If a patient is on enforced bed rest, it is important to institute an in-bed physical therapy program to maintain joint range of motion, muscle strength, and, if possible, aerobic conditioning. Not only does such a regimen play a major role in mobilizing the patient later, but it also provides great psychological benefit.

### VENOUS THROMBOEMBOLISM PROPHYLAXIS

Prevention of thromboembolic disease is a critical issue in orthopaedic surgery. Recent studies have highlighted the pervasiveness of this problem among several orthopaedic patient populations (50,130,158). Without prophylaxis, a deep venous thrombosis may occur in 40% to 60% of patients undergoing total hip or knee arthroplasty. Proximal deep venous thrombosis may occur in 15% to 20%, and a fatal pulmonary embolism may occur in 0.5% to 2% (85). Risk factors that have been identified for thromboembolic disease include age (becoming clinically important by age 40 and increasing thereafter); prolonged immobility or paralysis; history of prior thromboembolism; cancer; major surgery (particularly operations on the pelvis and lower extremities); obesity; varicose veins; congestive heart failure; myocardial infarction; stroke; fractures of pelvis, hip, or leg; and possibly high-dose estrogen use (29).

Numerous methods of prophylaxis have been investigated, and authorities recommend both mechanical and pharmacologic methods. Intraoperative anesthetic techniques including hypotensive and epidural anesthesia have been shown to reduce the risk of thromboembolism (86,134). Mechanical methods include use of compression stockings and various pneumatic compression devices. Pharmacologic methods include dextran, aspirin, warfarin, heparin, and low-molecular-weight heparin.

Diagnosis of thromboembolic complications, most of which are asymptomatic, remains difficult. Methods for diagnosis of deep venous thrombosis include impedance plethysmography, fibrinogen I-125 scanning, venography, and duplex ultrasound. Diagnostic methods for pulmonary embolism are ventilation-perfusion scanning and pulmonary angiography. There is controversy over the ideal diagnostic testing modality because of variation in sensitivity and specificity of the different tests. They also vary in their ability to image different parts of the venous systems, and in the invasive risk they pose to the patient.

In cases where deep venous thrombosis is diagnosed, controversy also exists over whether all thrombi should be treated, what method of treatment should be used, and how long treatment should last. Low-molecular-weight heparin, which does not require laboratory monitoring, is increasingly the treatment of choice in the outpatient management of deep venous thrombosis (155). The numerous investigations and recommendations on this important subject are beyond the scope of this chapter. While many therapeutic methods have been shown to reduce the risk of thromboembolism, no single method is completely effective or applicable to all situations. Metaanalysis of recent randomized clinical trials has shown low-molecular-weight heparin to be superior to warfarin in prevention of deep venous thrombosis, but its use is associated with a greater number of minor bleeding complications (110). Each surgeon must assess the varying risk that thromboembolism presents to each individual patient, selecting the prophylactic method that appears to provide the greatest risk reduction when balanced against any potential risk of the treatment itself.

---

* Adapted from Chapman MW, Chapter 5, Operative Technique and Postoperative Management. In: Chapman MW, ed. *Operative Orthopaedics*, *2nd edition.* Philadelphia: JB Lippincott, 1993.

## CHAPTER REFERENCES

Each reference is categorized according to the following scheme: *, classic article; #, review article; !, basic research article; and +, clinical results/outcome study.


# 1. Abraham E. Immunologic Mechanisms Underlying Sepsis in the Critically Ill Surgical Patient. *Surg Clin North Am* 1985;65:991.

# 2. Allen JR. Transmission of Human Immunodeficiency Virus (HIV) by Blood and Blood Components. In: Moore SB, ed. *Transfusion-Transmitted Viral Diseases.* Arlington, VA: American Association of Blood Banks, 1987.

# 3. Alter HJ. You'll Wonder Where the Yellow Went: A 15-year Retrospective of Posttransfusion Hepatitis. In: Moore SB, ed. *Transfusion-Transmitted Viral Diseases.* Arlington, VA: American Association of Blood Banks, 1987.

* 4. American Academy of Orthopedic Surgery Task Force on AIDS and Orthopedic Surgery. *Recommendations for the Prevention of Human Immunodeficiency Virus (HIV) Transmission in the Practice of Orthopedic Surgery.* Rosemont, IL: American Academy of Orthopaedic Surgery, 1989.

# 5. American Academy of Orthopaedic Surgery. Blood Transfusions/HIV/Hepatitis. In: Kasser JR, ed. *Orthopaedic Knowledge Update 5.* Rosemont, IL: American Academy of Orthopaedic Surgery, 1995.

# 6. American Academy of Orthopaedic Surgery. Perioperative Medical Management. In: Kasser JR, ed. *Orthopaedic Knowledge Update 5.* Rosemont, IL: American Academy of Orthopaedic Surgery, 1995.

! 7. Anglen J, Apostoles PS, Christensen G, et al. Removal of Surface Bacteria by Irrigation. *J Orthop Res* 1996;14:251.

+ 8. Atlas SJ, Singer DE, Skates SJ. Changing Blood Use in the AIDS Era: The Case of Elective Hip Surgery. *Transfusion* 1994;34:386.

+ 9. Ayers DC, Murray DG, Duerr DM. Blood Salvage after Total Hip Arthroplasty. *J Bone Joint Surg* 1995;77A:1347.

+ 10. Bailey TE Jr, Mahoney OM. The Use of Banked Autologous Blood in Patients Undergoing Surgery for Spinal Deformity. *J Bone Joint Surg* 1987;69A:329.

+ 11. Baker RJ, Moinichen SL, Nyhus LM. Transfusion Reaction: A Reappraisal of Surgical Incidence and Significance. *Ann Surg* 1969;169:684.

! 12. Bannister GC, Auchincloss JM, Johnson DP, Newman JH. The Timing of Tourniquet Application in Relation to Prophylactic Antibiotics Administration. *J Bone Joint Surg* 1988;70B:322.

# 13. Barbara J, Flanagan P. Blood Transfusion Risk: Protecting against the Unknown: Worries over Variant CJD Should Not Detract from Work on Other, Better Known, Risks (editorial). *BMJ* 1998;316:717.

+ 14. Beer KJ, Lombardi AV, Mallory TH, Vaughn BK. The Efficacy of Suction Drains after Routine Total Joint Arthroplasty. *J Bone Joint Surg* 1991;73A:584.

# 15. Bell DM. Occupational Risk of Human Immunodeficiency Virus Infection in Healthcare Workers: An Overview. *Am J Med* 1997;109(suppl 5):9.

# 16. Bell W. The Hematology of Autotransfusion. *Surgery* 1978;84:695.

+ 17. Blevins FT, Shaw B, Valeri CR, et al. Reinfusion of Shed Blood after Orthopaedic Procedures in Children and Adolescents. *J Bone Joint Surg* 1993;75A:363.

* 18. Blount WP. Osteotomy in the Treatment of Osteoarthritis of the Hip. *J Bone Joint Surg* 1964;46A:1297.

# 19. Bose WJ. The Potential Use of Human Recombinant Erythropoietin in Orthopaedic Surgery. *Orthopaedics* 1996;19:325.

# 20. Bove JR, Sandler SG. HTLV-I and Blood Transfusion. *Transfusion* 1988;28:93.

+ 21. Canadian Orthopaedic Perioperative Erythropoietin Study Group. Effectiveness of Perioperative Recombinant Human Erythropoietin in Elective Hip Replacement. *Lancet* 1993;341:1227.

# 22. Cashman NR. A Prion Primer. *Can Med Assoc J* 1997;157:1381.

+ 23. Centers for Disease Control. Preliminary Analysis: HIV Serosurvey of Orthopaedic Surgeons, 1991. *MMWR Morb Mortal Wkly Rep* 1991;40:309.

+ 24. Centers for Disease Control. First 500,000 AIDS Cases—United States 1995. *MMWR Morb Mortal Wkly Rep* 1995;44:849.

* 25. Centers for Disease Control. Immunization of Health-care Workers: Recommendations of the Advisory Committee on Immunization Practices (ACIP) and the Hospital Infection Control Practices Advisory Committee (HICPAC). *MMWR Morb Mortal Wkly Rep* 1997;46(RR-18):1.

* 26. Centers for Disease Control. Public Health Service Guidelines for the Management of Health-care Worker Exposures to HIV and Recommendations for Postexposure Prophylaxis. *MMWR Morb Mortal Wkly Rep* 1998;47(RR-7):1.

+ 27. Chesi R, Cazzola A, Bacci G, et al. Effect of Perioperative Transfusions on Survival in Osteosarcoma Treated by Multimodal Therapy. *Cancer* 1989;64:1727.

# 28. Chou L, Reynolds MR, Esterhai JL Jr. Hazards to the Orthopaedic Trauma Surgeon: Occupations Exposure to HIV and Viral Hepatitis (A Review Article). *J Orthop Trauma* 1996;10:289.

* 29. Clagett GP, Anderson FA Jr, Heit J, et al. Prevention of Venous Thromboembolism: Fourth ACCP Consensus Conference on Antithrombotic Therapy. *Chest* 1995;108(suppl. 4):312S.

+ 30. Cobb JP. Why Use Drains? *J Bone Joint Surg* 1990;72B:993-995.

# 31. Cowell HR. Perioperative Red Blood-cell Transfusion (editorial). *J Bone Joint Surg* 1989;71A:1.

+ 32. Delamarter RB, Carr J, Saxton EH. HTLV-I Viral Associated Myelopathy after Blood Transfusion in a Multiple Trauma Patient. *Clin Orthop* 1990;260:191.

! 33. Dirschl DR, Duff GP, Dahners LE, et al. High Pressure Pulsatile Lavage Irrigation of Intraarticular Fractures: Effects on Fracture Healing. *J Orthop Trauma* 1998;12:460.

# 34. Dirschl DR, Wilson FC. Topical Antibiotic Irrigation in the Prophylaxis of Operative Wound Infections in Orthopaedic Surgery. *Orthop Clin North Am* 1991;22:419.

+ 35. Dugdale RW, Schutzer SF, Deafenbaugh MK, Bartosh RA. Compartment Syndrome Complicating Use of the Hemi-lithotomy Position during Femoral Nailing: A Report of Two Cases. *J Bone Joint Surg* 1989;71:1556.

+ 36. Edna T-H, Bjerkeset T. Association between Blood Transfusion and Infection in Injured Patients. *J Trauma* 1992;33:659.

# 37. Epps CH Jr. General Principles in the Prevention of Surgical Complications in Orthopaedic Surgery. *Clin Orthop* 1987;222:5.

+ 38. Faris PM, Ritter MA, Abels RI. The Effects of Recombinant Human Erythropoietin on Perioperative Transfusion Requirements in Patients Having a Major Orthopaedic Operation. *J Bone Joint Surg* 1996;78A:62.

+ 39. Fattovich G, Giustina G, Degos F, et al. Morbidity and Mortality in Compensated Cirrhosis Type C: A Retrospective Follow-up Study of 384 Patients. *Gastroenterology* 1997;112:463.

+ 40. Fernandez MC, Gottlieb M, Menitove JE. Blood Transfusion and Postoperative Infection in Orthopaedic patients. *Transfusion* 1992;32:318.

+ 41. Francavilla F, Rinaldi R, Cattelan AM, et al. Low Prevalence of Antibodies to Hepatitis C Virus in Hospital Employees (letter to the editor). *Infection* 1992;20:295.

# 42. Friedman LS, Maddrey WC. Surgery in the Patient with Liver Disease. *Med Clin North Am* 1987;71:453.

+ 43. Gannon DM, Lombardi AV, Mallory TH, et al. An Evaluation of the Efficacy of Postoperative Blood Salvage after Total Joint Arthroplasty: A Prospective Randomized Trial. *J Arthroplasty* 1991;1:109.

+ 44. Gargaro JM, Walls CE. Efficacy of Intraoperative Autotransfusion in Primary Total Hip Arthroplasty. *J Arthroplasty* 1991;6:157.

# 45. Gavin LA. Management of Diabetes Mellitus during Surgery. *West J Med* 1989;151:525.

# 46. Gerberding JL. Current Epidemiologic Evidence and Case Reports of Occupationally Acquired HIV and Other Blood-borne Diseases. *Infect Control Hosp Epidemiol* 1990;11:S558.

# 47. Gerberding JL. Procedure-specific Infection Control for Preventing Intraopertive Blood Exposures. *Am J Infect Control* 1993;21:364.

# 48. Gerberding J. Drug Therapy: Management of Occupational Exposure to Blood-borne Viruses (Review Article). *N Engl J Med* 1995;332:444.

+ 49. Gerberding JL, Schecter WP. Surgery and AIDS: Reducing the Risk (editorial). *JAMA* 1991;265:1572.

* 50. Geerts WH, Code KI, Jay RM, et al. A Prospective Study of Venous Thromboembolism after Major Trauma. *N Engl J Med* 1994;331:1601.

+ 51. Goldfinger D. Directed Blood Donations: Pro. *Transfusion* 1989;29:70.

* 52. Goldman L. Cardiac Risk and Complications of Noncardiac Surgery. *Ann Intern Med* 1983;98:504.

* 53. Goldman L, Caldera DL, Nussbaum SR, et al. Multifactorial Index of Cardiac Risk in Noncardiac Surgical Procedures. *N Engl J Med* 1977;297:845.

# 54. Goodnough LT, Monk TG, Andriole GL. Current Concepts: Erythropoietin Therapy (review article). *N Engl J Med* 1997;336:933.

+ 55. Goodnough LT, Rudnick S, Price TH, et al. Increased Preoperative Collection of Autologous Blood with Recombinant Human Erythropoietin Therapy. *N Engl J Med* 1989;321:1163.

+ 56. Goodnough LT, Vizmeg K, Sobecks R, et al. Prevalence and Classification of Anemia in Elective Orthopaedic Surgery Patients: Implications for Blood Conservation Programs. *Vox Sang* 1992;63:90.

+ 57. Goulet JA, Bray TJ, Timmerman LA, et al. Intraoperative Autologous Transfusion in Orthopaedic Patients. *J Bone Joint Surg* 1989;71A:3.

* 58. Gross JB Jr. Clinicians Guide to Hepatitis C. *Mayo Clin Proc* 1998;73:355.

# 59. Hadler SC, Margolis HS. Hepatitis B Immunization: Vaccine Types, Efficacy, and Indications for Immunization. In: Remington JS, Swartz MN, eds. *Current Topics in Infectious Disease.* Boston: Blackwell Scientific, 1992:282.

+ 60. Hargens AR, McClure AG, Skyhar MJ, et al. Local Compression Patterns beneath Pneumatic Tourniquets Applied to Arms and Thighs of Human Cadavers. *J Orthop Res* 1987;5:247.

+ 61. Healy WL, Pfeifer BA, Kurtz SR, et al. Evaluation of Autologous Shed Blood for Autotransfusion after Orthopaedic Surgery. *Clin Orthop* 1994;299:53.

+ 62. Henry DH. Experience with Epoetin Alfa in Acquired Immunodeficiency Syndrome Anemia. *Sem Oncol* 1998;25(3 suppl 7):64.

! 63. Herscovici D Jr, DiPasquale T, Sanders R. Comparison of Cloth Gloves Used in Orthopaedic Surgery: A Clinical and Experimental Evaluation. *J Orthop Trauma* 1998;12:106.

# 64. Hirsch IB, McGill JB, Cryer PE, White PF. Perioperative Management of Surgical Patients with Diabetes Mellitus. *Anesthesiology* 1991;74:346.

+ 65. Holland PV. Prevention of Transfusion-associated Graft-versus-Host Disease. *Arch Pathol Lab Med* 1989;113:285.

# 66. Hoofnagle JH. Hepatitis C: The Clinical Spectrum of Disease. *Hepatology* 1997;26(3 suppl 1):15S.

# 67. Hoppenfeld S, deBoer P. *Surgical Exposures in Orthopaedics: The Anatomic Approach,* 2nd ed. Philadelphia: JB Lippincott, 1994.

+ 68. Hynson JM, Katz JA, Bueff HU. Epidural Hematoma Associated with Enoxaparin (Case Reports). *Anesth Analg* 1996;82:1072.

+ 69. Johnson EE. Multiplane Correctional Osteotomy of the Tibia for Diaphyseal Malunion. *Clin Orthop* 1987;215:223.

! 70. Johnson GK, Robinson WS. Human Immunodeficiency Virus-1 (HIV-1) in the Vapors of Surgical Power Instruments. *J Med Virol* 1991;33:47.

+ 71. Kabalin CS, Yarnold PR, Grammer LC. Low Complication Rate of Corticosteroid-treated Asthmatics Undergoing Surgical Procedures. *Arch Intern Med* 1995;155:1379.

+ 72. Kaplan EB, Sheiner LB, Boeckmann AJ, et al. The Usefulness of Preoperative Laboratory Screening. *JAMA* 1985;253:3576.

+ 73. Keeling MM, Schmidt-Clay P, Kotcamp WW, et al. Autotransfusion in the Postoperative Orthopaedic Patient. *Clin Orthop* 1993;291:251.

+ 74. Kellam JF, Messer A. Evaluation of the Role of Coronal and Sagittal Axial CT Scan Reconstruction for the Imaging of Acetabular Fractures. *Clin Orthop* 1994;305:152.

# 75. Kellerman PS. Perioperative Care of the Renal Patient. *Arch Intern Med* 1994;154:1674.

# 76. Kinninmonth AW, Hutchinson JD. Full Face Protection in Orthopaedic Surgery: A Practical Appliance for Use in High Risk Cases. *Injury* 1991;21:117.

+ 77. Kiyosawa K, Sodeyama T, Tanaka E, et al. Hepatitic C in Hospital Employees with Needlestick Injuries. *Ann Inter Med* 1991;115:367.

+ 78. Klebanoff G. Early Clinical Experience with a Disposable Unit for the Intraoperative Salvage and Reinfusion of Blood Loss (Intraoperative Autotransfusion). *Am J Surg* 1970;120:718.

+ 79. Koval KJ, Rosenberg AD, Zuckerman JD, et al. Does Blood Transfusion Increase the Risk of Infection after Hip Fracture? *J Orthop Trauma* 1997;11:260.

# 80. Kwiatkowski TC, Hanley EN Jr, Ramp WK. Cigarette Smoking and Its Orthopaedic Consequences. *Am J Orthop* 1996;25:590.

! 81. Lamphear BP, Linnemann CC, Cannon CG, et al. Hepatitis C Virus Infection in Healthcare Workers: Risk of Exposure and Infection. *Infect Control Hosp Epidemiol* 1994;15:745.

+ 82. Lang GR, Richardson M, Bosse MJ, et al. Efficacy of Surgical Wounds Drainage in Orthopaedic Trauma Patients: A Randomized Prospective Trial. *J Orthop Trauma* 1998;12:348.

# 83. Lemos MJ, Healy WL. Blood Transfusion in Orthopaedic Operations: Current Concepts Review. *J Bone Joint Surg* 1996;78A:1260.

+ 84. Levine E, Rosen A, Sehgal L, et al. Physiologic Effects of Acute Anemia: Implications for a Reduced Transfusion Trigger. *Transfusion* 1990;30:11.

# 85. Lieberman JR, Geerts WH. Prevention of Venous Thromboembolism after Total Hip and Knee Arthroplasty. *J Bone Joint Surg* 1994;76A:1239.

+ 86. Lieberman JR, Huo MM, Hanmway J, et al. The Prevalence of Deep Venous Thrombosis after Total Hip Arthroplasty with Hypotensive Epidural Anesthesia. *J Bone Joint Surg* 1994;76A:341.

! 87. Louis S, Steinberg EL, Gruen OA, et al. Outer Gloves in Orthopaedic Procedures: A Polyester/Stainless Steel Wire Weave Glove Liner Compared with Latex. *J Orthop Trauma* 1998;12:101.

# 88. Luck JV Jr. Orthopaedic Surgery on the HIV-Positive Patient: Complications and Outcome. *Instr Course Lect* 1994;43:543.

# 88a. Luck JV Jr., Logan LR, Benson DR, Glasser DB. Human Immodeficiency Virus Infection: Complications and Outcomes of Orthopaedic Surgery. *J Amer Acad Orthop Surg* 1996;4:297.

! 89. MacMillan M, Petty W, Hendeles L. Effect of Irrigation and Tourniquet Application on Aminoglycoside Antibiotic Concentrations in Bone. *J Orthop Res* 1988;6:311.

+ 90. Marcello PW, Roberts PL. “Routine” Preoperative Studies: Which Studies in Which Patients. *Surg Clinic North Am* 1996;76:11.

# 91. Mandel RJ, Brown MD, McCollough NC III, et al. Hypotensive Anesthesia and Autotransfusion in Spinal Surgery. *Clin Orthop* 1984;154:27.

* 92. Mast JW. Preoperative Planning in the Surgical Correction of Tibial Nonunions and Malunions. *Clin Orthop* 1983;178:26.

# 93. Mast J, Jakob R, Ganz R. *Planning and Reduction Technique in Fracture Surgery.* Berlin: Springer-Verlag, 1989.

! 94. Mast S, Woolwine JD, Gerberding JL. Efficacy of Gloves in Reducing Blood Volumes Transferred during Simulated Needlestick Injury. *J Infect Dis* 1993;168:1589.

+ 95. McCue SF, Berg EW, Saunders EA. Efficacy of Double-gloving as a Barrier to Microbial Contamination during Total Joint Arthroplasty. *J Bone Joint Surg* 1981;63A:811.

# 96. Miller PJ, O'Connell J, Leipold A, Wenzel RP. Potential Liability for Transfusion-Associated AIDS. *JAMA* 1985;253:3419.

+ 97. Miller RD. Complications of Massive Blood Transfusions. *Anesthesiology* 1973;39:82.

+ 98. Miller RD, Robbins TO, Tong MJ, et al. Coagulation Defects Associated with Massive Blood Transfusions. *Ann Surg* 1971;174:794.

# 99. Mohr D, Jett JR. Preoperative Evaluation of Pulmonary Risk Factors. *J Ge Int Med* 1988;3:277.

+ 100. Moore SB, Taswell HS, Pineda AA, et al. Delayed Hemolytic Reaction. *Am J Clin Pathol* 1980;74:94.

+ 101. Murphy P, Heal JM, Blumberg N. Infection or Suspected Infection after Hip Replacement Surgery with Autologous or Homologous Blood Transfusions. *Transfusion* 1991;31:212.

* 102. National Institutes of Health. Consensus Conference: Perioperative Red Blood Cell Transfusion. *JAMA* 1988;260:2700.

* 103. National Institutes of Health. Consensus Development Conference Panel Statement: Management of Hepatitic C. *Hepatology* 1997;27(suppl 1):2S.

# 104. Nelson CL. Prevention of Sepsis. *Clin Orthop* 1987;222:66.

+ 105. Nelson CL, Bowe WS. Total Hip Arthroplasty in Jehovah's Witnesses without Blood Transfusion. *J Bone Joint Surg* 1986;65A:350.

+ 106. Nelson CL, Green TG, Porter RA, Warren RD. One Day versus Seven Days of Preventative Antibiotic Therapy in Orthopaedic Surgery. *Clin Orthop* 1983;176:258.

# 107. Nelson CL, Nelson RL, Cone J. Blood Conservation Techniques in Orthopaedic Surgery. *Instruct Course Lect* 1990;39:425.

+ 108. Ness PM, Bourke DL, Walsh PC. A Randomized Trial of Perioperative Hemodilution versus Transfusion of Preoperatively Deposited Autologous Blood in Elective Surgery. *Transfusion* 1992;32:226.

+ 109. Page PL. Directed Blood Donations: Con. *Transfusion* 1989;29:65.

+ 110. Palmer AJ, Koppenhagen K, Kirchof B, et al. Efficacy and Safety of Low Molecular Weight Heparin, Unfractionated Heparin and Warfarin for Thrombo-embolism Prophylaxis in Orthopaedic Surgery: A Meta-analysis of Randomised Clinic Trials. *Haemostasis* 1997;27:75.

! 111. Panlilo AL, Foy DR, Edwards JR, et al. Blood Contacts during Surgical Procedures. *JAMA* 1991;265:1533.

# 112. Pepino A, Cesarelli M, DiSalle F, et al. Preliminary Notes on the Conversion of Three-dimensional Images of Bone into CAD Structures for the Pre-operative Planning of Intertrochanteric Osteotomies. *Med Biol Eng Comput* 1993;31:529.

+ 113. Perkins HA, Samson S, Busch MP. How Well has Self-exclusion Worked? *Transfusion* 1988;28:601.

# 114. Perugia L, Traina GC. Current Concepts: AIDS and Surgery. *Int Orthop* 1994;18:397.

+ 115. Pineda AA, Brzica SM Jr, Taswell HF. Hemolytic Transfusion Reaction. *Am J Clin Pathol* 1980;74:94.

+ 116. Popovsky MS, Abel MD, Moore SB. Transfusion-related Acute Lung Injury Associated with Passive Transfer of Anti-leukocyte Antibodies. *Am Rev Respir Dis* 1983;128:185.

! 117. Puno RM, Vaughan JJ, Von Fraunhofer JA, et al. A Method of Determining the Angular Malalignments of the Knee and Ankle Joints Resulting from a Tibial Malunion. *Clin Orthop* 1987;223:213.

! 118. Puro V, Petrosillo N, Ippolito G, Italian Study Group on Occupational Risk of HIV and Other Bloodborne Infections. Risk of Hepatitis C Seroconversion after Occupational Exposure in Health Care Workers. *Am J Infect Control* 1995;23:273.

+ 119. Ragni MV, Crossett LS, Herndon JH. Postoperative Infection Following Orthopaedic Surgery in Human Immunodeficiency Virus-infected Hemophiliacs with CD4 Counts < or = 200/mm$^3$. *J Arthroplasty* 1995;10:716.

! 120. Raikin SM, Landsman JC, Alexander VA, et al. Effect of Nicotine on the State and Strength of Long Bone Fracture Healing. *Clin Orthop* 1998;353:231.

# 121. Reichard O, Schvarcz R, Weiland O. Therapy of Hepatitis C: Alpha Interferon and Ribavirin. *Hepatology* 1997;27(suppl 1):108S.

! 122. Reid HS, Camp RA, Jacob WH. Tourniquet Hemostasis: A Clinical Study. *Clin Orthop* 1983;177:230.

! 123. Ries M, O'Neill D. A Method to Determine the True Angulation of Long Bone Deformity. *Clin Orthop* 1987;218:191.

+ 124. Ritter MA, Keating EM, Faris PM. Closed Wound Drainage in Total Hip or Total Knee Replacement: A Prospective, Randomized Study. *J Bone Joint Surg* 1994;76A:35.

+ 125. Sanders R, Anglen JO, Mark JB. Oblique Osteotomy for the Correction of Tibial Malunion. *J Bone Joint Surg* 1995;77A:240.

! 126. Sanders R, Fortin P, Ross E, Helfet D. Outer Gloves in Orthopaedic Procedures: Cloth Compared with Latex. *J Bone Joint Surg* 1990;72A:914.

# 127. Sandler SG. HTLV-I and Other Retroviruses. In: Moore SB, ed. *Transfusion-Transmitted Viral Diseases.* Arlington, VA: American Association of Blood Banks, 1987.

+ 128. Sangeorzan BJ, Sangeorzan BP, Hansen ST Jr, Judd RP. Mathematically Directed Single-cut Osteotomy for Correction of Tibial Malunion. *J Orthop Trauma* 1989;3:267.

# 129. Scannell KA. Surgery and Human Immunodeficiency Virus Disease. *J Acquir Immune Defic Syndr* 1989;2:43.

+ 130. Schippinger G, Wirnsberger GH, Obernosterer A, Babinski K. Thromboembolic Complications after Arthroscopic Knee Surgery: Incidence and Risk Factors in 101 Patients. *Acta Orthop Scand* 1998;69:144.

! 131. Schreiber GB, Busch MP, Kleinman SH, Korelitz JJ. The Risk of Transfusion-transmitted Viral Infections. *N Engl J Med* 1996;334:1685.

# 132. Selik RM, Ward JW, Buehler JW. Trends in Transfusion-associated Acquired Immune Deficiency Syndrome in the United States, 1982 to 1991. *Transfusion* 1993;33:890.

! 133. Shapiro CN, Tokars JI, Chamberland ME, American Academy of Orthopaedic Surgeons Serosurvey Study Committee. Use of the Hepatitis-B Vaccine and Infection with Hepatitis B and C among Orthopaedic Surgeons. *J Bone Joint Surg* 1996;78A:1791.

+ 134. Sharrock NE, Salvati EA. Hypotensive Anesthesia for Total Hip Arthroplasty: A Review. *Acta Orthop Scand* 1996;67:91.

! 135. Shaw JA, Murray DG. The Relationship between Tourniquet Pressure and Underlying Soft-tissue Pressure in the Thigh. *J Bone Joint Surg* 1982;64A:1148.

# 136. Short LJ, Bell DM. Risk of Occupational Infection with Blood-borne Pathogens in Operating and Delivery Room Settings. *Am J Infect Control* 1993;21:343.

+ 137. Slater RR Jr, Weiner TM, Koruda MJ. Bilateral Leg Compartment Syndrome Complicating Prolonged Lithotomy Position. *Orthopaedics* 1994;17:954.

# 138. Smith TK. Prevention of Complications in Orthopaedic Surgery Secondary to Nutritional Depletion. *Clin Orthop* 1987;222:91.

# 139. Solanki D, McCurdy PR. Delayed Hemolytic Transfusion Reactions: An Often-missed Entity. *JAMA* 1978;239:729.

# 140. Spandorfer J. The Patient with Substance Abuse Going to Surgery. In: Merli GJ, Weitz HH, eds. *Medical Management of the Surgical Patient*, 2nd ed. Philadelphia: WB Saunders, 1998.

+ 141. Stehling LC, Ellison N, Faust RJ, et al. A Survey of Transfusion Practices among Anesthesiologists. *Vox Sang* 1987;52:60.

# 142. Stehling L, Zauder HL. How Low Can We Go? Is There a Way to Know? *Transfusion* 1990;30:1.

# 143. Stevens PM. Computer-assisted Preoperative Planning (CAPP) on an Office Personal Computer. *Orthop Rev* 1987;16:678.

! 144. Stevens PM. Radiographic Distortion of Bones: A Marker Study. *Orthopaedics* 1989;12:1457.

! 145. Sutton PM, Greene T, Howell FR. The Protective Effect of a Cut-resistant Glove Liner: A Prospective, Randomised Trial. *J Bone Joint Surg* 1998;80B:411.

# 146. Tetgmeier GE. Blood Transfusion and the Transmission of Cytomegalovirus. In: Moore SB, ed. *Transfusion-Transmitted Viral Diseases.* Arlington, VA: American Association of Blood Banks, 1987.

+ 147. Thaler M, Shamiss A, Orgad S, et al. The Role of Blood from HLA-homozygous Donors in Fatal Transfusion-associated Graft-versus-Host Disease after Open Heart Surgery. *N Engl J Med* 1989;321:25.

+ 148. Thomason HC III, Wilson FC, Lachiewicz PF, et al. Knee Arthroplasty in Hemophilic Arthropathy. *Clin Orthop* 1999;360:169.

+ 149. Thomson JD, Callaghan JJ, Savory CG, et al. Prior Deposition of Autologous Blood in Elective Orthopaedic Surgery. *J Bone Joint Surg* 1987;69A:320.

+ 150. Turner RH, Capozzi JD, Kim A, et al. Blood Conversation in Major Orthopaedic Surgery. *Clin Orthop* 1990;256:299.

+ 151. Vamvakas EC, Moore SB, Cabanela M. Blood Transfusion and Septic Complications after Hip Replacement Surgery. *Transfusion* 1995;35:150.

+ 152. Velanovich V. The Value of Routine Preoperative Laboratory Testing in Predicting Postoperative Complications: A Multivariate Analysis. *Surgery* 1991;109:236.

+ 153. Ward JW, Grindon AJ, Feorino PM, et al. Laboratory and Epidemiologic Evaluation of an Enzyme Immunoassay for Antibodies to HTLV III. *JAMA* 1986;256:356.

+ 154. Ward JW, Holmberg SD, Allen JR, et al. Transmission of Human Immunodeficiency Virus (HIV) by Blood Transfusions Screened as Negative for HIV Antibody. *N Engl J Med* 1988;318:473.

# 155. Weitz JI. Drug Therapy: Low-molecular-weight Heparins (review article). *N Engl J Med* 1997;337:688.

+ 156. Wilhelm JA, Matter L, Schopfer K. The Risk of Transmitting Cytomegalovirus to Patients Receiving Blood Transfusion. *J Infect Dis* 1986;154:169.

# 157. Williams DN, Gustilo RB. The Use of Preventative Antibiotics in Orthopaedic Surgery. *Clin Orthop* 1984;190:83.

+ 158. Williams JS, Hulstyn MJ, Fadale PD, et al. Incidence of Deep Vein Thrombosis after Arthroscopic Knee Surgery: A Prospective Study. *J Arthroscopic Rel Res* 1995;11:701.

+ 159. Wilson WJ. Intraoperative Autologous Transfusion in Revision Hip Arthroplasty. *J Bone Joint Surg* 1989;71A:8.

# 160. Wright JG, McGeer A. Human Immunodeficiency Virus Transmission between Surgeons and Patients in Orthopaedic Surgery. *Clin Orthop* 1993;297:272.

+ 161. Woolson ST, Marsh JS, Tanner JB. Transfusion of Previously Deposited Autologous Blood for Patients Undergoing Hip Replacement Surgery. *J Bone Joint Surg* 1987;69A:325.

+ 162. Wysowski DK, Talarico L, Bacsanyi J, Botstein P. Spinal and Epidural Hematoma and Low-molecular-weight Heparin. *N Engl J Med* 1998;338(24):1774.

# CHAPTER 6

# INSTRUMENTATION AND IMPLANTS

*Michael W. Chapman*

**M. W. Chapman:** Department of Orthopaedics, University of California—Davis, Sacramento, California 95817.

Care of Instruments
Nonpowered Instruments
Powered Instruments
Care of Implants
Surgical Instrument Sets
Periosteal Elevators
Retractors
Chisels and Osteotomes
Gouges
Curets
Bone-Cutting Forceps
Rongeurs
Bone Rasps
Mallets
Bone-Holding Instruments
Bone Drills
Screwdrivers
Hand Bone Saws
Plate Benders
Miscellaneous Instruments
Chapter References

To perform effective, safe, and rapid surgery, the surgeon must have sharp and functioning instruments. The care, maintenance, and ownership of surgical instruments and implants is, for the most part, the province of the hospital and its operating room staff. A few surgeons, particularly in highly specialized fields such as microvascular surgery or arthroplasty, own their own surgical tools. Surgeons might want to consider purchasing, maintaining, and using their own instruments in the case of particularly delicate instruments, those that are ineffective if damaged, and those that as a rule are not in good condition in the average, busy operating room.

The surgeon has a responsibility not to abuse or misuse instruments, to be familiar with the instruments and implants, and to inform the operating room staff well in advance if specialized or backup instrumentation or implants are required for a particular procedure. After the instruments are open on the back table, review the steps of the surgery with the scrub nurse to be certain that all instruments are present, in good shape, and functioning. Do this review before the skin incision is made; do not delegate this responsibility.

If the surgeon is using new instrumentation for the first time, it is wise to go over the instrumentation at a time separate from the first surgery. In hospitals that have motor skills workshops, it may be worthwhile to go through a motor skills exercise using the equipment.

## CARE OF INSTRUMENTS

### NONPOWERED INSTRUMENTS

In orthopaedic surgery, there is frequently a need to grasp and manipulate large, tough structures such as tendons, ligaments, and bone. Most forceps and clamps used in general surgery are not designed to handle these structures and can be damaged if used inappropriately.

The metals for instruments are fabricated with less regard to corrosion resistance and are designed more to meet functional needs, such as cutting, wear resistance, and weight. After each use, clean instruments thoroughly, usually with an ultrasonic cleaner. Some must be disassembled for proper cleaning. After cleaning, dry them thoroughly and store them properly to avoid corrosion.

The following are guidelines for the use of nonpowered surgical instruments that will spare problems for the surgeon, patient, and instruments.

- Never use microsurgical instruments for routine hand surgery.
- Handle tendon, ligaments, periosteum, and other soft tissues with toothed forceps, which provide a better grip, crush less, and have a smaller surface area of contact than do nontoothed forceps. The teeth of a large Kocher clamp provide such advantages if you must firmly grip or pull a tendon or ligament.
- Do not use Kelly clamps, hemostats, mosquitoes, or other similar instruments to grasp musculoskeletal tissues. Using them in such a way springs the tines and makes them useless for routine soft-tissue use.
- To suture tendons and ligaments, use a heavy-duty needle holder with diamond-patterned jaws to grip the needle firmly. Round needles are very difficult to pass through ligaments. Instead, use a cutting needle unless you think the suture may cut out of the tissue.
- The only instrument that should be used for hammering is a mallet. In particular, do not use the handles of power instruments, whose delicate machinery may be broken by any type of pounding.
- Do not use dull or chipped osteotomes, chisels, gouges, or periosteal elevators. It is particularly damaging to sharp instruments to use them to remove hardware. Metal-to-metal contact chips and dulls blades. Ask the operating room staff to set aside a special set of older sharp instruments to be reserved for hardware removal.
- Sharp, straight drill points are essential to avoid bone necrosis and to obtain secure fixation. Because drill points are difficult to resharpen correctly, replace them frequently.

### POWERED INSTRUMENTS

The major responsibility of caring for powered instruments belongs to the operating room staff. The surgeon can help by being certain that the power tool is properly assembled and that it is not used for anything other than its intended purpose.

Proper assembly is important to performance; improper assembly may damage power transfer interfaces. Know your power instruments and make sure that the scrub nurse assembles them properly. Excessive noise or overheating could be an indication of mechanical problems or inadequate lubrication. Stop using the instrument immediately; continued use may result in freezing of the components.

The neglect of a simple maintenance operation—lubricating the instrument—may result in its destruction, requiring replacement or major overhaul. Care of these expensive, sophisticated instruments cannot be casual. The operating room staff must set up a mandatory maintenance program.

Power tools, ranging from large reamers for the acetabulum to fine powered instruments for arthroscopy, are delicate instruments. Most are gas powered; treat the hose carefully to avoid gas leakage and loss of power. Do not sharply angulate, crimp, or penetrate the hose. Use compressed air or nitrogen. Never use oxygen because of the danger of fire.

Optimal operation requires proper operating pressures, as designated by the manufacturer. For most instruments, proper pressure is approximately 6 bar (90 psi).

Nevertheless, a central air system should have the capacity to provide 9.6 to 12 bar (145 to 180 psi). It is best if power systems evacuate their gases out of the operative field. The gas must be sterile, and sterility is usually accomplished by means of a filter. If instruments are run by compressed air from a central system, use of a filter may be necessary to eliminate condensed water, dirt, or rust, which may interfere with the function of the power equipment.

A standard assortment of orthopaedic power instruments is illustrated in Figure 6.1. Most power instruments are damaged if immersed in water. After each use, they must be wiped, thoroughly cleaned with an air jet, and immediately oiled. See the manufacturer's directions for maintenance.

***Figure 6.1.*** Assorted power tools, including reciprocating and oscillating saws. The middle tool serves as a reamer or drill. A single power source is used. (Courtesy of Hall Surgical, Division of Zimmer, Santa Barbara, CA.)

## CARE OF IMPLANTS

Orthopaedic implants come packaged individually from the factory with high-quality surface finishes. Maintenance of the finish is critical. Avoid scratching or nicking it to prevent the formation of stress risers that can lead to premature implant failure. Store implants in their original containers, and return them to their containers if they are opened in the operating room. A second choice is a properly designed storage rack that holds the implants securely, does not scratch them, and prevents implants from rubbing against each other. Never store implants loose and unprotected in a tray or drawer.

Inspect implants carefully before implantation. Significant scratches or nicks are justification for rejecting an implant, particularly in the case of a prolonged implantation (e.g., total hip prostheses) or high-stress situations (e.g., plate fixation of a nonunion). Never reuse implants that have been removed from patients; they have been subjected to fatigue stress, and they may be close to failure. Discard screws used temporarily for external compression or other high-stress uses.

Contour plates to fit the bone as smoothly as possible to minimize formation of stress risers. Avoid bending through screw holes, and use templates so that bending of the plate is accomplished with minimal manipulation. Excessive bending of a plate, particularly reverse (back-and-forth) bending, increases its likelihood of failure. The only implants that can be reused are unstressed ones—for example, a screw that has been replaced because it is of incorrect length.

Do not mix implants from different manufacturers. Although the designs appear identical, small differences often exist that can cause mechanical or material incompatibility.

## SURGICAL INSTRUMENT SETS

Organize surgical instruments into a series of sets. A general instrument set is required for the incision and exposure of soft tissues and for closure. Major orthopaedic operations usually require a general surgery soft-tissue instrument set. A second set contains orthopaedic instruments needed for most bone surgery, such as periosteal elevators, chisels and osteotomes, gouges, mallets, drills and drill points, rasps, forceps, rongeurs, and bone-holding instruments. A third set contains some type of powered equipment for drilling and cutting bone. A fourth set contains specialized instruments for the procedure at hand. For fracture fixation, it consists of internal fixation instruments and implants, and, in total joint replacement, instruments for total joints. These specialized instruments are discussed in separate chapters, with the surgical procedures. General instruments are discussed in this chapter.

### PERIOSTEAL ELEVATORS (FIGURE 6.2.)

***Figure 6.2.*** Periosteal elevators.

Periosteal elevators are chisel-like instruments with rounded tips that are designed to elevate periosteum and muscle fibers from bone. Unless they are kept very sharp, they are ineffective in cutting ligament and inserting tendon, for which a scalpel is more useful. Use a periosteal elevator against the acute angle of muscle fiber insertions. When used on the obtuse angle, it skids off into the soft tissues. Examples include (**A**) the Langenbeck periosteal elevator, 8 in. (20 cm) long, and (**B**) the Key periosteal elevator, which is available with blades from ¼ in. (6.4 mm) to 1 in. (25 mm) wide. Handles are from 6¾ in. (171 mm) to 8¼ in. (210 mm) long. These are the most useful elevators for general bone work, excluding the spine. The Freer septum elevator (**C**) has both sharp and blunt blades available with a 7½-in. (191 mm) handle. The Freer and Joseph elevators are useful in foot, hand, and spine injury and in pediatric cases. Many styles of Cobb periosteal elevators (**D**) are available. They are most useful in spinal surgery. They have 11-in. (279 mm) handles in most cases and have blades from ½ in. (13 mm) to 1¼ in. (32 mm) wide. (Courtesy of Zimmer, Warsaw, IN.)

### RETRACTORS (FIGURE 6.3.)

***Figure 6.3.*** Retractors.

Specialized soft-tissue retractors are described with the procedures that require them. Several useful retractors are designed to bear against bone while atraumatically retracting the soft tissues. Hohmann, cobra, and Bennett retractors, used singly or in combinations, are essential in most major long-bone surgery and particularly surgery of the hip and pelvis. Small-tipped retractors such as the Hohmann retractor are preferable because they cause less stripping of the periosteum than other types do. The Hohmann retractor (**A**) is available with blades from $^{11}/_{16}$ in. (17 mm) to $1^{11}/_{16}$ in. (43 mm) and handles from 9¼ in. (235 mm) to 10¾ in. (273 mm). Aufranc cobra retractors (**B**) have pointed, blunt, and blunt serrated tips. Overall lengths are approximately 10 to 11 in. (25 to 28 cm). These are used widely for hip surgery. Bennett retractors (**C**) are available in two blade widths—¾ in. (44 mm) and 2½ in. (64 mm). They are the most useful retractors in hip fracture repair and in major long-bone surgery. The Blount retractor (**D**) is designed to be used as a pair on either side of the bone. Length is 10¾ in. (273 mm). These are available with a single tine. (Courtesy of Zimmer, Warsaw, IN.)

**CHISELS AND OSTEOTOMES (FIGURE 6.4.)**

***Figure 6.4.*** Chisels and osteotomes.

Chisels and osteotomes are derived from woodworkers' tools. Chisels have a cutting edge with a flat back parallel to the long axis of the tool and a beveled edge; osteotomes are tapered on both sides. These instruments are available in sets with widths varying from 4.7 to 50 mm ($^{3}/_{16}$ to 2 in.). For general orthopaedic use, these instruments should have large, knurled handles that enable them to be grasped easily and that minimize fatigue of the hand. They are designed to be used with mallets. Smaller varieties are available for hand surgery, such as the Smith-Peterson osteotome (**A**). Notice the double taper on the cutting edge. Overall length is 8 in. (20 cm). These are available in ¼-in. to 1¼-in. widths, with straight or curved blades. The Lambotte osteotome (**B**) has a length of $9^{3}/_{8}$ in. Straight and curved blades are available, and widths are ¼ to 1½ in. The Hibbs chisel (**C**) has a length of 9 in., may be straight or curved, and comes with widths of ¼ to 1½ in. One side of the blade tip is straight. The Hoke osteotome (**D**) is 5½ in. long, is straight or curved, and comes in widths of $^{1}/_{8}$ to ½ in.; it is useful for work on small bones. (Courtesy of Zimmer, Warsaw, IN.)

**GOUGES (FIGURE 6.5.)**

***Figure 6.5.*** Gouges.

Gouges also derive from woodworking tools. They are curved from side to side and are designed to scoop bone away. They may be straight or curved in the long axis. Gouges are used primarily to harvest bone grafts and to prepare bone for the receipt of a bone graft. Hibbs gouges (**A**) are available with straight or curved blades in widths from ¼ in. (6.4 mm) to 1½ in. (38 mm). Handles are 9 in. (229 mm) long. Both the Hibbs and Smith-Petersen gouges are excellent for most bone surgery. Cobb spinal gouges (**B**) have blades $^{5}/_{16}$ in. (7.9 mm) wide and are 11 in. (279 mm) long. The blades available are straight or curved with a medium, sharp, or reverse curve. These gauges are especially designed for spinal surgery. (Courtesy of Zimmer, Warsaw, IN.)

**CURETS (FIGURE 6.6.)**

***Figure 6.6.*** Curets.

Curets are spoon-shaped cutting instruments designed to scrape or remove bone with a twisting action of the handle. The most effective curets are fitted with large, long handles. The spoon sizes range from 000 to 6. The Brun bone curet (**A**) has a hollow handle, but others (**B**) may have solid handles. Curets have 6½-in. (165 mm) or 9-in. (229 mm) handles and straight or curved oval cups from size 000 to 6. Curets come in many forms, including Cobb curets. (Courtesy of Zimmer, Warsaw,

IN.)

**BONE-CUTTING FORCEPS (FIGURE 6.7.)**

***Figure 6.7.*** Bone-cutting forceps.

Bone-cutting forceps are based on the same construction principles as wire cutters and are available in many sizes. Single-action forceps are precise and useful for small or soft bone work. Double-action forceps are required for most applications. Forceps do not cut well near their tips and are most effective if the bone is placed in the depths of the jaws. Stabilize both sides of the bone while using forceps because sudden closure of the jaws could cause a piece of bone to be ejected from the operating field. The Stille-Liston bone-cutting forceps (**A**) is 10½ in. (267 mm) long; the blades are straight or curved. The Liston bone-cutting forceps (**B**) has straight blades with overall length from 5½ in. (140 mm) to 8½ in. (216 mm). Ruskin-Liston bone-cutting forceps (**C**) have straight and angled-up blades and an overall length of 7¼ in. (184 mm). Ruskin bone-splitting forceps (**D**) have a length of 7¼ in. (184 mm) and are available with delicate and standard jaws. Stille-Horsley rib forceps (**E**) are 10½ in. (267 mm) long with bayonet jaws. They are designed to transect ribs. All but the Liston forceps are double-action forceps, which have better cutting power than single-action forceps but somewhat less precision. (Courtesy of Zimmer, Warsaw, IN.)

**RONGEURS (FIGURE 6.8.)**

***Figure 6.8.*** Rongeurs.

Rongeurs are based on the same mechanical principles as forceps, but the cutting end resembles a double set of opposed curets. Use of rongeurs follows the same principles as the use of forceps. One effective method of using a rongeur is to stabilize one cup against the bone surface and cut or scrape with the other cup. Rongeurs are available in 20 or more different designs. The bites are available in oval, round, and other patterns. They can be used on bone and to remove tough soft tissues such as fibrous scar. Many are specially designed for spinal or neurosurgical applications. Four typical designs are illustrated. Small, large, straight, and curved bites are available for the Ruskin rongeur (**A**). Its length is 7¼ in. (184 mm). The Stille-Leur rongeur (**B**) has a 10-mm bite and straight or curved blades. Its lengths are 8½ in. (216 mm) and 10½ in. (267 mm). The Echlin duckbill rongeur (**C**) has a narrow, angular jaw in the plane of the handles. Bites of 2, 3, and 4 × 10 mm can be taken. Its length is 9 in. (229 mm). The Cushing rongeur (**D**) has a 5-in. (127 mm) shaft with 2 × 10-mm bite and straight or up- and down-angled jaws. (Courtesy of Zimmer, Warsaw, IN.)

**BONE RASPS (FIGURE 6.9.)**

***Figure 6.9.*** Bone rasp.

A variety of files or rasps is available for smoothing and shaping bone surfaces. Most effective are those resembling woodworking tools. The fine patterns seen in metalworking tools fill so rapidly with bone that they are less effective. The Putti bone rasp has round and semiround ends or flat tapered and curved ends. Its overall length is 11¾ in. (30 cm) or 10½ in. (27 cm). (Courtesy of Zimmer, Warsaw, IN.)

**MALLETS (FIGURE 6.10.)**

***Figure 6.10.*** Mallet.

Mallets are also designed after woodworking tools. They are not hammers. Most mallets are composed entirely of stainless steel and are available in different sizes. Most surgeons feel that the metal-to-metal contact of a steel mallet on a steel instrument provides the best proprioceptive feedback. Shock-absorbing faces of plastic or other materials are available, but their tendency to rebound makes them less effective than all-metal ones. The orthopaedic bone mallet shown here is all stainless steel. Its length is 7¾ in. (197 mm), and its weight is 1 lb (454 g) or 2 lb (908 g). Mallets are also available in aluminum with nylon or metal heads. Most surgeons prefer all metal. (Courtesy of Zimmer, Warsaw, IN.)

**BONE-HOLDING INSTRUMENTS (FIGURE 6.11.)**

***Figure 6.11.*** Bone-holding instruments.

A multitude of instruments are designed to hold and manipulate bones. For major diaphyseal fractures, one of the most useful bone holders is the Lowman bone-holding forceps (**A**). It is particularly useful if there is a need to hold a plate against the bone. Its disadvantage is that it requires considerable soft tissue stripping to place. The Lowman bone clamp (**A**) is available in three lengths [4¾ in. (121 mm) to 8 in. (203 mm)] and three jaw sizes [3/4 in. (19 mm) to 1¼ in. (32 mm)]. It is calibrated to measure the diameter of bone and can be disassembled to apply or remove. In my hands, it is the most effective bone-holding clamp, particularly for the femur and humerus. It holds plates to bone with excellent security. In the Lane bone-holding forceps (**B**), toothed jaws provide a firm grip on bone but are not ideal for holding plates. A ratchet makes them self-retaining, an important feature. Available in 13-in. (33 cm) and 17-in. (43 cm) lengths, they are useful only for large bone surgery. The Kern bone-holding forceps are nearly identical in appearance but are supplied in 6½ in. (165 mm) and 8½ in. (216 mm) lengths for small bone work. In self-retaining bone-holding forceps (**C**), the teeth are designed to grip bone. They are not to be used on plates. Verbrugge forceps (**D**), designed to hold plates on bone, have offset handles to facilitate placement. Tenaculum forceps (**E**) resemble a stout towel clip. They are excellent for reducing and holding small bone fragments, particularly in cancellous areas, and they often are used in pairs. Tenaculums are much kinder to the soft tissues. (A, B, C, E are courtesy of Zimmer, Warsaw, IN.)

**BONE DRILLS (FIGURE 6.12.)**

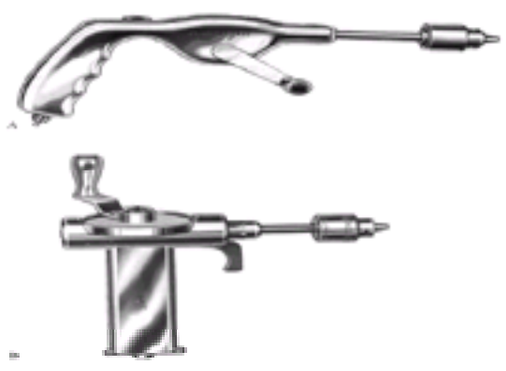

***Figure 6.12.*** Bone drills.

Effective, versatile power tools have reduced the use of hand drills, which are not as useful as well-designed power tools because they require the use of two hands. Additionally, the wobble introduced by the hand activating the drill handle produces a less accurate drill hole than a power drill. Nevertheless, always keep hand drills available in case the power drills fail. Hand drills are more efficient to use than power drills for tasks such as inserting traction pins. To run smoothly, drills must be cleaned and lubricated frequently. The universal bone drill (**A**) is available in various combinations of 11-in. (279 mm) and 13-in. (330 mm) lengths and $^{5}/_{32}$-in. (4.0 mm) and ¼-in (6.4 mm) chucks. The drill uses a 2-to-1 gear ratio and is cannulated for long pins and wires. A small hand drill (**B**) (Bunnell type), 5-in. long, cannulated, with a $^{5}/_{32}$-in. chuck, is designed for small bone surgery. (Courtesy of Zimmer, Warsaw, IN.)

**SCREWDRIVERS (FIGURE 6.13.)**

***Figure 6.13.*** Screwdrivers.

Various types of screwdrivers are available, including simple screwdrivers and automatic ones that retain the screw on the screwdriver tip and release it automatically (trinkle drive). Screw heads that require different screwdriver tips include single slot, cruciate, Phillips, woodruff (i.e., cruciate with rounded teeth), torx drive, and the hexagonal hole. The hexagon is used most commonly today, but the torx provides more turning power and is less likely to slip, particularly in titanium screws. Free bits for use in power drives are available. Do not use power to drive screws into osteoporotic or pathologic bone. Have the proper screwdriver available when removing hardware implanted by others. Sometimes you can determine which one you need by radiographic examination, but often you must review the operative report. With an automatic screwdriver (**A**), a grip holds the screw onto the bit. They are available with single slot, cruciate, or universal bits. These screwdrivers have a unique handle shape to increase grip power (**B**) and have a hexagonal tip. The torx driver provides the best turning power and is least likely to slip, particularly in titanium screws. (B is courtesy of Zimmer, Warsaw, IN.)

**HAND BONE SAWS (FIGURE 6.14.)**

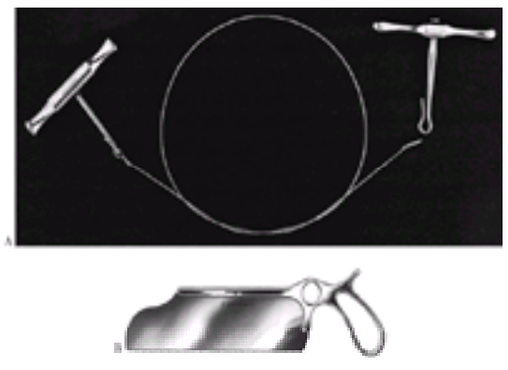

***Figure 6.14.*** Hand bone saws.

Gigli spiral saw wires (**A**) are commonly used to transect bone when power tools are deemed unnecessary or dangerous. They are useful for cutting away from vital structures, such as the sciatic nerve in Salter's innominate osteotomy. To effectively use handles, keep the wire taut, and do not bend the wire more than approximately 45°. The sharper the curve of the wire, the more likely it is to jam. Protect the soft tissues with retractors. The Gigli spiral saw (**A**) is available in 12-in. (305 mm) and 20-in. (508 mm) lengths with a pair of handles. The Satterlee bone saw (**B**) is used for amputations, but most surgeons have abandoned it in favor of power saws. (B is courtesy of Zimmer, Warsaw, IN.)

**PLATE BENDERS (FIGURE 6.15.)**

***Figure 6.15.*** Plate benders.

Tools for bending plates are derived from the old corset trade. Available are hand-held bending irons for small plates (**A**), and presses for large plates (**B**). Take care not to score or crease plates during bending, and avoid weakening the plates by reverse or repeated bending.

**MISCELLANEOUS INSTRUMENTS (FIGURE 6.16.)**



***Figure 6.16.*** Miscellaneous instruments.

Bone awls (**A** and **B**) are employed for perforating cancellous bone and thin cortical bone when a drill is not useful or desirable, as in a classic Bankart repair of the shoulder. Bone awls are available with curved and straight tapered tips, like the Zuelzer bone awl (**A**) and Rush rod awl-reamer (**B**) shown here. Bone hooks (**C**), available in various sizes and shapes, are used to retract and manipulate bone fragments. These are available in many sizes and shapes. The inside diameter of the hooks range from $^{3}/_{8}$ in. (9.5 mm) to 1 in. (25 mm). Bone tamps (**D**) are used to pack bone graft into place and to countersink wires. These are 6 in. (152 mm) long, with a $^{3}/_{8}$-in. (9.5 mm) or ½-in. (13 mm) end diameter. (B—D are courtesy of Zimmer, Warsaw, IN.)

**CHAPTER REFERENCES**

Seguin F, Texhammer AR: *A-O/ASIF Instrumentation.* New York: Springer-Verlag, 1981.

# CHAPTER 7

# ANESTHESIA AND PAIN MANAGEMENT

*Dennis L. Fung*

**D. L. Fung:** Department of Anesthesiology, University of California, Davis, Sacramento, CA, 95817.

Pathophysiology
Principles of Treatment
Assessment, Indications, Relative Results
Classifications
Preoperative Management
Preoperative Planning
Choice of Anesthetic
Anesthetic Technique
General Anesthesia
Intraoperative Management
Airway Management
Monitoring
Positioning
Fluid Management
Blood Loss Management
General Rehabilitation and Postoperative Principles
Postoperative Pain
Goals for Chronic Pain Management
Posttraumatic Pain Conditions
Chronic Pain Procedures
Pitfalls and Complications
Intraoperative Thromboembolism
Latex Allergy: Anaphylactic Shock
Malignant Hyperthermia
Chapter References

## PATHOPHYSIOLOGY

For the orthopaedic patient, anesthesia and pain management involve preventing or controlling the response to acute (surgical) pain and chronic (pathologic) pain. The response to acute pain is motor (withdrawal), psychological (pain), emotional (fear), and autonomic (hypertension, tachycardia) (Table 7.1). The response to chronic pain is more complex because of the adaptations that occur. A chronic pain patient's response is somewhere between stoicism and amplified emotion. The International Association for the Study of Pain (IASP) defines pain as “An unpleasant sensory and emotional experience associated with actual or potential tissue damage or described in terms of such damage” (36a). This definition does not include a description of how a patient in pain looks. Only the patient's description of his subjective experience matters.

| *Modality* | *Response* |
|---|---|
| Sensory-psychological | Pain perception |
| Motor | Withdrawal, involuntary muscle spasm, immobility, pulmonary splinting |
| Emotional | Anxiety, fear, anger, uncooperativeness |
| Autonomic | Hypertension, tachycardia, diaphoresis, bradycardia |
| Other | Decreased gastrointestinal mobility, urinary retention, myocardial ischemia |

***Table 7.1. The Response to Noxious Stimulation***

The neurologic components involved in pain are nociceptors, primary afferent fibers, ascending nociceptive tracts, higher centers in the brain, descending pain modulating tracts, and centers in the spinal cord. The detailed anatomy and physiology of pain continues to be an area of active research. The sites where interventions are currently available are listed in Table 7.2. Despite the scientific knowledge about anesthesia and analgesia, the practices of anesthesia and pain management have a decidedly empirical nature. Drugs that block the motor and autonomic response to acute pain are well understood, as are the drugs that block nerve conduction. Promising areas of research currently focus on the role of the spinal cord, *N*-methyl-D-aspartate (NMDA) receptors, and gamma-aminobutyric acid (GABA) receptors in the mechanism of anesthesia and chronic pain.

| *Anatomic site* | *Examples of interventions* |
|---|---|
| Nociceptive nerve endings | NSAIDs<br>Capsaicin<br>Local anesthetic infiltration<br>Intravenous regional anesthesia<br>Intraarticular local anesthetic |
| Afferent nerve fibers | Local anesthetic nerve block |
| Spinal cord | Epidural local anesthetic, opioid, clonidine<br>Intrathecal local anesthetic, opioid<br>Spinal cord stimulator<br>TENS |
| Brain | Opioids<br>Suggestion |

NSAIDs, nonsteroidal anti-inflammatory drugs; TENS, transcutaneous electrical nerve stimulation.

***Table 7.2. Anatomic Sites for Pain Intervention***

## PRINCIPLES OF TREATMENT

The anesthetic goal is to control the response to surgery without complications and usually with a quick return of physiologic function. This should be accomplished while minimizing the unpleasantness of the perioperative experience for the patient. There are numerous options for controlling the response to surgery, but they all have limitations and risks. Anesthetic complications arise from invasive procedures, drugs, devices, and decisions. Complications are avoided by assessing the patient,

assessing the anesthetic implications of the operation, selecting an anesthetic that will accomplish the goals, modifying the anesthetic according to the patient's response and the operative requirements, and managing the risks. Risk management consists of anticipating adverse effects, preventing them if possible, looking for them, and controlling them. Even with careful planning, unanticipated problems arise. Early recognition can often be gained by vigilant routine monitoring. This is important because the evolution of some problems is extremely rapid. Problem-solving skills and experience are needed. The source of a problem is the operation, the patient, the anesthetic, or sometimes a combination of these factors. Sometimes multiple problems arise and need to be prioritized so that the most rapidly fatal problems are dealt with first.

## ASSESSMENT, INDICATIONS, RELATIVE RESULTS

Patient assessment is an essential ingredient of anesthetic risk management. Cardiovascular and pulmonary disease, obesity, pregnancy, and many other conditions increase the possibility for anesthetic-related complications. The subsets of orthopaedic patients who require careful assessment are the pediatric, the geriatric, and the trauma patients. Table 7.3, Table 7.4 and Table 7.5, respectively, summarize some of the specific considerations for these patients.

| Problem | Implication |
|---|---|
| Unusual syndromes and anomalies | Anesthetic implications unknown; preoperative literature search or consultation needed. Facial and upper airway anatomy can cause difficult intubation. |
| Congenital deformities | Limited positioning, access for catheter insertion, airway management, and monitoring. |
| Malignant hyperthermia (MH) risk | More common in children than in adults. May occur with greater frequency in Duchenne's muscular dystrophy, central core disease, King-Denborough syndrome, myotonia congenita, osteogenesis imperfecta, Schwartz-Jampel syndrome, blepharophimosis, and, possibly, arthrogryposis.* |
| Abnormalities of the odontoid process | Risk of spinal cord injury during intubation. If disasters are to be avoided, stability should be determined, if possible, before the patient is brought to the operating room.† |
| Severe scoliosis | Possible pulmonary hypertension, cor pulmonale and right-sided heart failure. When vital capacity is less than 40% of predicted, postoperative ventilation will usually be needed. |

* Brandom BW, Carroll JB, Rosenberg H. Malignant Hyperthermia. In Motoyama EK, ed. *Anesthesia for Infants and Children*, 5th ed. Philadelphia: C.V. Mosby Co., 1990:777.
† Hubbley HM, Rabiner JE: Orthopedic Disease. In Katz J, Steward D (eds.) *Anesthesia and Uncommon Pediatric Diseases*. Philadelphia: W.B. Saunders Company, 1987:162.

***Table 7.3. Pediatric Special Risks***

| Problem | Implication |
|---|---|
| Increased incidence of cardiopulmonary disease | Risk of perioperative death increases with advancing age. Postoperative myocardial infarction, pulmonary complications, infection, and pulmonary embolus account for most of the mortality. |
| Arthritis | Limited positioning and pressure injury a greater risk. Fiberoptic intubation may be required when arthritis involves the neck, temporomandibular joint, or styloid processes. |
| Carotid or vertebral artery disease | Head and neck position requires careful attention. Risk of hypotension. |
| Prone to postoperative delirium | The incidence of postoperative mental confusion in elderly Swedish patients with femoral neck fractures was 33%.* Surprisingly there was no difference between patients receiving epidural and those receiving general anesthesia. CNS medications can be a source of problems, especially benzodiazepines. |
| Arthritis, stroke, and antithrombotic medications | Chronic use of corticosteroids necessitates perioperative coverage. Hematoma risk from regional anesthesia and drugs that impair coagulation. |

* Berggren D, Gustafson Y, Eriksson B, et al.: Postoperative Confusion after Anesthesia in Elderly Patients with Femoral Neck Fractures. Anesth Analg 1987;66:497.

***Table 7.4. Geriatric Special Risks***

| Problem | Implication |
|---|---|
| Multiple injuries | Requires assignment of priorities. Some injuries are delayed in their clinical presentation. If a patient with head injury is given a general anesthetic for an orthopaedic procedure, the recognition of CNS deterioration may be delayed. |
| Unstable neck | Requires precautions to avoid spinal cord damage. The patient in cervical fixation may require fiberoptic intubation or tracheostomy. In an emergency, an assistant applies axial traction during laryngoscopy. If laryngoscopy and intubation are not readily accomplished, a cricothyroidotomy may have to be performed. |
| Hemorrhage and resuscitation | When the patient has required massive fluid resuscitation, the question must be asked "Is the patient stable enough to undergo a lengthy orthopaedic procedure?" Critical care can be provided in the operating room but with limited ability to examine the patient and to intervene surgically. |
| Hypothermia | The patient may arrive hypothermic and may continue to be exposed to low ambient temperatures during surgery. |
| Incomplete information | Past medical history and current medication list may be unavailable. Risk of untreated diseases like diabetes and risk of anaphylactic reactions or drug interactions. |
| Illicit drugs and alcohol | Trauma injuries have a high association with excessive alcohol and illicit drug use. Altered response to anesthetic drugs and physiologic stress may be observed. |
| Hyperkalemic cardiac arrest | In the first few days following burn injury, extensive muscle trauma, or denervation, fatal hyperkalemia can occur when succinylcholine is given. This response to succinylcholine lasts several months. Consequently, the choice of muscle relaxants is restricted to nondepolarizing agents. |

***Table 7.5. Trauma Special Risks***

## CLASSIFICATIONS

Since the early 1940s, the American Society of Anesthesiologists' Physical Status (ASA-PS) classification has been used to grade the preoperative physical condition of surgical patients (38). The current, revised classification appears in Table 7.6 (34). This classification has proven useful in assessing the effect of a patient's preoperative condition on the subsequent response to anesthetic techniques and drugs. The ASA-PS communicates succinctly to other anesthesiologists and surgeons the assessor's evaluation of the patient. It serves statistically as an ordinal covariate for an individual patient. The distribution of ASA-PS in a patient population is useful in comparing one population with another. A consistent correlation between ASA-PS and perioperative mortality has been reported in two large series (27,51). This consistency is evident despite the fact that ASA-PS does not include a priori information about anesthetic or surgical risk, such as known difficult airway or expected major blood loss. To be useful as a covariate, the ASA-PS should be consistent between different rating anesthesiologists. Consistency has been tested in a small series. When presented with 10 different patient descriptions, 4 patient characteristics that cause anesthesiologists to differ in their assignment of ASA-PS are age, anemia, a history of previous myocardial infarction, and obesity (36).

| Physical status | Description | Example |
|---|---|---|
| 1 | Healthy | Torn medial meniscus |
| 2 | Mild systemic disease | Controlled hypertension |
| 3 | Moderate to severe systemic disease, not incapacitating | Poorly controlled hypertension |
| 4 | Severe systemic disease that is a constant threat to life | Congestive heart failure |
| 5 | Moribund, not expected to live 24 hours irrespective of the operation | Cardiogenic shock |
| E appended | Emergency | Risk of death or permanent, incapacitating disability |

***Table 7.6. ASA Physical Status***

In recent years, the Mallampati classification of airway anatomy has been used to predict the likelihood of difficult endotracheal intubation (25). This classification is described in Figure 7.1. It basically estimates the relative sizes of the mouth and the tongue. The mobility of the neck is an additional factor. This classification has

become a routine part of the preoperative assessment; although it is not infallible, it indicates the possible need to prepare for a difficult intubation. Patients with class 3 or 4 airways are increasingly likely to require nonroutine methods for intubation. Laryngoscopy grades, described in Figure 7.2, provide a succinct indication of the view during direct laryngoscopy. Patients in grades 3 or 4 are likely to be difficult to intubate because the glottic opening is not visible.

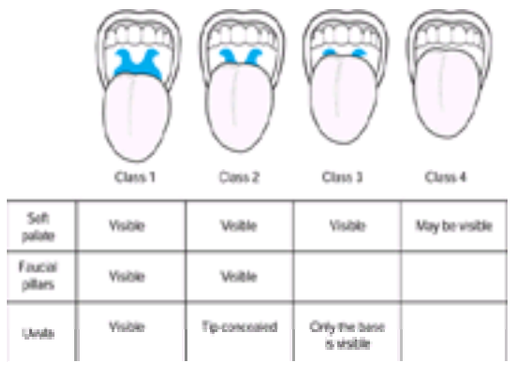


***Figure 7.1.*** The Mallampati airway classification is based on assessing the relative size of the oropharyngeal cavity and the tongue. Classes 3 and 4 are predictive of difficult laryngoscopy. Limited neck mobility and a short neck are also predictive of difficulty.

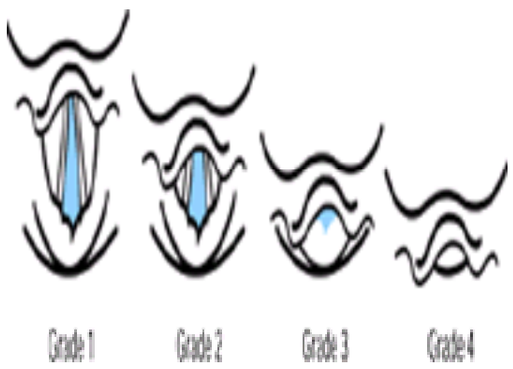


***Figure 7.2.*** The airway grade classification is based on the view that is obtained by direct laryngoscopy. It is partially dependent on laryngoscopy technique and skill.

Anesthetic depth is classified as either “light” or “deep.” At one time, the stages of ether anesthesia were used to describe the depth of anesthesia. With newer agents that are used in combinations, the stages are difficult to identify by simple observation and are no longer clinically relevant. It is common to rely on the end-tidal anesthetic concentration (MAC, or minimum alveolar concentration) as an indication of depth, although it is really a measure of dose. Neurophysiologic correlates of anesthetic depth have been proposed, but none has as yet been widely accepted. The bispectral index, which is based on the computer-processed electroencephalogram (EEG), is currently of interest.

Anesthetic techniques are classified broadly as general, regional, or local anesthesia with or without sedation. Anesthetic agents are also broadly classified by route of administration, pharmacologic class, and clinical application.

Chronic pain may be roughly classified as neuropathic or somatic. These classifications correspond loosely to pain arising from nerves or pain from nonneural tissues. A third category comprising psychogenic pain, arising from thought disorder, is considered to represent few patients, although many chronic pain patients fear that they will be placed in this category.

## PREOPERATIVE MANAGEMENT

The shift from inpatient to outpatient surgery, the elimination of routine laboratory testing and x-rays, and the elimination of routine preoperative admission the night before surgery have been adopted to reduce the costs of surgical procedures. As with other attempts to reduce costs, care must be exercised to ensure adequate preparation for the operation and the anesthetic. Some patients benefit from preoperative medical consultation and additional testing and therapy. Others benefit from postponement of surgery until they have recovered from acute illness or exacerbation of a chronic illness. To avoid the cost of canceling a scheduled case on the day of surgery, we have a system of preoperative screening and evaluation. Patients are screened by means of a questionnaire that is completed during the preoperative surgical clinic visit. Patients who score above a threshold number of points are referred to the anesthesia presurgical unit (PSU), where they are evaluated by either a nurse practitioner or an anesthesiologist. In addition, all hospital admission requests (HAR) for surgery are screened for patients who might benefit from early evaluation. Timely medical consultations can thus be obtained. Patients who have medical problems but do not need to be seen in the anesthesia presurgical clinic are evaluated by chart review or telephone interview, or both. The evaluation results are available by computer in the operating room.

The goal is to avoid last-minute delays and cancellations for anesthetic reasons. Issues that are addressed in the PSU include identification of medical problems that should be evaluated or controlled, recommendations for perioperative management of medications, and recommendations for preoperative testing. Algorithms have been proposed for preoperative evaluation of patients with symptomatic cardiovascular disease (2,14). See Figure 7.3 for an example. The American College of Cardiology/American Heart Association and also the American College of Physicians have published recommendations for evaluating patients who have coronary artery disease (18a). Factors that correlate with increased risk of perioperative cardiac morbidity are the presence of acute congestive heart failure, recent (within 2 months) myocardial infarction, unstable angina, diabetes, limited exercise tolerance, and the type of operation. Guidelines for preoperative testing have resulted in reductions in routine laboratory tests, chest films, and electrocardiograms (ECGs), except in specific populations. See Table 7.7 for the guidelines that we use. Lastly, misunderstandings about the management of medications can cause delays or cancellations. Our current recommendations for medications to be continued or discontinued are listed in Table 7.8. The type of anesthetic is not selected in the PSU because that is decided by the anesthesiologist who eventually cares for the patient in the operating room. Information about the various types of anesthesia is provided, however, and one hopes that this preliminary discussion will save time on the day of surgery.

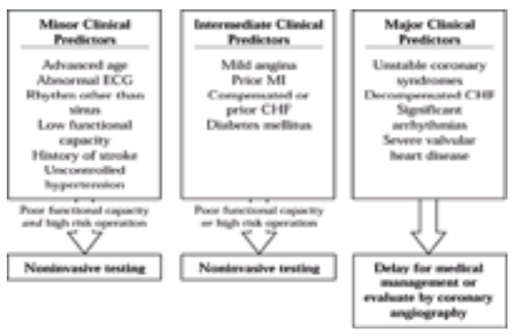


***Figure 7.3.*** The initial steps in the guidelines. The clinical predictors are grouped according to significance for severe coronary artery disease. The patient's functional capacity and the risk of the operation determine whether further testing or medical management are indicated.

| Test | Recommendation |
|---|---|
| Chest x-ray study | All patients over age of 60 and all other patients with a specific clinical indication noted on the medical record should have a preoperative chest x-ray study. A normal chest x-ray study within 1 year of surgery can be used if there has been no intervening clinical event. |
| ECG | All men age 40 and older, women age 50 and older, and all other patients with a specific clinical indication noted on the medical record should have a preoperative ECG. A normal ECG within 6 months of surgery can be used if there has been no intervening clinical event. |
| CBC, serum chemistries, urinalysis | Specific clinical indications should determine the need for these tests. Normal test results within 4 weeks of surgery can be used if there has been no intervening clinical event. |
| PT, PTT, platelet count | Clinical history or specific clinical indications should determine the need for these tests. |

*University Hospital Consortium Recommendations

***Table 7.7. Guidelines for Preoperative Laboratory Testing****

| Medication | Continue | Discontinue |
|---|---|---|
| Angina/Coronary artery disease | Nitrates, Beta blockers, calcium antagonists | |
| Anticoagulants | Varied | Coumadin |
| Anxiety | Valium, Librium, Ativan, Buspar | |
| Arrhythmia | Quinidine, procainamide, Norpace, Mexiel | |
| Asthma | Theophylline, MDI, corticosteroids, cromolyn, antihistamines | |
| Renal Insufficiency, Congestive heart failure | Digoxin | Diuretics |
| Constipation | | All vasal sedatives |
| Contraception | Progestins, estrogen | |
| Depression | Tricyclics, quadricyclics, Prozac, MAO inhibitors | |
| Diabetes | Reduced insulin dose | Oral antihyperglycemics |
| Hiatal hernia, gastric reflux | H2 blockers, Reglan | Sucralfate, Tums |
| Hypertension | Beta blockers, calcium antagonists, clonidine, ACE inhibitors | Diuretics |
| Hypogonadism | Testosterone, Testoscomgen, ACTH | |
| Hypothyroidism | Synthroid, Levothyroxine, thyroid | |
| Immunosuppression, cancer chemotherapy | Corticosteroids, methotrexate, all other chemotherapy | |
| Myasthenia gravis | Anticholinesterases, corticosteroids, immunosuppressants | |
| Pain | Opioids, Tylenol | Hold aspirin 10 days, hold NSAIDs 3 days |
| Parkinson's disease | L-dopa, Sinemet, Deprenyl | |
| Psychosis | Haldol, phenothiazines, diazepam/lithium, lithium | |
| Seizure disorder | Phenytoin, tegretol, valproic acid | |

MDI, inspiration metered dose; ACTH, adrenocorticotropic hormone; MAO, monoamine oxidase inhibitor

***Table 7.8. Medications that Should be Continued or Discontinued Preoperatively***

## PREOPERATIVE PLANNING

### CHOICE OF ANESTHETIC

The choice of anesthetic technique begins with consideration of the operative requirements. Other factors are patient illness and medications, expected duration of the procedure, position on the table, blood loss, and preferences of surgeon, patient, and anesthesiologist. It might appear that the risk of complications should be least with local anesthesia and greatest with general anesthesia, but patients under inadequate local anesthesia have experienced acute myocardial infarction and patients under spinal anesthesia have experienced respiratory arrest and anoxia. Reports that correlate morbidity or mortality with type of anesthesia are difficult to interpret when the type of anesthetic has not been randomly assigned. Furthermore, factors such as the quality of postoperative respiratory and nursing care influence the outcome from general anesthesia.

### ANESTHETIC TECHNIQUE

See Table 7.9 for a summary of anesthetic techniques.

| Technique | Advantages | Risks |
|---|---|---|
| Local anesthesia with or without sedation | Prompt and postoperative analgesia<br>Absence of respiratory and cardiovascular effects<br>Rapid onset | Local anesthetic toxicity<br>Incomplete analgesia<br>Excessive sedation<br>Uncooperative patient |
| Peripheral nerve block with or without sedation | Prompt and postoperative analgesia<br>Absence of respiratory and cardiovascular effects<br>Large operative field without stress from clinical infliction of anesthesia<br>Rapid onset | Local anesthetic toxicity<br>Nerve trauma<br>Incomplete analgesia<br>Excessive sedation<br>Uncooperative patient |
| Regional anesthesia, spinal (also provided) | Prompt and postoperative analgesia<br>Absence of significant respiratory effects<br>Large operative field without stress from clinical infliction of anesthesia | Local anesthetic toxicity<br>Sympathetic hypotension<br>Total spinal or high block<br>Nerve trauma<br>Spinal hematoma<br>Infection<br>Postdural puncture headache<br>Incomplete analgesia |
| Regional anesthesia, epidural (also provided) | Same as spinal plus<br>Rapid onset<br>Slower block depending on dose and concentration | Sympathetic hypotension<br>Total spinal or high block<br>Nerve trauma<br>Spinal hematoma<br>Infection<br>Postdural puncture headache<br>Incomplete analgesia |
| Regional anesthesia, combined spinal-epidural | Same as epidural | Local anesthetic toxicity<br>Nerve trauma<br>Hypotension<br>Infection<br>Incomplete analgesia |
| Regional anesthesia, Bier block (also IV regional) | Same as epidural | Local anesthetic toxicity<br>Tourniquet pain<br>Incomplete analgesia or duration of block changes despite repeat |
| Intravenous regional block (also Bier block) | Absence of respiratory and cardiovascular effects<br>Large operative field without stress from clinical infliction of anesthesia<br>Rapid onset and recovery | Local anesthetic toxicity<br>Tourniquet pain<br>Incomplete analgesia or duration of block changes despite repeat |
| Inhalational anesthesia | Rapid onset<br>Flexible duration<br>Versatility | Respiratory and cardiovascular depression<br>Nausea stress management<br>Risk of aspiration<br>Malignant hyperthermia risk |
| Intravenous anesthesia (also TIVA) | Same as inhalational anesthesia plus<br>Reduced risk of malignant hyperthermia | Respiratory depression, low blood pressure, cardiovascular depression (less with orthokinetic anesthetics)<br>Nausea stress management<br>Risk of awareness |

TIVA, total intravenous anesthesia.

***Table 7.9. Anesthetic Techniques. A Brief Summary***

#### *Local Anesthesia and Sedation*

Peripheral nerve blocks and infiltration with local anesthetic are sufficient for limited procedures in cooperative patients. The primary risks are local anesthetic toxicity and inadequate analgesia. Allergy to local anesthetics is rare. Most reactions are due to epinephrine absorption or high blood concentrations of local anesthetic. Allergic reactions occur to the antioxidant (bisulfite) (41) or the preservative (methylparaben) in the commercial preparations (32). Although they are extremely rare, allergies to both lidocaine and bupivacaine have been reported (7). Skin testing with a preservative-free agent will identify true allergy to local anesthetic (39). Toxicity results from inadvertent intravascular injection or from excessive dose. The maximum recommended dose depends on the size of the patient, the site of injection, the particular agent, and the use of epinephrine (Table 7.10). Frequently used supplements are midazolam for sedation and amnesia, and an opiate such as fentanyl for analgesia. Oxygen, pulse oximetry, periodic verbal contact, and observation reduce the risk of hypoxia and respiratory depression.

| *Name (trade name)* | *Dose (mg) without epinephrine* | *Dose (mg) with epinephrine* | *Concentration %* | *Approximate duration (h)* | *Chemical class* |
|---|---|---|---|---|---|
| Bupivacaine (Marcaine) | 175 | 225 | 0.25 | 2–4 | Amide |
| Chloroprocaine (Nesacaine) | 800 | 1000 | 1.0 | 0.5–1.0 | Ester |
| Etidocaine (Duranest) | 300 | 400 | 0.5 | 2–4 | Amide |
| Lidocaine (Xylocaine) | 300 | 500 | 0.5 | 1–2 | Amide |
| Mepivacaine (Carbocaine, Polocaine) | 400 | 500 | 0.5 | 1.5–3.0 | Amide |
| Prilocaine (Citanest) | 600 | | 0.5 | 1–2 | Amide |
| Procaine (Novocaine) | 1000 | | 1.0 | 0.5–1.0 | Ester |
| Ropivacaine (Naropin) | 150 | 200 | 0.2 | 2.0–4.0 | Amide |

***Table 7.10. Recommended Maximum Local Anesthetic Doses for Infiltration***

Grand mal seizure and intractable cardiac arrhythmias are the most serious complications resulting from high blood concentrations of local anesthetic. A peak blood concentration occurs immediately following intravascular injection or premature release of the tourniquet during intravenous regional block. A delayed peak (20 to 30

min) occurs after regional blocks. The priorities in managing toxic reactions are oxygenation, cardiovascular resuscitation, if necessary, and suppression of seizures. Intractable ventricular dysrhythmias have been associated with bupivacaine and etidocaine cardiotoxicity (1). Possible mechanisms are inhibition of calcium release from sarcoplasmic reticulum (24) or use-dependent block of sodium channels on myocardial cells (10). There may also be a central nervous system (CNS) contribution to the cardiotoxicity (6). The best treatment of this complication has not been determined, but recommendations include bretylium or amiodarone (19).

***Regional Anesthesia***

Subarachnoid (spinal), epidural (peridural), and brachial plexus (axillary and interscalene) blocks are the most commonly used techniques for regional anesthesia. Combination nerve blocks, such as ankle block, sciatic-femoral block, elbow block, and wrist block, are less commonly used but should be considered for high-risk patients. Epidural and sometimes spinal anesthesia is difficult to achieve in the foot or ankle (18). This may be due to the large size of the L-5 and S-1 nerve roots.

Technical difficulties and the slow onset of block both increase the time the surgeon waits before surgery can start. Clear-cut landmarks for needle insertion and easily identified endpoints for needle position [cerebrospinal fluid (CSF), arterial blood, paresthesia] make a block easier to perform; obesity and spinal deformity are sources of difficulty. A block that has been easy to perform can nevertheless take up to 20 minutes to produce adequate anesthesia. Neutralization of local anesthetics with sodium bicarbonate may hasten the onset. Agents are usually selected for the duration of block they produce. An epidural block with lidocaine lasts 1 to 2 hours or 2 to 4 hours with bupivacaine. In the less vascular vicinity of peripheral nerves, lidocaine lasts 2 to 4 hours and bupivacaine lasts 6 to 12 hours.

Nerve block or infiltration, intravenous analgesia, nitrous oxide analgesia, or general anesthesia can supplement regional blocks that are anatomically incomplete or inadequate in duration. As in the selection of anesthetic technique, the best choice depends on the patient (pain tolerance), the surgical problem (need for immobility), and the operation (time remaining to completion, intensity of noxious stimulation). One particular danger is that intravenous sedation and analgesia with or without nitrous oxide can progress insidiously to general anesthesia without protection against aspiration or without adequate ventilation and oxygenation. On the other hand, a general anesthetic superimposed on an incomplete epidural or spinal anesthetic can be complicated by the presence of a sympathetic block.

Tourniquet pain represents an incomplete or receding block. It starts to be a problem approximately 1 hour after tourniquet inflation. Under general anesthesia, progressive hypertension is noticed. Overtreatment can result in hypotension when the tourniquet is released. Tourniquet release can also cause transient hypercapnia and elevation of intracranial pressure in head-injured patients if ventilation is not temporarily increased. There is a slight temperature elevation with tourniquet inflation and a decrease after tourniquet release.

Tourniquet hypertension [30% or greater increase in either systolic or diastolic blood pressure (BP)] is more common under general anesthesia than under regional anesthesia. It is not prevented by a sympathetic block. Technical details have been shown to have some influence over the efficacy of a spinal (subarachnoid) block in the prevention of tourniquet hypertension. The amount of anesthetic; the particular anesthetic agent; the addition of epinephrine, clonidine, or morphine; and even the concentration of added glucose have been shown to have some effect. Differential blockade of some fiber types but not of others may explain the occurrence of tourniquet hypertension despite adequate sensory level as determined by pinprick. Tourniquet pain is probably mediated by unmyelinated, slow-conducting C fibers. Explanations include a gate theory mechanism of large fiber block and small fiber activity. The superiority of intrathecal bupivacaine compared with tetracaine may be due to the longer residence of bupivacaine at the nerve fiber.

Recommendations to eliminate tourniquet pain and hypertension are to use subarachnoid block rather than general anesthesia or epidural anesthesia, obtain an adequate pinprick level, and add either epinephrine or clonidine but not glucose. Alkalinization of the agent may improve the success with mepivacaine epidural anesthesia so that it is comparable to an intrathecal block with bupivacaine (47). Alkalinization is thought to enhance the onset and intensity of a block by increasing the nonionized form and by increasing neuronal pH.

Reports have accumulated over the years documenting problems associated with tourniquet use. These problems are summarized in Table 7.11. A high incidence of venous thrombus embolism has been discovered after tourniquet deflation. Metabolic products and cooled blood may be part of the problem. When hypotension persists or is catastrophic, pulmonary embolism becomes a serious concern.

| *While inflated* | *After deflation* |
|---|---|
| Hypotension | Hypotension |
| Pain | Pulmonary embolism of clotted blood |
| Cuff leak causing bleeding | Pulmonary edema |
| Migration of cuff (obese patient) | Cooling |
| Skin injury secondary to pinching | Transient hypercarbia and metabolic lactic acidosis |
| Neurovascular change secondary to excessive pressure | Bleeding |
| Exclusion of systemic drugs, e.g., antibiotics | Venous stasis secondary to incomplete deflation |
| Sickle cell thrombosis | Release of tapped drugs (e.g., sufentanil)<br>Myoglobinuria acute renal failure<br>Release of emboli (blood clots) |

***Table 7.11. Tourniquet Problems***

**Epidural and Subarachnoid Block** The incidence of deep vein thrombosis during hip surgery under general anesthesia is between 60% and 70%. Regional anesthesia [both spinal (11,49) and epidural (30)] reduces the incidence of postoperative deep vein thrombosis to 20% to 40%. Proposed mechanisms include increased lower limb blood flow, reduced activation of factor VIII, reduced viscosity, and enhanced release of plasminogen activators. Additional advantages that have been claimed for regional anesthesia include a lower risk of aspiration and pulmonary complications, reduced blood loss, prophylaxis against phantom limb pain, reduction of the stress response, and the ability to continue the analgesia postoperatively.

The major side effect of both epidural and subarachnoid (spinal) block is hypotension from sympathectomy. Hypotension is more likely to occur if a patient is hypovolemic or if the block is extensive. Consequences of uncontrolled hypotension include nausea, vomiting, apnea, stroke, and myocardial infarction. The side effect that patients fear is permanent neurologic injury. Although this complication is rare, it can occur from traumatic needle insertion, infection, epidural hematoma, spinal cord ischemia, or cerebral ischemia. See also the discussion in the section on Pitfalls and Complications.

The onset of an epidural block is slower than that of a spinal block, and this factor is sometimes used to advantage in patients with potentially unstable cardiovascular responses. Disadvantages of an epidural block are that it is usually less intense than a spinal block and a larger dose of local anesthetic is required. Thus, there is greater risk of an inadequate block, and there is risk of either a total spinal block or local anesthetic toxic reaction from accidental intrathecal or intravenous injection. It is usually assumed that a failed spinal anesthetic is due to faulty technique or a defective drug, but cases have been reported in which both possibilities were excluded with the implication that certain patients are truly resistant to spinal anesthesia. In some instances, these patients were resistant to lidocaine but not to bupivacaine (40).

Postspinal headaches are more common in young females and with the use of larger gauge needles. A spinal headache may be distinguished from meningitis by postural relief and by the absence of obtundation, leukocytosis, and fever. Fluid, caffeine, and abdominal binders offer some symptomatic relief. The headache is completely relieved in 90% of patients by epidural injection of 10 to 20 ml of freshly drawn, autologous blood. Untreated headaches can progress to abducens nerve palsy or auditory deficits.

**Brachial Plexus and Intravenous Regional Block** Because the brachial plexus is contained within a fascial sheath, the various approaches—axillary, subclavian, or interscalene—all produce a similar result, provided that an appropriate volume of local anesthetic is deposited. The distribution of anesthesia is more extensive with the more proximal injection sites. An axillary approach is used when the forearm or hand is the operative site. Interscalene block is used when the elbow, upper arm, or shoulder is to be operated on or when the axilla is unavailable. The technique of eliciting paresthesias is associated with persistent postoperative paresthesia, possibly due to nerve trauma (42). Location of nerves can be achieved less traumatically by using a nerve stimulator.

Intravenous regional (Bier) block is easy to perform and is rapid in onset and recovery. Tourniquet pain becomes a problem after an hour. Risk of local anesthetic toxicity is significant, especially during injection (leak under the cuff) and after release of the tourniquet, because a toxic dose is deliberately placed intravascularly. The tourniquet is usually deflated briefly and quickly reinflated to release only part of the dose over 10 to 15 minutes.

### GENERAL ANESTHESIA

Although general anesthesia is almost universally applicable, there are sometimes reasons for considering alternatives. Examples include a full stomach, obesity, reactive airway disease, malignant hyperthermia (MH), generalized muscle disease, a need to monitor neurologic status, and pregnancy. There can be advantages to combining regional and general anesthesia. For long procedures and when general anesthesia might cause excessive cardiac depression, regional anesthesia reduces the amount of general anesthetic needed. When postoperative analgesia with epidural opiates is indicated, a combined anesthetic can be given for the procedure and the regional anesthetic can be continued postoperatively using opiates with or without local anesthetic. Whether the combination of general and regional anesthesia reduces the risk of deep vein thrombosis has not been tested.

## INTRAOPERATIVE MANAGEMENT

### AIRWAY MANAGEMENT

Subpopulations of orthopaedic patients present the anesthesiologist with airway management challenges. The pediatric patient who has skeletal deformity may also have facial and airway malformation. Elderly patients with deformity of rheumatoid arthritis may have cervical spine and arytenoid process arthritis. The trauma victim may have facial or cervical spine injury and multiple orthopaedic injuries. Key questions that should be answered before undertaking airway management are

1. Is difficult intubation likely?
2. Is difficult ventilation likely?
3. Will the patient consent to or cooperate with airway management procedures?

The answers to these questions form the basis for the following management decisions:

1. Is a surgical airway needed?
2. Is awake intubation indicated?
3. Is it necessary to maintain spontaneous ventilation?

Congenital and acquired conditions that result in a deformed or unstable cervical spine may require fiberoptic intubation. Practice guidelines from the ASA (46) provide recommendations regarding airway evaluation, preparations, and management. A portion of the guideline algorithm listing airway management options is shown in Figure 7.4. The risk of hypoxic injury is probably greatest once anesthesia has been induced and intubation has been unsuccessfully attempted. As long as mask ventilation can be adequately provided and as long as there is no risk of gastric content aspiration, fiberoptic intubation can be performed under general anesthesia. Alternatively, the patient can be allowed to recover from anesthesia for awake intubation. In pediatric patients, awake fiberoptic intubation may not be an option. Finally, some orthopaedic procedures present specific threats to a secure airway. Operations that require repositioning of the patient to a lateral or a prone position require special attention to avoid accidental extubation or mainstem intubation.

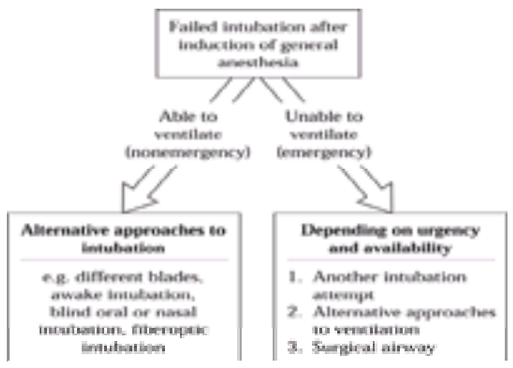


***Figure 7.4.*** A portion of the airway algorithm that proceeds from failure to intubate after inducing anesthesia. Other portions not shown involve the preoperative assessment and planning of airway management.

### MONITORING

Decisions about monitoring are closely related to the problem of fluid management. During major procedures lasting more than 3 hours and with anticipated blood loss of more than 20% of blood volume, an arterial catheter, central venous pressure (CVP) or pulmonary artery (PA) catheter, and Foley catheter are commonly used. Invasive monitoring is likely to be required in elderly patients undergoing lengthy hip fracture surgery because the risk of myocardial infarction correlates with the duration of surgery. Conservation of blood by intraoperative hemodilution or induced hypotension also warrants closer, more invasive monitoring.

Correction of scoliosis requires monitoring for spinal cord function. Both methods in common use—somatosensory evoked potentials and the wake-up test—mimpose restrictions on the anesthetic agents. In the case of somatosensory-evoked potential monitoring (posterior spinal cord function), nitrous oxide with narcotic and low concentrations of volatile anesthetics can be used. A stable anesthetic depth is required during the monitoring period, and nondepolarizing muscle relaxants are given to suppress electromyographic (EMG) interference. When the wake-up test (anterior spinal cord function) is used, low solubility volatile anesthetics, such as desflurane or sevoflurane, will prevent prolonged emergence. Recovery from nitrous oxide usually occurs in 5 or 10 minutes. A nerve stimulator can be used to maintain a partial neuromuscular block, thus avoiding excessive movement during reawakening.

In procedures that expose large veins and in total hip arthroplasty (45), venous air embolism is a possibility. Precordial Doppler ultrasound is a sensitive monitor for air in the right side of the heart, and a central venous catheter is one method for removing some of the air. Hypotension during methylmethacrylate cementing of hip prostheses was initially attributed to monomer escape into the circulation, causing vasodilation or myocardial depression. Recent evidence implicates air embolism as the cause of hypotension in up to 57% of arthroplasty patients. This hypotension is usually inconsequential but may cause impaired pulmonary blood flow and hypoxemia or paradoxical embolism. Cardiac arrest has been reported to result from paradoxical embolism to the coronary arteries (8). In recent years, transesophageal echocardiography (TEE) has been used increasingly as a less invasive alternative to pulmonary artery catheterization. Air and thrombotic emboli can be visualized, as can ventricular dimensions and wall motion. The primary limitations to more general use are the cost of equipment and the substantial training and experience required for interpretation.

Finally, the expense and effort devoted to acquiring and applying any monitoring device is wasted if the person who should make use of the information is inattentive, distracted, or inexperienced.

### POSITIONING

Nonsupine position can cause injuries, either directly (pressure or stretch) or indirectly (decreased perfusion pressure or impaired gas exchange). In addition, the transition to a new position can cause loss of monitoring, loss of intravenous catheters, or loss of the airway. Traction injuries to joints and nerves can also result from position change. The major risks of prone position are injury to the face, impaired inferior vena cava flow, and injury to nerves. Cardiopulmonary function is not significantly different from that in the supine position if the abdomen is not compressed. The lateral position is more disturbing to cardiopulmonary function. Because of the cephalad shift of the diaphragm during general anesthesia, ventilation-perfusion matching is altered, resulting in arterial blood gas changes. Thus, a patient undergoing hip surgery in the lateral decubitus position will have better gas exchange with regional anesthesia and spontaneous ventilation than with general anesthesia. The lateral position places patients at risk for nerve injury, vascular compression, and pressure injury to the dependent side of the face and head. Of particular importance is the “axillary roll” to prevent compression of the subclavian artery between the clavicle and humerus. In the lateral position, the pulse oximeter placed on the dependent arm can be used to detect arterial compression. Complications can occur from intraoperative movement out of position, so the patient's position should be monitored. Finally, nonsupine positioning and draping limits access to the patient for monitoring or other procedures.

## FLUID MANAGEMENT

The objectives of fluid management are replacement of preoperative deficits, replacement of ongoing insensible losses (maintenance), compensation for third-space loss, and compensation for blood loss. Anesthesiologists use additional fluid as a carrier for drugs and to compensate for the vasodilation of anesthesia. The amount of third-space loss is clinically unmeasured and depends on the degree of tissue trauma. For orthopaedic procedures, 2 ml/kg/hour above maintenance is commonly used. Errors in fluid management include excessive reliance on BP or urine output as endpoints, because both are indirect measures of fluid volume status. When BP or urine output are not normal after giving the most liberal estimate that can be justified, additional information is usually sought by measuring cardiac filling pressures.

Fluid management includes decisions about the need for blood products. Transfusion risks are of continuing concern, but improvements in donor screening and blood unit testing have improved to the point where some are beginning to question the need to avoid allogenic transfusion in favor of autologous donation (15a) (see Chapter 5). Measures to avoid autologous transfusion of blood products include cell saving, hemodilution, and induced hypotension. Blood loss during total hip replacement can be reduced 30% by either induced hypotension or regional anesthesia (48,52).

## BLOOD LOSS MANAGEMENT

The risk and cost of transfusion has stimulated a variety of practices. Risks of transfusion are listed in Table 7.12. Tourniquet hypertension may lead to myocardial ischemia in patients with coronary artery disease or ventricular hypertrophy. Many of the serious complications occur with release of the tourniquet. To the already established use of extremity tourniquet and induced hypotension have been added measures to recover the patient's blood loss and avoid transfusion by using autologous blood (Table 7.13). A tourniquet is the traditional method to control blood loss during extremity surgery and to improve visibility.

| *Type of Reaction* | *Risk* |
|---|---|
| Immunologic due to antibodies to<br>Red cells<br>Leukocytes<br>Plasma proteins | Hemolysis<br>Urticaria<br>Noncardiogenic pulmonary edema (rare)<br>Anaphylaxis<br>Febrile reactions (0.5–1.0%)<br>Immunologic suppression |
| Nonimmunologic due to storage<br>Hypothermia<br>Metabolic acidosis<br>Hypocalcemia (citrate toxicity)<br>Hyperkalemia<br>Coagulation factor deficiency | Primarily with rapid administration and/or large volumes |
| Volume overload (congestive failure) | With rapid volume administration and/or inability to tolerate rapid transfusion (e.g., poor ventricular function) |
| Infectious disease transmission<br>Viral (hepatitis, HIV, HTLV CMV)<br>Bacterial<br>Protozoal (malaria, toxoplasmosis) | Increased risk in immune-compromised patients<br><br>Increased risk when the blood donor is from an endemic area |

CMV, cytomegalovirus; HIV, human immunodeficiency virus; HTLV, human T-cell lymphotropic virus.

***Table 7.12. Transfusion Risk***

| *Method* | *Anesthetic Implication* |
|---|---|
| Tourniquet | Hypotension after approximately 1 hour<br>Tourniquet pain after approximately 1 hour<br>Deflation syndrome: hypotension, embolism, transient respiratory and metabolic acidosis, cold blood |
| Induced hypotension | Invasive cardiovascular monitoring may be indicated<br>Risk of unappreciated hypovolemia and organ hypoperfusion |
| Hemodilution | Decreased oxygen capacity and risk of organ ischemia |
| Red cell salvaging | Continuous blood loss, but only intermittently returned<br>Eventual washout of coagulation factors<br>Drug recycling |
| Bank blood and products | Risk of transfusion reaction and infection |
| Autologous blood donation | Preoperative anemia and earlier need for transfusion<br>Acute hemodilution if performed immediately preoperatively |

***Table 7.13. Blood Conservation***

### *Induced Hypotension*

Simple hydraulics suggests that the rate of blood loss should be reduced if systemic BP is reduced. Systemic BP can be reduced by anesthetics, regional anesthesia, and vasodilating drugs. Inhalation anesthetics produce both vasodilation and myocardial depression. The possibility of organ ischemia and infarction has to be considered and discussed with patients. Induced hypotension is contraindicated in patients who have coronary artery disease, cerebrovascular disease, chronic obstructive pulmonary disease, and anemia. Normovolemic hemodilution is contraindicated if induced hypotension is used. How far can systemic BP be safely reduced? Clinical studies suggest that a systolic BP less than 65 mm Hg is the lower limit. Approximately 700 ml of whole blood is conserved, and operative time is shorted (3,48).

Induced hypotension as a measure for reducing blood loss continues to generate some controversy (12). The normal brain tolerates reduction to 55 to 60 mm Hg mean arterial pressure (MAP). MAP is used rather than systolic BP because the arterial catheter system can distort the arterial pressure waveform; systolic pressure will be affected, but MAP will not. Because patients with chronic hypertension are unable to autoregulate cerebral blood flow (CBF) at 50 mm Hg MAP, their pressures should be reduced only to 50 mm Hg below their usual MAP. Contraindications to induced hypotension include fever, anemia, and occlusive cerebrovascular disease. Because hypocapnia will reduce CBF, a normal $Pa_{CO_2}$ should be maintained. Isoflurane at high concentrations lowers MAP by vasodilation but maintains cardiac output. When evoked responses are monitored, nonanesthetic drugs such as sodium nitroprusside (SNP), nitroglycerine (NTG), and trimethaphan are used to lower MAP. SNP has a rapid onset, short duration, and consistent effect. It vasodilates with little effect on cardiac output. The side effects of SNP include cyanide toxicity, rebound hypertension from plasma renin activity, coagulopathy, pulmonary shunting, reduced tissue oxygenation, and hypothyroidism. Severe reductions in BP may impair spinal cord perfusion enough to alter evoked responses. The risk of pressure injury is increased by hypotension. Rebound hypertension can be prevented by gradual return to normal MAP, propranolol pretreatment, or captopril. Coagulopathy is due to platelet disintegration and inhibition of platelet aggregation (22,28). Pulmonary shunting is due to the vasodilation of pulmonary vasculature (9). Tissue oxygenation may be preserved better with NTG, because SNP but not NTG diverts blood flow to arteriovenous shunts (20).

### *Autologous Blood*

Preoperative autologous blood donation requires advance preparation and is limited by the time that it takes for red cell production. Erythropoiesis is not stimulated until the hematocrit is less than 30%. Exogenous erythropoietin can be used but increases the cost of the procedure. There has not been a rigorous study of risk versus benefits of preoperative donation. Mathematical modeling predicts that the benefit is small. On the other hand, the patient generally becomes anemic and the threshold for transfusion is reached earlier. The patient who donates for herself is then exposed to risks of transfusion, possibly unnecessarily. The administrative cost of preoperative donation is more than for homologous transfusion.

One method for eliminating the administrative cost of donation is phlebotomy with isovolemic hemodilution. This is done with the patient in the operating room but before surgical blood loss. The patient's blood is kept in the operating room. Diluted blood is lost, and the patient's own blood is returned to maintain hematocrit at the transfusion threshold. As with preoperative donation, mathematical modeling predicts little benefit unless large volumes of blood are withdrawn (4 to 5 units) and surgical blood loss is large (2000 ml) (4). In addition, either large volumes of crystalloid or colloid replacement must be given to achieve hemodilution without hypovolemia.

### *Cell Washing*

Cell washing and reinfusion reduces the need for banked blood, with little apparent risk to the uninfected patient. Blood is collected by suction and then heparinized and washed. The concentrated red blood cells, minus clotting factors and platelets, are then available for reinfusion into the patient. The effect of autotransfusion on

coagulation has been studied using the Sonoclot device (15). A brief period of hypocoagulability, followed by a tendency to hypercoagulability, was observed. The conventional cell-washing devices require collection of 1000 ml before the blood can be efficiently processed. This is a significant disadvantage in smaller patients who may need to be transfused with bank blood before their own washed cells are available.

Preoperative phlebotomy, hemodilution, and posthemorrhage reinfusion of the patient's own blood are well tolerated under anesthesia because oxygen requirements are reduced. If anemia persists postoperatively, increased oxygen consumption from shivering should be prevented with small doses (12.5 mg) of intravenous meperidine.

#### *Transfusion*

The risk of transfusion has declined with advances in donor screening and blood testing. Of continuing concern in orthopaedics are the studies that show increased rates of postoperative infection in total joint replacement and spine surgery when allogenic blood has been used (16,31,,50). Transfusion has also been implicated in tumor recurrence after cancer surgery.

In 1996, the ASA published a Practice Guideline for Blood Component Therapy (37). One effect of these guidelines is to encourage use of laboratory testing to establish that indications for transfusion of a component have been met. In this way, it is hoped that unnecessary component therapy and attendant risks can be avoided.

Blood substitutes, such as purified hemoglobin and perfluorochemicals, are under development. At present, limited clinical trials are in progress. These substitutes are expensive and less efficient than blood, but they may eventually be useful in normovolemic hemodilution.

## GENERAL REHABILITATION AND POSTOPERATIVE PRINCIPLES

### POSTOPERATIVE PAIN

Postoperative pain is acute pain. Several studies document the undertreatment of pain in hospitalized patients (13,26). Risks of inadequate analgesia include myocardial infarction, impaired ambulation and ventilation, and reduced cooperation. Risks of analgesia include impaired consciousness, respiratory depression, and delayed recognition of postoperative complications, such as myocardial infarction or compartment syndrome.

The surgeon usually manages postoperative pain. The goal is a rapid return to function. An increased interest in postoperative pain management by anesthesiologists and hospital pharmacists is reflected in the increasing availability of patient-controlled analgesia (PCA) and regional opioid analgesia.

#### *Preemptive Analgesia*

Acute pain is easier to control when it is treated early rather than late (53). The neural basis for this clinical observation may reside in the posterior horn of the spinal cord. Noxious stimulation produces an activation of spinal neurons that persists and enhances the response to repeated noxious stimulation. Numerous methods to reduce the need for postoperative analgesia have been tried. The effective preemptive techniques include opioid analgesia, local anesthetic infiltration of the incision site, nonsteroidal antiinflammatory drugs (NSAIDs), and regional anesthesia.

#### *Patient-Controlled Analgesia*

Because it compensates for the pharmacokinetic and pharmacodynamic differences between patients, PCA is particularly useful for severe postoperative pain. When given limited control for self-administration of intravenous opioids to control postoperative pain, the majority of patients do not become narcotic addicts. The constant infusion (basal rate) provides consistent analgesia for the patient who has constant pain at rest, and supplemental analgesia (bolus doses) will be available for dressing change, position change, or ambulation. Contraindications to PCA have included children, drug addicts, and patients unable to understand or unable to operate the device. In pediatric patients, there is risk that a parent will operate the device or that the child will fail to use it. However, PCA has been used successfully in children as young as 5 years old. Patients with alcoholism or other drug addiction require larger doses. Whether these patients are more difficult to wean from PCA remains controversial. Risk of respiratory depression is greatest during sleep, following abrupt reduction of painful stimulation, or following coadministration of sedatives.

#### *Continuous Opioid or Local Anesthetic*

With catheter placement, epidural and brachial plexus anesthesia can be continued postoperatively in infusion of local anesthetic (5,33). Good clinical demonstrations of benefit are currently lacking, but theoretical advantages are improved tissue perfusion, prevention of phantom pain, reduction in pulmonary complications, and prevention of venous thrombosis. On the other hand, an insensitive extremity places the patient at risk for unrecognized ischemic or pressure injury. Sympathectomy may predispose the patient to hypotension. Accumulation of the drug may result in local anesthetic toxicity.

The advantage of epidural opioid infusion over intravenous infusion is based on the premise that an effective concentration of spinal opioid can be achieved without producing systemic analgesic concentrations that can be produced by intravenous infusion. In addition, the side effects of spinal opioid should be comparable or less than the side effects of intravenously administered opioid. Morphine and fentanyl are the opioids that are commonly infused epidurally. Because of its relatively higher lipid solubility, fentanyl is more rapidly distributed to the epidural vascular structures and removed to the systemic circulation. Consequently, its distribution in the neuraxis is more restricted. Morphine migrates rostrally over several hours, eventually reaching the brain stem. Both drugs can produce respiratory depression.

**Epidural Analgesia** Epidural injection of opiates, such as morphine and fentanyl, produces analgesia without sympathectomy, anesthesia, or impaired motor function. Pruritus, urinary retention, and sedation occur commonly. A less frequent but significant hazard is delayed respiratory depression from cephalic spread of the opiate, especially morphine. Sedation from the upward spread of morphine usually precedes respiratory depression. With daily monitoring, epidural catheters are used for up to a week. Systemic infection and systemic anticoagulation are contraindications.

Epidural hematoma is a catastrophic complication of epidural anesthesia. Epidural analgesia has only rarely been a cause of permanent neurologic injury. An alarming incidence of this complication has recently been reported in patients receiving low-molecular-weight heparin for thromboembolism prophylaxis. The issue of anticoagulation and neuraxial anesthesia (both epidural and subarachnoid) is the subject of a recent collection of expert reviews (21). Risks are summarized in Table 7.14. Epidural hematoma frequently presents as persistent back pain with patchy analgesia or motor weakness. Rapid diagnosis by magnetic resonance imaging (MRI) and neurosurgical decompression is the only hope for reversal of neurologic deficits. The diagnosis may be delayed by the use of high concentrations of local anesthetic, intravenous sedation or analgesia, or the inability to communicate with the patient.

| |
|---|
| Anatomic abnormalities of the spinal cord or vertebral column |
| Impaired hemostasis |
| Difficult needle placement |
| Female gender |
| Increased age |
| History of easy bruising |
| Blood encountered during needle or catheter placement |
| Indwelling neuraxial catheter |

***Table 7.14. Risk Factors for Epidural Hematoma***

Epidural abscess (35) can be less dramatic in presentation than epidural hematoma. This can cause delayed diagnosis. Signs of infection may not occur until later in the course of the hospital stay or might not be evident until several days after the catheter is removed. Thirteen cases of epidural abscess have been reported in the literature. The estimated incidence is estimated to be 1:13,000 patients. Daily examination and monitoring of the catheter site for inflammation and suppuration is

considered to be essential, as are noting unexpected motor or sensory deficits. Clinical factors that may interfere with the diagnosis include immobilization that inhibits access to the patient's back for examination of the epidural site, use of local anesthetic concentrations that are high enough to produce sensory and motor block, and the presence of wound infection. Clinical signs that should raise suspicion of epidural abscess include prolonged use of the epidural catheter, incomplete analgesia, and new neurodeficits. If neural compression is not present, then antibiotic therapy with or without percutaneous catheter drainage may be successful. Otherwise, surgical drainage is necessary. The risk–benefit ratio of epidural analgesia must be carefully considered in patients who may be difficult to monitor postoperatively.

### *Brachial Plexus*

Prolonged extremity block is occasionally used for postoperative analgesia or for treatment of reflex sympathetic dystrophy. Brachial plexus block by axillary or supraclavicular approaches can be used for prolonged infusion, but it is difficult to maintain a catheter in position. The interscalene approach is associated with a high incidence of phrenic nerve paralysis. For long-term infusions, the subclavian approach to the brachial plexus provides a site that is easier to maintain in terms of catheter stability and dressings. The long-acting local anesthetic bupivacaine, in 0.125% to 0.25% solution, can be infused up to 5 ml/hour. A maximum of 400 mg/24 hours is recommended. The primary hazard is accumulation of drug to toxicity levels. Because bupivacaine is eliminated by the liver, dose reduction or alternatives should be considered when hepatic function is impaired.

## GOALS FOR CHRONIC PAIN MANAGEMENT

Because our understanding of chronic pain is incomplete, diagnosis frequently consists of syndrome classification, and therapy is largely empiric. Many problems can be handled in so-called block clinics, but intractable problems may need the combined expertise and resources of a multidisciplinary pain clinic. Psychological issues assume a larger role for the patient who has to contend with chronic pain.

The management of chronic pain is complex and frequently multidisciplinary. Anesthesiology training provides skill in the safe application of drugs by intravenous and perineural injection. The following sections discuss the techniques that are used in our pain management clinic.

Pain has a protective and diagnostic role. It stimulates avoidance of further injury and provides information about the injury. When the source of pain has been identified, the benefits of pain may no longer outweigh the cost in terms of suffering, reduced function, and stress. Research into pain mechanisms has led to advances in the management of postoperative and posttraumatic pain. Spinal cord opiate receptors demonstrate the efficacy of intrathecal and epidural opiate injections. When occupied by an agonist drug, opiate receptors on primary afferent neurons inhibit the release of substance P. The spinal gate control hypothesis explains the efficacy of transcutaneous electrical nerve stimulation (TENS) and dorsal column stimulation (29). Research has given objective support to the well-established clinical observation that pain tolerance and experience are highly variable between individuals as well as for the same individual. This variability is the rationale behind PCA devices, which allow the patient to self-administer analgesics within prescribed limits (17). At present, clinical measurement of pain is based on patient responses, such as the visual analog pain scale or the amount of drug delivered by a PCA device. An objective measure is needed.

## POSTTRAUMATIC PAIN CONDITIONS

Extremity injuries are associated with sympathetic-maintained pain (reflex sympathetic dystrophy and causalgia) and phantom limb pain. The classic picture of sympathetic-maintained pain in the acute phase is that of a closely guarded, hyperesthetic, edematous, painful limb that is relieved by sympathetic block. Pain and joint stiffness are consistent features of the subacute and chronic stages, but the appearance of the affected limb becomes one of disuse atrophy. When associated with a partial nerve injury, this syndrome is referred to as causalgia. A series of sympathetic ganglion blocks (cervicothoracic or stellate for the arm, lumbar sympathetic at L-2 for the leg) frequently results in resolution of the pain over time. Alternatively, intravenous regional bretylium and TENS also provide relief. Physical therapy is an important component of treatment.

Two kinds of postamputation pain are commonly encountered. The easiest to manage is stump pain due to local causes such as scar, ischemia, infection, bony irregularities, and neuroma. Treatment is focused on the cause. Phantom limb pain is notoriously refractory to treatment. Unlike the nondebilitating phantom sensations that amputees experience, phantom pain is severe and occurs in 5% to 10% of amputees. The pain is typically described as burning, cramping, or crushing. Numerous therapies are available, including antidepressant and anticonvulsant drugs, TENS, nerve blocks, and surgery, but no one therapy is uniformly successful (43). When amputation is preceded by pain, preoperative regional anesthesia that is continued into the postoperative period may reduce the likelihood of phantom pain.

## CHRONIC PAIN PROCEDURES

### *Trigger Point Injections*

Myofascial pain is a common accompanying complaint. The relief of muscle pain and spasm by trigger point injections is empirically based. The mechanism of pain and its relief are still unsettled. Diagrams of trigger point locations and the pattern of radiating pain to assist in the diagnosis and treatment can be found in Travell and Simons' text (44). Local anesthetic injection is frequently used, but steroids, saline, and NSAIDs have also been injected with reported relief. Local therapy directed at the muscle is recommended after relieving the trigger point pain. The risks are local bleeding, infection, trauma to nerves, and in the chest wall, pneumothorax.

### *Sympathetic Blocks (Stellate, Lumbar Sympathetic)*

The IASP has classified reflex sympathetic dystrophy (RSD) and causalgia as complex regional pain syndrome (CRPS) type I and type II, respectively. CRPS I is an infrequent sequela of skeletal and soft-tissue injury, usually to an extremity. CRPS II is a complication of partial injury to a mixed peripheral nerve. They are both under the broader classification of neuropathic pain. Sympathetic blocks are usually performed for the diagnosis or treatment of complex regional pain syndrome. Effectiveness of the block is most easily documented by the use of skin temperature liquid crystal strips. Skin temperature can rise to 33° to 34°C. The duration of the block depends on the pharmacokinetics of the particular local anesthetic, but the duration of analgesia may last longer. Occasionally, patients experience progressively longer periods of relief after repeated block. When relief occurs, physical therapy should immediately follow the onset of block. Other therapies for CRPS I include medications, such as gabapentin, clonidine and terazocin, biofeedback, and spinal cord stimulation.

CRPS I of the upper extremities may be relieved by local anesthetic block of the stellate ganglion (inferior cervical ganglion plus T-1 sympathetic ganglion). An anterior approach is commonly used. Take care to avoid injection into the carotid artery, the vertebral artery, or the dural sleeve. Other nerves that can be blocked are the recurrent laryngeal, the phrenic, and branches of the brachial plexus.

CRPS I of the lower extremities may be relieved by local anesthetic block of the lumbar sympathetic chain (L-1 through L-3). A posterior approach is commonly used and is efficiently executed using fluoroscopic guidance. A large volume of anesthetic is injected to achieve cephalad and caudad spread of the solution along the sympathetic chain. Take care to avoid posterior spread with resultant nerve root block and intravascular injection into the inferior vena cava (IVC) or aorta.

Repeated sympathetic block of the upper extremity can also be produced by placement of a brachial plexus catheter. The subclavian approach is used because the catheter is less likely to be dislodged. Perform this procedure with sterile conditions and dressings, followed by frequent examination for possible infection of the catheter skin site. The catheter can be used for continuous or repeated local anesthetic injections in conjunction with physical therapy.

### *Intravenous Regional Block (Bretylium)*

Intravenous regional block with norepinephrine-depleting drugs can provide long-lasting sympathectomy and relief of pain from CRPS I. The procedure is similar to surgical anesthesia with the Bier block technique. An intravenous catheter is placed in the distal part of the extremity. This procedure may be difficult when venoconstriction is part of the clinical presentation. Mechanical venous distention can be produced by inflating the double pneumatic tourniquet above venous pressure range and then wrapping an Esmarch bandage in reverse direction from proximal to distal to squeeze blood into the distal portion of the venous system. If this procedure fails to produce satisfactory venous dilation, a regional anesthetic block may have to be performed, for example, a brachial plexus block or epidural block. A regional block may also be used when a patient is unable to tolerate the discomfort of tourniquet ischemia. Various sympatholytic drugs have been injected (guanethidine, reserpine, and bretylium). At present, only bretylium is available in the United States. Clinical trials with guanethidine have been conducted to assess the efficacy of intravenous regional sympathectomy in CRPS I. The results suggest that, despite the clinical improvement that is observed in some patients under controlled conditions, the efficacy is small.

When the effect of repeated regional local anesthetic block is too brief, prolonged sympathectomy is usually attempted using radiofrequency or surgical ablation. Although the initial response may be gratifying relief, frequently the pain returns. This is attributed to incomplete ablation, but it may actually be a deafferentation phenomenon. A more promising technique for lasting analgesia may be achieved with spinal cord stimulation. The results of this relatively recent therapy are still being

evaluated in clinical trials. Individual patients have experienced significant long-term relief.

***Epidural Steroid Injection (Cervical, Lumbar, Caudal)***

Epidural steroid injection is effective in reducing or relieving pain in 60% of patients at three months followup who have acute lumbar radiculopathy (11a). With chronic lumbar radiculopathy, there is less likelihood of benefit from epidural steroids. In the lumbar region, 80 mg of methylprednisolone diluted in normal saline are injected epidurally (8a,11a,41a). Watts and Silagy (52a) in a meta-analysis of the literature concluded that epidural steroids, up to 60 days followup, increased the odds ratio of pain relief (75% improvement) to 2.61 (95% confidence interval: 1.9–3.8) when compared with placebo. Although risks are minimal, they include adrenal suppression, infection, and epidural abscess.

Several steroid injection procedures are used in the management of chronic cervical and lumbar spine pain and radiculopathies. Peridural (epidural) injection, selective nerve injection, sacroiliac joint injection, and facet injection of steroid are offered empirically as pain reduction therapies. The specific corticosteroid agents and dose, the number and interval between injections, and the adjunctive therapies vary widely. Therapeutic efficacy has not been established in a way that can be easily applied to individual patients. Methylprednisolone (Depo-Medrol) and triamcinolone (Aristocort) are commonly used. Our clinic uses triamcinolone. The amount that causes significant side effects is unknown and possibly varies from one patient to the next.

Epidural steroid injection is the most frequently used steroid technique for lumbar pain. The indications vary from very conservative recommendations to an almost universal trial in patients with back pain lasting over a few weeks. The recent onset of symptoms or a recent exacerbation seem to be favorable prognostic signs for relief by epidural steroids. The procedure is similar to that used for epidural anesthesia. A sitting position is used to simplify the location of midline, particularly in large patients. The sitting position, however, tends to decrease the interspinous space, making needle insertion more difficult. This can be overcome by using the paramedian approach. There is concern that what is perceived as an epidural injection is actually not in the epidural space. One often quoted result is that there is a 30% failure rate without resorting to fluoroscopy. Loss of resistance to air or saline injection can be misleading if the needle leaves the interspinous ligament and enters the paraspinous area. Quantification of the pressure required to infuse saline through the needle and injection of local anesthetic to produce a transient block have been recommended. Epidural needle placement under fluoroscopy with contrast injection is considered by many to be the gold standard and has been recommended when the patient's size or spine presents an anatomic challenge or when an injection without fluoroscopy guidance has not resulted in relief. Some advocate performing the initial steroid injection with fluoroscopy guidance in all patients.

***Selective Nerve Root Block***

When spinal or foraminal stenosis is identified and suspected of causing radicular pain, selective nerve root injections are performed for both therapeutic and diagnostic reasons. This procedure is done with fluoroscopy. For lumbar nerve root injections, the patient is placed in a prone position with a pillow under the hips. The image of the lumbar pedicles is a landmark for directing the needle to the foramen beneath it. Outline the nerve root by injection of a small amount of contrast. To avoid epidural block, inject only small volumes of local anesthetic with steroid.

***Facet Injection: Diagnostic and Therapeutic***

The sacroiliac joint is occasionally the source of low lumbar pain. Patrick's test, pain on crossed-leg external rotation at the hip joint, is one of the tests used to identify sacroiliac joint pain. Injection can be performed with or without fluoroscopy.

Pain arising from disorders of the facet (zygapophyseal) joints is difficult to localize by examination. Imaging studies are not reliable in identifying pain-producing pathology of the facet joints. Frequently, a therapeutic trial injection of local anesthetic and corticosteroid of the joint capsule or the medial branch nerve at various levels is undertaken, in search of a pain-relieving procedure. When reproducible relief is achieved by either intracapsular or medial branch nerve block, the patient becomes a candidate for radiofrequency coagulation of the medial branch nerve. Fluoroscopy is essential for both the medial branch and the intracapsular injections. With the patient in prone position and with the fluoroscopy tube positioned to identify the joint space, direct the needle either toward the joint space or toward the medial, upper edge of the transverse process. Facet block is a relatively low-risk procedure. Excessive volume injection into the capsule can cause capsular rupture.

***Neurolytic Block (Cryoanalgesia, Radiofrequency Coagulation, Alcohol and Phenol Injection)***

Peripheral nerve injuries, such as neuroma or entrapment, are also treated as neuropathetic pain syndromes. Before spinal cord stimulation, neurolytic block with phenol, freezing (cryoanalgesa), and radiofrequency coagulation neurolysis are usually attempted. Neurolytic blocks are usually temporary, lasting from a few weeks to months. Dysesthesias and pain are sometimes produced by neuritis or possibly by the additional deafferentation. Because precision of needle placement is essential, nerve stimulation and fluoroscopy with contrast are usually employed.

***Implantable Pumps for Intrathecal Opioids***

Chronic benign pain can be relieved by long-term opioid administration. Long-term exposure to opioids can result in significant tolerance and corresponding large doses. Drugs can be administered continuously for spinal analgesia by means of a chronically implanted catheter and pump. This method for opioid administration has been used with success in the treatment of postlaminectomy pain syndrome. Not every chronic pain patient is a suitable candidate for an intrathecal pump. The patient's pain must be suppressed by opioids, and the patient must demonstrate psychological stability.

***Spinal Cord Stimulation***

Nerve root avulsion injuries and phantom pain are forms of deafferentation pain, a subset of neuropathetic pain syndromes that do not respond to sympathetic or additional neuroablative procedures. The primary therapies are medications, such as anticonvulsants, antidepressants, opioids, and neurostimulation.

## PITFALLS AND COMPLICATIONS

### INTRAOPERATIVE THROMBOEMBOLISM

Orthopaedic patients are at increased risk for thromboembolism. When pulmonary embolism occurs intraoperatively, the combined effects of embolism, anesthesia, and blood loss may be catastrophic. Impaired cardiac output can lead to severe, refractory hypotension and tissue ischemia. Occlusion of pulmonary blood flow can lead to carbon dioxide retention and tissue acidosis. Embolism has recently been detected using echocardiography following the release of a thigh tourniquet during total knee arthroplasty. Sudden hypotension at any time during a procedure presents a diagnostic problem, and one of the considerations is the possibility of major pulmonary embolus. The presence of a large increase in arterial-to-end tidal carbon dioxide difference, elevated venous pressure, or evidence of decreased peripheral perfusion, such as failing pulse oximeter, point to the possibility of pulmonary embolism.

### LATEX ALLERGY: ANAPHYLACTIC SHOCK

Allergy to latex is increasingly recognized as a hazard to patients and health care workers (23). Orthopaedic patient populations who have frequent exposure to latex products include patients with spina bifida, congenital urologic anomalies, and spinal cord injuries. Approximately 40% of children with myelomeningocele test positive for latex allergies. Because of this high prevalence, it has become routine to treat patients in these categories with latex allergy precautions. Latex-containing items used in anesthesia include tourniquets for starting intravenous injections, gloves, breathing circuit reservoir bags, intravenous infusion injection ports, and stoppers on medication vials.

Anaphylactic reactions rather than skin rash have been reported. Successful management depends on prompt recognition and treatment. Anaphylactic and anaphylactoid reactions occur unexpectedly and to a variety of foreign substances besides latex. The combination of sudden, profound hypotension, tachycardia, cutaneous flush, and bronchoconstriction is easily recognized. A delayed diagnosis may result if significant hemorrhage is occurring and the cutaneous flushing is not apparent. Treatment for anaphylaxis consists of 1 mg of intravenous epinephrine, rapid infusion of crystalloid solution, oxygen, and a bronchodilator if bronchoconstriction is evident (23a). For hypotension, 5 to 10 mcg of intravenous epinephrine is recommended (23a). Further exposure to the antigen should be avoided. Corticosteroids and antihistamine may be helpful in controlling symptoms. Repeat doses of epinephrine may be needed after the initial resuscitation. (See Table 7.15.)

| |
|---|
| 100% oxygen |
| IV crystalloid infusion (usually require several liters) |
| If hypotensive, reduce or eliminate anesthetics and give IV epinephrine. |
| Remove or discontinue all suspected antigens (latex, antibiotics, dextran, hetastarch, muscle relaxants) |
| $H_1$ and $H_2$ histamine receptor antagonists |
| Corticosteroid |
| Bronchodilator |
| May require repeated treatment |

***Table 7.15. Treatment for Anaphylaxis***

## MALIGNANT HYPERTHERMIA

MH is a rare genetic syndrome consisting of hypermetabolism, hyperthermia, and acidosis triggered by exposure to potent inhalation anesthetics and succinylcholine. The incidence is approximately 1:15,000 (pediatric) to 1:50,000 (adults). A higher incidence of MH has been associated with some of the myopathies, such as King-Denborough syndrome and central core disease. The abnormal response of susceptible patients to inhalation anesthetics can be demonstrated in muscle biopsy specimens in the presence of caffeine stimulation. When a patient has been identified as MH susceptible by history or muscle biopsy, the anesthetic agents must be restricted to nontriggering drugs. An episode of MH is potentially fatal. Dantrolene is an effective treatment. At least 36 vials of dantrolene should be available in any location where general anesthesia is given.

Signs of MH, such as tachycardia, hypercapnia, and fever, are easily recognized. Dilemmas arise because none of the clinical signs is specific. The intraoperative diagnosis of MH is also difficult when the onset is gradual. The possibility of MH is easier to recognize when muscle rigidity, tachycardia, hypercapnia, and rapidly increasing temperature follow shortly after exposure to the anesthetic. Management of MH is summarized in Table 7.16. After a fulminant MH episode is controlled, the patient should be observed in an intensive care unit for at least 24 hours because recurrence is possible. Controversy exists among anesthesiologists as to whether to proceed with elective surgery when succinylcholine causes masseter spasm, an event that is sometimes followed by an MH episode. Consultation regarding the preoperative preparation or crisis management of MH is available through the Malignant Hyperthermia Association of the United States (MHAUS) hotline number, 1-800-MH-HYPER. Additional information is available on the MHAUS website, <www.mhaus.org>.

| |
|---|
| Discontinue triggering agents (usually inhalation anesthetics, but also succinylcholine) |
| Hyperventilate with 100% oxygen |
| IV dantrolene (may need to be repeated) |
| Active cooling |
| Look for and treat metabolic acidosis, hyperkalemia, and DIC |
| Maintain urine output (IV fluids and diuretics) |
| DIC, disseminated intravascular coagulation. |

***Table 7.16. Management of Malignant Hyperthermia***

## CHAPTER REFERENCES

Each reference is categorized according to the following scheme: *, classic article; #, review article; !, basic research article; and +, clinical results/outcome study.


+ 1. Albright GA. Cardiac Arrest following Regional Anesthesia with Etidocaine or Bupivacaine. *Anesthesiology* 1979;51:285.

+ 2. American College of Physicians. Guidelines for Assessing and Managing the Perioperative Risk from Coronary Artery Disease Associated with Major Noncardiac Surgery. *Ann Intern Med* 1997;127:313.

+ 3. Barbier-Bohm G, Desmonts JM, Couderc E, et al. Comparative Effects of Induced Hypotension and Normovolaemic Haemodilution on Blood Loss in Total Hip Arthroplasty. *Br J Anaesth* 1980;52:1039.

! 4. Becher ME, Rosenfeld M. Mathematical and Computer Model of Acute Normovolemic Hemodilution. *Transfusion* 1994:34:176.

+ 5. Berger A, Tizian C, Zenz M. Continuous Plexus Blockade for Improved Circulation in Microvascular Surgery. *Ann Plast Surg* 1985;14:16.

! 6. Bernards CM, Artru AA: Hexamethonium and Midazolam Terminate Dysrhythmias and Hypertension Caused by Intracerebroventricular Bupivacaine in Rabbits. *Anesthesiology* 1991;74:89.

+ 7. Brown DT, Beamish D, Wildsmith JAW. Allergic Reaction to an Amide Local Anaesthetic. *Br J Anaesth* 1981;53:435.

+ 8. Camann WR, Sacks GM, Schools AG, et al. Nearly Fatal Cardiovascular Collapse During Total Hip Replacement: Probably Coronary Arterial Embolism. *Anesth Analg* 1991;72:245.

+ 8a. Carette S, Leclaire R, Marcoux S, et al. Epidural Corticosteroid Injections for Sciatica Due to Herniated Nucleus Pulposus. *N Engl J Med* 1997;336:1634.

+ 9. Casthely PA, Lear S, Cottrell JE, et al. Intrapulmonary Shunting during Induced Hypotension. *Anesth Analg* 1982;61:231.

+ 10. Clarkson CW, Hondeghem LM. Mechanism for Bupivacaine Depression of Cardiac Conduction, Fast Block of Sodium Channels during the Action Potential with Slow Recovery from Block during Diastole. *Anesthesiology* 1985;62:396.

+ 11. Davis FM, Quince M, Laurenson VG. Deep Vein Thrombosis and Anaesthetic Technique in Emergency Hip Surgery. Br Med J 1980;281:1528.

+ 11a. Dilke TF, Burry HC, Grahame R. Extradural Corticosteroid Injection in Management of Lumbar Nerve Root Compression. *Br Med J* 1973;2:635.

+ 12. Donald JR. Induced Hypotension and Blood Loss during Surgery. *J R Soc Med* 1982;75:149.

+ 13. Donovan M, Dillon P, McGuire L. Incidence and Characteristics of Pain in a Sample of Medical-surgical Inpatients. *Pain* 1987;30:69.

+ 14. Eagle KA, Brundage BH, Chaitman BR, et al. Guidelines for Perioperative Cardiovascular Evaluation for Noncardiac Surgery. Report of the American College of Cardiology/American Heart Association Task Force on Practice Guidelines. Committee on Perioperative Cardiovascular Evaluation for Noncardiac Surgery. *Circulation* 1996;93:1278.

+ 15. Ekback G, Schott U, Axelsson K, Carlberg M. Perioperative Autotransfusion and Functional Coagulation Analysis in Total Hip Replacement. *Acta Anaesthesiol Scand* 1995;39:390.

+ 15a. Etchason J, Petz L, Keeler E, et al. The Cost Effectiveness of Preoperative Autologous Blood Donations. *N Engl J Med* 1955;332:719.

+ 16. Fernandez MC, Gottlieb M, Menitove JE. Blood Transfusion and Postoperative Infection in Orthopedic Patients. *Transfusion* 1992;32:318.

# 17. Ferrante FM, Ostheimer GW, Covino BG, eds. *Patient-Controlled Analgesia.* Boston: Blackwell Scientific Publications, 1990.

+ 18. Galindo A, Hernandez J, Benavides O, et al. Quality of Spinal Extradural Anesthesia: The Influence of Spinal Nerve Root Diameter. *Br J Anaesth* 1975;47:41.

# 18a. Guidelines for Assessing and Managing the Perioperative Risk from Coronary Artery Disease Associated with Major Noncardiac Surgery. American College of Physicians. *Ann Internal Med* 1997;127:309.

! 19. Haasio J, Pitkanen MT, Kytta J, et al. Treatment of Bupivacaine-induced Cardiac Arrhythmias in Hypoxic and Hypercarbic Pigs with Amiodarone or Bretylium. *Reg Anesth* 1990;15:174.

+ 20. Hauss J, Schonleben K, Spiegel H, et al. Nitroprusside- and Nitroglycerin-induced Hypotension: Effects on Hemodynamics and on the Microcirculation. *World J Surg* 1982;6:241.

+ 21. Heit JA, Horlocker TT, eds. Neuraxial Anesthesia and Anticoagulation. *Supplement to Regional Anesthesia and Pain Medicine.* 1998:23:129.

+ 22. Hines R, Barash PG. Infusion of Sodium Nitroprusside Induces Platelet Dysfunction in Vitro. *Anesthesiology* 1989;70:611.

+ 23. Holzman RS. Latex Allergy: An Emerging Operating Room Problem. *Anesth Analg* 1993;76:635.

# 23a. Levy H. *Anaphylactic Reactions in Anesthesia and Intensive Care, 2nd ed.* Boston: Butterworth-Heinemann, 1992.

+ 24. Lynch C III. Depression of Myocardial Contractility in Vitro by Bupivacaine, Etidocaine, and Lidocaine. *Anesth Analg* 1986;65:551.

+ 25. Mallampati SR, Gatt SP, Gugino LD, et al. A Clinical Sign to Predict Difficult Tracheal Intubation: A Prospective Study. *Canadian Anaesthetists Society Journal* 1985;32:429.

+ 26. Marks RM, Sachar EJ. Undertreatment of Medical Inpatients with Narcotic Analgesics. *Ann Intern Med* 1973;78:173.

+ 27. Marx GF, Mateo CV, Orkin LR. Computer Analysis of Post Anesthetic Death. *Anesthesiology* 1973;39:54.

+ 28. Mehta P, Mehta J, Miale TD. Nitroprusside Lowers Platelet Count. *N Engl J Med* 1978;299:1134.

+ 29. Melzack R, Wall PD. Pain Mechanisms: A New Theory. *Science* 1965;150:971.

+ 30. Modig J, Borg T, Karlstrom G, et al. Thromboembolism after Total Hip Replacement: Role of Epidural and General Anesthesia. *Anesth Analg* 1983;62:174.

+ 31. Murphy P, Heal JM, Blumberg N. Infection of Suspected Infection after Hip Replacement Surgery with Autologous or Homologous Blood Transfusions. *Transfusion* 1991;31:212.

+ 32. Nagle JE, Fuscaldo JT, Fireman D. Paraben Allergy. *JAMA* 1977;237:1594.

+ 33. Neimkin RJ, May JW Jr, Roberts J, et al. Continuous Axillary Block through an Indwelling Teflon Catheter. *J Hand Surg* 1984;9:830.

* 34. New Classification of Physical Status. *Anesthesiology* 1963;24:111.

+ 35. Nordberg G, Mark H. Epidural Abscess after Epidural Analgesia Treated Successfully with Antibiotics. Case Report. *Acta Anaesthesiol Scand* 1998:42:727.

+ 36. Owens WD, Felts JA, Spitznagel ED Jr. ASA Physical Status Classifications: A Study of Consistency of Ratings. *Anesthesiology* 1978;49:239.

# 36a. Pain Terms: A List with Definitions and Notes on Usage. Recommended by the IASP Subcommittee on Taxonomy. *Pain* 1979;6(3):249.

+ 37. Practice Guidelines for Blood Component Therapy. A Report by the American Society of Anesthesiologists Task Force on Blood Component Therapy. *Anesthesiology* 1996;84:732.

+ 38. Saklad M. Grading of Patients for Surgical Procedures. *Anesthesiology* 1941;2:281.

+ 39. Schatz M. Skin Testing and Incremental Challenge in the Evaluation of Adverse Reactions to Local Anesthetics. *J Allergy Clin Immunol* 1984;74:606.

+ 40. Schmidt ST, Moorthy SS, Dierdorf SF, et al: A Series of Truly Failed Spinal Anesthetics. J Clin Anesth 1990;2:336.

+ 41. Schwartz H, Sher TH. Bisulfite Sensitivity Manifesting as Allergy to Local Dental Anesthesia. *J Allergy Clin Immunol* 1985;75:525.

+ 42. Selander D, Edshage S, Wolff T. Paresthesiae or No Paresthesiae? *Acta Anaesth Scand* 1979;23:27.

+ 43. Sherman RA, Sherman CJ. Prevalence and Characteristics of Chronic Phantom Limb Pain among American Veterans—Results of Trial Survey. *Am J Phys Med* 1983;62:227.

# 44. Simons DG, Travell JG, Simons LS. *Travell & Simons' Myofascial Pain and Dysfunction: The Trigger Point Manual, 2nd ed.* Baltimore: Williams & Wilkins, 1999.

+ 44a. Snoek W; Weber H; Jorgensen B. Double blind evaluation of extradural methyl prednisolone for herniated lumbar discs. *Acta Orthop Scand* 1977;48:635.

+ 45. Spiess BD, Sloan MS, McCarthy RJ, et al: The Incidence of Venous Air Embolism during Total Hip Arthroplasty. *J Clin Anesth* 1988;1:25.

+ 46. Task Force on Management of the Difficult Airway. Practice Guidelines for management of the Difficult Airway. *Anesthesiology* 1993;78:597.

+ 47. Tetzlaff JE, Yoon HJ, Walsh M. Regional Anaesthetic Technique and the Incidence of Tourniquet Pain. *Can J Anaesth* 1993;40:591.

+ 48. Thompson GE, Miller RD, Stevens WC, Murray WR. Hypotensive Anesthesia for Total Hip Arthroplasty: A Study of Blood Loss and Organ Function (Brain, Heart, Liver, and Kidney). *Anesthesiology* 1978;48:91.

+ 49. Thorburn J, Louden JR, Vallance R. Spinal and General Anesthesia in Total Hip Replacement: Frequency of Deep Vein Thrombosis. Br J Anaesth 1980;52:1117.

+ 50. Triulzi DJ, Vanek K, Ryan DH, et al: A Clinical and Immunologic Study of Blood Transfusion and Postoperative Bacterial Infection in Spinal Surgery. *Transfusion* 1992;32:517.

+ 51. Vacant CJ, Van Houten RJ, Hill RC. A Statistical Analysis of the Relationship of Physical Status to Postoperative Mortality in 68,388 Cases. *Anesth Analg* 1970;49:564.

+ 52. Vazeery AK, Lunde O. Controlled Hypotension in Hip Surgery. *Acta Orthop Scand* 1979;50:433.

52a. Watts RW, Silagy CA. A Meta-analysis on the Efficacy of Epidural Corticosteroids in the Treatment of Sciatica. *Anaesth Intensive Care* 1995;23:564.

+ 53. Woolf CJ, Chong M-S. Preemptive Analgesia—Treating Postoperative Pain by Preventing the Establishment of Central Sensitization. *Anesth Analg* 1993;77:362.

# CHAPTER 8

# SOFT-TISSUE MANAGEMENT

*Thomas P. Whetzel and Thomas R. Stevenson*

**T. P. Whetzel and T. R. Stevenson:** Division of Plastic Surgery, University of California Davis, Sacramento, California 95817.

Principles of Wound Management
Wound Closure by Skin Apposition
Primary Closure
Delayed Primary Closure
Secondary Closure
Skin Grafting
Split-Thickness Skin Grafts
Full-Thickness Skin Grafts
Skin Flaps
Musculocutaneous Flaps
Flap Design
Tissue Expansion
Pitfalls and Complications
Necrosis of Wound Edges
Seromas and Hematomas
Acute Infection
Compartment Syndrome and Neurovascular Injury
Injury to Nerves
Chapter References

A skin wound is common to most operative procedures, and surgeons of every discipline are faced with soft-tissue management problems. If the wound is created in an operating room, a sterile environment is assumed, as are gentle handling of tissues, sharply incised margins, and little contamination by foreign bodies. In a wound sustained in the civilian or military environment, however, avulsive trauma, bacterial contamination, and the presence of foreign bodies are the rule. Management principles remain the same for all wounds, although certain aspects of care will need to be emphasized depending on the particular wound.

## PRINCIPLES OF WOUND MANAGEMENT

Successful wound closure depends on adequate preparation. For a wound to heal primarily, it must be cleansed of devitalized tissue, foreign bodies, and bacteria. Although these prerequisites usually exist in the operative wound, such is not the case in the traumatic one.

Debridement of the traumatic wound prepares it for closure. The patient usually has discomfort from wound examination and cleansing; pain may compromise the surgeon's ability to debride adequately. Therefore, administration of local, regional, or general anesthesia is usually appropriate before treatment is begun. Apply a topical antibacterial to the surrounding skin to minimize subsequent introduction of pathogenic organisms.

- Vigorous flushing of the wound with sterile saline dislodges foreign bodies and bacteria. Pulse irrigation is particularly effective in removing contaminants. Begin with irrigation and use it throughout the debridement. In type II or worse open fractures, use at least 10 L of saline.
- To minimize blood loss in an extremity wound, tourniquet hemostasis is often used, but tourniquets interfere with the ability to detect devitalized muscle.
- Perform sharp debridement using forceps, a scalpel, and scissors.
- Excise devascularized skin, fat, subcutaneous tissue, and muscle. Soft tissue of questionable viability is usually sacrificed. One exception is if removal of possibly viable skin or muscle would result in exposure of an important structure (major vessel, nerve, bone, or joint), whose integrity would then be compromised. In this case, injured but potentially viable skin or muscle can be left in place for 24 to 48 h before being reinspected. At the point where viability can be accurately determined, the injured tissue is either left in place to continue healing or debrided, and an appropriate reconstructive alternative chosen. With the routine use of microsurgical techniques, which allow replacement of larger amounts of tissue, debridement can be more extensive when necessary. It is better, however, to leave a wound open, returning the patient to the operating room for serial examinations and debridements, than to excise what would ultimately be viable tissue during the initial operation.
- A wound containing questionably viable or contaminated tissue should never be closed because this would predispose the patient to a serious or life-threatening infection.
- The use of prophylactic antibiotics in traumatic wounds is controversial, but most surgeons administer a broad-spectrum parenteral or oral antibiotic perioperatively.

Once the wound has been cleansed and adequately debrided, closure can commence. The goal is rapid healing and recovery of function by maximizing vascularity in the wound environment. If this requirement cannot be met by primary wound closure, another technique is chosen. The appropriate graft or flap method is selected based on the likelihood of success, expected donor-site morbidity, and anticipated appearance of the wound (including the donor site).

## WOUND CLOSURE BY SKIN APPOSITION

### PRIMARY CLOSURE

Primary wound closure involves secure positioning of the wound skin margins adjacent to one another during the healing process. Close approximation confines the inflammatory response to a minimal local area, permits rapid reepithelialization across a narrow gap, and yields the smallest possible scar (10,25).

- Commence closure with approximation of any fascial wound using absorbable sutures.
- Subcutaneous tissue and fat are often closed in an attempt to obliterate dead space, minimize localized fluid accumulation, and reduce the risk of infection. The potential benefits of dead space closure must be weighed against the risks of devitalizing tissue by crushing it when sutures are tied and adding additional foreign bodies (the sutures themselves).
- The skin is usually approximated in two layers. Stitches of an absorbable material are placed through the papillary and reticular dermis, and the knots are buried deeply by being tied on the side toward the subcutaneous tissue (21). This strong dermal layer accepts most of the tension applied across the wound.
- The more superficial layer of skin closure includes the epidermis and upper portion of the dermis. Sutures are passed in either a continuous or interrupted fashion, using absorbable or nonabsorbable materials. Continuous sutures can be placed more quickly than interrupted ones, although interrupted sutures have the theoretical advantage of producing less ischemia of the wound margins. In any event, the superficial layer of sutures provides accurate approximation of the skin edges, with the goal of minimizing the resultant scar. Because these sutures are usually left exposed where they cross the wound, they may leave visible epithelialized tracks along their entire course as well as at the sites where they enter the skin. Removing the skin sutures within 7 days of placement may minimize the severity of skin scarring.
- There are alternatives to the superficial exposed skin suturing technique (4). The same layer may be closed using a buried intracuticular suture that leaves no marks in the skin surface. This method requires more operative time, and, if a nonabsorbable suture is used, it may be more difficult to remove. Staples can substitute for skin sutures; these have the advantage of rapid application. They should be removed as soon as possible to minimize scarring. Surgical wound closure tapes can be placed rapidly and removed with little discomfort. Tapes are more difficult to apply accurately, however, and the swelling that occurs in the immediate postoperative period may result in increased tension and blistering of the skin along the tape margins. Tape is often used to reinforce a sutured wound or provide support once skin sutures have been removed.

### DELAYED PRIMARY CLOSURE

Immediate wound closure is not appropriate in every case. Heavy bacterial contamination or the presence of important but questionably viable tissue may preclude primary wound closure even if approximation of the skin is technically possible. In some cases, local swelling may also prevent wound closure under minimal tension.

Delayed primary wound closure implies skin-edge apposition performed several days after the initial wound, usually by 5 days or so, so that the tensile strength of the wound at 14 days is the same as if it had been closed primarily.

- At the time of the original surgical intervention, a decision to delay closure is made. The wound is packed loosely with moist sterile gauze, and a bulky dressing is applied. Skin sutures may be placed at this time but not tied, obviating the need for later anesthesia.
- Once the wound environment has been shown to be free of significant bacterial contamination, devitalized tissues, and excessive swelling, closure may be done by tying the previously placed sutures or using primary suturing techniques. The interval between initial wound preparation and delayed primary closure is usually 2 to 4 days.
- Open fracture wounds are usually closed on or after the fifth day.

### SECONDARY CLOSURE

Closure by secondary intention is reserved for wounds in which primary or delayed primary closure is impossible and a more complex reconstruction is not indicated. These situations arise when patients present with small skin avulsion wounds or superficial abrasions. The small full-thickness skin wound that has been left untreated for several days and some fingertip amputations are examples of wounds that may be allowed to heal secondarily. After cleansing and debridement, a nonadherent dressing is applied, and daily dressing changes are begun. The wound heals through a process of contraction, granulation, and epithelialization.

## SKIN GRAFTING

### SPLIT-THICKNESS SKIN GRAFTS

Some wounds are not amenable to management by primary, delayed primary, or secondary closure. Examples include large burns involving the epidermis and all layers of the dermis, sizable avulsion injuries, and extensive areas of skin loss as might occur with tumor removal. In such cases, a split-thickness skin graft (STSG) can be used for secure wound coverage (20). An STSG is a sheet of skin consisting of the entire epidermis and some of the dermis (Fig. 8.1).

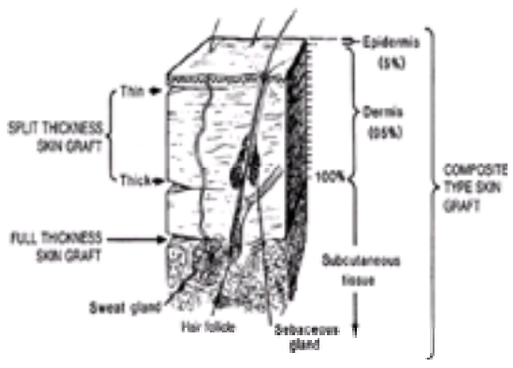


***Figure 8.1.*** Thickness of skin grafts. The split-thickness graft consists of all the epidermis and part of the dermis; the full-thickness graft consists of all the epidermis and all the dermis.

There are several prerequisites for a wound to successfully sustain an STSG (44). The recipient site must be free of heavy bacterial colonization or invasion, with fewer than $10^5$ bacteria per gram of tissue. All necrotic tissue and foreign bodies must be removed. The site must be well vascularized, although not necessarily exhibiting growth of granulation tissue. An STSG survives poorly when applied to bone denuded of periosteum, tendon stripped of peritenon, or cartilage separated from perichondrium.

The STSG “takes” through a process that revascularizes the transplanted skin from the underlying wound bed (8,46). Adherence of the graft to the recipient bed is maintained by a fibrin clot that forms within minutes after skin transfer. For the first 24 to 48 h after transfer, the graft survives in an avascular state by imbibing nutrients from wound fluids. Within 48 to 72 h after grafting, examination of the successful STSG discloses circulating blood cells in the graft, with generalized circulation being restored by the fourth to seventh day. Processes proposed to explain this circulatory restoration include attachment of vessels from the bed to vascular channels within the graft and/or invasion of the graft by recipient-site vessels that form new vascular channels throughout the grafted dermis. Whatever the mechanism, the grafted skin begins to turn pink by the fourth or fifth postoperative day. From that point, graft adherence becomes more dependent on vascular ingrowth and fibroplasia.

Decisions that pertain to the thickness of a particular STSG are made based on the demands of the wound, availability of donor sites, and training of the surgeon. The thinner STSGs (0.008 to 0.012 in.) tend to take more easily than thicker grafts (>0.016 in.). Thicker grafts may provide more durable wound coverage and contract less than the thinner ones. An STSG of intermediate thickness (0.012 in. to 0.016 in.) often is the best compromise.

Appropriate donor sites for STSGs include the lower extremities, buttock, trunk, and occasionally the upper extremities. The scalp provides an excellent donor site for STSGs to the face, although raising a thick graft may result in alopecia. Place the donor site in an area on which the patient does not lie; avoid the posterior thigh and the back. Avoid selecting a donor site immediately adjacent to the recipient wound, so that differing site-dressing requirements do not interfere with one another. Select a donor site that is aesthetically acceptable and easily concealed, such as the buttock in a woman and the proximal thigh in a man.

Several instruments are available for raising an STSG, including free-hand knives with or without a guard, drum dermatomes, and air-driven or electrically driven devices (Fig. 8.2). Each instrument is suitable, although the air-driven and electrically driven devices are often more readily accessible, are easier to assemble and clean, and reliably raise a graft of uniform thickness. Drum dermatomes are useful in obtaining larger sheet grafts, compared with those raised by other instruments. Except for the drum dermatomes, successful graft raising using the other instruments is facilitated by antiseptic donor-site preparation, application of a lubricant (mineral oil, blood, soap used for skin cleansing), maintenance of donor-site skin tension by an assistant, and smooth, steady advancement of the instrument during the cutting process.

***Figure 8.2.*** Dermatome and mesher are useful in skin grafts. The electric dermatome is useful for obtaining grafts of uniform thickness.

As soon as it is raised, the STSG undergoes primary contraction. Ten to twenty percent of the graft's surface area is lost, probably as a result of recoil of dermal elastic fibers.

Meshing of an STSG is a process in which multiple staggered rows of full-thickness incisions are placed in the graft (14). These incisions are made by applying the STSG to the obliquely ridged side of a plastic skin carrier, then passing skin and carrier through a device with numerous circular cutting blades. Depending on the length and location of the cuts, the resultant meshed graft can be expanded to a surface area of 1.5 or more times its original surface area. Thus, a larger wound can be covered using a smaller donor site. Fluid accumulating beneath the graft can escape through the interstices, discouraging hematoma or seroma formation. A meshed graft conforms more accurately than does an unmeshed one to an irregular wound bed, but one disadvantage of the meshed graft is its inferior esthetic appearance when compared with the unmeshed graft (Fig. 8.3).

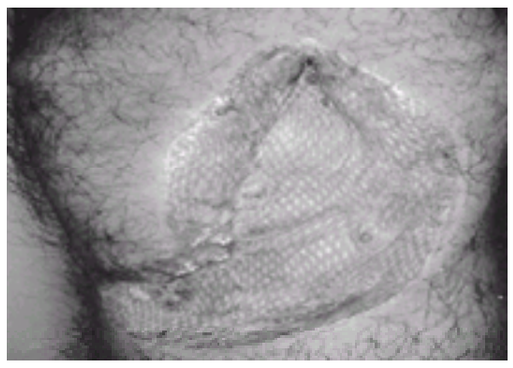

***Figure 8.3.*** Symmetric patterned scarring typical of a healed meshed (1.5:1) split-thickness skin graft.

Once the STSG has been raised and if necessary meshed, it should be secured to the recipient site. While final preparations are being made, the graft can be stored in a saline- or blood-soaked sponge. After an inspection of the recipient site has confirmed adequate debridement and hemostasis, transfer and trim the graft to fit the wound precisely. Avoid small areas of graft overlapping intact skin, as the STSG will not take and may become a nidus for infection. Secure the STSG into position using absorbable or nonabsorbable sutures, staples, or surgical wound closure tapes.

Application of a dressing to the grafted wound is as important as any other step in achieving a healed wound. In rare cases, no dressing is applied at all. Treat the margins with an antibiotic ointment and evacuate immediately any observed fluid accumulation. This technique is occasionally used for grafting of the face, where dressings are difficult to apply, or for STSG coverage of a free microvascular muscle flap, where constant access to the flap must be provided for monitoring its circulation. Usually the recipient site is dressed to preserve a clean environment, to prevent graft disruption by trauma from an external source, to serve as a splint to protect against patient motion with resultant shearing of the graft from its bed, and to maintain uniform, constant pressure on the graft to discourage seroma or hematoma formation.

A suitable dressing consists of one layer of nonadherent gauze covered by a soft, bulky, pliable, absorbent material held in place by tie-over sutures or, in the case of an extremity, by a circumferential wrap. This is reinforced with a splint or cast to limit joint mobility above and below the grafted site. Occasionally, if a meshed graft has been applied over a previously contaminated wound, the dressing is soaked initially and continuously with an antibiotic solution. An alternative in irregular wounds is to apply bulky saline-soaked cotton over the nonadherent gauze. This conforms well to the wound, keeps the graft moist, and acts as a wick to keep fluids from accumulating beneath the graft. Overwrap the cotton with conforming gauze rolls or a bias-cut stockinette.

After 3 to 7 days, remove the dressing and inspect the wound. Earlier dressing removal would be indicated for any local or systemic signs of infection. After the initial dressing is removed, perform a dressing change every 24 h for an additional 7 to 14 days.

The donor site may be dressed initially with a fine-mesh gauze impregnated with petroleum jelly and a topical antibiotic (3). This is covered by a bulky dressing for 24 h, at which time the entire dressing, except for the fine-mesh gauze, is removed. The gauze dries and forms a stable eschar. Reepithelialization of the donor site proceeds from basal cells contained within the residual deep dermal appendages. Over 1 to 2 weeks, the gauze separates spontaneously, leaving a closed, often scaly donor-site scar. Flaking and itching can be controlled through application of a skin lotion. Alternative methods of STSG donor-site wound management range from the use of no dressing to placement of a synthetic skin substitute, either permeable or impermeable to water.

As healing progresses, the STSG undergoes several changes. Its color changes from an early pink hue to a more waxy yellowish color, often lighter than the surrounding skin. Prolonged sun exposure may, however, result in persistent hyperpigmentation. Maturation of the STSG is accompanied by secondary contraction during approximately the first 3 months of healing, followed by a gradual softening of the scar (12). Thinner STSGs contract more than thicker grafts (45).

**FULL-THICKNESS SKIN GRAFTS**

A full-thickness skin graft (FTSG) consists of the entire dermis and epidermis. FTSGs shrink by up to 40% in surface area immediately on being raised as a result of elastic fiber recoil within their substance (primary contraction). When sutured in place, however, they tend to contract less than STSGs during the fibroblastic and remodeling phases of wound healing (secondary contraction). This feature is particularly important when skin grafts are planned for the hands and feet (Fig. 8.4) (26). An FTSG is often selected over an STSG when wound contracture would result in a loss of maximum joint function.

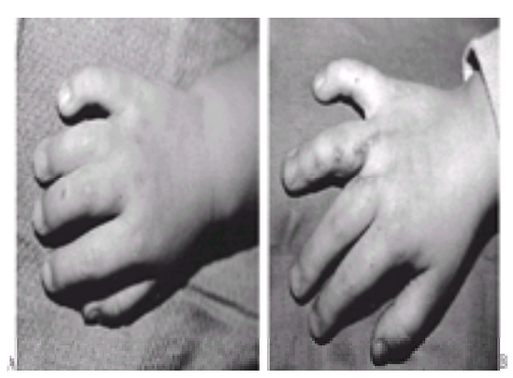

***Figure 8.4.*** **A:** Simple syndactyly involving the ring and index fingers. **B:** Syndactyly release through the use of interdigitating flaps and full-thickness skin grafts. Scar contracture has been minimized.

The selection of an FTSG donor site depends on the amount of skin required. Because a full thickness of skin is removed, the resultant wound cannot heal by reepithelialization but must be either closed primarily, resurfaced with an STSG, or covered with a vascularized flap. A large ellipse of lower abdominal or groin skin for grafting can be removed and the resultant defect sutured under little or no tension with the patient in a sitting position. Other FTSG donor sites include the medial arm, retroauricular region, inferior gluteal fold, and supraclavicular area.

Success of an FTSG depends on a clean, well-vascularized bed, a properly prepared graft, and a secure dressing. The principles of bed preparation are the same as those for STSGs. After the FTSG has been raised, all fat and loose connective tissue are removed from the deep surface, exposing the dermis. The FTSG is sutured in place and covered with a compression dressing, and the area is immobilized in a fashion similar to the STSG technique. Wounds are usually inspected in 5 days at the time of the first dressing change. A bluish hue is typical for the FTSG when initially exposed; this changes to a more normal skin tone over 3 to 7 days (2).

## SKIN FLAPS

A skin flap is created by incising the margins of a previously outlined region of skin and subcutaneous tissue, leaving it attached to the body in an area large enough to maintain flap vascularity. The skin flap carries its own blood supply, making it ideal for covering poorly vascularized wounds. Such wounds include those containing bare tendon, cartilage, or bone. Wounds in an area of previous irradiation have poor vascularity and often require a skin flap for closure.

Skin flaps may be classified based on the anatomy of their blood supply (11). Vascular anatomy thus characterizes the random, axial, fasciocutaneous, and musculocutaneous flaps (19). In every flap, the final common pathway for arterial inflow and venous egress to and from the dermis and epidermis consists of the dermal and subdermal vascular plexuses.

### *Random Skin Flaps*

The random flap consists of skin and subcutaneous tissue elevated with the underlying dermal and subdermal vascular plexuses (Fig. 8.5). Dimensions of the random flap are determined by the size of the defect to be closed. If a random flap is larger than a certain size, its tip may die. In the past, the ratio of flap length to width was thought to be important, although now it appears that absolute flap length is the more important factor in determining random flap survival (24,40). Generally, however, skin flaps are still designed with a 1:1 width-to-length ratio.

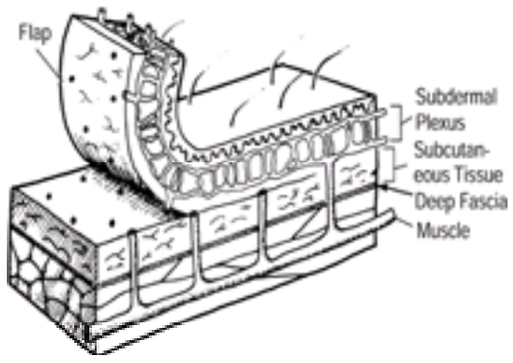


***Figure 8.5.*** Random flap in which the skin is supplied by the subdermal plexus only.

Survival length may be increased by using a delay procedure (42). Part of the surgical margin of the flap is incised and sutured immediately. Seven to 14 days later, the flap is elevated and transposed. During this interval, the flap becomes better vascularized and/or more tolerant to ischemia, which allows it to survive to a greater length than would be possible without the delay.

Random flaps generally require less time, effort, and technical ability to elevate than do other types of flaps. They are usually designed immediately adjacent to the wound requiring reconstruction, obviating the need for a distant donor site (Fig. 8.6). Sometimes the random flap's donor site cannot be closed primarily but requires a skin graft.

***Figure 8.6.*** **A:** Neurotrophic ulcers of the heel and first metatarsal head. **B:** Ulcers covered with random-pattern flaps. The flap donor sites were closed with split-thickness skin grafts.

### *Axial Skin Flaps*

The axial skin flap has a defined, recognizable artery contained within its vascular pedicle (Fig. 8.7) (7,37). Examples include the groin and posterior thigh flaps, containing the superficial circumflex iliac and descending branch of the inferior gluteal vessels, respectively (29,36). An axial pattern flap will survive to a greater length than will a random skin flap of similar dimensions. The pedicle of an axial skin flap can occasionally be narrowed to contain only the vascular pedicle, making it easier to transpose if somewhat more difficult to elevate (Fig. 8.8) (16,17). Unfortunately, not all skin territories are supplied by a single dominant vessel, which limits the number of donor sites for axial flaps.

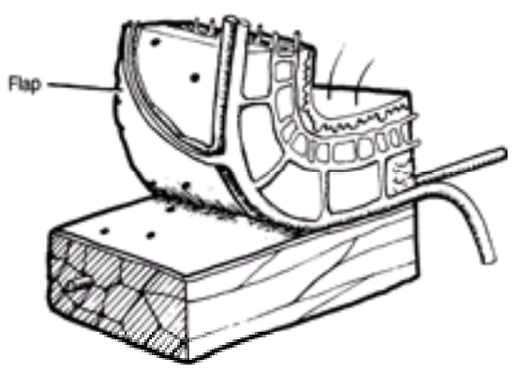


***Figure 8.7.*** Axial flap with an identifiable artery running in the longitudinal axis of the flap.

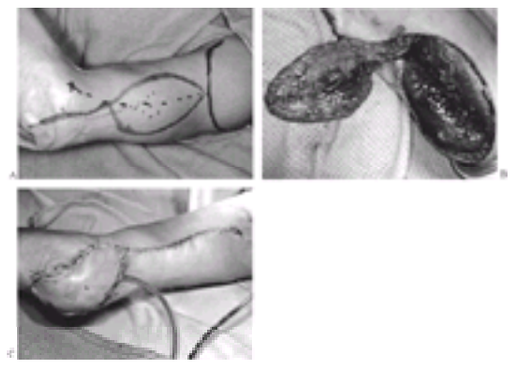

***Figure 8.8.*** **A:** Lateral arm flap designed to close wound of the olecranon. **B:** Lateral arm flap elevated on its distal vascular pedicle (posterior radial collateral artery and vein). **C:** Flap inset.

**Groin Flap—Operative Technique** The groin flap is located lateral to the femoral artery, paralleling the inguinal ligament. It is a skin flap containing the superficial circumflex iliac artery (SCIA) and thus can be designed longer than it is wide because of its direct arterial cutaneous blood supply.

The groin flap is used primarily to resurface the hand and forearm. It is usually attached to or inset into a hand defect and then left attached for a period of 2 to 3 weeks before division of the flap from the groin. The advantages of this flap are that the vascularity is quite good and that the flap can be readily thinned before coverage of the defect. The disadvantages are that the hand remains in a dependent position and that the positioning and immobilization for some patients can be quite challenging.

- Identify and, with a marking pen, draw the superficial circumflex iliac artery location on the skin. Outline the flap by centering it over the anticipated artery location. The flap width can vary between 5 and 15 cm; the length can extend from the femoral artery out to the anterior superior iliac spine with reasonable safety. The flap can be elevated without a delay procedure.
- The SCIA originates from the femoral artery and courses laterally 2.5 to 3.0 cm below and parallel to the inguinal ligament. The flap is usually raised from lateral to medial. While dissecting medially over the sartorius muscle, dissect deeply to include the sartorius fascia with the flap over the medial half of the muscle. This avoids transecting the SCIA as it dives down to the superficial femoral artery (SFA) just superficial to the sartorius fascia on the medial border of this muscle. Staying above the deep fascia during the dissection all the way to the SFA risks transecting the main arterial pedicle (SCIA) of the flap.
- You may extensively thin the distal or lateral aspect of the flap that is to be set into the upper extremity defect as long as the subdermal plexus is left intact.
- In most cases, the flap pedicle is divided at 2 to 3 weeks. The groin defect can often be closed primarily, without the need for a skin graft. Inset the flap at the time of division or later, when it softens.

### *Fasciocutaneous Flaps*

The fasciocutaneous flap receives its blood supply from vessels that reach the skin by passing through fascial septa between muscle bellies and then fanning out at the level of the deep fascia, giving off perforating vessels that supply blood to the overlying skin (Fig. 8.9) (9). This type of flap is better vascularized and will survive to a greater length than will a random flap of comparable dimensions. Fasciocutaneous flaps have been described in the head and neck region, trunk, and extremities (43). The size and location of an individual flap can be tailored to accommodate the reconstructive needs (Fig. 8.10). One disadvantage of the fasciocutaneous flap is the frequent need for a skin graft at the donor site, leaving a conspicuous deformity (15).

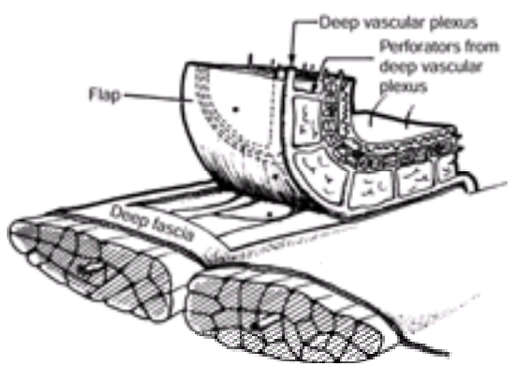


***Figure 8.9.*** A fasciocutaneous flap consists of skin, subcutaneous tissue, deep fascia, and the deep vascular plexus, which is fed by a few perforators and in turn sends perforators up through the subcutaneous tissue to the dermal plexus.

***Figure 8.10.*** **A:** Fasciocutaneous flap designed adjacent to exposed tibia. **B:** Fasciocutaneous flap elevated. **C:** Healed wound.

### *Muscle Flaps*

The use of muscle flaps in the reconstruction of lower extremity defects was introduced in the 1970s when it was realized that muscles could be moved around a single blood vessel supply site (the pedicle) and maintain excellent vascularity. Muscles were classified by Mathes according to the number of pedicles and their relative contribution to the blood supply (32). For example, the gastrocnemius muscle has a single dominant pedicle consisting of the sural artery, whereas the soleus muscle receives a dominant pedicle from the peroneal artery and a second dominant pedicle from the posterior tibial artery. In addition, the soleus muscle has several minor pedicles given off by the posterior tibial artery distally. Muscles may be detached from their origin and insertion, and moved, tethered only by their dominant (or major) pedicle, while maintaining excellent perfusion. Their viability is less certain when a minor pedicle is used as a point of transfer or rotation. The distance a muscle can move while tethered by its vascular pedicle is known as its arc of rotation. Veins are found consistently to run with the arterial pedicles. The most appropriate muscle for transfer is one with a vascular pedicle close to or just proximal to the recipient site; this allows for an adequate arc of rotation.

**Indications** Muscle flaps are ideally suited for covering defects with large, irregular dead spaces or cavitary lesions with exposed bone or metal. Muscle flaps are superior to skin flaps for resisting infection with bacterial contamination (6) and are routinely used in the treatment of osteomyelitis (33) after thorough debridement. They also are helpful in poorly vascularized wounds secondary to radiation injury or chronic scarring, and they provide excellent vascularity to support the incorporation of bone grafts. Their use is now routine for type IIIB fractures of the lower extremity, infected total hip or knee wounds, and large traumatic wounds.

As our experience with muscle flaps continues to grow, the timing of flap coverage for significant traumatic wounds continues to be refined. Although the issue of ideal timing of flap coverage for type III tibial injuries has been debated in the literature (5,47), it is now generally agreed that coverage should be undertaken within the first 5 to 7 days after injury, before wound colonization has occurred.

Free flaps are now considered a routine option in the management of many wounds that would have received regional muscle flaps only a few years ago. Unrestricted by the anatomic limits of regional flaps, microsurgical transfers are improving function and esthetics and in some instances accelerating healing. Regional muscle flaps, however, remain the foundation of lower-extremity reconstruction proximal to the tibial distal third.

**Medial and Lateral Gastrocnemius Flaps**

*Anatomy* The gastrocnemius muscle has two heads, each arising from a femoral condyle (Fig. 8.11). The medial and lateral gastrocnemius muscles fuse at the distal portion of the popliteal fossa and join with the soleus to insert into the Achilles tendon. The medial gastrocnemius is usually 2 to 3 cm longer than the lateral gastrocnemius and is slightly more anteromedial. This gives the medial gastrocnemius a significantly greater arc of rotation than the lateral muscle.

***Figure 8.11.*** The medial and lateral heads of the gastrocnemius are retracted to show their neurovascular pedicles consisting of sural vessels and branches of the tibial nerve. The soleus muscles lie immediately deep to the gastrocnemius. (Strauch B, Vasconez LO, Hall-Findlay EJ. *Grabb's Encyclopedia of Flaps.* Boston: Little, Brown, 1990:1696.)

Each muscle has one dominant pedicle consisting of the sural artery and vein given off by the popliteal artery at the level of the knee joint. The sural arteries run distally with the tibial nerve branches for several centimeters before entering the muscle bellies on their anterior surfaces.

*Indications* The medial and lateral gastrocnemius muscles can be used separately because they have separate blood supplies and may be divided at the posterior raphe. The arc of rotation of the medial muscle is much greater than that of the lateral muscle because the medial muscle is longer and the lateral muscle is restricted by the fibular head (Fig. 8.12). This is most relevant for covering anterior defects. If the lateral head is transferred anteriorly, it uses up much of the available length traversing the fibular head. For anterior knee defects, even those that are slightly anterolateral, the medial gastrocnemius is almost always more effective. Proximal tibial defects in the region of the tuberosity are the most easily covered; however, the arc of rotation is reliable over the entire knee and patella and the proximal third of the tibia.

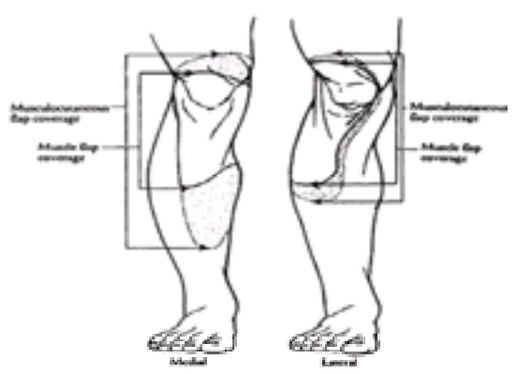

***Figure 8.12.*** The areas of coverage of the medial and lateral gastrocnemius muscle flaps (*solid line*) and gastrocnemius musculocutaneous flaps (*dashed line*). Note that the lateral muscle does not cover the entire patella comfortably. (Strauch B, Vasconez LO, Hall-Findlay EJ. *Grabb's Encyclopedia of Flaps.* Boston: Little, Brown, 1990:1697.)

Common indications for this flap are infected tibial plateau fractures, skin breakdown over a total knee prosthesis, coverage of arthrodesis after pyarthrosis, closure of a wound over femoral or total knee prosthesis for osteogenic sarcoma, and type IIIB open fractures.

*edial Gastrocnemius Flap—Operative Technique*

- Make a long incision under tourniquet control just posterior to the medial aspect of the tibia to within 5 to 10 cm of the medial malleolus (Fig. 8.13). Usually the saphenous vein is encountered with this incision; reflect it to either side of the wound.

***Figure 8.13.*** **A:** High-energy comminuted tibial plateau fracture wound months after open reduction with internal fixation with exposed bone and screws. **B:** Medial gastrocnemius flap is elevated after extensive debridement. **C:** Wound 7 days postoperatively with skin graft and bolsters in place. **D:** Healed wound 2 months postoperatively.

- Incise the deep fascia, exposing the gastrocnemius muscle head. Dissect this deep fascia away from the muscle in a loose areolar plane to the posterior midline where the raphe between the medial and lateral gastrocnemius should be identifiable. Sometimes the division of these muscles is indistinct.
- Dissect the gastrocnemius away from the underlying soleus muscle. The plantaris tendon should be clearly visible lying on the superficial surface of the soleus muscle. The gastrocnemius muscle is easily separated from the soleus in the proximal-to-distal direction until the Achilles insertions are reached. Leave a cuff of tendon insertion in continuity with the distal gastrocnemius muscle so that this can be used for suturing later and for traction during proximal flap dissection. Divide the midline raphe and free the gastrocnemius as far proximally as needed to reach and comfortably cover the defect. For defects in the tuberosity area, very little further dissection is needed.

- Maneuvers to increase the arc of rotation or length of usable flap include incising the fascia near the origin of the muscle close to the femoral condyle. This may give 1 to 2 cm of extra length. Sometimes this may require taking down the insertions of the semimembranosus and semitendinosus muscles. To get further length, the origin of the gastrocnemius can be divided from the femoral condyle, although this is seldom necessary. It is also possible, as a last resort, to flex the knee and get even further reach of the flap. With division of the origin it is important not to put the pedicle under too much tension because it is no longer protected by the tendinous attachments when stretched. The flap will heal and allow straightening of the knee, usually in 2 to 3 weeks, if this maneuver is necessary.
- Set the flap into the defect after thorough debridement by placing bolster sutures through the skin 2 to 3 cm from the wound edge. It is important to undermine the edges of the wound to achieve this inset. The flap can be tunneled under the skin bridge to the defect or directly inset by incising the skin between the flap and the defect. We generally do not tunnel with significant defects. The flap can be widened with multiple scorings of the fascia on the deep aspect of the muscle if needed. If the defect is very large, consider a free flap or possibly a gastrocnemius musculocutaneous flap, which has a cutaneous extension (Fig. 8.12).
- Cover the flap with a meshed split-thickness skin graft. The flap will atrophy and lose some of its bulky appearance with time. This is partially dependent on whether the innervation is left intact.
- Place a flat Jackson Pratt drain in the donor wound, and place another drain under the flap. Apply a posterior leg splint. Change the skin graft dressing in 3 to 5 days. The extremity remains elevated and splinted after dressing changes for 2 to 3 weeks.

*Lateral Gastrocnemius Flap—Operative Technique*

The lateral gastrocnemius muscle can be raised in a similar fashion with a lateral longitudinal incision. Care must be taken with the peroneal nerve, and transposition is more limited around the fibular head.

**Soleus Flaps**

*Anatomy* The soleus muscle originates from the tibia, the fibula, and the interosseous membrane. Its insertion is joined with the gastrocnemius into the Achilles tendon. The peroneal artery supplies the proximal and lateral half of the muscle, and the medial distal half of the muscle is supplied by the posterior tibial artery (Fig. 8.14). This vascular anatomy allows the muscle to be split in half longitudinally and used as a split soleus muscle flap if a smaller flap is desired. A distally based soleus flap is described based on perforating vessels of the posterior tibial artery, although this flap generally is not as reliable.

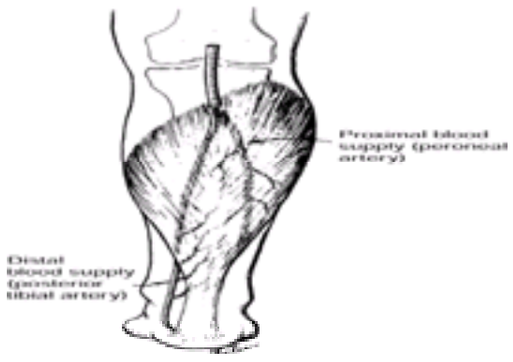


***Figure 8.14.*** The soleus muscle is supplied proximally and laterally by the peroneal artery and medially and distally by the posterior tibial artery. The muscle may be split longitudinally for use as a hemisoleus flap. [Swartz WM, Jones NF. Soft Tissue Coverage of the Lower Extremity. *Curr Probl Surg* 22(6):34;1985.]

*Indications* The soleus muscle flap is the first choice for middle-third defects of the tibia. Even in extensively damaged extremities with midshaft fractures and lacerations of the soleus, it can still be used with confidence. The usual indication is exposed bone or a type III fracture of the middle third of the tibia with some skin loss. Use of the flap acutely will provide well-vascularized, stable coverage and ensure the likelihood of rapid recovery. The soleus flap should be considered when plates and screws are used midshaft with any compromise in soft-tissue coverage.

*Operative Technique*

- A medial approach is easiest. Make a long incision just posterior to the medial border of the tibia from the insertions of the hamstring muscles down to within several centimeters of the medial malleolus (Fig. 8.15).

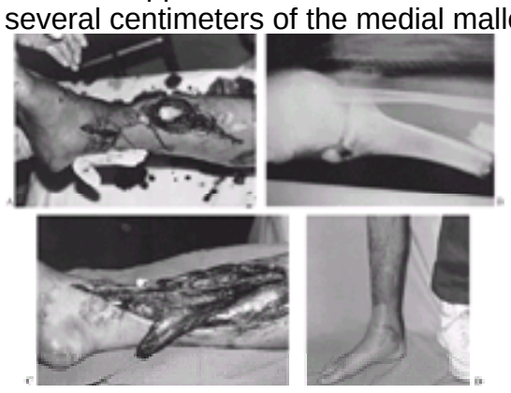

***Figure 8.15.*** **A:** Type IIIB tibial fracture with exposed anterior tibial tendon and exposed fracture site. **B:** Radiograph of open tibial fracture and malleolar fracture, which were reduced and fixed with an interlocking nail. **C:** Soleus flap ready for transposition over fracture site and exposed tendon. **D:** Ambulatory patient 2 months postoperatively with healed wound.

- Under tourniquet control, develop the plane between the soleus and gastrocnemius, which is primarily loose areolar tissue. The plantaris should be visualized on the surface of the soleus muscle. Dissecting distally, identify the insertions into the Achilles tendon that join with gastrocnemius insertions. Shave a thin portion of fascia off the tendon with the soleus rather than stripping the muscle fibers off freely.
- Then dissect the soleus muscle proximally, identifying perforating branches of the posterior tibial artery. Tie these off rather than cauterizing them. It is often necessary to divide the soleus sharply from the flexor digitorum muscles as the dissection proceeds proximally. The muscle can be split longitudinally to use only half of the flap (hemisoleus flap); alternatively, the entire muscle can be used, which is more common.
- Transfer the muscle flap to the defect by dividing the skin between the muscle and the defect and insetting the flap as before. Cover the flap with a split-thickness skin graft on all exposed portions.
- Place a drain in the donor site and under the flap. A posterior splint with elevation continues for 2 to 3 weeks.

**Rectus Femoris Flap**

*Anatomy* The rectus femoris muscle originates from the inferior iliac spine and inserts into the patella. Its blood supply consists of one or two dominant pedicles, which are branches of the lateral femoral circumflex artery, which is in turn a branch of the profunda femoris artery (Fig. 8.16). Innervation from the femoral nerve accompanies the vascular pedicles in the proximal third of the muscle. This is generally 8 to 10 cm inferior to the inguinal ligament. Rotation of the muscle around this vascular pedicle will reach the trochanter and the lateral genital area. A skin paddle can be elevated with the muscle if necessary.

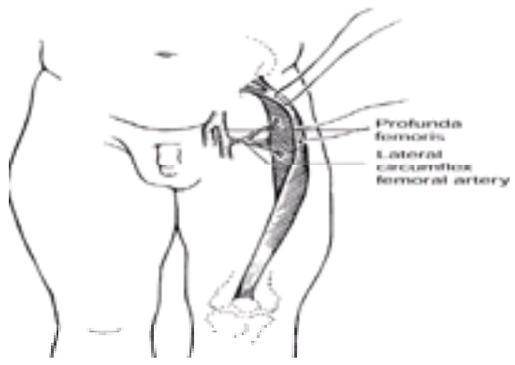


***Figure 8.16.*** Anatomy of rectus femoris muscle. Two to three pedicles from the lateral circumflex femoral artery enter the proximal third of the muscle belly. (Mathes SJ, Nahai F. *Clinical Atlas of Muscle and Musculocutaneous Flaps.* St. Louis: CV Mosby, 1979:44.)

*Indications* Meland and associates concluded that the rectus femoris was the muscle flap of choice for the recalcitrant total hip arthroplasty wound (39). After removal of their prostheses, 27 patients with chronically infected hip wounds were successfully treated with muscle flaps, 23 of which were rectus femoris flaps. All patients had their hip arthroplasty reimplanted at least 12 months following the muscle flap.

This flap can be used for any deep or chronic wound of the hip or proximal thigh. Other choices for the hip region are the vastus lateralis muscle or rectus abdominis muscle; these should be considered before resorting to a free flap.

*Operative Technique*

- Make a longitudinal incision over the rectus femoris muscle from just below the inguinal crease down to 5 to 10 cm above the patella. Carry the dissection through the deep fascia, identifying the rectus femoris muscle. Dissect it out from distal to proximal, taking care to avoid damaging the pedicle when entering the region 10 cm below the inguinal ligament.
- To reach the acetabulum, transpose the muscle or tunnel beneath the vastus lateralis muscle to reach the hip defect.
- Debride the edges of the hip defect to allow a layered closure. Close the donor and recipient sites over drains. If the rectus femoris does not completely fill the dead space of the acetabulum and hip wound, consider adding the vastus lateralis or another muscle flap.
- It is important to close the quadriceps muscles on either side of the rectus femoris in the midline to partially offset its functional loss.

**Vastus Lateralis Muscle Flap**

*Anatomy* The vastus lateralis muscle originates from the trochanter of the femur, the lateral intermuscular septum, and the gluteal tuberosity, and it inserts into the patella (Fig. 8.17). Its blood supply is from descending branches of the lateral femoral circumflex artery; these branches enter the muscle close to 10 cm below the anterior iliac crest. Innervation is from the femoral nerve entering close to the vascular pedicle. The arc of rotation of this muscle is most useful for filling acetabular defects. Most other defects of the thigh can be reconstructed with skin grafts.

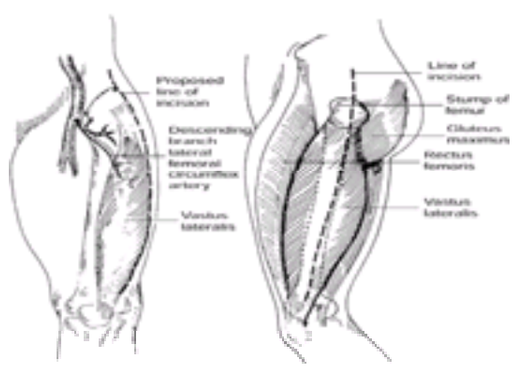


***Figure 8.17.*** Anatomy of vastus lateralis muscle. The dominant vascular pedicle is the descending branch of the lateral femoral circumflex. *Dotted line* indicates the surgical incision from anterior and lateral view. (Collins DN, Garvin KL, Nelson CL. The Use of the Vastus Lateralis Flap in Patients With Intractable Infection After Resection Arthroplasty Following the Use of a Hip Implant. *J Bone Joint Surg* 69:512;1987.)

*Indications* The vastus lateralis is a second choice for difficult hip wounds and can be used in addition to the rectus femoris if a large dead space is present. The thigh has such abundant soft tissue that muscle flaps are rarely needed outside of the hip region, and skin grafts usually suffice.

*Operative Technique*

- Make a long lateral incision from the trochanter to just anterior to the lateral femoral condyle. Incise the fascia lata and expose the vastus lateralis muscle. Identify the intermuscular septum between the rectus femoris and the vastus lateralis. Dissection in this plane is aided by using a Gelpi self-retaining retractor to spread the intermuscular septum.
- Identify and protect the lateral femoral circumflex artery, its transverse branch to the tensor fascia lata muscle, and its descending branch to the vastus lateralis. This should be 8 to 10 cm distal to the anterior superior iliac spine.
- Separating the vastus lateralis from the intermedius is the most difficult part of the operation and can be quite bloody; it requires sharp dissection (Fig. 8.18). Cut the tendinous insertion of the vastus lateralis 8 cm proximal to the patella and then mobilize the muscle from distal to proximal with a periosteal elevator, heading toward the pedicle (Fig. 8.19). Mobilize enough of the muscle to fill the dead space, and close the wound comfortably.

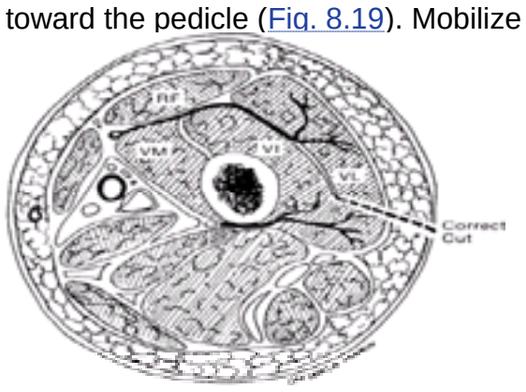


***Figure 8.18.*** Cross section through the distal thigh demonstrates posterior vascular perforators and the plane of transection for freeing the vastus lateralis muscle. (Collins DN, Garvin KL, Nelson CL. The Use of the Vastus Lateralis Flap in Patients With Intractable Infection After Resection Arthroplasty Following the Use of a Hip Implant. *J Bone Joint Surg* 69:512;1987.)

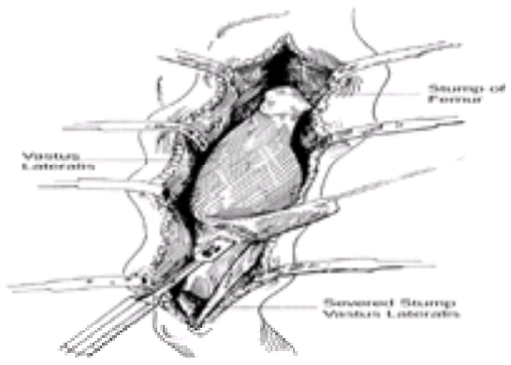


***Figure 8.19.*** Technique for freeing the vastus lateralis is demonstrated. (Collins DN, Garvin KL, Nelson CL. The Use of the Vastus Lateralis Flap in Patients With Intractable Infection After Resection Arthroplasty Following the Use of a Hip Implant. *J Bone Joint Surg* 69:512;1987.)

- Often a split-thickness skin graft is necessary to cover an exposed portion of the muscle flap, which should not be closed too tightly.
- Place a drain in the donor site and in the hip wound beneath the flap. Three weeks of relative immobility assists the healing of the wound.

**Tibialis Anterior Muscle Flap**

*Anatomy* The anterior tibialis muscle originates on the lateral condyle of the tibia, the upper lateral surface of the tibia, and the interosseous membrane and inserts on the base of the first metatarsal bone and the medial cuneiform bone. Its blood supply is derived from multiple perforators, usually six to eight, along the entire length of the anterior tibial artery. Innervation is via branches of the deep peroneal nerve. This type of blood supply with multiple minor pedicles is referred to as segmental supply and does not allow for significant arcs of rotation without risk of necrosis. This muscle is also important for dorsiflexion and inversion of the foot and must have its tendon continuity preserved. Techniques for longitudinal splitting of the muscle belly while preserving tendon function have been developed using a medial or external split (22,41).

*Indications* Longitudinal splitting techniques allow the tibialis anterior to close an adjacent wound with a maximum width of 5 cm and a length as long as the muscle belly. Such a flap is convenient for coverage of midtibial defects. Often this flap can serve as the lateral portion of a muscle sling around an injured tibia with the medial portion of the sling fashioned with a medial gastrocnemius flap. Splitting the tibialis anterior longitudinal muscle requires a split-thickness skin graft by design.

*Operative Technique*

- The defect is almost always directly adjacent to the tibialis anterior muscle with exposed tibia. Make the skin incision longitudinally along the edge of the defect and proceed just deep to the fascia covering the tibialis muscle. Reflect the fascia and skin laterally, exposing the muscle.
- Identify the septum when dividing the tibialis anterior and the extensor digitorum. Incise the muscle as far lateral in the septum as possible and develop a 1.5-cm-thick flap of muscle (Fig. 8.20). Leave some muscle fibers on the tibialis tendon to allow for skin graft take. Flip the anterolateral portion of the muscle over 180° to cover the tibial defect (Fig. 8.21). Inset the muscle into the undermined medial edge of the wound, and apply a split-thickness skin graft.

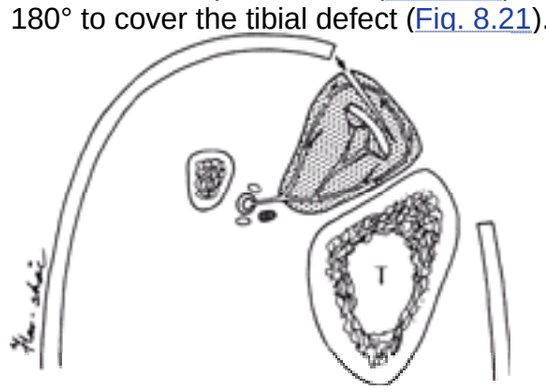


***Figure 8.20.*** Tibialis anterior muscle, which is supplied by the anterior tibial artery, is shown. The muscle is supplied by vessels that surround the medial tendon (*T*, tibia). The external longitudinal splitting incision is started on the medial border of the muscle. Muscle fibers are preserved overlying the tendon. (Hirshowitz B, Moscona R, Kaufman T, Harshai Y. External Longitudinal Splitting of the Tibialis Anterior Muscle for Coverage of Compound Fractures of the Middle Third of the Tibia. *Plast Reconstruct Surg* 79:408;1987.)

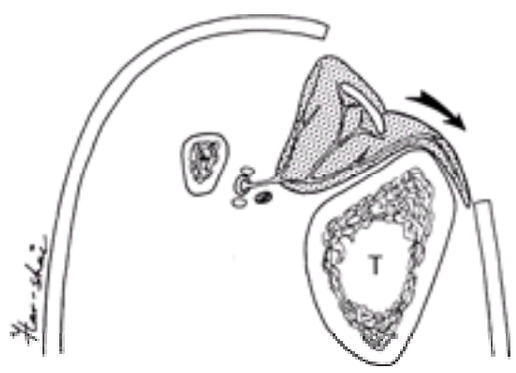


***Figure 8.21.*** Tibialis anterior muscle has been incised medially, and a 1.5-cm flap of muscle is turned 180° to cover the tibial shaft. (Hirshowitz B, Moscona R, Kaufman T, Harshai Y. External Longitudinal Splitting of the Tibialis Anterior Muscle for Coverage of Compound Fractures of the Middle Third of the Tibia. *Plast Reconstruct Surg* 79:4107;1987.)

- A medial gastrocnemius or a soleus flap could possibly be required medially to complete coverage of the wound. A posterior splint and bulky dressing are applied, and the leg is elevated for 2 to 3 weeks.

**Rectus Abdominis Flap**

*Anatomy* The rectus abdominis muscle is a long thin flat muscle that originates from the pubic symphysis and inserts on the costal cartilages of the fifth, sixth, and seventh ribs. It has three and sometimes four tendinous intersections that cross it in a transverse direction. Its blood supply is from the inferior epigastric artery and from the superior epigastric artery. The inferior epigastric artery is the dominant pedicle and supplies the skin overlying the muscle as well as the muscle from the pubis to several centimeters above the umbilicus (Fig. 8.22). Flaps can be designed using the muscle alone or with a skin paddle (myocutaneous flap). Innervation is segmental from the 7th through 12th intercostal nerves. The arc of rotation can be extended inferiorly by islanding the muscle flap on the inferior epigastric pedicle and moving it inferior to the inguinal ligament. The flap can also be made longer by taking an extended skin paddle of abdominal skin. The musculocutaneous perforators of the flap can support abdominal skin overlying the oblique muscles as far as the anterior axillary line (Fig. 8.23).

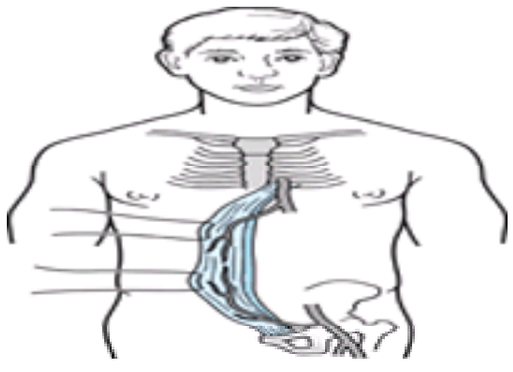

***Figure 8.22.*** The rectus abdominis muscle originates from the pubic symphysis and inserts on the costal cartilage of the fifth, sixth, and seventh ribs. The dominant pedicle is the inferior epigastric artery; however, the entire muscle and overlying skin can survive on the superior epigastric artery as well. (Mathes SJ, Nahai F. *Clinical Atlas of Muscle and Musculocutaneous Flaps.* St. Louis: CV Mosby, 1979:15.)

***Figure 8.23.*** A male patient is shown who sustained a traumatic injury of the left leg with exposure of the left trochanter. A left rectus abdominis musculocutaneous flap with an extended skin paddle was rotated 90° in a clockwise direction to cover the exposed hip. The flap was rotated around the inferior epigastric pedicle. The flap donor site is evident as a left paramedian abdominal incision.

*Indications* The rectus abdominis can be used for pelvic and hip wounds when thigh muscles are not available. It can cover pubic bone and iliac wing osteomyelitis. It can also be used for the hip joint when necessary. It can be passed either preperitoneally behind the pelvic bones or anteriorly across the inguinal region. Also, the trochanter can be covered when the extended skin paddle is taken with the muscle flap. The rectus abdominis can also be transferred as a free flap using the inferior epigastric vessels for anastomosis with the recipient vessels. Often the muscle is transferred to distal third defects of the lower extremity or foot.

*Operative Technique*

- An incision is made overlying the length of the rectus muscle (paramedian incision). At the inferior portion of the wound, the incision is sometimes angled off laterally to overlie the point at which the inferior epigastric artery and vein originate from the external iliac vessels. This allows better exposure of the inferior epigastric vessels.
- If a skin paddle is chosen, it is kept in continuity with the muscle during the flap elevation. The anterior rectus fascia is incised around the base of the skin island, and the muscle is dissected free from the posterior sheath. Areas of the tendinous intersectons are quite adherent to the muscle, and dissection is tedious in these areas. If a large portion of the anterior rectus sheath is taken with a skin paddle, then synthetic mesh is used to close the anterior rectus sheath defect and prevent future herniation.
- The flap is usually transposed to the defect using a direct inset and making an incision through the skin from the flap to the defect. If the flap is transferred free, the epigastric vessels are carefully dissected down to the external iliac vessels. Often there will be two almost equal-sized inferior epigastric veins, which will join into one single vein before emptying into the external iliac vein. We often try to transect the vein at this common site.

**Gracilis Flap**

*Anatomy* The gracilis muscle is a long thin muscle that originates from the pubic symphysis and inserts on the medial tibial condyle. As an accessory thigh adductor, it contributes minimally to thigh adduction and is thus expendable for reconstructive purposes. The main arterial pedicle is usually the medial femoral circumflex, which is a branch of the profunda femoris artery. This vessel enters the muscle approximately 8 to 10 cm from the origin of the gracilis, at the pubic tubercle. There are minor pedicles distally originating from the superficial femoral artery, but these are usually divided during elevation of the flap (Fig. 8.24). The entire muscle survives well on circulation from the proximal dominant pedicle. The gracilis muscle can be used with an overlying skin paddle, which can be as large as 10 by 30 cm.

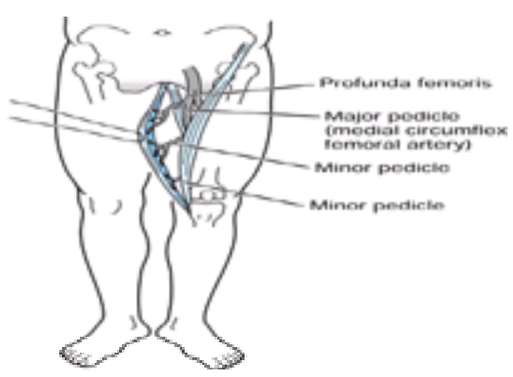


***Figure 8.24.*** The gracilis muscle originates from the pubic symphysis and inserts on the medial tibial condyle. The dominant pedicle is the medial femoral circumflex, which is most commonly a branch of the profunda femoris artery. The minor pedicles, located more distally, are usually divided during elevation of the flap. (Mathes SJ, Nahai F. *Clinical Atlas of Muscle and Musculocutaneous Flaps.* St. Louis: CV Mosby, 1979:349.)

*Indications* As a muscle flap alone, the gracilis can reach and fill small defects of the groin and pubic region; however, it is usually transferred microsurgically to distant sites for greatest usefulness. When the skin paddle is included, the flap gains length and a greater arc of rotation. It can be used in the pelvis over the pubic symphysis and the ischium, and to cover groin wounds near the femoral vessels.

*Operative Technique*

- It is not trivial to locate the gracilis muscle accurately, especially when edema, obesity, or distortion of the anatomy is present. When the patient is in a lithotomy or frog-leg position, the adductor longus can be easily palpated as a tendinous structure in the medial groin area originating from the pubic symphysis. Rolling over the adductor longus muscle in a posteroinferior direction with one's fingers brings one to the anterior edge of the gracilis muscle proximally. The distal tendon inserts on the medial tibial tubercle and is often seen during the dissection in a position below the inferior edge of the sartorius muscle. It can be palpated as a round tendinous structure in this distal location.
- When the gracilis is used as a muscle flap, an incision is made overlying the muscle, and the dissection is carried down to the gracilis muscle. The main pedicle is found coming out between the adductor longus and magnus muscles in the fascial septum. Often one artery and two identifiable veins constitute the pedicle. If a

skin paddle is desired, care must be taken to accurately position the skin paddle over the muscle and not disrupt the connection of the muscle and its surrounding fascia to the skin. We have found that inclusion of increasing amounts of fascia around the gracilis muscle enhances the circulation to the overlying skin. It should be noted that historically the distal cutaneous territory of the gracilis muscle has not been considered reliable from a vascular standpoint.

## MUSCULOCUTANEOUS FLAPS

Although not purely skin flaps, this versatile class of flaps carries a skin component and has found wide clinical application (31,34). The musculocutaneous flap is composed of muscle and a segment of overlying skin (35). This skin segment or island is nourished by vessels originating from and draining into the underlying muscle. Left attached to its major vascular pedicle(s) or transferred microsurgically, the muscle can be separated from its origin and insertion and moved great distances to provide a stable reconstruction (Fig. 8.25).

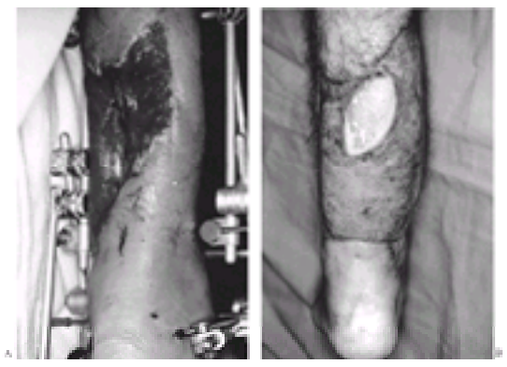

***Figure 8.25.*** **A:** Soft-tissue wound of posterior leg. **B:** Latissimus dorsi musculocutaneous flap used to achieve wound closure. Much of the muscle has been covered with a skin graft. The skin island was preserved as a marker of flap viability.

Virtually every muscle has been investigated as a potential base for a musculocutaneous flap. Some of the most versatile ones are the latissimus dorsi, deltoid, rectus abdominis, gluteus maximus, tensor fascia lata, and rectus femoris. Each of these flaps can be transposed through a large arc of rotation and used to provide bulk for dead space obliteration, well-vascularized tissue, and stable skin coverage at the site of reconstruction (6).

## FLAP DESIGN

Flaps located adjacent to the site of reconstruction may be classified as either rotation or advancement in design. The rotation flap moves through an arc of rotation as it is lifted from its origin and placed over the defect for reconstruction (27). Although generally thought of as semicircular in shape, rotation flaps also include transposition, bilobed, and rhomboid flaps. The classic Z-plasty is in reality two transposition (rotation) flaps designed, raised, and interposed to break up, lengthen, or redirect an unfavorable linear scar (13,18,38). The donor site of many rotation flaps can be closed primarily without a skin graft (28).

The advancement flap is not moved through an arc of rotation but is advanced along a straight line into the required defect. Advancement flaps may be vascularized through a retained skin pedicle or by perforating vessels from underlying fascia or muscle. When it is designed in a rectangular shape and subsequently advanced, excess skin at each corner of the flap's base may need to be excised. The V-to-Y advancement flap leaves no skin excess at its site of elevation. The donor-site defect of most advancement flaps can be closed by primary suturing (Fig. 8.26).

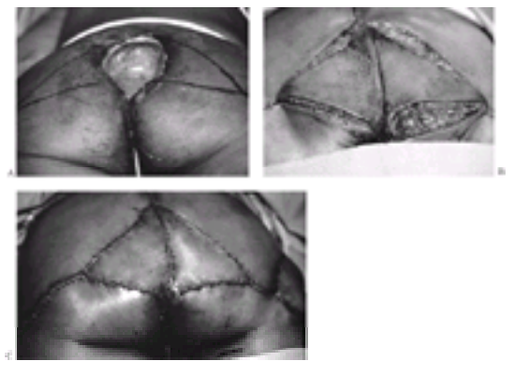

***Figure 8.26.*** **A:** Sacral pressure sore. V–Y advancement flaps designed for wound closure. **B:** Flaps elevated. **C:** Wound closed.

## TISSUE EXPANSION

Through tissue expansion, additional skin can be made available for advancement into an adjacent wound to achieve closure (23). The technique requires two operative procedures. Initially, a collapsed silicone rubber bag (the tissue expander) is inserted subcutaneously near the defect to be covered. Usually the expander is placed through a separate incision made at a distance from the wound margin. After 1 to 3 weeks, when healing of the skin wound is ensured, saline is introduced into the expander through a self-sealing port, either contained within the expander or attached by Silastic rubber tubing. Every 3 to 7 days 60 to 120 mL of saline is injected. The overlying skin increases in surface area as the bag expands. This increase reflects stretching of the skin, thinning of the dermis, and recruitment of skin from adjacent areas. After maximum volume has been reached, the expander is removed at a second operation, and the expanded skin is advanced over the site to be reconstructed (Fig. 8.27). Primary wound closure is usually possible.

***Figure 8.27.*** **A:** Tissue expanders placed adjacent to grafted defect. The expanders have been fully inflated. **B:** Expanders removed, expanded skin advanced, skin graft excised, and wound closed.

Tissue expansion is more successful when applied to wounds proximal to the knee or elbow. This technique is best used to treat healed wounds, as placement of an expander adjacent to an open wound is often complicated by infection within the expander pocket, necessitating its removal (1,30).

## PITFALLS AND COMPLICATIONS

Complications can be divided into those associated directly and locally with the operative procedure (seroma, hematoma, infection, and technical problems with fixation) and systemic complications (thrombophlebitis, pulmonary embolism, and others). All surgeons will encounter complications, so be prepared by taking appropriate steps to minimize the risk of complications and be ready to manage complications if they occur. Local wound complications are minimized by careful preoperative planning; gentle, rapid, and precise surgical technique; and appropriate aftercare. Systemic complications are minimized by careful preoperative workup, ensuring that the patient's medical condition is as good as possible before surgery; good anesthesia practices with good pulmonary ventilation throughout the case; appropriate maintenance of blood volume; and immediate mobilization of the patient after surgery, if possible.

### NECROSIS OF WOUND EDGES

Necrosis of the margins of a wound has several causes. The most common is probably excessively strong retraction for prolonged periods. Rough handling contributes as well. Curvilinear or sharply angled incisions that produce flaps may also predispose to wound necrosis because of ischemia of the tips of the flaps; this is particularly true when flaps are distally based. Straight-line incisions are safest, particularly in the lower extremity. Preexisting large-vessel disease, as in arteriosclerosis, or small-vessel disease, as in diabetics, also predisposes to wound necrosis. Special precautions are necessary, particularly in diabetics undergoing foot surgery. In some cases, surgery may be contraindicated.

Excessive tension in the skin or overly tight sutures placed too closely together or too far from the wound edge also devascularize the skin along the incision. Avoid tension in wound closures. When a tourniquet is used, it is sometimes advisable to deflate it just before skin closure so that the telltale pallor of skin ischemia can be detected when sutures are placed. If excessive tension is required to close a wound after elective surgery, it is often prudent to leave the wound open until edema subsides. Closure can then be done on a delayed basis. In some cases closure with a local rotation flap or STSG may be necessary. Although cosmetically undesirable, this may be a better alternative than wound-edge necrosis, which exposes tendons, bone, or fixation devices.

Curvilinear, S-shaped, or C-shaped incisions can create problems about the knee and ankle. Most major knee surgery is best performed through a straight, longitudinal incision placed over the anterior aspect of the knee. This incision usually results in a cosmetically acceptable scar. It also provides wide exposure of the knee and is an excellent exposure if subsequent reconstructive surgery, such as total knee arthroplasty, becomes necessary. In the ankle, straight vertical incisions directly over the malleoli are preferable to the L-shaped or C-shaped incisions often advised. Straight vertical incisions provide excellent exposure and carry a minimal risk of necrosis.

If marginal wound necrosis occurs but tendons, fixation devices, and neurovascular bundles are not exposed, corrective surgery may not be necessary. Maintain cleanliness and keep the wound covered. This will allow the necrotic area to marginate and the wound to close by secondary intention. However, healing by secondary intention can take considerable time, secondary infection may occur, and the scar may be cosmetically undesirable. If enough skin is available so that closure without tension is possible, early excision of the necrotic area with repeat closure is often desirable. Early plastic reconstructive surgery may be necessary when necrosis results in exposure of metallic fixation devices.

### SEROMAS AND HEMATOMAS

Good wound hemostasis will normally prevent the postoperative formation of seromas or hematomas, particularly if suction drainage is used. However, certain factors predispose to seroma or hematoma formation: large wounds in obese patients, large exposed bone surfaces, dead space, and uncontrolled hemorrhage secondary to coagulopathies. If a tourniquet is used, it may be wise to let the tourniquet down to ensure that hemostasis has been achieved before closure. If necessary, the tourniquet can be reinflated for a short period to accomplish closure. Hypotensive anesthesia may also predispose the patient to postoperative hemorrhage when the blood pressure returns to normal. In these cases, wound suction drainage is of paramount importance.

We usually change most dressings at 24 h after surgery, as the application of a fresh, dry dressing makes the patient more comfortable and the wound can be checked for formation of a seroma or hematoma. Seromas or hematomas that require intervention are those resulting in significant postoperative swelling, accompanied by moist wound edges with either serous or serosanguineous discharge. Persistence of drainage predisposes to secondary retrograde infection of the hematoma through the wound. If a seroma or hematoma is not accompanied by local or systemic evidence of infection, it can usually be observed for a few days, with dressing changes being done as frequently as necessary to keep them dry. Careful sterile technique is necessary. If any evidence of infection develops, such as reddening about the wound or a persistent fever, or if the drainage persists for more than 72 h, return the patient to surgery for exploration of the wound and evacuation of the seroma or hematoma. At that time, try to detect and control any potential sources of hemorrhage. Close the wound in a watertight fashion over a suction drainage system. Take aerobic and anaerobic cultures of both the fluids and the tissues of the wound. If local or systemic signs of infection are present, it is prudent to begin appropriate antibiotics until the results of cultures are received. Early evacuation of a hematoma, particularly in hip and spine surgery, is important to avoid the complication of secondary infection.

### ACUTE INFECTION

Acute infection often presents initially as a seroma or hematoma and is treated as outlined previously. If cultures of the hematoma are positive, assume that acute infection has occurred. Acute postoperative infection may have local signs of infection without systemic signs, systemic signs of infection without local findings, or both. When both are present, infection is presumed to be present. Typical local signs of infection, such as erythema, swelling, tenderness, and exudate, even in the absence of systemic signs, require immediate action. Usually immediate exploration of the wound, to look for infection and to obtain cultures, is necessary. In borderline cases in which it is uncertain whether exploration of the wound is indicated, perform deep aspiration to look for exudate and obtain cultures. Avoid swab cultures of exudate from the surface of the wound, as these often grow contaminants and confuse the clinical picture.

Perform deep aspiration with an 18-gauge needle or larger after sterile preparation of the skin. Probe the operated area down to bone, if necessary, to look for retained hematoma, seroma, or exudate. Send the material obtained for immediate Gram stain and aerobic and anaerobic cultures. If any organisms are seen on Gram stain, at least 10,000 organisms/mL are present in the wound, and infection can be presumed. Immediate exploration of the wound for debridement and irrigation is necessary. If exposure of the underlying tissues or an implant is not of great concern, leave the wound open and close it on a delayed basis. Where exposure of a joint or implant is of concern, reclosure of the wound over a tube-suction system may suffice. Consultation with an infectious-disease specialist is often helpful in designing appropriate immediate antibiotic therapy, in classifying the organism(s), and in determining antibiotic sensitivities.

In soft-tissue infections, a regimen of 7 to 10 days of systemic intravenous antibiotics usually suffices, followed by oral antibiotics. Acute infections involving bone or implants almost always require bactericidal levels of intravenous antibiotics for at least 3 weeks, followed by oral antibiotics for an additional 3 weeks. Unless there are particular risk factors, or it appears that there is an established bone infection, 6 weeks of intravenous antibiotics, as often required for the treatment of osteomyelitis, is usually unnecessary.

### COMPARTMENT SYNDROME AND NEUROVASCULAR INJURY

Compartment syndromes are discussed in detail in Chapter 13. Compartment syndrome, as a complication of surgery, usually occurs in association with acute traumatic injuries where the initial injury causes the compartment syndrome. Compartment syndrome after elective surgery is very unusual. The most common causes are closure of the deep fascia in the presence of significant muscle swelling after prolonged elective surgery and hemorrhage into a closed compartment following undetected rupture of an artery. The two most common areas in which these problems arise are the forearm and the leg.

After major surgery on the radius and ulna, swelling of the forearm musculature is common, and closure of the deep fascia is difficult. Unless absolutely no tension is present, leave the deep fascia open and close only the subcutaneous fat and skin. The same applies to procedures on the diaphysis of the tibia, particularly posterolateral bone grafting, when approximation of the muscles but not the deep fascia is indicated. Be aware of the dangers in performing surgery in the proximal third of the tibia, where inadvertent and unrecognized laceration of one of the arteries of the popliteal artery trifurcation can occur, producing a compartment syndrome.

Compartment syndrome is best prevented by the measures previously discussed. Early recognition is of paramount importance. Unexpectedly severe postoperative pain should always raise the question of compartment syndrome. Dressings must be released and the part examined to rule out increased intracompartmental pressures. If there is any question, take intracompartmental pressure measurements. Release of the surgical closure or fasciotomy may be necessary.

### INJURY TO NERVES

The most common surgical injury to nerves is transection of or trauma to a subcutaneous sensory nerve, resulting in numbness in the distribution of the nerve and

formation of a painful neuroma. Always keep the location of important sensory nerves in mind when making incisions. Identify and protect sensory nerves in the surgical field. In some cases, injury to subcutaneous nerves is unavoidable. Long, anterior exposures of the knee usually involve the sensory branches of the infrapatellar branch of the saphenous nerve. The ilioinguinal exposure of the acetabulum involves the lateral femoral cutaneous nerve of the thigh. In these cases, warn the patient before surgery that injury to these nerves is likely and describe the consequences. The patient must accept these consequences if the surgery is to be performed.

Injury to deep motor or mixed sensory and motor nerves—such as the sciatic nerve at the hip, common peroneal nerve at the knee, and ulnar nerves—is avoided by identifying the nerve at the time of surgery and providing appropriate protection. In many cases this involves appropriate positioning of the extremity to avoid tension on the nerve. For example, in surgery of the hip or acetabulum, keep the knee flexed to 90° and the hip extended, as retraction of the sciatic nerve is often necessary and excessive tension must be avoided. Avoid retraction of a nerve if possible. If it should prove necessary, encircle the nerve with a broad rubber (Penrose) drain and gently hold the nerve out of danger. Retract nerves gently and discontinue retraction as soon as it is no longer necessary. Dissection of a nerve free from its bed over prolonged distances risks devascularization and injury to the nerve and should be performed only if essential to the operative procedure. Intraoperative monitoring of nerve functions by somatosensory evoked potentials is now commonly used for spine surgery and pelvic and hip surgery that threatens the sciatic nerve.

If a nerve paresis or palsy is detected postoperatively, check the dressings to ensure they are not tight. Ensure that splints or other appliances are not applying pressure to the nerve. Inspect the wound to ensure that local pressure problems are not present. If the nerve was observed at surgery and protected throughout the case, and you are certain that intraoperative damage did not occur, watchful waiting usually suffices; most nerves will show return of function within a short time. If the nerve involvement is unexpected, if extrinsic causes of nerve pressure have been ruled out, and if you suspect that some component of the procedure may be causing pressure on the nerve that could be relieved by surgical intervention, early exploration of the nerve may be indicated.

**CHAPTER REFERENCES**

Each reference is characterized according to the following scheme: *, classic article; #, review article; !, basic research article; and +, clinical results/outcome study.


+ 1. Austad ED. Complications in Tissue Expansion. *Clin Plast Surg* 1987;14:549.

! 2. Birch J, Branemark PI. The Vascularization of a Free Full-Thickness Skin Graft. *Scand J Plast Reconstruct Surg* 1969;3:1.

+ 3. Brady SC, Snelling CFT, Chow G. Comparison of Donor Site Dressings. *Ann Plast Surg* 1980;5:238.

+ 4. Buncke HJ, Harris GD. Skin Coverage for Challenging Hand Injuries. In Strickland JW, Steichen JB, eds. *Difficult Problems in Hand Surgery.* St. Louis: CV Mosby, 1982.

+ 5. Byrd HS, Spicer TE, Cierny G III: Management of Open Tibial Fractures. *Plast Reconstr Surg* 1985;76:719.

+ 6. Chang N, Mathes S. Comparison of the Effect of Bacterial Inoculation in Musculocutaneous and Random Pattern Flaps. *Plast Reconstr Surg* 1982;70:1.

+ 7. Chase RA. Early Salvage in Acute Hand Injuries with a Primary Island Flap. *Plast Reconstr Surg* 1971;48:521.

! 8. Clemmesen T. Experimental Studies on the Healing of Free Skin Autografts. *Dan Med Bull* 1967;14(Suppl 2):1.

+ 9. Cormack GC, Lamberty BGH. A Classification of Fasciocutaneous Flaps According to Their Patterns of Vascularization. *Br J Plast Surg* 1984;37:80.

+ 10. Crikelair GF. Surgical Approach to Facial Scarring. *JAMA* 1960;172:140.

+ 11. Daniel RK, Kerrigan CL. Skin Flaps: An Anatomical and Hemodynamic Approach. *Clin Plast Surg* 1979;6:181.

+ 12. Davis JS, Kitlowski EA. The Immediate Contraction of Cutaneous Grafts and Its Cause. *Arch Surg* 1931;23:954.

+ 13. Davis JS, Kitlowski EA. The Theory and Practical Use of the Z Incision for the Relief of Scar Contractures. *Ann Surg* 1939;109:1001.

+ 14. Davison PM, Batchelor AG, Lewis-Smith PA. The Properties and Uses of Nonexpanding Machine-Meshed Skin Grafts. *Br J Plast Surg* 1986;39:462.

+ 15. Dickson WA, Dickson MG, Roberts AHN. The Complications of Fasciocutaneous Flaps. *Ann Plast Surg* 1987;19:234.

+ 16. Fatah MF, Davies DM. The Radial Forearm Island Flap in Upper Limb Reconstruction. *J Hand Surg* 1984;9-B:234.

+ 17. Foucher G, Braun JB. A New Island Flap Transfer from the Dorsum of the Index to the Thumb. *Plast Reconstruct Surg* 1979;63:344.

+ 18. Furnas DW, Fischer GW. The Z-Plasty: Biomechanics and Mathematics. *Br J Plast Surg* 1971;24:144.

+ 19. Gilbert DA: An Overview of Flaps for Hand and Forearm Reconstruction. *Clin Plast Surg* 1980;7:123.

+ 20. Hauben DJ, Baruchin A, Mahler D. On the History of the Free Skin Graft. *Ann Plast Surg* 1982;9:242.

+ 21. Hermann JB, Kelly RJ, Higgins GA. Polyglycolic Acid Sutures. *Arch Surg* 1970;100:486.

+ 22. Hirshowitz B, Moscona R, Kaufman T, Harshai Y. External Longitudinal Splitting of the Tibialis Anterior Muscle for Coverage of Compound Fractures of the Middle Third of the Tibia. *Plast Reconstruct Surg* 1987;79:407.

! 23. Johnson PE, Kernahan DA, Bauer BS. Dermal and Epidermal Response to Soft-Tissue Expansion in the Pig. *Plast Reconstruct Surg* 1988;81:390.

+ 24. Kerrigan CL. Skin Flap Failure: Pathophysiology. *Plast Reconstruct Surg* 1983;72:766.

! 25. La Van FB, Hunt TK. Oxygen and Wound Healing. *Clin Plast Surg* 1990;17:463.

+ 26. Lee KK, Magargle RK, Posch JL. Free Full-Thickness Skin Grafts from the Palm to Cover Defects of the Fingers. *J Bone Joint Surg* 1970;52-A:559.

+ 27. Lister GD. The Theory of the Transposition Flap and its Practical Application in the Hand. *Clin Plast Surg* 1981;8:115.

+ 28. Lister GD, Gibson T. Closure of Rhomboid Skin Defects: The Flaps of Limberg and Dufourmentel. *Br J Plast Surg* 1972;25:300.

+ 29. Lister GD, McGregor IA, Jackson IT. The Groin Flap in Hand Injuries. *Injury* 1973;4:229.

+ 30. Manders EK, Schenden M, Furrey J, et al. Soft-Tissue Expansion: Concepts and Complications. *Plast Reconstruct Surg* 1984;74:493.

# 31. Mathes SJ, Nahai F. *Clinical Atlas of Muscle and Musculocutaneous Flaps.* St. Louis: CV Mosby, 1979.

+ 32. Mathes SJ, Nahai F. *Clinical Applications for Muscle and Musculocutaneous Flaps.* St. Louis: CV Mosby, 1982.

+ 33. Mathes SJ, Alpert BS, Chang N. Use of the Muscle Flap in Chronic Osteomyelitis: Experimental and Clinical Correlation. *Plast Reconstruct Surg* 1982;69:815.

# 34. McCraw JB, Vasconez LO. Musculocutaneous Flaps: Principles. *Clin Plast Surg* 1980;7:9.

+ 35. McCraw JB, Dibbell DG, Carraway JH. Clinical Definition of Independent Myocutaneous Vascular Territories. *Plast Reconstruct Surg* 1977;60:341.

+ 36. McGregor IA, Jackson IT. The Groin Flap. *Br J Plast Surg* 1972;25:3.

+ 37. McGregor IA, Morgan G. Axial and Random Pattern Flaps. *Br J Plast Surg* 1963;26:202.

+ 38. McGregor IA. The Z-Plasty. *Br J Plast Surg* 1966;19:82.

+ 39. Meland NB, Phillip GA, Weiss HC. Management of the Recalcitrant Total-Hip Arthroplasty Wound. *Plast Reconstruct Surg* 1991;88:681.

+ 40. Milton SH. Pedicled Skin Flaps: The Fallacy of the Length–Width Ratio. *Br J Surg* 1970;57:502.

+ 41. Moller-Larsen F, Peterson NC. Longitudinal Split Anterior Tibial Muscle Flap With Preserved Function. *Plast Reconstruct Surg* 1984;74:398.

+ 42. Pang CY, Forrest CR, Morris SF. Pharmacological Augmentation of Skin Flap Viability: A Hypothesis to Mimic the Surgical Delay Phenomenon or a Wishful Thought? *Ann Plast Surg* 1989;22:293.

+ 43. Ponten B. The Fasciocutaneous Flap: Its Use in Soft-Tissue Defects on the Lower Leg. *Br J Plast Surg* 1981;34:215.

+ 44. Robson MC, Krizek TJ. Predicting Skin Graft Survival. *J Trauma* 1973;13:213.

+ 45. Rudolph R. Inhibition of Myofibroblasts by Skin Grafts. *Plast Reconstruct Surg* 1979;63:473.

+ 46. Simahel J. The Healing of Skin Grafts. *Clin Plast Surg* 1977;4:409.

+ 47. Yaremchuk MJ, Brumback RJ, Manson PN, et al. Acute and Definitive Management of Traumatic Osteocutaneous Defects of the Lower Extremity. *Plast Reconstruct Surg* 1987;80:1.

# CHAPTER 9

# BONE GRAFTING, BONE GRAFT SUBSTITUTES, AND GROWTH FACTORS

*Michael W. Chapman and Juan J. Rodrigo*

**M. W. Chapman:** Department of Orthopaedics, University of California Davis, Sacramento, California, 95817.
**J. J. Rodrigo:** Department of Orthopaedics, University of California Davis, Sacramento, California, 95817.

Autografts
- Introduction
- Histology and Physiology
- Autogenous Bone Grafts
- Operative Techniques: Harvesting Bone Grafts

Allografts
- Introduction
- Immunologic Considerations
- Operative Techniques
- Synthetic Bone Grafts and Growth Factors
- Complications

Authors' Perspective
Chapter References

## AUTOGRAFTS

### INTRODUCTION

Bone grafting is a very old surgical procedure. The first recorded bone implant was performed in 1668. Bone grafts are used to treat various disorders, including delayed union and nonunion of fractures, congenital pseudoarthrosis, and osseous defects from trauma, infection, and tumors (157). Grafts are used in reconstructive surgery to help secure prosthetic devices and perform arthrodeses, and in dentistry to reconstruct the mandibular and maxillary ridges and to treat periodontal disease. Bone grafts are also used in plastic and facial surgery for reconstruction.

### HISTOLOGY AND PHYSIOLOGY

Bone grafts provide a latticework for ingrowth by host bone and supply living osteogenic cells to the host bed, and growth factors induce bone formation by the host (7,8,9,22,30,31,48,50,51,53,62,63,65,73,74,103,123,127,147,148,149,150,151,152,153 and 154,159,162,166).

Phemister introduced the term *creeping substitution* (61,115). He believed that transplanted bone was invaded by vascular granulation tissue, causing the old bone to be resorbed and subsequently replaced by the host with new bone. Phemister's concept remains valid; however, Abbott and associates have shown that, in addition, surface cells in the bone graft survive and participate in new bone formation (1,2). Ray and Sabet (124) and Arora and Laskin (5) also confirmed the fact that superficial cells in the bone graft probably survive transplantation and contribute to new bone formation. The percentage of cells that survive transplantation is unknown, but cell survival seems to be improved by minimizing the interval between harvest and implantation and by keeping the graft moist and at physiologic temperatures.

In cancellous bone grafts, the necrotic tissue in marrow spaces and haversian canals is removed by macrophages. Granulation tissue, preceded by the advance of capillaries, invades the areas of resorption (122). Pluripotential mesenchymal cells differentiate into osteoblasts, which begin to lay seams of osteoid along the dead trabeculae of the bone graft. Osteoclasts resorb the necrotic bone, and eventually most of the bone graft is replaced by new host bone. Finally, the old marrow space is filled by new marrow cells (25).

In cortical bone, the process of incorporation is similar but much slower, because invasion of the graft must be through the haversian canals of the transplant (38). Osteoclasts resorb the surface of the canals, creating larger spaces into which granulation tissue grows. As this granulation tissue penetrates the center of the cortical graft, new bone is laid throughout the graft along enlarged haversian canals. Depending on the size of the graft, complete replacement may take many months to a year or more (46).

#### *Structure of Grafts*

Bone grafts may be cortical, cancellous, or corticocancellous. If structural strength is required, cortical bone grafts must be used. However, the process of replacement produces resorption as early as 6 weeks after implantation; in dogs, it may take up to 1 year before the graft begins to regain its original mechanical strength (45). Drilling holes in the graft does not appear to accelerate the process of repair, but it may lead to the early formation of biologic pegs that enhance graft union to host bone (17).

Cancellous bone has poor mechanical strength except when loaded in compression after being packed into an area of bone defect. For example, in repairing fractures of the tibial plateaus in which cancellous bone has been lost as a result of crushing, cancellous bone graft can be packed to support the articular surface of the plateau, and can bear significant loads during rehabilitation. When the strength of cortical bone combined with the more rapid incorporation that is characteristic of cancellous bone is desirable, combined corticocancellous grafts may be used. When a bone graft has a cortical and cancellous surface, incorporation is enhanced by exposing the cancellous portion to the surrounding soft tissues to facilitate vascular invasion.

#### *Sources of Grafts*

Bone graft terminology has changed, leading to some confusion. In this text, we use the new terminology. The correlation between the two is shown in Table 9.1. For most applications, autogenous bone graft is indicated. Other types of bone grafts are indicated only if autogenous bone graft is unavailable or if it is insufficient and must be augmented. Another exception is when structural whole or partial bones, with or without joint articular surfaces, are needed for reconstruction of massive whole or partial bone defects (10,13,19,20,44,56,57 and 58,76,81,91,92,95,106,108,146,156,165). This occurs most commonly in tumor surgery, in which preserved or fresh allografts are used (49,66,72,78,88,89,100,101,111,112). This is discussed in more detail later in this chapter and in Chapter 20, Chapter 106, Chapter 126, and Chapter 128. For practical reasons, isografts are almost never used in human surgery. Although xenografts have been tried in various forms in the past, they have never met with much success, because of the immunologic response of the host.

| *New term* | *Old term* | *Source of graft* |
|---|---|---|
| Autograft | Autograft | Same person |
| Syngraft | Isograft | Identical twin or inbred strain (in animals) |
| Allograft | Homograft | Same species |
| Xenograft | Heterograft | Different species |
| Synthetic | | Manufactured |

***Table 9.1. Bone Graft Terminology***

## AUTOGENOUS BONE GRAFTS

### *Multiple Cancellous Chips or Strips*

At the present time, autogenous cancellous bone is the most osteogenic bone graft available and, therefore, is the most widely used. Cancellous bone can be taken in strips or morcellized into fine pieces that pack readily into small cracks or holes, or it can be used to fill large, irregular voids. When packed firmly and contained, cancellous bone provides good support against compression.The best source of cancellous bone is the ilium, although the metaphyseal region of most long bones can be a source of bone graft. It is the principle type of graft used for fractures, nonunions, and for arthrodesis of the spine. If cancellous bone is in limited supply, it can be taken as corticocancellous strips.

### *Single-onlay Cortical Bone Grafts*

The single-onlay cortical bone graft was used most commonly before the development of good quality internal fixation and was employed for both osteogenesis and fixation in the treatment of nonunions (Fig. 9.1*A*). The tibia is the most common source of this graft; the split fibula can also be used. The most common indication for this graft today is bone grafting and stabilizing the cervical spine, although with modern techniques it is rarely used. In osteoporotic bone, screws commonly do not achieve adequate fixation. Even metal washers and nuts are inadequate, because the bone collapses when they are tightened. In this situation, a nonunion or fracture site can be bridged with a cortical bone graft and a plate applied to the opposite cortex. The screws can then be placed through the bone into the bone graft, resulting in a reasonably solid construct. For this purpose, it is preferable to use one half or three quarters of the thickened portion of the superior border of the iliac crest rather than the tibia. If a long, straight graft is needed, the fibula is preferred. The tibia is used as a last resort, because a donor site of this size creates a large stress riser in the tibia that, unless protected for a prolonged period of time, can lead to pathologic fracture.

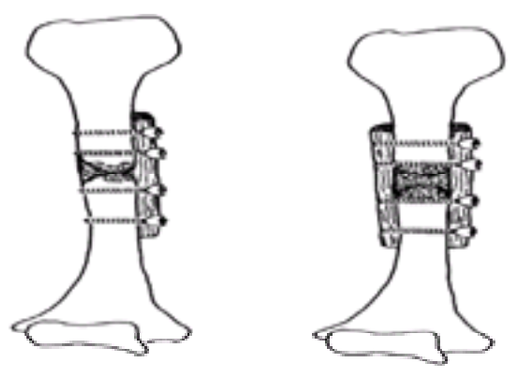

***Figure 9.1.*** **A:** A single-onlay cortical bone graft is shown. A single-onlay cortical graft may be used to treat nonunion of the humerus. A cancellous graft is placed at the nonunion site. We have not used this technique in the last 20 years; instead, we would internally fix the nonunion with a compression plate, performing an onlay cancellous bone graft. **B:** The use of the classic dual onlay cortical bone graft is almost exclusively limited to the treatment of congenital pseudoarthrosis of the tibia. The space between the two grafts and between the two ends of the bone at the nonunion site is packed with cancellous bone. In some nonunions of the humerus with osteoporotic bone, a compression plate is used, but this is supplemented on the opposite cortex by a cortical onlay graft to provide good screw fixation. Although only four screws are illustrated, this type of grafting requires a minimum of six screws with good fixation of both cortices on either side of the nonunion site. Dual onlay grafting is mostly of historic interest. See the text for further information.

### *Dual-onlay Cortical Bone Graft*

Boyd developed the dual-onlay cortical bone graft technique in 1941 for the treatment of congenital pseudarthrosis of the tibia (12). This technique is interesting for its historical significance (Fig. 9.1*B*).We have not found an indication for this graft since the early 1980s. Ilizarov techniques are more useful for severe problems of this type. A version of this technique using allograft is useful for revision total joint arthroplasty to replace bone insufficiency.

### *Inlay Bone Grafts*

Albee popularized the inlay bone graft for the treatment of nonunions (3,4). Inlay grafts are created by a sliding technique, graft reversal technique, or as a strut graft. Although originally designed for the treatment of nonunion of the tibia, these techniques are also used for arthrodesis and epiphyseal arrest (Fig. 9.2*A*, Fig. 9.2*B* and Fig. 9.2*C*).

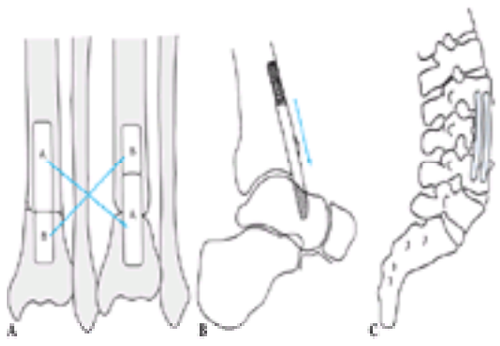

***Figure 9.2.*** **A:** A sliding graft may be used to treat nonunion of the distal tibia. **B:** In this case, a sliding graft is used as a component of ankle arthrodesis. This type of graft is more likely to be used for a previously failed ankle fusion or for fusion in the absence of the body of the talus. Internal fixation and additional graft in the ankle joint is not illustrated. **C:** Strut grafts for anterior spinal fusion. Strut grafts are very useful for bridging defects in the anterior spine and for providing support for anterior spinal fusion. Grafts from the ribs, fibula, and bicortical iliac crest are useful for strut grafting, depending on the size of the graft needed. Two rib grafts are shown bridging L-2–L-4.

### *Sliding Graft*

- Drill four holes at each corner of the sliding graft. Cut the rectangular graft with a water-cooled saw blade.
- After the graft is removed, if there is a solid fibrous union between sections A and B, it is simply flipped end for end and then impacted back into the slot. If it is in two pieces, section A is slid distally, and section B is placed proximally. Section A now bridges the fracture site (Fig. 9.2A).

This technique is rarely used today, because internal fixation combined with onlay cancellous bone graft provides a better result. This technique may be combined with internal fixation if there is limited space to place a cancellous graft. The disadvantages of the sliding or reversed bone graft are that, after the cuts are made, the graft fits loosely in the bed, and it creates stress risers proximally and distally to the nonunion site. It is most safely used in metaphyseal rather than diaphyseal regions. Its use today has been supplanted by rigid internal fixation and cancellous onlay bone grafting. Onlay bone grafting has the additional advantage of providing a higher polar moment of inertia than does the inlay technique. A common use of the strut graft is for anterior vertebral fusion at all levels of the spine. Ribs, fibula, or sections of

iliac crest are useful for this application (Fig. 9.2*C*). The reverse inlay graft is useful for nonunions of the medial malleolus.

### *H-Grafts*

The H-graft is a corticocancellous graft that is usually harvested from the ilium and is specifically designed to achieve posterior fusion of the cervical spine.

### *Peg and Dowel Grafts*

Dowel grafts were developed for the grafting of nonunions in anatomic areas, such as the scaphoid and femoral neck, where onlay bone grafting was impractical. In the carpal scaphoid, the dowel is fashioned from dense cancellous bone (see Chapter 42). The use of the dowel graft for the management of nonunion of the femoral neck is illustrated in Figure 9.3. Free microvascularized fibula grafts are more commonly used today. A corticocancellous graft of appropriate length and approximately 25 mm wide is harvested from the ilium or the tibia. The curvature of the ilium often makes it difficult to obtain a straight graft of sufficient length.

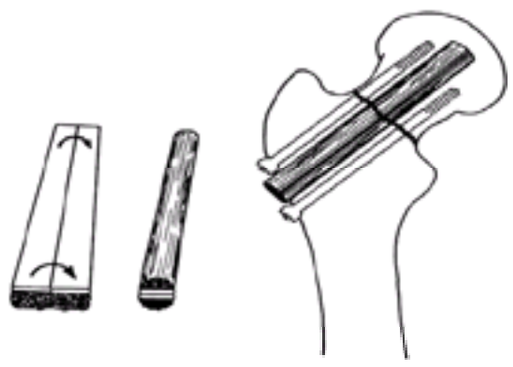

***Figure 9.3.*** Dowel graft for nonunion of the femoral neck.

### *Dowel Graft for Femoral Neck Nonunion*

- Use a water-cooled power saw to cut this graft to avoid breakage.
- Split the graft into two longitudinal sections. Make the cut *in situ*.
- Place the two longitudinal grafts back to back, with the cortex in the interior of the graft; then shape it to form a dowel.
- Temporarily fasten the two sections together with cerclage absorbable sutures.
- Ream a hole from the lateral cortex of the femur, across the femoral neck nonunion site, and into the femoral head using a standard, hip-nail reamer.
- Drive the graft into this hole across the nonunion site, taking care not to break the graft.
- Achieve additional fixation with multiple compression screws. This graft can also be combined with a compression hip screw if sufficient space is available. A fibula can be used for this purpose as well and is mechanically stronger. Yoo (163), following the technique originated by Urbaniak (see Chapter 125), uses a free microvascularized fibula with anastomosis to the lateral circumflex femoral artery for avascular necrosis of the femoral head. The usefulness of this technique in nonunions has not been established, however. On occasion, a Meyers muscle-pedicle bone graft (96) or a valgus osteotomy is used (see Chapter 29).

In most instances, dowel grafts have been replaced by microvascularized fibular grafts and, on occasion, the quadratus muscle-pedicle graft popularized by Meyers (see Chapter 29) or valgus osteotomy (96,97,98 and 99,163). Peg grafts have also been used to bridge the tibia and fibula to produce proximal and distal tibiofibular synostosis (94). Occasionally, these grafts are used for spine fusions as well (84).

### *Medullary Grafts*

Medullary grafts are not indicated for the diaphysis of major long bones. Grafts in this location interfere with restoration of endosteal blood supply; because they are in the central axis of the bone, they resorb rather than incorporate. The only possible use for a medullary graft is in the metacarpals and the metatarsals, where the small size of the bone enhances incorporation. Even in this location, however, internal fixation with onlay or intercalary cancellous bone grafting may be a superior method.

### *Osteoperiosteal Grafts*

In osteoperiosteal grafts, the periosteum is harvested with chips of cortical bone. These grafts have not been proven to be superior to onlay cancellous bone grafting, are more difficult than cancellous bone to harvest, and may involve greater morbidity; they are rarely used today.

### *Pedicle Grafts*

Pedicle grafts may be local (139) or moved from a remote site using microvascular surgical techniques (see Chapter 36). In local muscle-pedicle bone grafts, an attempt is made to preserve the viability of the graft by maintaining muscle and ligament attachments carrying blood supply to the bone or, in the case of diaphyseal bone, by maintaining the nutrient artery. Two examples are the transfer of the anterior iliac crest on the muscle attachments of the sartorius and rectus femoris for use in the Davis type of hip fusion (see Chapter 106) and the transfer of the posterior portion of the greater trochanter on a quadratus muscle pedicle for nonunions of the femoral neck (see Chapter 29) (96,97,98 and 99). Although technically more difficult, pedicle grafts have the advantages of a high percentage of cell survival, rapid incorporation, and increased active participation of the grafted cells in the healing process. Free, microvascularized fibular grafts are used to replace major deficiencies in long bones (see Chapter 36) and have been effectively used to treat avascular necrosis of the femoral head (see Chapter 125) (163).

## OPERATIVE TECHNIQUES: HARVESTING BONE GRAFTS

### *Ilium*

The iliac crest is an ideal source of bone graft because it is relatively subcutaneous, has natural curvatures that are useful in fashioning grafts, has ample cancellous bone, and has cortical bone of varying thickness. Removal of the bone carries minimal risk and usually there is no significant residual disability. Abbott (1) demonstrated that the posterior third of the ilium is thickest (Fig. 9.4). This is confirmed by computer tomography (CT) scans (Fig. 9.5).

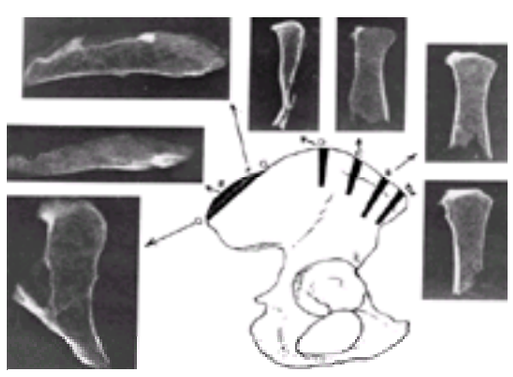

***Figure 9.4.*** These cross sections of the iliac crest show the width of the bone and the cancellous bone available for grafting. The posterosuperior iliac spine area provides the most bone, and the central section of the ilium at point D is quite thin and is of no use in bone grafting. (From Abbott LC. The Use of Iliac Bone in the Treatment of Ununited Fractures. In *American Academy of Orthopaedic Surgeons: Instructional Course Lectures,* Vol. 2. Ann Arbor, MI: J. W. Edwards, 1944, with permission.)

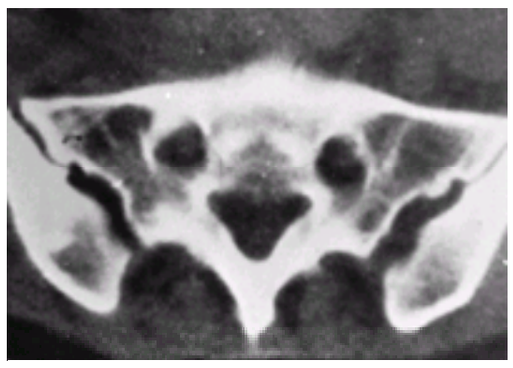

***Figure 9.5.*** This CT scan of the pelvis at the level of the posterosuperior iliac spine illustrates the thickness of the ilium posteriorly and the amount of cancellous bone available.

**Posterior Iliac Grafts** The region of the posterosuperior iliac spine is the best source of cancellous bone.

- To procure bone, position the patient in the prone position. It can also be harvested from the uppermost crest in the lateral decubitus position. Prepare a wide area of skin and eliminate possible contamination from the rectal area by placing an adhesive plastic sheet transversely across the buttocks, fitting it carefully into the gluteal crease cephalad to the rectum.
- Make a straight vertical incision directly over the posterosuperior iliac spine or a curvilinear incision that parallels the iliac crest (Fig. 9.6*A*). The length of incision depends on the size of the graft needed and the obesity of the patient, but an incision of at least 7.5 cm is needed. To prevent injury to the cluneal nerves, avoid straight transverse incisions and try not to carry incisions too far laterally. A transverse incision is more likely to result in dehiscence and can be painful if it lies along the belt line.

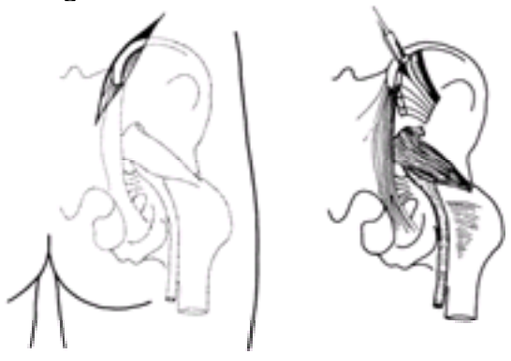

***Figure 9.6.*** A posterior iliac graft is shown.

- Dissect sharply through the fat to the prominence of the posterior iliac crest. Identify the origin and fascia of the gluteus maximus insertion on the crest. With a cautery knife, incise the origin of the gluteus maximus and dissect it free from the crest subperiosteally. If the entire posterior iliac area is to be harvested, take down the gluteus from approximately 2.5 cm superior to the posterosuperior iliac spine and inferior as far as the posteroinferior spine. With a large key elevator, elevate the gluteus off the outer wall of the ilium down to the level of the sciatic notch. Avoid injury to the superior gluteal nerve and vessels. Obtain retraction with two Taylor retractors.
- The outer wall of the ilium is removed by first outlining the area to be harvested by cutting through the outer table of the ilium with a sharp osteotome, as illustrated in Figure 9.6*B*. If an onlay cancellous bone graft is to be performed, harvest corticocancellous strips with a curved gouge. Remove all underlying cancellous bone down to the inner table of the ilium with a curved gouge and curets of an appropriate size. There is considerable cancellous bone superiorly and medially under the rim of the ilium that requires a curet for removal. Try not to perforate the inner wall of the ilium.
- Obtain hemostasis by applying a thin layer of bone wax over bleeding points on the bone. Irrigate the donor site thoroughly and remove excess wax. Perform routine closure over suction drainage. Because bone graft sites tend to ooze considerably after surgery, apply a large, bulky dressing.

**Anterior Iliac Grafts** Large grafts of cancellous and corticocancellous bone can be harvested from the anterior ilium. (Figure 9.7)

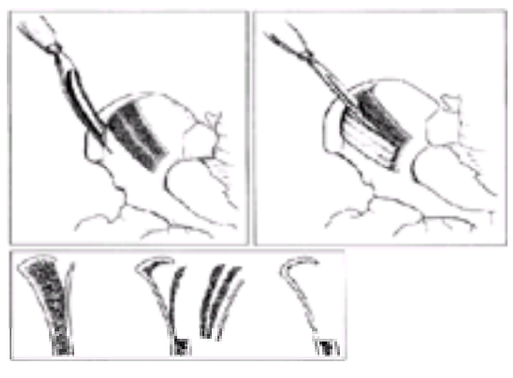

***Figure 9.7.*** **A, B:** Harvesting of an anterior iliac graft is shown. **C:** This cross-sectional view shows the extent of the bone harvested. The outer table is not broached. (From Weber BG, Cech O. *Pseudarthrosis.* Bern, Switzerland: Hans Huber, 1976, with permission.)

- Place the patient in a supine position. Make an incision parallel to the crest and 1 cm proximal to it. Do not incise anterior to the anterior superior iliac spine to avoid injury to the lateral femoral cutaneous nerve to the thigh. Incise with a cautery knife along the iliac crest, avoiding muscle. Posteriorly retract the overhanging abdominal musculature proximally to remain on the subcutaneous border of the ileum. This approach will significantly reduce hemorrhage and postoperative pain. Subperiosteally, dissect the abdominal musculature and, subsequently, the iliacus from the inner wall of the ilium.
- Outline the area to be harvested with straight and curved osteotomes (Fig. 9.7*A*). Cut the strips, which will be removed. The middle ilium is paper thin, but the anterior column just above the acetabulum is quite thick.
- Harvest the corticocancellous strips with a gouge.
- Remove additional cancellous bone with gouges and curets (Fig. 9.7*B*). Do not broach the outer table (Fig. 9.7*C*).
- Closure and postoperative management are the same as for a posterior graft. We prefer to harvest from the inner wall, because it is much easier for the surgeon and the patient has less postoperative pain than with other sites. The outer wall can be harvested as well. Watch for postoperative ileus and treat appropriately.

## HINTS AND TRICKS

***General Principles***

- Position the patient for harvest of the pelvis to optimize skin preparation, draping, and surgical access to the donor site.
- Exclude the perineum from the operative field with an adherent plastic drape.
- Thoroughly prepare the skin for surgery and drape over a sufficiently wide area so that the skin incision can be made entirely through an iodophor-impregnated adherent plastic drape.
- Place skin incisions slightly above or below the crest to avoid painful scars over bony prominences.
- Avoid surgical injury to the lateral femoral cutaneous nerve anteriorly and the cluneal as well as sciatic nerves posteriorly through proper incision placement and careful dissection.
- Dissect directly down to the bone, minimizing any undermining of subcutaneous fat off the fascia.
- Expose bone by using an electrocautery knife on the lowest setting possible to detach the fascial origins and insertions.
- Dissect muscle off bone subperiosteally with a large key-type elevator to avoid wandering into and injuring muscle.
- Minimize soft-tissue dissection and stripping, exposing only those areas necessary to harvest the graft.
- Take only as much bone graft as is needed.
- Before beginning the bone graft harvest, be certain that there is complete control of bleeding from the soft tissues.
- Immediately control bleeding from any significant bone bleeders.
- After harvest is completed, use hemostatic agents to minimize postoperative bleeding.
- Use postoperative wound suction in nearly all donor sites because postoperative hemorrhage is difficult to predict.
- Monitor postoperative blood loss closely to permit timely management of unexpected blood loss by temporary cessation of suction, possible re-exploration, and blood replacement.
- Close the wound in layers using meticulous technique with watertight closure of the fascia, closure of the subcutaneous fat in two or more layers in obese patients, and meticulous skin closure to minimize scar formation.
- Change postoperative dressings as frequently as necessary to maintain a dry dressing.
- Protect donor sites postoperatively with limited weight bearing and activities where the risk of pathologic fracture through the donor site is high (older osteoporotic women or long bone harvest sites).

***Posterior Iliac Crest***

- Keep the skin incision small and avoid lateral extension, which risks injury to the cluneal nerves.
- A curved linear incision parallel to the posterior iliac crest placed directly over the posterior iliac spine somewhat superior and medial to the crest approximately 5 to 6 cm in length usually permits harvesting of the entire outer cortex and underlying cancellous bone. Obese patients require larger incisions.
- Do not remove the origins and insertions of the spinal fascia and musculature from the ileum unless the entire nonarticular posterior superior iliac spine portion of the crest is to be harvested.
- Identify the location of the superior and inferior gluteal neurovascular bundles as well as the sciatic nerve and avoid injury to these structures by avoiding excessive retraction and appropriate placement of retractors.
- When harvesting large grafts, avoid penetration into the sacroiliac joint.
- Perform soft-tissue closure as described above, under General Principles.
- Restriction of activity and protected weight bearing postoperatively is necessary only to relieve pain. Pathologic fracture secondary to bone graft harvest is nearly unheard of in this area.

***Anterior Iliac Crest***

- Avoid injury to the lateral femoral cutaneous nerve by keeping all dissection posterior to the anterosuperior iliac spine.
- Minimize soft-tissue dissection and use small windows on the superior aspect of the crest when limited amounts of only cancellous bone are to be harvested.
- Where corticocancellous graft is required, remain in the anterior one quarter to one third of the crest above the acetabulum, avoiding the thin, nearly purely cortical bone in the middle third.
- Expose and harvest only the inner or outer table (we prefer the inner table to avoid injuring the abductor muscles) when corticocancellous graft is required.
- When full-thickness crest is harvested, avoid fracture by remaining at least 3 cm posterior to the anterosuperior iliac spine, harvesting the graft with a water-cooled oscillating saw rather than an osteotome, and placing drill holes at the end of the saw cuts, if necessary, to minimize the stress riser effect.
- When large anterior grafts are harvested that require more posterior exposure of the crest, avoid incising the abdominal musculature by carefully identifying the interval between the abductor hip musculature and the abdominal muscles, retracting the abdominal muscles superiorward, and dissecting along the subcutaneous border of the crest.
- Meticulously close the abdominal muscles to the abductor musculature to minimize the risk of hernia.
- Protect patients postoperatively with limited weight bearing where the risk of fracture is high.

**Bicortical Grafts** Full-thickness bicortical grafts may be necessary for spinal fusion or for replacement of major bone defects in metaphyseal regions, such as in nonunions of the distal humerus or in opening wedge osteotomies. Coronal grafts are illustrated in Figure 9.8.

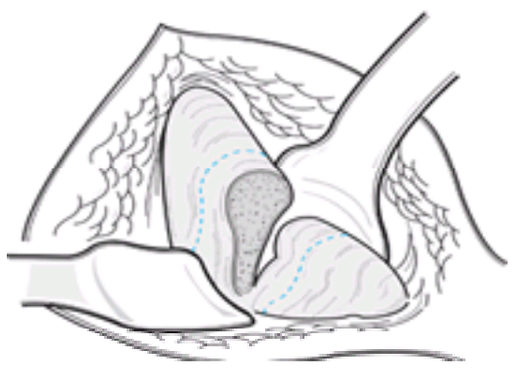

***Figure 9.8.*** Full-thickness segments of the ilium are useful for many types of bone grafting, particularly for anterior arthrodesis of the spine and fusion of the ankle and subtalar joints. Segments shorter than 30 mm rarely cause cosmetic problems. (From Abbott LC. The Use of Iliac Bone in the Treatment of Ununited Fractures. In: *American Academy of Orthopaedic Surgeons: Instructional Course Lectures,* Vol. 2. Ann Arbor, MI: J. C. Edwards, 1944, with permission.)

To harvest a bicortical graft from the anterior aspect of the ilium, follow the procedure described below:

- Expose both sides of the ilium from the anterosuperior iliac spine posteriorly as far as is needed for the graft desired (Fig. 9.9).

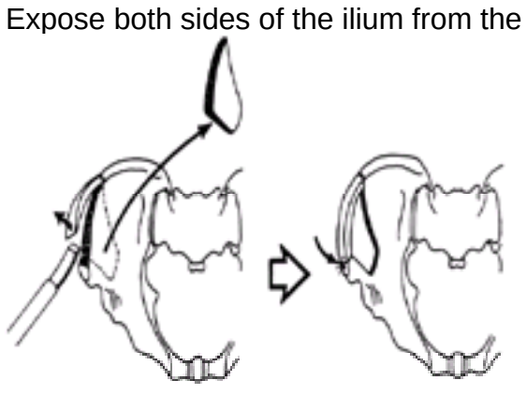

***Figure 9.9.*** A large bicortical graft is shown.

- With a thin, curved osteotome that is 1 cm wide, enter the iliac crest approximately 15 to 20 mm posterior to the anterosuperior iliac spine.
- Make a cut parallel to and beneath the thickened rim of the crest for a distance of 7 to 10 cm, depending on the size of the patient and the size of the graft needed.
- Gently pry the crest upward, producing a greenstick fracture at its posterior aspect. Posteriorly, leave the periosteum and muscle attachments intact to prevent the fragment from becoming free.
- Remaining at least 2 cm posterior to the anterior border of the ilium between the two iliac spines, drive an osteotome downward to the depth of graft desired, or use an oscillating saw. It is important to remain at least 2 cm or more superior to the dome of the acetabulum.
- Make a second posterior cut to produce the width of graft desired, and then connect these cuts in the depths of the wound on both sides with a curved osteotome. Using a saw results in a stronger graft.
- Carefully remove the graft and place it in a moist sponge in a basin on the back table until it is ready for use.
- Obtain hemostasis, and return the iliac crest to its anatomic position. Place 2 mm drill holes on either side of the initial osteotomy on the top of the crest. Through these holes, place a #1 nonabsorbable suture and tie it securely to hold the crest in place. This fixation is surprisingly stable.
- Securely suture the periosteum and overlying muscles with interrupted sutures to help hold the crest in place. Use suction drainage.

Grafts that require structural strength, such as for anterior spine fusion, are best harvested with a saw, because they are stronger than those harvested with osteotomes. We use this graft about two to three times per year, and we have yet to see the donor site fill in. One fracture did occur through the anterior remnant of the ilium at its base, but this fracture healed without problems by having the patient limit activities and use crutches. No hernias have occurred, and most patients have no symptoms within 6 months of graft harvest.

### *Other Sources of Cancellous Bone*

In treating small bone defects secondary to trauma or small tumors, it may be most convenient to harvest the graft from the ipsilateral extremity undergoing operation. The graft can often be taken through the same incision or through a small, separate incision. Most of these sites can be harvested through a small, 2.5 to 5.0 cm longitudinal incision placed over the subcutaneous surface of the end of the bone.

- Make a small cortical window in the metaphyseal or epiphyseal region with a 6 mm osteotome or large drill. Use curets to harvest the graft. Typical sites are illustrated in Figure 9.10 (64). If the greater trochanter of the femur is used, avoid taking the graft from the lateral aspect rather than the preferred anterior site. The lateral location may result in trochanteric bursitis or a snapping iliotibial band. A similar technique is used to harvest bone from between the two tables of the ileum through a small window in the crest just posterior to the anterosuperior iliac spine.

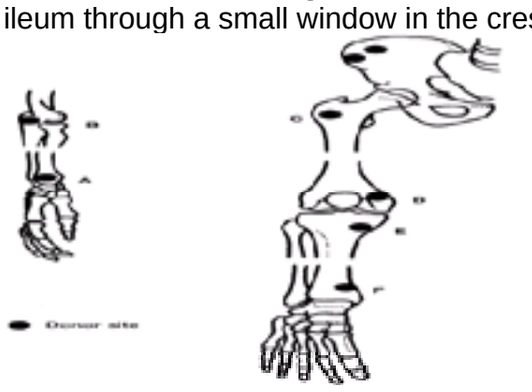

***Figure 9.10.*** Peripheral sources of cancellous bone graft are illustrated. If only a small amount of cancellous bone is needed or if it is contraindicated or inconvenient to use the iliac crest, other sites of cancellous bone are the styloid of the radius (**A**), the olecranon (**B**), the anterior aspect of the greater trochanter (**C**), the distal femoral condyle (**D**), the proximal tibia (**E**), and the distal tibia (**F**). (From Heim U, Pfeiffer KM. *Small Fragment Set Manual.* New York: Springer-Verlag, 1974, with permission.)

### *Tibia*

If a long, straight, large section of a cortical or corticocancellous bone is needed, harvest it from the proximal tibia.

- Use a tourniquet, and prepare and drape the extremity, as described in Chapter 5. Make a straight, longitudinal incision over the middle of the anteromedial surface of the tibia. Expose the anteromedial surface of the tibia by subperiosteal dissection. Transverse incisions through the periosteum at the proximal and distal ends of the longitudinal incision improve exposure.
- Outline the graft to be taken and drill a 3 to 4 mm hole in the cortex at each of the four corners of the graft (Fig. 9.11). With a water-cooled oscillating saw, cut the graft. Avoid cutting beyond the drill holes, because fracture of the tibia is then much more likely to occur. Cut through the cortex at an oblique angle to assist in removal of the graft.

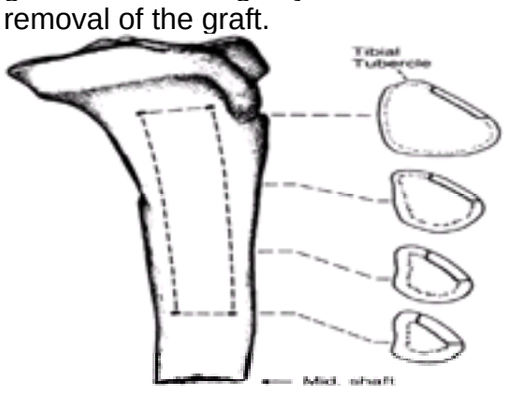


***Figure 9.11.*** A tibial graft is shown. A large, corticocancellous graft can be removed from the proximal tibia on its anteromedial surface. (From Boyd HB, Lapinski SP. Causes and Treatment of Nonunion of the Shafts of the Long Bones. In: *American Academy of Orthopaedic Surgeons: Instructional Course Lectures,* Vol. 17. St. Louis: C. V. Mosby, 1960.)

- Carefully pry the graft out of the tibia with a curved osteotome. To avoid dropping the graft, it is prudent to insert a threaded Steinmann pin into one end of the graft; the assistant can then use this pin to help pull the graft out of the donor site and to hold onto it. Remove cancellous bone from the proximal tibia as necessary. Avoid the subchondral bone of the proximal tibia and, in children, avoid the physeal plate.
- After removal of the graft, release the tourniquet and secure hemostasis. Because bone wax interferes somewhat with bone regeneration in this location, it is best to control bleeding with a collagen product. In adults, the periosteum and subcutaneous tissue are closed in one layer. Drainage is important, but avoid excessive, early suction because this can promote bleeding from the bone graft site.

### *Fibula*

Remove the shaft of the fibula through Henry's approach, as described in Chapter 3.

- The entire proximal three quarters can be used, if necessary, but rarely is the proximal end needed. Avoid injury to the peroneal nerve. Never remove the distal fourth of the fibula, because it is essential to the stability of the ankle. The syndesmosis ligaments must be left intact, and a short portion with the interosseous membrane attached must also be retained.

## HINTS AND TRICKS

***Harvest from the Metaphysis of Long Bones***

- Harvest is usually best from the ipsilateral extremity being operated on to avoid morbidity in another extremity.
- Long bone metaphyseal bone is much less dense than the iliac crest in most adults, and in older patients it contains less red marrow. For that reason, use metaphyseal cancellous bone only when small amounts of less dense cancellous bone are required.
- Keep skin incisions small; expose only the area to be harvested; avoid injury to local neurovascular structures; and avoid harvesting through sites where chronic bursitis or tendonitis might be a problem, such as the tip of the olecranon or the lateral prominence of the greater trochanter.
- Avoid harvesting excessive bone immediately adjacent to the subchondral bone of the joint.
- Avoid penetration of joints.

- The entire fibula can be removed through the interval between the peroneal muscles and the posterior compartment, avoiding transection of any muscles. Remove the fibula subperiosteally from distal to proximal to avoid injury to muscles. A number of perforating blood vessels may be encountered; these vessels must be coagulated or ligated.
- Facilitate removal by making the distal transverse cut first. Carefully dissect circumferentially around the fibula, avoiding injury to the peroneal vessels. Place two small, blunt retractors anteriorly and posteriorly to protect the muscles.

## HINTS AND TRICKS

***Harvest of the Midshaft Fibula***

- For specific techniques related to free microvascular transfer of the fibula, see Chapter 36.
- As opposed to the advice given earlier regarding minimizing the size of skin incision, in this case a generous longitudinal incision over the subcutaneous border of the fibula is usually necessary to minimize the risk of complications to neurovascular structures.
- Depending on the level of harvest, carefully identify the portions of the common peroneal nerve at risk in the exposure used. Protect these nerves, avoiding excessive retraction.
- Use intermuscular intervals to dissect to the fibula and expose it by careful subperiosteal dissection. Avoid diving into the deep soft tissues, which risks injury to the deep neurovascular structures.
- Identify and carefully ligate arterial perforators to the fibula.
- Never harvest the distal quarter of the fibula. Leave the syndesmosis and a portion of the intraosseous ligaments intact and attached to the distal portion.
- Use Henry's extensile exposure for the common peroneal nerve and proximal fibula in harvesting the proximal third to avoid injury to neurovascular structures.

***Harvest of Diaphyseal Cortical Bone***

- In general, the harvest of diaphyseal cortical bone from the upper extremity and the femur is contraindicated because of the risk of fracture. This should be done only if this is the only reasonable alternative. In our careers, we have never harvested from these sites.
- In our experience, harvest of tibial diaphyseal bone is virtually never necessary today because of the availability of alternative techniques. Neither of us have harvested a diaphyseal tibial cortical graft in the last 20 years.
- If a tibial cortical graft is the only graft possible, then take the following steps to minimize the risk of complications:
- Keep the bone graft as small as possible.
- Use adequate-sized drill holes at the corners of the harvest site and use a sharp water-cooled oscillating saw that is kept constantly cool to harvest the graft, avoiding any overcutting beyond the drill holes.
- If possible, harvest from either the lateral or posterior surfaces of the tibia because the muscle coverage lessens the risk of soft-tissue complications and makes it more likely that the defect will heal to the greatest extent possible.
- Harvest from the subcutaneous border is most convenient and provides the largest surface for graft but is problematic because of the thin soft-tissue coverage.
- Tibial diaphyseal harvest sites must be protected for a prolonged period of time, probably for at least 6 months in a well-fitted cast brace, with the patient's activities limited to normal sedentary walking using crutches initially and then a cane. Sports activities or more vigorous activities must be avoided for at least 1 year and, in some individuals with larger graft sites, perhaps for several years.
- Decisions regarding when to cease protection and allow the patient more vigorous activities are probably best judged through the use of CT scans of the donor site.
- Because these grafts are exceedingly rare today, no definite guidelines can be given. One of us has seen only two diaphyseal tibial graft harvest sites in the past 20 years, both of which were referred to him for secondary fracture of the tibia. One patient responded to plate fixation and autologous bone grafting. The other patient, who was infected, required multiple surgical procedures but eventually healed, after control of the infection and double plate fixation and autologous bone graft.

- Use a water-cooled saw to transect the fibula. Grasp the segment to be removed with bone-holding forceps, maintaining gentle traction on the bone, and dissect subperiosteally from distal to proximal until the segment of the fibula to be removed is exposed. Transect the upper end in a similar fashion. If the entire proximal fibula is to be removed, avoid injury to the peroneal nerve and the trifurcation of the popliteal artery.
- After removal, repair the insertion of the biceps tendon with strong, nonresorbable suture to the remnants of the proximal tibiofibular ligaments.

## ALLOGRAFTS

### INTRODUCTION

The clinical application of bone allografting became prevalent in the first two decades of the 20th century, after the experimental work of Ollier and Axhausen. In 1907, Lexer (82) was the first to perform allogeneic whole joint transplantation, and he had performed 25 by 1925. In 1942, Inclan reported the storage of autogeneic and allogeneic bone, and this report stimulated many similar clinical efforts at preservation, sterilization, and delayed reimplantation. Although the superiority of fresh autogeneic grafts repeatedly has been confirmed in experimental studies and clinical experience, allogeneic implants preserved by freezing, freeze-drying after sterilization with ethylene oxide, chemical sterilization, or gamma irradiation are nonetheless widely used. Bone is more commonly transplanted in the body than any other tissue or organ except blood. Only recently has attention been paid to other musculoskeletal tissues for allografting, such as cartilage, tendons, ligaments, and menisci.

The terminology of bone grafting and other musculoskeletal grafting has been confusing (Table 9.1). Urist (149) recommends the term *implant* for nonviable bone; an example is frozen, freeze-dried, sterilized bone, a derivative of whole bone that lacks viable cellular components but potentially contains inductive protein that can stimulate osteogenesis.

A graft may be orthotopic (transplanted to the same site in the recipient that it occupied in the donor, e.g., distal femur to distal femur); heterotopic (transplanted to a different site but one occupied by the same tissue as in the donor, e.g., fibula to spine); or ectopic (transplanted to a site normally occupied by a different type of tissue, e.g., fascia lata as a tendon graft). Ectopic sites for bone grafting have been used mainly in investigating osteogenesis and, rarely, for temporary clinical storage of bone.

In general, allografts are used to fill bone defects or replace missing bone segments and to promote the healing of nonunited fractures. Cancellous bone or morcellized cortical bone is most often used for filling cysts or cavities (Fig. 9.12); cortical bone is optimal for reconstructing defects that require a certain form and strength (Fig. 9.13). Although a cortical bone graft is strong when first implanted, the incorporation process frequently weakens it, so a fatigue fracture may occur many months to years after implantation (14). Therefore, plates or intramedullary devices are frequently used to augment the strength of the graft during incorporation.

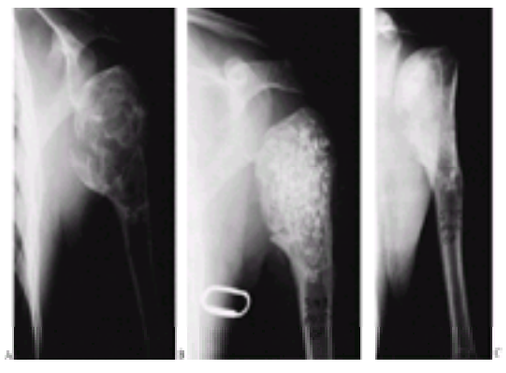

***Figure 9.12.*** This is a unicameral bone cyst in a young adult with a pathologic fracture. It was curetted and packed with freeze-dried and partially decalcified allograft (AAA) bone **(B)**. Five-year followup shows healing with excellent graft incorporation and remodeling **(C)**.

***Figure 9.13.*** A proximal femoral allograft was used to replace the proximal femur in a patient with a giant cell tumor. A custom metallic prosthesis was used to thread through the allograft.

### *Bone and Tissue Banking*

Guidelines for the procurement, processing, and clinical use of bone have been established by the American Association of Tissue Banks. The goals of bone banking are to preserve the physical integrity of the implant and its inductive proteins, reduce immunogenicity, and ensure sterility. In general, a minimal interval (less than 24 hours) between the death of the donor and the time of procurement is desirable. Following the proper procedure for consent is essential.

Harvested bone is fashioned into various sizes and shapes, and soft tissues and cells are removed to reduce immunogenicity. Freezing to –70°C in a sterile state effectively decreases immunogenicity and maintains sterility; this is generally recommended for osteoarticular allografts (86). Because the osteoarticular allografts frequently need to be matched for size, the height and sex of the donor should be recorded by the bone bank to permit as close a match as possible with the recipient (68). This method of storage decreases the strength of the allograft by about 10% (7). Ethylene oxide sterilization also is effective, although it may destroy bone-inductive proteins. The bone is preserved by freeze drying after removal of ethylene oxide (79,118). Freezing to –70°C and freeze drying reduce the immunogenicity of the implant but with some compromise to its mechanical strength. Freezing bone decreases its tensile and compressive strength by about 10% each, whereas freeze drying decreases torsional strength by about 50% and compressive strength by about 10% (114). The process of replacement by host bone entails a transient reduction of approximately 50% of strength. Sterilization of bone by heating to more than 62°C, by autoclaving, or by gamma irradiation disrupts the physical and chemical nature of bone and alters its mechanical properties (18,35). Bone implants subjected to these physically damaging processing methods perform poorly. Bone subjected to freeze drying, partial demineralization, or freezing incorporates more slowly than fresh autografts or syngeneic grafts (11,107,161).

Osteoarticular shell allografts must be stored in a fresh state for 24 to 72 hours until the donor has been adequately screened. The joint surfaces usually are stored *in situ* in the donor body at 4°C in a morgue environment. This ensures adequate viability of the cartilage for transplantation (133,146).

Quality control measures must be enforced to avoid the transfer of bacterial, fungal, or viral pathogens to the recipient. Such measures should include patients' histories and screening tests for hepatitis, acquired immunodeficiency syndrome (AIDS), and syphilis.

Table 9.2 shows storage techniques commonly used for various types of musculoskeletal allografts. Their applications have been well summarized by Czitrom (37).

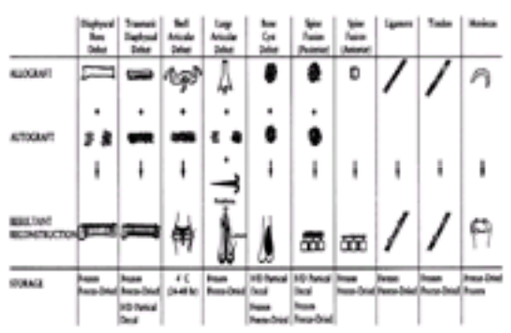

***Table 9.2. Various Methods of Storing and Using Musculoskeletal Allografts for Different Orthopaedic Needs***

### *Biology of Allograft Incorporation*

A successful bone graft eventually will be incorporated into the skeletal system of the host. In the process of incorporation, new bone deposited by the recipient envelopes and replaces the donor bone tissue. How rapidly the graft is incorporated depends on its size, structure, position, fixation, and genetic composition. The role of the graft in stimulating incorporation may encompass osteoconduction, osteoinduction, and osteogenesis.

**Osteoconduction** Glass tubes, porous ceramics, porous plastics, and autoclaved deproteinized bone all provide a scaffold into and around which bone formation can occur (150). This function of the graft as a scaffold for ingrowth is referred to as *osteoconduction.*

Induction occurs when “two or more tissues of different natures or properties become intimately associated, and alterations of the developmental course of the interactants results” (150). Bone matrix contains protein inductive factors, such as bone morphogenetic proteins (BMP), which, if released from the matrix by fracture, osteoclastic resorption, or chemical treatment, can induce nearby mesenchymal tissues to differentiate into osteoblasts. This factor is discussed in more detail later in this chapter.

Bone grafts in which preparation of the graft has not destroyed the BMP are capable of osteoinduction in addition to osteoconduction. An osteoinductive graft may be incorporated more rapidly than one that is merely osteoconductive.

**Osteogenesis** Osteogenesis in a bone graft refers to direct formation of new bone by living cells of the graft. Osteogenesis, together with the absence of an immune response, is the basis for the superior clinical performance of autografts. Although most of the autogenically transplanted osteocytes die and leave empty lacunae, preosteoclasts, preosteoblasts, and osteoclasts can survive (149). In contrast, cells from a fresh allograft quickly elicit antibody production and cell-mediated immunity, and are destroyed by the recipient.

**Revascularization and Biologic Incorporation** Revascularization of a fresh autograft seldom occurs by microanastomosis with existing microvessels. This process is more common in cancellous bone and is aided in cortical bone by removal of the periosteum (18). Most autografts and alloimplants revascularize only by invasion of capillary sprouts from the host bed during the resorption of the old matrix (creeping substitution). Creeping substitution involves invasion of the allograft by osteoclasts, and these, in turn, are followed by a blood vessel bud. New osteons are laid down around the many blood vessels that invade the graft (115).

In addition to creeping substitution, large allografts also may be incorporated by a process of serial stress fractures that result in graft remodeling. Periodically a region of stress concentration may microfracture, followed by local remodeling. Later, this process may occur in another region. The clinical manifestation of this may be a complaint of rapid onset of pain, often after very minor trauma, frequently with negative radiographic findings. The patient should be put on crutches or other support until the pain is gone, in order to prevent a catastrophic failure of the graft.

### *Selection and Preparation of the Graft*

The criteria that characterize an ideal graft follow from the goal of restoring structural stability to bones or joints with mechanical properties equal to adjacent bone and with an acceptable cosmetic result. Therefore, the graft should be strong, potentially viable, nonreactive (nontoxic, noncarcinogenic), sterile, storable, capable of being shaped during surgery, and affordable.

The eventual choice of a graft depends on the type of structural and osteogenic functions desired, the size and shape of various donor bones, and whether viable articular cartilage needs to be transplanted. The morbidity attendant on procuring an autogeneic graft is often a limiting factor in bone graft surgery; however, the use of some autogeneic corticocancellous bone is almost essential in certain applications (such as posterolateral lumbar and cervical spine fusions and to supplement allografts at the osteosynthesis site). Alloimplants seldom result in fusion across transverse processes or posterior arch structures; autolyzed, antigen-extracted allogeneic (AAA) bone may be an exception (151). Some autograft bone should almost always be used with allografts because it helps to avoid nonunion and stimulates incorporation.

### *Types of Grafts and their Indications*

**Bone Allografts and Alloimplants** Fresh allogeneic bone is no longer used in clinical transplantation because of the major immune response to the transplanted tissues. As discussed above, in the section on Bone and Tissue Banking, freezing and freeze drying are useful storage measures that reduce the immunogenicity of the implant. Alloimplants may be successfully used in many applications, from craniofacial restoration to spinal operations and whole joint transplantation. Donor bone is either removed aseptically or secondarily sterilized with gaseous ethylene oxide or gamma irradiation (119). The bone is then frozen or freeze dried for preservation and reduction of immunogenicity.

Frozen or freeze-dried bone contains numerous transplantation alloantigens (149). Furthermore, while in the frozen or freeze-dried state, bone loses its inductive factors due to enzymatic autodigestion by intracellular and extracellular enzymes. Accordingly, Urist developed a protocol for the preparation of chemosterilized, AAA bone that would preserve the inductive factors (149,150 and 151,153). In this method, chloroform-methanol is used to extract lipids and cell membrane lipoproteins (4 hours); 0.6 N hydrochloric acid extracts acid-soluble proteins and demineralizes the surface (24 hours); and neural phosphate buffer in the presence of sulfhydryl-group enzyme inhibitors removes endogenous intracellular and extracellular transplantation antigens (72 hours). The bone is then frozen and freeze dried.

For this treatment, bone must be excised from the donor within 8 to 12 hours of death (minimal biodegradation time) if the donor has not been stored in a morgue environment (4°C). If morgue storage has been used, a 12- to 24-hour wait is acceptable. Prolonged storage at –18° to 0°C and immediate freeze drying must be avoided, because both reduce the level of inductive factors through autodigestion. Sterilization by irradiation with more than 2.0 mrad further denatures the BMP. The principal disadvantage of AAA bone is decreased strength; therefore, it is rarely used when strength is an important consideration. Urist and Dawson have used it for spine fusions with a clinical success rate of 80% and a pseudarthrosis rate of 12% (151). Urist also reported its successful application in 8 of 10 patients who underwent arthrodesis of the knee, ankle, and wrist (150). The addition of fresh autogenic cancellous bone (including marrow) to AAA bone creates a composite graft with enhanced osteogenic capacity.

The osteoinductive capacity of demineralized bone was described by Urist (147,148). More recently, others have used demineralized alloimplants in craniofacial restoration (51). AAA bone is not generally available for clinical use at this time; however, other methods of partial demineralization are being used for some preparations.

**Cartilage as Allograft** Allogeneic cartilage, in theory, should not trigger an immune response after transplantation because the potentially immunogenic chondrocytes are buried in the cartilage matrix and, therefore, are inaccessible to the host's immune system. Late immune responses, such as lymph node hyperplasia, have been noted, however, and the role of cartilage in eliciting an immune response remains controversial (33,34,39,40,41,42 and 43,67,80,160). If this immune response is strong, it can lead to destruction of cartilage by a pannuslike reaction and a joint fluid inflammatory response (128,130,131,132,133,134,135,136 and 137).

The late deterioration in allograft cartilage is not clearly understood, but again this could be an immune response, cellular or humoral, to histocompatibility antigens (20,60,66,113,121). Deterioration of the joint surfaces also may be the result of misfit and eventual mechanical degeneration. Avoidance of these problems requires exacting surgical technique (109) and excellent matching of donor and recipient sizes (68,129).

**Large Composite Allografts** Fresh allografts of whole or half joints have been performed clinically for nearly 100 years (82,83,108,110,111 and 112,156). Mankin and colleagues reported preliminary results of massive allograft transplantations performed for malignant or aggressive bone tumors (76,89). Their improved allograft procurement technique involved freezing the segments to decrease the immunogenicity of the bony portion and glycerinization of the cartilage to maintain chondrocyte viability during freezing and thawing. The complication rate was high, but the tumor recurrence rate was low and the outcome generally successful. Poitout has also reported high success rates using a similar technique of liquid nitrogen storage and cartilage cryopreservation (116). Koskinen proposed the addition of autograft bone at the osteosynthesis site and noted an improvement in the union rate (78). He also advocated strong internal fixation throughout the entire length of the allograft to protect it from late fatigue fracture.

**Xenograft Materials**

*Bovine Bone Xenograft* Transfer of tissues between species typically elicits a severe immune response from the recipient; consequently, xenograft tissues must be treated to remove antigenic proteins. Xenograft cancellous bone usually is obtained from cattle. The freshly harvested bone is washed in water, extracted with hydrogen peroxide to oxidize and partially remove proteins, delipidized with fat solvents, and dried in acetone. It is then sterilized by gamma irradiation. The resulting product (Kiel bone or Surgibone) is structurally strong and elicits only a very weak antigenic response in humans. The deproteinizing process also deactivates or removes inductive factors, so the Kiel bone serves as an osteoconductive scaffold; it is not inductive, however, as is demineralized human bone matrix. Salama and Weismann report excellent results using Kiel bone soaked in autogeneic marrow as a composite graft material (138). Xenogenic bovine bone is more widely used in Europe than in North America.

*Type I Collagen Xenografts* Another bovine xenograft material in common use is type I collagen, derived mostly from bovine skin (145). The collagen is dissolved and then reconstituted, leading to fibrillar type I collagen with other antigenic proteins removed. Collagen by itself is low in antigenicity. Collagen xenografts are most widely used in dermatology and plastic surgery; collagen sponges also are used for hemostasis in general surgery. For orthopaedic applications, collagen may be combined with autogenous marrow and a ceramic composed of sintered hydroxyapatite and tricalcium phosphate to form a composite implant; such implants have been shown of be equal in effectiveness to autologous bone in fresh bone defects in humans (24,32).

*Composite Xenografts* Urist and others (147,149) have noted that composite implants formed from various combinations of ceramic, demineralized bone matrix, marrow, and type I collagen exhibit a synergism among the components, resulting in faster and more abundant bone formation. Although the biochemical basis of this process is not well understood, it seems likely that such composite implants may prove to be clinically useful.

## IMMUNOLOGIC CONSIDERATIONS

The antigen–antibody response to allografts varies considerably in reported series (144). Studies of small osteoarticular fresh human allografts performed by Urovitz et

al. (155) have demonstrated little evidence for antihistocompatibility (anti-HLA) antibodies in the serum of the hosts, whereas patients receiving massive frozen allografts in the series reported by Rodrigo et al. (130) showed high titers of anti-HLA antibodies that remained positive as long as 5 years after transplantation.

In osteochondral grafting, fresh cartilage of low immunogenicity and fresh subchondral bone that is highly immunogenic are transplanted. With the use of a free avascular osteochondral allograft for replacement of the end of a long bone, one desires the devitalized bone to be remodeled through “creeping substitution” at an appropriate rate (52,128) and the cartilaginous surface to remain viable. Cartilage is transplanted primarily for destroyed joints in the form of shell allografts (joint cartilage plus 5 to 10 mm of subchondral bone). A strong immune response to the bone can destroy the adjacent cartilage, even though cartilage resists destruction by antibody and cellular resorptive mechanisms (33,34). In addition, the cartilage may become more immunogenic with time after transplantation. One study indicated that the cartilage cells did not express class I and class II antigens before transplantation, but they did after transplantation; the expression of antigen became stronger with time. It was suggested that an immune or inflammatory response must occur first to stimulate the chondrocytes' expression of HLA antigens by the release of lymphocytes. If the recipient develops an immune response against donor histocompatibility antigens, the protection of cartilage from destruction is only relative; a low grade, slow, immunologically mediated inflammatory response ensues, characterized by increased synovial fluid and white blood cell counts, antibody response, and pannus reactions that can destroy the cartilage (132,133).

Transplantation of allogeneic cortical and cancellous bone elicits an immune response that delays healing at the osteosynthesis site and blocks revascularization, resorption, and appositional new bone formation. Long-term studies show no difference in the morphology of eventual repair of autografts and allografts (77,126,158). Decalcified allografts repair at a faster rate than those that are only frozen, although they are mechanically weaker (106).

## OPERATIVE TECHNIQUES

### *Allografts for Spine Surgery*

The choice of grafting material depends on the anatomic and spatial constraints of the area to be stabilized and the osteogenic capacity of the host bed in orthotopic bone grafting. In general, vertebral bodies, which are rich in cancellous bone and marrow, provide far greater numbers of osteoprogenitor cells for remodeling a graft than spinous processes, facets, and transverse processes, which are composed mostly of cortical bone. Hence, demands placed on a graft destined for posterolateral areas of the spine are greater than those imposed on bone grafted to an intervertebral body location. For posterolateral grafting of the spine, fresh autogeneic bone, either alone or in a composite graft, is considered essential because the graft provides surviving osteogenic precursor cells and inductive factors. Frozen or freeze-dried devitalized allogeneic cortical and cancellous bone may be used for cervical and lumbar interbody fusions when less is demanded of the graft and when the recipient bed is rich in marrow. At these locations, the incidence of fusion is the same with allogeneic bone and fresh autografts, although the rate at which the allograft fuses is slower (6,26,91,142).

At times, vertebral bodies of the cervical, thoracic, and lumbar spine are lost because of degenerative processes, infection, or neoplasia. Struts of allogeneic fibular bone can be used effectively to restore stability; these struts are eventually incorporated and remodeled. Even in the presence of recent osteomyelitis, devitalized allogeneic bone can fuse and provide structural support for the weakened spine (16). For large, multilevel defects of several vertebral bodies, a femoral allograft frequently will fill the defect and provide the correct curvature. In these cases, additional internal fixation to protect the graft throughout its length is advocated.

Long fusions that are necessary in operations for scoliosis frequently are performed in young children who do not have enough bone present in the iliac crests to provide adequate amounts of autograft. In these cases, allograft bone (frozen, freeze-dried, or AAA bone) may be morcellized and mixed with the child's own bone to provide adequate amounts of graft material. More recently, titanium cages filled with various grafting materials have been used for interbody fusions. See Chapter 146 for more details.

- During an operation, protect the sterility of the graft at all stages. Avoid prolonged exposure to air and saline and prolonged heating, which can destroy cells and inductive factors (7,120,153). Create an optimal host bed, preferably with marrow-rich cancellous bone margins. Heating the recipient bed with power burrs or coating bleeding interface with bone wax also destroys viable host cells and impairs subsequent incorporation.
- Fashion the graft during the operative procedure to mortise implants tightly into host bone. Spread the allograft contact sites with autograft, and apply supplemental barrel stave–like strips of bone graft to the osteosynthesis site. Orient the graft *in situ* to provide axial alignment of donor cortical bone with erect posture of the patient and maximum exposure of the cancellous areas of donor bone to the host's marrow-containing cancellous bone. Forces across the host–graft interface should maximize contact compression with ambulation of the patient.
- Use suction for the first 48 hours after the operation to reduce hematoma formation within perosseous soft tissues, thereby reducing pain and preventing donor bone from floating in a large blood clot. Early postoperative ambulation and mild exercise stimulate blood flow and osteogenesis within the graft, provided the graft is secure within the recipient bed. External splinting appliances, as well as the patient's muscle spasm and pain, tend to stabilize the graft. Educating the patient with respect to proper posture, weight bearing, turning, and exercising, especially when the graft is most vulnerable, is critical for avoiding fatigue fractures and pseudarthrosis.

### *Allografts for Tumor Surgery*

Allografts for major tumor surgery have been used during the past 50 years, and recent results have approached 85% good or excellent (72,76,116,124). The needs for grafting in tumor surgery vary considerably, depending on whether the defect is diaphyseal, ligamentous, tendinous, or cavitary (cysts).

**Large Diaphyseal Defects** When large diaphyseal bone losses are present, Ilizarov methods are often the best for replacement (see Chapter 32). Other alternatives for replacement include the following: sliding cortical autografts from the remaining bone above or below the defect, large corticocancellous bone grafts from the iliac crest, vascularized fibular autografts, morcellized autograft placed around an intramedullary rod (23), and allograft bone with or without autograft (78,88). Autogeneic bone alone is always preferable to an unsupplemented allograft bone. When autograft sources are insufficient, allogeneic bone can be used in combination with the autograft. When allograft bone is used alone, it should be protected by a plate or rod throughout its entire length to prevent a fatigue fracture when the allograft bone weakens because of remodeling. Many years later, when the plate or rod begins to weaken, the allograft bone will have been replaced sufficiently to provide the needed strength (Fig. 9.14). In many cases, gradual stepwise removal of the plates and screws is advisable to dynamize the allograft.

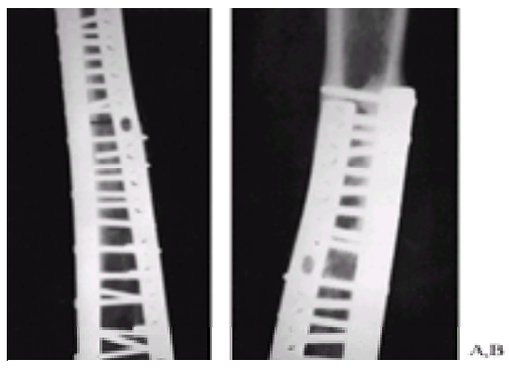


***Figure 9.14.*** A midshaft femur freeze-dried allograft for a central chondrosarcoma is shown. The allograft showed good revascularization 8 years postoperatively, when one plate was removed for bursitis.

**Large Composite Defects** When bone and joint losses are present, the alternatives for replacement include the following: a large osteoarticular allograft, a large diaphyseal allograft with a custom metallic joint replacement threaded through the allograft, and a joint fusion using sliding autografts with or without allograft bone. Preliminary evidence suggests that diaphyseal allografts used in combination with joint replacements are superior to large osteoarticular allografts for replacement of large osteoarticular defects (10).

Transplantation of large whole- or half-joint allografts has been reported during the last several decades (37,88,89,100,101,108,110,111 and 112). Results were varied, and in all cases complications led to a failure of normal joint function; however, the operations worked well as salvage procedures. The more recent technique of threading a long-stem customized joint replacement through a large diaphyseal allograft (10) appears to give better results, at least in the short term.

Acetabular allografts can be fashioned from morcellized iliac crests, femoral heads, or an allogeneic acetabulum itself (Fig. 9.15). All of these grafts are best protected

by screws, a porous fixed acetabular component, a plate, or some combination of these items.

***Figure 9.15.*** A large acetabular allograft (**B**) for a low-grade fibrous histiocytoma (**A**) of the acetabulum is shown.

**Large Cystic Defects** When large cysts are present in diaphyseal bone, they can be filled with autografts in most cases. However, when the cysts are so large that there is inadequate autogeneic bone available from the iliac crests, allogeneic bone (preferably AAA bone) may be morcellized and supplemented with autograft to fill the cyst cavity (Fig. 9.12).

***Allografts for Joint Surface Defects (Shell Allografts)***

Because abrasion chondroplasty and arthroplastic reconstruction for joint surface defects can yield poor results (47,56,81,87), biologic resurfacing of joint defects is being tried. The concept of an autogenous free periosteal graft coupled with continuous passive motion (105) or autogenous cartilage cell implant combined with perichondrium is in early clinical trials and has demonstrated mixed success (see Chapter 86). The use of autogenous osteoarticular autografts is an acceptable means of reconstruction (134,140,141). However, this technique has the disadvantage that the available graft materials seldom have a suitable shape for reconstructing a given defect.

Somewhat better known is the use of shell allografts, involving the transplantation of a devascularized, osteoarticular allograft with a small bony component. Studies of osteoarticular shell allografts in humans have not been followed long enough or often enough to determine their outcome, but several authors have reported promising early results (56,57 and 58,97). Of the shell allografts that have failed, some appear to have had a significant pannus reaction (75), suggesting that an immune response was induced by the cells of the subchondral bone (36,136).

The specific techniques in performing shell allografts vary to a certain extent, because the defects vary considerably.

- If a small joint surface defect exists, then make an attempt to resect only that part of the joint surface. Press fit a clear plastic or wax material over the joint surface defect to use as a template, and make a cut in the cartilage approximately 3 to 4 mm around the defect. In this way, a circumferential or geometric cut is made in good viable cartilage just to the edge of the defective cartilage.
- Cut approximately 5 to 10 mm into subchondral bone with an osteotome, and remove the entire joint surface defect. Inspect the subchondral bone, and curet any remaining defective subchondral bone. If there is a large crater, as in avascular necrosis of the hip, pack it with a fresh autogeneic iliac crest bone graft.
- Prepare the small allograft piece from a donor joint that has been recently procured. Procurement requires taking the specimen in a sterile fashion and keeping it sterilely stored at 4°C with capsule intact. The end of a long bone is sufficient for small defects.
- Place the plastic template that was used to mark the size of the defect over the donor cartilage surface; mark the donor surface cartilage with a knife, and cut a corresponding piece from the donor surface, being sure to make the piece slightly larger than what was removed from the recipient. Remove approximately 1 cm of subchondral bone with the donor cartilage. Press fit the perfectly sized donor piece into the defect.
- If there is good fixation at this point, no further fixation is needed. However, it is better to err on the side of obtaining good fixation, if possible. Small threaded Steinmann pins may be drilled from the side into the subchondral bone, and small screws also may be used for this purpose. Either procedure would be better than passing screws across the cartilaginous surface through the tidemark. If the anatomy of the joint does not allow this technique, then drill four small (2.7 mm) holes in the four quadrants of the graft, bringing the drill holes out through cortical bone at some place distant from the graft along the metaphyseal region of the bone. Pass another suture in a crisscross fashion through the other two holes, and tie it over bone. This approach provides fixation of the graft until the subchondral bone heals, and by that time the suture will dissolve. The latter method is not as good as using screws or small pins, because it involves drilling through the tidemark and the pressure of suture across the donor cartilaginous surface. Another reasonable alternative is the use of bioresorbable pins placed in a divergent pattern through the allograft into recipient bone.
- Place the patient's joint in a temporary splint after adequate closure is obtained, and allow the joint to rest for 2 to 3 days. Once the bleeding has stopped and the wound has begun sufficient healing, start continuous passive motion if adequate fixation of the graft has been obtained at surgery. Continue the continuous passive motion for 3 months, if possible. Do not allow full weight bearing for 6 to 9 months, at which time radiographs should show adequate healing of the subchondral bone interfaces. If possible, evaluate the graft approximately 1 year after surgery using diagnostic arthroscopy to assess for an immune rejection phenomenon, which is characterized by pannus covering the graft. If this reaction occurs, the prognosis for the graft is poor.
- Preoperative and postoperative serum studies can help predict an immune response. Obtain serum samples before surgery and at 6 weeks, 12 weeks, and 1 year after the surgery. Test these serum samples against donor lymphocytes, if they are obtained at the time of the graft procurement, or a panel of typed lymphocytes in a standard lymphocyte toxicity assay. A strong antibody response does not necessarily mean that the graft will be rapidly destroyed. Diagnostic arthroscopy is the only sure way to determine the health of the graft.
- If a large shell allograft is needed, such as in replacement of the entire hemijoint surface of a joint or replacement of a medial or lateral side of both the proximal and distal joint surfaces, then different techniques are needed. In these cases there is usually a large defect due to a severe traumatic episode, such as a gunshot wound.
- Procure the allograft specimen as an entire joint specimen, and transport it to the operating room in sterile saline at 4°C with the capsule intact. Transplantation of the joint surfaces should be done approximately 48 hours from the time of procurement. There is evidence to suggest that with this type of storage, the subchondral bone cells will die before the cartilage cells; this may be advantageous when trying to prevent an immune response against the subchondral bone that could eventually damage the donor cartilage (133). For this reason the specimens are not transplanted when they are fresh and warm.
- Debride the defect in the joint of all scar tissue down to healthy bleeding bone. Fashion the shell allograft pieces to fit the defect, leaving intact on the graft any ligaments needed to replace ligaments missing in the recipient. Fix the graft through subchondral bone with threaded Steinmann pins, screws, or staples placed from the side and not passing through the donor cartilage surface.
- If good fixation is obtained at the time of surgery, then begin continuous passive motion within a short time after surgery. If only marginal fixation is obtained, however, then immobilize the entire joint for 6 weeks or, at most, allow a few degrees of motion in a protective brace. Allow partial weight bearing for 3 to 6 months until adequate healing of the subchondral bone interfaces is evident on radiography; this may require tomographic evaluation. A second assessment with an arthroscope 1 year after surgery may be desirable to determine whether a severe immune reaction is occurring. Serial preoperative and postoperative serum histocompatibility testing also can be done to monitor the immune response.

**Results and Prognosis** An overall success rate of approximately 75% can be expected (97). As shown by the results of McDermott et al. (Table 9.3), shell allografts have been most successful in patients who have suffered traumatic damage to their joint surfaces (92). These patients have had success rates of 69% to 92%. Patients with osteoarthritis also have satisfactory results with a success rate of 42%. Patients with osteochondritis dissecans and avascular necrosis have had the poorest results, with a success rate of only about 25%. The reason for this poor showing may be that there is inadequate healing of the osteosynthesis site because of a poor blood supply to the subchondral bone.

| | No. of patients | No. (percent) successful |
|---|---|---|
| Trauma | | |
| Tibial plateau | 36 | 25 (69) |
| Femoral condyle | 12 | 11 (92) |
| Osteoarthritis | 24 | 10 (42) |
| Osteochondritis dissecans | 4 | 1 (25) |
| Osteonecrosis | | |
| SONK | 11 | 3 (27) |
| Steroids | 3 | 0 (0) |
| Totals | 90* | 50 (56) |

* Five patients had a second graft, and results listed are for the final graft; five patients had grafts of the patella (two) or talus (three) and are not included, thus accounting for 90 patients of an initial 100 grafts.

McDermott AG, Langer F, Pritzker KP, Gross AE. Fresh Small-Fragment Osteochondral Allografts. Long-Term Follow-Up Study on First 100 Cases. Clin Orthop 1988;197:96.

***Table 9.3. Effects of Etiology on the Results of Shell Allografts***

### *Allografts for Revision of Total Joint Arthroplasty—Revision Arthroplasties*

Allografts for revision arthroplasties have been used primarily in the hip. Major segmental defects in the acetabulum as well as the proximal femur may occur after multiple revision arthroplasties. These defects can be reconstructed with allografts (see Chapter 106). Acetabular defects may be divided into rim defects, medial wall defects, and global defects.

**Rim Defects** The rim defects can be subcategorized into superior rim, posterior rim, or combinations of superior and posterior rim defects. Most of the superior and posterior rim defects can be reconstructed using a bicortical piece of autogenous iliac crest. If the defect is large, as in the superior and posterior rim defect, a proximal femoral head or distal femur allograft is usually better to reconstruct the defect.

- Cut and shape the proximal graft to provide the bone stock that is necessary, and fix it to the pelvis with two to three screws.
- Use a screw-fixed porous ingrowth type of acetabular component that has screw holes near the rim, so that the screws securing the component can be used as additional fixation of the allograft.
- Butter the allograft with autogeneic marrow and morcellized iliac crest bone to stimulate healing at the osteosynthesis site.
- The screws going through the metal backing of the acetabulum component should pass into good recipient bone to protect the allograft during its remodeling. These grafts may take up to 10 years to be completely resorbed and replaced by recipient bone; therefore, they should be protected with partial weight bearing with a cane during this time.

**Medial Wall Defects** In medial wall defects with thinning of the medial wall, use morcellized autograft packed under a fixed porous ingrowth acetabular component. If the medial wall defect is segmental and large, then it may be adequate to use a large outer table of autogeneic iliac crest, plus morcellized graft with a fixed porous component. It may be necessary also to use a femoral head allograft fashioned to fill the defect. Again, a porous acetabular component is desirable because it will fix the allograft to the recipient autogeneic surfaces and protect it during remodeling.

**Combination Medial Wall and Rim Defects** The combination of a medial wall defect and a rim defect results in a very large defect. In these cases, use a large femoral head allograft or distal femur allograft.

- Debride the allograft of all cartilage and soft tissue, and fix it with a few screws to the recipient pelvic wall. Coat the surfaces with autogeneic bone and marrow before fixation.
- Once it is in position, ream the allograft using standard reaming techniques, and place a screw-fixed acetabular component, fastening additional screws through the porous component into the allograft and into the remaining recipient pelvic wall.
- Occasionally, an acetabular reinforcement cage with an acetabular component cemented into it is necessary. Prolonged protection with partial weight bearing using a cane for up to 5 years is recommended to allow complete incorporation of the allograft material.

**Global Defects** For very large global defects, a complete acetabular allograft is necessary. When harvesting the allograft for these cases, preserve the ischial ramus, pubic ramus, and superior acetabular bone.

- Fix the graft with screws and plates to the recipient pelvic bone. If a bipolar proximal femoral component is to be used, then use an anterior as well as posterior column plate to fix the allograft.
- Coat the surfaces of the allograft with autograft to stimulate healing and union.
- If a total hip replacement is to be used, install an acetabular cage after reaming the allograft acetabulum and coating it with autogeneic bone. Place the screws fixing the acetabular component so that they pass through the allograft and into recipient autogenous bone. Take care to keep the ischial part of the cage on the anterior ischial tuberosity so it does not irritate the sciatic nerve.

**Proximal Femoral Defects** Proximal femur defects may be categorized as one of three types. The first is an intramedullary defect due to diffuse focal resorption of intramedullary bone around the bone cement interface; the second is a medial calcar defect; and the third is a global proximal femoral defect.

- The intramedullary defect is best treated with morcellized autogenous bone plus a porous ingrowth type of prosthesis. If the amount of bone lost is too great to be replaced with autogenous bone, however, mix autogenous iliac crest bone with morcellized allograft bone as a slurry, and pack the defect with this combination autograft and allograft before seating the proximal femoral component.
- For medial calcar defects, cut and fashion a medial calcar allograft to fit the defect. Fix this graft with wires, screws, or a combination of both before seating the proximal femoral component. In these cases, the porous coating should be at least two thirds the length of the stem.
- A global defect of the proximal femur may encompass bone loss of several centimeters in length. In these cases, cut an entire proximal femur allograft and fashion it to fit the defect, making a step cut at the osteosynthesis site. Prepare allograft on the back table including reaming, then cement the proximal femoral component into place in the allograft.
- Remove all excess cement from the osteosynthesis step cut site on the allograft, and then cement the distal stem into place. Additional fixation is usually necessary at the osteosynthesis site in the form of a plate, screws, or cerclage wires.
- In addition, place strips of autogeneic iliac crest around the circumference of the osteosynthesis site, and hold them in place with cerclage wires. This method stimulates healing at the osteosynthesis site.
- Postoperative management of these patients includes suction drainage of any postoperative hematomas and bed rest for 3 to 4 days until bleeding has stopped. At this time, mobilize the patient and allow partial weight bearing using a walker or crutches for several months until the osteosynthesis site has adequately healed. Follow graft healing on serial radiographs. Healing of the osteosynthesis site can be expected to take twice as long as normal bone healing, that is, 3 to 6 months rather than 6 weeks to 3 months. Replacement of the large grafts may take several years, and for this reason patients should use a cane for several years to protect the prosthesis and the graft until it has been solidly incorporated and replaced by recipient bone. Serial bone scans are helpful in interpreting this replacement process. The allograft will become “hot” on bone scan within a few weeks to a few months after the operative procedure, and it will remain hot for several years. If quantitative bone scans can be done when the scan turns “colder,” this is probably an indication that significant strength has been regained to allow full weight bearing.

### *Allografts for Trauma*

The use of bone and joint allografts after severe traumatic destruction of skeletal parts presents many more difficult problems than replacement of tumor or arthritis defects. Severe soft-tissue injuries usually accompany the bony trauma, and many of the wounds have been previously infected (Fig. 9.16). Therefore, the surgeon is frequently operating in an area of decreased blood supply, poor skin coverage, and persisting organisms from previous infections. Most of the experience with allograft use in the treatment of traumatic defects has come from the wartime experience, and the following important prerequisites should be followed (15):

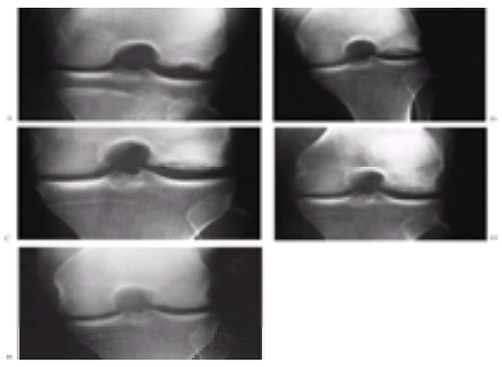

***Figure 9.16.*** This is a femoral condyle shell allograft. Shown are a preoperative traumatic defect (**A**); immediate postoperative radiograph (**B**); replacement of subchondral bone in progress (**C**); full replacement of subchondral bone at 2 years after surgery (**D**); and appearance of the graft 11 years after surgery (**E**). (Courtesy of Dr. Frank Palumbo, Carmichael, CA.)

1. The distal anatomic parts are functionally intact.
2. Good skin coverage must be present or obtainable at the time of surgery. (Remember that a collapsed soft-tissue space will be filled with bone, which creates a stress on the previous skin coverage.)
3. Evidence of infection is absent.
4. Circulation is adequate.
5. Abundant cancellous autograft is available for supplementation of the bony surfaces of the allograft.
6. The graft is protected until healing is complete.

Failure to adhere to these principles places the graft at significant risk of failure.

**Diaphyseal Bone Defects** A number of technical principles have been developed in the treatment of diaphyseal defects. First, morcellized bone appears to incorporate faster than large segmental allografts. Jeshrani and Bencivenga found that 5 of 5 cortical grafts without morcellized grafts failed, 3 of 3 cortical grafts with morcellized graft succeeded, and 17 of 17 grafts with only morcellized bone healed well (71). Osteogenesis and revascularization of the morcellized bone begins to occur within 10 days, and bacteria are much less likely to survive in these small, rapidly revascularized pieces than in a large, nonviable piece of allograft bone (18).

Second, when a large cortical graft is needed to bridge a gap in the femur, humerus, or other isolated long bone, it is recommended that half of an allograft shaft be used with morcellized autogeneic bone packed around it (Fig. 9.17) (9). This approach has two advantages: It maximizes the morcellized graft material, and it decreases the volume of cortical bone that might distend the already shrunken surrounding soft tissue. Extreme care must be taken to protect the large cortical allograft until it has been incorporated; this may take as long as 2 to 3 years. The protection can be provided by a cast, brace, internal fixation with rods or plates, or a combination of these techniques.

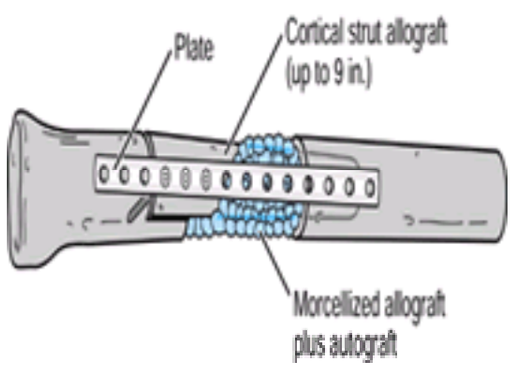


***Figure 9.17.*** Diaphyseal strut allograft after trauma should be reduced in volume and surrounded by abundant morcellized graft.

Third, it is usually not advisable to use a large cortical allograft for tibial bone loss. In this case, a proximal and distal tibiofibular synostosis is obtained first; then progressive grafts made of morcellized, mixed autograft, and allograft bone are used to bridge the defect (94). This may require a number of successive grafts. It is possible that synthetic bone materials mixed with autogenous graft may prove to be at least as good as allograft material for filling such defects. Alternatively, bone transport by Ilizarov techniques might be the best way to bridge the defect (see Chapter 32).

Careful soft-tissue technique, avoiding infection, and the maximal use of morcellized autografts with allografts can give the results shown in Table 9.4 (15). A good result is defined as restored bone continuity and no need for a brace. Satisfactory results are those with restored bone continuity but with the need for bracing. A failure is defined as an amputation.

| *Involved bone* | *No. of grafts* | *Results* | | | |
|---|---|---|---|---|---|
| | | *Good* | *Satisfactory* | *Poor* | *Failure* |
| | | *Upper extremity* | | | |
| Humerus | 7 | 2 | 3 | 2 | 0 |
| Ulna | 4 | 2 | 1 | 1 | 0 |
| Radius | 3 | 1 | 1 | 1 | 0 |
| Totals | 14 | 5 | 5 | 4 | 0 |
| | | 70% | | | |
| | | *Lower extremity* | | | |
| Femur | 7 | 2 | 2 | 2 | 1 |
| Tibia | 9 | 2 | 2 | 2 | 3 |
| Totals | 16 | 4 | 4 | 4 | 4 |
| | | 50% | | | |

Adapted from Brown RH, Townsend GB. Segmental Defects in Open Fractures of Long Bones. Med Ann DC 1970;39:333.

***Table 9.4. Results of Allograft-Autografts for Traumatic Bone Loss***

**Articular Surface Defects** When articular surface defects are due to trauma, replacement is the same as previously described in this chapter. The success rate is considerably better when shell allografts are used for traumatic defects than when used for primary arthritic conditions such as osteoarthritis and avascular necrosis (Table 9.2).

The success rates of large fresh osteochondral allografts has not yet been determined for posttraumatic conditions. The success rates could be considerably worse because of problems with avascular necrosis and collapse of subchondral bone. Using artificial joints threaded through the allograft may prove to be a better method to treat posttraumatic defects of the ends of long bone, as has been the case with large tumors or failed total joint replacements.

**SYNTHETIC BONE GRAFTS AND GROWTH FACTORS**

### *Induction*

Osteoinduction is the process of inducing pluripotential, primitive mesenchymal stem cells to differentiate into osteoblasts. The process of induction has been intensely investigated by Urist et al., and others (7,8,143,147,148,149,150,151,152,153 and 154). Induction of bone formation occurs, in part, as a result of nonsoluble, noncollagenous, bone morphogenetic proteins, as well as other inductive proteins (21,22,48,50,51,53,103,127,147,148,149,150,151,152,153 and 154,159). The most intensely studied of these proteins is from those composing the BMP super family. These proteins are summarized in Table 9.5.

| BMP subfamily | Generic name | BMP designation |
|---|---|---|
| BMP 2/4 | BMP-2A | BMP-2 |
| | BMP-2B | BMP-4 |
| BMP 3 | Osteogenin | BMP-3 |
| | Growth/differentiation factor-10 (GDF-10) | BMP-3B |
| Op-1/BMP-7 | BMP-5 | BMP-5 |
| | Vegetal related-1 (Vg-1) | BMP-6 |
| | Osteogenic protein-1 (Op-1) | BMP-7 |
| | Osteogenic protein-2 (Op-2) | BMP-8 |
| | Osteogenic protein-3 (Op-3) | BMP-8B |
| | Growth/differentiation factor-2 (GDF-2) | BMP-9 |
| | BMP-10 | BMP-10 |
| | Growth/differentiation factor-11 (GDF-11) | BMP-11 |
| GDF-5,6,7 | Growth/differentiation factor-7 (GDF-7) or cartilage-derived morphogenetic protein-3 (CDMP-3) | BMP-12 |
| | Growth/differentiation factor-6 (GDF-6) or cartilage-derived morphogenetic protein-2 (CDMP-2) | BMP-13 |
| | Growth/differentiation factor-5 (GDF-5) or cartilage-derived morphogenetic protein-1 (CDMP-1) | BMP-14 |
| | BMP-15 | BMP-15 |

* BMP-1 is not a BMP family member with seven canonical cysteines. It is a procollagen-C proteinase related to *Drosophila* Tolloid.
From Reddi AH, Role of Morphogenetic Proteins in Skeletal Tissue Engineering and Regeneration. *Nature Biotechnology* (1998)16:247, with permission.

***Table 9.5. The BMP Superfamily in Mammals****

The most intensively studied of these BMPs thus far has been recombinant BMP2 (rhBMP-2) and rhBMP-7, also known as osteogenic protein-1 (OP-1).

In one of the earlier studies, Heckman et al. (63) found that when species-specific BMP was placed in a canine radius nonunion model using a polylactic acid carrier, that a higher incidence of union occurred as compared with that of controls. Yasko et al. (162), using human rhBMP2 in a critical defect model in the femora of rats, were able to demonstrate successful union compared with controls. This was dose related, requiring a large dose of 11.0 µg to achieve union. Gerhart et al. (48), using the same protein but in a segmental defect in the femur of sheep stabilized by a plate, showed no bony union in their negative control groups but complete union in their experimental group and autograph controls. Similar results were demonstrated in a rabbit critical defect model (166). A significant number of human clinical trials are now under way with these very interesting proteins. Recently published studies have demonstrated successful use of a human BMP to augment one-stage lengthening of femoral nonunions (73). When the appropriate carrier vehicles are combined with the appropriate protein or proteins, there is a high likelihood that they may replace the use of autologous bone graft and nonstructural allografts to a great extent. Future research in tissue engineering may result in synthetic structural grafts as well.

### *Bone Marrow*

Autologous red bone marrow, usually obtained by aspiration in adults from the axial skeleton, contains a small but significant number of pluripotential mesenchymal stem cells and inductive factors that have been used to treat nonunions (27,28). Connolly et al. (27,28) have demonstrated the efficacy of repeated injection of tibial nonunions as a substitute for open operative grafting.

### *Conduction*

As opposed to induction discussed above, conduction consists of the growth of host bone into a bone graft or matrix by the growth into available channels in the graft of vascular buds, followed by the laying down of osteoblasts along these channels with subsequent bone formation. In some cases, osteoclastic resorption along the channels may be a part of this process, but this is not necessary with many materials. From the standpoint of a material introduced into a bone defect site, this represents a passive rather than an active phenomenon as in bone induction. Bone conduction can occur through an open matrix, such as one would find in granules packed loosely together, or through structural channels, such as found in some types of coral, in which the ideal size appears to be somewhere between 250 and 600 µ in diameter. A number of synthetic or naturally derived bone-filling materials, some of which promote bone formation through conduction, are now on the market or under investigation. If these materials are used as a carrier vehicle for inductive proteins, then induction would of course also play a role. In their review of the role of bone substitutes, Hollenger et al. (69) provide a list of those available in the United States as of 1996. This list is summarized in Table 9.6.

***Table 9.6. Bone Substitutes Available in the United States***

For orthopaedic applications, the most commonly used materials at this time are Collagraft, Grafton, and ProOsteon 500. The Norian SRS material has received considerable attention recently, but it is still in clinical trials and is not available for general use.

### *Grafton*

Grafton is a form of demineralized bone matrix. It is nonstructural and supplied as a particulate. It may retain some bone induction capability. Most surgeons use it to graft fracture repairs where some assistance is desired but the surgeon either does not wish to incur the morbidity of harvesting a bone graft or is not prepared to harvest a bone graft. Otherwise, most surgeons seem to be using it as an adjunct to autologous bone grafting to expand the bone graft, particularly in spine fusions.

### *Collagraft*

Collagraft is a nonstructural graft supplied in strips that, after rehydration, becomes soft and can be packed into bone defects or laid on the surface of bone. In laboratory and clinical studies, it has proven to be equally efficacious as autologous bone graft in the experimental models and clinical applications chosen (24,32,59,90,93,102). Collagraft has not experienced much popularity, however, because the most common application of this type of material is to fill metaphyseal defects where some structural integrity is necessary that the Collagraft material does not offer.

### *ProOsteon*

This hydroxyapatite is provided in two differing porosities with cross-connected channels and is manufactured by the chemical transformation of the calcium carbonate skeleton of a marine coral. It has been shown in canine critical defect models to incorporate well with excellent bone growth into the open channels of the graft (90,93). Currently this material is approved by the Food and Drug Administration (FDA) for the filling of metaphyseal defects. It is used at our institution for filling the defects in juxtaarticular fractures such as those in the distal radius, in tibial plateau fractures, and in pilon ankle fractures. We also use it to fill defects created by the removal of small benign bone tumors (104). This material is available both in block and granular form. Because it is a very brittle material it is difficult to work with. It is quite weak

in shear and tension. When contained in a bone cavity totally surrounded by bone, where the cavity is firmly packed with the material, it offers reasonable resistance to compression, sufficient enough that it is practical for reconstruction of tibial plateau fractures. Additional support with internal fixation is required. Excessive packing can crush the blocks and granules and reduce their porosity, potentially interfering with bone ingrowth, but this problem has not been documented in practice.

Complications from the use of these materials are few. Because it is essentially pure hydroxyapatite, it illicits no immune response. Occasionally, joint surfaces will settle because of structural weakness in the material, but this can usually be avoided by appropriate internal fixation. Because it is a foreign body, it could potentially be a problem if infection were to occur. However, the studies noted earlier actually show a slightly lower infection rate with ProOsteon when compared with autologous bone. If significant infection were to occur, then resolution of the infection would most likely require removal of the ProOsteon. Lastly, the granules can occasionally get into anatomic sites that are not desirable. In packing the granules into bony defects, they often become adherent to the surrounding soft tissues. Although in our experience this results in no untoward effects, it does produce a less pleasing radiograph. It is a somewhat laborious task to pick each of the particles off the soft tissue. In addition, we have seen one case of a ProOsteon 500 arthrogram of a knee in which a surgeon packed the granules into the defect of a severe tibial plateau fracture, apparently unaware that there was an opening in the joint surface that allowed passage of the granules into the joint space. One year after this occurrence, we arthroscoped the knee and found the knee joint cartilage and menisci to be in perfect condition, with no evidence of untoward effects from the granules. The granules were all adherent to the synovium and were visible through the arthroscope but appeared to be covered by a thin membrane as they were apparently incorporated into the synovium. Therefore, removal of the granules was impractical and seemingly unnecessary. Whether there will be any long-term untoward effects of this complication remains to be seen.

### *Norian SRS*

The Norian material is in a new unique class of injectable calcium phosphates. To a mixture of three different calcium phosphates and calcium carbonate, a sodium phosphate solution is added, resulting in a paste that is formable and injectable for approximately 5 minutes. It is biocompatible as it sets at physiologic temperatures and Ph. The dahllite in the paste hardens after about 10 minutes, obtaining an initial compressive strength of approximately 10 mPa. Within 12 hours, full strength is achieved, with a maximum compressive strength of approximately 55 mPa and tensile strength of 2.1 mPa (29). Orthopaedic surgeons have been seeking some type of bone glue and injectable synthetic bone replacement for years, and this is the first commercially available implant of its type to be shown to be clinically useful. It is not truly a bone glue but can immobilize and fix cancellous bone fragments into place by mechanical interlocking. Cortical bone fragments pressed into the material can likewise be immobilized by mechanical interlocking. When the material has set, it is a relatively solid material that does not offer any porosity for bone conduction. Animal studies show that the material is replaced by host bone in a manner similar to bone remodeling on the surface of the implant. The rate of remodeling and whether or not the Norian material will eventually be entirely replaced by host bone in humans has not yet been established. Preliminary clinical studies suggest that the Norian SRS material may be useful in weak osteoporotic bone, Colles' fractures of the distal radius, tibial plateau fractures, other juxtaarticular fractures involving cancellous bone, and possibly in spinal reconstruction and revision acetabular arthroplasty (29,54). At the time of this writing, this material was not yet approved by the FDA for general use. Within the lifetime of this edition of *Chapman's Orthopaedic Surgery*, no doubt this material will be widely employed. Two potential complications exist: Material may penetrate into the intraarticular space when it is injected percutaneously; and when a large amount of material is used relative to the size of the bone, particularly if it covers the vast majority of the fracture interfaces, delayed or nonunion could occur. To the best of our knowledge, neither of these problems have been reported in the literature.

## COMPLICATIONS

Complications in bone grafting are limited almost exclusively to the usual surgical complications that can occur at the bone graft harvest site. Complications in the use of allografts result primarily from the problem of graft rejection due to immunologic intolerance, and late graft failure due to weakening of the allograft through bone remodeling. The other major concern is disease transmission, in particular the viruses of hepatitis B, and C, and human immunodeficiency virus (HIV). Through donor screening, testing, and implant processing, these risks have been minimized. The major risk remains with fresh composite allografts in which bone and cartilage are transplanted. Donor screening programs have minimized this risk, but they remain real. The complications and risks associated with the use of allografts are discussed in some detail earlier and will not be considered further here.

The risks associated with the use of synthetic bone graft materials and other types of processed bone are quite small and related primarily to either premature mechanical failure of the graft, or nonunion due to lack of incorporation of the graft, lack of ingrowth, or inappropriate use of the material for the clinical situation. The most common problem we have seen has been the packing of a fresh fracture defect site or site of a nonunion with an osteoconductive material that offers no bone induction where the host bed is incapable of thoroughly healing the gap site, resulting in nonunion of the fracture or persistence of the nonunion. This problem can be avoided by using autologous bone and adding purely conductive materials only when necessary.

Because bone inductive proteins have not yet become available in the United States for general use and because the clinical trials reported are quite limited, potential complications of these proteins, other than lack of efficacy, or perhaps immunologic adverse response, are not yet known.

### *Bone Graft Harvest Sites*

In 1989, Younger and Chapman (164) reported a major complication rate of 8.5% and minor complication rate of 20.6% at 243 bone graft donor sites harvested by all types of surgeons at their institution. Potential early complications include wound dehiscence, infection, seromas and hematomas, pain, inadvertent injury of adjacent joints, muscle or bowel herniation, and injury to important structures such as nerves, vessels, and the ureter. Intermediate and long-term complications include an ugly or painful scar; bony deformity; fracture, with or without nonunion; chronic pain; persistence of neurologic injury; and reflex sympathetic dystropy, as well as others. Younger and Chapman reported a higher incidence of complications in patients undergoing posterior spine fusion in which the bone graft was harvested through the same incision as used for the spine surgery. Hugh and Bohlman (70), however, focused on the incidence of fractures at the iliac bone graft harvest site, finding 14 patients with fractures out of approximately 400 fusions divided equally between the cervical and lumbar spine. These were either avulsion fractures of the anterosuperior iliac spine or fractures of the iliac wing. All patients were treated nonoperatively with excellent long-term outcomes. They identified older women with osteopenic bone as being particularly prone to this complication. In 1997, Goulet et al. (55) reviewed 170 patients from whom bone grafts were harvested. Major complications occurred in four (2.4%) in whom deep infection developed. Thirty-seven patients (21.8%) had minor complications. Several of their patients (18.7%) continued to report pain more than 2 years postoperatively. In spite of this incidence, the vast majority of patients were functioning well at 2 years postoperatively. Simple rules to minimize the risks of complications in bone graft donor sites are detailed in the Hints and Tricks sidebars throughout this chapter.

### *Seroma and Hematoma*

Large seromas or hematomas usually manifest themselves within the first few days by a large swelling at the incision site with clear or serosanguineous drainage. These lesioms are usually not a problem if they are contained by a tightly closed fascia. However, a large seroma or hematoma presenting in the subcutaneous area may require aspiration and compression dressing or exploration of the wound for drainage, control of bleeding points, and repeat closure over suction drainage. This is important because these lesions can be very slow to resolve, and persistent drainage can lead to retrograde infection of the donor site.

### *Infection*

Postoperative wound infection nearly always occurs early, within the first 1 to 3 weeks. Early surgical intervention to drain and debride the operative site is nearly always indicated. Gram's stain and deep cultures are important, along with early institution of appropriate intravenous bacteriocidal antibiotics. If surgical and medical treatment is performed early, most patients respond quickly to treatment, and chronic osteomyelitis is rare. Chronic osteomyelitis in a donor site requires thorough debridement of all nonviable bone and treatment, as outlined in Chapter 133.

### *Peripheral Nerve Injury with Neuritis or Causalgia*

Although most patients tolerate an area of loss of sensation, some develop painful neuromas that can be disabling and even lead to reflex sympathetic dystropy. Simple loss of sensation due to a neuropraxia of the nerve secondary to retraction is usually managed well by appropriate counseling of the patient and watchful waiting. Persistent complaints with a definite trigger point, Tennel's sign, or palpable neuroma usually merit surgical exploration of the nerve. Magnification should be used for careful inspection of the nerve. If an intact nerve is found with minimal intraneural scarring, then simple decompression with neurolysis may suffice. If a neuroma or dense intraneural scarring is found, then resection of the injured segment with repair of the nerve, or in some cases resection with burying of the proximal stump, may be indicated depending on the nerve involved and the patient.

### *Pseudoaneurysm*

Acute vascular injuries that do not threaten the viability of important structures or the extremity are usually dealt with at the time of initial injury with ligation of the vessel. Injury of larger vessels that are important to function or limb survival require acute repair and intervention of a vascular surgeon when the orthopaedic surgeon is not qualified to perform vascular repairs. The most vexing late complication of a vascular injury is a pseudoaneurysm in which the initial vascular injury was not

appreciated by the surgeon. Most typically, these lesions present as a mass or swelling that may or may not be painful. On physical examination, they may be pulsatile or have a bruit on oscultation or palpation. Ultrasound or arteriogram, or both, is usually necessary to make a diagnosis, and vascular surgery consultation for surgical correction is nearly always indicated.

### *Post-harvest Fracture*

The most common fracture is avulsion of the anterosuperior iliac spine or a split in the anterior column resulting in inferior and anterior displacement of the anterior fragment to which the sartorius and occasionally the rectus femuris are attached. The vast majority of these fractures can be treated nonoperatively with limited weight bearing with crutches. Union usually occurs within 6 to 10 weeks. The patient may be left with some deformity of the pelvis, but usually this is asymptomatic and not of cosmetic concern. For the most part, these fractures occur in elderly osteoporotic women. Occasionally, they occur in young active athletes. In these cases, open reduction and internal fixation may be indicated.

Fractures of long bones due to bone graft harvest in metaphyseal areas with minimal displacement can usually be treated nonoperatively. Displaced unstable mid-diaphyseal fractures, particularly in the tibia and femur, are usually best treated with closed reamed intramedullary nailing. Reaming of the medullary canal grafts the defect site, and if necessary, additional cancellous bone can be added by the intramedullary or subperiosteal route (23). Intramedullary nailing usually allows early weight bearing and return to function. Because these fractures can be very slow to heal, the intramedullary nail provides prolonged protection of the fracture site.

### *Dropped Bone Graft*

All surgeons fear the day when an important autologous bone graft just harvested from the patient is accidentally dropped to the floor of the operating room. Little has been written about what to do in this circumstance other than to abandon the graft and harvest another one, if available. Presnal and Kimbrough (117) found that 50 surplus bone grafts dropped in the operating room in their institution and submitted for culture were sterile. Therefore, they recommended that, if a bone graft that had been dropped on the operating room floor was to be implanted in the patient, extensive sterilization was not essential. Our approach to the dropped graft is as follows:

- If a second graft can be harvested with no or minimal additional morbidity for the patient, then discard the dropped graft and harvest a second graft.
- If the dropped graft is essential and an additional harvest would subject the patient to additional morbidity, then treat the graft as follows and use it:
- Irrigate the graft using a pulsatile irrigator with two or more liters of saline depending on the size of the graft.
- Then soak the graft in a basin on the back table for at least 10 minutes in either an antibiotic solution or in a very dilute solution of povidone-iodine. Povidone has been shown to be cytotoxic to osteoblasts, so the solution should be weak and the surgeon must realize that this may result in death of any viable osteoblasts in the graft.
- The graft can then be inserted directly from the antibiotic solution, or, if povidone solution was used, it should then again be irrigated to remove any residual iodophor.
- If the graft happens to be cancellous bone, then adding an antibiotic such as tobramycin powder to the graft may be useful because cancellous bone graft has been recommended as a vehicle for local antibiotic delivery. Lindsey et al. (85) have shown that local Tobramycin does not appear to affect the normal healing characteristics of bone graft in a canine femoral defect.

Careful monitoring of the patient postoperatively and appropriate postoperative intravenous bacteriocidal antibiotics are appropriate. Counseling of the patient is wise.

## AUTHORS' PERSPECTIVE

For nonunions and major bone defects secondary to fractures for which Ilizarov techniques are not being used, we prefer autologous bone graft harvested from the iliac crest. If any significant amount of cancellous bone is needed, then we nearly always use the posterior ilium, in spite of the inconvenience of this operative site because of the large amount of bone available from this location. In addition, the morbidity of this harvest site is much less than one located anteriorly. Neither one of us does spine surgery, so the issues of bone grafting and spine arthrodesis will be addressed in the spine section.

For small fresh fracture defects, we harvest bone grafts from the metaphyseal section of the same limb segment or ipsilateral limb. For contained metaphyseal defects secondary to fractures such as in the tibial plateau, or for small benign tumors requiring bone graft, we use Pro-Osteon 500 granules and blocks usually in combination. One of the authors of this chapter (JRR), whose practice is predominantly revision total joint arthroplasty, uses a considerable amount of allograft, both in a morcellized form for impaction bone grafting in cavitary defects of the femur and as structural grafts in major proximal femoral, acetabular, or other areas. In addition, he uses whole bone allografts with joint surfaces in an occasional resection for malignant tumors and an occasional shell allograft for joint resurfacing. Although his experience is small, it is consistent with the literature discussed in this chapter. The techniques used by both of us are reflected in the sections of this chapter discussing indications and surgical technique.

## CHAPTER REFERENCES

Each reference is categorized according to the following scheme: *, classic article; #, review article; !, basic research article; and +, clinical results/outcome study.,


+ 1. Abbott LC. The Use of Iliac Bone in the Treatment of Ununited Fractures. In *American Academy of Orthopaedic Surgeons: Instructional Course Lectures,* Vol. 2. Ann Arbor, MI: J. W. Edwards, 1944.

* 2. Abbott LC, Schottstaedt ER, Saunders JB, et al. The Evaluation of Cortical and Cancellous Bone as Grafting Material. A Clinical and Experimental Study. *J Bone Joint Surg* 1947;29:381.

* 3. Albee FH. Transplantation of a Portion of the Tibia into the Spine for Pott's Disease. *JAMA* 1911;57:85.

* 4. Albee FH. Evolution of Bone Graft Surgery. *Am J Surg* 1944;63:421.

! 5. Arora BK, Laskin DM. Sex Chromatin as a Cellular Label of Osteogenesis by Bone Grafts. *J Bone Joint Surg* 1964;46-A:1269.

+ 6. Aurori BF, Weierman RJ, Lowell HA, et al. Pseudarthrosis after Spinal Fusion for Scoliosis. *Clin Orthop* 1985;199:153.

! 7. Bassett CAL. Clinical Implications of Cell Function in Bone Grafting. *Clin Orthop* 1972;87:49.

# 8. Bassett CAL, Ruedi-Lindesker A. Bibliography of Bone Transplantation. *Transplantation* 1964;2:688.

+ 9. Boden SD, Schimandle JH, Hutton WC, et al. Lumbar Intertransverse-Process Spinal Arthrodesis with Use of a Bovine Bone-Derived Osteoinductive Protein. *J Bone Joint Surg* 1995;77-A:1404.

+ 10. Borja FJ, Mnaymneh W. Bone Allografts in Salvage of Difficult Hip Arthroplasties. *Clin Orthop* 1985;197:123.

! 11. Bos GD, Goldberg VM, Gordon NH, et al. The Long-Term Fate of Fresh and Frozen Orthotopic Bone Allografts in Genetically Defined Rats. *Clin Orthop* 1985;197:245.

* 12. Boyd HB, Lapinski SP. Causes and Treatment of Nonunion of the Shafts of the Long Bones. In *American Academy of Orthopaedic Surgeons: Instructional Course Lectures,* Vol. 17. St. Louis: C. V. Mosby, 1960.

# 13. Brien RE, Terek RM, Healey JH, Lane JM. Allograft Reconstruction after Proximal Tibial Resection for Bone Tumors. *Clin Orthop* 1994;303:116.

# 14. Bright RW, Burchardt H. The Biomechanical Properties of Preserved Bone Grafts. In: Friedlaender GE, Mankin HJ, Sell KW, eds. *Osteochondral Allografts.* Boston; Little, Brown & Co, 1983.

+ 15. Brown RH, Townsend GB. Segmental Defects in Open Fractures of Long Bones. *Medical Annals of the District of Columbia,* 1970;39:555.

! 16. Brown TD, Rodin EL, Martin RB, Burn OB. Finite Element Studies of Some Juxta-articular Stress Changes due to Localized Subchondral Stiffening. *J Biomed* 1984;17:11.

! 17. Burchardt H, Glowczewskie FP, Enneking WF. Allogenic Segmental Fibular Transplants in Azathioprine-immunosuppressed Dogs. *J Bone Joint Surg* 1977;59-A:881.

# 18. Burwell RG. The Fate of Bone Grafts. In: Apley AG, ed. *Recent Advances in Orthopaedics.* London: Churchill, 1969:115–207.

+ 19. Buttermann GR, Glazer PA, Bradford DS. The Use of Bone Allografts in the Spine. *Clin Orthop* 1996;324:75.

+ 20. Campbell CJ. Homotransplantation of Half and Whole Joints. *Clin Orthop* 1972;87:146.

! 21. Chalmers J, Ray RD. The Growth of Transplanted Foetal Bones in Different Immunological Environments. *J Bone Joint Surg* 1962;44-B:149.

! 22. Chalmers J, Rush J. Observations on the Induction of Bone in Soft Tissues. *J Bone Joint Surg* 1975;57-B:36.

+ 23. Chapman MW. Closed Intramedullary Bone-grafting and Nailing of Segmental Defects of the Femur. *J Bone Joint Surg* 1980;62-A:1004.

+ 24. Chapman MW, Bucholz R, Cornell C. Treatment of Acute Fractures with a Collagen-Calcium Phosphate Graft Material: A Randomized Clinical Trial. *J Bone Joint Surg* 1997;79A:495.

# 25. Chase SW, Herndon CH. The Fate of Autogenous and Homogenous Bone Grafts: A Historical Review. *J Bone Joint Surg* 1955;37-A:809.

* 26. Cloward RB. The Anterior Approach for Removal of Ruptured Cervical Discs. *J Neurosurg* 1958;15:602.

+ 27. Connolly JF, Guse R, Lippiello L, Dehne R. Development of an Osteogenic Bone Marrow Preparation. *J Bone Joint Surg* 1989;71-A:684.

+ 28. Connolly JF, Guse R, Tiedeman J, Dehne R. Autologous Marrow Injection as a Substitute for Operative Grafting of Tibial Nonunions. *Clin Orthop* 1991;266:259.

! 29. Constantz BR, Ison IC, Fulmer NT, et al. Skeletal Repair by In Situ Formation of the Mineral Phase of Bone. *Science* 1995;267:1796.

+ 30. Cook SD, Baffes GC, Wolfe MW, et al. The Effect of Recombinant Human Osteogenic Protein-1 on Healing of Large Segmental Bone Defects. *J Bone Joint Surg* 1994;76-A:827.

# 31. Cook SD, Rueger DC. Osteogenic Protein-1. *Clin Orthop* 1996;324:29.

+ 32. Cornell CN, Lane JM, Chapman MW, et al. Multicenter Trial of Collagraft as Bone Graft Substitute. *J Orthop Trauma* 1991;5:1.

! 33. Craigmyle MBL. Antigenicity and Survival of Cartilage Homografts. *Nature* 1958;182:1248.

! 34. Craigmyle MBL. Regional Lymph Node Changes Induced by Cartilage Homo- and Heterografts in the Rabbit. *J Anat* 1958;92:74.

! 35. Craven PL, Urist MR. Osteogenesis by Radio-isotope Labelled Cell Populations in Implants of Bone Matrix under the Influence of Ionizing Radiation. *Clin Orthop* 1971;76:231.

! 36. Czitrom AA, Axelrod T, Fernandes B. Antigen Presenting Cells and Bone Allotransplantation. *Clin Orthop* 1985;197:27.

! 37. Czitrom AA, Lauger F, McKee N, Gross AE. Bone and Cartilage Allotransplantation. *Clin Orthop* 1986;208:141.

! 38. Delloye C, Verhelpen M, d' Hemricourt J, et al. Morphometric and Physical Investigations of Segmental Cortical Bone Autografts in Canine Ulnar Defects. *Clin Orthop* 1992;282:273.

! 39. Elves MW. Immunological Studies of Osteoarticular Allografts. *Proc R Soc Med* 1971;64:644.

! 40. Elves MW. A Study of the Transplantation Antigens on Chondrocytes from Articular Cartilage. *J Bone Joint Surg* 1974;56-B:178.

! 41. Elves MW. Humoral Immune Responses to Allografts of Bone. *Int Arch Allergy Immunol* 1974;47:708.

! 42. Elves MW, Ford CH. The Development of Humoral Cytotoxic Antibodies after the Allografting of Articular Surfaces of the Knee Joint in Sheep. *J Bone Joint Surg* 1971;53-B:554.

! 43. Elves MW, Ford CH. A Study of the Humoral Immune Response to Osteoarticular Allografts in Sheep. *Clin Exp Immunol* 1974;17:497.

+ 44. Emerson RH, Malinin TI, Cuellar AD, et al. Cortical Strut Allografts on the Reconstruction of the Femur in Revision Total Hip Arthroplasty. *Clinical Orthop* 1992;285:35.

* 45. Enneking WF, Burchardt H, Puhl J, et al. Physical and Biologic Aspects of Repair in Dog Cortical Bone Transplants. *J Bone Joint Surg* 1975;57-A:237.

* 46. Enneking WF, Morris JL. Human Autologous Cortical Bone Transplants. *Clin Orthop* 1972;87:28.

+ 47. Friedman MJ, Berasi CC, Fox JM, et al. Preliminary Results with Abrasion Arthroplasty in the Osteoarthritic Knee. *Clin Orthop* 1984;182:200.

! 48. Gerhart TN, Kirker-Head VS, Kriz MJ, et al. Healing Segmental Femoral Defects in Sheep Using Recombinant Human Bone Morphogenetic Protein. *Clin Orthop* 1993;293:317.

+ 49. Gitelis S, Heligman D, Quill G, Piasecki P. The Use of Large Allografts for Tumor Reconstruction and Salvage of the Failed Total Hip Arthroplasty. *Clin Orthop* 1988;231:62.

! 50. Glowacki J. Cellular Reactions to Bone-derived Material. *Clin Orthop* 1996;324:47.

! 51. Glowacki J, Kaban CB, Murray JE, et al. Application of the Biological Principle of Induced Osteogenesis for Craniofacial Defects. *Lancet* 1981;1:959.

! 52. Goldberg VM, Lance EM. Revascularization and Accretion in Transplantation. Quantitative Studies of the Allograft Barrier. *J Bone Joint Surg* 1972;54-A:807.

# 53. Goldring SR, Goldring MB. Cytokines and Skeletal Physiology. *Clin Orthop* 1996;324:13.

+ 54. Goodman SB, Bauer TW, Carter D. Norian SRS Cement Augmentation in Hip Fracture Treatment. *Clin Orthop* 1998;348:42.

+ 55. Goulet JA, Senunas LE, DeSilva GL, et al. Autogenous Iliac Crest Bone Graft, Complications and Functional Assessment. *Clin Orthop* 1997;339:76.

+ 56. Gross AE, McKee NH, Langer F, Pritzker K. Surgical Techniques and Clinical Experience with Articular Allografts at the Knee. In: Friedlaender GE, Mankin HJ, Sell KW, eds. *Osteochondral Allografts: Biology, Banking, and Clinical Applications.* Boston: Little Brown & Co, 1984.

+ 57. Gross AE, McKee NH, Pritzker KPH, Langer F. Reconstruction of Skeletal Deficits at the Knee. *Clin Orthop* 1983;174:96.

+ 58. Gross AE, Silverstein EA, Fal J, et al. The Allotransplantation of Partial Joints in the Treatment of Osteoarthritis of the Knee. *Clin Orthop* 1975;108:7.

! 59. Gruendel RE, Chapman MW, Yee T, Moore DC. Autogenous Bone Marrow and Porous Biphasic Calcium-Phosphate Ceramic for Segmental Bone Defects in the Canine Ulna. *Clin Orthop* 1991;266:244.

+ 60. Hagerty RF, Braid HL, Bonner WM Jr, et al. Viable and Non-viable Human Cartilage Homografts. *Surg Gynecol Obstet* 1967;124:485.

* 61. Harkins HN, Phemister DB. Simplified Technic of Onlay Grafts. *JAMA* 1937;109:1501.

+ 62. Harrington KD, Johnston JO, Kaufer HN, Luck JV Jr. Limb Salvage and Prosthetic Joint Reconstruction for Low-grade and Selected High-grade Sarcomas of Bone after Wide Resection and Replacement by Autoclaved Autogeneic Grafts. *Clin Orthop* 1986;211:180.

! 63. Heckman JD, Boyan BD, Aufdemorte TB, Abbott JT. The Use of Bone Morphogenetic Protein in the Treatment of Non-Union in a Canine Model. *J Bone Joint Surg* 1991;73A:750.

# 64. Heim U, Pfeiffer KM. *Small Fragment Set Manual.* New York: Springer-Verlag, 1974.

* 65. Heiple KG, Chase SW, Herndon CH. A Comparative Study of the Healing Process Following Different Types of Bone Transplantation. *J Bone Joint Surg* 1963;45-A:1593.

! 66. Herndon CH, Chase SW. Experimental Studies in the Transplantation of Whole Joints. *J Bone Joint Surg* 1952;34-A:564.

! 67. Heyner S. The Antigenicity of Cartilage Grafts. *Surg Gynecol Obstet* 1973;136:298.

+ 68. Highgenboten CL, Jackson A, Aschliman M, Meske NB. The Estimation of Femoral Condyle Size. An Important Component in Osteochondral Allografts. *Clin Orthop* 1989;246:225.

+ 69. Hollinger JO, Brekke J, Gruskin E, Lee D. Role of Bone Substitutes. *Clin Orthop* 1996;324:55.

+ 70. Hu RW, Bohlman HH. Fracture at the Iliac Bone Graft Harvest Site after Fusion of the Spine. *Clin Orthop* 1994;309:208.

+ 71. Jeshrani MK, Bencivenga A. Comparative Value of Cortical and Cancellous Bone as Grafting Material in Bone Defect of Different Origins. *East Afr Med J* 1978;55:228.

+ 72. Jofe MH, Gebhardt MC, Tomford WW, Mankin HJ. Reconstruction for Defects of the Proximal Part of the Femur Using Allograft Arthroplasty. *J Bone Joint Surg* 1988;70-A:507.

+ 73. Johnson EE, Urist MR. One-Stage Lengthening of Femoral Nonunion Augmented with Human Bone Morphogenetic Protein. *Clin Orthop* 1998;347:105.

+ 74. Johnson EE, Urist MR, Finerman GA. Repair of Segmental Defects of the Tibia With Cancellous Bone Grafts Augmented with Human Bone Morphogenetic Protein. A Preliminary Report. *Clin Orthop* 1988;236:249.

! 75. Kandel RA, Gross AE, Ganel A, et al. Histopathology of Failed Osteoarticular Shell Allografts. *Clin Orthop* 1985;197:103.

+ 76. Kattapuram SV, Phillips WC, Mankin HJ. Intercalary Bone Allografts: Radiographic Evaluation. *Radiology* 1989;170:137.

! 77. Kingma MJ, Hampe JF. The Behavior of Blood Vessels after Experimental Transplantation of Bone. *J Bone Joint Surg* 1964;46-B:141.

+ 78. Koskinen EVS. Wide Resection of Primary Tumors of Bone and Replacement with Massive Bone Grafts. An Improved Technique for Transplanting Allogeneic Bone Grafts. *Clin Orthop* 1978;134:302.

+ 79. Kreuz FP, Hyatt GW, Turner TC, Bassett AL. The Preservation and Clinical Use of Freeze-Dried Bone. *J Bone Joint Surg* 1951;33-A:863.

! 80. Lance EM, Fisher RL. Transplantation of the Rabbit Patella. *J Bone Joint Surg* 1970;52-A:145.

+ 81. Laskin RS. Unicompartmental Tibiofemoral Resurfacing Arthroplasty. *J Bone Joint Surg* 1978;60-A:182.

+ 82. Lexer E. Die Verwenbdung der Freien Knockenplastik Nebst Versuchen Uper Gelenkversteifung und Gelenktransplantation. *Arch Klin Chir* 1908;86:939.

+ 83. Lexer E. Joint Transplantation and Arthroplasty. *Surg Gynecol Obstet* 1925;40:782.

+ 84. Lin PM. Posterior Lumbar Interbody Fusion Technique; Complications and Pitfalls. *Clin Orthop* 1985;193:90.

! 85. Lindsey RW, Probe R, Miclau T, et al. The Effects of Antibiotic-Impregnated Autogeneic Cancellous Bone Graft on Bone Healing. *Clin Orthop* 1993;291:303.

+ 86. Malinen TI, Martinez OV, Brown MD. Banking of Massive Osteoarticular and Intercalary Bone Allografts—12 Year Experience. *Clin Orthop* 1985;197:44.

! 87. Mankin HJ. The Response of Articular Cartilage to Mechanical Injury. *J Bone Joint Surg* 1982;64-A:460.

# 88. Mankin HJ. Complications of Allograft Surgery. In: Friedlaender GE, Mankin HJ, Sell KW, eds. *Osteochondral Allografts.* Boston: Little, Brown & Co, 1983.

+ 89. Mankin HJ, Fogelson FS, Thrasher AZ, Jaffer F. Resection and Allograft Transplantation in the Treatment of Malignant Bone Tumors. *N Engl J Med* 1976;294:1247.

! 90. Martin RB, Chapman MW, Holmes RE, et al. The Effects of Bone Ingrowth on the Strength and Noninvasive Assessment of a Coralline Hydroxyapatite Material. *Biomaterials* 1989;10:481.

+ 91. McCarthy RE, Peek RD, Morissy RT, Hough AJ. Allograft Bone in Spinal Fusion for Paralytic Scoliosis. *J Bone Joint Surg* 1986;68-A(3):370.

+ 92. McDermott AG, Langer F, Pritzker KP, Gross AE. Fresh Small-fragment Osteochondral Allografts. Long-Term Follow Up Study on First 100 Cases. *Clin Orthop* 1985;197:96.

! 93. McIntyre JP, Shackelford JF, Chapman MW, Pool RR. Characterization of a Bioceramic Composite for Repair of Large Bone Defects. *Bull Am Ceram Soc* 1991;70:1499.

+ 94. McMaster PE, Hohl M. Tibiofibular Cross-peg Grafting. *J Bone Joint Surg* 1965;47-A:1146.

95. Mellonig JT, Bowers GM, Bailey RC. Comparison of Bone Graft Materials: II. New Bone Formation with Autografts and Allografts: A Histological Evaulation. *J Periodontol* 1981;52:297.

+ 96. Meyers MH. The Role of Posterior Bone Grafts (Muscle Pedicle) in Femoral Neck Fractures. *Clin Orthop* 1980;152:143.

+ 97. Meyers MH, Bucholz RW, Jones RE. Surgical Techniques and Clinical Experience with Fresh Osteochondral Allografts of the Hip. In: Friedlaender GE, Mankin JH, Sell KW, eds. Osteochondral Allografts: Biology, Banking, and Clinical Applications. Boston: Little, Brown & Co, 1984.

+ 98. Meyers MH, Harvey JP, Moore TM. Treatment of Displaced Subcapital and Transcervical Fractures of the Femoral Neck by Muscle-Pedicle Bone Graft and Internal Fixation. *J Bone Joint Surg* 1973;55-A:257.

+ 99. Meyers MH, Harvey JP, Moore TM. The Muscle-Pedicle Bone Graft in the Treatment of Displaced Fractures of the Femoral Neck: Indications, Operative Technique, and Results. *Orthop Clin North Am* 1974;5:779.

+ 100. Mnaymneh W, Malinin TI, Lackman RD, et al. Massive Distal Femoral Osteoarticular Allografts after Resection of Bone Tumors. *Clin Orthop* 1994;303:103.

+ 101. Mnaymneh W, Malinen TI, Makley JT, Dick HM. Massive Osteoarticular Allografts in the Reconstruction of Extremities Following Resection of Tumors not Requiring Chemotherapy and Radiation. *Clin Orthop* 1985;197:76.

! 102. Moore DC, Chapman MW, Manske D. The Evaluation of a Biphasic Calcium Phosphate Ceramic for Use in Grafting Long-bone Diaphyseal Defects. *J Orthop Res* 1987;5:356.

# 103. Mundy GR. Regulation of Bone Formation by Bone Morphogenetic Proteins and Other Growth Factors. *Clin Orthop* 1996;323:24.

+ 104. Nicholas RW, Lange TA. Granular Tricalcium Phosphate Grafting of Cavitary Lesions in Human Bone. *Clin Orthop* 1994;306:197.

! 105. O'Driscoll SW, Salter RB. The Induction Neochondrogenesis in Free Intra-articular Autografts under the Influence of Continous Passive Motion. *J Bone Joint Surg* 1984;66-A:1248.

! 106. Oikarinen J. Experimental Spinal Fusion with Decalcified Bone Matrix and Deep Frozen Allogeneic Bone in Rabbits. *Clin Orthop* 1982;162:210.

! 107. Oklund SA, Prolo DJ, Gutierrez RV, King SE. Quantitative Comparisons of Healing in Cranial Fresh Autografts, Frozen Autografts, and Processed Autografts and Allografts in Canine Skull Defects. *Clin Orthop* 1986;205:269.

+ 108. Ottolenghi CE. Massive Osteocarticular Bone Grafts. Technique and Results of 62 Cases. *Clin Orthop* 1972;87:156.

+ 109. Pap K, Krompecher S. Arthroplasty of the Knee: Experimental and Clinical Experiences. *J Bone Joint Surg* 1961;43-A:523.

+ 110. Parrish FF. Allograft Replacement of All or Part of the End of a Long Bone Following Excision of a Tumor: Report of 21 Cases. *J Bone Joint Surg* 1973;55-A:1.

+ 111. Parrish FF. Treatment of Bone Tumors by Total Excision and Replacement with Massive Autologous and Homologous Grafts. *J Bone Joint Surg* 1966;48-A:968.

# 112. Parrish FF. Homografts of Bone. *Clin Orthop* 1972;87:36.

+ 113. Peer LA. Cartilage Grafting. *Br J Plast Surg* 1954;7:250.

! 114. Pelker RR, Friedlaender GE, Markham TC, et al. Effects of Freezing and Freeze-Drying on the Biomechanical Properties of Rat Bone. *J Orthop Res* 1984;1:405.

* 115. Phemister DB. The Fate of Transplanted Bone and Regenerative Power of Its Various Constituents. *Surg Gynecol Obstet* 1914;19:303.

+ 116. Poitout D, Novakovitch G. Use of Allografts in Oncology and Traumatology. *Int Orthop* 1987;11:169.

+ 117. Presnal BP, Kimbrough EE. What to Do About a Dropped Bone Graft. *Clin Orthop* 1993;296:310.

+ 118. Prolo DJ, Oklund SA. Composite Autogeneic Human Cranioplasty: Frozen Skull Supplemented with Fresh Iliac Corticocancellous Bone. *Neurosurgery* 1984;15:846.

+ 119. Prolo DJ, Pedrotti PW, White DH. Ethylene Oxide Sterilization of Bone, Dura Mater, and Fascia Lata for Human Transplantation. *Neurosurgery* 1980;6:529.

! 120. Puranen J. Reorganization of Fresh and Preserved Bone Transplants: An Experimental Study in Rabbits Using Tetracycline Labelling. *Acta Orthop Scand* 1966;(Suppl)92:9.

! 121. Rasi HB. The Fate of Preserved Human Cartilage. *Plast Reconstr Surg* 1959;24:24.

! 122. Ray RD. Vascularization of Bone Grafts and Implants. *Clin Orthop* 1972;87:43.

! 123. Ray RD, Degge J, Gloyd P, et al. Bone Regeneration: An Experimental Study of Bone-grafting Materials. *J Bone Joint Surg* 1952;34-A:639.

! 124. Ray RD, Sabet TY. Bone Grafts: Cellular Survival Versus Induction. *J Bone Joint Surg* 1963;45-A:337.

# 125. Reddi HA. Role of Morphogenetic Proteins in Skeletal Tissue Engineering and Regeneration. *Nature Biotechnology* 1998;16:247.

! 126. Reynolds FC, Oliver DR. Experimental Evaluation of Homogenous Bone Grafts. *J Bone Joint Surg* 1950;32-A:283.

# 127. Riley E, Lane JM, Urist MR, et al. Bone Morphogenetic Protein-2. *Clin Orthop* 1996;324:39.

# 128. Rodrigo JJ. Modulation of Immune Responses Associated with Bone Allografts. In: Friedlaender GE, Mankin HJ, Sell KW, eds. *Osteochondral Allografts.* Boston: Little, Brown & Co, 1983.

+ 129. Rodrigo JJ. The Problem of Fit in Osteocartilaginous Allografts. In: Friedlaender GE, Mankin HJ, and Sell KW, eds. *Osteochondral Allografts.* Boston; Little, Brown & Co, 1983.

! 130. Rodrigo JJ, Fuller TC, Mankin HJ. Cytotoxic HL-A Antibodies in Patients with Bone and Cartilage Allografts. *Trans Orthop Res Soc* 1976;1:131.

! 131. Rodrigo JJ, Gray JM, Thompson EC. Temporary Suppression of Humoral Cytotoxic Antibodies with Double Dose Cyclosphosamide Treatment in Rats Receiving Distal Femur Allografts. *Trans Orthop Res Soc* 1984;9:265.

! 132. Rodrigo JJ, Leathers MW, Thompson EC, et al. Osteocartilaginous Shell Allografts in Dogs. *Trans Orthop Res Soc* 1983;8:319.

! 133. Rodrigo JJ, Reynolds H, Thorson E, et al. Cement Coating of Osteoarticular Allografts in Rats to Prevent the Immune Response. *Trans Orthop Res Soc* 1987;12:274.

! 134. Rodrigo JJ, Sakovich L. Osteocartilaginous Allografts as Compared with Autografts in the Treatment of Knee Joint Osteocartilaginous Defects in Dogs. *Trans Orthop Res Soc* 1977;2:92.

! 135. Rodrigo JJ, Sakovich L, Travis C, Smith G. Osteocartilginous Allografts as Compared with Autografts in the Treatment of Knee Joint Osteocartilaginous Defects in Dogs. *Clin Orthop* 1978;134:342.

! 136. Rodrigo JJ, Schnaser AM, Reynolds HM Jr, et al. Inhibition of the Immune Response to Experimental Fresh Osteoarticular Allografts. *Clin Orthop* 1989;243:235.

! 137. Rodrigo JJ, Thompson EC, Gray JM. Inhibition of the Antibody Response with Cyclosporin A after Distal Femur Allografts in Rats. *Trans Orthop Res Soc* 1983;8:165.

+ 138. Salama A, Weissman SL. The Clinical Use of Combined Xenografts of Bone and Autologous Red Marrow. *J Bone Joint Surg* 1978;60-B:111.

+ 139. Shapiro MS, Endrizzi DP, Cannon RM, Dick HM. Treatment of Tibial Defects and Nonunions Using ipsilateral Vascularized Fibular Transposition. *Clin Orthop* 1993;296:207.

+ 140. Shively RA, Maylack FH, Simmons DJ. Autogenous Articular Cartilage and Osteochondral Grafts. *Trans Orthop Res Soc* 1986;11:281.

! 141. Skoog T, Johansson SH. The Formation of Articular Cartilage from Free Periochondral Grafts. *J Plast Reconstr Surg* 1976;57:1.

+ 142. Stabler CL, Eismont FJ, Brown MD, et al. Failure of Posterior Cervical Fusions Using Cadaveric Bone Graft in Children. *J Bone Joint Surg* 1985;67-A:370.

# 143. Stevenson S, Emery AE, Goldberg VM. Factors Affecting Bone Graft Incorporation. *Clin Orthop* 1996;324:66.

! 144. Stevenson S, Shaffer JW, Goldberg VM. The Humoral Response to Vascular and Nonvascular Allografts of Bone. *Clin Orthop* 1996;323:86.

! 145. Tauro JC, Parson JR, Ricci J, Alexander H. Comparison of Bovine Collagen Xenografts to Autografts in the Rabbit. *Clin Orthop* 1991;266:271.

! 146. Tomford WW, Henry WB, Aubrey BJ, et al. A Study of Factors Important in Large Frozen Allograft Transplantation. *Trans Orthop Res Soc* 1987;12:91.

* 147. Urist MR. Bone: Formation by Autoinduction. *Science* 1965;150:893.

! 148. Urist MR. Surface-Decalcified Allogeneic Bone (SCAB) Implants. *Clin Orthop* 1968;56:37.

# 149. Urist MR. Bone Transplants and Implants. In: Urist MR, ed. *Fundamental and Clinical Physiology of Bone.* Philadelphia: J. B. Lippincott, 1980.

+ 150. Urist MR. Chemosterilized Antigen-Extracted Surface-Demineralized Allogeneic (AAA) Bone for Arthrodesis. In: Friedlaender GE, Mankin HJ, Sell KW, eds. *Osteochondral Allografts.* Boston: Little, Brown & Co, 1983.

+ 151. Urist MR, Dawson E. Intertransverse Process Fusion with the Aid of Chemosterilized Autolyzed Antigen-Extracted Allogeneic (AAA) Bone. *Clin Orthop* 1981;154:97.

! 152. Urist MR, Earnest F, Kimball KM, et al. Bone Morphogenesis in Implants of Residues of Radioisotope-Labelled Bone Matrix. *Calcif Tissue Res* 1974;15:269.

! 153. Urist MR, Mikulski AJ, Boyd SD. A Chemosterilized Antigen Extracted Bone Morphogenetic Alloimplant. *Arch Surg* 1975;110:416.

# 154. Urist MR, Silverman BG, Buring K, et al. The Bone Induction Principle. *Clin Orthop* 1967;53:243.

+ 155. Urovitz EP, Langer F, Gross AE, West M. Cell Mediated Immunity in Patients Following Joint Allografting. *Trans Orthop Res Soc* 1976;1:132.

+ 156. Volkov M. Allotransplantation of Joints. *J Bone Joint Surg* 1970;52-B:49.

# 157. Weber BG, Cech O. *Pseudarthrosis.* Bern, Switzerland: Hans Huber, 1976.

+ 158. Wilson PD. Follow-up Study of the Use of Refrigerated Homogenous Bone Transplants in Orthopaedic Surgery. *J Bone Joint Surg* 1951;33-A:307.

# 159. Wozney JM. Bone Morphogenetic Proteins and Their Gene Expression. In: *Cellular and Molecular Biology of Bone.* Academic Press, Inc., 1993.

# 160. Yablon IG. Immune Responses to Matrix Components. In: Friedlaender GE, Mankin HJ, Sell KW, eds. *Osteochondral Allografts.* Boston: Little, Brown & Co, 1983.

! 161. Yang C-Y, Simmons DJ, Lozano R. The Healing of Grafts Combining Freeze-Dried and Demineralized Allogeneic Bone in Rabbits. *Clin Orthop* 1994;298:286.

! 162. Yasko EK, Lane JM, Fellinger ER, et al. The Healing of Segmental Bone Defects, Induced by Recombinant Human Bone Morphogenetic (rhBMP-2). *J Bone Joint Surg* 1992;74-A:659.

+ 163. Yoo MC, Chung DW, Hahn CS. Free Vascularized Fibula Grafting for the Treatment of Osteonecrosis of the Femoral Head. *Clin Orthop* 1992;277:128.

+ 164. Younger EM, Chapman MW. Morbidity at Bone Graft Donor Sites. *J Orthop Trauma* 1989;3:192.

+ 165. Zatsepin ST, Burdygin VN. Replacement of the Distal Femur and Proximal Tibia with Frozen Allografts. *Clin Orthop* 1994;303:95.

! 166. Zegzula HD, Buck DC, Brekke J, et al. Bone Formation with Use of rhBMP-2. *J Bone Joint Surg* 1997;79-A:1778.

# CHAPTER 10

# FRACTURE HEALING AND CLOSED TREATMENT OF FRACTURES AND DISLOCATIONS

*Acknowledgement: The section on fracture healing was a separate chapter in the second edition and was written by Michael Madison and R. Bruce Martin. Substantial portions of their original chapter are retained in this revision.*

*Michael W. Chapman*

**M. W. Chapman:** Department of Orthopaedics, University of California Davis, Sacramento, California, 95817.
**M. Madison:** University of California Davis, Sacramento, California, 95817.
**R. B. Martin:** Department of Orthopaedic Surgery, University of California Davis, Sacramento, California, 95817.

A. Fracture Healing
The Fracture Event
Three Phases of Fracture Healing
Primary Bone Healing
Variables In Fracture Repair
Blood Supply
Age
Season
Species
Type of Marrow
Temperature
Endocrine and Autocrine Factors
Metabolic Bone Disorders
Mechanical Environment of Fracture Healing
Electrical Phenomena In Fractures
Assessment of Fracture Healing
Biologic Intervention In Fracture Healing
B. Closed Treatment of Fractures and Dislocations
Closed Versus Operative Methods
General Indications for Closed Treatment
Children's Fractures
Undisplaced Fractures
Poor Bone Quality
Unfixable Fractures
Systemic Contraindications to Surgery
Local Contraindications to Surgery
Psychosocial Problems
General Principles of Closed Management
Injury Mechanics and Soft-Tissue Hinges
Soft-Tissue Bridge and Fragment Interlocking
Traction
Fracture Stability
Delayed Union and Malunion
Preservation of Function
Materials and Equipment
General Principles of Application of Plaster of Paris Casts
Application of a Short Leg and Sarmiento Cast
Extending the Short-Leg Cast Into a Long-Leg Cast
Delbet Cast
Cylinder Cast
Long-Leg Cast-Brace
Hip Spica Casts
Flexion Body Jacket
Hyperextension Body Jacket
Minerva Cast
Shoulder Spica Cast
Plaster Bolero
Plaster Velpeau
Short-Arm Cast
Muenster Short-Arm Cast
Long-Arm Cast for a Colles' Fracture
Gauntlet Cast
Thumb Spica Cast
Hanging-Arm Cast
Wedging Casts
Splints
Lower Extremity Splints
Upper Extremity Splints
Hand Splints
Splinting Fingers
Complications of Casts and Splints
Pressure Sores
Burns
Allergic Dermatitis
Cast Window Blisters
Vascular Compromise, Compartment Syndrome, and Nerve Injury
Malposition
Stiffness, Disuse, and Reflex Sympathetic Dystrophy
Traction
Indications
History of Traction
Basic Knots
Skin Traction
Russell's Traction
Skeletal Traction
Traction Treatment of Femoral Shaft Fractures
Traction for Fractures of the Tibia
Upper Extremity Traction
Complications of Traction

Chapter References

# A. FRACTURE HEALING

***Michael Madison and R. Bruce Martin***

Spontaneously healed fractures are not uncommon in the skeletons of wild animals and in archaeologic human skeletons. This kind of fracture is typically a closed, low-energy fracture with only slight displacement. Pain probably forced the injured person to protect his extremity until the fracture healed, and subsequent bone remodeling smoothed out any rough step-offs at the fracture site. The role of the surgeon in treating simple fractures of this type may indeed be as Voltaire characterized it: “to amuse the patient while nature heals the injury.”

In the last 400 years, a fundamentally different type of fracture has become increasingly common. This is the high-energy industrial, vehicular, or ballistic fracture that overwhelms the body's capacity to repair it. It demands clinical intervention, the goal of which is to convert the fracture to a facsimile of a low-energy fracture that the body is biologically equipped to repair. If the reduction, fixation, and soft-tissue management of a high-energy fracture are successful, the fracture can heal by the same cascade of events that typifies healing of a low-energy fracture.

## THE FRACTURE EVENT

Bone's lamellar and osteonal structures direct crack propagation in certain predetermined directions. The lamellar junctions and cement lines of bone are weak, and they crack more easily than the bulk of the material. These weak interfaces are oriented so that the cracks travel along and around the bone, rather than directly across it. Energy that would quickly break a bone is used in forming longitudinal or circumferential cracks that do not cause failure and that can be repaired by remodeling (50).

The material strength of bone differs in various modes of loading. It is strongest in compression, weakest in shear, and intermediate in tensile failure stresses. When a bone is fractured by compression, it tends to fail along planes that carry the highest shear stresses, which reach the failure level first; these planes typically are at an angle of 45° to the load direction. When a bone is bent, the highest stresses are tensile and compressive; failure begins on the tensile side and propagates toward the compressed side. When the crack enters the compressed tissue, it again tends to travel along the 45° planes of maximum shear, causing splitting, butterfly chips, or other types of comminution.

Bones loaded in torsion tend to break in tension and longitudinal shear because the transverse shear stress created by the twisting is across rather than along the fibers. The tensile stresses, however, lie at a 45° angle to the fibers and have only to separate them rather than to break through them to cause failure. Torsion typically produces a break that spirals around the bone at this angle and returns to its starting point along a longitudinal shear stress plane.

The greater the energy, the more likely the bone is to break into many pieces. The energy is propagated through the bone as a stress wave (similar to a sound wave or an earthquake), and the greater its magnitude, the more likely it is that many parts of the bone will reach a failure criterion virtually simultaneously. The velocity of a stress wave in bone is about 3,000 m/sec. The energy required to break a bone is small compared with that encountered in daily activities.

For example, it takes only about 15 joules (J) of energy to break the shaft of an adult tibia or femur. The energy released when a 70 kg person falls to the ground from a standing position is about 500 J. The ability to absorb this energy using eccentric muscle contractions and deformations of soft tissues usually prevents fractures from occurring in insignificant falls. If this ability is impaired by surprise, restrictions, or incapacity, fracture occurs easily. The propensity of elderly people to fracture their bones easily reflects the weakness of their bones and the weakness of the muscles and ligaments that fail to adequately absorb the applied energy, which instead is transmitted to the bones.

Soft-tissue deformation absorbs energy during an accident in two ways. First, loads applied perpendicular to the tissues compress them and propagate stress waves up and down the body. The tissues effective in this way are skin, fat, and muscle (and fur on animals or clothing on humans). Second, tissues such as fascia, tendons, ligaments, joint capsules, and contracted muscle brace bones against bending by supporting part of the tensile stresses. They absorb energy as they are stretched, but they must be nearly as stiff as the bone to be effective. One implication of these mechanisms of energy dissipation is that in very high energy (high-power) fractures, damage to the soft tissues tends to parallel the degree of damage to the bone; thus, the most severe fractures tend also to have severe impairment of the associated soft tissues on which fracture healing depends.

## THREE PHASES OF FRACTURE HEALING

In 1975, Cruess and Dumont proposed that fracture healing may be considered to consist of three overlapping phases: an inflammatory phase, a reparative phase, and a remodeling phase (21). This scheme, based largely on descriptive histology, has been widely reiterated. Others have divided fracture healing into four or five phases (30,53,99). These divisions are somewhat arbitrary and reflect differences in emphasis more than in content. Common to all is the concept that the fracture initiates a biologic cascade, a sequence of steps activated by and depending on the previous steps. For convenience, we describe fracture healing in terms of the three phases recognized by Cruess and Dumont, noting that the reparative phase combines several processes.

The inflammatory reaction immobilizes the fracture: Pain causes the patient to protect the injured part, and swelling hydrostatically splints the fracture. At the tissue level, the inflammatory phase is identical to the typical inflammatory response of most tissues to traumatic injury. Vasodilation and hyperemia, presumably mediated by histamines, prostaglandins, and various cytokines, accompany invasion of the injury site by neutrophils, basophils, and phagocytes that participate in clearing away necrotic debris. The fracture hematoma becomes organized as a developing fibrin network that provides pathways for cell migration. It is also presumed that during the inflammatory phase, various noncollagenous protein growth factors that regulate cell migration and differentiation and that normally are trapped in the bone matrix are released into solution, where they become active (25,59). The inflammatory phase peaks within 48 hours and is quite diminished by 1 week after fracture.

The reparative phase becomes activated within the first few days after fracture and persists for several months. Its chief feature is the development of a reparative callus tissue in and about the fracture site that gradually is transformed to bone. The callus may consist of cartilage, fibrous tissue, osteoid, woven bone, and vessels.

The primary callus response is the direct response of bone to local inflammation, whether the inflammation is caused by fracture, infection, a foreign body, or a neoplastic process (44,53). Two salient features of the primary callus response deserve mention. The first is that the response appears to be relatively independent of mechanical factors, as evidenced from the significant primary callus response to a foreign body or at the end of an amputation stump (i.e., half-fracture), or the cap of callus that may appear at the protruding end of a hollow intramedullary rod (44,53). Second, the primary callus response does not continue indefinitely. If the primary callus (i.e., the provisional callus) has failed to unite two sides of a fracture within a few weeks, it may cease to grow and be resorbed, as may be observed of the callus at the amputation stump or on one side of a large segmental defect.

If the primary callus is successful in connecting the fracture ends, healing progresses to the stage of bridging callus or hard callus. Although bridging callus seems to imply the directed growth of tissue outward from the viable regions distal and proximal to the fracture, the hard callus seems to differentiate simultaneously throughout its distribution, rather than growing as an advancing front. Calcification of the callus may be by direct bone formation by osteoblasts or by endochondral ossification, depending on the local oxygen tension (4). Typically, growth of a large callus greatly outpaces the ingrowing vessels, and endochondral ossification predominates. In a small, mechanically stable defect, such as a drill hole, primary (intramembranous) woven bone formation predominates.

The cellular components of the callus derive chiefly from the marrow and the periosteum. The number of osteoblasts and osteocytes present at the time of fracture is insufficient to sustain the high anabolic demands of the growing callus (30). The differentiation of pluripotential mesenchymal cells, fibroblasts, and chondroblasts is the primary source of callus cells. (Induction refers to the differentiation of mesenchymal cells into chondroblasts or osteoblasts in tissues that do not normally form bone, as observed in various animal experiments. Induction in this sense is not directly applicable to fracture healing.)

As the callus calcifies and becomes rigid, the fracture becomes internally immobilized, and the examiner may consider the fracture to be healed. The initial calcification is remodeled by osteoclasts and osteoblasts, leading to the replacement of calcified cartilage and woven bone by lamellar bone in the final (remodeling) phase of fracture healing. This phase represents the normal remodeling activity of bone, although it may remain accelerated in the region of the fracture for several years, replacing each volume several times over. In children, the remodeling phase proceeds more vigorously and includes *modeling* (independent resorption and formation) and *remodeling* (formation coupled to resorption). The result of the remodeling phase is a gradual modification of the fracture region under the influence of mechanical loads until it reaches some threshold of optimal shape, which typically is similar to the shape it had before fracture.

## PRIMARY BONE HEALING

In the presence of perfect apposition of the fracture fragments and rigid fixation, as may be achieved for instance by compression plating an osteotomy, the callus response may be suppressed altogether. In this case, healing proceeds by normal osteonal bone remodeling. As an increasing number of osteons cross the fracture site, the two sides become united. Although primary bone healing has been considered by some to be a goal of fracture repair, it offers no particular advantage over normal, callus-mediated (i.e., secondary) bone repair (75,86). It proceeds very slowly, especially in adults, and the intermediate stages are weak. A second potential disadvantage of primary bone healing is that, unlike callus-mediated healing, it does not progress in an anaerobic environment.

## VARIABLES IN FRACTURE REPAIR

### BLOOD SUPPLY

The afferent supply to an intact long bone comprises three systems, which may anastomose among themselves (76,77 and 78,94,95). The medullary system, which chiefly supplies the diaphysis, derives from the nutrient artery. The metaphyseal system supplies chiefly the cancellous bone of the proximal and distal metaphyses and anastomoses with the medullary system. In a child with open physes, the epiphysis and metaphysis have separate blood supplies. After closure of the physes, these two anastomose and are thereafter referred to as the metaphyseal system.

The periosteal blood supply derives from vessels in the periosteum, especially at regions of fascial or tendinous attachments. These vessels penetrate and supply the outer third or less of the cortex. Wherever the surface of the bone is covered by articular cartilage, a periosteal blood supply is absent. Regions of bone in which a large proportion of the surface is articular, such as the talus, carpal scaphoid, and femoral head, are therefore at particular risk for ischemic damage after trauma because they lack a major source of vascularity (31,32).

The efferent vascular system of bone includes the medullary vein, which drains much of the medullary and endosteal cortical portion of the bone before exiting through the same foramen by which the nutrient artery enters, and a system of periosteal veins. Anastomosis between the afferent and efferent arms of the vascular system is through marrow sinusoids in the medullary region or through small arterioles within the haversian systems. There is no capillary bed per se. Rhinelander observed that the principal direction of blood flow is centrifugal, from the endosteum to the periosteum (76). Parallel to this is a centrifugal bulk flow of interstitial fluid along a pressure gradient from approximately 20 mm Hg in the medullary canal to near zero peripherally (67,87).

The effect of fracture on the blood supply to a bone depends on the nature and severity of the fracture. In a minimally displaced fracture, the small vessels in cortical bone are disrupted, resulting in ischemic death of the osteocytes near the fracture line, but the major medullary and periosteal vessels may be sufficiently elastic to remain intact. The medullary system may be the primary source of the vascular hyperplasia that supplies the callus.

With a greater degree of displacement and disruption of the medullary vascular system, the metaphyseal or periosteal vessels may play a greater role in vascularization of the callus. Rhinelander considered that a fourth afferent vascular system, arising from adjacent soft tissues (especially muscle), could serve as the primary source of new vascular growth after a displaced fracture in which the medullary and periosteal systems were grossly disrupted (77,78). Support for this concept comes from the observation that fracture healing is enhanced by the use of muscle flaps. A study of segmental tibial fractures in dogs demonstrated significantly increased blood flow 30 days after injury for the fractures covered with muscle flaps compared with those covered by skin alone (79).

Vasodilation and angiogenesis occur rapidly after fracture. In experimental fractures of canine tibias, the regional blood flow near the fracture reached its maximum (six times normal) by 10 days after injury and was still elevated 4 months later. Blood flow in the same tibia but distant from the fracture site was also elevated, reaching its peak 1–3 weeks after injury and declining gradually thereafter (68). Gupta et al. showed that blood vessels crossed the fracture line after about 3 weeks in fractured dog tibias (36). In humans, failure of transfracture vessels to form by 10 weeks, as indicated by osseous phlebography, is considered a sign of impending nonunion (74).

Internal fixation with plates and screws may cause periosteal ischemia directly beneath the plate, but the procedure otherwise does not interfere with regional revascularization (73). Placement of a reamed intramedullary nail obliterates the medullary blood supply, however, shifting the source of vessel ingrowth to the metaphyseal, periosteal, and soft-tissue systems (77). In a canine study, fixation with an intramedullary nail led to reduced blood flow at 14 and 90 days and reduced callus formation compared with fixation with a plate, although all fractures united regardless of fixation method (3). A nonreamed nail or a tight-fitting nail that is fluted leaves channels in the medullary cavity that soon are invaded by medullary arteries.

The blood flow to bone can be manipulated pharmacologically by vasoconstrictors, vasodilators, and their antagonists. Brinker et al. propose that use of these agents to promote local blood flow in bone may prove useful therapeutically in managing delayed unions or infected fractures (13).

### AGE

It is well known that fractures heal much more vigorously in children than in adults. In elderly people, fracture healing may proceed very slowly, and what is normal healing in a 75-year-old patient would be a delayed union in a young person. Slow healing does not seem to be an inherent cellular problem of aging, because osteoblasts from trabecular bone grown in culture show similar metabolic characteristics regardless of the age of the donor (24).

### SEASON

Circulating levels of vitamin D metabolites in geriatric fracture patients exhibit strong seasonal variation, with higher levels in summer, when solar radiation is greatest. It has been suggested that impaired dietary intake of vitamin D in the elderly shifts the balance toward endogenous vitamin D, which depends on solar ultraviolet radiation as a catalyst (56,57). This finding has been shown to correlate with the seasonal incidence of hip fractures, although an unequivocal relationship to fracture healing has not been demonstrated.

### SPECIES

Rats and rabbits heal fractures very readily. Because neoteny has played a significant role in their evolution, rodents may be considered better models of fracture healing in human children than in human adults. Much experimental work on fracture healing and on bone induction that has been done on rodents cannot be assumed to apply directly to adult humans (12).

### TYPE OF MARROW

At birth, most bones have red marrow. As a child ages, the red (hemopoietic) marrow in the appendicular skeleton is replaced by yellow (fatty) marrow, beginning with the toes and fingers and proceeding proximally. In the adult, the red marrow is confined chiefly to the axial skeleton, with a small amount of red marrow remaining in the proximal femur. Red marrow is highly osteogenic, and bones with red marrow (e.g., ilium, vertebral bodies, ribs) generally heal readily compared with regions of yellow marrow (e.g., tibial diaphysis).

### TEMPERATURE

The “warm bones” (i.e., the axial skeleton) heal more readily than the “cold bones” (i.e., the appendicular skeleton) (40). The axial bones are also those that retain red marrow, a fact that may in part explain their more vigorous healing. Temperature, however, may also be a factor in fracture healing: It has been shown that fractures of vertebral bodies in mice heal much more rapidly when kept at higher temperatures (63).

### ENDOCRINE AND AUTOCRINE FACTORS

Cortisone generally is catabolic for the skeleton and diminishes the size of a fracture callus. It also causes a deficit in the bone laid down during remodeling of the callus. Growth hormone, on the other hand, has the capacity to increase callus volume, but it is effective therapeutically only in the absence of normal endogenous growth hormone. Experimentally, growth hormone has accelerated healing in old rats (2). Parathyroid hormone and thyroxine increase the rate of bone remodeling; abnormally low values of these hormones reduce the rate of remodeling in the final phase of fracture repair. Serum calcitonin and 24,25-$(OH)_2$-$D_3$ are significantly elevated during the first 6 weeks of fracture healing, but their effects on fracture healing are not entirely clear (57).

Disturbing the bone marrow (e.g., by reaming the medullary canal) appears to liberate a systemic circulating factor that stimulates bone growth or mineral apposition elsewhere in the skeleton. This phenomenon has been shown experimentally in rodents and in patients undergoing marrow aspiration (23,26). It has long been known

that patients with severe head injuries heal fractures very aggressively and have a high propensity to make heterotopic bone. Serum from these patients stimulates osteoblasts in tissue culture, compared with serum from patients with other fractures (8). These observations suggest that one or more circulating systemic agents may regulate fracture healing, but these agents have not been identified.

### METABOLIC BONE DISORDERS

Fractures in patients with rickets or osteomalacia heal normally, but the resulting bone tissue has a mineral deficit. Similarly, fractures in osteoporotic patients heal normally, but the remodeled fracture site is osteoporotic.

## MECHANICAL ENVIRONMENT OF FRACTURE HEALING

In general, the strength or stiffness of any structure depends on the product of a geometric factor and the strength or stiffness of the material within. If the geometric factor is made larger, the structure can be made of a weaker material and be just as strong (Fig. 10.1). A callus composed of material that is relatively weak, for example, can nonetheless achieve the strength of the intact bone if its diameter is greater.

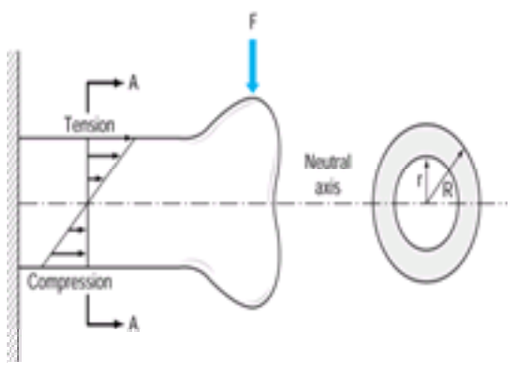


***Figure 10.1.*** For a bone loaded in bending by a force *F*, at any cross section there is tensile stress on the upper surface and compression on the lower surface. Consequently, there is a line through the middle of the section where the stress is zero; this is called the neutral axis. The contribution of each moiety of bone in the cross section is the product of its area and the square of its distance from the neutral axis. For a tube, the cross-sectional moment of inertia (CSMI) is p/4($R^4 - r^4$). The section modulus equals the CSMI divided by *R*.

This principle governs the “engineering philosophy” of fracture healing: The strength and stiffness required for functional union are achieved rapidly by formation of a callus that has poor material but has a high section modulus (large diameter). Woven bone and calcified cartilage, although weaker than lamellar bone, can be produced two to five times faster. By locating much of this material farther from the center of the bone than the original cortex, nature compensates for the mechanical inferiority of the callus materials.

Figure 10.2 illustrates this principle, using dimensions typical of a large bone fracture callus. The external callus itself may easily achieve twice the section modulus of the intact cortex, and the total callus may have triple this value. The callus material needs to be only one third to one half as strong as cortical bone for the callus to return the bone to normal strength. By the same token, the strength of an abundant, mineralized callus can substantially exceed that of the original and adjacent cortex.

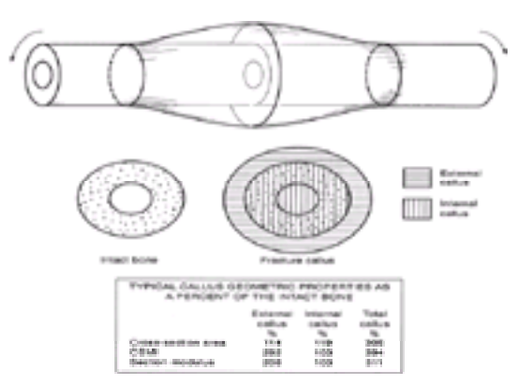

***Figure 10.2.*** A typical long-bone fracture callus. The external callus is defined as that located outside the original bone cortex; the remainder of the callus is the inner callus. Assuming that the diameters of the endosteal, periosteal, and callus periphery are 10, 25, and 35 mm, respectively, the geometric properties of the callus are shown as percentages of the intact bone in the table. Note that the section modulus of external callus alone substantially exceeds that of the intact bone, although its area is only slightly greater.

Clinical intervention to stabilize the mechanical environment is one of the principles of fracture management. We now recognize that absolute rigidity should not be the goal of mechanical intervention, because it entails two potential disadvantages: Stress protection by fixation devices may cause bone resorption, and lack of motion at the fracture site inhibits callus formation (72). Fracture healing seems to benefit from a certain amount of controlled axial loading and micromotion, although how much is “just right” is unknown (34,45,54). Ribs heal with quite a bit of motion; a tibia probably tolerates much less. The use of less rigid materials (e.g., titanium rather than stainless steel) and the intramedullary rather than cortical placement of fixation devices (which decreases the sectional modulus) tend to increase the amount of micromotion at the fracture site (101). In a study of fractured dog femurs, Uhthoff et al. found that cortical bone loss due to stress protection beneath titanium plates was about one third that under stainless-steel plates, which were 50% stiffer than the titanium plates (97). Terjesen and Apalset found that 70% to 95% reductions in plate stiffness resulted in a 16% to 100% increase in callus size (92).

As a fracture heals, loads ideally should be borne increasingly by the bone and less by fixation devices. This gradual shift can be achieved by using unlocked intramedullary devices or by dynamizing locked nails or external fixators. Resorbable implants that are now on the market also have great potential for effecting a gradual transition of load bearing from the device to bone, provided that their resorption kinetics can be adequately regulated. Plates and screws are much less amenable to a gradual shift of load bearing to the bone.

## ELECTRICAL PHENOMENA IN FRACTURES

When bone is mechanically loaded, so-called stress-generated potentials are produced by at least two mechanisms (1,35). Streaming potentials are produced when interstitial fluids are forced through the calcified matrix by dilatation of some regions and compression of others. Piezoelectric potentials are produced by deformation of the collagen molecules. Both electrical potentials are transient when produced by physiologic loads, because streaming occurs only while deformation is in progress, and piezoelectric potentials produced by a prolonged load are canceled by migration of opposite charges in the interstitial fluids. A permanent electrical polarization is associated with collagen in bones, however, and this permanent polarization appears to be altered when fracture occurs (2). The fracture site becomes negatively charged (7). It has been postulated that this polarization is related to the cascade of biological events that result in repair.

This idea has its origins in the observation that cells in amphibian serum are morphologically altered when exposed to an electrical field (7,9). Because osteoblast stem cells may include circulating mesenchymal cells, investigators thought that stress-generated potentials might be responsible for the differentiation of osteoblasts and play a role in fracture healing and Wolff's law (i.e., a bone develops the structure most suited to resist the forces acting on it). Laboratory investigations show that bone formation is promoted in the neighborhood of a cathode, that fresh fractures in animals gain strength more quickly when electrically stimulated, that disuse osteopenia is inhibited by electrical treatment, and that bone and cartilage cells in culture exhibit increased DNA synthesis and other changes when electrically stimulated (28,29,38,43,47,52,65,66,82). These findings suggest that the functions of skeletal cells may be selectively altered by electrical signals arising from normal loading,

fracture, or clinical intervention. This hypothesis has been tested in numerous clinical trials involving various types of fracture nonunions.

The experiments have usually employed one of two methods for introducing alternating electrical currents in the bone. Brighton et al. implanted a cathode directly into the fracture site and passed about 20 µA of electricity to a supercutaneous anode (12). Bassett et al. passed electricity through a pair of wire coils disposed on either side of the fractured limb to induce an alternating magnetic field in the region of the fractured bone (5). Magnetic fields penetrate tissues much more readily than electrical fields, and the amount of current required is low enough to allow battery power. The alternating magnetic field induces similarly varying electrical fields and currents in the tissues at the fracture site.

Using these and similar methods, investigators have generally claimed that treatment of fracture nonunions has been substantially more dependable than more conventional methods (i.e., grafting). These claims have been disputed by critics who assert that the studies have not been adequately controlled. For various reasons, it has been difficult to do well-controlled human studies, but the laboratory work strongly supports the theory that electrical currents or fields modulate cell function in the skeleton. See Table 10.1 for a summary of factors influencing fracture healing.

***Table 10.1. Factors Influencing Fracture Healing***

## ASSESSMENT OF FRACTURE HEALING

Fracture healing is a continuing process that may progress for several years. Although the criterion is somewhat arbitrary, a fracture is usually considered healed when the bone can tolerate the loads normally experienced in everyday activities. Traditionally, healing has been determined by evidence of bridging callus on radiographs and by stiffness across the fracture site during clinical manipulation. These traditional measures of healing are sufficient for the purposes of fracture management; for some experimental studies or for careful evaluation of devices or techniques, however, a more precise determination of the progress of fracture healing is useful. Three general methods are currently available.

The motion of the bone across the fracture site in response to a known load can be measured; this is a refinement of the clinician's subjective feel of stiffness when she manipulates the fracture. Typically, a strain gauge attached to an external fixator is used to measure the deflection of a tibia in response to known applied loads (17,22). An example of fracture healing measured in this way is shown in Figure 10.3.

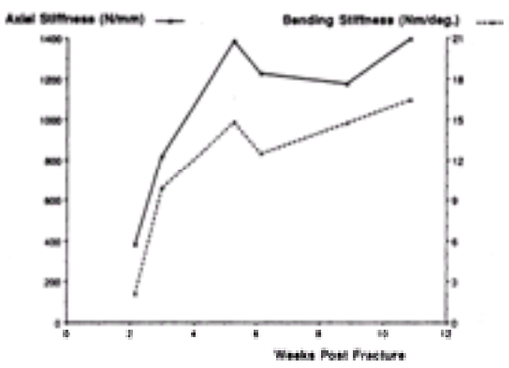


***Figure 10.3.*** Increase in axial stiffness (*solid line*) and bending stiffness (*dashed line*) of a healing distal-third spiral tibia fracture as measured from an instrumented external fixator. Threshold values of fracture stiffness for safely removing the fixator are 1,000 newtons per millimeter (N/mm) in axial loading (in this patient, reached at 4 weeks) and 15 newton-meters (Nm) per degree in bending (in this patient, reached at 10 weeks). (From Cunningham JL, Kenwright J, Kershaw CJ. Biomechanical Measurement of Fracture Healing. *J Med Eng Technol* 1990;14:92.)

A second technique for measuring fracture healing is to cause the fractured bone to vibrate by tapping it with a hammer or vibrating it with a shaker, and then measuring the resonant frequency of the bone as a whole or the attenuation of the impulse as it crosses the fracture site (19,71). Healing is assessed by comparison to the intact, contralateral bone.

The third method of measuring fracture healing depends on measuring the velocity of an ultrasonic wave (from an ultrasound unit) across the fracture site (33). As the fracture heals, wave velocity increases. As with the vibrational tests, healing is measured by comparison with the contralateral uninjured bone.

## BIOLOGIC INTERVENTION IN FRACTURE HEALING

Although progress in treating fractures in the last 50 years has focused on perfecting the management of the mechanical environment, it seems likely that future progress will emphasize the biologic side of fracture healing. Currently, two avenues of biologic intervention are being developed. Stimulation of osteogenesis involves enhancement of the migration, division, differentiation, or metabolism of cells that normally carry out fracture repair. A clinical example is delayed primary fixation, in which surgical intervention a week or so after the fracture may reactivate or amplify the cascade of fracture healing (30,100). Electrical stimulation also is presumed to enhance osteogenesis, as is the therapeutic use of protein growth factors. Support of osteoconduction involves the provision of a substrate or scaffold along which osteogenic cells can migrate and on which angiogenesis and osteogenesis can occur. Provision of osteoconductive material is particularly important in repair of a segmental defect. Collagen is the natural osteoconductive material, although other proteins and ceramics are being used experimentally and clinically as osteoconductors. The combination of an osteoconductive material with a stimulant of osteogenesis promises to provide a very effective synthetic bone graft.

Although current clinical applications of biologic agents are still fairly primitive, this area holds great promise for further improvements in the regulation of fracture healing. Clinical application of biologic agents would fulfill a prophetic remark made by Dr. Girdlestone 70 years ago, when he foresaw the future of orthopaedics shifting from “carpentry to gardening.”

# B. CLOSED TREATMENT OF FRACTURES AND DISLOCATIONS

***Michael W. Chapman***

## CLOSED VERSUS OPERATIVE METHODS

In this century, especially since the 1970s, there has been a remarkable change in the treatment of fractures and dislocations. When I began my orthopaedic surgery resident training in 1963, the standard of care for fractures of the shaft of the femur was skeletal traction, which required an average of 3 months of hospitalization. The

standard today is closed, locked intramedullary nailing with an average hospital stay of 4–7 days.

The reasons for this tremendous change have been advances in anesthesia, improvements in sterile technique, and advances in the technology of internal fixation. We can now operate on patients who were previously not candidates for surgery, perform surgery with a minimal risk of infection, and internally fix on a reliable basis fractures that were previously not fixable. Operative treatment now dominates the treatment of musculoskeletal trauma to such an extent that residents today have far less training in the principles of closed management.

The predominance of operative methods in fracture treatment is driven by our outcome-oriented society. Patients expect not only that fractures will heal, but that they will heal in anatomic position with restoration of normal function. Often these expectations are unrealistic in view of the severe injuries that occur in our high-velocity society. Many injuries are now occurring in the context of the multiply injured patient, where the need for early mobilization makes nonoperative techniques impractical. For example, in the Orthopaedic Trauma Service at the University of California, Davis Medical Center, the average number of fractures per patient is 3.5. Surgical techniques offer the ability to restore anatomy close to normal. The rigid fixation obtained often allows early mobilization and rehabilitation, which optimizes the outcome.

Despite the many advantages of operative care, nonoperative care remains the foundation on which treatment of musculoskeletal trauma is based. There are many indications for nonoperative care, and modern orthopaedic surgeons must be as skilled in nonoperative as they are in operative techniques. A sound knowledge of nonoperative techniques also makes the use of operative techniques more effective and safer. Closed treatment requires as much thoughtfulness, technical expertise, and attention to detail as does surgery.

Although this textbook covers primarily operative orthopaedics, I feel it is essential to provide information on nonoperative care, and this information is scattered throughout the chapters in these volumes. This section of this chapter on closed treatment of fractures and dislocations lays the groundwork for the other chapters in this section of the text on treatment of fractures. Although modern textbooks on fracture care, such as those by Rockwood (80,81) and Browner (14) and their colleagues, cover these techniques in detail, the interested reader will find it very enjoyable and educational to go back to two classic works on fracture care, Watson-Jones's *Fractures and Joint Injuries* (98) and Charnley's *The Closed Treatment of Common Fractures* (18). A monograph by Bleck et al. (10) on plaster cast techniques and a manual by Freuler et al. (27) provide good detail on nonoperative management techniques using plaster and splints.

In nature, the vast majority of fractures heal in the presence of motion, although deformity is common. Union occurs because the vascular supply to the bone and surrounding soft tissues is usually good, and the physiologic stimulus of continued use of the limb enhances callus formation and strengthens the callus formed. In the initial healing process, an ensheathing callus is formed that begins to immobilize the fracture fragments. Early during fracture healing, motion can still occur at the fracture, but translation of the fracture fragments and shortening is usually impossible after the initial ensheathing callus has formed.

Charnley (18) draws an analogy to a fist gripping a stick (Fig. 10.4). Most bone in fracture callus comes from endosteal tissues, which quickly fills in the ensheathing callus. As it becomes progressively thicker, total immobilization of the fractured bone ends occurs. This method of healing has the mechanical advantage of producing a callus that is much larger in diameter than the fractured bone. It takes advantage of the increased polar moment of inertia created by the thick callus. After complete consolidation, in fact, this thickened area of bone is often stronger than the unaffected shaft (Fig. 10.5). The bone ends themselves are usually somewhat avascular because of the injury and do not directly participate in this early phase of healing.

***Figure 10.4.*** An analogy between early fracture callus and a fist gripping a stick. The ensheathing callus represented by the fist is stationary and markedly reduces the motion of the stick, but the stick and the bones of the fracture can still move inside the clenched fist. (From Charnley J. *The Closed Treatment of Common Fractures, 3rd ed.* Baltimore: Williams & Wilkins, 1963.)

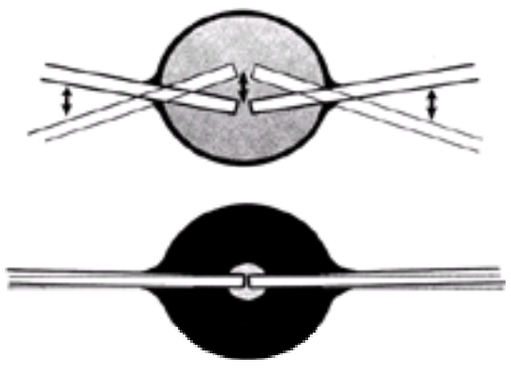

***Figure 10.5.*** As the circumferential callus fills with bone, the ensheathing callus becomes thicker, shrinks on the enclosed fragment, and eventually eliminates motion in the bone fragments. The increased moment of inertia relative to the adjacent normal bone makes the healed site stronger than the adjacent bone for a period of time. (From Charnley J. *The Closed Treatment of Common Fractures, 3rd ed.* Baltimore: Williams & Wilkins, 1963.)

Once completely immobilized within the callus, the bone ends are slowly revascularized and remodeled. The large peripheral callus is slowly resorbed and the shape of the bone returns toward normal after several years of remodeling. This type of union is virtually 100% successful in nature in ribs, clavicles, and membranous bones. In the mid diaphysis of such bones as the tibia, the limitations of blood supply and excessive motion produced by attempted use of the limb commonly lead to nonunion.

The purpose of nonoperative treatment methods, then, is to hold the broken bone in a position as close to its anatomic position as possible to prevent malunion, to reduce excessive motion in order to prevent nonunion, and to allow earlier function than would otherwise be possible. In addition, the immobilization substantially reduces pain.

By contrast, surgery, which involves soft-tissue dissection and direct mechanical trauma to bone, reduces the blood supply to bone and the surrounding soft tissues. Except for closed intramedullary nailing, bone union usually takes longer if operative methods are used. Because of the prolonged period necessary for revascularization, rigid fixation over long periods of time is usually required. With rigid fixation, bone union occurs by direct osteonal modeling and callus formation is suppressed; this results in slower and mechanically less strong union. The combined risks of devascularization, slower and weaker bone union, and operative complications must be offset by the advantages to be gained by operative treatment.

## GENERAL INDICATIONS FOR CLOSED TREATMENT

### CHILDREN'S FRACTURES

Internal fixation is almost never indicated in children, except for displaced intraarticular fractures; some avulsion fractures with wide displacement, such as those of the medial epicondyle of the elbow; and shaft fractures of the femur in older children who have severe, life-threatening multiple injuries. Certain fractures that are difficult to

manage by closed technique, such as supracondylar fractures of the humerus, are now routinely treated with percutaneous pin fixation.

Children have a tremendous capacity to remodel bone as they grow, and during the active growing years long-bone fractures of the lower extremity are commonly accompanied by some overgrowth. Nonunion is rarely a problem in children. Despite prolonged immobilization, in contrast to adults, the vast majority of children very quickly regain normal joint motion and muscle strength. For those reasons, children's fractures are nearly always treated with closed techniques. See Chapter 164 on the operative treatment of children's fractures.

### UNDISPLACED FRACTURES

Undisplaced fractures are nearly always treated without surgery. Internal fixation is rarely indicated, as the fracture is in anatomic position and will heal rapidly. Notable exceptions include undisplaced fractures of the femoral neck, which usually require percutaneous pin or screw fixation to prevent displacement.

### POOR BONE QUALITY

With our aging population, osteoporosis is becoming a common problem. Osteoporotic bone is very difficult to fix internally, and therefore nonsurgical methods are commonly indicated in the very elderly. Nonoperative treatment methods, however, can severely impede the mobility of the elderly. Methods such as cast-bracing are often used to avoid prolonged bed rest. Compromises are usually necessary so that early rehabilitation is possible. For example, Colles' fractures in the very elderly are almost always treated in short-arm casts rather than long-arm casts.

### UNFIXABLE FRACTURES

Severe comminution, particularly with bone loss, is a common problem following high-energy trauma. Many intraarticular fractures, such as those of the tibial plateau and ankle, may not be fixable because of severe comminution. These cases require either external fixation or nonoperative methods.

### SYSTEMIC CONTRAINDICATIONS TO SURGERY

Severe medical illness may contraindicate surgical intervention; and certain systemic diseases, such as an immunodeficiency, may make the hazards of surgery sufficiently high that nonoperative methods are required.

### LOCAL CONTRAINDICATIONS TO SURGERY

Severe skin lesions, local skin infections, or other soft-tissue conditions may contraindicate surgery and make nonoperative methods necessary.

### PSYCHOSOCIAL PROBLEMS

Certain types of operative intervention require excellent cooperation on the part of the patient to ensure an optimal result. Patients with psychiatric or personality disorders, or who otherwise cannot participate in postoperative care, may need to be treated by nonoperative means.

## GENERAL PRINCIPLES OF CLOSED MANAGEMENT

### INJURY MECHANICS AND SOFT-TISSUE HINGES

Fractures can be the result of direct or indirect forces. Direct injuries may break the bone directly under the blow, usually by imparting a bending force. Indirect injuries occur when the limb is twisted or angulated distally, causing a more proximal injury; an example is the spiral fracture of the tibia that occurs in the typical external-rotation, twisting injury associated with skiing accidents. When these injuries occur, the soft tissues tend to be disrupted on one side of the fracture and left intact as a hinge on the other. For example, in fractures of the tibia caused by bending forces, the periosteum and muscle envelope on the convex side of the fracture is often disrupted, but the soft-tissue envelope on the concave side remains intact (Fig. 10.6 and Fig. 10.7).

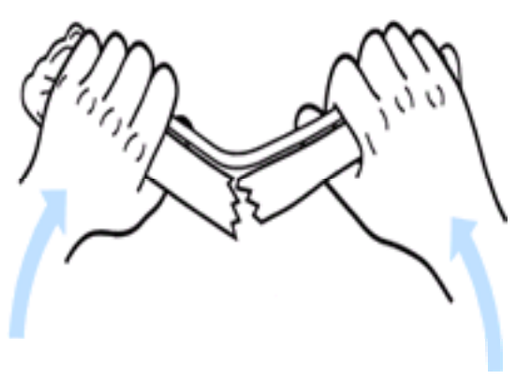

***Figure 10.6.*** Soft-tissue hinge. When the fracture breaks because of bending, the soft tissues disrupt on the convex side and remain intact on the concave side. (Redrawn from Charnley J. *The Closed Treatment of Common Fractures, 3rd ed.* Baltimore: Williams & Wilkins, 1963.)

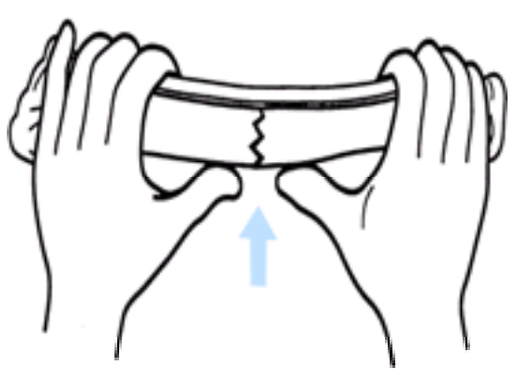

***Figure 10.7.*** Three-point fixation. When the fracture is reduced and three-point fixation applied, the fracture becomes stable. (Redrawn from Charnley J. *The Closed Treatment of Common Fractures, 3rd ed.* Baltimore: Williams & Wilkins, 1963.)

Usually it is difficult for the patient to know the precise mechanism of injury, but it can be inferred by the configuration of the fracture. For example, in bimalleolar fractures of the ankle, a transverse fracture of the medial malleolus and a spiral fracture of the lateral malleolus are compatible with an external rotation-eversion force causing the fracture. With this knowledge, it is possible to reduce the fracture by reversing the mechanism of injury, taking advantage of the soft-tissue hinge to stabilize the fracture. With appropriate maneuvers, the soft tissues guide the displaced fragments back to their normal position. This mechanism applies to many fractures, including Colles' fractures and supracondylar fractures of the humerus and femur.

Knowing the location of the soft-tissue hinge allows the surgeon to take advantage of three-point fixation, which produces tension in the intact soft tissues and therefore compression across the fracture site. This compression immobilizes the fracture (Fig. 10.7). This principle is used in nearly all cast and splint immobilization of fractures. Applying the three-point fixation principle usually requires a splint or cast that appears overreduced. A straight cast will usually contain a crooked bone; a

curved cast will generally contain a well-aligned bone.

**SOFT-TISSUE BRIDGE AND FRAGMENT INTERLOCKING**

Although the intact soft-tissue hinge is usually an advantage, in some cases it can be an impediment to reduction. The best example is in fractures of the distal radius and ulna in children. The periosteum is quite thick. With complete dorsal displacement and overriding, straight longitudinal traction to reduce the fracture is ineffective because the soft-tissue hinge is too short to allow reduction of the fracture fragments (Fig. 10.8). In this case, reduction requires that the fracture be deformed, as in the mechanism of injury, and overreduced. Three-point fixation can then take advantage of the soft-tissue hinge to hold the reduction. Because of the extreme deformity required to reduce fractures of this type, it is usually advisable to do the reduction under general or regional anesthesia so that it can be gentle and need be performed only once or twice.

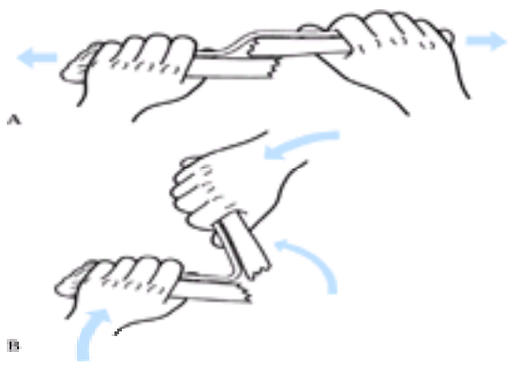


***Figure 10.8.*** **A:** Mechanism of fragment interlocking produced by an intact soft-tissue hinge, typically seen in fractures of the distal radius and ulna in children. Traction does not allow the fragments to be disimpacted and brought out to length. **B:** Reproduction of the mechanism of fracture to hook on the ends of the fracture. Notice that angulation beyond 90° is usually required. (Redrawn from Charnley J. *The Closed Treatment of Common Fractures, 3rd ed.* Baltimore: Williams & Wilkins, 1963.)

**TRACTION**

The soft-tissue envelope and intact ligaments also provide an aid to reduction. An analogy is to picture pieces of macaroni strung on a string. When the string is loose, the pieces are haphazardly arranged; with tension on the string, they line up. The same principle applies to comminuted fractures of the shaft of the femur. Axial skeletal traction, by putting tension on the soft-tissue envelope around the femur, lines up the bone segments.

A soft-tissue impediment to traction alignment of fractures can be the hydraulic effect of soft-tissue swelling. Shortening in fractures is generally not caused by muscle spasm, but rather by the hydraulic effect of soft-tissue swelling. With bleeding and edema, the soft-tissue envelope around the fracture increases the pressure inside the deep fascia. Since the geometric shape that contains the largest volume is a sphere, the limb's normal oblong, tubular shape becomes spherelike. The limb shortens, causing the bone fragments to override (Fig. 10.9). Traction to correct this overriding may cause compartment syndrome by elongating the thigh and increasing the intracompartmental pressure.

***Figure 10.9.*** Effect of hydraulics on fracture shortening. The normal shape of the thigh is that of a tube or sausage. With a fracture, hemorrhage into the thigh occurs, which causes it to assume the shape of a sphere, thus inducing shortening in the fracture.

**FRACTURE STABILITY**

Oblique, spiral, and comminuted fractures are inherently unstable unless the soft-tissue envelope has been little disturbed. The initial radiograph often points to the degree of soft-tissue injury and instability. In fractures of the tibia with unstable patterns, plaster of Paris cast management alone usually results in shortening equal to that seen on the original radiograph (Fig. 10.10). Excessive shortening is a hallmark of more severe soft-tissue injury, and without special measures to prevent shortening, the fracture will heal in a shortened position. Transverse fractures with good end-to-end contact are stable against shortening; the challenge is simply to control angular and rotational deformity, which can usually be done with a cast or splint (Fig. 10.11).

***Figure 10.10.*** The amount of shortening seen on the initial postinjury x-rays indicates the degree of soft-tissue stripping that has occurred about the fracture site.

***Figure 10.11.*** In stable fractures such as this transverse fracture, shortening is rarely a problem, but care must be taken to avoid angulation and malrotation.

If there is a good soft-tissue hinge and the potential for three-point fixation, then with proper immobilization many seemingly unstable fractures are potentially stable against shortening. A typical example is the Colles' fracture, which is inherently unstable in shortening. If the fracture is adequately immobilized with a three-point fixation cast, shortening can usually be prevented (Fig. 10.12).

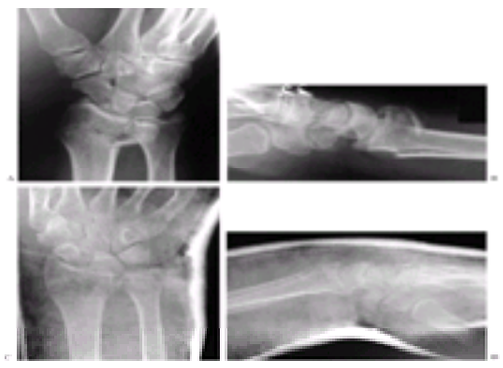

***Figure 10.12.*** **A,B:** The inherent instability in shortening of this Colles' fracture is due to the crush of bone that occurred at the time of injury. **C,D:** After reduction, the three-point fixation achieved in the cast helps maintain position and length.

**DELAYED UNION AND MALUNION**

Late deformity can be a problem in fractures that do not heal within the expected time. This is particularly a problem in the tibia, where weight-bearing treatment may make control of angulation difficult. In other fractures, the strong pull of one muscle group or another induces typical deformities such as late varus in intertrochanteric or subtrochanteric fractures of the femur, posterior angulation in supracondylar fractures of the femur, and varus in fractures in the shaft of the humerus.

**PRESERVATION OF FUNCTION**

In closed fractures, in the absence of sepsis, the joints above and below the fracture can be expected to gain nearly full anatomic motion and certainly functional motion, if the fracture heals within the expected time and immobilization is not prolonged. On the other hand, associated soft-tissue injuries, sepsis, and prolonged immobilization for treatment of delayed union or nonunion often lead to loss of joint motion and atrophy of muscle, which are difficult to reverse. Follow the simple rules in Table 10.1 to minimize problems with limb rehabilitation.

Certain fractures are best not immobilized at all, but treated with early, protected, gentle active motion. Examples are surgical neck fractures of the humerus in the elderly, stable fractures of the radial head and neck, and minimally displaced fractures of the calcaneus.

## MATERIALS AND EQUIPMENT

Although skin-tight plasters were popular at one time, they are no longer used because they present the danger of pressure sores and compartment syndrome. Freuler et al. have shown that the additional immobilization provided by using unpadded plaster is not worth the many risks (27).

Tubular stockinet of cotton, synthetics, or a combination is available in widths from 2 to 12 inches and serves as a useful liner under most casts (Fig. 10.13). When treating fresh fractures, I prefer not to line the entire cast with stockinet because, if swelling occurs, the stockinet can be quite difficult to cut. Place the tubular stockinet only at the ends of the cast for trimming (Fig. 10.14). When applying stockinet around joints, avoid wrinkles by cutting the stockinet on the concave surface and overlapping it (Fig. 10.15 and Fig. 10.16). Tubular stockinet can be cut on the bias to produce a bandage material that is stretchable and conforms well to the extremity but is not elastic. It is very useful for overwrapping splints and soft dressings (Fig. 10.17). Heavier specialized knitted stockings are used for cast-braces where more uniform compression of the limb is desirable, and thicker material is necessary to protect the limb from the plaster, as the limb will be used much more actively in a cast-brace.

***Figure 10.13.*** Tubular stockinet is used to line and trim the end of casts, and it has many other uses. It is available in widths from 2 to 12 inches.

***Figure 10.14.*** Tubular stockinet used to trim the ends of a short-leg cast.

***Figure 10.15.*** To avoid wrinkles in the stockinet under casts, cut along the concave surface of joints.

***Figure 10.16.*** After cutting the stockinet, overlap it to produce a smooth contour.

***Figure 10.17.*** Tubular stockinet can be cut on the bias and is very useful for overwrapping splints and dressings.

For padding, most surgeons now use a sheet cotton commonly known as Webril that comes in rolls 2, 3, 4, and 6 inches wide (Fig. 10.18). This sheet cotton is fairly noncompressible and, if used thick enough over bony prominences, can serve as the only padding material in the cast.



***Figure 10.18.*** Sheet cotton for padding casts comes in rolls in widths of 2, 3, 4, and 6 inches.

Felt is useful for providing extra padding and is available as black felt or a more dense white felt, available up to ½-inch thick. It can be stripped in half to produce thinner sheets as necessary. Also useful is synthetic foam padding with adhesive backing, which can be adhered to the limb over particularly sensitive or prominent areas. The disadvantage of synthetic foam is that it is more compressible and less likely to be effective.

Circumferential casts of differing materials have been used since first developed by the ancient Egyptians. The first plaster bandages were used by Andonius Mathijsen, a Flemish army surgeon, in 1852. The plaster of Paris used in plaster bandages is derived from gypsum. Plaster of Paris is made by pulverizing and heating gypsum to dehydrate it; the result is anhydrous calcium sulfate. When water is added, it crystallizes back into gypsum in an exothermic reaction. This exothermic reaction produces enough heat that if a cast is overly thick and laid on an impervious surface such as a plastic-covered pillow, second-degree burns can occur.

Commercial plaster bandages are made by coating gauze with the plaster of Paris, using starch as an adhesive.

Various chemicals are added to create different setting times and handling characteristics. Most plaster is available in either a standard or fast-setting variety. Extra-fast-setting plaster, which sets in 2–4 min, is useful in clubfoot casts on small children. Standard or fast-setting plaster requires 5–8 min. Setting times are affected by ambient temperature, humidity, thoroughness of wetting, and water temperature. Long crystal lengths make a stronger cast, and the ideal water temperature is about 22°C (72°F). The plaster should generally be soaked for about 4 min.

Commercial bandages are available in rolls 2, 3, 4, 5, 6, and 8 inches wide and in varying sizes of splints (Fig. 10.19 and Fig. 10.20). Splints are available in 3 × 15, 4 × 15, 5 × 30, and 5 × 45 inches. Luck describes the parameters affecting plaster strength and use (48).

***Figure 10.19.*** Commercial plaster of Paris rolls are available in widths of 2, 3, 4, 5, 6, and 8 inches. The type of gauze used and the plaster formulation vary from manufacturer to manufacturer.



***Figure 10.20.*** Plaster splints are available commercially in many sizes. Use them in multiple layers to create adequate strength.

Plaster rolls with elastic fibers in them are also available. The weave of the gauze and elastic fibers allows the cast to be applied more tightly and with more uniform molding over irregular surfaces. It is useful as the initial layer in cast-braces. It is very easy to apply elastic cast materials too tightly; use them with caution.

Plaster of Paris with incorporated resins that make the plaster stronger and more water-resistant is also available, but for the most part it has been replaced by entirely synthetic or fiberglass cast materials. These materials are lightweight and strong and can be applied in much thinner constructs than plaster of Paris. They are not weakened by immersion in water. They are available in many colors and are very popular with patients. The disadvantages of the synthetic materials are that they are far more expensive, much more difficult to apply, and not as versatile as plaster of Paris. In addition, it is very difficult to mold fractures through synthetic materials, and they are generally not used in the initial treatment of unstable fractures. Because of the rigidity of the fiberglass, they cannot be spread. They can, however, be quite useful as an overwrap of one or two layers on regular plaster of Paris casts to increase their strength and protect the outer surface. Allergy is also more common with the synthetic cast materials; in plaster of Paris, it is nearly unheard of.

Other materials useful in the cast room are gauze rolls, tape, muslin bandage, elastic (Ace) bandages, and various dressing materials. A plentiful supply of good-quality disposable rubber gloves is essential, as plaster should always be handled with gloved hands to prevent the rough texture of your skin from dragging the plaster out of the gauze as it is rubbed, producing a rougher and less desirable cast finish. Cornstarch and baby powder are useful for dusting the skin, particularly where skin contact, such as in the axilla, may result in irritation. Do not use talcum powder, as it is too rough.

Small blocks of wood or commercially available plastic cast wedges are useful for cast wedging and holding split casts open. Long wood sticks or rolled newspapers are useful for making reinforcing bars for shoulder and hip spica casts. An indelible pencil for writing the diagnosis, drawing the fracture, or entering other useful information on the cast is handy (Fig. 10.21).

***Figure 10.21.*** An indelible pencil is useful for writing on casts. When using an oscillating saw, be sure that the blade is sharp and does not overheat. Use one finger as a fulcrum on the cast to stabilize the blade and cut by pushing downward (*arrow*) and pulling upward (*arrow*) when the cast saw is moved along. Avoid bony prominences. Never draw the saw longitudinally, as it can cut skin.

Equipment essential to a well-furnished cast room includes hooks in the ceiling for suspension, broad stainless-steel or synthetic work surfaces on which to spread plaster, mechanical or hydraulic tables that can be elevated for plaster application, special orthopaedic tables for the application of spica casts, bandage scissors, disposable #10 and #20 blades, an electric cast saw with an attached vacuum (Fig. 10.21), and special tools for cutting, bending, and splitting casts (Fig. 10.22). Various types of foam-rubber bolsters and stands or devices for supporting the limb during plaster application are available and are quite useful, particularly when the surgeon must work unassisted.

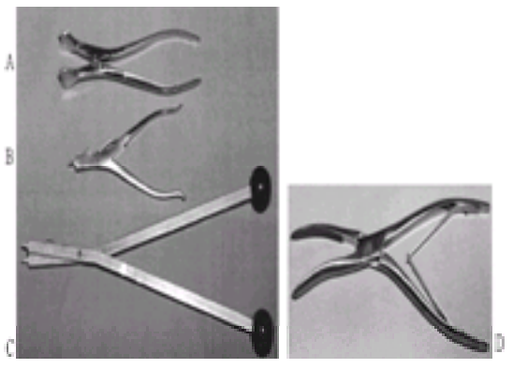

***Figure 10.22.*** Cast spreaders. **A:** A two-handed cast spreader. **B:** Cast spreader designed to be used with one hand; the thin tine is quite useful. **C:** Another two-handed cast spreader that uses the same tine principle as (**B**). **D:** A cast bender for softening the edges of casts.

## GENERAL PRINCIPLES OF APPLICATION OF PLASTER OF PARIS CASTS

The application of a standard below-knee cast will be used to demonstrate the general principles of plaster cast application.

### APPLICATION OF A SHORT LEG AND SARMIENTO CAST

#### *Positioning*

If you are working with an assistant, have him support the leg with one hand in the popliteal fossa and support the ankle in a neutral position with the other hand. If the forefoot is grasped with the extended fingers and thumb through the first toe web space, it is easily held without fatigue, and the cast can be applied over the assistant's fingers with ease. The additional width produced by the assistant's hand also leaves more room for the toes to move once the cast is completed (Fig. 10.23).

***Figure 10.23.*** The assistant supports the lower extremity for application of a short-leg cast. The hand grips the toes by extending the fingers over the metatarsal heads. The cast is applied over the assistant's fingers, which gives room for the toes to move.

If you are working alone, several different techniques are possible. In Fig. 10.24, the patient holds a muslin bandage to maintain the foot in a steady position with the ankle at 90°. In unstable tibial fractures, the thigh can be supported on a well-padded arm board, using an ankle traction bandage with a pail attached; water can be poured into the pail to provide some traction for stabilization of the limb. Placing the forefoot on the knee (Fig. 10.25) helps stabilize the limb, holds the ankle at 90°, and allows the surgeon to control rotation. This technique is described in more detail in Chapter 24 on fractures of the tibia and fibula, where the removable ankle-traction bandage is illustrated in some detail.

***Figure 10.24.*** When the surgeon has to work without an assistant, the patient can help maintain proper position of the foot by holding onto a muslin bandage placed beneath the toes.

***Figure 10.25.*** When applying a lower extremity cast for a fresh fracture, increased stability can be obtained by applying an ankle traction bandage to which a bucket can be attached. Add enough water to the bucket to stabilize the limb. Maintain a right-angle position of the ankle and proper rotation by balancing the metatarsal heads on your knee.

#### *Padding*

Apply end pieces (Fig. 10.14) or a full-length stockinet (Fig. 10.15), or if desired start with Webril. As mentioned, full-length tubular stockinet is generally not

recommended on acute fractures. The general rule in the use of Webril is to use the smallest width practical for the limb and to hold the Webril off the limb, keeping it under constant tension. The smaller-diameter roll allows the Webril to contour to the limb more easily. The tension helps apply it smoothly and allows the Webril to tear when it needs to go around sharp corners such as the heel.

- Begin at the metatarsal heads. Cover the toes so that adequate Webril is present to protect the toes from plaster and so that a turnback of Webril can be done at the completion of the cast for padding the end.
- After applying five layers around the metatarsal heads, begin to progress up the foot, overlapping the Webril to produce at least two layers of thickness and, depending on the application, a maximum of four; for most cast applications, two layers is sufficient. Note that the surgeon has skipped the heel with the Webril (Fig. 10.26).

***Figure 10.26.*** Application of Webril. Hold the Webril off the extremity and apply it with tension to achieve a smooth wrap two to four layers thick.

- Winding figure-eight Webril around the heel and instep results in inadequate padding of the heel and too much Webril in the instep. The former will result in a heel sore, and the latter will make cutting of the Webril very difficult if the cast needs to be split.
- Pad the heel with separate, independent strips of Webril that are torn so that they do not overlap the anterior aspect of the cast.
- Apply five layers of Webril over bony prominences and the heel if felt is not used (Fig. 10.27). If the Webril does not conform well, simply pull away the loose border, leaving a smooth layer of Webril behind (Fig. 10.28).

***Figure 10.27.*** Pad the heel with separate strips of Webril. Do not use a figure-eight wrap, which places too much Webril over the instep.

***Figure 10.28.*** When applying Webril, loose edges can be smoothed by simply pulling them away.

- Carry the initial short-leg section as high as the tibial tubercle, wrapping the Webril well above the patella. The padding shown in Fig. 10.29 is also suitable for application of a Sarmiento short-leg walking cast.

***Figure 10.29.*** The Webril padding has been completed.

### *Plaster Application*

- Fill a plaster bucket with clean, tepid water (70° to 75°F). If considerable molding is necessary, or if a fracture must be reduced within the plaster, use cold water. If a fast setting time is desired, water up to 95°F can be used. Avoid water over this temperature, as the hot water combined with the exothermic reaction of the plaster may be hot enough to injure the skin.
- Assemble all the plaster needed to apply the cast before dipping any plaster in the water. For a short-leg cast on an average 70 kg male, one 4-inch roll for the foot and three 6-inch rolls for the leg usually suffice. To reinforce the bottom of the cast or to add a walker, 10 to 15 thicknesses of a 5 × 15-inch splint, overwrapped with a portion of a 4-inch roll, suffice.
- If the water temperature is cool and the surgeon applying the cast is skilled, all the plaster rolls can be dipped simultaneously. All the rolls will set nearly simultaneously, providing ideal bonding between the layers of plaster. If warmer water is used or if the applier is less skilled, dip the rolls in sequence; preferably, have an assistant dip them.
- Move rapidly to allow adequate time for rubbing in the plaster and molding.
- Turn back a tail on the plaster gauze to help identify it after the plaster is wet. Dip the roll vertically into the water. The water must be deep enough to cover the plaster rolls even after the several rolls are dipped. Be sure the water is clean: water that is cloudy with plaster of Paris from previously applied casts will accelerate the setting of the plaster.
- Let the rolls stand in the water until no more bubbles rise from the roll (Fig. 10.30). If several rolls were dipped simultaneously, lift them all out at once and,

without squeezing, allow them to drain vertically on the tabletop.

***Figure 10.30.*** Dip the plaster rolls vertically in a bucket of clean water at 70° to 75°F; allow the roll to soak until all bubbles finish rising from it.

- Take the first roll to be used, grasp it at both ends, and squeeze it between your palms like an accordion. This technique will express excess water out of the plaster without distorting the roll and without losing excess plaster from the gauze (Fig. 10.31).

***Figure 10.31.*** Gently squeeze the water out of the roll by accordioning it from either end. Twisting or manipulating the roll will result in excessive loss of plaster.

- Do not twist or overmanipulate the rolls; twisting them makes them more difficult to work with and it squeezes excess plaster out of the outer layers of the roll. The assistant, if present, should hand the roll to the surgeon with the free end exposed and readily available.
- The general principle in applying plaster is to use the widest roll that can be applied to the extremity in a practical manner. In this way, the plaster is applied rapidly with a minimum of seams.
- Begin with the 4-inch roll around the metatarsal heads. Apply it distally to the middle of the toes. Use the 4-inch roll entirely on the foot. As much as possible, allow the plaster to roll on the surface of the extremity.
- Push the roll; rarely if ever pull it. Usually it is possible to change the direction of the plaster not by picking up the roll but simply by taking a tuck. For extreme direction changes, it may be necessary to pick up the roll, but avoid pulling the plaster (Fig. 10.32). Once the plaster is started in a figure-eight wrap around the foot and up around the lower ankle, it will usually seek its own course and nicely cover the foot without any special effort to change its direction.

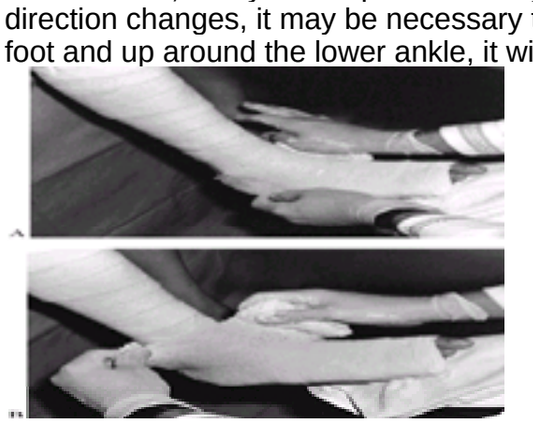

***Figure 10.32.*** **A:** Begin with a 4-inch roll at the metatarsal heads; use this roll on the foot and ankle. Notice that the plaster roll is pushed, not pulled. **B:** To change the direction of the roll, place the leading edge in the direction you want the roll to go. This maneuver produces a loose corner of plaster, seen here in the surgeon's left hand. Take a tuck with the left hand and smooth it down on the posterior aspect of the leg. For sharp changes of directions, pick up the roll with the right hand, but in general leave the roll on the extremity.

- Next, take a 6-inch roll, begin on the foot, and move rapidly up the leg. Apply a single layer of plaster all the way to the knee. The art of rolling plaster smoothly and skillfully now comes into play. If the plaster roll begins to progress upward on the extremity at too sharp an angle, it must be brought back to a transverse direction around the limb by taking a tuck. Do so by sliding the fingers of the assisting hand underneath the edge of the roll closest to you and gently sliding the plaster back to a horizontal relationship to the longitudinal axis of the limb and then smoothing out the tuck produced. It is best to place tucks over soft tissue rather than bone (Fig. 10.33). When crossing joints on their concave surface, slide the roll so that it passes smoothly over the concavity.

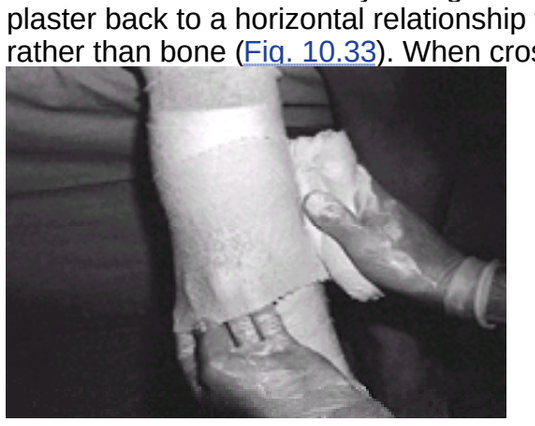

***Figure 10.33.*** On the midportion of the limb, take tucks by slipping the hand under the near edge of the plaster and sliding it until it is transverse to the long axis of the limb. Smooth out the tuck posteriorly and continue rolling.

- Avoid pulling the edge of the roll into the angle of the instep, popliteal fossa, antecubital fossa, or other, similar areas. After each roll is applied, thoroughly rub in the plaster until the gauze pattern can no longer be seen. Rubbing ensures that the layers will unite into one solid, strong layer of plaster, rather than be laminated. This difference is illustrated in Figure 10.34.



***Figure 10.34.*** **A:** These cross sections from well-molded splints show no evidence of lamination. The layers of plaster have consolidated into one solid piece. **B:** In this inadequately molded cast, the layers have laminated and are peeling apart, producing a very weak cast.

- Once enough plaster has been applied, thoroughly rub the cast in and mold the plaster. Special three-point molding may be necessary to maintain fracture position. Do this type of molding with the flat of the palm so that the areas of molding are broad, with the compression distributed over a broad area of soft tissue.
- Try to avoid any direct pressure on bony prominences unless the area is well padded.
- Do not use your fingers or fingertips; they dent the plaster, producing areas of high pressure. Molding pressures must be gentle; hard molding nearly always results in skin problems and pain.
- Plaster applied to the foot will set first (because it was applied there first). Begin molding distally. Mold to match the arch of the foot, restoring both the longitudinal and transverse arches (Fig. 10.35). Then gently mold the plaster with your palms from anterior to posterior to bring out the relief of the malleoli. This molding provides a snug fit to the anterior aspect of the leg, which provides support for the tibia. It pushes more plaster to the posterior aspect of the cast, creating a channel for the Achilles tendon and posterior muscles to function, making a more functional cast (Fig. 10.36).

***Figure 10.35.*** Once all the plaster has been applied and rubbed in, begin molding at the foot. Restore the longitudinal and transverse arches of the foot.

***Figure 10.36.*** In the region of the ankle and shaft of the tibia, gently pull the plaster with the palms of the hands from anterior to posterior to mold it carefully about the malleoli and secure a snug fit to the shaft of the tibia.

- Stop the molding as soon as the plaster begins to set—you will feel it stiffen—to avoid cracking the plaster or producing buckles in the cast. Let the plaster come to a firm set. If splints are to be used to reinforce the cast, apply them between the next-to-last and the last roll of plaster, thereby incorporating them into the cast. The use of splints is discussed in detail later in this chapter.

### *Trimming the Cast*

As soon as the plaster has set well enough that it will not break when handled or set on a padded surface (usually 7–10 min after dipping of the plaster), trim the ends of the cast.

- I prefer to use a disposable #10 or #20 blade. It is quick, produces a very smooth edge, and is much more effective than a cast saw on a “green” cast. If the cast is allowed to dry, then a cast saw must be used. Take care to avoid cutting the patient or yourself when using a knife. A cast of appropriate thickness is easy to trim, is not too heavy, and does not give off too much heat during setting. In casts for the lower extremity, the average thickness should be about ¼ inch on nonreinforced surfaces and no more than $^{5}/_{16}$ inch or so on reinforced surfaces.
- The trick to trimming with a knife is to make a cut in the edge of the plaster and produce a corner that the fingers can grasp easily. Set the blade into the cut and pull the plaster against the knife blade while gently pushing down with the blade; the plaster will usually cut quite easily. If you find that you must push considerably with the knife, get a new blade or change to a cast saw to avoid injuring yourself or the patient (Fig. 10.37).

***Figure 10.37.*** A green cast is easily trimmed with a disposable #10 or #20 blade, following the instructions in the text.

- In standard short-leg casts, trim the cast to the base of the toes, leaving the metatarsal heads covered. If necessary, spread the cast at the end to allow full range of motion for the toes. Toe plates are generally contraindicated as they restrict motion of the toes. Use them only if the cast is being applied for toe pathology.

### *Trimming the Cast Ends*

There are two easy methods for producing a neat, well-padded end to the cast.

- Turn a cuff of Webril to cover the plaster and then turn back the tubular stockinet (Fig. 10.38). If stockinet is not used, cut the plaster and Webril on the lateral aspect of the fifth toe and medial aspect of the great toe, turning back the cuff to an appropriate level.

***Figure 10.38.*** When tubular stockinet is used, trim the edge of the cast just distal to the metatarsal heads, turn back a layer of Webril to pad the end of the cast, and turn back the tubular stockinet, securing it in place with a few wraps of circumferential plaster.

- Then incorporate either the stockinet or the Webril with a few turns of a fresh roll of plaster (Fig. 10.39).

***Figure 10.39.*** If tubular stockinet is not used, cut the Webril and plaster on the lateral and medial aspects and turn it back to produce a soft cuff, which is then secured with a few turns of fresh plaster.

- When trimming surfaces such as the abdominal hole in a spica cast where it is not easy to use a roll, the Webril or stockinet can be adhered to the cast by first stapling it in position (using a staple short enough that it will not penetrate the full thickness of the cast). Then trim with two layers of splints cut to fit the area, or take a sloppy, wet roll of plaster and coat the raw Webril, thus incorporating it into the surface of the cast.

A completed and trimmed Sarmiento (84) short-leg, weight-bearing cast is shown in Fig. 10.40 (described in detail in Chapter 24). I have modified the trimming of the upper end of Sarmiento's cast: I begin the trim proximal to the patella and carry it directly posteriorly to the hamstrings. A channel for the hamstrings is then created sufficiently deep to allow the flexion desired. Notice that the cast is molded above and extends almost horizontally posteriorly over the femoral epicondyles (Fig. 10.40*C*). The upper edges are bent away to allow full extension of the knee. On the front view, notice that the cast is molded in well over the epicondyles of the femur. Although there is a mold over the patellar tendon, it is not emphasized. The mold over the medial and lateral condyles of the tibia, and around the epicondyles of the femur, is more important to obtain good rotational control proximally. Note that the cast is trimmed out posteriorly to allow good knee flexion without impingement on the hamstring tendons. Avoid pressure over the common peroneal nerve at the fibular head. I prefer this molding and trimming of the Sarmiento cast to that more traditionally described because it is technically simpler to do and resembles the configuration of a patellar tendon suspension (PTS) below-knee prosthesis, which provides better molding at the knee.

***Figure 10.40.*** Completed Sarmiento short-leg weight-bearing cast. **A:** Frontal view. Notice the contouring of the cast to the anatomy of the leg, the flat molded surfaces over the subcutaneous borders of the tibia and anterior compartment, and the spacious fit around the toes. **B:** Side view. Notice that the cast has been flattened over the upper gastrocsoleus area to push the tibia forward in the cast. This increases containment and improves the hydraulic support for the fracture. **C:** My modification of the trimming of the upper end of Sarmiento's cast.

**EXTENDING THE SHORT-LEG CAST INTO A LONG-LEG CAST**

A long-leg cast can be made from a short-leg cast whether the initial cast was applied at the standard short-leg level at the tibial tubercle or was extended to a Sarmiento-type cast for a better hold. As long as Webril has been applied well proximal to the plaster, then the next plaster rolls can simply be applied over the upper end of the short-leg cast and then extended up the thigh.

- Some surgeons prefer to petal the upper end of the cast and turn the plaster back, placing an additional roll of Webril beneath it to ensure that padding is adequate at the upper end of the cast (Fig. 10.41). The petals are then turned down and the plaster for the thigh portion is applied.

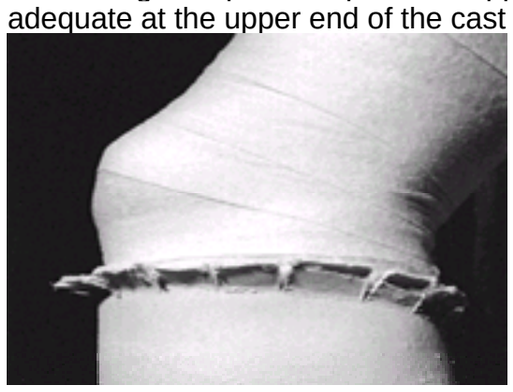

***Figure 10.41.*** Extending a short-leg cast into a long-leg cast. If enough Webril has been applied above the short-leg cast, it can be extended into a long-leg cast by simply applying plaster over the upper end of the existing cast. If padding is inadequate, some surgeons prefer to petal the cast as shown here, placing more padding beneath the plaster and then turning the petals back down, incorporating them into the cast.

- Three or four 6-inch rolls are usually sufficient for the average-size man, and a 10-layered 5 × 30-inch splint is often useful to reinforce the knee. I prefer to apply the splints as a V, with the point of the V placed in the region of the tibial tubercle and the vertical arms carried up the medial and lateral aspects of the knee. The

splints are thus at right angles to the plane of flexion and extension of the knee and provide maximum reinforcement. Carry the average long-leg cast proximally over the prominence of the greater trochanter and leave at least a handbreadth below the groin to facilitate perineal care. This space makes it simpler for the patient to sit on a toilet, yet the cast still provides good support proximally. The molding for this cast is well described in Chapter 24 on fractures of the tibia and fibula. A well-molded, completed cast for weight-bearing is shown in Figure 10.42.

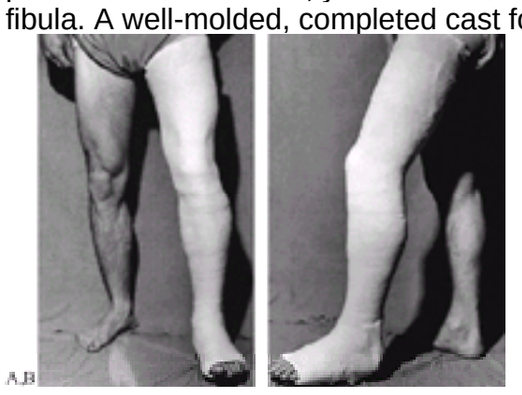

***Figure 10.42.*** Long-leg weight-bearing cast. **A:** Notice that the below-knee portion of the cast is molded exactly as described for the Sarmiento cast. Just above the femoral epicondyles and patella, mold the plaster on the medial and lateral sides to provide good rotational hold about the distal femoral condyles. Molding pushes plaster anteriorly and posteriorly, creating channels for the hamstring and patellar tendons. Mold the plaster proximally like a quadrilateral socket. Notice the oblique angle that carries the plaster up to the level of the greater trochanter. **B:** Notice the anatomic molding of this cast. The knee is in about 5° to 7° more flexion than necessary.

- Apply walking casts with the knee nearly in full extension. Avoid hyperextension or full extension, which may result in knee discomfort. Usually 5° of flexion is appropriate.

***Walking Shoes and Heels***

Most surgeons today use commercially available walking shoes (Fig. 10.43). The walking shoe is removable; the patient can take it off at night to make the cast lighter and to avoid getting the bed linens dirty. A walking shoe also provides some protection for the foot portion of the cast.

***Figure 10.43.*** Commercial-type walking shoe.

For the agile, physically active patient, a walking heel is an excellent alternative. Its smaller surface area allows the foot to twist on the floor more easily than with cast shoes (Fig. 10.44). Because it places the patient's foot somewhat higher off the floor, the walking heel gives a wider range of motion for the knee during gait.

***Figure 10.44.*** Applying a walking heel. **A:** Before trimming the cast, apply a 10- to 15-layer splint along the plantar aspect of the foot and up the back of the heel. Place the walking heel at the mid foot and pack plaster underneath it to place it at right angles to the foot in both the longitudinal and frontal planes. **B:** Secure the walking heel to the cast with a 4-inch roll of plaster, thoroughly incorporating the heel. **C:** The completed walking heel is at right angles to the longitudinal axis of the leg. **D:** The walking heel is in the middle of the foot. If the heel is placed too far anteriorly, the patient will back-knee; if placed too far back on the heel, the patient will contact on the forefoot and break down the cast.

**DELBET CAST**

The Delbet cast is a short-leg walking cast that leaves the foot free—in essence, a cylinder cast of the leg. It is useful when full foot and ankle motion is desired and a mid-shaft fracture of the tibia and fibula is fairly stable. Because these casts tend to slip down and cause pressure on the foot, a heel cup and ankle hinge are usually attached for suspension (Fig. 10.45).

***Figure 10.45.*** **A:** A Delbet walking cast is applied in exactly the same manner as a Sarmiento cast. Distally, the foot is left free, and the cast is molded carefully over both malleoli and left high enough above the instep and heel to allow full ankle motion. Suspension usually requires application of an ankle hinge with a heel cup. **B:**

This side view shows the molding over the malleoli.

**CYLINDER CAST**

The cylinder cast is used to treat ligament injuries of the knee and stable fractures about the knee joint where rotational control is not of great concern. Generally, it is used as a weight-bearing cast; therefore, the foot is left free.

Application is simplified by supporting the foot on a second table or stool with the lateral or medial side of the knee downward, depending on which side has the ligament injury. In a medial collateral ligament injury, place the lateral side downward. Gravity automatically reduces the knee joint (Fig. 10.46*A*). This is also a good position for control of cruciate ligament instability.

***Figure 10.46.*** Cylinder cast. **A:** For a medial collateral ligament injury, place the foot on a supporting surface and rotate the limb so that the lateral side is downward. Gravity therefore closes the medial joint line. Use the opposite position for a lateral collateral ligament injury. In this case, a skintight cast is used by rolling a snug stockinet over the leg. Use Webril to pad around the bony prominences at the ankle and the knee, and trim the cast at the hip. Place two layers of Webril down the anterior aspect of the cast for removal with a cast saw. The plaster is now applied directly over this padding and the stockinet. **B:** The completed cylinder cast has been carefully molded to the leg, particularly above the femoral condyles to provide suspension. Note that the cast stops well above the malleoli so that if it drifts downward, it will not contact the malleoli and cause pressure sores.

Suspension of these casts can be challenging. Adhesive ointments such as Ace adherent or tincture of benzoin can be applied to the extremity and then a snug tubular stockinet rolled over it to adhere the cast to the leg. Strips of adhesive tape on the leg turned up into the cast from the lower end serve the same purpose. All of these methods have the disadvantage of placing a chemical adherent beneath the cast, which may elicit an allergic response. In the lean athletic leg, good molding of the cast (Fig. 10.46*B*) will result in adequate suspension. In obese patients, suspenders may be necessary to keep the cast up.

**LONG-LEG CAST-BRACE**

The long-leg cast-brace always incorporates hinges at the knee, either polycentric metal hinges or plastic hinges. The ankle can be hinged as well. Rotational control, particularly for treatment of fractures of the middle to proximal femur, can be facilitated by adding a hip hinge. The cast-brace was developed during the Vietnam War for the treatment of fractures of the shaft of the femur. It can also be used for treatment of tibial plateau fractures. It is most useful for treatment of supracondylar fractures of the femur. Shaft fractures can also be treated, but the incidence of shortening and malunion is significant. It has even been extended to the treatment of subtrochanteric fractures of the femur.

Figure 10.47*A* shows the specialized equipment needed for application of a long-leg cast-brace: two types of hinges, a polycentric steel one and a polycentric plastic one; a quadrilateral plastic socket for the upper thigh and plastic heel cup with plastic ankle hinge; a cast-brace stocking (extra heavy and specially padded); adhesive synthetic pads and an elastic wrap for the knee; corset-bending irons for adjusting the knee hinges; and a jig and hose clamps for holding the hinges in proper position.

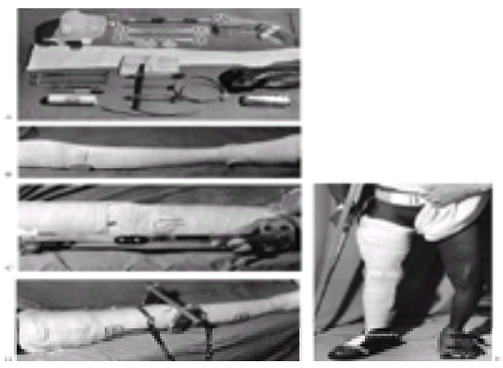

***Figure 10.47.*** Long-leg cast-brace with hip hinge. **A:** The specialized equipment needed for application of a long-leg cast-brace. **B:** Special heavy stockinet is applied over the limb and the elastic sleeve over the knee. **C:** The center of a metal polycentric knee hinge will be placed directly over the epicondyles. **D:** Apply the hinges to the cast with the jig and hose clamps and incorporate them well into the cast. **E:** The completed cast-brace.

- Apply the special heavy stockinet over the limb and the elastic sleeve over the knee (Fig. 10.47*B*).
- Place synthetic adherent pads over the fibular head and malleoli. A plastic quadrilateral socket at the upper brim may or may not be used.
- Apply a well-molded long-leg cast as already described, or apply the cast in a leg and thigh section (Fig. 10.47*C*).
- Carefully locate the medial and lateral epicondyles of the femur and mark them with a pen. The center of a metal polycentric knee hinge will be placed directly over the epicondyles.
- Carefully mold the hinges to fit the lateral and medial sides of the leg, avoiding impingement of the metal on bony prominences. Both hinges must be located symmetrically and parallel to each other, in line with the knee's axis of bending.
- Apply the hinges to the cast with the jig and hose clamps and incorporate them well into the cast (Fig. 10.47*D*).

In the completed cast-brace shown (Fig. 10.47*E*), the ankle is incorporated into the cast and a hip hinge and wristband are added to increase proximal control.

With the advent of closed intramedullary, interlocking nailing, cast-braces are little used today in North America for the treatment of fractures of the shaft of the femur. Interested readers will find the articles of Mooney (61,62) and others (20,36,46,55,58) worth reading, particularly for details of the technique of application. Many fractures in the lower extremity cannot be treated by internal fixation, so we use cast-bracing with reasonable frequency. It should be part of the repertoire of every orthopaedic surgeon treating lower-extremity fractures.

**HIP SPICA CASTS**

A spica is a bandage that is applied in successive V-shaped crossings, resembling a spike of grain (the meaning of the Latin word *spica*); this configuration is produced by a figure-eight wrap around the torso and then around the limb. With the advent of internal fixation, spica casts are little used in adults, but they are commonly used in children for the treatment of hip dysplasia, for postoperative immobilization, and for the treatment of fractures.

### *Children's Single-leg Hip Spica*

A pediatric, tabletop adjustable orthopaedic table (Fig. 10.48*A*) greatly facilitates the application of the single-leg hip spica cast in children. Sometimes spica casts can be applied with just heavy sedation, but usually an anesthetic is required.

***Figure 10.48.*** Pediatric hip spica cast. See text for details.

- Support the child' shoulders and upper thorax on the table and the pelvis on the perineal post, which should be well padded.
- A single assistant can support the legs and apply any traction necessary (Fig. 10.48*B*).
- Trimming of the cast is greatly facilitated by first applying tubular stockinets. One size of stockinet will be necessary for the torso and another for the lower extremity.
- Thoroughly pad with Webril. Felt is usually unnecessary in children, but small ¼-inch-thick pads can be placed over the anterior superior iliac spines, around the rib cage, and over the sacrum if necessary.
- If only one surgeon is available, it is usually easiest to apply the long-leg cast first as a cylinder from the ankle to the hip, carefully molding it and allowing it to set. The direction of the spica wrap used to move up onto the torso is illustrated in Figure 10.48*B*.
- Then the cast can progress up onto the torso. If two sets of hands are available, the torso and long-leg portion can be applied simultaneously, which provides better integration between the long-leg cast and torso portion. Extra padding around the upper edge of the cast at the ribs makes it more comfortable.

The specifics of how the plaster is best applied are outlined as follows. In general, the cast should extend from the xiphoid process to the metatarsal heads.

- The initial rolls of plaster should be fairly thin (usually three or four layers) (Fig. 10.48*C*).
- To avoid a cast that is too heavy and to reinforce it where the stress is greatest, apply five-thickness splints on the lateral aspect of the extremity, extending up onto the torso. Also, wrap a splint around the upper chest cage and around the pelvis to reinforce the edge of the cast, which will become the border for the perineum and buttocks.
- Thoroughly wrap these in with another series of rolls of plaster, taking care to not make the cast too thick.
- Create a generous hole over the abdomen to make breathing easy and to ventilate the cast. To facilitate the abdominal hole, cut a star with the cast saw (Fig. 10.48*D*). It is then easy to bend the flaps upward and cut them off with either the cast saw or a sharp scalpel.
- Trim the cast well above the perineum to avoid soiling. Over the buttocks, allow adequate room for bowel movements; do not trim the cast above the prominence of the sacrum, however, as the patient's buttocks will protrude out of the cast posteriorly and develop pressure sores on the upper sacrum.
- In a single-leg hip spica cast, trim the opposite hip to allow flexion to 90°. Carefully trim the cast to make it comfortable. Softening the upper edge of the cast with a cast bender after the plaster has set makes it more comfortable.
- When the cast has been completed, apply 2- to 3-inch-wide plaster splints to trim and seal the tubular stockinet down to the cast. (The cast in Fig. 10.48*E* is about 2–3 inches below the xiphoid, which is somewhat too low. Most patients are more comfortable if it is at the level of the xiphoid.)

### *Adult Double or 1½ Hip Spica Cast*

The principles for application of an adult double or 1½ hip spica cast are the same as those for the children's. In adults, a fracture table is essential. Figure 10.49*A* shows an anesthetized patient on the fracture table with a long-leg cast already applied to the left lower extremity to stabilize an unstable knee.

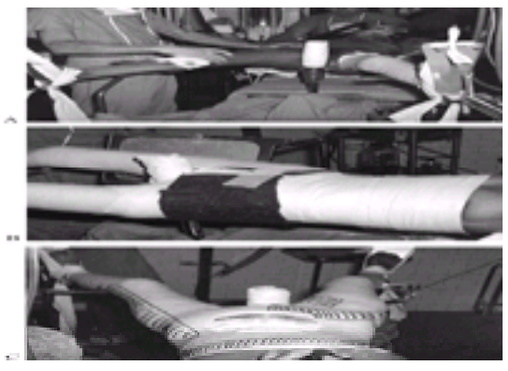

***Figure 10.49.*** Adult double-hip spica cast. See text for details.

- Place the patient supine on a fracture table (Fig. 10.49*A*). Note the padded perineal post and special foot plates. Plaster can be applied directly over the foot plates, and they can then be slid out of the plaster; this is a very convenient feature. The knees are held in 10° or so of flexion by knee supports, which are also slid out of the cast after application.
- In adults, use felt to pad all bony prominences. A single sheet of ¼-inch-thick felt around the pelvis provides good padding over the sacrum and anterior superior iliac spines (Fig. 10.49*B*). Rubbing the felt over the end of a smooth-ended pole or stick will produce a small bulge in the felt that fits nicely over the anterior superior iliac spine or other bony prominences. Run a similar sheet of felt about 3 inches wide up the entire length of the spine, and apply another sheet around the upper edge of the cast.
- The nearly completed cast before application of the feet is shown in Fig. 10.49*C*. Trimming has yet to be completed, although the abdominal hole has been cut out. Shown in the photograph are the locations of the splints used to reinforce the cast. The cast should consist of an initial layer of plaster of about four thicknesses, overlaid by splints, and then thoroughly incorporated with rolls. The reinforced regions should be about $^{5}/_{16}$-$^{3}/_{8}$ inch thick and the nonreinforced portions about ¼ inch thick.

### *Adult Weight-bearing Single Hip Spica Cast*

The weight-bearing single-hip spica cast is useful for adults. Sometimes it is necessary to immobilize the hip and femur in a hip spica cast that will be used for walking. These casts fit much better if they are applied with the patient in the weight-bearing position (Fig. 10.50*A*).

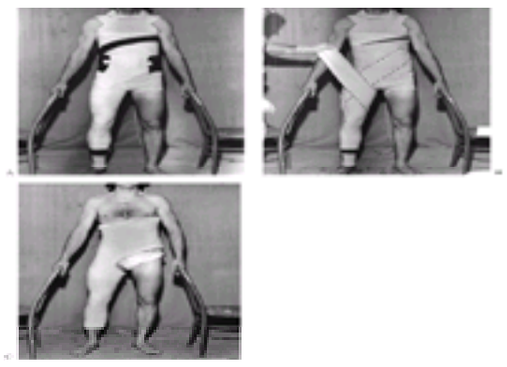

***Figure 10.50.*** Adult single-leg weight-bearing hip spica. See text for details.

- I find it easiest to have the patient stand between two chairs, using the chairs for support.
- Apply a tubular stockinet of the appropriate diameter.
- Pad with Webril and felt as previously described. Notice that the cast will stop well above the ankle to avoid ankle impingement if it settles.
- Make the upper edge of the cast oblique, high on the side opposite the extremity to be immobilized, and low on the rib cage on the immobilized side. The midportion should cross the xiphoid. Keeping the cast high on the chest wall opposite the immobilized extremity counterbalances the weight of the leg and makes the cast more comfortable. The oblique angle makes it easier for the patient to sit.
- Allow plenty of room for the perineum and the function of the opposite hip.
- First apply rolls of plaster to a thickness of about four layers; then apply reinforcing splints and more rolls to incorporate them (as described previously). Notice the direction of the splints (Fig. 10.50*B*).
  The completed cast is illustrated in Figure 10.50*C*.

**FLEXION BODY JACKET**

A flexion body jacket is most commonly used to treat low back pain, although it is used less often today because of the increasing sophistication and effectiveness of orthotic appliances. The purpose of the cast is to provide three-point fixation, straightening hyperlordosis of the lumbar spine and increasing intra-abdominal pressure by compression on the abdomen. Generally, the patient should remain fairly active and do both abdominal and spinal muscle-strengthening exercises while in the cast.

- Stand the patient about 18 inches from a table and have him lean over, rest his hands on the table, and suck in his abdomen, rounding up his back (Fig. 10.51*A*).

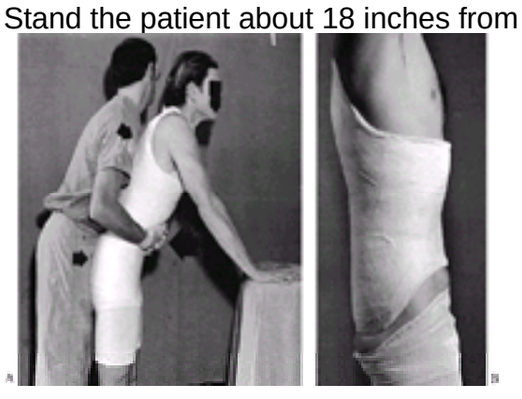

***Figure 10.51.*** Flexion body jacket. See text for details.

- Apply a tubular stockinet tied over his shoulders and extending down onto his legs.
- Wrap the torso thoroughly with Webril; felt is usually not needed.
- Apply circumferential rolls of 6- or 8-inch plaster from well below the hips to the xiphoid and well up onto the back. Splints up the spine and across the back are useful in reinforcing the high posterior portion of the cast.
- Apply the cast rapidly so that three-point molding can be applied, as illustrated in Fig. 10.51*A*. The direction of the molding is indicated by the arrows.
- The completed flexion body jacket (Fig. 10.51*B*) extends well down over the buttocks to the gluteal crease and extends to about T-4. The abdominal portion is narrower but well molded to produce abdominal compression over the mid abdomen.

**HYPEREXTENSION BODY JACKET**

Hyperextension body jackets are commonly used for the treatment of compression fractures of the spine in the region of the thoracolumbar junction. Most surgeons apply them by placing the patient on a fracture table in the supine position on Goldthwait irons, steel bands that can be adjusted to produce a desired degree of hyperextension of the spine. This is the simplest and most controlled method for applying this cast.

Another method is to place the patient prone on the canvas strap of a Bell orthopaedic table with the feet suspended from the overhead frame (Fig. 10.52). The fracture is placed directly over the middle of the canvas strap, and the strap is slowly loosened until the desired reduction is obtained. The cast is then applied and the canvas strap pulled out of the cast.

***Figure 10.52.*** Use of a bell table and canvas strap for reduction of a thoracolumbar junction fracture and application of a hyperextension body jacket.

The classic method of Watson-Jones, suspending the patient between two tables, is described here.

- Suspend the patient between two tabletops and allow her back to hyperextend to a comfortable position.
- Apply the cast as previously described. The plaster must be brought down over the pubic symphysis and high on the chest just short of the sternal notch. As the cast sets, these two areas must be molded as illustrated in Fig. 10.53*A*.

***Figure 10.53.*** Watson-Jones method for reduction of a compression fracture of the spine at the thoracolumbar junction with application of a hyperextension body jacket. See text for details.

- Notice that the completed hyperextension body jacket (Fig. 10.53*B*) is low over the pubic symphysis and high on the chest to maintain the position of hyperextension. Posteriorly, it extends from the gluteal crease to the mid-thoracic spine. For comfort, place an abdominal hole.

**MINERVA CAST**

With the sophistication of current halo jackets, Minerva casts are now rarely used, but they may provide better immobilization for unstable injuries at C-1–C-2. A loose halo jacket may impart undesired motion to the upper cervical spine when it is connected to a halo; the Minerva avoids this situation. In most situations, the Minerva is applied with the patient supine on an orthopaedic table in gentle head-halter traction. If the cervical or upper thoracic spine is stable (for example, after internal fixation) and protection until healing is desired, a better-fitting cast can be obtained by applying the cast with the patient in the upright position. Do it only after the patient has been mobilized somewhat, to avoid postural hypotension.

- Seat the patient comfortably on a stool next to the fracture table (Fig. 10.54*A*).

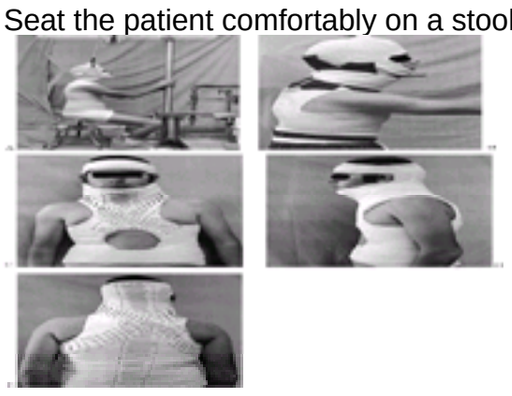

***Figure 10.54.*** Minerva jacket. See text for details.

- Use the overhead traction assembly to provide head-halter traction to support the cervical spine in the desired position, which generally is neutral.
- Supervise the patient carefully, because he may faint from postural hypotension (an assistant can be assigned this job).
- Padding around the chin, occiput, and neck is important (Fig. 10.54*B*). Take a ¼-inch piece of felt wide enough to extend from the acromion to the lower edge of the ear, and from the sternal notch to somewhat beyond the chin. Make it long enough to go around the entire neck. Make transverse cuts alternating from side to side so that it fits nicely around the neck, as illustrated. Hold it in place with a soft cervical collar, which will be incorporated into the cast.
- Put a circumferential piece of felt around the iliac crest and add a third piece along the spine if you wish. If a cervical collar is used, the cervical traction is usually not necessary. Use the basic principles for plaster application outlined for the spica cast.
- Apply the body jacket and the occipital portion of the cast.
- After it has set, add the headband. Use 4- and 6-inch rolls of plaster to obtain a base layer, and then apply splints as illustrated on the cast (dotted lines, Fig. 10.54*C*).
- Apply a 15-layer-thick splint on the entire spine up onto the occiput; this splint forms the backbone of the cast and gives it stability. Once it sets, the head will be secured to it.
- Secure the head by wrapping a circumferential roll of 3-inch plaster around the head, connecting the head portion firmly to the previously applied occipital portion.
- Trim as indicated in Fig. 10.54*C*, Fig. 10.54*D* and Fig. 10.54*E* (the front, side, and posterior views). Notice the location of splints drawn on the cast.

**SHOULDER SPICA CAST**

With the advent of sophisticated orthotic braces, the spica cast is less commonly used for the shoulder. A spica cast is more versatile, however, and often more comfortable than an abduction shoulder brace. It is used to treat humerus fractures, to protect soft-tissue injuries about the shoulder, and in surgical repairs of the shoulder and proximal humerus.

- I usually apply this cast using a regular operating table and a “slippery stick,” a piece of hardwood about 3–4 inches wide, 1 inch thick, and at least 6 feet long, which has been sanded into an ellipsoid shape, thicker in the middle and tapering to the sides. The stick is highly varnished and can be coated with mineral oil or lubricant jelly to make it slide more easily.
- Place the stick under the patient's spine and head. A solid stool or part of the anesthesia machine can be brought in to support the head of the stick. With two assistants holding the patient's arms on both sides to balance her torso, the operating table can then be slid toward the feet until it just supports the buttocks. The torso is left completely suspended in space on the stick.
- Before this maneuver, it is often wise to apply a long-arm cast, which will subsequently be incorporated into the spica cast. Keep the long-arm cast light, as the reinforcement necessary to connect it to the body jacket portion will make it quite heavy. Another method is to use the versatile attachments provided by a Chick-Langren orthopaedic table to completely preposition the patient for the shoulder spica cast (Fig. 10.55*A*). The basic principles of padding are used as described for other jackets surrounding the torso.

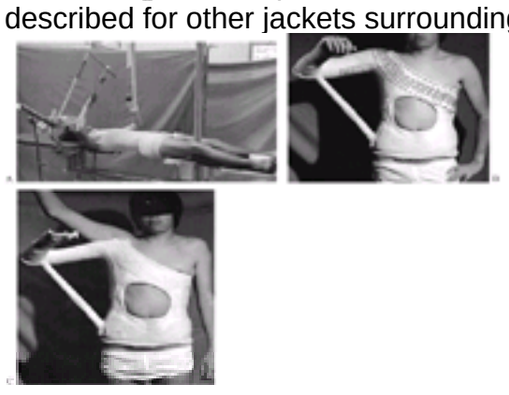

***Figure 10.55.*** Shoulder spica cast. See text for details.

- The completed cast extends well down over the iliaccrest (Fig. 10.55*B*). The proper length is important for stability. If the cast is left too high, the weight of the arm will cause it to swing, and the edge of the cast will dig into the rib cage or the top of the iliac crest, causing pain. Note that the side of the cast opposite the immobilized arm is kept high to provide support for the arm.
- Spica casts can break easily at the junction of the extremity and the body portions of the cast; therefore, a reinforcing rod, as used here, is useful. It can be made by rolling up newspaper and covering it with plaster; a wood stick covered with plaster can be used as well. A similar stick should be used between the legs on a double hip spica or a 1½ hip spica.

- Figure 10.55*B* shows the position of the splints in this cast. Once early healing occurs, the top of the cast can be removed and exercises can begin (Fig. 10.55*C*).

**PLASTER BOLERO**

The plaster bolero (Fig. 10.56) is useful for treating unstable fractures of the clavicle that require hyperextension of the two shoulders to maintain position. It can also be applied to one shoulder, incorporating the upper arm if necessary.

***Figure 10.56.*** The plaster bolero is applied using splints across the top of the shoulders and a circumferential wrap around the chest. This bolero has not yet been trimmed.

- The bolero is best applied with the patient sitting on a chair, facing the back of the chair. An assistant holds the arms in extension to reduce the fracture.
- Apply the bolero with felt and good Webril padding over the fracture site.
- Mold it carefully and then trim it to allow as much shoulder motion as desired.

**PLASTER VELPEAU**

The shoulder Velpeau dressing is generally used only as a soft-tissue dressing to immobilize the shoulder or humerus. When combined with a sugar-tong splint on the humerus, it is very effective for immobilizing fractures of the shaft of the humerus. Otherwise, it is the utilitarian method for immobilizing the shoulder when secure fixation is desired. Overwrap the soft Velpeau with plaster if better immobilization is desired or if patient compliance might be a problem.

- Place abdominal pads or other padding into the axilla and over the skin of the arm and the chest wall to avoid skin irritation (Fig. 10.57*A*). Powder with baby powder or cornstarch to absorb moisture from perspiration.

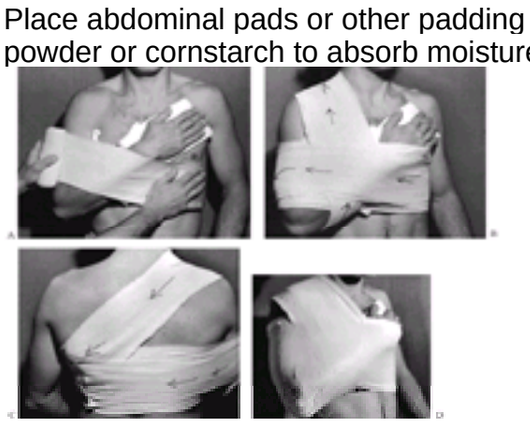

***Figure 10.57.*** Soft and hard shoulder Velpeau dressings. See text for details.

- Using a 6- or 8-inch-wide bias-cut stockinet, begin on the chest wall below the arm and bind the arm gently to the chest with a circumferential wrap (front view, Fig. 10.57*B*; back view, Fig. 10.57*C*). After a half-dozen wraps, pass it beneath the elbow and vertically over the ipsilateral shoulder to support the arm.
- Overwrap the bias-cut stockinet with Webril and then overwrap in the same manner with two 6- or 8-inch rolls of plaster (Fig. 10.57*D*).
- After application, check at the medial epicondyle of the elbow to be sure there is no pressure over the ulnarnerve. In acute fractures of the distal portion of the humerus, this amount of elbow flexion may not be possible initially due to swelling. In that case, use a sling and simply bind the arm to the chest wall in a sling-and-swath technique.

**SHORT-ARM CAST**

The short-arm cast can be used to immobilize the wrist and the base of the finger metacarpals for a host of disorders. The application of a short-arm cast to maintain the reduction of a relatively stable Colles' fracture is shown in Figure 10.58.

***Figure 10.58.*** Short-arm cast for immobilization of a stable distal radius fracture. See text for details.

- In stable fractures, place the patient supine on the treatment table, rest the elbow on the tabletop, and form the hand as if holding a soft-drink can.
- Apply a tubular stockinet at either end of the cast (Fig. 10.58*A*). On the hand, carry the tubular stockinet to the tip of the fingers. I prefer somewhat more stockinet around the base of the thumb and wrist than illustrated here.
- For the average-size adult, 3-inch Webril is best for padding (Fig. 10.58*B*). Obtaining smooth, adequate padding about the hand can be difficult. Use a figure-eight wrap; when you encounter the thumb, simply pull the Webril down over the tip of the thumb, as illustrated, allowing the thumb to poke through the Webril. This produces a nice layer of padding around the base of the thumb.
- Carry the Webril distally about 2 cm distal to the prominence of the metacarpal heads.
- Apply plaster using two or three 4-inch rolls, depending on the size of the limb (Fig. 10.58*C*). In small adults or older children, use a 3-inch roll. I do not find it necessary to use splints, although some surgeons prefer them. A nice trick for obtaining a smooth wrap around the thumb, palm, fingers, and wrist is to leave the 4-inch roll at its full width and apply it as a figure eight around the wrist, with the thumb in one hole of the eight and the fingers in the other, leaving the roll at full width as it passes through the palm. The result is a very smooth application of plaster with very nice coverage of the palm and wrist. The direction of this wrap is indicated by the dotted lines in the photograph.
- Carry the plaster proximally to the level desired. Apply it rapidly, and thoroughly rub it in (Fig. 10.58*D*). Try to keep the cast no more than ¼ inch thick.

- Begin molding by reproducing the transverse arch of the palm, as illustrated.
- Then mold the forearm to the normal oval shape of the forearm (Fig. 10.58*E*).
- Do not stop the cast on the dorsal side more proximal than the metacarpal heads, as swelling will cause it to compress the dorsal veins, with resulting increased swelling of the digits. Placing the cast over the prominence of the metacarpal heads allows these veins to drain through the intermetacarpal spaces.
- How the cast is molded and how far proximally it is carried at the elbow determine how much motion in supination and pronation will remain. The more the cast is made into an oval shape and the higher on the elbow it is carried, the less motion there will be.
- Trim the completed cast at the elbow flexion crease to allow full elbow flexion without impingement of the plaster into the antecubital fossa (Fig. 10.58*F*).
- When trimming the cast around the hand, first cut the plaster to the desired level with a scalpel (Fig. 10.58*G*). Trim the cast on the dorsal side to the prominences of the metacarpal heads and cut the palmar side down to allow flexion of the fingers to 90° and good apposition of the thumb.
- Turn a Webril cuff over the edge of the cast, and then cut a small hole in the stockinet for the thumb. Pull the entire tubular stockinet back over the thumb and palm of the cast and secure it about the wrist with a few rolls of plaster. This makes trimming the cast simple and eliminates the need for a bar of plaster in the first web space. The material on the palm also enhances the grip for objects.
- Note that restoration of the normal transverse arch of the palm allows the patient to easily touch the thumb to the tips of the fourth and fifth fingers.
- The trim around the fingers covers the top of the metacarpal heads and then inclines forward to allow flexion to 90° at the metacarpophalangeal joints (Fig. 10.58*H*).

**MUENSTER SHORT-ARM CAST**

The Muenster short-arm cast is used to immobilize the forearm and wrist when flexion and extension of the elbow, but limited supination and pronation, are desired. It might be indicated for a fracture of the radius and ulna where pronation and supination are thought to be a destabilizing factor, or for postoperative protection of internal fixation of the forearm, where supination and pronation must be avoided. Application of this cast (Fig. 10.59) requires a simple modification of the standard short-arm cast just discussed.

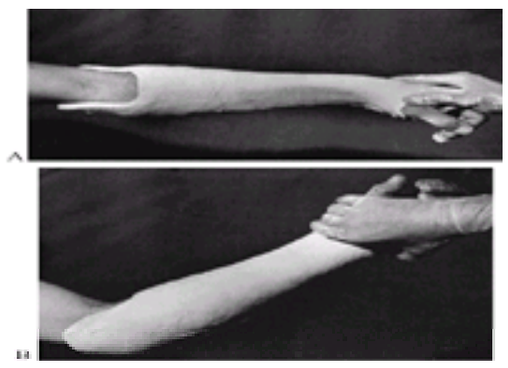

***Figure 10.59.*** Muenster short-arm cast. **A:** The Muenster short-arm cast is applied in the same fashion as the short-arm cast just described, but the cast is carried up onto the distal arm and then subsequently trimmed down to the configuration seen here. Notice that the proximal end of the cast grips the epicondyles of the humerus as in the supracondylar portion of a Sarmiento cast. It is cut out well over the antecubital fossa to allow full flexion of the elbow. **B:** In this side view, notice the extensions of the cast over the epicondyles and the grip on the back of the olecranon. Trim the posterior aspect of the cast to allow full extension.

**LONG-ARM CAST FOR A COLLES' FRACTURE**

Do not use the Cotton-Loader position, as this can lead to a carpal tunnel syndrome. In very loose-jointed patients, it may be necessary to hold the wrist in a position of about 30° to 45° of flexion, rather than the 90° into which it may fall by virtue of gravity alone.

- Apply stockinet and Webril for padding as discussed for the standard short-arm cast.
- Do not use finger traps to reduce Colles' fractures, because it is difficult to evaluate the stability of the fracture while it is hanging in finger traps.
- Carry out the reduction by first applying countertraction to the humerus. To correct shortening and radial deviation, pull traction on the thumb with one hand.
- With the other hand, grasp the end of the radius, placing your thumb directly over the distal fragment at Lister's tubercle. Reduce the dorsal angulation and simultaneously pronate the forearm to reduce the supination, holding traction on the thumb. This technique maintains correction of length and keeps the wrist in ulnar deviation.
- Allow the arm to hang passively off the side of the treatment table (Fig. 10.60*A*) with the elbow extended. With the hand hanging in this position, it is possible to determine the degree of remaining dorsal tilt, restoration of length, and so forth.

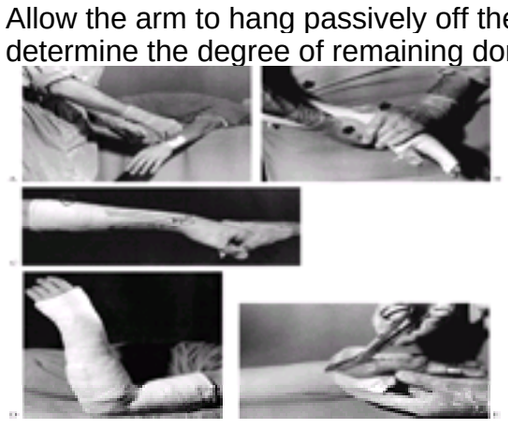

***Figure 10.60.*** Long-arm cast for Colles' fracture. See text for details.

- It may be helpful to have an assistant gently grasp the fingers and the thumb to open the web space and to hold the hand ulnarly deviated and the wrist pronated.
- If the fracture maintains good position, with perhaps slight support on the thumb and fingers by an assistant, then with three-point molding in a long-arm cast there is a high likelihood that an anatomic position can be maintained until union occurs.
- If, however, the fracture shifts into malposition, it is unlikely that a cast alone will maintain the reduction. In this case, use percutaneous Kirschner wire fixation, an external fixator from the radius to the second metacarpal, or a combination of the two. Occasionally, internal fixation may be necessary when there is disturbance of the articular surface of the radius that is amenable to internal fixation.
- Apply the plaster rapidly and smoothly as for the short-arm cast, then mold the cast gently by reproducing the forces used to reduce the fracture (Fig. 10.60*B*).
- Three-point molding is important: One point of pressure is your thigh, the second is over the dorsal aspect of the distal fragment (not on the hand), and the third is the counterpressure point along the palmar aspect of the forearm. All of these molding areas should be very broad and gentle to avoid pressure points. The molding is indicated by the arrows.
- In the completed molding of the forearm portion of the cast (Fig. 10.60*C*), notice the flat spot in the cast over the dorsum of the distal radial fragment, which is drawn on the cast. The direction of the molding is indicated by the arrow.
- Note the smooth broad area of molding along the palmar side of the radius, which is continuous with the curvature of the thumb.
- In the completed long-arm cast (Fig. 10.60*D*), Webril rather than stockinet was used to trim the ends of this cast.
- The elbow is flexed to 90° and the forearm is moderately pronated. Note the ulnar deviation in the wrist. An indication of some of the molding that was done after the cast was applied can be seen by the small wrinkle in the cast on the ulnar side of the hand.
- When using Webril alone to trim the cast, a useful method for trimming of both the fingers and the thumb is to make a longitudinal cut with a pair of scissors or a scalpel along the radial aspect of the thumb as far proximally as desired, and a similar cut along the ulnar border of the hand (Fig. 10.60*E*). The plaster can then be turned back as illustrated on the thumb and then captured with a few circumferential rolls of plaster to complete the molding.

**GAUNTLET CAST**

The gauntlet cast is useful to immobilize fractures of the metacarpals of the hand and for minor wrist injuries. For fractures of the fourth and fifth metacarpals, I prefer to use an ulnar gutter splint (described below), but the gauntlet cast is quite useful for fractures at the base and in the mid shaft of the metacarpals. It also can be used for the typical boxer's fracture of the neck of the metacarpal. In the latter case, the cast must be carried distally enough to allow molding on the volar aspect of the

metacarpal head. If rotational instability is of concern, it may be necessary to buddy-tape or splint the fingers.

- Apply this cast in a fashion identical to that of the forearm cast just described, but stop it at the junction of the middle and distal thirds of the forearm (Fig. 10.61*A*).

***Figure 10.61.*** Gauntlet cast. See text for details.

- Carry it distally over the affected metacarpals. It may need to be somewhat longer than the standard forearm cast, and in fact it may extend up to the midportion of the proximal phalanx, particularly for fractures of the third and fourth metacarpals.
- Place a felt pad over the dorsal aspect of the fractured metacarpal and over the palmar aspect of the metacarpal head.
- Use three-point molding to maintain the reduction of the fracture (Fig. 10.61*B*).

**THUMB SPICA CAST**

The thumb spica cast is used primarily for fractures of the scaphoid and other instabilities of the carpal bones amenable to cast treatment. It also is used for fractures involving all elements of the thumb itself. In scaphoid fractures, most surgeons use a long-arm thumb spica cast for the initial 6 weeks of immobilization and then convert to a short-arm spica cast (Fig. 10.62).

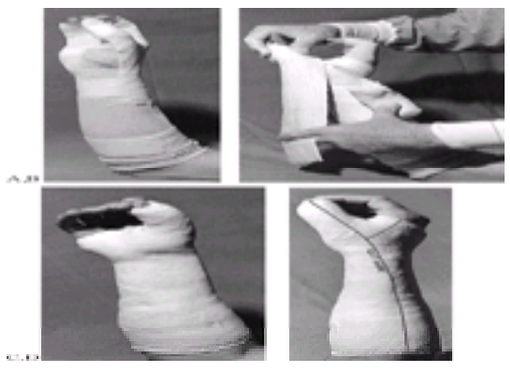

***Figure 10.62.*** Short-arm thumb spica cast. See text for details.

Although I rarely use an unpadded cast, it is shown in Figure 10.62*A* for the purpose of illustration. When applied to acute injuries, the cast must be univalved.

- Apply a tubular stockinet over the forearm and hand as done for the forearm cast, and apply a second tubular stockinet over the thumb. Some custom shaping is necessary to obtain a snug fit.
- Carry the Webril distal to the end of the thumb. Apply Webril padding about the palm of the cast and around the distal phalanx of the thumb. Apply a double-thickness strip of Webril along the dorsal aspect of the thumb, wrist, and forearm for removing the cast, and secure it with a circumferential wrap of Webril.
- Position the hand as if holding a soft-drink can to maintain proper position of the thumb relative to the fingers.
- First apply a roll of plaster to the forearm about four layers thick (Fig. 10.62*B*). Then use a 3 × 15-inch splint, five to seven layers thick, and apply it around the thumb as a splint, as illustrated. This will lap around the thumb enough that it will not be necessary to actually wrap plaster circumferentially around the thumb. If a 3-inch roll is not wide enough, use a 4-inch roll.
- Incorporate this splint and the rest of the hand using the technique already described for a forearm cast.
- The completed cast is carried well up on the forearm, but not so far that it interferes with the antecubital fossa (Fig. 10.62*C*).
- Notice that the thumb is easily opposed to the first and second fingers. A common mistake with this cast is to get the thumb out into the ape-hand position, which makes it impossible for the patient to obtain three-jawed-chuck prehension. The patient will not be able to function with the cast on. Notice that on the thumb the cast is carried distally to the middle of the fingernail. This length provides adequate immobilization yet leaves the tip of the thumb available for prehension. Making the cast shorter allows the patient to jack the hand up in the cast by flexing the distal phalanx over the end of the cast, introducing significant motion into wrist injuries, which should be avoided.
- The line for univalving the cast and for removal has been indicated by writing on the completed cast (Fig. 10.62*D*). This must always be done on casts applied with minimal padding, as in this case. When the cast is univalved, split the underlying stockinet as well.

**HANGING-ARM CAST**

The hanging-arm cast is used to treat fractures of the humerus in all areas, including those of the surgical neck. The principle of the hanging-arm cast is that it relies on traction for fracture reduction rather than molding of the cast, although molding is useful in supracondylar fractures. In shaft fractures, the angle of varus and valgus can be changed by the location of the suspension hook and the length of the sling that hangs the cast from the neck.

For this cast to be effective, the patient must be able to remain upright most of the time during the first few weeks after the fracture and must not rest the cast on any surface. Sleeping at night with the head and upper thorax at a 45° angle usually suffices. Once the fracture becomes fairly sticky, the cast can be removed and other methods of immobilization used. The difficulties inherent in using this cast have limited its use. The best indication today is a fracture of the surgical neck of the humerus that requires traction for treatment.

- Apply a standard long-arm cast (Fig. 10.63*A*).

***Figure 10.63.*** Hanging-arm cast. See text for details.

- Prepare a suspension sling. Determine the length of sling and location of the suspension point appropriate for the fracture. Shortening the suspension sling will

produce varus; lengthening will produce valgus. Moving the suspension point toward the hand will induce more varus, and toward the elbow, valgus. In this completed hanging-arm cast, a section of coat hanger was used to produce a loop incorporated into the cast with plaster.
- A loop can also be made by passing a 2-inch roll of plaster around the cast, leaving approximately a handbreadth loop (Fig. 10.63*B*). Use your finger to twist this loop down to the cast, forming a plaster loop (Fig. 10.63*C*).

## WEDGING CASTS

Casts can be wedged on an acute basis to correct fracture alignment, or wedged progressively on a serial basis to correct joint contractures. Cast wedging to treat deformity or contractures requires great care to avoid complications such as pressure sores and peripheral nerve palsy. Techniques for the correction of contractures are beyond the scope of this chapter and are discussed in detail by Bleck et al. (10).

For correction of fracture alignment, wedges can be uniplanar or biplanar. If a fracture has angulation in both the anteroposterior and lateral planes, it is theoretically possible to place the axis of the hinge in the plane of maximum deformity and correct both angulations with a single wedge. This technique is tricky but perhaps worth a try; the alternative, changing the entire cast, may ultimately be necessary. Another option is to simply remove a 1- to 2-inch segment of cast, align it properly, and reseal the cast. This technique is more hazardous than wedging, as it is possible to offset the longitudinal alignment of the cast, producing pressure sores.

Three wedges are commonly used—the opening wedge, the closing wedge, and the central-hinging wedge. The opening wedge is most common, as it is simple and produces distraction. Almost all angulation in fractures is accompanied by some shortening, so distraction is an advantage.

### *Opening Wedges*

- Make a transverse cut in the cast, leaving the cast intact for a width of about 1 inch on the convex side of the deformity. Gently straighten the cast to the desired position.
- Place a wedge in the opening to hold it in position, and take a radiograph to confirm proper position.
- Seal the cast after removing the wedge.

### *Closing Wedges*

The closing wedge is used when compression or shortening at the fracture site is desired; indications for it are rare. The procedure is opposite that of the opening wedge.

- Remove a wedge of plaster and close the cast on the convex side.
- Avoid pinching the skin in the closing wedge.

### *Central Hinging Wedge*

A useful technique is a combination of the preceding two methods that hinges the cast directly over the fracture site and introduces neither lengthening nor shortening.

- Place a radiograph of the extremity alongside the cast and mark the location of the fracture site. This can also be done by taping a radiopaque object such as a coin or paper clip to the cast and taking a radiograph. This allows accurate localization of the fracture.
- To preview what needs to be done, draw the fracture on the cast (Fig. 10.64*A*). In this case, a mid-shaft transverse fracture of the tibia and fibula has 15° of valgus angulation.

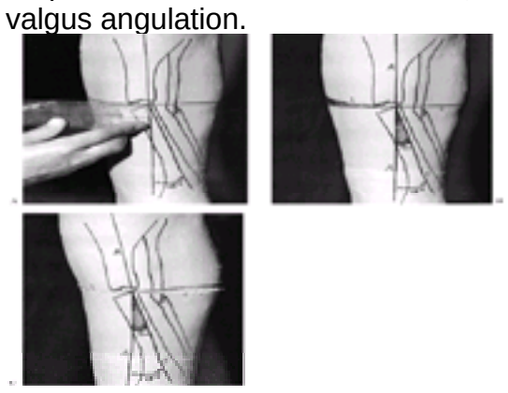

***Figure 10.64.*** Wedging a cast with a central hinge. See text for details.

- Draw a line parallel to the proximal fragment down the length of the anterior aspect of the cast. At the fracture site, draw a transverse line at right angles to the first line. Measure the distance from the center of the fracture site to the edge of the cast (in this case, about 5 cm).
- Draw a line from the fracture site in line with the angulated fragment and mark the angle to be corrected (in this case, 15°).
- To determine the width of wedge to be taken (Fig. 10.64*B*), measure from the fracture site distalward 5 cm, and measure the width of the base of the wedge produced by this measurement (here, 13 mm). This is the width of the wedge that will be removed from the cast along line C, as illustrated.
- From the hinging point, make a single cut along line C on the concave side of the deformity to the exact midline posteriorly (Fig. 10.64*C*).
- On the opposite, convex side of the deformity, remove the wedge outlined by your measurements.
- Leave about a 6- to 12-mm segment of plaster anteriorly and posteriorly, which will serve as the hinge for the wedge.
- Now gently close the wedge as illustrated, bringing line B in line with line A.
- Notice that there are three guides to whether the appropriate amount of angulation has been corrected: the alignment of lines A and B, the closure of the wedge along line C, and the opening of the wedge of the cast on the opposite side of line C.
- Place a cast wedge in the defect produced in the cast, and temporarily tape the cast in this position. Take an x-ray to confirm that the appropriate amount of correction has been made.
- Seal the cast with a single 6-inch roll. Wrap circumferentially around the cast and then gently mold the plaster into the defect to completely fill it. Avoid producing a ridge on the inside of the cast. Complete the coverage of the wedge and thoroughly rub it in.

## SPLINTS

Well-applied plaster splints can be used for nearly all the smaller tasks performed by casts, except for the spica casts. The primary advantages of splints are that they are lighter in weight than casts, allow for swelling of the limb, and are removable. They are, however, much weaker, and the fact that they are removable may pose a problem in noncompliant patients.

The strongest and best-conforming splints are made by first applying a full cast. After drying, bivalve the cast and trim the edges.

## LOWER EXTREMITY SPLINTS

### *Short-leg Splint*

- On a tabletop, lay out a length of Webril, three layers thick, that is about 4 inches longer than the splint desired and somewhat wider than the plaster to be used (Fig. 10.65*A*).

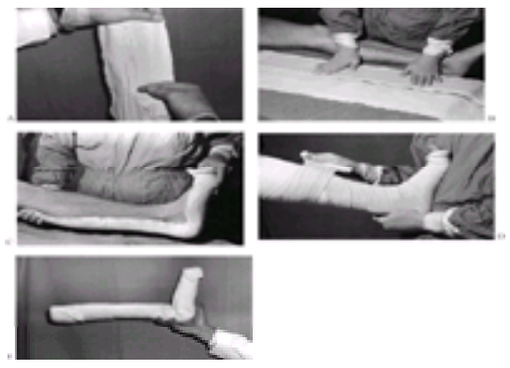

***Figure 10.65.*** Short-leg splint. See text for details.

- Make a splint of appropriate length and width, either using commercially available splints or by unrolling a roll of plaster. For most lower extremities, a splint 10 layers thick with reinforcement to 15 layers around the foot and ankle is usually sufficient.
- Take the 10 to 15 layers of plaster splints as a unit, fold them in half without creasing the plaster at the fold, and grasp the two ends between the fingers of one hand.
- Dip the splints into water and let them soak thoroughly. Since little molding time is required for splints and fast setting is an advantage, use warmer water or extra fast setting plaster.
- Remove the splints from the water, bunch them into a ball while maintaining good control of the ends of the splints, and express excess water from the splints.
- Then unfold the splint out to full length and strip the splint between two fingers, as illustrated, to remove excess water.
- Lay the splint on the prepared Webril and thoroughly rub the splint in to ensure that all the layers are amalgamated (Fig. 10.65*B*).
- Place over it a layer of Webril similar to the one used for the bottom of the splint.
- Apply the splint to the leg, holding the foot in the appropriate position (Fig. 10.65*C*).
- Now wrap the splint into place with bias-cut stockinet, maintaining good position until the splint hardens (Fig. 10.65*D*). If not wrapped too tightly, elastic bandages can be used as well.
- Figure 10.65*E* shows the completed short-leg splint. Notice that the Webril has been turned down over the edges for trimming and padding.

### *Long-leg Splint*

- A snug-fitting long-leg posterior splint applied by multilayering produces a very strong and smoothly conformed splint with a thin, smooth edge (Fig. 10.66*A*).

***Figure 10.66.*** Long-leg splint using multilayered technique and reinforcing ridge. See text for details.

- Position the extremity in the desired position.
- Pad as desired. In this case, the splint is being applied directly to tubular stockinet. Padding or protection should be placed over the heel, malleoli, and fibular head.
- Take thin splints (only two or three layers thick) and apply them in a series of sequential layers, thoroughly rubbing in the plaster with each layer.
- A trick for reinforcing the cast at weak points such as the heel is to draw up the last splint with the fingers into a reinforcing ridge (Fig. 10.66*B*).
- Once set, the splint can be removed and is ready for trimming (Fig. 10.66*C*).

## UPPER EXTREMITY SPLINTS

### *Sugar-tong Splint for the Humerus*

The sugar-tong splint is the most useful immobilization device for the management of fractures of the shaft of the humerus. Critical to its success is three-point molding. I have not found it useful to carry the splint any higher than the tuberosities of the humerus. Avoid pressure over the ulnar nerve.

- Loop a single long splint padded with Webril on both sides around the elbow and along the medial and lateral sides of the arm (Fig. 10.67*A*).

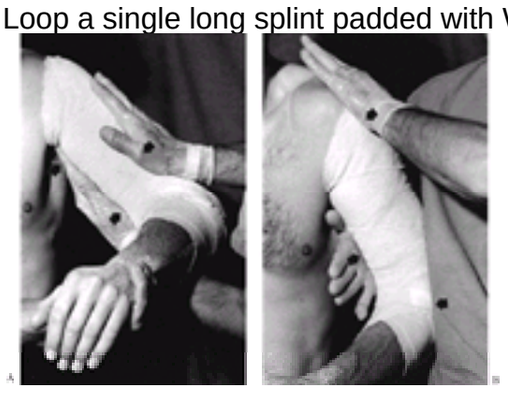

***Figure 10.67.*** Sugar-tong splint for fractures of the shaft of the humerus. See text for details.

- Overwrap it with bias-cut stockinet, keeping the splint snug around the elbow. Do not impinge on the axilla. Carry the splint up to the greater tuberosity of the humerus.
- The vast majority of shaft fractures require three-point molding into valgus or varus, depending on configuration. Overmolding is necessary to obtain and maintain the correct position.
- Molding into valgus is necessary for most supracondylar fractures. The torso is used as the molding point over the lateral aspect of the elbow (Fig. 10.67*B*).

### *Long-arm Splint*

The long-arm splint is particularly useful when it is necessary to immobilize the elbow and forearm or if a circumferential cast is undesirable, as in supracondylar fractures of the humerus. With the long-arm splint shown in Figure 10.68, the antecubital fossa is left completely open to check the pulse and allow for swelling.

***Figure 10.68.*** Long-arm splint. See text for details.

- Apply this splint to the dorsal side of the arm and forearm, extending to the base of the metacarpal heads (Fig. 10.68*A*). These splints often break at the elbow. An excellent method of reinforcement is to apply a splint at a 45° angle along the medial and lateral sides of the elbow, although this leaves the antecubital fossa and volar side of the arm and forearm completely open. The splint can be applied with a roll of plaster, as illustrated.
- The splint is wrinkled on the lateral side of the elbow from having been molded around the elbow joint (Fig. 10.68*B*). This wrinkling can sometimes produce irregularities in the cast that are uncomfortable or that can impinge on the ulnar nerve.
- To produce a smooth fit of splints around joints, cut the splint as illustrated and allow it to overlap. The overlap also reinforces the splint on its two sides.

***Short-arm Double Splint for a Colles' Fracture***

For Colles' fractures, many surgeons prefer splints to casts because splints easily accommodate swelling, are lightweight, and in some cases are easier to mold than a circumferential plaster. In addition, they can be tightened by overwrapping as swelling decreases.

- Precut the splints to conform to the palm of the hand and to fit around the thumb (Fig. 10.69*A*).

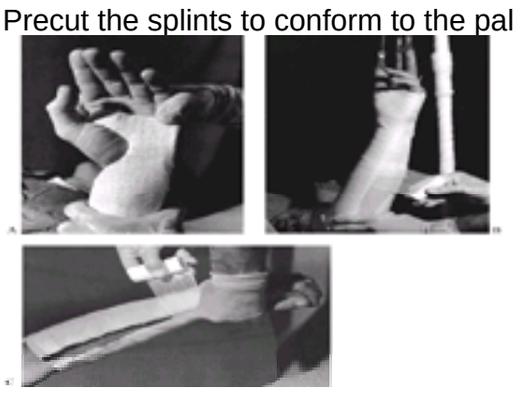

***Figure 10.69.*** Short-arm splint for Colles' fracture. See text for details.

- Produce a snug-fitting splint by reducing the fracture in fingertraps and padding with tubular stockinet and some Webril (Fig. 10.69*B*).
- Apply the volar and dorsal splints in the multilayered technique (Fig. 10.67). Overwrap the splints directly with a roll of gauze. This gauze will stick to the plaster.
- Apply these splints rapidly so there will be plenty of time for molding.
- After the splint sets, cut the gauze along either the ulnar or the radial border, depending on the fracture being treated. Then overwrap with a gauze or other wrap to obtain the desired fit (Fig. 10.69*C*).

**HAND SPLINTS**

Splinting of the hand can be accomplished in many ways, some of which are quite complicated. Hand splints are often combined with wire splints, padded aluminum splints, and outriggers with elastic bands. Splints of metal or polymers are commercially available and are often custom-fabricated by occupational or hand therapists.

In this chapter, we focus on splints for the treatment of acute hand injuries. Splints are often used to treat nerve injuries, paralysis, and burns and are otherwise used to position the disabled hand. The use of splints for the treatment of traumatic and nontraumatic disorders of the hand and wrist is discussed in some detail throughout the many chapters in the section on the hand. Please refer to a chapter on a specific disorder to find recommendations on splinting, if applicable.

***Thumb Spica Splint***

The thumb spica splint is a convenient, lightweight method for immobilizing nearly all soft-tissue and bony injuries of the thumb, metacarpal, phalanges, and associated joints. It can be used as a temporary splint for the wrist and carpal bones. It is very useful as the first stage of a thumb spica cast, as it minimizes the need to wrap rolls of plaster around the thumb. Once hardened, it can be removed for exercise or examination of the limb and replaced.

- Use seven to ten layers of 3 × 15-inch plaster splints overlaid on both sides with Webril to construct the splint (Fig. 10.70*A*).

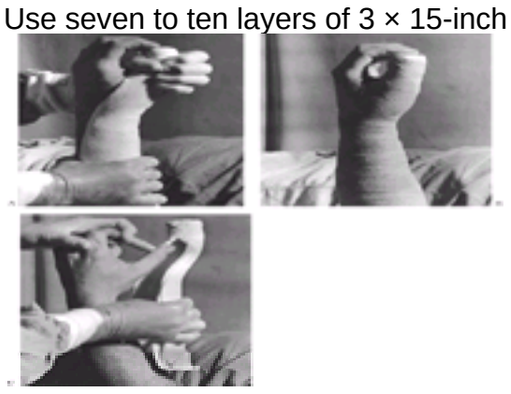

***Figure 10.70.*** Thumb spica splint. See text for details.

- Turn the Webril over the edges of the splint to give it a smooth edge.
- Apply the splint along the radial aspect of the forearm, extending onto the thumb as far distally as the middle of the thumbnail. The splint should fit circumferentially around the thumb. The splint width will vary according to the size of the patient.
- Molding around the thumb with the thumb in a position of three-jawed-chuck prehension is usually preferred.
- The completed splint (Fig. 10.70*B*) has been overwrapped with an elastic bandage; this is ideal for molding it to the arm while it sets. If there is any concern about having an elastic wrap on the extremity, replace it with bias-cut stockinet or other nonelastic wrap after the splint has set.
- Notice how nicely this splint can be removed from the thumb (Fig. 10.70*C*), leaving the circumferential thumb portion intact. It can be slid back onto the thumb and gently pushed proximally to obtain a snug fit, and rewrapped into place.

***Ulnar Gutter Splint***

Application of the ulnar gutter splint is identical to that of the thumb spica splint. If extended out to the tip of the digit, it can serve to immobilize injuries of the ulnar

fingers and ulnar metacarpals, or it can immobilize the wrist with the fingers free, depending on its distal extent. Splints that are 3 × 15 inches will just cover the fifth finger in medium-size adults and children; wider splints are necessary to incorporate the ring finger. A very wide splint, such as a 6-inch splint, can be used to incorporate the entire hand. It is my favorite splint for immobilizing boxer fractures of the neck of the fifth metacarpal (Fig. 10.71).

***Figure 10.71.*** Ulnar gutter splint.

- Select the appropriate length and width of splint for the immobilization. Use the ulnar gutter splint to immobilize a boxer fracture of the fifth metacarpal after it has been reduced.
- Use a 3 × 15-inch splint as described for the thumb spica splint. For large hands, a 4 × 15-inch splint may be necessary.
- Carry the splint to the midportion of the middle phalanx of the little finger, allowing the more distal joints free to flex.
- Use three-point molding to reduce the fracture in place, with one point over the palmar aspect of the head of the fifth metatarsal and a broader area of molding over the dorsal shaft of the metacarpal. Rotation is usually not a problem in these fractures.
- If there is more proximal shaft comminution, then buddy-tape the little finger to the ring finger.
- In more unstable injuries, outrigger splints may be indicated, which can be incorporated into the ulnar gutter splint.
- Take care when molding this splint to avoid excessive pressure, as pain or skin injury could occur. Placing a $^{1}/_{8}$-inch piece of felt over the molding points is helpful in distributing pressure.

**SPLINTING FINGERS**

Several general principles are useful to remember in splinting the fingers.

- Splint only the joints that must be splinted; allow free movement of the other joints to prevent stiffness in the hand.
- The primary problems in the immobilization of major fractures of the fingers are malrotation, dorsal angulation at the fracture site in metacarpal fractures, and palmar angulation in fractures of the phalanges. These problems are usually avoidable by proper splinting, but severe instability, recurrent deformity, or the presence of other soft-tissue injuries may necessitate internal or external fixation.
- When splinting fingers, check carefully for proper rotation. As each digit is fully flexed to the distal palm, it reaches a specific contact point on the thenar eminence; these points differ from person to person (Fig. 10.72). Good rotation can usually be ensured by taping the injured digit to an adjacent noninjured digit. The index and little fingers have only one neighboring finger to be taped to. Tape the long finger to the ring finger, leaving the index free for function. Tape the ring to the long finger, because the long finger gives the proper rotation more reliably than the little finger (in some patients, the little finger is internally rotated and would splint the ring finger in malrotation).

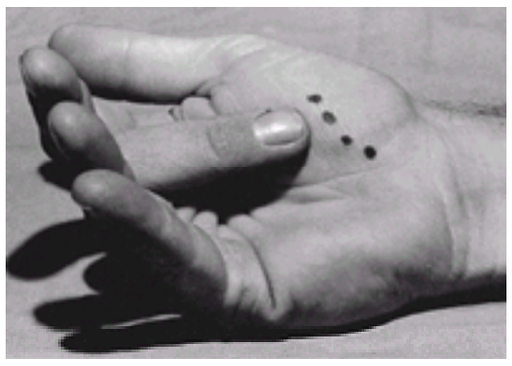

***Figure 10.72.*** Notice the contact points produced by contact of each of the fingers with the thenar eminence. This rotational alignment must be reproduced when unstable fractures in the fingers are immobilized.

Various polymeric and metal splints are available that can be used with or without casts or plaster splints on the wrist (Fig. 10.73). Many newer plastic splints are available as well.



***Figure 10.73.*** Splints for the fingers. From *top* to *bottom*, an aluminum gutter splint for the finger designed to be used on the palmar side, a straight four-sided aluminum finger splint (generally not recommended because it splints the digit in full extension), a wire finger splint; strips of aluminum with adherent foam, and foam-padded mallet-finger splints.

***Splinting to Allow Finger Flexion***

Motion can be preserved by leaving the distal joints free or by allowing limited motion of the digit while splinting it to prevent recurrence of deformity or dislocation. For example, a dorsal finger splint can be incorporated into a short-arm cast or volar wrist splint to immobilize injuries that are stable in flexion but unstable in extension. The splint in Figure 10.74 blocks extension of the finger but allows nearly full flexion.

***Figure 10.74.*** Finger splint allows limited motion.

- Fashion a 3 × 5-inch Webril-padded plaster splint of about 10 thicknesses for the wrist.
- Incorporate the foam-padded aluminum splint into the splint on the palmar side and into a second splint on the dorsal side.
- To achieve good incorporation and to reduce bulk, peel the foam from the portions of the splint inserted into the plaster. Notice that the splint has been bent to maintain the index finger in flexion, thus stabilizing an injury that is unstable in extension.

The splint, while protecting the finger, allows excellent flexion for early motion. A similar splint could be used if the index and long fingers were taped together.

***Padded Aluminum Splint for More Immobilization***

To splint more unstable injuries of the fingers, complete immobilization except for the distal interphalangeal joint may be necessary. For splinting the index and/or long fingers, a foam-padded aluminum splint can be bent into a complete loop and incorporated into a palmar wrist splint (Fig. 10.75).

***Figure 10.75.*** Padded aluminum splint of the index finger incorporated into a wrist splint.

- Splint the metacarpophalangeal joint as close to 90° of flexion as feasible. Note that the proximal interphalangeal joint has also been immobilized at 90°.
- Bend the splint into a full loop with your hand. Bend the splint down until the loop is sufficiently tight that you can bring your fingers into the appropriate position.
- Strip the foam off the aluminum where the splint will be incorporated into the cast. Tape the ends of the splint together. This produces a nice, stable loop on which the finger will be set.
- Position the volar wrist splint no more distal than the proximal flexion crease of the palm, as this position is necessary to achieve the desired flexion of the fingers. The splint illustrated here is slightly too distal.
- Leave the fingertips free. Encourage early motion to avoid flexor tendon tie-down and stiffness.
- To avoid maceration between the fingers, place Webril or gauze between the digits. The tape fastening the fingers to the splint must be snug but not tight.

***Splinting a Proximal Interphalangeal Joint Injury***

A padded aluminum splint can be applied dorsally for injuries of the proximal interphalangeal joint (Fig. 10.76*A*). The finger is held in the functional position with two pieces of tape. The technique can also be used for mallet finger.

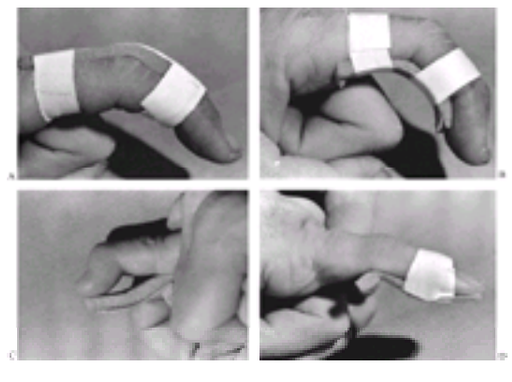

***Figure 10.76.*** Use of padded aluminum splints for finger injuries. See text for details.

- Cut the splint to size with a large bandage scissors.
- Smooth the cut edges of the splint. Allow the foam to extend somewhat beyond the ends of the splint to protect the finger.
- Figure 10.76*B* shows the splint on the palmar aspect of the finger.
- To splint a mallet finger (Fig. 10.76*C*), fashion a splint to reach from the tip of the finger to the middle of the middle phalanx.
- Smooth the ends of the splint and leave plenty of foam over the edge of the splint to pad its edge. Notice the bend in the splint that will place the digit in slight hyperextension at the distal interphalangeal joint.
- Apply the splint to the palmar aspect of the digit and tape it into position over the distal interphalangeal joint (Fig. 10.76*D*). Sometimes this procedure is painful because of the injury, and a more indirect means of taping must be used. Usually the tape must be applied somewhat loosely initially and then gradually tightened over a couple of days as the tenderness and swelling subside. Because these splints get wet, the patient must replace them frequently, taking care not to allow the joint to drift into flexion. Off-the-shelf plastic splints are available for this application, but I prefer to use custom-molded splints. Generally, immobilization of the proximal interphalangeal joint is unnecessary in a mallet finger.

## COMPLICATIONS OF CASTS AND SPLINTS

### PRESSURE SORES

Pressure sores are most common over bony prominences, at the edges of the cast, or over flexion surfaces such as the instep and antecubital fossa. With good plaster

technique, pressure sores should be extremely rare in patients with normal sensation. They are most common in patients with sensory loss such as paraplegics, and in those with peripheral nerve disorders, including peripheral neuropathy from diabetes and other disorders. Head-injured patients who cannot communicate, small children, and the very elderly are also at risk. Try to avoid circumferential casts in these patients, particularly in paraplegics. On the other hand, short-leg antiequinus casts are often used to prevent heel-cord contractures in head-injured patients who are comatose and spastic. I have been very successful in avoiding pressure sores by appropriate padding and careful cast application.

Figure 10.77 shows a common source of pressure. Note that the cast is very thin over the olecranon and very thick over the antecubital fossa because of inappropriate cast application. Avoid excessive plaster over the flexor surface of joints. In addition, in this case the forearm portion of the cast was too long, so when the forearm was flexed at the elbow to 90°, the forearm part of the cast impinged on the antecubital fossa, producing a potential site for pressure necrosis of skin. Solve this problem by removing the antecubital part of the cast with a window, and reapply the plaster in this area; it may be easier to apply a new cast.

***Figure 10.77.*** Cast sores. Notice the inappropriate application of this long-arm cast with impingement of the forearm portion of the cast into the antecubital fossa, which could well cause a pressure sore or neurovascular injury.

The lower extremity is particularly susceptible to cast sores, especially over the heel and instep (Fig. 10.78 and Fig. 10.79). The patient with an impending cast sore initially complains of discomfort in the cast, usually in a region where pressure would be expected, such as over the heel, instep, patella, olecranon, or antecubital fossa. This discomfort quickly becomes an unrelenting, severe, burning pain. It may last for several hours up to several days, depending on the severity of the pressure and whether or not the patient can gain temporary relief by shifting in the cast or repositioning. Eventually, the pain usually subsides in part and the patient becomes more comfortable; at this point a full-thickness ulceration has usually occurred. Subsequently, staining on the cast, a foul smell, or systemic evidence of infection will call attention to this neglected problem.

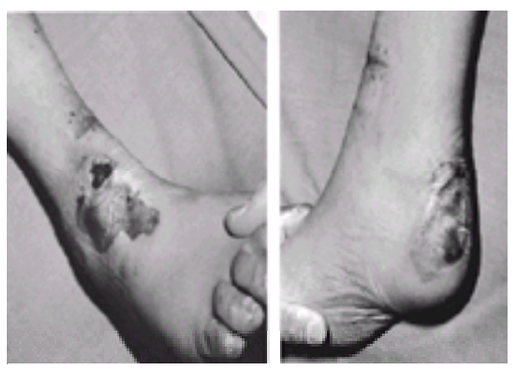

***Figure 10.78.*** These pressure sores over the instep and heel of the foot were caused by a long-leg cast applied to a patient with a fracture of the proximal tibia who was multiply injured and unconscious for 3 days. Although the initial cast was probably applied in an appropriate manner, subsequent swelling in the cast, about which the patient could not complain, led to these pressure ulcers. These full-thickness ulcers resulted in exposure of the Achilles tendon and calcaneus, and full exposure of the extensor tendons of the ankle; major plastic reconstructive surgery was required. These problems could have been avoided by univalving the cast and spreading it widely initially, or by using splints with frequent inspection of the skin.

***Figure 10.79.*** This pressure sore in the groin occurred at the upper edge of a cast-brace used to treat a lower extremity injury in a paraplegic. Even though the cast was well applied and appropriately padded, it was inadequate in this patient with impaired sensation.

Pressure sores can be quite severe, resulting in total loss of coverage over bony prominences or full exposure and loss of tendons, ligaments, and nerves. They can require major reconstructive surgery and result in permanent, major, long-term deficits. Avoid pressure sores by observing indications, by using appropriate technique, and by using immediate decompression of circumferential casts or snugly applied splints in patients complaining of pain or discomfort. In almost all cases, keep the offending area visible by placing a large window in the cast, by splitting the cast and spreading it, by bivalving the cast, or by removing the cast completely.

Pressure sores can also be caused by failure to trim the cast and pad it appropriately at its ends (Fig. 10.79) or by holding the cast inappropriately when it is wet, causing dents with the fingers or hand.

**BURNS**

As the exothermic reaction of setting takes place in plaster and fiberglass materials, enough heat can be generated to cause a severe burn, particularly if there is no way for the heat to dissipate. This is a greater problem in patients with impaired sensation. To avoid burns, try not to apply casts thicker than ¼ to $^{3}/_{8}$ inch in a single layer. For a thicker cast, it is wiser to apply a thin cast initially, reinforcing it after it has set. This is commonly done by overlaying plaster casts with a thin layer of fiberglass.

Plastic-covered pillows present a problem for the unwary. Fresh casts are often laid on pillows as they set. Burns can occur because the setting plaster can not dissipate heat while lying against the plastic. Avoid setting fresh casts down on any impervious surface, and do not cover freshly set casts.

**ALLERGIC DERMATITIS**

In my experience, allergy to cast materials is exceedingly rare. Skin irritation under the cast is most likely to be caused by exudate from wounds soaking the cast padding, or from particles of plaster dust getting into the cast and abrading the skin. I do not believe I have ever seen a true allergy to either the padding materials or to plaster of Paris, although it has been reported. An occasional reaction to the tubular stockinet occurs; in patients with a history of allergy or dermatitis, do not use tubular stockinet directly against the skin. Synthetic materials are more likely to cause allergies, so be alert to this possibility. Change materials if allergy is a problem.

### CAST WINDOW BLISTERS

When casts are windowed or split, part of the extremity is exposed while most of the limb is incorporated in the cast. Any swelling that occurs will bulge into the window or split and may create excessive pressure against the skin along the edges of the split or window. The result is a pressure sore or more commonly a blister in the window or split. Fill any windows or splits with soft compressible material, such as felt or multiple layers of Webril or dressings, and overwrap with bias-cut stockinet or plaster to keep firm compression.

### VASCULAR COMPROMISE, COMPARTMENT SYNDROME, AND NERVE INJURY

Direct impairment of vascular function due to casts or splints rarely occurs; the vessels are buried deeply enough that direct compression is almost never a problem. Excessive swelling, however, can cause compartment syndrome; avoid it by using splints. In any type of acute injury, or if there is any possibility of swelling, I always split longitudinally and univalve circumferential casts. Bivalving casts does not decompress the limb nearly as well as spreading a cast that has been univalved, as the bivalved cast can open only in one plane. See Chapter 27 on compartment syndrome for more details.

Direct compression injury can occur in the ulnar nerve at the elbow, the radial nerve at the lateral epicondyle, and the median nerve at the wrist. In the lower extremity, the most common and serious problem is paralysis of the foot and toe dorsiflexors due to paralysis involving the common peroneal nerve at the fibular neck. This paralysis may produce a permanent drop foot and must be avoided. Any neurologic complaints—pain, burning, dysesthesia, weakness, or paresthesias—demand immediate attention. Window, remove, or adjust the cast or splint. In some cases, such as carpal tunnel syndrome at the wrist, repositioning to decrease intracompartmental pressure may be necessary.

### MALPOSITION

Malposition can influence the alignment of fractures and the positioning of joints. The measures necessary to mold fractures appropriately to maintain position have been described. When treating fracture–dislocations and dislocations, remember the positions of stability for the joint, and position the extremity appropriately. Keep in mind that very unstable injuries of the elbow and knee may not be adequately immobilized by a long-arm or long-leg cast and may require extension into spica casts. Joints may be stable in a slightly flexed position but completely unstable in extension. Position may be so critical that when splints and casts are applied by technical personnel to potentially unstable injuries, physician supervision is usually necessary to ensure that appropriate position is maintained.

Inappropriate positioning of the extremity during cast application may result in annoying problems, if not prolonged disability. When applying a long-leg cast, for example, do not hold the extremity by the heel with the patient in the supine position, as gravity will cause the knee to drop into hyperextension, which is very uncomfortable for the patient. Other common positions to avoid are toe hyperextension, excessive flexion of the knee when it is unnecessary, excessive flexion of the hip, or any varus or equinus of the foot when not indicated.

### STIFFNESS, DISUSE, AND REFLEX SYMPATHETIC DYSTROPHY

Once the discomfort of the injury passes, it is important to immediately embark on a rehabilitation program. All joints not immobilized should be carried through active range-of-motion exercises daily, and passive exercise is generally indicated for joints or digits that cannot be moved actively. Generally, it is safe to begin immediate isometric exercises of the immobilized muscles.

In the upper extremity, encourage immediate functional use of the extremity when feasible. Avoid slings when possible. In Colles' fractures, for example, use of a sling may produce a stiff shoulder due to disuse. To avoid swelling in the first few days, the patient is better encouraged to carry the extremity resting on the head and thereafter to use it as much as possible as if it were normal.

In the lower extremity, weight bearing should begin as soon as possible and should be actively encouraged when indicated. In general, tibial fractures should be treated with weight-bearing functional plaster casts and braces rather than non-weight-bearing, long-leg, bent-knee casts. Convert from casts to functional braces as soon as practical and safe. Early involvement of a physical therapist or hand therapist is often indicated.

Patient education is very helpful for avoiding complications. Every orthopaedic office, clinic, and emergency room should have a standard handout to educate patients about the care of casts and splints and to warn about the symptoms that must be brought to the physician's attention.

## TRACTION

Continuous traction is indicated in the treatment of fractures when reduction of the fracture or proper length of the limb cannot be maintained by the static immobilization provided by casts and splints. It is necessary in the presence of deforming forces caused by soft-tissue tension in the muscles, tendons, and ligaments, and by hydraulic forces generated by bleeding into and swelling in the soft-tissue envelope surrounding the fracture. Traction may also be necessary to treat unstable dislocations, particularly of the hip, where static methods are inadequate or impractical. Because of the sophistication of modern methods of internal and external fixation, it is uncommon to treat fractures or dislocations definitively in traction. Disadvantages include the need for prolonged bed rest and prolonged and expensive hospitalization. Additionally, the return to function is slow; the patient is recumbent in traction for so long that muscle atrophy, joint stiffness, and general cardiovascular deconditioning result.

Traction is almost never used for upper extremity problems, as current methods of internal and external fixation are usually superior. At the University of California, Davis, Medical Center, a busy level 1 trauma center with more than 3,000 trauma admissions per year, I have not used traction since the 1980s for even the temporary treatment of a disorder in the upper extremities, but olecranon pin traction is described below because it is a very useful method that I used frequently in the 1960s and early 1970s.

Musculoskeletal surgeons should be familiar with the use of traction, as it is a good backup method for situations where internal and external fixation are impossible. In particular, it may be useful in the management of major soft-tissue injuries in the upper extremity because the overhead suspension provides ready access for wound care. With the advent of percutaneous pin fixation for supracondylar fractures of the humerus in children, traction treatment has virtually disappeared and in most Western countries is not indicated.

Traction is still commonly used in the lower extremity, however. Common indications are Malgaigne injuries of the pelvis with vertical instability, fractures of the hip and shaft of the femur, and fractures of the tibia and fibula. Unstable posterior dislocations of the hip are often immobilized in skeletal traction until soft-tissue healing occurs. Skin traction is commonly used to immobilize elderly patients with fractures of the hip as an emergency measure before performing internal fixation. Skeletal traction through either the distal femur or the proximal tibia is used for the temporary and early treatment of unstable fractures of the pelvic ring and acetabulum, the hip in younger patients, and femoral shaft and supracondylar fractures of the femur. Where traction is used for vertically unstable fractures of the pelvic ring, fixation is often supplemented by an external fixator on the pelvic ring.

In the vast majority of the injuries mentioned, internal or external fixation is the definitive method of treatment; however, local soft-tissue and systemic conditions may contraindicate surgery and necessitate prolonged definitive treatment in traction. Since external fixator and intramedullary nailing have not been tested in the face of the major mass casualties produced by war, skeletal traction remains the only proven treatment for high-velocity gunshot wounds of the femur in a military situation. It is highly likely that external fixation is a better treatment method, but its efficacy in this specialized situation has not been proven.

### INDICATIONS

Common indications for skeletal traction in the lower extremity in our institution are the following.

- Vertically unstable fractures of the pelvic ring where external fixation cannot maintain vertical stability, and where internal fixation of the posterior portions of the pelvic ring is impossible
- Fractures of the acetabulum with minimal displacement where internal fixation is not indicated, the fracture is potentially unstable, and the patient is a good

candidate for treatment in traction (i.e., young, with isolated injuries)

- Unstable fractures of the acetabulum where either local bone or soft-tissue conditions or systemic factors contraindicate internal fixation
- Fractures of the hip (basilar neck, intertrochanteric, or subtrochanteric) where local soft-tissue or bone conditions or systemic conditions contraindicate surgery
- Fractures of the shaft and supracondylar area of the femur for which internal or external fixation is contraindicated
- Comminuted fractures of the tibial plateaus where traction is necessary to maintain alignment and facilitate early motion, and where internal or external fixation is not possible or feasible. (Sometimes, traction may be supplemented with closed reduction, or limited open reduction of the articular surfaces with percutaneous fixation with wires or cannulated screws, with the metaphyseal portion being managed in traction.)
- Fractures of the shaft of the tibia and fibula where delay in initial treatment or unacceptable shortening in a plaster cast requires correction. (In such cases, it is desirable to regain length before internal or external fixation, or where severe soft-tissue problems preclude cast immobilization or any type of fixation.)
- Comminuted pylon fractures of the distal tibia and fibula and ankle joint, where early motion of the ankle joint is desired and internal or external fixation is contraindicated

## HISTORY OF TRACTION

Those interested in the history of traction should read Peltier's excellent article (70). In it he states that Malgaigne credited Guy de Chauliac with the first use of continuous isotonic traction for the treatment of fractures of the femur; this was 600 years ago, and traction remains today an effective and safe treatment for fractures (49). Initial efforts at traction treatment were frustrated by the surgeons' inability to obtain a firm grasp on the extremity to apply traction. Skin traction had obvious limitations. In addition, skin traction meant that the limb had to be treated in full extension, resulting in frequent shortening and malalignment.

The first really effective method for continuous longitudinal traction for femur fractures was introduced by Sir Hugh Owen Thomas in 1890 (93). The full-ring Thomas splint used today is identical to the one Thomas developed. His original method used skin traction and treated the fracture in full extension (Fig. 10.80).

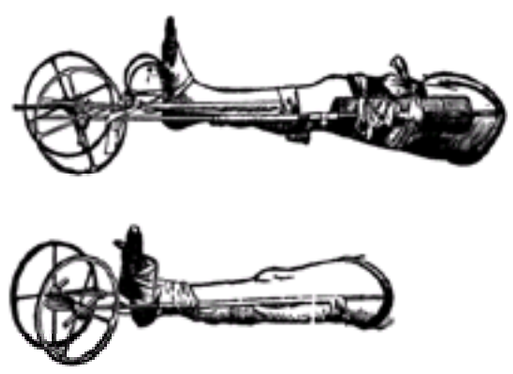

***Figure 10.80.*** This long splint, designed by Sir Hugh Owen Thomas for the treatment of fractures of the shaft of the femur, was described by him in 1890. Note the use of skin traction and treatment of the fracture in full extension. The wheels at the end of the splint were used to facilitate traction. The full-ring Thomas splint itself remains unchanged today. (From Peltier LF. A Brief History of Traction. *J Bone Joint Surg Am* 1968;50:1603.)

Percival Pott in 1773 recognized the need to flex the hip and knee to reduce the tension in the muscles and soft tissues that caused deforming forces on the fragments of the femoral shaft. Most surgeons endorsed his ideas, and traction treatment was modified thereafter to incorporate flexion of the joints above and below the injury (70). Pott used his method with the limb lying on its side, a position that was hardly practical. Mayor (51) and Sauter (85) developed the concept of balanced suspension of splints, which enabled the limb to be suspended in a flexed position. Suspension and traction in combination were first introduced by Nathan Smith prior to the American Civil War and published in 1867 (Fig. 10.81) (88,89 and 90). During the Civil War, Hodgen further refined Smith's splint and provided a mechanism for providing both suspension and traction through the splint (39). The Hodgen splint saw considerable use during World War I (64). Hodgen splints were still available at San Francisco General Hospital when I did my residency there in the early 1960s; they were used in combination with skeletal traction (Fig. 10.82).

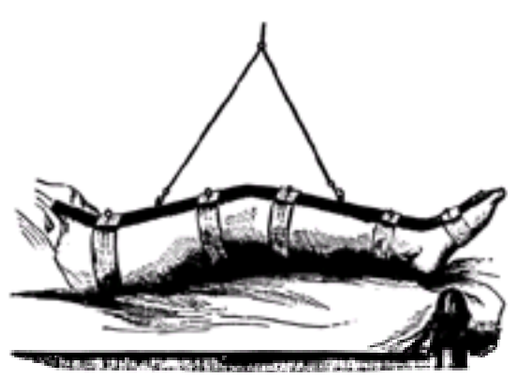

***Figure 10.81.*** Nathan Smith introduced suspension in the treatment of fractures of the femur with this suspended traction splint. No effort was made to incorporate traction. (From Peltier LF. A Brief History of Traction. *J Bone Joint Surg Am* 1968;50:1603.)

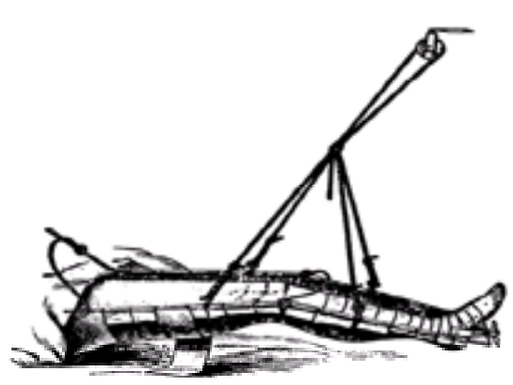

***Figure 10.82.*** Hodgen, in 1865, modified Thomas's splint, incorporated Smith's suspension, and produced an apparatus that could be used for both traction and suspension. (From Peltier LF. A Brief History of Traction. *J Bone Joint Surg Am* 1968;50:1603.)

Up to this point, traction was applied most commonly through the splint itself. The concept of applying adhesive plaster directly to the skin of the leg for traction was introduced somewhat before the Civil War and is used today with only slight modifications. Although Crosby initially proved its effectiveness, Gurdon Buck's 1861 publication describing his experience using skin traction for the treatment of 21 patients with fractures of the shaft of the femur led to the method being known as Buck's traction (Fig. 10.83) (16). A modification of Buck's original method is still the standard method of applying skin traction today.

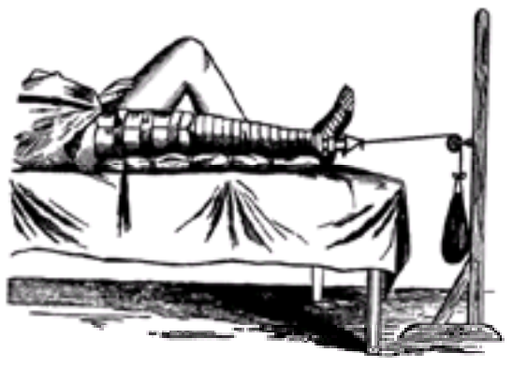

***Figure 10.83.*** Buck, in 1883, improved the ability to apply traction to the skin by his method of isotonic skin traction with treatment of the fracture in extension. (From Peltier LF. A Brief History of Traction. *J Bone Joint Surg Am* 1968;50:1603.)

Thomas Bryant of Guy's Hospital in London was quick to adapt Buck's method to the treatment of fractures of the shaft of the femur in young children (Fig. 10.84) (15). Although much care is required to avoid complications from the traction, Bryant's traction remains a useful method for treating subtrochanteric fractures of the femur in infants and young children.

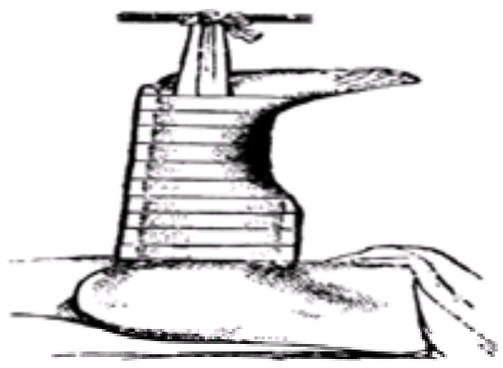

***Figure 10.84.*** Bryant, in 1879, modified Buck's method for the treatment of fractures of the femur in children. This method is still occasionally used today for infants and small children with subtrochanteric fractures of the femur when initial traction at 90° of flexion of the hip is necessary to obtain a satisfactory reduction. Most young children's femur fractures are treated today with closed reduction and immediate spica cast. Care must be taken in the application of the skin traction to avoid skin problems and decubitus ulcers about the knee and ankle. Although Bryant's original illustration shows only one leg in traction, most surgeons put both legs in traction. This method is suitable for small children under 2 years of age. It should not be used in children older than 2 years of age because of the risk of ischemia and compartment syndrome caused by the overhead position of the extremities. Enough weight is applied to lift the buttocks slightly off the bed. Subtrochanteric fractures in this age group quickly become stable; therefore, Bryant's traction is rarely used for more than 3 weeks. (From Peltier LF. A Brief History of Traction. *J Bone Joint Surg Am* 1968;50:1603.)

Australian surgeon R. Hamilton Russell further refined treatment with skin traction by combining Buck's traction method with a sling system that allowed the limb to be treated in flexion (Fig. 10.85) (83). Russell described his method in 1921 and it is still used today when skeletal traction is not required.

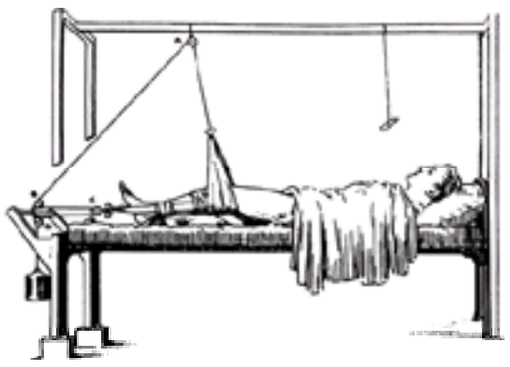

***Figure 10.85.*** In 1924, Russell introduced his flexion method for the treatment of fractures of the shaft and the femur, which used skin traction; see Fig. 10.90. (From Peltier LF. A Brief History of Traction. *J Bone Joint Surg Am* 1968;50:1603.)

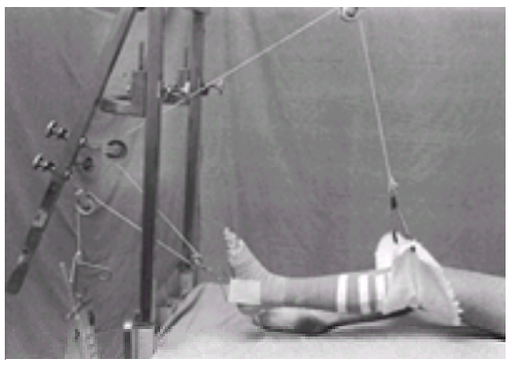

***Figure 10.90.*** Although it is almost never used today, this is an illustration of Russell's traction as used with modern traction materials. Skin traction is applied as demonstrated in the previous figure.

With the discovery of x-rays in 1895, surgeons quickly realized that malunions of fractures of the femoral shaft were quite common when treated with these methods. Although methods of skeletal fixation and traction had been described several years before, Pearson in 1919 introduced the first popular method of skeletal traction, using a type of ice tong to grasp the distal femur (69). At the same time, he popularized an attachment to the Thomas splint that allowed the knee and hip to be flexed (Fig. 10.86). Tongs did not provide secure attachment to bone, and skin problems were common.

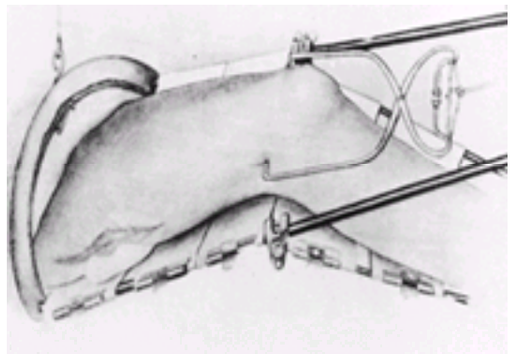

***Figure 10.86.*** Pearson, in 1919, introduced the successful use of skeletal traction on the femur. He combined this with attachment to the Thomas splint, which allowed the knee to be flexed, improving the reduction of fractures of the femur and making the traction practical. (From Peltier LF. A Brief History of Traction. *J Bone Joint Surg Am* 1968;50:1603.)

Traction by skeletal pins was introduced by Fritz Steinmann of Switzerland in 1907 (91). Two years later, Martin Kirschner introduced the use of small-diameter tensioned wires (41,42). Both of these methods are used today, little changed from the original introduced nearly a century ago. Lorenz Böhler, the well-known surgeon from Vienna, modified and improved these methods and popularized them throughout the world (11).

Modern methods of traction use new materials and manufacturing methods to refine these basic techniques, but they remain much the same. The principles established by our ancestors centuries ago remain valid.

**BASIC KNOTS**

Knots tied in traction ropes must be guaranteed not to slip, must be easy to tie, and most important must be easy to untie for adjustment of traction. Three basic knots are very useful and should be known by all who use traction: the square knot, bowline, and clove hitch. Frayed rope ends are unsightly and can be unsafe if the unraveling of the rope gets caught in the traction apparatus or causes failure of a knot. Wrap the rope end circumferentially with tape and then cut across the tape to produce a neatly trimmed end.

The *square knot* (Fig. 10.87*A*) is the most common and useful knot for tying a rope to itself or to other objects. Note the direction of the strands of the rope in this illustration. At either end of the knot, the free strands must pass on the same side of the loop to avoid a granny knot. Take care: If the two overhand knots are not laid flat, a series of slip knots can be produced, and they will slip.

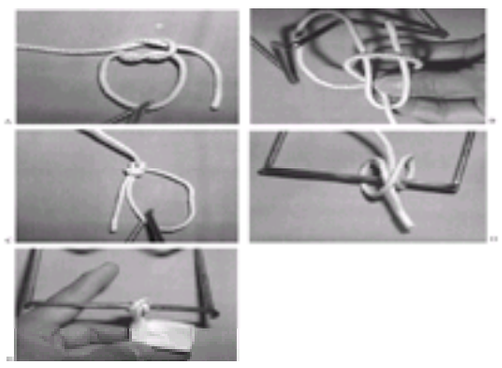

***Figure 10.87.*** Knots for traction. See text for details.

The *bowline knot* (Fig. 10.87*B*, Fig. 10.87*C*) is used to attach the rope to itself around an object, or to join two ropes. Make a loop in the rope. In the illustration, the loop is being held by the left hand. Notice that the vertical portion of the rope (“the tree”) comes from beneath the horizontal component of the loop (“the ground with a hole in it”). The direction of the free end of the rope is easy to remember using this mnemonic. The upright strand represents a tree with its roots under ground, and the loop is a hole in the ground adjacent to it. Think of the end of the rope as a rabbit. The rabbit jumps out of its hole, runs around the tree, and dives back into its hole. Grasp the two free ends and pull the knot snugly together.

The *clove hitch* (Fig. 10.87*D*, Fig. 10.87*E*), a common knot used in sailing and horseback riding, is used to attach the rope to a fixed object such as a post or a splint. It is two half-hitches reversed on each other and tied around the splint. In the completed clove hitch (Fig. 10.87*E*), tape the free end of the line to the rope to ensure that the clove hitch will not unwrap. Notice that the end of the tape is folded back on itself and left free so that the knot can be easily adjusted. This versatile knot can be loosened and slid along the splint and retightened to adjust the line of pull.

**SKIN TRACTION**

The principles for application of skin traction are the same for the upper and lower extremities. Avoid pressure over bony prominences and superficial nerves and vessels. The material used to apply the traction should be adhered to the limb over as wide an area as possible to avoid concentrated areas of traction and shear lines where blisters might occur. Commercial off-the-shelf devices for skin traction for the lower extremity use a soft foam liner and Velcro straps; often, a support for the foot is included. These are quite useful and work well for temporary traction in patients who will be going to surgery shortly for stabilization of femur fractures. Generally, longitudinal pull of more than 5 pounds is impractical with these devices. For stronger traction and for prolonged traction, I recommend application of skin traction using one of the two following methods.

***Buck's Skin Traction***

- Wrap four layers of Webril around the foot and ankle to protect the bony prominences and neurovascular structures.
- Next, wrap a 4-inch elastic bandage gently around the foot and ankle (Fig. 10.88*A*).

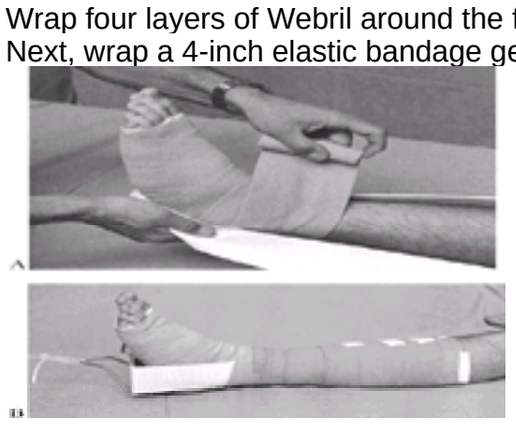

***Figure 10.88.*** Buck's skin traction. See text for details.

- Apply a traction strip and then incorporate it with the elastic wrap.
- Incorporate the traction strip with the elastic bandages to just below the common peroneal nerve (Fig. 10.88*B*).

- Double the traction strip back on the leg and complete incorporation with the elastic bandage.
- Place the traction loop or block through the traction strip at the bottom of the foot and apply the traction rope. The traction loop or block is important to prevent traction from causing excessive pressure over the malleoli. This simple method allows application of traction for up to 5 pounds for short periods of time. If the traction is used for more than 24–36 hours, it should be unwrapped daily for skin inspection and then replaced.

***Modified Buck's Skin Traction***

- Apply Webril around the foot and ankle to protect neurovascular structures and bony prominences (Fig. 10.89*A*).

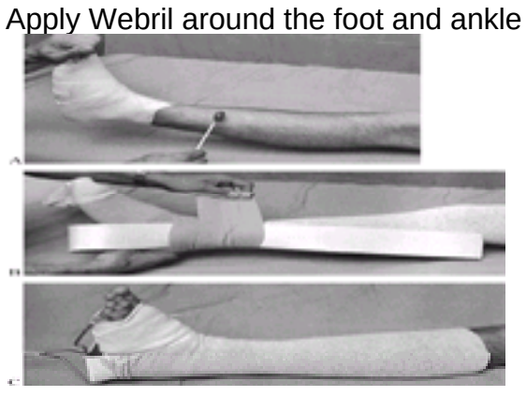

***Figure 10.89.*** Modified Buck's skin traction. See text for details.

- Coat the leg circumferentially with tincture of benzoin or other commercial skin adherent. Be sure the patient is not allergic to these adhesives, as serious blistering or rash can occur. Here, the adherent is applied to the skin below the knee. If traction heavier than 5 pounds is to be used, extend the coverage to the upper thigh.
- In children, the traction is routinely adhered to the mid thigh or upper thigh to increase the area of pull.
- Roll a snug tubular stockinet up the leg as high as necessary. Use one long enough that it can be doubled back down over the traction strip (Fig. 10.89*B*).
- Now apply the traction strip with the elastic wrap.
- Finally, pull the tubular stockinet back down over the elastic wrap and traction strip and secure it in place with some tape at the foot (Fig. 10.89*C*). This method of traction may allow skin traction up to 7 pounds, but care must be taken over 5 pounds to avoid skin problems or ischemia.
- With this method, the traction can be left in place for substantial periods of time without having to be removed, assuming that the patient is asymptomatic and comfortable.
- In an alternative method used on our pediatric service, Elastoplast strips are initially applied longitudinally and then held in place with a continuous row of circumferential strips. This works extremely well but must be used with caution to avoid skin problems.

**RUSSELL'S TRACTION**

Classic Russell's traction with skin traction is little used today, as this more complicated method is unnecessary for short-term preoperative traction, and skeletal traction is much more effective for long-term treatment. In Russell's traction (Fig. 10.90), a sling is placed beneath the knee and distal femur to help eliminate the posterior angulation common in distal fractures of the shaft of the femur. The pulley system combined with the suspension pulley provides a vector of pull along the axis of the femur, and the effective traction is roughly double the weight that is hung, excluding the effect of friction in the pulley system.

A fleece-lined sling is placed under the knee and distal femur. The traction–suspension rope inclines distalward from the knee sling and then passes through two pulleys on the frame and one mounted to the bottom of the foot, producing a combination of suspension and traction roughly in the axis of the femur. I no longer use this method, as modified Russell's traction with a skeletal pin is much safer and more effective.

**SKELETAL TRACTION**

Skeletal traction can be applied with smooth or threaded Steinmann pins, smooth Kirschner (K-) wires, or specialized screws or bolts designed for the greater trochanter of the femur or olecranon of the ulna. Smooth pins, which tend to slide back and forth in the bone, can become loose in the bone and damage the skin. For this reason, threaded pins are useful. Specialized traction pins, threaded only in the midportion, are ideal. Steinmann pins are larger, and tension is unnecessary to provide rigidity. For that reason, larger pins are necessary to avoid bending. Do not use those with diameters less than ¼ inch. K-wires are designed to be tensioned: They gain their rigidity from the tension and are quite effective. Because of their small diameter, avoid threaded wires, as they break often. Most K-wires are 1–2 mm in diameter; larger diameters cannot be effectively tensioned and are usually not used.

The typical sites for transverse traction pins are the olecranon, distal femur at the level of the epicondyles, proximal tibia at or below the tibial tubercle, distal tibia just proximal to the ankle joint, or calcaneus. I do not use threaded pins in the olecranon because of the risk of injuring the ulnar nerve. Knowledge of the location of the neurovascular bundles in the lower extremity is necessary for proper pin placement.

For femur fractures, I prefer traction through the proximal tibia using a large-threaded Steinmann pin (Fig. 10.91). I find it more comfortable for the patient and it interferes less with knee motion than do femoral pins. This is the best location and type of pin for the technique of closed intramedullary nailing that I use (see Chapter 20).

***Figure 10.91.*** Insertion of a tibial traction pin. See text for details.

To prevent K-wires from slipping, stack 2 × 2-inch gauze pads on the pin between the skin and the traction bow. This must be a snug stack that prevents the bow from moving in relation to the leg (illustrated in Chapter 24).

***Insertion of a Steinmann Traction Pin into the Proximal Tibia***

- Figure 10.91*A* shows a patient in whom a previous traction pin became loose and is being replaced. The entry and exit wounds for the pin are somewhat more distal to the tibial tubercle than I prefer.
- Use sterile technique with gloves. Prepare the skin with an iodophor or equivalent disinfectant. Square off the knee and proximal tibia with sterile towels.
- Always insert the pin from lateral to medial, to minimize the risk to the common peroneal nerve. Additionally, this technique allows the pin to be started on a bone surface at right angles to the penetration angle of the pin. In adults, I prefer to locate the pin at the tibial tubercle about one and one-half finger breadths posterior to the anterior border of the fibula.
- Anesthetize the skin and deep tissues down to the periosteum with a local anesthetic.
- Use a #11 blade to make the initial skin incision. Here, the incision is being made transversely, but it is best to make it vertically in the longitudinal axis of the leg. Make the skin incision slightly smaller than the diameter of pin to be used to produce a snug fit of the skin around the pin and to prevent sliding of the skin on the

pin, which increases the risk of infection. At the same time, accurate location of the skin entry point to the bone portal is essential to avoid gathering of the skin on the pin. If the latter occurs, the skin must be incised to relieve the tension. Close the excessive length of wound with an appropriate suture to maintain the snug fit around the pin.

- Always insert traction pins with hand drills, as power will produce excessive heat and kill the bone unless the bone is predrilled (Fig. 10.91*B*). Predrilling is usually not necessary and is inconvenient in the emergency-room setting. Be certain that the tip of the pin is sharp. Two-sided points are preferable to four-sided points.
- Push the pin down to bone and drill the pin through the tibia.
- When the pin tents the skin on the medial side, make a nick with the knife blade. An assistant can provide resistance to facilitate piercing the skin with the pin.
- In Fig. 10.91*C*, notice the location of the pin and the snug fit of the skin around the pin in the absence of tension. Remember that hip and femur fractures often lie in external rotation. Be certain to hold the leg rotationally straight while the pin is inserted, or it will be malpositioned for traction.
- Dress the pin with circumferential Kerlix or similar dressing (Fig. 10.91*D*). Antiseptic or antibiotic solutions on the pin at the skin interface are unnecessary. As long as the pin is properly inserted and does not loosen, daily skin care is unnecessary. Keeping a clean sterile occlusive dressing in place as illustrated here suffices.

### *Skeletal Traction with a Western Boot*

The “Western boot” is a versatile method of skeletal traction (Fig. 10.92). It is very comfortable for the patient, as the foot is fully supported, the traction pin is protected, the thigh is suspended independently, and there is no traction splint or apparatus near the buttocks or groin to interfere with personal hygiene. This modification of Charnley's modification of Russell's traction (18) is called the Western boot because it was developed at San Francisco General Hospital, where the staff often decorated the cast to look like a cowboy boot. In addition to being comfortable and versatile, this method allows early motion of all joints and permits the patient to do resistive exercises against the pull of the traction, and a continuous passive motion motor can be attached to the thigh suspension rope to produce continuous passive motion of the hip and knee.



***Figure 10.92.*** “Western boot” traction. See text for details. [(D) from Charnley J. *The Closed Treatment of Common Fractures*, 3rd ed. Baltimore: Williams & Wilkins, 1963.]

- Insert a ¼- or $^{5}/_{16}$-inch threaded Steinmann pin (Fig. 10.91). Place sterile 4 × 4-inch gauze pads over the Steinmann pin.
- Prepare the extremity for application of a short-leg cast. Use tubular stockinet and Webril as needed. The heel and bottom of the foot are at risk for pressure sores, so place a piece of felt over the bony prominences.
- Tie a traction rope to either side of the Steinmann pin, long enough to extend about 2–3 inches beyond the bottom of the foot. Tie this to the overhead bed frame to help hold the leg up while the cast is applied.
- Now apply a short-leg cast. Begin by incorporating the leg with a roll of plaster two layers thick.
- Once the initial two layers of circumferential plaster have been applied, place a 10- to 15-layer splint along the posterior aspect of the leg and foot (Fig. 10.92*B*).
- Place a second splint around the upper end of the cast, incorporating the Steinmann pin.
- Bring the rope that was attached to the Steinmann pin down alongside the cast and hold it in place opposite the heel of the cast.
- Now thoroughly incorporate the rope and the splints into the cast. Keep the rope sufficiently posterior that the anterior third of the cast can be removed.
- Once the cast has been completed, slip a small pulley onto the traction rope.
- When the cast is dry, remove the anterior half to avoid putting pressure on the foot and ankle if the cast should slip (Fig. 10.92*C*). The foot can be lifted out of the cast for skin care. The bottom of the cast supports the ankle and prevents an equinus contracture. The open top permits active motion of the toes and ankle into dorsiflexion and plantar flexion.
- The cast is usually not dry enough to window for several hours. Normally, I window the day after application.
- The importance of the cast's incorporating the Steinmann pin and surrounding the leg is illustrated in Fig. 10.92*D*.
- In Fig. 10.92*D*, on the left, the leg is allowed to lie on the slings on a Thomas splint. The result is compression of the soft tissues of the leg, which can be uncomfortable and can produce a common peroneal nerve palsy. Distortion of the skin around the pin can cause pressure sores. In Fig. 10.92*D*, on the right, the calf is suspended within the rigid cast. Suspension prevents skin problems and minimizes the risk of common peroneal nerve palsy. It also reduces the risk of pin-track infection by immobilizing the pin and reducing the motion between the pin and skin.
- The completed Western boot incorporated into Russell's traction is shown in Fig. 10.92*E*. The cast has yet to be given its final trim.
- Notice that the rope and pulley configuration is identical to that described by Russell, except the suspension rope from the Steinmann pin inclines backward, toward the head of the patient. This inclination is necessary to prevent the knee from dropping into full extension. This is convenient for the patient, as there is nothing on the thigh or buttock and groin.

The amount of traction needed to pull the femur out to length and maintain position is quite variable, depending on the size and muscle mass of the patient, and on the hydraulic forces at the fracture site. A good general rule is to apply 1 pound of traction for every 7 pounds of body weight. Prolonged skeletal traction over 35 pounds is usually uncomfortable and not well tolerated. In this patient, where about 25 pounds of traction were desired, a 15-pound weight was placed on the end of the rope. The additional weight compensates somewhat for the friction in the pulley system. This type of traction is ideal for the pelvis, acetabulum, and proximal femur, but it does not offer adequate stability for fractures of the femoral shaft or supracondylar fractures.

For fractures of the shaft or supracondylar area of the femur, and for additional stability under other circumstances, add an independent thigh sling (Fig. 10.92*F*), which may offer sufficient stability that a shaft fracture can be treated definitively. Additional stability may require the use of a Thomas splint.

Another advantage of the Western boot is that it is easily adapted for fixed traction or for fixed traction combined with longitudinal traction (Fig. 10.92*G*). In this case, the suspension ropes have been removed and a half-ring Thomas splint has been slipped under the limb. The traction rope is tied to the end of the splint and a windlass used to apply traction. To avoid excessive pressure in the groin, a traction rope has been tied to the end of the splint and a rope with a weight hung off the end of the stool.

This arrangement can be used to transport the patient to another hospital or ancillary diagnostic facilities. This method can be used to get patients with multiple injuries out of bed early. For mobilization of the patient with multiple injuries who is in traction, I prefer roller traction.

## TRACTION TREATMENT OF FEMORAL SHAFT FRACTURES

In his classic work *The Closed Treatment of Common Fractures*, Charnley includes a beautiful discussion of the mechanics of conservative treatment of femoral shaft fractures (18). The discussion here is based on his principles, and Figure 10.93, Figure 10.94 and Figure 10.95 are from his text.

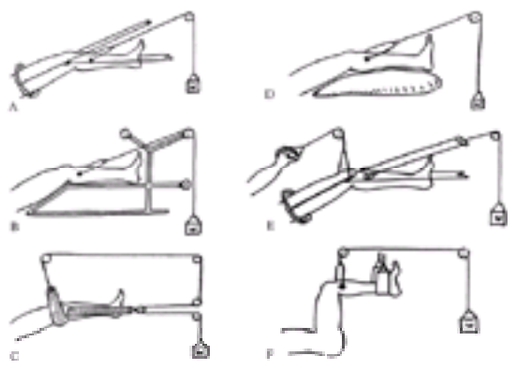

***Figure 10.93.*** Various femur traction methods. **A:** Thomas splint with Pearson attachment. **B:** Böhler-Braun frame. **C:** Russell's traction. **D:** Perkin's traction. **E:** Fisk's traction. **F:** 90-90 traction. (I prefer a distal femoral rather than a tibial pin for most 90-90 traction). (From Charnley J. *The Closed Treatment of Common Fractures, 3rd ed.* Baltimore: Williams & Wilkins, 1963.)

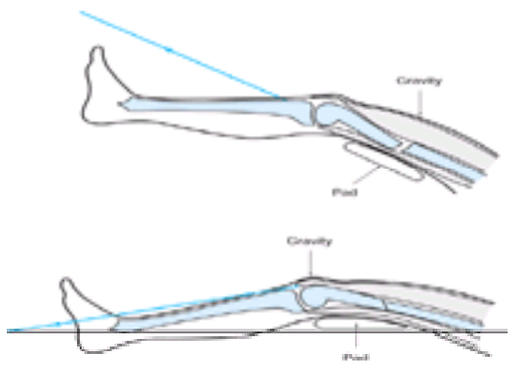


***Figure 10.94.*** Charnley's modification of Thomas's traction for fractures of the femur. **Top:** The line of traction is in the line of the femur, and the pad is low. Gravity causes the fracture to sag into posterior angulation. **Bottom:** In Charnley's modification, the Thomas splint is placed posterior to the femur, a pad is placed under the fracture site, and the line of traction is adjusted to pull below the longitudinal axis of the femur. This results in correction of the deformity. (From Charnley J. *The Closed Treatment of Common Fractures, 3rd ed.* Baltimore: Williams & Wilkins, 1963.)

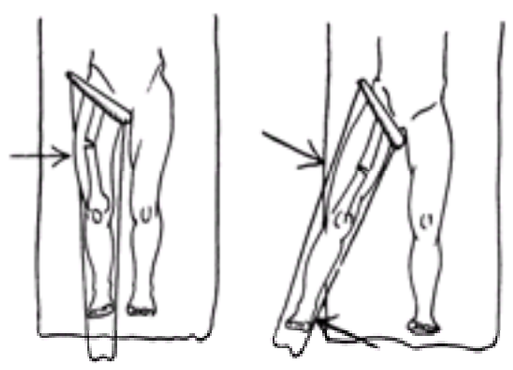

***Figure 10.95.*** Control of varus angulation. **A:** If the Thomas splint is placed in direct line with the body, varus angulation commonly occurs due to the pull of the hip abductors and iliopsoas, which pull the proximal fragment into abduction. **B:** This is nicely corrected by abducting the splint to bring the distal fragment into line with the proximal fragment, relaxing the muscle forces about the hip. To maintain this position, the direction of the traction line and suspension lines must be in line with and parallel to the Thomas splint. (From Charnley J. *The Closed Treatment of Common Fractures, 3rd ed.* Baltimore: Williams & Wilkins, 1963.)

Various methods of traction have been described for skeletal traction of the femur (Fig. 10.93). The Thomas splint with Pearson attachment (Fig. 10.93*A*) is the most commonly used. The Thomas splint simply cradles the femur and plays no active role in controlling deformity.

The Braun frame (Fig. 10.93*B*) is almost never used today for the femur because of its many disadvantages. The frame is heavy and interferes with nursing care. The angles of the frame and the pulley positions cannot be adjusted. Deformity is quite common because no dynamic forces can be built into this frame for management of the alignment of the fracture.

Russell's traction (Fig. 10.93*C*) has already been discussed. Skeletal traction methods are superior.

With Perkins's traction (Fig. 10.93*D*), no splintage is used at all. The limb is placed on a pillow and there is a single traction line. Although simple, there is a major disadvantage: When the patient lifts to get on a bed pan, the fracture commonly angulates. We use Perkins's traction in our intensive care units for multiply injured patients when we want to keep the method of treatment as simple as possible. Commonly, we combine it with a cast-brace, which allows the nursing staff to mobilize the patient by rolling or moving him to a bedside chair. The cast-brace provides good stability, and a single traction line is easy for the nursing staff to manage.

Fisk's traction (Fig. 10.93*E*), a modification of Thomas's method, allows 90° of knee movement for early rehabilitation. A continuous passive motion machine can be attached to the handpiece line (Fig. 10.90).

In 90-90 traction, useful for subtrochanteric fractures of the femur, the iliopsoas pulls the proximal fragment into flexion. Because a tibial traction pin tends to straighten out the knee, most surgeons prefer a femoral pin for 90-90 traction. A simple sling is used to suspend the calf and foot.

The most effective method of controlling position, however, is Charnley's modification of the Thomas splint method. Although most fractures reduce well with the simple application of longitudinal traction in a properly applied splint, it is more humane to do the initial application of traction, particularly if a Western boot is to be used, in the operating room under regional or general anesthesia. If traction alone does not result in adequate alignment, then manipulate the fracture under anesthesia to achieve a good reduction and make the necessary adjustments in the traction lines to ensure maintenance of position.

In general, the Thomas splint with traction is used to maintain reduction rather than actually achieve reduction. Femoral shaft fractures tend to heal with recurvatum (posterior angulation of the fracture), varus of the distal fragment, and external rotation. External rotation is easily managed by placing the tibial pin in proper position and applying longitudinal traction. The anterior superior iliac spine, mid patella, and first web space of the toes should be longitudinally aligned. Any tendency for excessive external rotation can be managed by attaching a small traction rope to the lateral side of the traction pin and hanging on it a 1-pound weight, but it is rarely necessary to do so.

Posterior angulation at the fracture site is avoided by using gravity as an assistant. Charnley emphasizes that a pad must be placed below the fracture site, and the angle of the traction line must be adjusted downward to impart a forward thrust at the fracture site and a posterior thrust at the distal femur to correct the deformity. This position is achieved by aligning the Thomas splint posterior to the axis of the femur, placing a pad beneath the fracture site, and adjusting the pull of the traction line to be below (posterior to) the longitudinal axis of the femur as viewed from the side (Fig. 10.94).

Varus deformity is prevented by abducting the leg at the hip (Fig. 10.95). To maintain this position, all traction and suspension lines should be in the longitudinal axis of the extremity as far as the first pulley. In Figure 10.95*B*, for example, the pulleys at the foot would need to be on long bars beyond the side of the bed, and the pulley at

the upper end of the splint would need to be on the left side of the patient for a right femur fracture. This method, as I use it, is shown in Fig. 10.96.

***Figure 10.96.*** Treatment of a femoral fracture using a Thomas splint with a Pearson attachment.

#### *Traction Technique for the Femur*

- Use a half-ring Thomas splint. Place the ring on top of the thigh rather than beneath the buttocks. This arrangement is much more comfortable for the patient and eliminates interference with the bedpan. It is much easier to change the bed linen, and the splint is kept much cleaner.
- Connect a Pearson attachment to the Thomas splint to permit flexion of the knee. In supracondylar fractures, the effect of the pad under the fracture can be mimicked by placing the attachment of the Pearson splint at the fracture site.
- Use a commercially available single synthetic fleece suspension sling, attached to the splints with plastic clips, to support the limb. A pad has been placed beneath the fracture site in Figure 10.96; note that a Western boot is in place, which provides the advantages already discussed.
- Wrap the suspension rope around the ring of the Thomas splint twice to prevent the rope from slipping on the ring and to allow control of rotation of the splint. In this case, the weight has been hung at the head of the bed. I recommend hanging all weights at the foot of the bed, because traction bars at the head of the bed can damage the wall. Having the weights at the foot of the bed makes them easy to adjust, as well.
- Use a single line of rope to suspend the Pearson attachment from the Thomas splint and to suspend the Thomas splint from the overhead frame. A clove hitch is used on the end of the Thomas splint, which allows the angle of knee flexion to be easily adjusted without untying any knots. In this case, a fixed line is used.
- Use pulleys and weights at the lower end if desired to provide suspension, but they add to the complexity of the arrangement and are usually unnecessary. The traction line in this case passes only slightly below the longitudinal axis of the femur, as the fracture is in the upper mid shaft.
- Place sufficient weight on the balanced suspension so that when the patient lifts to get on a bedpan, the limb rises easily with the torso.

#### *Cast-Brace Traction*

Before the development of cast-braces, femur fractures needed to be maintained in traction until bridging callus was evident on both the anteroposterior and lateral views and the fracture was clinically stable. In the average adult, callus formation requires 6–12 weeks. At that point, we would leave the patient in balanced suspension but remove the traction; if no shift in the fracture was noted after several days, a single leg or 1½ spica cast would be applied and maintained until union occurred. Because this approach requires prolonged hospitalization and excessively long bed rest and immobilization, cast-brace traction became popular.

A combination of cast-bracing with traction has been described by Connolly and King (20), Hardy (37), Lesin et al. (46), McIvor et al. (58), Meggitt et al. (55), and Mooney et al. (61,62), as well as others. The method is called roller traction when the cast-brace is combined with traction through a single overhead line connected to a pulley that rolls on the overhead bar of the traction frame (60). With this method of treatment, the patient is much more mobile in bed and the fracture is more securely supported. As soon as the patient is comfortable and there is early soft-tissue stability of the fracture site (usually in 3–6 weeks), the patient can begin to get up on crutches or a walker and begin non-weight-bearing crutch walking a few times a day.

Since the tibial traction pin is incorporated into the cast-brace, the cast-brace provides traction by virtue of gravity while the patient is upright, producing “ambulatory traction.” Frequent radiographic monitoring of the fracture is necessary during this mobilization to ensure that good alignment is maintained, as angulation is common with this technique. As soon as the patient is getting out of bed with a physical therapist twice daily and radiographs show no further shift in the fracture site, traction can usually be discontinued and treatment thereafter continued in the cast-brace. When sufficient consolidation of the fracture has occurred that shortening can no longer occur, the traction pin can be removed and weight bearing begun.

This method, popularized by the military during the Vietnam War, enables the average young healthy patient to be out of traction and discharged from the hospital by 6–8 weeks after fracture. The cast-brace must be maintained until solid union has occurred, which usually requires at least 10–12 weeks.

### TRACTION FOR FRACTURES OF THE TIBIA

The usual indication for traction treatment of fractures of the tibia is soft-tissue problems precluding external or internal fixation. In addition, severe comminution, especially in the presence of poor-quality bone, may necessitate treatment in traction to initiate early motion of the knee or ankle. Use a traction pin through the calcaneus or distal tibial metaphysis, as indicated. The leg can be placed on a Braun frame, or for more convenient nursing in a Thomas splint with a Pearson attachment for balanced suspension. In most cases, traction is maintained for only a short time, until the soft-tissue problems resolve and a cast or cast-brace can be applied. The basic principles already described apply.

### UPPER EXTREMITY TRACTION

#### *Dunlop Traction*

Unstable supracondylar fractures of the humerus in children are rarely treated in traction because closed reduction with percutaneous pin fixation gives far superior results (Fig. 10.97). Rarely, operative fixation is contraindicated and treatment in traction may be necessary.

***Figure 10.97.*** Dunlop traction for supracondylar fractures in children, as modified by Allen and Gramse. (From W. P. Blount's classic textbook, *Fractures in Children.* Baltimore: Williams & Wilkins, 1955:279.)

- First, apply skin traction to the forearm using the techniques described for modified Buck's traction.
- Leave the hand and fingers free for neurovascular examination. The radial pulse should be accessible.
- It is usually best to place the patient in the orthopaedic bed (Fig. 10.97) in which she will be immobilized and to perform the closed reduction in that bed to prevent

loss of reduction when she is moved from the operating table to the ward bed.

- Reduce the fracture, then apply sufficient traction from the forearm to hold the arm level with the floor.
- Fashion a sling for the arm from a commercial fleece sling or from felt inserted into tubular stockinet. It must be sufficiently wide that at least the lower third of the arm is covered.
- Attach to it sufficient weight to maintain reduction (rarely more than 1–2 pounds).
- To avoid malrotation and varus or valgus alignment, the patient's torso must be maintained in correct relationship to the line of traction.
- Note the sheet doubled around the torso. It is quite difficult to keep the average child in this position for very long. Despite these disadvantages, I managed dozens of these fractures with this method in the 1960s and early 1970s with reasonably good success.

### *Overhead Olecranon Pin Traction*

Like Dunlop traction, olecranon pin traction is rarely indicated today; I have not used it since the early 1980s. Most fractures of the humerus are now better managed with external or internal fixation. Rarely, a particular combination of systemic disease and soft-tissue and bone problems may necessitate treatment in overhead traction. An example might be a fracture of the humerus associated with burns, in which overhead traction may be the optimal method.

- Using sterile techniques, place an appropriate-size K-wire transversely through the olecranon. Always insert this pin from medial to lateral, taking care to avoid injury to the ulnar nerve. In Figure 10.98 the pin is not dressed, but I advise placing sterile 2 × 2-inch gauze pads between the skin and the K-wire bow to protect the pin entry site, and to prevent the bow from sliding back and forth. If the bow slides toward the medial side of the forearm and impinges on the ulnar nerve, ulnar nerve palsy and erosion of skin and nerve can occur.

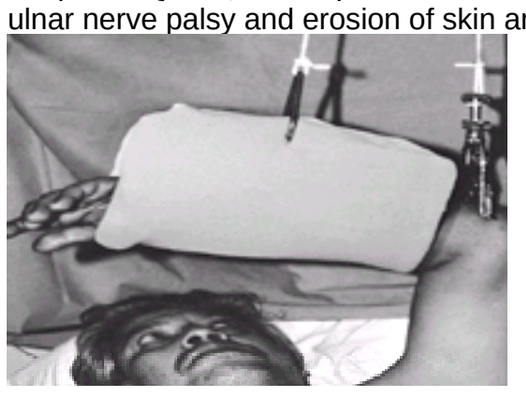

***Figure 10.98.*** Overhead olecranon pin traction.

- Apply sufficient traction to maintain appropriate length and the reduction.
- Suspend the forearm with a sling. The sling here is rather large. Smaller slings that can be more easily removed may facilitate physical therapy and hand function.

## COMPLICATIONS OF TRACTION

Table 10.2 lists general recommendations for avoiding complications of traction, which follow the principles of those for casts and splints. Generalized cardiovascular deconditioning and atrophy of muscle occur very rapidly in patients on complete bed rest and traction. The physical therapist should visit all patients in traction within the first few days of treatment to initiate a physical therapy program for maintenance of cardiovascular conditioning and joint range of motion and strength. Stretching exercises, particularly of the Achilles tendon, are necessary to avoid contractures. Splinting may be necessary.

| |
|---|
| Immobilize only those joints necessary to adequately immobilize the fracture. |
| Institute isometric exercises for all muscles immobilized and a gentle resistance program for those outside the immobilization. |
| Always have the patient perform a daily range-of-motion exercise program for joints that are not immobilized and are adjacent to the immobilized segment. |
| Whenever possible, use cast-braces or other functional braces. It may be impossible to begin with these, but use them as soon as possible. |
| Patients in traction can often be treated with early motion of even those joints immobilized by the traction. Use of roller traction methods often allows the patient to be out of bed, into a chair, or walking early during traction treatment. |
| Use cast-brace traction whenever possible to permit early mobilization of the patient. When the knee is immobilized, do patellar mobilization exercises to maintain elasticity in the quadriceps retinaculum. |

***Table 10.2. Avoiding Complications of Traction***

A program of progressive resistance exercises using light weights or elastic bands will help maintain muscle strength. All joints that can be moved through a full range of motion passively or actively without interfering with the treatment of the fracture or dislocation should be exercised vigorously throughout the day. Cardiovascular conditioning is very difficult to maintain while in traction, but a general exercise program is very helpful. It is usually possible to move the joints to some extent and to do isometric exercises of the muscles above and below the fractured bone; encourage the patient to do so as soon as possible.

Pressure sores and injuries to the nerves are avoided by careful attention to the techniques described. Remember that excessive traction on a swollen limb can precipitate compartment syndrome. If symptoms develop, reduction of the traction may be necessary.

Make every attempt to avoid decubitus ulcers. The key factor is an active, vigorous patient who frequently does pull-ups on the overhead frame to allow good circulation to the skin. Good nursing care to maintain a clean perineum and dry sheets is imperative. An egg-crate foam mattress or similar device should routinely be used, and alternated with an air mattress if necessary. The more complicated beds used for the care of quadriplegics are rarely practical with traction.

Thrombophlebitis is common in patients on prolonged bed rest, and secondary pulmonary embolism can be fatal. Some type of prophylaxis is indicated in nearly all patients (see Chapter 5 for more details).

Remember that traction rarely remains as initially adjusted. It requires constant attention to maintain optimal alignment and position, ensure patient comfort, optimize nursing care, and prevent complications.

## CHAPTER REFERENCES

Each reference is categorized according to the following scheme: *, classic article; #, review article; !, basic research article; and +, clinical results/outcome study.


! 1. Athenstaedt H. Pyroelectric and Piezoelectric Properties of Vertebrates. *Ann N Y Acad Sci* 1974;238:68.

! 2. Bak B, Andreassen TT. The Effect of Growth Hormone on Fracture Healing in Old Rats. *Bone* 1991;12:151.

! 3. Barron SE, Robb BA, Taylor WF, Kelly PJ. Effect of Fixation with Intramedullary Rods and Plates on Fracture Site Blood Flow and Bone Remodeling in Dogs. *J Bone Joint Surg Am* 1977;59:376.

# 4. Bassett CAL. Environmental and Cellular Factors Regulating Osteogenesis. In: Frost HM, ed. *Bone Biodynamics.* Boston: Little Brown, 1964:233.

# 5. Bassett CAL, Mitchell SN, Norton L, et al. Electromagnetic Repairs of Nonunions. In: Brighton CT, Black J, Pollack SR, eds. *fElectrical Properties of Bone and Cartilage. Experimental Effects and Clinical Applications.* New York: Grune & Stratton, 1979:605.

! 6. Bassett CAL, Pawluk RJ, Pilla AA. Augmentation of Bone Repair by Inductively Coupled Electromagnetic Fields. *Science* 1974;184:575.

! 7. Becker RO, Murray DG. A method for Producing Cellular Dedifferentiation by Means of Very Small Electrical Currents. *Trans N Y Acad Sci* 1967;29:606.

! 8. Bidner SM, Rubins IM, Desjardins JV, et al. Evidence for Humoral Mechanism for Enhanced Osteogenesis after Head Injury. *J Bone Joint Surg Am* 1990;72:1144.

! 9. Binderman I, Somjen D, Shimshoni Z, et al. Stimulation of Skeletal-derived Cell Cultures by Different Electric Field Intensities Is Cell Specific. *Biochem Biophys Acta* 1985;844:273.

# 10. Bleck EE, Duckworth N, Hunter N. *Atlas of Plaster Cast Techniques, 2nd ed.* Chicago: Year Book Medical, 1974:160.

# 11. Böhler L. *Technik der Knochenbruchbehandlungen.* Wien: Wilhelm Maudrich, 1929.

# 12. Brighton CT, Friedenberg ZB, Black J. Evaluation of the Use of Constant Direct Current in the Treatment of Nonunion. In: Brighton CT, Black J, Pollack SR, eds. *Electrical Properties of Bone and Cartilage. Experimental Effects and Clinical Applications.* New York: Grune & Stratton, 1979:519.

! 13. Brinker MR, Lippton HL, Cook SD, Hyman AL. Pharmacological Regulation of the Circulation of Bone. *J Bone Joint Surg Am* 1990;72:964.

# 14. Browner BD, Jupiter JB, Levine AM, Trafton PG. *Skeletal Trauma.* Philadelphia: WB Saunders, 1992:1991.

* 15. Bryant, T. *The Practice of Surgery, A Manual.* London: Churchill, 1872.

* 16. Buck G. An Improved Method of Treating Fractures of the Thigh Illustrated by Cases and a Drawing. *Trans N Y Acad Med* 1861;2:232.

! 17. Burny F, Donkerwolcke M, Bourgois R, et al. Twenty Years' Experience in Fracture Healing Measurements with Strain Gauges. *Orthopedics* 1984;7:1823.

* 18. Charnley J. *The Closed Treatment of Common Fractures, 3rd ed.* Baltimore: Williams & Wilkins, 1963:272.

! 19. Collier RJ, Donarski RJ. Non-invasive Method of Measuring Resonant Frequency of a Human Tibia in Vivo. *J Biomed Eng* 1987;9:321.

+ 20. Connolly J, King P. Closed Reduction and Early Cast-Brace Ambulation in the Treatment of Femoral Fractures. Part I: An In Vitro Quantitative Analysis of Immobilization in Skeletal Traction and a Cast-brace. *J Bone Joint Surg Am* 1973;55:1559.

# 21. Cruess RL, Dumont J. Healing of Bone, Tendon, and Ligament. In: Rockwood CA, Green DP, eds. *Fractures.* Philadelphia: JB Lippincott, 1975:97.

! 22. Cunningham JL, Kenwright J, Kershaw CJ. Biomechanical Measurement of Fracture Healing. *J Med Eng Technol* 1990;14:92.

! 23. Einhorn TA, Simon G, Devlin VJ, et al. The Osteogenic Response to Distant Skeletal Injury. *J Bone Joint Surg Am* 1990;72:1374.

! 24. Evans CE, Galasko CSB, Ward C. Effect of Donor Age on Growth in Vitro of Cells Obtained from Human Trabecular Bone. *J Orthop Res* 1990;8:234.

! 25. Fisher LW, Termine JD. Noncollagenous Proteins Influencing the Local Mechanisms of Calcification. *Clin Orthop* 1985;200:362.

! 26. Foldes J, Naparstek E, Slatter M, et al. Osteogenic Response to Marrow Aspiration: Increased Serum Osteocalcin and Alkaline Phosphatase in Human Bone Marrow Donors. *J Bone Miner Res* 1989;4:643.

* 27. Freuler F, Wiedmer V, Bianchini D. *Cast Manual for Adults and Children.* Berlin: Springer-Verlag, 1979:248.

! 28. Friedenberg ZB, Andrews ET, Smolenski BI, et al. Bone Reaction to Varying Amounts of Direct Current. *Surg Gynecol Obstet* 1970;131:894.

! 29. Friedenberg ZB, Zemsky LM, Pollis RP, Brighton CT. The Response of Non-traumatized Bone to Direct Current. *J Bone Joint Surg Am* 1974;56:1023.

! 30. Frost HM. The Biology of Fracture Healing. *Clin Orthop* 1989;248:283.

! 31. Gelberman RH, Mortensen WW. The Arterial Anatomy of the Talus. *Foot Ankle* 1983;4:64.

! 32. Gelberman RH, Panagis JS, Taleisnik J, Baumgaertner M. The Arterial Anatomy of the Human Carpus. *J Hand Surg [Am]* 1983;8:367.

! 33. Gerlanc M, Haddad D, Hyatt GW, et al. Ultrasonic Study of Normal and Fracture Bone. *Clin Orthop* 1975;111:175.

! 34. Goodship JE, Kenwright J. The Influence of Induced Micromovement upon the Healing of Experimental Tibial Fractures. *J Bone Joint Surg Br* 1985;67:650.

! 35. Grodzinsky AJ. Electromechanical and Physicochemical Properties of Connective Tissues. *Crit Rev Bioeng* 1983;9:133.

! 36. Gupta RC, Gupta SC, Gupta KK. Experimental Study on Osseous Phlebography and Fracture Healing. *Indian J Med Res* 1980;72:293.

+ 37. Hardy AE. The Treatment of Femoral Fractures by Cast-Brace Application and Early Ambulation. A Prospective Review of 106 Patients. *J Bone Joint Surg Am* 1983;65:56.

! 38. Hassler CR, Rybicki EF, Diegle RB, Clark LC. Studies of Enhanced Bone Healing via Electrical Stimuli. *Clin Orthop* 1977;124:9.

* 39. Hodgen JT. On the Treatment of Gunshot Fractures of the Femur and Tibia. *Am Med Times* 1863;7:169.

! 40. Jacobs RL, Ray RD. The Effect of Heat on Bone Healing. *Arch Surg* 1972;104:687.

* 41. Kirschner M. Ueber Negelextension. *Beitr Klin Chir* 1909;64:266.

* 42. Kirschner M. Verbesserungen der Drahtextension. *Arch Klin Chir* 1927;148:651.

! 43. Korenstein R, Somjen D, Fischler HK, Binderman I. Capacitative Pulsed Electrical Stimulation of Bone Cells. *Biochem Biophys Acta* 1984;803:302.

* 44. Kuntscher G. *The Callus-Problem.* Altner PC, trans. St. Louis, MO: Warren H. Green, 1974:146.

! 45. Lanyon LE, Rubin CT. Static Versus Dynamic Loads as an Influence on Bone Remodeling. *J Biomech* 1974;17:897.

+ 46. Lesin B, Mooney V, Ashby M. Cast-Bracing for Fractures of the Femur. A Preliminary Report of a Modified Device. *J Bone Joint Surg Am* 1977;59:917.

! 47. Levy DD, Rubin B. Inducing Bone Growth in Vivo by Pulse Stimulation. *Clin Orthop* 1972;88:218.

* 48. Luck JV. Plaster of Paris Casts: An Experimental and Clinical Analysis. *JAMA* 1944;124:23.

* 49. Malgaigne JF. *Recherches Historiques et Pratiques sur les Appareils Employés dans le Traitement des Fractures en Général Depuis Hippocrate jusqu'à Nos Jours.* Paris: H. Cousin, 1841.

# 50. Martin RB, Burr DB. *The Structure, Function, and Adaptation of Compact Bone.* New York: Raven Press, 1989.

* 51. Mayor ML. *Mémoire sur L'Hyponarthecie ou sur le Traitement des Fractures par la Planchette.* Geneva, 1827.

! 52. McElhaney JH, Stalnaker R, Bullard R. Electric Fields and Bone Loss of Disuse. *J Biomech* 1968;1:47.

! 53. McKibbin B. The Biology of Fracture Healing in Long Bones. *J Bone Joint Surg Br* 1978;60:150.

! 54. Meadows TH, Bronk JT, Chao YS, Kelley PJ. Effect of Weight-bearing on Healing of Cortical Defects in the Canine Tibia. *J Bone Joint Surg Am* 1990;72:1074.

+ 55. Meggitt BF, Juett DA, Smith JD. Cast-Bracing for Fractures of the Femoral Shaft: A Biomechanical and Clinical Study. *J Bone Joint Surg Br* 1981;63:12.

! 56. Meller Y, Kestenbaum RS, Galinsky D, Shany S. Seasonal Variation in Serum Levels of Vitamin D Metabolites and Parathormone in Geriatric Patients with Fractures in Southern Israel. *Isr J Med Sci* 1986;22:8.

! 57. Meller Y, Kestenbaum RS, Schany S, et al. Parathormone, Calcitonin, and Vitamin D Metabolites During Normal Fracture Healing in Geriatric Patients. *Clin Orthop* 1985;199:272.

+ 58. Melvor J, Ross P, Landry G, Davis L. Treatment of Femoral Fractures with the Cast-brace. *Can J Surg* 1984;27:592.

! 59. Mizuno K, Mineo K, Tachibana T, et al. The Osteogenic Potential of Fracture Hematoma. *J Bone Joint Surg Br* 1990;72:822.

+ 60. Montgomery S, Mooney V. Femur Fractures: Treatment with Roller Traction and Early Ambulation. *Clin Orthop* 1981;156:196.

+ 61. Mooney V. Cast Bracing. *Clin Orthop* 1974;102:159.

+ 62. Mooney V, Nickel V, Harvey J, Svelson R. Cast-Brace Treatment for Fractures of the Distal Part of the Femur. *J Bone Joint Surg Am* 1970;52:1563.

! 63. Mostafa AGSA, El Attar S, Mili F, Wright EA. The Effect of Environmental Temperature on the Rate of Healing of Fractures in Tail Vertebrae of Mice. *J Bone Joint Surg Br* 1980;62:102.

* 64. Nifong FG. *The Hodgen Wire Cradle Extension Suspension Splint: The Exemplification of This Splint with Other Helpful Appliances in the Treatment of Fractures and Wounds of the Extremities and Its Application in Both Civil War and Practice.* St. Louis, MO: CV Mosby, 1918.

! 65. Norton LA. Effects of a Pulsed Electromagnetic Field on a Mixed Chondroblastic Tissue Culture. *Clin Orthop* 1982;167:280.

# 66. Norton LA, Bourret LA, Rodan GA. Molecular Changes in Hard Tissue Cells in Response to Bioelectric Proliferative Signals. In: Becker RO, ed. *Mechanism of Growth Control.* Springfield, IL: Charles C. Thomas, 1981:180.

! 67. Otter MW, Palmieri VR, Cochran GVB. Transcortical Streaming Potentials Are Generated by Circulatory Pressure Gradients in Living Canine Tibia. *J Orthop Res* 1990;8:119.

! 68. Paradis GR, Kelley PJ. Blood Flow and Mineral Deposition in Canine Tibial Fractures. *J Bone Joint Surg Am* 1975;57:220.

* 69. Pearson MG, Drummond J. *Fractured Femurs: Their Treatment by Caliper Extensions.* London: Oxford University Press, 1919.

* 70. Peltier LF. A Brief History of Traction. *J Bone Joint Surg Am* 1968;50:1603.

! 71. Peltier RR, Saha S. Wave Propagation across a Bony Discontinuity Simulating a Healing Fracture. *J Biomech* 1985;18:745.

! 72. Perren SM. Physical and Biological Aspects of Fracture Healing with Special Reference to Internal Fixation. *Clin Orthop* 1979;138:175.

! 73. Perren SM, Cordey J, Rahn BA, et al. Early Temporary Porosis of Bone Induced by Internal Fixation Implants. *Clin Orthop* 1988;232:139.

+ 74. Puranen J, Kaski P. The Clinical Significance of Osteomedullography in Fractures of the Tibial Shaft. *J Bone Joint Surg Am* 1974;56:759.

* 75. Rahn BA, Gallinaro P, Baltensperger A, Perren SM. Primary Bone Healing: An Experimental Study in the Rabbit. *J Bone Joint Surg Am* 1971;53:783.

* 76. Rhinelander FW. The Normal Microcirculation of Diaphyseal Cortex and Its Response to Fracture. *J Bone Joint Surg Am* 1968;50:784.

* 77. Rhinelander FW. Effects of Medullary Nailing on the Normal Blood Supply of the Diaphyseal Cortex. *Instr Course Lect* 1973;22:161.

+ 78. Rhinelander FW. Tibial Blood Supply in Relation to Fracture Healing. *Clin Orthop* 1974;105:35.

! 79. Richards RR, Schemitsch EH. Effect of Muscle Flap Coverage on Bone Blood Flow Following Devascularization of a Segment of Tibia. *J Orthop Res* 1989;7:550.

# 80. Rockwood CA Jr, Green DP, Bucholz RW, eds. *Fractures in Adults, 3rd ed.* Philadelphia: JB Lippincott, 1991:2182.

# 81. Rockwood CA Jr, Wilkins KE, King RE, eds. *Fractures in Children.* Philadelphia: JB Lippincott, 1991:1500.

! 82. Rodan GA, Bourret LA, Norton LA. DNA Synthesis in Cartilage Cells is Stimulated by Oscillating Electric Fields. *Science* 1978;199:690.

* 83. Russell RH. Theory and Method on Extension of the Thigh. *Br Med J* 1921;2:637.

* 84. Sarmiento A. A Functional Below-the-Knee Cast for Tibial Fractures. *J Bone Joint Surg Am* 1967;49:855.

* 85. Sauter JN. *Answeisung, die Beinbrüche der Gleidmassen.* Konstanz: 1812.

*86. Schenk R, Willenegger H. Histologie der Primaren Knochenheilung. *Arch Klin Chir* 1963;19:593.

! 87. Seliger WG. Tissue Fluid Movement in Compact Bone. *Anat Rec* 1970;166:247.

* 88. Smith N. Observations on Fractures of the Femur with an Account of a New Splint; and Addenda. In: Smith NR, ed. *Medical and Surgical Memoirs.* Baltimore: William A. Francis, 1831.

* 89. Smith NR. A New Instrument for the Treatment of Fractures of the Lower Extremity. *Maryland Virginia Med Surg J* 1860;14:1.

* 90. Smith NR. *Treatment of Fractures of the Lower Extremity by Use of the Anterior Suspensory Apparatus.* Baltimore: Kelly & Piet, 1867.

* 91. Steinmann FR. Eine Neue Extensionsmethode in der Frakturenbehandlung. *Zentralbl Chir* 1907;34:938.

! 92. Terjesen T, Apalset K. The Influence of Different Degrees of Stiffness of Fixation Plates on Experimental Bone Healing. *J Orthop Res* 1988;6:293.

* 93. Thomas HO. *The Treatment of Deformities, Fractures and Diseases of Bones in the Lower Extremities.* London: HK Lewis, 1890.

! 94. Trueta J. The Role of the Vessels in Osteogenesis. *J Bone Joint Surg Br* 1963;45:402.

! 95. Trueta J. Blood Supply and the Rate of Healing of Tibial Fractures. *Clin Orthop* 1974;105:11.

# 96. Uhthoff HK. Fracture Healing. In: Gustilo RB, Kyle RF, Templeman DC, eds. *Fractures and Dislocations,* St. Louis, MO: Mosby, 1993:45.

! 97. Uhthoff HK, Bardos DI, Liskova-Kiar M. The Advantages of Titanium Alloy over Stainless Steel Plates for the Internal Fixation of Fractures. *J Bone Joint Surg Br* 1981;63:427.

# 98. Watson-Jones R. *Fractures and Joint Injuries, 4th ed.* Baltimore: Williams & Wilkins, 1962:1073.

! 99. White AA III, Panjabi MM, Southwick WO. The Four Biomechanical Stages of Fracture Healing. *J Bone Joint Surg Am* 1977;59:188.

+ 100. Wilber MC, Evans EB. Fractures of the Femoral Shaft Treated Surgically. *J Bone Joint Surg Am* 1978;60:489.

! 101. Woo SL-Y, Lothringer K, Akeson WH, et al. Less Rigid Internal Fixation Plates: Historical Perspectives and New Concepts. *J Orthop Res* 1984;1:431.

# CHAPTER 11

# PRINCIPLES OF INTERNAL AND EXTERNAL FIXATION

*This chapter combines five chapters from the second edition of Operative Orthopaedics, written by Timothy J. Bray and David C. Templeman (screw fixation), Fred Behrens (external fixation), David H. Gershuni (wire and pin fixation), Thomas P. Rüedi (plate fixation), Harry B. Skinner (materials), and myself. Much of the original material by these authors has been retained in this chapter, and I wish to acknowledge and thank them for their contributions.*

*Michael W. Chapman*

**M. W. Chapman:** Department of Orthopaedics, University of California, Davis, Sacramento, California, 95817.

A. Introduction
Metallic Alloys
Mechanical Properties of Implant Materials
Stainless Steel Versus Titanium for Bone Fixation Implants
Implant Polymers
Ceramics
Composite Materials
B. Principles of Wire, Cable, and Pin Fixation
Kirschner Wires
Material Features
Indications for Use
Steinmann Pins
Material Features
Indications for Use
Pins Incorporated in Casts
Technique of Pin Introduction
Tension Band Wires
Principles of Use
Technique of Application
Cerclage Wiring
Principles of Use
Temporary Wiring
Definitive Wiring
Cables
C. Principles of External Fixation
Terminology and Components
Fixation Pins
Fixator Frames
Basic Concepts
Limb Anatomy
Mechanical Demands
Preoperative Considerations
Configurations
Combined Internal and External Fixation
Surgical Techniques
Pin Insertion
Frame Application
Postoperative Care
Care of the Pin Sites and Frame
Getting Fractures to Heal in External Fixation
Soft-Tissue Coverage
Bone Grafts
Changing Fixator Stiffness and Axial Micromotion
Secondary Internal Fixation
Pitfalls and Complications
Chronic Pain
Pin-Site Drainage and Infection
Deformity, Delayed Union, and Nonunion
D. Principles of Screw Fixation
General Principles
Cortical Screws
Cancellous Screws
Special Features
Instruments and Techniques for Screw Insertion
Drill Points
Power Source
Measuring Screw Depth
Tapping
Screwdrivers
Surgical Techniques
Lag Screw Fixation
Fixation of Articular Fractures
Specialized Screws
Double-Threaded Screws
Crosslocking Screws
Cannulated Screws
Absorbable Screws
Fixation of Tendons and Ligaments
Suture Anchors
E. Principles of Plate Fixation
Development of Plate Functions
Static Compression
Dynamic Compression (Tension Band Plate)
Neutralization
Buttress Function
Physiology of Plate Fixation
Newer Plate Systems
General Principles of Plate Fixation
Location
Surgical Techniques
Exposure
Reduction and Plate Application

Indirect Reduction Techniques
Wave Plates
Double Plates
Specialty Plates
F. Principles of Intramedullary Nailing
Advantages and Disadvantages
Effects of Nailing and Reaming on Bone and Systemic Physiology
Types of Nails
Reamed Nails
Nonreamed Nails
Locking Nails
Specialized Nails
Indications
Closed Fractures
Open Fractures
Technical Considerations
Timing
Entry Sites
Fracture Reduction
Reaming
Nail Size
Interlocking Nails
Surgical Techniques
Cross Locking
Free-Hand Targeting
Postoperative Care
Pitfalls and Complications
Malposition
Delayed Union
Nonunion
Neurologic Injury
G. Principles of Hardware Removal
Surgical Techniques
Removal of Plates and Screws
Postoperative Care
Chapter References

# A. INTRODUCTION

Orthopaedics is a highly technical specialty that employs an incredibly broad range of techniques, from fine microvascular surgery to bone fixation implants, to large metallic and polymeric composite implants for joint replacement, to sophisticated methods of external fixation involving all regions of the skeleton. Successful use of these implants and devices requires sophisticated technical knowledge on the part of the surgeon, as well as respect for the biology of the tissues being handled, for the best chance of a successful result. The surgeon must be certain that the indications for surgery are appropriate and that the patient is suitable for the operation: Even the best-performed procedure will fail if the indications are not correct and if the patient cannot benefit.

The technical aspects of applying internal and external fixation implants are critical to achieving bone union in the appropriate position and to avoiding implant failure. It is essential that resident and neophyte surgeons master the general principles and that mature surgeons constantly remind themselves of them, particularly when they are employing fixation techniques that they do not perform often.

## METALLIC ALLOYS

The biocompatibility of metallic alloys is based on the presence of a constituent element that has the ability to form an adherent oxide coating that is stable and chemically inert. Materials that do not form stable oxides or that permit the oxide to become detached from the underlying metal, such as common carbon steel, are not biocompatible and continue to undergo degradation in the body. The common metallic alloys [e.g., cobalt chromium (ASTM F75-82, ASTM 799-82), titanium alloy (ASTM F136-79), and stainless steel (ASTM F55, F56)] have at least one element that forms an adherent oxide coating. The composition of these alloys is shown in Table 11.1. Detailed specifications of the composition are given in the American Society for Testing and Materials (ASTM) standards.

| Cobalt-Chromium Alloys | ASTM F75-82 (Cast) | ASTM 799-82 (Forged) |
|---|---|---|
| Chromium | 27–30% | 26–30% |
| Molybdenum | 5–7% | 5–7% |
| Iron | 0–0.75% | 0–1.5% |
| Nitrogen | 0 | 0–0.25% |
| Cobalt | Balance | Balance |
| (plus nickel, silicon, manganese: 1% each) | | |
| **Titanium Alloy (ASTM F136–79)** | | |
| Aluminum | 5.5–6.5% | |
| Vanadium | 3.5–4.5% | |
| Trace elements | — | |
| Titanium | Balance | |
| **Stainless Steel (ASTM F55–56)** | | |
| Chromium | 17–20% | |
| Nickel | 12–14% | |
| Manganese | 2.0% | |
| Molybdenum | 2–4% | |
| Trace elements | — | |
| Iron | Balance | |

***Table 11.1. Nominal Compositions of Implant Alloys***

Composition varies somewhat depending on the intended use of the material. For example, if ductility is not a requirement, carbon is used to strengthen cobalt-chromium alloy (F75-82), although carbon reduces the alloy's ductility. Other phases present in each alloy tend to stabilize the crystal structure. Forged cobalt-chromium alloy is strengthened by nitrogen as a minor impurity. Certain elements are deleterious to the properties, such as oxygen in a titanium alloy, which tends to make it brittle. Similarly, carbon in stainless steel decreases ductility unless it is allowed to precipitate in the grain boundaries as chromium carbide, where it decreases resistance to corrosion.

Implant alloys are manufactured by melting the appropriate elements together to produce a liquid solution that subsequently becomes a solid solution of each element in the matrix after cooling. This material is shipped as a bar, rod, or plate for further processing by the implant manufacturer. Titanium alloy can be shaped by machining from bar stock or sheet stock; stainless steel implants can be produced the same way. After initial forming of the more ductile version of the cobalt-chromium alloys, forging significantly strengthens the alloy and brings it to its final shape by applying mechanical work. The casting process can be used for titanium alloy or cobalt-chromium alloy to produce intricate shapes. A wax mold of the prosthesis is coated with ceramic and fired. The wax melts out of the ceramic mold (i.e., lost wax process); after cooling, liquid metal is poured into the ceramic shape and allowed to solidify. Final shaping is done by machining and grinding. Machining and forging done under appropriate conditions do not diminish the mechanical properties of the alloy. However, investment casting typically weakens the material by causing an increase in the grain size. This mostly affects the fatigue life, because for most materials the fatigue strength is inversely proportional to grain size.

## MECHANICAL PROPERTIES OF IMPLANT MATERIALS

The yield stress is the transition point between elastic deformation and plastic or permanent deformation. Deformation at strains lower than this level obey Hook's law, which states that the elastic modulus (Young's modulus) is the proportionality constant in the linear portion of the stress-strain curve below the yield point. Fatigue strength refers to the ability of a material to resist repetitive loading. Typical yield and fatigue strengths and elastic moduli are presented in Table 11.2.

| Material | Yield (MPa) | Fatigue (MPa) | Modulus (GPa) |
|---|---|---|---|
| CoCr (cast) | 518 | 255 | 221 |
| CoCr (forged) | 898 | 759 | 221 |
| Ti-6Al-4V | 863 | 552 | 110 |
| Stainless steel 316L | 241 | 180 | 193 |

***Table 11.2. Typical Yield and Fatigue Strengths of Metal Alloys Used in Orthopaedic Surgery***

The elastic modulus is an intrinsic property of a material generated by the attraction of atoms within the material, and it has essentially no variation with thermal or mechanical history. Fatigue strength, however, can be significantly improved or diminished by heat treatment. Cast cobalt-chromium alloy has a fatigue strength of about 255 megapascals (MPa), which is only about twice that of the cast stainless steel used in total hip prostheses in the early 1970s that failed in fatigue. Titanium alloy, although quite strong in fatigue strength in the “as received” or forged condition, can undergo significant deterioration of its fatigue properties as a result of applying a porous coating. Failure is caused by the creation of stress concentration sites by the porous coating, and the grain growth caused by the heat treatment used to apply the porous coating. Much of the deterioration in properties of titanium alloy can be alleviated by the use of a diffusion bonding process that lowers the temperature of sintering. The notch sensitivity problem is managed by design modifications that remove the porous material from areas subjected to tensile loading. These concerns regarding the effect of porous coating do not apply to implants for internal fixation.

Surface hardness is tested by indentation tests, such as the Rockwell test or the Vickers test, in which the material is indented by a very hard object. The resistance to this plastic deformation indicates the tensile strength of the material and its wear properties. These tests are suitable for metallic alloys.

**STAINLESS STEEL VERSUS TITANIUM FOR BONE FIXATION IMPLANTS**

For decades, stainless steel has been the most widely used material for bone fixation implants. The 3.16L alloy is still used most commonly; however, other stainless steel alloys are also in use and provide useful characteristics such as increased strength in hip fixation implants, which can be subjected to high bending loads and fatigue stress because of delayed healing (Table 11.1). A major concern about stainless steel implants has been their stiffness, which is approximately seven times that of human bone. Uhthoff and Dubus (103) and others (16,27,63) have demonstrated in animal experiments that when rigid internal fixation is applied with stainless steel implants, prolonged exposure of the bone can lead to porosis and weakening of the bone due to stress protection. This is also seen in total joint arthroplasty, particularly about the proximal portions of the stem in the femoral components of total hip arthroplasty. Perren et al. (81,82) have shown that the porosity and weakening observed is in part due to the revascularization response resulting from the surgical procedure itself; in spite of this, however, stress protection remains a significant problem, particularly where the size and stiffness of the implant is significant compared to that of the bone. Chapman et al. (27), in a review of 174 forearm fractures, found no refractures of the radius or ulna after removal of AO 3.5 mm dynamic compression (DC) plates, whereas in all three patients in whom the larger narrow DC plates and 4.5 mm screws were used, refractures occurred either through the screw holes or the fracture site.

Therefore, orthopaedic surgeons have sought a material for plates and nails that is closer to bone in its mechanical characteristics, yet would be stiff enough to permit fracture healing and strong enough to avoid fatigue failure prior to fracture union. Titanium and its alloys, widely used in military aircraft and submarines, have proven, in part, to meet this need. Most manufacturers have used a titanium alloy containing 6% aluminum and 4% vanadium (6-4 titanium). The mechanical characteristics of commercially pure (CP) titanium were not suitable for internal fixation implants until recently; however, the AO group has used plates and screws of CP titanium, which have proven to be clinically useful. By utilizing particular forging and other techniques, they have been able to render the CP titanium sufficiently strong. Other alloys of titanium, particularly beta alloys, offer even better mechanical properties for internal fixation implants than the 6-4 titanium, and some of these are listed in Table 11.1. Overall, titanium alloys are approximately twice as flexible as stainless steel and at least one-third stronger. A primary disadvantage of titanium is that it is difficult to manufacture, which increases costs. Also, it is more brittle than stainless steel: Cracks occurring from notches in the metal tend to propagate much more easily than in stainless steel, which influences implant design and how the surgeon uses the implants. Titanium alloys become particularly useful in smaller implants, such as nonreamed intramedullary nails, and in smaller plates, which employ smaller-diameter screws, where the superior strength of the titanium results in much less screw and nail breakage compared with stainless steel. In spite of the increased cost, most major implant manufacturers today offer bone fixation implants composed of titanium. Some entire implant systems, both plates and intermedullary nails, are offered in titanium.

In addition, titanium is more resistant to corrosion than stainless steel, which has a tendency to experience crevice corrosion at the contact point between screw heads and plates. Plate failure can take place through these corrosion pits. Titanium aggressively forms an oxide, which provides superior passivation of the implants. I have removed numerous titanium plates and screws and have never seen any visible evidence of crevice corrosion.

All metallic implants release a small quantity of metallic ions into the local soft tissues and general circulation. Although concerns have been raised about the potential toxic or carcinogenic effects of these minute amounts of ions, and sarcomas have been described in association with implants, no evidence has been presented that implants are a significant health risk to patients. On the other hand, current implant materials have been used for approximately 60 years. Whether exposure to these implants for up to 80 or 90 years in our long-lived population will produce diseases is not yet known. When placing these implants in children and young adults, a discussion with patients and their parents regarding this issue is appropriate. If concerns are expressed after implantation, and removal of the implant will not incur unacceptable risks, then removal is usually advised.

## IMPLANT POLYMERS

Four polymers find application in orthopaedic surgery on a routine basis. These are ultrahigh-molecular-weight polyethylene (UHMWPE), polypropylene, polytetrafluoroethylene (PTFE, Teflon), and polymethylmethacrylate. Other polymers show promise as matrix materials for composite biomaterials, including polysulfone (UDEL), polyethersulfone, and polyetheretherketone (PEEK). Their chemical structures are shown in Fig. 11.1.

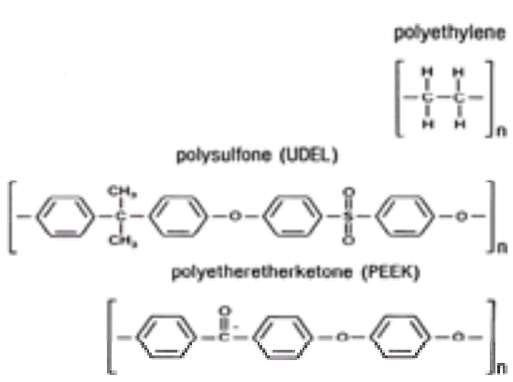


***Figure 11.1.*** Chemical structures of implant polymers.

Polymers are manufactured under heat and pressure to produce addition or condensation reactions. Condensation reactions produce polymers by a combination of an organic acid and an organic base to produce water or an alternative third compound (Fig. 11.2). Reactive moieties on both ends of each type of molecule permit the reaction to grow long chains. Additional polymerization produces the polymer chains by adding one more link to a chain that was begun by an initiator molecule reacting with a carbon double bond, such as found in ethylene. Most implant polymers are thermoplastic, because they can be melted and cooled until solid again with no composition change.

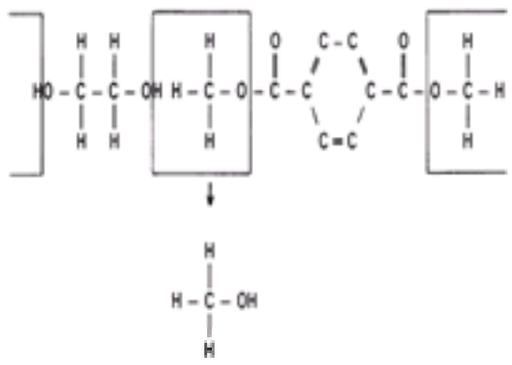

***Figure 11.2.*** A condensation reaction showing the method used to produce polyester (Dacron).

Although injection molding of polymers from the melt is possible, molding of granules of a polymer under heat and pressure, called compression molding, is more common for production of polyethylene components. Machining of implants from stock is another technique that can be used. Both methods produce acceptable articular surfaces for implants.

The uses for polymeric materials are more diverse than for metallic implants, but their interchangeability is not as great. Polypropylene is used as a ligament augmentation device for knee reconstructive surgery, UHMWPE is used as the bearing surface in total joint arthroplasty, and Teflon is expanded to form a Gore-tex material used in knee reconstructive surgery. Polymethylmethacrylate is partially polymerized, provided as granules, and combined with monomer and an initiator to form a final polymerized mass (e.g., Zimmer bone cement). When copolymerized with polystyrene, polymethylmethacrylate is used in a similar manner to form Simplex-P (Howmedica, Rutherford, NJ).

Polylactic and polyglycolic acids, polyglactin (copolymers of the two acids), and polydioxanone find their main uses as resorbable suture materials under the brand names Dexon (Davis and Geck; US Surgical, Norwalk, CT), Vicryl, and PDS (both manufactured by Ethicon, Johnson and Johnson, Somerville, NJ). These materials are also available as resorbable pins, primarily for fracture fixation in the hand, foot, ankle, and skull (3). These materials can be made relatively stiff and are slow to resorb. Polylactic acid is now available as screws and pins because its slow rate of resorption may reduce the level of inflammatory response. Attempts at improving the stiffness of polylactic acid have included mixture with hydroxyapatite fibers.

## CERAMICS

A ceramic is a nonmetallic, nonorganic material, usually produced by high-temperature processing. Typically, ceramics have high thermal and electrical resistance and high elastic modulus, low ductility, and low tensile strength. Excellent biocompatibility results from chemical inertness.

Carbon (Pyrolite) is produced by deposition of carbon from a gas-phase breakdown of gases such as methane ($CH_4$) or methyltrichlorosilane ($CH_3SiCl_3$) to produce carbon-silicon compounds with various proportions of silicon, typically 10% to 20%.

Ceramic materials are characterized by very high strengths, but brittle failure occurs after minor plastic deformation. Although the failure strength is quite high in many cases, relatively low failure stresses can occur occasionally.

Attempts have been made to form plates from ceramics, but they have not proven practical because of the inability to conform them to the bone, and because of their high failure rate caused by their brittle nature. Because of the unique characteristics of ceramics, they enjoy much more practical application in the bearing surfaces of total joint replacement prostheses and in the coatings of prosthetic implants where direct bone–implant ingrowth is desired.

## COMPOSITE MATERIALS

A composite is a combination of two or more materials in which the mechanical performance of the composite is superior to that of either component alone. In man-made composites, usually one component is a fiber and the other is a matrix material. Bone itself achieves most of its mechanical properties as a natural composite material composed of calcium phosphate ceramics in a highly organized collagen matrix.

The first composite to come into general use, initially made by an orthopaedic surgeon, was the plaster of Paris bandage. This has been refined to fiberglass with a polymeric matrix in the current synthetic casting materials. A composite for internal prosthetic applications is based on the addition of chopped carbon fiber to improve the mechanical properties of polyethylene components.

Materials used in composites intended for implantation must be biocompatible. Three potential matrix materials that have undergone at least preliminary biocompatibility studies are thermoplastic and have similar structures (Fig. 11.1). These are UDEL, polyethersulfone, and PEEK, discussed above. The fiber materials strengthen and stiffen the matrix and can be used as chopped fibers or as long fibers. The chopped fiber material usually produces a composite that is isotropic, having stiffness and strength properties that do not vary with direction. The long fibers can be woven, wound, or formed in many geometric orientations to provide desirable mechanical properties. Only carbon fiber is being studied for orthopaedic applications.

Composite structures are typically produced from laminates. A laminate is a thin sheet of composite material in which all the fibers run in one direction and are held together by a thin coating of the polymer matrix material. It is produced by passing the fibers through the polymer, allowing it to be coated, and subsequently sticking the layers together and pressing them. This laminate is combined with other laminates to form a bulk composite; the properties of this composite vary depending on the orientation of each layer of the laminate. The primary direction of the fibers is called the zero direction, and other layers, or laminae, are oriented in relation to this (e.g., 0°, 45°, -45°, 90°, +30°, and -30°) to vary the properties of the polymer. A polymer that has equal numbers of layers in the 0°, 45°, -45°, and 90° orientations is called a pseudoisotropic polymer because the mechanical properties in any direction in the fiber plane are the same. An alternative means of producing a composite structure is to wind one or more continuous fibers in a particular orientation to form the desired prosthetic shape.

The mechanical properties of primary concern are the strength and the modulus. The strength generally mirrors the modulus, and both of these depend on the orientation of fibers. The elastic modulus can be estimated for laminated structures from the two “rules of mixtures.” The modulus parallel to the fibers ($E_{parallel}$) is proportional to the amount of fiber in a simple linear relationship:

$$E_{parallel} = E_f V_f + E_m V_m$$

in which $E_f$ and $E_m$ are the moduli of the fiber and matrix, respectively, and $V_f$ and $V_m$ are the volume fractions of the fiber and matrix, respectively. In the range of typical polymer fiber used in a laminate of 0.4–0.7 volume fraction fiber, the elastic modulus varies linearly in that range parallel to the fibers. The modulus relationship perpendicular to the fibers is more complicated and less applicable to all composites:

$$E_{perpendicular} = \frac{E_f E_m}{(E_f V_m + E_m V_f)}.$$

Because carbon fiber polymeric materials are strong and radiolucent, roentgenographic examination of fractures fixed with external fixation devices made of these materials can be performed with relative ease. Similarly, halo rings made of these materials are compatible with magnetic resonance imaging, allowing studies of the brain and cervical cord to be performed.

Plates and intermedullary nails manufactured from carbon composites have been used experimentally for internal fixation. Their potential advantages include radiolucency (making observation of fracture healing easier), the ability to vary the modulus of the material, and the potential for using an absorbable polymer. None of these materials are currently in clinical use because of the inability to modify the shapes of the implants intraoperatively to fit the bone; because of liberation of carbon fibers into the adjacent tissues; and because the difficulties of predicting the resorption of polymers in larger load-bearing implants, as opposed to screws and pins, has

thus far precluded their use for these larger implants. No doubt, implants in this category will be available in the future, perhaps even containing bone inductive proteins.

## B. PRINCIPLES OF WIRE, CABLE, AND PIN FIXATION

In France in the late 18th century, brass and iron wires were used for fracture fixation. Later, silver wire was introduced by Lister to treat a patellar fracture. Parham and Martin (77) described steel bands used around the shaft of fractured long bones in 1913, and in 1922 Johnson developed stainless steel, which is the material still used for most types of wire and pin fixation. This form of fixation includes fine Kirschner wires, larger Steinmann pins, and flexible wire used for provisional and definitive fracture stabilization, osteotomy fixation, and skeletal traction.

### KIRSCHNER WIRES

#### MATERIAL FEATURES

Martin Kirschner (1879–1942), a surgeon from Heidelberg, Germany, was the first to use thin wire pins for fracture management, in 1909. Kirschner, or K- wires are manufactured in lengths from 7 to 31 cm and in diameters from 0.6 to 3.0 mm. They may be smooth or threaded, but threaded wires have poorer bending strengths for a given pin diameter and may be difficult to remove at a later date. The wire may be pointed at one or both ends. In the latter case, the pin can be inserted antegrade from the fracture site to exit from the distal fragment and then retrograde back into the proximal fragment. K-wires may be trocar or diamond pointed (Fig. 11.3). The trocar point is somewhat easier to insert into dense cortical bone and there is less of a tendency to overheat.

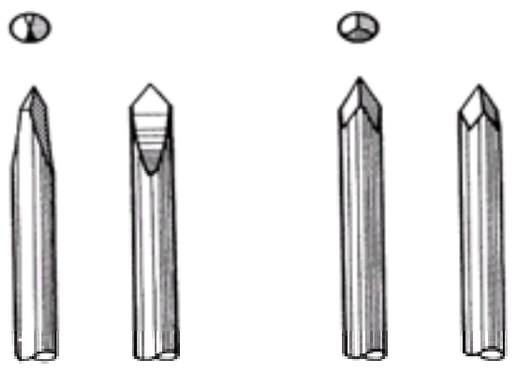

***Figure 11.3.*** Ends of Kirschner wires or Steinmann pins with trocar points on *right* and diamond points on *left*.

Because of their flexibility, K-wires are normally introduced with a power drill and a pin stabilization system, which may be a telescopic guide attached to the end of the drill chuck, or an external guide with a handle. The drill itself may have the capability of rapid locking and release of the wire; advancement therefore can be made from the barrel of the drill, which acts as the guide. Small-diameter pins can be inserted through large bore needles. An alternative is to introduce a gentle bow into the wire while drilling. This prevents oscillation of the wire. Two disadvantages of this technique are that the direction of the wire may be more difficult to control and the wire will overheat more rapidly. When K-wires are used, wire cutters and instruments for wire bending are required. The wire benders may be simple metal tubes into which part of the wire is inserted before being manipulated, or special pliers can be used (Fig. 11.4).

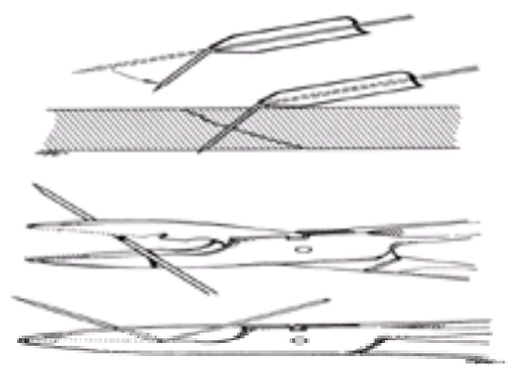

***Figure 11.4.*** Instruments for wire bending. **A:** A metal tube with a flanged end. **B:** Special pliers.

#### INDICATIONS FOR USE

***Traction***

K-wires, even those with 3 mm diameters, are quite flexible, but the wire may be stiffened by applying tension with a traction bow. The construct is thus made strong enough to apply a load of approximately 20 kg, providing the bone is able to sustain this weight (Fig. 11.5).

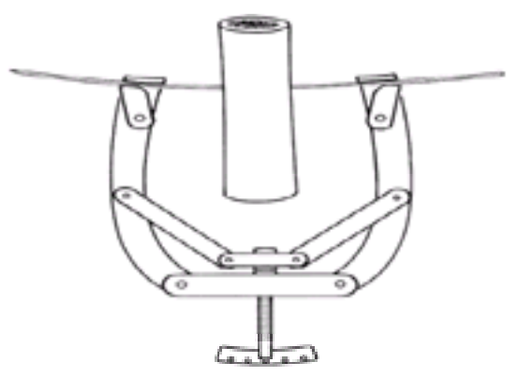

***Figure 11.5.*** Kirschner wire tensioner and traction bow.

K-wires are frequently used for the application of skeletal traction, particularly in children, in whom smaller traction loads are required and the cosmetic advantages of a smaller skin entry point pertain. K-wires can be used in any of the common sites for skeletal traction in the treatment of extremity fractures such as the upper end of the tibia, the lower end of the femur, the olecranon, and the digits. In children, passage of traction pins across the upper tibia risks damage to the physis, resulting in its partial closure and a subsequent growth deformity. If the proximal tibia must be used, the wire must be inserted posterior and distal to the physeal line.

For a given load on the traction system, the force per unit area directed against the bone by the K-wire is greater than that exerted by a larger-diameter pin. Osteopenic

bone is therefore a relative contraindication to use of a K-wire for traction. See Chapter 10 for additional details.

***Provisional Fixation***

An important principle of internal fixation of fractures, especially in the presence of comminution, in which the definitive fixation of two fragments may impede the subsequent reduction of the rest of the fracture, is that the fracture be initially provisionally fixed. K-wires are particularly useful, and many of them may be used in combination, with little damage to the bone or its vascularity. They may be used alone or in combination with bone-holding forceps or cerclage wires. A complicated fracture can be fully and accurately reduced and temporarily fixed with K-wires. Radiographs may then be taken on the operating room table to demonstrate the anticipated result or to demonstrate any defects in the reduction and facilitate their correction (Fig. 11.6).

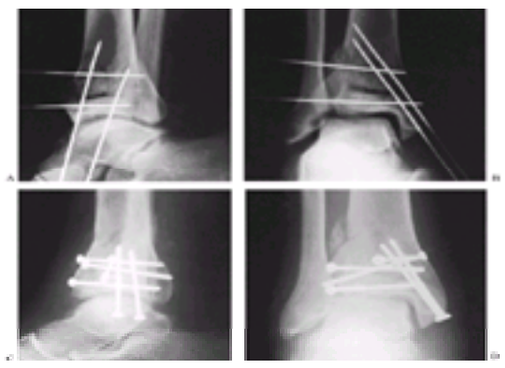

***Figure 11.6.*** Tibial plafond fracture. **A:** Lateral radiograph shows provisional Kirschner wire fixation. **B:** AP radiograph shows provisional Kirschner wire fixation. **C:** Lateral radiograph after definitive screw fixation. **D:** AP radiograph shows definitive screw fixation.

Careful planning is required during insertion of provisional K-wire fixation to prevent the wires from interfering with the later exchange to the definitive fixation with, for example, plates and screws. Where K-wires are to be replaced by lag screws, introduce the wires in the same direction that will be used later for the screw fixation. Nonparallel K-wires will interfere with production of satisfactory compression by lag screws across the fracture site (Fig. 11.6). If crossed wires must be placed, remove them after the screw is in place and before final compression. A simple trick to facilitate plate application in the presence of multiple K-wires is, first, to place the plate on the bone and mark the location of the holes on the bone with a marking pen. Then, insert all the K-wires through the location of the holes.

***Definitive Fixation***

K-wire fixation can be employed successfully where the subsequent loading on a fractured bone is anticipated to be small because the fracture is close to a joint or if the overall length of the bone is not great. Thus, intra- and extraarticular fractures of the phalanges, metacarpals, and metatarsals, and other bones of the carpus, tarsus, and distal radius, may be stabilized with crossed Kirschner wires.

- Insert the first K-wire at right angles to the fracture plane.
- Compress the fracture fragments and place a second K-wire obliquely to lock and maintain the compression (Fig. 11.7). In the fixation of transverse phalangeal fractures, it has been found that four crossed wires provide the strongest fixation; and in oblique phalangeal fractures, three wires at right angles to the fracture provide the best stabilization (106). Stabilization with K-wires in these cases must almost always be supplemented and protected by plaster-cast fixation, but early motion is important.

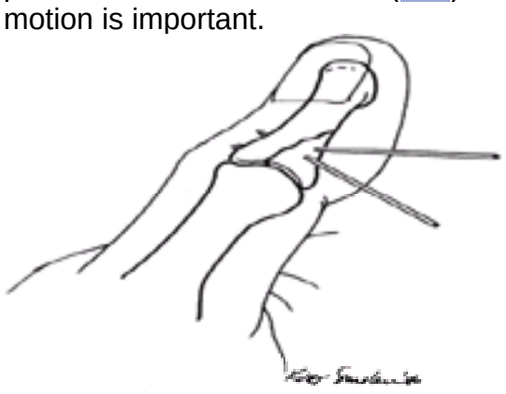

***Figure 11.7.*** Kirschner wire fixation of an intraarticular phalangeal fracture. One wire is inserted at right angles to the fracture line, and the second wire locks the reduction by its oblique insertion.

Another common use for K-wire fixation is in supracondylar fractures of the humerus in children: After closed or open reduction, two K-wires inserted from the lateral side can maintain good reduction when combined with external cast immobilization (see Chapter 164).

If K-wires are used for definitive fixation and the proximal end of the wire is left straight, there is a significant likelihood of migration of the wire into or from the bone. Therefore, the exposed end of the wire should always be bent with an appropriate instrument if it will be left buried. If only a very small segment of the wire is left exposed above the surface of the bone, it may be very difficult to find later when metal removal is required. Another alternative is to leave the end of the wire longer and just under the skin to facilitate removal. Pressure on the skin from within (and possibly from without due to dressings or plaster casts) may produce skin necrosis and infection around the wire tip. It is therefore recommended that either the wires be left buried with a bent end to facilitate removal, or the tip of the wire be left protruding by a centimeter or so from the skin. Prevent tension on the skin around the wire and protect it from unwanted blows. Either cap the wire with a commercially available wire cap or bend the end of the wire over. The former is preferable as it prevents catching the end of the wire on clothing. Reaction of the skin around the thin wire is minimal and infection unusual as long as it is stable in the bone. Subsequent removal of the pin is almost always easy and relatively pain free. In situations where K-wires are used in a tension band construct and functional postoperative therapy will be instituted, bend the ends of the wires into a U shape and impact them into the bone.

The special use of tensioned wires used in ring fixation and distraction techniques is described in Chapter 32.

## STEINMANN PINS

### MATERIAL FEATURES

In 1911, Fritz Steinmann (1870–1933), a surgeon in Bern, Switzerland, introduced pins that were thicker than those of Kirschner but otherwise very similar.

Steinmann pins are made in diameters of 3 to 6 mm and in lengths of 150 to 300 mm. The pointed end is usually of the trocar or diamond-pointed design (Fig. 11.3), but cove points are also available (Fig. 11.8). The cove point has a positive rake angle, which cuts bone rather than scraping it as occurs with the trocar and diamond tips. Flutes facilitate removal of chips from the hole made in the bone. Heat generation when using the cove point is probably less than with the trocar or diamond-tip Steinmann pin. In general, however, predrilling with the appropriate drill bit is recommended before pin placement into cortical bone. Predrilling is usually not necessary in cancellous bone.

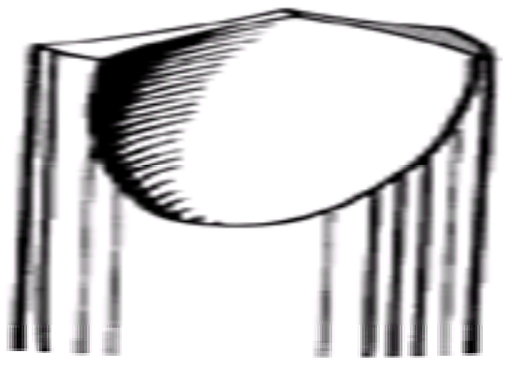

***Figure 11.8.*** The cove point of a Steinmann pin.

Steinmann pins can be smooth or threaded. The threading of the pin facilitates fixation within the bone so that infection, which is facilitated by metal–bone motion, is prevented. Steinmann pins that are threaded only in the central region are easier to introduce and are as effective as fully threaded pins (Fig. 11.9). The thread diameter is 0.5 mm larger than the pin, so that the threaded segment is no weaker than the remainder of the pin.

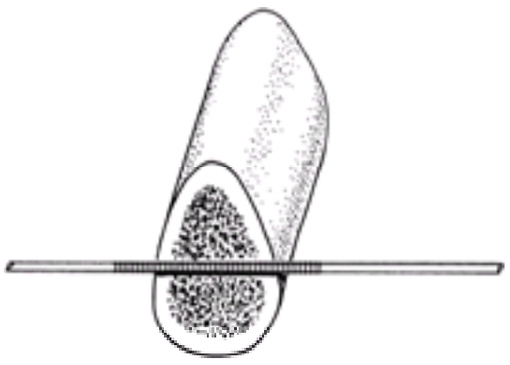

***Figure 11.9.*** Centrally threaded Steinmann pin with the threads spanning the cortices of the bone.

#### INDICATIONS FOR USE

Steinmann pins are used mainly for traction through the femur, the tibia (proximal or distal end), or the os calcis. Traction is best applied with the use of a Böhler stirrup or bow, which fits over the ends of the pin. The design of the clamps holding the pin is such that movement of the stirrup does not rotate the Steinmann pin and cause it to loosen, because the bearings on the stirrup clamps allow free rotary movement on the pin (Fig. 11.10). See Chapter 10 for technical details.

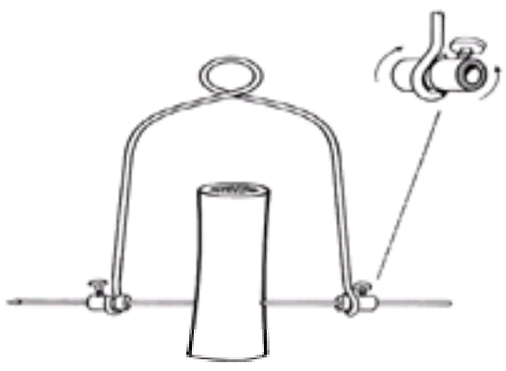

***Figure 11.10.*** Böhler traction stirrup showing its fixation to the Steinmann pin while allowing rotary movements of the stirrup around the pin.

#### PINS INCORPORATED IN CASTS

The incorporation of one or two transverse Steinmann pins into each end of a long bone fracture and then, after reduction, incorporation of the pins into a cast (i.e., “pins-and-plaster” technique) was used for many years. The stability of this construct is not very satisfactory, however. There is always a tendency for the plaster cast to loosen and, by its weight transmitted to the pins, provoke pin loosening and pin tract reactions (see Chapter 10). The use of pins-and-plaster techniques has largely been replaced by the more efficient and advantageous external skeletal fixators, which are discussed later in this chapter and in the various sections on fractures.

#### TECHNIQUE OF PIN INTRODUCTION

Steinmann pins can be introduced with a Jacob's chuck and T-handle or hand drill into soft bone, but this technique tends to lead to inaccurate pin placement. Particularly in hard cortical bone, such as the upper end of the tibia in young people, free-hand introduction of a Steinmann pin is very difficult and inaccurate; in this situation, always predrill the pin tract with a drill bit having a cutting tip that does not generate heat. The use of a power drill to insert the Steinmann pin directly into dense bone may generate sufficient heat to cause bone necrosis; infection frequently ensues with loss of fixation and development of a ring sequestrum and osteomyelitis.

Similar considerations for the introduction of Schanz pins, which are partially threaded at their pointed tips and are used in the external fixation of bones, are discussed later in this chapter.

- Make an initial skin stab incision with its long axis in the line of subsequent traction pull.
- Use a soft-tissue guide over the appropriate drill bit and drill a pin tract at right angles to the subsequent traction pull.
- Then introduce the Steinmann pin by hand into the bone with a Jacobs chuck and T-handle, making the skin incision at the exit site of the pin tip. Little heat is generated with a sharp drill, so bone necrosis does not occur; infection, loosening, and sequestrum formation are much less likely, and greater accuracy of pin placement is achieved.
- Apply a Böhler traction bow or stirrup to the pin and apply traction.
- Release any skin compression developed on applying the traction by incising the skin next to the pin; this is necessary to prevent skin necrosis and subsequent infection. Keeping a snug fit of the skin on the pin in the absence of tension on the skin minimizes motion of the skin on the pin and helps to prevent infection, so close any excessive incision. Keep the pin sites dressed in a sterile fashion and cap the pointed tip of the Steinmann pin to prevent injuries.

### TENSION BAND WIRES

#### PRINCIPLES OF USE

In regions such as the olecranon and patella, an understanding of active and passive muscle forces allows the use of a minimal amount of fixation material to obtain

excellent fracture stability and immediate functional movements of the contiguous joints. The principle of the tension band wire is that tensile fracture distracting forces, which the wire can easily absorb, are converted into stabilizing compression forces passing through the bone. It is essential that the cortex distant from the tension band side be strong enough to bear the applied compressive load. Loss of bone stock or poor bone quality will allow development of bending stresses, leading to wire fatigue and failure of the fixation. Tightening of the tension band wire produces static compression, particularly through the cortex under the wire. On active joint flexion, dynamic compression results across the whole of the fracture surface.

The wire used for this technique should have considerable ductility, combined with a high yield point and ultimate tensile strength. The wire is usually available in diameters from 0.4 to 1.5 mm made from type 316 stainless steel or Vitallium. The modulus of elasticity of Vitallium is higher than that of steel and for the same strain should support higher loads than stainless steel of equal diameter. Wire is weakened by cold working (e.g., kinking, bending, twisting), so care must be taken to avoid damage during implantation.

**TECHNIQUE OF APPLICATION**

The tension band method can occasionally be used with wire alone, as in a transverse fracture of the patella in which an irregular fracture line allows perfect reduction by interdigitation of the fracture surfaces (Fig. 11.11). In most situations, however, axial rotational stability cannot be obtained without the addition of two parallel, longitudinally placed K-wires (Fig. 11.12). In comminuted fractures, the K-wires also assist in providing some interfragmentary stability, which is completed by the tension band wire. The K-wires must be inserted in a parallel fashion. Crossed wires provide much less rotational stability and interfere with interfragmental compression. The K-wires also provide anchorage points around which the tension band wire can be placed.

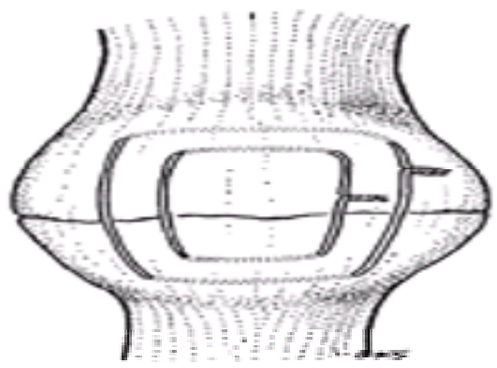

***Figure 11.11.*** Transverse patellar fracture stabilized by two tension band wires.

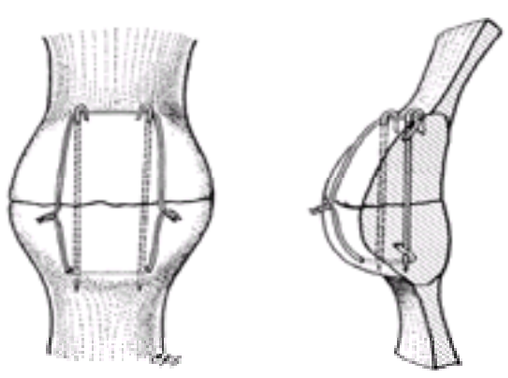

***Figure 11.12.*** Transverse patellar fracture stabilized with two parallel, longitudinally placed K-wires and tension band wire.

Tension band wiring of a fractured olecranon is described to illustrate the principles of the technique (Fig. 11.13).

***Figure 11.13.*** Transverse olecranon fracture stabilized with two parallel, longitudinally placed K-wires and a figure-eight tension band wire.

- After exposure of the fracture, place a 2 mm drill hole 2–3 cm distal to the fracture in a transverse fashion, passing just ventral to the dorsal cortex (Fig. 11.13). Then pass a 1.0 mm (18-gauge) or a 1.2 mm (16-gauge) diameter wire through the hole and displace the wire distally out of the proximal fracture field.
- To control fragment rotation, insert two 1.6 mm diameter K-wires parallel from the tip of the olecranon into the distal fragment (Fig. 11.13). This can be achieved using a 2 mm triple guide, or the wires can be inserted retrograde from the fracture site to exit the tip of the olecranon.
- After fracture reduction, advance the 2 K-wires 3 or 4 cm into the distal fragment. Alternatively, the wires can be inserted in an antegrade manner from the tip of the olecranon before fracture reduction, allowing their accurate placement within the medullary canal to be confirmed before reduction and driving of the wires across the fracture site. With more experience, after anatomic reduction of the fracture, the K-wires can be inserted from the tip of the olecranon across the fracture site and into the distal fragment. More secure fixation is obtained by drilling the wires through the anterior cortex rather than placing them in the medullary canal.
- Place the ductile wire around the protruding proximal tips of the K-wires in a figure-eight fashion. Be certain that they are against bone. Throw a simple loop in the midpoint of one limb of the figure eight, and complete the opposite limb by twisting the two ends of the wire (Fig. 11.13). Twisting the loop and two ends of the wire alternately allows well-controlled and equal tension in the whole figure-eight wire. Achieve wire tightening with bullet-nosed pliers, being careful that the wire ends are arranged in a helical fashion one around the other and that the pliers do not score the tensed wire. Shorten the twisted wire ends and the twisted loop to about three helical twists, and bend the wire ends away from the subcutaneous region to lie alongside the bone. Bend the proximal protruding K-wires twice, shorten them appropriately, and then impact them, like a staple, into the bony tip of the olecranon (Fig. 11.13); this prevents migration of the pins. Even with some comminution of the olecranon, the tension band wire technique can still be used after reduction and fixation of the minor fracture fragments with lag screws; thus, excision of the olecranon can usually be avoided.
- Commence immediate postoperative active flexion exercises for the elbow; extension exercises should proceed with more care because the bone–fixation complex is less stable in extension. If the proximal ends of the K-wires are not sufficiently impacted into bone, they can back out and protrude under and even through the skin (68). Another occasional complication is for the tension band wire to cut out of the distal fragment if it has not been inserted deeply enough below the dorsal cortical surface. After fracture union, the tension band wires tend to be uncomfortable. Removal is often necessary. The tension band wiring technique can similarly be employed for transverse and comminuted patellar fractures, fractures of the femoral greater trochanter, fractures of the malleoli (particularly where small or osteoporotic fragments are involved), and fractures of the distal end of the clavicle (Fig. 11.12 and Fig. 11.14).

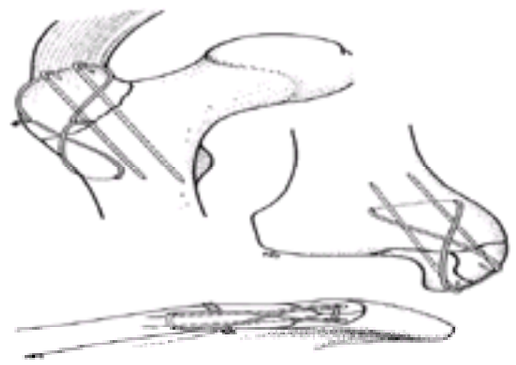

***Figure 11.14.*** Tension band wiring techniques employed to stabilize greater trochanteric, comminuted medial malleolar, and distal clavicular fractures.

## CERCLAGE WIRING

### PRINCIPLES OF USE

Cerclage wiring techniques have some utility for provisional fixation of long-bone fractures or for definitive fixation, usually in combination with other fixation devices.

The wire applicable for cerclage is of the same type as that described for use in tension band wiring. Wire diameters of 0.8 to 1.25 mm are commonly used, and the strength varies directly with the square of the diameter. Two wires may be twisted to form a double strand, which may have greater flexibility than a single wire and is less likely to slip on the bone. Some cerclage wires are manufactured with a loop in one end, so that after passage around the bone the other end can be threaded through the loop and kinked backward to quickly achieve temporary fixation (Fig. 11.15). Regular wire can be tightened around the bone by twisting the two ends one around the other in a helical fashion with the aid of bullet-nosed pliers or one of the many available wire tighteners, while maintaining adequate tension on the wire (Fig. 11.15). A minimum of two full twists is necessary for maximum strength with 1.0 or 1.2 mm diameter wire, and the pitch of the twists should be as high as possible (50).

***Figure 11.15.*** Methods of joining ends of wire. **A:** One end of the wire is passed through a loop in the other end and kinked backward for temporary fixation. **B:** Helical twisting at a high pitch at the ends of the wire for temporary or definitive fixation. **C:** Technique like (**A**) but with one end of the wire passed under itself and against the underlying bone.

Any method of securing the wire ends that is stronger than the yield strength of the wire is satisfactory. For definitive cerclage wiring, it has been suggested that tying a formal square knot between the wire ends produces a fixation least likely to disengage (50). After the first throw of the knot and subsequent tightening, however, it is very difficult to maintain wire tension during the second throw of the knot (47,86). Although it is unlikely to completely unfold, with time the knot will commonly relax and precipitate failure of fixation. Knots therefore are suitable only for wire securing soft tissues. Helical twisting of the wire ends is easily applied, maintains the initial fixation tension, and will untwist only at tension loads beyond an acceptable limit. Anchoring the twisted wire tips by folding them down into a predrilled hole has been shown to produce the least slippage compared with other methods (48). The AO loop with bending of the free end under the wire also produces a satisfactory fixation strength, but the passing of the free end of the wire between bone and the tightly opposed cerclage can be very difficult (Fig. 11.15) (50,111).

Wire of insufficient strength can fail during clinical use by yielding, elongating, or fatiguing due to repetitive loading. This is especially true if the wire has in any way been scored before or during application (29).

Permanent cerclage wire fixation has sometimes been condemned as interfering with the periosteal circulation and thus producing bone necrosis. However, it has clearly been shown that the bone cortex receives most of its vascular supply in a centrifugal fashion from the medullary cavity, and even complete loss of periosteal blood supply may not lead to cortical necrosis. The periosteal vessels also tend to pass vertically into the cortex and not run along the cortical surface. Therefore, thin cerclage wires placed circumferentially at intervals are unlikely to severely damage periosteal blood supply in mature or immature bone (46,85,112). This contrasts with previously used wide Parham bands, which did eliminate periosteal blood supply from relatively wide segments of underlying bone (77,85). Recent modifications of Parham bands, as described by Partridge, are made of nylon and have elevations on the underside of the band that prevent wide contact and constriction on the bone by the band (78). This modified form of cerclage fixation may be useful in situations in which severely osteoporotic bone prevents other forms of stable internal fixation.

The method, however, has been condemned when used to control butterfly fragments in femoral shaft fractures, in which erosion of the bands into the cortical bone has sometimes been found (54).

The use of cerclage wire placed like a purse string circumferentially around the bone in the treatment of patellar fractures is now considered obsolete. This technique is not efficient and permits fracture fragment separation and mobility (108). Tension band wiring techniques described in this chapter are much more applicable to the problem.

### TEMPORARY WIRING

During fixation of diaphyseal fractures in which a butterfly fragment is diametrically opposite the line of approach to the bone, the judicious application of a temporary cerclage wire may hold the butterfly fragment reduced so that lag screws may be inserted into it (Fig. 11.16). After stable screw fixation, remove the cerclage wire.

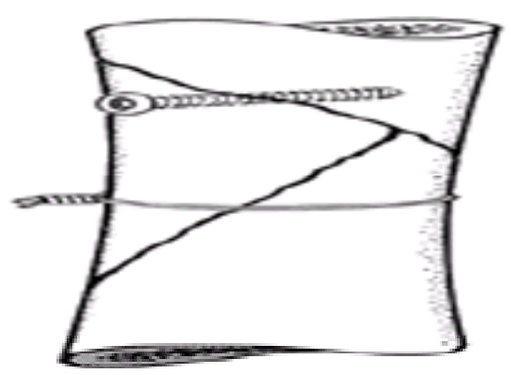

***Figure 11.16.*** Temporary cerclage wiring to facilitate lag screw fixation.

Temporary cerclage wires may also be used prophylactically around the femur to prevent splitting during press-fit insertion of an uncemented femoral prosthesis.

### DEFINITIVE WIRING

The use of cerclage wires inserted through small incisions to treat oblique or spiral diaphyseal fractures appears at first to be attractive (24,86). Even if stable fixation is initially obtained, however, the likelihood of the development of fracture angulation and loss of stability is significant because of the inevitable loading of the bone. Supplementation with some form of external casting is required, and this obviates early functional treatment of the limb. Stable closed intramedullary nailing of a diaphyseal fracture usually solves the problem more efficiently than cerclage wiring alone. However, several cerclage wires may be used in a supplementary fashion at 1 cm intervals along the shaft with intramedullary nailing (Fig. 11.17) or Ender rodding and as an adjunct to the Zickel nail in subtrochanteric fractures (53,73,118).

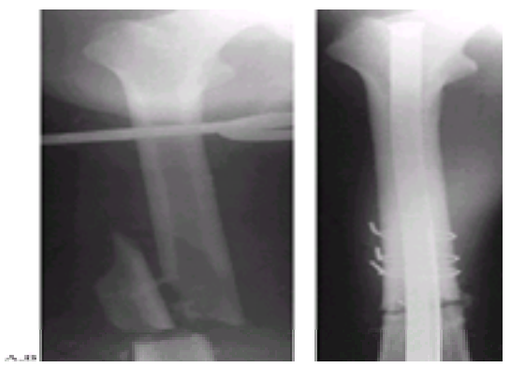

***Figure 11.17.*** **A:** AP radiograph of femoral fracture with one large, free fragment. **B:** AP radiograph of femoral fracture treated with intramedullary nailing and three cerclage wires.

- Pass the wires at 90° to the long axis of the bone so as not to slip longitudinally and loosen. All cerclage wires around the bone should be placed under the same tension to distribute the subsequent strain evenly between the wires; a wire tightener whose tension can be calibrated is necessary.
- Use a wire passer to facilitate passage of the wire around the bone and minimize soft-tissue trauma.
- Obtain anatomic reduction of the fracture before wire tightening; otherwise, wire loosening in the postoperative period is likely as settling of fracture fragments occurs. Cerclage wiring techniques may also be used in the proximal femur where a fracture has occurred during or after the insertion of a femoral prosthesis. Cerclage wiring can be very effective in this situation if care is taken to slightly notch the bone to prevent the wire from sliding distally along the taper of the femur.

### CABLES

Dall and Miles (34) have developed a cerclage system employing two different sizes of cable that can be crimped to a grappling device. Similar devices are available from most orthopaedic implant companies. The mechanical properties of the multifilament cable are superior to monofilament wire in resistance to fatigue, and the cable has a higher yielding and breaking strength. The cable is also easy to work with because it does not have a tendency to kink. The cable-grip system was originally developed to facilitate reattachment of the greater trochanter in total joint arthroplasty, but it has proven to have many applications in internal fixation (34).

## C. PRINCIPLES OF EXTERNAL FIXATION

Since their first application in 1853, the indications, popularity, and designs of external fixators have changed continuously. A variety of reliable pin fixators are now available with different clinical and mechanical properties (13). Ring fixators have become accepted tools for correcting limb-length discrepancies and malalignments, compensating for bone loss, and correcting soft-tissue contractures (72). Additional indications for ring fixators include severely comminuted peri- or intraarticular fractures, particularly in osteopenic patients. Recent efforts to make external fixators safer and more effective have made them invaluable tools in the care of injured and deformed patients. The devices are as reliable as plaster casts and internal fixation, yet more versatile, and they encompass a wider range of indications (13,14,37). External fixators are most useful when other methods of skeletal fixation seem too risky or when temporary fixation is required until tenuous soft-tissue conditions have resolved and definitive internal fixation is safer.

Although the general principles of use are very similar for pin and ring fixators, this chapter focuses on pin fixators that predominate in the treatment of acute, traumatic, and infective conditions. See Chapter 32 for a thorough discussion of ring fixators. Comminuted juxtaarticular fractures, particularly in the proximal and distal tibia and distal femur, are now frequently managed with hybrid external fixators, putting to best use the advantages of a ring fixator adjacent to the joint and a unilateral half-pin fixator on the diaphysis.

### TERMINOLOGY AND COMPONENTS

Although the many different pin fixator designs can be confusing, closer analysis shows that each device comes with a limited number of similar components. These can be assembled into four frame types with distinct clinical properties and mechanical features (9,13).

#### FIXATION PINS

Half-pins are available with threads of various lengths on one end and rounded or sharp tips. I prefer self-cutting and self-tapping pins (Fig. 11.18) as they are simple to use. Various diameters and lengths are available, from the smallest for the digits up to the largest for the femur and pelvis.

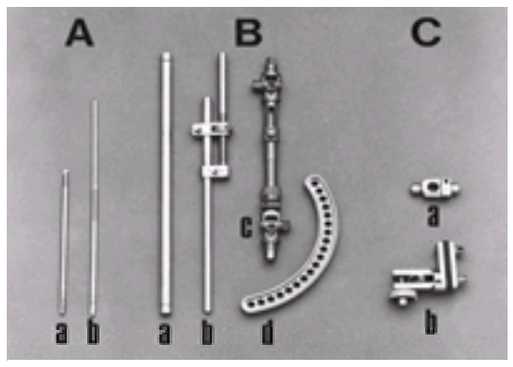


***Figure 11.18.*** **A:** Pins. *a*, Half-pins; *b*, centrally threaded transfixion pins. **B:** Connecting elements. *a*, Simple rod; *b*, rod with compression and distraction capabilities; *c*, rod with terminal universal articulations and capability for compression, distraction, and free axial sliding; *d*, circular connecting element. **C:** Articulations. *a*, Simple, adjustable clamp; *b*, universal clamp.

Full or transfixion pin designs with a threaded central portion provide good bone fixation without irritating the skin.

Connecting rods or ring elements connect the pins in the same or in different bony fragments. Complex rods have in addition a built-in capability to compress or

distract, provide axial loading across the fracture at specific loads and excursions, and provide articulations for angular adjustments.

Simple articulation components connect two isolated pins, two rods, or a pin and a rod. Modular articulations hold two or more pins in one clamp, which is connected by a universal joint to a longitudinal rod.

Instrumentation usually includes wrenches, some with quantitative torque-measuring capabilities, to tighten the articulations; hand-held devices to insert and remove pins; drill bits; drill guides; depth gauges; pin caps; removable compression devices; and pin cutters.

### FIXATOR FRAMES

The three-dimensional structure that is built with the components of a device is called a fixator frame or fixation configuration. In accordance with a frame's space requirements, we differentiate between unilateral and bilateral frames (11) and multiplanar devices. Each of the former two frame types can be applied in a one- or two-plane configuration. One-plane configurations are less cumbersome, and two-plane configurations are more effective in neutralizing bending and torsional moments (Fig. 11.19).



***Figure 11.19.*** The four basic configurations of external fixation frames. (From Behrens F, Searls K. External Fixation of the Tibia: Basic Concepts and Prospective Evaluation. *J Bone Joint Surg Br* 1985;68:246, with permission.)

One-plane unilateral or half-frames are versatile (11,14,37). In the past, however, they were afflicted by a high rate of pin tract infections, malunions, nonunions, and component failures (25,96,105). Weight bearing was often possible only after advanced consolidation of the fracture callus. Most of the mechanical disadvantages of these configurations have been resolved through the introduction of stiffer components or a combination of stiffer components and mechanical optimization of frame designs (10,37,41). Two-plane unilateral frames (e.g., Delta frame, tent frame, triangular frame) can provide increased frame stiffness even with the use of relatively weak components, but they are more cumbersome and may interfere with wound access and secondary operative procedures (9,11).

One-plane bilateral configurations (e.g., quadrilateral frame, bilateral frame) were frequently used during the 1970s, when it was felt that the transfixion pins and the bilateral longitudinal support system would render them considerably stiffer than the traditional unilateral designs (56,105). Subsequent mechanical studies showed that these frames are rather weak in resisting sagittal bending moments (12,19). The insertion of multiple closely spaced transfixion pins caused compartment syndromes, neurovascular injuries, and impairment of musculotendinous units with resulting joint stiffness (11). One-plane bilateral frames are therefore considered unsafe in most locations and have been largely abandoned. The stiffest configurations, two-frame bilateral frames, have been advocated for the management of infected and unstable fractures, in particular pylon fractures of the ankle, or to provide optimal conditions for bone healing. Although mechanically better balanced than one-plane bilateral frames, they are not commonly used today; new unilateral fixators work as well and are not afflicted with all the disadvantages and complications caused by transfixion pins and bilateral rods.

## BASIC CONCEPTS

To be safe and effective, the application of a fixator frame must avoid iatrogenic injuries (11,14,48). The frame must minimize obstruction to other operative procedures, be adaptable to a wide variety of injury patterns, and be stiff enough to maintain alignment under various loading conditions. Its use should facilitate full weight bearing yet produce a low rate of serious complications. These goals are best achieved by adhering to three basic principles (9,11,14). In decreasing order of importance, these principles demand that an applied frame minimize the risk of injury to the vital limb anatomy, provide ready access for wound debridement and secondary procedures, and meet the mechanical demands of the patient and the injury.

### LIMB ANATOMY

The shape and size of the soft-tissue corridor through which pins can be safely inserted is primarily determined by the location of the main vessels, nerves, and musculotendinous units. Of the two limb segments that make up the lower extremity, the distal segment is much better suited for the application of an external fixator, because the principal bone lies eccentrically and the pins can be inserted through a subcutaneous bony corridor (14,42).

Sequential cross sections of the lower leg (Fig. 11.20) show that in the proximal third of the tibia, pin placement is safe within an arc of 220°, which extends from the posteromedial border of the tibial plateau to the proximal tibiofibular joint (42). Excluded is a small rectangular area overlying the patellar tendon. This safe anteromedial corridor decreases to 140° just below the tibial tubercle and to 120° at the ankle joint. Therefore, half-pins are safest distal to the tibial tubercle. Full transverse pins tie down the muscles of the anterior compartment; in certain locations neurovascular structures are threatened by injury from a pin, so their use should be minimized and their insertion should be done judiciously.

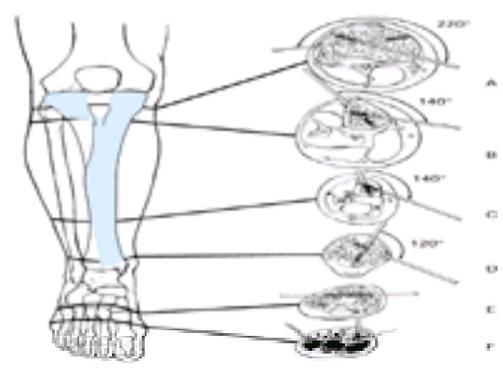

***Figure 11.20.*** The “safe corridor” for pin insertion in the lower leg. **A:** Proximal to the tibial tubercle, pins can be safely inserted within an arc of 220°. **B:** Just below the tibial tubercle, the safe arc decreases to 140°. **C:** In the distal third of the leg, the safe arc remains 140°, but the anterior tibial vessels and deep peroneal nerves become vulnerable as they cross the lateral tibial cortex. **D:** Above the ankle joint, the safe arc is 120°. **E,F:** Pins in the tarsal or metatarsal bones may be used to splint the ankle joint if neurologic or soft-tissue injuries prevent the application of an external support. (From Behrens F, Searls K. External Fixation of the Tibia: Basic Concepts and Prospective Evaluation. *J Bone Joint Surg Br* 1985;68:246, with permission.)

Two potentially dangerous pin exit areas deserve special attention. Proximally, a pin can pierce the protective posterior muscle layer and injure the posterior neurovascular structures. This is prevented if the pin exit area is limited to the medial third of the posterior tibial cortex. In the distal third, the anterior tibial vessels are vulnerable along the lateral tibial cortex, which therefore should be avoided. Whenever possible, pin placement should be limited to areas where the tibia lies subcutaneously.

In the proximal segment of the lower extremity, the femur is circumferentially covered with soft tissues. There is no ideal corridor available as all pins pierce the thigh musculature before they are seated in the bone (3). Preferred pin placement is from the lateral side, just anterior to the intermuscular septum. Half-pins are essential because they transfix only the vastus lateralis. Sometimes the pins can be inserted anterior to the lateral intermuscular septum and posterior to the vastus lateralis, but they still limit the excursion of the iliotibial band and thus restrict knee motion while the fixator is in place (3,9). Medial-pin exit sites that are between the midfemur and the distal fifth are in a danger zone, because in this region the superficial femoral vessels and the saphenous nerve are tightly held in the adductor canal and are vulnerable to pin injury. If pins in these locations are essential, place them using open technique and avoiding the neurovascular bundles. These same considerations apply to the upper extremity. Only the subcutaneous borders of the long bones are reasonably safe, but even there tendons and cutaneous nerves are still at risk of injury. In general, place upper-extremity fixation pins with open technique.

The regional anatomy in the lower leg limits the choice of safe frame types to one- or two-plane unilateral configurations. Within the safe soft-tissue corridor, the best pin location, frame geometry, and frame placement are determined by the size and severity of soft-tissue lesions, and by the comminution and stability of the bone injury. Adapt each frame to the injury at hand to permit the best possible wound access for initial care, repeated debridements, and secondary soft-tissue procedures such as the transfer of local and distant soft-tissue flaps and the placement of bone grafts. Within the safe corridor, place pins and frames away from the injured area and the principal access routes. If an injury involves mainly the medial side of the leg, apply the frame anteriorly or anterolaterally; a lateral injury may call for a medial or anteromedial frame (Fig. 11.21).

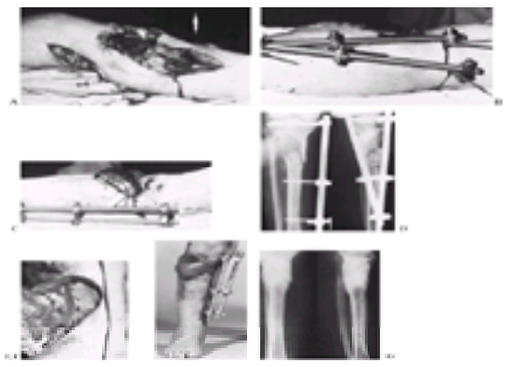

***Figure 11.21.*** A gunshot wound involving the lateral aspect of the proximal tibia with severe loss of soft tissue and bone. **A:** Initial appearance from the lateral side. **B:** Stabilization by an external fixator placed on the medial side. **C:** The soft-tissue defect covered by a lateral gastrocnemius flap; there is no interference from the fixator frame. A split-skin graft was used to cover the muscle flap. **D:** Radiographs at this stage. **E:** Elevation of the healed gastrocnemius flap to allow the skeletal defect to be bone grafted. **F:** At 5 months, the fracture has healed, and the patient has borne full weight for 4 weeks. **G:** Radiographs 1 year after the injury. (From Behrens F, Searls K. External Fixation of the Tibia: Basic Concepts and Prospective Evaluation. *J Bone Joint Surg Br* 1985;68:246, with permission.)

## MECHANICAL DEMANDS

To be mechanically effective, the stiffness of a fixator frame should control the prevailing forces and moments at the fracture site. Information based on the size and weight of the principal lower extremity segments and the distribution of the muscles surrounding the femur and tibia indicate that, in the supine position, sagittal bending moments are two to five times larger than the moments acting in the frontal plane. After a patient is weight bearing, compressive loads and torsional moments around the longitudinal axis gain in importance (11). However, there is little change in the ratio of anteroposterior-to-frontal bending moments. This suggests that regardless of other mechanical properties, a fixator frame in the lower extremity should be about two to five times stiffer in the sagittal than in the frontal plane (12). For tibial fixators, this stiffness ratio is most easily achieved if the principal pin plane is oriented in an anteroposterior (AP) direction. Although clinically appropriate, lateral femoral frames are not ideal mechanically because they are relatively inefficient in resisting fragment motion in the sagittal plane. To counteract this tendency, spread the pins in each principal bony fragment as far apart as possible. Use stiff longitudinal rods and double-stack them if necessary (3).

The size of the fixator components and the frame geometry are other factors that influence the application of a mechanically effective frame. Assuming that stainless steel components are used, the pins should have a diameter of at least 5 mm, and the longitudinal rods should have a diameter of 8 mm or more. The articulations must not slip within the range of clinically applied torques. Experimental work has shown that the following methods increase frame stiffness in one or more loading modes (10,12):

- Increasing the pin spread within each main bony fragment (14)
- Reducing the distance between the bone and the longitudinal rods (13)
- Attaching a second longitudinal rod to the same pin plane (10)
- Erecting a second half-frame at an angle to the first (i.e., creating a two-plane unilateral frame)

These mechanical measures alone or in combination can accommodate most tibial and femoral injury patterns without the need for bilateral frames. Unilateral frames suffice for most upper-extremity injuries.

## PREOPERATIVE CONSIDERATIONS

The successful and effective use of external fixation devices rests on thorough preoperative planning (14). Although much of this planning process occurs before the fixator is applied, it must anticipate the most likely time course of healing and the principal variations and potential complications that might be encountered.

In the initial assessment, note the patient's age, size, premorbid condition, socioeconomic circumstances, and the cause, severity, and extent of the injuries. Determine whether external fixation is the best method for treating the patient's injuries, what is the best device and in what configuration, whether the fixator will be used alone or in conjunction with internal fixation (Fig. 11.22), what equipment is available, and what surgical skills are needed. Determine also if the full frame should be applied immediately or completed at a later time, and whether the fixator will remain in place until the fracture is healed or will be replaced with a cast or internal fixation as soon as the soft-tissue conditions permit (14).



***Figure 11.22.*** **A:** Comminuted proximal tibial fracture in an elderly patient, showing a combination of external and internal fixation to stabilize the comminuted periarticular fracture pattern in an osteopenic patient. **B:** Radiotranslucent carbon fiber rods facilitate assessment of the fracture site and proper timing of secondary intervention, yet provide sufficient stability to allow for soft-tissue consolidation.

If there is a choice of several devices, the sturdier designs are preferred for patients who are heavy or who have an unstable fracture pattern. For the younger child, a wrist or upper extremity device may be sufficient. When rapid application is essential or proper radiographic control unavailable, fixators with full universal joints at both

ends are ideal, because they facilitate alignment and length adjustments at a later time (88,96).

When dealing with complex fracture patterns that require repeated assessment of healing, devices composed of radiolucent carbon fiber components are advantageous.

## CONFIGURATIONS

The factors that determine location and configuration of a particular fixator frame depend on the extent of the soft-tissue injury within the safe corridor, the stability and location of the fracture, the size of the patient, the presence of associated lesions, the size of the fixator components, and the designs of the fixator articulations (14).

When using simple fixators that allow for free pin spread and provide moderately stiff components, 80% to 90% of the applied frames are of a one-plane unilateral design (13). For devices that provide universal articulations but lack the mechanical advantage of maximal pin spread (e.g., Hoffmann apparatus, Orthofix), the risk of slippage at the articulations is considerable. With these fixators, take care to use undamaged functioning articulations and possibly double-stacked one- or two-plane unilateral frames (96). These configurations are preferred for fractures with segmental bone loss or extensive comminution (Fig. 11.23, *item 2, lower drawing*). One-plane frames with double rods (Fig. 11.19, *upper drawing*) have a rigidity pattern similar to that of two-plane unilateral frames, but they are less cumbersome and allow better wound access (10). Due to their greater rotational rigidity, two-plane unilateral frames may be still preferable for the management of infected nonunions and lesions that are accompanied by substantial bone loss.



***Figure 11.23.*** The recommended configuration of fixator frames for different bone and soft-tissue injuries. The location and extent of the lesion is indicated, on the *left*, by the *crosshatched area*. The preferred frame is shown, with *solid bars* representing the pins; on the *right* are the indications for the use of the configuration. (From Behrens F, Searls K. External Fixation of the Tibia: Basic Concepts and Prospective Evaluation. *J Bone Joint Surg Br* 1985;68:246, with permission.)

One-plane unilateral frames are ineffective in stabilizing comminuted proximal and distal periarticular fractures, which often provide only short metaphyseal or epiphyseal fragments for pin insertion. With simple frame modifications (Fig. 11.21*B*; Fig. 11.23, *items 3 and 4*), however, these fractures are easily managed. Proximally, where the safe corridor opens wide, subchondral pin placement affords anchorage for two or more half or full pins (Fig. 11.21*B*, Fig. 11.21*C* and Fig. 11.24*D*). Over two or more longitudinal rods, these pins are then rigidly connected to several distal pins, which in the tibia are placed close to the sagittal plane. After the application of these frames, the knee is moved through a full range of motion to ensure free mobility of joint capsule, pes anserinus, and iliotibial band. Distal tibial fragments as short as 2 or 3 cm long can be stabilized by inserting two or more pins on either side of a longitudinal rod (Fig. 11.23, *item 4)*. For the immobilization of distal intraarticular fractures, a talar or calcaneal pin is connected with two rods to two or more anterior half-pins in the proximal tibia (Fig. 11.23, *item 5*). Hybrid frames work well and to some extent have replaced these frames. These are presented in more detail in Chapter 23 and Chapter 25.

***Figure 11.24.*** A grade 3 open tibial fracture with bone loss in a patient with other open fractures. **A:** Clinical appearance on admission. **B:** Radiographic appearance on admission. **C,D:** Stabilization of the fracture with two-plane bilateral pin configuration proximally and three anterior pins distally. Bone graft had been delayed for 3 months because of adult respiratory distress syndrome. **E:** At 8 months, after the patient had started full weight bearing, the frame was gradually reduced. As a last step before removal, the proximal pin was loosened. **F:** Radiographs 1 year after injury.

## COMBINED INTERNAL AND EXTERNAL FIXATION

Additional internal fixation is occasionally employed in the management of type II or IIIA open tibial fractures with two or three comminuted fragments. After anatomic reduction and interfragmental compression with screws, a relatively rigid external frame is applied instead of a neutralization plate. This approach has been quite successful in metaphyseal fractures, which generally heal within 2 to 3 months. In the diaphysis, however, high complication rates, mainly in the form of refractures, have been common. This is not surprising, because in cases of avascular diaphyseal fragments bony union is often delayed for more than a year. Additional detail on this issue is provided in Chapter 24.

## SURGICAL TECHNIQUES

- Drape the limb to keep the injury zone and the adjacent joints accessible in the operating field. Avoid adhesive plastic drapes where pins will be inserted, as they tend to wind up on drill points and pins and may be inadvertently transported deep into the wound. An image intensifier helps to assess proper pin location, pin depth, and fragment alignment, and it is particularly valuable in dealing with closed fractures that do not allow direct manipulation of the fracture fragments.

### PIN INSERTION

- Make a skin incision just large enough to accommodate the drill point and pin sleeves to be used. Most manufacturers provide matched protective sleeves for drilling, depth measurement, and pin placement.
- In deeper bones, incise the deep fascia (a small *x* often facilitates guide sleeve placement); separate muscle fibers with a Metzenbaum scissors or a small elevator and elevate the periosteum at the pin site. Many half-pins are now available with specially designed tips that are self-cutting and self-tapping and have flutes to deliver bone fragments. To avoid overheating, bone necrosis, and pin breakage, never insert these with power but rather with hand drills provided by the manufacturer.

The following technique applies to pins that require predrilling, which make up the majority of pins used today.

- Insert the protective sleeves down to the bone.

- Gently impact the teeth of the sleeve or trochar into the bone, if called for by the manufacturer.
- Drill the initial hole with the size called for by the manufacturer for the pin diameter to be used. Use power, cool the drill, and avoid overheating the bone.
- Usually one drill size suffices. In some cases, the near cortex must be drilled with a larger diameter to accommodate a larger smooth shank on the pin.
- Select the appropriate pin and the thread length: in some systems, a depth gauge is required, or the drill may be calibrated.
- Insert the pin until at least one full thread penetrates through the opposite cortex. Carefully monitor this with the fluoroscope, as in some systems the pin cannot be reversed without loosening.
- Many half-pin systems allow selection of a total thread length that is 5 mm less than the overall diameter of the bone at the site where the pin is inserted. This permits the wider nonthreaded shaft of the pin to fit tightly into the proximal drill hole and places a smooth shank at the level of skin. This reduces skin irritation and doubles the bending stiffness of the pin (Fig. 11.25).

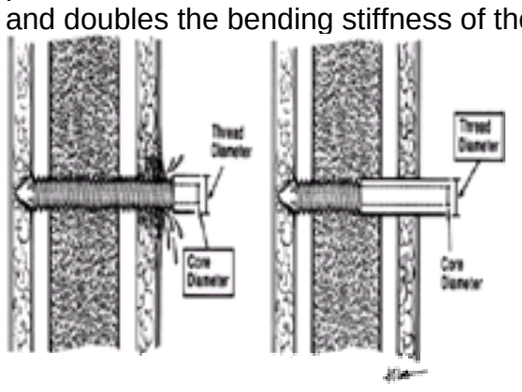


***Figure 11.25.*** Seating of half-pins. **A:** Threaded pin portion protrudes beyond the skin. This tends to cause skin irritation and pin-tract infection. Pin stiffness is determined by the core diameter. **B:** Threaded pin portion is limited to the distal cortex. The smooth shaft rarely irritates the skin. Pin stiffness is determined by the larger thread diameter. (From Behrens F. General Theory and Principles of External Fixation. *Clin Orthop* 1989;241:15, with permission.)

- Once the entire frame has been assembled and the fracture reduced, check the skin around each pin to be certain that tension on one side of the pin is not present. This is indicated by gathering of the skin. If there is tension, incise skin where it is gathered until it lies tensionless around the pin.
- Differential motion of skin on the pin can result in bacterial contamination of deeper tissues; therefore, gently close any excessive incision about the pin with a fine nylon suture that can be removed when the skin is healed.

The sequence of subsequent pin insertion depends on the type of fixator used. Many frames allow independent pin insertion, in which case be certain that the limb or the fracture is aligned and insert the next pin most distant from the initial pin. The initial pin should have been the most extreme pin at the other end of the bone. Insert the second pin using either a template guide or the preassembled fixator as a guide.

In some frames, the pins are applied in clusters in the proximal and distal fragments. With these fixators, independent arrangement of the pins anywhere along a fixator bar, such as in the unilateral frame, is not possible as the pins are inserted through a clamp or ring that holds the cluster of pins in one fragment in a more-or-less fixed arrangement relative to the others. The exceptions are Ilizarov type ring fixators, where pins can be placed anywhere along the 360° arc of the ring, and pin clamps that allow a limited range of placing the pins longitudinally on the bone. With these fixators, maintenance of overall alignment of the limb is less crucial, as universal adjustment clamps permit reduction of the fracture after the fixator has been applied; however, each fixator has a limited range of adjustment. It is possible to apply pin clusters so out of alignment with each other that reduction cannot be achieved. Therefore, it is always prudent to maintain general overall alignment of the limb, particularly rotation, as any type of fixator is applied. The following steps describe the technique for a typical fixator of this type.

- Using the manufacturer's guide or the fixator itself, insert the pins in one fragment and then the other. A wide spread of the pins within the range allowed by the clamp increases stability. Always apply the two outer pins on a given clamp first, to be certain that all pins will be anchored in bone.
- Now reduce the fracture; with the universal joints loose, obtain anatomic reduction. Tighten the universal joints or adjustments once reduction is achieved.
- If fracture-fragment alignment is not satisfactory on subsequent fluoroscopic examination or x-rays, loosen the universal joints and repeat the reduction maneuver.

### FRAME APPLICATION

The design of the clamps largely determines the sequence of steps for the application of a fixator frame (9). With simple fixators, each pin is independently connected to the longitudinal rod in several steps as follows (3).

- Insert one pin into each main fragment, generally starting with the pins close to the joints (i.e., farthest from the fracture). Maintain gross alignment of the limb (14).
- Reduce the fracture. Apply adjustable clamps to each pin and connect them by a longitudinal rod. Then manually reduce the fragments and tighten the two clamps to achieve temporary reduction. Proper rotational alignment is crucial (13).
- Insert the remaining pins (10).
- Adjust the fixator. Adjustments in the plane of pin insertion are easily achieved by loosening the pins. For angular adjustments in another plane, replace the longitudinal rod by two shorter ones that are connected over a central universal joint. For the correction of significant rotational malalignment, all pins except one in each fragment must be exchanged.

### HINTS AND TRICKS

Whenever possible, achieve an anatomic reduction. For simple transverse or interdigitating fractures, axial compression of the fracture site provides additional stability. When axial compression is attempted with unilateral frames, the fracture fragments have a tendency to angulate away from the longitudinal rods. It is advantageous to start with the fracture fragments angled toward the rod(s). With increasing compression, the fracture fragments tend to straighten into anatomic alignment.

Proper rotational alignment and length is ensured by comparing the injured to the opposite limb, if it is uninvolved; for assessment of alignment, however, obtain AP and lateral radiographs that include the joints above and below.

## POSTOPERATIVE CARE

In the early postoperative period, elevate the injured extremity, for example in balanced suspension with the calf muscles supported with a sling (Fig. 11.26). Support the ankle joint in 5° to 10° of dorsiflexion with a prefabricated splint. If the patient has sustained a severe soft-tissue injury (in particular, compartment syndrome requiring fasciotomy, or palsy or paresis of the common peroneal or posterior tibial nerves) or bony injury distal to the ankle joint, replace the ankle splint with a transtarsal pin (Fig. 11.20*E*) or two metatarsal pins that are connected to the external fixator frame (Fig. 11.20*F*).

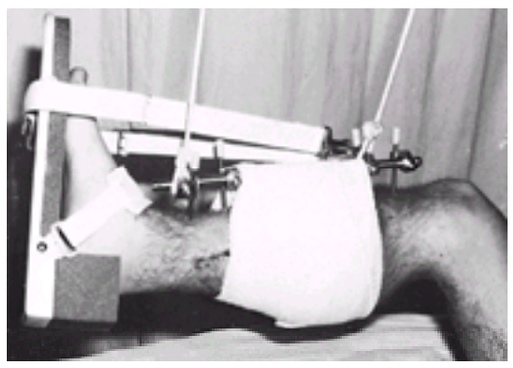

***Figure 11.26.*** The early postoperative management of an open tibial fracture. The limb is suspended, the calf is supported, and the ankle joint is splinted in 5° to 10° of dorsiflexion.

As soon as the leg wounds permit, begin twice-daily, passive, active-assisted, and active range of motion exercises of knee and ankle joints. Follow with isometric muscle strengthening exercises across both joints and mobilization with crutches or a walker. As soon as tolerated, encourage the patient to partially bear weight on the injured extremity, progressing to full weight bearing as the fracture consolidates, if the fracture type and external fixator permit. If this course is conscientiously followed, approximately 70% of all patients with tibial fractures can advance to full, unsupported weight bearing before the fixator is removed or replaced by a different method of immobilization. Weight bearing has little to do with pin tract infection or pin loosening. Patients with segmental bony defects must be limited to bearing with only the weight of the limb.

### CARE OF THE PIN SITES AND FRAME

After the initial operative procedure and any subsequent debridements, or additional soft-tissue or bony reconstructive procedures, the limb will generally be encased in a bulky postoperative dressing, which precludes access to the pin sites. Because the patient returns often to the operating room for wound debridement and subsequent reconstruction, there is no necessity for pin care by the nursing staff on the ward. In fact, exposing an open fracture wound on the ward unnecessarily invites contamination with nosocomial organisms. When the wound has stabilized and repeat operations are no longer necessary or are infrequent, it is appropriate for the nursing staff to begin pin care, particularly since the patient must be educated in this important aspect of care of the external fixator in an outpatient setting. Unless the patient is hospitalized for a prolonged period of time and is nonambulatory, pin care in the hospital differs little from what I prefer to have patients do at home. There is little in the literature to prove that one pin-care regimen is superior to another (98). I have found the following program to be effective and simple for nursing staff and patient. Using this regimen, I have had external fixator pins located in cortical bone in place as long as 1 year with no complications.

- In the hospital setting, because the soft tissues are still edematous, serum and hematoma oozes from the pin sites and dries as a crust around the pins. This can be a source of bacterial colonization and skin irritation. Once a day, the nursing staff should expose the entire external fixator and all of the pin sites, and wipe down the pins and frame.
- The dried exudate can be removed by any method that is gentle, comfortable for the patient, and effective. Cleaning with a 50% hydrogen peroxide solution, or simply washing the pin sites with sterile gauze and soapy water are equally effective. (Although many surgeons apply antibiotic or antiseptic ointment to the pin sites, I have not found these to be of any value, and this risks sensitizing the patient to the material used.)
- Dress the pin sites with a 2×2 or 4×4 gauze cut to fit snugly around the pin. (There are commercial sponges available for this purpose, but I have found these to be less effective than simple gauze bandages.) Wrap these into place to stabilize the skin and prevent vertical motion of the skin on the pin. This helps reduce bacterial contamination of the pin site caused by movement of the skin along the pin, and it makes the patient more comfortable. Once bulky dressings are no longer needed for the wound, these small gauze bandages can be held in place by plastic clips placed on wires or half-pins and slid down against the dressing to stabilize the skin. These were an innovation of Ilizarov and have proven to be very useful.

After discharge from the hospital, daily showers are simple for the patient and provide the easiest method for pin-site and frame care. As soon as the wound allows, have the patient take a daily shower, thoroughly scrubbing the external fixation frame and all of the pins and wires with ordinary soap and water (avoid strong soaps and those heavily perfumed) using a clean, fresh washcloth. Removal of tough crust is facilitated by a soft surgical brush and a child's toothbrush. After the shower, the patient should dry the apparatus and pin area with a freshly laundered towel different from the one used for the rest of the body, and dress the pin sites as described above. For the second pin-care episode each day, it is necessary only to clean the pin sites themselves using similar techniques.

Pin-site irritation or inflammation occurs at one time or another in most patients, but, if good technique is used, pin-tract infection should be uncommon (this is discussed below in the Pitfalls and Complications section).

Educate all patients about the mechanics of their frame, in particular how to keep the frame and pin clamps tight. If they are incapable of understanding, or of maintaining the frame, a relative or caregiver who will take this responsibility must be involved. Provide the patient with a wrench, or other appropriate tools, so that the components of the frame can be checked at least weekly to be certain that they remain tight.

Once the patient's condition has stabilized and it is evident that good care is being taken of the pin sites and frame, reliable patients may be able to go up to 6 weeks between follow-up visits. Less reliable patients may need to be seen by the surgeon weekly, and they may need frequent visits by a home health nurse to do pin-site and frame care.

## GETTING FRACTURES TO HEAL IN EXTERNAL FIXATION

Many closed and open fractures treated with external fixation are of such severity that they will not heal readily without additional biologic or mechanical measures.

### SOFT-TISSUE COVERAGE

Severe open fractures heal faster if they are covered with adequate soft tissue, in particular muscle, which is a source of neovascularization (116). If coverage is not possible locally, free muscle or composite flaps should be placed early, because this tends to prevent the development of local wound colonization and subsequent osteomyelitis. This is a prerequisite for the success of later bone reconstructive procedures (88,105) (see Chapter 8 on soft-tissue management and Chapter 12 on open fractures for more detail).

### BONE GRAFTS

Many adult patients with severe open tibial fractures need bone grafts to get the fracture to unite. When dealing with a Gustilo type IIIA or lower grade clean open wound that allows local closure after appropriate debridement, I may place an autogenous cancellous bone graft at the time of soft-tissue closure. After massive wound contamination, infection, or delayed closure with a flap, as in type IIIB or IIIC open fractures, wait until the soft tissues are fully recovered and there is no evidence of infection. This often requires 6 or more weeks. Reckling and Waters (83) place a cancellous or corticocancellous bone graft, often in conjunction with osteoperiosteal elevation through an anterior or medial incision. At the University of California, Davis, Trauma Center, we prefer the posterolateral approach applying a large cancellous autologous iliac graft, and we usually perform a tibiofibular synostosis (see Chapter 26 and Chapter 31).

### CHANGING FIXATOR STIFFNESS AND AXIAL MICROMOTION

Many surgeons elect to replace the external fixator with a patellar tendon-bearing or long-leg cast as soon as soft-tissue coverage has been obtained (56,96). This is often successful in patients with stable fractures. However, unstable fractures and even stable fracture patterns often angulate after fixator removal, even if immobilized in a long-leg cast. I prefer to hold these fractures in the external fixator until they are healed. After advancing the patient to full, unsupported weight bearing, gradually dismantle the more complex configurations (e.g., two-plane unilateral, one-plane unilateral with double rods) to one-plane configurations with a single anterior or anteromedial rod (Fig. 11.24). Then, sequentially loosen the pin clamps, starting with the pins closest to the fracture site, until the load is held only by the most proximal and most distal pins.

Another option is to loosen all the pins in the proximal or distal main fragment. This permits free axial loading while preserving angular and rotatory alignment (13). Although attractive and logical, there is no proof that this approach leads to an increased rate of fracture healing. Easier to use are tube-type and other fixators that can be dynamized, some with very specific control over the excursion and amount of loading.

Early induction of axial micromovement at the fracture site has been shown to increase the rate of fracture healing (43,58). This is achieved with the help of a pneumatic actuator temporarily connected to the fixator. The actuator induces a loading regimen of 1 mm displacement at 0.5 Hz for 30 minutes each day. With this approach, a 20% reduction in the average healing time was achieved in a controlled trial of complex tibial fractures (59).

### SECONDARY INTERNAL FIXATION

Delayed union or progressive malunion after a tibial fracture often is best handled by replacing the external fixator with an intramedullary rod or a plate. Internal fixation following removal of external fixator pins where infection has occurred, particularly osteomyelitis, is generally contraindicated until the infection has been eradicated. Although there is little information about results and complications after plating, indiscriminate secondary intramedullary nailing has been shown to have a high infection rate (70). However, secondary nailing can be performed with only a slightly increased infection rate if the procedure is carried out very early or within 4–6 weeks of fixator application (15). Even with these restricted indications, it is safest to place the limb in a cast for 2–4 weeks before proceeding with intramedullary nailing to allow the pin tracks to heal. Unless extraordinary circumstances prevail, avoid intramedullary nailing after local soft-tissue or bony infection or in a patient who once had a pin

tract infection, because the sequelae of an infected medullary canal can be disastrous.

## PITFALLS AND COMPLICATIONS

### CHRONIC PAIN

Patients who experience more chronic pain than expected, particularly when associated with weight bearing or exercise, nearly always have a loose pin or wire. Once soft tissues have healed, the patient has recovered from the initial trauma and/or surgery, and the fracture site has begun to consolidate, the average patient should be quite comfortable in the fixator, requiring minimal across-the-counter pain medication. Pain is a greater problem when a vigorous rehabilitation program is in progress and the patient has pins through large soft-tissue envelopes such as in the thigh, where muscles, tendons, and fascia are constantly being tethered by or are moving on pins and wires. In these cases, careful monitoring of the rehabilitation program to minimize discomfort, and close cooperation among the patient, surgeon, and physical therapist, are essential.

In the vast majority of cases, however, pain is due to a loose pin. This is usually accompanied by evidence of pin-site irritation, discussed below. In the early stages, pin loosening can be difficult to detect. Most frequently, resorption of bone occurs in the near cortex, resulting in micromotion of the pin in this cortex, while the opposite cortex holding the tip of the pin remains solid. Early detection of this requires loosening the clamp attached to the pin and then careful palpation of the pin, wiggling it back and forth to detect this micromotion. Later, a radiolucent zone about the pin can be detected radiographically. This is a sure sign of pin loosening.

If the patient is midway in the course of fixator treatment, removal of the loose pin is necessary; it may be either left out or replaced with another pin in a sound location at least 15 mm or more from the original site. If the patient is nearing the end of treatment (e.g., the fixator needs to be left on for only an additional 1–2 weeks) and there is no evidence of infection, then shifting the pin clamp location on the fixator, slightly bending the pin to bring it against one cortex of its hole, will occasionally stabilize the pin and allow the patient to complete treatment. This is a temporizing measure that does not solve the underlying problem of pin loosening and should be used only in these special circumstances.

Pin loosening that results in pain is particularly a problem in ring and hybrid external fixators using tensioned wires in metaphyseal bone. Continuation of tensioned wire fixation where loosening of the wires has occurred guarantees persistent pain for the patient and eventually further pin complications of more severity. In the case of tensioned wires in metaphyseal bone, detection of loosening usually requires detaching the ring from the rest of the external fixator and manipulation of the ring to detect motion of the pin in the bone.

### PIN-SITE DRAINAGE AND INFECTION

Pin-site problems manifest themselves as a progression of symptoms from slight pin-site tenderness, swelling, and erythema, to substantial serous exudate, to evidence of frank infection with purulent exudate at the pin site with or without evidence of abscess formation. If the patient has clinical evidence of infection and a radiolucent zone around the pin on a radiograph, then bone infection is usually present. In my experience, the most common cause of pin-site complications is loosening of the pin in the bone. In metaphyseal bone, this is most commonly the result of simple mechanical loosening due to the weak structure of the cancellous bone. In cortical bone, it is most commonly due to improper surgical technique producing necrosis of the bone as a result of overheating drill points or fixation pins. In the latter case, a remodeling response is precipitated in the bone immediately surrounding the pin, which rapidly leads to pin loosening and in some cases formation of a ring sequestrum around the pin, seen after pin removal when the central beam of the x-ray is directed along the axis of the pin hole. Management of pin-site irritation and infection is illustrated in Table 11.3. The pin must be removed, the soft tissues and bone thoroughly debrided, and appropriate antibiotics prescribed.

***Table 11.3. Management of External Fixator Pin Site Problems***

Note that oral antibiotics have only a small role to play in managing pin-site irritation. The typical situation in which a patient requires oral antibiotics occurs when the pins pass through a thick soft-tissue envelope, which, because of the patient's activities and rehabilitation, are moving on the pin, resulting in contamination and a low-grade cellulitis in the absence of any evidence of pin loosening or infection. This is most common in limb-lengthening and deformity-correction procedures where tensioned wire ring fixators or hybrid frames are being utilized. In these cases, I have found that a few patients do well on oral cephalosporins for 10 days or more if episodes of cellulitis occur. Always be alert for pin loosening and evidence of deeper infection.

Superficial cultures of pin tracts, regardless of clinical appearance, have no place in the management of pin-site complications. These cultures are nearly always positive, usually represent normal skin flora, and are of no help in prescribing appropriate treatment. I take cultures only when formal deep debridement of a infected or potentially infected pin site is carried out. These cultures are taken at the level of bone, preferably from a curetting of the pin tract.

### DEFORMITY, DELAYED UNION, AND NONUNION

Progressive deformity in the fixator is usually caused by either pin loosening, loosening of components on the frame, or both. If deformity is noticed prior to consolidation of the fracture, then usually it is correctable by addressing pin or frame problems. Because of the nature of the fractures treated with external fixators, delayed union and nonunion are common and are best approached by manipulation of the frame or by bone grafting, as described previously. Conversion to some type of internal fixation is much less common unless done very early, as has been discussed. These issues are addressed in much more detail in chapters on each specific bone and on nonunions in this section of the book.

# D. PRINCIPLES OF SCREW FIXATION

## GENERAL PRINCIPLES

Screws can be used to attach implants such as plates and prosthetic devices to bone, to fix bone to bone, and to fix soft tissues such as ligaments and tendons to bone. Perhaps the most important use of screw fixation is interfragmentary compression, which improves the mechanical stability of internal fixation by increasing the friction between bone fragments. This minimizes micromotion between the fragments by minimizing the effects of torsion, shear, and bending forces.

As described by Müller et al., interfragmentary compression can be static or dynamic (71). Interfragmentary compression with a lag screw is the best example of static compression. A screw functions as a lag screw when the threads obtain purchase only in the far cortex, and the thread of the screw or a nonthreaded portion of the screw passes freely through the cortex immediately beneath the screw head. Screws can be made to function as lag screws either by overdrilling the near cortex to prevent the threads from gripping, or by having smooth shanks in the portion adjacent to the screw head. Clearly, interfragmentary compression cannot occur if the screw threads cross the fracture site, unless compression is achieved by a bone-holding forceps at the time the screw threads cross the fracture. The screw then maintains, but does not itself exert, compression.

The holding power of a screw in bone is most dependent on the density and quality of the bone. Other factors related to the strength of screw fixation are the overall surface area of thread in contact with the bone and the configuration of the thread relative to the structure of the bone. Whether the hole is tapped or untapped influences the frictional force developed between the screw and the bone, and thus the tendency of the screw to back out. Because bone is either cortical or

cancellous, and each type has very different structural characteristics, two types of specialized screws have been developed—cortical and cancellous (Fig. 11.27 and Fig. 11.28).

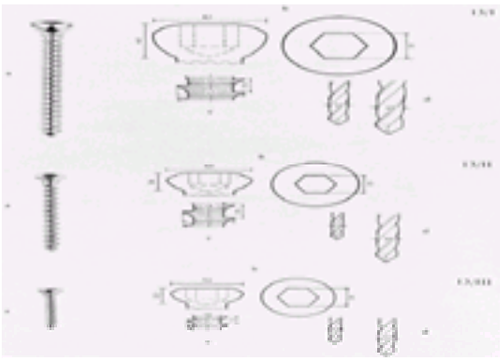

***Figure 11.27.*** Cortical screws. **Top:** A 4.5 mm cortical screw with a core diameter of 3 mm, outside thread diameter of 4.5 mm, and thread pitch of 1.75 mm. Notice that the underside of the screw head is hemispherical in cross section. A 3.2 mm drill bit is used for the threaded hole and a 4.5 mm drill bit for the gliding hole. **Center:** A 3.5 mm cortical screw. In the AO system, two varieties of this screw are now available—one with threads like those on a machine screw, known as the 3.5 mm cortical screw, and the one here, the 3.5 mm cancellous screw. The screw illustrated has a core diameter of 1.9 mm, an outside diameter of 3.5 mm, and a thread pitch of 1.75 mm. A 2 mm drill bit is used for the threaded hole, and a 3.5 mm drill bit for the gliding hole. **Bottom:** The 2.7 mm cortical screw is used for fixation of small fragments, as in the hand and foot. The thread has a core diameter of 1.9 mm and an outside diameter of 2.7 mm. The threads have a 1 mm pitch. A 2 mm drill bit is used for the threaded hole and a 2.7 mm bit for the gliding hole. (From Müller ME, Allgöwer M, Schneider R, Willenegger H. *Manual of Internal Fixation*. New York: Springer-Verlag, 1979:33, with permission.)

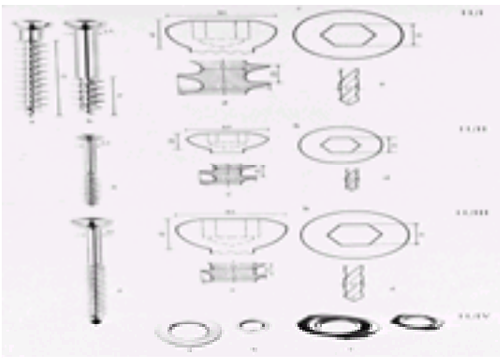

***Figure 11.28.*** Cancellous bone screws. **Top:** The two upper screws are standard AO 6.5 mm cancellous screws with spherical heads. The shafts are 4.5 mm in diameter, with 16 mm and 32 mm thread lengths. The screw threads have a core diameter of 3 mm, an outside diameter of 6.5 mm, and a thread pitch of 2.75 mm. For most applications, a 3.2 mm drill tip is used. If the shaft must pass through thick cortical bone, drill the cortex with a 4.5 mm drill. **Center:** A 4 mm cancellous screw with a core diameter of 1.9 mm, an outside diameter of 4 mm, and a thread pitch of 1.75 mm. A 2 mm drill bit is used. **Bottom:** Malleolar screw. The screw thread has the same profile as the 4.5 mm cortical screw, but a portion of the shank is unthreaded. The drill bit is 3.2 mm. Note the cutting tip, which allows the screw to be self-tapping in cancellous bone. In the ankle, this screw is used less often than the 4 mm cancellous screw. Various washers are available for both the 6.5 mm and the 4 mm screws. (From Müller ME, Allgöwer M, Schneider R, Willenegger H. *Manual of Internal Fixation*. New York: Springer-Verlag, 1979:28, with permission.)

## CORTICAL SCREWS

Typical stainless-steel cortical screws used for large-fragment and small-fragment fixation are shown in Figure 11.27 (3). These screws have spherical heads and are threaded for the full length of the shafts. A hexagonal screwdriver is used. Because there are no flutes on the tips of these screws, the bone must first be tapped to create threads for the screw. The advantage of tapping is that more engagement of the screw threads into bone is possible (Fig. 11.29). Because taps provide four cutting flutes, microfracture of the bone is less likely to occur. Theoretically, this produces better hold of the screw in bone. Disadvantages of tapping are that it requires an extra step in the operative procedure and, because a rather smooth track is established, the screw is more likely to loosen by backing out when it is subjected to cyclical stress.

***Figure 11.29.*** Tap for the 6.5 mm cancellous screw **(a)**; short- and long-threaded taps for the 4.5 mm cortical screw **(b)**; key handle for the 4.5 mm and 3.5 mm taps **(c)**; 3.5 mm tap **(d)**; handle for the 3.5 mm and 2.7 mm taps **(e)**; and 2.7 mm tap **(f)**. (From Müller ME, Allgöwer M, Schneider R, Willenegger H. *Manual of Internal Fixation*. New York: Springer-Verlag, 1979:35, with permission.)

Self-tapping screws using a four-flute tap-like cutting tip are also used. They are manufactured from a titanium alloy, and variations are available from several manufacturers (Fig. 11.30). These new screw designs surpass the holding power of non-self-tapping screws and are stronger due to their larger diameter and the use of titanium alloy. The major advantages are that the extra step of tapping is eliminated, and the screw is less likely to back out because of better frictional hold between the screw threads and bone. The only disadvantage is that 3–5 mm of screw tip must protrude from the bone to achieve maximum thread surface in contact with bone in the opposite cortex.

***Figure 11.30.*** Self-tapping titanium alloy cortical screw.

## CANCELLOUS SCREWS

Compared with cortical screws, cancellous screws (Fig. 11.28 and Fig. 11.31) have larger threads with a higher pitch and usually a smaller core diameter, providing more surface area for purchase on bone. Because cancellous bone is fairly soft and easily deformed, tapping usually is not required. If the screw is inserted through cortical bone first, however, it is usually necessary to tap the cortex; for this reason, taps are provided for cancellous screws.



***Figure 11.31.*** Self-tapping titanium alloy cancellous screws.

To obtain the best hold when placing a screw in cancellous bone, do not tap. As the screw penetrates, it compresses the bone to either side, thereby increasing the bone density in the immediate vicinity of the screw thread; this improves the holding power. Typically, cancellous screws have smooth shanks in the portion immediately adjacent to the screw head so that an automatic lag effect occurs without having to overdrill the near cortex. This is significant in the larger 6.5 mm screws, where a very large hole would need to be drilled in the near cortex to produce a lag effect. Varying thread lengths are available (16 and 32 mm). Fully threaded cancellous screws are available as well.

Today, many surgeons use cortical screws for internal fixation of the pelvis and fixation in the cancellous bone of juxtaarticular fractures such as those of the tibial plateau. These screws are inserted without tapping and take advantage of the compressive effect of the bone around the screw, as described above. Sometimes, a tap must be used to initiate penetration of the screw through the thin cortical cortex. If the opposite cortex is to be penetrated and it is more than one or two thread widths in diameter, pressure must be maintained against the screw to penetrate the cortex and to prevent stripping of the screw. This is the major disadvantage of this technique. The major advantage is that taps and the aggressive threads of cancellous screws do not need to be used in areas where excessive penetration of these sharp cutting surfaces may threaten neurovascular structures, and, in addition, a larger surface area of purchase of the screw threads on bone results in more holding power. This is a particularly good technique with self-tapping screws.

## SPECIAL FEATURES

Most screws today have a spherical head that allows the screw to be angulated in all directions within a washer or plate while maintaining concentric contact between the screw and the side of the plate. The only disadvantage of the spherical head is that it is more prominent when used without a plate. This necessitates countersinking to avoid prominence of the head and to avoid the stress created by asymmetric contact of the underside of the head with the edge of the predrilled screw hole. Washers (Fig. 11.28) often must be used with cancellous screws because the screw head tends to bury into the thin cortex overlying cancellous bone.

A specialized use for the spherical screw head (Fig. 11.32) is in achieving interfragmentary compression. The screw head is driven asymmetrically in the specially designed screw hole of the dynamic compression plate, which was pioneered by the AO Group (71). This design eliminates the need for an external compression device but has the disadvantage of limiting the angulation with which the screw can be driven. Extreme angulation of the screws may reverse the compression force to some extent. The amount of compression achievable is less than that possible with an outboard compression device, described below in the General Principles of Plate Fixation section.

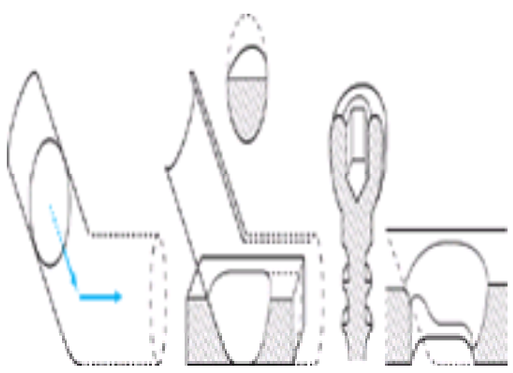

***Figure 11.32.*** Gliding-hole principle of the dynamic compression plate, in which the spherical underside of the screw glides down the incline plane of the screw hole in the plate. Interfragmental compression is achieved using a plate, without an external compression device. (From Müller ME, Allgöwer M, Schneider R, Willenegger H. *Manual of Internal Fixation*. New York: Springer-Verlag, 1979:71, with permission.)

Specialized washers for fixing tendons and ligaments to bone have spiked undersurfaces. Also available are nuts with attached washers and screws. These improve fixation when the screw threads fail to gain purchase because of poor bone quality or technical error. A unique asymmetric nut is available in the Alta system (Fig. 11.33).

***Figure 11.33.*** This Alta nut is usually used to lock two plates together in the system, but it can be used free as a washer-nut on the opposite cortex to enhance fixation

in soft bone. The rectangular shape enhances delivery to the tip of the screw and increases the binding to the opposite surface (magnified).

## INSTRUMENTS AND TECHNIQUES FOR SCREW INSERTION

### DRILL POINTS

Drill points (Fig. 11.27 and Fig. 11.29) must be sharp and straight. Dull drill points will overheat and “kill” bone. This can lead to premature mechanical failure of fixation and also predisposes to infection. Bent drill tips wobble, producing a hole larger than that required for the screw and thereby compromising fixation. When a dozen or more drill holes are made during a fixation procedure, drill points become dull and usually need to be replaced for the next procedure. If a drill point is inadvertently run against a metal surface such as a retractor, replace it, as dulling of the tip compromises its cutting power and can overheat bone. Use the proper-diameter drill point for each size of screw used. For cortical screws, use a drill point equal to or slightly larger than the core diameter of the screw. To produce a lag effect with cortical screws, use a drill point equal to or slightly larger than the outside diameter of the threads in the near cortex. For the screws used in the AO systems, the appropriate sizes of drill points are shown in Fig. 11.27 and Fig. 11.28.

### POWER SOURCE

For screw fixation, hand drills are not as effective as power drills, primarily because the wobble introduced by hand drilling produces a slightly larger hole than desired. Power drills offer more precision and are preferred. The major danger with both hand and power drills is overheating due to excessive drilling speeds, particularly if drill points are dull. High-speed drills designed for inserting wires or for use with high-speed burrs are not suitable for inserting screws. The usual drilling speed for drill points is 600 to 700 rpm. To avoid bone necrosis, continually cool the drill point during drilling by irrigation with sterile saline. If drilling is prolonged, withdraw the drill point and frequently clean its flutes of bone.

The soft tissues around bone, particularly neurovascular structures, must be protected during drilling. In addition, avoid scratching fixation devices such as plates. To protect soft tissues and plates, use drill sleeves over the drill point. Drill sleeves also give better purchase on bone and increase the accuracy of drilling.

Proper drilling depth is established through practice. As a drill point begins to exit a cortical bone surface, it slows slightly and the pitch of the drilling sound changes. Use this as a signal to ease pressure on the drill, and prepare to arrest the forward motion of the drill to avoid overpenetration.

### MEASURING SCREW DEPTH

Some drilling systems provide measurements on the drill shaft to determine screw length, but for the most part separate depth gauges are used (Fig. 11.34). Incorrect measuring can occur if you accidentally hook only the near cortex, or hook soft tissues or a bone surface other than the one desired, on the far side. In addition, improper mounting of the measuring tine in the depth gauge can produce erroneous measurements. After insertion of screws, always verify appropriate screw lengths either by palpation or by intraoperative radiographs, and check the depth gauge if lengths are inappropriate. In most situations, the appropriate screw length is such that one full thread exits the far cortex. This is unnecessary with cancellous screws in most applications and in fact may be inadvisable where the sharp tip of the screw threatens soft tissues on the opposite side of the bone.

***Figure 11.34.*** Alta depth gauge. Insert the hook into the screw hole, hook the far cortex and read the screw length off the shank. This gauge automatically adds 3 mm to compensate for the self-tapping tip of the screw.

There are other nuances affecting screw length to be aware of. In the AO and similar systems, cortical screws are generally available in 2 mm increments. The depth gauge measurement is designed to place just one thread of the tip of the screw through the opposite cortex when the screw head is fully seated. If measurement indicates an odd number, such as 21 mm, then the next larger screw is used, in this case 22 mm. This ensures that the maximum number of threads is always engaging the far cortex.

In self-tapping screw systems, such as the Alta system, 3 mm or so of the tip of the screw is made up of the flutes, which are a part of the self-tapping feature. To be certain that a maximum number of screw threads engage the far cortex, depth gauges in these systems usually compensate for this and provide a measurement that allows approximately 3 mm of the screw tip to protrude beyond the far cortex. In addition, self-tapping screws are more frequently available in titanium systems where the plates being used are quite flexible and conform much more closely to the bone than steel. This may result in the screw tip protruding through the opposite cortex 5 mm or more, particularly in the first several screws used to fix the plate to the bone. Therefore, it is important to check the screw lengths by either palpation or radiographic visualization after completion of insertion of all screws in the plate, as it may be necessary to replace them if excessive length of the tip beyond the opposite cortex poses a problem. Penetration of 5 mm or so in many locations where the screw tip is well buried and not in the vicinity of neurovascular structures presents no problem; if the screw tips are on a subcutaneous border beneath skin, however, they can be quite bothersome to the patient and must be adjusted. If an in-between-size screw is needed in these systems, choose the next smaller screw, rather than the next longer screw as in AO system.

### TAPPING

If a self-tapping screw is used and excessive torque is required to insert it, back it out, clean the flutes, and readvance the screw. This avoids microfractures of the bone. Very dense cortical bone may require tapping of the near cortex. The screws most commonly used require tapping (Fig. 11.29). The correct tap for a given screw diameter must be used. In the AO system, a short tap is provided where lag screw fixation with cortical screws makes tapping of the near drill hole undesirable. Tapping can be done by hand or with power. To avoid microfracture of the bone and breakage of the tap, reverse the tap for a half turn every several terms to clear bone chips. Use low rpm settings and frequent reversals if tapping with power.

### SCREWDRIVERS

Many different screwdriver bits and heads are available, but the most commonly used are hex-socket-type heads and modified cruciate heads, in which the tines are rounded at the corners. Many names are applied to the latter tips, but they are most often referred to as Woodruff tips. A standard industrial screwdriver tip recently introduced is the Torx used in the Alta system. It provides superior driving torque, particularly in titanium alloy screws. It fits snugly into the screw, providing a self-retaining feature that is helpful in screw placement.

When driving screws, maintain axial alignment to the hole drilled. Once the medullary canal is entered, it is possible to miss the opposite drill hole. Inexperienced surgeons should always drive screws by hand; hand-driving is also necessary when the bone quality is poor. A power driver with a screwdriver tip is useful when multiple screws are being inserted into cortical bone, but this technique requires experience.

Make screws snug but avoid overtightening, which can result in fracture of the bone or failure of the screws. Overtightening also predisposes the screw to premature failure. In healthy young cortical bone, it is generally recommended that about 25 inch-pounds be applied to the screw. This can be learned by using a torque

screwdriver; experienced surgeons can sense the appropriate tightening of a screw.

## SURGICAL TECHNIQUES

### LAG SCREW FIXATION

Whenever a screw crosses two bone surfaces, as in a fracture or osteotomy, use the principles of lag screw fixation (Fig. 11.35):

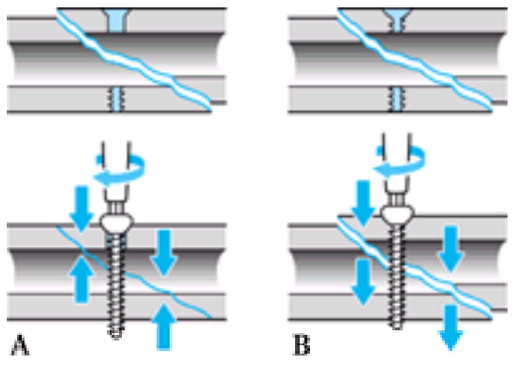


***Figure 11.35.*** Lag screw fixation. A: Overdrilling the near cortex produces a “lag” effect and interfragmentary compression. B: Threading both cortices leaves a gap between the two bone fragments. (From Müller ME, Allgöwer M, Schneider R, Willenegger H. *Manual of Internal Fixation*. New York: Springer-Verlag, 1979:37, with permission.)

- For effective interfragmentary compression, overdrill the cortex adjacent to the screw head, so thread purchase is achieved only in the opposite fragment.
- Notice that threading both fragments produces persistent distraction between the fragments.

When fixing a plate to bone where the screw does not cross a fracture or osteotomy interface, better purchase is obtained by bicortical fixation. In rare circumstances, it is undesirable to reduce the distance between two bone surfaces; the classic example is in fixation of the distal tibiofibular syndesmosis. In this situation, it is undesirable to overcompress the joint between the tibia and the fibula after reduction has been achieved. Instead, use a fully threaded cortical screw in each of the four cortices of the tibia and fibula, engaging all cortices with threads. To achieve lag screw fixation with cortical screws, two techniques are available, depending on which screw hole is drilled first: the gliding hole or the threaded hole.

#### *Gliding-Hole-First Technique*

- In simple fractures where most of the fracture line is visible, reduce the fracture anatomically and hold it with bone-holding forceps.
- To provide optimal alignment between the screw holes and to prevent displacement of the fracture as the screw is tightened, insert one or more interfragmentary lag screws, drilling the gliding hole first, then placing a drill sleeve and drilling the threaded hole (Fig. 11.36).

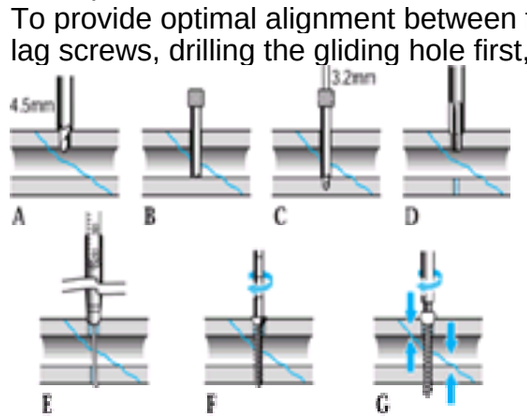


***Figure 11.36.*** Fixation with a lag screw after reduction of the fracture using the gliding-hole-first technique. (From Müller ME, Allgöwer M, Schneider R, Willenegger H. *Manual of Internal Fixation*. New York: Springer-Verlag, 1979:37, with permission.)

- Protect the soft tissues by using a 4.5 mm tap sleeve as a drill guide. Drill the gliding hole in the near cortex with a 4.5 mm drill bit (Fig. 11.36A).
- Insert a drill sleeve into the hole until it makes contact with the opposite cortex. This sleeve has an outer diameter of 4.5 mm and an inner diameter of 3.2 mm (Fig. 11.36B).
- Drill the opposite cortex with a 3.2 mm drill bit (Fig. 11.36C).
- Use a countersink to create a recess for the screw head in the near cortex (Fig. 11.36D).
- Use the large depth gauge to measure screw length (Fig. 11.36E).
- Tap the drill hole in the opposite cortex with the short 4.5 mm tap (Fig. 11.36F).
- Insert the correct-length 4.5 mm cortical screw until the fracture site is snugly approximated. If more than one screw is to be placed across a fracture, do not completely tighten the screws until they are all in place (Fig. 11.36G).

When the fracture site is not well visualized, or when the configuration of the fracture or osteotomy will make accurate screw placement difficult, drill the gliding hole first either from the outside or inside in the near bone fragment before reducing the fracture. This permits precise placement of the drill hole, which ensures that the screw does not enter the fracture line and that adequate bone stock is available for purchase (Fig. 11.37).

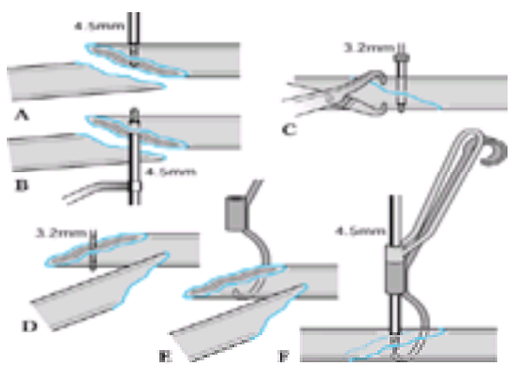


***Figure 11.37.*** Screw fixation prior to reduction of the fracture, using the gliding-hole-first technique. (From Müller ME, Allgöwer M, Schneider R, Willenegger H. *Manual of Internal Fixation*. New York: Springer-Verlag, 1979:39, with permission.)

- Locate the appropriate site in one bone fragment for the gliding hole. Drill the hole using the 4.5 mm drill through a tap sleeve (Fig. 11.37A, Fig. 11.37B).
- More accuracy can sometimes be obtained by drilling from inside to outside (Fig. 11.37B).

- Reduce the fracture, insert the drill sleeve, drill the threaded hole, and complete the screw fixation (Fig. 11.37C).

***Threaded-Hole-First Technique***

- Where it is not convenient to make the gliding hole first, drill the threaded hole with the 3.2 mm drill bit inside to outside first (Fig. 11.37D).
- Insert the pointed drill guide into this hole (Fig. 11.37E).
- Reduce the fracture, place a 4.5 mm tap sleeve through the sleeve of the pointed drill guide, and drill the gliding hole with a 4.5 mm drill, taking care to maintain appropriate alignment. While maintaining reduction, insert a screw and complete the fixation (Fig. 11.37*C*, Fig. 11.37*D* and Fig. 11.37*E*).

***Lag Screw Fixation of a Spiral Fracture***

Figure 11.38 illustrates the principles applied to the fixation of a long, spiral fracture. In general, lag screw fixation of an oblique or spiral fracture requires neutralization by a plate if sufficient stability is to be achieved to allow immediate rehabilitation without external protection. In very long or oblique diaphyseal fractures, and in some similar fracture configurations in the epiphysis and metaphysis, it may be possible to achieve good fixation with lag screws alone. When only lag screws are used, however, external protection with a functional brace and delayed weight bearing are advised. For fixation of a noncomminuted diaphyseal fracture with lag screws alone, the fracture length must be at least three times the diameter of the shaft at the site of the fracture.

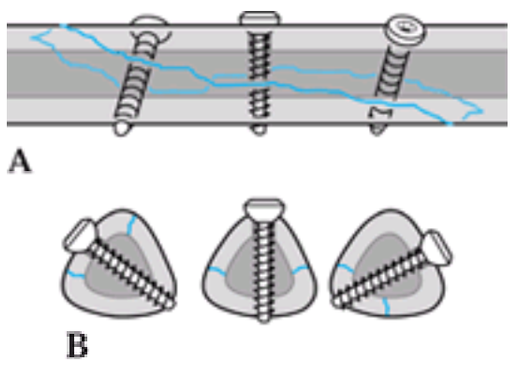


***Figure 11.38.*** Interfragmentary screw fixation of a long spiral fracture, showing the appropriate orientation of the screws along the fracture. Note that they are approximately at right angles to the long axis of the bone, yet spiral about the bone to maintain optimal alignment to the plane of the fracture lines. (From Müller ME, Allgöwer M, Schneider R, Willenegger H. *Manual of Internal Fixation*. New York: Springer-Verlag, 1979:41, with permission.)

Place screws at right angles to the fracture lines in each section of the fracture to obtain maximum interfragmentary compression. Proper placement avoids shear stresses that will cause the fracture to slide on itself. In spiral fractures, this requires the screws to spiral down the fracture site. In addition, in most fracture configurations, the screws are best placed at right angles to the long axis of the shaft of the bone, because longitudinal compressive forces will cause the screws to tighten rather than loosen.

**FIXATION OF ARTICULAR FRACTURES**

Internally fix fractures in the epiphyseal and metaphyseal regions with cancellous screws and washers, using lag screw fixation. At least two (often three) screws are required to prevent the fragments from rotating. Unless the bone is osteoporotic, cancellous screws need not exit the opposite cortex. In fact, in articular locations this is usually inadvisable because the sharp tip of the screw may impinge on neurovascular structures or present an uncomfortable prominence under the thin skin over joints. A typical configuration is shown in Fig. 11.39.

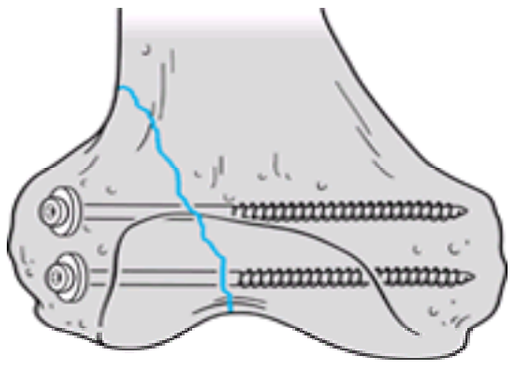

***Figure 11.39.*** Lag screw fixation of an intraarticular fracture of the femoral condyles using two 6.5 mm cancellous screws with washers. (From Müller ME, Allgöwer M, Schneider R, Willenegger H. *Manual of Internal Fixation*. New York: Springer-Verlag, 1979:31, with permission.)

Figure 11.40 shows the application of 4 mm cancellous screws to internally fix an intraarticular fracture of the talus in an immature limb. Note that the two screws are perfectly parallel because the drill holes were placed with the pointed drill guide, which guarantees parallel drill holes. This is important for optimal lag effect. Figure 11.41 shows similar screws used in a more common application, a displaced fracture of the medial malleolus. Again, the pointed drill guide is used to ensure that the screws are parallel. The versatility of interfragmentary cancellous screw fixation is shown in Fig. 11.42, in which a displaced acetabular fracture is fixed with three screws because it was inconvenient to place a plate. As described, nontapped cortical screws also work very well in the pelvis if the fracture surfaces are well compressed by bone-holding forceps.

***Figure 11.40.*** Displaced fracture of the body of the talus in an immature ankle has been internally fixed with two 4.5 mm cancellous screws.

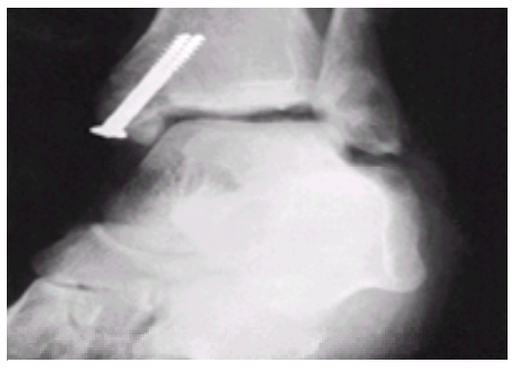

***Figure 11.41.*** Fixation of a displaced fracture of the malleolus with two 4 mm cancellous screws.

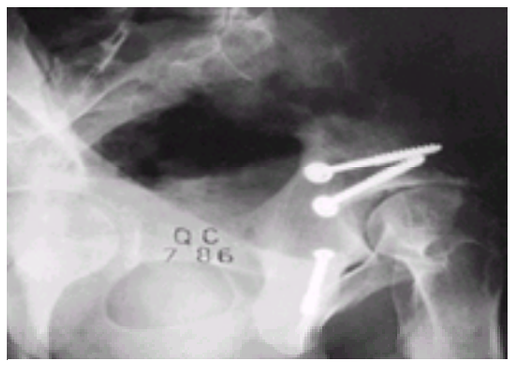


***Figure 11.42.*** Internal fixation of a complex fracture of the acetabulum using only cancellous lag screws. Although these were sufficient in this patient, in some fractures plate fixation would be required as well.

When intraarticular fractures in cancellous bone, such as a vertical spilt fracture of a lateral tibial plateau, are fixed with interfragmentary screws alone, vertical shear forces tend to displace the condyle inferiorly. This can be neutralized by placing a buttress screw to support the fragment. Either a cancellous or a cortical screw can be used, depending on the location of the fracture and the quality of the bone.

- Place a drill hole immediately adjacent to the inferior tip of the proximal fragment, and drill in a bicortical fashion at right angles to the longitudinal axis of the tibia.
- Then place a screw with a washer. Be certain that the screw shaft contacts the tip of the fragment and the washer is brought snugly against the inferior spike of bone. This will prevent inferior shift of the fragment (Fig. 11.43).

***Figure 11.43.*** Buttress screw (antiglide screw). Insert at the tip of the condylar fragment with the washer overlapping the proximal fragment, to prevent inferior subsidence of the condyle.

## SPECIALIZED SCREWS

### DOUBLE-THREADED SCREWS

The Herbert screw is another implant used for interfragmentary compression. Threads are present at both ends of the screw, with a pitch differential between the leading and trailing threads. Interfragmentary compression is achieved by the difference in thread pitch, so a screw head is not required. The absence of a screw head makes it possible to insert Herbert screws through articular surfaces without the head being prominent. Originally designed for scaphoid fractures, current indications include osteochondral fractures, osteochondritis dissecans, capitellar fractures, radial head fractures, and small joint arthrodesis. A disadvantage is that the Herbert screw can be difficult to remove. The Herbert screw used in an illustrative case is shown in Fig. 11.44.

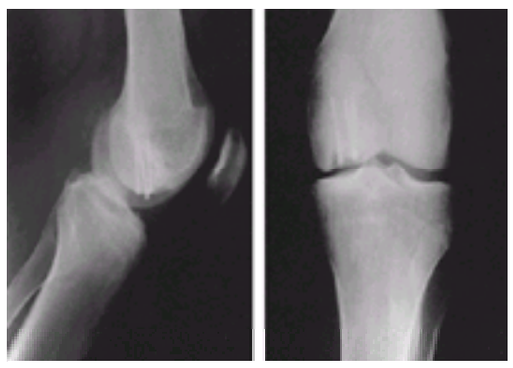

***Figure 11.44.*** Internal fixation of osteochondritis dissecans by Herbert screws. The trailing thread is countersunk beneath the articular surface of the medial femoral condyle.

### CROSSLOCKING SCREWS

Strong screws are required for interlocking of intramedullary nails. Most systems use a smooth-shanked screw with special features to ease removal (Fig. 11.45).

***Figure 11.45.*** Crosslocking screw. Note the thick shank and low profile thread to enhance strength.

### CANNULATED SCREWS

Cannulated screws have a hollow core that allows screw insertion over a previously placed guide wire (Fig. 11.46). Potential benefits of this system are less soft-tissue dissection and the presence of a guide wire for provisional fixation and for accurate screw placement (Fig. 11.47). These screws are most often used for percutaneous fixation or femoral neck fractures, where fluoroscopic imaging of guide-wire placement helps to ensure appropriate screw length and screw position. Placement requires initial placement of a guide wire. A hollow drill is used over the guide wire and a cannulated tap is used if required. Cannulated screws are best inserted under fluoroscopic control. A depth gauge or measurement from a calibrated drill bit determines the length of screw to be used.

***Figure 11.46.*** A cannulated screw can be inserted over a previously placed guide wire.

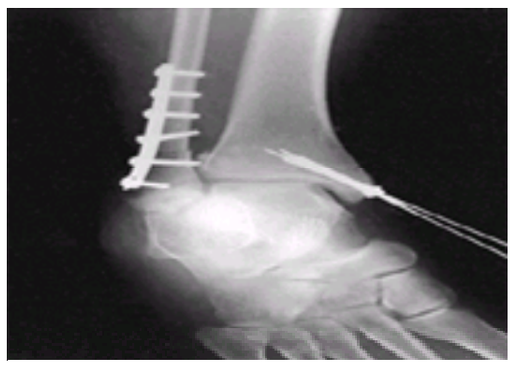

***Figure 11.47.*** Intraoperative radiograph of internal fixation of medial malleolus fragments using cannulated screws. The guide wires are helpful in achieving and maintaining the reduction of the fracture until screw insertion is completed.

The disadvantages are that the screws are weaker than noncannulated screws, particularly in the small fragment size, and they break more easily when removal is attempted (Fig. 11.48).

***Figure 11.48.*** Percutaneous internal fixation of a femoral neck fracture with multiple cannulated screws.

### ABSORBABLE SCREWS

Polylactic acid and other polymers are now used to manufacture absorbable screws. Indications include children when hardware removal can be avoided, and in the internal fixation of juxtaarticular fractures such as those of the medial malleolus, where high strength is not required and removal of hardware is often required because of the subcutaneous location of the screw. Bucholz et al. (23) have described good success with absorbable screws.

## FIXATION OF TENDONS AND LIGAMENTS

Ligaments and occasionally tendons can be attached to bone for repair or reconstruction using a cancellous bone screw driven through the soft-tissue structure, with a spiked washer to obtain purchase on the ligament or tendon. Although this works well, one disadvantage is that the area of soft tissue fixed with the screw and washer becomes avascular due to the pressure. Sometimes this avascularity will lead to failure of fixation before adequate soft-tissue healing.

Other ingenious techniques have been devised to secure ligaments and tendons to bone, either by bone blocks or by indirect fixation. Daniel et al. described a step-cut tibial channel to capture the tendon preparation (35). Sutures are passed through the tendon preparation using a double-loop technique and are then tied to the head of

a cancellous screw (Fig. 11.49). The interference screw technique (Fig. 11.50) described by Lambert is easier to perform and in my opinion provides better fixation (65).

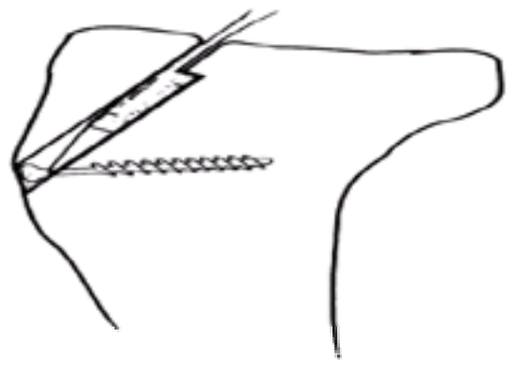

***Figure 11.49.*** Step-cut tibial channel for fixation of a bone ligament preparation for reconstruction of the anterior cruciate ligament. Sutures placed through the bone–tendon preparation by double-loop technique are tied to the head of a cancellous screw. (From Daniel DM, Robertson DB, Flood DL, Biden EN. Fixation of Soft Tissue. In: Jackson DW, Drez D Jr, eds. *The Anterior Cruciate Deficient Knee.* St. Louis: CV Mosby, 1987, with permission.)



***Figure 11.50.*** Interference-fit fixation of the bone plug on a bone–tendon preparation for reconstruction of the anterior cruciate ligament using a 30-mm-long, 6.5-mm-wide cancellous screw. Fixation depends on a snug fit of the bone plug in the drill hole. (From Lambert KL. Vascularized Patellar Tendon Graft with Rigid Internal Fixation for Anterior Cruciate Ligament Insufficiency. *Clin Orthop* 1983;172:885, with permission.)

### SUTURE ANCHORS

Since the previous edition of this book, a large number of suture anchors have become available that are based on the molly bolt principle or that are screws. Sutures of various sizes and materials are attached to these devices. When needing to attach ligament, tendon, or capsule to bone, these devices are inserted into the cancellous bone at the attachment site, securing the suture to the bone, which is then used to attach the soft tissue (Fig. 11.51). These have offered significant improvements, particularly where arthroscopic repairs are performed.

***Figure 11.51.*** Mitek suture anchor (magnified).

## E. PRINCIPLES OF PLATE FIXATION

Except for simple lag screw fixation, plates are probably the oldest means of fracture stabilization. Many types of plates have been applied to bone, some by screws, others with the help of wire loops. However, not until Danis in 1949 were plates applied with axial loading (compression) of the bone and fracture underneath (36). It was observed that this type of compression fixation leads to fracture healing without visible external callus (*soudure autogène*, or direct bone healing). From this observation, in the late 1950s, Müller developed the original AO round-hole compression plate with the removable compression device. Bagby and Janes developed a similar plate (7,8). Since that time, plating has become a well-established means for fixation of a large variety of fractures and nonunions, and many different plate designs, forms of application, and plate functions have been described. For a review of the literature, see *The Dynamic Compression Plate* by Allgöwer et al. (2).

Although there is virtually no fracture that could not in principle be fixed with a plate, other devices for fracture fixation, such as the interlocking nail and the external fixator, have advantages over plates in certain situations, especially in diaphyseal fractures of the femur and tibia.

Plates may be classified according to either type (shape and size) or function. Both type and function often correspond to a specific application (for example, the L-shaped buttress plate for fractures of the tibial plateau). On the other hand, a given plate may have different functions, depending on (a) the mechanical configuration of the bone–plate conjunction, resulting in static compression, dynamic compression (tension band), neutralization, and buttressing; (b) which part of the bone is stabilized (metaphysis or diaphysis); and (c) the specific fracture configuration.

### DEVELOPMENT OF PLATE FUNCTIONS

The original AO round-hole compression plate was thought to provide static compression of a diaphyseal fracture, thereby leading to rapid bony union, as was shown experimentally in sheep (82). After fracture reduction, compression or axial loading was applied with the help of the removable compression device. Today, it is known that in most cases the originally instituted compression force of up to 80–90 kilopascals (kp) was lost after the remaining screws were introduced into the round holes of the plate. The reason for the success of the so-called compression plate, therefore, was most probably not compression in the first place, but rather the better method of fracture fixation with newly designed implants that were also applied differently (e.g., by power drilling, pretapping). In hypertrophic nonunions, the primary achievement of the compression plate was better approximation of the nonunited fragments and optimal stabilization, allowing calcification of the interposed tissues. If properly placed on the tension side (convexity) of the nonunion, the compression plate acts as a tension band, which actually provides dynamic rather than static compression.

With increasing knowledge about the physiology of fracture healing, it became evident that to stimulate bone remodeling by creeping substitution, a signal was needed. The best way to transmit or generate this signal appeared to be physiologic loading of bone by controlled weight-bearing. For this purpose, the original AO/ASIF

(Association for the Study of Internal Fixation) round-hole plates were probably somewhat less forgiving when not ideally applied. Too much axial loading could lead to fatigue failure of the plate or loosening of the screws rather than to bony union.

In 1965, the dynamic compression plate (AO/ASIF DCP) was introduced. The self-compressing effect by eccentric screw placement, combined with the possibility of a gliding or sliding effect (Fig. 11.52) between the screw head and the plate hole, allowed a more physiologic force transmission within bone during weight bearing. Furthermore, thanks to the spherical configuration of both screw head and plate holes, the compression instituted initially was maintained throughout the procedure, even if the screws were not placed at a right angle to the plate.

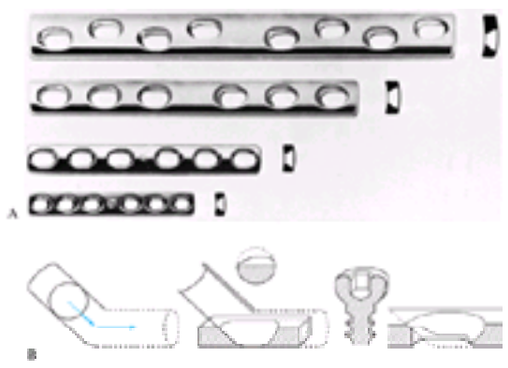

***Figure 11.52.*** **A:** Dynamic compression plates of different dimensions. From *top* to *bottom*: broad, 4.5 mm; narrow, 4.5, 3.5, 2.7 mm. **B:** Schematic representation of the spherical gliding principle of the DCP. (From Müller ME, Allgöwer M, Schneider R, Willenegger H. *Manual of Internal Fixation*. New York: Springer-Verlag, 1979:235, with permission.)

## STATIC COMPRESSION

Static compression is best demonstrated on the model of a transverse fracture (Fig. 11.53). Tensile pre-stressing of a straight plate produces axial compression in the fracture. The area underneath the plate is compressed, while the opposite cortex shows a gap. To increase the amount of bone surface being compressed (including the opposite cortex), it is advisable to contour the plate to approximate the cortex opposite the plate. Another possibility to prevent a slight gapping of the osteotomy or fracture line in the far cortex is to place a lag screw across the fracture or osteotomy plane (Fig. 11.54).

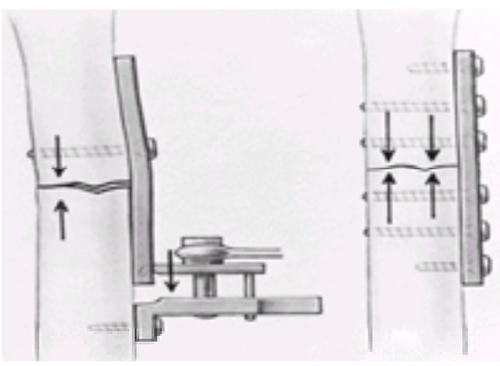

***Figure 11.53.*** Static compression in a transverse fracture (humerus) fixed with a slightly overcontoured plate. Axial compression is obtained via the removable tension device. **A:** Plate application with the tension device. **B:** Equal distribution of compressive forces. (From Müller ME, Allgöwer M, Schneider R, Willenegger H. *Manual of Internal Fixation*. New York: Springer-Verlag, 1979:223, with permission.)

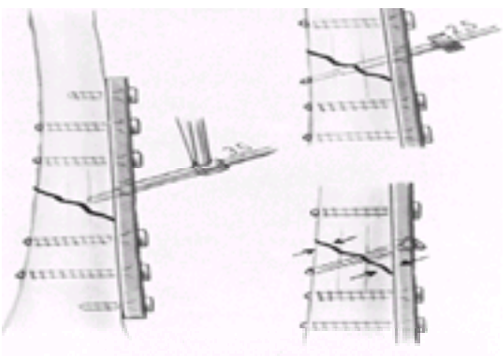

***Figure 11.54.*** Fracture fixation is improved by placing an interfragmentary lag screw through the plate. **A:** Placement of interfragmentary lag screw across a 3.5 plate; drilling of a gliding hole with a 3.5 mm drill bit. **B:** Drilling of a threaded hole with a 2.5 mm drill bit and corresponding drill guide. **C:** Interfragmentary compression across plate and fracture is achieved by tightening the lag screw. (From Müller ME, Allgöwer M, Schneider R, Willenegger H. *Manual of Internal Fixation*. New York: Springer-Verlag, 1979, with permission.)

Most transverse diaphyseal fractures are best treated by a medullary nail. The indications for a static compression plate, therefore, are less common; these include transverse fractures of the humerus and forearm bones.

## DYNAMIC COMPRESSION (TENSION BAND PLATE)

From his experience in mechanics, Pauwels borrowed the principle of tension band fixation and demonstrated its application in operative fracture treatment (79). Every eccentrically loaded bone is subjected to bending stresses and deforms in a typical manner, with a gap on the convex or tension side and compression on the concave side of the bone (Fig. 11.55*A*). To restore the load-bearing capacity of an eccentrically loaded bone, the tensile forces on the convex side must be absorbed by a tension band (wire or plate) (Fig. 11.55*B*). The bone itself—especially the cortex opposite the tension band—must be able to withstand axial compression; this requires a medial buttress, usually supplied by the intact cortex. Thus, the implant absorbs the tension forces, and the underlying bone the forces resulting from compression. Loading (e.g., by partial weight-bearing) results in a dynamic increase of the axial interfragmental compression. In the absence of a medial buttress, which absorbs the compression forces, the plate is subjected to repeated bending stresses, which inevitably lead to fatigue failure and implant breakage (Fig. 11.55*C*).

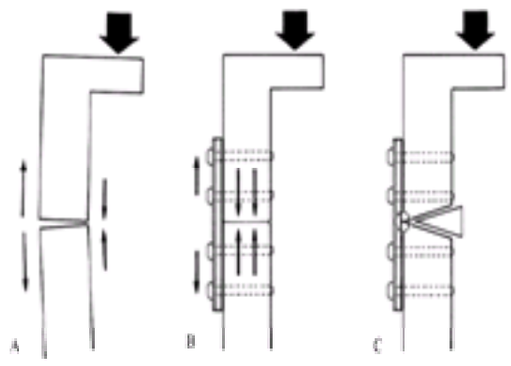

***Figure 11.55.*** Tension band plate in femur. **A:** Eccentric loading of the femur results in tensile forces on the lateral side and compression on the medial aspect of the bone. **B:** In the presence of a good bony buttress, the lateral plate acts as a tension band. The plate is therefore stressed only in tension, the bone in compression. **C:** In the absence of a bony buttress—due to a cortical defect—the plate undergoes cyclic bending, leading rapidly to fatigue breakage.

Except for the femur, olecranon, and patella, it is difficult to identify the tension or compression side of a fresh fracture, but in a malunion the aspect (lateral, medial, or posterior) on which the tensile forces are most active is usually clearly visible (Fig. 11.56). The best indications for a tension band plate, therefore, are fractures in the subtrochanteric area of the femur (requiring a 95° blade plate or broad DCP), certain olecranon fractures (one-third tubular or 3.5 mm plate), and nonunions.

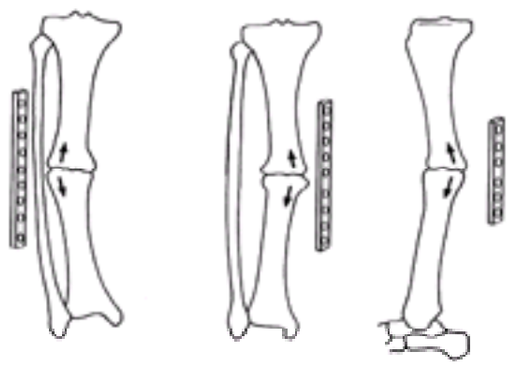

***Figure 11.56.*** Tension band plate in nonunions. To act as a tension band, the plate must always be placed on the tension or convex side of the bone. **A:** Lateral position. **B:** Medial position. **C:** Posterior position. (From Müller ME, Allgöwer M, Schneider R, Willenegger H. *Manual of Internal Fixation*. New York: Springer-Verlag, 1979:731, with permission.)

## NEUTRALIZATION

By far the most common function of a plate is neutralizing or protecting an interfragmentary lag screw fixation (Fig. 11.57). Most fractures can be reduced by interfragmentary lag screw fixation alone (Fig. 11.57*B*), but in many instances this fixation will not suffice for early active movement or partial weight bearing. To protect the lag screw fixation from bending, torsion, and shearing forces, a neutralization or protection plate is added (Fig. 11.57*C*).

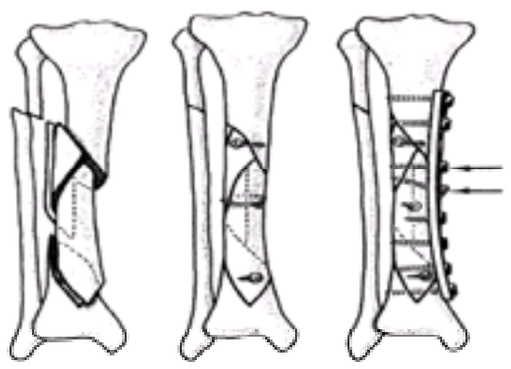

***Figure 11.57.*** Neutralization plate in the tibia. **A:** Comminuted, multifragment fracture. **B:** After anatomic reduction and preliminary fixation with two lag screws and a cerclage wire. **C:** A neutralization or protection plate has been added on the medial aspect of the tibia, with two additional lag screws through the plate (*arrows*). (From Müller ME, Allgöwer M, Schneider R, Willenegger H. *Manual of Internal Fixation*. New York: Springer-Verlag, 1979:33;581, with permission.)

After screw fixation, carefully contour the plate and fix to the bone with all screws in a neutral position. Place a lag screw across the fracture through the plate whenever possible, as this greatly improves the neutralizing bone/plate system (Fig. 11.57*C*).

## BUTTRESS FUNCTION

In the metaphyseal area of most bones, one encounters intraarticular fractures that are a combination of cleavage (T or Y), with or without impaction of cartilage and subchondral cancellous bone. After reconstruction of the articular surface and grafting of the bone defect, one or two buttress plates will fix the articular fragments to the shaft and support or buttress the metaphyseal area (Fig. 11.58). Typical indications for buttress plating are fractures of the distal humerus, the tibial plateau, and the tibial pylon, and compression fractures of the distal radius. Accordingly, all T and L-shaped plates are designed for buttress functions. If a DCP with gliding holes is applied for buttressing, the screws must be introduced at the end of the gliding slope to prevent further collapse.

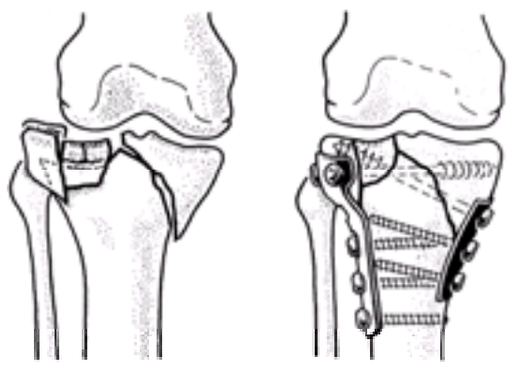

***Figure 11.58.*** Buttress plates in tibial plateau fracture. **A:** Bicondylar plateau fracture with impaction of lateral articular surface. **B:** Reduction and stable fixation with two buttress plates: L or T plate laterally, tubular plate medially. (From Müller ME, Allgöwer M, Schneider R, Willenegger H. *Manual of Internal Fixation*. New York: Springer-Verlag, 1979:33;573, with permission.)

Weber described a special kind of buttress plate, an antiglide plate (107). For this purpose Weber usually applies semi- or one-third-tubular plates in such a way as to prevent the tip of an oblique fracture from displacing due to muscle pull. For example, in a type B fracture of the lateral malleolus (Fig. 11.59), the three-hole, one-third-tubular plate is placed posteriorly and thereby locks the tip of the distal fragment into an anatomically correct position.

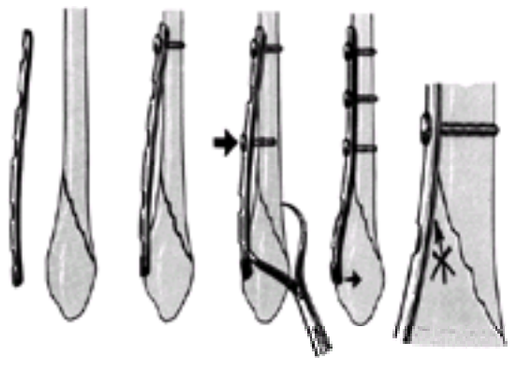

***Figure 11.59.*** Antiglide plate (Weber). A 3.5 dynamic compression plate or one-third tubular plate placed dorsally on the distal fibula prevents dislocation of distal fragment. (From Müller ME, Allgöwer M, Schneider R, Willenegger H. *Manual of Internal Fixation*. New York: Springer-Verlag, 1979:33;609, with permission.)

## PHYSIOLOGY OF PLATE FIXATION

Before the revolution in plate fixation was started by the AO Group in the late 1950s, the major problems encountered in plate fixation of fractures, other than the usual surgical complications, were early plate failure, screw breakage, and screw pullout. Plates were relatively weak, and the principles of obtaining a biomechanically stable reconstruction through improvements in interfragmentary contact were not yet well known. Screws were still based on designs from the woodworking and metal industries, and their thread designs were not ideal for fixation in bone. In addition, most screws were self-tapping; this self-tapping feature was not well designed and led to microcracks, which hindered the hold of the screw in bone.

The introduction of the much more rigid fixation obtainable with AO implants led to a new set of clinically significant problems: bone loss under the plate, fracture at the ends of the plates, or refracture through the fracture site or screw holes after plate removal. Anderson et al. (5) and Hidaka and Gustilo (52) had a 22% incidence of refracture after plate removal using the standard, narrow 4.5 mm AO plate on fractures of the radius and ulna. Chapman et al. (27) were able to eliminate refractures in plate fixation of the radius and ulna by using the AO/ASIF 3.5 mm system.

Laboratory investigation of this problem has shown two possible causes: stress protection, and devascularization followed by revascularization. Studies by Woo et al. (115), Coutts et al. (32), Uhthoff and Dubus (103), and others demonstrate that stiff plates, when applied to healing fractures, result in weaker fracture callus and, when left in place for prolonged periods, weakening of the bone under the plate due to bone resorption. These authors felt that this effect was due to “stress shielding.” In accordance with Wolff's law, introducing a rigid member across a fracture site alters the signals influencing the homeostatic mechanisms controlling bone apposition and resorption, so that the fracture heals with weaker callus and bone resorption occurs under the plate and in the surrounding cortex.

Swiontkowski and Senft (102) and others have demonstrated devascularization of the cortex secondary to soft-tissue stripping and disturbance of the intrinsic blood supply to bone by the application of the plate and insertion of screws. Revascularization of the bone results in bone resorption. The hypervascularity associated with that is most evident under the plate.

Both of these factors are important, and newer plate designs have addressed both issues by producing more flexible plates from materials with a lower modulus of elasticity, such as titanium, titanium alloys, carbon fiber, or polymer, and by newer configurations. Only titanium is currently in use clinically, however.

## NEWER PLATE SYSTEMS

Many plating systems are now available that use CP titanium, 6-4 titanium alloy (described above, in the section on Implant Materials), or other alloys. Titanium is more flexible than surgical steel, yet stronger. Howmedica (Rutherford, NJ) produces a modular bone fixation system from 6-4 titanium in an attempt to optimize the environment for fracture healing. The modular system allows plates of different lengths and types to be interconnected by dovetailing (Fig. 11.60). This modular feature reduces the need for soft-tissue stripping to place the plates. The use of larger oval holes in the plate, which will accommodate two screws, permits fixation with shorter plates and increases the range of angles through which screws can be placed; this enhances fixation. The railed design of the plate limits plate contact with the bone to potentially enhance revascularization. A new plate from the AO Group known as the limited contact dynamic compression plate (LCDCP), also of titanium, is an effort to achieve the same goals (Fig. 11.61).



***Figure 11.60.*** Alta modular titanium plating system. **A:** The Alta channel plate (extension plate) features a railed undersurface, holes for single or double 5.0 mm screws, and a rounded configuration for insertion into a dovetail. **B:** The underside of an Alta distal femoral fracture plate, showing the dovetail connection between the two plates. If needed, they can be preassembled and fixed together with a screw and nut. **C:** Alta compression hip screw with the side plate dovetail holding a four-hole channel plate. Note the double screw hole configuration. The channel plate is available in three lengths. **D:** The channel plates can be connected with this double dovetail. This modularity drastically reduces the implant inventory and increases versatility. **E:** The distal femoral fracture plate seen from its top surface. The notch in the end of the plate permits insertion of two interfragmentary screws. The three double screw holes permit multiple screw fixation into the condyles. **F:** The dovetail is also featured in the Alta 3.7 mm small reconstruction plate, which has oval holes to accommodate two 3.7 mm screws or a 5.0 mm cortical screw (enlarged photograph). **G:** Specialized L, T, and U plates can be interlocked with the dovetail of the 3.7 mm plates. (Illustrations courtesy of Howmedica, Rutherford, NJ.)



***Figure 11.61.*** The AO titanium low-contact dynamic compression plate. Its unique configuration offers fewer stress concentration points and less contact with bone to enhance preservation of the blood supply to bone.

New screw-thread and cutting-flute designs have eliminated the need for tapping, removing one step from the fixation process. The self-cutting threads and titanium material provide better frictional hold between the screw and bone, preventing screw backout. The new four-fluted design of the Alta screw reduces the heat of insertion and prevents microcracks of the cortex.

Considerable experimental and clinical work has been done with polymeric and carbon fiber plates as well (103). Their modulus of elasticity is even closer to that of bone, but they cannot be molded during surgery and some tend to be quite brittle. Thus far, they have not been found to be practical in clinical applications. Other efforts to make plate and screw fixation more compatible with normal bone physiology have been directed toward the development of resorbable plates and screws, or placing resorbable surfaces on the plate–bone or plate–screw interface. Resorption results in eventual loosening of the construct, thereby allowing more physiologic transmission of stresses. All of these are experimental at present and have not entered clinical practice.

## GENERAL PRINCIPLES OF PLATE FIXATION

### LOCATION

Earlier in this chapter, I emphasized that plates should be used as tension bands if possible and therefore placed on the convex surface of bones. This is particularly true for the radius, where plates are usually placed on the dorsal lateral surface, and for the femur, where they are placed anterolaterally. In the humerus, plate location is dictated more by the anatomy of the surgical exposure, and generally the plate is placed laterally or dorsally. The bending forces about the tibia are less predictable, but generally plates are best placed on the lateral surface because of the excellent soft-tissue coverage provided. In general, try not to place plates in subcutaneous locations, as skin slough or infection may result in plate exposure. In addition, plates in subcutaneous locations are more likely to produce symptoms. However, the practical aspects of fixation demand placement of plates in subcutaneous locations in some circumstances, such as plating of the olecranon and the lateral malleolus.

## SURGICAL TECHNIQUES

### EXPOSURE

The following principles apply to fixation of most diaphyseal fractures with plates:

- When exposing the fracture, limit soft-tissue stripping to just the surface on which you expect to place the plate. Avoid the use of retractors and bone-holding forceps, which require circumferential stripping of bone. Fine-pointed tenaculum-type bone-holding forceps are best.
- There seems to be no advantage to leaving the periosteum intact beneath the plate. For most plates in common use today, application of the plate on the periosteum results in complete loss of blood supply to the periosteum. In addition, the fixation of the plate to bone is less secure, due to the intervening soft tissue. It is more difficult to obtain an anatomic reduction, particularly in comminuted fractures. On the other hand, maintaining soft-tissue attachments to bone is important. Newer “point contact” plates may change this advice.
- If very small butterfly fragments are involved, maintaining soft-tissue attachments to the butterfly may make the fixation of the fracture exceedingly difficult and may result in less-than-optimal reduction. In such cases, I do not hesitate to detach small bone fragments from soft tissues to enhance the ability to obtain fixation. These small fragments usually revascularize very quickly.
- To ensure that bone union occurs in the presence of such comminution, however, apply a cancellous bone graft across the comminuted zone.
- Accurate reduction and apposition of butterfly fragments is particularly important when their absence would leave a gap opposite the plate. This dramatically increases the bending stresses on the plate and could lead to early fatigue failure of the plate.
- After exposing the fracture site, clean the fracture ends of all organized hematoma and soft tissue. Strip the periosteum from the fracture ends 1–2 mm, just enough to delineate the fracture surface.

### REDUCTION AND PLATE APPLICATION

Transverse fractures that are inherently stable can be reduced before plate application, and this simplifies fixation. Unstable fractures pose a challenge, particularly if excessive soft-tissue stripping is to be avoided. In simple oblique or spiral fractures, or those with small butterfly fragments where there is good cortical contact, often the fracture can be reduced with a small tenaculum forceps and preliminary fixation obtained with an interfragmentary lag screw. Application of the plate then is simplified. In more unstable and comminuted patterns, a different approach may be necessary. If a major butterfly is present, the best approach may be to fix the butterfly to one fragment with an interfragmentary lag screw, which then may produce a stable pattern that can be reduced and easily plated. If this is impossible, I advise using the plate to provide the mechanism for reduction of the fracture:

- Precontour the plate, select the approximate location for the plate, and choose the point for the first screw hole on one side of the fracture. If necessary, lay the plate on the surface of the bone on one side of the fracture and mark the site for the screw with a methylene blue marking pen.
- Drill for the screw without the plate in place, and then secure the plate to one fragment with one screw.
- Tighten the screw to achieve reasonable stability, but do not overtighten it, as this may interfere with the reduction. Then reduce the fracture and stabilize it using a tenaculum or small plate-holding forceps on the side of the plate not attached to bone.

Fixation of the plate to one side of the fracture before reduction is immensely helpful. This avoids the common struggle in which the fracture is reduced and held with multiple bone forceps, but then the surgeon finds that the plate cannot be placed. Removing the forceps to place the plate then results in loss of stability, and a prolonged struggle ensues to hold the reduction while applying the plate.

### INDIRECT REDUCTION TECHNIQUES

For very comminuted fractures, such as in the supracondylar region of the femur and in pylon fractures, use indirect reduction techniques as popularized by Mast to avoid devascularization of the many bone fragments (71). To achieve length, apply a femoral distractor and then use it to pull the fracture out to length; or, fix the plate to one fragment and use the plate itself to distract the fracture out to length, using the outboard plate compression device or a lamina spreader between the end of the plate and an outboard screw.

- With distraction, nudge the intercalary comminuted fragments into reasonably good position.
- With severe comminution, achieve good plate fixation above and below the fracture, but do not attempt fixation of the multiple small fragments. Application of a bone graft to the comminuted section through the fracture site, prior to reduction, to accelerate union may be wise.
- In small, good-quality bones, apply screws through five or six cortices (up to three bicortical screws) for fixation on either side of the fracture. In the humerus, tibia, and femur, use solid bicortical fixation through the cortex, with four screws on each side of the fracture. In long spiral or oblique fractures, some of these screws should be interfragmentary lag screws.

## WAVE PLATES

Another interesting method for plate fixation popularized by the AO group and recently used successfully by Jupiter et al. (33,55) is the wave plate. Although this is potentially applicable to acute comminuted fractures in a technique similar to that described previously as an indirect reduction technique, for the most part it has been limited to the treatment of nonunions of the diaphysis of large bones such as the humerus and femur.

- Contour a large broad plate to fit the bone proximally and distally to the nonunion site, producing a wave in the plate that lies free of the cortex and bypasses the nonunion site and fracture callous (e.g., in hypertrophic nonunions). Solidly fix this to the proximal and distal fragments with at least four bicortical screws above and four below. Then pack bone graft around the nonunion site, including the area beneath the plate.

The principle of this technique is that it requires minimal stripping of soft tissues around the nonunion site and, therefore, maximally protects vascularity. In addition, it makes available the largest surface area for revascularization. The major disadvantage of the technique is that is does not provide nearly as secure fixation as more rigid techniques such as the double plates described below. If the patient bears excessive weight on an unstable nonunion site, premature fracture of the plate through one of the empty screw holes in the wave section can occur.

## DOUBLE PLATES

For simple fractures, I do not use double plates: Their application requires too much soft-tissue stripping, and the rigid fixation produced may cause stress protection osteopenia. Indications for double plates are difficult nonunions, particularly where bone quality is less than optimal, and fracture configurations where solid bone contact on the cortex opposite a single plate is impossible. Typical examples are subtrochanteric and supracondylar fractures of the femur. A second plate should always be smaller, both in overall size and length, than the major fixation plate, and it should be substantially shorter to avoid a stress riser at the end of two plates of similar length. The strongest construct is when the plates are placed at right angles to each other. For example, in the subtrochanteric region, after fixation with a hip screw with a side plate, use a four- or six-hole narrow 4.5 mm plate. In the supracondylar region, a similar principle applies, and even a small fragment plate can be used (Fig. 11.62 and Fig. 11.63).

***Figure 11.62.*** Double plate fixation of an intertrochanteric fracture.



***Figure 11.63.*** Reconstruction of a supracondylar fracture of the femur with double plate fixation using a 95° condylar screw with an extension plate laterally and a broad plate anteromedially. Note that the anteromedial plate is shorter than the lateral plate to minimize the stress at the upper ends of the plates.

After fixation of a fracture with a single plate, always stress the fracture to see if micromotion occurs through the fracture site. If it does, either interfragmentary screw fixation or a second plate is usually required.

## SPECIALTY PLATES

Specialty plates are usually designed for fixation in the metaphyseal or epiphyseal portions of the long bones, or they are designed for the spine or pelvis (Fig. 11.64). Reconstruction plates have become quite popular since the early 1990s for the fixation of fractures where bending of the plates in three planes is necessary to achieve adequate conformity to bone. The most common sites for this are the distal humerus and the acetabulum and pelvis.

***Figure 11.64.*** **A:** The 3.5 mm AO reconstruction plate is used for fibula, radius, ulna, pelvis, and other metaphyseal fractures. **B:** AO tibial lateral buttress plate for fixation of fractures of the tibial plateaus. The plate is thick in the diaphyseal portion and thin in the metaphyseal section. **C:** An AO miniplate for small bones. (Courtesy of Synthes, Paoli, PA.)

The notched reconstruction plates bend easily in all three planes. Make bends in the plane of the plate before twisting or bending vertically to the plane of the plate. Apply a malleable template to the bone first. Use the template to determine the bends on the plate. Bending is less injurious to the plate and easier with the use of special bending presses. Bending is more accurate and safer if the plate is held by an assistant while the surgeon bends the plate. Bend in small increments to avoid overbending. Reverse bending of the plate substantially weakens it and is not recommended. Avoid kinking the plate. Bends are best distributed throughout the length

of the plate. Make bends between the screw holes. Avoid nicking the plate, particularly in titanium, where a stress riser effect might occur.

# F. PRINCIPLES OF INTRAMEDULLARY NAILING

## ADVANTAGES AND DISADVANTAGES

For the diaphysis of weight-bearing bones, intramedullary nailing is a fixation method superior to plates or external fixation, because the location of the rod in the intramedullary canal virtually guarantees proper axial alignment. Rotational alignment can be ensured with interlocking screws. In stable fractures, weight bearing is not only feasible but preferable; in an intramedullary location, nails, unlike plates and external fixation methods, are load-sharing devices, being subjected to small, bending loads. Breakage of intramedullary implants is thus minimized. Intramedullary nails can be placed using percutaneous closed techniques that minimize soft-tissue dissection, thereby decreasing the risk of infection. An additional advantage of intramedullary nails is that removal is often unnecessary. When needed, removal can usually be done from one end of the nail, using a small incision. Refracture after removal is uncommon, as no significant stress riser is left in the bone.

One disadvantage of intramedullary nailing is the fact that the size of the intramedullary canal may limit the size of nail that can be used; this limits the bending strength of the nail unless extensive reaming is performed. Intramedullary nails without cross-locking screws do not provide as good rotational control as do plates or external fixation. Intramedullary nails, particularly reamed nails, interfere with the endosteal blood supply, which makes up to 90% of the vascular supply to the diaphysis of long bones. This disadvantage may be minimized by using nonreamed and fluted nails. In closed fractures, the clinical significance of this disadvantage is limited, since revascularization from the surrounding muscle takes place rapidly (84,85 and 86). In open fractures, particularly of the tibia, in which stripping of the periosteum and muscle and bacterial contamination occur, the risk of infection in devascularized bone subjected to intramedullary nailing is significant. In addition, the techniques for inserting intramedullary nails by closed technique can be technically demanding.

## EFFECTS OF NAILING AND REAMING ON BONE AND SYSTEMIC PHYSIOLOGY

Reaming of the medullary canal and intramedullary nailing embolizes marrow contents into the general circulation and results in microembolization to many solid organs including the lung. In addition, there are dramatic acute effects on the diaphyseal blood flow (87).

Embolization of fat and marrow elements into the general circulation through the copious venous channels in the bone marrow has been demonstrated in animals (69,101), and embolization has been demonstrated in humans by transesophageal echocardiography and other measures (80,109). The degree of embolization is influenced by various factors (38,51). Nearly all manipulations of the intramedullary cavity cause some increase in pressure; however, Duwelius et al. (38) have shown the highest pressures with insertion of an awl into the medullary canal to open it. Reamer design can greatly influence pressurization of the canal. The lowest pressures can be obtained by using reamers with a small shaft diameter relative to the diameter of the cutting flutes, and where the design of the flutes optimizes depressurization of the canal. The presence of a fracture, slowing the rate of progression of the reamer down the canal, and increasing the rotational speed of the reamer have been found to reduce the intramedullary pressure and amount of embolization. Vent holes in the distal femur have not been shown to reduce reaming pressures reliably.

Whether this embolization is of clinical significance is controversial. Pape et al. (75) and Kröpfl et al. (62) have expressed the view that embolization of marrow contents to the lungs in patients with severe multiple injuries in whom there is pulmonary compromise or where there has been direct lung trauma is of concern; therefore, they recommend the use of nonreamed nails in patients with severe multiple injuries and/or pulmonary compromise. Many other investigators, however, have shown only transitory changes in pulmonary function in animals (92,114). Other investigators in well-designed prospective randomized and multi-institutional studies have not been able to demonstrate any significant adverse effects of reamed nailing in multiply injured patients with and without pulmonary compromise (17,109).

In view of this concern, surgeons should use instrumentation and techniques to minimize the amount of marrow and fat embolization. In addition, using caution in patients with severe pulmonary trauma or preexisting compromise of pulmonary dysfunction is wise.

The blood flow to the diaphysis of long bones can be reduced to one third of normal by reaming initially; however, this stimulates a strong hyperemic reaction that in experimental animals can reach several times normal by 2 to 4 weeks after fracture (49,76). Revascularization of the cortex occurs by reversal of the normal centrifugal blood supply to a centripetal supply coming from the surrounding muscle and periosteum. Nails that fit the cortex tightly interfere with this revascularization, so the use of smaller or fluted nails enhances reestablishment of blood supply to the marrow cavity and cortex (44,45,114). In reamed intermedullary nailing, the fracture healing process is dependent on revascularization of the diaphysis from the surrounding soft tissues; therefore, reamed nailing is potentially more dangerous to bone, particularly if infection intervenes and the soft-tissue envelope is compromised. The hyperemic response in the bone is echoed by increase in the blood flow to all the soft tissues of not only the injured leg but the contralateral extremity as well (4,6). In open fractures of the tibia with exposed bone, muscle flap coverage of a devascularized cortex has been shown to be important to revascularization and bone union (88,89,95). The hyperemic response to renailing, however, leads to high rates of union in the tibia and femur reported up to 98% (16,22). This has led to arguments about whether reamed or unreamed nailing is the best procedure for diaphyseal fractures. Schemitsch et al. (93,94) showed no difference between these two types of nailing in an animal model, from the standpoint of the vascular profusion of the bony callus formed at the fracture site at up to 12 weeks and in the strength of union of the callus. On the other hand, studies by this same research group showed that, in a canine fracture model, overall tibial blood flow was reduced by 63% with limited reaming and 83% with full reaming. These data suggest that in severe open fractures, in particular of the tibia, the best of all worlds may be achieved by gentle, limited reaming to provide maximum protection to the blood supply but still allow the use of a 10 mm or larger nail, which provides adequate mechanical strength for union in the vast majority of cases.

## TYPES OF NAILS

### REAMED NAILS

The classic reamed nail is the hollow, open-section nail of Küntscher (45,49). Most other reamed nails are variations of the Küntscher nail, such as the AO nail, and the various interlocking nails, such as the Grosse-Kempf (Howmedica, Rutherford, NJ), Klemm (Richards, Memphis, TN), Alta (Howmedica), Russell-Taylor (Richards), Uniflex (Biomet, Warsaw, IN), AO Universal (Synthes, Wayne, PA), and others (Fig. 11.65) (40,57,71). Fluted nails, such as the Sampson (Zimmer, Warsaw, IN), are little used since the introduction of more advanced locking nails (1). Reaming provides a precise fit for the nail in the intramedullary canal, thereby reducing the incidence of nail incarceration and improving the stability of fixation. Reaming permits the use of larger nails, which are stronger than smaller ones. A nail with a 12 mm diameter is 1.25 times stronger in bending than one with an 11 mm diameter.



***Figure 11.65.*** **A:** Intramedullary nails that require reaming. (*1*) A Küntscher nail, designed for open nailing, which is straight, nontapered, and slotted throughout. (Courtesy of Zimmer, Warsaw, IN.) (*2*) A Küntscher nail, designed for closed nailing, which has a curved, tapered tip, and is slotted throughout. (Courtesy of Howmedica, Rutherford, NJ.) (*3*) A Grosse-Kempf nail with a curved, tapered tip, a closed section at the upper end, an oblique cross-locking screw proximally, and two transverse cross-locking screws distally. (Courtesy of Howmedica, Rutherford, NJ.) **B:** Alta intramedullary locking nail for the femur. This is a solid-section, cannulated nail with a hexagonal cross section with smooth flutes to enhance revascularization. It is made of a titanium alloy. Two transverse 5.0 mm diameter cross-locking screws are used distally and proximally, eliminating the need for right and left nails. (Courtesy of Howmedica, Rutherford, NJ.)

### NONREAMED NAILS

Single, nonreamed, nonlocking nails have been designed for most of the long bones, including the femur [the Schneider nail (97) and the Hansen-Street nail (100), both

no longer manufactured], the tibia [the Lottes nail (Howmedica, Rutherford, NJ) (67)], the humerus [the Sampson nail (1)], and the forearm [the Sage nail (Smith Nephew Richards, Memphis, TN) (91)] (Fig. 11.66). Single, nonreamed nails are simple to insert and are associated with improved preservation of the endosteal blood supply and rapid revascularization (71,73,84). Their disadvantages include an increased likelihood of impaction during driving and, because smaller nails must be used, their relative weakness, particularly in bending.

***Figure 11.66.*** Intramedullary nails designed to be used as single nails without reaming. (Note: illustrations are not proportional.) **A:** A Schneider nail with a solid, four-fluted cross section and self-broaching ends. (Courtesy of Howmedica, Rutherford, NJ.) **B:** A Harris condylocephalic nail that is made from a titanium alloy (Ti-6A1-4V), curved in two planes, and designed for percutaneous, retrograde fixation of extracapsular hip fractures. (Courtesy of Zimmer, Warsaw, IN.) **C:** A Lottes tibial nail, which is solid, specially curved to fit the tibia, and has a triflanged cross section. These nails are available in $^{5}/_{16}$ -inch (8 mm) and $^{3}/_{8}$ -inch (9.5 mm) diameters. (Courtesy of Howmedica, Rutherford, NJ.)

Some nonreamed intramedullary nails are designed to be used in groups. The best example is Rush rods, which have been designed for all the long bones of the body (Fig. 11.67) (90). Ender pins have a similar design (Fig. 11.68) (39,40,73,74). Multiple Steinmann pins and Kirschner wires can also be used as intramedullary nails. These devices have all the advantages of nonreamed single nails, but provide better rotational control; as a cluster, they are generally stronger than single nails. However, they are technically more difficult to use and provide relatively poor axial stability.

***Figure 11.67.*** Rush rods are available in four diameters—¼ inch (6.4 mm), $^{3}/_{16}$ inch (4.8 mm), $^{1}/_{8}$ inch (3.2 mm), and $^{3}/_{32}$ inch (2.4 mm)—and in a variety of lengths that are proportional to all the major long bones. Rush rods are solid, with an oblique tip and hooked end that are designed to be inserted percutaneously. These rods must be prebent by the surgeon to obtain three-point fixation in the canal. (Courtesy of Howmedica, Rutherford, NJ.)

***Figure 11.68.*** Ender pins, which are solid with an oblique tip and an eye in a flange at the other end, were originally designed for percutaneous, closed treatment of extracapsular hip fractures. Special sizes are available for the humerus and tibia. They are used in groups. (Courtesy of Howmedica, Rutherford, NJ.)

Several intramedullary nails, particularly for the tibia, are designed to be used reamed or nonreamed. Some of these newer nails are made of titanium alloys. Titanium nails drive more easily due to their flexibility and are stronger than stainless-steel nails.

**LOCKING NAILS**

Since 1988, when the first edition of this book was published, locking intramedullary nails have gained wide acceptance and have revolutionized fracture care. The Grosse-Kempf (Howmedica Rutherford, NJ) (57) and Klemm (no longer manufactured) (60) nails were the first generation of locking nails. Many new second-generation designs are available, and they address a wide range of problems in the femur, tibia, and humerus. Although available, locking nails for the forearm have not yet gained wide use.

Locking nails have made single nonlocking nails obsolete. The only advantages of nonlocking single nails are their simplicity and low cost.

Nearly every fracture combination in the femur can be addressed by percutaneous fixation techniques. Except for the Brooker-Wills nail (Biomet, Inc., Warsaw, IN) (Fig. 11.69) with its flanges, and the expandable tip of the Seidel nail (Howmedica, Rutherford, NJ), which is used exclusively for the humerus, all current designs use two or more distal transverse cross-locking screws, as in the Alta intramedullary rod (Howmedica, Rutherford, NJ) (Fig. 11.65*B*) (110). Proximal fixation includes inclined screws, as in the Grosse-Kempf nail (Fig. 11.65*A*); two transverse screws, as in the Alta (Fig. 11.65*B*); and specialized screws through the nail designed to secure fixation in the femoral head, as in the Russell-Taylor nail (Smith Nephew Richards, Memphis, TN) or the Alta CFX nail (Howmedica, Rutherford, NJ) (Fig. 11.70). The Alta nail is designed to have its two proximal cross-locking screws located just distal and proximal to the lesser trochanter when the top of the nail is flush with the cortex at its entry hole. This permits the surgeon to set the nail more proximally to secure fixation in the femoral neck without having the nail protrude above the tip of the greater trochanter (Fig. 11.71). This allows fixation of subtrochanteric fractures that include even the lesser trochanter.

***Figure 11.69.*** Brooker-Wills nail fixing a fracture of the femur, AP roentgenogram. This nail is a variation of the Küntscher nail with flanges deployed through slots in the tip of the nail for distal stability. They are deployed internally, and it has an oblique cross-locking screw proximally. With the advent of more advanced cross-locking designs, this nail has disappeared from the marketplace. (Courtesy of Andrew Brooker, M.D., Baltimore, MD.)

***Figure 11.70.*** Russell-Taylor reconstruction nail, a third-generation nail. Proximal locking into the femoral head makes it useful for hip fractures. (Courtesy of Howmedica, Rutherford, NJ.)



***Figure 11.71.*** **A:** Subtrochanteric fracture of the femur at the level of the lesser trochanter. **B:** Fracture fixed with an Alta intramedullary nail and two transverse cross-locking screws inserted across the femoral neck. Distal cross-locking screws were used as well.

The Alta nail, along with some other systems, offers the unique advantage that the surgeon can combine hip fixation systems with the intramedullary nail for the fixation of intertrochanteric–subtrochanteric fractures, and concomitant ipsilateral fractures of the femoral neck and femoral shaft (Fig. 11.72).

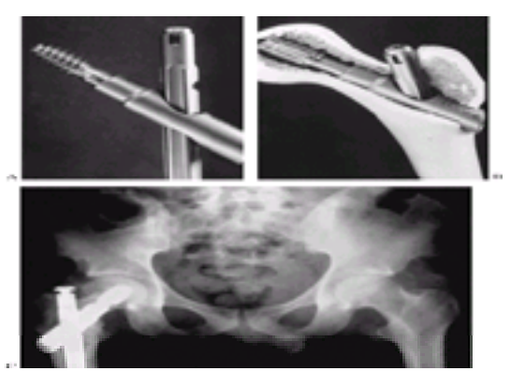

***Figure 11.72.*** **A:** Alta intramedullary nail with rod connector and hip screw used to fix concomitant ipsilateral femoral neck and shaft fractures, as well as subtrochanteric fractures of the femur. **B:** Alta rod connector in a plastic femur, combined with a hip bolt for fixation in the femoral head. **C:** Fracture of the femoral neck fixed with an Alta bolt. A rod connector and an intramedullary nail are used to fix an ipsilateral concomitant femoral shaft fracture. (Courtesy of Howmedica, Rutherford, NJ.)

## SPECIALIZED NAILS

Since the initiation of early locking nail designs, many specialized nails for particular problems have been developed based on the locking principle. The Zickel nail (117,118) for subtrochanteric and supracondylar fractures of the femur is now obsolete because it is not a fully cross-locked nail, and the Sage nail (91) for fractures of the radius and ulna has been replaced by plates, again because cross locking is not available.

An early specialized nail was the gamma nail (Howmedica, Rutherford, NJ) (Fig. 11.73), developed initially in a short design for fixation of intertrochanteric and some intersubtrochanteric fractures. This nail has been extremely successful in Europe but has not gained much popularity in North America. When it was introduced, the principle of overreaming and sliding the nail in by hand was not appreciated by early users in North America and this led to an unacceptable incidence of additional subtrochanteric fractures of the femur. The gamma nail is now available in a long device that functions like most reconstruction nails, except that a single locking screw is used in the femoral head and neck. Nearly every manufacturer now offers a third-generation, so-called reconstruction nail; in this system, different types of screws are inserted through the reinforced larger proximal section of the nail up into the head neck fragment of the femur. When combined with distal cross-locking screws, these devices enable the surgeon to stabilize single or combination fractures from the femoral neck to the supracondylar area of the femur. Similar design concepts have now been applied to the humerus as well.

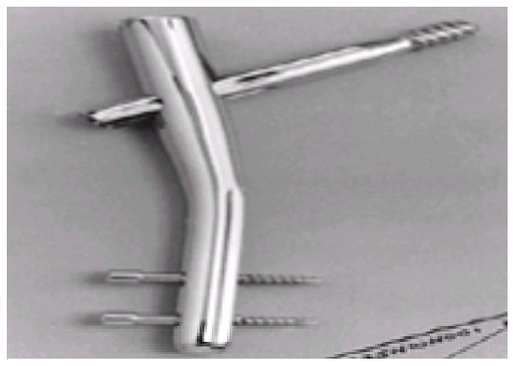

***Figure 11.73.*** Gamma nail. This intramedullary device is designed for proximal intramedullary fixation of intertrochanteric and some subtrochanteric fractures. It is available in a long version as well.

## INDICATIONS

### CLOSED FRACTURES

The use of intramedullary nails is most appropriate in patients with displaced, closed fractures of the lower extremity, who have unstable fracture patterns and in whom early weight-bearing and rehabilitation is advantageous. Fracture patterns (Fig. 11.74) are important to consider in making therapeutic decisions (21,22,26,113). Unless some type of supplemental external protection is used, simple oblique or spiral fractures are the only fractures that are nearly always stable after reamed or nonreamed intramedullary nailing without locking (Fig. 11.74*A*, Fig. 11.74*B*). The fracture configurations in Fig. 11.74*C*, Fig. 11.74*D*, Fig. 11.74*E*, Fig. 11.74*F* and Fig. 11.74*G* generally remain unstable with the use of routine reamed or nonreamed nails, and interlocking nails are required. Noninterlocking nails must not be used in the latter group of fractures unless special precautions are taken to prevent shortening and malrotation. Protection for 6 to 12 weeks is often necessary, depending on the fracture configuration.

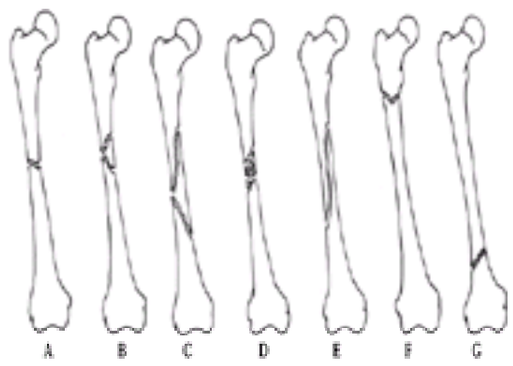


***Figure 11.74.*** **A:** Midshaft transverse or short oblique fractures are stable and therefore ideal for closed intramedullary nailing. **B:** Midshaft fractures with short butterfly fragments are also stable if there is 50% or greater contact between the proximal and distal fragments. **C:** Midshaft fractures with large butterfly fragments and less than 50% contact are unstable after routine nailing. An interlocking nail in the static mode should be used. **D:** Segmental comminution requires statically interlocked nails. **E:** Long spiral or oblique midshaft fractures may be stable with routine nails. Intraoperative comminution occurs often. It is prudent to insert a locking nail and then lock if necessary. **F:** Short oblique or transverse fractures within 2–5 cm of the lesser trochanter require a standard interlocking nail or a reconstruction nail. **G:** Short oblique or transverse supracondylar fractures no closer than 10 cm from the knee are ideal for an interlocking nail. (From Chapman MW. Closed Intramedullary Nailing of Femoral-Shaft Fractures: Technique and Rationale. *Contemp Orthop* 1982;4:213, with permission.)

Even simple transverse fractures can easily malrotate. Fractures often have unseen cracks that can progress and lead to instability. I lock nearly all nails at both ends now. Even in transverse fractures, I prefer to distally lock the rod first, impact the fracture with the slap hammer driver, and then lock proximally. With such good bone contact, immediate weight-bearing is almost always possible.

The treatment of choice for most closed fractures of the femoral shaft in adults and older adolescents is closed intramedullary nailing (30,113). A review of the literature comparing closed intramedullary nailing to open intramedullary nailing, plate fixation, and cast-brace treatment confirms this view (110).

In the tibia, most closed fractures are best treated by nonoperative means, using a weight-bearing cast or cast-braces (see Chapter 24). Closed nailing is reserved for fractures that develop unacceptable malposition with routine closed treatment or are obviously unstable at the outset.

Indications for intramedullary nailing of the humerus are rare. Most of these fractures are nicely managed by closed technique. The few fractures that do require surgical intervention are usually best treated by plates and screws, but selected indications for reamed and nonreamed intramedullary nails are discussed in Chapter 15. In displaced fractures of the forearm, the best results in adults have been reported with plate fixation; indeed, the use of intramedullary nails has been associated with an increased incidence of nonunion and angulation (5). Locked forearm nails have not proven to be superior to plates.

### OPEN FRACTURES

Intramedullary nailing of open fractures remains controversial. However, Brumback et al. (20) and Lhowe and Hansen (66) have shown that nailing of open fractures of the femur can be done with an acceptable complication rate, provided the benefits of the procedure outweigh the risks. Although Hansen et al. recommend immediate nailing of all open fractures of the femur, the infection rate may be lower if nailing is delayed in type IIIB open fractures. Immediate stabilization of all femur fractures is important for victims of multiple trauma to salvage life. Intramedullary nailing is the procedure of choice for most of these patients.

For isolated open fractures of the femoral shaft, perform a meticulous irrigation and debridement, including thorough irrigation of the bone and medullary canal at the fracture site, and initiate appropriate intravenous therapy as described in detail in Chapter 12 on Open Fractures. In Gustilo grades 1, 2, and 3A fractures, I almost always carry out locked intramedullary nailing. Since the fracture site is open, nailing is simplified and the majority of these cases can be stabilized on a regular operating table with the patient in the lateral decubitus position using an antegrade approach. I leave the traumatic wound open and perform delayed primary closure at approximately 5 days. It is important to protect the vascularity of the femur in open fractures, so I use gentle, minimal reaming and usually an 11 mm nail. In large men, this nail can often be implanted without reaming. Although the risk of infection is low, this makes recovery more likely if infection does ensue, as the diaphysis will be better vascularized and less likely to become a sequestrum. In isolated high-grade 3B or C open fractures of the femur, which are exceedingly rare, I also consider immediate intramedullary nailing using a nonreamed or minimally reamed small nail, as long as the wound is not highly contaminated and the delay from time of injury to surgery is not more than 6 hours. Brumback et al. (20) had an exceedingly low rate of infection after immediate-reamed nailing of open fractures of the femur and encountered an unacceptable infection rate only when debridement and nailing was delayed for more than 24 hours. In the presence of exceedingly severe soft-tissue wounds, high levels of contamination, and delay in treatment, my treatment of choice is external fixation with conversion to reamed intramedullary nailing when the soft tissues have recovered, the wounds are closed, and there is no evidence of infection. The procedure for conversion from external fixation to nailing is described above, in the section on external fixation.

My approach to open fractures of the tibia is similar to that of the femur. Early studies comparing nonreamed intramedullary fixation with Lottes nails with external fixation showed comparable results (67,104). As a result, when locking nails became available, nonreamed locking nails quickly became the stabilization method of choice for the vast majority of open fractures of the tibia as reflected in discussion in Chapter 24 (note the results listed in Table 24.7). External fixation is reserved for those fractures that are unsuitable for nailing because of their configuration, or in those that are highly contaminated and irrigation and debridement has been excessively delayed, as discussed for the femur. Because of their small size, nonreamed nails have experienced significant failure rates, with fracture of screws reported up to 30%, and delayed and nonunion rates reported up to 20%; therefore, some centers have studied minimally reamed and fully reamed nails for the fixation of open fractures. This is discussed in detail in Chapter 24. Recent reports, particularly those from Court-Brown et al. (31), have shown complication rates in reamed

nailing of open fractures to be comparable to those with nonreamed nails with improved union rates, less hardware breakage, and fewer malunions.

My approach to this issue is to now always try to place 10-mm-diameter titanium nails, which permits the use of the strongest 5-mm-diameter cross-locking screws (Fig. 11.75). With this device, fixation is secure and hardware failure exceedingly rare. A nail this size can be passed unreamed in about 40% of men, and with the passage of only one or two reamers in the remainder. Women require somewhat more reaming, so in the smallest I will use a 9 mm nail.



***Figure 11.75.*** Alta titanium tibial–humeral intramedullary locking nails. These nails can be used reamed or nonreamed and are available in 6–14 mm diameters. The 10–14 mm diameter nails use a 5 mm cross-locking screw. The 8.25 and 9 mm nails use a 3.7 mm cross-locking screw, and the 6 and 7 mm nails can be locked proximally. Notice the extender and tab, which attach to the proximal end of the nail to enhance proximal cross locking. (Courtesy of Howmedica, Rutherford, NJ.)

I have nearly abandoned nailing of the humerus, because if the fracture is open I much prefer plate and screw fixation as it better preserves the blood supply to the diaphysis, and injury to the rotator cuff is avoided.

## TECHNICAL CONSIDERATIONS

### TIMING

When using a closed technique to treat closed fractures, nailing can be done as soon as practical after injury. However, evidence suggests that if nailing is done with an open technique, a delay in nailing of 7 to 10 days may increase the union rate by taking advantage of the secondary injury phenomenon (25,28,99).

### ENTRY SITES

With reamed rods, which are generally fairly rigid, the entry site must be directly above the intramedullary canal. Eccentric entry sites, particularly in the femur and tibia, can result in incarceration of the nail or comminution. At the proximal end of the femur, the entry site for reamed nails is in the thin cortex at the base of the greater trochanter, at the site of its junction with the superior aspect of the femoral neck (see Chapter 20) (Fig. 11.76). The entry site on the femur for retrograde nailing is centralized on the intramedullary canal on both AP and lateral views with the fluoroscope and distally in the intercondylar notch just posterior to the articular cartilage and anterior to the origin of the anterior cruciate ligament (see Chapter 20).

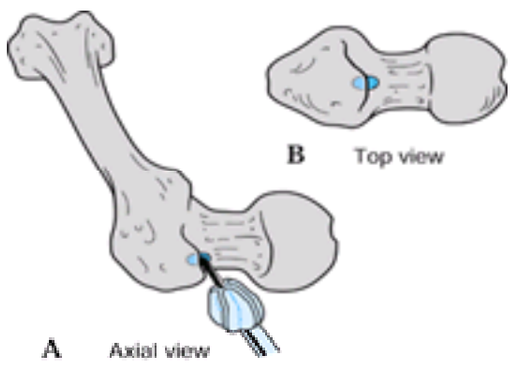


***Figure 11.76.*** Entry point for the medullary nail. **A:** This axial view, seen from the femoral head looking distally, represents the position of the femur in relation to the surgeon. Insert the guide pin at the base of the greater trochanter at its junction with the femoral neck in the region of the insertion of the obturator internus. Note that this entry point is neither on the femoral neck nor on the tip of the trochanter. Drive the pin into the medullary canal with a mallet. **B:** This direct view of the top of the femur better illustrates the proper location for the entry hole, which is directly above the medullary canal. (From Chapman MW. Closed Intramedullary Nailing of Femoral-Shaft Fractures: Technique and Rationale. *Contemp Orthop* 1982;4:213, with permission.)

For entry into the femur, most surgeons now use a guide pin and cannulated reamer rather than an awl; this offers better control and facilitates the use of the fluoroscope to identify the proper entry site. In the tibia, the most direct route is to split the patellar tendon and enter the bone just proximal to the tibial tubercle. To avoid injury to the patellar tendon, some surgeons enter just medial or lateral to it.

Because of the obvious advantages of not splitting the patellar tendon, I used the medial parapatellar approach for a year or so at the University of California, Davis, Medical Center. Although nailing can be successfully carried out through this portal, I found that in the hands of less experienced surgeons it was difficult to obtain an entry site directly over the medullary canal, resulting in unacceptable angulation of the nail relative to the longitudinal axis of the medullary canal. In addition, I have not seen any significant long-term consequences from splitting the patellar tendon. For that reason, I now always split the patellar tendon. In the tibia, flexible nails such as the Ender are usually inserted on the flares of the metaphysis of the proximal tibia. This technique is discussed in more detail in Chapter 24.

In the humerus, reamed nails are introduced at the proximal end. To avoid injury to the rotator cuff, try to locate the entry site just distal to the insertion of the rotator cuff tendons on the lateral aspect of the humerus, just below the prominence of the greater tuberosity, if the nail design permits. Many nails must be inserted through the cuff. Unfortunately, these result in residual shoulder symptoms in many patients. The entry sites for the radius and ulna are discussed in Chapter 16.

For nonreamed, flexible nails, an eccentric entry site is usually used to take advantage of three-point fixation of the curved nail within the medullary canal. Generally, these nails are inserted distally through the supracondylar flares of the long bones. Because of the limited space in the epicondyles of the humerus, the entry site advised for Ender nails in the humerus is centrally posterior, just proximal to the olecranon fossa. At entry sites, avoid impingement on neurovascular structures; to avoid stress risers, do not make the holes too big. The nails should not be prominent enough to produce bursae or skin problems.

### FRACTURE REDUCTION

Generally, the earlier a fracture is nailed, the easier is reduction of the fracture. Shortly after injury, the hydraulic effects of edema fluid can cause shortening and rigidity of the limb segment, which may make fracture reduction extremely difficult. If nailing is not done before this degree of edema occurs, gentle traction may be necessary to regain length and alignment gradually as the edema subsides. If intramedullary nailing is absolutely indicated, it may even be advantageous to distract the fracture slightly before surgery to facilitate reduction. With maintenance of length and early nailing, reduction is usually easy.

In fractures of the femur, reduction is most easily achieved by placing the distal fragment in a neutral position, avoiding tightness of the iliotibial band, which could otherwise result in shortening and a fixed valgus deformity (Fig. 11.77). The neutral position is achieved with 15° to 20° of hip flexion, and with the distal fragment level with the floor in the lateral decubitus position. It can also be achieved in the supine position. The proximal fragment is then aligned with the distal one by manipulating it with an intramedullary nail placed temporarily in the proximal fragment (Fig. 11.78). The Alta system has a fracture manipulation tool that enhances fracture reduction

and guide-pin placement, and it can also be used to measure nail length (Fig. 11.79).

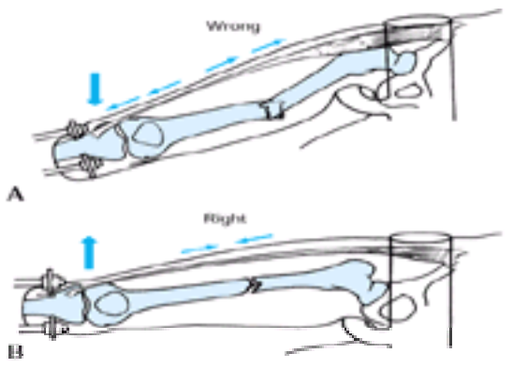


***Figure 11.77.*** **A:** In the adducted position, the iliotibial band is tight, shortening the fracture and causing a fixed valgus deformity. **B:** A "neutral" position relaxes the iliotibial band, facilitating reduction. (From Chapman MW. Closed Intramedullary Nailing of Femoral-Shaft Fractures: Technique and Rationale. *Contemp Orthop* 1982;4:213, with permission.)

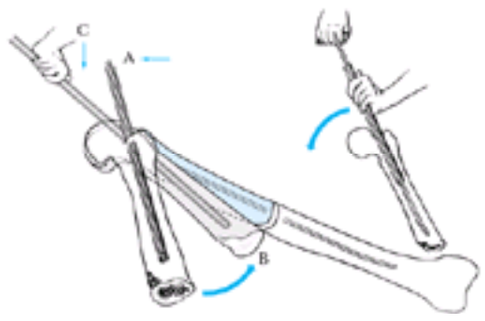


***Figure 11.78.*** In manipulating the proximal fragment, lateral pressure at point *A* brings the distal end of the proximal fragment to point *B*. Downward pressure at point *C* then moves the proximal fragment into alignment with the distal fragment. Careful, methodical, and thoughtful technique usually permits quick passage of the guide pin. (Illustration by Beverly A. Kessler, courtesy of LTI Medica, New Scotland, NY, and the Upjohn Co., Kalamazoo, MI, copyright LTI.)



***Figure 11.79.*** Alta fracture manipulation tool. This device is used to manipulate the proximal fragment to reduce the fracture, enhance driving the guide pin, and measure the length of the nail. (Courtesy of Howmedica, Rutherford, NJ.)

When the supine position is used for femoral nailing, the torso may obstruct manipulation of the proximal fragment. Direct manipulation of the fracture site is often necessary. To avoid radiation exposure of the surgeon, use manipulation devices such as the crutch and strap advocated by Küntscher. Use the fracture table for fractures of the femur and tibia to facilitate reduction. As the tibia is subcutaneous, direct manual manipulation results in reduction in most cases.

In the upper extremity, fracture tables are rarely used. Reduction is achieved by a combination of manipulation of the proximal fragment with the nail and direct manual manipulation of the distal fragment and fracture site.

In open nailing, the key to reduction is to angulate the fracture. Approximate the corners of the cortices of the proximal and distal fragments at an acute angle and then straighten the fracture into appropriate alignment. If nonreamed nails are used, this manipulation is facilitated by placing the nail in the proximal fragment before manipulation. In reamed nailing, use an incision just large enough to achieve manipulation; after the reaming guide pin is placed, close the wound and proceed as for closed nailing. These techniques are described in more detail in the chapters devoted to fractures of each long bone.

**REAMING**

Reamers must be sharp, and the surgeon must consider the relationship between the size of the reamers and the nail. A 12 mm reamer is not necessarily equal in diameter to a 12 mm nail. Because flexible reamers follow a curvilinear pathway, overreaming is usually necessary for most nails. Most nails require overreaming from 0.5 to 2 mm over the size of the nail, depending on the type of nail, the configuration of the fracture, and the canal of the bone.

***Reaming Technique for the Femur, Tibia, and Humerus***

- Insert a ball-tipped reaming guide pin across the fracture to the subchondral bone in the distal fragment.
- Begin with an end-cutting reamer, generally 8.5 to 9.0 mm in diameter. To avoid overheating and excessive pressure in the intramedullary canal, push the reamer slowly.
- Pay attention to the sound and speed of the reamer. Slowing of the reamer and intermittent catching are signs of impending jamming. In this situation, maintain full power, withdraw the reamer, clean it, and then readvance.
- When substantial cortical bone is being reamed, clean the reamer frequently to maintain effective cutting action. On the first pass of the reamer past the fracture site, visualize it on the fluoroscope to ensure that reaming is progressing appropriately; thereafter, it is not usually necessary to visualize the reamer.
- To avoid eccentric reaming and to allow the reamer head to pass the fracture site, an assistant may need to manipulate the fracture site gently.
- On withdrawal of the reamer, have an assistant hold a surgical towel or pad on the end of the guide pin to prevent its withdrawal along with the reamer. Driving the guide pin into the solid cancellous bone near the subchondral plate helps to stabilize the pin. Avoid grasping the guide pin with a bare surgical glove, as sudden turning of the guide pin will wrap up and rupture the glove.
- On withdrawal, the reamer will occasionally "hang up" at the fracture site or at the entrance to the bone because of the slight shoulder in the design of some reamer heads. Overcome this by advancing the reamer with full power, then retract it vigorously. If this is unsuccessful, try pulling the reamer eccentrically with an Army/Navy retractor while the power is on.
- It is safest to ream progressively in 0.5 mm increments. If the canal is large, after passing the end-cutting reamer, progress in 1 mm increments until firm contact of the reamer with cortical bone is established. Thereafter, progress in 0.5 mm increments.
- In general, avoid overreaming of the canal by more than 2 mm, as excessive thinning of the cortex may result in comminution during the drive of the nail. The exception is in reconstructive procedures and in young patients who have small canals, where considerable reaming may be required to accommodate a nail of adequate size.

- Occasionally, the entry hole for the nail, particularly in femoral nailing, is eccentric and off-line in relation to the canal. Correct this with the last reamer by pulling it eccentrically in the direction of the central axis of the canal with an Army/Navy retractor while reaming the entry hole. This will produce an oval hole that will permit proper entry of the nail.
- If a reamer breaks or jams, remove it by pulling it out with the ball-tipped guide pin. Reamers must be powered by high-torque, low-rpm power sources designed specifically for intramedullary reaming.
- Avoid excessive pressurization of the canal by using reamers with large open cutting flutes and small-diameter shafts. Use a vent hole in the distal femur when indicated, and advance the reamers slowly using the highest rate of revolution provided by the power reamer.

### NAIL SIZE

Obtain preoperative radiographs of the fractured long bone, including the proximal and distal joints. These help to rule out irregularities in the bone that might preclude nailing, and they also aid in the selection of an appropriately sized nail. If a full complement of intramedullary nails is available, it is usually unnecessary to measure patients for nail size before surgery unless they are of unusual stature. If there is any question, obtain AP and lateral radiographs of the opposite normal limb at a tube-distance of 1 m. Tape a nail of the appropriate size to the side of the limb for reference, or a radiographic ruler can be used; alternatively, a Küntscher measuring device—the ossimeter—may be used to measure length and width (Fig. 11.80). The ossimeter has two scales, one of which takes into account the magnification caused by the x-ray at a 1-meter tube distance. In most cases, a nail reaching to within 1–2 cm of the subchondral bone distally is indicated. In reamed nailing, the width of nail is better determined by the feel of the reamers than by radiographic measurements, although the approximate size to be used can be determined from preoperative radiographs. Diameter is critical in nonreamed nails, especially when a snug fit is anticipated. The radiograph is helpful in determining nail size before surgery, but, again, the feel of the nail as it is driven is most important.

***Figure 11.80.*** A Küntscher ossimeter is a Plexiglas measuring device used to measure canal diameter and bone length from roentgenograms taken at a 1 m tube distance. A “real” scale and a special exploded scale (to allow for radiographic magnification) are available.

In comminuted fractures, it may be difficult to determine the proper nail length. A radiograph of the opposite normal bone with an appropriate-size nail taped to the extremity is quite helpful.

### INTERLOCKING NAILS

Numerous designs of interlocking nails for the femur, tibia, and humerus and forearm are now available. The most common types of interlocking nails use transverse screws distally and oblique, or transverse screws proximally (Fig. 11.70, Fig. 11.71, Fig. 11.72, Fig. 11.73, Fig. 11.75, and Fig. 11.77). The guides for proximal cross locking are effective. Never subject nails to extremely hard driving, as distortion of the proximal end of the nail may interfere with both proximal and distal cross locking. Difficulties in passing the proximal cross-locking screw are almost always due to distortion of the proximal end of the rod or a loose connection between the nail and the guide. Before driving the rod, check all connections of the driver and guide.

## SURGICAL TECHNIQUES

### CROSS LOCKING

- To perform proximal cross locking, lock the proximal screw guide securely into place. Use the drill sleeve and an appropriate drill point for drilling. If the drill point contacts the rod, immediately withdraw it to avoid breakage.
- After drilling, measure the screw length with the depth gauge. Often this requires fluoroscopy, as it is difficult to feel the opposite cortex with the depth gauge. If the bone in the region where the cross-locking screws are being inserted is nearly round, then screw lengths can be determined by measuring directly on the fluoroscope monitor. The diameter of the rod is known (e.g., 12 mm). Have a nonsterile assistant or nurse mark the width of the rod on a piece of paper placed on the monitor screen and then use that as a reference to measure the width of the bone at the cross-locking hole. This is quick, easy, and accurate within 2 mm or so. It is not reliable when locking on a sloping surface such as the proximal tibia.
- Insert the screw, taking care to avoid cross threading the rod in threaded designs. The heads of most cross screws are quite prominent. Insert them to bring the top of the screw head flush with the bone of the greater trochanter to avoid trochanteric bursitis and a snapping iliotibial band, and prominent screw heads in other locations.

Guiding devices for distal cross locking do not work as well as those for proximal cross locking due to the flexibility of these long guides and distortion of the nail. The Alta system offers a rod-mounted distal cross-locking guide for the femoral, tibial, and humerus nails. The fluted design of the Alta nails minimizes nail distortion in rotation and varus and valgus. The rod will bend in the anteroposterior plane, and this is adjusted for by the guide. It can be used with percutaneous technique, minimizing exposure to x-rays (Fig. 11.81).



***Figure 11.81.*** Alta cross-locking guide for the femur. The guide mounts on the driver for the nail and is used for proximal and distal cross locking. The guide is radiolucent and has a system that facilitates percutaneous screw insertion with minimal use of x-rays. (Courtesy of Howmedica, Rutherford, NJ.)

Other manufacturers offer guides, some of which are based on a stabilizer probe placed at right angles to the cross-locking screws, which must be inserted down to articulate with the rod through a separate stab wound and hole drilled in the femur. These have met with mixed success. Laser light guides that mount on the C-arm head are used to facilitate free-hand targeting but are not in wide use as they do not eliminate the need to use x-ray. Guides using detection of a magnetic field can eliminate the need for x-ray except to verify screw position and length. They are just now in clinical trials.

### FREE-HAND TARGETING

Free-hand methods for placing distal cross screws work well with all current designs.

- Position the heads of the C-arm fluoroscope for a lateral view of the distal end of the rod. Provide maximal clearance between the lateral side of the limb and the head of the C-arm. Align the C-arm with the first of the two distal cross holes. The cross hole to be targeted must be located directly in the center of the fluoroscope screen, must be perfectly superimposed, and must be round (Fig. 11.82). Achieving this alignment can be difficult. It may save time for the surgeon to break scrub to align the fluoroscope head while the radiology technician operates the controls of the C-arm. It saves considerable operating time if all controls on the C-arm are loosened and if the head is moved into position under direct fluoroscopy. Spot images can also be used but are much more time-consuming.

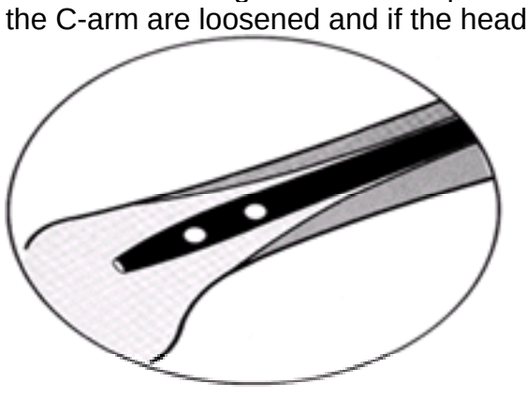

***Figure 11.82.*** Lateral fluoroscopic view of the distal screws in an intramedullary nail. Notice that the hole, which is to be cross locked, is in the center of the screen and is perfectly superimposed.

- Use a long, very sharp $^{1}/_{8}$-inch (0.3 mm) Steinmann pin or a sharp drill point mounted on a radiolucent targeting handle, or held in a Kocher clamp to pinpoint the area of penetration of the bone and to avoid exposing the surgeon's hands to the central beam of the fluoroscope. Bring the tip of the pin or drill point into the fluoroscope image, placing it on the skin directly over the screw-hole image. Mark the location for the skin incision.
- Make a 1 cm longitudinal incision directly over the screw hole down to bone. Insert the pin percutaneously to the cortex of the bone. Again, bring the tip of the pin into the fluoroscopic image at an angle to the fluoroscope beam and locate the tip of the pin directly in the middle of the screw hole (Fig. 11.83). Once located, carefully tip the pin to place it vertical to the cortex and directly in line with the fluoroscope head in all planes.

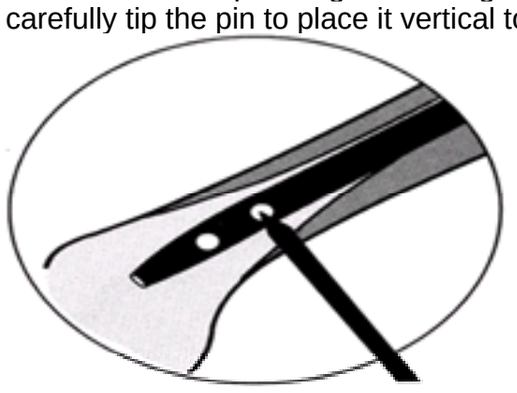

***Figure 11.83.*** Lateral fluoroscopic view of the tip of the pin in proper location before being swung into alignment with the cross holes.

- Maintaining this alignment, mallet the pin into the cortex. It is often possible to insert the pin directly into the near hole on the rod.
- Once this hole is made, insert the appropriate-size drill point and, while maintaining alignment with the fluoroscope head, drill the hole through the rod and the opposite cortex.
- Remove the power source, leaving the drill point in place. Verify with the C-arm that the drill point is directly in the center of the hole. Verify its position on the AP view. If you plan to insert two screws, leave the first drill point in place as it is a useful guide to the proper drilling angle for the second hole. Insert the second drill point with the same technique. Some systems have a hand-held guide that can be slipped over the first drill point to provide guidance for the second hole. Repeat the procedure just described.
- Now insert the appropriate-size screw. Once the initial pin or drill is through the rod and bone, I prefer to place a drill sleeve over the pin and then do subsequent drilling and screw insertion through the guide as this avoids getting lost in the soft tissues. With this technique, radiation exposure is minimized and only 5 minutes or so are needed to insert each screw.

Partially radiolucent power units that use a gunsight principle for targeting are available but are not widely used, as the drill points tend to “walk” on the cortex, and the power units are large and cumbersome.

## POSTOPERATIVE CARE

The postoperative regimen used depends on the bone nailed, the quality of the bone, the stability of the fracture, and whether an interlocking nail has been used. If a noninterlocking nail has been used, the patient must be protected against shortening, angulation, and malrotation until early bone union has occurred. Because interlocking nails are used in the vast majority of cases, this discussion will be focused on locked nails.

In the femur, if the fracture pattern is stable and there is good bone contact over at least a 50% diameter of the cortex with an adequate-size nail and cross screws for the patient, patients can be encouraged to bear weight as tolerated using crutches or a walker. In my experience, the average patient will not attain full weight bearing before 6 weeks. During this period, the supporting musculature is quite weak and quadriceps control is poor; therefore, the patient has little control of the knee. Begin isometric exercises, followed by progressive resistance exercises, as soon as practical to reeducate the quadriceps and hamstring and other muscles. In the meantime, use a knee immobilizer to protect the knee. This can be discontinued when the patient regains good quadriceps control. In unstable fracture patterns, particularly where there is extensive comminution or lack of good bone contact between the major proximal and distal fragments, limit weight bearing to the weight of the leg until periosteal callus is seen bridging the fracture site on two views. At that point, weight bearing can be progressed as the fracture consolidates.

This same philosophy can be applied to the tibia; however, it is usually easier because the patients normally have good control over their knee. A patellar-tendon-bearing brace or similar protective orthosis is often useful, particularly in unstable fractures of the tibia.

In the humerus, external protection is usually unnecessary and the patient can begin immediate gentle range-of-motion exercises of the shoulder and elbow. Resistive muscle rehabilitation can usually begin as soon as bridging callus is seen, or earlier in stable patterns.

## PITFALLS AND COMPLICATIONS

### MALPOSITION

Although malposition of the fracture with subsequent malunion is unusual in intramedullary nailing, the surgeon must pay close attention to avoid it. In simple fracture patterns, establishing overall alignment of the bone and matching the fracture pattern usually results in good alignment, particularly since the bone automatically aligns itself on the rod. In simple fracture patterns, the most common problem of alignment is malrotation. Verify that the patient's position has not shifted on the operating table prior to driving the rod, and be certain that rotation is comparable to the opposite uninjured extremity. In bilateral cases, align the first web space of the toes with the patella and the center line of the hip.

In complex comminuted fractures, particularly those extending into the metaphysis, angular malalignment of the distal or proximal metaphyseal fragments can occur, particularly since it is difficult to ascertain overall alignment on the fluoroscope. Inspect the limb clinically after insertion of the nail. It is occasionally prudent to get long

AP and lateral radiographs immediately after insertion of the nail to be certain that proper alignment is present prior to placement of cross-locking screws. Once the nailing has been completed and the patient is lying in the supine position on the operating table, carefully examine the operated extremity. It is better to detect and correct malalignment now than to have to return the patient to the operating room or to allow malalignment to persist.

Another source of unexpected malalignment is when cross-locking screws appear to have gone through the nail on an AP view, but have actually missed the nail. Careful examination with the fluoroscope after completion of insertion of each screw is essential to be certain that the screw has in fact passed through both the bone and the locking holes in the nail. Take final plain films in the operating room to confirm the fluoroscopic visualization.

### DELAYED UNION

Delayed union is most common in fractures of the tibia due to their increased severity. Delayed union and nonunion in the femur and humerus is unusual with intramedullary nailing because of the copious blood supply available from the surrounding muscular envelope. Other than the deleterious effects of the initial trauma, the most common cause of delayed or nonunion is distraction in the operative site. Brumback et al. have shown that dynamization of locked nails or removal of cross-locking screws before nail removal is unnecessary to achieve union (22). On the other hand, where the fracture pattern is stable and union is delayed (no evident callus bridging the fracture site by 12 weeks after nailing), dynamization may sometimes be indicated. For dynamization to be effective, it is necessary to remove screws from the end of the nail farthest from the fracture site. It is important that, when the fracture site impacts with weight bearing, it becomes rotationally stable. Dynamization of a straight transverse fracture may lead to increased rotational instability and progression to nonunion.

### NONUNION

The incidence of nonunion after closed intramedullary nailing of fractures of the femur is less then 1% to 2%, and only slightly higher in the tibia. The risk of nonunion can be minimized by utilizing closed techniques, and by ensuring good bone contact, preferably impaction, and stable cross locking with nails of sufficient size. If nonunion occurs, most cases are responsive to exchange nailing. Use closed-technique reaming to a larger nail and then provide compression across the fracture site with a compression device and lock the nail in compression. Of course, this is not applicable to fracture patterns that are axially unstable, where open bone grafting may be needed. This is discussed in detail in Chapter 26, Chapter 30, and Chapter 31.

### NEUROLOGIC INJURY

In nailing of fractures of the humerus, the primary nerve at risk is the radial nerve. Although closed nailing techniques have been advocated for the humerus and used successfully, I have seen one radial nerve transected by an intramedullary nail or reamers using closed technique. For that reason, unless there are special circumstances precluding open nailing, I prefer to expose the fracture site to ensure that the radial nerve is not in danger, and then to perform nailing using open technique.

In the femur, the most common palsy is that of the pudendal nerve, which is usually due to inadequate padding or use of too small a perineal post, plus excessive traction for a prolonged period of time. If femur fractures are nailed early, within 24 hours, strong traction is rarely required. If traction is required to reduce a transverse fracture, apply it only long enough to reduce the fracture, and then release. Proper technique should prevent the vast majority of pudendal nerve palsies. Fortunately, nearly all recover without residual effects.

Paresis of the sciatic nerve or its components is usually due to excessive traction with the hip in a flexed position and the knee straight. For that reason, I always keep the knee flexed about 45°, and more if possible, during closed intramedullary nailing of the femur on a fracture table. The methods described above to avoid pudendal palsy are also applicable to avoid sciatic nerve palsy. Direct surgical injury to the nerve is also possible. The exposure used for closed intramedullary nailing is usually not large enough to allow formal exploration of the sciatic nerve, but look for the nerve in the surgical field. In small women with dysplasia of the hip, and in some Asians, the sciatic nerve rests very close to the greater trochanter when the hip is flexed 15° to 20° for nailing.

Transient paresis of the lateral femoral cutaneous nerve can also occur due to pressure from the traction post on the fracture table. To avoid this, use a well-padded post of adequate size and avoid excessive traction.

In closed nailing of the tibia, the nerve at risk is the common peroneal. Paresis can be caused by placing the popliteal bar against the common perineal nerve and then applying excessive traction for prolonged periods of time. To avoid problems, use a thigh bolster that is at least 4 in. in diameter and well padded. Place it under the distal thigh rather than in the popliteal fascia. The region of the common perineal nerve near the head of the fibula should always be free of impingement.

Fortunately, most peripheral nerve palsies secondary to intramedullary nailing are neuropraxias, which recover nicely within a reasonably short period of time.

## G. PRINCIPLES OF HARDWARE REMOVAL

In adults, I do not feel that routine removal of plates, screws, wires, or intramedullary nails is indicated. The primary indication for removal is pain due to the implants, or a request by the patient for removal for reasons important to her. Another possible indication is a plate or screw on the diaphysis of a long bone, which is a stress riser in a patient involved in sports or in an occupation carrying increased risk for fracture, or increased risk for a fracture of worse severity because of the presence of the hardware.

In children, unless removal poses unacceptable morbidity, we advise routine removal of implants, particularly if they are composed of titanium. The rational is that implants in children tend to become very tightly integrated to bone and are commonly overgrown by bone, making subsequent removal exceedingly difficult if not impossible. There do not appear to be any adverse effects of leaving current stainless-steel and titanium implants for up to 40 years. However, the long-term effects of leaving these implants in place for 60–70 or more years is not known; therefore, removal in children seems advisable.

In addition, high-performance athletes may complain that their limb feels not as lively as before they received the implant. This is usually caused by stiffening of the bone segment from the presence of the implant. Removal of the implant is usually necessary for the bone to regain its normal flexibility.

### SURGICAL TECHNIQUES

#### REMOVAL OF PLATES AND SCREWS

Almost always, implants can be removed through the original surgical incision. To obtain a nice scar, unless contraindicated, I usually excise the old wound and use plastic closure techniques to ensure good cosmesis. Superficial cutaneous nerves and other structures are more at risk in hardware removal than at the time of initial surgery, as they are frequently bound down in scar. Look for these to avoid injury. Occasionally, the pain associated with hardware is due to nerve entrapment or a neuroma. Treat this at the same time.

- In removing plates and screws, remove only the bone covering the screw head or plate that interferes with its removal.
- It is easy to strip screws, making their removal very difficult. Be certain that the head of the screw is completely cleaned of bone and that a good-quality screwdriver without a worn tip is firmly engaged into the screw head.
- Taking a slight turn in the direction of tightening often breaks any bone adherent to the screw and makes turning the screw outward easier. If the screw breaks or if broken screws are encountered, there are screw removal sets available from several manufacturers. These usually require overdrilling of the screw. On the other hand, in adults, a broken screw tip in the opposite cortex may not be in a position that will bother the patient and can be left in place.
- When removing plates and screws, avoid creating a stress riser in the bone that might lead to refracture. If the plate is totally uncovered and does not easily lift off the bone, place an osteotome beneath the plate and drive along the underside of the plate parallel to the bone and plate. This usually results in fairly easy removal. The sharp instruments used for hardware removal should be from a special set reserved for that purpose, to avoid damaging high-quality instruments used for initial surgery.
- Once the screws and plates have been removed, resist the temptation to curet the screw holes. This is not necessary for healing and simply makes the screw hole wider, thus increasing the risk of refracture.
- In most cases, the plate will be surrounded by a ridge of bone that has grown up around the edges of the plate. Never remove these ridges, as they serve to reinforce the bone in the early remodeling phase after hardware removal. Nubbins of bone sticking up from the screw holes can be removed if necessary for patient comfort.

Many of the considerations discussed here are not applicable to nails, as they are removed utilizing closed percutaneous techniques, and a significant stress riser is not left in the bone. The major challenge in removing intramedullary nails, particularly in the femur, is identifying the end of the nail and inserting the removal instruments. This is particularly a problem in the femur, where a bone cap commonly forms over the proximal end of the nail. Good surgical exposure and use of a fluoroscope to locate the top and the longitudinal axis of the nail is very helpful. A fluoroscope should also always be used for removal of screws for the same reason. Most intramedullary nails are now provided with cap screws that prevent bone growth into the threads of the nail. I like to place a reaming guide pin down to the top of the nail when there is a bone cap on the nail: I then use a reamer to expose the top of the nail. It is then fairly easy to remove the cap screw, insert the rod remover, and extract the nail. Many intramedullary nailing systems have removal instrumentation that is different from that used to insert the nail. Be certain to follow the manufacturer's recommendations and use the appropriate instrumentation.

## POSTOPERATIVE CARE

In the case of intramedullary nails, as soon as the patient is comfortable, he or she can be weaned off crutches to bear full weight, assuming that the fracture is solidly healed and does not have a defect in it. Once full muscle rehabilitation has been achieved, patients can return to sports and occupational activities without limitations.

In the case of plates and screws, however, more caution needs to be taken because removal of the plate and screws leaves the bone in a weakened condition with holes that are stress risers. If the fixation device is confined to the metaphyseal or epiphyseal regions of the bone, then generally the same guidelines as applied to nails can be used. In the mid diaphysis, however, assuming that the fracture is solidly healed, patients can return to functional use of the limb as tolerated, but they must avoid any activity that would predispose them to fracture until the diaphysis remodels and the screw holes fill in. The timing on this depends on the bone, the age of the patient, and the particular fracture and implant involved.

The highest-risk situation is in the athlete competing in a contact sport. I recommend the following as a general protocol: Typically, the athlete sustains the fracture during the active season (let us assume the sport is football and the fracture occurred in October). If the fracture heals within the expected time and the callus is adequate to support stress, I permit the athlete to return to a general conditioning program, avoiding high-risk activities or contact sports, by 6–8 months after the initial injury. The football player could then engage in fall practice in August and return to competitive football in the fall, approximately 1 year after injury. If intramedullary nails are in place, no special precaution or protective device is necessary.

If the plates are on the upper extremity, then a protective brace is indicated. The athlete should recognize that if a second severe trauma occurs, a fracture at the end of the plates could result. If plates are in the lower extremity, on the mid diaphysis of the femur or tibia, I would not permit the athlete to play contact sports that season. When that season is over, the time would be opportune for the removal of the implant, as by then it would be approximately 18 months since the injury and the bone should be solidly healed. In the case of plates, I would preclude high-risk activity or contact sports for approximately 6 months after removal. Then the patient could gradually return to full-contact activities by approximately 9 months after implant removal, assuming that the appearance of bone is satisfactory on radiographs.

## CHAPTER REFERENCES

Each reference is categorized according to the following scheme: *, classic article; #, review article; !, basic research article; and +, clinical results/outcome study.


+ 1. Allen WC, Heiple KG, Burstein AH. A Fluted Femoral Intramedullary Rod. *J Bone Joint Surg Am* 1978;60:506.

* 2. Allgöwer M, Kinzl L, Matter P, et al. *The Dynamic Compression Plate.* New York: Springer-Verlag, 1977.

+ 3. Alonso J, Geissler W, Hughes JL. External Fixation of Femoral Fractures: Indications and Limitations. *Clin Orthop* 1989;241:83.

! 4. Anderson GI, Richards RR, Paitch B, et al. Soft Tissue Blood Flow after Segmental Osteotomy of the Canine Tibia. *Ann Plast Surg* 1991;127:49.

+ 5. Anderson LD, Sisk TD, Tooms RE, Park WI. Compression Plate Fixation in Acute Diaphyseal Fractures of the Radius and Ulna. *J Bone Joint Surg Am* 1975;57:287.

+ 6. Ashcroft GP, Evans NT, Roeda D. Measurement of Blood Flow in Tibial Fracture Patients Using Positron Emission Tomography. *J Bone Joint Surg Br* 1992;75:673.

* 7. Bagby GW, Janes JM. An Impacting Bone Plate. *Proc Staff Meetings Mayo Clinic* 1957;32:55.

* 8. Bagby GW, Janes JM. The Effect of Compression on the Rate of Fracture Healing Using a Special Plate. *Am J Surg* 1958;95:761.

# 9. Behrens F, Allgower M, Fernandez DL, et al. External Fixation. In: Müller ME, Allgower M, Schneider R, Willenegger H, eds. *Manual of Internal Fixation. Techniques Recommended by the AO-ASIF Group.* New York: Springer-Verlag, 1991:367.

+ 10. Behrens F, Johnson W. Unilateral External Fixation: Methods to Increase and Reduce Frame Stiffness. *Clin Orthop* 1989;241:48.

+ 11. Behrens F, Searls K. External Fixation of the Tibia. Basic Concepts and Prospective Evaluation. *J Bone Joint Surg Br* 1986;68:246.

! 12. Behrens F, Johnson WD, Koch TW, et al. Bending Stiffness of Unilateral and Bilateral Fixator Frames. *Clin Orthop* 1983;178:103.

# 13. Behrens F. A Primer of Fixator Devices and Configurations. *Clin Orthop* 1989;241:5.

# 14. Behrens F. General Theory and Principles of External Fixation. *Clin Orthop* 1989;241:15.

+ 15. Blachut PA, Meek RN, O'Brien PJ. External Fixation and Delayed Intramedullary Nailing of Open Fractures of the Tibial Shaft. *J Bone Joint Surg Am* 1990;72:729.

+ 16. Bone LB, Johnson KD. Treatment of Tibial Fractures by Reaming and Intramedullary Nailing. *J Bone Joint Surg Am* 1986;68:877.

+ 17. Bosse MJ, MacKenzie EJ, Riemer BL. Adult Respiratory Distress Syndrome, Pneumonia, and Mortality Following Thoracic Injury and a Femoral Fracture Treated with Intramedullary Nailing with Reaming or with a Plate. *J Bone Joint Surg Am* 1997;79:799.

+ 18. Böstman OM. Absorbable Implants for the Fixation of Fractures. *J Bone Joint Surg Am* 1991;73:148.

! 19. Briggs BT, Chao EYS. The Mechanical Performance of the Standard Hoffmann-Vidal External Fixation Apparatus. *J Bone Joint Surg Am* 1982;64:566.

+ 20. Brumback RJ, Ellison PS Jr, Poka A, et al. Intramedullary Nailing of Open Fractures of the Femoral Shaft. *J Bone Joint Surg Am* 1989;71:1324.

+ 21. Brumback RJ, Reilly JP, Poka A, et al. Intramedullary Nailing of Femoral Shaft Fractures. Part I: Decision-Making Errors with Interlocking Fixation. *J Bone Joint Surg Am* 1988;70:1441.

+ 22. Brumback RJ, Uwagie-Ero S, Lakatos RP, et al. Intramedullary Nailing of Femoral Shaft Fractures. Part II: Fracture-Healing with Static Interlocking Fixation. *J Bone Joint Surg Am* 1988;70:1453.

+ 23. Bucholz RW, Henry S, Henley MB. Fixation with Bioabsorbable Screws for the Treatment of Fractures of the Ankle. *J Bone Joint Surg Am* 1994;76:319.

+ 24. Buhler J. Percutaneous Cerclage of Tibial Fractures. *Clin Orthop* 1974;105:276.

* 25. Burny F. Traitement par Osteotaxis des Fractures Diaphysaires du Tibia: Etude de 115 Cas. *Acta Orthop Belg* 1972;38:280.

# 26. Chapman MW. Closed Intramedullary Nailing of Femoral-Shaft Fractures: Technique and Rationale. *Contemp Orthop* 1982;4:2.

+ 27. Chapman MW, Gordon JE, Zissimos AG. Compression Plate Fixation of Acute Fractures of the Diaphyses of the Radius and Ulna. *J Bone Joint Surg Am* 1989;71:159.

* 28. Charnley J, Guindy A. Delayed Operation in the Open Reduction of Fractures of the Long Bones. *J Bone Joint Surg Br* 1971;43:664.

+ 29. Clarke RP, Shen WD, Bierbaum R. Trochanteric Osteotomy. Analysis of Pattern of Wire Fixation Failure and Complications. *Clin Orthop* 1979;41:102.

* 30. Clawson DK, Smith RF, Hansen ST. Closed Intramedullary Nailing of the Femur. *J Bone Joint Surg Am* 1971;53:681.

+ 31. Court-Brown CM, McQueen MM, Quaba AA, Christie J. Locked Intramedullary Nailing of Open Tibial Fractures. *J Bone Joint Surg Br* 1991;73:959.

! 32. Coutts RD, Harris WH, Weinberg EH. Compression Plating: Experimental Study of the Effect on Bone Formation Rates. *Acta Orthop Scand* 1973;44:256.

+ 33. Cove JA, Lhowe DW, Jupiter JB, Siliski JM. The Management of Femoral Diaphyseal Nonunions. *J Orthop Trauma* 1997;11:513.

+ 34. Dall DM, Miles AW. Reattachment of the Greater Trochanter: The Use of the Trochanter Cable-grip System. *J Bone Joint Surg Br* 1983;65:55.

+ 35. Daniel DM, Robertson DB, Flood DL, Biden EN. Fixation of Soft Tissue. In: Jackson DW, Drez D Jr, eds. *The Anterior Cruciate Deficient Knee.* St. Louis: Mosby, 1987.

* 36. Danis R. *Théorie et Pratique de l'Ostéosynthèse.* Paris: Masson, 1949.

+ 37. De Bastiani G, Aldegheri R, Brivio LR. The Treatment of Fractures with a Dynamic Axial Fixator. *J Bone Joint Surg Br* 1984;66:538.

! 38. Duwelius PJ, Mullins RJ, Woll TS. The Effects of Femoral Intramedullary Reaming in a Sheep Lung Model: A Pilot Study. *Orthop Trans* 1995;19:152.

+ 39. Ender HG. Treatment of Pertrochanteric and Subtrochanteric Fractures of the Femur with Ender Pins. In: *The Hip (Proceedings of the Hip Society)*. St. Louis: Mosby, 1978:187.

+ 40. Ender J, Simon-Weider R. Die Fixierung der Trochanterem Beicle nil Remden Elastichen Condylemargelin. *Acta Chir Aust* 1972;1:40.

+ 41. Evans M, Kenwright J, Tanner KE. Analysis of Single-Sided External Fracture Fixation. *Eng Med* 1979;8:133.

# 42. Eycleshymer AC, Schoemaker DM. *A Cross-sectional Anatomy.* New York: Appleton-Century-Crofts, 1911.

! 43. Goodship AE, Kenwright J. The Influence of Induced Micromovement upon the Healing of Experimental Tibial Fractures. *J Bone Joint Surg Br* 1985;67:650.

! 44. Gothman J. Arterial Changes in Experimental Fractures of the Rabbit's Tibia Treated with Intramedullary Nailing: A Microangiographic Study. *Acta Chir Scand* 1960;120:289.

! 45. Gothman J. Arterial Changes in Experimental Fractures of the Monkey's Tibia Treated with Intramedullary Nailing. *Acta Chir Scand* 1961;121:56.

! 46. Gothman L. Local Arterial Changes Associated with Experimental Fractures of the Rabbit's Tibia Treated with Encircling Wires. A Microangiographic Study. *Acta Chir Scand* 1962;123:1.

+ 47. Green RA, Zins JE. The “Knot Twist”: A New Method of Securing Wire Loops—An Assessment of Mechanical Properties. *Plast Reconstr Surg* 1988;81:956.

# 48. Green S. Complications of External Skeletal Fixation: Causes, Prevention and Treatment. Springfield, IL: Charles C. Thomas, 1981.

! 49. Gruendnes O, Reikeras. Acute Effects of Intramedullary Reaming on Bone Blood Flow in Rats. *Acta Orthop Scand* 1993;64:203.

! 50. Guadagni JR, Drummond DS. Strength of Surgical Wire Fixation. A Laboratory Study. *Clin Orthop* 1986;209:177.

! 51. Heim D, Schlegel U, Perren SM, et al. Intramedullary Pressure in Reamed and Unreamed Nailing of the Femur and Tibia: An in Vitro Study in Intact Human Bones. *Injury* 1993;23(suppl 3):56.

+ 52. Hidaka S, Gustilo RB. Refracture of Bones of the Forearm after Plate Removal. *J Bone Joint Surg Am* 1984;66:1241.

+ 53. Johnson KD, Johnston DWC, Parker B. Comminuted Femoral Shaft Fractures: Treatment by Roller Traction, Cerclage Wires and an Intramedullary Nail or an Interlocking Intramedullary Nail. *J Bone Joint Surg Am* 1984;66:1222.

+ 54. Jones DG. Bone Erosion beneath Partridge Bands. *J Bone Joint Surg Br* 1986;68:476.

+ 55. Jupiter J, Rüedi T. Intraoperative Distraction in the Treatment of Complex Forearm Nonunions. *J Hand Surg* 1992;17A:416.

+ 56. Karlstrom G, Olerud S. Percutaneous Pin Fixation of Open Tibial Fractures: Double Frame Anchorage Using the Vidal-Adrey Method. *J Bone Joint Surg Am* 1975;57:915.

* 57. Kempf I, Grosse A, Beck G. Closed Locked Intramedullary Nailing. *J Bone Joint Surg Am* 1985;67:709.

+ 58. Kenwright J, Goodship AE. Controlled Mechanical Stimulation in the Treatment of Tibial Fractures. *Clin Orthop* 1989;241:36.

! 59. Kenwright J, Goodship AE, Kelly DJ, et al. Effect of Controlled Axial Micromovement on Healing of Tibial Fractures. *Lancet* 1986;2:1185.

* 60. Klemm K, Schellmann WD. Dynamische und Statische Verriegelung des Marknagels. *Monatsschr Unfallheilk* 1972;75:568.

* 61. Konig F. Ueber die Implantation von Elfenbein zum Erzatz von Knochen und gelenkenden nach Experimentellen und Klinischen Beobachungen. *Beitr Klin Chir* 1913;85.

+ 62. Kröpfl A, Berger U, Neureiter H, et al. Intramedullary Pressure and Bone Marrow Fat Intravasation in Unreamed Femoral Nailing. *J Trauma* 1997;42:946.

* 63. Küntscher G. Practice of Intramedullary Nailing. Springfield, IL: Charles C. Thomas, 1967.

* 64. Küntscher G. The Intramedullary Nailing of Fractures. *Clin Orthop* 1968;60:5.

+ 65. Lambert KL. Vascularized Patellar Tendon Graft with Rigid Internal Fixation for Anterior Cruciate Ligament Insufficiency. *Clin Orthop* 1983;172:885.

+ 66. Lhowe D, Hansen ST Jr. Immediate Nailing of Open Fractures of the Femoral Shaft. *J Bone Joint Surg Am* 1988;70:812.

* 67. Lottes JO. Medullary Nailing of the Tibia with the Triflange Nail. *Clin Orthop* 1974;105:253.

+ 68. Macko D, Szabo RM. Complications of Tension Band Wiring of Olecranon Fractures. *J Bone Joint Surg Am* 1985;67:1396.

! 69. Manning JB, Bach AW, Herman CM, et al. Fat Release after Femur Nailing in the Dog. *J Trauma* 1993;35:709.

+ 70. Maurer DJ, Perkow RL, Gustilo RB. Infection after Intramedullary Nailing of Severe Open Tibial Fractures Initially Treated with External Fixation. *J Bone Joint Surg Am* 1989;71:835.

# 71. Müller ME, Allgöwer M, Schneider R, et al. *Manual of Internal Fixation*, 3rd ed. Berlin: Springer-Verlag, 1990.

+ 72. Paley D, Catagni MA, Argani F, et al. Ilizarov Treatment of Tibial Nonunions with Bone Loss. *Clin Orthop* 1989;241:146.

+ 73. Pankovich AM. Adjunctive Fixation in Flexible Intramedullary Nailing of Femoral Fractures. *Clin Orthop* 1981;157:301.

+ 74. Pankovich AM, Goldflies ML, Person RL. Closed Ender Nailing of Femoral Shaft Fractures. *J Bone Joint Surg Am* 1979;61:222.

+ 75. Pape HC, Regal G, Dwenger A, et al. Influences of Different Methods of Intramedullary Nailing on Lung Function in Patients with Multiple Trauma. *J Trauma* 1993;35:709.

! 76. Paradjs GR, Kelly PJ. Blood Flow and Mineral Deposition in Canine Tibial Fractures. *J Bone Joint Surg Am* 1975;57:220.

* 77. Parham FW, Martin ED. A New Device for the Treatment of Fractures. *New Orleans Med Surg J* 1913;21:451.

# 78. Partridge AJ. Nylon Cerclage and Nylon Plate Fixation in Osteoporotic Fractures. In: Uhthoff HK, ed. *Current Concepts of Internal Fixation.* New York: Springer-Verlag, 1980.

* 79. Pauwels F. *Gesammelte Abhandlungen zur Funktionellen Anatomie des Bewegungsapparates.* New York: Springer-Verlag, 1965.

+ 80. Pell ACH, Christie J, Keating JF, et al. The Detection of Fat Embolism by Transesophageal Echocardiography during Reamed Intramedullary Nailing. *J Bone Joint Surg Br* 1993;75:921.

! 81. Perren SM, Huggler A, Russenberger M, et al. The Reaction of Cortical Bone to Compression. *Acta Orthop Scand Suppl* 1969;125:19.

* 82. Perren SM, Russenberger M, Steinemann S, et al. A Dynamic Compression Plate. *Acta Orthop Scand Suppl* 1969;125:31.

+ 83. Reckling FW, Waters CH III. Treatment of Non-unions of Fractures of the Tibial Diaphysis by Postero-lateral Cortical Cancellous Bone-Grafting. *J Bone Joint Surg Am* 1980;62:936.

* 84. Rhinelander FW. The Normal Microcirculation of Diaphyseal Cortex and Its Response to Fracture. *J Bone Joint Surg Am* 1968;50:784.

+ 85. Rhinelander FW. Tibial Blood Supply in Relation to Fracture Healing. *Clin Orthop* 1974;105:34.

+ 86. Rhinelander FW. Minimal Internal Fixation of Tibial Fractures. *Clin Orthop* 1975;107:188.

* 87. Rhinelander FW, Phillips RS, Steel WM, Beer JC. Microangiography in Bone Healing. Part II: Displaced Closed Fractures. *J Bone Joint Surg Am* 1968;50:643.

! 88. Richards RR, Orsini EC, Mahoney JL, Vershuren R. The Influence of Muscle Flap Coverage on the Repair of Devascularized Tibial Cortex: An Experimental Investigation in the Dog. *Plast Reconstr Surg* 1987;79:946.

! 89. Richards RR, Schemitsch EH. Effect of Muscle Flap Coverage on Bone Blood Flow Following Devascularization of a Segment of the Tibia: An Experimental Investigation in the Dog. *J Orthop Res* 1989;7:550.

* 90. Rush LV. *Atlas of Rush Pin Techniques.* Meridian, MS: Berivon, 1956.

* 91. Sage FP. Medullary Fixation of Fractures of the Forearm. A Study of the Medullary Canal of the Radius and a Report of 50 Fractures of the Radius Treated with a Prebent Triangular Nail. *J Bone Joint Surg Am* 1959;41:1489.

! 92. Schemitsch EH, Jain R, Turchin DC. Pulmonary Effects of Fixation of a Fracture with a Plate Compared with Intramedullary Nailing. *J Bone Joint Surg Br* 1997;37:984.

! 93. Schemitsch EH, Kowalski MJ, Swiontkowski MF. Soft Tissue Blood Flow in Reamed versus Unreamed Locked Intramedullary Nailing: A Fractured Sheep Tibia Model. *Ann Plast Surg* 1996;36:70.

! 94. Schemitsch EH, Kowalski MJ, Swiontkowski MF, Harrington RM. Comparison of the Effect of Reamed and Unreamed Locked Intramedullary Nailing on Blood Flow in the Callus and Strength of Union Following Fracture of the Sheep Tibia. *J Orthop Res* 1995;13:382.

! 95. Schemitsch EH, Weinberb JA, McKee MD. The Relative Importance of the Intramedullary, Intracortical, and Extraosseous Soft Tissue Blood Flow to the Repair of Devascularized Canine Tibial Cortex. *Ann Plast Surg* 1997;38:623.

+ 96. Schmidt A, Rorabeck CH. Fractures of the Tibia Treated by Flexible External Fixation. *Clin Orthop* 1983;178:162.

* 97. Schneider HW. Use of the Four-Flanged Self-Cutting Intramedullary Nail for Fixation of Femoral Fractures. *Clin Orthop* 1968;60:29.

# 98. Searls K, Heichel S, Niemuth P, et al. External Fixation: General Principles of Patient Management. *Crit Care Q* 1983;6:45.

+ 99. Smith JEM. The Results of Early and Delayed Internal Fixation of Fractures of the Shaft of the Femur. *J Bone Joint Surg Br* 1964;46:28.

* 100. Street DM. 100 Fractures of the Femur Treated by Means of the Diamond-Shaped Medullary Nail. *J Bone Joint Surg Am* 1951;33:659.

! 101. Sturmer KM. Measurement of Intramedullary Pressure in an Animal Experiment and Propositions to Reduce the Pressure Increase. *Injury* 1997;24:623.

! 102. Swiontkowski MF, Senft D. Cortial Bone Microperfusion: Response to Ischemia and Changes in Major Arterial Blood Flow. *J Orthop Res* 1992;10:337.

! 103. Uhthoff HK, Dubus FL. Bone Structure Changes in the Dog under Rigid Internal Fixation. *Clin Orthop* 1971;81:165.

+ 104. Velazco A, Whitesides TE Jr, Fleming LL. Open Fractures of the Tibia Treated with the Lottes Nail. *J Bone Joint Surg Am* 1983;65:879.

* 105. Vidal J, Buscayret C, Connes H, et al. Traitment des Fractures Ouvertes de Jambe par le Fixateur Externe en Double Cadre. *Rev Chir Orthop* 1976;62:433.

! 106. Viegas SF, Ferren EL, Self JT. Comparative Mechanical Properties of Various Kirschner Wire Configurations in Transverse and Oblique Phalangeal Fractures. *J Hand Surg* 1988;13A:246.

+ 107. Weber BG. *Die Verletzungen des Oberen Sprunggelenkes. Aktuelle Probleme in der Chirurgie*, 3rd ed. Stuttgart: Huber, 1972.

+ 108. Weber MJ, Janecki CJ, McLeod P, et al. Efficacy of Various Forms of Fixation of Transverse Fractures of the Patella. *J Bone Joint Surg Am* 1980;62:215.

+ 109. Wenda K, Runkel M, Degrief J, et al. Pathogenesis and Clinical Relevence of Bone Marrow Embolism in Medullary Nailing Demonstrated by Intraoperative Echocardiography. *Injury* 1993;24(suppl 3):73.

+ 110. White GW, Healy WH, Brumback RJ, et al. The Treatment of Fractures of the Femoral Shaft with the Brooker-Wills Distal Locking Intramedullary Nail. *J Bone Joint Surg Am* 1986;68:865.

! 111. Wilson JW. Knot Strength of Cerclage Bands and Wires. *Acta Orthop Scand* 1988;59:545.

! 112. Wilson JW, Rhinelander FW, Stewart CL. Microvascular and Histologic Effect of Circumferential Wire on Appositional Bone Growth in Immature Dogs. *J Orthop Res* 1985;3:412.

* 113. Winquist RA, Hansen S Jr, Clawson DK. Closed Intramedullary Nailing of Femoral Fractures: A Report of 520 Cases. *J Bone Joint Surg Am* 1984;66:529.

! 114. Wolinsky PR, Sciadini MF, Parker RE. Effects on Pulmonary Physiology of Reamed Femoral Intramedullary Nailing in an Open Chest Model. *J Orthop Trauma* 1996;10:75.

# 115. Woo SL-Y, Lomringer KS, Akeson WH, et al. Less Rigid Internal Fixation Plates: Historical Perspectives and New Concepts. *J Orthop Res* 1984;1:431.

+ 116. Yaremchuk MJ, Brumback RJ, Manson PN, et al. Acute and Definitive Management of Traumatic Osteocutaneous Defects of the Lower Extremity. *Plast Reconstr Surg* 1987;80:1.

* 117. Zickel RE. An Intramedullary Fixation Device for the Proximal Part of the Femur: Nine Years' Experience. *J Bone Joint Surg Am* 1976;58:866.

+ 118. Zickel RE. Subtrochanteric Femoral Fractures. *Orthop Clin North Am* 1980;11:555.

# CHAPTER 12

# OPEN FRACTURES

*Michael W. Chapman*

**M. W. Chapman:** Department of Orthopaedics, University of California Davis, Sacramento, California, 95817.

Goals of Treatment
Classification
Treatment in the Emergency Room
Systemic Antibiotics
Antibiotic-Impregnated Beads
Principles of Wound Debridement
Surgical Techniques
Irrigation
Debridement Technique
Wound Closure
Fracture Stabilization
Casts and Skeletal Traction
External Fixation
Internal Fixation
Bone Grafting
Amputation
Open Fractures in Children
Pitfalls and Complications
Author's Perspective
Chapter References

## GOALS OF TREATMENT

The goals in the treatment of open fractures are to prevent infection, achieve bone union, avoid malunion, and restore the limb and patient to full function as early as possible. Of these, it is most important to avoid infection, as infection is the most common complication leading to nonunion and loss of function. The most important prognostic factor that determines the long-term result in open fractures is the amount of energy absorbed by the limb at the time of initial injury. This determines the amount of devitalized soft tissue and the level of contamination, which are more important than the configuration of the fracture (1,5,12,30,42). The latter, however, is a good indicator of whether a fracture is the result of high-energy or low-energy forces. Comminution and wide displacement are almost always associated with high-energy injuries. The classification of open fractures developed by Gustilo and Anderson is a good guide to the severity of injury and permits some prognostication and recommendations for treatment (32,35).

## CLASSIFICATION

Although wound size plays a role in the classification of open fractures, it is a mistake to use this as the overriding factor in determining the classification. Extremely severe soft-tissue crushing is often associated with punctate wounds. The entire extent of the injury must be taken into account in applying this classification.

A type I open fracture (Fig. 12.1) has a wound that is usually less than 1 cm long and is caused by low-energy forces. Generally, it is caused by the bone piercing the skin rather than a penetrating object. It is not associated with significant crushing or muscle damage. Fractures of this type that occur in highly contaminated environments, such as a farmyard, are classified as type III fractures.

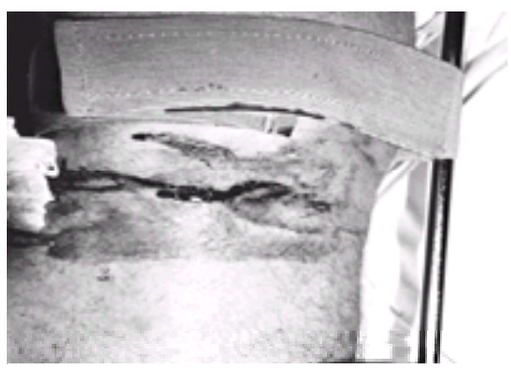

***Figure 12.1.*** Type I open fracture of the tibia.

A type II open fracture (Fig. 12.2) has a wound that is more than 1 cm long and is associated with moderate deep muscle damage secondary to the high energy absorbed at the time of injury. A type II open fracture is considered to be transitional between type I and type III open fractures.

***Figure 12.2.*** Type II open fracture of the tibia.

A type III open fracture (Fig. 12.3) is caused by high-energy forces, is usually associated with wounds more than 10 cm long, and involves extensive muscle damage. The fracture is often widely displaced or comminuted. Any open fracture with one or more of the following characteristics is classified as type III: high-velocity gunshot wounds, shotgun wounds, displaced segmental fractures, fractures with significant diaphyseal segmental loss, concomitant vascular injuries requiring repair, and fractures occurring in highly contaminated environments, such as farmyards. Fractures associated with crushing caused by high-velocity motor vehicle accidents are

usually type III injuries.

***Figure 12.3.*** Type IIIB open fractures of both tibias.

Type III injuries are further broken down into three subgroups (34). In type IIIA open fractures, there is limited periosteal and muscle stripping from bone, and major plastic reconstructive procedures, such as flaps, are not required to achieve bone coverage. In type IIIB fractures, there is extensive soft-tissue stripping from bone. Soft-tissue defects that result in exposed bone require reconstructive procedures to restore soft tissue coverage. In a type IIIC open fracture, a major vascular injury requires repair to salvage the limb. The AO/ASIF group has a classification that grades the soft tissue injury incorporating the degree of injury to the skin, muscle, tendon, and neurovascular structures; it is used in conjunction with the AO/ASIF alphanumeric fracture classification system (62). Tscherne and associates have reported on an open fracture score that takes into account the AO/ASIF fracture classification and grades bone loss; skin, muscle, and soft tissue injury; neurovascular injury; compartment syndrome; time from injury to initial treatment; contamination; and results of cultures. Using a combination of these scores, they grade open fractures into types I to IV. They validated this score in a study of 651 open fractures (77). I find the latter two classifications to be too complex for day-to-day clinical use; instead, they are more suited to clinical research. We continue to use the Gustilo classification; however, the reader needs to be aware that even this simple system is subject to significant variation in interobserver agreement (28).

## TREATMENT IN THE EMERGENCY ROOM

In the emergency room, quickly assess the patient for vital body functions and resuscitate and stabilize as necessary. During resuscitation and immediate evaluation, splint the patient's fractures and cover open wounds with sterile compression dressings. Soak the dressing immediately adjacent to the wound with a dilute povidone-iodine solution, particularly if the patient will not be undergoing immediate debridement. I no longer obtain cultures of open fracture wounds in the emergency room, as studies have not shown this to be useful in making therapeutic decisions (52,61). Use traction for femoral fractures. Immediately after resuscitation and stabilization, perform a complete history and physical examination. Evaluate the extremities for neurovascular function, possible compartment syndrome, and soft-tissue injury, and record the findings. Then obtain appropriate radiographs. Certain open fracture-dislocations and dislocations, such as widely displaced dislocations of the ankle, subtalar joint, knee, or elbow, are best reduced immediately in the emergency room. This usually can be accomplished with premedication and no anesthesia. Open fracture-dislocations of the hip and shoulder almost always require general or regional anesthesia. Fracture reduction under anesthesia is generally easier for both patient and surgeon.

## SYSTEMIC ANTIBIOTICS

To prevent tetanus, administer tetanus immune globulin and tetanus toxoid. The globulin is not required if the patient has had toxoid in three or more doses within the last 10 years. Start intravenous bactericidal antibiotics as soon as possible. In types I and II open fractures, the antibiotic of choice is usually a cephalosporin; I prefer cefazolin sodium. For the average adult, a loading dose of 1 to 2 g, followed by 1 g every 8 h, is effective. For patients with farmyard injuries or other open fractures in which there is a risk of infection with *Clostridium,* give 4 to 5 million units of penicillin every 6 h as well. In type III open fractures, give an aminoglycoside intravenously—3 to 5 mg/kg of lean body weight per day—in divided doses at 8-h intervals. I begin with gentamicin. Monitor serum levels of the aminoglycosides to ensure therapeutic levels and to avoid toxicity. Obtain a complete blood count, urinalysis, blood urea nitrogen level, serum creatinine levels, liver function test, and audiometry test as soon as practical after the initiation of therapy and then at appropriate intervals (33,66,67).

The length of time for which antibiotic therapy should be continued remains in question. Common practice in most major trauma centers in North America is to give antibiotics for the first 3 days (33,36). Antibiotics are then discontinued unless postdebridement cultures and the patient's clinical course suggest that infection has occurred. An advantage of discontinuing antibiotics after 3 days is that the patient will not be receiving antibiotics at the time of delayed primary closure, which takes place about 5 days after injury in uncomplicated open fractures. At the time of delayed closure, obtain repeat cultures and reinstitute a 3-day course of antibiotics. If the results of the cultures are negative, and the patient's clinical course is progressing satisfactorily, discontinue the antibiotics at the end of the second 3-day regimen. Detection of organisms on Gram stain of tissues from the wound at the time of delayed primary closure suggests that there are more than 10,000 organisms per cubic millimeter in the wound; this indicates heavy contamination or infection. With this finding, it may be necessary to continue antibiotics for at least 3 weeks, and closure may have to be delayed (62). If infection is evident, cultures and antibiotic sensitivity tests may indicate the need to change the antibiotic regimen to one that is specific for treatment of the infecting organism(s). In more extensive, severe type III open wounds, a continuous course of antibiotics is usually indicated until successful wound closure. For more information on this complex topic, see publications by Gustilo (33,36,84), Patzakis (66,68), and others (9,28,58,73,90).

## ANTIBIOTIC-IMPREGNATED BEADS

Almost any antibiotic available in a powder form can be added to beads made of polymethylmethacrylate. They are not commercially available in the United States but can be manufactured by the surgeon in the operating room by mixing 1 g of tobramycin powder into one batch of polymethylmethacrylate using a bead maker (available from Department of Orthopaedics, Hennepin County Hospital, Minneapolis, MN); this produces a string of 30 6-mm beads on a wire. Antibiotics leach from the surface of the beads to produce wound levels of antibiotics several times higher than that achieved by the intravenous route, and systemic absorption is negligable (20). They are not approved for sale by the Food and Drug Administration.

Seligson and associates placed beads in debrided open fracture wounds, which were left open and covered with a watertight, oxygen-permeable membrane (opsite), producing a “bead pouch” (25). This not only produces high levels of local antibiotics but also protects soft tissue and bone from desiccation and further contamination. The bead pouch is renewed at the time of each debridement until wound closure.

Eckman et al. (25), in a comparative study, were able to reduce the infection rate using antibiotics alone from 39% to 7.3% when the bead pouch was added to their usual systemic antibiotics. Bead pouch treatment remains investigational at this time but is promising (65).

## PRINCIPLES OF WOUND DEBRIDEMENT

The objectives of irrigation and debridement are delineated in Table 12.1.

| |
|---|
| Removal of foreign material |
| Excision of nonviable tissues |
| Elimination of bacterial contamination |
| Creation of a wound that can be closed and heal without infection |

*Table 12.1. Objectives of Irrigation and Debridement*

## SURGICAL TECHNIQUES

Begin irrigation and debridement of the open fracture with the usual surgical preparation and draping. During preparation, remove gross debris from the wound, using copious amounts of preparation solution. In extremity wounds, a tourniquet is placed, if possible, but is not inflated unless hemorrhage cannot be controlled by routine surgical means. This is because the hypoxia imposed by a tourniquet interferes with the physiologic response of muscle necessary to determine its viability.

### IRRIGATION

- Irrigate the wound with copious amounts of normal saline solution. Irrigation is most effective when a mechanical irrigator with a shower-type head is used. The pulsating lavage produced is very effective in loosening and washing away debris. Moreover, high volumes of solution can be run through the wound in a short period of time. The degree of contamination and the size of the wound determine the extent of initial irrigation. For an average type II wound of the tibia, begin with 2 L.
- Irrigate the wound at intervals throughout the debridement process to clear the wound of debris on a continuous basis. At the completion of debridement, topical antibiotics can be added to the last 2-L bag of irrigation solution. The type and concentration of topical antibiotic is the surgeon's choice. I most commonly use 50,000 units of bacitracin per liter of solution.
- For large wounds try to use 10 L of irrigation by the time the debridement is completed. Anglen and associates compared bulb syringe irrigation to pulse lavage and found the latter to be 100 times more effective in reducing bacterial count (2). They also compared adding bacitracin or neomycin or soap detergent (castile soap) to the solution. They found no benefit from the antibiotics, but the detergent was very effective in reducing the bacterial count. Kellam and associates have shown that solutions of povidone-iodine or hydrogen peroxide decrease osteoblast function; therefore, they are not recommended as routine irrigation solution (47).

### DEBRIDEMENT TECHNIQUE

- Extend the wound as large as necessary to irrigate and debride all contaminated and nonviable tissue using extensile incisions (Fig. 12.4).

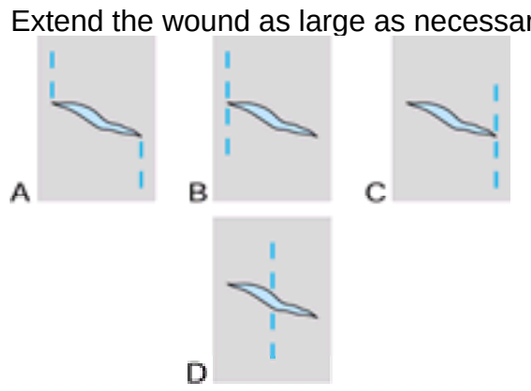


***Figure 12.4.*** Methods of extension of a traumatic transverse or oblique wound. **A:** This Z-plasty technique produces two large flaps and risks necrosis of the tips of the flaps. **B,C:** Both of these methods also produce large flaps. **D:** Crossing the wound results in the smallest flaps. This minimizes the risk of flap necrosis and is the incision of choice.

- Remove all ragged, contaminated skin edges, establishing a surgical wound edge that is at right angles to the skin and suitable for closure. Be conservative in skin removal, as skin coverage can be a problem in certain areas such as in the lower extremity distal to the knee and in the hand. Skin flaps with a length-to-base ratio greater than 2:1, particularly those that are distally based, will often exhibit some necrosis at the tip of the flap. It is often difficult to predict flap viability at the time of initial debridement. Inflating the tourniquet for a brief period of time and then deflating it to produce hyperemia in the flap will often delineate devascularized portions, which can then be excised. Leave marginal skin, as it can be debrided later. If extensive, nonviable flaps are removed and skin coverage is a potential problem, split-thickness skin grafts can be removed from the debrided flaps in areas where the skin is in good condition. Use a Padgett dermatome. This skin can be banked for later use or placed immediately as a meshed split-thickness skin graft.
- Subcutaneous fat has a poor blood supply. Debride all contaminated or devascularized fat. The fascia is also relatively avascular and, if contaminated, should be excised.
- In type II or worse fractures, perform prophylactic fasciotomy at the time of debridement through the open fracture wound. If the wound is not large enough to perform the fasciotomy under direct vision, use a Metzenbaum scissors to split the fascia beneath the skin. Releasing the fascia of one major compartment, such as the anterior tibial compartment in the leg, is usually sufficient. If a significant compartment syndrome is present or expected, formal four-compartment fasciotomy is indicated.
- Debride all nonviable and contaminated muscle. Color and bleeding are not good determinants of muscle viability, as hematoma renders the muscle dark and arteriolar bleeding can persist in totally nonviable muscle. The best indicators of viability are the muscle's response to a stimulus and its ability to rebound to normal appearance after being pinched gently with a pair of forceps. Viable muscle fibers contract in response to either the gentle pinch of a pair of toothed forceps or stimulation with a nerve-stimulating device or electrical coagulator on a low setting. Muscle that does not respond and in which a prominent forceps imprint is left is usually nonviable and should be debrided. In type III open fractures, entire compartments or muscle–tendon units may appear nonviable. It may be quite difficult to determine nonviability at the time of initial debridement. In major wounds, leave intact marginal muscle necessary to preserve muscle–tendon units that are important for future function. A tendon with only 10% of the muscle remaining produces surprisingly good function. If marginal muscle is left intact, repeat debridement within 24 to 36 h and then as frequently as necessary to remove all nonviable muscle.
- Exposed tendons and bone not covered by peritenon or periosteum will desiccate and die within several days, particularly if not kept moist. Therefore, irrigate peritenon and periosteum copiously rather than debriding it. Try to cover tendons without peritenon and bone without periosteum with soft tissue.
- Totally detached cortical fragments of bone that are contaminated are generally discarded. If internal fixation is performed, and the bone fragment is critical to the construct, and if it can be adequately debrided, retain it. If infection occurs, the fragment must be discarded. When large nonviable fragments such as these are reimplanted, bone grafting is almost always advisable. Try to preserve all soft-tissue attachments to bone fragments. Free fragments of cancellous bone that can be debrided adequately are left in the fracture bed as bone graft. Swiontkowski has described criteria for bone debridement using laser Doppler flowmetry (83).

### WOUND CLOSURE

After initial debridement, it is never an error to leave the traumatic wound open. The infection rates with type I open fractures are equal to those reported in elective orthopaedic surgery, however (18,35,49,72). Therefore, many surgeons do primary closure of type I open fractures and occasionally of mild type II wounds (24). The surgeon who elects to close these wounds must exercise caution: gas gangrene can be a complication of primary closure of type I or mild type II open fracture wounds if the surgeon has underestimated the degree of contamination. Most type I wounds are so small that closure will occur spontaneously, without surgical closure. Never close type III open fracture wounds primarily, and the same applies to most type II wounds. This is particularly true if primary internal fixation using plates has been done.

- Cover bone without periosteum, tendons without peritenon, and neurovascular structures with muscle, fascia, or subcutaneous fat. Perform this without formal wound closure. In wounds with large flaps, where retraction of skin edges may occur, place loose tacking sutures to prevent flap retraction. In either of the latter two instances, if closed spaces are created, place a suction tube for drainage.
- With types I and II wounds, a return to surgery within less than 5 days after the initial operation is usually unnecessary. Type III wounds, as well as heavily contaminated wounds, however, require repeat debridement before 5 days, and usually within 36 h. Repeat the debridements at 36- to 48-h intervals until a clean completely viable wound is present.
- After 5 days, if the wound appears clean and little or no nonviable tissue is present, delayed primary closure can be performed after irrigation and minimal debridement. Delay closure of the wound for a few more days if significant debridement is required. Accomplish delayed closure without tension. Split-thickness skin grafting is often necessary. Wounds that can be closed to within 1 cm can be allowed to close by secondary intention, provided vital structures are not exposed and scarring is not a major consideration. Strive to achieve coverage of bone by 5 to 10 days. Wounds requiring local flaps or free microvascularized flaps are often ready for flap coverage within 5 to 10 days, sometimes earlier. In my opinion, applying flaps to close the wound before 5 days is usually not

indicated. When performing delayed closure, use as little suture material as possible; monofilament sutures are best.

## FRACTURE STABILIZATION

Fracture stability is essential for initial wound care and for fracture union (10). Restoring normal length and alignment of the extremity minimizes dead space and restores muscle planes to their normal position. This reduces the space available for serum and hematoma, which are pabulum for bacterial growth. Stabilizing the soft tissues may increase local wound resistance to infection by facilitating neovascularization, white blood cell migration, and diffusion of nutrients. Bone fixation often eliminates the need for casts, splints, and skeletal traction, thereby allowing optimal access to the limb for wound care. Early stability provides an opportunity for early muscle and joint rehabilitation, which, in turn, reduces edema, facilitates lymphatic and venous return, lowers the incidence of deep vein thrombosis, and improves the overall physiology of the limb.

### CASTS AND SKELETAL TRACTION

Use traditional casts for type I and low-grade type II fractures with stable configurations when external or internal fixation is unnecessary. This usually applies to fractures distal to the elbow and knee (10,26). Immobilize only the necessary muscle groups and joints. Encourage early joint and muscle rehabilitation. Administer isometric exercises to immobilized muscles.

Use skeletal traction for fractures of the femoral diaphysis in patients who do not have multiple injuries where delayed nailing is planned.

Nearly all open femur fractures can be nailed immediately. In type IIIC fractures, immediate skeletal stabilization is nearly always indicated. Although traction and cast bracing may constitute definitive treatment, skeletal traction is most often used for temporary immobilization until closed intramedullary nailing is done. Skeletal traction may also be useful for some fractures of the humerus and the tibia in which soft-tissue injuries mitigate against casts or splints and when subsequent early internal fixation is planned. Skeletal traction for definitive treatment of fractures of the tibia is not advisable because of the high incidence of nonunion. Although skeletal traction can be used for the definitive treatment of fractures of the humerus, the prolonged hospitalization required and high incidence of nonunion makes external or internal fixation the treatment of choice.

### EXTERNAL FIXATION

External fixation provides excellent stability without the need for circumferential plaster dressings. Compared with internal fixation, external fixation has several advantages: external fixation devices are relatively easy to apply and are easily adjusted during healing; there are no metallic implants at the fracture site; and there is usually ready access to the wound. Its disadvantages include the awkwardness of the frame for patients; the potential for pins to injure neurovascular structures and to tie down muscle–tendon units, thereby interfering with joint motion and rehabilitation; possible interference by the pins in plastic reconstructive procedures; and pin loosening and secondary infection, which remain significant problems. In addition, external fixation has a higher incidence of delayed and nonunion, particularly in the tibia. The primary indication for external fixation is very severe, highly contaminated type III open fractures where plating or nailing is either contraindicated or not technically feasible. Open unstable fractures of the pelvis are usually best initially stabilized with external fixation (76). Intra-articular fractures require internal fixation; however, external fixation is useful for providing neutralization when more extensive internal fixation is impossible or contraindicated. Hybrid frames are commonly used today to treat high-energy fractures of the metaphysis such as bumper fractures of the proximal tibia and pylon fractures of the distal tibia (87). Ring, Ilizarov-type fixators are useful in similar problems, especially where there is segmental bone loss that may be amenable to bone segment transport (55,78).

Fractures less suitable for external fixation are those that are stable, as well as type I and mild type II open fractures for which casts and splints are adequate. The thick muscle coverage of the femur and the humerus makes external fixation less suitable and internal fixation safer. When fixation crosses a joint, external fixation can be used, but internal fixation may be preferable.

In some open fractures, particularly in the femur and tibia, the surgeon may choose to initially apply external fixation with a plan for early conversion to either an intramedullary nail or a plate. Superior results to primary nailing have been reported (2). This alternative is discussed in detail in Chapter 11 and Chapter 24.

### INTERNAL FIXATION

The role of internal fixation in open fractures remains somewhat controversial (5,11,13,18,19,29,38,41,44,48,56,59,64,81,85,86,91). Over the past several years, however, many trauma centers have reported the use of primary internal fixation in open fractures with good results and an acceptable rate of complications (18,20,23,49,54,63,71,72). In the combined results of three earlier reports, 403 open fractures were treated with early internal fixation (18,20,72). The acute infection rate was 8.2%; most of the infections occurred in type III open fractures. The incidence of late, chronic osteomyelitis was only 0.5%, however. There was a 2.2% incidence of amputation, all in type III open fractures of the tibia.

#### *Indications*

Indications for primary internal fixation of open fractures include the following:

- Fractures in patients with multiple injuries in whom external fixation is impractical and stabilization is necessary to preserve life.
- Patients with severely mutilated or amputated limbs undergoing reimplantation in whom external fixation is impractical.
- Intra-articular fractures.
- Open fractures of the major long bones, in elderly patients, where external fixation is impractical and where immediate mobilization for the salvage of life and function justifies the risk of the procedure.
- Major vascular injuries requiring repair that accompany open fractures and where external fixation is not the best choice.
- Selected fractures of the hand, forearm, and foot (6,22,69,70,88).
- Open fractures of the shafts of the femur, tibia, humerus, radius, and ulna are now generally stabilized primarily using reamed or unreamed intramedullary nails in the femur, tibia, and occasionally the humerus; the forearm bones and humerus are generally plated, except where the fracture is not suitable for internal fixation or the severity of the soft tissue injury and level of contamination preclude immediate internal fixation.

In patients with multiple injuries, immediate internal fixation of open fractures of the femur and the humerus is usually necessary (27). Open fractures of the pelvis are generally stabilized with external fixation. If internal fixation is required to obtain a satisfactory functional result, it is delayed until the risk of infection is minimized and is usually done posteriorly using percutaneous techniques if possible (see Chapter 17).

For an optimal result in intraarticular fractures, anatomic reduction of the joint surface must be achieved with interfragmentary lag screw fixation, and early joint motion must be instituted (9). This requires rigid internal fixation. In type I open intraarticular fractures, primary internal fixation should be done, as the incidence of infection is the same as with elective orthopaedic surgery. Type II open fractures treated with primary internal fixation are associated with reported infection rates of 5% to 8%, and type III fractures in the recent past have been reported to have infection rates of 26% to 41% (16,18,20,49,72). Because of the risk of infection in more severe fractures, consider fixation of the joint surface fragments with screws and wires and stabilization of the metaphyseal portion of the fracture with external fixation. This can then be converted to plate fixation when the wound status permits, if necessary.

The most controversial open fracture is that of the shaft of the tibia. Although external fixation has been the fixation method of choice in the recent past, the more recent literature overwhelmingly supports primary intramedullary nailing as the stabilization method of choice (3,8,21,39,46,78,79,82). Most reports are on unreamed nailing; however, minimally reamed or fully reamed nails inserted acutely or on a delayed basis have received more attention recently because of the breakage rates in the smaller nails and screws required for nonreamed nailing as well as the significant incidence of delayed union. See Table 12.2 and Chapter 24 on fractures of the tibia for more detail.

| Reference | Study | No. of fractures | No. of grade III | Infection rate | Malunions | Nonunions | Delayed unions |
|---|---|---|---|---|---|---|---|
| Antich-Adrover et al. (3) | External fixation with secondary intramedullary nailing | 17 | 12 (71%) | 1 (6%) | 0 | 1 (6%) | 0 |
| Cole et al. (21) | Nonreamed intramedullary nails | 35 | 26 (52%) | 1 (2%) | 2 (4%) | 0 | 1 (2%) |
| Fleming et al. (29) | External fixation | 104 | 48 (46%) | 22[a] (21%) | 32 (31%) | 3 (3%) | 12 (12%) |
| | Nonreamed intramedullary nails | 70 | 33 (56%) | 9 (13%) | 4 (6%) | 9 (13%) | 13 (19%) |
| Keating et al. (46) | Reamed intramedullary nailing | 159 | 43 (45%) | 6 (6%) | 7 (6%) | 9 (6%) | — |
| Sanders et al. (76) | Nonreamed intramedullary nailing | 46 | 22 (54%) | 6 (13%) | 0 | 1 (2%) | 20 (43%) |
| Schandelmaier et al. (78) | External fixation | 19 | 19 (100%) | 2 (11%) | 2 (11%) | 1 (5%) | 2 (11%) |
| | Nonreamed intramedullary nailing | 32 | 32 (100%) | 3 (9%) | 2 (6%) | 0 | 0 |
| Shearer et al. (80) | Reamer | 32 | 11 (34%) | 0[b] | 0 | 0 | 0 |
| Tsuchiyama et al. (82) | Nonreamed intramedullary nailing | 41 | 14 (34%) | 1 (2%) | 0 | 0 | — |

[a] 52% pin-track infection rate.
[b] 18% pin-track infection rate.

***Table 12.2. Results of Intramedullary Nailing and/or External Fixation of Open Tibial Fractures***

### *Internal Fixation of Open Fractures—Operative Technique*

- Start appropriate intravenous antibiotics as soon as possible.
- To minimize the risk of infection, perform a meticulous irrigation and debridement as described above.
- After debridement, reprep the limb and redrape unless the wound is exceptionally clean. Use a new and separate surgical setup.
- Perform internal fixation through the open fracture wound or through an extensile exposure from the open fracture wound. Separate, elective incisions are rarely necessary.
- Minimize soft tissue dissection, preserve bone vascularity as best possible, and assure that the fixation is stable.
- Close the elective portion of the wound; try to cover the implants and any exposed bone with soft tissue; and, in the vast majority of cases, leave the traumatic wound open, closing it by delayed primary closure if indicated.

## BONE GRAFTING

Because delayed union and nonunion are common in open fractures, adjunctive measures to accelerate and assure fracture healing such as dynamization of intramedullary nails, use of electrical stimulation or ultrasound, and autogenous, cancellous bone grafting are often indicated (see Chapter 26) (4). Bone grafting is recommended for severely comminuted fractures, fractures with bone loss, and particularly fractures fixed with plates and screws. Primary bone grafting, often from local bone, is done when reconstruction of articular and juxta-articular fractures requires cancellous bone graft to fill defects.

Because of the risk of infection, the timing of bone grafting is of concern. Type I fractures in which delayed primary closure is unnecessary can be grafted immediately. Fractures subjected to delayed primary closure can be grafted at the time of delayed closure. In severe type III open fractures, or in wounds that are marginal, it is best to delay cancellous bone grafting until after the soft tissues have recovered from the acute trauma and the risk of infection is minimal. This is generally 6 to 12 weeks after injury in most severe open fractures.

The most common cause of failure of grafting is the use of inadequate bone. This usually occurs when bone is taken from the anterior iliac crest. For most major open fractures, insufficient bone is present in the anterior crest. I recommend that bone grafts be taken from the area of the posterosuperior iliac spine. This requires preoperative planning, as the patient must be in the prone or lateral decubitus position to remove this graft.

## AMPUTATION

In some injuries, immediate or early amputation may be the treatment of choice (51). Immediate amputation is usually indicated in the following situations:

- Severe open fractures with associated vascular injuries requiring repair (type IIIC) when the injury cannot be repaired or the warm ischemia time is over 8 h.
- The limb is so severely crushed that minimal viable tissue remains for revascularization.
- There is irreversible associated soft tissue injury and neurologic damage that will result in final function worse than that provided by a prosthesis.
- The presence of multiple injuries where immediate amputation to control hemorrhage or to reduce the adverse systemic effects of retaining low-viability or infected tissue may be life-saving.
- When limb salvage may be life-threatening in the presence of severe chronic disease such as diabetes mellitus with severe peripheral vascular disease and neuropathy.
- A mass casualty situation where salvage of life, transportation of the victim, or the need to direct scarce resources to more severely injured casualties is indicated.

Particularly in severe open fractures of the tibia, salvage may require repeated operations and prolonged disability for 2 years or more. The personal, emotional, sociologic, and economic consequences of expensive and prolonged treatment may cause the patient to select amputation early during treatment. Lange argues that type IIIC open fractures of the tibia with laceration of the posterior tibial nerve should be amputated and provides relative indications similar to those discussed above (51). Johanson and associates developed the “mangled extremity severity score” (MESS) (43). Factors they graded include energy dissipation, hemodynamic status, age of the victim, and limb ischemia. A score of 7 or higher on their scale predicted amputation with a high degree of confidence. Amputation is most frequently an issue in open fractures of the tibia. Chapter 24 contains an extensive discussion of these issues. In borderline situations it may be best to defer the decision about amputation for a second look, as this gives an opportunity to discuss the situation with the patient and family and to take into account all of the issues (75). In spite of the recent pessimism in the literature regarding the outcomes in the salvage of severe open fractures, Hertel et al. (40), in an analysis of 39 type IIIB or IIIC open fractures, found the long-term functional outcomes to be better and costs less with limb salvage.

## OPEN FRACTURES IN CHILDREN

Open fractures in children differ from those in adults in the following ways:

- The injuries are often less severe.
- The healing capacity of the soft tissues is excellent.
- Bone that is devitalized can be saved if it is not contaminated or left exposed.
- The bone-healing capacity of children is remarkable, particularly those under the age of 12 years (31). Bone defects will often heal spontaneously, and bone grafting is usually not required.
- Infection is rare if adequate irrigation and debridement are performed.
- Where the soft tissue injury is mild, cast immobilization often suffices.
- External fixation works well where the soft tissue injury requires ready access or the fracture is unstable. It can usually be left in place until union of the fracture (4).
- The general principles of care as outlined in this chapter apply except as noted above.
- The social and psychological impact of these severe injuries, particularly in terms of time lost from school, should not be underestimated (53).

## PITFALLS AND COMPLICATIONS

The most common complications include acute infection, osteomyelitis, nonunion, malunion, and loss of function. Remarkable progress has been made since the early 1970s in reducing the rate of these complications. A review of Table 24.7 in Chapter 24 on tibial fractures and Table 12.2 in this chapter shows a drop in acute infection rates of up to three- to fourfold and similar trends in the other complications as well. Infection rates of 6% or less are now reported (3,8,21,46,78,79 and 80,82). These excellent results reflect compulsive adherence to the principles of treatment outlined in this chapter. For specific details on the management of these complications, please refer to the chapters on the fracture of concern and to the following chapters dealing with the management of complications: Chapter 132, Chapter 133, and Chapter 135 on infection and Chapter 26, Chapter 27, Chapter 28, Chapter 29, Chapter 30, Chapter 31 and Chapter 32 on nonunions and malunions.

## AUTHOR'S PERSPECTIVE

For the overall management of open fractures, I follow the principles outlined in this chapter. I use antibiotic bead pouches with tobramycin when the wound severity and level of contamination justify their use. I strive to close all wounds by 10 days after injury with full-thickness coverage. I work closely with my orthopaedic and plastic surgery colleagues, whose skills in local and free flaps are essential to achieving an optimal result (see Chapter 8, Chapter 35, and Chapter 36).

From the standpoint of fixation in adults, I have the following preferences. In type I and low-grade type II fractures, I usually perform primary internal fixation if indicated by the fracture, leaving the traumatic wound open and closing it on a delayed primary basis. In type III fractures, I use the following protocol:

- In intra-articular fractures, I use interfragmentary fixation of the articular portion with “biological” plate fixation of the metaphyseal portion in low-grade fractures and hybrid or other external fixation in high-grade open fractures. Occasionally I will convert the external fixation to internal fixation when the soft tissue envelope permits and the conversion is the best alternative for the patient.
- For fractures in the upper extremity, I use primary internal fixation with plates and screws in most cases (17), reserving external fixation for those where the bone is not amenable to internal fixation or where the wound makes primary internal fixation inadvisable.
- In hip fractures, I use primary internal fixation except where not fixable.
- For femoral shaft fractures, I favor reamed locked intramedullary nailing in most cases (15,20); I use nonreamed locked nailing in patients with multiple injuries, where the speed of surgery is important and compromised pulmonary status is a problem.
- For supracondylar femur fractures, see the item above on intra-articular fractures.
- For tibial plateau and pylon fractures, see the item above on intra-articular fractures.
- For tibial shaft fractures, I use locked intramedullary nailing, either nonreamed or with gentle reaming sufficient to place a nail (usually 10 mm in diameter) that permits the use of large cross locking screws (4.5 to 5.0 mm in diameter) (42,45,89). I use external fixation only when the fracture configuration or surgical situation does not permit nailing. I try to convert external fixation to a nail early if it is feasible (57,60).
- For foot fractures, I favor primary internal fixation using small fragment screws and plates and wires.

### CHAPTER REFERENCES

Each reference is characterized according to the following scheme: *, classic article; #, review article; !, basic research article; and +, clinical results/outcome study.


+ 1. Andersen MN, McDonald K, Stephens JG. A Study of the Effect of Open and Closed Treatment on the Rate of Healing and Complications in Fractures of the Tibial Shaft. *J Trauma* 1961;1:290.

! 2. Anglen J, Apostoles S, Christensen G, Gainer B. The Efficacy of Various Irrigation Solutions in Removing Slime-Producing *Staphylococcus. J Orthop Trauma* 1994;8:390.

+ 3. Antich-Adrover P, Marti-Garin D, Murias-Alvarez J, Puente-Alonso C. External Fixation and Secondary Intramedullary Nailing of Open Tibial Fractures. *J Bone Joint Surg* 1997;79B:433.

+ 4. Bartlett CS III, Weiner LS, Yang EC. Treatment of Type II and Type III Open Tibia Fractures in Children. *J Orthop Trauma* 1997;11:357.

+ 5. Bauer GCH, Edwards P, Widmark PH. Shaft Fractures of the Tibia: Etiology of Poor Results in a Consecutive Series of 173 Fractures. *Acta Chir Scand* 1962;124:386.

+ 6. Bergeritz SE, Thureborn E. Shaft Fractures of the Lower Leg: Open Versus Closed Reduction. *Acta Chir Scand* 1957;114:235.

+ 7. Blick SS, Brumback RJ, Lakatos, et al. Early Prophylactic Bone Grafting of High-Energy Tibial Fractures. *Clin Orthop* 1989;240:21.

+ 8. Bonatus T, Olson SA, Lee A, Chapman MW. Nonreamed Locking Intramedullary Nailing for Open Fractures of the Tibia. *Clin Orthop* 1997;339:58.

+ 9. Bray TJ, Endicott M, Capra SE. Treatment of Open Ankle Fractures. Immediate Internal Fixation Versus Closed Immobilization and Delayed Fixation. *Clin Orthop* 1989;240:47.

* 10. Brown PW, Urban JG. Early Weight-Bearing Treatment of Open Fractures of the Tibia. *J Bone Joint Surg* 1969;51-A:59.

+ 11. Burwell HN. Plate Fixation of Tibial Shaft Fractures, a Survey of 181 Injuries. *J Bone Joint Surg* 1971;53-B:258.

+ 12. Carpenter EG, Dobbie JJ, Siewers CF. Fractures of the Tibia and Fibula. Comparative End Results from Various Forms of Treatment in a Teaching Hospital. *Arch Surg* 1952;64:443.

# 13. Chapman MW. Immediate Internal Fixation in Open Fractures. *Orthop Clin North Am* 1980;11:579.

# 14. Chapman MW. Role of Bone Stability in Open Fractures. *AAOS Instruct Course Lect* 1982;31:75.

+ 15. Chapman MW, Blackman RC. Closed Intramedullary Nailing of Femoral Shaft Fractures: A Comparison of Two Techniques. *J Bone Joint Surg* 1976;58-A:732.

+ 16. Chapman MW, Goldstein J, Redman S. Results in the Treatment of 259 Open Fractures. Paper presented at the Annual Meeting of the AAOS, Atlanta, 1984.

+ 17. Chapman MW, Gordon E, Zissimos A. Compression Plate Fixation of Acute Fractures of the Diaphyses of the Radius and Ulna. *J Bone Joint Surg* 1989;71-A:159.

+ 18. Chapman MW, Mahoney M. The Role of Internal Fixation in the Management of Open Fractures. *Clin Orthop* 1979;138:120.

+ 19. Claffey T. Open Fractures of the Tibia. *J Bone Joint Surg* 1960;42-B:407.

+ 20. Clancey GJ, Hansen ST Jr. Open Fractures of the Tibia: A Review of 102 Cases. *J Bone Joint Surg* 1978;60-A:118.

+ 21. Cole JD, Ansel LJ, Schwartzberg R. A Sequential Protocol for Management of Severe Open Tibial Fractures. *Clin Orthop* 1997;315:84.

+ 22. Connolly J. Management of Fractures Associated with Arterial Injuries. *Am J Surg* 1970;120:331.

+ 23. D'Aubigne MR, Maurer P, Zucman J, Masse Y. Blind Intramedullary Nailing for Tibial Fractures. *Clin Orthop* 1974;105:267.

* 24. Davis AG. Primary Closure of Compound-Fracture Wounds. *J Bone Joint Surg* 1948;30-A:405.

+ 25. Eckman JB Jr, Henry SL, Mangino PD, Seligson D. Wound and Serum Levels of Tobramycin with the Prophylactic Use of Tobramycin-Impregnated Polymethylmethacrylate Beads in Compound Fractures. *Clin Orthop* 1988;237:213.

+ 26. Edwards P. Fracture of the Shaft of the Tibia: 492 Consecutive Cases in Adults. *Acta Orthop Scand [Suppl]* 1965;76:9.

* 27. Ellison PS Jr, Poka A, Lakatos R, et al. Intramedullary Nailing of Open Fractures of the Femoral Shaft. *J Bone Joint Surg* 1989;71-A:1324.

# 28. Esterhai JL Jr. Management of Soft-Tissue Wounds Associated with Open Fractures. *AAOS Instruct Course Lect* 1990;39:483.

+ 29. Gallinaro P, Crova M, Denicolai F. Complications in 64 Open Fractures of the Tibia. *Injury* 1973;5:157.

# 30. Gregory CF. Open Fractures. In Rockwood CA, Green DP, eds. *Fractures, vol 1.* Philadelphia: JB Lippincott, 1975.

+ 31. Grimard G, Naudie D, Laberge LC, Hamdy RC. Open Fractures of the Tibia in Children. *Clin Orthop* 1996;332:62.

* 32. Gustilo, RB. Management of Open Fractures and Complications. *AAOS Instruct Course Lect* 1982;31:64.

* 33. Gustilo RB. Use of Antimicrobials in the Management of Open Fractures. *Arch Surg* 1979;114:804.

# 34. Gustilo RB, ed. *Management of Open Fractures and Their Complications. Saunders' Monographs in Clinical Orthopaedics, vol 4.* Philadelphia: WB Saunders, 1982.

* 35. Gustilo RB, Anderson JT. Prevention of Infection in the Treatment of 1025 Open Fractures of Long Bones. *J Bone Joint Surg* 1976;58-A:453.

# 36. Gustilo RB, Merkow RL, Templeman D. The Management of Open Fractures. *J Bone Joint Surg* 1990;72-A:299.

* 37. Hampton OP. Basic Principles in the Management of Open Fractures. *JAMA* 1955;159:417.

+ 38. Hedenberg I, Pompeius R. Shaft Fractures of the Lower Leg: Comparing the Early Results of Open and Closed Treatment in 120 Cases. *Acta Chir Scand* 1959;118:339.

+ 39. Henley MB, Chapman JR, Agel J, et al. Treatment of Type II, IIIA, and IIIB Open Fractures of the Tibial Shaft: A Prospective Comparison of Unreamed Interlocking Intramedullary Nails and Half-Pin External Fixators. *J Orthop Trauma* 1998;12:1.

+ 40. Hertel R, Strebel N, Ganz R. Amputation versus Reconstruction in Traumatic Defects of the Leg: Outcome and Costs. *J Orthop Trauma* 1996;10:223.

+ 41. Holstad HA. Primary Osteosynthesis versus Conservative Treatment of Compound Fractures of Long Tubular Bones. *J Oslo City Hosp* 1962;12:225.

+ 42. Holbrook JL, Swiontkowski MF, Sanders R. Treatment of Open Fractures of the Tibial Shaft: Ender Nailing Versus External Fixation. A Randomized, Prospective Comparison. *J Bone Joint Surg* 1989;71-A:1231.

+ 43. Johanson K, Daines M, Howie T, et al. Objective Criteria for Amputation after Lower Extremity Trauma. Paper presented at the Orthopaedic Trauma Association Annual Meeting, Dallas, 1988.

+ 44. Johansson O. Viewpoints on Primary Osteosynthesis in Compound Fractures. *Acta Chir Scand* 1953;105:474.

+ 45. Kaltenecker G, Wruhs O, Quaicoe S. Lower Infection Rate after Interlocking Nailing in Open Fractures of Femur and Tibia. *J Trauma* 1990;30:474.

+ 46. Keating JF, O'Brien PI, Blachut PA, et al. Reamed Interlocking Intramedullary Nailing of Open Fractures of the Tibia. *Clin Orthop* 1997;338:182.

! 47. Kellam J, Ramp W, Nisholason N, Kaysinger K. Effects of Wound Irrigation Solutions on Osteoblast Function. Paper presented at the Orthopaedic Trauma Association, New Orleans, l993.

+ 48. Ketenjian AY, Shelton ML. Primary Internal Fixation of Open Fractures: A Retrospective Study of the Use of Metallic Internal Fixation in Fresh Open Fractures. *J Trauma* 1972;12:756.

+ 49. La Duca JN, Bone LL, Seibel RW, Border JR. Primary Open Reduction and Internal Fixation of Open Fractures. *J Trauma* 1980;20:580.

+ 50. Lam SJ. The Place of Delayed Internal Fixation in the Treatment of Fractures of the Long Bones. *J Bone Joint Surg* 1964;46-B:393.

+ 51. Lange RH. Limb Reconstruction versus Amputation Decision-Making in Massive Lower Extremity Trauma. *Clin Orthop* 1989;243:92.

+ 52. Lee J. Efficacy of Cultures in the Management of Open Fractures. *Clin Orthop* 1997;339:71.

+ 53. Levy AS, Wetzler M, Lewars M, et al. The Orthopedic and Social Outcome of Open Tibia Fractures in Children. *Orthopedics* 1997;20:593.

* 54. Lottes JO, Hill LJ, Key AJ. Closed Reduction, Plate Fixation, and Medullary Nailing of Fractures of Both Bones of the Leg. *J Bone Joint Surg* 1952;34-A:861.

+ 55. Lowenberg DW, Feibel RJ, Louie KW, Eshima I. Combined Muscle Flap and Ilizarov Reconstruction for Bone and Soft Tissue Defects. *Clin Orthop* 1996;332:37.

+ 56. Madsen E, Madsen PC. Primaer Osteosynthese ved Crustrakturer. *Nord Med* 1958;60:1478.

+ 57. Maurer DJ, Merkow RL, Gustilo RB. Infection after Intramedullary Nailing of Severe Open Tibial Fractures Initially Treated with External Fixation. *J Bone Joint Surg* 1989;71-A:835.

+ 58. McGraw JM, Lim EV. Treatment of Open Tibial Shaft Fractures. External Fixation and Secondary Intramedullary Nailing. *J Bone Joint Surg* 1988;70-A:900.

+ 59. McNeur JC. The Management of Open Skeletal Trauma with Particular Reference to Internal Fixation. *J Bone Joint Surg* 1970;52-B:54.

+ 60. Merritt K. Factors Increasing the Risk of Infection in Patients with Open Fractures. *J Trauma* 1988;28:823.

+ 61. Moore TJ, Mauney C, Barron J. The Use of Quantitative Bacterial Counts in Open Fractures. *Clin Orthop* 1989;248:227.

# 62. Muüller ME, Allgöwer M, Schneider R, Willenegger H. *Manual of Internal Fixation.* Berlin: Springer-Verlag, 1991.

+ 63. Mukhopadhaya B. Medullary Nailing of Open Fractures. *J Bone Joint Surg* 1970;52-B:793.

+ 64. Olerud S, Karlstrom G. Tibial Fractures Treated by AO Compression Osteosynthesis. *Acta Orthop Scand [Suppl]* 1972;140:3.

+ 65. Ostermann PA, Henry SL, Seligison D. The Role of Local Antibiotic Therapy in the Management of Open Fractures. *Clin Orthop* 1993;259:102.

# 66. Patzakis M. Management of Open Fractures. *AAOS Instruct Course Lect* 1982;31:62.

* 67. Patzakis MJ, Harvey JP, Ivler D. The Role of Antibiotics in the Management of Open Fractures. *J Bone Joint Surg* 1974;56-A:532.

# 68. Patzakis MJ, Wilkins J. Factors Influencing Infection Rate in Open Fracture Wounds. *Clin Orthop* 1989;243:36.

+ 69. Rich NM, Metz CW, Hutton JE Jr, et al. Internal versus External Fixation of Fractures with Concomitant Vascular Injuries. *J Trauma* 1971;11:463.

+ 70. Riska EB, Von Bonsdorff H, Hakkinen S, et al. Primary Operative Fixation of Long Bone Fractures in Patients with Multiple Injuries. *J Trauma* 1977;17:111.

# 71. Rittmann WW, Perren SM. *Cortical Bone Healing after Internal Fixation and Healing.* New York: Springer-Verlag, 1974.

+ 72. Rittmann WW, Schibli M, Matter P, Allgöwer M. Open Fractures: Long-Term Results in 200 Consecutive Cases. *Clin Orthop* 1979;138:132.

+ 73. Robinson D, On E, Hadas N, et al. Microbiologic Flora Contaminating Open Fractures: Its Significance in the Choice of Primary Antibiotic Agents and the Likelihood of Deep Wound Infection. *J Orthop Trauma* 1989;3:283.

# 74. Rockwood CA Jr, Green DP, Bucholz RW, Heckman JD. *Fractures in Adults, 4th ed.* Philadelphia: Lippincott-Raven, 1996.

+ 75. Rosenberg GA, Patterson BM. Limb Salvage versus Amputation for Severe Open Fractures of the Tibia. *Orthopedics* 1998;21:343.

+ 76. Rothenberger PA, Velasco R, Strate RG, et al. Open Pelvic Fracture: A Lethal Injury. *J Trauma* 1978;18:184.

+ 77. Ruedi T, Border JR, Allgoewer M. Appendix B: Classification of soft tissue injuries. In: *Manual of Internal Fixation.* New York: Springer-Verlag, 1991.

+ 78. Sanders R, Jersinovich I, Anglen J, et al. The Treatment of Open Tibial Shaft Fractures Using an Interlocked Intramedullary Nail Without Reaming. *J Orthop Trauma* 1994;8:504.

+ 79. Schandelmaier P, Krettek C, Rudolf J, et al. Superior Results of Tibial Rodding Versus External Fixation in Grade 3B Fractures. *Clin Orthop* 1997;342:164.

+ 80. Shtarker H, David R, Stolero J, et al. Treatment of Open Tibial Fractures with Primary Suture and Ilizarov Fixation. *Clin Orthop* 1997;335:268.

* 81. Soto-Hall H, Horwitz J. The Treatment of Compound Fractures of the Femur. *JAMA* 1946;130:128.

+ 82. Stegemann P, Lorio M, Soriano R, Bone L. Management Protocol for Unreamed Interlocking Tibial Nails for Open Tibial Fractures. *J Orthop Trauma* 1995;9:117.

+ 83. Swiontkowski MF. Criteria for Bone Debridement in Massive Lower Limb Trauma. *Clin Orthop* 1989;243:41.

# 84. Tsukayama DT, Gustilo RB. Antibiotic Management of Open Fractures. *AAOS Instruct Course Lect* 1990;39:487.

+ 85. Veliskakis KP. Primary Internal Fixation in Open Fractures of the Tibial Shaft. *J Bone Joint Surg* 1959;41-B:342.

+ 86. Wade PA, Campbell RD. Open Versus Closed Methods in Treating Fractures of the Leg. *Am J Surg* 1958;95:599.

+ 87. Weiner LS, Kelley M, Yang E, et al. The Use of Combination Internal Fixation and Hybrid External Fixation in Severe Proximal Tibia Fractures. *J Orthop Trauma* 1995;9:244.

# 88. Weissman SL, Khermosh O. Orthopedic Aspects in Multiple Injuries. *J Trauma* 1970;10:377.

+ 89. Whitelaw GP, Wetzler M, Nelson A, et al. Ender Rods Versus External Fixation in the Treatment of Open Tibial Fractures. *Clin Orthop* 1990;253:258.

! 90. Worlock P, Slack R, Harvey L, Mawhinney R. The Prevention of Infection in Open Fractures. An Experimental Study of the Effect of Antibiotic Therapy. *J Bone Joint Surg* 1988;70-A:1341.

+ 91. Zadik FR. Primary Internal Fixation of Compound Fractures. *J Bone Joint Surg* 1953;35-B:146.

# CHAPTER 13

# COMPARTMENT SYNDROMES

R. Scott Meyer and Scott J. Mubarak

**R. S. Meyer:** Department of Orthopaedics, University of California, San Diego, Medical Center, San Diego, California 92103.
**S. J. Mubarak:** Department of Orthopaedics, University of California, San Diego, and Pediatric Orthopaedic and Scoliosis Center, Children's Hospital, San Diego, California 92123.

Definition and Classification
Pathophysiology
Anatomy
Forearm
Leg
Etiology
Assessment and Indications
Diagnosis
Principles and Techniques of Pressure Monitoring
Preoperative Management
Surgical Techniques
Forearm Decompression
Leg Decompression
Fractures and Compartment Syndrome
Prophylactic Fasciotomy
Treatment of Chronic Compartment Syndrome
General Rehabilitation and Postoperative Principles
Pitfalls and Complications
Authors' Perspective
Prevention
Early Recognition
Pressure Monitoring
Early Treatment
Operative Techniques
Chapter References

## DEFINITION AND CLASSIFICATION

A compartment syndrome is a condition in which accumulating fluid and/or external compression creates high pressure within a closed fascial space, reducing perfusion of the tissues within that compartment below a level necessary for viability. Compartment syndromes develop in skeletal muscles enclosed by relatively noncompliant osseofascial boundaries. A buildup of pressure within these compartments is not easily dissipated because of the inelasticity of the muscle-investing fascia and surrounding bone. If pressure remains sufficiently high for several hours, normal function of the muscles and nerves is jeopardized, and necrosis eventually results. Permanent loss of function and a Volkmann's limb contracture may occur. Prompt diagnosis is therefore essential, with immediate treatment to reinstate capillary perfusion and prevent irreversible sequelae. Surgical decompression is accomplished by fasciotomy, which allows the muscles to increase in volume and reduces pressure within the fascial enclosure.

Compartment syndromes may be acute or chronic, based on cause and reversibility (33). An acute compartment syndrome (ACS) is a severe form, usually following trauma, in which intracompartmental pressure is elevated to a high level for long enough that capillary flow is impeded and decompression is necessary to prevent necrosis and preserve limb viability. Commonly used terms for ACS are anterior tibial syndrome, calf hypertension, compartmental syndrome, Volkmann's ischemia, and impending ischemic contracture (27). The terms Volkmann's ischemia and impending ischemic contracture should not be used, however, because they do not define the cause of the ischemic problem (e.g., compartment syndrome or arterial injury). Volkmann's contracture is the residual limb deformity that is the last stage of muscle and nerve necrosis after an ACS.

Chronic compartment syndrome (CCS) is mild and recurrent. It is most commonly associated with exercise and occurs when intracompartmental pressure is raised sufficiently to produce ischemia, pain, and/or neurologic deficit. The symptoms spontaneously resolve with rest; in the rare instance when exercise is continued despite pain and neuromuscular deficit, however, a CCS may evolve into a full-blown acute form that requires immediate decompression. Synonyms for CCS include chronic exertional compartment syndrome, exercise ischemia, exercise myopathy, and recurrent compartment syndrome.

## PATHOPHYSIOLOGY

Common to all compartment syndromes is elevated intracompartmental pressure with subsequent ischemia of muscle, nerve, and other compartment contents. In ACS the cause of the elevated pressure is fluid accumulation from hemorrhage, extracellular edema, and intracellular edema within the confines of a closed, noncompliant osseofascial compartment (41). Intracellular fluid accumulation is associated with membrane pump changes that lead to an increase in intracellular calcium concentration and subsequent shifts of water into the cell. Interstitial fluid accumulation results, at least in part, from elevated capillary permeability, which is caused by ischemia (41). The elevated intracompartmental pressure causes further muscle ischemia, which leads to further edema production. An edema–ischemia cycle is thus established; without decompression, muscle infarction and other irreversible damage will ensue (Fig. 13.1).

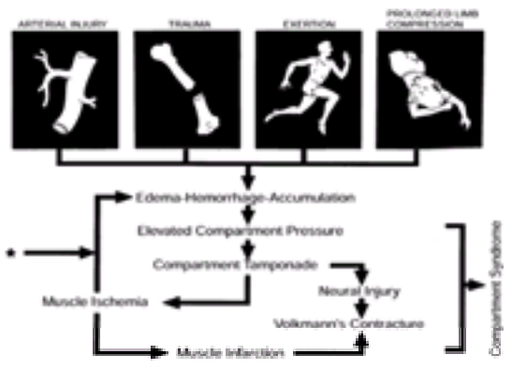


***Figure 13.1.*** Pathophysiology of a compartment syndrome, which can be initiated by arterial injury, trauma, exercise, or prolonged limb compression associated with alcohol or drug overdose. Common to all compartment syndromes are elevated intracompartmental pressure and subsequent ischemia. The *asterisk* marks the point of entry of decompression (fasciotomy) into the cycle. Without decompression, a self-perpetuating ischemia–edema process occurs, and irreversible damage, including Volkmann's contracture, may ensue. (From Mubarak SJ, Hargens AR, Owen CA, and Akeson WH. Muscle Pressure Measurement with the Wick Catheter. In: Goldsmith HS, ed. *Practice of Surgery.* New York: Harper & Row, 1978.)

Starling's law describes fluid transport across the capillary wall. Variables included in this equation include hemodynamic factors (capillary pressures), colloid osmotic factors, and permeability factors (41). In tissues at heart level, capillary blood pressure normally ranges from 20 to 30 mm Hg; when compartment pressure rises above this level, muscle perfusion is jeopardized (3,8). Hargens et al. confirmed that the capillary pressure in the anterolateral compartment, at heart level, of normotensive

dogs was 20 to 30 mm Hg and believed that intracompartmental pressures above this level led to collapse of the thin-walled capillaries (18).

It is important to understand that, despite decreased capillary perfusion from elevated intracompartmental pressure, arterial pressure is almost always adequate to maintain distal flow in the larger vessels. Therefore, distal pulses are usually present and should not be used to rule out the presence of a compartment syndrome.

The pathophysiology of CCS is not well known. Styf et al. have shown that normal muscle contractions during exercise can generate very high pressures (100 to 200 mm Hg) and that the muscle is perfused during the periods of muscle relaxation (60). In cases of CCS, the compartment pressure during relaxation is significantly higher than normal (above 35 mm Hg), and muscle blood flow decreases. This presumably leads to ischemic pain, although this has not been proved. The primary cause of elevated relaxation pressures is also not known. Hypotheses include muscle hypertrophy, fascial thickening, aberrant anatomy, and vessel occlusion (10,32,57).

## ANATOMY

The compartments of the leg and the forearm are involved most frequently in compartment syndrome and are discussed in detail in this chapter. Compartment syndromes of the hand and foot are discussed in Chapter 33, Chapter 45, Chapter 65, and Chapter 11. Compartment syndromes can also arise in the shoulder, arm, thigh, buttocks, and spine. It is essential to understand the compartmental anatomy of the extremities in order to diagnose and treat acute and chronic compartment syndromes effectively.

### FOREARM

The forearm consists of three compartments: volar, dorsal, and mobile wad (Fig. 13.2). The volar compartment contains the flexors and pronators of the forearm and wrist. These muscles may be further subdivided into (a) a superficial group consisting of the pronator teres, flexor carpi radialis, palmaris longus, flexor carpi ulnaris, and flexor digitorum and (b) a deep group consisting of the flexor digitorum profundus, flexor pollicis longus, and pronator quadratus. It is essential to decompress adequately the entire course of the median nerve as it courses through this compartment. Proximally it enters the forearm between the two heads of the pronator teres muscle and then runs the length of the forearm between the flexor digitorum superficialis and profundus muscles before it enters the carpal tunnel.

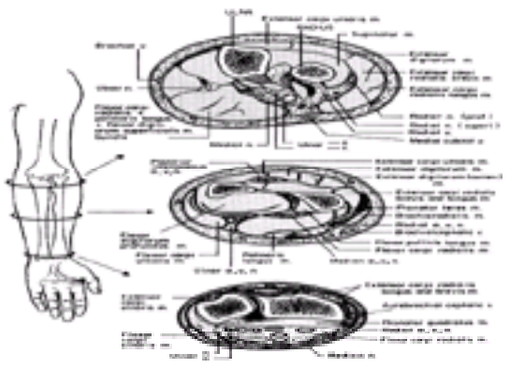

***Figure 13.2.*** Forearm compartments: transverse sections through the left forearm at various levels. (From Mubarak SJ, Hargens AR. *Compartment Syndromes and Volkmann's Contracture.* Philadelphia: WB Saunders, 1981.)

The dorsal or extensor compartment of the forearm also contains two groups of muscles. The superficial layer consists of the extensor digitorum communis, extensor digitorum minimi, and extensor carpi ulnaris. The deep layer consists of the supinator, abductor pollicis longus, extensor pollicis brevis, and extensor pollicis longus.

The third compartment of the forearm, the mobile wad, consists of three muscles: the extensor carpi radialis longus, extensor carpi radialis brevis, and brachioradialis.

### LEG

The leg is the most common part of the extremities to be involved in compartment syndrome. There are four compartments in the leg, with the anterior compartment the one most commonly involved in both ACS and CCS (Fig. 13.3). The anterior compartment contains the tibialis anterior, extensor digitorum longus, extensor hallucis longus, and peroneus tertius muscles as well as the deep peroneal nerve, which supplies all of them. The deep peroneal nerve also supplies the extensor digitorum brevis and supplies sensation to the first dorsal web space in the foot.

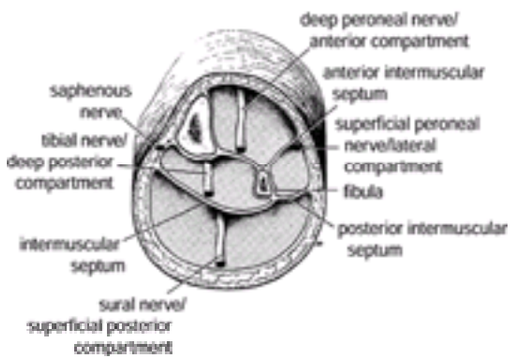


***Figure 13.3.*** Cross section of the middle lower third of the left leg, illustrating the four compartments with their associated peripheral nerves. (From Mubarak SJ, Owen CA. Double-Incision Fasciotomy of the Leg for Decompression in Compartment Syndromes. *J Bone Joint Surg* 1977;59-A:184.)

The lateral compartment of the leg contains the peroneus longus and brevis muscles. The common peroneal nerve runs in this compartment as it winds around the neck of the fibula, and after the deep peroneal branch enters the anterior compartment, the superficial peroneal nerve continues down the leg in the lateral compartment. In the lower third of the leg it pierces the fascia and runs in the subcutaneous tissues to the foot, where its two terminal branches, the medial and intermediate dorsal cutaneous nerves, supply sensation to the dorsum of the foot.

The deep posterior compartment of the leg can be troublesome because it is not as accessible to palpation as are the other compartments. This compartment contains the popliteus, flexor hallucis longus, flexor digitorum longus, and tibialis posterior muscles as well as the tibial nerve, which supplies them. The tibial nerve runs between the soleus and tibialis posterior muscles proximally and between the flexor digitorum longus and flexor hallucis longus muscles distally before it enters the foot to supply the plantar muscles and provide sensation to the sole of the foot. Clawing of the toes after a tibial fracture suggests previous compartment syndrome of the deep posterior compartment of the leg or the deep calcaneal compartment of the foot.

The least involved compartment of the leg is the superficial posterior compartment, whose surrounding fascia is less constrained. Contained in this compartment are the plantaris, gastrocnemius, and soleus muscles, as well as the sural nerve, which pierces the fascia in the lower third of the leg and supplies sensation to the lateral aspect of the foot.

## ETIOLOGY

An acute compartment syndrome can be caused by either an increase in compartment volume (e.g., postfracture swelling) or a decrease in compartment size (e.g.,

tight circumferential cast). In some cases, both factors may play a role (e.g., casted tibia fracture).

Fractures are the most common cause of ACS because of increased swelling within the compartment (Fig. 13.4). Other causes include soft-tissue injuries, osteotomies, bleeding disorders, burns, crush injuries, limb compression (e.g., drug overdose), and postischemic swelling following arterial occlusion. Compartment syndrome has also been reported following snake bites (13), massive fluid resuscitation in critically injured patients (5), inadvertent use of hypertonic saline during intravenous regional anesthesia (22,43), inadvertent extravasation of toxic substances during intravenous or intraarterial administration (4), intraosseous fluid administration in children (52), and the use of fluid pumps during arthroscopy (6,28,47).

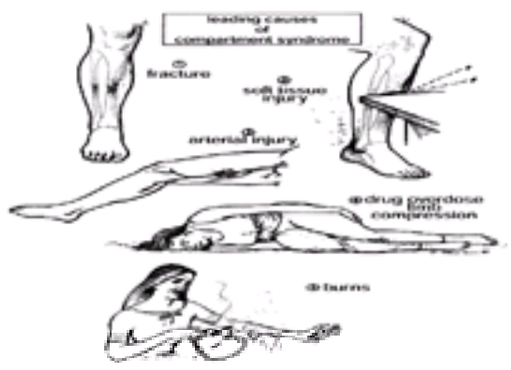


***Figure 13.4.*** Leading causes of compartment syndrome. (From Mubarak SJ, Hargens AR. *Compartment Syndromes and Volkmann's Contracture.* Philadelphia: WB Saunders, 1981.)

When a decrease in compartment size leads to an ACS, the constriction may be extrinsic or intrinsic. Extrinsic compartment constriction may be caused by a tight bandage or cast or by the noncompliant eschar that forms in severe burns. Intrinsic constriction may be iatrogenic in nature by the surgical closure of fascial defects. These fascial defects may represent autofasciotomy from increased intracompartmental pressure or may be the result of fascial incisions used in the operative treatment of fractures (e.g., tibial plateau).

Another possible intrinsic cause of decreased compartment size is stretching of a relaxed compartment. Gershuni et al. showed that passive ankle and knee position significantly affected intracompartmental pressures of the leg (16). Pressures as high as 40 mm Hg were noted in the deep posterior compartment of normal volunteers with full passive ankle dorsiflexion.

Compartment stretching can also occur in the operative treatment of fractures. For example, late treatment of a shortened long bone fracture by open reduction and internal fixation, such as in a nonunion and/or malunion, can stretch the compartments back to their original length. This effectively reduces the compartment size and can significantly increase intracompartmental pressure. Similarly, in the operative treatment of acute femur or tibia fractures, compartment syndrome is occasionally seen following intramedullary nailing. In such cases, there is considerable swelling of the thigh or leg with resultant shortening of the fracture. When the limb is placed in traction and the fracture is reduced, the size of the compartments is decreased; this can lead to a sudden increase in intracompartmental pressure.

Although it is usually not difficult to identify the cause of an ACS, less is known about the etiology of CCS. As mentioned above, there are several hypotheses, all related to anatomy. Styf suggested that CCS of the anterior compartment of the leg may be related to vessel occlusion by local muscle herniations (57). Chronic exercise may lead to significant muscular hypertrophy, which essentially “outgrows” its noncompliant fascial covering. The fascia itself may be abnormally thick or tight. Martens and Moeyersoons have hypothesized that the fascia in these patients is abnormally noncompliant and does not accommodate the increased muscle volume seen during exercise (32). Detmer et al. reported increased fascial thickening in 25 of 36 samples from patients with CCS (10). Fascial scarring may also be present in cases where a specific traumatic event is associated with CCS (30,45,61).

## ASSESSMENT AND INDICATIONS

### DIAGNOSIS

#### *Acute Compartment Syndrome*

The first and most important symptom of an impending acute compartment syndrome is pain that is greater than expected from the primary clinical problem, such as a fracture or contusion. Frequently, the patient has been observed for a period of time with minimal or stable pain and then rapidly develops pain out of proportion to what is expected. This may be associated with a need for larger and larger doses of narcotic analgesia. The pain is usually described as a deep, throbbing feeling of unrelenting pressure and is not responsive to change in position of the extremity. The absence of pain in ACS is almost always related to a superimposed central or peripheral sensory deficit.

The earliest and only objective finding of a compartment syndrome is a swollen, palpably tense compartment that is a direct manifestation of increased intracompartmental pressure (Fig. 13.5). Subcutaneous edema can mask the underlying swelling and increased pressure of the compartment. Despite its relative specificity for compartment syndrome, the tenseness of a compartment is difficult to quantify and remains a crude indicator of increased intracompartmental pressure. In addition, the deep posterior compartment is difficult to palpate, and an isolated syndrome of this compartment can be missed if the examiner feels a sense of security in the absence of palpably tense compartments.

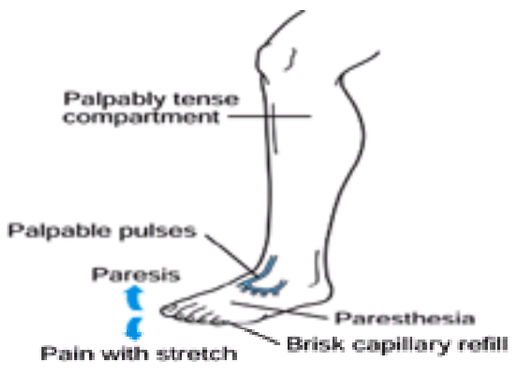


***Figure 13.5.*** Early findings of a compartment syndrome. Increased pressure leading to a palpably tense compartment is the earliest sign. (Redrawn from Mubarak SJ, Hargens AR, Owen CA, and Akeson WH. Muscle Pressure Measurement with the Wick Catheter. In: Goldsmith HS, ed. *Practice of Surgery.* New York: Harper & Row, 1978.)

Pain with passive stretch of the muscles of the involved compartment(s) is a common finding. Unfortunately, pain is subjective and depends on the reliability of the patient and the patient's threshold of pain. After any injury associated with a compartment syndrome, all patients have pain, and differentiating this from ischemic muscle pain can be quite difficult. The examiner must be wary of the fact that pain on stretch may be absent later in the course of the compartment syndrome because of anesthesia secondary to nerve ischemia, which complicates the evaluation of pain.

Paresis or weakness of the muscles of the involved compartment is likewise difficult to interpret and may arise secondary to nerve involvement, primary muscle ischemia, guarding because of pain, or a combination of all three.

Paresthesias are common when ischemia of the nerves of the involved compartments is present. Provided that the patient is conscious and can cooperate, a careful

sensory examination is extremely helpful in evaluating a patient with ACS. Each compartment of the forearm and leg has at least one peripheral nerve coursing through it, and careful sensory examination of the hand or foot can help confirm the compartment(s) involved. Initially, the sensory deficit may manifest itself as paresthesia only. With delay in treatment, hypoesthesia progressing to anesthesia is inevitable. In cooperative patients, any sensory deficit after an injury must be explained.

As mentioned above, unless there is an associated major arterial injury or disease, peripheral pulses are palpable and brisk capillary refill is found routinely in the patient with ACS. Although the compartment pressure may be high enough to cause muscle and nerve ischemia, only on rare occasions is it elevated sufficiently to occlude a major artery (Fig. 13.6). If palpation of distal pulses is difficult because of soft-tissue swelling, Doppler studies are used to confirm their presence. It is crucial that the treating physician be aware that the peripheral pulses are generally intact with compartment syndromes and avoid a false sense of security by palpating a pulse and deciding all is well. Moreover, the skin circulation is satisfactory and the hand and foot are pink and viable, unlike the ischemic appearance seen with an arterial injury.

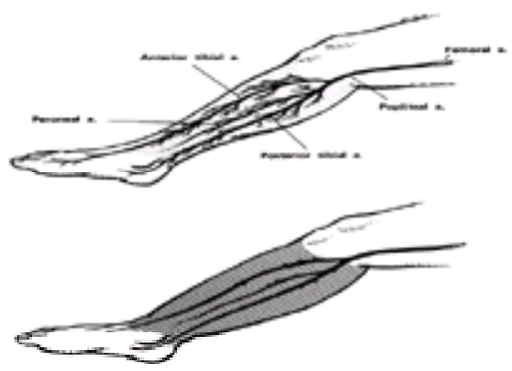

***Figure 13.6.*** Ischemia associated with compartment syndromes. **A:** At tissue fluid pressures below 30 mm Hg, blood flows normally from arteries to arterioles and into capillaries. **B:** When intracompartmental pressure rises above 30 mm Hg, blood flow is confined to large arteries, veins, and nonnutritional arteriovenous anastomoses. Typically, pulses are present distal to the region of the elevated tissue pressure. This may give the physician a false sense of security because he may assume that normal circulation exists in the muscle compartment. (From Mubarak SJ, Hargens AR. *Compartment Syndromes and Volkmann's Contracture.* Philadelphia: WB Saunders, 1981.)

The differential diagnosis for patients with limb injuries and neurovascular deficits is primarily limited to compartment syndrome, arterial injury, and peripheral nerve injury (Table 13.1). Identification of these problems is important because the treatments are vastly different. A compartment syndrome must be treated by immediate fasciotomy. A major arterial injury requires immediate surgical restoration (e.g., repair of the artery or thrombectomy). A peripheral nerve injury associated with a fracture or severe soft-tissue injury is most commonly a neuropraxia, and the initial treatment of choice is usually observation.

| Clinical finding | Compartment syndrome | Arterial injury | Nerve injury |
|---|---|---|---|
| Increased compartment pressure | + | - | - |
| Pain with stretch | + | + | - |
| Paresthesia or anesthesia | + | + | + |
| Paresis or paralysis | + | + | + |
| Intact peripheral pulses | + | - | + |

***Table 13.1. Clinical Findings of Compartment Syndrome, Arterial Occlusion, and Neuropraxia***

These three conditions frequently coexist, and their clinical findings can overlap (Table 13.1). All three may have an associated motor or sensory deficit and pain. An arterial injury usually results in absent pulses, poor skin color, and decreased skin temperature. Unfortunately, however, there can be a delay in diagnosis when poor blood flow is attributed to other factors such as hypovolemia, local compression, or “kinking” of the vessel from significant limb deformity. As mentioned, the patient with a compartment syndrome routinely presents with intact peripheral circulation. Isolated nerve injuries usually give little pain, and the diagnosis is often by exclusion of the other two entities. Doppler studies, arteriography, and intracompartmental pressure measurements are frequently required to aid in the differential diagnosis of these three conditions.

### *Chronic Compartment Syndrome*

The hallmark symptom of CCS is extremity pain induced by exercise or other exertion. The treating physician must have a high index of suspicion to correctly identify patients with CCS.

The patient with CCS may range from a casual weekend jogger to an enthusiastic marathon runner. Nonrunners may also be at risk (e.g., weightlifters). The majority are young, active men, and the symptoms are frequently bilateral. In most cases, the patient reports recurrent pain that is initiated by exercise over the anterior or lateral compartment of the leg. Symptoms have usually been present for months by the time medical attention is sought. For runners, the onset of pain is reproducible for a specific speed and distance. It is usually necessary for the patient to discontinue his run and rest for a few minutes, similar to the situation in elderly patients with vascular claudication. This is variable, however, and some individuals may continue to run at a reduced speed. The pain may persist for hours.

Pain with CCS is described as a feeling of pressure or cramping in the compartment and may be achy, sharp, or dull. Occasionally, there may also be associated numbness or weakness. The most common compartments involved in CCS are the anterior and/or lateral compartments of the leg; however, it has also been reported in the posterior compartments of the leg (46), thigh (48), foot (31), back (62), forearm (30,45), and hand (59).

Few findings are gleaned from the physical examination before the patient exercises. Muscle hernias, occurring in 60% of Reneman's patients, may be clinically more obvious after exercise (50,51). Pedowitz et al. summarized the physical examination findings in 45 patients with CCS (48). Muscle herniation through a fascial defect was present in 46% of these patients. Most of these defects are located in the lower third of the leg overlying the anterior intermuscular septum between the anterior and lateral compartments (Fig. 13.7). In this location, the fascial defect may represent an enlargement of the orifice through which a branch of the superficial peroneal nerve (e.g., medial dorsal cutaneous nerve) exits the lateral compartment. Muscle herniation may cause superficial peroneal nerve irritation and even neuroma formation (12). After exercise, a sensation of increased fullness over the anterior compartment may be experienced, and occasionally hypoesthesia on the dorsum of the foot is documented. There should be no changes in the peripheral pulses after exercise.

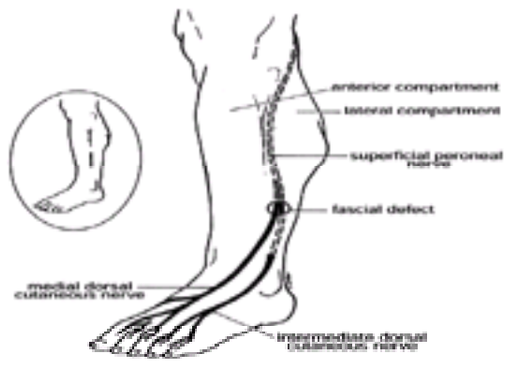


***Figure 13.7.*** Relationship of superficial peroneal nerve branches to fascial defect, commonly seen with chronic exertional compartment syndromes. **Inset:** Incision used for fasciotomy and exploration of the defect and nerves. (From Garfin SR, Mubarak SJ, Owen CA. Exertional Anterolateral Compartment Syndrome: Case Report with Fascial Defect, Muscle Herniation and Superficial Peroneal Nerve Entrapment. *J Bone Joint Surg* 1977;59-A:404.)

Because the history and physical examination findings are usually inadequate for the definitive diagnosis of CCS, objective intracompartmental pressure measurements are needed. Unfortunately, there still exists significant controversy over the critical pressure criteria used for the diagnosis of CCS. In addition, different investigators have used different catheter systems to obtain their data. It is important to define abnormally high pressures in relation to normative data from a control population using the same pressure measurement system.

Based on the work by Styf et al., it is logical to obtain intracompartmental pressures during the period of muscle relaxation when microcirculatory perfusion occurs (60). In CCS, resting intracompartmental pressure is elevated (Fig. 13.8). In our lab, objective criteria for the diagnosis of CCS were developed by Pedowitz et al. using slit catheter determinations of static pressures before and after exercise (46). Pressures are measured before exercise and 1 and 5 minutes after exercise. One or more of the following criteria are diagnostic of CCS: rest pressure ³15 mm Hg, 1-minute postexercise pressure ³30 mm Hg; and 5-minute postexercise pressure ³20 mm Hg.

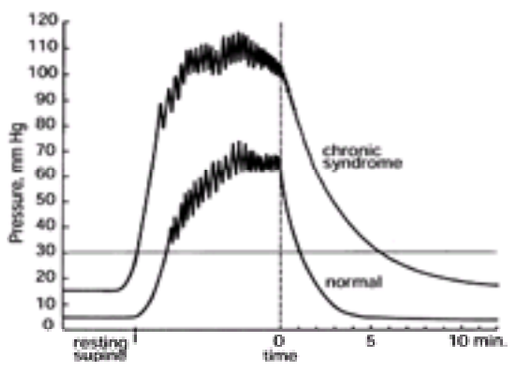


***Figure 13.8.*** Illustrative anterior compartmental pressures recorded with the wick catheter during exercise of a normal person and a patient afflicted with a chronic anterior compartment syndrome. The resting pressure of the chronic syndrome is elevated over that of the normal control. During exercise, the pressure rises to more than 75 mm Hg and remains greater than 30 mm Hg for more than 5 minutes in this patient with chronic compartment syndrome. (From Mubarak SJ, Hargens AR. *Compartment Syndromes and Volkmann's Contracture.* Philadelphia: WB Saunders, 1981.)

The measurement of intracompartmental pressure is invasive, and recently there have been studies using a noninvasive technique of near-infrared spectroscopy to diagnose CCS (7,37). This technique holds promise for future research and clinical diagnosis in patients with CCS and other skeletal muscle disorders.

The differential diagnosis for CCS includes other causes of exercise-induced extremity pain. These include stress fracture, periostitis, tendinitis, peripheral nerve entrapment, vascular claudication, venous stasis, and neurogenic claudication. Plain radiography, bone scintigraphy, ultrasound, magnetic resonance imaging, electromyography, and nerve conduction studies may be useful in determining the correct diagnosis other than CCS.

**PRINCIPLES AND TECHNIQUES OF PRESSURE MONITORING**

A variety of means exist for measuring compartmental pressure, including the needle techniques popularized by Reneman (50) and Whitesides et al. (63) and the infusion technique advocated by Matsen et al. (33). We have employed the wick and slit catheter technique for measurement of tissue pressure in compartment syndromes. The wick technique was first described in 1968 by Scholander et al. (56). The wick catheter used in our patients was based on the original design, but instead of cotton a piece of braided polyglycolic acid suture was employed as the wick in the end of the catheter. The development of the clinical wick catheter began in 1973, and the first human use studies began in 1974 (Fig. 13.9). (40).

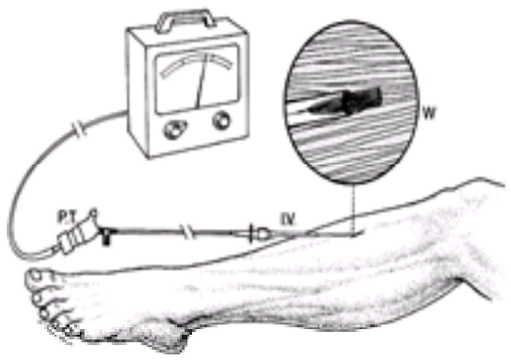


***Figure 13.9.*** Wick catheter technique for measuring equilibrium tissue fluid pressure continuously in a muscle compartment. Intravenous placement unit (*I.V.*) aids insertion of the sterilized saline-filled catheter. Before insertion, connect the wick catheter to a pressure transducer (*P.T.*) and recorder and calibrate it. A close-up view of the catheter tip (*W*) illustrates how catheter patency and continuous fluid transmission are maintained by the numerous wick fibers. (From Owen CA, Mubarek SJ, Hargens AR, et al. Intramuscular Pressure with Limb Compression. Clarification of the Pathogenesis of the Drug-Induced Compartment Syndrome/Crush Syndrome. *N Engl J Med* 1979;300:1169.)

The slit catheter (Slit Catheter, Howmedica, Inc., Rutherford, NJ), first developed by Rorabeck et al., is a modification of the wick catheter principle and incorporates its features: accuracy, reproducibility, large area of tissue fluid pickup, immediate measurement of equilibrium tissue pressure, and continuous monitoring of intramuscular pressure during contraction and exercise (Fig. 13.10) (55). The primary advantages of the slit catheter are that it is less prone to coagulation in long-term measurements, it has a faster response time during exercise studies, and its manufacture is readily accomplished and is more uniform than that of the wick catheter. Styf and Koörner have described a microcapillary infusion technique using a catheter with side holes near the tip that has excellent dynamic properties when compared with the wick, and is very useful in studying chronic compartment syndromes (58).

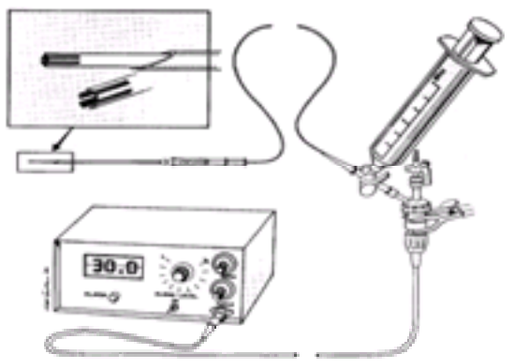


***Figure 13.10.*** Slit catheter technique for continuous measurement of intracompartmental pressure. Before inserting it into a muscle compartment, connect the sterile slit catheter to a pressure transducer and digital recorder and then fill it with saline using a 30-ml syringe. The catheter tip protrudes from the insertion needle during filling so that the tip can be checked for air bubbles (**upper left**). Before insertion into muscle, pull the catheter entirely within the needle. (From Mubarak SJ, Hargens AR. *Compartment Syndromes and Volkmann's Contracture.* Philadelphia: WB Saunders, 1981.)

The Camino catheter is a fiberoptic transducer-tipped pressure-monitoring catheter system (Camino Laboratories, San Diego, CA) that uses a unique method of obtaining pressure measurements without the disadvantages of the long fluid-filled catheters with external transducers (9). The Camino catheter operates by using a light-sending and receiving system that responds to movements of a mirror diaphragm when pressure is applied to the catheter tip. The movement is sensed by light signals emitted from a “sending” light fiber; the reflected light is sent to an amplifier through a “receiving” light fiber. The light sent and received is analyzed by a microcomputer and converted into digital and analog signals directly related to the applied pressure. This pressure-measuring instrument has its sensor near the catheter tip, which eliminates the need to make adjustments for hydrostatic pressure. The fiber optic cable has a relatively large diameter, however, and can be uncomfortable during long-term monitoring.

Small portable pressure-monitoring systems have also been developed. These work best, and are most accurate, when used with high-pressure tubing and a slit catheter at the end. Simple needles often plug with tissue and are much less accurate. An example of a portable unit commonly used is the Stryker Pressure Monitor System (Stryker, Kalamazoo, MI). The Stryker system is hand-held, with a prefilled, sterile, disposable syringe (Fig. 13.11). It can be used for intermittent measurement or continuous monitoring. When possible, it should be used with a slit-tip catheter rather than the fenestrated needle.

***Figure 13.11.*** The Stryker system is a small portable monitoring system (Stryker, Kalamazoo, MI). It is most accurate if used with high-pressure tubing and a slit catheter.

In certain settings, the treating physician may not have immediate access to a wick catheter, slit catheter, or even a portable unit with a side-ported needle. In these situations, intracompartmental pressure measurements can be readily obtained with an existing arterial line setup and a catheter that has been cut at the tip. A simple 18-gauge needle and a mercury manometer (Whitesides technique) (63) can also be used, but it is important to recognize that this method is considered the least accurate. Moed et al. compared measurement of intracompartmental pressures using a slit catheter, a Stryker portable unit with a side-ported needle, and a simple 18-gauge needle with a mercury manometer (36). They found that the values obtained with the simple needle were consistently higher, by an average of 18 to 19 mm Hg, than those obtained with the other two methods. They found no statistical difference between the values obtained with the slit catheter compared with the side-ported needle unit.

In the evaluation of a patient with a possible compartment syndrome, obtain multiple pressure measurements throughout each compartment. This is particularly important in patients with a long bone fracture and suspected compartment syndrome. Heckman et al. showed that, in cases of closed tibia fractures, there exists a relationship between intracompartmental pressure and distance from the actual fracture site (24). The highest pressures were routinely found at or within 5 cm of the fracture site. On the basis of these data, the authors recommend using the highest recorded intracompartmental pressure as an indicator for fasciotomy.

### *Indications*

Many compartment syndromes can be diagnosed clinically without the need for intracompartmental pressure measurements. In these cases, documentation of the elevated compartment pressures is confirmatory. However, patients are frequently encountered in whom there is difficulty in eliciting or interpreting the physical examination findings. In these patients, the measurement of intracompartmental pressure is particularly valuable in the diagnosis and as a criterion for decompression.

In the uncooperative or unreliable patient, a careful physical examination may be difficult, and measurement of intracompartmental pressures may be extremely valuable. Children with fractures and other severe soft-tissue injuries may be so frightened that examination is impossible. Polytrauma patients frequently have closed head injuries and may be intoxicated from drugs and/or alcohol, making examination difficult.

Intracompartmental pressure measurement is essential in unresponsive individuals. Obtunded patients, intubated and paralyzed patients, and comatose patients are unable to cooperate with a physical examination, and palpably tense compartments are the only finding they can demonstrate. It is essential in these patients to have a high index of suspicion.

Lastly, pressure measurements are valuable in patients in whom the diagnosis is inconclusive. A patient may have an evolving or early compartment syndrome in which their pain is clearly out of proportion to what is expected from their injury. On examination they may have palpably tense compartments but may not yet have developed other classical findings such as pain on passive muscle stretch and sensory deficits. A patient may also have a nerve deficit attributable to other causes. It is often difficult to differentiate neuropraxia secondary to stretch or contusion of a peripheral nerve from neurologic deficits resulting from increased intracompartmental pressure.

### *Pressure Threshold for Fasciotomy*

Acute compartment syndrome has been recognized clinically for more than 100 years. Despite significant advances in the understanding of the etiology and pathophysiology of this syndrome, disagreement still remains on the pressure threshold for fasciotomy. One possible reason for the different published thresholds may be the technique of measurement. As discussed above, the needle techniques usually give higher pressure readings when compared with a slit catheter or side-ported needle. In addition, there remains disagreement on whether there exists an absolute critical closing pressure, that is, a tissue pressure beyond which capillary circulation ceases and ischemia ensues, or whether this ischemic threshold is relative to the patient's systemic blood pressure.

Whitesides et al. initially recommended fasciotomy when intracompartmental tissue pressure rose to within 10 to 30 mm Hg of the patient's diastolic blood pressure (64). This recommendation was then modified slightly by Heckman et al. to perform fasciotomy when the measured intracompartmental pressure rises to within 10 to 20 mm Hg of the patient's diastolic blood pressure (23). For example, this would represent an absolute pressure of 50 to 60 mm Hg in a patient with a diastolic blood pressure of 70 mm Hg. This recommendation is based on their work in a canine model where histologic evidence of muscle regeneration did not occur until the 8-hour

pressurization level was within 20 mm Hg of the dog's diastolic blood pressure. Necrosis and fibrosis of muscle did not occur until the 8-hour pressurization level was within 10 mm Hg of the dog's diastolic blood pressure.

Heppenstall and colleagues, using phosphorus nuclear magnetic resonance spectroscopy to measure the metabolic activity of muscle, also concluded that the perfusion pressure gradient between systemic blood pressure and intracompartmental tissue pressure was important in determining the ischemic threshold for muscle (25,26). In their canine model, using a slit catheter to determine intracompartmental pressures, they determined that normal cellular metabolism can occur as long as the intracompartmental tissue pressure was no closer than 30 mm Hg to the mean arterial blood pressure (MAP). Hypertension would therefore have a “protective” effect on muscle perfusion and would raise the absolute pressure threshold for fasciotomy, whereas hypotension, as is frequently seen in the polytraumatized patient, would effectively lower the threshold. In addition, these authors noted that in traumatized muscle, cellular damage was noted when the tissue pressure was within 40 mm Hg of the animal's MAP.

Matsen et al., in a clinical study using their needle-infusion technique, reported that no patient with an absolute pressure less than 45 mm Hg developed a compartment syndrome (35). Almost all patients with intracompartmental pressures greater than 50 mm Hg, however, were noted to have true compartment syndromes. Matsen et al., using an external compression device to elevate intracompartmental pressure, and using themselves as volunteers, also demonstrated that elevating the limb to approximately 50 cm above the level of the heart lowered the tolerance of the leg to increased intracompartmental pressures by as much as 35 mm Hg (34). They attributed this to the relative hypotension of the limb and to decreased perfusion pressure.

Rorabeck and colleagues, using the slit catheter, recommend decompression for resting pressures in the range of 30 to 40 mm Hg (55). We have used similar pressure thresholds in our practice. Our clinical and animal studies support the conclusion that the threshold intracompartmental pressure at which fasciotomy is recommended is 30 mm Hg for 8-hour pressurization in an acute compartment syndrome (18,19 and 20,40). Using a similar dog model, our lab has also demonstrated that the pressure threshold is lowered during systemic hypotension (65). Because the total time of elevated tissue pressure and the absolute pressure levels before measurement are usually unknown in most cases of ACS, we recommend that intracompartmental pressure greater than 30 to 35 mm Hg, combined with other positive clinical findings, warrants fasciotomy (Fig. 13.12).

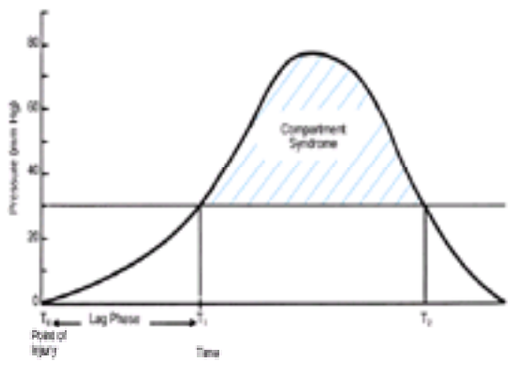


***Figure 13.12.*** The time between injury and the onset of a compartment syndrome may vary from hours to days (lag phase, $T_0$ to $T_1$). The ischemia of the muscle and nerves of the compartment does not take place until the pressure rises to more than 30 mm Hg (*horizontal line*). Thus, the time from injury to diagnosis and treatment is only a relative indicator of the ischemic period unless the tissue pressure has been monitored from the point of injury. (From Gelberman RH, Garfin SR, Hergenroeder PT, et al. Compartment Syndromes of the Forearm: Diagnosis and Treatment. *Clin Orthop* 1981;161:252.)

Despite continued disagreement on the pressure threshold for irreversible tissue damage, all authors agree that intracompartmental pressure measurement is only one of many factors that play a role in determining the need for fasciotomy. Any absolute pressure threshold is a relative indication for decompression that should be tempered by several patient factors, including overall condition, systemic blood pressure, peripheral perfusion, trend of symptoms and signs, trend of intracompartmental pressures, and the cooperation and reliability of the patient.

## PREOPERATIVE MANAGEMENT

In evaluating a patient with a traumatized limb, carefully document the time of injury as well as the initial and subsequent examinations. Perform and record a sensory examination to include light touch, pin prick, and two-point discrimination. The nurses and treating physician must monitor these values frequently. Perform intracompartmental pressure measurements when indicated and carefully document them as well.

You must have a high index of suspicion in all cases of possible compartment syndrome. The consequences for a patient from a missed compartment syndrome can be devastating. The best way to ensure early diagnosis and treatment is to understand the pathophysiology of the syndrome, take all possible cases seriously, and deal with them on an emergency basis.

When the diagnosis of an acute compartment syndrome is considered, but the exam is equivocal and/or the intracompartmental pressure is not high enough to warrant a fasciotomy, take all measures possible to attempt to prevent a full-blown compartment syndrome from occurring. Initially, remove all constrictive dressings and split or remove any casts (Fig. 13.13). Garfin et al. used a canine model to show that a cast can restrict volume expansion of a compartment by 40% (14). In addition, univalving and spreading the cast decreased compartment pressure by as much as 65%.

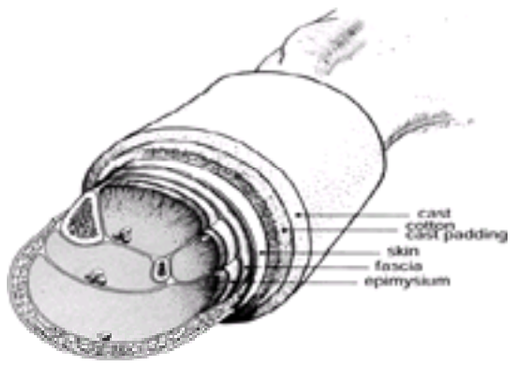


***Figure 13.13.*** The circumferential cast is the first envelope that must be opened to decrease intracompartmental pressures. In laboratory studies, we have demonstrated that cast univalving and spreading decreased the intracompartmental pressure by as much as 65%. (From Garfin SR, Mubarak SJ, Evans KL, et al. Quantification of Intracompartmental Pressure and Volume under Plaster Casts. *J Bone Joint Surg* 1981;63-A:449.)

The position of the limb in a patient at risk for developing a compartment syndrome is important. Frequently the limb is elevated to decrease swelling. Matsen and colleagues have shown, however, that elevation of the limb reduces mean arterial pressure as well as the arteriovenous gradient and thereby reduces capillary flow (34). Leaving the limb dependent may increase the mean arterial pressure, but significant swelling may occur and also increase the risk of developing a compartment syndrome. Therefore, place any extremity with an incipient compartment syndrome, or at risk of developing a compartment syndrome, at the level of the heart.

## SURGICAL TECHNIQUES

Take the patient with an established acute compartment syndrome emergently to the operating room for decompressive fasciotomy.

- Place a tourniquet on the limb but do not elevate it unless absolutely necessary. Administer prophylactic antibiotics intravenously.

- We recommend long extensile skin incisions, both to supplement the fascial decompression and to prevent iatrogenic injury to nearby vessels, tendons, and nerves. Carefully debride obvious areas of muscle necrosis at the initial operation, but areas of muscle with uncertain vascularity can be left until the patient is returned to the operating room in 24 to 72 hours, when muscle viability can be determined more accurately.
- At the completion of all fasciotomies, measure the pressure in several areas of each compartment to ensure adequate decompression.

## FOREARM DECOMPRESSION

It is important to identify the important neurovascular structures of the forearm, particularly the median nerve, when decompressing a forearm compartment syndrome. For this reason, use an extensive volar skin incision, avoiding a more limited “percutaneous” approach. Two common approaches to the volar forearm and a single dorsal approach are used to release the three forearm compartments.

### *Volar Curvilinear Approach*

The volar approach of Henry is an excellent incision for release of the volar compartment.

- Begin the skin incision proximal to the antecubital fossa on the ulnar aspect of the arm and cross the antecubital fossa horizontally in the flexion crease (Fig. 13.14). Extend the incision down the forearm in an S shape to the wrist flexion crease and then cross the crease into the palm to allow release of the carpal tunnel.

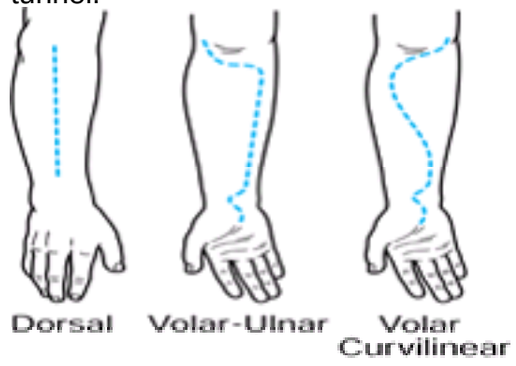


***Figure 13.14.*** The dorsal and volar incisions used for forearm decompression. Both volar incisions provide excellent exposure to the major neurovascular structures. The volar curvilinear incision also provides access to the mobile wad compartment. (Redrawn from Gelberman RH, Zakaib GS, Mubarak SJ, et al. Decompression of Forearm Compartment Syndromes. *Clin Orthop* 1978;134:225.)

- Incise the superficial fascia throughout the length of the forearm. Identify the median nerve proximally and release the lacertus fibrosus.
- Release the proximal edge of the pronator teres and the proximal edge of the flexor digitorum superficialis. Follow the median nerve into the forearm between the flexor digitorum superficialis and profundus and decompress it all the way to the carpal tunnel. Preserve the palmar cutaneous branch of the median nerve.
- Incise the transverse carpal ligament to release the carpal tunnel.
- Inspect the deep volar muscles (flexor digitorum profundus, flexor pollicis longus, and pronator quadratus) and release their respective fascial coverings as needed. With undermining of the skin, the mobile wad can also be reached through this approach.

### *Volar Ulnar Approach*

- Begin the incision on the lateral aspect of the arm above the antecubital fossa. Extend it horizontally across the elbow flexion crease, down the ulnar border of the forearm, and then continue into the palm (Fig. 13.14).
- Carry out the remainder of the decompression as described above for the Henry approach.

Gelberman et al. compared the two volar approaches to the forearm and found no significant differences between the two in regard to adequate decompression (15). The mobile wad, however, cannot be easily reached through the volar ulnar approach, and a second dorsal incision is needed to release this compartment.

### *Dorsal Approach*

After release of the volar compartment, pressures in the dorsal and mobile wad compartments can be measured to determine whether decompression is needed. If there is any question as to the need for decompression, proceed with fasciotomy. The dorsal incision is similar to that used in the Thompson approach and can extend from the lateral epicondyle to the midportion of the wrist (Fig. 13.14). Usually the entire skin incision is not needed, and with adequate undermining of the skin, the fascia of the dorsal and mobile wad compartments is readily released. As previously mentioned, the mobile wad can also be released from the volar curvilinear approach of Henry.

## LEG DECOMPRESSION

The leg is the most common area to be involved in compartment syndrome. As described above, there are four compartments in the leg. In general, all compartments must be released in acute compartment syndrome of the leg.

### *Double-incision Approach*

This approach was described by Mubarak et al. and is used routinely in our practice for fasciotomy of the four leg compartments (38).

- To approach the anterior and lateral compartments, make a longitudinal skin incision 20 to 25 cm long, halfway between the fibular shaft and tibial crest (Fig. 13.15). This lies approximately over the anterior intermuscular septum dividing the anterior and lateral compartments and allows easy access to both. Undermine the skin edges proximally and distally to provide wide exposure of the fascia.

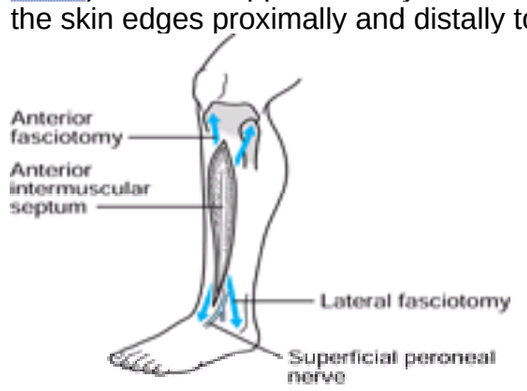


***Figure 13.15.*** The two-incision technique for four-compartment release of the leg. Anterolateral incision, step 1. (Redrawn from Mubarak SJ, Hargens AR. Diagnosis and Management of Compartment Syndromes. In: *AAOS: Symposium on Trauma to the Leg and Its Sequelae.* St. Louis: CV Mosby, 1981.)

- Make a small transverse incision in the midportion of the leg, just through the fascia, to identify the anterior intermuscular septum that separates the anterior compartment from the lateral compartment (Fig. 13.16). Identification of this septum is necessary to identify the superficial peroneal nerve, which lies in the lateral compartment next to the septum.

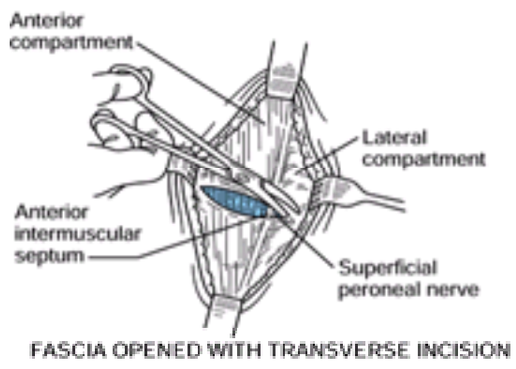


***Figure 13.16.*** Anterolateral incision, step 2. (Redrawn from Mubarak SJ, Hargens AR. Diagnosis and Management of Compartment Syndromes. In: *AAOS: Symposium on Trauma to the Leg and Its Sequelae.* St. Louis: CV Mosby, 1981.)

- Using a 12-in. (31-cm) Metzenbaum scissors, open the anterior compartment fascia. Visualization is aided by retraction with right-angle retractors. Push the scissors with the tips open slightly in the direction of the great toe distally and proximally toward the patella (Fig. 13.17). If there is any question whether the tip of the scissors has strayed from the fascia, lengthen the skin incision to ensure complete fascial release. Blind repeat attempts to complete the fasciotomy are dangerous and can injure vascular, nervous, and tendinous structures.

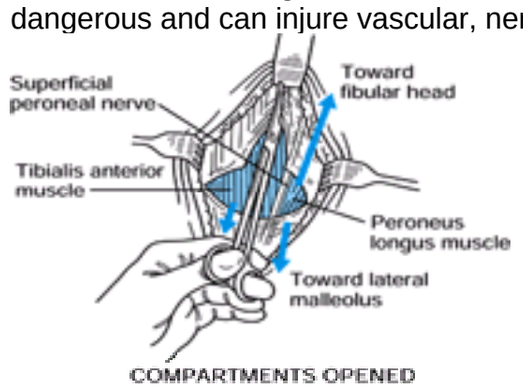


***Figure 13.17.*** Anterolateral incision, step 3. (Redrawn from Mubarak SJ, Hargens AR. Diagnosis and Management of Compartment Syndromes. In: *AAOS: Symposium on Trauma to the Leg and Its Sequelae.* St. Louis: CV Mosby, 1981.)

- Make the lateral compartment fasciotomy in line with the fibular shaft. Direct the scissors proximally toward the fibular head and distally toward the lateral malleolus. In this way the fascial incision is posterior to the superficial peroneal nerve. Adequate visualization is essential, so do not hesitate to extend the skin incision if necessary.
- Make a second longitudinal incision, 20 to 25 cm long, on the posteromedial side of the leg to approach the superficial and deep posterior compartments (Fig. 13.18). Place this incision 2 to 3 cm posterior to the posterior tibial margin. If the incision is too anterior, the tibia may be left exposed after the skin edges retract. An anterior incision also risks injury to the saphenous vein and nerve, which course along the posterior margin of the tibia.

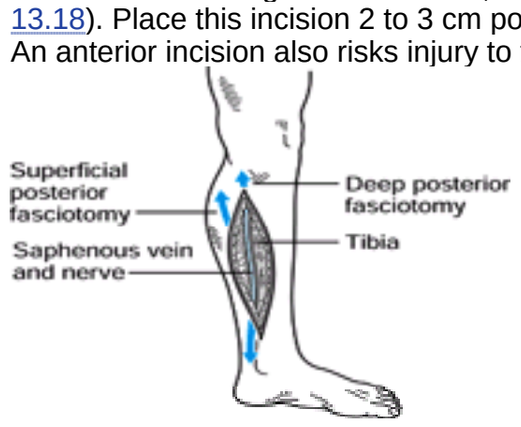


***Figure 13.18.*** Posteromedial incision, step 1. (Redrawn from Mubarak SJ, Hargens AR. Diagnosis and Management of Compartment Syndromes. In: *AAOS: Symposium on Trauma to the Leg and Its Sequelae.* St. Louis: CV Mosby, 1981.)

- Undermine the skin edges and retract the saphenous vein and nerve anteriorly. Make a transverse fascial incision to allow identification of the septum between the deep and superficial posterior compartments (Fig. 13.19). Identify the tendon of the flexor digitorum longus in the deep posterior compartment and the Achilles tendon in the superficial posterior compartment.

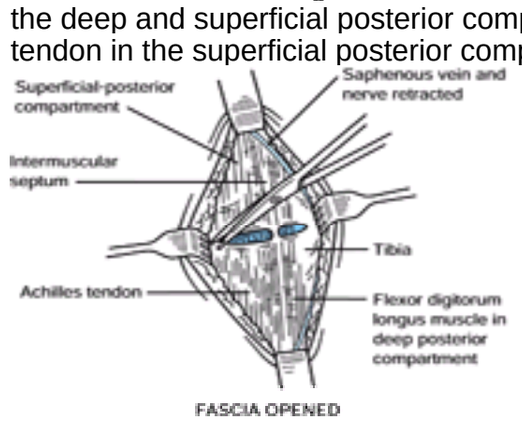


***Figure 13.19.*** Posteromedial incision, step 2. (Redrawn from Mubarak SJ, Hargens AR. Diagnosis and Management of Compartment Syndromes. In: *AAOS: Symposium on Trauma to the Leg and Its Sequelae.* St. Louis: CV Mosby, 1981.)

- It is usually easiest to decompress the superficial posterior compartment first by extending the fasciotomy proximally as far as possible and then distally behind the medial malleolus. Release the deep posterior compartment distally and then proximally under the soleus bridge (Fig. 13.20). Release the soleus if it attaches to the tibia distally more than halfway. In cases where both the deep and superficial compartments are anchored to the posteromedial edge of the tibia, there is no identifiable intermuscular septum and the deep posterior compartment should be released from within the superficial posterior compartment by retraction of the soleus off the tibia.

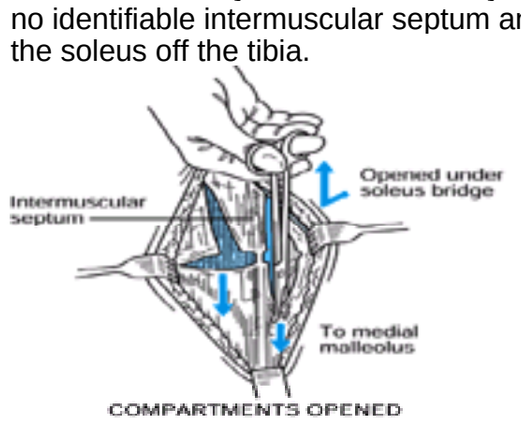


***Figure 13.20.*** Posteromedial incision, step 3. (Redrawn from Mubarak SJ, Hargens AR. Diagnosis and Management of Compartment Syndromes. In: *AAOS:*

*Symposium on Trauma to the Leg and Its Sequelae.* St. Louis: CV Mosby, 1981.)

- This completes a four-compartment decompression (Fig. 13.21). If intraoperative pressure monitoring was used during the procedure, or if there is any doubt as to the adequacy of the decompression, check final intracompartmental pressures.

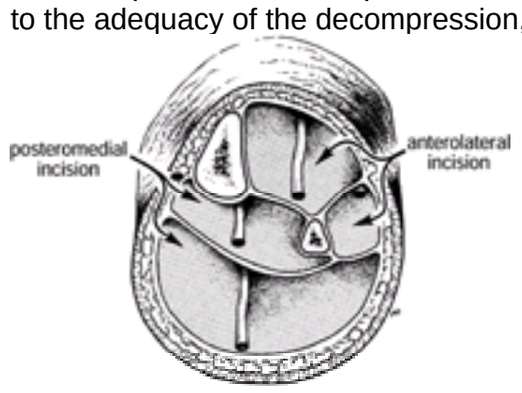


***Figure 13.21.*** Decompression of the four compartments. (From Mubarak SJ, Owen CA. Double-Incision Fasciotomy of the Leg for Decompression in Compartment Syndromes. *J Bone Joint Surg* 1977;59-A:184.)

### *Single-incision Approach*

Matsen and colleagues described a single-incision approach to all four compartments of the leg (33,35). Centered over the lateral compartment, the incision must be extensile in order to allow easy decompression of all four compartments.

- Make an incision from the head of the fibula to the lateral malleolus. Undermine the skin at the level of the deep fascia both anteriorly and posteriorly in the middle third of the wound sufficiently to visualize the posterior edge of the anterior compartment, the lateral compartment, and the anterior edge of the superficial posterior compartment.
- Make a transverse incision with a knife through the deep fascia, beginning in the anterior compartment, crossing the lateral compartment, and extending into the posterior compartment. With careful inspection you can now identify the anterior intermuscular septum running longitudinally between the anterior and lateral compartments and the posterior intermuscular septum running between the lateral and posterior compartments. It is very important to take this step, because identification of the three compartments can be difficult in the traumatized, distorted, and swollen limb. This transverse incision is similar to that illustrated above for the two-incision technique (Fig. 13.19 and Fig. 13.20).
- Using a knife or Metzenbaum scissors, as described above for the two-incision technique, incise the deep fascia of the anterior, lateral, and superficial posterior compartments for the full length of each compartment. Be certain to decompress all muscle proximally. Distally, at the level of the musculotendinous junctions, further decompression is usually not necessary.
- Identify the deep posterior compartment. Dissect the soleus free from its origin on the posterior intermuscular septum in the middle or proximal third of the wound. In the nonswollen limb the deep compartment lies about 1 cm deep to the superficial posterior compartment, but in a limb with severe compartment syndrome this compartment may be as deep as 2.5 cm. Release the deep fascia of this compartment throughout its full length in a similar manner. As with any technique, take care to avoid injury to the neurovascular structures, particularly the common peroneal nerve proximally and its branches distally.

Decompression by fibulectomy was described by Patman and Thompson (44) and popularized by Kelly and Whitesides (29). We do not advise fibulectomy, as it destabilizes tibia fractures and removes an important structure for reconstruction of the leg. It is mentioned for historic interest only.

## FRACTURES AND COMPARTMENT SYNDROME

When compartment syndrome is combined with fractures of any of the long bones, perform external or internal fixation of the fracture at the time of compartment decompression (17,33,53). The obvious advantage of immobilizing the fracture is that care of the fasciotomy wound is facilitated. The technique chosen for stabilization should minimize further soft tissue damage if possible, and in the lower extremity intramedullary nailing is an excellent choice. In some lower extremity fractures, particularly high-grade tibia fractures, intramedullary nailing may not be the optimal technique, and external fixation may be a more prudent choice. The major disadvantage of an external fixator is that mobilization of the skin for delayed primary closure is more difficult, and skin grafting is usually required. For forearm fractures, compression plates are the recommended choice for fixation.

In cases of long bone fractures, you should recognize the high risk that exists for the development of an acute compartment syndrome. Gershuni et al. have shown that, in the case of tibia fractures and acute compartment syndrome, a good functional result can be obtained if the compartment syndrome is readily identified and adequately treated before irreversible muscle and nerve damage occur (17). In cases where the compartment syndrome is missed, or treatment is delayed, the patient may have a poor functional outcome despite adequate treatment and healing of the tibia fracture.

In the operative treatment of long bone fractures, particularly in the treatment of femur and tibia fractures with intramedullary nailing, you should be aware of the possibility of inducing a compartment syndrome. This was discussed above in the etiology of acute compartment syndromes. In all cases of intramedullary nailing of the femur and tibia, carefully inspect the thigh and leg for tight compartments. If there is any evidence of increased intracompartmental pressure, measure the pressure in all compartments before the end of the procedure. If indicated, perform fasciotomies immediately.

## PROPHYLACTIC FASCIOTOMY

Consider a prophylactic fasciotomy for any patient with a high probability of developing a compartment syndrome (33). Anterior and lateral compartment fasciotomies should be considered in patients undergoing tibia osteotomies or leg-lengthening procedures, or when the tibia is used as a donor bone graft site. When debriding an open tibial fracture, release those compartments accessible through the exposed wound.

Patients who have sustained an arterial injury or developed a thrombus or who have had a femoral artery bypass are especially prone to developing compartment syndromes. In our experience, patients with postischemic compartment syndrome have a poor prognosis because the period of ischemia caused by the arterial injury is added to the compartment syndrome that results after reinstitution of arterial flow. If the arterial ischemia has been present for more than 4 to 6 hours, prophylactic fasciotomy of the leg or forearm is warranted at the time of arterial repair.

## TREATMENT OF CHRONIC COMPARTMENT SYNDROME

After the diagnosis of chronic compartment syndrome has been established by history, physical examination, and intracompartmental pressure measurement, fasciotomy is usually required. After the diagnosis and surgical treatment are outlined to patients, however, many prefer to limit their running or alter their exercise program. The patient choosing nonoperative treatment must also be counseled about the possibility of developing an acute compartment syndrome if the symptoms are ignored and the activity is not modified (39). In our experience, most patients who desire to maintain a given level of jogging or running require fasciotomy.

### *Chronic Anterior Compartment Decompression*

The technique for decompression of the leg in CCS is the same as that used for ACS; however, the skin incisions can be much smaller, in the range of 5 to 6 cm (Fig. 13.22).

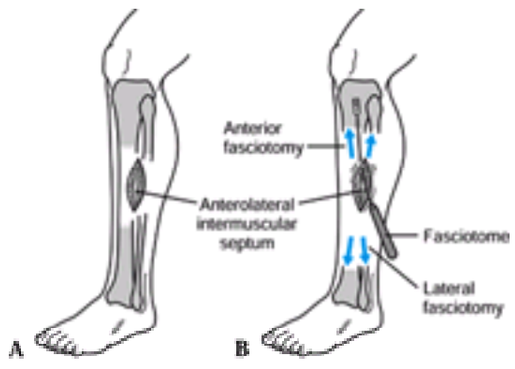


***Figure 13.22.*** Chronic anterior compartment decompression: anterolateral fasciotomies in the absence of a fascial hernia. (Redrawn from Fronek J, Mubarak SJ, Hargens AR, et al. Management of Chronic Exertional Anterior Compartment Syndrome of the Lower Extremity. *Clin Orthop* 1987;220:217.).

- Place a small 5-cm incision between the tibial crest and fibular shaft, overlying the anterolateral intermuscular septum. In the absence of a fascial hernia, place the incision in the midportion of the leg.
- Extensive undermining and a fasciotome aid limiting the skin incision while still performing a safe and satisfactory fasciotomy (Fig. 13.23).

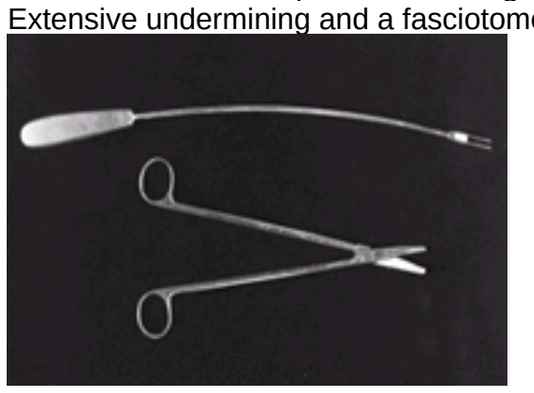

***Figure 13.23.*** A 12-in. Metzenbaum scissors (**bottom**) or a fasciotome (**top**) is useful for decompression of the leg. (From Mubarak SJ, Hargens AR. Diagnosis and Management of Compartment Syndromes. In: *AAOS: Symposium on Trauma to the Leg and Its Sequelae.* St. Louis: CV Mosby, 1981.)

- Muscle hernias frequently occur in the lower third of the leg in the area overlying the anterior intermuscular septum. This is the site of emergence through the fascia of one or both sensory branches of the superficial peroneal nerve (Fig. 13.24). For this reason, make the skin incision over the hernia and perform the fasciotomy at the fascial defect. This allows easy decompression of both the anterior and lateral compartments and allows simultaneous decompression of the nerve.

***Figure 13.24.*** Intraoperative photograph of a fascial defect, bulging peroneus brevis muscle, and a medial dorsal cutaneous nerve exiting from the defect. The intermediate dorsal cutaneous nerve has developed a neuroma. (From Garfin SR, Mubarak SJ, Owen CA. Exertional Anterolateral Compartment Syndrome: Case Report with Fascial Defect, Muscle Herniation, and Superficial Peroneal Nerve Entrapment. *J Bone Joint Surg* 1977;59-A:404.)

- Do not close the fascial defect associated with a muscle hernia because of the risk of precipitating an acute compartment syndrome.
- After making the skin incision, carry out decompression of the anterior and lateral compartments as described earlier (Fig. 13.25).

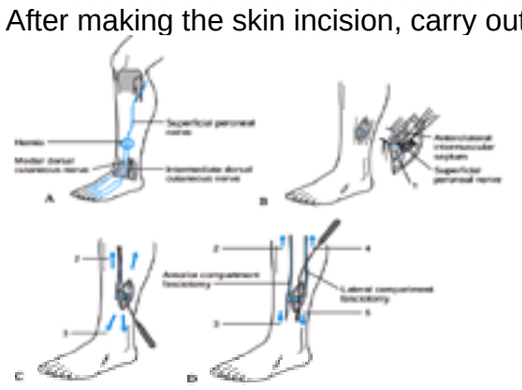

***Figure 13.25.*** Chronic anterior compartment decompression: anterolateral fasciotomies in the presence of a fascial hernia. **A:** Place the incision over the fascial defect, with attention to the superficial peroneal nerve and its branches. **B:** Enlarge the defect across the intermuscular septum (*1*) to gain entry into both compartments. **C:** Achieve complete longitudinal release of the anterior compartment by passing the fasciotome in the direction of the patella proximally (*2*) and distally in the direction of the great toe (*3*). **D:** In the lateral compartment, direct the scissors or fasciotome posterior to the fibular head (*4*) and lateral malleolus (*5*). (Redrawn from Fronek J, Mubarak SJ, Hargens AR, et al. Management of Chronic Exertional Anterior Compartment Syndrome of the Lower Extremity. *Clin Orthop* 1987;220:217.)

- With CCS of the anterior compartment, we usually recommend release of both the anterior and lateral compartments. In cases of posterior compartment decompression, perform fasciotomy of the posterior compartments as described above for ACS, but through a smaller incision.

## GENERAL REHABILITATION AND POSTOPERATIVE PRINCIPLES

- Following adequate compartment decompression, pack the wounds loosely open with saline-dampened gauze and apply a bulky dressing.
- Never close the skin incisions immediately after fasciotomy. At 24 to 72 hours after fasciotomy, return the patient to the operating room for repeat debridement if necessary and partial or even complete skin closure. Frequently the compartment syndrome is associated with an open fracture, and the patient is returned to the operating room several times for repeat debridement related to the fracture and soft tissue injury.
- Most commonly, fasciotomy wounds are not amenable to delayed primary closure, and split-thickness skin grafting is necessary for wound closure. With the two-incision technique in the leg, one wound can usually be closed primarily on a delayed basis, and the other wound covered with a split-thickness skin graft. In the case of compartment syndrome associated with open fractures, quantitative cultures can be used to determine the appropriate time for skin grafting.
- Begin active and active-assisted range of motion of the adjacent joints on the second day after fasciotomy. After split-thickness skin grafting, immobilize the limb for 3 to 5 days to decrease sheer forces across the graft and allow full incorporation. When the skin graft has incorporated, reinstitute range-of-motion exercises.
- In contrast to fasciotomy after ACS, close the wound with an interdermal running stitch after fasciotomy for CCS. Apply a light dressing and allow the patient

weight bearing as tolerated with the use of crutches as needed. After suture removal at 2 to 3 weeks, initiate light running and progress exercises as tolerated over the next 3 to 6 weeks according to the patient's abilities and pain tolerance.

## PITFALLS AND COMPLICATIONS

Most pitfalls and complications of compartment syndrome are related to a delay in diagnosis and treatment and/or to inadequate decompression. The sequelae in such cases can be devastating to the patient. Despite an abundance of clinical and basic science work on the subject, compartment syndromes remain poorly understood. Because of their relatively infrequent occurrence, they may be overlooked by a treating physician who does not deal often with patients at risk, namely the polytraumatized patient and the intravenous drug user. In addition, the clinical findings of a compartment syndrome are rather subjective and rely heavily on patient cooperation.

The classic sequela from an untreated or untimely treated compartment syndrome is Volkmann's ischemic contracture of the extremity (Fig. 13.26). This results in a limb with a varying amount of deformity and functional loss, depending on the severity of the muscle and nerve injury. Muscles, nerves, tendons, bone, vessels, and skin can all be affected by the ischemia from a compartment syndrome. Irreversible muscle damage has been shown to occur after 4 to 6 hours of complete ischemia (21). Hargens et al. showed in a canine model that, at a pressure of 30 mm Hg, irreversible muscle necrosis occurred at 8 hours (20). In addition, they noted that this 8-hour threshold can be shorter in cases of hypotension. Irreversible nerve damage occurs after 6 to 12 hours of ischemia at intracompartmental pressures between 30 and 40 mm Hg (19,54).

***Figure 13.26.*** Volkmann's ischemic contracture in a child who suffered compartment syndrome of the forearm. Note the deformities of the wrist and hand. (From Mubarak SJ, Hargens AR. *Compartment Syndromes and Volkmann's Contracture.* Philadelphia: WB Saunders, 1981.)

A high index of suspicion, early diagnosis, and immediate institution of treatment will help prevent Volkmann's ischemic contracture and restore normal function to a limb that has suffered a compartment syndrome. In addition, if there is any question as to the adequacy of decompression, intracompartmental pressure measurements should be obtained in the operating room after fasciotomy.

There also exists the potential for significant iatrogenic injury during the treatment of compartment syndrome. Nerves, blood vessels, and even tendons can be injured during compartment release if careful attention is not paid to compartmental anatomy and if there is inadequate visualization. In such cases, immediately repair the injured structure(s).

## AUTHORS' PERSPECTIVE

### PREVENTION

The best way to avoid an acute compartment syndrome and its possible sequelae is to understand its pathophysiology and focus on prevention of the disorder. We routinely univalve and spread all casts used in the treatment of closed fractures of the long bones or use splints in the acute postinjury period before placement of a potentially constricting cast. In patients undergoing surgical procedures that have an associated risk of compartment syndrome, such as tibial osteotomies and open treatment of tibial plateau fractures, we usually perform a prophylactic fasciotomy.

There have been reports in the literature on the development of compartment syndrome in the well leg from positioning on the fracture table (2,11). Similarly, there have been many reports in the urology and gynecology literature on the development of compartment syndrome in legs placed in the lithotomy position (1,42,49). Most commonly, these patients are in the lithotomy or hemilithotomy position for prolonged periods of time (>4 hours). Heavy patients and periods of intraoperative hypotension may also be risk factors, although this has not been studied.

We have experienced three such cases of compartment syndrome in the well leg from positioning on the fracture table. All cases involved heavy patients and prolonged time in the well-leg holder. These cases, along with those reported in the literature, prompted an investigation in our lab into the pathophysiology of this complication.

We studied eight healthy volunteers positioned in the hemilithotomy position on a fracture table and found that the well-leg holder caused a significant increase in calf intramuscular pressure and a significant decrease in ankle blood pressure. More importantly, the well-leg holder caused a significant decrease in *P*, the difference between ankle blood pressure and calf intramuscular pressure. In the lateral compartment *P* averaged only 31 mm Hg, a level very close to the ischemic threshold of muscle as reported by Heppenstall et al. (25).

We recommend the use of alternate patient positions for complicated fracture cases which may take several hours to complete. We frequently place both legs in traction boots and “scissor” the limbs (Fig. 13.27), or use the lateral position on the fracture table. Supine or lateral positioning on an image table without the use of traction are also good alternatives. If the hemilithotomy position is used, we recommend palpating the well-leg compartments and temporarily lowering the limb every 2 to 3 hours. After all fluoroscopic images have been obtained, the well leg should be immediately placed into a more relaxed, lowered position.

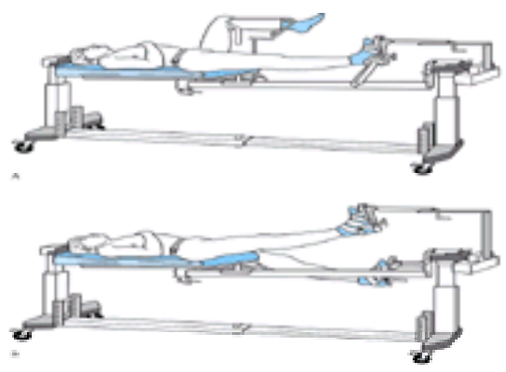

***Figure 13.27.*** Several cases have been reported in the literature of compartment syndrome of the leg from the use of a well-leg holder. This places the limb at 90° of flexion at both the hip and knee, and the elevated leg rests on a support (**A**). In complicated fracture cases, which may take several hours to complete, we recommend alternate limb positioning, such as the “scissors” position (**B**).

## EARLY RECOGNITION

Frequent patient rounds by the treating physicians and nurses to examine the peripheral neurovascular status are extremely important. We educate our nurses, medical students, and residents on the evaluation and early recognition of patients with compartment syndrome.

Having a high index of suspicion is the best way to recognize an early compartment syndrome. Often, the patient is unable or unwilling to cooperate with a physical exam, and the treating physician must rely on his or her knowledge of the disorder and use early intracompartmental pressure monitoring. The risk of measuring compartment pressures is nominal compared with the risk of missing a compartment syndrome. We generally teach residents and students that the time to measure intracompartmental pressures is when they first think about it.

## PRESSURE MONITORING

We most commonly use the slit catheter connected to an arterial line pressure transducer and recorder to measure compartment pressures. These are readily available in intensive care units, recovery rooms, emergency rooms, and, of course, the operating room. We also use the hand-held Stryker unit with the slit catheter or the side-ported needle. We avoid the use of an 18-gauge needle alone. When measuring pressures, we take multiple readings throughout each compartment and immediately document them. In patients who are obtunded or comatose and who are in a monitored setting, we frequently employ continuous intracompartmental pressure monitoring when initial pressures are elevated but not above the threshold for fasciotomy.

## EARLY TREATMENT

An acute compartment syndrome is a true surgical emergency. Although it may take 4 to 6 hours for irreversible muscle damage to occur, it is usually impossible to determine the length of time the compartment pressure has been elevated and at what pressure. Furthermore, delaying treatment usually leads to poor outcome.

## OPERATIVE TECHNIQUES

For forearm compartment syndrome, we perform Henry's curvilinear volar incision, as this allows access to the entire forearm, neurovascular structures, mobile wad, and radius if fixation is required. After volar release, the dorsal compartment is measured, and, if necessary, this compartment is released through a single dorsal incision.

For compartment syndrome of the leg, we routinely use the two-incision technique. This allows excellent visualization and easy release of all compartments. The deep posterior compartment is readily accessible through the medial incision, even in patients with severe swelling. Usually one of the incisions can be closed in a delayed fashion, and skin grafting is then required only for the second wound. A potential disadvantage to the two-incision technique is that it tempts the inexperienced surgeon to use short incisions in the midcalf. We use fairly extensive incisions, as the risks of “blind” fasciotomy are significant. Another potential disadvantage to this technique is uncovering of the posteromedial edge of the tibia if the skin incision is not properly placed. It is very important to make the posteromedial incision several centimeters below the posterior margin of the tibia in order to prevent this complication.

Other authors have advocated the use of the single lateral incision for fasciotomies of the leg (33,35). One advantage to this technique is that it is cosmetically more acceptable, as it is less visible from the front. It must be an extensile incision, and this minimizes the risk of injury to neurovascular structures. Although the wound could potentially be closed secondarily in its entirety, this is usually not the case; similar to the two-incision technique, a portion of the wound usually requires coverage with a split-thickness skin graft. A potential disadvantage to the single-incision technique is that the deep posterior compartment is more difficult to reach, particularly in a very swollen limb. The approach, however, is similar to the Harmon posterolateral approach to the tibia for bone grafting, an approach used commonly by many orthopaedic surgeons.

We routinely place a tourniquet on the limb but do not elevate it unless absolutely necessary. Inflation of the tourniquet during compartment release simply adds to the ischemia time. With careful dissection, blood loss can be kept to a minimum. Debridement of obviously necrotic and other nonviable muscle is done primarily at the time of compartment decompression. If, however, the viability of an area of muscle is in question, we do not debride this area but rather reevaluate the wound in 24 to 48 hours. In acute compartment syndrome, we never close the fasciotomy wounds primarily and always return the patient to the operating room in 24 to 48 hours for repeat debridement. Frequently, a patient may require multiple debridements before the wound is clean enough for delayed primary closure or split-thickness skin grafting.

After fasciotomy, we frequently place vessel loops through staples placed near the wound edges. This prevents the skin edges from retracting significantly, and they can also be intermittently tightened to help decrease the wound size, particularly in the sick patient who is too unstable to return to the operating room within the first few days after fasciotomy. It is very important not to place the vessel loops too tight initially. The dermotomy is an essential component to compartmental release, and tightening the skin could significantly increase the intracompartmental pressure.

Occasionally we have employed the use of a skin closure system, such as the Sure-Closure (Life Medical Sciences, Inc., Princeton, NJ), to help close fasciotomy wounds in a delayed fashion. There are several such devices on the market; when properly used, they can obviate the need for a skin graft or at least significantly decrease the size of the graft.

## CHAPTER REFERENCES

Each reference is categorized according to the following scheme: *, classic article; #, review article; !, basic research article; and +, clinical results/outcome study.


# 1. Adler LM, Loughlin JS, Morin CJ, Haning RV Jr. Bilateral Compartment Syndrome after a Long Gynecologic Operation in the Lithotomy Position. *Am J Obstet Gynecol* 1990;162:1271.

# 2. Anglen J, Banovetz J. Compartment Syndrome in the Well Leg Resulting from Fracture-Table Positioning. *Clin Orthop* 1994;301:239.

! 3. Ashton H. The Effect of Increased Tissue Pressure on Blood Flow. *Clin Orthop* 1975;118:15.

# 4. Benson LS, Sathy MJ, Port RB. Forearm Compartment Syndrome Due to Automated Injection of Computed Tomography Contrast Material. *J Orthop Trauma* 1996;10:433.

# 5. Block EFJ, Dobo S, Kirton OC. Compartment Syndrome in the Critically Injured Following Massive Resuscitation: Case Reports. *J Trauma* 1995;39:787.

# 6. Bomberg BC, Hurley PE, Clark CA, McLaughlin CS. Complications Associated with the Use of an Infusion Pump During Knee Arthroscopy. *Arthroscopy* 1992;8:224.

! 7. Breit GA, Gross JH, Watenpaugh DE, et al. Near-Infrared Spectroscopy for Monitoring of Tissue Oxygenation of Exercising Skeletal Muscle in a Chronic Compartment Syndrome Model. *J Bone Joint Surg* 1997;79-A:838.

! 8. Burton AC. On the Physical Equilibrium of Small Blood Vessels. *Am J Physiol* 1951;164:319.

! 9. Crenshaw AG, Styf JR, Mubarak SJ, Hargens AR. A New Transducer-Tipped Fiber Optic Catheter for Measuring Intramuscular Pressures. *J Orthop Res* 1990;8:464.

+ 10. Detmer DE, Sharpe K, Sufit RL, Girdley FM. Chronic Compartment Syndrome: Diagnosis, Management, and Outcomes. *Am J Sports Med* 1985;13:162.

# 11. Dugdale TW, Schutzer SF, Deafenbaugh MK, Bartosh RA. Compartment Syndrome Complicating Use of the Hemilithotomy Position During Femoral Nailing: A Report of Two Cases. *J Bone Joint Surg.* 1989;71-A:1556.

# 12. Garfin SR, Mubarak SJ, Owen CA. Exertional Anterolateral Compartment Syndrome: Case Report with Fascial Defect, Muscle Herniation, and Superficial Peroneal Nerve Entrapment. *J Bone Joint Surg.* 1977;59-A:404.

# 13. Garfin SR, Mubarak SJ, Davidson TM. Rattlesnake Bites: Current Concepts. *Clin Orthop* 1979;140:50.

* 14. Garfin SR, Mubarak SJ, Evans KL, et al. Quantification of Intracompartmental Pressure and Volume Under Plaster Casts. *J Bone Joint Surg* 1981;63-A:449.

# 15. Gelberman RH, Zakaib GS, Mubarak SJ, et al. Decompression of Forearm Compartment Syndromes. *Clin Orthop* 1978;134:255.

! 16. Gershuni DH, Yaru NC, Hargens AR, et al. Ankle and Knee Position as a Factor Modifying Intracompartmental Pressure in the Human Leg. *J Bone Joint Surg* 1984;66-A:1415.

# 17. Gershuni DH, Mubarak SJ, Yaru NC, Lee YF. Fracture of the Tibia Complicated by Acute Compartment Syndrome. *Clin Orthop* 1987;217:221.

* 18. Hargens AR, Akeson WH, Mubarak SJ, et al. Fluid Balance within the Canine Anterolateral Compartment and Its Relationship to Compartment Syndromes. *J Bone Joint Surg* 1978;60-A:499.

* 19. Hargens AR, Romine JS, Sipe JC, et al. Peripheral Nerve-Conduction Block by High Muscle-Compartment Pressure. *J Bone Joint Surg* 1979;61-A:192.

* 20. Hargens AR, Schmidt AA, Evans KL, et al. Quantitation of Skeletal Muscle Necrosis in a Model Compartment Syndrome. *J Bone Joint Surg* 1981;63-A:631.

* 21. Harman JW. A Histological Study of Skeletal Muscle in Acute Ischemia. *Am J Pathol* 1947;23:551.

# 22. Hastings H, Misamore G. Compartment Syndrome Resulting from Intravenous Regional Anesthesia. *J Hand Surg* 1987;12:559.

! 23. Heckman MM, Whitesides TE Jr, Grewe SR, et al. Histologic Determination of the Ischemic Threshold of Muscle in the Canine Compartment Syndrome Model. *J Orthop Trauma* 1993;7:199.

! 24. Heckman MM, Whitesides TE Jr, Grewe SR, Rooks MD. Compartment Pressure in Association with Closed Tibial Fractures. The Relationship between Tissue Pressure, Compartment, and the Distance from the Site of the Fracture. *J Bone Joint Surg* 1994;76-A:1285.

! 25. Heppenstall RB, Sapega AA, Scott R, et al. The Compartment Syndrome. An Experimental and Clinical Study of Muscular Energy Metabolism Using Phosphorus Nuclear Magnetic Resonance Spectroscopy. *Clin Orthop* 1988;226:138.

* 26. Heppenstall RB, Sapega AA, Izant T, et al. Compartment Syndrome: A Quantitative Study of High-Energy Phosphorus Compounds Using $^{31}$P-Magnetic Resonance Spectroscopy. *J Trauma* 1989;29:1113.

* 27. Jepson PN. Ischemic Contracture. Experimental Study. *Am J Surg* 1926;84:785.

# 28. Kaper BP, Carr CF, Shirreffs TG. Compartment Syndrome after Arthroscopic Surgery of the Knee. A Report of Two Cases Managed Nonperatively. *Am J Sports Med* 1997;25:123.

# 29. Kelly RP, Whitesides TE Jr. Transfibular Route for Fasciotomy of the Leg. *J Bone Joint Surg* 1967;48-A:1022.

# 30. Kutz JE, Singer R, Lindsay M. Chronic Exertional Compartment Syndrome of the Forearm: A Case Report. *J Hand Surg* 1985;10:302.

# 31. Lokiec F, Siev-Ner I, Pritsch M. Chronic Compartment Syndrome of Both Feet. *J Bone Joint Surg* 1991;73-B:178.

# 32. Martens MA, Moeyersoons JP. Acute and Effort-Related Compartment Syndrome in Sports. *Sports Med* 1990;9:62.

* 33. Matsen FA III, Mayo KA, Sheridan GW, Krugmire RB Jr. Monitoring of Intramuscular Pressure. *Surgery* 1976;79:702.

* 34. Matsen FA III, Mayo KA, Krugmire RB, et al. A Model Compartmental Syndrome in Man with Particular Reference to the Quantification of Nerve Function. *J Bone Joint Surg* 1977;59-A:648.

* 35. Matsen FA III, Winquist RA, Krugmire RB. Diagnosis and Management of Compartmental Syndromes. *J Bone Joint Surg* 1980;62-A:286.

! 36. Moed BR, Thorderson PK. Measurement of Intracompartmental Pressure: A Comparison of the Slit Catheter, Side-Ported Needle, and Simple Needle. *J Bone Joint Surg* 1993;75-A:231.

! 37. Mohler LR, Styf JR, Pedowitz RA, et al. Intramuscular Deoxygenation During Exercise in Patients Who Have Chronic Anterior Compartment Syndrome of the Leg. *J Bone Joint Surg* 1997;79-A:844.

* 38. Mubarak SJ, Owen CA. Double-Incision Fasciotomy of the Leg for Decompression in Compartment Syndromes. *J Bone Joint Surg* 1977;59-A:184.

# 39. Mubarak SJ, Owen CA, Garfin SR, Hargens AR. Acute Exertional Superficial Posterior Compartment Syndrome. *Am J Sports Med* 1978;6:287.

* 40. Mubarak SJ, Owen CA, Hargens AR, et al. Acute Compartment Syndromes: Diagnosis and Treatment with the Aid of the Wick Catheter. *J Bone Joint Surg* 1978;60-A:1091.

* 41. Mubarak SJ, Hargens AR. *Compartment Syndromes and Volkmann's Contracture.* Philadelphia: WB Saunders, 1981.

# 42. Neagle CE, Schaffer JL, Heppenstall RB. Compartment Syndrome Complicating Prolonged Use of the Lithotomy Position. *Surgery* 1991;110:566.

# 43. Ouellette EA, Kelly R. Compartment Syndromes of the Hand. *J Bone Joint Surg* 1996;78-A:1515.

# 44. Patman RD, Thompson JE. Fasciotomy in Peripheral Vascular Surgery. *Arch Surg* 1970;101:663.

# 45. Pedowitz RA, Toutounghi FM. Chronic Exertional Compartment Syndrome of the Forearm Flexor Muscles. *J Hand Surg* 1988;13:694.

! 46. Pedowitz RA, Hargens AR, Mubarak SJ, Gershuni DH. Modified Criteria for Objective Diagnosis of Chronic Compartment Syndrome of the Leg. *Am J Sports Med* 1990;18:35.

# 47. Peek RD, Haynes DW. Compartment Syndrome as a Complication of Arthroscopy. A Case Report and a Study of Interstitial Pressures. *Am J Sports Med* 1984;12:464.

# 48. Raether PM, Lutten LD. Recurrent Compartment Syndrome in the Posterior Thigh. *Am J Sports Med* 1982;10:40.

# 49. Reddy PK, Kaye KW. Deep Posterior Compartmental Syndrome: A Serious Complication of the Lithotomy Position. *J Urol* 1984;132:144.

* 50. Reneman RS. *The Anterior and the Lateral Compartment Syndrome of the Leg.* The Hague: Mouton, 1968.

* 51. Reneman RS. The Anterior and Lateral Compartmental Syndrome of the Leg Due to Intensive Use of Muscles. *Clin Orthop* 1975;118:69.

# 52. Ribeiro JA, Price CT, Knapp RD Jr. Compartment Syndrome of the Lower Extremity after Intraosseous Infusion of Fluid: A Report of Two Cases. *J Bone Joint Surg* 1993;75-A:430.

* 53. Rorabeck CH, McNab I. The Anterior Tibial Compartment Syndrome Complicating Fractures of the Shaft of the Tibia. *J Bone Joint Surg* 1976;58-A:549.

* 54. Rorabeck CH, Clark KM. The Pathophysiology of the Anterior Tibial Compartment Syndrome: An Experimental Investigation. *J Trauma* 1978;18:299.

* 55. Rorabeck CH, Castle GSP, Hardie R, Logan J. Compartmental Pressure Measurements: An Experimental Investigation Using the Slit Catheter. *J Trauma* 1981;21:446.

! 56. Scholander PF, Hargens AR, Miller SL. Negative Pressure in the Interstitial Fluid of Animals. *Science* 1968;161:321.

+ 57. Styf JR, Koörner LM. Chronic Compartment Syndrome of the Leg. Results of Treatment by Fasciotomy. *J Bone Joint Surg* 1986;68-A:1338.

! 58. Styf JR, Koörner LM. Microcapillary Infusion Technique for Measurement of Intramuscular Pressure During Exercise. *Clin Orthop* 1986;207:253.

# 59. Styf JR, Forssblad P, Lundborg G. Chronic Compartment Syndrome in the First Dorsal Interosseous Muscle. *J Hand Surg* 1987;12:757.

* 60. Styf JR, Koörner LM, Suurkula M. Intramuscular Pressure and Muscle Blood Flow During Exercise in Chronic Compartment Syndrome. *J Bone Joint Surg* 1987;69-B:301.

# 61. Styf JR, Koörner LM. Diagnosis of Chronic Anterior Compartment Syndrome in the Lower Leg. *Acta Orthop Scand* 1987;58:139.

# 62. Styf JR, Lysell E. Chronic Compartment Syndrome in the Erector Spinae Muscle. *Spine* 1987;12:680.

* 63. Whitesides TE Jr, Haney TC, Hirada H, et al. A Simple Method for Tissue Pressure Determination. *Arch Surg* 1975;110:1311.

* 64. Whitesides TE Jr, Haney TC, Morimoto K, Hirada H. Tissue Pressure Measurements as a Determinant for the Need of Fasciotomy. *Clin Orthop* 1975;113:43.

! 65. Zweifach SS, Hargens AR, Evans KL, et al. Skeletal Muscle Necrosis in Pressurized Compartments Associated with Hemorrhagic Hypotension. *J Trauma* 1980;20:941.

# CHAPTER 14

# MANAGEMENT OF POLYTRAUMA

*Lawrence B. Bone*

**L. B. Bone:** Department of Orthopaedics, State University of New York at Buffalo, Buffalo, New York 14215.

Preoperative Management
Field Triage
Emergency Room Management
Principles of Treatment
Pelvic Ring Injuries
Fractures with Concomitant Vascular Injury
Fractures and Compartment Syndrome
Fractures with Open Soft-Tissue Injury
Unstable Spine Fracture-Dislocations
Fracture Treatment in the Secondary Phase
Stabilization of Musculoskeletal Injuries Under Special Circumstances
Conclusions
Chapter References

Injury to the musculoskeletal system is commonly associated with blunt trauma. An isolated injury rarely poses any threat to life, but, when associated with multiple injuries, a musculoskeletal injury assumes greater significance. Trauma is the leading cause of death in persons between the ages of 1 and 45 years. It is estimated that there are 150,000 deaths annually from accidents alone. The cost in lost years and dollars from death and disability exceeds that of heart disease, stroke, and cancer combined (1). Trauma remains a major social and economic affliction (2). Proper management can greatly reduce the mortality and morbidity associated with these injuries (6).

## PREOPERATIVE MANAGEMENT

### FIELD TRIAGE

Management of the multiply injured patient begins in the field with initial contact by the emergency medical technicians. Their job is to initially evaluate and, if necessary, resuscitate the patient; to extricate the patient; and to safely transport him or her to the appropriate facility. The emergency medical technicians should obtain a history of the accident to better understand the mechanism of injury and relate that information to the treating physician. They should assess the airway and, when properly trained, perform endotracheal intubation if needed. Although intravenous access is beneficial, it should not be obtained at the expense of time in transfer of the patient from the scene to the trauma center (Table 14.1).

| |
|---|
| Blood pressure below 90 mm Hg |
| Pulse faster than 120 beats/min |
| Respirations >35 and <12 respirations per minute |
| Penetrating head or torso trauma |
| Unconscious or deteriorating level of consciousness or lateralizing neurologic signs |
| Traumatic amputation above the wrist or above the ankle |
| Flail chest |
| Two or more proximal long bone fractures |

***Table 14.1. Criteria for Automatic Triage to a Trauma Center***

Patients who are hypotensive secondary to their injuries are often placed in pneumatic antishock garments (PASG). When there is life-threatening hemorrhage and severe loss of blood pressure, these garments may be inflated to 100 mm Hg, and the patient is sent immediately to the trauma center for resuscitation and gradual release of the PASG. If prolonged use of the garments is necessary, do not inflate to more than 30 mm Hg because of the increased risk for compartment syndrome and soft-tissue loss with lower extremity injuries (7). The PASG has been a good device for initially stabilizing pelvic fractures, helping to tamponade hemorrhage with some reduction and stabilization of the pelvic fracture or separation (12).

### EMERGENCY ROOM MANAGEMENT

Initial management of the multiply injured patient in the emergency room has been well studied, and protocols have been developed by the Committee for Trauma of the American College of Surgeons (6). Their courses on advanced trauma life support (ATLS) have shown that assessment of the patient in an orderly fashion has improved the care and reduced the incidence of missed injuries. Patient management requires rapid primary evaluation, resuscitation of vital functions, a more detailed secondary assessment, and definitive care.

#### *Primary Survey*

**Airway** The primary concern for any injured patient is to establish an airway for adequate oxygenation. In establishing and maintaining an airway, it is important to control the cervical spine to avoid iatrogenic neurologic injuries if the cervical spine is unstable. Examine the trauma patient to be certain that the airway is cleared of any obstructions, such as foreign objects, loose teeth, blood, mucus, or vomitus. In the unconscious patient, protect the cervical spine with longitudinal traction. Keep the mandible elevated to clear the airway of the patient's tongue. Take a cross-table lateral radiograph of the cervical spine as soon as possible to rule out cervical injury that could be exacerbated with motion. Quickly assess the patient's ability to oxygenate by inspecting an arterial blood gas sample to see whether the arterial blood is red or dark, indicating the state of oxygenation.

**Breathing** Inspect the patient's chest for movement to assess air exchange. Airway patency does not necessarily mean that the patient is adequately exchanging oxygen; this can be determined through an arterial blood gas sample. Inspect for evidence of a flail segment in the chest with paradoxic movement. Cover and clean open chest wounds with a Vaseline gauze dressing. If the patient does not appear to be ventilating adequately (i.e., patient is using accessory muscles in the neck to help breathe), and the arterial blood gas is dark, perform endotracheal intubation. If you are not experienced in endotracheal intubation, use a mask and bag valve device with an oral airway first to oxygenate the patient. Endotracheal intubation in the trauma patient can be difficult and should be performed by the most experienced hands. Causes of inadequate oxygenation must be found. If no flail segments are visible, palpate the rib cage for tenderness or crepitus caused by rib fractures.

Auscultate the chest to listen for proper breath sounds bilaterally to help rule out a pneumothorax. If no cause is found for the patient's inadequate oxygenation, perform bilateral tube thoracostomy to decompress potential bilateral pneumothoraces.

Perform endotracheal intubation to obtain control of the airway and provide adequate oxygenation for any patient with inadequate or labored ventilation or flail chest and for patients who are unconscious and unable to control the airway, those with facial fractures, multiply injured patients, and those with deteriorating blood oxygenation. If a cervical spine injury is suspected or has not been ruled out, perform nasotracheal or fiberoptic intubation with proper longitudinal control of the head and cervical spine. Oral endotracheal intubation is preferred because a larger tube can be placed. Rarely, a surgical cricothyroidectomy may be needed to obtain access to the airway.

**Circulation** Hypotension is a result of hypovolemia in the trauma patient until proved otherwise. Shock is caused by and defined as inadequate oxygen delivery to soft tissues. Assess cardiac output by palpation of peripheral pulses and observe skin color and capillary refill. As a general rule, if the radial pulse is palpable, the systolic blood pressure is 80 mm Hg. The femoral pulse indicates a pressure of 70 mm Hg, and the carotid pulse a pressure of 60 mm Hg. Normally, capillary refill requires less than 2 s. A delay of longer than 2 s indicates hypotension. Additional indicators of hypovolemia are decreased bicarbonate and acidosis found in the arterial blood gas samples. Hemorrhagic shock requires rapid fluid resuscitation. Initially, insert two large-bore angiocaths and give a 2-L bolus of lactated Ringer's solution.

Occasionally, a trauma patient is hypotensive secondary to nonhypovolemic shock. Rule out causes of myocardial dysfunction such as cardiac contusion with arrhythmias or cardiac tamponade or myocardial infarction. A history of direct blow to the sternum from a deceleration injury suggests myocardial contusion. The combination of distended neck veins, decreased arterial pressure, and muffled heart sounds (Beck's triad) is diagnostic of a cardiac tamponade. Electrocardiographic changes may indicate an acute myocardial infarction. In the patient with a history of cardiac injury, perform cardiac monitoring and insert a Swan-Ganz catheter. In the patient with the clinical suggestion of a cardiac tamponade, decompress the tamponade emergently with pericardiocentesis. Monitor arrhythmias secondary to myocardial infarction or contusion and manage with appropriate medication.

The patient in hypovolemic shock is best monitored by pulse, blood pressure, and urine output. Repeat arterial blood gases as necessary. The effectiveness of oxygenation is reflected through the oxygen saturation ($Po_2$), and the effectiveness of fluid resuscitation through the pH and bicarbonate levels. Constantly reassess the patient to be certain adequate resuscitation and oxygenation are maintained. Prolonged shock contributes to pulmonary distress syndrome, hepatic dysfunction, renal failure, gut-origin septic state, and multisystem organ failure.

Evaluate the patient's level of consciousness with a brief neurologic examination. The Glasgow Coma Scale (Table 14.2) was developed as an easy and reproducible scale for evaluating the patient's level of consciousness (10). A score may range from 3 to 15, with a score of less than 8 signifying serious neurologic injury. Repeat determinations of the Glasgow Coma Scale are helpful in determining changes in the patient's mental status. In addition to the Glasgow Coma Scale, evaluate for focal signs such as unequal pupils and doll's eyes, which point to an expanding intracranial lesion.

| | |
|---|---|
| **Eye opening** | |
| Spontaneous | 4 |
| To voice | 3 |
| To pain | 2 |
| None | 1 |
| **Verbal response** | |
| Oriented | 5 |
| Confused | 4 |
| Inappropriate words | 3 |
| Incomprehensible sounds | 2 |
| None | 1 |
| **Motor response** | |
| Obeys commands | 6 |
| Purposeful movement | 5 |
| Withdraw to pain | 4 |
| Flexion to pain | 3 |
| Extension to pain | 2 |
| None | 1 |
| **Possible score** | 3 to 15 |

***Table 14.2. Glasgow Coma Scale***

### *Secondary Survey*

**Extremity Injuries** Palpate and examine the extremities, looking for abnormal swelling, instability, or crepitus suggesting musculoskeletal injury. Perform a careful neurologic examination. Check pulses bilaterally for any decrease in peripheral blood flow. Perform arteriography in any patient with major skeletal injury in whom the distal pulses in the injured limb are weaker than those in the opposite extremity. Be alert for vascular injury in patients with supracondylar humerus fractures, supracondylar femur fractures, dislocations of the knee, and crush injuries of the tibia. Reduce dislocations as soon as possible, dress open fractures and extremity wounds, and splint fractures immediately. Splint femur fractures with traction. Begin appropriate bacteriocidal broad-spectrum intravenous antibiotics in patients with open fractures.

**Neurologic Examination** Perform an in-depth neurologic examination. Reassess the patient's level of consciousness with the Glasgow Coma Scale and pupillary reflexes. Assess rectal tone and perianal sensation. Examine and palpate the back for swelling and tenderness. Obtain appropriate spine radiographs. Remember that the cervical spine should be assumed to be injured and protected until radiographic evidence reveals otherwise.

## PRINCIPLES OF TREATMENT

The basic principle of management of the musculoskeletal injury in the polytrauma patient is to obtain a stable skeleton as early as possible, given the overall condition of the patient. Once the patient is properly resuscitated and hemodynamically stable, then stabilization of the skeleton can reduce the physiologic response to trauma and lessen the risk of adult respiratory distress syndrome (ARDS) and multiple system organ failure (2,3,11,17,21). Priorities include external fixation of the anterior pelvis of hemodynamically unstable patients, reduction of dislocations, repair of vascular injuries, debridement of open fractures, stabilization of long bone fractures (especially the femur), and stabilization of the unstable spine (Table 14.3).

| | Hemodynamics | |
|---|---|---|
| Priorities | Unstable | Stable |
| Higher | 1. Dislocations<br>2. Vascular injuries requiring repair*<br>3. Unstable pelvic ring<br>4. Femur<br>5. Open fractures<br>6. Other wounds<br>7. Unstable spinal fractures | 1. Dislocations<br>2. Vascular injuries requiring repair*<br>3. Open fractures<br>4. Unstable pelvic ring or femur<br>5. Unstable spinal fractures |
| Lower<br>Do if possible, otherwise delay until patient is more stable (but as soon as possible)* | 8. Intraarticular fractures<br>9. Other long bone injuries<br>10. Deep hand injuries | 6. Intraarticular fractures<br>7. Other long bone injuries<br>8. Deep hand injuries |

*May require immediate amputation to save life.
*Special considerations: Unstable spine fractures with progressive neurologic deficit are exceedingly rare but require immediate intervention after hemodynamic stability is achieved and an unstable pelvic ring is stabilized. Unstable acetabular fractures require traction. If simple, fix immediately; otherwise, delay and do ASAP. Humeral shaft is often best managed by immediate fixation.

***Table 14.3. Priorities in the Operative Treatment of Musculoskeletal Injuries in the Multiply Injured Patient***

Intraarticular fractures can be splinted or spanned with external fixators until the soft tissue swelling subsides. Upper extremity fractures, if not treated definitively at the initial surgery, can be fixed at a later time.

The Committee on Trauma of the American College of Surgeons developed an outline of management (Table 14.4) for the optimal care of the injured patient with musculoskeletal trauma (6). The algorithm in Fig. 14.1 is a guide to the management of the multiply injured patient with fractures.



***Table 14.4. Care of the Injured Patient with Musculoskeletal Trauma***

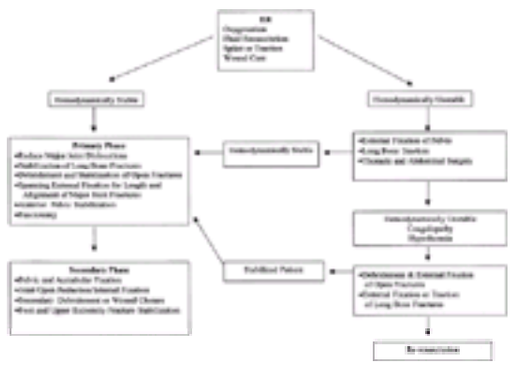

***Figure 14.1.*** Multiple trauma algorithm.

## PELVIC RING INJURIES

The patient with unstable pelvic ring injuries who is hemodynamically unstable should have an anterior external fixator applied to temporarily stabilize the pelvis and reduce the bleeding into the pelvis (12). This is an emergency procedure that should be done before angiography. It can be done in the emergency department or in the operating room. If possible, it should be performed on the unstable patient before a laparotomy.

## FRACTURES WITH CONCOMITANT VASCULAR INJURY

The combination of a fracture and vascular injury requires prompt management. Although there is some debate about which should be addressed first, vascular injuries or fractures, I strongly believe that vascular repair should be performed first. This should be performed after temporary stabilization of the fracture.

Temporary fracture stabilization can be done with an external fixator, a femoral distractor, or with the patient placed in traction on a fracture table. This will place the fractured bone at proper length and provide minimal stabilization to the limb for vascular repairs. Reconstruction of the vascular repair has priority to reduce the time of ischemic hypoxia to the limb.

## FRACTURES AND COMPARTMENT SYNDROME

The patient with multiple trauma is at special risk to develop a compartment syndrome because of systemic hypotension. A high index of suspicion is needed. Limbs with crush injuries and/or vascular injuries in patients subjected to prolonged shock with fluid resuscitation may experience reperfusion injury and require fasciotomies (20). Although the lower leg and forearm are the most common places to develop a compartment syndrome, any closed compartment is at risk. Open fractures as well as closed injuries may be associated with compartment syndrome.

## FRACTURES WITH OPEN SOFT-TISSUE INJURY

Treat all open fractures acutely. Proper cleansing, irrigation, and debridement of devitalized tissue are essential. Perform immediate stabilization to reduce fracture motion and further soft tissue damage. Use external fixation or, more commonly now, unreamed or minimally reamed intramedullary nails to stabilize open long bone fractures. Periarticular and intra-articular fractures can be plated or stabilized with tensioned-wire external fixators. Delay soft tissue closure of traumatic wounds. Grade IIIB injuries should have soft tissue reconstruction (local or free flaps) within 72 h if possible (20).

## UNSTABLE SPINE FRACTURE-DISLOCATIONS

Unstable spine fracture-dislocations are best stabilized in the primary phase, 24 to 48 h postinjury (15). This allows the patient to be mobilized. Patients who exhibit progressive loss of neurologic function on repeat neurologic examination should be decompressed and stabilized acutely.

## FRACTURE TREATMENT IN THE SECONDARY PHASE

With the patient's hemodynamic and respiratory status stable, additional fracture management can be addressed: fractures of the acetabulum or posterior pelvis; closed upper extremity fractures; and intraarticular fractures. Perform secondary evaluation of open wounds at this time. Special care needs to be given to those patients with continued respiratory insufficiency, febrile septic state, and liver dysfunction. Patients with decreased platelets (less than 180,000), neutrophil elastase greater than 85 ng/dl, and C-reactive protein greater than 11 ng/dl are at risk of secondary organ failure with secondary surgery 72 h postinjury (22).

## STABILIZATION OF MUSCULOSKELETAL INJURIES UNDER SPECIAL CIRCUMSTANCES

### *Head Injury*

Management of the head-injured patient with multiple injuries presents a special problem. Most of these patients are intubated in the field or in the emergency room because of their severe injuries. It is important to rapidly reverse hypovolemic shock and to maintain high oxygen transport to reduce further neurologic damage. Physical examination followed by computed tomography of the head is needed for diagnosis of the injury. The neurosurgeon treats the patient with an intracranial lesion that needs decompression in the operating room under general anesthesia. If neurosurgical decompression is unnecessary, perform intracranial monitoring through an intracranial bolt or ventricular catheter. Increased intracranial pressure can be managed medically with fluid management and osmotic diuretics and by decreasing the serum carbon dioxide ($PCO_2$) with hyperventilation. If necessary, cerebral spinal fluid can be withdrawn to reduce intracranial pressure (16,19).

In a life-threatening situation, such as a ruptured spleen, lacerated liver, or aortic arch rupture, the head-injured patient must undergo general anesthesia. The patient should also undergo early total care with management of the musculoskeletal system for open fractures and long bone injuries and timely care of spinal, pelvic, and acetabular fractures. With proper monitoring of intracranial pressure, good fluid resuscitation, and oxygen transport, the patient usually can tolerate the anesthetic for the musculoskeletal care that is essential for stabilization and early mobilization (18,21).

Operative stabilization with intramedullary rods, plating of periarticular fractures, and external fixation is preferable to casting or traction. Unresponsive or combative head-injured patients cannot be monitored for swelling or pressure sores inside a cast and do not tolerate traction well.

### *Pulmonary Contusion and Femur Fractures*

Early stabilization of femur fractures in the polytrauma patient has been shown to reduce the risk of adult respiratory distress syndrome (ARDS) and respiratory dysfunction as well as to reduce time on a ventilator, time in the intensive care unit, and cost of care (2,11,17). Recent research has shown that manipulation of the femoral canal—that is, entering the proximal canal, placement of a guide rod, reaming and placement of an intramedullary nail—causes fat and marrow contents to be released into the venous system and embolized to the heart and lungs (9,23). There was some concern that this embolization caused the development of ARDS in those patients with already compromised oxygenation because of chest injury, that is, pulmonary contusion (13,14). How- ever, good animal and clinical studies have shown no increased ARDS with acute intramedullary nailing of femur fractures in patients with pulmonary contusion (5,24,25).

Intubate and oxygenate these patients appropriately. They need to be well hydrated and hemodynamically stabilized. Acute fracture stabilization can be safely performed with intramedullary nailing. Because there is less embolization with the unreamed femoral nail, this is the recommended treatment of choice in patients with pulmonary contusion or other compromise of pulmonary function (3,21). If the patient is not well oxygenated or hemodynamically stable, then temporary fracture stabilization with external fixation can be performed.

Those patients who are not hemodynamically stable after surgery for life-threatening injuries of the chest or abdomen, or who have a coagulopathy or hypothermia, should be taken to the intensive care unit, resuscitated, warmed, and well oxygenated. With a stable patient, fracture fixation can proceed as outlined. In critical situations where the patient is systematically unstable, perform temporary stabilization with external fixation.

## CONCLUSIONS

Early total care of the multiply injured patient reduces the risk for life-threatening complications such as ARDS and multiple system organ failure. Protocols need to be developed that include management of general surgical and neurosurgical injuries, followed by fracture stabilization. Special considerations have to be made for the patient with pulmonary contusion or head injuries. These considerations do not prevent proper stabilization of the skeleton.

**Case Study** The following case report illustrates how effective early total care can be. (Case of Michael Chapman, M.D., University of California, Davis, Department of Orthopaedic Surgery, Sacramento, California.)

*History* A 29-year-old woman sustained multiple injuries in a high-speed motor vehicle accident. After a prolonged extrication from her vehicle, she was transported by helicopter to the University of California, Davis, Medical Center. She was found to be unconscious at the scene of the accident but subsequently regained consciousness and had a score on the Glasgow Coma Scale of 15. On arrival in the emergency room, she was complaining of left-sided chest pain and was short of breath.

*Physical Examination* Vital signs in the emergency room showed blood pressure 100 over 60, heart rate 158, and respiration 20. She was in shock and hemodynamically unstable despite efforts at resuscitation. Her abdomen was swollen and tender throughout. She was intubated in the emergency room, and a left chest tube was placed for a hemopneumothorax. She had obvious deformity of all four extremities with wounds on the left upper and left lower extremities consistent with multiple open fractures. Her wounds were dressed, and fractures splinted. Further orthopaedic evaluation and x-rays were not possible because of the patient's unstable status. She was rushed immediately to the operating room for a laparotomy.

*Surgery* At surgery, laparotomy revealed a ruptured spleen and liver, laceration of the colon, and a perinephric hematoma. The spleen was removed, and a partial lobectomy of the liver was performed. The laceration of the colon was repaired. After the laparotomy she was hemodynamically stable. Because of the potential for a head injury, she then had a CT scan of the head, which was negative. She was then returned to the operating room for orthopaedic evaluation and procedures.

Physical evaluation of the patient under anesthesia and multiple x-rays revealed a normal cervical, thoracic, and lumbar spine and the following 10 fractures:

1. Grade II open, somewhat comminuted midshaft fracture of the left humerus (Fig. 14.2).

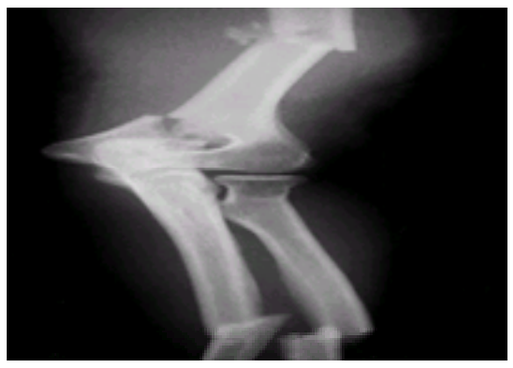

***Figure 14.2.*** Anteroposterior x-ray of the left arm, elbow, and forearm showing fractures of the midshaft humerus, medial condyle of the humerus, and midshaft radius and ulna.

2. Closed fracture of the medial condyle of the humerus (Fig. 14.2).
3. Grade II open transverse midshaft fractures of the left radius and ulna (Fig. 14.2).
4. Closed midshaft fracture of the right humerus (Fig. 14.3).



***Figure 14.3.*** Fracture of the right humeral shaft.

5. Closed transverse fracture of the distal third of the right ulna (Fig. 14.4).

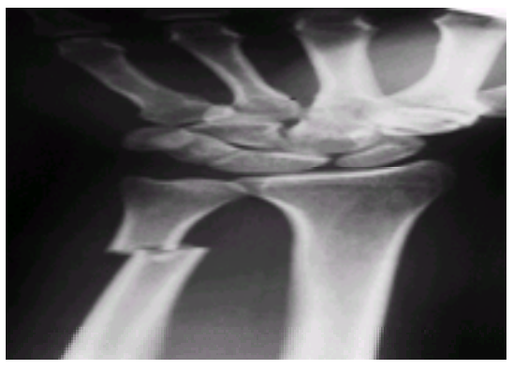

***Figure 14.4.*** Fracture of the right distal ulna.

6. Grade II open, midshaft, slightly comminuted fracture of the left femoral shaft (Fig. 14.5).

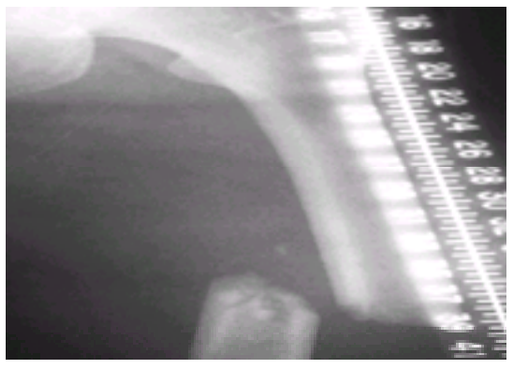

***Figure 14.5.*** Fracture of the shaft of the left femur. Note that no fracture of the femoral neck can be seen.

7. Grade II open, severely comminuted pylon fracture of the left ankle involving the tibia and fibula (Fig. 14.6).

***Figure 14.6.*** Comminuted pylon fracture of the left distal tibia and fibula.

8. Closed transverse midshaft fracture of the right femur (Fig. 14.7).

***Figure 14.7.*** Midshaft fracture of the right femur.

9. Careful examination of both hips and AP and lateral x-rays in internal rotation showed no evidence of fracture of the femoral neck. In follow-up, an undisplaced fracture of the left femoral neck was found and fixed with cannulated screws.
10. Pelvic x-rays showed minor pubic rami fractures.

*Orthopaedic Procedures* Two orthopaedic teams were available, an attending surgeon with a second-year resident and a trauma fellow with a third-year resident. The patient was on a radiolucent operating table, and a fluoroscope was available. The patient was rolled into the right lateral decubitus position, and the left lower and left upper extremities were operated simultaneously. All of the open fractures were irrigated and debrided, and the wounds were left open. The midshaft fracture of the left humerus was double-plated with a 3.7 titanium plating system. The left elbow was opened through a medial approach, and the medial condyle fracture was fixed with two interfragmentary screws (Fig. 14.8). The midshaft fractures of the left radius and ulna were compression plated (Fig. 14.9). In the lower extremity, the open midshaft femur fracture was nailed with a nonreamed antegrade femoral nail using open technique (Fig. 14.10). The proximal cross-locking screw was placed, but distal cross-locking was not carried out in order to save time. The pylon fractures of the left distal tibia and fibula were reduced after debridement of the wound, and the leg was placed in a delta-frame-type external fixator (Fig. 14.11).

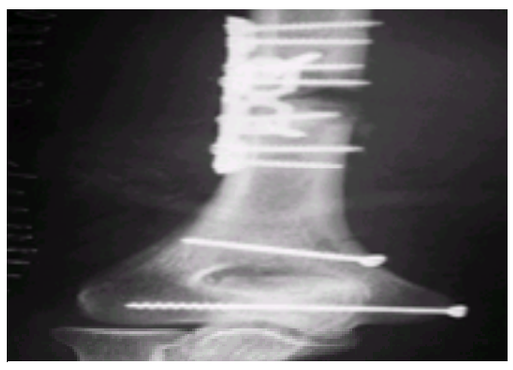

***Figure 14.8.*** Left humerus and elbow after fixation.

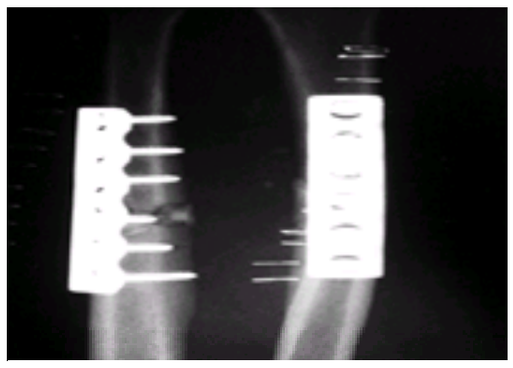

***Figure 14.9.*** Left forearm after fixation.



***Figure 14.10.*** Left femur after initial nailing.

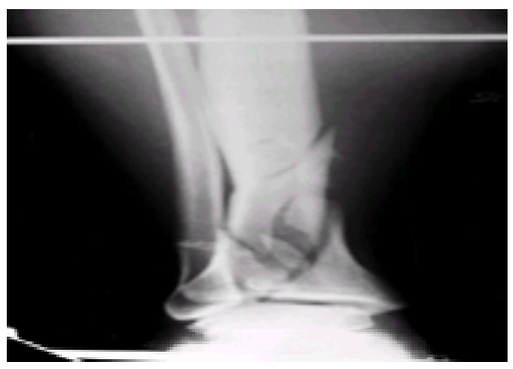

***Figure 14.11.*** Left pylon fracture of the tibia and fibula after external fixation.

The patient was then rolled into the left lateral decubitus position, and simultaneous surgery was carried out on the right upper and right lower extremities. The humerus fracture was internally fixed with an antegrade intramedullary nail utilizing closed technique. The right femur was fixed with an intramedullary nail, nonreamed, inserted antegrade, with a small exposure of the fracture site to permit reduction and passage of the nail. Distal cross-locking was not carried out (Fig. 14.12).



***Figure 14.12.*** Right femur after initial nailing.

The total time from arrival in the operating room for the general surgical procedures until completion of the last orthopaedic procedure and transfer to the surgical intensive care unit was 20 h, including the time required to take her to the CT scanner for examination of her brain.

In the intensive care unit she did extremely well and was extubated on her second postoperative day. Her chest tube was removed on the third postoperative day. On the fifth day after injury, she was returned to the operating room, where all of her open wounds were redebrided, irrigated, and closed. Because of segmental deficiency in the left humerus, a bone graft from the left iliac crest was placed. The distal cross-locking was carried out on both femoral nails, and the pylon fracture was reduced, closed, and fixed with two percutaneously inserted cannulated screws (Fig. 14.13).

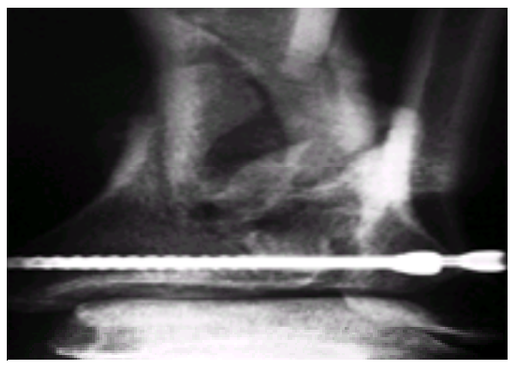

***Figure 14.13.*** Anteroposterior view of left tibia at 6 weeks, at time of removal of external fixator.

Postoperatively it was possible to begin range-of-motion and rehabilitation on all of her extremities. She was discharged from the hospital on her ninth postoperative day, transferring from bed to wheelchair.

We recommended that she avoid weightbearing on all of her extremities until at least 6 weeks postoperatively. Apparently through a misunderstanding, the patient began full weightbearing on both lower extremities and her left upper extremity at about 4 weeks postinjury. Because of that, she bent the plates in the left humerus and bent her right femoral nail.

At 41 days after injury, she was returned to the operating room, where plates on the left humerus were converted to a locked intramedullary nail. The right femoral nail was exchanged for a statically locked reamed nail. At that time she was complaining of pain in the left hip. X-rays revealed an undisplaced fracture of the left femoral neck. This was fixed with percutaneous cannulated screw fixation anterior to the femoral nail (Fig. 14.14). There was excellent early callus around the pylon fracture; therefore, her external fixator was removed, and she was placed in a cast.

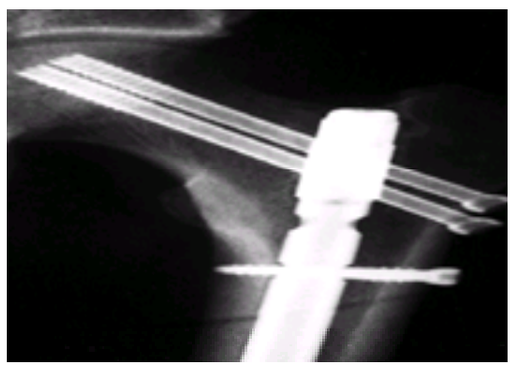

***Figure 14.14.*** Left femoral neck fracture after screw fixation at 6 weeks, anteroposterior view.

By 9 weeks she was fully weightbearing on all extremities and rehabilitating nicely. At 20 weeks she showed delayed union of the right femoral fracture; therefore, her nail was dynamized by removing the distal cross-locking screws.

She went on to heal all of her fractures uneventfully and subsequently married and returned to work. She has excellent function in all of her extremities with no limitations other than some minor loss of motion in her left hip and about 50% loss of motion in her left ankle.

*Commentary* The scenario of this patient outlines the excellent results that can be achieved but also illustrates some of the pitfalls and complications that can occur in these challenging patients. This patient was cared for in the early 1990s. Today she would be managed in the supine position on a radiolucent table with the femur fractures fixed with retrograde nails and the upper extremity injuries managed simultaneously by two teams (Table 14.5).

| | |
|---|---|
| Floating knee, stable pattern | Femur: IM nail, antegrade or retrograde<br>Tibia: Unreamed IM nail |
| Floating knee, unstable pattern | Femur: External fixator converted to nail as soon as possible<br>Tibia: External fixator converted to nail as soon as possible |
| Hip and femoral shaft fractures<br>Subcapital hip fracture | Cannulated screws or hip screw<br>Retrograde femoral nail or plate |
| Intracapsular hip fracture | Hip screw<br>Retrograde femoral nail or plate, or second-generation nail (reconstruction nail) in experienced hands |
| Acetabular and femoral fractures<br>Anterior acetabular fracture | Antegrade femoral nail |
| Ordered posterior approach to acetabulum | Retrograde femoral nail |
| Acute posterior approach to acetabulum | Antegrade femoral nail |
| Anterior pelvic stabilization with C/D or C/U injury | Acute anterior symphysis plating |
| Multiple extremity injuries | Two teams, contralateral upper and lower extremities injured/fixed whenever possible |

***Table 14.5. Management of Combined Injuries***

The scenario following this patient's abdominal surgery could also have found her to be hemodynamically unstable, with a coagulopathy and hypothermia. The patient would then have been best managed either with temporary external fixation of her femur and tibia fractures or, generally more appropriately, with temporary skeletal traction, then taken to the intensive care unit and reresuscitated. Once her vital signs were stable and oxygenation was adequate, and she was rewarmed and no longer coagulopathic (generally within 12 to 24 h), she could be returned to surgery where, again, two teams could be used to perform the surgery as described.

## CHAPTER REFERENCES

Each reference is categorized according to the following scheme: *, classic article; #, review article; !, basic research article; and +, clinical results/outcome study.


# 1. Baker SP. Injuries: The Neglected Epidemic. Stone Lecture, 1985 American Trauma Society meeting. *J Trauma* 1987;27:343.

* 2. Bone L, Johnson J, Weigelt J, et al. Early Versus Delayed Femoral Fracture Stabilization: A Prospective Randomized Study. *J Bone Joint Surg* 1989;71-A:336.

+ 3. Bone LB, Anders MJ, Rohrbacher BJ. Treatment of Femoral Fractures in Multiply Injured Patients with Thoracic Injury. *Clin Orthop* 1998;347:57.

* 4. Border JR, Hassett J, LaDuca J, et al. The Gut Origin Septic States in Blunt Multiple Trauma (ISS = 40) in the ICU. *Ann Surg* 1987;205:427.

+ 5. Bosse MJ, MacKenzie EJ, Riemer BL, et al. Adult Respiratory Distress Syndrome, Pneumonia, and Mortality Following Thoracic Injury and a Femoral Fracture Treated Either with Intramedullary Nailing with Reaming or with a Plate. *J Bone Joint Surg* 1997;79-A:799.

# 6. Burgess A. Musculoskeletal Management. In: Resources for Optimal Care of the Injured Patient. Chicago: Committee on Trauma, American College of Surgeons, 1993:48.

+ 7. Christensen KS. Pneumatic Antishock Garments (PASG): Do They Precipitate Lower-Extremity Compartment Syndromes? *J Trauma* 1986;26:1102.

+ 8. Committee on Trauma, American College of Surgeons. *Advanced Trauma Life Support Course.* Chicago: American College of Surgeons, 1985.

+ 9. Heim D, Schlegel U, Perren SM. Intramedullary Pressure in Reamed and Unreamed Nailing of the Femur and Tibia: An *in Vitro* Study in Intact Human Bones. *Injury* 1993;24(Suppl 3):S56.

+ 10. Jennit B, Teasdale GR. Predicting Outcome in Individual Patients after Severe Head Injury. *Lancet* 1986;1:1031.

+ 11. Johnson KD, Cadambi A, Seibert GB. Incidence of Adult Respiratory Distress Syndrome in Patients with Multiple Musculoskeletal Injuries: Effect of Early Operative Stabilization of Fractures. *J Trauma* 1985;25:375.

+ 12. Moreno C, More EE, Rosenberger A. Hemorrhage Associated with Major Pelvic Fracture: A Multispecialty Challenge. *J Trauma* 1986;26:987.

+ 13. Pape HC, Auf'm'Kolk M, Paffrath T, et al. Primary Intramedullary Femur Fixation in Multiple Trauma Patients with Associated Lung Contusion: A Cause of Post-traumatic ARDS? *J Trauma* 1993;34:540.

+ 14. Pape HC, Regel G, Sturm JA, Tscheim H. Influence of Thoracic Trauma and Primary Femoral Intramedullary Nailing on the Incidence of ARDS in Multiple Trauma Patients. *Injury* 1993;24(Suppl 3):S82.

+ 15. Schlegel J, Bayley J, Yuan H, Fredricksen B. Timing of Surgical Decompression and Fixation of Acute Spinal Fractures. *J Orthop Trauma* 1996;10:323.

+ 16. Seelig JM, Becker DP, Miller JD, et al. Traumatic Acute Subdural Hematoma: Major Mortality Reduction in Comatose Patients Treated Within Four Hours. *N Engl J Med* 1981;304:1511.

+ 17. Seibel R, LaDuca J, Hassett JM, et al. Blunt Multiple Trauma (ISS-36), Femur Traction, and the Pulmonary Failure-Septic State. *Ann Surg* 1985;202:283.

+ 18. Shackford SR, Hollingworth-Fridlund P, Cooper GF, Eastman AB. The Effect of Regionalization upon the Quality of Trauma Care as Assessed by Concurrent Audit Before and After Institution of a Trauma System: A Preliminary Report. *J Trauma* 1986;26:812.

+ 19. Stone JL, Lowe RJ, Jonasson O, et al. Acute Subdural Hematoma: Direct Admission to a Trauma Center Yields Improved Results. *J Trauma* 1986;26:445.

# 20. Tscherne H. The Management of Open Fractures. In Tscherne H, Gatzen I, eds. *Fractures with Soft-Tissue Injuries.* Berlin: Springer-Verlag, 1984:11.

+ 21. Tscherne H, Regel G, Pape HC, et al. Internal Fixation of Multiple Fractures in Patients with Polytrauma. *Clin Orthop* 1998;347:62.

+ 22. Waydhas C, Nast-Kolb D, Trupka A, et al. Posttraumatic Inflammatory Response, Secondary Operations, and Late Multiple Organ Failure. *J Trauma* 1996;40:624.

+ 23. Wenda K, Runkel M, Degreif J, et al. Pathogenesis and Clinical Relevance of Bone Marrow Embolism in Medullary Nailing—Demonstrated by Intraoperative Echocardiography. *Injury* 1993;24(Suppl 3):S73.

! 24. Wozasek GE, Simon P, Redl H, et al. Intramedullary Pressure Changes and Fat Intravasation During Intramedullary Nailing: An Experimental Study in Sheep. *J Trauma* 1994;36:202.

! 25. Wozasek GE, Thurnher M, Redl H, Schlag G. Pulmonary Reaction During Intramedullary Fracture Management in Traumatic Shock: An Experimental Study. *J Trauma* 1994;37:249.

# CHAPTER 15

# FRACTURES AND DISLOCATIONS OF THE SHOULDER GIRDLE AND HUMERUS

*Christopher G. Finkemeier and Robert R. Slater, Jr.*

**C. G. Finkemeier and R. R. Slater, Jr.:** Department of Orthopaedic Surgery, University of California, Davis, Sacramento, California 95817.

Scapular Fractures
- Relevant Surgical Anatomy
- Radiographic Evaluation
- Scapular Body Fractures
- Glenoid Neck Fractures
- Fractures of the Glenoid Rim and Glenoid Cavity
- Fractures of the Acromion
- Scapular Spine Fractures
- Fractures of the Coracoid Process
- Superior Shoulder Suspensory Complex Injuries
- Scapulothoracic Dissociation
- Complications

Clavicle Fractures
- Functional and Surgical Anatomy
- Radiographic Evaluation
- Classification of Clavicle Fractures
- Patient Assessment
- Treatment
- Operative Techniques
- Authors' Preferred Method
- Postoperative Management
- Complications

Fractures of the Proximal Humerus
- Relevant Anatomy and Pathophysiology
- Patient Assessment
- Radiographic Evaluation
- Classification
- Treatment Indications and Methods
- Conclusions
- Complications

Fractures of the Shaft of the Humerus
- Relevant Anatomy
- Classification
- Nonoperative Treatment
- Indications for Surgery
- Radial Nerve Injury
- Delayed Union and Nonunion
- Operative Techniques
- Conclusions
- Complications

Traumatic Dislocations of the Shoulder Girdle
- Glenohumeral Dislocations
- Acromioclavicular Dislocations
- Sternoclavicular Dislocations

Chapter References

> The shoulder girdle of man, with its relatively long clavicles and the synovial joints at both ends of this bone, exemplifies an appropriate compromise between the claims laid upon the skeleto-muscular system concerning stability and mobility.
>
> A. E. Ljunggren (82)

## SCAPULAR FRACTURES

Scapular fractures account for approximately 1% of all fractures in the body and 3% of all injuries involving the shoulder girdle. Although scapular fractures are relatively uncommon injuries, they are important not only because of the problems they create for shoulder function but also because they may be the harbinger of other injuries. Scapular fractures usually are diagnosed in patients who have sustained violent blunt trauma, and up to 96% of patients with those fractures have associated injuries (2). For that reason, scapular fractures have been referred to as “sentinel injuries” (Table 15.1) (51,138).

| | |
|---|---|
| Rib fractures | 44–96% |
| Pulmonary injury | 10–53% |
| Head injury | 23–77% |
| Clavicle fracture | 26–39% |
| Extremity fractures | |
| Upper | 6–22% |
| Lower | 23–28% |
| Spinal column injury | 13–21% |
| Arterial injury | 3–13% |
| Brachial plexus injury | 4–13% |

***Table 15.1. Common Injuries Associated with Scapula Fractures (2,86,103,138)***

### RELEVANT SURGICAL ANATOMY

The scapula is almost completely covered by muscle on both its anterior and posterior surfaces (Fig. 15.1). The muscles keep the scapula relatively protected from injury and help explain why most fractures occur only after high-energy impact and why fractures of the scapular body frequently can be treated nonoperatively. The lateral aspect of the scapula has three bony processes, each related to important soft tissue structures that can influence surgical decision making:

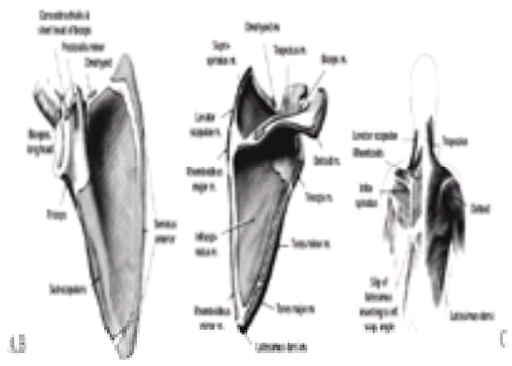

***Figure 15.1.*** **A:** Muscle attachments on the anterior aspect of the scapula. **B:** Muscle attachments on the posterior aspect of the scapula. **C:** Posterior muscles covering the scapula. (From Butters KP. Fractures and Dislocations of the Clavicle. In: Rockwood CA Jr, Green DP, Bucholz RW, Heckman JD, eds. *Fractures in Adults.* Philadelphia: JB Lippincott, 1996;1165.)

1. The *coracoid process* projects anteriorly, superiorly, and laterally from the anterior-superior border of the scapula. The pectoralis minor, coracobrachialis, and short head of biceps originate from it (Fig. 15.2), and all three muscles may contribute to the deforming forces acting on scapular fractures. The conoid and trapezoid ligaments, which make up the coracoclavicular ligament complex, originate from the coracoid process and insert on the inferior surface of the clavicle (Fig. 15.2). The ligaments are key stabilizing structures for the distal clavicle, and their integrity is an important factor in deciding whether or not surgical treatment is indicated. The suprascapular nerve traverses the superior border of the scapula through the scapular notch located just medial to the base of the coracoid process, and the brachial plexus and axillary artery and vein travel below the coracoid process adjacent to its base (Fig. 15.3).

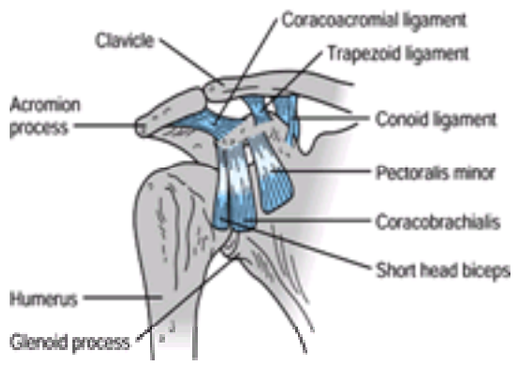


***Figure 15.2.*** Important soft tissue attachments of the coracoid process.

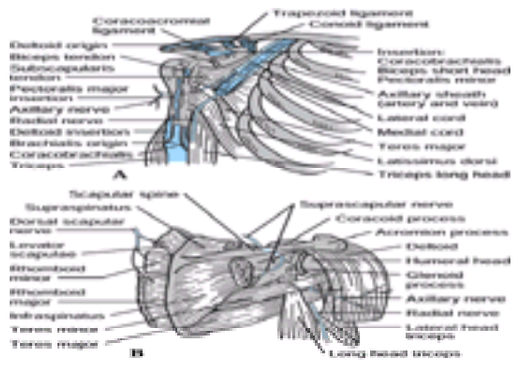

***Figure 15.3.*** **A:** Relationships of the vital neuromuscular structures to the anterior shoulder girdle. **B:** Relationships of the important neurologic structures to the posterior shoulder girdle.

2. The *acromion* is the lateral extension of the scapular spine. It curves anteriorly to form the acromioclavicular joint with the clavicle (Fig. 15.2 and Fig. 15.3). The supraspinatus and infraspinatus muscles travel below the acromion to insert into the humeral head (Fig. 15.1 and Fig. 15.3). The potential for impingement on these muscles from a fractured and tilted acromion is an important determinant of operative treatment. The coracoacromial ligament is a stout ligament that runs between the coracoid process and the anterior-inferior aspect of the acromial process (Fig. 15.2). Occasionally this ligament may be used to stabilize a distal clavicle rendered unstable by injury, but it should be preserved whenever possible to maintain the integrity of the coracoacromial arch (122).
3. The *glenoid process (neck)* is the lateral extension of the scapular body and supports the glenoid fossa, which is the articular platform for the humeral head. Relative to the scapular spine, the glenoid fossa is retroverted an average of 6° (129). Posteriorly, the suprascapular nerve and artery run along the base of the glenoid process as they exit the spinoglenoid notch before supplying the infraspinatus muscle (Fig. 15.3). These structures are at risk for injury during a posterior approach to the glenoid and from displaced fracture fragments.

One other feature of the bony anatomy of the scapula has relevance for surgical decision making. The thin bone that makes up a large portion of the scapular body is not well suited for internal fixation. There are, however, regions that have bone stock adequate to accommodate screw or wire fixation, including the coracoid process, the acromial process, the base of the scapular spine, the glenoid process, and the lateral scapular border (44).

Finally, the concept of the superior shoulder suspensory complex (SSSC), popularized by Goss (45), should be understood because it provides a useful framework for considering shoulder injuries and their treatment. The SSSC is a bony and soft tissue ring composed of the glenoid process, the coracoid process, the acromial process, the coracoclavicular (CC) ligaments, the acromioclavicular (AC) joint, and the distal end of the clavicle. This ring is supported by two bony struts: the clavicle superiorly and the lateral border of the scapula inferiorly (Fig. 15.4).

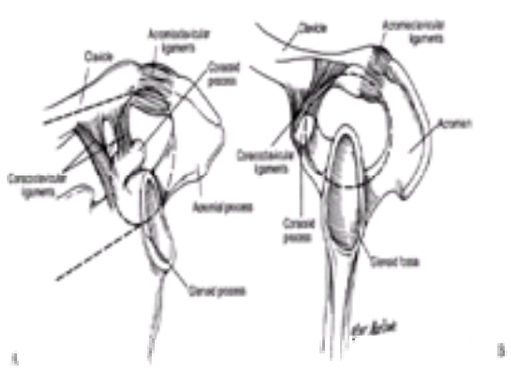

***Figure 15.4.*** Superior shoulder suspensor complex. **A:** Anteroposterior view of the bone–soft-tissue ring and superior and inferior bone struts. **B:** Lateral view of the bone–soft-tissue ring. (© 1995 American Academy of Orthopaedic Surgeons. Reprinted from Goss TP. Scapular Fractures and Dislocations: Diagnosis and Treatment. *J Am Acad Orthop Surg* 1995;3:22, with permission.)

Isolated injuries to the components of the SSSC such as AC separations or isolated distal clavicle fractures are typically stable injuries and respond well to nonoperative treatment. When the SSSC is injured in two places, however, a so-called double disruption (Fig. 15.5), one or both of the injuries may become significantly displaced because the ring is left unstable. Double disruptions often lead to delayed union, malunion, or nonunion and secondarily to decreased strength and muscle fatigue and, possibly, neurovascular compromise. Osteoarthrosis may result when one of the disruptions involves a joint surface. Examples of double disruptions of the SSSC include a clavicle fracture together with an AC joint disruption, a glenoid neck fracture with either an AC joint disruption or clavicle fracture, and unusual combinations such as ipsilateral fractures of the acromion and coracoid process (45). The most common sequela is anterior, medial, and inferior displacement of the scapula secondary to the weight of the arm and the combined pull of the pectoralis major, pectoralis minor, and latissimus dorsi muscles.

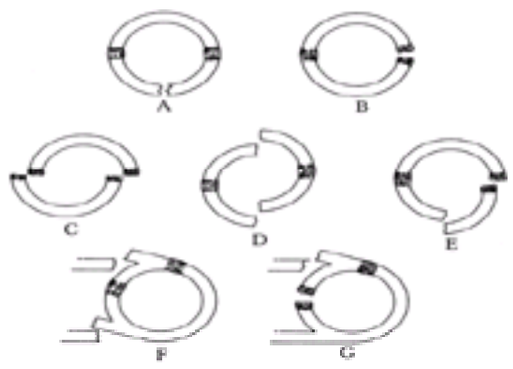


***Figure 15.5.*** Types of traumatic ring/strut disruptions. Single disruptions of the bone–soft-tissue ring may be a break (**A**) or a ligament disruption (**B**). Double disruptions of the bone–soft-tissue ring may be a double-ligament disruption (**C**), a double break (**D**), or a combination of a bone break and a ligament disruption (**E**). Other double disruptions may be a break of both struts (**F**) or a break of one strut and a ring disruption (**G**). (© 1995 American Academy of Orthopaedic Surgeons. Reprinted from Goss TP. Scapular Fractures and Dislocations: Diagnosis and Treatment. *J Am Acad Orthop Surg* 1995;3:22, with permission.)

## RADIOGRAPHIC EVALUATION

A high index of suspicion is necessary to make the diagnosis of a scapular fracture in an acutely injured patient. In one large series, one third of the scapular body fractures were not diagnosed or recorded at the time of the patients' admission to the hospital (138). Scapular fractures may be evident on the chest x-ray obtained as part of the initial evaluation of a multiply injured patient. More often, special-view radiographs—including scapular anteroposterior, scapular lateral, and axillary views—are necessary to better define the fracture pattern. Computed tomography (CT) scans are useful for detailed assessment and preoperative planning of intraarticular and glenoid neck fractures. Frequently they can be obtained when the patient goes to the CT scanner for evaluation of other injuries.

Scapular fractures are best characterized by anatomic regions because the criteria for operative and nonoperative treatment and the expected outcomes vary accordingly. The regions and the approximate incidence of scapular fractures that occur in each are scapular body (35%), glenoid neck (27%), acromion (12%), scapular spine (11%), glenoid fossa (10%), and coracoid process (5%) (Fig. 15.6) (2). Diagnosis and treatment of these fractures are discussed by anatomic region.

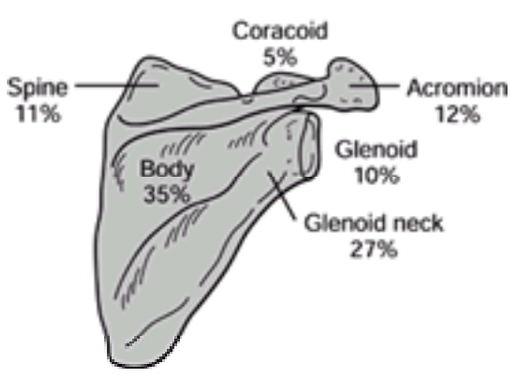


***Figure 15.6.*** Incidence of scapular fractures by anatomic location. (From Ada JR, Miller ME. Scapular Fractures: Analysis of 113 Cases. *Clin Orthop* 1991;269:174.)

## SCAPULAR BODY FRACTURES

The body of the scapula is covered with dense muscular attachments (Fig. 15.1); therefore, extreme force usually is necessary to produce scapular body fractures. Because of the rich blood supply to this region and the stabilizing effect of the surrounding muscular envelope, healing usually occurs uneventfully, and nonunion is rare. Focus treatment on symptomatic relief. Prescribe ice to the local area and sling immobilization of the arm for comfort. Within a week of injury, begin pendulum exercises and advance to the use of overhead pulleys and active-assisted range-of-motion exercises as soon as the patient's symptoms allow. Malunion with significant displacement may produce a snapping or grating sensation with scapulothoracic motion, but patients rarely complain of restricted motion or pain that limits function (2).

## GLENOID NECK FRACTURES

Fractures of the glenoid neck occur in three basic patterns (Fig. 15.7): (a) fracture of the anatomic neck; (b) fracture of the surgical neck; and (c) fracture of the inferior neck coursing inferior to the scapular spine to exit along the medial scapula border, leaving the superior portion of the glenoid intact (Fig. 15.8) (46). These fracture patterns can be identified on the standard shoulder trauma x-ray series, but CT scans are helpful in clearly defining the fracture anatomy and assessing associated injuries to the shoulder girdle.

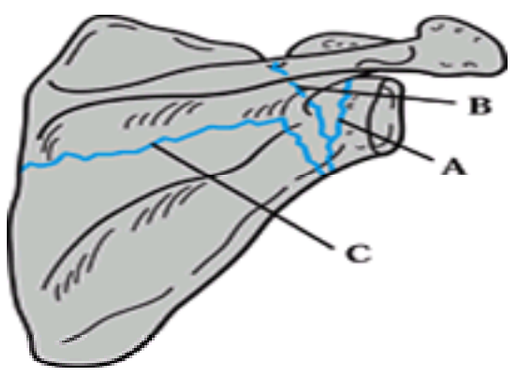


***Figure 15.7.*** Three major fracture patterns of the glenoid process. **A:** Anatomic neck. **B:** Surgical neck. **C:** Fracture of the inferior neck, which then courses along the inferior aspect of the scapular spine to exit at the medial border of the scapula. (Redrawn from Goss TP. Fractures of the Glenoid Neck. *J Shoulder Elbow Surg* 1994;3:42.)

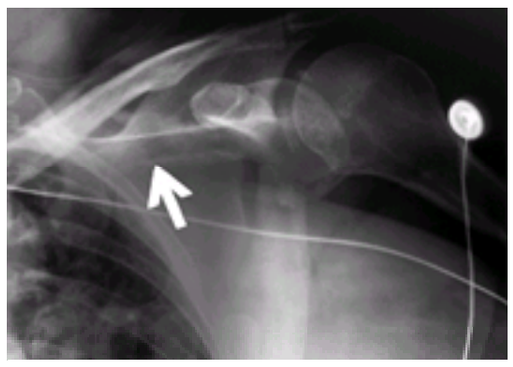

***Figure 15.8.*** Anteroposterior radiograph illustrating a type C glenoid neck fracture. This is not a complete fracture of the glenoid neck because the superior portion of the glenoid remains intact.

In addition to fracture pattern, fracture displacement is important for deciding treatment. Excessive translation and angulation can lead to shoulder dysfunction from altered rotator cuff mechanics and pain. Therefore, we consider glenoid neck fractures as one of two types, as suggested by Goss (46). Type I fractures are undisplaced or insignificantly displaced; type II fractures are displaced at least 1 cm or angulated at least 40° (Table 15.2). Any fracture pattern (A, B, or C) may be either type I or type II. Type I fractures are usually stable and heal satisfactorily because the superior shoulder suspensory complex is disrupted in only one place. Therefore, treatment is nonoperative and aimed at symptom relief. Provide an arm sling for patient comfort and ice the injured region. Instruct the patient to begin gentle pendulum exercises within 1 week and progressively increase use of the arm and shoulder as pain allows. The goal is to promote healing without developing debilitating shoulder stiffness, which often follows prolonged immobilization.

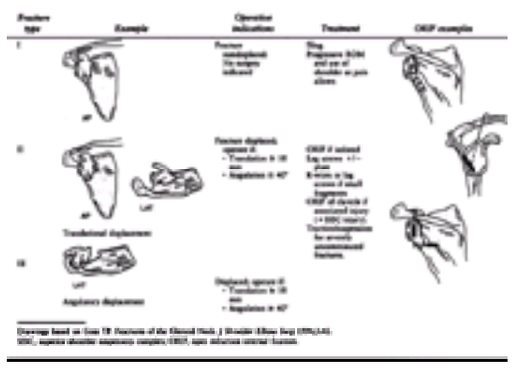

***Table 15.2. Glenoid Neck Fractures***

Type II fractures require operative treatment for optimum results (2,141). If the displaced glenoid neck fracture is an isolated injury without a secondary disruption of the SSSC, then treat the fracture via open reduction and internal fixation (ORIF) through a posterior approach. Use interfragmentary fixation and/or a buttress plate as the fracture pattern dictates.

Frequently, in the setting of a type II glenoid neck fracture, there is an associated disruption in the SSSC, rendering the shoulder complex unstable. Most often the clavicle is fractured also; less commonly, the acromioclavicular joint is disrupted. Several authors have described this combination of injuries and the need for ORIF of one or both of them. Herscovici (55), Rikli (117), and Goss (46) suggest that ORIF of the associated injury—a clavicle fracture, for example—would indirectly reduce the glenoid neck fracture and is sufficient to restore stability to the shoulder complex. Leung et al. (81) recommended ORIF of both injuries, suggesting that more rigid fixation would allow more vigorous rehabilitation and better final results.

***Authors' Preferred Operative Technique***

- If the displaced glenoid neck fracture is an isolated injury, then approach the fracture directly through a posterior approach. Retract the deltoid with an appropriate retractor rather than detaching it from its origin on the scapular spine whenever possible. Retract the infraspinatus superiorly and the teres minor inferiorly to reach the glenoid neck.
- Use either a 3.5-mm reconstruction plate as a buttress plate or interfragmentary screw fixation to stabilize the fracture depending on the fracture configuration and fragment size (Table 15.2).
- If the glenoid neck fracture is associated with a second injury such as a clavicle fracture or acromioclavicular joint disruption, then address the injury that is more accessible first. Usually that means open reduction and plate fixation of the clavicle (Fig. 15.9). If the fixation is solid and reduces the associated glenoid neck fracture within the criteria listed above, then no further internal fixation is required. If the glenoid neck remains displaced beyond acceptable criteria, however, then we openly reduce and fix that fracture also.

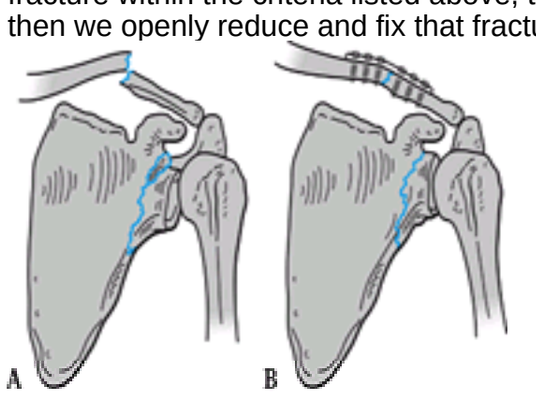


***Figure 15.9.*** **A:** Displaced glenoid neck fracture associated with a clavicle fracture. **B:** Indirect reduction of glenoid neck fracture after open reduction and internal fixation of the clavicle.

- Postoperatively, apply a sling and swathe or shoulder immobilizer and prescribe narcotics and local ice for pain control. Instruct the patient to begin progressive passive range-of-motion (ROM) exercises 48 to 72 hours after surgery. Allow functional use of the shoulder within defined limitations depending on the surgical approach and associated injuries. Patients should strive to achieve full shoulder motion by 8 to 12 weeks after surgery. Begin strengthening exercises at 12 weeks. The patient should avoid heavy lifting with the injured arm until that time.

**FRACTURES OF THE GLENOID RIM AND GLENOID CAVITY**

Fractures of the glenoid cavity make up approximately 10% of all scapular fractures, and only 10% of these are significantly displaced (2,62,86). If a glenoid fracture is suspected from physical exam (pain, swelling, ecchymosis, crepitus) or after review of a chest radiograph, obtain a shoulder trauma series to confirm the diagnosis, rule out a dislocation of the glenohumeral joint, and help determine if surgery is indicated. A CT scan is helpful for delineating the articular fracture pattern and is recommended before operative treatment.

Treat minimally displaced glenoid fossa and rim fractures not associated with humeral head subluxation or dislocation nonoperatively with early progressive ROM exercises as the patient's pain decreases. Progressive shoulder strengthening begins when shoulder ROM has returned to normal. The majority of patients with glenoid

cavity fractures can be treated in this fashion. Functional outcome is usually excellent, but it can take 6 to 12 months to reach maximum recovery.

In contrast, displaced glenoid cavity and rim fractures can lead to decreased range of motion, painful osteoarthrosis, and chronic instability (2,29,76). Although the exact amount of displacement or stepoff of the articular surface necessary to cause significant morbidity is unknown, many authors believe that residual displacement of 5 to 8 mm should be reduced and stabilized in accordance with the principles of displaced intraarticular fractures in other anatomic regions (51,67). The indications, approaches, and techniques for operative treatment of these injuries are dependent on the degree of displacement and the fracture pattern.

Ideberg developed a classification scheme based on his experience with 300 glenoid fractures (Table 15.3) (62). Type I fractures represent a substantial portion of the glenoid rim and occur when a lateral force drives the humeral head into the glenoid rim. These should be differentiated from small capsular avulsions of bone associated with shoulder dislocations. They are considered unstable if they are displaced at least 1 cm or involve at least 25% of the anterior rim or 33% of the posterior rim (6,51,76,133).

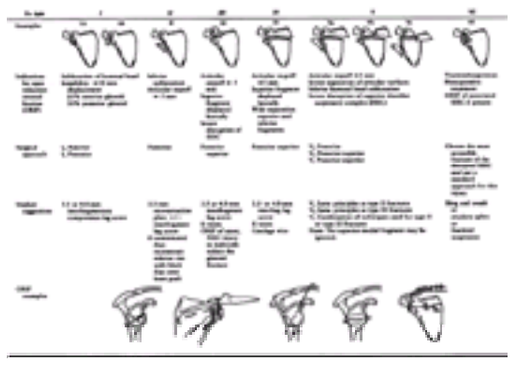

***Table 15.3. Glenoid Rim and Glenoid Cavity Fractures (44,62)***

Type II fractures involve the glenoid fossa and can have several different fracture patterns depending on the position of the humeral head at the time of injury and the direction of the applied force. Type II fractures that are displaced 5 mm or more or associated with inferior subluxation of the humeral head require open reduction and internal fixation (47,51) (Fig. 15.10).

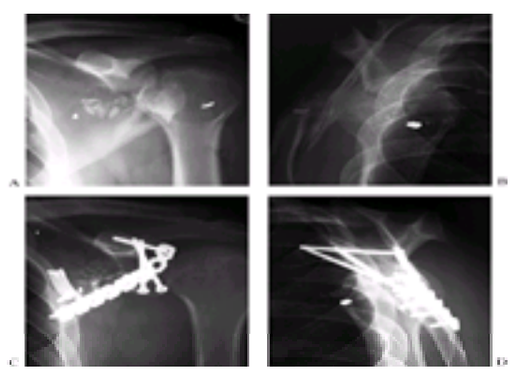

***Figure 15.10.*** **A:** Anteroposterior radiograph illustrating a comminuted type II glenoid fossa fracture. **B:** Lateral radiograph of fracture. **C:** Postoperative AP radiograph illustrating interfragmentary lag screws utilizing the coracoid process for good screw purchase. **D:** Postoperative lateral radiograph.

Type III and IV fractures require open reduction and internal fixation if there is an articular stepoff of 5 mm or more, lateral displacement of the superior fragment, or wide separation of the inferior and superior fragments. A posterosuperior approach is recommended for reduction of the fragments (44) and placement of a 3.5-mm or 4.0-mm interfragmentary lag screw from the superior fragment into the inferior fragment. When there is an associated injury to the SSSC, reduction and fixation of the glenoid surface may indirectly reduce the second injury of the double SSSC disruption. However, open reduction and fixation of the associated injury should be performed as well if fixing the glenoid surface does not reduce the second injury adequately. Type V fractures require open reduction and internal fixation if there is an articular stepoff of 5 mm or more, inferior displacement of the inferior glenoid fragment with subluxation of the humeral head, wide separation of the joint surfaces, or an associated SSSC injury leading to a separated superior glenoid fragment (44).

Type VI fractures are severely comminuted and rarely amenable to open reduction and internal fixation. Several nonoperative approaches to these difficult fractures have been advocated, including (a) a sling and swathe followed by early ROM; (b) immobilization in a shoulder abduction (“airplane”) splint and early ROM above the level of the splint as the patient's symptoms allow; and (c) traction-suspension therapy with ROM within the ranges allowed by the traction setup (44,141).

In summary, the goal in treating fractures of the glenoid rim and fossa is to achieve a smooth articular surface and enough bony stability to allow full shoulder function. Frequently that can be achieved nonoperatively. In cases in which fracture displacement is significant and anatomic alignment cannot be achieved by closed manipulation, open reduction and internal fixation are indicated. Surgical approach, fixation techniques, and postoperative rehabilitation follow the principles outlined above for treatment of glenoid neck fractures.

**FRACTURES OF THE ACROMION**

For the purposes of this discussion, the acromion is defined as the bony continuation of the scapular spine lateral to the spinoglenoid notch. Acromion fractures account for 8% to 12% of all scapula fractures (2,86) and can occur in two areas: zone 1 fractures occur in the anatomic acromion, and zone II fractures occur more medially near the scapular spine and descend toward the spinoglenoid notch (Fig. 15.11) (107). Zone 1 fractures have been subclassified by Kuhn et al. (75) into three main types: Type IA fractures are avulsion injuries of the tip; type 1B fractures are nondisplaced, true fractures of the acromion (Fig. 15.12*A*); Type II fractures are displaced but do not decrease the subacromial space; Type III fractures are displaced such that the subacromial space is decreased (Fig. 15.12*B*).

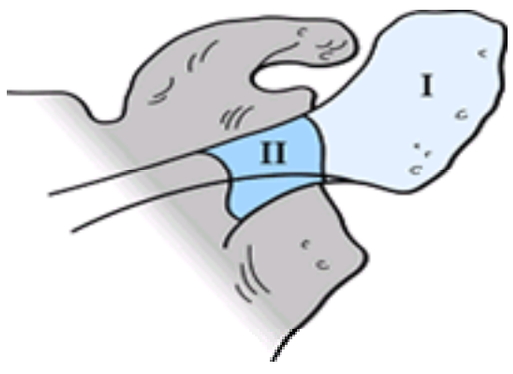


***Figure 15.11.*** **Zone I:** Location of fractures occurring in the anatomic acromion. **Zone II:** Location of fractures occurring in the medial acromion between the spinoglenoid notch and the anatomic acromion.

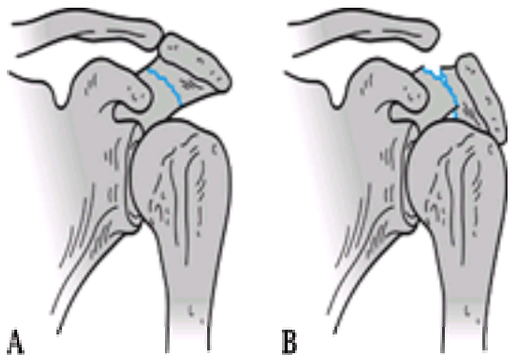


***Figure 15.12.*** **A:** Nondisplaced acromion fracture; operative treatment not indicated. **B:** Displaced acromion fracture resulting in a decreased subacromial space; this fracture requires ORIF.

The majority of acromial process fractures can be treated nonoperatively. Although nonunion or pseudarthrosis may result from fractures treated nonoperatively, most of these are not painful and do not lead to functional impairment (75). The occasional nonunion that is painful can be treated with bone grafting and internal fixation. There are however several indications for acute surgical treatment (Table 15.4). Avulsion fractures can be repaired with heavy suture through drill holes in the acromion. Zone 1 fractures are best stabilized with a tension band construct, either with cannulated 4.0 mm partially threaded screws or Kirschner (K-) wires and either 18-gauge wire or heavy suture (Fig. 15.13*A*). Zone 2 fractures are best stabilized with a 3.5 mm reconstruction plate (Fig. 15.13*B* and Fig. 15.14).

| |
|---|
| Significantly displaced avulsion fractures of the deltoid origin (48) |
| Acromial process fractures that reduce the subacromial space (75,107) |
| Marked displacement of zone 2 fractures (107) (Fig. 15.11) |
| Associated fractures of the coracoid base or acromioclavicular joint leading to a double disruption of the superior shoulder suspensory complex (SSSC) (48) |
| Segmental fractures leading to an unstable intermediate segment (48) |

***Table 15.4. Indications for Operative Treatment of Acromion Fractures***

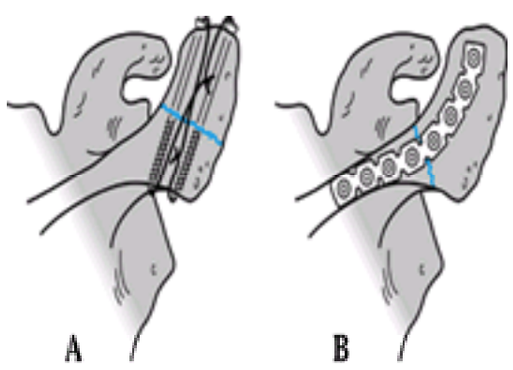


***Figure 15.13.*** **A:** Tension band construct of a zone I acromion fracture using cannulated 4.0 screws and 18 gauge wire. K-wires can be used as well. **B:** Zone II fracture fixed with a contoured, curved 3.5-mm reconstruction plate.

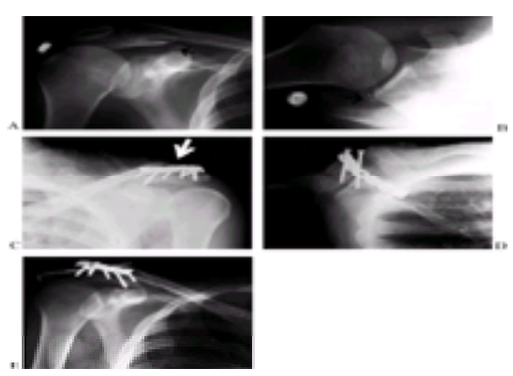

***Figure 15.14.*** **A:** Anteroposterior radiograph showing a displaced fracture of the acromion at the junction of zone I and zone II with a type III pattern (i.e., tilted down toward the humeral head, causing impingement). **B:** Axillary view showing the widely displaced acromion fracture. **C:** After fixation of the acromion fracture with two parallel cannulated 4.0-mm screws and a neutralization 3.5-mm reconstruction plate, the AC joint was displaced, revealing a double disruption of the SSSC. The AC joint was reduced and pinned with a single 0.062 K-wire. **D:** Postoperative axillary view before placement of the K-wire, demonstrating the hardware placement. **E:** Anteroposterior radiograph 4 weeks postop showing the single 0.062 K-wire that was used to pin the AC joint. Note the bend in the end of the K-wire to prevent migration. The patient had full range of motion of his shoulder.

Double disruptions of the SSSC involving the acromial process and the coracoid base usually are treated adequately with fixation of the acromial process fracture alone (47). If the second injury involves the acromioclavicular joint, however, then temporary fixation with an additional pin across the AC joint may be necessary. If pins are used around the shoulder girdle complex, they must be bent to avoid migration and should be removed once the injured structures have healed.

***Authors' Preferred Treatment***

The majority of acromial fractures can be treated nonoperatively with a sling to support the arm for comfort. Begin pendulum and active-assisted ROM exercises within the first several days. The patient may increase the use of the involved extremity as her pain allows.

For acromion fractures in the anatomic or Zone I region that require ORIF, we prefer a tension band technique with two cannulated 4.0 screws and heavy number 5 suture or 18 gauge wire. Do not use screws that project beyond the bony surface because they could eventually cut the suture running over their edges. For more medial acromion fractures, we recommend using a curved pelvic 3.5 mm reconstruction plate which has oval holes and allows angled screw insertion if necessary (Fig. 15.14). Use standard surgical approaches (see Chapter 1) to the shoulder girdle to expose, reduce and internally fix the fracture.

Postoperatively, begin pendulum exercises as soon as the wound is sealed. If the deltoid required surgical repair due to traumatic injury or take-down during surgery,

avoid active abduction and forward elevation for 4–6 weeks. In all other cases, begin active-assisted exercises within the first 2 weeks to avoid shoulder stiffness. Have the patient use a sling when sitting up or walking, and a pillow under the ipsilateral elbow when in bed to relieve the downward pressure on the acromion from the weight of the arm.

## SCAPULAR SPINE FRACTURES

The scapular spine is surrounded by the muscles of the rotator cuff, deltoid and trapezius. Fractures in this region are commonly associated with scapular body fractures and can lead to some degree of pain and weakness. In one series, 70% of patients with scapular spine fractures had abduction weakness and pain at rest from 3 to 7 years after their injury and many of these patients also had night pain (2). Nevasier (100) referred to this phenomenon as a “pseudorupture” of the rotator cuff caused by hemorrhage and scarring of the supra- and infraspinatus muscles related to the fractures which are frequently comminuted and displaced. Because patients with these injuries may develop problems either acutely or on a delayed basis, some authors advocate that scapular spine fractures should be reduced and surgically stabilized (2,51). To date, there are no published reports that provide definite indications for surgery.

## FRACTURES OF THE CORACOID PROCESS

Fractures of the coracoid process account for 5% to 7% of all scapula fractures (2,86). The typical mechanism of injury is an avulsion fracture caused by traction on the conjoined tendon and/or the coracoclavicular ligaments. Occasionally a direct blow by the humeral head at the time of glenohumeral dislocation produces the fracture (48,108). In general, coracoid process fractures can be treated nonoperatively (48,50,84), although associated injuries may warrant surgery. Prescribe a sling for patient comfort for the first week or two, and then begin progressive range of motion exercises. Avoid heavy lifting and weight training for 8 to 12 weeks since the short head of the biceps brachii and the pectoralis minor (as well as the coracobrachialis) muscles originate from the coracoid and forceful contraction of those muscles might displace the fracture (Fig. 15.2).

Open reduction and internal fixation may be indicated in exceptional cases. For example, a coracoid fracture in a high performance athlete who relies on the precise functioning of his/her upper extremity warrants ORIF. Another indication for surgery is an associated injury such as a type III AC disruption (see below), acromion fracture, glenoid neck fracture, or clavicle fracture that results in wide displacement of the associated injury or both injuries. In most cases, fixation of the associated injury is all that is needed, and doing so indirectly reduces the coracoid process fracture and allows it to heal in satisfactory position. Delayed treatment of an avulsion fracture is occasionally necessary in patients who develop soft tissue irritation from the displaced bony fragments. In those cases, reduce and internally fix large fragments, or, if the bony fragments are small, excise them and suture the conjoined tendon to the remaining coracoid process.

## SUPERIOR SHOULDER SUSPENSORY COMPLEX INJURIES

A standard shoulder trauma series of radiographs plus a CT scan will delineate the presence of these injuries and assist in choosing a treatment plan and surgical strategy. Anterior and posterior 45° oblique views may be beneficial to show fracture displacement (45). If AC or distal clavicle injuries are suspected, AP shoulder radiographs obtained while 10-lb weights are suspended from the patient's wrists can be used to accentuate the disruptions and aid in the diagnosis.

Unacceptable displacement of one or both of the SSSC injuries is an indication for surgery. Only recently has attention in the literature been focused on the complex nature of these injuries (45), and, therefore, precise criteria for operative intervention are unknown. The surgeon must rely on his judgment as to the likelihood that the displacement will lead to delayed or nonunion and/or adverse biomechanical and functional outcomes. The more widely displaced the injured structures are, the more likely surgical intervention will be beneficial.

The operative strategy for these combined injuries is straightforward. Identify the injury that is easiest to approach surgically, perform the site-appropriate reduction and stabilization utilizing the techniques described above, and then evaluate the secondary disruption for persistent displacement and instability. Once the initial injury has been reduced and stabilized, it usually produces an indirect reduction of the secondary injury and makes the whole shoulder complex sufficiently stable so that ORIF at the second site is not necessary. For example, ORIF of the clavicle will usually reduce and stabilize an associated glenoid neck fracture, and K-wire fixation or coracoclavicular ligament reconstruction in selected type III AC separations and all type V AC separations (see below) will reestablish the clavicle as the stable superior buttress of the shoulder girdle (Fig. 15.9).

Postoperative management is injury specific. For most of the cases, except those with pins across the AC joint, prescribe sling support for 1 to 3 weeks in conjunction with pendulum exercises. After 2 to 3 weeks, start active assisted ROM exercises and add gentle strengthening exercises after 6 and 8 weeks. By 3 months, most patients should have full shoulder motion and be using their shoulders for all activities of daily living.

## SCAPULOTHORACIC DISSOCIATION

Scapulothoracic dissociation is essentially a closed forequarter amputation caused by severe blunt trauma and traction to the upper extremity. Beneath an intact layer of skin, there is disruption of the scapular rotators, subclavian vessels and the brachial plexus (22,109). Bone and joint injuries such as AC separations, clavicle fractures, and sternoclavicular (SC) disruptions complete the clinical picture.

Diagnosis may be delayed because of multiple other severe injuries that necessarily divert the resuscitation efforts to life-saving maneuvers. In addition, ipsilateral musculoskeletal injuries may mistakenly be identified as the cause of neurovascular deficits. However, careful attention to the mechanism of injury (thrown motorcyclist or farming accident), critical assessment of the position of the scapulae in relation to the spinous processes (the medial borders should normally be equidistant from the spinous processes) (Fig. 15.15), and a thorough physical exam (absent pulses, neurologic compromise, severe swelling over the shoulder region) can lead the resuscitation team to the correct diagnosis. Further workup includes upper extremity angiography to identify the level of the arterial lesion and guide the surgical strategy for vascular repair.

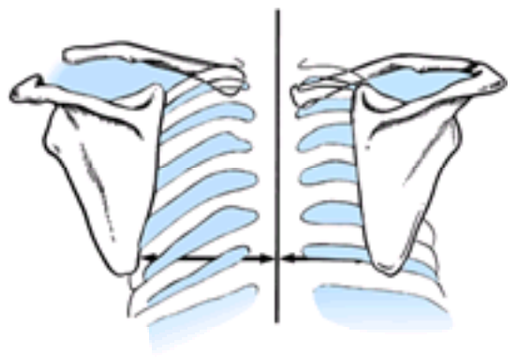

***Figure 15.15.*** Diagnosis of scapulothoracic dissociation can be verified by observing significant lateral displacement of the scapula and shoulder girdle on the affected side. This can be determined by comparing the distance from the medial border of the scapula to the spinous processes between the affected and unaffected sides. (From Butters KP. Fractures and Dislocations of the Clavicle. In: Rockwood CA Jr, Green DP, Bucholz RW, Heckman JD, eds. *Fractures in Adults.* Philadelphia: JB Lippincott, 1996;1189.)

The first goal of treatment for this condition is to restore perfusion to the affected limb. Frequently, that requires a saphenous vein graft to repair the avulsed subclavian or axillary arteries or a shunt. Next, explore the brachial plexus and reapproximate any transected nerves with appropriate microsurgical techniques. It is much easier to perform the nerve repairs acutely than later, when they are encased in scar. Finally, establish bony stability where needed such as by plating or pinning a clavicle fracture or reconstructing the AC joint to restore the length and stability of the shoulder girdle, protect the neurovascular repairs, and create a stable environment for soft-tissue healing.

In the past, amputation or glenohumeral disarticulation was recommended for patients who presented with complete neurologic deficits in the affected limb (22,31). Recent improvements in microsurgery, however, have allowed surgeons to salvage limbs that might have been amputated previously. Partial neurologic deficits generally have a good prognosis in terms of return of function and sensation (31). The decision to amputate a revascularized, viable limb because of neurologic or other soft-tissue injuries should be delayed and made only after multidisciplinary consultation and discussion with the patient and family. More specific indications and a

discussion of treatment options regarding brachial plexus injuries are beyond the scope of this chapter but are found elsewhere in this book (see Chapter 60).

### COMPLICATIONS

There are several potential pitfalls and complications to avoid when managing scapular fractures. The first is the failure to recognize a double disruption of the SSSC. If one overlooks one or both disruptions in the suspensory complex, further displacement and instability of the shoulder complex may result when movement is initiated. Conversely, a rehabilitation program that is not vigorous enough can be equally problematic and result in excessive shoulder stiffness. A well-designed and supervised exercise program is the key to success.

Another pitfall to avoid is injury of the suprascapular nerve when operating on the scapula. The nerve may be injured at the spinoglenoid notch by careless medial dissection during the posterior approach to the glenoid neck or excessive traction on the infraspinatus muscle. Finally, avoid placing K-wires across the AC joint or into the scapula wherever possible. In rare cases when they are used temporarily to fix small fragments, bend the ends of K-wires to prevent pin migration. Remove them 4 to 6 weeks postoperatively before beginning vigorous shoulder motion to avoid pin breakage and interference with motion.

## CLAVICLE FRACTURES

Clavicle fractures account for approximately 4% of all fractures and 35% to 43% of shoulder girdle injuries. Fractures occur most commonly in the middle third of the bone (76%–82%) and less often in the distal (12%–21%) and medial (3%–6%) thirds (103,127) (Fig. 15.16). Proximal clavicle fractures tend to occur in elderly men; middle-third fractures tend to occur in children (typically undisplaced), adolescents (displaced), and young male adults (comminuted); distal-third fractures are frequent in middle-aged patients (103).

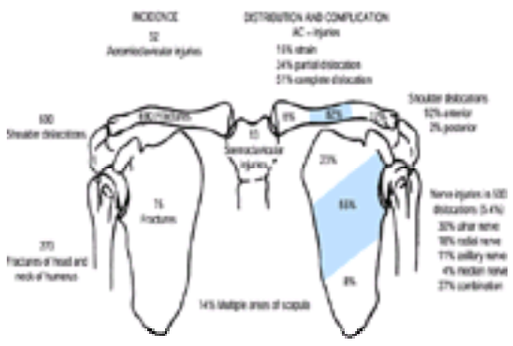

***Figure 15.16.*** An analysis of 1,603 shoulder girdle injuries among which were 690 fractures of the clavicle. (From Rowe CR. An Atlas of Anatomy and Treatment of Midclavicular Fractures. *Clin Orthop* 1968;58:29.)

### FUNCTIONAL AND SURGICAL ANATOMY

The structural unit of the sternum and both attached clavicles has been likened to a yoke and serves to keep the shoulder girdle positioned laterally throughout a wide range of motion, enhancing upper extremity function (82). The clavicle also provides a base for muscular attachments of the shoulder girdle, allows maximum upper extremity range of motion for better positioning of the hand, protects vital neurovascular structures, facilitates optimum respiration and circulation via the attached secondary muscles of respiration, and contributes to the cosmetic appearance of the neck region (82,90). The clavicle is an S-shaped bone, concave arteriorly at its lateral end and convex anteriorly at its medial end, and subcutaneous throughout its entire length. The cross-sectional anatomy changes along its lateral-to-medial course from flat to tubular to prismatic (Fig. 15.17). The junction from the flat region to the tubular region is a stress riser; that fact, coupled with the effect of the first rib acting as a fulcrum near the same spot over which the clavicle rides as superior-lateral load is applied to it, explains the high incidence of fractures in that region. The medial end of the clavicle is firmly attached to the sternum and first rib by stout ligaments, the only articulating connection of the upper extremity to the axial skeleton. Laterally, the clavicle is attached to the coracoid process by the coracoclavicular ligaments (Fig. 15.2) and to the acromion by the acromioclavicular ligaments.

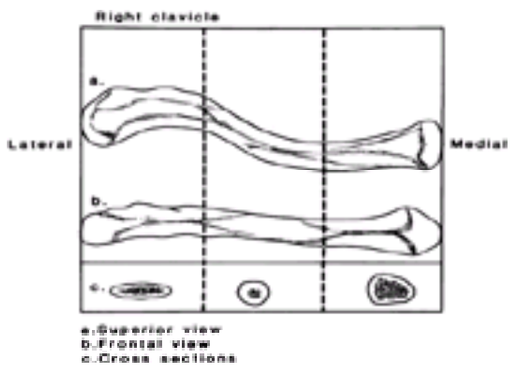


***Figure 15.17.*** The clavicle appears straight when viewed from the front (**B**) but as an S-shaped double curve when viewed from above (**A**). The lateral end of the clavicle is flat in cross section (**C**), whereas the medial aspect is more tubular. (From Craig EV. Fractures and Dislocations of the Clavicle. In: Rockwood CA Jr, Green DP, Bucholz RW, Heckman JD, eds. *Fractures in Adults.* Philadelphia: JB Lippincott, 1996;1111.)

The relationship of the soft-tissue attachments and neurovascular structures with the clavicle help explain some patterns of injuries seen clinically and highlight potential complications to avoid when treating them. For example, because of their insertions, the sternocleidomastoid and trapezius muscles pull the medial aspect of the clavicle superiorly after clavicle fractures (Fig. 15.18). The subclavian artery and vein as well as the brachial plexus pass between the junction of the middle and medial third of the clavicle and the first rib and need to be protected during plating of clavicle fractures. The strong tubular portion of the clavicle, clothed on its underside by the subclavius muscle and fascia, overlies these vital structures, which may account for the low incidence of neurovascular injury associated with clavicle fractures.

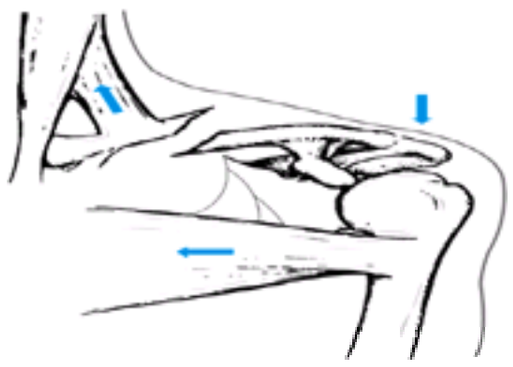

***Figure 15.18.*** Muscle forces acting on fractures of the middle third of the clavicle to render them potentially unstable.

## RADIOGRAPHIC EVALUATION

Begin radiographic evaluation with two views of the clavicle: an AP view on a large film that includes the upper third of the humerus, shoulder girdle, and upper lung field and a 45° cephalad “oblique” view (126). Together these views are sufficient for evaluating most clavicle fractures except those in the medial third and will show associated musculoskeletal injures, screen for a pneumothorax, and show both the superior–inferior and anterior–posterior displacement of the clavicle. In fractures that have been treated with internal fixation or in cases of questionable nonunion, an abduction lordotic view is an alternate method of getting a second view at 90° for a more complete representation of the clavicle (116). Distal third fractures are more difficult to assess because of overlapping bony structures. Anterior–posterior oblique stress films with the patient standing and while 10-lb weights are suspended from each wrist should be sufficient to diagnose an unstable distal clavicle fracture or acromioclavicular separation. Computed tomographic scans are useful for evaluating medial clavicle fractures because plain films are usually inadequate for assessing anterior–posterior displacement.

## CLASSIFICATION OF CLAVICLE FRACTURES

Clavicle fractures are classified into three groups according to location in the bone because prognosis and treatment vary according to type. Group I (middle-third) fractures are the most common, accounting for approximately 80% of all clavicle fractures. Approximately 97% of fractures in this group are mild to moderately displaced and can be treated nonoperatively, with certain exceptions, outlined below. However, 3% of middle-third clavicle fractures are completely displaced and shortened. This small group of fractures accounts for 90% of nonunions in middle-third fractures and therefore may warrant early open reduction and internal fixation (139).

Group II (distal) fractures occur in the distal third of the bone and account for approximately 10% of clavicle fractures. Critical to the behavior and treatment of these injuries is the condition of the coracoclavicular ligaments. If they are both disrupted, the shoulder girdle loses its superior strut, and the fracture displaces because of four main forces (95) (Fig. 15.19). If the ligaments are not disrupted, the same displacement pattern will still occur if the ligaments are attached to an inferior butterfly fragment (111). The displacement caused by these forces may account for the reported 30% nonunion and 45% delayed union of these fractures when treated nonoperatively (32). Group II fractures can be further subdivided into five subtypes based on fracture location because the anatomic details of the fracture play a role in treatment options (Table 15.5; Fig. 15.20).

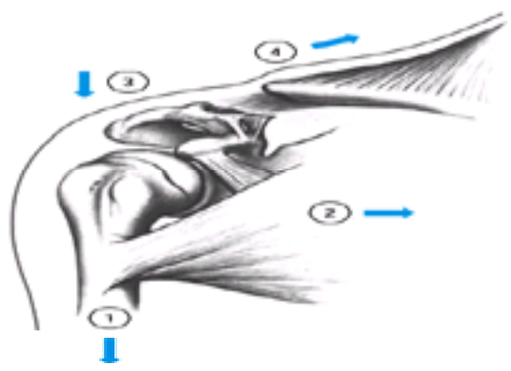


***Figure 15.19.*** The four displacing forces that act on the clavicle and shoulder girdle in type II fractures: (*1*) the weight of the arm, (*2*) the latissimus dorsi, the pectoralis major and minor muscles, (*3*) scapular rotation, and (*4*) the trapezius muscle. The first three forces act only the distal segment, while the trapezius muscle pulls the shaft upward and backward. (From Neer CS II. Fractures of the Distal Third of the Clavicle. *Clin Orthop* 1968;58:45.)

| | |
|---|---|
| Group I | Middle-third fractures |
| Group II | Distal-third fractures |
| Type I | CC ligaments intact to medial segment: minimal displacement (93,96) |
| Type II | CC ligaments detached from the medial segment with the trapezoid ligament attached to the lateral segment. Displacement of fracture with drooping of shoulder. |
| Type III | Articular surface fractures |
| Type IV | Ligaments attached to periosteum (children), with displacement of the proximal fragment. |
| Type V | Comminuted, with ligaments not attached proximally or distally, but to a third, inferior fragment (111) |
| Group III | Medial third fractures (26) |
| Type I | Minimal displacement |
| Type II | Significant displacement (ligaments ruptured) |
| Type III | Intraarticular fractures |
| Type IV | Epiphyseal separation (children and young adults) |
| Type V | Comminuted |

CC, coracoclavicular.

***Table 15.5. Classification of Clavicle Fractures***

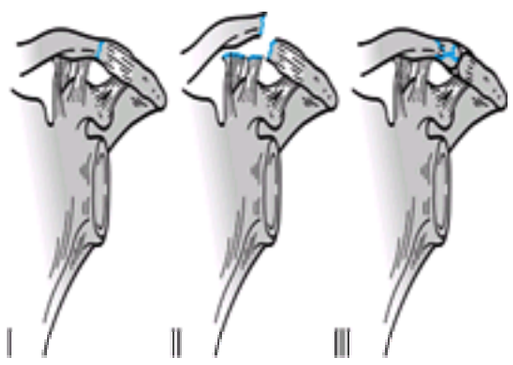


***Figure 15.20.*** Fractures of the distal clavicle. Type I fractures occur lateral to the coracoclavicular ligaments. Type II fractures functionally detach the coracoclavicular ligaments from the medial fragment of the clavicle. Type III fractures are intraarticular and involve the acromioclavicular joint. Types IV and V are not shown.

Group III (medial) clavicle fractures are usually stable because of the supporting sternoclavicular ligaments (Table 15.5).

## PATIENT ASSESSMENT

Proper evaluation of a patient with a clavicle fracture includes a complete history, a careful neurovascular exam of the shoulder and ipsilateral upper extremity, and appropriate imaging. The mechanism and events surrounding the injury as well as the patient's preexisting medical problems provide useful information about the amount of energy and forces which produced the fracture as well as important clues about associated injuries. Most clavicle fractures are closed, isolated injuries sustained in low energy falls (103); however, they also occur in high energy accidents. Although neurovascular injuries and open fractures are uncommon, subclavian artery and vein injuries, severe chest trauma, and brachial plexus injuries all have been reported. Unfortunately, associated injuries often are missed initially (9,61,118,127); look carefully for them to avoid delays in diagnosis.

## TREATMENT

More than 200 methods have been described to treat fractures of the clavicle (26). Group I, middle one-third, clavicle fractures can generally be treated nonoperatively. A figure-of-eight bandage with or without plaster reinforcement has long been recommended and is one very good treatment option (Fig. 15.21) (3,26,119,127). See

Chapter 10 for a description of the use of a plaster bolero. The goal of this method is to reoppose the bone ends as much as possible by simultaneously raising the lateral fragment upward and backward while depressing the medial fragment. The advantage of a figure-of-eight brace is that it leaves the ipsilateral hand free for use while splinting the fracture helps keep the patient's shoulders back and the clavicle out to length, minimizing the chance of the bone healing in a shortened position. The disadvantages of this method include the difficulty many patients have keeping the brace adjusted properly and the potential skin problems caused by the brace, as well as impairment of patients' agility, personal hygiene needs, and comfort while sleeping (5).

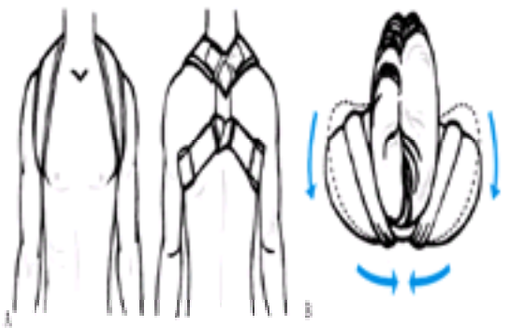

***Figure 15.21.*** **A:** A commercial figure-of-eight support. **B:** Superior view of the patient, showing how the figure-of-eight support pulls the shoulder up and backward. (From Dameron TB Jr, Rockwood CA Jr. Fractures and Dislocations of the Shoulder. In Rockwood CA Jr, Wilkins KE, King RE, eds. *Fractures in Children,* Philadelphia: JB Lippincott, 1984;618.)

Alternatively, middle-third clavicle fractures may be treated with an arm sling (5,118). Although a sling does nothing to correct shortening or displacement at the fracture site, it is often more comfortable and convenient for patients than a figure-or-eight brace and yet leads to the same rate of union and excellent function as can be achieved with more restrictive treatment methods (5,105).

Treated nonoperatively, the vast majority of middle-third clavicle fractures heal uneventfully and with little or no functional limitations. The nonunion rate for middle-third clavicle fractures ranges from 0.1% in Neer's series of 2,235 patients to 15% in Hill's series of 242 consecutive patients (57,94). Higher rates of nonunion in middle-third clavicle fractures have been associated with high-energy fractures, wide displacement (1–2 cm), refracture, soft tissue interposition by the trapezius muscle, and operative treatment (57,65,83,94,127,139,145).

Operative treatment of middle-third clavicle fractures is indicated in some situations (Table 15.6). The most commonly encountered indication is an open fracture, which should be treated with thorough wound irrigation, debridement, and stable internal fixation (49). The exception may be an isolated clavicle fracture with a small (grade I) inside-out puncture wound, which could be treated by irrigating and debriding the wound and treating the fracture with sling immobilization. If the wound requires surgical treatment anyway, however, then rigid internal fixation of the fracture at the same time is indicated, as the wounds heal much better when the clavicle is stabilized because the fractured ends tend to displace into the wound.

| |
|---|
| Open fractures |
| Fractures that threaten the overlying skin (rare) |
| Double disruptions of the SSSC |
| Fractures that are widely displaced (≥2 cm) |
| Fractures in multiply injured patients |
| (a) Ipsilateral upper extremity injuries needing early mobilization |
| (b) Lower extremity injuries requiring crutch walking |
| Fractures in patients with neuromuscular disease who are unable to self-regulate their activities and would not tolerate a brace |
| Symptomatic "bump" at union site, hypertrophic callus |

SSSC, superior shoulder suspensory complex.

***Table 15.6. Indications for Operative Treatment of Middle-Third Clavicle Fractures***

Other indications for surgical treatment of group I fractures are less common. Associated neurovascular injuries that do not improve with attempted reduction warrant surgery to decompress and prevent further damage to the underlying structures (9). Fractures that are displaced upward to the point of tenting and threatening the integrity of the skin may need reduction and fixation if closed maneuvers fail to reduce the clavicle. As outlined above, double disruptions of the SSSC that include a clavicle fracture require reduction and stabilization of at least one of the injuries. Surgical treatment of the clavicle fracture is logical in this setting because it is usually the most accessible and simplest disruption to fix.

Widely displaced fractures may benefit from early operative intervention. It has been shown that middle-third clavicle fractures with more than 2 cm of displacement or 15 mm of shortening are at increased risk for nonunion (34,57,83). Thompson reviewed more than 100 middle-third clavicular nonunions reported in the literature and found that 90% of the original fractures had displacement greater than 100%, overriding more than 1 cm, or had severe comminution (139). Although fractures with this much displacement are uncommon, accounting for 3% of all middle-third clavicle fractures, they warrant open reduction and internal fixation.

Clavicle fractures in the multiply injured patient may need operative management. If a patient has associated ipsilateral upper extremity fractures treated surgically and would benefit from early mobilization of the affected limb, then ORIF of the clavicle fracture is indicated. Patients with bilateral upper extremity injuries including a clavicle fracture benefit from immediate clavicle fixation because it frees up one upper extremity so the patient may perform independent activities of daily living, and patients with lower extremity fractures and a clavicle fracture benefit from fixation of the latter because it facilitates the use of crutches or a walker for early mobilization. Finally, stabilization of clavicle fractures is indicated for patients with multiple ipsilateral rib fractures because it helps stabilize the hemithorax, resulting in less pain and better pulmonary hygiene (102). Other relative indications for the surgical treatment of clavicle fractures are listed in Table 15.6.

## OPERATIVE TECHNIQUES

### *Middle-Third Fractures*

Three types of fixation are available for middle-third clavicle fractures: intramedullary devices, plates, and external fixators. Intramedullary fixation can be accomplished with smooth or threaded K- wires, Steinman pins, Knowles pins, Hagie pins, or cannulated screws (26,77,101,102,150). The advantages of using intramedullary devices are several: less surgical dissection and soft tissue stripping is needed, and the hardware is less prominent. Disadvantages include possible pin migration and poor rotational control during elevation of the extremity above shoulder level. Most techniques using intramedullary devices utilize the S-shaped curve of the clavicle for hardware placement, a small anterior incision, exposure of the bone ends, and retrograde insertion of the chosen pin or device. Once the fracture is reduced, the pins are advanced back across the fracture into the anterior cortex of the medial fragment. Ngarmukos (102) has had good success with two 2-mm smooth K-wires inserted retrograde into the medial fragment and then antegrade into the lateral fragment. The ends of the wires are bent down around the clavicle proximally. If these pins back out, they are very prominent and easy to remove. Two wires are used to prevent rotation. Removal of K-wires is recommended once the fracture has healed (102). In contrast, Knowles pins and screws do not need to be removed unless hardware-related symptoms develop (101).

Plating of acute clavicle fractures, when indicated, is advocated as the preferred fixation method by many authors (91,113,118). Biomechanically, plate fixation is superior to intramedullary fixation because it better resists the bending and torsional forces that occur during elevation of the upper extremity above shoulder level. Patients treated with plate fixation can be allowed full range of motion once their soft tissues have healed. Disadvantages of plate fixation include the necessity for increased exposure and soft-tissue stripping; potential damage to the supraclavicular nerves, which cross through the surgical field; slightly higher infection rates (15); and the risk of refracture after plate removal (15). Despite these shortcomings, plate fixation utilizing careful surgical technique and appropriate use of autogenous bone

grafting is an excellent method of treatment for these injuries.

Careful soft-tissue handling and minimal periosteal stripping are prerequisites for optimum outcome. Many investigators have recommended the use of a 3.5-mm AO/ASIF dynamic compression plate (DCP) or a low-contact dynamic compression plate with at least three screws (six cortices) in both the medial and lateral fragment and an interfragmentary lag screw whenever the fracture pattern allows it. Bostman (15) found no difference between using 3.5-mm DCPs and 3.5-mm AO/ASIF reconstruction plates; both provided acceptable fixation and rigidity. One-third of tubular plates have a high rate of fatigue failure when used for clavicle fractures and should be avoided (15,113). The plates should be precontoured and placed superiorly (best) or anteriorly (second best). Autogenous bone graft should be used in comminuted fractures with bone loss.

External fixation of the clavicle is mentioned for the sake of completeness, but its indications are few. Schuind et al. (132) reported a 100% union rate and normal shoulder function without pleural injury and only two low-grade pin site infections utilizing a Hoffman-type fixator for selected indications. It may be indicated for severe open fractures with poor quality overlying skin. Ballmer and Hertel (8) recommended eternal fixation with a small AO external fixator for severely displaced fractures with extreme angulation and tenting of the skin, open fractures, and fractures associated with neurovascular injury. External fixation may also be indicated for treatment of clavicle fractures in the face of infection or infected nonunions following plate removal. Even in these cases, plate fixation should be considered first and used whenever possible.

### *Distal-Third Fractures*

The treatment of distal-third clavicle fractures is based on their classification. Type I fractures are stable because of the intact surrounding ligaments and can be treated effectively with sling immobilization and progressive use of the shoulder as pain allows (96). Most type I fractures heal within 4 to 6 weeks with little to no residual shoulder dysfunction.

Type II fractures are more difficult to treat nonoperatively because of the deforming forces. The trapezius pulls upward and posteriorly on the medial fragment, which is no longer tethered by the coracoclavicular ligaments and thus becomes widely displaced from the lateral fragment. Some authors have reported satisfactory results after nonoperative treatment of these fractures, but management is difficult (26,104,119). In contrast, Neer (95,96) and Edwards (32) both reported a nonunion rate of approximately 30% in type II fractures treated nonoperatively and a union rate of 100% when these fractures were treated operatively with either coracoclavicular screws or transacromial K-wires (32,95,96). Based on the high rates of delayed union and nonunion, difficult rehabilitation and residual shoulder pain associated with nonoperative treatment in several studies, many surgeons recommend operative treatment of type II fractures (26,32,43,56,95,96,118).

Several surgical treatment options are possible: transacromial K-wires with or without a tension band (32,96,118), coracoclavicular screw (8,32), plate fixation (56), and coracoclavicular banding or taping with or without acromioclavicular fixation utilizing dacron or other synthetic materials (56). Each of the techniques has been used successfully; the choice of one technique over another should be based on the size of the distal fragment, patient and fracture anatomy, and surgeon's preference. If there is a noncomminuted, 2- to 3-cm distal piece, then a small-fragment AO T-plate or two K-wires with a tension band placed outside the acromioclavicular joint are good choices for fixation. On the other hand, comminuted and/or small distal fragments require transacromial wire fixation, coracoclavicular screw fixation, or coracoclavicular ligament repair. Operative treatment can be problematic. Kona et al. (72) reported 19 cases of type II distal clavicle fractures treated with a variety of surgical techniques that had an overall 32% nonunion rate, 30% infection rate, and 56% unsatisfactory results. Three nonunions and all five patients with a poor result had transacromial K-wire fixation, prompting the authors to recommend avoiding any transacromial wire fixation for these fractures.

Type III fractures (those with intraarticular extension) of the distal clavicle generally can be treated nonoperatively with a sling for support (104) and gradual return to normal use of the extremity as pain allows. If the fracture is unstable, however, then treatment should be similar to that for type II fractures. In severely comminuted fractures, primary excision can be performed with repair or reconstruction of the coracoclavicular ligaments using the Weaver-Dunn procedure (143) as necessary to stabilize the clavicle. If painful posttraumatic arthrosis or osteolysis develops, the distal clavicle can be resected (93).

Type IV fractures occur in skeletally immature patients and can mimic an AC joint dislocation. Most heal well with nonoperative treatment unless severely displaced (26). If operative treatment is necessary, then open reduction and suture repair of the periosteal sleeve is recommended. Type V fractures can be treated by following the same principles used to treat type II injuries.

The outcome after distal clavicle resection for posttraumatic pain is unclear. Petersson (112) compared the results of distal clavicle excision for idiopathic arthritis in 27 patients and for posttraumatic pathology in 34 patients and found no difference. On the other hand, Eskola et al. (33) reported that a poor result was more common in patients who had had a fracture of the distal clavicle compared to patients with primary osteoarthritis and warned against performing the procedure in athletes or patients with physically strenuous occupations. The authors also found that patients did better if less than 10 mm was excised from the lateral clavicle.

### *Medial-Third Clavicle Fractures*

Most medial clavicle fractures are stable because of the surrounding ligamentous attachments (type I, Table 15.5) and can be treated nonoperatively with a sling for comfort and return to normal function as the patient's pain allows (3). Surgical treatment of medial clavicle fractures is rarely indicated and limited to cases in which there is wide displacement of the fracture fragments or impingement on vital neurovascular structures. When treated operatively, the fracture may be fixed using heavy sutures passed through drill holes in the bone or, alternatively, with a small low-profile plate. Pin fixation should be avoided because of the possibility for hardware migration into subjacent vital organs.

## AUTHORS' PREFERRED METHOD

We treat the vast majority of middle-third clavicle fractures nonoperatively. Our preference is to support the ipsilateral extremity with a sling for comfort. As the fracture begins to heal and becomes less painful, we instruct the patient to begin active-assisted ROM exercises. Once the fracture is clinically stable, discontinue the sling and begin overhead exercises and gentle strengthening. Healing takes 4 to 8 weeks in most patients. Symptoms dictate the return to desired activities. Avoid contact sports for at least 6 weeks, and then the shoulder must be carefully padded when the athlete returns to play.

### *Plate Fixation of the Clavicle*

If surgery is indicated for a middle-third clavicle fracture, we prefer plate fixation.

- Use Langer's lines for the skin incision and expose the superior surface of the clavicle.
- Avoid undermining the skin flaps and damaging the supraclavicular nerves. Limit the subperiosteal dissection to the fracture site.
- Reduce and align the fracture with a pointed tenaculum and place a lag screw across the fracture whenever possible. If regaining the length of the clavicle is difficult, a small AO external fixator can be used to hold the bone ends out to length; this is rarely necessary.
- Precontour the chosen plate and place it superiorly on the clavicle. It is important to achieve solid fixation with three screws (six cortices) on each side of the fracture.
- Place a small drain in the subcutaneous layer and perform a plastic closure with a subcuticular suture.

We prefer to treat the majority of type I and III distal clavicle fractures with a sling to support the injured extremity for 1 to 2 weeks. Patients are instructed to start pendulum exercises within the first week and to begin using the involved extremity as their pain allows.

The treatment of type II fractures depends on the size of the lateral fragment and the stability of the fracture. If a type II fracture is diagnosed using stress films, but the nonweighted x-rays show little displacement, then the fracture is treated nonoperatively with a sling for 6 to 8 weeks. Follow-up x-rays after 1 to 2 weeks are essential to rule out further displacement. If, however, a type II fracture is easily diagnosed without weighted views and is widely separated (100% the diameter of the shaft), then we recommend open reduction and internal fixation using wire fixation.

- Make an incision in Langer's lines and expose the fracture site with careful soft-tissue handling techniques.
- If the lateral fragment is large enough (2–3 cm), use a wire tension band (18 gauge) combined with two extraarticular K-wires drilled across the fracture from lateral to medial (Fig. 15.22). Bend the wires to avoid pin migration.

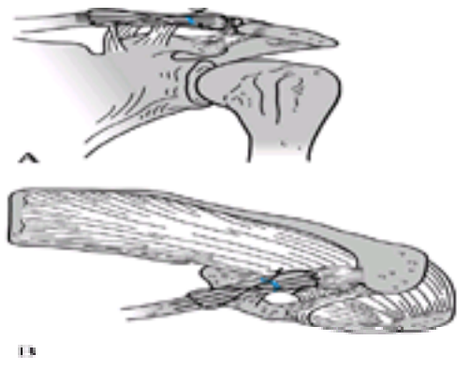

***Figure 15.22.*** Anteroposterior (**A**) and superior (**B**) views of the shoulder showing placement of two K-wires and a tension band used to stabilize a type II distal clavicle fracture.

- Anatomic fracture reduction usually reapproximates the torn coracoclavicular ligaments sufficiently for healing, but reinforce them with sutures whenever possible.
- If the lateral fragment is too small or comminuted to hold K-wires, then drill the K-wires through the acromion, across the AC joint, and into the medial clavicle fragment, spanning the small distal piece. Use an 18-gauge wire tension band dorsally for additional stability.
- If a Type III fracture is an extension of a type II fracture or is comminuted and unstable, then we prefer to treat this injury with a superiorly placed tension band of mersiline or dacron tape with an additional coracoclavicular loop. Transacromial K-wires may or may not be used depending on the amount of comminution of the clavicle. We do not advocated acute distal clavicle resection unless there is severe comminution and wide displacement of the fragments. Assess the stability of the coracoclavicular relationship ligaments so that repair or reconstruction of the coracoclavicular ligaments can be addressed at the same time.

### POSTOPERATIVE MANAGEMENT

Have patients wear a sling for the first 1 to 2 weeks for comfort but remove it twice a day to perform pendulum exercises and active-assisted ROM exercises below shoulder level. We encourage patients to use the affected extremity for routine activities of daily living below shoulder level as their pain allows. After 3 to 4 weeks, when the wound is completely healed and the patient is comfortable, institute active-assisted ROM exercises above shoulder level and full return to activities of daily living. Most patients resume all normal activities 8 to 12 weeks postoperatively. If the plate is prominent and bothersome to the patient, it can be removed after the fracture heals, but this is not routine.

### COMPLICATIONS

Most authors agree that poor technique and soft-tissue handling were significant factors in the rates of nonunion and other complications reported in the earlier literature. Therefore, whatever approach is chosen, take great care to avoid excessive soft-tissue stripping, work to achieve solid fixation, and plan on acute bone grafting for fractures that are highly comminuted or where there is bone loss. When exposing middle-third clavicle fractures, be cognizant of the small supraclavicular nerves that cross through the operative field and try to preserve them.

Other reported complications from the operative treatment of distal clavicle fractures include pin migration, coracoid fracture (89), lysis of drill holes in the clavicle when dacron tape is used (89), wound-healing problems (56), K-wire failure (32), and infection (72). To prevent pin migration, always bend the ends of the pins. Although coracoid fracture and lysis of drill holes have been reported after use of synthetic tapes to stabilize chronic AC separations, this may not be a problem when they are used to help stabilize distal clavicle fractures if bony union occurs and relieves stress on the implants (43). Minimize wound-healing problems and infection by not undermining skin flaps, by handling soft tissues carefully, and by waiting for acutely damaged skin to improve before operating. Use stout K-wires, such as two 2-mm pins as opposed to smaller pins, to decrease the chance for hardware failure. Never use threaded wires. If distal clavicle resection is done acutely, carefully assess the stability of the remaining clavicle after the resection. If it is unstable, repair or reconstruct the coracoclavicular ligaments.

## FRACTURES OF THE PROXIMAL HUMERUS

Fractures of the proximal humerus occur most often in the elderly and are twice as common in women as in men. Typically they result from falls from a standing height. Although much less common, proximal humeral fractures do occur in younger male patients also, but these usually are the result of high-energy motor vehicle or motorcycle collisions (Table 15.7) (123). Approximately 85% of proximal humeral fractures are nondisplaced by Neer's criteria and can be treated nonoperatively. The remaining 15% of proximal humeral fractures require careful decision making based on an understanding of the anatomy of the proximal humerus, the nature of the injury, the quality of the patient's bone, and the limitations of the fixation devices currently available.

| *Age group* | *Predominant sex* | *Mechanism* |
|---|---|---|
| Elderly | Female | Low-energy falls |
| <40 years | Male | High-energy motor vehicle or motorcyle accident |

***Table 15.7. Causes of Fractures of the Proximal Humerus***

### RELEVANT ANATOMY AND PATHOPHYSIOLOGY

Codman (23) was one of the first surgeons to recognize that fractures of the proximal humerus occur along the lines of the physeal scar, potentially creating four separate fragments (Fig. 15.23). Neer (97,98) later incorporated this concept into his widely known classification system for proximal humeral fractures. Muscular attachments to these fragments create the various patterns of displacement seen on the initial x-rays (Table 15.8). The vascular supply to the proximal humerus has been well studied and described by Gerber et al. (42) and Laing (78) (Fig. 15.24). Utilizing injection techniques, Gerber et al. (42) found that the anterolateral branch of the anterior humeral circumflex artery ascends within the intertubercular groove lateral to the biceps tendon and enters the humeral head where the groove meets the greater tuberosity. Once the anterolateral branch becomes intraosseous, it becomes the arcuate artery, which supplies the entire epiphysis and all but small portions of the proximal humerus. The posterior circumflex artery supplies only a small portion of the posteroinferior head and the posterior portion of the greater tuberosity. There are abundant anastamoses between arteries, but they occur proximal to the point where the anterolateral branch becomes intraosseous. If there is arterial damage close to this point, the humeral head is at risk for osteonecrosis. If the blood supply is disrupted more proximally, then the humeral head will more likely remain viable and perfused through anastamoses to the anterolateral branch.

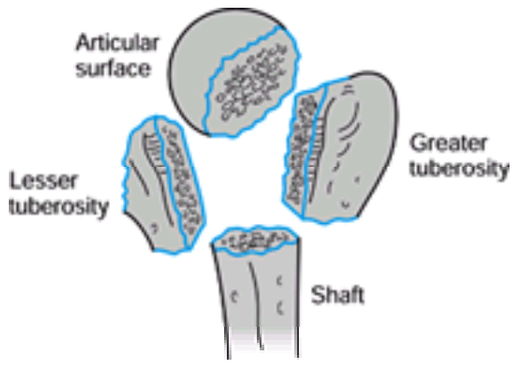


***Figure 15.23.*** Four segments of the proximal humerus as described by Codman.

| *Bone fragment* | *Muscle attachment(s)* | *Displacement of bone fragment* |
|---|---|---|
| Anatomic head | None | None, unless dislocation is present |
| Lesser tuberosity | Subscapularis | Medial |
| Greater tuberosity | Supraspinatus<br>Infraspinatus<br>Teres minor | Posterior and superior |
| Humeral shaft | Pectoralis major<br>Latissimus dorsi<br>Deltoid | The pectoralis major pulls the proximal shaft anteriorly, and both this and the latissimus dorsi pull the proximal shaft medially<br>The deltoid pulls the proximal shaft proximally and into abduction |

***Table 15.8. Displacement Patterns in Fractures of the Proximal Humerus***

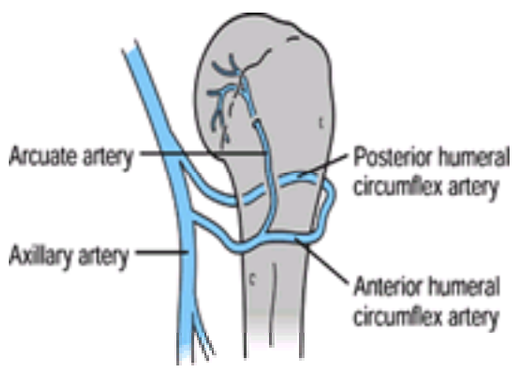


***Figure 15.24.*** Blood supply to the proximal humerus.

**PATIENT ASSESSMENT**

Patients with injuries to the shoulder girdle often have associated injuries. The mechanism of injury is important. A fracture sustained in a high-energy accident in a young person is more likely to be associated with other injuries than is a low-energy fall in an elderly person. Follow Advanced Cardiac Life Support (ACLS) principles when prioritizing the evaluation of a patient with a shoulder injury (see Chapter 14). During the physical examination, always note the appearance of the injured shoulder compared to the opposite side. An anterior fracture-dislocation will cause a fullness or bulging in the anterior aspect of the shoulder, whereas a posterior fracture-dislocation may leave a hollow impression in the anterior aspect of the shoulder. Assess the radial and ulnar artery pulses and perform a distal sensory and motor neurologic exam. Nerve injuries occur in association with proximal humeral fractures and dislocations in up to 45% of cases (28); they are more common in elderly patients and in the presence of a hematoma. Careful written documentation of the neurologic exam may seem tedious at the time of the initial evaluation but is essential for comparison later in the patient's treatment course. Sensory loss does not always correlate with motor dysfunction (28), and this should be noted. If pulses are absent, then a vascular consultation may be indicated.

**RADIOGRAPHIC EVALUATION**

Adequate radiographs are essential for the proper classification and treatment of proximal humeral fractures. A standard trauma series should include a true AP radiograph of the scapula, a lateral scapular view, obtained with the patient in a 60° anterior oblique position, and an axillary view. Computed tomography scans provide the most reliable information and are helpful in several circumstances including the evaluation of intraarticular fractures to assess the degree and nature of damage to the joint surface and the evaluation of fracture displacement, particularly the greater and/or lesser tuberosities (Fig. 15.25).

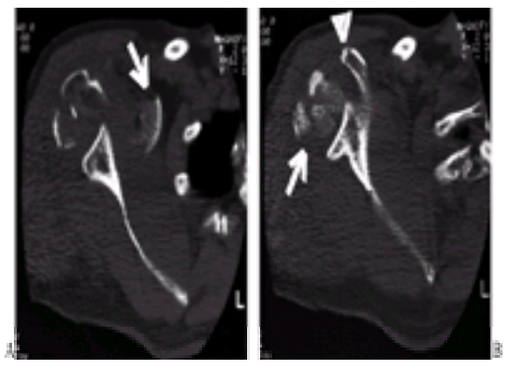

***Figure 15.25.*** Computed tomographic scans are helpful in evaluating fractures of the humeral head and the degree of articular surface involvement and in ruling out fractures of the glenoid surface. In this case, (**A**) the extensive comminution of the humeral head is evident (*arrow*) at the level of the coracoid process (*arrowhead*). Inferiorly (**B**), medial displacement of a segment of the humeral head is evident (*arrow*) at the level of the inferior glenoid, but there is no damage to the glenoid surface.

**CLASSIFICATION**

Based on Codman's description of the four parts of the proximal humerus (23)—anatomic head, greater tuberosity, lesser tuberosity, humeral shaft—Neer, in 1970, devised his classic four-part classification of proximal humerus fractures (Fig. 15.26) (97,98). To be considered displaced, one or any combination of the four bone fragments must be separated by 1 cm or more and/or angulated more than 45°. Fractures that do not fulfill these criteria are considered non- or minimally displaced and referred to as a “one part fracture.” Neer emphasized the relationship between displacement and the vascular supply to the head of the humerus. The greater the number of displaced fragments, the higher the risk of osteonecrosis. For example, a two-part fracture of the greater tuberosity is much less likely to develop

osteonecrosis than a four-part fracture.

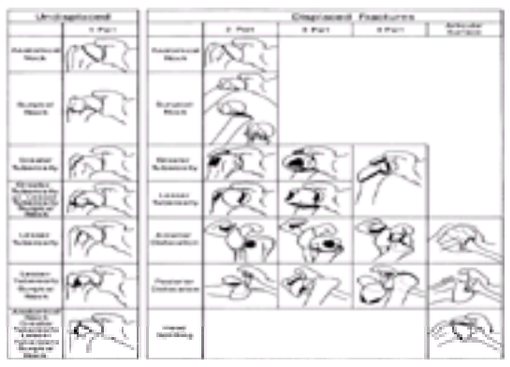

***Figure 15.26.*** Neer's four-part fracture classification.

The AO group expanded Neer's classification to include other fracture patterns that do not fit neatly into Neer's scheme (AO classification). One such addition is the so-called four-part valgus impacted fracture (64), which seems to have a lower risk of osteonecrosis (26%) than the four-part fractures Neer described (90%) (Fig. 15.27) (97). Head-splitting and impression fractures are special fractures that do not fit the four-part scheme. Head impression fractures are graded by the percent of head involvement: less than 20%; between 20% and 45%; and greater than 45% (12). The AO classification is more detailed but also more cumbersome and is used mostly as a research tool. The Neer classification has been shown to have poor intra- and interobserver correlation (11), but it is still the most widely used and commonly accepted classification scheme for proximal humeral fractures in North America.

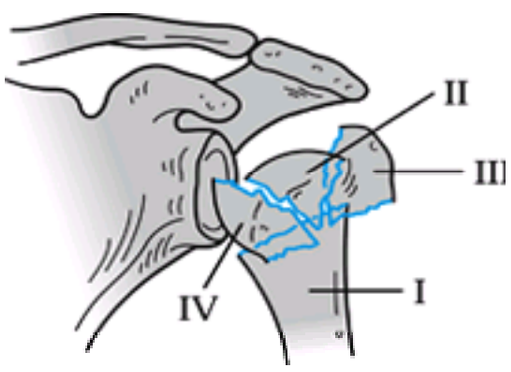


***Figure 15.27.*** Four-part valgus impaction fracture. (Redrawn from Jakob RP, Miniaci A, Anson PS, et al. Four-Part Valgus Impacted Fractures of the Proximal Humerus. *J Bone Joint Surg* 1991;73-B:295.)

## TREATMENT INDICATIONS AND METHODS

### *Nonoperative Management*

Most fractures of the proximal humerus can be managed nonoperatively. Factors important in the decision-making process include the fracture pattern and classification as well as the patient's general health, age, occupation, and avocations. Consider also whether additional benefits might be gained from surgical stabilization of the fracture so a patient with multiple injuries could begin moving the arm and shoulder sooner.

Closed reductions of simple fractures may convert them to “one-part fractures” amenable to nonoperative treatment and should always be tried first. This may occur at the level of the surgical neck of the humerus (106). Also, two-part fracture-dislocations of the shoulder where the displaced part is the greater tuberosity may be amenable to nonoperative treatment if the shoulder can be reduced and the greater tuberosity fragment reduces. These fractures require close follow-up to make sure they do not displace later as a result of the muscle forces acting on them.

Treatment principles for managing proximal humeral fractures nonoperatively are similar to those for managing other shoulder girdle injuries nonoperatively. The goal is to provide comfort and pain relief acutely for the patient and begin rehabilitation as promptly as possible. Immobilize the arm in a sling or collar and cuff initially (see Chapter 10), and begin gentle pendulum exercises within a few days. Once the proximal fragments move together as a unit with the humeral shaft as the shaft is rotated passively, active ROM exercises can be started, usually within 14 days (73).

### *Operative Management*

**Two-Part Fractures** Two part fractures may fail initial attempts at nonoperative management. If reduction maneuvers in the emergency department are unsuccessful, attempt a closed reduction in the operating room under general anesthesia. If the fracture is irreducible, then an open reduction is indicated to look for possible soft tissue interposition at the fracture site. If the fracture is reducible but unstable, percutaneous pins or an interlocking intramedullary nail can be used to stabilize and secure the reduction. If an open reduction is performed, a small clover-leaf plate, modified clover-leaf plate (35), or a blade plate (66) (Fig. 15.28) can be used to fix the fracture. In osteopenic bone, however, plates and screws should be avoided because of the risk of hardware pullout and failure. Ender's nails with a figure-of-eight tension band neutralize rotational and translational forces and provide adequate fixation to allow early ROM (Fig. 15.29). Tension band suturing or wiring alone usually do not provide fixation rigid enough to allow early ROM in patients with osteoporosis.

***Figure 15.28.*** **A:** Preoperative AP radiograph of a two-part surgical neck proximal humerus fracture. Note that although the greater tuberosity is fractured, it is not displaced and therefore not considered a displaced “part.” **B:** Scapular lateral view of fracture. **C:** Postoperative AP radiograph showing reduction and fixation with a 4.5 reconstruction plate fashioned into a “blade” plate. The patient also had a #5 nonabsorbable suture placed in a figure-of-eight tension band, which cannot be visualized. **D:** Postoperative axillary view of fracture fixation.

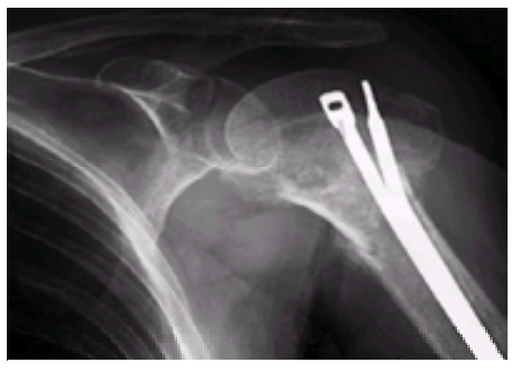

***Figure 15.29.*** Anteroposterior radiograph illustrating the use of two Ender's rods and #5 nonabsorbable suture tension band to stabilize an unstable, comminuted, two-part proximal humerus fracture in an elderly patient with osteopenic bone.

Two-part fractures at the anatomic neck are difficult to reduce closed and to stabilize with internal fixation, even when open reduction is performed. Theoretically, the blood supply to the head is totally disrupted, making osteonecrosis very likely. Therefore, hemiarthroplasty may be indicated for these fractures, especially for elderly patients (131). In young patients and those with good bone stock, every attempt should be made to preserve the humeral head and perform ORIF. Other salvage procedures or a delayed hemiarthroplasty can always be done later if osteonecrosis develops or the fixation fails.

As mentioned above, two-part fractures involving the greater tuberosity can sometimes be treated nonoperatively (Fig. 15.30), but they must be watched carefully, and management can be difficult. If the greater tuberosity fragment displaces, then open reduction and internal fixation may be indicated (Fig. 15.31). McLaughlin (88) found that shoulder function correlated well with residual greater tuberosity displacement. Fragments displaced more than 1.0 cm lead to permanent disability, but fragments displaced less than 0.5 cm rarely caused problems. Fragments displaced between 0.5 cm and 1.0 cm lead to prolonged recovery time, and 20% of cases require late reconstruction for persistent pain. In patients with good quality tissues, heavy nonabsorbable suture or wire in a figure-of-eight tension band construct placed into the tendonous insertion of the rotator cuff provides satisfactory fixation to allow early motion. If the bone quality is good, a lag screw with a washer is a good technique to provide additional fixation as long as the screw head does not impinge on the acromion (25). These fractures are commonly associated with anterior glenohumeral dislocation and longitudinal rotator cuff tears. Repair the rotator cuff as part of the surgical procedure.

***Figure 15.30.*** Two-part fracture-dislocation of the glenohumeral joint with avulsion of the greater tuberosity (*arrow*) (**A**). Reduction produced near-anatomic reapproximation of the tuberosity fragment (**B**). This injury can be managed nonoperatively but requires careful follow-up and monitoring to make sure there is no subsequent displacement.

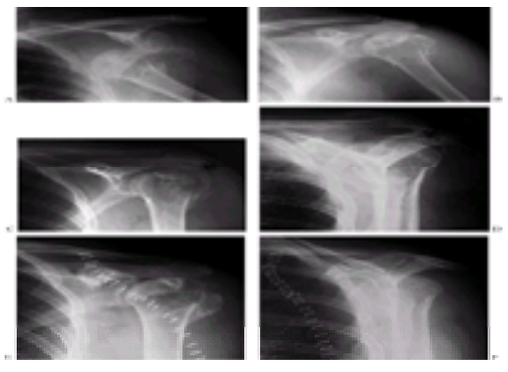

***Figure 15.31.*** **A:** Anteroposterior radiograph showing a two-part greater tuberosity fracture-dislocation before reduction. **B:** Anteroposterior radiograph showing the fracture-dislocation reduced with no apparent residual displacement of the greater tuberosity fragment. There is evidence of an old injury to the proximal humerus, however. **C:** Anteroposterior radiograph 10 days later showing displaced greater tuberosity fragment. **D:** Scapular lateral view showing the displaced greater tuberosity fragment. **E:** Postoperative AP radiograph showing reduction of the greater tuberosity (i.e., the fragment can no longer be seen above the humeral head). **F:** Postoperative scapular lateral view.

Two-part fractures involving the lesser tuberosity are less common, and when they do occur, they are frequently associated with posterior glenohumeral dislocations. Following reduction of the shoulder dislocation, the lesser tuberosity fragment may reduce to a satisfactory position. If that is the case, then immobilize the arm and shoulder in neutral or slight external rotation (12). If the lesser tuberosity remains significantly displaced (greater than 1 cm), then ORIF is indicated.

**Three-Part Fractures** Three-part fractures of the proximal humerus are difficult to treat with closed reduction and short-term immobilization because of the rotational forces exerted on the humeral head by the rotator cuff muscles, which are attached to the tuberosities (Table 15.8). However, a recent prospective, randomized study by Zyto et al. (153) comparing nonoperative versus tension-band osteosynthesis failed to demonstrate any difference in function between the two groups at 1 and 2 years, although the surgical group had more anatomic position of the tuberosities. Although this study may be reassuring for the patient and surgeon faced with a fracture where surgery is contraindicated, the general view expressed in the literature is that open reduction and internal fixation form the treatment of choice for these injuries, especially in younger, active patients with good bone quality, whereas older patients with poor bone stock should be treated with an arthroplasty.

Several surgical techniques have been advocated. One approach is to use threaded K-wires or cannulated screws percutaneously or through limited incisions (63,115). Some authors recommend open reduction and fragment fixation with wires or heavy nonabsorbable suture (24,97,131), but others advocate open reduction and internal fixation with plates and screws (Fig. 15.32) (35,136). With all the techniques, the treatment objective is to provide stable fixation for early ROM without disrupting any remaining blood supply to the bone fragments and to avoid implants that will cause subacromial impingement or other complications such as pin migration. Many studies have reported poor results and unacceptable rates of osteonecrosis (74) utilizing plate and screw fixation for three-part fractures. In elderly patients with osteopenic bone, screws and K-wires may fail because of poor fixation. Therefore, plates and screws should be reserved for younger patients with good bone quality. On the other hand, patients with severe osteopenia may not be good candidates for suturing or wiring. For those patients, a hemiarthroplasty may be the best option (24).

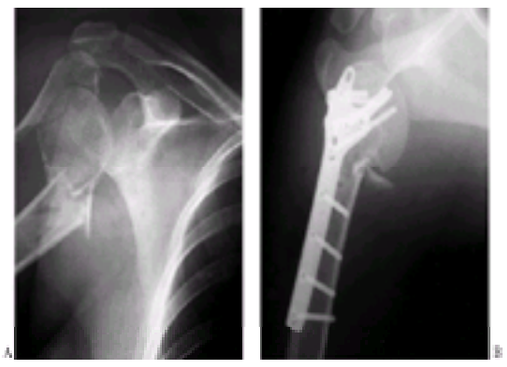

***Figure 15.32.*** **A:** Preoperative AP radiograph of a comminuted three-part proximal humerus fracture. **B:** Postoperative AP radiograph illustrating the use of a clover-leaf plate and #5 nonabsorbable suture tension band as fixation.

**Four-Part Fractures** Osteonecrosis of the humeral head is common after displaced four-part fractures of the proximal humerus (97). For this reason most authors recommend early hemiarthroplasty for the majority of patients (Fig. 15.33). Once again, younger, active patients with good bone stock are the exception; for them, open reduction and internal fixation should be attempted first, even though the risk of nonunion and osteonecrosis is high (12,24,52,97,134). Stableforth (134) reported the results of a prospective, randomized study comparing nonoperative treatment versus hemiarthroplasty for four-part displaced proximal humeral fractures and compared the results to cases of impacted four-part fractures treated nonoperatively. He found that the prosthesis group and the impacted group had similar results, which were dramatically better in terms of function and range of motion than the group with displaced fractures treated nonoperatively. All patients had some pain; in the patients with displaced fractures treated nonoperatively, however, functional disability and sleep difficulties because of pain were far more common.

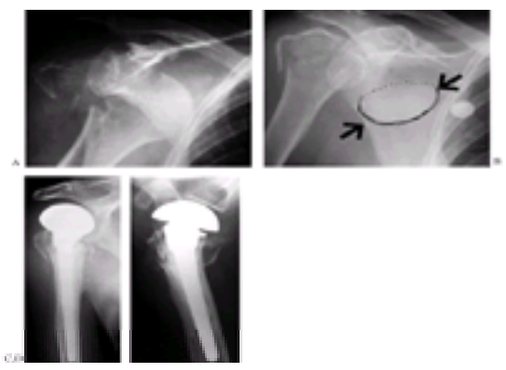

***Figure 15.33.*** Comminuted fracture-dislocation (**A**) of the proximal humerus in a 76-year-old woman with osteoporosis. Attempted reduction left a large section of the humeral head articular surface displaced medially and inferiorly (*arrows*) (**B**). This was treated with a cemented hemiarthroplasty (**C,D**).

Techniques for fixing displaced four-part fractures include using multiple K-wires, cannulated screws (63,115), clover-leaf plates (136), and heavy sutures. If hemiarthroplasty is selected as the treatment method, several technical details should be considered (Fig. 15.34).

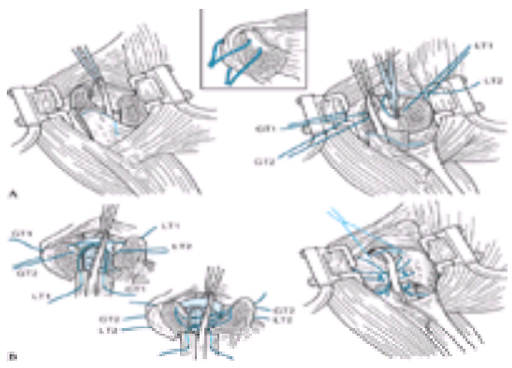

***Figure 15.34.*** Hemiarthroplasty. **A:** Deltopectoral approach for a four-part fracture. **B:** Prosthetic replacement with four-part fracture. GT1, greater tuberosity and suture #1; GT2, greater tuberosity and suture #2; LT1, lesser tuberosity and suture #1; LT2, lesser tuberosity and suture #2.

***Hemiarthroplasty***

- Use an anterior deltopectoral surgical approach (see Chapter 1). Do not detach the deltoid muscle from the clavicle.
- Identify all fracture fragments and clean them of hematoma. Excise the free floating head fragment.
- Preserve the tuberosity fragments with the attached rotator cuff muscles. The long head of the biceps is the key to the rotator interval between the lesser and greater tuberosities. Insert heavy, nonabsorbable sutures into the edges of these fragments for traction and later repair of both the greater and lesser tuberosities.
- Prepare the intramedullary canal of the humeral shaft according to the instructions provided by the manufacturer. Restoration of proper humeral length and retroversion (30° to 40°) is essential for optimum glenohumeral mechanics. Select the appropriately sized prosthesis and cement the prosthesis in place. The humeral head replacement is cemented high enough for the tuberosities to be returned to their normal position. The fin is just posterior to the biceps groove.
- Reapproximate the tuberosities to each other with the two heavy sutures seen in Figure 15.34 and to the prosthesis to restore the rotator cuff. Harvest bone graft from the excised humeral head and pack it around the secured tuberosities to promote healing. Pass cross sutures for each tuberosity through drill holes in the shaft, the holes in the fin of the prosthesis, and around the opposite tuberosities. All sutures are tied with both tuberosities reduced below the articular surface. Close any remaining gaps in the rotator cuff with heavy, nonabsorbable sutures.
- Initiate supervised passive and active-assisted ROM exercises early to prevent stiffness.

The four-part valgus impacted fracture, in which the anatomic head is impacted into the humeral shaft in valgus position, is one subtype of comminuted proximal humeral fractures that warrants special attention (Fig. 15.27). The incidence of osteonecrosis after these fractures is approximately 26% versus up to 90% in the classic Neer displaced four-part fracture, most likely because the fracture fragments remain in close proximity to each other and the blood supply to the humeral head is preserved. Jakob et al. (64) recommended elevation and repositioning of the fractured head fragment where necessary to make a smooth joint surface and improve glenohumeral mechanics. Closed reduction can be attempted and open reduction performed where necessary. Then stabilize the fracture using limited internal fixation; K-wires usually suffice. In cases where the head fragment is laterally or posteriorly displaced, the vascular supply is probably disrupted, and hemiarthroplasty becomes the treatment of choice.

***Head-Splitting and Impression Fractures***

Fractures that split the articular surface of the humeral head are treated based partially on the degree of comminution. If there are two large pieces amenable to fixation, perform open reduction and internal fixation with two or more interfragmentary lag screws. If the articular surface is comminuted, then hemiarthroplasty is the technique of choice.

Impression fractures typically result from posterior dislocations with anterior head impaction against the posterior rim of the glenoid (Fig. 15.26). Acute impression

fractures that involve less than 20% of the joint surface can be treated nonoperatively with the arm held in external rotation for 6 weeks (52). If the impression fracture is between 20% and 45% of the joint surface and less than 6 months old, transfer the lesser tuberosity into the defect and secure it with a screw. Shoulder spica immobilization with the shoulder in external rotation for 6 weeks is recommended postoperatively (130). Impression fractures involving more than 45% of the joint surface or associated with dislocations present for more than 6 months should be treated with hemiarthroplasty. In these cases, the usual retroversion of 30° to 40° is not recommended. Instead, cement the prosthesis in neutral rotation to help restore stability to the glenohumeral joint.

#### *Rehabilitation and Postoperative Principles*

Postoperatively, patients will be most comfortable if their shoulders are immobilized for 24 to 72 hours in a shoulder immobilizer or sling and swathe. Once the surgical incision is dry and any drains are removed, however, patients should begin circumduction pendulum exercises. If good fixation was achieved, patients start active-assisted ROM early (a pulley system works well). If the deltoid was released from the acromion and repaired, only passive exercises should be performed for the first 4 to 6 weeks to allow for healing of the deltoid. In general, the rehabilitation of a proximal humeral fracture should follow a program very similar to that proposed for other shoulder procedures.

### CONCLUSIONS

We treat nondisplaced (“one-part”) fractures nonoperatively, and two-part fractures as well if they can be reduced and held in good position. We recommend an attempt at closed reduction in the emergency room with conscious sedation. To reduce these fractures, apply longitudinal traction while the arm is gently flexed. Adduction of the distal shaft will help improve medial translation as the shoulder is flexed. Counterpressure within the axilla may be helpful to stabilize the humeral head during reduction. Position the proximal shaft under the humeral head and impact it. We do not recommend more than one or two attempts at closed reduction in the emergency department. Further attempts at closed reduction should be done under general anesthesia in the operating room.

We use percutaneous pinning for fractures that are easily reduced but unstable. Insert two pins from the proximal lateral and proximal anterior shaft directed into the humeral head, and add a third pin from the greater tuberosity into the proximal shaft. For fractures that can not be reduced, we perform an open reduction and fix the fracture internally. We use a blade plate for young patients with good bone quality and Ender's rods with tension band nonabsorbable sutures in patients with osteopenic bone.

We surgically treat greater tuberosity fractures that are displaced more than 5 mm. We use a deltoid-splitting approach, being careful not to split the deltoid more than 5 cm from the lateral edge of the acromion to avoid axillary nerve injury. If the fragment is large enough, we use a 4.5-mm or 6.5-mm interfragmentary lag screw with a washer to compress the fragment. We add a figure-of-eight tension band suture through the rotator cuff insertion for additional fixation. Avoid placing the screw high in the tuberosity fragment where it would impinge on the acromion.

We recommend ORIF of three-part proximal humeral fractures in patients with sufficient bone stock to hold the fixation. Patients with poor bone stock are treated with hemiarthroplasty. Similarly, young patients (second to fourth decades) with four-part fractures may be candidates for attempts at ORIF, but all others are treated with hemiarthroplasty or total shoulder arthroplasty if the glenoid has arthritic changes.

### COMPLICATIONS

Failing to make the proper diagnosis is the first pitfall to avoid. Posterior fracture-dislocations are often overlooked, especially in patients who have been victims of electroconvulsive therapy and grand mal seizures. Careful radiographic assessment of patients with suspected shoulder injuries is critical. The axillary view is frequently the most useful for diagnosing posterior fracture-dislocations and should be obtained as part of all shoulder trauma workups. A careful neurovascular examination of the involved extremity should not be deferred or neglected because axillary artery injuries and brachial plexus injuries are common in this setting, with incidences of 5% and 6.2%, respectively (134), especially in patients with high-energy mechanisms. A palpable pulse may be present because of the collateral circulation around the shoulder girdle, but look for signs of vascular injury including an expanding hematoma, paresthesias, and pallor. More commonly, the axillary nerve is in danger of injury with fractures of the proximal humerus. In addition, iatrogenic axillary nerve injury is possible if the deltoid is split too far distally (>5 cm from the lateral edge of the acromion) to expose a greater tuberosity fracture.

Malunion of the greater tuberosity in a superior or medial location may cause impingement syndrome with as little as 5 mm displacement. Osteotomy and replacement of the greater tuberosity to its anatomic position for large displacements or exostectomy and acromioplasty for small displacements may be required. Three-part proximal humerus malunions are much more complex and typically require prosthetic replacement to obtain satisfactory results. Nonunion may occur even in two-part fractures at the surgical neck and is frequently caused by overdistraction using hanging arm casts, soft-tissue interposition, inadequate immobilization, overly aggressive physical therapy, an uncooperative patient, or preexisting glenohumeral stiffness (135).

Nonunion of the tuberosity fragments following humeral head replacement is a difficult problem and can be avoided in most cases by not removing too much bone from the fragments and by securely fixing the fragments to each other, the prosthesis, and the humeral shaft. Avascular necrosis may occur in up to 90% of four-part fractures (97), although other authors have reported lower rates (136). Humeral head replacement usually provides satisfactory pain relief. Postoperative stiffness is a particularly troublesome problem for many patients. Factors important in the development of a stiff shoulder include prolonged immobilization, development of heterotopic ossification, significant malunion, and nonunion. It is far better to prevent stiffness by a well-organized physiotherapy program than to treat stiffness after it has developed. Finally, inferior subluxation of the humeral head after closed or operatively treated proximal humeral fractures may appear worrisome, but in most cases it is transient and resolves within 1 to 3 weeks as the deltoid and rotator cuff muscles regain their normal tone. If the inferior subluxation follows hemiarthroplasty and does not resolve, the prosthesis may be positioned incorrectly too far down the shaft after excessive bone was removed from the proximal humerus, and this may be an indication for revision.

## FRACTURES OF THE SHAFT OF THE HUMERUS

Fractures of the humeral shaft are relatively common injuries. There is a wide array of good options for their treatment and controversy over the best methods for many situations. Appropriate decision making for operative and nonoperative treatment depends on a thorough understanding of the regional anatomy, fracture pattern and classification, and factors unique to the injured patient.

### RELEVANT ANATOMY

The shaft of the humerus is defined as extending from the upper border of the insertion of the pectoralis major proximally to the supracondylar ridge distally (146). On cross section the shaft is cylindrical proximally, and it narrows in the AP diameter distally as it approaches the supracondylar ridges. The deltoid muscle inserts on the deltoid tuberosity, which is on the anterolateral surface of the proximal shaft and extends to a level roughly halfway down the arm. The medial and lateral intermuscular septae divide the arm into anterior and posterior compartments. The posterior surface is covered by the triceps muscle and serves as the origin for the lateral and medial heads of that muscle; those muscle origins delineate the spiral groove. The radial nerve courses through the spiral groove with the profunda brachii artery as they traverse from the posterior arm compartment proximally to the anterior compartment distally. The anterior compartment contains three muscles, the coracobrachialis, biceps brachii and brachialis, and the brachial artery and median nerve. The ulnar nerve passes from the anterior to the posterior compartment as it travels from proximal to distal and enters the cubital tunnel.

Key to understanding the deforming forces at work on a humeral shaft fracture are the muscle insertions and the effect of gravity. Displacement of the proximal fragment will depend in large part on whether the fracture occurs proximal or distal to the insertions of the deltoid and pectoralis major muscles as outlined above in the section on proximal humeral fractures (Fig. 15.35). The distal fragment is always distracted to some degree by the weight of the limb, and this phenomenon is the key to some methods of nonoperative fracture management.

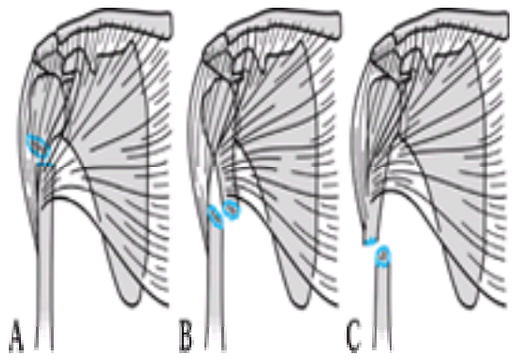


***Figure 15.35.*** The muscular attachments to the proximal humerus shaft will cause predictable deformity depending on the location of the fracture. **A:** The proximal fragment is abducted and externally rotated by the rotator cuff muscles when the fracture occurs above the level of the pectoralis insertion. **B:** The deltoid muscle displaces the distal fragment proximally and laterally when the fracture occurs between the deltoid and the pectoralis major. **C:** Fractures distal to the insertion of the deltoid muscle result in abduction of the proximal humerus.

## CLASSIFICATION

There is no classification system for humeral shaft fractures that is accepted universally. In principle, however, humeral shaft fractures can be classified by their location in the bone (relative to the muscle insertions), fracture pattern, and associated soft-tissue injuries (Table 15.9) because these factors influence treatment decisions. Transverse fractures of the midshaft usually occur from low-energy trauma, but they unite slowly and have a higher rate of nonunion. Oblique and spiral fractures have a larger fracture surface area and usually progress to union without surgery. Oblique fractures in the distal third of the shaft may be difficult to immobilize nonoperatively and are more often associated with neurologic injuries (59). Segmental fractures are difficult to reduce and maintain in satisfactory alignment, and nonoperative management may lead to nonunion at one or both fracture levels. Comminuted fractures are especially challenging because they may be difficult to align and hold by closed methods and also are difficult to fix surgically.

| |
|---|
| Location of fractures |
| Above the pectoralis major insertion |
| Below the pectoralis major insertion |
| Below the deltoid insertion |
| Midshaft |
| Distal third |
| Fracture pattern |
| Transverse |
| Oblique |
| Spiral |
| Segmental |
| Comminuted |
| Soft-tissue injury |
| Closed |
| Open |
| Grades I, II, or III |
| Neurovascular injury |

***Table 15.9. Factors Influencing Treatment of Humeral Shaft Fractures***

Soft-tissue injuries frequently dictate the treatment for humeral shaft fractures. Open fractures need urgent surgical management and have a lower rate of complications when treated with adequate debridement and stable fixation (20). Treatment of radial nerve injuries is controversial, as outlined below, but may be an indication for surgery. Fractures associated with vascular injuries require surgical stabilization to help protect the vascular repair.

## NONOPERATIVE TREATMENT

Most humeral shaft fractures can be treated nonoperatively with a greater than 90% rate of union (7,130,149). Several methods of treatment have been described and work well. Options include a hanging arm cast, coaptation splints, Velpeau sling, collar-and-cuff sling, abduction humeral splint or shoulder spica cast, and functional brace. The goals of each treatment method are to keep the patient comfortable, establish union with acceptable alignment, and restore full function (see Chapter 10).

Our preferred method is to treat the patient acutely with a U-shaped plaster coaptation splint that extends well above the fracture line laterally. Medially, the plaster should cup the elbow but not extend very high. If the splint is brought up toward the axilla on the medial side, it frequently ends at the level of the fracture and levers it into varus. A sling is also provided for patient comfort. After 7 to 10 days, when the acute swelling subsides, we switch to a functional brace. The humeral functional brace was first described by Sarmiento in 1977 (130). It works by compressing the soft tissues circumferentially to produce fracture alignment, and it has been shown to be very effective for treating closed humeral shaft fractures (7,130,148,149).

## INDICATIONS FOR SURGERY

Several indications for surgical treatment of humeral shaft fractures are summarized in Table 15.10. Some of the specific indications deserve special comment.

| |
|---|
| Acute fractures |
| Polytrauma patient |
| Bilateral fractures of the humerus |
| Floating elbow |
| Unacceptable position |
| Change in neurologic status with closed reduction |
| Vascular injury |
| Open fracture |
| Segmental fracture |
| Obesity |
| Poor compliance |
| Pathologic fracture |
| Chronic fracture problems |
| Nonunion |
| Delayed union |
| Malunion |
| Infection |

***Table 15.10. Possible Indications for Operative Treatment of Humeral Shaft Fractures***

### *Polytrauma Patient*

Nonoperative treatment of a humeral shaft fracture requires a cooperative patient who is able to use gravity to help maintain fracture alignment. This requires that the patient sleep propped up in bed to avoid angulation at the fracture site, which may occur in the supine position. This does not apply to the multiply injured patient, who is often intubated, at bed rest, and not able to use gravity in the reduction and alignment of the humeral fracture. When there are other fractures of concern, it is advantageous to have free use of the injured upper extremity to facilitate rehabilitation (10,16). This is particularly true in patients with bilateral humeral fractures.

### *Floating Elbow*

When there are ipsilateral fractures of the humerus and the proximal radius and/or ulna, it leaves the elbow unstable or “floating.” Nonoperative treatment of this lesion

leads to high rates of nonunion, malunion, and elbow stiffness (79,121). In this setting, both the humerus and forearm fractures should be internally fixed to achieve optimum results (79).

### *Failed Closed Reduction*

Guidelines for acceptable alignment for humeral shaft fractures were proposed by Klenerman (71), and they have been endorsed by several authors since then: a maximum of 3 cm of shortening, 20° anterior or posterior angulation and 30° of varus. United fractures with up to this much deformity still allow full functional use of the upper extremity. If attempts at closed reduction can not produce or maintain the fracture within these parameters, then surgery is indicated. Closed reduction may be lost in fractures that are managed nonoperatively because of muscle forces, the inability of the patient to comply with the physician's instructions, or the inability to immobilize the fracture adequately in obese patients.

## RADIAL NERVE INJURY

A radial nerve injury may occur in association with humeral shaft fractures in up to 18% of cases (110,114). Most commonly this occurs with middle-third shaft fractures (69). The Holstein-Lewis fracture, an oblique fracture in the distal third, is also well known for its association with radial nerve injury (59). Management of the radial nerve injury is controversial. Most injuries are neurapraxias or axonotmesis, and 90% will resolve in 3 to 4 months (41,69). The problem is in diagnosing the remaining 10% that will not recover and deciding when surgical exploration is indicated.

Some authors recommend surgical exploration after 3 or 4 months following a closed injury if is there is no evidence of neurologic recovery (4,114). The advantages of waiting include the fact that enough time would have passed for recovery from neurapraxia, the associated fracture will have healed, and the results of secondary nerve repair may equal those of primary repair. If the initial injury is open, the nerve is more likely—64% in one series (38)—to be partially or completely lacerated or incarcerated in the fracture site, which is one reason to explore these injuries early.

### *Authors' Preferred Management with Radial Nerve Injury*

We perform early exploration for radial nerve injuries associated with open fractures, including any penetrating injury, and any time there is a nerve palsy that develops after fracture reduction or surgical treatment. Also, at the time of surgery, particularly when humeral shaft fractures are plated, the radial nerve is carefully dissected out and identified along its entire course through the operative field so that there is no question about its integrity postoperatively. If there is a radial nerve palsy associated with a closed fracture that is present from the time of initial presentation, we treat it expectantly. If there is no recovery clinically by 6 weeks, we obtain a baseline electromyelogram (EMG); an EMG before 3 weeks is not useful. If there is no clinical improvement by 12 weeks, a second EMG is obtained; if it confirms that there is no interval recovery of nerve function, then we explore the nerve surgically with the intention of performing neurolysis, repair, or sural nerve grafting as the intraoperative findings dictate.

## DELAYED UNION AND NONUNION

Definitions of time to delayed union and nonunion of humeral shaft fractures have been debated. Foster et al. (37) defined fractures ununited by 4 months as delayed unions and ununited by 8 months as nonunions. In contrast, based on their retrospective reviews, Mast et al. (85) and Foulk and Szabo (39) determined that fractures of the humeral shaft that have not begun to unite at 6 to 10 weeks probably will not unite unless the treatment is changed. This is consistent with the literature, which states that the average time to union of these fractures is 8 to 12 weeks (7,21,71). To optimize outcome and minimize the patient's disability time, surgery should be performed as soon as a delayed union or nonunion is suspected (see Chapter 27).

## OPERATIVE TECHNIQUES

### *Plate Osteosynthesis*

- Use Henry's anterolateral exposure or a midline posterior approach for fractures within the distal third of the humeral shaft (see Chapter 1). The plate may be placed on the posterior or anterolateral aspects of the bone. Use generous incisions to avoid excessive retraction on the soft tissues with careful soft tissue dissection and bone-handling techniques.
- Identify and protect the radial nerve and others as necessary.
- Reduce the fracture as accurately as possible and use lag screws for interfragmental compression wherever possible (oblique or spiral fractures). Then apply the chosen plate, in compression mode whenever possible. At least six cortices of screw purchase are needed in the major fragments, both proximal and distal to the fracture (Fig. 15.36), and some authors recommend eight to 10 cortices on each side of the fracture (152). In transverse and short oblique fracture patterns, a compression plate works especially well. Prebending the plate over the fracture site ensures closure of the fracture on the cortex opposite the plate.

***Figure 15.36.*** **A:** Radiograph of an acute middiaphyseal humerus fracture associated with a vascular injury to the brachial artery. **B:** Postoperative AP radiograph illustrating proper fixation principles utilizing an interfragmentary lag screw and a compression plate. **C:** Postoperative lateral radiograph.

The AO group has recommended the broad 4.5-mm dynamic compression plate (DCP) for use on the humerus because the offset hole alignment may allow better fracture fixation and because of biomechanical test results on femur fractures. Testing results on the femur were extrapolated to the humerus, but the need for such a large plate has not been tested directly on humeral fractures. A 4.5-mm broad DCP may be best for large patients, but a narrow 4.5-mm DCP should be used in patients with smaller bones. Dabezies treated 44 consecutive acute fractures of the humeral shaft with plate osteosynthesis (27). Union was achieved in all at an average of 12 weeks. Nine fractures in small patients were plated with the 3.5-mm DCPs, and all healed.

Bone grafts have an important role in treating humeral shaft fractures, particularly if the fracture is plated or openly reduced. Cancellous bone grafts should be used in fresh fractures where there is bone loss, particularly for a cortical defect or comminution. In an open fracture with significant soft-tissue damage, bone grafting is useful but is withheld until there is adequate soft-tissue coverage to cover the graft. This may be at the time of delayed primary closure or skin grafting or when the fracture is plated after initial temporary stabilization with an external fixator. Cancellous bone grafting also should be used routinely in treating nonunions.

Results from plate fixation have been excellent. Foster et al. reported 100% union with a good ROM of the shoulder and elbow in 27 patients with multiple injuries treated acutely using plate osteosynthesis for the humerus (37). Similar results have been reported by others (10,142). Plating also works well for humeral nonunions and is still considered the gold standard (92,124,125), although union rates for nonunions treated with intramedullary fixation and plates are nearly equivalent (147).

### *Intramedullary Devices*

Intramedullary nails work well for most long bone diaphyseal fractures including the humerus. They can function as load-sharing devices and are subjected to smaller bending loads than plates because plates sit further from the bone's mechanical axis. There is less stress shielding of the cortex with nails than plates, and the risk of stress fracture after implant removal is less with nails than plates. Less dissection is necessary to insert them, and the fracture site need not be disturbed directly. They are more technically demanding to insert properly, however, and they should not be used when there is a radial nerve palsy that requires exploration anyway or to treat nonunions when there is a true pseudarthrosis that requires open debridement. Two types of intramedullary devices have been used: flexible nails and rigid interlocking nails.

### *Interlocking Nail Technique*

- Place the patient in a semireclining (beach-chair) position close to the edge of the table with a rolled towel between the shoulder blades.
- Prep the entire extremity from the neck to the fingertips and drape the arm free.
- Make a longitudinal incision starting at the lateral acromion and extending distally approximately 4 cm in line with the deltoid. Split the deltoid muscle in line with its fibers for 2 to 5 cm but not further to avoid injuring the axillary nerve.
- Next, incise the supraspinatus tendon laterally in line with its fibers to expose the lateral edge of the humeral head articular surface and the medial edge of the greater tuberosity.
- Make a starting hole with an awl in the sulcus between the articular surface and the greater tuberosity. This entry point is directly in line with the medullary canal of the proximal humerus and lessens the risk of creating an iatrogenic fracture of the proximal humerus, particularly if the shaft fracture is proximal or has fracture lines that extend proximally.
- Use a T-handled hand reamer to enter the intramedullary canal through the starting hole made by the awl.
- Then, with fluoroscopic assistance, reduce the fracture and pass a 3-mm bulb-tipped guide wire down the shaft, across the fracture site, and into the cancellous bone of the metaphysis of the distal humerus.
- If reaming is indicated, ream the proximal medullary canal using a flexible reamer, beginning with the end-cutting 8-mm reamer. Do not ream distally in the humerus where the medullary canal thins and flattens. In general, open fractures should not be reamed.
- Overream the canal 0.5 mm in young patients with hard bone to avoid incarcerating the nail.
- Carefully determine nail length using a second guide wire of identical length and/or a preoperative template of the opposite humerus. This is important because if the nail is too long, it may impinge in the distal humerus, causing potential distraction of the fracture site, fracture of the distal humerus, or nerve injury.
- Once the canal has been reamed to the appropriate diameter (9 to 11 mm), exchange the reaming guide wire for a smooth-tipped wire through a plastic tube in standard fashion and drive the selected nail across the fracture over the guide wire.
- Reaming may be advantageous when treating femur or tibia fractures because it allows placement of a larger nail, which is mechanically stronger; these advantages are less important in humeral shaft fractures (1), however, and reaming is detrimental to the endosteal blood supply of the humerus (115). Reserve reaming for cases in which the intramedullary canal is too narrow to accommodate a small interlocking nail. If the canal is reamed, it is important to be aware of the possibility of injuring the radial nerve during the reaming, especially in midshaft fractures. If there is any doubt about soft-tissue interposition at the fracture site, make a small incision laterally and palpate the fracture site during the reaming to be sure the radial nerve is not damaged. It is not likely that the small incision will negate the advantages of “closed” intramedullary nailing.
- Whether or not reaming is done first, once the rod is inserted the proximal end must be driven flush with the cortical surface of the proximal humerus or below it to avoid nail impingement in the subacromial space.
- Carefully check the reduction and length of the humerus clinically and radiographically. Then irrigate and close the wound in standard fashion. Apply a shoulder immobilizer for postoperative comfort.

### *Ender Nail Technique*

Flexible nails such as Ender nails and Hackenthal nails can be inserted antegrade or retrograde, but several must be inserted together to stabilize the fracture, and they do not control rotation (30,53). Rigid interlocked nails provide better stability and rotational control (54). They may be inserted retrograde or antegrade, but if inserted antegrade through the rotator cuff they frequently cause subacromial impingement symptoms and must be removed after the fracture heals.

- Place the patient in the supine or prone position on a fully radiolucent operating table, according to the surgeon's preference.
- The Ender nails can be inserted using either closed or open technique, but radiographic control intraoperatively with a C-arm fluoroscope is essential.
- Prepare and drape the entire upper extremity free, including the shoulder.
- The Ender nails are inserted through the midportion of the posterior cortex of the distal humerus, approximately 2 cm proximal to the olecranon fossa. For this reason, make a longitudinal midline vertical incision on the posterior aspect of the arm, approximately 3 to 5 cm in length, just proximal to the tip of the olecranon.
- Incise directly down through the subcutaneous fat and deep fascia in the midline and split the muscle fibers of the triceps in the midline, down to the distal humerus, which is exposed by subperiosteal dissection.
- Identify the superior edge of the olecranon fossa and then use a 2- to 3.5-mm drill point to outline an oval-shaped entry site on the posterior surface of the humerus with the distal end approximately 15 to 20 mm proximal to the upper edge of the olecranon fossa. The flat ends of the Ender nails will be left lying on the external surface of the humerus and must be placed sufficiently proximally that impingement from the olecranon is avoided. The oval hole outlined with the drill points should be 10 to 15 mm in width and 20 to 25 mm in length along the longitudinal axis of the humerus, depending on the size of the bone and the size of Ender nails to be used. Usually, two Ender nails are placed. This hole must be large enough to accommodate these two pins side by side and be long enough to avoid accidental fracture of the proximal cortex from the pressure of the pin.
- Use a small thin osteotome to connect the drill holes and remove the window. Use a small-angled rongeur to smooth out the edges of the hole and make it large enough to accommodate two Ender nails of appropriate size.
- Ender nails are available in 3-, 4-, and 5-mm diameters. In the average humerus, 3-mm pins will be used. In some very large individuals, a 3- and a 4-mm pin, or on occasion two 4-mm pins, may be used.
- Determine length by pulling on the arm to bring the fracture out to length, laying an Ender nail on the arm as close to the bone as possible, and then visualizing it with the fluoroscope.
- Next insert the first Ender nail with the insertion tool. This T-wrench not only allows one to drive the Ender nail but to control it in rotation which is essential for reducing the fracture and for spreading the pins within the humeral head. Sometimes it may be necessary to bend the tip of the pin gently in order to obtain the position desired.
- Drive the pin under fluoroscopic control to the fracture. Reduce the fracture with longitudinal traction and then, under fluoroscopic control, insert the tip of the pin into the medullary canal of the proximal fragment. Twist the pin to reduce the fracture and drive it proximalward to within 1 cm of the subchondral bone of the humeral head. In dealing with a fracture of the cervical neck, the same technique can be used.
- With one pin in place, it is then fairly simple to drive a second pin beside the first, placing the tip of the pin into the opposite portion of the humeral head. This divergence of the pins provides better fixation and superior control over rotation.
- Impact the fracture to improve stability when the configuration allows.
- Close the wound in a routine fashion, dress sterilely, and support the arm in a shoulder immobilizer.
- Postoperatively, Ender nails do not provide absolute stability; therefore, some motion at the fracture site can occur during the early phases of healing. Gentle pendulum exercises can almost always be initiated as soon as the patient is reasonably comfortable. Active use of the hand, wrist, and elbow are essential. As soon as the first callus is visualized at the fracture site, which is normally between 4 and 8 weeks, there is usually sufficient stability that the patient can begin active motion and overhead rehabilitation exercises.

### *External Fixation*

There are few indications for treating humeral shaft fractures definitively with external fixation. This technique should be reserved for open fractures with significant soft-tissue injuries (17,58,150) and for the rare patient with multiple injuries where stabilization is important and speed essential. It stabilizes the fracture without adding further soft-tissue injury from the surgical trauma. Typically a single frame is placed along the lateral aspect of the arm with two pins above and two below the fracture site. If the Shanz pins are placed laterally, then a limited open approach is recommended to avoid injury to the radial nerve. The frame is usually used as a temporary fixation device until the soft tissues heal and the fracture can be treated with another device or replaced by a functional brace.

### *Postoperative Management*

We recommend use of a shoulder immobilizer and local ice to the arm for initial postoperative comfort. These are used for 2 to 3 days until the incisional and muscle pain decrease and the swelling diminishes. Keep an axillary pad in place to prevent skin maceration. Institute gentle ROM exercises within a few days, depending on the stability of the fixation. It is important to stress the importance of vigorous finger, wrist, and elbow motions to prevent stiffness. Add shoulder pendulum exercises as the patient's pain and fracture stability allow and advance to active-assisted shoulder ROM exercises within a few weeks. A sling is suggested until full muscle function returns without pain. Strengthening exercises are avoided for 12 weeks or until the fracture heals.

## HINTS AND TRICKS

- The most troublesome complication is fracture of the humerus through the entry hole, which results in a supracondylar fracture. Avoid this by being certain that the entry hole is smooth, without stress risers, and is large enough to avoid pressure on the adjacent bone by the Ender nails. If there is any question, always use the smaller, more flexible pins to avoid iatrogenic fracture of the cortex.
- Do not use this technique for fractures in the distal half of the humerus. Look for microcracks in the distal fragment, as these can lead to comminution of the distal fragment if this technique is used.
- Assure appropriate placement of the pins in the proximal fragment by careful visualization with the fluoroscope at multiple angles through as wide an arc of motion as can be obtained with the fluoroscope and no less than 90°.
- Avoid retrograde migration of the Ender nails by assuring that the fit in the canal is snug. If the pins are somewhat loose, the risk of migration can be minimized by wiring the tips of the pins together or by securing the pins to the distal fragment with either a screw or malleable wire through the eye of the Ender nail secured in the bone of the humerus.
- Avoid elbow pain from impingement by assuring that the distal ends of the pins lie flat against the cortex and do not impinge on the olecranon fossa.

## CONCLUSIONS

Intramedullary nailing of humeral shaft fractures has not had the same rate of success as intramedullary nailing of femur and tibia fractures. In addition, problems from subacromial impingement have been reported in almost every series utilizing antegrade humeral nailing. Therefore, for humeral shaft fractures treated operatively, particularly because of failed nonoperative treatment, open fractures, or fractures with neurovascular complications, we prefer open reduction and internal fixation with plates and screws using an anterolateral approach. Bone grafting is used following the principles outlined above. We are careful to identify the radial nerve and retract it gently out of the way to avoid injury to it, verifying that it is intact at the conclusion of the case. We treat nonunions with plate fixation (Fig. 15.37) also, but we prefer to make a posterior approach to the humeral shaft and dissect out the radial nerve to be sure it is not injured or incarcerated in the nonunion site (see Chapter 27 for more detail on nonunions).

***Figure 15.37.*** **A:** Anteroposterior radiograph of a middiaphyseal humeral nonunion. **B:** Postoperative AP radiograph illustrating proper surgical technique utilizing a compression plate and autogenous bone grafting.

We reserve intramedullary nails for the multiply injured patient who needs a load-sharing device to facilitate rehabilitation, but only if those fractures can be reduced easily so that there is no question about possible soft-tissue interposition at the fracture site. Our list of indications for intramedullary nails also includes pathologic fractures, fractures associated with osteopenic bone, and fractures underlying burns.

## COMPLICATIONS

### *Plate Fixation*

Infection following open reduction and internal fixation is a major concern. Fortunately, the humerus is surrounded by a well-vascularized muscular envelope, and when careful soft-tissue techniques are used, infection rates of less than 1% should be anticipated (14). Grade III open fractures have higher rates of infection after plate fixation, which has led some authors to recommend external fixation for these injuries. However, deep infections in pin sites from external fixators can be equally problematic.

Radial nerve palsies can complicate ORIF. The strategy for management is discussed above.

Hardware failure and nonunion may result from inadequate initial fixation of acute fractures (Fig. 15.38) but are seen even more commonly after plate fixation of the delayed unions and nonunions where screw fixation to the bone may be suboptimal because of disuse osteopenia. These problems may be minimized by operating sooner when nonunion is suspected, using a longer plate with at least six and preferably eight cortices above and below the fracture, adding cancellous bone graft, and using a cast brace postoperatively to augment the fracture fixation and decrease stress on the implants.

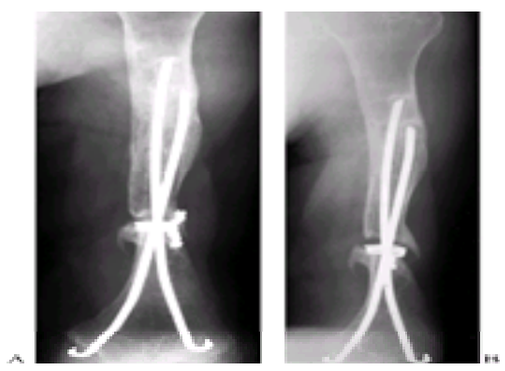

***Figure 15.38.*** Nonunion in a patient referred for treatment of a humeral shaft fracture treated with Rush rods and cerclage wiring. This was rotationally unstable, as seen by these attempted AP (**A**) and lateral (**B**) views, which demonstrate rotation at the nonunion site. Combining open reduction and wiring with intramedullary devices risks devascularizing the fracture site, a risk factor for nonunion, and is not recommended.

### *Intramedullary Nails*

One of the most common complications seen after antegrade intramedullary nailing of humeral shaft fractures is subacromial bursitis and impingement, causing shoulder pain and decreased ROM. Be sure to use the proper length nail to ensure that the proximal end is flush with the greater tuberosity or buried beneath its cortex. Also, distraction at the fracture site is a pitfall to avoid at all costs, as it can cause a nonunion. If retrograde nailing is done through the condyles, there is a risk of condylar fracture. If this does occur, the condyles should be reattached with lag screws at the time of nailing.

### *External Fixation*

The most troublesome complication we see after external fixation of humeral fractures is elbow stiffness. We prefer not to use external fixation for humeral fractures, but when it is necessary, we do everything possible to start elbow motion early. Avoid using fixators that span the elbow and prevent motion.

Using an external fixator as the definitive fracture management technique after open fractures may increase the potential for delayed or nonunion. This problem may be reduced by bone grafting (14). An alternative is to use the external fixator temporarily until soft-tissue coverage has been obtained and then convert to another method

of fixation such as plates. Unfortunately, pin tract infections that develop in the interim may preclude internal fixation. In some cases, the temporary fixator may be removed after the soft tissues heal and the fracture is treated to union with a functional brace. (See Chapter 11 for the principles of external fixation.)

## TRAUMATIC DISLOCATIONS OF THE SHOULDER GIRDLE

Dislocations of the shoulder girdle joints are common injuries. When they occur in association with fractures, fracture management often dictates the treatment strategy and follows the principles outlined in the previous sections of this chapter. The evaluation and management of glenohumeral, acromioclavicular, and sternoclavicular joint injuries and instability are covered separately in detail in other chapters of this textbook (see Chapter 78 and Chapter 80). However, the principles of diagnosing and treating acute dislocations of the shoulder joints are important to keep in mind when considering fractures of the shoulder girdle and therefore they are reviewed here, also.

### GLENOHUMERAL DISLOCATIONS

The glenohumeral joint is dislocated more often than any other major joint (68), usually as a result of a sports injury or a fall, but many other etiologies have been reported. Effective treatment depends on making the correct diagnosis promptly as well as recognizing and treating associated injuries. Injury classification also helps direct treatment appropriately.

#### *Classification*

Glenohumeral dislocations can be classified by direction, chronicity, and mechanism. The direction describes the position of the humeral head relative to the glenoid and is most often anterior, but may be posterior, inferior ("luxatio erecta"), or, rarely, intrathoracic. The dislocation may be acute or chronic. Unreduced dislocations presenting or diagnosed after 3 weeks are considered chronic (see Chapter 80).

Injury mechanism can be classified as traumatic or atraumatic. Traumatic instabilities are further characterized as a subluxation or true dislocation of the joint. Atraumatic instabilities can be voluntary or involuntary and may be related to congenital general ligamentous laxity. Some patients with voluntary instability are able to dislocate and relocate their glenohumeral joints almost painlessly. Those patients are poor surgical candidates.

#### *Radiographic Evaluation*

Evaluate patients with suspected shoulder dislocations radiographically in the same way as patients with shoulder girdle fractures (see above). Critical to evaluating the joint are two views, one of which is a lateral view that shows the glenoid fossa well, to rule out a posterior dislocation. The axillary or transaxillary (Y) views are best for that purpose.

Internal rotation views of the shoulder are useful for demonstrating the Hill-Sachs lesion, which is a defect in the posterolateral aspect of the humeral head caused by impaction of the humeral head against the anterior glenoid rim at the time of an anterior dislocation. Impaction lesions of the glenoid rim, the counterpart of the Hill-Sachs defect, are difficult to demonstrate with plain radiographs and are seen better with CT scans. Magnetic resonance imaging studies may be helpful for evaluating rotator cuff pathology but are not indicated for acute trauma. As in all cases, postreduction radiographs should always be obtained after the joint is reduced.

#### *Anterior Dislocations*

The most common direction of glenohumeral joint dislocation is anterior (84%) (19). Usually the mechanism of injury is forced external rotation of the shoulder while the arm is abducted, levering the humeral head against the anterior capsule. As the restraining effect of the anterior glenoid labrum and capsule are exceeded, the head of the humerus dislocates anteriorly and usually comes to rest below the coracoid process. In approximately 85% of patients, the glenoid labrum is detached from the anterior glenoid rim (a Bankart lesion). The remaining cases occur with interstitial stretching or frank rupture of the capsule without significant detachment of the labrum (Fig. 15.39). This has been proposed as a possible explanation for the decreased incidence of recurrent dislocation in older patients (>40 years). Anterior shoulder dislocation is usually an injury of adolescents and young adults, with most patients being between the ages of 12 and 50 years.

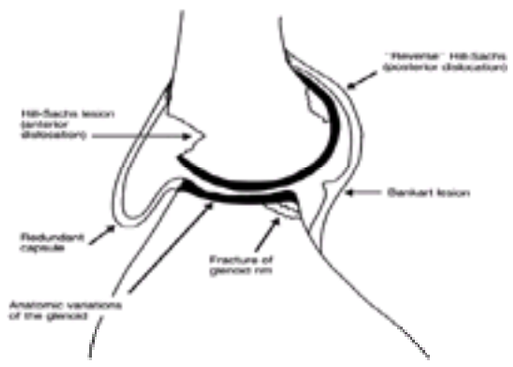


***Figure 15.39.*** Some of the anatomic lesions around the glenohumeral joint that may result in or from instability.

On physical exam, the humeral head is palpable anteriorly in the subcoracoid position, and there is loss of the normal lateral and posterior contours because of the vacant glenoid. Neurovascular examination is usually normal, but there may be an axillary nerve palsy. This can be difficult to detect before reduction because pain prevents the patient from contracting the deltoid or abducting the shoulder. Decreased sensation to light touch laterally over the deltoid may be the only detectable sign of an axillary nerve injury but is frequently subtle and unreliable. Less commonly, other neurovascular injuries occur (13).

**Treatment** After the diagnosis has been made, prompt reduction of the dislocation is the treatment of choice. The key to reduction of any joint dislocation is muscle relaxation, as evidenced by the ease with which most joints can be reduced under general anesthesia with complete muscle paralysis. General anesthesia is rarely necessary to reduce acute shoulder dislocations, however, unless there is interposed soft tissue or an associated fracture with an incarcerated bony fragment.

Many reduction maneuvers have been described, dating back to antiquity. Most rely on the principles of traction, leverage, or rotational forces, and there is considerable overlap between methods. One of the safest and most effective means of reducing an anterior shoulder dislocation relies on traction and countertraction and is best accomplished with an assistant (Fig. 15.40), although it can be done with one person using her foot against the patient's chest wall for countertraction.

***Figure 15.40.*** Traction–countertraction maneuver for reducing an anterior glenohumeral dislocation. (Reprinted with permission from Rockwood CA Jr, Thomas SC, Matsen FA III. Subluxations and Dislocations about the Glenohumeral Joint. In: Rockwood CA Jr, Green DP, Bucholz RW, eds. *Fractures in Adults, 3rd ed.* Philadelphia: JB Lippincott, 1991:1091.)

Alternatively, a modification of Kocher's method works well. It is relatively easy on the patient, can be performed by one individual without force, and is usually successful. The key to this method is avoidance of traction, which induces secondary muscle spasm, increasing the patient's pain and making reduction more difficult. Elevate the patient's elbow above the midcoronal plane and then gently externally rotate it using a hand placed on the patient's wrist. If done slowly, it takes little effort to externally rotate the patient's shoulder. Slowly abduct the extremity during this process to about 90°. It is important to continue external rotation beyond the midcoronal plane. Reduction is usually accomplished by these maneuvers, but if it is not, then the arm is adducted fully across the chest and internally rotated as in the last two maneuvers of Kocher's method.

**Postreduction Management** Regardless of the method selected, once the joint is reduced the patient's pain is decreased dramatically and promptly. For that reason, it is important not to administer an excessive dose of sedation and narcotics to achieve the reduction, particularly in older patients; this is because once the joint is reduced and the pain stimulus has diminished, the residual effects of the medications may cause dangerous respiratory depression. After the reduction, obtain confirmatory radiographs. Immobilize the shoulder in a sling or shoulder immobilizer. The duration of immobilization is controversial, but most authors recommend 4 to 6 weeks total, during which time a rehabilitation program is initiated. The goal is to avoid recurrent dislocations without excessive stiffness. Patients older than 40 should be immobilized for less time (2 weeks) because they are more likely to have problems from stiffness and rotator cuff injuries than from recurrent instability (70).

### *Posterior Dislocations*

Posterior glenohumeral dislocations are uncommon and account for 2% to 4% of all shoulder dislocations (87,126). They warrant particular attention, however, because they are so frequently overlooked; in 60% to 80% of cases (128), the initial diagnosis is missed, and that often leads to major shoulder dysfunction. The mechanism of injury is a posteriorly directed force acting on an adducted and internally rotated humerus. It can also result from violent muscle contractions and therefore may be seen after grand mal seizures, electroshock treatment, or electrocution injuries and should be ruled out in patients complaining of shoulder pain after such events.

On physical examination, the shoulder is usually held internally rotated, and the patient is unable to abduct or externally rotate the joint. It may be possible to feel the fullness of the humeral head posteriorly unless the patient is examined late, when chronic swelling masks this finding. If the diagnosis is made months after the initial injury, there may be atrophy of the shoulder musculature despite the return of limited abduction and external rotation.

**Treatment** If a posterior dislocation is diagnosed acutely, it may be reduced by rotating the arm to the neutral position and gently levering the humeral head anteriorly into the glenoid. Reduction of posterior dislocations may be difficult because they are often diagnosed late. Chronic dislocations are much more difficult to treat. They may be irreducible by closed methods and can present with muscle contracture, periarticular fibrosis, associated fractures, or heterotopic bone formation. Commonly, open reduction is necessary together with joint debridement and attempts at soft-tissue repair or muscle advancement into the defect in the humeral head.

**Postreduction Management** Acute posterior dislocations that have been reduced and are stable may be treated with a sling. If postreduction examination reveals significant instability, however, then the shoulder should be immobilized in neutral or slight external rotation. A variety of orthoses are available to hold the extremity in that position. Rehabilitation of the injured structures is based on principles outlined above for other shoulder injuries, with an emphasis on strengthening the rotator cuff muscles.

**Surgical Indications** It is not common to see shoulder dislocations that are irreducible in the absence of fractures, but it does happen, usually because of soft-tissue interposition in the joint or because of severe muscle spasm in large, muscular patients. In those cases, general anesthesia may be necessary to obtain reduction. Occasionally an open reduction is necessary when closed reduction fails in spite of general anesthesia. An anterior deltopectoral approach is recommended for most dislocations, although associated injuries or wounds may warrant an alternate approach.

Postoperative treatment depends on the pathology found at the time of surgery and the stability achieved after the reduction and repair of any injured soft tissues. Generally, the shoulder should be immobilized in a shoulder immobilizer or sling and swathe immediately postoperatively. Pendulum exercises can be started in 1 or 2 days, and a graduated rehabilitation program instituted within the first 2 weeks. Less stable injuries require longer periods of immobilization.

**Complications** The most frequent complication after a glenohumeral dislocation is recurrent dislocation. The rate of recurrence correlates with patient age: 70% to 90% for patients younger than 20 years, 60% for patients between 20 and 40 years of age, and only 10% for patients older than 40 (60). The key to minimizing recurrence is patient education about what joint positions are likely to be unstable based on the original direction of dislocation and careful adherence to a well-designed rehabilitation program that strengthens the weakened shoulder muscles. Those joints that are unstable despite these precautions warrant surgical treatment for chronic instability (see Chapter 80).

Other complications are less common. Neurologic injuries following glenohumeral dislocations are usually transient. Brachial plexus injuries are uncommon, but their presence suggests a more violent shoulder injury. Most often they are neurapraxias and recover, but more significant injuries also occur, such as in scapulothoracic dissociation (see above). Isolated axillary nerve palsies usually resolve within 3 months. In the interim, the shoulder should be supported to prevent persistent inferior subluxation and stretching of the soft tissues. Rotator cuff injuries are more likely in older patients in association with glenohumeral dislocations and should be suspected in patients over 40 with persistent weakness of shoulder abduction (144).

## ACROMIOCLAVICULAR DISLOCATIONS

Acromioclavicular (AC) joint dislocations and subluxations (“shoulder separations”) account for approximately 15% of all shoulder girdle dislocations (18,140). The true incidence is probably much higher because patients with low-grade injuries may not seek medical attention. The mechanism of injury is typically a direct blow or fall on the shoulder, in which the acromion is driven downward, tearing the AC joint capsule and restraining ligaments. The most common mechanisms are sports related, but they also occur in motor vehicle accidents. The same mechanism of injury that causes acromioclavicular joint disruptions can also cause sternoclavicular dislocations and fractures of the clavicle or acromion.

### *Classification*

Classification of injuries involving the acromioclavicular joint is shown in Fig. 15.41 (120). The classification hinges on a combination of physical examination and radiographic findings, and as with most classifications in orthopaedics, higher numbers indicate more severe and complex injuries. Types I, II, and III are most common. Types IV through VI are uncommon and usually are caused by higher-velocity injuries; they are characterized by the unusual displacement of the clavicle. It is important to thoroughly evaluate the shoulder girdle clinically and to study the radiographs carefully to avoid overlooking other injuries that may occur in combination with AC joint injuries.

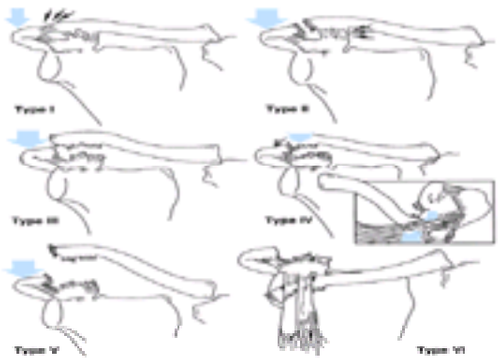

***Figure 15.41.*** Classification of acromioclavicular (AC) joint injuries. Type I, sprain of the AC ligaments; type II, AC joint disruption with sprained coracoclavicular (CC) ligaments; type III, complete disruption of the AC joint and CC ligaments; type IV, complete disruption of the AC joint and CC ligaments and posterior displacement of the distal clavicle into the trapezius muscle; type V, wide displacement of the distal end of the clavicle (one to three times normal distance) associated with detachment of the deltoid and trapezius muscles from the distal clavicle; type VI, inferior displacement of the distal clavicle below the coracoid process associated with detachment of the deltoid and trapezius muscles from the distal clavicle.

### *Treatment*

Treatment varies according to injury classification. Injury types I and II may be considered AC ligament sprains or disruptions, but both may be treated symptomatically with an arm sling for patient comfort. Symptoms usually subside within 1 to 2 weeks, but the patient should be cautioned against heavy use of the shoulder until shoulder motion is painless and equal to the preinjury status. Treatment for type III injuries is controversial. Many authors recommend nonoperative management with a sling for comfort, pointing to the higher complication rate from operative treatment (40,137). A Kenny-Howard sling can be used to maintain joint reduction but requires a motivated, compliant patient and diligent attention to detail to be effective and avoid skin complications (137). Others advocate early surgical treatment, and a wide variety of surgical methods have been described for treating this lesion. The occupational demands and goals of the patient are critical to decision making. Type III injuries can be treated late if symptoms persist after initial nonoperative treatment (see Chapter 78), and that is our preferred approach.

The more severe injuries (types IV, V, and VI) are usually treated surgically because of the extreme displacement of the clavicle and detachment of the deltoid and trapezius muscles. Many different operations have been devised, including transarticular pins, ligamentous repair, synthetic slings (mersilene), and screws securing the clavicle to the coracoid to reduce the AC joint.

#### Bosworth Screw Fixation of AC Joint Dislocations

- Position the patient in the beach-chair position on the operating room table and pay particular attention to supporting and securing the patient's head and neck appropriately.
- Drape the shoulder so that free access is possible from the middle of the patient's neck to the elbow and from the medial border of the scapula posteriorly to the midline of the chest anteriorly.
- Make a 6- to 10-cm-long strap-like incision in Langer's lines beginning 2 cm posterior to the clavicle and carried anteriorly to a point just medial to the coracoid process, centered over the AC joint.
- Undermine the skin flaps to expose the AC joint, the distal 5 cm of the clavicle, and the anterior deltoid muscle fibers.
- Detach the anterior deltoid from its origin on the clavicle enough to visualize the base of the coracoid process and the coracoclavicular ligaments as well as the remnants of the AC joint capsule and ligaments. In some cases, the deltoid and trapezius muscle fascia may have been stripped away as part of the initial injury.
- Grasp the distal end of the clavicle with a towel clip or tenaculum, retract it, and debride the joint.
- Tag the torn ends of the coracoclavicular (CC) ligaments and any remnants of the AC joint capsule or ligaments with nonabsorbable sutures but do not tie them yet.
- Reduce the clavicle to the acromion and drill a $^{3}/_{16}$-in. hole through the clavicle, aiming for the base of the coracoid process. Use a smaller drill bit ($^{9}/_{64}$ in.) to make a hole through the base—not the waist—of the coracoid.
- Measure the distance from the top of the clavicle to the bottom of the coracoid process with a depth gauge and then insert the proper size Bosworth screw. Be sure the screw enters the hole in the coracoid process and does not skive off medially or laterally.
- Obtain intraoperative radiographs to verify proper screw placement before beginning the final steps of the procedure. See Figure 15.42.

***Figure 15.42.*** Postoperative anteroposterior x-ray of the shoulder with Bosworth screw in place. Note that the acromioclavicular joint has been reduced and the coarse lag threads of the screw are well seated into the coracoid process.

- Tie the previously placed sutures in the CC ligaments and remnants of the AC joint capsule and ligaments. Then turn the screw one half-turn tighter to draw the clavicle slightly closer to the coracoid and relieve any tension on the sutures. Remember that the primary purpose of the screw is to temporarily hold the clavicle reduced vertically and horizontally to the scapula and to take tension off the coracoclavicular ligaments until they have healed.
- Repair the deltoid to the clavicle and anterior acromion with nonabsorbable sutures passed through small drill holes in bone.

#### Alternative Fixation Methods for Treating AC Joint Dislocations

- In some cases it may be possible or desirable to repair the AC joint disruption using local soft-tissue remnants and reinforcing the repair with pins across the joint or other material looped around the clavicle and coracoid.
- Position and prep the patient and expose the AC joint as described above.
- For pin fixation of the AC joint, most authors recommend the use of small, smooth or threaded Steinman pins. The technique of exposure and hardware placement follows the principles outlined for treating distal clavicle fractures (see above).
- If heavy sutures, tape (mersilene), or other synthetic material is used to reinforce the repaired CC ligaments, expose the base of the coracoid as described for the Bosworth screw.
- Pass a curved vascular clamp under the coracoid process, carefully hugging the bone with the clamp as it is passed. It is usually easier to pass the clamp from medial to lateral.
- Grasp the selected material with the clamp and pass it under the coracoid and then over the top of the clavicle. Tie it securely to reapproximate the clavicle to the coracoid, keeping the AC joint reduced, and then tie the sutures previously placed in the CC ligaments.
- Anchor the reinforcing loop to the clavicle with additional nonabsorbable sutures.

**Postoperative Management** Postoperatively, patients should support their arms in a sling for the first 2 weeks, but be allowed to perform activities of daily living as their comfort allows. The sling can be discontinued after 2 weeks, but heavy lifting should be avoided for 6 weeks. If a Bosworth screw or pins are used, remove them 8 weeks after surgery; normally that is done in the office with local anesthetic. Regardless of the fixation or repair technique selected, patients should avoid contact sports for 12 weeks.

### *Complications*

In the long run, most patients with AC joint injuries recover excellent shoulder function. Heavy laborers and patients who use their shoulders frequently for overhead lifting may develop chronic symptoms, but they are rarely severe or disabling. For patients with significant symptoms or complaints related to chronic AC dislocation, several successful surgical options are available (see Chapter 78). The simplest treatment is excision of the distal 1 to 1.5 cm of the clavicle. Other options rely on reconstructing the CC ligaments, usually in combination with distal clavicle excision as in the Weaver-Dunn procedure (143). Acromioclavicular arthritis may develop after AC joint injuries, for which resection of the distal end of the clavicle (Mumford procedure) is an effective treatment.

## STERNOCLAVICULAR DISLOCATIONS

Injuries to the sternoclavicular joint represent only 3% of shoulder girdle dislocations (19). Because they are unusual and sometimes subtle, their diagnosis is often delayed, especially in the multiply injured patient. Anterior dislocations are significantly more common than posterior dislocations, but because of their potential for associated mediastinal compression, posterior injuries are more frequently reported. The reported ratio of anterior to posterior injuries varies from approximately 3 to 1 to 20 to 1 (99).

The sternoclavicular joint is a moderately mobile ball-and-socket joint having approximately 30° of anterior and posterior slide and upward elevation. It is also capable of 25° to 50° of rotation around the long axis of the clavicle. The ligamentous structures binding the medial clavicle to the sternum are very strong (Fig. 15.43), and therefore traumatic dislocations are usually indicative of significant force and often accompany rib and sternal fractures and other chest injuries. Most dislocations result from direct trauma, but indirect forces transferred from lateral compression on the shoulder also may injure the sternoclavicular joint.

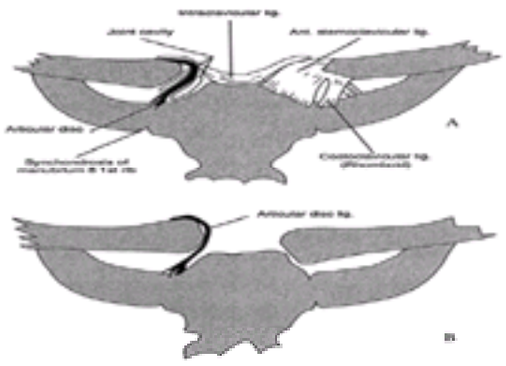

***Figure 15.43.*** The sternoclavicular (SC) joint area. **A:** Normal anatomy. **B:** Dislocated SC joint. The articular disc ligament serves as a check-rein, preventing medial displacement of the clavicle. (Redrawn with permission from Rockwood CA, Green DP. *Fractures in Adults.* Philadelphia: Lippincott-Raven, 1996.)

On physical examination, the region of the SC joint is tender and swollen. The most striking finding is the asymmetry between the injured and uninjured SC joints. If the joint is dislocated anteriorly, there may be an appreciable prominence, and if the dislocation is posterior, there may be a hollow depression. Posterior dislocations may present with breathing or swallowing difficulties or even cyanosis secondary to compression of the trachea, esophagus, or underlying vascular structures (36,80). Plain radiographs of the sternoclavicular joint are difficult to obtain and interpret, as mentioned above with fractures of this region. Computed tomography scans are best for evaluating suspected joint injuries.

***Treatment***

Anterior dislocations and subluxations are usually easy to reduce but often recur when pressure is removed from the medial end of the clavicle. Whether or not the reduction can be maintained, isolated SC joint injuries should be treated symptomatically. Provide a figure-of-eight clavicle strap or a sling for comfort. The anterior prominence and mild asymmetry persist in most cases but are not functional problems. Operative reduction and internal fixation for acute cases and resection of the medial end of the clavicle for chronic cases have been reported but are rarely indicated (see Chapter 78).

Posterior dislocations should be reduced promptly because of their potential for compression of the underlying structures. Numerous reduction methods have been advocated. Usually, manual traction on the clavicle is sufficient. It is helpful to place a rolled towel posteriorly between the patient's scapulae and apply posteriorly directed force on the lateral clavicle to help lever the medial end of the clavicle anteriorly at the SC joint. Sometimes a sterile towel clip is useful as a handle for grasping the clavicle and guiding the reduction.

Surgery is indicated for posterior dislocations that are irreducible. Make an incision anteriorly directly over the joint and reduce the clavicle under direct visualization. In the absence of fractures, soft-tissue repair alone is recommended rather than internal fixation so as to avoid complications from the latter.

Postoperatively, in the rare cases when surgery is necessary, and after reductions of SC joint dislocations, a figure-of-eight clavicle strap is recommended because it keeps the patient's shoulders up and back, helping maintain the reduction. Unlike anterior dislocations, posterior dislocations are usually stable after reduction.

***Complications***

Complications after injuries and dislocations of the SC joint are uncommon and are related primarily to posterior dislocations. These include compression or laceration of the carotid sheath or subclavian vessels and injury to the trachea or esophagus. Neurologic sequelae are rare, but compression of the recurrent laryngeal nerve and thoracic outlet syndrome have been reported. Complications related to chronic anterior subluxation or dislocation of the sternoclavicular joint are usually cosmetic. The residual prominence over the sternoclavicular joint may be tender but is best treated with benign neglect (see Chapter 78).

## CHAPTER REFERENCES

Each reference is categorized according to the following scheme: *, classic article; #, review article; !, basic research article; and +, clinical results/outcome study.


+ 1. Achecar F, Whittle AP. *Unreamed vs. Reamed Interlocking Nailing of Humeral Shaft Fractures.* Louisville, KY: Orthopaedic Trauma Association, 1997.

* 2. Ada JR, Miller ME. Scapular Fractures: Analysis of 113 Cases. *Clin Orthop* 1991;Aug:174.

+ 3. Allman FL. Fractures and Ligamentous Injuries of the Clavicle and Its Articulation. *J Bone Joint Surg* 1967;49A:774.

+ 4. Amillo S, Barrios RH, Martinez-Peric R, Losada JI. Surgical Treatment of the Radial Nerve Lesions Associated with Fractures of the Humerus. *J Orthop Trauma* 1993;7:211.

+ 5. Andersen K, Jensen PO, Lauritzen J. Treatment of Clavicular Fractures: Figure-of-Eight Bandage versus a Simple Sling. *Acta Orthop Scand* 1987;57:71.

+ 6. Aston JW, Gregory CF. Dislocation of the Shoulder with Significant Fracture of the Glenoid. *J Bone Joint Surg* 1973;55A:1531.

* 7. Balfour GW, Mooney V, Ashby ME. Diaphyseal Fractures of the Humerus Treated with a Ready-Made Fracture Brace. *J Bone Joint Surg* 1982;64A:11.

# 8. Ballmer FT, Hertel R. Other Applications of the Small AO External Fixator to the Upper Limb. *Injury Int J Care Injured* 1994;25:S-D64.

+ 9. Barbier O, Malghem J, Delaere O, et al. Injury to the Brachial Plexus by a Fragment of Bone after Fracture of the Clavicle. *J Bone Joint Surg* 1997;79B:534.

+ 10. Bell MJ, Beauchamp CG, Kellam JK, McMurtry RY. The Results of Plating Humeral Shaft Fractures in Patients with Multiple Injuries. *J Bone Joint Surg* 1985;67B:293.

* 11. Bernstein J, Adler LM, Blank JE, et al. Evaluation of the Neer System of Classification of Proximal Humeral Fractures with Computerized Tomographic Scans and Plain Radiographs. *J Bone Joint Surg* 1996;78A:1371.

# 12. Bigliani LU, Flatow EL, Pollock RG. Fractures of the Proximal Humerus. In: Rockwood CA, Green DP, Bucholz RW, Heckman JD, eds. *Fractures in Adults, Vol 1.* Philadelphia: Lippincott-Raven, 1996: 1055.

+ 13. Blom S, Dahlback LO. Nerve Injuries in Dislocations of the Shoulder Joint and Fractures of the Neck of the Humerus. *Acta Chir Scand* 1970;136:461.

# 14. Bone LB. Fractures of the Shaft of the Humerus. In: Chapman MW, ed. *Operative Orthopaedics.* Philadelphia: JB Lippincott, 1993;425.

+ 15. Bostman O, Manninen M, Pihlajamaki H. Complications of Plate Fixation in Fresh Displaced Midclavicular Fractures. *J Trauma* 1997;43:778.

* 16. Brumback RJ, Bosse MJ, Poka, A, Burgess AR. Intramedullary Stabilization of Humeral Shaft Fractures in Patients with Multiple Trauma. *J Bone Joint Surg* 1986;68A:960.

+ 17. Burny F, Demolder V, Hinsenkamp M, Rasquin C. Treatment of Humeral Fractures with an External Fixation Device. 62 Case Reports. *Acta Orthop Belg* 1979;45:47.

# 18. Cave EF. *Fractures and Other Injuries.* Chicago: Year Book, 1961.

# 19. Cave ER, Burke JF, Boyd RJ. *Trauma Management.* Chicago: Year Book, 1974.

+ 20. Chapman NW, Mahoney M. The Role of Internal Fixation in the Management of Open Fractures. *Clin Orthop* 1979;138:120.

* 21. Christensen S. Humeral Shaft Fractures, Operative and Conservative Treatment. *Acta Chir Scand* 1967;133:455.

+ 22. Clements RH, Reisser JR. Scapulothoracic Dissociation: A Devasting Injury. *J Trauma* 1996;40:146.

# 23. Codman EA. *The Shoulder.* Boston: T Todd, 1934.

+ 24. Cofield RH. Comminuted fractures of the proximal humerus. *Clin Orthop* 1986;230:49.

+ 25. Cornell CN, Levine D, Pagnani MJ. Internal Fixation of Proximal Humerus Fractures Using the Screw-Tension Band Technique. *J Orthop Trauma* 1994;8:23.

# 26. Craig EV. Fractures of the Clavicle. In: Rockwood CA, Green DP, Bucholz RW, Heckman JD, eds. *Rockwood and Green's Fractures in Adults, Vol 2.* Philadelphia: Lippincott-Raven, 1996;1109.

+ 27. Dabezies EJ, Banta CJ, Murphy CP, D'Ambrosia RD. Plate Fixation of the Humeral Shaft for Acute Fractures, With and Without Radial Nerve Injuries. *J Orthop Trauma* 1992;6:10.

+ 28. DeLaat EAT, Visser CPJ, Coene LNJEM, et al. Nerve Lesions in Primary Shoulder Dislocations and Humeral Neck Fractures. *J Bone Joint Surg* 1994;76-B:381.

# 29. DePalma AF. *Surgery of the Shoulder.* Philadelphia: JB Lippincott, 1983.

+ 30. Durbin RA, Gottesman MJ, Saunders KC. Hackenthal Stacked Nailing of Humeral Shaft Fractures. *Clin Orthop* 1983;179:168.

+ 31. Ebraheim NA, An HS, Jackson WT, et al. Scapulothoracic Dissociation. *J Bone Joint Surg* 1988;70A:428.

+ 32. Edwards DJ, Kavanagh TG, Flannery MC. Fractures of the Distal Clavicle: A Case for Fixation. *Injury* 1992;23:44.

+ 33. Eskola A, Santavirta S, Viljakka HT, et al. The Results of Operative Resection of the Lateral End of the Clavicle. *J Bone Joint Surg* 1996;78A:584.

+ 34. Eskola A, Vainionpaa S, Myllynen P, et al. Surgery for Ununited Clavicular Fracture. *Acta Orthop Scand* 1986;57:366.

+ 35. Esser RD. Treatment of Three- and Four-Part Fractures of the Proximal Humerus with a Modified Cloverleaf Plate. *J Orthop Trauma* 1994;8:15.

+ 36. Ferrandez L, Yubero J, Usabiaga J, et al. Sternoclavicular Dislocation. Treatment and Complications. *Ital J Orthop Traumatol* 1988;14:349.

+ 37. Foster RJ, Dixon GL, Bach AW, et al. Internal Fixation of Fractures and Nonunions of the Humeral Shaft. Indications and Results in a Multicenter Study. *J Bone Joint Surg* 1985;67A:857.

+ 38. Foster RJ, Swiontkowski MF, Bach AW, Sack JT. Radial Nerve Palsy Caused by Open Humeral Shaft Fractures. *J Hand Surg* 1993;18A:121.

# 39. Foulk DA, Szabo RM. Diaphyseal Humerus Fractures: Natural History and Occurrence of Nonunion. *Orthopaedics* 1995;18:333.

* 40. Galpin RD, Hawkins RJ, Grainger RW. A Comparative Analysis of Operative vs. Nonoperative Treatment of Grade III Acromioclavicular Separations. *Clin Orthop* 1985;193:150.

+ 41. Garcia A Jr, Maeck BH. Radial Nerve Injuries in Fractures of the Shaft of the Humerus. *Am J Surg* 1960;99:625.

! 42. Gerber C, Schneeberger AG, Vinh T. The Arterial Vascularization of the Humeral Head. *J Bone Joint Surg* 1990;72-A:1486.

+ 43. Goldberg JA, Warwick OA, Bruce JM, et al. Type 2 Fractures of the Distal Clavicle: A New Surgical Technique. *J Shoulder Elbow Surg* 1997;6:380.

# 44. Goss TP. Current Concepts Review: Fractures of the Glenoid Cavity. *J Bone Joint Surg* 1992;74A:299.

* 45. Goss TP. Double Disruptions of the Superior Shoulder Suspensory Complex. *J Orthop Trauma* 1993;7:99.

# 46. Goss TP. Fractures of the Glenoid Neck. *J Shoulder Elbow Surg* 1994;3:42.

# 47. Goss TP. Scapular Fractures and Dislocations: Diagnosis and Treatment. *J Am Acad Orthop Surg* 1995;3:22.

# 48. Goss TP. The Scapula: Coracoid, Acromial, and Avulsion Fractures. *Am J Orthop* 1996;25:106.

* 49. Gustilo RB, Anderson JT. Prevention of Infection in the Treatment of One Thousand and Twenty-Five Open Fractures of Long Bones. *J Bone Joint Surg* 1976;58A:453.

+ 50. Hak DJ, Johnson EE. Avulsion Fracture of the Coracoid Associated with Acromioclavicular Dislocation. *J Orthop Trauma* 1993;7:381.

* 51. Hardegger FH, Simpson LA, Weber BG. The Operative Treatment of Scapular Fractures. *J Bone Joint Surg* 1984;66B:725.

+ 52. Hawkins RJ, Switlyk P. Acute Prosthetic Replacement for Severe Fractures of the Proximal Humerus. *Clin Orthop* 1993;289:156.

+ 53. Henley MB, Chapman JR, Claudi BF. Closed Retrograde Hackethal Nail Stabilization of Humeral Shaft Fractures. *J Orthop Trauma* 1992;6:18.

! 54. Henley MB, Monroe M, Tencer AF. Biomechanical Comparison of Methods of Fixation of a Mid-Shaft Osteotomy of the Humerus. *J Orthop Trauma* 1991;5:14.

+ 55. Hercovici D, Fiennes A, Allgower M, et al. The Floating Shoulder: Ipsilateral Clavicle and Scapular Neck Fractures. *J Bone Joint Surg* 1992;74B:362.

+ 56. Hessmann M, Kirchner R, Baumgaertel F, et al. Treatment of Unstable Distal Clavicular Fractures with and without Lesions of the Acromioclavicular Joint. *Injury Int J Care Injured* 1996;27:47.

+ 57. Hill JM, McGuire MH, Crosby LA. Closed Treatment of Displaced Middle-Third Fractures of the Clavicle Gives Poor Results. *J Bone Joint Surg* 1997;79B:537..

+ 58. Hinsenkamp M, Burny F, Andrianne Y. External Fixation of the Fracture of the Humerus, A Review of 164 Cases. *Orthopaedics* 1984;7:1309.

* 59. Holstein A, Lewis G. Fractures of the Humerus with Radial Nerve Paralysis. *J Bone Joint Surg* 1963;45A:1382.

* 60. Hovelius L. Anterior Dislocation of the Shoulder in Teen-Agers and Young Adults: Five-Year Prognosis. *J Bone Joint Surg* 1987;69A:393.

+ 61. Howard FM, Shafer SJ. Injuries to the Clavicle with Neurovascular Complications: A Study of Fourteen Cases. *J Bone Joint Surg* 1965;47A:1335.

# 62. Ideberg R. Fractures of the Scapula Involving the Glenoid Fossa. In: Bateman JE, Welsh RP, eds. *Surgery of the Shoulder.* Philadelphia: BC Decker, 1984.

+ 63. Jaberg H, Warner JJP, Jakob RP. Percutaneous Stabilization of Unstable Fractures of the Humerus. *J Bone Joint Surg* 1992;74-A:508.

+ 64. Jakob RP, Miniaci A, Anson PS, et al. Four-Part Valgus Impacted Fractures of the Proximal Humerus. *J Bone Joint Surg* 1991;73-B:295.

+ 65. Jupiter JB, Leffert RD. Non-union of the Clavicle. *J Bone Joint Surg* 1987;69-A:753.

+ 66. Jupiter JB, Mullaji AB. Blade Plate Fixation of Proximal Humeral Non-unions. *Injury* 1994;25:301.

+ 67. Kavanagh BF, Bradway JK, Cofield RH. Open reduction and internal fixation of displaced intra-articular fractures of the glenoid fossa. *J Bone Joint Surg* 1993;75A:479.

+ 68. Kazar B, Relovszky E. Prognosis of Primary Dislocation of the Shoulder. *Acta Orthop Scand* 1969;40:216.

# 69. Kettlekamp DB, Alexander H. Clinical Review of Radial Nerve Injury. *J Trauma* 1967;7:424.

+ 70. Kiviluoto O, Pasila M, Jaroma H, Sundholm A. Immobilization after Primary Dislocation of the Shoulder. *Acta Orthop Scand* 1980;51:915.

* 71. Klenerman L. Fractures of the Shaft of the Humerus. *J Bone Joint Surg* 1966;48B:105.

+ 72. Kona J, Bosse MJ, Staeheli JW, Rosseau RL. Type II Distal Clavicle Fractures: A Retrospective Review of Surgical Treatment. *J Orthop Trauma* 1990;4:115.

+ 73. Koval KJ, Gallagher MA, Marsicano JG, et al. Functional Outcome after Minimally Displaced Fractures of the Proximal Humerus. *J Bone Joint Surg* 1997;79-A:203.

+ 74. Kristiansen B, Christensen SW. Plate Fixation of Proximal Humerus Fractures. *Acta Orthop Scand* 1982;57:320.

# 75. Kuhn JE, Blasier RB, Carpenter JE. Fractures of the Acromion Process: A Proposed Classification System. *J Orthop Trauma* 1994;8:6.

+ 76. Kummel BM. Fractures of the Glenoid Causing Chronic Dislocation of the Shoulder. *Clin Orthop* 1970;69:189.

# 77. Kyle RF, Schmidt AH. Open Reduction and Internal Fixation of Fractures and Nonunions. In: Thompson RC, ed. *The Shoulder.* New York: Raven Press, 1995;183.

! 78. Laing PG. The Arterial Supply of the Adult Humerus. *J Bone Joint Surg* 1956;38-A:1105.

+ 79. Lange RH, Foster RJ. Skeletal Management of Humeral Shaft Fractures Associated with Forearm Fractures. *Clin Orthop* 1985;195:173.

+ 80. Leighton RK, Buhr AJ, Sinclair AM. Posterior Sternoclavicular Dislocations. *Can J Surg* 1986;29:104.

+ 81. Leung KS, Lam TP. Open Reduction and Internal Fixation of Ipsilateral Fractures of the Scapular Neck and Clavicle. *J Bone Joint Surg* 1993;75A:1015.

* 82. Ljunggren AE. Clavicular Function. *Acta Orthop Scand* 1979;50:261.

+ 83. Manske DJ, Szabo RM. The Operative Treatment of Mid-Shaft Clavicular Non-Unions. *J Bone Joint Surg* 1985;67-A:1367.

+ 84. Martin-Herrero T, Rodriquez-Merchan C, Munuera-Martinez L. Fractures of the Coracoid Process: Presentation of Seven Cases and Review of the Literature. *J Trauma* 1990;30:1597.

+ 85. Mast JW, Spiegel PG, Harvey JP, Harrison C. Fractures of the Humeral Shaft. A Retrospective Study of 240 Adult Fractures. *Clin Orthop* 1975;112:254.

+ 86. McGahan JP, Rab GT, Dublin A. Fractures of the Scapula. *J Trauma* 1980;20:880.

* 87. McLaughlin HL. Posterior Dislocation of the Shoulder. *J Bone Joint Surg* 1952;34A:584.

+ 88. McLaughlin HL. Dislocation of the Shoulder with Tuberosity Fracture. *Surg Clin North Am* 1963;43:1615.

+ 89. Moneim MS, Balduini FC. Coracoid Fracture as a Complication of Surgical Treatment by Coracoclavicular Tape Fixation. *Clin Orthop* 1982;168:133.

# 90. Moseley HF. The Clavicle: Its Anatomy and Function. *Clin Orthop* 1968;58:17.

+ 91. Mullaji AB, Jupiter JB. Low-Contact Dynamic Compression Plating of the Clavicle. *Injury* 1994;25:41.

# 92. Muller ME, Thomas RJ. Treatment of Nonunion in Fractures of Long Bones. *Clin Orthop* 1979;138:141.

* 93. Mumford EB. Acromioclavicular Dislocation. A New Operative Treatment. *J Bone Joint Surg* 1941;23:167.

+ 94. Neer CS II. Nonunion of the Clavicle. JAMA 1960;172:1006.

+ 95. Neer CS II. Fracture of the Distal Clavicle with Detachment of the Coracoclavicular Ligaments in Adults. *J Trauma* 1963;3:99.

+ 96. Neer CS II. Fractures of the Distal Third of the Clavicle. *Clin Orthop* 1968;58:43.

* 97. Neer CS II. Displaced Proximal Humeral Fractures. Part II: Treatment of Three-Part and Four-Part Displacement. *J Bone Joint Surg* 1970;52-A:1090.

* 98. Neer CS II. Displaced Proximal Humerus Fractures. Part I: Classification and Evaluation. *J Bone Joint Surg* 1970;52-A:1077.

+ 99. Nettles JL, Linscheid R. Sternoclavicular Dislocations. *J Trauma* 1968;7:158.

# 100. Nevaiser J. Traumatic Lesions: Injuries in and about the Shoulder Joint. *AAOS Instruct Course Lect* 1956;13:187.

+ 101. Neviaser RJ, Neviaser JS, Neviaser TJ. A Simple Technique for Internal Fixation of the Clavicle: A Long Term Evaluation. *Clin Orthop* 1975;109:103.

+ 102. Ngarmukos C, Parkpian V, Patradul A. Fixation of Fractures of the Midshaft of the Clavicle with Kirschner Wires: Results in 108 Patients. *J Bone Joint Surg* 1998;80B:106.

+ 103. Nordqvist A, Petersson C. The Incidence of Fractures of the Clavicle. *Clin Orthop* 1994;300:127.

+ 104. Nordqvist A, Petersson C, Redlund-Johnell I. The Natural Course of Lateral Clavicle Fracture: 15 (11–21) Year Follow-up of 110 Cases. *Acta Orthop Scand* 1993;64:87.

+ 105. Nordqvist A, Redlund-Johnell I, von Scheele A, Petersson CJ. Shortening of Clavicle after Fracture: Incidence and Clinical Significance, a 5-Year Follow-up of 85 Patients. *Acta Orthop Scand* 1997;68:349.

# 106. Norris TR. Fractures and Fracture Dislocations of the Glenohumeral Complex. In: Chapman MW, ed. *Operative Orthopaedics.* Philadelphia: JB Lippincott, 1993;405.

+ 107. Ogawa K, Naniwa T. Fractures of the Acromion and the Lateral Scapular Spine. *J Shoulder Elbow Surg* 1997;6:544.

# 108. Ogawa K, Toyama Y, Ishige S, et al. Fracture of the Coracoid Process: Its Classification and Pathomechanism. *J Jpn Orthop Assoc* 1990;64:909.

+ 109. Oreck SL, Burgess A, Levine AM. Traumatic Lateral Displacement of the Scapula: A Radiographic Sign of Neurovascular Disease. *J Bone Joint Surg* 1984;66A:758.

* 110. Parkes AR. A Report on Traumatic Ischaemia of Peripheral Nerves with Some Observations on Volkman's Ischaemic Contracture. *Br J Surg* 1945;32:403.

+ 111. Parkes JC, Deland JT. A Three-Part Distal Clavicle Fracture. *J Trauma* 1983;23:437.

+ 112. Petersson CJ. Resection of the Lateral End of the Clavicle: A 3 to 30-Year Follow-up. *Acta Orthop Scand* 1983;54:904.

+ 113. Poigenfurst J, Rappold G, Fischer W. Plating of Fresh Clavicular Fractures: Results of 122 Operations. *Injury* 1992;23:237.

+ 114. Polloc FH, Drake D, Bovill EG, et al. Treatment of Radial Neuropathy Associated with Fractures of the Humerus. *J Bone Joint Surg* 1981;63A:239.

+ 115. Resch H, Povacz P, Frohlich R, Wambacher M. Percutaneous Fixation of Three- and Four-part Fractures of the Proximal Humerus. *J Bone Joint Surg* 1997;79-B:295.

+ 116. Riemer BL, Butterfield SL, Daffner RH, O'Keefe RMJ. The Abduction Lordotic View of the Clavicle: A New Technique for Radiographic Visualization. *J Orthop Trauma* 1991;5:392.

+ 117. Rikli D, Regazzoni P, Renner N. The Unstable Shoulder Girdle: Early Functional Treatment Utilizing Open Reduction and Internal Fixation. *J Orthop Trauma* 1995;9:93.

# 118. Ring D, Jupiter JB, Miller ME, Ada JR. Injuries to the Shoulder Girdle: Part II. Fractures of the Clavicle. In: Browner BD, Jupiter JB, Levine AM, Trafton PG, eds. *Skeletal Trauma, Vol 2.* Philadelphia: WB Saunders, 1998;1670.

+ 119. Rockwood CA. Treatment of the Outer Clavicle in Children and Adults. *Orthop Trans* 1982;6:472.

# 120. Rockwood CA, Williams GR, Young DC. Injuries to the Acromioclavicular Joint. In: Rockwood CA, Green DP, Bucholz RW, Heckman JD, eds. *Rockwood and Green's Fractures in Adults.* Philadelphia: Lippincott-Raven, 1996;1354.

+ 121. Rogers JF, Bennett JB, Tullos HS. Management of Concomitant Ipsilateral Fractures of the Humerus and Forearm. *J Bone Joint Surg* 1984;66A:552.

+ 122. Romeo AA, Loutzenheiser T, Rhee YG, et al. The Humeroscapular Motion Interface. *Clin Orthop* 1998;350:120.

# 123. Rose SH, Melton LJ III. Epidemiologic Features of Humeral Fractures. *Clin Orthop* 1982;Aug:24.

* 124. Rosen H. Compression Treatment of Long Bone Pseudarthroses. *Clin Orthop* 1979;138:154.

+ 125. Rosen H. The Treatment of Nonunions and Pseudarthrosis of the Humeral Shaft. *Orthop Clin North Am* 1990;21:725.

+ 126. Rowe CR. Prognosis in Dislocations of the Shoulder. *J Bone Joint Surg* 1956;38A:957.

# 127. Rowe CR. An atlas of anatomy and treatment of midclavicular fractures. *Clin Orthop* 1968;58:29.

+ 128. Rowe CR, Zarins B. Chronic Unreduced Dislocations of the Shoulder. *J Bone Joint Surg* 1982;64A:494.

! 129. Saha AK. Dynamic Stability of the Glenohumeral Joint. *Acta Orthop Scand* 1971;42:491.

* 130. Sarmiento A, Kinman PB, Galvin EG, et al. Functional Bracing of Fractures of the Shaft of the Humerus. *J Bone Joint Surg* 1977;59A:596.

# 131. Schlegel TF, Hawkins RJ. Displaced Proximal Humeral Fractures: Evaluation and Treatment. *J Am Acad Orthop Surg* 1994;2:54.

+ 132. Schuind F, Pay-Pay E, Adrianne Y, et al. External Fixation of the Clavicle for Fracture Non-union in Adults. *J Bone Joint Surg* 1988;70A:692.

+ 133. Sinha J, Miller AJ. Fixation of Fractures of the Glenoid Rim. *Injury* 1992;23:418.

+ 134. Stableforth PG. Four-Part Fractures of the Neck of the Humerus. *J Bone Joint Surg* 1984;66-B:104.

+ 135. Sturzenegger M, Fornano E, Jakob RP. Results of Surgical Treatment of Multifragmented Fractures of the Humeral Head. *Arch Orthop Trauma Surg* 1982;100:249.

+ 136. Szyszkowitz R, Seggl W, Schleifer P, Cundy PJ. Proximal Humeral Fractures: Management Techniques and Expected Results. *Clin Orthop* 1993;292:13.

* 137. Taft TN, Wilson FC, Oglesby JW. Dislocation of the Acromioclavicular Joint: An End-Result Study. *J Bone Joint Surg* 1987;69A:1045.

# 138. Thompson DA, Flynn TC, Miller PW, et al. The Significance of Scapular Fractures. *J Trauma* 1985;25:974.

+ 139. Thompson JS. Operative Treatment of Certain Clavicle Fractures. An Orthopaedic Controversy. *Orthop Trans* 1988;12:141.

+ 140. Thorndike A Jr, Quigley TB. Injuries to the Acromioclavicular Joint: A Plea for Conservative Treatment. *Am J Surg* 1942;55:250.

+ 141. Van Wellen PAJ, Casteleyn PO, Opdecam P. Traction-Suspension Therapy for Unstable Glenoid Neck Fracture. *Injury* 1991;22:57.

+ 142. Vander Griend R, Tomasin J, Ward EF. Open Reduction and Internal Fixation of Humeral Shaft Fractures. *J Bone Joint Surg* 1986;68A:430.

* 143. Weaver JK, Dunn HK. Treatment of Acromioclavicular Injuries, Especially Complete Acromioclavicular Separation. *J Bone Joint Surg* 1972;54A:1187.

+ 144. Wenner SM. Anterior Dislocation of the Shoulder in Patients Over 50 Years of Age. *Orthopedics* 1985;8:1155.

+ 145. Wilkins RM, Johnston RM. Ununited Fractures of the Clavicle. *J Bone Joint Surg* 1983;65-A:773.

* 146. Williams PL, Warwick R, Dyson M, Bannister LH. *Gray's Anatomy.* New York: Churchill Livingstone, 1989.

+ 147. Wu CC, Shih CH. Treatment for Nonunion of the Shaft of the Humerus: Comparison of Plates and Seidel Interlocking Nails. *Can J Surg* 1992;35:661.

# 148. Zagorski JB, Aych GA, Latta LL, McCollough NC. Modern Concepts in Functional Fracture Bracing: The Upper Limb. In: *Instructional Course Lectures, Vol 36.* Park Ridge, IL: American Academy of Orthopaedic Surgeons, 1987;377.

+ 149. Zagorski JB, Latta LL, Zych GA, Finnieston AR. Diaphyseal Fractures of the Humerus: Treatment with Prefabricated Braces. *J Bone Joint Surg* 1988;70A:607.

+ 150. Zenni EJJ, Kreig JK, Rosen MJ. Open Reduction and Internal Fixation of Clavicular Fractures. *J Bone Joint Surg* 1981;63A:147.

+ 151. Zinman C, Norman D, Hamoud K, Reis ND. External fixation for severe open fractures of the humerus caused by missiles. *J Orthop Trauma* 1997;11:536.

# 152. Zuckerman JD, Koval KJ. Fractures of the Shaft of the Humerus. In: Rockwood CA, Green DP, Bucholz RW, Heckman JD, eds. *Rockwood and Green's Fractures in Adults.* Philadelphia: Lippincott-Raven, 1996;1025.

+ 153. Zyto K, Ahrengart L, Sperber A, Tornkvist H. Treatment of Displaced Proximal Humerus Fractures in Elderly Patients. *J Bone Joint Surg* 1997;79-B:412.

# CHAPTER 16

# FRACTURES AND DISLOCATIONS OF THE ELBOW AND FOREARM

*This chapter incorporates chapters from the second edition that were written by Bernhard G. Weber, H. David Moehring, Jerald L. Cooper, Robert D. D'Ambrosia, Bruce A. Mallin, and T. David Sisk.*

*Michael W. Chapman*

**M. W. Chapman:** Department of Orthopaedics, University of California-Davis Medical Center, Sacramento, California, 95817.

Fractures of the Distal Humerus
- Treatment Considerations
- Anatomic Considerations
- Biomechanics of Internal Fixation
- Classification
- Open Reduction and Plate Fixation of a T-Type Supracondylar Humerus Fracture
- Postoperative Care
- Results

Olecranon Fractures
- Classification
- Biomechanics of Internal Fixation
- Treatment
- Postoperative Care

Monteggia Fracture Dislocation
- Classification
- Treatment
- Postoperative Care

Coronoid Process Fractures
- Treatment

Radial Head and Neck Fractures
- Classification
- Treatment
- Postoperative Care

Elbow Dislocations
- Mechanism of Injury
- Classification
- Physical Findings
- Radiographic Findings
- Treatment
- Surgical Indications

Posterolateral Rotatory Instability Of The Elbow

Fractures of the Shaft of the Radius and Ulna
- Classification
- Assessment
- Surgical Anatomy
- Closed Treatment
- Open Treatment
- Timing
- Surgical Approaches
- Plate and Screw Fixation
- Intramedullary Fixation

Isolated Fractures of the Radius

Isolated Fractures of the Ulna

Floating Elbow

Open Fractures of the Forearm

Pitfalls and Complications
- Supracondylar Humerus Fractures
- Nonunion, Malunion, and Failure of Fixation
- Neurovascular Injuries
- Compartment Syndrome
- Heterotopic Ossification
- Radius–Ulnar Synostosis
- Chronic Dislocation of the Elbow
- Postoperative Infection
- Forearm Fracture After Plate Removal

Chapter References

## FRACTURES OF THE DISTAL HUMERUS

Fractures of the elbow are uncommon compared to other serious joint injuries, constituting only about 4.3% of all fractures. In contrast to shaft fractures, joint fractures are almost always treated by open reduction and internal fixation; conservative treatment is the exception.

### TREATMENT CONSIDERATIONS

In spite of the fact that surgical techniques for the treatment of fractures of the distal humerus have advanced substantially over the past 20 years and now are quite sophisticated, the rate of complications remains quite high (21,69,83,86,87,91,92 and 93,116,124,169). Such complications include nonanatomic reduction of articular surfaces, malunion, nonunion, residual stiffness of the elbow, heterotopic ossification, posttraumatic osteoarthrosis, and generalized functional disability. These injuries are being treated more often now with coexisting multiple injuries or in an extremity with complex ipsilateral open injuries, which previously may have led to amputation. In the very elderly, osteopenia often compromises internal fixation, and total elbow arthroplasty is a reasonable alternative (32).

Elbow and forearm fractures continue to present major problems to orthopaedic traumatologists because of the high occurrence of comminution, the large and complex articular surfaces involved, the close proximity of important nerves and vessels, and the poor soft-tissue coverage. In spite of the best treatment, the result may be poor because of the magnitude of the original injury. In the vast majority of fractures, ideal treatment consists of early open reduction with replacement of any lost bone, and rigid anatomic fixation of the joint surfaces and adjoining metaphyseal bone, with early aggressive active range-of-motion and strengthening exercises (69,94,169). As with all intraarticular fractures, good technique requires careful preoperative planning, adequate exposure of the joint and fracture, biomechanically sound internal fixation, and protection of neurovascular structures. Flexibility on the part of the surgeon and the availability of a wide range of plates and screws are necessary (2,20,87,93,122,130,171,172).

Comminuted elbow fractures in which the bone is osteopenic and the patient is over 70 years old can be nearly impossible to fix. Primary total elbow arthroplasty is a reasonable alternative in these patients, particularly if they have coexisting arthrosis or rheumatoid arthritis. Cobb et al. (32) performed arthroplasty in 21 elbows in 20 consecutive patients, whom they followed for a mean duration of 3.3 years with a minimum follow-up of 2 years. Fifteen elbows had an excellent result, five had a good result, and one was not ratable. Of these, one required revision for a fracture of the ulnar component sustained in a fall.

## ANATOMIC CONSIDERATIONS

The elbow joint consists of three articulations: the radial-capitellar, the trochlear-olecranon, and the proximal radial-ulnar. The distal humerus consists of two divergent osseous columns, one lateral and one medial, which flare and are separated by the thin or absent bone of the olecranon fossa, and are connected together distally by the trochlea. The end of the lateral column becomes the capitellum. The lateral column is in approximately 20° of valgus relative to the midline of the humeral shaft, whereas the medial column is at a 40° to 45° angle. Viewed from a lateral perspective, the capitellum is tilted 30° to 40° anteriorly, and the trochlea 10° to 20° (Fig. 16.1). The articulation between the trochlear notch of the olecranon and the trochlea is the most important joint of the elbow because it provides the flexion–extension arc of elbow motion as well as approximately half of the intrinsic stability of the elbow (83). Reconstruction of the normal shape of the trochlea is therefore critical to restoration of good motion and stability in the elbow. Because the majority of intraarticular fractures split through the narrow waist of the trochlea with some comminution, there is a tendency during internal fixation to narrow the trochlea. Avoid this, however, because it creates a noncongruous elbow, which will interfere with motion and lead to osteoarthrosis.

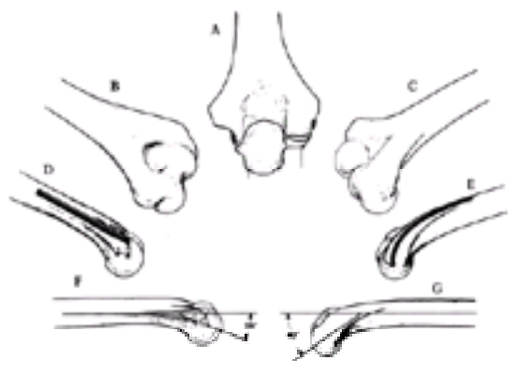


***Figure 16.1.*** Surgical anatomy of the distal humerus. **A:** Aspect from the back. **B:** Posteroulnar aspect. **C:** Posteroradial aspect. **D:** Fixation plate along the ulnar pillar, flat profile. **E:** Fixation plate along the radial pillar, bent and twisted contour. **F:** Tilt of the trochlea humeri and its crest, 25°. **G:** Tilt of the capitellum and its crest of 40°.

## BIOMECHANICS OF INTERNAL FIXATION

The anatomic shape of the elbow joint, in particular the ulnar–humeral articulation, is such that the trochlear notch of the olecranon surrounds almost 100° of the trochlea, making the elbow one of the most stable joints in the body (119,138). The olecranon, in its articulation with the trochlea, contributes significantly to anterior–posterior stability, as well as varus, valgus, and rotatory stability. Resection of increasingly larger amounts of the proximal end of the olecranon leads to a linear decrease in the stability of the elbow. Resection of only 25% of the olecranon process decreases the resistance of the elbow to valgus load by 50%. The coronoid process plays an important role, in that it resists posterior displacement of the elbow joint, particularly in flexion, and the anterior band of the medial collateral ligament attaches near the base of the coronoid process; therefore, large fractures involving the coronoid process may result in incompetence of this ligament. In spite of its small size, the radial head contributes to stability and the transmission of longitudinal force across the elbow joint. The load borne by the radial–capitellar joint is maximal when the forearm is pronated and the elbow extended and loaded longitudinally. The continuity of the radial head is most important when there is associated ligament instability in the elbow and in particular when there is incompetence in the intraosseous membrane and distal radial ulnar joint of the forearm (an Essex-Lopresti lesion).

Restoration of a T- or Y-type comminuted intraarticular fracture of the distal humerus requires reconstruction of an equilateral triangle consisting of the lateral column, the medial column, and the trochlea. Fortunately, even in the elderly, the cortical bone of the medial and lateral columns usually provides good purchase for bone screws. In a biomechanical study of internal fixation of the distal humerus, Helfet and Hotchkiss (61) found that double-plate construction with the two plates at right angles, a medial plate on the medial column and a posterior plate on the lateral column, provided the strongest fixation regardless of whether the plate was a one-third tubular or a 3.5 mm reconstruction plate. Schemitsch et al. (154) looked at plates of two designs placed in five different configurations. They found that when cortical contact was present, dual plates placed medially and laterally—whether at 90° to each other or in the same plane—provided equivalent rigidity. When a cortical gap was present, however, they found that the combination of an anatomically designed lateral buttress J-plate and a medial reconstruction plate gave the greatest rigidity. In practice, 3.5 mm reconstruction plates or their equivalent, particularly in titanium, give the best opportunity to obtain a close fit of the plates to the complex surfaces of the distal humerus, and when placed posteriorly on the lateral condyle and medially on the medial condyle, they provide the strongest construct. Interfragmentary screw fixation from the capitellum through the trochlea usually ensures good stability of the articular surface. Reestablishment of good bone contact throughout the construct, using tricortical bone graft from the iliac crest if necessary, substantially improves fixation and chances for union.

Olecranon osteotomy, if used for exposure, is another source of complications if the fixation fails. The biomechanically soundest technique appears to be a chevron type osteotomy through the nonarticular portion of the olecranon, predrilled and fixed with interfragmentary screw fixation augmented by a tension band wire.

## CLASSIFICATION

The Association for the Study of Internal Fixation (AO-ASIF) classification (Fig. 16.2) is the most commonly used scheme for determining treatment and clinical research. The Orthopaedic Trauma Association and the International Society for Fracture Repair recently expanded the AO classification (125) to provide a more detailed breakdown to enhance the accuracy of clinical reports. Their system, however, contains 38 separate fractures of the distal humerus. Jupiter and Mehne (86) divide distal humerus fractures into three major groups: extracapsular, transcolumnar, and intraarticular, which includes single- and bicolumnar fractures and articular fractures involving the capitellum and the trochlea (21,86) (Table 16.1).

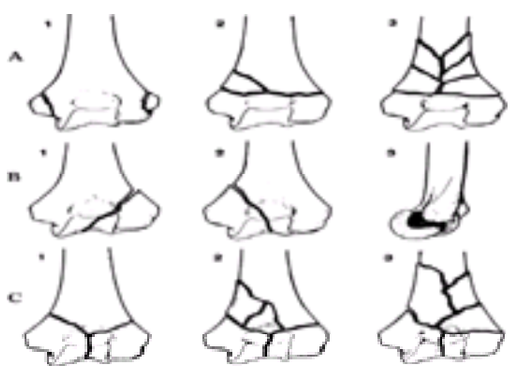


***Figure 16.2.*** A-O Classification of distal humeral fractures. Type A—Extraarticular fractures: A1 epicondylar avulsions; A2 supracondylar fractures; A3 supracondylar fractures with comminution. Type B—Unicondylar fractures: B1 fracture of the lateral condyle; B2 fracture of the medial condyle; B3 tangential fracture of the condyle. Type C—Bicondylar fractures: C1 T- or Y-shaped fractures; C2 T- or Y-shaped fractures with comminution of one or two pillars; C3 extensive comminution of the condyles and pillars.

| | |
|---|---|
| I. Intraarticular fractures | |
| A. Single-column | |
| 1. Medial | |
| a. High | |
| b. Low | |
| 2. Lateral | |
| a. High | |
| b. Low | |
| B. Bicolumnar | |
| 1. Y pattern | |
| a. High | |
| b. Low | |
| 2. H pattern | |
| 3. Lambda pattern | |
| a. Medial | |
| b. Lateral | |
| C. Capitellar | |
| D. Trochlear | |
| II. Extraarticular intracapsular fractures | |
| A. Transcolumnar fractures | |
| 1. High | |
| a. Extension | |
| b. Flexion | |
| c. Abduction | |
| d. Adduction | |
| 2. Low | |
| a. Extension | |
| b. Flexion | |
| III. Extracapsular fractures | |
| A. Medial epicondyle | |
| B. Lateral epicondyle | |

Reprinted with permission from Jupiter JB, Mehne DK. Fractures of the Distal Humerus. Orthopaedics 1993;16:624.

***Table 16.1. Classification of Fractures of the Distal Part of the Humerus***

High T-fractures are those that divide both columns proximal to the olecranon fossa, whereas low T-fractures traverse the olecranon fossa just proximal to the trochlea. The latter may be the most common fracture pattern in the elderly, and they are difficult to treat because of the small distal fragment. Y- or T-fractures begin in the center of the trochlea, probably due to the olecranon trochlear ridge being impacted into the trochlea, which causes a fracture line to propagate vertically from the trochlear notch and then split to cross each column obliquely. An H-fracture is a bicolumnar fracture with a fracture of the medial column around the medial epicondyle and a split of the lateral column into a T or Y pattern, producing a free-floating trochlear fragment. In a medial lambda fracture, the proximal fracture line exits medially and the lateral fracture line extends distally to the level of the lateral epicondyle. In a lateral lambda fracture, the fracture is high on the lateral column and exits near the medial epicondyle with the intraarticular component next to the capitellum. A particularly difficult fracture is a shear fracture in the frontal plane involving the anterior portion of the capitellum and lateral half of the trochlea. This results in the characteristic double-arc sign seen on the lateral radiograph of Figure 16.3.

***Figure 16.3.*** Coronal shear fracture of the distal end of the humerus. **A:** This vertical shear fracture involves the capitellum and most of the trochlea, resulting in separation, proximal migration, and rotation of the distal articular surface of the humerus. **B:** This anterior lateral oblique view shows that the main fracture line is in the coronal plane. **C:** Lateral radiograph showing the double-arc sign (*arrow*): One arc represents the lateral ridge of the trochlea and the other, subchondral bone of the capitellum. **D:** Postoperative lateral radiograph showing anatomic reduction of the fracture and internal fixation with two 4.0 mm AO screws and a Herbert screw. (With permission from McKee MD, Jupiter JB, Bamberger HB. Coronal Shear Fractures of the Distal End of the Humerus. *J Bone Joint Surg [Am]* 1996;78:49.)

## OPEN REDUCTION AND PLATE FIXATION OF A T-TYPE SUPRACONDYLAR HUMERUS FRACTURE

### *Patient Position*

The supine, prone, and lateral decubitus positions are all useful. The supine position (Fig. 16.4*A*) is good for lateral approaches to the elbow. Holding the elbow in position is difficult, however, in complex fractures. If using the supine position, place an arm board alongside the table, on which the medial side of the elbow can rest when doing lateral approaches. For medial approaches, a small hand table is useful. For the posterior approach, use the prone position (Fig. 16.4*B*), with the upper arm supported on an arm rest and the elbow flexed to 90°. This position is useful for less complex fractures and when the anterior iliac crest is not needed for structural bone graft. This position is less convenient for the anesthesiologist. For complex fractures, I prefer the lateral decubitus position (Fig. 16.4*C*), supporting the upper arm on a well-padded obstetric knee support. The advantage of this position is that it makes both the anterior and the posterior iliac crests on the ipsilateral side available. In addition, the elbow can be flexed to 120°, which improves exposure when using a comprehensive posterior triceps-splitting approach, and the entire upper extremity can be easily lifted off the holder if needed. In general, these procedures tend to be long, and positioning can be uncomfortable for the patient, so use a general anesthetic in most cases. A tourniquet is useful for the initial dissection, particularly when identifying and transferring the ulnar nerve. (Use a sterile tourniquet.) Once the soft-tissue dissection has been completed, the tourniquet can be released and removed, thus avoiding prolonged tourniquet times.

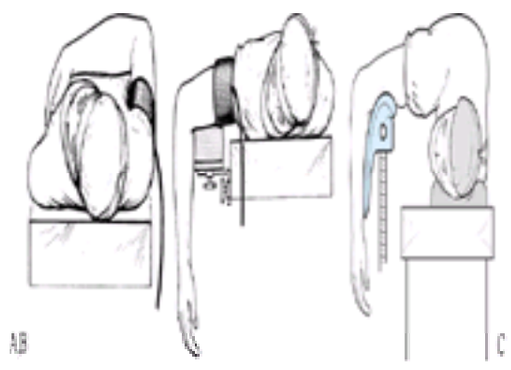

***Figure 16.4.*** Various positions for surgical repair of fractures around the elbow. **A:** Supine position. **B:** Prone position with the upper arm on an arm rest. **C:** Lateral decubitus position with the arm over a well-padded obstetric knee support.

### *Surgical Approaches*

The various surgical approaches to the elbow are described in Chapter 1. For fractures of the lateral column and capitellum, a lateral approach is best. For medial column and epicondylar or trochlear fractures, a straight medial approach works well. For nonarticular supracondylar fractures, a triceps-splitting approach suffices if plates do not need to extend beyond the upper edge of the olecranon fossa onto the medial and lateral columns. For intraarticular T-type fractures, a comprehensive posterior exposure is best, using either the comprehensive triceps-splitting approach described in Chapter 1, or an olecranon osteotomy reflecting the olecranon superiorward by splitting the triceps both medially and laterally.

The osteotomy of the olecranon for exposure of the posterior humerus and elbow joint proceeds as follows:

- Prepare a midline screw hole for the fixation screw using the lag technique. Drill a 4.5 mm hole to just opposite the apex of the elbow joint. Place a guide, and drill with a 3.2 mm drill through the anterior cortex (Fig. 16.5*A*). Tap the hole.

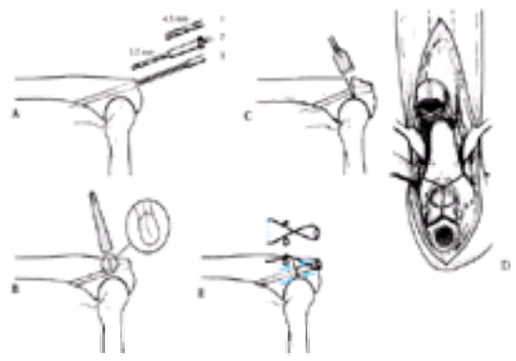

***Figure 16.5.*** Osteotomy of the olecranon. **A:** Screw hole preparation. **B:** Incomplete osteotomy. **C:** Final crack for osteotomy. **D:** Approach to the distal humerus. **E:** Lag screw and tension band fixation.

- Using a water-cooled oscillating saw, make a chevron osteotomy with the apex distalward (Fig. 16.5*B*). Cut down to but not through the subchondral bone of the olecranon. Place this at the apex of the joint where there is almost no articular cartilage.
- Complete the osteotomy with an osteotome, levering the proximal piece of the olecranon to crack through into the joint (Fig. 16.5*C*). Take care to not injure the articular cartilage of the humerus.
- Split the triceps medially and laterally in line with the olecranon and reflect it proximally (Fig. 16.5*D*)
- Repair the olecranon with a 4.5 mm cortical screw using the lag technique, augmented by a tension band wire placed around the head of the screw (Fig. 16.5*E*).

In isolated medial approaches or comprehensive posterior approaches, identify and protect the ulnar nerve. In most cases, transfer of the nerve anteriorly is recommended to avoid impingement on the nerve by plates or screws placed medially, and to avoid incorporation of the ulnar nerve into periarticular scar during healing. Techniques for transfer of the ulnar nerve are described in Chapter 51, Chapter 52, and Chapter 57. I prefer to transfer into a subcutaneous pocket, taking care to release the medial intermuscular septum in the arm, and dissecting the ulnar nerve well down into the flexor carpi ulnaris to avoid any tension or kinking of the nerve proximally and distally. Try to maintain soft-tissue attachments to all bone fragments to preserve their blood supply. This is most important for the articular fragments and less important for smaller metaphyseal fragments.

***Fracture Fixation***

- Identify all fracture fragments and clean them of organizing hematoma. Often there are free fragments. It is useful to make a drawing of the distal end of the humerus on a cloth or a piece of paper on the back table and use this to assemble the fragments in their correct orientation.
- Once all the fracture surfaces and fragments are identified, develop a strategy for assembling the fracture. A few minutes of careful thought spent working out a strategy may save an hour or more of operating time because assembling the fracture anatomically, maintaining it in position, and applying fixation can be extremely demanding technically.

If one column is intact, fixation is greatly simplified and the fragments on the other column can be assembled against the intact column. If both columns are fractured, particularly if there is bone loss, the difficulty increases. In looking at the fracture, think about the sequence of assembling the fragments, because not infrequently the fragments key into each other in such a way that if the order of reduction is not appropriate it may be impossible to assemble the fracture after it is partially fixed.

A good approach is to think about turning a multifragmented fracture into a simple two-part fracture, assembling the articular pieces as one unit and the metaphyseal fragments as another unit, and then finally joining them together. Another approach is to assemble one column and fix it in stable anatomic position and then assemble the other column against it. Nonanatomic reduction of fracture lines cannot be tolerated, particularly in the early phases of reconstruction, because a small error in the assembly of one fragment or fracture line will multiply itself as the reconstruction proceeds, making achievement of an anatomic reduction impossible. Loose articular fragments, particularly those from the groove of the trochlea, are often too thin or too small to hold with internal fixation, even resorbable pins. Often these will reduce into a stable position if held in position as the trochlea and trochlear capitellar fragments are internally fixed, keying these into place and locking them in position.

The key components of internal fixation are the following:

- Anatomic reduction and preliminary fixation with Kirschner wires
- Interfragmentary lag screw fixation of the articular condyles
- Fixation of the lateral column with a well-molded posterior plate
- Fixation of the medial column with a medial plate extending down to, and on occasion wrapping around, the medial epicondyle
- Multiple interfragmentary screws, usually through the plates but sometimes independent of the plates, to secure the fracture construct together
- Cannulated screws are preferred by some surgeons because these can be placed over the preliminary Kirschner wires (K-wires), which greatly simplifies fixation. Keep in mind, however, that these screws are much more expensive and weaker than standard screws.

Figure 16.6 shows initial interfragmentary screw fixation of the articular component of a Y-fracture.

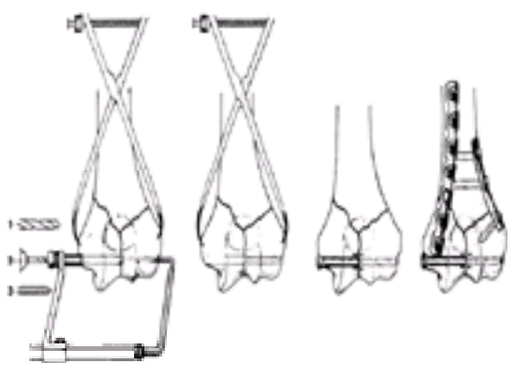

***Figure 16.6.*** Screw fixation of the two condyles in a Y-fracture. **A:** Screw hole preparation. **B:** Screw hole for a lag screw. **C:** Lag screw inserted. **D:** Plate fixation of the condyles to the shaft.

- Reduce the fracture and hold it securely with a sharp bone holding forceps. Under fluoroscopic control, insert a K-wire from the medial epicondyle through the center of the lateral aspect of the capitellum over which a cannulated screw will be inserted, or use the anterior cruciate ligament (ACL) guide, as depicted in Figure 16.6*A*.
- Insert a 4.5 or 4.0 mm cancellous lag screw, depending on the size of the elbow, and compress the fracture. In most cases, the fracture surfaces are sufficiently irregular that compression makes them stable. If the fragments tend to rotate as the screw is tightened, place a second K-wire more proximally to control rotation.
- Next, reduce the proximal fragment to the reassembled distal fragment and secure the position with a 2 mm K-wire inserted from the medial epicondyle across the medial limb of the fracture to exit the lateral cortex of the proximal fragment, and a second wire from the lateral condyle across the T-component to exit the medial cortex of the proximal fragment.
- Then apply plates to both columns (Fig. 16.6*D*). This shows the use of a one-third tubular plate laterally along the supracondylar ridge, and a 3.5 mm reconstruction plate along the posterior aspect of the medial column. I prefer to place a small reconstruction plate along the medial aspect of the medial column and the posterior aspect of the posterior column (Fig. 16.7). With the medial location, it is usually possible to get a minimum of two and sometimes three screws into the distal fragment. In most fractures, the plate can stop just proximal to the prominence of the epicondyle. In more comminuted fractures, it may be necessary to bend the plate around the tip of the epicondyle, represented by the dotted lines on Fig. 16.7*A*, which adds still another screw. Transfer the ulnar nerve if this is done. Note the three-dimensional contouring required for the plate on the lateral condyle (Fig. 16.7*B*, Fig. 16.7*C* and Fig. 16.7*D*). These plates must be contoured exactly, so that the fracture does not displace. Use templates and bend them to match the bone. I prefer titanium plates because they are more forgiving and are less likely to displace the fracture.

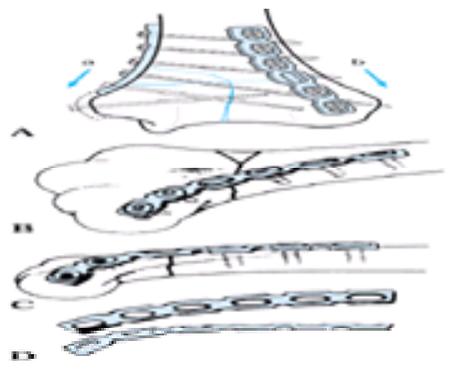

***Figure 16.7.*** Plate fixation of a Y-type fracture of the humerus with dual plate fixation. **A:** Use of 3.5 mm reconstruction plates: The lateral plate is molded to fit the posterior aspect of the lateral column and a second plate is molded to fit along the medial supracondylar ridge. **B–D:** Note that contouring the plate to fit the lateral column requires a twist in three dimensions.

- For simple single-condyle fractures, an interfragmentary screw across the condyles and a one-third tubular plate conformed to fit the supracondylar ridge act nicely as a buttress plate (Fig. 16.8). Fix the articular portion of the fracture with an interfragmentary lag screw. Then contour a semitubular plate to fit snugly on the supracondylar ridge and secure it with two screws proximally. This plate has a buttress function that prevents proximal migration of the fractured condyle. Insert a third screw distally.

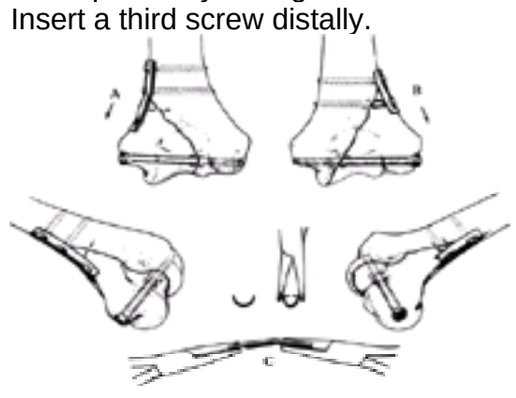

***Figure 16.8.*** Methods for fixation of unicondylar fractures of the humerus. **A:** Technique for a fracture on the ulnar side. See text for details. **B:** A similar technique is illustrated for a fracture on the opposite side. **C:** Contouring of the plate with pliers.

- Coronal shear fractures are difficult to fix, and success depends on the size of the fragment. Alternatives for fixation include multiple K-wires, resorbable pins, resorbable screws, Herbert screws, and 4.0 or 2.7 mm cancellous screws. Because the anterior fragment is small, fixation nearly always has to be through the articular surface; therefore, all implants need to be countersunk below the articular surface.

### *Repair of Fractures with Bone Defects*

The most common defects are caused by comminution in the metaphyseal portion of the olecranon fossa (which usually does not require replacement), fragmentation of the supracondylar ridge, or loss of the midsubstance of the trochlea. The superior margin of the iliac crest provides ideal graft for replacing these deficiencies (Fig. 16.9).

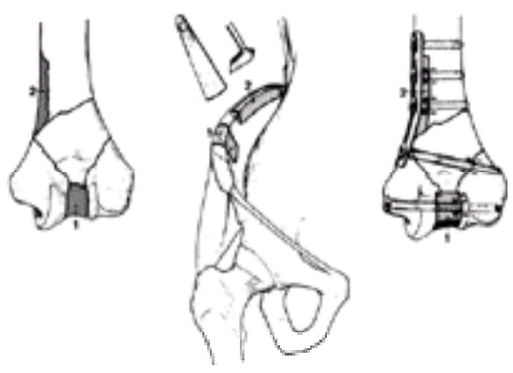

***Figure 16.9.*** Bone grafting for bone defects. **A:** Examples of bone defects. **B:** Harvesting corresponding bone grafts from the iliac crest. **C:** Incorporating the bone grafts into the corresponding defects.

### *Wound Closure, Dressing, and Splinting*

- After completion of the fixation, take anteroposterior (AP) and lateral plain radiographs to confirm the reduction and ensure that the internal fixation has been appropriately placed. Sometimes, it is wise to leave the K-wires placed for preliminary fixation, because they add to the strength of the construct. If left, be certain that they are not protruding excessively from the opposite cortex, and cut them flush with the near cortex if you plan to leave them permanently.
- Next, carry the elbow through a full range of motion to be certain that there is no micromotion or evidence of weakness in the construct, particularly at the ends of range of motion. If such is detected, add more fixation or plan to use postoperative bracing, which prevents the elbow from reaching the range of motion that causes micromotion in the fracture site.
- Place a small suction drain at the level of bone and close the wound in layers. Apply a bulky sterile dressing and splint the elbow in nearly full extension. This position accommodates swelling better, and most patients rehabilitate better from the extended position than from the flexed position.

See Figure 16.10 for an example of a difficult case.

***Figure 16.10.*** Comminuted intraarticular supracondylar fracture of the humerus with double plate fixation. **A:** AP radiograph showing extreme comminution of the distal humerus in a 17-year-old girl who fell off a horse. The medial and lateral columns are fractured. There is comminution around the olecranon fossa. The junction between the trochlea and the capitellum is comminuted, with the majority of the trochlear notch consisting of two completely free fragments. **B:** Lateral radiograph

showing the comminution with complete anterior displacement of the capitellum, which is dislocated free from the radial head. **C:** Postoperative AP radiograph showing reconstruction of the articular components with a lateral to medial lag screw. The two K-wires provide additional fixation for the free fragments. The integrity of the medial and lateral columns has been restored with 3.7 titanium Alta (Howmedica, Rutherford, NJ) reconstruction plates. The fracture is anatomic. **D:** Lateral radiograph of the fixation showing anatomic reduction. It was possible to start immediate motion in this elbow. At 6 months follow-up, the fracture had healed and the patient's range of motion was from 10° to 135° of flexion, with full supination and pronation. Note that this was done with a comprehensive posterior triceps-splitting approach, and olecranon osteotomy was not necessary.

### POSTOPERATIVE CARE

Postoperatively, after elbow fixation, elevate the entire extremity above the level of the heart. Observe carefully for excessive swelling and compartment syndrome. Once swelling has abated and the drain has been removed, remove the bulky compression dressing, apply a supportive brace, and begin active range-of-motion exercises. Set fixed limits on the brace if necessary, according to an examination under anesthesia.

Allow the patient to rest with the elbow in extension and work on the range of motion from that position. Discontinue the braces as soon as feasible. If the patient has difficulty gaining range of motion, use dynamic flexion and extension splints on alternating nights. Avoid resistive exercises and any heavy use of the extremity until fracture healing has occurred, which is generally in 10–14 weeks.

### RESULTS

McKee et al. (101) reported surprisingly good results in the treatment of shear fractures of the distal articular surfaces of the humerus in six patients. All united without evidence of osteonecrosis. Functional outcomes were good, with an average flexion contracture of 15° with further flexion to 141°. In T-type bicondylar fractures, Helfet and Schmeling (62) reported an average of 75% excellent to good results.

## OLECRANON FRACTURES

Fractures of the olecranon process are common in adults (23). Numerous treatment methods have been advocated, but none is clearly superior. The fracture is usually caused by either direct trauma to the olecranon or a fall on the outstretched hand. Restoration of stable elbow function and rapid mobilization are the goals of treatment.

### CLASSIFICATION

Nondisplaced olecranon fractures that are stable and have an intact triceps aponeurosis are generally grouped separately. With this injury, the patient can extend the injured elbow against gravity without causing displacement of the fragments. If there is a question about stability, examine under fluoroscopy to document it.

Displaced olecranon fractures are classified according to the fracture line and degree of comminution. A modification of Colton's classification (34) separates these into four types (Fig. 16.11):

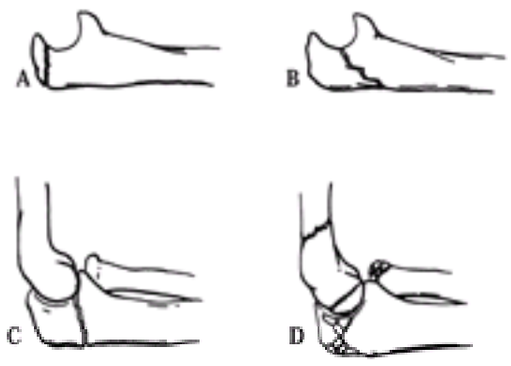


***Figure 16.11.*** Colton classification of olecranon fractures. **A:** Type I, avulsion of the olecranon process. **B:** Type II, fracture from the deepest portion of the semilunar notch. **C:** Type III, fracture at the most distal portion of the olecranon.

- Type I is an avulsion fracture, which may be either intra- or extra-articular (Fig. 16.11*A*). The fragment is often small (less than 50% of the olecranon process) and may have an oblique or a transverse fracture line.
- Type II (Fig. 16.11*B*) is a fracture that runs transversely or obliquely from the deepest portion of the semilunar notch to the subcutaneous border. With increased injury force, comminution of a centrally depressed wedge fragment can be present.
- Type III (Fig. 16.11*C*) involves a fracture through the more distal part of the olecranon and may be associated with anterior subluxation of the radius and ulna. Here the fracture line is near the tip of the coronoid process and may produce a variant of the Monteggia lesion.
- Type IV (Fig. 16.11*D*) is a severely comminuted olecranon fracture, usually caused by major direct trauma, and is often accompanied by other elbow injuries. Multiple fracture lines are seen with frequent depression of fragments. Associated fractures of the radial head, distal humerus, and forearm can be seen.

The AO classification (122) has been modified recently by the Orthopaedic Trauma Association (125) into eight types.

Morrey (117) has not found any of the previous classifications to be useful to him for clinical decision making; therefore, he proposed the Mayo classification:

- Type I: *Undisplaced fracture*
- Type II: *Displaced stable fracture*: Fracture fragments are separated by more than 3 mm, but the collateral ligaments of the elbow are intact and the forearm is stable in its relationship to the humerus. This type can be subclassified as noncomminuted type IIA or comminuted type IIB.
- Type III: *Displaced unstable fracture*: The fracture is displaced and the forearm is unstable in relationship to the humerus. This is a fracture dislocation, and it can be subcategorized into noncomminuted type IIIA or comminuted type IIIB. The latter is the most difficult to treat and has the poorest prognosis.

### BIOMECHANICS OF INTERNAL FIXATION

Prayson et al. (132) compared four different methods of tension band wiring. They compared a monofilament wire in a traditional figure-eight loop with K-wires inserted from the tip of the olecranon into the anterior cortex or intramedullary, to similar constructs using cables in both figure-eight and circular loops. They found that insertion of the K-wires from the tip of the olecranon into the anterior cortex and the use of cable provided superior fixation to intramedullary K-wires and monofilament wire. In a prospective randomized study, Hume and Wiss (74) compared tension band wiring to plate fixation. Although plate fixation required longer operative time, it did not have an increased complication rate, and the clinical results were superior to tension band wire. Postoperative loss of reduction occurred in 53% of patients fixed with tension band wires and in only 5% after plating. With plates, good clinical results were 26% more common, and good radiographic results were 39% more common.

### TREATMENT

Nondisplaced olecranon fractures may be managed by maintaining the elbow in a semiflexed position (to 90° of flexion, if tolerated) with a cast or splint. Obtain repeat radiographs at 5–7 days to ensure maintenance of reduction. Early, protected range of motion may begin at about 1 week. Rarely, one encounters an undisplaced fracture in a person in whom nonunion or displacement is not tolerable, such as in a professional throwing athlete. A tension band wiring can be applied with minimal exposure, which allows more aggressive early rehabilitation with minimal risk of displacement.

Treatment of displaced olecranon fractures (Colton types II–IV and Mayo types II–III) has been the topic of a significant amount of research and discussion through the

years. Alternative methods include open reduction and internal fixation or fragment excision, and reconstruction of the triceps mechanism (49,70,77,176). I favor anatomic reduction with internal fixation when possible, with early mobilization.

In Colton type I (avulsion) fractures, tension band wiring of the intraarticular fracture restores the continuity of the extensor mechanism and allows early range of motion. For the extraarticular fragment, treatment depends on fragment size and patient age. In the young person with a significant bony fragment, open reduction and internal fixation allows bone-to-bone healing. If the patient is older or the fragment size is limited, excision and reattachment of the triceps mechanism is preferred.

For Colton type II (transverse or oblique) fractures, internal fixation options include tension band wiring with associated K-wires or a screw (or screws) (79), and intrafragmentary compression screws with or without neutralization plating. I prefer a tension band wire with K-wires or a single screw of appropriate size. This method transforms tension forces into compressing forces across the fracture site (176). Active elbow flexion increases compression and stability because of the tension band construct. Plate fixation plus an interfragmentary compression screw is more stable than a tension band wire but requires more exposure (74).

For Colton type III fractures (fracture–subluxations), those that propagate from the distal third of the olecranon are potentially unstable. The biceps and brachial muscles may cause anterior subluxation of the radial head and displacement of the distal fragment of the ulna. This adds a compressive force to the posterior surface of the olecranon, making tension band wiring less effective (71). Therefore, I recommend rigid internal fixation with interfragmentary compression screws augmented by a neutralization plate. In some cases, a reverse obliquity of the fracture line may result in a proximal fragment too small for plate fixation. In this case, use an intramedullary compression screw to prevent anterior subluxation (Fig. 16.12). Failure to recognize this specific fracture pattern may result in unsatisfactory fixation.

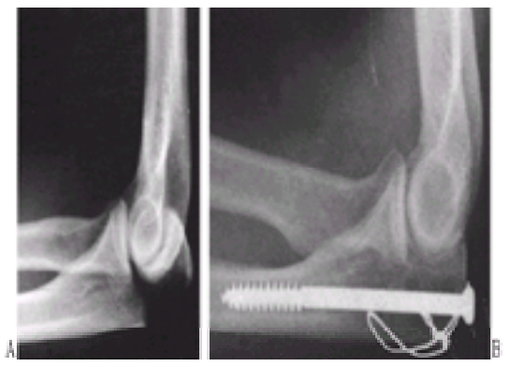

***Figure 16.12.*** **A:** A type III olecranon fracture in which the proximal fragment is insufficient for plating. Gross instability with anterior subluxation of the radius and ulna is noted at the time of surgery. **B:** Fixation using an intramedullary cancellous screw and tension band wiring.

Because of the high energy that causes Colton type IV (comminuted) injury, the fracture is frequently complex and is usually a challenge to reduce and fix (Fig. 16.13). If the fracture extends beyond the coronoid process, length must be restored. Fractures of the coronoid process must be adequately reduced and fixed to preserve stability (117). Reconstruct the joint surface using interfragmentary screw compression wherever possible. Bone graft is frequently needed. Then contour a 3.5 to 3.7 mm reconstruction plate to fit along the posterior–lateral cortex to buttress the fragments and help neutralize the deforming forces (Fig. 16.13*C*, Fig. 16.13*D*). A semitubular plate is usually too weak (152). Other possibilities for fixation include tension band wiring and the use of modified plates such as the hook plate (173). Tension band wiring alone is often unstable, allowing telescoping of the fragments with loss of articular congruity. Treatment of these difficult fractures must be individualized, with fixation based on the fracture pattern.

***Figure 16.13.*** Type IV olecranon fracture. **A:** Lateral view of a comminuted olecranon fracture with an associated radial head fracture and subluxation. **B:** AP view. **C:** Contoured plate fixation along the posterolateral cortex with interfragmentary compression where possible. **D:** AP view after fixation.

### *Excision*

Previously it was thought that primary excision of the proximal fragment in an olecranon fracture did not significantly impair power or stability (49). However, as discussed in the earlier section on biomechanics, there is a nearly linear relationship between loss of any portion of the olecranon and increasing instability in the elbow with loss of power in extension (4,138,176). Excision in young active patients is not recommended unless it is the only alternative available. In the elderly or inactive patient for whom comminution or poor bone quality limits the ability to internally fix the olecranon, approximately 40% of the proximal olecranon can be excised as long as the triceps is securely reattached so that early motion is possible (104). This will generally result in acceptable range of motion and power in sedentary patients.

### *Tension Band Wire Fixation*

- Position the patient prone with the extremity free over the side of the operating table and with the humerus supported on a movable padded arm board (122). This provides direct visualization of the posterior aspect of the elbow, allows free flexion and extension, and permits the entire extremity to be supported if desired. Prepare and drape the extremity free. A sterile tourniquet is useful.
- Make a dorsal longitudinal incision beginning 2.5 cm proximal to the olecranon, and gently curve laterally around the olecranon process to avoid crossing directly over its tip, as this may lead to a painful scar. Carry dissection down sharply to the fascia overlying the triceps tendon, and develop medial and lateral thick fasciocutaneous flaps. Identify and protect the ulnar nerve; it does not need to be mobilized in the vast majority of cases. Inspect the fracture site and clean the fragments.
- Make a small drill hole in the distal fragment to accept one tine of a reduction forceps. Insert the other tine into the proximal fragment, reduce the fracture anatomically, and compress it. Sometimes, two bone-holding forceps are necessary (Fig. 16.14*A*).

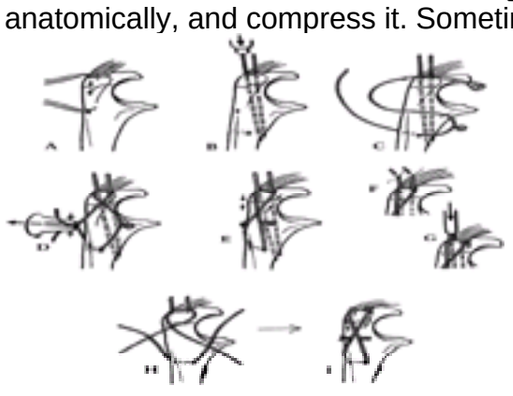

***Figure 16.14.*** Tension band wire fixation of an olecranon fracture. See text for a full description. **A:** Reduction of the fracture with reduction tines. **B:** Initial fixation with two 1.6 mm K-wires and placement of the transverse drill hole in the distal fragment. **C:** Initial passage of the 18-gauge malleable wire with a loop bent in one

side. **D:** Twisting the malleable wire on both sides to apply compression. **E:**. Compression across the fracture. **F:** Cutoff of excess length of the K-wires. **G:** Wires bent over and pounded into the olecranon, trapping the tension band wire. **H,I:** Accomplishment of the same fixation using double wires. (From Müller MS, Allgöwer M, Schneider R, Willenegger H. *Manual of Internal Fixation*, 2nd ed. New York: Springer-Verlag, 1979, with permission.)

- About 1 cm volar to the dorsal border of the ulna, drill a 2.5 mm transverse hole in the distal fragment (Fig. 16.14*B*). Next, drill two parallel 1.6-mm-diameter K-wires from the tip of the olecranon at the insertion of the triceps across the fracture and exiting the anterior cortex. These provide best fixation if they are close to the articular surface. Visualization with a C-arm fluoroscope on the lateral view during insertion is helpful. Use of a three-hole pointed guide ensures that the wires are parallel.
- Take an 18-gauge malleable wire of appropriate length, twist a loop into its midsection, and pass it volar to the proximal end of the K-wires through the triceps mechanism. Be certain that the wire is against the K-wires and the olecranon. Pass it in a figure-eight fashion through the transverse hole in the distal fragment (Fig. 16.14*C*).
- With the wires crossed, use a wire twister to tighten the free ends of the wire together. Tighten the loop alternately on opposite sides to produce even compression across the fracture site. Bend the free ends of the wire over, making certain that they are not prominent, and cut off the excess wire (Fig. 16.14*D*, Fig. 16.14*E*).
- Next, cut off excess K-wire, bend it into a sharp loop, and pound it into the tip of the olecranon across the tension band wire (Fig. 16.14*F*, Fig. 16.14*G*). Carry the elbow through a full range of motion to test the stability of the construct, and close the wounds in layers. Apply a bulky soft dressing, and immobilize the arm in a splint in about 30° of flexion.

### POSTOPERATIVE CARE

In most elbows, immediate active motion through nearly a full range of motion is possible. Patients must avoid any lifting or heavy use of the elbow until it is healed. This is a problem in multiply injured patients who spend the majority of their time in bed, because they tend to use their upper extremities to move themselves about the bed. Warn patients to avoid this. Where the fracture is comminuted or the bone osteoporotic and fixation marginal, determine the safe range of motion intraoperatively and apply a postoperative brace, setting the limits of the brace in the safe zone and allowing the patient early active motion. Once the fracture is healed, which is usually in 6–10 weeks, a full rehabilitation program is possible.

### HINTS AND TRICKS

- If there is segmental comminution in the fracture, tension band wiring is contraindicated because it will narrow the fossa of the olecranon and produce an incongruous joint. These require an intercalary bone graft and plate fixation. (This procedure will be described later.)
- Perfect position of the K-wires can be obtained by inserting them retrograde from the fracture site out the tip of the olecranon, and then inserting them antegrade after reduction of the fracture. This usually eliminates the need for a fluoroscope.
- Because of the cartilage at the insertion of the triceps into the olecranon, and because of the bulk of the triceps insertion, getting the malleable wire against the K-wires and directly against bone can be challenging. Sometimes, drilling a transverse hole through the olecranon just beneath the K-wires is easier.
- An 18-gauge wire may be too bulky in petite patients. For small patients, use a 20-gauge wire. Avoid unnecessary kinks or twists in the malleable wire, because this can lead to premature failure.
- To avoid excessive penetration of the K-wires from the anterior cortex, insert them through the cortex and then withdraw them approximately 1 cm; when the wires are pounded home, this will place them in optimal position.
- Bending the K-wires to fit over the malleable wire can be difficult. Leave the K-wire protruding 2–3 cm. Grasp it with thin-nosed pliers and place over the wire a small metal suction tip; use it to bend the wire to a 90° angle. Cut off all but 5 mm of the bent end. Then twist the wire 90° to bring it over the malleable wire. Make a small stab wound in the triceps to accept the K-wire and pound it home with a small punch. Be certain (with a lateral radiograph or fluoroscopic image) that the K-wire is fully buried, trapping the malleable wire.

## MONTEGGIA FRACTURE DISLOCATION

Originally described as a fracture of the proximal third of the ulna with anterior dislocation of the radial head, the Monteggia fracture–dislocation is a term now used to describe almost all ulna fractures associated with radial–humeral joint disruption. Although the ulna fracture is seldom undiagnosed, the associated dislocation of the radial head may elude the examiner in as many as one quarter of the cases (15,52). Regardless of the radiographic view of the elbow, a line drawn down the central axis of the radius and through the center of the radial head should always pass through the middle of the capitellum. Any shift in this alignment indicates subluxation or dislocation of the radial head. Always look for this when fractures of the ulna are present.

### CLASSIFICATION

A well-accepted and commonly used classification of the Monteggia lesion is that of Bado (Fig. 16.15) (9,10,134). The categories have in common a dislocation of the radial–humeral joint associated with a fracture of the ulna or with lesions at the wrist. Four types of fracture–dislocations are described, based on the direction of the radial head dislocation. A series of equivalent injuries is also described with respect to the mechanism of injury and treatment:

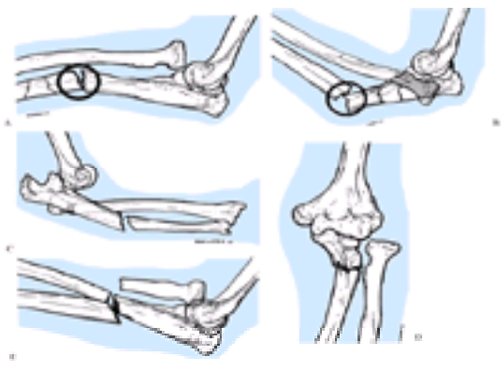

***Figure 16.15.*** Bado classification of Monteggia fracture–dislocations. **A:** Type 1. Ulnar diaphysis fracture with anterior angulation and associated anterior dislocation of the radial head. **B:** Type 2. Posterior dislocation of the radial head and fracture of the ulnar diaphysis with posterior angulation. **C:** Type 2–equivalent lesion with posterior dislocation of the elbow, fracture of the ulnar shaft and posterior angulation, and fracture of the head or neck of the radius. **D:** Type 3. Fracture of the ulnar shaft and associated lateral radial head dislocation. **E:** Type 4. Fracture through the proximal third of the radius and ulna at the same level, with associated anterior subluxation of the radial head. (From Reckling FW, Cordell LD. Unstable Fracture-Dislocations of the Forearm. The Monteggia and Galeazzi Lesions. *Arch Surg* 1968;96:999, with permission.)

- Type 1: Anterior dislocation of the radial head associated with fracture of the ulnar diaphysis at any level with anterior angulation (Fig. 16.15*A*): the most common Monteggia lesion, seen in about 60% to 80% of cases (10,134)
- Type 2: Posterior or posterolateral dislocation of the radial head and fracture of the ulnar diaphysis with posterior angulation (Fig. 16.15*B*, Fig. 16.15*C*)
- Type 3: Lateral or anterolateral dislocation of the radial head accompanied by a fracture of the ulnar metaphysis (Fig. 16.15*D*)
- Type 4: Anterior dislocation of the radial head associated with fractures of the proximal third of the radius and ulna at the same level (Fig. 16.15*E*)

Bado also described equivalent lesions for type 1:

- Anterior dislocation of the radial head alone
- Fracture of the ulnar diaphysis with a fracture of the neck of the radius
- Fracture of the neck of the radius
- Fracture of the ulnar diaphysis with fracture of the proximal third of the radius, where the radius fracture is proximal to the fractured ulna
- Fracture of the ulnar diaphysis with anterior dislocation of the radial head and fracture of the olecranon

- Posterior dislocation of the elbow and fracture of the ulnar diaphysis, with or without fracture of the proximal radius

Type 2 equivalents (Fig. 16.15C) are epiphyseal fractures of the dislocated radial head or fractures of the neck of the radius. Bado described no equivalents for Monteggia lesion types 3 and 4.

## TREATMENT

Compared to other forearm fractures, the Monteggia fracture dislocation is more likely to result in disability and permanent stiffness of the elbow (15,19,134,140). To the surgeon, this lesion is possibly the most challenging forearm injury. To enhance the chances of obtaining a satisfactory result, the following are needed:

- Anatomic and rigid internal fixation of the ulna fracture, with bone grafting as needed
- Anatomic reduction of the radial head dislocation
- Sufficient period of adequate immobilization in unstable injuries, and early motion in stable injuries

However, even with the most meticulous attention to these details, poor function may result.

The preceding principles can be applied to the skeletally mature patient, for whom it is generally accepted that operative intervention is indicated. However, the Monteggia lesion in children has been successfully treated by closed reduction and casting. Open treatment in a child with this injury is the exception.

### *Approaches to Treatment*

The approach to treatment is based on Bado's classification. In most series, type 1 injuries account for 60% to 80% of cases. In the series of Ring et al. (138,140), however, Bado type 2 was most common. The preferred treatment for type 1 is compression plate fixation of the ulnar fracture, with supplemental autogenous bone grafting if comminution is significant. Anatomic reduction and restoration of length is mandatory or the radial head will remain subluxed. Usually, the radial head reduces spontaneously after fixation of the ulna. If it does not, then either reduction of the fracture is inadequate or there is soft-tissue interposition. Inadequate reduction of the ulna mandates repeat reduction and fixation. Soft-tissue interposition, seen in fewer than 10% of cases, requires open visualization of the radiohumeral joint. A torn and interposed annular ligament is the usual offender; this requires reduction of the radial head and repair of the ligament. Interposition of the radial nerve is a rare cause of the unreduced radial head.

In type 2 injuries with posterior or posterolateral dislocation of the radial head, a fracture of the radial head or neck may be seen. Some surgeons perform early excision in these cases (15,19); however, I prefer to fix the radial head fracture because of its contribution to stability of the elbow. Radial head fractures may be seen in any of the other Monteggia lesion types as well. Treatment of the ulna fracture is anatomic restoration and plating (Fig. 16.16).

***Figure 16.16.*** Type 2 Monteggia lesion. **A:** Posterior radial head dislocation in association with a proximal ulna fracture. **B,C:** Anatomic restoration of the ulna fracture with plate fixation and interfragmentary compression, and reduction of the radial head.

The type 3 lesion is seen almost exclusively in children and is best treated closed. However, if seen in an adult, treat as described for a type 2 lesion.

For a type 4 lesion, open reduction and internal fixation of the radius and ulna fractures clearly constitutes the treatment of choice. Radial head reduction usually follows anatomic reduction of both bone fractures.

### *Plate Fixation*

- The operative approach to stabilize the Monteggia lesion is initially the same as for the isolated ulnar fracture. Position the patient supine with the involved arm on an arm board or across the patient's chest. Alternatively, place the patient in the lateral decubitus position with the arm supported on a bolster and the elbow flexed 90°. Prepare and drape the arm free. A sterile tourniquet is useful.
- Make an incision just lateral to the subcutaneous border of the ulna, centered over the fracture site, carrying the dissection through the subcutaneous tissue. Identify the fascia and periosteum between the extensor carpi ulnaris and the flexor carpi ulnaris muscles, and split this layer directly over the subcutaneous border. Take care to preserve soft-tissue attachments to bone. Limit the placement of retractors and bone clamps to the subperiosteal level; this will avoid damage to the ulnar nerve and artery, which lie under the flexor carpi ulnaris in this dissection.
- Identify the bone fragments and clean them of hematoma. Reduce the fracture anatomically, taking care to fully restore length because this is necessary to reduce and stabilize the radial head. Reduction can be difficult, especially in comminuted fractures, and in particular when there is a large free coronoid process. Sometimes, attaching the plate initially to the proximal fragment with a single screw and then using it to reduce the fracture is helpful.
- Try to use 3.5 mm regular or reconstruction plates or their equivalent. Semitubular plates tend to be too weak, but they do fit nicely along the subcutaneous border of the ulna and contour around the proximal tip of the olecranon. In very comminuted fractures, I often use a 3.5 mm plate as the primary plate and then use a two- to four-hole one-third tubular plate as a second plate to buttress comminution. Three plate locations are possible: the subcutaneous border, the lateral surface, or the medial surface. In most cases, the medial surface is best because it requires the least contouring and provides better fixation in the proximal fragment. The screws are directed from medial to lateral, so bicortical purchase can be obtained, whereas a plate over the subcutaneous border precludes bicortical fixation in the proximal fragment. Sometimes the plate works best laterally; however, the proximity of the dissection to the radial head increases the risk of a radial–ulnar synostosis. Plates along the subcutaneous border may work best when there is substantial comminution along this border that needs buttressing, but they have the disadvantage noted previously and in addition are quite prominent beneath the skin and therefore usually require removal (Fig. 16.16).
- Bone-graft comminuted fractures and those with missing bone substance. Small deficiencies that are nonarticular can be bone grafted with cancellous bone harvested from the iliac crest. Segmental loss or deficiencies in the articular surface often require a structural tricortical bone graft from the superior crest of the ilium to maintain length. As long as the congruity of the humeral ulnar joint is preserved, segmental deficiencies in the articular surface are usually well tolerated.
- Should intervening soft tissue prevent radial head reduction, open the radiohumeral joint; this is likely to occur in fewer than 10% of cases. The joint may be visualized by extending the incision proximally toward the lateral epicondyle of the humerus. Detach the anconeus muscle and the ulnar extensor muscles subperiosteally from the ulna and retract them anteriorly. Take care to protect the radial nerve and its branches, as the posterior interosseous nerve passes over the radial neck. Although uncommon, the nerve itself may even be the soft tissue blocking reduction. Once the joint is opened, reduce the radial head and repair the annular ligament under direct visualization if necessary.
- Ensure hemostasis and close the wound in layers. Apply a sterile dressing and then splint the forearm in a position that offers the best stability for the radial head, which is generally 90° of flexion and full supination. Occasionally, the reverse is true.

## HINTS AND TRICKS

- Special consideration is necessary if the Monteggia lesion is seen more than 4–6 weeks after injury as a result of inadequate treatment or misdiagnosis. Significant ulnar malunion requires corrective osteotomy, and an ulnar nonunion requires reduction, plating, and bone grafting. It is best to preserve the radial head, but persistent dislocation may require resection. The minimally subluxed radial head is probably best left alone, especially if adequate function is present. Minor degrees of ulnar angulation may also be acceptable in these late-presenting cases. A less-than-optimal result is often seen in these patients.
- Combinations of different types of internal fixation are often necessary in these difficult fractures. If the fracture has been plated but the proximal fragment is short or osteoporotic, adding a tension band wire to the plate may significantly increase the strength of the construct. It is important to fix large coronoid process fragments. This can be difficult and is discussed in more detail in the next section.
- In comminuted, unstable, displaced fractures (Mayo type IIIB), internal fixation alone may be inadequate. In these cases, Morrey (117) uses a distraction-type external hinge fixator (DJG, Howmedica, Rutherford, NJ). He begins with continuous passive motion with the distraction device in place, and then he encourages active assisted motion. He removes the fixator under anesthesia at approximately 4 weeks and then relies heavily on splints to protect the collateral ligaments. To help restore motion, he uses adjustable splints to encourage motion in one direction at night and the opposite motion during the day.

### POSTOPERATIVE CARE

Immobilize in a long-arm cast with moderate to full supination for about 2–3 weeks. For type 1, 3, and 4 lesions, maintain flexion at 90°. Position type 2 lesions at 70° of flexion. After removal of the cast, begin active motion. Avoid extremes of motion to prevent recurrent radial head subluxation. A motion restricting brace may be helpful.

## CORONOID PROCESS FRACTURES

Coronoid process fractures have been classified by Regan and Morrey (135) as follows:

- Type I is a small chip fracture that has no clinical importance but suggests the possibility of an elbow dislocation.
- Type II involves 50% of the coronoid process and may or may not be associated with an unstable elbow.
- Type III is a fracture of the entire coronoid process.

### TREATMENT

Type I fractures require no treatment other than symptomatic, although careful evaluation of the elbow to look for major ligamentous injury is essential.

In type II fractures, if the ulnar humeral joint is unstable, fixation is indicated (Fig. 16.17). If fixation is not possible, the elbow may be stabilized with the distraction external fixator without fixation of the fragment.

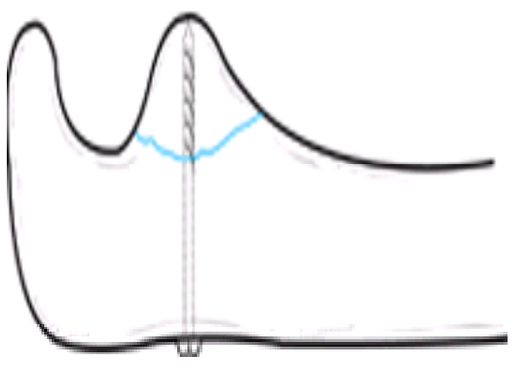

***Figure 16.17.*** Fixation of a type 3 fracture of the coronoid process with a 4.0 mm lag screw.

In type III fractures, open reduction and internal fixation are indicated if the fracture is not too comminuted and therefore unfixable. Loss of fixation or redisplacement of these is common; therefore, Regan and Morrey (135) neutralize the deforming forces across the elbow with a distraction hinge external fixator. In comminuted fractures, they do not excise the bone fragments, as this can lead to chronic elbow instability, but stabilize them with #5 nonresorbable sutures to the shaft of the ulna using the distraction device to provide stability. Early motion in all of these fractures is important.

Using these indications, Regan and Morrey (135) were able to obtain satisfactory results in 90% of patients with type I fractures and 67% with type II, but only 25% for type III, showing the difficulty of these fractures.

## RADIAL HEAD AND NECK FRACTURES

Fractures of the radial head are a common injury about the elbow, and management remains controversial (3,115). The vast majority of these injuries result from an axial load transmitted across the radiocapitellar joint with the forearm in a pronated position. The key factors in clinical decision making are elbow motion and stability. Assessment of the distal radioulnar joint is essential so that associated Essex-Lopresti–type injures (44,163,170) do not result in mismanagement and increased disability.

Take AP and lateral radiographs of the elbow and wrist. Often a posterior fat pad sign, with or without an anterior fat pad sign, is all that is seen, indicating a hemarthrosis secondary to a radial head fracture. The radiocapitellar view, a modified lateral of the elbow joint with the tube angled 45° toward the radial head, has been shown to be useful in detecting and evaluating fractures of the head of the radius (56).

### CLASSIFICATION

The most widely used and accepted classification of radial head fractures is Mason's (97):

- Type I: Undisplaced (Fig. 16.18*A*)

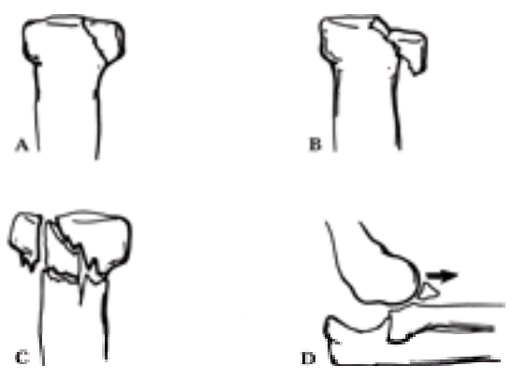


***Figure 16.18.*** Mason's classification of radial head fractures. **A:** Type I radial head fracture, nondisplaced. **B:** Type II injury with marginal fracture and displacement. **C:** Type III radial head fracture demonstrating comminution of the entire head. **D:** Type IV injury—ma radial head fracture in association with an elbow dislocation. (From Mason ML. Some Observations on Fractures of the Head of the Radius with a Review of 100 Cases. *Br J Surg* 1954;42:123, with permission.)

- Type II: Marginal fracture with displacement (Fig. 16.18*B*)
- Type III: Comminution involving the entire head (Fig. 16.18*C*)

About 10% of all radial head fractures occur in association with an elbow dislocation. This may result in altered treatment and prognosis; thus others have designated this as a type IV injury (Fig. 16.18*D*).

The Orthopaedic Trauma Association and the International Society for Fracture Repair classification system (125) provides a much more detailed classification, which includes fractures of both the head and neck, both as isolated injuries and in combination with fractures of the ulna. Because all clinical studies published to date use the Mason classification, I use it here.

**TREATMENT**

The goal of treatment is to maintain good elbow function and thus to retain adequate motion and joint stability. To evaluate function acutely, aspirate the elbow and then instill local anesthetic into the elbow joint. This affords two benefits. First, it decompresses the joint and relieves pain (68). Second, once the elbow becomes relatively painless, it is possible to determine whether there is a bony block to motion or not. This procedure is important in all radial head fractures in which closed treatment is being considered.

Much controversy exists concerning the advantages and disadvantages of radial head excision. Advocates feel that it allows early motion and less morbidity for most type II and III fractures (77). Others have disputed this mode of therapy, noting complications of subluxation of the distal radioulnar joint, elbow pain, and cubitus valgus deformity following excision (25,45,110,114,138). Since the radial head has a role as a significant stabilizer of the elbow, recommendations for early excision have probably been overstated. Proponents of saving the head in all fracture types note that late excision is still a viable option that has been shown to give good results (18,117,118,126,179).

To preserve stability of the elbow and prevent proximal radial migration, prosthetic replacement with silicone rubber has been proposed (60,120,121,161). I no longer use silicone implants because they are unstable and lead to silicone synovitis. This view is supported by others (112). Certainly, the routine use of a prosthesis in the treatment of radial head fractures is not favored. Situations in which its use may be indicated are fractures associated with elbow or distal radioulnar instability, for which a rigid stable replacement such as a metallic head or allograft might be useful. We have used both at the University of California Davis Medical Center, but our experience and that of others is limited, and effectiveness is not yet proven (82,162).

Because of the failure of other methods to obtain consistent, reliably satisfactory results in Mason type II, III, and IV fractures, I recommend reconstruction of the radial head and neck with anatomic restoration of the radiohumeral joint, despite its technical difficulty. Current indications for open reduction and internal fixation are as follows:

- The main fragment includes more than one quarter of the articular surface.
- The fragment is displaced more than 2 mm.
- There are additional lesions of the capitellum or fracture of the proximal ulna, as well as a ruptured collateral ligament or distal radioulnar joint injury (51).
- Clinical exam reveals less than 70° of forearm rotation in both directions, or less than 20° to 140° of flexion.

Small and minifragment screws can be used to reconstruct the radial head, and miniplates can be used on the neck. Try to place fixation where it will not encounter the proximal radioulnar joint (sigmoid notch). Countersinking the screw head is necessary if it is placed within the articular circumference. An alternative method of fixation is the Herbert differential pitch bone screw, which allows for placement beneath the articular surface (98). Absorbable pins may be used as well (127). Long-term studies evaluating operative reconstruction of these injuries are needed before there will be widespread acceptance (117). Treatment is based on the fracture type.

Treat Mason type I undisplaced radial head fractures by aspiration and evaluation for any block to motion. If there is no bony block to motion, then begin early active range of motion after pain has subsided. Initial splinting provides comfort while allowing full pronation and supination. Take frequent follow-up radiographs to check for displacement.

Type II fractures are most controversial. If the fracture pattern is amenable to internal fixation, I favor anatomic restoration (Fig. 16.19). Otherwise, nonoperative treatment is advocated, again with aspiration and evaluation of motion (53). If problems persist, perform late excision.

***Figure 16.19.*** Mason type II radial head fracture. **A:** Marginal fracture of the radial head involving more than one third of the articular surface. **B:** Open reduction and internal fixation with two minifragment screws, obtaining anatomic reduction and interfragmentary compression.

Type III comminuted fractures in most elbows are best treated with complete excision within 48 hours after fracture. The elbow will be stable to valgus stress if the medial collateral ligament is intact. There appears to be no advantage to removal of just the displaced fragments. If examination under anesthesia in type III injuries reveals satisfactory motion, pursue nonoperative treatment, with late excision of the radial head if the result is not satisfactory. However, late excision of the radial head after type III fractures does not give nearly as good results as it does after type II fractures (4,117). With the increasing sophistication of mini-fragment fixation systems, more surgeons are attempting to reconstruct and internally fix these fractures (45,120,147). For stable elbows, Morrey (117) advocates excision, and I agree. In complex fractures with instability of the elbow or an Essex-Lopresti lesion, however, treatment is exceedingly difficult. Fixation of the radial head and neck with a miniplate and screw system may be essential to a stable elbow.

Treat type IV fractures, with a posterior dislocation of the elbow together with a radial head fracture, by initial reduction of the dislocation and then treatment of the radial head according to the principles just described. Preservation of the radial head in these injuries is important to maintain stability and thus is highly recommended (25,81,117,179). When extirpation of the head is unavoidable, consider repair of the torn ligaments or use of a distraction external fixation or a temporary radial head prosthesis.

***Excision or Repair of the Radial Head and Neck***

- Position the patient supine with a pad under the ipsilateral shoulder. Prepare and drape the arm free and rest it on the patient's chest or a small arm table. Use a sterile tourniquet.
- Use a Kocher approach (see Chapter 1). Incise the skin beginning at the lateral humeral epicondyle. Extend obliquely across the radial head, ending at the posterior border of the ulna. Identify and split the fascia between the anconeus muscle and the extensor carpi ulnaris muscle, then spread these two muscles and their associated fascia to bring the underlying capsule of the radiohumeral joint into view. To aid exposure, detach part of the superior anconeus from the lateral epicondyle of the humerus. Pronate the forearm to roll the radial nerve and its posterior interosseous branch to a more anterior position. Then incise the posterolateral aspect of the capsule. Take care not to carry the incision past the annular ligament because this risks injuring the posterior interosseous nerve. Also, avoid applying too much tension with retractors anteriorly or distally because this also risks nerve injury.
- Identify the fracture fragments and clean them of hematoma. In Mason type II fractures, if the fragment has good soft-tissue attachments, try to maintain them. Reduce the fracture and internally fix it with a 2.7 mm screw using lag technique. Try to use two screws if the size of the fragment will permit. Other screw sizes may be indicated for smaller or larger fragments. Countersink the screw heads beneath the articular surface.
- In comminuted fractures, the entire radial head may be free fragments. Assemble the fragments on the back table, internally fixing them in a similar manner. If a

portion of the radial head is intact, fix the preassembled radial head to the intact fragment. If the entire head is comminuted, it can be entirely assembled and internally fixed on the back table. At this point, you are dealing with a neck fracture.

- To internally fix a neck fracture, determine the portion of the radial head and neck that does not encounter the sigmoid notch, and use it for the site of a minifragment T-plate. Fashion this plate to fit the contour of the radial head and neck. Securely fix it using compression techniques if possible. Examine the construct before closure to determine its stability and the safe range of motion.
- Thoroughly irrigate the joint and wound and close the wound in layers. Apply a sterile dressing and splint the elbow in the most stable position.
- For resection of comminuted fragments of the radial head, remove all fragments and thoroughly irrigate the elbow joint. Using a high-speed burr, smooth off the stump of the proximal radius level with or slightly distal to the proximal edge of the annular ligament. Purse-string the capsular remnants and annular ligament around the stump of the proximal radius to increase its stability. Be certain not to restrict motion.

***Replacement of the Radial Head***

- Replacement of the radial head with an allograft is no different from fixation of a radial neck fracture as described above. Secure fixation is required if union is to occur.
- Prosthetic replacement with a metallic prosthesis is rarely performed and is specific to the few prostheses available. Please see the manufacturer's instructions. The surgical approach and soft-tissue techniques are roughly the same.

**POSTOPERATIVE CARE**

Early motion is essential for a good result. Having determined the safe and stable range of motion under anesthesia prior to wound closure, apply a motion-limiting brace and begin active motion as soon as the patient's pain and soft-tissue swelling are controlled. Dynamic splinting after 6 weeks may be helpful in gaining range of motion, as previously described. Avoid resistive exercises or heavy use of the elbow until fracture union has occurred.

**HINTS AND TRICKS**

- Holding and reducing these small fragments, which are in many cases covered entirely by articular cartilage, can be very challenging. Insertion of a 1.6 mm K-wire into the fragments to act as a “joystick” helps to grasp the fragments, reduce them, and hold them in position while internal fixation is applied.
- Prior to reduction of a free fragment, drill the screw hole. This guarantees good position of the screw and easier insertion.
- When using the T-plate, if there is insufficient space proximal to the annular ligament, the plate can be slid under the ligament and a screw inserted through a small stab wound. Take care to avoid injury to the branches of the posterior interosseous nerve.
- Sometimes, after fixation, the radial head remains unstable and tends to sublux. This is usually the result of nonanatomic reduction of an associated ulnar fracture. First, be certain that the ulnar fracture is out to length and anatomic. If instability continues and cannot be controlled by positioning of the elbow, insertion of a 2 mm K-wire from the radius into the ulna will provide temporary stability. This increases the risk of synostosis of the radius and ulna. Leave it sufficiently prominent that removal is easy at 3 weeks, when there is usually sufficient stability to begin motion.

## ELBOW DISLOCATIONS

Traumatic dislocation of the elbow is a common injury, second in frequency only to shoulder dislocation (81,105,118,157). It is usually sustained by active older children, adolescents, and young adults. Elbow injuries occurring in younger or older patients are more likely to involve fractures. Pure dislocations or those with small periarticular fractures are the subjects of this section.

### MECHANISM OF INJURY

The usual cause of elbow dislocation is a fall on the outstretched arm. Motor-vehicle accidents are also a common cause of elbow dislocation, frequently with associated systemic injury. These are often higher-energy injuries, and the mechanism may involve axial compressive loading on a slightly flexed elbow. In most cases, a posterolateral dislocation occurs with tearing of the radial collateral ligament and lateral capsule (157). Associated fractures are more likely to occur in higher-energy injuries. With hyperextension of the elbow, the capsular constraints are torn and the humerus is driven through the capsule anteriorly, tearing the brachialis muscle. The anterior portion of the medial collateral ligament appears to be the primary stabilizer in resisting valgus stress and is a pivot point that allows the radius and ulna to dislocate posteriorly when the lateral ligamentous constraints are torn (Fig. 16.20) (72,157). The final position is usually posterolateral, but depending on the resultant force vector, straight posterior or posteromedial dislocation may occur.

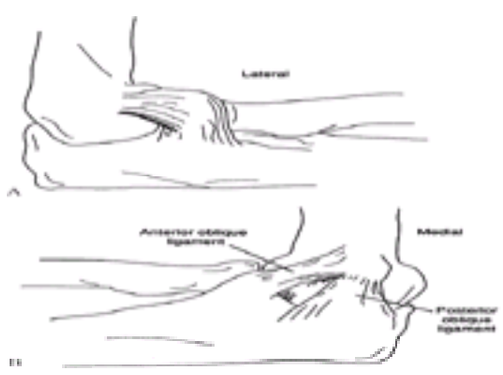


***Figure 16.20.*** The collateral ligaments of the elbow. **A:** Lateral. **B:** Medial. (Redrawn with permission from Rockwood CA, Green DP. *Fractures in Adults.* Philadelphia: JB Lippincott, 1974.)

Other directions of elbow dislocation are distinctively uncommon. The rare anterior dislocation occurs with extreme hyperextension and may be associated with extensive tearing of the brachialis musculature, or neurovascular injury. Straight lateral dislocations are also rare and are associated with extensive tearing of the medial ligamentous restraints. The reverse is true for the uncommon medial dislocation or subluxation. Divergent dislocations are rare high-energy injuries associated with extensive soft-tissue injury to the interosseus membrane, joint capsule, and collateral and annular ligaments (Fig. 16.21). Usually, this strong musculoligamentous complex binds the radius and ulna securely, so that both bones dislocate together in a linear fashion. Therefore, isolated dislocation of either bone is uncommon, although dislocation of the radial head is frequently associated with fractures of the proximal ulna (139) (i.e., Monteggia type 1 injury) (Fig. 16.22). In children, the ulnar fracture can be subtle, consisting only of mild ulnar bowing in association with a dislocation of the radial head, which is usually anterior but uncommonly may be posterior or lateral. Occasionally, the radial head remains dislocated after attempted reduction of an elbow dislocation. Congenital or developmental dislocation of the radial head with superimposed acute trauma may present difficulty in diagnosis. These conditions are usually bilateral, and radiographic evaluation of the opposite elbow is helpful in securing the diagnosis.

***Figure 16.21.*** Divergent dislocation of the elbow.

***Figure 16.22.*** Anterior dislocation of the radial head. The radius and capitellum are not colinear.

Displaced radial head fractures are uncommonly associated with dislocation of the distal radioulnar joint (Essex-Lopresti injury). This injury has been discussed previously with radial head fractures.

**CLASSIFICATION**

Modification of Hamilton and Stimson's long-established classification is shown in Figure 16.23 (105). This system includes uncommon varieties of dislocation. However, from a practical standpoint, approximately 90% of elbow dislocations encountered are posterior or posterolateral (Fig. 16.24).

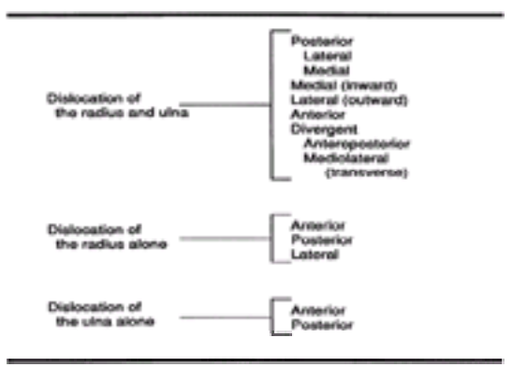


***Figure 16.23.*** Classification of adult elbow dislocations. (From Stimson LA. *A Treatise on Fractures.* Philadelphia: Henry C. Lea's Son, 1890, with permission.)

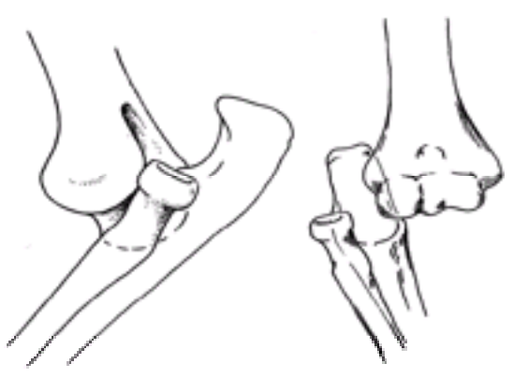

***Figure 16.24.*** Posterolateral elbow dislocation.

**PHYSICAL FINDINGS**

The conscious patient has severe pain. The elbow is swollen and usually held in slight flexion, often supported by the uninjured hand. The forearm is foreshortened, and the olecranon and radial head are prominent posteriorly in the typical dislocation. Neurovascular function is usually intact but needs to be accurately assessed. With rare anterior dislocation, neurovascular injury may be present. Crepitus or extensive ecchymosis implies a fracture dislocation. Soft-tissue abrasions about the elbow may exist, although open dislocation is uncommon.

**RADIOGRAPHIC FINDINGS**

Radiographs in two planes reveal the type of dislocation. They should be scrutinized carefully for associated periarticular fracture, especially of the radial head, coronoid process of the ulna, or medial epicondyle (Fig. 16.25). The latter fracture is seen more commonly in children and is the most likely culprit in irreducible elbow dislocation. When fracture of the medial epicondyle accompanies elbow dislocation, it usually reduces with elbow relocation. Occasionally, it is incarcerated in the joint, preventing reduction and requiring surgical treatment. In the unlikely event that physical examination suggests a vascular injury, obtain an arteriogram promptly.

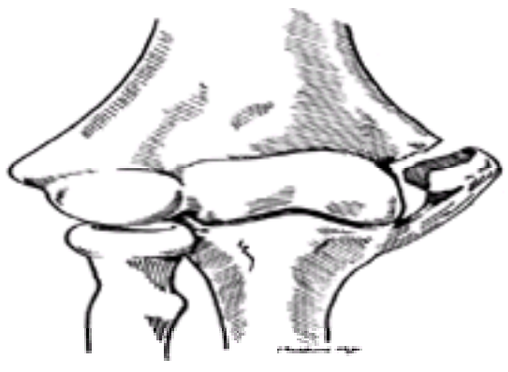

***Figure 16.25.*** Fracture of the medial epicondyle.

**TREATMENT**

Reduce the elbow as soon as possible using closed manipulation. Closed reduction usually is not difficult. Most elbow dislocations can be reduced in the emergency room under conscious sedation. Various methods of reduction have been described. All techniques involve correcting any lateral or medial displacement. Figure 16.26 depicts a method in which the arm hangs off the end of a well-padded table and the patient is prone and relaxed. With the elbow flexed at 90°, apply gentle but firm traction on the forearm while grasping the distal humerus with your opposite hand, and apply thumb pressure on the posteriorly displaced olecranon. Some physicians advise mild hyperextension to diminish impingement of the coronoid process, but this is usually not necessary. After reduction, gently flex and extend the elbow to ensure that reduction is complete and to ascertain stability. Confirm reduction on radiographs.

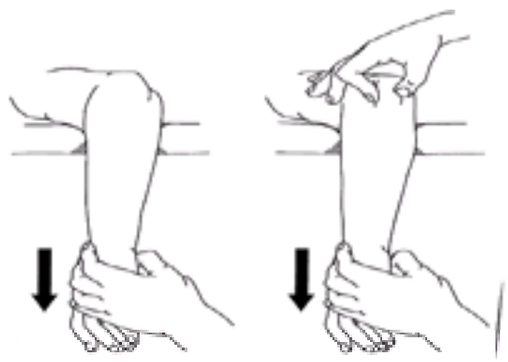

***Figure 16.26.*** Closed reduction of a posterior dislocation of the elbow. (Redrawn with permission from Rockwood CA, Green DP. *Fractures in Adults.* Philadelphia: JB Lippincott, 1974.)

Reduce anterior dislocations by slight flexion and posterior displacement of the forearm, accompanied by gentle traction. The rare divergent dislocation usually requires separate reductions of the ulna and then of the radius. Gross instability or residual subluxation may require open reduction and repair of the annular ligament and capsuloligamentous complex.

**SURGICAL INDICATIONS**

Most elbow dislocations unaccompanied by major periarticular fracture are not difficult to reduce. Inability to reduce an elbow dislocation promptly requires careful reevaluation of radiographs and physical findings to ascertain the impediment. The most frequent indications for operative intervention are irreducible dislocation, associated fractures, incongruous joint after reduction, gross instability or neurovascular injury, and unreduced (chronic) dislocations (44).

***Irreducible Dislocations***

The usual cause for the inability to reduce an acute dislocation is an entrapped medial epicondyle. This is somewhat more common in children. In most cases, the fracture of the medial epicondyle reduces with reduction of the elbow dislocation. An attempt may be made to reduce the incarcerated fragment by having the patient activate the flexor–pronator muscle mass to which the fragment may be attached. Otherwise, treatment is by open reduction and extraction of the fragment from the elbow joint, followed by internal fixation or excision of the fragment, depending on its size. Before skeletal maturation, significant displacement should be treated by open reduction and pinning of the medial epicondylar fragment.

***Associated Fractures***

Many fractures occur with dislocations of the elbow; when fractures and severe ligament injuries are associated, treatment can be difficult. For the most part, treatment of these is focused on treatment of the fractures, which usually results in stability of the elbow. This is discussed in detail in the preceding section.

***Incongruous Joint***

Soft-tissue interposition is a less common cause of the inability to reduce an acute dislocation, and it may involve entrapment of the annular or collateral ligaments, or buttonholing of the radial head through the posterolateral capsule. The joint may be asymmetric or incongruous after reduction for the same reasons. Fragments remaining in the joint or interposed soft tissue require surgical removal. Small fragments that do not compromise joint congruency or interfere with motion can be observed and, if necessary, removed at a later date.

***Ligamentous Instability***

Most elbow dislocations are reasonably stable after reduction. Occasionally, the lateral capsuloligamentous complex and, rarely, the medial ligamentous structures are extensively torn, necessitating repair because of gross instability (Fig. 16.27) (44,64,81). Use strong absorbable sutures anchored through drill holes in bone to ensure postoperative stability and allow early mobilization. With medial side instability, repair the medial collateral ligament, especially its anterior portion. Gross instability may require both medial and lateral capsuloligamentous repair. Postoperatively, maintain the elbow in the position of greatest stability until sufficient healing has taken placed to allow protected graduated exercises, usually in a dynamic splint (72,157).

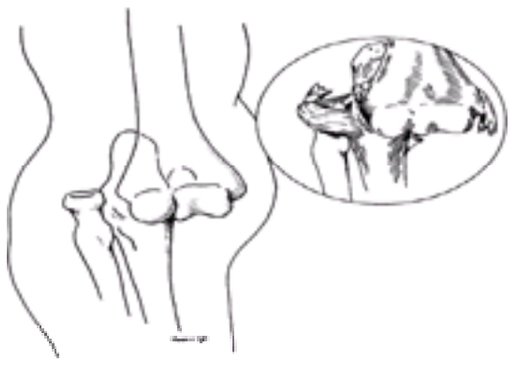

***Figure 16.27.*** Ligamentous injury accompanying elbow dislocation.

***Unreduced Dislocations***

Elbow dislocations presenting late may require general anesthesia for reduction. After 2–3 weeks, open reduction is often necessary, usually through a long extensile posterolateral approach. Dislocations existing beyond this time present with progressively increasing musculotendinous retraction, scarring, and articular degeneration. Arthrodesis or arthroplasty may be indicated for the significantly symptomatic patient.

## POSTEROLATERAL ROTATORY INSTABILITY OF THE ELBOW

O'Driscoll et al. (124) have described recurrent posterolateral rotary instability of the elbow as a clinical entity that can be distinguished from dislocation of the elbow and is unrelated to dislocation of the radial head. Their patients complained of locking or snapping of the involved elbow. Diagnosis is based on the lateral pivot-shift

test of the elbow, which involves supinating the forearm and applying a valgus moment and an axial force to the elbow while flexing it from full extension. Flexion past about 30° produces a sudden palpable and visible reduction of the radiohumeral joint. The essential lesion is felt to be laxity or detachment of the lateral ulnar collateral ligament. Surgical intervention involves restoring the functional integrity of this ligamentous complex.

Recurrent dislocation of the elbow is distinctly unusual (64,105). Therefore, start motion early in joints that are stable after reduction. A brief period of immobilization (1–5 days) is all that is necessary for stable injuries. Immobilize in a padded posterior splint with the elbow flexed to 90°. Initiate gentle passive and progressive active assistive and active range of motion as soon as practical.

Unstable injuries without associated fracture of the radial head or coronoid process are unusual, but they should be protected for longer periods in the position of maximal stability. Usually, this is 90° or more of flexion at the elbow. Advise the patient of the symptoms and signs of repeat dislocation. As with fractures requiring reductions, a repeat examination at 24–48 hours is recommended, with radiographs taken to confirm that reduction has been maintained. Follow the patient closely during the first 10–14 days; if dislocation recurs, it can be promptly recognized and treated (75). Numerous studies have shown that patients who are mobilized early have the best results and are most likely to regain normal or near-normal elbow extension.

## FRACTURES OF THE SHAFT OF THE RADIUS AND ULNA

The five joints of the forearm (ulnohumeral, radiohumeral, proximal radioulnar, distal radioulnar, and radiocarpal) constitute a delicately arranged mechanism that may be disrupted in any or all of its parts by a shaft fracture of the radius or ulna. Shortening, angulation, or malrotation of either of these bones will cause functional problems at the wrist or elbow. If functional disability is to be avoided following fracture, precise anatomic reduction is necessary; even a very minor nonanatomic variation of healing may constitute a malunion. Because the muscles of supination and pronation apply rotational and angulatory forces to the radius and ulna, maintenance of reduction after displaced or unstable fractures requires rigid internal fixation (24). Treatment of fractures of the radius or ulna depends on the amount of displacement and the degree of stability of the fracture pattern.

### CLASSIFICATION

The classification of forearm fractures is simple and straightforward. It is based on the level of the fracture(s), from proximal to distal; the bone(s) that are involved; the degree of displacement, angulation, and rotation; the presence or absence of overriding, segmentation, or comminution; and whether the fracture is open or closed. The Orthopaedic Trauma Association and the International Society for Fracture Repair system (125) classifies shaft fractures into 36 types; these are not clinically useful, although they are used in clinical investigation.

Fractures of the ulnar shaft that commence at about the level of the coronoid process, extending to about midshaft, and that occur in conjunction with dislocation of the radial head are known as Monteggia fractures and have been discussed previously in this chapter (1,9,10,15,19,40,133,134,151,158).

Fractures of the proximal third of the radius are characterized by rotational problems; these are discussed later in this chapter.

Midshaft fractures of the radius or ulna, or both, present with varying configurations, depending on the mechanism by which the injury was inflicted and the degree of violence involved (37). The fractures are typically transverse or short oblique if they are simple. Alternatively, in high-energy injuries, they may exhibit extensive comminution or segmentation, with significant soft-tissue involvement.

Fractures of the lower half of the ulna are known as “nightstick fractures,” an obvious reference to the mechanism of injury. Fractures of the radius with disruption of the distal radioulnar joint are termed Galeazzi or Piedmont fractures (90,108,109,113).

### ASSESSMENT

Perform clinical and radiologic evaluation, together with careful attention to the condition of the soft tissues. Often the deformity of the forearm with fractures of one or both bones will be evident immediately. Refrain from excessive manipulation to avoid further damage to soft tissues. Note any evidence of neurologic or vascular compromise. Check the patient periodically to confirm the continuing integrity of circulatory and neurologic function.

Radiographs must include x-ray views in two orthogonal planes of the entire forearm, including both the elbow and the wrist joints. Fractures of the radius and ulna can be complicated by subtle injuries to these joints. Radial–ulnar disassociation with rupture of the central band of the intraosseous ligament can be difficult to detect and is often diagnosed late (166,170). Especially when fractures of the proximal radius and/or radial head and neck show shortening, look for evidence of proximal subluxation of the radius at the distal radioulnar joint. Comparison films to the opposite normal side may be necessary. On clinical examination, more pain than would be expected and tenderness at the distal radioulnar joint should suggest this injury.

### SURGICAL ANATOMY

The ulna, which is relatively straight, has a stable articulation with the distal humerus at the elbow and runs virtually subcutaneously distally to the ulnar styloid at the wrist. The radius is bowed along its length from the widened distal end, which articulates with the carpus, to just distal to the bicipital tuberosity (at the insertion of the biceps tendon). There, it angles at about 13° opposite to the bow to articulate with the capitellum. The radius and ulna form a joint at the distal end, where the strutlike radius sweeps and rotates around the relatively fixed distal ulna with motions of pronation and supination.

In treating fractures in the forearm, the radial bow and proper interosseous space must be maintained for normal motion to be achieved. Schemitsch and Richards (153), as discussed previously, showed that restoration of the radial bow is related in a directly linear fashion to the quality of the outcome. Normal rotation of the forearm requires a normal bow in the radius. The normal maximum radial bow, measured by the distance between the radius in the ulna across the interosseous membrane, is 15 mm. To get 80% of normal range of motion, this bow must be within 1.5 mm. The same relationship is related to grip strength. Both the amount of bow and the location are important.

Moore et al. (113) demonstrated the importance of the interosseous ligament to the axial stability of the distal radioulnar joint in cadavers. They showed that osteotomy of the radius allows axial movement of the radius of 3 mm and division of the triangular fibrocartilage increases the movement to 6 mm, whereas division of the central band of the interosseous membrane produced more than 10 mm of proximal migration of the radius. In mechanical tests of cadaver intraosseous membranes, Wallace et al. (170) demonstrated elongation of about 10 mm of the central band before failure. In a preliminary study, they demonstrated that ultrasound may be of value in detecting tears of the interosseous membrane.

Markolf et al. (96) showed that when the elbow is in valgus alignment with contact of the radial head against the capitellum, the main pathway for load transmission from the hand to the elbow is through the radius. When the hand was loaded, with the forearm in neutral rotation, the mean force in the proximal ulnar–humeral joint was only 12%, whereas when the elbow was in varus alignment and the forearm in neutral rotation, 93% of the force was transferred via the interosseous membrane through the ulna. It is evident that transfer of a load from the wrist through the radius and ulna to the elbow is complex and dependent on the anatomy of the wrist, the soft-tissue attachments between the radius and the ulna, and the position of the forearm. Radial–ulnar load-sharing changes significantly when the distal end of the radius is shortened by as little as 2 mm, emphasizing the need for anatomic reduction.

The forces of muscle groups originating or inserting at different levels of the radius and ulna are associated with various deformities after fixation. For example, a fracture in the proximal third of the radius, occurring between the supinator insertion and the pronator teres insertion, results in supination of the proximal fragment and pronation and angulation of the distal radius. In addition to supination, the biceps brachii tends to flex the proximal radial segment. If the fracture occurs distal to the insertion of the pronator teres, both fragments are likely to be found in neutral rotation (Fig. 16.28).

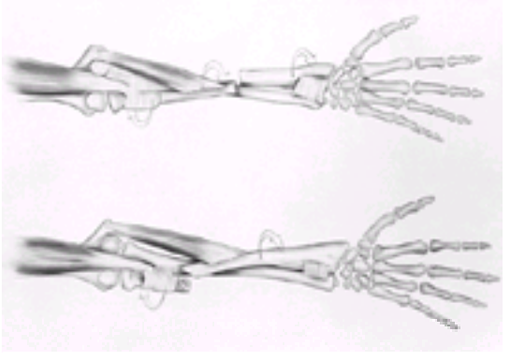

***Figure 16.28.*** Rotational deformities vary according to the level of the radial fracture. (After Watson-Jones R. *Fractures and Joint Injuries*, vol. 2, 4th ed. Edinburgh: E & S Livingstone, 1955. In: Rockwood CA, Green DP, eds. *Fractures*, 2nd ed. Philadelphia: JB Lippincott, 1984:443, with permission.)

Distally, the insertion of the pronator quadratus pronates the distal radial fragment. In the presence of an intact radius, fractures of the ulnar shaft are comparatively less affected. Muscles attaching to the proximal ulna are resisted by the stability of the elbow joint. The radial head, of course, is not restricted by that joint. Distally the ulna has little mobility and relatively weak muscle attachments, so it is not often displaced.

**CLOSED TREATMENT**

Fractures of one or both bones of the forearm, if essentially undisplaced and stable, may be successfully treated by closed methods (14,33,35,36,149,150). This requires meticulous attention to molding of the plaster to maintain the necessary relationships among the radius, ulna, and interosseous membrane. The fracture must be evaluated weekly to ensure that no loss of position has occurred. The technique for closed treatment is well outlined in an excellent book by Charnley (31). See Chapter 10 for additional information on application of upper extremity casts. Isolated ulnar shaft fractures with less than 10° of angulation can be treated with casts or braces (149,150).

Sarmiento et al. (150) treated 287 isolated fractures of the ulnar shaft with prefabricated functional braces resulting in a 99% union rate and good to excellent functional results in 96% of the cases.

Only in children does the salubrious effect of growth and remodeling offer an alternative to the otherwise mandatory surgical treatment of displaced or unstable forearm fractures, assuming that adequate alignment and proper rotation of the fragments can be obtained and maintained by closed methods. Angulation in the plane of joint motion is most likely to improve with growth and remodeling. However, rotational deformities and loss of normal interosseous space cannot be expected to improve with growth and remodeling, even in very young patients. The cut-off ages are in the range of 10–12 years in girls and 12–14 years in boys. At these ages, surgical treatment must strongly be considered for displaced fractures of the forearm.

**OPEN TREATMENT**

All displaced, unstable fractures of the radius and ulna in adults are best treated with internal fixation (6,7,20,22,38,42,43,54,59,65,66,78,89,107,111,122,123,131,141,148,153,155,159,160,163,164,166), including isolated fractures of the ulna with angulation greater than 10°, Monteggia fracture–dislocations, and Galeazzi fractures.

Open fractures warrant immediate irrigation, debridement, administration of antibiotics, and stabilization of the fracture by internal or external fixation (see Chapter 12). Compartment syndrome, which must be treated by fasciotomy, also warrants stabilization of fracture fragments by internal or external fixation.

**TIMING**

Fractures are best internally fixed as soon after injury as practical, preferably before the onset of swelling. With delay, fracture blisters secondary to swelling can develop. Ruptured fracture blisters or abrasions that are more than 6–8 hours old may be contraindications for surgery. At least 7–10 days may be required for abraded skin and fracture blisters to heal and for swelling to subside.

Chapman et al. (29) have shown that immediate fixation of open fractures of the forearm of all grades can be done with minimal risk of infection if thorough irrigation and debridement are done. Only 1 of 49 open fractures plated primarily became infected, and that resolved with treatment.

**SURGICAL APPROACHES**

Plan the surgical approaches for the treatment of forearm fractures after considering the level of the fracture (especially important in radius injuries), the protection afforded any neurovascular structures that may be encountered, and the best means of providing efficient exposure with minimal soft-tissue damage. Open wounds may require a modification of the “ideal” surgical approach.

Four basic exposures are recommended:

1. Straight ulnar approach to the ulnar shaft
2. Volar antecubital approach to the proximal radius
3. Dorsolateral approach to the radial shaft, from the radial head to the distal quarter of the shaft
4. Palmar approach to the distal third of the radius

Approach ulnar fractures with the patient lying supine or partially turned toward the side contralateral to the fracture. In this way, the arm can be pronated across the chest to facilitate access by the surgeon and the assistant.

Approach very proximal radial fractures through either a volar antecubital incision or a dorsolateral approach (63). The dorsolateral approach provides an excellent extensile approach to the radius from the elbow to the wrist. The key to the exposure is the identification and meticulous reflection of the posterior interosseous nerve along with the supinator muscle off the proximal third of the radius. Exposure of the middle third presents no problems. The distal third of the radius is usually approached volarly, but the dorsal approach is useful as well.

The specific approaches are thoroughly discussed in Chapter 1 and in the classic book by Henry (63).

**PLATE AND SCREW FIXATION**

Bagby (11,12 and 13), Danis (39), and others (5,47,48,65,76,107,128,129,168,177) established the principles used today in plate fixation of forearm fractures. The most appropriate treatment for unstable fractures of the bones of the forearm is open reduction and internal fixation using plates and screws. Anderson et al. (5,6 and 7) used the 4.5 mm, round-holed, narrow plate in their series and established the efficiency of plate fixation of the forearm bones in North America. These plates are rather large for the forearm and have a 22% incidence of refracture of the bone after plate removal. The 3.5 mm AO-ASIF dynamic compression plate; its more recent version, the low contact dynamic compression (LCDC) plate; and similar plates such as the Alta reconstruction titanium plate are now the most commonly used plates in adults and have made it possible to apply these techniques to even small-boned patients such as adolescents and most women.

In a series of 129 fractures of the radius and ulna fixed with the AO 3.5 mm plate, Chapman et al. (29) had a union rate of 98.5%, with 92% excellent or satisfactory functional results, and no refractures after removal of the 3.5 mm plates. Newer, equivalent-size titanium plates are now available that are stronger yet more flexible than stainless-steel plates.

***Operative Technique***

- Place the patient supine on the operating table. A hand table is useful. Prepare and drape the entire upper extremity. Use a tourniquet.
- Expose the affected bone(s) using one of the surgical approaches described previously.
- Expose the fracture site with as little soft-tissue stripping as possible. Up to 2 mm of periosteal stripping, limited to each side of the fracture site to ensure anatomic reduction, should be sufficient. It is unnecessary to strip the periosteal sleeve completely around the shaft of either the radius or ulna to apply a plate. Expose the bone only directly under the plate (174). Some surgeons advocate applying the plate extraperiosteally, but I see no advantage in that. Be sure that no important structure, such as a nerve, major vessel, or tendon, is trapped beneath the plate.
- If the fracture configuration results in a stable reduction, reduce it and then fit the plate to the bone. If the fracture is not stable due to a butterfly fragment, initial interfragmentary fixation with a lag screw may be worthwhile if it can be done easily without devascularizing the fragment. Otherwise, always apply the plate to one fragment first with a snug (but not tight) screw next to the fracture site. The second major fragment along with the comminuted zone can be reduced to this plate–bone combination. This greatly facilitates reduction and minimizes soft-tissue stripping. Use only pointed tenaculum-type bone-holding forceps. These can be applied without soft-tissue stripping and do not crush soft tissues.
- Contour the plate so that accurate bony contact is made over its entire length. Use of the eccentric holes in the dynamic compression plates has eliminated the need for an external compressing device, but in some cases the external compressor is helpful in reducing the fragments. After applying the plate to one of the major fragments, if necessary use the articulated tension device to distract the fragments by placing the hook end against the end of the plate. This facilitates reduction. Then reverse the hook to apply tension to the plate and to compress the fracture. Fix the plate to the other major fragment using the appropriate screws (Fig. 16.29).

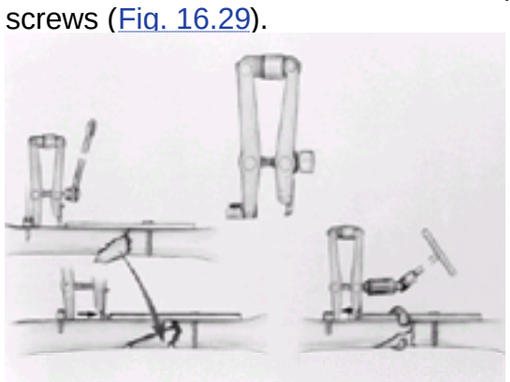

***Figure 16.29.*** Use of the articulated tension device to assist in initial reduction and for subsequent stabilization of comminuted fragments. (From Müeller ME, Allgöwer M, Schneider R, Willenegger H. *Manual of Internal Fixation*, 2nd ed. New York: Springer-Verlag, 1979, with permission.)

- Comminution may make it impossible to achieve perfect alignment and good screw fixation in the comminuted area. Use “biologic” fixation techniques for reduction of the comminuted fragments. Apply a minidistractor or external fixator with pins inserted at sites remote from the comminuted or segmental portion. Distract the fragments sufficiently to obtain good alignment. Then bridge the comminuted or defect areas by attaching a well-contoured plate over the intact extreme ends of the fracture. The plate acts as a strut over the comminuted area. Graft the comminuted area with autologous cancellous bone for any bone loss (Fig. 16.30).

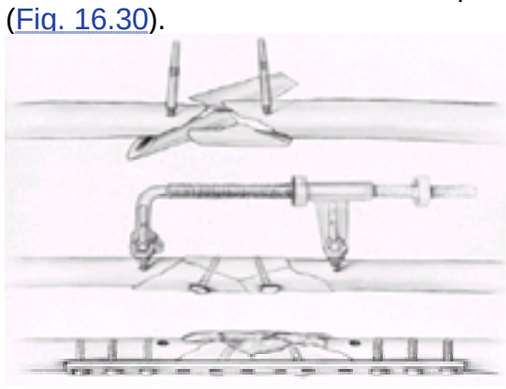

***Figure 16.30.*** Use of the distractor to assist with reduction and preliminary stabilization of comminuted fractures. (From Müeller ME, Allgöwer M, Schneider R, Willenegger H. *Manual of Internal Fixation*, 2nd ed. New York: Springer-Verlag, 1979, with permission.)

- In general, use 3.5 mm dynamic compression plates with 3.5 mm cortical screws with 1.25-pitch threads (122). This pitch allows the screws to grip the cortex of the bone with additional threads, which improves the pullout strength. Also, these screws are much stronger than the earlier designs of 3.5 mm cortical screws. The 3.7 mm titanium reconstruction modular (Alta) plates as well as the AO-LCDC and similar plates work well. The screws must achieve good fixation in at least five cortices on each side of the fracture. Increase this to six to eight cortices in unstable fractures or in poor-quality bone.
- Lag screw fixation across the fracture and any associated fragments increases the strength of the construct by up to 40%. Usually these screws are applied before axial compression of the fracture by the plate. The most accurate placement is achieved by placing drill holes in the bone fragments before reduction, using either a “threaded-hole first” or “gliding-hole first” technique.
- Ideally, place the plate on the tension side of the bone, which is dorsolateral on the radius and dorsal on the ulna. In the distal third of the radius, plates are best placed on the volar aspect to avoid Lister's tubercle and the extensor tendons. Semitubular or one-third tubular plates are recommended only in unusual circumstances, because they are quite weak. Examples of fixation are shown in Figure 16.31, Figure 16.32, Figure 16.33 and Figure 16.34.

***Figure 16.31.*** A closed Galeazzi fracture in a 25-year-old man. **A:** Preoperative AP and lateral radiographs. **B:** Postoperative radiographs show fixation with a six-hole, 3.5 mm dynamic compression plate. Note the bicortical screws in the end holes and the separate interfragmentary screw. (From Chapman MW, Gordon JE, Zissimos AG. Compression Plate Fixation of Acute Fractures of the Diaphysis of the Radius and Ulna. *J Bone Joint Surg [Am]* 1989;71:159, with permission.)

***Figure 16.32.*** A closed Monteggia fracture in an 18-year-old man. **A:** Preoperative AP and lateral radiographs. **B:** Postoperative radiographs show fixation with a seven-hole, 3.5 mm dynamic compression plate, augmented by an olecranon bone graft. Note the use of the center hole as the site for an interfragmentary

screw. (From Chapman MW, Gordon JE, Zissimos AG. Compression Plate Fixation of Acute Fractures of the Diaphysis of the Radius and Ulna. *J Bone Joint Surg [Am]* 1989;71:159, with permission.)

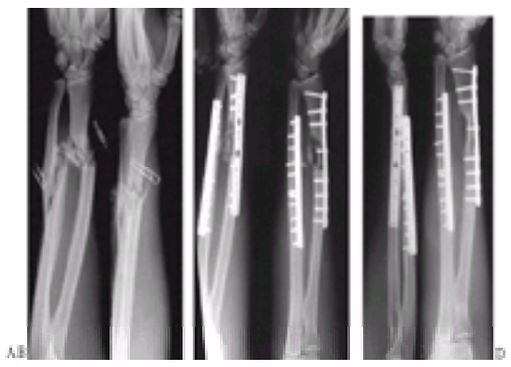

***Figure 16.33.*** A Gustilo type IIIA open fracture of the radius and ulna secondary to a high-velocity gunshot wound in a 32-year-old man. **A:** Preoperative AP and lateral radiographs. **B:** Postoperative radiographs showing fixation with ten-hole, 3.5 mm dynamic-compression plates on the radius and ulna. These were augmented by a tricortical iliac-crest bone graft to the radius and cancellous bone to the ulna at the time of delayed primary closure, 3 days after injury. **C:** AP and lateral radiographs showing union at 33 months. A normal range of motion was achieved. (From Chapman MW, Gordon JE, Zissimos AG. Compression Plate Fixation of Acute Fractures of the Diaphysis of the Radius and Ulna. *J Bone Joint Surg [Am]* 1989;71:159, with permission.)

***Figure 16.34.*** **A:** Monteggia type 1 fracture with associated fracture of the radial head. **B:** The ulna was treated with open reduction and internal fixation with a compression plate; the radial head was excised. Today, some would make more of an effort to fix the radial head fracture.

- Generally, bone grafting of fresh fractures that have been accurately reduced and firmly fixed is unnecessary. If unexpected comminution is encountered, or if you prefer not to harvest a bone graft, collagen–calcium phosphate graft material has been proven to be as efficacious as autologous cancellous bone (28). It would appear that routine bone grafting of fractures that are well reduced and have good bone contact is unnecessary, whereas fractures with defects probably do best when the defects are filled with autologous cancellous bone. Complete segmental defects require structural bone graft, such as tricortical graft from the iliac crest (Fig. 16.33), or, for larger defects, a vascularized fibular graft (55,84).
- After stabilization, close only the subcutaneous layer and the skin. Use suction drains that are brought out from the operative site through percutaneous stab incisions. Drainage prevents the development of a postoperative hematoma. There is no need to close the deep fascia; doing so may produce a compartment syndrome.

Whether bone grafting is necessary for comminuted fractures is controversial. Chapman et al. (26,29) performed autologous cancellous bone grafting at the time of delayed primary closure of all open fractures of the forearm that were plated. They also bone grafted those with comminution and bone deficiency. They had no nonunions in 49 open fractures and an overall rate of union of 98.5% in 129 fractures. Wright et al. (177) studied 198 forearm fractures treated with plate fixation with and without bone grafting. Their union rate in those that were not grafted was 98%. On that basis, they concluded that bone grafting of comminuted forearm fractures was not necessary.

### *Postoperative Care*

Apply a long-arm bulky compressive (Robert Jones–type) dressing with a palmar or dorsal splint for a few days postoperatively while soft-tissue swelling decreases. Remove drains within 24 to 48 hours, depending on the amount of drainage. Keep the forearm elevated 10 cm above the heart. Begin active and passive range-of-motion exercises of the fingers, wrist, and elbow shortly after surgery.

Encourage active and active-assisted range-of-motion exercises of the hand, wrist, and elbow. Obtain radiographs just before wound closure and then again 6 weeks and 3 months postoperatively, and then every 4 to 6 weeks until union occurs. Allow protected use of the limb throughout healing, but prohibit contact sports and the lifting of heavy objects of more than 2 kg during this time. Union usually occurs in 16–24 weeks, at which time a full rehabilitation program without restrictions can begin.

## INTRAMEDULLARY FIXATION

Jones et al. (80) in a laboratory study compared the stability of LCDC plates and fluted intramedullary rods for the fixation of fractures of the radius and ulna. They showed that the intact ulna is more important than the radius to forearm stability in bending and torsion. Therefore, if the radius is fractured but the ulna remains intact, medullary nailing will produce constructs with greater stiffness, particularly in torsion, than if the ulna is fractured and the radius is intact. In the case of fractures of both bones, they found that nails resulted in significantly less stiffness in torsion as well as in distraction and compression as compared to plates. Torsional stiffness with intramedullary nails was 2% of intact specimens, whereas with plates it was 83%.

Rush (143), Sage (144,145 and 146), and others (95,156) popularized intramedullary nailing of forearm fractures in the late 1950s and the 1960s. Medullary nailing was attractive at the time because closed treatment of displaced forearm fractures in adults was not achieving acceptable levels of function and the principles of plate fixation and the smaller stronger plates had not yet been popularized by the AO group. In addition, the percutaneous techniques of intramedullary nailing that avoided open incisions was appealing because infection rates in open internal fixation at that time were higher than they are now. As pointed out in the previous discussion on the biomechanics of internal fixation, plates offer superior stability to nail designs currently available. Nailing with smooth nonlocking nails such as rush rods often requires additional immobilization in a long-arm cast, which interferes with restoration of forearm motion. Other problems of intramedullary nailing include the following:

- Small intramedullary canals may preclude nailing or require the use of very small nails.
- Medullary canals less than 3 mm in diameter contraindicate intramedullary nailing with most devices.
- The double curve of the radius makes nailing, especially with closed technique, difficult. Restoration of the normal bow of the radius can be difficult.
- If open reduction is required to place intramedullary nails, then plate fixation is preferable because medullary nails offer less rigid fixation, and the combination of occluding the medullary canal and stripping the periosteum devascularizes the fracture to the point that the risk of nonunion is higher.
- Distraction at the fracture site and loosening with nonlocking nails can lead to nonunion.
- Combining intramedullary nailing, such as for the ulna, with plate fixation of the radius results in a higher incidence of nonunion in the ulna than when plate fixation is used for both, because there is often persistent gapping at the fracture site of the ulna.

More recent locking nail designs such as the ForeSight nail (Smith and Nephew, Memphis, TN), the Lefèvre nail (42), and others offer improved fixation due to their proximal and distal cross-locking capability. These designs (e.g., the Sage nail) often have fluted cross sections, and this offers additional fixation. There is little

published on these newer nails, nor is a prospective randomized study comparing plates to nails available; therefore, their effectiveness remains unproven at present.

***Indications and Contraindications***

Indications for intramedullary nailing include the following:

- Poor skin conditions precluding open surgery at the fracture site
- Diaphyseal fractures in patients with severe osteoporosis, where screws would not be expected to hold
- An occasional segmental fracture not suitable for plate fixation
- An occasional patient with multiple injuries for whom intramedullary nailing can be done more quickly and with less soft-tissue trauma, when access to the extremity is necessary and cast mobilization is contraindicated

Contraindications to intramedullary nailing are active infection precluding surgery, an open growth plate, and a medullary canal smaller than 3 mm in diameter.

***Sage Intramedullary Nailing***

Intramedullary nailing of the forearm using specifically designed implants was developed by Sage in 1959 (144). His nail has a triangular cross section, which provides reasonable rotational stability if good cortical contact is obtained. The ulnar nail is relatively straight, but the nail for the radius is specifically contoured to maintain the normal anatomic bow of the radius, and it is designed to enter the radius on the dorsal lateral aspect of the radial styloid. Newer locking nail systems have evolved from the Sage nail. In the radius, the ForeSight nail (Smith and Nephew, Memphis, TN) is similar to the Sage nail but is designed to enter on the dorsum of the radius 5 mm proximal to the joint line, just lateral to Lister's tubercle. The True-Flex nail (Encore Orthopaedics, Austin, TX) and the SST stainless steel nail (Biomet, Warsaw, IN) are both designed to enter on the ulnar side of Lister's tubercle on the dorsum of the distal radius. The techniques for locking nails are specific to each appliance. The reader is referred to the manufacturer's instructions.

The surgical technique associated with insertion of Sage nails is fairly generic to intramedullary nailing of the forearm. Although nailing can be done using closed technique under fluoroscopic control, Sage performed his nailings open and this is the technique discussed here.

- Be certain that a complete set of Sage nails and insertion equipment is available. This consists of nails for the radius and ulna, a combination driver and extractor, a 3 mm drill, and two reamers that are slightly smaller than their respective nails. Nails for the ulna are available in 4 and 5 mm diameters and three lengths (22.9, 25.4, and 27.9 cm). Nails for the radius are available in similar diameters and are available in 1.3 cm increments from 20.3 to 27.9 cm.
- Position the patient supine on the operating table. For nailing of the ulna alone, it is convenient to place the patient's arm across his chest. For other nailings, place the arm on a hand table. This description applies to nailing of both bones. Nail the ulna first.
- Expose the fracture of the ulnar shaft through a longitudinal incision on the subcutaneous border. Expose only the ends of the bone. Minimize soft-tissue stripping.
- Deliver the end of the proximal fragment into the wound and insert an ulnar nail to test for fit. If too small, enlarge it first with a 3.2 mm drill and then with a reamer. Drive the reamer through the tip of the olecranon until the tip can be felt beneath the skin.
- Select an ulnar nail of correct length and diameter.
- With the elbow flexed to 90°, drive the nail retrograde up the proximal fragment and through a small stab incision, and bring it out the tip of the olecranon.
- Reduce the fracture anatomically and drive the nail into the distal fragment. Do not seat the nail completely until radiographs are taken and the radius is fixed.
- Expose the fracture of the radius through an appropriate incision.
- Deliver the fractured ends into the wound and check for nail size in the medullary canal.
- Reduce the fracture and lay a nail along the radial border of the forearm to determine length. The nail should extend from the styloid to within 1.3 cm of the radial head.
- Flex the wrist over a folded towel and deviate it ulnarward so that the radial styloid is accessible (Fig. 16.35). Make a longitudinal incision 2.5 cm long over the radial styloid, and carry it down to the bone at its proximal end but only through the skin distally. Reflect the periosteum.

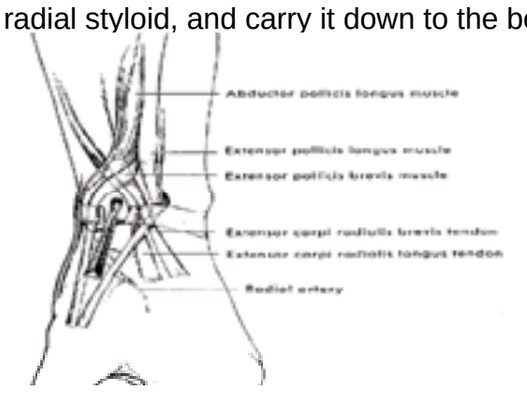


***Figure 16.35.*** Medullary nailing of the radius. The nail enters the bone at the radial styloid. (Courtesy of Dr. F. P. Sage.)

- Drill a hole with a 3.2 or 4.8 mm drill through the exposed cortex, and then gradually angle the handle distally until the drill is directed toward the lateral epicondyle of the humerus. Advance the drill for 5 or 6 cm, thus producing an oval hole at the point of insertion and a channel that nearly parallels the medullary canal (Fig. 16.36).

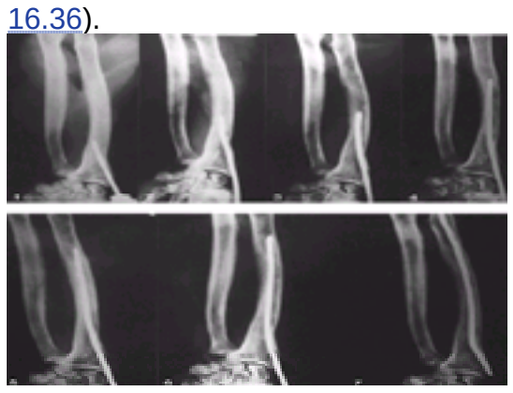

***Figure 16.36.*** Sequence of insertion of the prebent Sage nail for the radius, steps 1 to 7. A hole is drilled in the distal radius, entering the medullary canal from the radial styloid. The nail is bent as it advances in the canal and finally springs back to its prebent shape, maintaining the radial bow. (From Stewart MJ. Intramedullary Fixation of Forearm Fractures. In: Larmon WA, ed. *Instructional Course Lectures of the American Academy of Orthopaedic Surgeons,* Vol. 15. Ann Arbor, MI: J. W. Edwards, 1958:50.)

- Insert the point of the nail with the nail rotated so that its dorsal or long bow parallels the long arc of the radius. With the wrist in flexion and ulnar deviation, insert the nail by hand in a proximal direction as far as possible. If it cannot be pushed in by hand for 6 cm, the angle of insertion is too acute. Withdraw the nail, and drill the channel of insertion more obliquely. Then thread the driver on the nail and, while the nondominant hand exerts pressure to depress the nail toward the ulna, drive the nail in with the dominant hand. If marked resistance is met, angle the nail back and forth a few degrees, and then drive it in with moderate blows until it reaches the fracture. If there is an undisplaced butterfly fragment at the fracture, hold it with a clamp; reduce the fracture, and drive the nail into the proximal fragment, leaving 1.3 cm exposed at the radial styloid.
- Check the position of the fracture and the position and length of the nail with AP and lateral radiographs of the radius and ulna. If the nails are of correct length, finish seating them (Fig. 16.37). Observe the fractures under direct vision to be sure that no distraction occurs. As recommended by Sage, place autogenous iliac bone grafts about all fractures of the radius and ulna fixed by medullary nails (Fig. 16.38).

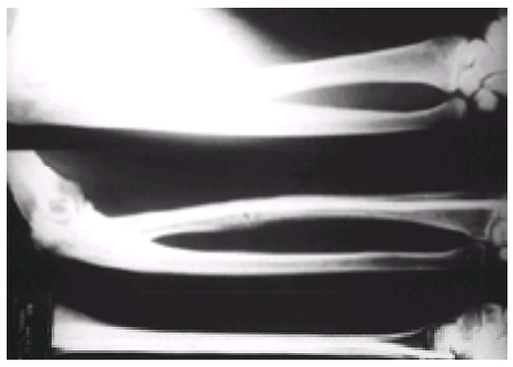

***Figure 16.37.*** Displaced fracture of the radius treated with a prebent Sage nail. Note excellent maintenance of the radial bow.

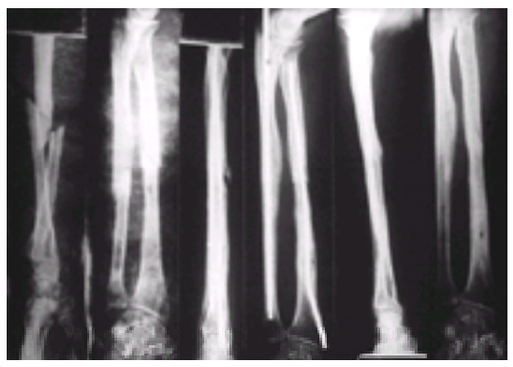

***Figure 16.38.*** Displaced both-bone fracture treated with Sage nails. Both fractures are united at 2 years; nails have been removed. Note that there is some loss of the normal radial bow, which is one of the problems that can occur with nailing.

**HINTS AND TRICKS**

- Avoid excessive stripping of bone fragments, because nailing interferes with the revascularization of the fracture through the endosteal canal, so preservation of the periosteum and muscle attachments is important. To ensure union, bone graft all fractures nailed with open technique.
- Do not drive nails into a tight medullary canal, because comminution of the bone, penetration of the nail through the bone, or incarceration may occur.
- Be certain that the nail at the styloid is not near any of the wrist tendons, which could be abraded by running over the end of the nail, leading to rupture.

***Postoperative Care***

Apply a long-arm cast with the elbow in 90° of flexion and the forearm in neutral rotation. Continue the cast for 8–12 weeks, at which time enough bridging callus is usually present. The use of functional cast bracing may permit earlier mobilization of the wrist and elbow if the nailing is stable. Locked nails do not usually require cast mobilization. Gentle early active range of motion can be encouraged in most cases.

***Results***

Zinar et al. (180), using a modified titanium Street forearm nail, reported a 97.5% rate of union and 92% good to excellent results in 50 patients with 75 fractures of the forearm. DePedro et al. (42), using the Lefèvre locking nail, experienced a 100% union rate in 20 patients treated with isolated ulna or both-bone fractures.

## ISOLATED FRACTURES OF THE RADIUS

Isolated displaced fractures of the radius are common. Remember, if the radial fracture is displaced or shortened, the distal radioulnar joint must be subluxed or dislocated. Failure to appreciate the distal radioulnar joint injury may result in compromised functional results and significant symptoms in the wrist, even though the fracture has been internally fixed and has healed. Open reduction and internal fixation of the radial fracture in anatomic position is required. The distal radioulnar joint disruption can usually be treated by closed means. After recognizing that the ligamentous structures and articular disc have been ruptured, they are almost always adequately reduced if the radial alignment and length are restored and rigidly internally fixed, and if the forearm is kept in a fully supinated position for 6 weeks. Open reduction of the distal radioulnar joint is required only if closed reduction in supination fails to achieve reduction. The Galeazzi type of fracture–dislocation usually requires cast immobilization for 6 weeks, with the forearm supinated for soft-tissue healing and stabilization of the distal radioulnar joint.

An isolated fracture of the radius at the junction of the middle and distal thirds without distal radioulnar disruption has been referred to as the “fracture of necessity,” or the Piedmont fracture. The former term was coined to indicate that open reduction and internal fixation are necessary to produce acceptable functional results. The muscle forces acting on this fracture result in angulation of the fracture toward the ulna, compromising the interosseous space and resulting in loss of pronation and supination even if union is complete.

Fractures of the proximal third of the radius are difficult primarily because of the dangers to the deep branch of the radial nerve when exposing and reducing the fracture (as discussed previously).

## ISOLATED FRACTURES OF THE ULNA

Isolated fractures of the ulnar shaft without involvement of the elbow or wrist joint are treatable with functional braces. Sarmiento et al. (150) reported on the outcomes in 287 patients. Union occurred in 99%, and overall good to excellent functional outcomes occurred in 96% of their patients. Fractures in the distal third did best, averaging a loss of 5° of pronation, compared to an average loss of 12° of pronation in fractures in the proximal third. Fractures of the ulna associated with disruption of the proximal radial ulnar joint are Monteggia fractures (discussed earlier). In adults, plate fixation of these fractures is nearly always necessary (Fig. 16.34). Indications for plate fixation of fractures in the middle and distal third include the following:

- Open fractures for which soft-tissue management requires stabilization of the bone in nearly anatomic position
- Displaced both-bone fractures
- Segmental fractures
- Fractures for which satisfactory position cannot be obtained
- An occasional patient, such as a dentist or musician, who needs to return early to a highly skilled occupation requiring fine use of the upper extremity; such a patient may require immediate internal fixation.

## FLOATING ELBOW

The “floating elbow” is usually caused by a high-energy injury resulting in fractures of the humerus and both bones of the forearm. These high-energy injuries are often the result of direct trauma with severe open fractures involving bone loss and accompanying neurologic or vascular injury (84,178). The principles of treatment do not differ much from those already described for open fractures. In some cases, the magnitude of soft-tissue injury and bone loss precludes effective internal fixation; therefore, external fixation in two planes bridging the elbow joint from the proximal humerus to the distal forearm is necessary. If the level of wound contamination is not excessive and comminution is not too severe, then primary plate fixation of the humerus and the forearm, accompanied by local or free-flap coverage if necessary, usually gives the best results, because this gives the best opportunity to restore the anatomy of the forearm and permits early joint motion and rehabilitation. Yokoyama et al. (178) reported on 15 floating elbow injuries, one of which led to immediate amputation. In 10 of these, immediate internal fixation was performed, and in three the

fractures were internally fixed on a delayed basis. In spite of this severe injury, 10 of the 15 had a good or excellent results. Complications were common, however, including one deep infection, two nonunions of the humerus, two nonunions of the forearm, one malunion of the humerus, and one forearm bone refracture.

## OPEN FRACTURES OF THE FOREARM

Chapter 12 presents a thorough discussion of open fractures. Except for fractures that are unsuitable for plate fixation due to location or comminution, or those that are extraordinarily contaminated, immediate plate fixation is usually indicated (26,27,28,29 and 30,57,58,112). The next best alternative is external fixation (8,137). Fractures in the epiphyseal areas may be suitable for fixation (16,41). In 49 open fractures plated immediately, Chapman et al. (29) had only one infection (2%), and this resolved with treatment. Others (5,6 and 7,112) have shown similar results.

Meticulous debridement and copious irrigation are essential. Stable fixation with minimal soft-tissue dissection is also required. Initially, leave the wounds open or use an antibiotic bead pouch. Cover exposed bone and neurovascular structures by muscle. Administer intravenous antibiotics. Delayed primary wound closure, flap coverage if necessary, and bone grafting are usually indicated 5 days or more after injury if the wound is free of evidence of infection.

## PITFALLS AND COMPLICATIONS

### SUPRACONDYLAR HUMERUS FRACTURES

Kundel et al. (92) showed 52% excellent to good late results in 77 intraarticular fractures of the distal humerus treated by open reduction and internal fixation. Nerve injuries resulting from the fracture occurred in 26 patients, and 49% had heterotopic bone formation; the results were less favorable in patients with open fractures and those with multiple injuries. Helfet and Schmeling (62) reported an incidence of only 4% of heterotopic ossification, 4% infection, 7% ulnar nerve palsy, 5% failure of fixation, and 2% nonunion. This rate of complications is what would be expected with today's modern techniques. Neither of these authors mention postoperative stiffness, which in my experience is the primary reason patients have poor outcomes (50,167).

### NONUNION, MALUNION, AND FAILURE OF FIXATION

Early failure of internal fixation of all upper extremity fractures is most commonly due to inadequate fixation, poor patient cooperation, or poor-quality bone (17,67,73,106,136,159). The nature and magnitude of the original injury, because of comminution, may also lead to failure, but the devascularization associated with comminution and severe soft-tissue injuries is more likely to lead to infection or to failure of union. In the absence of infection, the most common causes of failure in the reconstruction of supracondylar fractures of the humerus are poor preoperative planning and failure to follow the principles outlined in this chapter. This can lead to the use of inadequate appliances, or to failure to achieve sufficient stability in the fracture site that early rehabilitation can be tolerated without failure. Fortunately, reconstruction of nonunions and intraarticular malunions of the distal humerus is surprisingly successful, with final functional arcs of motion averaging 100° (83,84,85,103) (see Chapter 27 for more details).

Common errors in the plate fixation of bones in the forearm are failure to choose a plate of adequate length; using plates that are too small, such as one-third tubular plates; and failure to eliminate micromotion in the fracture site. Interfragmentary compression with screws should always be done, if feasible.

As discussed previously, the need for bone grafting forearm fractures after plate fixation is debatable (29,177). In fractures with bone loss or substantial comminution, or where there has been significant soft-tissue stripping, I believe that bone grafting is prudent. Collagraft (Zimmer, Warsaw, IN) (28) has been shown in forearm fractures to be equal in efficacy to autologous cancellous bone graft. This eliminates the morbidity of taking an iliac crest graft. On the other hand, securing a small amount of cancellous bone through a stab incision on top of the iliac crest incurs minimal morbidity. Fortunately, with good technique, union rates of 97% to 98% can be expected. Most nonunions respond well to repeat plate fixation and bone grafting (see Chapter 27).

### NEUROVASCULAR INJURIES

Neuropathy in the ulnar nerve at the elbow can be caused by the original injury, operative manipulation of the nerve, inadequate release of the soft tissues around the nerve in a transfer, and postoperative fibrosis around the nerve. The best approach is to avoid any additional ulnar neuropathy by gentle neurolysis of the nerve and well-executed anterior transfer. Ulnar nerve neurolysis and transposition during reconstruction after failure of primary treatment of elbow fractures has a reasonable chance of providing good pain relief, improvement in sensation, and even improvement in hand strength and dexterity (102).

Injury of the median nerve most commonly occurs at the elbow and may coexist with injury of the brachial artery. In fractures, there may be direct contusion or stretching of the nerve over displaced fragments, and in dislocations the nerve can slip around the medial condyle and be stretched across the back of the trochlea. Trapping of the nerve in the trochlear sulcus with compression is possible. In the vast majority of cases, the injury is a neuropraxia, which responds to reduction of the elbow and observation. The posterior interosseous branch of the radial nerve is vulnerable in type I Monteggia fractures because of anterior dislocation of the radial head (175). The vast majority of these recover with nonoperative care. In closed injuries, exploration of any of these nerves around the elbow and the forearm is rarely indicated. If recovery is not seen by the time the fracture heals, then nerve conduction and electromyographic and nerve conduction studies are indicated to determine the nature of the lesion and the need for surgical exploration.

Vascular injuries are uncommon. In fractures of the distal humerus and with injuries around the elbow, any evidence of impaired circulation, unless it returns to normal immediately after a closed reduction, merits an arteriogram. With a disruption of the brachial artery, the collateral supply about the elbow often prevents loss of limb, but poor circulation can lead to long-term pain and dysfunction. Obtain vascular surgery consultation if there is any question of whether a brachial artery exploration and repair are indicated.

### COMPARTMENT SYNDROME

Compartment syndrome is uncommon after pure elbow dislocations but is more common after high-energy displaced fractures of the distal humerus, elbow, and forearm. At the time of irrigation and debridement of open fractures about the elbow and in the forearm, it is usually fairly easy to do an open or semipercutaneous fasciotomy of the deep fascia of the compartment in which you are operating. This prophylactic procedure adds little morbidity and may prevent an occasional compartment syndrome. After internal fixation of elbow and forearm injuries, do not close the deep fascia, because closure can precipitate a compartment syndrome. Postoperatively monitor patients carefully for signs of compartment syndrome, measure intracompartmental pressures when there is any question, and proceed with fasciotomy when the diagnosis is made. In the forearm, fasciotomy usually requires release from proximal to the lacertus fibrosis to the midpalm, including release of the carpal tunnel (see Chapter 13).

### HETEROTOPIC OSSIFICATION

Heterotopic ossification (HO) about the elbow is actually unusual in the absence of associated predisposing causes such as head injury, high-energy trauma, or thermal injury (88,99,138,165) (Fig. 16.39) (see Chapter 124). Prophylactic treatment with diphosphonate, nonsteroidal anti-inflammatory agents such as indomethacin, and low-dose radiation therapy have been advocated and used with success in total hip replacement and other disorders. I have no experience with using prophylaxis for HO around the elbow. The treatment consists of resection of the heterotopic bone after full maturation, usually in combination with a soft-tissue release of the elbow to gain range of motion (99) (see Chapter 27).

***Figure 16.39.*** Heterotopic ossification following prosthetic replacement of the radial head and tension band wire fixation of a fracture of the olecranon.

## RADIUS–ULNAR SYNOSTOSIS

Radius–ulnar synostosis is most common following fractures of both bones at the same level, particularly when plate fixation of both bones is performed and the hematoma between the bones communicates (88). Minimize the risk of synostosis by limiting dissection so that the hematoma between the two fractures does not communicate, by not placing bone graft in the interosseous space, and by beginning early pronation and supination. Maturation of a synostosis usually requires 12 or more months. Although attempts to surgically remove a synostosis early may result in a recurrence, Jupiter and Ring (88) showed slightly improved results when resection was performed before 12 months in 17 limbs treated by resection and interposition fat graft (see Chapter 27).

## CHRONIC DISLOCATION OF THE ELBOW

Persistent dislocation of the elbow after injury is usually due to a fracture of the coronoid process with displacement, severe comminution that precludes fixation, or failure of fixation (discussed in more detail in Chapter 27). Use of a functional external fixator in unstable elbows may avoid this complication. Moritomo et al. (114) have described successful reconstruction of the coronoid process for chronic dislocation of the elbow using a graft from the olecranon in two cases.

## POSTOPERATIVE INFECTION

Infection after internal fixation of upper extremity fractures, even in the presence of open fractures, is unusual, with infection rates generally below 2% (29). When acute infection occurs early after plate fixation and the plate is stable, irrigation and debridement of the wound, combined with administration of intravenous antibiotics, usually results in resolution of infection. An antibiotic bead pouch may be helpful. Low-grade persistent infection can often be managed by appropriate antibiotic coverage until the fractures are healed. Plate removal at that point usually results in resolution of the infection. Major infections, particularly when there is loose fixation, usually require removal of the implants and conversion to external fixation (see Chapter 135).

## FOREARM FRACTURE AFTER PLATE REMOVAL

Lindsey et al. (94) have demonstrated that retention of diaphyseal plates, with a mean follow-up of more than 8 years, results in no significant change in forearm bone density and grip strength. Mih et al. (107) compared 62 patients who had their forearm plates removed at an average of 19 months after insertion, to 113 patients who retained their forearm plates. The complication rate was much higher in those in whom the plates were removed, including seven refractures through screw holes or through the original fracture site. They recommended against routine removal of forearm plates. Factors that predispose to refracture are the degree of initial displacement and comminution, the use of large screws (implants using screws larger than 3.5–3.7 mm in diameter are rarely necessary), premature removal of the plate, and lack of postremoval protection (29,67,142). To avoid this complication, I use titanium plating systems with screws 3.7 mm in diameter or smaller, and I do not remove these plates unless they are symptomatic or the patient desires removal. In some athletes, such as football linemen, for whom there is substantial risk of trauma to the forearm, removal may be indicated to avoid the stress riser at the end of the plate, but avoidance of refracture may require skipping a playing season.

## CHAPTER REFERENCES

Each reference is categorized according to the following scheme: *, classic article; #, review article; !, basic research article; and +, clinical results/outcome study.


+ 1. Alder S, Fay GF, MacAusland WR Jr. Treatment of Olecranon Fractures; Indications for Excision of the Olecranon Fragment and Repair of the Triceps Tendon. *J Trauma* 1962;2:597.

# 2. Allan BL Jr. Review of Brunner CF, Weber BG. Special Techniques in Internal Fixation. (New York: Springer-Verlag, 1982) *J Bone Joint Surg [Am]* 1982;64:797.

+ 3. Amer O, Ekengren K, von Schreeb T. Fractures of the Head and Neck of the Radius: A Clinical and Roentgenographic Study of 310 Cases. *Acta Chir Scand* 1957;112:115.

+ 4. An K, Morrey BF, Chao EY. The Effect of Partial Removal of Proximal Ulna on Elbow Constraint. *Clin Orthop* 1986;209:270.

* 5. Anderson LD. Compression Plate Fixation and the Effect of Different Types of Internal Fixation on Fracture Healing. *J Bone Joint Surg [Am]* 1965;47:191.

# 6. Anderson LD, Bacastow DW. Treatment of Forearm Shaft Fractures with Compression Plates. *Contemp Orthop* 1984;8:17.

* 7. Anderson LD, Sisk TD, Tooms RE, et al. Compression Plate Fixation in Acute Diaphyseal Fractures of the Radius and Ulna. *J Bone Joint Surg [Am]* 1975;57:287.

+ 8. Andrianne Y, et al. Hoffman External Fixation of Fractures of the Radius and Ulna: A Prospective Study of 53 Patients. *Orthopaedics* 1984;7:845.

* 9. Bado JL.*The Monteggia Lesion.* Springfield, IL: Charles C. Thomas, 1962.

* 10. Bado JL. The Monteggia Lesion. *Clin Orthop* 1967;50:71.

* 11. Bagby GW. Clinical Experience of a Simplified Compression Bone Plate. *Am J Orthop Surg* 1968;10:302.

* 12. Bagby GW, Janes JM. An Impacting Bone Plate. *Proc Staff Meeting Mayo Clin* 1957;32:55.

* 13. Bagby GW, Janes JM. The Effect of Compression on the Rate of Fracture Healing Using a Special Plate. *Am J Surg* 1958;95:761.

# 14. Böhler L.*The Treatment of Fractures.* (English 5th ed., translated from German 13th ed. by Tretter H, et al.). New York: Grune & Stratton, 1956–1958.

+ 15. Boyd HB, Boals JC. The Monteggia Lesions: A Review of 159 Cases. *Clin Orthop* 1969;66:94.

+ 16. Brady LP. Double-Pin Fixation of Severely Comminuted Fractures of the Distal Radius and Ulna. *South Med J* 1963;56:307.

+ 17. Brakenbury PH, Corea JR, Blakemore ME. Nonunion of the Isolated Fracture of the Ulnar Shaft in Adults. *Injury* 1981;12:371.

+ 18. Broberg MA, Morrey BF. Results of Delayed Excision of the Radial Head after Fracture. *J Bone Joint Surg [Am]* 1986;68:669.

+ 19. Bruce HE, Harvey JP, Wilson JC Jr. Monteggia Fractures. *J Bone Joint Surg [Am]* 1974;56:1563.

# 20. Brunner CF, Weber BG.*Special Techniques in Internal Fixation.* New York: Springer-Verlag, 1982.

# 21. Bryan RS, Morrey BF. Fractures of the Distal Humerus. In: Morrey BF, ed. *The Elbow and Its Disorders.* Philadelphia: WB Saunders, 1985:302.

+ 22. Burwell HN, Charnley AD. Treatment of Forearm Fractures in Adults with Particular Reference to Plate Fixation. *J Bone Joint Surg Br* 1964;56:404.

+ 23. Cabenela ME. Fractures of the Proximal Ulna and Olecranon. In: Morrey BF, ed.*The Elbow and Its Disorders.* Philadelphia: WB Saunders, 1985.

+ 24. Caden JG. Internal Fixation of Fractures of the Forearm. *J Bone Joint Surg [Am]* 1961;43:1115.

+ 25. Carn RM, Medige J, Curtain D, Koenig A. Silicone Rubber Replacement of the Severely Fractured Radial Head. *Clin Orthop* 1986;209:259.

+ 26. Chapman MW. The Use of Immediate Internal Fixation in Open Fractures. *Orthop Clin North Am* 1980;11:579.

# 27. Chapman MW. Role of Bone Stability in Open Fractures. *Instr Course Lect* 1982;31:75.

+ 28. Chapman MW, Bucholz R, Cornell C. Treatment of Acute Fractures with a Collagen-Calcium Phosphate Graft Material: A Randomized Clinical Trial. *J Bone Joint Surg [Am]* 1997;79:495.

+ 29. Chapman MW, Gordon JE, Zissimos AG. Compression Plate Fixation of Acute Fractures of the Diaphysis of the Radius and Ulna. *J Bone Joint Surg [Am]* 1989;71:159.

+ 30. Chapman MW, Mahoney M. The Role of Early Internal Fixation in the Management of Open Fractures. *Clin Orthop* 1979;138:120.

# 31. Charnley J. *Closed Treatment of Common Fractures*, 3rd ed. Edinburgh: E & S Livingston, 1970.

+ 32. Cobb TK, Morrey BF, Bernard F. Total Elbow Arthroplasty as Primary Treatment for Distal Humeral Fractures in Elderly Patients. *J Bone Joint Surg [Am]* 1997;79:826.

+ 33. Cole JM, Obletz BE. Comminuted Fractures of the Distal End of the Radius Treated by Skeletal Transfixation in Plaster Cast: An End-Result Study of 33 Cases. *J Bone Joint Surg [Am]* 1966;48:931.

+ 34. Colton CL. Fractures of the Olecranon in Adults: Classification and Management. *Injury* 1973;5:121.

+ 35. Cooney WP. External Fixation of Distal Radial Fractures. *Clin Orthop* 1983;180:44.

+ 36. Cooney WP, Dobyns JH, Linscheid RL. External Pin Fixation for Unstable Colles' Fractures. *J Bone Joint Surg [Am]* 1979;61:840.

+ 37. Corea JR, Brakenbury PH, Blakemore ME. The Treatment of Isolated Fractures of the Ulnar Shaft in Adults. *Injury* 1981;12:365.

+ 38. Cruess RL. The Management of Forearm Injuries. *Orthop Clin North Am* 1973;4:969.

+ 39. Danis R.*Theorie et Pratique D'Osteosynthese.* Paris: Masson, 1949:95.

+ 40. Deliyannis SN. Comminuted Fractures of the Olecranon Treated by the Weber-Vasey Technique. *Injury* 1973;5:19.

+ 41. De Oliveira JC. Barton's Fractures. *J Bone Joint Surg [Am]* 1973;55:586.

+ 42. DePedro JA, Garcia-Navarrete F, Garcia DeLucas F, et al. Internal Fixation of Ulnar Fractures by Locking Nail. *Clin Orthop* 1992;283:81.

+ 43. Dodge HS, Cady GW. Treatment of Fractures of the Radius and Ulna with Compression Plates: A Retrospective Study of 119 Fractures in 78 Patients. *J Bone Joint Surg [Am]* 1972;54:1167.

+ 44. Durig M, Muller W, Ruedi TP, Gauer EF. The Operative Treatment of Elbow Dislocation in the Adult. *J Bone Joint Surg [Am]* 1979;61:238.

+ 45. Ebraheim NA, Martin CS, Jacob Z, et al. Internal Fixation of Radial Neck Fracture in a Fracture Dislocation of the Elbow. *Clin Orthop* 1992;276:187.

+ 46. Edwards GS Sr, Edwards GS Jr, Jupiter JB. Radial Head Fractures with Acute Distal Radioulnar Dislocation. Essex-Lopresti Revisited. *Clin Orthop* 1988;234:61.

* 47. Eggers GWN. Internal Contact Splint. *J Bone Joint Surg [Am]* 1948;30:40.

* 48. Eggers GWN, Shindler TO, Pomerat CM. The Influence of Contact-Compression Factor on Osteogenesis in Surgical Fractures. *J Bone Joint Surg [Am]* 1949;31:693.

+ 49. Gartsman GM, Sculco TP, Otis JC. Operative Treatment of Olecranon Fractures. *J Bone Joint Surg [Am]* 1981;63:718.

+ 50. Gates HS, Sullivan FL, Urbaniak JR. Anterior Capsulotomy and Continuous Passive Motion in Treatment of Post-Traumatic Contracture of the Elbow. *J Bone Joint Surg [Am]* 1992;74:1229.

+ 51. Geel CW, Palmer AK, Ruedi T, Lautenegger AF. Internal Fixation of Proximal Radial Head Fractures. *J Orthop Trauma* 1990;4:270.

+ 52. Givstra PE, Killoran PJ, Furman RS, et al. The Missed Monteggia Fracture. *Radiology* 1975;110:45.

+ 53. Goldberg I, Peylan J, Yosiporitch Z. Late Results of Excision of the Radial Head for an Isolated Closed Fracture. *J Bone Joint Surg [Am]* 1986;68:675.

+ 54. Grace TG, Eversmann WW Jr. Forearm Fractures: Treatment by Rigid Fixation with Early Motion. *J Bone Joint Surg [Am]* 1980;62:433.

+ 55. Grace TG, Eversmann WW Jr. The Management of Segmental Bone Loss Associated with Forearm Fractures. *J Bone Joint Surg [Am]* 1980;62:1150.

+ 56. Greenspan A, Norman A, Rosen H. Radial Head-Capitellum View in Elbow Trauma: Clinical Application and Radiographic-Anatomic Correlation. *Am J Radiol* 1984;143:355.

# 57. Gustilo RB. *Management of Open Fractures and Their Complications*, vol. 4. Philadelphia: WB Saunders, 1982.

+ 58. Gustilo RB, Mendoza RM, Williams DN. Problems in the Management of Type III (Severe) Open Fractures: A New Classification of Type III Open Fractures. *J Bone Joint Surg* 1984;24:742.

+ 59. Hadden WA, Reschauer R, Seggl W. Results of AO Plate Fixation of Forearm Shaft Fractures in Adults. *Injury* 1982;15:44.

+ 60. Harrington IJ, Tountas AA. Replacement of the Radial Head in the Treatment of Unstable Elbow Fractures. *Injury* 1981;12:405.

! 61. Helfet DL, Hotchkiss RN. Internal Fixation of the Distal Humerus: A Biomechanical Comparison of Methods. *J Orthop Trauma* 1990;4:260.

+ 62. Helfet DL, Schmeling GJ. Bicondylar Intraarticular Fractures of the Distal Humerus in Adults. *Clin Orthop* 1993;292:26.

* 63. Henry AK. *Extensile Exposure,* 2nd ed. Edinburgh: E & S Livingston, 1957.

+ 64. Herring JA. Recurrent Dislocation of the Elbow. *J Pediatr Orthop* 1989;9:483.

+ 65. Hertel R, Pisan M, Lambert S, Ballmer FT. Plate Osteosynthesis of Diaphyseal Fractures of the Radius and Ulna. *Injury* 1996;8:545.

+ 66. Hicks JH. Fractures of the Forearm Treated by Rigid Fixation. *J Bone Joint Surg Br* 1961;43:680.

+ 67. Hidaka S, Gustilo RB. Refracture of Bone of the Forearm after Plate Removal. *J Bone Joint Surg [Am]* 1984;66:1241.

+ 68. Holdsworth BJ, Clement DA, Rothwell PNR. Fractures of the Radial Head—The Benefit of Aspiration: A Prospective Controlled Trial. *Injury* 1987;18:44.

+ 69. Holdsworth BJ, Mossad MM. Fractures of the Adult Distal Humerus. Elbow Function after Internal Fixation. *J Bone Joint Surg Br* 1990;72:362.

+ 70. Horne G, Tanzer TL. Olecranon Fractures: A Review of 100 Cases. *J Trauma* 1981;21:469.

! 71. Horner SR, Sadasivan KK, Lipka JM, Saha S. Analysis of Mechanical Factors Affecting Fixation of Olecranon Fractures. *Orthopedics* 1989;12:1469.

+ 72. Hotchkiss RN, Weiland AJ. Valgus Stability of the Elbow. *J Orthop Res* 1987;5:372.

+ 73. Hughston JC. Fracture of the Distal Radial Shaft: Mistakes in Management. *J Bone Joint Surg [Am]* 1957;39:249.

+ 74. Hume MC, Wiss DA. Olecranon Fractures: A Clinical and Radiographic Comparison of Tension Band Wiring and Plate Fixation. *Clin Orthop* 1991;285:92.

+ 75. Husband JB, Hastings H. The Lateral Approach for Operative Release of Post-traumatic Contracture of the Elbow. *J Bone Joint Surg [Am]* 1990;72:1353.

! 76. Hutzschenreuter P, et al. Some Effects of Rigidity of Internal Fixation on the Healing Pattern of Osteotomies. *Injury* 1969;1:77.

+ 77. Janssen RPA, Vegter J. Resection of the Radial Head after Mason Type-III Fractures of the Elbow—Follow-up at 16 to 30 Years. *J Bone Joint Surg Br* 1998;80;231.

+ 78. Jinkins WJ Jr, Lockheart LD, Eggers GWN. Fractures of the Forearm in Adults. *South Med J* 1960;5:669.

+ 79. Johnson RP, Roetker A, Schwab JP. Olecranon Fractures Treated with AO Screw and Tension Bands. *Orthopaedics* 1986;9:66.

+ 80. Jones DJ, Genley MB, Schemitsch EH, Tencer AF. A Biomechanical Comparison of Two Methods of Fixation of Fractures of the Forearm. *J Orthop Trauma* 1995;9:198.

+ 81. Josefsson PO, Gentz CF, Johnell O, Wendeberg B. Dislocations of the Elbow and Intra-Articular Fractures. *Clin Orthop* 1989;246:126.

+ 82. Judet T, DeLoubresse CG, Pirou P, Charnley G. A Floating Prothesis for Radial Head Fractures. *J Joint Bone Surg Br* 1996;78:244.

+ 83. Jupiter JB. Complex Fractures of the Distal Part of the Humerus and Associated Complications. *J Bone Joint Surg [Am]* 1994;76:1252.

+ 84. Jupiter JB, Gerhard HJ, Guerrero J, et al. Treatment of Segmental Defects of the Radius with Use of the Vascularized Osteoseptocutaneous Fibular Autogenous Graft. *J Bone Joint Surg [Am]* 1997;79:542.

+ 85. Jupiter JB, Goodman LF. The Management of Complex Distal Nonunions in the Elderly by Elbow Capsulotomy, Triple Plating, and Ulnar Nerve Neurolysis. *J Bone Joint Surg* 1992;1:37.

+ 86. Jupiter JB, Mehne DK. Fractures of the Distal Humerus. *Orthopaedics* 1992;15:826.

+ 87. Jupiter JB, Neff U, Regazzoni P, Allgöwer M. Unicondylar Fractures of the Distal Humerus: An Operative Approach. *J Orthop Trauma* 1988;2:102.

+ 88. Jupiter JB, Ring D. Operative Treatment of Post-Traumatic Proximal Radioulnar Synostosis. *J Bone Joint Surg [Am]* 1998;80:248.

+ 89. Knight RA, Purvis GD. Fractures of Both Bones of the Forearm in Adults. *J Bone Joint Surg [Am]* 1949;31:775.

+ 90. Kraus B, Horne G. Galeazzi Fractures. *J Trauma* 1985;25:1093.

+ 91. Kuhn JE, Louis DS, Loder RT. Divergent Single-Column Fractures of the Distal Part of the Humerus. *J Bone Joint Surg [Am]* 1995;77:538.

+ 92. Kundel K, Braun W, Wieberneit J, Rüter A. Intraarticular Distal Humerus Fractures. *Clin Orthop* 1996;232:200.

+ 93. Letsch R, Schmit-Neuerburg KP, Sturmer KM, Walz M. Intra-Articular Fractures of the Distal Humerus. Surgical Treatment and Results. *Clin Orthop* 1989;241:238.

+ 94. Lindsey RW, Fenison AT, Doherty BJ, et al. Effectsof Retained Diaphyseal Plates on Forearm BoneDensity and Grip Strength. *J Orthop Trauma* 1994;8:446.

+ 95. Marek FM. Axial Fixation of Forearm Fractures. *J Bone Joint Surg [Am]* 1961;43:1099.

! 96. Markolf KL, Lamey D, Yang S, et al. Radioulnar Load-Sharing in the Forearm. A Study in Cadavera. *J Bone Joint Surg [Am]* 1998;80:879.

* 97. Mason ML. Some Observations on Fractures of the Head of the Radius with a Review of 100 Cases. *Br J Surg* 1954;42:123.

+ 98. McArthur RA. Herbert Screw Fixation of Fracture of the Head of the Radius. *Clin Orthop* 1987;224:79.

+ 99. McAuliffe JA, Wolfsen AH. Early Excision of Heterotopic Ossification about the Elbow Followed by Radiation Therapy. *J Bone Joint Surg [Am]* 1997;79:749.

+ 100. McKee MD, Bowden SH, King GJ, et al. Management of Recurrent, Complex Instability of the Elbow with a Hinged Fixator. *J Bone Joint Surg Br* 1988;80:6.

+ 101. McKee MD, Jupiter JB, Bamberger HB. Coronal Shear Fractures of the Distal End of the Humerus. *J Bone Joint Surg [Am]* 1996;78:49.

+ 102. McKee MD, Jupiter JB, Bosse G, Goodman L. Outcome of Neurolysis During Post-Traumatic Reconstruction of the Elbow. *J Bone Joint Surg Br* 1998;80:100.

+ 103. McKee MD, Jupiter JB, Toh CL, et al. Reconstuction after Malunion and Nonunion of Intraarticular Fractures of the Distal Humerus. *J Bone Joint Surg Br* 1994;76:614.

+ 104. McKeever FM, Buck RM. Fractures of the Olecranon Process of the Ulna. *JAMA* 1947;135:1.

+ 105. Mehlgoff TL, Noble PC, Bennett JB, Tullos HS. Simple Dislocation of the Elbow in the Adult. Results after Closed Treatment. *J Bone Joint Surg [Am]* 1988;70:238.

+ 106. Midgley RD. Volkmann's Ischemic Contracture of the Forearm. *Orthop Clin North Am* 1973;4:983.

+ 107. Mih AD, Cooney WP, Idler RS, Lewallen DG. Long-Term Follow-Up of Forearm Bone Diaphyseal Plating. *Clin Orthop* 1994;299:256.

+ 108. Mikic ZD. Galeazzi Fracture-Dislocations. *J Bone Joint Surg [Am]* 1975;57:1071.

+ 110. Mikic ZD, Vukadinovic SM. Late Results in Fractures of the Radial Head Treated by Excision. *Clin Orthop* 1983;181:220.

+ 111. Milliner S, Nunley JA. Treatment of Isolated Fractures of the Shaft and Ulna. *Orthopaedics* 1982;5:1604.

+ 112. Moed BR, Kellam JF, Foster RJ, et al. Immediate Internal Fixation of Open Fractures. Diaphysis of the Forearm. *J Bone Joint Surg [Am]* 1986;68:1008.

+ 113. Moore TM, Klein JP, Patzakis MJ, Harvey JP Jr. Results of Compression-Plating of Closed Galeazzi Fractures. *J Bone Joint Surg [Am]* 1985;67:1015.

+ 114. Morimoto H, Tada K, Yoshida T, Kawatsu N. Reconstruction of the Coronoid for Chronic Dislocation of the Elbow. Use of a Graft from the Olecranon in Two Cases. *J Bone Joint Surg Br* 1998;80:490.

# 115. Morrey BF. Radial Head Fracture. In: Morrey BF, ed. *The Elbow and Its Disorders.* Philadelphia: WB Saunders, 1985.

+ 116. Morrey BF. Post-traumatic Contracture of the Elbow. *J Bone Joint Surg [Am]* 1990;72:601.

# 117. Morrey BF. Current Concepts in the Treatment of Fractures of the Radial Head, the Olecranon, and the Coronoid. *J Bone Joint Surg [Am]* 1995;77:316.

# 118. Morrey BF, ed.*The Elbow and Its Disorders.* Philadelphia: WB Saunders, 1985.

! 119. Morrey BF, Askew LJ, An KN, Chao EY. A Biomechanical Study of Normal Elbow Motion. *J Bone Joint Surg [Am]* 1981;63:872.

+ 120. Morrey BF, Askew RPT, Chao EY. Silastic Prosthetic Replacement for the Radial Head. *J Bone Joint Surg [Am]* 1981;63:454.

+ 121. Morrey BF, Chao EY, Hui FC. Biomechanical Study of the Elbow Following Excision of the Radial Head. *J Bone Joint Surg [Am]* 1979;61:63.

# 122. Müller ME, Allgöwer M, Schneider R, Willenegger H. *Manual of Internal Fixation*, 2nd ed. New York: Springer-Verlag, 1979.

+ 123. Naiman PT, Schein AJ, Siffert RS. Use of ASIF Compression Plates in Selected Shaft Fractures of the Upper Extremity. A Preliminary Report. *Clin Orthop* 1970;71:208.

+ 124. O'Driscoll SW, Bell DF, Morrey DF. Posterolateral Rotatory Instability of the Elbow. *J Bone Joint Surg [Am]* 1991;73:440.

# 125. Orthopaedic Trauma Association and the International Society for Fracture Repair. Fracture Dislocation Compendium. *J Orthop Trauma* 1996;10(suppl 1):11.

+ 126. Patel VR, Elliot DS. Salvage of the Head of the Radius after Fracture Dislocation of the Elbow. *J Bone Joint Surg Br* 1999;81:306.

+ 127. Pelto K, Boistman O, Tokkanen P. Treatment of Radial Head Fractures with Absorbable Polyglycolide Pins: A Study on the Security of Fixation in 38 Cases. *J Orthop Trauma* 1994;8:94.

! 128. Perren SM. Physical and Biological Aspects of Fracture Healing with Special Reference to Internal Fixation. *Clin Orthop* 1979;138:175.

! 129. Perren SM, Huggler A, Russenberger M, et al. The Reaction of Cortical Bone to Compression. *Acta Orthop Scand* 1969;125(suppl):19.

+ 130. Perry CR, Gibson CT, Kowalski MF. Transcondylar Fractures of the Distal Humerus. *J Orthop Trauma* 1989;3:98.

+ 131. Pollock FH, Pankovich AM, Prieto JJ, et al. The Isolated Fracture of the Ulnar Shaft. *J Bone Joint Surg [Am]* 1983;65:339.

! 132. Prayson MJ, Williams JL, Marshall MP, et al. Biomechanical Comparison of Fixation Methods in Transverse Olecranon Fractures: A Cadaveric Study. *J Orthop Trauma* 1997;11:565.

+ 133. Reckling FW. Unstable Fracture-Dislocations of the Forearm (Monteggia and Galeazzi Lesions). *J Bone Joint Surg [Am]* 1982;64:857.

+ 134. Reckling FW, Cordell LD. Unstable Fracture-Dislocations of the Forearm: The Monteggia and Galeazzi Lesions. *Arch Surg* 1968;96:999.

+ 135. Regan W, Morrey B. Fractures of the Coronoid Process of the Ulna. *J Bone Joint Surg [Am]* 1989;71:1348.

+ 136. Rettig AC, Waugh TR, Evanski PM. Fracture of the Olecranon: A Problem of Management. *J Trauma* 1979;19:23.

+ 137. Riggs SA Jr, Cooney WP III. External Fixation of Complex Hand and Wrist Fractures. *J Trauma* 1983;23:332.

# 138. Ring D, Jupiter B. Current Concepts Review: Fracture Dislocation of the Elbow. *J Bone Joint Surg [Am]* 1998;80:566.

+ 139. Ring D, Jupiter JB, Sanders RW, et al. Transolecranon Fracture–Dislocation of the Elbow. *J Orthop Trauma* 1997;11:545.

+ 140. Ring D, Jupiter JB, Simpson NS. Monteggia Fractures in Adults. *J Bone Joint Surg [Am]* 1998;80:1733.

+ 141. Rosacker JA, Kopta JA. Both-Bone Fractures of the Forearm: A Review of Surgical Variables Associated with Union. *Orthopaedics* 1981;4:1353.

+ 142. Rumball K, Finnegan M. Refractures after Forearm Plate Removal. *J Orthop Trauma* 1990;4:124.

* 143. Rush LV, Rush HL. A Technique for Longitudinal Pin Fixation of Certain Fractures of the Ulna and of the Femur. *J Bone Joint Surg* 1939;21:619.

* 144. Sage FP. Medullary Fixation of Fractures of the Forearm: A Study of the Medullary Canal of the Radius and a Report of 50 Fractures of the Radius Treated with a Prebent Triangular Nail. *J Bone Joint Surg [Am]* 1959;41:1489.

# 145. Sage FP. Fractures of the Shaft of the Radius and Ulna in the Adult. In: Adams JP, ed. *Current Practice in Orthopaedic Surgery*, Vol. 1. St. Louis: CV Mosby,1963.

# 146. Sage FP. Fractures of the Shafts and Distal Ends of the Radius and Ulna. *Instr Course Lect* 1971;20:91.

+ 147. Sanders RA, French HG. Opened Reduction and Internal Fixation of Comminuted Radial Head Fractures. *Am J Sports Med* 1986;14:130.

+ 148. Sargent JP, Teipner WA. Treatment of Forearm Shaft Fractures by Double-Plating: A Preliminary Report. *J Bone Joint Surg [Am]* 1965;47:1475.

+ 149. Sarmiento A, Cooper JS, Sinclair WF. Forearm Fractures: Early Functional Bracing, A Preliminary Report. *J Bone Joint Surg [Am]* 1975;57:297.

+ 150. Sarmeinto A, Latta LL, Zych G, et al. Isolated Ulnar Shaft Fractures Treated with Functional Braces. *J Orthop Trauma* 1998;12:420.

+ 151. Scharplatz D, Allgöwer M. Fracture-Dislocations of the Elbow. *Injury* 1975;7:143.

# 152. Schatzker J. Fractures of the Olecranon. In: Schatzker J, Tile M, eds.*The Rationale of Operative Fracture Care.* Berlin: Springer-Verlag, 1987.

+ 153. Schemitsch EH, Richards RR. The Effect of Malunions on Functional Outcome after Plate Fixation of Fractures of Both Bones of the Forearm in Adults. *J Bone Joint Surg [Am]* 1992;74:1068.

! 154. Schemitsch EH, Tencer AF, Henley MB. Biomechanical Evaluation of Methods of Internal Fixation of the Distal Humerus. *J Orthop Trauma* 1994;8:468.

# 155. Sisk TD. Compression Plate Fixation for Fractures of the Radius and Ulna. *Strateg Orthop Surg* 1982;2:1.

+ 156. Smith H, Sage FP. Medullary Fixation of Forearm Fractures. *J Bone Joint Surg [Am]* 1957;39:91.

! 157. Sojbjerg JO, Helmig P, Kjaersgaard-Andersen P. Dislocation of the Elbow: An Experimental Study of the Ligamentous Injuries. *Orthopaedics* 1989;12:461.

* 158. Speed JS, Boyd HB. Treatment of Fractures of the Ulna with Dislocation of Head of Radius (Monteggia Fracture). *JAMA* 1940;115:1900.

+ 159. Stern PJ, Drury WJ. Complications of Plate Fixation of Forearm Fractures. *Clin Orthop* 1983;175:25.

+ 160. Street DM. Intramedullary Forearm Nailing. *Clin Orthop* 1986;212:219.

+ 161. Swanson AB, Jaeger SH, La Rochelle D. Comminuted Fractures of the Radial Head. *J Bone Joint Surg [Am]* 1981;63:1039.

+ 162. Szabo RM, Hotchkiss RN, Slater RR Jr. The Use of Frozen-Allograft Radial Head Replacement for Treatment of Established Symptomatic Proximal Translation of the Radius: Preliminary Experience in Five Cases. *J Hand Surg* 1997;22A:269.

+ 163. Teasdall R, Savoie FH, Hughes JL. Comminuted Fractures of the Proximal Radius and Ulna. *Clin Orthop* 1993;292:37.

+ 164. Teipner WA, Mast JW. Internal Fixation of Forearm Diaphyseal Fractures: Double Plating versus Single Compression (Tension Band) Plating—A Comparative Study. *Orthop Clin North Am* 1980;11:381.

+ 165. Thompson HC, Garcia A. Myositis Ossificans: Af-termath of Elbow Injuries. *Clin Orthop* 1967;50:129.

+ 166. Trousdale RT, Amadio PC, Cooney WP, Morrey BF. Radio-Ulnar Dissociation. A Review of Twenty Cases, *J Bone Joint Surg [Am]* 1992;74:1486.

+ 167. Urbaniak JR, Hansen PE, Beissinger SF, Aitken MS. Correction of Post-Traumatic Flexion Contracture of the Elbow by Anterior Capsulotomy. *J Bone Joint Surg [Am]* 1985;67:1160.

+ 168. Venable CS. An Impacting Bone Plate to Attain Closed Coaptation. *Ann Surg* 1951;133:808.

+ 169. Waddell JP, Hatch J, Richards R. Supracondylar Fractures of the Humerus--Results of Surgical Treatment. *J Trauma* 1988;28:1615.

+ 170. Wallace AL, Walsh WR, van Rooijen M, et al. The Interosseous Membrane in Radio-Ulnar Dissociation. *J Bone Joint Surg Br* 1997;79:422.

+ 171. Weber BG. 10-Jahre Reinraumtechnik im Operationssaal für orthopädische Chirurgie. *VDI-Berichte* 1980;386:157.

# 172. Weber BG, Brunner C, Freuler F.*Treatment of Fractures in Children and Adolescents.* New York: Springer-Verlag, 1980.

+ 173. Weseley MS, Barenfeld PA, Risenstein AL. The Use of the Zuelzer Hook Plate in Fixation of Olecranon Fractures. *J Bone Joint Surg [Am]* 1976;58:859.

+ 174. Whiteside LA, Lesker, PA. The Effects of Extraperiosteal and Subperiosteal Dissection: 1. On Blood Flow in Muscle. *J Bone Joint Surg [Am]* 1978;60:23.

+ 175. Witt JD, Kamineni S. The Posterior Interosseous Nerve and the Posterolateral Approach to the Proximal Radius. *J Bone Joint Surg Br* 1998;80:240.

+ 176. Wolfgang G, Burke F, Bush D, et al. Surgical Treatment of Displaced Olecranon Fractures by Tension Band Wiring Technique. *Clin Orthop* 1987;224:192.

+ 177. Wright RR, Schmeling GJ, Schwab JP. The Necessity of Acute Bone Grafting in Diaphyseal Forearm Fractures: A Retrospective Review. *J Orthop Trauma* 1997;11:288.

+ 178. Yokoyama K, Itoman M, Kobayashi A, et al. Functional Outcomes of “Floating Elbow” Injuries in Adult Patients. *J Orthop Trauma* 1998;12:284.

# 179. Zagorski JB. Complex Fractures about the Elbow. *Instr Course Lect* 1990;39:265.

+ 180. Zinar D, Street D, Wolgin MA. As Reported by Crenshaw AH Jr, in: Canale ST, ed. *Campbell's Operative Orthopaedics*. Philadelphia: Mosby, 1998:2346.

# CHAPTER 17

# FRACTURES AND DISLOCATIONS OF THE PELVIC RING

*Dana C. Mears and Sridhar M. Durbhakula*

**D. C. Mears and S. M. Durbhakula:** Division of Orthopaedic Surgery, Albany Medical Center, Albany, New York, 12208.

Pathophysiology
General Mechanisms of Injury
Associated Hemorrhage and Implications for Therapeutic Intervention
Neurologic Injuries with Pelvic Trauma
Visceral Injuries with Pelvic Trauma
Open Pelvic Fractures
Aging: Its Impact on Pelvic Fractures
Mechanisms of Injury to the Pelvic Ring
Pelvic Stability: Correlation with Anatomic Disruptions
Principles of Management
Resuscitation and Triage
Control of Hemorrhage
Urologic Management
Nutritional Considerations
Pediatric Pelvic Fractures
Geriatric Pelvic Fractures
Assessment, Indications, and Relative Results
Clinical Assessment
Radiographic Assessment
Classification
Pennal and Tile Classification
Letournel Classification
Bucholz Classification
AO/ASIF–OTA–SICOT Classification
Preoperative Management
General Principles
Pelvic Stabilization
Preoperative Planning
The Columns of the Pelvis
Complex Pelvic Disruptions
Optimal Timing for Delayed Internal Fixation
Surgical Techniques
General Considerations
External Pelvic Fixation
The Use of a Pelvic Clamp
Internal Fixation of the Pelvis by Open Methods
Percutaneous Internal Pelvic Fixation
Postoperative Care and Rehabilitation
Early Postoperative Physical Therapy
Late Objectives of Rehabilitation
Pain Management
Thromboembolic Prophylaxis
Follow-Up
Management of External Fixation
Pitfalls and Complications
General Pitfalls
Complications
Authors' Perspectives
Chapter References

Significant or displaced fractures of the pelvic ring constitute a diverse group of skeletal injuries that usually result from motor-vehicle accidents, industrial trauma, sporting events, or falls from great heights. Apart from isolated fractures of individual bones of the pelvic ring or avulsion fractures documented in athletes, the typical pelvic ring disruption is notable for the immense amount of force needed to provoke a displacement of the pelvic ring. A patient who sustains such an injury is likely to present with other serious or life-threatening injuries involving the musculoskeletal, respiratory, central nervous, gastrointestinal, urologic, and cardiovascular systems (14). The management of a pelvic ring fracture, therefore, requires concomitant diagnosis and treatment of the other systemic and musculoskeletal injuries.

Historically, the management of the patient with a pelvic ring fracture has focused on the emergency care of the associated injuries with an initial neglect of the osseous disruption. Usually, the immobilization of the pelvic fracture was accomplished by bed rest and possibly the application of a pelvic sling, skeletal traction, or a hip spica cast. Such marginally effective methods of stabilization are inadequate for the control of profuse retroperitoneal hemorrhage, which often complicates acute pelvic disruption. Furthermore, bed rest and especially the use of a pelvic sling were notable for extraordinary discomfort and general failure to achieve an accurate reduction of a displaced fracture–dislocation.

All of these methods were associated with nearly complete immobilization of the patient, with the concomitant complications of prolonged, enforced recumbency including urinary retention, urinary tract infections, pulmonary emboli, infections, decubitus ulcers, and sloughing of soft tissues under a sling. In the past, most traumatologists tried to minimize complications by reacting to problems that arose during or after a period of enforced recumbency rather than anticipating the need for surgical intervention. Historically, this reactionary format has characterized the whole management protocol for pelvic trauma, including investigative procedures. During the 1990s, McMurtry et al. (35) and Tile (70) emphasized the need for a thorough diagnostic workup in virtually all patients with pelvic and acetabular fractures so that the associated injuries and the nature of the pelvic osseous disruption are accurately documented.

There is a widespread—and incorrect—notion among traumatologists that most pelvic fracture victims who survive these injuries have few major late problems. Retrospective analyses of pelvic fracture victims are notable for the high incidence of late problems, however, including pelvic pain, abnormalities of gait, limb-length discrepancy, permanent nerve damage, and genitourinary tract problems. During the 1990s, external fixation was recognized as an effective method to control the profuse retroperitoneal hemorrhage associated with major pelvic fractures and to lessen the typically severe pelvic pain (57). When all the available series in which this method has been used to manage unstable pelvic disruptions are analyzed, about 40% of the patients complain of late pelvic pain with or without a persistent deformity or a mobile nonunion (69,70). Early open reduction and internal fixation appears to reduce the incidence of these late problems (51). Nevertheless, with the potential complications of the surgery—particularly where an exposure of the pelvis necessitates anatomic approaches that are not widely used for typical orthopaedic procedures—other complications, including major neurovascular injuries and visceral insults, are likely to occur unless the surgical team is appropriately trained.

The indications for and techniques of pelvic reconstruction are undergoing rapid change. This chapter is based on our experience and the recommendations of other surgeons with an interest in this field.

## PATHOPHYSIOLOGY

### GENERAL MECHANISMS OF INJURY

Fractures and dislocations of the pelvis constitute a highly diverse group of injuries that are characterized by the force of the provocative blow; the site(s), magnitude, and nature of adjacent soft-tissue disruption; the quality of the involved tissues; and the potential presence of a total hip replacement (16,70). A pelvic disruption is the hallmark of violent or major trauma (Table 17.1).

| |
|---|
| Motor-vehicle accident (i.e., car/motorcycle, pedestrian involvement) |
| Industrial incident |
| Sporting event |
| Fall (greater than 6 ft) |
| Crushing injury (e.g., falling tree) |
| Gunshot and projectile related |

***Table 17.1. Sources of Violent or Major Trauma to the Pelvis***

### *Major Trauma*

Depending on the vector and magnitude of the provocative blow, specific injury patterns are likely to ensue that involve diverse supportive elements of the pelvic ring (Fig. 17.1). The injury patterns (69) are characterized by the sites of disruption and the magnitude and direction of displacement (Fig. 17.2). The external rotation injuries are further subdivided by the magnitude of the diastasis of the pubic symphysis and the potential presence of a sagittal malrotation or posterior displacement of the involved hemipelvis (Fig. 17.3). A crushing injury is typified by a logger who sustains a blow by an errant tree that strikes his pelvis. The force of the blow is likely to displace the involved portion of the pelvis, especially the iliac wing, into the intraabdominal cavity to provoke a frank or occult injury to the bowel or bladder (Fig. 17.4). Upon elastic recoil of the fracture fragments, a seemingly benign radiographic picture can mask a serious visceral impairment.

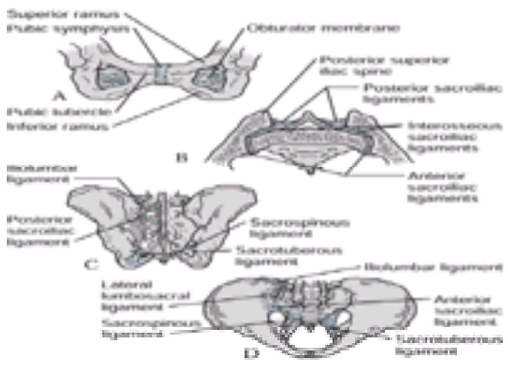


***Figure 17.1.*** Schematic views of the pelvis with the principal ligamentous supports. **A:** Symphysis pubis fibrocartilage. **B:** Posterior sacroiliac ligaments. **C:** Posterior view. **D:** Anterior view.

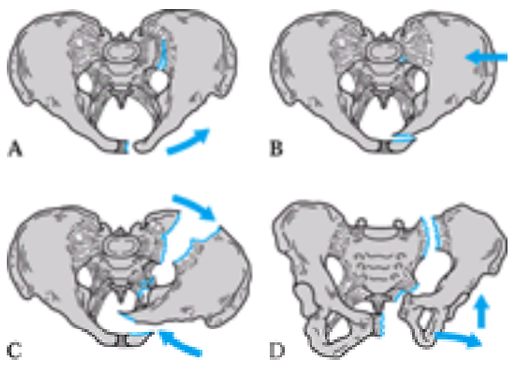


***Figure 17.2.*** Schematic view of the principal pelvis injury patterns as determined by the vector of the provocative blow. **A:** Anteroposterior compression or external rotation injury. **B:** Stable lateral compression or internal rotation injury. **C:** Unstable lateral compression or internal rotation injury. **D:** Unstable vertical shear disruption.

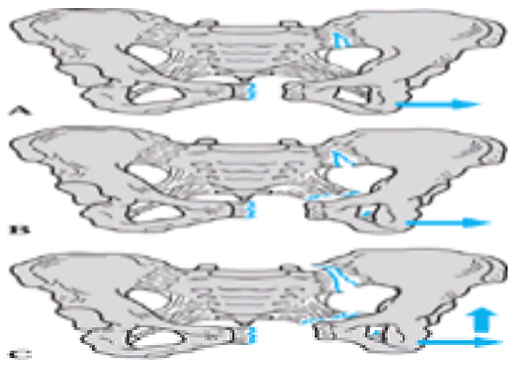


***Figure 17.3.*** Subclassification of a diastasis of the symphysis by the vector and magnitude of the displacement of the involved hemipelvis. **A:** External rotation. **B:** External and sagittal malrotation. **C:** Posterior displacement with sagittal and external malrotation.

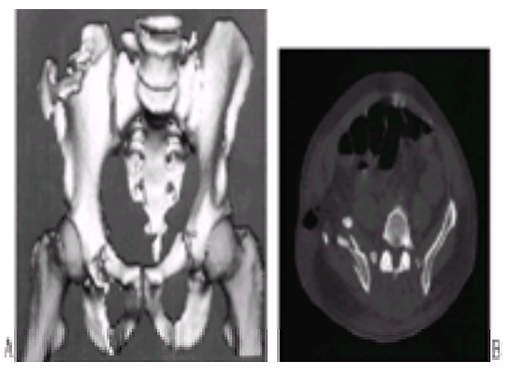

***Figure 17.4.*** The three- (3D) and two-dimensional (2D) CT views display a stable iliac fracture in a logger of 42 years who was struck by an errant tree. In the 2D CT, the highly displaced loop of small bowel superficial to the lateral ilium accompanied the elastic recoil of the iliac fragments, producing a small bowel obstruction.

### *Moderate and Minor Trauma*

With the rapidly aging Western population, an explosive increase in pelvic trauma secondary to moderate or minor trauma involving osteopenic bone is being encountered (46,55). Osteopenia varies widely in etiology and severity (Table 17.2), and in the most florid cases it accounts for pathologic and insufficiency fractures in which no relevant traumatic insult can be identified. While the healing potential of the bone varies greatly across this spectrum of clinical problems, overall the postirradiation group displays the poorest healing potential. A representative example is shown in Fig. 17.5.

| |
|---|
| Postmenopausal |
| Steroid induced |
| Postirradiation |
| Congenital and metabolic bone disease |
| Fall from ground level |

***Table 17.2. Moderate and Minor Trauma Involving Osteopenic Bone***

***Figure 17.5.*** Outlet view of a woman of 64 years with eight radiation-induced pathologic fractures and nonunions of bilateral superior and inferior rami, lateral ilia, and sacral ala.

### *Periprosthetic Fractures*

Another group of patients have a periprosthetic fracture of the pelvis that acutely or belatedly follows the insertion of a total hip arthroplasty. The injury patterns are markedly heterogeneous, depending on the force of the injury and the presence of osteopenia, typically secondary to steroid ingestion or irradiation. In such a clinical case, the fracture may extend from the sacral ala into the adjacent posterior ilium and across the quadrilateral surface, with loosening of the cup (Fig. 17.6).

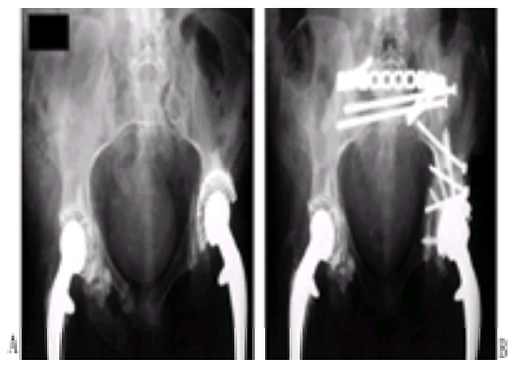

***Figure 17.6.*** Pre- and postoperative AP pelvic views of a steroid-dependent lupus patient of 35 years who developed an insufficiency fracture of the left sacral ala that extends along the left greater sciatic buttress and across the quadrilateral surface with loosening of the acetabular cup. **A:** Preoperative view. **B:** Postoperative view after internal fixation and cup revision.

## ASSOCIATED HEMORRHAGE AND IMPLICATIONS FOR THERAPEUTIC INTERVENTION

At the time of a traumatically induced pelvic fracture, some degree of hemorrhage is inevitable. The principal sites of bleeding are outlined in Table 17.3 The anticipated sites of major hemorrhage correlate with the region of the pelvis fracture, the vector of the provocative blow, and the magnitude of pelvic displacement. For example, a displaced fracture of the posterior ilium that exits through the roof of the greater sciatic notch is likely to be associated with an injury to the superior gluteal vessels.

| |
|---|
| Intraosseous vessels |
| Periosteal, capsular, and adjacent intramuscular vessels |
| Intrapelvic vessels |
| Gluteal |
| Obturator |
| Pudendal |
| Hypogastric |
| External and internal iliac |
| Common iliac and aorta |
| Intraabdominal bleeding |
| Visceral |
| Major intraabdominal vessels |
| External bleeding through an open wound |

*Table 17.3. Principal Sites of Hemorrhage after a Pelvic Fracture*

For a displaced fracture with marked external rotation of one or both hemipelvi, in which the ligamentous floor of the pelvis is disrupted, a large volume of blood may collect in the retroperitoneal space (42) and extravasate into the scrotum, the thighs, and superiorward. With pelvic instability, possibly combined with a consumption coagulopathy in a hypothermic patient, the volume of blood that may be extravasated around the pelvis is truly enormous, and it may require 50 or more units of blood to be transfused. These pathologic responses to major pelvic trauma are minimized by prompt immobilization of the pelvis, correction of major deformity, direct control of hemorrhage from large vessels or tamponade of smaller ones, along with general resuscitation of the patient. In the presence of a large open wound, packing is a critical measure to provide tamponade (51).

A variety of cutaneous manifestations of pelvic fractures provide a source of potential clinical problems (Table 17.4). The cutaneous disruptions as well as visceral injuries provide a source of contamination for the bone and can lead to an infection of the pelvis and hip joint (Table 17.5).

| |
|---|
| Extensive ecchymosis and soft-tissue swelling (Grey-Turner syndrome) |
| Disruption of the subcutaneous fat along with ecchymotic skin and potentially the deep fascia (Morelle-Lavelle lesion) |
| Open wounds around the pelvis |
| Perineal laceration or puncture wound |
| Extensive perineal laceration around the entire inner thigh (wide abduction injury) |
| Presacral laceration |
| Perianal or vaginal laceration |

*Table 17.4. Cutaneous Manifestations of Pelvic Trauma*

| |
|---|
| Open fracture–dislocation with cutaneous penetration |
| Pelvic fracture with an injury of the large or small bowel |
| Communication of the pelvic fracture with the bladder or urethra |
| Communication of the pelvic fracture with the vagina |

*Table 17.5. Potential Sources of Infection for the Injured Pelvis and Hip Joint*

## NEUROLOGIC INJURIES WITH PELVIC TRAUMA

Accompanying neurologic injury is one of the principal sources of late complications after pelvic trauma. The potential sites for neurologic impairment are listed in Table 17.6.

| |
|---|
| Lumbosacral plexus |
| Presacral plexus |
| Sciatic nerve |
| Femoral nerve |
| Other motor nerves around the pelvis (e.g., gluteal, obturator, pudendal) |
| Lateral femoral cutaneous nerve of the thigh |
| Genitofemoral, ilioinguinal |
| Lumbosacral nerve roots |

*Table 17.6. Potential Sites of Neurologic Impairment with Pelvic Trauma*

The mechanisms of injury include stretching, contusion, laceration, and iatrogenic injury resulting from the surgery. Direct compression of the nerve, caused, for example, by a displaced sacral bone fragment in a foramen, may benefit from surgical decompression. Other types of neurologic injury do not respond favorably to available surgical measures.

## VISCERAL INJURIES WITH PELVIC TRAUMA

Visceral injuries are a potential source of life-threatening complications in a pelvic fracture (Table 17.7) (51,52,60,67,73). Injury to the lower urinary tract is a common consequence of a disruption of the anterior pelvic ring, and it can involve the ureter or, more commonly, the bladder and urethra. Urologic injury occurs in as many as 25% of all cases involving disruption of the pelvic ring, and it is more common with bilateral disruptions of the pubic arch. In the setting of a fractured pelvis, extraperitoneal bladder rupture at the anterolateral aspect near the neck is more common than intraperitoneal rupture along the bladder dome; the converse is true in blunt pelvic trauma without ring disruption. The overall occurrence rate of a pelvic fracture with a concomitant bladder injury is reported to be as high as 15%. Urethral injury is common with a disruption of the anterior pelvic ring, such as a pubic ramus fracture; 65% of these injuries are complete disruptions. The incidence of concomitant bladder neck injury is as high as 2.5%. There is an increased likelihood for shearing of the significantly longer male urethra, with a reported occurrence rate up to 11% for male versus 6% for female patients. In the typical lateral compression type of pelvic fracture, displacement of the pubic ramus relative to the ischial ramus results in a classic urethral disruption just distal to the apex of the prostate gland. If both rami are displaced as a combined unit, the injury is likely to occur at the juncture of the membranous urethra and the bulbous urethra. While no consistent association between a specific urologic injury and a specific mechanism of pelvic fracture has been reported, generally the severity of the pelvic injury pattern determines the extent of the urologic injury.

| |
|---|
| Intrapelvic |
| Intestinal: large and small bowel |
| Urinary: bladder and urethra |
| Genital: vaginal, occasionally other |
| Intraabdominal |

***Table 17.7. Potential Sites of Visceral Injury with a Pelvic Fracture***

Clinical features that are suggestive of a urethral tear include the presence of blood at or around the urethral meatus, local swelling, the inability to void, gross hematuria, or a high-riding prostate gland. If any of these signs are present, obtain a dynamic retrograde urethrogram prior to the insertion of a urinary catheter to rule out a significant urethral injury. After catheterization, do a static cystogram to evaluate the bladder. In female patients, a meticulous gynecologic examination is essential, particularly in the presence of vaginal bleeding.

Previously, deferral of internal fixation of a pelvic fracture in the presence of a concomitant urologic injury was a common error, which occurred because of the fear of a postsurgical infection secondary to urinary contamination of the surgical wound. In actuality, these concerns have been exaggerated. Routt et al. (60) reported a low rate of infection and a 30% incidence of late urologic complications when definitive internal fixation of a pelvic fracture was combined with indirect stabilization of a urethral disruption with a temporary stent by the use of two magnetic catheters. Currently, with the diverse methods that are available to stabilize a pelvic disruption in the presence of urethral trauma, an alternative strategy for fixation can be used that minimizes the risk of a wound infection. Admittedly, most urologists favor a delayed urethral reconstruction, which in their view lowers the risk of impotence, incontinence, and urethral stricture. When the urologic injury is a rupture of the bladder, an acute surgical repair may be indicated, while concomitant fixation of the anterior pelvic arch with a plate is strongly recommended. Likewise, concomitant injuries of the urethra and bladder may warrant immediate surgical repair. In the presence of a stable pelvic fracture and an extraperitoneal bladder injury, nonoperative management of both problems may be undertaken. In the case of an unstable pelvic ring disruption with a contaminated suprapubic catheter, external fixation of anterior disruptions of the pelvis can be used to supplement open or percutaneous treatment of the posterior pelvic disruption.

**OPEN PELVIC FRACTURES**

Traditionally, open pelvic trauma has possessed a considerable mortality, although more recent series have displayed mortalities that are comparable to those for closed injuries (7,11,25,52,77). The principal sites for the open fracture and associated wounds are shown in Table 17.8. Irrespective of the mechanisms of injury (Table 17.9), the presence of an open wound is usually due to tremendous energy dissipation on the pelvic ring resulting in an unstable fracture dislocation.

| |
|---|
| Rami: perineal laceration, impalement of urethra or bladder |
| Sacrum: presacral laceration, rectal laceration |
| Ilium: blunt trauma, missile, small-bowel laceration |

***Table 17.8. Principal Bony Sites and Associated Injuries in Open Pelvic Trauma***

| |
|---|
| Impalement of the skin from within by a sharp bony fragment |
| Impalement or laceration of the skin by a sharp object from without |
| Marked and forceful displacement of the lower extremity to avulse the skin (e.g., the wide abduction of a lower extremity) |
| Extensive abrasive loss of skin around the pelvis |
| Bony impalement of the bowel or bladder |
| Missile, gunshot, or other source of penetrating wound. |
| Crushing insult (logger's fracture) with impalement of the bowel by a displaced bony fragment, especially ilium |

***Table 17.9. Causes for an Open Pelvic Fracture or Dislocation***

Even in the presence of a small and seemingly benign open wound, a highly unstable pelvic fracture may be found for which stabilization is indicated. In the past, internal fixation was felt to be contraindicated in open fractures because of the increased risk of infection. While external fixation remains the most common method of stabilization, improved wound care and newer techniques have made internal fixation an option. Several different strategies for definitive pelvic fixation may be considered, depending on the type and site of the wound, the magnitude of contamination, the fracture pattern, and the resources of the surgical team (Table 17.10).

| |
|---|
| Minor contamination with small or large wound |
| Acute external fixation |
| Percutaneous internal fixation |
| Acute internal fixation inserted through the open wound |
| Moderate contamination |
| Acute external fixation |
| Secondary, optimally percutaneous, internal fixation |
| Heavy contamination (e.g., feculent soiling) |
| Acute debridement |
| External fixation |
| Deferral of internal fixation until the risk of a deep infection is minimized, if possible at all |

***Table 17.10. Alternative Methods of Pelvic Stabilization Based on Characteristics of the Open Fracture Wound***

When the open wound is in proximity to the perineum or anal sphincter, or when it involves a viscus, a diversion colostomy is necessary to divert feces away from the open wound. Other implications of the impact of the open wound on global management are outlined in Table 17.11.

| |
|---|
| Consideration for diversion colostomy, particularly with perineal or perianal wound |
| Serial debridement |
| Special considerations for closure of the wound |
| Enlarged role for acute external fixation |
| Definitive care of an associated visceral injury |
| Considerations for how to achieve definitive stabilization of the pelvis |

***Table 17.11. Impact of an Open Wound on Management Decisions***

## AGING: ITS IMPACT ON PELVIC FRACTURES

The explosive increase in the aging population in North America and Europe is having a profound impact on pelvic fracture management (29). This statistical trend is anticipated to be even more dramatic over the next half century (Table 17.12).

| |
|---|
| In 1995, the population over the age of 65 years had 28% of all fatal injuries and represented 12% of the population. |
| By 2020, 52 million people will be over the age of 65 years. |
| By 2040, 68 million people will be over the age of 65 years. |

From Lowner JH, Koval KJ. Polytrauma in the Elderly. *Clin Orthop* 1995; 318:136.

***Table 17.12. Anticipated Changes in the U.S. Over 65 Population***

Whereas previously pelvic fractures were primarily due to violent trauma in young adults, currently more than 50% of pelvic fractures occur in the over-60 population (Fig. 17.7), with a female predominance that reflects postmenopausal osteoporosis (46,55). The elderly experience higher mortality and late morbidity than younger patients with comparable injuries (Table 17.13) (29,34). In the elderly person, the potential for intensive-care management and the duration of hospitalization and rehabilitation are likely to be much greater, resulting in increased costs.

| |
|---|
| Major trauma: enhanced comminution and impaction |
| Minor trauma: significant source of symptomatic fractures |
| Insufficiency and pathologic fractures: major source of clinical problems |

***Table 17.13. Implications for Injury Patterns in the Elderly***

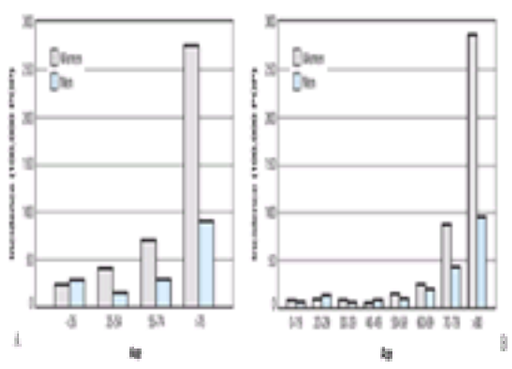

***Figure 17.7.*** Incidence of pelvic fractures for the United States and Sweden with respect to sex and age. **A:** Rochester, Minnesota, 1976–1985. (From Melton LJ, Sampson JM, Morrey BF, Ilstrup DM. Epidemiologic Features of Pelvic Fractures. *Clin Orthop* 1981;155:43.) **B:** Skaraborg County, Sweden, 1976–1985. (From Ragnarsson B, Jacobsson B. Epidemiology of Pelvic Fractures in a Swedish County. *Acta Orthop Scand* 1992;63:297.)

While the pretraumatic comorbidities that may be encountered in the elderly are extraordinarily varied, certain problems (Table 17.14) are frequent cofactors that impact heavily on the management of the pelvic fracture. Antecedent cardiac disease compromises the cardiac reserve during the stressful early posttraumatic period and renders the patient vulnerable to serious arrhythmia and myocardial infarction. Posttraumatic atelectasis, possibly in association with multiple rib fractures or a pneumothorax, is immeasurably aggravated by pretraumatic pulmonary disease. Hepatic dysfunction in alcoholics may impair coagulation and compromise the prognosis for retroperitoneal hemorrhage. The trauma may dislodge a preexisting plaque in the common or external iliac artery, resulting in a cold, pulseless limb that requires medical or surgical intervention. With central neurologic impairment, such as pretraumatic senility, intention tremor, or generalized weakness, the rehabilitation after a pelvic fracture may be greatly impeded. Not infrequently in the elderly, the general anesthetic required for initial care will be the only anesthetic that is possible for the first 4–6 weeks of posttraumatic care because of complications.

| |
|---|
| Ischemic heart disease |
| Obstructive airway disease |
| Hepatic dysfunction with resultant coagulopathy |
| Peripheral vascular disease |
| Central neurologic impairment |

***Table 17.14. Geriatric Comorbidities That Frequently Impact on Pelvic Fracture Management***

After an extensive open reduction, the elderly and infirm have a higher incidence of intraoperative hemorrhage, wound infection, and necrosis of flaps (22). External fixation pins tend to loosen quickly. Table 17.15 lists guidelines that can aid in the management of pelvic fractures in the elderly.

| |
|---|
| Limit the use of definitive external fixation. |
| Minimize the use of extensile approaches and large wounds. |
| Where feasible, consider percutaneous internal fixation. |
| Try to internally fix the pelvis acutely, as later surgery is often not possible. |
| In the elderly with multiple medical problems, an acute external frame with a closed reduction and, if necessary, longitudinal traction may be the best fixation that realistically can be achieved. |

***Table 17.15. Fixation Strategies in the Elderly and Infirm***

## MECHANISMS OF INJURY TO THE PELVIC RING

The principal injury patterns correlate with the vector of the provocative blow (Table 17.16). From the observations of Burgess et al. (5) and Dalal et al. (10), the force vectors and pelvic injury patterns also correlate with the anticipated patterns of additional injuries to the abdomen, intrapelvic contents, chest, and head, as well as with the potential for significant hemorrhage. A single anteroposterior (AP) pelvic radiograph, therefore, provides insight into the force vector and the likelihood for co-injuries for which appropriate diagnostic tests can be initiated promptly.

| |
|---|
| Anteroposterior: AP compression/external rotation injury |
| Lateral: lateral compression/internal rotation injury |
| Vertical: vertical shear fracture |

From Burgess AR, Eistridge BJ, Young JW, et al. Pelvic Ring Disruptions. Effective Classification System and Treatment Protocols. *J Trauma* 1990;30:848, and Dalal SA, Burgess AR, Siegel JH, et al. Pelvic Fractures in Multiple Trauma: Classification by Mechanism Is Key to Pattern of Organ Injury, Resuscitation Requirement, and Outcome. *J Trauma* 1989; 29: 981.

***Table 17.16. Principal Pelvic Fracture Patterns Based on the Vector of the Provocative Force***

## PELVIC STABILITY: CORRELATION WITH ANATOMIC DISRUPTIONS

### *Pelvic Anatomy*

The anatomic basis for pelvic stability is displayed in Figure 17.1. The crucial stabilizing ligaments extend from the sacrum, across the sacroiliac (SI) joints and posterior; they transmit weight-bearing forces either across the hip joints, into the lower extremities for ambulation, or into the ischial tuberosities for sitting. The crucial posterior SI ligaments stabilize the SI joints, along with the iliolumbar, sacrospinous, and sacrotuberous ligaments. With its ring-like configuration, the pelvis is intrinsically highly stable and resistant to deforming forces.

### *Determinants of Pelvic Instability*

The characteristic patterns of pelvic disruption correlate with the vector and magnitude of the provocative blow and the strength of the pelvic ring (Fig. 17.2). Subtle changes in the force vector markedly alter the pattern of the disruption. A direct lateral blow on the posterior ilium usually causes a stable lateral compression injury with impaction of the sacral ala, and accompanying unilateral or bilateral ramus fractures. A blow to the anterior portion of the lateral ilium results in an internal rotational moment that creates an unstable injury in which the ilium sustains a vertical or crescent fracture with the sacral ala acting as a fulcrum (69). With the rotational deformity of the ipsilateral hemipelvis, the sharp edges of the ramus fractures can impale the bladder or occasionally the bowel.

### *Anteroposterior Compression Injury*

The force of the trauma correlates with the width of the diastasis of the pubic symphysis and other manifestations of the injury (Fig. 17.3). With a diastasis of 2 cm or less, the symphyseal and diminutive anterior SI ligaments are disrupted while the rest of the pelvic ligaments are spared. With a diastasis of 5 cm or more, the sacrotuberous and sacrospinous ligaments are torn on one or both sides and sagittal malrotation of the involved hemipelvis is present. With a diastasis beyond 10 cm, the posterior SI ligaments are torn so that the involved ipsilateral hemipelvis also displaces posteriorly.

### *Vertical Injury*

With a vertical shear injury, the iliolumbar ligaments, along with the posterior SI ligaments, are disrupted (Fig. 17.2). With vertical displacement of the pelvis, the ipsilateral lower lumbar transverse processes are fractured. This is pathognomonic of this injury.

### *Sacral Fractures*

Many different sacral fractures (12,68) can be encountered in stable and highly unstable variants (Fig. 17.8; Table 17.17). Lumbosacral dissociation is caused by high

energy falls, such as endured by a suicidal jumper or a paratrooper who sustains a forceful landing on his feet (62). In this insult, usually a comminuted sacral fracture is greatly complicated by a forward displacement of the first sacral body upon the fifth lumbar vertebra.

| |
|---|
| Impacted alar fracture |
| Sacroiliac fracture dislocation |
| Transforaminal sacral fracture |
| Bilateral transforaminal sacral fracture |
| Comminuted variants (H fractures) |
| Lumbosacral dissociation |

***Table 17.17. Patterns of Sacral Fractures***

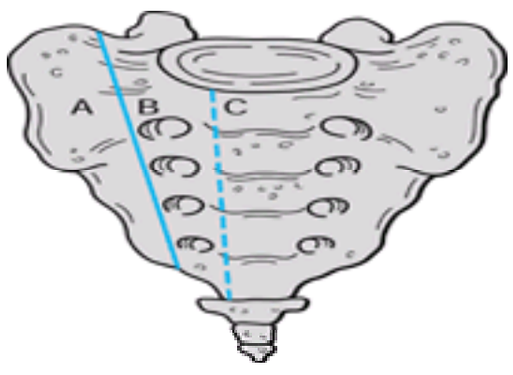


***Figure 17.8.*** Pattern of sacral fractures. **A:** Transalar. **B:** Transforaminal. **C:** Central.

### *Avulsion Fractures*

Avulsion fractures occur in athletes, especially short-distance runners. The site of the involved fragment is highly variable and includes the anterior superior and inferior spines and the ischial tuberosity, caused by the sartorius, the rectus femoris, and the hamstrings, respectively. While most of these heal uneventfully, a few, especially the larger ones, progress to a symptomatic nonunion.

### *Occult Fractures*

Occult fractures are usually insufficiency fractures; a technetium bone scan or magnetic resonance imaging (MRI) may confirm the diagnosis (18). The most common occult fracture is a sacral injury for which overlying gas shadows may hamper radiographic visualization. A computed tomography (CT) scan is helpful.

## PRINCIPLES OF MANAGEMENT

### RESUSCITATION AND TRIAGE

Follow the general principles of trauma resuscitation and initial care (5,51) discussed in detail in Chapter 14. If the patient is hemodynamically unstable and has an unstable pelvis, then early stabilization may be very important, as discussed below.

### CONTROL OF HEMORRHAGE

### *Initial Evaluation and Treatment*

An algorithm that outlines appropriate measures for the control of hemorrhage is provided in Fig. 17.9. For conspicuous external bleeding, apply a pressure dressing. The pelvis can be quickly and temporarily stabilized by wrapping a sheet tightly around it and securing it with a clamp. On arrival in the emergency department, the patient may be in a pneumatic antishock garment. Deflate it carefully to avoid precipitous hypotension. If hypotension does occur, reinflate the garment and transfer the patient to the operating room so that, upon removal of the suit, immediate alternative surgical measures to restore hemodynamic stability can be undertaken. The diagnosis of intraabdominal hemorrhage can be made by ultrasound (45,54), peritoneal lavage, or minilaparotomy. Abdominal and pelvic CT scans are useful as well (3,63).

***Figure 17.9.*** Algorithm that outlines the therapeutic measures for the control of hemorrhage in the patient with a pelvic fracture.

### *Emergent Pelvic Stabilization*

External pelvic fixation is a highly effective method to control intrapelvic bleeding associated with a major pelvic fracture (57). For initial emergent application, pelvic clamps have been devised that permit rapid application and compression of the pelvis directly over the lateral ilium at the level of the SI joints (16,17,51,52,76). The clamp is intended for temporary application with subsequent replacement by a suitable technique of internal fixation once hemodynamic stability has been achieved. These devices have not been popular because of potential complications from misapplication.

Reduction of the pelvic fracture produces an increase in interstitial tissue pressure and provides a tamponade of the retroperitoneal bleeding. It also markedly reduces the volume of the true pelvis in which extravasated blood may accumulate. Reduction and compression of the cancellous fracture surfaces reduces the rate of bleeding. Nevertheless, contraindications to the use of external pelvic fixation for the control of hemorrhage need to be clearly understood (Table 17.18). With a

bilaterally unstable posterior injury, the frame cannot control the pelvic ring. Adding temporary longitudinal skeletal traction to the affected side, combined with external fixation, may be of some help. In the presence of iliac comminution and florid osteoporosis, the pins do not achieve sufficient pelvic anchorage. In a small child, the disproportionately small pelvis is not a realistic target for effective anchorage of the pins.

| |
|---|
| Fracture of iliac crest and anterior inferior spine that eliminates any realistic site for insertion of a pin |
| Bilateral sacroiliac dislocations or comparable bilateral posterior injuries |
| Bilateral both-column or high anterior column acetabular fractures |
| Stable pelvic ring with source of intrapelvic hemorrhage |
| Bleeding of a major pelvic vessel (i.e., aorta, iliac, or femoral vessels) |
| Late presentation |
| Marked osteoporosis |
| Small child |

***Table 17.18. Relative Contraindications to External Pelvic Fixation for Control of Acute Hemorrhage***

### *Angiography*

As an alternative to or in combination with fixation, use angiographic embolization of autologous blood clots or Gelfoam clots in combination with the insertion of a stent (1). An example is displayed in Figure 17.10. Angiographic embolization can be done without violating the peritoneal barrier and with minimal risk of infection. It is unsuitable, however, for the management of venous bleeding, and it requires appropriate radiographic resources. In dire circumstances, it can be used to control bleeding of relatively large vessels, such as the internal iliac artery. Such a procedure, however, possesses a considerable morbidity, including necrosis of the gluteal muscles.

***Figure 17.10.*** Arteriographic views of a 21-year-old man after a pelvic fracture with acute open reduction and internal fixation (ORIF) of sacral and left acetabular fractures. Persistent hemorrhage from the left hypogastric artery is identified arteriographically and secondarily controlled with a standard gel foam embolus. **A:** Arteriogram. **B:** During embolization. **C:** After embolization.

### *Direct Surgical Control*

For the management of bleeding from vessels that are greater than 5 mm in diameter, such as the femoral and common iliac arteries, operative intervention is usually necessary. At least three separate strategies, or various combinations of these, may be appropriate (Table 17.19). A direct repair of a major artery has a high likelihood for a successful result. Aortic cross-clamping is a desperate measure that may provide a brief period of tolerable ischemia while a source of uncontrolled hemorrhage is identified and controlled. Acute retroperitoneal packing can also be effective and may permit a concomitant or sequential open reduction and internal fixation of the pelvis (66).

| |
|---|
| Direct surgical repair |
| Cross-clamp the aorta (20 min maximum) to facilitate repair |
| Packing of the retroperitoneal space |

***Table 17.19. Methods of Intraoperative Vascular Control of Major Intrapelvic Hemorrhage***

## UROLOGIC MANAGEMENT

Catheterize the urinary bladder to document urinary output as a crucial determinant of adequate volume resuscitation. In the presence of a major pelvic fracture, urinary catheterization requires special consideration (Table 17.20). The incidence of concomitant injury to the bladder or urethra is about 20% (52,53,60,67,73). A Foley catheter can be placed directly into the bladder of a female patient. In male patients, first obtain a urethrogram if there is any suspicion of a urethral injury. Attempts to pass a catheter blindly through a partially disrupted male urethra can aggravate a partial tear and result in a stricture, incontinence, or impotence. If the urethrogram indicates the passage of contrast medium into the bladder without extravasation, advance the catheter into the bladder. Then perform a cystogram to exclude a rupture of the bladder.

| |
|---|
| Female patient: Insert Foley catheter. |
| Male patient: Obtain urethrogram.<br>Intact urethra: Insert Foley catheter.<br>Disrupted urethra: Consider indirect alternatives, including use of suprapubic cystoscopy and drainage, urethral stent, or magnetic catheters. |
| Obtain intravenous pyelogram to assess kidneys and ureters. |

*Table 17.20. Urologic Management for a Pelvic Fracture Victim*

Finally, undertake an intravenous pyelogram to assess the kidneys and ureters. In the typical pelvic fracture victim, a large pelvic hematoma usually distorts the image of the bladder. The hematoma requires no specific treatment, although it may indicate a large blood loss and the need for supplementary fluid or blood replacement. If a urethral injury is identified, a suprapubic cystoscopy may be indicated. This procedure can be technically difficult in the presence of a large pelvic hematoma.

Recently, as a therapeutic alternative, radiographically visible stents have been inserted primarily into the site of the urethral disruption. Also, magnetic catheters have been devised, which permit simultaneous urethral and suprapubic insertions (53,60). After the magnetic coupling of the catheters at the site of the rupture, advance the urethral catheter into the bladder and remove the suprapubic catheter. The newer methods that eliminate any suprapubic source of sepsis are superior to the more traditional suprapubic catheter.

### NUTRITIONAL CONSIDERATIONS

Patients with pelvic fractures and concomitant multiple trauma are likely to undergo a lengthy period of nutritional depletion following the acute resuscitation. Nutritional demands are exceptionally great, and oral dietary intake is limited by ventilatory support and multiple visits to the operating room. Certain patients, notably those who are alcoholic and others with peculiar voluntary dietary restrictions, may be nutritionally depleted at the time of injury. Others, especially those with morbid obesity, are vulnerable to a rapid onset of malnutrition following admission, which may not be recognized by the therapeutic team. For these reasons, a sound scheme of nutritional support is necessary for each patient (6).

### PEDIATRIC PELVIC FRACTURES

Children struck by vehicles can sustain the triad of a pelvic disruption, femoral shaft fracture, and closed head injury (42). Prompt evaluation for a potential intracranial injury is crucial (Table 17.21). Conventional radiographs may not reveal all pelvic injuries, especially when the triradiate cartilage is involved. A three-dimensional (3D) CT is especially useful in this scenario (30,44). External fixation is greatly hampered by the small size of the pediatric pelvis, but a double hip spica cast works well. Flexion of the hips and knees aids indirect reduction of the pelvis by suitable rotation of either hemipelvis. Occasionally, for an unstable and displaced injury, especially one that involves the triradiate cartilage, an open reduction and internal fixation is indicated.

Predilection for associated injuries

Impact on diagnostic imaging and injury recognition

Anatomic considerations
- Triradiate cartilage
- Disproportionately small pelvis
- Limitations of external fixation

Stabilization and therapeutic options
- External fixation if large enough
- Hip spica immobilization
- Internal fixation

*Table 17.21. Implications of a Pediatric Pelvic Fracture for Clinical and Radiographic Evaluation and Treatment*

### GERIATRIC PELVIC FRACTURES

At the other extreme of age, a geriatric fracture also poses special considerations (Table 17.22). Because of the predilection of the elderly for diverse pretraumatic comorbidities, the homeostatic compensatory mechanisms to cope with multiple trauma may be heavily compromised. Similarly, the patient may not possess the reserves to cope with reconstructive surgery. In the presence of osteopenic bone, pelvic imaging may be hampered, particularly in a case of an insufficiency or pathologic fracture. The use of a CT scan, a technetium bone scan, or an MRI merits consideration to confirm the site(s) and nature of the injury (18). A prior history of pelvic irradiation therapy may provide a predisposition for an insufficiency fracture. If prior heavy irradiation of the pelvis is documented, then the role for extensive open surgical reconstruction is markedly diminished, with greatly increased surgical risk and potential for postoperative wound dehiscence. Overall, in the elderly, the role for minimally invasive reduction strategies and percutaneous fixation is increased, while the place for full open reduction and external fixation is diminished.

Significance of comorbidities

Problems with imaging

Prior pelvic irradiation therapy

Strategies for pelvic fixation

*Table 17.22. Implications of a Geriatric Pelvic Fracture for Clinical and Radiographic Evaluation and Treatment*

## ASSESSMENT, INDICATIONS, AND RELATIVE RESULTS

### CLINICAL ASSESSMENT

Before treating pelvic disruption, rigorously characterize the injury by its clinical and radiologic features (Table 17.23). Try to determine the direction of the injuring force from the history, and by inspecting for sites of contusion or ecchymosis. The history of a high-energy motor-vehicle or industrial accident increases the likelihood of a major unstable injury and concomitant visceral or neurovascular insults. Examine the pelvic region for evidence of asymmetry or instability, or the presence of an open wound. A laceration in the groin, scrotum, or perineal region or of the vagina and rectum is highly suspicious of an open pelvic fracture. An apparent deformity of the lower extremity in the absence of a fracture in the lower limb may indicate a pelvic fracture.

| |
|---|
| Clinical |
| Gross inspection (e.g., open wounds, deformities) |
| Comprehensive neurovascular assessment |
| Urogenital and rectal exams |
| Radiologic evaluation |
| Standard views (AP, inlet, outlet, Judet) |
| Computed tomography (CT) |
| Fluoroscopy and stress views |
| Specialized exams: 3D CT, angiogram, magnetic resonance imaging, bone scan, ultrasound |

***Table 17.23. Clinical and Radiographic Assessment of the Pelvic Fracture Victim***

## RADIOGRAPHIC ASSESSMENT

If there is marked hemodynamic instability, limit the initial radiographic assessment of the pelvis to an AP view. Once hemodynamic and other urgent considerations permit, obtain additional radiographic views so that the injury can be precisely characterized (Fig. 17.11). At least three views are required: AP, inlet, and outlet. To obtain an inlet view of the supine patient, direct the x-ray beam from the head to the midpelvis at about 45° with respect to the radiographic table or 45° from the vertical reference axis. Such a projection is perpendicular to the pelvic brim and illustrates the true pelvic inlet as well as anteroposterior displacement of a pelvic disruption. To obtain an outlet projection of a supine patient, direct the beam from the foot to the pubic symphysis at 45° with respect to the radiographic plate. The outlet projection discloses superior displacement of the posterior half of the pelvis and either superior or inferior displacement of the anterior portion of the rami. Apparent limb-length discrepancy originating from elevation of the hip joint secondary to a rotational displacement is highlighted, along with avulsion fractures of the transverse processes of the lower lumbar vertebrae or ramus fractures.

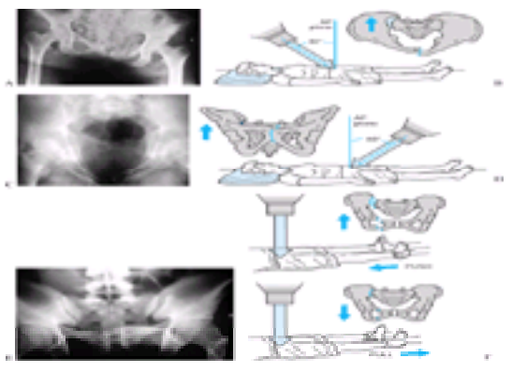

***Figure 17.11.*** Radiographic and schematic views of conventional pelvic images. **A:** AP radiographic view. **B:** Schematic method for inlet view. **C:** Radiographic inlet view. **D:** Schematic method for outlet view. **E:** Radiographic outlet view. **F:** Schematic assessment for pelvic instability.

If the AP view indicates a possible acetabular disruption, obtain supplementary Judet or oblique obturator and iliac views. Obtain these views by rolling the injured patient carefully from one side to the other to provide 45° views. Occult pelvic instability may be detected by AP radiographs before and after the application of longitudinal traction on the relevant lower extremity (Fig. 17.11).

Computed tomography is indispensable for documenting sites of pelvic disruption, displacement, and comminution. Its foremost role is to clarify posterior disruption of a pelvic ring fracture. A sacral fracture that is virtually invisible on plain radiographs is readily seen on CT. The degree of separation and instability of a SI joint or sacral fracture is evident. At a minimum, obtain five standard transaxial sections at 2 cm intervals (Fig. 17.12). The most superior section demonstrates the iliac wings and the adjacent SI joints. A second section displays the principal part of the sacrum and the adjacent SI joints. The third section projects the dome of the acetabulum with a circular cross section. The fourth section transects the midacetabular region, where the femoral head opposes the anterior and posterior columns. The most inferior section reveals the inferior pubic ramus and the ischial tuberosity at the level of the greater trochanter.

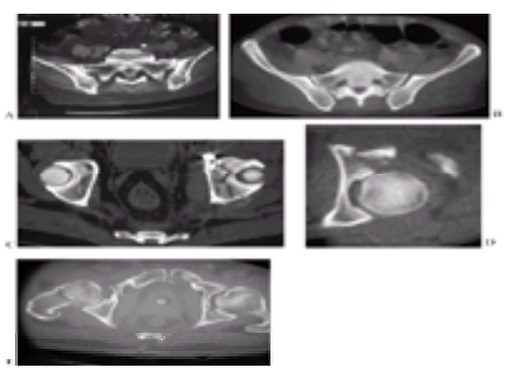

***Figure 17.12.*** Standard pelvic CT images at 2 cm intervals. **A:** SI joints with stable sacral alar lateral compression fracture. **B:** Sacral body and SI subluxation. **C:** Acetabular dome with transverse fracture. **D:** Mid-acetabular region with posterior wall fracture. **E:** Symphysis and rami.

Formulating a detailed plan for the surgical reconstruction of a comminuted, displaced pelvic fracture requires an accurate 3D radiographic perspective to define the optimal method or surgical approach, open reduction, and stabilization. When reviewing the conventional two-dimensional (2D) radiographs and CT scans, even an experienced surgeon has difficulty with the extensive mental integration needed to realize a 3D image. Computer programs now can produce 3D surface reformations, or so-called 3D CT images (44), from sets of contiguous axial computed scans of the pelvis (Fig. 17.13). While the images may be unavailable for truly emergent cases, they can be obtained within 1–12 hours after the arrival of the patient in the radiology suite. Document vascular injuries either by a conventional arteriogram (52) or a 3D CT with a prior insertion of radiopaque catheters into the relevant artery and vein (Fig. 17.14) (20).

***Figure 17.13.*** Three-dimensional CT scans of two hemipelves. **A:** A posterior T-type fracture. **B:** Disarticulated “dome” view of posterior column–posterior wall fracture.

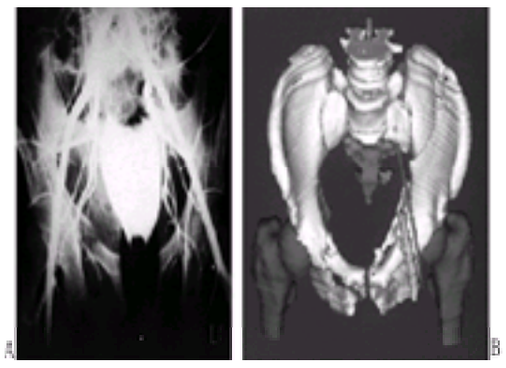

***Figure 17.14.*** Arteriographic studies of pelvic fractures. **A:** Conventional arteriograph. **B:** 3D CT of a left both column acetabular fracture with radiopaque catheters in the left external iliac vessels.

## CLASSIFICATION

### PENNAL AND TILE CLASSIFICATION

Pennal and associates (50) classify the principal pelvic ring disruptions based on the direction of the injuring force and the degree of pelvic disruption (Table 17.24). Injuries may result from anteroposterior compression, lateral compression, vertical shear, or combinations of these forces (Fig. 17.2). This classification provides insight into the nature of the injury, the morbidity, the potential sites of disruption, and the degree of pelvic instability; and it provides some therapeutic guidelines.

TYPE A: Stable
- A1: Fractures of the pelvis not involving the ring
- A2: Stable, minimally displaced fractures of the ring

TYPE B: Rotationally unstable, vertically stable
- B1: Open book
- B2: Lateral compression, ipsilateral
- B3: Lateral compression, contralateral (bucket handle)

TYPE C: Rotationally and vertically unstable
- C1: Rotationally and vertically unstable
- C2: Bilateral
- C3: Associated with an acetabular fracture

From Tile M. Pelvic Ring Fractures: Should They be Fixed? *J Bone Joint Surg Br* 1988; 70:1, and Pennal GF, Tile M, Waddell JP, et al. Pelvic Disruption: Assessment and Classification. *Clin Orthop* 1980; 151:12.

***Table 17.24. Pennal and Tile Classification of Pelvic Fractures***

#### *Anteroposterior Compression Injury*

An anteroposterior compression injury, also known as an external rotation deformity, results from a blow that strikes the posterior ilium or the anterior pelvis to disrupt the symphysis and the anterior SI ligaments of one or both SI joints. Usually, the crucial posterior SI complex is spared so that the injury is vertically stable, although in a few of these cases the posterior SI ligaments are violated to produce an unstable hemipelvis.

#### *Lateral Compression Injury*

A lateral compression injury arises from a direct blow to the lateral ilium. A stable impacted fracture of the sacrum or, rarely, the adjacent SI joint may result. In the presence of an anterolateral or posterolateral force, however, the ipsilateral hemipelvis rotates inwardly around the site of the posterior disruption, involving the SI joint or the adjacent sacrum or ilium. While they are characterized as “rotationally unstable,” in actuality the injuries may be completely stable, rotationally unstable, or unstable in a rotational and posterior direction. Usually, the contralateral rami are fractured, or sometimes the ipsilateral pubic rami or all four rami are disrupted.

#### *Vertical Shear Injury*

The vast majority of vertical shear injuries are highly unstable and have complete instability of the posterior ligament of one or both SI joints. Most of the patients are victims of falls from a great height or high-speed crashes. Usually, the associated anterior ring disruption is a diastasis of the symphysis pubis. Supplementary radiologic findings may be consistent with an unstable lateral compression or a vertical shear injury with avulsion fractures of the sacrotuberous and sacrospinous ligaments from the ischial spine of the adjacent sacrum. Another possible associated injury is an avulsion of the transverse processes of L-4 or L-5 at the site of the origin of the iliolumbar ligaments. With the marked posterior displacement, which is well documented in the inlet view or CT scan, the likelihood for profuse hemorrhage secondary to injuries of the superior gluteal vessels is high. An uncommon vertical injury has to be carefully distinguished from the much more commonly encountered pattern with a rotational deformity in a sagittal plane and possibly in a coronal plane. Serious hemorrhage and neurologic complications are uncommon with the latter type.

### LETOURNEL CLASSIFICATION

Two other classification schemes for pelvic fractures are available. LeTournel (26) classified them by the site of injury as a combination of two or more of five elementary patterns. This method provides an anatomic description of the sites of involvement and eliminates the mechanism of injury, which usually is poorly defined and generally irrelevant to the treatment. The five sites of injury are listed in Table 17.25. Denis et al. (12) also classified sacral fractures by the region of involvement, using transalar, transforaminal, or central (Fig. 17.8).

Anterior vertical fracture: divides the obturator ring or adjacent parts of the pubic body

Transiliac fracture: extends from the greater sciatic notch to either the iliac crest or occasionally to the anterior border of the iliac wing

Transsacral fracture: extends along the outside or the inside of the foramina, possibly to propagate obliquely across the sacrum from superior to inferior

Pure separation of the symphysis pubis

Pure disruption of the sacroiliac joint

From LeTournel E. Diagnosis and Treatment of Nonunions and Malunions of Acetabular Fractures. *Orthop Clin North Am* 1990; 21:769.

***Table 17.25. Classification of Pelvic Fractures after LeTournel and Judet***

## BUCHOLZ CLASSIFICATION

In 1981, Bucholz (4) provided a classification scheme based on an anatomic assessment of multiple-trauma victims in whom pelvic injuries were examined at autopsy (Fig. 17.3; Table 17.26). The clinical significance of the Bucholz scheme was a correlation with therapeutic recommendations. While a group 1 injury responded well to conservative management, a group 2 disruption usually required closed reduction with external or internal fixation. Uniformly, a group 3 pattern required an open reduction with internal fixation of the anterior and posterior injury sites.

| | |
|---|---|
| Group 1: | Isolated diastasis of up to 2 cm with disruption of the tenuous anterior sacroiliac ligaments |
| Group 2: | Wider diastasis with a disruption of the sacrospinous, sacrotuberous, and anterior sacroiliac ligaments |
| Group 3: | Complete disruption of all the sacroiliac ligamenes with triplane displacement of the hemipelvis |

From Bucholz RW. The Pathological Anatomy of Malgaigne Fracture–Dislocations of the Pelvis. *J Bone Joint Surg Am* 1981; 63:400.

***Table 17.26. Bucholz Classification of Anteroposterior Compression or External Rotational Injury Patterns***

## AO/ASIF–OTA–SICOT CLASSIFICATION

More recently, a comprehensive alpha-numeric classification scheme has been devised by the collaborative efforts of Arbeitsgemeinschaft für Osteosynthesefragen (AO), the Americn Society of Internal Fixation (ASIF), the Orthopaedic Trauma Association (OTA), and Societé Internationale de Chirugie Orthopaedic et Traumatologie (SICOT) (71). The AO/ASIF–OTA–SICOT scheme has gained acceptance as the definitive method of classifying pelvic fractures (Fig. 17.15; Table 17.27), particularly for clinical research.

***Table 17.27. Comprehensive Classification Scheme of Pelvic Fractures***

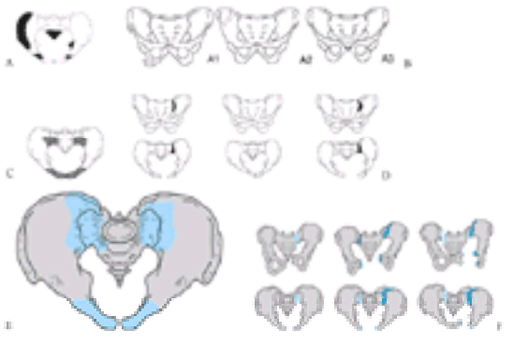

***Figure 17.15.*** Schematic views of the AO–OTA–SICOT alphanumeric classification of pelvic fractures. **A:** Sites of type 61-A stable injuries. **B:** Type 61-A subcategories by injury sites. **C:** Sites of type 61-B partially unstable injuries. **D:** Type 61-B subcategories by injury sites and displacement. **E:** Sites of type 61-C completely unstable injuries. **F:** Type 61-C subcategories by injuries sites. (From Tile M, Helfet DL, Kellam JF, et al.*Comprehensive Classification of Fractures in the Pelvis and Acetabulum.* Berne, Switzerland: Maurice E. Müller Foundation, 1995.)

## PREOPERATIVE MANAGEMENT

### GENERAL PRINCIPLES

Once hemodynamic stability is achieved and appropriate diagnostic studies have been completed, outline a definitive management protocol. The management priorities are established through discussions between various surgical teams. If a hemodynamically stable patient has an unstable pelvic fracture, definitive surgical stabilization can be undertaken on the day of the acute injury. In the multiple-trauma victim, however, a considerable delay may be necessary between the time of the injury and the first realistic date for internal fixation. In either event, the goals of management include anatomic and functional objectives (Table 17.28). Also, pelvic stabilization should minimize the likelihood of late problems such as a painful nonunion or malunion of the pelvis.

| |
|---|
| Anatomic restoration |
| Relief of pelvic pain |
| Patient mobilization (e.g., bed-to-chair transfers, partial weight-bearing gait) |
| Expeditious discharge from the hospital |
| Minimal predilection for late complications |

*Table 17.28. Objectives of Definitive Pelvic Fracture Management*

## PELVIC STABILIZATION

While the preferred techniques of stabilization remain controversial, the authors' experience has led to an algorithm that facilitates the selection of the optimal stabilization technique for almost any type of pelvic ring disruption (Fig. 17.16). While the algorithm provides a number of viable therapeutic options, the need for internal fixation has increased in the 1990s as internal fixation provides much more stable fixation than external fixation. With internal fixation, the frequency of postoperative follow-up is decreased, whereas external fixation requires ongoing supervision, including pin-track care. The placement of percutaneous lag screws provides a stable method of internal fixation that requires even less surgical exposure than the application of external fixation (37). In fact, once a surgeon gains familiarity with techniques of percutaneous surgical stabilization, the indications for external fixation as a definitive method of pelvic fixation diminish rapidly.



***Figure 17.16.*** Algorithm for the optimal stabilization techniques for various patterns of pelvic ring disruption.

### *Stable and Rotationally Unstable Patterns*

Stable injuries include those that are undisplaced or minimally displaced as a result of a low-velocity lateral compressive force. Begin with bed rest and mobilize the patient as soon as possible. Progress weight bearing as tolerated. Most patients bear full weight in 3–6 weeks.

In most anteroposterior and lateral compression injuries, there is a simple but displaced pelvic fracture, and the posterior SI ligaments and the sacrum are intact; this scenario is quite common. Treatment options include plate fixation, a simple anterior external frame, or percutaneous fixation of the SI joint. Perform surgical stabilization when the diastasis of the pubic symphysis is greater than 2 cm. If an emergency laparotomy is done, stabilize the pubic symphysis with a plate. Plate fixation also can be used for unilateral or bilateral anterior ramus fractures using a midline vertical incision (24). As an alternative, external fixation can be used to manage an unstable anterior injury with minimally displaced ramus fractures. Where the rami are significantly displaced and impinging on skin or genitourinary organs, perform an open reduction. This minimizes the risk of a persistent nonunion or malunion that can lead to pain and dyspareunia. Where a pubic diastasis is open, or a colostomy or a suprapubic catheter is present, consider a closed reduction with percutaneous fixation of the ipsilateral SI joint.

### *Complete Posterior Instability*

For vertical shear fractures of the posterior pelvis accompanied by superior migration of the hemipelvis, first apply skeletal traction to correct the vertical displacement. Two alternative strategies are available. An open reduction and plate fixation of the symphysis or rami restores the alignment of the pelvic ring, so that percutaneous fixation of the posterior injury is feasible. If realignment of the anterior pelvic ring does not align the SI joint, extend the incision to an ilioinguinal approach and openly reduce and internally fix the SI joint.

If a transforaminal sacral fracture is comminuted, perform a posterior approach and plate the fracture, avoiding compression of the sacral nerve roots. If possible, add supplementary percutaneous screw fixation into the S-1 sacral body to avoid the need for anterior fixation (36). If percutaneous fixation is impossible, anterior column fixation or external fixation are alternative measures, although the former is preferred.

### *Complex Pelvic Disruptions*

The complex ring disruptions are listed in Table 17.29. Most pelvic fractures with bilateral unstable SI dislocations and pubic symphysis diastasis are usually caused by vertical shear injuries. For these highly unstable injuries, use a bilateral ilioinguinal approach to achieve open reduction of the symphysis and SI joints simultaneously. In certain instances, where skeletal traction has provided an accurate reduction of one or both SI joints, it is feasible to undertake percutaneous fixation of the SI joints after fixation of the symphysis. As an alternative, reposition the patient in a prone fashion for a posterior approach to the SI joints and perform either lag-screw fixation or transiliac plate fixation.

| |
|---|
| Bilateral unstable posterior disruption with an anterior disruption |
| Unilateral unstable posterior fracture with an iliac fracture and an anterior disruption |
| Unilateral posterior fracture, anterior disruption, and acetabular fracture, with or without an iliac fracture |
| Various patterns of comminuted fractures with unilateral or bilateral unstable posterior disruptions, bilateral acetabular and/or iliac fractures, and bilateral rami fractures with or without diastasis of the symphysis |

*Table 17.29. Patterns of Complex Pelvic Ring Disruptions*

### *The Crescent Fracture*

For an unstable SI joint with multiple rami fractures or a pubic diastasis with an iliac “crescent” fracture (i.e., a lateral compression injury), suitable immobilization may be achieved in one of two ways. First, through an iliofemoral approach, perform an open reduction of the lateral ilium with lag screws and plates. Then employ an anterior vertical or Pfannenstiel approach for the anterior injury. If these reductions are accurate, perform a percutaneous fixation of the contralateral SI joint. Alternatively, provided that the imaging technique is mastered, a retropubic screw can be inserted via a medial entry site to stabilize both of the superior ramus fractures (61).

## PREOPERATIVE PLANNING

Since most pelvic fractures have at least two principal injury sites, a variety of options are available. In the presence of an open posterior wound, an anterior approach or percutaneous stabilization of an SI dislocation is indicated; in the presence of a left lower quadrant colostomy, however, a posterior approach to an SI dislocation

may be preferred.

When an unstable hemipelvis is malrotated, the sequence of reduction can be initiated at the anterior or the posterior injury. The least invasive approach is to reduce the pelvic ring and plate it anteriorly, followed by percutaneous posterior fixation. By 3 weeks after the injury, reduction of the entire pelvic ring through a limited approach is more difficult and may be impossible. In this situation, a single or bilateral ilioinguinal exposure permits a simultaneous open reduction of the anterior and posterior disruptions. Reduction of an SI joint is easier from the anterior approach than from posteriorly. The stability of anterior SI plating is comparable to that obtained with lag screws across the SI joint. Simultaneous reduction of the anterior and posterior disruptions through an ilioinguinal approach is more efficient and avoids a major liability of sequential anterior and posterior exposures: An imperfect anterior reduction may produce posterior malalignment that cannot be corrected.

In the presence of an unstable hemipelvis, the number of sites that require fixation remains controversial (36,42,69). For the classic pubic symphysis diastasis with an SI dislocation, definitive fixation of the two injuries is well accepted. If the posterior injury is a simple displaced iliac fracture, isolated fixation of the ilium suffices. If the accompanying anterior injury, such as a symphysis diastasis, is not repaired, typically there is a minor residual external rotation of the hemipelvis; usually this is not of functional significance. If the iliac fracture is comminuted, then anterior and posterior fixation is indicated.

A simple vertical sacral fracture, with associated multiple pubic rami fractures, may be sufficiently stabilized solely by percutaneous cannulated screws across the sacrum. Within 3–4 weeks, callus forms on the ramus fractures so that walking with crutches can be started. This strategy avoids the application of an anterior external fixator or more aggressive surgery. If the rami fractures are markedly displaced and unstable, then plate them through a lower midline abdominal incision.

### THE COLUMNS OF THE PELVIS

If an unstable hemipelvic injury is complicated by comminution or osteoporosis, more stable fixation is indicated. The pelvic ring can be perceived as a system of three columns: the rami, the sacral body, and the posterior sacral elements (36) (Fig. 17.17). For a typical unstable injury, surgical fixation of two columns is recommended. For the most unstable injury patterns or in patients with osteoporosis, fixation of all three columns is advisable. Examples include unstable fractures fixed late, osteoporotic sacral nonunions or malunions, and displaced pathologic pelvic ring disruptions.

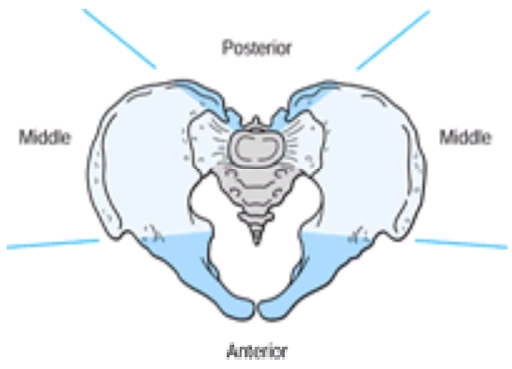


***Figure 17.17.*** Schematic view of the pelvic columns to aid in the fixation of unstable injuries.

### COMPLEX PELVIC DISRUPTIONS

An unstable SI disruption with multiple rami fractures or symphysis diastasis complicating an acetabular fracture, with or without propagation into the ilium, is another consequence of a lateral compression injury. First, undertake an open reduction and internal fixation of the acetabulum. For an ipsilateral SI fracture, fix it through the same exposure or do percutaneous fixation. Then stabilize the rami with plates or retrograde screws, or external fixation.

Violent trauma produces several patterns of injury, including unilateral or bilateral acetabular fractures, bilateral SI disruptions or other equivalent posterior injuries, and bilateral ramus fractures, with or without a diastasis of the symphysis (75). In most of these patients, virtually all of the principal ligamentous supports of the pelvic ring are severely compromised. As a rule, each site of pelvic disruption must be stabilized with internal fixation.

### OPTIMAL TIMING FOR DELAYED INTERNAL FIXATION

Although the use of external fixation as part of the emergency treatment for hemorrhage and pain control is well established, the optimal timing for delayed fixation of closed fractures remains unclear. Whenever the patient is unstable or at risk for excessive hemorrhage, defer surgery for 24–48 hours after the injury. Further delay is likely to result in pulmonary, thromboembolic, and urologic complications. When the patient's general condition is satisfactory, early surgical intervention permits the most rapid recovery and minimizes the risk of complications.

Contraindications to internal fixation include the systemic problems just discussed, highly contaminated open fractures, concomitant infection, inadequate bone quality or bone stock, a severely injured soft-tissue envelope, and a surgical team that is not experienced or an operating room that is not equipped for this difficult surgery.

## SURGICAL TECHNIQUES

### GENERAL CONSIDERATIONS

#### *Operating Table*

The radiolucent Jackson or similar table is ideal for pelvic reconstruction (Fig. 17.18). It is completely radiolucent, and the absence of a central post enhances imaging with the C-arm. Newer models provide longitudinal and/or lateral skeletal traction.

***Figure 17.18.*** A Jackson radiolucent operating room table and modern C-arm image intensifier.

#### *Image Intensifier*

The most recent designs of image intensifier, with a 9 in. or 12 in. field size and high-resolution capabilities, are a major technological advance for pelvic reconstruction. The integral software package permits magnification of focal areas of interest. While the Siemens, Philips, and OEC-Toshiba models, as well as others, are excellent

for pelvic applications, the OEC-Toshiba has a unique advantage. Its C-arm gantry possesses an extra articulation that greatly simplifies the iliac and obturator oblique views.

### *Special Views*

For pelvic reconstruction, intraoperative image intensification is necessary. The radiographic technician needs to know the AP, inlet, outlet, iliac, and obturator views, along with the direct lateral view of the sacrum (37,61). Once the patient is positioned on the operating table, and prior to draping, rehearse the views to be sure that they can be obtained. Correct any obstruction of the image by an ill-positioned upper extremity, arm board, or other object.

Position and drape to optimize imaging. Use radiolucent bolsters. Drape with adhesive drapes and use skin staples to avoid the use of towel clips.

### *Reduction Techniques and Tools*

Reductions can be done closed for percutaneous fixation or external fixation, or open (Table 17.30). Instrumentation and implants specifically designed for pelvic surgery are essential. Currently, the Synthes instrumentation (Synthes, Inc., Wayne, PA) is the most complete. Tenaculum forceps are available in diverse sizes with straight and curved jaws (Fig. 17.19, Fig. 17.20 and Fig. 17.21). The special pelvic forceps are exceptionally large with respect to the length of the jaws and handles, and they provide a high degree of mechanical advantage. The symmetrical King Tong and the asymmetrical Prince Tong are the most useful models.

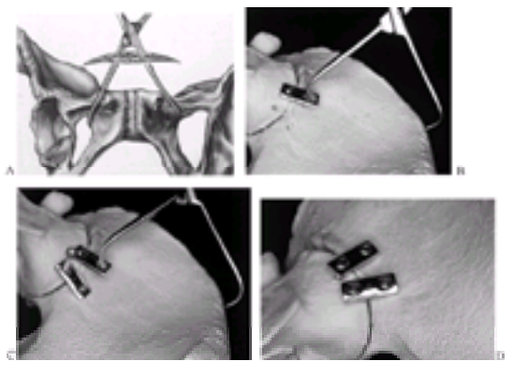

***Figure 17.19.*** The use of tenaculum forceps for pelvic reductions. **A:** Symphysis pubis. **B:** Anterior SI joint in conjunction with a plate. **C:** SI joint after stabilization with a second plate. **D:** After plate fixation and removal of the forceps.

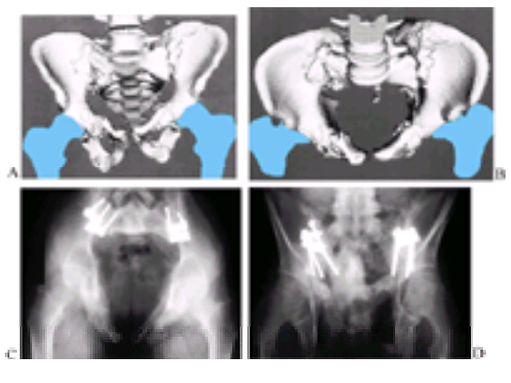

***Figure 17.20.*** Bilateral sacroiliac dislocation in an 18-year-old man in whom anterior SI open reductions were performed. **A:** Anterior 3D CT view. **B:** Inlet 3D CT view. **C:** Postoperative inlet view. **D:** Postoperative outlet view.

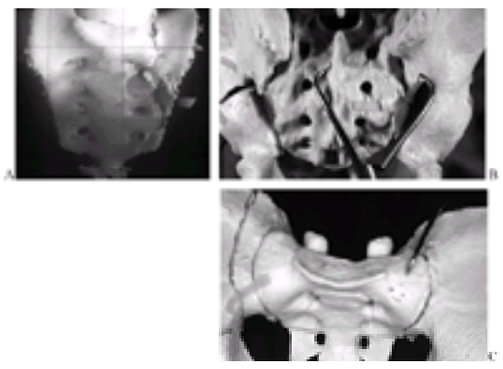

***Figure 17.21.*** Fixation of a sacral fracture with a tenaculum forceps. **A:** 3D CT with displaced alar fragment. **B:** Schematic view with reduction of the ala from a posterior approach. **C:** Posterior reduction of a transforaminal fracture.

| Closed methods | Open methods |
|---|---|
| Skeletal traction | Pelvic clamps |
| Longitudinal via femur or tibia | External fixation |
| Lateral via greater trochanter | Pushing tools: ball-ended spike, narrow osteotome |
| Manual manipulation and use of gravity | Prying tools: narrow osteotome, Cobb elevator |
| Lateral position (gravity) | Twisting tools: external fixation pin, Steinmann pin |
| Manual control of the lower extremity | Bone holding forceps: pointed jaw or tenaculum, Lane-bone-Farabeuf, pelvic clamps |
| | Distraction tool (e.g., femoral distractor) |
| | Cables |
| | Lag screws |
| | Threaded rods |

***Table 17.30. General Strategies and Instrumentation for the Reduction of Pelvic Fractures***

### *Fixation Devices*

**Screws** For pelvic fixation, kits of specialized fixation devices are available that provide unique attributes for stabilization of the pelvis (Table 17.31). Of the small-fragment screws, the 4.0 mm fully threaded cancellous design affords excellent purchase in the pelvis. For the crucial load-bearing portions such as the SI joints, we prefer the larger core-diameter of the 4.5 mm cortical or 6.5 mm cancellous screws. The strength of fixation is exponentially related to the length of the thread in bone (42). Wherever possible, we use longer screws. For example, where the available bone stock is limited, such as in the superior pubic rami, long screws of smaller

diameter provide more effective fixation than shorter ones of a larger diameter.

| |
|---|
| Screws |
| 4.0 mm fully threaded cancellous |
| 4.5 mm cortical |
| 6.5 mm cancellous |
| Cannulated screws |
| 4.5 mm cancellous |
| 7.3 mm cancellous |
| Plates |
| Standard, 3.5 mm or 4.5 mm |
| Reconstruction, 3.5 mm or 4.5 mm |
| Hook or spring plates, 3.5 mm one-third tubular |
| Cables or wires, 2.0 mm |

***Table 17.31. Principal Fixation Devices for Internal Pelvic Fixation***

**Cannulated Screws** For the large cannulated screws, the various brands utilize corresponding guide wires with a range of diameters between 2.8 and 3.2 mm (37). The 2.8 mm wires are readily inserted but bend easily, whereas 3.2 mm wires are significantly stiffer, but because of greater frictional forces during their insertion they can heat up and cause thermal damage. We prefer 2.8 mm wires, although many pelvic surgeons prefer the larger wires.

Most available cannulated screws can be inserted over a threaded-tip guide wire or a drill bit. Threaded-tip guide wires usually remain in position when the drill is removed, whereas drill bits tend to back out. Threaded-tip guide wires provide relatively poor feedback to the surgeon, which can lead to accidental penetration of the adjacent soft tissues, threatening important structures. Drill bits provide better feedback, although they are more likely to break during insertion.

We prefer cannulated screws that are self-drilling and self-tapping, as this eliminates the need for drilling and tapping. The risk for injury to soft tissues is minimized by using an oscillating power drill. In the dense pelvic bone of young adult men, partial drilling and tapping may be necessary to avoid broken implants.

**Plates** Conventional plates are useful for the reduction of injuries such as an SI joint separation. For anterior SI fixation, use two of the two-hole 3.5 mm or 4.5 mm plates. The narrower span between the 3.5 mm holes is ideal for SI fixation and is consistent with the use of 4.5 mm cortical screws (Fig. 17.19 and Fig. 17.20). Typically, the displaced ilium is posterior and superior to the adjacent sacrum. Anchor the plates to the sacrum with a screw. With the superior displacement corrected, place a screw in the ilium through the plate. Tightening the screw reduces the ilium to the sacrum. In contrast, highly flexible reconstruction plates (Fig. 17.22) are used where the objective is to contour the plate to the underlying curved surface of the pelvis without displacement of the fracture, such as along the iliac crest and true pelvic brim. The 4.5 mm and some steel 3.5 mm reconstruction plates are too stiff for this application. They must be contoured perfectly to the bone prior to insertion of the screws. We prefer the more flexible, straight 3.5 mm reconstruction plates, particularly those of titanium.

***Figure 17.22.*** The use of a flexible reconstruction plate on the symphysis pubis and rami. **A:** Model with inlet view. **B:** Model with outlet view. **C:** AP radiograph with diastasis bilateral ramus fractures and right SI dislocation. **D:** Postoperative AP view with anterior plates and anterior SI fixation.

The 4.5 mm reconstruction plate is useful for posterior fixation of the sacrum and the SI joints (42,52). It can be contoured to fit directly on the irregularly curved surface of the sacrum. In large men, this plate also can be used for fixation of the pubic symphysis.

Spring or hook plates, which are fashioned by the surgeon from tubular or small titanium plates, are useful to buttress thin and comminuted or osteopenic bone (19) on the quadrilateral, posterior, and anterior surfaces of the acetabulum and the posterior surface of the sacrum. The most useful length is a three-hole, 3.5 mm one-third tubular plate. Fashion the hooks at one end of the plate by cutting the end of the plate obliquely through the middle of the screw hole and then bending the resulting tines into hooks using a large needle holder. Bend a gentle convex curve into the plate so that the hooks engage the bone and buttress the fracture as the central screw is tightened. The hooks must not impale important adjacent structures.

**Cables and Wires** Cables or 16-gauge wires provide a minimally invasive way to reduce and immobilize diverse segments of the pelvis (43) (Fig. 17.23). While conventional cable passers can be used, a useful tool for passing along the inner pelvic wall is a Statinski vascular clamp. The insertion of passing tools is hazardous, particularly in the presence of a marked pelvic deformity or delayed surgery, where neurovascular structures may be malpositioned and tethered to the bone, making them more vulnerable to traction injury or a laceration. Cables also may be threaded through the cannulation of screws as a way to augment screw fixation in osteopenic bone (Fig. 17.24).

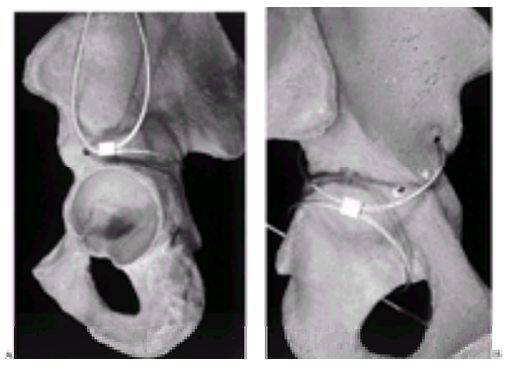

***Figure 17.23.*** Cable fixation of the pelvis. **A:** Fixation from the greater sciatic notch to the anterior inferior iliac spine (AIIS). **B:** Buttressing the quadrilateral surface.

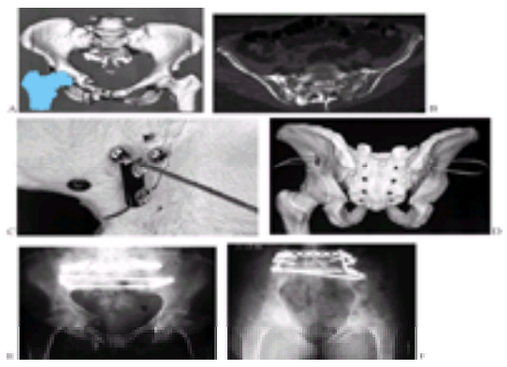

***Figure 17.24.*** Multiple views of a bilateral sacral insufficiency fracture in a 78-year-old woman after irradiation therapy. **A:** 3D CT anterior view. **B:** CT scan of the sacrum. **C:** Screw heads of cannulated screws with a cable and a two-hole plate at the level of S-1. **D:** Posterior view after passage of the cable. **E:** Postoperative AP view. **F:** Postoperative inlet view.

**Threaded Rods** Threaded rods are useful for immobilizing a sacral fracture when using an open or percutaneous technique (8,16,65,70). While mechanically effective, the reduction must be anatomic. Rods are usually symptomatic postoperatively and require removal. We prefer transverse plate fixation rather than rods, as plates provide more predictable fixation with a low morbidity, and they rarely need removal.

### *Intraoperative Neurologic Monitoring*

Intraoperative neurologic monitoring helps minimize the risk of iatrogenic neurologic injury, especially with respect to the peroneal division of the sciatic nerve, lumbosacral plexus, and the sacral nerve roots. Formerly, somatosensory evoked potential (SSEP) monitoring was popular, but continuous electromyographic (EMG) motor monitoring has proven to be better (23,72). Disadvantages of SSEPs include the need for highly trained personnel, a significant incidence of spurious results, and a latent period of potentially up to a few minutes between an intraoperative injury to a sensory nerve and a significant alteration of the SSEP signal. Continuous EMGs have the advantage of reflecting instantaneously any compromise to a motor nerve, with a minimum of false negative results. The method also is simpler than SSEPs.

We use SSEPs to monitor the S-1 nerve root using penile or labial electrodes, but we prefer continuous EMGs for monitoring the peroneal division of the sciatic nerve. While both techniques can be used to monitor sciatic nerve function, it is not clear that the use of both methods is better than the use of EMGs alone.

### *Surgical Approaches to the Pelvis*

See Chapter 2 for surgical approaches to the pelvis. The following description focuses on specific applications for the pelvic ring, including the authors' preferences. The available approaches are outlined in Table 17.32.

| |
|---|
| Anterior |
| Pfannenstiel |
| Midline lower abdominal |
| Ilioanterior |
| Ilioinguinal |
| Bilateral ilioinguinal |
| Posterior |
| Unilateral longitudinal or curvilinear |
| Transverse presacral |
| Midline longitudinal presacral |
| Lateral and extended lateral |
| Iliofemoral |
| Extended iliofemoral |
| Triradiate |
| Ischiopubic |

***Table 17.32. Pelvic Surgical Approaches***

**Pfannenstiel and Vertical Midline** The Pfannenstiel approach is widely used for exposure of the symphysis, although a midline lower abdominal incision provides a comparable view. For unilateral or bilateral ramus fractures, the midline lower abdominal incision provides a minimally invasive and rapid approach. This approach provides visualization of the pelvic brim to the SI joint and the entire quadrilateral surface. It has a lesser morbidity than the ilioinguinal approach and achieves a comparable visualization. If the rami and lateral ilium need to be exposed, the midline lower abdominal approach can be combined with a limited incision along the iliac crest for what has been termed the ilioanterior approach (Fig. 17.25) (24)

***Figure 17.25.*** Multiple views of bilateral ramus fractures, right SI disruption, and left SI fracture dislocation where an ilioanterior approach was used along with an iliofemoral exposure for the left-sided crescent fracture. **A:** Preoperative AP view. **B:** Preoperative anterior 3D CT view. **C:** Intraoperative outlet view. **D:** Postoperative AP view.

**Posterior Sacroiliac** For posterior exposure of the SI joint, we prefer a straight longitudinal incision to a curvilinear incision. The transverse presacral incision (Fig. 17.26 and Fig. 17.27) is useful when exposure of the sacrum and both SI joints is needed (38,39). Cosmetically, it is superior to two parallel vertical incisions, as plastic reconstruction of a wound slough from the latter is complicated. Although a transverse incision is cosmetically superior to a midline vertical approach, a proximal extension to the upper lumbar spine requires a vertical incision (52).

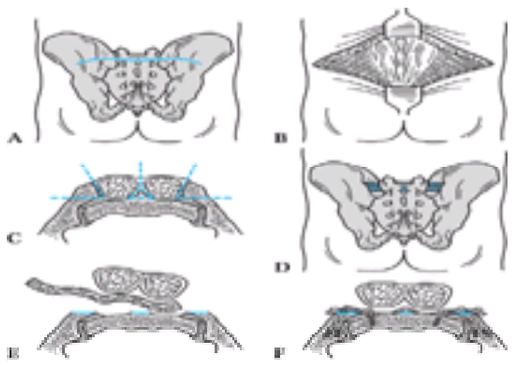

***Figure 17.26.*** The transverse presacral approach. **A:** Cutaneous incision. **B:** Exposed posterior iliac crests, gluteus maximus, and paraspinous muscles. **C:** Bilateral elevation of the paraspinous muscles and preparation of the notches in the posterior superior spines. **D:** Subperiosteal tunnel across the back of the sacrum for plate insertion. **E:** Insertion of the inverted plate. **F:** Cross section of the screw fixation.

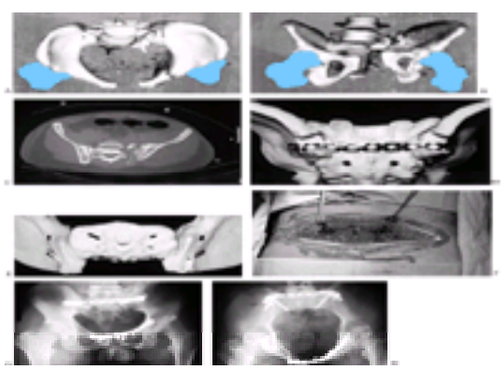

***Figure 17.27.*** Transiliac plate fixation of a comminuted vertical sacral fracture and plate fixation of a symphyseal diastasis and left anterior column fracture in a 34-year-old man. **A:** Preoperative inlet 3D CT. **B:** Preoperative outlet 3D CT. **C:** Preoperative CT scan. **D:** Model of an intraosseous tunnel created for a 4.5 mm reconstruction plate. **E:** Model of a contoured plate resting in the intraosseous tunnel. **F:** Intraoperative view of a plate resting beneath the paraspinous muscles. **G:** Postoperative AP view. **H:** Postoperative inlet view.

**Posterior for Threaded Rods** Transiliac rods (Fig. 17.28) can be applied through the transverse presacral incision or through short vertical incisions over the lateral aspects of the posterior superior spines. Restore accurate alignment of the pelvis prior to the insertion of the sacral rods. Advance the threaded bars through parallel rows of drill holes that are prepared under image intensification, secure the nuts to the rods, and compress the fracture. Overreduction is possible in view of the mechanical advantage of the threaded system.

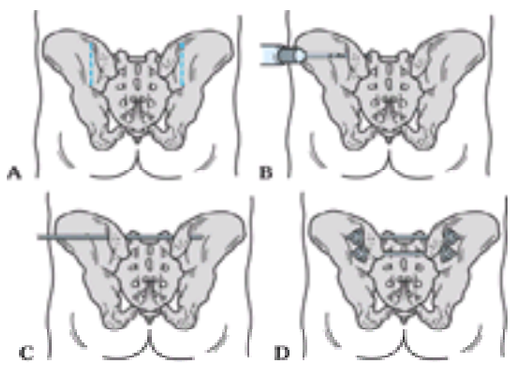

***Figure 17.28.*** Technique for transiliac rod fixation. **A:** Cutaneous incisions. **B:** Site for preparation of a drill hole in the posterior superior spine. **C:** Insertion of a threaded rod. **D:** Final view.

**Iliofemoral Approach** We prefer the standard iliofemoral approach for exposure of an iliac crescent fracture and the adjacent SI joint (28). We reserve the extended iliofemoral and triradiate approaches for complex injuries with associated acetabular fractures. Limited versions of both exposures have been described that eliminate the need for an osteotomy of the greater trochanter or a corresponding detachment of the gluteal insertions (21,41).

**Ischiopubic Approach** Use an ischiopubic incision to expose the inferior pubic ramus (Fig. 17.29) (see Chapter 2). This permits visualization from the base of the acetabulum across the ischial tuberosity to the inferior aspect of the symphysis, which is particularly useful for a nonunion.

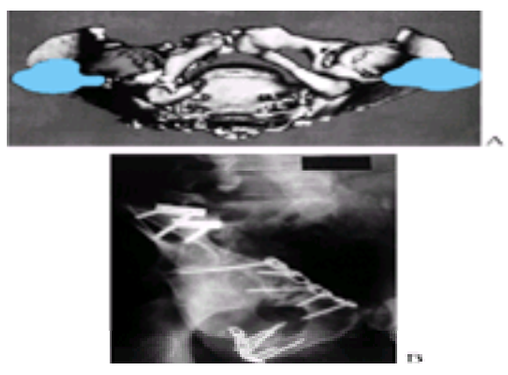

***Figure 17.29.*** The use of an ischiopubic approach to stabilize the inferior pubic ramus in a 42-year-old man. **A:** Inferior 3D CT view. **B:** Postoperative obturator oblique view.

## EXTERNAL PELVIC FIXATION

### *General Considerations*

The following description refers to the application of the Hoffmann-II system. Whichever system is used, a typical frame uses 5 mm threaded half-pins inserted into the anterior ilium. Simple frames use one or two, and rarely three, 5 mm half-pins per hemipelvis, inserted into the anterior iliac crest near the anterior superior iliac spine (ASIS) or the anterior inferior iliac spine (AIIS) (42,52). Where the frame is intended for temporary stabilization for a few days, or when the injury pattern is rotationally

unstable but vertically stable, one pin per hemipelvis suffices. When the pelvis is unstable, insert two pins per hemipelvis, spacing the pins widely to achieve optimal stability. For a markedly obese patient with an unstable pelvis, three pins per hemipelvis may be necessary. We prefer to place the pins into the gluteal tubercle, ASIS, and AIIS.

- Prior to the procedure, determine the required number and length of pins. Organize the appropriate drill sleeves, drill bits, pins, and frame constituents.
- Position the patient supine on a radiolucent table.
- Unless speed is important, take AP, inlet, and outlet views with the image intensifier to assess the deformity and determine the strategy for reduction. If there is superior migration of the hemipelvis, apply longitudinal skeletal traction to restore leg lengths. Correct a diastasis of the symphysis with a rotational deformity after the half-pins have been inserted, using the pins as reduction tools.
- If reduction of the pelvis is not necessary, place the pins through small stab wounds directly over the entry point. If reduction is required, particularly of external rotation, make bilateral oblique incisions in the skin where the reduced pelvis will eventually lie. The incisions must not parallel the iliac crest but be in line with the direction of pin movement. For example, with 5 cm of pubic diastasis, place each incision 2–2.5 cm medial to the crest.

***Percutaneous Technique with Four Pins***

Percutaneous techniques are most frequently used where the pelvis is only minimally displaced and where intraoperative image intensification is available.

- Identify the pin entrance sites on the superior aspect of the iliac crest at the gluteal tubercle and at the ASIS or AIIS.
- Make a stab incision over the site and cut down to the top of the iliac crest. At the AIIS, the ilium is deeper than at the ASIS. Spread the tissues with a small periosteal elevator.
- Slide a 2.0 mm Kirschner (K-) wire subperiosteally down the inner table of the pelvis parallel to the axis of the pin to be inserted to act as a guide pin. Some surgeons slide a second K-wire down the outer table as well to help define the position of the ilium. Use the C-arm for this and verify that the wires are placed appropriately.
- Drill a 4.0 mm hole at the entry site for the pins, through the cortex but not into the cancellous bone between the tables. A short entry hole minimizes the risk of accidental penetration of the cortex.
- Under fluoroscopic control, insert two Schanz-type long threaded half pins into each ilium so that they advance between the two cortices of the bone. Angulate the pins so that they are divergent from each other in the AP plane. The deeper the pins, the better the fixation, but avoid penetration of the opposite cortex or the hip joint. Leave enough pin protruding to connect the frame at an appropriate height (Fig. 17.30*A*, Fig. 17.30*C*).

***Figure 17.30.*** Insertion of half pins for external pelvic fixation. **A:** Anterior outlet view to highlight appropriate target zone for pins between the iliac tables. The view also displays errant pin tracks from a closed insertion technique without image guidance. **B:** Optimal pin sites on the anterior iliac crest. **C:** Ancillary pin site on the anterior inferior spine. **D:** Outlet view with optimal alignment for a percutaneously inserted pin.

- Attach an 8 mm carbon fiber or other suitable bar of appropriate length to each pin with a pin-bar clamp. Attach the two sets of bars to each other with a bar-to-bar clamp in the midline. Be certain that the frame will not encroach on the abdomen when the patient sits up. Adding cross bars between each set of bars increases stability.
- Reduce the pelvis under fluoroscopic visualization.
- Prior to the final assembly and tightening of the frame, turn the patient into a lateral position and manipulate the hemipelvis until the deformity is corrected.
- When the final position is secured, check the skin about the pins and extend the wounds to relieve any tension where skin has gathered on the pelvis.
- Then close the subcutaneous fat and skin snugly about the pins and dress the wounds.
- Take a full series of plain radiographs before leaving the operating room to check the reduction and pin position.

***Open Technique***

The technique is identical except for the surgical exposure.

- Two different skin incisions can be made. An incision parallel to the iliac crest is simplest, but skin tension frequently requires that the incision be “T”ed. Separate 2.5-cm-long incisions can be made for each pin. Place these in line with the skin tension on the pins, roughly at right angles to the iliac crest.
- Expose the top of the crest and inner table by subperiosteal dissection so that the pins can be placed under direct vision. Some surgeons expose the outer table as well, but usually this is unnecessary.
- Proceed as previously described for the remainder of the procedure.

**THE USE OF A PELVIC CLAMP**

A pelvic clamp is designed for rapid and minimally invasive temporary pelvic stabilization. Currently, two designs of pelvic clamp are available. The original Ganz design (16,17) (Fig. 17.31) immobilizes the region of the SI joints for optimal mechanical fixation. The liability of the design is the proximity of the greater sciatic notches, with the potential for a significant neurovascular injury. The Browner design utilizes anterior iliac pins that afford considerably greater safety, but the frame provides less stability. Whichever method is used, the surgical team needs to be familiar with the techniques for insertion of the pins and erection of the frame. These clamps should be used only by surgeons who have had experience with them, as routine frames are safer. While a clamp can be applied in an emergency room, sterile technique must be maintained.

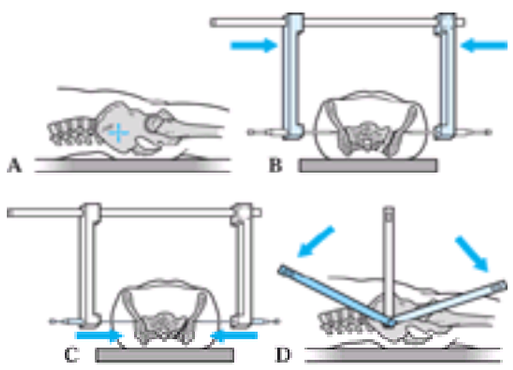


***Figure 17.31.*** Schematic views of the Ganz type of external pelvic clamp (17). **A:** Site for pin insertion. **B:** Maneuver for pelvic reduction. **C:** Postreduction with tightening of the locking nuts. **D:** Potential displacement of the frame.

**INTERNAL FIXATION OF THE PELVIS BY OPEN METHODS**

### *General Considerations*

Prior to a pelvic reconstruction, mentally prepare and write out a surgical strategy that defines the injuries, positioning, and intraoperative tactics and alternatives (Table 17.33). Where sequential reductions are planned through separate surgical incisions, as a rule the first one is the most accurate. If the first one is imperfect, the magnitude of the error is progressively magnified from the second to the third or fourth stage. Once a first stage is completed and the patient is repositioned for the second one, any error in the first stage cannot be eliminated without reopening the first wound.

| |
|---|
| Assess the preoperative images and characterize the injuries. |
| Identify crucial concomitant fractures (e.g., acetabulum, femur, lumbosacral spine). |
| Define surgical priorities (e.g., timing and accuracy of the reduction). |
| Tabulate the sequence of multiple open reductions and plan simultaneous reductions. |
| Outline alternative tactics where problems might arise (e.g., inadequate exposure, difficult reduction, inadequate fixation). |

***Table 17.33. Preoperative Planning for an Internal Fixation***

The rigid ring structure of the pelvis dictates the need for one of two tactics. In the first strategy, the priorities for accuracy of reduction are (a) acetabulum, (b) sacrum and SI joints, and (c) rami and symphysis. Certain associated injuries, however, are linked. For example, about 20% of transverse acetabular fractures are associated with an ipsilateral SI subluxation as an external rotation deformity. Unless the SI joint is reduced initially, the acetabulum cannot be accurately realigned. In this instance, start the reduction with the SI joint and follow with the acetabulum. The second strategy is simultaneous reductions of multiple displaced injuries using more extensile surgical approaches (24).

Concomitant femoral and/or lumbosacral spine injuries necessitate alternative strategies, as outlined in Table 17.34.

| |
|---|
| Fractures of the femoral neck and pelvis |
| Start with the femoral neck. |
| If the femoral neck and ipsilateral acetabulum are involved, irrespective of the exposure, preservation of any residual capsular sources of blood supply is essential. |
| Femoral shaft and ipsilateral acetabulum or pelvic ring |
| Avoid skeletal traction where the perineal post displaces ramus fractures, as a potential source of urological injury. |
| Use anterograde or retrograde femoral nail. |
| If the femur is the higher priority, a femoral distractor may be used for the closed reduction. |
| If the femur and ipsilateral acetabulum are involved, avoid a dissection from the greater trochanter to the acetabulum as a pathway for heterotopic bone or infection. |
| For a Kocher-Langenbeck approach, the femur is repaired first for appropriate control of the leg. |
| For an ilioinguinal approach, either the femur or the acetabulum can be addressed first. |

***Table 17.34. Alternative Approaches for Pelvic and Femoral Fractures***

### *Vector and Magnitude of Pelvic Deformity as an Indication for Internal Fixation*

We feel that a pelvic deformity that exceeds 15° of malrotation or 2 cm of linear displacement in any plane merits consideration for open reduction and internal fixation. For example, an external rotation injury can be characterized by the amount of widening of the symphysis or the degree of malrotation of the hemipelvis. If a symphysis diastasis is less than 2.5 cm, nonoperative treatment is usually possible. Wider diastasis usually has sagittal malrotation, reflected in the AP radiograph by the involved ramus being higher than the uninvolved side. This indicates that the ipsilateral sacrospinous and sacrotuberous ligaments are compromised. If the diastasis is wider then 5 cm, the posterior injury is bilateral, or it is a highly unstable unilateral disruption in the form of SI dislocation or a sacral fracture. If deformity is evident in the sagittal or coronal planes, the injury pattern is even less stable than if the deformity is only in the transverse plane. Both of the latter usually require internal fixation to prevent nonunion and malunion of the pelvic ring. In type C injuries, the hemipelvis is usually posteriorly displaced, whereas true vertical displacement is uncommon. Vertical displacement is easily confused with sagittal malrotation of the hemipelvis. On the AP radiograph, vertical displacement is consistent with a hemipelvis that is high riding but otherwise a replica of the contralateral hemipelvis. In sagittal deformity, the ischial tuberosities are at different levels, although the tops of the iliac crests are symmetrical and the involved hemipelvis shows a change in the shape of the pelvic brim.

### *Internal Fixation of the Symphysis and Adjacent Rami*

Different plating systems are used for the symphysis (31). Specialized plates are available, but they have not been proven to be superior despite increased costs. Both 3.5 mm and 4.5 mm reconstruction plates are commonly used. We prefer the 3.5 mm plates with longer screws. In our experience, two screws per ramus (Fig. 17.22) is adequate. Two plates mounted at right angles to one another provide the strongest construct, but one plate is sufficient and decreases the soft-tissue stripping.

- Expose the pubic symphysis and adjacent pubic rami through a Pfannenstiel or lower midline abdominal incision (Chapter 2). The distal portions of the rectus abdominus muscle insertions usually can be left intact, while the more proximal portions of the muscle are reflected in a lateral direction from the anterior and superior portions of the superior rami.
- Place the tines of a tenaculum forceps into the obturator foramen and reduce the symphysis
- Contour a four- to five-hole 3.5 mm or 4.5 mm reconstruction plate to fit on the superior surface of the rami and symphysis.

**HINTS AND TRICKS**

- Palpate or visualize the obturator foramen as a guide to the acetabulum.
- Do not insert a screw that is directed toward the center of the acetabulum.
- If a screw in the area of the acetabulum is essential, insert the screw more posteriorly and along the pelvic brim.
- If a retrograde pubic screw is used, for image intensification use inlet, outlet, and iliac and obturator oblique views.

- Insert the first two screws adjacent to the symphysis, parallel to the joint and the posterior surface of the rami. Protect the bladder and determine screw direction by palpating or visualizing the posterior aspect of the symphysis. Be certain that the screws are bicortical. Insert the other two screws.
- Close the wound in a layered fashion over a suction drain.

### *Fixation of Bilateral Pubic Rami*

- Use a vertical midline abdominal incision.
- Look carefully for a corona mortis and ligate it.
- Contour four- or five-hole 3.5 mm plates to fit along the superior posterior aspects of the pelvic brim.
- Insert screws using radiographic control to ensure that the screws miss the hip joint.
- Alternatively, use the retrograde medullary superior ramis screw fixation technique, as described previously.

- Close in layers over a suction drain.

***Fixation of the Inferior Pubic Ramus***

Acute fixation of the inferior pubic ramus is not common: In most cases, it is done for a late painful nonunion. Stabilization may require a bone graft for a defect (Fig. 17.29).

- Position the patient in the lateral decubitus position on a radiolucent table with maximum flexion of the ipsilateral hip and knee, which are uppermost.
- Prep and drape carefully to exclude the rectum and genitalia.
- Make an ischiopubic exposure (Chapter 2).
- Reduce the fracture with a small tenaculum or lion-jaw forceps.
- Contour and apply a 3.5 mm reconstruction plate.
- Use the obturator oblique view to ensure that screws do not penetrate the acetabulum and hip joint.
- Close in layers over a suction drain.

**HINTS AND TRICKS**

- For a late presentation with a fixed deformity, a structural bone graft may be needed to reestablish the continuity of the ischium.
- Where the fracture is higher in the ischium and transverse, use lag screws inserted directly in the prominent portion of the ischial tuberosity. (See Fig. 17.39 on p. 578.)

***Anterior Fixation of the Sacroiliac Joint***

- Position the patient supine on a radiolucent table.
- Expose the inner ilium, anterior SI joint, and lateral 2.5 cm of sacrum through an ilioinguinal approach (Chapter 2).
- If fixation of the symphysis is required, expose it simultaneously.
- Clear the SI joint of debris and soft tissues.
- Attach a three-hole 3.5 mm plate to the sacral ala in a convenient location, leaving room for a second plate. Use a 4.5 mm cortical screw.
- Place a large tenaculum forceps with one point in the lateralmost hole of the plate and the other on the iliac crest, and reduce the SI joint.
- Contour a second, similar plate and fix it to the sacrum with one screw and to the ilium with two screws.
- Remove the forceps and insert the remaining screws in the first plate.
- Verify the reduction and screw placement with the C-arm using inlet and outlet views.

***Lag-Screw Fixation of the Posterior Sacroiliac Joint***

This technique rests on a clear understanding of the local anatomy (Fig. 17.32). Whether open or closed technique for screw insertion is used, the irregularity of the posterior margins of the SI joint impedes assessment of the reduction. The undersurface or superior surface of the SI joint can be palpated, but intraoperative imaging is essential. Accurate reduction is necessary to provide a safe and predictable site for the fixation screws. For assessment of the target zone in the sacrum, the direct lateral image is the optimal view. When the AP, inlet, and outlet views are used without a lateral image, the most common error is a screw that appears to be satisfactorily positioned but that, on the lateral view, is in fact superior to the S-1 body.

**HINTS AND TRICKS**

- During the exposure, use bone wax on the intraosseous veins at the base of the internal iliac fossa to control bleeding.
- If the articular cartilage of the SI joint is damaged, thoroughly remove it to achieve a fusion.
- Direct the screws parallel to the SI joint.
- Diverge the plate position to increase stability.
- Tightening of the first iliac screw should reduce the posterior displacement of the ilium.

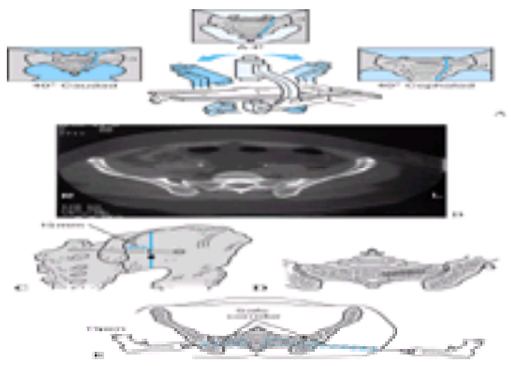

***Figure 17.32.*** The use of intraoperative image intensification for iliosacral screw insertion. **A:** General method for the prone patient. **B:** CT of SI malreduction where iliosacral screw insertion is not technically feasible. **C:** Landmarks for screw insertion. **D:** SI cross section with ideal screw placement. **E:** Target zones for iliosacral screws with an open or closed technique.

- Position the patient halfway between prone and lateral so that the involved ilium is parallel to the table.
- Make a vertical incision at the posterior superior spine.
- Palpate the inferior margin of the SI joint through the greater sciatic notch.
- Reduce the SI joint with a tenaculum forceps and check the reduction radiographically (AP, inlet, outlet, and obturator oblique views).
- Identify the insertion site for lag screws on the lateral ilium, halfway between the posterior superior spine and the anterior aspect of the roof of the greater sciatic notch.
- Insert two 6.5-mm-long threaded cancellous screws or corresponding 7.3 mm cannulated screws.
- Assess final imaging using AP, direct lateral, inlet, and outlet views.

***Fixation of the Ilium for a Crescent or Lateral Iliac Fracture***

This technique (Fig. 17.25) is perhaps the least complex technically, with a relatively low risk for injury to neurovascular bundles or viscera, apart from the superior gluteal vessels. The fixation is outstanding, so an accompanying pubic symphysis diastasis or ramus fracture does not have to be immobilized. Since the posterior SI ligaments are intact, the SI joint is stabilized upon fixation of the fracture.

**HINTS AND TRICKS**

- With the posterolateral position, gravity facilitates the reduction.
- Palpation over the superior aspect of the SI joint of the alar region is helpful in the reduction.
- While drilling, feel the drill bit advance across three cortical layers: the superficial iliac table and the iliac and sacral subchondral bone at the SI joint. Do not penetrate a fourth dense layer of bone, which represents the S-1 foramen or the anterior aspect of the sacrum.
- Measure 50–60 mm of penetration of the drill and select a corresponding screw. Usually, the S-1 foramen is 55 to 65 mm deep from the lateral ilium and thereby is avoided.
- Use a direct lateral sacral view to ensure that the screws are anchored in the S-1 body.

## HINTS AND TRICKS

- Carefully protect the superior gluteal vessels.
- Direct the screws through the iliac crest between the tables.
- Insert the inferior screws into the posterior inferior spine.
- Use the iliac and obturator oblique views to guide the fixation.
- Limit the use of SI screws to comminuted fractures or for the rare occasion when the posterior SI ligaments are completely torn.

- Position the patient halfway between prone and lateral.
- Drape the ipsilateral lower extremity free.
- Make a limited iliofemoral approach and reflect the hip abductors to expose the fracture.
- Reduce the fracture with tenaculum forceps and positioning of the leg.
- Apply a 3.5 mm reconstruction plate along the iliac crest.
- Where the inferior half of the fracture is a simple configuration, insert two 4.5 mm cortical or 6.5 mm cancellous screws using lag technique.
- If the inferior half of the fracture is comminuted, apply a 3.5 mm plate on the lateral ilium.

### *Fixation of the Sacrum with a Transverse Plate*

This fixation (Fig. 17.27) has relatively low morbidity and the stability is outstanding. We usually insert supplementary iliosacral screws for two-column pelvic fixation. An alternative is to fix the anterior column where iliosacral screws are not appropriate. If vertical displacement of a sacral fracture is present, use preoperative skeletal traction to reduce it. Maintain traction during the procedure.

- With the patient prone, make a transverse presacral exposure at the level of S-1.
- Expose the fracture and remove any displaced foraminal fragments.
- Reduce the fracture with a large tenaculum and King Tong forceps.
- Make notches in the posterior superior spines.
- Contour and apply a 4.5 mm reconstruction plate with seven to nine holes.
- Insert 4.5 mm cortical or 6.5-mm-long threaded cancellous screws into both ends of the plate. At each end, two screws course between the iliac tables. A third screw is inserted into the adjacent empty hole at either end of the plate which is directed into the sacral ala.

## HINTS AND TRICKS

- If a large anterior sacral alar fragment is present, reduce it by inserting a tenaculum forceps superior to the SI joint, under image control.
- As an alternative, the transverse plate can be applied superficial to the S-2 segment.
- Direct the sacral alar screws parallel to the SI joint on divergent pathways. Do not fill the central presacral screw holes that are over the spinal canal and foramina.

- Verify position with AP, inlet, and outlet images.
- If a supplementary iliosacral screw is used, insert it before applying the plate to optimize imaging.

## HINTS AND TRICKS

- If a supplementary transverse fracture line is present, apply an additional hook plate near the lateral margin of the bone.
- As an alternative to the lengthy transverse plate, short plates that solely bridge the fracture can be used. The exceedingly limited safe target zones for the screws need to be clearly understood (52).

### *Sacral Fixation with Alternative Plates*

Bridging plates across a transforaminal fracture have been used by Pohlemann et al. (52). While the method is technically elegant, the sites for safe and effective screw placement are small and anatomically variable and therefore hazardous to the sacral nerves. Prior to performing this procedure, observe the technique in the hands of an experienced surgeon.

### *Sacral Fixation with Transverse Rods*

This method (Fig. 17.28) utilizes two rods that span from one posterior superior iliac spine to the other. It is suitable for a single site of posterior injury, such as a vertical sacral fracture. For a bilateral SI dislocation, it affords no intrinsic pelvic stability unless supplementary iliosacral screws are used. Perhaps the most frequent shortcoming of the method is failure to obtain an accurate or acceptable reduction, particularly when using minimally invasive techniques, where malunion can occur. The method also depends on the presence of good quality bone. With osteopenia, premature loss of fixation is likely.

- Use the same approach as described for the insertion of posterior lag-screw fixation of the SI joint, with the addition of a smaller exposure on the contralateral side to expose the lateral aspect of the iliac wing anterior to the posterior spine.
- Reduce the fracture.
- Place drill holes through the posterior tubercles of the ilium just dorsal to the sacral lamina.
- Place two rods posterior to the sacrum and 2–4 cm apart, between the two intact posterior tubercles of the iliac wings.
- Place the first rod just proximal to the S-1 foramen and the second rod just distal to the S-2 foramen.
- Insert the rods proximally to avoid entering the sacrum and endangering the nerve roots within the sacral canal.
- Alternatively, use cannulated rods and imaging to help guide the rod placement.
- Insert nuts and washers to compress the system.

## HINTS AND TRICKS

- Based on its intrinsic biomechanical limitations, limit the use of this technique to the fixation of a unilateral unstable sacral fracture, or use it in combination with posterior screw fixation to stabilize an SI joint dislocation or a bilateral sacral disruption.
- Avoid overzealous compression of the fracture site, particularly in the presence of foraminal fractures, to minimize the risk of neurologic compromise.

### *Fixation of a Lumbosacral Dissociation with a Sacral Fracture*

These complex injuries of the sacrum are most difficult to reduce (60) (Fig. 17.33). The anterior displacement of the sacrum is aggravated by prone positioning of the patient, so the reduction is challenging and potentially hazardous. A pointed reduction forceps or hook must be cautiously inserted around the lateral margins of the sacrum to the edges of the anterior surface to achieve the reduction. With the proximity of the rectum, the maneuver must be done with care. A variety of plates, lag screws, and cables have been used to anchor the sacrum. Supplementary compression rods with pedicular screws may be needed to immobilize the lower lumbar spine to the sacrum (16).

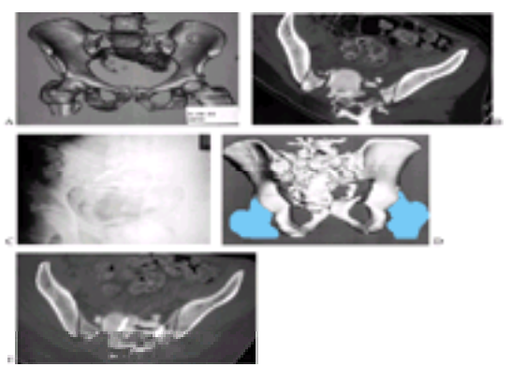

***Figure 17.33.*** A lumbosacral dissociation in a man of 29 years, in whom a combination of cable fixation and lag screws was used. **A:** Preoperative anterior 3D CT view. **B:** CT scan. **C:** Postoperative AP view. **D:** Postoperative 3D CT posterior view. **E:** Postoperative CT scan.

- Make a suitable midline longitudinal exposure of the sacrum and relevant portions of the lumbar spine.
- To reduce the anterior displacement of the sacrum, insert a tenaculum forceps from the lateral margin of the displaced segment of sacrum to the neighboring anterior surface and reduce it.
- Apply a transverse plate across the S-1 and S-2 segments, possibly with associated hook plates.
- Immobilize the sacrum to the lumbar spine. Distraction or compression rods can be used to anchor the relevant lumbar spinal segment to the two transverse plates by the use of hooks placed over the superior or inferior margins of the transverse sacral plates. Alternatively, pedicular screws can be employed (16).
- Three major technical problems must be overcome: sacral realignment, and fixation and immobilization of the sacrum to the lumbar spine.

## PERCUTANEOUS INTERNAL PELVIC FIXATION

### *General Considerations*

We prefer to use a 7.3 mm cannulated screw for the principal structural portions of the pelvic ring, notably for iliosacral fixation, and 4.5 mm screws for periacetabular fixation. We use drill sleeves to protect the adjacent soft tissues.

Appropriately position the patient on a radiolucent table with a wholly radiolucent draping technique that eliminates towel clips. A modern image intensifier with a large field size of 9–12 inches is strongly recommended. The appropriate radiographic views for effective guidance of the relevant screws need to be clearly understood and technically feasible. Prior to draping, rehearse the views to ensure their feasibility (Fig. 17.32). Table 17.35 lists the indications and contraindications of the procedure.

| |
|---|
| Indications |
| A minimally displaced or realigned fracture |
| Availability of the appropriate tools and imaging |
| A fracture that can be stabilized in compression |
| Contraindications |
| Excessive displacement and failed reduction |
| Anatomic variants that compromise the target zone for screws |
| Inability to obtain suitable images (e.g., technical, paralytic ileus, contrast medium, obesity) |
| The lack of suitable tools or technical expertise |
| The presence of a comminuted transforaminal sacral fracture where stability in a neutral position, without compression, is needed to avoid neurologic injury. (Iliosacral screws can supplement a posterior plate but not replace it.) |

***Table 17.35. Indications and Contraindications for Percutaneous Internal Pelvic Fixation***

This technique is not useful for iliosacral or posterior iliac fixation. Unstable but well-aligned fractures can be fixed *in situ.* In more complex disruptions, open reduction and fixation of an anterior ring disruption such as a diastasis of the symphysis may realign the posterior ring so that percutaneous stabilization is feasible.

### *Percutaneous Fixation of the Sacroiliac Joint*

Percutaneous iliosacral fixation is feasible in a supine, prone, or lateral position, although imaging is slightly more difficult in the lateral position (33,52,58). When open anterior ring fixation immediately precedes the iliosacral fixation, we prefer the supine position (Fig. 17.34). When the patient is positioned prone for an accompanying procedure, maintain that position. In the presence of external fixation, the lateral position greatly facilitates reduction of an SI dislocation. Irrespective of the position, the method for screw insertion is similar.

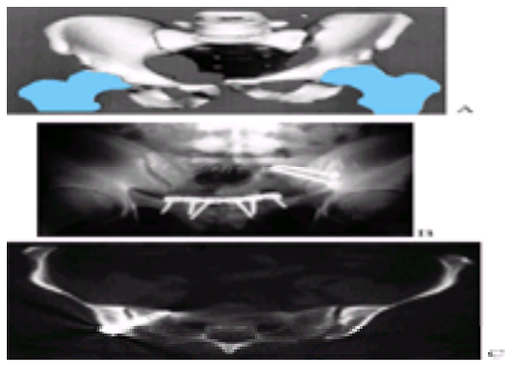

***Figure 17.34.*** An example of iliosacral screw fixation in a man of 33 years. **A:** Anterior 3D CT scan. **B:** Postoperative outlet view. **C:** Postoperative CT scan.

- After positioning and draping, place a 2.8 mm threaded tipped guide pin transversely on the exposed abdominal wall or on the skin of the back at the S-1 level. With AP imaging, draw a line along the pin on the trunk, including the relevant side to provide a guide to pin placement.
- Make a 2 cm transverse incision on the lateral flank, along the line that is halfway between the greater trochanter and the posterior surface of the back.
- Spread the underlying soft tissues to bone.
- Insert the guide wire and drill sleeve to the bone and confirm the position in the AP view.
- Using power, advance the guide wire just across the SI joint (use AP, inlet, outlet, and direct lateral views).
- If the first wire is not where you want it, leave it in place and insert a second wire, using the first as a supplementary guide.
- Advance the guide wire to the level of the S-1 foramen.
- Insert a second guide wire into the S-1 body.
- Measure for screw length with a depth gauge and insert the appropriate long-threaded screws of 45–60 mm in length.

**HINTS AND TRICKS**

- For the ideal inlet view, adjust the gantry until the anterior margins of S-1 and S-2 coincide.
- Use the AP view for transverse orientation, the inlet for AP positioning, the outlet for the S-1 foramen and superior S-1 endplate, and the direct lateral of S-1 for location of the screw tips.
- If the screw is 45 mm, use the obturator oblique view to confirm that the screw threads are not across the joint so it can be lagged together.
- Do not use screws longer than 60 mm.
- For bilateral screw insertion, insert all of the guide wires before any screws to optimize imaging.

### *Iliosacral Screws for Sacral Fixation*

While the method for sacral immobilization with iliosacral screws is similar to that described for an SI joint, there are some additional considerations (59). Once the

screw passes beyond the S-1 foramen, the potential for neurologic injury increases. The target zone for the iliosacral screw markedly diminishes, while the corresponding demands imposed on the intraoperative imaging increase. Anatomic variations of the L5–S1 articulation can further compromise the target zone available in the sacrum (Fig. 17.35).

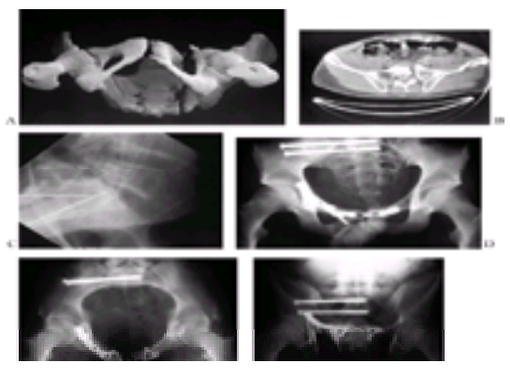

***Figure 17.35.*** Percutaneous iliosacral screw fixation of a transforaminal sacral fracture with an initial open reduction of the right superior pubic ramus in a 31-year-old man. **A:** Inferior 3D CT scan. **B:** CT scan. **C:** Intraoperative direct lateral sacral view. **D:** Postoperative AP view. **E:** Postoperative inlet view. **F:** Postoperative outlet view.

- Using the supine or prone position, draw a reference line as described previously.
- As described under iliosacral screw insertion for the SI joint, make a lateral incision and insert a guide wire into the S-1 body. Place it mid axially from anterior to posterior, and centralized between the superior endplate and the S-1 foramen (use AP, lateral, inlet, and outlet views).
- Advance the guide wire to the level of the contralateral S-1 foramen.
- For an unstable fracture, insert a second guide wire for another iliosacral screw that is anterior and inferior to the first but still in the S-1 body.
- Measure for depth and insert two long threaded screws of appropriate length.
- Obtain final imaging.

## HINTS AND TRICKS

As an alternative site, the S-2 body can be used, although the target zone is much smaller than S-1. To account for the variable degree of lumbar lordosis, select the inlet view where the anterior margins of S-1 and S-2 are superimposed. The direct lateral view is crucial to determine appropriate insertion of the guide wire.

### *Bilateral Transforaminal Sacral Fractures*

Bilateral transforaminal sacral fractures are usually comminuted and highly unstable. If unstable, plate fixation is recommended to augment iliosacral screws. For bilateral transforaminal sacral fractures without additional comminution, either of two strategies for iliosacral screw fixation can be used. Insert either ipsilateral screws for each injury site (Fig. 17.36) or insert long screws that transfix both sides of the sacrum. The latter method necessitates an anatomic reduction, the absence of congenital sacral anomalies, and highly accurate placement of the guide wires. Where bilateral transfixing screws are inserted, advance the guide wires with a perfectly transverse orientation and mid axial from anterior to posterior in S-1 (Fig. 17.24). The screws are usually 120–150 mm long.

***Figure 17.36.*** Bilateral sacral alar fixation in a man of 41 years. **A:** Preoperative anterior 3D CT view. **B:** CT scan. **C:** Intraoperative AP view. **D:** Postoperative inlet view.

### *Percutaneous Iliac Fixation*

Certain vertical iliac fractures with minimal displacement and extending from the iliac crest to the greater sciatic notch are appropriate for percutaneous screw fixation (52). For the more posterior injuries that are at or posterior to the anterior border of the SI joint, use the prone position. If the iliac fracture is further anterior, either a prone or a supine position is feasible. In the prone position, the insertional site is the posterior superior spine (Fig. 17.37). In the supine position, use the anterior inferior spine. Insert two parallel screws into either site with a spacing of about 15 mm. Keep in mind the divergent pathway of the ilia, from posterior to anterior throughout the target zone (52).

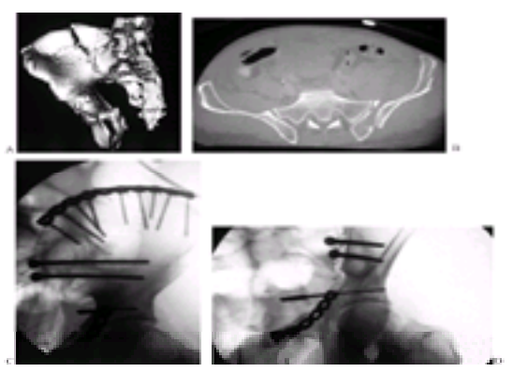

***Figure 17.37.*** The method for percutaneous insertion of a transiliac screw to immobilize the posterior ilium. **A:** Iliac oblique 3D CT view. **B:** CT view. **C:** Intraoperative iliac oblique view. **D:** Intraoperative obturator oblique view.

- Place the patient prone.
- Make a 10 mm stab wound that is about 20 mm superior to the posterior superior spine.

## HINTS AND TRICKS

When using the supine position, use a similar technique, with the anterior inferior spine as the initial target for the guide wire. Direct the guide wire toward the posterior superior spine.

- Insert a guide wire into the wound and down to bone. Direct the guide wire on the iliac oblique view toward the anterior inferior spine and on the obturator oblique view between the inner and the outer iliac tables.
- Advance the guide wire until at least 35 mm is into bone beyond the fracture.
- Insert a second parallel guide wire.
- Measure for and drive the two screws.

***Percutaneous Fixation of the Superior Pubic Ramus***

It is possible to fix the superior pubic ramus with a screw inserted antegrade from laterally, or alternatively retrograde from medially. The former is difficult and hazardous. The antegrade screw is not recommended for routine use, as the obliquity of the screw, the limited target zone of bone, and the juxtaposition of the external iliac vessels makes the technique hazardous. When inserted retrograde, the shorter length of the screw limits the technical complexities, although a virtually anatomically reduced fracture is necessary (52,61) (Fig. 17.38).

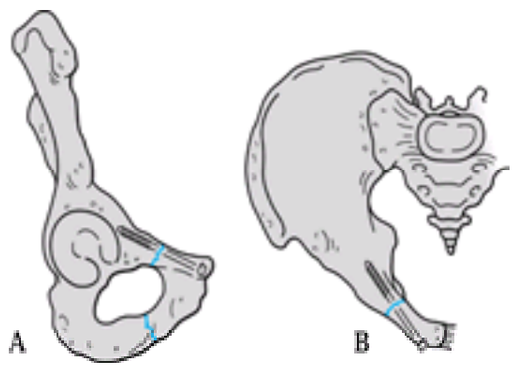


***Figure 17.38.*** Schematic views of the insertion of a percutaneous retrograde ramus screw. **A:** Obturator oblique view. **B:** Iliac oblique view.

- With the patient in the supine position, make a 10 mm incision anterior, medial, and slightly inferior to the pubic tubercle.
- Perform a closed reduction of the injured hemipelvis.
- Advance a guide wire to bone. On an oblique outlet fluoroscope view, direct the guide wire into and up the superior pubic ramus. On the inlet view, direct the guide wire parallel to the inner border of the true pelvic brim.
- Advance the guide wire beyond the fracture.
- Measure for screw length and insert an appropriate 3.5 mm or 4.5 mm cortical screw and tighten.

## HINTS AND TRICKS

Drape the ipsilateral lower extremity free to permit passive movement of the hip after screw insertion.

***Percutaneous Fixation of the Ischium***

The posterior portion of the ischium and the lower posterior column of the acetabulum can be fixed using percutaneous screws. The entry site for the screw is the ischial tuberosity with vertical orientation of the screw along the posterior column (Fig. 17.39).

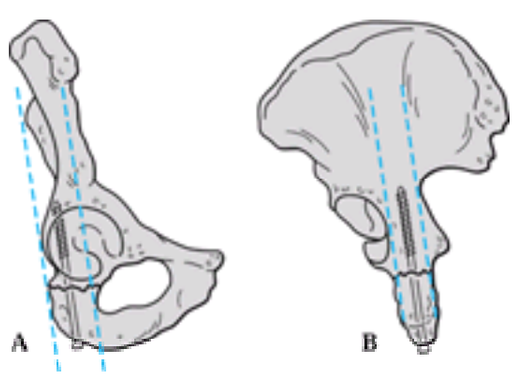


***Figure 17.39.*** Schematic views of the insertion of a percutaneous posterior column screw via the ischial tuberosity. **A:** Obturator oblique view. **B:** Iliac oblique view.

- Place the patient supine on a radiolucent table with the hip fully flexed and the knee at 45° to 80°. Abduct the hip and place the leg in stirrups, or on a Mayo stand.
- After suitable draping, palpate the ischial tuberosity and make a 10 mm incision.
- Insert the guide wire to bone and image (AP, internal oblique, and outlet views).
- Direct the guide wire vertically toward the gluteal tubercle. While imaging on the internal oblique view, direct the guide wire parallel to the posterior border of the greater sciatic notch, halfway between the notch and the posterior acetabular rim. On the oblique outlet view, direct the guide wire so that it passes halfway between the posterior acetabular rim and the most posterior margin of the obturator foramen. At a more superior level, the guide wire is halfway between the posterior acetabular rim and the center of the anterior inferior spine.
- Insert a 4.5 mm screw of appropriate length.
- Prior to skin closure, move the hip to be certain that the screw is not in the joint.

***Cable and Heavy Wire Fixation***

**General Considerations** Cables of 2.0 mm diameter and 14- to 18-gauge wires can be used for supplementary reduction and fixation. The ringlike configuration of the pelvis makes cables and wires particularly useful (43).

None of the available cable systems were designed with the pelvis as the principal site for intended use. When a cable is tightened, it shortens its pathway. To control the pathway and the vector of displacement of the bone, we usually pass the cable through a small drill hole in the pelvis. In this way, the displacement of the tightening cable and its effect on bony alignment can be controlled. Many cable systems possess a tightening mechanism at one end of the cable that blocks its insertion into a drill hole. In some applications, both ends of the cable have to be passed through drill holes. In this situation, the use of a “double-ended” cable or wire is essential.

Most tools used to pass cables or wires are based on a semicircle designed for the femoral shaft. Such a design does not work well on the pelvis. For example, at the greater sciatic notch, the semicircular design can injure the sciatic nerve. As an alternative, use a Statinski vascular clamp, which has angled jaws and a blunt tip and is available in various sizes that work well on the pelvis.

Various tools for tightening cables are available in many sizes. They vary from excessively bulky to low-profile configurations. Some tighteners can be removed while a cable is provisionally held tight. We prefer to use double-ended cables with a low-profile tightener. Cable fixation is useful for a wide variety of unusual problems, such

as sacral dissociation (Fig. 17.33).

**Lateral Ilium**

- Whether a medial or lateral exposure is used, pass the cable through the greater sciatic notch.
- Anteriorly pass it around the base of or through a drill hole in the anterior inferior spine. Align the lateral ilium and tighten and secure the cable (Fig. 17.23).

**Posterior Column**

- At the base of the posterior column, pass the cable through the lesser sciatic notch. Then pass it through a drill hole at the base of the anterior inferior spine.
- After reduction of the fracture, tighten and secure the cable.

**Quadrilateral Surface** Certain pelvic and acetabular fractures include a large quadrilateral surface fragment that is difficult to fix. The opposing articular surface of the hip joint eliminates most of the bone from consideration for screw fixation. Buttress plates are highly vulnerable to late displacement. A cable or heavy wire can be used to supplement a plate on the pelvic brim (Fig. 17.23).

- Reduce the iliac and superior pubic ramus portions of the fracture and apply a plate along the pelvic brim.
- Drill 2.5 mm holes through two the central holes in the plate that exit on the quadrilateral surface.
- Prepare a 4×5 cm structural bone graft from the inner iliac table and make two corresponding drill holes in it.
- Pass the cable or wire down through the pelvic brim, out through the quadrilateral table, and through the holes in the structural graft. Then retrograde the cable through the quadrilateral surface and pelvic brim.
- Tighten and secure the cable.

**Sacrum** Where osteopenia of the sacrum hampers lag-screw fixation, a cable can be used to supplement the fixation (Fig. 17.33).

- Under image intensification, inset two iliosacral screws that just traverse the entire posterior width of the pelvis (120–150 mm length).
- Through a transverse posterior exposure, identify the sites of the screw heads and screw tips.
- Pass a cable through the cannula of one screw.
- Apply a two-hole 3.5 mm plate on either end of the cable and feed each end of the cable through the second hole in the appropriate plate.
- Retrograde one end of the wire through the second cannulated screw.
- Tighten and secure the cable.

## POSTOPERATIVE CARE AND REHABILITATION

The postoperative regimen for the pelvic fracture patient varies considerably, depending on the specific nature of the injury and the presence of a wide variety of associated injuries to the appendicular skeleton or spine. Nevertheless, certain general principles provide helpful guidelines. The fundamental goal is to mobilize the patient as rapidly as possible without an excessive likelihood for a loss of the pelvic reduction.

Early after stable fixation of a pelvic fracture, begin chair transfers and resume protected ambulation (16,40,42,64). The morale of patients with these severe injuries is low because of the physical impact of the injury, the vocational and financial implications, and sometimes the injuries to other family members or friends in the same accident. Rapid mobilization is a great boost to morale. Outpatient and home-based rehabilitation is preferred to institutionalization. If inpatient therapy is needed, arrange for it to be near the patient's home so that friends and family members can visit easily.

### EARLY POSTOPERATIVE PHYSICAL THERAPY

For isolated pelvic fractures with stable fixation, and whenever the general condition of the patient permits, begin bed-to-chair transfers, possibly with a sliding board the day of surgery. This facilitates pulmonary toilet and heightens morale. Encourage the patient, as soon as practical, to begin touchdown walking. About 6 weeks later, advance the patient to a partial weight-bearing gait, and progress to full weight bearing over the next 6–8 weeks. Prescribe progressive resistance exercises to the muscle groups around the pelvis and in lower extremities, with emphasis on the hip abductors and the quadriceps muscles.

Where external pelvic fixation without supplementary internal fixation is used, the activity level depends on the degree of pelvic instability. For a vertically stable injury, early touchdown gait training may be feasible. For an equivocally stable situation, encourage bed-to-chair transfers. Defer gait training for 6 weeks until the external frame is removed. At home, use a wheelchair and a bedside commode.

### LATE OBJECTIVES OF REHABILITATION

Three issues to be addressed are overall motor function, specialized needs for persistent physical disability, and vocational planning. A generalized weakened state follows most pelvic fractures, especially in multiple trauma, because of malnutrition and prolonged disuse. Nutritional advice is needed after discharge.

Begin early focal progressive resistance exercise of the pelvic muscles, followed in a month with a generalized strengthening program. Include water therapy with a pool, ambulation, and swimming. At 6 weeks after the injury, initiate an aerobic exercise program with, for example, a stationary bicycle or a rowing machine. Full rehabilitation often requires 1–2 years of enthusiastic participation in a program. Return to a laboring job is likely to require at least 6–12 months.

A frequent problem is foot drop. Acutely, provide a resting ankle–foot orthosis along with a custom-molded shoe insert. Initiate passive stretching exercises of the heel cord, and muscle stimulation. As recovery progresses, institute active and active assistive exercises.

### PAIN MANAGEMENT

For the initial postoperative period, the use of patient-controlled anesthesia (PCA) with narcotics is effective in alert patients (15). While patient satisfaction is usually good, nausea, urinary retention, drowsiness, confusion, and overdosage can occur. Within a day or so, oral narcotics usually replace the PCA. A muscle relaxant may be necessary to manage muscle cramps.

Epidural analgesia with an indwelling catheter provides effective pain control, but an indwelling Foley catheter is usually required. Resultant motor weakness may interfere with mobilization.

When significant pain persists for more than a few days, look for persistent pelvic instability; wound hematoma; infection; dysesthetic pain from a nerve root, plexus, or a peripheral nerve injury; and other causes.

A significant problem is late dysesthetic pain resulting from lumbosacral plexus injury, scarring, or reflex sympathetic dystrophy. Referral to a pain management specialist clinic may be necessary to identify the cause. Reassure the patient that substantial or complete recovery is likely over a period of many months (42,51,52,70).

### THROMBOEMBOLIC PROPHYLAXIS

Because of the high risk for deep venous thrombosis (DVT) and pulmonary embolus (PE) in pelvic trauma and reconstruction, routine prophylaxis is indicated (47,48 and 49). The role for differing regimens is controversial. We use early mobilization from bed, as well as either low-molecular-weight heparin or coumadin for a postoperative period of 2–3 weeks. When long-term prophylaxis is indicated we use coumadin.

We use inferior vena cava (IVC) filtration in high-risk patients (2,74). In patients transferred late to us, and in other high-risk patients, we do a duplex ultrasound evaluation. If clots are found in the thigh veins, we insert an IVC filter prior to surgery. Another option is transient heparinization, with a temporary reversal for the pelvic surgery followed by reanticoagulation with heparin, coumadin, or low-molecular-weight heparin (see Chapter 5 for more details).

### FOLLOW-UP

Remove sutures or skin staples 2–3 weeks after insertion. Examine the patient and obtain radiographs at 6 and 12 weeks after surgical management or acute trauma. Most pelvic injuries heal by 12 weeks.

With the recent socioeconomic pressure for prompt return to work, at least in some capacity, a few salient observations may be helpful. For sedentary workers with a stable pelvis, part-time return to work may be feasible within 2–3 weeks after injury. Typically, a patient can tolerate 2–4 hours per day provided that suitable transportation is feasible. Within 12 weeks, the sedentary worker may resume full-time work in an incremental fashion.

At the opposite extreme, a heavy laborer is likely to require a disability period of 6–12 months. About half of the individuals complain of long-term posterior pelvic or low back pain that impairs their recovery and may necessitate industrial retraining or work modifications.

### MANAGEMENT OF EXTERNAL FIXATION

For details on pin-site care, see Chapter 11.

All the available external frames are subject to spontaneous loosening of the clamps. Provide patients with wrenches so that they can tighten all the nuts weekly until the frame is removed. Typically, the frame is removed under a short-acting general anesthetic as an outpatient procedure.

In some cases, isolated external fixation is used to immobilize the pelvis. When the horizontal bars that connect the opposing hemipelves are removed, the residual portions of the frame can be grasped and manipulated to document the degree of pelvic stability. When persistent instability is evident, which is unusual, reassemble the frame. After pin removal, irrigate with weak betadine solution and apply dry dressings. Allow a partial weight-bearing gait with crutches, and in the next month progress to full weight bearing. In more severe pelvic disruption, progress weight bearing over an 8-week period. When a stable union is evident radiographically and clinically, resume full activity.

#### *Supplementary Fixation*

External fixation provides only limited fixation of an unstable pelvic injury. Therefore, it is important to be able to recognize the various clinical presentations of inadequate fixation, and to mount an appropriate response.

Isolated external fixation alone may result in hemodynamic instability and instability of the pelvis.

- Once the pelvic instability is recognized, use supplementary skeletal traction for vertical instability.
- If the general condition improves, add or replace with internal fixation.

Another example is isolated external fixation for a presumed stable injury. The patient may complain of persistent posterior pelvic pain that hampers sitting, transfers, or gait; or radiographic loss of reduction is noted when the patient is mobilized.

- Obtain additional radiographs or use CT to confirm an occult unstable posterior injury.
- Perform secondary posterior internal fixation with possible replacement of the frame by anterior internal fixation.

A third example is an unstable fracture managed with isolated external fixation in an ill, elderly individual. In view of the comorbidities, there is usually no possibility of later internal fixation.

- After 6 weeks of conservative treatment, remove the frame and associated skeletal traction.
- Mobilize the patient to tolerance.
- Once the general condition and nutrition of the patient have stabilized, evaluate the residual pelvic problem clinically and radiographically.

## PITFALLS AND COMPLICATIONS

### GENERAL PITFALLS

While a seemingly endless list of pitfalls could be cited, the most salient examples are highlighted here.

- Lack of an integrated acute resuscitative protocol. Prior to the emergency management of these patients, the trauma team must have a cohesive resuscitative and diagnostic protocol.
- Needless deferral of definitive pelvic reconstruction. Deferral of definitive surgical treatment of the disrupted pelvis beyond the optimal period of a few days after injury leads to enforced recumbency with its complications: increased technical difficulties with open reduction, increased pain, and other systemic problems.
- Inadequate preoperative imaging. A thorough understanding of the injury through a complete radiographic assessment, including CT and potentially 3D CT, is necessary to formulate an appropriate operative strategy.
- Inadequate preoperative planning and lack of appropriate resources for effective pelvic reconstruction. Pelvic fractures and disruptions are complex. Meticulous preoperative planning and often consultation with a more experienced surgeon, even in another location, is necessary to devise appropriate fixation and avoid complications. Early transfer of the patient to a regional center that possesses specialized resources and experience may be prudent.
- Excessive use of external fixation. External fixation is useful for open pelvic fractures, unstable pelvic injuries with acute hemodynamic instability, and external rotation injuries with a symphysis diastasis, but it is not a particularly effective method for many unstable disruptions. External fixation compromises the cutaneous envelope and increases the risk of infection. External fixation tends to be overused on stable but perhaps slightly deformed internal rotation injuries, where immediate weight bearing to tolerance would be a better choice.

### COMPLICATIONS

#### *Uncontrolled Hemorrhage*

After a pelvic fracture, a constellation of problems and associated major injuries can result in fatal hemorrhage. Prolonged extrication at the accident site, delays in transfer of the patient to an appropriate treatment facility, hypothermia, and antecedent comorbidities are contributing factors. The risk of hemorrhage can be minimized with standing protocols for resuscitation and an integrated team approach to management.

Hemodynamically unstable patients usually require immediate laparotomy in the operating room and early reduction and stabilization of pelvic disruptions. See Chapter 5 and Chapter 14 for more details.

#### *Complications of External Fixation*

Most complications of external fixation are the result of pin loosening or infection, and inadequacies of the reduction and fixation. Improper insertion and location of fixation pins in the ilium usually results in early loss of fixation. This leads to pain, loss of reduction, and pin-track infection. Open insertion of the pins with exposure of both tables of the ilium minimizes the risk in the hands of less experienced surgeons. A snug fit of the skin around the pins to avoid excessive motion at the skin–pin interface or skin tension at the pin site minimizes the risk of wound problems.

The limited stability of external fixation means that unstable pelvic injuries merit serious consideration for supplementary internal fixation or replacement with internal fixation.

#### *Complications of Internal Fixation*

Other than infection, most complications of internal fixation of the pelvis are caused by a lack of appreciation for the complexity of the deformity, particularly rotary displacement, which results in inadequate fixation leading to persistent instability, nonunion, and malunion. Referral of the patient to a center that specializes in treating

pelvic injuries is advisable in many cases. A thorough understanding of the mechanism of injury, the 3D pathologic anatomy, complete imaging, and careful preoperative planning will minimize these risks. The risk of postoperative infection of pelvic surgery is significant, as the coexistence of other injuries compromises the patient's immunologic status and provides additional sites for bacterial contamination and infection, such as intravenous lines and suprapubic catheters. For that reason, minimally invasive, percutaneous techniques are advantageous. The soft-tissue envelope around the pelvis may also be compromised, requiring alternative approaches or delay in the surgery. See Chapter 18 for more details.

**Neurologic Complications** Neurologic injury is a major cause of long-term morbidity after a pelvic ring disruption, particularly a posterior ring disruption. The incidence of neurologic injury varies between 2% and 50% (23,51,56,72), depending on the mechanism and severity of the injury. Typically, the injury involves the lumbosacral trunk and/or the superior gluteal nerve. The lumbosacral trunk is injured as a result of traction from significant external rotation and posterosuperior displacement of the hemipelvis. The superior gluteal nerve usually is injured directly by fracture fragments near the SI joint. Neurologic assessment may be hampered by the presence of a concomitant head injury, intubation, and the influence of medications used for sedation or anesthesia. Carefully assess bowel and bladder function to rule out sacral plexus injury. Urologic consultation may be helpful. Myelography and EMG studies can help in the diagnosis after 3 weeks.

Recovery from neurologic injury is unpredictable (13,51). Most nerve injuries are traction induced and require early conservative treatment. Some advocate prompt exploration and decompression of sacral nerve roots, although results have not demonstrated a clear benefit (52). The results of surgical repair of the sciatic nerve are poor, so surgical exploration is limited to situations where impalement of the nerve on a bone spike or in a fracture merits removal of the offending bone fragment.

**Symptomatic Hardware** Most retained hardware is not symptomatic unless it is immediately subcutaneous. The unusual problems are a painful plate on the anterior iliac crest that is aggravated by a belt, or a plate on the superior pubic rami and symphysis in a lean individual that causes dyspareunia. Be aware that pain near hardware may represent an occult nonunion, for which a CT scan, tomograms, or a technetium bone scan merit consideration. Rather than removal, revision of the fixation and bone graft may be necessary. Transverse posterior rods are nearly always symptomatic and merit removal.

### *Thromboembolism*

Deep venous thrombosis (DVT) with the potential for a subsequent fatal PE is a common complication of a pelvic fracture for which the risk can be minimized by the use of appropriate prophylactic measures. The availability of enhanced DVT screening techniques such as magnetic resonance venography has led to earlier and more frequent detection of proximal and distal clots in the venous system (2,47,48 and 49,74). While a distal thrombus is not as likely to embolize, a proximal thrombus is at high risk for dislodgement and fatal PE. In a pelvic fracture victim, the incidence of DVT is 35% to 60%, and the incidence of a proximal clot is 25% to 35%. The incidence of a subsequent PE is 2% to 12%, with a 0.5% to 10% risk of a fatal PE. These rates may become much higher if the patient has sustained polytrauma with the involvement of multiple organ systems. A high injury severity score, increased age, a direct venous injury, multiple blood transfusions, a concomitant lower extremity or spinal cord injury, and a past history of venous stasis disease increase the risk. Prophylaxis and treatment for thromboembolic disease are discussed in Chapter 5.

### *Persistent Pelvic Pain*

About 60% of pelvic fracture victims have prolonged posterior pelvic pain (13,42,51,70). Other sites of late discomfort are less common. Frequently, the specific site of the pain is difficult to identify. More than half of patients with pelvic fractures have also sustained injuries to the lumbosacral spine. Examples include fractures of the transverse and spinous processes, a crack in a vertebral body, a herniated nucleus pulposus, and a traumatic spondylosis or spondylolisthesis. Associated neurologic injury is common as well. The SI joint may be a source of pain because of instability or posttraumatic arthritis. All of these possibilities must be considered.

Electromyographic studies and nerve conduction velocities and an MRI or myelography may be useful for evaluating neurologic pain. Evaluate the SI joint with plain radiographs and CT as well as a CT-guided injection of local anesthetic and a technetium bone scan. Before considering fusion of a posttraumatic arthritis seen on a CT scan, it is important to check for increased activity on a bone scan and temporary relief of pain after a CT-guided injection of xylocaine. If these tests are negative, an SI fusion is unlikely to result in relief of pain.

### *Nonunion and Malunion*

Late deformities and a nonunion can involve one or more sites around the pelvic ring (13,27,32,36,51). These are discussed in Chapter 28.

### *Urologic and Gynecologic Problems*

Information about the influence of a pelvic fracture on female genitourinary, sexual, and reproductive function (9,51) is limited. Late sequelae may include incontinence, urinary dysfunction, dyspareunia, dysmenorrhea, and difficulty with vaginal delivery and overall sexual function. Overall, serious problems appear to be relatively uncommon. Even after surgical fixation of the symphysis and both SI joints, a vaginal delivery is uneventful in many women. Evaluation for potential cephalopelvic disproportion, however, is necessary. In male patients, impotence and urinary dysfunction are the most common long-term genitourinary problems after a pelvic fracture. In 145 male and female patients, Tscherne et al. (51) reported only a 6% incidence of long-term urologic disturbance and less than a 1% incidence of impotence and dyspareunia. In contrast, other studies have reported rates of complete impotence as high as 50% (60,67,73). Further study is clearly needed.

## AUTHORS' PERSPECTIVES

While there is a well-defined role for the use of external fixation in selective pelvic fractures, in many regions excessive reliance on external fixation remains a problem. As more orthopaedic surgeons become familiar with the alternative techniques of internal fixation, this problem should resolve.

A thorough diagnostic evaluation using plain radiographs and CT is crucial for preoperative planning to avoid inadequate fixation. Because of the highly diverse fracture patterns, the presence of concomitant injuries, and other variables of age and pretraumatic health of the patients, the surgeon must be familiar with a wide range of surgical methods and choose those best suited to the circumstances. With the rapidly aging population and increasing incidence of insufficiency fractures, improved fixation strategies for osteopenic bone are needed. Because of the obvious advantages of minimally invasive techniques, such as cannulated screw fixation under image guidance, these techniques are being expanded and refined. Closed reduction of these injuries remains a challenge.

New techniques such as surgical navigation with computer-aided technologies are progressing rapidly. With the limited size of bony targets and irregular columns of bone suitable for screw fixation, computer-aided navigation should be an enormous technical advance for pelvic surgery.

To minimize blood replacement, erythropoietin is available new as a therapeutic aid. Between the period of acute resuscitation and the definitive pelvic reconstruction, the use of erythropoietin may help to lessen transfusion needs (40). Late pelvic pain remains a perplexing problem that needs further investigation to identify etiologies and design therapeutic interventions.

## CHAPTER REFERENCES

Each reference is categorized according to the following scheme: *, classic article; #, review article; !, basic research article; and +, clinical results/outcome study.


+ 1. Agolini SF, Shah K, Jaffe J, et al. Arterial Embolization Is a Rapid and Effective Technique for Controlling Pelvic Fracture Hemorrhage. *J Trauma* 1997;43:395.

+ 2. Becker DM, Philbrick JT, Selby JB. Inferior Vena Cava Filters: Indications, Safety, Effectiveness. *Arch Intern Med* 1992;152:1985.

+ 3. Berg EE, Chebuhar C, Bell RM. Pelvic Trauma Imaging: A Blinded Comparison of Computed Tomography and Roentgenograms. *J Trauma* 1996;41:994.

+ 4. Bucholz RW. The Pathological Anatomy of Malgaigne Fracture-Dislocations of the Pelvis. *J Bone Joint Surg [Am]* 1981;63:400.

+ 5. Burgess AR, Estridge BJ, Young JW, et al. Pelvic Ring Disruptions: Effective Classification System and Treatment Protocols. *J Trauma* 1990;30:848.

+ 6. Bynoe RP, Kudsk KA, Fabian TC, Brown RO. Nutrition Support in Trauma Patients. *Nutr Clin Pract* 1988;3:137.

+ 7. Chapman MW, Mahoney M. The Role of Internal Fixation in the Management of Open Fractures. *Clin Orthop* 1979;138:120.

+ 8. Comstock CP, Marjolein CH, Goodman SB. Biomechanical Comparison of Posterior Internal Fixation Techniques for Unstable Pelvic Fractures. *J Orthop Trauma* 1996;10:517.

+ 9. Copeland CE, Bosse MJ, McCarthy ML, et al. Effect of Trauma and Pelvic Fracture on Female Genitourinary, Sexual and Reproductive Function. *J Orthop Trauma* 1997;11:73.

+ 10. Dalal SA, Burgess AR, Siegel JH, et al. Pelvic Fractures in Multiple Trauma: Classification by Mechanism Is Key to Pattern of Organ Injury, Resuscitation Requirements, and Outcome. *J Trauma* 1989;29:981.

+ 11. Davidson BS, Simmons GT, Williamson PR, Buerk CA. Pelvic Fractures Associated with Open Perineal Wounds: A Survivable Injury. *J Trauma* 1993;35:36.

+ 12. Denis F, Steven D, Comfort T. Sacral Fractures: An Important Problem, Retrospective Analysis of 236 Cases. *Clin Orthop* 1988;227:67.

+ 13. Dujardin FH, Hossenbaccus M, Duparc F, et al. Long-Term Functional Prognosis of Posterior Injuries in High-Energy Pelvic Disruption. *J Orthop Trauma* 1998;12:145.

+ 14. Eastridge BJ, Burgess AR. Pedestrian Pelvic Fractures: 5-Year Experience of a Major Urban Trauma Center. *J Trauma* 1997;42:695.

+ 15. Follin SL, Charland SL. Acute Pain Management: Operative or Medical Procedures and Trauma. *Ann Pharmacother* 1997;31:1068.

+ 16. Gansslen A, Hufer T, Reilmann H, et al. Besondere Situationen am Berckenring. In: Tscherne H, Pholemann T, eds. *Tscherne Unfallchirurgie: Becken und Acetabulum.* Berlin: Springer, 1998;205.

+ 17. Ganz R, Krushell R, Jacob R, Kuffer J. The Antishock Pelvic Clamp. *Clin Orthop* 1991;267:71.

+ 18. Gotis-Graham I, McGuigan L, Diamond T, et al. Sacral Insufficiency Fractures in the Elderly. *J Bone Joint Surg Br* 1994;76B:882.

+ 19. Goulet JA, Mason DL, Roubeau JP, Goldstein SA. Comminuted Posterior Wall Acetabular Fractures: A Biomechanical Evaluation of Fixation Methods. *J Bone Joint Surg [Am]* 1994;76:1457.

+ 20. Gruen DS, Mears DC, Cooperstein LA. Three-Dimensional Angio-Computed Tomography: New Technique for Imaging the Acetabulum and Adjacent Vessels in a Patient with Acetabular Protrusio. *J Arthroplasty* 1989;4:353.

+ 21. Helfet DL, Bartlett CS, Malkani AL. Acetabular Fractures: Extended Iliofemoral Approach. In: Wiss DA, ed.*Master Techniques in Orthopedic Surgery: Fractures.* Philadelphia: Lippincott-Raven, 1998:675.

+ 22. Helfet DL, Borrelli J, DiPasquale T, Sanders R. Stabilization of Acetabular Fractures in Elderly Patients. *J Bone Joint Surg [Am]* 1992;74:753.

+ 23. Helfet DL, Koval KJ, et al. Intraoperative Somatosensory Evoked Potential Monitoring During Acute Pelvic Fracture Surgery. *J Orthop Trauma* 1995;9:28.

+ 24. Hirvansalo E, Lindahl J, Bostman O. A New Approach to the Internal Fixation of Unstable Pelvic Fractures. *Clin Orthop* 1993;297:28.

+ 25. Jones AL, Powell JN, Kellam JF, et al. Open Pelvic Fractures: A Multicenter Retrospective Analysis. *Orthop Clin North Am* 1997;28:345.

* 26. LeTournel E. Les Fractures du Cotyle, Etude d'une Serie de 75 Cases. Thesis, Université de Paris, 1961.

+ 27. LeTournel E. Diagnosis and Treatment of Nonunions and Malunions of Acetabular Fractures. *Orthop Clin North Am* 1990;21:769.

+ 28. LeTournel E, Judet R. *Fractures of the Acetabulum, 2nd ed.* New York: Springer 1993;67.

+ 29. Lowner JH, Koval KJ. Polytrauma in the Elderly. *Clin Orthop* 1995;318:136.

+ 30. Magid D, Fishman EK, Ney DR, et al. Acetabular and Pelvic Fractures in the Pediatric Patient: Value of Two- and Three-Dimensional Imaging. *J Pediatr Orthop* 1992;12:621.

+ 31. Matta JM. Indications for Anterior Fixation of Pelvic Fractures. *Clin Orthop* 1996;329:88.

+ 32. Matta JM, Dickson KF, Markovich GD. Surgical Treatment of Pelvic Nonunions and Malunions. *Clin Orthop* 1996;329:199.

+ 33. Matta JM, Saucedo T. Internal Fixation of Pelvic Ring Fractures. *Clin Orthop* 1989;242:83.

+ 34. McCoy GF, Johnstone RA, Duthie RB. Injury to the Elderly in Road Traffic Accidents. *J Trauma* 1989;29:494.

+ 35. McMurtry R, Walton D, Dickinson D, et al. Pelvic Ring Disruption in the Polytraumatized Patient: A Management Protocol. *Clin Orthop* 1980;151:22.

+ 36. Mears DC. Das Management von Beckenpseudarthrosen und Bechenfehlstellongen. *Orthopade* 1996;25:441.

+ 37. Mears DC. Pelvic and Acetabular Fractures. In: Asnis SE, Kyle RF, eds.*Cannulated Screw Fixation: Principles and Operative Techniques.* New York: Springer, 1996:97.

+ 38. Mears DC, Capito CP, DeLeeuw H. Posterior Pelvic Disruptions Managed by the Use of the Double Cobra Plate. *Instr Course Lect* 1988;37:18.

+ 39. Mears DC, Durbhakula SM. Transiliac Plate Fixation. In: Tornetta P, ed.*Techniques in Fracture Surgery.* Philadelphia: Mosby Year-Book, 2000 (in press).

+ 40. Mears DC, Durbhakula SM, Miller B. Developments in Blood Management: The Potential Role for Epoetin Alfa in Orthopedic Trauma. 1999;22(Suppl.1):S151.

+ 41. Mears DC, MacLeod MD. Acetabular Fractures: Triradiate and Modified Triradiate Approaches. In: Wiss DA, ed.*Master Techniques in Orthopedic Surgery: Fractures.* Philadelphia: Lippincott-Raven, 1998:697.

# 42. Mears DC, Rubash HE.*Pelvic and Acetabular Fractures.* Thorofare, NJ: Slack, 1986;121.

+ 43. Mears DC, Shirahama M. Stabilization of an Acetabular Fracture with Cables for Acute Total Hip Arthroplasty. *J Arthroplasty* 1998;13:104.

+ 44. Mears DC, Ward AJ, Wright MS. The Radiological Assessment of Pelvic and Acetabular Fractures Using Three-Dimensional Computed Tomography. *Int J Orthop Trauma* 1992;2:196.

+ 45. Melanson SW, Heller S. The Emerging Role of Bedside Ultrasonography in Trauma Care. *Emerg Med Clin North Am* 1998;16:165.

* 46. Melton LJ, Sampson JM, Morrey BF, Ilstrup DM. Epidemiologic Features of Pelvic Fractures. *Clin Orthop* 1981;155:43.

+ 47. Montgomery KD, Geerts WH, Potter HG, Helfet DL. Thromboembolic Complications in Patients with Pelvic Trauma. *Clin Orthop* 1996;329:68.

+ 48. Montgomery KD, Geerts WH, Potter HG, Helfet DL. Practical Management of Venous Thromboembolism Following Pelvic Fractures. *Orthop Clin North Am* 1997;28:397.

+ 49. Montgomery KD, Potter HG, Helfet DL. The Detection and Management of Proximal Deep Venous Thrombosis in Patients with Acute Acetabular Fractures: A Follow-Up Report. *J Orthop Trauma* 1997;11:330.

* 50. Pennal GF, Tile M, Waddell JP, et al. Pelvic Disruption: Assessment and Classification. *Clin Orthop* 1980;151:12.

+ 51. Pohlemann T, Bosch U, Gansslen A, Tscherne H. The Hannover Experience in Management of Pelvic Fractures. *Clin Orthop* 1994;305:69.

# 52. Pohlemann T, Lobenhoffer PL, Tscherne H. Operative Therapies. In: Tscherne H, Pohlemann T, eds.*Tscherne Unfallchirvigie: Becken und Acetabulum.* Berlin: Springer, 1998:135.

+ 53. Porter JR, Takayama TK, Defalco AJ. Traumatic Posterior Urethral Injury and Early Realignment Using Magnetic Urethral Catheters. *J Urol* 1997;158:425.

+ 54. Porter RS, Nester BA, Dalsey WC, et al. Use of Ultrasound to Determine Need for Laparotomy in Trauma Patients. *Ann Emerg Med* 1997;29:323.

+ 55. Ragnarsson B, Jacobsson B. Epidemiology of Pelvic Fractures in a Swedish County. *Acta Orthop Scand* 1992;63:297.

+ 56. Reilly MC, Zinar DM, Matta JM. Neurological Injuries in Pelvic Ring Fractures. *Clin Orthop* 1996;329:28.

+ 57. Riemer BL, Butterfield SL, Diamond DL, et al. Acute Mortality Associated with Injuries to the Pelvic Ring: The Role of Early Patient Mobilization and External Fixation. *J Trauma* 1993;35:671.

+ 58. Routt MLC, Kregor PJ, Simonian PT, Mayo KA. Early Results of Percutaneous Iliosacral Screws Placed with the Patient in the Supine Position. *J Orthop Trauma* 1995;9:207.

+ 59. Routt MLC, Simonian PT. Closed Reduction and Percutaneous Skeletal Fixation of Sacral Fractures. *Clin Orthop* 1996;329:121.

+ 60. Routt ML, Simonian PT, Defalco A. Internal Fixation in Pelvic Fractures and Primary Repairs of Associated Genitourinary Disruptions—A Team Approach. *J Trauma* 1996;40:784.

+ 61. Routt MLC, Simonian PT, Grujic L. The Retrograde Medullary Superior Pubic Ramus Screw for the Treatment of Anterior Pelvic Ring Disruptions. *J Orthop Trauma* 1995;9:35.

+ 62. Roy-Camille R, Saillant G, Gagana G, Mazel C. Transverse Fracture of the Upper Sacrum; Suicidal Jumper's Fracture. *Spine* 1985;10:838.

+ 63. Rubin GD, Silverman SG. Helical (Spiral) CT of the Retroperitoneum. *Radiol Clin North Am* 1995;33:903.

+ 64. Seekamp A, Regel G, Tscherne H. Rehabilitation and Reintegration of Multiply Injured Patients: An Outcome Study with Special Reference to Multiple Lower Limb Fractures. *Injury* 1996;27:133.

+ 65. Shaw JA, Mino DE, Werner FW, Murray DG. Posterior Stabilization of Pelvic Fractures by Use of Threaded Compression Rods. Case Reports and Mechanical Testing. *Clin Orthop* 1985;192:240.

+ 66. Stylianos S. Abdominal Packing for Severe Hemorrhage. *J Pediatr Surg* 1998;33:339.

+ 67. Taffet R. Management of Pelvic Fractures with Concomitant Urologic Injuries. *Orthop Clin North Am* 1997;28:389.

+ 68. Templeman D, Goulet J, Duwelius PJ, et al. Internal Fixation of Displaced Fractures of the Sacrum. *Clin Orthop* 1996;329:180.

+ 69. Tile M. Pelvic Ring Fractures: Should They Be Fixed? *J Bone Joint Surg Br* 1988;70:1.

# 70. Tile M. *Fractures of the Pelvis and Acetabulum, 2nd ed.* Baltimore: Williams and Wilkins, 1995.

+ 71. Tile M, Helfet DL, Kellam JF, et al.*Comprehensive Classification of Fractures in the Pelvis and Acetabulum.* Berne, Switzerland: Maurice E. Müller Foundation, 1995.

+ 72. Vrahas M, Gordon RG, Mears DC, et al. Intraoperative Somato-Sensory Evoked Potential Monitoring of Pelvic and Acetabular Fractures. *J Orthop Trauma* 1992;6:50.

+ 73. Watnik NF, Coburn M, Goldberger M. Urologic Injuries in Pelvic Ring Disruptions. *Clin Orthop* 1996;329:37.

+ 74. Webb LX, Rush PT, Fuller SB. Greenfield Filter Prophylaxis of Pulmonary Embolism in Patients Undergoing Surgery of Acetabular Fracture. *J Orthop Trauma* 1992;6:139.

+ 75. Whitbeck MG Jr, Zwally HJ II, Burgess AR. Innominosacral Dissociation: Mechanism of Injury as a Predictor of Resuscitation Requirements, Morbidity, and Mortality. *J Orthop Trauma* 1997;11:82.

+ 76. Witschger P, Heini P, Ganz R. Pelvic Clamps for Controlling Shock in Posterior Pelvic Ring Injuries. Applications, Biomechanical Aspects, and Initial Clinical Results (German). *Orthopade* 1992;21:393.

+ 77. Woods RK, O'Keefe G, Rhee P, et al. Open Pelvic Fracture and Fecal Diversion. *Arch Surg* 1998;133:281.

# CHAPTER 18

# FRACTURES OF THE ACETABULUM, HIP DISLOCATIONS, AND FEMORAL HEAD FRACTURES

*Steven A. Olson and Joel M. Matta*

**S. A. Olson:** Associate Professor, Chief Orthopaedic Trauma, Department of Orthopaedic Surgery, University of California Davis, Medical Center, Sacramento, California, 95817.
**J. M. Matta:** Los Angeles, California, 90017.

Fractures of the Acetabulum
- Assessment
- Classification
- Indications for Surgery
- Choice of Surgical Approach
- Techniques of Reduction and Internal Fixation
- Operative Techniques
- Postoperative Care
- Complications

Hip Dislocations and Fractures of the Femoral Head
- Mechanism of Injury and Classification
- Evaluation
- Reduction of the Dislocation
- Postreduction Care
- Fractures of the Femoral Head
- Complications

Chapter References

## FRACTURES OF THE ACETABULUM

Judet and Letournel introduced the concept of anterior and posterior columns of the innominate bone (25). The acetabulum is contained between these two columns, as they meet in the shape of an inverted **Y** in the innominate bone. The anterior column, which consists of the iliac wing and pelvic brim, extends to the pubic symphysis and contains the anterior one half of the acetabular articular surface. The posterior column consists of the greater and lesser sciatic notches, the retroacetabular surface, and the majority of the quadrilateral surface (25). Similarly, the posterior column contains the posterior one half of the acetabular articular surface. The goal of surgical treatment of fractures of the acetabulum is an accurate reconstruction of the articular surface (28).

The terminology used to describe the anatomic aspects of the innominate bone is important in the discussion of acetabular fractures. We emphasize several descriptive terms in the discussion of acetabular fractures. The internal iliac fossa, the quadrilateral surface, and the retroacetabular surface describe large cortical surfaces of the innominate bone. The pelvic brim marks the junction of the internal iliac fossa and quadrilateral surface. The sciatic notch marks the junction of the quadrilateral surface and the retroacetabular surface (Fig. 18.1).

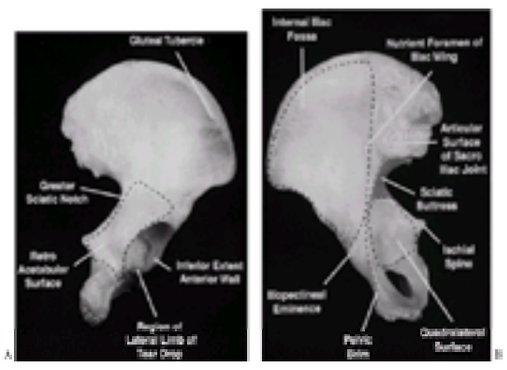

***Figure 18.1.*** **A:** Anatomic regions of the internal aspect of the innominate bone are illustrated. The pelvic brim is contiguous anteriorly with the internal iliac fossa and is its medial border inferior to the sacroiliac joint. The pelvic brim also serves as the anterior border of the quadrilateral surface, which is bounded by the pelvic brim anteriorly, the greater and lesser sciatic notches posteriorly, the obturator foramen inferiorly, and the sciatic buttress superiorly. The iliopectineal eminence lies directly over the anterior wall of the acetabulum. The nutrient foramen of the iliac wing is a consistent landmark found adjacent to the sacroiliac joint. **B:** The external aspect of the innominate bone is shown. The retroacetabular surface is outlined. The greater and lesser sciatic notches make up the posterior border of the retroacetabular surface. (Reproduced with permission from Fractures of the Acetabulum—Classification and Radiographic Assessment. In: *Oxford Textbook of Orthopaedics and Trauma.* Oxford Press, *in press.*)

### ASSESSMENT

To understand the radiographic anatomy of acetabular fractures, the surgeon must appreciate how the radiographic landmarks of the pelvis correlate with the actual bony anatomy of the innominate bone. Six basic landmarks of the acetabulum are described on the anteroposterior (AP) view (Fig. 18.2*A*) (25). The iliac oblique and obturator oblique radiographic views are 45° oblique views of the pelvis. Both of these views are often referred to as Judet views (Fig. 18.2*B* and Fig. 18.2*C*) (25).

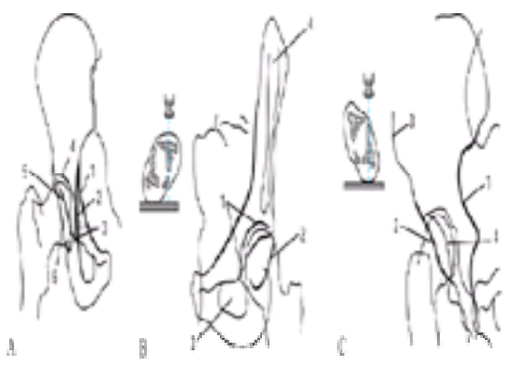

***Figure 18.2.*** **A:** The normal radiographic lines of the acetabulum are shown as they appear in the anteroposterior radiographic view. *1,* The iliopectineal line; *2,* the ilioischial line; *3,* the roentgenographic U, or teardrop; *4,* the roof; *5,* the anterior rim; and *6,* the posterior rim. The iliopectineal line corresponds to the inferior three fourths of the pelvic rim and is a landmark of the anterior column. The ilioischial line represents a posterior portion of the quadrilateral surface seen in tangent by the x-ray beam, and it is generally considered a landmark of the posterior column. Similarly, the roof of the acetabulum represents a portion of the superior acetabular

subchondral bone seen in tangent by the x-ray beam. The medial limb of the teardrop is likewise formed from the obturator canal and inferior portion of the quadrilateral surface, seen in tangent by the x-ray beam. The anterior and posterior rims represent the lateral margin of the acetabular articular surface anteriorly and posteriorly, respectively. In the AP view, the anterior rim is typically medial to the posterior rim. **B:** The normal radiographic landmarks of the obturator oblique view. *1,* The iliopectineal line; *2,* posterior rim; *3,* obturator ring; *4,* anterosuperior iliac spine. The obturator oblique view is taken with a 45° rotation of the affected hip, away from the x-ray cassette. The iliopectineal line, as visualized on this view, has a similar relationship with the pelvic brim as on the AP view. The posterior rim of the acetabulum is best seen on this view. Fractures of the posterior wall and subtle amounts of anterior subluxation of the femoral head are best detected on the obturator oblique view. **C:** The normal radiographic landmarks of the iliac oblique view. *1,* posterior border of innominate bone; *2,* anterior rim; *3,* anterior border of iliac wing; *4*, posterior rim. Oblique views with appropriate rotation have the tip of the coccyx superimposed on the femoral head on the obturator oblique view. (All images reproduced with permission from Judet, R, Judet, J, Letournal E. Fractures of the Acetabulum: Classification and Surgical Approaches for Open Reduction. *J Bone Joint Surg* 1964;64A:1615.)

Computerized tomography (CT) can also be used to visualize acetabular fractures (18). In the majority of cases, the fracture pattern can be identified and thus classified from plain films alone. Plain films are usually best for assessing the congruence between the femoral head and the roof of the acetabulum. Plain-film radiography has been the standard by which articular displacement has been measured, both before and after surgery. In the emerging age of digital radiography, however, in which the size of the AP pelvis and Judet views is altered, the CT image may become a more reliable method of articular assessment. CT is better suited for evaluating certain fracture characteristics including marginal impaction, rotation of major fragments, coronal fracture lines, and incarcerated osteochondral fragments (Fig. 18.3) (18,28,51).

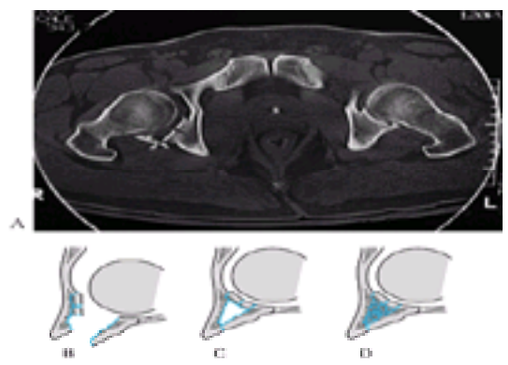

***Figure 18.3.*** **A:** Computerized tomography can demonstrate marginal impaction. (Reproduced with permission from Olson SA, Matta JM. Surgical Treatment of Acetabulum Fractures. In: Browner BD, Jupiter JB, Levine AM, Trafton PG, et al., eds. *Skeletal Trauma,* 2nd ed. Philadelphia: WB Saunders, 1997;1181.) **B:** The impacted articular surface and posterior wall fragments and posterior wall fractures are shown. **C:** The impacted articular fragments are elevated to match the contour of the femoral head, and bone graft is placed behind them to fill the defect created by their reduction. **D:** The posterior wall fracture is then reduced. (Modified from Letournel E, Judet R. *Fractures of the Acetabulum.* Berlin: Springer-Verlag, 1993.)

## CLASSIFICATION

Anatomic classification systems enable the surgeon to gain a thorough understanding of the fracture and its displacement pattern before intervening surgically. Such knowledge helps determine what maneuvers may be necessary to reduce the displacement of a particular pattern and which surgical approach will be used to treat the fracture (28,38,62). Letournel's classification is the most widely used system (25,28). It comprises five simple fracture types and five associated types (28).

### *Simple Patterns*

1. Posterior wall fractures typically disrupt the posterior rim of the acetabulum, a portion of the retroacetabular surface, and a segment of the articular cartilage (28). Instability of the hip (subluxation or dislocation of the femoral head) can be associated with this fracture pattern. Marginal impaction of the articular cartilage commonly occurs and should be diagnosed preoperatively on plain films or CT scan (Fig. 18.3) (3). Marginal impaction of the articular suface and underlying cancellous bone occurs when the femoral head subluxes into a displaced major fracture line. The articular surface of the edge of the major fracture line is displaced secondary to impaction of the underlying cancellous bone, with malrotation of the overlying articular surface. In Figure 18.3, marginal impaction is noted as a change in the radius of curvature of the articular surface. It is important for surgeons to recognize this radiographic feature of articular displacement so that they can correct the displacement. Complex posterior wall fractures can involve the entire retroacetabular surface and include a portion of the greater or lesser sciatic notch and the ischial tuberosity. The ilioischial line remains intact on the AP view (Fig. 18.4*A*).

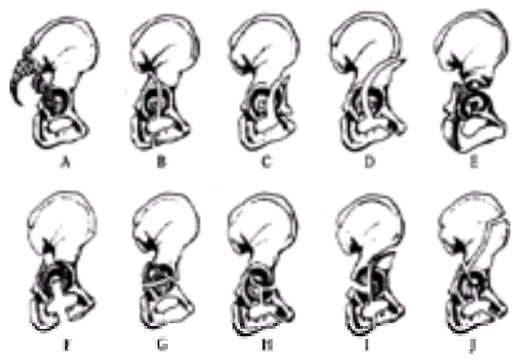

***Figure 18.4.*** Classification of acetabulum fractures according to Letournel. Posterior wall fracture (**A**); posterior column fracture (**B**); anterior wall fracture (**C**); anterior column fracture (**D**); transverse fracture (**E**); associated posterior column and posterior wall fractures (**F**); associated transverse and posterior wall fractures (**G**); **T**-shaped fracture (**H**); associated anterior and posterior hemitransverse fractures (**I**); fracture of both columns (**J**). (Reproduced with permission from Matta JM, Merrit PO. Trauma: Pelvis and Acetabulum. In: Fitzgerald RH, ed. *Orthopaedic Knowledge Update II*. American Academy of Orthopaedic Surgeons, 1987:348.)

2. Posterior column fractures affect only the ischial segment of the bone (28). The retroacetabular surface is displaced with the posterior column. The fracture line separating the anterior from the posterior column commonly enters the obturator foramen, and an associated fracture of the inferior pubic ramus is typical. Fractures that run just posterior to the obturator foramen, splitting the ischial tuberosity, constitute a transitional pattern between the posterior wall and posterior column. The ilioischial line is typically displaced and disassociated from the teardrop. Uncommonly, when a large portion of the quadrilateral surface remains intact and in continuity with the posterior column, the teardrop and a portion of the pelvic brim are displaced with the posterior column (Fig. 18.4*B*).
3. Fractures of the anterior wall disrupt the central portion of the anterior column (28). Comminution of the quadrilateral surface occurs in most cases; fracture of the inferior pubic ramus is less often seen. The AP and obturator oblique radiographs show displacement of the iliopectineal line. The AP and iliac oblique radiographs show interruption or displacement of the anterior rim contour (Fig. 18.4*C*).
4. Anterior column fractures can occur anywhere on the column (28). Very low fractures involve only the superior ramus and pubic portion of the acetabulum. High fractures can involve the entire anterior border of the iliac wing. The fracture line typically runs in the coronal plane through the superior acetabulum. The iliopectineal line is displaced. Medial translation of a portion of the roof or the entire roof can be seen with displacement of a high or intermediate type of anterior column fracture. This type of displacement also can be seen with anterior column and posterior hemitransverse fractures, and both-column fracture patterns as well (Fig. 18.4*D*).
5. Transverse fractures divide the innominate bone into two portions (28). An oblique sagittal plane fracture line crosses the acetabulum at a variable level and is often displaced. The innominate bone is then divided into a superior part composed of the iliac wing and a portion of the roof of the acetabulum; the lower part of the bone, the ischiopubic segment, is composed of an intact obturator foramen with the anterior and posterior walls of the acetabulum. Letournel subdivided transverse fractures as *transtectal*, a transverse fracture line that crosses the superior acetabular articular surface; *juxtatectal*, a transverse fracture line that crosses at the junction of the superior acetabular articular surface and superior cotyloid fossa; and *infratectal*, a transverse fracture line that crosses through the

cotyloid fossa (Fig. 18.4*E*).

### *Associated Patterns*

1. The association of a posterior column and posterior wall fracture splits the posterior column into a larger posterior column component and an associated posterior wall component (28). The ilioischial line is typically displaced and disassociated from the teardrop (Fig. 18.4*F*).
2. The association of a transverse fracture with a posterior wall fracture shows features of both—a typical transverse configuration with one or more separate posterior wall fragments (28). A fracture of the inferior pubic ramus is not typically associated with this very common pattern (Fig. 18.4*G*). In the case of a displaced posterior wall fracture, pay careful attention to the plain films to avoid missing a nondisplaced transverse fracture line.
3. The **T**-shaped fracture is similar to the transverse fracture except that a vertical fracture line runs along the quadrilateral surface and acetabular fossa (the stem of the **T**), which separates the anterior from the posterior column (28). An associated fracture of the inferior pubic ramus is typically present. This vertical fracture line can enter the obturator foramen or leave it intact, exiting through the ischium (Fig. 18.4*H*).
4. The anterior plus posterior hemitransverse fracture combines an anterior wall or anterior column fracture with a horizontal transverse component, which typically traverses the posterior column at a low level (Figure 18.4*I*) (28). The distinction between the associated anterior column and posterior hemitransverse and **T**-shaped patterns is often subtle. In the anterior column plus posterior hemitransverse fracture, the anterior component is typically at a higher level and is more displaced than the posterior component, whereas the **T**-shaped fracture is a transverse fracture with an additional fracture line splitting the anterior and posterior columns of the ischiopubic portion. The femoral head typically follows the displacement of the anterior column in the associated anterior column plus posterior hemitransverse pattern, whereas the femoral head typically follows the posterior column in a **T**-shaped pattern.
5. Fractures of both columns constitute a distinct category in which the anterior and posterior columns are separated from each other. All articular segments are detached from the intact portion of the posterior ilium, which remains attached to the sacrum (Fig. 18.4*J*) (28). The surgeon should differentiate transverse, associated transverse plus posterior wall, **T**-shaped, and anterior plus posterior hemitransverse fractures—all of which show involvement of the anterior and posterior columns of the acetabulum—from both-column fractures. In those four fracture types, a portion of the articular surface remains in its normal position, attached to the intact portion of the ilium. The both-column fracture is therefore unique, with its division of all segments of articular cartilage from the ilium. The both-column fracture is associated with the spur sign, in which the obturator oblique radiographic view prominently reveals the fractured edge of the intact posterior iliac wing relative to the medially displaced articular segments. This sign is pathognomonic of a both-column injury (Fig. 18.5) (28).

***Figure 18.5.*** An obturator oblique view demonstrates the spur sign of a both-column fracture. This spur represents the intact portion of the iliac wing as seen prominent and laterally (*arrow*) on this view because the remainder of the articular segments of the acetabulum have been displaced medially. (Reproduced with permission from Olson SA, Matta JM. Surgical Treatment of Acetabulum Fractures. In: Browner BD, Jupiter JB, Levine AM, Tafton PG, eds. *Skeletal Trauma,* 2nd ed. Philadelphia: WB Saunders, 1997;1181.)

As with all anatomic classification systems, there is some overlap between fracture types in Letournel's system. If this system of classification were perfectly symmetric, there would be more than 10 categories. The extra groups are included within the 10 fracture types; for example, associated anterior column and anterior wall are included with anterior column fractures. Similarly, a fracture of the anterior wall plus posterior hemitransverse fracture is included with anterior column plus posterior hemitransverse fracture. Associated posterior column and anterior hemitransverse fractures, as well as associated transverse and anterior wall fractures, are considered **T**-shaped fractures. Table 18.1 outlines some tips for classification.

1. Fractures that involve the iliac wing are one of three types*
   (a) Anterior column
   (b) Anterior column and posterior hemitransverse
   (c) Both-column
2. Fractures that involve both the anterior and posterior columns are one of five types
   (a) Transverse
   (b) Transverse and posterior wall
   (c) T-shaped
   (d) Anterior column and posterior hemi-transverse
   (e) Both-column

* A posterior wall fragment extending into the iliac wing has been described in an exceptional case of a transverse plus posterior wall pattern (28).

***Table 18.1. Simple Tips for Classification of Fractures of the Acetabulum***

## INDICATIONS FOR SURGERY

Operative treatment is indicated for most displaced acetabulum fractures to decrease the incidence of posttraumatic arthritis. It also permits the patient to return to normal function earlier than nonoperative treatment. Nonoperative treatment, however, is successful in a minority of displaced acetabulum fractures. Indications for nonoperative treatment are based on the condition of the patient, analysis of the fracture configuration, and congruence of the hip joint.

The decision to operate is based on the initial series of plain films and CT scans (52,54). In patients who are candidates for surgery, attempts at closed reduction by manipulation under anesthesia or skeletal traction are not applicable for the treatment of displaced fractures of the acetabulum. Typically, significant displacements tend to recur over time. If the surgeon concludes from the initial radiographs that an accurate reduction of the articular surface is necessary for a good prognosis, surgery is usually indicated. Nonoperative treatment is reserved for patients with nondisplaced fractures, those with tolerable incongruity or displacement, and those in whom surgery is contraindicated. (See Table 18.2 and Table 18.3 for specific criteria.)

*Strong indications*

5 mm or greater displacement of fractures in the superior acetabulum (fracture line crossing the superior 10 mm CT subchondral arc)

Loss of congruence (subluxation) of the femoral head with the acetabulum on any of the three radiographic views

Posterior wall fractures associated with instability of the femoral head

Incarcerated osteochondral fragment with a nonconcentric reduction

*Relative indications*

2 to 5 mm of displacement of fracture involving the superior acetabulum (in the superior 10 mm of the CT subchondral arc)

5 mm or more of marginal impaction

50% involvement of the posterior wall with a stable hip

Polytrauma

Ipsilateral displaced femoral neck fracture requiring open reduction

***Table 18.2. Indications for Surgical Treatment***

| *Strong indications* |
|---|
| The presence of the first three of the following criteria |
| 1. CT subchondral arc is intact through the superior 10 mm of the acetabulum |
| 2. Femoral head remains congruent with the acetabulum on all three plain radiographic views taken out of traction. |
| 3. There is no associated posterior wall fracture with instability of the hip. |
| 4. A retained small osteochondral fragment in the acetabular fossa with no associated incongruence of the femoral head. |
| *Relative indications* |
| Severe systemic compromise, such as adult respiratory distress syndrome, multisystem organ failure, postinjury myocardial infarction |
| Active sepsis, either locally or systemic |
| Severe overlying soft tissue injury or bacterial contamination |
| Severe osteopenia preventing adequacy of fixation |

***Table 18.3. Indications for Nonsurgical Treatment of Acetabular Fractures***

Displaced fractures that should be considered for nonoperative treatment are usually in one of two categories (54). In one group, a large portion of the acetabulum remains intact and the femoral head remains congruous with this portion of the acetabulum. In the other group, a secondary congruence is present following only moderate displacement of a both-column fracture.

A large portion of the acetabulum may remain intact with any of several different fracture types. Many low anterior column fractures that involve only the pubic portion of the acetabulum can be treated nonoperatively. Rarely, low **T**-shaped or transverse fractures can be treated nonoperatively. In the case of posterior wall fractures, indications for surgical stabilization include in-stability or subluxation of the hip, associated marginal impaction of the articular surface, and retainedosteochondral fragments with joint incongruence (54).

Various studies have attempted to correlate the size of the posterior wall fracture with the degree of instability of the hip (8,27,64). Each study reports three ranges of fracture size; in the first, the hip is stable; in the second, the hip is unstable; and in the third, instability is inconsistent, varying from 20% to 65% width of the posterior wall, depending on the method of measuring the posterior wall defect. Small posterior wall fractures associated with a stable hip joint that have a congruent reduction can be managed nonoperatively. Careful follow-up is needed to monitor for signs and symptoms of late instability in the initial months following injury.

Carefully examine the congruity of the hip joint on radiographs and CT images. Loss of the normal congruent relationship of the femoral head with the acetabulum is frequently associated with osteochondral fragments incarcerated within the acetabulum (54). Review the three standard radiographic views of the pelvis (AP, obturator oblique, and iliac oblique) to detect loss of parallelism between the curvature of the femoral head and acetabular articular surface on all three views (28). Similarly, evaluate CT images to detect widening of the distance between the anterior and posterior walls or acetabular fossa, and the femoral head (54). Loss of congruency between the femoral head and acetabular articular surface is often associated with the development of degenerative arthritis of the hip.

When considering operative treatment, it is useful to assess the size of the intact portion of the acetabulum, which can be determined using roof arc measurements (34,35 and 36). We prefer to make them on CT scans. A CT scan of the superior acetabular articular surface from the vertex to 10 mm inferior to the vertex is equivalent to an area described by all three roof arc measurements of 45° (Fig. 18.6) (52). At 10 mm below the acetabular vertex, the subchondral bone appears as a ring or arc (Table 18.2 and Table 18.3).

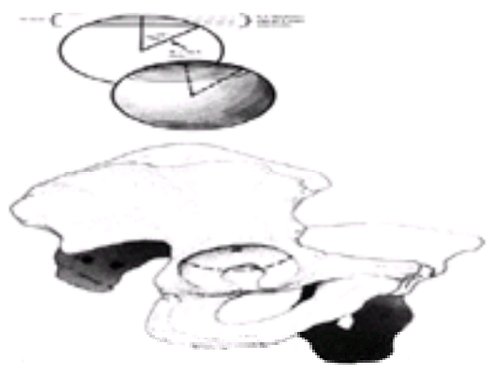

***Figure 18.6.*** The acetabulum with a line at the level of CT image at 10 mm inferior to the vertex of the acetabulum. The area of the acetabular articular surface, superior to this line, represents the minimum amount of intact bearing surface necessary for consideration of nonoperative treatment. This area is equivalent to the area intact when all three roof arc measurements are 45°. The inset diagram illustrates evaluation of the superior acetabulum by CT to 10 mm inferior to the vertex, in 2 mm intervals. (Reproduced with permission Olson SA, Matta JM. The Computerized Tomography Subchondral Arc: A New Method of Assessing Acetabular Articular Continuity After Fracture (A Preliminary Report). *J Orthop Trauma* 1993;7:402.)

Both-column fractures with secondary congruence present a unique situation. In both-column fractures, all articular segments are detached from the intact ilium (28). Even though displacement of the fracture has occurred, the fracture fragments can remain congruously grouped around the femoral head despite medial and proximal displacement of the femoral head and some rotational displacement of the fragments (28,54). Assess the three standard radiographic views of the pelvis to detect loss of parallelism between the curvature of the femoral head and acetabular articular surface. Consider loss of parallelism on any of the three views to be an indication for surgery.

The goal of nonoperative treatment is to reduce the fracture and to prevent displacement from worsening. Skeletal traction through a proximal tibia pin is often used. Neufeld roller traction is a useful form of treatment that allows motion of the hip and knee while the patient is in traction (40). Traction should not be so great that it distracts the femoral head from the acetabulum. Skeletal traction, particularly if initiated early while the fracture hematoma is liquid, can occasionally produce a surprisingly good reduction (62). Release of traction before complete healing, however, typically results in redisplacement of the fracture. We believe that lateral skeletal traction through the greater trochanter is not beneficial and can even cause severe problems such as infection of the greater trochanter or soft tissues lateral to the hip joint. Do not use traction through the greater trochanter if any surgical treatment is being considered.

Percutaneous techniques of fixation for minimally displaced and nondisplaced acetabular fractures have been described (58). Percutaneous fixation of moderately displaced (2–5 mm) acetabular fractures may not improve the reduction and often provides less-than-optimal fixation. Percutaneous fixation has also been used in nondisplaced fractures to allow early patient mobilization (58). In our experience, patients with nondisplaced acetabular fractures can be moved from bed to chair without risk of significant displacement. Percutaneous fixation techniques may have potential benefits, but at this time definitive indications for percutaneous fixation have not been developed.

Surgery is usually undertaken 2 to 3 days following the injury, when the initial bleeding from the fracture and intrapelvic vessels has subsided. Generally, use skeletal traction preoperatively for posterior fracture patterns with hip instability out of traction. In displaced transtectal fracture patterns, traction can help prevent erosion of the femoral head cartilage on the residual intact acetabular roof. It is also indicated for associated femoral fractures.

Skeletal traction has been commonly advocated for improving patient comfort preoperatively, but we have not found it necessary. Schedule surgery before 10 days, ideally, so that the fracture fragments remain mobile. Three weeks after injury, bony callus is usually present, which makes reduction of the fracture more difficult. Advanced age is not an absolute contraindication to surgery (19). Factors such as general medical status, pre-existing arthrosis, and bone quality may affect decision

making.

## CHOICE OF SURGICAL APPROACH

No one surgical incision is ideal for all fractures of the acetabulum. Following radiographic analysis and classification of the fracture, the surgeon should be able to draw the fracture configuration on a model or drawing of the innominate bone (32). Preoperative considerations should include an understanding of the fracture configuration on the outside and inside of the innominate bone, and of the orientation of the fracture planes. This information combined with appreciation of the benefits and limitations of each surgical approach will allow the surgeon to select the appropriate surgical procedure.

All surgical approaches provide some access to both anterior and posterior columns, but each has its advantages and disadvantages. We prefer to use the Kocher-Langenbeck, the ilioinguinal, or the extended iliofemoral approach. Alternatively, the triradiate approach gives an exposure roughly comparable to that of the extended iliofemoral but provides limited access to the posterior portion of the iliac wing.

The Kocher-Langenbeck approach provides the best access to the posterior column. The ilioinguinal approach gives the best access to the anterior column and the inner aspect of the innominate bone. The extended iliofemoral approach gives the best simultaneous access to the two columns, but it does not expose the anterior column as well as the ilioinguinal approach does (28,37,61). We prefer to choose a surgical approach with the expectation that the entire reduction and fixation can be performed through that single approach.

Position the patient appropriately for the single approach—that is, prone for the Kocher-Langenbeck approach, supine for the ilioinguinal approach, and lateral for the extended iliofemoral approach. Although the extended iliofemoral provides the best access, it has the longest recovery period and the highest incidence of ectopic bone formation (16,53). It is therefore preferable to choose the ilioinguinal or Kocher-Langenbeck approach, if feasible. See Table 18.4 for indications for the extended iliofemoral approach.

| |
|---|
| Displaced both-column fractures with an extensive posterior wall and column comminution. |
| Displaced both-column fractures with displacement of the greater sciatic notch or posterior iliac wing involving the sacroiliac joint. |
| Displaced transrectal T-shaped fractures. |
| Displaced transverse posterior wall acetabular fractures, or T-shaped variants with posterior wall acetabular fractures in which the posterior wall component is a complex pattern, involving a significant portion of the greater sciatic notch. This injury pattern requires that the articular surface be visualized to adequately reduce the transverse component prior to reconstructing the posterior wall. |
| Severe intraarticular comminution of the articular surface requiring direct visualization and reduction of the articular surface. |
| Fractures older than 21 days involving both the anterior and posterior column of the acetabulum. |

***Table 18.4. Indications for the Extended Iliofemoral Approach***

Combined approaches performed either concurrently or successively are required less frequently and are usually less desirable than the single approach. Concurrent use of the ilioinguinal and Kocher-Langenbeck limits the access of the anterior column through the Kocher-Langenbeck approach and posterior column through the ilioinguinal approach. Successive ilioinguinal and Kocher-Langenbeck approaches allow full use of both exposures but require intraoperative repositioning (54). The use of combined exposures is reserved for injuries such as an associated anterior column and posterior hemitransverse pattern with significant displacement of both the anterior column and low posterior hemitransverse components, or juxtatectal or infratectal **T**-shaped fractures with significant displacement of both anterior and posterior columns. See Chapter 2 for a description of the approaches.

## TECHNIQUES OF REDUCTION AND INTERNAL FIXATION

Once the surgeon has completed preoperative radiographic evaluation and has chosen the approach, re-duction of the fracture remains the primary problem.Reduction of an acetabular fracture can be extremely challenging. The technique of reduction is always tailored to fracture type. Even for a specific fracture type, the choice of technique frequently depends on the exact configuration of the individual fracture (28,33,54).

Use of a fracture table helps in the reduction and maximizes the possibilities of each surgical approach. The fracture table lessens the need for extensile as well as dual approaches (28). It does not directly reduce the fracture but facilitates reduction by returning the femoral head to normal position and aiding visualization of the interior of the joint. An alternative to the fracture table is the A-O femoral distractor (Synthes USA, Paoli, PA), which can be placed between the ilium and proximal femur to apply distraction across the hip joint. Although the femoral distractor can be effective, the direction of pull it provides is sometimes not ideal and it can block access to the wound.

Various kinds of reduction forceps are useful for reducing acetabulum fractures. Several different types can grasp the heads of screws, including Farabeuf clamps, adapted to grasp 3.5 mm or 4.5 mm diameter screws, and Jungbleuth forceps (A-O pelvic reduction forceps, Synthes USA, Paoli, PA). Pointed reduction forceps are helpful, as is a ball spike-tipped instrument that can be used for pushing fracture fragments. A femoral head corkscrew or Schantz screw can be inserted into the bone to control rotational displacement (Fig. 18.7).



***Figure 18.7.*** Instruments for acetabulum fracture reduction are shown.

The reduction and fixation usually proceed in a stepwise fashion, with reduction followed by fixation of individual fragments, with progressive assembly of the fracture fragments. Initial lag screw fixation (28,54) usually allows removal of the reduction forceps, followed by more definitive plate fixation (Fig. 18.8) (50). Assess the reduction by visualization and palpation of the accessible fracture lines. It is usually preferable to visualize the final reduction on the articular surface, although sometimes the surgical approach might preclude visualization. The final articular reduction can be inferred to be correct by reduction of the fracture lines on the extraarticular cortex of the innominate bone.



***Figure 18.8.*** Plates and screws used for acetabulum fixation are illustrated.

It is usually helpful to include extraarticular fragments in the reduction and fixation; these fragments are commonly found along the pelvic brim, sciatic notch, and iliac crest. These small fragments often provide an essential guide to the reduction of the larger articular fragments and aid in providing final stability (28). In reducing the initial fragments, it is important to obtain absolutely accurate reduction. Any errors in reduction will be magnified as other fracture fragments are reduced. Preliminary fixation with Kirschner wires may be useful, but we prefer to use interfragmentary screws. Screws work best that are 3.5 mm (or similar sizes) and must be available in lengths exceeding 100 mm. Unless you need to penetrate thick cortical bone, insert these screws without tapping; their purchase in the bone is enhanced by the compression of cancellous bone adjacent to the screw. The AO (Synthes U.S.A., Paoli, PA) oscillating drill attachment is useful to minimize the risk of injury to soft tissues. You need special long, flexible-handled drill guides and depth gauges, and a full set of straight and precontoured 3.5 mm or similar reconstruction plates. Make certain that a set of large fragment screws is available.

## OPERATIVE TECHNIQUES

### *Posterior Wall Fractures*

- Use the Kocher-Langenbeck approach.
- Consider positioning the patient prone for isolated posterior wall fractures with marginal impaction, as well as complex patterns involving the greater sciatic notch. The prone position prevents subluxation of the femoral head, which may complicate reduction.
- Maintain capsular attachments to posterior wall fragments to enhance vascularity of the posterior wall fragment and improve postreduction stability.
- Expose the entire fracture and clean it of hematoma.
- In the case of marginal impaction, elevate the impacted articular surface with underlying cancellous bone. Use the femoral head as a template for reduction of the impacted articular segment. Be certain that the femoral head is in a reduced position (Fig. 18.3*A*) (3,28).
- Stabilize the marginal impaction. Use bone grafting behind the elevated articular surface to fill the void left by impacted bone. (The role of bone graft substitutes in supporting marginal impaction is unclear at this time.) Bone graft is commonly obtained from the ipsilateral greater trochanter (Fig. 18.3*B*, Fig. 18.3*C* and Fig. 18.3*D*).
- Reduce the posterior wall fragments using the acetabular rim and the retroacetabular surface as guides. Consider using screws for provisional interfragmentary fixation.
- Contour a 3.5 mm or similar reconstruction plate to buttress the posterior wall fragment. The plate should curve to parallel the rim of the acetabulum (Fig. 18.9).

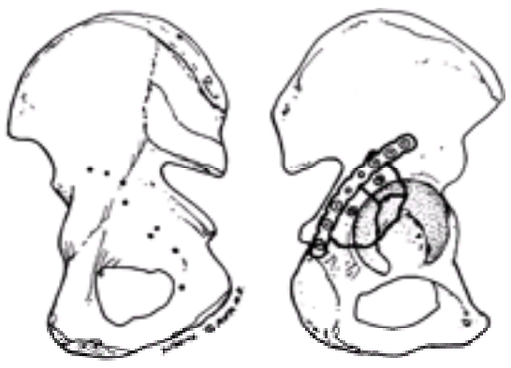

***Figure 18.9.*** Fixation of a posterior wall fracture through the Kocher-Langenbeck approach is shown.

- Undercontour the plate to buttress the posterior wall.
- Apply the first screw into the ischial tuberosity (in an inferior and anterior direction), initially leaving it three to five turns loose.
- Apply a screw superior to the posterior wall fragment, through the plate. Hold the plate and fracture in a reduced position with a ball spike to ensure that the plate is congruent superiorly with the iliac wing.
- Tighten the ischial screw to tension the plate, and buttress the posterior wall fracture.
- Ideally, insert one or two interfragmentary screws through the posterior wall fragment, either through or outside of the plate.
- Use springplates to hold small rim pieces with capsular attachments in place (30). We recommend not excising bony fragments from the capsular attachments, because it is difficult to reattach the hip capsule securely (Fig. 18.10).

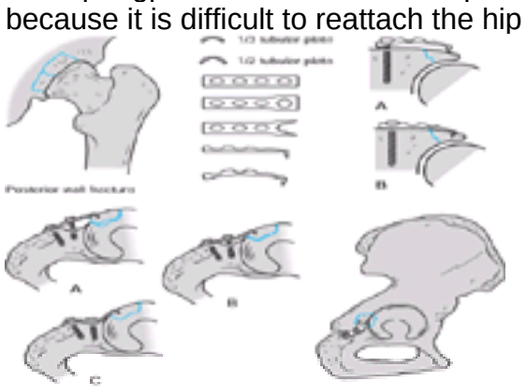

***Figure 18.10.*** Springplates are illustrated. This type of fixation can be used to secure small periarticular fragments. Top Figures: A one-third tubular or reconstruction plate is flattened. The end hole is divided, and the remaining two tines bent. Bottom Figures: The spring effect of applying the plate allows the prongs to stabilize as small fragments. Often these plates can be buttressed with an overlying posterior wall plate, using a common hole to allow a screw to secure both plates at once. (Modified from Mast J, Jakob R, Ganz R. *Planning and Reduction Technique in Fracture Surgery.* Berlin: Springer-Verlag, 1989.)

### *Posterior Column Fractures*

- Position the patient prone and use the Kocher-Langenbeck approach.
- Reduce the fracture with Farabeuf or Jungblueth forceps. Insert a Shantz pin, if necessary, in the ischial tuberosity to control rotation (Fig. 18.11) (28).

***Figure 18.11.*** A pelvic reduction (Jungbleuth) forceps is used to reduce the posterior column fracture line. A Shantz pin in the ischial tuberosity is used to help control rotation of the posterior column fragment.

- Assess reduction, using the fit to the posterior rim and greater sciatic notch as guides. Assess the retroacetabular surface and quadrilateral surface for rotation of the posterior column fragment.
- Obtain fixation with an interfragmentary screw and, if possible, double plates.

***Anterior Column Fractures***

- Position the patient supine and use an ilioinguinal approach.
- Fractures that are incomplete near the iliac crest usually must be completed to gain access to and reduce the joint.
- Initially, reconstruct comminuted fragments at the level of the pelvic brim. These small fragments often provide important keys to reduction of the larger anterior column segment.
- The displacement of the anterior column fragment is typically in external rotation, medial translation, and flexion. Reduction requires that these elements of displacement be addressed. Internal rotation, lateral translation, and a posteriorly directed force usually are required to reduce the anterior column segment. Lateral or distal traction can aid in obtaining the reduction (Fig. 18.12).

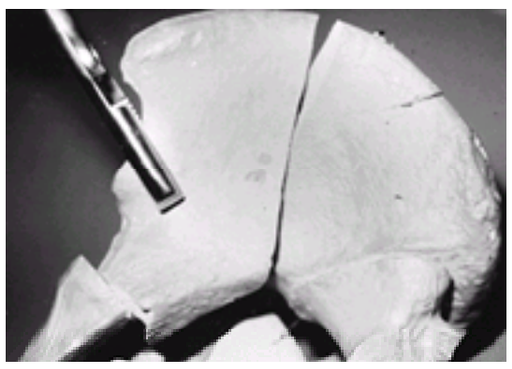

***Figure 18.12.*** Control of the anterior column rotation can be performed with a Farabeuf forceps about the inner spinous notch, as shown. A ball spike or other instrument applied to the inferior iliac fossa in combination with a Farabeuf forceps can provide a force to counteract the deformation and displacements of the anterior column.

- Impaction of the articular surface should be recognized preoperatively. Occasionally, by externally rotating or distracting the anterior column fragment, the surgeon is able to work through the fracture to reduce the impacted fragment. In other cases, you may need to reduce the anterior column first. Then use a tamp or other instrument to reduce the articular surface through a drill hole in the innominate bone, the way you would to reduce the articular surface in a centrally depressed tibial plateau fracture.
- Assess the fracture reduction along the internal iliac fossa and at the pelvic brim. It is often necessary and important to palpate a fracture line that extends posterior to the pelvic brim on the quadrilateral surface. You must be certain that there is no excessive residual medial translation of the anterior column segment.
- For initial fixation, insert interfragmentary screws perpendicular to the fracture plane; insert additional interfragmentary screws or plates at the iliac crest.
- In most cases, neutralize the interfragmentary screws with a reconstruction plate along the pelvic brim.

***Anterior Wall Fractures***

- Position the patient supine and use an ilioinguinal approach.
- It is necessary to mobilize all windows of the ilioinguinal approach.
- Quadrilateral surface comminution is commonly associated with significantly displaced anterior wall fractures.
- Use lateral and distal traction to assist in the reduction.
- It may be impossible to insert interfragmentary screws into the anterior wall directly because of the risks of intraarticular screw placement. Reduce the anterior wall under direct vision and buttress it with a plate on the pelvic brim.
- Quadrilateral surface comminution can often be secured with a lagscrew from the lateral surface of the iliac wing inserted just above the acetabulum into the quadrilateral surface. Leave the screw slightly long (approximately 5 mm) to act as a buttress inside the quadrilateral surface.

***Transverse Fractures***

- For most fracture patterns, position the patient prone and use the Kocher-Langenbeck approach.
- Use a Jungbleuth forceps to distract the fracture. Clean the fracture of hematoma, and reduce the ischiopubic segment.
- Reduce the fracture by levering the ischiopubic segment posteriorly and laterally. Insert a Schantz pin, if needed, in the ischium for rotational control. Avoid excessive compression of the transverse fracture. The transverse fracture is most often an oblique fracture line in the sagittal plane. Excessive compression leads to malreduction with the shearing of the fracture fragments along the fracture line. Place a small angled forceps through the greater sciatic notch, if necessary, to control rotation.
- An alternative reduction technique is to use an antiglide plate on the retroacetabular surface. This technique requires accurate contouring of the plate before application.
- Use the posterior rim and the greater sciatic notch as guides to the reduction. Palpate the retroacetabular surface and quadrilateral surface to assess rotation of the ischiopubic segment.
- Gain initial fixation with a lag screw across the anterior column. Begin the anterior column screw approximately 1 cm lateral to the apex of the greater sciatic notch and run it parallel to the quadrilateral surface. Direct the screw toward the superior pubic ramus. Use fluoroscopy to place this screw.
- If possible, place a posterior column interfragmentary screw as well. At this point, remove the Jungbleuth forceps.
- Apply a posterior plate to tension the fracture posteriorly, as described for posterior wall fractures.
- Note that applying the posterior plate in an undercontoured manner, as described for a posterior wall fracture, before placing the anterior column interfragmentary screw causes a gap in the anterior portion of the transverse fracture line.

***Transverse Fractures with an Associated Posterior Wall Fracture***

- Position the patient prone and use the Kocher-Langenbeck approach.
- Reduce and provisionally stabilize the transverse component first.
- Use the posterior wall fracture as a window to view the articular reduction of the transverse fracture.
- The reduction techniques are similar to those used for a transverse fracture.
- Use anterior and posterior column lag screws or an anterior column lag screw and posterior column plate for provisional fixation.
- Reduce the posterior wall, as described above in the posterior wall fracture section.
- Stabilize the posterior wall with a buttress plate, as described above (Fig. 18.13).

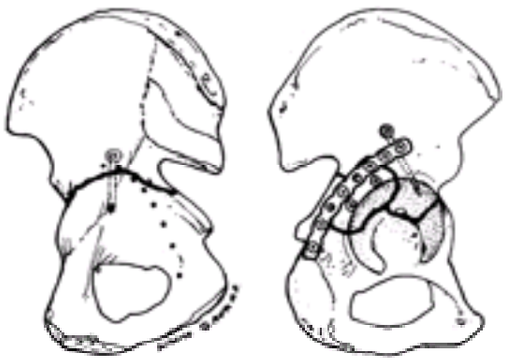

***Figure 18.13.*** Fixation of an associated transverse and posterior fracture through the Kocher-Langenbeck approach.

### *Combined Posterior Column and Posterior Wall Fractures*

- Position the patient prone and use the Kocher-Langenbeck approach.
- Reduce the posterior column segment first, as described above in the posterior column section.
- Provisionally fix the posterior column fragment with an interfragmentary screw or with a plate that will not interfere with the reduction or fixation of the posterior wall fracture.
- Reduce the posterior wall fracture and plate it (see posterior wall section, above).

### *Anterior Column Fracture Plus a Posterior Hemitransverse Fracture*

- Position the patient supine and use an ilioinguinal approach. Fractures with a markedly displaced anterior column component and a displaced low posterior column component may benefit from sequential ilioinguinal and Kocher-Langenbeck approaches.
- First address the anterior column or anterior wall component.
- Reduce the anterior column, as detailed above, in the anterior column section.
- Insert interfragmentary screws in the anterior column to gain initial fixation.
- Often, you can assess the reduction of the posterior column fracture on the quadrilateral surface. The typical displacement is medial translation of the posterior column. Use a large or so-called King Tong clamp or an offset clamp from the AO pelvic reduction instruments (Synthes USA, Paoli, PA) to reduce the quadrilateral surface segment. Place one tine on the external surface of the iliac wing, and one tine on the quadrilateral surface to provide a lateral displacement force through the posterior hemitransverse component.
- Use posterior column screws to fix the posterior hemitransverse fracture. Insert the screws through the most lateral window of the ilioinguinal approach, parallel to the greater sciatic notch and contained within the posterior column. Use the **C**-arm fluoroscope to confirm position; obtain an iliac oblique view.
- Neutralize the entire construct with a plate on the anterior pelvic brim (Fig. 18.14).

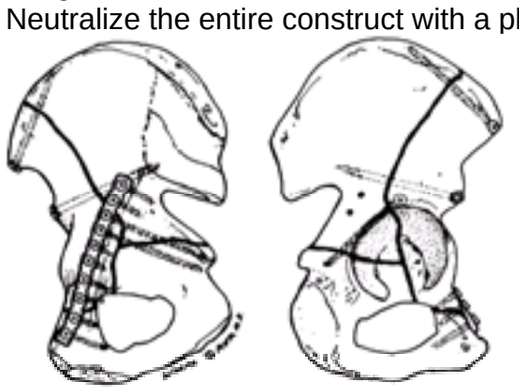

***Figure 18.14.*** Fixation of an associated anterior column and posterior hemitransverse fracture through the ilioinguinal approach.

### **T**-*type Fracture*

- Significant displacement of both anterior and posterior column segments of the **T**-type fracture are especially difficult to manage. Displaced transtectal **T**-shaped fractures can be managed through an extended iliofemoral approach. Significant displacement of juxtatectal and infratectal **T** shapes may require sequential Kocher-Langenbeck and ilioinguinal approaches. In the situation in which there is significant displacement of both anterior and posterior portions of the **T**-shaped fracture, address the less comminuted portions first (Fig. 18.15).

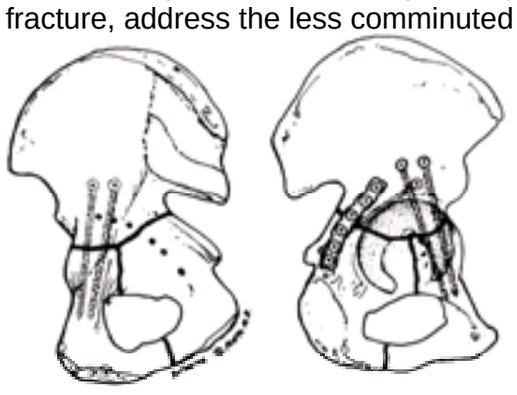

***Figure 18.15.*** Fixation of a **T**-shaped fracture through the extended iliofemoral approach.

- Most commonly, the **T**-shaped fracture involves significant displacement of either the anterior or posterior column component; the other is minimally displaced. In this case, a single surgical approach is usually adequate.
- Carefully inspect the level of the fracture. It is often possible to treat a low anterior column fracture component in a **T** pattern (below the superior 10 mm CT subchondral arc) without surgery, addressing only the posterior column component of the injury.
- Reduce and fix the anterior and posterior column components, as described in the sections on the anterior and posterior columns, above.

### *Both-column Fractures*

- In the majority of instances of both-column fractures, position the patient supine and use the ilioinguinal approach. Approximately one quarter to one third of cases require an extended iliofemoral approach. The ilioinguinal is preferable, when possible, because it involves minimal stripping of the outer aspect of the innominate bone, which decreases the postoperative recovery time and decreases the amount of heterotopic ossification postoperatively.
- When choosing the ilioinguinal approach, first reduce the anterior column and fix it provisionally.
- Lateral traction is frequently necessary to lateralize the femoral head before the anterior column can be adequately reduced.
- The anterior column fracture is reduced and internally fixed, as described in the section on the anterior column.
- Reduce the posterior column segment through the second window of the ilioinguinal approach. The posterior column is typically medially displaced, with occasional distal translation. Reduce the fracture with a reduction forceps, placing one tine on the quadrilateral surface, and the other tine on the outer aspect of the iliac wing. Assess the reduction both visually and by palpating the quadrilateral surface and the contour of the greater sciatic notch (Fig. 18.16).

***Figure 18.16.*** Reduction of the posterior column component of a both-column fracture through the ilioinguinal approach is shown. The posterior column is visualized through the second window of the approach. The reduction is performed by lateralizing the medially displaced posterior column following provisional fixation of the anterior column.

- To fix the posterior column, insert lag screws from the internal iliac fossa, near the pelvic brim, into the posterior column. Use an image intensifier to confirm reduction and screw placement.
- When choosing the extended iliofemoral approach, position the patient in the lateral position on the fracture table. The extended iliofemoral approach allows the surgeon to perform a nearly circumferential capsulotomy (avoiding transsection of the capsular attachments to the posterior wall fragments) and provides the most commanding view of the articular surface.
- In most cases, reduce the anterior column and fix it initially to the intact portion of the ilium.
- Occasionally, if the posterior column segment is large and involves a portion of the sacroiliac joint, it is often easiest to proceed with reduction of the posterior column first.
- In most cases, use a two-screw technique to reduce the fragment. Use the Farabeuf forceps to grasp the screw left prominent in each fracture fragment.
- Following reduction, fix the posterior wall and column as described in previous sections (Fig. 18.17).

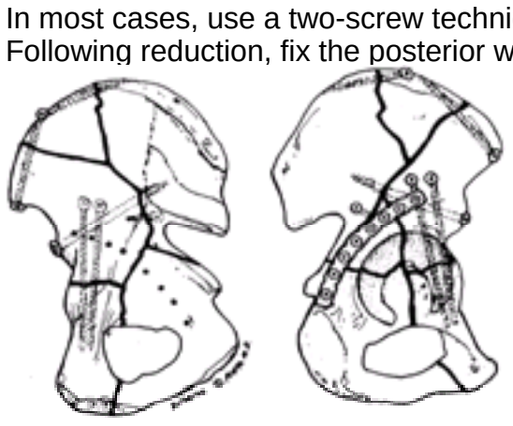

***Figure 18.17.*** Fixation of a both-column fracture through the extended iliofemoral approach.

## POSTOPERATIVE CARE

At the completion of the operation, obtain at least an AP pelvis radiograph in the operating room. The iliac oblique and obturator oblique views can be obtained in the operating room or later. Following gait training, and prior to discharge, obtain another AP pelvic radiograph to confirm that loss of reduction has not occurred during ambulation. Obtain a single AP pelvic radiograph at each follow-up examination.

Place the patient on bed rest for the first postoperative day, or longer if you have used the extended iliofemoral approach. Have a physical therapist institute passive motion of the hip and extremity. Alternatively, use the continuous passive motion machine. At 3 to 7 days after surgery, pain has usually subsided enough so that the patient can start gait training. Allow up to 15 kg of weight bearing. Encourage the patient to ambulate with a step-through gait and a heel-toe walking motion, using crutches or a walker.

Instruct the patient in active flexion, abduction, and extension exercises to be performed at the hip while standing (active abduction and passive adduction are prohibited for the first 4 weeks with the extended iliofemoral approach). Continue limited weight bearing for 8 weeks postoperatively. At that point, the patient can bear weight to tolerance using external support only, as needed. If the fracture has been reduced accurately and ectopic bone does not develop, the range of motion can be expected to return to about 90% of normal. Physical therapy is therefore directed primarily toward regaining muscle strength at the hip, particularly abductor muscle strength (53).

### *Results of Surgery*

The goal of surgical treatment of acetabular fractures is to restore the normal shape and contour of the acetabular or articular surface accurately and thereby to restore the hip joint's normal capacity. The results of surgical treatment of acetabular fractures are generally reported on those who underwent surgery within the first 3 weeks after injury and those who waited longer than 3 weeks. Letournel observed that in delayed surgeries, fractures were more difficult to reduce and had less favorable outcomes (28).

Letournel reported 569 acetabular fractures that were surgically repaired within 21 days of injury (28). In 418 (73.5%) cases (Table 18.5), articular reductions were reported as perfect, implying that the articular surface and radiologic landmarks of the acetabulum were returned to normal alignment on the AP pelvis and 45° oblique views of the pelvis. Osteoarthritis was reported in 97 cases (23%), 43 (10.2%) had a perfect reduction, and 54 (12.9%) had an imperfect reduction (Table 18.6). Of 492 cases available for a minimum of 2 years of follow-up, 366 had a perfect reduction. An excellent or very good clinical grade applied in 283 (77%) cases, and 316 (86%) had a good, very good, or excellent result. Of 126 imperfect reductions (including secondary congruence), 24 (19%) had an excellent clinical grade and 81 (64%) had a good, very good, or excellent result (28).

| | *Perfect reductions* | *Imperfect reductions* | *Total* |
|---|---|---|---|
| Posterior wall | 119 | 8 | 127 |
| Posterior column | 10 | 3 | 13 |
| Anterior wall | 7 | 2 | 9 |
| Anterior column | 19 | 3 | 22 |
| Transverse | 15 | 6 | 21 |
| T-shaped | 21 | 9 | 30 |
| Transverse + posterior wall | 79 | 38 | 117 |
| Posterior column + posterior wall | 18 | 2 | 20 |
| Anterior column + posterior hemitransverse | 34 | 16 | 50 |
| Both columns | 96 | 62 | 158 |
| Total | | | |

(From Letournel E. *Fractures of the Acetabulum*. Berlin: Springer-Verlag, 1993, with permission.)

***Table 18.5. Accuracy of Reduction by Fracture Type for 567 Acetabular Fractures Surgically Repaired within 21 Days of Injury***

| | *Perfect reduction + OA* | *Imperfect reduction + OA* |
|---|---|---|
| Posterior wall | 19 | 3 |
| Posterior column | 0 | 0 |
| Anterior wall | 1 | 1 |
| Anterior column | 1 | 1 |
| Transverse | 0 | 2 |
| T-shaped | 0 | 4 |
| Transverse and posterior wall | 12 | 17 |
| Posterior column and posterior wall | 3 | 0 |
| Anterior column and posterior hemitransverse | 1 | 3 |
| Both-column | 6 | 21 |

(From Letournel E. Fractures of the Acetabulum. Berlin: Springer-Verlag, 1993, with permission.)

***Table 18.6. Number of Cases Developing Osteoarthritis (OA) Versus Accuracy of Reduction by Fracture Type for 492 Acetabular Fractures Surgically Treated within 21 Days of Injury***

At 20 years (or longer) of follow-up, Letournel reported that 28 of 35 cases initially graded excellent remained excellent (40 of 75 cases were lost to follow-up) (28). The outcome of fractures followed for more than 20 years showed that none of three very good results and four of eight good results maintained the initial clinical grade. Letournel also noted that patients with initially excellent clinical results who had developed an asymptomatic collarette of osteophytes about the femoral head had an increased incidence of osteoarthritis, 22% and 53% at 20- and 25-year follow-up, respectively (28).

Matta has reported on 262 displaced acetabular fractures treated surgically within 21 days of injury and followed for 2 to 13 years (38). Reductions were graded on the maximum articular displacement seen on the AP pelvis and 45° oblique radiographic views of the pelvis. Reductions were categorized as anatomic: 0 to 1 mm maximal displacement; imperfect: 2 to 3 mm maximal displacement; and bad: more than 3 mm maximal displacement. Clinical outcome was determined by a modified d'Aubigne and Postel hip score (Table 18.7). The quality of reduction per fracture type is listed in Table 18.8.

| | | |
|---|---|---|
| Pain subscale | | |
| 6 — No pain | | |
| 5 — Slight or occasional | | |
| 4 — Pain after ambulation, resolves with rest | | |
| 3 — Moderately severe, permits ambulation | | |
| 2 — Severe, prevents ambulation | | |
| Ambulation subscale | | |
| 6 — Normal | | |
| 5 — Slight limp, no cane | | |
| 4 — Long distance with cane or crutch | | |
| 3 — Limited even with support | | |
| 2 — Very limited | | |
| 1 — Immobilization | | |
| Range of motion subscale | *Hip#1* | *Hip#2* |
| Flexion-extension | | |
| Abduction | | |
| Adduction | | |
| Internal rotation (prone) | | |
| External rotation (prone) | | |
| Total ROM | | |
| Percent of range of motion = (Total ROM Pulsed/Total ROM Normal) × 100 | | |
| 6 — 95–100% | | |
| 5 — 80–94% | | |
| 4 — 70–80% | | |
| 3 — 60–70% | | |
| 2 — 50–60% | | |
| 1 — <50% | | |
| Clinical grade = total points (pain + ambulation + ROM) | | |
| 18 — Excellent | | |
| 15–17 — Good | | |
| 10–14 — Fair | | |
| <10 — Poor | | |

***Table 18.7. Modified d'Aubigne and Postel Clinical Grading System***

| | *Anatomic reductions* | *Imperfect reductions* | *Bad reductions* |
|---|---|---|---|
| Posterior wall | 21 | — | — |
| Posterior column | 7 | 1 | — |
| Anterior wall | 3 | — | — |
| Anterior column | 12 | — | — |
| Transverse | 8 | 1 | — |
| T-shaped | 16 | 10 | 3 |
| Transverse and posterior wall | 48 | 10 | 2 |
| Posterior column and posterior wall | 10 | — | — |
| Anterior column and posterior hemitransverse | 7 | 6 | 2 |
| Both-column | 52 | 24 | 9 |
| Total | 185 | 52 | 18 |

(From Matta JM. Fractures of the Acetabulum: Reduction Accuracy and Clinical Results of Patients Operated within Three Weeks of Injury. *J Bone Joint Surg* 1996;78A:1632, with permission.)

***Table 18.8. Accuracy of Reduction by Fracture Type for Acetabular Fractures Treated Surgically within 21 Days of Injury***

Of these patients, 199 (75%) had good or excellent clinical results (Table 18.9) and 92% of excellent and good clinical results were also graded excellent or good radiologically with no or minimal changes of osteoarthritis (38). Anatomic reductions ($p$ = .002) paired with a congruent relationship of the femoral head to the superior acetabulum ($p$ = .04) were associated with a good or excellent outcome (38). Age greater than 40 years and increasing complexity of the fracture decreased the likelihood of a perfect reduction. Anatomic reductions in patients over the age of 40 years, however, are not associated with a decreased incidence of good or excellent clinical results. Kaplan-Meyer survivorship analysis of these data indicates that an excellent radiographic appearance of the hip joints at 2 years after surgery indicates an 85% likelihood of excellent hip function at 10 years after fracture (56).

| | *E* | *G* | *F* | *P* |
|---|---|---|---|---|
| Posterior wall | 9 | 6 | — | 7 |
| Posterior column | 2 | 3 | 2 | 1 |
| Anterior wall | 3 | 1 | 1 | — |
| Anterior column | 9 | 1 | 1 | 1 |
| Transverse | 5 | 3 | — | 1 |
| T-shaped | 6 | 18 | 2 | 5 |
| Transverse and posterior wall | 23 | 21 | 4 | 13 |
| Posterior column and posterior wall | 7 | 2 | — | 1 |
| Anterior column and posterior hemitransverse | 8 | 5 | 1 | 1 |
| Both-column | 36 | 33 | 9 | 12 |
| Total | 104 | 93 | 21 | 42 |

* Clinical results with a minimum of 2 years of follow-up are E, excellent; G, good; F, fair; and P, poor.
(From Matta JM. Fractures of the Acetabulum: Reduction Accuracy and Clinical Results of Patients Operated within Three Weeks of Injury. *J Bone Joint Surg* 1996;78A:1632, with permission.)

***Table 18.9. Clinical Result (Modified d'Aubigne and Postel Score) by Fracture Type for Acetabular Fractures Treated Surgically within 21 Days of Injury****

Other authors have reported less favorable results following surgical treatment of acetabular fractures, with up to 43% incidence of poor results (21,26,68). These reports typically represent the outcomes of patients at a single institution whose operations were performed by a number of different surgeons. As a result, the statistics cannot be compared with any one surgeon's experience with these complex injuries. The results of Letournel and Matta emphasize the correlation of accuracy of articular restoration with improved clinical outcome (28,38). Mayo has reported similar results (39).

These results reflect the work of surgeons with a dedicated interest in the treatment of acetabular fractures. The importance of the knowledge, interest, and experience of the operating surgeon in the treatment of these complex injuries cannot be overemphasized. We disagree with the philosophy of approaching acetabular fracture reconstruction as restoration of bone stock for a future total hip replacement. Inherent in this way of thinking is the assumption that the development of osteoarthritis is inevitable. This misconception may lead some surgeons to accept significant malreductions of the articular surface, leading to the development of unnecessary

disability caused by osteoarthritis of the hip. We believe the goal of obtaining a perfect reduction must be in the mindset of the operating surgeon as she undertakes reduction and fixation of acetabular fractures (54).

Although not all acetabular fractures have a good outcome, it is difficult to predict which fractures will have a poor outcome following open reduction and internal fixation. The long-term follow-up data of Letournel and Matta suggest that a minority of patients will require further hip surgery following acetabular fracture reconstruction (28,38). We do not recommend total hip arthroplasty as a primary treatment for fractures of the acetabulum.

Displaced acetabular fractures treated surgically later than 21 days after injury are challenging to even the most experienced surgeons. There is increased difficulty in mobilizing fracture fragments and reducing the articular surface. Johnson et al. reported on 188 fractures treated surgically between 21 and 120 days after injury (24). There was an increased incidence of sciatic nerve palsies (12%) and osteonecrosis of the femoral head (13%), with 50% of the osteonecrosis occurring with persistent dislocation for more than 3 weeks. Overall, there was a 65% incidence of good or excellent results. The poorest results occurred in simple anterior wall fractures, simple posterior wall fractures, associated transverse and posterior wall fractures, and **T**-shaped fractures.

### COMPLICATIONS

The most common serious complications following surgical treatment of an acetabulum fracture include infection of the surgical wound, iatrogenic sciatic nerve palsy, periarticular ectopic bone formation, and thromboembolic complications. Posttraumatic arthritis is the most common late complication (28).

If the patient is in generally good condition and has no associated injuries, the risk of infection should be no higher than for other types of major hip surgery. Most patients with acetabular fractures, however, have associated injuries, including injuries to the abdominal and pelvic viscera, chest, or the extremities. A bladder rupture or a bowel, rectal, or vaginal injury can increase the chance of infection in the surgical wound and can influence the indications for surgery.

A relatively common problem associated with acetabular fracture is local soft-tissue injury, including local wounds, abrasions, and a closed degloving injury (17). With the closed degloving injury, the subcutaneous tissue is torn away from the underlying fascia. There is a significant cavity that contains hematoma and liquefied fat between the subcutaneous tissue and deep fascia. The degloving injury occurs as a result of the blunt trauma that has caused the acetabular fracture. When this lesion is present over the greater trochanter, it is known as a Morel-Lavalle lesion (17). Drain and debride these areas before or at the start of surgery to decrease the risk of infection. After drainage and debridement, it is advisable to leave this area open through the surgical incision or a separate incision. Dressing changes and wound packing are sometimes necessary over a prolonged period, until the wound has closed secondarily or with delayed primary closure. In our experience, primary excision of the necrotic fat and immediate closure over drainage tubes has been unsuccessful.

Infection of the surgical wound does remain a concern, even without associated injuries. There is an increased risk of postoperative hematoma formation in the large wounds that are necessary for acetabular surgery. Make liberal use of suction drains. Good hemostasis at the time of wound closure is essential. During the procedure, keep the large areas of exposed soft tissue moist and irrigated frequently with antibiotic solution. It is often helpful to place moist sponges over exposed soft tissue to prevent desiccation.

Always strive to preserve soft-tissue pedicles to all bone fragments to maintain the blood supply to the bone. If a fragment is devascularized, it generally revascularizes rapidly, as long as no infection develops. In the presence of infection, however, bacteria rapidly colonize an avascular fragment, and it will usually need to be debrided and excised. Some bloody drainage can seep from the wound for the first 1 or 2 days after surgery, but it should subside rapidly. It is not uncommon for a clear, yellow, serous drainage to be present for as long as 10 days after surgery without infection being present. If the wound has been benign for a number of days, and bloody or cloudy yellowish drainage then occurs, the patient should be returned to the operating room immediately for irrigation and debridement of the wound. If a wound hematoma is present, the amount of hematoma is usually much greater than initially suspected, and surgical drainage is indicated.

If you suspect infection, do not wait for the results of culture of a wound aspiration but proceed with reopening the wound. If it is later found that no infection was present, little harm has been done. If an infection is in fact present at the time of the earliest clinical suspicion, then you have acted properly by treating the infection expeditiously. Hip aspiration may be particularly helpful in evaluating fractures in which the surgical approach has been ilioinguinal.

If the infection is extraarticular, it can probably be controlled successfully and the functional result will not be impaired. In the case of an intraarticular infection, however, the cartilage of the joint is almost invariably destroyed and hip function is significantly impaired.

Iatrogenic sciatic nerve palsy may be caused by too vigorous or prolonged retraction of the nerve (20,28). This event occurs primarily with the Kocher-Langenbeck approach and mainly involves the peroneal branch of the sciatic nerve (28). There is also a small chance of a stretch injury to the sciatic nerve with the extended iliofemoral approach and a slight possibility of injuring the femoral nerve by stretch injury during the ilioinguinal approach, but these outcomes are unusual. The surgeon must constantly monitor the force and duration of pull that surgical assistants place on retractors in the vicinity of the sciatic nerve. It is helpful to keep the patient's knee flexed at least 60° and preferably at 90°, and the hip extended whenever the Kocher-Langenbeck or extended iliofemoral approach is used (28). Several authors have reported using neurologic monitoring with somatosensory evoked potentials or electromyography (20,44,65). This technique is not available in every center. If a nerve palsy develops, it is best treated with an ankle-foot orthosis. Iatrogenic nerve palsies are often a form of axonotmesis (13). Electromyography can be helpful in determining reinnervation of affected muscle groups.

Ectopic bone formation is influenced by the surgical approach and probably also by the initial muscle trauma suffered by the patient (16,45,46). The combination of the two injuries creates an inflammatory response that triggers the formation of bone. Several factors have been correlated with heterotopic ossification: the extended iliofemoral approach, multiple (two or more) findings at time of surgery, **T**-shaped fractures, associated head or chest trauma, and male sex (16,26,45,66).

Ectopic bone formation, or heterotopic ossification (HO), most commonly occurs with the lateral exposure of the innominate bone. The incidence of significant ectopic bone formation is highest with the extended iliofemoral approach, followed by the Kocher-Langenbeck approach; it is almost nonexistent with the ilioinguinal approach (28). Prevention of ectopic bone formation should, in part, be directed toward choosing the ilioinguinal approach whenever possible and limiting muscle trauma during surgery.

Indomethacin given in a dose of 25 mg tid perioperatively, and for several months following surgery, has been reported to be helpful in decreasing the incidence and extent of ectopic bone formation (46). A prospective randomized series comparing indomethacin to no prophylaxis, however, showed no difference in the incidence of HO (31). Postoperative radiation has been shown to be effective in decreasing the incidence of ectopic bone formation, but the long-term carcinogenic effects are unknown (42). The combination of indomethacin and postoperative radiation has been reported to be very effective in preventing nearly all HO (47). The risk of HO may be reduced by avoiding elevation of the periosteum, minimizing muscle trauma, preventing hematomas, and by debridement of devitalized tissue following completion of internal fixation of the acetabular fracture.

Patients develop a significant amount of ectopic bone, as seen on radiographs, but muscle function and range of motion may remain satisfactory. Radiographic evaluation should include AP and 45° oblique views of the pelvis (48). In other patients, rotation and abduction are limited; if patients can extend the hip to the neutral position and have flexion of at least 90°, however, they might be happy with the result and have no need for further surgery. CT is important to locate HO about the hip when excision is being considered (54).

Whenever possible, surgery for excision of ectopic bone should be delayed for 6 to 12 months following injury. If it is performed at this time, there is usually no problem with recurrence and motion can be expected to return to more than 80% of normal, assuming no arthritis is present. Some patients show a spontaneous regression of ectopic bone over several years. If the indications for excision of the bone are equivocal, it might be best to wait, with the hope of some spontaneous regression of the ectopic bone with improvement of motion. See Chapter 124 for more details.

There is significant potential for deep venous thrombosis (DVT) and pulmonary embolism with fractures of the acetabulum (49,67). A 33% incidence of preoperative proximal DVT detected with magnetic resonance imaging (MRI) venography has been reported (49). We normally use pneumatic compression boots on both lower extremities from the time of admission until the patient is fully ambulatory. In older and high-risk patients, partial anticoagulation is begun with heparin following surgery. Patients are discharged to home with warfarin anticoagulation until they are ambulating actively, typically for 3 to 4 weeks following surgery (14). The level of anticoagulation with warfarin is maintained at about 1.5 times normal, an international ratio (INR) of 2 to 3. Although the potential for thromboembolic complications is always present, the surgeon must be cautious about too much anticoagulation, because a large-wound hematoma can have a devastating effect on the patient if a deep infection in the hip results.

## HIP DISLOCATIONS AND FRACTURES OF THE FEMORAL HEAD

### MECHANISM OF INJURY AND CLASSIFICATION

Dislocation of the femoral head produces a significant trauma to the hip joint. Motor vehicle accidents or other high-energy traumas account for the majority of hip dislocations. Athletic injuries, falls, and other causes are less common. Hip dislocations are generally categorized by the direction of dislocation of the femoral head, either posterior or anterior. Posterior dislocation accounts for approximately 90% of all traumatic hip dislocations (12). Posterior dislocation is typically caused by axial load on the femoral shaft with the hip in the position of flexion and adduction. The most commonly cited classification is that of Thompson and Epstein (Table 18.10) (12). Acetabular fractures associated with posterior hip dislocations have been postulated to result from impact of the femoral head on the hip with the thigh in a flexed and adducted position. Epstein reported that fractures of the femoral head occurred in 9% of posterior hip dislocations (12).

| | |
|---|---|
| Type I | A pure hip dislocation without fracture |
| Type II | Posterior dislocation with a large single fracture of the posterior acetabular rim |
| Type III | Posterior dislocation with a comminuted fracture of the rim of the acetabulum |
| Type IV | Posterior dislocation with fracture of the acetabular rim and floor (acetabulum fracture other than posterior wall pattern) |
| Type V | Posterior dislocation with fracture of the femoral head, plus other fractures |

***Table 18.10. The Classification System of Posterior Dislocations of Thompson and Epstein (11).***

Anterior dislocations account for 10% of all hip dislocations (12). Anterior dislocations can be divided into pubic or obturator dislocations. Well over 90% of all anterior dislocations are obturator in nature. We have not personally managed a patient with a pubic anterior dislocation.

Anterior dislocations are associated with a higher incidence of femoral head fracture (4,9). DeLee reported 12 of 22 patients with anterior hip dislocations who sustained femoral head fractures (9). The majority of these cases were impaction fractures of the femoral head. The articular impaction presumably resulted from impingement of the femoral head against the anterior rim of the acetabulum as it rebounded against the anterior rim of the acetabulum. Anterior dislocation typically occurs when the hip is overabducted and overextended.

Pipkin proposed a classification describing fractures of the femoral head associated with hip dislocation (Fig. 18.18) (55). Pipkin's classification is commonly used with or without a hip dislocation when there is a displaced osteochondral fragment of the femoral head. Brumback et al. proposed a classification system that separates anterior dislocations of the hip with either a femoral head impaction fracture or transchondral loss into a distinct group (4). No uniform system exists to quantify femoral head impaction following hip dislocation.

## EVALUATION

### *Posterior Dislocations*

Hip dislocations frequently accompany a wide spectrum of injury, ranging from isolated trauma to significant polytrauma. The classic position of the lower extremity with a posterior hip dislocation is one of shortening of the involved extremity, with flexion, adduction, and internal rotation of the extremity at the hip (Fig. 18.19) (1,2,12). This classic position may not be seen if a significant acetabular fracture or fracture of the femoral shaft coexists with the hip dislocation. Injury to the sciatic nerve has been reported to occur in approximately 10% of all hip dislocations (12). The involvement of the sciatic nerve may be partial or complete. More severe involvement of the peroneal division of the sciatic nerve is typical. A detailed neurologic exam, which may be difficult to obtain in the emergency setting, is important. Carefully examine the patient's neurologic status both before and after reduction of the hip.

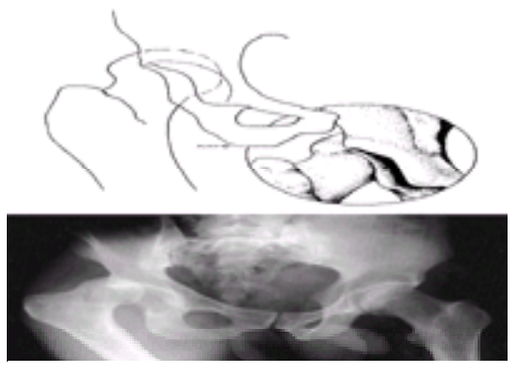

***Figure 18.19.*** Posterior dislocation of the hip is shown. The adducted and internally rotated position of the femur is classic for this type of dislocation. The overlapped appearance of the femoral head and the roof of the acetabulum on the radiograph is pathognomonic for dislocation of the femoral head.

### *Anterior Dislocations of the Hip*

In anterior dislocations of the hip, the femoral head is displaced anteriorly and inferior to the acetabulum in the region of the obturator foramen, with the extremity held in extension, wide abduction, and external rotation at the hip (Fig. 18.20) (12). Carefully examine for possible injury to the femoral artery and femoral nerve.

***Figure 18.20.*** Anterior dislocation of the hip is shown in these drawings. The obturator (inferior) presentation shown is by far the most common pattern. It is characterized by abduction and external rotation of the femur. Impaction fractures of the femoral head are common with this type of dislocation.

### *Radiographic Evaluation*

Initial evaluation of patients with suspected hip dislocation requires an AP view of the pelvis. The majority of hip dislocations can be diagnosed on this view. The

addition of a cross-table lateral view should confirm an anterior or posterior dislocation. Following reduction of the hip dislocation, repeat the AP radiograph of the pelvis and lateral view of the hip, looking for evidence of incongruent reduction of the femoral head. If there is a question of an acetabular fracture, 45° oblique views of the pelvis (Judet views) are indicated (54). CT is helpful for evaluation of residual incongruence between the femoral head and the acetabulum, evaluation of acetabular fractures identifying femoral head fractures, and identification of retained osteochondral fragments within the hip joint (15).

**REDUCTION OF THE DISLOCATION**

Once the diagnosis of dislocation of the femoral head is established, perform reduction of the hip as soon as possible, ideally with complete muscular relaxation under a regional or general anesthesia to minimize the risk of chondral injury to cartilage of the femoral head. In addition, it is possible to examine the hip while the patient is still under anesthesia to assess the stability following reduction. Such assessment may aid in deciding postoperative care.

Reduction of the hip can also be accomplished in the emergency room setting with appropriate intravenous sedation. Use short-acting paralyzing agents with caution and only when appropriate airway management is available. Delay in reduction of hip dislocations has been shown to increase the incidence of avascular necrosis. Yue et al. reported that posterior dislocation of the hip causes kinking of the external iliac artery over the pelvic brim, impeding flow through the medial femoral circumflex artery in cadaver specimens (69). Perform reduction of the femoral head early, ideally within 6 hours of injury, to minimize the risk of avascular necrosis (12,22).

Carefully evaluate the initial radiographs to look for associated fractures of the femoral head and femoral neck. When these associated fractures are present, the reduction should be accomplished under general anesthesia, preferably with image intensifier control to ensure that significant displacement of the femoral neck fracture does not occur. In selected cases, fixation of the femoral neck fracture before reduction may be necessary.

Several methods of reduction of a dislocated hip have been described that involve traction in line with the existing deformity. For posterior dislocations, the Allis and Bigelow maneuvers are performed with the patient supine; an assistant provides countertraction to the pelvic ring (Fig. 18.21) (1,2). The Stimpson maneuver, performed with the patient prone, eliminates the need for countertraction on the pelvis. Other injuries and the need for sedation may contraindicate the prone position (59).

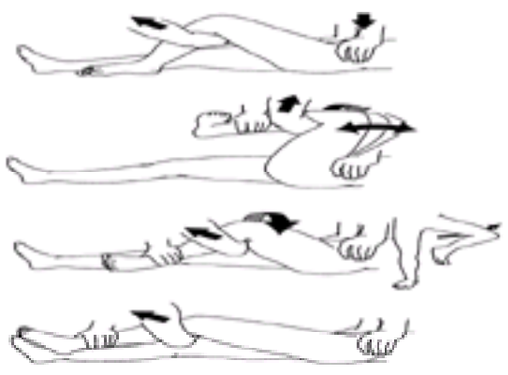

***Figure 18.21.*** The Bigelow reduction maneuver for a posterior dislocation of the hip.

Reduction of a posterior dislocation requires traction on the involved hip in a flexed and adducted position. Gentle rotational oscillation of the hip may assist in easing it over the acetabular rim into the socket.

The same maneuver can be used with the patient in the lateral decubitus position. Use of a sheet around the pelvis for countertraction provides the surgeon added mechanical advantage. Once the femoral head has been located, the hip is easily abducted and extended accompanied by restoration of leg lengths and external rotation of the hip. In rare instances, the dislocation may be irreducible and requires open reduction through a posterior approach (5).

Anterior hip dislocations may also be reduced by applying traction in line with the deformity in abduction, with progressive flexion of the hip and neutral rotation (12). This technique allows the femoral head to move superiorly and posteriorly into the acetabulum. Rarely it may be converted, temporarily, to a posterior dislocated position before location of the hip.

Following relocation of the hip, obtain an AP radiograph of the pelvis and look for incongruence between the femoral head and acetabulum, as well as for fractures of the femoral head and femoral neck, and retained osteochondral fragments. Obtain a cross-table lateral view of the hip if there is a question about the adequacy of the reduction or of a femoral neck fracture. Persistent incongruence of the hip joint with retained osteochondral fragments requires open reduction and removal of the intraarticular debris. CT can also be used to assess the hip joint for incongruence and retained osteochondral fragments following reduction of a hip dislocation (7,51).

Routine use of CT following hip dislocation is controversial (15). CT is indicated, however, whenever the surgeon suspects the presence of a significant retained osteochondral fragment or other foreign body within the hip joint. Occasionally, small osteochondral fragments are seen in the acetabular fossa which are attached to the ligamentum teres. When these osteochondral fragments are present, AP and Judet views of the hip, CT, or both are indicated to assess the femoral head for a congruent reduction. There is no need for surgical intervention as long as a congruent reduction between the femoral head and acetabulum is present (54). Perform neurovascular examination immediately after reduction.

**POSTREDUCTION CARE**

Epstein reported a series of hip dislocations in which skeletal traction was used following reduction of the femoral head (11). More recent series have demonstrated similar results without postreduction skeletal traction (57). Several authors have speculated that postreduction traction would provide the benefit of decompressing the injured hyaline cartilage while the torn capsule heals (12,57). This observation, however, has not been borne out in clinical results.

After reducing the femoral head, examine the hip for stability by gently flexing the hip from 0° to 90° with the hip in neutral rotation. Those patients who have a stable hip to 90° of hip flexion must avoid excessive flexion, adduction, and internal rotation of the hip and can be permitted to walk with crutches with limited weight bearing for 4 to 7 days after reduction. Weight bearing can be gradually increased after that point. Continue these precautions for at least 6 weeks after dislocation as healing of the soft tissues takes place.

If examination of the hip dislocation demonstrates instability between 45° and 90° of flexion, protect against dislocation with an orthosis. Use either a knee mobilizer or hip abduction brace for 6 weeks and allow the patient to walk using crutches as described above. If the hip is unstable at 45° or less of flexion, we recommend skeletal traction for approximately 3 weeks postoperatively, followed by bracing or crutches as described above.

Hip dislocations associated with fractures of the acetabulum require treatment of the acetabular fracture, as outlined in the first part of this chapter. Hip dislocations associated with femoral neck fractures are, fortunately, a rare occurrence. Treatment of these injuries requires careful reduction of the hip under image intensification control. Make every attempt to ensure that the femoral neck is not displaced during reduction. If there is any question regarding displacement of the femoral neck during the attempt at reduction, fixate the femoral neck before performing open or closed reduction of the femoral head dislocation. Place a Schantz pin from the lateral cortex up into the femoral head, attached to a **T**-handle to reduce the shear forces across the femoral neck and aid the reduction. Hip dislocations with a displaced femoral neck fracture are an absolute indication for open reduction of the femoral neck fracture and femoral head dislocation.

**FRACTURES OF THE FEMORAL HEAD**

Pipkin type I fractures of the femoral head are the most common type of femoral head fracture (Fig. 18.18) (55). It is important to characterize the inferior femoral head fragment and fracture line on plain films. Moed et al. described the use of CT to determine the plane of inclination of the femoral head fracture relative to the sagittal plane (43). Plain radiographs taken with the x-ray beam oriented at this inclination were shown to provide good evaluation of the fracture and subsequent healing.

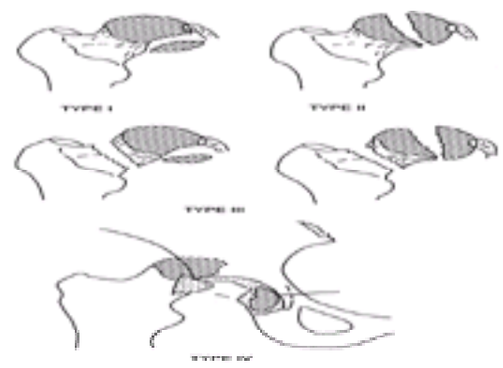

***Figure 18.18.*** The figure shows the classification of femoral head fractures, as described by Pipkin type I, a fracture of the femoral head below the fovea. Type II is a fracture of the femoral head that extends above the fovea. Type III is a fracture of the femoral head, either type I or type II, with an associated fracture of the femoral neck, and type IV is a fracture of the femoral head, either type I or type II, with an associated acetabulum fracture.

Pipkin type I fractures that are reduced anatomically may be successfully managed in postoperative traction or, on occasion, in pelvic-hip orthoses for 6 weeks (22,29). Displaced Pipkin type I fragments treated nonsurgically have poor clinical outcomes (11,22,29). Excise comminuted fragments. Large fragments without comminution can be successfully treated with open reduction and internal fixation. Epstein (10) recommended a posterior approach for open reduction and internal fixation of these fractures, but recently Swionkowski et al. and other authors (8,29,60) have advocated an anterior approach. Typically a Smith-Peterson approach or direct anterior approach to the hip can be used with an arthrotomy along the acetabular rim, with a **T** extension in the anterior hip capsule. These fragments can be stabilized with various small fragment screws countersunk below the articular cartilage or with absorbable screws (Fig. 18.22).

***Figure 18.22.*** **A:** An anteroposterior (AP) view of the left hip demonstrates a dislocation of the femoral head with a femoral head fracture. **B:** An iliac-oblique view of the involved hip after closed reduction. This demonstrates continued subluxation of the femoral head, and displacement of the inferior Pipkin type I fragment. **C:** Computerized tomography scan of the left hip demonstrates a mismatch between the Pipkin fragment and the residual femoral head. **D, E:** AP and lateral views of initial fixation with two small countersunk screws with anatomic restoration of the femoral head and normal congruence of the hip joint. The surgery was performed through an iliofemoral approach. **F:** AP view of the left hip at 1 year of follow-up. There is a small amount of heterotopic ossification that does not limit the patient's range of motion. The joint space is maintained, and the fracture is healed.

### *Pipkin Type II Fractures*

Pipkin type II injuries involve the superior portion of the femoral head (Fig. 18.18), which is important in load transmission across the hip joint (55). Pipkin type II fractures that are reduced anatomically may be treated in traction for 6 weeks (6,11,22,29). Reserve internal fixation of anatomically reduced Pipkin type II injuries for those patients in whom prolonged traction is contraindicated. Displaced Pipkin type II fractures require open reduction of the fragment through an anterior approach (60).

Although it is technically feasible to perform an open reduction of a Pipkin type II fracture through a posterior approach (12), this procedure requires redislocation of the hip. Additionally, soft-tissue attachments of the head fragment to the ligamentum teres must be cut in order to reduce and fix the fracture. Visualization of the fragment is limited, compromising the procedure.

### *Pipkin Type III Fractures*

Pipkin type III fractures present a serious challenge (Fig. 18.18) (55). A fracture of the femoral neck can accompany either a type I or type II femoral head fracture. In this situation, reduction and fixation of the femoral neck fracture are of paramount importance to help restore normal blood supply to the femoral head. An anterior approach to the hip joint provides direct access to both the femoral neck and femoral head, allowing the surgeon to perform an open reduction of both fractures.

Iatrogenic fracture of the femoral neck during forceful attempt at closed reduction of a dislocated hip has been reported (12). Carefully inspect prereduction radiographs for evidence of a femoral neck fracture. If you find a nondisplaced femoral neck fracture, it is advisable to perform percutaneous fixation of the femoral neck before attempting reduction of the hip. In this case, use either a posterior or anterior approach to the hip. The outcome of type III Pipkin injuries is frequently poor; satisfactory outcomes have been reported in a minority of cases (11,22,29). For this reason we recommend open reduction and internal fixation, particularly in the young patient with this complex injury.

### *Pipkin Type IV Fractures*

Pipkin type IV fractures have combined type I or type II femoral head fractures with an associated acetabular fracture (Fig. 18.18). In this situation, treat the acetabular fracture as described in the previous section (55). If the femoral head fracture is nondisplaced, it can be treated with 3 to 4 weeks of traction postoperatively. If mobilization is contemplated, however, it may be necessary to perform internal fixation or excision of the femoral head fragment. Consider sequential surgical approaches for an unstable inferior posterior wall fracture that requires open reduction. Use internal fixation, followed by an anterior approach, to repair or excise a femoral head fragment. Occasionally, a superior posterior wall segment can be treated through a Smith-Peterson approach at the time of incision or repair of the femoral head fragment.

### *Femoral Head Impaction Fractures*

Impaction or indentation of the femoral head is commonly associated with anterior dislocation of the hip. This kind of injury has been shown to predispose patients to posttraumatic arthritis (9). At this time, there is no effective treatment for reduction and fixation of femoral head impaction injuries. Intertrochanteric osteotomy to move the fracture away from the typical superior location has been proposed as a treatment method to prevent the development of arthritis in small femoral head impaction injuries. There are no data, however, to demonstrate that this method prevents the development of posttraumatic arthritis in the long term.

## COMPLICATIONS

Entrapment of the femoral head by soft tissues can prevent relocation of a dislocation and require open reduction (5).

Osteonecrosis of the femoral head following isolated hip dislocations has been reported in 2% to 17% of injuries (10,22). Epstein reported a 25% incidence of avascular necrosis with dislocation of the hip for 24 hours before reduction (12). Recent work by Yue et al. has demonstrated that posterior dislocation is associated with kinking of the external iliac artery over the pelvic brim and causes obstruction of flow in the medial femoral circumflex artery (69). Prompt reduction of the femoral head is recommended following the diagnosis of dislocation to decrease the incidence of osteonecrosis. Osteonecrosis often does not manifest clinically for 12 to 36 months

following injury. Letournel reported an incidence of osteonecrosis of 7% with posterior fracture dislocation of the hip associated with acetabular fractures (28).

### *Traumatic Arthritis*

Traumatic arthritis is a significant long-term complication of hip dislocation (21,23,41). Upadhyay et al. reported a long-term follow-up of 74 cases of isolated hip dislocations (63). They noted a 16% incidence of traumatic arthritis, with an additional 8% incidence of arthritis secondary to avascular necrosis. In their series, manual laborers were more likely than sedentary workers to develop traumatic arthritis of the hip following hip dislocation.

## CHAPTER REFERENCES

Each reference is categorized according to the following scheme: *, classic article; #, review article; !, basic research article; and +, clinical results/outcome study.


* 1. Allis OH. *The Hip.* Philadelphia: Dornan Printer, 1895.

* 2. Bigelow HJ. Luxations of the Hip Joint. *Boston Med Surg J* 1870;5:1.

+ 3. Brumback RJ, Holt ES, McBride MS, et al. Acetabular Depression Fracture Accompanying Posterior Fracture Dislocation of the Hip. *J Orthop Trauma* 1990;42:8.

+ 4. Brumback RJ, Kenzora JE, Levitt JE, et al. Fractures of the Femoral Head. In: Brand RA, ed. *The Hip. Proceedings of the Fourteenth Open Scientific Meeting of the Hip Society.* St. Louis: CV Mosby, 1987.

+ 5. Bucholz RW, Wheeless G. Irreducible Posterior Fracture-Dislocations of the Hip. The Role of the Iliofemoral Ligament and the Rectus Femoris Muscle. *Clin Orthop* 1982;167:118.

+ 6. Butler JE. Pipkin Type-II Fractures of the Femoral Head. *J Bone Joint Surg* 1981;63A:1292.

+ 7. Calkins MS, Zych G, Latta L, et al. Computerized Tomography Evaluation of Stability in Posterior Fracture Dislocations of the Hip. *Clin Orthop* 1988;227:152.

+ 8. DeLee JC, Evans JA, Thomas J. Anterior Dislocation of the Hip and Associated Femoral-Head Fractures. *J Bone Joint Surg* 1990;62A:960.

# 9. Epstein HC. *The Hip. Proceedings of the Seventh Open Scientific Meeting of the Hip Society.* St. Louis: CV Mosby, 1979:17

+ 10. Epstein HC, Wiss DA, Cozen L. Posterior Fracture Dislocation of the Hip with Fractures of the Femoral Head. *Clin Orthop* 1985;201:9.

* 11. Epstein HC. Posterior Fracture-Dislocations of the Hip; Long-Term Follow-up. *J Bone Joint Surg* 1974;56:1103.

# 12. Epstein HC. *Traumatic Dislocations of the Hip.* Baltimore: Williams & Wilkins, 1980.

+ 13. Fassler PR, Swiontkowski MF, Kilroy AW, Routt ML Jr. Injury of the Sciatic Nerve Associated with Acetabular Fracture. *J Bone Joint Surg* 1993;75A:1157.

+ 14. Fishmann AJ, Green RA, Brooks LR, Matta JM. Prevention of Deep Vein Thrombosis and Pulmonary Embolism in Acetabular and Pelvic Fracture Surgery. *Clin Orthop* 1994;305:133.

+ 15. Frick SL, Sims SH. Is Computed Tomography Useful After Simple Posterior Hip Dislocation? *J Orthop Trauma* 1995;9:388.

+ 16. Ghalambor N, Matta JM, Bernstein L. Heterotopic Ossification Following Operative Treatment of Acetabular Fracture: An Analysis of Risk Factors. *Clin Orthop* 1994;305:96.

+ 17. Hak DJ, Olson SA, Matta JM. Diagnosis and Management of Closed Internal Degloving Injuries Associated with Pelvic and Acetabular Fractures: The Morel-Lavalle Lesion. *J Trauma* 1997;42:1046.

+ 18. Harley J, Mack L, Winquist R. CT of Acetabular Fractures. *Am J Radiol* 1982;138:413.

+ 19. Helfet DL, Borrelli J Jr, DiPasquale T, Sanders R. Stabilization of Acetabular Fractures in Elderly Patients. *J Bone Joint Surg* 1992;74A:753.

+ 20. Helfet DL, Schmeling GJ. Somatosensory Evoked Potential Monitoring in the Surgical Treatment of Acute, Displaced Acetabular Fractures. Results of a Prospective Study. *Clin Orthop* 1994;301:213.

+ 21. Hougaard K, Thomesn PB. Coxarthrosis Following Traumatic Posterior Dislocation of the Hip. *J Bone Joint Surg* 1987;69A:679.

+ 22. Hougaard K, Thomsen PB. Traumatic Posterior Fracture-Dislocation of the Hip with Fracture of the Femoral Head or Neck, or Both. *J Bone Joint Surg* 1988;70A:233.

+ 23. Jacob JR, Rao JP, Ciccarelli C. Traumatic Dislocation and Fracture Dislocation of the Hip. A Long-Term Follow-Up Study. *Clin Orthop* 1987;214:249.

+ 24. Johnson EE, Matta JM, Mast JW, Letournel E. Delayed Reconstruction of Acetabular Fractures 21–120 Days Following Injury. *Clin Orthop* 1994;305:20.

* 25. Judet R, Judet J, Letournel E. Fractures of the Acetabulum. Classification and Surgical Approaches for Open Reduction. *J Bone Joint Surg* 1964;46A:1615.

+ 26. Kaempffe FA, Bone LB, Border JR. Open Reduction and Internal Fixation of Acetabular Fractures: Heterotopic Ossification and Other Complications of Treatment. *J Orthop Trauma* 1991;5:439.

+ 27. Keith JE, Brashear HR, Guilford WB. Stability of Posterior Fracture-Dislocations of the Hip: Quantitative Assessment Using Computed tomography. *J Bone Joint Surg* 1988;70A:711.

# 28. Letournel E. *Fractures of the Acetabulum,* 2nd ed. New York: Springer-Verlag, 1993.

+ 29. Marchetti ME, Steinberg GG, Coumas JM. Intermediate-term Experience of Pipkin Fracture-Dislocations of the Hip. *J Orthop Trauma* 1996;10:455.

# 30. Mast J, Jakob R, Ganz R. *Planning and Reduction Technique in Fracture Surgery.* New York: Springer-Verlag, 1989.

+ 31. Matta JM, Siebenrock KA. Does Indomethacin Reduce Heterotopic Bone Formation After Operations for Acetabular Fractures? A Prospective Randomized Study. *J Bone Joint Surg* 1997;79B:959.

# 32. Matta J. Operative Indications and Choice of Surgical Approach for Fractures of the Acetabulum. *Techniques Orthop* 1986;1:13.

# 33. Matta J, Letournel E, Browner B. Surgical Management of Acetabular Fractures. *Instr Course Lect* 1986;35:382.

+ 34. Matta J, Anderson L, Epstein H, Hendrick P. Fractures of the Acetabulum.: A Retrospective Analysis. *Clin Orthop* 1986;205:220.

+ 35. Matta JM, Mehne D, Roffi R. Fractures of the Acetabulum: Early Results of a Prospective Study. *Clin Orthop* 1986;205:241.

+ 36. Matta JM, Merritt PO. Displaced Acetabular Fractures. *Clin Orthop* 1988;230:83.

+ 37. Matta JM. Operative Treatment of Acetabular Fractures Through the Ilioinguinal Approach. A Ten Year Perspective. *Clin Orthop* 1994;305:10.

+ 38. Matta JM. Fractures of the Acetabulum: Accuracy of Reduction and Clinical Results in Patients Managed Operatively within Three Weeks after the Injury. *J Bone Joint Surg* 1996;78A:1632.

+ 39. Mayo KA. Open Reduction and Internal Fixation of Fractures of the Acetabulum: Results in 163 Fractures. *Clin Orthop* 1994;305:31.

* 40. Mays J, Neufeld AJ. Skeletal Traction Methods. *Clin Orthop* 1974;102:144.

+ 41. McKee MD, Garay ME, Schemitsch EH, Kreder HJ, Stephen DJ. Irreducible Fracture-Dislocation of the Hip: A Severe Injury with a Poor Prognosis. *J Orthop Trauma* 1998;12:223.

# 42. Mears DC, Rubash H. *Pelvic and Acetabular Fractures.* Thorofare, NJ: Slack, 1986.

+ 43. Moed BR, Maxey JW. Evaluation of Fractures of the Femoral Head Using the CT-directed Pelvic Oblique Radiograph. *Clin Orthop* 1993;296:161.

! 44. Moed BR, Maxey JW, Minster GJ. Intraoperative Somatosensory Evoked Potential Monitoring of the Sciatic Nerve: An Animal Model. *J Orthop Trauma* 1992;6:59.

+ 45. Moed BR, Maxey JW. The Effect of Indomethacin on Heterotopic Ossification Following Acetabular Fracture Surgery. *J Orthop Trauma* 1993;7:33.

+ 46. Moed BR, Karges DE. Prophylactic Indomethacin for the Prevention of Heterotopic Ossification after Acetabular Fracture Surgery in High-Risk Patients. *J Orthop Trauma* 1994;8:34.

+ 47. Moed BR, Letournel E. Low-Dose Irradiation and Indomethacin Prevent Heterotopic Ossification after Acetabular Fracture Surgery. *J Bone Joint Surg* 1994;76B:895.

+ 48. Moed BR, Smith ST. Three-View Radiographic Assessment of Heterotopic Ossification After Acetabular Fracture Surgery. *J Orthop Trauma* 1996;10:93.

+ 49. Montgomery KD, Potter HG, Helfet DL. Magnetic Resonance Venography to Evaluate the Deep Venous System of the Pelvis in Patients Who Have an Acetabular Fracture. *J Bone Joint Surg* 1995;77A:1639.

# 50. Müller ME. *Manual of Internal Fixation.* New York: Springer-Verlag, 1979.

+ 51. Olson SA, Maurizi MG, Hassien J, Pearl AJ. A Review of Computerized Tomography Evaluation of Acetabular Fractures: Part 2. *Contemporary Orthopaedics* 1991;23:436.

+ 52. Olson SA, Matta JM. The Computerized Tomography Subchondral Arc: A New Method of Assessing Acetabular Articular Continuity After Fracture (A Preliminary Report). *J Orthop Trauma.* 1993;7:402.

+ 53. Olson SA, Matta JM. Factors Related to Hip Muscle Weakness Following Fixation of Acetabular Fractures. *Orthopaedics* (*in press*).

# 54. Olson SA, Matta JM. Surgical Treatment of Acetabulum Fractures. In: Browner B, Jupiter J, Levine A, et al, eds. *Skeletal Trauma,* 2nd ed. Philadelphia: WB Saunders,1997:899.

* 55. Pipkin G. Treatment of Grade IV Fracture-Dislocation of the Hip. A Review. *J Bone Joint Surg* 1957;39A:1027.

+ 56. Reilly MC, Matta JM. The Correlation between Early Radiographic Results and Long-Term Clinical Outcome Following Fracture of the Acetabulum. *J Am Acad Orthop Surg* 1998.

+ 57. Schlickewei W, Elsasser B, Mullaji AB, Kuner EH. Hip Dislocation without Fracture: Traction or Mobilization After Reduction? *Injury* 1993;24:27.

+ 58. Starr AJ, Reinert CM, Jones AL. Percutaneous Fixation of the Columns of the Acetabulum: A New Technique. *J Orthop Trauma* 1998;12:51.

* 59. Stimson LA. Five Cases of Dislocation of the Hip. *N Y Med J* 1889;50:118.

+ 60. Swiontkowski MF, Thorpe M, Seiler JG, Hansen ST. Operative Management of Displaced Femoral Head Fractures: Case-Matched Comparison of Anterior Versus Posterior Approaches for Pipkin I and Pipkin II Fractures. *J Orthop Trauma* 1992;6:437.

+ 61. Teague DC, Graney DO, Routt ML Jr. Retropubic Vascular Hazards of the Ilioinguinal Exposure: A Cadaveric and Clinical Study. *J Orthop Trauma* 1996;10:156.

# 62. Tile M. *Fractures of the Pelvis and Acetabulum,* 2nd ed. Baltimore: Williams & Wilkins, 1995.

+ 63. Upadhyay SS, Moulton A, Burwell RG. Biological Factors Predisposing to Traumatic Posterior Dislocation of the Hip. A Selection Process in the Mechanism of Injury. *J Bone Joint Surg* 1985;67:232.

+ 64. Vailas JC, Hurwitz S, Wiesel SW. Posterior Acetabular Fracture-dislocations: Fragment Size, Joint Capsule, and Stability. *J of Trauma* 1989;29:1494.

+ 65. Vrahas M, Gordon RG, Mears DC, et al. Intraoperative Somatosensory Evoked Potential Monitoring of Pel-vic and Acetabular Fractures. *J Orthop Trauma* 1992;6:50.

+ 66. Webb LX, Bosse MJ, Mayo KA, et al. Results in Patients with Craniocerebral Trauma and an Operatively Managed Acetabular Fracture. *J Orthop Trauma* 1990;4:376.

+ 67. White RH, Goulet JA, Bray TJ, et al. Deep-Vein Thrombosis after Fracture of the Pelvis: Assessment with Serial Duplex-Ultrasound Screening. *J Bone and Joint Surg* 1990;72A:495.

+ 68. Wright R, Barrett K, Christie MJ, Johnson KD. Acetabular Fractures: Long-Term Follow-up of Open Reduc-tion and Internal Fixation. *J Orthop Trauma* 1994;8:397.

+ 69. Yue JJ, Wilber JH, Lipuma JP, et al. Posterior Hip Dislocations: A Cadaveric Angiographic Study. *J Orthop Trauma* 1996;10(7:447.

# CHAPTER 19

# FRACTURES OF THE HIP AND PROXIMAL FEMUR

*I want to thank the following authors from the second edition, whose previous contributions are included in part in this chapter: Timothy J. Bray, David C. Templeman, Richard F. Kyle, Sara J. Campbell, Donald A. Wiss, and Hans G. Ender.*

*Michael W. Chapman*

**M. W. Chapman:** Department of Orthopaedic Surgery, University of California Davis, Sacramento, California, 95817.

A. Epidemiology and Mechanisms of Injury
B. Fractures of the Femoral Neck
Osseous and Vascular Anatomy of the Proximal Femur
Biomechanics of the Fracture
Classifications
Anatomic Classification
The Garden Classification
Pauwels's Classification
Evaluation and Preoperative Management
History
Physical Examination
Preoperative Management
Timing of Surgery
Indications for Surgery
Nondisplaced Femoral Neck Fractures
Displaced Fractures
Types of Fixation
Types of Arthroplasty
Surgical Techniques
Closed Reduction and Percutaneous Multiple-Screw Fixation
Open Reduction
Compression Hip Screw Fixation
Hemiarthroplasty
Postoperative Care
Pitfalls and Complications
C. Intertrochanteric Fractures
Anatomy and Biomechanics
History of Treatment
Classification
Surgical Techniques
Sliding Hip Screw Technique
Open Technique on a Regular Table
Second-Generation Interlocking Nails and Rods
Primary Prosthetic Replacement
Pitfalls and Complications
D. Subtrochanteric Femur Fractures
Biomechanics
Classification
Nonoperative Treatment
Indications for Surgery
Devices and Techniques
Reamed Intramedullary Nails
Plates and Screws
External Fixation
Open Fractures
Results
Author's Perspective
Pitfalls and Complications
Delayed Union and Nonunion
Malunion
Infection
Chapter References

## A. EPIDEMIOLOGY AND MECHANISMS OF INJURY

Hip fractures have a bimodal age distribution: Approximately 97% occur in patients over 50 years of age (the incidence increases with age), and only 3% in patients under 50. In the latter group, they occur most commonly between 20 and 40 years of age, usually in men, and are due to high-energy trauma associated with sports and industrial and motor-vehicle accidents (106,136). In this young group, most hip fractures are subtrochanteric or basicervical. In contrast, fractures of the hip in patients between 40 and 50 years of age usually occur in alcoholics or patients with multiple medical diseases, whose fractures are related to osteoporosis.

Fractures in the elderly are serious injuries, often occurring in the terminal years of life, and they have a major impact on society, our health care system, and the cost of care (45). Annually, 250,000 fractures of the hip occur in the United States. The number of fractures is projected to double by the year 2050 as the population ages (78). Health care costs for fractures exceed $6 billion per year. Martin et al. [quoted in Koval and Zuckerman (78)] showed that in Canada from 1972 to 1984 the incidence of initial fractures of the proximal femur in persons older than 50 years increased 60% in women and 42% in men. The incidence increased exponentially with age, doubling for every 6 years of age and reaching a maximum incidence of 4% of women over 90. Martin et al. attributed this increase to a gradual decline in physical activity, which contributes to the bone loss (78). At 1 year after a hip fracture, mortality rates in elderly people range from 14% to 36% (78). The highest risk of mortality occurs in the first 6 months after fracture; after 1 year the mortality rate approaches that of persons who have not sustained a hip fracture.

Koval and Zuckerman (78), in an extensive study of functional recovery after fracture of the hip, state that the factors influencing morbidity and mortality are best understood if broken into three phases: the patient status before the fracture, preoperative management, and postoperative care. Age at the time of fracture does not necessarily correlate with a higher mortality rate. Systemic illnesses, however, such as congestive heart failure, coronary artery disease, diabetes mellitus, chronic obstructive pulmonary disease, and rheumatoid arthritis have been shown to increase the mortality rate. Koval and Zuckerman (78) pointed out other preoperative factors that worsened the prognosis, including cerebral dysfunction in the form of chronic organic brain syndrome, cerebral vascular disease, or psychiatric illness; and permanent habitation in an institution as opposed to a home.

An increased mortality rate after fracture of the hip is associated with male sex, advanced age, untreated or poorly controlled systemic disease, cerebral dysfunction, institutionalization, internal fixation before control of medical comorbidities, and postoperative complications.

White et al. (149) used the preoperative grading system of the American Society of Anesthesiologists to predict mortality. They found that grade 1 or grade 2 patients

had a 1-year mortality rate of 8%, whereas grade 3 and 4 patients had a 1-year mortality rate of 49% (Table 19.1).

| Grade | Description |
|---|---|
| I | A normal healthy patient |
| II | A patient who has mild systemic disease |
| III | A patient who has severe systemic disease that is not incapacitating |
| IV | A patient who has incapacitating systemic disease that is a constant threat to life |
| V | A moribund patient, not expected to survive for 24 hours with or without surgery |
| VI | Added to any class for surgery on an emergency basis |

Modified from: White BL, Fisher WD, Laurin CA. Rate of Mortality for Elderly Patients after Fracture of the Hip in the 1980s. *J Bone Joint Surg Am* 1987;69:1335.

***Table 19.1. Classification of Physical Status According to the System of the American Society of Anesthetists***

Zuckerman et al. (160) examined the effect of timing of internal fixation on mortality. They concluded that patients with two or fewer comorbidities benefited by internal fixation of the hip within 2 days after admission, whereas delay to better treat comorbidities and better prepare the patient for surgery was beneficial for patients with three or more comorbidities.

The goals of treatment of a hip fracture, other than reducing mortality, are to return the patient to walking, and to give her sufficient independence that she can live at home with or without assistance. The factors that have been reported to be predictors of return to ambulation are male sex, younger age, absence of mental impairment, and use of a cane or walker before injury. The factors that predict discharge to home are younger age, independent ambulation before fracture, capability in activities of daily living, and the presence of another person in the home. Similar factors apply to return to activities of daily living. In addition, Zuckerman et al. (159) showed that an interdisciplinary hospital program specifically designed to manage elderly patients with hip fractures resulted in fewer postoperative complications, fewer incidences of treatment in an intensive care unit, significantly improved ability to walk at the time of hospital discharge, and fewer transfers to a nursing home.

For a discussion of hip fractures in children (61,76,99,102), see Chapter 164.

# B. FRACTURES OF THE FEMORAL NECK

## OSSEOUS AND VASCULAR ANATOMY OF THE PROXIMAL FEMUR

The femoral side of the hip is made up of the femoral head with its articular cartilage, and the femoral neck, which connects the head to the shaft in the region of the lesser and greater trochanters. The synovial membrane incorporates the entire femoral head and the anterior neck, but only the proximal half of the neck posteriorly. The shape and size of femoral necks vary widely. In our practice, for example, there is a large discrepancy between those seen in small Asians and those in large blacks. The neck–shaft angle does not vary much, however, and is approximately 130° ± 7° (104). Anteversion of the femoral neck is 10° ± 7° in normal individuals, with no variation between the sexes (103). The diameter of the femoral head ranges from 40 to 60 mm, depending on the size of the individual (63). The thickness of the articular cartilage varies from 4 mm at the apex of the head to 3 mm at the periphery (63). In contrast to the medial femoral neck as seen on an anteroposterior (AP) radiograph of the hip, the calcar femorale is a dense plate of bone that originates from the posterior medial portion of the femoral shaft, where it blends into the neck of the femur and extends superiorly toward the greater trochanter, fusing with the posteriorcortex of the femoral neck. It is more of a posterior than a medial structure (134).

The vascular supply to the femoral head arises from three sources (Fig. 19.1). In the majority of persons, the major blood supply to the head comes via the lateral epiphyseal vessels, which penetrate into the bone of the femoral head at its junction with the neck. As seen in Figure 19.1, these vessels are supplied by the subsynovial intracapsular arterial ring, which derives from the ascending cervical arteries running beneath the synovium of the femoral neck. These vessels originate from the extracapsular arterial ring, which is primarily the termination of the medial femoral circumflex artery on the posterior aspect of the hip along the intertrochanteric basicervical line. The lateral femoral circumflex artery on the anterior aspect of the neck also contributes to this blood supply; however, the medial femoral circumflex artery usually dominates. The artery of the ligamentum teres usually originates from the anterior obturator artery but it contributes to the blood supply of only a small area of the femoral head near the attachment of the ligamentum teres. Intraosseous cervical vessels derived from the femoral neck also penetrate into the femoral head but are not the major blood supply (24,25,142).

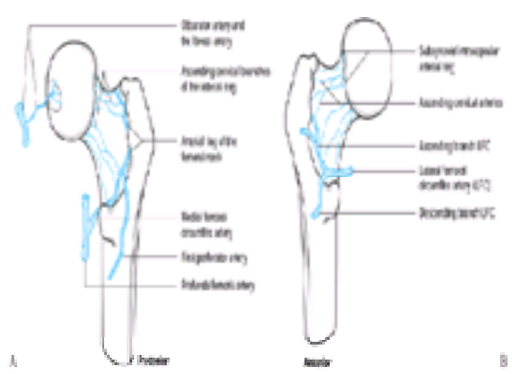

***Figure 19.1.*** Posterior (**A**) and anterior (**B**) views of the hip, showing the extraosseous blood supply to the femoral head.

A fracture of the femoral neck disrupts the intraosseous cervical vessels, making femoral head viability totally dependent on the retinacular vessels and the artery of the ligamentum teres. Displacement of the femoral neck fracture nearly always results in severe compromise of the blood supply to the head (27,28,98,119).

Another possible source of devascularization of the head is the accumulation of an intracapsular hematoma, which can interfere with venous outflow from the head and perhaps vascular inflow. As a result, some authors recommend routine aspiration of the hip or incision of the hip joint capsule after fracture (30,134). Opinions on this are not uniform, however (38).

If the fracture is not totally displaced, resulting in complete disruption of the epiphyseal vessels, mild to moderate distortion of alignment at the fracture site may compromise intact vessels. After 12 hours of disruption of the blood supply to the femoral head, all cells within the head are most likely necrotic. Therefore, in any patient in whom an effort will be made to preserve the femoral head, the fracture should be gently reduced as soon as possible. This can be achieved in the emergency room by aspiration of the hip and injection of a small amount of local anesthetic to provide pain relief. Simple longitudinal traction and mild gentle internal rotation, placing the limb in 5–7 pounds (2.3–3.1 kg) of Buck's traction with the leg lying on a pillow, will nearly always result in marked improvement in position, thus optimizing the opportunity for early return of blood flow to the femoral head (131,133). Anatomic reduction and excellent stability optimize the conditions for rapid revascularization across the fracture into the femoral head. This can occur by lumen-to-lumen reconnection of existing blood vessels. The foveal blood supply may be important in this revascularization. Rotary and valgus malposition have an adverse effect, not only on the retinacular blood supply, but on that of the foveal blood vessel as well (125).

The method of fixation also influences vascularity to the femoral head. Fixation devices placed in the superior lateral aspects of the femoral head can inadvertently injure the lateral epiphyseal vessels. Devices that are driven into the head rather than being screwed into the head or inserted in an atraumatic manner can lead to an increased incidence of aseptic necrosis (132). Twisting of the femoral head while inserting hip screws and using large implants that occupy a substantial cross-sectional area in the femoral neck have also been identified as increasing the incidence of avascular necrosis (84).

Unfortunately, no attempt to determine the viability and vascular supply to the femoral head at the time of internal fixation has produced uniformly reliable results;

therefore, the decision as to whether to preserve the femoral head or to go on to hemiarthroplasty remains a clinical surgical decision.

## BIOMECHANICS OF THE FRACTURE

The vast majority of femoral neck fractures occur when an elderly person falls from a standing position, resulting in a direct blow over the greater trochanter. It has been hypothesized that fatigue fractures of the femoral neck in the elderly with very osteoporotic bone may be the precipitating cause of the fall rather than the fall being the causal factor. It appears that this is highly unusual and that the vast majority of fractures are indeed caused by a fall (70). Femoral fractures in young and middle-aged adults are usually caused by high-velocity vehicular trauma or a fall from a substantial height, resulting in axial loading of the femur while the hip is abducted (70). This same method of loading with the hip in adduction is more likely to result in a dislocation with or without associated fractures of the posterior acetabulum or femoral head (40). Extreme external rotation tightening the anterior capsule and perhaps leading to impingement of the posterior cortex of the femoral neck on the acetabular rim can cause fracture as well and is compatible with the marked posterior comminution of the neck frequently seen in displaced fractures (5,116).

Postmenopausal and senile osteoporosis predispose to fracture; by 65 years of age, 50% of women show bone mineral content below the threshold for fracture, and by 85 years of age this climbs to 100% (105). Osteomalacia plays a much smaller role—Wilton et al. (151) found that only 2% of a large population of patients who had sustained fractures of the femoral neck showed evidence of osteomalacia.

## CLASSIFICATIONS

Three classifications are commonly applied to femoral neck fractures: These describe the anatomic location of the fracture (148), the degree of displacement of the fracture fragments (48,52,53), and the direction of the fracture angle in the frontal plane (97).

### ANATOMIC CLASSIFICATION

Fractures of the femoral neck located just distal to that portion of the femoral head covered by cartilage are termed *subcapital*, fractures in the midportion of the neck are termed *transcervical*, and those at the base of the neck are termed *basilar neck* fractures (Fig. 19.2). The first two are intracapsular and the third can be partially intracapsular and extracapsular posteriorly. Subcapital fractures are at greatest risk for disruption of the blood supply to the femoral head, transcervical fractures have a somewhat lower risk, and the risk is extremely low in basilar neck fractures. This is dependent mostly on the degree of displacement, which is addressed better by the Garden classification, discussed next. Fractures with a high shear angle, such as high-velocity fractures in young persons, can begin in the basilar neck area, traverse the femoral neck proximally, and exit in a subcapital location. Usually these are not displaced because they are commonly associated with fractures of the shaft of the femur, which dissipates most of the energy. If displaced, these fractures have an incidence of avascular necrosis of the femoral head similar to that seen in displaced subcapital fractures.

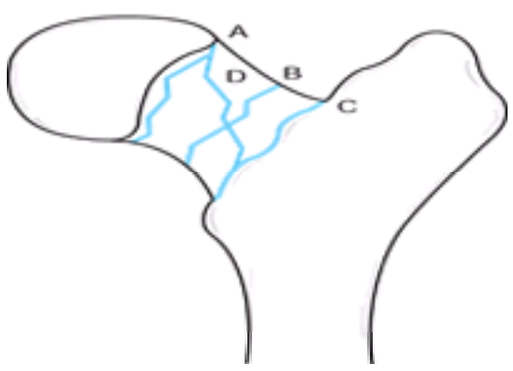


***Figure 19.2.*** Types of intracapsular fractures of the femoral neck: subcapital (**A**), transcervical (**B**), basilar neck (**C**), and high-angle shear fracture typical of those seen in ipsilateral concomitant fractures of the hip and femoral shaft (**D**).

Other than the effects of the location of the fracture on the blood supply to the femoral head, the major importance of the anatomic location of the fractures is its influence on the choice of internal fixation device. Subcapital fractures and proximal transcervical fractures are usually best internally fixed with multiple screws, which threaten the blood supply to the femoral head least, and leave the largest cross-sectional area in the femoral neck for bone healing and revascularization. More distal fractures, in particular those that are basilar neck and have a high shear angle, do not provide enough bone stock for adequate purchase of the multiple screws in the distal fragment; therefore, sliding compression hip screws with side plates are indicated for basilar neck fractures, particularly in young active individuals.

### THE GARDEN CLASSIFICATION

The Garden classification (7,48,49,50,51,52 and 53) applies to subcapital fractures and focuses on the degree of displacement (Fig. 19.3). Barnes, Garden, et al. (7), in a large multi-institutional study, found a reasonably good correlation between the Garden classification and the incidence of nonunion and avascular necrosis, as indicated in Table 19.2. The interrater reliability of orthopaedic surgeons using the Garden classification is not particularly good; therefore, from a practical viewpoint, most surgeons lump Garden stage I and II fractures together as “undisplaced” and Garden stage III and IV fractures together as “displaced.” Undisplaced fractures, if internally fixed in good position and stable, have a favorable prognosis, with union rates of 95% or better and an incidence of avascular necrosis of under 10%, whereas displaced fractures have rates of avascular necrosis as high as 40% (in Garden stage IV fractures) and nonunion rates of 10% or more. This difference in prognosis is the key factor in deciding whether to perform prosthetic replacement of the femoral head or internal fixation in elderly patients with these fractures. This is discussed in more detail later.

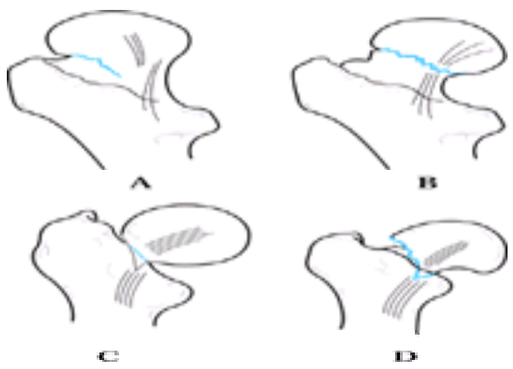


***Figure 19.3.*** Garden classification of femoral neck fractures. **A:** Stage I: Incomplete fracture that is abducted and impacted. **B:** Stage II: Complete fracture without displacement. Note that the compression trabeculae are aligned. **C:** Stage III: Complete fracture with partial displacement. The neck is still in apposition posteroinferiorly; therefore, the fragments have rotated in opposite directions like two cogwheels. Note that the compression trabeculae are angulated. **D:** Stage IV: Complete fracture with full displacement. Contact between the fracture surfaces is lost. The distal fragment is in full external rotation and lies anterior to the proximal fragment. The proximal fragment is free to resume its natural position in the acetabulum; therefore, the compression trabeculae lie in their normal alignment.

| Garden classification fracture state | Nonunion (%) | Late segmental collapse (%) |
|---|---|---|
| I | 1 | 15 |
| II | Not reported | Not reported |
| III | 30 | 26 |
| IV | 34 | 27 |

From Barnes R, Brown JT, Garden RS, Nicoll EA. Subcapital Fractures of the Femur. *J Bone Joint Surg Br* 1976;58:2.

***Table 19.2. Correlation between the Garden Classification of Subcapital Femoral Fractures and Rates of Nonunion and Late Segmental Collapse at 36 Months Follow-Up***

### PAUWELS'S CLASSIFICATION

Pauwels's classification (97) is based on the angle the fracture line makes with the horizontal (Fig. 19.4). Pauwels's type I fracture is the most horizontal, is often impacted, and therefore with internal fixation tends to stabilize with weight bearing, whereas the Pauwels's type III fracture is nearly vertical, experiences a large degree of shear with weight bearing, and is therefore unstable.

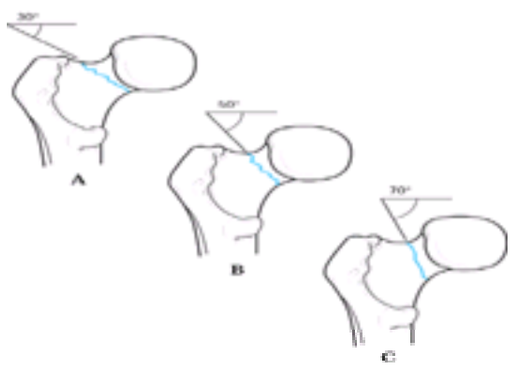


***Figure 19.4.*** Pauwels's classification of intracapsular hip fractures. **A:** Type I: Fracture is 30° to 49° from the horizontal. **B:** Type II: Fracture is 50° to 69° from the horizontal. **C:** Type III: Fracture is 70° or more from the horizontal.

All of these classifications are based on the interpretation of routine AP and lateral radiographs. For reproducible interpretation, the AP view must show the femoral neck in full profile, which requires internal rotation; in addition, the cross-table lateral must also not have a rotational component. It is quite difficult to obtain these radiographs in the emergency room setting. Once the patient is taken to surgery, repeat the AP and lateral plain films, or obtain good fluoroscopic views with the patient on the fracture table and the hip positioned for ideal radiographic views.

There are limitations to these classifications, in that none of them take into account the maximum displacement that occurred at the time of injury, the degree of vascular or capsular damage, or the amount of comminution of the posterior femoral neck, which makes the fracture more difficult to reduce and much more unstable (6).

## EVALUATION AND PREOPERATIVE MANAGEMENT

### HISTORY

The vast majority of fractures of the femoral neck occur in the elderly; therefore, the history is usually one of a slip and fall and landing on the side, resulting in a direct blow to the lateral aspect of the greater trochanter. Pathologic fractures are suggested when the patient's hip suddenly “gives way” during normal activities of daily living, associated with sudden severe pain, which then leads to a fall. Fractures of the femoral neck in young active adults are rare and nearly always due to high-energy trauma. In all fractures of the femoral shaft, a concomitant ipsilateral fracture of the femoral neck must be suspected (as discussed in Chapter 20). The past medical history, the social and family history, and a review of systems are very important, as indicated in the previous discussion on epidemiology. Associated diseases and social circumstance have a major influence on the outcome in fractures of the femoral neck and must be considered early for discharge planning.

### PHYSICAL EXAMINATION

Typically, the affected extremity shows shortening and excessive external rotation. The hip is tender, and any motion usually produces severe pain. A gentle blow to the bottom of the heel usually results in hip pain. Because the fracture is intracapsular and the capsule is usually intact, the amount of external rotation and shortening seen is much less than that seen in intertrochanteric fractures or fractures of the shaft. In the latter, shortening of an inch or more may be present, and the lateral border of the foot lies completely flat on the examining table. In neck fractures, shortening is usually less than 1 inch and the degree of external rotation does not usually allow the foot to lie completely flat on the tabletop unless the hip is abducted. Usually there is not much swelling, and large ecchymosis or hematomas such as seen in intertrochanteric or subtrochanteric fractures is not usually found. The surrounding hip joint capsule limits bleeding from the fracture; therefore, anemia is rarely a problem.

### PREOPERATIVE MANAGEMENT

In the emergency room, immediately apply Buck's traction (Chapter 10) with approximately 5 pounds (2.3 kg), with the foot in neutral rotation, the knee and hip slightly flexed, and the calf supported on one to two pillows. This immediately increases patient comfort and places the fracture in a more anatomic position, which minimizes distortion of the vessels providing the blood supply to the femoral head. The flexed position helps accommodate the increased intracapsular pressure that might be present from a hematoma. Immediate AP and cross-table lateral radiographs will confirm the diagnosis. It is important to plan the preoperative workup and radiography to minimize moving the patient, because transfers are painful and risk further comminution of the fracture.

Although the importance of an intracapsular hematoma as a threat to the blood supply to the femoral head remains somewhat controversial (70), I routinely place an 18-gauge or larger-diameter needle into the hip joint through either a lateral or an anterior approach to detect and aspirate any hematoma, but more important, to inject 5 ml of 0.5% Bupivacain without epinephrin. This usually provides dramatic pain relief and permits gentle further reduction of the fracture in the Buck's traction, if indicated.

For the majority of these patients, early internal fixation is indicated, so immediate consultation with the primary-care physician or a medical consultation is indicated to clear them for surgical treatment.

### TIMING OF SURGERY

The decision of when to carry out surgical treatment is based on whether the fracture is displaced, and on the health of the patient (16) (Table 19.3). Zuckerman et al. (160) showed that healthy patients with two or fewer comorbidities did better if the hip was treated within 48 hours of admission, whereas unhealthy patients with three or more comorbidities benefited from delay in surgery to treat comorbidities, which reduced the incidence of postoperative medical complications. In healthy patients with nondisplaced fractures, perform internal fixation ideally within 24 hours but no later than 48 hours to avoid the complications of prolonged immobilization. In healthy

patients with displaced fractures, particularly where salvage of the femoral head with internal fixation is to be performed, take the patients to surgery urgently because early anatomic reduction and internal fixation optimizes the conditions for preservation of the blood supply to the femoral head. In unhealthy patients with three or more comorbidities, whether the fracture is displaced or undisplaced, treatment in Buck's traction as outlined previously and thorough medical workup and treatment of comorbidities are indicated prior to surgical treatment.

| *Fracture type* | *Patient comorbidities* | *Timing* |
|---|---|---|
| Nondisplaced | Healthy | 24 hr |
| Displaced | Healthy | Urgent |
| Nondisplaced | Unhealthy (3 comorbidities) | Buck's traction to prevent displacement<br>Delay 48 hr<br>Preoperative medical clearance |
| Displaced | Unhealthy (3 comorbidities) | Reduce fracture closed and place in skeletal traction<br>Delay 48 hr<br>Preoperative medical clearance |

From Bray, TJ. Femoral Neck Fracture Fixation Clinical Decision Making. Clin Orthop 1993; 289:20.

***Table 19.3. Timing of Fixation***

If surgery is contraindicated, femoral neck fractures can be treated in skeletal traction utilizing a proximal tibial or distal femoral traction pin with an internal rotation component to the traction to reduce the fracture. Because these fractures often require 6 months to heal, this is rarely practical. I have not used nonoperative treatment in traction for a femoral neck fracture in the past 30 years. In the elderly, when operative treatment is not possible, it is usually better to abandon treatment of the fracture and mobilize the patient as symptoms permit. Many of these patients are very sedentary or confined to nursing homes, so they will often go on to a relatively pain-free nonunion, which is compatible with their level of function. The other alternative is a head and neck resection, but the decision to perform this procedure is usually best delayed to see how the patient does with simple neglect of the fracture.

## INDICATIONS FOR SURGERY

### NONDISPLACED FEMORAL NECK FRACTURES

Crawford et al. (29) showed that stable fractures that were impacted into moderate valgus could be successfully managed nonoperatively with initial traction for symptomatic relief followed by limited protected weight bearing. Bentley (9), however, showed in his series that 16% of stable fractures treated nonoperatively subsequently displace, resulting in a much worse prognosis. For that reason, the nonoperative treatment of stable impacted femoral neck fractures is of historical interest only. The low morbidity of percutaneous cannulated screw fixation of these fractures is such that the benefits of surgical stabilization far outweigh the risks (Fig. 19.5).

***Figure 19.5.*** Percutaneous cannulated screw fixation of an impacted, Garden stage I, subcapital hip fracture. **A:** AP radiograph of the hip fracture prior to fixation. **B:** Lateral radiograph. **C:** AP radiograph after cannulated screw fixation. **D:** Lateral radiograph; ideally, the screws could be spread out somewhat more and be more parallel.

### DISPLACED FRACTURES

In active adults, try to treat all femoral neck fractures, whether displaced or undisplaced, with internal fixation rather than prosthetic replacement (Fig. 19.5, Fig. 19.6). Even in displaced fractures such as a Garden stage IV where treatment is delayed, good internal fixation in anatomic position usually results in union of the fracture even though the incidence of avascular necrosis may be 40% or more. This means that up to half of these patients may have a satisfactory outcome, which is always superior to an arthroplasty, in both the short and the long term. In addition, if these patients are followed closely, subsequent conversion to an arthroplasty, if required, is not compromised.

***Figure 19.6.*** Cannulated screw fixation of a displaced subcapital hip fracture: **A:** AP radiograph showing a fully displaced Garden stage IV subcapital fracture. **B:** Lateral radiograph of the displaced fracture. **C:** AP radiograph after closed reduction and cannulated screw fixation. **D:** Lateral radiograph after fixation.

There is no question that patients do better in the long run if their fracture heals; they experience no avascular necrosis, and they retain their own femoral head. Because modern techniques of percutaneous, multiple-cannulated-screw fixation has a low morbidity, I feel that fixation is indicated in all nonpathologic, displaced fractures regardless of the patient's age, assuming that their bone quality is sufficiently good that the screws can be expected to hold. The controversy as to whether to perform internal fixation or prosthetic replacement arises for patients 65 years of age or more (127). People are living much longer today and, as a result of better living conditions and health care, are physiologically quite young in their middle 60s and are remaining athletically active into their middle 70s and occasionally even into their early 80s. For that reason, the decision of whether to internally fix or replace a displaced femoral neck fracture should be based on life expectancy, the presence of chronic disease, bone quality, and level of function at the time of fracture, as well as on expected function. In our practice, this means that we commonly internally fix displaced fractures in active 70-year-olds who have no comorbidity, and we reserve prosthetic replacement for patients who are physiologically in their 80s (64). In a meticulous review of the literature on fractures of the femoral neck, Swiontkowski (134) stated that major deficiencies in the design of most studies did not permit a meta-analysis of the literature to prove whether primary internal fixation or a prosthetic replacement in older patients provided the best results

(5,19,31,57,62,65,67,68,69,70 and 85,86,101,107,123,127,153).

On the basis of my personal experience, visits to many other institutions, and a review of the literature, I have drawn the following conclusions regarding this controversy:

- In community-based practices in North America, the vast majority of displaced femoral neck fractures in patients over 65 years of age are currently treated with hemiarthroplasty (Fig. 19.7).

***Figure 19.7.*** Hemiarthroplasty for a week-old Garden stage IV subcapital fracture of the femoral neck. **A:** AP radiograph showing a fully displaced fracture with some erosion of the head and femoral neck due to delay in fixation. **B:** Lateral radiograph. **C:** AP radiograph after cemented bipolar hemiarthroplasty. **D:** Lateral radiograph.

- Although more displaced fractures are treated with internal fixation at academic trauma centers, the art of successful closed reduction, in my opinion, is being lost because of the default to arthroplasty.
- In most published series, the early complication rate, including infection, other wound complications, dis-location of the prosthesis, and medical complications, are higher after hemiarthroplasty than after multiple-percutaneous-screw fixation (16,67,69,70,74,86,101,123,127).
- Because of average reported incidences of 16% for avascular necrosis and 32% for nonunion in the series of Söreide et al. (127), the need for reoperation after internal fixation was 35% at 2 years, compared to an average incidence of revision of arthroplasty of between 12% and 15%. This means that approximately 65% of patients after internal fixation either have a successful outcome, or failure of their fixation does not result in sufficient symptoms to require revision surgery. In more active patients between 65 and 75 years of age, this may well be acceptable because of the advantages of retaining the patient's own hip in this group.
- Rehabilitation after internal fixation, in spite of perceptions to the contrary, is usually faster because, with a good reduction and stable fixation, immediate weight bearing and rehabilitation can be instituted. The same is true in hemiarthroplasty, but the larger incision and risk of redislocation makes rehabilitation slower.

## TYPES OF FIXATION

Many different methods of internal fixation (2,80,92,126) have been used in the past; however, today most surgeons prefer three to four 5–7 mm in diameter lag screws utilizing cannulated screw techniques because of the advantages of placing guide pins prior to the screws (135). Various types of compression hip screws have also been used. I use three cannulated screws routinely and reserve the standard compression hip screw for high shear angle fractures in young vigorous patients for whom the stronger device is needed to resist deforming forces across the fracture site. I will often augment the latter with a 6–7 mm cannulated screw to improve rotational control. In patients with severe osteoporosis, augmentation with apatite cements has been used to increase the strength of the fixation construct, but at this time this is an experimental technique (59).

## TYPES OF ARTHROPLASTY

The types of arthroplasty available include unipolar, such as the older Austin Moore (57) or similar prostheses (62,67,68,69 and 85,101,153), or the newer bipolar prosthesis, including those that can be converted to a total hip. These are available in both cemented and noncemented versions (Fig. 19.7).

In addition to the factors already mentioned, indications for arthroplasty include the following:

- Inability to achieve a satisfactory reduction when open reduction with preservation of the femoral head is not indicated
- Severe neck comminution that precludes a satisfactory outcome
- Some pathologic fractures
- Coexisting arthritis

Some neurologic conditions characterized by spasticity, contractures, or poor motor control have been mentioned as indications for arthroplasty; however, the increased incidence of dislocation in this group may in some cases make internal fixation a better choice. Kenzora et al. (74), in a prospective outcomes study, compared noncemented unipolar prostheses to cemented or press-fit bipolar prostheses. Patients with the bipolar prostheses had better pain relief and function compared to the unipolar prostheses at 2 years follow-up. The total cost of the bipolar was approximately 30% more than the unipolar. Cornell et al. (26), in a smaller study comparing cemented unipolar and bipolar prostheses, at 6 months follow-up found no differences in hip rating outcomes; therefore, they suggested that the less expensive unipolar prostheses might be justified. Neither study addressed the issue of whether conversion to total hip arthroplasty was easier, or less expensive, with the bipolar prosthesis designed for conversion to a total hip. Based on personal experience and a review of the literature, I have drawn the following conclusions regarding this controversial issue:

- Because most patients undergoing arthroplasty for fracture of the hip are over 65 years of age, in appropriate quality bone, a cemented prosthesis is more likely to offer early function and minimize the risk of long-term thigh pain.
- In patients with a limited lifespan or who have low functional demands, a unipolar prosthesis is less expensive and less likely to dislocate, and it provides satisfactory function.
- A cemented bipolar prosthesis offers optimal function and is more important in the younger group of patients, for whom eventual conversion to total hip arthroplasty might be necessary. A bipolar that offers conversion to total hip arthroplasty without removal of the femoral stem should be used.
- Total hip arthroplasty is indicated only in patients with coexisting arthritis or pathology of the acetabulum that makes a hemiarthroplasty impractical (124).

Some authors advocate routine total hip replacement in view of the revision rate of hemiarthroplasty previously mentioned, but I do not subscribe to that approach at the present time (23,26,33,55,66,72,108,123,137). An algorithm for the decision-making cascade is presented in Figure 19.8.

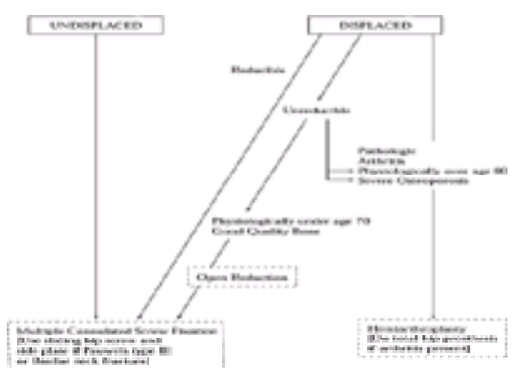


***Figure 19.8.*** Treatment of adult subcapital hip fractures.

## SURGICAL TECHNIQUES

### CLOSED REDUCTION AND PERCUTANEOUS MULTIPLE-SCREW FIXATION

- Administer a general or regional anesthetic. When this is contraindicated, the procedure can be done under local anesthesia in a cooperative patient; use conscious sedation supervised by an anesthesiologist.
- Gently transfer the patient to an orthopaedic fracture table that is compatible with the use of a fluoroscope.
- In undisplaced fractures, and in those in satisfactory position for fixation when a reduction is not required, place the affected hip in neutral abduction, in neutral flexion–extension, and in sufficient internal rotation to place the femoral neck parallel to the floor, assuming that this will not displace the fracture. Apply only enough traction to stabilize the limb on the table while avoiding disimpaction of the fracture site. Fractures that have good apposition but are simply angulated beyond the desirable range can often be reduced in this manner without a formal reduction maneuver, as described next.
- In fully displaced fractures, use the following protocol:
  - It is critical in the reduction of displaced fractures to have the pelvis completely stable on the fracture table. This is best achieved by putting both lower extremities in longitudinal traction.
  - Using a perineal post in the groin, secure both feet firmly into traction stirrups, padding the feet well to avoid bruising or injury to neurovascular structures. Abduct the uninvolved hip to 45° or as needed to allow access for the C-arm fluoroscope, and place the limb in sufficient traction to tip the pelvis slightly toward the unaffected hip. If an adduction contracture of the hip precludes placing this limb in abduction-traction, then place it in a 90°-90° leg holder, but stabilize the pelvis by padding and binding the thigh to the vertical post of the leg holder. A separate post mounted on the fracture table above the iliac crest of the uninvolved hip will work as well, if available (Fig. 19.9).

***Figure 19.9.*** Patient on a fracture table for percutaneous screw fixation of a subcapital hip fracture. Note that the uninvolved hip is in traction and abducted 45°, permitting access for the C-arm. The fractured limb is in the reduced position with the lower extremity in line with the body and internally rotated to bring the femoral neck level with the floor. The C-arm fluoroscope is best located between the legs.

  - Bring the fluoroscope in between the legs. Make certain that good-quality AP and lateral images of the fractured hip are obtainable. Lock the base of the fluoroscope and adjust it so that both views can be obtained without having to shift the position of the base.
  - Gently place sufficient traction on the fractured hip to pull it out to length and disengage the fracture fragments.
  - Place the hip in approximately 45° of abduction and 45° of external rotation.
  - Then gently and slowly adduct the hip to neutral while simultaneously internally rotating the hip to bring the femoral neck parallel to the floor. Having an assistant provide a lifting and internal rotation pressure on the greater trochanter may assist in the reduction.
- Now visualize the hip on an AP view (Fig. 19.10). One of three situations will usually be present. The fracture may be anatomic (Fig. 19.10*A*), or there may be a valgus reduction (Fig. 19.10*B*), where the femoral neck is supporting the femoral head. Note that point *X* on the neck lies somewhat medial and distal to the matching point *Y* on the head. As long as the valgus angle does not exceed 15°, either of these positions is acceptable. Excessive valgus interferes with the ability to place the screws. This can be eliminated by easing off on the traction. If the fracture is in varus (Fig. 19.10*C*), where point *X* lies lateral and superior to point *Y*, then further reduction is necessary using the maneuver described next.

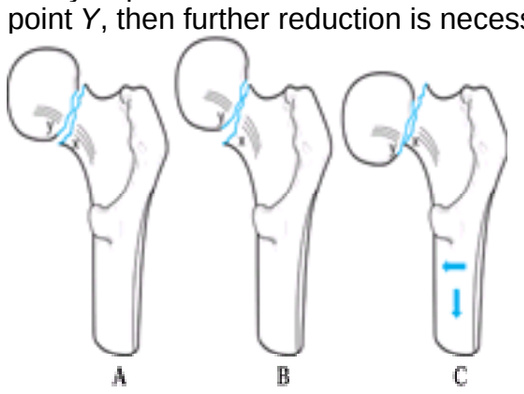


***Figure 19.10.*** Reduction of a subcapital fracture on the AP view. **A:** Anatomic reduction. **B:** Valgus reduction. Notice that the femoral neck supports the head. This is acceptable. **C:** Varus reduction. There is no support of the femoral head by the neck. Do not accept this reduction. Convert this to anatomic reduction (A) or valgus reduction (B) by applying traction and pushing the femoral shaft medially, as indicated by the *arrows*.

- Under fluoroscopic control, pull additional traction to bring point *X* even with or slightly distal to point *Y*, then displace the neck medially to bring point *X* slightly medial to point *Y* to provide support for the femoral head. Achieve this by stabilizing the femoral shaft with a hand on the medial side of the knee, while pushing on the greater trochanter with the other hand to drive the femoral neck beneath the head (Fig. 19.11). Do this using frequent spot images on the fluoroscope to control the reduction and to avoid comminution of the neck.

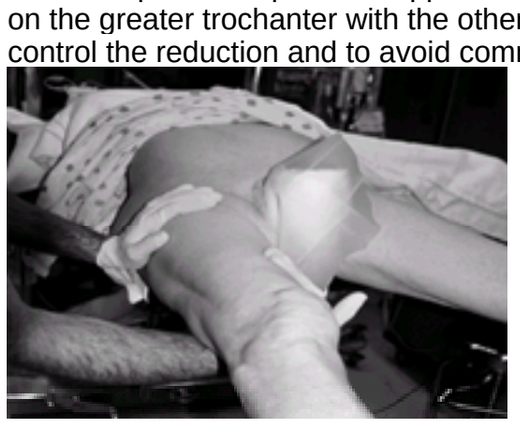

***Figure 19.11.*** Reduction maneuver for varus position on the AP view. Apply traction and then shift the femoral neck medially beneath the femoral head by supporting the medial aspect of the knee with one hand and pushing on the trochanter with the other as illustrated.

- With this maneuver, sometimes the neck will not remain in the reduced position because of excessive traction. To stabilize the reduction in that situation, hold the fracture reduced and release the traction enough to engage the fracture fragments.
- Now look at the fracture on the lateral view. Normally you will see one of the three situations illustrated in Figure 19.12. The fracture may be anatomic (Fig. 19.12*A*), or the fracture may be reduced in a stable configuration, with point *W* representing the posterior proximal corner of the femoral neck, displaced posterior to and supporting the posterior corner of the femoral head as represented by *Z* (Fig. 19.12*B*). As long as the neck is not posteriorly displaced more than 15% of the width of the neck at the fracture, this position is acceptable.

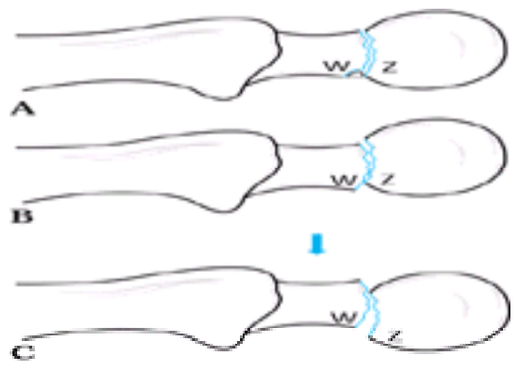


***Figure 19.12.*** Reduction of a subcapital fracture on the lateral view. **A:** Anatomic reduction. **B:** Neck posterior reduction. This is acceptable because the neck supports the femoral head and prevents it from collapsing posteriorly. **C:** Neck anterior reduction. This is unacceptable. Convert it to anatomic reduction (A) or neck posterior reduction (B) by pushing the shaft posteriorly.

- If, however, point *Z* on the femoral head lies posterior to point *W* on the femoral neck, particularly if there is any comminution of the posterior neck, then this position is unstable and further reduction is necessary (Fig. 19.12*C*). To solve this problem, place your hand directly over the intertrochanteric region on the anterior surface of the hip and gently push the proximal femoral shaft posteriorly (Fig. 19.13) to obtain an anatomic or slightly overcorrected position (Fig. 19.12*A*, Fig. 19.12*B*).

***Figure 19.13.*** Reduction maneuver for displacement on the lateral view. To provide support for the femoral head posteriorly, push the shaft posteriorly with the palm of your hand located over the proximal femur as illustrated.

- If the fracture will not remain in the reduced position because of excessive traction, use the technique just described to engage the fracture fragments in the reduced position.
- Once a final position is obtained on the lateral view, return the C-arm to the AP view to verify that the reduction has not been lost on this view.
- Acceptable ranges of angulation after reduction are 130° to 150° of valgus on the AP view, and less than 15° of either anterior or posterior angulation on the lateral view.
- Insertion of the initial guide pin for the cannulated screws is greatly facilitated by having the femoral neck parallel to the floor. This provides a reference for pin insertion on the lateral view. Place a Kirschner (K) wire as a radiopaque guide on the anterior aspect of the hip for guidance in the AP view. When using a percutaneous technique, this also helps to localize the site of the incision used for inserting the guide pins and screws.
- Sterilely prep the hip and, under fluoroscopy, lay a 0.062 mm K-wire on the anterior aspect of the skin of the hip so that it subtends an angle of 130° with the femoral shaft and is located directly over the middle of the femoral head and neck. Once this location is established, mark it. Then pierce the K-wire into and out of the skin on the anterolateral aspect of the hip, securing the pin with a section of skin approximately 5 mm in length. Do the same maneuver at the tip of the pin over the femoral head. This will secure the K-wire and prevent it from shifting. The distal end of the K-wire then marks the region for the skin incision, which can be marked. Then cut off the excessive projection of the pin laterally, leaving the K-wire on the anterior aspect of the hip (Fig. 19.14).



***Figure 19.14.*** A K-wire pierced through the skin in two places on the anterior surface of the thigh in line with the femoral neck, as seen on the fluoroscope image, provides a guide to the incision and fixation.

- Now sterilely drape. I prefer the fully transparent, lateral wall drape because the ability to fully visualize the patient and the C-arm greatly facilitates orientation for placement of the guide pins. It also facilitates communication with the x-ray technician who will be standing behind this drape.
- Make a longitudinal skin incision on the mid-lateral aspect of the thigh approximately 2–3 cm in length, and incise the underlying subcutaneous fat and deep fascia in line with the angle of the K-wire.
- Use a Cobb elevator to further establish the hole in the fascia and to longitudinally split the muscles down to the femur, where a small amount of periosteal elevation can be done to expose the bone just below the greater trochanter on the lateral cortex where the guide pins and screws will enter.
- Insert three or more guide pins or cannulated screws. I prefer titanium lag screws, 6–7 mm in diameter and self-tapping. The somewhat larger diameter provides additional strength, but more important, it allows the use of a larger guide pin that is stiff enough to prevent deflection during insertion.
- The details of insertion of guide pins and screws depends on the manufacturer, but the general principals are as follows:
  - The configuration of screw placement I strive for is illustrated in Figure 19.15. Swiontkowski (134) has shown that three screws provide sufficient stability, and that four or more screws are usually not necessary. This minimizes the number of screws and maximizes the surface area available for healing and revascularization. The keystone position is screw 1, which is placed in the midline on the lateral view and 5–10 mm proximal to the inner cortex of the medial femoral neck on the AP view. Insert this guide pin first, staying parallel to the guide K-wire and maintaining an angle of approximately 130°. This position is less likely to disrupt the reduction, and it is a good position for securing the reduction.

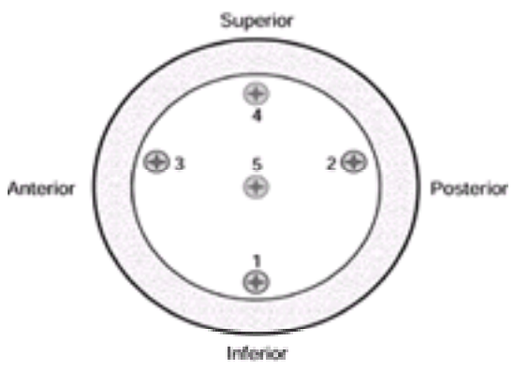


***Figure 19.15.*** Screw positions for fixation of femoral neck fracture as seen on a cross section of the femoral neck. Keep all screws in the inner two-thirds of the head to avoid accidental penetration of the articular surface of the femoral head. Try to use positions *1*, *2*, and *3*, inserting the guide pins and screws in that order. If more than three screws are desired, use positions *4* and *5*. Caution: Site *4* is the most risky for injuring the extraosseous blood supply to the

head.

- Next, place guide pin 2, which is important to support the posterior neck.
- Place guide pin 3. In Figure 19.15, screw positions 2 and 3 are shown in the midsection of the femoral head, but they can be placed more superiorly if more spread between the screws is desired.
- Guide pin positions 4 and 5 are usually not necessary, but if additional fixation is required, place 4 next and then 5. Position 4 is good for neutralizing tension across the superior aspect of the fracture, but usually it is not placed because of the risk of injury to the blood supply to the femoral head if the superior cortex were accidentally penetrated.
- To avoid accidental penetration of the articular surface, keep the guide pins within the central two thirds of the head (93), as shown in Figure 19.15.
- I prefer to use guide pins that have a threaded tip that can be secured into the subchondral bone of the femoral head; then I drill for the screw 5–10 mm short of the tip of the guide pin. This helps prevent dislodgement of the guide pin on removal of the drill.
- Measure for the depth of the drill and screw length.
- Now overdrill the guide pin with the drillpoint specified by the manufacturer for the screw being used. Do this under direct fluoroscopic control to avoid accidental penetration of the hip and/or loss of the guide pin.Do not use the screws to apply the initial compression. With the three guide pins in place and before inserting the screws, loosen the traction somewhat and impact the fracture by pounding directly on the greater trochanter. Visualize this on the fluoroscope. At this point, measure for screw length and then in-sert the screws and washers, compressing the fracture site (Fig. 19.6).
- Select a screw length that will permit compression of the femoral neck while placing the tip of the screw no closer than 7 mm to subchondral bone. Now insert the appropriate-length lag screw with a washer, being certain that the screw threads do not lie across the fracture site.
- Remove the guide pins, irrigate the wound, and close in layers.
- Prior to breaking sterile technique, obtain AP and lateral radiographs.

### OPEN REDUCTION

If satisfactory position cannot be obtained after the closed reduction maneuvers as described, and if the patient is sufficiently young and healthy that internal fixation rather than hemiarthroplasty is indicated, perform an open reduction. The usual cause of failure of reduction is severe comminution of the femoral neck, which usually occurs posteriorly. The key to success of open reduction is the avoidance of further damage to the blood supply to the head, achievement of a stable anatomic reduction, and good stable fixation in good-quality bone. Because of the threat to the blood supply of the head caused by any type of bone grafting of the comminution of the posterior neck, do not bone graft the femoral neck.

- For this procedure, leave the patient on the fracture table with the fracture in the best-reduced position obtainable.
- Prep the hip and then use traditional draping rather than the translucent drape sheet. Sterilely drape the head of the fluoroscope so that it is available throughout the procedure.
- Expose the lateral aspect of the greater trochanter and the hip through a Watson-Jones approach (Chapter 3). Expose the femoral neck through a longitudinal anterior midline incision in the hip joint capsule parallel to the femoral neck. “T” this at the base of the femoral neck only enough to visualize the fracture for reduction.
- Irrigate the hip to remove any blood clots and to provide good visualization of the femoral neck fracture.
- Now reduce the fracture by direct manipulation of the femoral neck under direct visualization, using the C-arm and the traction arm of the fracture table, which is manipulated by an assistant surgeon. This direct manipulation must be gentle and it must avoid disruption of the lateral epiphyseal vessels or any other soft-tissue connections to the femoral head. The pointed pusher from the pelvic fracture tray and small elevators are helpful. I almost never use reduction forceps. If forceps are necessary to grasp the femoral neck, use only a large pointed tenaculum forceps on a portion of the neck where injury to the blood supply will not occur.

#### HINTS AND TRICKS

- Place the femoral neck parallel to the floor to facilitate insertion of the screws. In some fractures, more internal rotation may be necessary to reduce posterior angulation at the fracture on the lateral view because of posterior neck comminution.
- If the overall alignment of the fracture is satisfactory, with the exception of residual posterior tilt of the head caused by posterior neck comminution, this tilt can often be reduced by placing the first guide pin along the posterior neck using the guide pin to push the head into acceptable position.
- If, after the reduction sequence just described, the fracture remains in unsatisfactory position on either view, then repeat the entire sequence once more. If satisfactory reduction is not present after that, proceed with either open reduction or hemiarthroplasty.
- Insertion of guide pins can be difficult because they tend to “walk” along the femoral shaft when power is activated. Palpate the lateral cortex of the femur with the guide pin anteriorly and posteriorly to be certain that the initial guide pin is directly in the center of the shaft. Verify the location of the entry point of the guide pin and begin initially with the guide pin at right angles to the longitudinal axis of the femur. Once the guide pin has entered the cortex just barely enough to obtain purchase, but before penetrating so deep that its angle cannot be changed, align the guide pin on the AP and lateral views.
- The surgeon can easily judge alignment on the AP view, but the nurse or an assistant must visualize the guide pin on the lateral projection to keep it parallel to the floor.
- Once all three guide pins are fully inserted, it often saves time to next impact the fracture, because then the initial measurement of screw length will be more accurate.
- In hard cortical bone, tapping of the lateral cortex and/or the femoral head may be necessary prior to insertion of the screw. Avoid inserting screws where excessive torque is required, because this may displace the fracture.
- Always use washers on the screws to permit compression of the fracture and to avoid penetration of the lateral cortex by the screw head.
- Do not place screws at more than 135° of valgus because this narrows the cross-sectional area of the femoral neck available for screw insertion and may necessitate entry of the screws at or below the lesser trochanter, which increases the risk of subtrochanteric fracture (117).
- Take time to ensure that the entry of each guide pin and screw is perfect, because mistakes requiring additional unused drill holes in the lateral aspect of the femur predispose the patient to subtrochanteric fracture.
- If a screw must be changed, insert the guide pin back into the screw before the change because this greatly facilitates location of the hole in the lateral cortex and ensures that the screw passes down the same track.
- When there is any question about the quality of reduction or location of the screws, examining the hip on the AP view under direct live fluoroscopy by rotating the hip through a full range of motion provides a three-dimensional visualization of the hip that is very helpful.

- Because these fractures are very unstable, it is often necessary to manually reduce the fracture and then hold it while an initial guide pin is placed by an assistant surgeon, as previously described. Once one guide pin has been placed, the fracture usually is stable and the insertion of fixation screws can proceed as described for closed percutaneous fixation.
- In young patients with a high-shear-angle (Pauwels's type III) transcervical or basilar neck fracture, a compression hip screw with side plates may be indicated. The screw and plates are inserted with the technique described in Section C of this chapter on intertrochanteric fractures.
- Keep the hip joint capsule open until internal fixation is completed, because this will ensure maintenance of reduction and will assist in the visualization of placement of the fixation.
- Obtain final radiographs prior to wound closure, and then irrigate the wound, place a suction drain, and close in layers.

### COMPRESSION HIP SCREW FIXATION

See the discussion on compression hip screw fixation of intertrochanteric fractures in section C of this chapter.

### HEMIARTHROPLASTY

The technique for hemiarthroplasty is described in Chapter 105.

## POSTOPERATIVE CARE

After internal fixation, nearly all patients can be mobilized to a bedside chair the day after surgery and can begin immediately to walk using a walker or crutches. Assuming that the reduction is stable, fixation good, and bone stock acceptable, most elderly patients can be allowed to bear weight as tolerated. Most patients will voluntarily begin with the weight of the leg and by 6 weeks will be capable of full weight bearing with assistive devices, although most elderly patients will continue to use assistive devices for a number of additional months until they regain muscle strength and endurance, and the fracture is healed. There is no point in keeping these patients non-weight-bearing because the simple maneuvers of getting on a bedpan, getting out of bed, and rising from a sitting position in a chair subject the internal

fixation to the same forces as nonassisted full weight bearing (3).

The least stress on the implants and femoral neck occurs when the patient slides the affected lower extremity along the floor without activating hip musculature. This is best achieved by weight bearing to the weight of the limb, combined with the use of a walker or crutches. The latter regimen should be used in younger persons with unstable fracture patterns until fracture healing occurs at about 6 months. We monitor patients with physical examination and radiographs at 6 and 12 weeks, 6 months, and 12 months after injury and then follow them yearly as needed. Avascular necrosis can occur even 2 years or more after injury.

### PITFALLS AND COMPLICATIONS

The most common complications following internal fixation of fractures of the femoral neck include avascular necrosis, which, in large series including all grades, occurs in approximately 25% of fractures; nonunion, which in large series occurs in up to 25%; and early failure of fixation. Because percutaneous techniques are used, infection is uncommon, but it can occur. Most other complications are related to perioperative medical problems.

In the elderly, nonunion and avascular necrosis generally require prosthetic replacement. For a discussion of the treatment of nonunions of the femoral neck in younger patients, see Chapter 29. Infection after internal fixation generally does not result in osteomyelitis or pyarthrosis and can be treated with irrigation and debridement of the wound, delayed primary closure after debridement, and an appropriate course of intravenous bacteriocidal antibiotics based on the results of culture. In most cases, the fixation implants can be left in place. If pyarthrosis or osteomyelitis occurs, then failure of fixation normally results, and head and neck resection as a definitive procedure or followed by late total joint arthroplasty is usually required. For complications following hemiarthroplasty, see Chapter 105.

## C. INTERTROCHANTERIC FRACTURES

Half of all hip fractures are intertrochanteric. The mortality rates associated with these fractures varies from 10% to 30% within the first year of injury (9). One year after hip fracture, the life expectancy of the patient returns to the normal value for the age group. In general, there is a slightly greater mortality rate for intertrochanteric fractures than for intracapsular fractures; this is because of the advanced age of patients who suffer intertrochanteric fractures. Patients who are in nursing homes before the fracture have the highest morbidity and mortality rate (30%) and are least likely to resume ambulation (71). In the socially independent population, most patients recover to their previous levels of functioning if complications do not occur.

Compared to patients with femoral neck fractures, patients with intertrochanteric fractures are significantly older, more likely to be limited to home ambulation, and more dependent in their activities of daily living; therefore, they tend to have an overall poorer prognosis (77,78).

### ANATOMY AND BIOMECHANICS

Intertrochanteric fractures occur in the peritrochanteric area about the insertion site of the abductor musculature, a region with a very generous blood supply. Marked bleeding may result after fracture, so watch carefully for excessive blood loss. The nonunion and avascular necrosis rate in intertrochanteric fractures is less than 1% because of the ample blood supply in this region.

When a high-energy intertrochanteric fracture produces comminution, a large fragment of the posteromedial wall of the femur, often including the lesser trochanter, splits free. This bony buttress is important to the stability in the intertrochanteric region; therefore, its comminution results in an unstable fracture.

To correctly apply sliding fixation devices for these fractures, it is essential to understand the mechanics of the devices and the forces that they must withstand. The magnitude and direction of the force exerted across the hip joint are dictated by body weight and the muscles acting on the hip. Pauwels (97) and others (46,69,96,110) showed that the forces acting on the hip in single-limb stance amount to about three times the body weight applied at an angle of 159° to the vertical plane. This same force acts on any hip fixation device placed across the fracture site.

A sliding device that has a screw-plate angle closest to this force vector allows optimal sliding of the hip screw and impaction of the fracture. The closer the nail-plate angle is to the resultant force across the hip, the more force is available to assist impaction (82) (Fig. 19.16). Devices of lower angles are subject to lower forces parallel to the sliding axis of the device and greater forces perpendicular to the axis; these perpendicular forces act to jam or bend the device, thereby preventing impaction. Technically, however, the surgeon cannot place the sliding device at an angle greater than 150°. It is desirable mechanically to place the sliding fixation device at as high an angle as clinically possible and still maintain placement of the fixation device in the center of the femoral head to prevent cutout. Fixation of the medial fragment, particularly if it is large, allows bony impaction and creates a stable osteosynthesis with less shortening. For this reason, in addition to bony impaction with a higher-angle device, interfragmentary fixation of a large medial fragment is desirable when possible.

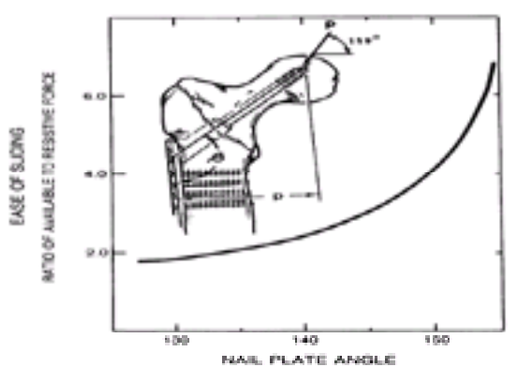


***Figure 19.16.*** The ratio of available to resistive forces for the initiation of sliding, plotted against nail-plate angle (b), assuming a constant applied load (*P*) and constant offset (*p*), for the fracture shown in the *inset.*

The need to position the nail at the ideal angle should not overshadow the need for a secure purchase in the center of the femoral head (81) (Fig. 19.17). If you cannot effectively place a high-angle device deep into the center of the femoral head, use a lower-angle device to obtain optimal placement in the head. The lower-angle devices must be used in patients who are small and have varus hips. Most sliding devices are available in 5° increments at the nail-plate junction; in unstable fractures, select the highest angle that allows center head placement. This optimizes both fixation of the fracture and ease of sliding the device, allowing impaction of the fracture fragments.

| POSITION | INCIDENCE | | APICAL DISTANCE OF NAIL TIP FROM SUBCHONDRAL BONE (mm) | FAILURES | |
|---|---|---|---|---|---|
| | NO. | PERCENT | | NO. | PERCENT |
| 2/2 | 34 | 46 | 11/12 | 0 | 0 |
| 2/3 | 22 | 30 | 14/7 | 1 | 4.5 |
| 2/1 | 4 | 5 | 9/5 | 0 | 0 |
| 1/2 | 6 | 8 | 12/18 | 2 | 33 |
| 1/3 | 4 | 5 | 14/11 | 1 | 25 |
| 3/3 | 4 | 5 | 15/16 | 1 | 25 |

***Figure 19.17.*** Failure rate versus nail position in Kyle type III fractures.

Den Hartog et al. (35), in addition to emphasizing the importance of central placement of the screw combined with a 150° angle plate, showed the importance of reestablishing bony contact between the femoral shaft and the main head and neck fragment medially. In their cadaveric study, they accomplished this with a limited osteotomy of the greater trochanter.

Although osteotomies were once very popular (37,114), more recent clinical experience with newer sliding hip screws has not demonstrated an advantage of osteotomy over anatomic reduction or use of a valgus reduction and high-angle nail to restore the medial buttress (36,54). Equally important, addition of an osteotomy has been found to increase operating time, blood loss, and contribute to excessive shortening and occasionally external rotation of the extremity. Introduction of the Medoff sliding plate, which achieves compression not only along the femoral neck but also along the longitudinal axis of the femoral shaft, has not shown improved results over traditional compression hip screws, and the added complexity of the device may add to longer operating times and increased blood loss (147).

At our institution, the most common mechanism of failure today is the head and neck fragment cutting off the hip screw, due to severely osteoporotic bone in the very elderly or in those with metabolic bone disease. Fatigue failure of sliding screws occurs but is rare (128). This observation has been echoed by others (155). Modi-fication of the traditional hip screw by replacement of the screw with a dome plunger (Alta, Stryker-Osteonics-Howmedica, Rutherford, NJ) uses the principle of an expandable molly bolt, which resists cutout by compressing the cancellous bone of the femoral head around the expandable dome, by providing a larger smooth surface area rather than sharp threads, and by providing a mechanism for delivery of bone cement that integrates the dome plunger with the cancellous bone of the femoral head. The dome plunger alone fails at a load 50% higher than that of stainless steel lag screws. Adding cement augmentation supports higher loads, and it eliminates failure by cutout through the femoral head (21) (Fig. 19.18). Intramedullary fixation devices, which combine a hip screw with either a short or long intramedullary nail such as the Gamma nail (Stryker-Osteonics-Howmedica, Rutherford, NJ), have the theoretical advantages of percutaneous insertion, a lower bending moment on the fixation device, and an intramedullary buttress that precludes excessive medial migration of the shaft. Biomechanical comparison of intramedullary devices to sliding hip screw devices have not demonstrated any distinct advantage of one system over the other; however, the intramedullary devices transmit progressively decreasing loads to the proximal femur with increased instability of the fracture, and failure of the intramedullary devices occurred through the distal cross-locking holes when short-stemmed devices were used (87,109).

***Figure 19.18.*** **A:** The Alta dome plunger (Howmedica, Rutherford, NJ) when implanted in the femoral head provides superior resistance to cutout in osteoporotic bone, compared to compression hip screws. **B:** Insertion of the plunger into the dome expands it like a molly bolt. **C:** Polymethylmethacrylate cement can be placed in the dome and, when the plunger is driven home to expand the dome, the cement is extruded into the surrounding cancellous bone, as illustrated here, resulting in superior fixation in osteoporotic bone. **D:** AP radiograph of a dome-plunger in a femoral head.

The primary principle in the treatment of intertrochanteric hip fractures is to reestablish the continuity of bone between the head and neck fragment and the shaft and to place the fixation device central in the femoral head. This will allow the bone to carry the majority of the load transmitted across the hip (46), minimizing the risk for failure, and allowing frail patients to be mobilized early with sufficient weight bearing so that they can gain a reasonable degree of independence.

## HISTORY OF TREATMENT

The treatment of intertrochanteric fractures has advanced greatly in the last three decades. In the early 1900s, patients suffering intertrochanteric fractures were simply placed in traction in bed for prolonged periods of time until healing, or more commonly until death. In the 1930s, Smith-Peterson (126) introduced his nail, which allowed immediate fixation and earlier mobilization. Unstable fractures remained a problem, so in the mid 1960s, various osteotomies were advocated by Dimon and Hughston (37) and Sarmiento (113,114) that used rigid fixation devices to create a stable fracture from an unstable configuration. Unfortunately, both of these procedures have been associated with increased morbidity and mortality due to the increased surgery, and postoperative shortening was not well accepted by patients. During this same period, Clawson (22) and Massie (89) introduced sliding devices that allowed impaction of fracture fragments. These devices have led to superior results in the treatment of intertrochanteric fractures.

Intramedullary devices were introduced in the 1970s in the form of the Ender nail (11,39) and the condylocephalic nail (60) for fixation of intertrochanteric fractures. These devices are placed retrograde from entry sites near the knee using percutaneous technique under fluoroscopic control. Theoretical advantages include the decreased bending moment on the device as previously described for the Gamma nail; elastic fixation, which was proposed to aid fracture healing; and percutaneous technique, which hastened fracture union by preserving the blood supply to the fracture and decreased operating time and blood loss. In spite of early reports of high rates of success, later series showed a high incidence of varus deformity and knee pain caused by the distal migration of pins (121,130). This led to a high incidence of reoperation for pin extraction and correction of deformity, which was a problem in elderly patients. Shortening and external rotation were problems in many of those who otherwise healed uneventfully. This has led most authorities to recommend abandoning these devices for fixation of intertrochanteric fractures. However, some surgeons believe that there is still a place for Ender nails in the elderly debilitated patient who has a stable fracture and who can tolerate only minimal operative intervention. The details of the surgical technique described later in this chapter are critical. The most recent development has been the antegrade intramedullary devices such as the Gamma nail, which are very popular in central Europe but seem to have outcomes similar to sliding hip screws (8,58,83,144). These are discussed in more detail later in section D on second-generation interlocking nails.

## CLASSIFICATION

A fracture classification system is of value only if it leads to better care of the fracture or permits a more accurate prognosis. In intertrochanteric fractures, the classification should allow the surgeon to predict the stability of the fracture because stability is the key to selection of treatment as well as prognosis.

Intertrochanteric fractures can first be classified as stable or unstable. In the stable intertrochanteric fracture, the posteromedial buttress remains intact or is minimally comminuted, and therefore substantial collapse of the fracture fragments is unlikely. In the unstable intertrochanteric fracture, however, a large segment of the posteromedial wall is fractured free and comminuted, and therefore the fracture tends to collapse into varus.

The classification proposed by Evans (41,42) and Boyd and Griffin (15) is useful because it further divides stable fractures into those without comminution, those with minimal comminution, and those that are subtrochanteric. A modification of Boyd's classification is that of Kyle, Gustilo, and Premer (81), which recognizes four basic intertrochanteric fracture types. Type I fractures consist of nondisplaced stable intertrochanteric fractures without comminution (21%) (Fig. 19.19*A*). Type II fractures represent stable, minimally comminuted but displaced fractures (36%); these are fractures that, once reduced, allow a stable construct (Fig. 19.19*B*). Stable fractures are not a problem and hold up well with any type of fixation device. The unstable type III intertrochanteric fracture (28%) is a problem fracture and has a large posteromedial comminuted area (Fig. 19.19*C*). The unstable type IV fracture is uncommon (15%) and consists of an intertrochanteric fracture with a subtrochanteric component (Fig. 19.19*D*). This is the most difficult type of fracture to fix because of the great forces imposed by muscle forces and weight bearing on the subtrochanteric region of the femur (81,150).

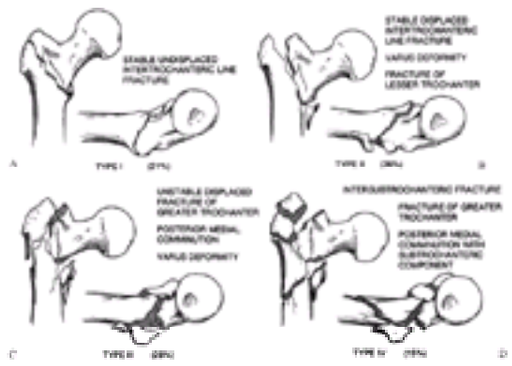

***Figure 19.19.*** **A:** Type I intertrochanteric fracture. **B:** Type II intertrochanteric fracture. **C:** Type III intertrochanteric fracture. **D:** Type IV intertrochanteric fracture.

## SURGICAL TECHNIQUES

### SLIDING HIP SCREW TECHNIQUE

- Place the patient supine on an orthopaedic fracture table (Fig. 19.20) after administration of a general or regional anesthetic. Place the unaffected leg into gentle traction to stabilize the pelvis on the peroneal post, and abduct the hip 45° to provide access for the C-arm fluoroscope.

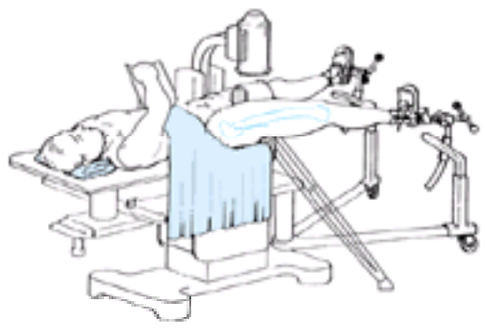

***Figure 19.20.*** Supine position on a fracture table for fixation of an intertrochanteric fracture with a compression hip screw or Ender nails. Note that both legs are in traction with the C-arm located between the legs. In comminuted unstable fractures where gravity causes the fracture to sag posteriorly, support the fracture site with a crutch placed under the proximal femur or greater trochanter, as illustrated.

- Apply gentle traction to the affected leg and use image intensification to discern the fracture elements.
- Reduce the fracture with traction in line with the body and enough internal rotation to place the femoral neck parallel to the floor on the lateral view. Confirm reduction on the AP and lateral views with image intensification.
- Type I fractures are undisplaced, so they do not require a reduction maneuver and simply need to be placed in the appropriate position for pinning, as previously described.
- Type II fractures require somewhat more vigorous traction and internal rotation to close the fracture. Internally rotating the hip to bring the femoral neck parallel to the floor usually suffices. This helps to orient the surgeon to the placement of the guide pin on the lateral view. Sometimes slight valgus in these fractures produces a more stable position, particularly if there is some medial comminution.
- Type III and type IV unstable fractures require more vigorous traction and should be reduced in valgus of 140° to 150° because this is more likely to result in good bone contact medially. The valgus will compensate for the shortening that may be necessary to gain good bone contact medially, and it will reduce the bending moment on the fracture site.
- If traction alone does not reduce the fracture, then abduction to obtain the appropriate position on the AP view may be necessary. On the lateral view, gravity often causes the fracture to sag posteriorly, producing excessive anterior angulation of the head and neck fragment. This may be difficult to manage but can often be corrected by supporting the trochanteric region with a crutch placed under the hip and angled to be out of the way of the C-arm (Fig. 19.20).
- Prepare and drape the hip in the usual manner. Make an incision over the lateral aspect of the thigh, beginning at the flare of the greater trochanter and extending 12–15 cm distally. Carry dissection down through the skin and subcutaneous tissue to the fascia lata. Split the fascia lata along its posterior extent, trying to avoid the muscle belly of the tensor fascia lata. This exposes the vastus lateralis. Retract the vastus lateralis superiorly with a rake and split it longitudinally if it is thin, or reflect it anteriorly from the lateral intermuscular septum and subperiosteally off the lateral aspect of the femoral shaft. Detach the origin as necessary. Retract the vastus lateralis and fascia lata anteriorly with a Bennett retractor.
- Under fluoroscopic control, place a guide pin along the mid-anterior aspect of the femoral shaft and neck, in line with the angle planned for the hip screw (141) (Fig. 19.21). The guide pin should appear to lie within the center of the femoral head on the AP radiograph, and parallel to the inferior femoral neck. This helps to locate the site for the hole drilled in the lateral aspect of the shaft.

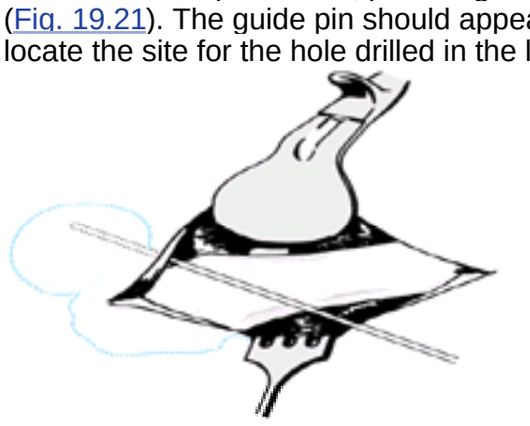

***Figure 19.21.*** Position of preliminary guide pin along the anterior aspect of the femoral neck.

- Using a drill slightly larger than the size of the selected guide pin, perforate the lateral aspect of the femoral shaft at the appropriate level as dictated by the guide pin (Fig. 19.22). If the femoral head and neck lie posterior on the lateral view, start the drill hole slightly anterior; if they are anterior, start the drill hole slightly posterior.

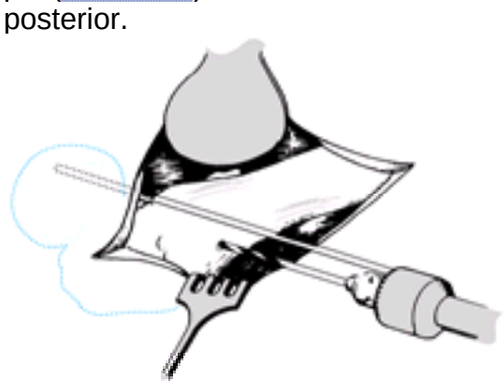

***Figure 19.22.*** Drilling through the lateral cortex of the femoral shaft. Make the hole large enough to accommodate variable positions of the guide pin.

- Prior to insertion of the guide pin, be certain that the fracture is well reduced on both the AP and lateral views. If the fracture is sagging posteriorly, adjust the crutch (if it is being used), or place a bone hook on the posterior aspect of the fracture and lift the fracture to reduce the posterior sag and to place the femoral neck in line with the shaft or in slight anteversion.
- Now insert the guide pin specified by the manufacturer for the type of sliding hip screw being used. In most systems, side plates with angles from 130° to 150° at 5° increments are available. If this is the case, some surgeons prefer to insert the guide pin freehand, without using an angle guide, placing the guide pin as close to the medial cortex of the neck of the femur as will accommodate the hip screw, and ending up with the tip of the guide pin in the dead center of the femoral head on both AP and lateral views. Once satisfactory position of the guide pin has been obtained, they use the angle-measuring device provided by the manufacturer to select the side plate angle that is closest to the pin they have inserted. This technique can lead to a maximum error on the AP view of 2.5°, which is usually tolerable. I prefer to insert the guide pin through a guide set at the desired angle, so that more precision can be gained in the placement of the hip screw, which reduces the risk of displacing the fracture (Fig. 19.23). In young, dense bone, the guide pin may need to be drilled, but in the average elderly patient it can be driven with a mallet. The tip of the hip screws should not lie closer than 7 mm to the subchondral bone of the femoral head. This needs to be taken into account, depending on the particular instrumentation being used.

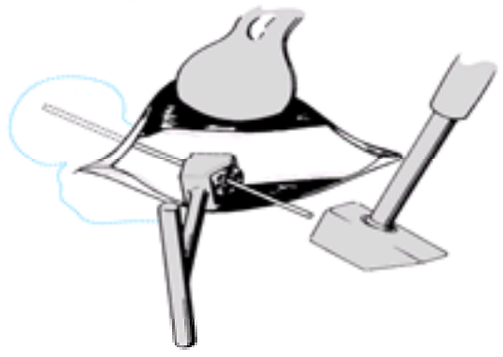

***Figure 19.23.*** Use a guide to establish the angle of the guide pin in the femoral neck. Insert the guide pin through the guide using a drill or mallet, placing it dead center in the femoral head. On the AP views, some surgeons prefer to have the guide pin somewhat inferior to the midline of the head.

- Determine the length of screw to be used by measuring the amount of the guide pin that is inside the proximal femur and the head and neck fragments (Fig. 19.24). Once the length has been measured, it is advisable in most systems to drive the guide pin up to subchondral bone so that the guide pin is not accidentally removed when the channel for the hip screw is reamed.

***Figure 19.24.*** Use a depth gauge to determine the length of the hip screw. Plan to place the screw no closer than 7 mm from the subchondral bone of the head.

- Then place a step drill over the guide pin and ream a hole in the lateral aspect of the femoral shaft to the appropriate depth. Depending on the device used, place a tap over the guide pin and advance it across the fracture site into the neck and head fragment to the level of the desired position of the screw (Fig. 19.25).

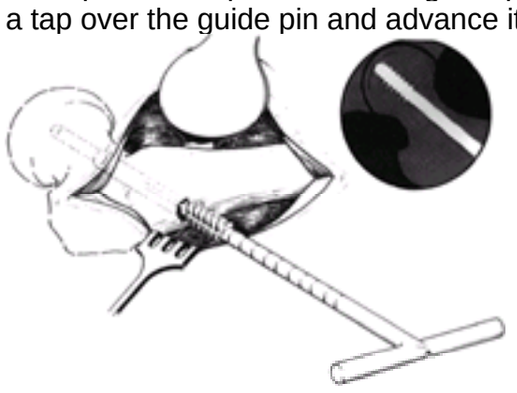

***Figure 19.25.*** Place a tap over the guide pin and tap the dense cancellous bone of the femoral head. In osteoporotic bone, tapping is usually not necessary or advisable.

- Place the screw or nail over the guide pin and insert it to the proper level under image intensification (Fig. 19.26).

***Figure 19.26.*** In most systems, the sliding hip screw and side plate can be preassembled and the hip screw then screwed into place over the guide pin.

- After seating the screw, insert the plate, ensuring that it is parallel to the femoral shaft and lies snugly against it. A fixed nail-plate angle device that does not lie parallel to the shaft after the screw has been inserted may cause a subtrochanteric fracture if forced down on the shaft. If an inappropriate angle has been selected, so that the plate diverges by more than 5° from the shaft, select a plate with the proper nail-plate angle.
- Fix the plate to the lateral aspect of the shaft with three or four bicortical bone screws (Fig. 19.27). Secure medial fragments with screw technique or a circlage cable, if possible. This is possible in most current designs by the oval-shaped hole in the side plate. Use image intensification during the final seating of the screw to ensure that it is well located in the femoral head and within 7 mm of subchondral bone.

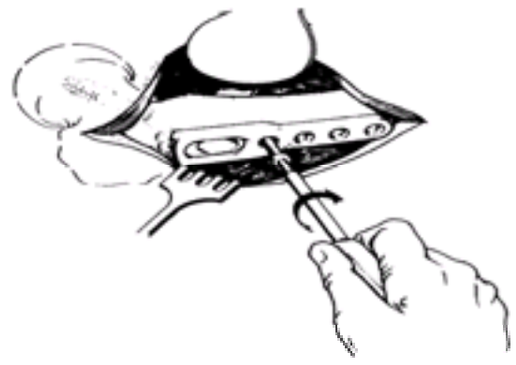

***Figure 19.27.*** Fit the plate snugly against the femoral shaft and secure it with at least three bicortical screws.

- The sliding between the hip screw and the side plate now allows impaction of the fragments to a stable position. Release traction from the affected hip and grasp the patient at the knee through the sterile drapes to ensure that traction is released and that impaction can occur. Accomplish impaction by a direct blow on the plate with an impactor. Then insert a compression screw, if available, to secure the position. Obtaining impaction with the compression screw alone is usually not advisable because in weak bone the screw can be pulled out of the femoral head (Fig. 19.28).

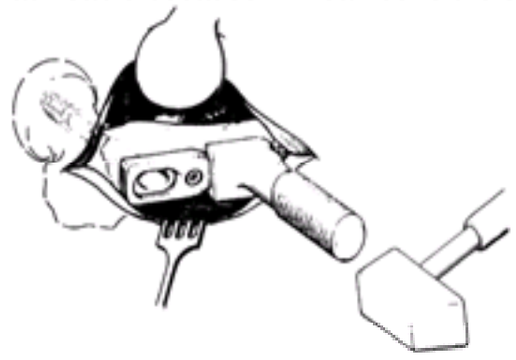

***Figure 19.28.*** Release the traction on the foot and impact the fracture using the impaction device.

- Last, rotate the hip through its full range of motion under fluoroscopic visualization to ensure that the nail is within the confines of the femoral head and the fracture is stable.
- Thoroughly irrigate the wound, ensure hemostasis, place a suction drain, close the wound in layers, and apply a sterile compressive dressing.

See the AP and lateral radiographs of Figure 19.29 for a typical case.

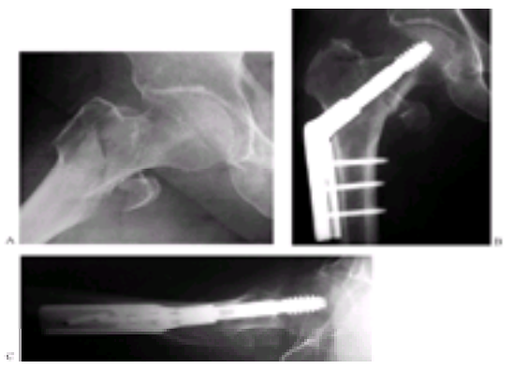

***Figure 19.29.*** Sliding compression hip screw and side plate fixation of an intertrochanteric fracture. **A:** AP radiograph of a comminuted intertrochanteric fracture. **B:** AP radiograph of fixation with a compression hip screw. **C:** Lateral radiograph.

The patient may sit within a few hours of surgery or the day after surgery, as dictated by comfort. As soon as practical, begin ambulation with aids, allowing weight bearing on the injured extremity as tolerated if solid fixation of a stable reduction has been obtained. Progress weight bearing as tolerated. Take radiographs at weekly intervals for the first 2 weeks to ensure proper impaction of the fragments and function of the sliding device. If there is a subtrochanteric component to the fracture, or the bone quality or reduction is marginal, delay weight bearing until callus is seen on radiographs.

**OPEN TECHNIQUE ON A REGULAR TABLE**

Comminuted four-part intersubtrochanteric fractures can be very difficult to internally fix on a fracture table. I prefer to place these patients in a lateral decubitus position on a regular operating table and expose the base of the neck as well as the shaft with a limited Watson-Jones exposure.

- Visualize the femoral head and fracture with a C-arm fluoroscope placed in the AP position over the top of the patient. The C-arm of the fluoroscope must be sterilely draped. It can be rotated up over the torso out of the way when it is not needed and then swiveled into the AP position on the hip when used.
- Expose the fracture with a limited Watson-Jones exposure. In this type of fracture, the greater trochanter is fractured and free of the shaft fragment; therefore, the trochanteric fragment and the shaft can be pushed posteriorly out of the way to expose the base of the head and neck fragment. This needs to be exposed only enough to have good visualization of the base of the neck, and a good feeling for the axis of the neck anteriorly.
- Insert a guide pin into the inferior half of the base of the neck parallel to the medial neck under fluoroscopic control to place the guide pin dead center in the middle of the femoral head on both the AP and lateral views. Obtain fluoroscopic visualization of the head and neck fragment by manipulating this fragment alone, rather than by moving the extremity or the C-arm. With a **T**-handle on the guide pin and a sharp pointed tenaculum grasping the base of the femoral neck, rotate it to obtain perfect AP and lateral views. Then ream the channel for the hip screw and insert the hip screw under direct fluoroscopic control. Judge the proper length screw by measuring the guide pin in the head and neck fragment and adding to it the width of the femoral shaft at the level of the hip screw.

## HINTS AND TRICKS

- If patients are thin and lightly muscled, a direct split of the vastus lateralis is easiest and quickest. In younger, heavily muscled patients, or in comminuted fractures where extension of the approach into a Watson-Jones exposure may be necessary, release the vastus lateralis from the anterior and lateral aspects of its origin, elevate it off the lateral intermuscular septum, and reflect it anteriorly as a single unit. This provides a clean exposure for management of comminuted fragments in the subtrochanteric area, facilitates a Watson-Jones exposure, and allows identification of the proximal arterial perforators for control of bleeding.
- Many different types of hip screws and instrumentation systems are available. Most of these offer various guides and mechanisms for setting the depths of reamers, for example. Do not rely solely on these mechanical devices, but visualize the insertion of tools and implants on fluoroscopy at all times. Use of the step image minimizes radiation exposure of the patient and surgeon.
- If the patient is being treated supine on a fracture table, and reduction of the fracture is difficult or maintenance of the reduction is challenging, do not hesitate to extend the exposure somewhat proximallytin the manner of Watson-Jones to gain exposure of the base of the femoral head and neck fragment, because this greatly facilitates reduction.
- Most stable fracture patterns can be done through a relatively small incision. Three bicortical screws in the plate are nearly always sufficient. The plate can be slid subperiosteally beneath the vastus lateralis and the screws inserted through a stab wound in the muscle, which minimizes soft-tissue dissection. Where longer plates are needed, the modular Alta system (Howmedica, Rutherford, NJ) facilitates this minimally invasive technique.
- Controlled impaction of the fracture on the table under fluoroscopic control produces immediate stability of the fracture in most hips. Careful examination under fluoroscopy will, in most cases, demonstrate sufficient stability in the fracture site to confidently allow early weight bearing.
- During rehabilitation, even though you are allowing early weight bearing, always have the patient use an assistive device. In the elderly, walkers are usually the best—not so much for protection of the fracture, but to prevent the patient from having another fall and sustaining additional injuries.

- Once the hip screw is securely in place, select either a 145° or 150° side plate and slip it onto the hip screw to the appropriate depth. Then bring the femoral shaft into proper alignment with the head and neck fragment, align the side plate on the lateral aspect of the shaft, and secure it loosely with a Lowman bone-holding for-ceps.
- Then, under fluoroscopic control, impact the head and neck fragment and the shaft together to restore cortical continuity, particularly along the medial side. Be certain that rotation is correct. Then secure the plate to the shaft of the femur with an appropriate number of bicortical screws, and secure the hip screw to the side plate with the compression screw.
- In some cases, the fragments of the greater trochanter will lie in appropriate position; however, in many cases a circlage cable placed around the medial neck of the femur, at the level of the lesser trochanter, or around the base of the hip screw and subsequently through a drill hole in or over the top of the greater trochanter, will reestablish the continuity of the abductor mechanism.
- Close the wound over a suction drain in a routine manner.

Postoperatively, keep these very unstable fractures on limited weight bearing to the weight of the leg until bridging callus is seen on radiographs.

The advantages of this technique are that the set-up time is much quicker because a fracture table is not involved; the effect of gravity, which causes the fracture to sag, is eliminated, making reduction much easier; and the relative positions of the patient and surgeons plus the limited open exposure make the procedure quicker and easier than when the patient is in the supine position on a fracture table. The disadvantages are the increased soft-tissue exposure and, perhaps, some increased blood loss.

## SECOND-GENERATION INTERLOCKING NAILS AND RODS

Type IV intertrochanteric/subtrochanteric fractures may be fixed with Ender nails or a second-generation interlocking nail such as a Gamma-type interlocking nail. Use full-length second-generation interlocking nails when there is distal extension of the femoral shaft fracture, or if a distal femoral shaft fracture is combined with an intertrochanteric/subtrochanteric fracture. Ideally, the piriform fossa should be intact for the entry point of a standard intramedullary nail. But Gamma nails enter at the tip of the trochanter, which is nearly always intact, and Ender nails enter distally. The techniques for insertion of Gamma and Ender nails are described next. See Chapter 20 for the interlocking nail technique.

### *Gamma Nail Technique*

- Position the patient supine on a fracture table and reduce the fracture anatomically as previously described for insertion of a compression hip screw. Access to the tip of the trochanter must be unimpeded; therefore, if the patient is heavily muscled or obese, tilt the torso toward the opposite side. Be certain that high-quality AP and lateral views on the C-arm fluoroscope can be obtained, and then prepare and drape the hip and thigh in the usual fashion.
- Make a longitudinal incision 3–4 cm long, directly over the tip of the greater trochanter. Carry this directly down to bone and expose the tip of the greater trochanter by splitting the muscle fibers of the gluteus maximus and medius.
- Insert a guide pin into the tip of the trochanter and open it with a reamer.
- Then insert a ball-tip guide pin across the fracture into the shaft of the femur, and use flexible reamers to ream the intramedullary canal 2–3 mm larger in diameter than the Gamma nail to be inserted. The proximal femur down to the lesser trochanter must be reamed to at least 17 mm in diameter to accommodate the nail. Remove the guide pin.
- Assemble the appropriate-size Gamma nail on the driver, selecting the valgus angle most suitable for the fracture. More comminuted fractures can be nailed in more valgus. Available angles are 125°, 130°, and 135°. The nail is 17 mm in diameter proximally and 11 mm in the shaft portion. Ten degrees of anteversion is built into the nail. When the reduction is done, if the femoral neck is placed parallel to the floor, then the nail can be inserted in a neutral position, which facilitates proper placement.
- Under fluoroscopic control, locate the entry site for the hip screw and make a 2.5 cm longitudinal incision in the skin, over the lateral aspect of the hip, at the appropriate point. Carry dissection sharply down through the deep fascia and vastus lateralis, and expose sufficient lateral femur just below the greater trochanter in a subperiosteal manner. Assemble the targeting jig on the nail. Insert the appropriate guide sleeve (tissue protector) down to bone, make a starting point with the awl, and insert a guide pin under fluoroscopic control. Make certain that the guide pin on the AP view is at or inferior to the midline of the neck, and that it is dead center on the lateral view, with the guide pin ending up dead center in the femoral head. Be certain that the angle of the targeting jig matches that of the nail.
- Measure the length of the hip screw off the guide pin.
- Now ream over the guide pin to the appropriate depth for the hip screw, and tap the hole if hard cancellous bone is present.
- Then insert the appropriate-length hip screw to the appropriate depth, under fluoroscopic control; confirm that it is in appropriate position, and then release the traction and impact the fracture to ensure good bone contact and a stable position. Particularly in osteoporotic bone, it is essential that good medial bone contact occur.
- Finally, place the set screw through the top of the nail to secure the position of the hip screw. Tighten it, and then loosen it one-quarter turn to permit sliding between the hip screw and the nail.
- If the fracture is unstable and comminuted, and further resistance to shortening and additional rotational control is desired, distally cross-lock the nail, using the cross-locking guide for the short Gamma nail and the free-hand technique for the long Gamma nail.
- After closure of the wounds and application of a sterile dressing, take AP and lateral radiographs on the fracture table to be certain that the fracture is well reduced and in stable position, and that the Gamma nail is in appropriate position (Fig. 19.30).

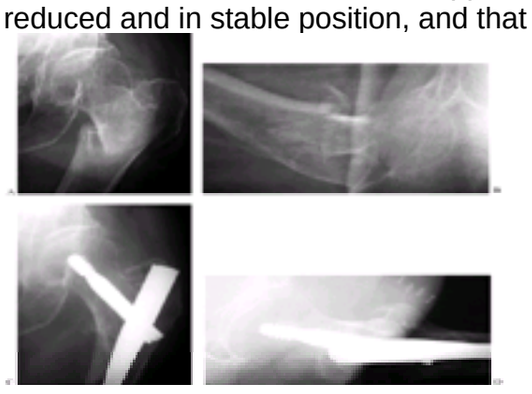

***Figure 19.30.*** Gamma nail fixation of an intertrochanteric fracture. **A:** AP radiograph of a comminuted intertrochanteric fracture with severe osteoporosis. **B:** Lateral radiograph. **C:** AP radiograph of fixation of the fracture with a long Gamma nail. **D:** Lateral radiograph.

Mobilize the patient as soon as possible after surgery, following the routine described for the compression hip screw.

***Ender Nail Technique***

Ender's technique of fixing intertrochanteric hip fractures, which was extended to include shaft fractures using multiple solid elastic stainless steel nails, using a retrograde percutaneous approach, became popular in the 1970s (11,39). Although some surgeons still use Ender nailing as their primary means for fixing hip fractures, the technique is not used much in North America today. The nails offer little resistance to shortening in unstable fracture patterns, and fractures tend to externally rotate. Prominence of the nails at the knee may require a second operation to remove them. In addition, because the fixation is much less rigid than with a compression hip screw, patients experience more pain postoperatively and do not rehabilitate as quickly. Ender nailing of the femur, tibia, and humerus, however, is a very useful technique that should be in the armamentarium of every surgeon treating these fractures, because in the femur there are certain situations for which the nail is ideal:

## HINTS AND TRICKS

The key points in the Gamma nail fixation technique are the following:

- Anatomic reduction of the fracture prior to insertion of the nail.
- Proper entry point with overreaming of the nail so that the intramedullary nail can be pushed into place by hand without using a mallet.
- Proper seating of the nail so that the screw is in line with the femoral neck and located dead center in the femoral head, or perhaps somewhat inferior on the AP view.
- Improper technique can lead to microcracks in the proximal portion of the femur, near the end of the nail, which can cause femoral shaft fractures (100). This risk can be minimized by proper surgical technique with the short Gamma nail, or by using the long Gamma nail if bone quality is poor.

- Use it for internal fixation of fractures in the proximal femur when the condition of the skin about the hip precludes a surgical approach at the hip.
- Use it for severely ill patients with stable fracture patterns, in whom percutaneous technique with minimal soft-tissue dissection offers the advantages of rapidity and minimal blood loss.
- Use it for patients with hip fractures in severely osteoporotic bone, in whom a medullary device is preferred because of the risk of a pathologic fracture at the site of the plate and a hip screw. Exercise caution with Ender nails, because supracondylar fractures can occur through the distal entry holes.
- Use it for fractures in children and adolescents with open physes, where internal fixation is required but larger intramedullary devices would threaten the growth plates or blood supply to the femoral neck. Ender nails are currently the device of choice for older children with femoral shaft fractures accompanied by multiple injuries, who require intramedullary fixation of the femur (see Chapter 164).

The Ender nail technique for fixing intertrochanteric hip fractures is as follows:

- Place the patient supine on a fracture table in the same position as described for the sliding hip screw. In type I and II fractures, reduce the fracture anatomically. In type III and IV fractures, use a valgus reduction of up to 150° because this greatly facilitates insertion of the Ender nails. Because of the tendency of the nails to run straight rather than curve into the femoral head fragment as much as you might like, comminuted fractures are often easier to fix than more simple fracture patterns reduced anatomically. Ender advises placing the hip in more internal rotation than you would for a traditional hip screw to compensate for the tendency of the fractures to externally rotate as they compress into stable position. In unstable fracture patterns, the crutch beneath the greater trochanter is very useful in Ender nailing, because having a straight shot proximally into the femoral head and neck fragment from the medullary canal on both views greatly facilitates the nailing.
- Prepare and drape the knee circumferentially from the mid thigh to below the tibial tubercle.
- Because the primary entry site for the Ender pins is in the distal medial femur, stand between the legs with your assistant on the lateral side of the knee, and the operating nurse behind you. Locate the C-arm just above the affected hip on the lateral side, making certain that good-quality AP and lateral views can be obtained without moving the base of the C-arm.
- Make a longitudinal skin incision 7 cm long, beginning just distal to the medial epicondyle and extending proximalward. Split the deep fascia just anterior to the medial intermuscular septum, and reflect the vastus medialis anteriorly to expose the femur subperiosteally just above the superior medial geniculate artery. Identify and protect the superior medial geniculate artery because this is the landmark to the entry site for the pins. Laceration of this artery can lead to profuse bleeding. Ligate it if it is in the way or if significant bleeding occurs.
- Next, make the entry hole for the nails (Fig. 19.31). The distal end of this hole should be 1 cm proximal to the medial geniculate artery. The hole needs to be at least 15 mm wide to accommodate two 4.5 mm Ender nails side by side, and it must have a length of 20–25 mm to accommodate at least three nails without causing enough pressure on the proximal end of the hole to lead to unexpected fracture of the entry hole or distal femur. Make an initial entry hole with a Steinmann pin or drill point, and follow this with a Küntscher awl. Use this to enter the cancellous bone of the metaphysis of the femur. Take care to not use it to open the harder cortical bone near the diaphysis, because this can lead to fracture of the cortex. Follow the awl with a small-angled rongeur and use this to develop an oval hole with a smooth contour. Use a nail as a reference to be certain that the hole is of adequate size. The longitudinal axis of this hole must be directly in line with the shaft of the femur, and it is better placed slightly more posterior than anterior, because the nails in a more anterior position are more likely to result in knee pain.

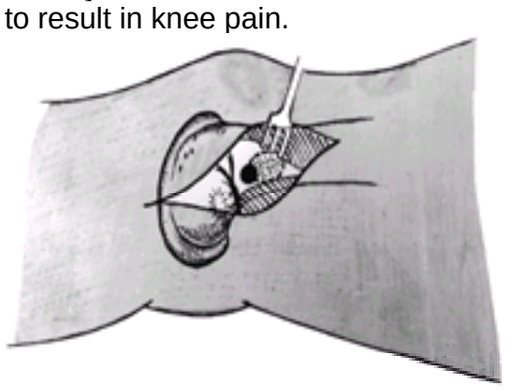

***Figure 19.31.*** Entry site for retrograde Ender nailing of a hip fracture just proximal to the medial epicondyle. See text for full description.

- Use a Küntscher skin protector distally. Standard femoral nails are 4.5 mm in diameter, with lengths of 34 to 49 cm. Shorter nails of 4 mm diameter from 28 to 44 cm long are available for smaller people. Be certain that reduction of the hip fracture has been maintained. Determine the nail length by inserting a forceps into the distal end of the entrance hole as a landmark, and then placing the nail on the anterior aspect of the thigh with the tip directly over the femoral head. The nail length will be correct when the tip touches or is just slightly distal to the subchondral bone of the weight-bearing portion of the femoral head (use visualization on a fluoroscopic image) and the flange of the nail rests on the cortex immediately distal to the entry hole. The nail will bend as it is being inserted, shortening its effective working length and resulting in the tip of the nail lying approximately 5–7 mm below the subchondral bone of the femoral head. If the nail length is not quite correct after insertion, leave the nail in place and insert a second nail of appropriate length prior to withdrawing the first nail. Sometimes the first nail can be left in as a stacking nail (see later) if multiple nails are to be used to gain stability in a wide medullary canal.
- Nails are available with a C or an S curvature. For intertrochanteric fracture, use the C nails. In anatomic reductions, particularly when placing the first nail along the medial femoral neck, bending the tip of the nail to increase its curvature is helpful as long as the bend in the nail is not so much that it impedes the passage of the nail down the medullary canal. The tip of the nail has a smooth bevel that facilitates passage of the nail when it encounters a cortex. When passing the nails, think about driving the tip of the nail along the curvature of the femur, as you would drive a car down a winding highway. Insert the first nail by hand with the **T**-handled driver into the hole, matching the curvature of the nail to the curvature of the femur. Begin at an angle of approximately 45° to the longitudinal axis of the femur, and then reduce the angle to come in line with the femur as the nail progresses proximally. The nail passes smoothly across the fracture and into the head and neck fragment if it is twisted to stay in the middle of the medullary canal until it reaches the level of the lesser trochanter. At the lesser trochanter twist the nail internally to place the maximum curvature along the medial aspect of the femoral neck. Insert this first nail just past the fracture site, being certain that it is firmly located in the proximal fragment, but do not insert it to its full depth until all of the nails are in place. Next, insert a second and third nail, making an effort to fan the nails in the femoral head on both the AP and lateral views (Fig. 19.32). Once all three nails are into the head and neck fragment, they can be sequentially driven as a group to within 5–7 mm of the subchondral bone of the head. Distally, the nails should lie flush with the medial cortex of the femur, above the epicondyle (Fig. 19.33).

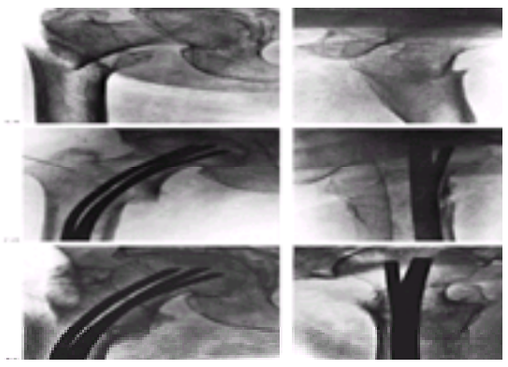

***Figure 19.32.*** Ender nail fixation of a four-part intertrochanteric hip fracture. **A,B:** In this impacted pertrochanteric fracture, the impaction of the proximal fragment into the trochanteric region and the posterior angulation are easily discernible on the lateral view. **C,D:** Fixation after overreduction in a slight valgus position was performed with three nails. Full weight bearing three days after surgery led to the anatomic position and collapsing of the diastasis seen in the intraoperative lateral view. **E,F:** Follow-up after 1 year shows solid healing in good position.

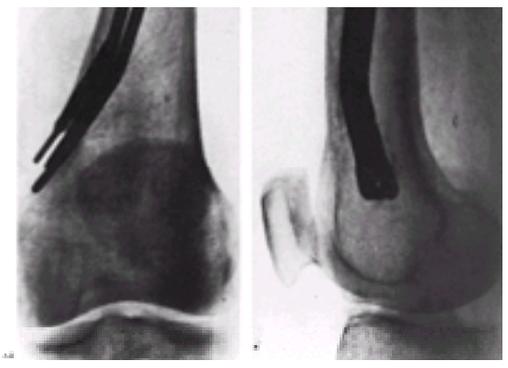

***Figure 19.33.*** Note the entrance site for the nails, which is proximal enough to the medial epicondyle that the nails lie flat along the bone surface (**A**) and are angulated somewhat posteriorly on the lateral view (**B**).

- The technique for combined intersubtrochanteric fractures or for subtrochanteric fractures is the same, except one or more nails are inserted through a lateral portal into the greater trochanter using a technique identical to that described for the medial side (Fig. 19.34).

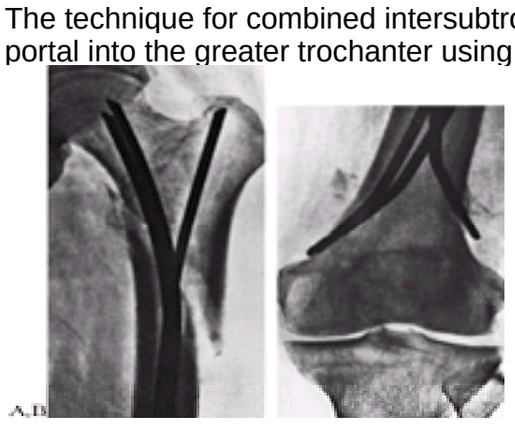

***Figure 19.34.*** **A:** In subtrochanteric fractures, arrange the nails in a **V** formation in the proximal fragment so that two or more nails are inserted from the medial condyle into the femoral neck or head, and one or more into the greater trochanter. **B:** Note the separate entrance hole in the lateral condyle, just opposite the medial entrance hole.

- When the nails are in place, loosen the traction and maximally impact the fracture site, visualizing the head and neck fragment on the AP view to be certain that the nails do not penetrate the femoral head into the joint.
- Ensure hemostasis in the soft tissues, and then close the wound in layers. Suction drains are usually not advisable because if there is continued bleeding from the medullary canal, excessive blood loss into the suction drain may occur. Usually it is better to simply let a small hematoma form, which tamponades the medullary canal. This is rarely a problem.

**HINTS AND TRICKS**

- Frequent fluoroscopic visualization during nailing, using the step mode on the fluoroscope to limit radiation exposure, is advisable to be certain that the nails are following the desired track, and that nails already inserted are not accidentally pushed proximally too far as the other nails are inserted.
- Stable fracture patterns in patients with narrow medullary canals can often be managed with two nails, but most fractures do best if fixed with three. It is rarely necessary to use more than three, but if the nails are loose in the medullary canal, add short nails that extend only into the isthmus portion of the femur to jam the nails to prevent back-out.
- Be certain that the flats of the nails distally lie flush and parallel to the cortex, lying on solid cortical bone. Prominent nails can cause knee pain. Nails that are too short can accidentally spring into the medullary canal of the femur and then, if they back out, can penetrate the knee joint or at a minimum be very difficult to remove.
- To produce a more stable fixation construct, some surgeons wire the distal ends of the nails together through the extraction hole. Ender nails can be interlocked distally by placing a screw through the eye of the nail, but this risks penetration of the articular surface of the femoral head if excessive shortening occurs and therefore is not recommended as a routine procedure.
- When driving a nail, be careful not to hold it too far from the long axis of the femur, particularly as it progresses proximalward, because this may produce excessive pressure on the proximal medial surface of the entry hole, resulting in a fracture of the cortex above the hole. This can cause a major stress riser, which can lead to supracondylar fracture of the femur.
- Nail removal is usually not necessary, but up to a third of patients experience knee pain that requires removal of the nails. This can be accomplished through a small incision, using the Ender nail extraction tool. This is most easily inserted by placing the extraction tip beneath the nail toward the bone and twisting it into the extraction hole of the nail.
- Be certain that postoperative radiographs cover the entire length of the femur, so that the position on both AP and lateral views can be fully assessed at the hip and the position at the entry hole can be fully visualized as well.
- In unstable subtrochanteric and comminuted fractures for which unacceptable shortening is predictable, Ender advises keeping the patients in postoperative traction until early callus is seen on radiographs. With this technique, this averages between 3 and 4 weeks. It is the need for postoperative traction in these unstable fractures that has limited the use of Ender nails in favor of interlocking nails, which offer far superior stability.

Postoperatively, mobilize patients as soon as they can tolerate. Use assistive devices for ambulation and limit weight bearing to the weight of the leg until bridging callus is seen on radiographs, which is usually at about 6 weeks. At this time, progress weight bearing as tolerated until full weight bearing is achieved. In stable fracture patterns, this usually occurs within 1–2 or more weeks, but in unstable patterns, particularly those with a subtrochanteric component, full weight bearing is often delayed until 12 or more weeks after surgery.

## PRIMARY PROSTHETIC REPLACEMENT

The vast majority of inter- and subtrochanteric fractures can be treated with primary internal fixation. Indications for primary prosthetic replacement using a proximal

femoral replacement prosthesis would include the following:

- Peritrochanteric fractures in the presence of severe arthritis of the hip, especially if the hip is stiff
- Pathologic fractures in which the bone stock precludes internal fixation
- Unstable, severely comminuted fractures in the very elderly, whose bone is so osteoporotic that internal fixation, even with cement augmentation, is expected to fail

The last indication is controversial, but a prospective randomized study by the Stappaerts group (18,129) that compared compression hip screws to a Vandeputte endoprosthesis in these fractures suggested that primary prosthetic replacement might have fewer early complications and satisfactory functional results.

### PITFALLS AND COMPLICATIONS

Complications of fixation of intertrochanteric fractures are minimal compared with other hip fractures if the surgeon uses the appropriate device and pays close attention to the mechanical principles involved. The overall failure rate using a sliding hip screw or nail of newer alloys should not exceed 10%. Nail breakage is extremely rare with use of current high-technology metals. The infection rate in intertrochanteric fractures should not exceed 1% to 2% with the use of prophylactic antibiotics. Acute infection usually responds well to irrigation and debridement, possibly implantation of antibiotic-impregnated beads, and intravenous antibiotics if the fracture construct is stable. Avascular necrosis is extremely rare in intertrochanteric fractures and has not been reported to occur in more than 1% of patients in any series (122). If nonunion does occur, the success rate after removal of the device and renailing in a more valgus position is 90%; for this reason, repeated fixation is recommended.

Failure with Gamma nails is usually caused by a varus reduction with a too-superior placement of the nail, which results in the head and neck fragment cutting off the hip screw. This can usually be salvaged by rereduction and nailing in a valgus position, either with a new Gamma nail or with conversion to a compression hip screw. The other complication in Gamma nails is fracture of the femur at the tip of a short Gamma nail. This is best treated by conversion to a long Gamma nail. Failure in Ender nails is usually caused by a varus reduction, persistent instability, and failure to fill the canal with nails, which results in back-out of the nails and collapse at the fracture site. This can often be corrected by rereducing the fracture, reinserting the same nails using proper technique, and adding nails to produce stability. Supracondylar fracture at the entry hole can be managed by circlage wiring in many cases. Instability and displacement, however, may require conversion to a condylocephalic interlocking nail or plate fixation distally.

## D. SUBTROCHANTERIC FEMUR FRACTURES

The subtrochanteric area of the femur has been defined as the region between the lesser trochanter and the junction of the proximal and middle third of the femur. Although fractures in this area affect all age groups, there are two peak ages of incidence. The first occurs during late adolescence and early adulthood, when high-energy trauma from motor-vehicle and motorcycle accidents causes displaced or comminuted fractures (1). With these mechanisms of injury, severe injuries to other organ systems are frequent. The other age group of increased incidence is the geriatric population, for whom minor slips and falls are common, often resulting in subtrochanteric fractures. Metastasis from tumors (e.g., lung and breast cancer) often cause pathologic subtrochanteric fractures through compromised bone stock.

These troublesome injuries combine many of the least desirable features of intertrochanteric and femoral shaft fractures. If they are comminuted, stable internal fixation may be difficult to achieve with plates and screws. Moreover, the predominantly cortical nature of the subtrochanteric region prolongs healing times (120). For even the experienced traumatologist, subtrochanteric fractures may present formidable problems in management (120).

### BIOMECHANICS

The subtrochanteric region is an area of high stress concentration (4,20,43,44,73,115,138,146). The proximal end of the femur has been likened to a cantilevered arch that transfers the force of weight bearing from the lower extremity to the hip and pelvis. Vertical loading forces on the femoral head generate a large moment arm in the proximal femur, concentrating compressive forces medially and tension forces laterally. When comminution, bone loss, or tumors create deficiencies in the medial cortex, the delicate balance of forces is altered, leading to deformity.

If the medial cortex can be reconstituted at the time of surgery, a plate placed laterally acts as a tension band, allowing impaction with protected weight bearing. If the medial cortical contact is not restored, bending stresses are concentrated in one small area of the plate, which often results in mechanical failure of the internal fixation device with delayed union, nonunion, or malunion of the fracture (143). Until recently, restoration of the continuity of the medial cortex of the proximal femur has been the key to success. However, the superior strength and mechanics of locked intramedullary nails combined with closed nailing techniques have eliminated the mandate to reconstitute the medial cortex at the time of surgery (13,17,152). The major advantage of intramedullary fixation is that it allows the bone to carry a substantial portion of the load, which significantly reduces the risk of implant failure while preserving the blood supply to bone when a percutaneous technique is used, which hastens healing.

Ever since the introduction of locked intramedullary nails in the 1980s, the indications for closed nailing of subtrochanteric fractures have dramatically expanded. Locking the nail into good-quality bone above and below the fracture site produces immediate fracture stability. Patients can be mobilized shortly after surgery without fear of loss of length or malrotation. The load-sharing intramedullary nail lies within the weight-bearing axis of the leg and is better suited to resist torsional and bending forces than a plate and screws.

### CLASSIFICATION

There is no universally accepted method of classification for subtrochanteric femur fractures. In 1949, Boyd and Griffin (15) classified trochanteric fractures of the hip into four types. In their classification, type III injuries were pure subtrochanteric fractures, and the type IV fractures were combined intertrochanteric–subtrochanteric fractures. Fielding and Magliato (44) in 1966, and Zickel et al. (156,157) a decade later, classified subtrochanteric fractures according to radiographic appearance. Since that time, several investigators have modified existing classifications or proposed new ones (115,118,145).

In 1978, Seinsheimer (118) developed a classification for subtrochanteric fractures that allowed the surgeon to analyze results based on a specific fracture group or subtype (Fig. 19.35). The IIIA subtrochanteric fracture was associated with a poor outcome in eight of nine patients treated with internal fixation in his series. In what is probably the most widely used classification of subtrochanteric fractures, the Association for the Study of Internal Fixation (AO-ASIF) group (91) divides these injuries into three basic types and ten subtypes, based on their radiographic appearance (Fig. 19.36).

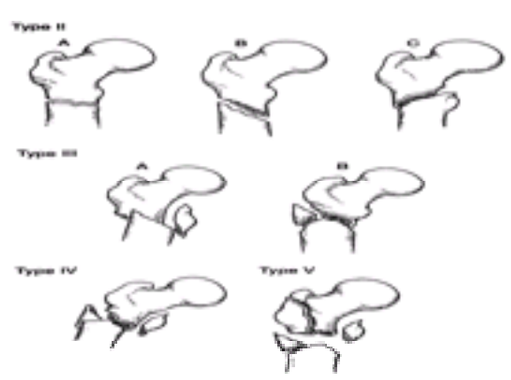


***Figure 19.35.*** The Seinsheimer classification of subtrochanteric femur fractures.

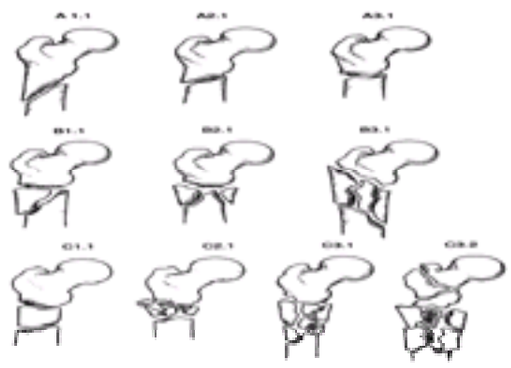

***Figure 19.36.*** The AO-ASIF classification of subtrochanteric femur fractures.

Classifications that influence treatment or prognosis are the most useful. Unfortunately, anatomic fracture classifications fail to address associated conditions commonly seen with subtrochanteric femur fractures, although they often influence treatment or outcome. The factors that play a dynamic role in fracture management have been termed the *personality* of the fracture. Among these are the amount of fracture displacement, the extent of soft-tissue injury, the presence or absence of open wounds, associated neurovascular injuries, the degree of osteoporosis, multiple trauma, and complex ipsilateral injuries (e.g., ipsilateral femoral neck or segmental fractures). A large number of fracture patterns are seen in clinical practice, and some do not fit neatly into any classification scheme. This emphasizes the fact that every case must be individually evaluated and that the “personality” of the fracture must be considered in selecting the method of treatment.

## NONOPERATIVE TREATMENT

During the past 30 years, there has been nearly a complete elimination of nonoperative treatment in adults and a corresponding increase in operative treatment of subtrochanteric fractures. A thorough understanding of the anatomy and biomechanics of the subtrochanteric region is essential if nonoperative treatment is to be used. Powerful hip and thigh muscles lead to significant deformities after fracture. The iliopsoas and hip abductors cause flexion, abduction, and external rotation of the proximal fragment, and the strong pull of the adductors produces shortening and varus of the distal fragment. Skeletal traction followed by a spica cast or a cast brace 4–6 weeks later is still the method of choice for most fractures in childhood and early adolescence.

Skeletal traction is occasionally indicated in adults with subtrochanteric fractures with extreme fracture comminution. Lack of appropriate implants and surgical inexperience make operative intervention hazardous (34). Although this method of treatment eliminates many operative complications, such as anesthetic complications, blood loss, and infection, it is not without its own complications. In adults, prolonged costly hospitalization is necessary, and acceptable alignment may be difficult to achieve despite frequent adjustments of the traction. Knee stiffness and varus malunion remain common problems after skeletal traction. Furthermore, traction treatment is usually contraindicated in the multiply injured or elderly patient.

In adults, skeletal traction for 8–12 weeks followed by a hip spica cast is invariably required. Traction modalities depend on the patient's body habitus and the radiographic fracture pattern. For some patients, a Thomas splint and Pearson knee attachment can be effective. In other patients, alignment is better maintained with a modified form of Russell's traction using a proximal tibial pin. If the hip must be flexed more than 45°, or if significant external rotation is required to achieve alignment, a distal femoral pin with 90°-90° traction may be more practical (Fig. 19.37). Approximately 30–40 lbs (14–18 kg) of traction is required to reduce the fracture in adults. After length and alignment are restored, the weight can usually be decreased (see Chapter 10).

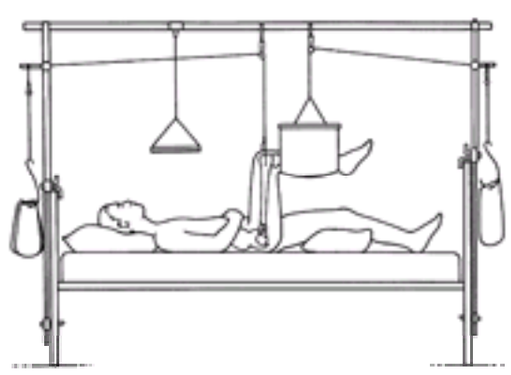

***Figure 19.37.*** Treatment of a subtrochanteric fracture in skeletal traction using a distal femoral traction pin and the 90°-90° position.

Anatomic reduction of the fracture fragments is not practical with treatment in traction, but restoration of overall length and alignment is important. Do not accept more than 5° to 7° of varus, or 10° of anterior or posterior angulation if possible. Limb shortening of 1.0–1.5 cm does not usually compromise functional results. While the patient is in traction, institute a full rehabilitation program with upper extremity weight lifting, as well as range-of-motion and strengthening exercises of the uninvolved lower extremity. As the fracture begins to consolidate, range-of-motion exercises of the hip and knee in traction are usually possible.

One of the most common errors in nonoperative treatment of subtrochanteric fractures is premature termination of traction and application of a spica cast (20). Because of the tremendous forces concentrated in the subtrochanteric region, discontinuing traction earlier than 8–12 weeks usually leads to a varus deformity. This can occur even if the patient is immobilized in a hip spica. The cast should not be applied until the fracture site is no longer tender and radiographs show abundant callus formation. To minimize the risk of varus deformity, cast braces must include a pelvic band, which holds the hip in an abducted position. Application of a fracture brace should not lull the surgeon into a false sense of security. Careful attention to the details of fracture reduction and the application of the cast or brace are crucial to success. Examine the patient and take radiographs at 1 and 3 weeks after cast application to guard against unrecognized loss of reduction. Protect the fracture until it is healed, which may take as long as 6 months (see Chapter 10).

## INDICATIONS FOR SURGERY

Internal fixation of displaced subtrochanteric femur fractures has gained widespread acceptance as surgical techniques and implants have improved over the past 40 years. The combination of properly engineered implants, a better understanding of soft-tissue handling, perioperative antibiotics, and improved anesthetic methods have made internal fixation safe and effective (111). The goals of surgical treatment of subtrochanteric femur fractures are anatomic alignment, stable internal fixation, rapid mobilization of the patient, and early functional rehabilitation of the limb. However, it is important to remember that internal fixation of subtrochanteric fractures is difficult.

The surgical techniques remain complex, and it is essential to have complete sets of instruments and implants, and experienced surgical, nursing, and physiotherapy staff. If these criteria are met, the following may be considered indications for surgery:

- Displaced subtrochanteric fractures in adults
- Fractures in multiply injured patients
- Most open fractures
- Associated vascular injuries requiring repair
- Severe ipsilateral limb injuries
- Unacceptable alignment after attempted closed treatment
- Pathologic fractures
- Certain fractures around a hip prosthesis

There are no absolute contraindications to surgical stabilization, but there are several relative contraindications to internal fixation:

- Active infection
- Severely contaminated high-energy open fractures (grade IIIB)
- Massive comminution or bone loss
- Severe osteopenia
- Fractures in hemodynamically unstable, multiply injured patients
- Unavailability of adequate implants
- Unavailability of experienced surgeons

In isolated closed subtrochanteric femur fractures that require surgery, perform internal fixation as soon as practical, and within the first 48 hours if possible. If surgery is delayed at all, place the patient in skeletal traction. Stabilize closed fractures in patients with multiple injuries during or at the conclusion of the thoracic, abdominal, vascular, or neurosurgical procedures, if possible.

## DEVICES AND TECHNIQUES

There are two major types of internal fixation devices widely used in the management of subtrochanteric femur fractures: locking intramedullary nails and plates. Because the spectrum of injuries to the subtrochanteric region is so great, no single implant can be suitable for every case. Careful assessment of the patient and a critical review of the radiographs and the personality of the fracture are essential.

### REAMED INTRAMEDULLARY NAILS

Conventional reamed intramedullary nailing of subtrochanteric fractures with Küntscher-type nails does not provide reliable fixation of the proximal part of the femur because of its wide medullary canal. Their use is restricted to transverse or short oblique fractures without comminution. Even with these simple fracture patterns, shortening, malrotation, or nail back-out often leads to unacceptable results. In comminuted fractures, supplemental fixation with cerclage wires or unicortical plates has frequently been necessary. The major advantage of intramedullary fixation is that it allows the bone to carry a substantial portion of the load. This significantly reduces the risk of implant failure. Additionally, fixation can be done using closed nailing techniques, minimizing soft-tissue disruption at the fracture site with better preservation of periosteal blood supply.

#### *First-Generation Interlocking Nails*

Since the introduction of locked medullary nails in the early 1980s, the indications for closed nailing of proximal femoral fractures has expanded (17,152). All closed adult subtrochanteric fractures below the level of the lesser trochanter can be safely nailed with a first-generation nail, regardless of the fracture pattern or degree of comminution (Fig. 19.38). Nails with transverse proximal locking, such as the Alta nail (Howmedica, Rutherford, NJ), can be used for fractures at or above the lesser trochanter (Fig. 19.39). Closed locked intramedullary nailing is the current treatment of choice in adults for all acute nonpathologic subtrochanteric femur fractures that require operative stabilization.

***Figure 19.38.*** **A:** A comminuted subtrochanteric femur fracture in a 23-year-old man was the result of a motorcycle accident. **B:** Length and alignment were restored after static locked intramedullary nailing. **C:** At 6 months, the fracture is healed.

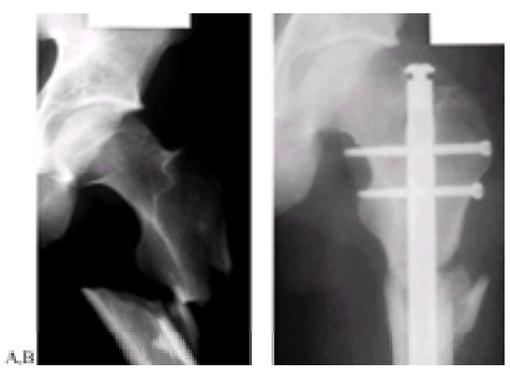


***Figure 19.39.*** **A:** AP radiograph of a subtrochanteric fracture. **B:** Radiograph after fixation with a standard Alta intramedullary nail with static proximal and distal cross-locking. Note the location of the proximal transverse cross-locking screws in the femoral neck.

Two types of interlocking nailing—static or dynamic—can be performed, depending on the fracture location and configuration. In static locking, screws are inserted in the proximal and distal fragments. Rotational stresses are minimized, and shortening at the fracture site is prevented. With dynamic nailing of subtrochanteric fractures, a proximal screw is inserted. Rotational movement is neutralized, but shortening of the fracture site is not always prevented. Because of the small proximal fragment in subtrochanteric fractures, always lock subtrochanteric fractures proximally.

Distal locking is strongly advised in Winquist-Hansen (see Chapter 20) comminution types II, III, and IV and in long spiral fractures. If any doubt exists about the stability of fixation after nailing, the nail should be statically locked. Locking the nail into the bone above and below the fracture site produces immediate fracture stability. Distal locking adds little to the procedure, so I now statically lock all nails. Patients can then be mobilized shortly after surgery without fear of malrotation or loss of length. Closed locked femoral nailing can now be performed routinely in the vast majority of patients who previously would have required open reduction and internal fixation or prolonged traction. Early mobilization should reduce postoperative medical complications, maintain joint motion, and decrease hospital stay (Fig. 19.40).

***Figure 19.40.*** **A:** Displaced subtrochanteric femur fracture of a 31-year-old woman who sustained multiple injuries in a motor-vehicle accident. **B:** Closed intramedullary interlocking nailing restored the length and alignment. No attempt was made to reduce the medial butterfly fragment. **C:** Follow-up at 14 months showed union of the fracture with incorporation of the butterfly fragment.

The technique of reamed locked intramedullary nailing of femur fractures is described in Chapter 11 and Chapter 20; therefore, only those features pertinent to subtrochanteric fractures are emphasized here.

Patients can be operated on using closed technique on a fracture table in the lateral decubitus or supine position, or open exposure of the fracture site can be done with the patient in the lateral decubitus position on a regular table. I prefer the lateral decubitus position on a regular table for most comminuted subtrochanteric fractures. Positioning on a fracture table in the lateral position is somewhat more difficult than in the supine position, but the fixation of the fracture is greatly facilitated because there is far superior access for the instrumentation, and reduction of the fracture is much simpler. The supine position is much more familiar to most surgeons and therefore is preferred by many. The flexed adducted position of the proximal fragment, however, makes reduction of the fracture difficult, and the patient's buttocks and thigh are frequently in the way of the instrumentation, particularly in heavily muscled or obese patients. I use the lateral position with open technique when speed is essential, or when the patient is already on a regular operating table because of general surgical procedures that have just been completed for multiple injuries. In addition, in intertrochanteric–subtrochanteric combinations, open technique makes obtaining a satisfactory reduction and solid fixation easier at the expense of a larger wound, more blood loss, and more threat to the blood supply of bone.

Particular issues in using closed technique, whether lateral or supine, are as follows:

- The proximal fragment is frequently quite flexed and externally rotated. This alignment is often difficult for the surgeon to ascertain. It is critical that the very best images on the C-arm be obtained, and this can be difficult in large patients. Because of the position of the proximal fragment, it is quite easy to place the starting point much too anterior and too medial on the femoral neck. When using first-generation nails, be certain that the starting point is directly over the intramedullary canal.
- Again, because of the flexed–adducted position of the proximal fragment, reaming of the proximal fragment may be eccentric and produce malposition when the nail is inserted. Avoid this by paying attention to the alignment of the proximal fragment. If satisfactory position cannot be maintained, make a small incision and insert a bone hook or bone-holding forceps to hold the proximal fragment in proper position. Sometimes the fracture must be opened.
- My custom is to distally cross-lock first, and then to use the driver on the nail to back-slap the nail to ensure optimal contact between the proximal fragment and the shaft, so that the femur can load-share when there is greater than 50% contact between the fragments.
- Nails such as the Grosse-Kempf (Howmedica, Rutherford, NJ), with an oblique proximal cross-locking screw, require an intact lesser trochanter to obtain adequate fixation in the proximal fragment. Nails that offer transverse cross-locking screws proximally, such as the Alta nail, can be positioned more proximally (the Alta nail is specifically designed to do this), and the cross-locking screws can be inserted into the medial femoral neck, which gives excellent fixation and does not threaten the mechanical integrity of the femoral neck or the blood supply to the femoral head (158) (Fig. 19.39).

***Second-Generation Intramedullary Nails***

The dramatic success of first-generation interlocked nails for complex subtrochanteric fractures expanded the indications for closed nailing of these difficult injuries. However, as the indications for nailing were extended to more proximal fractures, an increased incidence of implant and proximal screw failures were noticed in comminuted fracture patterns. Furthermore, most first-generation nails provided inadequate fixation if the fracture extended above the level of the lesser trochanter. These problems led to the development of a new generation of interlocked nails that provided better fixation by directing screws into the head of the femur, and that allowed distal interlocking (Fig. 19.41). These implants are called reconstruction or second-generation nails. They have an increased wall thickness proximally, stronger and larger proximal screws, and reliable proximal targeting devices.

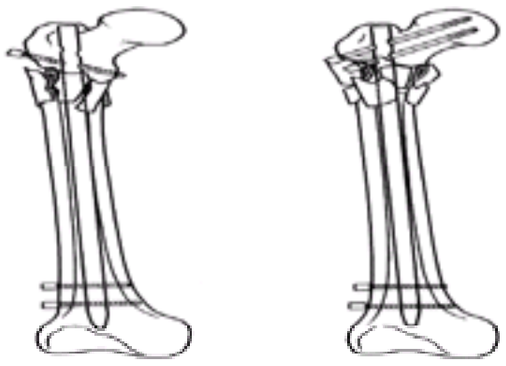

***Figure 19.41.*** **A:** A first-generation interlocking nail. **B:** A second-generation (reconstruction) interlocking nail.

The best indication for the use of a reconstruction or second-generation nail is a “high” subtrochanteric fracture, in which the lesser trochanter is fractured but the greater trochanteric mass remains intact (Fig. 19.42). With this fracture pattern, most conventional first-generation interlocked nails may not provide stable fixation. The use of a second-generation nail for a combined intertrochanteric–subtrochanteric fracture requires considerable surgical experience because these fractures are very difficult to fix (Fig. 19.43). If fracture comminution involves the greater trochanter or the region of piriformis fossa, reconstruction nailing is associated with an increased incidence of complications, particularly varus deformities and implant cutout. A Gamma nail might be a better alternative because it enters through the top of the trochanter (see previous section). In these complex fractures, treatment with a compression hip screw or an angled blade plate may be a better alternative. Although reconstruction or second-generation nailing remains an exciting new surgical technique, there are few published reports of treatment results.

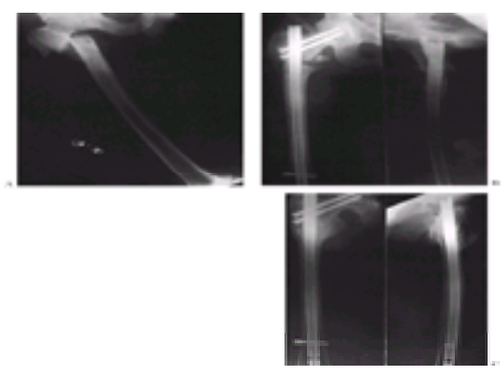

***Figure 19.42.*** **A:** Displaced subtrochanteric femur fracture sustained by a 27-year-old man who fell from a roof. Notice the linear fracture extension into the greater

trochanter. **B:** Fixation was achieved with a second-generation reconstruction nail. **C:** Follow-up at 60 months shows union of the fracture.



***Figure 19.43.*** **A:** Comminuted intertrochanteric–subtrochanteric femur fracture sustained by a 23-year-old woman involved in a motor-vehicle accident. **B:** Treatment with a reconstruction nail provided stable fixation and early mobilization and weight bearing. **C:** Follow-up at 15 months confirmed that the fracture was soundly united.

French and Tornetta (47) analyzed the results in 45 Russell-Taylor type IB subtrochanteric fractures stabilized with a reconstruction nail. Their intraoperative complication rate was 13.5%, with the most frequent problem being varus malposition. The final outcomes, however, were excellent: 100% of the fractures healed at an average of 13.5 weeks. There were no implant failures and 96% of patients gained greater than 120° of knee motion.

Bose et al. (12) reported on their experience with the use of the Russell-Taylor reconstruction nail (Smith Nephew Richards, Memphis, TN) for five ipsilateral femoral neck and shaft fractures and six comminuted subtrochanteric fractures. All of the fractures united. Technical errors occurred in three patients, and three patients ended up with malalignment or shortening, demonstrating that this method of fixation is challenging.

Rodriguez-Alvarez et al. (107) reported their experience with 42 patients treated with the Gamma nail, of which 31 were subtrochanteric fractures. All 31 subtrochanteric fractures healed, but 16 patients had shortening that averaged 1.7 cm with a range of 1 to 4 cm. Six healed with varus deformity, and three of those also had external rotation deformity. Apparently, these authors did not cross-lock the nails distally. An acceptable reduction of the hip must be achieved and maintained during the insertion of the hip screw. In the vast majority of fractures, distally cross-locking is advisable to avoid the shortening and external rotation deformity encountered by Rodriguez-Alvarez et al. See Chapter 11 and in particular Chapter 20 for details on the surgical technique for these devices.

### *Zickel Nails*

Zickel (156,157) provided the first major advance in the treatment of subtrochanteric fractures when he introduced his reinforced nail, which provided proximal cross-locking into the femoral head and neck in the early 1970s. His nail enjoyed its greatest success in the treatment of impending and acute pathologic fractures in the subtrochanteric area (10,32,112). The Zickel nail is no longer used, for the most part, because it does not provide distal cross-locking. Complete stabilization of the fracture requires additional fixation at the fracture site, and refracture of the femur upon removal of the nail has been reported (10,94,139,154).

### *Ender Nails*

Ender nails have been advised for the management of subtrochanteric fractures (79,95). As discussed in the previous section on intertrochanteric fractures, the Ender nail has particular advantages in unusual situations where the soft tissues around the hip preclude the use of any device that enters from around the hip and where a retrograde device inserted through the knee, such as the Ender nail, is particularly advantageous. As pointed out in the discussion on Ender nails in the intertrochanteric fracture section, the Ender nail does not offer enough stability in unstable subtrochanteric fractures to permit immediate mobilization of the patient. Either the fracture must be opened and supplementary fixation applied, or the patient must be protected in traction postoperatively. For that reason, Ender nails are rarely used now for the treatment of subtrochanteric fractures.

### *Postoperative Care after Nailing*

After stable locked reamed intramedullary nailing, patients can be mobilized from bed to chair as soon as they can tolerate it, and can begin crutch ambulation. If the patient's bone quality is good, the fracture is a stable pattern, and if there is at least 50% cortical contact between the proximal and distal fragments, then 50% weight bearing with crutches is usually possible immediately. Weight bearing can be progressed to full weight bearing once bridging callus is seen on both AP and lateral views. In unstable fractures, patients can bear weight to the weight of the leg, but they must not progress weight bearing until bridging callus is seen on two views. In nearly all patients, there is sufficient stability that knee and hip range-of-motion exercises can begin immediately. An aquatic therapy program and use of a stationary bicycle are useful for building range of motion and enhancing muscle strengthening while the fixation must be protected. Healing usually requires 12–24 weeks.

## PLATES AND SCREWS

Modern concepts in the surgical management of subtrochanteric femur fractures using plates was developed by the AO-ASIF group (91). When internal fixation of subtrochanteric fractures was first promoted by this group, the technique aimed at anatomic reduction and stable fixation of all fragments. Primary bone healing was found to be possible if fracture gaps were closed and if rigid stabilization was achieved. However, in comminuted fractures for which extensive soft-tissue dissection was necessary to achieve anatomic reduction, the incidence of delayed union, nonunion, infection, and implant failure was significant (4) (Fig. 19.44). The favorable experience with interlocked nailing for comminuted subtrochanteric fractures gave the surgeon the opportunity to treat difficult fractures with much less soft-tissue dissection. It showed conclusively that anatomic alignment rather than anatomic reduction combined with stable fixation results in a high percentage of favorable fracture outcomes. However, interlocked nailing did not solve the dilemma of difficult intraarticular or epiphyseal-metaphyseal fractures. For these injuries, plate and screw osteosynthesis remains the treatment of choice (56,75,90).

***Figure 19.44.*** **A:** Highly comminuted subtrochanteric femur fracture sustained by a 29-year-old man in a motor-vehicle accident. **B:** Open reduction internal fixation with a 95° angled blade plate. **C:** At 10 months, there was plate failure and nonunion. **D:** After repeat plating with a supplemental iliac crest bone graft, the fracture united at 14 months.

With a better understanding and appreciation of the role of the soft tissues and fracture repair, the methods and techniques of internal fixation have gradually evolved during the past decade into a method termed biological fixation. The aim of current fracture treatment is to achieve stable rather than rigid fixation with a minimum of

soft-tissue dissection and implants. The goal is to preserve the blood supply to bone to enhance early callus formation.

A key component to this is detailed preoperative planning. Perform the surgery on paper or on the computer before going to the operating room. Executed properly, this surgical tactic shortens operative time, minimizes intraoperative decision making, and improves surgical results. In preoperative planning for a subtrochanteric femur fracture, take high-quality radiographs of the intact femur and the injured side. Using plastic templates, trace the fracture and its subsequent reduction, the type and size of implants, and the exact position of screws on tracing paper. Multiple drawings are frequently necessary to arrive at the optimal fixation construct with the least soft-tissue dissection. Careful preoperative planning ensures that the proper implants are available at the time of surgery (56,75,90). When subtrochanteric fractures are reduced open and fixed with plates, always consider autologous bone grafting.

### *The 95° Blade Plate*

- Perform surgery on a standard operating table or a fracture table with biplanar image intensification (75). Make a standard lateral approach to the proximal femur (see Chapter 3). Take down the vastus lateralis from its origin at the base of the greater trochanter, and carefully detach it to expose only the lateral aspect of the proximal femur. Do not dissect the anterior and medial soft-tissue envelope. To protect the anterior and medial tissues, avoid using Bennett-, Cobra-, and Hohmann-type retractors.
- To achieve the desired position for the blade on the AO 95° blade plate on the AP view, enter in the region of the prominence of the greater trochanter. Be sure that the contour of the lateral plate matches that of the femur, with the blade traversing transversely into the center of the femoral neck, inferior to the midline of the neck. On the lateral view, the chisel should be absolutely dead midline. Because the corners of the chisel can accidentally penetrate the articular surface if the tip of the blade plate is placed too close to subchondral bone, always leave it a minimum of 1 cm from subchondral bone on any view. Prior to inserting the seating chisel, drive a 2 mm K-wire into the bone, visualizing it on the AP and lateral views, just superior to where the seating chisel will be placed and exactly parallel to the anticipated path.
- Either using the triple drill guide or free hand, use a 4.5 mm drill point to open up three drill holes in the lateral cortex, transverse to the long axis of the femur in the plane that the blade will sit. In hard young bone, removing about 5 mm of the inferior edge of this hole with a small osteotome at a 45° angle allows room for the bend of the blade plate to seat into the greater trochanter.
- Take the seating chisel (a tuning fork mallet can be slipped over it to provide additional rotational control) and drive it with the **U**-shape of the blade facing superiorly to match that of the blade on the blade plate. Confirm proper position on AP and lateral views with the fluoroscope.
- The length for the blade is measured directly from the seating chisel at the lateral cortex. Now insert the seating chisel into the proximal femur, matching the level determined in the preoperative drawings.
- In patients positioned on a regular operating table, a modified Watson-Jones approach (Chapter 3) and an anterior arthrotomy of the hip with visualization of the femoral head and neck help to guide the placement of the seating chisel. In patients positioned on a fracture table, exposure of the femoral head and neck is not necessary because the position of the seating chisel and blade can be determined solely with the aid of the image intensifier.
- Next, secure the side plate to the lateral side of the femur with bone-holding forceps. Reduce the subtrochanteric fracture to the plate by one of three techniques. One method uses the fracture table to restore length by longitudinal skeletal traction. A second technique to overcome significant shortening uses the femoral distractor (Fig. 19.45). Initial overdistraction often permits gentle teasing of comminuted fracture fragments into near-anatomic positions. A third method of reduction uses the articulating tension device as a distractor (Fig. 19.46). With the fracture temporarily overdistracted, the medial fragments often reduce spontaneously because of their soft-tissue attachments, or they may be reduced by gentle manipulation. Try not to manipulate fragments from the cortical surfaces to avoid soft-tissue stripping. Anatomic reduction is carried out whenever possible, but neither anatomic reduction nor restoration of the medial buttress is absolutely necessary when a biologic approach is employed.

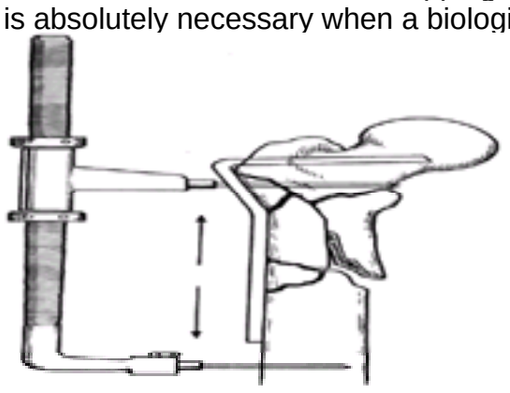

***Figure 19.45.*** Indirect reduction technique using a 95° angled blade plate and the femoral distractor.

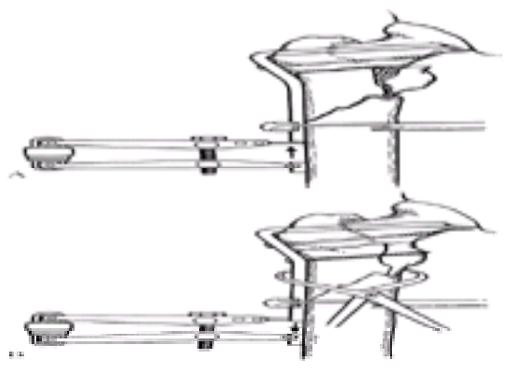

***Figure 19.46.*** Indirect reduction technique uses the articulating tension device. **A:** In distraction. **B:** In compression.

- Regardless of the reduction maneuver, after the comminuted fracture fragments are realigned axially, compress the fracture using the articulating tension device. The blade plate then acts as a lateral tension band, with compressive forces transmitted through the fracture and the restored medial cortex. If the medial comminuted fracture fragments are not keyed into place because of extensive comminution, they are considered a vascularized bone graft and left *in situ.* Supplemental bone graft is not required if the medial soft-tissue envelope has been respected. However, the plate should still be loaded to partially offset varus tendencies. Occasionally, supplemental interfragmentary screws outside the plate increase the stability of the fixation.
- Always apply an autologous cancellous bone graft when the soft tissue has been stripped medially. Or, a bone graft can be inserted medially through the fracture before reduction and fixation of the fracture.

### *Compression Hip Screw*

The sliding compression hip screw with a long side plate has been advocated by several orthopaedists for the treatment of subtrochanteric fractures (4,73,115,140,145). In the past, orthopaedic implant manufacturers warned against its use in subtrochanteric fractures, but newer devices with improved design and materials with higher fatigue strengths have overcome many of the obstacles to its use in the treatment of subtrochanteric fractures. The compression hip screw is more forgiving of imperfect insertion than the blade plate, allowing for sliding impaction of the fracture surfaces with slight medialization of the shaft. Secure fixation in the proximal and distal fragments allows controlled collapse with a decrease in the bending moment and resultant forces. This method of treatment is attractive in high subtrochanteric fractures and in those with proximal extension into the intertrochanteric region. These devices usually must be used in a keyed or locked mode to prevent rotation between the compression hip screw and the barrel of the side plate. A keyless system may lead to instability between the proximal and distal fragment with institution of hip flexion. In cases with medial comminution, place bone graft medially to hasten fracture union (14). This is usually necessary because, unlike the 95° blade plate technique, indirect reduction techniques are not as easily accomplished with a compression hip screw.

### *The 95° Dynamic Condylar Screw*

The compression screw with a 95° sided blade was developed for the treatment of supracondylar and intercondylar fractures of the femur, and it has been adapted for use in the proximal femur. The dynamic condylar screw appears to be a reasonable alternative to the fixed angled plate for the surgeon who only occasionally uses this device (111). However, as with all laterally based plates, reconstruction of the medial calcar is important. Many orthopaedic surgeons suggest cancellous bone grafting if the medial cortex cannot be restored at the time of surgery (73,88).

In all plate devices, if the medial side of the fracture cannot be rendered stable, then consider double plate fixation to reduce the risk of fatigue fracture of the side plate. Use a smaller plate such as a 4.5 mm, four- to six-hole narrow plate placed anteriorly through a modified Watson-Jones exposure.

***Postoperative Care after Plate Osteosynthesis***

After internal fixation with a 95° blade plate, a 95° dynamic condylar screw, or a compression hip screw, mobilize patients as soon as their overall condition permits. If stable fixation has been achieved at the time of surgery, protected crutch ambulation can begin on the second or third postoperative day. Depending on the fracture pattern and the completeness of restoration of the medial cortex, protected weight bearing can usually begin at 4 to 6 weeks. This is gradually increased as clinical symptoms subside and radiographs show progressive fracture union. Do not allow full unrestricted weight bearing until at least 12 weeks, at which time callus should be seen bridging the fracture on two views. Failure to show progressive signs of radiographic union 4–6 months after internal fixation is cause for concern. Bone grafting, with or without revision of the internal fixation, should be considered to prevent delayed union, nonunion, or mechanical failure of the implant.

## EXTERNAL FIXATION

External fixation is used infrequently in the management of subtrochanteric femur fractures. The most common indication for its use is severe open fractures, particularly grade IIIB injuries in multiply injured patients. Depending on the location of the wounds and the degree of fracture comminution, fixation into the iliac crest may be necessary. For most patients, the external fixator is a temporary device used for initial management of the fracture and soft tissues. After control of the soft tissues is achieved, delayed internal fixation can be done. Place fixator pins to avoid areas of planned surgical incisions and implant placement, if possible. The major advantages of external fixation are rapid application, minimal soft-tissue dissection, and the ability to maintain length, provide wound access, and mobilize the patient. Problems associated with its use include pin loosening and infection, loss of knee motion secondary to binding of the quadriceps mechanism, increased risk of delayed union and nonunion, and loss of reduction after its removal.

## OPEN FRACTURES

Open fractures constitute approximately 3% to 5% of all subtrochanteric femur fractures, excluding gunshot wounds. The traumatic wound is usually anterior or lateral but may be located anywhere. As with all open fractures, thorough irrigation and debridement of the fracture and traumatic wounds remain the single most important step in the prevention of infection. Serial debridement may be necessary in many grade III open fractures. With few exceptions, the traumatic wound should be left open. If immediate internal fixation of the open fracture is performed, the surgical extensions can be closed, but the open fracture wounds should not be closed primarily. Although immediate internal fixation is done in most cases, it is not indicated for all fracture patterns. The risk-to-benefit ratio for the patient must be carefully assessed when contemplating primary internal fixation. Advantages of immediate internal fixation in open subtrochanteric fractures include ease of wound care, pain relief, and mobilization of the patient and the injured limb. The major disadvantage of immediate internal fixation is the increased risk of infection as a consequence of further soft-tissue dissection and interference with local blood supply.

In patients with grade I, II, or IIIA open subtrochanteric femur fractures, I favor definitive internal fixation after debridement of the traumatic wounds. Treatment of most grade IIIB and IIIC open subtrochanteric fractures depends on the circumstances. Some of these fractures may be more safely managed with external fixation or skeletal traction and delayed internal fixation.

For less-experienced fracture surgeons, delayed internal fixation of all grades of open subtrochanteric fractures may be advisable. After irrigation and debridement of the wounds, the injured limb can be splinted or placed in skeletal traction. Subsequent surgery can be carefully planned with optimal operating room personnel. Unfortunately, many open subtrochanteric fractures occur in patients with multiple injuries, and failure to stabilize the fracture early often leads to missed opportunities. Associated injuries and pulmonary problems may delay definitive fixation for days or weeks. This increases the technical difficulty of the procedure, contributes to patient morbidity, and compromises the full benefits of internal fixation.

## RESULTS

The superiority of interlocking nails in the treatment of subtrochanteric fractures, compared to blade plates and the Zickel nail, was shown by Brien et al. (17) in a nonrandomized, nonconsecutive series. They had 21 patients in the Zickel nail group, 25 treated with blade plates, and 33 treated with the interlocking nail. Operating times were longest and blood loss greatest with the blade plates. Operating times were shortest and blood loss lowest with the interlocking nail. Combining the incidence of malunion, nonunion, and infection, the overall complication rate in the Zickel group was 57%; in blade plate patients, 36%; and in the nail patients, only 9%, with two malunions, one nonunion, and no infections.

## AUTHOR'S PERSPECTIVE

For subtrochanteric fractures where the lesser trochanter is intact—and even for some where it is fractured but the head and neck and trochanters are one solid unit—I prefer to use a standard Alta titanium intramedullary nail that has two transverse cross-locking screws both proximally and distally. When this nail is seated with its top flush with the top of the femoral neck, the transverse locking screws are located just superior to and inferior to the lesser trochanter. Seating the nail more proximally to place it level with the tip of the trochanter places these two screws in the femoral neck, and seating it 1 cm proximal to the tip of the greater trochanter allows the most proximal screw to be placed into the femoral head. Placement of the screws in the femoral neck eliminates any need to worry about the position of the screws relative to the axis of the femoral neck fragment, which is one of the more difficult technical aspects of placing reconstruction nails, whose screws must traverse up the femoral neck and into the femoral head. Whether these screws are in the posterior, medial, or anterior cortex is irrelevant because a solid hold is obtained in all of these positions, and none of these creates a significant stress riser in the femoral neck, or has ever been shown to interfere with the blood supply to the head (158).

When there is comminution extending into the trochanteric region, I prefer to do these fractures in the lateral-decubitus position on a regular operating table, under fluoroscopic control, utilizing an Alta CFX nail (Howmedica, Rutherford, NJ). When the trochanters are so comminuted that the head and neck fragment is totally free and the entry site for an intramedullary device is essentially destroyed, my implant of choice is usually a compression hip screw and occasionally a blade plate. When using this open technique, it is very difficult to preserve the anterior and medial soft-tissue attachments to the femur; therefore, I routinely do autologous bone grafting.

## PITFALLS AND COMPLICATIONS

Most of the pitfalls and complications have been discussed in the text under the individual techniques. The most common complication of subtrochanteric fractures of the hip is early failure of fixation, with failure of the side plate when hip screws or 95° blade plates are utilized, and cutting of the femoral head and neck fragment off the hip screws when the bone is osteoporotic and there is inadequate medial stability. Because of the large muscle forces around the hip, which are encountered even with the simplest of day-to-day activities such as getting in and out of a chair, fatigue failure of appliances inadequately supported by a good reduction can occur fairly early. Although fracture reduction is under the control of the surgeon, comminution and poor bone quality can preclude adequate stability, so subtrochanteric fractures continue to be a problem. Whenever early failure occurs in a subtrochanteric fracture, infection should be looked for as well. Most early device failures can be treated by early reoperation, replacement with a similar or stronger device, addition of additional fixation such as an anterior plate, and copious autologous bone grafting. Postoperatively, these patients must be very carefully protected until bone union occurs. They must be taught how to get on and off toilets and in and out of chairs, and how to walk to minimize the stress on their implants.

### DELAYED UNION AND NONUNION

Delayed union and nonunion can also manifest itself as implant failure, but with intramedullary devices this is less common. Lack of any visible callus at the fracture site at 3 months after fracture is characteristic of delayed unions. The chances of these progressing to a nonunion are high; therefore, some surgeons feel that bone grafting at 12 weeks, if bridging callus is not seen, is indicated to prevent a nonunion. Nonunions in compression hip screws and blade plate devices at 6 months are usually best treated by conversion to an intramedullary implant combined with bone graft. Nonunion in intramedullary devices is uncommon and can often be treated with exchanged reamed intramedullary nailing to a larger device, usually done by closed technique, but sometimes combined with bone graft with the addition of a unicortical plate. See Chapter 29 for more details.

### MALUNION

Malunion is usually characterized by varus, shortening, and external rotation. Treatment of these complications is complex, usually requiring an osteotomy and repeat

internal fixation. Leg-length discrepancy often requires management with Ilizarov techniques or closed intramedullary shortening of the opposite femur (see Chapter 29, Chapter 30, and Chapter 32).

## INFECTION

Acute infection is usually evident within the first 4 postoperative weeks. Management depends on the severity of the infection and the organism involved. Acute staphylococcal and streptococcal infections without intramedullary involvement, regardless of the device used, usually respond to thorough irrigation and debridement of the wound, closure over antibiotic-impregnated beads, and treatment with appropriate bacteriocidal intravenous antibiotics. Most patients respond quickly, showing resolution of systemic and local signs of infection within a few days. The wound can be reopened again in 5–7 days for removal of the beads; closure over suction drainage or reinstallation of beads can be repeated as many times as is necessary to control the acute infection. Some type of antibiotic treatment for up to 6 weeks is usually required. In more benign infections, intravenous antibiotics followed by oral antibiotics suffice. See Chapter 132 and Chapter 135 for more details.

Chronic infection can be complex to treat if it is accompanied by nonunion with unstable implants. Chronic infection in the presence of bone union usually responds nicely to removal of the implant, debridement, and antibiotic therapy as already described. This complex topic is addressed in detail in Chapter 133 and Chapter 135.

## CHAPTER REFERENCES

Each reference is categorized according to the following scheme: *, classic article; #, review article; !, basic research article; and +, clinical results/outcome study.


# 1. Allgöwer M, Border JR. Advances in the Care of the Multiple Trauma Patient. *World J Surg* 1983;7:1.

+ 2. Arnold CC, Lempberg RK. Fracture of the Femoral Neck. *Clin Orthop* 1977;122:217.

+ 3. Arnold WD. The Effect of Early Weight Bearing on the Stability of Femoral Neck Fractures Treated with Knowles Pins. *J Bone Joint Surg Am* 1984;66:847.

+ 4. Asher MA, Tippett JW, Rockwood CA. Compression Fixation of Subtrochanteric Fractures. *Clin Orthop* 1976;117:202.

+ 5. Askin SR, Bryan RS. Femoral Neck Fractures in Young Adults. *Clin Orthop* 1976;114:259.

+ 6. Banks HH. Factors Influencing the Result in Fractures of the Femoral Neck. *J Bone Joint Surg Am* 1962;44:931.

* 7. Barnes R, Brown JT, Garden RS, Nicoll EA. Subcapital Fractures of the Femur. *J Bone Joint Surg Br* 1976;58:2.

+ 8. Baumgaertner MR, Curtin SL, Lindskog DM. Intramedullary Versus Extramedullary Fixation for the Treatment of Intertrochanteric Hip Fractures. *Clin Orthop* 1998;348:87.

+ 9. Bentley G. Treatment of Non-displaced Fractures of the Femoral Neck. *Clin Orthop* 1980;153:93.

+ 10. Bergman GD, Winquist RA, Mayo KA, Hansen ST. Subtrochanteric Fracture of the Femur: Fixation Using the Zickel Nail. *J Bone Joint Surg Am* 1987;69:1032.

+ 11. Böhler J. Percutaneous Intramedullary Nailing of Intertrochanteric Fractures. In: *The Hip: Proceedings of the Third Open Scientific Meeting of the Hip Society.* St. Louis: CV Mosby, 1975:167.

+ 12. Bose WJ, Corces DA, Anderson LD. A Preliminary Experience with the Russell-Taylor Reconstruction Nail for Complex Femoral Fractures. *J Trauma* 1992;33:71.

! 13. Bostrom MPG, Lyden JP, Ernberg JJ, et al. A Biomechanical Evaluation of the Long Stem Intramedullary Hip Screw. *J Orthop Trauma* 1995;9:45.

+ 14. Boyd HB, Anderson LD. Management of Unstable Trochanteric Fractures. *Surg Gynecol Obstet* 1961;112:633.

+ 15. Boyd HB, Griffin LL. Classification and Treatment of Trochanteric Fractures. *Arch Surg* 1949;58:853.

# 16. Bray TJ. Femoral Neck Fracture Fixation, Clinical Decision Making. *Clin Orthop* 1997;339:20.

+ 17. Brien WW, Wiss DA, Becker V. Subtrochanteric Femur Fractures: A Comparison Between the Zickel Nail, 95 Degree Blade Plate and Interlocking Nail. *J Orthop Trauma* 1991;5:458.

+ 18. Broos PL, Rommens PM, Deleyn PR, et al. Pertrochanteric Fractures in the Elderly: Are There Indication of Primary Prosthetic Replacement? *J Orthop Trauma* 1991;5:446.

+ 19. Chan RNW, Hoskinson J. Thompson Prosthesis for Fractured Neck of Femur: A Comparison of Surgical Approaches. *J Bone Joint Surg Br* 1975;57:437.

# 20. Chapman MW, Zickel RE. Subtrochanteric Fractures of the Femur. In: Chapman MW, ed. *Operative Orthopaedics.* Philadelphia: JB Lippincott, 1988:361.

! 21. Choueka J, Koval JJ, Kummer FJ, et al. Biomechanical Comparison of the Sliding Hip Screw and the Dome Plunger. *J Bone Joint Surg Br* 1995;77:277.

+ 22. Clawson DK. Trochanteric Fractures Treated by the Sliding Screw Plate Fixation Method. *J Trauma* 1964;4:737.

+ 23. Coates RL, Armour P. Treatment of Subcapital Femoral Fractures by Primary Total Hip Replacement. *Injury* 1979;11:132.

! 24. Corck HV. A Revision of the Anatomy of the Arteries Supplying the Upper End of the Human Femur. *J Anat* 1965;99:77.

! 25. Corck HV. An Atlas of the Arterial Supply of the Head and Neck of the Femur in Man. *Clin Orthop* 1980;152:17.

+ 26. Cornell CC, Levine D, O'Doherty JO, Lyden J. Unipolar Versus Bipolar Hemiarthroplasty for the Treatment of Femoral Neck Fractures in the Elderly. *Clin Orthop* 1998;348:67.

! 27. Cotta M. A Histological Study of a Vascular Necrosis of the Femoral Head after Transcervical Fracture. *J Bone Joint Surg Br* 1965;47:749.

! 28. Cotta M. The Histological Appearances of Late Segmental Collapse of the Femoral Head after Transcervical Fracture. *J Bone Joint Surg Br* 1965;47:777.

+ 29. Crawford EJP, Emory RJH, Hansell DM, et al. Capsular Distention and Intracapsular Pressure in Subcapital of the Femur. *J Bone Joint Surg Br* 1988;70:195.

+ 30. Crawford HB. Impacted Femoral Neck Fractures. *Clin Orthop* 1969;66:90.

+ 31. D'Arcy J, Devas M. Treatment of Fractures of the Femoral Neck by Replacement with the Thompson Prosthesis. *J Bone Joint Surg Br* 1976;58:279.

+ 32. Davis AD, Meyer RD, Miller ME, Killian JT. Closed Zickel Nailing. *Clin Orthop* 1985;201:138.

+ 33. Delamarter R, Moreland JR. Treatment of Acute Femoral Neck Fractures with Total Hip Arthroplasty. *Clin Orthop* 1987;218:68.

+ 34. DeLee JC, Clanton TO, Rockwood CA. Closed Treatment of Subtrochanteric Fractures of the Femur in a Modified Cast-Brace. *J Bone Joint Surg Am* 1981;63:773.

+ 35. Den Hartog BD, Bartal E, Cooke F. Treatmemt of the Unstable Intertrochanteric Fracture. *J Bone Joint Surg Am* 1991;73:726.

* 36. Desjardins AL, Roy A, Paiement G, et al. Unstable Intertrochanteric Fracture of the Femur. *J Bone Joint Surg Br* 1993;75:445.

* 37. Dimon JH, Hughston JS. Unstable Intertrochanteric Fractures of the Hip. *J Bone Joint Surg Am* 1967;49:440.

+ 38. Drake JK, Meyers MH. Intracapsular Pressure and Hemarthrosis Following Femoral Neck Fracture. *Clin Orthop* 1984;182:172.

+ 39. Ender J, Simon-Widner R. Die Fixierung der Trochanteren Bruche mit Runden Elastischen Condylennagelen. *Acta Chir Aust* 1970;1:40.

# 40. Epstein HC. *Traumatic Dislocation of the Hip.* Baltimore: Williams & Wilkins, 1980.

+ 41. Evans EM. The Treatment of Trochanteric Fractures of the Femur. *J Bone Joint Surg Br* 1949;31:190.

+ 42. Evans EM. Trochanteric Fractures: A Review of 110 Cases Treated by Nail-Plate Fixation. *J Bone Joint Surg Br* 1951;33:192.

+ 43. Fielding JW, Cochran GB, Zickel RE. Biomechanical Characteristics and Surgical Management of Subtrochanteric Fractures. *Orthop Clin North Am* 1974;5:629.

+ 44. Fielding JW, Magliato HJ. Subtrochanteric Fractures. *Surg Gynecol Obstet* 1966;122:555.

+ 45. Frandsen PA, Kruse T. Hip Fractures in the County of Funen, Denmark. Implications of Demographic Aging and Changes in Incidence Rates. *Acta Orthop Scand* 1983;54:681.

# 46. Frankel VH. *The Femoral Neck: Function, Fracture Mechanism and Internal Fixation—An Experimental Study.* Springfield, IL: Charles C. Thomas, 1960.

+ 47. French BG, Tornetta P III. Use of an Interlocked Cephalomedullary Nail for Subtrochanteric Fracture Stabilization. *Clin Orthop* 1998;348:95.

* 48. Garden RS. Low-Angle Fixation in Fractures of the Femoral Neck. *J Bone Joint Surg Br* 1961;43:647.

* 49. Garden RS. Stability and Union in Subcapital Fractures of the Femur. *J Bone Joint Surg Br* 1964;46:630.

* 50. Garden RS. The Structure and Function of the Proximal End of the Femur. *J Bone Joint Surg Br* 1964;43:576.

# 51. Garden RS. Scientific Thinking and Clinical Research. *Proc Mine Med Off Assoc* 1967;46:399.

+ 52. Garden RS. Malreduction and Avascular Necrosis in Subcapital Fractures of the Femur. *J Bone Joint Surg Br* 1971;53:183.

# 53. Garden RS. Reduction and Fixation of Subcapital Fractures of the Femur. *Orthop Clin North Am* 1974;5:683.

+ 54. Gargan MF, Gundle R, Simpson AHRW. How Effective are Osteotomies for Unstable Intertrochanteric Fractures? *J Bone Joint Surg Br* 1994;76:789.

+ 55. Gebhard JS, Amstutz HC, Zinar DM, Dorey FJ. A Comparison of Total Hip Arthroplasty and Hemiarthroplasty for Treatment of Acute Fracture of the Femoral Neck. *Clin Orthop* 1992;282:123.

+ 56. Gerber C, Mast JW, Ganz R. Biological Internal Fixation of Fractures. *Arch Orthop Trauma Surg* 1990;109:295.

+ 57. Glass KE. Moore Arthroplasty Operations. *J Bone Joint Surg Br* 1965;47:598.

+ 58. Goldhagen PR, O'Connor DR, Schwarze D, Schwartz E. A Prospective Comparative Study of the Compression Hip Screw and the Gamma Nail. *J Orthop Trauma* 1994;8:367.

+ 59. Goodman SB, Bauer TW, Carter D, et al. Norian JRS Cement Augmentation in Hip Fracture Treatment. *Clin Orthop* 1998;348:42.

+ 60. Harris LJ. Closed Medullary Nailing of Inter- and Subtrochanteric Fractures. *Orthop Trans* 1978;2:196.

+ 61. Heiser JN, Oppenheim WL. Fractures of the Hip in Children: A Review of Forty Cases. *Clin Orthop* 1980;149:177.

+ 62. Hinchley JJ, Day PL. Primary Prosthetic Replacement in Fresh Femoral Neck Fractures. *J Bone Joint Surg Am* 1964;46:223.

! 63. Hoaglund ET, Low WD. Anatomy of the Femoral Neck and Head. with Comparative Data from Caucasians and Hong Kong Chinese. *Clin Orthop* 1980;152:10.

+ 64. Hodson JT, Kenzora JE, Hebel JR, et al. Eight-year Outcome Associated with Clinical Options in the Management of Femoral Neck Fractures. *Clin Orthop* 1998;348:59.

+ 65. Holmberg S, Kalen R, Thorngren KG. Treatment and Outcome of Femoral Neck Fractures. An Analysis of 2418 Patients Admitted from Their Own Homes. *Clin Orthop* 1987;218:42.

+ 66. Hunter GA. A Comparison of the Use of Internal Fixation and Prosthetic Replacement for Fresh Fractures on the Neck of the Femur. *Br J Surg* 1974;56:229.

+ 67. Hunter GA. A Further Comparison of the Use of Internal Fixation and Prosthetic Replacement for Fresh Fractures of the Femur. *Br J Surg* 1974;61:382.

+ 68. Hunter GA. Should We Abandon Primary Prosthetic Replacement for Fresh Displaced Fractures of the Neck of the Femur? *Clin Orthop* 1980;152:158.

! 69. Inman VT. Functional Aspects of the Abductor Muscles of the Hip. *J Bone Joint Surg Am* 1947;29:607.

+ 70. Jarnio GB, Thorngren KG. Background Factors to Hip Fractures. *Clin Orthop* 1993;287:41.

* 71. Jewett EL. One-Piece Angle Nail for Trochanteric Fractures. *J Bone Joint Surg* 1941;23:803.

+ 72. Johnson JTH, Crothers O. Nailing Versus Prosthesis for Femoral Neck Fractures. A Critical Review of Long-term Results in Two Hundred and Thirty-nine Consecutive Private Patients. *J Bone Joint Surg Am* 1975;57:686.

# 73. Johnson KD. Current Techniques in the Treatment of Subtrochanteric Fractures. *Techniques Orthop* 1988;3:14.

+ 74. Kenzora JE, Magaziner J, Hudson J, et al. Outcome after Hemiarthroplasty for Femoral Neck Fractures in the Elderly. *Clin Orthop* 1998;348:51.

+ 75. Kinast C, Bolhofner BR, Mast JW, Ganz R. Subtrochanteric Fractures of the Femur: Results of Treatment with the 95° Condylar Blade Plate. *Clin Orthop* 1989;238:122.

+ 76. Kofoed H. Femoral Neck Fractures in Young Adults. *Injury* 1984;14:146.

+ 77. Koval KJ, Aharonoff GB, Rokito AS, et al. Patients with Femoral Neck and Intertrochanteric Fractures. *Clin Orthop* 1996;330:166.

# 78. Koval KJ, Zuckerman JD. Current Concepts Review: Functional Recovery after Fracture of the Hip. *J Bone Joint Surg Am* 1994;76:751.

+ 79. Kudera H, Bohler N, Collon DJ. Treatment of Intertrochanteric and Subtrochanteric Fractures of the Hip by the Ender Method. *J Bone Joint Surg Am* 1976;58:604.

# 80. Kyle RF. Techniques of Fixation for Femoral Neck Fractures in Young Adults. *Techniques Orthop* 1986;1:33.

+ 81. Kyle RF, Gustilo RB, Premer RF. Analysis of 622 Intertrochanteric Hip Fractures: A Retrospective and Prospective Study. *J Bone Joint Surg Am* 1979;61:216.

! 82. Kyle RF, Wright TM, Burstein AH. Biomechanical Analysis of the Sliding Characteristics of Compression Hip Screws. *J Bone Joint Surg Am* 1980;61:1308.

+ 83. Lindsey RW, Teal P, Probe RA, et al. Early Experience with the Gamma Interlocking Nail for Peritrochanteric Fractures of the Proximal Femur. *J Trauma* 1991;31:1649.

+ 84. Linton P. Type of Displacement in Fractures of the Neck of the Femur. *J Bone Joint Surg Br* 1949;31:184.

+ 85. Lunt HRW. The Use of Prosthetic Replacement of the Head of the Femur as Primary Treatment for Subcaptial Fractures. *Injury* 1971;3:107.

+ 86. Lu-Yao GL, Keller RB, Littenberg B, Wennberg JE. Outcomes after Displaced Fractures of the Femoral Neck. A Meta-analysis of One Hundred and Six Published Reports. *J Bone Joint Surg Am* 1994;76:15.

! 87. Mahomed N, Harrington I, Kellam J, et al. Biomechanical Analysis of the Gamma Nail and Sliding Hip Screw. *Clin Orthop* 1994;304:280.

+ 88. Malkawi H. Bone Grafting in Subtrochanteric Fractures. *Clin Orthop* 1982;168:69.

* 89. Massie WK. Extracapsular Fractures of the Hip Treated by Impaction Using a Sliding Nail-Plate Fixation. *Clin Orthop* 1962;22:180.

# 90. Mast J, Jakob R, Ganz R. *Planning and Reduction Technique in Fracture Surgery.* Berlin: Springer-Verlag, 1989.

# 91. Müller ME, Allgöwer M, Schneider R, Willenegger H. *Manual of Internal Fixation*, 3rd ed. Berlin: Springer-Verlag, 1991.

# 92. Myers M. *Fractures of the Hip.* Chicago: Year Book Medical, 1985 (chaps. 2–4).

+ 93. Noordeen MHH, Lauy CBD, Briggs TWR, Ross MF. Unrecognized Joint Penetration in Treatment of Femoral Neck Fractures. *J Bone Joint Surg Br* 1993;75:448.

+ 94. Ovadia DN, Chess JL. Intraoperative and Postoperative Subtrochanteric Fracture of the Femur Associated with Removal of the Zickel Nail. *J Bone Joint Surg Am* 1988;70:239.

+ 95. Pankovich AM, Tarabishy IE. Ender Nailing of Intertrochanteric and Subtrochanteric Fractures of the Femur. *J Bone Joint Surg Am* 1980;62:635.

! 96. Paul JP. Forces at the Human Hip Joint. PhD Thesis, University of Glasgow, 1967.

* 97. Pauwels F. *Der Schenkelhalsbruch ein Mechanisches Problem: Grandlagen des Heilungvorganges. Pronose und Kaisale Therapie.* Stuttgart: Ferdinand Enke, 1935.

+ 98. Phemister DB. Fractures of the Neck of the Femur, Dislocation of the Hip and Obscured Vascular Disturbances Producing Aseptic Necrosis of the Head of the Femur. *Surg Gynecol Obstet* 1934;59:415.

+ 99. Protzman RP, Burkhalter WE. Femoral Neck Fractures in Young Adults. *J Bone Joint Surg Am* 1976;58:689.

+ 100. Radford PJ, Needoff M, Webb JK. A Prospective Randomized Comparison of the Dynamic Hip Screw and the Gamma Locking Nail. *J Bone Joint Surg Br* 1993;75:789.

+ 101. Raine GET. A Comparison of Internal Fixation and Prosthetic Replacement for Recent Displaced Subcapital Fractures of the Neck of the Femur. *Injury* 1972;5:25.

+ 102. Ratliff AH. Fractures of the Neck of the Femur in Children. *J Bone Joint Surg Br* 1962;44:528.

+ 103. Reikeras O, Bjerkreim I, Kolbenstvedt A. Anteversion of the Acetabulum and Femoral Neck in Normals and in Patients with Osteoarthritis of the Hip. *Acta Orthop Scand* 1983;54:18.

! 104. Reikeras O, Hoiseth A, Reigstad A, Fonstelien E. Femoral Neck Angles: A Specimen Study with Special Regard to Bilateral Differences. *Acta Orthop Scand* 1982;53:775.

+ 105. Riggs BL, Wakner HW, Dunn WL, et al. Differential Changes in Bone Mineral Density of the Apendiculum and Axial Skeleton with Aging: Relationship to Spinal Osteoporosis. *J Clin Invest* 1981;67:328.

+ 106. Robinson CM, Court-Brown CM, McQueen MM, Christie J. Hip Fractures in Adults Younger than 50 Years of Age. *Clin Orthop* 1995;312:238.

+ 107. Rodriguez-Alvarez J, Casteleiro-Gonzolez R, Laguna Aranda R, et al. Indications for Use of the Long Gamma Nail. *Clin Orthop* 1998;350:62.

+ 108. Rodriquez-Alvarez J, Herrara A, Canales V, Serrano S. Epidemiologic Factors, Morbidity and Mortality after Femoral Neck Fractures in the Elderly. A Comparative Study: Internal Fixation vs. Hemiarthroplasty. *Acta Orthop Belg* 1987;53:472.

! 109. Rosenblum SF, Zuckerman JD, Kummer FJ, Tam BS. A Biomechanical Evaluation of the Gamma Nail. *J Bone Joint Surg Br* 1992;74:352.

! 110. Rydell WW. *Forces Acting on Femoral Head Prosthesis.* Copenhagen: Munksgaard, 1966.

+ 111. Sanders R, Regazzoni P. Treatment of Subtrochanteric Femur Fractures Using the Dynamic Condylar Screw. *J Orthop Trauma* 1989;3:206.

+ 112. Sangeorzan BJ, Ryan JR, Salciccioli GG. Prophylactic Femoral Stabilization with the Zickel Nail by Closed Technique. *J Bone Joint Surg Am* 1986;68:991.

+ 113. Sarmiento A. Intertrochanteric Fractures of the Femur. 150° Angle Nail-Plate Fixation and Early Rehabilitation: A Preliminary Report of 100 Cases. *J Bone Joint Surg Am* 1963;45:706.

+ 114. Sarmiento A, Williams EM. The Unstable Intertrochanteric Fracture: Treatment with a Valgus Osteotomy and I-beam Nail-Plate—A Preliminary Report of 100 Cases. *J Bone Joint Surg Am* 1970;52:1309.

+ 115. Schatzker J, Waddell JP. Subtrochanteric Fractures of the Femur. *Orthop Clin North Am* 1980;11:539.

+ 116. Scheck M. The Significance of Posterior Comminution in Femoral Neck Fractures. *Clin Orthop* 1980;152:138.

+ 117. Schmidt RG, Gregg JR. Subtrochanteric Fracture Complicating Multiple Pin Fixation of the Hip: An Orthopaedic Dilemma. Paper presented at the American Academy of Orthopaedic Surgeons Scientific Program, January 24, 1985, p. 38.

+ 118. Seinsheimer F. Subtrochanteric Fractures of the Femur. *J Bone Joint Surg Am* 1978;60:300.

+ 119. Sevitt S. Avascular Necrosis and Revascularization of the Femoral Head after Intracapsular Fractures. *J Bone Joint Surg Br* 1964;46:270.

+ 120. Shelton ML. Subtrochanteric Fractures of the Femur. *Arch Surg* 1975;110:41.

+ 121. Sherk HH, Foster MD. Hip Fractures: Condylocephalic Rod Versus Compression Screw. *Clin Orthop* 1985;192:255.

+ 122. Shih L, Chen T, Lo W. Avascular Necrosis of the Femoral Head—An Unusual Complication of an Intertrochanteric Fracture. *J Orthop Trauma* 1992;6:382.

+ 123. Sikorski JM, Barrington R. Internal Fixation Versus Hemiarthroplasty for the Displaced Subcapital Fracture of the Femur. A Prospective Randomized Study. *J Bone Joint Surg Br* 1981;63:357.

+ 124. Sim FH, Sigmond ER. Acute Fractures of the Femoral Neck Managed by Total Hip Replacement. *Orthopedics* 1986;9:35.

+ 125. Smith FB. Effects of Rotary and Valgus Malpositions on Blood Supply to the Femoral Head. *J Bone Joint Surg Am* 1959;41:800.

* 126. Smith-Peterson MN, Cave EF, VanGorder GW. Intracapsular Fractures of the Neck of the Femur—Treatment by Internal Fixation. *Arch Surg* 1931;23:715.

+ 127. Söreide O, Mölster A, Raugstad TS. Internal Fixation vs. Primary Prosthetic Replacement in Acute Femoral Neck Fractures: A Prospective Randomized Clinical Study. *Br J Surg* 1979;66:56.

+ 128. Spivak JM, Zuckerman JD, Kummer FJ, Frankel VH. Fatigue Failure of the Sliding Screw in Hip Fracture Fixation: A Report of Three Cases. *J Orthop Trauma* 1991;5:325.

+ 129. Stappaerts KH, Deldycke J, Broos PLO, et al. Treatment of Unstable Peritrochanteric Fractures in Elderly Patients with a Compression Hip Screw or with the Vandeputte (VDP) Endoprosthesis: A Prospective Randomized Study. *J Orthop Trauma* 1995;9:292.

# 130. Strathy GM, Johnson EW Jr. Enders Pinning for Fractures about the Hip. *Mayo Clin Proc* 1984;59:411.

+ 131. Stromqvist B, Hansson LI, Ljung P, et al. Preoperative and Postoperative Scintimetry after Femoral Neck Fracture. *J Bone Joint Surg Br* 1984;66:49.

+ 132. Stromqvist B, Hansson LI, Palmer J, et al. Scintillometric Evaluation of Nailed Femoral Fracture with Special Reference to Type of Osteosynthesis. *Acta Orthop Scand* 1993;54:340.

+ 133. Stromqvist B, Nilsson LT, Egund M, et al. Intracapsular Pressures in Undisplaced Fractures of the Femoral Neck. *J Bone Joint Surg Br* 1988;70:192.

+ 134. Swiontkowski MF. Intracapsular Fractures of the Hip. *J Bone Joint Surg* 1994;76:129.

! 135. Swiontkowski MF, Harrington RM, Keller TS, Van Patten PK. Torsion and Bending Analysis of Internal Fixation Techniques for Femoral Neck Fractures. The Role of Implant Design and Bone Density. *J Orthop Res* 1987;5:433.

+ 136. Swiontkowski MF, Winquist RS, Hansen S. Fractures of the Femoral Neck in Patients between the Ages of Twelve and Forty-Nine Years. *J Bone Joint Surg Am* 1984;66:837.

+ 137. Taine WH, Armour PC. Primary Total Hip Replacement for Displaced Subcapital Fractures of the Femur. *J Bone Joint Surg Br* 1985;67:214.

! 138. Tencer AF, Johnson KD, Johnston DWC, Gill K. A Biomechanical Comparison of Various Methods of Stabilization of Subtrochanteric Fractures of the Femur. *J Orthop Res* 1984;2:297.

+ 139. Thomas WG, Villar RN. Subtrochanteric Fractures: Zickel Nail or Nail-Plate. *J Bone Joint Surg Br* 1986;68:255.

# 140. Trafton PG. Subtrochanteric-Intertrochanteric Femoral Fractures. *Orthop Clin North Am* 1987;18:59.

# 141. Tronzo RG. Surgery of the Hip Joint. Philadelphia: Lea & Febiger, 1973.

! 142. Trueta J, Harrison MHM. The Normal Vascular Anatomy of the Femoral Head in Adult Man. *J Bone Joint Surg Br* 1953;35:442.

+ 143. Valasco R, Comfort T. Analysis of Treatment Problems in Subtrochanteric Fractures of the Femur. *J Trauma* 1978;18:513.

+ 144. Valverde JA, Alonso MG, Porro JG, et al. Use of the Gamma Nail in the Treatment of Fractures of the Proximal Femur. *Clin Orthop* 1998;350:56.

+ 145. Waddell JP. Subtrochanteric Fractures of the Femur: A Review of 130 Patients. *J Trauma* 1979;19:582.

! 146. Wainer RA, Wright PH, Gilbert JA, Taylor DF. Biomechanics of Ender Rods, Compression Screw, and Zickel Nail in the Fixation of Stable Subtrochanteric Femur Osteotomies. *J Orthop Trauma* 1990;4:58.

+ 147. Watson JT, Moed BR, Cramer KE, Karges DE. Comparison of the Compression Hip Screw with the Medoff Sliding Plate for Intertrochanteric Fractures. *Clin Orthop* 1998;348:79.

# 148. Watson-Jones R. *Fractures and Joint Injuries*, 4th ed, Baltimore: Williams and Wilkins, 1955.

+ 149. White BL, Fisher WD, Laurin CA. Rate of Mortality for Elderly Patients after Fracture of the Hip in the 1980s. *J Bone Joint Surg Am* 1987;69:1335.

+ 150. Wile PB, Panjabi MM, Southwick WO. Treatment of Subtrochanteric Fractures with a High-Angle Compression Hip Screw. *Clin Orthop* 1983;175:72.

+ 151. Wilton TJ, Hosking DJ, Pawley E, et al. Osteomalacia and Femoral Neck Fractures in the Elderly Patient. *J Bone Joint Surg Br* 1987;69:338.

+ 152. Wiss DA, Brien WW. Subtrochanteric Femur Fractures Treated with Interlocking Nails. *Clin Orthop* 1992;283:231.

+ 153. Wrighton JD, Woodyard JE. Prosthetic Replacement for Subcaptial Fractures of the Femur: A Comparative Survey. *Injury* 1971;2:287.

+ 154. Yelton C, Low W. Iatrogenic Subtrochanteric Fracture: A Complication of Zickel Nails. *J Bone Joint Surg Am* 1986;68:1237.

+ 155. Yoshimine F, Latta LL, Milne EL. Sliding Characteristics of Compression Hip Screws in the Intertrochanteric Fracture: A Clinical Study. *J Orthop Trauma* 1993;7:348.

* 156. Zickel RE. An Intramedullary Fixation Device for the Proximal Part of the Femur. *J Bone Joint Surg Am* 1976;58:866.

+ 157. Zickel RE. Subtrochanteric Femoral Fractures. *Orthop Clin North Am* 1980;11:555.

! 158. Ziran BH, Sharkey NA, Smith TS, et al. Modified Transverse Locking Nail Fixation of Proximal Femoral Fractures. *Clin Orthop* 1997;339:82.

+ 159. Zuckerman JD, Sakales SR, Fabian DR, Frankel VH. Hip Fractures in Geriatric Patients. Results of an Interdisciplinary Hospital Care Program. *Clin Orthop* 1992;274:213.

+ 160. Zuckerman JD, Skovron ML, Koval KJ, et al. Postoperative Complications and Mortality Associated with Operative Delay in Older Patients Who Have a Fracture of the Hip. *J Bone Joint Surg Am* 1995;77:1551.

# CHAPTER 20

# DIAPHYSEAL FRACTURES OF THE FEMUR

*This chapter is dedicated to the memory of Richard C. Maurer, M.D., who wrote the section on periprosthetic fractures in the second edition.*

*Michael W. Chapman*

**M. W. Chapman:** Department of Orthopaedics, University of California Davis, Sacramento, California, 95817.

A. Femoral-Shaft Fractures
Classification
Grading of Soft-Tissue Injuries
Grading of Fracture Patterns
Biomechanics
Treatment Options
Nonoperative Treatment
External Fixation
Open Intramedullary Nailing
Standard Nonlocked or Flexible Nails
Antegrade, Interlocked, Reamed Nailing Using Closed Technique
Reamed Versus Nonreamed, Locked, Closed Intramedullary Nailing
Retrograde Nailing through the Knee
Plate Fixation
Open Fractures
Surgical Techniques
Reamed and Nonreamed, Locked, Antegrade, Closed Intramedullary Nailing
Retrograde Intercondylar Nailing
Plate Fixation of the Femoral Shaft
External Fixation with an Ao Fixator or Wagner Device
Ipsilateral Concomitant Fractures of the Hip and Shaft
Significant Cortical Loss
Results
Pitfalls and Complications
Malunion
Nonunion
Nail or Screw Breakage
Infection
Neurovascular Injury
Avascular Necrosis
Heterotopic Ossification about the Hip
Joint Stiffness and Muscle Weakness
Author's Perspective
B. Periprosthetic Fractures of the Femur
Classification
Type and Location of Prosthesis
Type and Configuration of Fracture Line
Status of Prosthesis Fixation
The Vancouver System
Surgical Techniques
Postoperative Care and Rehabilitation
Results
Pitfalls and Complications
Acknowledgement
Chapter References

## A. FEMORAL-SHAFT FRACTURES

There are major physiologic reasons to avoid prolonged bed rest in fracture treatment. Immobilization is implicated in complications ranging from constipation and atelectasis to osteoporosis and pulmonary embolism, the last of which can cause death. For patients with multiple injuries, the complications of immobilization can lead to significantly increased morbidity and mortality (see Chapter 14). Fractures of the femoral shaft are of special significance because of the femur's size and proximal position in the lower extremity, necessitating long periods of bed rest with nonoperative treatment. This problem has stimulated two different approaches to treatment: the nonoperative approach of cast bracing, and operative treatment using intramedullary nails or plates.

Early techniques of open, retrograde (meaning insertion initially into the proximal fragment in a retrograde direction, as opposed to retrograde insertion through the knee, which is addressed later in this chapter) placement of medullary nails for stable, mid-shaft fractures had an unacceptable rate of infection. With the introduction of closed medullary nailing, infection became a rare problem, and early mobilization was possible with stable fracture patterns (18). With open reduction, adjunctive cerclage wiring was used in unstable and comminuted cases. Because the nail extended the full length of the femur, there was no stress riser effect. Devascularization of a significant portion of the inner wall of the femur occurs as a result of reaming, but this is rarely clinically significant (see Chapter 11). Because in most fractures the nail functions as a load-sharing device, rather than bearing all of the load, axial loading across fractures with stable patterns is encouraged, thus promoting callus formation.

Medullary nailing is the fixation of choice for virtually all diaphyseal femur fractures. Reaming and nailing can be performed immediately after injury for most open femur fractures. It was once feared that this practice would lead to complications such as infection, fat embolism, nonunion, or, in the case of the patient with multiple injuries, adult respiratory distress syndrome (ARDS) and multiple organ failure. It is now recognized that infection is not a major problem and union rates are actually improved; fat embolism, ARDS, and other problems are all substantially decreased or prevented by femur stabilization soon after injury.

The current designs of interlocking nails permit stabilization of proximal diaphyseal as well as subtrochanteric and associated femoral neck fractures and very distal supracondylar fractures. As experience with interlocking femoral nails has grown, it has become apparent that interlocking of femoral fractures using proper technique does not delay union and that the early removal of locking screws (dynamization) to facilitate fracture union is not typically required (7,8,11,12,39). Further impetus for the use of interlocking nails has come with the finding that a number of femur fractures are more comminuted than initially recognized, necessitating the added fixation of locking screws.

### CLASSIFICATION

Two types of classification are necessary for fractures of the femur: a grading system for soft-tissue injuries and a system for classifying the fracture pattern (33,57,73).

### GRADING OF SOFT-TISSUE INJURIES

The grading of soft-tissue injuries is more an art than a science. The system developed by Gustilo and Anderson (33) for open fractures and that of Tscherne for closed injuries, which has been modified by the AO group (55,67,73), are the most widely used. See Chapter 12 for details.

### GRADING OF FRACTURE PATTERNS

The purpose of grading the fracture pattern is to assess the intrinsic stability of the fracture and guide the selection of treatment. In most diaphyseal femur fractures, this translates into a decision about whether to lock the nail proximally, distally, or at both locations. Pattern, location, and degree of comminution contribute to overall fracture stability. For example, short oblique fracture patterns are usually stable with standard (i.e., unlocked) nailing when they occur near the isthmus and are comminuted not more than Winquist-Hansen type II (Fig. 20.1) (18). At more proximal or more distal locations, or if more comminuted, these fractures are not stable under axial loading. On the other hand, even in apparently stable patterns such as the short oblique fracture, there can be a split extending proximally or distally from the fracture site that cannot be seen on preoperative or even postoperative radiographs. With weight bearing, this can shift, resulting in malposition. As a result, I now statically lock all fractures of the femoral shaft proximally and distally, impacting the fracture site to maximize bone apposition and thereby eliminating any gap, when nailing Winquist-Hansen type I and type II fractures. For the purposes of this chapter, the Winquist-Hansen classification is simple, practical, and useful for clinical decision making, particularly if it is applied to the proximal, middle, and distal thirds of the diaphysis. The Orthopaedic Trauma Association has adopted and expanded the classification of the AO Group. Their system is much too detailed and complex for presentation here but is very useful for exploring the nuances of fracture management and for research. Interested readers are referred to the Special Edition of the Journal of Orthopaedic Trauma devoted to this classification system (57).

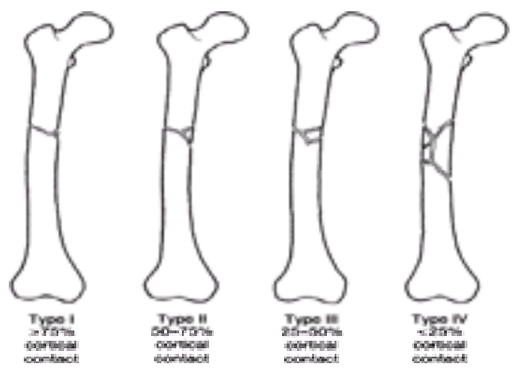


***Figure 20.1.*** The Winquist-Hansen classification of comminution in fractures of the femoral shaft.

## BIOMECHANICS

The biomechanics and physiology of intramedullary nailing in the subtrochanteric area and the hip are addressed in detail in Chapter 11 and Chapter 19. A few comments are required here, however. Measures of torsional rigidity, bending stiffness, and resistance to compression (shortening) have shown conclusively that first-generation interlocked nails using either an oblique proximal cross-locking screw and transverse distal cross-locking screws, or transverse cross-locking screws both proximally and distally, are mechanically superior to unlocked nails and to early designs such as the Brooker-Wills with internally deployed distal fins (5,15,31,35,42). Some interlocking nails are provided with cross-locking holes in both the anteroposterior (AP) and mediolateral planes and/or have a slotted hole available so that the fracture will compress with weight bearing.

In recent systems developed for insertion without reaming, the maximum diameter is smaller, and therefore the cross-locking screws have had to be of smaller diameter as well. In spite of modifications in both design (solid nails) and materials (titanium alloys), these smaller nails have an increased breakage rate. In resisting torsional forces, one screw proximally and distally appears to be just as effective as two screws (35). For fractures in the distal third of the femur, where there is no effective contact between the inner wall of the cortex and the nail in the distal fragment, two transverse cross-locking screws are necessary to provide adequate stability (15). Stability in supracondylar fractures is enhanced with larger-diameter nails, insertion to subchondral bone at the knee, and use of two cross-locking screws (15,31,34). In mid-diaphyseal fractures with stable patterns, Winquist-Hansen I and II, one cross-locking screw proximally and distally is adequate. In Winquist-Hansen III and IV patterns, use the maximum number of cross screws available in the nail design being used (34).

## TREATMENT OPTIONS

### NONOPERATIVE TREATMENT

Nonoperative treatment is standard in children and young adolescents. In mid to late adolescents and in some younger children who have associated multiple injuries, particularly head injuries, internal fixation with devices such as the Ender nail is necessary to avoid injury to the growth plates (see Chapter 19 and Chapter 164). In adults, the indications for treatment of femur fractures in balanced suspension and skeletal traction and/or functional cast braces have nearly disappeared due to the tremendous advantages of intramedullary nailing, particularly since the sophistication of current techniques has reduced the incidence of complications to very acceptable levels. In addition to the systemic risks of nonoperative care already mentioned, the prolonged bed rest and immobilization (3 to 6 months) is not tolerable to most patients today, and it is accompanied by a significant incidence of malunion, nonunion, and permanent joint stiffness, particularly in the knee.

In regions of the world where sophisticated intramedullary techniques are not available or where the risks of surgery are unacceptable, nonoperative management remains the mainstay; the techniques for it are discussed in detail in Chapter 10. In recent years, I have not used balanced suspension and skeletal traction as the sole method for treating a fracture of the femur in adults. I use functional cast braces combined with intermittent traction for supracondylar fractures of the femur in situations where surgery is contraindicated, such as in the presence of serious systemic illness in the elderly, coexisting infection in the region of the fracture, or comminution and severe osteoporosis. Using a well-molded cast-brace with intermittent tibial pin traction, it is possible to mobilize these patients to a chair at bedside within the first week after fracture and to obtain a reasonably good outcome in most cases (49,51).

### EXTERNAL FIXATION

External fixation of closed fractures and of most open fractures of the shaft of the femur is rarely indicated today but still has a specific role in the armamentarium of the trauma surgeon (1,26,27,36). Indications for external fixation include the following:

- Patients with multiple injuries who are hemodynamically unstable or who have a particular combination of injuries in which rapid stabilization of the femur with minimal soft-tissue trauma is essential
- Some femoral-shaft fractures in children and adolescents (see Chapter 164)
- High-grade or severely traumatized open fractures where external fixation may be a temporary or definitive method of stabilization
- Some femur fractures with an associated vascular injury that requires repair, where internal fixation is either difficult or contraindicated
- The rare fracture in which systemic or local factors contraindicate internal fixation

### OPEN INTRAMEDULLARY NAILING

The standard of care for the vast majority of fractures of the diaphysis of the femur today is locked intramedullary nailing utilizing closed percutaneous techniques. Direct open reduction of the fracture may be indicated in the following cases:

- The fracture is not reducible by closed technique, or a bone fragment is incarcerated in the canal, which precludes passage of a guide pin or the nail.
- The patient is a victim of multiple-system injuries and is on a regular operating table where convenience and speed are best facilitated by a modified open nailing (see Chapter 11, Chapter 12, and Chapter 14).
- The fracture is open, and irrigation and debridement of it exposes the fracture site.

- A preexisting deformity or implant is present in the femur, necessitating open osteotomy and/or hardware removal to make nailing possible.

When opening the fracture, it is usually possible to make an incision directly over it and then to dissect through the quadriceps where the femur has torn it, rather than make a separate independent approach. The incision need be only large enough to admit the fingers to facilitate passage of the guide pin across the fracture site. Once this has been achieved, and if good fluoroscopic visualization is available, it is usually possible to close the wound and proceed with nailing as one would for closed technique. This has the advantage of minimizing the amount of time the wound is open, and it allows the medullary contents and reamed bone to accumulate around the fracture site following reaming, which enhances union.

**STANDARD NONLOCKED OR FLEXIBLE NAILS**

Standard reamed or nonreamed nails, such as the original Küntscher nail (76), are rarely used today in most developed countries, but because of the simplicity and low cost of the procedure, it can be performed open with either antegrade or retrograde technique in areas of the world where more sophisticated locking nail techniques under fluoroscopic control are not available. A typical case is illustrated in Figure 20.2. Flexible nonreamed nails such as the Ender nail (see Chapter 19) can be inserted both antegrade and retrograde, and either singly or multiply, and are used today most commonly in femur fractures in children or early adolescents who require internal fixation. The Ender nail did not provide enough control of malrotation and shortening to be used routinely in fractures of the diaphysis in adults. Its simplicity and low cost, particularly when combined with temporary skeletal traction and cast bracing, make it a very useful technique in less developed countries.

***Figure 20.2.*** **A:** The classic indication for medullary nailing of a short, oblique, mid-isthmus fracture. **B:** A standard medullary nail is placed. **C:** After removal 16 months later, there is a smooth, well-remodeled callus, and the general shape of the bone is quite normal, with no significant varus or valgus and some maintenance of an anterior bow. Ideally, a medullary nail should restore this normal anterior bow and result in a normal position of the knee. Because the pattern and location of the fracture allowed secure fixation with a standard medullary nail, no interlocking was performed, although I now lock nearly all nails. The nail was intentionally left slightly short in this fracture because an open epiphysis was present distally, even though this patient was very close to the end of growth. Additionally, cancellous bone near the knee is quite dense in young patients, making it difficult to drive the nail farther.

**ANTEGRADE, INTERLOCKED, REAMED NAILING USING CLOSED TECHNIQUE**

The standard of care today for nearly all fractures of the diaphysis of the femur is antegrade, interlocked, reamed nailing using closed technique (10,11,12,14,16,17,39,45,61,72,77,78 and 79). The main focus of this chapter will be on this technique. Reconstruction nails providing fixation into the femoral head and neck in combination with distal locking are not indicated in the vast majority of diaphyseal fractures of the femur and are reserved for subtrochanteric fractures, some pathologic fractures in the proximal femur, and some concomitant ipsilateral fractures of the hip and femoral shaft (see Chapter 19).

Brumback et al. (11,12,16) and Wiss et al. (78) have all shown that the best results come from interlocked nailing that maximizes bone apposition at the fracture site, with the use of closed techniques and no direct intervention at the fracture site by open means, and with static interlocking even in segmental fractures of the femur.

**REAMED VERSUS NONREAMED, LOCKED, CLOSED INTRAMEDULLARY NAILING**

It is interesting to see how history repeats itself. When Küntscher and others first developed intramedullary nailing prior to World War II, nails were generally inserted without reaming. When all the advantages of using larger, reamed nails became apparent, unreamed nails for the femur nearly disappeared in developed countries. As we began to carry out early reamed, locked nailing of fractures of the femur in patients with increasingly severe multiple injuries, investigators at a number of important trauma centers in both Europe and North America raised the issue of whether embolization of the contents of the medullary canal to the lungs was a significant factor in increasing morbidity (discussed in detail in Chapter 11).

Nonreamed nailing is attractive because of the decreased operating time and decreased blood loss (24,72). In addition, the introduction of retrograde nailing through the intercondylar notch of the knee was particularly useful with nonreamed techniques. In a prospective randomized trial comparing unreamed to reamed nails, Clatworthy et al. (24) found that union was slower in the unreamed group, and a high incidence of implant failure in the nonreamed nails led them to discontinue the study early. Both they and Tornetta and Tiburzi (72) found no advantage in fixing routine femoral fractures with nonreamed nails and recommended the routine use of reamed nails because of quicker union and fewer implant failures with the larger nails. They did not believe that the quicker operating time and somewhat lower blood loss in the nonreamed groups was a sufficient advantage to justify their use. This remains controversial, however. Most surgeons recommend unreamed nails for severely and multiply injured patients with concomitant severe pulmonary compromise or injury (see Chapter 11).

**RETROGRADE NAILING THROUGH THE KNEE**

In North America, the group at Harbor View Hospital in Seattle (61,71) introduced retrograde nailing of the femur through a lateral epicondylar portal with the use of a Küntscher-style nail, primarily as a means of fixing the femoral shaft in combined concomitant ipsilateral fractures of the shaft and femoral neck. The technique has now been abandoned in favor of using an entry through the intercondylar notch of the femur, because the eccentric entry site made reduction difficult and resulted in persistent varus deformity (64,68,71).

The current technique of retrograde nailing through the knee has recently become popular because of the previously successful experiences nailing tibias through this same approach and the challenge of stabilizing a femur fracture in a quick, efficient manner in patients with multiple injuries, whom orthopaedic surgeons frequently found in the supine position on a regular operating table after general surgical procedures. Devices used for retrograde nailing have included specially designed short nails that provide additional screw fixation in the distal fragment and were not designed to penetrate beyond the isthmus (46), standard locked intramedullary nails designed for antegrade use (52), and long retrograde nails designed for this technique. These can be used reamed or nonreamed. The cross-locking screws are somewhat more distal than standard nails, thereby increasing the range of supracondylar fractures that can be handled. All current designs use AP cross-locking proximally, as most surgeons view it as technically easier to accomplish because of improved fluoroscopic visualization (30,32,35,37,52,53,58,63).

Retrograde insertion of a femoral nail through the intercondylar notch has some advantages over antegrade nailing:

- Elimination of the need for a fracture table in most cases
- A much easier starting point without the risks associated with proximal entry in the pyriformis fossa, which include injury to the sciatic nerve, fracture of the femoral neck, avascular necrosis of the femoral head, comminution of the proximal femur due to eccentric entry, and heterotopic bone at the nail entry site

Intercondylar retrograde insertion of nails requires arthrotomy of the knee and partial reaming of the articular cartilage at the roof of the intercondylar notch; therefore, potential risks include the following:

- Early knee dysfunction
- Patellofemoral pain
- Loss of knee motion
- Arthrosis of the knee
- Knee sepsis
- The tendency to use smaller nails, which could increase the rate of nonunion and risk of implant breakage

- Subtrochanteric fracture at the proximal tip of the nail
- Less secure fixation distally, particularly in osteoporotic bone, since the more recently designed nails tend to place cross-locking screws in the cancellous bone of the metaphysis rather than through cortical bone at the metaphyseal diaphyseal junction

As the following brief review of the literature will show, some of these concerns have been borne out through recent clinical experience, and others have not proven to be a problem. Large numbers of retrograde nails have been used only in the last 5 years. Only time will tell whether this technique will continue to be used for difficult fractures of the femur or, in the long run, replace antegrade nailing. ElMaraghy et al. (29) studied the effect of nail entry and reaming in the canine femur on arterial profusion of the anterior and posterior cruciate ligaments. They demonstrated that profusion in the anterior cruciate ligament is decreased by 52% and in the posterior cruciate ligament by 49% acutely. Whether this returns to normal with time and whether it has any significant clinical effects on either healing or function of these two ligaments is currently not known.

Morgan et al. (54) studied the effect of the entry site on patellofemoral contact area and pressures. When they used the intact femur for comparison, they found no differences unless the nail was left 1 mm proud of the cartilage and this resulted in statistically significant increases in the mean pressure at 120° of flexion, and in the maximum pressure at 90° of flexion. Their studies suggest that the intercondylar entry hole does not have any significant biomechanical effects on patellofemoral function as long as good surgical technique is followed. To this point, no study has been sufficiently large or long enough to state whether this entry site will increase the incidence of later arthrosis, but, based on the experience in sports medicine with various intraarticular reconstructive procedures of the knee, this does not appear to be a problem.

Because of the popularity of proximal cross-locking in the anterior posterior plane, Riina et al. (63) studied the relationship of the femoral artery and nerve to the proximal third of the femur. They demonstrated that the femoral artery that lies medial to the femur has up to 15 branches in the proximal third of the femur, but the closest lies 4 cm distal to the lesser trochanter. The femoral nerve lies medial but has multiple branches crossing the anterior femur, the first of which crosses 4 cm distal to the pyriformis fossa; the fewest are above the lesser trochanter. Riina et al. recommended that AP cross-locking always be performed above the lesser trochanter to minimize risk to these structures.

A review of recently published larger studies (30,32,35,37,46,52,53,58) showed only one infection, which resulted in a septic knee, among 271 fractures followed for between 1 and 2 years. The infection responded to treatment and did not result in osteomyelitis. There were 10 nonunions (3.7%), which were more common with smaller unreamed nails and for the most part responded to reamed exchange nailing or local bone graft for bone deficiency. Only two rotary malunions were reported. When there was no concomitant injury to the knee, all authors reported that knee motion returned to normal or nearly normal, with minimal long-term complaints. No cases of arthrosis were reported, but of course the follow-up is quite short. Union seemed to be faster and the incidence of nonunion lower when reamed nails larger than 10 mm in diameter, with larger cross-locking screws, were used.

The results with retrograde nailing appeared to be comparable to those reported with antegrade nailing, but there is neither sufficient evidence nor a long-enough follow-up at the present time to state whether retrograde nailing will replace antegrade nailing as the method of choice for stabilization of fractures of the shaft of the femur. Considering the fact that the published series thus far had a higher incidence of open fractures and multiply injured patients, the results are quite encouraging.

There is no question that a role for retrograde nailing of the femur has now been firmly established. Current indications include the following:

- Multiple injuries, when nailing on a regular table in the supine position and use of an unreamed nail are advantageous
- Combination fractures of the femoral shaft and tibial shaft, when nailing of both fractures through the same entry site is possible
- Communicant ipsilateral fractures of the femoral neck and shaft, when independent fixation of the shaft and neck fractures is desired
- Ipsilateral fractures of the acetabulum and pelvis, when avoidance of a surgical wound about the hip makes surgery of the pelvis and acetabulum on a delayed basis less risky
- Pregnant or massively obese patients when proximal access to the hip or lateral decubitus positioning for nailing is difficult
- Periprosthetic fractures in the distal femur when retrograde nailing is superior to open fixation or antegrade nailing

### PLATE FIXATION

For fractures of the diaphysis, from the lesser trochanter to 10 cm proximal to the knee joint, locked intramedullary nailing is the treatment of choice and has replaced plate fixation. Plating a mid-diaphyseal femur fracture involves a much larger surgical procedure, more blood loss, and a higher incidence of nonunion and loss of knee motion than medullary nailing (67). Plate fixation is indicated in the following cases:

- For femur fractures in settings where inadequate experience with intramedullary nailing or nonavailability of intraoperative fluoroscopy or instruments and implants makes medullary nailing impractical
- When a vascular repair has been done and plate fixation is feasible through the same surgical approach and/or is less risky to the vascular repair than intramedullary nailing
- In ipsilateral concomitant fractures of the femoral neck when retrograde nailing or antegrade nailing using reconstruction nails is not available or when there is preexisting knee pathology that prevents the knee from being flexed beyond the 45° angle that is necessary to obtain the proper entry site
- For nonunions or malunions of the femur when the medullary canal is obliterated or an open osteotomy and/or bone graft is required, when nailing will be more difficult than plate fixation, or when the devascularization of the femur caused by reaming is not desirable
- When skin conditions or other factors at the hip and knee, such as a preexisting arthrodesis, preclude intramedullary nailing

## OPEN FRACTURES

Acute open femoral fractures can be effectively treated by reamed or nonreamed medullary nailing without significantly increased rates of infection or nonunion (4,10,45,75,77). Perform an immediate, thorough, layer-by-layer irrigation and debridement, and institute appropriate bactericidal intravenous antibiotics as soon as possible. Then re-prepare and redrape so that a clean operative field is available for intramedullary nailing. Gustilo grades I, II, and IIA and AO grades IO1, IO2, and IO3 of open fractures may be routinely treated in this fashion. Individually assess Gustilo grade IIIB and AO grade IO4. If these more severe grades are highly contaminated, have marginal soft tissues that cannot be debrided at the initial debridement, or are neglected (more than 12 hours old), then consider primary external fixation if the patient needs to be mobilized immediately. If up to 2 weeks in skeletal traction is not contraindicated in isolated fractures, then this is an alternative. Locked intramedullary nailing can be done when the wound is closed and there is no evidence of infection.

Early conversion from an external fixator to intramedullary nailing does not carry an increased infection rate as long as there has been no infection along the pin tracks. It may be prudent to remove the external fixator, debride the pin tracks, and close them (maintaining the patient in traction for a few days until these wounds are sealed) before carrying out intramedullary nailing. Gustilo grade IIIC and AO grades IO4 and NV3–5 fractures can be initially stabilized with an external fixator, although plating may be preferred if little additional periosteal stripping is necessary.

After immediate nailing, close the elective portions of the wounds and leave the traumatic wound open, performing delayed primary closure within 5 days if the wound is ready. The huge muscle mass around the femur facilitates revascularization and provides excellent coverage of bone and implants; therefore, flaps are rarely if ever indicated except in fractures around the knee. More recent studies have shown no infections or nonunions in 28 patients with Gustilo grade I–IIIA open fractures (4), and no infections and only two delayed unions in a series of 56 patients with open fractures of the femur due to low-velocity gun-shot wounds treated with immediate interlocked reamed nailing (77). Routine bone grafting is not necessary to secure adequate rates of union in open femur fractures treated by nailing unless there is segmental bone loss.

Although unreamed nails have shown efficacy and decreased rates of infection in open fractures of the tibia, no data support their superiority over reamed nails for open fractures of the femur.

Williams et al. (75) compared primary to delayed intramedullary nailings in 42 patients with open fractures, including 33% with grade III injuries, and had overall infection and nonunion rates of 2.4%, with no significant difference between the two groups (see Chapter 12 on open fractures).

## SURGICAL TECHNIQUES

### REAMED AND NONREAMED, LOCKED, ANTEGRADE, CLOSED INTRAMEDULLARY NAILING

### *Timing*

There is a major advantage to performing closed nailing as soon as possible in cases of multiple trauma and in isolated fractures. In addition to the physiologic advantages of early fracture stabilization and patient immobilization, it is technically easier to nail a femur immediately after the injury. Muscle spasm, contracture, hemorrhage, and swelling are less prominent, making the closed reduction easier. The decreased length of hospitalization contributes to the cost-effectiveness of acute trauma care.

### *Preoperative Considerations*

Thoroughly evaluate the patient, treat all of her injuries, and ensure hemodynamic stability. Obtain AP and lateral radiographs of the entire fractured femur, including the entire hip joint and knee joint. Look carefully for occult fractures of the femoral neck. This requires a high-quality AP radiograph taken with the hip in internal rotation to be certain that the femoral neck is in full profile (usually done under anesthesia in the operating room). Obtain a high-quality cross-table lateral view of the hip as well.

Place the fractured femur into skeletal traction as soon as possible, as this is important to maintain length and to stabilize the thigh, thereby reducing pain, reducing hemorrhage, and maintaining overall alignment and length, which facilitates later nailing. Two choices exist for skeletal traction. A transverse ¼-inch-diameter or larger pin placed at the level of the tibial tubercle is most frequently used. Its advantages are that it is not a potential contaminator of the femoral canal (if nailing is to be delayed over 24 hours) and does not interfere with the tip of the nail as it is driven to the distal end of the femur. Its disadvantages include a tendency to cause knee extension as traction is applied on the fracture table, and a limited ability to control a short distal fragment of femur.

A distal femoral pin, if placed anteriorly, can provide better control in distal fractures without interfering with nail placement. To position the traction pin, place a 0.062-inch or larger, smooth Kirschner wire (K-wire) just distal to the superior patellar pole, keeping it as anterior as possible. In this position, it is likely to remain out of the path of the approaching nail, particularly with nail designs that employ an anterior bow. For a distal fracture that is to be nailed with the patient in the lateral decubitus position, insert the traction pin somewhat obliquely so that it runs in a distal–medial to proximal–lateral direction. The resultant pull through a traction bow tends to counteract the valgus alignment caused by gravity.

The major disadvantage of a distal femoral pin, whether a K-wire or a Steinmann pin, is that if the distal fragment is not placed into appropriate position for nailing, the pin holds it in a fixed position, which can make reduction of the fracture and driving of the nail exceedingly difficult. It also interferes with distal cross-locking. The tibial pin allows the distal femoral fragment to “float,” so alignment is simplified. This issue is addressed in more detail during the following discussion on fracture reduction. I prefer to use a proximal tibial Steinmann pin.

In rare cases in which the patient cannot be placed on a fracture table or cannot undergo countertraction from the perineal post, it is possible to apply traction and reduce the fracture by means of a modified femoral distractor (Fig. 20.3). The Synthes (Paoli, PA) Universal Femoral Distractor utilizes an accessory targeting device that attaches to the proximal targeting guide of their universal nail system. The targeting guide allows placement of the proximal Schanz pin into the lesser trochanter through a small stab incision (Fig. 20.3*A*). Place the distal Schanz pin parallel to the femoral articular surface, distal to the intended location of the nail tip, taking care not to traumatize the adjacent femoral artery, vein, or nerve (Fig. 20.3*B*). With the fixator in place, distraction can be achieved as well as control of flexion/extension, varus/valgus, and rotation (Fig. 20.3*C*). Utilize a radiolucent table and an image intensifier (Fig. 20.3*D*).

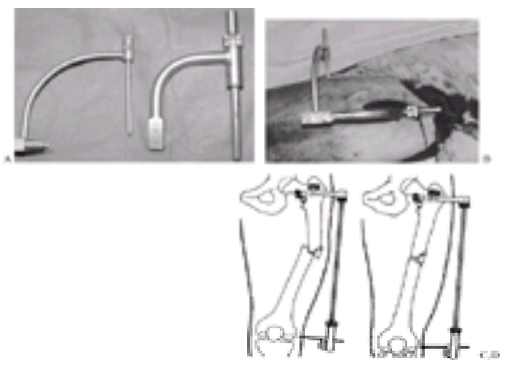

***Figure 20.3.*** Use of a femoral distractor to provide traction for medullary nailing. **A:** A Synthes accessory targeting device (*left*) and the proximal targeting guide to which it attaches (*right*). **B:** Placement of the distal Schanz pin. **C:** The fixator in place. **D:** Reduction of the fracture with distraction.

Baumgaertel et al. (6) found the AO femoral distractor as efficacious as a fracture table and a better time saver. Some surgeons even advocate nailing fractures on a regular table, using hand traction and manipulation rather than the distractor, as they found the distractor to be technically challenging and time-consuming (79). This manual technique, however, requires a very experienced surgical team and is technically difficult, and the surgeon must be prepared to open the fracture if reduction cannot be achieved. I recommend against this technique for routine nailing in the hands of the average surgeon, and I advocate use of a tibial pin on a fracture table.

### *Positioning of the Patient*

Patients can be positioned in the lateral decubitus or supine position on a fracture table or on a radiolucent operating table for closed intramedullary nailing. Most surgeons prefer a fracture table and use the supine position because they are most comfortable with this position, as they use it on a frequent basis for hip fractures. The only advantage of the supine position is easier positioning of the patient and assessment of rotation. Particularly for heavily muscled or obese patients, the supine position makes access to the nail entry point at the proximal end of the femur challenging, and impingement of the instrumentation against the table or the side of the patient makes fracture reduction and execution of the nailing much more difficult.

On the other hand, the lateral decubitus position is much more technically exacting, it requires the surgeon and usually two assistants to position the patient, and judging rotation can be more difficult. In addition, in multiply injured patients and in those with pulmonary injury or spine fractures, the lateral decubitus position is a greater threat to the spine and compromises pulmonary function. In the latter instances, the supine position is indicated. In addition, the supine position is much more convenient for bilateral fractures and carrying out simultaneous procedures. Because the nailing is much easier, I much prefer the lateral position.

#### Lateral Positioning

- For lateral positioning, I use a ¼-inch-diameter or stronger transverse Steinmann pin placed transversely through the proximal tibia and dressed with a circumferential sterile dressing. I use a Chick-Langren fracture table (Fig. 20.4).

***Figure 20.4.*** Lateral decubitus positioning on a Chick-Langren table using a proximal tibial traction pin. **A:** Posterior view. Note that the perineal post between the legs supports the proximal fragment and is positioned to allow the anterior-superior iliac spine to contact the vertical component of the post. The fractured femur is uppermost. **B:** Frontal view of the same setup. **C:** View from the head of the patient. (Disregard the dashed lines drawn on the patient.)

- Before moving the patient to the fracture table, be certain that the table is level and properly located in the room with reference to the anesthesia equipment and lights, and that the C-arm has been placed on the appropriate side of the table. Make sure that all appropriate equipment is mounted on the table and in the appropriate position for the patient. Having everything “pre-prepared” greatly facilitates positioning.
- While the anesthesiologist controls the airway and positions the upper extremities, have an assistant control both lower extremities, roll the torso, and secure the patient to the table.
- Once the patient is in the lateral position, place the T-shaped pelvic perineal post and secure it so that the vertical portion lies just distal to the anterior superior iliac spine (Fig. 20.4*A*). Elevate the perineal post to help support the proximal fragment in a horizontal position and allow the genitalia to drape below the post. Make sure the groin and all bony prominences are well padded by the appropriate pads. Also be certain that the greater trochanter on the down side is supported by the table; the table is adjustable for this purpose.
- Secure the tibial pin into the tibial pin traction holder attached to the traction arm of the fracture table, and manually pull sufficient traction to stabilize the patient on the pelvic perineal post and to bring the fracture out to length. In transverse fractures, slight distraction is an advantage initially. Place the femur parallel to the floor with the hip flexed approximately 20° to 25° and the hip internally rotated just enough to place the heel slightly above the patella, which is about 10° to 15°. This compensates for the fact that patients in the lateral decubitus position tend to slump somewhat forward during the nailing, which can induce an external rotation deformity. On the Chick-Langren table, the traction assembly provides sufficient support that it is not necessary to support the leg distal to the traction pin unless the bone quality is poor; in that case, fashion a sling to the overhead arm of the table to support the leg. Allow the knee to flex freely, as this permits flexion of the knee as traction is applied, thereby avoiding stretch on the sciatic nerve.
- Never apply traction through the foot with the knee extended and with the hip in the flexed position, because this will cause a sciatic nerve stretch injury even if used for as little as an hour. Excessive traction and inadequate padding cause pudendal nerve palsy. Maintain traction on the femur only until the guide pin is placed, and then loosen it as much as possible to avoid this problem.
- Secure the lower, unoperated leg onto a well-padded leg holder, placing the leg holder just proximal to the knee to support it and padding the peroneal nerve well to avoid injury. I prefer circumferential tape over a blanket into which the leg is wrapped, as this provides good stability and can be a source of traction in the event of bilateral femur fractures. Initially, position the lower leg as close as possible to the upper, operated leg in all planes to facilitate use of the C-arm.
- Secure the upper extremities to double-airplane splints, securing the uppermost upper extremity to stabilize the thorax in a directly vertical position. After positioning the patient, check all bony prominences and neurovascular structures with the anesthesiologist to be certain that everything is padded and protected.
- Bring in the C-arm fluoroscope on the anterior side of the patient. Place it exactly at right angles to the femur and in a position where the entire length of the femur from the hip to the knee can be seen easily on both the AP and lateral views without repositioning the base of the C-arm.
- Prepare the injured thigh from the iliac crest to the tibial pin circumferentially, and drape it so that the buttocks and all but the most medial aspect of the thigh down to the tibial pin are available.
- Under fluoroscopic control, extend the down leg at the hip just enough so that the fracture site and proximal femur can be clearly seen on the lateral view. Keeping the lower extremities as close together as possible facilitates passage of the C-arm from the AP to the lateral position. Extending the uninvolved hip permits better visualization of the fractured femur on the lateral view. The least extension is required for supracondylar fractures, and the most for subtrochanteric fractures.

**Supine Position on a Fracture Table**

- Place the patient in the supine position on the fracture table and secure the tibial pin into the traction apparatus on the table (Fig. 20.5). With the perineal post in place, reduce the fracture and secure the patient's position on the table by applying manual traction. The difference from the lateral position is that the thigh is slightly adducted to expose the trochanter better (avoid excessive adduction, as this tightens the iliotibial band, which produces valgus malalignment of the fracture) and the leg is placed in neutral rotation. Raising the traction holder to flex the hip 15° to 20° greatly facilitates access to the entry site. To facilitate exposure of the hip, tilt the torso to the opposite side by using either a kidney rest or a tape-and-bolster arrangement. Avoid too much tilt, which also tightens the iliotibial band. On the Chick-Langren table, the support under the buttocks is in three sections, and the lateralmost section on the operative side can be lowered out of the way to facilitate exposure. The key to this positioning is the flexion of the hip, which allows the instrumentation to pass beneath the patient rather than impinging on his side, as occurs if the hip is left in full extension. Place the opposite leg in a 90°-90° leg holder, making certain that the pelvis is stabilized to the table or to the vertical post of the leg-holding device. Bring the C-arm between the legs, and position it to be certain that AP and lateral views from the hip to the knee can be acquired without moving the base of the machine.

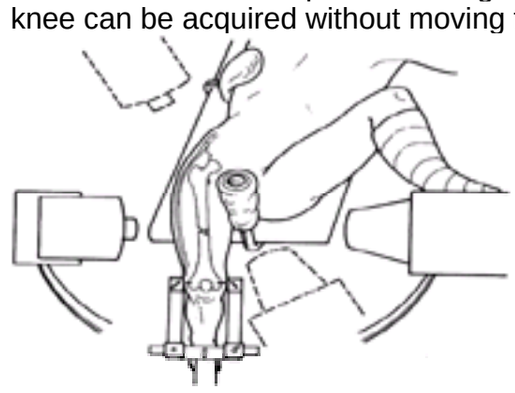

***Figure 20.5.*** Supine positioning with use of a distal femoral traction pin.

- The knee can be left to flex freely, as described for the lateral decubitus technique, or a small footstool can be brought in to support the foot. Since it is dependent, apply an elastic support hose.
- Prepare and drape the thigh free, as already described for lateral decubitus nailing.

***The Skin Incision and Trochanteric Starting Point***

- Begin the incision at the tip of the trochanter, and extend it proximally in line with the fibers of the gluteus maximus and the femoral shaft (Fig. 20.6). The length of the incision is determined by the soft-tissue thickness. Continue dissection sharply through the gluteus maximus fascia, and then split the gluteus fibers bluntly. Stay posterior to the gluteus medius, palpate the trochanteric tip, and with your palm facing upward, slide a finger down the posterior medial border of the trochanter. You will encounter a sharp bump at the mid-portion of the trochanter. This represents the old physeal line of the trochanter and is known as the quadrate tubercle (Fig. 20.6*A*). Then slide your finger directly forward into a fossa located at the junction of the femoral neck with the underside of the posterior central aspect of the trochanter. By common usage this is called the pyriformis fossa, which is actually nearest to the insertion of the obturator externus. This is the usual entry site for a femoral nail because it is directly over the medullary canal (Fig. 20.6*B*). (See the section on intramedullary nailing in Chapter 11.)

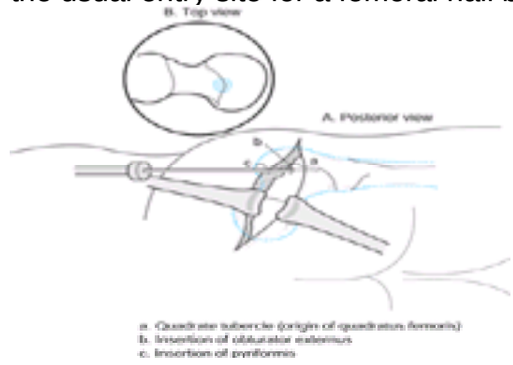


***Figure 20.6.*** **A:** Posterior view of the buttocks with the posterior aspect of the greater trochanter exposed. *a*, quadrate tubercle, the origin of quadratus femoris; *b*, insertion of the obturator externus tendon; *c*, insertion of the pyriformis tendon. **B:** *Top view* of the femur. Note that the entry site is directly over the medullary canal and tucked up under the greater trochanter, encroaching only minimally on the femoral neck.

- In the past, a Küntscher awl was used to penetrate the cortex at this point. Some surgeons still prefer it, but most have now converted to using a guide pin over which is passed a reamer. This procedure is easier, can be done percutaneously, and is more accurate and easily visualized under fluoroscopy. The danger of accidentally slipping off the posterior aspect of the trochanter into vital structures such as the sciatic nerve is eliminated. Most any guide pin combined with a reamer used for nailing hip fracture suffices. I use the 3.2-mm guide pin for the Alta hip screw (Howmedica, Rutherford, NJ) and drill over it with either a 14 mm or an 8 mm reamer, depending on the size of the patient.

- Place the tip of the guide pin on the tip of your finger, palpating the pyriformis fossa, and hold the tip upward against the underside of the greater trochanter at its junction with the femoral neck. Control the guide pin with a guide pin holder or a T-wrench. The guide pin can be used to palpate the anterior and posterior aspects of the neck to be certain that you are central or slightly posterior. Then use a mallet to drive the guide pin into the soft bone on the underside of the greater trochanter at its junction with the neck. Do not drive it in more than 15–20 mm. Then visualize the guide pin on a fluoroscope, confirming that the entry point is directly over the medullary canal on both the AP and lateral views. (See Hints and Tricks below.)

***Reduction of the Fracture and Insertion of a Ball-Tipped Reaming Guide Pin***

- Reduce the fracture, and insert a long ball-tipped reaming guide pin down the medullary canal to the subchondral bone at the knee. Other than finding the appropriate starting point, this can be the most difficult and challenging portion of the procedure; it is described and illustrated in Chapter 11. Many different methods have been advocated for reducing femur fractures closed, many of which utilize various external manipulation devices, such as mobile concentric rings or a crutch with a strap. The technique described here utilizes manipulation of the proximal fragment with an intramedullary device, makes reduction of the fracture far simpler than by external manipulation, follows a logical progression, and minimizes operating time and x-ray exposure (43).
- Key points are the positioning of the distal fragment in a neutral position in both the lateral and supine positions, as already described. Because of muscle pull, the proximal fragment typically lies flexed and adducted, more so in proximal fractures. Subtrochanteric fractures with the lesser trochanter intact are externally rotated as well. The key to reduction is aligning the proximal fragment with the distal rather than the reverse.

**HINTS AND TRICKS**

- Driving the guide pin with a mallet is superior to inserting it with a power drill, as drilling tends to cause the guide pin to “walk” on the cortex and thereby presents the risk of tearing your surgical glove. More important, the guide pin should drive easily, demonstrating that it is on the thin cortex on the underside of the greater trochanter. If hard cortical bone is encountered through which the guide pin cannot be driven with the mallet, you are too far medial on the femoral neck. This also minimizes the risk of injuring the lateral epiphyseal vessels, which provide blood supply to the femoral head.
- Although it is ideal to have the guide pin directly in line with the femoral canal, this is difficult to do. It is easiest to insert the guide pin at right angles to the slope of the femoral neck at the insertion point. This means that the guide pin will be inclined from posterior to anterior on the lateral view. Because the overhanging trochanter forces the guide pin medially, it often has a lateral to medial inclination on the AP view. This is not important as long as the guide pin enters the neck at the appropriate starting point and it has not been inserted more than 20 mm.
- Now, under fluoroscopic control, place the appropriate-size reamer over the guide pin and ream through the outer cortex into the medullary canal. As soon as the guide pin is totally covered by the reamer, direct the reamer under fluoroscopic control directly down the medullary canal as far as the lower edge of the lesser trochanter. This will open the medullary canal and ensure that the ball-tipped guide pin to be inserted next does not hang up on cancellous bone in the proximal femur. Remove the reamer and guide pin.

- Use a fracture reduction tool (Stryker, Osteonics, Howmedica, Rutherford, NJ) or a long, 11- to 12-mm-diameter intramedullary nail inserted into the proximal fragment. Place into the reduction tool the ball-tipped reaming guide pin. It is helpful to place a gentle, smooth bend of 10° to 20° in the distal 2.5 cm of the guide pin, as this facilitates manipulation of the guide pin around corners. Attach a T-handle to the proximal end of the guide pin.
- Place this assembly into the proximal fragment, and manually, gently lodge the reduction tool into the proximal fragment.
- Using the step image on the fluoroscope to minimize radiation exposure, push your hand anteriorly, which extends the proximal fragment, and bring it directly in line with the end of the distal fragment on the lateral view. Place the guide pin at the exit of the distal fragment, but do not cross the fracture site yet.
- Making certain that you do not change position on the lateral view, now push your hand toward the floor, which abducts the proximal fragment and brings it directly in line with the distal fragment on the AP view. Place the guide pin directly in the center of the medullary canal on this view, then push it 2–4 cm into the proximal fragment. If your alignment is perfect, you will immediately feel crepitus as the guide pin encounters the rough endosteal surface of the medullary canal. With this feedback demonstrating that the guide pin is in the medullary canal, insert it down to subchondral bone at the knee, ensuring that it is in, on both views.
- If you feel no crepitus or resistance to penetration of the guide pin, then most likely it is out into the soft tissues on the other view. In that case, realign the guide pin on the view on which you are working, and repeat the procedure for the following view.
- Perform the reduction maneuver and insertion of the guide pin on step images, as this dramatically lowers radiation exposure in comparison with live imaging. If you are unsuccessful after two or three attempts to pass the guide pin, then it is likely that there is a small fragment in the medullary canal, or that there is some other reason, such as soft-tissue interposition, that the guide pin is not passing. In this circumstance, try inserting the guide pin under direct fluoroscopic control, and the image will tell you what is occurring.
- If there is a small fragment in the canal, use hand T-reamers (AO Synthes, Paoli, PA) to clear the canal.
- The usual cause of failure to enter the distal fragment is losing the position on one view by inadvertent movement of the hands when switching to the other view. This takes practice, and after several nailings using the technique, this problem nearly disappears.
- In rare fractures, some external manipulation is necessary because of extreme swelling in the thigh or other impediments to manipulating the proximal fragment.
- In supracondylar fractures of the femur, where an anterior traction pin has not been placed in the distal femur, the distal femoral fragment may remain quite flexed. Reduce this by pushing on the posterior proximal end of the distal fragment to reduce its flexed position and hold alignment while the guide pin is passed.
- Ideally, the guide pin should be directly centered in the condyles of the femur on both AP and lateral views. This is not critical, however; if reasonable alignment of the fracture is maintained during reaming and if only the isthmus of the femur is reamed, the position of the guide pin distally is irrelevant unless you are nailing a very distal supracondylar fracture where there is a tendency for the distal fragment to lie in valgus and flexion.

***Measuring for the Length of Nail***

- Ensure that the guide pin is distally where you want the distal end of the nail to end. In most systems, nail length is determined by placing an identical second guide pin at the tip of the trochanter and then measuring from the top of the guide pin in the femur to the top of the second guide pin. Make adjustments if a shorter nail is desired.
- In the Alta system, the length of nail is measured directly off the fracture reduction tool, which for the Alta standard nail places the top of the nail flush with the top of the femoral neck rather than even with the tip of the trochanter. This allows for some adjustment of the position of the nail if a more proximal position of the cross-locking screws is desired.

***Reaming the Medullary Canal***

- To minimize pressurization of the canal, which leads to embolization of bone marrow, and to avoid overheating and jamming of the reamers, it is important to use conical (as opposed to cylindrical) reamer heads that have deep flutes to deliver reamings proximally, and reverse cutting flutes.
- Run reamers at the highest available RPM on a power reamer because this makes cutting most efficient, but push the reamer slowly down the medullary canal to minimize pressurization. Visualize the passage of the first couple of reamers across the fracture site to be certain that everything is going smoothly. Fluoroscopic imaging thereafter is usually not necessary unless problems are encountered.
- Begin with the smallest reamer in the set and progress in 1 mm increments until the first reamer contacts the inner cortex of the canal. Then progress in 0.5 mm increments until the desired diameter is reached. Once cortical contact is made, feel the reamer head with your hand as it is removed after each pass to be certain that it is not overheating. If you encounter hard reaming with slow progress of the reamer, extract the reamer and clean the flutes of cortical bone to increase cutting efficiency and to avoid jamming the reamer when it is withdrawn. Do not allow the reamer to pull itself distally because this may cause it to screw down the medullary canal, which inadequately reams the canal and may make extraction of the reamer difficult. For most reamed nailings, reaming of 2 mm after initial cortical contact suffices. Most systems provide reamers from approximately 8 to 17 mm in diameter. More reaming can be done if a larger nail is indicated. Do not ream the metaphyseal cancellous bone distal to the isthmus, because driving the rod into this bone increases the quality of fixation. In supracondylar fractures, it is necessary to enter only the mouth of the fragment to be certain that the nail will pass smoothly. Be certain that the guide pins used are straight and are not nicked. Imperfect guide pins can cause jamming between the guide pin and the reamer head when it is withdrawn, causing inadvertent removal of the guide pin and loss of reduction of the fracture.

**HINTS AND TRICKS**

- Broken reamers or shafts are highly unusual but are usually easily removed by extracting the bullet-tipped guide pin along with the broken reamer.
- To ensure that the guide pin does not accidentally withdraw, hold it in the femur with a lap tape over the proximal end of the pin (do not use your gloved hand because, if the wire starts to turn with the reamer, it will tear the glove). When the back of the reamer obscures the guide pin, it may be necessary to insert a second guide pin into the back of the reamer to hold the guide pin in place.
- After the length of nail has been measured, driving the guide pin farther with a mallet to lodge it into the subchondral bone of the knee often prevents accidental removal. This is particularly important in supracondylar fractures with a short distal fragment.
- In fractures of the femur, venting of the femur has not proven to be of any value, because during reaming the medullary canal vents through the fracture site.
- At the completion of reaming, thoroughly irrigate and clean the buttocks wound to minimize the risk of heterotopic bone formation.

- Now insert a plastic tube over the reaming guide pin down the medullary canal, making certain that it is across the fracture site, and exchange the reaming

ball-tipped guide pin for a driving guide pin.

### *Selecting and Driving the Intramedullary Nail*

- In systems of reamed, locked nails manufactured from titanium alloys, an 11-mm-diameter nail for women and a 12-mm-diameter nail for men provide sufficient strength and stability. In stainless-steel systems, some manufacturers recommend a 12 mm nail for women and a 13 mm nail for men. Smaller nails may be necessary in very small people, and larger-diameter nails may be necessary in large men or in the elderly, where the medullary canal tends to be capacious. The relationship between the maximum diameter reamed and the size of the nail is based on the manufacturer's recommendations, but in most cases overreaming by 1 mm provides a suitable fit. Some manufacturers recommend overreaming even more, particularly in femurs that have a fairly marked anterior bow.
- Assemble the nail on the driver and drive the medullary nail down the medullary canal across the fracture site, using the driver provided by the manufacturer. At this point, only minimal traction should be necessary, and in fact, traction on the extremity should have been released as soon as the fracture was reduced and the guide pin passed, assuming that traction is not necessary to maintain overall alignment or length. A nail that drives hard can be the result of an eccentric entry site or insufficient reaming. Do not persist in driving the nail because of the risk of nail incarceration or comminution of the femur. Reassess the entry site; oval it in the correct direction, if necessary, and consider reaming somewhat larger.
- In comminuted fractures where determination of length may be difficult, a good guide is to preoperatively measure the opposite extremity from the prominence of the trochanter to the lateral epicondyle of the femur and relate this to the length of nail to be used.
- Avoid distraction at the fracture site. If distraction occurs when you drive the nail, then drive it slightly deeper, cross-lock distally, and use the driver assembly to backslap the nail to approximate the fracture ends; then lock proximally. In supracondylar fractures, be certain to provide support beneath the fracture site medially as the nail is driven to ensure that it is centered in the distal fragment and that alignment is good.
- Visualize the nail as it passes into the mouth of the distal fragment to ensure that it does not hook up on a cortex and cause comminution. Most nails today have a bullet-nose design, which minimizes the risk of comminution.
- Visualize the nail fluoroscopically to be certain that it is in the appropriate location and that the fracture is both rotationally and axially in good alignment.

### *Cross-Locking the Nail*

- In nearly all nail systems today, distal cross-locking is best accomplished by freehand cross-locking under fluoroscopic control (discussed in Chapter 11). The jigs now available for distal cross-locking have had mixed success. Hand-held fluoroscopic guides and laser-guided systems facilitate freehand cross-locking.
- Proximal cross-locking can be done with a jig or guide system in all nails.
- When cross-locking is completed, verify on a lateral view that the screws have passed through the nail. They can appear on the AP view to be in, and yet have missed the nail.
- If a screw misses the nail, then correcting it can be quite difficult because the drill point or screw tends to drop into the old screw hole. A quick and simple way to solve this problem is to expose the screw hole, widen it with a larger drill point so that the near hole in the nail is now exposed, and then insert the screw under direct vision. This results in loss of purchase in the near cortex, but, when combined with a second screw, it provides adequate fixation on the opposite cortex as long as bone quality is good.
- In osteoporotic bone, if fixation is too distal, it will provide poor purchase because of the poor-quality cortical and cancellous bone in the very distal regions of the femur. In addition, very distal fixation may place the screws intraarticularly, which can irritate the knee joint. In these situations, use a shorter nail so that cross-locking occurs in the better-quality bone of the more proximal metaphysis.
- It is almost always advisable to have three to five threads of the screw extending through the opposite cortex, because this greatly facilitates removing the medial section of screw if the screw breaks.
- In osteoporotic bone, washers and backup nuts enhance fixation.
- In stable patterns such as Winquist-Hansen I and II, where there is good cortical contact at the fracture, a single screw proximally and distally usually suffices. This saves operating time and money. If single screws are used where two or three cross-locking holes are available, always place the screw in the hole closest to the fracture site to eliminate a stress riser effect in the nail. This is particularly important in supracondylar fractures (15).
- If you are using percutaneous techniques, measurement of screw length with the depth gauge through the nail can be difficult. You can measure screw lengths directly off the fluoroscope monitor screen by using the known width of the nail as a reference for measuring the AP width of the cortex at the site of the cross-locking screw in the femur. The only time this is not reliable is when cross-locking distal to the epicondyle, where the sloping surface of the distal femur may cause you to insert a screw that is too long.
- If the nail has a cap screw, insert this to prevent bone growth into the nail and to make extraction of the nail easier. In addition, it prevents the oozing of marrow contents out the proximal end of the nail, which can lead to heterotopic bone formation.
- Thoroughly irrigate the wound, debride any muscle injured by the procedure, and close the wounds in layers. Confirm the quality of reduction and placement of the implants on final AP and lateral radiographs before awakening the patient.

### *Special Considerations for Supine Nailing*

The overall technique for supine nailing is very similar to that for lateral nailing, and the following guidelines are quite useful:

- When approaching the entry site for the nail, do not use a direct mid-lateral incision, but use the same incision as for lateral decubitus nailing, beginning at the tip of the trochanter and passing proximally in line with the fibers of the gluteus maximus. A direct lateral approach goes through the gluteus medius, damaging it. The thick muscle envelope in this area makes access to and visualization of the proper entry site extremely difficult. In addition, entry this far superior makes it exceedingly difficult to avoid injury to the base of the femoral neck because of the overhanging trochanter. A more posterior approach is better.
- In extremely obese people or where the greater trochanter overhangs significantly, entry into the pyriformis fossa in the supine position can still be difficult. This is also a challenge when there is a concomitant ipsilateral fracture of the femoral neck, where the guide pin tends to enter the fracture site rather than the pyriformis fossa, which is just a few millimeters lateral to the fracture line.
- In these cases, place the guide pin directly into the tip of the greater trochanter. Ream the entry site into the greater trochanter and then use an instrument such as an Army-Navy retractor to push or pull the reamer medially while reaming, to create an oval entry hole that is centered directly over the medullary canal. This oval hole is larger than is needed for the nail, but I have seen no adverse consequences of this technique.
- Position the operating table as high as is practical, and plan to have the instrumentation enter in line with the femur, which is posterior to the side of the patient. Note that this is nearly identical to the lateral decubitus position. This greatly facilitates manipulation of instrumentation and reduction of the fracture, as well as driving the nail. The only disadvantage is that it is awkward because of the inclination of the instrumentation toward the floor.
- Cross-locking distally in the supine position can sometimes be difficult because the locks on the C-arm prevent achieving appropriate alignment of the x-ray tube with the cross-locking holes in the nail. As long as the fracture is well impacted and rotationally stable, it is often easier to rotate the leg to bring the cross-locking holes in line with the central beam of the fluoroscope than to try to line it up using the fluoroscope mechanics.

### *Postoperative Care*

- Always examine patients carefully in the operating room under anesthesia to be certain that alignment, particularly rotation, has been restored. Always try to achieve perfect alignment. Some asymmetry in rotation is acceptable as long as it does not exceed 15° and the patient can rotate in both directions beyond neutral. Shortening up to 10 mm is either asymptomatic or easily compensated for by an in-the-shoe lift. Shortening of 15 mm or more, although nicely corrected with a shoe lift, is quite noticeable to most patients and is likely to be the source of complaints. Shortening over 20 mm is unacceptable to the vast majority of patients, and correction is required in most patients who have shortening over 25 mm. Except in distal supracondylar fractures of the femur, alignment in the sagittal plane is nearly always guaranteed by the contour of the nail. The most common malalignment in supracondylar fractures is recurvatum. Recurvatum of up to 10° or so is acceptable in most patients as long as they do not have lax joints or a preexisting hyperextension problem at the knee. Try to avoid varus or valgus malalignment of over 5°. Over 10° often requires correction.
- As soon as the patient will tolerate it, begin hip and knee range-of-motion and muscle-strengthening exercises for the entire extremity. Do not forget the hip abductors; persistent weakness in these due to the operative approach is common (3). It usually takes 6 weeks to gain enough joint motion and muscle rehabilitation that the patient can walk safely without assistive devices. In Winquist I and II stable patterns, full weight bearing can progress as quickly as possible, and most patients can bear full weight without assistive devices by 6 weeks. In Winquist III and IV patterns, bridging callus must be seen on two views before progression to full weight bearing is acceptable.

See Figure 20.7 for a typical case of locked, antegrade, closed intramedullary nailing.

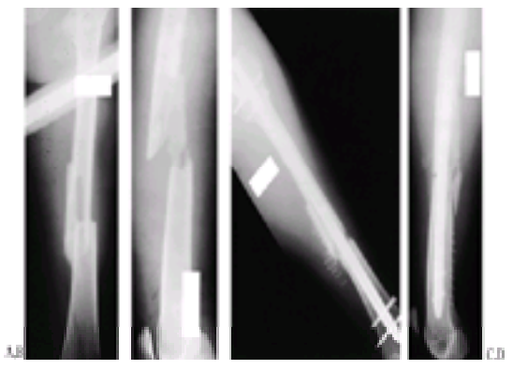

***Figure 20.7.*** Femoral fracture treated with antegrade, closed, locked intramedullary nailing. **A:** AP radiograph showing fracture. **B:** Lateral radiograph. **C:** Postoperative AP radiograph. Note the cross-locking screws about the lesser trochanter and, distally, the bicortical cross-locking screws. The fracture is in excellent alignment. **D:** Lateral radiograph.

***Antegrade Nailing on a Regular Radiolucent Table with a Universal Femoral Distractor***

- The lateral decubitus position with the fractured femur uppermost is preferable, although some use the supine position with bumps under the back and midsacrum to make the entry site for the nail available.
- Prepare and drape the extremity completely free, including the buttocks for the entry site.
- Apply the AO distractor (Fig. 20.3). Make the anterior insertion of a Schanz pin into the medial aspect of the femur at the lesser trochanter carefully to avoid injury to the femoral nerve and artery.
- Reduce the fracture and perform antegrade nailing as described previously.
- When you are cross-locking, the distractor may be in the way, particularly distally. If the fracture is sufficiently stable, remove the distractor and proceed with cross-locking as usual. In cross-locking with the leg free on a radiolucent table, it is useful to have the assistant position and stabilize the leg for cross-locking rather than shift the head of the C-arm to align it.

**RETROGRADE INTERCONDYLAR NAILING**

- Position the patient in the supine position on a fully radiolucent table. Place a 3–5 cm soft bump under the ipsilateral buttocks and a large bolster under the knee and thigh so that the knee sits flexed at approximately 45°.
- If a universal distractor will be used to gain length and aid reduction, apply a Schanz pin proximally just above the lesser trochanter and distally through the femoral condyles posterior to the nail entry site, attach the distractor, and make appropriate adjustments. Many fractures can be nailed without a distractor, particularly if an unreamed technique is used, which is discussed below.
- Make a midline longitudinal incision from the inferior pole of the patella to the tibial tubercle. Split the patellar tendon the full length of the incision, and reflect the fat pad inferiorly. Identify the intercondylar notch. One centimeter anterior to the anterior edge of the posterior cruciate ligament, insert a guide pin under fluoroscopic control (Fig. 20.8). On the AP view, make certain that this is in the midline and aligned with the femoral canal. Laterally, the guide pin must be aligned with the long axis of the distal fragment of the femur and be central in the canal. (This usually results in an entry hole that is 50% on nonarticular surface in the intercondylar notch and 50% into the articular cartilage.) Over this pin, ream with an appropriate-size end-cutting reamer. In most cases, this will remove a few millimeters of articular cartilage at the superior edge of the intercondylar notch. Ream until the medullary canal is entered. Use a protector to prevent injury to the patellar tendon, and irrigate and suck during reaming to remove any loose reamings from the knee joint.

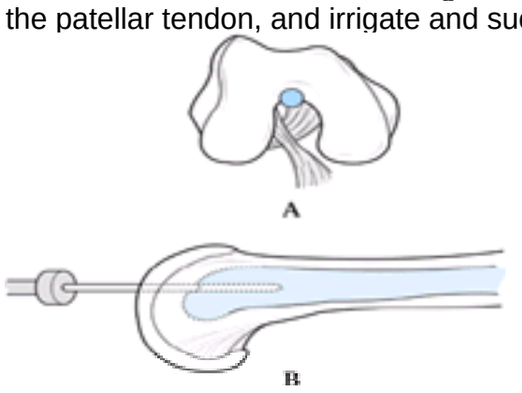


***Figure 20.8.*** Entry site for retrograde femoral nailing. **A:** Placement of the guide pin for the reamer. **B:** Lateral view showing the guide pin directly in line with the medullary canal of the femur.

- For unreamed nailing, select the appropriate diameter and length of nail. I prefer to use a standard Alta medullary nail, which provides two transverse cross-locking screws both proximally and distally. This is the same nail used for antegrade nailing. For unreamed applications, I always try to insert a 10 mm nail because it allows use of the 5 mm cross-locking screws, but a 9 mm nail is acceptable. Although specially designed retrograde nails are available at our institution, I prefer this nail because, when it is fully inserted, the two distal cross-locking screws are at the epicondyle and slightly above, placing them in cortical bone, which provides better fixation than more distal locking. I prefer medial-lateral rather than anterior-posterior locking proximally. I select a nail that will place the two proximal cross-locking screws in the region of the lesser trochanter, which is the safest zone for neurovascular structures and avoids the problem of a stress riser in the subtrochanteric area.
- Insert the unreamed nail up to the fracture site, making certain that the fit is not too tight. With the aid of an assistant, reduce the fracture and, using the nail as a lever to assist, pass the nail across the fracture site and drive it into the proximal fragment.

**HINTS AND TRICKS**

- The most important and sometimes challenging aspect of retrograde nailing is being certain that the top of the nail is countersunk below the subchondral bone of the intercondylar notch. It is important to understand the anatomy of your nail and driver as seen on fluoroscopy, so that there is no question where the most distal extent of the nail is. I always countersink the nail at least 10 mm below the subchondral bone to allow room for the cap screw and for any parallax error.

- For reamed technique, the method is identical to that already described for reamed nailing. The fracture manipulation tool for controlling the distal fragment is equally advantageous here.
- Nail length is critical because the nail must be countersunk below the subchondral bone distally, the fracture must be at appropriate length, and the proximal cross-locking should be at the level of the lesser trochanter.
- First, cross-lock distally, using the cross-locking guide, then impact the fracture and cross-lock proximally, using either the Alta distal cross-locking guide or freehand technique.
- With the other leg lying flat on the table, visualization of the cross-locking holes at the lesser trochanter is easy because the two thighs are at different levels. Even if overlap occurs, with a good C-arm both femurs can be visualized and the femur with the nail in it is easily identified and targeted.
- When using systems that provide a cap screw, be certain to take this into account when setting the depth of the nail at the knee (Fig. 20.9).



***Figure 20.9.*** Retrograde nailing of a femur fracture. **A:** AP radiograph showing a fracture of the shaft of the femur in a patient with multiple injuries. **B:** Postoperative AP radiograph showing retrograde nailing through the intercondylar notch of the knee with proximal and distal cross-locking. **C:** Lateral radiograph.

- After completion of the nailing, thoroughly irrigate the knee joint to remove any loose bone, do a meticulous interrupted closure of the patellar tendon, and close the subcutaneous fat and skin in a routine fashion.

***Postoperative Care***

Postoperative care is the same as that already described for antegrade nailing.

**PLATE FIXATION OF THE FEMORAL SHAFT**

Although a medullary nail is the preferred method of operative fixation for most diaphyseal femoral fractures, there are situations in which plate fixation is appropriate (7,47,48,55).

- Place the patient in the supine or lateral decubitus position on a radiolucent table. Make a midlateral longitudinal incision over the fracture, and sharply incise the iliotibial tract. Beyond this, the exposure is guided by the muscle disruption and periosteal stripping that are already present. Carefully clear the major fragment ends of soft tissue and the lateral or anterolateral surface where the plate will be located.
- Reduce the fracture, typically by means of traction on the distal fragment. Maintain the anterior bow by placing a bolster posterior to the femur as distraction is applied. This can be effectively accomplished by means of a femoral distractor, as described by Mast (Fig. 20.3). If small, comminuted fragments are present, do not strip them in an attempt to produce an anatomic reduction. Tease them into the best position possible, but do not worry about fixation. Fix large butterfly fragments anatomically by means of lag screws. Maintain correct rotation by using the linea aspera and fracture configuration as a guide.
- Apply a single, broad plate to the lateral or anterior surfaces, obtaining eight cortices of fixation in both proximal and distal fragments, preferably augmented with lag-screw fixation between the major fragments. Before fixation is completed, obtain compression if there is good cortical contact by using an articulated tensioning device. The resulting construct may leave several plate holes unfilled and some comminuted fragments unreduced, but it will have correct length and alignment (Fig. 20.10).

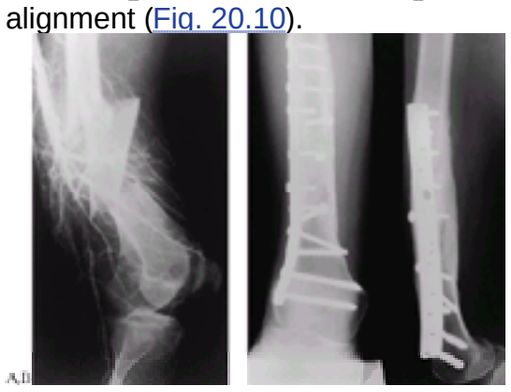

***Figure 20.10.*** Plate fixation of a femur fracture. **A:** Lateral radiograph showing a comminuted mid-shaft grade IIIC open femur fracture with an associated transection of the femoral artery. **B:** Postoperative AP and lateral radiographs. The artery has been repaired, and the femur has been fixed with interfragmentary screws and a broad plate.

- Apply autologous cancellous bone graft for medial comminution. If graft can be introduced through the fracture to the medial cortex before final reduction, less stripping of bone is required. Otherwise, carefully pack graft over the anterior cortex to rest medially and wherever comminution is extensive. Close the wound in layers over a suction drain.
- Postoperatively, begin immediate active-assisted range-of-motion exercises and mobilization identical to the postoperative program for patients with nailed fractures. Continue touchdown weight bearing for 6 weeks, and then advance to partial weight bearing once bridging callus seen on two views has developed. Begin full weight bearing when the fracture has healed.

Plate removal may be advisable in active young people, particularly if they engage in a sport or have a vocation in which heavy stress on the femur or trauma may occur. Usually, we wait at least 18 months after the time of plating, and remove the plate only if the bone is solidly healed and the callus has remodeled. (See Chapter 11 for advice on plate removal.) After removal, patients can progress to full weight bearing with crutches as soon as they can tolerate it, but they must limit their activities to just walking and nonimpact activities such as swimming and stationary bicycle until 6 months after removal to prevent refracture.

**EXTERNAL FIXATION WITH AN AO FIXATOR OR WAGNER DEVICE**

- Although not essential, the use of a fracture table is quite helpful in the application of external fixation. An image intensifier speeds up the procedure. Position the patient and reduce the fracture with traction. It is important to realize that, although small amounts of angular deformity can be corrected after the pins have been placed, rotational correction may be impossible to correct in some fixators. Therefore, the initial reduction should be as close to perfect as possible and should not be made with the expectation that the device can later be adjusted to compensate for an inadequate reduction.
- For an AO or Wagner fixator, use Schanz pins 6 mm in diameter, for which 4.5 mm holes are drilled in both cortices. To minimize tie-down of the quadriceps, apply the fixator laterally. Make a lateral stab wound over the femur at the level of the lesser trochanter. Carry it down through the deep fascia, then use a small elevator to slide posterior to the quadriceps and anteriorly to the lateral intermuscular septum. Elevate a small area on the femur.
- Drill the femur through a drill guide with a 4.5 mm drill point, and insert a Schanz pin bicortically. Place the fixator over the pin, adjust the fixator for length and alignment, and place the second Schanz pin through the distalmost hole of the fixator or through a guide if one is provided by the manufacturer. Place this pin at or just proximal to the lateral epicondyle.
- Adjust the fixator, confirm proper position of the fracture, and insert the two innermost pins. Some prefer to use three pins in each fragment.
- Achieve final reduction, lock the pin holders, and then apply compression across the fracture if possible.
- Follow the instructions for pin care outlined in Chapter 11. Regularly check the tightness of the clamps that secure the pins. Begin partial weight-bearing and active range-of-motion exercises immediately. At 8 to 12 weeks, the device may be replaced by a cast brace if callus has appeared and the fracture location and pattern are appropriate. Otherwise, the fixator can remain in place until the bony union is strong enough to eliminate the need for a cast brace, which is usually at least 4 months after fracture (Fig. 20.11) (26).

***Figure 20.11.*** Femur and tibial shaft fractures treated in external fixation.

**IPSILATERAL CONCOMITANT FRACTURES OF THE HIP AND SHAFT**

Ipsilateral concomitant fractures of the hip and femoral shaft are unusual and pose a difficult treatment problem. Most of these are intracapsular fractures, with a high shear angle similar to a Pauwels type III fracture of the femoral neck. However, the fracture tends to begin distally in the base of the neck and extend across the neck, exiting in a subcapital location. Many of these are initially completely undisplaced and therefore are difficult to diagnose. In a review of the literature, Swiontkowski et al. (71) noted that in 10 articles on the subject, roughly one third of the femoral neck fractures reported were not detected initially. Casey and Chapman (18) postulated that most of the force in an ipsilateral femoral neck and shaft fracture is dissipated in the femoral shaft fracture, therefore often resulting in undisplaced or minimally displaced fractures of the femoral neck, which therefore have less soft-tissue damage and a much lower incidence of avascular necrosis of the femoral head than would be expected.

In every fracture of the shaft of the femur, an ipsilateral fracture of the femoral neck must be ruled out. Routine radiographs of the femur must include the hip joint with a good-quality AP and cross-table lateral views. From a practical viewpoint, many of these radiographs are taken in the emergency room under duress and do not give an ideal view of the femoral neck. For that reason, it is wise, prior to nailing a femoral-shaft fracture, to obtain a good-quality AP radiograph of the hip while it is in internal rotation, to throw the neck into full profile, with the patient on the fracture table and under anesthesia. A good-quality lateral must be taken as well, which the fracture table optimizes. If you detect a femoral neck fracture, you may need to alter treatment plans. When nailings are completed, repeat the radiographs of the hip, because hairline fractures not seen on initial films may appear after the vigor of a nailing. Any patient who has unexpected proximal thigh or hip pain in the postoperative period should have these radiographs repeated because these fractures may appear even up to 6 weeks later in spite of good-quality initial films. Computed tomography, magnetic resonance imaging, and bone scans are more sensitive than routine radiographs, but it is not practical and probably not economically feasible to order one or more of these studies on every patient with a femoral shaft fracture.

If the femoral neck fracture is picked up early, is not displaced, and is internally fixed in good position, the outcomes are usually good. Union rates approaching 100% and rates of avascular necrosis under 15% can be expected (71). Because of the risk of displacement of these fractures, which worsens the prognosis, they should be treated as surgical emergencies and internally fixed as soon as possible. Most are either undisplaced or can be reduced well on a fracture table with traction and gentle internal rotation despite an unstable shaft fracture. For that reason, fixation of the shaft is not always necessary to achieve a satisfactory reduction of the femoral neck. One can choose between fixation of the femoral neck or fixation of the shaft first, using independent fixation or a single device that provides combined fixation of both fractures. Alternatives for fixation include the following:

- Combined fixation with a gamma nail or reconstruction type nail
- Antegrade nailing of the femoral shaft with a standard nail or the AO “miss a nail,” followed by fixation of the femoral neck with independent screws in front of the nail (Fig. 20.12)

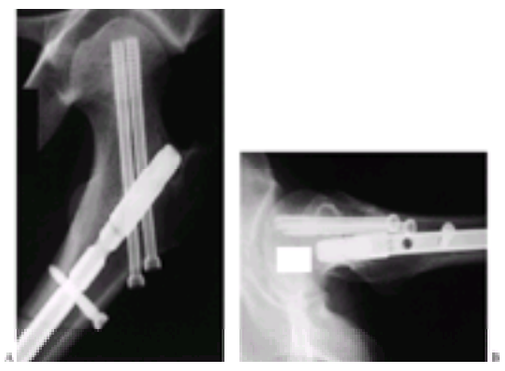

***Figure 20.12.*** Independent fixation of an ipsilateral concomitant fracture of the femoral shaft and neck. **A:** This basilar femoral neck fracture was not apparent on the initial radiographs after locked nailing of the femoral shaft fracture. The fracture subsequently displaced slightly, revealing its presence. The fracture reduced anatomically with closed reduction. Fixation was achieved with two cannulated screws placed in front of the intramedullary nail. **B:** Lateral radiograph. If this fracture had been noted at the time of initial nailing, then fixation with a retrograde nail and independent screw fixation would have been a better approach.

- Independent fixation of the hip with multiple screws or a compression hip screw combined with independent fixation of the femoral shaft with an intercondylar retrograde nail or a plate
- Other possible combinations

Use of gamma or reconstruction nails for such a combination can be quite challenging and requires considerable experience. For surgeons without extensive experience with these devices and this combination of fractures, independent fixation is probably easier and more reliable. In undisplaced fractures, multiple screw fixation, as described in Chapter 19 for the femoral neck, usually works well. If fractures are displaced, they tend to be much more unstable, and in young, vigorous individuals, a device such as a sliding compression hip screw, which provides better purchase on the shaft of the femur, may be indicated. In most cases, for the femoral shaft I now recommend a retrograde nail through the intercondylar notch at the knee, and occasionally plate fixation in select cases.

## HINTS AND TRICKS

- If the femoral shaft will be fixed first, particularly with an antegrade nail such as a reconstruction nail, achieve preliminary fixation of the femoral neck fracture with a suitable-size, smooth Steinmann pin placed from the lateral cortex up the femoral neck and head along the anterior cortex, where it will not be in the way of the medullary nail.
- Do not fix fractures in nonanatomic position, as this significantly increases the risk of nonunion and failure. In displaced fractures that will not reduce, open the fracture through a modified Watson-Jones approach to secure fixation in anatomic position.
- When using independent fixation, try to fix the hip first.
- When using intramedullary nails, overream so that the nail can be driven gently, which avoids stressing the femoral neck fracture.

Postoperative care is determined by the healing of the femoral neck. This may require as long as 6 months, during which time the patient must not bear more weight than the weight of the leg, using assistive devices.

### SIGNIFICANT CORTICAL LOSS

A substantial segment of cortex may be lost at the scene of injury or be completely detached from soft tissues at the time of initial debridement. Remove contaminated free cortical fragments when debriding open fractures, because they may become infected (Fig. 20.13). Although shortening of as much as 1.5 cm is usually tolerated, avoid larger discrepancies and maintain length with an interlocking nail. Many femurs heal even with a gap of several centimeters, particularly in patients under 20 years of age. Cortical losses of 3 cm or more are more likely to not heal. The initial nailing is not definitive and may be performed using a smaller-diameter nail with little reaming, because little weight bearing will be permitted. Several weeks after healing of the soft-tissue envelope, the patient may undergo a bone-grafting technique described by Chapman (see Chapter 30) (Fig. 20.13). Remove the initial nail and ream the canal to accept a larger nail of appropriate diameter. Using a chest tube, pass a slurry of iliac crest cancellous graft and reamings down the medullary canal into the fracture site, followed by placement of a new statically locked nail. The graft incorporates over several months, after which time weight bearing is progressively increased. Another alternative is a microvascularized fibula (40).

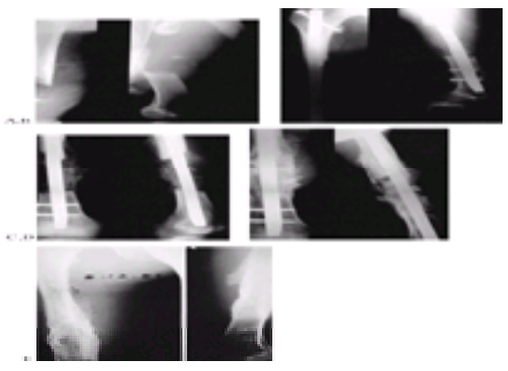

***Figure 20.13.*** **A:** A grade III open fracture of the femur with approximately 10 cm of cortical loss at the scene of injury. The fracture was initially irrigated, debrided, and stabilized with a narrow-diameter, statically locked medullary nail. Local wound care consisted of dressing changes, with uneventful healing of the soft-tissue envelope. **B:** At 1 month from injury, the original nail was removed and the canal reamed to accept a 15 mm, statically locked nail. Simultaneously, a large amount of cancellous bone was harvested from the iliac crest and introduced into the fracture gap through a chest tube, using a technique described by Chapman (22). **C:** At 1 month from grafting, early callus can be seen forming across the fracture site. **D:** At 3 months from grafting, further callus formation is evident. **E:** At 15 months from fracture, the femur has completely reconstituted and hardware has been removed.

## RESULTS

Since the introduction of interlocked intramedullary nails and current methods for irrigation and debridement of open fractures, the results in fractures of the shaft of the femur are truly remarkable. In closed fractures utilizing closed intramedullary techniques with reamed nails, reported union rates are from 98% to 100%, with infection rates only from 0% to 1% (4,6,12,17). In low-grade open fractures, Gustilo I through IIIA, comparable results are achievable (3). In grade IIIB open fractures, the infection rate after initial nailing approaches 11% (10). Therefore, a more sanguine and cautious approach is indicated for severe open fractures.

## PITFALLS AND COMPLICATIONS

Complications specific to fractures of the shaft of the femur include malunion, nonunion, hardware breakage, infection, neurovascular injury, avascular necrosis of the femoral head, heterotopic ossification at the hip, and loss of joint motion.

### MALUNION

With attention to detail, malunion can be avoided in the vast majority of cases. Varus or valgus malunion is most common in high subtrochanteric fractures, where varus is most commonly the result of an eccentric entry point, which, when combined with a large medial bone deficiency, results in loss of position of the proximal fragment during the nailing. Be certain that the entry site is correct. In some cases, it may be necessary to insert a Schanz pin into the proximal fragment to control it during nailing, or to open the fracture to reduce and stabilize it directly. In supracondylar fractures nailed in the lateral position, valgus may occur because of the angulation induced by gravity on the fracture, and recurvatum at the fracture can occur in the supine position. Keeping the guide pin centralized, and controlling the distal fragment as the nail is driven down into it, will usually prevent these problems. Control with a Schanz pin on a T-handle or opening the fracture may occasionally be necessary. Shortening most commonly occurs when there is significant comminution, which makes judgment of length difficult. Follow the recommendations in the section on "Selecting and Driving the Intramedullary Nail" to avoid leg-length discrepancy.

Rotational malunion is the most difficult to avoid. Preoperative evaluation of the range of motion of the opposite hip and attention to the angle of progression of the foot when the patient is lying in the supine position on the operating table often provides good guidelines as to how the rotational alignment of the fractured limb should be set. Yang et al. (80) recommend preoperative evaluation of the anteversion angle of the intact femur to provide more accurate assessment of rotation. With the advent of nonreamed small locked intramedullary nails, torsional distortion of these nails has been a new and unexpected cause of rotational deformity. This can be avoided by using stiffer nonreamed or larger reamed nails (41). Careful postoperative examination of the patient on the operating table usually reveals any deformity, particularly in rotation. Plan to correct this at the time of the initial surgery rather than having to bring the patient back for repeat surgery or reconstructive surgery.

### NONUNION

As mentioned earlier, nonunion is uncommon, and the treatment is addressed in Chapter 30. For the most part, nonunions occur in open fractures or in those with significant comminution or segmental bone loss, particularly if they are treated with small nonreamed nails. Any distraction in the fracture site, despite the tremendous healing capability of the femur, can also lead to nonunion. In segmental bone loss, early bone grafting, either open or with closed intramedullary technique, is indicated as soon as the soft-tissue envelope has recovered. In open fractures or where nonreamed nails were used, when no callus has formed by 12 weeks after injury, consider conversion to a large reamed locked nail. In delayed unions or nonunions where the problem seems to be distraction in the fracture site, dynamization may be sufficient if rotational stability will be maintained. Otherwise, exchange reamed locked nailing and compression are best.

### NAIL OR SCREW BREAKAGE

Breakage may occur early in small-diameter nonreamed nails that use small screws, and late in larger reamed nails when the patient has continued to bear weight in the face of a nonunion. Removal of the side of a screw where the screw head is, presents little problem. Removal of the opposite segment of the screw may require an independent medial approach and, occasionally, overreaming of the screw. Removal of the proximal end of the nail with the extractor presents few problems. Removal of the remainder of a cannulated nail can be done in many ways, but I find that inserting a ball-tipped guide pin through the tip of the nail and then jamming it with a non-ball-tipped guide pin and extracting the nail with a T-handle on the ball-tipped guide pin usually works best.

### INFECTION

Acute infections with antibiotic-sensitive organisms occurring within a few weeks after nailing, where the nail is stable and there is no involvement of the medullary canal, may respond to simple irrigation and debridement of the wound, delayed primary closure, and intravenous antibiotics. When the medullary canal is involved, particularly with more difficult or resistant organisms, nail removal, debridement of the infected wound and medullary canal by reaming, intravenous antibiotics, and placement of antibiotic-impregnated beads into the medullary canal are usually required. Stability can be maintained by either longitudinal traction, if early renailing is anticipated, or external fixation. If the patient responds quickly to antibiotics, then early renailing after resolution of the infection may be possible. Otherwise, the fracture may need to be managed definitively in an external fixator (see Chapter 135).

### NEUROVASCULAR INJURY

Palsies in the upper extremities and in the unaffected lower extremity can be avoided by using appropriate positioning and padding. Pudendal nerve palsy is correlated with excessive traction; you can minimize it by using a large, well-padded perineal post and minimizing the amount and duration of traction used for intramedullary nailing on a fracture table (9). Sciatic nerve palsies usually present as a total common peroneal nerve palsy and partial posterior tibial nerve palsy. Although direct surgical injury of a nerve in the incision in antegrade nailing is possible, it is exceedingly rare. In very small individuals, especially when the hip is flexed 20° or more, the sciatic nerve may drift quite close to the trochanter. If there is any question about the location of the sciatic nerve, lengthen the wound and explore it before placing sharp instruments for entering the proximal femur. In most cases, sciatic nerve paresis is caused by a combination of traction and excessive flexion of the hip with the knee in extension. Avoid this problem by never putting the foot into a traction stirrup but rather applying traction through a proximal tibial or distal femoral pin, allowing the knee to flex freely to accommodate for stretch on the sciatic nerve.

### AVASCULAR NECROSIS

Avascular necrosis of the femoral head secondary to antegrade femoral nailing is exceedingly rare but has been reported. It is most likely caused by interruption of the blood supply to the femoral head as a result of encroachment of the nail entry onto the superior aspect of the femoral neck (2). Avoid this complication by avoiding reamed nails in very small patients or in children with open physes. If antegrade nailing is indicated, use of flexible nails such as the Ender nail through the tip of the trochanter provides a good alternative.

### HETEROTOPIC OSSIFICATION ABOUT THE HIP

In a review of 80 patients undergoing antegrade reamed nailing, Brumback et al. (13) found an incidence of 26% of heterotopic ossification. They found that irrigation with pulsatile lavage did not affect either this incidence or the severity. Notably, the nail used in their study had an open top that would permit the ooze of marrow contents into the hip region postoperatively. It is rare that this heterotopic ossification is sufficient to be symptomatic, but it is a significant impediment to nail removal, and infiltration into the gluteus medius musculature can result in significant damage to the muscle at the time of attempted removal of the ossification or of a medullary nail. It has been my experience that heterotopic ossification can be minimized by the following:

- Taking care to carefully protect the gluteus maximus and medius as well as other soft tissues about the hip during antegrade nailing
- Thoroughly irrigating and debriding the wound at the terminus of the procedure, to remove any marrow contents or bone that might predispose to heterotopic ossification
- Using an intramedullary nail that has a cap screw that closes the nail off and prevents retrograde oozing of marrow contents postoperatively. If the heterotopic ossification is symptomatic, the treatment is removal of it after it has matured, which is usually at least 1 year after injury.

#### JOINT STIFFNESS AND MUSCLE WEAKNESS

Since the advent of modern techniques, loss of motion in the hip and knee after fractures of the shaft of the femur is uncommon unless there is concomitant ipsilateral injury of these two joints. It is important, however, to institute an early range-of-motion and muscle-strengthening program because neglect of rehabilitation can lead to stiffness and persistent weakness. A particular problem is weakness of the abductors in antegrade nailing, apparently due to the traumatic effect of the nailing on the gluteus medius and maximus muscles as well as a tendency to neglect those muscles during rehabilitation. Always include abductor strengthening exercises in the rehabilitation program.

### AUTHOR'S PERSPECTIVE

For closed fractures of the shaft of the femur from just above the lesser trochanter to 2.5 cm proximal to the lateral epicondyle, and in both closed and open fractures grades I through IIIA, my preferred treatment is reamed locked nailing with an Alta titanium intramedullary nail—using an 11 mm nail in women and a 12 mm nail in men—which provides two transverse cross-locking screws proximally and distally. For routine diaphyseal fractures, I place two proximal transverse cross-locking screws proximally and distally, with two proximal transverse cross-locking screws at the level of the lesser trochanter.

In high subtrochanteric fractures, I move the rod more proximally, up to 1 cm proximal to the tip of the greater trochanter, and cross-lock into the femoral neck. In grade IIIB open fractures, when I feel that initial intramedullary nailing is the best approach, I use a nonreamed nail, planning conversion to a reamed nail as soon as the risk of infection has passed and the soft-tissue envelope has recovered. When I believe the risk of infection is too high, I use external fixation.

For retrograde nailing through the intracondylar notch of the knee, I prefer to use a standard Alta nail rather than a special retrograde nail, and I always try to use a nail 10 mm or larger so that the largest transverse cross-locking screws can be used. This is now my treatment of choice for patients with severe multiple injuries in whom rapid atraumatic fixation of the fracture in the supine position on a regular radiolucent table is necessary. I also prefer this technique for fixation of shaft fractures below a femoral neck fracture, using independent fixation of the femoral neck with either multiple screws or a sliding compression hip screw, depending on the configuration of the fracture. I rarely plate a diaphyseal fracture of the femur, reserving this technique for patients in whom the configuration of the femur or absence of a medullary canal precludes intramedullary nailing, or in whom a vascular repair has been done that is least threatened by plate fixation as opposed to nailing. I reserve single-plane half-pin external fixation for grade IIIB (and higher) open fractures and the occasional polytrauma patient in whom retrograde nailing is not possible.

## B. PERIPROSTHETIC FRACTURES OF THE FEMUR

Fracture of the femur associated with a prosthetic implant is not unusual and is increasing in incidence (21,23,25,38,44,50,59,60,62,66,69,74). The second leading cause of revision hip arthroplasty at the Mayo Clinic is now periprosthetic fracture (44). The overall prevalence is between 0.1% and 1.1% of total hip prostheses. Periprosthetic fractures can occur acutely at the time of initial implantation of the prosthesis or later. Factors that predispose to periprosthetic fractures include the following:

- Intraoperative creation of cracks, defects, or windows in the bone that are not bypassed with a stem of sufficient length
- Extravasation of cement out of bone defects that results in an unhealed stress riser
- Severe cortical erosion from a loose femoral component
- Hip surgery prior to prosthetic replacement, because of weakening of the bone or because of holes left from previous implants

These fractures usually occur in elderly patients with osteoporosis who have had total joint replacement of the hip or knee. Because the bone is weak, and on one side of the fracture the medullary canal is occupied by the prosthesis, internal fixation becomes a major challenge. Many surgeons have recommended nonoperative treatment for these fractures, but experience has shown that nonoperative treatment leads to a high rate of local and systemic complications (38). Local complications include fracture nonunion, femoral shortening, femoral deformity, and prosthetic loosening. These complications require major secondary surgery for correction. Prolonged bed rest and immobilization can produce life-threatening complications. These risks for nonoperative treatment, combined with the high likelihood of the need for future revision arthroplasty, have led to a recommendation of internal fixation for all displaced fractures associated with femoral prostheses, whenever clinically possible.

### CLASSIFICATION

Fractures of the femur associated with an implanted femoral prosthesis can be classified on the basis of type and location of prosthesis, the type and configuration of fracture line, and the status of prosthesis fixation (i.e., whether it is stable or loose).

#### TYPE AND LOCATION OF PROSTHESIS

The following situations may be encountered:

***Surface Replacement of the Proximal Femur***

Fractures associated with surface replacements of the hip usually occur at the femoral neck just distal to the prosthesis. Treat by converting the surface replacement to a standard total hip replacement arthroplasty. In the unusual case in which a fracture occurs at or distal to the intertrochanteric region, you may treat it by the usual operative methods for similar fractures *not* associated with a prosthesis.

***Stemmed Replacement of the Proximal Femur***

Stemmed prostheses of the proximal femur may be further subdivided into those in which the femoral stem and cement, or the stem alone occupies the entire medullary canal, and those in which the femoral stem occupies only a portion of the medullary canal. In fractures in which the entire medullary canal is filled with a prosthetic stem, with or without cement, placement of a new prosthesis with a longer stem provides intramedullary fixation (Fig. 20.14). An alternative method is to fix the fracture with a plate, supplemented with bone grafting (Fig. 20.15, Fig. 20.16). Secure the plate with bicortical screws in the femur distal to the prosthesis, and with unicortical or tangential screws proximally where the medullary canal is filled by the prosthetic stem (Fig. 20.16). Another method of securing the plate proximally is to use cerclage wires or cable systems (Fig. 20.17). If an uncemented stem occupies only a portion of the femoral canal, it is sometimes possible to gain adequate fixation by passing small flexible intramedullary rods, such as Ender or Rush rods, across the fracture site and into the medullary canal adjacent to the prosthetic stem (Fig. 20.18).

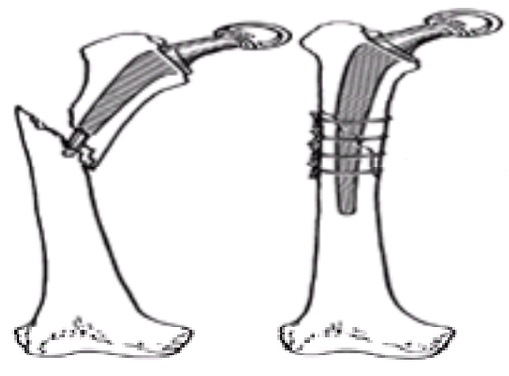

***Figure 20.14.*** Use of a long-stemmed femoral prosthesis and cerclage wires to hold the reduction of a long oblique fracture.

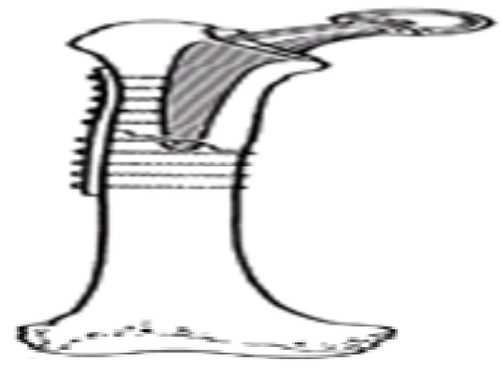

***Figure 20.15.*** Plate and screw fixation of a fracture at the tip of a proximal femoral prosthesis.

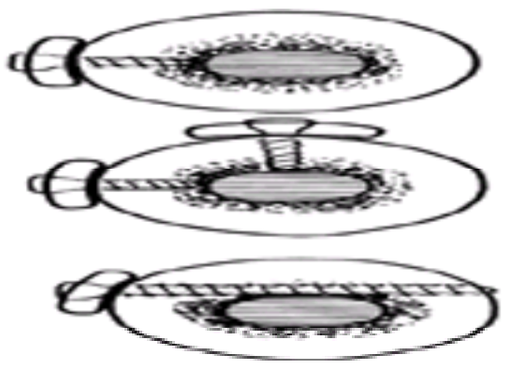

***Figure 20.16.*** Three possible methods of plate and screw placement to be used if the intramedullary stem prevents central bicortical screw placement. The goal is to obtain a solid purchase on eight cortices on each side of the fracture.

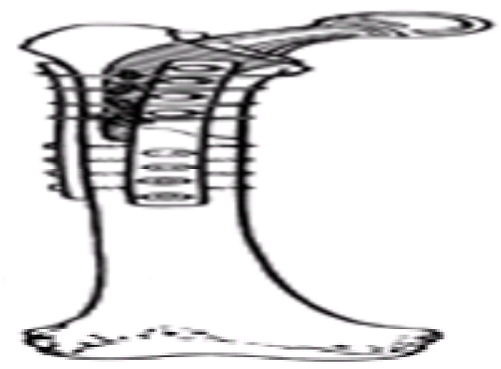

***Figure 20.17.*** Use of cerclage wires to secure fixation of a plate to the proximal femur segment.

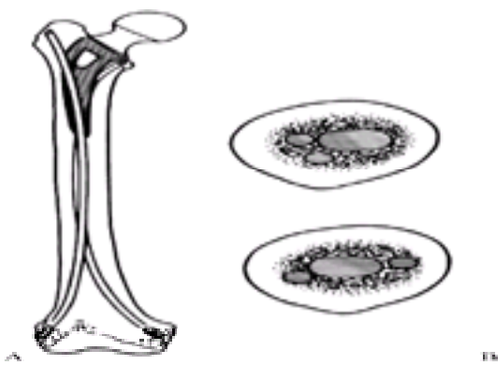

***Figure 20.18.*** **A:** Flexible small intramedullary rods are used to internally fix fractures of the femoral shaft distal to the tip of an uncemented proximal femoral prosthesis that fills the entire canal. **B:** Possible intramedullary placement if the prosthesis stem is not cemented and does not fill the entire canal.

### *Femoral Prosthesis Associated with Knee-Replacement Arthroplasty*

Fractures around total knee prosthesis can include femoral prosthesis associated with knee replacement arthroplasty; distal femoral surface replacement without a stem; cemented distal femoral replacement with an intramedullary stem; and uncemented distal femoral replacement with an intramedullary stem. Fractures of the distal femur just proximal to a total knee replacement are most often associated with anterior notching of the femur caused by poor placement of the cutting guides during total knee arthroplasty. The notching causes weakening of the femur just above the prosthesis, and delayed fracture propagating from the stress riser is not an uncommon complication.

Distal femoral prostheses not associated with a femoral stem are essentially surface replacement prostheses. In fractures that occur proximal to a nonstemmed prosthesis, alternatives include a condylar blade plate or compression screw with side plate screws (Fig. 20.19), retrograde nails (Fig. 20.20), and antegrade nails (Fig. 20.21). In fractures associated with a distal femoral prosthesis that has an intramedullary stem, a revision can be done using a longer stem (Fig. 20.22) or a plate-and-screw fixation with tangential placement of the screws to avoid the stem.

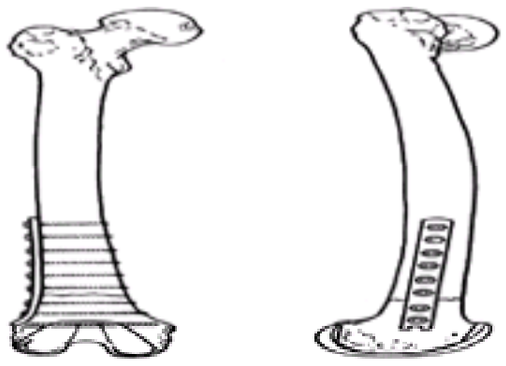

***Figure 20.19.*** Blade plate and screw fixation above a distal femoral surface replacement.

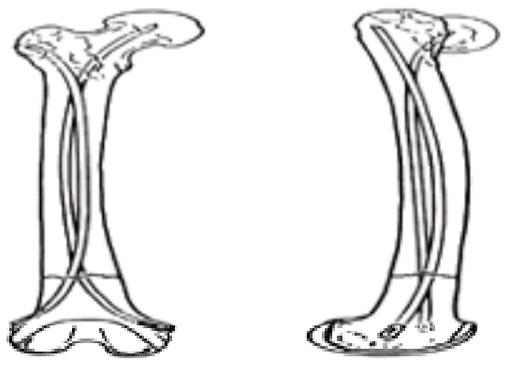

***Figure 20.20.*** Ender or Rush rod fixation above a distal femoral surface replacement.

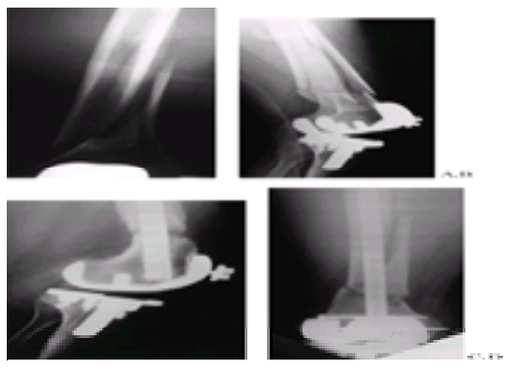

***Figure 20.21.*** Antegrade closed nail fixation of a supracondylar fracture of the femur proximal to a total knee prosthesis. **A:** Preoperative AP radiograph showing the fracture. **B:** Preoperative lateral radiograph. **C:** Postoperative lateral radiograph showing fixation with an antegrade Alta nail whose tip was cut off to allow more distal placement. **D:** AP radiograph.

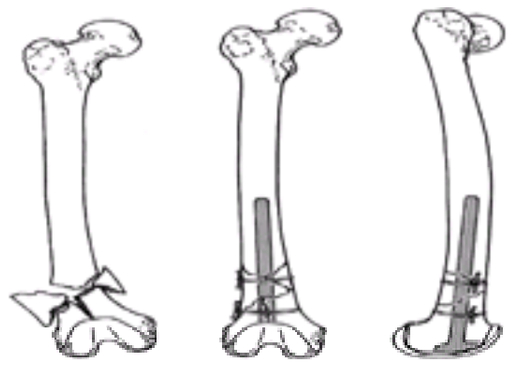

***Figure 20.22.*** A custom long-stemmed distal femoral component used to internally fix a comminuted distal femoral fracture above a short-stemmed distal femoral prosthesis.

## TYPE AND CONFIGURATION OF FRACTURE LINE

### *Proximal to or at the Tip of the Prosthetic Stem*

The most common fractures of the femur associated with femoral prostheses are transverse or short oblique fractures at, or proximal to, the tip of the femoral stem [Johansson type I (38)]. Long oblique or spiral fractures in this location are less common. The fractures usually result from trauma at a stress riser created by the transition between the stiff one-prosthesis segment and adjacent, less stiff bone. If the fracture is transverse or short oblique, there is a high risk of displacement, shortening, and nonunion. Internal fixation is recommended. If the fracture has a spiral or long oblique course, displacement may be minimal, and if there is no associated loosening of the prosthesis, treatment can be nonoperative, consisting of traction followed by fracture bracing and crutches.

### *Around the Prosthesis*

For fractures to occur around the prosthesis, a portion of the prosthesis must be loose. Johansson type II fractures occur around the prosthesis and extend to beyond the distal tip of the prosthesis with dislodgement of the stem from the distal canal. The prosthesis may have been loose before injury, or the fracture itself may break the prosthesis from its fixation to the surrounding bone. In these situations, the fracture must be reduced and internally fixed, and the prosthesis must be revised (Fig. 20.23).

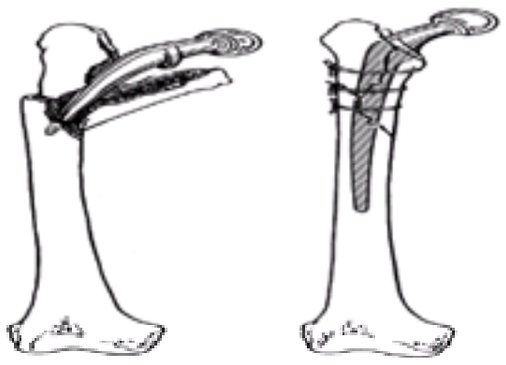

***Figure 20.23.*** Use of a long-stemmed proximal femoral prosthesis with cerclage wires to contain fragments around the stem.

### *At a Distance from the Prosthesis*

Fractures that occur at a distance from the prosthesis (Johansson type III) may be treated by plate fixation. However, the interval of bone between the end of the plate and the tip of the prosthetic stem is subject to high stresses and is a potential site of future fracture.

## STATUS OF PROSTHESIS FIXATION

If the prosthesis remains tight and well fixed to bone, aim fracture management at reestablishing bony alignment and achieving union. If the prosthesis is loose, fracture fixation is necessary, and the prosthesis must be reimplanted with a longer stem and recemented or, if a porous-coated long-stemmed prosthesis is used, bone-grafted. Frequently, cerclage wires or cables are required to “gather in” bone fragments or to oppose oblique fractures around the prosthesis (Fig. 20.23). Chandler and Tigges (21) recommend reinforcing the fracture site with allograft when a proximal femoral fracture occurs at or distal to a well-fixed femoral stem, or proximal to a well-fixed knee replacement. They recommend the following technique.

### *Fixation with Allograft Reinforcement*

- Expose the fracture, reduce it anatomically, and temporarily stabilize it with cerclage wires or cables (Fig. 20.24*A*, Fig. 20.24*B*).

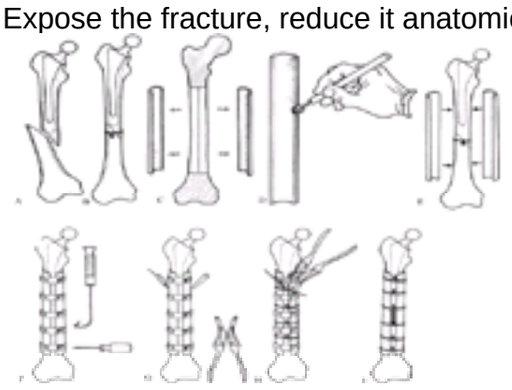

***Figure 20.24.*** Allograft strut treatment for a proximal femoral fracture at the end of a prosthesis. **A:** Fracture of the femoral shaft just distal to the stem of a prosthesis. **B:** The fracture has been reduced and temporarily fixed. **C:** An allograft split into two equal pieces. **D:** Machining the endosteal surface of a graft. **E:** Placement of the two grafts on the femur. **F:** Use of hose clamps to secure the allografts to the femur. **G:** Passing the cerclage wires around the struts. **H:** Tightening the wires. **I:** The hose clamps have been removed, and the autologous graft has been applied. (Reproduced with permission from Chandler HP, Tigges RG. The Role of Allografts in the Treatment of Periprosthetic Femoral Fractures. In: Cannon WD, ed. *Instructional Course Lectures,* Vol. 47. Rosemont, IL: American Academy of Orthopaedic Surgeons, 1998.)

- Obtain an allograft femoral or tibial shaft of appropriate size, harvest the diaphyseal portion, and split it into two equal medial and lateral shells in the sagittal plane to provide biological bone plates. Fresh frozen allografts are preferred, but freeze-dried allografts are also thought to be effective (Fig. 20.24*C*).
- Machine the endosteal inside surfaces of the grafts with a high-speed burr to conform them to the outside contours of the recipient femur (Fig. 20.24*D*).
- Place these on the medial and lateral sides of the femur, preserving the soft-tissue attachments to the linea aspera, which contain the extraosseous blood supply to the femur. Make the struts long enough to extend at least 10 cm beyond the fracture both proximally and distally (Fig. 20.24*E*).
- Apply the allograft struts to the fracture, and compress them into place with commercial hose clamps (Fig. 20.24*F*).
- With a wire passer, pass double #16 stainless-steel cerclage wires around the struts at 2–4 cm intervals (Fig. 20.24*G*).
- Tighten the wires with a Harris wire tightener (Johnson & Johnson, Raynham, MA) (Fig. 20.24*H*). When the allograft has been secured with the wires, remove the hose clamps.
- Graft the fracture with autologous cancellous bone from the iliac crest to hasten healing (Fig. 20.24*I*).

Use protected weight bearing to 60 pounds (27 kg) until 12 weeks, then advance weight bearing.

For femoral fractures distal to a well-fixed femoral stem or proximal to a well-fixed knee replacement, Chandler and Tigges (21) recommend retrograde intramedullary nails—assuming that the knee prosthesis permits insertion of the nail, and recognizing that in total hip replacement there is the potential for a stress riser between the proximal end of the medullary nail and the distal end of the stem of the prosthesis (21,56,65,70).

Where rods cannot be used, plate fixation is indicated. Pack autologous cancellous bone around the fracture site. However, comminution and the osteopenic bone frequently found in this group of patients result in poor screw fixation. To circumvent this problem, harvest an allograft from either a tibia or a femur (probably better from a comparable femur). Chandler and Tigges (21) back up the plate on the opposite cortex with an allograft strut harvested from the identical location on the allograft femur so that the strut fits the host femur accurately (Fig. 20.25, Fig. 20.26). Their technique includes the following.

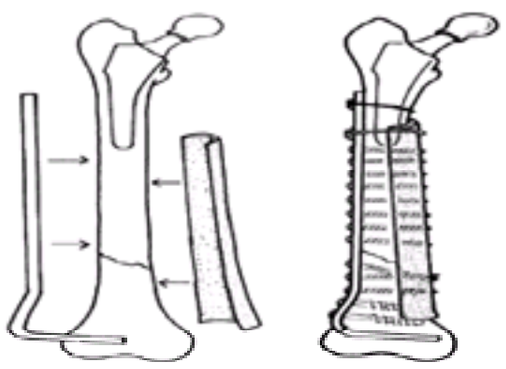

***Figure 20.25.*** An allograft shell placed on the opposite cortex to reinforce the fixation and provide a structural bone graft. (From Chandler HP, Tigges RG. The Role of Allografts in the Treatment of Periprosthetic Femoral Fractures. *J Bone Joint Surg Am* 1997;79:1422.)

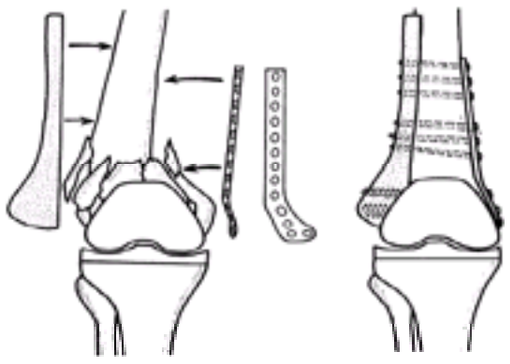

***Figure 20.26.*** The use of an allograft in combination with a buttress plate to reconstruct a comminuted supracondylar fracture of the femur immediately above a total knee prosthesis in an elderly patient whose bone quality precluded effective fixation with the screws.

- Expose the distal femur and total knee through a medial parapatellar incision.
- Reduce the fracture, and temporarily hold it reduced with cerclage wires or a K-wire while the plate is fitted to one cortex and the allograft strut to the opposite cortex.
- Stabilize the plate and strut to the host femur with cerclage cables or wires in the area of an intramedullary stem, and use screws elsewhere (Fig. 20.17).

Their postoperative care is the same as that already described.

**THE VANCOUVER SYSTEM**

Duncan and Masri (28) have modified Johansson's (38) classification system to create the Vancouver System. Their classifications for fractures about a total hip prosthesis follow.

- Type A: Trochanteric fractures
- Type B: Fractures about the stem or tip
  - B1: Well-fixed stem
  - B2: Loose stem
  - B3: Associated bony deficiency or destruction
- Type C: Fractures distal to the tip

Lewallen and Berry's (44) recommendations for these include the following:

- Type A. Treat simple avulsion fractures of the greater or lesser trochanter in the presence of a well-fixed stem nonoperatively. For severe periprosthetic osteolysis, replace the component that is the source of the microparticles.
- Type B1. These usually can be treated with internal fixation.
- Type B2. Revise the loose component.
- Type B3. Revise the component.
- Type C. Internal fixation usually suffices.

Lewallen and Berry (44) emphasize that in all types of fractures associated with a loose femoral component, the best treatment is revision unless medical problems or advanced age contraindicates this extensive surgery.

## SURGICAL TECHNIQUES

Femur fractures in which a prosthesis is in place are long and difficult surgical cases requiring excellent support and careful preoperative planning. If possible, have autogenous blood and a cell saver available. A laminar flow unit or ultraviolet radiation may reduce the infection rate.

- Expose the proximal femur according to your preference. If the proximal femoral prosthesis is to be revised, trochanteric osteotomy greatly facilitates exposure and removal of the prosthesis and cement. Extend the exposure distally to expose the femoral shaft and the full extent of the fracture. This facilitates fracture reduction, fixation, cementing, packing of bone graft, and passage of the prosthetic stem across the fracture under direct vision.
- Occasionally, longitudinal splitting of the proximal fragment by the fracture at the time of surgery can prove to be an advantage, and by opening the proximal femoral segment “like a book,” you can easily remove the prosthesis and cement. Repair the split proximal fragment with cerclage wires or cables.
- It is best to approach distal femoral prostheses associated with fractures by the anteromedial parapatellar incision if the prosthesis is to be revised. If the prosthesis is tight and there is enough bone stock proximal to the prosthesis to use standard means of internal fixation, you may use lateral or combined medial and lateral incisions over the distal femur for a blade plate or condylar medullary rods.
- Occasionally, fractures proximal to a total knee prosthesis can be managed by closed reduction on a fracture table and either antegrade or retrograde fixation with a locked medullary nail, utilizing closed technique (Fig. 20.20, Fig. 20.21).
- Since the procedure to replace the femoral prosthesis in the presence of a fracture is essentially a revision, the technique is very similar to revision arthroplasty, with the exception of needing to address the fracture. The technical details of revision arthroplasty for the hip are addressed in Chapter 106, and those for the fracture about the total knee, in Chapter 109. Specifics about the fixation have already been addressed in the preceding descriptions.

### HINTS AND TRICKS

- In revision arthroplasty when intramedullary stem fixation alone may be adequate, custom prostheses can be ordered that have cross holes in the distal stem through which transverse cross-locking screws can be inserted. The only disadvantage of this approach is that it creates a stress riser at the location of the prosthesis for both the bone and the prosthesis.
- For combining cable fixation and plates, special designs are now available in which the cable is accommodated by modifications or additions to the plate, resulting in more secure fixation than is provided by wrapping a cable around a standard plate.
- In repeat surgery of this type, and when a loose prosthesis is present, infection is increased. Hold off on preoperative antibiotics until cultures and specimens from the prosthesis bed and fracture have been submitted to pathology. Then administer appropriate bactericidal intravenous antibiotics, and continue them until the cultures are reported to be negative. Positive cultures require appropriate long-term intravenous antibiotic therapy.

## POSTOPERATIVE CARE AND REHABILITATION

Ideally, fracture fixation must be sufficiently solid so that the patient can be out of bed and ambulatory by the 4th or 5th postoperative day. In patients with good bone stock and strong intramedullary fixation, weight bearing can progress as with any fracture fixed with an intramedullary device. For patients who have had a trochanteric osteotomy and reattachment, use at least 6 weeks of touchdown weight bearing to avoid displacement of the trochanter. If the femoral prosthesis has been exchanged, the usual postoperative precautions associated with joint replacement to prevent dislocation and other complications are necessary.

## RESULTS

Johansson et al. (38) reported on 35 patients with 37 periprosthetic fractures following total hip replacement after a follow up averaging 3.9 years (range, 2–9 years). Their results were dismal, with unsatisfactory outcomes in 22 fractures (59%). The most common problem was prosthetic loosening, which occurred in ten, followed by malunion with loosening in three, nonunion in three, massive heterotopic bone in one, infection in three, and two unsatisfactory outcomes in primary Girdlestone resections. Seven immediate postoperative fractures that were treated in traction all had unsatisfactory results. Johansson et al. had a total of 30 complications (60%) in their 22 patients. Improvement in techniques to handle these difficult problems have shown markedly improved results. Chandler et al. (20) in 1993 achieved anatomic union in 100% of periprosthetic fractures treated with their technique of onlay grafting, with all returning to their functional status prior to fracture. In a later

report in 1996 (19), using the combination of a metal plate and an allograft strut, they achieved anatomic union in 21 of 22 patients.

In a recent series from the Mayo Clinic, Lewallen and Berry (44) analyzed outcomes in revision total hip arthroplasty for 97 postoperative periprosthetic femoral fractures in 94 patients, with an average followup of 5 years (range, 2–14 years). Eighty-five percent of the fractures healed, but stable long-term fixation of the femoral stem was achieved in less then 50% of the hips. Overall, 20% had only minimal symptoms in spite of the radiographic evidence of loosening; however, 33% had loosening with severe pain. Use of a proximally porosis-coated implant without cement was associated with the poorest results. An important observation in their series was the occurrence of a spontaneous fracture, in the absence of a traumatic event, in more the 50% of their patients who had Vancouver type B3 fractures in which the bone loss and comminution were severe. This points out that a periprosthetic fracture is a very serious occurrence in the typical elderly patient with a total hip or total knee arthroplasty. Although nonoperative care for minimally displaced acute periprosthetic fractures in traction has reasonably good outcomes, nearly all of these require major surgery, with significant risks and a high rate of complications. Although much progress has been made toward solving this problem in the last 20 years, more is needed.

## PITFALLS AND COMPLICATIONS

Operative complications of treating fractures associated with femoral prostheses usually stem from difficulties of cement and prosthesis removal or inadequate preoperative planning. A variety of prosthetic alternatives, including cemented and uncemented devices of various stem sizes and lengths, must be available to deal with unexpected technical problems.

Always have available a long-stemmed power burr and intramedullary reamers and curets for removal of cement. It is important to know the techniques for removal of broken hardware from the medullary canal, including the use of an image intensifier, to avoid cortical perforation during reaming. Preoperative planning should include careful silhouetting of the femur and fracture with appropriate templates to determine prosthesis size and to match components for the revision. Appropriate plates, screws, and intramedullary rods must be available. It is not uncommon to change techniques from those planned because of intraoperative findings at the time of surgery. Multiple options must be open to achieve optimal fixation.

Postoperative complications usually arise from inadequate prosthetic fixation or refracture. If cement fixation is insufficient, the prosthesis will become loose, particularly in patients in whom the original prosthesis loosened because of periprosthetic cortical lysis. In patients in whom a prosthesis is left in place and plates and screws or cerclage techniques are used to stabilize the fracture, fixation is always less then ideal. Take care to delay weight bearing until the fracture has united, because excessive and premature weight bearing may lead to loss of fixation, displacement, and nonunion, requiring reoperation. Patients who have a stress riser between the end of the prosthesis and an adjacent plate are always at risk of refracture and must be cautioned to avoid trauma to the leg.

## ACKNOWLEDGEMENT

This chapter in the second edition was written by Sigvard T. Hansen, Jr., and David W. Lhowe. Portions of their original, excellent chapter are included here.

### CHAPTER REFERENCES

Each reference is categorized according to the following scheme: *, classic article; #, review article; !, basic research article; and +, clinical results/outcome study.


+ 1. Alonzo J, Geissler W, Hughes JL. External Fixation of Femoral Fractures. Indications and Limitations. *Clin Orthop* 1989;241:83.

+ 2. Astion DJ, Wilber JH Scoles PV. Avascular Necrosis of the Capital Femoral Epiphysis after Intramedullary Nailing for a Fracture of the Femoral Shaft. A Case Report. *J Bone Joint Surg Am* 1995;77:1092.

+ 3. Bain GI, Zacest AC, Paterson DC, et al. Abduction Strength Following Intramedullary Nailing of the Femur. *J Orthop Trauma* 1997;11:93.

+ 4. Baixauli F Sr, Baixauli EJ, Sanchez-Alepuz E, Baixauli F Jr. Interlocked Intramedullary Nailing for Treatment of Open Femoral Shaft Fractures. *Clin Orthop* 1998;350:67.

! 5. Bankston AB, Keating EM, Saha S. The Biomechanical Evaluation of Intramedullary Nails in Distal Femoral Shaft Fractures. *Clin Orthop* 1992;276:277.

+ 6. Baumgaertel F, Dahlen C, Stiletto R, Gotzen L. Technique of Using the AO-Femoral Distractor for Femoral Intramedullary Nailing. *J Orthop Trauma* 1994;8:315.

+ 7. Bostman O, Varjonen L, Vainionpaa S, et al. Incidence of Local Complications after Intramedullary Nailing and after Plate Fixation of the Femoral Shaft Fractures. *J Trauma* 1989;29:639.

+ 8. Browner B. Pitfalls, Errors, and Complications in the Use of Locking Küntscher Nails. *Clin Orthop* 1986;212:192.

+ 9. Brumback RJ, Ellison TS, Molligan H, et al. Pudenal Nerve Palsy Complicating Intramedullary Nailing of the Femur. *J Bone Joint Surg Am* 1992;74:1450.

+ 10. Brumback RJ, Ellison PS, Poka A, et al. Intramedullary Nailing of Open Fractures of the Femoral Shaft. *J Bone Joint Surg Am* 1989;71:1324.

+ 11. Brumback RJ, Reilly JP, Poka A, et al. Intramedullary Nailing of Femoral Shaft Fractures. Part I: Decision-making Errors with Interlocking Fixation. *J Bone Joint Surg Am* 1988;70:1441.

+ 12. Brumback RJ, Uwagie-Ero S, Lakatos RP, et al. Intramedullary Nailing of Femoral Shaft Fractures. Part II: Fracture-healing with Static Interlocking Fixation. *J Bone Joint Surg Am* 1988;70:1452.

+ 13. Brumback RJ, Wells JD, Lakatos R, et al. Heterotopic Ossification about the Hip after Intramedullary Nailing for Fractures of the Femur. *J Bone Joint Surg Am* 1990;72:1067.

# 14. Bucholz RW, Jones A. Current Concepts Review, Fractures of the Shaft of the Femur. *J Bone Joint Surg Am* 1991;73:1561.

+ 15. Bucholz RW, Ross RW, Lawrence KL. Fatigue Fracture of the Interlocking Nail in the Treatment of Fractures of the Distal Part of the Femoral Shaft. *J Bone Joint Surg Am* 1987;69:1391.

+ 16. Butler MS, Brumback RJ, Ellison TS, et al. Interlocking Intramedullary Nailing for Ipsilateral Fractures of the Femoral Shaft and Distal Part of the Femur. *J Bone Joint Surg Am* 1991;73:1492.

+ 17. Cameron CD, Meek RN, Blachut PA, et al. Intramedullary Nailing of the Femoral Shaft: A Prospective, Randomized Study. *J Orthop Trauma* 1992;6:448.

+ 18. Casey MJ, Chapman MW. Ipsilateral Concomitant Fractures of the Hip and Femoral Shaft. *J Bone Joint Surg Am* 1979;61:502.

+ 19. Chandler HP, Danylchuk K. Treatment of Distal Femoral Fractures Proximal to a Total Knee Replacement or Distal to the Stem of a Total Hip Replacement in Osteopenic Patients. Presented as a poster exhibit at the annual meeting of the American Academy of Orthopaedic Surgeons, Atlanta, Georgia, February 25, 1996.

+ 20. Chandler HP, King D, Limbird R, et al. The Use of Cortical Allograft Struts for Fixation of Fractures Associated with Well-fixed Total Joint Prostheses. *Semin Arthroplasty* 1993;4:99.

# 21. Chandler HP, Tigges RG. The Role of Allografts in the Treatment of Periprosthetic Femoral Fractures. An Instructional Course Lecture. *J Bone Joint Surg Am* 1997;79:1422.

+ 22. Chapman MW. Closed Intramedullary Bone Grafting and Nailing of Segmental Defects of the Femur. *J Bone Joint Surg Am* 1980;62:1004.

+ 23. Clancy GJ, Smith RF, Madenwald MB. Fracture of the Distal End of the Femur below Hip Implants in Elderly Patients. *J Bone Joint Surg Am* 1983;75:491.

+ 24. Clatworthy MD, Clark DI, Gray DH, Hardy AE. Reamed versus Unreamed Femoral Nails. A Randomized, Prospective Trail. *J Bone Joint Surg Br* 1998;80:485.

+ 25. Culp RW, Schmidt RG, Hanks G, et al. Supracondylar Fracture of the Femur following Prosthetic Knee Arthroplasty. *Clin Orthop* 1987;222:112.

+ 26. Dabezies EJ, D'Ambrosia R, Shuji H, et al. Fractures of the Femoral Shaft Treated by External Fixation with the Wagner Device. *J Bone Joint Surg Am* 1984;66:360.

+ 27. De Bastiani G, Aldegheri R, Renzi Brivio L. The Treatment of Fractures with a Dynamic Axial Fixator. *J Bone Joint Surg Br* 1984;66:538.

# 28. Duncan CP, Masri BA. Fractures of the Femur after Hip Replacement. *Instr Course Lect* 1995;44:293.

! 29. ElMaraghy AW, Schemitsch EH, Richards RR. Femoral and Cruciate Blood Flow after Retrograde Femoral Reaming: A Canine Study Using Laser Doppler Flowmetry. *J Orthop Trauma* 1998;12:253.

+ 30. Gellman RE, Paiement GD, Green HD, Coughlin RR. Treatment of Supracondylar Femoral Fractures with a Retrograde Intramedullary Nail. *Clin Orthop* 1996;332:90.

+ 31. George CJ, Lindsey RW, Noble PC, et al. Optimal Location of a Single Distal Interlocking Screw in Intramedullary Nailing of Distal Third Femoral Shaft Fractures. *J Orthop Trauma* 1998;12:267.

+ 32. Gregory P, DiCicco J, Karpik K, et al. Ipsilateral Fractures of the Femur and Tibia: Treatment with Retrograde Femoral Nailing and Unreamed Tibial Nailing. *J Orthop Trauma* 1996;10:309.

# 33. Gustilo RB, Anderson JT. Prevention of Infection in the Treatment of 1025 Open Fractures of Long Bones. *J Bone Joint Surg Am* 1976;58:452.

! 34. Hajek PD, Bicknell HR Jr, Bronson WE, et al. The Use of One Compared with Two Distal Screws in the Treatment of Femoral Shaft Fractures with Interlocking Intramedullary Nailing: A Clinical and Biomechanical Analysis. *J Bone Joint Surg Am* 1993;75:519.

+ 35. Herscovici D Jr, Whiteman KW. Retrograde Nailing of the Femur Using an Intercondylar Approach. *Clin Orthop* 1996;332:98.

# 36. Hughes JL. External Skeletal Fixation. Part V. Wagner Apparatus: A Portable Traction Device for the Femur. *Instr Course Lect* 1984;33:158.

+ 37. Janzing HMJ, Stockman B, Van Damme G, et al. The Retrograde Intramedullary Nail: Prospective Experience in Patients Older Than Sixty-five Years. *J Orthop Trauma* 1998;12:330.

+ 38. Johansson JE, McBroom R, Barrington TW, Hunter GA. Fracture of the Ipsilateral Femur in Patients with Total Hip Replacement. *J Bone Joint Surg Am* 1981;63:1435.

+ 39. Johnson KD, Tencer AF, Blumenthal S, et al. Biomechanical Performance of Locked Intramedullary Nails in Comminuted Femoral Shaft Fractures. *Clin Orthop* 1986;206:151.

+ 40. Jupiter JB, Bour CJ, May JW. The Reconstruction of Defects in the Femoral Shaft with Vascularized Transfers of Fibular Bone. *J Bone Joint Surg Am* 1987;69:365.

+ 41. Krettek C, Miclau T, Blauth M, et al. Recurrent Rotational Deformity of the Femur after Static Locking of Intramedullary Nails. *J Bone Joint Surg Am* 1997;79:4.

! 42. Kyle RF, Schaffhausen JM, Bechtold JE. Biomechanical Characteristics of Interlocking Femoral Nails in the Treatment of Complex Femoral Fractures. *Clin Orthop* 1991;267:169.

+ 43. Levin PE, Schoen RW, Browner BD. Radiation Exposure to the Surgeon During Closed Locked Intramedullary Nailing. *J Bone Joint Surg Am* 1987;69:761.

# 44. Lewallen DG, Berry DJ. Periprosthetic Fracture of the Femur after Total Hip Arthroplasty. In Instructional Course Lectures. *J Bone Joint Surg Am* 1997;9:1881.

+ 45. Lhowe DW, Hansen ST. Immediate Nailing of Open Fractures of the Femoral Shaft. *J Bone Joint Surg Am* 1988;70:812.

+ 46. Lucas SE, Seligson D, Henry SL. Intramedullary Supracondylar Nailing of Femoral Fractures. A Preliminary Report of the GSH Supracondylar Nail. *Clin Orthop* 1993;296:200.

+ 47. Magerl F, Wyss A, Brunner C, Binder W. Plate Osteosynthesis of Femoral Shaft Fractures in Adults. *Clin Orthop* 1979;138:62.

# 48. Mast J, Jakob R, Ganz R. *Planning and Reduction Technique in Fracture Surgery.* Berlin: Springer-Verlag, 1989.

# 49. Mays J, Neufelf AJ. Skeletal Traction Methods. *Clin Orthop* 1975;102:141.

+ 50. McLauchlan GJ, Robinson CM, Singer BR, Christie J. Results of an Operative Policy in the Treatment of Periprosthetic Femoral Fracture. *J Orthop Trauma* 1997;11:170.

+ 51. Meggitt BF, Juett DA, Smith JD. Cast-bracing for Fractures of the Femoral Shaft. A Biomechanical and Clinical Study. *J Bone Joint Surg Br* 1981;63:12.

+ 52. Moed BR, Watson JT. Retrograde Intramedullary Nailing, without Reaming, of Fractures of the Femoral Shaft in Multiply Injured Patients. *J Bone Joint Surg Am* 1995;77:1520.

+ 53. Moed BR, Watson JT, Cramer KE, et al. Unreamed Retrograde Intramedullary Nailing of Fractures of the Femoral Shaft. *J Orthop Trauma* 1998;12:334.

+ 54. Morgan E, Ostrum RF, DiCicco J, et al. Effects of Retrograde Femoral Intramedullary Nailing on the Patellofemoral Articulation. *J Orthop Trauma* 1999;12:12.

# 55. Muüller ME. *Manual of Internal Fixation*, 3rd ed. New York: Springer-Verlag, 1990.

+ 56. Murrell GA, Nunley JA. Interlocked Supracondylar Intramedullary Nails for Supracondylar Fractures after Total Knee Arthroplasty. A New Treatment Method. *J Arthroplasty* 1995;10:37.

# 57. Orthopaedic Trauma Association: Fracture and Dislocation Compendium. *J Orthop Trauma* 1996;1(suppl 10):31.

+ 58. Ostrum RF, DiCicco J, Lakatos R, Poka A. Retrograde Intramedullary Nailing of Femoral Diaphyseal Fractures. *J Orthop Trauma* 1998;12:464.

+ 59. Pankovich AM, Tarabishy I, Barmada R. Fractures below Non-cemented Femoral Implants, Treatment with Ender Nailing. *J Bone Joint Surg Am* 1981;63:1024.

+ 60. Parrish TF, Jones JR. Fracture of the Femur following Prosthetic Arthroplasty of the Hip: Report of Nine Cases. *J Bone Joint Surg Am* 1964;46:241.

+ 61. Patterson BM, Routt ML Jr, Benirschke SK, Hansen ST Jr. Retrograde Femoral Nailing: A Procedure for Severe Injuries. *J Orthop Trauma* 1993;7:155.

+ 62. Ponzer S, Tidermark J, Toörnkvist H. Retrograde Nailing of Femoral Fractures Distal to a Moore Prosthesis. *J Orthop Trauma* 1998;12:588.

+ 63. Riina J, Tornetta P III, Ritter C, Geller J. Neurologic and Vascular Structures at Risk during Anterior-posterior Locking of Retrograde Femoral Nails. *J Orthop Trauma* 1998;12:379.

+ 64. Riquelme AG, Rodriguez AJ, Mino GL, Sanmartin RM. Treatment of the Femoral and Tibial Fractures with Grosse and Kempf Locking Nails. *Clin Orthop* 1992;283:86.

+ 65. Ritter MA, Keating EM, Faris PM, Meding JB. Rush Rod Fixation of Supracondylar Fractures above Total Knee Arthroplasties. *J Arthroplasty* 1995;10:213.

+ 66. Roffman M, Mendes DC. Fractures of the Femur after Total Hip Arthroplasty. *Orthopaedics* 1989;12:1067.

+ 67. Ruedi T, Luscher JN. Results after Internal Fixation of Comminuted Fractures of the Femoral Shaft with DC Plates. *Clin Orthop* 1979;138:74.

+ 68. Sanders R, Koval KJ, DiPasquale T, et al. Retrograde Reamed Femoral Nailing. *J Orthop Trauma* 1993;7:293.

+ 69. Scott RD, Turner RH, Leitzes SM, Aufranc OA. Femoral Fractures in Conjunction with Total Hip Replacement. *J Bone Joint Surg Am* 1975;57:494.

+ 70. Smith WJ, Martin SL, Mabrey JD. Use of Supracondylar Nail for Treatment of a Supracondylar Fracture of the Femur following Total Knee Arthroplasty. *J Arthroplasty* 1996;11:210.

+ 71. Swiontkowski MF, Hansen ST, Kellam J. Ipsilateral Fractures of the Femoral Neck and Shaft. A Treatment Protocol. *J Bone Joint Surg Am* 1984;66:260.

+ 72. Tornetta P III, Tiburzi D. The Treatment of Femoral Shaft Fractures Using Intramedullary Interlocked Nails with and without Intramedullary Reaming: A Preliminary Report. *J Orthop Trauma* 1997;11:89.

# 73. Tscherne H, Gotzen L, eds. *Fractures with Soft Tissue Injuries.* Berlin: Springer-Verlag, 1984.

+ 74. Wang G, Miller TO, Stamp WG. Femoral Fracture following Hip Arthroplasty. *J Bone Joint Surg Am* 1985;67:956.

+ 75. Williams MM, Askins V, Hinkes EW, Zycy GA. Primary Reamed Intramedullary Nailing of Open Femoral Shaft Fractures. *Clin Orthop* 1995;318:182.

+ 76. Winquist R, Clawson DK, Hansen ST. Closed Intramedullary Nailing of Femoral Fractures. *J Bone Joint Surg Am* 1984;66:529.

+ 77. Wiss DA, Brien WW, Becker V Jr. Interlocking Nailing for the Treatment of Femoral Fractures Due to Gunshot Wounds. *J Bone Joint Surg Am* 1991;73:598.

+ 78. Wiss DA, Brien WW, Stetson WB. Interlocked Nailing for Treatment of Segmental Fractures of the Femur. *J Bone Joint Surg Am* 1990;72:724.

+ 79. Wolinsky PR, McCarty EC, Shyr Y, Johnson KD. Length of Operative Procedures: Reamed Femoral Intramedullary Nailing Performed with and without a Fractures Table. *J Orthop Trauma* 1998;12:485.

+ 80. Yang KH, Han DY, Jahng JS, et al. Prevention of Malrotation Deformity in Femoral Shaft Fracture. *J Orthop Trauma* 1998;12:558.

# CHAPTER 21

# SUPRACONDYLAR AND ARTICULAR FRACTURES OF THE DISTAL FEMUR

*Roby D. Mize*

**R. D. Mize:** Dallas, Texas, 75205.

Clinical Assessment
Classification
Nonoperative Treatment
Indications for Surgery
Relative Indications
Contraindications
Principles of Treatment
Preoperative Management and Planning
Internal Fixation
Fixation Devices
Surgical Approaches
Surgical Techniques
Osteotomy of the Tibial Tubercle
Fracture Reduction
Hoffa Fragment
Indirect Reduction
Dynamic Condylar Screw System
Bone Grafts
95° Angled Plate Blade
Cloverleaf Condylar Plate
Medial/Lateral or Lateral and Anteromedial Double Plates
Antegrade Interlocking Intramedullary Nailing
The Supracondylar Nail
The Green-Seligson-Henry (GSH) and other Retrograde Intramedullary Nails
Wound Closure and Postoperative Care
External Fixation
Pitfalls and Complications
Chapter References

Fractures of the distal femur (i.e., the distal 15 cm of the femur) in the adult account for only 7% of all femoral fractures, but because of our modern lifestyles and high-velocity means of transportation, these injuries are being seen with increasing frequency. Fractures of the distal femur are often complex injuries that present the surgeon with numerous potential complications. Although there has been an increasing trend toward internal fixation of fractures of the distal femur, the management of these fractures remains controversial (4,9,16,26,31,38,40,41,46,51,52,54,55,58,70).

Among young patients, this injury is usually a component of multiple trauma due to high-velocity, high-energy incidents, such as motor vehicle accidents or falls from a height. In particular, motorcycle accidents are a prime cause for these fractures in the 17- to 30-year-old patient. The elderly patient may present with a fracture resulting from trivial trauma, such as falling on the flexed knee. Both groups benefit by early mobilization.

In the past, this injury was treated by skeletal traction for a variable duration, followed by some form of cast or brace immobilization (10,11,42). Complications associated with the closed management of this fracture have led to the proposal of a number of alternative methods of internal fixation. In 1966, Stewart (60) and, in 1967, Neer (45) and their associates reported large series of distal femur fractures treated by both open and closed methods. Most of the surgically treated patients required prolonged supplemental immobilization, negating the advantages of open reduction and internal fixation. This led both groups to recommend closed management strongly, despite their findings that this method results in significant problems—primarily varus and valgus angulation, internal rotation deformity, and inadequate recovery of knee motion.

Although early attempts at internal fixation of distal femur fractures frequently gave unacceptably high rates of malunion, nonunion, and infection, improved techniques of internal fixation have yielded results far superior to those achieved with nonsurgical management. Meticulous internal fixation has been shown to yield good to excellent results in 60% to 80% of cases and allows immediate mobilization of the patient and the extremity, minimizing the cardiopulmonary and other multisystem sequelae of long-term immobility (50). A number of excellent devices are now available that provide improved techniques for fixation of these fractures. These include, but are not limited to, the 95° angled blade plate, the 95° condylar screw, the cloverleaf condylar plate, combined medial/lateral or lateral and anterior double plates, the antegrade intramedullary (IM) nail, and the retrograde supracondylar nail.

## CLINICAL ASSESSMENT

Fractures of the distal femur often occur in patients who have sustained multisystem trauma, usually characterized by injuries of the head, chest, abdomen, and other parts of the skeletal system. The immediate objective is to identify and treat life-threatening problems and initiate protocols to achieve and maintain cardiovascular and cardiopulmonary stability. Although these fractures rarely are life-threatening, they do contribute to the hemodynamic response to trauma and may involve neurovascular structures to the extent that limb viability is jeopardized. Always include careful clinical and radiographic assessment of the pelvis and bilateral lower extremities in the initial trauma workup. Assessment of the implications of these fractures and planning for surgical intervention should be done during the early resuscitative period. Ordinarily, internal fixation can be completed initially and certainly by the third post-trauma day, depending on the extent of other injuries. Look for local swelling, painful crepitus with motion, and deformity of the thigh. Apply hand traction and be gentle when realigning the deformity before splinting it. Carefully assess the soft tissues. A small puncture wound over the distal thigh or suprapatellar pouch area may represent an open fracture. Suspect neurovascular damage if there is distal coolness, pallor, diminished pulses, or increased fullness in the popliteal space. Immediate arteriography may be indicated if evidence of circulatory impairment is present or neurologic compromise is possibly due to a vascular lesion.

Take a complete series of good-quality radiographs of the entire limb and pelvis, if indicated. Identify ipsilateral as well as contralateral fractures or dislocations of the pelvis, hip, knee, and lower leg. These associated injuries are often missed in the initial assessment.

## CLASSIFICATION

The classification of fractures traditionally serves to organize approaches to treatment and provides a basis for comparing results of various treatments. Developing a workable classification system for fractures of the distal femur is problematic because the fractures have an infinite number of configurations and the injury is always associated with other considerations such as injury of the soft tissues that play an important role in determining the approach to treatment and its outcome. I recommend using a combined system that accommodates both the anatomic characteristics of the fracture and its “personality.”

The AO/ASIF classification developed by Müller and associates (43) is excellent. A1, A2, and A3 are fractures proximal to the condyles with the condyles intact. B1, B2, and B3 are variations of a single condylar fracture. C1, C2, and C3 are the more complex multicondylar fractures combined with associated supracondylar fractures (Fig. 21.1). Other factors that establish the fracture's personality include

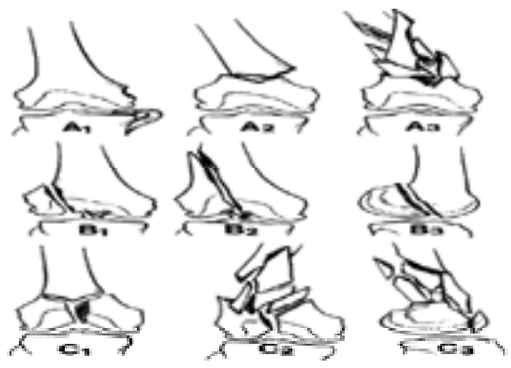


***Figure 21.1.*** Müller's classification of fractures of the distal femur. (Redrawn from Müller ME, Allgower M, Schneider R, Willenegger H. *Manual of Internal Fixation,* 2nd ed. New York: Springer-Verlag, 1979, with permission.)

- Degree of displacement.
- Degree of comminution.
- Extent and degree of soft-tissue damage (whether open or closed).
- Associated neurovascular damage.
- Degree of articular damage.
- Bone quality (osteopenia).
- Severity of multisystem injuries.
- Other fractures.

All of these factors must be considered and evaluated individually when formulating a management plan.

## NONOPERATIVE TREATMENT

Because of the morbidity of prolonged bed rest, skeletal traction and balanced suspension is almost never used today. This is discussed in Chapter 10. In 1979, Mooney et al. (42) introduced the ambulatory cast-brace. In 1974, Mays and Neufeld (36) introduced roller traction, which when combined early with a cast-brace, allowed early mobilization of the patients and early restoration of knee motion.

Indications for closed treatment include the elderly patient with severe, massive comminution or osteopenia, or both; the rare, nondisplaced fracture; and nonintraarticular fractures in older children or young adolescents.

Associated problems with cast-bracing include shortening, angular and rotational deformities, restriction of joint motion, incongruity of the articular surface, residual traumatic arthritis, delayed unions and nonunions (infrequent), and the need for prolonged hospitalization. Meticulous attention to detail is required to achieve a satisfactory outcome.

## INDICATIONS FOR SURGERY

The objectives of surgical treatment of fractures of the distal femur are anatomic reduction and stable fixation. Numerous studies support the use of internal fixation in these difficult fractures (4,9,16,19,20,26,31,38,40,41,46,52,53,54,56,58,70). Prerequisite to selection of the surgical method is adequate institutional support, which includes appropriate instrumentation, skilled and experienced operating room personnel, a knowledgeable assistant surgeon, and experienced physical therapy support. A knowledge of closed methods of treatment is essential and should always be considered as the decision for operative management is weighed.

If the above-mentioned criteria are met, the following may be considered indications for surgery:

- Extraarticular fractures in which acceptable reduction cannot be obtained or maintained.
- Displaced intraarticular fractures. Distal femoral fractures combined with ipsilateral (floating knee) or contralateral fractures to begin early mobilization of the knee and to facilitate control of the limb. Fix bilateral femoral fractures internally to facilitate general care.
- Supracondylar femur fractures in patients with multiple system injuries.
- Obesity. Extremely obese patients are best managed by internal fixation because of the difficulty in treating them with skeletal traction or a cast-brace.
- Vascular repair. A distal femur fracture associated with vascular damage should be stabilized to protect the vascular repair.

### RELATIVE INDICATIONS

The management of elderly patients must be individualized. Advanced age alone should not be considered a contraindication to internal fixation. In 1982, Mize et al. showed good to excellent results in 8 of 11 elderly patients treated with internal fixation (40). Surgical fixation is preferred to minimize the hazards of prolonged bed rest. However, in the presence of osteopenia, obtaining stable fixation is difficult and may be impossible. Adjunctive methyl methacrylate has been shown to be effective, and postoperative use of a cast-brace may be indicated (63). The importance of diligent preoperative planning, meticulous intraoperative technique, and comprehensive postoperative management is important. With such care, good to excellent results can be obtained through surgical intervention.

#### *Open Fractures*

All open fractures require meticulous irrigation and debridement plus appropriate intravenous antibiotics. Primary internal fixation is usually advisable in Gustilo grade I and II fractures. In grade III fractures, limited internal fixation of the articular fractures with external fixation of the metaphyseal component may lower the risk of infection. Later conversion to internal fixation is often done after the soft tissues have recovered.

### CONTRAINDICATIONS

The contraindications to surgical fixation of fractures of the distal femur are patients with massive, severe comminution; severe osteopenia; or the presence of infection or severely contaminated soft tissues that cannot be adequately debrided.

## PRINCIPLES OF TREATMENT

The AO/ASIF has developed principles of management that are central to successful surgical intervention:

- Good preoperative planning.
- Gentle handling of soft tissue.
- Accurate anatomical reduction.
- Rigid, stable internal fixation.
- Bone grafting of any defects.
- Early, active rehabilitation of the limb and the patient.

Good results can be expected in most cases when basic AO/ASIF principles are followed. In a classic article in 1979, Schatzker and Lambert demonstrated the importance of strict adherence to the basic recommendations (54). They used AO instruments and implants, and when they evaluated their results, two distinct groups emerged. When the basic principles of accurate reduction and stable fixation were followed, good to excellent results were achieved in 71% of the cases. In the other group, despite using the same instruments and implants, the basic principles were not followed, and only 21% of this group showed good to excellent results. This study revealed that if the requirements of accurate reduction and stable fixation are met, good results can be achieved in most cases. Furthermore, this study should serve as a warning of the difficulty of surgical treatment of distal femur fractures.

## PREOPERATIVE MANAGEMENT AND PLANNING

Unless immediate surgery is indicated, place the injured limb in balanced suspension with tibial pin traction. Perform surgery immediately or within 24 to 48 hours after the injury. A radiograph of the opposite normal femur is helpful for preoperative planning. A tunnel view of the intercondylar notch is helpful in judging the displacement of vertical fractures into the joint. Use templates to draw the outlines of the femur and fracture lines. Determine the type, size, and position of the implants and the need for a bone graft. Select all necessary instruments, implants, and back-up devices. The chief surgeon must review and discuss the procedure step by step with the assistant surgeons and surgical staff. This type of careful preoperative planning is important to smooth surgical technique and a successful outcome.

## INTERNAL FIXATION

### FIXATION DEVICES

Fractures of the distal femur may be repaired using cancellous screws, a dynamic condylar screw system, a 95° angled blade plate, a cloverleaf-type condylar plate, combined medial/lateral or lateral/anterior double plates, an antegrade interlocking IM nail, or a retrograde supracondylar nail, depending on the type of fracture, available instrumentation, and the surgeon's experience and skill. I prefer the AO/ASIF system.

#### *Lag Screws*

Interfragmentary compression using AO 6.5 mm cancellous, or similar, screws may suffice for simple stable intra-articular unicondylar fractures (Müller type B1 or B2). Washers are usually necessary, and one screw should always be in a buttress position.

#### *AO 95° Angled Blade Plate*

The angled blade plate has been one of the most commonly used devices in the past for internal fixation of fractures of the distal femur (Fig. 21.2*A*). Because of its one-piece construction and the broad, flat blade, the blade plate provides stable fixation for most fracture types, but the one-piece characteristic of the blade plate also accounts for the difficulty in using it. Precision and correct alignment in all three planes is required for the insertion of this device.

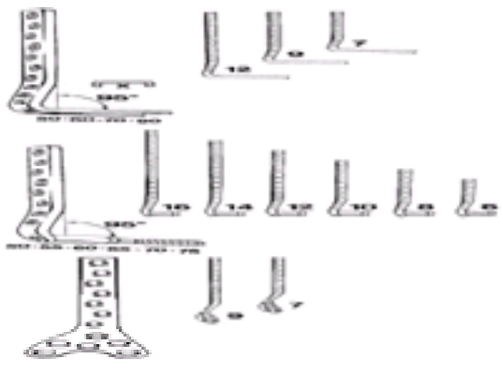

***Figure 21.2.*** **A:** The ASIF 95° condylar angled blade plate. **B:** The ASIF 95° dynamic condylar screw and side plate system. **C:** The ASIF heavy condylar plate designed to fit the lateral side of the distal femur.

#### *Dynamic Condylar Screw*

The dynamic condylar screw (DCS) system (Fig. 21.2*B*), is a supracondylar plate combined with a lag screw (16,18,30,49,52,53,56,71). This two-piece device is more forgiving and allows correction in the sagittal plane after the lag screw is inserted. Precise seating is also easier because the channel is precut directly over a guide wire. The cannulated triple reamer used for cutting the hole for the screw has less risk of disrupting split condyles than the seating chisel, especially in young, hard, cancellous bone. The DCS also has an advantage in that it provides interfragmentary compression of condylar fragments (37).

### SURGICAL APPROACHES

For internal fixation, the distal femur can be exposed through a straight lateral, anterolateral, anteromedial, or straight medial approach. These surgical approaches are described in Chapter 3. Complex intraarticular fractures are best exposed through an anterolateral approach such as that used for total knee arthroplasty, displacing the patella medially. This approach provides access for lateral implants and permits access to the articular condyles.

## SURGICAL TECHNIQUES

### OSTEOTOMY OF THE TIBIAL TUBERCLE

Only rarely is osteotomy of the tibial tubercle necessary, but it is described here for completeness.

- To reflect the tibial tubercle, extend the incision to a point about 15 mm distal to the tuberosity. Extend the retinacular dissection along the lateral margin of the patellar tendon. At this point, the tibial tuberosity should be fully exposed so that the exact center can be identified.
- Make a 3.2 mm drill hole through this center and continue it carefully through the posterior cortex. Overdrill the hole in the anterior or near cortex with a 4.4 mm drill. Measure the distance between the anterior and posterior cortices so the appropriate-length 6.5 mm cancellous screw can be used later to stabilize the bone block.
- Tap the near cortical hole with a 6.5 mm tap.
- Identify the four cortices of the tibial tuberosity and make a drill hole at each corner through the near part of the cortex using a 3.2 mm drill.
- Carefully remove a block of cortical and cancellous bone consisting of the entire tibial tuberosity with the attached patellar tendon. To accomplish this, connect the four corner holes by osteotomies made with a narrow, straight osteotome or small sagittal saw, and lift the block out using ½-inch (1.3 cm) curved osteotome. The block should be about 1.5 cm thick.
- Reflect the bone block, with attached tendon and patella, medially to give complete exposure to the anterior and articular surfaces of the distal femur (Fig. 21.3).

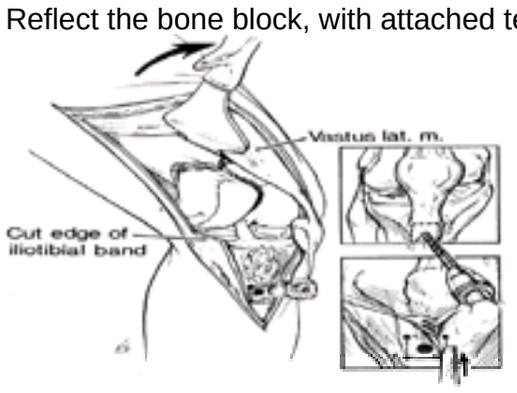


***Figure 21.3.*** After the tibial tuberosity is elevated, a good exposure of all components of the fracture is achieved. (Redrawn from Mize RD, Buchloz RW, Grogan DP. Surgical Treatment of Displaced, Comminuted Fractures of the Distal Femur. J Bone Joint Surg 64-A:878, 1982, with permission.)

## FRACTURE REDUCTION

- Following the surgical exposure, clean the fracture fragments of hematoma and inspect the entire knee joint. Then reduce and stabilize the intraarticular condylar fragments. For purposes of this discussion, the Müller type C1, which is a T or Y fracture with split condyles, will be used (Fig. 21.4).




***Figure 21.4.*** The Müller type C1, the so-called T or Y condylar fracture with split condyles.

- With the knee flexed at 90°, reduce the condyles anatomically and restore the articular surface and patellofemoral groove. Secure the reduction with large sharp pointed tenaculum bone-holding forceps. Provisionally fix the condyles with Kirschner wires (K-wires). Do not place the K-wires where they will interfere with fixation.
- Stabilize the condyles by placing two 6.5 mm cancellous screws with washers (Fig. 21.5). Choose the sites for screw placement carefully to avoid the entry site of the condylar lag screw or seating chisel. Insert the screws slightly proximal to the proposed site of the primary fixation device, and posterior and anterior to the middle of the shaft, well away from the anticipated path of the slide plate (Fig. 21.5*A*, Fig. 21.5*B*). The screws need not be parallel, nor should the threads bridge the fracture lines. Use washers to prevent sinking of the screw heads into the lateral cortex. Once the condyles are stabilized with accurate anatomic alignment, remove the temporary K-wires and fix the remainder of the fracture using either the DCS or the angled blade plate.

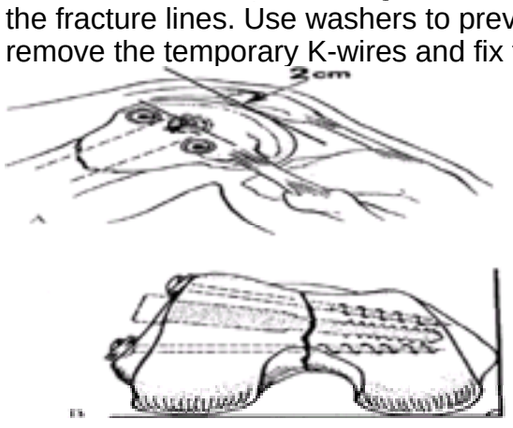


***Figure 21.5.*** **A:** The articular surface and split condyles have been restored and fixed with two 6.5 mm cancellous screws with washers. **B:** The screws are inserted slightly proximal to the proposed entry site of the large condylar screw, and posterior and anterior to the middle of the shaft, well away from the anticipated path of the side plate.

- Reduce the supracondylar component of the fracture. When there is minimal comminution in the metaphyseal area, reduce the condyles directly to the proximal fragment and temporarily fixed with multiple crossed K-wires or better stabilize with one or more 4.5 mm cortical lag screws inserted using lag technique.
- When there is comminution in the metaphyseal area, the side plate of the DCS, blade plate, or similar device is needed to maintain reduction. In such cases, insert the condylar lag screw into the distal fragment. Attach the side plate to the condylar screw, reduce the supracondylar component of the fracture, and stabilize it with the side plate. The angled blade plate and other devices can be used in a similar manner.

## HOFFA FRAGMENT

A coronal split in the femoral condyles, either medial, lateral, or both, particularly of the posterior part, may produce a Hoffa fragment. This is very difficult to manage because the entire fragment may be covered by articular cartilage and is devascularized. These fractures must be recognized, anatomically reduced, and solidly internally fixed. Fixation usually must be placed through the articular surface. K-wires and absorbable pins usually are not strong enough, and 4.0 mm cancellous or similar screws are required. Insert these screws down to the subchondral bone, well beneath the surface of the cartilage.

## INDIRECT REDUCTION

- Indirect reduction techniques use tension on the soft-tissue attachments to the bony fragments to pull and guide them back into their proper alignment (2,35,47). This process, also known as ligamentotaxis, has often been equated with the sails of a ship because the lines are pulled taunt, and wind fills the sail and holds it in the desired position. This technique is indicated in severely comminuted intraarticular fractures of the distal femur, one of the most difficult types to align and stabilize when traction is between the femur and tibia. The same principles apply to metaphyseal fractures.
- Strip soft tissues only in area where the plate will lie. Next, insert the blade plate or condylar screw (Fig. 21.6*A*). Insert two Schanz pins, one proximal to the side plate and one into the condyles through the most distal plate hole (Fig. 21.6B). Through distraction of the soft-tissue attachments, pull and guide the bony fragments into reasonable alignment. A small periosteal elevator or dental pick can be helpful to tease and guide fragments. By overdistracting, it becomes easier to tease fragments into better alignment (Fig. 21.6*C*). With the fragments restored to their proper alignment, turn the nuts on the distractor counter clockwise to “slightly compress” the comminuted zone (Fig. 21.6*D*).



***Figure 21.6.*** Indirect reduction of a supracondylar fracture of the femur. **A.** Reduce and fix the intraarticular fracture and insert a blade plate or condylar screw. **B.** Insert Schanz screws distal and proximal to the fracture and attach the distractor. **C.** Overdistract the fracture and tease comminuted fragments into position. **D.** Now slightly compress the comminuted zone to complete the reduction. **E,F.** Selectively insert screws to complete the fixation.

- After axial and rotational alignment have been verified, attach the proximal end of the plate to the femoral shaft, skipping the comminuted zone. Selectively insert lag screws to increase both the stability and fixation of the construct (Fig. 21.6*E*, Fig. 21.6*F*). With this technique, medial bone grafts are not necessary and are not recommended because they require stripping of the medial soft tissues for placement. Maintenance of soft-tissue attachments usually promotes rapid healing of the fracture because the blood supply to the comminuted fragments is maintained.

## DYNAMIC CONDYLAR SCREW SYSTEM

The DCS has two major components connected with a small compressing screw. It has a 95° angle between the screw and the side plate, and both the screw and side plate are available in a variety of lengths. The condylar screw must be inserted parallel to the knee joint on the anteroposterior view and on the lateral side of the femoral condyle so that the plate will lie flat on the lateral midshaft. Proper alignment may prove difficult until the technique, which involves the use of K-wires and the available aiming devices, is mastered. With practice in a motor skills workshop, experience with simple fractures, and good preoperative planning with close attention to detail, the technique can be mastered. Determine the position of the condylar screw by placing three K-wires (Fig. 21.7*A*, Fig. 21.7*B*, Fig. 21.7*C*, Fig. 21.7*D* and Fig. 21.7*E*).

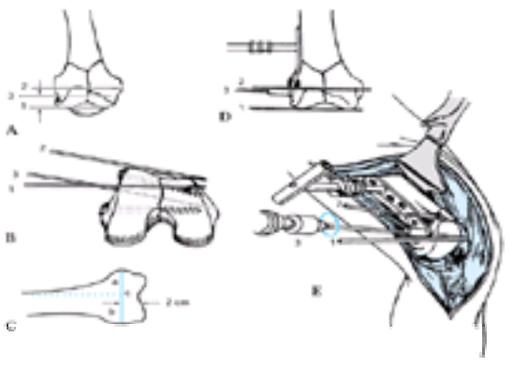

***Figure 21.7.*** Placement of the three directional guide wires.

- With the knee bent to 90°, insert a 2 mm K-wire transversely through the soft tissues of the anterior knee joint and parallel to the joint axis (Fig. 21.7*A*, wire 1). Insert a second wire (Fig. 21.7*A*, wire 2) anteriorly over the lateral and medial condyles to show the inclination of the patellofemoral joint. The distal femur is rhomboid-shaped; therefore, this wire will slope from anterolateral to posterior medial.
- The location of the site for insertion of the screw, and for a blade plate as well, must be precise if the side plate is to lie on the midportion of the lateral aspect of the femoral shaft. To determine this, measure 2 cm proximal to the articular surface and draw a line with a marking pen at right angles to the axis of the femoral shaft (Fig. 21-7*C*, line a). Then divide this line in half (line b). Draw a cross line (c) at the halfway point of the anterior half of line a. This will generally result in appropriate position of the guide pin for the screw. Verify with direct visualization.
- The DCS angle guide is a mirror image of the side plate and is used in placing the guide wire through the lateral condyle (Fig. 21.7*D*, Fig. 21.7*E*). Use a standard 9 inch or 230 mm guide wire. The guide pin must be parallel with the first and second guide wires. It is the definitive guide for the triple reamer and the subsequent placement of the large condylar lag screw. Insert it under fluoroscopic visualization until the medial cortex is reached. When the correct position of the guide pin has been verified, remove the first and second K-wires (Fig. 21.8*A*).



***Figure 21.8.*** **A:** Slip the cannulated condylar screw over the guide wire and into the reamed hole. **B:** Insert the dynamic compressing screw. **C:** Tighten the compressing screw, resulting in interfragmentary compression between the split condyles.

- Slip the direct measuring device over the guide wire and read the length of the guide pin that has been inserted into the femur (Fig. 21.8*B*). Reverse calibration on the measuring device allows direct measurement of the guide pin depth. After taking the measurement, advance the guide wire a few more millimeters to further engage the medial cortex to help prevent inadvertent removal of the guide wire with the triple reamer. Note that because of the rhomboidal shape of the femoral condyles, the guide pin should appear short on the AP view (Fig. 21.7*B*). Overpenetration will result in prominence of the point of the lag screw in the knee joint, which is painful.
- Assemble the triple reamer (Fig. 21.8*C*), which allows you to set the depth in 5 mm increments and has a locking nut to prevent slippage of the depth setting during the reaming procedure. Always verify that you have the correct triple reamer. To distinguish the condylar triple reamer from the one used for the hip, it is labeled DCS. Set the depth setting to about 10 mm less than the measurement taken from the direct measuring device. The reamed channel will end about 10 mm from the medial cortex. Slip the cannulated triple reamer over the guide wire to ream the channel.
- Occasionally, the guide wire will be inadvertently withdrawn with the triple reamer (Fig. 21.9*A*, Fig. 21.9*B*, Fig. 21.9*C* and Fig. 21.9*D*). If this happens, reinsert the wire; otherwise, there is a risk of misplacing the lag screw. This danger is especially great in elderly patients with osteopenic bone. To reposition the guide pin, first insert the short centering sleeve and then insert a lag screw backward into the sleeve (Fig. 21.9*C*). Reinsert the guide pin through the cannulated lag screw and correctly reposition it (Fig. 21.9*D*). Verify its correct position on the image intensifier.

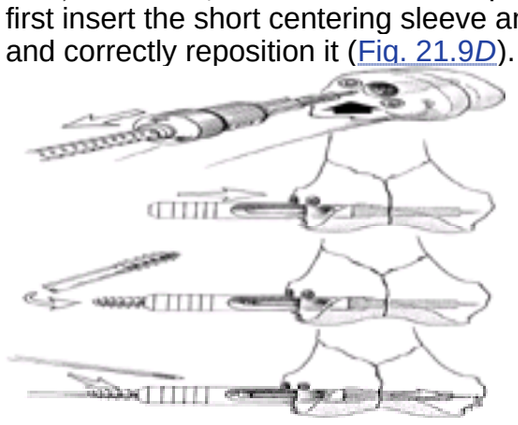

***Figure 21.9.*** **A:** The guide wire is inadvertently withdrawn with the triple reamer. **B:** To reinsert the guide wire, first insert the short centering sleeve. **C:** Next, insert a lag screw backward into the sleeve. **D:** Insert the guide wire into the cannulated lag screw and position it correctly.

- If the patient has hard cancellous bone, tap the reamed channel for the lag screw threads. Use the DCS tap with a short centering sleeve to tap to the same depth as the reamed channel. Do not pretap the channel in patients with osteopenic bone.
- Assemble the DCS and place it onto the wrench using the long centering sleeve. Position the assembly over the guide pin and insert the centering sleeve into the reamed hole (Fig. 21.10*A*). Insert the screw until the zero mark on the wrench reaches the lateral cortex. At this point, the tip of the lag screw is about 10 mm from the medial cortex, and the proximal end of the lag screw is even with the lateral cortex. In porotic bone, insert the lag screw to the 5 mm mark, which allows the tip of the lag screw to cut itself 5 mm beyond the prereamed channel. With the lag screw properly inserted, the T handle of the insertion wrench should be parallel with the shaft of the femur, otherwise, the slide plate cannot be slid onto the lag screw.

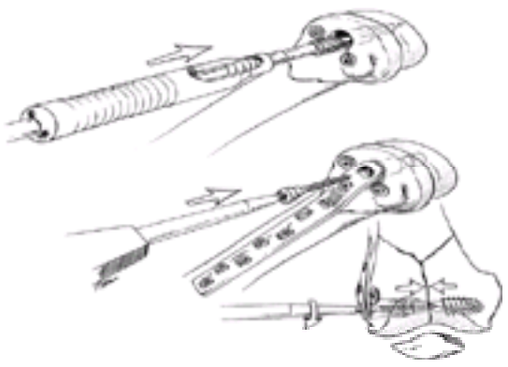

***Figure 21.10.*** **A:** Make the point of entry for the condylar lag screw about 2 cm from the knee joint and in line with the middle of the femoral shaft or slightly anterior. Place the third wire parallel with the knee joint axis and with the tip just penetrating the medial cortex. **B:** Reverse calibration on the measure device allows direct measurement of the guide pin depth if a standard 9-inch or 230 mm wire is used. **C:** The depth setting of the triple reamer should be 10 mm less than the measurement from the direct measuring device. The triple reamer is cannulated. Slip it over the guide wire.

- Remove the wrench with its centering sleeve and slide the appropriate-length side plate over the lag screw. Withdraw the guide pin. While an assistant surgeon applies firm counterpressure medially, use the impactor to seat the side plate gently. Insert the dynamic condylar compression screw (Fig. 21.10*B*, Fig. 21.10*C*). When fixing a T or Y fracture with split condyles, interfragmentary compression can be achieved with the compressing screw. Do not compress with the compression screw in osteopenic bone because the lag screw may pull out of the bone.
- Achieve supplemental fixation of the side plate to the distal fragment by inserting one or two 6.5 mm cancellous screws through the plate immediately proximal to the large condylar lag screw. Ensure that the proximal component of the fracture is well reduced. Use a tension device to achieve axial compression. After tension is applied to the plate, check the reduction and stability of the fixation. If both are satisfactory, complete screw fixation of the plate to the femoral shaft.

**BONE GRAFTS**

After the fracture has been stabilized, assess the condition of the medial cortex. Stability requires good cortical contact in compression. I advocate autologous bone grafting of most fractures of the distal femur that have medial defects (Fig. 21.11):

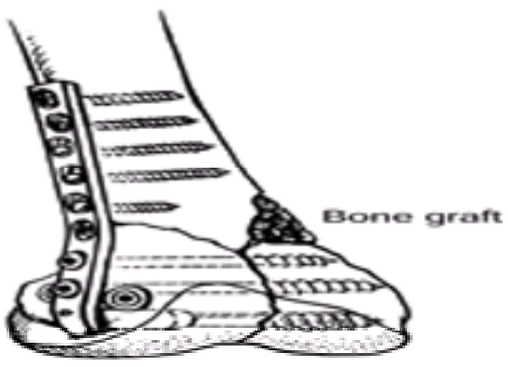


***Figure 21.11.*** Augment fixation of the condyles by placing two 6.5 mm cancellous screws through the round holes directly above the large condylar screw. Secure the side plate to the shaft with 4.5 mm cortical screws. Fill the medial defect with cancellous bone graft.


- Augment fixation of the condyles by placing two 6.5 mm cancellous screws through the round holes directly above the large condylar screw.
- Secure the side plate to the shaft with 4.5 mm cortical screws.
- Fill the medial defect with cancellous bone graft.


The exception to this would be the severely comminuted fracture, in which the technique of indirect reduction is used. Out of 68 cases, I have found that bone grafting was necessary in 59 (39). The medial side of the fracture is subject to compression forces with activity. If the medial side defect is present because of comminution, it will collapse under cyclic axial loading and create bending forces on the plate exactly opposite the defect. If the fracture does not heal in the usual time, the plate will break, often very quickly if the forces are great. Use autologous cancellous bone grafting to fill and buttress the medial defect. Failure to graft these defects can lead to implant failure, loss of reduction, and delayed union or nonunion. I prefer the anterior iliac crest as the donor site (Fig. 21.12).

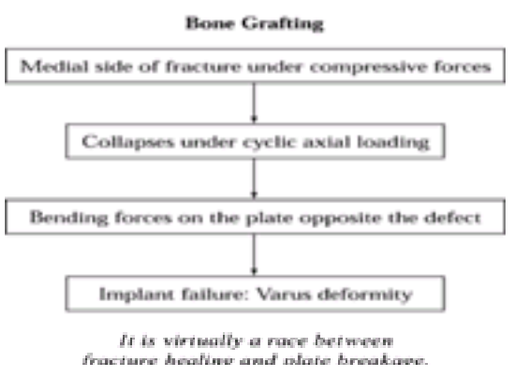


***Figure 21.12.*** The progression of a medial instability to varus deformity.

**95° ANGLED PLATE BLADE**

The condylar plate is a one-piece angled blade plate with a 95° fixed angle between the blade and the plate. The blade is U shaped, which contributes to the strength of this device. Owing to its one-piece construction and broad flat blade, the blade provides stable fixation for most fracture types. However, the one-piece configuration of the plate also makes it difficult to use. Precision and correct alignment in all three planes is required for the insertion of this device. The technical aspects for the use of this device can be found in Müller and associates' *Manual of Internal Fixation Technique Recommended by the AO Group* (44).

**CLOVERLEAF CONDYLAR PLATE**

The AO cloverleaf condylar plate is a one-piece device with a heavy proximal side plate configured like the broad dynamic compression plate and a cloverleaf-shaped distal portion precontoured to correspond to the lateral condylar surface of the distal end of the femur (Fig. 21.2*C*). The distal condylar section has six round holes to accommodate 6.5 mm cancellous screws. Never begin surgical fixation of the distal femur without having this implant or a similar plate for backup. For example, if the lateral condyle is comminuted or if there are multiple articular fracture lines in both the sagittal planes and the coronal planes, both the DCS system and the angled blade plate may be impossible to use. The cloverleaf condylar plate is an excellent device to salvage a failed DCS system or a 95° angled blade plate. Although the cloverleaf condylar plate is technically easier to apply, it should not be used indiscriminately. A major problem with this device is its lack of rigid interface between the heads of the screws and the plate; therefore, any deficiency of the medial cortex usually results in varus malalignment at 4 to 6 weeks postoperatively. If the fracture is not accurately reduced before this implant is introduced, distal fragment displacement into valgus alignment may result. In addition, the cloverleaf plate is not as strong

as either the condylar screw system or the blade plate.

### MEDIAL/LATERAL OR LATERAL AND ANTEROMEDIAL DOUBLE PLATES

A solution for the fracture with severe deficiency on the medial side is the use of double plates (7). If a lateral approach is used, a separate medial incision is usually required to apply a medial plate. If an anterolateral approach is used, a second plate can be applied at right angles to the lateral plate by placing it on the anterior cortex near the medial side through the same incision. Always bone graft any defects on the medial side. Sanders et al. (53) have discussed the use of double plating for unstable fractures of the distal femur. Some of the disadvantages to medial/lateral double plating include multiple surgical exposures, longer operating time, increased stripping of the soft-tissue attachments with decreased blood supply to bone fragments, and increased risk of infection. Chapman and Finkemeier (8) have shown improved results in nonunions using the anterolateral approach and lateral and anterior plates. The use of indirect reduction techniques has decreased the indication for double plate fixation.

### ANTEGRADE INTERLOCKING INTRAMEDULLARY NAILING

In 1984, Winquist et al. reported using closed intramedullary nail fixation of femoral shaft fractures (65). The well-known advantages of an IM device have been extended to include selected fractures of the distal femur (1,3,5,6,12,13,14,15,17,21,22,24,25,27,28,29,32,33,43,48,57,61,62,63,66,67 and 68). Antegrade nailing is limited to very specific cases for the distal femur because at least 10 cm of intact bone above the intercondylar notch is normally required. Essential to success is the ability to secure the two distal screws into intact bone. The surgical technique and indications are discussed in Chapter 20.

### THE SUPRACONDYLAR NAIL

The supracondylar nail developed by Zickle et al. (70) is a retrograde IM nail designed to be inserted through the medial and lateral condyles. The nail is then anchored to the condyles with large compression screws. The screws need to engage the opposite cortex for minimal fixation. In the case of Y or T condylar fractures, the condyles must be reduced and fixed with lag screws before the insertion of the nails.

This nail is most useful in the elderly with osteopenia. It controls angulation and rotation of the femur but allows axial impaction. This feature can be desirable in the elderly because it yields an increased union rate, although it results in some shortening (34,69). It is not suitable for younger patients because of the frequent complications of shortening (34,70). Since the development of retrograde interlocked IM nails, it is little used.

### THE GREEN-SELIGSON-HENRY (GSH) AND OTHER RETROGRADE INTRAMEDULLARY NAILS

Developed by Green, Seligson, and Henry, this nail is a cannulated, single-piece, stainless steel implant that is available in 11 and 12 mm diameters. It was initially designed for the elderly with a fracture of the distal femur. However, results were so good in the elderly that they have applied it to younger patients with the same good results (23,33). Suggested advantages of the GSH nail include a reduction in operating time and blood loss, and a reduction of devascularization of fracture fragments. All of these factors combine to create a lower incidence of complications (22). This technique is discussed in Chapter 20.

## WOUND CLOSURE AND POSTOPERATIVE CARE

- Insert tubes for suction drainage to prevent the formation of a hematoma. Close the synovial tissue and iliotibial band subcutaneous fat and skin in layers. If an anterolateral approach is used, a meticulously layered closure is important to prevent adhesions and to permit early vigorous knee motion. Do not suture the vastus lateralis to the intermuscular septum; doing so may retard knee motion. Meticulous closure of the skin is recommended. Apply a sterile dressing and splint the knee.
- As soon as the drains are removed, begin knee rehabilitation. Continuous passive emotion (CPM) is helpful to regain knee motion in the immediate postoperative period. The AO group advocates positioning the limb on a frame, with the hip and knee flexed 90°. This position, combined with CPM, prevents quadriceps contraction, helps decrease swelling, and enhances knee motion if the patient can tolerate it. Continue CPM full-time until gait training is initiated and then intermittently after gait training is started. If CPM is unavailable, maintain the limb in the 90°/90° position for 4 to 6 days. While the limb is on the frame, begin gentle, active, assisted range-of-motion exercises. Because of the risk of a flexion contracture, many surgeons prefer that the rest position be in full extension.
- If the fracture has been fixed rigidly, the patient may begin immediate partial weight bearing of about 10 kg. The patient who remains completely non-weight bearing with the hip and knee flexed may developed circulatory stasis and rapid disuse osteopenia.
- Maintain weight bearing to the weight of the lag using two crutches until there is clinical and radiographic evidence of healing of the fracture, which usually requires 12 to 16 weeks, at which time progress gradually to full weight bearing. Supplemental external support is usually not required, but a functional cast-brace may be desirable for the elderly patient with tenuous fixation, the patient with marked comminution, or the unreliable patient.

### EXTERNAL FIXATION

External fixation is rarely used today for the definitive treatment of supracondylar fractures of the femur because the transfixation pins tend to tie down the quadriceps mechanism and interfere with regaining knee motion (59). The primary indication for external fixation today is high-energy type II, IIIB, and C open supracondylar fractures of the femur, in which initial primary internal fixation of the metaphyseal portion of the fracture is thought to be too risky because of the potential for infection, or the fracture has occurred in the presence of other severe multiple injuries and the time required for definitive internal fixation is inadequate. In the instance in which the fracture has occurred along with other injuries, a simple anterior single bar frame, bridging from the femur to the tibia to provide temporary stability and alignment of the extremity until definitive internal fixation can be done, may be indicated. This can be a life-saving procedure because it stabilizes the limb and allows early mobilization of the patient.

In severe open fractures from crushing injuries such as being hit by the bumper of a high-speed vehicle, the soft-tissue envelope may be severely compromised and reconstruction may require a local or free flap, particularly if the injury extends across the knee joint into the tibial plateaus. In these cases, many surgeons prefer to perform limited internal fixation of the articular surface of the femur with lag screws and wires. The metaphyseal portion of the fracture is then managed with an external fixator from the shaft of the femur to the reassembled condyles or bridging to the tibia. When only the femur is fixed, use a hybrid circular fixator using tensioned wires in the articular fragments and half pins in the shaft.

Although the fracture can be managed definitively in an external fixator, if the degree of comminution and bone quality allows, most trauma surgeons today convert to plate fixation after the condition of the soft tissues has stabilized and the risk of infection has been minimized (see Chapter 32).

## PITFALLS AND COMPLICATIONS

Complications associated with the surgical management of fractures of the distal femur include neurovascular injury, thromboembolic disease, delayed union or nonunion, malunion, infection, joint contracture, knee instability, posttraumatic arthritis, implant failure, refracture after removal of the implant, and others. Although many of these problems cannot be avoided, the occurrence of some can be diminished by recognizing potential pitfalls in the various phases of treatment.

During the initial assessment, have a high index of suspicion for associated injuries to the head, chest, abdomen, and spine. Carefully evaluate the pelvis and all extremities for possible occult injuries. Ligamentous instability of the knee can occur with fracture of the distal femur and often cannot be determined until after the fracture is stabilized. Carefully evaluate the neurovascular function; if vascular injury is suspected, arteriography is indicated.

Good preoperative planning is essential and can minimize many of the intraoperative and postoperative complications. During this planning phase, determine the best surgical approach; the type, approximate size, and position of the implants; and the possible need for a bone graft. Making these decisions before surgery allows preparation of the appropriate instrumentation and implants, and a smoother surgical procedure with less wound exposure time.

Atraumatic surgical technique with minimal soft-tissue stripping, accurate anatomic reduction, stable fixation, and grafting of any bony defects cannot be overemphasized. Strict adherence to these principles will decrease the incidence of infection, implant failure, malunion, delayed wound and fracture healing, and nonunion. Accurate reconstruction of the articular surfaces is essential.

A common technical error while using the angled blade plate or the DCS is failure to appreciate the rhomboid shape of the distal femur. The blade or condylar screw must be directed somewhat posteriorly and be of proper length to avoid penetration of the anterior surface of the medial femoral condyle.

Considerable judgment is required in dealing with the fractures with severe osteopenia or comminution. Occasionally, these fractures are impossible to stabilize

surgically with any type of implant and surgery may not be indicated.

During the postoperative phase, early, active rehabilitation will serve to decrease swelling, avoid muscle contracture, enhance knee motion, and diminish the incidence of thromboembolic disease. During this phase, stress patient education. Early excessive weight bearing can lead to implant failure, resulting in deformity or delayed healing and the need for repeat surgery.

## CHAPTER REFERENCES

Each reference is categorized according to the following scheme: *, classic article; #, review article; !, basic research article; and +, clinical results/outcome study.


+ 1. Baumgaertel F, Dahlen C, Stiletto R, Gotzen L. Technique Using the AO-Femoral Distractor for Femoral Intramedullary Nailing. *J Orthop Trauma* 1994;8:315.

+ 2. Bone LB. Indirect Fracture Reduction: A Technique for Minimizing Surgical Trauma. *J Am Acad Orthop Surg* 1994;2:247.

+ 3. Bucholz RW, Ross SE, Lawrence KL. Fatigue of the Interlocking Nail in the Treatment of Fractures of the Distal Part of the Femoral Shaft. *J Bone Joint Surg* 1987;69-A:1391.

+ 4. Butler MS, Brumback RJ, Ellison TS, et al. Interlocking Intrameduallary Nailing for Ipsilateral Fractures of the Femoral Shaft and Distal Part of the Femur. *J Bone Joint Surg* 1991;73-A:1492.

+ 5. Chan PS, Luchetti WT, Campbell JT, Vresilovic EJ. Supracondylar Femur Fracture Above a Mature Knee Fusion Treated with a Long Locked Intramedullary Rod. *Am J Orthop* 1997;26:630.

# 6. Chapman MW. The Effect of Reamed and Nonreamed Intramedullary Nailing on Fracture Healing. *Clin Orthop* 1998;355S:S230.

+ 7. Chapman M, et al. Double Plating of Distal Femur Fractures: Indications and Technique. *Tech Orthop* 1994;9:210.

+ 8. Chapman MW, Finkemeier CG. Treatment of Supracondylar Nonunions of the Femur with Plate Fixation and Bone Graft. *J Bone Joint Surg* 1999;81-A:1217.

+ 9. Chiron HS, Tremoulet J, Casey P, Müller, M. Fractures of the Distal Third of the Femur Treated by Internal Fixation. *Clin Orthop* 1974;100:160.

+ 10. Connoly JF, Dehne E, LaFollette B. Closed Reduction and Early Cast-Brace Ambulation in the Treatment of Femoral Fractures. Part II: Results in 143 Fractures. *J Bone Joint Surg* 1973;55-A:1581.

+ 11. Connolly JF, King P. Closed Reduction and Early Cast-Brace Ambulation in the Treatment of Femoral Fractures. Part I: An In-Viro Quantitative Analysis of Immobilization in Skeletal Traction and Cast Brace. *J Bone Joint Surg* 1973;55-A:1559.

+ 12. Danzinger MB, Caucci D, Zecher SB, Covall DJ. Treatment of Intercondylar and Supracondylar Distal Femur Fractures Using the GSH Supracondylar Nail. *Am J Orthop* 1995;24:684.

+ 13. Dominguez I, Moro RE, De Pedro Moro JA, Cebrian Para JL, Lopez-Duran Stern L. Antegrade Nailing for Fractures of the Distal Femur. *Clin Orthop* 1998;350:74.

+ 14. Firoozbakhsh K, Behzadi K, DeCoster TA, et al. Mechanics of Retrograde Nail Versus Plate Fixation for Supracondylar Femur Fractures. *J Orthop Trauma* 1995;9:152.

+ 15. George CJ, Lindsay RW, Noble PC, et al. Optimal Location of a Single Distal Interlocking Screw in Intermedullary Nailing of Distal Third Femoral Shaft Fractures. *J Orthop Trauma* 1998;12:267.

+ 16. Giles JB, DeLee JC, Heckman JD, Keever JE. Supracondylar and Intercondylar Fractures of the Femur Treated with a Supracondylar Plate and Lag Screw. *J Bone Joint Surg* 1982;64-A:864.

+ 17. Goulet JA, Londy F, Saltzman CL, et al. Interlocking Intramedullary Nails—An Improved Method of Screw Placement Combining Image Intensification and Laser Light. *Clin Orthop* 1992;281:199.

+ 18. Hall MF. Two-Plane Fixation of Acute Supracondylar and Intracondylar Fractures of the Femur. *South Med J* 1978;71:1474.

+ 19. Halpenny J, Rorabeck CH. Supracondylar Fractures of the Femur: Results of Treatment in 61 Patients. *Can J Surg* 1984;66-A:606.

+ 20. Healy WL, Brooker AF Jr. Distal Femoral Fractures. Comparison of Open and Closed Methods of Treatment. *Clin Orthop* 1983;174:166.

+ 21. Helfet DL, Lorch DG. Retrograde Intramedullary Nailing of Supracondylar Femoral Fractures. *Clin Orthop* 1998;350:80.

+ 22. Henry SL, Trager S, Green S, Seligson D. Management of Supracondylar Fractures of the Femur with the GSH Intramedullary Nail: Preliminary Report. *Contemp Orthop* 1991;22:631.

+ 23. Henry SL, et al. Management of Supracondylar Fractures of the Femur with the GSH Supracondylar Nail: The Percutaneous Technique. *Tech Orthop* 1994;9:189.

+ 24. Iannacone WM, Bennett FS, DeLong WG Jr, et al. Intitial Experience with the Treatment of Supracondylar Femoral Fractures Using the Supracondylar Intramedullary Nail: A Preliminary Report. *J Orthop Trauma* 1994;8:322.

+ 25. Janzip H, Stockman B, Van Damme G, et al. The Retrograde Intramedullary Supracondylar Nail: An Alternative in the Treatment of Distal Femoral Fractures in the Elderly. *Arch Orthop Trauma Surg* 1991;118:92.

+ 26. Johnson KD, Hicken G. Distal Femoral Fractures. *Orthop Clin North Am* 1987;18:115.

+ 27. Koval KJ, Seligson D, Rosen H, Fee K. Distal Femoral Nonunion: Treatment with a Retrograde Inserted Locked Intermedullary Nail. *J Orthop Trauma* 1995;9:285.

+ 28. Krettek C, Konemann B, Miclau T, et al. A New Mechanical Aiming Device for the Placement of Distal Interlocking Screws in Femoral Nails. *Arch Orthop Trauma Surg* 1998;117:147.

+ 29. Kyle RF, Schaffhausen JM, Bechtold JE. Biomechanical Characteristics of Interlocking Femoral Nails in the Treatment of Complex Femoral Fractures. *Clin Orthop* 1991;267:169.

+ 30. Laskin RS, Zimmerman AJ. The Displaced Intercondylar T-Fracture of the Distal Femur. A Simplified Method of Internal Fixation. *Orthop Rev* 1975;4:49.

+ 31. Leung KS, Shen WY, So WS, et al. Interlocking Intramedullary Nailing for Supracondylar and Intercondylar Fractures of the Distal Part of the Femur. *J Bone Joint Surg* 1991;73-A:332.

+ 32. Lonner BS, Lonner JH, Sadker AH. Retrograde Femoral Nailing Between an Ankylosed Hip and a Stiff Knee. *J Orthop Trauma* 1995;9:266.

+ 33. Lucas SE, Seligson D, Henry SL. Intramedullary Supracondylar Nailing of Femoral Fractures. A Preliminary Report of the GSH Supracondylar Nail. *Clin Orthop* 1993;296:200.

+ 34. Marks DS, Isbister ES, Porter KM. Zickel Supracondylar Nail for Supracondylar Femoral Fractures in Elderly or Infirm Patients. A Review of 33 Cases. *J Bone Joint Surg* 1994;76-B:596.

# 35. Mast J, Jakob R, Ganz R. Planning and Reduction Technique in Fracture Surgery. New York: Springer-Verlag, 1989.

* 36. Mays J, Neufeld AJ. Skeletal Traction Methods. *Clin Orthop* 1974;102:144.

+ 37. Merchan EC, Maestu PR, Blanco RP. Blade-plating of Closed Displaced Supracondylar Fractures of the Distal Femur with the AO/ASIF System. *J Trauma* 1992;32:174.

# 38. Mize RD. Complex Fractures of the Distal End of the Femur. In: Meyers MH, ed. *The Multiple Injured Patient with Complex Fractures.* Philadelphia: Lea & Febiger, 1984.

+ 39. Mize RD. Surgical Management of Complex Fractures of the Distal Femur. *Clin Orthop* 1989;240:77.

# 40. Mize RD. Treatment of Fractures of the Distal Femur. *Orthop Surg Update Series* 1985;4:1.

+ 41. Mize RD, Bucholz RW, Grogan DP. Surgical Treatment of Displaced, Comminuted Fractures of the Distal End of the Femur. *J Bone Joint Surg* 1982;64-A:871.

* 42. Mooney V, Nickel VL, Harvey JP Jr, Snelson R. Cast-Brace Treatment for Fractures of the Distal Part of the Femur. *J Bone Joint Surg* 1970;52-A:1563.

+ 43. Morgan E, Ostrum RF, DiCicco J, et al. Effects of Retrograde Femoral Intramedullary Nailing on the Patellofemoral Articulation. *J Orthop Trauma* 1999;13:13.

# 44. Müller ME, Allgower M, Schneider R, Willeneger H. *Manual of Internal Fixation Technique Recommended by the AO Group,* 3rd ed. New York: Springer, 1991.

* 45. Neer CS II, Grantham SA, Shelton ML. Supracondylar Fractures of the Adult Femur. A Study of 110 Cases. *J Bone Joint Surg* 1967;49-A:591.

+ 46. Olerud S. Operative Treatment of Supercondylar-Condylar Fractures of the Femur. Technique and Results in 15 Cases. *J Bone Joint Surg* 1972;54-A:1015.

+ 47. Ostrum RF, Geel C. Indirect Reduction and Internal Fixation of Supracondylar Femur Fractures without Bone Graft. *J Orthop Trauma* 1995;9:278.

+ 48. Perry CR. Bone Repair Techniques, Bone Graft, and Bone Graft Substitutes. *Clin Orthop* 1999;360:71.

+ 49. Prichett JW. Supracondylar Fractures of the Femur. *Clin Orthop* 1984;184:173.

+ 50. Radford PJ, Howell CJ. The AO Dynamic Condylar Screw for Fractures of the Femur: Injury. *Br J Acc Surg* 23:89, 1992.

# 51. Regazzoni P, Reudi T, Allgower M. The Dynamic Condylar Screw Implant System for Fractures of the Distal Femur. *AO/ASIF Dialogue* 1986;1:8.

+ 52. Sanders R, Regazzoni P, Reudi TP. Treatment of Supracondylar-Intercondylar Fractures of the Femur Using the Dynamic Condylar Screw. *J Orthop Trauma* 1989;3:214.

+ 53. Sanders R, Swiontkowski M, Rosen H, Helfet D. Double-Plating of Comminuted, Unstable Fractures of the Distal Part of the Femur. *J Bone Joint Surg* 1991;73-A:341.

+ 54. Schatzker J, Lambert DC. Supracondylar Fractures of the Femur. *Clin Orthop* 1979;138:77.

+ 55. Seligson D, Kristianson TK. Use of the Wagner Apparatus in Complicated Fractures of the Distal Femur. *J Trauma* 1978;18:795.

+ 56. Shewring DJ, Meggitt BF. Fractures of the Distal Femur Treated with the AO Dynamic Condylar Screw. *J Bone Joint Surg* 1992;74-B:122.

+ 57. Sinha AK, Mani GV. Retrograde Nailing for Distal Femoral Fractures in Paget's Disease. *Injury* 1996;27:514.

+ 58. Slatis P, Ryoppy S, Huittinen VM. Osteosynthesis of Fractures of the Distal Third of the Femur. *Acta Orthop Scand* 1971;42:162.

# 59. Stein H, Makin M. Use of the Wagner Apparatus in Fractures of the Lower Limb. *Orthop Rev* 1980;9:96.

+ 60. Stewart MJ, Sisk TD, Wallace SL. Fractures of the Distal Third of the Femur. A Comparison of Methods of Treatment. *J Bone Joint Surg* 1996;48-A:784.

+ 61. Taylor JC. Treatment of Distal Femoral Fractures with the Russell-Taylor Nail. *Tech Orthop* 1994;9:225.

+ 62. Tornetta P 3rd. The Treatment of Femoral Shaft Fractures Using Intramedullary Interlocked Nails with and without Intramedullary Reaming: A Preliminary Report. *J Orthop Trauma* 1997;11:89.

+ 63. Tornetta P 3rd, Tiburzi D. Antegrade Interlocked Nailing of Distal Femoral Fractures After Gunshot Wounds. *J Orthop Trauma* 1994;8:220.

+ 64. Varriale PL, Evans PEL, Sallis JG. A Modified Technique for Fixation of Pathologic Fractures in the Lower Femur. *Clin Orthop* 1984;199:256.

+ 65. Winquist RA, Hansen ST Jr, Clawson DK. Closed Intramedullary Nailing of Femoral Fractures. *J Bone Joint Surg* 1984;66-A:529.

+ 66. Wolinsky PR, McCarty EC, Shyr Y, Johnson D. Length of Operative Procedures: Reamed Femoral Intramedullary Nailing Performed with and without a Fracture Table. *J Orthop Trauma* 1998;12:485.

+ 67. Wolinsky PR, McCarty EC, Shyr Y, Johnson D. Reamed Intramedullary Nailing of the Femur: 551 Cases. *J Trauma* 1999;46:392.

+ 68. Wu CC, Shih CH. Interlocking Nailing of Distal Femoral Fractures: 28 Patients Followed for 1–2 Years. *Acta Orthop Scand* 1991;62:342.

+ 69. Zickel RE. The Zickel Supracondylar Nail. *Tech Orthop* 1994;9:217.

+ 70. Zickle RE, Hobeika P, Robbins DS. Zickel Supracondylar Nails of Fractures of the Distal End of the Femur. *Clin Orthop* 1986;212:79.

+ 71. Zimmerman AJ. Intra-articular Fractures of the Distal Femur. *Othop Clin North Am* 1979;10:75.

# CHAPTER 22

# PATELLAR FRACTURES

*Timothy J. Bray*

**T. J. Bray:** American Board of Orthopaedic Surgery, Reno Orthopaedic Clinic, Reno, Nevada, 85903.

Pathophysiology
Biomechanics of the Patellofemoral Joint
Mechanisms of Injury
Diagnosis
Classification
Principles of Treatment
Indications for Surgery
Displaced Transverse Fractures
Extensively Comminuted and Displaced Fractures
Longitudinal, Marginal, and Avulsion Fractures
Osteochondral Fractures Associated with Patellar Dislocation
Preoperative Management
Surgical Techniques
Tension Band Wiring
Screw Fixation
Partial Patellectomy with Reattachment of the Patellar Ligament
Total Patellectomy–Acute
Elective Total Patellectomy
Results
Postoperative Care and Rehabilitation
Pitfalls and Complications
Author's Perspective
Chapter References

## PATHOPHYSIOLOGY

Fractures of the patella are not uncommon and often result in residual patellofemoral arthralgia, quadriceps weakness, restricted knee motion, and degenerative arthritis. The goals of surgical treatment are to reestablish continuity of the extensor mechanism and to restore a smooth articular surface using stable internal fixation to permit early knee motion.

### BIOMECHANICS OF THE PATELLOFEMORAL JOINT

Despite early conclusions to the contrary, the patella has an important role in both quadriceps and knee joint function (6,14,20,22,26). By increasing the lever arm of the quadriceps mechanism, the patella improves extensor power, particularly during the last 30° of extension. Maquet's proposal that the patella reduces tibiofemoral contact stresses has been established in experimental animal studies (7,17). Excision of the patella can cause pain, extensor weakness, extensor lag, knee instability, and decreased flexion arc. In one series, as many as 90% of patients undergoing patellectomy following fracture had continued pain, and 60% complained of instability (34).

### MECHANISMS OF INJURY

Fractures of the patella result from both indirect and direct forces (28). Unexpected falls can generate violent contractions of the quadriceps muscle as a result of the effort to regain balance, and patellar fracture may occur. Failure of the patella secondary to an imposed tensile load can result in a displaced transverse fracture associated with tearing of the medial and lateral retinacula. A direct blow to the patella transmits compressive forces that can cause a longitudinal, stellate, or comminuted fracture of the patella. These injuries are usually not widely displaced because of preservation of the quadriceps expansions. Abrasions or lacerations of the skin may be seen in fractures caused by direct forces.

Lateral dislocation of the patella can generate shearing forces that produce an osteochondral fracture of the articular surface of the medial facet of the patella or of the lateral femoral condyle. These fragments are usually less than 1 to 2 cm in diameter, but larger fragments occasionally occur. More recently, patellar fractures are occasionally seen as complications of total knee arthoplasty or are secondary to the harvest of a patella graft for reconstruction of the anterior cruciate ligament (41).

### DIAGNOSIS

Displaced patellar fractures are readily apparent from the history and physical examination. Conspicuous findings include a history of direct trauma or an unexpected fall, with resulting pain and swelling about the anterior knee; inability to extend the leg actively against gravity; and a palpable defect between the patellar fragments and in the extensor retinacula. Nondisplaced fractures may have a similar history but lack impressive physical findings, demonstrating only tenderness to palpation and pain with resisted motion of the knee. A patellar dislocation is suggested by a history of a noncontact, valgus, external rotation injury to the knee with sudden collapse, requiring extension of the leg to relieve the incurred pain and deformity. Subsequent giving way, locking, catching, and swelling suggest an osteochondral fracture.

The radiographic examination for a patellar fracture should include anteroposterior and lateral views. A tangential patellar view with the knee in 30° of flexion is helpful in evaluating longitudinal fractures of the patella and in locating osteochondral fractures following patellar dislocation. Comparison radiographs of the opposite knee may be helpful in cases of bipartite patella, which can usually be distinguished by its superolateral location and well-rounded margins.

## CLASSIFICATION

No comprehensive classification scheme exists to account for all patellar fractures. Traditionally, they have been categorized by degree of displacement and fracture line configuration, but this system may fail to assess the degree of articular surface injury, which significantly influences the outcome. Bostman classified comminuted and displaced fractures by the degree of articular stepoff and by vertical and horizontal displacement of major fragments in an effort to evaluate the results of various treatment regimens (4).

We define displaced patellar fractures by the amount of displacement, the anatomic portion of the patella involved, the fracture line configuration, the amount of comminution, and the amount of articular incongruity. For this discussion, we recognize four groups of patellar fractures (Fig. 22.1):

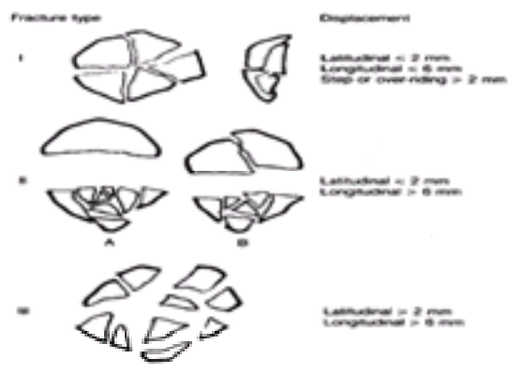


***Figure 22.1.*** The classification of fractures is shown. See text for details.

- Transverse fractures of the patella, with and without comminution
- Extensively comminuted and displaced patellar fractures
- Longitudinal, marginal, and avulsion fractures of the superior and inferior poles of the patella
- Osteochondral fractures associated with patellar dislocation.

## PRINCIPLES OF TREATMENT

### INDICATIONS FOR SURGERY

In a patellar fracture that is essentially nondisplaced—that is, one in which there is less than 2 cm of separation, displacement, or stepoff—closed treatment is indicated if the retinaculum is intact. Retinacular integrity can be determined by the patient's ability to extend the knee completely, thereby demonstrating the intact continuity of the quadriceps mechanism. Injection of a local anesthetic into the knee may be helpful. It is most unusual for the extensor mechanism to be disrupted in a nondisplaced patellar fracture. If the extensor mechanism is disrupted, regardless of the radiographic findings of the patella, the knee should be explored and the retinaculum and patella repaired.

I recommend a cylinder cast for treatment of nondisplaced patellar fractures with an intact retinaculum (see Chapter 10). However, a long leg cast made with the new lightweight fiberglass materials may be more comfortable and prevent the downward shift and supermalleolar irritation that can occur in cylinder casts. Allow 6 weeks of casting, with the knee in a few degrees of flexion, followed by 6 weeks of progressive flexion in a universal hinged knee brace. Quadriceps exercises with straight leg raising can begin early, and full weight bearing is possible once quadriceps control is established, and the fracture is healed.

Surgical treatment is indicated for intraarticular fractures with more than 2 mm of articular displacement. The specific treatment depends on the fracture type (Fig. 22.2).

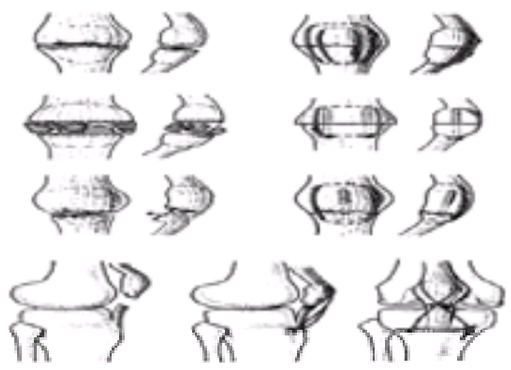

***Figure 22.2.*** **A:** A transverse fracture of the patella can be stabilized with tension band wires on the anterior surface of the patella. **B:** A comminuted fracture of the patella with two large superior and inferior bony fragments can be stabilized with excision of the comminuted portion and stabilization with two 4.0 interfragmentary compression screws and a tension band. **C:** In a fracture of the inferior third of the patellar pole, a single 4.0 mm cancellous screw can be used in an interfragmentary compression mode and completed with a tension band wire. **D:** Rupture of the infrapatellar tendon can be repaired with a Tevdek suture. A figure-of-eight tension band wire protects the repair and allows for early mobilization. (From Müller ME, Allgöwer M, Schneider R, Willenegger H. *Manual of Internal Fixation.* New York: Springer-Verlag, 1979, with permission.)

### DISPLACED TRANSVERSE FRACTURES

#### *Without Comminution*

Although external fixation was used in the 19th century, most authors today favor open reduction and internal fixation (23,25). Fixation by a circumferential wire loop, interfragmentary screw fixation, tension band wiring, and combinations thereof have proved successful (4,5,13,14,24,29). Screws combined with tension band wires provide biomechanically superior fixation (8). A circumferential wire loop (cerclage) can be placed through the soft tissue adjacent to the patella or through holes drilled transversely or longitudinally (Magnuson technique) in the patellar fragments. This technique is biomechanically unsound and requires postoperative immobilization. To eliminate postoperative immobilization and allow early knee motion, the AO group developed tension band wiring (29).

As described originally, the first cerclage wire is passed around the insertions of the patellar and quadriceps tendons and rests on the anterior surface of the patella. The wire is tightened to close the fracture gap on the anterior surface of the patella, potentially leaving a small gap on the posterior articular surface. A second wire is then placed transversely inside the area of the first wire through the proximal and distal fragments. The tension band neutralizes the tension forces across the anterior patella so that during flexion, quadriceps compressive forces develop at and help to reduce and oppose the articular surface. Subsequently, to provide better proximal and distal purchase for the tension band, two parallel Kirschner wires (K-wires) are placed longitudinally through the patellar fragment. Weber et al. showed the superiority of the modified tension band wiring and Magnuson techniques in maintaining fixation of transverse patellar fractures while allowing early motion (43). This is now the recommended technique. Replacement of the monofilament wire with braided cable (1 mm) provides even stronger fixation (33).

In significantly displaced fractures, there is usually an associated tear of the medial and lateral retinacula. Repair of the retinacula provides additional stability to the fixation.

#### *With Comminution of the Distal Fragment*

In displaced transverse fractures with comminution of the distal fragment, make an effort to preserve as much of the patellar articular surface as possible. If the fracture fragments are large enough, use interfragmentary screw fixation, which is performed and supplemented with a tension band. If more than half of the articular surface of the patella can be preserved, whether it is intact or restored with interfragmentary screw fixation, then small comminuted intraarticular fragments about the distal pole can be excised with advancement of the patellar tendon (1,19,39).

### EXTENSIVELY COMMINUTED AND DISPLACED FRACTURES

Satisfactory results have been reported with use of the tension band wire and its modification in treating comminuted and displaced patellar fractures (Fig. 22.2), although most authors recommend patellectomy when less than half of the articular surface of the patella remains intact (4). Techniques for patellectomy include

transverse primary repair, longitudinal repair, cruciate-type repair with advancement of the quadriceps and patellar tendon, and tubulation (12,22,32,35,37). If patellectomy is chosen, it is important to reestablish the continuity of the medial and lateral patellar retinacula, as well as to ensure that tracking of the remaining tendon is normal.

Berg (2) advocates tibial tubercle osteotomy and inversions of the patella to facilitate aligning the articular surface in comminuted fractures. All six patients he treated this way had residual symptoms but only one had a poor result. He believes that preservation of the patella for future reconstructive surgery may be worthwhile in some cases.

### LONGITUDINAL, MARGINAL, AND AVULSION FRACTURES

Open reduction and internal fixation with interfragmentary screw fixation is the preferred treatment for longitudinal, marginal, and avulsion injuries. In the case of quadriceps or patellar tendon avulsion, supplemental cerclage wiring can be used to diminish stresses at the repair interface. In small marginal and longitudinal fractures that are not amenable to internal fixation, use closed immobilization; excise the fragment or patella for late disability and pain.

### OSTEOCHONDRAL FRACTURES ASSOCIATED WITH PATELLAR DISLOCATION

Osteochondral injuries can include a partial-thickness chondral flap, full-thickness chondral detachment, and osteochondral fracture. Arthroscopy has proven useful in the treatment of these disorders. Partial-thickness chondral injuries can be treated by arthroscopic resection of the flap alone. Injuries that extend only to subchondral bone require careful treatment and are discussed in Chapter 86.

## PREOPERATIVE MANAGEMENT

Plan the procedure on the basis of anteroposterior, lateral and two oblique radiographic views of the knee. Determine the need for fluoroscopy, a radiolucent table, types of fixation and instrumentation required, alternative fixation needs, and postoperative immobilization requirements. Most patients appreciate knowing preoperatively what to expect.

The treatment of most patellar fractures can be scheduled electively in outpatient surgery facilities. Preoperatively, the knee should be splinted in extension in a well-padded knee immobilizer to protect the soft tissues and to prevent further articular damage.

In the event of deep abrasions or an open fracture, treat the patella fracture emergently. In the polytrauma patient, the patella fracture is a low-priority injury unless it is an open injury. I fix all open fractures of the patella; depending on the degree of contamination, a second surgical debridement may be required before final skin closure.

## SURGICAL TECHNIQUES

### TENSION BAND WIRING

The basic principles of this technique are described in Chapter 11.

- Prepare and drape the patient in the routine fashion. I usually use a tourniquet.
- Make a midline vertical incision beginning 2 inches above the superior pole of the patella and extend it distally to the middle of the patellar ligament. Using sharp dissection, divide the subcutaneous tissue down to the quadriceps retinaculum, preserving the patellar ligament periatenon.
- Raise medial and lateral skin flaps to explore the medial and lateral extensions of the retinacular tear. Identify the apex of the extensor retinacular tear.
- Identify the patellar fracture, separate the two fracture fragments, irrigate the knee joint copiously, and examine it for evidence of loose fragments and articular injury. The anterior cruciate and the anterior horns of both menisci can be inspected easily using this approach. Clean the fracture surfaces with a scalpel, and dissect the retinaculum and periosteum free from the fracture edges on the anterior border of the patella. Using gentle curettage, remove the clotted blood and fibrous tissue from the fracture surfaces to help ensure anatomic reduction.
- Using the 2.0 mm drill guide, place two parallel 0.062 inch K-wires retrograde through the superior patellar fragment. The wires will exit the superior pole of the patella and extend through the extensor retinaculum (Fig. 22.3). Place the wires in the midpatella to allow appropriate mechanical stability for the tension band principle. If they are placed too close to the articular surface, compression forces will be neutralized during knee flexion (Fig. 22.4).

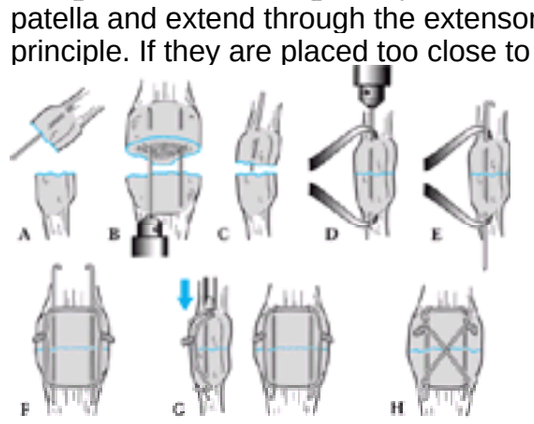


***Figure 22.3.*** Tension band wire fixation of a patellar fracture; see text for details.

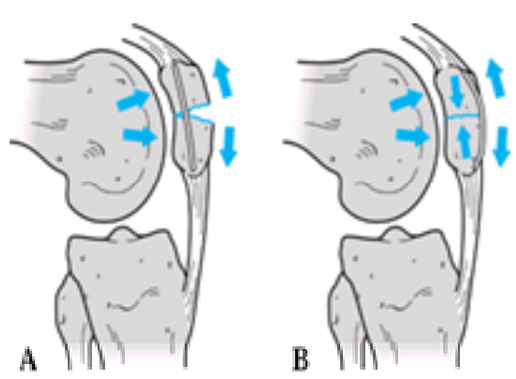


***Figure 22.4.*** **A:** Inappropriate position of the tension band wire causes separation fragments on the tension side of the patella during knee flexion. **B:** Correct placement of the tension band wire for fixation of transverse patellar fractures neutralizes the tension side of the patella and, on subsequent flexion of the knee, exerts compressive forces across the fracture at the joint surface.

- Next, use a medium-pointed reduction forceps to obtain an anatomic reduction of both fragments (Fig. 22.3*D*). Then, drill the previously placed K-wires through the inferior fragment to exit near the patellar ligament (Fig. 22.3*E*).
- Using 18-gauge wire, with a small loop on one side, secure the superior and inferior patellar fragments to the 0.062 inch K-wires with an oval or figure-of-eight configuration (Fig. 22.3*F*, Fig. 22.3*G* and Fig. 22.3*H*). Ensure that the 18-gauge wire is in direct contact with the bone of the superior pole of the patella and the exiting K-wire. The tendency of allowing the quadriceps tendon and the patellar ligament to interpose between the K-wire and the 18-gauge wire leads to loosening of the tension band and failure of fixation. Often, small vertical incisions are required along the line of the tendon fiber to allow the loop of 18-gauge wire to fit snugly against the exiting K-wire. Tighten the figure-of-eight tension band wire on both the medial and lateral sides to apply an equal distribution of tension on the wire. An alternative is to place the tension band wire through transverse drill holes in the patella.
- Remove the reduction forceps and bring the knee into full extension. Palpate and inspect the articular reduction through the medial or lateral retinacular tears. Once the fixation is determined to be stable and anatomic, trim the excess wires. Bend the ends of the wire proximally to a 180° loop, and drive the wire into the

bone fragment to trap the K-wire. Be certain that the K-wires distally are long enough to prevent the 18-gauge wire from dislodging, but not so long that they will irritate the patellar tendon.

- Next, repair the medial and lateral tears of the quadriceps retinaculum. Begin at the apex of the tears medially and laterally and use figure-of-eight sutures of #0 to #2 weight. Reapproximate the tear but do not shorten it too much or the result may be loss of knee flexion. Close the subcutaneous fat and skin. A small drain left in the knee joint for overnight may prevent a hemarthosis.
- After surgery, apply a long leg bulky dressing, and elevate the leg for 24 to 48 hours before the patient is discharged from the hospital. Place the extremity in a universal hinge brace with Velcro straps but allow no motion until the wounds are completely healed and dry. After 10 days, begin active flexion to between 20° and 40° and gradually advance it over the next 6 weeks. The patient can begin isometric exercises immediately if the fixation is secure and if he bears full weight on the site using crutches with the hinges on the brace locked in full extension. Most fractures heal by 6 to 8 weeks, at which time protection can be discontinued and full rehabilitation instituted.

## SCREW FIXATION

- If the fracture is not conducive to tension band wiring alone, screw fixation using 4.0 mm cancellous screws can be done with or without a supplementary tension band wire (Fig. 22.5*A*, Fig. 22.5*B*). Screw fixation is more applicable to stellate fractures in which tension band principles are more difficult to apply.

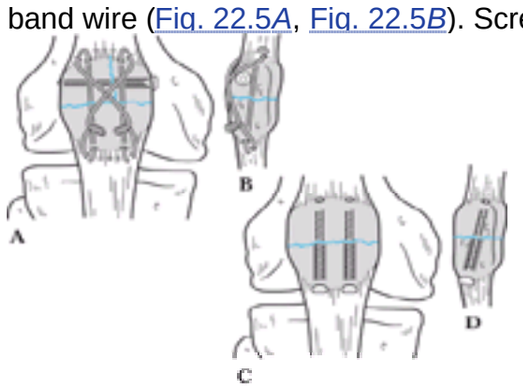


***Figure 22.5.*** **A, B:** Interfragmentary compression screw and tension band wire for a comminuted fracture. **C, D:** Fixation with interfragmentary lag screws.

- Use the same approach for joint irrigation and retinacular repair. Use the pointed reduction forceps for temporary reduction before screw placement or retrograde technique can be used as described in Fig. 22.3*A*, Fig. 22.3*B*, Fig. 22.3*C*, Fig. 22.3*D* and Fig. 22.3*E*.
- Using a 2.0 mm drill bit, stabilize the two fragments using the lag technique with 4.0 mm cancellous screws placed perpendicular to the fracture surface (Fig. 22.5*C*, Fig. 22.5*D*). Screw fixation provides stability and compression, but it is not nearly as reliable as when a tension band is present. I try to use a tension band in all cases.
- Cannulated screw fixation with tension band wire techniques has gained popularity recently (Fig. 22.6). Applying the advantage of compression screw technique and tension band principles enhances stability and helps prevent failure of fixation at higher loads.

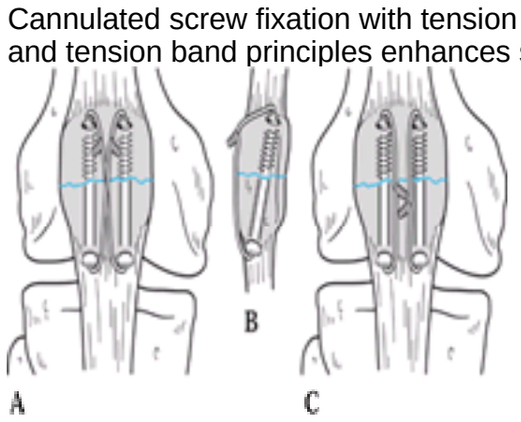


***Figure 22.6.*** Two different methods for combining cannulated screws with tension band wires through the screws.

- Stabilize the fracture using 4.0 mm cannulated screws, as described above.
- Pass an 18-gauge wire through the holes in the screws in a crossed wire fashion or separately for each screw. Bend the wire twists away from the anterior skin to prevent irritation as with all tension band techniques. Combinations of transverse or longitudinally placed screws are acceptable, depending on the fracture classification or direction of fracture lines. This technique does not apply to comminuted fractures in osteoporotic bone but rather to young patients with large fixable fracture fragments.

## PARTIAL PATELLECTOMY WITH REATTACHMENT OF THE PATELLAR LIGAMENT

Often, the inferior half or less of the patella is so severely comminuted that internal fixation or tension band fixation cannot be used (Fig. 22.7); in such a case, partial patellectomy is required (15).

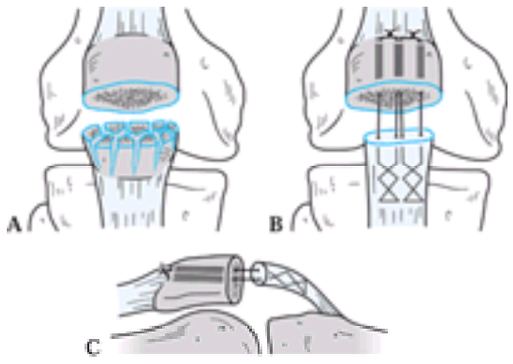


***Figure 22.7.*** Marder (27) technique for partial patellectomy and repair of the patellar tendon. See text for details.

Previously, it was recommended that the patellar tendon be reattached to the posterior aspect (articular surface) of the remaining portion of the patella. Recent studies of the patellofemoral contact areas and pressures in human cadavers following partial patellectomy with reattachment of the patellar tendon at anterior, middle, and posterior positions on the remaining patellar fragment have been performed. These studies have demonstrated that regardless of the position of reattachment, there is a decrease in patellofemoral contact area and an increase in mean patellofemoral contact pressure following partial patellectomy (27). An anterior position of reattachment of the tendon significantly minimizes this effect, however (27). An adequate result requires strict attention to detail.

- Prepare the extremity in the usual fashion. Make a vertical longitudinal incision as described previously and identify the fracture. Raise skin flaps medially and laterally to identify the apex of the retinacular tear.
- Shell out the fragments of the inferior pole of the patella while protecting the patellar tendon.
- On the proximal pole, remove all articular cartilage fragmentation to provide a congruent, smooth patellofemoral joint preventing the later migration of loose osteochondral fragments into the patellofemoral joint.
- Using a 2.0 or 3.2 mm drill, make three longitudinal parallel holes in the anterior third of the patella, exiting the quadriceps tendon at the superior pole of the patella (Fig. 22.7*A*, Fig. 22.7*B* and Fig. 22.7*C* ). Place one hole in the center of the patella on the frontal view, and place the medial and lateral holes parallel to and at the normal width of the patellar tendon remaining in solid bone.
- Place two 5-0 Tevdek sutures, or similar-weight sutures, into the patellar ligament, beginning at the tibial tubercle; weave them in Bunnell fashion to exit the most

superior edge of the disrupted patellar tendon. Use a suture passer or wire inserted from the superior pole of the patella through each of the drill holes to pull the suture through the holes in the patella, thereby securing the patellar tendon to the fractured surface of the patella. Pass the two central sutures through the central drill hole. Tie the two sutures to securely fasten the patellar tendon to the fractured patella. Avoid trapping the quadriceps tendon between the superior pole of the patella and the suture.

- Then repair the medial and lateral retinaculum as described above in the technique for tension wire fixation of the patella. Irrigate the wound copiously, close it in layers over a suction drain, and place the leg in a long leg bulky dressing with splints.
- Allow 20° of motion (0° to 20°) in a universal brace with hinges; after 6 weeks, advance motion by 20° per week until full flexion and extension are obtained at 12 weeks. Encourage isometric quadriceps exercises early. Muscle electrical stimulation may help prevent quadriceps atrophy. Full weight bearing is possible with the hinges of the brace locked in extension.

### HINTS AND TRICKS

The anterior half or more of the knee joint can be inspected through this limited anterior approach. Use this opportunity to look for loose osteochondral fragments and to deal with other associated injuries.

- The passage and recovery of K-wires and drill points in the quadriceps mechanism and patellar tendon can be challenging. Use a #15 blade to create a 3 to 5 mm long cruciate incision through the soft tissues down to bone and scrape any cartilage at the tendon attachment off bone. Use serrated drill guides to prevent migration of wires and drills.
- Use drill points or K-wires with holes in the tip to permit passage of wires or sutures in a single step.
- Fluoroscopic guidance is useful to less experienced surgeons or where multiple screws are placed.
- Tension band wires are more reliable when passed through transverse drill holes or through cannulated screws.

### TOTAL PATELLECTOMY—ACUTE

Total patellectomy is indicated when comminuted patellar fractures are so severe that no form of fixation will provide a reasonable reduction. Although there have been reports of patellofemoral pain after total patellectomy, advocates of this procedure suggest that the degree of disability is reduced, the surgery is less complicated, and the patients have an earlier return to functional activities than do patients undergoing marginal fixation (15,16).

- Approach the knee and expose the fracture as described above.
- Shell out the comminuted fragments with a #15 blade, preserving the soft-tissue attachments as much as possible.
- Repair the retinacular tears as described above and carry the figure-of-eight sutures across the area of the patellectomy. Oppose the torn surfaces firmly but do not shorten the quadriceps mechanism any more than is necessary to obtain a good repair. Occasionally, a Bunnell-type repair of the patellar tendon, as described earlier for partial patellectomy, is necessary on both sides of the tendon.
- Wound management and rehabilitation are as described above.

### ELECTIVE TOTAL PATELLECTOMY

If repair of a fractional patella is unsuccessful or patellectomy is required for primary (rare) or painful posttraumatic patellofemoral arthritis, use the following technique:

- Expose the quadriceps mechanism and patella through an anterior midline longitudinal incision.
- Incise the quadriceps retinaculum longitudinally in the midline over the patella with an electrocautery knife.
- Split the patella in the midline longitudinally by first cutting through the anterior three quarters with an oscillating saw and then completing the fracture with an osteotome by prying the two fragments apart. A lamina spreader can be used as well. Avoid injury to the articular surface of the femur.
- Shell out the two fragments, preserving all soft-tissue attachments. Ensure hemostasis.
- Repair the longitudinal split in the quadriceps retinaculum with interrupted #1 or #2 figure-of-eight sutures. Close the subcutaneous tissues and skin.
- Immediate protected knee motion, weight bearing, and muscle rehabilitation are usually possible because the quadriceps mechanism is in continuity.

## RESULTS

Unfortunately, the vast majority of published studies on the results and outcomes from treatment of patellar fractures are retrospective studies and there is very little standardization of the methods used to analyze results. Böaustman et al. (4) have used the most comprehensive clinical grading scale published so far, which includes evaluation of pain, stair-climbing, giving way, use of aids for walking, return to work, and evaluation of range of motion, atrophy, and presence of an effusion. They looked at 219 patients treated nonoperatively for nondisplaced fractures. All patients had less than 4 mm of residual articular incongruity. Fifty-four percent had excellent results, 44% had good results, and there were only two failures. Their results agree with those of others, showing that the nonoperative treatment of nondisplaced fractures gives excellent results with failure rates under 5%. Although open reduction and internal fixation gives better results in displaced fractures, even widely displaced fractures of the patella can be treated nonoperatively with reasonable outcomes if surgery is contraindicated (31).

Of the various surgical techniques for internally fixing transverse fractures of the patella and more comminuted fractures, anterior tension band wiring, particularly when combined with cannulated screws, gives the best results. Accumulated results from several studies show 57% excellent results, 29% good results, and 14% poor results (4,5,22a,23a,29a,34a). Berg (3) in 10 patients showed 70% excellent or good results based on the hospital for special surgery knee score utilizing figure-of-eight tension band wires placed through parallel cannulated compression screws. Recently, heavy, nonabsorbable sutures or biodegradable, self-reinforced polyglycolide tension bands have been used to replace the traditionally used wire to eliminate the need for later wire removal. These methods have proven to be equally efficacious (10,11). Smith et al. (36) looked at the complications of operative treatment of patellar fractures in a consecutive series of 87 fractures treated over a five-year period. Their major complication was displacement of the fracture of 2 mm or more which occurred in 11 fractures. They attributed this to technical errors in five fractures and patient noncompliance in the remainder. There were no deep infections. Two patients had superficial infections which resolved. The high incidence of displacement emphasizes the importance of surgical technique in repairing displaced patellar fractures. It is important to establish, on the operating table immediately following fixation, how much flexion can safely be done before placing excessive stress on the repair. It is important to make sure that patients stay within the safe range of motion during early rehabilitation until the fracture is healed. Nine of their patients required removal of the implants because of pain. For that reason, consider using newer tension band techniques utilizing cannulated screws as the profile of the wires is much lower (3). Absorbable materials for the tension band are promising as well (10,11). Partial patellectomy with reanastomoses of the patellar tendon to the remnant fragment produces somewhat less favorable outcomes than restoration of the normal anatomy of the patella. Sutton et al. (38) showed that excision of one-third of the inferior pole of the patella resulted in an overall loss of 18° of motion. Partial patellectomy reduces the contact area between the patella and trochlea groove. This results in an increased incidence of anterior knee pain. However, retention of large fragments (making up 50% or more of the patella) improves quadriceps function compared to patellectomy and, overall, has reasonably good outcomes of 70% or so combined good and excellent results when a number of reports are summarized (4,29a,34a).

Total patellectomy may be necessary in very comminuted fractures but gives poorer results than partial patellectomy or operative repair. Comparison is difficult, however, as these three different treatments are applied to three entirely different fracture patterns, each involving different levels of energy of injury. Sutton et al. (38) showed that total patellectomy resulted in a 40% reduction in the strength of the extensor mechanism. This causes significant loss of ability to support body weight while stair-climbing. Wilkinson (44) examined 31 patients with 4.5 to 13 years of follow-up after total patellectomy and found that less than 25% of patients had an excellent result. He noted that knee function continued to improve for approximately 3 years before stabilizing. Einola et al. (16) followed 28 patients for an average of 7.5 years after total patellectomy and found good results in only 6 patients. Atrophy of the quadriceps was common, and he found that quadriceps power was within 75% of that of the normal knee in only 7 patients. He advised saving as much of the patella as possible. Scott (34) found only 4 of 71 patients who were pleased with the long-term outcome of their total patellectomy. Gèagunal et al. (18) found that the results of total patellectomy could be substantially improved by advancing the vastus medialis obliquus.

In commuted fractures of the patella, my current practice is to fix internally the patella and retain as much patella as possible as long as the articular surface can be reduced anatomically or with an incongruity of less than 2 mm. If the fixation fails or the patient has unacceptable symptoms after healing and rehabilitation, then elective patellectomy usually gives a result similar to that of total patellectomy done initially.

In open fractures of the patella, the outcomes depend primarily on the degree of soft-tissue injury (9,40). Catalano et al. (9) treated 79 open patellar fractures—the majority of which occurred in patients with multiple injuries—with irrigation and debridement, open reduction, and primary internal fixation with reconstruction of the extensor mechanism. They performed no primary patellectomies even in patients with severe comminution. They had only three failures of initial fixation and one asymptomatic nonunion. Using a modified Hospital for Special Surgery knee score they found good to excellent results in 17 of 22 patients at an average follow-up of 3 years. In these severe injuries, they advised thorough irrigation and debridement with primary reconstruction of the patella and extensor mechanism reserving total patellectomy as a salvage procedure. Torchia and Lewallen (40) reviewed 57 open patella fractures. They experienced somewhat less good outcomes particularly since their rate of deep infection was 10.7% which correlated directly with the magnitude of soft-tissue injury. They had no infections in Type I and Type II open

fractures. Their final recommendations for treatment were similar to those of Catalano et al.

## POSTOPERATIVE CARE AND REHABILITATION

Immediate postoperative care and rehabilitation have been described with each of the previously described procedures. Certain general principles apply to all of these procedures:

- After the repair is completed and while the wound is still open, gently carry the knee throughout range of motion to determine what the safe range is that does not place excessive stress on the repair.
- Passive range of motion exercises including continuous passive motion can begin as soon as the condition of the wound permits. Motion helps prevent intraarticular adhesions and tightness of the quadriceps retinaculum.
- As long as the quality of the bone and soft tissue is good and the repair solid, most patients can begin quadriceps isometric exercises immediately and can bear full weight in a brace with the knee locked into full extension.
- The hinge of the brace can be adjusted to permit increasing range of motion as healing advances.
- By 6 to 8 weeks, most patients should have good control of their quadriceps and hamstrings, be able to raise the leg straight against gravity, and flex the knee to 90°. If so, full, unprotected weight bearing can begin.
- By 12 weeks, patients should be 70% to 90% rehabilitated and have good strong quadriceps function and flexion to 135°.
- Bone repairs are slower to heal than soft-tissue repairs and are less predictable from the standpoint of stability. They require more cautious rehabilitation until bone union occurs, usually between 6 and 10 weeks.

## PITFALLS AND COMPLICATIONS

Loss of motion is one of the most common complications. Minor degrees of loss of terminal flexion after patellar fixation have little effect on functional outcome of the knee. Adherence to the guidelines for rehabilitation and a cooperative patient will minimize the risk of knee stiffness.

Inferior positioning of the patella, “patella baja,” is a well recognized, but rare, complication of inferior pole patellectomy and reconstruction of the patellar ligament. Patients with the condition have pain, loss of full flexion, and occasionally loss of terminal extension. Prevent it by avoiding overshortening of the quadriceps mechanism at the time of repair. Reconstruction requires preoperative comparative radiographs of the contralateral flexed knee to assess the appropriate lengthening required. The patellar tendon can be lengthened by a Z-lengthening procedure. It is usually preferable to a tibial tubercle osteotomy.

Loss of reduction due to failure of fixation may be related to poor-quality tissues, poor fixation techniques, poor patient compliance, and too rigorous a postoperative rehabilitation program. As with articular reductions, the joint accommodates small degrees of gap; however, stepoff of more than 2 mm or complete disruption may require repeat fixation or patellectomy.

Infection has been reported in 3% to 10% of cases and occurs most frequently with open fractures or fractures associated with deep, neglected abrasions. Acute infections may be salvaged with debridement, maintenance of fixation hardware, and appropriate antibiotics. Late infections with knee-joint involvement require aggressive debridement, removal of hardware, and an attempt at late reconstruction. Outcomes are often poor.

Nonunion is a rare problem that can result in a stable fibrous union requiring no treatment. Repair or patellectomy may be required (see Chapter 30).

Partial and total patellectomy decrease quadriceps mechanism strength but most patients function well (23,28,30,32).

## AUTHOR'S PERSPECTIVE

In young patients with repairable fractures, I make every effort to preserve the patella. I prefer to use cannulated screws with supplemental tension band wire fixation. I am more likely to perform partial or complete patellectomy in complex fractures in sedentary middle-aged or older patients or where osteoporosis is present. Success depends on direct supervision of the rehabilitation program by the surgeon.

## CHAPTER REFERENCES

Each reference is categorized according to the following scheme: *, classic article; #, review article; !, basic research article; and +, clinical results/outcome study.


* 1. Andrews JR, Hughston JC. Treatment of Patellar Fractures by Partial Patellectomy. *South Med J* 1977;70:809.

+ 2. Berg EE. Extensile Exposure of Comminuted Patella Fractures Using a Tibial Tubercle Osteotomy: Results of a New Technique. *J Orthop Trauma* 1998;12:351.

+ 3. Berg EE. Open Reduction Internal Fixation of Displaced Transverse Patella Fractures with Figure-Eight Wiring through Parallel Cannulated Compression Screws. *J Orthop Trauma* 1997;11:573.

+ 4. Böaustman O, Kivilvoto O, Nirhano J. Comminuted Displaced Fractures of the Patella. *Injury* 1981;13:196.

* 5. Bostrom A. Fractures of the Patella. *Acta Orthop Scand* 1972;143(suppl):1.

* 6. Brook R. The Treatment of Fractured Patella by Excision. A Study of Morphology and Function. *Br J Surg* 1936;24:733.

* 7. Bruce J, Walmsley R. Excision of the Patella. Some Experimental and Anatomical Observations. *J Bone Joint Surg* 1942;24:311.

! 8. Carpenter JE, Kasman RA, Patel N, et al. Biomechanical Evaluation of Current Patella Fracture Fixation Techniques. *J Orthop Trauma* 1997;11:351.

+ 9. Catalano JB, Iannacone WM, Marczyk S, et al. Open Fractures of the Patella: Long-term Functional Outcome. *J Trauma* 1995;39:439.

+ 10. Chatakondu SC, Abhaykumar S, Elliott DS. The Use of Non-absorbable Suture in the Fixation of Patellar Fractures: A Preliminary Report. *Injury* 1998;29:23.

+ 11. Chen A, Hou C, Bao J, Guo, S. Comparison of Biodegradable and Metallic Tension-band Fixation for Patella Fractures. 38 Patients Followed for 2 Years. *Acta Orthop Scand* 1998;69:39.

* 12. Compere CL, Hill JA, Lewinnek GE, et al. A New Method of Patellectomy for Patellofemoral Arthritis. *J Bone Joint Surg* 1979;61-A:714.

* 13. Crenshaw AH, Wilson FD. The Surgical Treatment of Fractures of the Patella. *South Med J* 1954;47:716.

# 14. DePalma AF. *The Management of Fractures and Dislocations.* Philadelphia: WB Saunders, 1959.

* 15. Duthie HL, Hutchinson JR. The Results of Partial and Total Excision of the Patella. *J Bone Joint Surg* 1958;40-B:75.

+ 16. Einola S, Aho AJ, Kallio P. Patellectomy After Fracture. Long-term Follow-up Results with Special Reference to Functional Disability. *Acta Orthop Scand* 1976;47:441.

! 17. Garr EL, Moskowitz RW, Davis W. Degenerative Changes Following Experimental Patellectomy in the Rabbit. *Clin Orthop* 1973;92:296.

+ 18. Gèagunal I, Taymaz A, Kèagose N, et al. Patellectomy with *Vastus Medialis Obliquus* Advancement for Comminuted Patellar Fractures: A Prospective Randomised Trial. *J Bone Joint Surg Br* 1997;79:13.

+ 19. Haajanen J, Karaharju E. Fractures of the Patella: 100 Consecutive Cases. *Ann Chir Gynaecol* 1982;70:32.

* 20. Haxton J. The Function of the Patella and the Effects of Its Excision. *Surg Gynecol Obstet* 1945;82:389.

! 21. Kaufer H. Patella Biomechanics. *Clin Orthop* 1979;144:51.

! 22. Kaufer H. Mechanical Function of the Patella. *J Bone Joint Surg* 1971;53-A:1551.

+22a. Levack B, Flannagan JP, Hobbs S. Results of Surgical Treatment of Patellar Fractures. *J Bone Joint Surg* 1985;67:416.

+ 23. Liang QY, Wu JW. Fracture of the Patella Treated by Open Reduction and External Compressive Skeletal Fixation. *J Bone Joint Surg* 1987;69-A:83.

+23a. Ma YZ, Zheng YF, Qu KF, et al. Treatment of Fractures of the Patella with Percutaneous Suture. *Clin Orthop* 1984;191:235.

# 24. Magnuson PB. *Fractures*, 2nd ed. Philadelphia: JB Lippincott, 1936.

* 25. Malgaigne JF. *Dennis System of Surgery, Vol. 1.* Philadelphia: Lea Brothers, 1895.

+ 26. Maquet P. Mechanics and Osteoarthritis of the Patellofemoral Joint. *Clin Orthop* 1979;144:70.

! 27. Marder RA, Swanson TV, Sharkey NA, Duwelius PJ. Effects of Partial Patellectomy and Reattachment of the Patellar Tendon on Patellofemoral Contact Areas and Pressures. *J Bone Joint Surg Am* 1993;75:35.

+ 28. McMaster PE. Fractures of the Patella. *Clin Orthop* 1954;4:24.

# 29. Müauller ME, Allgöauwer M, Willenegger H. *Manual of Internal Fixation. Technique Recommended by the AO Group.* New York: Springer-Verlag, 1970:175.

+29a. Nummi J. Operative Treatment of Patellar Fractures. *Acta Orthop Scand* 1971;42:437.

+ 30. Peeples RE, Margo MK. Function After Patellectomy. *Clin Orthop* 1978;132:180.

+ 31. Pritchett JW. Nonoperative Treatment of Widely Displaced Patella Fractures. *Am J Knee Surg* 1997;10:145.

+ 32. Reiley RE, DeSouza LJ. Patellectomy. An Alternate Technique. *Clin Orthop* 1974;103:170.

! 33. Scilaris TA, Grantham JL, Prayson MJ, et al. Biomechanical Comparison of Fixation Methods in Transverse Patella Fractures. *J Orthop Trauma* 1998;12:356.

+ 34. Scott JC. Fractures of the Patella. *J Bone Joint Surg* 1949;31-B:76.

# 34a. Seligo W. Fractures of the Patella. *Reconstr Surg Traumatol* 1971;12:84.

+ 35. Shorbe HB, Dobson CH. Patellectomy. Repair of the Extensor Mechanism. *J Bone Joint Surg* 1958;40-A:1281.

+ 36. Smith ST, Cramer KE, Karges DE, et al. Early Complications in the Operative Treatment of Patella Fractures. *J Orthop Trauma* 1997;11:183.

+ 37. Steurer PA Jr, Gradisar IA, Hoyt WA Jr, et al. Patellectomy: A Clinical Study and Biomechanical Evaluation. *Clin Orthop* 1979;144:84.

+ 38. Sutton FS Jr, Thompson CH, Lipke J, et al. The Effect of Patellectomy on Knee Function. *J Bone Joint Surg* 1976;58-A:537.

+ 39. Thompson JEM. Comminuted Fractures of the Patella. Treatment of Cases Presenting One Large Fragment and Several Small Fragments. *J Bone Joint Surg* 1935;17:431.

+ 40. Torchia ME, Lewallen DG. Open Fractures of the Patella. *J Orthop Trauma* 1996;10:403.

+ 41. Viola R, Vianello R. Three Cases of Patella Fracture in 1,320 Anterior Cruciate Ligament Reconstructions with Bone-patellar Tendon-bone Autograft. *Arthroscopy* 1999;15:93.

+ 42. Watkins MP, Harris BA, Wender S. Effect of Patellectomy on the Function of the Quadriceps and Hamstrings. *J Bone Joint Surg* 1983;65-A:390.

+ 43. Weber MJ, Janecki CJ, McLeod P, et al. Efficacy of Various Forms of Fixation of Transverse Fractures of the Patella. *J Bone Joint Surg* 1980;62-A:215.

+ 44. Wilkinson J. Fracture of the Patella Treated by Total Excision: A Long-term Follow-up. *J Bone Joint Surg* 1977;59-B:352.

# CHAPTER 23

# FRACTURES OF THE TIBIAL PLATEAU

*Kenneth A. Egol and Kenneth J. Koval*

**K. A. Egol:** Department of Orthopaedic Surgery, NYU–Hospital for Joint Diseases, New York, New York 10003.
**K. J. Koval:** Department of Orthopaedic Surgery, NYU–Hospital for Joint Diseases, New York, New York, 10003.

Mechanism of Injury
Initial Evaluation
Classification
Indications
Nonoperative Management
Surgical Techniques
Preoperative Planning
Surgical Exposure
Patient Positioning
Reduction Techniques
Arthroscopy
Fracture Fixation
Open Reduction and Fixation of a Typical Split-Central Depression Fracture of the Lateral Plateau
Postoperative Care
Pitfalls and Complications
Authors' Perspective
Chapter References

## MECHANISM OF INJURY

Fractures of the tibial plateau were originally described as “the fender fracture” (10) because they resulted primarily from low-energy pedestrian versus car bumper accidents (Fig. 23.1). The majority of tibial plateau fractures reported in the recent literature have resulted from high-speed motor vehicle accidents and falls from a height (7,21,48,50). Fractures of the tibial plateau are caused by direct axial compression, usually with a valgus (more common) or varus (less common) moment and indirect shear forces. The anterior aspect of the femoral condyles is wedge shaped; with the knee in full extension, the force generated by the injury drives the condyle into the tibial plateau (47). The direction, magnitude, and location of the force, as well as the position of the knee at impact, determines the fracture pattern, location, and degree of displacement.

***Figure 23.1.*** The classic mechanism of injury in tibial fractures is shown.

When a single compartment is involved in fractures of the tibial plateau, it is usually the lateral plateau (7,16,27,32,44,47,51,52). This is because the anatomic axis at the knee joint (which is normally in 7° of valgus) as well as the mechanism of injury usually causes a direct force from lateral to medial (30). Patient factors such as age and bone quality can also influence the fracture pattern. Elderly individuals with osteopenic bone are more likely to sustain depression-type fractures (4) because their subchondral bone is less likely to resist axially directed loads (Fig. 23.2). In contrast, younger individuals with denser subchondral bone are more likely to sustain cleavage-type fractures and have an associated ligamentous disruption (Fig. 23.3) (26,51,52).

***Figure 23.2.*** In pure depression fractures, the cancellous bone absorbs the energy, thus sparing the medial collateral ligament of injury.

***Figure 23.3.*** In split fractures, the cancellous bone does not compress, thus imparting the energy to the medial collateral ligament

## INITIAL EVALUATION

A tibial plateau fracture should be considered in the differential diagnosis any time a patient complains of pain and swelling about the knee following major or minor trauma. Decision making regarding the treatment of periarticular fractures about the knee depends on knowledge of the mechanism of injury, clinical stability, radiographic findings, and associated injuries. Initial evaluation of the knee following trauma includes palpation to elicit tenderness over a potential fracture or site of ligamentous disruption. Generally, hemarthrosis is present; however, significant capsular disruption may lead to dispersion into surrounding soft tissues.

Careful neurovascular examination of the extremity should follow documentation of the skin condition and presence of swelling. Because many of these injuries are produced by high-energy forces, the presence of compartment syndrome must be ruled out. If pulses are not palpable, perform Doppler studies. If the clinical signs of an impending compartment syndrome (pain out of proportion to the injury, pallor, pain on passive stretch of the toes, or impaired neurologic status) are present, compartment pressures must be measured. Pressures should also be measured in the unconscious patient with a tense, swollen leg.

Associated injuries of the supporting ligamentous structures around the knee have been well documented with tibial plateau fractures. Injury to the collateral ligaments have been reported to occur in 7% to 43% of cases (2,7,12,20,21,51,52), and ruptures of the anterior cruciate have been reported in up to 23% of high-energy injuries (2). Furthermore, meniscal injuries have been reported in up to 50% of tibial plateau fractures; the meniscus may be incarcerated within the fracture site (21,40,41,48). Ligamentous injuries may be difficult to diagnose on initial examination during the acute phase. Varus and valgus stress testing of the knee in near full extension can be performed under general anesthesia if one is unable to assess the knee properly in the emergency room (19). Split fractures of the lateral plateau have a high incidence of associated ligamentous injury, because the dense cancellous bone associated with split fractures does not compress. Energy is therefore not dissipated, and the force is imparted to the medial collateral ligament.

Open fractures about the knee are particularly problematic; thus, any open wound should be evaluated for the possibility of an open joint injury. Because an open joint injury is an absolute indication for surgical intervention (2,9,30), it is incumbent on the treating physician to make the diagnosis. If you are unsure as to whether the open wound communicates with the joint, instill at least 50 ml of sterile normal saline into the knee away from the wound. If fluid extravasation is noted, the diagnosis is confirmed (30). It should be stated that a negative injection test does not exclude the possibility of an open joint injury. Exploration of the knee in the operating room is indicated any time the suspicion for an open joint wound is significant.

Following the clinical examination, perform radiographic evaluation. The standard knee trauma series includes an anteroposterior (AP) view, a lateral view, and two oblique views. Owing to the 10° to 15° posterior slope of the articular surface of the tibia, a 10° to 15° caudally tilted plateau view provides more accuracy in assessing articular stepoff (Fig. 23.4) (19,37). In addition to providing an assessment of the fracture patterns, radiographs often provide evidence of associated ligamentous injury. Avulsion of the fibular head, the Segund sign (lateral capsular avulsion), and Pellegrini-Stieda lesion (calcification along the insertion of the medial collateral ligament) are indicative of associated ligamentous injury (12,17,19). Stress views may be helpful as well but take care not to displace the fracture further.

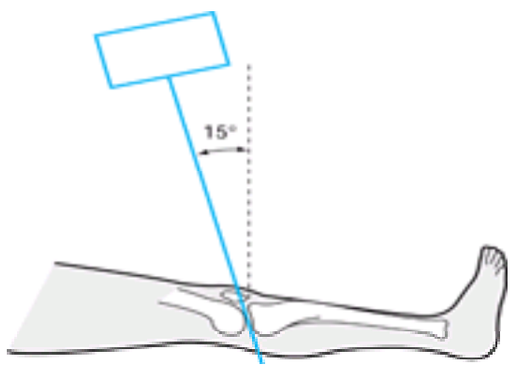


***Figure 23.4.*** To obtain a tibial plateau view, the x-ray beam is angle caudally 15°. (From Koval KJ, Helfet DL. Tibial Plateau Fractures: Evaluation and Treatment. *Journal of the American Academy of Orthopaedic Surgeons* 1995;3:86, with permission.)

Computed tomography (CT) has virtually replaced plain tomography for the evaluation of displaced tibial plateau fractures. CT scanning with sagittal reconstruction has increased the diagnostic accuracy in tibial plateau fractures and is indicated in cases of articular depression (Fig. 23.5) (19,43). CT scans have been shown to increase the interobserver and intraobserver agreement of the classification of tibial plateau fractures (8). Furthermore, these studies are excellent adjuncts in the preoperative planning of lag screw placement when percutaneous fixation is to be undertaken. Magnetic resonance imaging (MRI) has recently been suggested as a method for evaluation of these injuries as an alternative to CT scan and arthroscopy. MRI theoretically evaluates both the osseous as well as the soft-tissue components of the injury (6). Currently, however, no clear indication exists for the use of MRI in tibial plateau fractures.

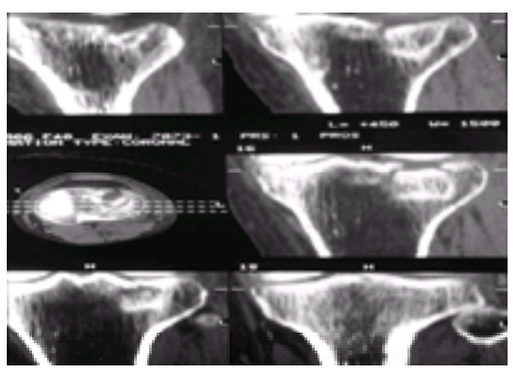

***Figure 23.5.*** A CT scan is shown with two-dimensional reconstructions demonstrating a pure depression fracture.

Use of arthroscopy has become more prevalent in the evaluation of tibial plateau fractures (16,23,40). With arthroscopy, one can examine the articular surface, menisci, and cruciates directly (Fig. 23.6). In addition, one can irrigate the joint of any loose debris and hematoma. However, development of compartment syndrome (related to the extravasation of arthroscopy fluid) has been reported in the literature (16,23,40).

***Figure 23.6.*** Arthroscopic view of a split fracture of the lateral tibial plateau. One can obtain good visualization of the articular surface, femoral condyles, and meniscus.

## CLASSIFICATION

Numerous classification systems have been proposed to describe tibial plateau fractures (1,17,18,36,39,47,51,52). The majority are very similar, with each system recognizing wedge, compression, and bicondylar types. The Hohl classification was the first widely accepted description of tibial plateau fractures (17), classifying these fractures into displaced and undisplaced. Under the displaced category, he recognized local compression, split compression, total condyle depression, and comminuted fractures.

Moore expanded Hohl's concepts, taking into account higher-energy injuries and resultant knee instability (36). His classification of fracture subluxations of the knee is divided into five types: Type 1 is a split fracture of the medial tibial plateau in the coronal plane; Type 2 an entire condyle fracture with the fracture line beginning in the opposite compartment and extending across the tibial eminence; Type 3 is a rim avulsion fracture (these fractures are associated with a high rate of associated neurovascular injury); Type 4 is another type of rim fracture, a rim compression injury, usually associated with some type of contralateral ligamentous injury; and Type 5 is a four-part fracture with the tibial eminence separated from the tibial condyles and the tibial shaft (Fig. 23.7) (36).

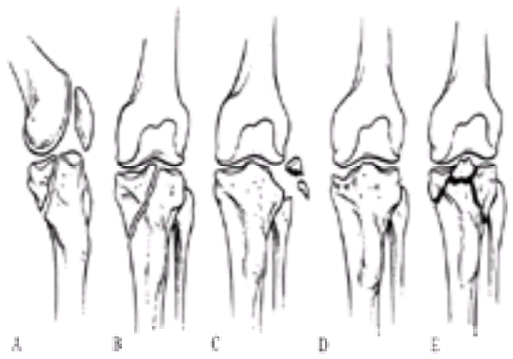


***Figure 23.7.*** The Moore classification of tibial plateau fractures. **A:** Split fracture of the medial plateau in the coronal plane. **B:** An entire condyle fracture. **C:** Rim avulsion fracture. **D:** A pure compression fracture. **E:** A four-part fracture.

Schatzker's classification of tibial plateau fractures (Fig. 23.8) is currently the most widely used and was the first to make the distinction between medial and lateral plateau fractures (51,52). Type I is a pure cleavage fracture of the lateral tibial plateau that results in a wedge-shaped fracture fragment. Type II is a cleavage fracture of the lateral tibial plateau in which the remaining articular surface is depressed into the metaphysis. Type III is a pure central depression fracture of the lateral tibial with an intact osseous rim. Type IV involves the medial tibial plateau and is divided into two subtypes: type A is a split fracture and type B is a depression fracture. Either type may be combined with a tibial spine fracture. Type V is a bicondylar fracture with the fracture line often forming an inverted **Y**; the metaphysis and diaphysis remain intact. Type VI is a tibial plateau fracture in which there is dissociation between the metaphysis and the diaphysis; these fractures may have varying degrees of comminution of one or both tibial condyles and the articular surface (51,52). Honkonen and Jarvinen have recently modified Shatzker's classification to take into account residual limb alignment. They divide type VI fractures into medially and laterally tilted fractures to take into account functional results in treated fractures with residual angulation (21).

***Figure 23.8.*** Schatzker's classification of tibial plateau fractures is shown. Types I to IV are defined as follows: **I:** A split fracture of the lateral tibial plateau. **II:** A pure depression fracture of the lateral tibial plateau. **III:** A split-depression fracture of the lateral tibial plateau. **IV:** A fracture of the medial tibial plateau. **V:** A bicondylar fracture of the tibial plateau. **VI:** A fracture of the tibial plateau with metaphyseal-diaphyseal dissociation.

The Arbeitsgemeinschoft füaur Osteosynthese Fragen (AO) classification is divided into three main categories (Fig. 23.9) and is most useful as a research tool. Type A fractures are extraarticular. Type B fractures are partially articular and are subdivided into three main categories: B1 fractures are pure splits, B2 fracture are pure depression, and B3 fractures are split depression. Type C fractures are complete articular fractures and are also subdivided into three subtypes: (a) being articular and metaphyseal simple, (b) articular simple and metaphyseal multifragmentary, and (c) articular multifragmentary (39).

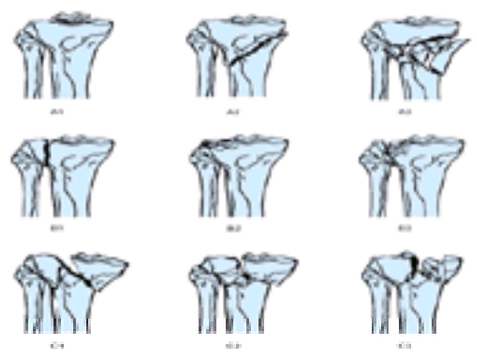

***Figure 23.9.*** The AO classification of tibial plateau fractures is shown.

## INDICATIONS

It is generally accepted that nondisplaced or minimally displaced fractures can be treated nonoperatively (7,18,32,45,52). The indications for nonoperative versus operative treatment of displaced tibial plateau fractures, however, vary widely in the literature. Numerous authors have reported excellent results with nonoperative treatment of displaced tibial plateau fractures (1,11,14,18,24,48,49), whereas others advocate anatomic restoration of the articular surface (7,51,52,54). The degree of

articular depression that can be accepted has varied and ranges from less than 2 mm to 1 cm (11,18,45,51). Most authorities today believe that more than 2 mm of offset in the weight-bearing portion of the articular surface is not acceptable in active patients. The need for surgery on tibial plateau fractures can also be based on instability of more than 10° of varus or valgus in the nearly extended knee compared with the contralateral side (32,44,45). This potential instability depends on the status of the rim of the tibial plateau. Split fractures are more likely to be unstable than pure depression fractures in which the rim is intact. Open fractures and fractures associated with vascular injury or compartment syndrome require urgent surgical intervention.

## NONOPERATIVE MANAGEMENT

Nondisplaced and stable fractures are best treated nonoperatively. Protected weight bearing and early range of knee motion in a hinged cast-brace are the authors' preferred method of treatment. Initiate isometric quadriceps exercises and progressive passive, active-assisted, and active range of knee motion exercises as the stability of the fracture permits. Allow partial weight bearing for 8 to 12 weeks, with progression to full weight bearing as tolerated thereafter.

Treatment with a long leg cast is primarily of historical interest. Significant quadriceps atrophy and restricted range of knee motion are likely to result from prolonged joint immobilization (18,19). Reserve treatment in a long leg cast for unreliable patients who cannot be trusted to bear partial weight; in this instance, the cast should be applied with the knee flexed to 45°. Cast immobilization may also be necessary in unstable fractures in which a cast brace is insufficient and, for some reason, surgery is contraindicated. Apley described the use of skeletal traction to provide alignment of displaced tibial plateau fractures yet allow for range of motion of the knee joint (1). This method involves the use of a Steinmann pin inserted transversely through the tibia, usually in the distal third below the fracture. Patients are restricted to bed rest for 6 weeks but allowed active range of motion exercises of the knee. The major limitations of this form of treatment include inadequate reduction of the articular surface and ineffective control of limb alignment (19). Furthermore, the extended period of hospitalization and recumbency are not cost-effective in today's health care environment. If the criteria for operative treatment are not met, cast bracing has provided excellent results (11,12,14,50).

## SURGICAL TECHNIQUES

### PREOPERATIVE PLANNING

One should understand the exact nature of the fracture before attempting any type of surgical intervention. Preoperative planning is essential for any complex injury because it forces the surgeon to understand the “personality” of the fracture and to prepare an operative strategy mentally. Radiographs of the contralateral extremity can serve as templates. Traction radiographs often allow better visualization of individual fracture fragments. Plan all aspects of fracture reduction and fixation to avoid technical pitfalls (Fig. 23.10). Furthermore, be certain that all needed equipment and implants are available.

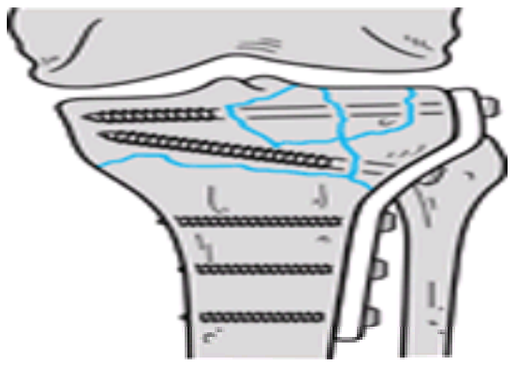

***Figure 23.10.*** An example of preoperative templating is illustrated.

The basic goals and principles for the treatment of tibial plateau fractures follow those of other articular fractures. First should be reconstruction of the articular surface, followed by reestablishment of tibial alignment. Buttress securely with bone graft or a bone graft substitute to support depressed articular fragments. Fracture fixation can involve the use of plates and screws, screws alone, external fixation, or combinations of these methods. Finally, adequate soft-tissue reconstruction that includes preservation or repair, or both, of the meniscus and ligaments may be required (54).

### SURGICAL EXPOSURE

Exposure of the tibial plateau can be gained through a variety of approaches. The surgical approach should provide maximum visualization, combined with preservation of all vital structures as well as minimal soft-tissue dissection and osseous devitalization (52).

- Make the skin incisions for tibial plateau fractures longitudinal and as close to the midline as possible. Because the majority of plateau fractures involve the lateral compartment, a lateral parapatellar incision and arthrotomy is often used. Medial fractures use a medial parapatellar approach. In either case, plan the incisions so that implants do not lie directly below the skin incision. Any flaps that are raised should be full thickness down to the crural fascia and retinaculum and include the subcutanous fat. We favor midline skin incisions in bicondylar fractures to allow access to both knee compartments and facilitate any future reconstructive procedures.
- Once the level of the capsule has been reached, make an arthrotomy. The arthrotomy can be submeniscal (52,54) (Fig. 23.11) or vertical, with division of the anterior horn of the lateral meniscus (19,25,41,42); division of the anterior horn of the meniscus near its origin has been shown to heal reliably at follow-up arthroscopy (25,41,42). With either approach, the split fracture component can be displaced open, and depressed fracture fragments can be elevated. In any case, all efforts should be made to preserve the meniscus.

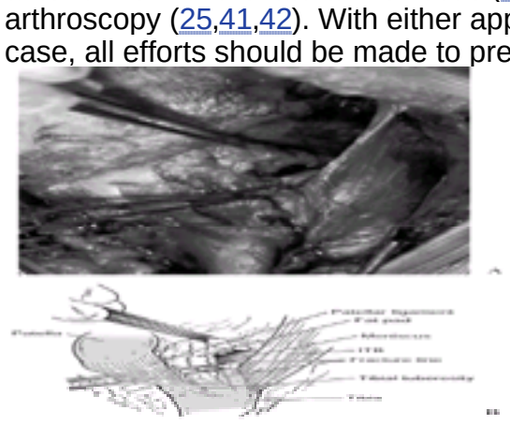

***Figure 23.11.*** The technique of submeniscal arthrotomy is shown. *ITB,* iliotibial band.

- Posteromedial fractures of the plateau can be approached through a separate incision, between the medial gastrocnemious and semitendinosus and then between the medial collateral ligament and the posterior oblique ligament (22,33).
- Occasionally, it is necessary to obtain better exposure of severely comminuted bicondylar fractures. If the tibial tubercle is a separate fragment and free, it can be reflected along with the patellar tendon to afford excellent exposure of both compartments. Because of the difficulties of repair, avoid actual osteotomy of the tibial tubercle. If the tubercle is intact, incise the patellar tendon in a **Z**-plasty fashion with the same resultant exposure (19,52). Following the completion of surgery and repair of the extensor mechanism, protect the patellar tendon using a tension band.

### PATIENT POSITIONING

- Position the patient supine, with a bolster under the knee or on a table where the foot of the table can be dropped.
- Prep and drape the ipsilateral iliac crest if a need for autogenous bone graft is contemplated.
- Furthermore, the patient's position should take into account the need for intraoperative image intensification, with the ability to obtain AP, lateral, plateau, and

oblique views. A fully radiolucent table is preferred.
- If arthroscopy is to be used, either a well-padded leg holder or post should be available.

## REDUCTION TECHNIQUES

- Reduction of tibial plateau fractures can be attained either by direct or indirect means. Direct reduction of the articular surface and tibial metaphysis can be performed either open (5,7,51,53) or by semiopen means (16,23,40).
- Indirect reduction techniques have been described in the literature (14,15,27,29,35). These methods use ligamentous and capsular attachments to the fracture fragments to indirectly reduce the joint surface and align the tibial shaft (Fig. 23.12). Indirect reduction techniques have the advantage of minimal soft-tissue stripping, thus protecting the blood supply to the bone fragment (35). However, ligamentotaxis does not work on centrally depressed articular fragments. For badly comminuted fractures, use of a femoral distractor with threaded pins placed into the femoral condyles and the tibial shaft can aid in fracture reduction (29,35,53).

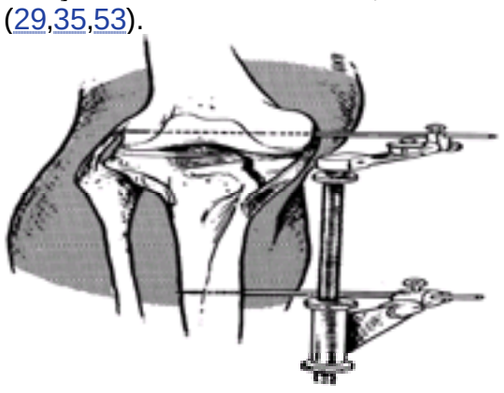

***Figure 23.12.*** The use of the femoral distractor to provide indirect reduction of a split fracture component.

- For unicondylar fractures, place the femoral distractor on the side of the fracture. For bicondylar fractures, use two femoral distractors or one distractor and an external fixator. Keep the threaded pins parallel to the joint surface.
- An alternative method for severe bicondylar fractures is to place the pins anteriorly, superior to the patella on the femoral side and distal to the fracture in the tibia. With this technique, however, the knee cannot be flexed (35). Spanning external fixators can be used in much the same way as the femoral distractor (57). The key is to place the pins far enough away from the fracture site so as not to compromise future reconstructive options (35).
- If segments of articular surface remain depressed following attempted indirect reduction or in a pure depression fracture, make a cortical window in the metaphysis, the site of which depends on the location of the depression (Fig. 23.13). Elevate the entire osteochondral segment en masse using bone tamps and punches (15,29,51,52).

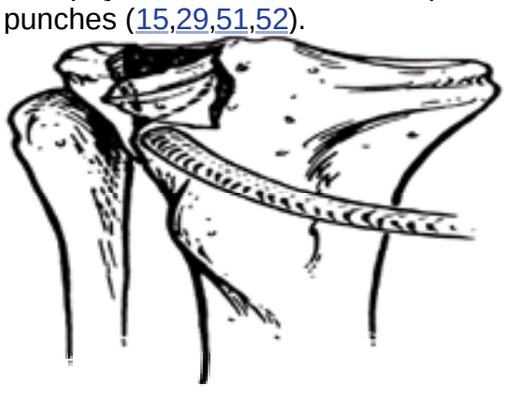

***Figure 23.13.*** Depressed segments of articular surface can be elevated using a curved tamp inserted through the anterior fracture line as shown here or through a cortical window.

- Following articular surface elevation, fill the void left by impacted cancellous bone with either autogenous bone graft, allograft, or bone graft substitute (27,29,51,57).

## ARTHROSCOPY

The use of arthroscopy has increased steadily since the early 1980s. Arthroscopic management of tibial plateau fractures is generally indicated for Shatzker Type I, II, and III fractures (16,29,40). The role of arthroscopy in these fractures is twofold: (a) as a diagnostic tool to assess the articular surface, menisci, and the cruciate ligaments accurately and (b) as an adjunct to treatment. For Type I fractures, pure splits that may be treated with closed reduction and percutaneous screw placement, arthroscopy permits debridement of loose joint fragments and repair of meniscal damage in addition to direct assessment of the articular reduction. For Type II and III fractures, depressed segments can be elevated through a cortical window under image intensification and confirmed visually with the arthroscope (16,29).

## FRACTURE FIXATION

### *Plates and Screws*

Plates have two functions when they are used for the treatment of tibial plateau fractures. They can act as a buttress against shear forces or function in a capacity to neutralize rotational forces. Owing to the tenuous soft-tissue envelope around the proximal tibia, thinner plates have been advocated. Recently, percutaneous plating, which is a more biologic approach, has been described (30a,47a) (Fig. 23.14). In this technique, the plate is slid subcutaneously without soft-tissue stripping. Some authors advise against double plating of the tibial plateau due to an increase in soft-tissue complications (58). These complications are more likely caused by the higher energy injury, resulting in greater soft-tissue injury than from double plating (55). One may need to use double plates for a bicondylar fracture if the far cortex has an unstable fracture pattern; the use of low-profile plates with minimal soft-tissue devitalization through a separate incision is recommended. In such cases, plan to use the major plate on the most unstable or displaced side, using a much smaller plate and very limited dissection on the opposite side. An alternative is to use adjunctive external fixation on the opposite side rather than a plate; however, pin tract infection is a risk.

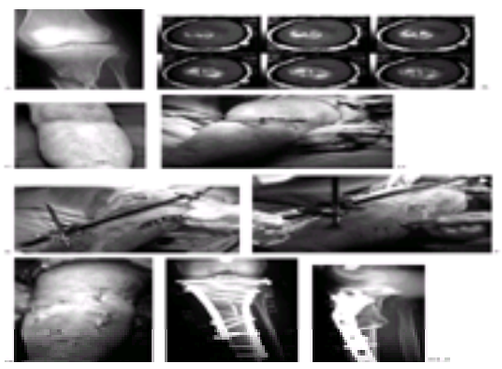

***Figure 23.14.*** A 45-year-old woman who sustained a Schatzker type VI fracture in addition to a closed femur fracture. **A:** Initial radiograph. **B:** CT scan. **C:** The swollen limb with evidence of healing blisters. **D:** Reduction of the articular surface and placement of 7.3 cannulated screws. **E:** A femoral distractor is used to align the tibial shaft followed by subcutaneous insertion of a tibial buttress plate. **F:** Screws are placed percutaneously under image intensification. **G:** Final appearance of the limb after placement of a second plate subcutaneously on the medial side. **H:** Postoperative radiographs.

### *External Fixation*

External fixation can involve either half-pins or thin wire, or a combination of the two (hybrids). External fixators may be placed across the fracture such that thin wires, with or without olive beads, capture fracture fragments or across the knee joint in a bridging fashion to make use of ligamentotaxis (38). The key is placement of the pin or wire 10 to 14 mm below the articular surface to avoid penetration of the synovial recess posteriorly. This approach will help minimize the development of a septic joint from a pin tract infection (46). Anatomic studies have shown cadavers to have some communication between the tibial-fibular joint and the knee joint. Thus a transfibular wire could potentially seed the knee joint if a pin tract infection were to develop (46). Place smooth wires parallel to the articular surface and below any percutaneously placed screws (Fig. 23.15). If an Ilizarov construct is used, place half pins and wires into the intact tibial diaphysis below the fracture (13,16,38,57) (Fig. 23.16).

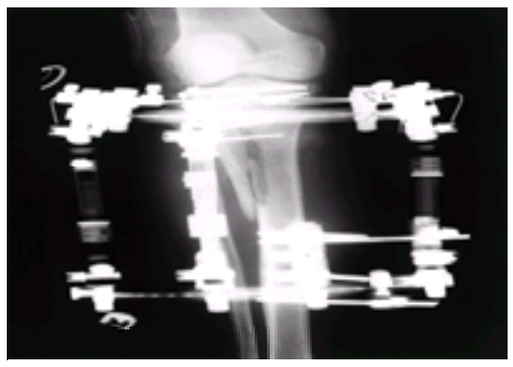

***Figure 23.15.*** Example of thin wires placed below percutaneously inserted lag screws.



***Figure 23.16.*** The use of an Ilizarov external fixator to stabilize a Schatzker VI fracture.

External fixators that span the knee joint may be either half-pin or smooth wire. These constructs can be used temporarily to allow the soft tissue envelope time to heal (Fig. 23.17). In certain situations, however, spanning external fixators used in conjunction with limited internal fixation may be considered definitive fixation and left on for a longer period of time.



***Figure 23.17.*** A patient with an open tibial plateau fracture with extensive comminution is shown. A bridging external fixator was applied for 10 days until the soft tissues allowed for definitive fixation.

## OPEN REDUCTION AND FIXATION OF A TYPICAL SPLIT-CENTRAL DEPRESSION FRACTURE OF THE LATERAL PLATEAU

- Position the patient supine on a radiolucent table, as described earlier.
- Make a longitudinal skin incision just lateral to the midline from 2 cm proximal to the joint line and long enough to expose the distal extent of the fracture.
- Make a inframeniscal incision through the meniscotibial ligament and continue this longitudinally distalward along the anterior border of the anterior compartment to identify the vertical fracture in the lateral condyle.
- Expose the lateral condyle just enough to apply the smallest buttress plate that will be strong enough to support the plateau.
- Open the fracture site through this exposure and hinge the lateral condylar fragment laterally enough to visualize the depressed central fragment.
- Elevate the central fragment to slightly higher than an anatomic position and pack an appropriate graft beneath it to maintain its position. Preliminary fixation with Kirschner wires may be necessary.
- Now reduce the main condylar fragment into anatomic position and secure it with a bone holding forceps. The central fragments should now be aligned anatomically because they tend to subside slightly during these maneuvers. If not, make adjustments as necessary.
- Now apply a buttress plate of your choice with cancellous lag screws through the superior most holes and cortical screws more distally. Confirm the result with radiographs (Fig. 23.18).

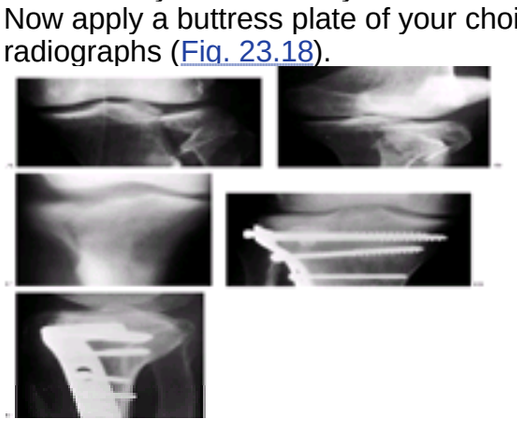

***Figure 23.18.*** **A:** Type 2 fracture (Schatzker) of the lateral tibial plateau, AP view is shown. **B:** Oblique view. **C:** AP tomogram showing the split in the plateau and the depressed central fragment. **D:** Postoperative AP radiograph after elevation of the central fragment, grafting with corraline hydroxyapatite, and fixation with a

buttress plate. **E:** Postoperative lateral view.

- Create a tension-free layered closure over a suction drain.

## POSTOPERATIVE CARE

Following surgical treatment, protect the knee in a hinged brace. Many authors have reported the benefits of early range of motion to the knee following tibial plateau fracture (1,18,47). Continuous passive motion from 0° to 30° may be started on postoperative Day 1 and increased as tolerated. Physiotherapy should consist of active and active-assisted range of motion to the knee, isometric quadriceps strengthening, and protected weight bearing. Progressive weight bearing depends on fracture healing. Some authors allow full weight bearing in cases in which there is an isolated lateral plateau fracture and in which a well-molded cast-brace is used to unload the affected compartment (11,49). For patients treated with external fixation, dynamization may be delayed 4 to 6 weeks following surgery and the fixator may be removed on radiographic evidence of fracture healing.

## PITFALLS AND COMPLICATIONS

Complications in the treatment of tibial plateau fractures can occur whether operative or nonoperative management is chosen. Complication rates of 10% to 12% (14,51,52) have been reported for patients treated nonoperatively and 1% to 54% (5,24,47,57) for those treated with surgery. Most complications that occur with nonoperative treatment are related to prolonged recumbency and include thromboembolic disease and pneumonia (14,27,47). In addition, peroneal nerve palsy has been reported to occur with cast-brace treatment (14). Finally, pin tract infection can occur in patients if tibial pin skeletal traction is chosen.

The most severe complication that occurs with operative treatment of tibial plateau fractures is infection. Infection rates range from 1% to 38% (5,24,31,57) depending on which technique is employed. Superficial infections occur in 3% to 38% of cases (5,24,47,57) and deep wound infections from 2% to 9.5% (5,24,57). Skin slough is a risk factor for late infection and is of particular concern in the proximal leg because of exposure of ligaments, bone, and implants. Factors relating to skin slough include the severity of the initial injury, poor surgical timing and improper soft-tissue techniques with extensive osseous devitalization and use of bicondylar implants (58).

Thromboembolic complications can occur following operative treatment of tibial plateau fractures (4). Deep vein thrombosis rates are reported to be 5% to 10% (5,31), with pulmonary embolus occurring in 1% to 2% of patients (5,24,31). Deep vein thrombosis prophylaxis includes the use of compression stockings, low-molecular weight heparin or coumadin; aggressive treatment of suspected pulmonary embolus is critical.

Late complications include painful hardware, loss of fixation, posttraumatic arthritis, and malunion. The most common late complication following operative treatment of tibial plateau fractures is so-called symptomatic hardware. The reported incidence is between 10% to 54% (4,27,57). Hardware may be removed usually 1 year following initial treatment. Loss of fixation is a complication that can be avoided by proper preoperative planning. Improper use of implants and the failure to use bone graft or bone graft substitutes adequately to buttress the articular surface may lead to loss of reduction or backout of hardware (loosening of screws or failure of fixation) (30,51). Posttraumatic arthrosis may result from the initial chondral damage or be related to residual joint incongruity (56). Good functional results can be obtained in the face of poor radiographic results, however, and they may be due to the preservation of the meniscus and its ability to bear a substantial portion of the load of the lateral compartment (12,20,27,32,56). Malunion can occur either intraarticularly because of inadequate reduction or loss of reduction or with respect to the articular surface to the tibial shaft. Patients with malunions with residual varus or valgus of greater than 10° have been shown to have a higher incidence of poor long-term functional results (21). Rare complications include popliteal artery lacerations, osteonecrosis, and nonunion (19,53).

## AUTHORS' PERSPECTIVE

We prefer to use the Shatzker classification to determine the choice of treatment. Our indications for surgery in addition to the absolute indications of open fracture, compartment syndrome, and vascular injury include instability of the nearly extended knee of greater than 10° compared with the uninvolved knee and unacceptable articular incongruence. The timing of surgery depends on the condition of the soft tissue. Early postinjury swelling represents hematoma. Within 8 to 12 hours following injury, the soft tissues become edematous. Fracture blisters may develop and are an indication of soft-tissue compromise. Earlier surgery in high-energy injuries through compromised soft tissues is inadvisable and may lead to a higher incidence of wound problems. Whenever possible, we prefer to use indirect reduction techniques with pointed bone forceps, a femoral distractor, and cortical bone windows, as described above.

Type I split fractures can generally be reduced closed with a large tenaculum forceps (29,52,54). Once reduced, we stabilize this fracture pattern with percutaneous 6.5 to 7.3 mm cancellous lag screws with washers (Fig. 23.19) (30,51). Recent biomechanical studies have shown no advantage to the addition of a buttress plate or an antiglide screw in the treatment of this fracture pattern in nonosteopenic bone (28). A thin plate may be helpful in patients with osteopenia.

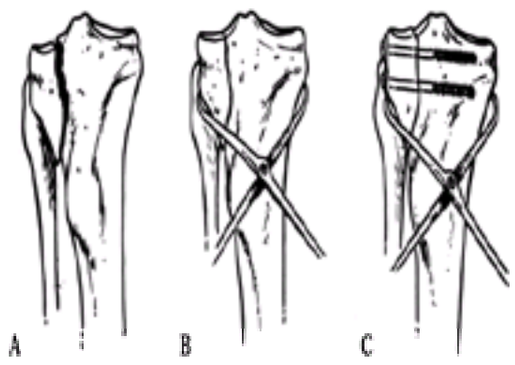


***Figure 23.19.*** **A:** Schatzker type I fracture is shown. **B:** Reduction of the split component with a tenaculum clamp. **C:** Placement of partially threaded lag screws across the fracture site.

Type II fractures have a depressed articular segment in addition to the split fragment. We have generally been dissatisfied with the quality of reduction achieved with indirect reduction and percutaneous fixation and usually perform a formal open reduction, as described above. We place 6.5 to 7.3 mm lag screws across the reduced split fracture fragments. Biomechanical testing has shown that subchondral Kirschner wires positioned as a horizontal array or cluster significantly enhance the load-bearing capacity of the articular surface (3). Therefore, we place three to four 3.5 mm cortical screws in the subchondral region, spread from anterior to posterior like leaves of a raft to support the articular surface. Because type II fractures tend to occur in older patients, these fractures may also require a thin buttress plate (30,52,54).

Type III fractures are pure depressions that we treat by elevation through cortical fenestrations (Fig. 23.20) and support with subchondral screws and bone graft. We view the articular reduction with an arthroscopy.

***Figure 23.20.*** A Schatzker type III fracture treated by elevation of the depressed segment through a cortical window. In this case, the fenestration was made medially to facilitate placement of the curved tamp.

For type IVa and V fractures we use indirect reduction using a femoral distractor. We usually reduce type IVb fractures open. Displaced type V fractures (bicondylar) may require two femoral distractors. If a closed reduction is not possible, these fractures are reduced open. Internal fixation of fracture types IV to VI generally requires the use of plate and screws. Type IV fractures require a medial buttress plate to counteract the shear forces acting on the medial plateau. We stabilize low-energy type V fractures with medial and lateral plates (51,55). We treat higher energy injuries with comminution with a combination of limited internal fixation and external fixation (13,34,57). Type VI fractures have metaphyseal-diaphyseal dissociation. Following articular reconstruction, we stabilize the tibial shaft using either a single plate, double plates, a single plate and a contralateral two-pin external fixator or a thin wire fixator. If the fracture is transverse, a single plate will suffice. Oblique fracture lines exiting the opposite cortex require a second plate or external fixator to resist shear forces. When we use a second plate we use minimal dissection (Fig. 23.21) and a thin plate (one half or one third tubular).

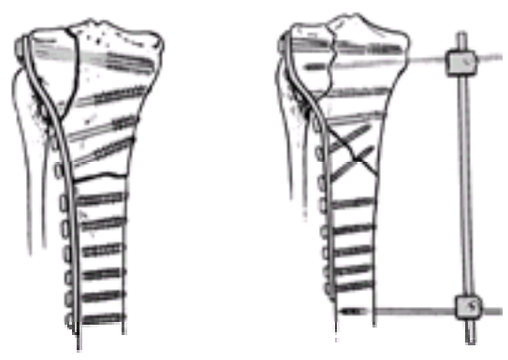

***Figure 23.21.*** Treatment of a Schatzker type VI fracture with either a plate (for a transverse shaft fracture) or a plate and a 2-pin ex-fix (for an oblique shaft fracture).

For higher-energy injuries with a compromised soft-tissue envelope, we prefer to use a temporary spanning external fixator. The spanning external fixator is used to allow the soft tissues to heal in the critically ill patient and in those with severe soft-tissue injuries. This can be converted to internal fixation or a hybrid frame as soft tissues allow or maintained as definitive treatment.

We thoroughly debride and irrigate open joint fractures to reduce bacterial contamination, and then perform open reduction and limited internal fixation of the articular surface. We perform repeat irrigation and debridement at 48 hours and as often as necessary thereafter. Injuries with extensive soft-tissue devitalization are temporarily spanned with an external fixator and converted later to a hybrid fixator or definitive internal fixation once the soft tissues have healed. There is no consensus on how long antibiotics should be continued following open joint injury, but we continue antibiotics for 48 hours following final debridement and wound closure over suction drainage tubes.

## CHAPTER REFERENCES

Each reference is categorized according to the following scheme: *, classic article; #, review article; !, basic research article; and +, clinical results/outcome study.


+ 1. Apley AA. Fractures of the Lateral Tibial Condyle Treated by Skeletal Traction and Early Mobilization. *J Bone and Joint Surg* 1956;38B:699.

+ 2. Benirshke SK, Agnew SG, Mayo KA, et al. Immediate Internal Fixation of Open Complex Tibial Plateau Fractures: Treatment by a Standard Protocol. *J Orthop Trauma* 1992;6:78.

! 3. Beris AE, Soucocos PN, Glisson RR, et al. Load Tolerance of Tibial Plateau Depressions Reinforced with a Cluster of K-wires. *Bull Hosp Jt Dis* 1996;55:12.

+ 4. Biyani A, Reddy NS, Chaudhury J, et al. The Results of Surgical Management of Displaced Tibial Plateau Fractures in the Elderly. *Injury* 1995;26:291.

+ 5. Blokker CP, Rorabeck CH, Bourne RB. Tibial Plateau Fractures: An Analysis of the Results of Treatment in Sixty Patients. *Clin Orthop* 1984;182:193.

+ 6. Brophy DP, O'Malley M, Lui D, et al. MR Imaging of Tibial Plateau Fractures. *Clin Radiol* 1996;51:873.

+ 7. Burri C, Batzke G, Coldewy J, Muggler E. Fractures of the Tibial Plateau. *Clin Orthop* 1979;138:84.

+ 8. Chan PS, Klimkiewicz JJ, Luchetti WT, et al. Impact of CT Scan on the Treatment Plan and Fracture Classification of Tibial Plateau Fractures. *J Orthop Trauma* 1997;11:484.

+ 9. Collins DN, Temple SD. Open Joint Fractures: Classification and Treatment. *Clin Orthop* 1989;243:48.

* 10. Cotton FJ, Berg R. Fender Fracture of the Tibia at the Knee. *N Engl J Med* 1929;201:989.

+ 11. DeCoster TA, Nepola JV, El-Khoury GY: Cast Brace Treatment of Proximal Tibia Fractures: A Ten Year Follow Up Study. *Clin Orthop* 1988;231:196.

+ 12. Delmarter RB, Hohl M, Hopp E. Ligament Injuries Associated with Tibial Plateau Fractures. *Clin Orthop* 1990;250:226.

+ 13. Dendrinos GK, Kontos S, Katsenis D, Dalas A. Treatment of High Energy Tibial Plateau Fractures by the Ilizarov Circular Fixator. *J Bone Joint Surg* 1996;78B:710.

+ 14. Dewilius PJ, Connolly JF. Closed Reduction of Tibial Plateau Fractures: A Comparison of Functional and Roentenographic End Results. *Clin Orthop* 1988;230:116.

+ 15. Dewilius PJ, Rangitsch MR, Colville MR, Woll TS. Treatment of Tibial Plateau Fractures by Limited Internal Fixation. *Clin Orthop* 1997;339:47.

+ 16. Gaunche CA, Markman AW. Arthroscopic Management of Tibial Plateau Fractures. *Arthroscopy* 1993;9:467.

* 17. Hohl M. Tibial Condylar Fractures. *J Bone Joint Surg* 1967;49A:1455.

* 18. Hohl M, Luck JV. Fractures of the Tibial Condyle: A Clinical and Experimental Study. *J Bone Joint Surg* 1956;38A:1001.

# 19. Hohl M, Moore TM. Articular Fractures of the Proximal Tibia. In: Evarts CM, ed. *Surgery of the Musculoskeletal System.* New York: Churchill-Livingstone, 1993: 3471.

+ 20. Honkonen SE. Degenerative Arthritis after Tibial Plateau Fractures. *J Orthop Trauma* 1995;9:273.

+ 21. Honkonen SE, Jarvivin MJ. Classification of Fractures of the Tibial Condyles. *J Bone Joint Surg* 1992;74B: 840.

# 22. Hoppenfeld S, de Boer P. The Knee. In: Hoppenfeld S, de Boer P, eds. *Surgical Exposures in Orthopaedics: The Anatomic Approach.* Philadelphia: JB Lippincott, 1994:429.

+ 23. Jennings JE. Arthroscopic Management of Tibial Plateau fractures. *Arthroscopy* 1985;1:160.

+ 24. Jensen DB, Rude C, Duus B, Bjern-Neilsen A. Tibial Plateau Fractures: A Comparison of Conservative and Surgical Treatment. *J Bone Joint Surg* 1990;72B:49.

+ 25. Karas EH, Weiner LS, Yang EC. The Use of an Anterior Incision of the Meniscus for Exposure of tibial Plateau Fractures Requiring Open Reduction and Internal Fixation. *J Orthop Trauma* 1996;10:243.

* 26. Kennedy JC, Bailey WH. Experimental Tibial Plateau Fractures. Studies of Mechanism and a Classification. *J Bone Joint Surg* 1968;50A:1522.

+ 27. Keough P, Kelly C, Cashman WF, et al. Percutaneous Screw Fixation of Tibial Plateau Fractures. *Injury* 1992;23:388.

! 28. Koval KJ, Polatsch D, Kummer FJ, et al. Split Fractures of the Lateral Tibial Plateau: Evaluation of Three Fixation Methods. *J Orthop Trauma* 1996;10:304.

+ 29. Koval KJ, Sanders R, Borrelli J, et al. Indirect Reduction and Percutaneous Screw Fixation of Displaced Tibial Plateau Fractures. *J Orthop Trauma* 1992;6:340.

# 30. Koval KJ, Helfet D. Tibial Plateau Fractures: Evaluation and Treatment. *J Am Acad Orthop Surg* 1995;3:86.

+30a. Krettek C, Niclaw T, Schandelmaier P, et al. Minimally Invasive Osteosynthesis for a Distal Femur Fracture Using a Parapatellar or Percutaneous Approach and Retrograde Plate Placement. Presented at AAOS Meeting, 1999, Anaheim, CA.

# 31. Lachiewicz PF, Funcik T. Factors Influencing the Results of Open Reduction and Internal Fixation of Tibial Plateau Fractures. *Clin Orthop* 1990;259:210.

+ 32. Lansinger O, Bergman B, Korner L, Anderson GBJ. Tibial Condylar Fractures: A Twenty Year Follow Up. *J Bone Joint Surg* 1986;68A:13.

+ 33. Lobenhoffer P, Gerich T, Bertram T, et al. Particular Posteromedial and Posterolateral Approaches for the Treatment of Tibial Head Fractures. *Unfallchirurgie* 1997;100:957.

+ 34. Marsh JL, Smith ST, Do TT. External Fixation and Limited Internal Fixation for Complex Fractures of the Tibial Plateau. *J Bone Joint Surg* 1995;77A:661.

# 35. Mast J, Jakob R, Ganz R. Reduction with Distraction. In: Mast J, Jakob R, Ganz R, eds. *Planning and Reduction Technique in Fracture Surgery.* Berlin: Springer-Verlag, 1989:130.

+ 36. Moore TM. *Fracture Dislocation of the Knee.* Clin Orthop 1981;156:128.

+ 37. Moore TM, Harvey JP. Roentenographic Measurement of Tibial Plateau Depression Due To Fracture. *J Bone Joint Surg* 1974;56A:155.

+ 38. Morandi MM, Landi S, Kilaghbian V, Randelli P. Shatzker Type VI Tibial Plateau Fractures Treated with the Ilizarov External Fixator. *Bull Hosp Jt Dis* 1997;56:46.

# 39. Müauller ME. The Comprehensive Classification of Long Bones. In: Müauller ME, Allgöauwer M, Schneider R, Willenegger H, eds. *Manual of Internal Fixation, 3rd ed.* Berlin: Springer-Verlag, 1995:118.

+ 40. O'Dwyer KJ, Bobic VR. Arthroscopic Management of Tibial Plateau Fractures. *Injury* 1992;23:261.

+ 41. Padanilam TG, Ebraheim NA, Frogameni A. Meniscal Detachment to Approach Lateral tibial Plateau Fractures. *Clin Orthop* 1995;314:192.

+ 42. Perry CR, Evans LG, Rice S, et al. A New Surgical Approach to Fractures of the Lateral Plateau. *J Bone Joint Surg* 1984;66A:1236.

+ 43. Rafii M, Firoonza H, Golimbu C, Bonamo J. Computed Tomography of Tibial Plateau Fractures. *Am J Roentgenol* 1984;142:1181.

+ 44. Rassmussen PS. Tibial Condylar Fractures as a Cause of Degenerative Arthritis. *Acta Orthop Scand* 1972;43:566.

* 45. Rassmussen PS. Tibial Condylar Fractures: Impairment of Knee Joint Stability as an Indication for Surgical Treatment. *J Bone Joint Surg* 1973;55A:1331.

+ 46. Reid JS, Vanslyke M, Moulton MJR. Safe Placement of Proximal Tibial Transfixtion Wires with Respect to Intracapsular Penetration. Presented at the Annual Meeting of the OTA. September 29, 1995. Tampa, FL.

+ 47. Roberts JM. Fractures of the Condyles of the Tibia. *J Bone Joint Surg* 1968;50A:1505.

+47a. Ruedi TP, Somner C, Leutenegger A. New Techniques in Indirect Reduction of Long Bone Fractures. *Clin Orthop* 1998;347:27.

# 48. Schulak DJ, Gunn DR. Fractures of the Tibial Plateau: A Review of the Literature. *Clin Orthop* 1975;109: 166.

+ 49. Scotland T, Wardlaw D. the Use of Cast Bracing as Treatment for Fractures of the Tibial Plateau. *J Bone Joint Surg* 1981;63B:575.

+ 50. Segal D, Mallik AR, Wetzler MJ, et al. Early Weightbearing of Lateral Tibial Plateau Fractures. *Clin Orthop* 1993;294:232.

* 51. Schatzker J, McBroom R, Bruce D. The Tibial Plateau Fracture: The Toronto Experience 1968–1975. *Clin Orthop* 1979;138:94.

# 52. Schatzker J. Fractures of the Tibial Plateau. In: Shatzker J, Tile M, eds. *The Rationale of Operative Fracture Care.* Berlin: Springer-Verlag, 1987:279.

# 53. Schatzker J. Tibial Plateau Fractures. In: Browner BD, Jupiter JB, Levine AM, Trafton PG, eds. *Skeletal Trauma.* Philadelphia: WB Saunders, 1992:1745.

# 54. Szyszkowitz R. Patella and Tibia. In: Müauller ME, Allgöauwer M, Schneider R, Willenegger H, eds. *Manual of Internal Fixation, 3rd ed.* Berlin: Springer-Verlag, 1995:554.

+ 55. Toulatios AS, Xenakis T, Soucacos PK, Soucacos PN. Surgical Management of Tibial Plateau Fractures. *Acta Orthop Scand* 1997;75:92.

+ 56. Volpin G, Dowd GSE, Stein H, Bently G. Degenerative Arthritis after Intraarticular Fractures of the Knee. *J Bone Joint Surg* 1990;72B:634.

+ 57. Weiner LS, Kelley M, Yang E, et al. The Use of Combination Internal Fixation and Hybrid External Fixation in Severe Proximal Tibial Fractures. *J Orthop Trauma* 1995;9:244.

+ 58. Young MJ, Barrack RL. Complications of Internal Fixation of Tibial Plateau Fractures. *Orthop Rev* 1994;2:149.

# CHAPTER 24

# FRACTURES OF THE SHAFTS OF THE TIBIA AND FIBULA

*Michael W. Chapman*

**M. W. Chapman:** Department of Orthopaedic Surgery, University of California Davis, Sacramento, California, 95817.

Goals of Treatment
Mechanism of Injury and Pathophysiology
Classification
Principles of Treatment
Nonsurgical Treatment
External Fixation
Intramedullary Nailing
Plate and Screw Fixation
Open Fractures
Amputation
Techniques of Nonoperative and Surgical Treatment
Emergency Care
Skeletal Traction
Closed Reduction and Cast Immobilization
Fracture Bracing
Pins and Plaster
External Fixation
Anatomic Considerations
Mechanical Considerations
Surgical Techniques
Unilateral Simple AO Fixator
Hoffmann II
Unilateral Frame for Fixation of Tibial Shaft Fractures
Semicircular Frame for Proximal Tibial Shaft Fractures
Postoperative Care
Pitfalls and Complications
Intramedullary Nailing
Positioning of the Patient
Setup for Intramedullary Nailing of the Tibia on a Chick-Langren Fracture Table
Nailing on a Regular Operating Table
Lottes Nailing
Ender Nails
Reamed and Nonreamed Locked Intramedullary Nailing
Reamed Technique
Unreamed Technique
Screw Fixation
Plate Fixation
Postoperative Care
Pitfalls and Complications
Infection
Loss of Skin and Soft Tissues
Neurovascular Injury
Compartment Syndrome
Fractures of the Shaft of the Fibula
Author's Perspective
Chapter References

Of all the long bones, the tibia and fibula have the highest incidence of diaphyseal fractures. These fractures are often caused by high-energy trauma. Because the shaft of the tibia is subcutaneous throughout its length and may have a diminished blood supply, severe complications and major disability are common outcomes, particularly when the fractures are open.

Fractures of the tibia and fibula can range from completely undisplaced fractures with minimal soft-tissue damage, to traumatic amputations. For this reason, the decision tree for treatment is complex. It must take into account many factors, including the patient's overall health, associated injuries, and the multiple factors bearing on the fracture itself, including the extent of soft-tissue injury, associated injuries of the thigh, knee, and foot, and the pattern of injury to the bone itself. Treatment is equally varied, ranging from simple walking-cast immobilization through complex procedures required to replace lost bone, soft tissues, and neurovascular structures.

It will not be possible in the context of this chapter to explicate all available techniques, but the general principles of soft-tissue management, closed treatment, external fixation, intramedullary nailing, and plate and screw fixation will be covered in such a way that the reader will be able to pursue other variations in treatment not discussed in this text. There is much material available in other chapters in *Orthopaedic Surgery*, as will be noted.

## GOALS OF TREATMENT

In the treatment of closed and open fractures of the shaft of the tibia and fibula, patients and physicians would like to achieve complete union in a reasonable period of time (less than 6 months) without complications. Alignment should be maintained. In nearly all patients, as much as 1 cm of shortening and 5° or less of angular deformity or malrotation are not significant. Preexisting tibia vara or valgum or toe-in or toe-out influence the significance of greater degrees of malalignment. External rotation is better tolerated than internal rotation.

As much as 10° of malalignment is compatible with good function in most patients. Merchant and Dietz (91), in a long-term follow-up (average, 29 years) of fractures of the tibial and fibular shafts, found no predisposition to arthritis in the knee or ankle, regardless of the degree of residual angulation. As the location of the deformity approaches the ankle or knee, however, malalignment results in maldistribution of articular surface pressures that may predispose a patient to premature osteoarthrosis (137,138).

## MECHANISM OF INJURY AND PATHOPHYSIOLOGY

Fractures of the tibia can result from minor repetitive trauma below the threshold of injury required for fracture, resulting in a stress (fatigue) fracture (see Chapter 96). They can also be a result of amputations caused by massive, high-energy direct trauma, such as occurs in motorcycle accidents. Fractures can be caused by indirect trauma, where the force is transmitted through the bone by twisting or bending, or by direct forces from direct impact against an object or from a penetrating missile.

The prognosis is determined as much by the severity of soft-tissue injury as by the type of fracture, and both depend on the amount of energy absorbed by the limb at the time of injury. Most fractures from indirect trauma, such as twisting injuries occurring in sports, generally result in low to medium absorption of energy, whereas high-speed motor-vehicle accidents and high-velocity missiles cause direct trauma and severe injury due to the high absorption of energy.

Slow rates of loading are characteristic of low-energy injuries and result in limited soft-tissue injury and simple fracture patterns. High rates of loading result in more energy absorption prior to fracture, thereby leading to explosive-type fractures that cause much more soft-tissue trauma and resultant severe comminution. Combinations of loading mechanisms can occur. In nearly all cases, direct trauma results in worse injuries than indirect trauma. If it is possible to obtain a good history,

a thorough knowledge of the mechanism of injury is important in classifying the fracture, which may bear directly on the choice of treatment.

Spiral fractures are caused by indirect loading in torsion, such as occurs in skiing. These are generally low-energy injuries with a good prognosis. High-energy, high-velocity torsional injuries result in comminution, which signals a worse prognosis, particularly if marked displacement is present. Short oblique and transverse fractures are generally caused by bending, which requires direct contact with the bone at or near the fracture site. These generally are worse injuries than spiral fractures and are often the result of high-energy trauma.

Crush injuries from direct trauma such as in motorcycle accidents or in the case of pedestrians being struck by vehicles are nearly always high-energy injuries with severe soft-tissue injury and severe comminution. In the absence of a good history, the mechanism of injury can often be inferred by the pattern of the fracture. Transverse or short oblique fractures, or comminuted fractures associated with fractures of the fibula with wide displacement, indicate disruption of the interosseous membrane and severe soft-tissue injury (22).

## CLASSIFICATION

Classification systems of fractures enable us to communicate more accurately with each other and to make better diagnostic and therapeutic decisions, and they facilitate comparison of clinical and laboratory research results. The difficulty with classification schemes is that to be truly useful they must take into account many different and occasionally unrelated factors, some of which may be difficult to quantify. More important, interobserver reliability is questionable, making the comparison between studies somewhat unreliable (21).

Using the Gustilo and Anderson classification for open fractures, probably the most widely understood and accepted classification for fractures in the world today, Brumback (21) asked the attendees at the 1992 meeting of the Orthopaedic Trauma Association (OTA), a group of highly experienced and skilled trauma surgeons, to classify 12 open tibial fractures. The interrater reliability was only 60%. It is useful to keep this fact in mind while reviewing various classification schemes.

In classifying fractures of the tibia, various authors have listed the factors in Table 24.1 as important to the treatment and outcomes in tibial fractures. Ellis (36) in 1958, and Nicoll (100) in 1964 both used a number of these factors to establish simple classification systems that predicted the time of union and incidence of delayed union and nonunion (Table 24.2, Table 24.3). They, as well as Edwards (35), identified the severity of the soft-tissue injury as probably the most important prognostic factor in the outcome of fractures of the tibia and fibula.

| |
|---|
| Mechanism of injury |
| Severity of soft-tissue injury |
| Closed versus open |
| Neurovascular injury |
| Compartment syndrome |
| Pattern of fracture |
| Location |
| Displacement |
| Comminution |
| Fibular fracture |
| Bone loss |
| Complications |
| Infection |
| Delayed union |
| Nonunion |
| Malunion |
| Concomitant injuries |
| Foot |
| Knee |

***Table 24.1. Factors Important to Treatment and Outcomes in Tibial Fractures***

| | | | | Predicted | |
|---|---|---|---|---|---|
| Severity score | Wound | Fracture displacement | Fracture comminution | Time to union | Delayed union (%) |
| Minor | None or small | None | Absent or minor | 10 weeks | 2 |
| Moderate | Small | Complete with angulation | Small | 15 weeks | 11 |
| Major | Major | Complete | Major | 23 weeks | 10 |

Based on closed-cast treatment of 343 fractures.
Delayed union, healing time > 20 weeks.
From Ellis H. The Speed of Healing after Fracture of the Tibial Shaft. *J Bone Joint Surg Br* 1958;40:42, with permission.

***Table 24.2. Ellis Classification***

| Factor | Remarks |
|---|---|
| Endogenous | |
| Age | Applies only to the growth period |
| Site of fracture | Applies only to cancellous end or cortical shaft |
| Comminution | Increases risk of delayed union to 15% |
| Initial displacement | Increases risk of delayed union to 27% |
| Severe soft-tissue injury | Increases risk of delayed union to 12% |
| Soft-tissue interposition | Rare in tibia |
| Gap due to bone loss exceeding 1 cm | Increases risk of delayed union to 65% |
| Ischemic fragment in segmental fracture | Increases risk of delayed union, but numbers too small for statistical quantification |
| Iatrogenic | |
| Infection | Increases risk of delayed union to 60% |
| Distraction | Increases risk, but numbers too small for statistical quantification |
| "Inadequate immobilization" (Watson-Jones) | Increases risk but depends on a definition of *inadequate* |

From Nicoll EA. Fractures of the Tibial Shaft. A Survey of 705 Cases. *J Bone Joint Surg Br* 1964;46:373, with permission.

***Table 24.3. Factors Affecting Rate of Union, Used by Nicoll for Classification***

Henley (54) used the Winquist and Hansen classification system for femur fractures (151) to provide indications for different patterns of cross locking in the use of interlocking nails (Fig. 24.1). I disagree somewhat with Henley's recommendations in that fracture types I, II, and III all have the propensity to be rotationally unstable and to require static locking. In addition, undetected hairline fractures can become displaced, resulting in an unstable pattern that can either shorten or cause malrotation. This issue is addressed in more detail in the discussion under intramedullary nails in this chapter.

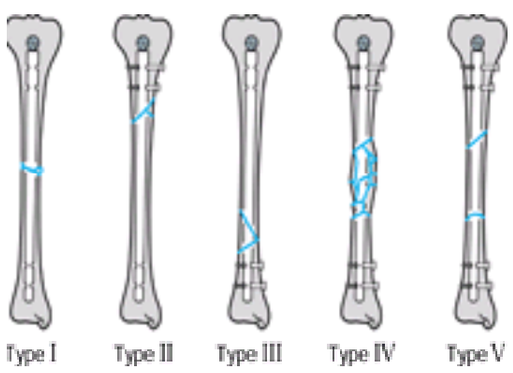

***Figure 24.1.*** Classification of tibial shaft comminution. (From Henley MB. Intramedullary Devices for Tibial Fracture Stabilization. *Clin Orthop* 1989;24, with permission.)

The American Society of Internal Fixation (AO/ASIF) classification, as developed by Müller et al. (99), has enjoyed worldwide acceptance; it was modified by Johner and Wruhs (64), taking into account the mechanism of injury, the initial displacement and comminution, and the severity of soft-tissue injury (Fig. 24.2). This classification was applied primarily to open reduction with plate and screw fixation.

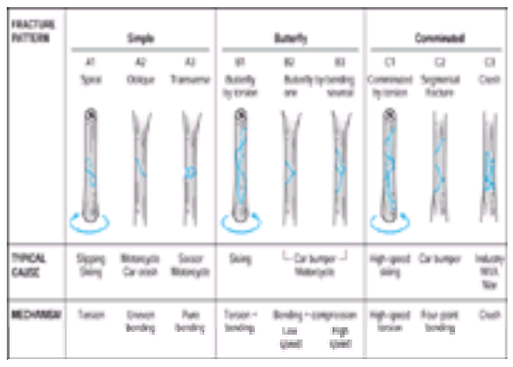

***Figure 24.2.*** Johner and Wruhs' classification system for tibial shaft fractures. (From Johner R, Wruhs O. Classification of Tibial Shaft Fractures and Correlation with Results after Rigid Internal Fixation. *Clin Orthop* 1983;178, with permission.)

In determining prognoses, Johner and Wruhs (64) found that initial displacement was unreliable, as the first radiography was often done after initial reduction and splinting of the fracture, whereas the fracture pattern and degree of comminution had significant influence. Spiral fractures were found usually to be due to lower-velocity indirect injuries and therefore were associated with less soft-tissue injury, whereas bending fracture patterns tended to be associated with higher-energy direct trauma with worse soft-tissue injury. Oni (105) confirmed these observations in a study of manually produced fractures in the rabbit tibia.

The OTA, in cooperation with the AO group, has recently published their classification, which is required for articles published in the *Journal of Orthopaedic Trauma* (106). In the OTA classification, the tibia is divided into its proximal, middle, and distal thirds, and a distinction is made between articular and extraarticular fractures (Fig. 24.3).



***Figure 24.3.*** OTA classification of tibial fractures. (From Orthopaedic Trauma Association Committee for Coding and Classification: Fracture and Dislocation Compendium. *J Orthop Trauma* 1996;10(suppl 1):45, with permission.)

Gustilo and Anderson (48) in 1976 proposed their three-level classification of open fractures, which they subsequently modified to include five levels (47,49). Their classification system is critical to understanding the treatment of open fractures of the tibia and is discussed in detail in Chapter 12. Grading of the degree of soft-tissue injury in closed fractures of the tibia is equally important, because the deep soft-tissue injury may be much more severe in a fracture, as a result of crushing of the midshaft tibia, compared with a minor type I open fracture occurring from indirect trauma, such as a spiral fracture in skiing. Tscherne and Gotzen (144) developed a classification of closed injuries, which is helpful in looking for potential complications and in deciding treatment (Table 24.4).

| Classification | Mechanism of injury | Skin injury | Muscle injury | Major neurovascular injury | Fracture pattern |
|---|---|---|---|---|---|
| 0 | Indirect | Absent or negligible | Negligible | None | Simple and undisplaced |
| 1 | Indirect | Superficial abrasion | Mild contusion | None | Simple with mild to moderate displacement |
| 2 | Direct | Deep contaminated abrasion and localized contusion | Deep contusion Impending compartment syndrome | Can be present, but no major arterial injury | Displaced, comminuted, or segmental fracture |
| 3 | Direct | Extensively contused or crushed, closed degloving | Severe muscle damage Decompensated compartment syndrome | Major arterial injury | Severe comminution and displacement |

From Tscherne H, Gotzen L. Fractures with Soft Tissue Injuries. Berlin: Springer-Verlag, 1984, with permission.

***Table 24.4. Classification of Soft-tissue Injuries***

Trafton (142) has attempted to pull all of these classifications together into a simple system that incorporates nearly all factors. To make it easy to use and clinically practical, he modified the systems of Ellis (36) and Edwards (35) with Leach's (77) modification and incorporated the soft-tissue grading systems of Gustilo (48) and Tscherne and Gotzen (144) (Fig. 24.4). This classification has not been verified by published clinical trials. Prior to surgery, it is often difficult to determine the soft-tissue grade; displacement of the tibial fracture itself is not reliable, as has already been pointed out. The pattern of fracture, however, is highly suggestive of the category in which Trafton would classify the fracture. This finding correlates rather well with expected problems or success in healing (Fig. 24.5).

| Fracture Characteristic | Minor | Moderate | Major |
|---|---|---|---|
| Displacement | 0%–50% diameter | >50% | Tibio-fibular diastasis |
| Comminution | 0-minimal | 0 or 1 butterfly fragments | ≥ Two free fragments or segmental |
| Wound | Open grade I; closed grade 0 | Open grade II; closed grade I | Open grades III-V; closed grades II-III |
| Available energy (history) | Low | Moderate | High; crushing |
| Mechanism (fracture pattern) | Spiral | Oblique/transverse | Transverse/fragmented |

*After Ellis[71] and Edwards,[87] with Leach's[88] modification. This system incorporates soft tissue wound grading, after Gustilo[89] and Tscherne,[90] and is proposed as a general means for clinical grading of tibial shaft fractures. Use the factor of greatest severity to grade the fracture.

***Figure 24.4.*** Trafton classification of tibial fractures (From Trafton PG. Tibial Shaft Fractures. In: Browner BD, Jupiter JB, Levine AM, Trafton PG, eds. *Skeletal Trauma*. Philadelphia: WB Saunders, 1992:1771, with permission.)

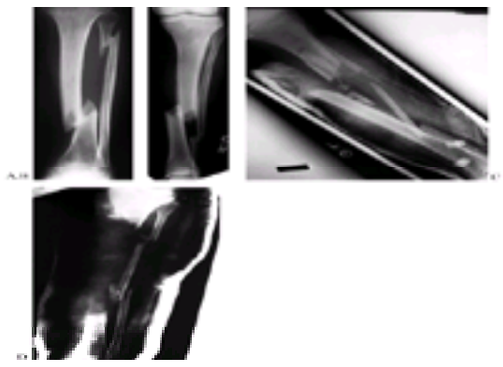

***Figure 24.5.*** Radiographic examples of the four grades of tibial fracture severity. **A:** Minor severity: spiral fracture caused by a simple slip and fall. **B:** Moderate severity: transverse fracture in a pedestrian struck by slowly moving vehicle. **C:** Major severity: comminuted fracture with tibial-fibular diastasis caused by a high-velocity motorcycle crash. **D:** Major severity: near amputation caused by a high-speed motorcycle accident; with segmental bone loss.

## PRINCIPLES OF TREATMENT

A wide variety of nonsurgical and surgical methods of treatment are available. They can be used in isolation or in interesting combinations involving two or more methods, depending on the particular fracture at hand, the age and health of the patient, and other imperatives that might be imposed by associated injuries (Table 24.5).

| |
|---|
| Nonoperative immobilization |
| Cast immobilization |
| Weight-bearing or non-weight-bearing |
| Long-leg, short-leg, or Delher case |
| Cast-brace |
| Short- or long-leg |
| Custom or prefabricated |
| Traction |
| Operative fixation |
| External fixation |
| Pins in plaster |
| Fullpin fixation (Hoffmann) |
| Half-pin fixation |
| Circular fixation with tensioned wires, half-pins, or combination |
| Hybrid fixation |
| Pinless external fixation |
| Intramedullary nailing |
| Flexible nails |
| Nonlocking nails |
| Locking nails, used reamed or nonreamed |
| Locking: none, dynamic, or static |
| Plate and screw fixation |
| Screws alone |
| Rigid plate fixation with compression |
| "Biological" fixation |
| Minimal-contact plates |
| Combinations of the above |
| Sequential use of the above |

***Table 24.5. Methods for Treating Fractures of the Tibia and Fibula***

Regardless of the method chosen, the surgeon must attain the goals listed in Table 24.6 to achieve a satisfactory outcome. Two algorithms for the treatment of shaft fractures of tibia and fibula are seen in Figure 24.6*A*, Figure 24.6*B*.

| |
|---|
| Address systemic issues to ensure survival of the patient and appropriate treatment of associated injuries. |
| Identify and treat vascular injuries that threaten limb survival. |
| Identify and treat (if possible) peripheral nerve injuries while preventing further nerve compromise. |
| Diagnose and treat compartment syndrome. |
| Irrigate, debride, and prevent infection in open fractures. |
| Achieve viable full-thickness soft-tissue coverage early, by 10 days if possible. |
| Restore and maintain the anatomy of the tibia within acceptable limits. |
| Achieve fracture union by 24 weeks or earlier. |
| Restore limb function with good ankle, subtalar joint, and knee motion with muscle strength comparable to normal. |
| Avoid complications, particularly infection, nonunion, and malunion. |

***Table 24.6. Treatment Goals***

***Figure 24.6.*** **A:** Management of soft tissues in open tibial fractures. **B:** Stabilization of adult fractures of the shafts of the tibia and fibula.

## NONSURGICAL TREATMENT

Nonsurgical treatment includes closed reduction and application of various types of casts or fracture braces, either with or without regional or general anesthesia (60,63). Pins in plaster can be included, although functionally this method is a form of external fixation. Ten key articles are detailed in Table 24.7.



***Table 24.7. Results of Treatment of Open and Closed Fractures of the Tibia and Fibula***

The modern era of physiologic treatment of fractures of the tibia with early weight bearing and joint range-of-motion and muscle-strengthening exercises began with experiences of the military during and after the Korean War. Dehne (27,28,29 and 30) and Brown and Urban (20) advocated early weight-bearing treatment of both closed and open fractures of the tibial shaft, applying a total-contact, well-molded, long-leg, weight-bearing cast. Sarmiento (120,121,122,123,124,125 and 126) recognized the advantages of the total-contact socket used for below-knee prostheses and applied these principles to fracture treatment, thus allowing early use of a cast that does not immobilize the knee. He further refined his method to employ custom-built and subsequently off-the-shelf prefabricated fracture braces that could be applied early in stable fractures and later in treatment of less stable patterns.

In his 1995 paper, Sarmiento reported on his experience treating 943 closed tibial shaft fractures with functional braces: He had only a 1% rate of nonunion and a 10% incidence of malunion. Other investigators (Table 24.7) showed nonunion rates of 0% to 4% and malunion rates of only 4% to 5%. This experience confirms closed reduction as the treatment of choice for stable fractures of the tibia (Fig. 24.6*B*).

Unstable fractures patterns (Fig. 24.1, Fig. 24.2, Fig. 24.3, Fig. 24.5, Fig. 24.6*B*) are more difficult to treat by closed means, and recent comparative studies between closed treatment and intramedullary nailing (Table 24.7) show superior results with locked intramedullary nailing (18,57). Bone et al. (18) in 1997, in a prospective randomized series, showed only a 2% incidence of nonunion and malunion in their nailing group as compared with 10% nonunion and 26% malunion rates in their cast group. Hallmarks of instability that would favor locked intramedullary nail fixation in adults and external fixation in children include comminution precluding less than 50% contact between the ends of the proximal and distal fragments, diastasis of the tibia and fibula indicating complete rupture of the interosseous membrane, widely displaced segmental fractures, and fractures with segmental bone loss (Fig. 24.5).

Extremely comminuted fractures in patients who are at high risk for operative intervention, however, or those who could not be expected to cooperate in postoperative care—in particular those who have fracture patterns that preclude external fixation without bridging the knee—may be best treated by nonsurgical means. Most grade I open fractures with stable patterns can be treated with casts, as care of the wound does not require the access permitted by internal or external fixation.

Achieving successful outcomes with cast and fracture brace management is as demanding of the surgeon as operative treatment, and it requires a cooperative patient (108). Frequent follow-up with radiography and frequent cast adjustments or changes may be necessary to permit healing with acceptable alignment and minimal shortening. The details of closed treatment are outlined later in this chapter and in Chapter 10.

## EXTERNAL FIXATION

External fixation has waxed and waned in popularity for the treatment of tibial fractures throughout most of the 20th century. Refinements in external-fixation pin technique, and frame designs with improved mechanics made it popular beginning in the late 1960s through the middle to late 1980s. During that period, external fixation was the stabilization method of choice for open fractures of the tibia (1,11,19,26,32,33,34 and 35,37,38 and 39,42,45,67,68,69 and 70,72,84,87,102,109,110,128,130,136,145,146,148). In the 1990s, however, locking intramedullary nailing has surpassed external fixation as the treatment of choice for unstable fractures of the tibia, particularly open fractures, where unreamed nailing has been found to provide superior results.

Santoro et al. (119) and Tornetta et al. (139) showed in prospective comparative studies that infection rates were similar, but union was delayed in the external fixators. The most significant difference, however, was an increased rate of malunion with external fixation treatment (Table 24.7). The primary reason for malunion is late angulation of the fracture after removal of the external fixator. Additionally, soft-tissue reconstructive procedures such as flaps are easier if there are no external fixation pins to contend with.

The primary indications for external fixation of diaphyseal fractures of the tibia and fibula today include the following: more severe open fractures; in children, fractures with unstable patterns that are not manageable in a cast; in adults, unstable grade II or worse open fractures of the tibia that have fracture patterns unsuitable for locked intramedullary nailing; conditions in which intramedullary nailing is contraindicated, such as previous active infection in the injured area; or systemic problems such as insulin-dependent diabetes mellitus associated with severe peripheral vascular disease.

It remains controversial whether external fixation or locked unreamed intramedullary nailing is the better method of stabilization for severe grade IIIB or C fractures. The survey of the literature in Table 24.7 shows a high rate of complications with these severe injuries, many of which are near-amputations. The incidence of problems in more recent studies, however, seems to be about the same in the two methods. The decision-making cascade as illustrated in Figure 24.6 will most likely be driven by a combination of factors including the need for local or free microvascular flaps, when a nail may be preferable to external fixation, or fracture combinations such as proximal or distal intraarticular fractures, when nail fixation is not possible.

External fixation can be combined with limited internal fixation such as interfragmentary screws or wires, or cerclage wires or cables (19) (Table 24.7). In some cases, reduction and maintenance of position of the fracture are required before the external fixator is applied. Segmental or large butterfly fragments, unless managed with additional pins on the external fixator, may not lie in good apposition to other bone fragments. For that reason, limited internal fixation may be of help. Unless inserted percutaneously, these techniques may result in additional soft-tissue stripping of the fracture fragments, resulting in devascularization and nonunion.

The major problem I have encountered when combining interfragmentary screw fixation with external fixation is losing the ability to know when fracture union has occurred—knowledge that is essential for timing the removal of the external fixator. In addition, the presence of interfragmentary screws rules out early weight bearing, which many types of external fixation today allow. With interfragmentary screw fixation, the micromotion usually seen in external fixation alone does not occur, and therefore periosteal callus formation is suppressed. Union takes longer, and a useful guideline to fracture healing—the radiographic appearance of bridging periosteal callus—is unavailable. In addition, when the time approaches for removal of the external fixation, it is common to remove the fixator, leaving the pins in place, to test the clinical stability of the fracture site. This additional clinical information is lost because of the rigidity provided by the interfragmentary screw fixation.

A common sequela of this situation occurs 4–6 months after the fracture, when the external fixator is removed and the patient is allowed to put weight on the site, either in or without a cast. The fracture, which has not yet healed, becomes displaced and often the screw breaks or the fracture becomes distracted, resulting in nonunion and frequently malposition. This situation then requires operative intervention. Therefore, I try to avoid combining interfragmentary screw fixation with external fixation in diaphyseal fractures. Early weight bearing is possible and the surgeon can use both radiographic and clinical criteria to judge when the external fixator can safely be removed.

### *Conversion of External Fixation to Other Types of Internal Fixation*

Table 24.7 lists five articles describing conversion of external fixation to intramedullary nailing, either early or late (13,65,85,140), and in the case of Siebenrock et al.

(131), conversion to a plate as well. The authors of these studies show that early conversion of external fixation to reamed intramedullary nailing, particularly in severe grade III open fractures, may offer particular advantages over external fixation, or unreamed or reamed intramedullary nailing alone.

The rationale for this approach is that primary external fixation causes less soft-tissue injury and avoids the potential contamination of the intramedullary canal and devascularization of the cortex associated with intramedullary nailing. Once the continuity of the soft-tissue envelope has been restored and the initial contamination eliminated, intramedullary nailing can be carried out, thus avoiding the late complications of external fixation and realizing the advantages of internal fixation.

The only downside of this approach is the difficulties that might be imposed by the external fixator in initial soft-tissue management and the necessity for a second operative procedure. Blachut et al. (13), with early conversion of external fixation to reamed intramedullary nailing in predominantly grade II and grade III open fractures, experienced only a 5% incidence of infection and 5% nonunion and malunion rates.

Siebenrock et al. (131) demonstrated the superiority of external fixation with conversion to an intramedullary nail within 4 weeks of fracture, to external fixation alone, or conversion to a plate where much higher incidences of infection, nonunion, and malunion were encountered. Maurer et al. (85) and Johnson et al. (65) showed advantages and disadvantages of late conversion of external fixation to reamed intramedullary nailing after failure of the former. Maurer et al. do not recommend this technique, because 7 of the 24 patients acquired deep infection. It is important to point out, however, that five of these patients had had a previous pin-track infection.

In 13 cases, Johnson et al. (65) experienced no difficulties. The lesson to be learned here is that conversion from external fixation to an intramedullary nail should be done early, before pin-track infection occurs. If deep infection does occur at a pin site, then the risk of infection after intramedullary nailing becomes very high and may be a contraindication to conversion to a nail. Tornqvist (140) had similar problems treating nonunions after external fixation with intramedullary nailing, where he experienced a 67% infection rate.

### *Types of External Fixation*

There are four types of external fixation: full-pin (Hoffmann) fixators, unilateral (AO half-pin), multiplanar (Fischer), and Ilizarov-type fixators. Although external fixation has been used in one form or another for most of the 20th century, the Hoffmann external fixator using multiple full pins inserted through the tibia was the device that popularized external fixation for fracture management in the 1970s and 1980s. Although the results from these types of fixators, as shown in Table 24.7, were quite acceptable, I am not aware that any of them continue to be used to any extent today.

Evolution in the design of external fixator pins and frames has relegated full-pin fixators to special uses such as the double delta frame for pylon fractures (see Chapter 11). The primary disadvantage of full-pin fixators is that the pins require insertion through the muscles of the anterior compartment, therefore precluding functional use of these muscles. In addition, the multiple pins in a single plane make it difficult to do plastic reconstructive procedures. Unilateral half-pin fixators can be applied in combinations in the anterior, posterior, and medial/lateral planes. They offer superior mechanical strength and rigidity compared with full-pin frames, but also versatility in half-pin placement to facilitate reconstructive soft-tissue procedures.

A wide range of unilateral external fixators is available for the tibia (see Chapter 6 and Chapter 11). Simple, inexpensive, single-bar fixators, such as the AO, use half-pins with simple universal clamps and a single carbon-fiber bar. Sophisticated fixators, such as the Hoffman II and the Monotube (both Howmedica, Rutherford, NJ) and the Orthofix (Orthofix, Richardson, TX), offer universal adjustable pin clamps that permit the frame to be applied before the fracture is anatomically reduced. These devices also enable the patient to put weight on the fracture site with controlled displacement and resistance to compression; this set of circumstances has been shown to enhance fracture healing. In addition, these modern half-pin fixators are adaptable for the management of combination fractures of the articular surfaces of the tibia and fractures of the diaphysis.

The Ilizarov fixator using either half-pins or tensioned wires is more complex to apply than simple uniplanar fixators, but it offers particular advantages in the management of complex associated fractures of the joint surfaces, metaphysis and diaphysis in particular, where the same fixator may be used to accomplish reconstructive procedures such as segment transportation to replace lost bone. These procedures are discussed in more detail in Chapter 23, Chapter 25, and Chapter 32.

## INTRAMEDULLARY NAILING

Intramedullary nailing of the tibia, particularly with nonreamed nails, was popularized by Lottes (79,80,81,82 and 83). He described his blind nailing technique in 1952 (81), but it was not until he and D'Aubigne et al. (7) published their two independent series (a total of 1273 fractures) in 1974 (Table 24.7) that the technique was more widely used. Their results were remarkably good, with acute infection rates of only 3%, and a low incidence of nonunions (2% to 2.5%). Because the Lottes nail could not be locked, fixation was always supplemented by a long-leg cast, and in spite of that, D'Aubigne reported a 16% incidence of malunions—the main reason the Lottes nail did not gain widespread use.

The orthopaedic community did not seem to pay attention to the excellent results with the Lottes nail in open fractures until Velazco et al. (147) showed a remarkably low acute infection rate of only 2% in 50 consecutive fractures, of which 65% were grade III (Table 24.7).

In the early 1980s, the flexible solid medullary nails developed by Ender for the femur were downsized and applied to the tibia. The Ender nail experienced brief popularity and is still used by some (86,92,152). The advantage of the Ender nail over the Lottes nail is that its smaller cross section, shape, and flexibility allow it to be more easily inserted, and the nail can be used to reduce the fracture. Because two nails are typically introduced, one from medial and one from lateral, and they are spread in a similar fashion distally, they offer better rotational control than the Lottes nail.

Levy et al. (78) found Ender nails to be superior to plaster-cast treatment in preventing varus deformity in tibia fractures with an intact fibula. Holbrook et al. (56), in a prospective randomized study that compared Ender nails to external fixation in the treatment of open fractures of the tibia, found Ender nails to be as effective as external fixation in types I and II open fractures. In a similar retrospective study, Whitelaw et al. (149) found Ender nails to be superior in a similar group of fractures.

In my experience, Ender nails work well, especially when combined with plaster cast or cast-brace immobilization in unstable fracture patterns. I no longer use Ender nails in adults, however, because they do not provide the stability of locked intramedullary nails, and most fractures heal with some posterior angulation. Although they can be locked on one end by inserting screws through the hole in the nail provided for the inserter, they do not provide adequate control against shortening. We keep a set of tibial Ender nails in our operating room for the rare situation when we want to place an intramedullary nail in a child with an open fracture of the tibia for which external fixation is not suitable, or in the occasional extremely unstable fracture for which external fixation is not suitable. With careful technique, the nail can be inserted without injury to either the proximal or the distal growth plates.

When internal fixation of a fracture of the diaphysis of the tibia is indicated, the fixation of choice today is a locked intramedullary nail (54,134,153). In closed fractures, most surgeons prefer to place a nail that uses transverse cross-locking screws of 4.5 mm or larger. Nails generally must be 10 mm or larger in diameter; reaming is often necessary. In open fractures, most surgeons prefer to use nails that do not require reaming, because in severe open fractures, the soft-tissue envelope around the tibia has been stripped and the outer cortex devascularized. Reaming has been demonstrated to devascularize the inner two thirds of the cortex or more (71,73,111).

The reaming, however, stimulates a strong hyperemic reaction, which in experimental animals reaches a level several times normal by 2–4 weeks after fracture (41,107). This revascularization of the diaphysis by reversal of the normal centrifugal blood supply of the cortex to a centripetal blood supply depends on the adequacy of blood supply from the periosteum and surrounding soft-tissue envelope, which is compromised in open fractures. This situation may predispose patients to infection and failure to heal the fracture.

The revascularization is influenced by the presence of an intramedullary nail. Nails that fit tight against the cortex interfere with revascularization, whereas fluted nails, or small-diameter nails that have limited contact with the endosteal cortex, allow more complete and rapid reestablishment of the blood supply to the cortex (43,44,62,107,143).

To place a nail 10 mm in diameter that permits use of larger cross-locking screws, gentle reaming with one or two reamers has been advocated. Hupel et al. (61) in a canine fracture model demonstrated that overall tibial blood flow was reduced by 63% with limited reaming, as opposed to 83% with full reaming. All blood flow normalized by 11 weeks after reaming. In animal models, osteotomy of the tibia as well as reaming increase blood flow in the muscle and skin surrounding the fracture (4,6). Richards et al. (112,113) in a canine model showed that muscle flaps significantly increase blood flow, cortical porosity, and intracortical formation of new bone. They also increase strength of union in an osteotomy. In the nailing of open fractures, early full-thickness soft-tissue coverage, preferably with muscles, is therefore of great value.

A review of the literature in Table 24.7 shows that the results with nonreamed locked intramedullary nails are excellent, but that delayed union rates are as high as

48%. For the most part, this delay results from the fact that these series involve high-energy open fractures, and unreamed nails tend to be flexible and relatively weak. Comparisons to use of external fixation, however, in particular the series of Santoro et al. (119) and Tornetta et al. (139), show results comparable or superior to those of external fixation. Unreamed or minimally reamed locked nails are therefore preferable to external fixation in open fractures. The major disadvantage of unreamed locked nails is that because they are small, there is an increased incidence of delayed union and broken hardware. Secondary procedures to convert to larger reamed locked nails or bone graft occur in 10% to 20% of fractures.

The results from reamed, locked intramedullary nails are excellent. Rates of infection, delayed union, nonunion, and malunion are low, with the best series reporting rates of less than 3% for all of these complications. Because acute reamed nailing of open fractures has higher rates of infection, however, initial nonreamed nail fixation or external fixation with subsequent conversion to a reamed nail, as discussed previously, is preferable in high-grade open fractures.

**PLATE AND SCREW FIXATION**

Müller et al. (95,96,97 and 98) advocated open reduction and the use of interfragmentary lag-screw and compression-plate fixation in displaced fractures of the tibia and fibula. Rüedi et al. (116) reported good to very functional results in 98% of 323 closed fractures. There was less than a 1% incidence of late osteomyelitis and a similarly low incidence of nonunion. There were three fixation failures and one refracture. Plate and screw fixation of open fractures is far more hazardous, as reflected by results in 101 open fractures, in which the overall rate of complications was 32%, including a 12% incidence of infection and a 7% incidence of nonunion (23,100,101,103).

The difficulty with plate fixation is that the complications of infection can be devastating, leading to osteomyelitis and even amputation. Since the development of closed intramedullary nailing with locking screws, the indications for plate fixation for diaphyseal fractures are rare. Fractures at the metaphyseal–diaphyseal junction are difficult to treat with intramedullary nails. Lange et al. (74), in 32 extraarticular fractures of the proximal third of the tibia treated with locked intramedullary nails, reported 84% with greater-than-acceptable angulation and advise consideration of plating or external fixation for these fractures. I often plate unstable fractures in the proximal third or distal fourth of the tibia when nonoperative treatment does not suffice.

**OPEN FRACTURES**

The worst open fractures encountered by most orthopaedic surgeons involve the tibia and fibula (which are often crushed in high-speed motor-vehicle accidents). It is extremely important to follow all the basic principles in the treatment of open fractures outlined in Chapter 12, including appropriate emergency care, early administration of appropriate intravenous bactericidal antibiotics, meticulous layer-by-layer wound irrigation and debridement, appropriate fracture stabilization, delayed wound closure, and early full-thickness soft-tissue coverage (66,75,88). Figure 24.6*A* presents the protocol for management of the soft tissues in open tibial fractures, and Figure 24.6*B* the protocol for stabilization of open tibial fractures.

In 1993, when the second edition of this book was published, numerous trauma centers were just beginning to use nonreamed intramedullary nailing. It has now become the stabilization method of choice for grades I, II, and IIIA open fractures. As noted in Table 24.7, it can be satisfactory for grade IIIB and C open tibial fractures as well, but the risk of infection is significant. For that reason, some surgeons still prefer initial external fixation for high-grade open tibial fractures. As discussed earlier in this chapter, many now have adopted the practice of passing one or two reamers gently to increase the medullary canal size to allow insertion of a 10 mm nail, which permits the use of larger transverse cross-locking screws. Laboratory evidence indicates that this method has less impact on the circulation to bone than full reaming, and clinical outcomes appear to be acceptable.

The more challenging decision is what to do after placement of small, unreamed locked nails or external fixation. In the case of the former, many fractures will go on to successful union, but delayed union with early failure of screws, and occasionally nails, can occur in up to 48% of cases (17). In fractures fixed with unreamed nails less than 10 mm in diameter, I delay weight bearing and keep a close watch on the fracture. If by 12 weeks there is no callus formation or evidence of progression toward union, or if there is evidence of impending hardware failure, I convert to a larger reamed locked intramedullary nail, on occasion combining its use with an open bone graft if there is segmental bone deficiency.

In the case of external fixation, if the patient tolerates the fixator well and there are no significant pin complications, the fracture can often be followed until union in the external fixator, particularly if the fixator allows early joint motion, muscle rehabilitation, and weight bearing. On occasion, I convert external fixation to a reamed intramedullary nail if the patient is unable to tolerate the external fixator or if there are socioeconomic reasons. I will not make this conversion in the case of pin-track infection. In most cases, I remove the external fixator and place the leg in a cast until pin-track healing has occurred, usually in 2–3 weeks, and then carry out nailing.

As with the small unreamed locked intramedullary nails, if by 12 weeks there is evidence of delayed union, I intervene surgically to hasten union. Choices include conversion to a large reamed intramedullary nail, or bone grafting of the fracture in the fixator, usually through a posterolateral approach, except in proximal fractures, where a posteromedial approach is utilized. I handle fractures with segmental bone deficiency in a similar manner by doing large posterolateral bone grafts spanning from tibia to fibula to produce a tibial–fibular synostosis, effectively bypassing the area of missing bone.

Success of these techniques requires a good-quality, full-thickness soft-tissue envelope. I make liberal use of local muscle flaps and free microvascular flaps to achieve muscle coverage of the fracture by 10 days, if possible.

I do not have enough experience with early conversion of external fixation to reamed locked medullary nailing in high-grade open fractures to comment; the articles listed in Table 24.7, however, support this as an alternative and effective technique.

Some surgeons have converted entirely to the use of Ilizarov-type ring fixation with half-pins, tension wires, or combinations thereof. I have used Ilizarov-type fixation in cases that called for primary shortening of the limb through the fracture site to achieve bone apposition and early soft-tissue closure (utilizing proximal or distal distraction osteogenesis to restore length to the limb). I also have used this method where the normal length of the limb has been maintained and a segment has been transported to fill a bone defect. These techniques are discussed in more detail in Chapter 32.

Because of the highly managed health care economy in the Sacramento region, I have not found Ilizarov techniques to be as suitable for our patients as the other methods discussed. The patients are often quickly transferred to other surgeons after their initial care, or they live a considerable distance from my hospital. For that reason, if I feel that an Ilizarov methodology is applicable, I am more likely to apply a simple unilateral fixator initially and then later convert the patient to an Ilizarov device when it is apparent that I will be carrying out the full course of treatment and the patient is an appropriate candidate for the method selected. In addition, I find the use of circular external fixators time consuming and technically demanding and therefore difficult to use in emergency situations, particularly in patients with multiple injuries. I find it better to apply these devices on an elective basis.

**AMPUTATION**

Perhaps one of the most important decisions is whether to amputate a severe open fracture of the tibia (51). It is destructive and wasteful to invest two or more years in an attempt to salvage a limb that is finally amputated because it is painful and dysfunctional. Over the past decade or so, clinical researchers in major trauma centers dealing with massively traumatized limbs have attempted to develop scoring systems to assist clinicians and patients and their families in the decision-making process. The surgeon and patient must decide whether early amputation is indicated for a mangled limb, or whether the major repeated surgeries required to salvage the limb would leave the patient with an extremity more useful than a below-knee prosthesis (Table 24.8).

| *Reference* | *Scoring systems* | *Acronyms* |
|---|---|---|
| 1985, Gregory et al. (46) | Mangled extremity syndrome | MES |
| 1987, Howe et al. (59) | Predictive salvage index | PSI |
| 1990, Helfet et al. (53) | Mangled extremity severity score | MESS |
| 1991, Russell et al. (117) | Limb salvage index | LSI |
| 1994, McNamara et al. (69) | Nerve, ischemia, soft-tissue injury, skeletal injury, shock, age index | NISSSA |

***Table 24.8. Mangled Limb Scoring Systems***

The most frequently studied of these is the mangled extremity severity score (MESS) (Table 24.9), and the most recent and most complete is the NISSSA (for nerve injury, ischemia, soft tissue injury, skeletal injury, shock, and age of patient) (Table 24.10). The literature on the reliability of these indices is mixed, however. In looking at the outcomes of free microvascularized flaps to the tibia, Laughlin et al. (76) in 14 open fractures, 8 grade IIIB, and 6 grade IIIC, experienced one related death and four early amputations. Of the remaining nine, six became infected, but all cleared with treatment and all of the fractures healed. Eight of the nine patients eventually returned to work, six to their preinjury occupations.

| Type | Characteristics | Injuries | Points |
|---|---|---|---|
| Skeletal/soft-tissue group | | | |
| 1 | Low energy | Soft wounds, simple closed fractures, small-caliber gunshot wounds | 1 |
| 2 | Medium energy | Open or multiple-level fractures, dislocations, moderate crush injuries | 2 |
| 3 | High energy | Shotgun blast, close range, high-velocity gunshot wounds | 3 |
| 4 | Massive crush | Logging, railroad, oil rig accidents | 4 |
| Shock group | | | |
| 1 | Normotensive hemodynamics | BP stable in field and in OR | 0 |
| 2 | Transiently hypotensive | BP unstable in field but responsive to intravenous fluids | 1 |
| 3 | Prolonged hypotensive | Systolic BP less than 90 mm Hg in field and responsive to intravenous fluid only in OR | 2 |
| Ischemia group | | | |
| 1 | None | A pulseless limb without signs of ischemia | 0* |
| 2 | Mild | Diminished pulses without signs of ischemia | 1* |
| 3 | Moderate | No pulse by Doppler, sluggish capillary refill, paresthesia, diminished motor activity | 2* |
| 4 | Advanced | Pulseless, cool, paralyzed and numb without capillary refill | 3* |
| Age group | | | |
| 1 | <30 yr | | 0 |
| 2 | >30, <50 yr | | 1 |
| 3 | >50 yr | | 2 |

*Points: ≥ 3 if ischemia time exceeds 6 hours.
OR, operating room; BP, blood pressure.

***Table 24.9. Mangled Extremity Severity Score***

| Type of injury | Degree of injury | Points | Description |
|---|---|---|---|
| Nerve injury (N) | | | |
| | Normal | 0 | No major nerve injury |
| | Minimal | 1 | Loss of superficial peroneal nerve, femoral nerve neuropathy |
| | Nerve partial | 2 | Tibial nerve neuropathy |
| | Nerve complete | 3 | Sciatic nerve injury |
| Ischemia (I) | | | |
| | None | 0 | Good no-foot pulse, no ischemia |
| | Mild | 1* | Reduced pulse, perfusion normal |
| | Moderate | 2* | No pulses, prolonged capillary refill, Doppler pulse present |
| | Severe | 3* | Pulseless, cool, ischemia, no Doppler pulse |
| Soft tissue concentration (S) | Low | 0 | Minimal or no SS contusion, no concentration (Gustilo type I [17]–[19]) |
| | Medium | 1 | Moderate SS injury, low velocity GSW, moderate concentration, clinical crush (Gustilo type II [17]–[19]) |
| | High | 2 | Moderate crush, degloving, high-velocity GSW, moderate SS injury may require multiple flap, considerable concentration (Gustilo type IIIA [17]–[19]) |
| | Severe | 3 | Massive crush, NOS injury, severe degloving, severe concentration, requires soft tissue flap (Gustilo type IIIB [17]–[19]) |
| Skeletal (S) | Low energy | 0 | Spiral fracture, oblique fracture, no or minimal displacement (Winquist and Hansen type I [1]–[3], Johnson and Weeks Ic, Ia [10]) |
| | Medium energy | 1 | Transverse fracture, minimal comminution, small-caliber GSW (Winquist and Hansen type II [1]–[3], Johnson and Weeks Ib, Ic, IIa [10]) |
| | High energy | 2 | Moderate displacement, moderate comminution, high-velocity GSW, bipedal, fragmental (Winquist and Hansen type III, IV [1]–[3], Johnson and Weeks Ib, Ic, IIa [10]) |
| | Severe energy | 3 | Segmental, severe comminution, bone loss (Winquist and Hansen type IV [1]–[3], Johnson and Weeks Ic, IIa [10]) |
| Shock (S) | Normotensive | 0 | Blood pressure normal, always >90 mm Hg, stable |
| | Transient hypotension | 1 | Transient hypotension in field or emergency room |
| | Persistent hypotension | 2 | Persistent hypotension despite fluids |
| Age (A) | Young | 0 | <30 yr |
| | Middle | 1 | 30–50 yr |
| | Old | 2 | >50 yr |
| Total score (S) 0 1 2 3 4 5 6 7 8 9 10 11 | | | |

*Injury severity score (ISS) ≥ 16.
†Injury severity score (ISS) < 16.
‡Injury severity score (ISS) ≥ 16.

***Table 24.10. NISSSA Rating Criteria***

Trabulsky et al. (141), in a study of 45 grade III open tibial fractures, performed free flaps in 78% with a 97% success rate of the flaps and overall salvage rate of 98%. There is little question that most limbs are salvageable using modern surgical techniques. Slauterbeck et al. (133), in a retrospective study of 43 severe open fractures, found the MESS to be accurate, as all nine limbs with a MESS greater than 7 went on to amputation and 34 with a score of less than 7 were salvaged.

Robertson (114), in a retrospective review of 152 open fractures, also found the MESS to be accurate in predicting the need for amputation but found that the score was not as reliable in predicting outcomes in young people with moderate injuries who had experienced no shock and who had an arterial injury requiring repair. Survival of the limb in this group was higher than the score would predict.

Studies by Georgiadis et al. (40) and Bonanni et al. (15) illustrate the problems with these scoring systems. Georgiadis et al. (40) compared 16 limbs salvaged with a free flap, with 18 that were treated early with below-knee amputation. In the salvaged group, he found an increased incidence of complications, an increased number of operative procedures, and an increased length of stay in the hospital. Furthermore, these patients were more likely to report themselves as severely disabled, and they reported less satisfactory performance in their occupational and recreational activities. Bonanni et al. (15) did a retrospective review of 89 severe open tibial fractures of which 58 were salvaged and 31 went on to primary amputation. They evaluated the MES, MESS, predictive salvage index (PSI), and limb salvage index (LSI) and found no predictive value in any of these measuring tools. Of the 58 that were salvaged, 31% eventually went on to delayed amputation.

It is often difficult to determine in the emergency room, or for that matter at the time of initial surgery, the full extent of injury to a limb. For that reason, I prefer to follow the simple guidelines of Lange et al. (74), erring on the side of preservation rather than amputation unless the limb is obviously nonsalvageable, or unless the limb presents a threat to the patient's life. It is critical, however, to take an early second look at the limb, at which time a definitive decision can usually be made. It is important to involve patients and their families as much as possible in this decision-making process.

The surgeon must make every effort to avoid discharging a patient from initial admission with a severely mangled limb that in the long run is not going to be salvageable or function better for the patient than a below-knee prosthesis. Lange et al. (74) have developed guidelines for primary amputation. In type IIIC fractures (i.e., those with a vascular injury requiring repair), primary amputation is indicated when the posterior tibial nerve is transected, or in crush injuries where the warm ischemia time is greater than 6 hours. Relative indications are serious associated polytrauma, severe ipsilateral foot trauma, or an anticipated protracted course to obtain soft-tissue coverage or tibial reconstitution. Consider primary amputation if one of the absolute indications or two or three of the relative indications are present. These criteria and the decision-making variables are listed in Table 24.11.

- Indications for primary amputation (type IIIC tibial fracture)
  - Absolute indications
    - Anatomically complete disruption of the posterior tibial nerve in adults
    - Crush injuries with warm ischemia time >6 hrs.
  - Relative indications
    - Serious associated polytrauma
    - Severe ipsilateral foot trauma
    - Anticipated protracted soft-tissue and osseous reconstruction
- Decision-making variables in limb salvage
  - Patient
    - Age
    - Chronic disease
    - Occupational considerations
    - Patient and family desires
  - Extremity
    - Mechanism of injury
    - Fracture pattern
    - Arterial/venous injury (location)
    - Neurologic status (anatomic)
    - Injury status of ipsilateral foot
    - Ischemia zone after revascularization
  - Associated
    - Magnitude of associated injury (injury severity score)
    - Severity and duration of shock
    - Warm ischemia time

From Lange RH, Bach AW, Hansen ST, Johnson KD. Open Tibial Fractures with Associated Vascular Injuries: Prognosis for Limb Salvage. J Trauma 1985;25:203, with permission.

***Table 24.11. Amputation versus Limb Salvage***

Caudle and Stern (24) have emphasized the importance of making the decision to amputate early. They eventually amputated in the cases of seven of nine type IIIC open fractures because of pain, sepsis, nonunion, or failure of the vascular repair. The results in the two that were salvaged were poor.

## TECHNIQUES OF NONOPERATIVE AND SURGICAL TREATMENT

### EMERGENCY CARE

- After addressing life- or limb-threatening emergencies, take a complete history and perform a physical examination. Carefully examine the involved extremity. In particular, look for any evidence of open injury, compromise of neurovascular function, or evidence of impending compartment syndrome. Record your findings.
- Gently restore the leg to grossly normal alignment, control hemorrhage from wounds with a compression dressing, and dress all open wounds with povidine-soaked sterile dressings. Apply a long-leg, well-padded splint.
- Elevate the limb on a pillow 10 cm above the level of the heart. Take anteroposterior (AP) and lateral radiographs that include the knee and ankle.

## SKELETAL TRACTION

Treatment of tibial fractures in traction was popularized by Böhler (14). Traction may be indicated to overcome unacceptable shortening that cannot be corrected by closed reduction, particularly in neglected fractures, although modern external fixators that provide distraction have limited the usefulness of this technique. Traction is most commonly used to maintain length when severe soft-tissue injury or other considerations make immediate incorporation in a cast or splint or performance of internal fixation impossible. Because traction may be followed by internal fixation, it is important to avoid pin-track complications.

- Place a transverse, smooth, Kirschner wire through the distal tibia (Fig. 24.7). Place povidine-soaked or dry sterile × gauze pads over the wire, using enough to prevent the wire from sliding. If internal fixation of the tibia is planned, place the wire in a similar fashion through the calcaneus.

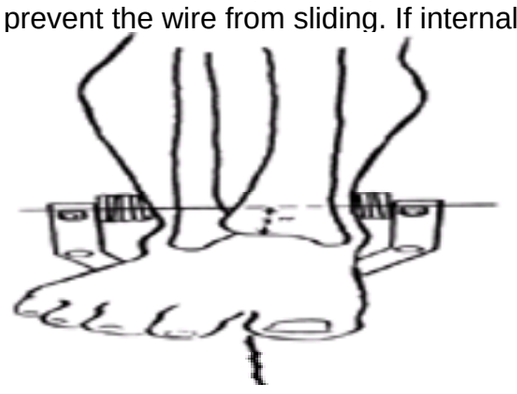

***Figure 24.7.*** Kirschner wire traction for fractures of the tibia and fibula. (From Chapman MW. Fractures of the Tibial and Fibular Shafts. In: Evarts CM, ed.*Surgery of the Musculoskeletal System.* New York: Churchill-Livingston, 1983, with permission.)

- Apply a traction bow that is large enough to fit around the foot.
- Support the fracture on a Böhler-Braun frame, a suspended Thomas splint, or a pillow (see Chapter 10).

### *Postoperative Care*

Institute physical therapy immediately to encourage movement of the ankle and avoid equinus contraction. Isometric exercises of the muscles in the lower extremity and limited knee motion are often possible in traction. As soon as length is regained or the soft-tissue problem is resolved, discontinue traction and implement other methods of stabilization.

## CLOSED REDUCTION AND CAST IMMOBILIZATION

Closed reduction and the application of a plaster cast is the most commonly used method for treating fractures of the tibia and the fibula. Weight-bearing methods were popularized by Dehne (27,28 and 29), Brown (20), and Sarmiento (120,121,122,123,124,125 and 126). I almost never use non-weight-bearing casts. The technique of applying an immediate weight-bearing cast is demanding and requires as much motor skill as internal fixation.

Initially, use a long-leg cast. Change to a Sarmiento cast or brace as soon as early axial and translational stability are present, usually about 4–6 weeks after injury. Use a Sarmiento cast initially in stable fractures in the distal half of the tibia.

Closed reduction and cast application usually do not require a regional or general anesthetic if the patient is cooperative. Medicate him well, and use local anesthesia. Place a padded crutch or board beneath the thigh and secure it to the table. Gently place hand traction on the leg and position it as illustrated in Figure 24.8.

***Figure 24.8.*** Position for application of a Sarmiento, short-leg, or the initial portion of a long-leg plaster cast for a fracture of the tibia. (From Chapman MW. Fractures of the Tibial and Fibular Shafts. In: Evarts CM, ed.*Surgery of the Musculoskeletal System.* New York: Churchill-Livingston, 1983, with permission.)

### *Application of a Removable Ankle Traction Bandage*

A traction bandage and gentle traction are used to stabilize the tibia (Fig. 24.9).

***Figure 24.9.*** Removable ankle traction bandage. (From Chapman MW. Fractures of the Tibial and Fibular Shafts. In: Evarts CM, ed.*Surgery of the Musculoskeletal System.* New York: Churchill-Livingston, 1983, with permission.)

- Cut a strip of muslin 65 cm in length and 2.5 cm wide, and bring the ends together. Make a second strip.
- Place one strip over the instep and one over the heel, and connect them with 12 mm tape level with the bottom of the foot. Locate the junction of the strips directly below the malleoli. Apply a thin layer of petroleum jelly beneath each strip to ease removal.
- Tie a bucket of water to the strips or use a foot loop. Apply enough traction (add water or increase foot pressure) to stabilize the fracture and achieve alignment.
- After cast application, cut the tape, remove the strips completely, and seal the cast. Do not leave the traction bandages in the cast, as they can cause pressure sores.

***Application of a Long-leg Weight-bearing Cast***

Note the anatomic molding in Figure 24.10.

***Figure 24.10.*** Long-leg weight-bearing cast. (From Chapman MW. Fractures of the Tibial and Fibular Shafts. In: Evarts CM, ed.*Surgery of the Musculoskeletal System.* New York: Churchill-Livingston, 1983, with permission.)

- Apply the short-leg section first up to the mid patella.
- Place a 15–20 cm piece of tubular stockinet at each end of the cast for trimming.
- Apply a double layer of cast padding with a triple layer over bony prominences. It must be free of wrinkles.
- Dip one 10 cm roll and three 15 cm rolls of plaster into 72°F water. Apply the 10 cm roll about the foot and ankle and follow with the 15 cm rolls. Apply rapidly and smoothly. Place tucks posteriorly.
- Mold the cast as it sets. Mold in the transverse and longitudinal arches of the foot and about the malleoli. The malleolar molding produces a posterior bulge for the Achilles tendon. Smooth the cast along the entire anteromedial border of the tibia. As the plaster sets, mold posteriorly to push the leg anteriorly to fit against the smooth anterior aspect of the cast. The cast should assume a triangular shape with a slight bulge for the sharp anterior border of the tibia and relatively flat surfaces over the posterior and anterior compartments and medial surface. Fit the cast to the medial and lateral flares of the proximal tibia.
- When the cast has set, extend the knee. Remove the ankle bandage. Trim the proximal end of the cast.
- Apply the thigh portion of the cast. Support the cast at the fracture site with the foot against an assistant's chest (or use a leg holder). Keep the knee flexed 5° short of full extension. Wrap on two layers of cast padding. Apply three or four 15 cm rolls of plaster. Extend proximally to the greater trochanter.
- Mold the cast above the medial and lateral epicondyles. This molding technique causes posterior bulging, which creates a channel for the hamstring tendons. Proximally, mold the cast over the anterior and lateral surfaces to produce a quadrilateral socket. This molding produces a snug fit over the greater trochanter and femoral triangle, which creates a channel for the adductor and hamstring tendons.
- Trim the ends of the cast, reinforce the foot, and apply a walker or walking boot.
- In acute fractures where swelling is a risk, place a single longitudinal cut along the full length of the anterior aspect of the cast over the muscle of the anterior compartment and spread the cast as needed. Reseal when the swelling resolves.

***Application of a Sarmiento-type Cast***

- After applying the below-knee cast as just described, carry the padding and plaster 5 cm proximal to the patella. Mold the leg portion of the cast and extend the knee to 45° of flexion.
- Mold the plaster to the flares of the tibia and over both femoral epicondyles. Mold the cast to gently grip the epicondyles, thereby creating an anterior channel for the patella and patellar tendon and a posterior channel for the hamstrings. Flatten the popliteal fossa to keep the leg against the anterior aspect of the cast.
- Trim the cast (Fig. 24.11). Notice that it is above the patella to avoid patellar impingement and give good support. Trim out the popliteal fossa to allow the amount of flexion desired. You may choose to limit flexion to 45° initially and then gradually increase it as fracture stability increases.

***Figure 24.11.*** Sarmiento type cast. (From Chapman MW. Fractures of the Tibial and Fibular Shafts. In: Evarts CM, ed.*Surgery of the Musculoskeletal System.* New York: Churchill-Livingston, 1983, with permission.)

***Postoperative Care***

Provide crutches or a walker and encourage the patient to be out of bed within 1–2 days and to bear weight as tolerated. The typical patient requires at least 3 weeks and up to 6 weeks to achieve full, unsupported weight bearing. The patient should strive to be independent of crutches by 6 weeks. Begin isometric exercises for all muscle groups immobilized in the cast. It is important to follow the patient at weekly intervals for the first 4–6 weeks when weight-bearing methods are used. Loss of reduction must be corrected early to avoid malunion.

Change casts at 4- to 6-week intervals, depending on the stability of the fracture. Stable fracture patterns and those that gain stability early may be converted to a Sarmiento cast or fracture-brace as early as 4 weeks. Protect tibial fractures for at least 12 weeks. The average healing time is 16–24 weeks. Fracture instability after 24 weeks is considered a delayed union.

**FRACTURE BRACING**

Fracture bracing, popularized by Sarmiento et al. (126), is very useful, particularly with prefabricated braces (Fig. 24.12). Although the description of this technique is beyond the purview of this text, it is fully described in the literature (120,121,122,123,124,125 and 126).

***Figure 24.12.*** Sarmiento type fracture brace with free ankle hinge. (From Chapman MW. Fractures of the Tibial and Fibular Shafts. In: Evarts CM, ed.*Surgery of the Musculoskeletal System.* New York: Churchill-Livingston, 1983, with permission.)

**PINS AND PLASTER**

With the availability of single-bar, half-pin external fixators, I almost never use the pins-and-plaster technique. When pins in plaster are used, at least three pins, two of which must be full pins, are required. External fixation requires only four half-pins and is much quicker and more versatile, so there is no reason to use pins in plaster. However, as it is a simple and inexpensive method, it continues to enjoy wide use, particularly in underdeveloped countries (5). I prefer a three-pin technique using a short-leg cast (Fig. 24.13).

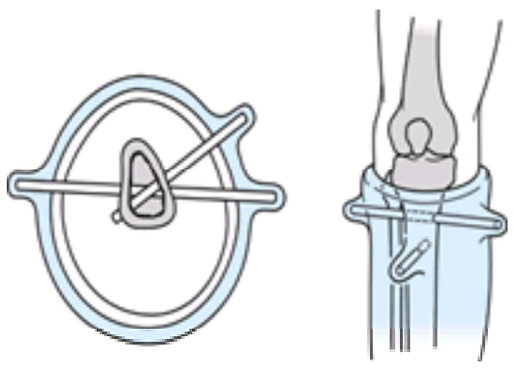

***Figure 24.13.*** Pins in plaster—two pin technique. (From Chapman MW. Fractures of the Tibial and Fibular Shafts. In: Evarts CM, ed.*Surgery of the Musculoskeletal System.* New York: Churchill-Livingston, 1983, with permission.)

- When pins are used in plaster, at least two proximal pins are needed to control the proximal fragment, and then only a short-leg cast is needed.
- Insert one large transverse Steinmann pin just distal to the tibial tubercle. Insert a second pin from anterior to posterior, slightly distal to the first pin. Engage the posterior cortex, but do not penetrate the soft tissues because of the risk of neurovascular injury. Leave the pins protruding 5 cm, and incorporate them into the cast. Use a distal transverse pin if necessary for the distal fragment.

***Postoperative Care***

Pin loosening is a common problem with pins and plaster, so weight bearing is usually contraindicated. Some patients can perform partial weight bearing with crutches if a distal pin is not used. If a distal pin is used, weight bearing is contraindicated. When this method is properly applied, and in the absence of complaints from the patient, inspection of the pin sites is unnecessary until cast removal. In stable patterns with rapid healing, remove the pins by 4–6 weeks and convert to a weight-bearing cast. In unstable patterns, prolonged immobilization may be necessary. Prolonged immobilization in pins and plaster is often complicated by delayed union and nonunion, and it may necessitate bone grafting.

**EXTERNAL FIXATION**

Chapter 11 covers in detail the basic principles of insertion of external fixation pins and application of simple fixators, as well as pin care and the general postoperative regimen for external fixation. The focus in this section will be on external fixation of the shaft of the tibia.

Complex fractures involving the tibial plateaus and proximal quarter of the tibia or the ankle joint may require special fixators, especially those using tensioned wires or hybrid fixators (see Chapter 23 on fractures of the tibial plateau, and Chapter 25 on ankle fractures). Other than Ilizarov fixators (Chapter 32), the most commonly used external fixators for the diaphysis of the tibia are those in which half-pins are inserted along a rigid, single-piece bar or tube, or into which pins are inserted either individually or as clusters through articulated pin holders that are mounted on an adjustable tube or bar or series of bars. Many interesting and useful combinations are commercially available.

In the second edition, we discussed in detail Hoffmann-type external fixators, which used through-and-through pins in clusters of up to four. Modern external fixators make such pin designs obsolete and therefore will not be described here. I still use some through-and-through pin fixator configurations for the tibia—in particular, a type of delta frame for pylon fractures (Chapter 25).

The simple single-bar systems are inexpensive and versatile. With their components, complex fixators can be built to meet almost any challenging combination of problems. The major disadvantage of fixators where the half-pins are mounted on a single bar is that the fracture must be nearly anatomically reduced during the application of the fixator; after application, there is minimal opportunity to make adjustments and achieve anatomic position. In addition, it is very difficult to “dynamize” these fixators when weight bearing across the fracture site becomes desirable.

To some extent, dynamization can be obtained by removing fixation rods, assuming more than one were initially applied, or by removing frames in other planes, assuming more than one plane was used. Adjusting the pin length also can achieve some element of dynamization, but the result is a type of cantilevered motion. The most recent designs, based mostly on tubes, incorporate mechanisms for allowing controlled dynamization of the fracture site over given amounts of compression at different spring-loads.

## ANATOMIC CONSIDERATIONS

Fixation pins are much less likely to loosen if inserted through cortical bone. For biomechanical reasons, it is desirable to have one set of pins in the proximal and distal fragment, as far from the fracture as practical, and a second set as close to the fracture site as practical. In the former, I always try to keep the pin at the metaphyseal–diaphyseal junction, so that the pin is transgressing some cortical bone rather than being placed in pure cancellous bone.

In the region of the fracture, I generally place the pins approximately 25–30 mm away from the fracture site or the area of nearest fracture line, to avoid accidentally inserting the pin through an unseen crack, and to minimize the risk of communication of the pin with the fracture hematoma. Because of the neurovascular structures in the leg, it is important to be aware of the safe anatomic corridors of pin insertion along the length of the tibia. These have been well described by Stuart Green (45), who divides the leg into four segments—A, B, C, and D—each representing a quarter section of the leg (Fig. 24.14).

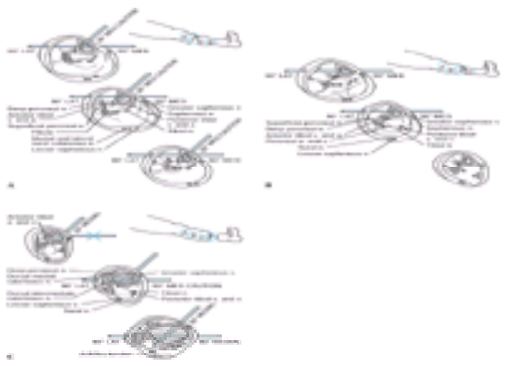

***Figure 24.14.*** Cross-sectional anatomy of the leg for external fixator pin placement, zones B, C, and D illustrated here. (From Green SA. *External Skeletal Fixation: Causes, Prevention, and Treatment.* Springfield, IL: CC Thomas, 1981, with permission.)

- In zone A, the risk of injury to nerves and vessels is small, as they lie posterior to the tibia. The common peroneal nerve divisions and anterior tibial artery and vein lie close to the fibula.
- In zone B, pin placement in the usual locations does not threaten the neurovascular bundles unless the soft tissues are penetrated too deeply posteriorly or the pin angle is incorrect. Be cautious with 30° medial half-pins.
- In zone C, transverse pins are reasonably safe. Pins entering the medial subcutaneous border threaten the anterior tibial artery and vein, and the deep peroneal nerve. A direction more anterior to posterior, engaging the posterior cortex, is safest for a half-pin in this section.
- In zone D, the anterior tibial artery and nerve are closely applied to the tibia and pass from mid tibia to anterior tibia as they travel distally. Transverse pins in the proximal third of this section are contraindicated. Place other pins with caution.

Insert pins through the middle of the medullary canal and avoid the anterior cortex if possible (Fig. 24.15). Driving pins through the solid anterior cortex can cause overheating and bone necrosis, which is often followed quickly by pin-loosening infection and osteomyelitis.

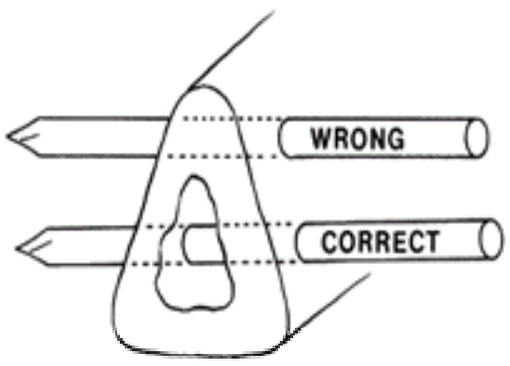


***Figure 24.15.*** Location for full and half pin placement: Avoid the anterior cortex, and place pins through the middle of the medullary canal. (From Chapman MW. Fractures of the Tibial and Fibular Shafts. In: Evarts CM, ed.*Surgery of the Musculoskeletal System.* New York: Churchill-Livingston, 1983, with permission.)

The configuration of the fracture may dictate the selection of the frame. The configuration must offer sufficient strength to adequately immobilize the fracture and should use the least injured soft tissue and bone for the pin sites. The frame must be constructed to allow optimal access for subsequent surgical debridements and reconstructive procedures, such as local, rotational, or free soft-tissue flaps.

## MECHANICAL CONSIDERATIONS

Behrens and Searls (12) have pointed out that the sagittal bending moments in the leg are about two to five times larger than those in the coronal plane. For that reason, the primary frame is best located as close as possible to the anterior–posterior plane. To maximize the initial stiffness of the frames, they advise increasing the spread of pins in each main fragment, reducing the distance between the bone and longitudinal rod, adding a second rod to the same pins, or adding a second half-frame as close as possible to 90° to the plane of the first frame.

The configurations they recommend for different tibial fractures are illustrated in Figure 24.16. They studied 69 fractures, of which 54 were open, and found that simple, one-plane frames were adequate for over 80%. In their series, 5 mm stainless-steel pins were used. Further stiffness can be obtained by using 6 mm pins. They encouraged their patients to try early partial weight bearing, progressing to full weight bearing as the fracture healed. They increased the load transmission across the fracture by the techniques previously described, including loosening the central pin articulations in their half-frames.

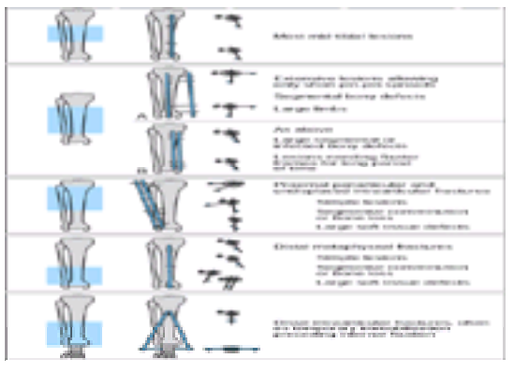

***Figure 24.16.*** Behrens and Searls' recommendations for different frame configurations based on location and type of fracture. (Redrawn from Behrens F, Searls K. External Fixation of the Tibia, Basic Concepts and Prospective Evaluation. *J Bone Joint Surg Br* 1986;68;246, with permission.)

## SURGICAL TECHNIQUES

I am describing the application of a simple AO unilateral plane and Delta frame fixator; the basic principles of these frames apply to many similar frames. I also describe the application of one of the more modern, sophisticated articulated frames that permit controlled dynamization. Again, the general principles are applicable to many others. Be sure to refer to the manufacturer's instruction manual for the specific frame you use.

### UNILATERAL SIMPLE AO FIXATOR

- With the single-bar frame, place the pins at right angles to the subcutaneous surface of the tibia, through the center of the bone. At the junction of the middle and distal thirds, avoid injury to the anterior tibial neurovascular bundle. If two half-pin frames will be used, place the first frame about 1 cm posterior to the anterior ridge of the tibia and close to the sagittal plane. Place the second frame 1 cm anterior to the posterior border of the tibia in the lateral plane. The angle between

these two frames will be 60° to 90°.

- Place the first pin just distal to the tibial tubercle using appropriate technique with predrilling as described in Chapter 11. (For purposes of this discussion, assume the fracture is mid diaphyseal.)
- Reduce the fracture. Precise reduction is not required, but the rotational alignment must be nearly normal.
- Insert the distalmost pin about 5 cm proximal to the ankle joint, in alignment with the proximal pin.
- Assemble four universal pin holders on the appropriate-length AO carbon fiber bar and secure the outermost holders to the two pins in place (Fig. 24.17).

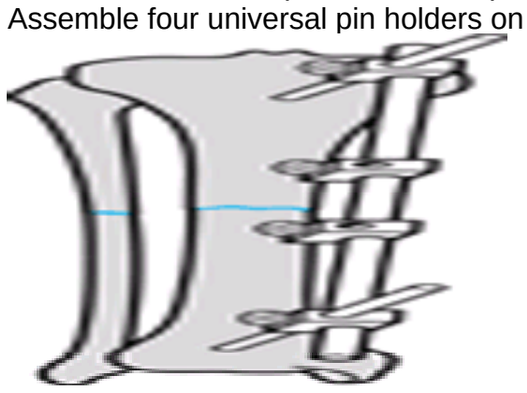

***Figure 24.17.*** Application of anteromedial half-pin single-plane AO external fixator. All four universal clamps are on the fixator bar. Place the most proximal and distal Schanz screws first. Align the fractures.

- Anatomically reduce the fracture. Secure the bar to the pins with the bar about 2.5 cm from the skin, unless greater distance is needed for wound care.
- While maintaining reduction, insert a second pin into the proximal fragment and the last pin into the distal fragment. Insert the pins through the universal pin holders, which act as guides, using the drill sleeve assembly. Place the pins about 2.5 cm from the fracture site, assuming there are no bone or skin problems to contraindicate this location.
- If the reduction is imperfect, loosen all universal clamps slightly and achieve a reduction as close to anatomic as possible. Tighten the pin clamps.
- If the fracture configuration allows, place it in compression, using hand pressure or the compression device (Fig. 24.18). Once the first half-pin frame is in place, application of a second frame is far simpler, because the fracture is already reduced. Follow the same technique. When two frames are used, use bars that are long enough to attach cross-connecting bars at each end.

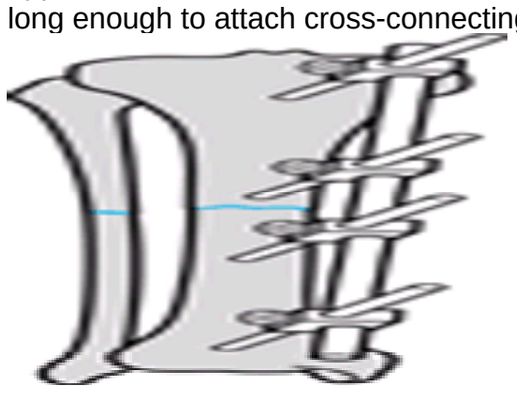

***Figure 24.18.*** Final configuration of single-plane AO external fixator. Place the two additional Schanz screws using the universal pin clamps as guides. Achieve compression across the fracture if possible.

### HOFFMANN II

The Hoffmann II (Howmedica, Rutherford, NJ) is a versatile external fixation system that represents the evolution of external fixation frames from the original design to a more sophisticated system. It allows use of single pins or clustered pins in almost any arrangement. Although it is always a good idea to have the limb roughly aligned as the initial fixator is applied, the frame allows reduction of the fracture after application of the fixation pins. Fracture manipulation tools are provided that apply to the frame (Fig. 24.19).



***Figure 24.19.*** Hoffmann II (Howmedica, Rutherford, NJ) external fixator. See text for details. **A:** Apex one-step pins and pin clamp. **B:** Unilateral fixation frame. **C:** Semicircular fixation frame for proximal tibial shaft fractures. **D:** Independent pin placement frame for distal tibial shaft fractures. (Photos courtesy of Stryker Osteonics Howmedica, Rutherford, NJ.)

One-step Apex (Howmedica, Rutherford, NJ) pins are 4 or 5 mm, self-drilling, self-tapping pins, and 6 mm blunt pins that require predrilling. A pin-to-rod coupling provides connection to the frame for a single pin with allowances for full three-dimensional rotation, and it accommodates 4 and 5 mm Apex pins. The spring-loaded mechanism allows snap-fit fixation and attaches to 8 mm rods. The pin coupling is locked through an easily accessible four-sided bolt mounted on its end. The pin clamp shown holds multiple pins, as in the original Hoffmann system.

### HINTS AND TRICKS

- Open the rod-to-rod and pin-to-rod couplings until the mechanical stop is reached, to guarantee proper snap fit of the component.
- Face all 7 mm square-head screws upward or to the outside of the fixator to facilitate adjustment.
- Do not bend connecting rods.
- Always use Apex pins with this device.
- Carefully think through the frame configuration to be used before applying it. Take into consideration the size of the patient, bone quality, fracture configuration, and need for soft-tissue reconstructive procedures.

### UNILATERAL FRAME FOR FIXATION OF TIBIAL SHAFT FRACTURES

The components required are two 8 mm connecting rods, two pin-clamp assemblies without posts, four 30° posts, four 8 mm rod-to-rod couplings, and four 5 mm one-step Apex pins (Fig. 24.19*B*).

- Obtain and maintain approximate alignment of the fracture.
- Insert the most proximal and most distal 5 mm pins through a small stab wound on the anterior surface of the tibia, as close as possible to the AP plane. Avoid

the thick anterior ridge of the tibia.
- Insert the pins with the hand-powered drill brace and appropriate-sized chuck. Use firm pressure; avoid excessive insertion speed to avoid overheating the pin and bone.
- Apply a pin clamp assembly to the proximal pin. Use it as a guide to insert the second pin as close as practical to the fracture site through the outside pin site.
- Repeat this procedure on the distal fragment.
- Insert 30° angled posts in an inverted **V** position (they can be assembled before you apply them to the pins).
- Connect the two pin-clamp assemblies together using four rod-to-rod couplings and 8 mm connecting rods of appropriate lengths and material.
- Hint: Keep rod-to-rod couplings on the inside of the frame and connecting rods as short as possible to increase stability of the frame.
- If the fracture is not anatomically reduced or not in the desired position, the rod-to-rod couplings can now be loosened and final position obtained either by direct manipulation of the fracture or with the use of the reduction wrench.

**SEMICIRCULAR FRAME FOR PROXIMAL TIBIAL SHAFT FRACTURES**

The semicircular frame (Fig. 24.19*C*) is applicable to fractures of the proximal shaft at the metaphyseal–diaphyseal junction, where an array of pins parallel to the tibial plateau and at different angles is desired to improve the strength of proximal fixation.

The components required are one curved aluminum semicircular rod; two 8 mm connecting rods; three 8/4, 5 mm pin-to-rod couplings; four 8/8 mm rod-to-rod couplings; one pin clamp assembly with no post; two 30° angled posts; and five 5 mm one-step Apex pins.

- Using the semicircular rod as a guide, insert three pins into the proximal tibia in a unilateral bicortical fashion.
- Connect the single pins to the semicircular rod using the pin-to-rod couplings.
- Place a classical parallel pin assembly with two 30° angled posts in an inverted **V** position as illustrated in Figure 24.19*C* and as described for the previous unilateral frame.
- Reduce the fracture and connect the pin-clamp assembly to the semicircular aluminum rod using four rod-to-rod couplings and manipulating the fracture either directly or with the assistance of the reduction wrench.

***Independent Pin Placement Frame for Distal/Tibial Shaft Fractures***

The independent pin placement frame fixator is recommended for extraarticular fractures of the shaft at the metaphyseal–diaphyseal junction (Fig. 24.19*D*).

The components required are two 8 mm connecting rods, one pin-clamp assembly with no post, two 30° posts, two 8/8 rod-to-rod couplings, two 5 mm 8/4 pin-to-rod couplings, and four 5 mm pins.

- Achieve approximate reduction of the fracture.
- Place a classical parallel pin assembly in the proximal fragment as illustrated in Figure 24.19*D* and as described previously.
- Independently, insert a 5 mm Apex pin into the medial surface of the tibia in the transverse plane, proximal and parallel to the ankle joint. Place a similar pin in the AP plane.
- Connect the proximal pin clamp assembly to the distal pins using pin-to-rod couplings and rod-to-rod couplings; use connecting rods of appropriate length and material.
- Achieve final reduction of the fracture if necessary by loosening the couplings to the rods and retightening after reduction.

***Orthofix Dynamic Axial Fixation***

The Orthofix (Richardson, TX) Dynamic Axial Fixation (DAF) has been employed widely for limb lengthening as well as fracture fixation. It uses half-pins for cortical and cancellous bone, with tapered threads that are designed to offer more uniform fixation in both the near and far cortex. Pins are inserted in parallel arrays through clustered pin holders like those the Hoffmann II uses, and the body of the fixator has ball joints for reduction of the fracture and final alignment. It provides for distraction and compression and dynamization as well. The pins can be placed transversely for the management of fractures at either end of the shaft of the tibia with the potential configurations seen in Figure 24.20. The components and instrumentation are illustrated in Figure 24.21.

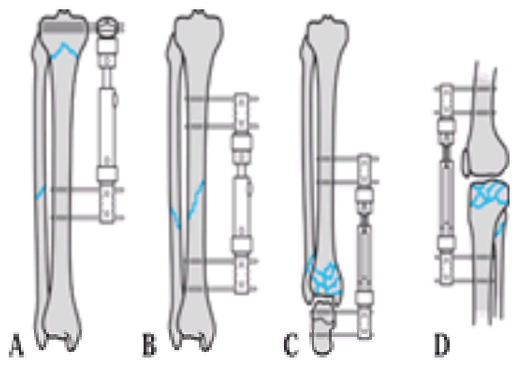


***Figure 24.20.*** Configurations for Orthofix Dynamic Axial Fixator (DAF). See text for details. **A:** Proximal tibial fracture using the **T**-pin clamp proximally. **B:** Midshaft tibial fracture with standard DAF. **C:** Pylon fracture of the distal tibia and ankle joint with articulated pin holder using pins in the talus and calcaneus. **D:** Severely comminuted fracture of the tibial plateaus with a fixator bridging the knee joint.

***Figure 24.21.*** **A:** Standard (*2*), long (*1*), and short (*3*) dynamic axial fixators (DAFs). **B:** DAF components. Central body (*1*). Straight-pin clamp (*2*). **T**-pin clamp (*1*). Component parts of the DAF (*4–9*). Distraction/compression module (*10,11*). Pin clamp cover (*12*). **C:** DAF instrumentation and components. Assembly guide template (*1*). Screw guide (*2*). Screw guide (*3*). **T**-wrench (*4*). Drill bits (3.2, 4.8 mm) (*5*). Template locking screw (*6*). 6 mm polyhedral Allen wrench (*7*). 3 mm Allen wrench (*8*). Tapered trocar (*9*). Template body for short fixator (*10*). Template accessory for articulated bodies (*11*). Angled template clamp (*12*). Template accessory for articulated body (*13*). **D:** DAF instrumentation. Silicone oil aerosol (*1*). Sterilizable screw covers (*2*). Interchangeable head hammer (*3*). Torque wrench (*4*). Fixator self-locking manipulation forceps (provided as a pair) (*5*). (Courtesy of Linda Krugman, Orthofix, Richardson, TX.)

***Standard Longitudinal Fixator***

- Obtain approximate reduction of the fracture and lay a template or fixator along the subcutaneous border of the tibia to determine the approximate location of the incisions for the screws, in particular to locate the most proximal screw, which will be placed first. Orient the fixator into either the anterior or medial/lateral plane as desired.

- At the location of the proximal screw, make a longitudinal incision sufficient to accept the screw guide. Cut down to the periosteum, and gently elevate it at the screw site with a small elevator.
- Insert a trocar into the correct-length screw guide under fluoroscopic control, making sure that the guide is perpendicular to the longitudinal axis of the bone. Make a pilot notch with the trocar. Withdraw the trocar from the guide, maintaining pressure on the screw guide handle. Using a mallet, tap the screw guide lightly to engage the cortex with its teeth (Fig. 24.22*A*).

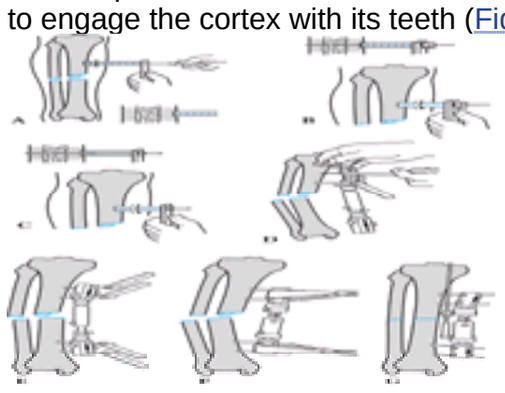

***Figure 24.22.*** Application of dynamic axial fixator (DAF). See text for full details. **A:** Insertion of the drill guide and trocar. **B:** Drilling the hole for a screw. **C:** Insertion of the screw. **D:** Application of the template to the first screw. **E:** Insertion of the remaining screws. **F:** Application of the DAF and reduction of the fracture. **G:** Compression of the fracture. (Courtesy of Linda Krugman, Orthofix, Richardson, TX.)

- Drill the cortex using a 4.8 mm drill for cortical screws and a 3.2 mm drill for cancellous screws. Avoid overheating the drill bit. The drill stops can be used to avoid overpenetrating the soft tissues beyond the far cortex (Fig. 24.22*B*).
- Remove the drill bit and drill guide while maintaining pressure on the screw guide handle. Insert the selected screw into the screw guide using the **T**-wrench. Under fluoroscopic control, insert the screw until at least two threads protrude beyond the second cortex. Since these screws are tapered, they cannot be repositioned by turning counterclockwise without loosening the screw (Fig. 24.22*C*).
- Leave the screw guide on the screw and apply one end of the template using the most external hole (Fig. 24.22*D*).
- Adjust the template body to the correct length and place drill sleeves into the second hole to be used in the proximal template clamp and into two holes in the distal. Place the screws as widely separated as the clamps will allow. In good-quality bone where the fixator will be reasonably close to the limb, two screws are usually enough. A third screw can be added when bone quality is poor or the fixator body is to be mounted at a significant distance from the limb. Note that to permit final adjustment at the fracture site, the body of the fixator must not be either fully compressed or fully extended. Although the ball joints of the fixator allow for final adjustment of position, and the body allows for additional compression or distraction, it is important to reduce the fracture as close to anatomic as possible while applying the fixator. Adjustments will be easiest if the body is kept parallel to the long axis of the diaphysis (Fig. 24.22*E*).
- Next, insert the most distal screw and then the two inner screws using the technique just described.
- Remove the template and attach the Orthofix DAF. Be certain that the body-locking screw is on the outside. Have the dot and arrow on the cam mechanism and the screws on the clamps facing upward to facilitate adjusting and locking the fixator. Position the fixator at least 1 cm from the skin and tighten the clamp screws using the Allen wrench (Fig. 24.22*F*).
- Achieve final reduction using the manipulation forceps, and then lock the cams and body-locking screw. Final locking of the cams employs the torque wrench that should be turned until the first click (Fig. 24.22*F*).
- Compression and distraction can be achieved by using the compressor distractor unit (Fig. 24.22*G*).

### POSTOPERATIVE CARE

Several different pin-care regimens work well. As long as the pins remain tight in bone, and skin necrosis does not occur, infection rarely becomes a problem. When swelling decreases, skin tension will sometimes develop on one side of a pin. Incise the skin on the tension side (where the skin is gathered against the pin) to relieve pressure. Dress the pins with sterile dressings. Light pressure on the skin limits skin motion and decreases the infection rate.

After 7–10 days, let patients shower but not bathe. Ask them to wash the frame and skin around the pin sites daily with mild soap, using a soft toothbrush on the skin around the pin sites and a soft surgical brush on the frame. All exudate must be removed from the skin. After showering, they should dry the frame and skin with a freshly laundered towel and then place ×-inch dressings on the pin sites with clips to minimize skin motion on the pins (Chapter 11). Advise patients to wear pants to protect the frame and skin.

If good contact of the major bone fragments has been achieved, the patient can begin partial weight bearing with crutches. Start with the weight of the leg. Once some fracture stability is achieved, usually between 6 and 12 weeks, allow the patient to progress to full weight bearing if the fracture and type of fixator permit. If weight bearing is permitted, frequent follow-up is necessary to ensure that the frame and pins remain tight and no displacement of the fracture occurs. Give your patients a wrench and ask them to check all fittings on a daily basis.

Stable, closed, or low-grade open fractures in good contact, as well as those that have been bone-grafted, can be expected to unite in the external fixator. As fracture stability increases, alter the frame design or use adjustments allowed by the frame design to reduce its stiffness to allow more weight bearing through the bone. In double half-pin fixators, the most medial frame can often be removed in 6–12 weeks. The same is true for delta frames, which can be reduced to the single anterior frame. Initially, a second bar can be mounted on the single-bar frame to increase its rigidity; the second bar is removed later. Further flexibility can be achieved by moving the bar farther away from the skin.

After the first 8–12 weeks, loosen the fixator and check the fracture for stability at 4- to 6-week intervals. When clinical stability is present, remove the fixator and place the patient in a short-leg fracture brace. If you question the adequacy of stability, leave the pins in place and the frame off for 1 week to be certain the fracture does not change position. Reapply the frame if it does.

Some surgeons prefer to remove external fixators early. Patient preference and pin problems can also precipitate early removal. If the fracture is unstable at the time of removal, shortening and deformity are common. Good immobilization in an appropriate cast or brace is important. In some cases, conversion to internal fixation may be desirable, but be advised that the infection rate is higher when internal fixation is preceded by external fixation.

The safest method to use is nonreamed intramedullary nails and closed technique. In these cases, remove the fixator, immobilize the fracture with a cast until the pin tracks are clean and dry, and then proceed with internal fixation. Do not use intramedullary nailing if the external fixator pins have been infected. Some surgeons advocate using external fixators only until soft-tissue problems in open fractures are resolved with early conversion to an intramedullary nail (Table 24.7).

## PITFALLS AND COMPLICATIONS

The most common and troublesome complication is pin-track drainage or infection. If a pin persistently drains, or is painful, most likely it is infected and loose. Loosen the clamp holding the pin and gently wiggle the pin back and forth. Usually it is loose in the near cortex. A radiograph may show a radiolucent zone around the pin.

Loose pins must be removed. Place a pin in a new site at least 15 mm away from the loose pin. If you cannot do so, try to get along with fewer pins, or remove the frame. If the pin is tight, then soft-tissue care with debridement, drainage, and local antibiotics or antiseptics is appropriate. Oral antibiotics are occasionally useful as well.

## INTRAMEDULLARY NAILING

### POSITIONING OF THE PATIENT

Regardless of the type of nail to be inserted, the positions used are similar. I prefer to use a fracture table with skeletal traction through the calcaneus. This setup (Fig. 24.23) offers the best opportunity to reduce the fracture before inserting the nail. More important, it allows the reduction to be maintained during the procedure. It also facilitates fluoroscopic visualization of the extremity.

***Figure 24.23.*** Setup for intramedullary nailing of the tibia. **A:** Chick-Langren fracture table set up for tibial nailing. The foot is in a foot holder. The thigh bolster is above the popliteal fossa. **B:** Setup on a regular radiolucent operating table using an arthroscopic leg holder.

**SETUP FOR INTRAMEDULLARY NAILING OF THE TIBIA ON A CHICK-LANGREN FRACTURE TABLE**

- On a Chick-Langren fracture table (Kirshner Medical, Greenwood, SC), place the uninjured lower extremity in a well-padded leg holder with the hip and knee flexed to 90° and abducted to give access for the C-arm.
- Position the injured extremity over a well-padded thigh support placed on the distal thigh. Avoid the popliteal fossa to avoid neurovascular injury.
- Secure the foot in a well-padded foot holder, if distal cross locking is not to be done. Alternatively, place it into a tibial pin traction device attached to a quarter-inch threaded Steinmann pin. The pin is placed transversely under sterile conditions through the calcaneus to permit adequate access to the distal tibia for cross locking.
- Bring the C-arm into place (Fig. 24.23*A*). It must be able to rotate unhindered from the AP to the lateral position, and you must be able to visualize the full length of the tibia.
- Prepare and drape the tibia so that full access is available from the knee joint to the ankle joint with the sheets draping down from the leg to cover the lower head of the C-arm. When the C-arm is brought into the lateral position, the head should remain beneath the drapes, preserving the sterile field. Sterilely drape the uppermost head of the C-arm.

**NAILING ON A REGULAR OPERATING TABLE**

If a regular operating table (preferably with a radiolucent top) is used, three alternatives are available for positioning and maintaining reduction. Using any of these positions, either open or closed nailing can be carried out with all of the intramedullary nails with which I am familiar. If closed nailing is to be carried out, I highly recommend the use of a fracture table.

- You may place an arthroscopic leg holder about the thigh and position it to support the lower extremity, with the knee flexed to 90° and the foot supported on the operating table (Fig. 24.23*B*).
- Alternatively, abduct the thigh, flexing the knee to 90°, allowing the foot and tibia to hang vertically off the side of the operating table. If you use this method, pump the table up so that the foot is just below your waist.
- The third alternative is to prepare and drape the extremity and then place a large sterile bolster under the thigh. Insert one transverse Schanz pin into the proximal tibia and a second one into the distal tibia or calcaneus. Attach to these an AO distractor and use it to apply traction to align the fracture.

**LOTTES NAILING**

The Lottes nail is little used today, but because it is simple and inexpensive it is still popular in underdeveloped areas (10). Lottes nails can be inserted by open or closed technique; unless the fracture is open, always try to use closed technique.

- Position the patient and drape the limb in the usual manner for lower extremity surgery. A tourniquet can be used.
- Make a 5 cm longitudinal incision, beginning at the level of the tibial tubercle, one fingerbreadth medial to the tubercle, and extend it proximally to the joint line. Split the patellar tendon or go to its medial side. Directly beneath this incision, expose the cortex of the tibia. Perforate the cortex with either a Küntscher awl or a half-inch drill point just proximal to the tibial tubercle. Avoid encroaching on the tibial tubercle or the articular surface. Lottes advocates a large drill point, but I have found it easier to use Küntscher awls. The disadvantage of the awl is that in a young patient with dense cancellous bone, sometimes the hole cannot be placed deep enough to actually enter the medullary canal, and a drill or a reamer may be necessary.
- Direct the entry hole straight down the medullary canal. The most common mistake is to perforate posteriorly. Press the handle of the awl or drill against the knee to achieve alignment with the medullary canal (Fig. 24.24). In the medial-lateral plane, follow the line of the anterior crest of the tibia.

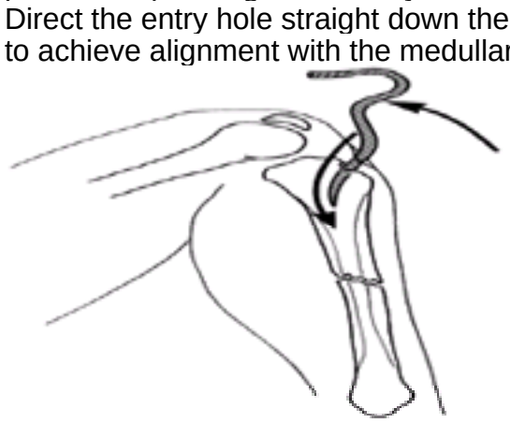

***Figure 24.24.*** Entry site for intramedullary nailing of the tibia.

- Next, select the appropriate-size Lottes nail. Although it is possible to determine the size preoperatively by measuring radiographs, it is unnecessary to do so unless the patient is unusually small or large. Determine nail length by laying the nail on the leg. Place the proximal end of the nail against the entry site. The distal end should be within 2.5 cm of the ankle joint, depending on the level of fracture being treated. Of the two diameters available, $^{5}/_{16}$ inch (8 mm) and $^{3}/_{8}$ inch (9.5 mm), select the appropriate diameter based on appraisal of the radiographs.
- Flex the knee to 90° or greater. With an assistant supporting the leg, drive the rod into the proximal fragment, taking care to maintain proper alignment.
- Avoid perforating the posterior cortex. The nail must move easily with each blow of the mallet. Impending impaction of the nail in the proximal fragment is characterized by an increase in the pitch of the sound of the mallet and by lack of forward movement of the nail. In the event of impaction, extract the nail and use a smaller nail.
- Drive the nail until it is at the fracture site. Ensure that the fracture is well reduced, and drive the nail into the distal fragment (Fig. 24.25). Drive the nail until the proximal end is level with bone. Because of the subcutaneous location of the entry site, too long a nail will result in a painful bursa. If a nail is found to be too short, extend it by adding the appropriate-size extension [$^{3}/_{8}$ inch (13 mm), ¾ inch (19 mm), or 1 inch (25 mm)].

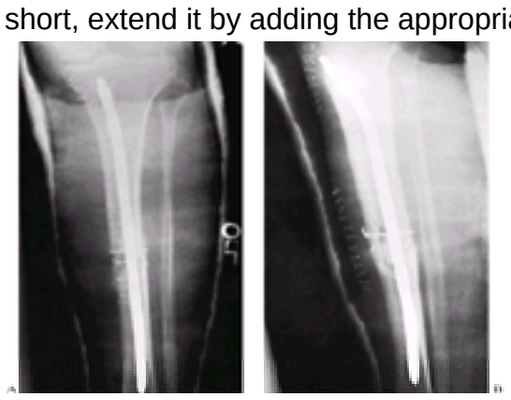

***Figure 24.25.*** **AP** (**A**) and lateral (**B**) radiographs of a Lottes nail fixing an open Gustilo grade II fracture of the tibia. Circlage wires were used to secure a butterfly fragment. This further devascularizes the fracture and is best avoided if the fragment is in reasonable apposition.

- Next, complete impaction of the fracture and examine for stability. If the fracture is unstable, additional stability can be obtained by plating a fracture of the fibula (Fig. 24.26) (94). Some surgeons feel that plating promotes delayed union of the tibia, but my experience with this combination in open fractures has been reasonably good, with results comparable to those with external fixation.

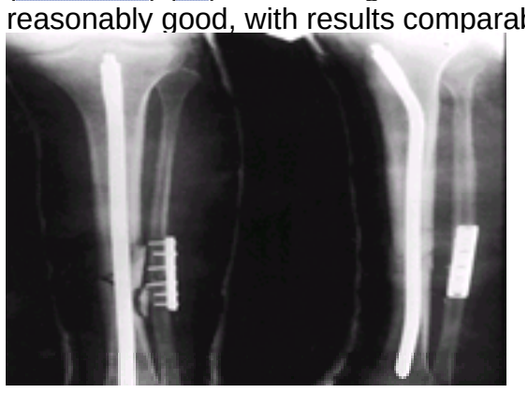

***Figure 24.26.*** AP and lateral radiographs of a Lottes nail fixing an unstable fracture of the tibia. The fibula has been plated to gain additional stability. Plating of the fibula may lead to delayed union of the tibia. Consider early bone graft of the tibia if callus formation is delayed.

- After wound closure, place the extremity in long-leg, well-padded splints to maintain the knee in 15° of flexion and the ankle at a right angle. See Figure 24.25 and Figure 24.26 for sample cases.

***Postoperative Care***

At the time of discharge from the hospital, or at 1 week postoperatively, remove the splints and apply either a long-leg cast, Sarmiento cast, or functional brace, depending on the stability of the fracture. If axial stability is present, allow weight bearing; otherwise, delay weight bearing until 6 weeks. In most cases, by 6 weeks there is enough stability that immobilization is no longer necessary and the patient can continue with crutches and weight bearing as tolerated. Continued instability at 6 weeks may necessitate further immobilization and delayed weight bearing. Begin joint and muscle rehabilitation as soon as possible.

**ENDER NAILS**

The preoperative and intraoperative preparation for Ender nails is identical to that for Lottes nailing. The Ender tibial nail is 4.0 mm in diameter. At least two nails are necessary for adequate stability; if the canal will accept more, they can be placed.

- Insert the Ender nails through 2.5 cm stab wounds located about 2 cm medial and lateral to the patellar tendon on the proximal tibial flare, about 2 cm below the joint line.
- Perforate the cortex with a Küntscher awl or a drill point. Insert the medial or lateral nail first, depending on the configuration of the fracture. If the fracture tends to angulate into varus, place the lateral nail first. In difficult fractures, it is sometimes helpful to drive both nails simultaneously, alternating the driving from one side to the other.
- The nail can be used to reduce the fracture. More or less curve can be bent into the tip to facilitate the reduction. Use the bend of the nail to fish the tip into the mouth of the distal fragment by twisting the nail, and then use the nail to reduce the fracture.
- Then drive the nails to the subchondral bone of the tibia distally, spreading the tips.
- Leave the flat of the proximal end of the nail lying against the cortex above the entry hole (Fig. 24.27).

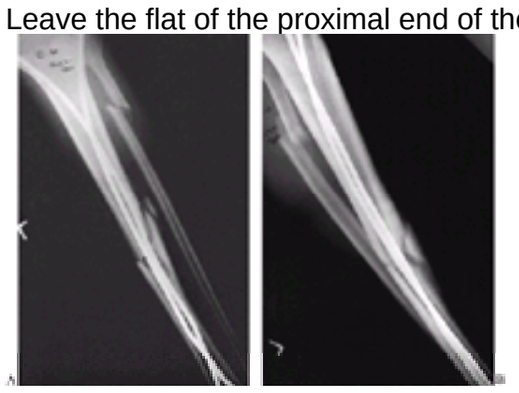

***Figure 24.27.*** AP (**A**) and lateral (**B**) radiographs of a fracture of the tibia and fibula stabilized with Ender pins. Notice the mild posterior angulation on the lateral view. This is a common problem with Ender nails. (From Chapman MW. Fractures of the Tibial and Fibular Shafts. In: Evarts CM, ed.*Surgery of the Musculoskeletal System.* New York: Churchill-Livingston, 1983, with permission.)

- Insert both Ender and Lottes nails with closed technique. If necessary, the fracture can be opened, but opening is discouraged as it increases the risk of infection and the rate of delayed union. In comminuted fractures, avoid the temptation to place cerclage wires for butterfly fragments, which would further devascularize the fragments and is nearly always unnecessary.
- Postoperative care is identical to that described for Lottes nails.

## REAMED AND NONREAMED LOCKED INTRAMEDULLARY NAILING

As nails with locking capabilities can be used without locking, nonlocking nails are now obsolete. Except for the cross-locking procedure, the techniques for all nails are nearly identical.

Nearly every manufacturer of bone fixation equipment in the world today has a locking nail for the tibia. Nails vary in the curvature, cross-sectional shape, cannulation, longitudinal curvature, and configuration of the cross-locking screws; but the general principles in their insertion and application are very similar. Cross locking is offered with round holes, which provide rigid locking, and oval holes with the capability for spontaneous compression at the fracture site while maintaining rotational control.

Some nail designs such as the Alta (Howmedica, Rutherford, NJ) offer add-on tabs or extensions at the proximal end of the nail. These extensions provide the opportunity to vary the length of the nail. They also allow for the addition of extra cross-locking screws in a very proximal location, which may be useful for high proximal fractures and undisplaced fractures of the tibial plateaus where proximal fixation is desired.

**REAMED TECHNIQUE**

As the general principles for insertion of most nails are similar, only the technique for the Alta system will be described. The nail can be inserted as a reamed or an unreamed nail.

Reamed nailing is easier and more trouble free when done on a fracture table. It is possible to perform reamed nailing on a regular operating table, but it is more difficult to pass the guide pin, and radiologic control is poorer. Refer back to the discussion on positioning the patient; the position for reamed intramedullary nailing of the tibia on the fracture table is shown in Figure 24.23*A*.

Two entry sites are possible: through the patellar tendon or medial to the tendon. I much prefer to go through the tendon, as I have seen no significant morbidity from splitting the tendon, and positioning the nail is greatly simplified (Fig. 24.28).

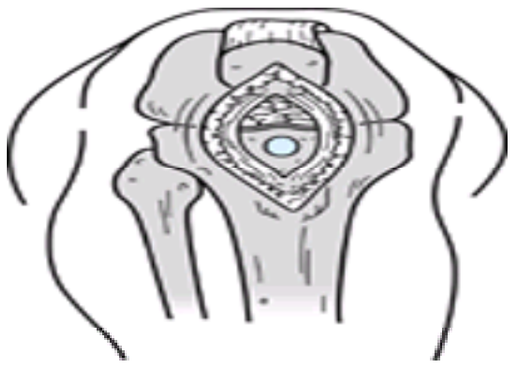

***Figure 24.28.*** Surgical approach and entry hole for intramedullary nailing of the tibia. See the text for a full description.

- If you choose to go through the tendon, make a longitudinal skin incision from 1 cm proximal to the distal pole of the patella, to 1 cm proximal to the tibial tubercle. Reflect the infrapatellar fat pad in a proximal direction. Perforate the cortex with a Küntscher awl just above the tibial tubercle. Maintain good alignment with the intramedullary canal of the tibia, taking care not to angulate posteriorly or laterally. Avoid impingement on the articular cartilage of the tibial plateau.
- Penetrate the cancellous bone of the metaphysis into the medullary canal. Insert the reaming ball-tipped guide pin into the proximal fragment, reduce the fracture by manual manipulation, and pass it into the distal fragment. Manipulation of the fracture is greatly assisted by placing a manipulator into the proximal fragment; this technique usually eliminates the need for an assistant. With appropriate-size reamers, ream the medullary canal throughout its isthmus to the size appropriate for the nail to be used. Usually 1.0 mm of overreaming is necessary.
- Determine nail length by comparative measurement of two identical guide pins, or measure directly by laying a nail on the tibia.
- Use a plastic tube to exchange the reaming guide pin for a driving guide pin.
- Select a nail of the appropriate length and diameter, and drive it into position, taking care to maintain good fracture alignment. In most cases, select the nail that will reach to within 1 cm of the ankle joint and will sit slightly below the level of the cortex at the entry point. This technique, using Alta instrumentation, is shown in Figure 24.29.

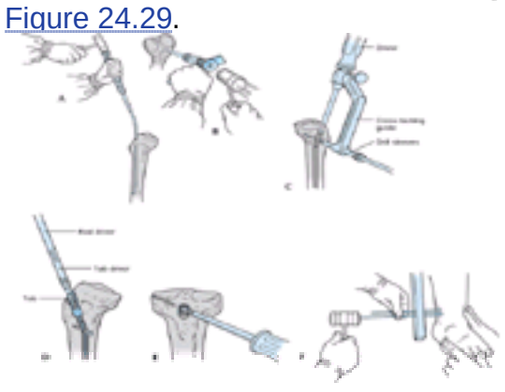

***Figure 24.29.*** Reamed intramedullary nailing using the Alta system. **A,B:** Driving the Alta tibial nail using the anvil as a crossbar to control rotation. **C:** Proximal cross locking with a jig. Insert drill sleeves down to bone (usually medially). Tap an appropriate-size drill point into the bone with a mallet to anchor its point and then drill through the nail and opposite cortex. Measure for screw length with a depth gauge off the outer drill sleeve. Then insert a transverse cross-locking screw through the sleeve. **D:** In the Alta system a tab (*shown here*) or cylindrical extender can be attached to the top of the rod. These provide holes for cross locking with up to two additional screws under direct vision. They are angled at 45° to the sagittal plane. Here the tab is secured to the nail with a screw. **E:** Transverse cross-locking screw being inserted into the tibia through one of the holes in a tab. **F:** Distal cross locking of a tibial nail is most easily accomplished from medial to lateral. Freehand technique is commonly used. (Courtesy of Howmedica, Rutherford, NJ.)

- If indicated, perform distal and proximal cross locking with the special guides provided, or by using freehand technique. The Alta nail is supplied in diameters from 6 to 14 mm. The 6 and 7 mm nails are solid and cannot be locked. The 8 and 9 mm nails are solid but have holes for cross locking with 3.7 mm transverse cross-locking screws. The 10 to 14 mm nails are cannulated for a guide pin and take 5 mm locking screws. (Fig. 24.30, Fig. 24.31, Fig. 24.32 and Fig. 24.33 demonstrate sample cases.)

***Figure 24.30.*** Alta locked intramedullary nailing using closed technique. **A:** Lateral radiograph of a transverse displaced tibial shaft fracture. **B:** Postoperative AP radiograph showing anatomic reduction and static locking with a reamed nail. Since there was 100% cortical contact in compression, the patient was permitted to bear weight as tolerated. **C:** Lateral view.

***Figure 24.31.*** Proximal shaft fracture of the tibia fixed with an Alta nail using the tab. **A:** AP radiograph showing a fracture in the proximal third. This fracture requires at least two screws in the proximal fragment to achieve adequate stability. Since this earlier design of the nail had only one proximal cross-locking hole, the tab and screw were added. **B:** Lateral radiograph.

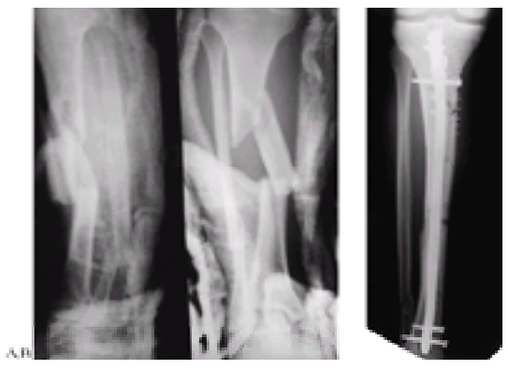

***Figure 24.32.*** Comminuted segmental fracture of the tibia treated with a locked Alta intramedullary nail and supplemental plate proximally. **A:** AP and lateral radiographs of a multisegmental fracture. **B:** Postoperative AP radiograph. On this film it can be seen that there were four separate fracture sites resulting in five major fragments. The proximal fracture was opened medially and stabilized with a 3.7 mm reconstruction plate, and the remainder of the fractures were stabilized by closed intramedullary nailing with static cross locking.

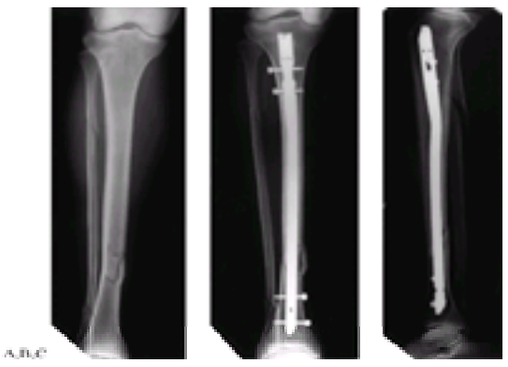

***Figure 24.33.*** Distal-third fracture of the tibia treated with a statically locked AO nail. **A:** AP radiograph showing the fracture. This could have been treated in a Sarmiento cast or cast-brace as well. **B:** AP radiograph taken postoperatively. **C:** Lateral radiograph.

**UNREAMED TECHNIQUE**

A nail of any size can be driven unreamed as long as it will fit into the medullary canal and can be driven with reasonable ease.

- Position the patient, reduce the fracture, prepare and drape the leg, and perform the surgical exposure and create the entry site for the nail as described for reamed nailing.
- Use sounds or a tibial nail to determine the diameter of the canal.
- Select a nail equal to, or 1 mm in diameter smaller than, the largest sound that will pass easily through the isthmus of the canal.
- Insert the nail while pressing the driver toward the knee to ensure proper alignment of the nail; direct the nail down the canal until it is at the distal end of the proximal fragment.
- Using the nail and driver as a lever, and with an assistant directly manipulating the fracture, drive the nail across the fracture into the distal fragment. Drive the nail to approximately 15–20 mm proximal to the ankle joint.
- The remainder of the procedure, such as cross locking, is identical to that for reamed nails.
- When locking, I usually cross-lock distally first, then adjust the position of the fracture by back-slapping on the driver to be certain that the bone fragments are in good contact. Then I lock proximally.

***Postoperative Care***

Apply a well-padded long-leg dressing with splints. Have patients wiggle their toes and begin isometric exercises in the splint. Three to 7 days after surgery, remove the splint and begin full rehabilitation.

Avoid a tight heel cord and equinus contracture with a rigorous physical therapy program. Use of a cast-brace that prevents equinus or a removable posterior night splint may be necessary in the first few weeks after surgery.

With stable fracture patterns and dynamic cross locking, allow the patient to progress to full weight bearing, with or without a brace, as tolerated. With static cross locking in stable patterns, I like to impact the fracture intraoperatively with the driver. In these cases, full weight bearing is usually possible immediately. In unstable fracture patterns, delay full weight bearing until callus can be seen bridging the fracture on radiographs.

Take caution with smaller nails that use transverse cross-locking screws 4 mm or less in diameter. Incidence of screw fracture with weight bearing on unstable fractures is as much as 30%. Removal of cross screws to dynamize the nail is usually necessary only in delayed unions with short oblique fractures.

## SCREW FIXATION

The indications for open reduction with only lag screw fixation are limited. The most common indication is a spiral or oblique fracture in the distal third of the tibia with an intact fibula, where unacceptable varus angulation of the distal fragment is present. These types of fractures are very difficult to control by closed means and respond well to interfragmentary screw fixation.

Many surgeons attempt to place lag screws percutaneously using cannulated screws. Intramedullary locking nails can often be used as well. The length of the fracture must be at least 3 times the diameter of the tibia at the level of the fracture. Approach the tibia through an anterior longitudinal incision, 1 cm lateral to the anterior crest of the tibia. Expose only the edges of the fracture fragments by subperiosteal dissection. Perform lag screw fixation with three or more screws.

A comparable fracture presenting a similar problem can be seen in the proximal third of the tibia, with or without an intact fibula, which may have persistent gapping and unacceptable angulation. Treat it in a similar manner. Interfragmentary screw fixation alone rarely provides sufficient stability; external protection is always necessary. In both of these fractures, a functional non-weight-bearing brace is recommended. Because these fractures are through cancellous bone, bone grafting is usually unnecessary.

Interfragmentary screw fixation alone for diaphyseal fractures is rarely, if ever, indicated. These fractures are better treated with a locked intramedullary nail. An occasional type I or low-grade type II open fracture with exposed fracture fragments will benefit from screw fixation. The fracture must be oblique or spiral and must be three times in length the width of the tibia at the site of the fracture (Fig. 24.34). In this circumstance, interfragmentary screw fixation combined with a single-bar external fixator might be indicated. Precise technique is critical. Details for this technique are discussed in Chapter 11.

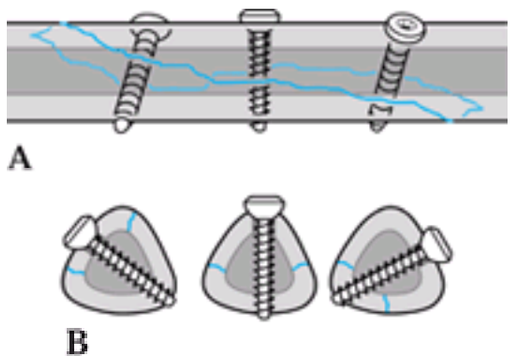


***Figure 24.34.*** **A:** Interfragmentary lag-screw fixation. The fracture is at least three times as long as the diameter of the bone. Insert three 4.5 mm cortical screws to lag the fracture together using a gliding hole in the near cortex. **B:** Keep the screws at right angles to the fracture. Accurate placement is guaranteed by using gliding-hole-first and threaded-hole-first techniques (see Chapter 11).

### PLATE FIXATION

The indications for plate fixation are intraarticular fractures, metaphyseal fractures requiring a buttress or neutralization plate to support interfragmentary screw fixation, and an occasional diaphyseal fracture for which intramedullary nailing or external fixation is not feasible (12). Because of the risk of infection, soft-tissue complications, and delayed union, plate fixation of fractures of the diaphysis of the tibia is the treatment of last choice. Broad or narrow 4.5 mm plates can be used, but the narrow plates are preferable (Fig. 24.35). Semitubular plates are too weak. Specialized **L** and **T** plates and spoon plates are available for the metaphyseal/epiphyseal regions.

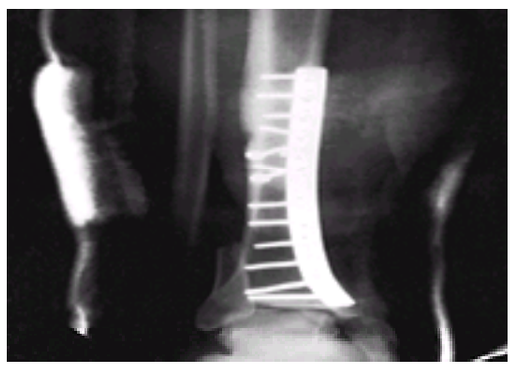

***Figure 24.35.*** Plate fixation of the tibia. A comminuted intra-articular fracture of the tibia and fibula seen on an AP radiograph showing plate and screw fixation.

Technically, it is easiest to place plates on the anteromedial subcutaneous border of the tibia. This is the location of highest risk, as skin problems or infection may result in exposure of the plate. It is much safer but technically more difficult to place plates on the lateral surface of the tibia. Plates may also be placed posteriorly on the tibia, but this approach is reserved for severely injured extremities, where the anterior soft tissues are unsuitable for surgery. The techniques are the same as those described in Chapter 11. I routinely bone-graft all diaphyseal fractures of the tibia subjected to plate fixation to accelerate and ensure union. With excessive swelling, do not close the deep fascia; in some cases, fasciotomy may be indicated. Skin closure must be without tension and atraumatic.

### POSTOPERATIVE CARE

Postoperatively, place the limb in a short- or long-leg Robert Jones dressing with splints. Elevate it on two pillows with the knee flexed to help control edema. As rigid internal fixation is usually achieved with plate and screw fixation, immediate touch-down weight bearing, mobilization, and rehabilitation of joints and muscles is possible. Weight bearing must be delayed until fracture union occurs.

In rigidly internally fixed fractures of the tibia, union may be difficult to judge, as minimal or no callus may form. Fractures of the diaphysis in adults rarely heal well enough to sustain weight bearing before 16 weeks. At 16 weeks or later, take AP, lateral, and two oblique radiographs to establish the presence of union. If union is judged to be present, begin careful, progressive weight bearing with crutches, and monitor frequently, to ensure that displacement does not occur.

## PITFALLS AND COMPLICATIONS

Fractures of the tibia present more problems and complications than in any other long bone of the body and are discussed in detail in multiple chapters. The most common acute complications directly related to the injury are infection (Chapter 132 and Chapter 135), loss of skin and soft tissues (Chapter 8 and Chapter 35), neurovascular injury, compartment syndrome (Chapter 13), and amputation (Chapter 120). Also discussed elsewhere are late complications such as delayed union, nonunion, and malunion (Chapter 31), and sympathetic dystrophy (Chapter 7).

### INFECTION

To eliminate infection with minimal morbidity, it must be recognized early, and irrigation and debridement must be done as expeditiously as possible. It is far better to explore a few too many suspicious-looking wounds than to miss an acute infection. Stability of the fracture is critical, and in most cases best achieved with external fixation. If plate and screw fixation is stable, leave it in place; it can be removed after union occurs.

Remove all acutely infected intramedullary nails, and in the tibia convert to external fixation. In mild infection with sensitive organisms, it is worthwhile in some cases to debride the tibia with reaming and to replace the nail with a larger one. In general, however, this method works best in the femur and does not have a high success rate in the tibia. It has been suggested that cannulated intramedullary nails may harbor organisms in their interiors, but a study by Singer and Seligson (132) showed that this is not true. Antibiotic-impregnated beads are useful.

### LOSS OF SKIN AND SOFT TISSUES

Loss of skin and soft tissues is a common problem in open fractures of the tibia. The skin and soft-tissue injury in closed fractures can be substantial as well. Progressive necrosis can lead to loss of both skin and underlying soft tissue, particularly if compartment syndrome intervenes. Early full-thickness soft-tissue coverage is important to reduce the incidence of infection and delayed union. At the time of original debridement of an open fracture, do not close the traumatic wound.

Delay reconstructive surgery to gain coverage until you are certain that further necrosis will not occur and infection is not present. Skin defects without exposed bone or major neurovascular structures can be handled either by primary closure or by split-thickness skin grafting. If periosteum is present, split-thickness skin grafting can be done directly on the periosteum. Although direct split-thickness grafting provides early coverage, it often does not provide durable long-term coverage, and replacement with full-thickness tissue is often necessary.

For skin and soft-tissue defects in the proximal third of the tibia, swing the medial head of the gastrocnemius muscle on its vascular pedicle for coverage. Apply split-thickness skin-grafts to the muscle pedicle as necessary.

Coverage of the middle and distal thirds of the tibia by local tissue is more difficult. In the middle third, the soleus will suffice. In the distal third, the flexor digitorum

longus makes a good pedicle graft. In this region, however, free microvascularized pedicles are often necessary. We no longer use cross-leg pedicle flaps.

## NEUROVASCULAR INJURY

The nerve most often injured in tibial fractures is the common peroneal nerve. This nerve injury is most often the result of the original trauma and is usually a neuropraxia or axonotmesis due to stretch. It can be difficult to detect in the limb with severe muscle injury. Direct severe injury to muscle looks similar. Examine the limb carefully at the time of initial injury, recording any evidence of sensory loss or motor weakness. Frequent repeat examinations are important. A laceration directly over the main bundle of the nerve requires exploration; otherwise, treatment is limited to observation, prevention of an equinus contracture, and muscle rehabilitation.

Because three arteries supply the lower extremity distal to the knee, vascular repair of a single artery laceration is rarely necessary. The limb does fairly well with just a posterior tibial artery, and in most healthy limbs, with just an anterior tibial and peroneal artery. If only the anterior tibial or peroneal artery is functional, some late symptoms caused by lack of blood supply to the posterior compartment muscles may occur. For that reason, lacerations of the posterior tibial artery are often repaired, particularly if the fate of the two other arteries is unknown. Good arteriography is necessary to establish the patency of these arteries in severely injured legs.

## COMPARTMENT SYNDROME

In the severely traumatized limb, intramedullary nailing may contribute to compartment syndrome (93). Perform careful monitoring in these cases. Diagnosis and treatment are described in Chapter 13.

## FRACTURES OF THE SHAFT OF THE FIBULA

In the absence of dislocations of the proximal or distal tibiofibular joints, fractures of the fibula accompanying a tibial fracture require no special treatment other than that described for the tibia. Isolated shaft fractures are usually the result of direct violence. Although treatment can be symptomatic, most such fractures are painful and do better if immobilized in a long-leg walking cast for 2–3 weeks, followed by a brace or Sarmiento-type cast until 6 weeks. If symptoms allow, a soft supportive dressing and crutches may be adequate. Always look carefully for associated disruptions of the proximal and distal tibiofibular joints.

## AUTHOR'S PERSPECTIVE

For closed fractures of the shaft of the tibia that have less than 1 cm of shortening, minimal displacement, and 50% or more cortical contact between the main proximal and distal fragments, I prefer closed reduction, application of either a Sarmiento or long-leg cast, and early weight bearing with a vigorous rehabilitation program. Unless there is a contraindication, I treat all other unstable fractures of the tibia with reamed, statically locked intramedullary nailing using a fracture table. I use a medullary nail 10 mm or larger in diameter so that I can take advantage of large transverse cross-locking screws.

In these cases, I use either a CAM walker or a night splint for symptomatic relief and to protect against an equinus contracture. I start the patient on a vigorous joint and muscle rehabilitation program. Because the majority of these fractures have unstable patterns, I delay weight bearing, other than the weight of the leg, until I see bridging callus on at least one view. I progress toward full weight bearing depending on the progression of healing. I persist with nonoperative treatment when there is a systemic or local contraindication to nailing.

For me, a relative contraindication to intramedullary nailing is a displaced fracture of the tibia at the proximal metaphyseal—diaphyseal junction. If for some reason this fracture is treated with intramedullary nail fixation, I take special precautions to be certain that the fracture remains anatomically reduced during the nailing. I may add extra fixation screws or a small unicortical plate, applied with minimal dissection, to prevent displacement of the fracture (Fig. 24.32).

Similar problems can be encountered in short oblique fractures of the distal tibia within 5–7 cm of the ankle joint. These are often better handled by either external fixation or open reduction and plate fixation, but they can be treated with locked intramedullary nails as an extended indication if special precautions are taken as described previously.

In open fractures of the tibia, I try to use unreamed locked intramedullary fixation in all fractures at the time of initial debridement. To avoid premature nail or screw failure, I always try to use a 10 mm or larger titanium nail, which permits insertion of the strong 5 mm transverse cross-locking screws. In smaller patients, I may have to pass one or two reamers gently to get up to 10 mm. I find this technique to be acceptable in the majority of cases. I leave the traumatic wound open in all cases and try to achieve full-thickness, good-quality soft-tissue closure by 10 days.

I use external fixation for open fractures and on occasion for closed fractures in the presence of multiple injuries where external fixation is more practical and expedient. I often convert these to reamed nailing early. In high-grade contaminated grade IIIB and C open fractures, I often begin with external fixation. After successful soft-tissue closure, and in the absence of any evidence of infection, I convert to a reamed intramedullary nail. In fracture patterns unsuitable for intramedullary nailing, I continue with the external fixator until fracture union.

I cannot recall having used interfragmentary screw fixation alone for a fracture of the diaphysis of the tibia in the past 10 years. In fractures that can be reduced anatomically closed, or with minimal open incisions, I use interfragmentary cannulated screws in the cancellous bone of the metaphysis, or epiphyseal region, which are not suitable for nailing.

I reserve plate fixation for intraarticular fractures of the proximal and distal ends of the tibia and for an occasional metaphyseal fracture that is not suitable for nailing or external fixation. I place the vast majority of plates on the lateral border of the tibia to take advantage of the better soft-tissue coverage. I take great pains to protect the blood supply to bone using “biological” fixation techniques. I use a much larger number of plates for the treatment of nonunions of the tibia, which I apply posteriorly along with a bone graft. This technique is discussed in Chapter 31. In treating compartment syndrome of the tibia, I always use single-incision, lateral four-compartment fasciotomy rather than dual lateral and medial incisions.

## CHAPTER REFERENCES

Each reference is categorized according to the following scheme: *, classic article; #, review article; !, basic research article; and +, clinical results/outcome study.


+ 1. Aho AJ, Nieminen SJ, Nylamo EI. External Fixation by Hoffmann-Vidal-Adrey Osteostixis for Severe Tibial Fractures: Treatment Scheme and Technical Criticism. *Clin Orthop* 1983;181:154.

+ 2. Alho A, Benterud JG, Høgervold HE, et al. Comparison of Functional Bracing and Locked Intramedullary Nailing in the Treatment of Displaced Tibial Shaft Fractures. *Clin Orthop* 1992;277:243.

+ 3. Alho A, Ekeland A, Strømsøe K, et al. Locked Intramedullary Nailing for Displaced Tibial Shaft Fractures. *J Bone Joint Surg Br* 1990;72:805.

! 4. Anderson GI, Richards RR, Paitich B, et al. Soft Tissue Blood Flow after Segmental Osteotomy of the Canine Tibia. *Ann Plast Surg* 1991;127:49.

+ 5. Anderson LD, Hutchins WC, Wright PE, Disney JM. Fractures of the Tibia and Fibula Treated by Casts and Transfixing Pins. *Clin Orthop* 1974;105:179.

! 6. Ashcroft GP, Evans NT, Roeda D, et al. Measurement of Blood Flow in Tibial Fracture Patients Using Positron Emission Tomography. *J Bone Joint Surg Br* 1992;75:673.

+ 7. d'Aubigne RM, Maurer P, Zucman J, et al. Blind Intramedullary Nailing for Tibial Fractures. *Clin Orthop* 1974;105:267.

* 8. Bach AW, Hansen ST Jr. Plates versus External Fixation in Severe Open Tibial Shaft Fractures. *Clin Orthop* 1989;241:89.

+ 9. Barquet A, Massaferro J, Dubra A, et al. The Dynamic AFIS-BM Tubular External Fixator in the Treatment of Open Fractures of the Shaft of the Tibia. *Injury* 1992;23:461.

+ 10. Bayne LG, Morris H, Wickstrom J. Evaluation of Intramedullary Fixation of the Tibia with the Lottes Nail. *South Med J* 1960;53:1429.

+ 11. Behrens F, Comfort TH, Searls K, et al. Unilateral External Fixation for Severe Open Tibial Fractures: A Primary Report of a Prospective Study. *Clin Orthop* 1983;178:111.

# 12. Behrens F, Searls K. External Fixation of the Tibia. *J Bone Joint Surg Br* 1986;68:246.

+ 13. Blachut PA, Meek RN, O'Brien PJ. External Fixation and Delayed Intramedullary Nailing of Open Fractures of the Tibial Shaft. *J Bone Joint Surg Am* 1990;72:729.

* 14. Böhler L. *The Treatment of Fractures*, 5th (English) ed. New York: Grune & Stratton, 1956–1958.

+ 15. Bonanni F, Rhodes M, Lucke JF. The Futility of Predictive Scoring of Mangled Lower Extremities. *J Trauma* 1993.34:99.

+ 16. Bone LB, Johnson KD. Treatment of Tibial Fractures by Reaming and Intramedullary Nailing. *J Bone Joint Surg Am* 1986;68:877.

+ 17. Bone LB, Kassman S, Stegemann P, France P. Prospective Study of Union Rate of Open Tibial Fractures Treated with Locked, Unreamed Intramedullary Nails. *J Orthop Trauma* 1994;8:45.

+ 18. Bone LB, Sucato D, Stegemann PM, Rohrbacher BJ. Displaced Isolated Fractures of the Tibial Shaft Treated with Either a Cast or Intramedullary Nail. *J Bone Joint Surg Am* 1997;79:1336.

+ 19. Bosse MJ, Staeheli JW, Reinert CM. Treatment of Unstable Tibial Diaphyseal Fractures with Minimal Internal and External Fixation. *J Orthop Trauma* 1989;3:223.

* 20. Brown PW, Urban JG. Early Weightbearing Treatment of Open Fractures of the Tibia. *J Bone Joint Surg Am* 1969;51:59.

* 21. Brumback RJ, Jones AL. Interobserver Agreement in the Classification of Open Fractures of the Tibia. *J Bone Joint Surg Am* 1994;76:1162.

+ 22. Burgess AR, Poka A, Brumback RJ, et al. Pedestrian Tibial Injuries. *J Trauma* 1987;27:596.

+ 23. Burwell HN. Plate Fixation of Tibial Shaft Fractures: A Survey of 181 Injuries. *J Bone Joint Surg Br* 1971;53:258.

+ 24. Caudle RJ, Stern PJ. Severe Open Fractures of the Tibia. *J Bone Joint Surg Am* 1987;69:801.

+ 25. Court-Brown CM, Christie J, McQueen MM. Closed Intramedullary Tibial Nailing: Its Use in Closed and Type I Open Fractures. *J Bone Joint Surg Br* 1990;72:605.

+ 26. Court-Brown CM, Wheelwright EF, Christie J, McQueen MM. External Fixation for type III Open Tibial Fractures. *J Bone Joint Surg Br* 1990;72:801.

* 27. Dehne E. Treatment of Fractures of the Tibial Shaft. *Clin Orthop* 1969;66:159.

* 28. Dehne E. Ambulatory Treatment of the Fractured Tibia. *Clin Orthop* 1974;105:192.

* 29. Dehne E, Deffer PA, Hall RN, et al. The Natural History of the Fractured Tibia. *Surg Clin North Am* 1961;41:1495.

* 30. Dehne E, Metz CW, Deffer PA. Nonoperative Treatment of the Fractured Tibia by Immediate Weightbearing. *J Trauma* 1961;1:514.

+ 31. Den Outer AJ, Meeuwis JD, Hermans J, Zwareling A. Conservative versus Operative Treatment of Displaced Noncomminuted Tibial Shaft Fractures. *Clin Orthop* 1990;252:231.

+ 32. Edge AJ, Denham RA. The Portsmouth Method of External Fixation of Complicated Tibial Fractures. *Injury* 1979;11:13.

+ 33. Edge AJ, Denham RA. External Fixation for Complicated Tibial Fractures. *J Bone Joint Surg Br* 1981;63:92.

+ 34. Edwards CC, Simmons SC, Browner BD, Weigel MC. Severe Open Tibial Fractures: Results Treating 202 Injuries with External Fixation. *Clin Orthop* 1988;230:98.

* 35. Edwards P. Fracture of the Shaft of the Tibia: 492 Consecutive Cases in Adults: Importance of Soft-Tissue Injury. *Acta Orthop Scand* 1965;(suppl.)76:1.

* 36. Ellis H. The Speed of Healing after Fracture of the Tibial Shaft. *J Bone Joint Surg Br* 1958;40:42.

+ 37. Etter E, Burri C, Claes HL, et al. Treatment by External Fixation of Open Fractures Associated with Severe Soft-Tissue Damage of the Leg: Biomechanical Principles and Clinical Experience. *Clin Orthop* 1983;178:80.

+ 38. Evans GA, Bang RL, Conrah MS, et al. The Value of the Hoffmann Skeletal Fixation in the Management of Cross Leg Flaps, Particularly Those Injuries Complicated by Open Fractures of the Tibia. *Injury* 1979;11:110.

+ 39. Fischer DA. Skeletal Stabilization with a Multiplane External Fixation Device: Design Rationale and Preliminary Clinical Experience. *Clin Orthop* 1983;180:50.

+ 40. Georgiadis GM, Behrens FF, Joyce MJ, et al. Open Tibial Fractures with Severe Soft-Tissue Loss. Limb Salvage Compared with Below-the-Knee Amputation. *J Bone Joint Surg Am* 1993;75:1431.

! 41. Georgiadis GM, Minster GJ, Moed BR. Effects of Dynamization after Interlocking Tibial Nailing: An Experimental Study in Dogs. *J Orthop Trauma* 1990;4:323.

+ 42. Gershuni DH, Halma G. The AO External Skeletal Fixator in the Treatment of Severe Tibia Fractures. *J Trauma* 1983;23:986.

! 43. Gøthman L. Arterial Changes in Experimental Fractures of the Rabbit's Tibia Treated with Intramedullary Nailing. A Microangiographic Study. *Acta Chir Scand* 1960;120:289.

! 44. Gøthman L. Arterial Changes in Experimental Fractures of the Monkey's Tibia Treated with Intramedullary Nailing. *Acta Chir Scand* 1961;121:56.

* 45. Green SA.*Complications of External Skeletal Fixation: Causes, Prevention, and Treatment.* Springfield, IL: Charles C. Thomas, 1981.

+ 46. Gregory RT, Gould RJ, Peclet M, et al. The Mangled Extremity Syndrome (M.E.S.): A Severity Grading System for Multisystem Injury of the Extremity. *J Trauma* 1985;5:1147.

# 47. Gustilo RB.*Management of Open Fractures and Their Complications.* Philadelphia: WB Saunders, 1982.

* 48. Gustilo RB, Anderson JT. Prevention of Infection in the Treatment of 1025 Open Fractures of Long Bones. *J Bone Joint Surg Am* 1976;58:453.

* 49. Gustilo RB, Mendoza RM, Williams DN. Problems in the Management of Type III (Severe) Open Fractures: A New Classification of Type III Open Fractures. *J Trauma* 1984;24:742.

+ 50. Haines JF, Williams EA, Hargadon EJ, Davies DRA. Is Conservative Treatment of Displaced Tibial Shaft Fractures Justified? *J Bone Joint Surg Br* 1984;66:85.

# 51. Hanson ST Jr. The Type IIIC Tibial Fracture. *J Bone Joint Surg Am* 1987;69:799.

+ 52. Hasenhuttl K. The Treatment of Unstable Fractures of the Tibia and Fibula with Flexible Medullary Wires: A Review of 235 Fractures. *J Bone Joint Surg Am* 1981;63:921.

+ 53. Helfet DL, Howey T, Sanders R, Johansen K. Limb Salvage versus Amputation. Preliminary Results of the Mangled Extremity Severity Score. *Clin Orthop* 1990;256:80.

+ 54. Henley MB. Intramedullary Devices for Tibial Fractures Stabilization. *Clin Orthop* 1989;240:87.

+ 55. Hoaglund FT, States JD. Factors Influencing the Rate of Healing in Tibial Shaft Fractures. *Surg Gynecol Obstet* 1967;124:71.

+ 56. Holbrook JL, Swiontkowski MF, Sanders R. Treatment of Open Fractures of the Tibial Shaft: Ender Nailing versus External Fixation. *J Bone Joint Surg Am* 1989;71:1231.

+ 57. Hooper GJ, Keddell RG, Penny ID. Conservative Management or Closed Nailing for Tibial Shaft Fractures. *J Bone Joint Surg Br* 1991;73:83.

+ 58. Howard MW, Zinar DM, Stryker WS. The Use of the Lottes Nail in the Treatment of Closed and Open Tibial Shaft Fractures. *Clin Orthop* 1992;279:246.

+ 59. Howe HR Jr, Poole GV Jr, Hansen KJ, et al. Salvage of Lower Extremities following Combined Orthopedic and Vascular Trauma. A Predictive Salvage Index. *Am Surg* 1987;53:205.

+ 60. Hughston JC, Whatley GS, Bearden JM. Tibia Fractures. *South Med J* 1969;62:931.

! 61. Hupel TM, Aksenov SA, Schemitsch EH. The Effect of Limited and Standard Reaming on Cortical Bone Blood Flow and Early Strength of Union Following Segmental Fracture. Presented at the Annual Meeting of the Orthopaedic Trauma Association, October, 1997.

! 62. Indekvam K, Lekven J, Engesaeter LB, et al. Effects of Intramedullary Reaming and Nailing on Blood Flow in Rat Femora. *Acta Orthop Scand* 1992;63:615.

+ 63. Jackson RW, Macnab I. Fractures of the Shaft of the Tibia: A Clinical and Experimental Study. *Am J Surg* 1959;97:543.

* 64. Johner R, Wruhs O. Classification of Tibial Shaft Fractures and Correlation with Results after Rigid Internal Fixation. *Clin Orthop* 1983;178:7.

+ 65. Johnson EE, Simpson LA, Helfet DL. Delayed Intramedullary Nailing after Failed External Fixation of the Tibia. *Clin Orthop* 1990;253:251.

+ 66. Johnson KD, Bone LB, Scheinberg R. Severe Open Tibial Fractures: A Study Protocol. *J Orthop Trauma* 1988;2:175.

! 67. Johnson WD, Fischer DA. Skeletal Stabilization with a Multiplane External Fixation Device: Biomechanical Evaluation and Finite Element Model. *Clin Orthop* 1983;180:34.

+ 68. Karlstrom G, Olerud S. Percutaneous Pin Fixation of Open Tibial Fractures: Double-Frame Anchorage Using the Vidal-Adrey Method. *J Bone Joint Surg Am* 1975;57:915.

+ 69. Karlstrom G, Olerud S. Stable External Fixation of Open Tibial Fractures: A Report of 5 Years of Experience with the Vidal-Adrey Double-Frame Method. *Orthop Rev* 1977;6:25.

+ 70. Karlstrom G, Olerud S. External Fixation of Severe Open Tibial Fractures with the Hoffman Frame. *Clin Orthop* 1983;180:68.

! 71. Kessler SB, Hallfeldt KKJ, Perren SM, Schweiberer L. The Effects of Reaming and Intramedullary Nailing on Fracture Healing. *Clin Orthop* 1986;212:18.

+ 72. Kimmel RB. Results of Treatment Using the Hoffman External Fixator for Fractures of the Tibial Diaphysis. *J Trauma* 1982;22:960.

! 73. Klein MP, Rahn BA, Frigg R, et al. Reaming versus Non-reaming in Medullary Nailing: Interference with Cortical Circulation of the Canine Tibia. *Arch Orthop Trauma Surg* 1990;109:314.

+ 74. Lange RH, Bach AW, Hansen ST, Johansen KH. Open Tibial Fractures with Associated Vascular Injuries: Prognosis for Limb Salvage. *J Trauma* 1985;25:203.

+ 75. Larsson K, Van der Linden W. Open Tibial Shaft Fractures. *Clin Orthop* 1983;180:63.

+ 76. Laughlin RT, Smith KL, Russell RC, Hayes JM. Late Functional Outcome in Patients with Tibia Fractures Covered with Free Muscle Flaps. *J Orthop Trauma* 1993;7:123.

# 77. Leach RE. Fractures of the Tibia and Fibula. In: Rockwood CA Jr, Green DP, eds. *Fractures in Adults*, vol. 2. Philadelphia: JB Lippincott, 1984:1593.

+ 78. Levy AS, Levitt LE, Gunther SF, Wetzler MJ. The Role of Ender Rodding in Tibial Fractures with an Intact Fibula. *J Orthop Trauma* 1990;4:75.

+ 79. Lottes JO. Intramedullary Fixation for Fractures of Shaft of Tibia. *South Med J* 1952;45:407.

* 80. Lottes JO. Blind Nailing Technique for Insertion of the Triflange Medullary Nail. *JAMA* 1954;155:1039.

# 81. Lottes JO. Intramedullary Nailing of the Tibia. *AAOS Instr Course Lect* 1958;15:65.

* 82. Lottes JO. Medullary Nailing of the Tibia with the Triflange Nail. *Clin Orthop* 1974;105:253.

* 83. Lottes JO, Hill LJ, Key JA. Closed Reduction, Plate Fixation and Medullary Nailing of Fractures of Both Bones of the Leg. *J Bone Joint Surg Am* 1952;34:861.

+ 84. Marsh JL, Nepola JV, Wuest TK, et al. Unilateral External Fixator until Healing with the Dynamic Axial Fixator for Severe Open Tibial Fractures. *J Orthop Trauma* 1991;5:341.

+ 85. Maurer DJ, Merkow RL, Gustilo RB. Infection after Intramedullary Nailing of Severe Open Tibial Fractures Initially Treated with External Fixation. *J Bone Joint Surg Am* 1989;71:835.

+ 86. Mayer L, Werbie T, Schwab JP, Johnson RP. The Use of Ender Nails in Fractures of the Tibial Shaft. *J Bone Joint Surg Am* 1985;67:446.

# 87. McCoy MT, Chao EYS, Kasman RA. Comparison of Mechanical Performance in Four Types of External Fixators. *Clin Orthop* 1983;180:23.

! 88. McGraw JM, Lim EVA. Treatment of Open Tibial Shaft Fractures. *J Bone Joint Surg Am* 1988;70:900.

+ 89. McNamara MG, Heckman JD, Corley FG. Severe Open Fractures of the Lower Extremity: A Retrospective Evaluation of the Mangled Extremity Severity Score (MESS). *J Orthop Trauma* 1994;8:81.

+ 90. Melis GC, Sotgiu F, Lepori M, Guido P. Intramedullary Nailing in Segmental Tibial Fractures. *J Bone Joint Surg Am* 1981;63:1310.

* 91. Merchant TC, Dietz FR. Long-term Follow-up after Fractures of the Tibial and Fibular Shafts. *J Bone Joint Surg Am* 1989;71:599.

+ 92. Merianos P, Cambouridis P, Smyrnis P. The Treatment of 143 Tibial Shaft Fractures by Ender Nailing and Early Weightbearing. *J Bone Joint Surg Br* 1985;67:576.

! 93. Moed BR, Strom DE. Compartment Syndrome after Closed Intramedullary Nailing of the Tibia: A Canine Model and Report of Two Cases. *J Orthop Trauma* 1991;5:71.

+ 94. Morrison KM, Ebraheim NA, Southworth SR, et al. Plating of the Fibula: Its Potential Value as an Adjunct to External Fixation of the Tibia. *Clin Orthop* 1991;266:209.

+ 95. Müller ME. Internal Fixation for Fresh Fractures and for Nonunion. *Proc Soc Med* 1963;56:455.

+ 96. Müller ME. Treatment of Nonunions by Compression. *Clin Orthop* 1965;43:83.

# 97. Müller ME, Allgöwer M, Schneider R, et al. *Manual of Internal Fixation*, 2nd ed. New York: Springer-Verlag, 1979.

# 98. Müller ME, Allgöwer M, Willenegger H.*Technique of Internal Fixation of Fractures.* New York: Springer-Verlag, 1965.

# 99. Müller ME, Nazarian S, Koch P, et al.*The Comprehensive Classification of Fractures of the Long Bones.* New York: Springer-Verlag, 1990.

* 100. Nicoll EA. Fractures of the Tibial Shaft. A Survey of 705 Cases. *J Bone Joint Surg Br* 1964;46:373.

* 101. Nicoll EA. Closed and Open Management of Tibial Fractures. *Clin Orthop* 1974;105:144.

+ 102. Olerud S. Treatment of Fractures by the Vidal-Adrey Method. *Acta Orthop Scand* 1973;44:516.

+ 103. Olerud S, Karlstrom G. Tibial Fractures Treated by AO Compression Osteosynthesis: Experiences from a 5-Year Material. *Acta Orthop Scand* 1972;140(suppl):1.

+ 104. Oni OOA, Hui A, Gregg PJ. The Healing of Closed Tibial Shaft Fractures. *J Bone Joint Surg Br* 1988;70:787.

! 105. Oni OOA, Stafford H, Gregg PJ. An Experimental Study of the Patterns of Periosteal and Endosteal Damage in Tibial Shaft Fractures Using a Rabbit Trauma Model. *J Orthop Trauma* 1989;3:142.

# 106. Orthopaedic Trauma Association Committee for Coding and Classification: Fracture and Dislocation Compendium. *J Orthop Trauma* 1996;10(suppl 1):45.

! 107. Paradis GR, Kelly PJ. Blood Flow and Mineral Deposition in Canine Tibial Fractures. *J Bone Joint Surg Am* 1975;57:220.

+ 108. Pun W-K, Chow S-P, Fran D, Leong JCY. A Study of Function and Residual Joint Stiffness after Functional Bracing of Tibial Shaft Fractures. *Clin Orthop* 1991;267:157.

+ 109. Puno RM, Teynor JT, Nagano J, Gustilo RB. Critical Analysis of Results of Treatment of 201 Tibial Shaft Fractures. *Clin Orthop* 1986;212:113.

+ 110. Rezaian SM. A New External Fixation Device for Treatment of Complicated Fractures of the Leg. *Injury* 1977;9:17.

! 111. Rhinelander FW. Tibial Blood Supply in Relation to Fracture Healing. *Clin Orthop* 1974;105:34.

! 112. Richards RR, Orsini EC, Mahoney JL, et al. The Influence of Muscle Flap Coverage on the Repair of Devascularized Tibial Cortex: An Experimental Investigation in the Dog. *Plast Reconstr Surg* 1987;79:946.

! 113. Richards RR, Schemitsch EG. Effect of Muscle Flap Coverage on Bone Blood Flow following Devascularization of Segment of Tibia: An Experimental Investigation in the Dog. *J Orthop Res* 1989;7:550.

+ 114. Robertson PA. Prediction of Amputation after Severe Lower Limb Trauma. *J Bone Joint Surg Br* 1991;73:816.

+ 115. Rubenstein RA Jr, Green JM, Duwelius PG. Intramedullary Interlocked Tibial Nailing: A New Technique (Preliminary Report). *J Orthop Trauma* 1992;6:90.

+ 116. Rüedi T, Webb JK, Allgöwer M. Experience with the Dynamic Compression Plate in 418 Recent Fractures of the Tibial Shaft. *Injury* 1976;7:252.

+ 117. Russell WL, Sailors DM, Whittle TB. Limb Salvage versus Traumatic Amputation. *Ann Surg* 1991;213:473.

+ 118. Sanders R, Jersinovich I, Angelen J, et al. The Treatment of Open Tibial Shaft Fractures Using an Unreamed Interlocked Intramedullary Nail. *J Orthop Trauma* 1994;8:504.

+ 119. Santoro V, Henley M, Benirschke S, Mayo K. Preoperative Comparison of Unreamed Interlocking Intramedullary Nails versus Half-Pin External Fixation in Open Tibial Fractures. *J Orthop Trauma* 1991;5:238.

* 120. Sarmiento A. A Functional Below-the-Knee Cast for Tibial Fractures. *J Bone Joint Surg Am* 1967;49:855.

* 121. Sarmiento A. A Functional Below-the-Knee Brace for Tibial Fractures. *J Bone Joint Surg Am* 1970;52:295.

* 122. Sarmiento A. Functional Bracing of Tibial and Femoral Shaft Fractures. *Clin Orthop* 1972;82:2.

* 123. Sarmiento A. Functional Bracing of Tibial Fractures. *Clin Orthop* 1974;105:202.

* 124. Sarmiento A, Gersten LM, Sobol PA, et al. Tibial Shaft Fractures Treated with Functional Braces. *J Bone Joint Surg Br* 1989;71:602.

* 125. Sarmiento A, Sharpe FE, Ebramzadeh E, et al. Factors Influencing the Outcome of Closed Tibial Fractures Treated with Functional Bracing. *Clin Orthop* 1995;315:8.

* 126. Sarmiento A, Sobol PA, Sew Hoy AL, et al. Prefabricated Functional Braces for the Treatment of the Tibial Diaphysis. *J Bone Joint Surg Am* 1984;66:1328.

* 127. Schatzker J. Compression in the Surgical Treatment of Fractures of the Tibia. *Clin Orthop* 1974;105:220.

+ 128. Schmidt A, Rorabeck CH. Fractures of the Tibia Treated by Flexible External Fixation. *Clin Orthop* 1983;178:162.

+ 129. Sedlin ED, Zitner DT. The Lottes Nail in the Closed Treatment of Tibia Fractures. *Clin Orthop* 1985;192:185.

* 130. Shaar CM, Krenz FP Jr, Jones DT. Fractures of the Tibia and Fibula—Treatment with the Stader Reduction and Fixation Splint. *Surg Clin North Am* 1943;23:599.

+ 131. Siebenrock KA, Schillig B, Jakob RP. Treatment of Complex Tibial Shaft Fractures. *Clin Orthop* 1993;290:269.

+ 132. Singer PJ, Seligson D. What's in a Nail? *J Orthop Trauma* 1990;4:331.

+ 133. Slauterbeck JR, Bretton C, Moneim MS, Clevenger FW. Mangled Extremity Severity Score: An Accurate Guide to Treatment of the Severely Injured Upper Extremity. *J Orthop Trauma* 1994;8:282.

+ 134. Solheim K, Bo O. Intramedullary Nailing of Tibial Shaft Fractures. *Acta Orthop Scand* 1973;44:323.

+ 135. Solheim K, Bo O, Langard O. Tibial Shaft Fractures Treated with Intramedullary Nailing. *J Trauma* 1977;17:223.

+ 136. Steinfield PH, Cobelli NJ, Sadler AH, Szporn MN. Open Tibial Fractures Treated by Anterior Half-Pin Frame Fixation. *Clin Orthop* 1988;228:208.

! 137. Tarr RR, Resnick CT, Wagner KS, Sarmiento A. Changes in Tibiotalar Joint Contact Areas Following Experimentally Induced Tibial Angular Deformities. *Clin Orthop* 1985;199:72.

! 138. Ting AJ, Tarr RR, Sarmiento A, et al. The Role of Subtalar Motion and Ankle Contact Pressure Changes from Angular Deformities of the Tibia. *Foot Ankle* 1987;7:290.

+ 139. Tornetta P III, Bergman M, Watnik N, et al. Treatment of Grade IIIB Open Tibial Fractures. *J Bone Joint Surg Br* 1994;76:13.

+ 140. Tornqvist H. Tibia Nonunions Treated by Interlock Nailing: Increased Risk of Infection after Previous External Fixation. *J Orthop Trauma* 1990;4:109.

+ 141. Trabulsky PP, Kerley SM, Hoffman WY. A Prospective Study of Early Soft Tissue Coverage of Grade IIIB Tibial Fractures. *J Trauma* 1994;36:661.

# 142. Trafton PG. Tibial Shaft Fractures. In: Browner BD, Jupiter JB, Levine AM, Trafton PG, eds. *Skeletal Trauma*. Philadelphia: WB Saunders, 1992:1771.

! 143. Trueta J, Cavadias AX. Vascular Changes Caused by the Küntscher type of Nailing. An Experimental Study in the Rabbit. *J Bone Joint Surg Br* 1955;37:492.

# 144. Tscherne H, Gotzen L.*Fractures with Soft Tissue Injuries.* Berlin: Springer-Verlag, 1984.

+ 145. Velazco A, Fleming LL. Open Fractures of the Tibia Treated by the Hoffman External Fixator. *Clin Orthop* 1983;180:125.

+ 146. Velazco A, Fleming LL, Nahai F. Soft-Tissue Reconstruction of the Leg Associated with the Use of the Hoffman External Fixator. *J Trauma* 1983;223:1052.

+ 147. Velazco A, Whitesides TE, Fleming LL. Open Fractures of the Tibia Treated with Lottes Nail. *J Bone Joint Surg Am* 1983;65:879.

* 148. Vidal J, Buscayret C, Connes H, et al. Guidelines for Treatment of Open Fractures and Infected Pseudoarthroses by External Fixation. *Clin Orthop* 1983;180:83.

+ 149. Whitelaw GP, Wetzler M, Nelson A, et al. Ender Rods versus External Fixation in the Treatment of Open Tibial Fractures. *Clin Orthop* 1990;253:258.

+ 150. Whittle PA, Russell TA, Taylor JC, LaVelle DG. Treatment of Open Fractures of the Tibial Shaft with the Use of Interlocking Nailing without Reaming. *J Bone Joint Surg Am* 1992;74:1162.

* 151. Winquist RA, Hansen ST Jr, Clawson DK. Closed Intramedullary Nailing of Femoral Fractures: A Report of Five Hundred and Twenty Cases. *J Bone Joint Surg Am* 1984;66:529.

+ 152. Wiss DA. Flexible Medullary Nailing of Acute Tibial Shaft Fractures. *Clin Orthop* 1986;212:122.

+ 153. Wiss DA, Stetson WB. Unstable Fractures of the Tibia Treated with a Reamed Intramedullary Interlocking Nail. *Clin Orthop* 1995;315:56.

+ 154. Zucman J, Maurer P. Primary Medullary Nailing of the Tibia for Fractures of the Shaft in Adults. *Injury* 1970;2:84.

# CHAPTER 25

# ANKLE FRACTURES AND DISLOCATIONS INCLUDING PYLON FRACTURES

*Robert H. Leland and Jeffrey W. Mast*

**R. H. Leland:** Department of Orthopaedic Surgery, Wayne State University School of Medicine, Hutzel Hospital, Detroit, Michigan 48201.
**J. W. Mast:** 2345 E. Prater Way, Sparks, Nevada 89434.

Mechanics and Anatomy
Radiographic Assessment
Classification
Ankle Fractures
Pylon Fractures
Principles of Treatment
low-Velocity Injuries
High-Velocity Injuries
Open Fractures
Assessment
Surgical Indications
Preoperative Planning
Nonoperative Treatment
Surgical Techniques
General Principles—Ankle Fractures
Medial Malleolus Fractures
Lateral Malleolus Fractures
Posterior Malleolus Fractures
Isolated Disruptions of the Distal Tibiofibular Syndesmosis
Fractures of the Tubercle of Chaput
Ligament Injuries
Pylon Fractures
Principles of Treatment
Limited Internal Fixation
External Fixation
External Fixation with Limited Internal Fixation
Open Reduction and Internal Fixation
Postoperative Care
Pitfalls and Complications
Authors' Perspective
Chapter References

The superiority of internal fixation over closed treatment for displaced fractures and dislocations of the ankle has been thoroughly demonstrated in the literature (14,22,32,33,37,38,39 and 40,43,47,53,56,60). In this chapter, we devote little attention to closed methods of treatment and discuss in detail modern internal fixation techniques. See Chapter 10 for more detail on closed treatment.

## MECHANICS AND ANATOMY

The ankle joint consists of the articulation between the tibia and the talus, the talus and the fibula, and the tibia and the fibula, along with the capsule and stabilizing ligamentous structures, and distal projections from the medial side of the tibia and from the distal fibula, which form the malleoli. Together, these structures form a geometric constraint to transverse movement of the talus (13,41,48,49 and 51,57). The ankle joint is commonly referred to as a mortise-and-tenon joint because of its appearance on the frontal radiograph (Fig. 25.1). This carpentry term describes a technique in which wood is joined by the insertion of a square peg into a square hole, thus offering great rigidity and stability. This particular geometry is best suited to resist rotation of the talus within the ankle mortise.

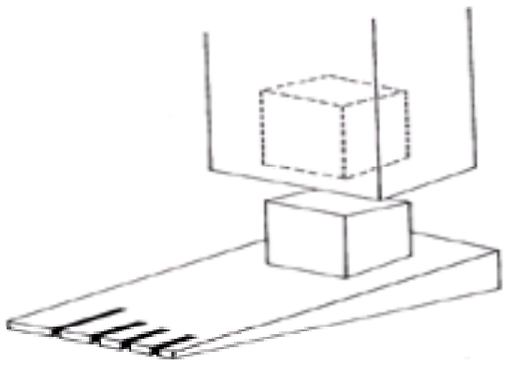

***Figure 25.1.*** carpenter's mortise-and-tenon joint, showing the squared-off appearance of the ankle joint seen on the mortise view.

The articular surface of the talus is somewhat wider anteriorly than it is posteriorly and, depending on the shape of the talus, requires a small amount of spreading of the malleoli during dorsiflexion of the foot. In many ankles but not all, any loss of this spreading motion can cause a loss of dorsiflexion. This shape of the articular surface offers some restraint toward posterior subluxation of the talus, but the greater restraint is the cup-shaped distal tibia, which projects distally at its posterior margin.

The ankle owes its soft-tissue stability to the capsule and its ligamentous condensations (Fig. 25.2). The medial ligamentous complex, called the deltoid ligament, consists of a superficial and a deep portion. The superficial portion is large and fan shaped and extends from the medial malleolus to a wide attachment on the talus, calcaneus, and navicular (Fig. 25.2*A*). The deep portion is a transverse ligamentous connection between the deep surface of the medial malleolus and the talus. This ligament inserts into the axis of rotation of the talus and is one constraint against lateral subluxation of the talus. This portion of the ligament is very short.

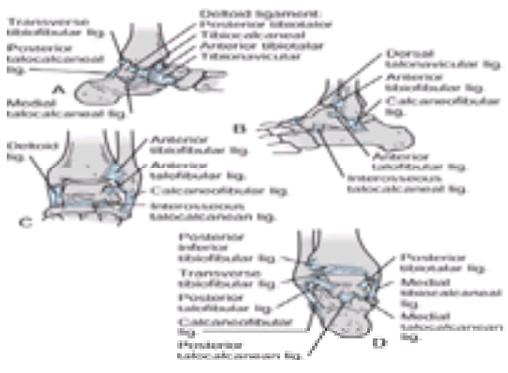

***Figure 25.2.*** **A:** Ligamentous anatomy at the ankle, from the medial side. The fan-shaped deltoid ligament extends distally from the medial malleolus to the calcaneus, talus, and navicular. **B:** Lateral ligamentous anatomy, showing the anterior and posterior talofibular ligaments and the calcaneofibular ligament, extending distally and posteriorly. **C:** Anterior view of the ankle, showing primarily the anterior tibiofibular ligament. **D:** Posterior view showing the posterior tibiofibular ligament.

The lateral ligamentous complex consists of the anterior and posterior talofibular ligaments and the calcaneofibular ligament (Fig. 25.2*B*). These three ligaments are helpful in preventing the tilting of the talus within the mortise. The tibia and fibula articulate with each other distally and are held together by a system of ligaments, including the interosseous membrane and the anterior and posterior tibiofibular ligaments (Fig. 25.2*C*, Fig. 25.2*D*). These ligaments allow the elastic widening of the ankle mortise during dorsiflexion and, to a certain degree, rotation of the fibula.

The sum of bony and ligamentous stability of the ankle joint results in motion best described as a simple hinge whose axis is parallel to the floor and externally rotated between 15° and 20° from the frontal plane (Fig. 25.3). The range of movement averages 20° of dorsiflexion and 40° of plantar flexion.

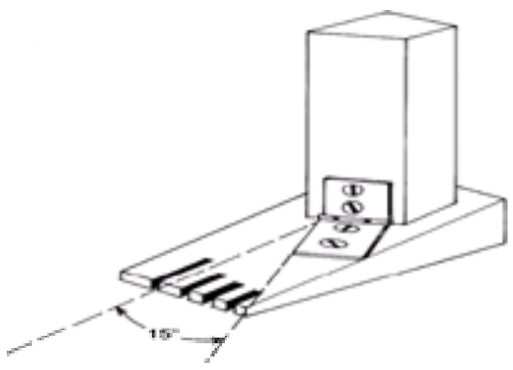


***Figure 25.3.*** The true axis of the ankle joint is externally rotated 15° from the axis of the foot. A radiograph through the axis of the foot will not give a true tangential view of the ankle joint.

## RADIOGRAPHIC ASSESSMENT

Proper radiographic examination of the ankle requires anteroposterior, lateral, and mortise views. The anteroposterior view is taken with the beam centered on the ankle joint and directed in the sagittal plane (Fig. 25.4*A*). The lateral view is taken with the beam centered on the ankle joint and directed in the frontal plane (Fig. 25.4*B*). The mortise view is taken with the leg internally rotated about 15° so the x-ray beam passes perpendicular to the axis of movement (Fig. 25.4*C*). The anteroposterior view combined with the mortise view allows detection of avulsion fractures of the malleoli, vertical fractures of the medial malleolus, and lateral subluxation of the talus. The lateral view is most helpful in outlining the configuration of the lateral malleolar fracture and in detecting anterior and posterior tibial fractures.

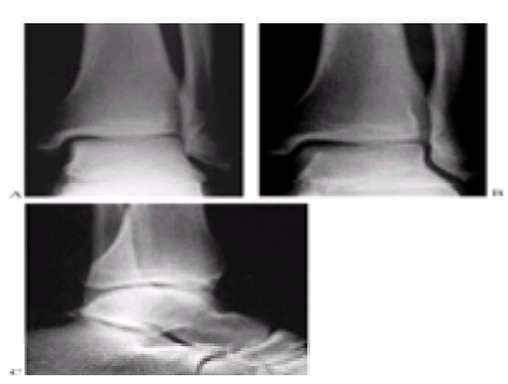

***Figure 25.4.*** **A:** A true anteroposterior view along the axis of the foot. **B:** The true mortise view with the foot internally rotated 15° clearly shows the entire joint space extending from the tip of the medial malleolus to the tip of the lateral malleolus. **C:**The lateral view of the ankle joint, showing the fibula line posterior to the tibia.

Diagnosis of occult instability of the distal tibiofibular syndesmosis requires careful interpretation of the radiographs, particularly for torsional injuries (Fig. 25.5). Stress views, particularly under anesthesia, may be helpful. Marginal impaction fractures, particularly in the anterolateral plafond of the tibia, can often be seen on plain radiographs but may require tomograms or CT scans. Full delineation of the various fracture fragments, particularly those involving the articular surface in pylon fractures, often requires CT with sagittal and frontal plane reconstructions. Comparison views of the opposite side occasionally prove useful for preoperative planning. Plain radiographs taken in traction are particularly useful in pylon fractures, as the traction achieves a rough reduction, restores length, and makes the fracture configuration easier to understand (24).

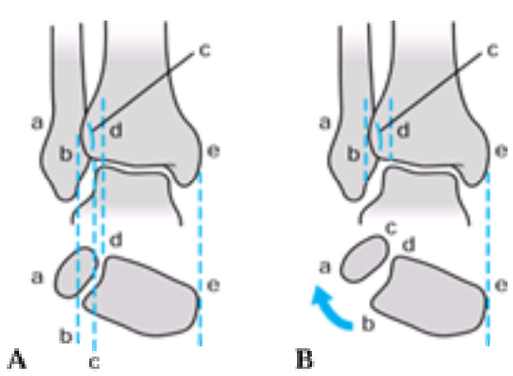


***Figure 25.5.*** **A:** Anteroposterior projection of an ankle joint: *a,* lateral border of the lateral malleolus; *b,* lateral border of the anterior aspect of the tibia; *c,* medial border of the fibula; *d,* lateral border of the posterior aspect of the tibia. **B:** Rupture of the anterior syndesmosis with external rotation of the fibula does not affect the apparent width of the syndesmosis *(c–d)* or the intermalleolar distance *(a–e).* However, the amount of overlap of the anterior portion of the tibia on the fibula, distance *a–b* and distance *b–c,* change. Distance *a–b* increases, and *b–c* decreases. In most ankles, distance *b–c* is over 50% of *a–c* on anteroposterior projections. Comparison radiographs of the normal ankle are very helpful. (Modified from Chapman MW. Fractures and Fracture-Dislocations of the Ankle (Chapter 34). In Mann RA, Coughlin MJ, eds. *Surgery of the Foot and Ankle,*6th edition. Philadelphia: Mosby, 1992:1448.)

## CLASSIFICATION

## ANKLE FRACTURES

A classification system is useful as it helps to determine the proper treatment or predict the outcome (18,21). Two classification systems stand out in any discussion of ankle fractures because they address these issues.

The first, devised by Lauge-Hansen, encompasses well over 95% of all ankle fractures (19,58). It divides ankle fractures into categories by mechanism of injury and secondarily into groups of increasing severity. Lauge-Hansen determined the mechanisms of injury in various fracture types by cadaveric experiment in which he created these fractures in a laboratory setting. He classified ankle fractures into four categories determined by the position of the foot at the time force is applied (pronated or supinated) and by the direction that force is applied (external rotation or straight) (Fig. 25.6). An external rotation force applied as the patient's body twists over the planted foot causes a supination–external rotation or pronation–external rotation injury. Straight forces, such as when the supinated foot is forced into further adduction, result in the injuries described as supination–adduction. The opposite is the pronation–abduction injury. Each of these four categories is subdivided into stages indicating increasing severity of injury. The higher the stage, the greater is the severity of the injury and, thus, the poorer the prognosis.

***Figure 25.6.*** The Lauge-Hansen classification of ankle fractures. **A:** The supination–eversion fracture. *Stage I:* The avulsion of the anterior talofibular ligament from the tibia or simple rupture of the ligament. *Stage II:* The classic oblique fracture of the distal fibula, beginning anteriorly at the joint line and extending obliquely and posteriorly toward the shaft of the bone. *Stage III:* Avulsion or rupture of the posterior tibiofibular ligament. *Stage IV:* Avulsion fracture of the medial malleolus. **B:** The supination–adduction fracture. *Stage I:* Avulsion of the tip of the lateral malleolus or rupture of the associated ligaments. *Stage II:* Vertical fracture of the medial malleolus, usually beginning at the plafond. **C:** The pronation–eversion fracture. *Stage I:* Avulsion of the medial malleolus or ruptured deltoid ligament. *Stage II:* Rupture or avulsion of the anterior tibiofibular ligament. *Stage III:* A high, short, oblique fracture of the fibula. *Stage IV:* A posterior lip fracture of the tibia. **D:** The pronation–abduction fracture. *Stage I:* Avulsion of the medial malleolus or ruptured deltoid ligament. *Stage II:* Rupture or avulsion of the syndesmotic ligaments. *Stage III:* A short, oblique fracture of the distal fibula at about the level of the ankle joint.

A second and equally popular classification scheme is that devised by Weber of the AO group (35). This classification scheme includes three major fracture types, depending primarily on the level of the fibular fracture.

In the Weber type A fracture, the fibula is avulsed distal to the syndesmotic ligaments, and the medial malleolus is fractured vertically (Fig. 25.7*A*). This fracture type, which roughly corresponds to Lauge-Hansen's supination–adduction type, is usually unstable, requiring internal fixation. There is often a small compression of the articular surface of the tibia, which should be elevated for complete reduction of the medial malleolus.

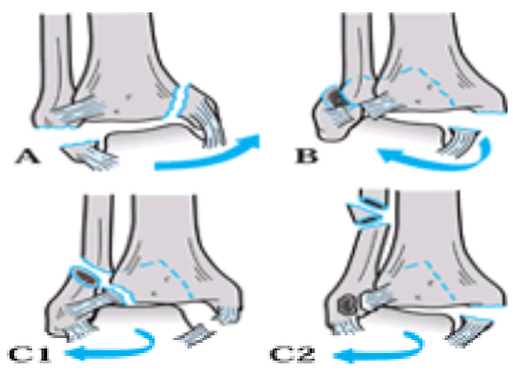


***Figure 25.7.*** The Weber classification of ankle fractures. **A:** Fracture of the fibula below the level of the tibial plafond and vertical fracture of the medial malleolus. **B:** Avulsion fracture of the medial malleolus and fracture of the fibula, beginning at the level of the tibial plafond. The posterior rim may also be fractured, as shown. **C:** An avulsion fracture of the medial malleolus or ruptured deltoid ligament with a short oblique fracture of the fibula, well above the level of the tibial plafond. Also, a posterior rim fracture of the tibia may be seen.

The Weber type B (Fig. 25.7*B*) includes an oblique fracture of the fibula, beginning at the level of the tibial plafond and extending proximally and posteriorly through the fibular shaft. The posterior lip of the tibia is usually fractured; the fragment may be large or small. Also included is an avulsion of the medial malleolus or rupture of the deltoid ligament. This category corresponds to the supination–external rotation type of Lauge-Hansen. When undisplaced, according to criteria to be detailed below, these can be treated by immobilization alone.

The Weber type C (Fig. 25.7*C*) is characterized by a fibular fracture that is entirely above the level of the tibial plafond. A large or small posterior lip fracture often accompanies this injury, as does a medial malleolar avulsion or deltoid ligament rupture. This category corresponds to Lauge-Hansen's pronation–external rotation type. The syndesmosis is always ruptured; the need for repair of this part of the injury is detailed later.

Both the Lauge-Hansen and the Weber classifications are well known and widely used. The Lauge-Hansen classification is of greater value in comparing the results of treatment because it accurately describes the severity of the injury. The Weber classification is more useful in deciding on the appropriate form of treatment.

## PYLON FRACTURES

A pylon fracture is one involving not only the articular surface but also the metaphysis. On occasion, it extends into the distal diaphysis as well. Most pylon fractures in urban trauma centers result from higher-energy vertical compressive forces during a fall from a height or a motor vehicle accident. Lower-energy injuries, often incorporating a torsional component, may result from activities such as snow or water skiing. The extent to which pure compressive loads are responsible for the injury is related to the final outcome. High-energy injuries not only produce greater comminution and compression of the fracture fragments but also produce greater soft-tissue damage, worsening the eventual outcome (54). (Note: The term *pylon* is from the French word “pilon” meaning to ram or hammer, referring to the mechanism of injury of this complex fracture.)

Foot position during impact in compressive-type injuries heavily influences the fracture pattern of the articular surface (7). Foot dorsiflexion during impact produces anterior articular impaction and comminution, whereas a plantarflexed foot is associated with posterior articular damage. Loading a supinated or pronated foot produces a characteristic pattern of articular damage, referred to in the European literature as medial or lateral gap patterns, respectively.

The most commonly used pylon classification is by Ruedi and Allgöwer (42) (Fig. 25.8). Type A fractures describe an intraarticular cleavage-type fracture without joint displacement. Type B fractures demonstrate intraarticular displacement with limited comminution. Type C fractures have intraarticular displacement with marked comminution. The classification has been further subdivided using the AO classification scheme (Fig. 25.9).

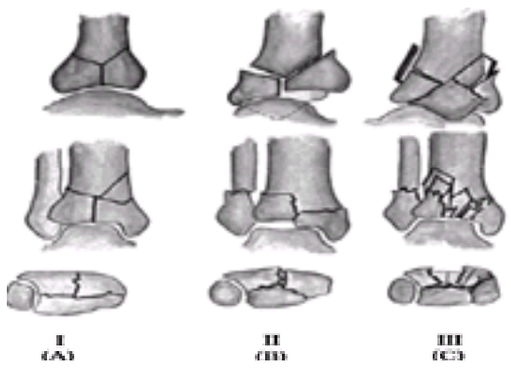


***Figure 25.8.*** Reudi and Allgöwer classification of pylon fractures.

***Figure 25.9.*** AO classification of pylon fractures.

## PRINCIPLES OF TREATMENT

The obvious goal of treatment is to restore function to the level before the insult. Restoring the original anatomy is the single best means to restore normal function. For this reason, closed treatment of ankle fractures is not recommended except when the initial displacement is within acceptable limits. Closed reduction of displaced ankle fractures is fraught with difficulty; it usually does not exactly restore the anatomy, it is often a tedious exercise, and it may require repeated reduction attempts to maintain the alignment within acceptable limits (9,16,27,45,59). Open treatment, on the other hand, offers the best possibility of restoring the anatomy to its original condition without forced manipulations or prolonged immobilization.

Close adherence to the principles advocated by the AO group offers the best chance of restoring the anatomy and maintaining that restoration throughout healing (30). One of the basic principles is the compression of fracture surfaces, one against the other, which causes friction and eliminates motion between the fractured parts (20). This compression usually is obtained with lag screws or sometimes with compression plates. One thing worse than inadequate closed reduction of ankle fractures is a poorly performed internal fixation. These techniques are exacting, and the surgeon must be attentive to detail to obtain a good result.

Internal fixation is indicated for all fractures of the articular surface of the ankle with displacement greater than 2 mm lateral or posterior at the lateral or medial malleolus (18). In the absence of a medial malleolar fracture, widening of the medial clear space greater than 2 mm must be considered an unacceptable displacement. Some surgeons would not accept widening of more than 1 mm in young active individuals.

### LOW-VELOCITY INJURIES

Low-velocity injuries typically result in simple minimally comminuted fracture patterns with mild to moderate soft-tissue injury. Lower-energy ankle fractures commonly occur in an elderly population with osteopenic bone, so fixation may be compromised. Although judicious soft-tissue handling and appropriate surgical timing are still necessary to avoid wound breakdown and infection, surgery usually can proceed immediately after presentation to the emergency room and preparation of the patient for surgery (6).

### HIGH-VELOCITY INJURIES

High-energy ankle fractures resulting from motor vehicle collisions and falls from significant heights pose problems in the management of the bony and soft-tissue injuries. Early closed reduction of these fractures is important to minimize further soft-tissue compromise and to decrease the risk of fracture blister formation. Soft-tissue swelling, as well as abrasions and blisters, may make early open reduction and fixation hazardous. Sometimes temporary external fixation may be advisable, but usually incorporation in well-padded long-leg splints or a cast with elevation of the limb suffices until the soft tissues recover sufficiently to permit fixation.

### OPEN FRACTURES

For open fractures, administer appropriate intravenous antibiotics to the patient as soon as possible. Open ankle and pylon fractures require immediate and thorough irrigation and debridement of nonviable tissue (10) (see Chapter 12). Whereas grade 1 injuries may be primarily closed following a thorough debridement, grade 2 and grade 3 injuries usually require repeated irrigation and debridement to minimize the risk of infection. Open injuries do not necessarily dictate the type of fixation that should be used to stabilize a fracture because both internal and external fixation principles can be applied, assuming thorough debridement and early soft-tissue coverage are performed. In severe open grade 3 pylon fractures, generally the soft tissues will not tolerate extensive internal fixation of the comminuted metaphyseal portion of the fracture. Most authorities treat these with limited fixation of the articular surface and hybrid or other external fixation (3,29). In some cases, conversion to biological internal fixation, once the soft tissues have recovered, is appropriate (3,48).

## ASSESSMENT

Perform a history and physical examination, including a thorough neurovascular examination and evaluation for compartment syndrome. If the patient has a history of vascular insufficiency or clinical findings suggestive of distal arterial compromise, perform noninvasive arterial Doppler studies preoperatively and consider vascular consultation to insure that the wound will have the capability of healing.

Gently palpate along the osseous and ligamentous structures, including the proximal fibula, lateral and medial malleoli, syndesmosis, and lateral and medial ligaments, to fully delineate all aspects of the injury. Carefully palpate the hindfoot, midfoot, and forefoot to rule out associated injuries.

## SURGICAL INDICATIONS

Minimally displaced (less than 1 to 2 mm) stable fracture patterns without disruption of the ankle mortise do not require operative treatment (59). The most common fractures treated closed are Weber A and B fractures without medial injury. All other displaced fractures about the ankle are optimally treated with anatomic reduction, stable internal fixation, and early range-of-motion exercise (15,26,60). Failure to restore the anatomic relationships and articular congruity of the ankle joint increases the risk of pain and loss of motion. Noncongruent ankles can quickly progress to severe degenerative arthritis.

Contraindications to operative treatment include medical conditions precluding safe operative intervention and vascular insufficiency or other skin conditions preventing safe wound healing. Patients with diabetes mellitus, particularly if they have peripheral neuropathy, have a much higher-than-average occurrence of infection and other

serious complications.

Severe displacement in an ankle injury, particularly dislocation, can lead to skin necrosis as a result of tension over bony prominences as well as increased swelling and neurovascular compromise. For that reason, markedly displaced ankles should have a provisional reduction performed before radiography unless it will be performed immediately.

After radiographic evaluation, place the provisionally reduced ankle injury in a well-padded cast that has been univalved or in gutter splints, which will hold the provisional reduction. A long-leg cast or splint is required for most ankle fractures. Those that are rotationally stable can be immobilized in a short-leg device. Elevate the limb 10 cm above the heart. Perform surgery as soon as practical. Delay of surgery more than 24 hours may lead to excessive swelling and fracture blisters, which may preclude surgery for a week or more, and that delay could compromise the ability to achieve an anatomic reduction.

## PREOPERATIVE PLANNING

If a full range of one-third tubular plates or their equivalent as well as screws are available in the operating room, then templating of routine ankle fractures is rarely necessary. Complex or very long lateral malleolus fractures may require templating to ensure that appropriate implants are available for fixation. Pylon fractures require detailed radiographic assessment of the articular surface of the tibial plafond and the fracture. For complex fractures, draw out the fracture lines on a line drawing traced from plain radiographs of the opposite normal side and use templates to sketch in the implants you plan to use. If staged open treatment following fixation of the fibula and external fixation is planned, radiographs following fibular reduction and provisional tibial–calcaneal fixation are useful in planning the definitive internal fixation.

## NONOPERATIVE TREATMENT

Extraarticular fractures of the distal tibia and fibula with stable patterns and all nondisplaced fractures of the ankle are suitable for nonoperative treatment. Usually a well-molded short-leg cast suffices, and immediate weight bearing is possible. Univalve all circumferential casts applied acutely and have patients elevate the injured limb 10 cm above their heart until swelling subsides. Fracture braces can be used for some stable lateral malleolus fractures (59).

Displaced fractures of the medial malleolus, with the exception of avulsion fractures of the nonarticular tip of the malleolus, require open reduction and internal fixation (ORIF) because they have a significant incidence of nonunion as a result of soft-tissue interposition.

Fractures of the articular portion of the lateral malleolus with displacement of 2 mm or more require operative treatment.

In patients with systemic or local contraindications to surgery, displaced fractures can be reduced, closed, and managed in well-molded long-leg casts. Precise knowledge of the mechanism of injury based on the Lauge-Hansen classification is necessary to provide appropriate three-point molding of the cast (Fig. 25.10).

***Figure 25.10.*** Molding a cast.

- Perform closed reduction as soon as possible.
- Use a general or regional anesthetic.
- Most fractures require a combination of adduction, internal rotation, and varus forces and positioning to achieve a satisfactory reduction.
- Apply a short-leg cast with three-point molding and check the reduction on AP, lateral, and mortise radiographs. Fluoroscopy alone is not adequate. Comparisons to the opposite side may be necessary to assure reduction of the syndesmosis if it is torn.
- If the reduction is adequate, extend the short-leg cast to a long-leg with the knee bent 10° to 15°.
- Postreduction, prevent swelling and routinely univalve the cast.
- Follow weekly with radiographs until you are comfortable that the fracture is stable. One or more cast changes may be necessary to maintain the reduction. The patient can usually be transitioned to a short-leg walking cast by 6 to 8 weeks.

## SURGICAL TECHNIQUES

### GENERAL PRINCIPLES—ANKLE FRACTURES

Strict adherence to the principles outlined here is essential. Meticulous handling of the soft tissues cannot be overemphasized. The surgeon's obligation is to minimize additional trauma to the ankle. Gentle reductions and careful technique are the best means of obtaining satisfactory results.

- Perform ORIF in a conventional operating room under general or regional anesthesia.
- Give appropriate antibiotics intraoperatively before the tourniquet is inflated, and continue them for 24 hours (three total doses).
- Tourniquets are useful when bleeding interferes with visualization of the reduction. Because of the rebound edema that occurs after tourniquet use, we now prefer to use good surgical hemostasis and operate without a tourniquet, if possible. Avoid prolonged tourniquet time and under no circumstances exceed a total of 2 hours.
- Generally, the supine position with a bump under the ipsilateral hip to facilitate lateral exposures suffices. The prone position is useful for some difficult trimalleolar fractures requiring posterior-lateral exposure of the ankle.
- Gently prepare and drape the extremity from the toes to the upper thigh. Use adhesive, povidone-impregnated plastic drapes where incisions will be made. Expose no bare skin or toes to the operative field.

Surgical exposures of the ankle and the skin incisions are described in Chapter 3. Some additional advice is appropriate here, however. In general, skin incisions should be longitudinal, straight, and located directly over the fracture. The posterior ankle can be exposed through the medial or lateral incisions by making them longer and shifting them somewhat posteriorly. A gentle curve in their distal portion may be helpful, but avoid creating flaps.

- The utilitarian incision for a pylon fracture is a straight anterior approach just lateral and parallel to the anterior tibial tendon. If the fracture pattern allows, rather than curve it medially distally, a straight incision carried well out onto the neck of the talus facilitates complete exposure of the anterior tibia and syndesmosis.
- Use a separate incision for the lateral malleolus and a separate short incision directly over the tip of the medial malleolus, if necessary, to insert malleolar screws (Fig. 25.11).

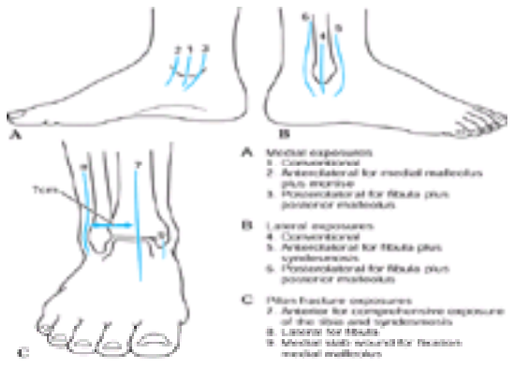

***Figure 25.11.*** Surgical incisions around the ankle.

- Avoid injury to subcutaneous sensory nerves.
- Carry dissection directly down to the periosteum. Expand exposure at the level of the periosteum.
- Minimize stripping of the periosteum. Expose only a 1- to 2-mm edge along the fracture lines.
- Thoroughly clean the fracture surfaces of hematoma.
- Explore the ankle as possible through the available surgical exposure and thoroughly irrigate to identify chondral injury and osteochondral fractures, and remove any loose fragments.
- In bimalleolar or trimalleolar fracture, consider exposing all of the fractures before inserting any internal fixation because this permits better inspection and irrigation of the ankle as well as facilitating ORIF.
- Obtain anatomic reductions and render them stable with one or more double sharp-pointed bone reduction forceps of appropriate size.
- Use completely stable fixation.
- Always obtain postoperative radiographs intraoperatively prior to wound closure.
- Close wounds in three layers: the periosteum if possible, subcutaneous tissue, and skin. Use atraumatic skin closure technique. Use $^{1}/_{8}$-in. suction drains in pylon fractures and severe trimalleolar fractures or when there is enough bleeding to justify their use.
- Apply a postoperative dressing and well-padded splints or a Robert-Jones dressing with splints (Fig. 25.12).

***Figure 25.12.*** The postoperative dressing. **A:** The dressing is well padded with cotton before plaster application; a foot plate is made of plaster splints, and a plaster stirrup on both medial and lateral sides covers the foot plate. The foot plate is then reversed over the stirrup for further strengthening. **B:** Close-up view showing the posterior aspect of the plaster. Plaster does not contact the patient's heel. **C:** A light coating of cotton is placed over the plaster to prevent the compression dressing from sticking to the plaster and becoming ineffective. Then it is wrapped with an elastic bandage. The foot is in neutral position.

## MEDIAL MALLEOLUS FRACTURES

Most medial malleolar fractures occur in conjunction with a lateral injury and should be approached after the lateral malleolus has been exposed. It is usually better to fix the lateral side first.

- Make an appropriate incision. Develop exposure utilizing dull retractors (Ragnals, Langenbecks), taking care to avoid damage to the saphenous nerve and vein. Strip the thick periosteal layer overlying the medial malleolus only enough to allow for visualization and reduction. It is imperative to visualize the anterior aspect of the fracture to insure an anatomic reduction.
- Inspect the medial gutter of the ankle joint to assess the talus for osteochondral injuries and to ensure that no loose fragments or infolded soft tissue is blocking the reduction. This is best accomplished by distracting the distal fragment with a dental pick.
- After anatomically reducing the fragment with a towel clip, sharp-tipped bone forceps, or dental pick, provisionally hold the reduction with a large Weber (two-point reduction) clamp (Fig. 25.13). Occasionally two small Weber forceps are required. Check for stepoffs between the fragments using a dental pick.

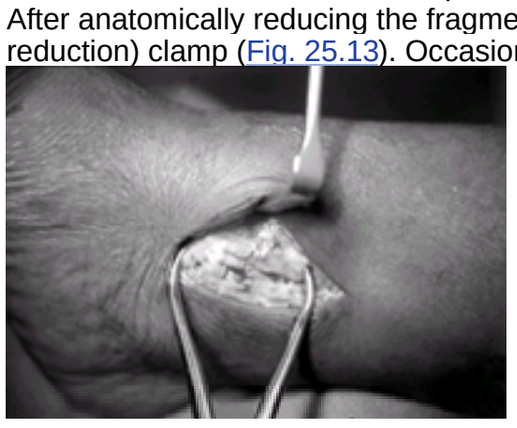

***Figure 25.13.*** Provisional reduction of medial malleolar fracture utilizing a large two-point reduction clamp.

- Screw fixation is usually optimal for most medial malleolus fractures. Place two parallel screws in lag fashion directed perpendicular to the fracture place. Screw diameter (4.0 mm, 3.5 mm, 2.7 mm) can be varied to accommodate the size of the distal fragment. The sharp-tipped triple drill guide depicted in Fig. 25.14 is useful to provide preliminary fixation with drill points and to assure that the screws are parallel (Fig. 25.15).

***Figure 25.14.*** This drill guide enables the operator to drill parallel holes to facilitate parallel screw placement. One hole can be drilled, and the drill bit left in place while the second drill bit is used to complete the procedure.

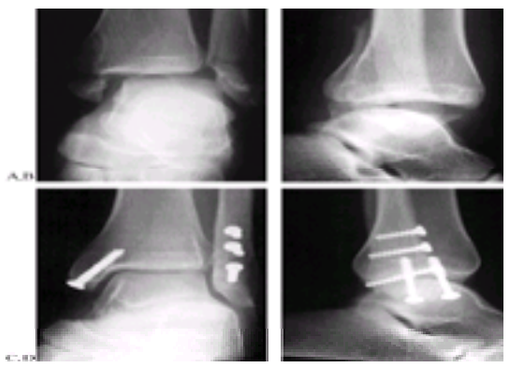

***Figure 25.15.*** **A,B:** Preoperative view of an SEIV fracture type or Weber type B fracture. **C,D:** Postoperative radiographs showing the use of lag screws alone on the oblique fracture of the distal fibula.

For oblique shear-type medial malleolous fractures, which commonly occur with supination–adduction injuries, screw fixation alone may be suboptimal because the distal fragment tends to displace proximally during screw tightening. In this instance, place an antiglide plate first (an appropriately contoured quarter tubular plate or one-third tubular plate), followed by the distally to proximally directed lag screws. An alternative method is to be certain that screws are at right angles to the fracture surface.

**LATERAL MALLEOLUS FRACTURES**

The methods for reduction and fixation of lateral malleolus fractures are dependent on the fracture pattern and mechanism. For most fractures about the ankle, reduce and fix the lateral malleolus first, restoring length and rotational alignment.

- Approach the majority of lateral malleolar fractures using incision 4 in Figure 25.11*B*. If posterior fixation or concomitant posterior malleolar reduction is anticipated based on preoperative planning, use incision 6, which is posterior.
- Consider the anatomic variations of the sural and superficial nerves to avoid inadvertent injury.

Weber A lateral malleolus, transverse–avulsion fractures are optimally treated with tension-band fixation because the fragment is usually too small for screws and a plate. This can be accomplished with Kirschner (K-) wires and malleable wire. Occasionally, a one-third tubular plate and screws work well. An intramedullary screw can be used as well but provides less rotational stability (Fig. 25.16).

***Figure 25.16.*** **A:** Preoperative anteroposterior radiograph of a supination-adduction type fracture or Weber type A. **B,C:** Postoperative radiographs illustrate the usex of an axial lag screw for the avulsion fracture of the distal fibula.

Weber B oblique fractures in the coronal plane ending at the level of the plafond can be stabilized with either a posterior antiglide plate (Fig. 25.17) or a lateral interfragmentary lag screw and a buttress plate (Fig. 25.18). Even though antiglide plating shows some biomechanical advantage (46), it should be reserved for short, oblique noncomminuted fracture patterns. For antiglide plating, a one-third tubular plate is optimal.

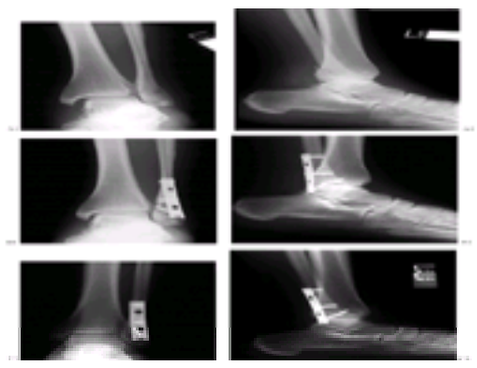

***Figure 25.17.*** **A:** Anteroposterior and lateral radiographs of a SER type lateral malleolar fracture. Notice the medial clear space widening consistent with medial ligamentous injury and dynamic instability. **B:** Postoperative radiographs demonstrating fixation with a posterior, antiglide technique. **C:** Radiographs 1 year postoperatively demonstrating osseous union and anatomic restoration of the ankle mortise.

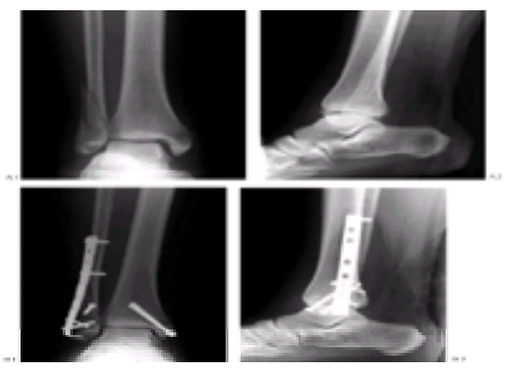

***Figure 25.18.*** **A:** Anteroposterior and lateral radiographs of a SER type bimalleolar fracture. **B:** Postoperative radiographs demonstrating various fixation techniques including stacked one-third tubular plates, push-pull screw (empty screw hole proximal to plate), and 2.7-mm screws utilized to secure small medial malleolar fragment.

### *Posterior Antiglide Plate*

- Minimally strip the posterior soft tissue extraperiosteally. Insert a 3.5-mm screw through the posterior antiglide plate from posterior to anterior just proximal to the fracture line. As the screw is tightened, the plate will reduce the fracture.
- Fine-tune the reduction with small Weber clamps until an anatomic reduction is achieved.
- With the fracture held anatomically reduced, place a 3.5-mm or 2.7-mm distal-posterior to proximal-anterior lag screw though the plate across the fracture. The 2.7-mm screw head is less prominent for the peroneal tendons and can be angled perpendicular to the fracture line.
- Place a 3.5-mm bicortical screw through the plate proximally to serve as a derotation screw (4) (Fig. 25.17).

### *Lateral Buttress Plate*

For lateral plating of these fractures, a one-third tubular plate, stacked one-third tubular plates, or 2.7-mm reconstruction plates provide satisfactory fixation.

- Mallet a one-third tubular plate flat distally and contour and rotate it to match the contours of the distal fibula. In cases where distal fixation is problematic, a hook can be fashioned out of the distal screw hole and impacted into the bone as an additional point of fixation (26). Do this by cutting the distal end of the plate off through the screw hole and then bending the resulting sharp ends toward the bone.
- Rather than placing a short unicortical 4.0-mm cancellous screw in the distal holes, 2.7- or 3.5-mm cortical screws can be angled proximally or distally to obtain additional cortical purchase and still avoid penetrating the articular surface in the lateral gutter.
- Two proximal bicortical screws and an anterior-to-posterior interfragmentary screw complete the fixation (Fig. 25.18). Additional screw fixation proximal to the fracture is rarely necessary and results in unbalanced fixation.

For shortened comminuted fractures or fractures operated on in a delayed manner, indirect reduction techniques are helpful in gaining the appropriate length and rotation.

- After fixing the plate distally, place a bicortical screw proximal to the plate and in line with it (24). This is known as a “push-pull” screw. Use a bone spreader between the push-pull screw and the plate to distract the distal fragment.
- After anatomic length has been achieved, correct rotational discrepancies before placing proximal screws.

### *Weber C Fracture*

Weber C distal fibula fractures require correction of length and rotational deformities of the distal fragment of the fibula as well as anatomic reduction and fixation of the syndesmosis (1). In a few of these injuries the anterior and interosseous ligaments of the syndesmosis are torn, but the posterior ligaments remain intact. Anatomic reduction and plate fixation of the fibula alone then restores the syndesmosis and renders it stable. Independent fixation of the syndesmosis then is unnecessary. Indirect reduction techniques are ideal for restoring appropriate length. Single one-third tubular plates are usually not strong enough to allow for distraction through the plate. Stacked one-third tubular or 3.5-mm dynamic compression plates (DCP) function well for this task. These plates require precise contouring, as they are too stiff to assume the contour of the lateral fibula when the screws are tightened.

- Following a lateral approach to the distal fibula, dissect along the anterior fibula to expose the anterior syndesmosis. Careful preoperative and intraoperative planning is required for precise placement of a screw from lateral to medial across the syndesmosis parallel to and 2 to 3 cm above the joint line.
- After fixing the plate to the distal fragment along the posterolateral aspect of the fibula, place a push-pull screw proximal to the plate. Distract through the plate until anatomic length, rotation, coronal plane alignment, and anatomic reduction of the syndesmosis have been accomplished. If there is cortical continuity between the distal and proximal fragments, the fracture can be loaded through the plate using the push-pull screw and a small Verbrugge clamp (24).
- Secure the plate proximally with two 3.5-mm bicortical screws.
- Then fix the syndesmosis.
- Position the hindfoot in slight inversion and the ankle in neutral dorsiflexion and hold the syndesmosis reduced with a two-point reduction forceps. The screw should parallel the joint and be directed from posterolateral to anteromedial at approximately a 15° angle (Fig. 25.19).



***Figure 25.19.*** **A:** Radiographs demonstrating a pronation type ankle fracture with syndesmotic disruption. Notice the avulsion fracture at the medial joint line. **B:** Radiographs following ORIF of the fibula and open reduction of the syndesmosis with transsyndesmotic fixation. **C:** Radiographs following union of the fracture. Radiolucency around the syndesmotic screw without failure is evident.

- Use a fully threaded 3.5-mm cortical screw across all four cortices of the fibula and tibia to secure fixation. In larger individuals, two 3.5-mm screws may be necessary. The fully threaded screw functions as a “position” screw by holding the reduced position, avoiding excessive compression of the syndesmosis.

## POSTERIOR MALLEOLUS FRACTURES

Posterior malleolus fractures often are small enough not to require fixation (28). Fractures can involve only the nonarticular portion of the posterior malleolus, and fragments that are attached to the fibula by the posterior distal tibiofibular ligaments are well reduced and stable after fixation of the fibula. If the fracture involves 25% or more of the articular surface, the talus tends to subluxate posteriorly, so fixation is indicated (8,31). Because the fracture can be oblique, there is a tendency to underestimate the size of the fragment. Computed tomography (CT) is useful in delineating the size and location of the fragment.

- Posteromedial fragments can usually be fixed through incision 3 on Figure 25.11*A*, which is used to fix the medial malleolus as well. Lengthen it as needed to gain adequate exposure. Posterolateral fragments can be approached in a similar way laterally through incision 6 on Figure 25.11*B*. Use the interval between the peroneal tendons and the flexor hallicus tendon. This incision must be large enough to permit tension-free exposure. The prone position is very helpful for this exposure and fixation.
- Use a dental tool, large Weber double-pointed forceps, or spiked ball-tip pusher to reduce the fragment. Lock the proximal edge of the fractured fragment into place first and then close the articular surface. Hold it securely with the reduction forceps.
- After provisional K-wire fixation, obtain definitive fixation with percutaneous anterior-to-posterior 3.5-mm or 2.7-mm lag screws placed through anterior stab wounds. Do not overtighten the screws because this may cause the posterior fragment to displace proximally and anteriorly (Fig. 25.20).

***Figure 25.20.*** A 28-year-old woman was involved in a high speed motor vehicle accident sustaining multiple injuries including this comminuted intraarticular pylon fracture of the left ankle. **A:** AP radiograph. **B:** Lateral radiograph, note the large posterior fragment. **C:** AP radiograph following open reduction and internal

fixation through an anterior approach for the tibia with application of a spoon plate. Today we would prefer the use of a smaller combination of plates. **D:** A lateral view showing management of the larger posterior malleolar fragment with anterior to posterior lag screw fixation accomplished through the anterior approach using a sharp-tipped tenaculum forceps to reduce the articular fragment by percutaneous means avoiding direct exposure of the posterior fragment.

### ISOLATED DISRUPTIONS OF THE DISTAL TIBIOFIBULAR SYNDESMOSIS

Disruptions of the syndesmosis require open reductions to insure anatomic restoration of the syndesmosis.

- Expose the syndesmosis anteriorly as previously described.
- Before reducing the distal tibial–fibular joint, confirm that the distal anterior tibial–fibular ligaments have not “buttonholed” into the joint, blocking the reduction. Clean out the syndesmosis but do not disturb the articular cartilage or curette the bone in order to prevent a synostosis from forming.
- Reduce the syndesmosis using a large pointed reduction forceps. Be certain that the fibula slides posteriorly into the sulcus in the tibia and is anatomic.
- Proceed with screw placement as described for Weber C fractures (8). A two-hole one-third tubular plate on the fibula may be used as well, particularly if two screws are placed (Fig. 25.21).



***Figure 25.21.*** **A:** Radiographs following pronation injury resulting in a medial ligamentous injury with syndesmotic disruption.**B:** Stress radiograph demonstrating syndesmotic disruption with comparative stress view of the uninjured ankle. **C:** Intraoperative radiograph with compression across the reduced syndesmosis. **D:** Radiographs following open reduction of the syndesmosis and internal transsyndesmotic fixation. **E:** Follow-up radiographs demonstrating maintenance of the syndesmotic reduction and development of (asymptomatic) intramembranous calcification.

- Repair of the anterior distal tibia–fibula ligaments can be performed with a nonabsorbable suture, although this is less important than anatomic reduction with stable screw placement.
- Repair of a concomitant rupture of the deltoid ligament is unnecessary. If the medial side is explored for other reasons, repair the ligament.

### FRACTURES OF THE TUBERCLE OF CHAPUT

- Use the lateral incision for lateral malleolar fixation to reduce and stabilize the tubercle of Chaput. Dissect anteriorly with a periosteal elevator along the anterior tibial–fibular ligament to provide access to the tubercle of Chaput.
- Use a dental pick, spiked pusher, or Weber clamp for reduction.
- Provisionally stabilize the fracture with K-wires and then place a lag screw from lateral to medial, securing the fragment.

### LIGAMENT INJURIES

Ligamentous injuries about the ankle that fail to disrupt the integrity of the ankle mortise and that fail to block anatomic reduction rarely require repair. Deltoid ligament tears in combination with lateral malleolar fractures do not require open treatment unless they prevent an anatomic reduction of the ankle mortise (12).

## PYLON FRACTURES

### PRINCIPLES OF TREATMENT

The goal of surgery is to achieve a precisely reduced joint surface maintained by stable internal fixation. If this can be achieved, functional postoperative treatment with early use of the muscles of the leg and physiologic activity of the joint can be instituted (34,35). Early use of the muscles prevents atrophy, and motion helps to repair injured cartilage (44). The fixation maintains the fracture in the correct position through the period of bone healing. Operatively achieved anatomic reduction and stable internal fixation can produce results impossible to achieve with other therapeutic approaches (2).

Operate on the fracture as soon as possible after injury. This window for intervention extends to about 10 to 12 hours after injury. If more time passes, interstitial edema increases, the skin loses its pliability, and fracture blisters appear. During this later period, surgery is contraindicated.

A closed reduction, external splinting incorporating a compression dressing, and elevation of the extremity may salvage the situation if it is too late to operate. Proper management during this period enables operative intervention when the skin starts to wrinkle, at about 8 to 10 days.

An alternative approach is to place a patient too unstable for emergent surgery into calcaneal pin traction on a Boehler frame and allow the traction to regain length and alignment of the limb. Elevation, reduction, and time allow the posttraumatic inflammatory period to pass. An idea of the relative ease of open reduction and internal fixation may be obtained by viewing radiographs of the reduction obtained by pure distraction during the traction period (23,24) (Fig. 25.22).

***Figure 25.22.*** **A:** Anteroposterior (AP) radiograph of a type C pylon fracture. Notice the shortening that contributes to displacement of the diaphyseal and articular fracture fragments. **B:** An AP radiograph of the same fracture with 10 kg (22 lb) of skeletal traction applied through the calcaneus. Notice how simple distraction has reduced most of the diaphyseal and epiphyseal fracture displacements. This is a good prognostic sign, indicating that indirect methods of reduction during surgery can allow an atraumatic reduction of the fracture, which then may be fixed by standard methods of internal fixation. **C:** Another AP projection of a type C pylon fracture. Although this fracture is more comminuted than the previous example, a more important indicator of problems in reduction during surgery is shown by its failure to reduce or improve with skeletal traction. **D:** Ten kilograms (22 lb) of traction applied to the calcaneal pin have not markedly improved the radiographic situation. Failure to improve during skeletal traction can be attributed to the interposition of soft tissue. In this fracture, the flexor hallucis and neuromuscular bundle have been displaced into the joint and block reduction of the posterior fragment.

Carry out surgery after the acute effects of the injury have subsided. This does not represent the ideal situation, however. Surgical intervention is rendered more difficult by the passage of time because the soft tissues are less pliable and the bony fragments become softer and somewhat adherent.

The severity of the injury plays the most important role in determining the final outcome. In high-energy injuries, impaction of the subchondral bone, fragmentation of the epimetaphyseal cortex, and irreparable abrasion of the cartilage of tibia and talus may dictate a poor result regardless of the surgeon's experience. Under these circumstances, the condition of the soft-tissue sleeve becomes critical.

If surgical intervention is attempted, the operative approach and surgical tactic for the reduction and fixation must be carefully planned. In these fractures, a preoperative drawing may be very enlightening. If the key fragments to be reduced and fixed cannot be identified and drawn, it may be that at surgery they cannot be reduced and fixed (48). A misguided attempt at anatomic reduction and internal fixation under circumstances in which stable fixation cannot be achieved can deteriorate into a lengthy struggle, resulting in frustration for the surgeon, intraoperative acceptance of malreduction, unstable fixation and ensuing skin slough, wound dehiscence, bone and tendon necrosis, and infection. Worse, the patient may be deprived of delayed reconstructive procedures that could produce an acceptable result.

Although indirect reduction techniques are useful in enacting a reduction, pylon fractures, like all articular fractures, should be reduced directly. Regardless of which operative approach to pylon fractures is employed, distraction techniques are required to restore alignment and reduce compressed articular fragments.

**LIMITED INTERNAL FIXATION**

Limited internal fixation as an isolated fixation technique should be reserved for undisplaced or anatomically reducible articular fracture patterns without metadiaphyseal extension that are potentially unstable and require additional stabilization. Isolated percutaneous screw fixation of periarticular fragments rarely provides sufficient stability to allow for early range of motion and likely necessitates cast immobilization to provide stability. This technique is best combined with external fixation, which is described below.

**EXTERNAL FIXATION**

External fixation techniques include large pin fixators, small wire fixators, and hybrid fixators (3,29). Reduction via external fixation relies on traction and resulting ligamentotaxis to help reduce the fracture fragments. Without direct visualization of the articular surface via open or arthroscopic means, treatment by external fixation relies on radiographic joint reduction, which is subject to errors. Although some small wire hybrid techniques do not cross the ankle joint, most large pin fixators rely on fixation that spans the ankle and often the subtalar joints, precluding early joint motion. If external fixation is used as a temporary treatment regimen while soft tissue swelling is allowed to subside, ensure that pin placement does not compromise future open treatment. Specific surgical techniques vary, depending on the type of external fixation employed. Correction of angular, rotational, and length discrepancies is accomplished by distracting through the fixator after connecting the fixator to proximal and distal pins and/or wires. Regardless of the fixator, it is essential that pins and wires be placed without causing thermal necrosis to the bone and soft tissue, which leads to infection and ring sequestrum formation (see Chapter 11 for more details).

**EXTERNAL FIXATION WITH LIMITED INTERNAL FIXATION**

Treatment by this method involves limited fixation to stabilize the articular fractures followed by “connecting” the restored joint to the tibial shaft with external fixation. Indirect reduction techniques aid in repositioning of fragments via ligamentotaxis (48).

- Before attempting reduction of the articular fracture fragments, connect a universal distactor to tibial and talar or calcaneal Schanz screws and correct for length and rotational and angular malalignments. Alternatively, some fixation systems allow for distraction through the fixator.
- Utilize limited well-planned incisions and stab wounds near the plafond to reduce fracture fragments under fluoroscopic radiographic control. Small elevators, dental picks, pushers, and K-wires are helpful in positioning fragments in a reduced position.
- After obtaining anatomic reduction and provisional stabilization with K-wires or guide wires for cannulated screws, secure the articular and periarticular fragments with interfragmentary screws.
- Following reduction and stabilization of the articular fragments, use the external fixator to secure the ankle and distal tibia to the tibial diaphysis.

A variety of small-wire, hybrid, and large pin fixators are available. Small-wire or hybrid fixator fixation that provides stable fixation without spanning the tibial–talar or talocalcaneal joints is preferable when technically feasible because it allows for early ankle (and subtalar) motion, satisfying one of the goals of operative pylon treatment (Fig. 25.23).

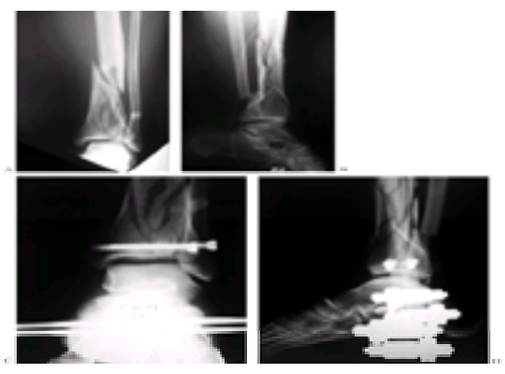

***Figure 25.23.*** Radiograph of a pylon fracture in a hybrid or Orthofix fixator with percutaneous screws. **A,B:** AP and lateral radiographs demonstrating an AO C type pylon fracture with marked metadiaphyseal comminution. **C,D:** Radiographs with a tibial-calcaneal spanning external fixator, reducing the fracture via ligamente taxis with limited internal fixation of the major articular fragments.

**OPEN REDUCTION AND INTERNAL FIXATION**

Open reduction and internal fixation performed well gives the best results (25,36,42). Poor soft-tissue handling, inappropriate surgical timing, excessive soft-tissue stripping, and use of excessively large implants, however, can lead to disastrous results.

Timing of pylon ORIF is based on basic soft-tissue injury principles. The safest time periods for open treatment are within 6 hours of the injury or at least 6 days from the injury (34). Staging of open treatment takes advantage of both these “windows of opportunity,” provisionally stabilizing the fracture to aid in soft-tissue healing and allowing for careful radiographic evaluation and preoperative planning.

As soon as possible after a patient with a pylon fracture presents to the trauma center, preferably within 6 hours from time of injury, perform ORIF of the fibula and provisional tibial–calcaneal external fixation.

- Carefully plan the fibular incision to allow for a 7-cm skin bridge between this and the future anterior tibial incision. Approach the distal fibula fracture essentially the same as for routine lateral malleolar fractures. Direct the incision slightly posteriorly to insure a safe skin bridge. Fibula fractures associated with pylon fractures typically occur proximal to the ankle mortise, but varying patterns may occur.
- Shortened fibulas from lateral compression modes of failure reduce well with indirect means. Following fixation to the distal fragment, place a 3.5-mm bicortical push-pull screw proximal to the plate. After distracting the fracture out to anatomic length with a bone spreader and correcting rotational malalignments, secure the plate to the proximal fragment. If cortical continuity exists, the fracture can be loaded using the push-pull screw.
- Place a 5.0-mm Schanz screw in the medial aspect of the tibia and calcaneus perpendicular to the ankle joint using standard techniques. Make sure the tibial pin is far enough proximal to avoid communication with the future tibial incision.
- Connect the pins to a single medial carbon fiber bar and distract the distal tibia out to length using the compression device (Fig. 25.24). Do not place any pins into the talus because this may compromise any incision required for definitive open treatment in the future.

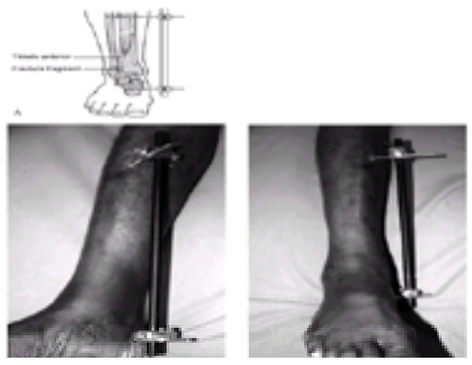

***Figure 25.24.*** **A:** Appropriate provisional external fixator placement following first stage of open treatment of a pylon fracture. **B:** Photographs following ORIF of the fibula fracture and application of a tibial–calcaneal fixator.

Definitive open treatment should be delayed until soft-tissue swelling diminishes. This usually occurs within 7 to 10 days but may take up to 3 weeks.

- Make an anterior tibial incision (Fig. 25.11*C*), leaving a 7-cm skin bridge between it and the fibular incision. This will vary somewhat based on the fracture pattern. The standard incision starts just lateral to the crest of the tibia and courses just anterior to the tibialis anterior tendon at the distal limb (34). A posterior (European) approach may occasionally be preferable to accommodate open fracture wounds, but this approach provides limited exposure of the articular surface.
- Dissect directly down to bone just lateral to the anterior tibial tendon and develop the exposure medially and laterally at the level of periosteum. Incise the anterior compartment fascia just lateral to the tibial crest and reflect the flap medially in an extraperiosteal manner, exposing the medial face of the tibia. Avoid violating the paratenon of the anterior tibial tendon at the distal aspect of the incision. Should the skin slough anteriorly, the paratenon will accept a split-thickness skin graft. In the absence of the paratenon, the tendon will desiccate, leading to infection and other problems.
- Make an anterior ankle arthrotomy and carry the exposure out onto the neck of the talus to visualize the reduction. Perform minimal periosteal stripping of the fracture fragments.
- Additional distraction through the medial fixator may aid in the reduction (23).
- Use a variety of dental picks, reduction forceps, and pushers to tease the fragments into anatomic alignment. Forceful reduction maneuvers are rarely beneficial and increase the risk of further fracture fragmentation. Thoughtful, methodic, fragment-by-fragment reduction and provisional fixation are essential.
- After reducing the fragments, perform provisional fixation with K-wires. If significant crush of metaphyseal bone exists, place autologous bone graft into the osseous defect to prevent collapse of the reduction and promote osseous union.
- After confirming an anatomic articular reduction visually and radiographically, replace the provisional K-wires with limited lag screw fixation.
- Various small and minifragment plates may additionally be contoured to adequately stabilize the periarticular fracture fragments and stabilize the metaphyseal component to the distal diaphysis of the tibia (Fig. 25.25). It is rare that a plate larger than 3.5-mm limited-contact DC plates is required.



***Figure 25.25.*** **A:** Anteroposterior radiographs of a C-type tibial pylon fracture. **B:** Radiographs following ORIF of the lateral malleolar component and application of a provisional tibial–calcaneal external fixator. **C:** Clinical photo before second stage of surgery. **D:** Anteroposterior radiographs following ORIF of tibial plafond and autogenous bone grafting of the metaphyseal defect. **E:** Weight-bearing radiographs following osseous union. **F:** Weight-bearing radiographs following hardware removal, demonstrating articular congruity and maintenance of tibial–talar joint space.

If skin closure is difficult because of tension, try to close all deep tissues over the bone and implants, leaving the fibular incision open, allowing for primary closure of the tibial wound with delayed closure or split-thickness skin grafting of the fibular incision. Delayed closures under sterile conditions are far safer than attempting to primarily close an overly tight wound.

## POSTOPERATIVE CARE

During the early postoperative period, keep the limb in a well-padded compression dressing and splints to prevent the foot from dropping into equinus. Elevate the limb until swelling subsides. Gentle range-of-motion exercises can begin as tolerated if the surgeon feels the fixation is stable. On the first postoperative office visit, apply a removable below-knee cast. Keep patients touch-down weight bearing but remove the cast or brace daily to perform active, active-assisted, and gentle passive ankle and subtalar range-of-motion exercises. Patients with persistent swelling despite stable internal fixation and an anatomically reduced fracture often benefit from a knee-high medium compression stocking. Based on the fracture pattern, continue limited weight bearing for at least 6 weeks. Most fractures require limited weight bearing and protection for 12 weeks.

## PITFALLS AND COMPLICATIONS

Complications may be loosely grouped into intraoperative (or technical) errors and early and late postoperative complications.

Technical mistakes typically involve failure to achieve anatomic reductions and failure to adequately stabilize the fracture. Articular incongruity and inability to restore the anatomic relationships of the ankle mortise increase the probability of postoperative pain and early posttraumatic arthrosis (52). Failure to achieve stable fixation allowing for early range of motion leads to “fracture disease” and chondrolysis. Malreductions that have yet to result in significant levels of joint destruction are amenable to restorative osteotomies (55). Advanced ankle joint destruction often requires arthrodesis as a salvage procedure. Early total ankle arthroplasty results from newer generation ankle prostheses are an encouraging alternative to joint fusion.

Wound healing delays, nonunions, and infection following operative treatment of ankle and pylon fractures present a difficult challenge to the orthopaedic surgeon. Frequently, these postoperative complications stem from decisions made before and during operative treatment. Proper surgical timing, avoidance of undue soft-tissue and osseous devascularization, utilizing appropriate-sized implants, and adhering to principles of treatment of open fractures prevent the majority of these potentially disastrous complications. Even though operative treatment utilizing external fixation is usually considered safer than open techniques, complications can result from either treatment protocol. Superficial wound infections and breakdowns may be amenable to local wound care and oral antibiotics. Deep infection and full-thickness wound sloughs must be treated with aggressive debridements of devitalized tissue, full-thickness soft-tissue coverage, and intravenous antibiotics. Salvage following these grave complications may require extraordinary techniques such as free tissue transfer or bone transport procedures in order to achieve osseous union and restore limb length and function. Failure to eradicate deep infection or achieve union may necessitate a below-knee amputation.

## AUTHORS' PERSPECTIVE

The complexity of surgery of ankle and pylon fractures is frequently underestimated, leading to pitfalls in treatment. Although various surgical modalities (internal fixation, external fixation) may be employed in the operative treatment of ankle fractures, ideal surgical treatment should produce anatomic restoration of the articular congruity of the tibial plafond and restoration of the ankle mortise with sufficient stability to allow for early joint motion. Each surgeon will choose different treatment

modalities in order to accomplish these goals. We routinely treat ankle and pylon fractures by open reduction and internal fixation. By protecting the soft tissues, operating during safe periods, preserving the osseous vascular supply, and utilizing appropriately sized implants, we have been able to avoid the majority of complications associated with ORIF. Other, less-invasive techniques may potentially minimize the risk of morbidity, but they often preclude anatomic restoration of the articular surface and prevent early restoration of ankle and subtalar motion.

## CHAPTER REFERENCES

Each reference is categorized according to the following scheme: *, classic article; #, review article; !, basic research article; and +, clinical results/outcome study.


! 1. Boden SD, Labropoulos PA, McCowin P, et al. Mechanical Considerations for the Syndesmotic Screw. *J Bone Joint Surg* 1989;71-A:1548.

+ 2. Bone LB. Fractures of the Tibial Plafond. The Pylon Fractures. *Orthop Clin North Am* 1987;18:95.

+ 3. Bone L, Stegemann P, McNamara K, Seibel R. Severely Comminuted and Open Tibial Pylon Fractures. *Clin Orthop* 1993;292:101.

+ 4. Brunner CF, Weber BG. *Special Techniques in Internal Fixation.* New York: Springer, 1982.

+ 5. Burwell HN, Charnley AD. The Treatment of Displaced Fractures at the Ankle by Rigid Internal Fixation and Early Joint Motion. *J Bone Joint Surg* 1965;47:634.

+ 6. Carragee EJ, Csongradi JJ, Bleck EE. Early Complications in the Operative Treatment of Ankle Fractures. *J Bone Joint Surg* 1991;73-B:79.

* 7. Destot E. *Traumatismes du Pied et Rayons des Malleoles, Astragale, Calcaneum, Avant Pied.* Paris: Masson, 1911.

+ 8. Edwards GS Jr, DeLee JC. Ankle Diastasis Without Fracture. *Foot Ankle* 1984;4:305.

+ 9. Eventov I, Salama R, Goodwin DRA, Weissman SL. An Evaluation of Surgical and Conservative Treatment of Fractures of the Ankle in 200 Patients. *J Trauma* 1978;18:271.

+ 10. Franklin JL, Johnson KD, Hansen ST Jr. Immediate Internal Fixation of Open Ankle Fractures. *J Bone Joint Surg* 1984;66-A:1349.

! 11. Harper MC. Posterior Instability of the Talus: An Anatomic Evaluation. *Foot Ankle* 1989;10:36.

! 12. Harper MC. The Deltoid Ligament. An Evaluation of Need for Surgical Repair. *Clin Orthop* 1988;226:156.

! 13. Harper MC. An Anatomic Study of the Short Oblique Fracture of the Distal Fibula and Ankle Stability. *Foot Ankle* 1983;4:23.

# 14. Hughes J. The Medial Malleolus in Ankle Fractures. *Orthop Clin North Am* 1980;11:649.

+ 15. Hughes JL, Weber H, Kuner EH. Evaluation of Ankle Fractures: Non-operative and Operative Treatment. *Clin Orthop* 1979;138:111.

+ 16. Hughes JL, Weber H, Willenegger H, Kuner EH. Evaluation of Ankle Fractures: Nonoperative and Operative Treatment. *Clin Orthop* 1979;138:111.

* 17. Inman VT. *The Joints of the Ankle.* Baltimore: Williams & Wilkins, 1976.

* 18. Joy G, Patzakis MJ, Harvey JP Jr. Precise Evaluation of the Reduction of Severe Ankle Fractures. *J Bone Joint Surg* 1974;56-A:979.

* 19. Lauge-Hansen N. Fractures of the Ankle. II. Combined Experimental-Surgical and Experimental-Roentgenologic Investigations. *Arch Surg* 1950;60:957.

+ 20. Leeds HC, Ehrlich MG. Instability of the Distal Tibiofibular Syndesmosis after Bimalleolar and Trimalleolar Ankle Fractures. *J Bone Joint Surg* 1984;66-A:490.

+ 21. Lindsjo U. Operative Treatment of Ankle Fractures. *Acta Orthop Scand [Suppl]* 1981;189:1.

+ 22. Lund-Kristensen J, Greiff J, Riegels-Nielsen P. Malleolar Fractures Treated with Rigid Internal Fixation and Immediate Mobilization. *Injury* 1981;13:191.

+ 23. Mast JW. Reduction Techniques in Fractures of the Distal Tibial Articular Surface. *Tech Orthop* 1987;2:29.

* 24. Mast JW, Jakob RP, Ganz R. *Planning and Reduction Techniques in Fracture Surgery.* Heidelberg: Springer-Verlag, 1989.

+ 25. Mast JW, Spiegel PG, Pappas JN. Fractures of the Tibial Pilon. *Clin Orthop* 1988;230:68.

+ 26. Mast JW, Teipner WA. A Reproducible Approach to the Internal Fixation of Adult Ankle Fractures: Rational, Technique and Early Results. *Orthop Clin North Am* 1980;11:6.

+ 27. Mayer PJ, Evarts CM. Fracture-Dislocation of the Ankle with Posterior Entrapment of the Fibula behind the Tibia. *J Bone Joint Surg* 1978;60-A:320.

+ 28. McDaniel WJ, Wilson FC. Trimalleolar Fractures of the Ankle. An End Result Study. *Clin Orthop* 1977;122:37.

+ 29. McDonald MG, Burgess RC, Bolano LE, Nicholls PJ. Ilizarov Treatment of Pilon Fractures. *Clin Orthop* 1996;325:232.

+ 30. Meyer TL Jr, Kumler KW. ASIF Technique and Ankle Fractures. *Clin Orthop* 1980;150:211.

! 31. Michelson JD, Magid D, Ney DR, Fishman EK. Examination of the Pathologic Anatomy of Ankle Fractures. *J Trauma* 1992;32:65.

+ 32. Mifsud RP, Batten RL. External Rotation and Abduction Fractures Around the Ankle Joint Treated by Internal Fixing Using AO Instrumentation. *Injury* 1979;11:33.

+ 33. Mitchell WG, Shaftan GW, Sclafani SJA. Mandatory Open Reduction: Its Role in Displaced Ankle Fractures. *J Trauma* 1979;19:602.

# 34. Müller ME, Allgöwer M, Schneider R, Willenegger H. *Manual of Internal Fixation, 3rd ed.* Berlin: Springer, 1990.

# 35. Müller ME, Allgöwer M, Schneider R, Willenegger H. *Manual of Internal Fixation, 2nd ed.* New York: Springer-Verlag, 1979.

+ 36. Ovadia DN, Beals RK. Fractures of the Tibial Plafond. *J Bone Joint Surg* 1986;68-A:543.

+ 37. Pankovich AM. Fractures of the Fibula at the Distal Tibiofibular Syndesmosis. *Clin Orthop* 1979;143:138.

+ 38. Pankovich AM. Fractures of the Fibula Proximal to the Distal Tibiofibular Syndesmosis. *J Bone Joint Surg* 1978;60-A:221.

+ 39. Pettrone FA, Mitchell G, Pee D, et al. Quantitative Criteria for Prediction of the Results after Displaced Fracture of the Ankle. *J Bone Joint Surg* 1983;65-A:667.

+ 40. Phillips WA, Schwartz HS, Keller CS, et al. A Prospective, Randomized Study of the Management of Severe Ankle Fractures. *J Bone Joint Surg* 1985;67-A:67.

! 41. Ramsey PL, Hamilton W. Changes in Tibiotalar Area of Contact Caused by Lateral Talar Shift. *J Bone Joint Surg* 1976;58-A:356.

* 42. Reudi T, Allgower M. The Operative Treatment of Intra-articular Fractures of the Lower End of the Tibia. *Clin Orthop* 1979;138:105.

+ 43. Roberts RS. Surgical Treatment of Displaced Ankle Fractures. *Clin Orthop* 1983;172:164.

! 44. Salter RB, Simmonds DF, Malcomb BW, et al. The Biological Effect of Continuous Passive Motion on the Healing of Full-Thickness Defects of Articular Cartilage: An Experimental Investigation in the Rabbit. *J Bone Joint Surg* 1980;62-A:1232.

+ 45. Sarkisian JS, Cody GW. Closed Treatment of Ankle Fractures: A New Criterion for Evaluation—A Review of 250 Cases. *J Trauma* 1976;16:323.

! 46. Schaffer JJ, Manoli A II. The Antiglide Plate for Distal Fibular Fixation. *J Bone Joint Surg* 1987;69A:596.

+ 47. Schatzker J, McBroom R, Dzioba R. Irreducible Fracture Dislocation of the Ankle Due to Posterior Dislocation of the Fibula. *J Trauma* 1977;17:397.

+ 48. Scheck M. Treatment of Comminuted Distal Tibial Fractures by Combined Dual Pin Fixation and Limited Open Reduction. *J Bone Joint Surg* 1965;47-A:1537.

+ 49. Segal D, Pick RY, Klein HA, Heskiaoff D. The Role of the Lateral Malleolus as a Stabilizing Factor of the Ankle Joint: Preliminary Report. *Foot Ankle* 1981;2:25.

+ 50. Svend-Hansen H, Bremerskov V, Baekgaard N. Ankle Fractures Treated by Fixation of the Medial Malleolus Alone. *Acta Orthop Scand* 1978;49:211.

! 51. Takebe K, Nakagawa A, Minami H, et al. Role of the Fibula in Weight-Bearing. *Clin Orthop* 1984;184:289.

+ 52. Teeny SM, Wiss DA. Open Reduction and Internal Fixation of Tibial Plafond Fractures. Variables Contributing to Poor Results and Complications. *Clin Orthop* 1993;282:108.

+ 53. Tunturi T, Kemppainen K, Patiala H, et al. Importance of Anatomical Reduction for Subjective Recovery after Ankle Fracture. *Acta Orthop Scand* 1983;54:641.

* 54. Weber BG. *Die Verletzungen des Oberon Sprunggelenkes.* Stuttgart: Verlag Han Huber, 1972.

# 55. Weber BG, Simpson LA. Corrective Lengthening Osteotomy of the Fibula. *Clin Orthop* 1985;199:61.

# 56. Wilson FC, Skilbred LA. Long-Term Results in the Treatment of Displaced Bimalleolar Fractures. *J Bone Joint Surg* 1966;48-A:1065.

# 57. Yablon IG, Heller FG, Shouse L. The Key Role of the Lateral Malleolus in Displaced Fractures of the Ankle. *J Bone Joint Surg* 1977;59-A:169.

# 58. Yde J. The Lauge-Hansen Classification of Malleolar Fractures. *Acta Orthop Scand* 1980;51:181.

+ 59. Yde J, Kristensen KD. Ankle Fractures. Supination–Eversion Fractures of Stage II. Primary and Late Results of Operative and Non-Operative Treatment. *Acta Orthop Scand* 1980;51:695.

+ 60. Yde J, Kristensen KD. Ankle Fractures. Supination-Eversion Fractures of Stage IV. Primary and Late Results of Operative and Non-Operative Treatment. *Acta Orthop Scand* 1980;51:981.

# CHAPTER 26

# PRINCIPLES OF TREATMENT OF NONUNIONS AND MALUNIONS

*In the second edition, portions of this chapter were written by Howard Rosen, Sir Dennis Paterson, Carl T. Brighton, and Peter M. Stevens. Their contributions are appreciated.*

*Michael W. Chapman*

**M. W. Chapman:** Department of Orthopaedics, University of California Davis, Sacramento, California, 95817.

A. Nonunions
Delayed Union
Nonunion
Pathophysiology and Etiology
Classification
Principles of Treatment
Objectives and Rationale
Diagnosis
Imaging
Nonoperative Treatment
Cast and Brace Immobilization
Electrical Stimulation
Ultrasound
Bone Marrow Injection
Surgical Treatment
Preoperative Planning
Bone Graft Alone
Plate Fixation With or Without Bone Graft
Postoperative Care
Intramedullary Nailing
Ilizarov Techniques
Postoperative Care
Infected Nonunions
B. Malunions
Definition of Malunion
Goals of Treatment
Defining the Deformity
Preoperative Planning
Types of Deformity
Single-Plane Deformity
Two-Plane Deformity
Three-Plane Deformity
Preoperative Preparation
Surgical Techniques
Transverse Osteotomy
Opening and Closing Wedge Osteotomies
Oblique (Single-Plane) Osteotomy
Crescentic (Dome) Osteotomy
Displacement Osteotomy
Stepcut Osteotomy
Postoperative Management
Pitfalls and Complications
Chapter References

## A. NONUNIONS

### DELAYED UNION

A healing fracture becomes a delayed union when it does not heal within the expected time after treatment. This very general definition reflects the multiple factors involved in determining when a fracture has become a delayed union. For example, a stable fracture of the distal radius in a healthy 33-year-old patient treated in a short-arm cast would be expected to heal by 6 weeks; if it does not heal by 12 weeks, it might be regarded as a delayed union. On the other hand, a displaced subcapital fracture of the femoral neck in a 70-year old treated with percutaneous cannulated screw fixation would be expected to heal in 6 months; it would be regarded as a delayed union if it had not healed by 6 months. Factors influencing the rate of union are the same as those that can lead to nonunion and are listed in Table 26.1.

| |
|---|
| Excess motion, due to inadequate immobilization |
| Gap between fragments |
| Soft-tissue interposition |
| Distraction by traction or hardware |
| Malposition, overriding, or displacement of fragments |
| Loss of bone substance |
| Loss of blood supply |
| Damage to nutrient vessels |
| Excessive stripping or injury to periosteum and muscle |
| Free fragments, severe comminution |
| Avascularity due to surgical intervention |
| Infection (?) |
| Bone death (sequestrum) |
| Osteolysis (gap) |
| Loosening of implants (motion) |
| General: Age, nutrition, steroids, anticoagulants, radiation, burns, etc., predispose to but do not cause nonunion. |

***Table 26.1. Causes of Nonunion***

Clinical signs of delayed union are persistent pain, tenderness, and motion at the fracture site. Radiographic hallmarks of delayed union are persistence of the fracture line, hypertrophic callus with a persistent fracture line, and minimal or no callus production (60,84) (Fig. 26.1). If internal fixation is present, fracture lines may be persistent or show evidence of resorption; there may be evidence of failure of fixation in the form of halos around screws, or there may be evidence of implant breakage.

***Figure 26.1.*** Microangiogram of a 6-week-old canine radius fracture, showing delayed union. Note the tremendous increase in vascularity and the inability of the capillaries to penetrate the fibrocartilage of this hypertrophic delayed union. (From Rhinelander FW. The Normal Microcirculation of Diaphyseal Cortex and Its Response to Fracture. *J Bone Joint Surg Am* 1968;50:784.)

## NONUNION

Nonunion is also difficult to define because of the many different factors that must be considered. In general, the absence of any clinical or radiographic evidence of progression of fracture healing for 2–3 months after the expected time period for healing constitutes a nonunion. Be cautious in applying this definition, as some progression toward union may occur that is not detectable by the usual means. This is evidenced by the fact that an occasional “nonunion” treated nonoperatively in a weight-bearing cast will eventually go on to union. In diaphyseal fractures of major long bones in adults, the diagnosis of nonunion should not be made until 6 months after the fracture (57,60). The clinical signs are discussed in the next section. Radiographically, a nonunion shows no evidence of bone bridging the fracture site. Finally, the diagnosis of nonunion infers that the fracture will not go on to union without some type of therapeutic intervention, either nonoperative or surgical.

## PATHOPHYSIOLOGY AND ETIOLOGY

In a nonunion, the normal fracture repair process occurs only minimally, is interrupted, or does not result in the formation of bridging bone; instead it produces only fi-brous tissue or cartilage, which is interposed in the fracture site in the absence of bony callus bridging between the two major fracture fragments (Fig. 26.2) (89). Unless obscured by overlying hypertrophic callus, a radiolucent line representing the zone of fibrous and/or cartilaginous tissue is evident on plain radiographs (Fig. 26.3).

***Figure 26.2.*** Roentgenographic appearance and histology of a 20-week experimental canine hypertrophic pseudarthrosis. A radiolucent area is intensely stained, unmineralized fibrocartilage and weakly stained fibrous tissue in the gap. Note cleftlike fissure of a neoarthrosis and sclerotic bone ends. (From Schenk RK. Histology of Fracture Repair and Nonunion. *Bulletin of the Swiss Association for Study of Internal Fixation*, Bern, Oct. 1978.)

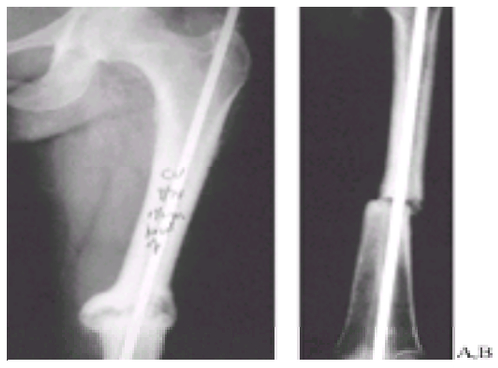


***Figure 26.3.*** **A:** Hypertrophic vascular nonunion 1.5 years after inadequate intramedullary nailing. Motion continues at the fracture with weight bearing. Bending, torsional, and shear stresses are not stabilized by the nail. **B:** Atrophic avascular nonunion 1 year after inadequate intramedullary nailing. Mechanical instability and avascularity have caused this nonunion.

When a nonunion is characterized by the production of cartilage in the presence of significant motion, often a cleft will develop in the cartilage. The surrounding fibrous tissue forms a pseudocapsule; with sealing of the bone ends and remodeling, a false joint, or pseudarthrosis, is formed. A serum transudate is usually found in these pseudarthroses, which is evident upon incision through the fibrous capsule into the pseudarthrosis as normal-appearing “joint fluid” exudes forth. Atrophic and oligotrophic nonunions (see the classification, below) are characterized by minimal or no formation of cartilage, a predominance of fibrous tissue formation, and what appears to be an aggressive osteoclastically mediated resorption of the bone ends, resulting in a pencil-like configuration of the ends of the major bone fragments. In part, this picture may be caused by actual mechanical erosion of the bone ends resulting from weight bearing or excessive motion. This picture is more common in the presence of pathologic nonunions, such as in congenital nonunions associated with neurofibromatosis (see Chapter 174, Chapter 178, and Chapter 180).

The etiology of delayed union and nonunion is complex (Table 26.1) (2,3,42,43,60,71,81). The most common cause of nonunion in wild animals, and in humans despite modern treatment, is excessive motion at the fracture site. Bone modeling and remodeling and fracture repair are mediated by cell behavior in response to many different signals, including mechanical ones. Molecular biological and cellular factors play a key role, but motion at the fracture site is the primary cause of nonunion: It results in cell and matrix disruption that prevents bridging of the fracture site by calcified or ossified tissue. A particularly unique mechanical situation is created by the rigid internal fixation of long-bone fractures with plates: The close apposition of the fracture fragments in the presence of micromotion introduces high strain rates across the fracture site that may play a role in nonunion (75). When the classical Arbeitsgemeinschaft für Osteosynthesefragen (AO) methods of rigid internal fixation are employed, particular care must be taken to eliminate micromotion between the fracture fragments through interfragmentary compression and fixation (60).

The second most common cause of nonunion is loss of blood supply to the bone ends at the fracture site or in the surrounding soft-tissue envelope. High-energy trauma resulting in severely displaced fractures, particularly if they are open, can devascularize the bone ends by severe stripping of soft tissues from the bone, as well as by interruption of the medullary and extramedullary blood supply. Certain fractures have a higher incidence of nonunion due to anatomic factors in the vascular supply to bone that result in loss of blood supply to one or more of the major bone fragments. Typical examples are displaced subcapital fractures of the femoral neck, which result in avascular necrosis of the femoral head and nonunion of the femoral neck; fractures at the waist of the carpal scaphoid, which result in avascularity of the proximal pole and nonunion; and fractures of the neck of the talus, which can result in loss of blood supply to the body of the talus, particularly if associated with a

subtalar or ankle dislocation.

Fracture treatment today, particularly in the multiply injured patient, involves the routine use of various methods of internal fixation for long-bone fractures, particularly in the lower extremity, and in periarticular and displaced intraarticular fractures. Inappropriate surgical techniques can lead to further devascularization of the bone through excessive soft-tissue stripping; obliteration of the intramedullary blood supply through reaming or the insertion of implants; necrosis of bone by overheating with power instruments; surgical interruption of major vessels that are critical sources of blood flow to bone, such as the medial circumflex femoral artery at the hip; and, finally, excessive coverage of bone surfaces with metallic implants, such as large double plates and intramedullary nail and plate combinations, which precludes revascularization of the bone. For the most part, these factors are under the control of the surgeon.

Infection, per se, does not cause nonunion, as union has been shown to occur in the presence of active infection (31). Uncontrolled infection, however, causes nonunion, predominantly because purulent material dissects under pressure within the intramedullary canal and along the subperiosteal surfaces of bone, resulting in bone necrosis. The inflammatory response to the infectious process may also lead to an excessive remodeling response causing osteolysis, which further slows the rate of union.

An anatomic cause of nonunion is the occurence of a major gap in the fracture site, which precludes bridging by healing callus. Such gaps are most commonly caused by interposition of soft tissue, in particular muscle, as well as periosteum, tendons, and nerves. Gaps can also result from the wide displacement of intercalary fragments in closed fractures and actual loss of bone substance in open fractures, particularly from close-range or high-velocity gunshot wounds.

Many general and systemic factors affecting general health play a role in fracture union but are not causal factors per se. Evidence suggests that excessive intake of nicotine through tobacco consumption may, by its effect on the microvasculature, play a significant factor in predisposing to delayed union or nonunion. Other important factors include a fracture in a previously irradiated extremity, severe malnutrition, and the use of medications such as anticoagulants, steroids, and anticonvulsants. Age is a factor insofar as it leads to rapid and nearly always successful union in patients with open physeal lines and in particular in newborns where fractures can heal in a matter of days.

## CLASSIFICATION

Factors that must be considered in the treatment of nonunions (Table 26.2) include the time elapsed since the original fracture or previous treatment, whether the nonunion is mobile or stable, and whether it is a synovial pseudarthrosis. The site, whether diaphyseal or metaphyseal, and the coexistence of shortening and angular or rotational deformity greatly influence treatment decisions, as does the presence of intact or broken internal fixation. It is, of course, critically important to know whether the nonunion is infected.

| |
|---|
| Time or degree |
| Delayed union |
| Nonunion |
| Mobile (gap) |
| Immobile |
| Synovial pseudarthrosis |
| Site and displacement |
| Diaphyseal |
| Nondisplaced |
| Displaced |
| Metaphyseal |
| Intraarticular |
| Extraarticular |
| Callus |
| Hypertrophic (vascular, reactive) |
| Elephant's foot |
| Oligotrophic |
| Atrophic (hypovascular, nonreactive) |
| No gap |
| Necrotic fragment |
| Gap |
| Infection |
| Noninfected |
| Infected |
| Nondraining (3 mo) |
| Draining |

[a]Acquired, not congenital.

***Table 26.2. Factors Involved in Nonunions[a]***

Whether the fracture is producing callus is a good indicator of its blood supply and potential for union, which is reflected in the Weber-Cech classification (101). This classification, proposed by Weber and Cech in 1976, is still the most useful system, although the presence of internal fixation, in particular intramedullary nails, makes it more difficult to use. They classified nonunions into two major groups based on whether the bone ends at the fracture site are vital—that is, whether they have a good blood supply. They examined plain radiographs to determine the amount of callus formation and correlated this with radioisotope studies to demonstrate the degree of blood supply (Fig. 26.4 and Fig. 26.5). Figure 26.4 shows vital nonunions, which have a good blood supply to both bone fragments and demonstrate various degrees of callus formation. Figure 26.4*A* is a hypertrophic, or elephant's foot, nonunion, which is usually caused by mechanical instability. Increasing the mechanical stability of the fracture site will often permit these to heal. In addition, they are usually responsive to electrical stimulation. It is important, however, to differentiate hypertrophic nonunions from true synovial pseudarthroses. Plain tomography or computed tomography (CT) scans with sagittal or frontal plane reconstruction will often show a cyst in the center of the hypertrophic nonunion. An excellent test is a technetium bone scan, which will show increased uptake throughout the fracture site, but the center will be cold, as seen in the pseudarthrosis of a mid-shaft humerus fracture (Fig. 26.6). The other two types of vascular nonunions are the horse's hoof (Fig. 26.4*B*) and oligotrophic nonunions (Fig. 26.4*C*). These nonunions form less bone, in part because of their lack of vitality, but this is also influenced by the bone they occur in and their location in the bone. The oligotrophic nonunion can be difficult to differentiate from the atrophic nonunion. This differentiation is important as the former has a much better prognosis as a result of its reasonably good blood supply.

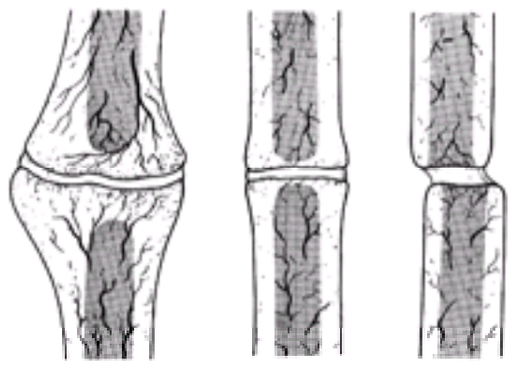

***Figure 26.4.*** Weber and Cech's classification of pseudarthrosis. These are the vascularized, or vital, nonunions, which have the biological potential to heal. **A:** Elephant's foot hypertrophy. **B:** Horse's hoof. **C:** Oligotrophic (often mistaken for atrophy). (From Weber BG, Cech O. *Pseudarthrosis.* Bern: Hans Huber, 1976.)

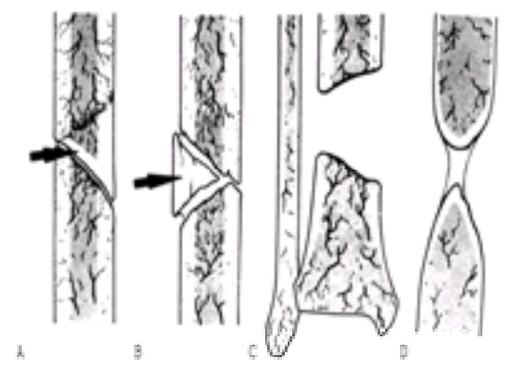


***Figure 26.5.*** Weber and Cech's classification of pseudarthrosis. These are the dysvascular, or nonvital, nonunions, in which lack of blood supply, a gap, or another factor limits their ability to heal without biological intervention. **A:** Dystrophic (torsion wedge with butterfly). **B:** Necrotic (comminuted fragments). **C:** Defect (gap). **D:**

Atrophic. (From Weber BG, Cech O. *Pseudarthrosis.* Bern: Hans Huber, 1976.)

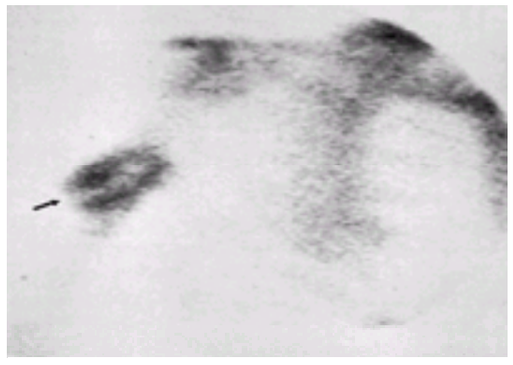

***Figure 26.6.*** Technetium-99m bone scan of a synovial pseudarthrosis of the right humerus. Note cold cleft (*arrow*) between hot ends. (From Esterhai JL, Brighton CT, Heppenstall RB, et al. Detection of Synovial Pseudarthrosis by $^{99m}$Tc Scintigraphy. *Clin Orthop* 1981;161:15.)

Figure 26.5 shows avascular or nonvital nonunions. Weber and Cech (101) characterized two nonunions occurring in comminuted diaphyseal fractures as dystrophic or torsion wedge nonunions with a butterfly fragment (Fig. 26.5*A*), and necrotic (Fig. 26.5*B*) due to comminuted fragments. In both, there is a devascularized butterfly fragment, which in the first instance heals to one side of the fracture and then is partially revascularized. The opposite side then has a vascularized main fragment abutting a necrotic surface on a comminuted fragment. The intervening gap is usually filled with fibrous tissue. In the necrotic nonunion, the healing process fails on both sides of the comminuted fragment, which produces a devitalized gap. Both of these nonunions require efforts to induce revascularization of the devascularized areas, as well as good mechanical stability for revascularization, and bone grafting to bridge the fracture site.

A defect or gap nonunion (Fig. 26.5*C*) is caused by loss of bone from the fracture site. In children with open physes and in some adolescents who are just nearing the end of growth, large gaps may bridge through periosteal new bone formation. In adults, however, even gaps 5 mm or less may lead to nonunion, particularly in the presence of intramedullary nails. To achieve union, gaps must be filled with bone or bone apposition achieved. Alternatives include Ilizarov segment transport, direct autologous bone grafting, allografts, or osteoconductive materials such as corraline hydroxyapatite, usually combined with a bone-inductive medium such as bone marrow, stem cells, or bone-inductive proteins.

The atrophic nonunion (Fig. 26.5*D*) is particularly difficult to treat because not only does it have a poor blood supply but a gap is often present. Bone quality may be poor, and it would appear that there is an active osteoclastically mediated resorption process, which in some cases is related to an underlying systemic disorder such as neurofibromatosis. This is the most common type of congenital nonunion. Dysplastic tissues in the nonunion site preclude successful long-term formation of bone capable of withstanding mechanical stress.

Infected nonunions must be recognized. A history of prior infection is important, but if the nonunion site shows no local signs of infection and there has been no active drainage for 6 months or more (particularly if the previous infection was caused by an antibiotic-sensitive organism that was successfully eradicated), then operative intervention can usually proceed. Nonunions with active signs of infection, however, usually require eradication of the infection first, with thorough irrigation and debridement, removal of all devitalized bone, good stability (usually with an external fixator), and achievement of good-quality, full-thickness soft-tissue coverage. It is possible to achieve union in the presence of active infection, but usually it must be eradicated before proceeding with treatment (54).

## PRINCIPLES OF TREATMENT

### OBJECTIVES AND RATIONALE

The primary objective in the treatment of nonunions is to achieve solid union of the fracture site, one that will endure and allow the patient to regain a good level of function. The latter requires that the limb be left with little or no shortening or malalignment, and that sufficient joint range of motion, muscle strength, and neurovascular function be restored that the limb is useful to the patient. If these objectives are reached, but the patient continues to have chronic disabling pain, then treatment may have been fruitless. The primary source of pain in most cases, however, is the nonunion itself. Healing of the nonunion usually resolves any pain problems. Reflex sympathetic dystrophy may be a problem in some patients, particularly if there is an associated neurologic injury, and especially one involving the brachial or lumbosacral plexus.

Longstanding nonunions subjected to repeated surgeries can lead to permanent long-term disability in the limb resulting from muscle atrophy and joint stiffness. If this interferes with the patient's return to work and resumption of a normal lifestyle, significant socioeconomic consequences can occur. This must be taken into account when proposing treatment for nonunions. Listen carefully to the wishes and needs of each patient, and understand his treatment objectives. For example, the best solution for a sedentary individual with a longstanding, infected nonunion of the tibia with shortening and deformity and poor function of the foot might be a below-the-knee amputation, if a good-quality, satisfactory stump can be obtained.

### DIAGNOSIS

Take a meticulous history of the present illness to characterize the nature of the original injury and the initial treatment, as well as all subsequent efforts to repair the nonunion, including the outcomes of these procedures, and complications. Particularly important is to establish whether infection has occurred at any time. Rule out any potential systemic aggravating factors that could possibly be treated, and review habits—in particular, tobacco use. There is substantial evidence that tobacco interferes with fracture healing and may predispose to nonunion, so it is prudent to try to persuade smokers with nonunions to stop smoking. Social history is important, as many operative procedures require a responsible, cooperative patient who will follow instructions and engage vigorously in a rehabilitation program.

The most typical complaint about the nonunion itself is pain in the fracture site, which is often severe and aggravated by motion or weight bearing. Ask patients whether they feel motion in the fracture site, as this may be an important clue. The direction in which they feel that motion or the mechanism of producing it may also be helpful.

Perform a thorough physical examination, with a complete review of systems, to be certain that the patient can handle the major surgery often required for nonunions. Evaluate the other components of the musculoskeletal system to discover other disorders that must be treated prior to, or concomitantly with, the nonunion to obtain a successful outcome.

In the physical examination, the pathognomonic sign of nonunion is motion in the fracture site, occasionally accompanied by crepitus. Some nonunions are grossly flail, but with internal fixation in place the detection of motion may be subtle. It is important to look for just a jiggle of motion in the fracture, which may occur in only one plane. This requires careful, meticulous, delicate examination with the fingertips, trying to elicit motion in all planes. If elicited, this is diagnostic regardless of the radiographic appearance. Extremely stable fibrous nonunions, and some nonunions in the presence of internal fixation, may have no motion in the fracture site.

Thoroughly evaluate limb alignment, joint range of motion, muscle strength, and neurovascular status. Accurately document shortening. This information is essential to planning an operative approach that will address all problems and provide the maximum opportunity for returning function to the limb.

### IMAGING

Plain radiographs in the anteroposterior (AP) and lateral planes, including the joints above and below the fracture site, are the minimum required. Oblique views are useful for detecting nonunions that are not in the plane of AP and lateral radiographs (Fig. 26.7). The key to diagnosis on plain films is placing the nonunion in line with the central beam of the radiograph. This often requires examination under fluoroscopy, rotating the limb until the fracture site is clearly seen and then taking a plain film. Tomograms are less useful today because of the x-ray scatter produced by often-present implants. CT scans with reconstruction in various planes are very useful, particularly for fractures in metaphyseal and juxtaarticular areas. I do not use magnetic resonance imaging (MRI) often in the evaluation of nonunions, but it is occasionally useful in intraarticular nonunions. Use technetium bone scans to rule out synovial pseudarthrosis in hypertrophic nonunions for which you are contemplating treatment with either electrical stimulation or closed intramedullary nailing (25). The former is not useful in the presence of synovial pseudarthrosis, and

the latter may cause you to open the fracture and perform a bone graft in addition to placing the intramedullary nail. I rarely use other types of scintigraphy to rule out infected nonunions, as this does not change my surgical approach in the vast majority of cases.

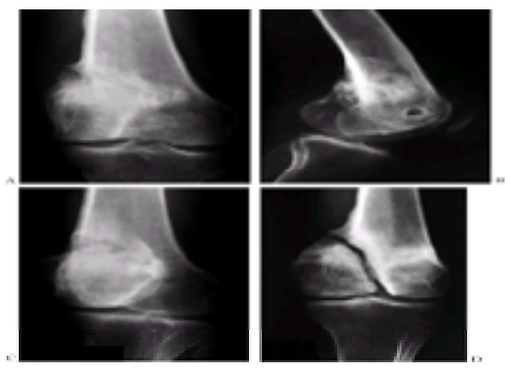

***Figure 26.7.*** Nonunion of the lateral condyle of the femur. This series of radiographs shows how difficult it is to detect some nonunions, and it demonstrates the importance of having the central beam of the x-ray exactly in line with the axis of the nonunion. **A:** AP view suggests the presence of a problem because there is partial unhealed fracture in the epicondylar area. Nonunion cannot be seen. **B:** Lateral view demonstrates apparent union. **C:** Oblique view likewise appears to show union of the condyle. **D:** Opposite oblique view shows clearly a well-established, stable fibrous nonunion of the medial condyle.

## NONOPERATIVE TREATMENT

### CAST AND BRACE IMMOBILIZATION

There is little role today for cast and brace immobilization alone in the treatment of nonunions, although a functional, weight-bearing cast or brace may be useful for a delayed union of a closed tibial shaft fracture (88). Simple, continued application of a well-fitted cast or brace combined with functional weight bearing in the absence of a prematurely healed fibula, which is preventing compression of the fracture site, may suffice. An oblique osteotomy of the fibula may be useful in some circumstances to allow the fracture to compress with weight bearing.

### ELECTRICAL STIMULATION

Yasuda (105) first demonstrated that electricity can induce or stimulate new bone formation. He observed that 1 microampere (µA) of constant direct current applied to a rabbit's femur by Vitallium needle electrodes inserted through the cortex into the medullary canal produced new bone formation, particularly in the vicinity of the negative electrode, or cathode. Since that first report, many investigators have demonstrated that electricity in its various forms—direct current, inductive coupling or pulsed electromagnetic fields (PEMFs), and capacitive coupling—can induce new bone formation using the proper electrical parameters (2,4,7,13,28,29,32,48,55,63,94). In tissue and bone cells, the initial response to electricity is increased bone cell proliferation and no change in or decreased matrix production and alkaline phosphatase activity (13,20,27,47,61,62,65,82,93). Later, matrix production increases and matrix calcification is stimulated or increased (18,27,60).

The actual cellular mechanism of electrically induced osteogenesis is not completely understood. Intracellular calcium and cyclic adenosine monophosphate (cAMP) have been shown to increase in some studies, but the results are neither significant nor consistent enough for intracellular calcium or cAMP to be considered the primary intracellular messenger of an extracellular electrical signal (12).

The physics involved in electrically stimulating bone formation is different for each of the three methods. The direct current method is the most complex, possessing electric, chemical, and mechanical effects, all of which may stimulate new bone formation. A constant direct current of 20 µA is applied to the electrodes, with the cathode located in the bone site and the anode located in the adjacent soft tissue or on the surface of the skin (Fig. 26.8). The electric current flowing between the electrodes probably is the predominant stimulus of the new bone formation. However, a chemical reaction also occurs at the electrodes, in which molecular oxygen is consumed and hydroxyl ions are produced, given the proper parameters of current and voltage (9,11):

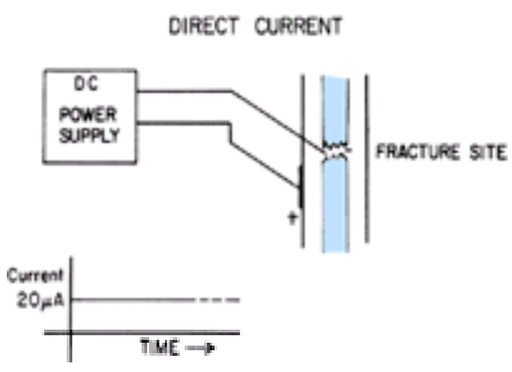


***Figure 26.8.*** Application of direct current (DC) to the fracture site of a nonunion. The negative electrode or cathode is inserted percutaneously.

$$2H_2O + O_2 + 4^{e-} \rightarrow 4OH^-$$

This lowers the local microenvironmental $Po_2$ (6,7) and raises the local pH. Both of these changes favor bone formation. Bone grows best in low $Po_2$ (6,7) (35–40 mm Hg) and when the pH at the bone–cartilage junction in the growth plate is alkaline (pH 7.7), which favors calcification (14,15,35). Mechanical effects from the trauma of inserting the cathode and postinsertion movement of the cathode may also stimulate osteogenesis in the direct current method (26).

In inductive coupling or PEMFs, there are an electric effect and a magnetic effect. A time-varying electric field is applied to a pair of matched coils placed on opposite sides of the extremity of interest, or to a single, flexible coil bent to conform to the extremity. The time-varying electric field applied to the coil(s) induces a time-varying magnetic field between the coils, and this induces a secondary time-varying electric field in the tissues, including bone, placed between the coils (Fig. 26.9). The configuration of the PEMF used for nonunions is shown in Fig. 26.10.

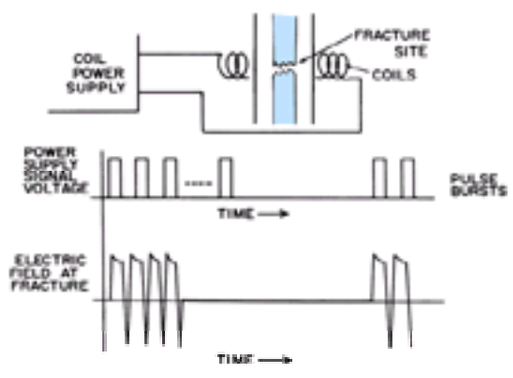


***Figure 26.9.*** Application of inductive coupling or pulsed electromagnetic fields to the fracture site of a nonunion.

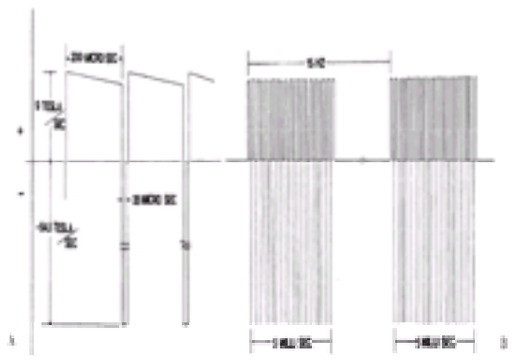

***Figure 26.10.*** The inductively coupled signal used for treating a nonunion. **A:** Dimensions of a single pulse. **B:** Dimensions of a pulse burst.

In capacitive coupling, there is only an electric effect; the magnetic field associated with capacitive coupling is negligible. A time-varying electric field is applied to a pair of electrodes placed on the surface of the skin on opposite sides of the injured extremity. The time-varying electric field applied to the electrodes produces a time-varying electric field in the tissues, including bone, between the electrodes (Fig. 26.11). The signal used in treating nonunions is a symmetrical sine wave with a peak-to-peak amplitude of 5 V and a frequency of 60 kHz. This produces in the fracture callus an average electric field of 80 mV/cm, with a range of 20 to 150 mV/cm, depending on the size of the limb and amount of fat in the extremity. The corresponding values for the current densities in the callus average 160 μA/cm$^2$, with a range of 40 to 300 μA/cm$^2$. These values for the electric field and current density produced in the fracture callus with capacitive coupling are probably similar to those generated by inductive coupling.

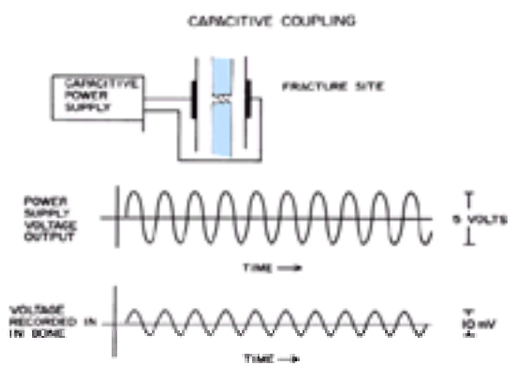


***Figure 26.11.*** Application of capacitive coupling to the fracture site of a nonunion.

The only effect all three treatment modalities have in common is the electric effect, and it is assumed to be the dominant effect in each of the methods of treating nonunion with electricity.

Noninvasive electrical stimulation is indicated for any delayed union or nonunion in which operative intervention is not absolutely required to obtain adequate reduction and fixation, to remove a synovial pseudarthrosis, or to fill a large bone defect (e.g., a gap at the fracture site that is greater in width than the radius of the bone at that level). If a delayed union or nonunion is already held in good position and in alignment from a previous internal fixation, or if the delayed union or nonunion can be held adequately in good position and alignment by appropriate cast immobilization, and if there is no large gap or synovial pseudarthrosis, treatment with noninvasive electrical stimulation may be indicated.

In my practice, the most common indication for electrical stimulation is a delayed union in good position, particularly of the diaphysis of the tibia or femur. Most typically, these are fractures that occurred in patients with multiple injuries, or they were open fractures that were treated initially with nonreamed, locked, intramedullary nail fixation. For that reason, they are in good position, but the magnitude of the initial injury, combined with the less stable fixation offered by a small nonreamed nail, leads to delayed union. If at 12 weeks after injury, there is no evidence of callus formation and the fracture site is still clearly visible, then the chances of going on to a nonunion are significant. This could lead to implant failure, angulation, and the necessity for surgery. At that time in the treatment, I typically offer my patients the opportunity for operative intervention, usually in the form of an exchanged, reamed, locked nailing or noninvasive electrical stimulation if they do not wish to undergo surgery.

Other indications for electrical stimulation include fractures in acceptable alignment, which can be adequately immobilized in functional casts or braces in patients who have significant contraindications to surgery, such as coexisting infection, poor-quality soft tissues, or severe systemic illness.

Contraindications to noninvasive electrical stimulation for treating nonunion include a large gap at the fracture site and synovial pseudarthrosis (25). Brighton (10) states that a large gap occurs in approximately 5% of all nonunions, and synovial pseudarthrosis in approximately 12%, particularly in the humerus and radius. He defines a large gap as one that is equal to or larger than the diameter of the cortex at the site of the nonunion. He cites severe osteoporosis as a relative contraindication, as it lowers the union rate with electrical stimulation to 25% or less. He defines osteoporosis as occurring when the combined thickness of both cortices adjacent to the fracture site is equal to less than 20% of the diameter of the bone at that level as measured from plain radiographs. Osteomyelitis in the nonunion site is not a contraindication, as Brighton (10) reported a 58% union rate in 102 nonunions in the presence of osteomyelitis.

Relative contraindications include the following:

- Nonunion of the humerus, because of the high incidence of synovial pseudarthrosis and the difficulties in achieving adequate immobilization of the fracture
- Nonunion of the diaphysis of the radius or the ulna, if prolonged immobilization in a long-arm cast will result in permanent loss of functional motion
- Nonunion of the shaft of the femur, because of the high incidence of synovial pseudarthrosis and the difficulties in adequately immobilizing the femur
- Any nonunion with unacceptable deformity that requires surgery for correction

***Technique for Pulsed Electromagnetic Fields***

- Apply a well-molded cast to immobilize the nonunion.
- Position the flexible coil over the nonunion site so that the entire site is within the “window” of the coil.
- Confirm the location of the coil with radiographs and secure it with Velcro straps. Incorporate the coil into the cast with an additional wrap of casting material if the patient is likely to be noncompliant (Fig. 26.12).

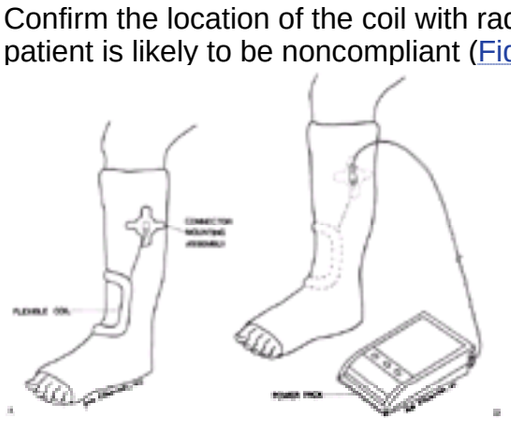

***Figure 26.12.*** Inductive coupling. **A:** The connector mounting assembly is positioned near the coil. (Newer models do not require this.) **B:** The flexible coil and mounting assembly can be incorporated into the cast.

- Connect the cable from the coil to the control unit, which can be worn on a belt or carried with an adjustable shoulder strap.
- Ideally, treat for 10 hours daily. The minimum use per day is 3 hours, but fracture healing will be slower.
- Encourage full function of the limb within the limits of the cast, including full weight bearing, unless motion of more than 5° of angulation will be induced at the fracture site.
- Examine and x-ray the fracture at 6-week intervals. If at 12 weeks the fracture is not yet healed but is showing evidence of progressive healing, continue treatment until healed. If at 12 weeks or later there is no evidence of progress toward healing, then change treatments. If a bone graft is done, consider combining it with an implantable stimulator.

### *Technique for Capacitive Coupling*

- Apply an appropriate plaster or fiberglass cast to immobilize the nonunion. At the level of the nonunion site, cut two $1^3/_4$-inch-square windows in the cast opposite each other with a cast saw. Place the windows 180° ± 20° to each other at the level of the nonunion, ±4.5 cm. Exact alignment of the windows on radiographs is necessary.
- Cut out the padding and stockinet under the windows. Peel the backing liner off each electrode, and place them on the skin centrally, one in each of the windows. Depending on the thickness of the cast, place an appropriate spacer over one or both of the electrodes to fill the gap in the cast to prevent window edema. To prevent a pressure sore, do not extend the spacer above the surface of the cast (Fig. 26.13*A*).

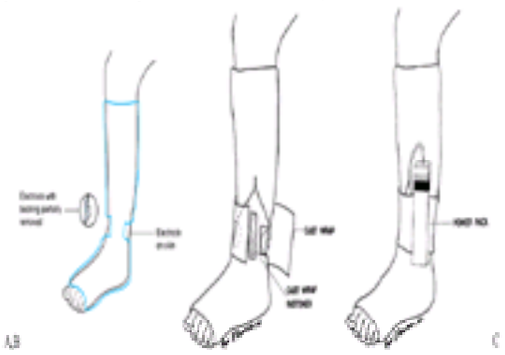

***Figure 26.13.*** Capacitative coupling. **A:** One self-adhering, flexible electrode is in place on the skin in one window, and the backing is partially removed from another electrode before its placement on the skin through the second window. **B:** After the electrodes are in place and connected to the appropriate leads, a cast wrap is placed around the cast and secured over a self-adherent fastener strip. **C:** The leads extend from the electrodes to the power supply.

- Place an adhesive-backed fastener strip along the long axis of the cast between the windows. Apply a cast wrap around the cast over the fastener strip, and secure it with a cast wrap fastener (Fig. 26.13*B*). Extend the leads from the electrodes to the power supply, fastened to the cast itself or to a belt clip to be worn on a belt at the waist (Fig. 26.13*B*, Fig. 26.13*C*).
- Monitor the power supply with the appropriate test meter, initially and at each office visit. Have the patient replace the 9 V alkaline battery daily and change the electrodes weekly.
- If the nonunion is in the lower extremity, use a weight-bearing cast unless there is more than 5° of motion at the fracture site. If there is more than 5° of motion, use a non-weight-bearing cast until motion is less than 5° (13), at which time a weight-bearing cast can be used.

### *Implanted Bone-Growth Stimulator*

The implantable electrical stimulation device is based on the direct current method popularized by Friedenburg et al. in 1971 (28,30). Dwyer developed an implanted bone-growth stimulator with its own battery pack based on cardiac pacemaker technology, and he used it successfully to treat failed posterior spinal fusions (23,24). The device in use today is a totally implanted stimulator that provides a constant direct current of 20 milliamperes (mA), using a single titanium cathode and two platinum anodes (66,67,68,69 and 70). The generator consists of a hermetically sealed casing, incorporating the anode and a silicone-insulated, flexible, stainless-steel lead that is joined to the titanium woven wire cathode by a connector. The connector provides increased resistance to fatigue failure and simplifies removal. The major advantages of the implanted stimulator are that it does not require patient cooperation and it ensures that the signal is being delivered to the appropriate site. The major disadvantage is the need for an operative procedure that requires strict attention to detail (66,69). In addition, a second incision may be required for implantation of the generator, and removal is advised after completion of treatment. Although the implanted stimulator has been used as an isolated treatment (40,61), most surgeons use it today as an adjunct to internal fixation and bone grafting, assuming the implantation of the electrode is compatible with the method used. Whether done as an isolated technique or in combination with internal fixation and bone grafting, the following technique is applicable.

- Identify the union site accurately. Mark on the bone a window that will allow insertion of an appropriate-size coil, bridging the fracture site in the longitudinal plane. In the typical adult tibia, this requires a window of 1 cm in width and 2–3 cm in length.
- The bone is often sclerotic, so this window is usually easiest to make by outlining its margin with multiple drill holes and then connecting them with a thin, sharp osteotome (Fig. 26.14*A*).

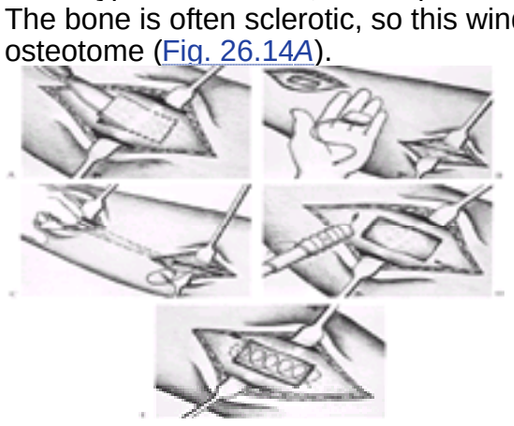

***Figure 26.14.*** Insertion of implantable stimulator. **A:** Preparation of the defect in the bone. **B:** Insertion of the generator. **C:** Placement of the cathode lead in the nonunion. **D:** Preparation of the cathode. **E:** Insertion of the cathode.

- Remove the window. Remove the underlying fibrous tissue and open the medullary cavity of both the proximal and distal fragments to the width of the original medullary cavity. This encourages revascularization and creates space to insert the cathode.
- Identify a site for the generator, which must lie at least 5 cm away from the cathode and beneath the deep fascia. Sometimes this can be placed percutaneously through the surgical site of the nonunion. If not, make a 3-cm-long skin incision over the desired location for the generator, incise the deep fascia, and then use an obturator or a Metzenbaum scissors to dissect between the nonunion site and the generator site. Place the generator into the wound beneath the deep fascia and pass the lead wire down to the nonunion site. Be certain that this route is straight, as it simplifies eventual removal, but leave some laxity in the line so that motion of the joints adjacent to the operative site does not cause tension on the wire (Fig. 26.14*B*, Fig. 26.14*C*).
- Using the cylindrical plastic guide provided with the stimulator, measure the width of the defect in the tibia and wind the titanium electrode around the guide to produce a helix big enough to completely bridge the width of the canal at the point of the nonunion. Use the guide to insert the helix into the nonunion site in the medullary canal and remove the guide, leaving the cathode helix in the defect (Fig. 26.14*E*). Replace the window that was removed from the bone to secure the helix in place. If there is adjacent internal fixation, be certain that the cathode does not touch the internal fixation: Bone can be packed between the two.
- Connect the lead to the coil, placing the connector away from the bone so that it will disconnect when the generator is later removed.
- Postoperatively, if internal fixation has not been used, immobilize and proceed as discussed for noninvasive electrical stimulation. If implants are present, follow the postoperative treatment appropriate for the implant used. This device cannot be used with intramedullary implants, as there would be no place to locate the cathode. The generator usually remains active for up to 1 year. After that time, remove the generator by making an incision directly over it and pulling gently in

line with the connecting wire. This will usually result in disconnection at the connector and removal of the generator as well as its stainless-steel lead.

#### *Results*

My use of electrical stimulation devices has declined substantially since they were first introduced for clinical use in the early 1980s, as most nonunions I encounter are better treated with surgery. In spite of the low risk with noninvasive techniques, most patients are anxious to get on with their lives and desire treatment methods that will quickly return them to functioning and that carry a higher success rate than the 74% to 79% union rates reported for noninvasive electrical stimulation (5). Therefore, my primary use is in delayed unions of the tibia for patients who select electrical stimulation as an alternative to surgical treatment, or in high-risk patients where surgery may be contraindicated. PEMFs and capacitive coupling are about equally efficacious, but capacitive coupling devices are more portable, they are applied for 24 hours each day, and placement of the electrodes is not as demanding as the placement of electromagnetic induction coils. In addition, in inductive coupling, a fixation plate may “shadow” a bone from the electromagnetic field if the width of the plate is perpendicular to the plane of the central axis of the coil. Other devices have become available that offer shorter treatment periods and other advantages, but there is little in the literature supporting their efficacy.

A large literature on the results of treatment with electrical stimulation describes outcomes varying from 74% to 79% in more than 2,400 nonunions (1,5,8,25,26,28,44,66,70,91,92). I have been able to identify only two prospective, randomized, blinded studies in this literature. Sharrard (92) treated 45 patients with delayed unions of the tibia between 16 and 32 weeks after fracture. They were placed in casts for 12 weeks and treated with PEMFs. In one group, the coil was active and in the other, inactive. He achieved a radiographic union rate of 25% in the active group, but only 4% in the dummy group; additionally, 45% achieved clinical union in the active group and only 12% in the dummy group. These results were statistically significant. Scott and King (91) reported the results of 21 long-bone nonunions, of which 10 were treated with an active capacitive coupler and 11 were treated with an inactive device. Six of those treated with the active device healed and none healed with the inactive device. These results were significantly different with a $p$ value of 0.004.

#### *Complications*

The only known complication of noninvasive electrical stimulation is minor skin irritation at the electrodes in capacitive coupling. This occurs in fewer than 3% of patients. Moving the electrodes to a fresh site or rotating electrodes on a weekly basis usually prevents this problem. Complications in the implanted device are the usual complications expected of surgery, with the exception of difficulties that might be encountered in removing the electrode. If the connector is located too close to the nonunion site, it and the connecting wire can be incorporated into bone so that when the generator is pulled on, the connecting wire shreds or breaks off at the generator, or somewhere along the wire, and a portion of it is left in the patient. If the surgeon feels that this must be removed, then direct exposure of the wire down to the nonunion site may be required.

### ULTRASOUND

Heckman et al. (33), in a prospective, randomized, double-blind study, showed that noninvasive, low-intensity pulsed ultrasound can accelerate overall clinical and radiographic healing in tibial shaft fractures by 38%. This echoed the previous animal and clinical studies of Duarte (21), Pilla et al. (78), and Xavier and Duarte (104). The specific mechanism by which ultrasound accelerates diaphyseal fracture repair is unknown. Possibilities include mechanical perturbation, and the direct stimulation of biological activity either directly by mechanical deformation of the cell membrane or indirectly by an electrical effect caused by cell deformation. Ryaby et al. (86) have shown that low-intensity pulsed ultrasound modulates adenylate cyclase activity and b-transforming growth factor synthesis. This has led to a significant number of yet unpublished animal and clinical studies over the past several years, which have suggested, but have not yet proven conclusively, that ultrasound may have the ability to cause nonunions to heal. At this time, ultrasound has not been approved by the U.S. Food and Drug Administration (FDA) for treatment of nonunions.

### BONE MARROW INJECTION

Connolly et al. (19,98,99) popularized the treatment of nonunions by injection with autologous bone marrow. This technique requires aspiration of autologous bone marrow through large bore needles from the iliac crest, and then injection of this into the nonunion site under fluoroscopic control. The efficacy of this technique has not been proven, as no randomized trials have been done. Connolly et al. (19) treated 20 ununited tibial fractures. Ten received cast immobilization and marrow injection, and eight of these achieved union. In the second group of 10 fractures, intramedullary nails were inserted as well, and all of this group achieved union.

Tiedeman (98,99) has demonstrated the efficacy of combining percutaneous injection of bone marrow and demineralized bone matrix in a canine model and in a case report of healing a large nonossifying fibroma. I do not use this method in my practice because multiple treatments are required and the effectiveness is not sufficiently high to justify its use.

## SURGICAL TREATMENT

### PREOPERATIVE PLANNING

The first step in preoperative planning for the treatment of nonunions is a thorough evaluation of the patient, and of the nonunion and the alignment of the limb segment involved, which together lead to the decision to operate. If there is coexisting malalignment, shortening, or joint stiffness that requires surgical treatment as well, then the preoperative planning can be fairly complex, as the methods for correcting each of these deficiencies must be taken into account. The basic principles in reestablishing limb length and alignment are discussed in detail in Chapter 32, which focuses on the preoperative planning for Ilizarov procedures. The preoperative planning for malunions is discussed later in this chapter.

An important aspect of decision making is evaluation of the soft-tissue envelope over the nonunion site. Internal fixation and bone grafting will not be successful unless the fracture site is well vascularized or some method is undertaken to enhance vascularization. In addition, operating through densely scarred, poorly vascularized skin and deep tissues may lead to wound complications and infection that could result in failure, even amputation. In circumstances where the soft-tissue envelope is poor, consultation with an orthopaedic or plastic surgeon with experience in local or free microvascularized flaps may be indicated. These procedures may be required as a prelude to the primary surgical treatment of the nonunion or as a concomitant procedure (see Chapter 8, Chapter 35, and Chapter 36). The thought process applied to each of the implant possibilities and bone grafting are discussed next.

### BONE GRAFT ALONE

In our practice at the University of California, Davis, Medical Center, bone graft alone is used most commonly for posterolateral bone grafting of the tibia (77). Since the majority of tibial fractures at our center are being treated today with locked, intramedullary nailing, this circumstance occurs usually after a more severe open fracture, where a locked, reamed nail is in place. If a small nonreamed nail is in place, we are more likely to perform exchange reamed nailing (40,52). In nonunions following weight-bearing cast treatment, when the location of the fracture, overall alignment, or bone quality precludes intramedullary nailing, we will bone graft from a posteromedial or posterolateral approach, using continued weight-bearing cast immobilization for stabilization. This approach is discussed in detail in Chapter 31.

Other circumstances for which we would consider bone graft alone include fractures in good alignment with stable fixation with plates or rods already in place, when revision of the fixation is not necessary and inlay or onlay bone graft is felt to be sufficient to push the fracture on to union.

The type and location of bone graft harvest is determined by the needs of the nonunion. The bone graft required may vary from a small amount of pure cancellous bone to a large amount of cancellous bone, cortical cancellous strips, or structural bicortical and tricortical bone graft used to replace bone deficiency from the injury itself or resulting from correction of deformity, such as opening wedge osteotomy through a nonunion site in metaphyseal bone. See Chapter 9 for details on bone grafting.

### PLATE FIXATION WITH OR WITHOUT BONE GRAFT

Plate fixation without bone graft is applicable to hypertrophic and well-vascularized nonunions where increasing the stability of the fracture site alone will result in union (60,83,85). Oligotrophic nonunions and all of the avascular nonunions require bone grafting. Because I do not wish to risk failure, I routinely bone graft all nonunions that I treat with plate and screw fixation. In hypertrophic nonunions and in the occasional horse's hoof nonunion, reduction of the bony callus for cosmetic reasons, either to correct deformity or to create a site for the plate, often provides sufficient bone graft. This bone is frequently sclerotic and not nearly as bone inductive or bone conductive as freshly harvested graft; therefore, I harvest iliac crest bone graft in the vast majority of nonunions that I plate. Plate and screw fixation combined with autologous bone graft is applicable to all types of nonunions.

General surgical techniques that apply to plate fixation and bone grafting in all sites are as follows:

- Position the patient so that the appropriate iliac crest or other bone graft can be harvested without having to reposition or reprep and redrape the patient. When large amounts of graft are needed, the best source is the posterior iliac spine, which is most easily harvested in the prone position but can also be harvested from the uppermost crest in the lateral decubitus position. When the nonunion must be treated in the supine position, the graft of necessity will need to be harvested first.
- When exposing nonunions for plate fixation and bone grafting, try to minimize subperiosteal stripping of the bone in order to preserve its blood supply. Application of a plate and bone graft usually requires exposure of only 50% of the overall circumference of the bone. Try not to use retractors that result in additional stripping.
- Once the nonunion is exposed, remove any existing hardware, which will interfere with treatment of the nonunion.
- In very stable, fibrous nonunions where there appears to be good blood supply to the bone ends [as demonstrated by punctate bleeding (paprika sign) when the cortex is shaved with an osteotome], a takedown of the nonunion site is usually unnecessary, as the fracture will normally heal with compression plate fixation combined with onlay bone grafting.
- If there is a synovial pseudarthrosis, if deformity needs to be corrected, or if there is an unstable, loose, fibrous union, remove all scar tissue in the fracture site, freshen the bone ends, and shape them to optimize cortical contact. Open the medullary canal fully on both the distal and proximal fragments.
- When debriding fracture sites, take appropriate soft-tissue and bone cultures. Unless frank purulence is encountered, I have not found Gram stains to be useful. Do not administer preoperative antibiotics until these cultures are taken. Once cultures are taken, administer appropriate intravenous antibiotics.
- Apply a plate to the fracture, incorporating interfragmentary screw fixation across the fracture site if possible. Whenever possible, I try to use an independent interfragmentary lag screw so that biplanar fixation is obtained. In the diaphysis of the large long bones such as the humerus, femur, and tibia, use broad plates; in smaller bones such as the forearm and fibula, use a 3.5 mm plate or the equivalent.
- For nonunions, I tend to use plates somewhat longer than I would for the initial fracture, placing at least four solid bicortical screws in each fragment.
- After the initial plate and interfragmentary screw fixation has been completed, carefully stress the fracture site under direct vision and examine for micromotion. If gaping in the fracture site occurs with stressing of the plate with your hand in the plane of the plate, supplemental fixation is needed. If the surgical situation precludes the addition of a second plate, then plan to use cast or brace immobilization postoperatively. In most cases, I apply a second plate at right angles to the initial plate, which is smaller in overall dimensions and shorter than the primary plate to avoid excessive stress protection at the fracture site, and to avoid a stress riser at the end of the plate. These supplemental plates can usually be applied with minimal additional exposure because they serve as tension bands to eliminate micromotion in the fracture site and therefore do not need to be large.
- Petal the cortex with a small osteotome for a distance at least equal to the diameter of the cortex at that point on the proximal and distal fragment, and then apply a solid layer of cancellous and/or cortical cancellous iliac crest bone graft along this exposed surface. It does no good to apply a bone graft over the top of the plate. Try to apply it on both sides of the plate construct if this can be done without excessive soft-tissue stripping.
- Perform a meticulous closure of the wound. A suction drain is nearly always advisable.
- Prior to closure, carefully examine the nonunion site and the joints above and below to determine how much motion can be allowed without placing excessive stress on the nonunion site.

## POSTOPERATIVE CARE

Take this assessment of allowable motion into account when designing the postoperative rehabilitation program. In a femur, for example, if full extension and flexion to 90° cause micromotion at the fracture site, plan to place the patient immediately after surgery into a functional brace that will limit extension to –10° and flexion to 80°. Continue this protection until bridging callus is seen across the nonunion site and it is stable and nontender to clinical examination.

In extensive procedures, swelling can be a problem, resulting in blistering of the skin and even compartment syndrome. In most cases, a bulky, well-padded splint postoperatively is important to allow for swelling. Elevate the limb 10 cm above the heart and observe it closely for swelling, which may require intervention.

After the risk of swelling has abated and the patient is more comfortable, replace the bulky dressing with a light dressing or functional cast or brace as indicated. Begin a joint range-of-motion and strengthening program as soon as possible, taking into account the limitations of the strength of the construct used to repair the nonunion. In all cases of plate fixation in the lower extremity, weight bearing must be limited to the weight of the limb until bridging callus across the nonunion site is seen on two radiographic views.

Continue intravenous or oral bacteriocidal antibiotics until the cultures are negative. If cultures are positive, continue antibiotics for at least 6 weeks. I find consultation with an infectious disease specialist helpful in determining the type and length of antibiotic therapy.

## INTRAMEDULLARY NAILING

### *Intramedullary Nailing as a Primary Procedure*

Locked intramedullary nailing is most useful for nonunions in the mid diaphysis in the tibia and the femur, however, it has been used in many bones including the malleoli (46) . It is not technically feasible in the forearm and does not work nearly as well as plates in the humerus. Closed technique is particularly advantageous, but it is usually difficult to perform in nonunions because the medullary canal is sealed and callus at the fracture site makes aligning the canal without opening the fracture exceedingly difficult. Primary intramedullary nailing, therefore, usually requires that the nonunion site be opened and the intramedullary canal reestablished and realigned.

Use an AO distractor in compression, or another device to compress the fracture site and lock the nail statically in compression. This eliminates micromotion in the fracture site and usually results in immediate relief of pain. If there is contact of 50% or more of the cortical surface between the proximal and distal fragments, weight bearing can progress rapidly if a large nail with 4.5 mm or larger transverse locking screws is used. I no longer treat nonunions with dynamic nails, as they tend to leave instability in the fracture site, particularly in rotation, which lowers the likelihood of union in spite of weight bearing. If a nonunion is opened for reamed intramedullary nailing, collect the reaming materials and apply them around the fracture site for a bone graft. Bone defects and avascular nonunions require autologous bone graft from the ilium as well.

### *Nail Dynamization*

Nonunions can occur with intramedullary nails in place. Since the advent of interlocking nails, most of these occur in the presence of static interlocking. The nonunion occurs either because of the severity of the original injury, or because some factor in the original nailing resulted in devascularization of the fracture site, or because the fracture was nailed with a gap as a result of either bone loss or inadvertent distraction of the fracture site. In some atrophic nonunions, it appears that an osteoclastic response at the fracture site results in resorption of bone, which also produces a gap.

Dynamization of the nail—that is, removing the cross-locking screws from one or both ends of the nail and then allowing the patient to bear weight on the nail—has been advocated as a method to eliminate the gap and stimulate union. Although this is a very simple method and can lead to union in a significant percentage of cases, it may not work in the tibia if the fibula has healed and maintains distraction, or if weight bearing does not stabilize the fracture and rotary instability continues. Another common error is to remove the cross-locking screws nearest to the fracture site, which can introduce not only rotary motion but also instability in other planes. For example, in a nonunion of the femur that is below the mid diaphysis, dynamize proximally rather than distally. The best indication for dynamization is a nonunion of the femur or tibia that already has a large reamed nail in place and where the fracture is oblique so that weight bearing will cause increasing stability, particularly in rotation.

### *Exchange Nailing*

Today, small diameter nails are frequently placed, either without reaming or with minimal reaming, to fix fractures of the tibia, the femur, and occasionally the humerus, particularly in patients with severe multiple injuries or open fractures. Occasionally, the result is a nonunion with breakage of the nail or screws. In these cases, exchange nailing is more difficult, and special techniques for removal of broken nails and screws are required.

### *Removal of Broken Screws*

The section of the screw with the screw head is easily removed with the appropriate screwdriver. To remove the opposite side of the screw, make an incision directly over the tip of the screw and expose it. If sufficient screw tip is exposed, it can be removed with commercially available screw removal instruments or grasped with a pair of pliers and twisted out. When performing routine cross-locking, it is always advisable to leave three to five threads protruding from the opposite cortex, assuming that this will not cause painful soft-tissue impingement in the event that removal of a broken screw is required. If the broken section of screw is buried, then removal requires overdrilling the broken segment with a hollow mill-reamer designed for screw removal under fluoroscopic control. This often leaves a fairly large hole in the bone. When repeat nailing is done, try to place the nail beyond this hole to avoid a stress riser at the end of the nail.

***Removal of Broken Nails***

The difficulty encountered in removing broken nail segments depends on the type of nail—whether cannulated or solid—and where the break occurs. In the femur, typical locations for nail failure are (a) through the proximal cross-locking hole or at the distal of the two proximal cross-locking holes where transverse locking screws are present, (b) in the midportion of the nail at the fracture site, or (c) in supracondylar fractures through the more proximal of the two distal transverse cross-locking holes. If failure occurs through the proximal half of the nail, then removal of the proximal portion is easily accomplished with the standard nail removal instrumentation. An “easy out” (a T-handled instrument with a tapered, spiral-threaded tip), if it is long enough, can be used to remove the distal portion after removal of the distal cross-locking screws.

Another technique that also works well is to place a ball-tipped reaming guide into the distal segment of the nail, with the ball-tip outside the tip of the nail, and then to drive a second guide down the inside of the nail to jam the first guide. Attaching a vice-grip pliers or a T-handled pin holder facilitates removal. A third technique, one that I have used successfully on a number of occasions, is to fashion a hook from a coat hanger at home in my workshop using a duplicate of the nail to make certain that the hook is ideally shaped for hooking the distal end of the nail. This is sterilized and then used in a fashion similar to the jammed guide pin technique. As a last resort, a small window can be made in the bone just below the distal end of the nail; the broken nail segment is then driven proximalward to be grasped and removed. Usually, the plan is to place a larger reamed nail for fixation. In this case, it is quite helpful to first ream the proximal canal to a larger diameter to facilitate manipulation of the instruments and removal of the broken nail segment.

When doing reamed exchange nailing, I always try to use the largest nail feasible for the bone involved to ensure adequate strength of the implant, to improve cortical contact and therefore stability, and to produce as much reaming material around the fracture site as possible.

As discussed in the next chapter on nonunions in the upper extremity, I no longer use intramedullary nails for the treatment of nonunions of the humerus. The single exception is when there is a nonunion with an intramedullary nail already in place. In these cases, closed reamed interlocked intramedullary nailing avoids opening the fracture site; in the few cases I have done this, it has worked 100% of the time. A contraindication to this technique is severe osteoporosis because of the high risks of fracture of the humerus and failure to obtain an adequate hold with cross-locking screws.

### ILIZAROV TECHNIQUES

Ilizarov techniques are discussed in detail in Chapter 32. Therefore, this discussion about the use of distraction compression techniques for the treatment of nonunions will be brief.

Ring fixators with tensioned wires and half-pins are indicated for nonunions that are accompanied by severe shortening and require concomitant lengthening; nonunions in which there is major bone deficiency that can be replaced only by segment transportation; and nonunions where there is severe bone deformity and/or soft-tissue contractures, which are best treated by Ilizarov techniques (17,36,37,38 and 39,90).

Ilizarov demonstrated that distraction at the appropriate rate and frequency results in osteogenesis, which can induce fibrous nonunions to heal. This will not work in synovial pseudarthroses, which must be ruled out by a technetium bone scan, and it does not appear to be efficacious in atrophic nonunions. The technique utilized at the nonunion site is to distract the nonunion approximately 5–10 mm and then to compress it, and to repeat this sequence until new bone formation is elicited, at which time the nonunion site is placed into compression. Throughout this process, the patient is encouraged to bear full weight to induce physiologic stress across the nonunion site, which also helps stimulate bone formation. The success rate with this technique in North America has been sufficiently low so that for most surgeons it is not the treatment of choice for nonunions, except when open surgical techniques are not suitable or are contraindicated, as discussed previously. In addition, in gap nonunions where segment transport is used to close a gap, union at the site between the transported segment and the static segment tends to be quite slow; therefore, most surgeons bone graft the junction site to accelerate union.

## POSTOPERATIVE CARE

Postoperative care differs considerably with the technique, so it is discussed in detail with each of the techniques in the next three chapters. In general, however, the most difficult decision is determining when to progress the patient's rehabilitation program, particularly passive manipulation of joints, resistive exercises to build muscle strength, and weight bearing, because all three rehabilitation activities stress the implants and nonunion site. Active range of motion protected by a brace with the joints locked to keep the range of motion within the safe zone, as discussed previously, can usually be instituted in nearly all patients who are reliable. In most cases, resistive exercises and passive manipulation of joints must be avoided until early union occurs. With plates in the lower extremity, weight bearing to the weight of the limb is usually possible immediately, but progression beyond that point must be avoided until union occurs. With intramedullary nails locked in compression and with good bone contact, weight bearing can usually progress as tolerated.

Union at the nonunion site can often be very difficult to judge, particularly with plates, because if the reconstruction has been done well the fracture site can often not be seen on the immediate postoperative films. It can be helpful to establish intraoperatively which particular view shows the fracture site best by examining it under fluoroscopy. This view can then be used postoperatively to monitor trabeculation and obliteration of the nonunion site. Otherwise, monitoring the consolidation of the onlay bone graft usually provides the best guide to union. Early union is heralded by bridging callus along the surface of the nonunion seen on at least two 90° opposed views. Full union is characterized by obliteration of the fracture line, and increased maturation and density in the periosteal new bone to resemble that of the nearby cortex. In any case, stable union usually requires a minimum of 3 months and often 6 months or more. This is particularly the case in closed intramedullary exchange nailing and where previous plate fixation has been converted to an intramedullary nail.

### HINTS AND TRICKS

With plate fixation, obtaining secure purchase of screws in bone that is osteoporotic in longstanding nonunions or in the elderly can be difficult. I have found the following techniques to be useful:

- In cancellous bone with an overlying thin cortical shell in metaphyseal and epiphyseal areas, place large cortical screws without tapping, to compress the cancellous bone around the screw and provide more threads for purchase in the cortical bone than cancellous screws do.
- In metaphyseal areas, use small-fragment double plates placed at 90° to each other to provide a sandwich effect, which adds stability.
  - Avoid excessive periosteal stripping, as this has the risk of excessive devascularization.
  - When inserting cortical screws in this application, run the screws from the two 90° plates close to each other so that the threads of the screws cross-engage; this often provides purchase where it would otherwise not be possible.
- When these measures fail and the screws still have inadequate purchase, inject liquid methylmethacrylate into each screw hole and then reinsert the screw while the cement is soft. This usually provides solid fixation. Do not allow the cement to enter the fracture site or the joint.
- In the diaphysis, injecting cement into the screw hole usually does not work well, because the cement tends to run into the medullary canal or into the fracture site; this could prevent healing. As a salvage procedure in an elderly patient when the only other alternative is prosthetic replacement, I will pack cement that is in the doughy phase into the medullary canal where the screws will be placed, keeping it well away from the fracture site. Once the cement is set, it can be drilled and tapped. Screw fixation is usually superb.
  - The difficulty with this technique is that it markedly devascularizes the cortex and absolutely precludes restoration of the medullary blood supply.
  - Healing in these cases is totally dependent on the periosteum and surrounding soft tissues. It cannot be assumed that the fracture itself will heal, so a copious onlay bone graft must be done in the hope that this will result in good union. If this fails, then prosthetic replacement with a specialized prosthesis may become necessary.
- Other alternatives include the intramedullary plate discussed in Chapter 30 and the use of autologous or allograft cortical struts. The latter are more successful and more readily available. Place these struts in the intramedullary canal, or better yet, on the cortex opposite the plate, and insert the screws into the allograft. Backup nuts and washers can also be used, but they tend to crush osteoporotic bone unless an allograft strut is utilized.

## INFECTED NONUNIONS

The principles of treatment of infection and management of acute and chronic osteomyelitis, pyarthrosis, and infected implants is discussed in detail in Chapter 132, Chapter 133, Chapter 134 and Chapter 135. Always attempt to control infection before treating the nonunion, unless it is obvious that this is not possible. In an infected nonunion of the tibia, for example, perform a thorough debridement of the nonunion site, including the fistula tract and scarred soft tissue, and remove all necrotic and infected bone as well as implants. Stabilize with external fixation. Begin bactericidal antibiotics and monitor with appropriate laboratory testing. As previously discussed, soft-tissue procedures such as local rotation musculofascial flaps or free microvascularized flaps may be necessary to revascularize the nonunion site and to provide a good environment for future operative intervention (54,76,102,103). In 6–12 weeks, if there are no systemic or local signs of infection and the wound has been clean and dry for at least 6 weeks, decide whether treatment of the nonunion will be carried out with an external fixator or by conversion to internal fixation with bone grafting

(41).

Bone grafting in the presence of continued positive cultures in a wound that is under control is possible, but this is the exception rather than the rule. If the patient has a difficult organism, such as a drug-resistant enterococcus, treatment of the nonunion in the external fixator is indicated. Copious bone graft should be applied and the external fixator checked and revised if necessary to ensure excellent stability. If conversion to internal fixation is deemed necessary, it is usually advisable to remove the external fixator and to apply an appropriate cast to allow the pin tracks to heal prior to surgery.

# B. MALUNIONS

## DEFINITION OF MALUNION

Theoretically, any bone that does not heal in an anatomic position is a malunion. Minor deviations of the alignment of bones from anatomic, however, usually cause no symptoms or functional deficit. The term *malunion*, therefore, applies to fractures that heal with either shortening, malrotation, or angulation, which produces unacceptable cosmetic deformity or significant functional deficit, or it alters the contact stresses in adjacent joints such that degenerative arthritis is more likely. There is considerable controversy as to what constitutes malunion. Merchant (53), for example, showed in a long-term study that considerable angulation in the tibia is compatible with good function and does not predispose to arthritis in the knee or ankle.

In today's sports-oriented, active population, however, even minor malalignment may lead to functional complaints, particularly in high-performance athletes. What constitutes sufficient malalignment to justify surgical correction will be addressed on a bone-by-bone basis in the following chapters.

Shortening rarely presents a problem in the upper extremities, but it can be a significant problem in the lower extremities. Walking with a shortened extremity produces a pelvic tilt and angulation at the lumbosacral junction, which can lead to chronic low back pain. This can be corrected by wearing a shoe lift; however, lifts over 15 mm in thickness usually must be applied, at least in part, to the outside of the shoe. This is expensive and often cosmetically unacceptable, and it cannot be done to some types of shoes. The lifts stiffen the soles and increase the weight of the shoe, which is a problem in sportswear. In addition, the increased height of the ankle off the floor predisposes to sprains of the ankle. Shortening of less than 2.5 cm in the lower extremity can usually be managed by shoe lifts, whereas shortening of 2.5 cm or more may require correction, particularly in active young people.

## GOALS OF TREATMENT

The goals of treatment are to restore limb alignment and, in the lower extremity, to reestablish an anatomic mechanical axis of weight bearing between the hip and ankle joints (34,49,50,56,58,59,64,72,73,95,106). Sometimes the goal may be to actually overcorrect alignment to redistribute the contact stresses in the knee as treatment for posttraumatic degenerative arthritis. Even if alignment is well corrected, the patient will not be happy if she has continued joint dysfunction, particularly stiffness. Concomitant arthroscopy to treat internal derangement of joints, to reconstruct ligaments, and soft-tissue procedures to restore motion, must be considered. The ultimate goal is to restore as much function as possible.

## DEFINING THE DEFORMITY

Angular deformities are nearly always in a single plane. Occasionally, a segmental fracture will result in a dual-plane deformity, as when a proximal fracture heals with deformity in one plane and the more distal fracture heals with deformity in another plane, and independent correction of deformity at each fracture site is necessary (96). The vast majority of malunions, however, are single fractures with angulation in a single plane. In the past, we considered these to be two-plane deformities, because angulation is seen on the AP and lateral views. However, they are really single-plane deformities that are greater than can be seen on the AP and lateral radiographs alone.

Radiographic analysis provides crucial information, however. Take plain AP and lateral radiographs of both the affected and the normal extremity, making certain that both are aligned with the central beam of the x-ray. Use as long a tube distance as possible and incorporate a radiographic ruler to assist in measurements. Either include in those views the joints above and below, or take separate views. In the lower extremity, determine the mechanical axis by taking weight-bearing AP and lateral radiographs, using long cassettes to include the hip and ankle joints. When trying to compare the axis of the knee joint relative to the ankle joint, it is often helpful to take independent AP films with the central beam at right angles, or with a 10° caudal tilt at the knee and AP at the ankle.

The detailed history and physical examination for evaluation of nonunions described earlier in this chapter applies also to malunions. Try to measure the degree of angulation and establish the plane in angular deformities. Compare rotation in the affected limb to that in the abnormal limb: This is often the best guide to malrotation. The same is true for shortening, which is discussed below.

Establishing the true degree of shortening can be difficult, particularly if there are contractures of the ankle, knee, or hip joint. I use all of the following methods before deciding on how much to equalize leg length.

- Measure leg lengths from the anterior/superior iliac spines to the medial malleoli and bottom of the feet.
- Measure leg lengths at the medial malleoli by marking the malleoli with a felt tip pen whose mark will transfer easily. With the pelvis level, pull down on both feet and touch the malleoli together, noting the leg-length discrepancy between the two marks.
- Stand the patient and place measuring blocks under the short side until the pelvis is level and the patient feels comfortable. I often shift the blocks back and forth in increments of $^1/_8$ to ¼ inch, without allowing patients to see what I am doing, to establish what correction they prefer.
- Confirm the measurements with radiographs. AP views of the hips and pelvis, knees, and ankles with a radiographic ruler in place at the maximum tube distance is usually accurate as long as the patient does not move during the examination. You may want to personally supervise these films to be certain that they are accurate. Next, place the blocks under the short side, correcting the discrepancy, and take a weight-bearing AP view of the pelvis, being certain that the cassette is level with the floor and the patient is standing perfectly erect. Comparison of all these measurements and discussion with the patient will usually lead to a decision to undertake a given correction. I rely mostly on the standing block measurements.

Angulation rarely occurs without translation. Correction of angulation alone, without addressing translational deformity, will leave the mechanical axis disturbed. In addition, there is almost always some malrotation and some degree of shortening. The radiographic appearance of these deformities, how to assess the mechanical axis, and how to measure deformity are discussed in detail in Chapter 32. Use the vector analysis technique described there to determine angulation and translation, and use the true mechanical axis technique to establish the mechanical axis.

The discussion in Chapter 32 focuses on the Ilizarov technique, but the process for characterizing the deformity is the same. The major difference in preoperative planning is that in the Ilizarov technique a simple transverse osteotomy is nearly always done, and the correction is taken through the distraction site by adjustment of the external fixator. This gives a great deal of latitude, as even if there are miscalculations, adjustments can be made in the external fixator frame as the deformity is corrected, to achieve good alignment.

## PREOPERATIVE PLANNING

Careful preoperative planning is essential. After internal fixation is in place and the skin closed, adjustments are very difficult to make, especially after closing wedge osteotomies, for example. Therefore, incomplete or inaccurate correction may require reoperation.

Rotational malalignment is usually best assessed clinically, but if precise measurements are desired CT scans are useful (22). In preoperative planning, take into account how changes in angulation and rotation will affect overall length of the extremity.

The basic method of preoperative planning employs overlay drafting, a technique borrowed from architects and engineers (16,34,51,58,74,95). Rotate and manipulate superimposed images of the major bone fragments until the desired bone configuration and limb alignment are achieved. This can be done with tracing paper, clear x-ray film, or a digitizing tablet coupled to a microcomputer (Fig. 26.15, Fig. 26.16, Fig. 26.17, Fig. 26.18 and Fig. 26.19,). For the sake of accuracy, include the joints proximal and distal to the osteotomy in the drawing. In the lower extremity, do mechanical axis drawings. If the deformity is unilateral, use a contralateral tracing as a template. This allows a prediction of the outcome (Fig. 26.15*C*, Fig. 26.16*B* and Fig. 26.17*B*). With the overlay technique, before and after views can be compared and different proposed solutions weighed, to select the plan that will best restore the mechanical axis and equalize limb lengths.

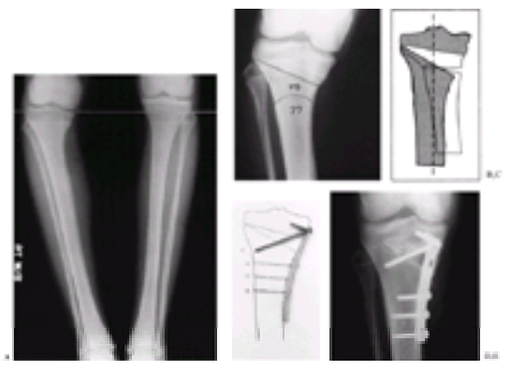

***Figure 26.15.*** **A:** Preoperative standing film shows 20° varus deformity of right tibia and 2 cm limb-length discrepancy. **B:** Options for surgical treatment include intraligamentous incomplete opening wedge and crescentic osteotomy. **C:** Overlay comparison of the two options in (B). The opening wedge (*shaded areas*) will gain an additional 1 cm of length while restoring the mechanical axis. **D:** The drawing serves as a template for sizing the tricortical iliac graft and preoperative contouring of the semitubular "hook plate." The fibula was not cut. **E:** The hook plate was compressed over the tricortical graft and an interfragmentary screw was placed through the plate. By placing the screw at the apex, a wide range of angles are available. (From Stevens PM. L-Plate Fixation for Osteotomies. *Orthopedics* 1991;14:767.)

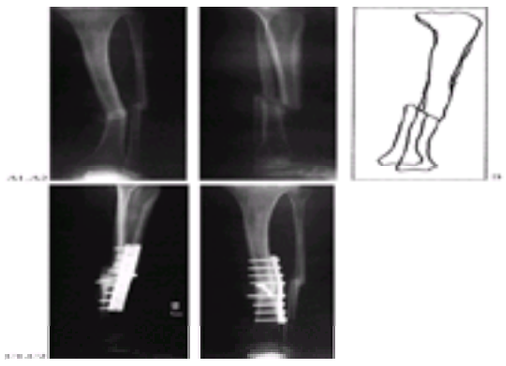

***Figure 26.16.*** **A:** Nonunion of the tibia, presenting as a two-plane deformity with 13° of varus, translocation, and 1.2 cm of shortening. **B:** Overlay drafting provides direct comparison with contralateral tibia serving as a template. **C:** After oblique osteotomy and realignment with the femoral distractor, the tibia was fixed with an interfragmentary screw and contoured neutralization plate.

***Figure 26.17.*** **A:** Radial malunion with synostosis, 6 mm shortening of the radius, wrist pain, and 0° pronation/supination. **B:** The difference in radial length and alignment is readily apparent on this digitized overlay comparison (left side is *white*; the template is *shaded* on the normal right side). **C:** The optimal plan calls for an opening wedge osteotomy through the radial malunion, excision of the synostosis with fat interposition, and stabilization with a precontoured DC plate. **D:** Intraoperatively, 70° each of pronation and supination were gained, while full radial length was restored with an autogenous tricortical bone graft. The transverse cut made insertion of an interfragmentary screw impractical.

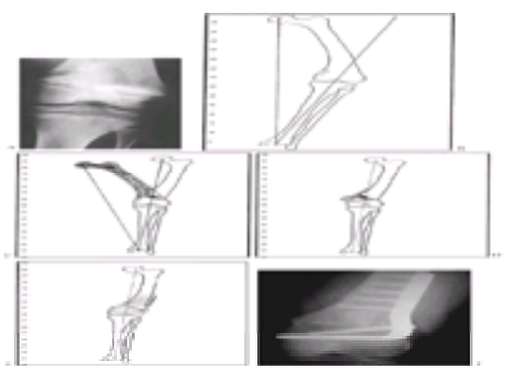

***Figure 26.18.*** **A:** This 13-year-old girl sustained a closed fracture of her distal femur, which led to asymmetrical closure of her distal femoral physis, resulting in 30° of varus and a 4.5 cm limb-length discrepancy. **B:** The digital tracing of her full-length standing film demonstrates the real versus the desired mechanical axis, and the lateral slope of her knee. **C:** A 32 mm medial opening wedge osteotomy would normalize the mechanical axis while restoring 3 cm of length. **D:** Although a medial 90° blade plate is more convenient to apply, it would be unacceptably prominent. **E:** Therefore, a 95° blade plate was applied through a lateral incision. The lateral femoral physis was curetted to prevent recurrent varus. **F:** By the fifth postoperative month, the patient had solid clinical and radiographic union, with symmetrical alignment and a 1 cm residual length discrepancy.

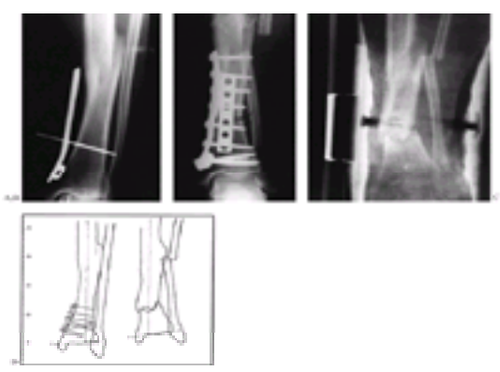

***Figure 26.19.*** **A:** Intraoperative "plan" for correction of 10° varus malunion of the tibia. **B:** The transverse diaphyseal osteotomy was unstable after application of a medial buttress plate without an interfragmentary screw. An anterior plate was added, requiring excessive soft-tissue stripping. Still, no lag screw was used; note the persistent gap. **C:** Wound slough and an infected malunion resulted. The limb was salvaged with debridement and electrical stimulation. This unfortunate sequence of

events could have been avoided by good preoperative planning. **D:** (*Left*) In retrospect, a preplanned, incomplete opening wedge supramalleolar tibial osteotomy, secured with tension band fixation, would have safely afforded excellent correction. The length discrepancy would have been 1.2 cm. (*Right*) The result in this case was 12° of valgus and a limb-length discrepancy of 3 cm.

## TYPES OF DEFORMITY

### SINGLE-PLANE DEFORMITY

Simple deformities occurring only in the frontal plane are uncommon (and in the sagittal plane even more so), and a single drawing suffices. Plan the degree of valgus or varus correction within the context of mechanical alignment (Fig. 26.15*C*). If there are deformities at two locations, combined or compensatory, a double osteotomy may yield the best biomechanical solution, keeping the joints horizontal and restoring the mechanical axis (Fig. 26.18*D*). Simple deformities in the sagittal plane often produce an unphysiologic arc of joint motion. Examples include dorsal tilt after a Colles' fracture, recurvatum of the knee, and ankle deformities. Wedge or displacement osteotomies can be planned on a tracing of the lateral radiograph. Maximum flexion and extension views help to delineate the desired degree of correction.

### TWO-PLANE DEFORMITY

The term *two-plane deformity* derives from the angulation seen on both AP and lateral radiographs (Fig. 26.16). As already discussed, all deformities at a single level are in fact in a single plane, but they are commonly midway between the AP and the lateral planes and thus are oblique. For example, femur fractures tend to angulate in an anterolateral direction, and tibias can be in almost any plane. It is important to understand the precise plane of the deformity and the actual angulation (see Chapter 32). This can be done by vector analysis or by using geometric calculations. Although these deformities can be corrected by approaching the angulations in the different planes sequentially, as described in the discussion of the AO oblique osteotomy below, a more precise technique, although more technically challenging, is to do a single-plane osteotomy that corrects the entire deformity.

A radiographic method of determining the plane of the deformity is to examine the limb segment under fluoroscopy, rotating the limb until there is no deformity seen on the x-ray film. This marks the plane of the deformity. Taking a second radiograph at exactly 90° to this plane permits measurement of the true angulation.

### THREE-PLANE DEFORMITY

Complex three-plane deformities include rotational malalignment. Determination of the degree of malrotation is based on the methods already described. Correction of malrotation in complex deformities can be incorporated into a single-plane osteotomy, or done in a stepwise fashion if the osteotomy is transverse or oblique as discussed in the next section. In some cases, a CT scan and a computer-generated, three-dimensional model may be beneficial for visualizing the necessary correction.

## PREOPERATIVE PREPARATION

On the templates or computer-generated drawings, identify the location of any structural bone grafts required, and place drawings of the hardware to be used. Hardware templates available from manufacturers are quite useful. If the preoperative plan is clear-cut and changes are not anticipated, preoperative contouring of plates can save considerable time in the operating room. Plan for alternative methods of fixation and be certain that appropriate implants are available. Also have available a simple universal external fixator and a femoral distractor, which may assist in intraoperative control of fragments pending definitive internal fixation.

When performing osteotomies to correct malalignment, intraoperative fluoroscopic control is invaluable, particularly for reestablishing the mechanical axis in the lower extremities. Because fluoroscopy does not give a large field of view, however, final alignment must be confirmed with radiographs that include the joints above and below. To facilitate the fluoroscopy, use fully radiolucent operating tables that allow free passage of the C-arm from the pelvis to the foot.

## SURGICAL TECHNIQUES

There are many options for the location and configuration of the osteotomy (Fig. 26.20). Personal preference may play a role, but place a premium on simplicity, stability, and predictability. Corrective osteotomies are best done at or near the site of deformity, which is determined by the point of intersection of the axes of the proximal and distal segments. The farther from this point an osteotomy is done, the more difficult it is to normalize the mechanical axis and the more likely it is that a zigzag compensatory deformity will result, which may be undesirable. Other factors demand consideration, however, including the condition of the soft tissues, history of infection, fixation problems, and anticipated healing time. If there are extenuating circumstances, a distant correction and compensatory deformity may be acceptable.

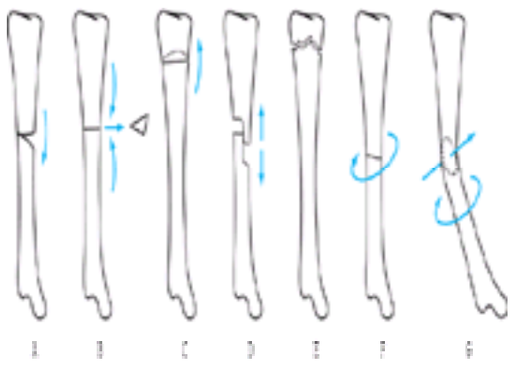

***Figure 26.20.*** Types of osteotomies. **A:** Opening wedge. **B:** Closing wedge. **C:** Displacement. **D:** Stepcut. **E:** Crescentic (dome). **F:** Transverse derotation. **G:** Oblique (single plane).

### TRANSVERSE OSTEOTOMY

A transverse osteotomy (Fig. 26.20*F*) is ideal for correcting rotation alone. Whether in the diaphysis or the metaphysis, it is important to ascertain that the plane of cut is transverse to the long axis of the bone to avoid inadvertently producing a frontal or sagittal deformity. Although simple to perform, a transverse osteotomy is relatively unstable and is not ideally suited for interfragmentary compression. It resists an axial load but is inherently weak if subjected to torsion or bending loads. Angular corrections can be difficult to control (Fig. 26.19). In the diaphysis, locked intramedullary fixation permits load sharing and excellent stability. If an open osteotomy is performed, requiring extensive exposure and periosteal stripping, intramedullary reaming and nailing may produce unacceptable devascularization and delayed healing. In such instances, plating or external fixation is preferable. Transverse metaphyseal osteotomies may produce cortical stepoff and the risk of intra- or postoperative invagination of the smaller fragment, resulting in overcorrection. The cancellous bone may provide marginal anchorage for screws, wires, and staples (17). Consider blade-plate fixation, double plates, or supplemental external splintage.

In the femur, correction of malrotation can be done using percutaneous “closed” intramedullary osteotomy with locked nail fixation (see Chapter 30 for details). For open osteotomies, it is critical that the degree of correction be accurately controlled and determined intraoperatively. Knight (45) describes a precision guide-pin technique for wedge and rotatory osteotomy of the femur and tibia. In 85% of 47 osteotomies, his correction was within 3° of the operative goal. Pulisetti et al. (79) describe a method using CT, in which the malrotation angle value in degrees can be translated into millimeters on the circumference of the diaphysis; they feel this virtually eliminates error in correcting rotation.

- Before making the osteotomy, place a 2 mm Kirschner (K-) wire, or a stronger pin, into the proximal fragment in an area that will not interfere with the internal

fixation and where soft-tissue distortion will not bend the pin.
- Place a similar pin distally, directly in line with the proximal pin. This establishes the starting point.
- Preoperatively bend a K-wire into a **V** to match the angle to be corrected. This will serve as an intraoperative guide.
- Mark the bone where the osteotomy will be made. Draw a longitudinal line on the bone across the osteotomy, or mark it with a slight nick from an osteotome to provide an additional reference.
- To facilitate fixation, a plate, if one is to be used, can be molded to the bone at the site of correction; it can be temporarily fixed to the proximal fragment with a single screw and then rotated out of position for the osteotomy. Once the osteotomy is done, this plate can be rotated back into position and secured to the distal fragment with a bone-holding forceps or a single screw for a preliminary check on the correction.
- Make the transverse osteotomy. Rotate the limb to the corrected angle and secure the osteotomy as described previously.
- Always sterilely prep and drape the opposite limb so that comparisons of rotation can be made. Do that at this time to be certain that the correction is accurate.
- Complete the fixation using a stable construct, and close and dress the wound.
- Finally, examine the anesthetized patient after wound closure and take final radiographs to be certain that the correction is as desired. If it is not, reprep and redrape and make adjustments as needed. If the surgery has been performed precisely, following these instructions, the need to reoperate should be minimal or nonexistent.

**OPENING AND CLOSING WEDGE OSTEOTOMIES**

The opening and closing wedge osteotomies are a variation of the transverse osteotomy. The most commonly used closing wedge osteotomy is a high tibial osteotomy performed to treat unicompartmental arthritis of the knee. Its advantages are simplicity, stability, and rapidity of healing. Disadvantages are that it can affect soft-tissue balance if close to joints, and it will result in some shortening. In addition, if an excessively large wedge is taken, overcorrection is possible.

The opening wedge osteotomy is easier to perform than a closing wedge, because the degree of deformity to be corrected can be established easily before committing to an irreversible cut. Also, the correction angle can be easily adjusted intraoperatively until the correct position is obtained. It offers the advantage of some gain in length. The disadvantages result from the fact that the opening wedge must be filled by a bone graft, which slows healing, nonunions can occur, and the intercalary bone graft used must remodel before full weight bearing can begin (Fig. 26.20*A*, Fig. 26.20*B*).

The uniplanar opening wedge osteotomy is most frequently performed in the cancellous bone of the metaphyses; it can be done in diaphyseal bone as well but with higher risk because of its slower healing. I have used this osteotomy most commonly in the proximal and distal tibia and occasionally in the distal femur. The ideal graft is harvested as a tricortical graft from the anterior ilium, using the cortical surface of the superior rim of the ilium as the portion of the graft that supports the opposing cortices at the osteotomy site (see Chapter 9). The following technique is for an opening wedge osteotomy of the proximal tibia.

- Under fluoroscopic control, place a K-wire parallel to the tibial plateau and just slightly superior to the site planned for the osteotomy.
- Using a water-cooled oscillating saw with a long blade, and providing appropriate protection for the soft tissues, make a transverse osteotomy parallel to the K-wire and at a right angle to the long axis of the tibia in the other plane. Stop 10 mm short of the opposite cortex.
- Gently correct the deformity, and plan to create a green stick fracture of the opposite cortex. If there is significant resistance to straightening the bone, drill the opposite cortex through the osteotomy with several drill holes to weaken it.
- Try to maintain the continuity of the cortex and soft tissues on the opposite cortex, as this significantly increases the stability of the osteotomy and hastens healing.
- When the correction is achieved, prop open the osteotomy with an appropriate-size prop. I have available an assortment of plastic blocks in 5 mm increments, which are useful for temporarily holding the osteotomy open.
- Measure the mechanical axis and take AP and lateral radiographs to be certain that the correction is complete.
- Measure the width of the opening wedge thus produced and the length of bone wedge needed, and harvest as many of these as are necessary to completely fill the defect. In the tibia, usually three wedges from the iliac crest are required.
- Drive the tricortical iliac crest wedges into the osteotomy site and stabilize it with a single large plate or with two small fragment plates placed at roughly right angles to each other. The osteotomy and grafts should be in compression at the completion of the fixation.
- Take final radiographs to confirm position.

The technique for a closing wedge osteotomy until the placement of the first K-wire is identical to that for an opening wedge osteotomy. The surgical technique then continues as follows:

- Place a second K-wire parallel to the first at the angle of wedge to be removed. Be certain that the K-wires are placed so that the narrow end of the osteotomy will just meet the opposite cortex.
- With the oscillating saw, make a transverse cut parallel to and just inferior to the proximal K-wire, being certain that the plane of the saw remains parallel to the joint. Stop just short of the opposite cortex (this is just slightly farther than for the opening wedge osteotomy).
- Now make the second saw cut, watching the blade carefully under fluoroscopic control to be certain that it stays parallel to the first cut and will meet the first cut precisely at the opposite cortex. A free saw blade placed in the first osteotomy provides a useful reference.
- Remove the wedge by placing a thin osteotome into the proximal osteotomy and a second into the distal osteotomy: Use these to pry out the wedge.
- Completely close the osteotomy and temporarily fix it with a plate as for the opening wedge osteotomy, or with a wire inserted across the osteotomy site.
- Evaluate the alignment discussed previously, and complete fixation of the osteotomy with a plate and screws. An external fixator can be used as well, but I prefer internal fixation. If the osteotomy is in the mid diaphysis, perhaps an intramedullary nail can be used if the overall alignment of the canal has been established.

**OBLIQUE (SINGLE-PLANE) OSTEOTOMY**

An oblique osteotomy (Fig. 26.20*G*) offers several advantages. It can correct all deformities with a single cut. It presents a broader surface area for healing, has superior bending and rotational stability, and can easily be compressed with an interfragmentary lag screw. By inserting the screw through a plate, the rigidity of fixation is increased by approximately 25%. (In the diaphyseal region, where both cortices must be cut, use a contoured neutralization plate.) However, the planning and execution are challenging (80,87). The plates can be difficult to apply, but they can be effective for a rotational deformity. The oblique osteotomy is especially useful in the metaphyseal region.

- Make an incomplete cut close to the joint, leaving an intact osteoperiosteal hinge for stability; a plate can then be applied in a tension-band fashion (Fig. 26.15, Fig. 26.21*A*, Fig. 26.21*D*). The addition of an interfragmentary screw further increases stability.

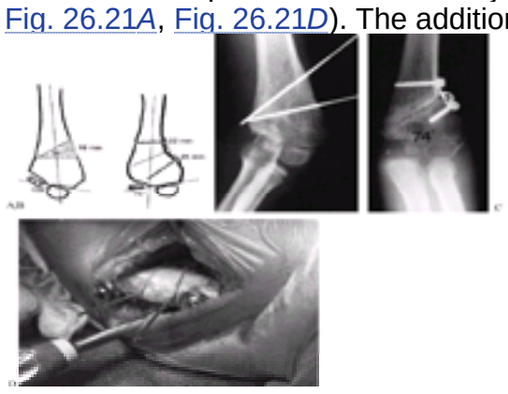

***Figure 26.21.*** **A:** Preoperative drawing for a patient with traumatic cubitus varus. The plan calls for minimal exposure, incomplete osteotomy, and tension band fixation; a 16 mm base equals a 30° wedge. **B:** Delineation of planned wedge with K-wires. **C:** Intraoperative confirmation of correction. **D:** Screws with washers are placed before osteotomy. The oscillating saw is guided by K-wires. Gradual closure of the gap is achieved, leaving a medial hinge for stability.

- Plan the cuts to avoid a cortical stepoff.
- Add or remove bone wedges to adjust the length and the mechanical axis (Fig. 26.15).

Excessive obliquity introduces shear forces, which to some extent are neutralized by the interfragmentary screw (97). For proximal or distal tibial corrections, it is generally not necessary to cut the fibula, unless rotation is also being corrected.

The proximity of the osteotomy to a joint influences the angular change required. In the proximal tibia, an intraligamentous opening wedge osteotomy offers the additional advantage of improving knee stability. In the immature patient, a one-plane or two-plane deformity in conjunction with a partial physeal arrest is often present.

A metaphyseal opening wedge osteotomy in a patient with less than 50% physeal closure facilitates the exposure for an epiphysiolysis. Realignment also reduces the eccentric load on the recovering physis. If the percentage of physeal closure precludes an epiphysiolysis, a transphyseal closing wedge osteotomy prevents recurrence of the deformity. In the event of a malunited Salter-Harris III or IV fracture, an osteotomy through the old fracture site permits anatomic reduction using tracings of the contralateral joint as a template.

A particularly useful oblique osteotomy is that described by the AO group (59). With one cut, angular deformity in the frontal and sagittal planes, shortening, and malrotation can be corrected in a stepwise fashion (Fig. 26.22). The major disadvantage is that it requires considerable soft-tissue exposure, which can lead to devascularization of the tips of the proximal and distal fragments. I have had two AO osteotomies that were technically well done but went on to a nonunion that was difficult to recover from, so I use this osteotomy infrequently.

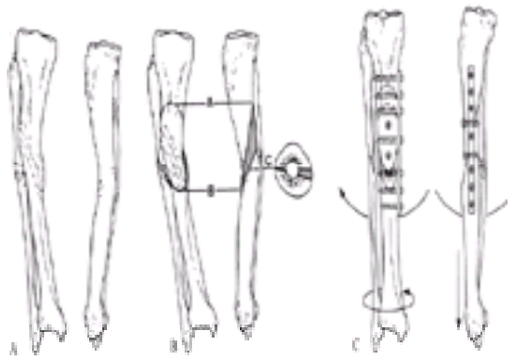

***Figure 26.22.*** The AO method for triplane osteotomy. **A:** Malunion of the tibia and fibula with 15° of valgus deformity, 15° of recurvatum, 15° of external rotation, and 2 cm of shortening. **B:** All of these deformities can be corrected by a single oblique, frontal-plane osteotomy made at the point of maximum deformity, at an angle of 60°. After the initial cut is made, remove a wedge from the distal fragment to correct the recurvatum; then remove a second wedge from the distal fragment to correct the malrotation. (A skilled surgeon can make both corrections with a single cut.) Next osteotomize the fibula. **C:** Restore length with a femoral distractor. Fix the osteotomy with two or three interfragmentary compression screws. Apply a neutralization plate with three bicortical screws above and below the osteotomy to either the lateral or medial surface. (I prefer the lateral surface.)

A much better osteotomy, although more technically challenging and difficult to plan, is the single-plane osteotomy described by Sangeorzan et al. (87), and independently by Rab (80). The technique is based on a mathematically precise calculation that characterizes the deformity. It allows the determination of an axis about which the distal fragment can be rotated to make it coincident with the proximal fragment. A plane perpendicular to this axis allows a single surgical cut to be made that will permit correction of the full deformity (Fig. 26.23). The technique requires four steps: precisely defining the location and angular measurements of the deformity in all planes; finding the angle of osteotomy required to correct the deformity; locating the starting point of the osteotomy referable to the transverse plane; and then cutting along this plane with an oscillating saw and rotating the distal segment relative to the proximal segment to bring them into the corrected position. Because the osteotomy is oblique, interfragmentary screw fixation works well, particularly when combined with a neutralization plate. The details of this technique are rather complex and beyond the scope of this chapter, but the articles by Sangeorzan et al. (87) and Rab (80) are excellent, and they provide additional references of interest.

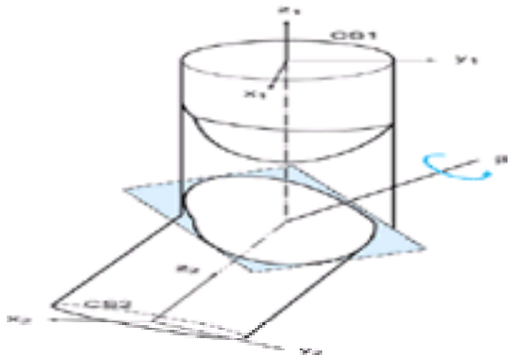

***Figure 26.23.*** A Sangeorzan mathematically directed single cut osteotomy. This drawing is a model of the malunion, which is shown as a cylinder with a localized bend and twist. The process of determining the deformity involves assigning a coordinate axis to each end of the bone where the proximal portion, *CS1*, represents the normally aligned segment and *CS2* is the malaligned distal segment. The axes are superimposed at the site of the deformity. All components of the deformity can be corrected by rotating CS2 about an axis, represented here as beta to make CS1 coincident with CS2. The axis, beta, is determined mathematically. The osteotomy is made in a plane perpendicular to the beta axis, which is represented by the *shaded area* in this drawing. The oblique interface of this osteotomy lends itself to lag-screw fixation. (For the details on the mathematical calculations, see Sangeorzan BJ, Sangeorzan BP, Hansen ST Jr, Judd RP. Mathematically Directed Single-Cut Osteotomy for Correction of Tibial Malunion. *J Orthop Trauma* 1989;3:267.)

**CRESCENTIC (DOME) OSTEOTOMY**

A crescentic or dome osteotomy works best in metaphyseal or epiphyseal cancellous bone, where the irregular nature of the bone and the cut provide good inherent stability, and the broad surface area and cancellous bone lead to rapid healing (Fig. 26.24). It is much more difficult to use in cortical bone, and I no longer use it in the diaphysis. It is ideal for correcting deformity near joints that are in a single plane, preferably the frontal plane. In preoperative planning, be certain that an undesirable shift of the mechanical axis will not occur. Some gain in length due to the correction of the deformity is possible but usually minimal. Although external fixation can be used, most require plate fixation (see Chapter 30). The following osteotomy is performed for correction of a pure valgus deformity of the ankle.

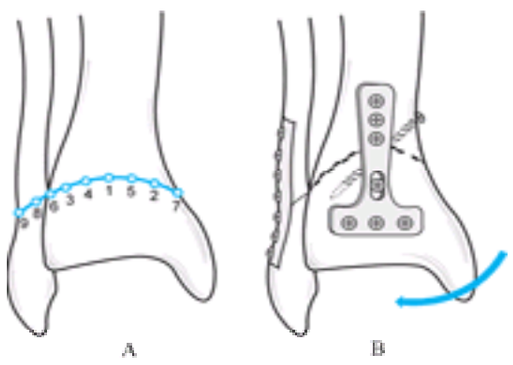


***Figure 26.24.*** Crescentic (dome) osteotomy of the distal tibia. See text for explanation.

- Expose the distal tibia through an anterior approach. If correction of the fibula is needed as well, plan to incorporate it into the dome osteotomy.
- The dome osteotomy usually works best if the concave side is directed toward the joint or distally. Localize the osteotomy at the site of the major deformity in the distal tibia, leaving enough room to secure plate fixation in the distal fragment.
- After anterior exposure of the tibia and fibula just proximal to the ankle joint, draw out a gentle curve (Fig. 26.24*A*), the radius of which will permit correction of the deformity. (Figure 26.24 shows a moderate, 15° varus deformity, and it depicts incorporation of the fibula, which is often not necessary.)

- Use appropriate-size drill points (in the figure, they are 3.5 mm in diameter, but this depends on the size of the bone). Insert the first drill point at the apex of the dome (in the figure, this is drawn on the anterior tibia), and drill it through the anterior and posterior cortices, keeping it exactly at 90° to the axis of the proximal shaft of the tibia.
- Next, place two additional drill points at a point midway between the first drill point and the medial and lateral cortices, keeping them exactly parallel to the first drill point.
- Add more drill points to fill in the intervals, spacing them about 5 mm apart (follow roughly the numbered sequence shown in the figure). Use the initial drill point as a guide to be certain that all the drills are parallel to each other, producing a perfect dome. In a typical adult tibia, about five or six drill points can be placed. It is very important that these all be parallel to each other along the roof of the dome osteotomy.
- When all drill points have been placed, remove them and connect the drill holes both anteriorly and posteriorly with a slim, ¼-inch (Hoke) osteotome (Fig. 26.24*B*). Do this by completing the osteotomy anteriorly first and then running the osteotome across the tibia to the posterior cortex.
- Next, rotate the osteotomy to obtain correction and impact it. The combination of drill holes and osteotome cuts produces two opposed cogwheels. At the appropriate point of correction, these can be interdigitated and then impacted, producing a surprisingly stable osteotomy. Obtain initial fixation with either K-wires or a single screw. I prefer to use at least two interfragmentary screws across the osteotomy for the primary fixation (see Chapter 30).
- Obtain plain radiographs and determine the mechanical axis to be certain the correction is as desired. Complete the fixation by stabilizing it with a neutralization plate on the tibia.
- If the fibula has been osteotomized, use a $^{1}/_{3}$-tubular plate on the fibula.
- Correction of a juxtaarticular deformity of this type is technically easier to do with a frontal plane oblique osteotomy. The advantages of the dome are that it requires less soft-tissue stripping and patients can bear weight immediately in most cases. Healing is also more rapid than with an oblique osteotomy.

### HINTS AND TRICKS

A very nice technique for determining the mechanical axis intraoperatively with the fluoroscope is to use a Bovie cord from the electrocautery unit, because this is radiopaque, readily available, and sterile for use in the operating field. Be certain to attach the cord to the drapes so that sufficient length is available to reach from the hip to the ankle.

- To establish the mechanical axis, center the C-arm over the femoral head and hold the Bovie cord so that it is located dead center on the femoral head. Mark this position on the skin.
- While holding the Bovie cord under tension, locate it directly over the center of the ankle mortice, visualizing the location on the fluoroscope, and mark this on the skin as well. Hold the Bovie cord on the skin so that parallax is minimized.
- Being careful not to move the Bovie cord from the center of the hip and ankle, use the fluoroscope to visualize the knee and record the image, print it, and place it on the operating room x-ray view box. On the normal side, the cord should pass directly through the center of the knee, which is usually just on the lateral side of the medial tibial spine.
- Make a similar determination on the abnormal side that is to be corrected.
- Once the correction is achieved in surgery, repeat this procedure on the operated side, to ensure that the mechanical axis is comparable to the normal or unoperated extremity. If bilateral deformities are being done, locate the cord directly in the center of the knee.
- Bone grafts are not usually required for osteotomies unless an opening wedge osteotomy is being performed. This may require several tricortical grafts harvested from the anterior superior iliac spine (see Chapter 9). In this case, be certain to prepare and drape the iliac crest.

### DISPLACEMENT OSTEOTOMY

The displacement osteotomy described by Wagner (100) is useful to address a major juxtaarticular deformity (Fig. 26.20*C*). It consists of a transverse metaphyseal osteotomy in which the periarticular fragment is rotated, impacting one corner of the metaphysis into the medullary canal of the other fragment. This transforms bending loads into compressive loads while preserving length and improving joint alignment.

### STEPCUT OSTEOTOMY

In rare cases, such as one-stage diaphyseal lengthening, a stepcut osteotomy may be convenient. However, it requires significant exposure, which devascularizes the bone ends, and fixation may be tenuous. Rotational and angular corrections are limited (Fig. 26.20*D*, Fig. 26.20*E* and Fig. 26.20*F*).

## POSTOPERATIVE MANAGEMENT

In the majority of osteotomies, after achieving a stable mechanical construct, early motion of the extremity is safe and desirable. Base the range of motion permitted, degree of weight bearing, and level of use of the extremity on the intraoperative assessment of the stability of the reconstruction. Avoid overstressing the implants until healing occurs.

## PITFALLS AND COMPLICATIONS

An inaccurate history or cursory clinical examination cannot yield sufficient information on which to base the decision to perform an osteotomy. For instance, ankylosis of a joint may preclude the successful realignment of a limb after an osteotomy, and a flail limb or unstable joint may not fare well after an osteotomy. When performing a varus-producing osteotomy of the upper femur, you must anticipate how the distance from the articular surface of the hip joint to the trochanter is altered; a patient with “good containment” but restricted abduction and a marked Trendelenburg gait is not likely to be pleased with the clinical outcome. A preexisting limb-length inequity may be exacerbated by an otherwise satisfactory angular correction. The radiographic examination is critical, so adequate radiographs are a prerequisite to planning.

Inadequate preoperative planning or poor execution of an osteotomy can quickly lead to complications, as demonstrated in Figure 26.19. Although there are innumerable reasons for failure of reconstructive osteotomies, most of them are avoidable. Perceptual and technical errors can be averted if you abide by the principles described here and pay attention to details.

Surgery is not an intuitive process: Planning is essential for consistent and predictable results. The use of hardware templates prevents embarrassing and costly mistakes in the operating room. Although a preoperative plan is no guarantee of success, it narrows the range of potential intraoperative errors and allows contingency plans to be formulated. Improper positioning and draping compromises surgery at every step, as does inadequate exposure. Excessive exposure is equally reprehensible and may lead to a poor outcome (Fig. 26.19).

Undercorrection leads to postoperative “recurrence” and possible progression of the deformity because the pathomechanics continue (Fig. 26.18). Overcorrection is equally undesirable. Strive to achieve a neutral mechanical axis and to balance the forces around a joint. The key to avoiding intraoperative pitfalls is prevention, thorough planning, adequate exposure, intraoperative control with radiographic documentation, and stable fixation.

Avoid intraoperative damage to skin muscle and neurovascular structures by careful dissection, gentle retraction, and extensile approaches. Vigorous retraction and excessive periosteal stripping are to be condemned. Never close wounds under tension; consider delayed closure or use of appropriate flaps when the wound is excessively swollen. Perform neurolysis or fasciotomies if indicated.

The risk of infection is ameliorated by the appropriate use of perioperative antibiotics and suction drainage of the wound. Treat infection aggressively with debridement and appropriate culture-specific antibiotics. If the osteotomy remains stable and the implant is intact, the hardware should be left in place. Implant failure or loss of fixation and alignment warrant reoperation with revision of fixation. If there is infection, consider external fixation. The long-term implications of overcorrection or undercorrection should be recognized and discussed with the patient, because residual deformities have the same pathomechanical significance as the original deformity. Use bone graft in osteotomies when the risk of delayed nonunion is high.

## CHAPTER REFERENCES

Each reference is categorized according to the following scheme: *, classic article; #, review article; !, basic research article; and +, clinical results/outcome study.


+ 1. Abeed RI, Naseer M, Abel EW. Capacitively Coupled Electrical Stimulation Treatment: Results from Patients with Failed Long Bone Fracture Unions. *J Orthop Trauma* 1998;12:510.

* 2. Anderson LD, Boyd HB, Johnston DS. Changing Concepts in the Treatment of Nonunion. *Clin Orthop* 1965;43:37.

# 3. Bassett CAL. Current Concepts of Bone Formation. *J Bone Joint Surg Am* 1962;44:1217.

+ 4. Bassett CAL. The Development and Application of Pulsed Electromagnetic Fields (PEMFs) for Ununited Fractures and Arthrodeses. *Orthop Clin North Am* 1984;15:61.

+ 5. Bassett CAL, Mitchell SN, Gaston SR. Treatment of Ununited Tibial Diaphyseal Fractures with Pulsing Electromagnetic Fields. *J Bone Joint Surg Am* 1981;63:511.

# 6. Bassett CAL, Mitchell SN, Norton L, et al. Electromagnetic Repairs of Nonunions. In: Brighton CT, Black J, Pollack SR, eds. *Electrical Properties of Bone and Cartilage.* New York: Grune & Stratton, 1979:605.

! 7. Bassett CAL, Pawluk RJ, Becker RO. Effects of Electrical Currents on Bone in Vivo. *Nature* 1964;204:652.

+ 8. Bassett CAL, Pilla AA, Pawluk RJ. A Nonoperative Salvage of Surgically Resistant Pseudarthroses and Nonunions by Pulsing Electromagnetic Fields. *Clin Orthop* 1977;124:128.

# 9. Black J, Brighton CT. Mechanisms of Stimulation of Osteogenesis by Direct Current. In: Brighton CT, Black J, Pollack SR, eds.*Electrical Properties of Bone and Cartilage.* New York: Grune & Stratton, 1979:215.

# 10. Brighton CT. Advanced Clinical Applications of Electromagnetic Field Effects: Bone and Cartilage. In: Brighton CT, Pollack SR, eds.*Electromagnetics in Biology and Medicine.* San Francisco: San Francisco Press, 1991.

! 11. Brighton CT, Adler S, Black J, et al. Cathodic Oxygen Consumption and Electrically Induced Osteogenesis. *Clin Orthop* 1975;107:277.

# 12. Brighton CT, McCluskey WP. Cellular Response and Mechanisms of Action of Electrically Induced Osteogenesis. In: Peck WA, ed. *Bone and Mineral Research*, 4th ed. Amsterdam: Elsevier Science, 1986:213.

! 13. Brighton CT, Okereke E, Pollack SR, Clark CC. In Vitro Bone Cell Response to a Capacitively Coupled Electrical Field. The Role of Field Strength, Pulse Pattern, and Duty Cycle. *Clin Orthop* 1992;285:255.

! 14. Brighton CT, Ray RD, Soble LW, Kuettner KE. In Vitro Epiphyseal Plate Growth in Various Oxygen Tensions. *J Bone Joint Surg Am* 1969;51:1383.

! 15. Brighton CT, Schaffer JL, Shapiro DB, et al. Proliferation and Macromolecular Synthesis by Rat Calvarial Bone Cells Grown in Various Oxygen Tensions. *J Orthop Res* 1991;9:847.

# 16. Brunner CF, Weber BG.*Special Techniques in Internal Fixation.* New York: Springer-Verlag, 1982.

+ 17. Cherny G III, Zorn KE. Segmental Tibial Defects: Comparing Conventional and Ilizarov Methodologies. *Clin Orthop* 1994;301:118

! 18. Colacicco G, Pilla A. Electromagnetic Modulation of Biological Processes: Influence of Culture Media and Significance of Methodology in the Calcium-Uptake of Embryonal Chick Tibia In Vitro. *Calcif Tissue Int* 1984;36:167.

+ 19. Connolly JF, Guse R, Tiedeman J, Dehne R. Autologous Marrow Injection as a Substitute for Operative Grafting of Tibial Nonunions. *Clin Orthop* 1991;266:259.

! 20. Doty S, Van Ostenbridge J. Differential Response of Cell Membrane–Associated and Lysosomal Enzymes to Pulsating Electromagnetic Fields. *Trans Bioelectr Repair Growth Soc* 1983;3:66.

+ 21. Duarte LR. The Stimulation of Bone Growth by Ultrasound. *Arch Orthop Trauma Surg* 1983;101:153.

+ 22. Dugdale TW, Degnan GG, Turen CH. The Use of Computer Tomographic Scan to Assess Femoral Malrotation after Intramedullary Nailing—A Case Report. *Clin Orthop* 1992;279:258.

+ 23. Dwyer AF. The Use of Electrical Current Stimulation in Spinal Fusion. *Orthop Clin North Am* 1975;6:265.

+ 24. Dwyer AF, Wickham GG. Direct Current Stimulation in Spinal Fusion. *Med J Aust* 1974;1:73.

+ 25. Esterhai JL, Brighton CT, Heppenstall RB, et al. Detection of Synovial Pseudarthrosis by 99mTc Scintigraphy: Application to Treatment of Traumatic Nonunion with Constant Direct Current. *Clin Orthop* 1981;161:15.

! 26. Esterhai JL, Friedenberg ZB, Brighton CT, Black J. Temporal Course of Bone Formation in Response to Constant Direct Current Stimulation. *J Orthop Res* 1985;3:137.

# 27. Fitton-Jackson S, Bassett C. The Response of Skeletal Tissues to Pulsed Magnetic Fields. In: Richards RJ, Rajan KT, eds.*Tissue Culture in Medical Research, II.* Oxford: Pergamon Press, 1981:21.

+ 28. Friedenburg ZB, Harlow MC, Brighton CT. Healing of Nonunion of the Medial Malleolus by Means of Direct Current: A Case Report. *J Trauma* 1971;11:883.

! 29. Friedenberg ZB, Roberts PG Jr, Didizian NH, Brighton CT. Stimulation of Fracture Healing by Direct Current in the Rabbit Fibula. *J Bone Joint Surg Am* 1971;53:1400.

! 30. Friedenberg ZB, Zemsky LM, Pollis RP, Brighton CT. The Response of Non-traumatized Bone to Direct Current. *J Bone Joint Surg Am* 1974;56:1023.

! 31. Friedrich B, Klaue P. Mechanical Stability and Post-Traumatic Osteitis: An Experimental Evaluation of the Relation Between Infection of Bone and Internal Fixation. *Injury* 1977;9:23.

# 32. Hassler CR, Cummings KD, Clark LC, et al. Augmentation of Bone Healing via Electrical Stimuli. In: Brighton CT, Black J, Pollack SR, eds.*Electrical Properties of Bone and Cartilage.* New York: Grune & Stratton, 1979:155.

+ 33. Heckman JD, Ryaby JP, McCabe J, et al. Acceleration of Tibial Fracture-Healing by Non-invasive, Low-Intensity Pulsed Ultrasound. *J Bone Joint Surg Am* 1994;76:26.

# 34. Horster G. Corrective Osteotomies of the Tibial Shaft. In: Hierholzer G, Muller KH, eds.*Corrective Osteotomies of the Lower Extremity After Trauma.* New York: Springer-Verlag, 1986.

! 35. Howell DS, Pita JC, Marquez JF, Madruga JE. Partition of Calcium Phosphate and Protein in the Fluid Phase Aspirated at Calcifying Sites in Epiphyseal Cartilage. *J Clin Invest* 1968;47:1121.

# 36. Ilizarov GA. The Principles of the Ilizarov Method. *Bull Hosp Joint Dis Orthop Inst* 1988;48:1.

! 37. Ilizarov GA. The Tension-Stress Effect on the Genesis and Growth of Tissues. I. The Influence of Stability of Fixation and Soft-Tissue Preservation. *Clin Orthop* 1989;238:249.

! 38. Ilizarov GA. The Tension-Stress Effect on the Genesis and Growth of Tissues. II. The Influence of the Rate and Frequency of Distraction. *Clin Orthop* 1989;239:263.

+ 39. Ilizarov GA, Devyatov A, Kamenin VK. Plastic Reconstruction of Longitudinal Bone Defects by Means of Compression and Subsequent Distraction. *Acta Chir Plast* 1980;22:32.

+ 40. Johnson EE, Marder RA. Open Intramedullary Nailing and Bone Grafting for Nonunion of Tibial Diaphyseal Fractures. *J Bone Joint Surg Am* 1987;69:375.

# 41. Johnson KD. Management of Malunion and Nonunion of the Tibia. *Orthop Clin North Am* 1987;18:157.

+ 42. Judet J, Judet R.*L'ostéogénèse et les Retards de Consolidation et les Pseudoarthroses des Os Longs. 8e Congrès S.I.C.O.T., New York 1960.* Brussels: Imprimeries des Sciences, 1961.

+ 43. Judet R, Judet J, Roy-Camille R. La Vascularisation des Pseudoarthroses des Os Longs d'après une étude Clinique et Expérimentale. *Rev Chir Orthop* 1958;44:5.

# 44. Kane WJ. The Use of Supplementary Electronic Bone Growth in Primary and Secondary Lumbosacral Fusions. In: Brighton CT, Black J, Pollack SR, eds.*Electrical Properties of Bone and Cartilage: Experimental Effects and Clinical Applications.* New York: Grune & Stratton, 1979.

+ 45. Knight JL. A Precision Guide-Pin Technique for Wedge and Rotatory Osteotomy of the Femur and Tibia. *Clin Orthop* 1991;262:248.

+ 46. Küntscher G. Die Nagelung der Malleolar Pseudoarthrose. *Mschr Unfalheilk* 1953;56:107.

! 47. Lavine LS, Lustrin I, Shamos MH. Experimental Model for Studying the Effect of Electric Current on Bone in Vivo. *Nature* 1969;224:1112.

+ 48. Lavine LS, Lustrin I, Shamos MH, Moss ML. The Influence of Electric Current on Bone Regeneration in Vivo. *Acta Orthop Scand* 1971;42:305.

+ 49. MacMahon EB, Coombs FK. Valgus/Varus Deformities of the Knee: Their Etiology and Clinical Significance. *Orthop Rev* 1984;13:57.

# 50. Macquet P. *Biomechanics of the Knee*, 2nd ed. New York: Springer-Verlag, 1983.

# 51. Mast J, Jakob R, Ganz R.*Planning and Reduction Technique in Fracture Surgery.* Berlin: Springer-Verlag, 1989.

+ 52. Mayo KA, Benirschke SK. Treatment of Tibial Malunions and Nonunions with Reamed Intramedullary Nails. *Orthop Clin North Am* 1990;21:715.

+ 53. Merchant TC, Dietz FR. Long-Term Follow-Up After Fractures of the Tibial and Fibular Shafts. *J Bone Joint Surg Am* 1989;71:599.

+ 54. Meyer S, Weiland AJ, Willenegger H. The Treatment of Infected Nonunion of Fractures of Long Bones. *J Bone Joint Surg Am* 1975;57:836.

! 55. Minkin C, Poulton BR, Hoover WH. The Effect on Direct Current on Bone. *Clin Orthop* 1968;57:303.

# 56. Morscher E. Pathophysiology of Posttraumatic Deformities of the Lower Extremity. In: Hierholzer G, Muller KH, eds.*Corrective Osteotomies of the Lower Extremities after Trauma.* New York: Springer-Verlag, 1986.

+ 57. Müller ME. Treatment of Nonunions by Compression. *Clin Orthop* 1965;43:83.

# 58. Müller M. Intertrochanteric Osteotomies. In: Evarts CM, ed. *Surgery of the Musculoskeletal System*, vol. 6. New York: Churchill Livingstone, 1983;57:2833.

# 59. Müller ME, Allgüower M, Schneider R, Willenegger H.*Manual of Internal Fixation of Fractures, 3rd ed.* New York: Springer-Verlag, 1990.

! 60. Nada M, Sato A. Calcification of Cartilaginous Matrix in Culture by Constant Direct Current Stimulation. *Clin Orthop* 1984;193:281.

! 61. Norton L, Baurret L, Majeska R, Rodan G. Adherence and DNA Synthesis Changes in Hard Tissue Cell Culture Produced by Electric Perturbation. In: Brighton CT, Black J, Pollack SR, eds.*Electrical Properties of Bone and Cartilage.* New York: Grune & Stratton, 1979:443.

! 62. Norton LA, Shleyer A, Rodan G. Electromagnetic Field Effects on DNA Synthesis in Bone Cells. *J Electrochem Soc* 1980;127:129C.

! 63. O'Connor BT, Charlton HM, Currey JD, et al. Effects of Electric Current on Bone in Vivo. *Nature* 1969;222:162.

# 64. Oest O. Special Diagnosis and Planning of Corrective Osteotomies. In: Hierholzer G, Muller KH, eds. *Corrective Osteotomies of the Lower Extremity after Trauma.* New York: Springer-Verlag, 1986.

! 65. Ohashi T. Electrical Callus Formation and Its Osteogenesis. *J Jpn Orthop Assoc* 1982;56:615.

+ 66. Paterson D. Clinical Use of the Osteostim—An Implanted Bone Growth Stimulator—For Impaired Bone Healing. *Instr Course Lect* 1982;31:103.

! 67. Paterson DC, Hillier TM, Carter RF, et al. Experimental Delayed Union of the Dog Tibia and Its Use in Assessing the Effect of an Electrical Bone Growth Stimulator. *Clin Orthop* 1977;128:340.

! 68. Paterson DC, Hillier TM, Carter RF, et al. Electrical Bone-Growth Stimulation in an Experimental Model of Delayed Union. *Lancet* 1977;1:1278.

+ 69. Paterson DC, Lewis GN, Cass CA. Treatment of Delayed Union and Nonunion with an Implanted Direct Current Stimulator. *Clin Orthop* 1980;148:117.

+ 70. Paterson DC, Simonis RB. Electrical Stimulation in the Treatment of Congenital Pseudarthrosis of the Tibia. *J Bone Joint Surg Br* 1985;67:454.

* 71. Pauwels F. Grundriss liner Biomechanik der Fracturheilung. *Verh Dtsch Orthop Ges* 34 Kongress, 1940.

# 72. Pauwels F.*Biomechanics of the Normal and Diseased Hip: Theoretical Foundation, Technique and Results of Treatment.* New York: Springer-Verlag, 1976.

# 73. Pauwels F.*Biomechanics of the Locomotor Apparatus.* New York: Springer-Verlag, 1980.

# 74. Perren S. Mechanical and Technical Principles of the Internal Fixation of Corrective Osteotomies. In: Hierholzer G, Muller KH, eds.*Corrective Osteotomies of the Lower Extremity after Trauma.* New York: Springer-Verlag, 1986.

# 75. Perren SM, Cordey J. The Concepts of Interfragmentary Strains. In: Uhthoff HK, ed. *Current Concepts of Internal Fixation of Fractures.* New York: Springer-Verlag, 1980.

+ 76. Pers M, Medgyesi S. Pedicle Muscle Flaps and Their Applications in the Surgery of Repair. *Br J Plast Surg* 1973;26:313.

+ 77. Phemister DB. Treatment of Un-united Fractures by Onlay Bone Grafts without Screw or Other Fixation and without Breaking Down of the Fibrous Union. *J Bone Joint Surg* 1947;29:946.

! 78. Pilla AA, Mont MA, Nasser PR, et al. Non-invasive Low-intensity Pulsed Ultrasound Accelerates Bone Healing in the Rabbit. *J Orthop Trauma* 1990;4:246.

+ 79. Pulisetti TD, Onwochei MO, Ebraheim NA, et al. Mathematical Precision in Rotational Corrective Osteotomy of the Femur. *J Orthop Trauma* 1998;12: 360.

+ 80. Rab GT. Oblique Tibial Osteotomy for Blount's Disease. *J Pediatr Orthop* 1988;8:715.

+ 81. Rhinelander FW. The Normal Microcirculation of Diaphyseal Cortex and Its Response to Fracture. *J Bone Joint Surg Am* 1968;50:784.

! 82. Rodan G, Johnson D. The Effect of Electromagnetic Fields on Alkaline Phosphatase in Osteoblast-like Cells in Culture. *Trans Bioelectr Repair Growth Soc* 1981;1:2.

+ 83. Rosen H. Compression Treatment of Pseudarthroses. *Clin Orthop* 1979;138:154.

# 84. Rosen H. Fracture Healing and Pseudarthrosis. In: Taveras JM, ed. *Radiology: Diagnosis—Imaging—Intervention*, vol. 5. Philadelphia: JB Lippincott, 1986.

# 85. Rosen H. The Treatment of Nonunions and Pseudarthroses of the Humeral Shaft. *Orthop Clin North Am* 1990;21:725.

! 86. Ryaby JT, Matthew J, Pilla AA, Duarte-Alves P. Low-intensity Pulsed Ultrasound Modulates Adenylate Cyclase Activity and Transforming Growth Factor Beta Synthesis. In: Brighton CT, Pollack SR, eds. *Electromagnetics in Medicine and Biology*. San Francisco: San Francisco Press, 1991:95.

+ 87. Sangeorzan BJ, Sangeorzan BP, Hansen ST, Judd RP. Mathematically Directed Single-Cut Osteotomy for Correction of Tibial Malunion. *J Orthop Trauma* 1989;3:267.

# 88. Sarmiento A.*Functional Treatment of Long Bone Fractures.* In: Abstracts, S.I.C.O.T. XIV World Congress, Kyoto, Japan, Oct. 1978.

! 89. Schenk RK. Histology of Fracture Repair and Non-Union. *Bulletin of the Swiss Association for Study of Internal Fixation*, Bern, Oct. 1978.

+ 90. Schwartsman V, Choi SH, Schwartsman R. Tibial Nonunions: Treatment Tactics with the Ilizarov Method. *Orthop Clin North Am* 1990;21:639.

+ 91. Scott G, King JB. A Prospective, Double-Blind Trial of Electrical Capacitive Coupling in the Treatment of Non-union of Long Bones. *J Bone Joint Surg Am* 1994;76:820.

+ 92. Sharrard WJW, Sutcliffe ML, Robson MJ, MacEachern AG. The Treatment of Fibrous Nonunion of Fractures by Pulsing Electromagnetic Stimulation. *J Bone Joint Surg Br* 1982;64:189.

! 93. Smith R, Nagel D. Effects of Pulsing Electromagnetic Fields on Bone Growth and Articular Cartilage. *Clin Orthop* 1983;181:277.

! 94. Stan S, Sansen W, Mulier JC. Experimental Study on the Electrical Impedance of Bone and the Effect of Direct Current on the Healing of Fractures. *Clin Orthop* 1976;120:264.

+ 95. Stevens P, Coleman S. Coxa Brevis: Its Pathogenesis and Rationale for Management. *J Pediatr Orthop* 1985;5:515.

+ 96. Stevens PM. Double Osteotomy for Lower Extremity Realignment. *Surg Rounds Orthop* 1988;35.

+ 97. Stevens PM. L-Plate Fixation for Osteotomies. *Orthopedics* 1991;14:767.

! 98. Tiedeman JJ, Connolly JF, Strates BS, Lippiello L. Treatment of Nonunion by Percutaneous Injection of Bone Marrow and Demineralized Bone Matrix: An Experimental Study in Dogs. *Clin Orthop* 1991;268: 294.

+ 99. Tiedeman JJ, Huurman WW, Connolly JF, Strates BS. Healing of a Large Nonossifying Fibroma after Grafting With Bone Matrix and Marrow: A Case Report. *Clin Orthop* 1991;265:302.

# 100. Wagner H. The Displacement Osteotomy as a Corrective Principle. In: Hierholzer G, Muller KH, eds.*Corrective Osteotomies of the Lower Extremity after Trauma.* New York: Springer-Verlag, 1986.

# 101. Weber BG, Cech O. *Pseudarthrosis.* Bern: Hans Huber, 1976.

+ 102. Weiland AJ, Daniel RK. Microvascular Anastomoses for Bone Grafts in the Treatment of Massive Defects in Bone. *J Bone Joint Surg* 1979;61:98.

+ 103. Weiland AJ, Moore JR, Daniel RK. Vascularized Bone Autografts: Experience with 41 Cases. *Clin Orthop* 1983;174:87.

+ 104. Xavier CA, Duarte LR. Estimulaca Ultra-sonica De Calo Osseo: Applicaca Clinica, Rev. *Brasileira Ortop* 1983;18:73.

# 105. Yasuda I. Fundamental Aspects of Fracture Treatment. *J Kyoto Med Soc* 1953;4:395.

# 106. Zeiler G, Pfeiffer U. Special Techniques of Internal Fixation for Corrective Osteotomies. In: Hierholzer G, Muller KH, eds.*Corrective Osteotomies of the Lower Extremities after Trauma.* New York: Springer-Verlag, 1986.

# CHAPTER 27

# NONUNIONS AND MALUNIONS OF THE UPPER EXTREMITY

*This chapter in the second edition was written by Deborah F. Bell and James F. Kellam. Portions of their chapter were used in this revision. Their contribution is greatly appreciated.*

*Michael W. Chapman*

**M. W. Chapman:** Department of Orthopaedics, University of California Davis, Sacramento, California, 95817.

Scapula
Clavicle
Operative Indications
Repair of Nonunion with Plate Fixation and Bone Graft
Osteotomy for Malunion
Intramedullary Hagie Pin Fixation and Bone Graft for Nonunion
Bumpectomy
Claviculectomy
Proximal Humerus
Operative Indications
Preoperative Planning
Repair of Nonunion with Double Plate Fixation and Bone Graft
Humeral Shaft
Operative Indications
Assessment
Plate Fixation and Bone Graft
Osteotomy for Malunion
Distal Humerussupracondylar and Intraarticularnonunions and Malunions
Operative Indications and Alternatives
Repair of Supracondylar Humerus Nonunion with Double Plate Fixation and Bone Graft
Osteotomy for Cubitus Valgus
Total Elbow Arthroplasty for Salvage of Distal Humeral Nonunion
Olecranon
Repair of Nonunion
Nonunion of the Neck of the Radius
Nonunion: Diaphysis of the Radius and Ulna
Repair of Nonunion with Plates and Bone Graft
Malunions of the Radiusand Ulna
Osteotomy
Resection of the Radial Head
Pitfalls and Complications
Synostosis
Posttraumatic Contracture of the Elbow
Author's Perspective
Chapter References

Because the upper extremity does not normally bear weight unless crutches or a cane are used routinely, osteoarthritis resulting from malalignment does not appear to be a major problem. However, malalignment compromising precise mobility of the hand or the ability to place the hand in space may be a major disability. The decision to correct malunions or nonunions in the upper extremity depends on the patient's functional demands and the presence of pain. If function is suitable without correction and pain is not a problem, surgery is not indicated.

## SCAPULA

Because the scapula is totally enclosed in an envelope of heavy muscles and lies on the posterior aspect of the thoracic cage, fractures that progress to symptomatic nonunion or malunion are exceedingly rare. Personally, I have never had to treat surgically either a nonunion or a malunion of the scapula. There are reports of nonunions of the base of the coracoid process, the scapular body and spine, and the acromion (2,21,33,52,55,105). Gupta et al. (33) reported successful treatment of a nonunion of the inferior third of the body of the scapula (the only case reported in the literature) with plate fixation and bone graft, resulting in dramatic improvement in function and relief of pain.

The epiphysis of the acromion is one of the last to unite and occasionally does not unite, remaining as an os acromiale. This should not be mistaken for a nonunion. True nonunions, if displaced inferiorly, can interfere with motion and cause impingement on the rotator cuff tendons. If symptoms justify, a small fragment can be excised. Reattachment of the deltoid must be solid and protected until healed to avoid deltoid deficiency. Excision of any substantial part of the acromion can lead to permanent deltoid weakness, and therefore, nonunions producing large fragments deserve repair. Repair can be challenging because of the thin cortical bone of the acromion, in which it is difficult to obtain secure fixation. Dounchis et al. (21) reported successful treatment of a nonunion of a fracture at the base of the acromion with plate and screw fixation combined with a tension band wire construct and autologous bone graft.

Nonunions of the coracoid process are more likely to be secondary to an osteotomy performed for reconstructive shoulder surgery as opposed to a fracture. If the nonunion is symptomatic, most can be successfully treated with freshening of the fracture site and internal fixation with a compression screw. Excision is also possible with reattachment of the muscles originating from the coracoid to surrounding soft-tissue structures.

## CLAVICLE

Although the clavicle is probably the most commonly fractured bone, nonunions are rare (82). The incidence of nonunion in clavicle fractures managed nonoperatively is between 0.1% and 1.9% (16,41,68,109). In those managed operatively, the incidence is higher, particularly with intramedullary fixation (91). Functionally disabling malunions are probably even rarer. In the series of 33 patients reported by Wilkins and Johnston (106), nonunion appeared to be more common after refracture or when associated with severe trauma (108). Patients with atrophic nonunions seemed to have fewer symptoms than those with hypertrophic pseudarthroses. Atrophic nonunions seem to be much more common than hypertrophic nonunions (39).

A nonunion of the clavicle in an adult is defined as an ununited fracture at least 16 weeks after injury. The anatomic location of the fracture affects the union rates; distal clavicular fractures have a higher rate of nonunion than middle-third fractures. A displaced, interligamentous distal-third fracture (Neer type II), in which the proximal fragment is detached from the coracoclavicular ligament, is unstable and has a higher nonunion rate (68,69,72).

Malunion of a clavicle is rarely a functional or clinically significant problem. Most clavicles heal in a malunited position, because they are usually treated in a figure-eight sling, which does not provide adequate enough immobilization to ensure anatomic position (see Chapter 15). It is very uncommon to require any form of treatment for a malunion of the clavicle, except for a cosmetic deformity (69). Occasionally, brachial plexus impingement can occur when there is abundant callus. Shortening of more than 15 mm can produce shoulder discomfort.

### OPERATIVE INDICATIONS

The indications for operative intervention in a nonunion or malunion of the clavicle include significant pain with use of the ipsilateral shoulder, compromising upper extremity function. Occasionally, hypertrophic nonunions cause extrinsic compression of the brachial plexus and the subclavian artery and vein (45). This problem may

also be responsible for a thoracic outlet syndrome (16). Thorough preoperative assessment, including a bone scan, appropriate angiography, electromyographic studies, and a thoracic or vascular surgical evaluation, may be indicated. The final indication for surgical correction of clavicular nonunion or malunion is correction of unsightly deformities. The patient must be aware that he or she is exchanging a deformity for a scar. Comparison of radiographs to the opposite, normal side are useful for planning a repair or osteotomy, particularly to estimate restoration of length. Operative techniques most commonly used today include plate fixation and bone graft (6,8,18,51,75,77,92,107), intramedullary Hagie pin and bone graft (4,12,107), and as a last resort, partial or total claviculectomy (59).

### REPAIR OF NONUNION WITH PLATE FIXATION AND BONE GRAFT

- Position the patient in a modified beach-chair position on the operating table (Fig. 27.1). Because it is difficult to position an x-ray plate beneath the shoulder once the patient is positioned and draped, place a cassette in position before the prep and drape. Pad it to protect the patient.

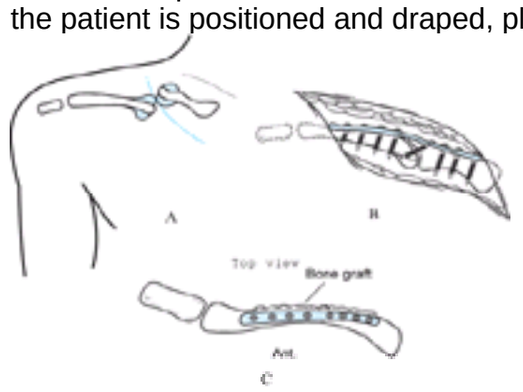


***Figure 27.1.*** Repair of nonunion of the clavicle by plate fixation and bone graft. **A:** Surgical approach in Langer's lines. **B:** Compression plate fixation with an interfragmentary compression screw. **C:** Top view—note placement of bone graft superiorly and posteriorly.

- Prepare and drape the patient, with the involved shoulder and extremity free. Be certain to prep all the way up to the corner of the mandible and drape widely to ensure adequate access to the clavicle.
- Make an incision of sufficient length, usually 10 to 12.5 cm, using Langer lines to minimize scarring. Carry the incision directly down to the clavicle and expose the superior surface by subperiosteal dissection. There usually is no need to develop subcutaneous flaps. In malunions and in hypertrophic nonunions, the main shaft of the clavicle can be buried and quite difficult to identify. Palpate the bone carefully as the incision down to bone is made. Simpson and Jupiter (92) mention identifying and preserving the cutaneous supraclavicular nerves crossing the anterior border of the clavicle in order to avoid dysesthesia postoperatively. I have not found it practical to preserve these nerves in the midportions of the wound. At the distal and proximal ends, they can be retracted. In spite of having transected these nerves in the midportion of the wound routinely, I have never had a patient complain of postoperative dysesthesia due to neuromas.
- Identify the nonunion. In the case of an oligotrophic or atrophic nonunion, try to identify the original fracture ends so that the fracture can be repaired as anatomically as possible. In most cases, it is worthwhile to plate the clavicle in anatomic position rather then fix it in malposition, because patients are much happier and function is better. In most cases, this requires taking down the nonunion, freshening the bone ends, and drilling the medullary canal to help revascularization.
- If there is a reasonably stable fibrous union in nearly anatomic position, then occasionally plate fixation *in situ* is adequate. In my experience, this is rare.
- In hypertrophic nonunions, it is worthwhile to shave the hypertrophic callus off the clavicle, taking care to identify the original clavicle encased in the callus (Fig. 27.1*A*). Morcelize this bone and use it for bone graft, because this saves harvesting an iliac crest graft.
- A gap may be present owing to bone resorption, extensive comminution, or bone loss in the case of open fractures. Plan to restore the full length of the clavicle, placing an intercalary tricortical bone graft of equal size to the clavicle. Harvest it from the superior rim of the anterior iliac crest (see Chapter 9).
- Once the nonunion has been reduced, apply a 3.5 AO limited contact compression plate, Alta 3.7 reconstruction plate, or equivalent to the superior surface of the clavicle, obtaining eight cortices of solid fixation both proximally and distally, if possible. Whenever possible, try to obtain interfragmentary compression across the nonunion site either independently of the plate or through the plate (Fig. 27.1*B*). Plates fit best on the superior clavicle and act as a tension band, requiring less molding than plates placed anteriorly (Fig. 27.1*C*). Superior plates also have the advantage of protection of the underlying structures on the inferior aspect of the clavicle by the subclavius muscle.

#### HINTS AND TRICKS

- To ensure proper length of the clavicle, measure the length of the opposite clavicle preoperatively and use this as a guide.
- Sometimes gaining length can be difficult. Facilitate this procedure by fixing the plate to one end of the nonunion first and then using a distractor or other instrument to distract. Application of a small external fixator with a pin medial and lateral to the plate to be used as a distractor also works nicely.
- Meticulous closure of the periosteum and deep fascia with the platysma provides a smooth contour over the clavicle and may eliminate the need for plate removal later.
- Nonunions in the proximal quarter and in the distal quarter of the clavicle are difficult to fix because of the small fragments available. For these nonunions, the Alta 3.7 reconstruction plate is quite useful because of its oval holes, which give more screws per unit length than in other plates. Augmenting fixation with a tension band figure-eight wire is useful as well.

- Petal the superior and posterior surfaces of the clavicle adjacent to the plate on both sides of the nonunion, and then apply a cancellous bone graft.
- Do a meticulous layered closure of the periosteum, deep fascia, and platysma. Use a plastic skin closure to provide the best scar. See Figure 27.2 for a typical case.

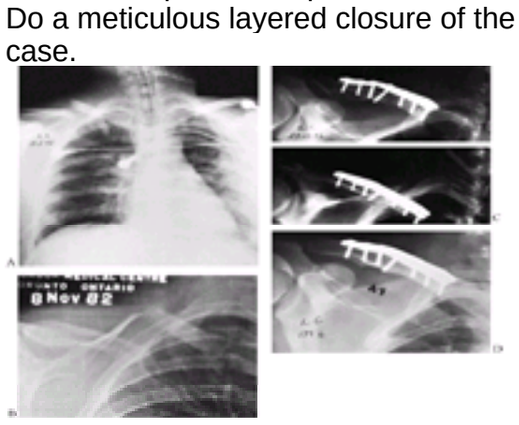


***Figure 27.2.*** Nonunion of the clavicle. **A:** A midshaft oblique fracture of the right clavicle at the time of injury. **B:** Six months after nonoperative treatment, this fracture is still grossly displaced and mobile with no evidence of union. **C:** Open reduction and internal fixation using a 3.5 mm dynamic compression plate. Notice the oblique lag screw across the nonunion site. A bone graft was also added. **D:** At 4 years, consolidation has occurred. The patient is asymptomatic and has not requested that the internal fixation be removed.

### OSTEOTOMY FOR MALUNION

- The technique is nearly identical to that described earlier for repair of nonunion. The only difference is that the old fracture site must be identified and an osteotomy made as much as possible through the old fracture site. I find that this usually works better than an arbitrary osteotomy, because an arbitrary osteotomy frequently results in a compensating deformity.
- Even a year or more after a malunion of a clavicle, the callus surrounding the original bone is more vascular, pink in appearance, and softer than the hard white native cortical bone of the clavicle.
- Slide an osteotome along the normal cortex of the clavicle, shaving off the callus until the malunion site is obvious.
- Use a small water-cooled oscillating saw to osteotomize through the old fracture site. Refashion the bone ends to make the clavicle as anatomic as possible, and then plate the clavicle as described earlier. Bone graft is not usually necessary, but any callus removed at the fracture site can be morcelized and packed about the osteotomy site.

**INTRAMEDULLARY HAGIE PIN FIXATION AND BONE GRAFT FOR NONUNION**

This is the technique described by Boehme et al. (Fig. 27.3) (4,5).

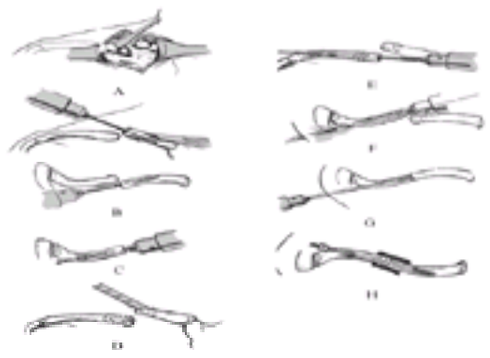

***Figure 27.3.*** Hagie pin fixation and bone graft of a nonunion of the clavicle. **A:** A skin incision exposing the nonunion. **B:** Drilling the medullary canal of the medial fragment. **C:** Drilling the medullary canal of the lateral fragment. **D:** Petaling the ends of the clavicle. **E:** Drilling the Hagie pin out the hole in the lateral fragment. **F:** Superior view of E. **G:** Reducing the fracture and driving the Hagie pin retrograde into the medial fragment. **H:** Superior view. A nut is applied to the Hagie pin to compress the fracture. (Redrawn from Matsen FA, III, and Rockwood CA, Jr. *The Shoulder.* Philadelphia: W. B. Saunders, 283, with permission.)

- Proceed as described earlier for plate fixation to the point where the nonunion is ready for internal fixation. Somewhat more exposure is needed because of the need to have access to both bone ends at the nonunion site for the intramedullary pin (Fig. 27.3*A*). Because a plate will not be placed, exposure of the entire superior surface is not necessary. Elevate the periosteum 2.5 cm off of each segment next to the fracture, trying to maintain the deep soft-tissue attachments to the clavicle.
- Drill the medullary canal of the proximal (medial) fragment with an appropriately sized drill point for the Hagie pin to be used (Fig. 27.3*B*). Be careful not to penetrate the clavicle anteriorly accidentally.
- Drill the medullary canal of the distal (lateral) fragment, exiting the clavicle medial and posterior to the acromioclavicular joint. Drill until the bit can be palpated on the posterolateral aspect of the shoulder where a stab wound is made (Fig. 27.3*C*).
- Freshen (petal) the ends of the clavicle at the nonunion site (Fig. 27.3*D*).
- Select a Hagie pin of the appropriate length and diameter so that the course threads on the tip of the pin will lie entirely within the medial fragment. Drill the Hagie pin retrograde with its fine-threaded ends laterally out from the nonunion site down the medullary canal of the lateral fragment, to bring the tip to the fracture site (Fig. 27.3*E*, Fig. 27.3*F*).

**HINTS AND TRICKS**

- Avoid smooth or threaded wire fixation across nonunions because of the risk of wire breakage and wire migration (see Chapter 78) (73,83,106).
- For distal clavicle nonunions, fixation in a short distal fragment can be enhanced by the use of a 3.5 mm or similar T plate, or a 3.5 mm plate with one of the screws in the plate placed into the base of the coracoid process (see Chapter 78). With this technique, take care to not excessively narrow the coracoclavicular interval. Avoid elevation of the arm above 90° until the coracoclavicular screw is removed after healing of the nonunion.
- Figure-eight tension band wires (without K-wires) are useful for augmenting plate or Hagie pin fixation (Fig. 27.4).

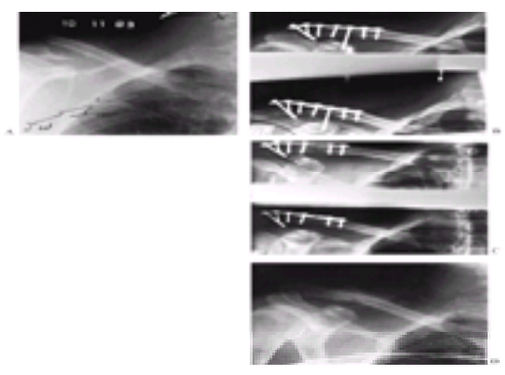

***Figure 27.4.*** Nonunion of a distal clavicle fracture. **A:** A 25-year-old skier suffered a displaced fracture of the distal third of his clavicle. Nonoperative treatment was unsuccessful. He had pain and an unsightly deformity at 6 months. The atrophic nonunion was completely mobile. **B:** Internal fixation was performed using a third-tubular plate. There is an interfragmentary screw across the fracture site and a coracoclavicular screw. The most distal screw runs obliquely through the longest portion of the acromion. A cancellous bone graft was applied. **C:** At 8 weeks, the coracoclavicular screw was removed. Before this, the patient had been allowed pendulum exercises with abduction of his shoulder to only 90°. After screw removal, full range of motion was instituted. **D:** A radiograph 1.5 years after operative intervention shows that the plate has been removed, and there is solid union of the nonunion.

- Reduce the fracture, then drill the Hagie pin into the medial fragment. When the pin is in place, the fracture site should be in excellent apposition and compression. If there is a gap, apply the nut to the lateral end of the pin and compress the fracture (Fig. 27.3*G*, Fig. 27.3*H*).
- Finish petaling the bone ends at the nonunion site for a distance of 2.5 cm on either side of the nonunion. Bone graft the fracture on all exposed surfaces except the anterior subcutaneous border. Boehme et al. (4) use osteal/periosteal rib grafts, as described by Dineen and Greshman (19); however, cancellous graft from the iliac crest works well also.
- Closure is as described previously.

***Postoperative Care***

Assuming that good fixation has been achieved, the postoperative care for all three of the above-mentioned procedures is similar. Protect the shoulder in a sling until the patient is comfortable. Begin passive circumduction exercises (Codmen's), progressing as quickly as the patient can tolerate. Patients can use the extremity for light activities of daily living but should avoid any strenuous use of the extremity, lifting of other than very light objects, and overhead activities until 6 weeks after the surgery. Between 6 and 12 weeks, depending on the state of union, progress with gentle overhead pulley exercises but avoid raising the arm against gravity or any strenuous use until the nonunion is solidly healed, which generally takes 10 to 12 weeks.

**BUMPECTOMY**

In many malunions, function is normal and the patient has no pain. The major concern is the bump from the malunion. In these cases, simple removal of the bump with an osteotome and smoothing of the clavicle suffices.

***Results***

The results of treatment of clavicular nonunions using the techniques described above are excellent, with success rates of 92% to 100% after the first operation (4,5,6,8,12,16,18,23,25,39,41,45,51,66,75,77,83,91,92,103,106,107).

## CLAVICULECTOMY

Removal of the clavicle is rarely indicated and usually results in only minimal morbidity (59). Patients usually complain of weakness and early fatigue when working with the extremity above the head. Some have chronic pain. Claviculectomy is usually indicated for some infected nonunions, major bone loss, or a painful nonunion that is unresponsive to surgical treatment. Sometimes, claviculectomy is necessary to relieve thoracic outlet syndrome. Claviculectomy may be combined with simultaneous resection of the first rib, which is usually done through an independent axillary exposure. To avoid an unsightly, painful, unstable clavicle, resect it only as indicated in Figure 27.5.

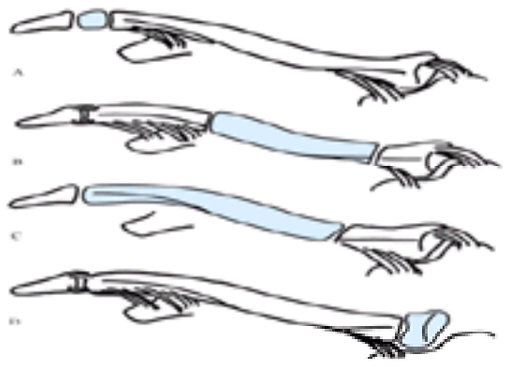

***Figure 27.5.*** Partial claviculectomy. Note that the remaining segment is always stabilized by ligaments. Shaded areas indicate resected parts of bone. **A:** Distal claviculectomy, usually done for acromioclavicular arthritis. This can be part of a Weaver-Dunn procedure (102). **B:** Resection of the medial intercalary two thirds. The lateral and medial segments are stabilized by their ligamentous attachments. **C:** Resection of the lateral two thirds, leaving a stable medial fragment. **D:** Resection of the medial end for arthritis or instability of the sternoclavicular joint. Instability of the remaining clavicle at its medial end may require stabilization to the first rib (see Chapter 78)

- Expose the clavicle, as described earlier for repair of a nonunion. Expose only that portion of the clavicle planned for resection.
- When resecting the mid two thirds of the clavicle or the distal two thirds, you can facilitate resection by entering the nonunion site or making an osteotomy just lateral to the ligaments, stabilizing the medial end of the clavicle. Expose it with careful circumferential subperiosteal exposure.
- Grasp this free end of the clavicle with a bone-holding forceps and then excise the clavicle in a subperiosteal manner from its bed to the distal resection site.
- Resection of the medial end of the clavicle as illustrated in Figure 27.5*D* requires special consideration because of the underlying major neurovascular structures. (See Chapter 78 for a description of this exposure and resection.)
- When resecting the clavicle distal to the attachments of the coracoclavicular ligaments, it is essential that these ligaments be intact or reconstructed (see Chapter 78) (102).

### HINTS AND TRICKS

- Resection of a deformed clavicle surrounded by dense scar can be challenging on occasion because of the closeness of the underlying neurovascular structures. The best technique is subperiosteal resection, keeping sharp instruments directly against the clavicle and avoiding penetration into the underlying soft tissues. The presence of the subclavius muscle and the clavipectoral fascia usually provides adequate protection for these vital structures.
- The major disadvantage of subperiosteal resection is that occasionally the clavicle partially reforms from the periosteum. This is particularly true in young adults. If reformation of a clavicular remnant is a problem, then an extra periosteal resection is indicated. This requires additional caution.
- Careful repair of the periosteum, deep fascia, and platysma usually results in the formation of a fibrous scar, which simulates the excised clavicle and gives a reasonable cosmetic result.
- Warn all patients that they will experience less strength and endurance in using the shoulder, particularly for overhead or pushing activities.

## PROXIMAL HUMERUS

Fractures of the proximal humerus account for 4% to 5% of fractures and occur most frequently in the elderly (40). Failure of this fracture to unite within 6 to 8 weeks constitutes a delayed union. At 12 weeks, an unstable fracture with no evidence of callus formation is unlikely to heal. Therefore, operative treatment is usually indicated. Nonunion of the surgical neck of the humerus is rare (93). Displaced fractures that remain unreduced owing to muscle forces, interposed deltoid or biceps, or treatment producing distraction may result in nonunion. In Neer's series (70,71), nonunions were more commonly associated with hanging casts or skeletal traction and displaced four-part fractures. The incidence of proximal humerus fractures in women is twice that in men. Osteoporosis and a short proximal fragment covered for the most part by articular cartilage makes treatment difficult (Fig. 27.6) (35). Therapeutic alternatives include symptomatic treatment only, open reduction, and internal fixation combined with a bone graft or prosthetic replacement. Because of the challenge of obtaining fixation in the proximal articular fragment, many different approaches have been used, including simple plate and screw fixation, double plate fixation, multiple stiff and malleable wires, Rush rods or Ender pins combined with malleable wires in a figure eight, and various types of blade plates or specially designed reconstruction plates for the proximal humerus (30,34,40,48,100). In elderly and in middle-aged adults with severe avascular necrosis of the humeral head, a reasonable alternative is prosthetic replacement of the proximal humerus. Because the nonunion is typically through the surgical neck, restoration of the insertion of the rotator cuff is important. If there is coexisting osteoarthritis of the shoulder joint, consider total shoulder replacement. In young patients who require a stable pain-free shoulder for heavy labor, consider arthrodesis (see Chapter 103) (Fig. 27.7).

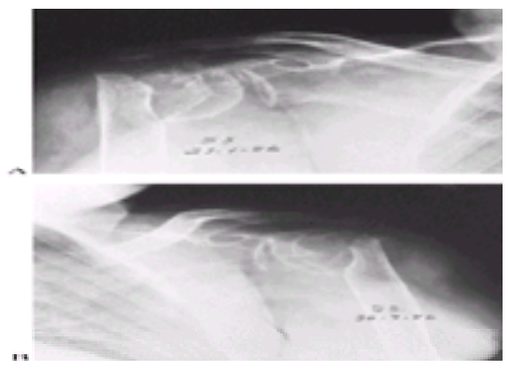

***Figure 27.6.*** Bilateral painless pseudarthrosis of the proximal humerus in a 72-year-old woman. This patient had adequate motion in her shoulders for her activities of daily living.

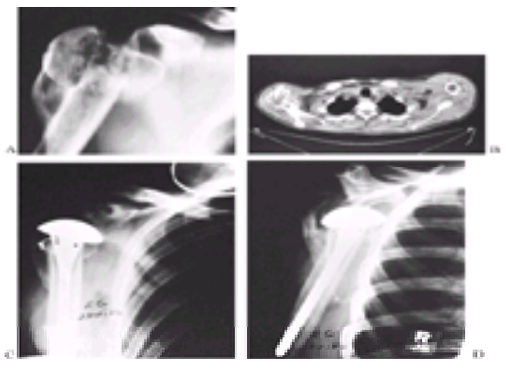

***Figure 27.7.*** Hemiarthroplasty for a malunited fracture of the proximal humerus. **A:** Malunion of a displaced four-part proximal humeral fracture. The glenoid is empty, and the humeral head fragment is rotated 180° laterally. This patient had significant pain and limited shoulder function. **B:** A CT scan of the shoulder shows the malunited humeral head in its rotated position. The greater tuberosity can be seen laterally to the head and appears to be not united in this picture. Notice the sclerotic humeral head, indicating avascular necrosis. **C, D:** A Neer hemiarthroplasty was inserted for the primary relief of pain. At the time of surgery, the humeral head was osteotomized and excised, and 90° of forward motion was obtainable in the operating room under anesthesia. The patient has done relatively well after surgery; he has mild residual pain with adequate function.

Isolated fractures of the tuberosities leading to nonunion are usually accompanied by major ruptures in the rotator cuff. The most likely avulsion fracture to progress to nonunion is one involving the posterolateral aspect of the greater tuberosity, involving the insertions of the infraspinatus and teres minor. On an anteroposterior (AP) view, these tend to be visualized posterior to the humeral head and, therefore, are easily missed. The major focus in repair of these is reconstruction of the rotator cuff, which is described in Chapter 79. Fixation of the tuberosity is usually best accomplished by placing it back into its bed and securing it with multiple figure-eight or horizontal nonabsorbable sutures interwoven through the insertion of the rotator cuff and the proximal fragment, and tied through drill holes in the proximal shaft of the humerus. Screws and other metallic fasteners usually fail because the avulsed fragment is a thin cortical shell and is usually full of multiple cracks.

## OPERATIVE INDICATIONS

Most fractures of the proximal humerus occur in elderly individuals, who, if sedentary, may function reasonably well with a painless pseudarthrosis or a malunion that does not interfere significantly with their activities of daily living. Consequently, premorbid patient activity, age, occupation, and hand dominance play important roles in the decision whether to surgically repair a proximal humerus nonunion (Fig. 27.6).

Malunions in the proximal humerus that require surgical correction are rare, because most patients get along well as long as the opposite shoulder is normal. Osteotomy to correct a malunion is most commonly indicated in active patients who are still working and require full use of their upper extremities for their occupational or sports activities. The most frequent malunion requiring correction is a surgical neck or a somewhat more distal fracture that has healed with apex anterior or lateral angulation, which limits forward flexion and abduction. Occasionally, this can be painful. Osteotomy has been used to treat recurrent anterior dislocation of the shoulder as well (104).

## PREOPERATIVE PLANNING

Repair of a nonunion of the proximal humerus or osteotomy to correct a malunion requires careful preoperative planning because of the challenge of obtaining adequate fixation in the proximal fragment. Rigid fixation is important to allow patients to begin fairly vigorous circumduction exercises immediately; otherwise, unacceptable shoulder stiffness may result. It is usually advisable to have a backup plan with the necessary implants and instrumentation available. In suitable patients, the backup to reconstruction of the fracture may be prosthetic replacement. Be certain to discuss this alternative with your patient, and have the prosthesis and instrumentation available in the event that repair of the nonunion is not technically feasible.

I have had a high rate of success treating difficult nonunions of the proximal humerus through the use of small fragment double plate fixation combined with iliac crest bone graft through a modified deltopectoral approach, which is described below.

## REPAIR OF NONUNION WITH DOUBLE PLATE FIXATION AND BONE GRAFT

- Expose the proximal humerus through a Henry's deltopectoral approach (see Chapter 1). Do not take down any of the origin of the deltoid or pectoralis major muscles. If more extensive exposure is required, take down the insertion of the deltoid in a subperiosteal manner, using a sharp knife or electrocautery knife. Take this down in continuity with the brachialis muscle. Identify and coagulate the large bleeders in this area. This provides ample exposure but does not require direct reattachment of the deltoid insertion to the humerus, because simple closure of this musculofascial sleeve restores the continuity of the deltoid.
- Occasionally, exposure of the joint is necessary, in which case a partial take down of the origin of the short head of the biceps and coracobrachialis from the tip of the coracoid are useful. This step provides excellent exposure, making the spiral compression plate described by Gill and Torchia (30) unnecessary.
- Expose the nonunion site laterally and anteriorly. Try to maintain soft-tissue attachments on the posterior and medial borders. These nonunions are nearly always pseudoarthroses or atrophic nonunions.
- Remove soft tissues from the fracture site and freshen the fracture ends, fashioning them to fit together in a manner that restores anatomic alignment and maximizes the contact of the bone surfaces. Open the medullary canal of the distal fragment and use a 2 mm drill point to drill the sclerotic surface of the nonunion in multiple places on the proximal fragment.
- Reduce the nonunion and secure the position with a bone-holding forceps. Often, these nonunions are oblique, and initial fixation can be done with an interfragmentary compression screw.
- Fashion two Alta small fragment reconstruction plates (or another, similar plate) to fit along the lateral and anterior borders of the fracture, extending up to the articular surface. The bevelled ends of the plates permit fixation close to the articular surface without impingement on the acromion or rotator cuff. Locate these plates as close to 90° to each other as possible. Secure the plates to the humerus with 3.7 cortical screws, which are bicortical where there is not articular cartilage. In the proximal fragment, it is often possible to obtain bicortical fixation on the proximal fragment through the anterior plate, whereas with the lateral plate, the direction of the screws is toward the articular surface; therefore, the screws must be placed short of the subchondral bone. Cortical screws inserted without tapping tend to get a better hold than cancellous screws. If they strip out, replace them with the larger cancellous screws. To improve fixation in osteoporotic bone, try cross-threading the screws against each other in the proximal fragment or, as a last resort, inject methacrylate into each screw hole individually.
- Gently petal the nonunion site up to the articular surface on the proximal fragment for at least 2.5 cm on the distal fragment, and apply finely morcelized cancellous bone in a solid layer along all available bone surfaces. The small, narrow profile of the Alta plates usually leaves ample room for application of a bone graft. If space is insufficient, further medial exposure makes a good location for bone graft (Fig. 27.8) .

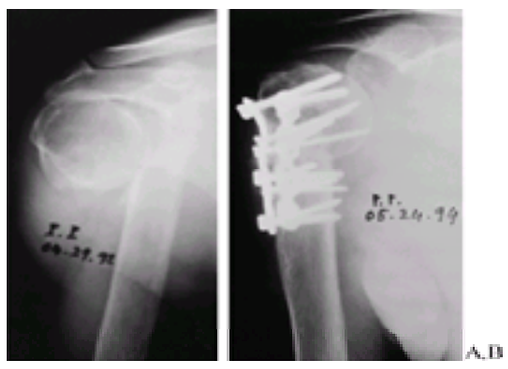


***Figure 27.8.*** Nonunion in the surgical neck of the humerus. **A:** An AP radiograph of the right shoulder of an 82-year-old man with a nonunion of the surgical neck of the humerus of 18 months' duration after treatment in a sling. **B:** An atrophic nonunion with an interposed biceps tendon was found at surgery and repaired with two Alta 3.7 plates. The screws were cross-threaded to improve fixation. An autologous iliac graft was applied. This was healed by 12 weeks, as seen here.

- Close the deltopectoral interval and the brachialis-deltoid interval, if necessary, in a single layer with interrupted resorbable sutures. Perform a plastic closure of the subcutaneous fat and skin.
- Immobilize the shoulder in a shoulder immobilizer.
- Alternative methods of internal fixation include blade plates fashioned out of third-tubular or semitubular plates (22). Although these plates are useful and low profile, I have found them to be weak. The construct can be reinforced by placing an oblique screw from the portion of the plate along the shaft up through the tip of the plate (see Chapter 26), but this is technically tricky. Specialized blade plates and reconstruction plates are now available as well (21,45,51).
- I no longer use large fragment T or L plates because they are difficult to bend and conform to the proximal humerus, and they can cause acromial impingement. Their broad surface area inhibits revascularization of the nonunion site.

If the construct is stable, most patients can begin gentle pendulum circumduction exercises within a few days. Allow patients to remove the shoulder immobilizer to

shower once the wound is sealed. Otherwise, have patients wear the shoulder immobilizer both night and day for the first 6 weeks to protect the repair. If at 6 weeks union seems to be progressing, then a more vigorous circumduction exercise program to maximize shoulder range of motion can begin. Avoid resistive exercises and active elevation of the arm until solid union has occurred, which usually requires 12 weeks. Thereafter, patients can engage in a full range-of-motion and strengthening program. Most patients with nonunions have very stiff shoulders, but I have found that they reacquire good (although rarely normal) functional range of motion and strength after about a year of vigorous rehabilitation.

Correction of a malunion at the same site employs essentially the same techniques except that a closing wedge osteotomy is made through the nonunion site to correct the deformity.

## HUMERAL SHAFT

Before the current functional methods of treatment, nonunion rates were as high as 30% for humeral fractures (42,72). With functional bracing, union can now be achieved in 92% to 95% of these fractures (72,88). Nonunion has been associated with inadequate immobilization, distraction of the fracture, soft-tissue interposition (particularly at the deltoid tubercle), and use of inappropriate nonrigid internal fixation (24,29). A fracture that is mobile and shows no evidence of callus at 12 weeks is unlikely to heal, particularly if a gap can be seen on radiographs (13,43). Hypertrophic delayed unions may be worth treating nonoperatively until 6 months, but I tend to intervene soon after 12 weeks to prevent long-term permanent joint stiffness from prolonged immobilization. As with nonunions in the proximal humerus, nonunions in the diaphysis are frequently challenging. Esterhai et al. (26) found that, in 46 nonunions, 62% were in elderly patients who were senile and had disuse osteoporosis. Forty-two percent were synovial pseudoarthroses; 20% were obese; and 5% had osteomyelitis. Of the patients they elected to treat with electrical stimulation, only 46% healed despite the fact that their group is the most expert in the world in electrical stimulation. For that reason, I do not believe that electrical stimulation is worth using in nonunions of the humerus unless it is a hypertrophic nonunion, proven by computed tomographic (CT) scan and bone scan not to be a synovial pseudoarthrosis. It must be well immobilized. Internal fixation is best for most patients, but consider electrical stimulation for patients in whom surgery is contraindicated or risky.

Malunion of the humeral diaphysis is rarely a functional or cosmetic problem. The soft-tissue coverage of the arm can obscure up to 20° of anterior or posterior angulation and up to 30° of varus. Shortening of as much as 2.5 cm does not lead to disability, and rotational malalignment can easily be compensated through the shoulder (24).

### OPERATIVE INDICATIONS

Treatments of nonunion and malunion are similar. Indications for surgery include

- An unstable delayed union of the humerus at approximately 8 weeks after injury, with an obvious gap on radiographs owing to bone loss or soft-tissue interposition, which precludes healing.
- An established nonunion of the humerus at 12 weeks that is unstable and painful or, if free of pain, is so mobile that effective functional use of the extremity is not possible.
- A severe malunion of the humerus, usually in younger, active patients, that is absolutely cosmetically unacceptable to the patient (usually severe varus with loss of carrying angle) or causes a functional deficit sufficient to interfere with normal activities of daily living, vocational activities, or sports.

### ASSESSMENT

Completely assess the patient's needs and current function in order to establish appropriate goals for the surgery. The shoulder and elbow may be quite stiff, and the patient may be using the nonunion as a false joint, particularly if it is a more distal nonunion close to the elbow. Stabilization of the nonunion may result in significant loss of motion, which the patient may find more disabling than the nonunion. Concomitant soft-tissue procedures and capsular release to increase elbow and, on occasion, shoulder motion may be essential to achieve a satisfactory result. The prolonged immobilization and disuse associated with nonunions of the humerus frequently lead to osteoporosis, which diminishes the holding power of screws. Pre-existing hardware with large radiolucent areas around the fixation device can also destroy bone stock. A thorough preoperative plan with alternatives is important so that the procedure will be successful. Operative techniques include the following:

- When a preexisting intramedullary nail is in place and alignment is acceptable, closed reamed locked exchange nailing is a good technique, but the bone stock must be adequate to provide good fixation for the cross-locking screws. Union is usually slower and less dependable then plate fixation with bone grafting (57).
- Initial primary intramedullary nailing with or without bone grafting almost always requires an open reduction, particularly because the radial nerve is at risk of injury with closed techniques. Nonlocked nails and the Seidel nail do not give a high enough success rate to justify their use for nonunions (15,17,78). Intramedullary techniques do not provide as good fixation as plates and necessitate opening the humerus proximally, which can lead to rotator cuff dysfunction and chronic shoulder pain. The loss of the intramedullary blood supply may slow union. For that reason, I believe the only role for intramedullary nailing for treatment of nonunions of the humerus is exchange nailing for a preexisting nail.
- Plate fixation with bone graft is the most commonly used and most effective method for treating nonunions of the diaphysis of the humerus. It includes variations such as standard AO-type compression plating, adjunctive interfragmentary screw fixation, wave plates, and intramedullary plates (13,66,79,81).
- A fibula split and then fixed on both sides of the nonunion as “plates” has been successful but, with modern internal fixation, is not indicated today. When bone stock is a major problem, however, use of a split fibula to provide a backup to the plate on the opposite cortex for screw fixation is quite useful and a good alternative to allograft (28).
- Difficult atrophic nonunions with loss of bone continuity or nonunions with major bone loss can be treated with plate fixation and a vascularized fibular graft through a medial approach (38).
- When osteopenia precludes good screw fixation, another alternative is the use of adjunctive bone cement, which must be combined with a copious bone graft, with recognition of the impact on the blood supply to bone (98).
- External fixation is useful when osteomyelitis contraindicates the placement of implants at the fracture site but has the disadvantage of frequent loosening of pins due to poor-quality bone, pin track infection owing to the mobile soft tissues in the upper extremity, and interference with shoulder and elbow rehabilitation owing to tie down of muscles by the external fixation pins (47).

### PLATE FIXATION AND BONE GRAFT

- Use Henry's extensile anterolateral approach to the humerus (see Chapter 1). The exploration of the radial nerve can be the most challenging part of this procedure, and bone quality may require a long plate; therefore, it is essential that the surgical approach be extensile to both ends of the humerus. Use a posterior approach only for supracondylar nonunions when exposure beyond the midshaft humerus is not necessary.
- The position of the radial nerve can be nonanatomic, and it commonly is involved in the soft-tissue scar or fracture callus. Identify the nerve in the interval between the brachialis and brachioradialis muscles distally and trace it past the nonunion site into the spiral grove. If the nerve is embedded in scar, it is usually necessary to place it in a vascular loop and protect it during the repair of the nonunion.
- It is rare to be able to fix the nonunion *in situ*; therefore, take the nonunion down, remove all fibrous tissue from between the bone ends, send a specimen for culture, freshen the bone ends, and open the medullary canals. Sculpt the ends of the bone fragments as necessary to maximize cortical contact and to ensure good alignment.
- Shortening up to 2.5 cm in most patients is acceptable if it is necessary to obtain apposition over the full width of the cortex. In elderly patients, in whom functional demands are lower, even more shortening is acceptable.
- Apply a broad plate with 4.5 to 5.0 mm cortical screws, obtaining at least eight cortices of solid fixation both proximally and distally. Many of the tricks for obtaining solid screw fixation are described earlier. Plates usually fit best along the anterolateral aspect of the humerus. In this location, they are free of the radial nerve and function as a tension band. Always try to obtain interfragmentary compression, either through the plate or, better, independent of the plate.
- After the initial plate and interfragmentary screw are in place, gently stress the construct, looking for micromotion in the fracture site. If it is present, or the hold of the screws is tenuous, I always put a second plate at right angles to the first plate along the anteromedial cortex. This plate should be a small fragment plate shorter than the original plate, with at least six cortices of fixation above and below. The shorter, lighter plate leaves more humerus exposed for revascularization and bone graft, and minimizes the risk of a stress riser at the end of the double plates.
- Petal the available bone surface with a quarter-inch osteotome for at least 2.5 cm proximal and distal to the fracture, and lay a morcelized cancellous bone graft along the humerus. If there is cortical deficiency, cortical cancellous grafts are useful.
- Place a suction drain and meticulously close the soft tissue. Close the intermuscular interval in which the radial nerve lies with a layer of sutures deep to the radial nerve to separate it from the plate and bone graft. This method prevents reincorporation of the nerve into the scar and fracture callus. Document this change in location in the dictated operative note. Then close the muscle envelope around the fracture site to ensure full muscle coverage, and close the subcutaneous fat and skin in a routine fashion. A drain is usually advisable.
- Place the arm in a sterile dressing and shoulder immobilizer.

#### *Postoperative Care*

Fixation is solid enough that most patients do not require protection, although I have them wear a shoulder immobilizer for the first 6 weeks to remind them not to use

the arm for anything but the lightest of activities of daily living. A Sarmiento-type fracture brace is also useful. Begin gentle, active range-of-motion exercises for the elbow and shoulder immediately, using circumduction exercises for the shoulder to avoid bending stresses on the plate. At 6 weeks, if healing is progressing well, overhead pulley exercises for the shoulder can begin. Avoid resistive exercises or any use of the extremity for other than light activities of daily living until solid union is documented, which is usually 12 or more weeks after surgery. Once solid union occurs, continue a vigorous range-of-motion and strengthening rehabilitation program to restore shoulder and elbow function (Fig. 27.9).

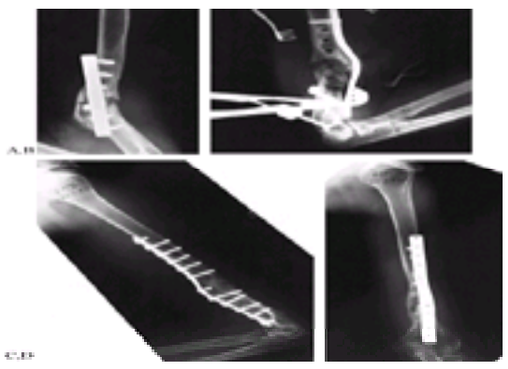

***Figure 27.9.*** A 25-year-old man who had previous plate fixation of a fractured humerus, which resulted in a painful nonunion. **A:** Notice the inadequate plate and the radiolucencies around the screws, demonstrating looseness of internal fixation. **B:** The contoured "wave" plate was placed on the tension side of the nonunion. **C, D:** The nonunion has consolidated. The most distal screw is unicortical, not blocking the olecranon fossa.

***Results***

Plate fixation with bone grafting for nonunions of the humerus is very successful, with union rates in various series reported from 91% in a difficult group of nonunions in elderly patients to 100% (29,38,49,57,66,81,89,103). The results with intramedullary fixation are much less predictable, with union rates reported from 54% to 87% (15,32,78).

**OSTEOTOMY FOR MALUNION**

Osteotomies for malunions of the diaphysis of the humerus are exceedingly rare. Most are performed for supracondylar nonunions with varus deformity and loss of the carrying angle. (See the next section.) The surgical technique is nearly identical to that described earlier for the nonunion. In most cases, a single-plane osteotomy permits correction of the deformity, and some length can be regained if the osteotomy is long enough. Stabilize it with an interfragmentary screw and a broad plate, as described earlier.

## DISTAL HUMERUSSUPRACONDYLAR AND INTRAARTICULARNONUNIONS AND MALUNIONS

Nonunions of the distal humerus can be classified as nonarticular (that is, supracondylar) or intraarticular (usually involving the lateral condyle, but involvement of the medial condyle is possible as well) (56). Nonunions in this region are exceedingly rare, because acute fractures about the elbow make up only 2% of all fractures and the cancellous bone in this region usually leads to union. Malunion is more common. Ackerman and Jupiter (1) treated only 20 patients with nonunions of the distal humerus during a 16-year period at a major referral center. A general orthopaedic surgeon may encounter only one of these nonunions in his or her career. Patients treated nonoperatively and those with neglected fractures frequently have considerable stiffness in the elbow joint and use the nonunion as a false joint to gain additional motion at the elbow. Knowledge of the available range of motion in the elbow is essential for preoperative planning. Lateral radiographs of the elbow joint in flexion and extension and the distal humerus usually demonstrate the true range of motion in the elbow and the instability in the fracture. In supracondylar nonunions, the cartilage of the joint is usually well preserved; therefore, a comprehensive soft-tissue release to regain elbow motion not only greatly enhances function but makes it more likely that the nonunion will heal by relieving stress on the nonunion site through the increased motion of the elbow joint. Previously open supracondylar fractures with nonunion, such as in side-swipe injuries, may have occurred because of bone loss. In a neglected nonunion that is functioning as the elbow joint, mechanical erosion of the bone ends frequently leads to shortening and loss of bone substance (Fig. 27.10 and Fig. 27.11). Reconstruction of these injuries can be difficult owing to the short articular fragment and the differential in size between the articular fragment and the shaft. Although the risk of failure is somewhat higher, use of a structural intercalary bone graft is sometimes necessary to reconstruct these difficult nonunions, as illustrated in Figure 27.11.

***Figure 27.10.*** AP and lateral radiographs of a 42-year-old man with a supracondylar nonunion of the humerus. He had only a 40° arc of motion in the elbow joint and had been using this pseudarthrosis for motion. Note the resorption of the proximal fragment and the size mismatch at the fracture site. See Figure 27-11 for management of this problem.

***Figure 27.11.*** **A:** Nonunion of a supracondylar fracture of the humerus in a 50-year-old woman. AP view shows 2.5 inches (7.5 cm) of bone loss. This fracture was open and was initially fixed with K-wires. No infection occurred, but it did not heal. A second operation at another institution, using bone graft and the K-wire fixation seen in this radiograph, was unsuccessful. **B:** Lateral view. **C:** The nonunion was treated with bone grafting and internal fixation in the following manner:

- Through a posterior approach, the hardware was removed, fracture ends curetted, and length restored.
- A bicortical graft from the ilium was harvested.
- The graft was shaped and fitted into the defect with some tension in the surrounding soft tissues to produce compression across the graft.
- Internal fixation with two AO 4.5 mm reconstruction plates, one on each pillar of the distal humerus was achieved.

**D:** Anteroposterior view 12 weeks after surgery, at which time union appears to have occurred. The plates stop at different levels proximally to reduce the stress-riser

effect, and six screws were placed in the short distal fragment. **E:** Lateral view. **F:** AP view of the pelvis showing the bone graft donor site.

Intraarticular nonunions are exceedingly rare and occur most commonly in the lateral condyle of the humerus. More commonly, fractures of the lateral condyle heal in malposition with cubitus valgus and continue to function fairly well throughout life. Patients with symptoms that require surgery usually present with tardy ulnar nerve palsy, decreased range of motion, and pain and apprehension with use of the elbow (53). Sometimes, corrective osteotomy must be performed at the time of repair of the nonunion to improve position using a tricortical graft in the nonunion site (53). Intraarticular debridement and release and balancing of the soft tissues may be necessary to improve or maintain motion.

## OPERATIVE INDICATIONS AND ALTERNATIVES

Indications for surgery include

- Intolerable pain from the nonunion.
- Deformity that is not compatible with the level of function the patient expects or is cosmetically unacceptable.
- Enough instability in the nonunion that the patient can no longer function at the level needed.
- Cubitus valgus with progressive ulnar nerve palsy. Treatment alternatives include
- Nonoperative treatment with supportive bracing.
- Surgical treatment, with repair of the nonunion through double plate fixation and bone graft.
- For cubitus valgus with a healed malunion of the lateral condyle or a stable fibrous union, a closing-wedge or opening-wedge osteotomy with plate fixation and a structural bone graft, if an opening wedge is performed. Anterior transfer of the ulnar nerve for tardy ulnar nerve palsy is usually necessary.
- In some cases, direct repair of a nonunion of the lateral condyle is possible, but usually there is sufficient remodeling that a satisfactory intraarticular contour is exceedingly difficult to obtain.

## REPAIR OF SUPRACONDYLAR HUMERUS NONUNION WITH DOUBLE PLATE FIXATION AND BONE GRAFT

- Position the patient in a lateral decubitus position on a regular operating table, with the operated extremity uppermost. Support the arm on a well-padded obstetrics and gynecology leg holder or similar device, permitting gravity to allow the forearm to dangle at an angle of 90°.
- Prepare and drape the extremity free up to the shoulder, and prepare the iliac crest for bone graft harvest as well.
- Approach the distal humerus and elbow joint through a straight midline incision just off the tip of the olecranon.
- Dissect along the deep fascia medially to the medial epicondyle, and identify the ulnar nerve. If tardy ulnar nerve palsy is present or if the nerve will be at risk because of the type of internal fixation to be done, perform an anterior transfer of the ulnar nerve. I prefer to place it in a subcutaneous pocket, taking care to release the medial intermuscular septum. Be certain that the nerve has no tension or impingement upon it.
- From here, the approach varies according to the needs of the particular situation. In a nonarticular supracondylar nonunion that is at least 4 cm proximal to the joint line, a midline triceps splitting approach often suffices for the procedure. If the nonunion is closer to the joint, or if there are significant intraarticular adhesions requiring a soft-tissue release, then full exposure of the articular surface of the humerus and the elbow joint is required. Do this through either an extended triceps splitting approach, as described in Chapter 1, or a chevron-type olecranon osteotomy. I prefer the triceps-splitting approach. For this approach to be successful, the joint capsule, triceps, and origins of the flexor and extensor muscle groups of the forearm are reflected to beyond the epicondyles in medial and lateral full-thickness flaps. Take care to preserve the triceps aponeurosis as it crosses the tip of the olecranon to avoid disrupting the continuity of the triceps mechanism.
- Now take down the nonunion, freshen the bone ends, and reshape them to obtain maximum cortical apposition and to correct deformity. Open the medullary canal proximally, and multiply drill the face of the distal fragment distally with a 2 mm drill point.
- Now internally fix with double plates, one on the posterior aspect of the lateral condyle and another along the medial supracondylar ridge at right angles to the posterolateral plate. Molding the plates to the bone is challenging; therefore, use 3.5 mm reconstruction plates or their equivalent.
- On the lateral side, fashion the plate to fit down to the articular surface of the lateral condyle, taking care to be certain that there is no impingement with the radial head when the elbow is in full extension. Try to obtain at least three cortical screws of fixation in the distal fragment. The most distal screws running from posterior to anterior are opposite the articular surface and therefore cannot be bicortical. I prefer to use nontapped cortical screws, because this seems to provide better purchase than cancellous screws. Approximately four bicortical screws of solid fixation in the proximal fragment are usually adequate. On the medial side, usually the plate does not need to extend around the medial curvature of the medial epicondyle unless the distal fragment is quite small. This plate normally provides excellent fixation, because the distal screws can extend transversely across the condyles in a bicortical fashion. Try to place a similar number of screws in both fragments medially as well.
- If an intercalary defeat is present that cannot be handled by direct apposition of the two fragments, use a technique similar to that described in Figure 27.11.
- Examine the elbow to determine the range of motion. A range of –20° of extension to 120° of flexion provides reasonably good function. If this is not present, consider a soft-tissue release (60,63).
- Excise all intraarticular adhesions.
- Inspect the olecranon and remove any osteophytes that are preventing full extension.
- Inspect the olecranon fossa and remove any osteophytes that are blocking full extension. If there is a block to flexion, make a window in the olecranon fossa to provide access to the coronoid fossa and permit removal of anterior osteophytes that may be blocking motion. This should provide extension to within 10° of neutral.
- If extension appears to be limited owing to a tight anterior capsule, then dissect carefully along the anterior aspect of the capsule from lateral to medial, isolating the capsule from the anterior soft-tissue structures. Then carefully excise the anterior capsule, taking care to avoid injury to the anterior neurovascular structures. This also provides excellent exposure for removal of any anterior osteophytes that might be impeding full flexion.
- When carrying the elbow through range of motion, be certain that the articular surface of the olecranon remains completely congruent with the distal end of the humerus rather than hinging open, which gives a false measurement of the available motion in flexion.
- Apply cancellous bone graft along the edges of the nonunion, taking care to not encroach on the joint.
- If a tourniquet is used, deflate it now and ensure good hemostasis. Drain the elbow. Meticulously close the posterior longitudinal wound. In the case of a triceps-splitting approach, close the deep capsule and deep triceps in a separate layer and then close the triceps aponeurosis and approximate the fascia of the extensor and flexor compartments of the forearm in a single layer with interrupted #0 resorbable sutures. Close the subcutaneous fat and skin in the usual manner. Take care to be certain that the ulnar nerve remains in good position.
- Most patients tolerate immobilization better in a position of about 20° of flexion than in one of 90°. Apply a bulky dressing and medial and lateral splints to support the elbow just short of full extension. Elevate the arm 10 cm above the heart.

### *Postoperative Care*

- Considerable swelling and occasionally even skin blistering or compartment syndrome can occur after extensive reconstructive procedures about the elbow. Monitor the patient carefully during the first 48 hours postoperatively. If the patient has pain beyond that expected, be certain to release the dressing fully and inspect the arm carefully. If swelling is excessive or compartment syndrome threatens, early release of the surgical incision down to the deep fascia, and occasionally even deeper, may be necessary. After swelling subsides, the wound is usually easily reapproximated.
- As soon as swelling subsides and the patient becomes comfortable, remove the bulky dressing and splint, apply a lightweight Bledsoe-type brace, and immediately begin active range-of-motion exercises. With this procedure, it is absolutely essential that the patient begin early aggressive, active motion under the supervision of a therapist. The goal is to achieve the full motion expected by 6 weeks after surgery. On the operative table, before awakening the patient, it is possible to examine the elbow under anesthesia to establish what the safe range of motion is before excessive stress is placed on the reconstruction of the nonunion. A brace can be set for this range of motion to protect the nonunion during this rehabilitation. When bone-to-bone apposition has been achieved, reasonably good stability is present at 6 weeks, but full union usually requires 12 to 16 weeks. Do not allow resistive exercises or use of the extremity for other than light activities of daily living until full union has occurred. I have not found continuous passive motion for the elbow to be of value.

## OSTEOTOMY FOR CUBITUS VALGUS

- Position the patient in the supine position on an operating table, and prepare and drape the operated extremity free as well as the iliac crest for bone graft.
- Make a longitudinal incision, beginning over the radial head and extending proximally along the midlateral aspect of the humerus. Dissect directly down to the lateral supracondylar ridge of the humerus, and expose the distal humerus down to the joint capsule by subperiosteal dissection. Place a sharp-tipped Hohmann retractor posteriorly and anteriorly to expose the distal humerus. Take care to avoid injury to the radial nerve. Under fluoroscope control, drill a 2 mm K-wire transversely across the humerus just proximal to the olecranon fascia and parallel to the elbow joint.
- While protecting the soft tissues, make a transverse osteotomy to but not through the medial cortex. Open the osteotomy by manipulation, which results in a greenstick fracture of the opposite cortex. Confirm restoration of the anatomic position on fluoroscopy.
- Harvest a tricortical iliac graft from the anterior ilium. Insert this into the defect, compress the defect, and internally fix it with a 3.5 reconstruction plate along the

posterolateral supracondylar ridge. Try to place at least one screw in an interfragmentary fashion.

- An alternative is to perform an oblique osteotomy in the frontal plane, which then permits correction of the deformity by simply rotating through the osteotomy site. Fix it with an anterior-to-posterior interfragmentary screw and a lateral neutralization plate. Although this technique is technically more difficult, I prefer it because union is faster and it eliminates the need to harvest a bone graft.
- Postoperative treatment is as described earlier.

### *Results*

From the standpoint of achieving union in nonunions, the results are quite good. Ackerman and Jupiter (1) achieved union in 17 of 18 patients, Sanders and Sackett (84) achieved union in five of five patients, and in my personal series of 12 patients, I achieved union in 100%. Those who required a soft-tissue release to achieve elbow motion or who have intraarticular fractures do less well from the standpoint of regaining elbow motion. Usually, pronation and supination are nearly normal. In some patients, we have had astoundingly good results, with gains in total motion of over 100°, and in others we have seen no improvement from the preoperative range of motion. The determining factors appear to be the degree of intraarticular adhesion and arthritis, and the ability of the patient to exercise in the face of discomfort during the postoperative recovery.

### TOTAL ELBOW ARTHROPLASTY FOR SALVAGE OF DISTAL HUMERAL NONUNION

Failed salvage of supracondylar nonunions can leave patients with a painful flail extremity with which they are unable to perform even the minimal activities of daily living. In these patients, particularly if they are elderly, total elbow arthroplasty provides a method for salvage (27,64). Morrey and Adams (64) reported on 36 consecutive patients with an average age of 68 years who underwent semiconstrained elbow replacement for distal humeral nonunion, with an average follow-up of somewhat more than 4 years. Of these patients, 86% had a satisfactory result and only two had a poor result. Patients showed a marked decrease in pain and an improvement in the overall mean arc of motion from 74° to 111°. This is a challenging procedure, however, as evidenced by the fact that seven patients had complications and five of these required reoperation.

## OLECRANON

Nonunion of the olecranon is usually due to neglect of the original fracture (such as in alcoholics who fail to seek treatment) or failed internal fixation (usually a tension band wire), or is secondary to major bone loss such as in side-swipe injuries. Neglected nonunions can do surprisingly well. They generally are free of pain with a 2- to 4-cm gap, and the only functional deficit is weakness in extension, which causes functional limitations but is compatible with light activities of daily living. In my experience, failure of internal fixation is most common when lightweight wires are used to fashion a tension band repair that is then subjected to repetitive heavy use by an uncooperative patient. It also occurs in patients who have been victims of multiple trauma, are on enforced bed rest, and tend to use their elbows for moving themselves in bed. Failure tends to occur early before these become established nonunions and can usually be treated by repeated internal fixation with stronger devices. Nonunions due to bone loss are much more challenging because they often involve a segment of the articular surface. Indications for surgery include pain and functional loss. Alternative methods of treatment in addition to bone graft include compression-plate fixation with a 3.5 reconstruction plate placed on either the medial or lateral surfaces of the olecranon and ulnar shaft; tension band plating with a hook plate, as illustrated in Figure 27.12; or repeat tension band wiring, using a combination of screws and 18-gauge wire for the tension band.

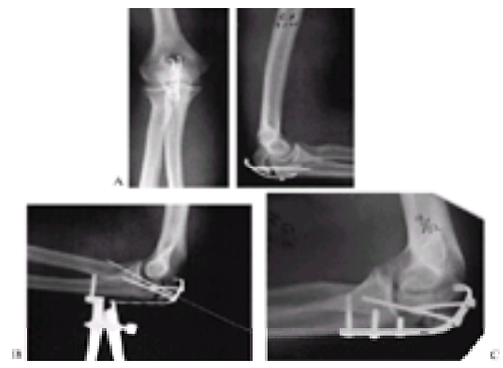

***Figure 27.12.*** Nonunion of the olecranon. **A:** Inadequate tension band fixation of an olecranon fracture resulted in a nonunion. **B:** Fixation has been removed, and a one third tubular plate has been fashioned as a hook plate, using the end hole as two sharp prongs. The tensioning device was applied after fixation of the plate to the olecranon fragment by a lag screw across the fracture site. Tensioning was then applied and supplemented by a long interfragmental fully threaded 3.5 mm screw. **C:** At 9 months, consolidation of the nonunion was occurring. This view also demonstrates the hook plate with its firm attachment into the olecranon.

### REPAIR OF NONUNION

- Expose the olecranon by subperiosteal dissection. If there is a stable fibrous nonunion in good position, internal fixation *in situ* is indicated.
- Otherwise, excise the fibrous tissue from the nonunion site, freshen the bone ends and open the medullary canal of the distal fragment, and reduce the fracture.
- Take care to not reduce the diameter of the olecranon fossa because this will produce incongruence in the elbow joint, which can lead to loss of motion, pain, instability, and precocious arthritis.
- If a gap is present, harvest a tricortical bone graft from the anterior iliac crest to interpose in the nonunion site. Place this so that it does not impinge on the articular cartilage. This will leave a gap in the articular surface, which is usually acceptable.
- Place a reconstruction plate along the medial or lateral border of the olecranon, and mold it carefully to maintain anatomic position.
- Apply a cancellous bone graft.
- After completion of the fixation, examine the elbow under anesthesia to determine the safe range of motion that can be used postoperatively without excessively stressing the construct.
- Close the wounds and apply a bulky soft dressing, splinting the elbow just short of full extension.
- After swelling has subsided, apply a Bledsoe-type brace with the locks set to permit a safe range of motion, and immediately begin active gentle motion. Avoid use of the extremity for anything but light activities of daily living until union occurs, which is generally no earlier than 8 weeks. Most heal by 12 weeks, but some take as long as 16 weeks if an intercalary bone graft has been used (Fig. 27.13).

***Figure 27.13.*** Nonunion of the olecranon. **A:** AP and lateral radiographs showing failure of a third tubular plate, resulting in nonunion. **B:** AP and lateral radiographs. This fibrous nonunion was in an acceptable position and, therefore, was treated with compression plate fixation and an interfragmentary compression screw *in situ,* resulting in rapid healing.

## NONUNION OF THE NECK OF THE RADIUS

This is an exceedingly rare nonunion; I was able to identify only one reported case of bilateral radial neck nonunion (58). This was treated with an inlay cancellous iliac

crest bone graft, followed by long-arm cast immobilization for 4 weeks, resulting in radiographic union by 10 weeks. Surprisingly, full pronation and supination returned.

## NONUNION: DIAPHYSIS OF THE RADIUS AND ULNA

Open reduction and plate fixation of displaced fractures of the diaphysis of the radius and ulna, whether both or only one is involved, has generally been considered mandatory in adults (3,7,10,14,20,31,36,37,44,46,65,67,76,85,86,94,95,97). Nearly anatomic reduction and early motion are necessary to avoid restriction of pronation and supination. Although the ulna may be treated with a closed reduction and functional bracing (87), plate fixation of the ulna and, on occasion, intramedullary nailing are necessary in significantly displaced fractures.

Current union rates for internally fixed forearm fractures are 98% or better, with good to excellent functional results and less than 30% loss of total pronation and supination (3,10,14,20,31,43,80). At least six to eight cortices of fixation, with a 3.5 mm system and compression techniques, should be used (65,94). Nonunions of the fractures of the shafts of the radius and ulna are now most commonly due to segmental bone loss, infection, or inadequate internal fixation with mechanical failure. Poor surgical technique with excessive soft-tissue striping can also lead to nonunion because of the devascularization of the bone ends (61,62).

### REPAIR OF NONUNION WITH PLATES AND BONE GRAFT

- Treatment of nonunions of the diaphysis of the radius and ulna does not differ significantly from primary internal fixation. Approach the ulna through a longitudinal incision along the subcutaneous border and the radius through a modified Thompson's dorsal radial approach. Making the skin incision on a line drawn from the tip of the radial styloid to the lateral epicondyle of the humerus, using the appropriate intermuscular interval, allows exposure of the radius from radial head to radial styloid (see Chapter 1).
- In most cases, loose screws or broken plates, or both, are present. Remove these and identify the nonunion site. If the overall alignment is acceptable and there is a stable fibrous nonunion, then simple plate fixation and compression usually suffice.
- In most cases, however, deformity is present. Most likely you will have to deal with shortening and angulation, and possibly intercalary bone loss. Restoring alignment in the ulna is not too difficult because, other than in the area of the olecranon, the bone for the most part is straight. Restoring the radial bow of the radius, however, can be difficult, and intraoperative radiographic guidance with either a fluoroscope or plain radiographs is very important. Occasionally, nonunions or malunions are complicated by synostosis or collapse of the interosseous membrane. This requires take down of the synostosis and shaving of the bone to restore the normal contour, as well as soft-tissue release in the area of the interosseous membrane. This can be quite challenging because of the presence of the neurovascular bundles in this area.
- Restore normal alignment and length. A temporary distractor or an external fixator may be necessary to hold the radius out to length. Place cancellous bone or a structural tricortical iliac crest bone graft into any bone deficiency, and apply a 3.5 mm or equivalent plate, using interfragmentary compression and longitudinal compression where possible. Try to obtain at least eight cortices of fixation proximal and distal to the fracture. In some cases in which there is no bone loss, the internal fixation can be carried out first and the bone graft applied second.
- Apply plates to the dorsal lateral aspect of the radius, where they act as a tension band, and on the ulna they can be placed on the subcutaneous border or slipped off to the side so that they are less prominent beneath the skin. When applying bone graft, do not impinge on the interosseous membrane because this may lead to synostosis or restriction in motion.
- After internal fixation, determine the safe range of motion in flexion and extension of the wrist and elbow, and in pronation and supination. This will be useful in instructing the patient about postoperative exercises.
- Close the muscle envelope over the fracture sites but leave the deep fascia open because of the predilection for swelling after these extensive procedures. Close the skin in a routine manner and place the arm in a bulky long arm splint with the elbow at 20° or so of flexion and the forearm in neutral supination and pronation. After swelling has abated, a lightweight brace or molded orthotic cuff is useful to remind the patient to be careful with the forearm. Have the patient begin active motion immediately, using the extremity only for light activities of daily living until union occurs. In the forearm, nonunions usually require at least 16 weeks and may require up to 6 months to heal solidly (Fig. 27.14 and Fig. 27.15).

***Figure 27.14.*** Delayed union of a Galeazzi fracture. **A:** An oblique fracture has been internally fixed using a semitubular plate with inadequate cortical purchase. There is no interfragmentary screw across the fracture. **B:** Union after fixation with a 3.5 mm dynamic compression plate placed on the dorsal radial surface with an interfragmentary screw, along with a cancellous bone graft.

***Figure 27.15.*** Atrophic nonunion of the ulna in a Monteggia fracture dislocation. **A, B:** Atrophic nonunion of the fracture of the ulna treated previously by cerclage wire and intramedullary fixation. **C:** A 3.5 mm dynamic compression plate and cortical cancellous bone grafting were used to stabilize the ulnar fracture. **D:** After 1 year, union had occurred. Restoration of the alignment and length of the ulna resulted in satisfactory position of the radius and functional forearm rotation.

## MALUNIONS OF THE RADIUSAND ULNA

Malunions in the forearm resulting in loss of forearm motion or rotation can be related to fixation of the radius in malposition; loss of the normal arc and spacing between the radius and ulna due to collapse of the bones toward the interosseous membrane; or to subluxation or internal derangements in the proximal radioulnar joint or the distal radioulnar joint. The latter problems in the joints are addressed in Chapter 43. It can be corrected by osteotomy to place forearm motion in a more functional range. It is difficult to increase the total range of motion because of intraosseous membrane contraction and soft-tissue scarring.

With increased dissection through the soft tissue, cross-unions may occur. Rotational problems are best managed at the time of acute fracture care. Radioulnar synostosis (3,5,50) may follow closed or open treatment. It appears to be related directly to the extent of injury to the interosseous membrane, because it is more common in fractures that are at the same level, in open fractures, and after internal fixation. Early motion can significantly reduce the incidence of this problem in internally fixed fractures.

Operative intervention for malunion is not always indicated. As long as the hand can be used appropriately and can be placed in the appropriate positions to perform day-to-day activities, no additional treatment is required. This usually is in the neutral or somewhat pronated position, allowing shoulder and elbow motion to compensate.

The precise definition of what constitutes a malunion in the forearm has been elusive, but recent work provides reasonably good guidelines (54,90,96). This is

particularly an issue when one considers the need for open reduction and internal fixation in adolescents, in whom the amount of remolding that is possible following healing in a nonanatomic position can be somewhat unpredictable. Matthews et al. (54) showed that with 10° of angulation in the radius, there was minimal functional loss in pronation and supination, whereas over 20° of angulation functional loss occurred. Tarr et al. (96) provided more specific information, in that they demonstrated in a cadaver study that greater than 10° of angulation in both bones located in the distal third of the forearm resulted in an average loss of range of motion of 12.5% ±pm 4.5%. If this same angulation was present in the middle third of the forearm, this loss increased to 16% ±pm 5.7%; therefore, angulation in the middle third of the forearm is tolerated less well than in the distal third. They found that the loss in supination and pronation secondary to rotational malposition was directly proportional to the degree of malrotation. Schemitsch and Richards (90), in a retrospective review of 55 patients with forearm fractures who underwent plate fixation at 6 years of follow-up, provided a new method of assessing radial bow and relating this to loss of motion. Although angulation over 10° in both bones has adverse functional effects, it appears that preservation of the normal bow of the radius is the more critical factor. In their patients, they compared the radial bow on comparison x-ray studies to the normal side and measured this according to the maximum distance between the radius and the ulna at the interosseous membrane. Their overall results in this group of patients were excellent, in that 54 or 55 fractures in the radius and ulna healed and 84% of the patients had satisfactory functional results. They demonstrated that restoration of the radial bow was directly correlated with the functional outcome and that completely normal motion required restoration of the radial bow to normal. In spite of the efforts made in their series to achieve anatomic reduction of both bones, their results show that this is difficult; the mean outcomes in their series were 64° in pronation and 74° in supination. The normal maximum radial bow, as measured at the interosseous membrane, in their series was 15 mm. To get 80% of normal range of motion, this had to be within 1.5 mm of normal. They found the same direct relationship to grip strength. Stated another way, if the maximum radial bow was within 4% to 5% of normal, then 80% of forearm range of motion and grip strength could be expected. As emphasized in the study conducted by Tarr et al. (96), both the location and the amount of the loss of radial bow were important. The overall results in their series were somewhat less good than previously reported; the unsatisfactory functional outcomes in their study were 16%, as compared to 15% for Anderson et al (3) and 9% for Chapman et al (14). They attributed this to the fact that the severity of injury was greater in their series in that all of their patients had fractures of both bones and greater numbers of fractures were open.

There is little in the literature on the use of osteotomy for correction of forearm malunion. Trousdale and Linscheid (99) reported on 27 osteotomies for malunion of the forearm, including 20 in the radius, two in the ulna, and five in both. Their indications were loss of motion in 20 (average loss 74°, range 20° to 120°), a painful distal radioulnar joint in six, and poor cosmesis in one. One of the most important findings in their study was that time had a significant effect on the improvement in range of motion. Patients operated on sooner than 12 months after the original injury gained an average of 29° of supination and pronation (range 20° to 160°, and in those operated on more than 12 months after injury the gains were less than half, averaging 30° (range –25° to 95°). Of the six patients operated on for distal radioulnar joint pain, three experienced marked improvement of their pain and achieved a stable joint, but the average loss of range of motion in the six patients was 7° (range –25° to 25°). The patient operated on for cosmetic problems was pleased with the appearance of the forearm but lost 10° of rotation. Their outcomes point out that it is possible to achieve significant improvement in patients with forearm malunions, but the surgery is better done earlier than later and does not have consistent results, and the fact that Trousdale and Linscheid had complications in 11 of their 27 patients demonstrates that the surgery is challenging.

### OSTEOTOMY

- Interoperative radiographic evaluation of the correction achieved is important; therefore, use a radiolucent hand table and fluoroscopy or plain radiographs, or both.
- Depending on whether osteotomies are planned for an isolated forearm bone or both bones, use the surgical approaches described earlier. Expose the site for osteotomy in a subperiosteal fashion. This should be at the maximum point of deformity. Use gentle technique to minimize soft-tissue injury and to avoid invading the interosseous space. When performing osteotomies of both the radius and ulna at the same level, it is important to try to prevent communication of the hematomas from the two operative sites because this could lead to synostosis.
- Perform an appropriate osteotomy, depending on the deformity to be corrected. In many cases, it is possible to identify the old fracture site and reassemble the fracture in anatomic position after removing excess callus and refashioning the bone ends. In more mature malunions, it is necessary to perform a formal osteotomy. Often this must be in an oblique plane to allow correction of angulation and rotary deformity, which are frequently combined. This can be challenging because the rotational component of the deformity is difficult to assess by radiography preoperatively. Some repeat shaping of the osteotomy site after intraoperative radiographs and examination for range of motion are usually necessary.
- Internally fix the osteotomy, taking care to place an appropriate bow in the plate on the radius to restore fully the radial bow. Obtain eight cortices of fixation proximal and distal to the osteotomy site with an interfragmentary screw across the osteotomy, if possible. The plates are best located just off the subcutaneous border of the ulna and on the dorsal radial aspect of the radius. You may make an exception for a very distal radius osteotomy, where the plate might be better placed palmerly.
- If the patient has pathology in the interosseous membrane or at the distal radioulnar joint (DRUJ), additional procedures to release contractures of the interosseous membrane or to address problems in the DRUJ may be necessary. See the discussion of treatment of synostosis below; see Chapter 43 for DRUJ problems.
- Perform a meticulous soft-tissue closure, leaving the deep fascia open. Initially immobilize the extremity in a well-padded long-arm splint, with the elbow at 90° and the forearm in neutral pronation and supination. As soon as pain subsides and the swelling is controlled, begin a supervised range-of-motion exercise program under the supervision of a hand therapist. Solid stability of the internal fixation is obviously necessary to obtain an optimal result, the latter requiring fairly vigorous early active range of motion without resistance.

Malunions of the radial head and neck can be reconstructed with an osteotomy, but in most cases, assuming that the radius and ulna are longitudinally stable and there are no major DRUJ problems, the easiest procedure producing the best results is radial head excision.

### RESECTION OF THE RADIAL HEAD

- Approach the radial head through a Kocher incision (see Chapter 1). Expose the radial head and proximal neck as far as the annular ligament. Take care to avoid injury to the posterior interosseous nerve.
- With a water-cooled mini-oscillating saw or high-speed burr, transect the radial neck just proximal to the radial head and smooth the edges to remove any osteophytes or malunited fragments.
- Leave the annular ligament intact. If it is disrupted and the proximal radius is unstable, reconstruct it.
- Close the wound in a routine fashion, apply a bulky sterile dressing and splint, and begin elbow and forearm exercises as soon as the patient will tolerate them.

## PITFALLS AND COMPLICATIONS

The complications of treating malunions and nonunions of the upper extremity are similar to those of all major surgery in the upper extremity, including infection, neurovascular injury, failure of the fixation, loss of joint motion, and others. The risk of these problems can be minimized by careful attention to patient selection and details of the surgery. The outcome depends strongly on a fully cooperative patient who is capable of performing exercises in the face of discomfort and who is completely compliant with postoperative instructions.

### SYNOSTOSIS

In my experience, synostosis between the radius and ulna is most common after severe proximal forearm fractures. It can be managed by radial head resection with excision of the synostosis, as described earlier. Restoration of forearm motion through excision of a synostosis is challenging because soft-tissue contracture and scarring frequently compromise the motion that can be gained, and avoiding injury to the anterior and posterior interosseous neurovascular bundles can be challenging. To prevent reformation of the synostosis, fat, muscle, and Silastic membranes have been used to fill the space between the radius and the ulna (9,50,74,101,108,109). If large raw areas of bone are left after excision of the synostosis, I find that coating these with a thin layer of bone wax and then filling the gap where the synostosis was present with autologous fat helps prevent reformation (Fig. 27.16).

***Figure 27.16.*** Synostosis of both bones of the forearm. **A:** A 25-year-old man sustained an open fracture of both bones of the forearm, which was treated with plate fixation. He developed a synostosis of his forearm in a nonfunctional position. **B:** This postoperative radiograph shows excision of the synostosis with a free fat graft packed in the area of the synostosis. At 9 months, he had functional forearm rotation, lacking the last 20° of supination and pronation.

## POSTTRAUMATIC CONTRACTURE OF THE ELBOW

Posttraumatic contracture of the elbow is a complex and challenging problem. Refer to the excellent review articles by Morrey (63) and Modabber and Jupiter (60) for a detailed discussion. For most activities of daily living, an elbow flexion and extension arc of motion from 30° to 130° is necessary. A marked impairment of the ability to position the hand in space occurs when a flexion contracture exceeds 45° and flexion is less then 110°. These are indications for operative treatment of contracture of the elbow. Lesser degrees of loss of motion may be an indication, depending on the patient's functional needs. Loss of motion can be caused by extrinsic contractures involving the joint capsule, ligaments, and osseous structures, and intrinsic contractures can be caused by intra-articular incongruity or malunions and adhesions. If there is significant loss of articular cartilage or if posttraumatic degenerative arthritis is present, fascial interposition arthroplasty may be necessary to gain a satisfactory outcome. This usually requires use of distraction with a specialized external fixator.

### *Release with Fascial Arthroplasty*

Methods for addressing both intrinsic and extrinsic contracture, with and without distraction, are available. Morrey's technique (63) is utilitarian and is commonly used for treatment of contractures (Fig. 27.17).

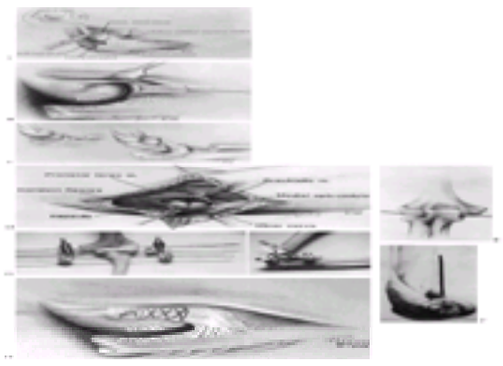

***Figure 27.17.*** Morrey fascial arthroplasty of the elbow. **A:** The reflected extensor mechanism, resected tip of the olecranon, released forearm extensors, and exposed anterior capsule. **B:** The reflected lateral collateral ligament and the anterior capsule resected to the medial side *(broken lines).* **C:** Joint surfaces to be smoothed with a burr *(dotted areas).* A fascial graft attached to the humerus and ulna, with sutures through bone. **D:** Medial approach. **E:** Location of the anatomic axis of rotation of the elbow in the frontal plane. **F:** Lateral view of the axis of rotation of the elbow. **G:** Mayo Clinic distraction device. **H:** Repair of the lateral collateral ligament to the humerus. (From Morrey BF. Post-traumatic Contracture of the Elbow. *J Bone Joint Surg* 1990;72-A:601.)

- Place the patient supine on an operating table with a sandbag under the operated side. Drape the upper extremity free.
- Prep and drape the ipsilateral lateral thigh for possible harvest of a fascial graft.
- Make an extensile posterolateral approach, using the interval between the anconeus and extensor carpi ulnaris (see Chapter 1). Expose as much of the elbow joint as necessary to achieve an adequate release by elevating the triceps from the posterior aspect of the humerus in continuity with the lateral forearm musculature and triceps aponeurosis. Dissect medially along the anterior aspect of the humerus joint capsule to expose the anterior structures (Fig. 27.17*A*).
- Excise the posterior tip of the olecranon process and any osteophytes, and remove the posterior capsule. Excise or release anterior capsular adhesions and structures as necessary. Lyse all intracapsular adhesions.
- If possible, preserve the lateral collateral ligament. If release is necessary, reflect it distally, releasing its humeral origin. Resect the anterior capsule (Fig. 27.17*B*). If anterior impingement is found, excise any bony osteophytes.
- If 50% or more of the articular surface of the elbow is not covered by hyalin cartilage, or if a significant malunion is present, recontour the joint and perform an interpositional fascial arthroplasty. Smooth the joint surfaces of the humerus and ulna with a burr (Fig. 27.17*C*).
- Make an 18 cm long incision over the lateral aspect of the thigh, and harvest a sheet of fascia 4 to 5 cm wide and 12 to 15 cm long.
- Trim the fascial graft to the appropriate size and shape, and attach it to the articular surface of the distal humerus through sutures along the edges of the humeral joint surface. This can be aided by front-to-back drill holes. Then double the fascial membrane back on itself to form a continuous double layer covering the olecranon. Secure the graft to the olecranon in a similar manner (Fig. 27.17*C*).
- Try to preserve the radial head, but excise it if it presents problems.
- If an external fixator will be applied or there is a need to complete the soft-tissue release, make a medial approach over the medial epicondyle. Split the flexor-pronator muscles in line with their fibers and complete the medial part of the capsulectomy. If necessary, perform an anterior transfer of the ulnar nerve (Fig. 27.17*D*).
- Apply a distraction or dial-compass external fixator.
- Under fluoroscopic control, insert a guide pin through the center of the capitellum, transversely across the condyles of the humerus, to exit the trochlea dead center. It is important that this be directly in line with the instant center of rotation of the elbow (Fig. 27.17*E*, Fig. 27.17*F*).
- Mount the external fixator on this pin, and then place two or more half pins into the distal humerus and two in the proximal ulna according to the directions of the manufacturer. Adjust the frame to ensure appropriate motion and to separate the joint surfaces 4 to 5 mm in all positions of the elbow. Remove the guide pin (Fig. 27.17*G*).
- Repair the lateral collateral ligament, using a Bunnell stitch placed through the drill holes in the humerus (Fig. 27.17*H*).
- Place a small suction drain and close the wounds in layers.
- Apply a sterile dressing and a bulky compression dressing.
- Begin motion as soon as possible. Morrey uses continuous passive motion.

**Postoperative Management** After 3 to 4 weeks, Morrey (63) removes the external fixator under anesthesia, gently examines the elbow (avoiding manipulation) to assess the end points of motion, and then uses turnbuckle splints, one for extension and one for flexion, to help the patient gain range of motion while continuing on an active daily exercise program. He uses the turnbuckle splints regularly for as long as 6 months following the routine outlined in Table 27.1.

Avoid inflammation by
1. Administration of antiinflammatory medication
2. Application of heat on rising
3. Application of ice at bedtime

Adjustment of turnbuckle splints by patient:
1. When sleeping, use splint in flexion or extension, whichever is needed most.
2. Patient should not be awakened by pain or excessive pressure.
3. During the day, the other splint should be use in the opposite direction.

Activity:
Patients should remove splint and use elbow for one-half hour each morning, afternoon, and evening.

From Morrey BF. Post-Traumatic Contracture of the Elbow: Operative Treatment, Including Distraction Arthroplasty. *J Bone Joint Surg* 1990;72A:601, with permission.

***Table 27.1. General Guidelines for Use of Turnbuckle Splints for the First Three Postoperative Months in the Treatment of a Stiff Elbow***

**Results** In six patients who Morrey (63) treated by release without distraction external fixation, the preoperative arc of total motion was 32°. Postoperatively, it increased to 74°. In those treated with distraction arthroplasty without interposition, total motion before operation was 32° and increased to a total average arc of motion of 99°. In the six treated with interpositional arthroplasty and distraction, motion increased from a total of 27° to 107°. The increases in pronation and supination were modest and were best in the interposition-distraction group.

## AUTHOR'S PERSPECTIVE

It is somewhat hazardous to generalize about the treatment of nonunions and malunions in the upper extremity, because these are uncommon problems that may appear only one or two times in the lifetime of an average surgeon. Large series are rare even in the hands of surgeons working in major referral centers. In addition, each patient's problem is unique and requires an individualized approach. Recognizing these limitations, my recommendations for the treatment of nonunions and malunions in the upper extremity are as follows:

- Use a careful soft-tissue technique with as limited exposure of bone as possible (usually two of the four quartiles of circumference available) in an effort to maintain the blood supply to the bone.
- Take down the nonunion site in most cases by fashioning of the bone ends to correct deformity and maximize surface area, opening the medullary canal and placing multiple shallow drill holes on metaphyseal fragments to encourage revascularization.
- Use solid internal fixation, eliminating any micromotion; try to obtain fixation in two planes, usually with a plate in one plane and an interfragmentary screw in the other, followed by autologous bone graft laid on a petaled cortical surface.
- During surgery under anesthesia, establish the safe range of motion possible for early rehabilitation. Institute early motion and then progress the rehabilitation program as the fracture consolidates.
- For nonunions of the surgical neck of the humerus, use 3.5 mm reconstruction double plate fixation combined with iliac crest bone graft.
- For mid-diaphyseal nonunions of the humerus, use broad plate fixation with interfragmentary screws combined with autologous bone graft.
- For supracondylar humerus nonunions, use double plate fixation with 3.5 mm or equivalent reconstruction plates, placing one plate on the posterior aspect of the lateral column and one on the medial aspect of the medial column combined with iliac crest bone graft.
- For elbow arthroplasty, I follow the tenets advocated by Morrey (63,64) as outlined earlier; using a straight posterior approach when accompanying bony reconstruction makes this a more convenient approach.
- For olecranon nonunion, use single and occasionally double plate fixation with small reconstruction plates combined with iliac crest bone graft (tricortical graft for bone deficiency).
- For nonunions of the radius and ulna, use small reconstruction plates or AO 3.5 LCDC plates with interfragmentary screws combined with cancellous bone graft or structural tricortical iliac crest graft for bone deficiencies.
- For malunions, I try to use oblique single plane oblique osteotomies with interfragmentary screw fixation and neutralization plates.
- Using these techniques, between 1980 and 1995 I was able to achieve union in 36 of 37 nonunions of the humerus and 100% healing of five nonunions in the radius and ulna.

## CHAPTER REFERENCES

Each reference is categorized according to the following scheme: *, classic article; #, review article; !, basic research article; and +, clinical results/outcome study.


+ 1. Ackerman G, Jupiter JB. Non-union of Fractures of the Distal End of the Humerus. *J Bone Joint Surg* 1988;70A:1.

+ 2. Ada JR, Miller ME. Scapular Fractures. Analysis of 113 Cases. *Clin Orthop* 1991;2679:174.

+ 3. Anderson LD, Sisk TD, Tooms RE, Park WI. Compression Plate Fixation in Acute Diaphyseal Fractures of the Radius and Ulna. *J Bone Joint Surg* 1975;57-A:287.

+ 5. Boehme D, Curtis RJ, DeHaan JT, et al. Treatment of Nonunion of Fractures of the Midshaft of the Clavicle with a Modified Intramedullary Hagie Pin and Autogenous Bone Grafting. *J Bone Joint Surg* 1991;73A:1219.

+ 6. Boyer MI, Axelrod TS. Atrophic Nonunion of the Clavicle. Treatment by Compression Plate, Lag-screw Fixation and Bone Graft. *J Bone Joint Surg* 1997;79B:301.

+ 7. Brackenburg PH, Corea JR, Blakemore ME. Non-Union of the Isolated Fracture of the Ulnar Shaft in Adults. *Injury* 1981;12:371.

+ 8. Bradbury N, Hutchinson J, Hahn D, Colton CL. Clavicular Nonunion. 31/32 Healed after Plate Fixation and Bone Grafting. *Acta Orthop Scand* 1996;67:367.

+ 9. Bret R. Post-Traumatic Radio-Ulnar Synostosis. *Clin Orthop* 1983;174:149.

* 10. Burwell HN, Charnley AD. Treatment of Forearm Fractures in Adults with Particular Reference to Plate Fixation. *J Bone Joint Surg* 1964;46-B:404.

+ 11. Butting TDJ. Post-Traumatic Radio-Ulna Gross-Union. *J Trauma* 1970;10:16.

+ 12. Capicotto PN, Kingsbury GH, Wilbur JH. Midshaft Clavicle Nonunions Treated with Intramedullary Steinmann Pin Fixation and Onlay Bone Graft. *J Orthop Trauma* 1994;8:88.

+ 13. Chacha PB. Compression Plating without Bone Grafts for Delayed and Non-Union of Humeral Shaft Fractures. *Injury* 1974;5:283.

+ 14. Chapman M, Gordon JE, Zissimos AG. Compression-plate Fixation of Acute Fractures of the Diaphyses of the Radius and Ulna. *J Bone Joint Surg* 1989;71A:159.

+ 15. Christensen NO. Kúntscher Intramedullary Reaming and Nail Fixation for Nonunion of the Humerus. *Clin Orthop* 1976;116:222.

+ 16. Connolly JF, Dehne R. Nonunion of the Clavicle and Thoracic Outlet Syndrome. *J Trauma* 1989;29:1127.

+ 17. Corradi M, Petriccioli D, Panno B, Marenghi P. Seidel Locked Nailing for the Treatment of Unstable Fractures and Nonunion of the Humerus. *Chirurgia Degli Organi di Movimento* 1996;81:189.

+ 18. Davids PH, Luitse JS, Strating RP, van der Hart CP. Operative Treatment for Delayed Union and Nonunion of Midshaft Clavicular Fracture: AO Reconstruction Plate Fixation and Early Mobilization. *J Trauma* 1996;40:985.

+ 19. Dineen JR, Greshman RB. Osteoperiosteal Grafts: A Preliminary Report of the Treatment of Fresh and Ununited Fractures of the Long Bones. *J Bone Joint Surg* 1962;44A:1653.

+ 20. Dodge HS, Cady GW. Treatment of Fractures of the Radius and Ulna with Compression Plates. *J Bone Joint Surg* 1972;54-A:1167.

+ 21. Dounchis JS, Pedowitz RA, Garfin SR. Symptomatic Pseudarthrosis of the Acromion: Report of a Case and Review of the Literature. *J Orthop Trauma* 1999;13:63.

+ 22. Duralde XA, Flatow EL, Pollock RG, et al. Operative Treatment of Nonunions of the Surgical Neck of the Humerus. *J Shoulder Elbow Surg* 1996;5:169.

+ 23. Edvardsen P, Vital O. Treatment of Post-Traumatic Clavicular Pseudarthrosis. *Acta Orthop Scand* 1977;48:456.

# 24. Epps CH, Jr., Grant RE. Fractures of the Shaft of the Humerus. In: Rockwood CA, Green DP, eds. *Fractures,* 3rd ed. Philadelphia: J. B. Lippincott, 1991:843.

+ 25. Eskola A, Vainionpää S, Myllynen P, et al. Surgery for Ununited Clavicle Fractures. *Acta Orthop Scand* 1986;57:366.

+ 26. Esterhai JL, Brighton CT, Heppenstall RB, Thrower A. Nonunion of the Humerus. *Clin Orthop* 1986;211:228.

+ 27. Figgie MP, Inglis AE, Mow CS, Eiffie HE. Salvage of Non-union of Supracondylar Fracture of Humerus by Total Elbow Arthroplasty. *J Bone Joint Surg* 1989;71A:1058.

+ 28. Fischer KA, Leatherman KD, Kotcamp WW. Fibular Bone Grafting in Non-union of the Humerus. *J Ky Med Assoc* 1972;70:921.

+ 29. Foster R, Dixon GL, Bach AW, et al. Internal Fixation of Fractures and Non-Unions of the Humeral Shaft. *J Bone Joint Surg* 1985;67-A:857.

+ 30. Gill DRJ, Torchia ME. The Spiral Compression Plate for Proximal Humeral Shaft Nonunion: A Case Report and Description of the New Technique. *J Orthop Trauma* 1999;13:141.

+ 31. Grace TG, Eversmann WW. Forearm Fractures: Treatment by Rigid Fixation with Early Motion. *J Bone Joint Surg* 1980;62-A:433.

+ 32. Gupta RC, Gavr SC, Tiwazi RC, et al. Treatment of Ununited Fractures of the Shaft of the Humerus with Bent Nail. *Injury* 1985;16:276.

+ 33. Gupta R, Sher J, Gerald W, Iannotti J. Non-union of the Scapular Body. A Case Report. *J Bone Joint Surg* 1998;80A:428.

+ 34. Heim V, Pfieffer KM. *Small Fragment Set Manual.* Berlin: Springer-Verlag, 1982.

+ 35. Horak J, Nilsoon BE. Epidemiology of Fracture of the Upper End of the Humerus. *Clin Orthop* 1975;112:250.

+ 36. Hughston JC. Fracture of the Distal Radial Shaft: Mistakes in Management. *J Bone Joint Surg* 1957;38-A:249.

+ 37. Jinkins WJ, Lekhart LD, Eggers GWN. Fractures of the Forearm in Adults. *South Med J* 1960;53:669.

+ 38. Jupiter JB. Complex Non-union of the Humeral Diaphysis. Treatment with a Medial Approach, an Anterior Plate, and a Vascularized Fibular Graft. *J Bone Joint Surg* 1990;72A:701.

+ 39. Jupiter JB, Leffert RD. Non-union of the Clavicle. *J Bone Joint Surg* 1987;69A:753.

+ 40. Jupiter JB, Mollaji AB. Blade Plate Fixation of Proximal Humeral Non-unions. *Injury* 1994;25:301.

+ 41. Karaharju E, Jovicainen J, Peltunen J. Treatment of Pseudarthrosis of the Clavicle. *Injury* 1982;13:400.

+ 42. Kennedy JC, Wyatt JK. An Evaluation of the Management of Fractures Through the Middle Third of the Humerus. *Can J Surg* 1957;1:26.

+ 43. Klenerman L. Fractures of the Shaft of the Humerus. *J Bone Joint Surg* 1966;48-B:105.

+ 44. Knight RA, Purvis GD. Fractures of Both Bones of the Forearm in Adults. *J Bone Joint Surg* 1949;31-A:755.

+ 45. Koss SD, Goitz HT, Redler MR, Whitehill R. Nonunion of a Midshaft Clavicle Fracture Associated with Subclavian Vein Compression. *Orthopaedic Review* 1989;18:431.

+ 46. Lam SJ. The Place of Delayed Internal Fixation in the Treatment of Fractures of the Long Bones. *J Bone Joint Surg* 1964;46-B:393.

+ 47. Lammens J, Bauduin G, Driesen R, et al. Treatment of Nonunion of the Humerus Using the Ilizarov External Fixator. *Clin Orthop* 1998;353:223.

+ 48. Leach RE, Premer RF. Non-union of the Surgical Neck of the Humerus: Method of Internal Fixation. *Minn Med* 1965;48:318.

+ 49. Loomer R, Kokan P. Non-union Fractures of the Humeral Shaft. *Injury* 1976;7:274.

+ 50. Maempel FZ. Post-traumatic Radio-Ulnar Synostosis. *Clin Orthop* 1984;186:182.

+ 51. Manske DJ, Rubert MS. The Operative Treatment of Midshaft Clavicular Non-unions. *J Bone Joint Surg* 1985;67-A:1367.

+ 52. Martin SD, Weiland AJ. Missed Scapular Fracture after Trauma. A Case Report and a 23-year Follow-up Report. *Clin Orthop* 1994;299:59.

+ 53. Masada K, Kawai H, Kawabata H, et al. Osteosynthesis for Old, Established Non-union of the Lateral Condyle of the Humerus. *J Bone Joint Surg* 1990;72A:32.

! 54. Matthews LS, Kaufer H, Garver DF, Sonstegard DA. The Effect on Supination-pronation of Angular Malalignment of Fractures of Both Bones of the Forearm. An Experimental Study. *J Bone Joint Surg* 1982;64A:14.

+ 55. McGinnis M, Denton JR. Fractures of the Scapular. A Retrospective Study of 40 Fractured Scapulae. *J Trauma* 1989;29:1488.

+ 56. McKee M, Jupiter J, Toh CL, et al. Reconstruction after Malunion and Nonunion of Intra-articular Fractures of the Distal Humerus. Methods and Results in 13 Adults. *J Bone Joint Surg* 1994;76:614.

+ 57. McKee MD, Miranda MA, Riemer BL, et al. Management of Humeral Nonunion after the Failure of Locking Intramedullary Nails. *J Orthop Trauma* 1996;10:492.

+ 58. Middleton RWD, Miles NM. A Report of a Case of Non-union following Fracture of the Neck of the Radius. *Injury* 1997;8:31.

+ 59. Middleton SB, Foley SJ, Foy MA. Partial Excision of the Clavicle for Nonunion in National Hunt Jockeys. *J Bone Joint Surg* 1995;77B:778.

+ 60. Modabber MR, Jupiter JB. Current Concepts Review. Reconstruction for Post-traumatic Conditions of the Elbow Joint. *J Bone Joint Surg* 1995;77A:1431.

+ 61. Moroni A, Caja VJ, Sabato C, et al. Composite Bone Grafting and Plate Fixation for the Treatment of Nonunions of the Forearm with Segmental Bone Loss: A Report of Eight Cases. *J Orthop Trauma* 1995;9:419.

+ 62. Moroni A, Rollo G, Guzzardella M, Zinghi G. Surgical Treatment of Isolated Forearm Non-union with Segmental Bone Loss. *Injury* 1997;8:497.

+ 63. Morrey BF. Post-traumatic Contracture of the Elbow, Operative Treatment, Including Distraction Arthroplasty. *J Bone Joint Surg* 1990;72A:601.

+ 64. Morrey BF, Adams RA. Semiconstrained Elbow Replacement for Distal Humeral Nonunion. *J Bone Joint Surg* 1995;77B:67.

+ 65. Müller ME, Allgower M, Schner R, Wilenegger H. *Manual of Forearm Fixation.* Berlin: Springer-Verlag, 1979.

+ 66. Müller ME, Thomas RJ. Treatment of Non-union in Fractures of Long Bones. *Clin Orthop* 1980;135:141.

+ 67. Naiman PT, Schein AJ, Simpert RS. Use of ASIF Compression Plates in Selected Shaft Fractures of the Upper Extremity. *Clin Orthop* 1970;71:208.

+ 68. Neer CS. Non-union of the Clavicle. *JAMA* 1960;172:1006.

+ 69. Neer CS. Fractures of the Distal Third of the Clavicle. *Clin Orthop* 1968;58:43.

+ 70. Neer CS. Displaced Proximal Humeral Fractures: I. Classification and Evaluation. *J Bone Joint Surg* 1970;52-A:1077.

+ 71. Neer CS. Displaced Proximal Humeral Fractures: II. Treatment of Three Part and Four Part Displacement. *J Bone Joint Surg* 1970;52-A:1090.

# 72. Neer CS, Rockwood CA Jr. Fractures and Dislocations of the Shoulder. In: Rockwood CA Jr, Green DP, eds. *Fractures,* 2nd ed. Philadelphia: J.B. Lippincott,1984:675.

+ 73. Neviaser RJ, Neviaser JS, Neviaser TJ, Neviaser JS. A Simple Technique for Internal Fixation of the Clavicle. *Clin Orthop* 1975;109:103.

+ 74. Olerud S. Post-traumatic Radio-ulnar Synostosis. *Acta Orthop Scand* 1981;52:460.

+ 75. Olsen BS, Vaesel MT, Sojbjerg JO. Treatment of Midshaft Clavicular Nonunion with Plate Fixation and Autologous Bone Grafting. *J Shoulder Elbow Surg* 1995;5:337.

+ 76. Pollock F, Parkovich AM, Prieto JJ, Lorenz M. The Isolated Fracture of the Ulnar Shaft. *J Bone Joint Surg*1983;65-A:339.

+ 77. Pyfer JB. Non-union of Fractures of the Clavicle. *Injury* 1978;9:268.

+ 78. Ranieri L, Olmi R. Non-union of the Humerus after Internal Fixation-treatment by Intramedullary Nailing and Grafting. *Ital J Orthop Traumatol* 1976;1:51.

+ 79. Ring D, Perey BH, Jupiter JB. The Functional Outcome of Operative Treatment of Ununited Fractures of the Humeral Diaphysis in Older Patients. *J Bone Joint Surg* 1999;81A:177.

+ 80. Rosacker JA, Kopta JA. Both Bones Fractures of the Forearm: A Review of Surgical Variables Association with Union. *Orthopedics* 1981;4:1353.

+ 81. Rosen H. Compression Treatment of Long Bone Pseudarthroses. *Clin Orthop* 1979;138:154.

+ 82. Rowe CR. An Atlas of Anatomy and Treatment of Mid Clavicular Fractures. *Clin Orthop* 1968;58:29.

+ 83. Sakellarides H. Pseudarthrosis of the Clavicle. *J Bone Joint Surg* 1961;43-A:130.

+ 84. Sanders RA, Sackett JR. Open Reduction and Internal Fixation of Delayed Union and Nonunion of the Distal Humerus. *J Orthop Trauma* 1990;4:254.

+ 85. Saoe FP. Medullary Fixation of Fractures of the Forearm. *J Bone Joint Surg* 1959;41-A:1489.

+ 86. Sarmiento A, Cooper JS, Sinclair WF. Forearm Fractures: Early Functional Bracing: A Preliminary Report. *J Bone Joint Surg* 1975;57-A:297.

+ 87. Sarmiento A, Kinman PB, Murphy RB, Phillips JG. Treatment of Ulnar Fractures by Functional Bracing. *J Bone Joint Surg* 1976;58-A:1104.

+ 88. Sarmiento A, Lotta LL. *Closed Functional Treatment of Fractures.* Berlin: Springer-Verlag, 1981.

+ 89. Scheck M. Surgical Treatment of Non-unions of the Surgical Neck of the Humerus. *Clin Orthop* 1982;167:255.

+ 90. Schemitsch EH, Richards RR. The Effect of Malunion on Functional Outcome after Plate Fixation of Fractures of Both Bones of the Forearm in Adults. *J Bone Joint Surg* 1992;74A:1068.

+ 91. Schwarz VN, Leixnering M. Technik und Ergebienisse der Klavikula—markdrahtung. *Zentrabl Chir* 1986;111:640.

+ 92. Simpson NS, Jupiter JB. Clavicular Nonunion and Malunion: Evaluation and Surgical Management. *Journal of the American Academy of Orthopaedic Surgeons* 1996;4:1.

+ 93. Sorensen KH. Pseudarthrosis of the Surgical Neck of the Humerus: Two Cases, One Bilateral. *Acta Orthop Scand* 1964;34:132.

+ 94. Stern PJ, Drury WJ. Complications of Plate Fixation of Forearm Fractures. *Clin Orthop* 1983;175:25.

+ 95. Street DM. Intramedullary Forearm Nailing. *Clin Orthop* 1986;212:219.

+ 96. Tarr RR, Garfinekl AI, Sarmiento A. The Effects of Angular and Rotational Deformities of Both Bones of the Forearm. An In Vitro Study. *J Bone Joint Surg* 1984;66A:65.

+ 97. Teipner W, Mast J. Internal Fixation of Forearm Diaphyseal Fractures. *Orthop Clin North Am* 1980;11:387.

+ 98. Trotter DH, Bovozi W. Nonunion of the Humerus: Rigid Fixation, Bone Grafting, and Adjunctive Bone Cement. *Clin Orthop* 1986;204:163.

+ 99. Trousdale RT, Linscheid RL. Operative Treatment of Malunited Fractures of the Forearm. *J Bone Joint Surg* 1995;77A:894.

+ 100. Wang GJ, Reger SI, Stamp WG. Non-union of Fractures of the Proximal Humerus: A Method of Treatment Using a Modified Plate. *South Med J* 1977;70:818.

+ 101. Watson FM, Eaton RG. Post-traumatic Radio-ulnar Synostosis. *J Trauma* 1978;18:467.

+ 102. Weaver JK, Dunn HK. Treatment of Acromioclavicular Injuries, Especially Complete Acromioclavicular Separation. *J Bone Joint Surg* 1972;54-A:1187.

# 103. Weber BG, Cecin O. *Pseudarthrosis.* New York: Grune & Stratton, 1976.

+ 104. Weber BG, Simpson LA, Hardegger F. Rotational Osteotomy for Recurrent Anterior Dislocation of the Shoulder Associated with a Large Hill-Sachs Lesion. *J Bone Joint Surg* 1984;66-A:1443.

+ 105. Wilber MD, Evans EB. Fractures of the Scapula. An Analysis of Forty Cases and a Review of the Literature. *J Bone Joint Surg* 1977;59-A:358.

+ 106. Wilkins RM, Johnston RM. Un-united Fractures of the Clavicle. *J Bone Joint Surg* 1983;65-A:773.

+ 107. Wu CC, Shih CH, Chen WJ, Tai CL. Treatment of Clavicular Aseptic Nonunion: Comparison of Plating and Intramedullary Nailing Techniques. *J Trauma* 1998;45:512.

+ 108. Yong-Ching K, Tschang SPK. Traumatic Radio-ulnar Synostosis Treated by Excision and a Free Fat Transplant. *J Bone Joint Surg* 1983;65-B:433.

+109. Zenni EJ, Kreig JK, Rosen MT. Open Reduction and Internal Fixation of Clavicular Fractures. *J Bone Joint Surg* 1981;63-A:147.

# CHAPTER 28

# NONUNIONS AND MALUNIONS OF THE PELVIS

*Ross K. Leighton*

**R. K. Leighton:** New Halifax Infirmary Site, QEII Health Sciences Centre, Halifax, Nova Scotia B3H 3A7, Canada.

Arthrodesis of the Sacroiliac Joint or Repair of Nonunion
Posterior Nonunions
Anterior Nonunions
Malunions of the Pelvis
Posterior Sacroiliac Complex Malunion
Anterior Malunions
Leg-Length Discrepancy
Modified Innominate Osteotomy
Leg Lengthening or Shortening
Urinary Symptoms
Author's Perspective
Chapter References

It has been commonly taught, and correctly so, that because of the cancellous nature of the pelvis, nonunion is rare. Nonetheless, nonunions can occur in the pelvis and have occasionally been described in the literature (4). Factors that may contribute to a pelvic nonunion include a delay in treatment, inadequate immobilization of the fracture, an unstable fracture pattern, high-energy trauma, and a large initial displacement of the fracture.

The most common symptom is sacroiliac pain secondary to instability of the posterior sacroiliac complex. This symptom, along with others (Table 28.1), is most likely to occur following a very unstable, severely displaced, vertical shear fracture (Fig. 28.1). Fractures caused by lateral compression can also lead to posterior complex pain, however.

| Complication | % Patients |
|---|---|
| Sacroiliac pain | 30 |
| Malunion | 9 |
| Permanent nerve damage | 5 |
| Leg-length discrepancy ≥1 cm | 4 |
| Nonunion | 3 |
| Impotence | 2 |
| Herniation through disrupted abdominal muscles or posterior inguinal canal | 1 |

[a] Average values based on data from Proman C, Stein A. Complicated Crushing Injuries of the Pelvis. *J Bone Joint Surg* 49-B:24;1967; Patterson FP, Morton KS. Neurologic Complications of Fractures and Dislocations of the Pelvis. *Surg Gynecol Obstet* 112:702;1961.

***Table 28.1. Major Complications Following Pelvic Fractures[a]***

***Figure 28.1.*** Very unstable vertical shear fracture of the pelvis.

Nonunion of the anterior pelvis is rare but can occur with any fracture mechanism. The anteroposterior and lateral compression types of injuries are the most commonly implicated in this type of nonunion. The nonunion is usually in the symphysis or pubic rami and may result in rotational instability of the pelvis with anterior or posterior pain. Anterior pelvic nonunions are rarely symptomatic and only occasionally require treatment.

Perform a good history and physical with adequate documentation of the problem. Once you are convinced that a nonunion exists, obtain plain radiographs with inlet and outlet views of the pelvis. Judet views may be indicated, depending on the fracture pattern (i.e., if there is an associated acetabular fracture). If further diagnostic information is needed, a CT scan and possibly a technetium bone scan may be helpful to confirm your suspicions. The technetium scan will help distinguish an atrophic from a hypertrophic nonunion. If your differential diagnosis does not exclude infection, do a CBC, a differential, and an erythrocyte sedimentation rate along with a comparison of technetium and gallium scans (Table 28.2).

| | Gallium | Technetium |
|---|---|---|
| Normal | Negative | Negative |
| Nonunion (atrophic) | Negative | Negative |
| Hypertrophic | Negative | Positive |
| Infection | Positive | ±Positive |

***Table 28.2. Interpretation of Radionucleotide Scans***

The only absolute indication for surgery is pain unrelieved by nonoperative treatment. Everything else is relative: leg-length discrepancy, gait abnormality, permanent nerve-root damage, or urinary disturbance. The area of pain must be accurately identified. Posterior versus anterior and joint-related pain versus bony nonunion must be clearly elucidated so that an appropriate treatment plan can be developed.

In general, the basis for promoting healing of any nonunion is copious cancellous or corticocancellous bone grafting, with or without rigid internal fixation. This is true with nonunions of the pelvis, and these principles must be followed to obtain a successful result. I feel that except for the rare occurrence of a painful nonunion of a pubic ramus, bone grafting should be combined with rigid internal fixation to provide stability and maintain anatomic reduction.

## ARTHRODESIS OF THE SACROILIAC JOINT OR REPAIR OF NONUNION

### POSTERIOR NONUNIONS

In surgery for posterior nonunions of the pelvis, I generally prefer the anterolateral approach described by Simpson et al. (29). This approach allows direct access to the sacroiliac joint, permitting bone grafting and fixation. In addition, because it is done in the supine position, it allows better orientation and ease of access to the pubis, if necessary. I consider the anterolateral incision to be the utility approach to the pelvis because it permits access to the sacroiliac joint, the iliac wing, and, by extension to the ilioinguinal incision, the anterior column of the acetabula, pubic rami, and symphysis. Thus, with the patient in the supine position, all areas of the pelvis can be approached; this allows easier mobilization and better orientation for final reduction.

#### *Anterior Sacroiliac Joint Plate—Operative Technique*

My colleagues and I have designed an anterior sacroiliac joint plate that we use to hold the reduced sacroiliac joint after fresh pelvic fractures (Fig. 28.2) (14). We also use this plate to stabilize sacroiliac nonunions (Fig. 28.3, Fig. 28.4, Fig. 28.5, Fig. 28.6 and Fig. 28.7). In laboratory tests using cadaver pelves, this plate provided equal or greater fixation than other available devices, external or internal, now used on the sacroiliac joint. When deformation to vertical and rotational loads was measured, the external fixator proved to be the weakest of all devices tested. Simpson et al. (29) have successfully used two two-hole, 4.5-mm narrow dynamic compression plates for the same purpose, but no biomechanical tests of this system have been reported to date.

***Figure 28.2.*** Anterior sacroiliac joint plate used to stabilize the sacroiliac joint.




***Figure 28.3.*** Anterior sacroiliac joint plate used to fuse the sacroiliac joint. The plate is available in a small size as well (20% smaller than the one shown).

***Figure 28.4.*** A 45-year-old woman with a very painful nonunion of the sacroiliac joint on the left plus symphyseal diastasis. Her initial fixation, months ago, was with an external fixator. Of note, she also had a nonunion of the tibia on the left and an L-5 nerve root deficit.

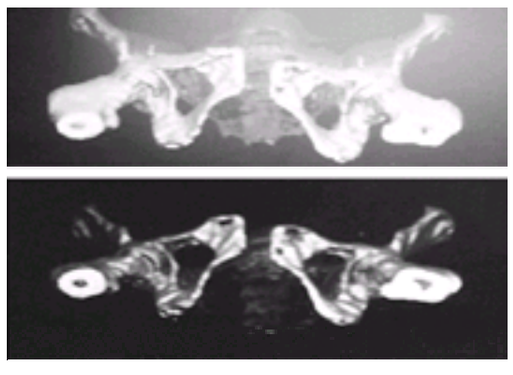

***Figure 28.5.*** Three-dimensional reconstructions from CT scans demonstrating the pathology present in Figure 28.4.

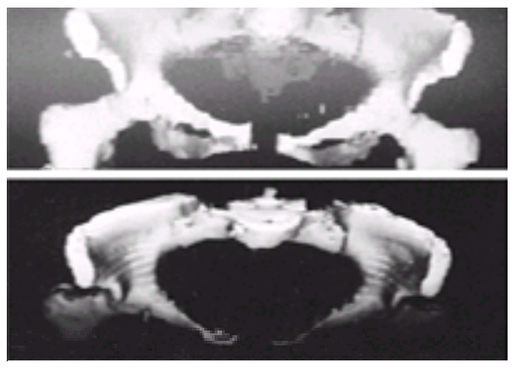

***Figure 28.6.*** Three-dimensional reconstructions from X ray demonstrating the pathology in Figure 28.4.

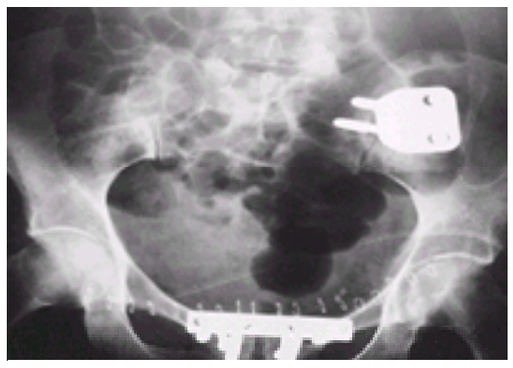

***Figure 28.7.*** Fixation of the left sacroiliac joint with the Terray sacroiliac joint plate and fixation of the symphysis with one plate superiorly and a bone graft fixed anteriorly with two screws. The L-5 nerve root deficit improved dramatically immediately after surgery.

- Prepare and drape the area of the pelvis and ipsilateral leg. Drape the leg free as if doing a hip procedure.
- Make a 15-cm incision along the iliac crest (Fig. 28.8). Divide the subcutaneous tissue and, with cutting cautery, divide the fascial attachment to the iliac crest. Locate the lateral cutaneous nerve of the thigh and retract it medially.

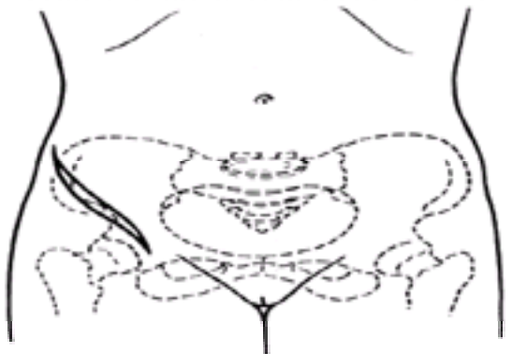

***Figure 28.8.*** Incision used for the anterolateral utility approach.

- Using a Cobb periosteal elevator, perform a subperiosteal dissection along the iliac crest back to the sacroiliac joint (Fig. 28.9). Once the joint is reached, keep the hip and knee flexed to allow relaxation of the femoral nerve and carry out a subperiosteal dissection over the sacral promontory.

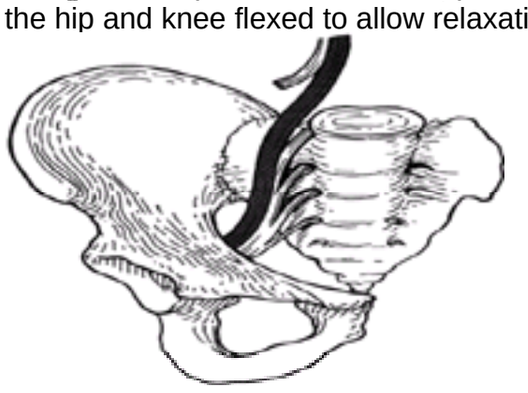

***Figure 28.9.*** This view of the sacroiliac joint and right hemipelvis demonstrates the course of the L-5 nerve root crossing the sacral promontory.

- Retract the L-5 nerve root anteromedially using a narrow, pointed Hohmann retractor placed over the anteroposterior aspects of the sacral promontory.
- Make a trough over the sacroiliac joint in its central portion. Obtain a graft from the anterior portion of the ipsilateral iliac wing and use it to fill the trough across the sacroiliac joint.
- Place the sacroiliac joint plate over the trough and secure it with 6.5-mm cancellous screws in the sacrum and cortical screws in the iliac wing (Fig. 28.10). Use a flexible drill to make the holes.

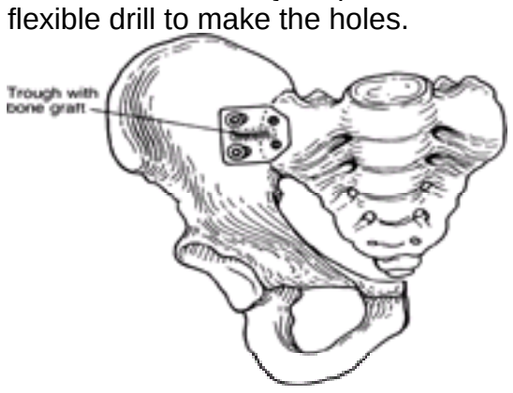


***Figure 28.10.*** Right hemipelvis with fusion of the sacroiliac joint showing the bone graft and plate placement.

- Direct the screws in the sacrum posteromedially and those in the iliac wing into the posterosuperior iliac spine. The plate is designed so that the two screws in the iliac wing produce compression across the sacroiliac joint. Thus, instant stability is achieved, usually with prompt reduction in the patient's pain.
- Irrigate the entire area copiously with bacitracin and normal saline. Place a suction drain in the wound and close it using #1 sutures in the deep fascia overlying

the iliac crest, 2-0 in the subcutaneous tissue, and 3-0 or skin staples for skin closure.

This approach has become my preferred method of treating sacroiliac joint disruptions with associated iliac wing fractures or those that cannot be reduced anatomically via a closed reduction.

***Fixation with Iliosacral Screws—Operative Technique***

Once the SI joint has been exposed, an alternative to the sacroiliac plate is fixation with iliosacral screws. These can be inserted with the patient in the supine position through small stab incisions laterally. Accurate placement of the screws is essential.

**HINTS AND TRICKS**

- Do not place a sandbag under the iliac crest because this rotates the pelvis away from you.
- Drape the ipsilateral leg free.
- Use of the flexible drill and tap from the AO/ASIF acetabular reconstruction set is very helpful.
- For plate fixation, use either the sacroiliac joint dynamic compression plate (Fig. 28.3) or two two- or three-hole, 4.5-mm narrow dynamic compression plates.
- Check the patient pre- and postoperatively for L-5, S-1, or sacral plexus nerve-root deficit.

- Place patient in the supine position on a radiolucent operating table.
- Use fluoroscopy as a guide. The procedure is based on the surface anatomic landmarks and good inlet and outlet views to determine an accurate starting point on the iliac wing. Position the imager to obtain a clear view of the sacral bodies. The view from above the transverse plane is termed the “inlet” view, and the anterior–posterior (AP) view is termed the “outlet” view. The lateral view of the sacral bodies is important. Record the angle of the inlet and outlet views on the imager for ease of repositioning.
- Identify landmarks on the pelvis to help find the insertion point of the guide wire. This is done by drawing a vertical line on the skin of the patient beginning at the anterior superior iliac spine (ASIS) and extending posteriorly toward the operating table. Draw a second horizontal line beginning at the posterior edge of the trochanter. These lines intersect to create a cross. The center of this cross represents the entry point of the guide wire seen in Fig. 28.11. A line should also be drawn to indicate the projections of the inlet and outlet image. These may also intersect to create a small triangle to again help determine the entry point of the guide wire, as seen in Figure 28.11. The main importance of these two lines, however, is to indicate the planes of adjustment of the pin on the inlet view and outlet view so that its track can be adjusted easily to avoid a malposition of the screw.

***Figure 28.11.*** Anatomic landmarks on the pelvis of a patient to help find the insertion point of the guide wire. (Note: The head of the patient is on the *left*, and the foot of the patient is on the *right*.)

- Incise the skin with a #15 blade.
- Insert and aim the guide wire for a cannulated screw to position the tip on the external aspect of the iliac wing just lateral to the posterior superior iliac spine, approximately 1 to 1.5 cm lateral to the SI joint. Take an image in both planes to confirm the guide wire's orientation.
- Position the guide wire relative to the spinal canal and the sacral promontory as seen on the inlet view (Fig. 28.12). The outlet view shows the pin's position relative to the S-1 and S-2 foramina (Fig. 28.13). Aim the guide wire to approach the sacral body in a posterior-to-anterior direction from caudad to cephalad. As the guide wire is advanced, check it frequently in both the inlet and outlet views. The pin should cross the midline.

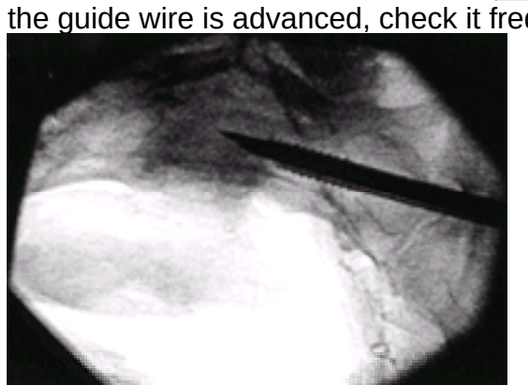

***Figure 28.12.*** Inlet view of the pelvis, showing the guide wire central to the spinal canal and sacral promontory.

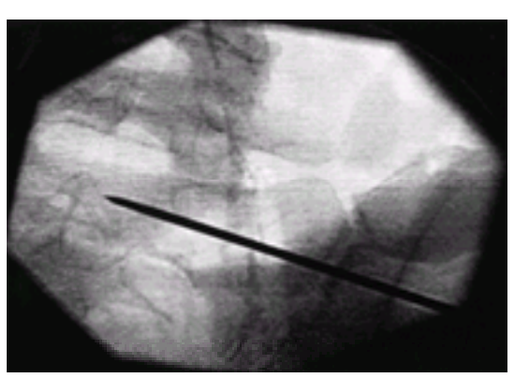

***Figure 28.13.*** Outlet view of the pelvis, showing the guide wire's relative position to the S-1 foramina with the pin in the midbody of S-1.

- Once the pins are in place, measure for screw depth and drill the iliac cortex and SI joint. Do not overdrill the full length of the guide wire to avoid pin pullout.
- Then insert self-tapping screws over the guide wire. See Chapter 17 for a somewhat different approach to this same fixation.

***Posterior Approach and Fixation with Iliosacral Screws—Operative Technique***

The absolute indication for this particular approach is for sacral nonunions, as these cannot be approached safely through the anterior approach, and it is useful for malunions as well (Fig. 28.15). Sacral malunions or nonunions are an absolute contraindication for the anterior SI joint plate.

***Figure 28.15.*** Computed tomographic scan illustrating nonunion of the right sacral alae.

- It may be used to treat fresh sacroiliac joint disruptions as well as nonunions and is preferred by some authors (5,6,12).
- Place the patient in the prone position (Fig. 28.16).

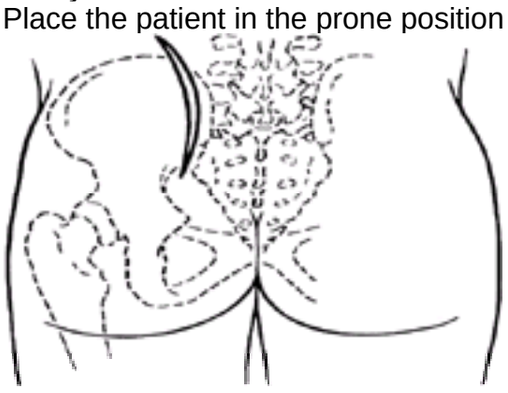

***Figure 28.16.*** Incision used for posterior approach to the sacroiliac joint.

**HINTS AND TRICKS**

- Use a full radiolucent table such as an OSI table.
- Start the guide pins low in the iliac wing area and aim caudad to cephalad and posterior to anterior to avoid a wire that partially exits the anterior cortex and can injure the L-5 nerve root.
- Do not tip the patient but raise the patient off the bed using a pad under the sacrum.
- Do not accept a screw position close to the foramina or sacral canal. The screws must be in “ideal” position. They must be dead center on the inlet and outlet view. If they are “close” to the canal or foramina, there is a 30% chance that they are malpositioned (12). The S-1 pedicle has adequate cross-sectional area for two to three 7.0-mm screws (Fig. 28.14).

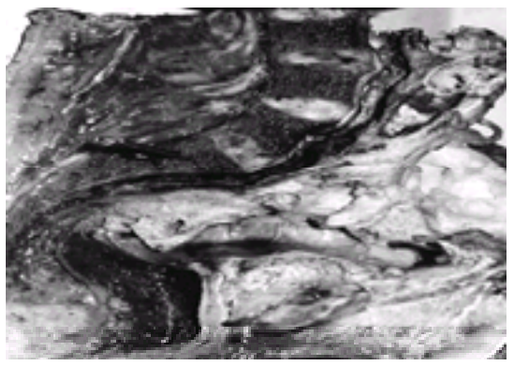

***Figure 28.14.*** Iliosacral screws in the midbody of S-1.

- Use an image intensifier to establish the orientation of the anterior sacral foramina on the outlet view and the spinal canal and sacral promontory on the inlet view.

The primary problem with this approach is poor visibility of the sacroiliac joint. It is difficult to obtain an accurate reduction, and extraarticular fusion is usually necessary, as opposed to an intraarticular fusion. Nerve root damage can occur from inaccurate placement of screws and is always of concern. However, careful technique and placement of screws in the “ideal” position, not close to the foramina or to the spinal canal, makes the chance of nerve injury slight (12).

- Identify the nonunion and curet the lesion out to allow for bone grafting.
- Insert a cancellous iliac bone graft after achieving adequate reduction (Fig. 28.17). Obtain the bone graft from the ipsilateral iliac crest, slightly anterior to the operative site, and through a separate incision. Perform an extra-articular fusion between the posterior spine of the ilium and the posterior sacrum by creating a trough and laying in a cancellous and cortical-cancellous graft. No fixation is used over the graft.

***Figure 28.17.*** The initial postoperative film after bone grafting and fixation of the sacral nonunion with iliosacral screws via the posterior approach.

- Position the screws as for the anterior approach with iliosacral screw fixation. The inlet and outlet views are, of course, reversed, as the patient is in the prone position. Again, caudad-to-cephalad and posterior-to-anterior positioning of the screws is essential to prevent injury to the L-5 nerve root. The case in Fig. 28.17 and Fig. 28.18 shows good fixation and healing of the sacral nonunion, and the patient was without pain 6 months after the repair.

***Figure 28.18.*** Six-month follow-up of the patient with a united sacral nonunion (pain-free with excellent mobility).

**HINTS AND TRICKS**

- Use a radiolucent back frame and a full radiolucent table, such as an OSI fracture table.
- Insert the screws to the midbody of S-1 or beyond in order to achieve adequate fixation.
- Make the skin incision laterally. Reflect the gluteus maximus off the spinous process so that its blood supply is not disturbed; this is needed for good healing.
- Use short-threaded screws if sacral malunions or nonunions are being treated.
- Insert the screws through a percutaneous stab incision laterally rather than through the surgical wound, as this requires more reflection of the soft tissues than desirable.
- Use guide wires for the cannulated screws, which should be at least 3.0 to 3.2 mm in diameter to avoid bending, which affects accuracy of placement.
- Use self-tapping screws.

- Irrigate the entire area copiously with bacitracin in normal saline.
- Reattach the gluteus maximus medially. Place a suction drain in the wound and bring it out laterally. Reapproximate the subcutaneous tissue and skin.

**Postoperative Regimen** According to our biomechanical testing (14), both the anterolateral and posterior methods give fixation that will approach about 50% of the normal strength of the pelvis. Therefore, it is possible to allow the patient to ambulate with crutches after the drain is removed at 48 h. Permit touch-down weightbearing for 6 weeks and partial weightbearing for a further 6 weeks. Full weightbearing is allowed once radiologic union is achieved at 10 to 12 weeks.

**ANTERIOR NONUNIONS**

Symphyseal widening, although fairly common following gross disruption of the pelvis, is rarely symptomatic. If the pelvis is rotationally unstable because of symphyseal nonunion, however, it may require treatment to relieve pain or bladder irritability. The only absolute indication for operative intervention is pain unrelieved by nonoperative measures. Anterior nonunions are not as common as those in the posterior portion of the pelvic ring but can be just as debilitating. The patient may complain of pain, clicking of the symphysis on ambulation, urinary problems, or clitoral irritation.

A preoperative workup must include an intravenous pyelogram, cystogram, and urethrogram to identify bladder or urethral impingement. A cystometrogram may be indicated if urinary complaints are the main symptoms. The approach to the problem, once identified, must be individualized to the patient and the site of nonunion.

***Nonunion or Instability of the Symphysis***

We prefer a special symphyseal plate (available from Terray Manufacture, Arenprior, Ontario; in conjunction with Zimmer USA) or a six-hole 3.5-mm pelvic reconstruction plate for fusion of the pubic symphysis (Fig. 28.19). In biomechanical studies done by Tile et al. (32; personal communication, 1984) and Leighton et al. (14), the symphyseal plate provided greater stability of the anterior pelvic ring, followed closely by the application of two plates. The single plate, although clinically successful, provided the least stability in biomechanical studies.

***Figure 28.19.*** Pelvis with symphyseal plate and bone graft to treat symphyseal nonunion.

When the nonunion is in the pubic rami, we prefer to use an onlay autologous bone graft. A nonunion in the pubic rami usually is atrophic, so a bone graft and internal fixation is required.

***Pubic Symphysis Fusion through a Pfannenstiel Approach—Operative Technique***

- Insert an indwelling Foley catheter before surgery to help identify the urethra and bladder.
- About 3 to 4 cm above the pubis, make a transverse skin incision 8 to 10 cm long.
- Divide subcutaneous tissue and identify the rectus abdominis muscle. Make a vertical midline incision through the rectus abdominis fascia; identify the two heads. Separate them in the midline and reflect laterally, taking care to protect the spermatic cord or round ligament.
- Once the rectus is reflected as much as needed, the symphysis is readily seen. Expose the symphysis and pubic rami with subperiosteal dissection to either side for a total of 10 to 12 cm. Make the exposure both superiorly and anteriorly along the superior pubic ramus.
- Once the body of each pubic ramus can be identified, dissect the bladder free of the symphysis.
- Place a retractor posterior to the symphysis to protect the bladder and urethra and remove the fibrous mass from the symphysis.
- Place a pointed reduction forceps in each obturator foramen and reduce the symphysis.
- An alternative to this technique is to use the pubic tubercles as a purchase point for the pointed clamps. This works best when a six-hole reconstruction plate is used.
- Once reduction is achieved, place the special symphyseal six-hole plate for a trial fit. It may be necessary to rongeur the pubic tubercles down slightly to obtain a flat surface. Bend the four tabs of the plate as necessary to achieve a close fit. Be certain that the lateral holes are sitting on the bone. There is a tendency for plates on the symphysis to shift anteriorly off the pubic rami.
- To place screws, drill through the two holes in the plate closest to the symphysis first. Palpate the posterior aspect of the symphysis to be certain that the drill points remain in the bone until they exit the lower border of the inferior pubic rami.
- Use fully threaded cancellous screws, which are usually 40 to 60 mm in length.
- Then drill the lateral holes to accept 4.5-mm cortical screws. Use cancellous screws if the bone quality is poor.
- Now place screws in the anterior holes of the plate while protecting the bladder with a retractor. Use cortical screws (3.5 mm with 4.5-mm washers or 4.5-mm screws; 4.5-mm washers are available from Zimmer USA) the average length of which is approximately 20 to 24 mm. If the quality of the bone is poor, use cancellous screws.

- Close the rectus muscle and fascia snugly. Place a drain behind the symphysis.

**Postoperative Regimen**

- Place the patient on bed rest for 24 h and then mobilize to a chair.
- Remove the suction drain at 48 h.
- At the same time, ambulate with crutches, allowing touch-down only on the more unstable side.
- Allow full weightbearing with crutches at 8 weeks. Discard the crutches when radiologic union occurs, which is usually at 10 to 12 weeks. Because the plate obscures the radiographic images, it is always difficult to be sure of radiologic union.

**HINTS AND TRICKS**

- Catheterize the patient so the urethra can be easily located.
- Always protect the posterior structures when drilling and tapping.
- A six-hole 3.5-mm reconstruction plate may be used, depending on the reduction obtained and stability required.

***Nonunion of the Pubic Rami—Operative Technique***

Nonunion of the pubic rami is very rare, and only a small percentage of these nonunions require surgical treatment. Consequently, no one has a great deal of experience in dealing with this problem. Be certain that this is the cause of the patient's pain before undertaking surgery. The treatment requires autologous bone graft, with or without internal fixation, depending on the type of nonunion (i.e., atrophic versus hypertrophic) and bone quality.

- To expose the superior pubic ramus, use the ilioinguinal approach described in Chapter 2. Protect the contents of the inguinal canal.
- Debride both ends of the nonunion and clear them of any fibrous tissue. Open the intramedullary canal on each side. Petal the cortical bone for 2 to 3 cm on each side of the nonunion using a small osteotome and a powered burr.
- Place cancellous bone graft around the site of nonunion in a barrel-stave fashion. Plate the ramus if additional stability is needed.
- Close the wound over a suction drain in the usual manner.

Rarely, the inferior pubic ramus may be the site of nonunion. This is usually an atrophic nonunion at the junction of the ramus with the ischial tuberosity. The patient has pain on sitting.

- Place the patient in the lithotomy position. In this position, the ischium is very easy to palpate.
- Incise directly down to the ischion and inferior pubic ramus. Take care to avoid the pudendal vessels, which exit anteromedially. Occasionally, the nonunion site may be more proximal, near the posterior column of the acetabulum. If this is the case, then use the standard Kocher-Langenbeck approach, as described in Chapter 3.

**HINTS AND TRICKS**

- If a small superior fragment is present, excise it.
- Use flexible drills and taps.

- Freshen the bone ends at the nonunion site and add copious autologous bone graft.
- Internal fixation is usually not required; however, a 3.5-mm reconstruction plate can be applied. Keep the patient touch-down weightbearing with crutches until radiographic union is achieved; this usually takes 8 to 14 weeks.
- If both the inferior and superior rami are involved, however, then plate the superior ramus with at least four cortices of fixation on either side of the fracture site. I also add an anterior external frame to increase stability.

***Nonunion of the Iliac Wing—Operative Technique***

Nonunion of the iliac wing is rare but is usually easy to correct.

- Use the anterolateral approach to the sacroiliac joint: it allows good visualization of the entire iliac wing.
- Identify the site of the nonunion. If the ununited fragment is small, then excise it. If it is a large fragment or involves the whole ileum, then use the methods described above for treating the nonunion.
- Expose the bone ends, freshen them, and achieve an anatomic reduction.
- Then place a lag screw from the anterior iliac crest across the fracture site and into the body of the ilium. Augment this with a wide 4.5-mm dynamic compression plate, fixing at least four cortices on either side of the fracture site.
- Apply an onlay bone graft. Close the wound in layers over a suction drain.

After the drain is removed at 48 h, mobilize the patient using crutches, with touch-down weightbearing on the affected side. Continue to protect the ilium until clinical or radiologic union is observed at 8 to 12 weeks.

## MALUNIONS OF THE PELVIS

Malunions of the pelvis are much more common than nonunions; however, little is available in the literature regarding these challenging problems. Slatis and Huittinen (30), in their review of 65 vertical shear fractures treated closed without internal or external fixation, noted a 46% incidence of late sequelae. These included pain from a malreduced posterior sacroiliac complex, limb-length discrepancy and gait abnormalities, urinary symptoms, and permanent nerve damage (Table 28.1). Bucholz has described the displacement of vertical shear fractures as being posterior, cephalad, and externally rotated, leading to a very prominent posterior superior iliac spine (2).

Other types of pelvic fractures can also result in malunion. A lateral compression injury usually results in an internal rotational deformity, which can lead to a major leg-length discrepancy and impingement of the rami on the bladder or perineum. In one variant of the lateral compression fracture, the pubic rami and the pubic body distal to the fracture are spun into a vertical position, which can cause impingement on the perineum and cause dyspareunia (Fig. 28.20). The anterolateral compression injury or “open book” fracture can heal in a widely displaced position, but this is rarely symptomatic. Iliac wing fractures, if left untreated, can heal in a malrotated or shortened position, but these malunions are not symptomatic.

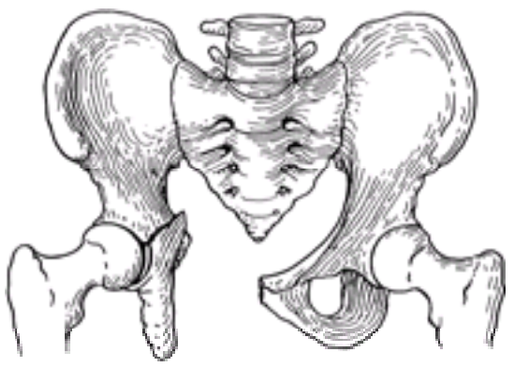

***Figure 28.20.*** Variant of a lateral compression injury with perineal impingement. If symptomatic, this may require reduction and fixation with symphyseal plates.

The vertical shear fracture is the most common cause of pelvic malunion because it is the most unstable fracture and, therefore, the most difficult to maintain in a

reduced position. For that reason solid fixation of the pelvic ring both posteriorly and anteriorly is recommended. Permanent nerve damage is present in a surprising number of pelvic fractures (5%) (13). L-5 and S-1 are the roots most commonly involved, but the sacral plexus can also be injured. It is important to document any problems and discuss them with the patient, because surgery will generally not improve a nerve palsy or causalgia.

The primary indication for surgery is pain unrelieved by nonoperative treatment. Many of these patients are involved in workers compensation or legal conflicts. It may be wise, therefore, to wait until these conflicts are resolved before undertaking surgery, as the indications are usually based on subjective symptoms and the outcomes are not very predictable. In my experience, most of these patients, if given time, can return to their normal daily activities without surgical intervention. A strong relative indication for surgery is a leg-length discrepancy of 2 cm or more.

The posterior pelvic ring is the area most likely to cause problems and is the most difficult to correct. Direct fusion of the area (see the discussion in Nonunions, above) is the mainstay of treatment, although reduction of any coexisting malunion or malposition is indicated also. Late reduction of a malpositioned sacroiliac joint is very difficult, however.

### POSTERIOR SACROILIAC COMPLEX MALUNION

The surgical technique for reduction requires mobilization of the anterior pelvic complex to readjust the position of the entire hemipelvis, which is why this type of surgery is so difficult and rarely indicated. This surgery is fraught with complications, and the results cannot be predicted reliably. If surgery is indicated, however, I recommend an anterior–lateral approach that must be individualized to the original fracture pattern. Most other authors have recommended a posterior approach, and certainly this can be used (5,6,12,13). A combined anterior and posterior approach is often required. Recently, the anterolateral approach has become popular (3,7,10).

#### *Operative Technique*

- If the original disruption occurred at the symphysis, use a Pfannenstiel incision to mobilize this area.
- When the deformity is in the pubic rami, individual osteotomies must be done through separate incisions. Approach the superior pubic ramus through an inguinal incision and inferior pubic ramus in the lithotomy position, as described above.
- Once the anterior pelvis has been mobilized, make an anterolateral utility incision to mobilize the posterior sacroiliac complex. Expose the ilium and the sacroiliac joint.
- Place small Kirschner wires parallel to each other in the sacrum and ilium in such a way that they will end up in the same plane once reduction has been achieved. These pins also serve as a guide to internal and external rotation of the pelvis.
- Use an osteotome and sharp dissection to mobilize the sacroiliac joint if required. It is extremely difficult to mobilize the hemipelvis. Much soft-tissue release is required along the inside and outside of the iliac wing.
- Once the hemipelvis is mobilized, place a clamp on the iliac wing to aid in its manipulation. Externally rotate the leg and apply traction. Reduce the pelvis, internally rotate the leg, and drive a wide staple across the sacroiliac joint along its posterosuperior edge.
- Place a bone graft across the joint as discussed above for nonunion.
- Apply the sacroiliac plate, using dynamic compression plating. I have found this method of fusing the sacroiliac joint to be successful, as have Rand (22), Tile (32), and Simpson et al. (29), but the total number of cases is small.
- Next check the alignment of the symphysis and the rami if they were involved. Be certain that the rotational alignment in the anteroposterior plane is correct. Posteriorly, this rotational alignment is most difficult to determine, and it is at this point that the advantages of the anterolateral utility incision are realized.
- Once reduction is achieved, apply the symphyseal plate along with bone graft.
- If independent osteotomies were used on the pubic rami, then use an anterior external fixator or internal fixation to stabilize the anterior pelvis.
- Close all wounds over suction drains in the usual fashion.
- As stated earlier, a combination of a posterior approach to the sacroiliac joint plus a Pfannenstiel incision can be used to accomplish the same result.

**Postoperative Regimen** Keep the patient on bed rest for 3 to 5 days and allow movement only from bed to chair for 2 to 3 weeks. Allow crutch walking at 3 weeks with touch-down weightbearing on the unstable side, continuing until union is achieved at about 12 to 16 weeks.

### ANTERIOR MALUNIONS

The symphysis can heal in a widely displaced position. This usually is secondary to an anteroposterior (open book) fracture, which is rarely symptomatic. If it is believed to be the cause of the patient's discomfort, treatment is the same as for a nonunion of the symphysis.

A lateral compression injury can result in malunion of the pelvis with the hemipelvis internally rotated and the symphysis healed in an overlapped position. If union has occurred, the anterior complex is rarely the cause of the problems. However, the real problem anteriorly is the variant of a lateral compression injury mentioned earlier in which the pubic rami fragments are rotated in the frontal plane (Fig. 28.20). If these structures impinge on the perineum and cause dyspareunia, treat the malunion either by excision, if the fragment is small, or by reduction and internal fixation.

#### *Operative Technique*

- Use an ilioinguinal approach plus a separate incision to osteotomize the inferior pubic ramus.
- Place patient in the lithotomy position. Expose and osteotomize the inferior pubic ramus first.
- Then make an ilioinguinal incision and expose the superior pubic ramus and the symphysis.
- Mobilize the fragment. If it is small, excise it; otherwise, fix it with a symphyseal plate.
- Mobilize the patient with crutches, touch-down weightbearing on the affected side, for 4 to 6 weeks.

## LEG-LENGTH DISCREPANCY

A strong relative indication for surgical intervention is leg-length inequality. I feel that if the discrepancy is 2 cm or more, then surgical intervention is justified. If the pelvis is not too deformed, and the patient is relatively young, I do a modified Salter osteotomy. With an older patient, or one who has a deformed pelvis but no real pain, a leg-lengthening or leg-shortening procedure is the treatment of choice. The shorter in stature the patient is, the more I would favor a lengthening procedure. Leg-length films are needed to document the true leg-length discrepancy. The leg length must be measured on these films from the anterosuperior iliac spine to the ankle, not from the acetabulum to the ankle as in standard leg-length films. Remember, the loss of height is within the pelvis and not in the femur or tibia.

### MODIFIED INNOMINATE OSTEOTOMY

The innominate osteotomy, as described by Salter, is modified in that a block of bone is used instead of a wedge of bone (Fig. 28.21) (9). In this way, the posterior aspect of the pelvic brim is opened, thus gaining length in the shortened extremity. This usually will allow an increase of 2 to 2.5 cm in leg length. By externally rotating the distal fragment, the osteotomy will allow correction of an internal rotation of the pelvis and permit the leg to assume its normal position.

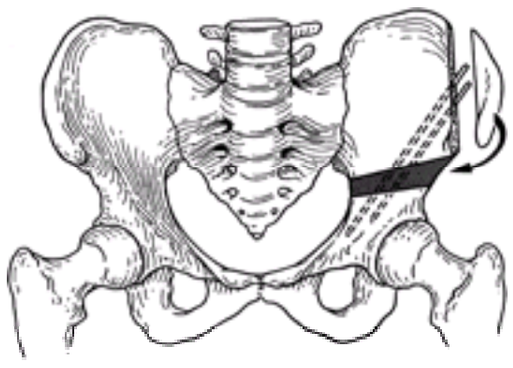

***Figure 28.21.*** Modified Salter innominate osteotomy. Note that the block of bone actually opens the posterior cortex.

### LEG LENGTHENING OR SHORTENING

The method for shortening the femur on the long side is detailed in Chapter 30. Leg lengthening using Ilizarov's method is discussed in Chapter 32.

## URINARY SYMPTOMS

The patient who complains of urinary symptoms must be carefully evaluated by the orthopaedist and a urologist. If the symptoms are attributed to pressure on the bladder secondary to pelvic deformity, then surgery may be helpful. An adequate preoperative workup must be done, including radiographic contrast studies and possibly a cystometrogram. If surgery is to be performed, make sure a catheter is inserted before the operative procedure. With a urologist's help, use a direct approach to the pubis through a Pfannenstiel incision and remove the excess bone to take the pressure off the bladder. An osteotomy of the pelvis to correct the deformity is rarely indicated for urinary symptoms alone. Nonunion at the symphysis can cause urinary symptoms with or without discomfort. The treatment in this case is symphyseal-plate fixation with bone grafting of the symphysis, as described above in the section on nonunions.

## AUTHOR'S PERSPECTIVE

Reconstructive surgery for nonunions or malunions of the pelvis is rare, and, therefore, there are few large series documenting results of treatment. Pennal and Massiah (20) have the largest series and report good results using the posterior approach to the sacroiliac joint. Their series consisted of 42 patients with nonunion and delayed union, 39 men and 3 women, with an average age of 35 years. Of the patients, 24 were treated nonoperatively and 18 by surgery. The surgery was aimed at stabilizing the nonunion and supplemental bone grafting. The operative group did better than the nonoperative group as far as returning to preinjury jobs and activities, and a solid union was achieved in 15 of the 18 treated with surgery.

Tile previously used the posterior approach but has advocated the anterolateral approach to avoid posterior skin sloughs (32). Rubash et al. (25) reported good results in all seven patients who underwent a direct approach to the malunion site. However, despite their expertise in surgery, the average operating time in these patients was 6 h, and the average blood loss was 1,200 mL.

The best results with pelvic fractures are obtained by anatomic reduction as early as practical. Late reduction and fusion are definitely much more difficult and hazardous. Fortuitously, since the mid-1990s, many companies have developed superior plate reduction clamps and pushers in order to allow for better and easier anatomic alignment of acute fractures. With the use of these advanced tools, and more rigid internal fixation, such as the iliosacral screws and symphyseal plates, anatomic reduction can be achieved and maintained while the pelvic ring heals. Although these techniques do not allow for perfect reduction in every case, they do allow for a very acceptable reduction in most patients. As stated earlier, it is very important that the source of the pain be identified as accurately as possible before any type of posttraumatic reconstruction is undertaken, as pain, particularly posterior pelvic and back pain, can have many origins other than from the bony pelvic ring.

### CHAPTER REFERENCES

Each reference is categorized according to the following scheme: *, classic article; #, review article; !, basic research article; and +, clinical results/outcome study.


+ 1. Bohlman HH, Pattee GA, McAfee P. Compression of a Sacral Nerve as a Complication of Screw Fixation of the Sacroiliac Joint: A Case Report. *J Bone Joint Surg* 1986;68-A:679.

+ 2. Bucholz RW. The Pathological Anatomy of Malgaigne Fracture-Dislocations of the Pelvis. *J Bone Joint Surg* 1981;63-A:400.

+ 3. Coady C, Smyth B, Petrie D, Leighton R. A New Symphyseal Plate. Biochemical Study Presented at the Canadian Orthopaedic Association Meeting in June 1995 and updated at the Canadian Orthopaedic Association Meeting in June 1998.

+ 4. Draejer F, Egbers HJ, Havermann D, Zimmerman M. Results Following the Conservative and Surgically Treated Injuries of the Pelvic Ring within the Scope of a Prospective Study. *Unfallchirurgerie* 1995;98:355.

+ 5. Duweliius PJ, Van-Allen M, Bray TJ, Nelson D. Computed Tomography-Guided Fixation of the Unstable Posterior Pelvic Ring disruptions. *J Orthop Trauma* 1992;6:420.

+ 6. Ebraheim NA, Coombs R, Jackson WT, Rusin JJ. Percutaneous Computed Tomography-Guided Stabilization of the Posterior Pelvic Fractures. *Can J Surg* 1990;33:492.

+ 7. Ebraheim NA, Coombs R, Rusin JJ, et al. Percutaneous CT-Guided Stabilization of Complex Sacroiliac Joint Disruption with Threaded Compression Bars. *Orthopaedics* 1992;15:1427.

# 8. Failainger MS, McGainty PLJ. Current Concepts Review—Unstable Fractures of the Pelvic Ring. *J Bone Joint Surg* 1992;74A:791.

+ 9. Goldstein A, Phillips T, Sciafani SJA. Early Open Reduction and Internal Fixation of the Disrupted Pelvic Ring. *J Trauma* 1986;26:325.

+ 10. Gruen GS, Leit ME, Gruen RJ. Functional Outcome of Patients with Unstable Pelvic Ring Fractures Stabilized with Open Reduction and Internal Fixation. *J Trauma* 1995;39:838.

+ 11. Kellam JF, McMurty RY, Paley D. The unstable pelvic fracture. *Orthop Clin North Am* 1987;18:25.

! 12. Lammens P, Logan M, Petrie D, et al. Percutaneous Iliosacral Screw Fixation—Is It Safe? Paper Presented at the Canadian Orthopaedic Association, June 1997, and at the Orthopaedic Trauma Association, October 1998.

+ 13. Latenser BA, Gentillo LM, Improved Outcome with Early Fixation of Skeletally Unstable Pelvic Fractures. *J Trauma* 1991;37:28.

! 14. Leighton RK. Biomechanical Study of Vertical Shear Fractures of the Pelvis. Paper Presented at the Annual Meeting of the American Academy of Orthopaedic Surgeons, San Francisco, 1997.

+ 15. Leung KS, Chien P, Shem WY, So WS. Operative Treatment of Pelvic Fractures. *Injury* 1992;23:31.

+ 16. Matta JM, Saucedo T. Internal Fixation of Pelvic ring fractures. *Clin Orthop* 1989;242:83.

+ 17. McLaren AC, Rorabec CH, Halpenny J. Long-Term Pain and Disability in Relation to Residual Deformity after Displaced Pelvic Ring Fractures. *Can J Surg* 1990;33:492.

18. Mears DC, Rubash HE. External and Internal Fixation of the Pelvic Ring. *AAOS Instruct Course Lect* 1984;33:144.

+ 19. Nelson DW, Duwelius PJ. CT-guided fixation of sacral fractures and sacroiliac joint disruption. *Radiation* 1991;180:527.

* 20. Pennal GF, Massiah KA. Nonunion and Delayed Union of Fractures of the Pelvis. *Clin Orthop* 1980;151:124.

+ 21. Pohmann T, Bosch U, Gansslen A, Tschernr H. The Hanover Experience in Management of Pelvic Fractures. *Clin Orthop* 1994;305:69.

+ 22. Rand JA. Anterior Sacroiliac Arthrodesis for Post-Traumatic Sacroilial Arthritis. A Case Report. *J Bone Joint Surg* 1985;67-A:157.

+ 23. Routt MLC, Kregor PJ, Mayo K. 103 Spine Percutaneous Iliosacral Screws for Fixation of the Disrupted Posterior Pelvic Ring after Indirect Reduction. Indications, Techniques, Errors and Results. Paper presented at the Orthopaedic Trauma Association Annual Meeting, Minneapolis, October, 1992.

+ 24. Routt MLC, Meier MC, Kregor PJ. Percutaneous Iliosacral Screws with the Patient Supine Technique. *Oper Tech Orthop* 1993;3:35.

# 25. Rubash HE, Nelson DD, Mears DC. Reconstructive Surgery of the Pelvis. Paper presented at the Annual Meeting of the American Academy of Orthopaedic Surgeon, New Orleans, 1982.

* 26. Salter RB. Innominate Osteotomy in the Treatment of Dislocation and Subluxation of the Hip. *J Bone Joint Surg* 1961;43-B:518.

+ 27. Shaw JA, Mino DE, Werner FW, Murray DG. Posterior Stabilization of Pelvic Fractures by Use of Threaded Compression Rods. Case Report and Mechanical Testing. *Clin Orthop* 1985;192:240.

+ 28. Shuler TE, Boone DC, Gruen GS, Peitzmann AB; Percutaneous Iliosacral Screw Fixation; Early Treatment for Unstable Posterior Pelvic RINg disruptions. *J Trauma* 1995;38:453.

* 29. Simpson LA, Waddell JP, Leighton RK. Anterior approach in stabilization of the disrupted sacroiliac joint. *J Trauma* 1987;27:1332.

* 30. Slatis P, Huttinen VM. Double Vertical Fractures of the Pelvis. *Acta Chir Scand* 1972;138:799.

+ 31. Taller S, Lukes R, Beran J, Bubenik J. CT-guided pelvic osteosynthesis. Preliminary report on a new operative technique. *Rozhl Chir* 1995;743:141.

# 32. Tile M. *Fractures of the Pelvis and Acetabulum.* Baltimore: Williams & Wilkins, 1984.

+ 33. Vanderschot P, Craninx L, Rommens P, Broos P. Functional results following the surgical treatment of unstable pelvic girdle fractures. *Acta Chir Belg* 1991;91:250.

# CHAPTER 29

# NONUNIONS AND MALUNIONS OF THE HIP

*Michael W. Chapman*

**M. W. Chapman:** Department of Orthopaedics, University of California Davis, Sacramento, California, 95817.

Nonunion of the Femoral Neck
Causes
Diagnosis
Timing of Surgical Intervention
Surgical Reconstruction
Intertrochanteric and Subtrochanteric Nonunion
Compression Hip Screw Fixation with Bone Graft
Malunion
Acknowledgment
Chapter References

## NONUNION OF THE FEMORAL NECK

Despite modern techniques and a better appreciation of what is necessary to achieve union in the femoral neck, most recent series continue to report an incidence of avascular necrosis that ranges from 20% to 25% and about a 10% rate of nonunion (4,7,8,14,16,17,18,19 and 20,28). These statistics show that union is possible in the presence of avascular necrosis. The live bone from the femoral neck can grow into the avascular bone of the femoral head or, in some cases, partial union may occur between viable sections of the femoral head and the neck. When union to an avascular femoral head occurs, complications generally do not develop until resorption of the avascular bone in the head occurs, resulting in segmental collapse (11).

### CAUSES

The most common cause today in developed countries of nonunion of the femoral neck is loss of blood supply to the femoral head. In developing countries, neglect of these fractures is common and leads to nonunion in most cases. Disruption of the blood supply is most likely to occur when the fracture displaces, resulting in tearing of the vessels; consequently, there is an increased incidence of avascular necrosis in displaced fractures (8). The incidence of avascular necrosis and nonunion is increased in young adults, probably because a greater force is required to break the femoral neck in this population. The greater force leads to increased displacement, which correlates with avascularity. Avascular necrosis is common, occurring in 20% to 25% of all femoral neck fractures; its incidence is greater with poor reduction (52%) and in young patients (90%) (13,19,29). A high index of suspicion for an avascular head should be accorded patients with marked shortening of the femoral neck after surgery. High-risk patients include those who have undergone pelvic irradiation therapy, those with alcoholism, and those receiving large-dose steroidal therapy. Patients with a great deal of initial displacement may do well, and displacement at injury should not be used as the sole reason for prosthetic replacement. Delay in treatment is associated with avascular necrosis; the incidence is nearly 100% after a delay of 7 days.

It has also been suggested that a rise in intracapsular pressure secondary to a hematoma may occlude the blood supply, leading to avascular necrosis (30,31). Currently, only two steps can be taken to improve the blood supply to the fracture site and head immediately after injury. First, obtain a reasonably good reduction by closed means as soon as possible to minimize distortion of the vessels. Second, decompress the intracapsular hematoma, either by aspirating the hip joint or by incising the capsule at the time of internal fixation.

Since little can be done to restore blood supply once it has been disrupted by a fracture, recent efforts have been aimed at diagnosing avascularity early so as to permit either revascularization of the head or, in older patients, immediate hemiarthroplasty (30).

Other than loss of blood supply, the most common causes of nonunion are inaccurate reduction and loss of fixation secondary to inadequate technique or poor bone quality. In most displaced femoral neck fractures, the fracture angulates into a varus position and the head collapses posteriorly (5). This results in posterior comminution of the femoral neck with loss of bone substance. Medial comminution of the calcar femorale does not occur often; however, the calcar may impact into the femoral head, crushing cancellous bone there. When major displacement disrupts soft tissues, reduction and maintenance of position can be extremely difficult. With the posterior bone deficit, malposition is common. When this is combined with severe osteoporosis, internal fixation is difficult. For this reason, the standard of practice for displaced fractures of the femoral neck (Garden type III or IV) in the elderly is immediate hemiarthroplasty (4,6,22,32).

### DIAGNOSIS

The patient with pain in the hip 2–6 months after fixation usually has delayed union with motion at the fracture site and loosening of the fixation. Pain from the fixation device itself is highly unusual, unless it is prominent at the hip, producing a trochanteric bursitis. Removal of the internal fixation device at this time causes instability, loss of position, and nonunion. With displacement, nonunion is fairly easy to diagnose by routine radiographs. In undisplaced fractures, nonunion can be very difficult to diagnose, particularly when a great deal of fixation hardware is present. In obese and elderly patients, soft-tissue density and bone porosis may make roentgenograms difficult to interpret. In addition, overlap of bone secondary to settling at the fracture site can suggest union when, in fact, a nonunion is present. The preoperative workup must establish whether union is present and whether the head is avascular.

Nonunion is best diagnosed by computed tomography (CT) with reconstruction or anteroposterior (AP) tomograms of the femoral neck. The cuts must be spaced closely, must extend through the entire femoral neck region, and must be taken with the hip in internal rotation to place the femoral neck into maximum profile. Fluoroscopic examination of the fracture site while oscillating it through 5° to 10° of rotation or varus–valgus positioning may also reveal instability at the fracture site. We have not found arthrography to be helpful in diagnosing nonunion. Magnetic resonance imaging (MRI) is very sensitive for detecting avascular necrosis and is very helpful in the diagnosis of nonunions, particularly in cancellous bone.

Displacement that is manifested as widening of the fracture line on radiography, increasing displacement of the fracture, any varus position, or any angulation of the femoral head of greater than 20° in relationship to the neck indicates impending failure. Each of these suggests a fracture that is not likely to heal and is an indication for operative intervention. Because their prognosis is otherwise good, this applies particularly to fractures that are initially minimally displaced (Garden type I or II) and that have been reduced incompletely or fixed insecurely.

It must be established that there is good blood supply to the femoral head before undertaking reconstruction. The viability of the femoral head is best determined by technetium-99m sulfur colloid bone scans (21). However, false-positive uptake of contrast material may be seen after 1 month, as blood from the creeping substitution process may be present, but on a scaffold of necrotic bone so extensive as to be doomed to collapse. Although an MRI scan is more reliable than a bone scan in determining whether the head is viable and suitable for reconstruction, it cannot be used if there is metallic fixation in the head unless the software can subtract the artifacts from the fixation devices.

All patients for whom hip reconstruction is being contemplated should undergo a sedimentation rate study, a joint aspiration culture, and, if the latter is suspicious, a gallium radioisotope study to rule out a septic process. In questionable cases involving an elevated sedimentation rate, leukocytosis on joint aspiration, or a positive gallium scan, an open biopsy and culture may be necessary.

### TIMING OF SURGICAL INTERVENTION

If there is evidence of instability—particularly if there is a halo about the fixation device—operative intervention is indicated, as further nonoperative care is unlikely to lead to fracture union. Not only does delay prolong the healing period, but nail penetration may destroy bone stock, blood supply, or acetabular cartilage, preventing

reconstruction. On the other hand, if the radiographs are suggestive of delayed union or nonunion but the fracture appears to be stable, well aligned, and well fixed continued treatment with touch-down weight bearing on crutches may lead to eventual union. If union does not occur within 6 months, a nonunion is likely. In young adults, avascularity of the head with an impending nonunion may precipitate a decision for early surgery. A muscle-pedicle bone graft may be considered in an effort to revascularize the head if there is no segmental collapse of the femoral head and no bone stock loss that would make stable fixation unlikely (16,17,18,19,20 and 21). In the elderly, however, if the fracture is stable, it is best to wait, as a satisfactory clinical outcome may be achieved.

Other considerations in the decision-making process are the patient's physical condition, the status of the femoral neck, degenerative changes in the hip joint, and the duration of the nonunion. In sedentary patients who are elderly or disabled and who are high-risk surgical candidates, it may be best to continue nonoperative care, using assistive devices for walking and appropriate analgesics. Disabling pain or deformity usually warrants surgery. Avascular necrosis in the femoral head substantially lowers the likelihood of success with internal fixation and bone grafting. In young, active patients, it is worthwhile to try to salvage the femoral head. Elderly patients, or those who cannot protect the injured hip because of Parkinson's disease, neurotrophic arthropathy, or other disabilities, should be considered for a prosthesis. Prosthetic replacement is indicated in patients who have less than a 15-year life expectancy and who are not progressing normally after conventional techniques of reduction and fixation. The operative timing of the hip replacement is not as urgent as that of the reconstructive procedures, but if the gait is unsatisfactory or if penetration of the metallic devices is likely, which would cause additional destruction of the acetabulum, try to save the acetabular surface.

With longstanding nonunion, or when the patient has been walking with an unstable nonunion, crushing and resorption of the femoral neck may occur. Loss of the femoral neck normally makes internal fixation and bone grafting impossible. Once a nonunion is diagnosed, it is important to move ahead with surgery to avoid resorption of the femoral neck.

The duration of nonunion per se has no role in the decision-making process. Longstanding nonunions are likely to be associated with resorption of the femoral neck or associated degenerative changes in the hip, and this must be taken into account.

## SURGICAL RECONSTRUCTION

Nonunion of fractures of the femoral neck can be treated by valgus osteotomy, internal fixation and bone graft, prosthetic replacement, Girdlestone resection, or hip arthrodesis. Preserving the femoral head is the primary consideration for younger patients (under 60 years old), very active patients, and obese patients (weighing more than 200 pounds), all of whom have poorer long-term results with total hip arthroplasty.

### *Valgus Osteotomy*

The principle of valgus osteotomy is to shift the weight-bearing line medially and, most importantly, to place the fracture plane more horizontally to reduce the shear stress on the fracture (1,2). The procedure is most successful when the fracture is undisplaced, when there is no femoral neck resorption, and when the femoral head is viable. An osteotomy can also be useful when the fracture line is vertical and resistant to valgus reduction, as may occur in high-velocity trauma. If healing has progressed but loss of leg length and hip mechanics secondary to varus positioning is a problem, osteotomy is indicated.

If there is greater than 20° of varus angulation in the fracture, the asymmetric forces exerted on the femoral head and neck lead to increasing displacement. Such a reduction is unacceptable. The angulated fracture may be remanipulated and renailed if it is detected within a few weeks of injury and the deformity is mild. If it is detected later, at the time of initial healing, or if it is accompanied by a severe deformity, a change in position will require force, or dissection that is likely to interrupt the blood supply. These delayed cases are more safely treated with an osteotomy. Since the procedure is performed in the intertrochanteric region, the risk of avascular necrosis is minimal.

The disadvantage of valgus osteotomy, particularly if the head and neck are placed in extreme valgus (greater than 150°), is that the trochanteric lever arm is shortened. A greater abductor pull is then required to counterbalance the body weight during the single-leg stance phase. If the abductors are weak, a Trendelenburg gait will result. If they are strong enough to avoid a Trendelenburg gait, pressure on the femoral head will be increased, possibly leading to early degeneration of the cartilage. For these reasons, the patient may need to use a cane permanently. There is usually enough neck resorption and shortening accompanying nonunion of the femoral neck for the valgus osteotomy to compensate and for leg length to remain relatively normal. Warn the patient, however, that a discrepancy in leg length—either too long or too short—may be a permanent outcome.

Because of the prolonged time required for union to occur after osteotomy, external immobilization is impractical. Therefore, rigid internal fixation is essential so that the patient can start touch-down weight bearing using crutches immediately after surgery.

**Surgical Options** The basic principles of valgus osteotomy were established by Pauwels in 1935 (27,28) and refined by Müller (23,24 and 25). As described by Weber and Cech (33), there are four types of valgus-transposition osteotomies: valgus intertrochanteric wedge osteotomy, valgus wedge prop osteotomy, valgus Y-shaped prop os- teotomy, and a variation described by Müller (Fig. 29.1, Fig. 29.2, Fig. 29.3 and Fig. 29.4). Weber and Cech (33) provide an exhaustive discussion of the treatment of femoral nonunion by osteotomy in their excellent text. The most common osteotomy used is the valgus intertrochanteric wedge osteotomy, the procedure for which is described in the following section.

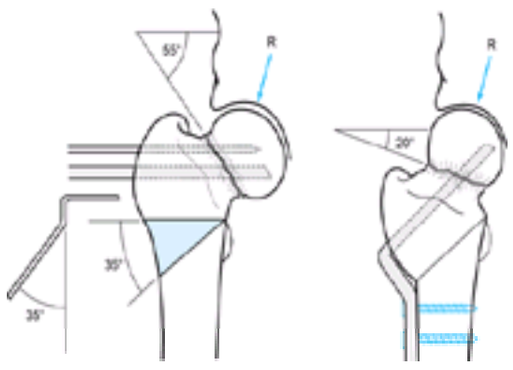

***Figure 29.1.*** A valgus intertrochanteric wedge osteotomy is performed to treat a nonunion of the femoral neck with a shear angle of 55°. A 35°, laterally based wedge is removed to place the nonunion 20° off horizontal. (From Weber BG, Cech O. *Pseudoarthrosis.* Bern: Hans Huber, 1976, with permission.)

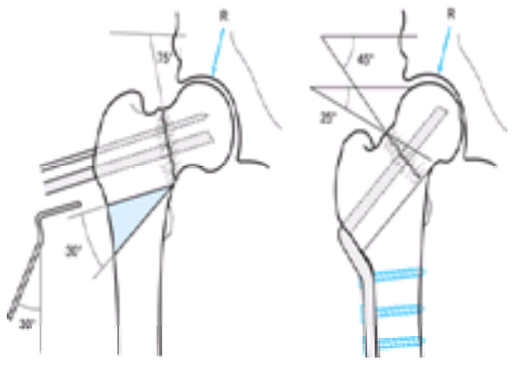

***Figure 29.2.*** A valgus wedge prop osteotomy is indicated when the fracture is nearly vertical, when there is minimal varus deformity, and when the femoral neck is fairly long. A 30° wedge is removed, reducing the fracture angle of 75° to 45°. This restores the normal anatomy of the neck–shaft angle. A 130° plate is then used to offset the shaft medially. This slides the distal femur beneath the femoral neck to support the nonunion site. (From Weber BG, Cech O. *Pseudoarthrosis.* Bern: Hans Huber, 1976, with permission.)

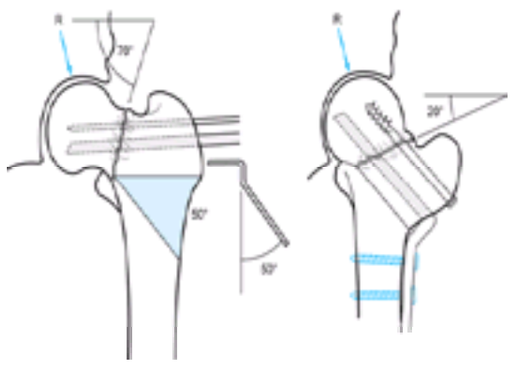

***Figure 29.3.*** A valgus Y-shaped prop osteotomy is indicated when there is significant varus deformity. This osteotomy can correct severe deformities with a valgus inclination of up to 70°. In this case, the nonunion is at a 70° angle, so a 50° wedge with its medial apex located at the fracture site is removed. A 50° blade plate is used. The lower cut of the osteotomy is placed to preserve the remnants of the calcar femorale. After correction and fixation, the nonunion is at 20°, the shaft is medially displaced, and the fracture site is supported by the medial shaft. Additional screws can be added to improve fixation. (From Weber BG, Cech O. *Pseudoarthrosis.* Bern: Hans Huber, 1976, with permission.)

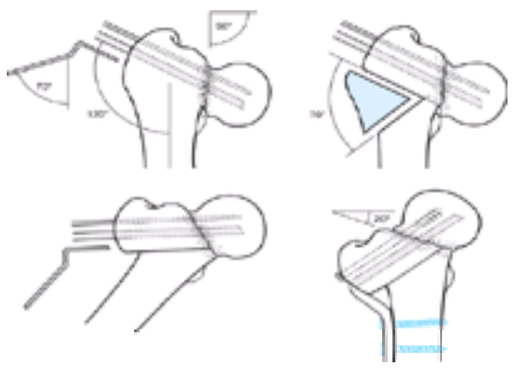

***Figure 29.4.*** Transposition osteotomy, as described by Müller, permits correction of severe varus deformity with inferior subsidence of the femoral head. The femoral neck and head in this example are 30° below horizontal, and therefore in 65° to 70° of varus. To correct this, a 70°, laterally based wedge is removed. Note that the proximal cut preserves the remaining calcar femorale on the distal fragment, as does the inferior cut. Careful preoperative planning is necessary to make this osteotomy match up as well as the one depicted here. After repositioning, the fracture line is within 20° of horizontal, and the shaft supports the fracture site and is medially displaced. (From Weber BG, Cech O. *Pseudoarthrosis.* Bern: Hans Huber, 1976, with permission.)

**Preoperative Planning** Obtain maximum abduction and adduction radiographs to ensure that the head of the femur moves freely within the acetabulum. If it does not, arthrotomy and lysis of adhesions may be necessary before acceptable motion is achieved. A fibrous ankylosis of the hip is usually accompanied by degradation of the articular cartilage, and it may be a contraindication for osteotomy. The goal of the osteotomy is to place the femoral neck fracture at an angle 20° to 30° off horizontal (Fig. 29.1). Preoperative planning must include a determination of the size of the bone wedge to be removed, the position of the seating chisel (which will determine the position of the blade plate in the proximal fragment), and the size and angle of the blade plate to be used (Fig. 29.5*A*, Fig. 29.5*B*, Fig. 29.5*C*, Fig. 29.5*D*, Fig. 29.5*E* and Fig. 29.5*F*).

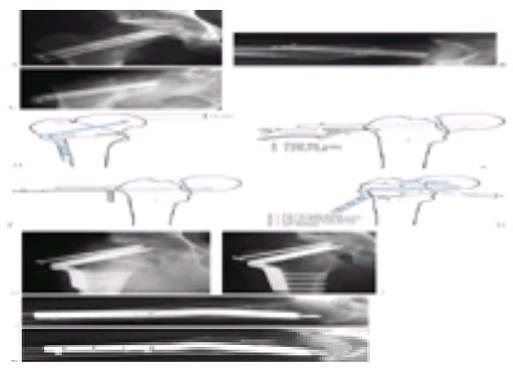

***Figure 29.5.*** **A:** This 42-year-old man sustained a femoral neck fracture in a bicycle accident. Note the high shear angle. Initial treatment was closed reduction and percutaneous multiple screw fixation in excellent position. This AP radiograph shows the hip at 2 months after surgery. **B:** Lateral view 2 months after surgery. **C:** AP radiograph at 8 months after fracture showing a nonunion with shortening and varus position. **D:** Preoperative planning drawing showing a reduction in the fracture angle from 60° to 30° off horizontal and a projected gain in length of 13 mm. **E:** Guide pin in place with 4.5 mm drill inserted through a triple drill sleeve to create a track for the chisel. **F:** Seating chisel in place. **G:** This 120° angled blade plate is in place with an independent 6.5 mm cancellous lag screw to gain further stability at the fracture site, as well as to compress it. Note the 4.5 mm cortical screw inserted through the impaction hole in the blade plate to secure the position of the blade. Place this after inserting the 6.5 mm lag screw. The illustration shows the location of the transverse osteotomy and the 30° wedge to be removed. **H:** Immediate postoperative AP radiograph. **I:** Immediate postoperative lateral radiograph. **J:** AP radiograph at 18-month follow-up showing union of the osteotomy and the fracture with no evidence of avascular necrosis or arthritis so far. **K:** Lateral radiograph at 18 months after osteotomy.

**Positioning and Surgical Approach** Performing an osteotomy on a fracture table affords the best radiologic control but is technically difficult. I prefer to place the patient in a semisupine position on a regular operating table (with bolsters to raise the operative site about 25° to 30°), or in the full lateral decubitus position. Use a Watson-Jones anterolateral approach. Obtain good exposure of the femoral head, neck, and shaft. Do not disturb the soft-tissue attachments to the femoral neck superiorly or posteriorly, to avoid injuring the blood supply to the femoral head. In Figure 29.5*A*, Figure 29.5*B*, Figure 29.5*C*, Figure 29.5*D* and Figure 29.5*E*, the femoral neck is at an angle of 60° in relation to horizontal; therefore, a 30° valgus osteotomy is performed to place the neck at a 30° angle to horizontal. Use an AO blade plate with an angle of 120° between the blade and the shaft portions and an angle of 30° between the shaft portion and the trochanteric bend in the plate. Perform the osteotomy as follows:

- Insert a guide pin through the lateral aspect of the greater trochanter, across the femoral neck, and into the femoral head just proximal to where the blade plate will be inserted. This must be parallel to the superior cut of the osteotomy and on the lateral view must be in the center of the femoral head. Obtain a full lateral view of the hip by rotating it into the frog position, with the hip flexed to 90° and with the C-arm fluoroscope in the cross-table position (Fig. 29.5*E*).
- Use the triple guide and 4.5 mm drill points to predrill the path for the seating chisel. This avoids deflection of the chisel by intramedullary callus and/or the dense bone around the nonunion. Drive the seating chisel parallel to and in line with the guide pin in the position determined by preoperative planning using fluoroscopic guidance. Most likely, it will enter somewhat proximal to the ridge of origin of the vastus lateralis. Place it in the inferior half of the femoral head. Determine the proper blade length for the blade plate by measuring off the chisel (Fig. 29.5*F*). Withdraw the chisel and insert the blade plate (Fig. 29.5*G*).
- With a water-cooled oscillating saw, make the proximal osteotomy cut parallel to the blade and just proximal to the lesser trochanter, as determined by preoperative drawings (Fig. 29.5*G*).
- With a template or goniometer, mark a 30° angle for the distal osteotomy and cut it with the oscillating saw, removing the appropriate-size wedge of bone from the distal fragment. Note that in this patient the wedge stops at the mid femur, so that as the osteotomy is closed more length will be gained to compensate for the shortening.
- Reduce the osteotomy into position, apply longitudinal compression, and secure the side plate to the femur with screws of an appropriate size. Morcelize or place the removed wedge as a structural graft medially in the osteotomy site. If desired, perform supplementary fixation of either the fracture or the osteotomy using cancellous screws with washers to achieve interfragmentary compression (Fig. 29.5*H*, Fig. 29.5*I*, Fig. 29.5*J* and Fig. 29.5*K*).

- Obtain hemostasis, place suction drainage, and close the wound in the usual fashion.

**Postoperative Care** Mobilize the patient as soon as symptoms permit. Maintain touch-down weight bearing until union occurs, usually in 3–6 months. Teach the patient to support the leg when making transfers, and to avoid straight-leg-raising exercises. Active and active-assisted range-of-motion exercises for the hip and knee, as well as light resistive exercises with the thigh and hip supported on a table surface, are permitted. Once union occurs, unrestricted rehabilitation is possible.

**Results** Weber and Cech (33) reported the results of osteotomy in the management of 85 patients with femoral neck pseudarthroses, 41 of whom were treated with transposition osteotomy. Of 23 osteotomies performed in patients with pseudarthroses but without femoral head necrosis, 21 healed, 1 failed as a result of infection, and 1 failed because of faulty technique. Fourteen of the patients so treated achieved normal function; 7 had good results but some shortening or diminished range of motion, and in 3 patients, partial avascular necrosis of the head occurred, leading to a poor outcome. In 7 of 13 patients with associated avascular necrosis, healing and revascularization of the femoral head occurred, producing a good result; the other 6 patients had poor results. The other 5 osteotomies were done in adolescents younger than 20 years of age. Of these patients, 1 achieved a normal hip, 3 had a good result, and 1 had a failure.

## HINTS AND TRICKS

- The location of the apex of the wedge osteotomy on the AP view determines how much length will be regained with the osteotomy. This can be predicted from the preoperative drawings (e.g., the case in Fig. 29.5). Having the apex of the osteotomy at the medial cortex is technically the easiest and results in the largest surface contact between the proximal and distal fragments, thereby reducing the risk of nonunion. As the apex is moved laterally, more length is gained but less surface contact is available between the head/neck and shaft fragments. When the apex is in the medial half, there is a tendency for the fragments to impact when compressed, but if the apex is in the lateral half, a gap is left medially, and it is important to fill this gap with a structural bone graft.
- I observed Dr. David Helfet perform this procedure at the Hospital for Special Surgery in New York. His technique is quite attractive. He places the patient on a fracture table and makes only a lateral approach, not exposing the hip. He inserts the blade plate and performs the osteotomy in a similar manner but often does not remove a wedge. Instead he simply forces the side plate down to the shaft and then impacts the osteotomy. This impales the distal fragment into the soft cancellous bone of the proximal fragment, resulting in excellent correction and providing excellent bone apposition. The only disadvantage of this technique is that it does not allow for sliding of the osteotomy to provide support across the fracture site (Fig. 29.2, Fig. 29.3 and Fig. 29.4). In addition, the relationship between the fragments at the osteotomy may not allow protrusion of the distal into the proximal fragment.
- When compression is applied across the osteotomy site with the external compressor, there is a tendency for the shaft to shift medially away from the plate, and for the blade plate to pull out of the proximal fragment. I avoid this by placing a 4.5 mm corti- cal bone screw of appropriate length through the compression hole just beneath the blade, which secures the blade into the femoral head. I keep a Lowman bone-holding forceps on the plate on the shaft to prevent the shaft from shifting away from the plate.
- In nonunions, it is always wise to supplement fixation with an independent cancellous leg screw and washer just superior to the blade plate.
- This procedure works best if the blade plate is placed in the inferior half of the head. Be certain that the square corner of the blade plate does not penetrate the femoral head. After insertion, examine the femoral head under direct fluoroscopy, rotating the hip to be certain accidental penetration has not occurred.
- Absorption of the femoral neck with shortening, or drift of the femoral neck into a severe varus or inferior position, requires modifications (Fig. 29.2, Fig. 29.3 and Fig. 29.4).

Marti et al. (15) reported on 50 nonunions of the femoral neck treated by abduction intertrochanteric osteotomy. Their union rate was 94%. At 7.1 years follow-up, 7 had required prosthetic replacement—the result of persistent nonunion in 3, fixation failure in 1, and avascular necrosis in 3.

### *Meyers's Pedicle Bone Graft*

The muscle-pedicle bone graft, originally described by Judet (12), has been modified by Meyers (16,17,18,19,20 and 21) and others (26) and popularized for the treatment of fresh fractures when there is extensive posterior neck comminution and a high risk of avascular necrosis. It is also useful in cases of nonunion. Although the technique is best suited for nonunion without significant displacement, we have successfully used it for displaced nonunion by repositioning the fracture through the old fracture site. Open reduction with a pedicle graft or other graft (26) may be necessary when a true synovial pseudarthrosis is present, or when there is severe loss of bone substance posteriorly with substantial retroversion of the head.

Meyers advocates performing a pedicle bone graft in the supine position on a fracture table with the limb in traction. Although this works well, I have found it to be much more convenient if the patient is placed in the lateral decubitus position with the leg draped free.

- Place a C-arm fluoroscope over the top of the table and cover it with a sterile drape for radiographic guidance. Good visualization, particularly on the lateral view, is necessary to achieve satisfactory internal fixation.
- Use a posterolateral approach to the hip (see Chapter 3). Distortion of anatomy as a result of shortening may displace the sciatic nerve into an unexpected position. Identify the nerve and protect it throughout the procedure. If the nerve must be retracted for exposure, keep the hip extended and the knee flexed to avoid putting tension on the nerve. Consider using somatosensory evoked potentials to monitor sciatic nerve function.
- Dissect the hip external rotator muscles, except the quadratus femoris, free from the underlying joint capsule with a Cobb elevator, and transect them at a bony level from the greater trochanter. Take care not to injure the underlying lateral epiphyseal vessels. Delineate the superior and inferior margins of the quadratus femoris muscle. Free it from the underlying capsule and soft tissues with a Cobb elevator, from its origin to insertion. The medial circumflex femoral artery abuts the upper margin of the quadratus femoris. As it is the source of the lateral epiphyseal vessels, avoid injury to this vessel.
- With an osteotome, mark the margins of the bone graft to be taken from the posterior ridge of the greater trochanter with the quadratus femoris attached (Fig. 29.6). To obtain a bone block of sufficient length, take the posterior margin of the greater trochanter from its tip to 1.5 cm distal to the lower edge of the insertion of the quadratus femoris. It is easiest to outline this block with a 0.5-inch osteotome, cutting the superiorposterior and inferior margins of the graft first. Pry the osteotomy open. This delineates nicely the posterior cortex beneath the quadratus femoris that needs to be cut. Cut this with the osteotome extending from proximal to distal beneath the quadratus femoris. The bone block should be at least 5.0–7.5 cm long, and 1.5–2.0 cm wide and deep. The superior part of the bone should extend beyond the upper margin of the quadratus femoris by about 2 cm.

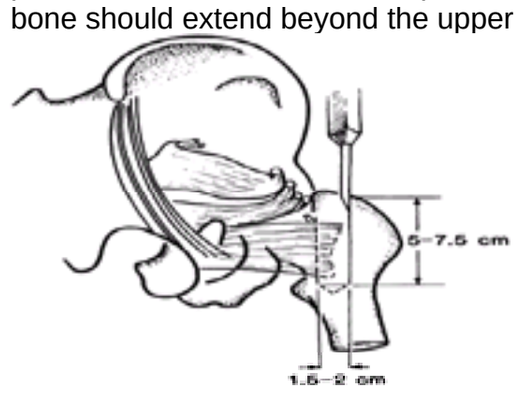


***Figure 29.6.*** Meyers's quadratus muscle pedicle bone graft. Remove the external rotator tendons from the greater trochanter, taking care to avoid injury to the medial femoral circumflex artery. Then harvest the bone graft as is outlined with the attached quadratus muscle.

- Retract the bone graft and attached quadratus femoris, freeing the underside of the muscle. Once mobilized, it should easily swing superiorly to lie against the posterior aspect of the femoral head and neck, without tension on the quadratus muscle.
- Incise the joint capsule using an H or T pattern to expose the femoral neck, the site of nonunion, and the posterior aspect of the femoral head. Identify the nonunion site and remove all fibrous tissue. In longstanding nonunion, the bone surfaces in the nonunion site may be quite sclerotic. If so, remove the sclerotic bone with a curet. Drilling may be necessary as well.
- At this point, access to the fracture site may be compromised by shortening and varus position. Achieve reduction and anatomic position either by manual traction and manipulation or by use of an AO femoral distractor with one Schanz pin in the supra-acetabular area and the other in the greater trochanter. The latter method is preferred.
- Fashion a site for the pedicle bone graft. Using a curet, osteotome, or mortising chisel, make a hole in the posterior aspect of the cancellous bone of the femoral head to accept the proximal end of the bone graft. The hole should extend into the femoral head at least 1–2 cm. Fashion the proximal end of the bone graft so that it fits snugly into the hole, making certain that the fracture is anatomically reduced and that there is good bone contact anteriorly. Fashion the graft so that it fits snugly against the posterior aspect of the femoral neck. If additional cancellous bone is needed to pack the defect in the femoral neck, harvest a graft from either the greater trochanter or the posterior ilium. Pack the cancellous bone firmly into the defect in the femoral head so that solid continuity between the head and neck fragments is achieved.
- In most cases, this step is followed by fixation of the femoral head and neck with three or four lag screws.

- Finally, screw the pedicle graft into place (Fig. 29.7). The order of placement of the screws depends on the stability of the fracture. Verify the accuracy of the reduction and placement of the fixation devices with the C-arm monitor.

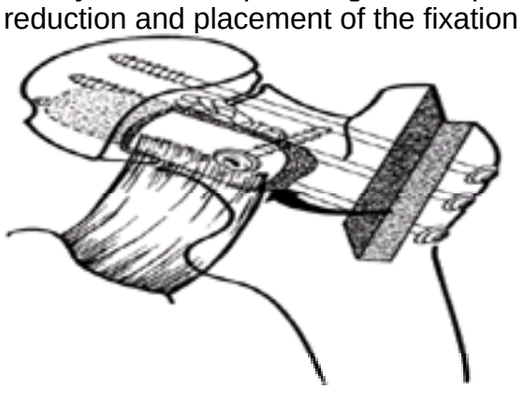

***Figure 29.7.*** A completed Meyers's quadratus pedicle bone graft. Note that the graft is inserted into the posterior femoral head through a hole in the posterior nonarticular aspect of the head. Secure the graft to the distal femoral neck with a single bicortical screw. Overdrill the graft to produce a lag effect. Use a washer on all screws. Pack cancellous bone graft into remaining areas of bone defect. Then fix the fracture with multiple cancellous screws.

- Close the hip joint capsule and reattach the external rotators to the greater trochanter by suturing them to the insertion of the gluteus medius. Place a suction drain and proceed with routine closure.

**Postoperative Care** The postoperative regimen is the same as described for intertrochanteric osteotomy. Full weight bearing must be delayed until complete consolidation of the fracture occurs. In most cases, the immediate postoperative radiographs appear to show union because of the density of bone created by the bone-grafting procedure. An AP tomogram or CT scan is often necessary to confirm that union has occurred. Figure 29.8 illustrates a typical case.

***Figure 29.8.*** **A:** Three months after intramedullary nailing of a femoral shaft fracture, a 39-year-old woman continued to have hip pain. This AP radiograph shows early healing of the shaft fracture but a nonunion with displacement of a femoral neck fracture. **B:** The lateral radiograph shows 90° of angulation in the fractured femoral neck. **C:** The intramedullary nail was removed and a Meyers's pedicle bone graft combined with multiple screw fixation was performed. This AP radiograph 5 months after the graft shows union of the fracture. **D:** Lateral radiograph shows excellent restoration of alignment with union of the fracture.

#### *Open Reduction, Internal Fixation, and Fibular Autograft*

In developed countries, most nonunions of the femoral neck occur after internal fixation. In underdeveloped countries, however, lack of access to medical care frequently results in neglected fractures of the femoral neck in young adults going on to nonunion in poor position. Nagi et al. (26) in India treated 52 cases by open reduction, fixation by compression hip screw, and a free fibular graft, at a mean of 5 months after the initial fracture. Of 40 fractures available for evaluation at 59 months mean follow-up, 38 were healed. Seven of 8 hips that showed avascular necrosis before surgery revascularized without collapse, while 7 others developed postoperative avascular necrosis. There were a considerable number of later failures, including collapse of the femoral head in 5, coxa vera in 11, fracture of the graft in 4, and penetration of the hip by the screw or graft in 9. Of the 40 fractures, satisfactory functional results were achieved in 35 and poor results in 5. I suspect that a microvascularized graft will provide superior results to a fibular graft, therefore in these cases, a Meyers's pedicle graft or free microvascularized fibular graft is worth consideration.

#### *Prosthetic Replacement*

Treatment by prosthetic replacement—either hemiarthroplasty or total hip arthroplasty—is limited to cases of nonunion of the femoral neck that are not salvageable by osteotomy or internal fixation and bone grafting (3). Avascular necrosis with segmental collapse is the most common reason for prosthetic replacement. Extensive resorption of the femoral neck, making reconstruction impossible, is also an indication. In some cases, even after successful union has been achieved, degenerative arthritis may intervene, in which case arthroplasty would be indicated. Hemiarthroplasty is adequate for hips without degenerative changes in the acetabulum. Total hip arthroplasty is indicated when degenerative changes are present in the acetabulum. The patient's age and activity level must be considered when determining whether to proceed with arthroplasty or to perform a hip fusion. Arthroplasty is reserved for patients who are physiologically older than 70 years of age, or in younger patients whose lifestyle is sedentary. Young adults (those physiologically younger than 50 years of age) who can continue to participate in sports are better candidates for arthrodesis because of the risk of prosthetic loosening. The techniques for hemiarthroplasty and total hip arthroplasty are described in Chapter 105.

#### *Hip Arthrodesis*

Hip arthrodesis is indicated in young adults with active lifestyles (9,10). Because of the absence of the femoral head and neck, fusion is difficult. The technique for fusion after removal of a total hip prosthesis is applicable to this group as well. To maintain length, ischiotrochanteric fusion may be necessary. Internal fixation of the proximal femur into the old acetabulum, combined with subtrochanteric osteotomy, is an alternative technique but usually results in unacceptable shortening (see Chapter 109).

#### *Infected Nonunion*

Infected nonunion of the femoral neck is very difficult to treat, often because of multiple resistant organisms. The femoral head is often totally avascular, and severe bone stock loss precludes arthrodesis or arthroplasty. Salvage by osteotomy or bone grafting and internal fixation is rarely, if ever, possible. If the fracture is superficially infected, debride all necrotic tissue and place at the fracture site polymethylmethacrylate beads (not yet approved by the U.S. Food and Drug Administration) containing an appropriate antibiotic—usually 1.2 g of tobramycin and 1 g of vancomycin in 10 g of bone cement. Close the wound, eliminating all the dead space. Plan to internally fix when the patient's wound heals, usually within 3–4 weeks. Infection cannot be cleared if the nail penetrates the hip, causing infection within the hip joint. The presence of septic arthritis requires resection of the head and neck fragment, insertion of antibiotic beads, and subsequent total hip reconstruction. Final treatment involves removal of all internal fixation hardware and necrotic bone, which usually leads to Girdlestone resection of the hip. After debridement, leave the wound open and treat with appropriate antibiotics. Secondary closure of the wound may be possible, but often healing by secondary intention becomes necessary, particularly when there is significant pelvic or acetabular involvement.

The functional outcome is rarely good. Shortening requires the use of a lift, and persistent instability nearly always warrants the use of a cane or single crutch for ambulation. Subsequent conversion to an arthrodesis is a consideration, but this is technically difficult, and infection may recur.

### INTERTROCHANTERIC AND SUBTROCHANTERIC NONUNION

Nonunion in the intertrochanteric area is very uncommon. Nonunion after nonoperative treatment is also rare. Nonunion can be manifested by a loss of fracture reduction, fracture of the fixation device, varus collapse of the fracture, or pulling of the screws from the shaft. Nails currently in use are strong at the nail–plate junction;

therefore, failures occur more often in bone than in the plate.

Nonunion after operative treatment is usually preceded by failure of fixation, with drifting of the fracture into a varus position and external rotation. Normally, this leads to good apposition of the bone fragments and union in malposition. The likelihood of nonunion is increased when hardware interposition, major bone loss, or excessive prolonged traction results in lack of good bone contact across the fracture site.

Infection after internal fixation may predispose a patient to nonunion. Since infection can also cause the fixation device to loosen, in any patient with an apparent nonunion, rule out infection with a sedimentation rate, aspiration of the hip, wound culture, and if necessary a biopsy of the fracture site.

Subtrochanteric nonunion is far more common than intertrochanteric nonunion, as the former is the highest stress area of the femur. Nonunion occurs after both operative and nonoperative treatment. The overall incidence of nonunion in the trochanteric and subtrochanteric region is about 1.5%. The most common cause of nonunion after internal fixation of subtrochanteric fractures is the use of a compression hip screw or blade plate device when the medial buttress is not established and bone graft has not been used. Early activity causes excessive bending motion of the unsupported plate, resulting in mechanical failure and subsequent nonunion.

Treatment of intertrochanteric and subtrochanteric nonunion requires operative intervention. Externally applied or semi-invasive methods of electrical stimulation are not indicated, as the incidence of true synovial pseudarthrosis in subtrochanteric and trochanteric nonunion is high, and the prolonged immobilization in a spica cast that is required for electrical stimulation is unacceptable if operative intervention is feasible.

The indications for operative intervention include unacceptable pain, unacceptable instability, or malposition that interferes enough with function to justify operative intervention. In sedentary or elderly patients in whom a stable, fibrous union has been achieved without pain, surgery may not be necessary as long as the malposition is acceptable. The treatment of intertrochanteric nonunion and high (within 1 inch of the lesser trochanter) subtrochanteric nonunion is nearly identical. Alternatives include AO condylar blade-plate fixation, compression hip screw with or without anterior plating, and intramedullary nails of the third-generation or reconstruction type. Subtrochanteric nonunions are best treated with intramedullary nails of the reconstruction type. The technique does not differ much from that used for fresh fractures (see Chapter 19 and Chapter 20). A sample case is illustrated in Figure 29.9. Contraindications to this approach include coexisting infection and osteopenic bone that is incapable of providing good fixation.

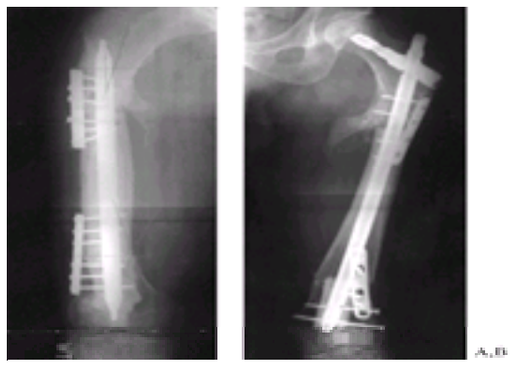

***Figure 29.9.*** **A:** AP radiograph of the femur of a 50-year-old man who was treated for a chondrosarcoma of the femur 9 months earlier. The tumor in the mid shaft was resisted; the shaft was autoclaved and reconstructed. There is a nonunion at the subtrochanteric junction, with subsidence into varus. **B:** The postoperative radiograph shows reconstruction by replacement of the dead diaphysis with an allograft and fixation with an Alta rod connector using a dome in the hip. The graft junction sites were grafted with autologous bone.

**COMPRESSION HIP SCREW FIXATION WITH BONE GRAFT**

Although the surgical procedure for treatment of intertrochanteric or subtrochanteric nonunion can be performed on a fracture table, I prefer to use a radiolucent operating table with the patient in the lateral decubitus position. The purpose of the fracture table is to use traction to correct the deformity; it also improves radiographic control. However, the same goals can be met by using an AO femoral distractor to correct malposition. A C-arm fluoroscope placed over the top of the patient, using a frog-leg position for the lateral view, is sufficient for radiologic control.

- Prepare the skin and drape the hip and affected lower extremity free.
- Use a Watson-Jones exposure (see Chapter 3). Adequate anterolateral exposure of the femoral neck and the adjacent proximal shaft is essential.
- If a fibrous nonunion is in good position, internal fixation *in situ* is possible; otherwise, the nonunion must be taken down, the medullary canal opened, and the fracture ends freshened. Correct shortening, malrotation, and varus malformation using an AO femoral distractor if necessary. A useful supplemental technique involves placing a hip screw and side plate into correct position in the proximal fragment and then reducing the proximal fragment, along with the side plate, to the shaft of the femur. The AO outrigger compression device can be placed in distraction to help gain length.
- If length of more than 15 mm is gained, maintain the hip in extension and the knee in flexion to avoid excessive traction on the sciatic nerve. Gaining more than 2.5 cm is technically challenging, and in some cases preoperative traction may be useful. In repositioning the fracture, try to reestablish medial contact between the femoral head/neck and shaft fragments. If good apposition is attained and interfragmentary screw fixation is possible, an anterior plate may not be necessary. If the medial buttress is not reestablished, place a medial bone graft and use an anterior plate.
- Once satisfactory position is achieved, fix the fracture internally with an appropriate-size compression hip screw with a side plate or other heavy-duty appliance. Screw fixation in at least eight cortices of the distal fragment is necessary. Attain interfragmentary screw fixation across the fragments if possible (Fig. 29.10). In both intertrochanteric and subtrochanteric nonunions treated with a hip screw, an anterior plate is useful. Use a 3.5 or 4.5 mm reconstruction plate. With an intertrochanteric nonunion, the plate must extend onto the base of the femoral neck, and proximal fixation may have to be achieved with only two screws. In subtrochanteric fractures, it is usually possible to place a six-hole plate with three screws in each major fragment. Distally, the anterior plate should be at least 2.5 cm short of the end of the side plate to avoid a stress riser at the end of the plate

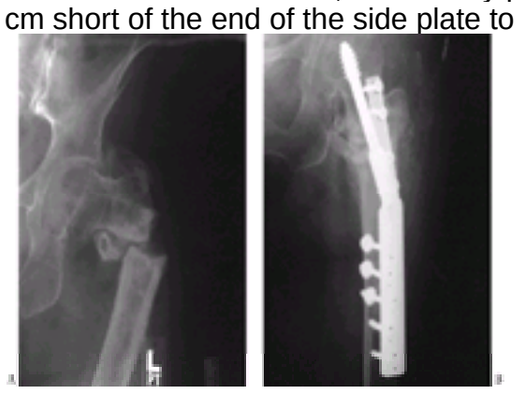

***Figure 29.10.*** **A:** A 55-year-old woman 3 years after an intertrochanteric fracture of the left hip. She was originally treated with a Smith-Peterson nail and Thorton side plate. This was complicated by infection with a penicillin-sensitive *Staphylococcus aureus.* Now she has painful nonunion with 1½-inch (3.75 cm) shortening. **B:** This was treated with reduction, autologous bone graft, and double plate fixation with a hip screw and semitubular plate. She healed and regained her lost leg length and function.

- Harvest a copious bone graft from the posterior ilium and apply it to the nonunion site.
- Place two deep suction drains and close the wound in the usual fashion. Balanced suspension will make the patient more comfortable in the immediate postoperative period.

***Postoperative Care***

As soon as symptoms allow, permit weight bearing to the weight of the leg with crutches or a walker. If good internal fixation has been achieved, active-assisted joint range-of-motion exercises can normally be started immediately. With the thigh supported, resistive exercise to muscles is also possible. Delay straight-leg-raising and

resistive exercises across the hip joint until healing occurs.

With good internal fixation and bone grafting, the immediate postoperative radiographs may show obliteration of the fracture. The time of postoperative bone union can, therefore, be difficult to judge. AP and lateral tomograms can be necessary to confirm union. In any case, the minimal amount of time required for union is 12 weeks; often 6 months is needed.

If the patient is elderly and sedentary or has a large bone defect, a proximal femoral replacement total hip or hemiarthplasty may be indicated. However, a prosthesis that preserves the trochanter is preferred. Prosthetic replacement of trochanteric bone usually results in poor muscle reattachment and consequent dislocation. The type of prosthetic reconstruction to use is quite variable and depends on many factors (see Chapter 105 and Chapter 106).

### HINTS AND TRICKS

- If there is marked osteoporosis in the femoral head, supplemental fixation with methylmethacrylate may be necessary. Make a nail track that does not enter the hip joint. Inject cement into the nail track before replacing the device in the neck. This procedure is, however, rarely necessary in fresh fractures treated with a sliding nail that reaches the center of the head, near the articular surface. If the purchase of screws in the femoral shaft is inadequate, remove some of them, pack methylmethacrylate into the medullary canal, let it set, and then drill and reinsert the screws. Do not allow methylmethacrylate to enter the fracture site. Always use a copious circumferential bone graft when methylmethacrylate is used.

## MALUNION

Malunion of fractures in the femoral neck and trochanteric region is associated with varying degrees of varus and shortening. External rotation is usually present as well, but occasionally internal rotation occurs. It is important to correct these deformities in children, as further shortening secondary to disuse may occur if the deformity is not corrected and normal function restored. Altered mechanics about the hip, which influence bone remodeling, may contribute to further shortening. Most cases of malunion in this region are treated with intertrochanteric or subtrochanteric osteotomy, using techniques similar to those described in the section on nonunion. With simple valgus osteotomy, it is easy to correct malrotation through the osteotomy site. Correction of the varus position and malrotation will also resolve a substantial amount of the shortening in most cases. Further length can be gained by sliding an intertrochanteric or subtrochanteric osteotomy, using the femoral distractor for distraction.

It is difficult, and somewhat hazardous for the sciatic nerve, to attempt to gain more than 2.5 cm in leg length at the time of surgery. Patients with leg-length discrepancies of more than 2.5 cm may have residual shortening. A secondary procedure, to lengthen the affected extremity or shorten the contralateral extremity, may subsequently be necessary to equalize leg lengths.

In the case of nonunion with extreme shortening and disjunction between the femoral head/neck fragment and the shaft, it may be necessary to take down the malunion, placing the patient either in traction or in an external fixator to regain length before fixation. Skeletal traction is preferred in most cases, as it is least invasive and does involve placement of pin tracks in the hip region, which might otherwise be a source of contamination with subsequent surgery.

The strongest fixation device with the best mechanical axis for a subtrochanteric nonunion is an intramedullary nail. The first choice is an interlocking or reconstruction nail (Fig. 29.9). An advantage of nails is the closed reaming process that provides bone graft to the fracture site and stimulates callus formation. Additionally, the nail provides lasting protection at a time when the partially avascular comminuted fragments are brittle and subject to refracture.

Nail plate fixation is desirable only in two-part subtrochanteric nonunion associated with a long, oblique fracture surface that is suitable for lag-screw fixation. The bone must be in good contact to carry compression forces. This oblique configuration may be relatively unstable with intramedullary nailing and tends to gap. Nail plates are also an alternative treatment for two-part nonunion with a transverse component. Accurate reduction, restoration of the medial buttress, and medial bone grafting are necessary. Limited weight-bearing until union occurs is essential.

Ilizarov methods have not been used commonly in North America for nonunions and malunions of the hip (see Chapter 32).

## ACKNOWLEDGMENT

This chapter is dedicated to the memory of Dr. Thomas H. Comfort, who, prior to his untimely death, was a coauthor of this chapter and a highly respected orthopaedic traumatologist.

## CHAPTER REFERENCES

Each reference is categorized according to the following scheme: *, classic article; #, review article; !, basic research article; and +, clinical results/outcome study.


* 1. Blount WP. Blade Plate Internal Fixation for High Femoral Osteotomies. *J Bone Joint Surg* 1943;25:319.

# 2. Blount WP. Proximal Osteotomies of the Femur. *Instr Course Lect* 1952;9:1.

+ 3. Bohlman HR. Replacement Reconstruction of the Hip. *Am J Surg* 1952;84:268.

+ 4. Boyd HB, Brindley HH. Nonunion of the Neck of the Femur: Study of 347 Cases. *Arch Surg* 1952;65:169.

* 5. Brown TD, Ferguson AB Jr. The Development of a Computational Stress Analysis of the Femoral Head: Mapping Tensile, Compressive, and Shear Stress for the Varus and Valgus Positions. *J Bone Joint Surg Am* 1978;60:619.

+ 6. D'Arcy J, Devas M. Treatment of Fractures of the Femoral Neck by Replacement with the Thompson Prosthesis. *J Bone Joint Surg Br* 1976;58:279.

+ 7. Dickson JA. The “Unresolved Fracture”—A Protest Against Defeatism. *J Bone Joint Surg Am* 1953;35:805.

+ 8. Garden RS, Mitchell WRD. The Treatment of Cervical Fractures of the Femur. *Proc R Soc Med* 1959;52:866.

+ 9. Gill AB. Arthrodesis of the Hip of Ununited Fractures. *J Bone Joint Surg* 1947;29:305.

+ 10. Huang CH. Treatment of Neglected Femoral Neck Fractures in Young Adults. *Clin Orthop* 1986;206:1171.

+ 11. Itay S, Horoszowski H, Israeli A. Corticosteroid-Induced Osteonecrosis of the Femoral Head. *Orthop Rev* 1984;13:23.

+ 12. Judet R. Traitement des Fractures du Col du Femur par Greffe Pediculee. *Acta Orthop Scand* 1962;32:421.

+ 13. Kyle RF. Operative Techniques of Fixation for Femoral Neck Fractures in Young Adults. *Tech Orthop* 1986;1:33.

+ 14. Malcolm BW, Schatzker J. Subluxation and Dislocation of the Hip: A Complication Following Hip Pinning. *J Trauma* 1981;21:152.

+ 15. Marti RK, Schuller HM, Raaymakers EL. Intertrochanteric Osteotomy for Nonunion of the Femoral Neck. *J Bone Joint Surg Br* 1989;71:782.

+ 16. Meyers MH. Role of Posterior Bone Grafts in Femoral Neck Fractures. *Clin Orthop* 1980;152:143.

+ 17. Meyers MH. Impacted and Undisplaced Femoral Neck Fractures. In: *The Hip: Proceedings of the Tenth Open Scientific Meeting of the Hip Society*. St. Louis: CV Mosby, 1982:239.

+ 18. Meyers MH. Osteonecrosis of Femoral Head Treated with Muscle Pedicle Grafts. *Orthop Clin North Am* 1985;4:741. .

+ 19. Meyers MH, Harvey JP Jr, Moore TM. Treatment of Displaced Subcapital and Transcervical Fractures of the Femoral Neck by Muscle-Pedicle Bone Graft and Internal Fixation. *J Bone Joint Surg Am* 1973;55:257.

+ 20. Meyers MH, Harvey JP Jr, Moore TM. The Muscle-Pedicle Bone Graft in the Treatment of Displaced Fractures of the Femoral Neck: Indications, Operative Technique, and Results. *Orthop Clin North Am* 1974;5:779.

+ 21. Meyers MH, Telfer N, Moore TM. Determination of the Vascularity of the Femoral Head with Technetium-99m Sulfur Colloid: Diagnostic and Prognostic Significance. *J Bone Joint Surg Am* 1977;59:658.

+ 22. Moore AT. The Self-Locking Metal Hip Prosthesis. *J Bone Joint Surg Am* 1957;39:811.

+ 23. Müller ME. *Die Huftnahen Femurosteotomien. 1. Auflage.* Stuttgart: Thieme, 1957.

+ 24. Müller ME. Zur Behandlung der Schenkelhalspseudarthrose. *Z Unfallmed Berufskr* 1957;50:125.

# 25. Müller ME, AllgAwer M, Schneider R, Willenegger H. *Manual of Internal Fixation.* New York, Springer-Verlag, 1979.

+ 26. Nagi ON, Dhillon MS, Goni VG. Open Reduction, Internal Fixation, and Fibular Autografting for Neglected Fracture of the Femoral Neck. *J Bone Joint Surg Br* 1998;80:798.

+ 27. Pauwels F. Der Schenkelhalsbruch ein Mechanisches Problem: Grundlagen d. Heilungsvorganges, Prognose und Kausale Therapie. Beilageheft zor Zeitschrift Für Orthopaedishe Chirogie, Ferdinand Enke, Stuttgart, 1935.

+ 28. Pauwels F. Spatfolgen der Schenkelhalsfraktur (Late Results of Fractures of the Neck of the Femur). *Hefte Unfallheilkd* 1953;45:22.

+ 29. Protzman R, Burkhalter W. Femoral Neck Fractures in Young Adults. *J Bone Joint Surg Am* 1976;58:689.

+ 30. Swiontkowski MF, Tepic S, Rahn BA, Perren SM. The Effect of Femoral Neck Fracture on Femoral Head Blood Flow. *Transactions of the 33rd annual meeting of the Orthopaedic Research Society.* 1987;12:255.

+ 31. Swiontkowski MF, Winquist RA, Hansen ST Jr. Fractures of the Femoral Neck in Patients between the Ages of 12 and 49 Years. *J Bone Joint Surg Am* 1984;66:837.

* 32. Thompson FR. 2.5 Years' Experience with a Vitallium Intramedullary Hip Prosthesis. *J Bone Joint Surg Am* 1954;36:489.

# 33. Weber BG, Cech O. *Pseudoarthrosis.* Bern: Hans Huber, 1976.

# CHAPTER 30

# NONUNIONS AND MALUNIONS OF THE FEMORAL SHAFT AND PATELLA

*Michael W. Chapman*

**M. W. Chapman:** Department of Orthopaedic Surgery, University of California, Davis, Sacramento, California, 95817.

Nonunions of the Femur
Midshaft
Supracondylar Area
Malunions of the Femur
Shaft
Supracondylar Area
Condylar Area
Nonunions and Malunions of the Patella
Nonunions
Malunions
Chapter References

## NONUNIONS OF THE FEMUR

Nonunions of the femur are rare, except in the femoral neck. Both nonoperative and operative treatment methods have high rates of union because of the excellent blood supply to the femur. The most common cause of nonunion (other than in the femoral neck) is an open fracture complicated by infection (15). The etiology of nonunion and the preferred methods of treatment for each section of the femur are quite variable.

### MIDSHAFT

This discussion focuses on nonunions of the midshaft from more than 2.5 cm distal to the lesser trochanter, to within 10 cm of the knee joint. Supracondylar nonunions are discussed in the next section of this chapter. See Chapter 29 for nonunions about the hip.

Because of the development and subsequent popularity of locked intramedullary nailing using closed techniques, nonunions of the femoral shaft are unusual (46). The literature up to 1979 reported an incidence of nonunion of 2.1% in open nailing of the femur and 0.2% in closed nailing of the femur (11). Today, the incidence in closed fractures remains less than 1%. Nonunion is more likely to occur when an open fracture is complicated by infection or when there is loss of bone substance. External fixation is usually indicated for infected nonunions (3). Infected nonunions are discussed in detail in Chapter 133 and Chapter 135. The incidence of nonunion is higher in nonoperative treatment of shaft fractures than with intramedullary nailing. Nonunion is most likely to be a complication of failure of plate fixation of the femur. Nonunions of fractures treated nonoperatively are usually accompanied by shortening, malrotation, and significant angulation. Nonunions accompanying intramedullary fixation are usually in good alignment, but a broken nail may be present. Nonunions with plate fixation are usually accompanied by failure of fixation. Good cortical contact is usually present, but angulation may be a problem.

Delayed union or nonunion after intramedullary nailing can be treated, if the medullary canal is in reasonable alignment, by removal of the original nail and closed reamed intramedullary renailing (27). An open procedure is necessary when alignment of the medullary canal is poor or there is hardware in place that requires removal. With closed intramedullary nailing, bone grafting is usually unnecessary (30). In open procedures, however, onlay cancellous bone grafting should be done routinely (21,36,37). Intramedullary nailing is the preferred method of fixation, except where distortion of the intramedullary canal makes nailing impossible (13). In such cases, plate fixation is indicated, and the principles described for plate fixation of supracondylar nonunions apply (35). Nonunions with defects or severe shortening may need specialized techniques such as allograft replacement, free microvascularized bone grafts (45), newer bone inductive methods (23,24), or Ilizarov techniques (see Chapter 32).

#### *Closed Intramedullary Nailing without Bone Grafting*

For closed intramedullary nailing of a nonunion of the shaft of the femur without bone grafting, follow the basic principles of closed intramedullary nailing described in Chapter 11, Chapter 19, and Chapter 20.

- Place the patient in a lateral decubitus position on a fracture table or on a radiolucent regular table, with the femur to be operated on uppermost. The supine position on a fracture table can be used as well.
- Expose the trochanteric region through a gluteus maximus–splitting incision.
- If an intramedullary nail is present, remove it. If it is a cannulated design, first place a 3.5 mm reaming guide pin. If the nail is broken, it is usually possible to remove it by closed technique. First, remove the broken proximal piece of the nail. Ream the proximal fragment until it is larger than the diameter of the remaining distal portion of the nail. In most nonunions in average-size patients, I use a 15 mm or larger nail. In large patients, I advise a 16 or 17 mm nail. Thus, it is possible to ream up to 15 to 17 mm.
- The distal fragment of the nail can then be removed by one of several techniques. It may be possible, under fluoroscopic control, to grasp its proximal end with a strong bronchoscopy forceps and pull it out. A set of specialized instruments for removal of nails and nail fragments designed by Dr. Robert Winquist is now available from Snap-On MPD (Kenosha, WI). In this set, one of the most useful devices I have found for removal of nails is a series of guidepins in various sizes with bullet tips, together with associated guidepins with no bullet. To remove a cannulated broken nail, insert (under fluoroscopy) the largest ball tip that will fit through the end of the nail and locate the ball just outside the tip of the nail. Then jam this guidepin by driving a non-ball-tip guidepin beside it. Attach the Jacobs chuck T-wrench with flanges to the ball tip guidepin and using a mallet, extract the broken segment. “Easy outs” and other special tools for broken nail removal are also available. If it is impossible to remove the distal section of the nail by one of these techniques, or if the nail is solid, make a small window in the bone distally and tap it out, or open the nonunion site to extract the remaining portion of the nail.
- Once the canal is clear, carry out closed nailing by the usual technique (see Chapter 11, Chapter 19, and Chapter 20). Use a nail at least 2 mm wider than the previous nail, if possible. Ream sufficiently to obtain good cortical contact on both sides of the nonunion, and use a nail that extends distally to within 1 cm of the subchondral bone of the knee. I always use statically locked interlocking nails. I prefer the Alta nail (Howmedica, Rutherford, NJ) because its slap-hammer driver facilitates compression of the fracture. In the vast majority of cases, I lock the nail distally first, impact the fracture by reversing the slap-hammer or by applying an AO distractor in compression, and then lock proximally (Fig. 30.1, Fig. 30.2, Fig. 30.3).

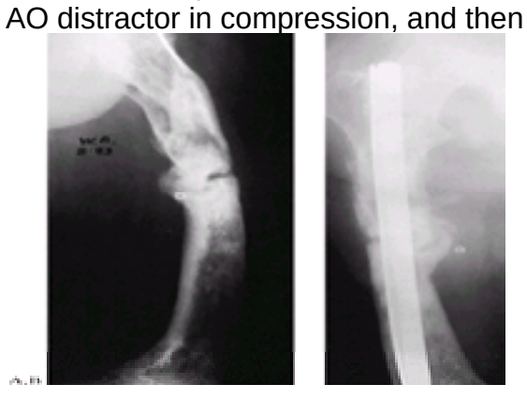

***Figure 30.1.*** **A:**Radiograph of a nonunion of the midshaft of the femur in a 47-year-old man who sustained the fracture 29 years earlier. Treatment was complicated by infection. Thirty previous operations had been performed. At this point, the limb was 1 inch short, the patient had had no recurrence of infection for 5 years, and he had a painful deformity of the femur. **B:** Closed intramedullary nailing using a 17-mm-diameter nail was performed. This AP radiograph shows early union 12 weeks after the procedure. The patient was treated before locking nails were available. Today, the fracture site would have been fixed in

compression with a statically locked nail.

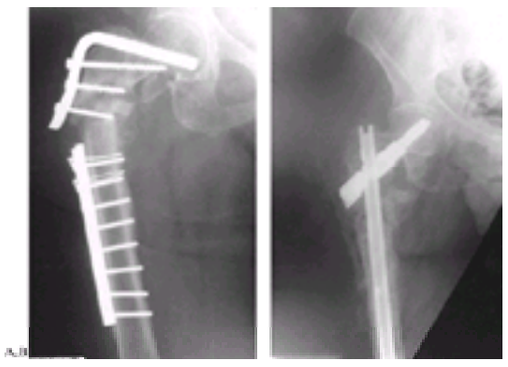

***Figure 30.2.*** **A:** AP radiograph of a subtrochanteric nonunion after blade plate fixation of a comminuted subtrochanteric fracture with failure of the plate. **B:** AP radiograph showing treatment with an Alta rod connector combined with a hip screw and an autologous bone graft.

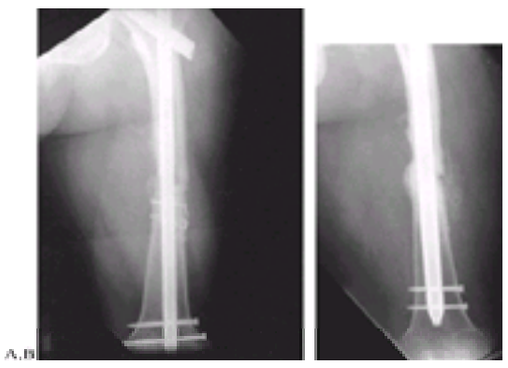

***Figure 30.3.*** **A:** AP radiograph of a 45-year-old man 1 year after ipsilateral concomitant fracture of the femoral neck and shaft treated with an Alta rod connector. There was union of the femoral neck and nonunion of the shaft fracture. **B:** The nonunion was treated by removal of the rod connector and repeat closed nailing with a larger nail with static locking in compression. This AP radiograph shows union 9 months after repeat nailing.

Unless pathologic bone or infection is present, the union rate after repeat reamed closed nailing of femoral nonunions is reported to be 53% to 78% after a single procedure and 87% to 95% after a second procedure (16,19,43). In my personal experience of 41 nonunions of the femoral shaft treated by this technique between 1983 and 1999, the union rate was 78% after one procedure and 95% after two procedures (16).

For proximal shaft and subtrochanteric nonunions, reconstruction nails that provide fixation into the femoral head are usually necessary (2,47) (Fig. 30.2).

***Open Intramedullary Nailing and Bone Grafting***

- If an open technique is indicated, place the patient in the lateral decubitus position on either a regular operating table or on a fracture table, depending on your preference and the technique to be used. Use a direct lateral approach to dissect posteriorly to the vastus lateralis and expose the femur by subperiosteal dissection (see Chapter 3). Preserve the medial and posterior soft-tissue attachments.
- If plates and screws are present, remove them. If an intramedullary nail is present, remove it as described previously. If the nail is broken, it is possible to remove it directly through the nonunion site rather than through the buttock incision. Special techniques are not usually required.

  In most cases, it is necessary to take down the nonunion, open the medullary canal, and freshen the ends of the fracture. Reduce the fracture and carry out locked intramedullary nailing. With an osteotome, petal the femur for 5 cm proximal and distal to the nonunion site and place copious cancellous bone graft around the nonunion site. Close in the usual fashion over a drain.

In most cases of exchanged reamed nailing for nonunions, the nonunion site is in compression and the femur is statically locked postoperatively. This provides solid fixation, which permits early weight bearing and a full rehabilitation program to work on joint range of motion and muscle strengthening. For the first 6 weeks after repair, it is advisable to ask the patient to use assistive devices, but I usually allow them to progress to full weight bearing as tolerated. Thereafter, patients can usually progress to full weight bearing but must avoid activities other than ordinary walking and nonimpact activities such as swimming and stationary bicycling until healing of the nonunion occurs, as heralded by bridging callus or disappearance of the nonunion site seen on two views.

***Dynamization for Delayed Unions or Nonunions***

Prior to the advent of interlocking nails, we treated nonunions with exchanged reamed nailing using first-generation nonlocking nails such as the Küntscher nail (7). This resulted in union rates of 90% or better. The principle with this technique was to allow full weight bearing on a nail, which would allow compression of the fracture site. The same philosophy applies to removing the cross screws from a locked screw to “dynamize” the fracture, allowing weight bearing to cause compression and pulsatile stimulus at the fracture site to promote union. This technique does work and is most effective when the fracture pattern is such that with impaction it becomes rotationally stable, such as in oblique nonunions. In many nonunions, however, the configuration is such that either excessive shortening will occur or rotational stability may ensue. I have also found that the dynamization worsens some patients' pain and is not well tolerated. Currently, I dynamize only when there is no comminution in the fracture site and an oblique pattern is present that will stabilize with weight bearing. It is necessary to remove the cross screws from only one end of the rod, and these should be at the end farthest from the fracture site. This applies only to delayed union or nonunions in the mid diaphysis. In all other fractures with delayed union or nonunion, a much higher success rate will be achieved with exchanged reamed locked nailing with compression across the fracture site.

**SUPRACONDYLAR AREA**

Supracondylar nonunions may be entirely extra-articular or may have an intra-articular component. With interlocking nails, it is possible to treat any nonunion that is sufficiently proximal to the knee joint (a distal segment of 10 cm is required) by placing two distal cross-locking screws. Modification of the nail by cutting off part of its tip to allow it to be placed more distally may permit the treatment of more distal nonunions, but this is a specialized technique. Custom nails can be ordered as well.

Recently, retrograde intramedullary nails inserted through the intracondylar notch of the femur—these nails are specially designed for this purpose—have been advocated for the treatment of supracondylar nonunions. Experience with these nails, however, has not proven successful (P. Tornetta III, personal communication 1999). The nails apparently do not provide sufficient purchase in the distal fragment because of disuse osteoporosis secondary to the nonunion. At present, I do not advise the use of retrograde supracondylar nails for supracondylar nonunions.

Most supracondylar nonunions require bone grafting and internal fixation using a variety of plates. Double-plate fixation comparable to that described for the trochanteric region may be indicated (see Chapter 29). Osteoporosis may make solid screw fixation difficult to achieve. In elderly patients, in cancellous bone, methacrylate can be inserted into the screw holes to improve screw fixation. Cement is not advisable in younger patients because if the appliance must be removed, considerable bone destruction may be necessary to remove it. Consequently, methacrylate is used only as a last resort. Back-up washers and nuts on the screws on the opposite cortex are often helpful. Another useful technique is to take a cortical or corticocancellous bone graft from the tibia or ilium, or a femoral allograft, place it opposite the plate, and fix the screws into this stronger bone. I believe this is more useful than dual-onlay grafts. See the section on periprosthetic fractures in Chapter

20 for a discussion of this technique.

Sometimes, severe osteoporosis, severe comminution of the distal femur, or destruction of the knee joint makes salvage of knee joint motion impractical and internal fixation of the nonunion extremely difficult. In such situations, consider immediate fusion of the knee in combination with treatment of the nonunion. This can be accomplished by double-plate fixation, or with a long intramedullary nail traversing the femur and knee joint into the proximal tibia (4,30). In the series by Beall et al. (4), fusion of the knee was not attempted, and after nail removal preoperative range of motion of the knee was maintained or increased in all cases.

In elderly patients with osteopenic bone and coexisting arthritis of the knee, the morbidity of and low success rate with internal fixation may not justify fixation. Total knee replacement with a modular distal femoral component in some with acute fractures and in difficult nonunions may be a better choice (18). Freedman et al. (18) used the Kinematic rotating hinge knee (Howmedica, Rutherford, NJ cin five patients with difficult distal femoral reconstructive problems after fracture of the femur, and four were restored to ambulatory status with good results on the Enneking rating system. One patient required amputation as a result of deep infection.

***Plate Fixation and Bone Grafting***

- If plate fixation and bone grafting are necessary, use the basic techniques for fixation of the shaft or supracondylar fractures of the femur (see Chapter 20 and Chapter 21). Place the patient in a supine position on a radiolucent operating table with a C-arm fluoroscope available.
- Use an anterolateral exposure (10) because visualization of the condyles of the femur and knee joint is often necessary. Try not to strip the medial and posterior surfaces. I have never found release of the patellar tendon to be necessary.
- Remove any hardware and correct any secondary deformity. A fibrous union in good position can be internally fixed in position; otherwise, take down the nonunion, freshen the bone ends, open the medullary canal, and refashion the bone ends to correct any deformity and maximize bone contact. Fixation choices include the AO 95° condylar blade plate, a dynamic compression screw and side plate, or the Alta distal condylar plate or 95° screw or bolt and side plate. I no longer use the AO condylar plate because it is difficult to use and not as versatile as the newer devices. (See Fig. 30.4, Fig. 30.5). Chapter 21 describes the full operative technique.

***Figure 30.4.*** **A:** AP radiograph of a 24-year-old woman 18 months after a T-type supracondylar fracture of the femur treated with an AO T plate. She has a painful nonunion with shortening and a varus deformity. **B:** AP radiograph of treatment with an Alta distal 95° condylar plate and screw combined with autologous bone graft.

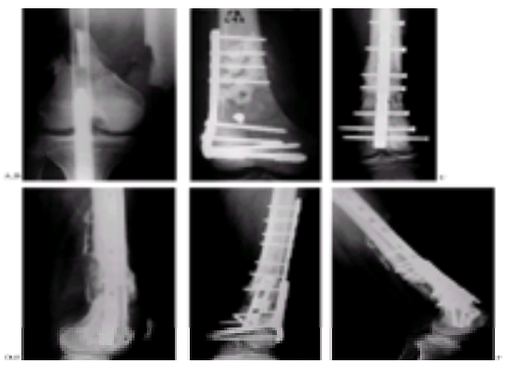

***Figure 30.5.*** Supracondylar femoral nonunion. **A:** AP radiograph of the femur in a 35-year-old man who sustained a grade 3A open comminuted supracondylar fracture. **B:** After irrigation, debridement, and plate fixation, the fracture became infected and went on to a nonunion. This AP radiograph shows the original internal fixation with antibiotic beads in place. **C,D:** The plate and screws were removed and after resolution of the infection, the original treating physician internally fixed the fracture with a retrograde supracondylar nail. Unfortunately, this failed as well, resulting in a persistent nonunion. **E,F:** I first encountered the patient 18 months after the original fracture. There had been no evidence of infection for 15 months. I removed the nail and screws, and through an anterolateral approach applied an Alta lateral plate assembly. I augmented this with a smaller anterior plate and applied an iliac crest bone graft. The nonunion healed in 16 weeks with no recurrence of infection. Knee motion was from full extension to 110° of flexion.

- If necessary, add a second anterior 3.5 or 4.5 mm narrow or reconstruction plate with six holes to place three bicortical screws in each fragment. Make this plate shorter than the side plate proximally. Obtain interfragmentary lag screw compression if possible.
- Petal the bone about the fracture site, apply an onlay cancellous bone graft, and close over suction drainage.

Other specialized plating techniques include the “wave” plate (14,38) and an intramedullary plate (31). Cove et al. (14) advise wave plating when treating nonunions where there is a segmental defect more than 5 cm in length, where there has been a history of sepsis, or where the medullary canal is unsuitable for intramedullary nailing. Wave plating involves molding the plate into a wave configuration so that it stands out from the femur throughout the zone of bone deficiency and nonunion. This permits the placement of a large volume of bone graft, which promotes union, makes for a structurally stronger union when it occurs, and permits the use of a free microvascularized fibular transfer. Using the wave plate method, Ring et al. (38) achieved union in 41 of 42 consecutive complex ununited fractures of the femoral shaft at an average of 6 months after fracture. Three required a second bone graft, and two had recurrence of infection; in one of these there was a persistent nonunion. Matelic et al. (31) have promoted the use of an AO dynamic compression plate placed in an intramedullary location to serve as a medial buttress in fresh fractures and nonunions where there is medial bone deficiency. The advantages of the intramedullary location are that less soft-tissue stripping (and thus devascularization) of the bone is necessary; more surface area at the fracture site is available for bone grafting; and the screw fixation from the accompanying lateral plate can be inserted through the intramedullary plate, increasing the strength of fixation and buttressing the medial cortex. The primary disadvantage of endosteal plating is that it is technically demanding, resulting in long surgery times and increased blood loss. In seven patients with complex nonunions of the distal femur, Cove et al. (14) achieved union in all with an average time to union of 19 weeks (Fig. 30.6).

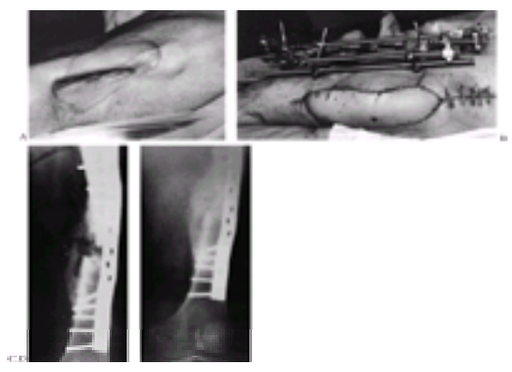

***Figure 30.6.*** Wave plate: **A:** A 27-year-old man presented with an infected nonunion of 13 months duration. **B:** Debridement was performed with application of an external fixator, using a latissimus free flap to cover the defect at a subsequent debridement 2 weeks later. **C:** Three weeks after soft-tissue coverage, the patient underwent stabilization using a 16-hole broad dynamic compression plate with wave configuration augmented with iliac crest bone graft. **D:** At 7 months, the fracture had consolidated, and the patient was fully weight bearing without pain. (From Cove JA, Lhowe DW, Jupiter JB, Siliski JM. The Management of Femoral Diaphyseal

Nonunions. *J Orthop Trauma* 1997;11:513, with permission.)

Figure 30.7 shows an AO broad plate used as a medial buttress, combined with a 95° angled blade. The technique of using a medial endosteal buttress plate is as follows (31):

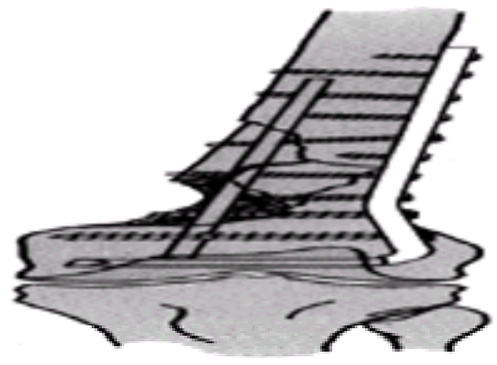

***Figure 30.7.*** Medial endosteal buttress plate. An AO broad plate is used as a medial buttress, combined with a 95° angled blade plate. (From Matelic TM, Monroe MT, Mast JW. The Use of Endosteal Substitution in the Treatment of Recalcitrant Nonunions of the Femur: Report of Seven Cases. *J Orthop Trauma* 1996;10:1, with permission.)

- Use an articulating tension device or a femoral distractor to distract the fracture.
- Use a gouge and curet to make a trough in the distal metaphysis on the medial aspect to allow the intramedullary plate to be seated against the blade.
- Insert the plate into the intramedullary canal in a retrograde fashion and then, using a curved impactor, drive it into the prepared trough to abut against the blade.
- Then reduce the fracture by diminishing the distraction force and allowing the fracture surfaces to oppose.
- Insert two or three screws into the lateral cortex only and impact them against the plate, pushing it medially.
- Insert the other screws through the holes in both plates. To accomplish this, use a 3.2 mm drill to drill the lateral cortex with the appropriate drill guide. Then pass a 1.6 mm Kirschner wire (K-wire) through the hole and use it to feel the holes on the medullary plate. When you know the direction, direct the drill in the same path toward the medial cortex, and penetrate it. Insertion of these screws is frequently skewed so that the screws actually thread the hole in the plate as they pass into the medial cortex. This ensures the blocking action of the plate. In Figure 30.7, the fifth screw from the top would have this effect. The medial plate is thus locked between the blade and the screws.

Postoperatively, begin motion immediately to preserve and improve knee range of motion. In most cases, continuous passive motion can be started after drain removal and continued until the patient can actively carry out range-of-motion exercises. Active assistive exercises with a therapist are helpful. With good internal fixation, external protection is usually unnecessary. Confirm the presence of bone union with four-plane radiographs or anteroposterior (AP) and lateral tomograms before beginning full weight bearing.

***Infected Nonunions of the Femur***

The treatment of infection is addressed in Chapter 132, Chapter 133, and Chapter 135. A few comments about the treatment of infected nonunions are pertinent here. The general principles in the treatment of infected femoral diaphyseal nonunions are well outlined in the algorithm advocated by Cove et al. (Fig. 30.8) (14). In treating infected nonunions, the first step in the vast majority of cases is eradication or control of the infection, followed by restoration of the soft-tissue envelope (23). Generally, this requires a radical debridement of the nonunion site, removing all scarred soft tissues that are impairing revascularization and all necrotic bone. Take cultures to identify the infecting organisms. In the femur, stabilization to maintain alignment and length is essential. Although traction can be used, in most cases the period of time that stabilization in the absence of internal fixation will be necessary is such that external fixation is best. If the infection can be resolved and there are particular advantages in converting from external to internal fixation, such conversion may occur, but definitive treatment to union in external fixation may be necessary. Usually, several debridements are necessary and treatment with intravenous antibiotics for up to 6 weeks, with suppressive oral antibiotics for longer, may be necessary.

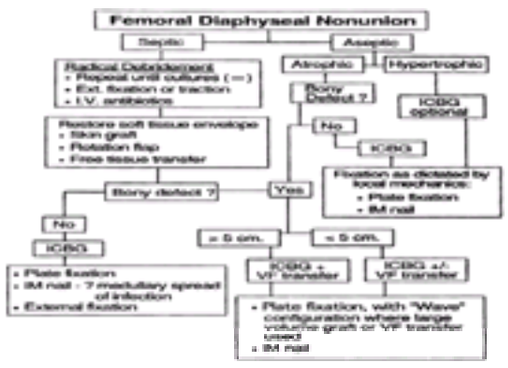


***Figure 30.8.*** Clinical algorithm for treating femoral nonunion. (From Cove JA, Lhowe DW, Jupiter JB, Siliski JM. The Management of Femoral Diaphyseal Nonunions. *J Orthop Trauma* 1997;11:570, with permission.)

The success of treatment of nonunion is greatly enhanced by having a well-vascularized muscular envelope completely around the fracture. This is usually not a great problem in the femur because of the large muscle envelope of the thigh, but skin grafts, rotation flaps, and free tissue transfer may be necessary to provide an appropriate environment for definitive treatment of the nonunion (40). Ilizarov techniques may be appropriate for the particular fracture (see Chapter 32 for details).

Once the infection is eradicated or well controlled, then iliac crest bone graft in external fixation usually suffices for those nonunions without a major gap. Usually, conversion from external fixation to intramedullary nailing is not appropriate because of the high risk of infection, but conversion from the external fixator to plates may be appropriate. In such cases, removal of the external fixator to allow the pin tracks to heal prior to open plate fixation is usually advisable. In the interim, stability and length can be maintained with a cast-brace with intermittent traction if necessary. For larger defects, iliac crest bone graft combined with a vascularized fibula may be necessary (46). Slätis and Paavolainen (41) advocate one-stage treatment of infected nonunions of the femoral shaft by excision of dead and infected tissue, resection of bone ends, cancellous bone grafting, and external fixation. They were successful in four of five cases. This small series, however, does not prove the efficacy of this method, and I prefer the staged approach advocated by Cove et al. (14) (Fig. 30.8).

In my own series of 21 supracondylar femoral shaft nonunions treated between 1983 and 1997, using plating and bone graft, I was able to achieve union in 95% (10). In most series, overall success rates for treatment of aseptic and septic nonunions of the femur are 70% to 97% (4,5,13,14,25,27,31,38,39,40 and 41).

## MALUNIONS OF THE FEMUR

### SHAFT

Malunions of the femoral shaft are not uncommon. In my experience, they occur most often after treatment with cast-braces, which is rare today, or after treatment of unstable and/or open fractures with small intramedullary nails. Almost all malunions of the shaft show combined deformities of malrotation, angulation, and shortening.

Shortening of more than 2.5 cm necessitates a cumbersome shoe lift and causes considerable inconvenience to active patients. It generally requires correction either by lengthening the shortened femur or by shortening the contralateral femur (12). Malrotation is better tolerated in external rotation than in internal rotation. As long as there is at least 10° to 15° of rotation beyond neutral in either external or internal rotation, patients rarely have functional problems. When they cannot rotate to neutral, significant functional problems usually require correction of the malrotation. Inability to rotate the extremity at least to a neutral position places the knee and ankle joints out of the plane of progression for walking. This produces an inefficient and unsightly gait and interferes with sports activities.

Minimal to moderate angulation is better tolerated than significant malrotation or shortening. There are three indications for correction of angulation: poor function, often accompanied by pain; poor cosmesis; and the potential for late degenerative arthritis due to abnormal stresses across the knee joint (26). Decisions to undertake surgical correction for the first two complaints depend not so much on the degree of angulation present as on the patient's complaints. Generally speaking, angulation of less than 10° rarely produces significant functional or cosmetic impairment. Angulation of more than 20° almost always creates problems for the patient. The effect of angulation on joint function and possible late degenerative arthritis is more difficult to judge. In most patients, angulation of less than 10°, particularly in the middle third of the shaft, rarely creates problems. The preexisting alignment of the patient's legs, however, has a major effect; for example, a patient with preexisting genu varum may not tolerate an additional 10° of varus angulation and may require surgical correction. Generally, angulation of more than 15° requires correction in active patients. These are multifactorial decisions that require close consultation with the patient. The goal of restoration of the mechanical axis of the extremity is discussed in Chapter 26 and Chapter 32.

The type of surgical procedure indicated for correction of malunion of the femur depends on the degree of deformity, the alignment of the medullary canal, and the location of the deformity. From a technical viewpoint, open procedures are the easiest to perform, but many deformities of the femur are correctable by closed intramedullary osteotomy and nailing techniques. Ilizarov techniques have added a whole new dimension to the treatment of malunions (see Chapter 32).

Malunions in recently united fractures have soft callus. In most cases, it is best to expose the fracture site, take down the malunion, and restore the normal anatomy of the femur. Late malunions with significant remodeling are difficult to take down through the original fracture site, and various osteotomies are applicable.

### *Closed Intramedullary Osteotomy*

Closed intramedullary osteotomy is a specialized technique that requires significant experience with closed intramedullary nailing (9,17,44). For this technique, the offset in the diameter of the medullary canal must be less than 25%. Alignment must be good enough to allow the passage of intramedullary instruments and a nail down the medullary canal of the femur past the deformity. The technique is best suited for correction of shortening of less than 5.0 cm and for correction of malrotation. In some cases, angulation is correctable as well, but often an open osteotomy to realign the femoral canal is necessary. In malunions of the middle third of the shaft, internal fixation with medullary nails rather than plates and screws is preferred because failure is less likely and immediate weight bearing is possible in most cases.

- Place the patient in the lateral decubitus position on a fracture table with the extremity to be operated on uppermost (see Chapter 11 and Chapter 20). Prepare and drape from buttocks to the tibial traction pin. Through a gluteus-splitting incision, expose the piriformis fossa of the femur.
- If an intramedullary nail is already in place, the procedure is greatly simplified; remove the nail and insert a reaming guide pin. If a nail is not present, it is necessary to reestablish the patency of the medullary canal. In some cases, a 3.5 mm guide pin can be passed directly down the canal, and reaming can proceed. In other cases, the medullary canal at the fracture site is blocked by callus and must be reopened. To achieve this, a set of recently sharpened, heavy, flagged Küntscher guide pins or hand reamers must be available. If angular deformity is present, one of the guidepins will need a bent tip.
- First, place a reaming guide pin down to the blockage and progressively ream the canal to the size required for the nail to be inserted. For these osteotomies, larger-than-normal nails are used; in the average-size man, I use at least a 16 mm nail. Enlarging the proximal canal allows better working room for the guides necessary to perforate the blockage.
- Insert a sharp-tipped guide pin of the appropriate curvature and drive it with a mallet into the bone blocking the canal. Take care to remain in the central axis of the canal. If a straight-tipped pin is used, this can be attached to a power source and the blockage drilled. If the bone is soft, direct penetration may be possible. Otherwise, it will be necessary to withdraw the sharp-tipped guide pin after penetrating 1 cm or so. Reinsert the reaming guide pin, and with the end-cutting reamer open the canal in the perforated portion. Alternate these two methods until the blockage is opened. If the blockage is in the proximal half of the femur, the hand reamers from the AO instrumentation are useful as well. This technique can be difficult and time consuming.
- Rather than spending inordinate amounts of time trying to open the canal by closed technique, I often open the malunion site and perform an open osteotomy. Once the canal is open, insert the reaming guide pin distally to the subchondral bone at the knee, and progressively ream the canal to the desired diameter.
- With closed technique, insert the Pearson intramedullary saw (Fig. 30.9) and transect the femur at the appropriate level. In preoperative planning, it is important to select an osteotomy site slightly proximal or distal to the fracture site in normal bone. Closed osteotomies at the old fracture site give the most precise correction, but an incomplete cut due to asymmetry of the canal will require osteoclasis, or percutaneous insertion of a 0.25-inch osteotome from the lateral side of the thigh, to complete the osteotomy.

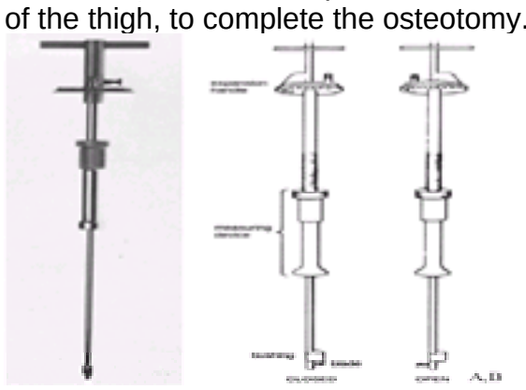

***Figure 30.9.*** Intramedullary saw for osteotomy of the femur using the closed intramedullary technique. The cutting blade at the distal end works on the principle of a cam and is available in diameters of 12 to 17 mm. (Courtesy of Biomet, Bourbon, IL.) **B:** Saw with parts labeled. (From Winquist RA, Hansen ST Jr, Pearson RE. Closed Intramedullary Shortening of the Femur. *Clin Orthop* 1978;136:54, with permission.)

- When straightening an angular deformity, drive the nail into the central portion of the distal femoral condyles. This will correct any angular deformity.
- If malrotation is present, place two Steinmann pins or Schanz screws, one above and one below the osteotomy, for rotational control before performing the osteotomy. Place these pins directly lateral, with one in the proximal fragment and one in the distal fragment, through only the lateral cortex of the femur. Do not penetrate the medullary canal proximally or the pin will interfere with the saw. Place the pins in alignment with each other initially, and then measure the angulation between the pins after correction of the deformity. Before surgery, make a template by bending a K-wire or cutting a piece of sheet aluminum to measure the rotational angle. A commercially available goniometer can be used instead, but this is more difficult to read.
- Maintaining rotational correction during the drive of the medullary nail can be difficult. For this reason, I prefer to use the Chick-Langren table (Kirshner Medical, Greenwood, SC), where the extremity is controlled by a large, threaded Steinmann pin through the proximal tibia or distal femur attached to the traction apparatus of the table. This gives nearly absolute control during the nailing.
- Then drive an interlocking nail, which can be statically locked. If the limb is less than 2.5 cm short, this discrepancy can usually be corrected at the same time by distraction and closed intramedullary bone grafting (Fig. 30.10) (8). Although length can be gained through the traction apparatus of the fracture table, it is more effective, and safer, to use an AO femoral distractor. Attach the two Schanz pins inserted as guides for correction of rotation to the femoral distractor. Distract slowly over 15–20 minutes. To avoid excessive traction on the sciatic nerve, do no soft-tissue releases and keep the knee flexed to 90° during the lengthening. Although I have had no difficulty with the sciatic nerve with acute lengthenings of less than 2.5 cm, it is advisable to use sensory-evoked potentials to monitor function in the sciatic nerve during lengthening. Johnson has performed acute lengthenings of 0.4–3.3 cm using an open technique with various bone grafting materials and has achieved healing in 18 of 19 patients (22,23).

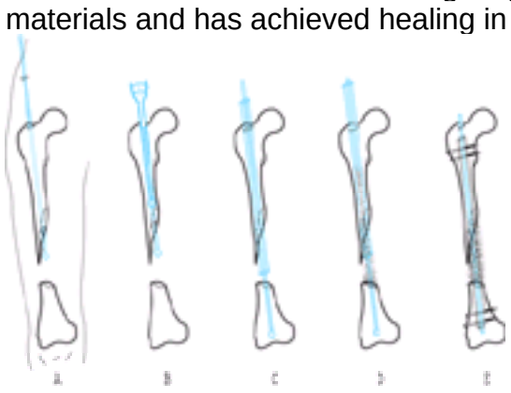

***Figure 30.10.*** Closed intramedullary bone grafting and nailing. **A:** Insert a guide pin. **B:** Ream the proximal femur. Do not ream in the gap if it is necessary to ream distally. Save the reamings. **C:** Pass the guide pin into the distal fragment. Insert a large chest tube down to the fracture. **D:** Push reamings and finely

morcelized graft down the chest tube by hand, using the flexible shaft from the AO medullary reamers. Overfill the defect site. **E:** Insert an intramedullary nail, which is statically interlocked. (From Chapman MW. Closed Intramedullary Bone Grafting and Nailing of Segmental Defects of the Femur. *J Bone Joint Surg Am* 1980;62:1004, with permission.)

- When lengthening is anticipated, save all medullary reamings and bone marrow. For lengthenings of less than 2.5 cm, this will provide enough grafting material to fill the defect. If insufficient graft is available, harvest cancellous bone from the inside of the greater trochanter through the entry site for the nail. If more is needed, obtain cancellous bone from the posterior ilium. Morcelize this bone finely with a bone-cutting forceps or bone mill.
- With the reaming guide pin in place, insert a large plastic chest tube down the medullary canal into the defect site. Cut the chest tube to allow about 4 inches to protrude from the top of the femur. Hold the chest tube in place with a Kocher clamp on the top of the tube. It is possible to place the chest tube by fluoroscopy using the radiographic marker in the chest tube. Insert the morcelized bone graft into the chest tube; do not place too much at one time because it may jam in the tube. Place the smaller, flexible AO reamer shaft, without the reaming head, over the guide pin and use it to push the graft into the defect site. Completely fill the defect site with cancellous bone and reaming materials. This is a meticulous and time-consuming technique. Overfill the defect site with graft. After inserting the bone graft, ensure that length has been maintained, then insert and statically lock an intramedullary nail.

I have used this technique in 15 patients. Union occurred in all 15, and no refractures occurred after removal of the nail. Substantial remodeling is necessary to achieve adequate strength, so I advise leaving the nail in for no less than 24 months. In the two cases for which lengthening of 4 cm or more was performed, supplemental open cancellous bone grafting was later necessary due to inadequate bone stock at the defect site (union had occurred, however).

This technique is also useful in selected defects in the femur caused by open fractures with bone loss. In the latter case, irrigate and debride the wound, initially leave it open, and subsequently close it. Maintain the length of the femur by skeletal traction. At 21 days, when the wound has healed satisfactorily and there is no evidence of infection, perform closed intramedullary bone grafting.

***Closed Intramedullary Shortening of the Contralateral Femur***

A separate lengthening procedure with an external fixator is usually necessary when the discrepancy is more than 2.5–3.0 cm. In these cases, an alternative technique to equalize leg lengths is to shorten the contralateral femur using a closed intramedullary technique. Shortening the contralateral femur is technically much easier and safer than lengthening. Although originally described by Küntscher, this method was popularized by Winquist et al. (44) (Fig. 30.9, Fig. 30.11). Although the technique shortens the patient's overall stature, and in large corrections will affect overall body proportions, it is technically a much simpler technique than lengthening, and it offers the advantages of immediate weight bearing, early union, and early return to function (Fig. 30.12).

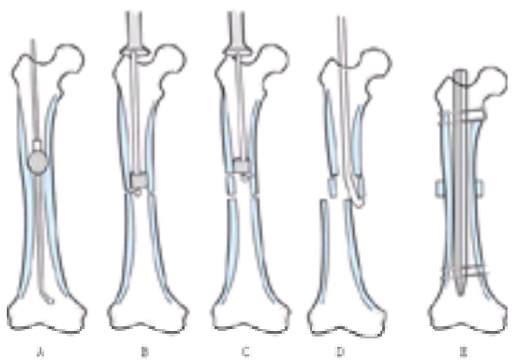

***Figure 30.11.*** Closed intramedullary shortening of the femur. **A:** Ream the medullary canal to the appropriate size—usually 15–16 mm in the average-size male. Remove the reaming guide pin. **B:** Make the distal saw cut first, in the middle of the isthmus of the femur. **C:** Make the second saw cut proximally at the appropriate distance from the distal cut. **D:** Insert the back-cutting chisel and split the intercalary fragment along the linea aspera. Manipulate the fragments outside the gap with the chisel, or push them out of the way with a small Küntscher nail. **E:** Insert the intramedullary nail over a driving guide pin and shorten the femur as the nail is driven. (Redrawn from Winquist RA, Hansen ST Jr, Pearson RE. Closed Intramedullary Shortening of the Femur. *Clin Orthop* 1978;136:54, with permission.)

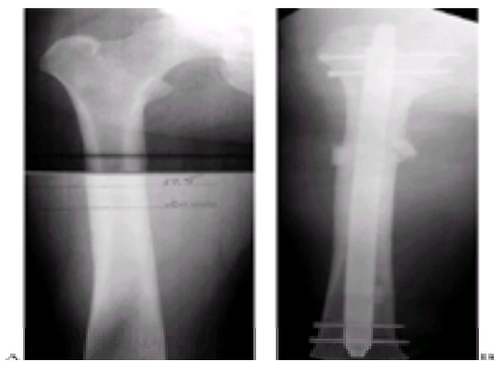

***Figure 30.12.*** **A:** Preoperative AP radiograph showing the planned osteotomy sites to equalize a leg-length discrepancy of 25 mm. **B:** Postoperative AP radiograph showing correction of the leg-length discrepancy with a locked Alta nail for fixation.

**Preoperative Planning** Preoperative planning is extremely important. Determination of the actual leg-length discrepancy can be difficult. I have not found scanograms to be consistently reliable, so I use them only for confirmation of other measurements. The best technique is to place blocks under the short leg of the standing patient to level the pelvis. Rely on your judgment of the correction of the discrepancy and the patient's feelings about the correction. Try to obtain a level pelvis and take into account any distortion of the pelvis that may be present from old trauma or developmental or congenital abnormalities. Then confirm the clinical measurement by taking an AP radiograph of the pelvis with the patient again standing on enough blocks to correct the leg-length discrepancy. Use either the film or a horizontal marker to establish a level plane of reference. Take full-length AP and lateral radiographs of the femur to be shortened to ensure that there is no abnormality that would contraindicate shortening.

If bilateral femoral trauma has occurred and shortening is to be performed on a previously fractured femur, the osteotomy must be performed in an area of normal bone, preferably proximal to the fracture site. Using the preoperative radiographs, plan the site of the osteotomies and measure their distance from the tip of the trochanter, taking into account x-ray magnification.

Intraoperative blood loss is usually less than 500 cc; however, postoperative bleeding into the thigh can result in up to a 40% drop in the hemoglobin level. In young healthy patients, transfusion is rarely required.

**Technique**

- Place the patient in the lateral decubitus position on a fracture table with the extremity to be operated on uppermost, and expose the entry to the medullary canal in the usual fashion (see Chapter 11 and Chapter 20).
- Insert a 3.5 mm reaming guide pin. Progressively ream the medullary canal to the desired size. In closed shortening, the saw is more likely to transect the femur if a larger saw is used and the canal is reamed widely. With a reamer of known diameter in the site of the proposed saw cut, visualize the femur on a lateral view. The size of the reamer provides a guide to the size of the saw needed to cut through the linea aspera. Take care in smaller patients not to overream the femur. Overthinning of the anterior cortex will result in comminution and inability to complete the osteotomy. Intraoperative monitoring of the reaming process by fluoroscopy avoids this problem. When reaming a closed intramedullary canal, make a 5 mm or larger drill hole in the distal metaphysis of the canal to decompress the canal to reduce the embolization of marrow contents. Proceed slowly with reaming and progress by 0.5 mm increments. Although it has been

reported, I have never encountered fat embolism syndrome or adult respiratory distress syndrome after closed intramedullary osteotomy (Fig. 30.11*A*) (20).

- Set the medullary saw for the most distal cut first. Insert the saw and verify by fluoroscopy that it is in the appropriate position. Make the saw cut. Because of the teardrop cross-sectional shape of the femur, if the saw used is too small, the cut may be incomplete posteriorly. Either place a larger saw or complete the osteotomy, either by osteoclasis or by placing a 5 mm osteotome percutaneously from a lateral approach to cut the remaining bridge. In most cases, sufficient reaming can be done to allow a large-enough saw to make a complete cut (Fig. 30.11*B*).
- Carefully set the measuring device on the saw for the second osteotomy, insert the saw, and verify correct position by fluoroscopy. The cam of the cutter is 15 mm long, providing a useful reference to verify the length between cuts. Make the second cut. An incomplete cut can make displacement of the intercalary fragment difficult. If only a small bridge of bone remains, insert a 12 mm Küntscher nail down to the proximal osteotomy and abduct the proximal fragment. A firm blow to the tip of the fragment will often break it free. If this does not occur easily, then percutaneously insert a 5 mm osteotome from a lateral approach and transect the bone bridge. Occasionally, bone spikes are left on the main shaft fragments, which will prevent complete shortening; these can be removed by a percutaneous osteotome if necessary (Fig. 30.11*C*).
- Next, split the intercalary fragment using the back-cutting osteotome supplied with the medullary saw. Under fluoroscopic control, insert the back-cutting osteotome and pull it firmly against the distal surface of the intercalary segment at the linea aspera. Hold it firmly in position and gently tap the handle of the saw with the slotted mallet to cut the intercalary fragment. A single cut usually splits the fragment into two halves (Fig. 30.11*D*).
- Displace the intercalary fragments out of the osteotomy site. This can be done by pulling them to the side with the back-cutting osteotome, or they can be pushed out into the soft tissues with a small Küntscher nail inserted into the medullary canal. As long as one end of the intercalary fragments lies outside the femoral shaft, they will come to lie outside the osteotomy site and adjacent to the femoral shaft when shortening is performed. The preferred location for the intercalary fragments is medial, although generally one fragment ends up medial and the other lateral.
- Insert a driving guide pin and drive an interlocking medullary nail into position; the nail should be 1 mm in diameter smaller than the canal was reamed. To accomplish shortening, it is easiest to drive the nail until it just exits the proximal fragment. Loosen the traction and manually shorten the femur to close the osteotomy and bring the tip of the nail just into the distal fragment. While manually holding the osteotomy closed and maintaining proper rotation, drive the nail into position. If distraction occurs during the drive, extract the nail until the osteotomy closes and then redrive it while holding the osteotomy closed. I always interlock both distally and proximally. Lock distally first, impact the osteotomy to close it and achieve compression, and then lock proximally (Fig. 30.11*E*).
- Wash and debride the entry wound thoroughly to help prevent heterotopic bone formation. Close the wounds in layers. Do not use a drain.

**Postoperative Care** After shortening, considerable hemorrhage into the thigh can occur. Without blood replacement, I have seen a drop in the hematocrit in some patients into the low 20s. Monitor the hemoglobin or hematocrit on a daily basis until it stabilizes. Immediately apply a knee immobilizer in the operating room, with good thigh coverage to compress the thigh; this may help control hemorrhage. Because of the shortening, patients lose some control of the quadriceps and hamstring muscles and will have an unstable knee immediately after surgery. The knee immobilizer controls the knee and allows immediate weight bearing. Start the patient immediately on knee range-of-motion and thigh muscle progressive resistance exercises. Patients can bear weight as tolerated wearing the knee immobilizer and using crutches. With shortening of 2 inches or less, most patients gain sufficient quadriceps control that the knee immobilizer can be abandoned after 6 weeks. Most patients will switch from crutches to a cane at that time, and within a few additional weeks will be fully weight bearing without assistive devices (Fig. 30.12).

## HINTS AND TRICKS

- Perform closed intramedullary shortening of the femur only in the lateral decubitus position on a suitable fracture table. Full access for the instrumentation is critical and is not really possible in many patients in the supine position. It may be feasible to do this procedure in the lateral decubitus position on a regular radiolucent operating table, but I have never attempted it.
- During preoperative planning, note how much anterior bow the femur has on the lateral view, and the thickness of the linea aspera. The saw is straight, so the cut needs to be located where the saw will fit. A very bowed femur will make passage of the saw very difficult distally. In addition, try to select an area for the osteotomy where the linea aspera can be cut completely through by an appropriate-size saw.
- Although routine intramedullary nailing can be done through a fairly small proximal incision in the buttocks, for this procedure I recommend an incision at least 10 cm in length with good exposure of the posterior aspect of the greater trochanter, because the need to repeatedly enter the canal with instrumentation requires good exposure. In addition, the length of the cut is determined by the placement of the measuring device of the intramedullary saw against the tip of the greater trochanter. It is necessary to reproduce this position when the saw is inserted for the second cut. This necessitates having no soft tissues in the way.
- Protect and be gentle with the gluteus musculature: One of the primary problems in rehabilitation is regaining abductor muscle strength.
- The entry for the nail must be directly above the medullary canal. An eccentric entry will complicate entry of the medullary saw and nail.
- Entering the saw into the medullary canal can be difficult. Reaming the entry hole several millimeters larger than the saw is helpful. When placing the saw, enter from slightly posterior to the long axis of the femur and screw the saw into place. The saw is easily bent, so be gentle with it.
- When seating the saw for the first cut, be certain that the measuring device is firmly implanted on the tip of the greater trochanter and that all components of the saw are fully closed. During the cut, be certain that this position is maintained. Reproduce it for the second cut. Lack of attention to these details can lead to incorrect shortening.
- When selecting the place for the two saw cuts, pick a place where there is no pathology in the femur, where there will be good purchase of the intramedullary rod with the inner wall of the cortex in both the proximal and distal fragments, and where the linea aspera is as narrow as possible. Be certain that you are within the operating length of the saw.
- When cutting with the saw, always advance it in a clockwise direction. Do not reverse it, as this may catch and break off the blade. Once the saw breaks through the anterior cortex, be careful not to advance it too much between cuts, as it may catch and again break. Never force the saw.
- The linea aspera is always the last section to be cut through. This can be enhanced by angulating the saw gently within the canal to press it against the posterior aspect. Try to avoid incomplete cuts, because subsequent completion of the cut is complicated, as is closure of the osteotomy.
- When driving the nail, if difficulties are encountered in keeping the osteotomy closed, use a nail that is smaller in diameter and/or shorter, because this will facilitate sliding of the bone on the nail. Recognize that this decreases the stability of the nailing.
- Shortening becomes increasingly difficult as the length of the intercalary segment removed increases. Little difficulty is encountered in shortening up to 3 cm. The most I have shortened at one time is 6.5 cm. Closure of the osteotomy in such extreme shortenings is difficult because of bunching of the soft tissues, and it may require use of an AO universal distractor placed into compression to close the osteotomy.
- For closed shortenings, I prefer the Alta system (Howmedica, Rutherford, NJ) because the versatility of the location of the cross-locking holes permits more flexibility in placement of the nail and the slap-hammer driver is very useful in closing down the osteotomy (as described early in this chapter).
- In preoperative planning, be certain to accommodate for the shorter nail that will be required once the femur is shortened. In shorter patients, nail size can be a problem because the large of amount of reaming necessary to use the saw requires a large-diameter nail, which may not necessarily be routinely available in short lengths. Be certain that nails of the appropriate length and diameter are available.
- The only nonunions I have seen in closed intramedullary shortenings have occurred when the osteotomy was not fully closed down, and when the nail used had a diameter that was more than 1 mm smaller than the saw. Be certain that the osteotomy is absolutely closed down tightly on both AP and lateral views. Beware of parallax, because if the central beam of the x-ray is not exactly at right angles to the osteotomy, you can be fooled. Try to use a nail that is no less than 1 mm in diameter smaller than the saw used.
- Finally, it is very important to carefully examine the extremity on the operating table under anesthesia after completion of the shortening, to be certain that leg length equalization is appropriate. For shortenings of 2.5 cm or more, plus or minus 5 mm will leave most patients satisfied, although I try to get them exact. Verify that rotation has not changed because occasionally the proximal fragment will rotate externally because of muscle pull, which will result in nailing in too much internal rotation. In more than 75 closed intramedullary shortenings, I have experienced this only a couple of times. We corrected it by reprepping the knee, pulling the distal cross-locking screws, rotating the femur to the correct position, and then reinserting the screws.

**Complications** Most problems and complications from closed intramedullary osteotomy of the femur can be avoided by following the technical guidelines just discussed. Avoid inadequate correction of deformity and inadequate fixation by good preoperative planning. Closed intramedullary osteotomies are technically challenging and require considerable experience with intramedullary nailing techniques. I advise that the surgeon gain considerable experience with routine fracture fixation using closed intramedullary nailing before attempting these osteotomy techniques. Avoid comminution by not overreaming. I have not had an infection or nonunion from closed shortening.

With shortening of less than 2.5 cm, muscle function returns rather quickly. By Biodex measurement (Biodex Medical Systems, Inc., Shirley, NY), most return to within a few percentage points of normal (9). With shortening of more than 2.5 cm, at least 1 year is required to achieve 90% of normal muscle function, and most patients are left permanently with about 5% of residual weakness. In my patients, this has never been of functional significance. Because union of the osteotomy is almost always present by 6 weeks and quite mature at 12 weeks, the reestablishment of muscle function and joint range of motion is the major determinant of return to sports and vocational activities.

Because equalization of leg lengths is generally performed in active patients, most will want the nails removed. Although I have removed them as early as 9 months after surgery, I advise most patients that removal is best delayed to 1 year.

Occasionally, a patient will develop some heterotopic bone about the tip of the medullary nail that is symptomatic. Because these patients are quite active, a nail that is left protruding will also be symptomatic. In most cases, you can emphasize to patients that you are operating on a normal extremity and that they will be left with some residual disability, including a scar in the buttock, and that some patients will have minor, long-term discomfort in the operative site. This has discouraged none of my

patients from having the surgery, because the benefits of equal leg lengths far outweigh these minor residuals.

### *Open Osteotomy with Intramedullary Nailing*

Open osteotomy is technically much simpler than closed osteotomy, but it has the disadvantage of slightly higher rates of infection and nonunion. Before interlocking nails were available, step-cut osteotomies were used to gain rotational control and better stability. With locked nails, a step-cut osteotomy is not necessary. In most instances, a straight transverse osteotomy can be used. When angular deformity is present, a transverse osteotomy will result in an open wedge-type osteotomy when the nail is driven. Graft all osteotomies with the reamings and autogenous cancellous bone if necessary.

- Place the patient on a fracture table as you would for the closed intramedullary nailing technique. Prepare and drape the entire thigh and buttocks area. Use a direct lateral approach (see Chapter 3) and expose the fracture site by subperiosteal dissection.
- If length needs to be regained, take down the fracture site in a step-cut fashion (Fig. 30.13). Apply a femoral distractor or use traction on the fracture table to gain length.

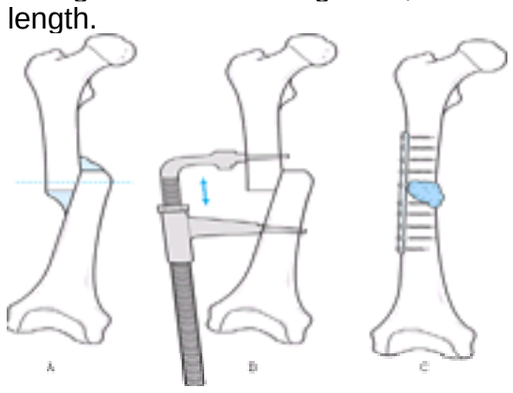

***Figure 30.13.*** **A:** Malunion of a midshaft fracture of the femur with angulation and overriding. Even a year after the original fracture, the original cortex can be differentiated from the surrounding callus. To restore length, shave off the callus and identify the original cortex. Take down the malunion through the old fracture site. **B:** Apply an AO femoral distractor and restore alignment and length. Avoid excessive tension on the sciatic nerve. **C:** Fix the osteotomy with a 10- to 12-hole broad dynamic compression plate. Interfragmentary screw fixation is recommended. Apply the callus removed earlier as a bone graft. Add additional graft if necessary. (From Müller ME, Allgöwer M, Schneider R, Willenegger H. Manual of Internal Fixation. New York: Springer-Verlag, 1979, with permission.)

- Align the femur and internally fix it with a locked intramedullary nail. Apply the reamings and/or a cancellous bone graft from the posterior ilium.

Postoperative care for open osteotomies with intramedullary nailing is the same as for osteotomies using the closed technique, as outlined previously. The complications are also the same. Because there is a somewhat increased risk of infection due to open technique, be certain to administer perioperative antibiotics.

## SUPRACONDYLAR AREA

### *Osteotomy with Plate and Screw Fixation and Bone Grafting*

Plate and screw fixation can be used for malunions of the shaft but is most commonly used for condylar or supracondylar malunions (1,6,29,32,34,39,42). It may be necessary in malunions of the shaft where malalignment of the medullary canal makes intramedullary nailing impossible. Many osteotomy techniques are possible, including opening wedge, closing wedge, step-cut, dome, and various types of oblique osteotomies. In most cases, shortening, angulation, and malrotation must be corrected with a single osteotomy. Closing-wedge osteotomies have the advantages of simplicity and good stability. The disadvantages are that they result in further shortening, and osteotomy site apposition is a problem when correction of significant rotation is also required. Opening-wedge osteotomies have the disadvantage of much less stability after fixation and require structural bone grafting. Union is slower than with closing wedge osteotomies, and remodeling of the graft is required. See Figure 30.13 for an illustration of open technique.

I prefer single-plane oblique osteotomies when treating combination deformities, and the dome osteotomy for isolated varus or valgus angulation in the metaphysis (33). An oblique osteotomy has the advantages of excellent stability, broad bone surfaces for union so that bone grafting is usually not required, and correction of all components of the deformity. Disadvantages are that considerable exposure of bone is required and meticulous preoperative planning and surgical execution are necessary for it to work. In about 20 osteotomies in the distal femur, I have had one failure due to nonunion, probably the result of overlengthening and devascularization of the bone ends. The technique described next is an AO oblique osteotomy for a supracondylar malunion (Fig. 30.14).

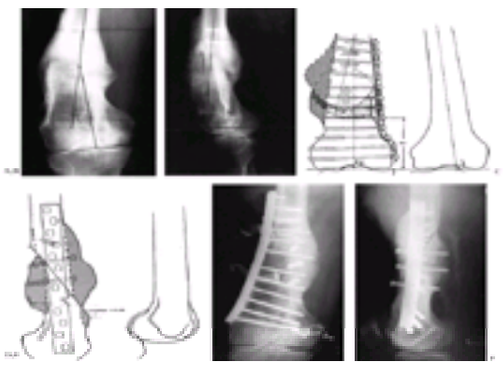

***Figure 30.14.*** **A:** AP radiograph of a malunion of the distal third of the femur in a 26-year-old athlete with 13° of varus, 15° of external rotation, and 1.5 cm of shortening. **B:** Preoperative lateral radiograph. **C:** Tracing of the contralateral normal femur, and the osteotomy and fixation planned for the malunion. A 12-hole plate and at least two interfragmentary screws are planned for fixation. **D:** Lateral tracing of the contralateral normal femur and the planned correction for the malunion. Notice that the osteotomy is at 60° to the transverse axis of the femur, which permits sliding to gain length. (The wedge removed to correct the malrotation is not illustrated.) **E:** Intraoperative AP radiograph of the completed osteotomy. **F:** Lateral radiograph of the completed osteotomy.

**Preoperative Planning** A frontal-plane or sagittal-plane osteotomy can be used; in most cases the former is better. Make tracings of the preoperative radiographs to determine the angular deformity to be corrected. Use clinical measurements to determine the amount of malrotation to be corrected. Use both clinical and radiographic assessments to determine the length to be corrected. Make a drawing of the proposed postoperative construct with internal fixation in place (Fig. 30.14*A*, Fig. 30.14*B*, Fig. 30.14*C* and Fig. 30.14*D*).

**Technique**

- Place the patient in the supine position on the operating table. Prepare and drape the extremity to be operated on. In distal osteotomies, a tourniquet can be used. It is often useful to prepare and drape the contralateral normal extremity as well because this permits intraoperative comparison. Be certain that the pelvis is level so that leg-length determinations are accurate.
- Expose the distal femur through an anterolateral approach (see Chapter 3). Place K-wires as guide pins in the proximal and distal segments. In the frontal plane, insert one K-wire in the distal fragment parallel to the knee joint. Insert a second wire into the proximal fragment at right angles to the shaft of the femur. Verify correct position by fluoroscopy or radiograph. Place a second set of K-wires in the sagittal plane, entering the anterior aspect of the femur. These are used to measure correction in the AP plane and can also be used to ascertain rotation. Place the wires at right angles to the knee joint distally and at right angles to the long axis of the femur in the proximal fragment. Put them in direct alignment with each other rotationally. Both of these sets of wires must be proximal and distal to the osteotomy site. Measure the distance between the anterior K-wires; this will be used to determine length.
- Through the middle of the fracture site in the frontal plane, make an oblique osteotomy at 60° to the long axis of the femur. Begin distally on the anterior surface of the femur and exit posteriorly. Open the osteotomy site with bone-holding forceps or retractors. Next, remove a wedge of bone from the distal fragment. The

base of the wedge will determine correction of rotation and any deformity in flexion or extension. Experienced surgeons can remove this with a single cut. Otherwise, take the wedge for correction of deformity in the sagittal plane first and then take a side-based wedge to correct rotation. Do not remove too large a wedge. It is better to take too small a wedge initially and then have to cut further. Accurate preoperative measurement, taking into account x-ray magnification, is necessary. Approximate the osteotomy site and slide the distal and proximal fragments against each other to correct varus or valgus angulation.

- At this point, overall axial alignment of the femur is corrected and only shortening remains. Apply a Lowman bone-holding clamp or other bone-holding forceps to the osteotomy site to hold it in loose apposition. Apply a femoral distractor and slowly distract the osteotomy site to gain length. Keep the knee flexed and use other precautions to avoid excessive traction on the sciatic nerve, as described earlier in this chapter. Once enough length has been obtained, temporarily fix the osteotomy site with two or three large Steinmann pins. Carefully assess the correction clinically and radiographically to ensure it is adequate.
- Begin internal fixation by inserting two or three anterior-to-posterior interfragmentary lag screws (either 6.5 mm cancellous screws or cortical screws with gliding holes). Fixation depends on the location of the osteotomy and bone quality. The osteotomy will now be stable, which simplifies plate fixation. With an osteotome or saw, remove excessive bone from the edges of the osteotomy to restore the normal contours of the femur. Then apply a broad plate on the lateral surface of the femur and obtain at least eight cortices of screw fixation in both fragments (Fig. 30.14*E*, Fig. 30.14*F*). If the osteotomy is very distal, a condylar blade plate or distal-compression screw device may be necessary. Morcelize the bone removed from shaping the femur and pack it about the osteotomy site.
- Release the tourniquet, if used, and secure hemostasis. Place two suction drains and close in the usual fashion.

**Postoperative Care** Initially, apply a bulky soft dressing. As soon as the patient is comfortable, remove the dressing and begin rehabilitation. Continuous passive motion may be helpful in restoring knee motion.

Allow only touch-down weight bearing until union occurs. During this period, progressive resistance exercises are possible as long as the thigh is supported on the exercise table. Avoid excessive weights. Because of the broad surfaces and intimate contact of the osteotomy, union occurs rapidly. It may be difficult to document union radiographically, however, because the osteotomy often appears healed on the immediate postoperative film. Four routine views, as well as AP and lateral tomograms, are often necessary to ascertain that union has occurred. When it does occur, begin full weight bearing.

***Crescentic (Dome) Osteotomy***

The techniques for dome osteotomies are discussed in detail in Chapter 26. The following technique is used for isolated varus or valgus deformities of the femur in the supracondylar area (Fig. 30.15).

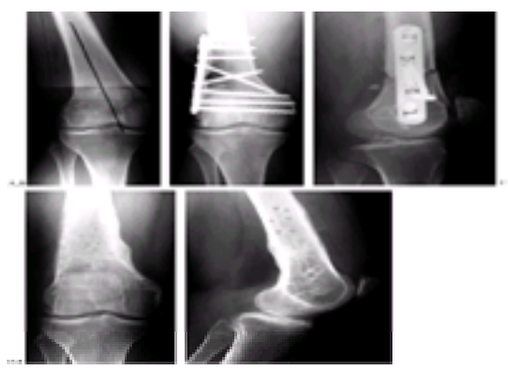

***Figure 30.15.*** Crescentic (dome) osteotomy. AP radiograph (**A**) of the right knee of a 42-year-old woman who has had moderately severe genu valgum since she was a child. She was having significant lateral compartment pain that interfered with her activities of daily living. Bilateral radiographs showed moderately advanced arthritis of the lateral compartment. She was treated with bilateral dome osteotomies; this shows the right side. The *black vertical line* on the lateral aspect of this radiograph shows the mechanical axis between the center of the femoral head and the center of the ankle joint, which here lies completely lateral to the joint. Note the tibial femoral angle of 16° of valgus. AP (**B**) and lateral (**C**) radiographs taken at the time of surgery show a dome osteotomy in the distal femur with excellent correction of her deformity and restoration of the mechanical axis to slightly medial of normal in order to unload her lateral compartment. Note that the “cog wheel” edges of the osteotomy are impacted and the osteotomy fixed with two interfragmentary screws through a lateral plate. If any micromotion exists in the osteotomy after this fixation, a small anterior plate can be added as well. AP (**D**) and lateral (**E**) radiographs taken after hardware removal approximately 2 years after the initial osteotomy show good maintenance of alignment and good preservation of the lateral joint space, with no evidence of progression of her arthritis. At the 8-year follow-up, she continues to do well with some evidence of progression of her arthritis. A similar osteotomy was done of the opposite leg with an equally good result.

- In the preoperative planning, be certain that a dome osteotomy will restore the normal mechanical axis of the knee, or if treating unilateral arthrosis that it will result in an appropriate shift of the mechanical axis.
- Use a direct anterior midline incision by either an anteromedial or anterolateral approach depending on the deformity to be corrected and the fixation planned.
- Perform the dome osteotomy using multiple drill points and an osteotome as described in Chapter 26. Make the osteotomy as distal as possible because this provides a larger area for the arc of the dome, which is technically easier and provides a broader surface area for union. Be certain to leave enough length in the distal fragment so that solid internal fixation with a lateral plate providing three bicortical screws of fixation in the distal fragment is possible.
- After completing the osteotomy, correct the deformity, impact the osteotomy, and secure initial fixation with one or two interfragmentary screws across the osteotnomy. Apply a broad plate laterally to provide neutralization, securing bicortical fixation with three screws distally and proximally.
- Prior to closure, repeat mechanical axis determination with the fluoroscope to be certain that the goals of the osteotomy have been met.
- Do a meticulous closure of the joint capsule and muscle, and apply a sterile dressing and knee immobilizer. Drain the knee and osteotomy site.

Patients can be mobilized from bedside to a chair on the first postoperative day. As soon as the drain is removed, begin knee range-of-motion and muscle rehabilitation exercises. These osteotomies are very stable and most patients can begin 50% weight bearing with assistive devices using a knee immobilizer immediately. Until the osteotomy heals, avoid straight-leg raising and excessive stress across the osteotomy site. Healing usually occurs in 6–8 weeks, at which time progression to full weight bearing without assistive devices and afull rehabilitation program can be instituted (Fig. 30.15*A*, Fig. 30.15*B*, Fig. 30.15*C* and Fig. 30.15*D*).

**CONDYLAR AREA**

Treatment of intra-articular malunions of the femoral condyles is difficult. It is best to identify malposition early and correct the deformity before remodeling takes place. Once remodeling has occurred, it becomes exceedingly difficult to realign the articular surfaces of the knee joint. Malunions of epiphyseal fractures in children involving the condyles are even more difficult because the malunion may be accompanied by growth arrest, and corrective osteotomy often threatens the integrity of the physis. Specialized techniques are necessary in children (see Chapter 168, Chapter 169, and Chapter 171).

Malunion of the lateral femoral condyle usually results in valgus, external rotation, and flexion deformity. Malunion of the medial condyle produces a similar deformity, but in varus. Most disabling is the malrotation that interferes with the articular surface of the patellar groove and produces malalignment of the patellar mechanism. Comminuted fractures with a transverse component produce a step-off in the articular surface that can interfere with patellar or tibial motion on the femur. Although patients can walk fairly well with the knee straight, function is impaired in flexion and during sports activities.

Correction is difficult because restoration of a normal articular surface is very difficult, and the amount of soft-tissue stripping of the fragments necessary to restore them to proper position risks avascular necrosis. Surgical techniques for medial and lateral condyles are similar.

- Place the patient in a supine position on the operating table and prepare and drape the entire extremity. As recommended previously, it may be advisable to drape the normal extremity as well for comparison. A tourniquet can be used.
- Use an anteromedial or anterolateral parapatellar incision long enough so that the articular surfaces of the femur can be easily seen and complete access to the fracture site gained. To achieve good alignment, it is often necessary to dislocate the patella.
- Maintain the soft-tissue attachments of the collateral ligaments, and as much joint capsule as possible, as well as the cruciate ligaments. In some distal femoral malunions, the femoral artery and vein are fibrosed to the posterior aspect of the femur. Dissect carefully in a subperiosteal manner along the posterior aspect of the femur, staying intimately against bone to avoid injury to the neurovascular structures. Keep the knee flexed to 90° during this dissection and when the osteotomy is made.
- Identify the fracture site at the articular surface. With osteotomes, take down the malunion. Progress from the articular surface proximalward, attempting to stay in the old fracture site. A similar technique is used for transverse malunions.
- With the condyle mobile, restore the alignment of the articular surface. Often this results in incongruity in the osteotomy or fracture site and requires some

carpentry to obtain good alignment of the articular surface with good closure and apposition of the fracture and osteotomy site. Most difficult to correct is rotational malalignment.

- Achieve temporary fixation with K-wires and obtain radiographs to ensure the correction is satisfactory. Internally fix the osteotomy with three or more interfragmentary 6.5 mm cancellous lag screws. In malunions, lag-screw fixation alone often is inadequate, and adding a plate to buttress the malunion is important.
- When closing, ensure that the patella is in good alignment. Use suction drains and apply a bulky soft dressing with splints. A typical case is illustrated in Fig. 30.16

***Figure 30.16.*** **A:** AP radiograph of the left knee in a 28-year-old man with a healed fracture of the lateral tibial plateau and an intra-articular malunion of the lateral femoral condyle. **B:** Lateral radiograph showing a 15 mm offset in the articular surface of the lateral condyle of the femur due to the malunion. **C:** The malunion was taken down through the old fracture site with an osteotome inserted from the articular surface. This radiograph taken 2 years after repair shows fixation with interfragmentary screws and a buttress plate. A bone graft was not necessary. **D:** Lateral view at 2-year follow-up. The articular surface is nearly anatomic. At 7-year follow-up, the patient was doing well and radiographs showed no degenerative changes.

Within 2 to 3 days postoperatively, remove the drains and bulky dressing, and begin rehabilitation using continuous passive motion. With solid internal fixation, an active rehabilitation program is possible. Keep the patient on touch-down weight bearing until union occurs. Again, multiplane radiographs and tomography may be necessary to confirm union.

In some cases, there will be sufficient degenerative changes in the knee that arthrodesis may be a better choice. Arthrodesis of the knee is so disabling, however, that I usually advise correction of the deformity followed by total knee arthroplasty.

## NONUNIONS AND MALUNIONS OF THE PATELLA

### NONUNIONS

Nonunions of the patella are unusual. They generally are due to nonoperative treatment of widely displaced fractures or failure of fixation, particularly as a result of infection. Treatment is unnecessary unless the patient has symptoms. A fibrous union can have acceptable function with minimal symptoms. Klassen and Trousdale (28) treated 20 patients with patellar nonunions, of whom seven were treated nonoperatively. They achieved an average knee range of motion of 120° with a Knee Society score of 83 with a function score of 75. Pain, lack of knee stability, or mechanical problems may require surgical treatment. Therapeutic choices are total patellectomy, partial patellectomy with repair of the quadriceps mechanism, or reconstruction of the patella. In nonunions, it is difficult to correct the irregularities in the patellar articular surface, so some type of patellectomy is generally indicated. Reconstruction uses the same principles of fixation and resection as described for patellar fractures in Chapter 22. Use compression screw fixation and a tension band wire. Bone graft is rarely necessary or possible, but a sliding inlay graft can be used in some cases. Of the 13 patients Klassen and Trousdale (28) treated operatively, all but one healed, achieving Knee Society scores of 94, a function score of 93, and an average knee range of motion of 109°.

### MALUNIONS

Malunions of the patella result in irregularities of the articular surface. As with condylar fractures, correction is possible but difficult. Joint-surface irregularity often persists. Total or partial patellectomy may be the best choice. In active patients, preservation of the patella is worthwhile, but do not allow persistent incongruity of the articular surface to precipitate patellofemoral arthritis or perhaps generalized arthritis in the knee.

- The surgical technique is similar to that described for femoral condyle malunions. Use a long, medial parapatellar approach.
- Invert the patella. Take down the malunion with osteotomes, working from the articular surface.
- Realign the patella. Obtain solid fixation with interfragmentary lag screws and a tension band wire.

After surgery, maintain knee motion with continuous passive motion and active assisted exercises. Judicious isometric muscle exercises are beneficial. Avoid straight-leg raising. Permit weight bearing with a knee immobilizer. Union will occur in 6–12 weeks. Thereafter, institute a full rehabilitation program and allow gradual return to normal activities.

## CHAPTER REFERENCES

Each reference is categorized according to the following scheme: *, classic article; #, review article; !, basic research article; and +, clinical results/outcome study.


+ 1. Altenberg AR, Shorkey RL. Blade-Plate Fixation in Nonunion and in Complicated Fractures of the Supracondylar Region of the Femur. *J Bone Joint Surg Am* 1949;31:312.

+ 2. Ashby ME, Anderson JC. The Use of the Zickel Device for a Malunited Subtrochanteric Femur Fracture. *JAMA* 1977;69:623.

+ 3. Barquet A, Silva R, Massaferro J, Dubra A. The AO Tubular External Fixator in the Treatment of Open Fractures and Infected Nonunions of the Shaft of the Femur. *Injury* 1988;19:415.

+ 4. Beall MS Jr, Nebel E, Bailey RW. Transarticular Fixation in the Treatment of Nonunion of Supracondylar Fractures of the Femur: A Salvage Procedure. *J Bone Joint Surg Am* 1979;61:1018.

+ 5. Beredjiklian PK, Naranja RJ, Heppenstall RB, et al. Results of Treatment of 111 Patients with Nonunion of Femoral Shaft Fractures. *Univ Penn Orthop J* 1999;12:56.

+ 6. Boyd HB, Lipinski SW, Wiley JH. Observations on Nonunion of the Shafts of the Long Bones, with a Statistical Analysis of 842 Patients. *J Bone Joint Surg Am* 1961;43:159.

+ 7. Brav E. The Use of Intramedullary Nailing for Nonunion of the Femur. *Clin Orthop* 1968;60:69.

+ 8. Chapman MW. Closed Intramedullary Bone Grafting and Nailing of Segmental Defects of the Femur. *J Bone Joint Surg Am* 1980;62:1004.

+ 9. Chapman MW, Duwelius PJ, Bray TJ, Gordon JE. Closed Intramedullary Femoral Osteotomy. *Clin Orthop* 1993;287:245.

+ 10. Chapman MW, Finkemeier CG. Treatment of Supracondylar Nonunions of the Femur with Plate Fixation and Bone Graft. *J Bone Joint Surg Am* 1999;81:1217.

+ 11. Chapman MW, Pugh GA, Wood J, et al. Closed Intramedullary Nailing of Femoral Shaft Fractures. *Orthop Trans* 1982;6:326.

+ 12. Christensen NO. Shortening in Pseudarthrosis: Treatment with Küntscher Distractor. *Acta Orthop Scand* 1970;41:363.

+ 13. Christensen NO. Küntscher Intramedullary Reaming and Nail Fixation for Nonunion of Fracture of the Femur and the Tibia. *J Bone Joint Surg Br* 1973;55:312.

+ 14. Cove JA, Lhowe DW, Jupiter JB, Siliski JM. The Management of Femoral Diaphyseal Nonunions. *J Orthop Trauma* 1997;11:513.

+ 15. Esterhai JL Jr, Brighton CT, Heppenstall RB, et al. Technetium and Gallium Scintigraphic Evaluation of Patients with Long Bone Fracture Nonunion. *Orthop Clin North Am* 1984;15:125.

+ 16. Finkemeier CG, Chapman MW. Intramedullary Nailing of Femoral Diaphyseal Nonunions. Submitted, 1999.

+ 17. Fischer D. Closed Shortening of the Femoral Shaft. Presented at the 39th annual meeting of the Association of Bone and Joint Surgeons, Charleston, South Carolina, 1987.

+ 18. Freedman EL, Hak DJ, Johnson EE, Eckardt JJ. Total Knee Replacement Including a Modular Distal Femoral Component in Elderly Patients with Acute Fracture or Nonunion. *J Orthop Trauma* 1995;9:231.

+ 19. Hak DJ, Lee SS, Goulet JA. The Success of Exchanged Reamed Intramedullary Nailing for Femoral Shaft Nonunions. Presented to the Orthopaedic Trauma Association, Vancouver, BC, Canada, October, 1998.

+ 20. Hamdy RC, Ehrlich MG. Subtrochanteric Derotation Osteotomy of the Femur Using Three or Four Wires. *Clin Orthop* 1994;302:111.

+ 21. Heppenstall RB. The Present Role of Bone Graft Surgery in Treating Nonunion. *Orthop Clin North Am* 1984;15:113.

+ 22. Johnson EE. Acute Lengthening of Shortened Lower Extremities after Malunion or Nonunion of a Fracture. *J Bone Joint Surg Am* 1994;76:379.

+ 23. Johnson EE, Urist MR. One-stage Lengthening of Femoral Nonunion Augmented with Human Bone Morphogenetic Protein. *Clin Orthop* 1998;347:105.

+ 24. Johnson EE, Urist MR, Finerman GA. Bone Morphogenetic Protein Augmentation Grafting of Resistant Femoral Nonunions. A Preliminary Report. *Clin Orthop* 1988;230:257.

+ 25. Kelly PJ. Infected Nonunion of the Femur and Tibia. *Orthop Clin North Am* 1984;15:481.

+ 26. Kettelkamp DB, Hillberry BM, Murrish DE, Heck DA. Degenerative Arthritis of the Knee Secondary to Fracture Malunion. *Clin Orthop* 1988;234:159.

+ 27. Kingsbury GH, Figgie HE III, Lacey SH, Figgie MP. Femoral Shaft Nonunion Treated by a Fluted Intramedullary Rod. *Clin Orthop* 1985;194:218.

+ 28. Klassen JF, Trousdale RT. Treatment of Delayed and Nonunion of the Patella. *J Orthop Trauma* 1997;11:188.

+ 29. Knight JL, Ratcliffe SS, Weber JK, Hansen ST Jr. Corrective Osteotomy of Femoral Shaft Malunion Causing Complete Occlusion of the Superficial Femoral Artery: A Case Report. *J Bone Joint Surg Am* 1980;62:303.

* 30. Küntscher G. Die Marknagelung der Pseudarthose. *Mschr Unfallheilk* 1949;1:1.

+ 31. Matelic TM, Monroe MT, Mast JW. The Use of Endosteal Substitution in the Treatment of Recalcitrant Nonunions of the Femur: Report of Seven Cases. *J Orthop Trauma* 1996;10:1.

* 32. Müller ME. Treatment of Nonunion by Compression. *Clin Orthop* 1965;43:83.

+ 33. Müller WE, Allgöwer M, Schneider R, Willenegger H. Manual of Internal Fixation. New York: Springer-Verlag, 1979.

+ 34. Müller ME, Thomas RJ. Treatment of Nonunion in Fractures of Long Bones. *Clin Orthop* 1979;138:141.

+ 35. Murray WR, Lucas DB, Inman VT. Treatment of Nonunion of Fractures of the Long Bones by the Two-Plate Method. *J Bone Joint Surg Am* 1964;46:1027.

* 36. Phemister DB. Splint Grafts in the Treatment of Delayed and Nonunion of Fractures. *Surg Gynecol Obstet* 1931;52:376.

* 37. Phemister DB. Treatment of Ununited Fractures by Onlay Bone Grafts without Screw or Tie Fixation and without Breaking Down on the Fibrous Union. *J Bone Joint Surg* 1947;29:946.

+ 38. Ring D, Jupiter JB, Sanders RA, et al. Complex Nonunion of Fractures of the Femoral Shaft Treated by Wave-plate Osteosynthesis. *J Bone Joint Surg Br* 1997;79:289.

+ 39. Rosen H. Compression Treatment of Long Bone Pseudarthroses. *Clin Orthop* 1979;128:154.

+ 40. Scott WA. Infected Nonunion of a Femur Treated with a Vascularized Fibular Graft. *Injury* 1985;16:455.

+ 41. Slätis P, Paavolainen P. External Fixation of Infected Nonunion of the Femur. *Injury* 1985;16:599.

# 42. Weber BG, Cech O. Pseudoarthrosis. Bern: Hans Huber, 1976.

+ 43. Weresh MJ, Hakanson R, Stover M, et al. The Failure of Reamed Intramedullary Exchange Nailing for Aseptic Ununited Femoral Shaft Fractures. Presented to the Orthopaedic Trauma Association, Louisville, KY, October, 1997.

+ 44. Winquist RA, Hansen ST Jr, Pearson RE. Closed Intramedullary Shortening of the Femur. *Clin Orthop* 1978;136:54.

+ 45. Wood MB. Femoral Reconstruction by Vascularized Bone Transfer. *Microsurgery* 1990;11:74.

+ 46. Wu CC, Chen WJ. Treatment of Femoral Shaft Aseptic Nonunions: Comparison between Closed and Open Bone-grafting Techniques. *J Trauma* 1997;34:112.

+ 47. Zickel RE. An Intramedullary Fixation Device for the Proximal Part of the Femur: 9 Years' Experience. *J Bone Joint Surg Am* 1976;58:866.

# CHAPTER 31

# NONUNIONS AND MALUNIONS OF THE TIBIA

*James A. Goulet and David J. Hak*

**J. A. Goulet:** Associate Professor, Section of Orthopaedic Surgery, The University of Michigan, Ann Arbor, Michigan, 48109.
**D. J. Hak:** Assistant Professor, Section of Orthopaedic Surgery, The University of Michigan, Ann Arbor, Michigan, 48109.

Incidence
Causes of Nonunion
Treatment Considerations in Tibial Nonunion
Electrical Stimulation and Ultrasound
Soft-Tissue Coverage in Tibial Nonunion
Bone Grafting
Anteromedial Approach for Tibial Bone Grafting
Posteromedial Bone Grafting
Posterolateral Approach for Tibial Bone Grafting
Open Cancellous Bone Grafting
Bone Morphogenetic Protein
Stabilization
External Fixation
Compression Plating
Ilizarov Technique
Intramedullary Nailing
Fibular Osteotomy
Dynamization of A Locked Nail
Nonunions with Segmental Bone Defects
Ilizarov Technique
Free Microvascular Bone Transfers
Chapter References

Nonunion of the tibial shaft is a common problem that is severe and disabling. Failure of tibial fractures to unite may lead to multiple operative procedures and prolonged hospitalization with years of disability before a union is obtained or amputation is performed. Although high rates of union have been obtained in some series of tibial fractures with simple methods, nonunion is frequently seen by practitioners treating tibial fractures (20,36,96,112,138).

Malunion of a tibial shaft fracture refers to healing of the fracture in a nonanatomic position. Functional malposition rather than cosmetic deformity constitutes an indication for surgical intervention.

The most frequently encountered problem in malunion is shortening. Shortening of less than 1 cm is acceptable. Shortening of greater than 15 mm may be symptomatic and necessitate a lift or leg-length equalization procedure. Varus and valgus angulation should be limited to less than 10°. Recurvatum is less well tolerated than anterior bowing and should not exceed 10°. Anterior bowing of less than 10° is rarely of functional significance but may be cosmetically unacceptable. Rotatory malalignment is better tolerated than varus-valgus angulation. Internal rotation exceeding 5° is noticeable, and that exceeding 10° is usually unacceptable. External rotation is better tolerated but will become noticeable when it exceeds 10° and may become functionally significant when it exceeds 15°. Pre-existing deformity such as genu varum and genu valgum, and pre-existing arthritis or joint instability may make angulation, which ordinarily would be acceptable, a problem sufficient to require correction. Experimental evidence, obtained from pressure-sensitive film, suggests that angular deformities in the distal third of the tibia are more likely to affect contact area and joint pressures in the ankle adversely, whereas proximal angular deformities have a larger impact on the knee joint (85,86,123). Although some degree of malalignment is common following tibial fractures treated nonoperatively, osteotomy is rarely indicated. Close follow-up of patients with acute tibial fractures and early intervention in cases that develop angular deformity will prevent most unacceptable malunions. Long-term clinical follow-up, however, has failed to show any adverse effect of moderate angular deformities on the subsequent development of knee or ankle arthritis (87).

## INCIDENCE

Although reporting methods and definitions vary from author to author, the incidence of nonunion and delayed union can be estimated from reports published in the literature. In 22 combined series covering 5517 fractures, the incidence of nonunion was 2.5% and the incidence of delayed union 4.4% (1,20,23,25,34,36,38,51,68,73,80,95,100,106,108,112,115,124,129,130,138,140). The studies included several large series of predominantly closed tibial fractures caused by low-energy trauma. Open fractures with gross contamination and extensive soft-tissue damage have a much higher incidence of nonunion and delayed union. In series of open tibial fractures, Clancy et al. (25) have reported a 13% incidence of delayed union, Widenfalk et al. (138) have reported a 31% incidence of delayed union, and Edwards et al. (40) have reported a 41% incidence of grade III fractures requiring bone grafting to achieve union. In type II and type III open tibial fractures, Velazco et al. (130) have reported a 14% rate of nonunion. An incidence of tibial nonunions and malunions above those reported in early series should be anticipated by the orthopaedic surgeon practicing today in view of an increasing incidence of high-energy trauma associated with motor vehicle accidents.

## CAUSES OF NONUNION

Many factors have been associated with delayed union or nonunion. Most are dictated by the injury, but others are within the surgeon's control. The incidence of nonunion, and especially of infected nonunion, increases with the severity of open fractures. The presenting factors cited as contributing to nonunion or delayed union include fracture displacement, bone loss, associated fibular fractures, comminution, and infection (41,68,73,80,95,108,128,133). Therefore, the nature of an injury plays a large role in determining the likelihood of union. A direct correlantion exists between the energy absorbed by the hard and soft tissues and the complications of wound healing, including delayed union, nonunion, infection, and skin slough (24,62).

The common anatomic factor that determines the rate of union of tibial fractures is the degree of preservation of the tibial blood supply. The anatomy of the tibial blood supply has been described in detail (78,94,104,126). The three vascular systems supplying the tibia are the nutrient vascular system, the periosteal vascular system, and the epiphyseal-metaphyseal vascular system. The nutrient and periosteal vascular systems are the most important in healing of tibial shaft fracture. The nutrient artery system, which arises from the entrance of the posterior tibial artery into the posterior tibial cortex, distal to the soleal line, is divided at its origin into ascending and descending branches. The nutrient vessels provide the endosteal blood supply to the tibia, which MacNab has shown to supply as much as the inner 90% of the cortex (78). Destruction of the endosteal blood supply is most extensive when the fracture occurs in the middle one third of the tibia, but the distribution of nonunions among proximal, middle, and distal thirds of the shaft appears to be equal (78,96). The periosteal blood supply receives segmental vascular contributions from the surrounding soft tissues, which, in turn, are largely supplied by the anterior tibial artery. Vessel penetration through the interosseous membrane and the posterior periosteum is abundant. The blood supply to the subcutaneous anteromedial periosteum, however, is more precarious and thus more easily destroyed. Rhinelander (104) has demonstrated that preservation of the periosteum results in cortical fracture healing through transient expansion of the periosteal blood supply to the inner cortical bone. The degree of periosteal stripping and the resultant amount of devascularized bone varies with the fracture type. Increased periosteal stripping, as seen in high-grade open fractures, contributes substantially to delayed union or nonunion.

Recent evidence has also highlighted the adverse affect of nicotine on bone healing (19,72,103). We strongly recommend that patients stop smoking before undergoing operative intervention on tibial nonunions.

Failure to manage tibial fractures properly has been shown to increase the incidence of nonunion. Distraction at the fracture site and failure to immobilize the fracture adequately are known to increase the time to union (27). Brown and Urban (20), Dehne et al. (36), and Sarmiento (112,113) have advocated early weight bearing with cast or cast brace treatment as a means of obtaining intermittent compression at the fracture site, and have reported low rates of nonunion in their respective series. Adherence to the principles of open fracture management, including aggressive multiple debridements, administration of antibiotics, and rigid immobilization of fracture

fragments, has also been shown to decrease the incidence of infection and nonunion substantially. These issues are more fully addressed in Chapter 26.

## TREATMENT CONSIDERATIONS IN TIBIAL NONUNION

Optimal treatment of tibial nonunions begins with a critical assessment (Fig. 31.1). The fracture configuration and location, classification of open fracture, and history of infection of previous external fixation are essential elements of the history. Physical examination determines the status of the soft tissue, the presence or absence of a draining sinus, and the neurovascular status of the foot. Radiographically assess initial and current fracture alignment, and make note of any significant bony defect that limits the choices for managing the nonunion.

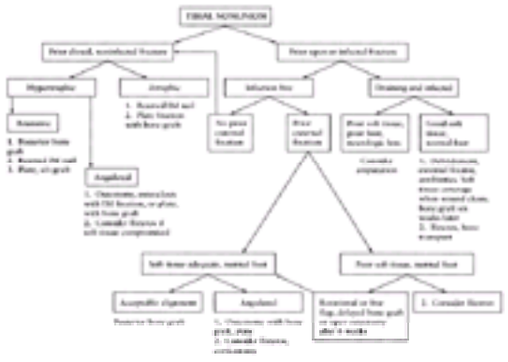

***Figure 31.1.*** Algorithm outlining a simplified approach to the treatment of tibial nonunion.

In patients with a history of an open fracture or a prior history of infection, investigate infection as one of the causal factors of nonunion. C-Reactive protein, sedimentation rate, and indium-labeled bone scans may be helpful to assess the likelihood of persistent infection. Do not administer preoperative antibiotics and obtain intraoperative cultures. Patients with active infection should undergo debridement and are frequently treated with a course of intravenous antibiotics. If a bone graft is required, stage this procedure after the infection has been treated to minimize the risk of graft infection and sequestrum formation.

Weber and Cech (135) classified pseudoarthroses into hypertrophic and atrophic varieties. The hypertrophic variety includes those that resemble an elephant's foot, a horse's foot, and the oligotrophic variety. These nonunions have adequate biologic potential and may go onto union by improvement in mechanical factors, such as improved stabilization or interfragmentary compression. The atrophic variety includes the dystrophic, gap, and end stage atrophic classifications. These nonunions lack adequate biologic potential and require bone grafting to stimulate successful healing.

The ultimate goal of a stable functional lower extremity should not be overlooked in attempts to achieve bone union. Amputation is a reasonable alternative to heroic efforts at gaining union in a tibia with major bone loss, infection, and posterior tibial nerve disruptions. Early amputation in those injuries in which limb salvage is inappropriate enhances patient survival; reduces pain, emotional distress, and disability; and shortens hospitalization time and costs (11,102). Limb salvage and reconstruction is indicated for salvageable injuries. Although it is more expensive and requires multiple operative interventions, better functional outcomes have been reported for limb salvage when compared with amputation (61).

Optimal treatment seeks to avoid what Müller et al. have termed fracture disease—muscle atrophy, muscle and tendon contractures, joint stiffness, and disuse osteoporosis (91). Many paths to fracture disease have been described. Prolonged immobilization in plaster has been demonstrated to result in a high percentage of fracture union, even in cases of open fractures, but it has also been associated with residual foot and ankle stiffness, knee stiffness, and muscle atrophy (20). Plaster immobilization is best limited to initial management of closed fractures and use in combination with bone grafting. Sarmiento (112,113) has advocated the use of patellar tendon–bearing cast and braces, which allow knee motion, and these aids should be substituted for long-leg casts whenever possible. In addition to encouraging union, therefore, you should initiate any new intervention with the goals of minimizing immobilization and hastening return of the patient to maximum activity with a low risk of complications from the intervention.

Infection, soft-tissue defects, atrophic nonunions, and malalignment substantially alter treatment options in tibial nonunions. The closed, uninfected nonunion with an anatomic alignment requires intervention only to achieve union; posterior lateral bone graft, closed reamed intramedullary nail, and application of a compression plate with or without bone graft are all acceptable solutions to the problem. Malalignment requires osteotomy or osteoclasis in addition to bone grafting and internal fixation. Atrophic nonunions require decortication of the nonunion site with bone grafting and internal fixation. Infected nonunions pose the greatest challenge. Acceptable approaches to infected nonunions include adequate debridement and soft-tissue coverage, in addition to bone stabilization and bone grafting.

## ELECTRICAL STIMULATION AND ULTRASOUND

Electrical stimulation has been proposed as a nonoperative alternative treatment for established nonunions. Considerable laboratory and clinical evidence has been accumulated to suggest that electrical stimulation enhances fracture healing (75). Three forms of electrical stimulation have been used clinically: direct current, capacitive coupling, and inductive coupling. The direct current method requires a surgical procedure for implantation and a second surgical procedure for removal. A successful union rate of 83.7% has been reported in 178 nonunions treated with adequate duration of constant direct current. This series included a 91.5% union rate in 82 tibial nonunions treated with contant direct current (15).

A percutaneous, or semiinvasive, method has been developed by Brighton et al. The cathode is inserted percutaneously directly into the nonunion site, requiring drilling across one bone cortex or fragment. Weight bearing is prohibited in the first 12 weeks of treatment (16). Complications in Brighton's series include pin tract infection (13.8%), broken wires (13%), recurrent osteomyelitis (4.2%), cathode dislodgement (3.6%), and battery pack failure. A “corrected” union rate (excluding all patients with “suboptimal” electricity or gaps greater than half the bone diameter) of 80% was reported for tibial nonunions (14).

Inductive coupling and capacitive coupling methods can both be administered with externally applied fields. Although these methods are noninvasive, they require patient compliance. Bassett et al. reported an 87% success rate using electrical stimulation in 127 tibial nonunions (5). Brighton and Pollack reported a 77% success rate of capacitive coupling electrical stimulation in the treatment of 22 established nonunions (17).

Two double-blind series have been reported. Sharrard (116) performed a prospective double-blind trial of capacitive coupling electrical stimulation treatment of tibial delayed unions. Successful healing was achieved by twelve weeks in five of 20 patients treated with electrical stimulation compared with one of 25 patients treated with the placebo unit. Scott and King (114) performed a prospective double-blind trial of capacitive coupling electrical stimulation treatment of nonunions in long bones. Successful union was achieved in six of the ten patients treated with electrical stimulation, while none of the eleven patients treated with the placebo unit healed.

Brighton et al. (18) compared direct current, capacitive coupling, and bone graft treatment of 271 tibial nonunions in a retrospective study using logistical regression. They identified seven risk factors that adversely affect union rates: duration of nonunion, prior bone graft, prior electrical treatment, open fracture, osteomyelitis, comminuted or oblique fractures, and atrophic nonunions. In the absence of any risk factors, they reported no significant difference in the success rates of the three treatment groups. Healing rates decreased with an increasing number of risk factors. Capacitive coupling had a poorer union rate in cases of atrophic nonunions and bone graft surgery had a poorer union rate if there had been a previous unsuccessful bone graft procedure.

We consider the use of electrical stimulation in delayed unions in which patients prefer nonoperative care, when further operative intervention is contraindicated due to severe medical problems, and occasionally, as an adjunct with other forms of surgical treatment in patients with poor prognostic factors, such as smokers.

Low-intensity ultrasound has also been shown to accelerate fracture healing (32,59). The role of ultrasound in the treatment of nonunions has not been explored. This method is discussed in more detail in Chapter 26.

## SOFT-TISSUE COVERAGE IN TIBIAL NONUNION

Successful management of tibial nonunions depends on viable soft-tissue coverage as well as on skeletal stability. During the past 20 years, an increased understanding of soft-tissue anatomy and physiology, as well as technical advances in tissue transfer, has improved limb salvage rates, improved function results, and

reduced the length of hospitalization for many patients. The effectiveness of aggressive debridement of necrotic tissue and attentive wound care in treating open tibial fractures was demonstrated by Dehne et al. (36) in 1961, but this treatment had the disadvantage of involving long hospital stays. In 1970, Witschi and Omer (140) reported on 84 open tibial fractures resulting from missile injuries in Vietnam. In all cases, routine wound care combined with delayed split-thickness skin grafting led to initial soft-tissue healing. Split-thickness skin grafts in more extensive degloving or avulsion injuries will not survive, however, if the recipient bed contains poorly vascularized fat or bone without periosteum. Such cases often require alternative methods of coverage involving transfer of more than skin.

Ger (49) popularized and refined the techniques of muscle flap coverage, which had been previously described by other authors, for the proximal two thirds of the tibial shaft. Gastrocnemius flaps for the proximal third and soleus flaps for the middle third of the tibia have since become standard. These axially based muscle flaps provide their own vascular system and permit application of a split-thickness skin graft.

The distal third of the tibia has posed a more difficult problem, which is best approached with free-tissue transfers and the techniques of microvascular anastomoses. Weiland et al. (137) have stressed the importance of achieving a clean surgical wound before performing free-tissue transfer or any reconstructive soft-tissue procedure. Initial success rates of 79% have been reported with latissimus dorsi flaps, but further follow-up revealed recurrent sepsis in an additional 20% of cases (136). Details of these procedures and results are described in Chapter 8, Chapter 35, and Chapter 36.

Coverage of small distal soft-tissue defects may also be obtained by local rotational flaps. Both bipedical flaps and distally based fasciocutaneous flaps have been described to obtain coverage of the lower leg (39,43). Although these procedures avoid the complexity and morbidity of a free-flap procedure, they do not provide any additional blood supply to improve the fracture healing potential.

## BONE GRAFTING

Many methods of bone grafting for tibial defects have been described. These include many forms of sliding-onlay grafts, inlay grafts, nonvascularized fibular transplants, and other techniques for creating tibiofibular synostosis (13,21,22,35,45,55,88,132). Cortical bone grafts have demonstrated weakness due to prolonged remodeling. They incorporate within 6 weeks of grafting, remain weak for at least 6 months, and in comparative series, have required a longer time to achieve union and have been associated with more complications than have cancellous grafts (42,63). Alternatives to cancellous bone grafting that have recently been proposed include the use of percutaneous marrow injections, human bone morphogenic protein, and synthetic bone graft substitutes (28,29,65,82). Although they are promising, these techniques are not all readily available to practicing physicians, and the precise role of each of these alternatives in a general orthopaedic practice has yet to be defined. Further details about these techniques are discussed in Chapter 9.

Cancellous bone grafting remains the single most useful form of bone graft. Anteromedial or posteromedial bone grafting is preferable for proximal nonunions (6). The posterolateral approach described by Harmon (58) is best in the distal two thirds of the tibia; it avoids the typical anteromedial open wound and places bone in the most vascular portion of the leg. In several large series, in which cancellous bone grafting was used for tibial nonunions, union rates of 87% to 100% have been reported (47,56,57,66,67,73,83,117,122). Local complications, which are uncommon, include stiffness, deformity, and loss of ankle motion. These complications have been ascribed to the initial injury but may be aggravated by further prolonged immobilization associated with bone grafting. Paresthesia in the sole of the foot and delayed vascular impairment have been reported but seem to be rare (66,67). Formation of a synostosis has been associated with, but is not clearly the cause of, ankle pain (118). Because these complications are uncommon and the union rate following posterolateral bone grafting is high, it is often used in conjunction with other procedures for angulated or infected nonunions.

Autogenous cancellous bone graft can be harvested from several locations. Some authors have advocated obtaining graft from the distal femur; however, the patient must not bear weight on the limb for 6 weeks postoperatively to protect against fatigue fractures (71). When an extensive amount of cancellous bone is required, we prefer to use the posterior pelvis because it provides the greatest quantity of graft. An acetabular reamer may be used to harvest cancellous bone graft efficiently from the posterior iliac wing, but we routinely use an osteotome and curets (110). Use of an oblique incision perpendicular to the iliac crest paralleling the fibers of the cluneal nerve has been advocated to decrease symptoms of numbness and tenderness at the donor site (26). Harvesting cancellous bone from the anterior iliac crest allows for supine positioning; however, a smaller amount of bone can be obtained. Iliac crest bone graft harvesting may result in donor site morbidity (46). Major complications have been reported to occur in 5.8% to 10% of cases, and minor complications have been reported in 10% to 39 % of cases (3,4).

### ANTEROMEDIAL APPROACH FOR TIBIAL BONE GRAFTING

For delayed unions or nonunions in the proximal third of the tibia, we prefer an anteromedial approach to a posterolateral approach. Owing to difficulties in management of the popliteal artery trifurcation and the vascular supply to the entire lower extremity, the former approach is safer and more easily accessible. Surgery can be performed with the patient supine, and the anterior iliac crest frequently provides enough bone graft for union to be achieved.

- The anteromedial approach provides a smaller tissue envelope for massive amounts of cancellous bone than does the posterolateral approach. The incision is frequently dictated by the injury. However, in virgin skin, make a straight vertical incision just medial to the tibial crest and straight to bone.
- Take great care in dissecting the soft tissues off the anterior tibia. The development of skin flaps will compromise soft tissue, cause skin sloughs, and may necessitate skin grafting or rotational flaps as salvage procedures.
- Once the cancellous bone has been harvested, shave the hypertrophic nonunion to recreate the normal contour of the bone, and pack the cancellous bone anteromedially and anterolaterally. Do not attempt to dissect deep into the anterior compartment along the lateral crest of the tibia; this may injure the already compromised soft tissues and vascular structures.

### POSTEROMEDIAL BONE GRAFTING

A posteromedial approach is useful for nonunions in the proximal third when the anterior soft tissues are poor or a pre-existing flap makes an anterior approach problematic. In addition, there is limited space for a bone graft anteriorly, particularly if plating is necessary. Posteromendially, the approach is simple and provides exposure from the knee joint to the ankle joint. Application of a plate posteriorly works well, and soft-tissue coverage is superior to an anterior approach.

- Make a longitudinal incision along the subcutaneous posteromedial border of the tibia beginning as proximal as necessary and extending distally.
- Avoid injury to the saphenous nerve and vein. Expose the posterior tibia by subperiosteal dissection.
- Expose the tibia as far laterally as required, avoiding injury to the vessels of the trifurcation.
- Apply plate fixation or bone graft as indicated.

### POSTEROLATERAL APPROACH FOR TIBIAL BONE GRAFTING

We prefer the posterolateral approach to the tibia with the patient prone. This allows a two-team approach; one surgeon can begin harvesting the bone graft from the posterior iliac crest while the other begins the approach to the tibia. This method decreases surgical operating time and provides optimal access to the posterior crest of the ilium and tibia (Fig. 31.2)

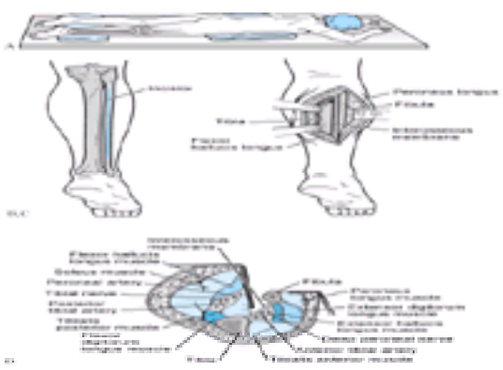

***Figure 31.2.*** **A:** Patient positioned prone for a posterolateral bone graft. **B:** Incision placed directly over fibula. Avoid the sural nerve distally. **C:** The interval between the lateral and posterior compartments is developed. **D:** Cross-sectional view of the approach developed between the continuum of fibula, interosseous membrane, tibia, and the tibialis posterior muscle. This interval protects the peroneal artery, the posterior tibial artery, and the tibial nerve from direct injury by interposing the tibialis posterior between the osseous and neurovascular structures.

- Depending on the level of the nonunion, make a generous skin incision from 10 cm above to 10 cm below the level of nonunion. Avoid injury to the sural nerve.
- Dissect longitudinally, medial to the palpable border of the fibula, between the gastrocnemius and soleus, and flexor hallucis longus and the peroneal muscles. After the fascia of the soleus has been entered, a fixed palpable fascia on the anteromedial border of the fibula provides a landmark for the next level of dissection. Avoid lateral stripping of the peroneal muscles from the fibula—this procedure unnecessarily compromises the regional blood supply.
- Reflect the soleus and flexor hallucis longus muscles using a periosteal elevator; take care to remain on the fibula while elevating in a longitudinal direction. Once the flexor hallucis has been completely freed, pass the elevator against the fibula anterior to the posterior tibial muscle and neurovascular bundle to elevate the posterior compartment from the fibula. Be very careful at this level to avoid inadvertent entry into the posterior tibial compartment, which could injure the posterior tibial neurovascular bundle. Dissection should always begin in areas of known anatomy far away from the fracture and nonunion site.

**HINTS AND TRICKS**

- With the patient in the prone position, the interosseous membrane is deep to the fibula and runs more or less anterior to posterior (vertically). Keep this in mind because it facilitates exposure of the membrane and contiguous tibia.
- Most nonunions are fibrous; therefore, it is not necessary to take down the nonunion site.
- In difficult nonunions, strongly consider extending the fusion mass across the interosseous membrane to incorporate the fibula. The creation of a tibiofibular synostosis may ensure a stable leg even if the nonunion does not heal. The synostosis rarely compromises ankle motion.
- To avoid compartment syndrome, do not close the deep fascia.

- Once the appropriate plane has been entered, carry the dissection to the nonunion site, which frequently is encased in a scar. At this point, elevate the posterior tibial compartment off the interosseous membrane with a periosteal elevator. Retract the posterior compartment, neurovascular bundle, soleus, and gastrocnemius with Bennett or Hohmann retractors.
- After the nonunion has been identified, “petal” or “shingle” the shaft from 5 cm above to 5 cm below the nonunion with a sharp ½-inch osteotome. Copiously irrigate the wound, secure hemostasis, and pack the harvested cancellous bone into this compartment. After the bone graft is in place, insert a suction drain, loosely close the soleus fascia to the peroneal fascia to hold the bone graft in position, and close the skin in the standard fashion. Finally, apply a long-leg Robert Jones dressing, which allows easy access to the wound and drain.
- Once the wound heals, most patients can be placed in a Sarmiento or short-leg cast and allowed to full weight bear until union occurs. This can require up to 6 months.

### OPEN CANCELLOUS BONE GRAFTING

Papineau (101) and Vidal et al. (131) have previously described the technique of open cancellous bone grafting for the treatment of nonunions. Cancelleous bone chips are added to the wound cavity once it has been covered by granulation tissue. The cavity must be cup shaped to contain the graft. The bone graft must be kept moist as the underlying granulation tissue invades and vascularizes the graft. Union rates as high as 94% have been reported by Roy-Camille et al. (107), but that level of success has not been achieved by other groups treating severe tibial defects.

We do not recommend the use of this technique but prefer to use more advanced techniques with lower complication rates. Four significant drawbacks have been outlined by Edwards et al. (40). First, complete and rapid dissolution of the bone may occur if there is any focus of infection adjacent to the wound bed. Second, graft resorption or nonunion will occur unless there is rigid fixation. Cast fixation is not adequate, and prolonged external fixation may be necessary. Third, delayed healing, which occurs especially in the posttraumatic hypovascular tissue bed and is another cause of prolonged external fixation, is common. Fourth, structurally significant remodeling and corticalization does not occur for many months after union has been achieved. Graft fracture has been reported when an open cancellous graft is used to replace circumferential diaphyseal bone loss (53). Protected weight bearing may be necessary for as long as 2 years. Open cancellous grafting, therefore, is inferior to other available methods and should not be used for large diaphyseal defects. It may be used for circumscribed metaphyseal bone defects if more advanced techniques requiring associated soft-tissue coverage procedures can not be performed.

## BONE MORPHOGENETIC PROTEIN

See Chapter 9 for a discussion of these promising proteins.

Numerous animal studies have shown promising results in the ability of bone morphogenetic protein (BMP) to heal critical segmental defects successfully (30,31,50,127,128,141,143,144).

To date, one clinical human study of BMP has been performed on patients with tibial nonunions. BMP-7 (also known as osteogenic protein-1) in combination with purified type I collagen was compared with autogenous bone graft in the treatment of 124 established tibial nonunions in a multicenter trial. Although the radiographic appearance of union in the BMP group lagged behind the autogenous bone graft group, the ultimate clinical success rate as defined by pain-free weight bearing and lack of need for reoperation was similar in the two groups. A persistent nonunion required reoperation in 16% of the BMP group and 18% of the autogenous bone graft group (93).

## STABILIZATION

### EXTERNAL FIXATION

Tibial nonunions have been treated with a variety of internal and external fixation devices. External fixation is the preferred method of stabilization in cases of previous infection with the risk of reactivation of quiescent sepsis, following grade II and grade III open fractures, and in the presence of thin secondary epithelium adherent to bone that might slough after surgical dissection (54). Experimentally and clinically, the single-frame anterior fixator using 4.5 mm or 5.0 mm half pins has been shown to be the best device (8,9,142). This form of external fixation provides free wound access, allows stabilization of bone fragments at a distance from the lesion, permits motion of adjacent joints, and encourages patient mobility. Pin tract drainage, reported to occur in 5% to 10% of all pins and responsible for removal or alteration of 1 out of 30 frames, may be minimized with compulsive local pin care (7,52).

### COMPRESSION PLATING

Compression plating for the treatment of closed tibial nonunions has been advocated by Müller (90,92), Rosen (105), and Weber (134). Success rates with compression plating alone have been reported to be high in the treatment of hypertrophic nonunions, but supplementary bone grafting is required for atrophic nonunions. Weber (134) reported union in 126 of 127 uninfected tibial nonunions in which compression plating was used. Like most other forms of internal and external fixation discussed in this outline, compression plating allows motion of adjacent joints and prevents “fracture disease.” Although they have been proven successful in uninfected tibial nonunions, compression plates do not tolerate weight bearing until healing has occurred. For this reason, we prefer reamed nailing or posterolateral bone grafting with functional casting or bracing to compression plating in the treatment of tibial nonunions with acceptable alignment. Compression plating is associated with unacceptably high infection rates in previously infected tibial nonunions (120).

Helfet (60) reported successful healing in 33 patients with malaligned tibial diaphyseal nonunions treated by indirect reduction with a femoral distractor, tension band plating, lag screw fixation, and autogenous bone grafting. Limiting the soft-tissue dissection by using the femoral distractor to achieve an indirect reduction was stressed as an important element of the success of this method.

Compression plating finds its greatest application in the treatment of uninfected angulated tibial nonunions. The plate may sometimes be used to realign the fracture if it is positioned on the tension side of the nonunion, placed under additional tension with an independently placed distractor, and then used as a template for fracture realignment. A closing wedge or oblique tibial osteotomy, with or without fibular osteotomy, may be necessary to allow adequate alignment of the tibia with the plate. Plate fixation may also be performed in conjunction with a posterolateral bone graft. In this case, apply the plate posteriorly where there is excellent muscle coverage.

Angular tibial malunions and nonunions with no history of previous infection can be treated with an oblique tibial osteotomy (Fig. 31.3, Fig. 31.4, Fig. 31.5 and Fig. 31.6 ). A method of mathematically directed single-cut osteotomy for correction has recently been well described by Sangeorzan et al. (111). We have found the guidelines that they have published to be useful in preoperative planning (109).

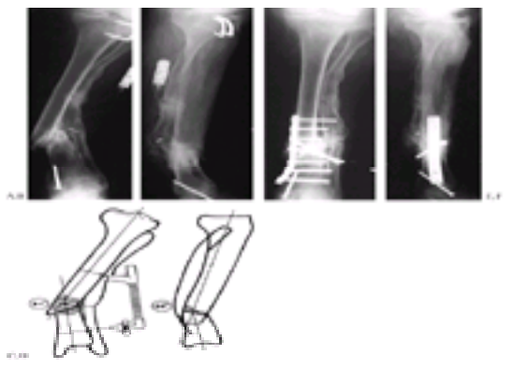

***Figure 31.3.*** **A, B:** The patient, a 75-year-old retired homemaker, sustained a closed tibia fracture 7 years ago. The fracture had been operated seven times previously, and the patient presented with pain and gross motion. Because of the high-risk nature of reconstruction, surgery was recommended only with the knowledge that amputation might result. Plate fixation was elected to stabilize the osteotomy to protect proximal bone for amputation if an infection occurred. **C, D**: On the frontal plane, a 31° valgus deformity must be corrected and the hypertrophic fibular osteotomized. The sagittal plane has a 20° apex posterior deformity, which can be corrected with a 2 cm wedge. The oblique nature of the osteotomy provides intrinsic stability to the plate fixation. The hypertrophic fibula may be used to anchor the plate screws with the severe osteopenia of the tibia. The AO/ASIF femoral distractor gives the surgeon mechanical advantage during straightening. **E, F:** The final result demonstrates near-anatomic alignment. The osteotomy is united, and the patient walks with a cane. To enhance stability, most screws were placed into the hypertrophic fibula, which offered better purchase than the osteoporotic tibia. Autogenous bone was harvested and packed around the osteotomy. Postoperatively, the patient was kept from weight bearing for 18 weeks and advanced as tolerated thereafter. After 1 year, she walks with a cane for support.

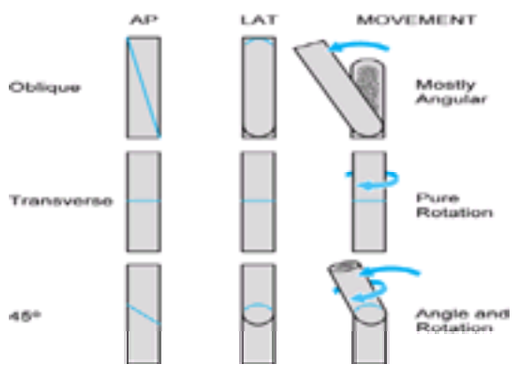


***Figure 31.4.*** The angle of a single-cut corrective tibial osteotomy determines possible corrections. A pure transverse osteotomy allows only rotational correction. A long oblique osteotomy leads to primarily angular correction, with slight rotational correction. Shorter oblique osteotomies, such as the 45° osteotomy shown, allows combined rotational and angular correction. The angle of the osteotomy can be precisely determined for complex deformities.

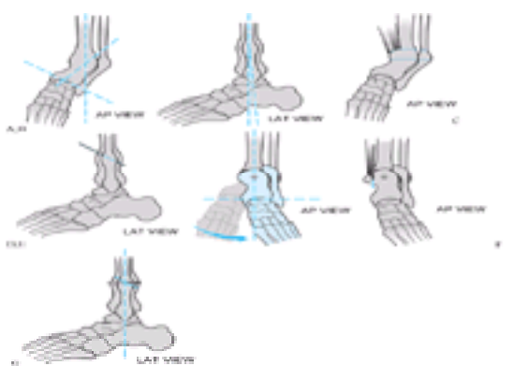

***Figure 31.5.*** Schematic of single-cut oblique tibial osteotomy for varus distal tibial nonunion. The deformity is entirely in the anteroposterior (AP) plane. **A, B:** AP and lateral views of deformity. **C, D:** Oblique osteotomy with an oscillating saw. **E, F:** Provisional single screw fixation of osteotomy. Neutral alignment attained. **G:** Oscillating saw used to resect excess overlapping bone.

***Figure 31.6.*** Radiographs of single-cut oblique osteotomy for varus distal tibial nonunion. The deformity is entirely in the AP plane. **A, B:** AP and lateral views of deformity. **C:** AP view of provisional single-screw fixation of osteotomy. Neutral alignment attained. **D.**Lateral view of provisional single–fixation of osteotomy. **E and F:** Alignment maintained with application of neutralization plate.

### *Preoperative Planning*

Mast (79) has described three sets of drawings necessary to achieve the desired end result; and the surgical tactic.

- First, the exact nature of the deformity must be outlined with tracing paper in the frontal and sagittal planes. Only when the exact nature of the deformity is well understood in both planes can the osteotomy be planned accurately.
- Identify the central axis of the tibial shaft and angular deformity, and outline the hypertrophic callus. Closely scrutinize the status of the fibula. Superimpose the deformity drawings on the contralateral normal tibia, which serves as a template so that correct alignment can be achieved in the frontal and sagittal planes, and also allows consideration for rotational realignment.
- Second, once the deformity has been identified and both free fragments have been superimposed onto the contralateral side, plan the appropriate contour of the bone and the level of the osteotomy, and thus define the desired end result. The type of osteotomy—opening wedge, closing wedge, oblique, or a combination of these types—can be given several trial runs with tracing paper superimposed on the contralateral side.
- Consider indirect reduction methods. The femoral distractor, the articulating tensioner-compression device, and pelvic reduction forceps used in distraction mode are all helpful in obtaining length, correcting angulation, and obtaining optimal rotational alignment. If a compression plate is used, determine the size of the plate, type and direction of the screws, and the positioning of interfragmentary compression screws.

## HINTS AND TRICKS

- Do not resect fibrous tissue in hypertrophic nonunions. Contour compression plates to fit over any callous or fibrous tissue. Stabilization of the nonunion allows calcification and conversion of the fibrous tissue into bone.
- Use interfragmentary lag screw fixation through the plate or independent of the plate whenever feasible.
- Fibrous tissue usually needs to be resected in atrophic nonunions. Re-establish the intramedullary canal by using drills or curets to debride fibrous tissue from the intramedullary canal.
- Use autologous cancellous bone graft in atrophic nonunions.
- Place the bone graft peripherally beneath healthy muscle, which will provide a good blood supply. Place no bone graft in the intramedullary canal.
- Use a sharp osteotome to “petal” or “shingle” the superficial cortex. This approach increases the surface area, elicits a “reinjury” response, and stimulates the incorporation of the bone graft.

- Third, with tracing paper or a discarded clear x-ray film, write each step of the surgical tactic and place it on the view box before the operation to assist the operating room personnel, the surgical assistant, and other surgical team members. In the preoperative plan, include special anesthesia needs, patient positioning, implants, reduction tools, dressings, and any postoperative orthopaedic appliances necessary for nursing care. Such compulsive planning allows the surgical team to be well informed and thus saves operating time and optimizes the flow of surgery.

### ILIZAROV TECHNIQUE

The Ilizarov technique has been used for the treatment of angular malunions. Inconveniences associated with the need for frequent postoperative visits, as well as a relatively high rate of pin tract problems and a lower rate of major complications, has tempered enthusiasm for this technique in less complicated cases. The versatility of this method, however, may make it the salvage procedure of choice for some of the more difficult tibial malunion problems that would otherwise not be amenable to functional limb salvage. This technique may be especially useful when shortening or compromised soft tissue complicate the more readily approachable simple angular malunion. Its benefits include early weight bearing and the ability to correct contracted soft tissues gradually in addition to the bone. Preoperative planning, as described earlier, is also recommended when the Ilizarov technique is used. Further details of this technique are described in Chapter 32.

### INTRAMEDULLARY NAILING

Intramedullary nailing has many applications in the treatment of the uninfected tibial nonunion. Nonreamed intramedullary nailing, as advocated by Lottes (77) for the treatment of nonunion, is a relatively simple procedure, especially if the tibia is well aligned. However, unreamed nails that are not interlocked do not provide adequate rotational control and function solely as a form of internal splint. Locked intramedullary nails have extended the indications for treatment of the initial fracture and nonunions (70).

Reamed tibial nails have a wider application than nonreamed nails, but prohibitively high infection and reinfection rates preclude their use in infected or previously infected tibial nonunions (74,76) (Fig. 31.7). Even recent reports advocating the use of reamed intramedullary nails in the setting of previous infection document a reinfection rate of 22% to 38% although union is achieved (89,119). In the patient with a noninfected tibial nonunion, the procedure stimulates the fracture site with the autogenous graft provided by the reamer and provides greater stabilization than does nonreamed nailing. Union rates of 95% to 100% have been reported with reamed nailing in tibial nonunions and delayed unions with no prior history of infection (12,25,33). Mean healing time with reamed nailing in this setting ranges from 4 to 9 months (12,25,33). Unlike compression plating, reamed intramedullary nailing offers the advantage of full weight bearing after treatment, in addition to allowing motion at the adjacent joints.

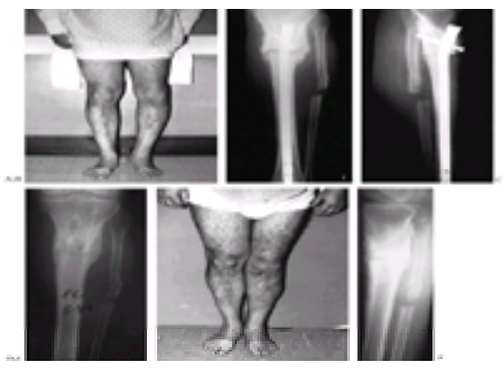

***Figure 31.7.*** **A to C:** The patient is a young male with genu varum and a 13° proximal varus deformity of the left tibia secondary to a closed proximal tibia fracture. A valgus-producing wedge osteotomy was performed with static locked tibial nailing and fibular osteotomy. The patient was discharged fully weight bearing. **D to F:** Two-year follow-up with hardware removed and the clinical result.

When using reamed tibial nails, adhere closely to the principles of management of tibial nonunions that is outlined earlier in this chapter. The tibial blood supply has usually been adequately re-established from surrounding soft tissues by the time reamed nailing for nonunion is considered. Take care to avoid stripping soft tissues, limiting surgery at the fracture site to the minimum necessary for achieving alignment. In a previously nonsurgically treated tibial nonunion, a very limited open procedure may be necessary to remove fibrous tissue and bone to align the canal. If the tibia is malaligned, a small osteotomy of the malunited fibula near the tibial fracture is frequently necessary to achieve tibial alignment. Whenever possible, perform reamed tibial nailing as a closed procedure.

Intramedullary nailing is a good option for uninfected tibial nonunions following previous unreamed nailing or a plate that has maintained canal alignment, facilitating the insertion of a reamed nail. Laboratory studies and clinical series validate this approach and show that vascularity is usually sufficiently re-established after plating to allow later intramedullary reaming (48,69,97). Minimize soft-tissue stripping when removing the plate. Subcutaneous plate and screw removal through multiple small incisions may be preferable to a larger incision if skin quality is poor.

When small nonreamed locked nails are used for open fractures, delayed union and nonunion is common. Fractures that show no callus or evidence of healing by 12 weeks after fracture and nonunions are excellent indications for closed exchange nailing with a locked reamed nail. Early exchange nailing prevents breakage of the cross screws or nail, which can complicate the procedure greatly.

We recommend the following technique:

- Prepare and drape the extremity in the usual fashion. Use a radiolucent operating table and a C-arm fluoroscope. A fracture table is usually not necessary.
- Remove the existing nail and cross screws or plate and screws.
- Insert a reaming guide pin.
- Ream the intramedullary to at least 2 mm larger than the nominal diameter of the canal or to a sufficient size to accommodate a nail that is 10 mm in diameter or larger, depending on the size of the patient.
- Place an AO femoral compression-distraction device with unicortical pins and compress the nonunion site.
- Perform a fibular osteotomy, if necessary (see later), to achieve compression.
- Insert the nail and lock it with two screws proximally and two screws distally.
- Postoperatively, patients can usually progress to full weight bearing if good stability and bone contact is achieved.

Some controversy exists concerning the role of intramedullary nailing following previous external fixation. Reamed nailing may be safely performed after short periods of external fixation before the development of pin tract colonization (2,10). Deep infection rates from 19% to 66% have been reported for reamed intramedullary nailing following prior longer term external fixation (81,84,125,139). The infection rate following intramedullary nailing is increased when there is a prior history of pin tract infection (81). Because of the risk of infection, we do not recommend reamed tibial nailing following prolonged external fixation and prefer to use posterolateral bone grafting.

## HINTS AND TRICKS

- If the canal is occluded, try to open it using “closed” technique with hand **Y**-handle reamers on a sharp-tipped large Küntscher-flagged guide pin driver across the nonunion. Ream the canal proximally first to give room to work. If this procedure is unsuccessful, it may be necessary to take down the nonunion openly.
- Culture the reamings and administer appropriate intravenous antibiotics until the cultures are negative.
- Locate the AO femoral distractor so that it does not interfere with the crosslocking of the nail. Use it to correct angular deformities as well (Fig. 31.8 and Fig. 31.9.).

***Figure 31.8.*** **A, B:** Tibial nonunion with deformity. Intramedullary Enders nails have broken. The patient was unable to walk for more than 1 year following loss of fixation. **C, D:** Realignment attained with removal of small diameter nails; replacement was done with a reamed interlocked nail. Ambulation was regained within 6 weeks, and healing of the fracture was evident within 2 months. Mild valgus and recurvatum persist.

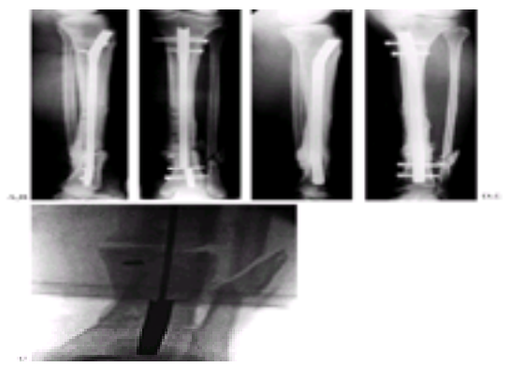

***Figure 31.9.*** A common problem with broken interlocking implants associated with distal tibial delayed unions. **A, B:** Broken tibial nail with nonunion at the junction of the middle third and distal third of the tibia. Plate fixation had initially been used unsuccessfully to treat this fracture. The large holes in the midtibia denote the location of broken screws that had been previously removed, requiring the use of hollow-milled drills. **C:** Intramedullary removal of a broken nail. Removal can be achieved with commercially available instruments that are specially designed for removal of broken intramedullary nails. The fracture site is not opened. **D, E:** Healed fracture after intramedullary nail exchange. The long interlocking screws were inserted to facilitate retrieval in anticipation of possible screw breakage and were later removed.

### FIBULAR OSTEOTOMY

Several authors have advocated isolated fibular osteotomy or resection for the treatment of tibial nonunions. The fibula usually heals before the tibia. With some resorption of bone at the fracture site, this process can interfere with apposition of the tibia and produce relative distraction. This is especially true with intramedullary nailing. The rationale for osteotomy is to permit the tibial fracture to compress with walking. In three series, results showed healing in 77%, with a mean time to union of 25 weeks in the first; 87% union rate, with time to union not reported in the second; and 100% union rate with a 14% refracture rate and a mean time to union of 18 weeks in the third (37,44,121). Advocates of fibular osteotomy cite the simplicity of the procedure, its isolation from a possible infected site, and its applicability in the presence of soft-tissue deficits. However, these arguments apply equally well to posterolateral bone grafting, which does not involve the additional risk of shortening and rotational deformity. Fibular osteotomy is a useful adjunct to other procedures in restoring tibial alignment, but we do not find it useful as an isolated procedure. There is no evidence that this technique used alone is effective in the treatment of infected tibial nonunions.

Our technique is as follows:

- Make a 4 to 5 cm long longitudinal incision directly over the lateral border of the fibula at the level of the tibial fracture. Avoid injury to neurovascular structures.
- Either split the peroneal muscles directly down to bone or dissect anteriorly or posteriorly in the intermuscular interval. Expose 2 to 2.5 cm of fibula by subperiosteal dissection.
- Place an anterior and posterior small sharp-tipped Hohmann retractor to protect the soft tissues.
- With an oscillating saw using a small blade, make a 45° longitudinal osteotomy. If necessary, complete the osteotomy medially with an osteotome to avoid injury to the deep soft tissues.
- Obtain hemostasis and close the wound in layers.

#### HINTS AND TRICKS

- Do not resect a section of the fibula because this procedure can lead to a symptomatic nonunion and negate the use of the fibula in future reconstructions.
- The oblique osteotomy allows shortening, and it heals rapidly.

### DYNAMIZATION OF A LOCKED NAIL

Dynamization of a locked nail by removing the cross screws from one or both ends of the nail to permit compresssion of the fracture with weight bearing is a common practice, is simple, and can be performed as an outpatient procedure. Fibular osteotomy may also be necessary. Beware, however, that dynamization can also increase instability, particularly in rotation, worsening the situation. Follow these guidelines for dynamization:

- In small nonreamed nails, strongly consider exchange reamed nailing as described earlier.
- Avoid dynamization in unstable fracture patterns that will shorten excessively or become rotationally unstable. The best configuration is a short oblique fracture.
- Remove the screws from only one end of the nail farthest from the fracture.
- Permit the patient to bear weight in an appropriate orthosis.

### NONUNIONS WITH SEGMENTAL BONE DEFECTS

Large segmental defects of the tibia are usually the result of severe open tibial fractures, the treatment of which is often associated with severe contamination, neurologic or vascular injury, and polytrauma. In the past, the treatment of choice for these injuries has frequently been amputation.

Before the popularization of Ilizarov techniques our approach to large segmental tibial defects has been initial surgical debridement, stable external fixation, and soft-tissue coverage, with late massive posterolateral cancellous bone grafting producing a tibia profibula synostosis (Fig. 31.10). Using this approach, a synostosis was created proximally and distally with internal fixation of the fibula to provide a strut for subsequent bone-grafting procedures. Achievement of a stable functional union could take up to 2 years, and multiple bone-grafting procedures were sometimes necessary. Intramedullary fixation and tibial plate fixation are associated with a higher risk of infection and, therefore, are not used in this setting. Although the length of treatment is prolonged, requiring multiple hospitalizations, massive

posterolateral bone grafting appears to be a viable alternative in the treatment of patients with severe segmental bone loss.

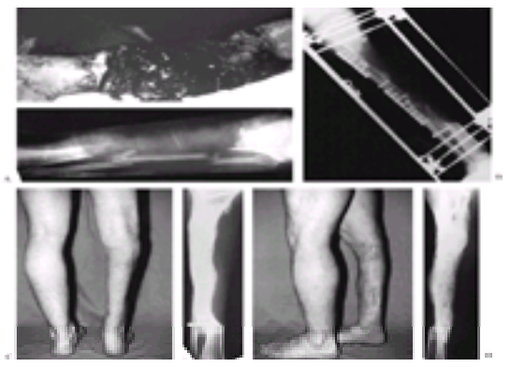

***Figure 31.10.*** **A:** The patient is a 25-year-old mill worker who had sustained a type III-C near-amputation of the tibia. The anterior tibial compartment and neurovascular structures were missing, leaving a major bone defect with normal plantar sensation to the foot. An amputation was advised, but the patient refused. **B:** The initial injury was treated with irrigation, debridement, and external fixation. After the soft tissues had been cleaned several times in the operating room, a delayed closure without major soft-tissue transfer was carried out. At 6 weeks, the patient had internal fixation of the synostosis of the tibia and fibula, and both posterior iliac crests were harvested for graft placement through a lateral skin incision. **C, D:** Two-year follow-up shows solid bone union and full weight bearing. The patient required a second osteosynthesis of the proximal synostosis with plate fixation and bone graft to achieve solid union. At present, he works in a steel mill, where he regularly lifts weights of 100 pounds; however, he uses a polypropylene removable orthosis to support his lack of an anterior compartment. Major bone defects can be treated with posterolateral bone grafting as an alternative to vascularized fibular transfers or amputation.

## ILIZAROV TECHNIQUE

More recently, segmental defects have been treated effectively using the Ilizarov technique of corticotomy and bone transport. The Ilizarov technique received much enthusiasm and was very popular when it was initially introduced in the United States in the early 1980s. Since then, its general use has decreased, but it remains a useful technique in specialized centers owing to its versatility. Because the Ilizarov technique is substantially different from other available techniques for treating segmental bone loss, a steep learning curve is likely to be encountered by the orthopaedist treating segmental bone loss with bone transport for the first time (99). Formal training in this technique is recommended before proceeding with any Ilizarov procedure. A relatively high rate of pin tract infections and other more significant problems are common. Good ancillary paramedical support is highly recommended. The technique is labor intensive, requiring a high level of patient compliance and frequent follow-up. Psychosocial issues and pain management often become challenging problems in the long-term care of these patients. At present, we limit the use of the Ilizarov technique to those patients for whom there are no other reasonable treatment alternatives. The Ilizarov technique for treatment of tibial nonunions and malunions is covered in greater detail in Chapter 32.

## FREE MICROVASCULAR BONE TRANSFERS

Free microvascular bone transfers may be useful for osseous reconstruction following extensive resections. First reported by Taylor and associates in 1978, the technique involves the isolation and transfer of a bone segment, most commonly the contralateral fibula (124). The technique has the advantages of a one-stage procedure. It is relatively independent of the recipient bed and other available procedures, has a fast union rate, and has the potential for graft hypertrophy. However, the surgical procedure is long and demanding, necessitates a vascular sacrifice, may lead to graft fracture, and creates a donor bone defect that may result in instability of the contralateral foot with restricted motion of the ankle and great toe (64,98). Consider the technique for defects longer than 6 cm. There is no role for this technique in infected nonunions until the infection is completely under control, adequate soft-tissue coverage has been obtained, and drainage has been eliminated, with the patient free of all antibiotics. Hypertrophy of the fibular graft may occur with time; however, problems with fatigue fractures remain a significant complication. Further aspects of this technique are considered in Chapter 36.

## CHAPTER REFERENCES

Each reference is categorized according to the following scheme: *, classic article; #, review article; !, basic research article; and +, clinical results/outcome study.


+ 1. Anderson LD, Hutchins WC, Wright PE, et al. Fractures of the Tibia and Fibula Treated by Casts and Transfixing Pins. *Clin Orthop* 1974;105:179.

+ 2. Antich-Adrover P, Marti-Garin D, Murias-Alvarez J, Puente-Alonso C. External Fixation and Secondary Intramedullary Nailing of Open Tibial Fractures: A Randomised, Prospective Trial. *J Bone Joint Surg* 1997;79B:433.

+ 3. Arrington ED, Smith WJ, Chambers HG, et al. Complication of Iliac Crest Bone Graft Harvesting. *Clin Orthop* 1996;329:300.

+ 4. Banwart JC, Asher MA, Hassanein RS. Iliac Crest Bone Graft Harvest Donor Site Morbidity: A Statistical Evaluation. *Spine* 1995;20:1055.

+ 5. Bassett CAL, Mitchell SN, Gaston SR. Treatment of Ununited Tibial Diaphyseal Fractures with Pulsing Electromagnetic Fields. *J Bone Joint Surg* 1981;63-A:511.

# 6. Behrens F. Bone Grafting: General Principles and Use in Open Fractures. *Instr Course Lect* 1981;30.

# 7. Behrens F. Introduction to External Skeletal Fixation. *Instr Course Lect* 1981;30:112.

# 8. Behrens F. External Skeletal Fixation: Basic Concepts and Applications in Open Tibial Fractures. *Instr Course Lect* 1984;33:124.

! 9. Behrens F, Johnson WD, Koch TW, Kovacevic N. Bending Stiffness of Unilateral and Bilateral Fixator Frames. *Clin Orthop* 1983;178:103.

+ 10. Blachut PA, Meek RN, O'Brien PJ. External Fixation and Delayed Intramedullary Nailing of Open Fractures of the Tibial Shaft. A Sequential Protocol. *J Bone Joint Surg* 1990;72A:729.

+ 11. Bonduarnt FJ, Cotler HB, Buckle R, et al. The Medical and Economic Impact of Severely Injured Lower Extremities. *J Trauma* 1988;28:1270.

+ 12. Bone LB, Johnson KD. Treatment of Tibial Fractures by Reaming and Intramedullary Nailing. *J Bone Joint Surg* 1986;68-A:677.

* 13. Boyd HB. The Treatment of Difficult and Unusual Non-unions, with Special Reference to the Bridging of Defects. *J Bone Joint Surg* 1943;25:535.

+ 14. Brighton CT. The Semi-invasive Method of Treating Nonunion with Direct Current. *Orthop Clin North Am* 1984;15:33.

+ 15. Brighton CT, Black J, Friedenberg ZB, et al. A Multicenter Study of the Treatment of Non-union with Constant Direct Current. *J Bone Joint Surg* 1981;63A:2.

+ 16. Brighton CT, Friedenberg ZB, Zemsky LM, Pollis PR. Direct Current Stimulation of Non-union and Congenital Pseudarthrosis—Exploration of Its Clinical Application. *J Bone Joint Surg* 1975;57-A:368.

+ 17. Brighton CT, Pollack SR. Treatment of Recalcitratnt Non-union with a Capacitively Coupled Electrical Field: A Preliminary Report. *J Bone Joint Surg* 1985;67A:577.

+ 18. Brighton CT, Shaman P, Heppenstall RB, et al. Tibial Nonunion Treated with Direct Current, Capacitive Coupling, or Bone Graft. *Clin Orthop* 1995;321:223.

+ 19. Brown CW, Orme TJ, Richardson HD. The Rate of Pseudarthrosis (Surgical Nonunion) in Patients Who Are Smokers and Patients Who Are Nonsmokers: A Comparison Study. *Spine* 1986;11:942.

+ 20. Brown PW, Urban JG. Early Weight-bearing Treatment of Open Fractures of the Tibia. *J Bone Joint Surg* 1969;51-A:59.

+ 21. Campanacci M, Zanoli S. Double Tibiofibular Synostosis (Fibula Pro Tibia) for Non-union and Delayed Union of the Tibia. *J Bone Joint Surg* 1966;48-A:44.

+ 22. Carnesale PL, Guerrieri AG. Fibular Transplant for Loss of Substance of Tibia: Report of a Case. *J Bone Joint Surg* 1955;37-A:204.

+ 23. Christensen NO. Kuntscher Intramedullary Reaming and Nail Fixation for Non-union of Fractures of the Femur and the Tibia. *J Bone Joint Surg* 1973;55-B:312.

+ 24. Cierny G III, Byrd HS, Jones RE. Primary Versus Delayed Soft Tissue Coverage for Severe Open Tibial Fractures. *Clin Orthop* 1983;178:54.

+ 25. Clancy GJ, Winquist RA, Hansen ST. Non-union of the Tibia Treated with Kuntscher Intramedullary Nailing. *Clin Orthop* 1985;167:226.

+ 26. Colterjohn NR, Bednar DA. Procurement of Bone Graft from the Iliac Crest: An Operative Approach which Decreases Morbidity. *J Bone Joint Surg* 1997;79A:756.

# 27. Connolly JF. Common Avoidable Problems in Non-unions. *Clin Orthop* 1985;194:226.

+ 28. Connolly JF, Guse R, Tiedeman J, Dehne R. Autologous Marrow Injection for Delayed Unions of the Tibia: A Preliminary Report. *J Orthop Trauma* 1989;3:276.

+ 29. Connolly JF, Guse R, Tiedeman J, Dehne R. Autologous Marrow Injection as a Substitute for Operative Grafting of Tibial Nonunions. *Clin Orthop* 1991;266:259.

! 30. Cook SD, Baffes GC, Wolfe MW, et al. Recombinant Human Bone Morphogenetic Protein-7 Healing in a Canine Long Bone Segmental Defect Model. *Clin Orthop* 1994;301:302.

! 31. Cook SD, Baffes GC, Wolfe MW, et al. The Effect of Recombinant Human Osteogenic Protein-1 on Healing of Large Segmental Bone Defects. *J Bone Joint Surg* 1994;76A:827.

+ 32. Cook SD, Ryaby JP, McCabe J, et al. Acceleration of Tibia and Distal Radius Fracture Healing in Patients Who Smoke. *Clin Orthop* 1997;337:198.

+ 33. Court-Brown CM, Keating JF, Christie J, McQueen MM. Exchange Intramedullary Nailing: Its Use in Aseptic Tibial Nonunion. *J Bone Joint Surg* 1995;77B:407.

+ 34. d'Aubigne RM, Maurer P, Zucman J, et al. Blind Intramedullary Nailing for Tibial Fractures. *Clin Orthop* 1974;105:267.

+ 35. Davis AG. Fibular Substitution for Tibial Defects. *J Bone Joint Surg* 1944;26:229.

+ 36. Dehne E, Metz CW, Deffer PA. Nonoperative Treatment of the Fractured Tibia by Immediate Weight Bearing. *J Trauma* 1961;I:514.

+ 37. DeLee JC, Heckman JD, Lewis AG. Partial Fibulectomy for Ununited Fractures of the Tibia. *J Bone Joint Surg* 1981;63-A:1390.

+ 38. Donald G, Seligson D. Treatment of Tibial Shaft Fractures by Percutaneous Kuntscher Nailing. *Clin Orthop* 1983;178:64.

+ 39. Dujon DG, Khan UD, Aslam S. Bipedicle Flaps: Simple Solutions for Difficult Problems in the Extremities. *Br J Plast Surg* 1997;50:641.

+ 40. Edwards CC, Jaworski MF, Aronson B. Hoffman External Fixation in Open Tibial Fractures with Tissue Loss. *J Bone Joint Surg* 1979;3:261.

+ 41. Ellis H. *A Study of Some Factors Affecting Prognosis Following Tibial Shaft Fractures.* Oxford, England: Bodleian Library, 1956.

+ 42. Enneking WF, Morris JL. Human Autologous Cortical Bone Transplants. *Clin Orthop* 1972;87:28.

+ 43. Erdmann MWH, Court-Brown CM, Quaba AA. A Five Year Review of Islanded Distally Based Fasciocutaneous Flaps on the Lower Limb. *Br J Plast Surg* 1997;50:421.

+ 44. Fernandez-Palazzi F. Fibular Resection in Delayed Union of Tibial Fractures. *Acta Orthop Scand* 1969;40:105.

+ 45. Flanagan JJ, Buren HS. Reconstruction of Defects of the Tibia and Femur with Opposing Massive Graft from the Affected Bone. *J Bone Joint Surg* 1947;29:587.

# 46. Fowler BL, Dall BE, Rowe DE. Complications Associated with Harvesting Autogenous Iliac Bone Graft. *Am J Orthop* 1995;24:895.

+ 47. Freeland AE, Mutz SB. Posterior Bone Grafting for Infected Ununited Fractures of the Tibia. *J Bone Joint Surg* 1976;58-A:653.

+ 48. Galpin RD, Veith RG, Hansen ST. Treatment of Failures after Plating of Tibial Fractures. *J Bone Joint Surg* 1986;68-A:1231.

* 49. Ger R. Muscle Transposition for Treatment and Prevention of Chronic Post-traumatic Osteomyelitis of the Tibia. *J Bone Joint Surg* 1977;59-A:784.

! 50. Gerhart TN, Kirker-Head CA, Kriz MJ, et al. Healing Segmental Femoral Defects in Sheep Using Recombinant Human Bone Morphogentic Protein. *Clin Orthop* 1993;293:317.

+ 51. Gershuni D, Halma G. The A-O External Skeletal Fixator: The Treatment of Severe Tibial Fractures. *J Trauma* 1983;23:986.

# 52. Green SA. Complications of External Skeletal Fixation. *Clin Orthop* 1983;180:109.

# 53. Green SA. Persistent Wound Infection. In: Green SA. *Complications of External Skeletal Fixation: Causes, Prevention, and Treatment.* Springfield, IL: Charles C Thomas, 1981.

+ 54. Green SA, Garland DE, Moore TJ, Barad SJ. External Fixation for the Uninfected Angulated Nonunion of the Tibia. *Clin Orthop* 1984;190:204.

+ 55. Hand FM. Crisscross Tibiofibular Graft for Nonunion of the Tibia. *Clin Orthop* 1953;I:154.

+ 56. Hanson LW, Eppright RH. Posterior Bone Grafting of the Tibia for Nonunion. A Review of Twenty-four Cases. *J Bone Joint Surg* 1966;48-AS:27.

* 57. Harkins HM, Phemister DB. Simplified Technique of Onlay Grafts for All Ununited Fractures in Acceptable Position. *JAMA* 1937;109:1501.

* 58. Harmon PH. A Simplified Approach to the Posterio-tibia or Bone Grafting and Fibular Transferral. *J Bone Joint Surg* 1945;27:496.

+ 59. Heckman JD, Ryaby JP, McCabe J, et al. Acceleration of Tibial Fracture-healing by Non-invasive, Low-intensity Pulsed Ultrasound. *J Bone Joint Surg* 1994;76A:26.

+ 60. Helfet DL, Jupiter JB, Gasser S. Indirect Reduction and Tension-Band Plating of Tibial Non-union with Deformity. *J Bone Joint Surg* 1992;74A:1286.

+ 61. Hertel R, Strebel N, Ganz R. Amputation Versus Reconstruction in Traumatic Defects of the Leg: Outcome and Costs. *J Orthop Trauma* 1996;10:223.

+ 62. Hoaglund FT, Slates JD. Factors Influencing the Rate of Healing in Tibial Shaft Fractures. *Surg Gynecol Obstet* 1967;124:71.

+ 63. Hoderman WD. Results Following Conservative Treatment of Fractures of the Tibial Shaft. *Am J Surg* 1959;98:593.

+ 64. Ito T, Kohno T, Kojima T. Free Vascularized Fibular Graft. *J Trauma* 1984;24:756.

+ 65. Johnson EE, Urist MR, Finerman GA. Distal Metaphyseal Tibial Nonunion. Deformity and Bone Loss Treated by Open Reduction, Internal Fixation, and Human Bone Morphogenetic Protein (hBMP). *Clin Orthop* 1990;250:P234.

+ 66. Jones KG. Treatment of Infected Nonunion of the Tibia Through the Posterolateral Approach. *Clin Orthop* 1965;43:103.

+ 67. Jones KG, Barnett HC. Cancellous Bone Grafting for Non-union of the Tibia Through the Tibia Through the Posterolateral Approach. *J Bone Joint Surg* 1955;37-A:1250.

+ 68. Karlstrom C, Olerud S. Fractures of the Tibial Shaft: A Critical Evaluation of Treatment Alternatives. *Clin Orthop* 1974;105:82.

+ 69. Karlstrom F, Olerud S. Secondary Internal Fixation. *Acta Orthop Scand* 1979;175(Suppl):1.

+ 70. Kempf I, Grosse A, Riguat P. The Treatment of Noninfected Pseudoarthrosis of the Femur and Tibia with Locked Intramedullary Nailing. *Clin Orthop* 1986;212:142.

+ 71. Krause JO, Perry CR. Distal Femur as a Donor Site of Autogenous Bone Graft. *J Orthop Trauma* 1995;9:145.

# 72. Kwiatkowski TC, Hanley EN Jr, Ramp WK. Cigarette Smoking and Its Orthopaedic Consequences. *Am J Orthop* 1996;25:590.

+ 73. Lamb RH. Posterolateral Bone Graft for Nonunion of the Tibia. *Clin Orthop* 1969;64:114.

+ 74. Laurent IE, Langenskoild A. Osteosynthesis with a Thick Medullary Nail in Non-union of Long Bones. *Acta Orthop Scand* 1967;38:341.

# 75. Levine LS, Grodzinsky AJ. Current Concepts Review: Electrical Stimulation of Bone Repair. *J Bone Joint Surg* 1987;69A:626.

+ 76. Lidgen L, Onnerfalt R. Infected Nonunion of the Tibial Shaft Treated with Kuntscher Intramedullary Reaming and Nail Fixation. *Acta Orthop Scand* 1982;53:669.

* 77. Lottes JD. Treatment of Delayed or Nonunion Fractures of the Tibia by Medullary Nail. *Clin Orthop* 1965;43:111.

! 78. MacNab I. Blood Supply of the Tibia. *J Bone Joint Surg* 1957;39-B:799.

# 79. Mast JW. Preoperative Planning in the Surgical Correction of Tibial Nonunions and Malunions. *Clin Orthop* 1983;178:26.

+ 80. Mayer L, Werbie T, Schwab JP, Johnson RP. The Use of Ender Nails in Fractures of the Tibial Shaft. *J Bone Joint Surg* 1985;67-A:446.

+ 81. Maurer DJ, Merkow RL, Gustilo RB. Infection After Intramedullary Nailing of Severe Open Tibial Fractures Initially Treated with External Fixation. *J Bone Joint Surg* 1989;71A:835.

! 82. McAndrew MP, Gorman PW, Lange TA. Tricalcium Phosphate as a Bone Graft Substitute in Trauma: Preliminary Report. *J Orthop* 1988;2:333.

# 83. McCarroll HR. The Surgical Management of Ununited Fractures of the Tibia. *JAMA* 1961;175:578.

+ 84. McGraw JM, Lim EVA. Treatment of Open Tibial-shaft Fractures: External Fixation and Secondary Intramedullary Nailing. *J Bone Joint Surg* 1988;70A:900.

! 85. McKellop HA, Sigholm G, Redfern FC, et al. The Effect of Simulated Fracture-angulations of the Tibia on Cartilage Pressures in the Knee Joint. *J Bone Joint Surg* 1991;73A:1387.

! 86. McKellop HA, Llinas A, Sarmiento A. Effects of Tibial Malalignment on the Knee and Ankle. *Orthop Clin North Am* 1994;25:415.

+ 87. Merchant TC, Dietz FR. Long-Term Follow-up after Fractures of the Tibial and Fibular Shafts. *J Bone Joint Surg* 1989;71A:599.

+ 88. Milch H. Tibiofibular Synostosis for Non-union of the Tibia. *Surgery* 1950;27:770.

+ 89. Miller ME, Ada JR, Webb LX. Treatment of Infected Nonunion and Delayed Union of Tibia Fractures with Locking Intramedullary Nails. *Clin Orthop* 1989;245:233.

* 90. Müller ME. Treatment of Non-unions by Compression. *Clin Orthop* 1965;43:83.

# 91. Müller ME, Allgower M, Schneider R, et al: Manual of Internal Fixation, 2nd ed. New York: Springer-Verlag, 1979.

* 92. Müller ME, Thomas RJ. Treatment of Non-union in Fractures of Long Bones. *Clin Orthop* 1965;43:141.

+ 93. Muschler GF, Perry CR, Cole JD, et al. *Treatment of Established Tibial Nonunions Using Human Recombinant Osteogenic Protein-1.* Presented at American Academy of Orthopaedic Surgeons, New Orleans, March 20, 1998.

! 94. Nelson G, Kelly P, Paterson L, et al. Blood Supply of the Human Tibia. *J Bone Joint Surg* 1960;42-A:625.

# 95. Nicoll EA. Closed and Open Management of Tibial Fractures. *Clin Orthop* 1974;105:144.

+ 96. Nicoll EA. Fractures of the Tibial Shaft: A Survey of 705 Cases. *J Bone Joint Surg* 1964;46-B:373.

+ 97. Olerud S, Karlstrom, G. Secondary Intramedullary Nailing of Tibial Fractures. *J Bone Joint Surg* 1972;54-A:1419.

+ 98. Osterman AL, Bora FW. Free Vascularized Bone Grafting for Large Gap Non-union of Long Bones. *Orthop Clin North Am* 1984;15:143.

# 99. Paley D. Treatment of Tibial Nonunion and Bone Loss with the Ilizarov Technique. *Instr Course Lect* 1990;39:185.

+ 100. Pankovich AM, Tarabishy IE, Yelda S. Flexible Intramedullary Nailing of Tibial Shaft Fractures. *Clin Orthop* 1981;160:185.

* 101. Papineau LJ, Alfagemo A, Delcourt JP, Pilon BL. Chronic Osteomyelitis of Long Bones—Resection and Bone Grafting with Delayed Skin Closure. *J Bone Joint Surg* 1976;52-B:138.

+ 102. Pozo JL, Powell B, Andrews BG, et al. The Timing of Amputation for Lower Limb Trauma. *J Bone Joint Surg* 1990;72B:288.

! 103. Raikin SM, Landsman JC, Alexander VA, et al. Effect of Nicotine on the Rate and Strength of Long Bone Fracture Healing. *Clin Orthop* 1998;353:231.

! 104. Rhinelander W. Tibial Blood Supply in Relation to Fracture Healing. *Clin Orthop* 1974;105:34.

+ 105. Rosen H. Compression Treatment of Long Bone Pseudarthrosis. *Clin Orthop* 1979;138:157.

+ 106. Rosenthal RE. Non-union in Open Tibial Fractures. *J Bone Joint Surg* 1977;59-A:244.

+ 107. Roy-Camille R, Reignier B, Saillant G, Berteaux D. Resultats de l'Intervention de Papineau: A Propos de 46 cas. *Rev Chir Orthop* 1976;62:347.

+ 108. Sakellarieds HT, Freeman PA, Grant BD. Delayed Union and Nonunion of Tibial Shaft Fractures. A Review of 100 Cases. *J Bone Joint Surg* 1964;46-A:557.

+ 109. Sanders R, Anglen JO, Mark JB. Oblique Osteotomy for the Correction of Tibial Malunion. *J Bone Joint Surg* 1995;77A:240.

# 110. Sanders R, DiPasquale T. A Technique for Obtaining Bone Graft. *J Orthop* 1989;3:287.

! 111. Sangeorzan BJ, Sangeorzan BP, Hansen ST Jr, Judd RP. Mathematically Directed Single-cut Osteotomy for Correction of Tibial Malunion. *J Orthop* 1989;3:267.

* 112. Sarmiento A, Sobol PA, Sew Hoy AL, et al. Prefabricated Functional Braces for the Treatment of Fractures of the Tibial Diaphysis. *J Bone Joint Surg* 1984;66-A:1328.

* 113. Sarmiento A, Gersten LM, Sobol PA, et al. Tibial Shaft Fractures Treated with a Functional Brace: Experience with 780 Fractures. *J Bone Joint Surg* 1989;71B:602.

+ 114. Scott G, King JB. A Prospective, Double-blind Trial of Electrical Capacitive Coupling in the Treatment of Non-union of Long Bones. *J Bone Joint Surg* 1994;76A:820.

+ 115. Sedlin ED, Zitner DT. The Lottes Nail in the Closed Treatment of Tibial Fractures. *Clin Orthop* 1985;192:185.

+ 116. Sharrard WJR. A Double-blind Trial of Pulsed Electromagnetic Fields for Delayed Union of Tibial Fractures. *J Bone Joint Surg* 1990;72-B:347.

+ 117. Simon JP, Hoogmartens M. The Value of Posterolateral Bone-grafting for Non-union of the Tibia. *Acta Orthop Belg* 1984;50:557.

+ 118. Skelley JW, Hardy AE. Results of Bone Grafts in the Treatment of Tibial Shaft Fractures. *Clin Orthop* 1981;158:108.

+ 119. Sledge SL, Johnson KD, Henley MB, Watson JT. Intramedullary Nailing with Reaming to Treat Non-union of the Tibia. *J Bone Joint Surg* 1989;71-A:1004.

+ 120. Smith JEM. Results of Early and Delayed Internal Fixation for Tibial Shaft Fractures. A Review of 470 Fractures. *J Bone Joint Surg* 1974;46-B:469.

+ 121. Sorenson KH. Treatment of Delayed Union and Nonunion of the Tibia by Fibular Resection. *Acta Orthop Scand* 1969;40:92.

+ 122. Souter WA. Autogenous Cancellous Strip Grafts in the Treatment of Delayed Union of Long Bone Fractures. *J Bone Joint Surg* 1974;51-B:469.

! 123. Tarr RR, Resnick CT, Wagner KS, Sarmiento A. Change in Tibiotalar Joint Contact Areas Following Experimentally Induced Tibia Angular Deformities. *Clin Orthop* 1985;199:72.

+ 124. Taylor GI, Miller GDH, Ham FJ. The Free Vascularized Bone Graft: A Clinical Extension of Microvascular Techniques. *Plast Reconstr Surg* 1978;55:533.

+ 125. Tornqvist H. Tibia Nonunions Treated by Interlocked Nailing: Increased Risk of Infection After Previous External Fixation. *J Orthop Trauma* 1990;4:109.

! 126. Trueta J. Blood Supply and the Rate of Healing of Tibial Fractures. *Clin Orthop* 105:11, 1974.

* 127. Urist MR. Bone: Formation by Autoinduction. *Science* 1965;150:893.

* 128. Urist MR, Mazet R Jr, McLean FC. The Pathogenesis and Treatment of Delayed Union and Non-union. A Survey of Eighty-five Ununited Fractures of the Shaft of the Tibia and One Hundred Control Cases with Similar Injuries. *J Bone Joint Surg* 1954;36-A:931.

+ 129. Velazco A, Fleming LL. Open Fractures of the Tibia Treated by the Hoffman External Fixator. *Clin Orthop* 1983;180:125.

+ 130. Velazco A, Whitesides TE, Fleming LL. Open Fractures of the Tibia Treated with the Lottes Nail. *J Bone Joint Surg* 1983;65-A:879.

+ 131. Vidal J, Connes H, Buscayet C, et al. Utilization de la Technique de Papineau dans le Traitement des Fractures Ouverts. *Acta Orthop Belg* 1976;42:49.

* 132. Wagner JG. Anterolateral Approach in Bone Grafting for Ununited Fractures of the Tibia. *Am J Surg* 1947;73:282.

+ 133. Watson-Jones R, Coltart WD. Slow Union of Fractures with a Study of 804 Fractures of the Shafts of the Tibia and Femur. *Br J Surg* 1942;30:260.

+ 134. Weber BG, Brunner C. The Treatment of Nonunions Without Electrical Stimulation. *Clin Orthop* 1981;161:24.

* 135. Weber BG, Cech O. *Pseudoarthrosis.* Bern, Switzerland: Hans Huber, 1976.

+ 136. Weiland AJ, Moore JR, Daniel RK. The Efficacy of the Free Tissue Transfer in the Treatment of Osteomyelitis. *J Bone Joint Surg* 1984;66-A:181.

# 137. Weiland AJ, Moore JR, Hotchkiss RN. Soft Tissue Procedures for the Reconstruction of Tibial Shaft Fractures. *Clin Orthop* 1983;178:42.

+ 138. Widenfalk B, Ponten B, Karlstrom G. Open Fractures of the Shaft of the Tibia. Analysis of Wound and Fracture Treatment. *Injury* 1979;11:136.

+ 139. Wiss DA, Stetson WB. Nonunion of the Tibia Treated with a Reamed Intramedullary Nail. *J Orthop* 1994;8:189.

+ 140. Witschi TH, Omer GE Jr. The Treatment of Open Tibial Shaft Fractures from the Vietnam War. *J Trauma* 1970;10:105.

# 141. Wozney JM, Rosen V. Bone Morphogenetic Protein and Bone Morphogenetic Protein Gene Family in Bone Formation and Repair. *Clin Orthop* 1998;346:26.

! 142. Wu J, Shyr HS, Chao EYS, Kelly PJ. Comparison of Osteotomy Healing under External Fixation Devices with Different Stiffness Characteristics. *J Bone Joint Surg* 1984;66-A:1258.

! 143. Yasko AW, Lane JM, Fellinger EJ, et al. The Healing of Segmental Bone Defects, Induced by Recombinant Human Bone Morphogenetic Protein (rhBMP-2). A Radiographic, Histological, and Biomechanical Study in Rats. *J Bone Joint Surg* 1992;74A:659.

! 144. Zegzula HD, Buck DS, Brekke J, et al. Bone Formation with Use of rhBMP-2 (Recombinant Bone Morphogenetic Preotein-2). *J Bone Joint Surg* 1997;79A:1778.

# CHAPTER 32

# MANAGEMENT OF FRACTURES, NONUNIONS, AND MALUNIONS WITH ILIZAROV TECHNIQUES

*In the second edition of this book,* Operative Orthopaedics, *Stuart A. Green was editor of a seven-chapter section on ring fixation and distraction techniques. To eliminate repetition and to provide a more coordinated presentation of the techniques developed by Professor G. A. Ilizarov, Dr. Green has reedited and consolidated the first five of those chapters, which now appear in this chapter as five parts. Much of the original material, both text and illustrations, has been retained, and we thank Drs. James Aronson, Dror Paley, Kevin D. Tetsworth, and J. Charles Taylor for their superb contributions to those second-edition chapters. Deborah F. Stanitski has consolidated the two second-edition chapters on pediatric applications into the new Chapter 171, located in Section IX.*

*Stuart A. Green*

**S. A. Green:** Department of Orthopaedic Surgery, University of California, Irvine, Orange, CA 92868.
**J. Aronson:** Department of Pediatric Orthopaedics, Arkansas Children's Hospital; Department of Orthopaedics, University of Arkansas for Medical Sciences, Little Rock, Arkansas, 72202.
**D. Paley:** Maryland Center for Limb Lengthening, and Reconstruction, University of Maryland, 21207.
**K. D. Tetsworth:** Maryland Center for Limb Lengthening, and Reconstruction, University of Maryland, 21207.
**J. C. Taylor:** Memphis, Tennessee, 38112.

A. The Biology of Distraction Osteogenesis
Definitions
Histology
Physiology
Pathophysiology
Noninvasive Monitoring
Acknowledgment
Chapter References
B. Deformity Correction by the Ilizarov Technique
Definition of Deformity
Evaluation of Lower Limb Deformities
Indications for Correction of Lower Limb Deformities
Preoperative Planning
Planning the Level of Osteotomy and Hinge Placement
Other Factors in Determining the Level of the Osteotomy
Determining the True Plane of the Deformity
Translation Deformities
Angulation/Translation Deformities
Multiapical Angular Deformities
Joint Laxity Deformities of the Knee
Indications for Distraction Osteotomy Versus Conventional Osteotomy
Basic Principles of Deformity Correction Using Circular External Fixation
Center of Rotation Hinge Technique
Push-Pull Constructs
Construct Considerations for Rotational Deformities
Translational Deformity Correction
Order of Corrections for Complex Deformities
Rate of Correction
Acknowledgments
Chapter References
C. The Technique of Circular External Fixation
Wire Technique
Muscle Positioning
Skin Considerations
Drilling
Skin Tension
Fixation to a Ring
Wire Tensioning
Anatomic Considerations
Femur
Tibia
Foot
Humerus
Forearm
Pin Insertion
Chapter References
D. Tension-Wire External Fixators for Acute Trauma
Biomechanics
Fracture Management
Technique for Tibial Fractures
Subacute Fracture Management
Pitfalls and Complications
Chapter References
E. Ilizarov-type Treatment of Nonunions, Malunions, and Posttraumatic Shortening
Nonunions
Atrophic Nonunions
Angulated Nonunions
Assessment
Correction
Oblique Nonunions
Assessment
Correction
Oblique Nonunions with Shortening
Assessment
Correction
Translational Malalignment
Assessment
Correction
Rotational Malalignment
Assessment
Correction
Segmental Defects
Assessment
Correction
Segmental Defect with Shortening
Assessment

Correction
Malunions
Assessment
Correction
Posttraumatic Shortening
Assessment
Correction
Chapter References

# A. The Biology of Distraction Osteogenesis

***James Aronson***

Distraction osteogenesis is a method of producing unlimited quantities of living bone directly from a special osteotomy by controlled mechanical distraction. The new bone spontaneously bridges the gap and rapidly remodels to a normal macrostructure for the local bone (1,2,13,14 and 15).

This method was developed and has been refined by Ilizarov in Kurgan, Siberia, since he first observed this process in one of his patients in about 1956 (8). Using ring external fixators and small-diameter (1.5–1.8 mm) wires under tension, Ilizarov has regenerated more than 18 cm of new bone from a single operative intervention, often doubling the baseline bone length (15,19).

These highly modular fixators can direct the new bone formation in any plane, as the distraction osteogenesis always follows the vector of applied force (13,14). Age is not a limitation so long as the patient has the potential to heal a fracture. The indications for this surgical technique are similar to those for traditional bone grafting and include limb lengthening, nonunions, pseudarthroses, and any osseous defect from trauma, tumor, or infection (12).

Distraction osteogenesis has been shown to regenerate completely vital bone, capable of bearing load, at about 1 cm of bone length per month in children, and 1 cm per 2 months in adults (10,11,18,19).

Ilizarov used the canine tibia to study distraction osteogenesis. By varying the stability of fixation, the energy of the osteotomy (i.e., the degree of vascular damage), and the rate and the rhythm of distraction, he has postulated that all four factors are critical to osteogenesis (13,14).

## DEFINITIONS

*Distraction osteogenesis* means new bone production between vascularized bone surfaces, separated by gradual distraction. Most commonly, the bone is separated by a corticotomy and then distracted at a rate of 1 mm per day (divided into a rhythm of 0.25 mm four times per day) following a 5-day or longer latency.

*Corticotomy* is a low-energy osteotomy of the cortex, preserving the local blood supply to both periosteum and medullary canal.

*Latency* is the period of time after a corticotomy when the initial healing response bridges the cut bone surfaces, before initiating distraction.

*Rate* is the number of millimeters per day at which the bone surfaces are distracted apart.

*Rhythm* is the number of distractions per day, in equally divided increments that total the rate.

*Transformation osteogenesis* means the conversion of nonosseous interpositions (e.g., fibrocartilage in nonunions, synovial cavities in pseudarthroses, or muscle in delayed unions) into normal bone by combined compres and distraction forces, sometimes augmented by a nearby corticotomy.

*Bone transportation* means the regeneration of intercalary bone defects by combined distraction and transformation osteogenesis.

*Healing index* means the number of months from operation to full, unaided weight-bearing for each centimeter of new bone length.

## HISTOLOGY

Histologic preparations demonstrate that the initial latency period appears to be no different from routine fracture healing, as might be expected. Fibrin-enclosed hematoma and inflammatory cell infiltration fill the gap at the corticotomy site. At the start of distraction, mesenchymal cells begin to organize a bridge of collagen and immature vascular sinusoids.

As distraction begins, the fibrovascular bridge seems to organize itself parallel to the direction of distraction. The collagen network becomes more dense and less vascular, almost resembling tendon, while the vascular channels remain at the edges closely approximated to the cut surfaces of the corticotomy segments (1,2,3,5,6 and 7).

During the first week of distraction, this central zone of relatively avascular fibrous tissue bridges the entire 6- to 7-mm gap, which is called the fibrous interzone (FIZ). Spindle-shaped cells resembling fibroblasts are loosely interspersed between collagen bundles; neither osteoid nor osteoblasts are present (Fig. 32.1). Bone mineral is distinctly absent (1,2,3,5,6 and 7).

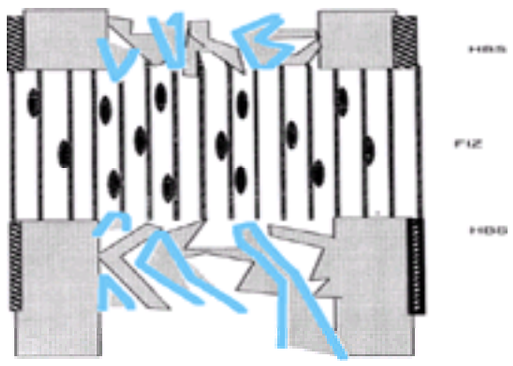


***Figure 32.1.*** Distraction osteogenesis, week 1. Spindle-shaped fibroblasts are interspersed among parallel bundles of collagen that bridge the two cut bone surfaces. This bridge covers the entire host bone surface (*HBS*), including periosteum, cortex, and cancellous bone in the medullary canal. The majority of blood vessels are located in the intramedullary region but do not cross the fibrous interzone (*FIZ*).

During the second week of distraction, osteoblastic cells appear in clusters adjacent to the vascular sinuses on either side of the FIZ. Collagen bundles become fused with a matrix resembling osteoid. The osteoblastic cells initially rest on the surface of these primary bone spicules and eventually become enveloped within, as the spicule is gradually enlarged by circumferential apposition of collagen and osteoid.

By the end of the second week, the osteoid begins to mineralize. These early bone spicules, called the primary mineralization front (PMF), extend from each corticotomy surface toward the central FIZ, resembling stalactites and stalagmites (3). This osteogenic process is seen uniformly covering the entire cross section of the cut bone, including periosteum, cortex, and medullary spongiosa (Fig. 32.2).




***Figure 32.2.*** Distraction osteogenesis, week 2. As the gap widens, the local blood supply intensifies on either side of the fibrous interzone, where microcolumns of new bone are produced by clusters of osteoblasts. These new bone cones form two primary mineralization fronts (*PMF*) located on both sides of the fibrous interzone.

From the third week on, this process continues, with the FIZ undulating across the center at an average thickness of 6 mm. As the distraction gap increases, the bridge is formed by the elongation of the new bone spicules. The tips of the spicules have a diameter of about 7–10 microns, while their bases have diameters of up to 150 microns at the corticotomy surfaces. Each microcolumn of new bone is surrounded by large, thin-walled sinusoids; this zone is called microcolumn formation (MCF) (Fig. 32.3) (17).

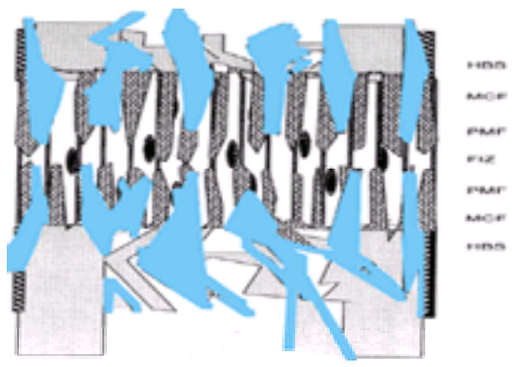


***Figure 32.3.*** Distraction osteogenesis, week 3. As distraction continues, length is gained by increasing the length of individual bone columns in the zones of microcolumn formation (*MCF*). The central fibrous interzone remains relatively avascular, while the large vascular sinuses continue to supply the areas of new bone formation at the primary mineralization fronts.

At the conclusion of distraction, the FIZ ossifies, creating one zone of MCF and completely bridging the gap (Fig. 32.4). During this 6-week consolidation period, the dogs studied by Ilizarov usually resumed weight bearing (1,2 and 3,6,7).

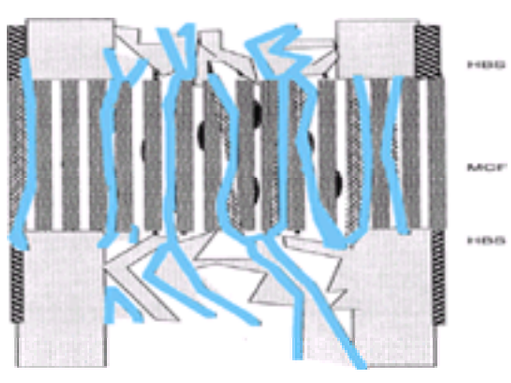


***Figure 32.4.*** Postdistraction consolidation. The microcolumns of bone and vascular sinuses bridge the fibrous interzone, leaving a uniform cross-sectional bridge of living bone tissue.

During the 6 weeks after frame removal, the osteogenic area remodels into cortex and medullary canal (Fig. 32.5). The bony columns take on the staining characteristics of mature lamellar bone, with cement lines and smaller osteocytes resting in lacunae. The fibrovascular tissue that filled the spaces around bone columns is replaced by normal-appearing marrow elements (1,2 and 3,6,7).

***Figure 32.5.*** The microcolumns of bone are easily remodeled into the cortex and medullary canal. Neovascularity has receded and bone-marrow elements fill the intramedullary spaces.

## PHYSIOLOGY

Probably the most important physiologic factors in successful distraction osteogenesis are the regional and local blood supply (17). Each column of new bone is completely surrounded by large vascular sinusoids. The clusters of osteoblasts that appear at the tip of each column are in close proximity to these sinusoids. India ink injection studies with Spalteholz clearing technique demonstrate that these vessels parallel the bone columns and the distraction force; however, very few vessels actually cross the FIZ, which remains relatively avascular (1,4).

Technetium scintigraphy of the osteogenic area shows an intensely hot region with a central cool area corresponding to the FIZ. The orderly zones of bone formation

seen in normal distraction osteogenesis involve collagen deposition, osteoid formation, and mineralization.

## PATHOPHYSIOLOGY

Certain conditions that reliably lead to poor osteogenesis are excessive rate, sporadic rhythm, initial diastasis, frame or bone-fixator instability, inadequate consolidation period, poor regional or local blood supply, and a traumatic corticotomy. It is easy to postulate that an initial diastasis would inhibit the formation of a primary fibrovascular bridge. Instability results in macromotion, especially shear forces that can disrupt the delicate bone and vascular channels. The importance of rate and rhythm may well involve the biosynthetic pathways on the cellular level by rate-limiting steps such as protein synthesis and mitosis. Peripheral vascular disease may limit regional vascularity, and a traumatic corticotomy can severely disturb the local blood flow.

## NONINVASIVE MONITORING

During the process of distraction osteogenesis, it is helpful to assess the progress of bone formation. Early on, the surgeon can adjust the latency to enhance osteogenic potential. During distraction, rate or rhythm adjustments may be necessary to optimize osteogenesis. During consolidation, it is important to know when the osteogenic area is strong enough to remove the fixator.

At the time of the corticotomy, assess the corticotomy for completeness by intraoperative fluoroscopy, distracting no more than 2 mm, angulating no more than 10° to 15°, and rotating no more than 20° to 30°. Often, the far cortex is incompletely fractured or cut through, allowing some diastasis, but multidirectional angulation will be blocked and rotation will be eccentric. The corticotomy must be complete to allow uniform distraction.

The corticotomy should be well reduced radiographically as the frame is fully assembled, to decrease local hemorrhage and to ensure that the osteogenic bridge is not compromised (Fig. 32.6). Either excess bleeding (local arterial injury) or lack of bleeding (systemic disease or local vascular insufficiency) at the time of corticotomy may indicate a local vascular deficiency. In these cases, the latency can be extended by up to 14 days; premature consolidation may occur as early as 14 days in the metaphyseal region and as early as 21 days in the diaphyseal region.

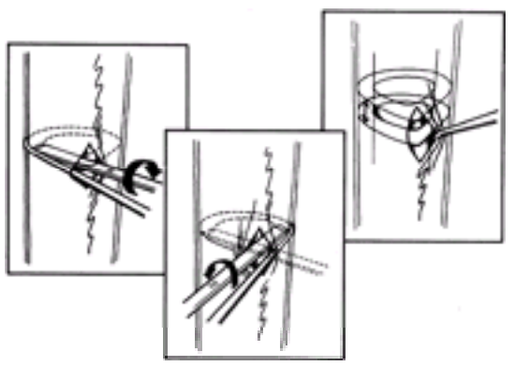

***Figure 32.6.*** Low-energy corticotomy technique in the adult canine tibia. Subperiosteal placement of a narrow osteotome allows the cortex to be cracked on two sides while the periosteal tube and spongiosa are preserved. With a torquing maneuver, the third and final side can be separated. A temporary diastasis of 2 mm is acceptable to ensure complete separation of the cortices. The cortical surfaces should be reopposed with the external fixator and the periosteal tube closed.

Standard radiography provides a good weekly or biweekly check on the progress of the distraction gap (length and alignment). Usually, by the third week of distraction new bone mineral appears as fuzzy, radiodense columns extending from both cut surfaces toward the center (Fig. 32.7). Perform orthogonal views parallel to adjacent fixator rings and between connecting rods at each visit for comparison.

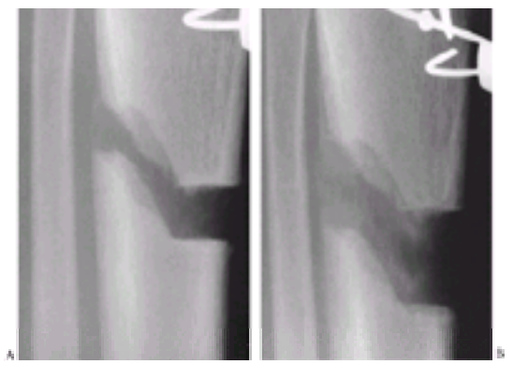

***Figure 32.7.*** **A:** After 7 days of distraction, the lateral view of a corticotomy shows an empty distraction gap. **B:** One week later. After 14 mm of distraction, the gap is filled by radiodense new bone extending from each surface toward a central radiolucent area, the fibrous interzone.

As distraction proceeds, the central FIZ remains an undulating radiolucent zone 4–8 mm wide, while more and more new bone is added from each end. The new bone should span the entire cross-sectional area of the host bone surfaces on both orthogonal views. If the new bone appears to be bulging and the FIZ is narrowing, then accelerate the distraction rate (14). If the new bone forms an hourglass appearance and the FIZ is widening, decelerate the distraction rate (9). The absence of new radiodensity by the third week of distraction may be cause for concern (2,3,9). Ultrasound can be used to diagnose cyst formation in the gap, which may require bone grafting. Ischemic fibrous tissue in the gap is an alternative explanation to delayed mineralization on the radiograph, and this may respond to slowing the distraction rate.

During consolidation, obtain plain radiography on a monthly basis until the osteogenic area has cortex and medullary canal on orthogonal views. Despite the appearance of these radiographic findings, the overall bone density may be severely reduced. Any area within the distraction gap that is less than 60% of the density of the normal side is at increased risk to buckle under normal loads.

## ACKNOWLEDGMENT

I gratefully acknowledge the help of Charles Stewart, an expert bone histologist, who has persevered with enthusiasm for many exciting years of discovery.

### CHAPTER REFERENCES

Each reference is categorized according to the following scheme: *, classic article; #, review article; !, basic research article; and +, clinical results/outcome study.


! 1. Aronson J. A Model for the Study of Mineralization in Skeletally Mature Animals. In: Glimcher MJ, Lian JB, eds. *The Chemistry and Biology of Mineralized Tissues. Proceedings of the Third International Conference on the Chemistry and Biology of Mineralized Tissues.* New York: Gordon & Breach, 1988:807.

# 2. Aronson J. The Biology of Distraction Osteogenesis. In: Bianchi-Maiocchi A, Aronson J, eds. *Operative Principles of Ilizarov.* Baltimore: Williams & Wilkins, 1990:42.

! 3. Aronson J, Good B, Stewart C, et al. Preliminary Studies of Mineralization During Distraction Osteogenesis. *Clin Orthop* 1990;250:43.

! 4. Aronson J, Harp JH, Walker CW, Dalrymple GV. Blood Flow, Bone Formation and Mineralization During Distraction Osteogenesis. *Trans Orthop Res Soc* 1990;15:589.

! 5. Aronson J, Harrison B. Mechanical Induction of Osteogenesis by Distraction of a Metaphyseal Osteotomy in Long Bones. *Trans Orthop Res Soc* 1987;12:180.

! 6. Aronson J, Harrison B, Boyd C, et al. Mechanical Induction of Osteogenesis: Preliminary Studies. *Ann Clin Lab Sci* 1988;18:169.

! 7. Aronson J, Harrison BH, Stewart C, Harp JH. The Histology of Distraction Osteogenesis Using Different External Fixators. *Clin Orthop* 1989;241:106.

# 8. Bianchi-Maiocchi A. Historical Review. In: Bianchi-Maiocchi A, Aronson J, eds. *Operative Principles of Ilizarov.* Baltimore: Williams & Wilkins, 1990:4.

# 9. Catagni M, Rengo C, Celentano L. Imaging Techniques. In: Bianchi-Maiocchi A, Aronson J, eds. *Operative Principles of Ilizarov.* Baltimore: Williams & Wilkins, 1990:53.

# 10. Cattaneo R, Catagni M. Lengthening of the Forearm. In: Bianchi-Maiocchi A, Aronson J, eds. *Operative Principles of Ilizarov.* Baltimore: Williams & Wilkins, 1990:335.

# 11. Cattaneo R, Villa A, Catagni M. Lengthening of the Femur. In: Bianchi-Maiocchi A, Aronson J, eds. *Operative Principles of Ilizarov.* Baltimore: Williams & Wilkins, 1990:310.

# 12. Chapman MW. Bone Grafting. In: Chapman MW, ed. *Operative Orthopaedics*, 2nd ed. Philadelphia: JB Lippincott, 1988:139.

+ 13. Ilizarov GA. The Tension-Stress Effect on the Genesis and Growth of Tissues: Part I. The Influence of Stability of Fixation and Soft-Tissue Preservation. *Clin Orthop* 1989;238:249.

+ 14. Ilizarov GA. The Tension-Stress Effect on the Genesis and Growth of Tissues: Part II. The Influence of the Rate and Frequency of Distraction. *Clin Orthop* 1989;239:263.

+ 15. Ilizarov GA. Clinical Application of the Tension-Stress Effect for Limb Lengthening. *Clin Orthop* 1990;250:8.

! 16. Kijimoto J, Yasui N, Goto T, et al. Bone Lengthening in Rabbits by Callus Distraction. *J Bone Joint Surg Br* 1988;70:543.

* 17. Trueta J, Trias A. The Vascular Contribution of Osteogenesis. *J Bone Joint Surg Br* 1961;43:800.

# 18. Villa A. Bone Lengthening. In: Bianchi-Maiocchi A, Aronson J, eds. *Operative Principles of Ilizarov.* Baltimore: Williams & Wilkins, 1990:285.

+ 19. Villa A, Paley D, Catagni MA, et al. Lengthening of the Forearm by the Ilizarov Technique. *Clin Orthop* 1990;250:125.

# B. Deformity Correction by the Ilizarov Technique

***Dror Paley and Kevin D. Tetsworth***

## DEFINITION OF DEFORMITY

A limb deformity is a deviation from normal anatomy. The deformity may include abnormalities of length, rotation, translation, or angulation (Table 32.1). Several other components of limb deformity should also be considered in individual cases: deficiency, malformation, contour, circumference, and proportion.

| | *Definition* |
|---|---|
| Deformity | |
| Length | Magnitude |
| Rotation | Magnitude, direction |
| Translation | Magnitude, direction, plane, level |
| Angulation | Magnitude, direction, plane, level |
| Mobility | |
| Fixed | Nonreducible |
| Mobile | Partially or completely reducible |

***Table 32.1. Limb Deformity Parameters***

To define a deformity, we need a concept of normal anatomy for comparison. In the lower limb, this usually is evaluated from long anteroposterior (AP) and lateral (LAT) radiographs taken in the standing position. The two considerations in evaluating the frontal plane mechanical axis of the lower extremity are joint alignment and joint orientation (29). The normal alignment of the hip, knee, and ankle joint centers is colinear. Frontal plane deformities lead to a mechanical axis deviation, which primarily affects the knee but also affects the subtalar, ankle, and hip joints. Normally, the line of weight-bearing force from the ankle to the hip joint passes through the medial tibial spine in the center of the knee (12,18). In mechanical axis deviation, it passes medial or lateral to the center of the knee.

The second consideration is the orientation of each joint to the mechanical axis line. Each joint has a normal anatomic inclination to both the mechanical axis and the anatomic axis of the limb segment (Fig. 32.8) (29). In the tibia, the mechanical and anatomic axes are the same, but in the femur they are different. The mechanical axis of the femur is defined as the line from the center of the hip to the center of the knee. This usually subtends a 6° angle to the anatomic axis of the femur, which runs from the piriformis fossa to the center of the knee joint. The knee joint line has been measured to be about 3° off the perpendicular, so that the distal femur is in slight valgus and the tibial diaphysis in slight varus.

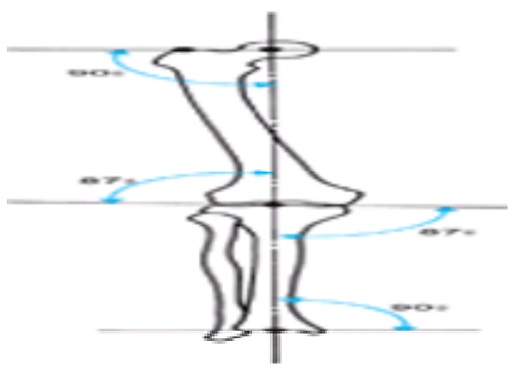

***Figure 32.8.*** The normal mechanical axis and joint orientation of the hip, knee, and ankle. The two components of the frontal plane mechanical axis are colinearity of the hip, knee, and ankle axis; and joint orientation of the hip, knee, and ankle relative to the mechanical axis in the angles shown.

The hip joint does not have as clear a reference line on the femoral side as do the other two joints. The orientation of the hip on the AP view can be characterized by the neck-shaft angle or by the line from the tip of the greater trochanter to the center of the femoral head. The radiographic projection of the neck-shaft angle, which defines the relationship of the femoral head to the anatomic axis, varies with hip rotation. The normal neck-shaft angle range is 125° to 131° (18,33). The diameter of the femoral head is about equal to the distance from the center of the femoral head to the tip of the trochanter. This defines the length of the neck of the femur. A line from the tip of the trochanter to the center of the femoral head defines the joint orientation of the hip. Its relationship to the mechanical axis does not change much with

rotation. This relationship is 90° ± 3° (3).

These reference lines and angles are useful in preoperative planning and in determining the deformity of each bone segment. Population norms for these lines have been measured (3). However, if the patient has a normal side that falls within the normal standard deviation, then use the specific angles from that side.

The other component of lower limb alignment is the orientation of the calcaneus to the tibia. The central axis of the body of the calcaneus is normally parallel with that of the tibia in the frontal plane. Due to the sustentaculum, the mid-body axis of the calcaneus is laterally translated relative to the mid-tibial axis (Fig. 32.9) (29).

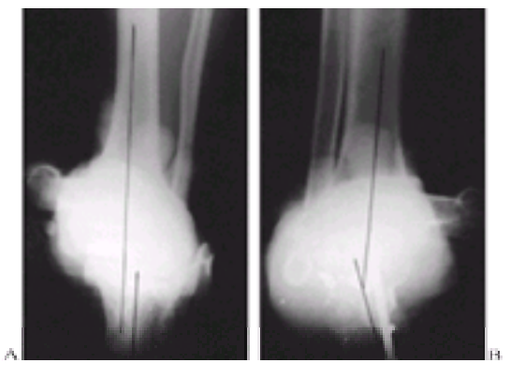

***Figure 32.9.*** Weight-bearing axis at the ankle and subtalar joints. (**A**) Normally, the central axis of the calcaneus is parallel and laterally displaced to that of the tibia. (**B**) When there is varus or valgus deformity in the ankle or subtalar joint, the heel will be inclined into varus or valgus, relative to the tibia. The amount of the deformity can be measured directly.

The acetabular alignment on the AP radiograph is defined by the sourcil, which is normally horizontal to the ground with a level pelvis (2). The center-edge (CE) angle defines the depth of the acetabulum. The normal CE angle is 20° to 30° (20). Higher values occur in protrusio acetabulum, while lesser angles are a feature of a dysplastic acetabulum. The pelvis is normally perpendicular to the spine in bipedal, equal leg-length stance. The weight-bearing axis through the pelvis to the hip joint is oriented 16° to the vertical (21).

The femoral head is oriented in 5° to 20° of anteversion from the posterior condylar axis (20). The proximal tibial articular surface has 8° to 12° of posterior tilt, while the distal tibial articular surface has 5° of anterior tilt relative to the mid-lateral axis (Fig. 32.10) (13).

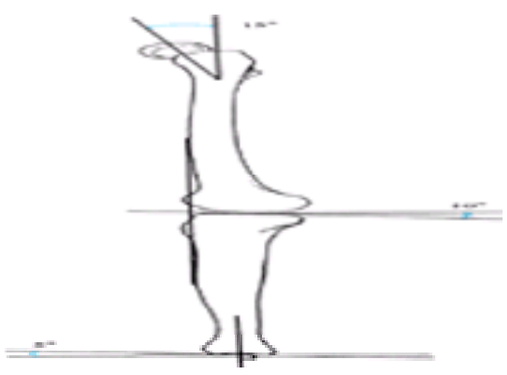

***Figure 32.10.*** The normal alignment and joint orientation on the long LAT view is marked. The mechanical axis line normally runs anterior to the midpoint of the femoral and tibial condyles. The inclination of the femoral neck varies between 5° and 15° of anteversion. The inclination of the proximal tibia varies between 8° and 12° of posterior tilt. The inclination of the distal tibia is approximately 5° of anterior tilt.

## EVALUATION OF LOWER LIMB DEFORMITIES

The radiographic evaluation should parallel and complement the findings of the clinical examination (Table 32.2). Include the hip, knee, and ankle on the same radiographic view, with the patella pointing forward. A 3-ft radiograph is long enough for patients under 5¢5² tall; for those over this height, a 51-in. x-ray cassette is needed to see the alignment of all three joints on one film (Fig. 32.11).



***Table 32.2. Clinical Evaluation Algorithms for Lower Limb Deformity***

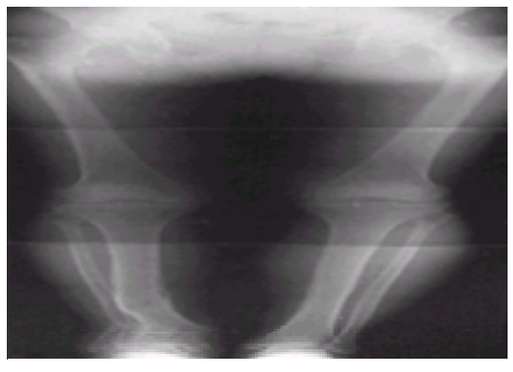

***Figure 32.11.*** A 51-in cassette is used to assess most adults. This provides a radiograph extending from the ground to the top of the pelvis. Notice that the patella should be centered over the middle of the femur to ensure proper alignment (left knee). If the patella points inward or outward (right knee), the alignment measurements will be misleading.

Evaluation of axial alignment may also involve radiographic assessment of fixed pelvic obliquity and scoliosis. This is best done by using blocks to equalize limb length and taking an erect AP x-ray of the pelvis and spine. Hip abduction and adduction radiographs may be necessary to rule out fixed pelvic obliquity on the basis of hip pathology and limitation of motion. Knee flexion deformity alters the alignment and length measured radiographically. Assess axial foot malalignment using a long axial radiograph that superimposes the axial view of the os calcis on the tibia. This can be useful to quantify the malalignment accurately (Fig. 32.9) (29).

Lateral alignment of the lower limb is less critical than frontal plane alignment, since it is in the plane of motion of all three joints. Obtain a long LAT radiograph of the femur and tibia in full knee extension centered over the knee (Fig. 32.10). Normally, the anterior surface of the distal femur is colinear with the anterior crest of the tibia in full extension. Similarly, a line drawn from the center of the hip to the center of the ankle will pass anterior to the midpoint of the knee on the LAT view. If lengthening is considered, the LAT view of the knee in full extension is important for evaluating knee subluxation, and for comparison in case of future knee subluxation. The midpoint of the femoral condyles on the LAT view is normally colinear with the midpoint of the tibial condyles in full extension (Fig. 32.12*A*). Any break in this line in full extension represents a subluxation (Fig. 32.12*B*) (24). If the knee subluxes or dislocates in extension, it is important to obtain a lateral radiograph in the degree of flexion where the knee reduces (Fig. 32.13).

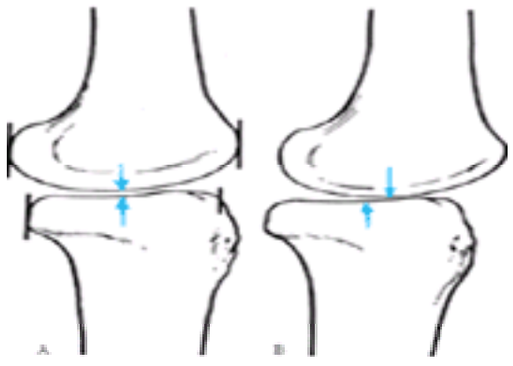

***Figure 32.12.*** When there is subluxation of the knee, the radiographic changes may be subtle. Subluxation of the knee can be defined on the LAT radiograph as a step in the midpoint of the femoral and tibial condyles. Normally, these two points are opposite each other (**A**). When there is a subluxation of the knee, the midpoint of the tibia will displace anteriorly or posteriorly away from the midpoint of the femur with the knee in extension (**B**).

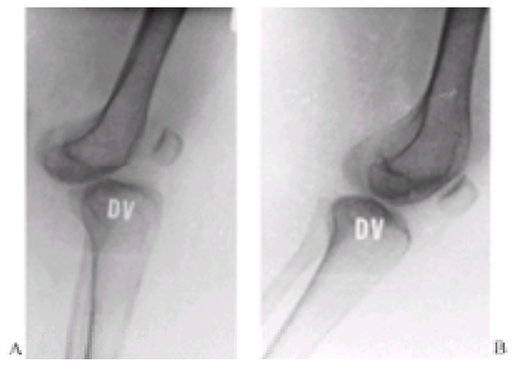


***Figure 32.13.*** **A:** The knee is dislocated in full extension. **B:** In 30° of flexion, the knee reduces.

The cross-table lateral of the hip is preferable to the frog-leg view in adults. Anteversion of the neck can be evaluated, as can head and neck deformities. LAT views of the ankle may be necessary in both flexion and extension to evaluate limitation of motion and its etiology (bone or soft tissue).

Torsional deformities can be quantified using some special radiographic views or computed tomography (CT) scanning (14,21). Clinical examination is still the best method to evaluate and quantify torsional deformity (Fig. 32.14) (10,21). Three-dimensional reconstruction CT scans are useful for the assessment of intraarticular deformities, especially those associated with joint deficiencies. Three-dimensional CT scans may one day be useful for planning deformity corrections.

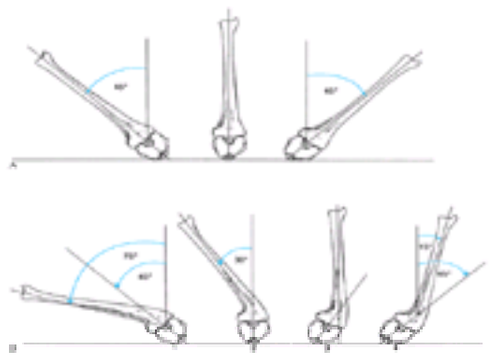

***Figure 32.14.*** **A:** Hip rotation is most accurately measured in the prone position. When the tibia is normal, the zero position is with the leg vertical. Notice that the patella points toward the examining table and the femoral condyles are horizontal. Rotation in one direction is internal; in the other direction it is external. The number of degrees is measured from the zero position. **B:** In the second series of diagrams, the same examination is performed for a 30° valgus deformity of the tibia. If the range of motion of the femur is judged from the tibial shaft, an incorrect assessment of 15° internal rotation (*part 4*) to 75° external rotation (*part 1*) will be made. The zero point should be selected with the patella pointing down and the femoral condyles level (*part 2*). The correct range of femoral rotation (45° internal to 45° external) may then be determined.

Stress x-rays, arthrographic studies, and magnetic resonance imaging (MRI) may be useful to visualize the contour of the joint surface and assess joint laxity, contracture, and luxation.

It is also important to evaluate lateral and medial laxity of the knee joint (Fig. 32.15). The joint lines of the distal femur and proximal tibia will be at an angle to each other on a standing radiograph; stress views will reveal the full extent of the laxity. If this is not corrected together with the deformity, then abnormal loading of the plateaus will continue despite limb realignment.

***Figure 32.15.*** **A:** The lateral collateral ligament is lax (*left*). On single-leg stance during gait, the adductor moment arm leads to a varus deformity through the knee joint. The lateral joint line opens to the point that the lateral collateral ligament becomes tight (*center*). With descent of the fibular head, the lateral collateral ligament can be tightened to correct the articular varus deformity (*right*). **B:** The medial collateral ligament is lax (*left*). Associated with a valgus deformity, the tibia subluxes laterally (*middle*). The medial collateral ligament can be retensioned by distraction of an osteotomy located proximal to its insertion (*right*). The distal end of the osteotomy runs distal to the tibial tubercle to avoid pulling the patellar tendon down.

## INDICATIONS FOR CORRECTION OF LOWER LIMB DEFORMITIES

Deformities of the lower limb may be symptomatic or asymptomatic. Deformity symptoms include pain and inflammation around joints, apparent or real joint restriction of motion, and gait dysfunction or alteration. Patients also present with aesthetic and psychosocial complaints regarding limb deformities.

In general, the goals in correcting a deformity are to relieve symptoms if present and to protect adjacent joints from development of osteoarthrosis secondary to the deformity. Without good data about the natural history of asymptomatic deformities and their contribution to later joint degeneration, it is difficult to specify exact indications for their surgical treatment (8,9,11,16,18,21,26,30,31 and 32). Isolated rotational deformities should not be treated unless symptomatic. They should be corrected as part of a comprehensive approach to the treatment of lower limb alignment.

The following deformities should be considered for treatment, even in asymptomatic patients: distal femoral mechanical valgus greater than 5°, proximal tibial mechanical varus greater than 5°, and mechanical axis deviation greater than 15 mm. Other asymptomatic deformities should be considered for correction prophylactically if radiographic evidence of degenerative joint disease is seen or if only clinical signs are detected (e.g., a positive Trendelenburg sign in a dysplastic hip, lateral thrust in a varus knee). Other deformities that should be considered for treatment include procurvatum deformity of the distal tibia greater than 15°, recurvatum deformity of the distal tibia greater than 10°, and varus or valgus deformity of the distal tibia greater than 10° when subtalar joint motion is restricted. Although these guidelines for deformity correction are based on the available literature, each patient must be evaluated individually.

It is important to identify and treat the correct deformity and not create a deformity in an effort to treat one. The best example is distal femoral valgus. Recommended treatment for genu valgum has included distal femoral osteotomy or proximal tibial osteotomy (Fig. 32.16) (7,9,28). An isolated deformity in the femur should never be treated by a corrective osteotomy of a normal tibia. This will lead to persistent joint inclination and eventual subluxation. Cooke et al. demonstrated that for combined distal femoral and proximal tibial deformities, the best operation is a corrective osteotomy at both levels (4,5). The first step in deformity correction, therefore, is to assess the deformity by accurately defining and describing it (Table 32.1, Table 32.2); then preoperative planning begins.



***Figure 32.16.*** A high tibial osteotomy was performed to correct a valgus deformity of the distal femur. In addition to the sloped joint orientation that was present preoperatively, the patient is now developing collapse into varus and lateral subluxation. This illustrates why a normal tibia should not be osteotomized to correct for a deformity in the distal femur.

## PREOPERATIVE PLANNING

The apical level of diaphyseal deformities is obvious, while the apices of metaphyseal and especially of juxtaarticular deformities are subtle or less clear. The first step is to determine the level of the apex of the angular deformity. With diaphyseal deformities, draw a line down the concave or convex cortex proximal and distal to the apex. The intersection of these two cortical lines is the true apex of deformity. For juxtaarticular and metaphyseal deformities, a more complex system is necessary to determine accurately the level of the deformity's apex.

We have developed a malalignment test for frontal plane mechanical axis deviation (Fig. 32.17). Required materials are a standing radiograph with the patella pointing forward, knee in extension, from hips to ankles, of both lower limbs, and a pencil, a long straight edge, and a goniometer or protractor.

***Figure 32.17.*** The malalignment test. This test determines the origin of frontal plane malalignment. *Step 0:* Draw HA, the mechanical axis line of the lower limb, from the center of the femoral head to the center of the ankle plafond. If this line passes medial to the medial tibial spine, there is medial mechanical axis deviation (MAD). If it passes lateral to the center of the knee, there is lateral MAD. *Step 1:* Draw HK, the mechanical axis of the femur, from the center of the femoral head to the center of the knee. Draw FC, the femoral condyle line. Measure the lateral angle HKF. This should be 87° ± 2°. Outside these limits, the femur is contributing to the MAD. *Step 2:* Draw KA, the tibial mechanical axis line, from the center of the knee to the center of the ankle. Draw the tibial plateau line TP. Measure the medial angle AKP. This should be 87° ± 2°. Outside these limits, the tibia is contributing to the MAD. *Step 3:* Compare the orientation of FC to TP. These should be parallel to each other. If they diverge more than 1° to 2°, there is joint laxity contributing to MAD. **A:** Femoral malalignment. **B:** Tibial malalignment. **C:** Joint laxity malalignment.

If a mechanical axis deviation is detected in step 0 (referring to Fig. 32.17), then steps 1 to 3 will indicate whether the deviation is in the femur or the tibia. If lines FC and TP are not parallel, then there is an intraarticular component to the mechanical axis deviation.

**PLANNING THE LEVEL OF OSTEOTOMY AND HINGE PLACEMENT**

The optimal level for an osteotomy is usually at the apex of an angular deformity. The choice of level is influenced by the proximity to the adjacent joint, the type of fixation, skin coverage, bone quality, and, in children, the physis. A deformity apex within the bone's metaphysis or diaphysis is suitable for osteotomy and fixation. A juxtaarticular deformity apex presents difficulties with both the osteotomy and fixation. In children, correcting a juxtaarticular deformity would cause a transphyseal separation, whereas in adults such a correction would necessitate a periarticular or intraarticular osteotomy. Therefore, the practical level for osteotomy is usually within the metaphysis in these deformities. For this reason, the metaphyseal and diaphyseal deformities will be grouped together under the name *metadiaphyseal*; the juxtaarticular type of deformity will be considered separately.

After identifying the deformed and normal bone(s) using the malalignment test, ascertain the apex of deformity. The osteotomy level can then be determined, taking into consideration the limitations imposed by the joint and physis and by the fixation method. Preoperative determination of tibial deformity with a normal femur is shown in Fig. 32.18 and Fig. 32.19.

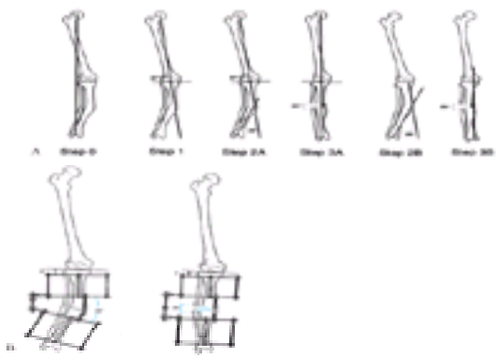

***Figure 32.18.*** **A:** The apparatus for correction of this angular deformity is preconstructed with two levels of fixation on either side of the hinge. The hinge level, plane, magnitude, and direction are built into the apparatus. Tibial diaphyseal deformity with a normal femur. *Step 0:* Draw the mechanical axis line to demonstrate the degree of mechanical axis deviation created by the obvious tibial diaphyseal deformity. The malalignment test was performed to confirm that the orientation of the distal femur is normal. *Step 1:* Since the femur is normal, draw the line from the center of the hip through the center of the knee and extend it distally. This is the mechanical axis of the proximal tibia. *Step 2A:* Draw a line from the center of the plafond extending proximally in line with the anatomic axis of the tibia. This is the mechanical axis of the distal tibia. The center of rotation of angulation is at the intersection of the two mechanical axis lines. The angular deformity measures 26°. *Step 2B:* The alternative method is to draw a line down the convex cortices of the deformity. These lines intersect at the same level and also demonstrate a 26° deformity. *Step 3A:* The deformity correction is performed on paper at the level of the apex of the deformity for a total of 26°. This realigns and overlaps the mechanical axis lines to reestablish the colinearity of the hip-knee-ankle axis. *Step 3B:* After opening wedge correction. This osteotomy also realigns the diaphyseal line of the convex cortex so that it is colinear. **B:** Tibial frame applied to correct deformity illustrated in A.

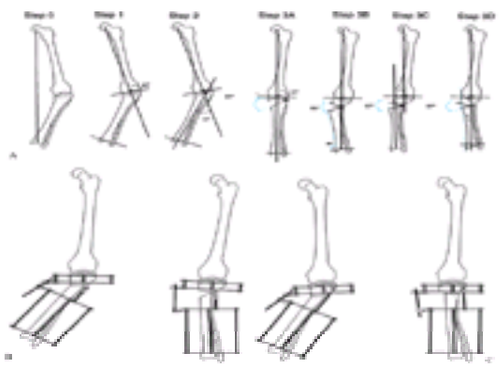

***Figure 32.19.*** **A:** Juxtaarticular tibial deformity with a normal femur. *Step 0:* Draw the mechanical axis line from the center of the femoral head to the center of the ankle. The malalignment test was performed to confirm that the varus mechanical axis deviation is due only to the tibia and that the femur is normal. *Step 1:* Draw the mechanical axis line of the femur and extend it distally. This is the mechanical axis of the proximal tibia. *Step 2:* Draw the line from the center of the ankle plafond extending proximally parallel to the anatomic axis of the tibia. This is the mechanical axis of the distal tibia. Note that the level of intersection of the two mechanical axis lines is at the level of the growth plate. The angular deformity measures 37°. *Step 3A:* The deformity may be corrected by a 37° opening wedge through the growth plate, thus realigning the mechanical axis and reestablishing normal joint orientation. *Step 3B:* Correction of the deformity at the level of the tibial metaphysis requires a 50° correction to realign the mechanical axis. This creates a malorientation of the knee and ankle. Notice that the mechanical axis now subtends a 96° orientation to the ankle joint instead of the normal 90°. *Step 3C:* If only 37° of deformity is corrected, then there is persistent varus mechanical axis deviation. The knee and ankle are oriented correctly to each other, but the mechanical axis is deviated due to a persistent translational deformity (*T*). *Step 3D:* To realign the mechanical axis at the level of the metaphysis, which is distal to the apex of the deformity, the correction should include both 37° of angular correction and lateral translation in the amount of T. The magnitude of T increases as the level of the osteotomy moves farther away from the apex of the deformity. **B:** If the hinge is placed at the level of the osteotomy, overcorrection is required to eliminate mechanical axis deviation. Note that the rings are not parallel at the end of correction because of overcorrection. **C:** The apparatus is preconstructed with the hinge at the level of the center of rotation of angulation. This leads to angulation and translation. The rings are parallel at the end of correction.

Preoperative planning for a deformity of the femur with a normal tibia is shown in Fig. 32.20, Fig. 32.21, Fig. 32.22 and Fig. 32.23. When the apex of the deformity is metadiaphyseal, do the osteotomy at the level of the apex, and place the hinge at the level of the apex. The correction angulates the bone ends. When the apex of the deformity is juxtaarticular, perform the osteotomy in the metaphysis at a level different from that of the apex, and place the hinge at the level of the apex. The correction causes translation and angulation of the bone ends.

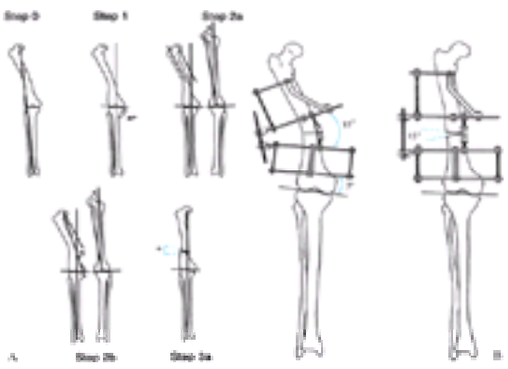

***Figure 32.20.*** **A:** Diaphyseal femoral deformity with a normal tibia. *Step 0:* Draw the line from the center of the femoral head to the center of the ankle, demonstrating a valgus mechanical axis displacement. The malalignment test confirms a normal tibial alignment. *Step 1:* Draw the mechanical axis line of the tibia from the center of the ankle to the center of the knee and extend it proximally. This is the mechanical axis of the distal femur. *Step 2a:* Draw the mechanical axis line of the femur on the opposite normal side. Draw the anatomic axis line of the normal side down the midshaft of the proximal femur. Measure the angle between the mechanical and anatomic axes (a). Draw the anatomic axis of the proximal femur on the deformed side. Draw a line from the center of the hip parallel to the anatomic axis. *Step 2b:* Draw a line from the center of the hip extending distally at a degrees to the last line. This is the mechanical axis of the proximal femur. This line intersects the distal

mechanical axis line at the apex of the deformity, demonstrating a 15° angular deformation. *Step 3a:* Correct the angular deformity through an osteotomy at the level of the apex of the deformity. The angular correction required to realign the mechanical axis is 15°. **B:** Apparatus before and after open-wedge correction with hinge at osteotomy level.

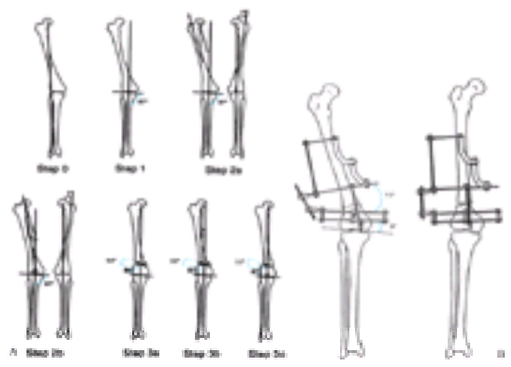

***Figure 32.21.*** **A:** Juxtaarticular femoral deformity with a normal tibia. *Step 0:* Draw the mechanical axis line from the center of the hip to the center of the ankle. This line passes lateral to the center of the knee, indicating a valgus mechanical axis deviation. The malalignment test confirms that the tibial alignment is normal. *Step 1:* Draw the mechanical axis line from the center of the ankle through the center of the knee and extend it proximally. This is the mechanical axis of the distal femur. *Step 2a:* Draw the mechanical axis line of the femur on the opposite normal side. Draw the anatomic axis line of the normal side down the midshaft of the proximal femur. Measure the angle between the mechanical and anatomic axes (7° in illustration). Draw the anatomic axis of the proximal femur on the deformed side. Draw a line from the center of the hip parallel to the anatomic axis. *Step 2b:* Draw a line from the center of the hip extending distally at 7° to the last line. This is the mechanical axis of the proximal femur. This line intersects the distal mechanical axis line at the knee joint, indicating a juxta-articular deformity measuring 11°. *Step 3a:* Since it is not possible to do an osteotomy so distal, the osteotomy is performed at the level of the distal metaphysis. Correction of the mechanical axis alignment by a pure angular correction at this level requires 14°, since the osteotomy is not at the level of the apex of the deformity. As in the tibial example, this produces a slight malorientation of the hip to knee joint lines. *Step 3b:* The correction of only 11° results in persistent valgus mechanical axis deviation. The deformity that remains is purely a translational one of amount *T*. *Step 3c:* The most accurate correction through a metaphyseal osteotomy is to combine 11° of angulation with lateral translation of amount *T*. *T* increases as the distance of the osteotomy to the true apex of the deformity increases. **B:** Apparatus with hinge at juxtaarticular center of rotation. Angulation and translation correction occur since the hinge is at a different level from the osteotomy.

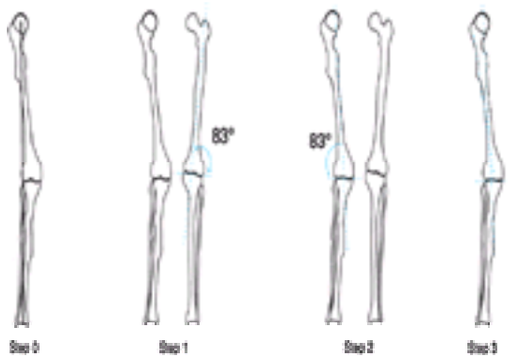


***Figure 32.22.*** Anatomic axis method of preoperative planning for femur. *Step 0:* There is a mechanical axis deviation (MAD) caused by a femoral deformity. Since there is a cup arthroplasty, the center of the femoral head, which is essential for mechanical axis planning, cannot be used. Therefore, anatomic planning is used. *Step 1:* Draw the anatomic axis line on the normal side down the midfemur and measure the lateral angle it subtends to the knee (83°). *Step 2:* Draw an 83° line from the center of the knee on the deformed side. This is the anatomic axis of the distal femur. *Step 3:* Draw the anatomic axis line of the proximal femur on the deformed side (midline proximal femur shaft). The intersection point of the two anatomic axis lines is the center of rotation of the angulation.

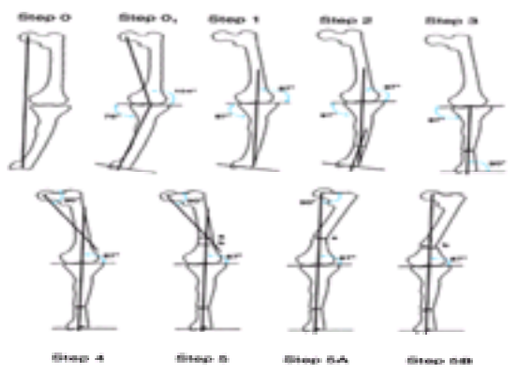

***Figure 32.23.*** Combined femoral and tibial deformities in the absence of a normal opposite side. *Step 0:* Draw the mechanical axis line from the center of the hip to the center of the ankle. This line passes medial to the center of the knee, indicating a varus malalignment. *Step* $0_1$*:* The malalignment test demonstrates a deformity in both tibia and femur. *Step 1:* Draw a line 87° to the knee orientation line. Extend this line both proximally and distally. *Step 2:* Draw a line perpendicular to the ankle plafond (or distal tibial shaft) and extend this line proximally. *Step 3:* Correct the tibial deformity at the level of the apex of the deformity, realigning the tibial mechanical axis and reorienting the ankle and knee. Extend the normalized tibial mechanical axis proximally. *Step 4:* Draw the mechanical axis of the proximal femur. If there is a normal opposite femur to compare, use the angle measured from the opposite side. If there is not a normal angle, use 90°. The intersection point indicates the apex of the deformity. *Step 5:* The osteotomy can be performed at the level of the intersection of the axes (*a*) or at a lower level (*b*). *Step 5A:* Draw the osteotomy at the level of the apex of the deformity, realigning the femoral mechanical axis with that of the tibia. Since this deformity is a bowing of the femur and not truly a uniapical angular deformity, the correction produces a sharp angulation in the cortex of the femur which may be associated with a cosmetic deformity. *Step 5B:* The osteotomy may be performed at a lower level combined with translation, to minimize the angulation in the shaft of the femur. This produces a better aesthetic appearance. The center of rotation of the second osteotomy (*b*) is still at level *a*.

## OTHER FACTORS IN DETERMINING THE LEVEL OF THE OSTEOTOMY

Several other factors must be considered in determining the level of the osteotomy. The apex may not always be the optimal level or even a possible place to perform the osteotomy for several reasons. In developmental and congenital deformities, the deformity is often at the level of the growth plate or joint and, therefore, is inaccessible for fixation or osteotomy. Angular corrections performed as opening or closing wedges not at the level of the apex of the deformity create secondary translational deformities (Fig. 32.24). To avoid this, the bone ends must be translated either acutely or by using a translation hinge. The translation needed can be minimized by performing the osteotomy as close as technically feasible to the true apex of the deformity. An alternative technique uses a hinge at the level of the osteotomy, correcting angulation first, followed by translation by modifying the frame.

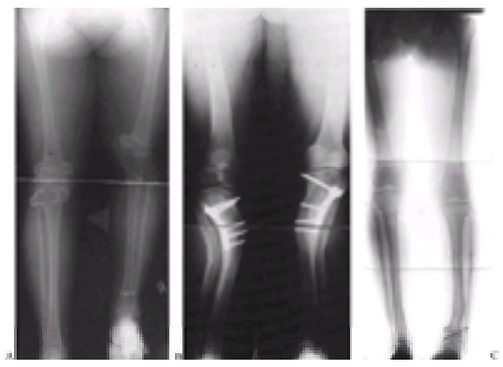

***Figure 32.24.*** Secondary translational deformities. **A:** The so-called golf club deformity of the distal femur is a result of repeated closing wedge varus osteotomies in the supracondylar metaphyseal region of the femur for the treatment of a juxtaarticular deformity of the distal femur. This produces a progressive medial translational deformity with each successive osteotomy. **B:** Medial translational deformities of the tibia are the result of repeated valgus osteotomies at the metaphyseal diaphyseal junction for the treatment of these juxtaarticular deformities of the tibia. In the right tibia, overcorrection was carried out to realign the mechanical axis similar to that described in Fig. 32.19, step 3B. On the left, the ankle and knee joints were reoriented but the mechanical axis was not fully corrected, leading to a persistent varus from the translational component of the deformity. **C:** A varus deformity of the distal tibia due to a malunion was treated by a supramalleolar osteotomy to realign the ankle to the knee joint. This correction ignores the mechanical axis deviation created by the malunion. It demonstrates again that angular correction not at the level of the apex of an angular deformity leads to a translational deformity.

Other situations in which the osteotomy is contraindicated at the apex include the presence of soft-tissue coverage problems or avascular, sclerotic, or previously infected bone (suboptimal for osteotomy). A translational correction of the osteotomy at a level above or below the apex is required.

If lengthening is a major consideration, the optimal level is in the proximal or distal metaphysis. It may be preferable to perform a metaphyseal-level corticotomy followed by a translational correction to realign the mechanical axis for both angulation and translation, or to perform two osteotomies, one for lengthening and one for deformity correction.

Malunions often present with combinations of angular and translational deformities. The translational component may either compensate or aggravate the mechanical axis deviation produced by the angular deformity. In the tibia, if translation is in the direction opposite the angular deformity, then the translation will produce a compensatory effect on the mechanical axis deviation. While this translation may not completely realign the mechanical axis, it will reduce the amount of deviation (Fig. 32.25). On the other hand, if the translation is in the same direction as the angular deformity, the mechanical axis deviation will be aggravated. The apex of the deformity in these cases is not at the malunited level of the two bone segments. Because of the translation, the true apex of the deformity will be either proximal or distal, depending on whether the translation is aggravating or compensatory. In the tibia, compensatory deformities will have an apex distal to the level of the malunion, but aggravating translational angulation deformities will have a true apex proximal to the level of the malunion.

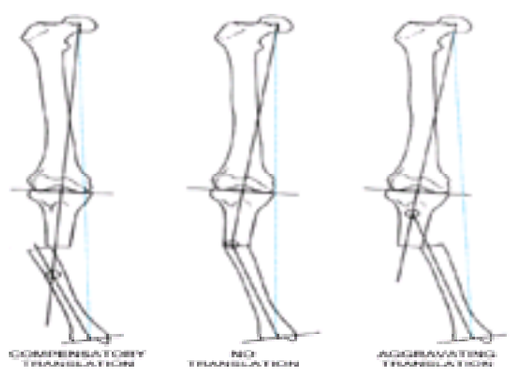


***Figure 32.25.*** Angular malunions of the tibia lead to varying degrees of mechanical axis deviation, depending on the degree of angulation, the level of the malunion, and the magnitude and direction of any associated translational deformity. These three varus malunions differ only in the magnitude and direction of the translational component of the malunion. The *center* malunion has pure angulation without translation of the bone ends. The malunion on the *left* has the same degree of angulation combined with translation toward the convexity of the deformity. The malunion on the *right* has the same degree of angulation combined with translation toward the concavity of the deformity. Notice the amount of mechanical axis deviation (MAD) in all three examples. The MAD is decreased when the translation is toward the convexity and increased when it is toward the concavity. The former is called compensatory translation, whereas the latter is called aggravating translation. Notice the point of intersection of the mechanical axis lines of the proximal and distal tibia. When there is no translation, the intersection is at the level of the malunion. When there is a compensatory translation, the intersection point is distal to the malunion. When there is aggravating translation, the intersection point is proximal to the malunion. The intersection point is considered to be the true apex of the angulation-translation deformity, while the malunion is considered to be the apparent apex.

In the femur, the opposite relationship exists (Fig. 32.26). By performing the osteotomy at the level of the true apex—the intersection point of the mechanical axis—the limb will realign both angulation and translation through a single hinge (Fig. 32.27). A translating hinge apex offers the added advantage of allowing an osteotomy through healthy bone rather than through a sclerotic, avascular, previously open, or infected region at the deformity's apex.

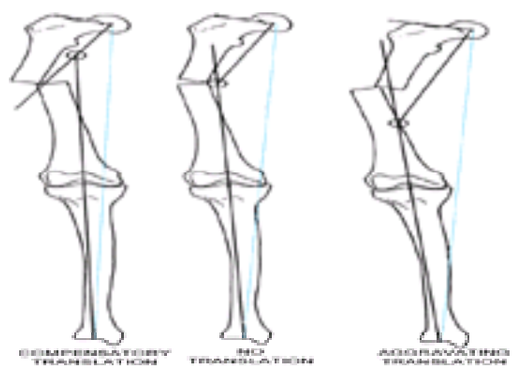


***Figure 32.26.*** Varus malunions of the femur are illustrated with and without aggravating or compensatory translation. Notice that in the femur, translation toward the convexity is aggravating, whereas translation toward the concavity is compensatory. The reason for this is that by convention we refer to translation as the distal fragment being translated relative to the proximal. If we think of the proximal fragment of the femur as the one that is translating, then the rules are similar to that described in the tibia (Fig. 32.25). Notice that the translational deformity shifts the true apex of the deformity either proximal or distal to the apparent apex at the level of the malunion.



***Figure 32.27.*** **A:** Varus malunion of the mid diaphysis of the tibia with compensatory lateral translation. **B:** The frame was applied with the hinges at the level of the true apex of the deformity, and the corticotomy was carried out at that level. **C:** Distraction of the concavity led to realignment of the tibia through an open-wedge correction. Notice the simultaneous correction of the angulation and translation, as demonstrated by the colinearity of the medial tibial diaphysis. The hinges are now straight and the rings are parallel, indicating completion of the deformity correction. **D:** After completion of the angular correction, the parallel rings were distracted to lengthen the tibia. **E:** Final AP standing radiograph demonstrates the alignment of the corrected malunion. There is a persistent leg-length discrepancy of 2 cm, which was accepted because of slow healing in this patient.

Most diaphyseal deformities can be corrected by an osteotomy at the level of the true apex. An osteotomy at the true apex corrects both angulation and translation of the malalignment simultaneously, but it does not correct any contour deformity created by the translated bone ends (Fig. 32.28). If the contour deformity is significant, then the osteotomy should be done at the level of the malunion. Translation and angulation must be corrected separately.

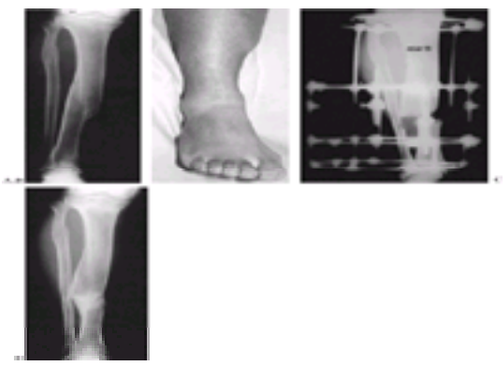

***Figure 32.28.*** **A:** Valgus malunion of the mid diaphysis of the tibia with aggravating lateral translation. There was a significant contour deformity created by the malunion. Preoperative planning demonstrates that the true apex of the deformity is proximal to the level of the malunion. Angular correction at this level simultaneously corrects for the translational component of the deformity. **B:** This leaves a persistent contour deformity that was unacceptable to the patient. **C:** Therefore, the alternative is to perform the correction at the level of the malunion to correct separately the angulation, translation, and the contour deformities. The radiograph demonstrates the angular and translational corrections, which were performed acutely followed by distraction to lengthen the tibia. **D:** The final radiograph demonstrates elimination of the angulation-translation and, as a result, of the contour deformity. The acute translational maneuver should be avoided because it contributes to delayed consolidation by disrupting the periosteum. It is preferable to correct the angulation gradually, followed by distraction to lengthen the tibia, followed by gradual translation.

**DETERMINING THE TRUE PLANE OF THE DEFORMITY**

Orthopaedic surgeons often describe angular deformities as varus, valgus, procurvatum, and recurvatum of the distal segment relative to the proximal segment. The terms *varus* and *valgus* describe angular deformities in the frontal plane; *procurvatum* and *recurvatum* describe angular deformities in the sagittal plane. Using this convention, a deformity with varus and recurvatum is described as a biplanar deformity. Careful analysis of most biplanar deformities reveals that they have but a single apex; moreover, the deformity lies in an oblique plane, somewhere between the frontal and sagittal planes (Fig. 32.29) (25,27). We perceive the deformity as biplanar because the standard radiographic views are obtained in the anatomic reference planes, which may be different from the plane of angulation. Geometrically speaking, however, two lines can subtend only one plane. If we consider each bone segment as a line, these two lines can form an angle with each other only in one plane, regardless of the presence of angulation, rotation, translation, or length of deformities. A second plane of angulation can exist only if a second angular deformity at another level is introduced into these bone segments or lines.

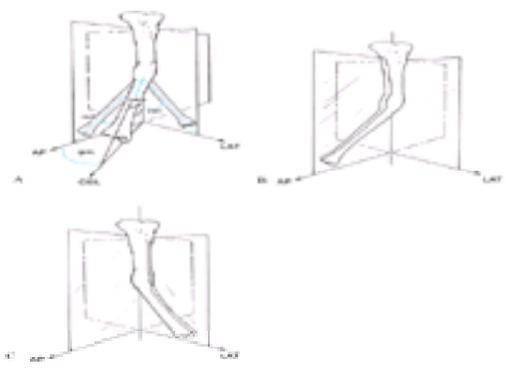

***Figure 32.29.*** **A:** Oblique plane deformity of the tibia. **B:** The AP projection of this tibia demonstrates a valgus deformity. **C:** The LAT projection of this tibia demonstrates a recurvatum deformity. The trigonometric exact formulae and graphic approximate formulae to calculate the magnitude (*obl*) and orientation of the oblique plane to the frontal plane (*pln*) are as follow:

$$\text{trigonometric: obl} = \tan^{-1}\sqrt{\tan^2 \text{ap} + \tan^2 \text{lat}}$$

$$\text{pln} = \tan^{-1}\frac{\tan \text{lat}}{\tan \text{ap}}$$

$$\text{graphic: obl} = \sqrt{a^2 + b^2} \text{ (Phythagorean Theorem)}$$

$$\text{pln} = \tan^{-1}\frac{\text{lat}}{\text{ap}}$$

There are several ways to determine the magnitude and true plane of a deformity in a plane oblique to the frontal plane. The simplest method is to rotate the limb until it appears straight (Fig. 32.30) (27). The true plane of deformity is the plane where the projection of a deformed limb appears straight. The plane 90° to this projection should demonstrate the maximum angulation profile of the deformity. Radiographs taken in these two planes can be used to determine the orientation of this plane and the magnitude of the true deformity.



***Figure 32.30.*** **A:** Malunion of the tibia with 20° of varus and 13 mm lateral translation. **B:** The LAT projection demonstrates 25° of procurvatum and 10 mm of posterior translation. **C:** Observation of the patient from the front demonstrates the varus deformity of the tibia. **D:** When the patient turns his foot inward, the varus deformity seems to disappear and the tibia appears straight. **E:** Examination from the side demonstrates the procurvatum deformity of the tibia. **F:** When the patient turns his foot inward again, the maximum angular profile of the deformity is seen. **G:** The maximum angular profile is captured radiographically on this LAT oblique view of the tibia. It measures 32°. **H:** An internal rotation AP oblique radiograph. In the plane of the deformity, the tibia appears straight. The translational component of the deformity can be appreciated on this view. **I:** The measurement of 20° varus and 25° procurvatum were plotted on a graph. The vector obtained by the point 20–25 represents the magnitude 32° and true orientation 51.5° to frontal plane of the oblique plane angular deformity. Superimposed on this graph, the magnitudes of translation on the AP and LAT are plotted. The magnitude of the oblique plane translation is 16 mm oriented 35° to the frontal plane. The translation and angulation planes are 88° apart. This confirms the radiographic findings. **J:** The malunion was split obliquely. **K:** Notice the appearance of the apparatus in relationship to the left hinge. The hinges have been placed relative to the apex of the oblique plane deformity. Notice that the distance of the hinge rods to the central bolts differs for the medial and the lateral hinge, demonstrating that the hinges are oriented obliquely to the anatomic planes. **L:** A true LAT view of the deformity aligns the hinges with the apex in the oblique plane. **M:** In this manner, distraction of the concavity leads to realignment of the diaphysis on the LAT view of the tibia simultaneous with realignment on the AP view. **N:** All that remains is to correct the translational deformity. **O:** By applying translational rods, the tibia was narrowed, bringing the cortical ends together side to side. **P:** Appearance of the callus at the time of the removal of the apparatus 23 weeks after application. Notice that there is no corticalization of the callus between the bone ends. The patient was, therefore, protected in a patellar tendon bearing cast. The final AP (**Q**) and LAT (**R**) radiographs demonstrate the recurrence of deformity that occurred because of the premature removal of the apparatus prior to complete corticalization of the distraction callus. Notice also the ring sequestrum from one of the pin sites (*arrow*).

The orientation of the oblique plane angular deformity can be calculated using trigonometric equations or a nomogram (29). The graphic method requires only a pencil and goniometer to calculate the magnitude and direction of the oblique plane deformity (Fig. 32.31). Bar and Breitfuss have published a nomogram to determine the true angular deformity and its oblique plane (1). Ilizarov plots the apical deviation from the axial midline on the AP and LAT views as *x* and *y* coordinates and determines the plane of deformity graphically (Fig. 32.32). The Ilizarov apparatus allows the surgeon to make use of these calculations. By determining the true plane of deformity, the surgeon can also determine the axis of the deformity's apex. The axis of the deformity is always perpendicular to the plane of the deformity (Fig. 32.33). By applying a hinge at the true apex of an oblique plane deformity perpendicular to the true plane of this deformity, the surgeon can simultaneously correct the AP and LAT projections of the deformity (Fig. 32.34). Alternatively, the apparatus could be applied to correct the deformity in the AP plane; afterward, the hinges would be reoriented to correct the deformity in the LAT plane. This is a more time-consuming and less-efficient method, but it is accurate.

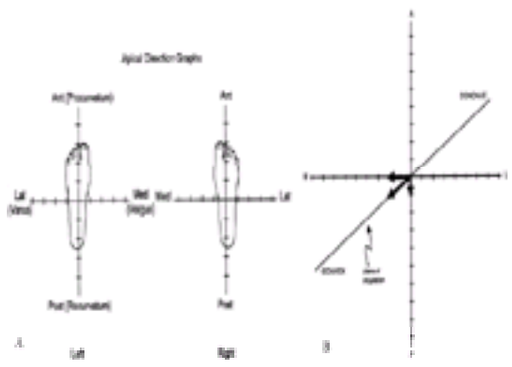

***Figure 32.31.*** **A:** Mark the direction of the apex of angulation on the axes of the graph (as if looking down at your own feet). **B:** Mark the magnitude of the AP and LAT angles (1 mm = 1°; AP, *x* axis; LAT, *y* axis). The resultant vector represents plane, magnitude, and apical direction.

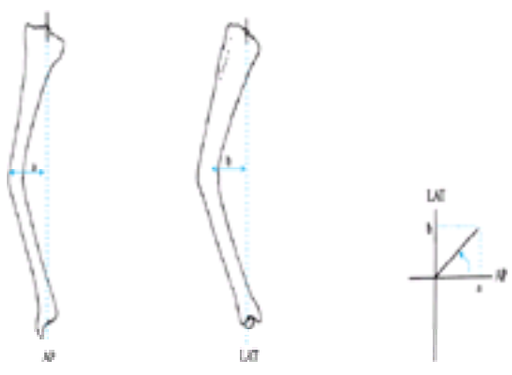

***Figure 32.32.*** Ilizarov's method for determining the plane of the oblique deformity. A line is drawn from the center of the knee to the center of the ankle on both the AP and LAT views. The distance from this line to the apex of the deformity is measured on both views. These are plotted on a graph, and the orientation of the resultant vector from the AP or LAT plane is measured. This represents the plane of the apex of the deformity.

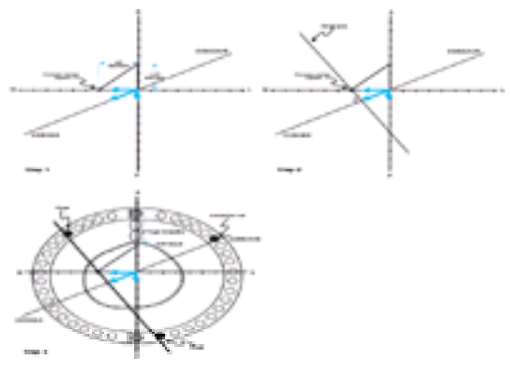

***Figure 32.33.*** Graphic preoperative planning of hinge placement in oblique plane deformities. *Step 1:* Measure the diameter of the tibia on the AP and LAT views and mark on the graph as shown. The lateral aspect of the tibia should be marked on the upper side of the *y* axis, and the width on the AP should be marked on the minus and plus sides of the *x* axis, for right and left legs respectively. These markings should be to normal scale, with 1 mm on the radiograph equal to 1 mm on the graph. The points on the *x* and *y* axes are connected with a line to form a triangle. This represents the cross section of the tibia at the level of the apex of angulation. If a different level or bone is chosen, the representative *x* section for that apical level should similarly be centered. *Step 2:* The hinge axis is always perpendicular to the plane of angulation. If an opening wedge hinge placement is chosen, it should be placed at the convex edge of the bone. The direction of the convexity is shown by the

*arrow.* The hinge axis is therefore drawn perpendicular to the plane of the angulation axis passing tangential to the convex cortex of the bone. *Step 3:* To determine the hinge holes, a ring of the appropriate size for the limb should be placed on the graph. To center the ring, the reference marks of the ring must be defined. The line connecting the central bolts represents the AP axis of the frame. Since the rings are normally centered over the lateral edge of the central bolts of the ring, it should be placed on the *y* axis. The ring is normally spaced two fingerbreadths from the anterior skin of the leg. This can be marked on the graph by noting the thickness of the anterior skin followed by a two-fingerbreadth space anterior to that. The position of the ring on the *y* axis fixes it in place. The hinges are placed in the holes where the hinge line intersects the ring. The distraction rod on the concavity is placed where the plane axis line intersects the ring on the concave side of the angulation.

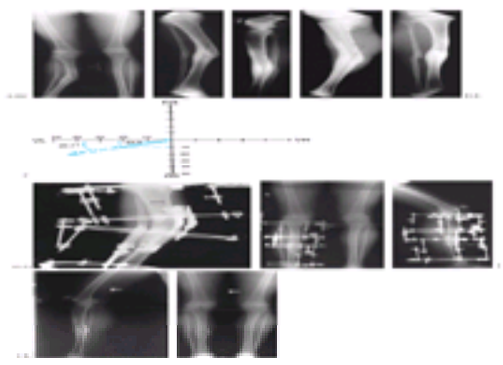

***Figure 32.34.*** **A:** Valgus malunion of the tibia with aggravating lateral translation. **B:** The deformity measures 22° of valgus with an apex proximal to the level of the malunion. **C:** On the LAT view, there is an 11° deformity, indicating that this is an oblique planar deformity with angulation and translation. **D:** The maximum profile of deformity is demonstrated on this oblique LAT radiograph and measures 24°. **E:** The radiograph in the plane of the deformity illustrates the translational component in the absence of angulation. **F:** Graphic determination of the magnitude and plane of the oblique deformity on a left leg graph demonstrates a 24.5° deformity oriented 26.7° from the frontal plane. (This is the same example shown in Fig. 32.29, Fig. 32.30, and Fig. 32.33.) **G:** The apparatus is applied so that the hinges are at the level of the true apex of the deformity which is proximal to the malunion. The corticotomy is performed at the same level. **H:** An open-wedge correction was carried out, realigning the mechanical axis of the lower limb. Note that all of the rings are parallel and the hinges are straight. **I:** On the LAT view, one can also appreciate the open wedge anteriorly with the correction of the recurvatum deformity. The rings are parallel on the lateral at the end of the correction. The follow-up AP (**J**) and LAT (**K**) radiographs demonstrate the restoration of AP and lateral alignment of the tibia.

## TRANSLATION DEFORMITIES

A translational deformity may also appear in two perpendicular planes (Fig. 32.35*A*, Fig. 32.35*B*). The direction of the true translational deformity can be calculated using the methods just described (Fig. 32.35*C*). Since translation is a direct linear measurement and not an angular deviation, the Pythagorean or graphic methods described are both accurate for the assessment of translation deformities in planes oblique to the frontal projection. Both the magnitude and the true plane of translation can be determined.

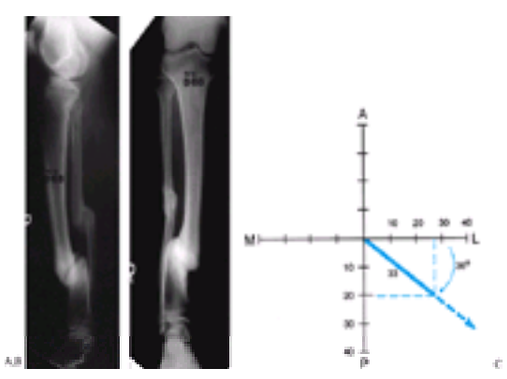

***Figure 32.35.*** **A,B:** Translational deformity may also be seen in two planes. This tibial nonunion has a posterior and lateral translational deformity. **C:** The posterior translation measures 2 cm, while the lateral translation measures 2.7 cm. When these are plotted on a graph, it demonstrates that the true translation is 33 mm in a plane oriented 36° to the frontal plane. This graph is drawn as for a right leg.

### ANGULATION/TRANSLATION DEFORMITIES

When angulation and translation occur together, the plane of angulation may be the same as or different from the plane of translation. If angulation and translation are in the same plane, they can be characterized as a single apex of angulation (Fig. 32.36). If this is in one of the anatomic planes (frontal or sagittal), one view will show angulation and translation while the other shows no deformity. If both are in the same oblique plane, the center of rotation will be at the same level on both AP and LAT radiographs. If angulation and translation are in different planes 90° apart, there will be one plane with only angulation and one with only translation (Fig. 32.37). This is readily appreciated when the deformations correspond to the anatomic planes; translation only is seen on one view and angulation only on the other view. If they are in different oblique planes, then both angulation and translation are present in both AP and LAT views. To differentiate this from angulation/translation in the same oblique plane, one must examine the levels of the center of rotation of the angulation on AP and LAT views. When they are in different planes, then the center of rotation on the AP view is at a level different from that on LAT view, usually one apex above and one below the fracture level. Angulation and translation may also be in different planes that are less than 90° apart (Fig. 32.37). The graphic method of oblique plane deformity assessment can be used to plot the plane of angulation and the plane of translation on the same graph (Fig. 32.30). The difference in planes between angulation and translation can then be measured from the graph.

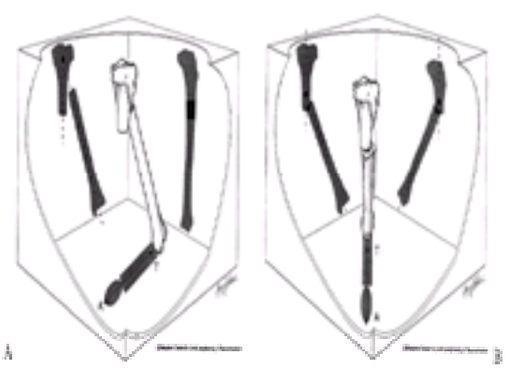

***Figure 32.36.*** Angulation-translation deformity in the same plane. **A:** Frontal plane angulation and translation. Angulation and translation are both in the frontal plane. No deformity is seen in the sagittal plane. Note that the center of rotation of the angulation is proximal to the fracture level. **B:** Oblique plane angulation and translation: same plane. Angulation and translation are seen on both AP and LAT views. The center of rotation of the angulation is the same on both views. This indicates that both angulation and translation are in the same oblique plane (see axial). The apical direction of angulation is marked with an *arrow A* and the direction of translation is marked *T*. This represents the same deformity shown in (**A**), rotated into an oblique plane.

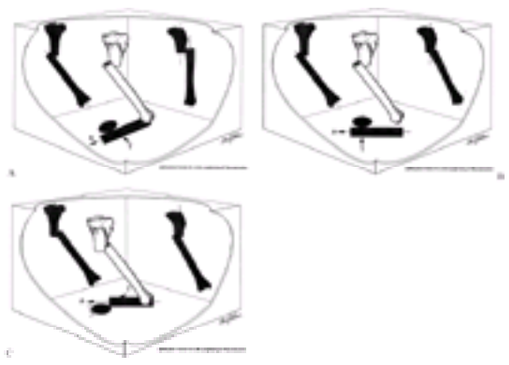

***Figure 32.37.*** Angulation-translation deformity in different planes. **A:** Frontal plane angulation with sagittal plane translation. The AP shows angulation with translation, whereas the LAT shows translation without angulation. The axial view shows the direction of the apex of angulation *A* relative to translation *T*. In this example, they are 90° apart. **B:** Oblique plane angulation-translation: different planes 90° apart. Angulation and translation are seen on both AP and LAT views. Note that the center of rotation is at a level on the AP that is different from that on the LAT. On the AP it is proximal to the osteotomy while on the LAT it is distal. This is the tipoff that the two are in different planes. On the axial view, the direction of angulation *A* and of translation *T* are 90° apart. This represents the same deformity shown in (**A**) rotated into an oblique plane. **C:** Oblique plane angulation-translation: different planes less than 90° apart. The AP and LAT projections are as before with angulation and translation seen on both views. The difference is that the plane of angulation *A* and translation *T* are different but less than 90° apart. This is one of the most common clinical situations.

The relationship between the planes of angulation and translation has ramifications on treatment. When both are in the same plane, there is a single center of rotation point that will correct both deformities by angulation alone. In nonunions, the hinge can be placed at this angulation-translation point; after distracting the ends apart, the angulation and translation are corrected by angulation around this hinge. If there is a malunion, an osteotomy may be performed at this level with opening or closing wedge correction. This corrects both angulation and translation together (Fig. 32.27).

If angulation and translation are in different planes, then several strategies may be pursued. Angulation may be corrected at the apical level on the AP, LAT, or oblique views (Fig. 32.30). Translation, if significant, will not correct with the angulation and requires a separate correction in the LAT, AP, or oblique plane (Fig. 32.30). Alternatively, a double-level osteotomy can be performed, correcting angulation and translation in the frontal plane with one osteotomy at the AP angulation-translation point and one osteotomy at the LAT angulation-translation point. This deformity is the only true “biplanar” deformity from a single fracture level.

Malrotation may also be a component of the deformity. Rotation is simply an angular deformity in the axial plane. Since all single-level angular deformities can be resolved into a single plane and a single axis of deformity, it should be possible to resolve the rotational component together with the angulation and translation. Sangeorzan et al. and other authors have demonstrated that combinations of angulation and rotation deformities can be resolved into a single axis of deformity using complex trigonometric computations and tables (27).

This geometric problem can also be solved in a simpler fashion. This *x-y-z* axis deformity can be computed as a simple extension of the method detailed previously (Fig. 32.38). This method is a reasonable approximation for deformities of up to 45° in the AP, LAT, or axial directions. Since most angular deformities are much less than 45°, this computation is a useful method and does not require trigonometry or complex nomograms.

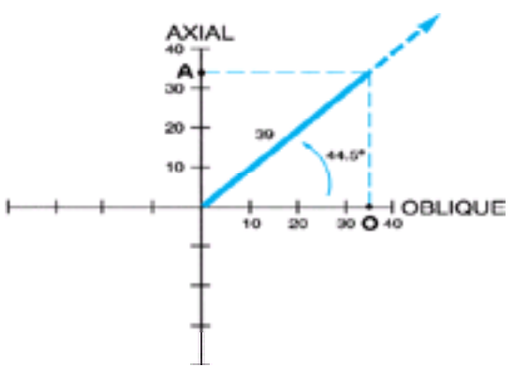


***Figure 32.38.*** If one adds rotation to the evaluation of angular deformity, then an *xyz* graph can be used to determine the orientation of the axis and magnitude of the deformity. The oblique plane deformity is calculated first in the method described. One then plots the oblique plane magnitude on the *x* axis and the rotational magnitude on the *z* or axial axis. In the example illustrated, there is a 25° varus angulation and a 25° procurvatum angulation, producing a 35° oblique plane deformity oriented 45° to the frontal plane. In addition, there is a 34° rotational deformity. This is plotted on the axial axis. The graph demonstrates a 39° angular deformity oriented at a 44.5° inclination to the transverse plane. This axis can be further qualified as oriented at 45° to the frontal plane on the transverse cut.

Combinations of angulation and rotation can be corrected either through a single hinge or sequentially. The correction requires a hinge that is oriented not in the transverse plane but inclined, in a vertical plane. This vertical inclined hinge will simultaneously correct the angular and rotational deformities (Fig. 32.39). If the osteotomy is done at the angulation-translation point, angulation, translation, and rotation are corrected simultaneously. The alternative, which is simpler, is to correct the angular deformity first, then to correct the rotational deformity using a derotation mechanism. While this method is more time consuming, it is easier for most surgeons to understand. However, some translational correction may be needed after derotation because of the eccentric location of the bones within the ring. The advantage of the single-hinge method is that no maltranslation results from the deformity correction.

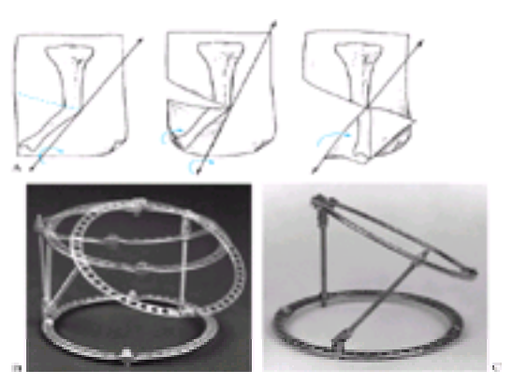

***Figure 32.39.*** **A:** Vertical inclined plane hinge. When the paper is folded with the tibia marked on it along a vertical oblique axis, the tibial diaphysis is both realigned as to its angular deformation and derotated. **B:** This principle can be applied to the Ilizarov apparatus. By using universal hinges, two rings can be connected by hinges at different levels. The axis of rotation is no longer parallel to the plane of the rings but rather is in a plane that is vertically oblique to the rings. **C:** In this simulation, the upper ring can be seen to pivot through the vertical oblique axis. Notice the position of the central bolt connecting the half rings on the moving ring relative to the central bolt on the stationary ring. In this reduced position, the central bolts are properly aligned. In the flexed position, the central bolts are rotated with respect to each other.

Conventional osteotomies also make use of these principles. By producing a single osteotomy in a vertical oblique plane, a surgeon can correct all of these deformities by sliding the bone surfaces perpendicular to the plane of the osteotomy (27,31).

## MULTIAPICAL ANGULAR DEFORMITIES

A more complex situation exists when there is more than one level of angulation. Each level and each plane of deformity must be delineated for each apex. Sometimes a single osteotomy can be used to correct a multiapical angular deformity, but usually more than one osteotomy is needed. Often one of the apices is obvious, while the other is subtle. This happens when one of the deformities is diaphyseal and the other is juxtaarticular. Examples are anteromedial and posterolateral bows of the tibia (Fig. 32.40). Usually, a varus or valgus diaphyseal deformity exists with a compensatory juxtaarticular angular deformity at the level of the proximal tibial physis. Correction requires two osteotomies: angulation-translation in the proximal tibia, and angulation in the mid-diaphyseal region. These are called compensatory bowing deformities because one deformity compensates for the other. There is usually little deviation of the mechanical axis.



***Figure 32.40.*** Anteromedial tibial bow. **A:** The frontal plane alignment of the tibia demonstrates an obvious varus deformity of the mid diaphysis and a subtle valgus deformity of the juxtaarticular region of the tibia. There is also a very mild distal femoral valgus and a leg-length discrepancy. **B:** The osteotomies were performed in the proximal metaphysis and in the mid diaphysis. The distal osteotomy is for the correction of the varus and the procurvatum deformities; the proximal osteotomy is for the correction of the juxtaarticular valgus deformity. Notice the pattern of the olive wires, which provide the necessary fulcrums and distraction points for this correction. **C:** The apparatus is shown in the immediate postoperative period. Each ring is oriented perpendicular to its own bone segment. The mid-diaphyseal hinge is properly located. The proximal tibial hinge was incorrectly located at the level of the osteotomy. This was one of the authors' earliest cases before the principles of angulation plus translation for juxtaarticular deformities were completely understood. **D:** At the end of the correction, all of the rings are parallel and the hinges are straight. **E:** The AP and LAT radiographs demonstrate the realignment of the tibia on both views, as well as double level lengthening to equalize the limb length. **F:** The final radiograph demonstrates the realignment of the tibia with slight undercorrection of the distal angular deformity and slight overcorrection of the proximal angular deformity, which made up for the lack of translation at the proximal osteotomy. The preoperative planning of this case is illustrated in Fig. 32.44.

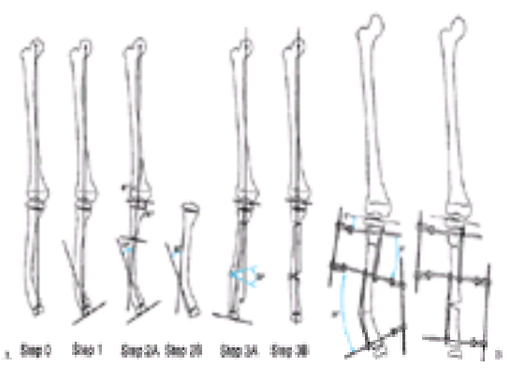

***Figure 32.44.*** **A:** Multiapical angular deformity of the tibia with a normal femur. *Step 0:* Draw the mechanical axis line from the center of the hip to the center of the ankle, demonstrating minimal varus mechanical axis deviation. The malalignment test was performed, demonstrating a normal distal femoral alignment. *Step 1:* Draw the proximal and distal tibial mechanical axis lines. Note that the intersection point is at a nondeformed level. The intersection of these two lines is not at the level of the obvious deformity. Notice that the proximal tibia also does not lie on this line. This indicates that there is a second apex of deformity. *Step 2A:* Draw the line perpendicular to the middle segment of the tibia and extend this line proximally and distally. This should intersect the mechanical axis of the distal tibia at the level of the true apex of deformity. *Step 2B:* The same center of rotation is located by the convex cortex method. *Step 3A:* Correct the first deformity at the level of the obvious apex. Extend the corrected distal mechanical axis line proximally. This intersects the proximal tibial mechanical line at the growth plate. This is the second apex. The second osteotomy is of angulation and translation to realign the tibia. **B:** The apparatus before and after correction.

True (noncompensatory) bowing is a continuous, multiapical deformity that develops in soft bone, as is seen in rickets, Paget's disease, and osteogenesis imperfecta (Fig. 32.41, Fig. 32.42 and Fig. 32.43). Whether due to remodeling or ongoing multiple stress fractures, these deformities demonstrate no single or double apex. While a bow can be considered to have a single apex, realignment through the apex corrects only the mechanical axis and does not improve the anatomic axis of the bone. It is preferable to perform at least two osteotomies to straighten a bowed bone. An alternative is to perform an osteotomy at a level different from that of the apex of the bow, and to combine this with a translational correction so as to eliminate some of the anatomic axis deformity.

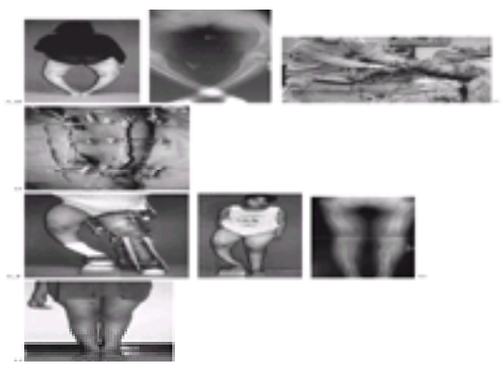

***Figure 32.41.*** **A:** Back view of an 18-year-old woman with severe bowleggedness from hypophosphatemic rickets. **B:** The radiographs demonstrate the severity of the preoperative deformity. Both legs do not fit on the width of a normal film, even when the legs are crossed. Notice the bowing in the femur. Notice that the bowing in the femur is diffusely distributed throughout the length of the femur, as is the bowing in the tibia. Notice also the lateral compartment joint laxity in the knee, which contributes to the varus deformity. **C:** The apparatus is shown during construction in the operating room. The femoral apparatus is applied first, followed by the tibial apparatus. The two devices need to be coordinated to allow at least 90° of free flexion of the knee. Care must be taken so that the most distal femoral and most proximal tibial rings do not collide. For this reason, incomplete rings ($^5/_8$ rings) open posteriorly are applied adjacent to the knee. **D:** The tibial apparatus from the frontal view. The hinges are locked at the measured deformity. The incision for the distal corticotomy of the tibia is shown adjacent to the hinge. There are two levels of fixation within the proximal and distal segments.**E:** At the completion of the realignment, all of the rings of both the femur and the tibia are parallel. Notice the axial increase in length from realignment of these severely bowed bones. **F:** After removal of the apparatus, the patient was left with a 10-cm leg-length discrepancy. The realigned limb stands in marked contrast to the uncorrected side. **G:** The second side was corrected after a 4-month hiatus. Notice that the left tibia was slightly overcorrected to try to compensate for the lateral knee joint laxity. On the right side, the proximal fibula was pulled down 1 cm to tighten the lateral knee joint. Notice that even in bipedal stance, the lateral knee joint is wider on the left than on the right leg. Notice also that the fibular head lies more distal on the right then on the left side. **H:** The final clinical appearance of both legs shows normal alignment with an excellent cosmetic and functional result.



***Figure 32.42.*** **A:** A lateral photograph of the marked anterior bow (“saber shin”) deformity of the leg in a 75-year-old woman. **B:** The LAT radiograph demonstrates monostotic Paget's disease with two levels of ununited stress fractures and an intact posterior fibular strut. **C:** A push construct was applied to the tibia. Notice the single level of fixation in the proximal and distal tibia and three floating levels of fixation on opposite sides of the stress fractures. Anteriorly, a sliding plate suspends the three floating half-rings. The threaded rods of this plate are used to push in the apex of the deformity. On the concave side, there are two distraction rods, of which only one can be seen on the photograph. Both a knee and an ankle Dynasplint unit were used to help prevent joint contractures. **D:** The apparatus is shown *in situ* at the beginning of the deformity correction. A fibular osteotomy was performed. The posterior aspect of the two nonunions can be seen to open slightly as the combined distraction and apical translation are carried out. **E:** At the end of the deformity correction, there is an opening wedge at both nonunion sites. The proximal and distal tibial rings as well as the three floating half rings are all parallel. **F:** The apparatus was removed when a complete wall of cortical bone was seen posteriorly and when the fibula had united. This correction also equalized the patient's leg lengths. **G:** The clinical appearance is excellent.

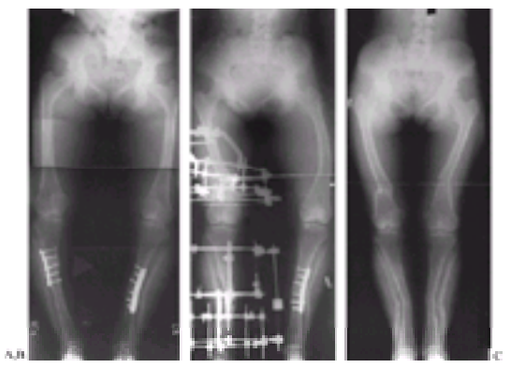

***Figure 32.43.*** **A:** Bilateral genu varum from varus deformities of both femurs and the right tibia. Both tibias have been previously operated on. The right tibia still has a varus deformity. The preoperative planning of the right side of this deformity was illustrated in Figure 32.23. **B:** A single level of osteotomy was chosen for both the tibia and the femur. One could justify two levels of osteotomy within each bone; however, since the amount of bowing in each bone was not severe, it was felt that this could be treated as a single apex angular deformity, recognizing that it truly was a multiapex angular deformity. Therefore, we chose to ignore the anatomic axis of the tibia and realign both the mechanical axis of the tibia and the joint orientation of the knee and ankle. This gives the patient a result similar to that achieved on the plated left side. The alternative would have been a combined proximal and distal tibial osteotomy, which would normalize both the anatomic and the mechanical axes of the tibia. An acute correction was performed in the femur at a level distal to the apex of the deformity, as described in Figure 32.23, to minimize the lateral indentation of the side that would result from a single-level, more proximal osteotomy at the apex. **C:** The result demonstrates complete realignment of the hip, knee, and ankle joint orientations, as well as the mechanical axis. On the opposite side, the osteotomy was performed slightly distal to the apex of the deformity and, therefore, a lesser amount of translation was needed. The result in terms of joint alignment and orientation is identical.

The steps for preoperative planning of multiapical angular deformities of the femur and/or tibia are shown in Figure 32.44. The clue that there is more than one apex of angulation is that the single center of rotation determined by the intersection of the proximal and distal mechanical axis lines is at a level where there is no “obvious” angulation (Fig. 32.44, step 1). In multiapical deformities, there is usually one obvious (diaphyseal, hip, or ankle) apex and one less obvious angulation apex. The obvious apex should be corrected first. The apex of this level may be chosen based on cortical or midbone lines, or, in the case of hip or ankle deformities, we know the apex is at the center of the joint. Once the first apex of angulation is corrected, it will point to the second apex.

## JOINT LAXITY DEFORMITIES OF THE KNEE

If lateral laxity of the knee is a cause of symptoms or malalignment, correct it together with the tibial or femoral varus angulation. With conventional techniques, the head of the fibula can be osteotomized and moved distally. By the Ilizarov method, the proximal fibula is pulled down to tighten (even overtighten) the lateral complex (Fig. 32.15, Fig. 32.41). The medial collateral ligament can also be tightened by distracting the tibia through an osteotomy proximal to the insertion of the medial collateral ligament. To tighten the medial collateral ligament without pulling down the patellar tendon, direct the osteotomy of the tibia obliquely, distally, and laterally, to exit below the tibial tuberosity (Fig. 32.15).

## INDICATIONS FOR DISTRACTION OSTEOTOMY VERSUS CONVENTIONAL OSTEOTOMY

An angular deformity of a bone may be corrected by opening wedge, dome, closing wedge, or angular displacement osteotomies. Both distraction and conventional methods use all of these osteotomy types. With conventional osteotomy, the correction is achieved acutely in the operating room; stability is achieved with internal or external fixation. The closing wedge technique is preferred because of the good bone-to-bone contact possible. Conventional opening wedge methods usually require a bone graft and have a higher incidence of nonunion. The dome osteotomy is a compromise between the opening and closing wedge, avoiding the length loss of the closing wedge method and offering some adjustability. The complications with these techniques include nonunion, osteomyelitis, compartment syndrome, nerve injury, and vascular injury (6). Accuracy of correction is often a problem, especially with the closing wedge technique. Even with meticulous planning, factors such as x-ray magnification, rotated x-rays, measurement error, the thickness of the saw blade, and the expertise of the surgeon all contribute to inaccuracy with conventional methods (19). After the operation, there is no nonoperative way to adjust incomplete correction (15,17).

Distraction osteotomies are less risky and more accurate. Since Ilizarov's technique is percutaneous, there is little risk of compartment syndrome, nerve injury, vessel injury, nonunion, or osteomyelitis. The correction is performed either acutely for small deformities or gradually for larger deformities (25). Gradual distraction prevents nerve stretch injuries, as can occur in the correction of a valgus tibial deformity. The distraction method is as accurate as one can measure on a radiograph, perhaps the greatest advantage of Ilizarov's technique. Even after acute corrections, adjustments can be made to fine-tune the correction until the exact alignment of the limb is achieved.

Oblique plane angular deformities are just as easy to correct as frontal or sagittal plane ones. More complex deformities, including rotation, translation, and limb-length discrepancy, can all be managed simultaneously. Multilevel and multibone corrections can be done since there is little blood loss and the apparatus can be applied to multiple levels and bones simultaneously. Lengthening can be performed for small and large discrepancies, as needed, at one or more levels. Associated problems of nonunion, contracture, and osteomyelitis can be treated at the same time. The apparatus allows for unrestricted weight bearing and personal hygiene; weight bearing is usually restricted with internal fixation, and bathing is difficult if a protective cast is used.

The main disadvantages of Ilizarov's method are those related to external fixation, including wearing a bulky apparatus for a prolonged period, pin infections, muscle transfixion, loss of joint range of motion, and pain. With proper application of the device, the last three problems should be minimal. More recently, with the use of half pins instead of transfixion wires, these problems have been significantly reduced.

Of course, the distraction osteotomy is most advantageous in treating complex deformities. Nevertheless, it still offers many advantages even for simple deformities that have a good conventional alternative, such as high tibial osteotomy. The decision to use Ilizarov's distraction method rather than a conventional osteotomy and fixation depends on all of these factors, not the least of which is the surgeon's experience in the application of the distraction osteotomy.

## BASIC PRINCIPLES OF DEFORMITY CORRECTION USING CIRCULAR EXTERNAL FIXATION

There are two types of constructs for correcting deformity: focal hinges, and push-pull constructs.

### CENTER OF ROTATION HINGE TECHNIQUE

The basic construct for angular deformity correction using hinges consists of two levels of fixation proximal and two levels distal to the apex of the deformity (Fig. 32.45). Each level of fixation is perpendicular to either the anatomic or the mechanical axis of the bone fragment to which it is affixed. The hinge connects the proximal and distal blocks of fixation, articulating between them at the desired center of rotation for correcting the angular deformity (23).



***Figure 32.45.*** **A:** Center of rotation hinge apparatus. There are two levels of fixation in each bone segment on opposite sides of the osteotomy. The rings are applied perpendicular to their respective bone segment. The hinge lies perpendicular to the ring. In this example, the hinge is applied over the apex of the deformity, with the hinge rod overlying the medial convex cortex of the tibia. On the concave aspect, there is a distraction rod connected by two twisted plates and a suspending post. The post connection to the twisted plate allows for self-adjustment of the distraction rod angle to that of the ring. **B:** After the correction is completed, all the rings are parallel and the hinge rods are colinear. Notice the open-wedge correction of the tibia and fibula and the change in angle between the distraction rod and the ring. **C:** For a juxtaarticular deformity of the tibia, the apparatus employs a translation hinge. Notice that the hinge is located over the level of the tibial physis. This is proximal to the upper ring. Two levels of fixation were achieved in each bone segment on opposite sides of the osteotomy. **D:** At the end of the correction there is an angulation and translation of the bone segments at the level of the osteotomy. The rings are now parallel and the hinge rod is straight. Notice again the change in orientation of the distraction rod to the rings.

If the hinge is placed at the apex of the deformity on the convex side, then distraction of the concavity will lead to an opening wedge correction (Fig. 32.34, Fig. 32.46*A*). If the hinge is placed at a distance from the convex side of the apex of the deformity, then lengthening will occur together with correction of angular deformity (Fig. 32.46*B*, Fig. 32.47). Placing the hinge on the concave side of the deformity will lead to compression of the bone ends with angular correction (Fig. 32.46*C*, Fig. 32.48). If the hinge is placed either proximal or distal to the level of the osteotomy, then translation of the bone ends will occur with angular correction during distraction of the concavity (Fig. 32.46*D*, Fig. 32.49).

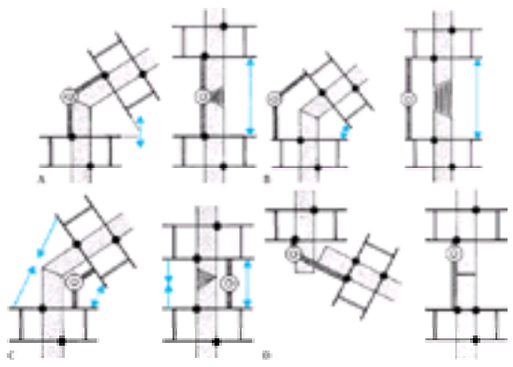

***Figure 32.46.*** **A:** Opening wedge hinge. The hinge is located at the level of the osteotomy overlying the convex cortex of the bone. Distraction of the concavity leads to an opening wedge correction without separation of the convex cortices of the bone. **B:** Distraction hinge. The hinge is located away from the convex cortex of the bone but still at the level of the osteotomy. Distraction of the concavity leads to simultaneous lengthening with angular correction. The regenerate has the appearance of a trapezoid, with a wider separation on the concave side than on the convex side. **C:** Compression hinge. If the hinge is located at the level of the osteotomy but on the concave side of the bone, distraction of the concavity will lead to compression of the bone ends. If the bone ends allow, this will produce a closing wedge type of correction. **D:** Translation hinge. If the hinge is located proximal or distal to the level of the osteotomy, distraction of the concavity will lead to translation of the bone ends. In this example, the hinge is located at the intersection point of the convex cortices of the two bones and, therefore, distraction of the concavity leads to correction of the angulation and translation of the bone ends.

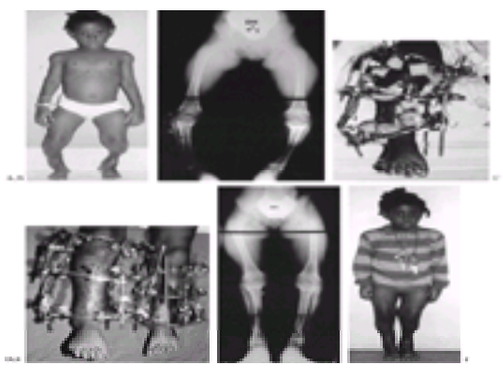

***Figure 32.47.*** Application of distraction hinges for lengthening and correction of deformity. **A:** A 5-year-old girl with bilateral genu varum and shortening due to meningococcemia septic emboli. She has skin grafts adherent to the bone and, therefore, distraction must be performed very gently. **B:** Standing radiographs show the deformities and the preoperative planning markings for the placement of olive wires. **C:** The apparatus has a hinge located lateral to the convex aspect of the osteotomy. To augment the stability of the fixation, the distal hinge has a threaded rod applied through the center of the anterior and posterior hinge point. This can be performed only with distraction hinges. **D:** Toward the end of the correction, notice the increased length achieved through the distraction hinges without lengthening on the hinge rods. All of the lengthening is performed by distraction of the concavity. Notice that this method is gentle on the skin and there were no skin problems. **E:** The final radiographs demonstrate 8 cm of lengthening of both tibias with realignment. Notice the bilateral triangular shaped tali. Both feet were plantigrade at the end of the correction. **F:** The final appearance of both legs at the end of the lengthening and correction of deformities.

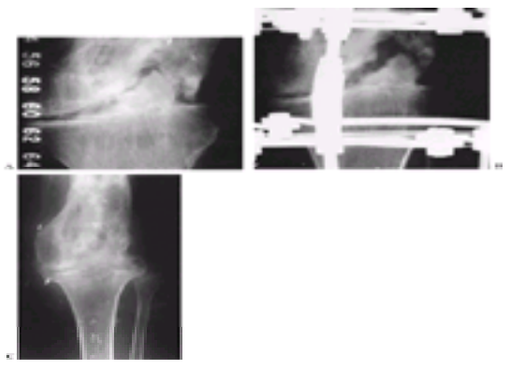

***Figure 32.48.*** Application of compression hinge. **A:** Valgus deformity with nonunion of knee arthrodesis site. **B:** The apparatus was applied with a hinge overlying the center of the knee joint so that distraction of the concavity would produce compression of the medial aspect of the nonunion and distraction of the lateral aspect of the nonunion. **C:** The final result demonstrates correction of deformity and union.

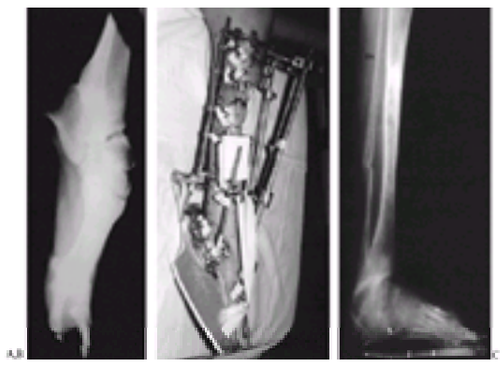

***Figure 32.49.*** **A:** Application of translation hinge. Equinus malunion of ankle arthrodesis. **B:** This was treated by a supramalleolar osteotomy with application of a translation hinge. The hinge was located at the level of the calcaneotibial fusion; the osteotomy was performed 3 cm proximal to that. **C:** Simultaneous lengthening, angulation, and translation were carried out. Notice the position of the tibia overlying the mid foot. The entire foot has translated posteriorly to give this girl a heel and to shorten the stiff forefoot, improving her ambulation. Notice the translational pattern of the trabeculae.

Therefore, it is important to keep the hinge at the level of the osteotomy to avoid any translation of the bone ends with respect to each other, unless translation is planned as part of the correction (23). Conversely, if translation of the bone ends is desired, then the proper level of the hinge needs to be selected. The level of the hinge is also governed by the bisector line of the angular deformity (Fig. 32.50).

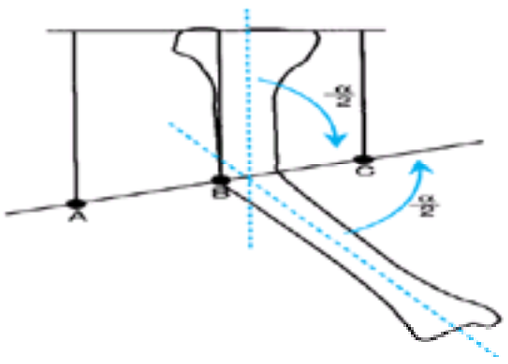


***Figure 32.50.*** Determination of hinge placement level by the bisector concept. *A*, distraction hinge; *B*, opening wedge hinge; *C*, compression hinge.

To ensure that the desired correction is produced, the bone must be prevented from slipping along the wires (Fig. 32.51). The bone must be locked into the apparatus in such a way that the bone ends will follow the angular correction of the rings. To create such a constrained system, the appropriate fulcrum and distraction points must be built in. The position of the fulcrum and distraction points is best described as a four-point bending maneuver (Fig. 32.52). The “rule of thumbs” is used to determine the location of the fulcrum and distraction points for simple angular corrections without translation of the bone ends (23,25). In coronal plane deformities, insert olive wires in the frontal plane according to the four-point bending rule of thumbs (Fig. 32.52). For sagittal plane deformities, use transverse smooth wires in the frontal plane at all four levels of the rule of thumbs instead of olive wires (Fig. 32.53). Alternatively, threaded half-pins can serve as fulcrums for either sagittal or coronal plane deformities. It is preferable to use two olives counteropposed on the same side as the fulcrum or distraction point whenever possible. In the femur, threaded half-pins often substitute for olive wires.

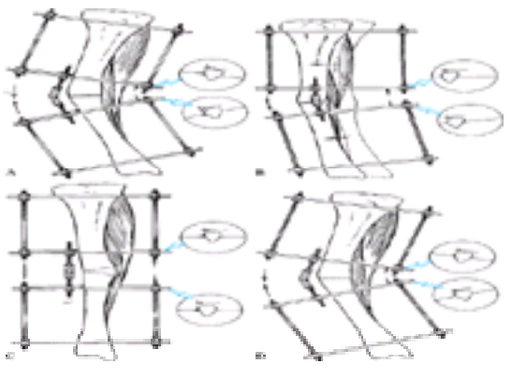

***Figure 32.51.*** The principle of constraint of the apparatus to the bone. **A,B:** If smooth wires only are used, distraction of the concavity of a deformity will lead to slippage on the smooth wires. The bone tends not to elongate with the correction but to move toward a part of the apparatus in which there is less elongation. Therefore, the bone moves from the convex side of the apparatus toward the concave side of the apparatus. This slippage leads to incomplete correction of the bone by the time the rings are in a corrected position, and it may lead to impingement of the skin against the ring on the convex side of the deformity. **C,D:** Applying olive wires over the apex of the deformity prevents slipping. The concave bone and soft tissues are forced to elongate.

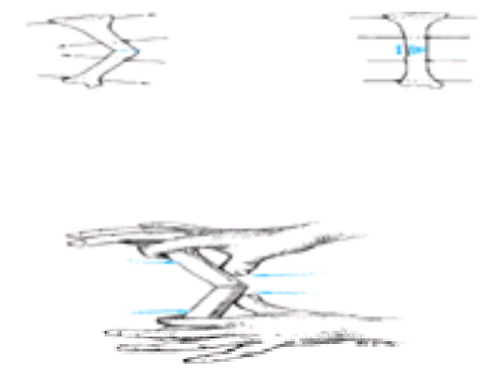

***Figure 32.52.*** The rule of thumbs. Four-point bending is the principle of correction in angular deformities. Olive wires are placed at the fulcrum point on opposite sides of the apex of the deformity and at the distraction points at either end of the bone. The location of the olive wires can be remembered by thinking of the four point bending rule of thumbs; the olive is located at the points where the thumbs press on the apex and the index fingers press on the ends of the bone.

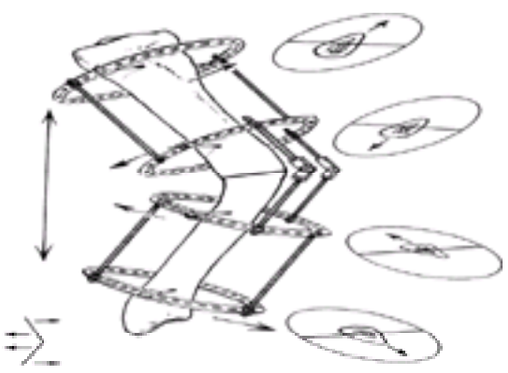

***Figure 32.53.*** In sagittal plane deformities, the transverse wires act to constrain the system in much the same way as olives do for frontal plane deformities.

For pure frontal plane translational correction, place the olives counteropposed between blocks but on the same side of the two levels of fixation within a block (Fig. 32.54) (25). Therefore, the proximal two olive wires are on the same side and the distal two olive wires are on the counteropposed side. In this pattern, the olives act to push the bone's distal segment from its translated position toward the properly aligned proximal segment.

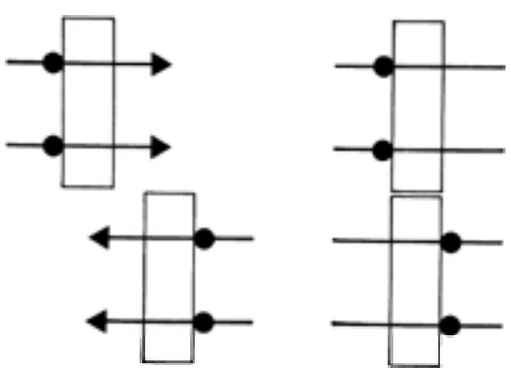

***Figure 32.54.*** For translational deformities, the olives should be counteropposed.

For a combined angular and translational deformity correction using a hinge, the olive wires are placed in a modified rule of thumbs to effect both translation and angulation (Fig. 32.55) (23). This requires the addition of a third olive wire on the side without the hinge. The third olive wire is the translation wire that forces the translational correction simultaneously with the angular correction. If half-pins are used, they act to constrain the construct, thus replacing the need for olive wires.

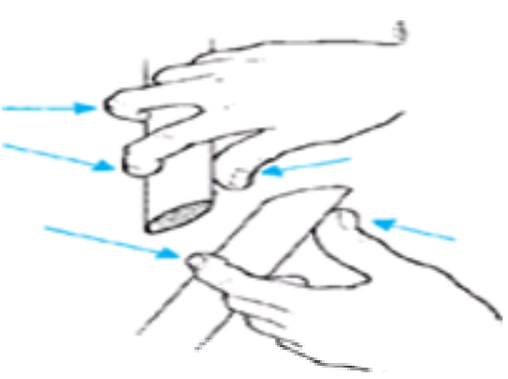

***Figure 32.55.*** The modified rule of thumbs helps determine the location of the olives for combined angulation translational corrections. While one fragment is held as usual between the index and thumb, the other fragment is held with the thumb and index at the same level on opposite sides of the bone and the middle finger in the previous location of the index finger. The olive pattern is illustrated in Fig. 32.46*D*.

In preoperative planning, first determine the level of osteotomy and identify the magnitude and true plane of the deformity. Construct an apparatus to correct the deformity. Construct two blocks of fixation, each with two levels of fixation. Plan the spacing between levels according to the strategy of correction. If only angular correction is required, then make the blocks as wide as possible, with only a handbreadth separating the blocks at the level of the deformity. If significant lengthening is planned, the distance between blocks must be greater to avoid skin entrapment. In this situation, the width of each block is narrower.

Place the hinge in the axis of rotation of the angular deformity, perpendicular to the plane of deformity. In addition to the plane of the hinge axis, the level of the hinge and its function must be chosen. Place a hinge either at the level of the osteotomy or at a different level. The latter will produce a translational effect during correction. Usually the hinge is placed at the level of the deformity's apex and the osteotomy is done as close to that level as other considerations permit. The function of the hinge as opening wedge or distraction will determine its distance from the center of the ring.

Once the hinge location is determined, set the hinge at the calculated magnitude of angular deformity and lock it in that position. Place a distraction rod between adjacent rings at a point halfway between the hinges on the opposite side of the limb. The preconstructed frame is then ready for application.

**PUSH-PULL CONSTRUCTS**

The push-pull construct uses one fixed level within each bone fragment and one floating level in each bone fragment (Fig. 32.56, Fig. 32.57) (23).

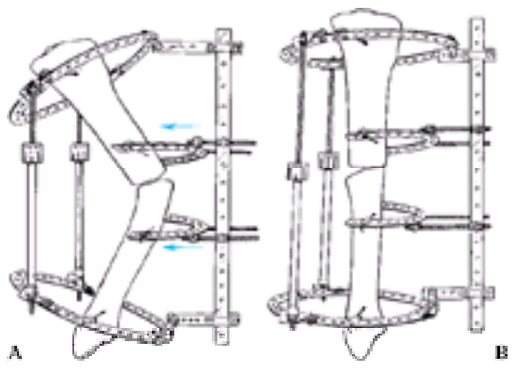


***Figure 32.56.*** Push construct. **A:** The push construct is shown applied to a procurvatum deformity of the tibia, similar to the example illustrated in Fig. 32.42. The proximal and distal rings are perpendicular to their individual bone segments. The middle half-rings are suspended from an anterior plate. The plate, connected via buckles to a perpendicular shorter plate, pivots on the ring on a hinge. The buckles allow the horizontal plates to slide up and down while the hinges allow the horizontal plate to alter its orientation to the ring as the deformity gradually corrects. The half-rings are connected by threaded rods from posts on either side of the long plate. On the concavity, there are two distraction rods connected by twisted plates and posts to allow auto-adjustment at either end. Only a single wire is needed on each of the floating half rings, and two wires are used at either end on the full ring. **B:** By coordinating the distraction on the concavity with the translation on the convexity, the deformity is gradually corrected. Notice that the buckles have moved toward each other on the long plate.

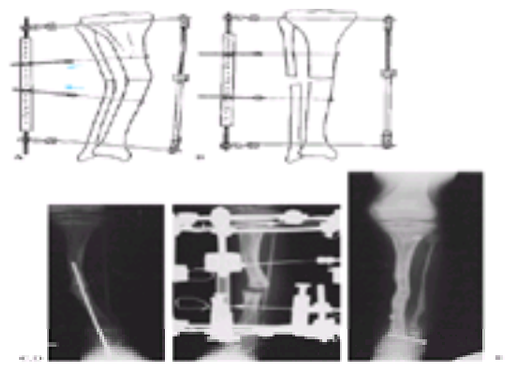

***Figure 32.57.*** Pull construct. **A:** The apparatus at the beginning of the correction, with olive wires on slotted threaded rods. The olive wires pull in the apex of the deformity, much the way the push wires push in the apex of the deformity. In the minor deformity shown, conical washers are used at each end for distraction. Alternatively, a focal hinge or twisted plate at either end could be used. **B:** The appearance of the construct at the end of correction. **C:** Preoperative AP roentgenograph of a patient whose congenital pseudoarthrosis of the tibia was previously treated by a nail and onlay grafting. Note the valgus ankle and proximal migration of the fibula. **D:** Distraction of the stiff pseudoarthrosis using a pull construct to correct the deformity. **E:** Union, lengthening, and realignment were all achieved. The fibula was transported distally. It was transfixed with a screw to keep it from proximal migration and a bone graft applied to synostose it to the tibia. It remains united 2 years later. (C, D, and E from Paley D, Catagni M, Argnani F, et al. Treatment of Congenital Pseudoarthrosis of the Tibia. Using the Ilizarov Technique. *Clin Orthop* 1992;280:91.)

- Affix the most proximal and most distal levels to a ring, and apply distraction rods on the frame's concavity.
- On the convex side, articulate the rings with a long plate. The articulation on the plate acts as both a pivot and a sliding joint. The apex of the deformity is either pushed or pulled into the concavity.
- A push construct uses smooth wires perpendicular to the plane of the deformity (Fig. 32.56). A pull construct uses olive wires in the plane of deformity. Connect the push smooth wires to a translational apparatus. Connect the pull olive wires using a slotted threaded rod translation apparatus (Fig. 32.57).

Because there is only one fixed level within each bone segment, this construct is less stable than the hinge construct. Therefore, this frame should be applied only to relatively stable pathologies such as stiff nonunions, bowing deformities with a large resistive tension band of soft tissue on the concavity (Fig. 32.42), and bones that do not have great loads applied to them, such as the forearm.

The most stable configuration for angular deformity correction is constructed by a mix of push and hinged constructs (Fig. 32.58). Two levels of fixation within each bone segment articulated with hinges and a distraction rod on the concavity are augmented by a push construct on the apical two rings of the deformity to achieve augmented fixation and augmented constraints on the deformity.

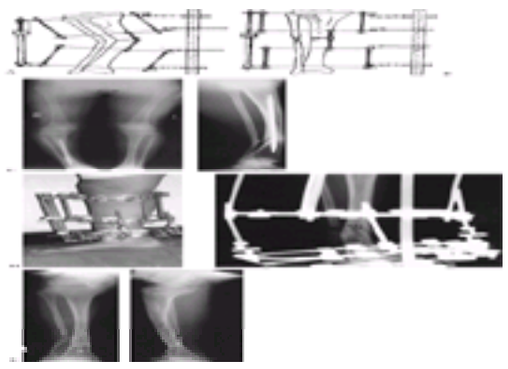

***Figure 32.58.*** Combination hinge and push constructs. **A:** The strongest construct of all combines the two levels of fixation of the hinge construct with the push construct. **B:** The construct at the end of deformity correction. **C:** The construct shown in (**A**) and (**B**) was applied to a congenital pseudoarthrosis, which had malunited, in an effort to fracture the bone without an osteotomy. **D:** Ilizarov calls this method metaphysealysis. It can be used to focus large concentrated forces on weak, narrow-diameter bone regions. Notice the fracture of the bone that has occurred. **E:** The final result, showing union and correction of the deformity.

## CONSTRUCT CONSIDERATIONS FOR ROTATIONAL DEFORMITIES

Most rotational deformities are corrected by rotational modifications of the basic hinge frame. The rotational vertical inclined plane hinge, while a theoretical possibility, is usually too complex to be readily applied (Fig. 32.49). Two types of rotational corrections can be achieved with the circular frame: acute and gradual.

The rotational correction can be performed acutely by disconnecting the frame and rotating one section with respect to the other. This can be done at the time of surgery. Because acute correction is too painful in most outpatient situations, a controlled acute method is preferable. One of these methods is to angle the rods between one ring and the other and then tighten them. If all the rods are angled one or two holes over, then an acute derotation of one or two holes is achieved (Fig. 32.59*A*, Fig. 32.59*B*), resulting in 5° to 10° of derotation, depending on the ring diameter. This can be repeated every few days until the correction is completed, usually with minimal discomfort. An alternative method is to shift the wire on the ring (Fig. 32.59*C*, Fig. 32.59*D*) so as to bow each end of the wire in an opposite direction like a pinwheel; when the wires are tensioned, the bone rotates. This method is usually too complex, time-consuming, and painful, since all the wires need to be loosened

and retensioned.

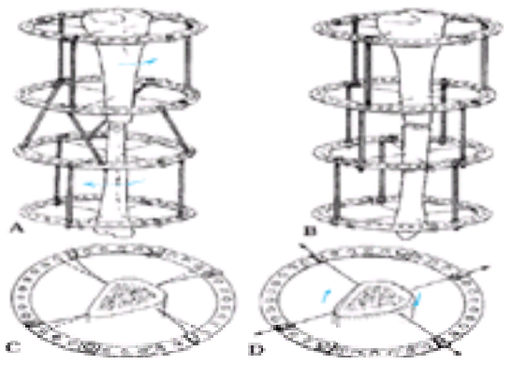

***Figure 32.59.*** **A:** Acute rotational correction can be achieved by moving the rods around the ring the same number of holes and then acutely tightening the nuts at either end of the rods, forcing the rods to become perpendicular to the ring and thus derotating the ring. **B,C,D:** Acute derotation can also be performed by advancing all the wires in the same direction by the same number of holes and then tensioning them acutely. This is very difficult, time consuming, and painful, and it is rarely done.

The gradual method can be applied in one of many constructs (Fig. 32.60*A*, Fig. 32.60*B*) at a set rate and rhythm determined by bone and soft-tissue considerations. The gradual method is the safest and involves the least amount of discomfort.

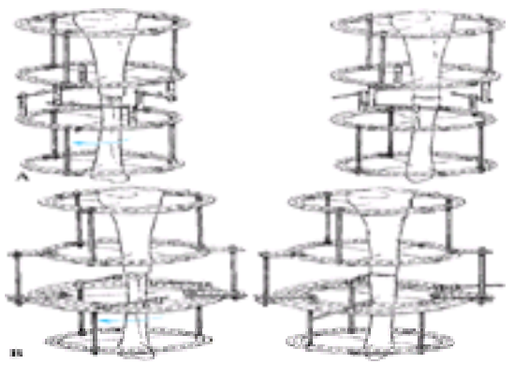

***Figure 32.60.*** Gradual derotation can be carried out by a variety of constructs. **A:** One method uses horizontal threaded rods articulating between a post on one ring and a threaded rod coming from the other ring. The threaded rod is connected by two nuts to one ring, while at the other end a buckle is attached to allow for axial support. Alternatively, a threaded rod can be connected between two posts, but this is less stable. Three of these constructs are connected around the ring. **B:** Another method of derotation is the ring within a ring. With this method, the proximal block is connected to the outer ring and the distal block to the inner ring. The articulation between the ring is by means of a pair of plates protruding from three or four locations. The plates are fixed to the inner ring but not to the outer ring. They sandwich the outer ring between either plate. A single horizontal threaded rod is used to motor the derotation.

Since derotation occurs between adjacent rings, the configuration's center of rotation is at the center of these rings. If the bone is located at the center of the ring, then the derotation will occur around the central axis of the bone. In most cases, however, the bone does not lie in the center of the ring: In both the thigh and the shank, the bone is eccentrically located within the soft-tissue mass. To center the bone within a ring, a ring of very large diameter would be needed, increasing the system's instability (Fig. 32.61).

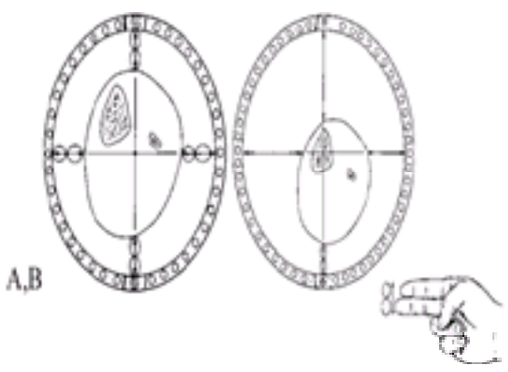


***Figure 32.61.*** **A:** The ring is normally centered around the leg so that there is a minimum of two fingerbreadths' (3–4 cm) space between the inner edge of the ring and the skin. Notice that the center of the ring lies posterior and lateral to the center of the tibia. **B:** To center the ring on the bone, it would be necessary to use a much larger ring to allow a minimum of two fingerbreadths' space between the ring and the skin. This leads to less stable fixation.

As the derotation occurs around the center of a ring, an eccentrically placed bone will move sideways during rotation (Fig. 32.62). External rotation of the tibia leads to lateral translation and internal rotation to medial translation (23). To a lesser extent, internal rotation is associated with posterior translation and external rotation with anterior translation. In the femur with its anterior location, the same relationships hold.

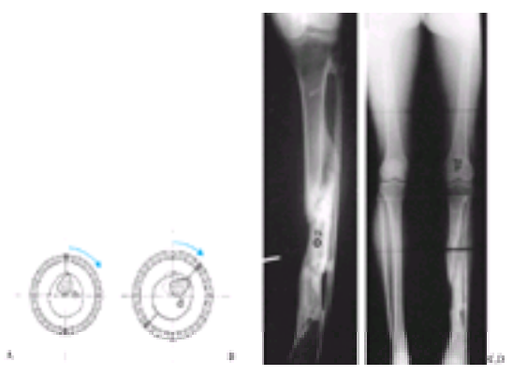

***Figure 32.62.*** **A:** Rotation of a ring that is centered on the leg and not on the bone leads to (**B**) lateral translation of the bone. **C:** This malunion required a correction of varus and rotation. There was also a lateral translational deformity. Notice that there are two lateral translations and one medial translation of the united fragments. The result is lateral translation. **D:** A corticotomy at the junction of the proximal and middle thirds of the tibia was performed, and the angular deformity corrected at that level. The bone was then lengthened and derotated. Because the ring was centered on the leg and not on the bone, a medial translational deformity, which can be seen, occurred. In this particular case, this was therapeutic because it realigned the translation of the tibia. Therefore, the translational effect of the derotation in some cases can be used to achieve a desired translational correction. Since the center of the ring is posterior to the tibia, internal rotation leads to medial translation, while

external rotation leads to lateral translation. This deformity must be factored into the realignment of the leg, especially in large derotations.

If significant translation occurs with derotation, a separate translational correction may be needed after derotation with either a translation device or a derotation-translation device. The former uses a translation frame modification to move the bone into the reduced position. The latter uses the translation-rotation point to reduce the fragments (Fig. 32.63). The translation-rotation point is on the bisector of the center of each bone segment. Where this bisector crosses the ring is the location of the rotation center.

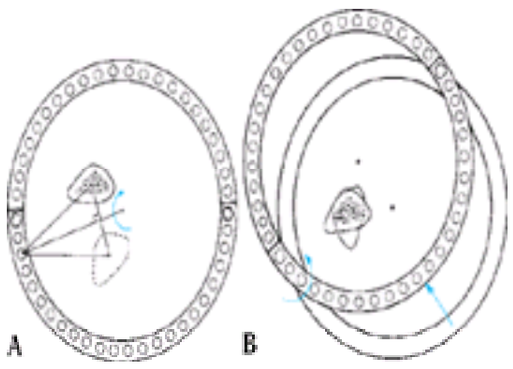


***Figure 32.63.*** **A:** To correct the translational deformity created by a derotation, one can use either conventional translational constructs or the more accurate translation rotation point. This point is located on the ring equidistant from the center of the two bone ends. The true plane of the translation must be identified, and then a point between on the line connecting the centers of the two bones is projected to the ring as the right bisector of that line. **B:** A threaded rod is connected between the adjacent rings at that point and the rings are derotated around that threaded rod to rotate one bone fragment into the other. This leads to reduction in the translational deformity without loss of the rotational correction.

## TRANSLATIONAL DEFORMITY CORRECTION

Translational deformity in combination with angulation was discussed earlier. Translation may also be corrected independently of angulation, either acutely or gradually. Acute translational correction may be achieved with olive wires and acute displacement using a wire tensioner (Fig. 32.64). Alternatively, acute correction will occur when tensioning an arced wire from both ends. Gradual translational correction can be achieved using gradual distraction on olive or arced wires using slotted threaded rods.

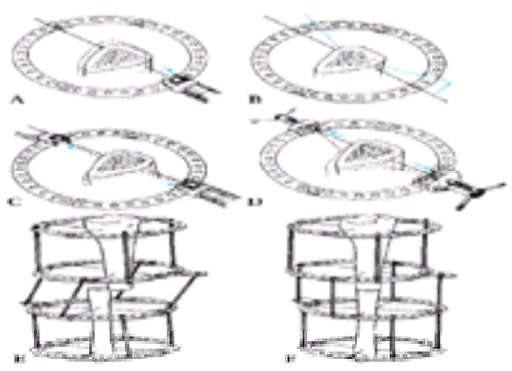

***Figure 32.64.*** **A:** Acute translational correction, which can be performed by olive or arced wires. An olive wire can be pulled from the nonolive end to translate the bone fragment. **B:** The same effect can be created perpendicular to the wire by using the arced wire. The wire is displaced one hole in the direction of the desired translation. **C:** Tensioners are applied to both sides of the wire to pull out the arc and thus displace the bone into the concavity of the arc. **D:** For large displacements, the original Russian wire tensioners are used. **E:** Another acute method of effecting a translational correction is similar to the acute rotational method by displacing the threaded rods. **F:** The acute translational correction is performed by tightening the nuts in the threaded rods.

The most controlled way to correct translation is to use translational threaded rods articulating between parallel rings (Fig. 32.65). This allows very gradual translational movement in any direction. Unlike the rotational rods, which are oriented tangential to the ring, the translational rods are oriented parallel to each other in the direction of translation.

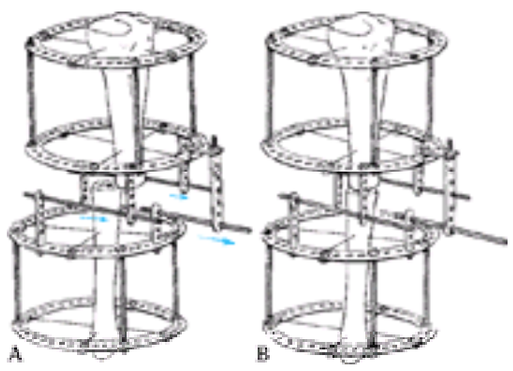


***Figure 32.65.*** **A:** Gradual translational corrections are carried out by connecting horizontal threaded rods all parallel to each other. Three of these connections are necessary. **B:** The end of the translational correction.

## ORDER OF CORRECTIONS FOR COMPLEX DEFORMITIES

Complex deformities may have components of angulation, rotation, translation, and shortening. In correcting combinations of deformity, the order of corrections is important. Complex deformities can be divided into two groups: those with and those without bone segments that must translate with respect to each other. Unlike lines on paper, segments of bone cannot slide past each other without colliding. Therefore, any manipulation that will lead to collision of one bone segment with another will cause obstruction and jamming of the system.

Therefore, the order of corrections can be planned depending on the likelihood of potential segment collision and jamming (Fig. 32.66). Collision and jamming may occur when translation or rotation of bone fragments is required as part of the correction. The propensity for collision and jamming depends on the configuration of the bone fragments with respect to each other and the contour of their bone ends. Of course, a transverse osteotomy through a bone with no overlap of the bone segments will allow movements of angulation, rotation, translation, and lengthening without collision and damage. On the other hand, if the two bone segments overlap, translation or angulation will be obstructed. In such a situation, the surgeon must first lengthen the limb and then correct angulation and translation together (Fig. 32.66,

Fig. 32.67). When there is an oblique or spiral osteotomy and rotational correction is required, lengthening must be done first to avoid collision and jamming of the oblique bone segments with each other.



***Figure 32.66.*** **A:** When a translational correction is to be performed at the same time as an angular correction by means of a translational hinge, jamming of the bone ends may occur. **B:** A valgus malnonunion of the distal tibia. A translational distraction hinge is in place to correct the length, angulation, and translation simultaneously. **C:** Notice that the angulation was corrected but the translation was not correctable because of jamming of the bone ends. The deformity should have been distracted first to separate the bone ends, and then the hinge should have been activated.

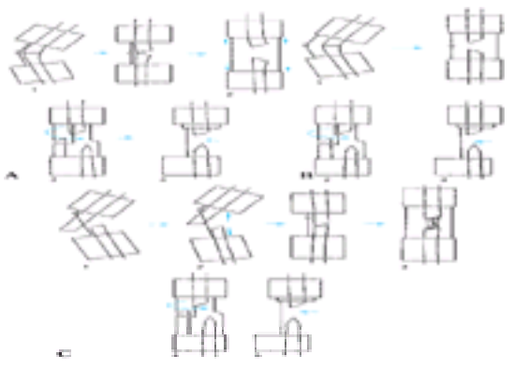

***Figure 32.67.*** Order of deformity correction. The order of correction depends on the risk of premature consolidation and the propensity for jamming of the bone ends. **A:** Order I: (*1*) angulation; (*2*) lengthening; (*3*) derotation; (*4*) translation. **B:** Order II: (*1*) simultaneous angular correction and lengthening; (*2*) derotation; (*3*) translation. **C:** Order III: (*1*) partial lengthening; (*2*) angulation; (*3*) lengthening; (*4*) derotation; (*5*) translation.

The order of corrections also depends on the expected rate of healing of the bone or the patient. In younger children, the expected rate of healing is faster than in adults. Open-wedge angulation correction carries a risk of premature consolidation on the convex side; this would prevent subsequent lengthening. This risk is small in adults but significant in children. Therefore, the order of corrections in adults and children may be different.

In patients with no risk of jamming and collision and in whom premature consolidation is not a concern, the order of corrections is angulation, lengthening, rotation, and translation (Fig. 32.67*A*).

In patients with no risk for jamming and collision but at risk for premature consolidation, the order is angulation and lengthening, rotation, and translation (Fig. 32.67*B*). In these patients, the angulation and lengthening may be done simultaneously using a distraction hinge or lengthening on the hinged rods at differential rates from the distraction rods. In this situation, some of the length and some of the angulation are corrected simultaneously until the angular deformity or the length discrepancy is completely corrected, leaving either residual angular or length deformity to correct. This is followed by derotation and translation.

If jamming and collision are expected, the order of corrections is lengthening, angulation, remaining lengthening, rotation, and translation (Fig. 32.67*C*).

It is preferable to carry out both rotation and translation through long segments of regenerated new bone, where the shearing effect of these displacements can be distributed along the soft bone and blood vessels. There is far greater shear between bone ends of an undistracted osteotomy (leading to disruption of medullary and periosteal tissues during translation or rotation) than there is between bone ends that are separated by several centimeters.

Perform translation after rotation because a translational displacement may occur during derotation of an eccentrically located bone. This displacement may be used if both the translational deformity and the rotational deformity are in the same direction. In these cases, the bone ends can be rotated, thereby correcting translation and rotation simultaneously.

If the bone is rapidly consolidating, perform the rotational correction, since rotation is possible with significantly consolidated regenerate bone. Correction of translation is difficult in the presence of advanced consolidation. Angulation is feasible even later than rotation in the face of advanced consolidation. Therefore, the order of deformity correction may need to be altered if the bone segments show evidence of premature or advanced consolidation. In these cases, the surgeon may want to correct translation first, derotate next, and finally correct the angulation.

**RATE OF CORRECTION**

The accepted average rate of distraction for osteogenesis and soft-tissue neohistogenesis is 1 mm/day in 0.25 mm intervals (12,22). In limb lengthening, all the distraction rods can be lengthened at this rate to create a separation of the bone fragments of 1 mm/day. In angular correction, a calculation must be made to obtain a rate of distraction of 1 mm/day of the osteotomy site. We use the geometric rule of similar triangles (Fig. 32.68), which allows us to calculate the rate of distraction of the threaded rods that will produce a 1 mm/day distraction rate at the level of the bone (23). As the lengthening proceeds, the rule of similar triangles must be recalculated because the distraction rod approaches the concave aspect of the bone. For small deformities this is inconsequential, but with large deformities it is significant.

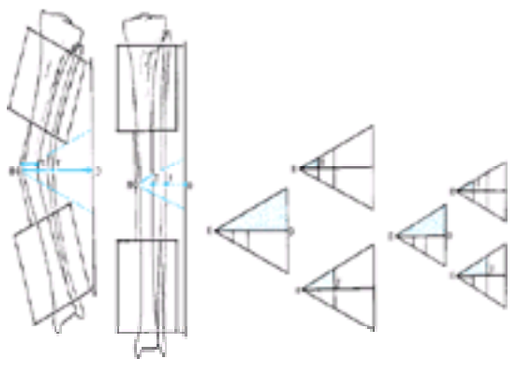

***Figure 32.68.*** Rule of similar triangles. The rate of distraction of the distraction rod *D* that will produce 1 mm of opening wedge at the concave cortex of the tibia *T* is calculated based on similar triangles. In the example shown, the ratio is 4:1. Therefore, it takes 4 mm of distraction at the distraction rod to produce 1 mm of opening wedge of the tibia. In contrast, the fibula lies halfway between the distraction rod and the hinge. Therefore, at 4 mm/day distraction, the fibula will lengthen 2 mm/day. Because the peroneal nerve is at the level of the fibula, it may be preferable to open the wedge relative to a 1 mm rate of the fibula rather than the tibia.

The deformity correction actually follows concentric circles (rather than triangles) that radiate around the hinge point. The calculation of the length of arc followed by the concentric circle at the radius *R* from the hinge is an approximation of the length of time needed to correct the deformity (Fig. 32.69) (10).

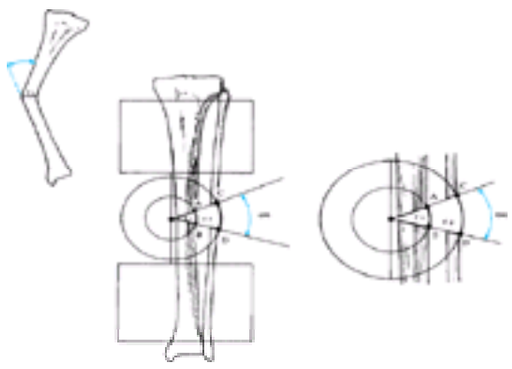

***Figure 32.69.*** The rule of concentric circles. Because the deformity correction is occurring around a hinge, the true pattern of correction follows the path of an arc of radius *r* where *r* is the width of the bone at the level of the osteotomy. Because the rate of correction is set to 1 mm/day at the concave cortex of the tibia, the length of the arc across the concave cortex is equal to the number of days it will take to correct the angular deformity. Arc length can be calculated as the number of degrees subtended by the arc divided by 360 times the circumference of the circle (2p*r*). For a deformity of magnitude a, the number of days to achieve correction of deformity is 2p*r*a/360.

The bone is not always the tissue that determines the rate of lengthening. For example, in a contracture of the knee, correction may be adjusted so that the sciatic nerve is distracted at a maximum of 1 mm/day (Fig. 32.70). The calculation of the length *R* is made from the center of the hinge to the sciatic nerve. Similarly, in valgus corrections of the tibia, the peroneal nerve may be the structure determining the rate of distraction.

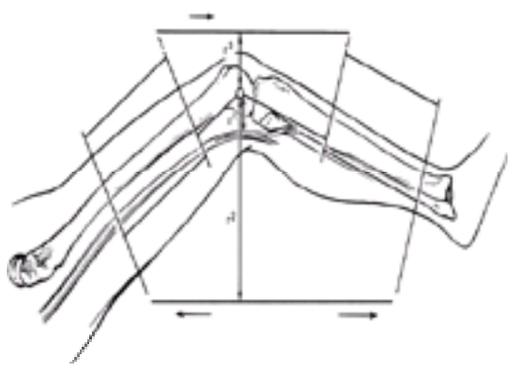

***Figure 32.70.*** Reciprocal rule of triangles. It is sometimes necessary to distract on one side of a deformity and compress on the other side. For example, in this knee contracture, the rate of distraction of the concave distraction rod is calculated by the rule of similar triangles. The rate of compression of the convex rod is a factor of $r^3$ to $r^2$, the rate of the distraction rod. In the example shown, the rate of distraction or compression is related to stretching of the most important tissue, which in this case is the sciatic nerve. The sciatic nerve is located at a distance of $r^1$ from the center of rotation. The length $r^1$ is used in the calculation of similar triangles.

Sometimes it is important to calculate not only the rate of distraction but also the rate of compression on the bone's opposite side. This can be done by the reciprocal rule of triangles (Fig. 32.71). In most cases, distracting one side at the rate of similar triangles and allowing the apparatus to self-adjust on the compression side avoids any errors of rate adjustment between the two sides.

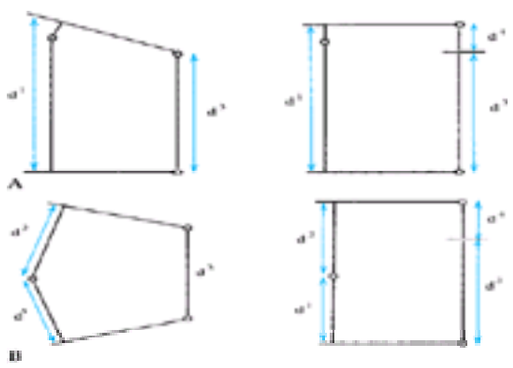

***Figure 32.71.*** Alternate method for calculating the treatment time for angular correction. A quick and simple method for calculating the total number of days of distraction until the rings become parallel is to subtract the length of the distraction rod between its connection point on the ring from the length of the hinge rods. **A:** When the hinge lies on the ring, the space between the rings is used as the length $d^1$. **B:** When the hinge lies between the rings, the lengths of the limb above and below the hinge are added ($d^1 + d^2$) and then $d^3$ is subtracted from the sum of the other two. The difference $d^4$ is then divided by the rate of distraction of rod $d^3$ to calculate the total treatment time.

Another method to calculate the time required for deformity correction is to measure the distance between the rings at the level of the hinge and the distance between the rings at the level of the distraction rod. The distance between rings at the hinge will change little before and after deformity correction if no distraction is carried out on the hinge rods. The difference between the hinge rod width and the distraction rod width divided by the rate of correction is an accurate approximation of the time needed for correction (Fig. 32.71). At the end of correction, the rings should be parallel if the apparatus was properly applied. Therefore, the difference between the distraction rod width and the hinged rod width will eventually be zero.

The rate of correction is also important for the push construct (Fig. 32.72). In the push construct, the apex of the deformity is being translated while the ends of the deformity are distracted.

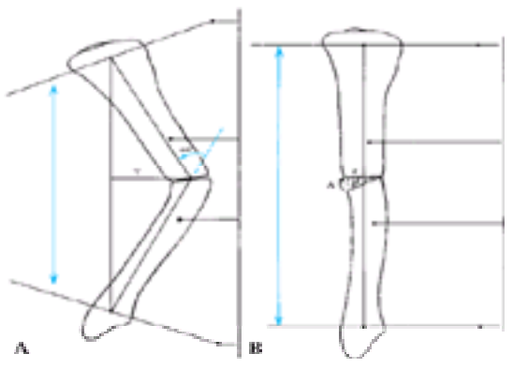

***Figure 32.72.*** **A.** Coordinate the rate of apical translation with that of concavity distraction. *Step 1:* Use the rule of similar triangles to calculate the rate of distraction at the distraction rod. *Step 2:* Use the 2pra/360 calculation to determine the number of days until complete deformity correction. *Step 3:* Measure the distance for complete apical translation from the center of the bone at the level of the apex to the line connecting the center of the joint above with the center of the joint below. *Step 4:* Divide the total distance to be translated (*T*) by the number of days of correction. This will be the rate for apical translation. **B.** Complete correction.

Correction of a pure translational deformity should be done at a rate of 0.5–1.0 mm/day. When translation is done through a lengthy distraction gap, 1 mm/day is used; 0.5 mm/day is used when translation is done through a narrow distraction gap or through an undistracted osteotomy.

The rate of correction for a rotational deformity is about 1 mm/day at the surface of the bone. The number of degrees of rotation to keep the surface rotation rate to 1 mm/day depends on the diameter of the bone: 12° for a 1 cm diameter bone, 6° for a 2 cm diameter bone, 4° for a 3 cm diameter bone, and 3° for a 4 cm diameter bone. The rate should be adjusted for small and large bones.

The rate of rotational correction using the gradual technique depends on the ring size. The number of degrees between adjacent holes is equal to 360° divided by the total number of holes. [The count should include the solid portion of the rings adjacent to the flare (four per ring, two per half-ring).] Dividing the number of millimeters per hole by the number of degrees per hole gives the number of millimeters per degree of arc. Multiply this by the number of degrees permissible for different-diameter bones to get the rate of correction. Divide this number by three or four times per day to split the rate into a dosed rhythm of correction. In most cases, this works out to be 1 mm three to five times per day.

It is important not to exceed these guidelines except when above-average bone formation is seen. These guidelines serve to optimize the new bone formation according to the basic biological principles of Ilizarov (12). They must be altered in situations of hypotrophic and hypertrophic bone formation. In the former, the rate may be cut by 25% to 50% as needed, while in the latter the rate may be increased by similar amounts.

## ACKNOWLEDGMENTS

We would like to thank Michael Leonard and Stacy Lund for all their work in preparing the illustrations.

### CHAPTER REFERENCES

Each reference is categorized according to the following scheme: *, classic article; #, review article; !, basic research article; and +, clinical results/outcome study.


+ 1. Bar HF, Breitfuss H. Analysis of Angular Deformities on Radiographs. *J Bone Joint Surg Br* 1989;71:710.

# 2. Bombelli R. *Osteoarthritis of the Hip*, 2nd ed. Berlin: Springer-Verlag, 1983.

+ 3. Chao EY, Neluheni EV, Hsu RW, Paley D. Biomechanics of Malalignment. *Orthop Clin North Am* 1994;25(3)375.

+ 4. Cooke TDV, Pichora D, Siu D, et al. Surgical Implications of Varus Deformity of the Knee with Obliquity of Joint Surfaces. *J Bone Joint Surg Br* 1989;71:560.

# 5. Cooke TDV, Siu D, Fisher B. The Use of Standardized Radiographs to Identify the Deformities Associated with Osteoarthritis. In: Noble J, Galasko CSB, eds. *Recent Developments in Orthopedic Surgery.* Manchester, U.K.:Manchester University Press, 1987.

* 6. Coventry MB. Upper Tibial Osteotomy for Osteoarthritis. *J Bone Joint Surg Am* 1985;67:1136.

* 7. Coventry MB. Proximal Tibial Varus Osteotomy for Osteoarthritis of the Lateral Compartment of the Knee. *J Bone Joint Surg Am* 1987;69:32.

+ 8. Halpern AA, Tanner J, Rinsky L. Does Persistent Fetal Femoral Anteversion Contribute to Osteoarthritis? *Clin Orthop* 1979;145:213.

+ 9. Healy WL, Anglen JO, Wasilewski SA, Krackow KA. Distal Femoral Varus Osteotomy. *J Bone Joint Surg Am* 1988;70:102.

+ 10. Herzenberg JE, Waanders NA. Calculating Rate and Duration of Distraction for Deformity Correction with the Ilizarov Technique. *Clin Orthop* 1991;22:601.

+ 11. Hubbard DD, Staheli LT, Chew DE, Mosca VS. Medial Femoral Torsion and Osteoarthritis. *J Pediatr Orthop* 1988;8:540.

* 12. Ilizarov GA. The Tension-Stress Effect on the Genesis and Growth of Tissues. Part II: The Influence of the Rate and Frequency of Distraction. *Clin Orthop* 1989;238:263.

# 13. Insall JN. Surgery of the Knee. New York: Churchill-Livingstone, 1984:2.

+ 14. Jakob RP, Haertel M, Stussi E. Tibial Torsion Calculated by Computerized Axial Tomography and Compared to Other Methods of Measurement. *J Bone Joint Surg Br* 1980;62:238.

+ 15. Johnson EE. Multiplane Correctional Osteotomy of the Tibia for Diaphyseal Malunion. *Clin Orthop* 1987;215:223.

+ 16. Krackow KA, Pepe CL, Galloway EJ. A Mathematical Analysis of the Effect of Flexion and Rotation on Apparent Varus/Valgus Alignment of the Knee. *Orthopaedics* 1990;13:861.

+ 17. Mast JW, Teitge RA, Gowda M. Preoperative Planning for the Treatment of Nonunions and the Correction of Malunions of the Long Bones. *Orthop Clin North Am* 1990;21:693.

+ 18. Moreland JR, Bassett LW, Hanker GJ. Radiographic Analysis of the Axial Alignment of the Lower Extremity. *J Bone Joint Surg Am* 1987;69:745.

+ 19. Morscher E. Development and Clinical Significance of the Anteversion of the Femoral Neck. *Reconstr Surg Traumatol* 1967;9:107.

# 20. Muller ME. Intertrochanteric Osteotomy: Indications, Preoperative Planning, Technique. In: Schatzker J, ed. *The Intertrochanteric Osteotomy.* Berlin: Springer-Verlag, 1984:25.

+ 21. Murphy SB, Simon SR, Kijewski PK, Wilkinson RH, Griscom NT. Femoral Anteversion. *J Bone Joint Surg Am* 1987;69:1169.

# 22. Paley D. Current Techniques of Limb Lengthening. *J Pediatr Orthop* 1988;8:73.

# 23. Paley D. The Principles of Deformity Correction by the Ilizarov Technique: Technical Aspects. *Tech Orthop* 1989;4:15.

+ Paley D. Problems, Obstacles, and Complications of Limb Lengthening by the Ilizarov Technique. *Clin Orthop* 1990;250:81.
24.

+ Paley D, Chadhray M, Pirone AM, Lentz P, Kautz D. Treatment of Malunions and Nonunions of the Femur and Tibia by Detailed Preoperative Planning and the Ilizarov Techniques. *Orthop Clin North Am* 1990;21:667.
25.

+ Prodromos CC, Andriacchi TP, Galante JO. A Relationship Between Gait and Clinical Changes Following High Tibial Osteotomy. *J Bone Joint Surg Am* 1985;67:1188.
26.

+ Sangeorzan BJ, Sangeorzan BP, Hansen ST, Judd RP. Mathematically Directed Single-Cut Osteotomy for Correction of Tibial Malunion. *J Orthop Trauma* 1989;3:267.
27.

+ Shoji H, Insall J. High Tibial Osteotomy for Osteoarthritis of the Knee with Valgus Deformity. *J Bone Joint Surg Am* 1973;55:963.
28.

+ Taylor C. Geometry of Hinge Placement. *Tech Orthop* 1990;5:33.
29.

+ Terjesen T, Benum P, Anda S, Svenningsen S. Increased Femoral Anteversion and Osteoarthritis of the Hip Joint. *Acta Orthop Scand* 1982;53:571.
30.

+ Wang JW, Kuo KN, Andriacchi TP, Galante JO. The Influence of Walking Mechanics and Time on the Results of Proximal Tibial Osteotomy. *J Bone Joint Surg Am* 1990;72:905.
31.

+ Wedge JH, Munkacsi I, Loback D. Anteversion of the Femur and Idiopathic Osteoarthritis of the Hip. *J Bone Joint Surg Am* 1989;71:1040.
32.

+ Yoshioka Y, Siu D, Cooke TDV. The Anatomy and Functional Axes of the Femur. *J Bone Joint Surg Am* 1987;69:873.
33.

# C. The Technique of Circular External Fixation

***Stuart A. Green***

The initial experience in both Europe and North America has confirmed Ilizarov's contention that small details of frame application can make a major difference in the clinical outcome of fractures treated by circular external fixation (1,2,8,9,10,11 and 12). This section reviews some of the technical details of applying a circular external fixator, using Ilizarov's technique and modifications of it. Modern circular external fixation techniques utilize both wires and pins at multiple levels for optimum fixation of osseous fragments.

## WIRE TECHNIQUE

When smooth wires are used to secure a bone fragment, a frame can slide back and forth along a limb unless two or more wires are used at each level of fixation. For maximum stability, the two wires should cross each other at a right angle. Unfortunately, anatomic constraints (neurovascular structures, muscles, and tendons) limit a surgeon's ability to insert wires crossing at 90° within a bone at most locations. For this reason, transfixion wires usually end up crossing each other at a more acute angle, diminishing fixator stability. Therefore, to enhance fixation, a surgeon must often use more than two wires at each level or alternatively must insert additional wires oblique to, or away from, the ring's plane.

To further improve stability, wire external fixation systems use wires with beads (“olive wires”) that abut the bone to prevent the bone from sliding along the wire, at least in the direction of the bead (Fig. 32.73). Olive wires can also be used to pull bone segments and to reduce fractures and for other applications.



***Figure 32.73.*** Beaded wires. Original design (**A**) and modified design (**B**).

### MUSCLE POSITIONING

To help maximize the functional use of the joints while a limb is in external fixation:

- Avoid synovial transfixion when possible.
- Do not impale tendons.
- Penetrate muscles at their maximum functional length.

This last rule, critical for a successful long-term application of an external fixator, means that the position of a nearby joint must change as the wire passes through the flexor and extensor muscle groups. For example, when inserting a wire from anterolateral to posteromedial in the distal femoral metaphysis, flex the knee to 90° before inserting the wire into the quadriceps, and push the wire straight down to the femoral cortex (Fig. 32.74) (14).



***Figure 32.74.*** Flex the adjacent joint when inserting wires into the extensor surface.

- Drive the wire through the bone with a power drill. As soon as the wire emerges through the far cortex, stop drilling, extend the knee, and hammer the wire through the opposite side of the limb with the hamstrings at maximum stretch. To drive a wire through soft tissue with a mallet, either tap the wire's end or grasp

the wire with pliers and strike the pliers with a mallet (Fig. 32.75).

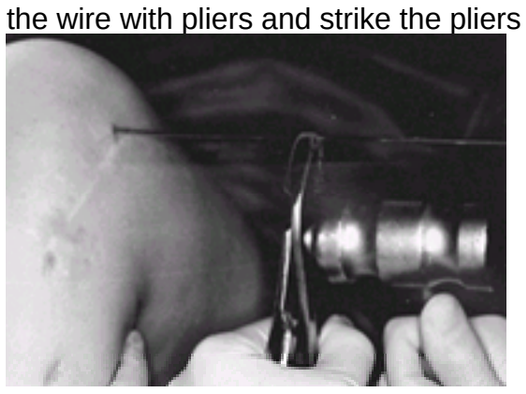

***Figure 32.75.*** Tap the wire through the soft tissues on the limb's far side with a pliers and mallet.

- When inserting a wire into the lower leg, plantar-flex the foot when transfixing the anterior compartment, invert the foot when inserting wires into the peroneal muscles, and dorsiflex the foot during triceps surae impalement (13,15).

**SKIN CONSIDERATIONS**

The preceding steps describe the optimum placement of wires through transfixed muscle; the position of the skin is another matter. Flexing the knee during femoral wire insertion pulls the lower anterior thigh skin distally, while the posterior skin slides a bit proximally. Transfixion of anterior thigh skin during flexion (the optimum position for quadriceps impalement) might cause a limitation of knee extension, impeding ambulation and perhaps leading to a knee flexion contracture. For this reason, before wire insertion, the skin must be shifted in a direction appropriate to adjacent joint motion. In determining which way to move the skin before inserting a wire, consider the following:

- When lengthening a limb, some redundant or loose skin and subcutaneous tissue should overlie the corticotomy site, where stretching will be greatest. Thus, when inserting supracondylar wires into the femur for lengthening through a distal corticotomy, pull the skin and subcutaneous tissues proximally during wire penetration, and at the same time flex and extend the knee to shift the muscles as previously described (Fig. 32.76). Likewise, displace the skin and subcutaneous tissues distally when applying the ring proximal to the proposed osteotomy site.

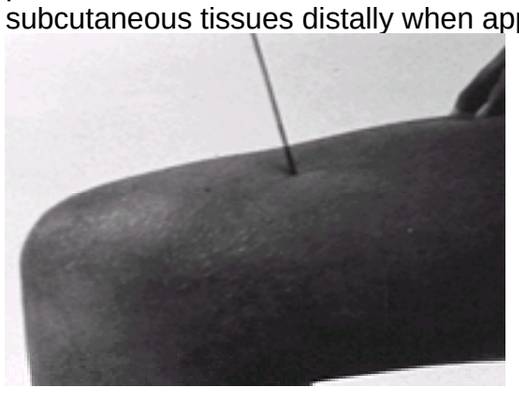

***Figure 32.76.*** Pull the skin proximally for lengthening before wire insertion.

- When correcting a deformity by an opening wedge corticotomy, the skin and soft tissues should be loose, if possible, on the deformity's concave side. In the case of a tibia varus correction, for example, shift the medial subcutaneous tissues downward during proximal ring application and upward while the distal ring is being applied.
- Whenever possible, select wire placement locations that normally have limited skin movement during flexion or extension of an adjacent joint, usually along the medial and lateral lines of a limb.

Proper wire insertion technique is one of the keys to successful circular external skeletal fixation. When inserting a wire, avoid necrosis of tissue caused either by “wrapping up” around the wire's tip or by thermal injury caused by heat build-up during drilling.

**DRILLING**

- Although transfixion wires are smooth, they have bayonet tips that can cause damage while spinning within soft tissues. For this reason, when inserting a wire, push it straight down through the soft tissues to the bone (Fig. 32.77). Begin drilling when the wire's tip is at the bone's surface.

***Figure 32.77.*** Hold the wire with a wet gauze to stabilize it during insertion.

- Stop drilling intermittently to prevent heat build-up. Cool the wire with irrigating solution during drilling, especially when penetrating dense cortical bone. As soon as the wire emerges from the bone's opposite side, stop drilling, and drive the wire through the limb's soft tissues with a mallet and pliers (6).
- If a wire emerges with blackened bone on its tip, then the wire has burnt the bone; remove the wire, cool it, and reinsert it elsewhere. Do not use a burnt bone hole for external skeletal fixation, as the bone around the hole has no resistance to invading microbes.

When using a power drill to insert a transfixion wire, the wire's flexibility may cause the wire to bend, reducing the accuracy of wire placement. While it seems appropriate to “chuck up” the wire closer to its tip, such a maneuver may nick the wire, leading to early breakage if the nick is located anywhere between the fixation bolts. Instead, grasp the wire with a 2×2 gauze pad soaked in antibiotic solution close to its blunt end and stabilize the spinning wire.

**SKIN TENSION**

- After inserting a wire, but before attaching it to a frame, check the wire–skin interface for evidence of tension while the limb is in its functional position—the knee extended, the ankle at neutral, and so forth. Skin tension creates a ridge of flesh on one side of a wire (Fig. 32.78*A*). To eliminate this tension on the side of a wire tip, withdraw the wire tip slowly (with the pliers-and-mallet technique) until the point drops below the skin surface (Fig. 32.78*B*). Shift the skin to a more neutral location and advance the wire until it penetrates the skin in an improved position (Fig. 32.78*C*).

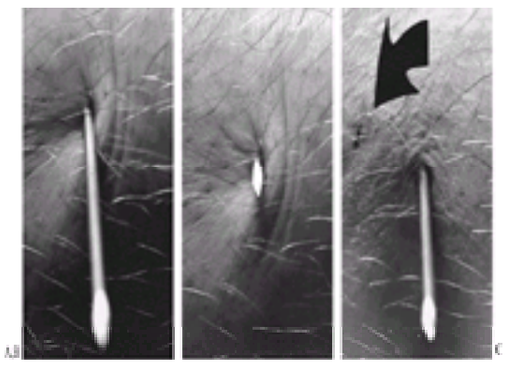

***Figure 32.78.*** Dealing with skin tension. **A:** Tension at a wire site. **B:** Withdraw the wire and allow the skin to shift. **C:** Drive the wire through the skin in a new position.

- If skin tension exists on the insertion side of a wire (Fig. 32.79*A*), snap off the wire's blunt end obliquely to create a point (Fig. 32.79*B*) and advance the wire to below the skin surface by the pliers-and-mallet method on the limb's far side (Fig. 32.79*C*). Adjust the skin with the point below the skin (Fig. 32.79*D*). Tap the wire back through the skin after a skin-position adjustment (Fig. 32.79*E*).

***Figure 32.79.*** Tension on the insertion side of a wire. **A:** Tension between two wires on the insertion side. **B:** Withdraw the wire and make a point on the blunt end. **C:** Pull the point below skin level. **D:** Adjust skin with the point below the skin. **E:** Advance the wire through the skin in a new position.

- If an olive wire causes skin tension on the side of the limb opposite the olive, simply back out the wire until the tip drops below the skin surface and make the correction described above. If the tension is on the olive side of the wire, enlarge the skin incision for the wire to relieve the tension.

Occasionally, another technique is needed to minimize wire–skin interface tension: modifying fixation after an acute deformity correction. For example, when a fixator is applied to manage a congenital coxa vara, part of the correction can be done immediately after subtrochanteric osteotomy. The skin, however, may be pulled distally on the transfixion wires as a valgus subtrochanteric angle is established. If this occurs, shift the skin upward after the correction and insert additional wires or pins before removing the ones causing the skin tension. Release any residual skin tension with a scalpel.

**FIXATION TO A RING**

Tensioning a wire when securing it to a ring will straighten any bend or curve in the wire. Soft tissues on either side of a bent wire may suddenly be stretched during wire tensioning, causing intense postoperative pain. Thereafter, the stretched soft tissues can become necrotic, providing nutrition for microorganisms that enter the limb through the wire holes. For this reason, do not bend a wire toward the frame during fixation; instead, use washers, posts, and other hardware to build up to and capture the wire where it lies (Fig. 32.80).



***Figure 32.80.*** Securing a wire off the plane of a ring. **A:** Wire $^{1}/_{8}$ in. off plane of ring. **B:** Wire secured with washers and a bolt.

With the Ilizarov apparatus, a wire passing over the center of a ring's hole is affixed with a cannulated fixation bolt (Fig. 32.81*A*). A wire passing between two holes along the surface of a ring is secured with a grooved fixation bolt (Fig. 32.81*B*). Other ring fixators on the market use similar techniques for preventing wire deflection during tensioning.



***Figure 32.81.*** Securing a wire on the plane of a ring. **A:** Cannulated fixation bolt used for wire over the center of a hole. **B:** Grooved fixation bolt for wire between two holes.

**WIRE TENSIONING**

The overall stability of the bone fragments within the configuration depends to a considerable extent on the amount of tension on the wires. Tensioning a wire axially stiffens it mechanically; with enough tension, a transfixion wire behaves like a stiff pin. Moreover, a deflection load applied to a tensioned wire (by weight bearing, for

example) increases wire tension even further, enhancing wire stiffness and resistance to additional deflection. When the deflection load is released, the wire usually springs back to its original position, although some permanent plastic deformation might occur. This mechanical behavior of tension wires stimulates osteogenesis in a bone-defect site, according to Ilizarov.

- Tension a wire with either a spring-loaded wire tensioner or by the fixation bolt method (winding the wire around its own fixation bolt). When using these methods, be sure to fix the wire securely to the ring on the limb's opposite side. A smooth wire can be tensioned on either side of the limb, but an olive wire cannot. If the olive wire is meant to serve as a stabilizing element in the assembly, fasten the wire to the ring on the olive side, with the olive firmly abutting the bone. If the olive is to pull a bone fragment into position before fixation, do not secure the olive side of the wire until the maneuver is completed.
- A spring-loaded dynometric wire tensioner (Fig. 32.82) is simple to use; both the barrel-shaped and pliers-shaped models are calibrated. Tension the wire to between 100 and 130 kg on a full ring, and to about 90 kg when the wire is spanning an open ring or on a pair of posts elevated from a ring's plane.

***Figure 32.82.*** Spring-loaded wire tensioner.

- With the fixation bolt method (Fig. 32.83), the wire is twisted around its own fixation bolt, tensioning it. The maneuver requires two hands, one for the nut and the other for the bolt. Have an assistant hold the ring stable.

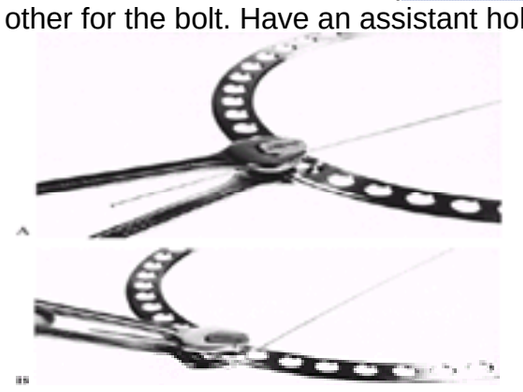

***Figure 32.83.*** Manual wire tensioning. **A:** Initial position. **B:** Final position.

- After fixing the wire to the ring on the opposite side, tighten the nut until the wire is loosely gripped. Next, rotate the fixation bolt and its nut together, twisting the wire 90° around its own fixation bolt. Because the wire displaces slightly with this method, try to displace the wire slightly during initial fixation so that it will be straight through the tissues when tensioning is complete.

## ANATOMIC CONSIDERATIONS

Transfixion wires endanger neurovascular structures if inserted without regard to cross-sectional anatomy. In 1981 I published a “zone system” atlas for pin placement to help ensure safe application of Hoffman pins, and I now use this atlas for inserting transfixion wires (3). Other atlases are also available for this same purpose.

### FEMUR

In The Classic Ilizarov Method, The Proximal Femur Is Secured With Anteroposterior Wires, And These Wires Are Attached To A Large, Thick, Curved Plate Surrounding The Patient's hip and pelvic area (14). The patient must use a special bed that incorporates a cut-out mattress to allow the posterior portion of the frame to be suspended while the patient is flat on her back.

When inserting wires into the femur, there are several basic problems. First, the bulk of the soft tissues causes difficulties, especially posteriorly, in the buttock. Second, the neurovascular bundles—especially the superficial femoral artery—can be damaged during wire insertion. The vessel is medial to the femur in its proximal third and posterior to the bone in the thigh's distal third. A safe practice is to mark the location of the vessel after palpating the femoral pulse. Third, the sciatic nerve prevents direct AP wire insertion. The proximal wires must cross at a fairly narrow angle in the upper thigh.

- When inserting wires into the proximal femur, mark the skin with the hip ring arch in an overcorrected (compensated) position, higher anteriorly and laterally. During femoral lengthening, the femur tends to angulate into varus with the apex of the deformity anterolateral. To correct this problem, the arch must be applied in a position that anticipates such a deformity. As lengthening proceeds, the arch is gradually rotated downward, becoming progressively more perpendicular to the bone's mechanical axis during elongation.
- Insert the first olive wire from anteromedial to posterolateral two fingerbreadths lateral to the femoral artery. Insert a second olive wire from back to front, 15° medial to the first wire. The posterior olive on this wire prevents the entire frame from displacing anteriorly while the patient lies in bed. A third wire is often inserted between the first two. Push all three of the proximal femoral wires through the soft tissues down to bone without drilling, and tap the wires through the soft tissues with pliers and mallet once the tip emerges through the opposite cortex.
- To stabilize a hip during femoral lengthening—especially a hip that might sublux or dislocate—it may be necessary to insert wires into the supraacetabular or iliac portion of the pelvis. Leave these wires in place (not allowing movement) until lengthening is complete. Thereafter, the wires are removed and hip motion is commenced.
- When an unstable deformity is in the middle third of the femur, a four-ring configuration may be necessary, with two rings above the deformity and two rings below it.
- For the distal femur, insert wires into either the transverse or the coronal plane. When selecting the transverse plane, cross the wires at an angle of no less than 60°. Likewise, insert olives from both directions for enhanced stability. In many situations, the distal femur can be stabilized with wires in the coronal plane; such wires permit greater freedom of knee motion than do wires that impale the hamstrings and the quadriceps.
- Whether the first pair of crossing wires is transverse or coronal, use at least one more drop wire to complete a distal femoral mounting. To improve distal femoral fixation, insert this wire some distance away from the first two, usually toward the level of the corticotomy or fracture.

### TIBIA

With the classic Ilizarov mounting for tibial lengthening, one ring with two crossed wires and a supplementary drop wire is used proximally, and a similar combination is used distally (15). The stretched soft tissues help stabilize the limb. More complex problems, such as a mobile synovial pseudarthrosis of the mid tibia, require far more stable configurations using three, four, or even more rings. Likewise, a deformity correction at two levels requires at least three rings.

The proximal ring for a tibial mounting usually incorporates a wire that passes through the fibular head and into the tibia to prevent subluxation of the proximal tibia–fibula joint during lengthening or deformity correction. A second wire through the tibia crosses the fibula wire, paralleling the medial face of the tibia. A third transverse drop wire is inserted across the tibia into the location used for skeletal traction. Additional wires are inserted as needed for greater stability. Distally, the fibula must usually be incorporated into the configuration with a distal fibulotibial wire. Additional crossed wires in the distal tibia complete the mounting. The strategic placement of the olives on these wires depends on the goal of fixator application. The principles of olive-wire placement were discussed earlier in this section.

### FOOT

Before Inserting Wires Into The Calcaneus, Consider The Diameter Of The Wires, The Number Of Wires, The Angles Between The Wires, The Direction Of Wire Insertion, The Plane Of The Wires, And The Method Of Fixing The Wires To Their Support Ring.

The diameter of the wires is determined by the age of the patient, the stiffness of the deformity, and the amount of osteoporosis present. In general, younger patients require smaller wires (1.5 mm) than older patients. The stiffer the deformity, the larger the diameter of the wire (up to 2.0 mm) required.

Similarly, the amount of osteoporosis and degree of deformity influence the number of wires selected. Usually, two crossed wires are inserted into the tubercle of the calcaneus, subtending an angle of about 60° between them. Use this configuration when correcting a deformity of the os calcis, such as equinus or calcaneus. When merely holding the bone to prevent development of equinus during tibial lengthening, use a single transverse wire. More than two wires may be necessary with marked osteoporosis. Keep the plane of the wires parallel to the plantar surface of the heel.

Next, consider the direction from which the wires are to be inserted. When correcting an equinus, insert both olive wires from the posterior part of the heel toward the forefoot. When correcting a cavus or calcaneus deformity, insert the olive wires from the forepart of the foot toward the heel. When correcting a forefoot adduction deformity, keep both olive wires on the medial side of the heel. When a valgus of the heel is being corrected, place the olive on the lateral side of the foot. In combined deformities such as talipes equinovarus, the position of the olives is determined by the nature of the pathology.

When correcting a hindfoot deformity, consider also the location of the wires within the calcaneus. When overcoming equinus, place the wires high in the tuber of the calcaneus to ensure good bone stock plantarward of the wires. When correcting a cavocalcaneal deformity, insert the wires lower in the bone to ensure a maximum stock of osseous tissues cephalad to the wires.

The insertion of forefoot wires also depends on the nature of the problem. To overcome forefoot adduction, keep the olive on the medial side of the foot; to correct forefoot abduction, place an olive on the foot's outer edge.

In general, insert metatarsal wires through the first and fifth metatarsals, passing under the necks of the second, third, and fourth. In certain circumstances, it may be necessary to insert additional wires into other metatarsal bones, especially when correcting a severe supination deformity. Pass these wires from the plantar surface of the foot out through the neck of the third or fourth metatarsal, exiting in the dorsolateral surface of the foot.

Many foot mountings use a three-point-bending principle to correct an adductovarus foot. The first and third points of force application (olives) are on the medial side of the calcaneus and first metatarsal, respectively. Place the counterpressure olive wire on the lateral side of the cuboid (or talar neck or other midfoot bone).

**HUMERUS**

In The Humerus, The Proximal And Distal Ends Of The Bone Can Be Secured With Three Wires Each. To Insert Wires Through The Proximal Humerus, Abduct The Arm 90° and externally rotate it 20°. Drive olive wires from both the anterior and posterior directions. The third wire is a drop wire off the plane of the ring.

In the distal humerus, insert olive wires crossing in the frontal plane, one from the lateral supracondylar ridge and one from the medial supracondylar ridge (Fig. 32.84). A drop wire (perpendicular to the bone's axis) completes the configuration. Extend the elbow when inserting wires anteriorly and flex the elbow when inserting wires in the posterior side of the limb. When a humeral mounting requires three levels of fixation, wires crossing in the mid-humeral area should be inserted with regard for the location of the neurovascular bundles, especially the radial nerve.

***Figure 32.84.*** Distal humeral fixation with wires crossing in the coronal plane.

In the distal humerus, when the elbow is flexed, the anterior lower-arm skin moves proximally while the posterior skin moves distally; with elbow extension, these tissues move in the opposite directions. Between the flexor and extensor surfaces, however, a fairly stable tissue plane exists, around which the upward-downward movement of the anterior and posterior tissues revolves. This plane of limited skin movement lies along the medial and lateral supracondylar ridges of the humerus, an ideal location for transfixion wire placement. Unfortunately, the distal humerus flattens and widens at the elbow. Two supracondylar transfixion wires (in the same transverse plane) will not have enough of an angle between them for stable fixation; it is better to cross the wires in the frontal plane.

- Insert the wires into both epicondyles, exiting the humerus proximally at the medial and lateral supracondylar ridges. Take care not to transfix either the ulnar or radial nerves. A third wire straight across from one supracondylar ridge to the other completes the mounting.
- After all wires are in place, flex and extend the elbow: there should be no block in either direction. A mechanical block to full extension means that one or more wires has entered the olecranon fossa of the distal humerus; such a wire must be repositioned.

**FOREARM**

The configuration for a forearm mounting depends on the pathology. In some cases, the two forearm bones are secured together with wires transfixing both the radius and the ulna. In other mountings, each bone has its own separate fixator, with one frame rotating within the other. Transfixion wires are particularly dangerous in the forearm. Consult a cross-sectional anatomy atlas at the time of wire insertion.

***Pin Technique—Operative Technique***

Many modern configurations use half-pins for diaphyseal bone fixation. In this way, muscle impalement with transfixion pins or wires is avoided.

- Avoid creating a cantilever system with pins perpendicular to the bone. Instead, our half-pins are splayed out in different directions and different planes, with some inserted obliquely into each bone segment (Fig. 32.85).



***Figure 32.85.*** Rancho mounting with divergent titanium half-pins.

- Furthermore, try to mount the half-pins as circumferentially around the bone as possible, attempting to gain purchase where the osseous surface is located subcutaneously (Fig. 32.86). The tibia and ulna are particularly suited to this type of mounting, because these bones are subcutaneous through their length (5).



***Figure 32.86.*** Rancho mounting with contoured ring sizing.

- The femur and humerus have subcutaneous surfaces proximally and distally. For juxtaarticular mountings, continue to use wires. Three or four wires can be easily inserted into fragments that are unsuitable for half- or full-threaded pins.

Titanium pins, although not as stiff as steel pins, seem particularly well tolerated by both bone and soft tissues. If a titanium pin site does become septic, we rarely observe the extensive inflammatory reaction (involving adjacent portions of the limb) that we have noted with steel implants. Occasionally, a threaded titanium pin becomes strongly bonded to bone, suggesting bone-to-metal bonding similar to the type of fixation that may occur with titanium total joint implants.

Titanium is more flexible than steel; hence, when correcting deformities with titanium half-pin configurations, more pin bending than one would expect with stainless-steel half-pins is noted. Therefore, use 5 mm titanium pins for tibial and humeral mountings and 6 mm titanium pins in the femur. For substantial lengthenings, steel pins have proven superior because of the added stiffness.

There are several reasons for using a circular configuration with the half-pins (4). First, whenever a rotational deformity requires gradual correction, a circular external fixator is the only apparatus that allows counterrotation of the configuration's sections. Second, a circular frame permits application of hinges and distractors anywhere around the circumference of a bone (Fig. 32.87). In this way, a hinge axis can be placed wherever needed to produce the desired bone-fragment angulation. Third, a circular fixator gives the option of using wires—especially olive wires—when needed for interfragmentary compression, reduction of fractures, or juxtaarticular fragment fixation.

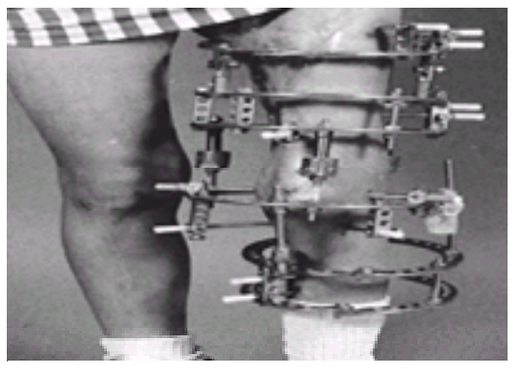

***Figure 32.87.*** Rancho mounting with titanium pins for managing complex deformities.

**PIN INSERTION**

Since fixators are in place for many months, meticulous pin technique is needed to ensure long-term fixation. When inserting half-pins, take the following measures, which should be used for routine external skeletal fixation as well (3,4 and 5):

- After making the skin incision, use a mosquito clamp to spread the tissues down to the bone (Fig. 32.88).

***Figure 32.88.*** Spreading tissues with a clamp.

- Next, use a joker or narrow periosteal elevator to elevate the periosteum from the bone at the pin site (Fig. 32.89). This measure reduces periosteal damage caused by the spinning drill bit.



***Figure 32.89.*** Elevating the periosteum with a “joker” before pin insertion.

- Use a drill sleeve and trocar with tangs (or points) that can be driven into the bone, ensuring both stability of the sleeve and less interposed soft tissues during drilling (Fig. 32.90).



***Figure 32.90.*** Sleeve and trocar system for pin insertion.

- Irrigate the drill bit with a cold irrigating solution during drilling.
- Use a stop-and-start drilling motion to prevent the drill bit tip from overheating (7).
- When penetrating dense cortical bone, periodically remove the drill bit from the sleeve and wipe out bone chaff from the flutes—another measure to prevent overheating.
- Use a depth gauge and insert a properly sized half-pin with a hand-held driver.

The use of half-pins in place of wires offers an added dimension to Ilizarov's methods (Fig. 32.91). Since we have been using half-pins for our mountings, problems with physical therapy (inhibition of muscle and joint action by wires) and pin sepsis have greatly improved (Fig. 32.92, Fig. 32.93) (6).

***Figure 32.91.*** The cube used for variable-angle pin insertion.

***Figure 32.92.*** Rancho mounting for femoral and tibial lengthening. A wire is used for this patient's hypoplastic fibular head.

***Figure 32.93.*** Rancho titanium pin mounting for bone transport. Notice the use of full pins in a location where no muscles are impaled.

## CHAPTER REFERENCES

Each reference is categorized according to the following scheme: *, classic article; #, review article; !, basic research article; and +, clinical results/outcome study.


# 1. Bianchi-Maiocchi A, ed. *Introduzione alla Conoscenza della Metodiche di Ilizarov in Ortopedia e Traumatologia.* Milan: Edizione Medi Surgical Video, 1983.

+ 2. Cattaneo R, Villa A, Catagni M, Tentori L, Cassi M. Application de la Methode d'Ilizarov dans l'Allongement de l'Humerus. *Rev Chir Orthop* 1986;72:303.

* 3. Green SA. *Complications of External Skeletal Fixation.* Springfield, IL: Charles C. Thomas, 1981.

# 4. Green SA. The Delta Frame for External Fixation of the Tibia. *Mediguide to Orthopaedics* 1983;3:1.

# 5. Green SA. The Use of Pins and Wires. *Tech Orthop* 1990;5:19.

# 6. Green SA. Physiotherapy during Ilizarov Fixation. *Tech Orthop* 1990;5:61.

+ 7. Green SA, Ripley M. Chronic Osteomyelitis of Pin Tracts. *J Bone Joint Surg Am* 1984;66:1092.

+ 8. Ilizarov GA. A Method of Uniting Bones in Fractures and an Apparatus to Implement this Method. *USSR Authorship Certificate 98471,* filed 1952.

+ 9. Ilizarov GA. A New Principle of Osteosynthesis with the Use of Crossing Pins and Rings. In: *Collection of Scientific Works of the Kurgan Regional Scientific Medical Society*. Kurgan, USSR, 1954:145.

+ 10. Ilizarov GA. The Tension-Stress Effect on the Genesis and Growth of Tissues: Part I. The Influence of Stability of Fixation and Soft-Tissue Preservation. *Clin Orthop* 1989;238:249.

+ 11. Ilizarov GA. The Tension-Stress Effect on the Genesis and Growth of Tissues: Part II. The Influence of the Rate and Frequency of Distraction. *Clin Orthop* 1989;239:263.

# 12. Ilizarov GA. *Transosseous Osteosynthesis.* Heidelberg: Springer-Verlag, 1991.

+ 13. Ilizarov GA, Devyatov AA, Trokhova VG. Surgical Lengthening of the Shortened Lower Extremities. *Vestn Khir* 1972;107:100.

+ 14. Ilizarov GA, Trokhova VA. Surgical Lengthening of the Femur. *Ortop Travmatol Protez* 1973;34:51.

+ 15. Ilizarov GA, Trokhova VA, Devyatov AA. Surgical Lengthening of Shortened Lower Limb. *Vestn Khir* 1972;108:100.

# D. Tension-Wire External Fixators for Acute Trauma

***J. Charles Taylor***

Although others have used highly tensioned small-diameter wires with external frames, G. A. Ilizarov in Kurgan, Siberia, was foremost in the development of techniques to treat a variety of orthopaedic problems, including fractures, nonunions, and deformities, using an innovative modular circular external fixator with tensioned wires. This section discusses the use of the Ilizarov method in the management of acute fractures and their complications.

## BIOMECHANICS

Many changes in external fixation design and use occurred in the 1980s, foremost of which is the shift toward half-pin frames and maintenance of the frame in place until union occurs in unstable fractures. The benefits of axial micromotion for fracture healing and bone remodeling have been well documented, leading to the techniques of dynamization and staged dismantling of half-pin fixators to improve fracture healing (3,7).

The Ilizarov frame is about 25% as stiff as uniplaner and biplaner fixators in the axial direction, while maintaining approximately equal stiffness to bending and torsional loads (4,13). These mechanical characteristics allow the beneficial effects of axial micromotion without the deleterious effects of torsional and translational shear.

Wire diameter and tension are the most important factors affecting frame stability (13). Other factors influencing frame stiffness are size, number, and location of the rings; divergence of the transfixing wires; use of olive wires; and distraction or compressive loads at the fracture or nonunion site (1,4,8,15). Intrinsic biomechanical factors unique to each patient include weight, cortical continuity, and integrity of the soft tissues.

Awareness of three axes–three rotations geometric analysis of fracture deformities has recently served as the basis for a new generation of external skeletal fixators that, in their most basic form, consist of two rings connected to each other by six struts. The struts can be manually lengthened or shortened in accordance with a pattern determined by a computer program that calculates the displacement of fragments secured (with pins and wires) to the rings. The coordinate information is determined by precise measurements from properly oriented x-ray views of the limb. The Taylor Spatial Frame is the first of such devices (14).

## FRACTURE MANAGEMENT

The use of a circular external fixator for acute trauma of the upper and lower extremities is common in Russia and parts of Western Europe, and increasingly in North America (7). Metaphyseal fractures may have extension into the articular and diaphyseal regions, greatly increasing the complexity of their management. To define better these complex injuries and to clarify treatment options, a new classification scheme (Fig. 32.94) is offered. The main metaphyseal injury is characterized as stable (S), unstable (U), or with diaphyseal extension (D). The three subgroups are 0, for absence of intraarticular extension; 1, for nondisplaced (2 mm or less) intraarticular extension; and 2, for displaced (more than 2 mm) intraarticular extension.

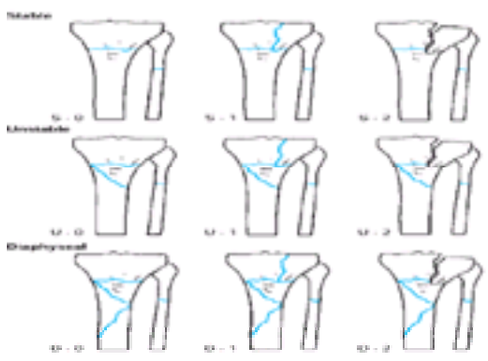

***Figure 32.94.*** SUD classification of metaphyseal fractures accounting for increasing degrees of instability and intraarticular extension.

In most cases, the metaphyseal injury precludes stabilization by intramedullary fixation. Treatment options are limited to closed methods, pin external fixation, tensioned-wire external fixation, and open reduction and internal fixation.

With progression from type S to type D, treatment shifts toward external fixation and away from open reduction. On the other hand, with progression from subgroup 0 to subgroup 2, open reduction becomes indicated. Acceptable reduction of the intraarticular portion of the fracture complex must be obtained. If reduction of the intraarticular portion of the fracture to less than 2 mm is not obtained with traction, recommend open reduction and internal fixation. The diaphyseal extension in type D fractures makes open stabilization an extensive procedure. For type D-2 fractures, perform an open reduction with limited internal fixation of the articular segments with cancellous screws, and then neutralize the metaphyseal and diaphyseal regions with external fixation. This method cannot make up for poor articular reduction, however.

The presence of a Gustilo type I or II open wound does not alter basic treatment guidelines. However, a type III wound, especially IIIB, favors stabilization with an external fixator. Less exposure is needed if performing a limited open reduction and external fixation, decreasing the amount of soft-tissue dissection, and limiting local vascular injury.

Stabilization of short periarticular fragments is possible with a circular external fixator. Because the wires are tensioned and supported circumferentially, a “trampoline” of fixation is provided (Fig. 32.95). Spanning the knee or ankle for 4 to 6 weeks is necessary on occasion, especially with elevation of the joint surface and bone grafting. Fixation is rigid enough to allow early motion and partial weight bearing.

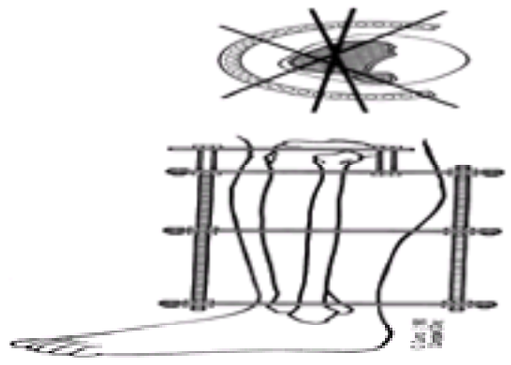

***Figure 32.95.*** Fixation of a tibial plateau fracture with three to four wires in subchondral bone provides a “trampoline” of support for articular fragments.

An open fracture with extensive bone loss is another indication for the Ilizarov method in acute trauma. The unstable fracture, soft-tissue defect, and bone loss are all managed successfully with one device and method. The first step in the management of these complex fractures is to determine if the limb is salvageable. A dysvascular, insensate extremity does not function better than a prosthetic limb. Other relative indications for circular fixation in acute trauma are open fractures, unstable closed fractures, and fractures with compartment syndrome.

Time-to-union is probably related to the quality of reduction and restoration of normal alignment (9). Accurate apposition and alignment at the time of initial application of a simpler trauma frame is easier than the use of articulated frames with subsequent reduction. Most fractures can be treated to union in the external fixator, but those of lower energy and more stability can be converted to functional bracing as healing of soft tissue allows.

***Technique for Fracture Stabilization***

The key to success with any circular fixator is preoperative planning. Assembling frames preoperatively greatly reduces intraoperative time.

- Obtain full-length anteroposterior (AP) and lateral x-ray films of the limb, including the joint above and that below. These full-length radiographs are used to select rods of proper length and approximate ring location.
- Determine ring size on the uninjured extremity. Two fingerbreadths' (2–3 cm) clearance is necessary for tibial mountings (Fig. 32.96), and two or three fingerbreadths' (about 3 to 6 cm) clearance is necessary for the femur (Fig. 32.97). Rings that are too large cannot support the transfixing wires adequately, and they impair osteogenesis (6).

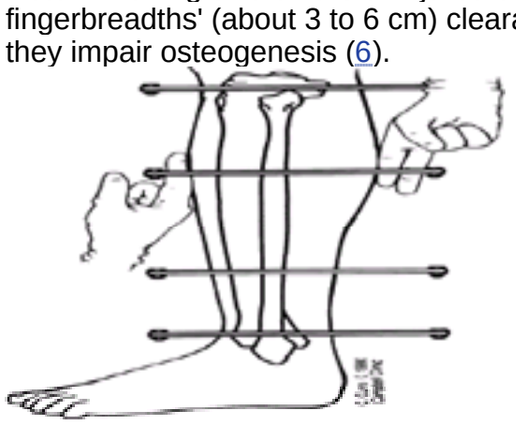

***Figure 32.96.*** Standard clearance for a typical tibial mounting with the frame aligned with the tibial crest is 2 to 3 cm.

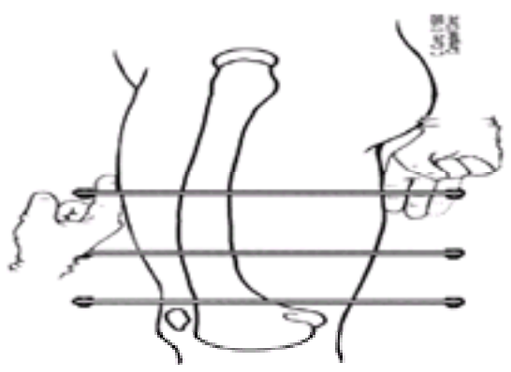

***Figure 32.97.*** Adequate soft-tissue clearance of a typical femoral mounting, with more space provided posteriorly.

- Because of the anatomic constraints of safe wire placement, 90° divergence is usually unobtainable (5,6,10). A second level of fixation in each segment improves the frames' stiffness to AP bending and torsion. Use two rings on large fragments, and a ring and drop post for smaller fragments.

***Lower Extremity***

Midfemur is the most proximal level to accommodate a complete ring comfortably.

- Accomplish fixation to the proximal femur by half-pins attached to femoral arch bars. Connect these arch bars to the remainder of the construct by rods and offset brackets. Make the most proximal arch bar a short arc to prevent interference with the abdomen when the hip is flexed.
- The entire lower extremity can be treated with a simple cylindrical frame from mid femur to the ankle, as shown in Figure 32.98. The thigh dictates ring size, which is usually one or two sizes larger than that normally used for the tibia. Make the frame parallel to the tibia on AP and lateral views. Center the femur at the level of the patella and align it in anatomic valgus with respect to the frame.



***Figure 32.98.*** Entire lower extremity treated with a cylindrical frame with ring size dictated by the diameter of the mid thigh.

- When the frame is confined to the femur, use a $^5/_8$ ring as the distal femoral ring to allow full flexion at the knee (Fig. 32.99). This $^5/_8$ ring may be attached to a

complete ring with heavy-weight sockets and may be made more resistant to deformity when tensioned wires are applied to the open section ring. The most proximal ring in a tibial mounting can be a $^5/_8$ ring attached to a complete ring, allowing maximal flexion and providing two levels of fixation (Fig. 32.100).

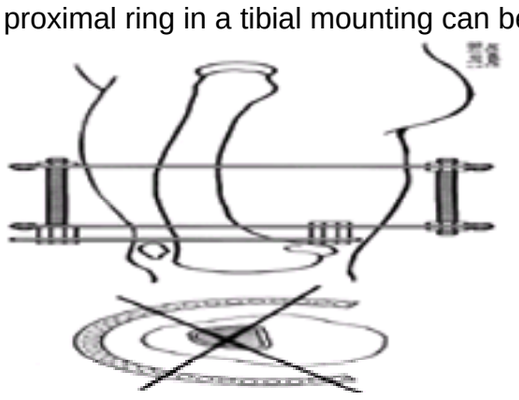

***Figure 32.99.*** Femoral mounting using a $^5/_8$ ring to allow full knee flexion.

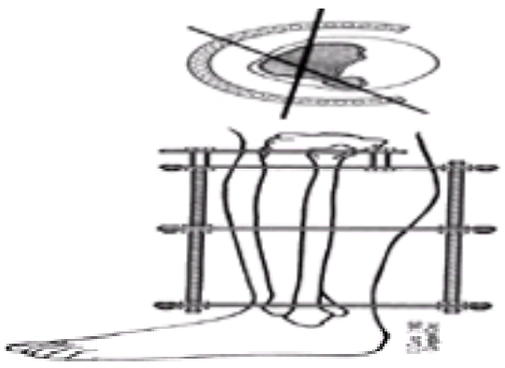

***Figure 32.100.*** Tibial mounting using a $^5/_8$ ring to allow full knee flexion.

- Include the foot in the frame for open fractures to prevent contractures and soft-tissue motion at the fracture site (2). Pilon fractures may require foot fixation for fracture stability. Remove the foot frame after soft-tis-sue healing, unless it is necessary for fracture stability. With injury to the peroneal nerve or anterior and lateral compartments, consider temporary incorporation of the foot to prevent equinus contracture. A stable foot mounting consists of two half-rings joined by plates with threaded extremities (Fig. 32.101). These special plates prevent the foot frame from distorting when the wires are tensioned. Usually the same size of half-rings are used for the tibial frame and for the foot frame.

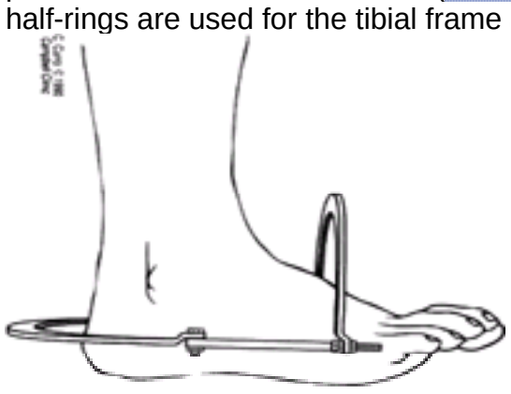

***Figure 32.101.*** Foot mounting using two half-rings coupled by two plates with threaded extremities.

- Select the frame size to allow 2 to 3 cm of clearance between the inner edges of rings and skin (11). Swelling and dependent edema create late changes in extremity dimensions and must be anticipated. More clearance is needed posteriorly for the lower extremity, and the femur requires more room for swelling than the leg. Figure 32.96 and Figure 32.97 show typical clearances for tibial and femoral frames.

***Upper Extremity***

- The Omega ring or ring with curved extremities is useful for the proximal humeral mountings, decreasing soft-tissue irritation and providing relatively more holes for the critical low-divergence mountings of the proximal humerus (Fig. 32.102). The safe angle between pins or wires is relatively small for short fragments, requiring two wires for fixation on the ring and a wire below or above the others. At the level of the distal humerus, the $^5/_8$ ring allows full elbow flexion (Fig. 32.103).

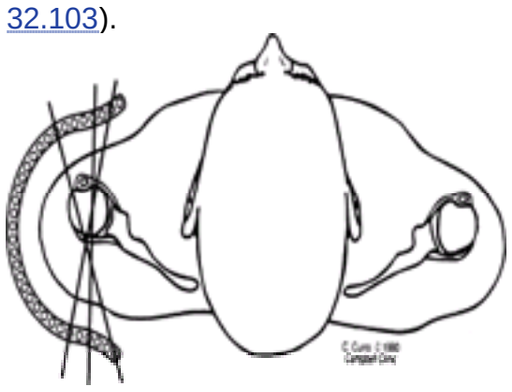

***Figure 32.102.*** Aerial view of the shoulder, demonstrating an omega ring for proximal humeral fixation.

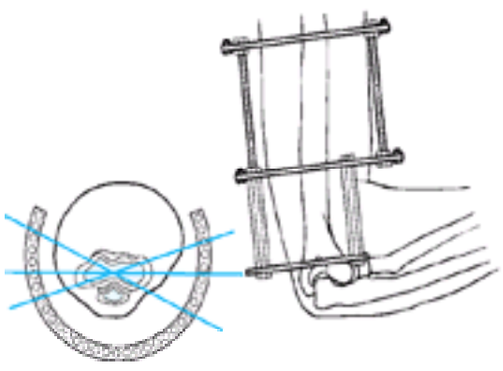

***Figure 32.103.*** Lateral view of the elbow with a $^5/_8$ ring at the level of the epicondyles to allow full elbow flexion.

- On a forearm mounting, a $^5/_8$ ring may be used on the dorsum of the proximal forearm to allow full elbow flexion. Provide fixation of the distal humerus by mediolateral wires in a short arc in the coronal plane, fixed to posts above and below the ring (Fig. 32.104). Fix the proximal humerus with anterior posterior wires in a small arc in the transverse plane.

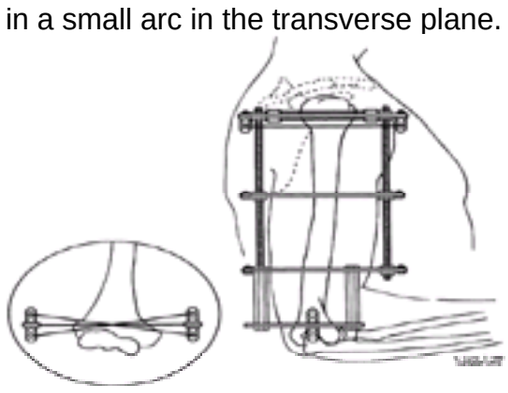

***Figure 32.104.*** Humeral mounting showing anteroposterior fixation of the proximal fragment and mediolateral fixation of the distal fragment. (*Inset*) Short arc of fixation achieved with drop posts above and below the ring.

**TECHNIQUE FOR TIBIAL FRACTURES**

- Position the patient supine on a fracture table with traction placed through an os calcis pin. Place the injured extremity in the 90°–90° intramedullary nailing position (Fig. 32.105) or straight traction in the heel-to-toe position.

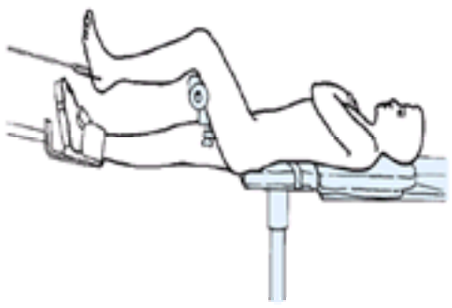

***Figure 32.105.*** Supine position for application of external fixation or tibial nailing.

- Elevate the buttocks support on the fracture table on the injured side, placing the extremity in neutral rotation with the patella pointing straight toward the ceiling (Fig. 32.106), allowing true AP and lateral orthogonal x-ray imaging.

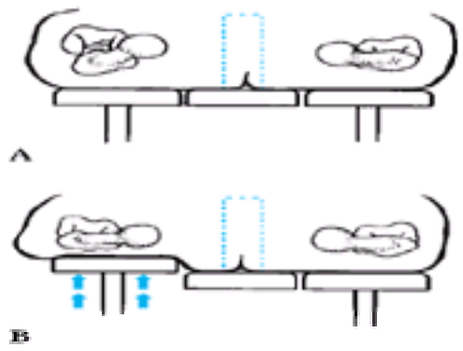


***Figure 32.106.*** **A:** Supine position on the fracture table. **B:** Use of buttock support to internally rotate proximal limb.

- Alternatively, place the patient on a radiolucent table extension using the external fixator for traction and reduction.
- Longitudinal traction reduces most fractures to within 10° or 15° of anatomic alignment.

The addition of hinges to the trauma frame, in our experience, has been unnecessary. Avoid excessive or prolonged traction to prevent neurologic or vascular injury.

- After prepping and draping the extremity, disconnect the ring connection bolts on one side of the preassembled frame and swing the frame open. Place the frame around the extremity and reassemble it, with adequate soft-tissue clearance and with coupling bolts aligned parallel to the crest of the tibia in AP and lateral planes (Fig. 32.107).

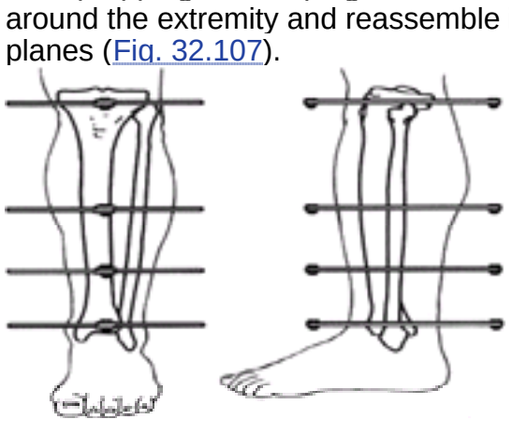

***Figure 32.107.*** Reference position of Ilizarov frame parallel to crest on anteroposterior (AP) and lateral views, with connecting bolts superimposed on AP view.

- To use this frame to treat the fracture in Figure 32.108*A*, hold the frame in this position with proximal and distal transverse reference wires placed parallel to the knee and ankle (Fig. 32.108*B*).

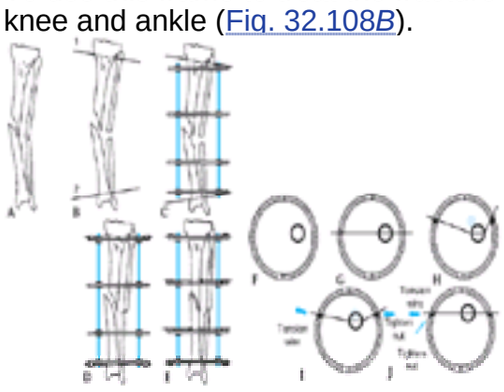

***Figure 32.108.*** **A:** Unreduced diaphyseal fracture. **B:** Proximal and distal coronal plane reference wires inserted parallel to the joint at the proximal and distal extent of proposed frame. **C:** Ilizarov trauma frame "clamshelled" around the leg. **D:** Reference wires tensioned with slight residual deformity. **E:** Residual deformity corrected with arched olive wire technique.
Parts **F** through **J:** show a cross section demonstrating the arched olive wire technique of residual deformity correction. **F:** Unreduced fracture fragments. **G:** An olive wire is inserted into one fragment. **H:** Arch the olive wire the amount necessary to reduce the fragment on the lateral view, and attach it loosely to the ring with wire fixation bolts. **I:** Slowly tension the wire until the fragment is reduced on the AP view with the trailing nut subsequently tightened. **J:** Further tension the wire to achieve final correction of AP displacement, and then tighten the leading nut.

- As the wires are secured to the frame and tension is applied (Fig. 32.108*C*), further correction of the fracture in the coronal plane is achieved (Fig. 32.108*D*).
- An alternative method for these initial steps is to suspend the frame with ordinary suction tubing placed around the extremity and secured to the frame with towel clips. Eccentrically cant the proximal and distal rings until they are parallel to the knee and ankle joints. After secure fixation with at least two wires to the proximal and distal rings, bring these two rings back parallel to their counterparts in the center of the frame, further reducing the fracture.

Achieve final fracture reduction with arched olive wires or traction on half-pins (Fig. 32.108*E*). For final correction of the residual displacement in the coronal plane (Fig. 32.108*F*), place an olive wire in a transverse fashion if safe (Fig. 32.108*G*), apply tension without securing it tightly to the frame, and pull the fragment toward the tensioner.

- Use image intensification to verify adequate reduction. To compensate for parallax curves on the image intensifier, place an olive wire longitudinally on the extremity as an alignment guide to confirm the reduction.
- After adequate correction is obtained in this plane, secure the wire to the frame on the olive side. If further correction is needed in the sagittal plane, connect the olive wire in an arched fashion (Fig. 32.108*H*). As the wire is tensioned, final correction is achieved (Fig. 32.108*I*, Fig. 32.108*J*).
- Eliminate any residual distraction (Fig. 32.109).

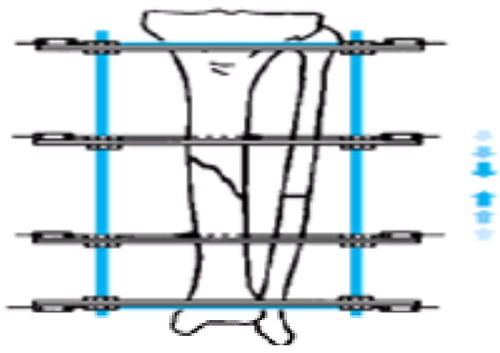

***Figure 32.109.*** Place the fracture under compression if axially stable, to eliminate residual distraction.

- In rare cases, two olive wires placed from opposite sides perpendicular to the fracture plane can reduce and compress the fracture (Fig. 32.110). This pattern of wire placement may not always be safe. In such a case, treat these fractures with lag screw fixation followed by external fixator placement (Fig. 32.111).



***Figure 32.110.*** **A:** In an unusual case, a minimally displaced articular fracture is amenable to reduction and fixation with opposing olive wires. **B:** Opposing olive wire. **C:** Additional wires are necessary for stability.

***Figure 32.111.*** **A:** A more universal technique of open reduction and limited internal fixation with a lag screw than that shown in Figure 32.110. **B:** The plane of fixation provided by subsequent wires. **C:** Divergence—and thus stability—are maximized within anatomic limits.

- Use axial computed tomography (CT) scans in preoperative planning to help determine the more appropriate method.
- We usually avoid interfragmentary screws or wires in the diaphyseal region, as interfragmentary fixation in the diaphyseal region is counterproductive to the axial flexibility of the Ilizarov external fixator; ideally, this promotes secondary fracture healing. I avoid interfragmentary screws or wires in the diaphysis because I have experienced delayed unions and nonunions with their use.
- Treat pilon fractures with significant shaft extension by first mounting the proximal tibia and foot in anatomic rotation, alignment, and apposition. Place a dummy ring just distal to the most distal ring fixing the proximal shaft fragment.
- Maintain distraction to achieve as much reduction as ligamentataxis provides (Fig. 32.112).

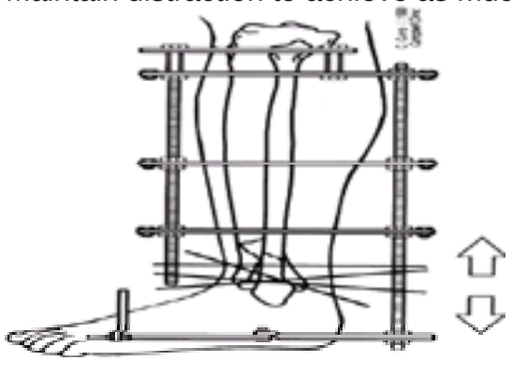

***Figure 32.112.*** Place pilon fractures under gentle traction after fixation of the proximal tibia and the foot.

- Elevate depressed articular fragments and fill large subchondral voids with autogenous graft.
- Maintain interfragmentary reduction with wires, which are subsequently attached to the dummy ring after that ring is translated into position (Fig. 32.113). Tension the wires and relieve any excessive traction.

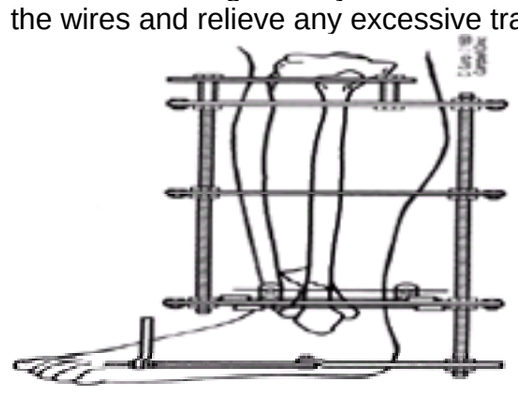

***Figure 32.113.*** After reduction and interfragmentary fixation with Ilizarov wires, attach the wires to a ring and add tension.

- Protect pilon and plateau fractures requiring bone grafting for 4 to 6 weeks by constructs spanning the joint.

## SUBACUTE FRACTURE MANAGEMENT

Reconstructive soft-tissue procedures are possible with circular tensioned wire fixators. Typical fracture frames are made up of four threaded rods linking four complete rings. Temporary removal of one rod allows 180° access to the leg for bone grafting delayed unions or for vascular access for free flaps (Fig. 32.114). Removal of the anteriolateral rod allows access to the dorsalis pedis artery, and removal of the posteromedial rod allows access to the posterior tibialis artery.

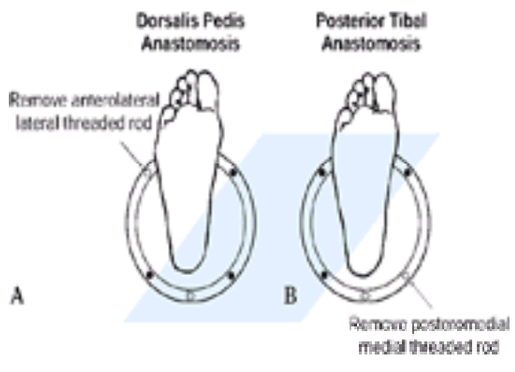


***Figure 32.114.*** **A:** Axial view of the limb showing 180° access to the anterolateral surface if a single anterolateral rod is removed for a rotation flap or free flap with the anterior tibial artery as donor. **B:** Axial view of limb showing 180° access to the posteromedial surface if a single posteromedial rod is removed for a rotation flap or free flap with the posterior tibial artery as donor.

In open fractures with bone loss, consider the circular external fixator for the primary treatment. Conventional treatment consists of debridement and delayed coverage with a rotation or free flap and possible internal or external fixation followed by autogenous bone grafting. Using a tensioned wire fixator, the wound undergoes the same serial debridement of all necrotic tissue (Fig. 32.115); if there is no exposed bone, exposed muscle can be covered with a split-thickness skin graft (Fig. 32.116). Later, the bone defect can be filled by performing a corticotomy and bone transport (Fig. 32.116). The tendency of soft tissue to move with the transported bone, and the normal tendency of split-thickness grafts to contract, fill in the soft-tissue and bone defects, eliminating the need for rotation or free flaps. If less than 2 cm of vascularized bone is exposed after debridement, consider further shortening of fragment ends to avoid the necessity for flap coverage. Then a simple skin graft can be used as described previously.

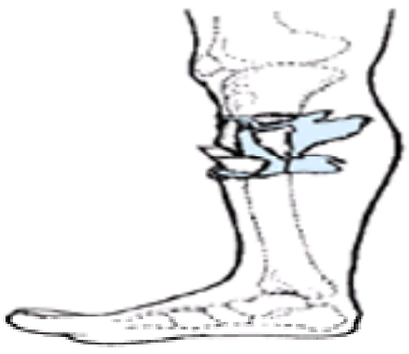

***Figure 32.115.*** Open tibial fracture with devitalized bone, muscle, and skin.

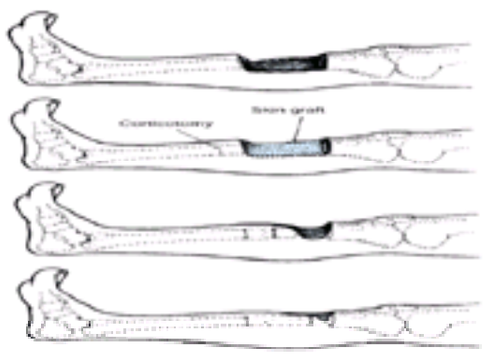

***Figure 32.116.*** **A:** Open fracture following debridement, with bone loss but no exposed bone. **B:** Split-thickness skin grafting of the soft-tissue defect and corticotomy in preparation for bone transport to obliterate the bone defect. **C:** Subsequent bone transport with regenerate bone filling the bone defect. **D:** Completion of transport and obliteration of bone defect.

If a significant amount of vascularized bone remains exposed after debridement, use a free or rotation flap (Fig. 32.117*A*). At the time of flap coverage, make a corticotomy, and prepare a fragment for transport into the bone defect (Fig. 32.117*B*, Fig. 32.117*C*). Although Ilizarov recommended a metaphyseal corticotomy for transport, diaphyseal corticotomy and transport of shorter fragments has also been successful.

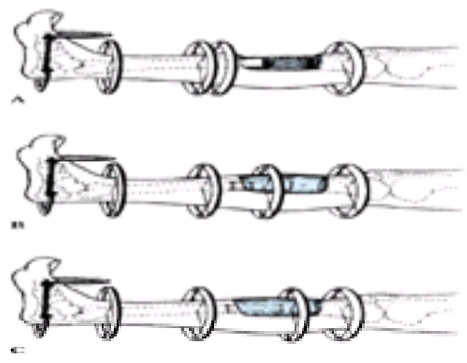

***Figure 32.117.*** **A:** Open tibial fracture following debridement, with exposed viable bone requiring a rotation or free flap. **B:** Bone transport through the flap with formation of regenerate bone. **C:** Completion of transport with obliteration of the bone defect.

## PITFALLS AND COMPLICATIONS

With careful determination of safe zones by level of fixation, acute neurovascular injury with transfixion wires is rare. In the immediate postoperative period, an unusually painful wire should be suspected of passing through a larger nerve and should be removed. Late neurovascular injury is exceedingly rare unless bone transport is performed or there is gross motion between bone fragments. This usually occurs during a reconstruction rather than with simple immobilization of a fracture. Flexion contractures of the knee and ankle occur less frequently with fracture treatment than with lengthening and can be prevented by active exercises and weight bearing in the frame.

The management of pins and pin sites is discussed earlier in this chapter and in Chapter 11.

Frame modification involving loosening of tensioned wires is uncomfortable for patients. Anesthetics are usually required. Swelling and dependent edema must be anticipated with circumferential external fixators; anterior soft-tissue clearance need not be as great as posterior. The rings can be quite close to the anterior thigh on the initial femoral mounting because dependent edema distends posteriorly. Few patients can sleep in positions other than supine with a femoral frame. For a typical adult tibial application with a distance of 36 cm between proximal and distal rings, the frame shifts 2 cm if the frame is canted only 3°.

- Accurately position the frame before it is attached to bone with tensioned wires. Place proximal and distal reference wires at the most proximal and distal points of attachment of the frame using an image intensifier (12).
- Insert reference wires in the coronal plane parallel to the joint, and attach the frame to these wires, establishing sufficient soft-tissue clearance at each end. Insert subsequent wires between these two extremes, further constraining the bone frame construct.
- If skin impinges on the frame near the end of treatment, slip thin pieces of cardboard, with a slot for the wires, between the skin and the frame. This prevents pressure necrosis against the edge of the rings by increasing the area of contact (Fig. 32.118, Fig. 32.119). If skin impinges on the frame early in the treatment, frame modification is almost always necessary. If problems exist at several rings but only along a short arc segment of each ring, shift the frame toward the impingement by reattaching all wire fixation bolts in new holes away from the impingement. If the skin impinges on a single ring, modify that ring by introducing two short plates between the ends of the half-rings, creating an “ellipse” oriented with its major axis toward the impingement (Fig. 32.120). Alternatively, use a saw to remove a segment of a ring if it will not affect stability.

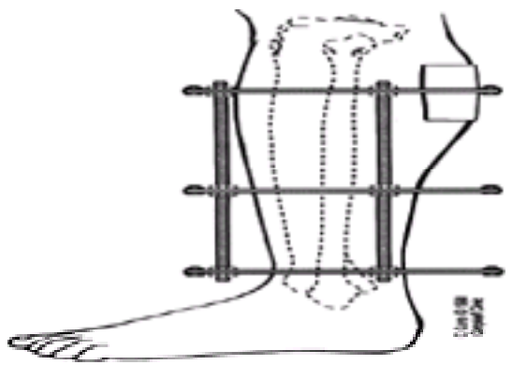

***Figure 32.118.*** Soft-tissue impingement on an Ilizarov ring.

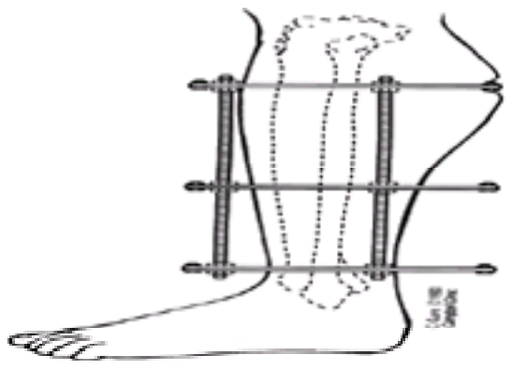

***Figure 32.119.*** Pressure is decreased over the metal ring by using a thin cardboard shim as a temporizing measure late in treatment.

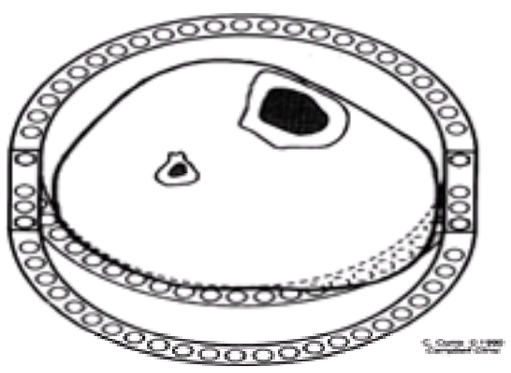

***Figure 32.120.*** Standard ring extended by two short plates to create an ellipse, eliminating impingement of skin on the ring.

- Salvage major problems of circumferential impingement at several levels by constructing a larger frame around the first frame. Position the rings of this larger frame at exactly the same levels. Straighten curled wire ends and attach wires to the outer frame at both ends. Loosen the wire fixation bolts on the smaller frame, and disassemble the smaller frame. Cannulated wire fixation bolts from the smaller frame may be taped against the new frame to prevent them from moving about. This modification can be performed without loosening wires or losing reduction.

---

All drawings in this section are copyrighted by the Campbell Clinic.

## CHAPTER REFERENCES

Each reference is categorized according to the following scheme: *, classic article; #, review article; !, basic research article; and +, clinical results/outcome study.


+ 1. Aronson J, Johnson E, Harp JH. Local Bone Transportation for Treatment of Intercalary Defects by the Ilizarov Technique: Biomechanical and Clinical Considerations. *Clin Orthop* 1989;243:71.

+ 2. Burgess AR, Poka A, Brumback RJ, et al. Pedestrian Tibial Injuries. *J Trauma* 1987;27:6.

+ 3. Edwards CC. Staged Reconstruction of Complex Open Tibial Fractures Using Hoffmann External Fixation: Clinical Decisions and Dilemmas. *Clin Orthop* 1983;178:130.

! 4. Fleming B, Paley D, Kristiansen T, et al. A Biomechanical Analysis of the Ilizarov External Fixator. *Clin Orthop* 1989;241:95.

+ 5. Green SA. Ilizarov External Fixation: Technical and Anatomic Considerations. *Bull Hosp Jt Dis Orthop Inst* 1988;48:28.

# 6. Ilizarov GA. Fractures and Non-unions. In: Coombs R, Green S, Sarmiento A, eds. *External Fixation and Functional Bracing.* London: Orthotext, 1989:347.

! 7. Ilizarov GA. Experimental Studies of Bone Elongation. In: Coombs R, Green S, Sarmiento A, eds. *External Fixation and Functional Bracing.* London: Orthotext, 1989:375.

! 8. Ilizarov GA. The Tension-Stress Effect on the Genesis and Growth of Tissues. *Clin Orthop* 1989;238:249.

+ 9. Lawyer RBJ, Lubbers LM. Use of the Hoffmann Apparatus in the Treatment of Unstable Tibial Fractures. *J Bone Joint Surg Am* 1980;62:1264.

+ 10. Lehman W, ed. *Operating Room Guide to Cross-Sectional Anatomy of the Extremities and Pelvis.* New York: Raven Press, 1989.

+ 11. Paley D. The Biomechanics of the Ilizarov External Fixator. Ilizarov Techniques for the Treatment of Nonunions, Bone Defects, Osteomyelitis, Fractures, Adult Limb Length Discrepancy and Deformity. Washington, DC, May 16–18, 1988.

# 12. Paley D. The Principles of Deformity Correction by the Ilizarov Technique: Technical Aspects. *Tech Orthop* 1989;4:1.

! 13. Podolsky A, Hein T, Chao EYS. Biomechanical Performance of Ilizarov External Fixators. Presented at the *Thirteenth International Conference on Hoffman External Fixation.* Mayo Clinic, Rochester, May 27–29, 1989.

+ 14. Taylor JC. *The Taylor Spatial Frame.* Memphis, TN: Smith & Nephew Richards, 1996.

+ 15. Wolfson N, Hearn TC, Thomason JJ, et al. Force and Stiffness Changes during Ilizarov Leg Lengthening. *Clin Orthop* 1990;250:58.


# E. Ilizarov-type Treatment of Nonunions, Malunions, and Posttraumatic Shortening

***Stuart A. Green***

“Restorative traumatology” is Ilizarov's name for the branch of orthopaedic surgery that deals with the treatment of trauma residuals. Indeed, Ilizarov's techniques for causing new bone formation within a widening distraction gap now offer patients the hope of having an injured limb restored to normal in ways never before thought possible (7,9,10,11 and 12). Skeletal defects, for example, can be eliminated without the need for bone grafting. Many types of nonunions can be stimulated to unite by gradual distraction of the fragment ends. Malunions of all sorts can be corrected, and posttraumatic limb shortening can be overcome.

To accomplish these goals, the surgeon must have a clear idea of the nature of the pathologic process responsible for the patient's problem. For example, a nonunion of long bone may be atrophic, hypertrophic, or a true synovial pseudarthrosis; the treatment plan differs for each type of failed bone healing (6). A malunion in valgus or varus may also have a rotational component and malalignment of the mechanical axis as well. See Chapter 26 for more details.

The following sections describe the principles of treatment of nonunions, malunions, and posttraumatic shortening with circular fixation devices.

## NONUNIONS

A stiff (hypertrophic) nonunion is usually accompanied by pain on motion of the nonunion and a feeling of resistance to manual deformation at the fracture site. Roentgenograms of a stiff nonunion reveal proliferative callus growing out from the fragments on both sides of the fracture line.

A loose (atrophic) nonunion moves easily during manual examination of the fracture site. The patient often experiences little or no pain. On roentgenograms, the fracture site may show either the features associated with an atrophic nonunion (no evidence of callus formation) or the characteristics of a synovial pseudarthrosis (rounding-off and sclerosis of the bone ends).

Grouping atrophic nonunions and synovial pseudarthroses together into the same category may seem, at first, unusual. However, both types of nonunions demonstrate similar difficulties with healing and require exploration and bone grafting of the nonunion site at the time an external fixator is applied. In an atrophic nonunion, the surgery focuses on freshening up the atrophic bone ends and removing any nonviable tissue from the fracture site. A synovial pseudarthrosis requires resection of the synovium and pseudocapsule, removal of the fibrocartilage covering the bones ends, and reopening of the intramedullary canals.

Stiff (hypertrophic) nonunions—so-called fibrous nonunions—usually heal with stable interfragmentary compression. If the nonunion is transverse (perpendicular to the bone's longitudinal axis), compression with either external or internal fixation will stimulate union. Many nonunions, however, are oblique and often combined with malalignment of the bone fragments in angulation, rotation, displacement (of the mechanical axes), and shortening. When any or all of these deformities are associated with a nonunion, the Ilizarov method permits gradual correction of all deformities, either simultaneously or in succession. In many cases, gradual *distraction* of a hypertrophic fibrous nonunion will stimulate osteogenesis in a manner similar to the new bone formation within a widening distraction gap. Before distraction, however, the nonunion site must be compressed 7 to 14 days, a procedure that Ilizarov claims stimulates the bone-growth process.

The treatment strategies described in this section focus on nonunions with viable bone ends that are not accompanied by sepsis.

## ATROPHIC NONUNIONS

Ilizarov has an interesting approach to atrophic and oligotrophic nonunions. He performs a corticotomy of the involved bone at a site where the surrounding soft tissues are healthy, then gradually transports the intercalary segment through the limb. This strategy is followed even when there is no segmental defect or shortening. For this reason, the regenerate new bone at the corticotomy site is often no more than 1 or 2 mm long. Nevertheless, Ilizarov claims good results with this tactic, based on two principles: first, the corticotomy increases the limb's local vascularity (a stimulus to healing); and second, the corticotomy serves to decrease the lever arm at the nonunion site by creating a temporary floating segment (between the corticotomy and the nonunion). This floating segment will more readily unite at the nonunion site under the influence of compression. We prefer to bone graft atrophic non-unions and use the circular fixator to eliminate shear forces at the nonunion site by using

counterpulling olive wires above and below a nonunion with an obliquity of greater than 30°.

## ANGULATED NONUNIONS

### ASSESSMENT

Before treating an angulated nonunion, determine the true plane of the deformity as well as the displacement of the deformity's apex from the original mechanical axis of the bone. Likewise, determine the true angle and plane of the deformity, the amount of rotational malalignment, and the direction and magnitude of any displacement of the fragments by applying the principles described by Paley and Tetsworth in the earlier section, Deformity Correction by the Ilizarov Technique. An appropriate configuration must be designed to correct the deformities and in the end achieve interfragmentary compression across the nonunion. Likewise, determine if the shortening is a result of angulation or the consequence of a true loss of limb length.

To determine if correction of an angular deformity alone will restore limb length, use one of the following two methods.

In the first method, make a tracing of the radiograph of the bone in the projection that demonstrates the maximum angulation. Cut out the tracing, transect it through the apex of the deformity, and straighten it out. Measure the length of the corrected cutout and compare it to a comparable roentgenogram of the contralateral limb.

In the second method, obtain roentgenograms of both limbs in the same projection, using the view that maximizes the angular deformity on the injured side. Draw a line on the convex side of the deformity from a fixed landmark on the bone's proximal end (such as the corner of the joint line) to the apex of the deformity. Draw a second line from the apex of the deformity along the deformity's convex edge to a landmark on the opposite edge of the bone (such as the tip of the medial malleolus). Add the lengths of these two lines together, and compare the sum to the length of a line from the same landmark on the uninvolved limb. If there is no true shortening of the bone, then the length of the convex side of the deformed bone should equal the length on the corresponding side of the normal bone. If it does not, lengthening will be needed.

### CORRECTION

In principle, the apparatus is applied with each ring perpendicular to the bone segment attached to it. In this way, the fixator configuration mimics the deformity. In actual practice, a mounting should exaggerate the deformity, with the rings tilted slightly into the deformity's concavity. During correction, resistant soft tissues deform the wires, causing the bone fragments to lag behind the rings during movement of the frame; the wires or pins of the configuration will bend as the rings displace faster than the bone fragments.

During application of the external fixator (according to the principles outlined in Section C), place a pair of hinges at the level of the apex of the angular deformity. Arrange this pair of hinges so that their central bolts form an imaginary line perpendicular to the plane of the deformity. The distance of this imaginary line from the apex of the bone's deformity depends on how much lengthening must accompany the angular correction. If, for example, eliminating the angulation results in normal limb length, then the imaginary rotation axis of the hinges should correspond exactly to the apex of the deformity (Fig. 32.121). In this manner, the regenerate bone resulting from the deformity correction will fill an “opening wedge” triangular gap. If, on the other hand, substantial lengthening is needed, moving the configuration's axis of rotation away from the deformity's apex along a line that bisects the deformity results in a trapezoid-shaped gap between the bone ends when the deformity is fully corrected (Fig. 32.122).

***Figure 32.121.*** Correction of angulation. **A:** Scheme of correction. The *black dot* is the axis of rotation of the configuration. **B:** Severe varus deformity with hypertrophic nonunion. **C:** Configuration for correction. **D:** New bone formation during distraction and correction.

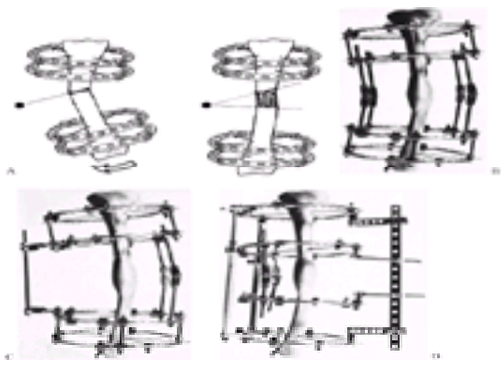

***Figure 32.122.*** Correction of angulation with simultaneous lengthening. **A:** Scheme of correction. The *black dot* is the axis of rotation for the configuration. **B:** Standard method of correcting a deformity by lengthening the hinges on the concave side of the deformity. **C:** Less stable configuration with a distractor attached with two twisted plates. **D:** Configuration for stiff nonunion using a pusher mechanism.

If any displacement accompanies an angular deformity—a common combination—the axis of rotation for the configuration's hinges are not on the bisector line of the deformity's angle, but at a point corresponding to the intersection of the mechanical axes of the bone fragments (Fig. 32.123). If lengthening is required along with correction of angulation and displacement, move this rotation point a distance away from the bone that is proportional to the lengthening needed.

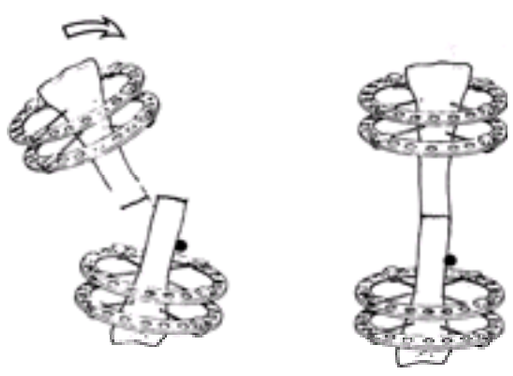

***Figure 32.123.*** Scheme of correcting angulation and displacement. The *black dot* is the axis of rotation for the configuration.

## OBLIQUE NONUNIONS

### ASSESSMENT

The plane of a nonunion is often oblique to the bone's mechanical axis. Moreover, the two main fracture fragments are often not along the same weight-bearing line, neven when the overall alignment of the limb is satisfactory (Fig. 32.124). In this situation, longitudinal compression with an external fixator (or by weight bearing) is likely to retard, not enhance, bone healing. The fixator will either hold the bone fragments apart if the frame is rigid (Fig. 32.125) or permit excessive shear at the nonunion site if the frame is dynamic, especially if the obliquity of the nonunion exceeds 30°.



***Figure 32.124.*** Scheme of oblique nonunion with displacement and shortening.

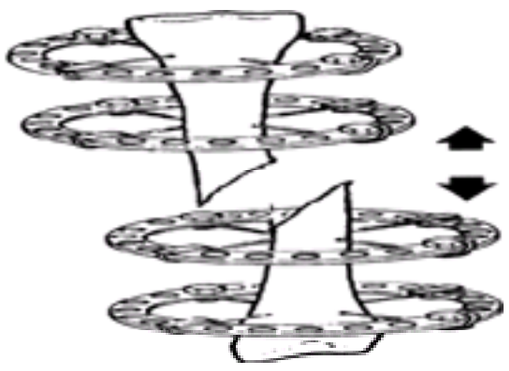

***Figure 32.125.*** Lengthening an oblique nonunion may increase the distraction gap.

### CORRECTION

To promote union in oblique hypertrophic nonunions, realign the fracture fragments, making their mechanical axes colinear, and obtain interfragmentary (usually side-to-side) compression of the nonunion. This combination of interfragmentary compression, axial realignment, and stability is well known to surgeons who use plates and screws to treat nonunions. When an external skeletal fixator is used, the reduction must be as good as that achieved with a plate and screws.

Since hypertrophic nonunions are stiff, reduction and realignment of the fracture fragments must occur gradually, using the apparatus to achieve reduction. Often, a push configuration using long plates in the mounting is needed to apply sufficient force on the deformity's apex.

Occasionally, the limb's alignment can be manually corrected while the patient is anesthetized, a maneuver that simplifies the frame considerably. When performing the manual correction, do not create a triangular gap on the deformity's concave side, as that will never be able to contribute to osseous healing.

Use axial interfragmentary compression when the limb length equals that of the contralateral side, and when the nonunion is transverse: simple axial compression will promote healing. With increasing obliquity of the nonunion site, modify the configuration to neutralize shear forces. Obtain interfragmentary compression by inserting counterpulling olive wires that traverse the limb from opposite directions (Fig. 32.126). Insert these wires either through the site of the nonunion itself or at some distance above and below it. Ilizarov recommends placing the wires through an oblique nonunion if there has been no history of sepsis. Clearly, such wires not only ensure interfragmentary compression but also help stabilize the nonunion that they cross.

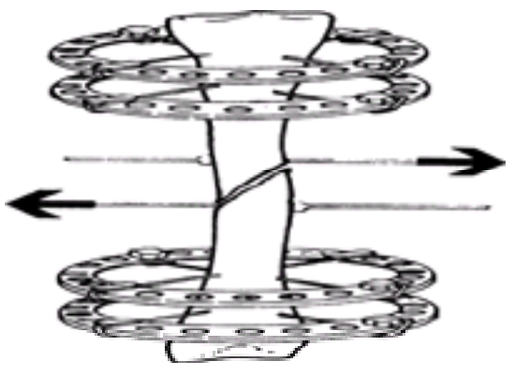

***Figure 32.126.*** Lengthening must be combined with interfragmentary compression, shown here with counterpulling olive wires.

Anatomic considerations generally limit the use of side-to-side olive wire interfragmentary compression to fracture lines in the sagittal plane, since the wires enter and exit the limb on its medial and lateral sides. When a nonunion is in the coronal plane, however, interfragmentary compression with olive wires would require the wires to enter or exit the limb in the anteroposterior direction. In most anatomic locations, such wires can be dangerous. For this reason, achieve interfragmentary compression of oblique coronal plane nonunions by inserting wires mediolaterally into each fragment and attaching the wires to rings or half-rings (Fig. 32.127). Connect these rings to the rest of the configuration in a manner that permits front-to-back interfragmentary compression at the nonunion site. If necessary, incorporate one or two long plates in the configuration to serve as a base for pushing and pulling the rings.

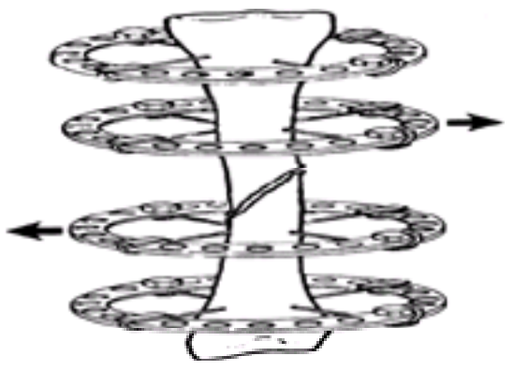

***Figure 32.127.*** Interfragmentary compression with counterpulling rings.

## OBLIQUE NONUNIONS WITH SHORTENING

### ASSESSMENT

Oblique nonunions associated with limb shortening usually result from either comminution at the fracture site, angulation, or displacement of the mechanical axes of the major fragments (Fig. 32.128). In the latter two cases, once the fragments are made coaxial, the shortening is eliminated.

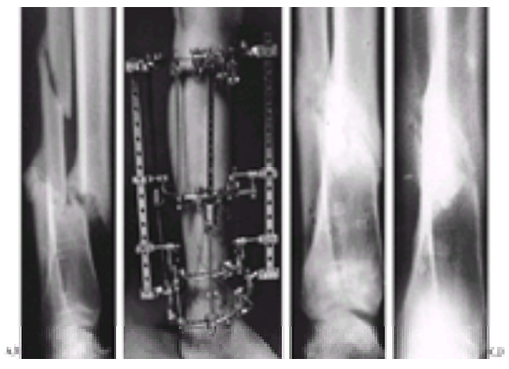

***Figure 32.128.*** Reduction of a displaced shortened nonunion. **A:** Eight months after injury. Tibial nonunion with full shaft width displacement and 1 in. of shortening. **B:** Frame for reduction of displacement and simultaneous lengthening. **C:** Appearance at the time of fixator removal. **D:** Appearance at 1-year follow-up.

When there has been a substantial comminution at the fracture site, there may actually be several nonunions responsible for the problem. Often, such injuries have been maintained in rigid external or internal fixation that inhibits osseous healing. When the fixator is removed, the fracture tends to gradually collapse as the scar tissue at the site of injury stretches. In some cases, one or more fracture lines may eventually unite, leaving only one site of retarded bone healing.

### CORRECTION

Distracting a hypertrophic nonunion after first compressing it stimulates osteogenesis. Anecdotal clinical experience of orthopaedic surgeons in Western countries suggests that bone formation with this technique is somewhat unpredictable. A more reliable strategy is to compress the nonunion (either longitudinally or side-to-side, depending on the obliquity of the fracture line) and lengthen the bone elsewhere—through healthy tissue—to overcome any residual limb shortening.

## TRANSLATIONAL MALALIGNMENT

### ASSESSMENT

As mentioned earlier, both angular deformities and oblique fracture lines are often associated with translation of the mechanical axis of the distal fragment with respect to that of the proximal fragment. Not only does such a malalignment retard osseous healing, but even if the bone did eventually heal in a malaligned position, the weight-bearing line would fail to pass through the centers of nearby joints, leading to either chronic joint pain, degenerative osteoarthritis, or both.

Determine the amount of translational displacement by drawing a line through the mechanical axis of each major fragment and measuring the distance between the lines after correction of angulation at the nonunion site. Be sure that the roentgenographic projection used for the measurement shows the displacement at its greatest.

### CORRECTION

When translational deformities coexist with angulation, the combined deformity can be eliminated by locating the center of rotation of the hinge axis at the proper place with respect to the fragments, as described in the previous section. When displacement exists without angulation, mutual translation of the fragments is accomplished by incorporating a translation assembly into the configuration. The mechanism for a translation assembly is simple yet elegant: Fix three pairs of horizontal rails to the respective rings with posts (Fig. 32.129). The entire configuration must be sturdy enough to prevent axial displacement during horizontal translation.



***Figure 32.129.*** Translation assembly using horizontal rails. **A:** Before translation. **B:** After translation.

## ROTATIONAL MALALIGNMENT

### ASSESSMENT

Malrotation often accompanies the angulation, displacement, and shortening affecting both nonunions and malunions. With the Ilizarov method, rotational malalignments are usually corrected last, after angulation, displacement, and shortening (Fig. 32.130). The reason for this is that the major bone fragments must be

aligned along the same axis to correct malrotation. Moreover, this axis must be in the center of the configuration. In this way, the bone fragments will rotate around a line passing through the center of the fixator's rings and the marrow canals, rather than through an axis that does not pass through either. Were the fragments to rotate around an eccentric axis, one fragment would displace transversely with respect to the other during rotation.

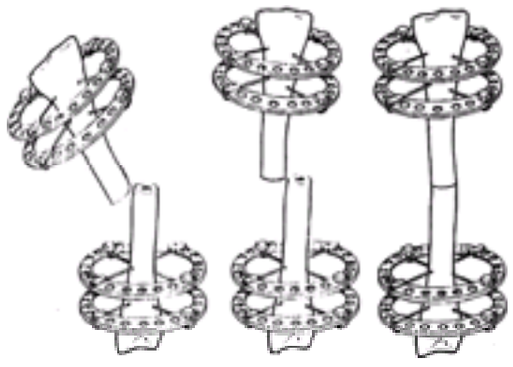

***Figure 32.130.*** Sequence of correction of rotational malalignment. Angulation is corrected first, and then displacement is addressed.

One of the advantages of using a circular external fixation system is the ability to rotate one ring with respect to another. When unilateral half-pin fixators are used to treat nonunions and malunions, this capacity for gradual rotational correction does not exist, no matter how adaptable the fixator may be.

**CORRECTION**

There are at least three different rotation assemblies. The most stable one uses sliding buckles as the interconnection between the rotating ring and the rest of the frame. The “motor” that provides the power to turn one ring with respect to another is made from a horizontal threaded rod spanning the space between the buckle and a post connected to the movable ring (Fig. 32.131).

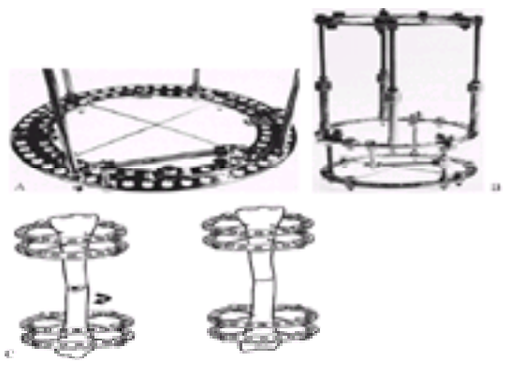

***Figure 32.131.*** Rotation assemblies. **A:** Nested rings, with the inner ring securing the wires. **B:** Buckles-and-bushings rotation assembly. **C:** The bone fragments must be coaxial—and in the center of the configuration—for counterrotation.

Another rotation mechanism is made from three horizontal threaded rods located between the two rings that must move with respect to each other. One end of each rod is connected via posts to the upper ring; the other attaches to posts on the lower ring. Decreasing the distance between the posts on each rod rotates one ring with respect to the other.

A third mechanism for counterrotation of the rings is constructed by placing one ring within another (Fig. 32.131). A pair of clamps made out of two short plates holds the pair of rings together. In clinical use, the wires are connected to the inner ring and the fixator to the outer one. A single horizontally oriented threaded rod attached with posts to each ring will motor the revolution of the inner ring with respect to the outer one.

One final point: With some limb segments—the lower leg and the forearm—the bones are eccentrically placed within the soft tissues. The tibia, for instance, is anterior and medial in the shank's cross section. Placing a fixator around the lower leg would result in a mounting that rotates around an axis in the soft tissues, rather than the correct location through the center of the bone. Turning one ring with respect to another in this situation would cause more displacement than rotation. For tibial mountings, therefore, a ring for a rotation assembly must be quite large with the bone—not the leg—centered within the frame (Fig. 32.132).

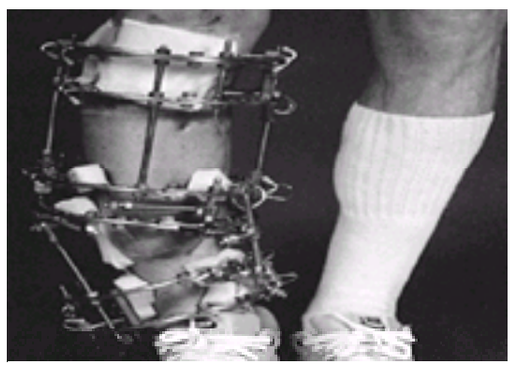

***Figure 32.132.*** Frame for correction of shortening, malrotation, angulation, and displacement.

## SEGMENTAL DEFECTS

### ASSESSMENT

Segmental defects may be caused by bone loss at the time of trauma, removal of nonviable fragments at initial debridement, or resection of necrotic bone during the care of an infected fracture. When a segmental defect is present, any angulation, rotation, translation, or combination of displacements can easily be corrected through the soft tissues at the level of the defect. For this reason, circular frame configurations designed to deal with segmental defects are usually rather simple: The configuration is tubular, with the connecting rods of the frame parallel to each other and to the bone's mechanical axis.

### CORRECTION

To eliminate the defect, make a corticotomy through healthy bone some distance from the defect; then pull the intercalary segment between the defect and the corticotomy through the tissues until the defect is closed (1,4,8,12,13,15). At the corticotomy site, new bone forms during distraction (Fig. 32.133).

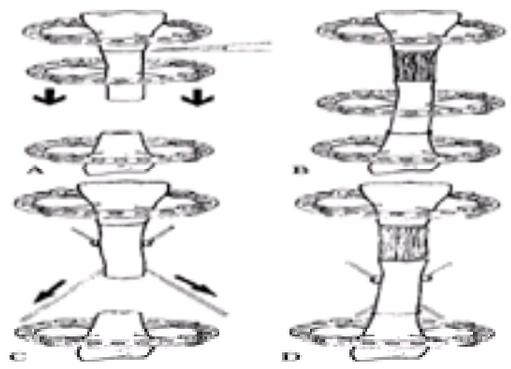

***Figure 32.133.*** Bone transport diagrams. **A,B**: Transport with a transport ring. **C,D:** Transport with oblique directional wires.

If the defect is smaller than 2.5 cm, it can be compressed acutely after appropriate debridement, and the bone can be lengthened through a corticotomy elsewhere.

It is unwise to acutely close a skeletal defect that is more than 2.5 cm, since the redundant soft tissues surrounding the defect tend to bulge when the fragments are brought together, creating an unsightly appearance to the leg and kinking both lymphatic and venous drainage. As this redundant skin is trapped between the wires, it cannot contribute to lengthening of the limb through another section of the bone. Therefore, the patient is left with a peculiar-looking limb with bulky redundant tissues at one level and tight, stretched skin at another. With this problem in mind, when dealing with a segmental defect of more than 2.5 cm, leave the soft tissues at length and eliminate the defect by gradual transport of the intermediate segment.

A segment of bone can be pulled through a limb with a transport ring and cross-wires, or with oblique directional wires. A transport ring and an attached pair of cross-wires is the most stable way to pull a bone fragment through tissue (Fig. 32.134). Unfortunately, the wires must cut through the skin and soft tissues as the ring and its attached bone segment move through the limb. At the end of bone transport, however, the crossed wires serve to enhance compression at the point of contact between the intermediate fragment and the target fragment.

***Figure 32.134.*** Bone transport frames. **A:** Transport with a transport ring. **B:** Transport with oblique directional wires.

When oblique directional wires are used to move a bone segment through a limb, there is far less cutting of tissues, since the wires start out nearly parallel to the limb's axis (Fig. 32.134). Unfortunately, such oblique wires often do not provide enough pressure at the end of bone transport to ensure stable interfragmentary compression between the intermediate fragment and the target fragment. For this reason, a pair of cross-wires connected to a ring must be attached to the intermediate fragment at the end of bone transport to enhance compression at the point of contact. In such a case, a second operation is required.

No matter how the intermediate fragment is pulled through the limb, it is obvious that the proximal fragment, the intermediate fragment, and the distal fragment must all be in line with each other lest the intercalary fragment miss its target. Although such a requirement seems simple, in actual practice the bone fragments tend to sag posteriorly on the operating table while a frame is being applied. Be sure to check the final alignment of the bone fragments on long x-ray films before the patient leaves the operating table.

Although frames can be modified on an out-patient basis afterwards, this is not preferred. A fragment of bone can be moved within its ring by detaching the transfixion wires from their fixation bolts and moving the wires over one or two holes on the ring.

The final general consideration in planning treatment for a skeletal defect deals with the shape of the bone ends at the docking site (Fig. 32.135). Unfortunately, it is difficult to match bone ends on opposite sides of a skeletal defect so that they fit well together when a defect is closed. The most predictable healing occurs when one fragment impales the marrow cavity of the other (Fig. 32.136). Of course, the surgeon must trim a point on the transported segment for such impalement to be possible. Regardless of the shape of the bone ends, we do not hesitate to insert a bone graft around the contact point between the transported and the target fragments whenever we suspect that healing will be delayed.

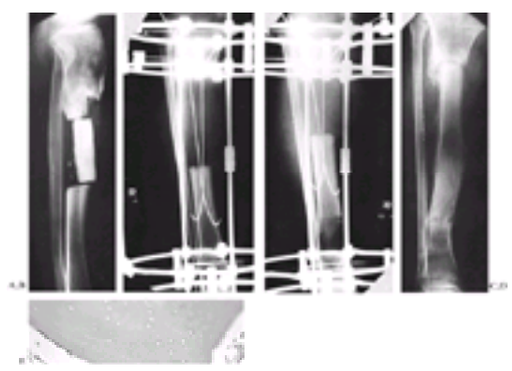

***Figure 32.135.*** Bone transport case requiring a small bone graft at the docking site. **A:** Initial condition. A block of methylmethacrylate is used as a spacer in the mid tibia. Multiple sinus tracts are present, draining pus. **B:** After removal of spacer and resection of nonviable bone. **C:** During bone transport with directional wires. **D:** A nonunion is noted at the docking site at the time of fixator removal. **E:** Biopsy demonstrating nonviable bone at the end of the intercalary fragment.

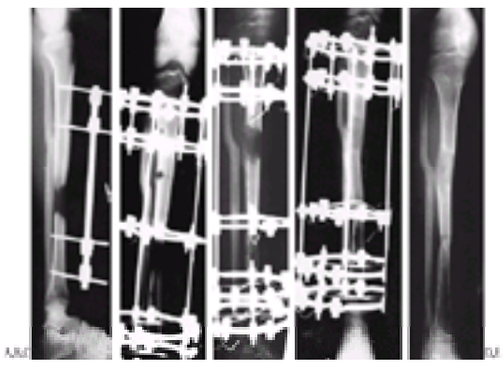

***Figure 32.136.*** Bone transport case with impalement of intercalary segment into target segment. The patient also has a cavity osteomyelitis caused by a pin. **A:** Initial condition, showing osteolysis around lower pin in proximal fragment. **B:** Radiograph at time of fixator application and corticotomy through the pin site. **C:** Radiograph at 6 weeks of distraction. **D:** Radiograph at end of distraction. **E:** Final appearance. No bone graft was needed.

## SEGMENTAL DEFECT WITH SHORTENING

### ASSESSMENT

Some segmental defects are accompanied by limb shortening. In many cases, simply stretching the defect will restore limb length. When a limb segment contains but a single bone, such as the humerus or the femur, shortening is eliminated either at the time the fixator is applied (by stretching the soft tissues of the defect to full length) or by lengthening through the corticotomy site after the intermediate fragment has completed its journey.

### CORRECTION

When there are two parallel bones in a shortened limb with a segmental defect, elongation after bone transport can occur only if there is a nonunion or osteotomy through the other bone in the limb segment. With an intact parallel bone, perform osteotomy of the intact bone at the same time as the corticotomy of the bone with the defect. Thereafter, both the corticotomy site of the bone with the defect and the osteotomy site of the intact bone are lengthened simultaneously (Fig. 32.137). When the limb is at full length, continue transport of the bone with the defect until the defect is eliminated.

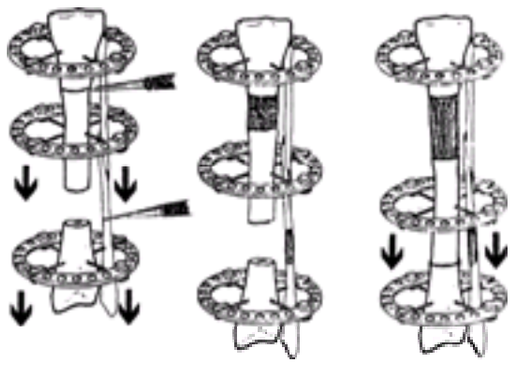

***Figure 32.137.*** Bone transport with shortening. The fibular and tibial corticotomies are made at the same time, and the limb is lengthened before bone transport.

## MALUNIONS

### ASSESSMENT

A Malunion is a fracture that is united in a suboptimal position. Dealing with a malunited fracture is in some ways simpler than managing a nonunion, yet in other ways it is more challenging. For instance, with a nonunion, it is usually possible to correct the deformity through the nonunion site. In correcting malunions, another option is to osteotomize the bone at a site away from the fracture deformity. In this manner, both dense corticalized fracture callus and damaged soft tissues at the fracture site are avoided. On the other hand, correcting a malaligned limb through a location that does not correspond to the apex of the true deformity may leave the patient with an ugly hump on the limb after the bone's axis is restored. For this reason, choose the osteotomy site carefully, with due consideration for the quality of bone available, the need for lengthening, and cosmesis (14).

Some malunions of segmental fractures are deformed at two levels. In these cases, corrective osteotomies must often be performed near both malunions. Most posttraumatic malunions result in limb shortening. Sometimes the shortening is a relatively straightforward matter: Simply unfolding an angulated malunion through its apex will restore length. In such patients, the loss of length is caused by the angulation. In other cases, realignment of the fragments fails to overcome loss of length.

Most malunions combine elements of not only angulation and shortening, but also translation (displacement) of the mechanical axes of the fragments, and rotation as well. Sometimes these deformities are not as apparent as angulation and shortening, but, unless the surgeon is aware of associated malalignments, the correction will be less than ideal.

To determine if true osseous shortening accompanies angulation, follow the recommendations in the above section on angulated nonunions.

When there has been loss of bone substance, overlap, translation, or some other combination of factors resulting in both angulation and true shortening of the bone, correcting the angulation and realigning the bone's mechanical axis will not result in restoration of limb length without using a distractional hinge or a translation hinge, or lengthening after deformity correction.

Certain common fracture patterns tend to produce consistent malunion deformities. For example, a distal tibial fracture with associated fracture of the fibula that has healed in a shortened position and angulated into valgus usually demonstrates external rotation of the distal tibial fragment and foot and lateral displacement of the distal fragment's mechanical axis compared to that of a proximal fragment. Malunions with varus of the tibia frequently are rotated inward and displaced medially.

The apex of any malunion deformity is located at the intersection of the mechanical axes of the principal fragments. In angulated malunions without concomitant displacement, the intersection point is at the level of the old fracture line. When displacement accompanies angulation, the intersection of the axes of the fragments is not at the fracture line, but at some point above or below the level of injury. Placing a corrective osteotomy at the level of the apex of the deformity corrects angulation of the fragments but does not improve translation of their mechanical axes. To correct such displacement, the cortical osteotomy must be level proximal or distal to the hinge axis at the apex of the deformity. When the level of the corticotomy and hinge axis of the configuration are not at the same level, correcting angulation automatically results in translation of the bone fragments. The geometry of correction in this manner was described earlier in this chapter by Paley and Tetsworth.

Angulation and axial displacement also can be corrected in separate steps, using a fixator configuration that incorporates assemblies for both angular correction and translation. Such frames are fairly complicated, since the translation mechanism involves multiple horizontal threaded rods connected to adjacent rings on both sides of the apparatus.

Rotational malalignments—usually seen combined with other deformities—must be corrected with an assembly that permits the corresponding rings to rotate with respect to each other. As a general principle, begin counterrotation of fragments after correction of angulation and restoration of limb length. In many situations, correction of displacement can accompany rotation, especially if the mechanical axes of the major bone fragments are not located within the center of their

corresponding rings.

### CORRECTION

After you fully understand the nature and complexity of the various deformities that require correction, make cutouts of the bone segments and perform the surgery with paper and tape before the actual operation.

To plan the correction, start with full-length standing roentgenograms of lower-extremity problems and corresponding films for upper-limb malunions. Also obtain roentgenograms of both the involved and normal bones in multiple projections, one of which shows the maximum deformity in profile, the view perpendicular to the true plane of the deformity. If there are two or more deformities in the bone that are oriented in different planes, then obtain separate roentgenographic projections of each deformity in its maximum profile. With long tracing paper, make cutouts of the abnormal bone and perform the osteotomies at appropriate levels to correct the deformity. In complex cases, make the tracings on large clear acetate sheets, using separate pieces for the proximal and distal fragments. In this way, the traced fragments can be rotated with respect to each other, using a thumbtack as the hinge axis. Moving the thumbtack around in different locations outside the contours of the fragments will often reveal the correct location of the point of rotation for correction of both angulation and displacement.

Once the fixator is in place, correction of malunions follows the principles of general deformity correction with the Ilizarov method.

## POSTTRAUMATIC SHORTENING

### ASSESSMENT

A leg-length discrepancy alters gait, interferes with spinal mechanics, may require ungainly shoe lifts, and often embarrasses the patient. Before the introduction of the Ilizarov methods, a posttraumatic leg-length discrepancy in an adult was usually managed with either a shoe lift, shortening the contralateral limb, or in rare instances lengthening with an open osteotomy and multiple surgeries. The discovery of bone's capacity to regenerate in a widening distraction gap has revolutionized the care of posttraumatic limb-length inequality (14).

Restoring length to a limb shortened by trauma presents fewer problems than elongating a congenitally short limb, for the following reasons. First, before injury, the neurovascular structures were at full length; with elongation, these structures are restored to their original status. Second, posttraumatic shortening usually involves a loss of length of 3–7 cm, whereas congenitally short limbs often demonstrate far greater inequality. Third, the skin and soft tissues are often redundant after posttraumatic shortening and therefore easy to lengthen.

In some situations, however, lengthening for posttraumatic shortening may present significant problems, especially if there is extensive scar tissue, preexisting microvascular repair, transposition flap surgery, or injury to neurovascular structures, muscles, or tendons. Also, damaged joints, internal fixation devices, disuse osteoporosis, articular contractures, head trauma, and other problems may complicate restoration of limb length for posttraumatic shortening.

### CORRECTION

In principle, lengthening of a traumatically injured limb follows the same methods used for limb elongation associated with other kinds of pathology. Apply a stable external skeletal fixator and perform a corticotomy through healthy bone surrounded by normal soft tissues (2,3,5). After a delay of 5–7 days, lengthen the limb using Ilizarov's guidelines. If the soft tissues around the corticotomy level are suboptimal, prolong the latency up to 14 days.

Distract the limb at a rate of 1 mm per day in four divided doses. Manage any delay of new bone formation in the distraction gap by slowing the rate of distraction to 0.5–0.75 mm per day (a distraction frequency of 0.25 mm every 8–12 hr). Concomitant deformities must be corrected during lengthening following the principles described in preceding sections.

Intensive physiotherapy must accompany any limb-lengthening program. Treat any joint that develops a contracture vigorously. Progression of a flexion contracture of the knee, for example, can lead first to posterior subluxation of the tibia on the femur, and then to frank dislocation of the knee joint. Likewise, lengthening a femur with either a valgus hip deformity or a shallow acetabular roof can lead to subluxation or dislocation of the hip.

A decline in the patient's ambulatory capacity during elongation (or deformity correction, or any other application of an external fixator) must be investigated and corrected. Often, pin or wire site sepsis is the problem. Muscle impalement or pain caused by irritation of tendons or synovium also interferes with gait. Contractures limit ambulation. Decreased weight-bearing leads to osteoporosis, a cause of pin or wire loosening. The loosened implants lead to fixator instability, which causes further pain and infections. This vicious cycle must be stopped as soon as it appears. Check for fixator stability and range of joint motion at each visit. Ask the patient about pain and any reasons for a decline in the ability to walk. If necessary, admit the patient to the hospital for intensive physiotherapy (primarily muscle stretching). Stop the lengthening for a week if necessary. Change any infected pins or wires if sepsis cannot be controlled with antibiotics.

If none of these measures work, do not continue lengthening. Instead, stop or even back up a bit and allow the bone to mature. Six or 8 months later, when joint function has been restored to normal and the patient is fully ambulatory, repeat the lengthening.

### CHAPTER REFERENCES

Each reference is categorized according to the following scheme: *, classic article; #, review article; !, basic research article; and +, clinical results/outcome study.


+ 1. Cattaneo R, Villa A, Catagni M, et al. Application de la Methode d'Ilizarov dans l'Allongement de l'Humerus. *Rev Chir Orthop* 1986;72:303.

+ 2. Green SA. *Complications of External Skeletal Fixation.* Springfield, IL: Charles C. Thomas, 1981.

+ 3. Green SA. Complications of External Fixation. *Clin Orthop* 1983;180:109.

+ 4. Green SA. Ilizarov External Fixation, Technical and Anatomic Considerations. *Bull Hosp Jt Dis Orthop Inst* 1988;48:28.

# 5. Green SA. Complications of External Fixation. *Instr Course Lect* 1989;33:138.

# 6. Green SA. Ilizarov Method of Treating Nonunions and Posttraumatic Osteomyelitis. In Browner B, ed. *Skeletal Trauma.* Philadelphia: WB Saunders, 1991:543.

* 7. Ilizarov GA. A Method of Uniting Bones in Fractures and an Apparatus to Implement this Method. *USSR Authorship Certificate 98471,* filed 1952.

* 8. Ilizarov GA. Basic Principles of Transosseous Compression and Distraction Osteosynthesis. *Ortop Travmatol Protez* 1971;32:7.

+ 9. Ilizarov GA. The Tension-Stress Effect on the Genesis and Growth of Tissues: Part I. The Influence of Stability of Fixation and Soft-Tissue Preservation. *Clin Orthop* 1989;238:249.

+ 10. Ilizarov GA. The Tension-Stress Effect on the Genesis and Growth of Tissues: Part II. The Influence of the Rate and Frequency of Distraction. *Clin Orthop* 1989;239:263.

+ 11. Ilizarov GA. Angular Deformities with Shortening. In: Coombs R, Green S, Sarmiento A, eds. External Fixation and Functional Bracing. Frederick, MD: Aspen, 1989.

+ 12. Ilizarov GA. Fractures and Nonunions. In: Coombs R, Green S, Sarmiento A, eds. External Fixation and Functional Bracing. Frederick, MD: Aspen, 1989.

+ 13. Morandi M, Zembo M, Ciotti M. Infected Tibial Pseudarthroses: A 2-Year Follow-Up in Patients Treated by the Ilizarov Technique. *Orthopedics* 1989;12:497.

# 14. Paley D. Current Techniques of Limb Lengthening. *J Pediatr Orthop* 1988;8:73.

+ 15. Paley D, Catagni M, Argnani F, et al. Ilizarov Treatment of Tibial Nonunions with Bone Loss. *Clin Orthop* 1989;241:146.

# CHAPTER 33

# MANAGEMENT OF VASCULAR DISORDERS IN THE UPPER EXTREMITY

*Peter J. Evans, David S. Ruch, Beth Paterson Smith, and L. Andrew Koman*

**P. J. Evans:** Department of Orthopaedic Surgery, Johns Hopkins University School of Medicine, Johns Hopkins Bayview Medical Center, Baltimore, Maryland 21224.
**D. S. Ruch, B. P. Smith, and L. A. Koman:** Department of Orthopaedic Surgery, Division of Surgical Sciences, Wake Forest University School of Medicine, Winston-Salem, North Carolina, 27157.

Acute Arterial Injuries
- Traumatic Arterial Injuries
- Arterial Injuries Due to Cannulation
- Arterial Injection Injury

Chronic Arterial Injuries
- Physiology of Chronic Arterial Injury and Subsequent Symptoms
- Posttraumatic Ulnar and Radial Artery Thrombosis
- Embolism
- Aneurysm
- Acquired Arteriovenous Fistula
- Arteritis

Vasospastic Disease
- Pathophysiology
- Classification
- Diagnosis
- Indications for Treatment
- Principles of Treatment
- Preoperative Management
- Operative Techniques
- Authors' Perspective

Chapter References

Vascular insufficiency is the result of altered blood flow significant enough to compromise cellular perfusion and function, and ultimately to cause cellular injury or death. Clinical symptoms of abnormal perfusion include pain, cold intolerance, numbness, ulceration, and gangrene. Symptomatic vascular disorders of the upper extremity interfere with health-related quality of life and diminish function. More than 10% of the general population and 20% to 30% of postmenopausal women suffer from abnormal microvascular flow secondary to trauma, congenital deformity, systemic processes, or genetic influences. This chapter presents an approach to the diagnosis and management of vascular disorders.

## ACUTE ARTERIAL INJURIES

### TRAUMATIC ARTERIAL INJURIES

Penetrating injuries account for more than 80% of acute vascular injuries to the upper extremity (7). Acute arterial trauma may accompany high-energy fractures or dislocations, and these injuries require careful evaluation (51). The management of arterial injuries has improved dramatically since the late 1940s. During World War II, only 3 of 2471 known reported cases of acute arterial repairs by end-to-end anastomosis were successful (15).

Today, trained surgeons skilled in the use of the operating microscope, microvascular instruments, and microsuture can achieve excellent vascular patency and replantation of complete upper extremity amputations. Thrombosis following the repair of noncritical arterial injuries, however, is common, even with the sophisticated microvascular techniques performed by experienced vascular surgeons. Successful management of acute vascular disorders requires (a) an understanding of the physiology of symptoms associated with vascular trauma; (b) a thorough knowledge of the pertinent vascular anatomy (Fig. 33.1) (2,12); (c) an assessment of associated injury to soft tissue, bone, and nerve; and (d) an appreciation of the natural history of the treated and untreated injury.

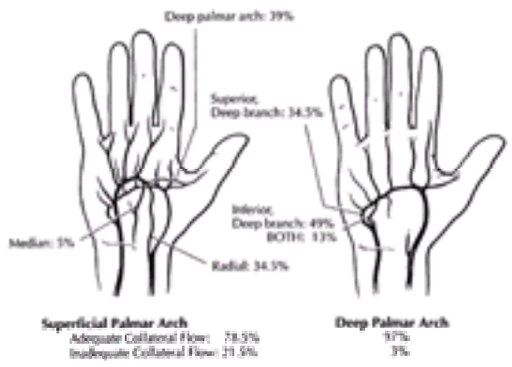


***Figure 33.1.*** The superficial palmar arch is completed by branches from the deep palmar arch, radial artery, or median artery in 78.5% of patients; the remaining 21.5% are incomplete. The deep palmar arch is completed by the superior branch of the ulnar artery, the inferior branch of the ulnar artery, or both in 98.5% of patients. (Modified from Koman LA, Urbaniak JR. Ulnar Artery Thrombosis. In: Brunelli, ed. *Textbook of Surgery.* Milano: Masson 1988:75; with permission.)

#### *Classification*

The three common patterns of arterial injuries are complete transection (Type 1), partial transection (Type 2), and nontransection (Type 3). These injuries can be further defined as either *critical*, wherein the absence of arterial reconstruction will produce tissue necrosis requiring amputation, or *noncritical*, wherein tissue survival is independent of arterial reconstruction (Table 33.1 and Table 33.2). Chronic arterial injury and vasospastic problems may also be classified (Table 33.3 and Table 33.4).

| | | |
|---|---|---|
| Type I | Complete arterial transection | A. Critical<br>B. Noncritical |
| Type II | Partial arterial laceration | A. Critical<br>B. Noncritical |
| Type III | Arterial thrombosis with intact vessel ± embolic events | A. Critical<br>B. Noncritical |
| Type IV | Venous injury | |

* Critical injury results in cell death without repair.

***Table 33.1. Acute Vascular Injuries: Wake Forest University Classification***

Objective evidence of inadequate collateral flow:
- Poor backbleeding
- Low backpressure

Transection distal to major collateral inflow

Previous injury to collateral vessel

Associated major nerve injury

Repair performance without compromise of extremity

***Table 33.2. Noncritical Arterial Injury: Relative Indications for Reconstruction***

| *Group* | *Characteristics* |
|---|---|
| I | Good collateral circulation<br>Near-normal sympathetic tone |
| II | Good collateral circulation<br>Abnormal sympathetic tone |
| III | Poor collateral circulation |

***Table 33.3. Classification of Chronic Arterial Injuries for Treatment***

| *Group* | *Pathophysiology* | *Etiology* |
|---|---|---|
| Group I | Raynaud's disease | Idiopathic |
| Group II<br>A<br>B | Raynaud's phenomenon<br>Adequate circulation<br>Inadequate circulation | Collagen vascular disease |
| Group III<br>A<br>B | Secondary vasospasm<br>Adequate circulation<br>Inadequate circulation | Vascular injury<br>Occlusion/embolus |
| Group IV | Secondary vasospasm | Nonvascular injury<br>Nerve/bone/soft-tissue damage |

***Table 33.4. Chronic Arterial Dysfunction: Wake Forest Classification of Occlusive, Vasospastic, and Vasoocclusive Disease***

### *Physiology of Arterial Injuries and Subsequent Symptoms*

Complete vessel division (Type 1) by trauma causes immediate retraction of the transected arterial ends away from the site of injury. Vasoconstriction, intraluminal thrombosis, and compression from surrounding soft-tissue hemorrhage result in a cessation of arterial bleeding, depending in part on the diameter of the vessel. The thrombosis usually propagates proximally and distally to a patent branch not more than several centimeters from the zone of injury. The amount of retraction and zone of injury determine whether end-to-end repair or interposition grafting is required to restore perfusion. Occasionally, arteries that are lacerated and transected completely by sharp bone fragments may be tethered by the fragments; retraction is prevented, and the result is uncontrolled hemorrhage.

Partial arterial injuries (Type 2) are most often secondary to lacerations from sharp glass or knives or bone fragments. Iatrogenic injuries may follow diagnostic arterial cannulation for hemodynamic monitoring, arterial blood sampling, or angiography, or they may result from inadvertent puncture with drill bits or screws (see later). The injured portions of the vessel wall retract and constrict, but because of the segment of vessel that remains intact, this retraction serves to enlarge the defect and increase the bleeding. Distal ischemia may not occur because of persistent flow or collateral circulation, but hemorrhage is typically much greater than with complete transection and may not stop with directly applied pressure (42). Although the normal coagulation mechanism may control bleeding, the thrombosis may develop a communication with the arterial lumen and stabilize (heal), expand (false aneurysm), or develop a communication with an adjacent injured vein [arteriovenous fistula (AVF)] (6).

Nontransection arterial injuries (Type 3) occur from blunt direct trauma or indirect shock waves from a high-velocity missile and may produce complete or partial flap tears of the intima or intramural hemorrhage; both diminish lumen diameter and compromise flow (Fig. 33.2). Potential sequelae may include thrombosis, periadventitial constriction, and aneurysm; all may occur with or without ischemia and may not be immediately symptomatic. After complete occlusion by thrombosis, recanalization can occur and may restore circulation without symptoms or may rethrombose and produce distant emboli.

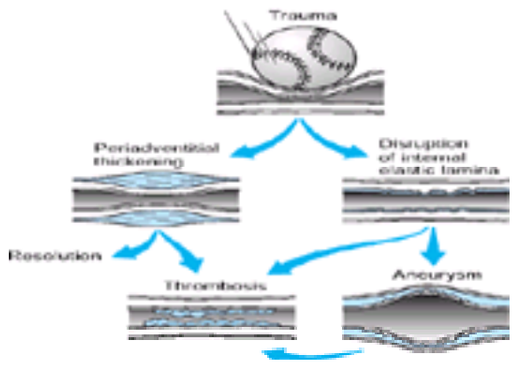


***Figure 33.2.*** A schematic depiction of occlusive mechanisms is shown. Acute or repeated trauma may cause direct intimal damage, leading to stasis and thrombosis (in most cases) or to aneurysm formation. Chronic low-grade trauma initially may produce periadventitial thickening; this results in constricted flow that may resolve spontaneously, may be relieved by surgical stripping of the adventitia, or may lead to subsequent intimal damage and secondary aneurysm formation, which may progress to thrombosis. (From Koman LA, Urbaniak JR: Ulnar Artery Thrombosis. In: Brunelli G, ed. *Textbook of Microsurgery.* Milan: Masson, 1988:75, with permission.)

Symptoms (pain, numbness, paraesthesias, weakness) following acute arterial injury are based on the adequacy of the collateral circulation, posttraumatic sympathetic tone, and vasomotor control mechanisms (Fig. 33.3) (1,42). In the presence of adequate collateral circulation and normal vasomotor control, patients with arterial injuries infrequently require vascular reconstruction (noncritical injury). An underlying neurologic, soft-tissue, or osseous injury, however, may alter sympathetic control in the remaining intact vessel or vessels, resulting in ischemic symptoms from an otherwise insignificant injury. Therefore, adequate anatomic vasculature may be compromised by inappropriate functional control that produces vasospasm, arteriovenous shunting, and resultant hypoperfusion. In the presence of inadequate collateral circulation, arterial injury results in distal ischemia that increases sympathetic tone, produces additional arterial spasm, decreases tissue perfusion, induces ischemia, and escalates symptoms. The effects of an arterial injury may be magnified in the presence of a concomitant nerve injury or underlying vasomotor control abnormality.

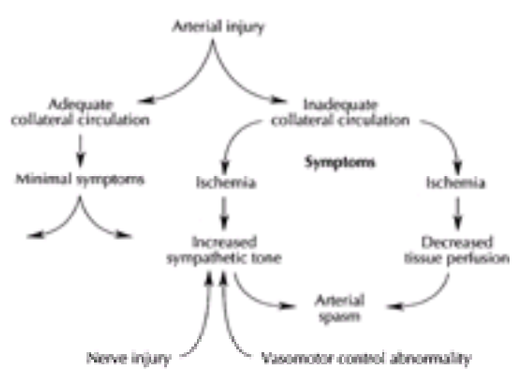


***Figure 33.3.*** Vascular injury precipitates a vicious circle of symptoms if insults occur at a crucial location, are associated with concomitant or pre-existing abnormalities of vasomotor control, or accompany nerve injury. (Reproduced from Koman LA, ed. *Bowman Gray School of Medicine Orthopaedic Manual*. Wake Forest University Orthopaedic Press: Winston-Salem, North Carolina, 1997, with permission.)

### *Natural History*

Although pulseless extremities may survive on small collateral and subdermal plexus flow, there is uniform agreement that the surgeon should revascularize one or both forearm vessels if both the radial and ulnar arteries are disrupted, if the vessels in the distal extremity are suitable, and if the patient's overall condition permits. During World War II, amputation (critical injury) after arterial injury occurred in 26% of brachial artery injuries requiring ligation below the origin of the profunda brachia and in 55% of injuries above this level. The amputation rate after ligation of both radial and ulnar arteries was 39%, whereas for single-vessel injuries the amputation rate dropped to 5%—an indication that the majority of single-vessel injuries are noncritical (25).

In the absence of osseous or neural injury, nonrepaired single vessels with adequate collateral circulation do not produce significant symptoms, do not impair function, and do not initiate significant cold sensitivity. Blood pressure decreases in the digits served by the damaged vessel in spite of a compensatory increase in the flow of the parallel artery (22). Symptoms depend on associated injuries and the ability of the remaining vasculature to respond appropriately to stress (39). The effect of a nonrepaired noncritical vessel on the completeness of nerve recovery following neurorrhaphy and the effect of the nerve injury on the function of remaining parallel microvasculature is unclear; data are conflicting.

### *Diagnosis*

Diagnosis of arterial injuries requires a high index of suspicion based on the history of the injury. Vascular injury may occur after penetrating wounds (80%) or fractures and needs to be considered when patients have injuries to adjacent neural structures. Initial physical examination may include profuse external bleeding (62%), hypotension (18%), expanding or pulsatile hematomas, thrills, bruits, and decreased peripheral pulses (43). A distal pulse is not a reliable sign of vascular integrity, however, and it is palpable in approximately one quarter of patients with a brachial artery disruption and in 50% of patients with an isolated radial or ulnar artery injury (24). Distal to arterial disruption, a palpable pulse may be secondary to retrograde flow through collateral circulation or wave transmission through the injured segment. The Allen test, which may be obtained using Doppler ultrasound, is the most accurate and reliable indicator of arterial patency in the hand and can document the direction of flow and the quality of the collateral circulation (2).

Noninvasive diagnostic techniques include hand-held Doppler ultrasound, pulse echo real-time ultrasonography, color duplex Doppler imaging, and radial or digital blood pressures (Table 33.5). As noted, when performed with and without parallel vessel compression, Doppler evaluation can detect the presence and direction of flow, whereas digital pressures can quantify the amount of flow when referenced to the brachial artery in the form of a digital brachial index (DBI) or radial brachial index (RBI). A DBI or RBI of £0.7 or less indicates inadequate flow and supports medical and surgical intervention; heavily calcified vessels, as seen in patients with diabetes, may produce higher pressures, which must be considered (8).

| | Anatomic structures* | Functional performance | Primary component of flow measured |
|---|---|---|---|
| Digital plethysmography | 0 | + + ½ | Total flow |
| Segmental arterial pressure | + | + + | Total flow |
| Real-time sonosonography | + + ½ | + | Total flow |
| Laser Doppler perfusion imaging | + | + + | Thermoregulatory (total flow) |
| Laser Doppler flowmetry | 0 | + + | Nutritional and thermoregulatory |
| Doppler duplex | + + | + + | Total flow |
| Skin surface temperature | 0 | + + | Total flow |
| Vital capillaroscopy | + + + | 0 | Nutritional flow |
| Technetium 99 | + | + + | Total flow |
| Magnetic resonance angiography | + + | 0 | Total flow |
| Contrast arteriography | + + + | + | Total flow |

* Rating: +, fair; + +, good; + + +, excellent; 0, not applicable

***Table 33.5. Direct Vascular Evaluation***

Invasive diagnostic techniques include arteriography; its role in acute extremity trauma, however, remains controversial (3,20). For most critical penetrating arterial injuries, the preceding assessments dictate obvious and appropriate surgical intervention. Arteriography is sought preoperatively if (a) surgery may compromise the patient or the extremity, (b) multilevel arterial damage is possible or probable (e.g., shotgun wound), and (c) extensive thrombosis or embolism is of clinical concern (e.g., injection or cannulation injuries). Relative indications for arteriography after blunt trauma include (a) suspicion of a proximal traction injury or distal occlusion (thrombosis or embolism), (b) detection of a partial arterial injury (e.g., intimal flap), and (c) suspicion of a false aneurysm.

Intraoperative assessment is required in all critical injuries but may also be required in cases in which the extent of damage and quality of collateral circulation are in question. Collateral flow can be assessed by the backflow from the injured vessel, qualitatively by the pulsatile flow or by quantitative measurement of the retrograde blood pressure (23,25). Although excellent retrograde flow (DBI >0.7) confirms adequate collateral circulation, poor flow may be transient secondary to vasospasm or hypotension and not predictive of collateral flow postoperatively. Alternative intraoperative measures available are qualitative assessment of capillary refill (22) or pulp turgor, and quantitative digital plethysmography or laser Doppler flowmetry.

### *Indications for Surgical Reconstruction*

Reconstruction is indicated in all cases of critical arterial injuries, assuming the absence of additional injuries or problems. Absolute indications for noncritical arterial injuries are not well defined, but relative indications include injuries in which additional flow would help to maintain pulsatile digital flow capable of responding to stress. Another relative indication is the presence of injury to adjacent neural structures (i.e., ulnar artery and nerve).

### *Surgical Reconstruction*

To obtain reliably patent anastomoses, the surgeon must use the proper instruments, appropriately sized needles, suture materials of appropriate diameter, adequate magnification, and meticulous microsurgical technique.

**Instrumentation** The selection of microsurgical instruments is, in part, at the surgeon's discretion. Instruments should be simple, corrosion resistant, and fabricated with nonglare material, and they should approximate accurately (Fig. 33.4). Scissors and needle holders should have nonlocking spring mechanisms and should be long enough to rest comfortably in the thumb-index finger web space. Sufficient length is important to minimize intrinsic muscle fatigue, decrease hand tremors, and help minimize technical errors.

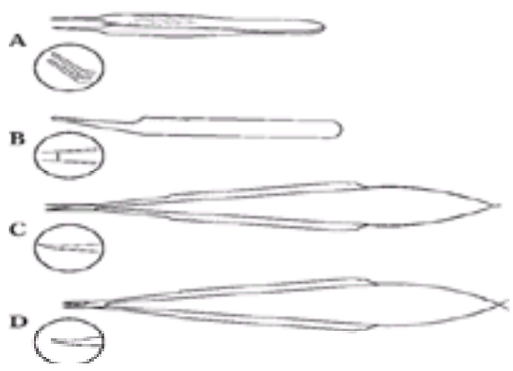


***Figure 33.4.*** Basic microsurgical instruments. **A:** Tying forceps may be used for tissue manipulation and suture handling and tying. **B:** Specialized forceps may be used to dilate vessels as well as to manipulate tissue and to handle sutures. **C:** Straight or adventitial scissors and curved or dissecting scissors (*inset*) are used for dissection, tissue preparation, and suture transection. **D:** Needles may be manipulated with curved or straight forceps or specialized needle holders.

*Forceps* Smoothly functioning forceps capable of holding without tearing are essential, with tip sizes ranging from 0.2 to 0.6 mm. Jeweler's forceps (straight #5 and #3) traditionally have been used as microsurgical forceps; however, their small tips are easily distorted, rendering them ineffective. Additionally, they are unavailable in lengths greater than 10 cm. Forceps made specifically for microsurgery are longer, are constructed with forged or case-hardened metals, have improved durability, and are not sharp. A variety of specialized forceps are available for vessel dilatation, stretching, and tissue manipulation.

*Scissors* Microscissors are extremely important. Ideally, they should be 15 to 18 cm long, and their tips should be of forged or case-hardened metal. Adventitial scissors are straight; dissecting scissors have a gentle curve. Tips may be pointed or slightly blunted; the latter are preferable for less experienced surgeons, because they decrease the possibility of damage to vessels. Handles may be straight, rounded, or flared. Many of the newer microscissors are counterbalanced to improve their feel and maneuverability.

*Needle Holders* Most microsurgeons prefer specialized needle holders with finely forged tips that have smooth action, such as jewelers forceps. Longer needle holders (15 to 18 cm), which are easier to handle and control than short ones, help minimize false needle passes, inadvertent vessel wall penetration, and trauma. Needle holders come with straight or curved jaws. A gently curved jaw facilitates handling, allowing the surgeon to roll the handle between the thumb and forefinger to rotate the needle through the vessel wall. Locking needle holders are not used with needles smaller than 150 to 200 µm. Locking and unlocking may bend the needle and tear vessel walls.

*Clamps* Single and double clamps are available in several sizes for vessel approximation or hemostasis (Fig. 33.5). Vessel clamps are designed to hold the vessel, to prevent bleeding, and to allow rotatory approximation. Disposable single and double clamps of varying sizes and pressures are now available and are suitable for 0.4 to 2.0 mm vessels. Specialized clamps include stay suture–holding frames, adjustable tension devices, and clamps with variably angled blades. The ideal clamp has enough tension to hold the vessel without damage and jaws 1.5 to 2.0 times wider than the diameter of the vessel. A clamp that exerts excessive pressure will damage the intima and media, and produce or increase the likelihood of thrombosis. Avoid using double-bar clamps to overcome tension during vessel approximation. Clamps are designed as anastomotic aids to facilitate vessel positioning, hemostasis, and suture management; they are not designed to overcome tension.

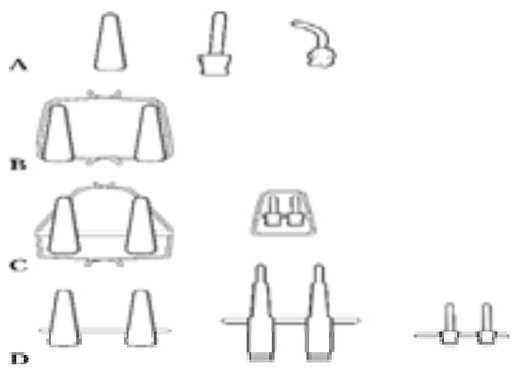


***Figure 33.5.*** Microclamps. A large variety of microclamps capable of holding 0.3 to 2.0 mm vessels is available.

*Special Instruments* Custom vessel dilators or smooth probes (e.g., lacrimal duct probes) are often helpful, but they may damage the intima if their surfaces are rough or if they are mishandled. Instruments to provide counterpressure are useful to facilitate needle passes in difficult situations or to avoid inadvertent penetration and tethering of the vessel.

*Suture Material and Needles* As a basic rule, choose the smallest needle that can pass through the vessel wall without bending and the smallest suture strong enough to approximate the vessel. Standard needle sizes range in diameter from 50 to 135 µm and in cord length from 2 to 5 mm. Suture material in sizes 10-0 to 11-0 (35 to

14 µm) is available on most needles.

*Magnification* The choice of magnification relates to vessel size. Large vessels in the proximal forearm or arm may be repaired reliably using loupe magnification (2.5× to 6.0×). Because magnification requires concomitant increases in light to be effective, it is often simpler to use an operating microscope than higher power loupes and a headlamp. Loupe magnification of 3.5× to 4.5× may facilitate gross dissection; vessel repair is then accomplished with the operating microscope at 6.0× to 30.0×. Inspecting the vessel carefully under high power identifies wall or intimal damage that would compromise patency. Resect abnormal vessels before repair.

**Exposure**

- In general, perform rigid skeletal fixation before vascular repair in cases involving skeletal trauma. In critical injuries, arterial or venous shunting may be used to prevent excessive warm ischemia.
- Explore wounds under loupe magnification using a tourniquet to provide a bloodless field.
- Use extensile incisions that incorporate traumatic wounds. If it is clinically indicated, perform fasciotomies. Identify transected and injured structures proximally and distally in normal tissue. Mobilize and tag them with vascular tapes or loops.
- Excise dead and necrotic tissue, and trim wound margins.
- Identify the periadventitial plane of the injured vessel proximally and distally to the transection site to allow rapid and safe dissection. Dissect vessels from surrounding tissues and place atraumatic vascular clamps on either side of the repair site.
- Ligate branches from the damaged artery in the proximity of the transection or cauterize with a bipolar cautery, leaving a 0.5 mm stump (Fig. 33.6). Manipulation of the media or intima is thereby minimized.

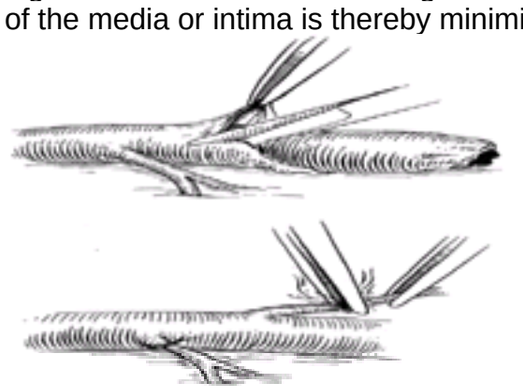

***Figure 33.6.*** Periadventitial tissue may be dissected safely after identification of the vessel lumen in the area of dissection. Avoidance of direct manipulation of the lumen minimizes trauma. Branches may be ligated with 8-0 nylon sutures or cauterized using a bipolar cautery.

- Remove the periadventitial tissue to reveal the vessel wall and lumen to prevent debris from interfering with passing or tying of sutures.
- Place but do not tie sutures if lacerated flexor tendons are adjacent to or would interfere with vascular anastomoses; after vascular repair, tendon approximation is possible without additional dissection. The possibility of damaging the vessel repair is thereby minimized. Performing tendon repair before vessel anastomosis may make exposure of the anastomotic site more difficult because of finger, hand, or wrist position, or because of the location of the tendon.
- Inspect both portions of the vessel to determine if the intima and media are suitable for anastomosis. Hemorrhage within the media, intimal disruption and multiple stellate tears, or telescoping of the intima are ominous findings and require additional resection back to the level of normal vessel. Intimal damage itself is an important but not definitive factor in long-term patency. Intimal damage, however, the most easily recognizable external sign of local trauma, may indicate significant additional damage and is associated with a higher rate of thrombosis. It is good practice to resect the vessel to see relatively normal intima.
- Place the vessel in an approximating clamp and repair it end to end (Fig. 33.7). Manage undue vessel tension by the use of reversed interposition vein grafting, *in situ* vein grafting with valvulotomy, antegrade vein grafting with valvulotomy, proximal and distal arterial mobilization, acute arterial lengthening, or bone shortening.

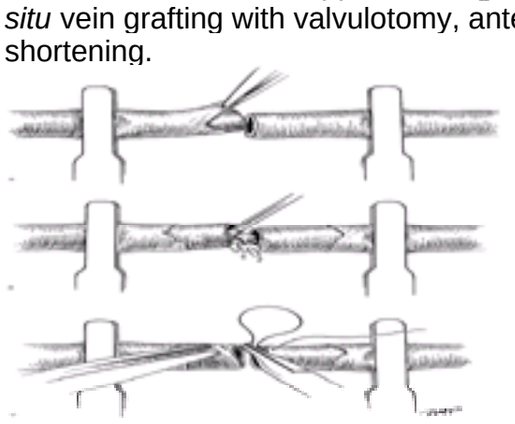

***Figure 33.7.*** Vessels may be placed in a bar clamp to facilitate positioning, control bleeding, and maximize ease of repair. **A:** Periadventitial tissue, which is highly thrombogenic if left within the lumen, is debrided to prevent clot formation and to facilitate visualization of the lumen. The vessel interior should then be irrigated with heparinized saline (**B**) and inspected under high-power magnification before the repair (**C**).

**End-to-End Vascular Repair**

- Perform a primary end-to-end repair, without placing excessive tension on the anastomotic site if possible. In sharp, nonsegmental injuries or when minimal artery has been resected, it is possible to achieve a tension-free anastomosis after resection of damaged vessel ends by moderately mobilizing the artery proximally and distally.
- Colored background material improves visualization and handling of suture, decreases glare, and improves contrast.
- Perform the anastomosis with or without vessel approximating clamps, which are used to hold the vessel in position, not to overcome excessive tension. It is easier to gain access to the anastomotic site by orienting the bar clamps with the open end away from the surgeon (Fig. 33.7).
- Under the operating microscope, adjust tension, expose the vessel, irrigate the lumens with heparinized saline, and remove debris or loose adventitial tissue. Make a final inspection of the intima, and, if the vessel is suitable, begin the anastomosis.
- After ensuring that the vessel is not twisted and that tension is not excessive, place stay sutures at 120°. Approximate the front wall by halving the distance with each suture, using a triangulation technique (Fig. 33.8).



***Figure 33.8.*** **A:** Minimal size discrepancies (10% to 20%) may be managed by careful triangulation. The first suture is placed, halving the distance between stay sutures. **B:** As the knot is tied, tension on the stay suture will ensure intimal apposition without buckling. **C:** Additional sutures are placed similarly.

- Rotate the bar vessel–approximating clamp 180° (open end toward surgeon) and approximate the back wall in a similar fashion.
- Minimize size or spacing discrepancies by applying tension to the adjacent sutures as you tie and triangulate the first throw of the knot (Fig. 33.9). Gently dilate the end of the smaller vessel, and cut it obliquely (not to exceed 30°). Perform end-to-side anastomosis, V-section, and closure of the end of the larger vessel,

longitudinal slit opening of the end of the smaller vessel, or interposition of appropriate graft material (Fig. 33.9).

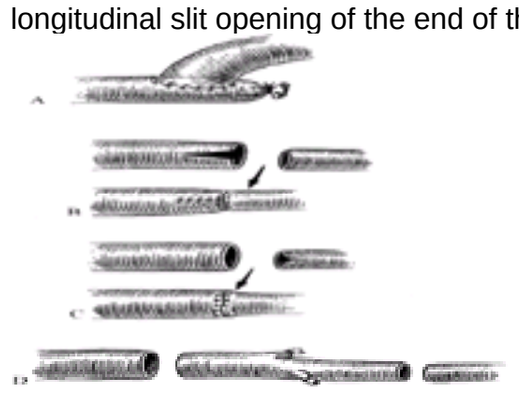

***Figure 33.9.*** Compensatory technique for size discrepancy. (**A**) End-to-side, (**B**) V-excision and closure, (**C**) V-opening, and (**D**) vein graft.

- Repair forearm level injuries with nonabsorbable 7-0, 8-0, or 9-0 sutures, and repair distal vessels with 9-0, 10-0, or 11-0 sutures.
- When the anastomosis is complete, inspect it and remove the clamp. Additional sutures may be necessary, but early leaks often stop spontaneously or you can stop them by placing fat over the anastomosis. Spaces of 0.3 mm or less between sutures generally do not require additional sutures. Technical errors in performing anastomoses can also cause turbulence and thrombosis (Fig. 33.10). Confirm patency by direct observation or by patency testing (Fig. 33.11).

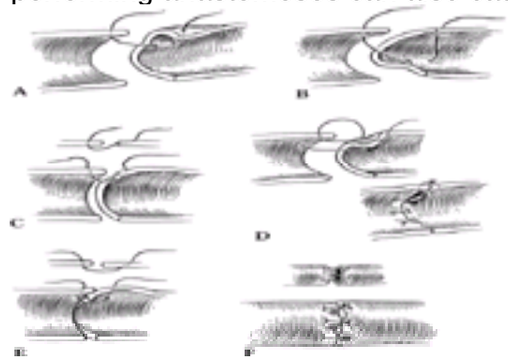

***Figure 33.10.*** Technical errors in anastomosis are shown. Side wall (**A**), back wall (**B**), failure to penetrate full vessel (**C**), uneven lateral placement (**D**), and uneven approximation of intima (**E, F**).



***Figure 33.11.*** The technique for patency testing is illustrated. **A:** Using minimal pressure, the vessel is occluded distal to the anastomosis. **B:** Blood is milked from the vessel, which flattens between the forceps. **C:** The proximal forceps is released, and blood fills the flattened area.

**Vascular Grafts for Arterial Repair** Use vein grafting to overcome excessive tension when, after appropriate debridement, you cannot mobilize the damaged vessel to achieve end-to-end reapproximation (27). Although it requires two anastomoses, vein grafting does not significantly lower patency rates, even when this procedure is used in more severe injuries. Several types of bypass grafts are reversed interposition veins, nonreversed *in situ* valvulotomized vein segments, noncritical arterial grafts, and synthetic or allograft material.

*Reversed Interposition Autologous Vein Grafting*

- For injuries to the radial artery, ulnar artery, or proximal superficial arch injuries, use the cephalic vein from the forearm, the distal saphenous or lesser saphenous vein, or a dorsal vein from the foot; they are equally effective (27,37,40). The volar forearm is an excellent source of veins for the digital vessels.
- To harvest veins, use longitudinal incisions, multiple transverse incisions, or endoscopic techniques. In general, longitudinal incisions allow meticulous vascular dissection, identification, and ligational branches, thus minimizing accidental injury to superficial peripheral nerves and facilitating the procedure. Harvest a segment of vein 15% to 20% longer than the measured defect. Ligate all branches with 4-0 or 5-0 suture, and coagulate them with bipolar cautery or microclip branches to prevent leakage (Fig. 33.6).
- Dilate the vein to inspect for injury, to compress valves, and to detect wall defects or unligated branches; if damage and problems persist after repair, harvest a new vein.
- At the time of surgery, dissect and mobilize the ends of the severed artery, and position vascular clips for later rapid identification. Typically, the vein graft is reversed and placed in position, but nonreversed valvulotomized veins may be used.
- Perform the more difficult anastomosis first because the extra degree of freedom allowed by the mobility of the vein graft makes repair easier and prevents technical errors. Repair the anastomosis as described above. Discrepancies in size are common with vein grafting; they can be overcome by using the techniques previously discussed or by using nonreversed valvulotomized grafts (Fig. 33.3 and Fig. 33.9).

In Situ *and Nonreversed Vein Grafting* The primary indications for *in situ* and nonreversed vein grafting are (a) the need for a large (greater than 7 cm) graft segment, (b) multiple distal anastomoses, and (c) significant size discrepancies between the proximal and distal ends. This type of grafting prevents the large discrepancy in lumen size at both ends found with reversed vein grafting and provides natural branching for multiple distal grafts. Incise all valves before revascularization. The risk of accidental vein damage is the limiting factor with the use of this type of grafting. Historically, many microvascular surgeons preferred reversed interposition vein grafting; new valvulotomes, endoscopic techniques, and documented efficacy support the judicious use of nonreversed valvulotomized vein grafts, however.

*Arterial Grafts* Despite theoretical advantages of a better size match, freedom of orientation, longer theoretical patency, and ease of dissection, few adequately sized donor arterial grafts are available and the use of arterial grafts is limited. If reconstruction of one artery is contraindicated and sufficient undamaged vessel is available, use it as an interposition graft.

*Temporary Shunting* Use temporary shunting to prevent or minimize prolonged warm ischemia. Use commercially available shunts or heparinized Silastic catheters. A variety of carotid endarterectomy shunts are available and are sized (e.g., 3 mm distal, 3 mm proximal) to fit 2.5 to 5.0 mm vessels. Smaller vessels can be shunted using neurosurgical ventriculoperitoneal shunts; however, these shunts require the surgeon to stabilize them with either suture ligatures or vascular keepers or clamps. Perform minimal dissection to avoid iatrogenic damage, place the shunts, and perfuse the distal extremity. Do a fasciotomy if overt or impending compartment syndrome exists.

*Conclusions* The need for arterial reconstruction requires an assessment of the adequacy of the collateral circulation and is based primarily on clinical judgement. Preoperative and intraoperative assessment of color, capillary refill (22), turgor, and back bleeding combined with quantitative measures of perfusion provide an estimate of the adequacy of the collateral circulation. Consider arterial reconstruction as part of a patient-oriented plan. Assuming that limb salvage is appropriate, circulation is restored in critical injuries or in the presence of poor collateral circulation (37). A DIB of 0.7 is a relative indication for reconstruction (refer to the discussion

on diagnosis of acute arterial injuries in the earlier section on the physiology of arterial injuries). The final decision regarding arterial reconstruction is often made in the operating room, after exploration. If collateral flow is good, reconstruction is optional and ligation is an appropriate option at the discretion of the surgeon. If symptoms secondary to decreased arterial perfusion occur in the perioperative period, elective arterial reconstruction may be achieved without compromising long-term symptoms or function.

At this time, the standard of care does not require arterial repair of isolated and noncritical vessels. Postoperative transfer to a facility for revascularization is appropriate if subsequent symptoms warrant it, assuming adequate preoperative, intraoperative, and postoperative evaluation and assessment have been performed. The reconstruction of brachial artery lacerations, particularly those injuries occurring above the origin of the profunda brachia, is indicated, if possible, in most situations. For single-vessel repairs of noncritical injuries, patency rates have improved from a maximum (100%) postoperative thrombosis rate in 1967 to a more acceptable rate, between 47% and 82% in 1982 (25). In combined radial and ulnar artery injury, it is preferable to reconstruct both vessels (25). Although the ulnar artery is larger anatomically, the radial artery often provides greater or equal flow in 88% of patients. If only one vessel can be repaired without significant additional intervention, assess distal perfusion after repair and base the decision regarding the second vessel on clinical judgement. The need for repair of a noncritical lacerated ulnar artery when an associated ulnar neurorhaphy is performed is controversial. Combined ulnar nerve and ulnar artery injury, however, is a relative indication for arterial reconstruction (43).

### ARTERIAL INJURIES DUE TO CANNULATION

#### *Natural History*

Complications arising from indwelling arterial catheters and cardiac catheterization most frequently involve the brachial and radial arteries (4,31,47,53). Repeated injuries to the arterial lumen following attempts to obtain blood from the artery causes vessel lacerations and intimal flaps and an increased likelihood of (a) pseudoaneurysm formation, (b) creation of AVFs, and (c) acute thrombosis with possible distal embolization. Despite a 23% incidence of occlusion of the radial artery following cannulation, few symptoms arise because collateral circulation is adequate, and the occluded vessel recanalizes spontaneously. In rare instances, acute ischemia and distal embolization (more frequent in the brachial artery) ensue (4).

#### *Diagnosis*

Vascular insufficiency causes pallor, decreased capillary refill, petechiae, and, later, pain. Bedside assessments can be performed using the Allen test or evaluation with a Doppler device. Arteriography is rarely indicated and may be contraindicated following cannulation events due to coexisting illnesses in this patient population.

#### *Treatment*

The patient's medical status dictates management of ischemia following cannulation injuries. In critically injured patients, evaluation may require exploration of the involved vessel in the intensive care unit or operating room under local anesthesia. Management options include one or more of the following: thrombolytic therapy, thrombectomy, embolectomy, and resection of the thrombosed segment and surgical reconstruction.

In an acute situation, expose the involved vessel and assess the extent of injury. Results following exploration, primary repair, patch grafting, and vein grafting are excellent, and wound complications are infrequent and manageable. Consider thrombolytic therapy for patients without complicating medical conditions but not in the immediate postoperative period following extensive nonvascular surgery.

#### *Conclusions*

The loss of a radial pulse without ischemic symptoms distally is not an indication for emergency surgery. In an awake and alert patient, monitor the extremity clinically. In an anesthetized or unconscious (e.g., head injury) patient, objective monitoring through use of the Allen test, placement of temperature probes, Doppler imaging with hand-held instruments, color duplex instruments, and laser perfusion instruments, or by measuring distal pressure (DBI) is recommended. Arteriography is indicated to answer specific clinical questions or to explain contradictory findings (20). Suspicion of proximal pathology unrelated to the cannulation injury is an indication for arteriography.

If symptoms and signs suggest vascular compromise, use heparin unless it is contraindicated. The use of thrombolytic agents is contraindicated in the presence of pseudoaneurysm, vascular laceration, and in most postoperative conditions (e.g., following heart surgery). In the presence of persistent distal ischemia (45), active bleeding, or aneurysm, surgical exploration is indicated to determine the extent of arterial damage. Surgery can include resection and ligation, arterial reconstruction, and thrombectomy or embolectomy.

### ARTERIAL INJECTION INJURY

#### *Natural History*

Arterial injection injuries occur in the workplace or are secondary to medical procedures. They may also be self-inflicted during drug abuse. Distal ischemia can occur following injection of a variety of pharmaceutical products (e.g., barbiturates, propoxyphene, and nonparenteral narcotics). Severe vascular events occur following workplace injury involving solvents, paint products, and lubricants injected through high-pressure devices, but fortunately intraarterial injection is infrequent. Injection injuries can result in acute, severe extremity ischemia on the basis of secondary vasospasm, chemical endarteritis, arterial blockage by acid crystals, activation of the clotting cascade, and localized compartment syndromes.

#### *Diagnosis*

Clinical history includes exposure to a high-pressure tool, a high-risk medical procedure, or drug abuse. Swelling, numbness, and discoloration often accompany symptoms of acute arterial insufficiency. Injection wounds often appear innocuous, but the combination of the mass of injected material, chemically induced inflammation, and increased interstitial pressure (compartment syndrome) may produce secondary vasospasm, thrombosis, and skin and soft-tissue necrosis. Diagnostic tests include Doppler evaluation, color duplex imaging, arteriography, and interstitial (compartment) pressure measurements. See Chapter 45 for more details.

#### *Treatment*

Unfortunately, end-artery occlusion within microvascular beds is common, and systemic anticoagulation is the only option. Treatment options include vasodilators, thrombolytic agents (e.g., urokinase) (55), steroids, heparin, and low-molecular-weight dextran. Surgical management includes revascularization of injured and repairable segments, fasciotomy, and, in some cases, amputation. Revascularization is difficult because of frequent involvement of small and distal vessels and diffuse distal vascular injury. If a discrete and reconstructable obstruction or obstructions exist, however, early exploration and embolectomy or thrombectomy or arterial repair (or both) is indicated. Associated compartment syndrome of the digits, hands, or forearms is common and an indication to perform immediate fasciotomy.

#### *Author's Preferred Approach*

Clinical examination should include Doppler ultrasound evaluation, which may provide definitive information. Perform contrast arteriography to determine whether or not reconstructable segmental occlusion is present and to evaluate the extent of distal microvascular compromise. Management depends on the etiologic agent, the location of the insult or insults, and the extent of damage. Treatment may involve one or more techniques, which may be performed sequentially or simultaneously. Manage diffuse thrombosis and embolism involving vessels of any size with thrombolytic therapy (e.g., urokinase), oral vasodilators, and close observation. Discrete, distal small vessel occlusion may respond to heparinization. It is important to monitor the patient for signs or symptoms of compartment syndrome. Perform a fasciotomy for elevated compartment pressures, as needed. Perform revascularization and thrombectomy if it is technically possible and clinically indicated. Repeat arteriography is often necessary to document the extent of large vessel versus small vessel involvement and to evaluate the effects of medical thrombolytic management.

## CHRONIC ARTERIAL INJURIES

### PHYSIOLOGY OF CHRONIC ARTERIAL INJURY AND SUBSEQUENT SYMPTOMS

Occlusive disease of the upper extremity may result from trauma, atherosclerosis, proximal embolic events, systemic disease, and hypercoaguable states. Significant arterial occlusion produces ischemia, vasospasm, and stress-induced symptoms; venous involvement may produce cyanosis and edema. Symptoms and signs depend on the existence of collateral vessels and normal functioning vasomotor and autonomic mechanisms (Fig. 33.2). Symptomatic chronic vascular events produce pain, cold sensitivity, and numbness and may cause ulceration, fibrosis from segmental cell death, and gangrene. The relationship of trauma to occlusive disease is well documented in laborers who use their palms as a hammer (40) or in individuals who participate in activities that expose them to repetitive palmar stress (e.g., baseball catchers).

Although the histologic picture, pathodynamics, and clinical consequences of atherosclerosis and chronic trauma are frequently similar, the etiologic mechanisms and prognosis differ. For example, posttraumatic ulnar artery thrombosis has a much better prognosis than does Buerger's disease. Repetitive trauma may produce localized thrombosis on the basis of periadventitial scarring and compression (10). Alternatively, trauma may cause intimal damage and expose the media, disrupt the internal elastic lamina, and expose endothelial collagen. The result can include aneurysmal dilatation, mural thrombosis, complete occlusion, and distal embolic events. This process is worsened in the presence of a hypercoaguable environment and stasis. In the presence of atherosclerosis or systemic disease, vessels appear to be more susceptible to trauma, and occlusion or aneurysm is more frequent. Regardless of the etiology, level, or extent of occlusion, the adequacy of collateral flow and sympathetic tone (Table 33.2) will affect clinical outcome and must be factored into a clinically useful classification (Table 33.3 and Table 33.4).

## POSTTRAUMATIC ULNAR AND RADIAL ARTERY THROMBOSIS

### *Natural History*

Compromise of the ulnar artery and proximal superficial palmar arch is the most common type of upper-extremity occlusion and has been described as ulnar artery thrombosis or hypothenar hammer syndrome (37,40). Symptoms of pain, cold sensitivity, numbness, and weakness occur following thrombosis, occlusion, or distal embolization of the ulnar artery within the confines of Guyon's canal (Fig. 33.12). Signs include the presence of a pulsatile or pulseless mass, absent flow through the ulnar artery by Allen's test, decreased ulnar sensibility, nailbed changes, decreased refill, diminished turgor, ulceration, and gangrene. Fortunately, ulceration and gangrene rarely occur. Ulnar artery thrombosis occurs most frequently in male laborers in the fifth decade of life. Patients often have a history of using the palm of the hand as a hammer and of using tobacco products.

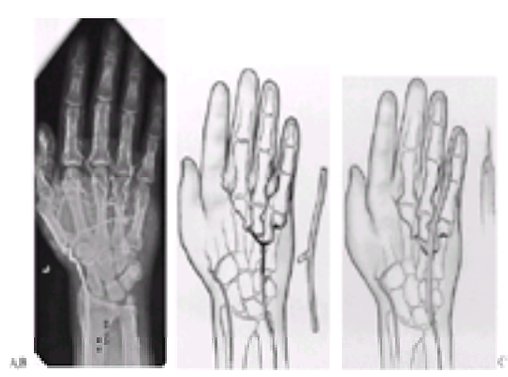

***Figure 33.12.*** **A:** A 52-year-old man sustained repeated trauma to the hypothenar area of his left hand. He presented with pregangrenous changes in his little finger. The arteriogram shows complete occlusion of the ulnar artery and superficial palmar arch with no flow to the proper digital artery to the little finger. The deep arch provides filling of the common digital artery to the ring and little fingers as well as the long and ring fingers, but there is no flow past the middle of the proximal phalanx in the proper digital artery on the radial side of the little finger. At surgical exploration, the ulnar artery, superficial arch, radial proper digital artery to the little finger, and proper digital artery to the ulnar side of the little finger were found to be thrombosed. **B:** Schematic depiction of the surgical findings in the same hand. The black areas represent areas of thrombosis; the cross-hatched areas represent areas of intimal damage. The reversed interposition 18 cm vein graft from the contralateral foot is shown next to the hand. **C:** One end of the graft was sewn end to end to the ulnar artery proximal to the area of intimal damage, and the other end was anastomosed end to end to the proper digital artery on the radial side of the little finger; one limb was placed end to end into the superficial palmar arch. Follow-up at 1 year (including Allen testing, high-resolution real-time ultrasonography, and Doppler evaluation) showed that the vein graft was patent. Symptoms were decreased, the finger ulceration had healed, and the patient was working. (From Koman LA, Urbaniak JR: Ulnar Artery Thrombosis. *Hand Clin* 1985:1:311, with permission from W.B. Saunders Co.)

Thrombosis of the radial artery, deep arch, and common digital vessels may also occur. Radial artery thrombosis often involves the deep branch of the radial artery within the anatomic snuffbox and is seen in women with collagen vascular disease.

### *Pathophysiology*

Human skin microcirculation comprises nutritional papillary capillary beds and nonnutritional thermoregulatory vessels. Distribution of flow between and within these beds varies by anatomic region (Fig. 33.13). Under normal conditions in the digits, 80% to 90% of total flow passes through thermoregulatory beds. In pathologic states, however, cellular hypoperfusion may result secondary to decreased total flow, abnormal distribution of nutritional and thermoregulatory components of flow, or both. Symptoms secondary to anatomic damage (e.g., arterial thrombosis) are managed by either increasing collateral flow or restoring arterial flow (Table 33.6 and Table 33.7). Symptoms secondary to abnormal functional (physiologic) control require alterations in vasoconstrictive and vasodilatory tone that, in turn, have a direct effect on collateral flow, total flow, and the distribution of flow between the nutritional and thermoregulatory beds.

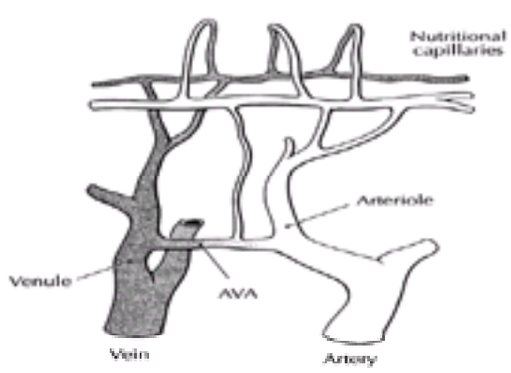


***Figure 33.13.*** A schematic diagram of a microvascular bed from the skin surface is shown. Nutritional perfusion occurs in papillary capillaries and is dependent on appropriate arteriovenous shunting. Excessive shunting through arteriovenous anastomoses (AVA) prevents or limits (shunts) nutritional flow. Nutritional flow can also be reduced by arteriole vasoconstriction and a decrease in total flow. (Reproduced from Koman LA, ed. *Bowman Gray School of Medicine Orthopaedic Manual*. Winston-Salem, North Carolina: Wake Forest University Orthopaedic Press, 1985, with permission.)

I. Increase collateral flow
   A. Reduce vasoconstrictor tone
      - Eliminate tobacco use
      - Biofeedback
   B. Increase nutritional flow
      - Calcium channel blockers
      - Pharmacologic intervention
   C. Sympathectomy
      - Chemical and pharmacologic
   D. Continuous autonomic blockade
   E. Dorsal column stimulator
   F. Surgical sympathectomy
      - Resection of thrombosed segment and ligation (Leriche procedure)
      - Adventitial dissection (peripheral/periarterial)
      - Cervicothoracic
II. Restore circulation
   A. Resection and end-to-end repair
   B. Thrombectomy
   C. Resection and vein graft
   D. Arterial bypass
   E. Thrombolytic therapy
   F. Arteriovenous reversal
   G. Stimpmial resurfacing

***Table 33.6. Treatment Options of Symptomatic Thrombosis***

| Large or medium vessels | Distal vessels | Collateral circulation | Treatment |
|---|---|---|---|
| Reconstructible | Reconstructible | Adequate | Reconstruction or Leriche procedure |
| | | Inadequate | Reconstruction |
| Reconstructible | Unreconstructible | Inadequate | Reconstruction |
| Unreconstructible | Unreconstructible | Marginal (DBI 0.5–0.7) | Periarterial Sympathectomy |
| Unreconstructible | Unreconstructible | Inadequate (DBI ≤ 0.5) | Periarterial Sympathectomy or Arteriovenous Reversal |

DBI, digital brachial index.

***Table 33.7. Treatment Options of Symptomatic Thrombosis Based on Pathology***

### *Diagnosis*

A pulsatile mass is found on examination in less than 10% of cases. Although an Allen's test demonstrating absence of flow through the suspected artery confirms the diagnosis, recanalized thrombosed vessels and aneurysms may demonstrate flow but will create abnormal hemodynamics, pressure gradients, or the presence of distal emboli. Doppler ultrasound, duplex scanning, plethysmography, digital brachial indices, stress testing, and arteriography help delineate structural and functional flow characteristics (35,36).

### *Principles of Treatment*

The goal of treatment is to restore pulsatile flow capable of responding to stress. The choice of treatment depends on sympathetic tone, the adequacy of the collateral circulation, and functional capability. Collateral flow can be increased by altering vasoconstrictor tone. Establish a regimen of biofeedback and oral pharmacologic interventions combined with environmental modifications. The patient should give up use of tobacco and caffeine, and should wear gloves, hats, and scarves to reduce convective heat loss. Nicotine patches used for smoking cessation do not adversely affect nutritional microcirculatory perfusion (21). Total flow may be maximized by the use of vasodilators such as tolazoline and thorazine; calcium channel blockers or adrenergic compounds may enhance nutritional flow. Partial sympathectomy may be effected by intraarterial medications (e.g., guanethidine) or epidural or brachial plexus sustained blocks, implanted dorsal column stimulators (30), or surgical options.

Classification of vascular injury based on anatomic and physiologic pathology aids in the selection of appropriate treatment options (Table 33.3 and Table 33.7). Most patients with secondary vasospasm and occlusive disease have adequate collateral circulation (Group IIIA) and require minimal intervention, such as calcium channel blockers or mild sympatholytics (Algorithm 33.1). Surgical options decrease vasoconstrictor tone, restore blood flow, or both. Surgery to decrease abnormal sympathetic tone includes resection and ligation of the thrombosed segment (Leriche sympathectomy), adventitial dissection (peripheral or periarterial sympathectomy), and cervicothoracic sympathectomy. Periarterial or peripheral sympathectomy is considered a salvage procedure and is reserved for otherwise unreconstructible disease with or without adequate collateral flow.

Assuming (a) technical feasibility and (b) a positive risk–benefit ratio, arterial reconstruction is appropriate in selected patients with adequate circulation (Group IIA and IIIA) and is the treatment of choice for patients with inadequate circulation (Group IIB and IIIB). Physical findings following surgical exploration that support the use of arterial reconstruction include (a) absence of a parallel arterial limb; (b) two-level or greater occlusion that compromises potential collateral flow; thrombosis extending beyond the origin or origins of common digital vessels; and (c) incomplete deep and superficial arches (40). Group IIIB patients, with secondary vasospasm and inadequate circulation, require the restoration of arterial flow for maximal recovery (39). Methods to restore arterial flow include use of thrombolytic agents and a variety of reconstructive arterial surgery techniques.

Thrombolytic therapy is indicated in embolic events, nonembolic thrombosis of the subclavian and ulnar artery, and intraarticular injection injury with medium vessel occlusion. Perform thrombolysis by introducing a percutaneous catheter proximal to the thrombus and introducing a thrombolytic agent, typically urokinase, a tissue plasminogen activator. Monitor therapy clinically and with serial arteriograms. Twelve to 72 hours of treatment may be necessary, followed by 3 to 6 months of anticoagulation therapy. Thrombolytic therapy is performed using interventional radiology or cardiology consultants, selective catheterization into or just proximal to the thrombosis is optimal, and a more acute occlusion may respond more dramatically than a chronic condition. The current agent of choice is urokinase, with the dose based on the patient's body weight, response to infusion, and the position of the catheter.

Embolectomy is valuable in selected patients and is used in conjunction with thrombolytic agents (i.e., urokinase) or following proximal resection of thrombosed areas and arterial reconstruction. The use of embolectomy catheters within the hand and digits is difficult and may produce vascular damage. The choice of a Fogarty catheter is based on the size of the arteries involved. In general, catheters 1 to 1.5 mm in diameter are used within the distal palm, whereas 2 to 3 mm catheters are appropriate at the wrist and forearm level. It is difficult to introduce embolectomy and thrombectomy catheters distal to the midpalm or distal palm without causing injury; carefully assess the risk–benefit ratio for the patient. After successful embolectomy, administer systemic anticoagulation therapy for 5 to 7 days. Administer intraoperative heparin by bolus (2,000 to 3,000 units), followed by a continuous infusion of heparin based on body weight. A typical 70 kg patient receives 600 to 1,000 units/hour. Obtain daily clotting studies and adjust dosage accordingly. Follow this systemic therapy with an oral anticoagulant (Coumadin) if it is clinically indicated.

In selected individuals, arterial reconstructive procedures have the potential to improve symptoms, to aid in healing, and to prevent premature amputation. End-to-end repair is rarely indicated or possible because of excessive tension at the repair site after removal of damaged artery. In instances in which vessels are tortuous, end-to-end repair is possible after resection of the most diseased segment. A critical evaluation of anastomotic sites is crucial; if a compromised vessel is included in the reconstruction, the likelihood of rethrombosis is high. For this reason, reversed interposition autologous vein grafting is most frequently used, as described above (Fig. 33.12 and Fig. 33.13).

The use of *in situ* and nonreversed interposition vein grafts requires incising the valves. The exposure and technique are similar to those for reversed interposition grafting, with the exception of vein placement and valvulotomy (Fig. 33.13). The use of expendable donor arterial grafts is not described for upper extremity reconstruction. Current data in the thoracic literature, however, support the use of arteries in preference to veins for coronary artery bypass and supports the expendability of internal mammary arteries and the radial artery. Therefore, the use of a contralateral radial artery graft for a critical upper extremity vascular problem provides an alternative to vein grafting.

Although they are infrequently used, bypass grafts occasionally are necessary in the upper extremity. Reversed interposition, *in situ* valvulotomized, or nonreversed valvulotomized vein grafts may be used from the parallel forearm vessel or from the brachial artery to a distal artery (Fig. 33.14).

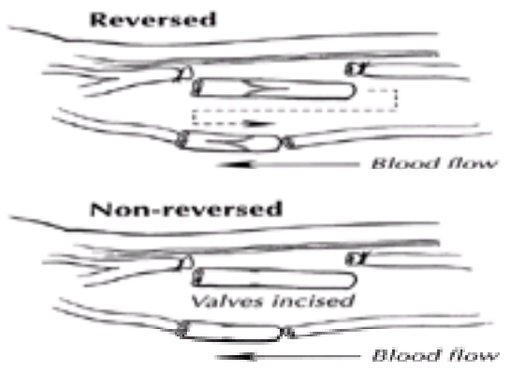


***Figure 33.14.*** Interposition vein grafting may be used to repair damaged arterial segments that would be under tension with an end-to-end repair. Reversed interposition grafts may be obtained from local veins (e.g., cephalic) after reversal. Alternatively, nonreversed veins may be used if the values are incised. (Reproduced from Koman LA, ed. *Bowman Gray School of Medicine Orthopaedic Manual*. Winston-Salem, North Carolina: Wake Forest University Orthopaedic Press, 1997; with permission.)

Patients with inadequate distal arterial reconstitution or poor outflow secondary to arteriosclerosis, or end-stage vasoocclusive or embolic disease may be treated with arterialization of venous flow (5,26,34). This procedure attempts to bypass the valves in the venous system by reversing flow through arteriovenous anastomoses to nutritional vascular beds (26,34). The proximal artery is identified, branches of the *in situ* venous system are ligated, valves are incised, and arterial flow is established through the venous system to the metacarpal phalangeal level. Theoretically, the delivery of systemic arterial flow to vessels of 150 µ or smaller renders distal valves relatively incompetent, allows flow reversal within the microcirculation, and perfuses nutritional capillaries retrograde through arteriovenous anastomoses. Salvage procedures are occasionally appropriate and involve transfer of omental free tissue to resurface and revascularize ischemic distal areas, nourished by proximal arterial and venous anastomoses.

***Operative Technique (Occlusive Disease)***

- Explore the involved arterial tree through an extensile incision. Excise damaged and compromised arterial segments, and reconstruct using end-to-end repair or reversed interposition grafting.
- End-to-end repair is difficult to achieve unless the segment involved is short and tortuous. Do not perform repair with the vessel under tension.
- Use interrupted 7-0 to 9-0 sutures on appropriately sized needles to achieve anastomoses. If grafts are necessary, choices include antegrade veins with incised valves, arterial grafts, prosthetic grafts, or, more commonly, reversed interposition vein grafts.
- Expose vessels, evaluate the vasculature, and initiate resection and ligation or repair. It is important to identify and excise damaged areas of artery. Often, areas of the vessel that remain patent have damaged internal elastic lamina and are at risk for future thrombosis.
- Resecting a central vessel segment that includes patent branches proximally and distally increase the probability that undamaged vessels are repaired.
- Harvest the appropriate-sized graft from either the upper or lower extremity. Although the cephalic and basilic veins are suitable, the distal saphenous vein at the ankle to midcalf level for ulnar artery and brachial lesion is optimal for ulnar artery lesions. The cephalic vein—if adequate—is used in radial artery occlusion. In selected patients who lack appropriate donor veins, the contralateral radial artery may be an option.
- Grafts, either *in situ* with the valves incised, or reversed, are appropriate. *In situ* grafts overcome the size discrepancies created by reversed grafts, with the larger proximal end needing to be anastomosed to the smaller distal artery. Multiple terminal branches are common in antegrade grafts with incised valves but are more difficult to find in reversed vein grafts.
- To accomplish *in situ* and bypass grafts using a valvulotomized vein, perform end-to-side repairs with an operating microscope. The grafts must be tensioned appropriately to prevent kinking.
- In short uncomplicated grafts involving the ulnar artery and superficial arch, it is appropriate to complete both end-to-end repairs before deflating the tourniquet.
- When reconstructing the radial artery within the anatomic snuffbox, perform the distal anastomosis (to the deep arch and princeps pollicis) before performing the proximal repair in order to facilitate the anastomosis.
- In larger or more complex grafts, deflate the tourniquet briefly in order to confirm flow through the vein graft.
- Use an operating microscope unless there is a clinical contradiction.
- After completing the more difficult anastomosis, if possible, trim the graft to size (10% longer than the defect), distend it with heparinized physiological saline (10 to 50 units/ml), and place it in its new bed in the wrist or palm. Take care not to twist the graft. Use 8-0 or 9-0 nylon suture on 100 to 135 µm needles for distal repair.
- Manage vessel size discrepancies using the most appropriate technique.
- If two or more distal anastomoses are necessary, accomplish end-to-end and end-to-side repairs in a series of steps. Complex reconstructions may be achieved by end-to-side anastomoses proximally and distally, Y grafts, and bypass grafting (Fig. 33.15).

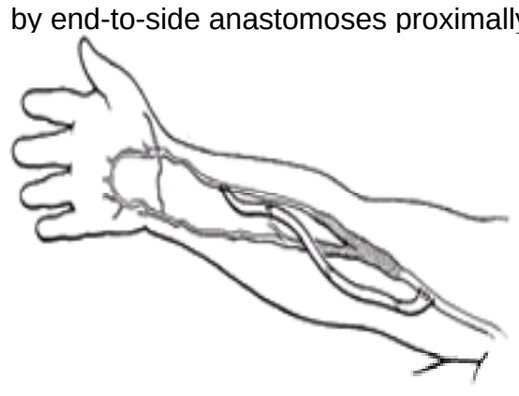

***Figure 33.15.*** Bypass grafting in the upper extremity is often advisable. For example, in this patient with severe occlusive disease associated with diabetic vasculitis and nephropathy and chronic dialysis, the brachial artery and the origins of both the radial and ulnar artery are both thrombosed (*solid lines*). Rather than dissecting the entire brachium and forearm, bypass grafting was performed using end-to-side repair into the brachial artery proximally and an end-to-side repair into the radial artery distally. A reversed interposition graft of 34 cm was used. (Reproduced from Koman LA, ed. *Bowman Gray School of Medicine Orthopaedic Manual*. Winston-Salem, North Carolina, Wake Forest University Orthopaedic Press, 1997; with permission.)

- Give systemic intraoperative heparin as one or two 2,000 to 5,000 unit boluses immediately before releasing the tourniquet. Irrigate all vessels with heparinized balanced solution.
- After all the anastomoses are complete, deflate the tourniquet, remove the clamps, and check the repair or repairs for patency and leaks. After obtaining hemostasis, close the wound in a single layer from wrist to digits. Place a single Silastic 7-French drain adjacent to but not touching the vein graft, if necessary.

**Postoperative Care**

- Apply a large, bulky hand and forearm dressing with dorsal plaster from fingertips to elbow with the hand in a functional position. Leave the drain in 12 to 36 hours.
- Assess the circulation in the hand based on clinical need. Commonly, evaluation every hour for 6 hours, then every other hour for 24 hours, is appropriate.
- Advise patients to stop using tobacco and caffeine. Place the patient in a warm, quiet environment. Start administering systemic intravenous dextran 40 infusion at 20 ml/hour in the operating room. In general, heparin is not necessary postoperatively; but consider systemic anticoagulation if abnormal distal vessels or marginal run-off compromise the anastomosis (37). Continue the infusion at 20 ml/hour for 2 to 5 days.
- Administer salicylates (125 mg/day). If sedation is necessary, use chlorpromazine (25 mg p.o. tid). Narcotic analgesia may be used as necessary.

***Conclusions***

Environmental modification, biofeedback, and pharmacotherapy are helpful in most patients with occlusive vascular disease and may ameliorate signs and symptoms secondary to pathologic vasospasm in patients with adequate primary and collateral circulation (Algorithm 33.1). When required, arterial reconstruction can reduce symptoms of pain, improve function, increase distal arterial perfusion, promote healing of ulcerations, and prevent gangrene in extremities with inadequate collateral circulation (Algorithm 33.2) (39). Successful reconstruction of occlusive lesions proximal to unreconstructible lesions increases total digital flow and nutritional flow

distal to inoperable digital occlusions while simultaneously decreasing symptoms, increasing function, and positively affecting health-related quality of life (39). In contradistinction, symptomatic improvement from Leriche (44) or peripheral sympathectomy procedures in patients with diffuse vasoocclusive digital disease occurs via an increase in the ratio of nutritional to total flow without increasing total microvascular perfusion.

## EMBOLISM

### *Natural History*

Emboli of the upper extremity often originate in the heart, subclavian artery, and superficial palmar arch. Upper extremity embolic events account for less than 20% of arterial emboli, and 70% are of cardiac origin. Cardiac emboli are created by mural thrombi that form after myocardial infarction or in association with atrial fibrillation. In general, cardiac emboli are large and affect the brachial artery, whereas emboli of arterial origin (noncardiac) are smaller, affecting wrist-level and digital-level vessels. Most emboli originate in the subclavian artery; they are commonly produced by mural thrombi secondary to thoracic outlet compression and poststenotic dilatation. Emboli from aneurysms or thrombotic events in the wrist and palm occur in and affect primarily the common and proper digital arteries.

### *Pathophysiology*

In contradistinction to occlusive disease, which may be insidious in onset, embolism often produces acute pain, pallor, and pulselessness. Paralysis occurs rarely and only after lesions proximal to muscle units; thus, it is not present in distal events. Secondary vasospasm may compromise undamaged collateral flow, and necrosis is common in untreated digits. The classic blue finger progresses to white and then black. The degree of damage depends on the amount of embolism, the extent of undamaged collateral vessels, the presence or absence of continued embolic events, and the source the of emboli.

### *Principles of Treatment*

As in occlusive disease, the goal in the treatment of embolism is to restore pulsatile flow and to normalize the distribution of the components of the flow.

### *Diagnosis*

Acute changes in upper extremity flow affecting multiple terminal vessels suggest embolic events. Symptoms of pain, pallor, pulselessness, and paralysis are not specific, but an acute onset suggests an arterial origin. Petechiae and varying degrees of cyanosis are common. Take a complete history and do a physical examination; obtain consultations for evaluation of embolic events and echocardiogram. The extent and location of the occlusion can be determined rapidly by segmental pressure measurements, and arteriography and color duplex imaging can pinpoint the embolic source. Arteriography using conventional techniques or magnetic resonance imaging is important to determine the extent of the damage (16).

### *Treatment*

Embolectomy followed by anticoagulation using heparin sulfate is the treatment of choice for large emboli. After embolectomy, initiate anticoagulation with heparin followed by Coumadin for approximately 3 months. Reperfusion injury following revascularization may result in a compartment syndrome requiring release. Embolism of arteries in the hand and the excision of embolic sources may require surgical explorations. For acute situations that do not respond to heparinization, use urokinase or streptokinase (17,55).

### *Conclusions*

For patients with acute signs and symptoms of embolism, we perform arteriography immediately. If lesions are found, we initiate thrombolytic therapy. If appropriate, we perform embolectomy, surgical reconstruction, or both.

## ANEURYSM

### *Natural History*

Aneurysms are either false or true. False aneurysms or pseudoaneurysms occur most frequently following penetration of the vessel wall, with subsequent hemorrhage and extravasation. The resultant hematoma in the soft tissues becomes organized, fibrosed, and recanalized. The lumen of this false vessel is in continuity with a true vessel and is distinguished from it by the absence of endothelial lining.

True arterial aneurysms result from injury to the vessel causing gradual dilation into a more uniform shape, compared with the saclike appearance of a pseudoaneurysm. Whereas false aneurysms commonly result from penetrating traumatic and iatrogenic incidents, true aneurysms occur most frequently in areas of arterial circulation that are exposed to repetitive trauma (e.g., the distal ulnar artery and superficial arch).

The incidence of false aneurysms following penetrating trauma is unknown. False aneurysms of the upper extremity accounted for 27% of all of the false aneurysms recorded in the Vietnam vascular registry (52). Aneurysms of the ulnar and digital vessels are evenly distributed between the true and false type, and ulnar artery aneurysms comprise the largest group of both true and false aneurysms (52). False aneurysms are frequently encountered in the axillary, brachial, anterior interosseous, and radial arteries but may also involve the radial artery within the anatomic snuffbox, the palmar arch, and the digits.

The time interval between the trauma and the clinical evaluation of an aneurysm may vary considerably between 2 weeks and 12 years. The natural history of both true and false aneurysm is characterized by a slow progression leading to thrombosis, the production of emboli, or both. The effect of thrombolytic agents on the natural history is unknown. However, the degree of turbulence in the re-created aneurysm and any abnormal coagulation properties are similar to the pretreatment state and rethrombosis is possible. In fact, because the components of Virchow's triad for thrombosis (stasis, turbulence, and hypercoagulability) is present, reocclusion is likely to occur.

### *Diagnosis*

An aneurysm is usually a painless, palpable mass; signs and symptoms occur secondary to mass effect or vascular insufficiency (13). Symptoms of localized pain from soft-tissue and neural compression can occur secondary to a mass effect; distal signs and symptoms occur most frequently from embolization.

Aneurysms are readily identified by Doppler ultrasonography, color duplex scanning, and B mode imaging. Arteriography, the gold standard, can define the extent of damage; delineate distal embolic events; differentiate the aneurysmal mass from an arteriovenous malformation, neural tumor, or malignancy; and, most important, aid in preoperative planning by assessing collateral flow and determining the possibility of reconstructing distal vessels (18).

### *Treatment*

The traditional treatment options for aneurysms include (a) resection and ligation, (b) excision of the damaged wall and patch graft, (c) resection with end-to-end repair, and (d) resection with interposition graft. The choice of treatment is determined by evaluating collateral flow and vasomotor tone. Resection of the aneurysm has been found effective, along with proximal and distal ligation of a noncritical radial or ulnar artery aneurysm; brachial vessels or critical vessels, in general, however, require arterial reconstruction. The long-term benefit of thrombolytic agents is unknown.

### *Conclusions*

Aneurysmal dilatation produces turbulence, thrombosis, recanalization, and embolism. Because of the risk of thrombosis and distal embolization, surgical treatment of both true and false aneurysms is recommended. Aneurysms may occur in the presence of adequate or inadequate circulation and may be accompanied by distal occlusive and embolic disease. If collateral flow is adequate, providing uniform digital pulp microcirculatory perfusion, either resection plus ligation of the aneurysm or arterial reconstruction is appropriate. When collateral flow is inadequate or occlusive, or embolic events occur distal to the aneurysm, arterial reconstruction using end-to-end repair or reversed interposition vein grafting or other techniques is advised. (See previous discussion of preoperative and intraoperative assessment and treatment techniques.) Until further data are available, we feel that thrombolytic therapy is relatively contraindicated in the treatment of upper extremity aneurysms.

## ACQUIRED ARTERIOVENOUS FISTULA

### *Natural History and Pathophysiology*

AVFs occur following trauma, infection, or iatrogenic trauma from catheterization or hemodialysis. Distal ischemia and neurologic symptoms are created by shunting, which causes a so-called steal phenomenon. Although most patients tolerate AVFs for dialysis, complications are common (11,46). Following end-to-end and end-to-side anastomosis of the radial artery to the cephalic vein (radiocephalic AVF), digital blood flow to the thumb may be reduced by up to 40% secondary to proximal shunting (steal phenomenon) (11). Arterial insufficiency is produced if distal perfusion decreases below a critical volume (DBI = 0.5). Dialysis-associated steal syndrome (DASS) occurs in 1% of side-to-side radiocephalic fistulas and in 6.4% of patients who have undergone forearm loop grafts (50a). The incidence increases significantly in the presence of pre-existing occlusive disease distal to the shunt.

Shunts may cause high-output cardiac failure characterized by progressive cardiomyopathy, fatigue, and dyspnea on exertion and may produce a higher than expected incidence of median and ulnar neuropathy. The incidence of median mononeuropathy following radiocephalic AVF approaches 70%—significantly higher than the 2% incidence in the contralateral hand. Neurologic symptoms are produced by neural ischemia, elevated interstitial pressure, diminished systolic pressure in the presence of pre-existing elevated carpal canal pressure, and venous distention compressing neural structures. Shunt reversal or banding may alleviate symptoms of arterial insufficiency secondary to inappropriate shunting, but neurolysis of involved nerves may be required.

### *Diagnosis*

On examination, a thrill or bruit is frequently present. A combination of neural or ischemic symptoms (whether due to a steal phenomenon or emboli) and the presence of an AVF support the diagnosis, which may be confirmed by an assessment of digital flow. A DBI of 0.5 to 0.7 is a harbinger of impending cell death and necrosis. Stress testing may be helpful to delineate the pathophysiology. An assessment of nutritional flow may be diagnostic. Arteriography is required to differentiate between aneurysm and thrombosis, to document emboli, and for preoperative planning.

### *Treatment*

Management options for symptoms secondary to AVF include sympatholytic agents, banding, and ligation. Surgical ligation of the venous limb of the shunt, leaving the artery intact, may be required if banding (decreasing shunt diameter) is inappropriate. The persistence of excessive arteriovenous shunting may produce severe neurologic and ischemic sequelae, which may require (a) shunt revision, (b) banding or ligation of the shunt, or (c) neurolysis of compressed nerves, or a combination thereof.

Banding or narrowing of the shunt increases the resistance through the shunt, increases blood flow distally in the digits, and may reverse symptoms if the shunt is 4 mm or more in diameter. Shunts smaller than 3 to 4 mm, however, may not produce sufficient flow for effective dialysis. Banding is indicated if the ulnar artery is patent and occlusion of the radial artery distal to the fistula causes a documented increase in distal perfusion. It is also indicated if occlusion of the venous limb increases digital flow and banding allows adequate flow for dialysis. Occlusion of the radial artery distal to side-to-side fistulas eliminates retrograde steal and increases thumb blood pressure significantly (11). Documentation of digital blood pressure before and after occlusion of the radial artery below the fistula provides valuable information in symptomatic patients with a DBI of less than 0.64 (Algorithm 33.3)

### *Conclusions*

Treatment must be patient oriented and must take into account the importance of vascular access in the dialysis-dependent patient. Decisions require the combined input of the patient, nephrologist, vascular access surgeon, and the hand surgeon. In general, severe symptoms following an AVF require surgical intervention. In the presence of pre-existing or acquired occlusive disease distal to the AVF, severe symptoms are frequent and are alleviated most effectively by elimination of the vascular steal, by minimizing abnormal sympathetic tone, and by arterial reconstruction of occlusive disease.

The treatment of ischemia in patients with AVFs is difficult and requires the involvement of the patient, the nephrologist, and the vascular surgeon. Symptoms often include (a) necrotic digital tips requiring amputation, (b) cyanotic digits, and (c) neurologic impairment. Digital blood pressures and peripheral nerve conduction velocity (PNCV) measurements guide the decision-making process. If temporary occlusion of the radial artery distal to the shunt reduces symptoms and improves capillary refill (22) and the DBI is less than 0.5, we consider banding or ligating of the shunt. If PNCVs are abnormal and the DBI is greater than 0.7, associated neurologic complaints may be reduced by neurolysis with excision of any venous compressive structure. If PNCVs are normal, distal perfusion is poor, the DBI is £ 0.5, and graft reversal represents an unacceptable burden, consider bypass grafting from the brachial artery to a vessel distal to the fistula (Algorithm 33.3).

## ARTERITIS

### *Natural History and Pathophysiology*

Arteritis of the upper extremity is encountered in thromboangiitis obliterans (TAO), giant cell arteritis, Wegener's granulomatosis, Takayasu's arteritis, polyarteritis nodosa, and collagen vascular disease, and it is seen in association with neoplastic disease. TAO (Buerger's disease) is an inflammatory occlusive disease of small and medium-sized vessels (9). Classic clinical characteristics include lower extremity involvement in young, predominantly male smokers (33). The male-to-female ratio of patients with TAO, however, is declining, with older patients more frequently seen and upper extremity involvement more common (41). Although arteriographic differentiation from atherosclerosis is relatively obvious, TAO is difficult to differentiate from scleroderma and collagen vascular disease. Histologically, arterial or venous thrombosis with lymphocytic and polymorphonuclear leukocyte infiltration into the thrombus and vessel wall is observed. If the patient quits smoking, disease progression decreases and the need for amputation is less likely.

### *Diagnosis*

Arteriographic findings typical of TAO include (a) small and medium vessel involvement, (b) segmental occlusive disease, (c) distal disease greater than proximal, (d) collateralization bypassing occlusive segments, and (e) normal proximal (e.g., brachial) vessels.

### *Principles of Treatment*

- Improve nutritional flow to improve the response to stress.
- Correct inappropriate arterial-venous shunting.
- Increase proximal and distal perfusion.

### *Preoperative Management*

All nonoperative management to maximize total and nutritional perfusion falls under the rubric of preoperative management. Use calcium channel blockers and other pharmacologic or mechanical means, including biofeedback, to decrease sympathetic tone, decrease abnormal shunting, and increase nutritional flow.

### *Preoperative Planning*

Preoperative planning in cases of arterial insufficiency requires (a) an understanding of the vascular anatomy and (b) an assessment of physiologic control. Therefore, studies to evaluate the form and function of the vascular tree are important and should include an estimate of

- Total flow—before and after stress [temperature and laser Doppler flow (LDF)],
- Nutritional flow (LDF, vital capillaroscopy), and
- Vascular anatomy (arteriography or magnetic resonance angiography) (16,20). Surgery should then be planned to
- Decrease sympathetic tone and increase nutritional flow by periarterial sympathectomy, and
- Increase total and nutritional flow by arterial reconstruction and periarterial sympathectomy (Table 33.7).

### *Operative Technique*

Direct treatment toward the relief of vasospasm and the restoration of anatomic channels by using vascular reconstruction, if necessary. The techniques used here are identical to those in acute and chronic reconstruction.

## VASOSPASTIC DISEASE

### PATHOPHYSIOLOGY

Under normal conditions, arterial vasoconstriction maintains blood pressure by the peripheral modulation of vascular resistance, directing blood to nutritional capillary beds, providing appropriate thermoregulatory control, and preventing excessive blood loss after trauma. However, inappropriate vasoconstriction may produce symptoms of pain and cold intolerance, interfere with health-related quality of life, and result in ulceration, gangrene, or both. Pathologic vasospasm produces inappropriate arterial and venous tone that persists in the presence of physiologic demands for increased flow or contrary to specific cellular metabolic needs. Inappropriate cold sensitivity, the most common symptomatic manifestation of vasospastic states, is frequent and affects 5% to 10% of the general population and 20% to 30% of premenopausal women. Vasospastic states are defined as primary (Raynaud's disease) in the absence of an identifiable etiology or secondary (Raynaud's phenomenon) in the presence of a causal condition (Table 33.8).

| | Disease | Phenomenon |
|---|---|---|
| History | | |
| Triphasic Color Change | Yes* | Yes |
| Age > 40 | No | Yes |
| Progression Rapid | No (>2 years)* | Yes |
| Underlying Occlusive or Systemic Disease | No* | Yes |
| Female Predominance | Frequent* | Occasional |
| Physical Examination | | |
| Trophic Findings (ulcer, gangrene) | Infrequent* | Frequent |
| Abnormal Allen test | No | Common |
| Bilateral | Frequent* | Infrequent |
| Lab Testing | | |
| Blood Chemistry | Normal | Frequently abnormal |
| Microangiology | Normal | Frequently abnormal |
| Angiography | Normal | Frequently abnormal |

* Criteria defining Raynaud's disease.

***Table 33.8. Raynaud's Disease versus Raynaud's Phenomenon***

Symptoms in vasospastic conditions result from inadequate vascular structure, inappropriate vascular control mechanisms, or both. Adequate tissue perfusion requires delivery of blood to nutritional capillary beds in sufficient quantity to fulfill metabolic needs, appropriate oxygen-carrying capacity, and diffusion of oxygen through intravascular spaces to functioning cellular structures. In the majority of patients, oxygen and metabolic-carrying capacity within the vascular system is adequate. In the absence of intravascular fibrosis and cell death, symptoms are secondary to inadequate delivery of blood products at a cellular level (ischemia). Vasospasm decreases total flow, shunts blood through nonnutritional thermoregulatory pathways, or, in some cases, does both.

### CLASSIFICATION

Although vasospastic disease, occlusive disease, and vasoocclusive disease are interrelated, they are physiologically distinct (Table 33.4). Group I patients have idiopathic Raynaud's disease, which is characterized by normal vascular architecture, no identifiable underlying etiology, and the presence of vasospasm. Group II patients exhibit Raynaud's phenomenon secondary to collagen vascular disease and may be classified as either (a) those with normal circulation or (b) those with compromised circulation. Group III patients have secondary vasospasm due to vascular injury and may be classified as either (a) those with uncompromised collateral flow or (b) those with abnormal collateral flow. Group IV patients without pre-existing or acquired structural or vascular abnormality have secondary vasospasm after sustaining an injury to nerves, soft tissue, bone, or any combination thereof. These categories provide criteria that allow treatment to be based on anatomic and physiologic considerations.

The clinical manifestations of vasospastic states result from inadequate nutritional perfusion, insufficient delivery of oxygen and metabolites to cellular structures, and the development of an anaerobic and acidotic tissue environment. Raynaud's phenomenon classically has three stages that progress from normal to blanched (white) to cyanotic (blue) to rubrous (red). Sympathetic hyperactivity stimulated by exposure to cold or other stresses initiates intense vasospasm with cessation of arterial inflow and the production of a white, blanched, and cool digit (stage 1). Stasis within the digit produces deoxygenated, pooled blood that appears cyanotic or bluish and produces the characteristic blue hue seen in stage 2 of the phenomenon. The rubor (redness) in stage 3 is secondary to reactive hyperemia from a rebound vasodilatation initiated by the ischemia; reperfusion is associated with burning pain, dysesthesias, or both. Therapeutic approaches are designed to increase microvascular flow and maximize capillary perfusion.

### DIAGNOSIS

Take a complete history, perform a physical examination, and order appropriate laboratory studies (35). Pursue a diagnostic strategy to delineate physiologic events (i.e., vessel structure, vascular function and control, and intravascular blood components) and to determine precipitating local or systemic processes or disease (e.g., collagen vascular disease, arterial occlusion, neurovascular compression, hematologic abnormality, trauma, smoking, drugs or toxins, central nervous system disease, or primary vasospasm). Specifically, diagnostic goals should

- Differentiate vasospastic from vasoocclusive states.
- Separate Raynaud's disease from secondary Raynaud's phenomenon.
- Evaluate the effects of structural compromise versus functional impairment.

The existence of nonhealing ulcerations and impending gangrene, which are associated with unilateral Raynaud's symptoms, is presumptive evidence of thrombosis or embolism.

Evaluate pulses, and look for trophic change, ulcerations, and infections. Wrist-level and digital Allen testing is a valuable screening test for distal occlusive disease and may be enhanced by digital plethysmography and measurement of segmental arterial pressures. Check capillary refill, turgor, skin integrity, and sensibility. Perform appropriate nerve conduction studies if there is a suspicion of neurologic dysfunction and neurologic symptoms. Use laboratory tests to look for hematologic or collagen vascular abnormalities.

The noninvasive vascular evaluations outlined previously may be employed in order to delineate the structural and functional influences on perfusion of the upper extremity. Digital plethysmography and temperature measurements with and without stress are most commonly used. Pressure gradients of greater than 20 mm of mercury between two levels in the same extremity or between the affected and contralateral extremity, or a DBI or an RBI of 0.7 or less, suggest stenosis or occlusion (8,48).

Collagen vascular disease can be diagnosed using vital capillaroscopy to document pathognomonic capillary morphologic changes including telangiectasias, abnormal capillary budding, and blunting, dilation, or deformation of papillary capillaries. At present, vital capillaroscopy is the only clinical method to assess directly the nutritional components of digital blood flow. A quantitative and qualitative assessment of digital perfusion is necessary to make an appropriate diagnosis and to plan medical care. Detailed assessments of digital temperature, laser Doppler flowmetry measurements of cutaneous perfusion, and vital capillaroscopy before and after stress allow a determination of the extent of arteriovenous shunting, the adequacy of nutritional flow, and an estimate of total flow available (35,36,50).

Laser Doppler flowmetry reflects nutritional perfusion and provides data regarding thermoregulatory flow components. Combined temperature and plethysmographic data correlate with total perfusion (38). Allen testing and pulse volume recordings provide data regarding vascular structure, which may be delineated maximally by contrast arteriography or—if available—magnetic resonance angiography (16,20). Structural data, complemented by stress testing, provide a functional assessment of extremity flow. A combination of both structural data and functional information is mandatory for optimal evaluation (36).

Contrast arteriography provides the best overall assessment of vascular pathology and structural integrity. Indications for arteriography include potential surgical intervention, unilateral Raynaud's phenomenon, progressive gangrene or ulceration, suspected occlusive or embolic disease, and clinical concerns regarding vascular structural integrity. For patients with decreased perfusion or vasospasm, use isosmotic contrast agents to enhance diagnostic capability and vasodilation through

intraarterial agents (e.g., tolazoline or nitroglycerine) or regional anesthetic block (e.g., axillary block). Vasospasm prevents visualization of vasculature that is otherwise adequate structurally, and the incorrect diagnosis that could result may affect treatment plans.

## INDICATIONS FOR TREATMENT

The majority of patients can be managed without surgery. The treatment of vasospastic disorders must be individualized. Management options include medical therapy, biofeedback, digital sympathectomy, and microvascular reconstruction. Patients with vasospastic symptoms, abnormal autonomic control, and absence of occlusive disease (Group I, Raynaud's disease), frequently respond to nonsurgical modalities and improve spontaneously over time. For patients in Group II (Raynaud's phenomenon) and Group III (occlusive disease), structural and functional information guides treatment decisions. With inadequate collateral circulation (Groups IIB and IIIB), vascular reconstruction is indicated, if possible. Although nonsurgical methods or peripheral sympathectomy may reduce patient symptoms, the prognosis is guarded. Patients in Group IV (secondary vasospasm and normal vasculature) improve with correction of the initiating traumatic event or with appropriate pharmacologic intervention.

## PRINCIPLES OF TREATMENT

- Decrease inappropriate vasospasm by nonsurgical management, if possible.
- Improve nutritional blood flow in the absence of occlusive disease using, in order (a) calcium channel blocker, (b) biofeedback, (c) oral pharmacologic agents, and (d) peripheral sympathectomy.
- In the presence of combined occlusive and vasospastic problems, correct repairable occlusive disease with or without periarterial sympathectomy (PAS).
- In the absence of repairable occlusive disease consider, in order (a) periarterial (peripheral) sympathectomy, (b) phenol or alcohol percutaneous proximal sympathectomy, (c) spinal cord stimulators, and (d) arteriovenous reversal. (Note that the up-regulation of peripheral receptors 6–12 weeks following traditional cervicothoracic sympathectomy may reexacerbate clinical complaints.)

## PREOPERATIVE MANAGEMENT

### *Environmental Modification*

Environmental modification includes advising the patient to stop smoking, avoid cold environments, alter activities to eliminate those that precipitate symptoms, and use protective garments. Cessation of smoking is the most important of these modifications. Patients who live in cold climates have more significant symptoms, which may be ameliorated by the use of mittens or hand-held heating devices. A distinct relationship exists between cold exposure of the head and neck and the reflex vasospasm of hands and feet. Advise patients to use scarves and hats.

### *Biofeedback*

Biofeedback involves instruction in methods that allow the conscious regulation of autonomic body processes. External monitors are used initially, allowing patients to observe how they can elevate their digital temperatures by changing their rate of breathing or thought processes. Biofeedback significantly alleviates symptoms in patients with groups I, IIA, IIIA, and nonneural Group IV etiology, but it is less effective in patients with Group IIB and Group IIIB symptoms (21).

### *Pharmacologic Management*

The goal of pharmacologic intervention is to interrupt or to mitigate sympathetic hyperactivity associated with vasospastic and vasoocclusive disease. Pharmacologic intervention works best in patients with adequate collateral circulation and redistributes flow to nutritional capillary beds by decreasing inappropriate shunting (Fig. 33.13). At present, calcium channel blockers are the drugs of choice for vasospastic symptoms, provide the most reliable palliation of symptoms, have an acceptable level of side effects, and present an excellent risk–benefit ratio (14). Calcium channel blockers prevent calcium influx in vascular smooth muscle and diminish sympathetically driven vasoconstriction. Nifedipine, 10 to 30 ml tid, or in long-acting form (30 to 60 ml qd), and amlodipine besylate (Norvasc), 5 to 10 mg qd, are the drugs employed most frequently. Other drugs include

- Tricyclic antidepressants (amitriptyline, 25-75 mg QHS)
- Serotonin reuptake inhibitors [fluoxetine hydrochloride (Prozac), 20 mg qd; sertraline (Zoloft), 25 to 50 mg qd, and paroxetine (Paxil), 20-50 mg qd]
- Sympatholytic drugs (prazosin hydrochloride, 1 to 2 mg bid to tid; terazosin hydrochloride, 1 to 2 mg qd; clonidine, 0.1 mg bid or by transdermal patch).

## OPERATIVE TECHNIQUES

Surgical options may restore near-normal physiologic function or provide short-term to intermediate-term palliation. Group IV patients with nonvascular injury seldom require surgery. Successful surgical intervention depends on the underlying etiology, the extent and location of vascular insults, and the extent of irreversible end-organ damage. Surgical options include reconstruction of occluded vessels and modification of sympathetic tone (Table 33.7).

### *Alteration of Sympathetic Tone*

Sympathetic tone may be altered by proximal cervicothoracic sympathectomy, Leriche sympathectomy (resection of thrombosed or occluded vessels and ligation) (44), or peripheral periarterial sympathectomy (19,38,54).

Proximal (cervicothoracic) sympathectomy decreases sympathetic tone and improves peripheral blood flow by permanent ablation of the cervical sympathetic trunk and may be performed through an axillary or cervical incision, or by endoscopic technique. Chronic sympathectomy secondary to cervicothoracic interruption of sympathetic fibers decreases total peripheral flow and produces upregulation of distal alpha-adrenergic receptors. It also decreases the efficacy of subsequent peripheral sympathetic modifiers. This procedure, which is often immediately effective, lasts only 6 to 12 weeks in many patients and, after that time, may increase sympathetic tone. Temporary posterior cervicothoracic sympathectomy by phenol injection under computer tomography control is reversible and may be of benefit during collateral vessel maturation.

Peripheral (periarterial) sympathectomy may be performed by a variety of techniques (32). Classically, Leriche observed that resection of a thrombosed segment of occluded artery with ligation proximal and distal stumps decreases abnormal sympathetic tone and improves distal perfusion through collateral circulation. Therefore, peripheral sympathectomy is performed by excision of thrombosed arteries with or without arterial reconstruction. In the presence of Group IIIA occlusive disease and secondary vosospasm, the structurally adequate but abnormally functioning circulation will respond and deliver adequate distal flow to fulfill metabolic requirements. However, in Group IIIB occlusive disease, there is inadequate collateral flow and sympathectomy will be inadequate to restore microvascular perfusion. In primary vasospastic conditions with or without occlusive disease (Groups IIA and IIB), peripheral sympathectomy of digital vessels or wrist-level vessels may be necessary to decrease optimally abnormal tone. The Leriche sympathectomy may be combined with multiple-level peripheral sympathectomy and arterial reconstruction.

1. A Leriche sympathectomy involves the excision and ligation of a thrombosed segment of artery, which interrupts the sympathetic connections from the peripheral nerves to the peripheral arteries as well as the sympathetic fibers that travel on and within the adventitia of peripheral arteries (49). It is preferable to begin in an area of near-normal tissue and to continue the dissection into the area of occlusion. In the case of the ulnar artery, transect the nerve of Henle as well as other connections with the ulnar nerve while protecting the ulnar nerve.
2. Periarterial sympathectomy decreases spasm in the collateral circulation and decreases inappropriate arteriovenous shunting, thereby increasing nutritional flow. If collateral circulation is inadequate or if there are multiple levels of occlusion, a Leriche-type sympathectomy may not provide sufficient palliation.
3. With a digital sympathectomy technique (Flatt and Wilgis) (19,54), digital arteries and nerves are identified through Bruner zigzag incisions from the distal palmar crease to the midportion of the proximal phalanx. All connections between the digital nerve and artery are transected, and the adventitia of the digital artery is stripped from the artery under the operating microscope (19).
4. A palmar or hand sympathectomy technique (Koman) (38) is used to achieve a sympathectomy of all four digits and the thumb. A description of the procedure follows:

- Expose the radial and ulnar artery, the superficial arch, and the three common volar digital arteries by means of three palmar incisions: two parallel 3 cm longitudinal incisions at the wrist and an oblique incision in the palm (Fig. 33.16).

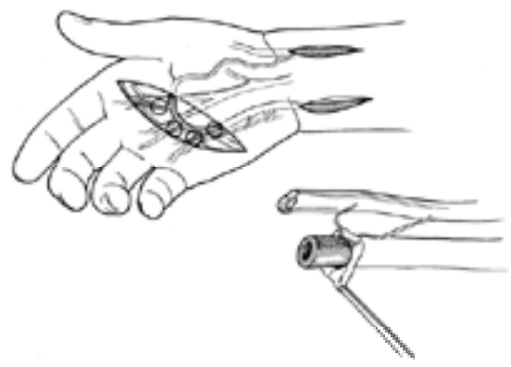

***Figure 33.16.*** Schematic representation of periarterial sympathectomy of the hand using longitudinal incisions to expose the radial and ulnar artery and an oblique incision in the palm to expose the superficial arch and the origins of the common volar digital arteries (Koman technique) is shown. A separate incision (not shown) may be used over the anatomic snuffbox to expose the radial artery. After initial dissection under loupe magnification, the operating microscope is used to strip the adventitial fibers from the vessels and to sever connections with parallel peripheral nerves. (Reproduced from Koman LA, ed. *Bowman Gray School of Medicine Orthopaedic Manual*. Winston-Salem, North Carolina, Wake Forest University Press, 1997; with permission.)

- Transect the connections between the radial and ulnar arteries and their respective nerves over a 3 cm segment. Dissect the adventitia of the radial and ulnar artery under the operating microscope over a length of 2 cm.
- Similarly, after exposure of the proximal portion of the superficial arch and the origins of the three common volar digital arteries, all connections from the peripheral nerves to the arteries are severed, and all periarterial adventitia containing neural tissues is dissected free.
- If there are significant symptoms in the thumb, make a fourth dorsal incision in the anatomic snuffbox, and expose and mobilize the deep branch of the radial artery and the origin of the deep arch. Remove the adventitia (Fig. 33.16) (38).

### *Arterial Reconstruction*

Arterial reconstruction is indicated in patients with refractory symptoms and inadequate collateral circulation (Group IIB and IIIB) (32,38). Vascular reconstruction in Group IIA and IIIA patients should be individualized as described previously. The goal of surgical reconstruction is to increase digital perfusion pressure and nutritional flow in ischemic digits (28,48) by (a) end-to-end repair, (b) interposition grafting, or (c) bypass grafting of the occluded vascular areas. Also important is functional modification of sympathetic tone resulting from the peripheral sympathectomy associated with the vascular resection. Successful arterial reconstruction in patients with underlying collagen-vascular disease increases total digital flow and nutritional flow, diminishes symptoms, and promotes healing of ulcers (38,39).

In extremities with inadequate collateral circulation or unreconstructible distal occlusion, successful reconstruction of a concurrent proximal occlusion increases total digital flow and nutritional flow, decreases symptoms, and allows ulcers to heal (39). In contradistinction, Leriche resection of the proximal occluded segment combined with peripheral digital and palmar sympathectomy improves nutritional flow by the elimination of inappropriate arteriovenous shunting but does not increase total flow (38). The technique for reconstruction is similar to that used in occlusive disease.

## AUTHORS' PERSPECTIVE

The selection of treatment modalities is determined by pathophysiology, and the treatment goal should be directed at appropriate distribution of digital flow to provide adequate nutritional capillary flow sufficient to meet metabolic demands under stressed and nonstressed conditions. Treatment decisions are aided by a knowledge of structural and functional characteristics and the classification of the vasospastic state (Table 33.4). For example, Raynaud's phenomenon with inadequate circulation (Group IIB) is the condition most refractory to treatment and Group IIB patients have the highest incidence of ulceration. Conversely, patients in Group I (Raynaud's disease) and Group IV (secondary vasospasm from a nonvascular injury) have the best prognosis, rarely have ulcerations, progress infrequently to gangrene, and often respond to oral medications or biofeedback and improve spontaneously.

Environment modification, pharmacologic agents, and biofeedback are often effective in Group I (Raynaud's disease), Group IIA (Raynaud's phenomenon with adequate circulation), and Group IV (secondary vasospasm without arterial compromise). These patients have normal vasculature, but abnormal vascular reactivity secondary to abnormal sympathetic control. In patients with inadequate collateral circulation or inadequate circulation (Groups IIB and IIIB), the prognosis is guarded unless arterial reconstruction can be successfully achieved. The use of periarterial sympathectomy in patients with inadequate circulation is a salvage procedure.

Selection of candidates for periarterial sympathectomy is controversial. An increased digital temperature or pulse volume recording and decreased symptoms after wrist or digital block with lidocaine or bupivacaine confirm abnormal sympathetic tone and that sympathectomy will provide palliation. Of note, in response to sympathetic blockade, patients with vasoocclusive disease and inadequate collateral circulation are unlikely to be able to increase digital temperatures—a reflection of total flow. In a percentage of these extremities, however, nutritional flow is maximized, inappropriate arteriovenous shunting is decreased, ulcers heal, and symptoms decrease. This group of patients benefits the most from periarterial sympathectomy. The surgeon must have a thorough knowledge of the diagnostic tests and their interpretation to identify them (38). Although surgical statistics would be improved by eliminating this group of patients, some of whom do not have sufficient flow to respond successfully, it is this group of patients that needs a palliative procedure the most. The role of arteriovenous reversal in vasoocclusive disease represents an additional modality and deserves investigation. Although short-term relief is dramatic, long-term efficacy has not yet been demonstrated in the peer-reviewed literature.

## CHAPTER REFERENCES

Each reference is categorized according to the following scheme: *, classic article; #, review article; !, basic article; and +, clinical results/outcome study.


! 1. Abramson DI. Neural Regulation of Cutaneous Circulation. *Advanced Biology of the Skin* 1972;12:207.

* 2. Allen EV. Thromboangiitis Obliterans: Methods of Diagnosis of Chronic Arterial Lesions Distal to the Wrist with Illustrative Cases. *Am J Med Sci* 1929;178:237.

+ 3. Anderson RJ, Hobson RW, Lee BC, et al. Reduced Dependency on Arteriography for Penetrating Extremity Trauma: Influence of Wound Location and Noninvasive Vascular Studies. *J Trauma* 1990;30:1059.

# 4. Babu SC, Piccorelli GO, Shah PM, et al. Incidence and Results of Arterial Complications among 16,350 Patients Undergoing Cardiac Catheterization. *J Vasc Surg* 1989;10:113.

+ 5. Baffour R, Danylewick R, Burdon T, et al. An Angiographic Study of Ischemia as a Determinant of Neovascularization in Arteriovenous Reversal. *Surg Gynecol Obstet* 1988;166:28.

+ 6. Ben-Menachem Y. Vascular Injuries of the Extremities: Hazards of Unnecessary Delays in Diagnosis. *Orthopedics* 1986;9:333.

+ 7. Borman KR, Snyder WM III, Weigelt JA. Civilian Arterial Trauma of the Upper Extremity. *Am J Surg* 1984;148:796.

# 8. Buehner JW, Koontz CL. The Examination in the Vascular Laboratory. *Hand Clin* 1993;9:5.

+ 9. Buerger L. Thrombo-angiitis Obliterans: A Study of the Vascular Lesions Leading to Presenile Spontaneous Gangrene. *Am J Med Sci* 1908;136:567.

# 10. Burrows ME. Pharmacology of Arterioles. *Biblthea Anat* 1981;20:334.

+ 11. Bussell JA, Abbott JA, Lim RC. A Radial Steal Syndrome with Arteriovenous Fistula for Hemodialysis. *Ann Intern Med* 1971;75:387.

* 12. Coleman SS, Anson BJ. Arterial Patterns in the Hand Based Upon a Study of 650 Specimens. *Surg Gynecol Obstet* 1961;4:409.

+ 13. Coursley G, Ivins JC, Barker NW. Congenital Arteriovenous Fistulas in the Extremities. *Angiology* 1956;7:201.

# 14. Czop C, Smith TL, Koman LA. The pharmacologic approach to the painful hand. *Hand Clin* 1996;12:633.

+ 15. Debakey ME, Simeone FA. Battle Injuries of the Arteries in World War II. *Ann Surg* 1946;123:534.

+ 16. Disa JJ, Chung KC, Gellad FE, et al. Efficacy of Magnetic Resonance Angiography in the Evaluation of Vascular Malformations of the Hand. *Plast Reconstr Surg* 1995;99:136.

+ 17. Earnshaw JJ, Cosgrove C, Wilkins DC, Bliss BP. Acute Limb Ischaemia: The Place of Intravenous Streptokinase. *Br J Surg* 1990;77:1136.

! 18. Edwards EA. The Anatomy of Collateral Circulation. *Surg Gynecol Obstet* 1958;107:183.

+ 19. Flatt AE. Digital Artery Sympathectomy. *J Hand Surg* 1980;6:550.

+ 20. Frykberg ER, Crump JM, Vines FS, et al. A Reassessment of the Role of Arteriography in Penetrating Proximity Extremity Trauma: A Prospective Study. *J Trauma* 1989;29:1041.

+ 21. Fulcher SM, Smith TL, Holden MB, Koman LA. Does Transdermal Nicotine Adversely Affect Digital Microvascular Flow During Acute Cigarette Withdrawal? *American Society for Reconstrucive Microsurgery* 1997;64(Abstract).

+ 22. Gelberman RH, Blasingame JP. The Timed Allen Test. *J Trauma* 1981;21:477.

+ 23. Gelberman RH, Blasingame JP, Fronek A, Dimick MP. Forearm Arterial Injuries. *J Hand Surg* 1979;4:401.

+ 24. Gelberman RH, Menon J, Fronek A: The Peripheral Pulse Following Arterial Injury. *J Trauma* 1980;20:948.

+ 25. Gelberman RH, Nunley JA, Koman LA, et al. The Results of Radial and Ulnar Arterial Repair in the Forearm. *J Bone Joint Surg* 1982;3:383.

+ 26. Graham AM, Baffour R, Burdon T, et al. A Demonstration of Vascular Proliferation in Response to Arteriovenous Reversal in the Ischemic Canine Hind Limb. *J of Surgical Research* 1989;47:341.

+ 27. Greenberg BM, Cuadros L, Jupiter JB: Interpositional Vein Grafts to Restore the Superficial Palmar Arch in Severe Devascularizing Injuries of the Hand. *J Hand Surg* 1988;13A:753.

! 28. Hamilton CA, Yakubu MA, Howie CA, et al. Desensitization and Down-regulation of Brain Alpha2-adrenoceptors by Centrally Acting Antihypertensive Drugs. *Br J Clin Pharmacol* 1990;30:131S.

! 29. Hansson R, Jonsson O, Lundstam S, et al. Effects of free radical scavengers on renal circulation after ischaemia in the rabbit. *Clin Sci* 1983;605.

+ 30. Jacobs MJHM, Jorning PJG, Joshi SR, et al. Epidural Spinal Cord Electrical Stimulation Improves Microvascular Blood Flow in Severe Limb Ischemia. *Ann Surg* 1988;207:179.

+ 31. Jones J, McLaughlin JF. Mechanical Efficiency of Children with Spastic Cerebral Palsy. *Dev Med Child Neurol* 1993;35:614.

+ 32. Jones NF. Ischemia of the Hand in Systemic Disease. *Clin Plast Surg* 1989;16:547.

+ 33. Joyce JW. Buerger's Disease (Thromboangiitis Obliterans). *Rheum Dis Clin North Am* 1990;16:463.

+ 34. King TA, Marks J, Berrettoni BA, Seitz WH. Arteriovenous Reversal for Limb Salvage in Unreconstructible Upper Extremity Arterial Occlusive Disease. *J Vasc Surg* 1993;17:924.

# 35. Koman LA. Current Status of Noninvasive Techniques in the Diagnosis of Upper Extremity Disorders. In: Evarts CM, ed. *Instructional Course Lectures.* St. Louis: C. V. Mosby Company, 1983:61.

# 36. Koman LA. Diagnostic Study of Vascular Lesions. *Hand Clin* 1985;2:217.

# 37. Koman LA. Venous Grafts for Ulnar Artery Thrombosis. In: Blair WF, ed. *Techniques in Hand Surgery.* Baltimore: Williams & Wilkins, 1996:1155.

+ 38. Koman LA, Smith BP, Pollock F, et al. The Microcirculatory Effects of Peripheral Sympathectomy. *J Hand Surg* 1995;5:709.

+*39. Koman LA, Smith TL, Smith BP, et al. Arterial Reconstruction in the Ischemic Hand and Wrist: Effects on Microvascular Physiology and Health-related Quality of Life. *J Hand Surgery* 1998;23A:773.

+*40. Koman LA, Urbaniak J. Ulnar Artery Insufficiency: A Guide to Treatment. *J Hand Surg* 1981;1:16.

+ 41. Labosky DA. Selective Heparinization of Venous Anastomosis in Latissimus Dorsi Free Flaps to Cover Lower-extremity Soft-tissue Defects. *Microsurgery* 1991;12:301.

! 42. Lawrence HW. The Collateral Circulation in the Hand. *Industrial Medicine* 1937;7:410.

+ 43. Lee RE. Acute Penetrating Arterial Injuries of the Forearm. *Am Surg* 1985;51:318.

+ 44. Leriche R, Fontaine R, Dupertuis SM. Arterectomy with Follow-up Studies on 78 Operations. *Surg Gynecol Obstet* 1937;64:149.

+ 45. McNamara MF, Takaki HS, Yao JST, Bergan JJ. A Systematic Approach to Severe Hand Ischemia. *Surgery* 1978;83:1.

+ 46. Mennes PA, Gilula LA, Anderson CB, et al. Complications Associated with Arteriovenous Fistulas in Patients Undergoing Chronic Hemodialysis. *Arch Intern Med* 1978;138:1117.

+ 47. Menzoian JO, Corson JD, Bush HL Jr, LoGerfo FW: Management of the Upper Extremity with Absent Pulses After Cardiac Catheterization. *Am J Surg* 1978;135:484.

# 48. Miller LM, Morgan RF. Vasospastic Disorders, Etiology, Recognition, and Treatment. *Hand Clin* 1993;9:171.

! 49. Morgan RF, Reisman NR, Wilgis EFS. Anatomic Localization of Sympathetic Nerves in the Hand. *J Hand Surg* 1983;8:283.

+ 50. Nunley JA, Koman LA, Urbaniak JR. Arterial Shunting as a Adjunct to Major Limb Revascularization. *Am Surg* 1981;193:271.

+ 51. Raskin KB: Acute Vascular Injuries of the Upper Extremity. *Hand Clin* 1993;9:115.

+ 52. Rich NM, Baugh JH, Hughes CW: Acute Arterial Injuries in Vietnam: 1,000 Cases. *J Trauma* 1970;10:359.

+ 53. Rich NM, Hobson RW, Fedde CW: Vascular Trauma Secondary to Diagnostic and Therapeutic Procedures. *Am J Surg* 1974;128:715.

! 54. Tsuru H, Negita S, Teranishi Y, Sasa M. Release of Sympathetic Neurotransmitter Evoked by Electrical Stimulation is Increased in the Chronically Decentralized Artery. *Jpn J Pharmacol* 1993;63:285.

+ 55. Widlus DM, Venbrux AC, Benenati JF, et al. Fibrinolytic Therapy for Upper-extremity Arterial Occlusions. *Interventional Radiology* 1990;175:393.

# CHAPTER 34

# REPLANTATION

*James R. Urbaniak*

**J. R. Urbaniak:** Division of Orthopaedic Surgery, Department of Surgery, Duke University School of Medicine, Durham, North Carolina 27710.

Indications for Replantation
Surgical Technique of Replantation
Preparation of the Amputated Part and Preoperative Care
Initial Management of the Amputated Part and Patient
Operative Sequence
Bone Shortening and Stabilization
Extensor Tendon Repair
Flexor Tendon Repair
Vascular Repair
Nerve Repair
Skin Coverage and Dressing
Major Limb Replantation
Shunting
Bone Fixation
Debridement
Sequence of Vessel Repair
Fasciotomies
Second Look
Postoperative Management and Rehabilitation
Environment
Anticoagulation and Antibiotics
Monitoring
Activity
Pitfalls and Complications
Acute Complications
Subacute Complications
Chronic Complications
Results
Chapter References

Successful clinical replantation of completely severed limbs has been possible for nearly 40 years. The first successful reattachment of a completely severed human limb was reported by Malt et al. in Boston in 1962 (55). Komatsu and Tamai (50) have been credited with successful replantation of a completely severed digit in 1965. Zhong-Wei et al. (102) reported the successful replantation of a severed digit the same year. Over the past three decades, several microsurgery centers throughout the world have achieved greater than 80% success rates in replanting severed digits, hands, and major limbs (6,7,10,14,32,33,34,37,45,47,48,52,57,63,64,68,70,77,82,87,96,99,100 and 101,103,104). Additional experience, subspecialization in microsurgery with the increased knowledge and surgical skills in this field, improvements in microscopes, ultrafine needles, microsuture materials, and other new and improved instruments have made replantation the procedure of choice for the management of many amputations (1,4,11,82,88,89).

The most important factor determining the patency of the anastomosis and survival of the replanted or revascularized part is the technical adequacy of the microvascular repair (82). Successful microsurgery requires familiarity with the operating microscope and microsurgical instruments and the careful handling of small vessels and surrounding tissues. These skills must be learned in the animal laboratory, not in the clinical operating room. After the surgeon has demonstrated proficiency in the repair of microvessels and nerves, in the animal laboratory, then these skills may be transferred to the operating room. In addition, replantation of amputated parts should be done by surgeons who are thoroughly trained in surgery of the upper extremity and hand and who have had sufficient clinical experience to be able to predict the outcome following replantation of a severed part.

## INDICATIONS FOR REPLANTATION

Among the factors that must be considered in deciding to replant an amputated extremity are the predicted morbidity to the patient; survival of the replanted part; functional outcome of the reconstructed limb; and the overall financial burden to the patient, insurance carrier, or society (83). The predicted function after replantation should be better than that of a prosthesis or amputation revision. Because the ultimate functional result may be unpredictable, the decision of whether to replant an amputated part is often difficult, even for the experienced reconstructive surgeon.

Replantation experience does help in the selection process. Based on the experience of more than 1,800 attempted replantations over a 25-year period by my colleagues and me, we have developed criteria for proper patient selection. The surgeon must understand that not only viability but also recovery of useful function determine success in replantation.

Factors that influence the selection process include the following:

- Level of amputation
- Severity of injury (guillotine versus crush or avulsion)
- Warm and cold ischemia times
- Age of patient
- Segmental injuries
- General health of patient
- Vocation
- Predicted rehabilitation

It is generally unwise to allow patients or families to make the decision regarding replantation because they will usually request replantation even in cases where there is little chance of survival or function of the replanted part. The final decision must rest with the surgeon in collaboration with the patient. Social, ethnic, and religious beliefs about the significance of loss of the amputated part do influence the surgeon's decision regarding replantation, however.

No listing of indications or contraindications for replantation is rigid or absolute, and the criteria, although generally similar for most replantation surgeons, vary with individual experience (83). Future experience with replantation and technological advances in externally powered prostheses are likely to further alter these criteria. On the basis of this standard, good candidates for replantation are those with amputations of the following types:

- Wrist (Fig. 34.1)

***Figure 34.1.*** Good candidates for replantation include amputations at the level of the wrist. **A,B:** A complete amputation at the wrist level in a 21-year-old man. **C,D:** The amount of digital flexion (**C**) and extension (**D**) seen in this patient 3 years following successful replantation. (From Porubsky GL, Urbaniak JR. Limb and Digital Replantation. In Flye MW, ed. *Principles of Organ Transplantation.* Philadelphia: WB Saunders, 1989.)

- Partial hand (through metacarpal level of palm) (Fig. 34.2)

***Figure 34.2.*** **A,B:** Complete amputation of the left index and long finger through the metacarpals in a 20-year-old man. The amputated part was reattached as a composite. **C,D:** Flexion (**C**) and extension (**D**) 1 year later. The patient lacks 5 mm of touching the distal palmar crease with the index finger and 4 mm with the long finger. He returned to work as a meatcutter 3.25 months after the injury.

- Thumb (Fig. 34.3)



***Figure 34.3.*** **A:** Dominant thumb of a 16-year-old boy was avulsed by a nylon rope. **B,C:** Replantation resulted in less than 5 mm of two-point sensory discrimination and individual interphalangeal and metacarpophalangeal flexion and extension. (From Urbaniak JR. *Replantation of Amputated Hands and Digits. American Academy of Orthopaedic Surgeons Instructional Course Lectures, Vol. 27.* St. Louis: CV Mosby, 1978.)

- Multiple digits
- Forearm
- Almost any body part of a child
- Elbow and above elbow (only sharply severed or moderately avulsed)
- Individual digit distal to the flexor superficialis insertion

Even though these are not necessarily rigid indications for replantation, if all other factors are favorable one should attempt replantation of these amputated parts.

Successful replantations at the level of the palm, wrist, and distal forearm result in good hand function (52,66,77,94,101) (Fig. 34.1). Usually, amputations proximal to the midforearm level are of a crushing or avulsing nature, which produces considerable muscle trauma. Myonecrosis and subsequent infection are common problems with this type of replantation, particularly at the elbow or brachial level; therefore, be extremely selective in choosing replantation at these levels.

Make every effort to salvage the amputated thumb in patients of all ages. A replanted thumb is far better than any type of reconstructed thumb to replace one that has been amputated (5,31,58,68,73,95) (Fig. 34.3). Attempt replantation even as far distal as the nail base if vessels for revascularization can be located. If the patient is healthy, there is no upper age limit (33,75).

When multiple digits are amputated, a decision must be made about whether to replant all or just some of the digits (47,82). The digits that are least damaged may be transposed to the most useful or least injured amputation stumps (2,71). For example, if the thumb and index finger have been completely amputated in a crushing injury and the distal thumb has irrepairable distal vessels, transpose the amputated index finger to the thumb stump. This alteration should result in excellent thumb function and cosmetic acceptability.

The level of the amputated digit influences the decision for replantation. Amputations at or distal to the distal interphalangeal joint of the fingers or the interphalangeal joint of the thumb can be successfully replanted if dorsal veins can be located on the amputated part (21,25,26,36,41,43,54,59,75,81,91,98). As a general rule, at least 4 mm of dorsal skin proximal to the base of the nail plate must be present for locating veins suitable for repair.

We replant amputations distal to the superficialis insertion; an excellent functional result can be achieved, and the operating time is not long (usually less than 4 h) (33,87). Replantations at this level are usually successful (greater than 90% viability rate), provide a good appearance, are not painful, allow good function, eliminate the potential for painful neuromas, and permit an early return to work (usually less than 3 months) (16,33,87).

In children, attempt to replant almost any amputated body part because, if the reattached part survives, useful function can be predicted (20,84).

Just as indications for replantation are not absolute, neither are contraindications. Injuries generally not considered ideal for replantation include:

- Amputations in patients with other serious injuries or diseases
- Amputations at multiple or segmental levels
- Severely crushed or avulsed parts
- Amputations in which the vessels demonstrate arteriosclerosis

- Amputations in mentally unstable patients
- Amputations with prolonged warm ischemia time (more than 6 h)
- Individual finger amputations in the adult at a level proximal to the superficialis insertion (proximal interphalangeal joint or proximal)

Severe crushing or avulsing amputations can often be salvaged with the use of vein grafts to replace the injured vessels (3,9,85); however, there are no methods for replacing the most distal vessels in the amputated part. Because arteriosclerotic plaques on the intima often preclude functional patency following the reanastomosis of small vessels, the arteries of older patients must be thoroughly evaluated under the microscope before reattachment. In addition, patients with diabetes mellitus may have diseased blood vessels, which would lessen the likelihood that repaired vessels will remain patent. Again, the experienced microsurgeon can determine the potential success of an anastomosis by studying the vessel structure under a high-powered microscope.

Although it is possible to reconstruct amputations that have been severed at multiple levels (for example, in the phalanges and midpalm or at the elbow and above the elbow, in the same patient), replantation is usually not recommended because the time commitment is large and the predicted outcome is uncertain (8).

The patient's mental stability is a component of the decision regarding replantation. Mental instability is not uncommon in patients who sustain completely amputated upper extremities, but it is often difficult to determine the patient's mental stability during the limited preoperative assessment stage.

Based on assessment of isolated digital replantation, we recommend not replanting the isolated finger amputation proximal to the flexor superficialis tendon insertion. Although the cosmetic result is excellent, the overall function of the hand is usually not improved; in fact, this digit sometimes gets in the way. Special considerations, such as for musicians, young women, and children, do influence selection, however (72,87). The patient with a replanted index finger that was amputated at the base will usually bypass the replanted digit to oppose the thumb to the long finger.

The surgeon must explain to the patient and family the chances of viability, length of surgery and hospitalization, anticipated functional outcome, predicted loss of time from work, and cost compared with an amputation revision. Equipped with all of this information, most patients and families will insist on replantation; therefore, the ultimate decision rests with the surgeon. On many occasions the final decision cannot be made until the vessels of the amputated part are carefully evaluated under the operating microscope.

## SURGICAL TECHNIQUE OF REPLANTATION

### PREPARATION OF THE AMPUTATED PART AND PREOPERATIVE CARE

#### *Preservation of the Amputated Part*

Preoperative physiologic storage of amputation parts is essential to achieve success in replantation. Generally, if the warm ischemia time of the amputated part exceeds 6 h, do not attempt replantation. If the amputated part contains muscle, the ischemia time is much more critical. Muscle is extremely sensitive to ischemia, compared with tissues such as skin, bone, and tendon (22,23).

Cooling reduces metabolic acidosis, muscle autolysis, and bacterial growth. All amputated parts should be cooled during the transportation to a replantation center. If the part is cooled, successful replantation is possible with cold ischemia times up to 12 h, or even longer if it is a digit; we have successfully replanted amputated digits with cold ischemia times up to 30 h. However, transportation of the amputated part and the patient should be as rapid as possible.

The amputated part may be preserved by one of the following two basic methods:

1. Wrap the part with gauze moistened with Ringer's lactate or saline solution and place it in a plastic bag, which is then placed on ice.
2. Alternatively, immerse the part in Ringer's lactate or saline solution in a plastic bag and place this bag on ice.

Both methods result in equal viability rates at 24 h, but we prefer the immersion method for the following reasons (92):

1. The part is less likely to become frozen (frostbitten).
2. The part is less likely to be strangled by the wrappings.
3. Instructions are easier to explain to the primary-care physician.
4. Maceration secondary to immersion is not a problem.

#### *Instruments*

The microsurgery instruments are described in detail in Chapter 33, so only the equipment essential for replantation surgery is mentioned here. A great variety of expensive microsurgery instruments are unnecessary; the appropriate instruments must be available, however, and the working ends must be well maintained for precision handling of the small microstructures, fine needles, and suture material (Fig. 34.4) (11,83,88). Basic replantation surgery instruments include the following:



***Figure 34.4.*** Basic microsurgery instruments for replantation. **Left to right, bottom row:** Micro-Pots (angled) scissors, spring-loaded curved tipped microscissors, spring-loaded needle holder, two jeweler's forceps, 30-gauge blunt needle syringe for irrigation. **Top row:** Lacrimal duct dilator (**below**), latex background material (**above**), microclip approximator (**below**), Van Beek nerve approximator (**above**), and small cotton absorbent sponge sticks.

- *Surgical loupes* of 3.5× to 4.5× are necessary for the initial debridement, exploration, and dissection of the amputated part and injured extremity.
- An *operating microscope* with magnification to at least 20× is essential. Preferably, the operating microscope should have a beam splitter and a double head that allows the surgeon and the first assistant to visualize the same microfield. Foot controls for focusing, zoom magnification, and horizontal *xy* movement are ideal. We use the microscope for the repair of any vessels distal to the axilla.
- *Microinstruments* should be at least 10 cm long to allow the handles to rest comfortably in the thumb–index webspace. Instrument handles at least 15 cm long are recommended for all microsurgery instruments to increase the versatility of the instruments when operating in deep fields.

Essential instruments include the following:

- A *spring-loaded needle holder* and *spring-loaded microscissors*
- Two sets *of jeweler's forceps*
- A *microtipped dilator* (lacrimal duct dilator)
- A *microirrigator* (30-gauge smooth-tipped needle)
- Various-sizes of (*approximator*) microclips mounted on some type of bar

The less complex the microclip the better; I prefer the disposable type with two plastic tips mounted on a metal sliding bar. The use of a new clip or microapproximator

for each procedure better assures a constant pressure of less than 30 g/cm. Other helpful equipment includes:

- Small *hemoclips* to tag the vessels and nerves and to use when isolating or harvesting vessels
- A *small-tipped bipolar cautery*, essential in isolating and mobilizing the vascular structures to be repaired.

Some type of colored rubber *background material* is useful in highlighting the vessels and suture material. I prefer a yellow background material, particularly if the lighting is low.

The level of the replantation determines the selection of needle and suture size for the vascular repairs. Table 34.1 suggests the appropriate needle and suture size for amputations at the wrist level or distal. An 8-0 or even 7-0 suture may be used proximal to the elbow.

| Location | Needle size | Suture size |
|---|---|---|
| Wrist and forearm | 130 | 9-0 |
| Palm | 100 | 10-0 |
| Proximal digit | 50–75 | 10-0 |
| Distal digit | 50 | 11-0 |

***Table 34.1. Needle and Suture Sizes for Wrist Amputation***

## INITIAL MANAGEMENT OF THE AMPUTATED PART AND PATIENT

### *Anesthesia*

Most replantations can be performed under axillary block with bupivacaine, a long-acting local anesthetic. Regional anesthesia is favored because of the peripheral autonomic block, which increases vasodilation and peripheral blood flow (25). Some inhalation anesthetics may result in vasospasm and diminished peripheral blood flow. General anesthesia is necessary in the uncooperative patient or for children 12 years old or younger. Keep the operating room warm at all times to diminish peripheral vasospasm caused by cooling of the body temperature.

### *Team Responsibilities*

It is advantageous for the replantation team to divide into two subteams (here designated teams A and B) when the patient and the amputated part arrive in the emergency room. This practice is more critical with major limb replantations. Surgeons without microsurgical experience may help prepare the amputated part and patient; however, they must be experienced in dissecting the small vessels lest irreparable damage may occur. They may, however, be quite helpful in the bone trimming, bone fixation, and tendon repair and subsequent wound coverage.

**Team A Responsibilities** Team A responsibilities include the following duties and surgical techniques:

- Immediately transport the amputated part to the operating room for initial cleansing with Hibiclens and sterile Ringer's lactate solution.
- Place the prepared amputated part on a bed of ice covered with a sterile plastic drape. If multiple digits are involved, these may be cooled by storage in a refrigerator or under ice packets until the appropriate time for replantation. Care must be taken not to freeze them.
- Under the operating microscope or with operating loupes (depending on the size of the amputated part), carefully debride the part or parts and identify and tag the nerves and vessels with small hemoclips. This identification and tagging of the neurovascular structures will save time when microsurgeons have to work in a bloody field at a later time. The ease in locating the tagged structures, particularly in multiple amputations, is definitely beneficial in the later stages of replantation, particularly if the procedure is lengthy and fatiguing.
- Make bilateral longitudinal midlateral incisions, which provide the most rapid and best exposure of the neurovascular structures on the digits (Fig. 34.5). Place the incisions slightly toward the dorsum so that both the dorsal and palmar skin flaps can be reflected to locate the veins, nerves, and arteries with ease.

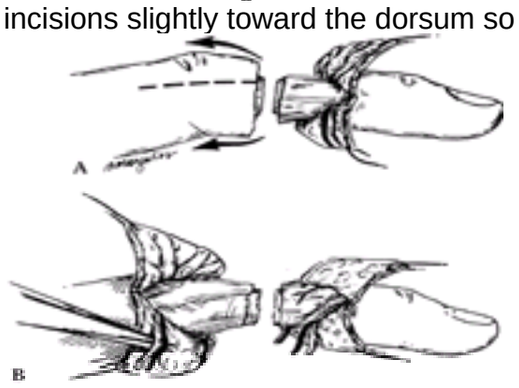


***Figure 34.5.*** **A:** Bilateral longitudinal midlateral incisions. **B:** Neurovascular bundles exposed palmarly and veins exposed dorsally. (From Urbaniak JR. Replantation in Children. In Serafin D, Georgiade NG, eds. *Pediatric Plastic Surgery.* St. Louis: CV Mosby, 1984:1168.)

- Using magnification, isolate the digital nerves and vessels for a distance of 1.5 to 2 cm and tag them.
- Identify the dorsal veins on the amputated part by reflecting the entire dorsal flap of skin and dissecting the subdermal tissue. In the amputated digit, locating and labeling the veins may be delayed until after arterial anastomosis, which makes identification of veins easier because of the backbleeding, particularly if the patient and amputation stump are ready to receive the amputated part. If the patient is not yet prepared to receive the amputated part, however, then search for the veins at this time to reduce the overall operating time.
- Continue additional debridement after isolation and labeling of the neurovascular bundles.
- Shorten and trim the bone appropriately on the amputated digit.
- Insert an intramedullary Kirschner wire retrograde in the amputated part so the part is prepared for immediate reattachment. If the bone is closely surrounded by soft-tissue structures, a 16-gauge hypodermic needle serves as an excellent protector guide for the 0.45 Kirschner wire.

**Team B Responsibilities** Team B's activities are concurrent with those of team A. Team B's responsibilities include the following tasks and techniques:

- Thoroughly evaluate the patient in the emergency room with a physical examination, radiographs of the chest and injured extremity, cardiogram, complete blood count, blood chemistries, urinalysis, blood type and cross-match, and activated partial thromboplastin time.
- Begin intravenous fluids and administer intravenous antibiotics and tetanus prophylaxis if indicated. Insert an indwelling urethral catheter if a long procedure is anticipated.
- Using magnification and tourniquet ischemia, debride the stump and locate and label the neurovascular structures in a manner similar to the preparation used by Team A on the amputated part.
- It may be difficult to locate the subcutaneous veins on the stump, particularly for the inexperienced surgeon. Because successful replantation depends on the patency of an adequate number of veins, this is a *critical point* of the operation. Isolating veins in the digit may be tedious and requires meticulous dissection and careful handling of these small structures. After one good vein is located in the subcutaneous layer, this vein may serve as a guide to direct the surgeon to similar veins in the same subdermal plane.

## OPERATIVE SEQUENCE

The sequence of repair of the severed structures in replantation will vary slightly depending on the level of amputation (digit versus levels proximal to the wrist) and type of injury (sharp versus avulsion). The technique of replanting amputated digits is described first because these amputations are much more common than the more proximal amputations. The variations in technique used for major limb replantations are described subsequently.

Repair for digit and hand replantation takes place in the order indicated in Table 34.2.

1. Vessel and nerve identification and labeling
2. Tissue debridement
3. Bone shortening and stabilization
4. Extensor tendon repair
5. Flexor tendon repair
6. Arterial anastomoses
7. Nerve repair
8. Venous anastomoses
9. Skin coverage (fasciotomies when indicated)

***Table 34.2. Order of Repair for Digit and Hand Replantation***

Once the vessels and nerves are located and tagged, protect these neurovascular structures during the debridement. *Do not, in haste to reestablish blood flow, compromise on the irrigation and debridement. A thorough wound debridement is essential*. A pulsating jet lavage is useful in severely contaminated major limb replantations. Excise all necrotic and potentially necrotic tissue, particularly muscle.

*All structures are repaired primarily, even if primary nerve grafting is necessary for approximation of the severed nerves*. It is much easier to make repairs at the time of the initial reconstruction than to reoperate secondarily through the repaired structures of the replanted part.

## BONE SHORTENING AND STABILIZATION

*Never anastomose arteries, veins, and nerves under tension*. Sufficient bone must be resected to ensure the ease of approximation of normal intima in the vascular anastomosis. Additionally, bone shortening allows easier skin coverage of the repaired veins, particularly on the dorsum of the digits. The amount of resected bone depends on the type of injury. In an avulsion or crushing type of injury, more bone must be resected until normal intimal coaptation is possible without tension. For the digit, it is usually necessary to resect 5 to 10 mm of bone; in amputations proximal to the hand, 2 to 3 cm of bone resection may be indicated. In the avulsion type of injury, even more bone resection is done. If it appears that a great deal of bone must be resected in the digit or in partial hand amputations, use *vein grafts* to make up the deficit in the arteries and veins rather than doing excessive bone shortening.

Many replantation surgeons emphasize that bone shortening is seldom necessary, and instead they recommend vein grafting when there is considerable intimal damage (52). Bone shortening should usually be chosen over vein grafting, however, because there is often concomitant damage to the nerves and other soft tissues. These injured structures can be more easily managed after bone shortening. However, do not hesitate to perform vein grafts when they are indicated (for example, when the loss of a potentially functional joint may result from bone shortening). This is particularly true for a child, for whom excessive bone resection should be avoided because it results in the excision or potential damage to the epiphysis and joint. Do not hesitate to perform interposition vein grafts when they are necessary; *it is quicker, easier, and less frustrating to perform an interposition graft than to redo a difficult anastomosis several times, or even one time.*

In replantation of the thumb, most of the bone shortening is done on the amputated part to preserve maximal length on the stump in case replantation fails. This is not always possible, as, for example, when attempting to preserve joint function. Several methods of bone fixation are available (Fig. 34.6) (41,79,86,97):

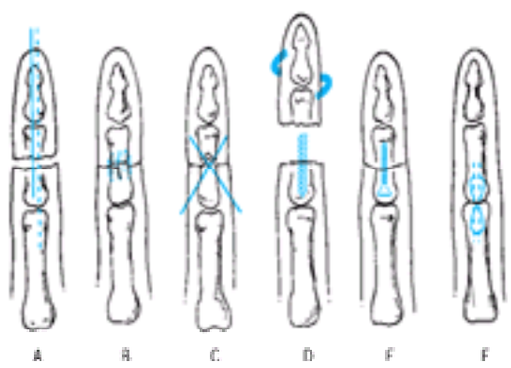


***Figure 34.6.*** Methods of bone fixation in replantation. **A:** Longitudinal intramedullary Kirschner wire or wires (an oblique Kirschner wire may be added to prevent rotation). **B:** Interosseous wiring. **C:** Crossed Kirschner wires. **D:** Intramedullary screw or bone peg. **E:** Miniplates and screws. **F:** Tension band technique.

- Longitudinal intramedullary Kirschner wire or wires
- Longitudinal intramedullary Kirschner wire plus oblique Kirschner wire to prevent rotation
- Crossed Kirschner wires
- Interosseous wiring
- Intramedullary screw or bone peg
- Miniplates and screws
- Tension band technique.

All these methods may be used to stabilize replantations; however, certain methods may be preferred in specific areas, such as near the joint or epiphyseal plates. When possible, it is preferable to perform bone stabilization in a digit with double axial Kirschner wires because the lowest nonunion and complication rates occur with this method (97). This is the easiest and quickest method when a motorized drill is used for careful pin placement. A large-bore hypodermic needle (16-gauge) is often used as a guide to prevent the surrounding soft tissue from wrapping up near the bone ends. *In more than 1,800 replantations, we have experimented with all methods of bone stabilization and prefer single or double axial Kirschner wire fixation for the following reasons:*

- Speed and simplicity of the technique
- Minimal bone exposure required
- Minimal skeletal mass needed for fixation
- Ease of reshortening or readjusting the bone approximation if deemed necessary
- In children, the likelihood of physeal damage is minimal with a single well-centered intramedullary longitudinal pin. A second axial intramedullary pin is frequently used for better stability (29).

Crossed Kirschner wires can cause potential damage in the repaired neurovascular bundles, either by contact or by tethering of the vessels or the protective retaining ligaments. I prefer crossed Kirschner wires for arthrodesis of joints. A chevron bone cut aids stabilization when crossed Kirschner wire fixation or the tension wiring is

used.

For arthrodesis or fixation near the joint, cut the Kirschner wire at the cortex and leave it permanently implanted.

Intramedullary screw fixation is ideal for thumb metacarpal stabilization in replanting a complete amputation at this level. This method is easy and rapid and provides immediate stability. Its use is limited in arthrodesis of other joints because some flexion is usually desired. Immediate fixation allows early motion of the digits; however, the screw is difficult to remove if the replanted digit becomes infected. Bone pegs or other intramedullary devices can be substituted for the screw. Intramedullary devices, however, are not favored in highly contaminated wounds.

For intraosseous wiring, drill four drill holes at 12, 3, 6, and 9 o'clock in each end of the bone. Then place two strands of 24-gauge wire perpendicular to each other. This provides good stability (86). It is particularly useful for fractures in the metaphyseal areas or even for primary joint fusions. Immediate or early motion is usually possible. It does take slightly more time than intramedullary pins, but the amputated part can be prepared by having the wires inserted in one end by one of the teams.

Plate-and-screw fixation is seldom indicated because nonunion is rarely a significant problem in replantation of digits. This method requires extensive bone exposure, with the possibility of further soft-tissue damage, and it also requires more time. In major limb replantation, however, it is the preferred method because of the precision and rigid fixation obtained (10,32,61).

One of the most difficult problems, even for the experienced hand surgeon, is obtaining proper digital alignment when replanting multiple digits. This may present a problem even when replanting a single digit. Check the relationships of the digits frequently in extension and flexion. Observe the cascade and rotation of fingertips; in general, when flexed, the fingertip should point to the scaphoid bone. Most replantations do survive, so take great care to achieve anatomic alignment and rotation of the replanted parts. In adults there are occasional indications for primary silicone implant arthroplasty with replantations at the joint level, such as an effort to save proximal interphalangeal joint function in a musician. This is particularly the case if one of the central digits (long or ring finger) is amputated at the proximal interphalangeal joint level. It is actually quicker and easier to perform a silicone implant arthroplasty than a primary fusion; however, the indications are not common. In addition to bone stabilization, whenever possible try to repair the periosteum, capsule, and ligamentous structures to provide better gliding of joints and tendons and to promote joint stability.

Make every effort to preserve joints in children.

**EXTENSOR TENDON REPAIR**

To provide additional stability, always repair extensor tendons primarily, just after bone stabilization. Use surgical loupes in extensor tendon repair, and keep in mind the following procedures:

- Using two horizontal mattress sutures of 4-0 polyester or absorbable suture is sufficient.
- It is important to repair the entire extensor mechanism, which may include repair of the extensor hood or lateral band.
- In some severe avulsion injuries, if no extensor tendons are available for repair, I recommend extensor tendon grafting as a secondary procedure.
- In the digits it is usually advisable to perform interphalangeal joint arthrodesis because of the difficulty in reconstructing the extensor mechanism as well as dealing with other injuries.
- In children, primary extensor tendon grafting is favored over interphalangeal joint fusion (67,78,84,90).

**FLEXOR TENDON REPAIR**

Attempt primary flexor tendon repair in almost all replantations. Secondary repair is rather difficult because of the excessive scarring around the repaired nerves, vessels, and joints. Secondary flexor tendon repair in replanted digits usually requires a two-stage silicone rod procedure in digits other than the thumb. Because this procedure amounts to two additional surgical procedures, it is wise to attempt primary repair as follows.

For retrieval of proximal stumps of flexor tendons, observe the following directions:

- Take care not to provoke spasm or damage to the proximal arteries.
- Try to retrieve the proximal stumps by flexing the wrist, massaging the palm, or extending the other digit.
- If these methods are unsuccessful, insert wall suction tubing in the proximal portion of the flexor sheath, turn on the suction, and withdraw the proximal stump.
- If all of these methods fail, make proximal incisions to locate the tendons (57).
- *Blind grasping* with some type of tendon retriever *must not be performed* because it may produce irreversible damage to the vital proximal vessels.

Another reason for performing primary flexor tendon repair is to relieve any undue compression or tethering of the proximal vascular tree that could be caused by proximal retraction of the severed flexor tendons.

Use a suture method in primary flexor tendon repair, with the following recommendations:

- The type of material best suited for suture repair is 4-0 polyester on a double-armed curved needle.
- The Tajima suture method is excellent for primary flexor tendon repair in replantation surgery (Fig. 34.7).

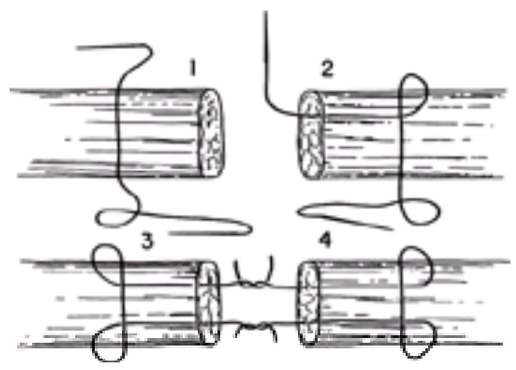


***Figure 34.7.*** The Tajima suture method. (From Urbaniak JR. Replantation in Children. In Serafin D, Georgiade NG, eds. *Pediatric Plastic Surgery.* St. Louis: CV Mosby, 1984:1168.)

- With the Tajima method, sutures can be placed in each end of the tendon initially, and the approximation secured any time during the procedure.
- This delayed coaptation has the advantage of allowing the digit to be held in full extension for better vascular and nerve repair, particularly in the area of the proximal phalanx.

Some primary repairs of flexor tendons in replanted digits may require subsequent tenolysis; however, do not do a tenolysis for at least 3 to 6 months after the primary repair.

If a delayed flexor tendon repair is necessary, it may be safely performed as long as 3 months after the initial replantation or revascularization. Usually the two-stage silicone rod method is indicated.

**VASCULAR REPAIR**

***Arterial Repair***

A thorough description of the microvascular technique is given here, and further details are presented in Chapter 33. Anastomose the arteries after bone fixation and

extensor and flexor tendon repair. The recommended number of arteries to repair is as follows:

- With the digit, it is advisable to repair both arteries when possible.
- At the palm or at the wrist level, anastomose all available arteries to increase the chances of survival (56). Some microsurgeons recommend the repair of only one digital artery to diminish the operating time; however, we have demonstrated that both vessels, even in multiple digital amputations, should be anastomosed to increase the survival rate (52).

**Preparation of the Arteries**

- Free the arteries from their surrounding connective tissue for a distance of 1.5 to 2 cm. Perform this dissection under the microscope with microsurgical instruments. Small branches from the arteries may be safely coagulated with bipolar cautery.
- Dissect a severed artery until *normal intima* is visualized under high-power magnification. Only normal intima must be reconnected (Fig. 34.8).

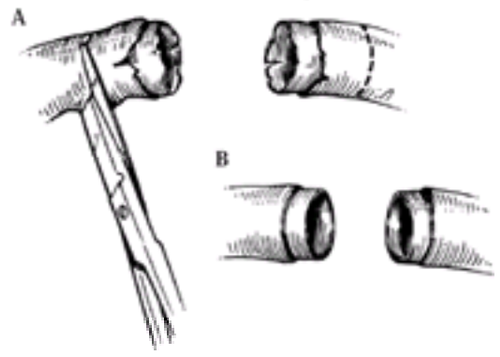


***Figure 34.8.*** Preparation of the vessel. **A:** The damaged portion must be resected until normal intima is visualized under high-power magnification. **B:** Minimal adventitia is stripped to make the lumen clearly visible.

- If vessels with normal intima cannot be approximated, further bone shortening is necessary; preferably, however, use interpositional vein grafting.
- *The two most critical factors in achieving successful microvascular anastomosis are the surgeon's skill and expertise and the ease of coaptation of normal intima to normal intima with minimal tension.*
- Assess the most distal and proximal portions of the exposed vessels to ensure there is no damage to the media or surrounding adventitia. Such an injury indicates the need for further arterial resection and vein grafting.

To establish blood flow:

- After sharply trimming the opened end of the proximal stump and enlarging it with jeweler's forceps or a dilator, an excellent pulsating blood flow must occur.
- Active spurting blood in a digital vessel should produce a persistent stream of at least 5 cm for about 20 to 30 seconds.

If sufficient blood flow cannot be obtained, proceed as follows:

- Do not use this vessel for repair.
- Take steps to relieve the proximal vasospasm that is present.
- Be certain that the patient is not hypotensive, hypovolemic, cold, acidotic, or in pain, because all these factors introduce unwanted vasospasm.
- Perform thorough irrigation of the proximal lumen with warm heparinized Ringer's lactate solution to relieve vasospasm.
- If it is certain that no proximal mechanical block exists, place papaverine in a 1:20 solution with normal saline directly on the proximal vessel or gently insert it into the lumen with a blunt needle. This maneuver usually provides an excellent pulsatile flow that lasts for at least 30 min.
- Exercise caution when using papaverine or similar dilating agents because the flow induced may be temporary and flow may be induced in vessels with damaged intima.

After excellent flow is established in the proximal stump:

- Insert the two vessel stumps into the approximating microclip. Coapt the ends without tension.
- If undue tension is present, use an interpositional vein graft obtained from the palmar forearm.
- Trim the vessel ends with sharp straight scissors so that no adventitia covers the ends of the lumen.
- Carefully dilate the lumen of each end with jeweler's forceps or a lacrimal duct dilator.
- Irrigate the lumen with heparinized Ringer's lactate solution and reinspect the intima for complete normalcy.
- Just before beginning the anastomosis, give an intravenous bolus of 3,000 to 5,000 U of heparin (decrease this dose in young children).

**Suture Technique**

- Apply two stay sutures of 10-0 monofilament nylon 180° apart. Do not tie the sutures too tightly because this will produce necrosis of the vessel wall.
- The distance from the needle insertion to the cut end of the vessel should be about one or two times the thickness of the arterial wall.
- Do not pinch or touch the intima with the jeweler's forceps.
- After the application of each knot, carefully irrigate the anastomosis site with heparinized Ringer's lactate and examine it to ensure the suture does not pierce the back wall.
- After the anterior wall is repaired, turn over the clip approximator and again examine the lumen under high-powered magnification to ensure that all sutures are properly placed.
- Place additional sutures in the back wall in a similar manner.
- Usually six to nine sutures are required to repair an artery 1 mm in diameter.
- In the small distal vessels, particularly in children, sometimes only four or five sutures are necessary for the anastomosis.

**Postanastomosis Observations** Within a few minutes after completion of the initial arterial anastomosis, the fingertip will begin to turn pink if there is adequate perfusion. Capillary refill should be excellent, and pulp turgor good. If the amputated part has been without blood flow for several hours and has been cooled for a prolonged period, a return of adequate perfusion to the distal part will be delayed. Under these circumstances, proceed with repair of the digital nerve and the opposite digital artery. In addition to warming the replanted part, this waiting period is often all that is necessary to achieve adequate distal perfusion.

***Tourniquet Use***

A pneumatic tourniquet around the upper arm may be used safely for each vascular anastomosis. The tourniquet is helpful in diminishing blood loss as well as decreasing operating time. If the microsurgery is skillfully and rapidly performed, the patency rate will not be affected by the ischemia.

Release the tourniquet at the conclusion of each anastomosis to ensure that the anastomosis is patent and blood flow is strong. The tourniquet may be inflated or deflated many times during the procedure for nerve, artery, and vein repair.

If all is going well and the operative field is not obscured by blood, then a tourniquet is unnecessary.

***Microclips***

- Because all available microclips produce some degree of vessel wall damage, do not apply them for more than 30 min (72).
- In a crushing or avulsion injury, and if the procedure is lengthy, consider giving serial doses of heparin (500 to 1,000 U every hour) intravenously. Adjust this dosage for children.
- After completion of the anastomosis, release the microclips; the blood flow across the anastomosis site should be immediate.

### *Shifting Arteries and Vein Grafts*

In some avulsion or crush injuries, undamaged arteries may be shifted. For example, in a ring-finger avulsion, the proximal ulnar digital artery may be shifted to the distal radial digital artery if these ends are less traumatized. In most instances, however, a vein graft is used if the distal artery is salvageable (85).

- For replantation of thumbs that have been avulsed or amputated, I prefer to use an interpositional vein graft from the ulnar digital artery of the amputated thumb to the first dorsal metacarpal artery, or to the dorsum of the hand, for an end-to-side anastomosis into the radial artery at the wrist. For expediency, the reversed vein graft is often anastomosed to the ulnar digital artery of the detached thumb before bone fixation (13).
- The final stage is the connection of the proximal end of the vein graft into the artery. We use interpositional vein grafts in about 20% of our replantations to obtain reapproximation of healthy arteries and veins. The palmar aspect of the wrist contains veins 1 to 2 mm in diameter that are appropriate for replantation of digits.
- Hint: If the use of vein grafts is anticipated, harvest the vein grafts from the forearm in the initial steps of replantation, using loupe magnification before bringing in the operating microscope, in an effort to save time.

### *Venous Repair*

In general, attempt to repair two veins for each artery. It may be necessary to mobilize or harvest veins to achieve this ratio (Fig. 34.9). *Perhaps the greatest error in venous anastomosis is trying to repair veins under tension*. If vein harvesting does not allow coaptation without undue tension, then *vein grafts* must be used. Following this principle will elevate the patency rate and diminish the surgeon's frustration as well.

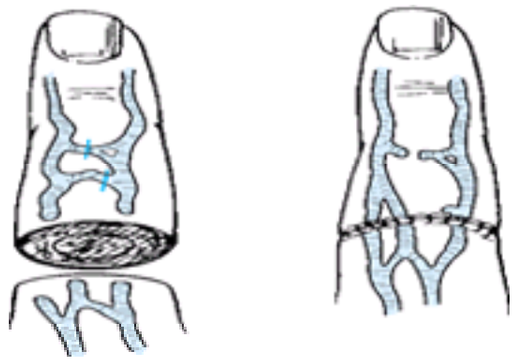

***Figure 34.9.*** The mobilization or harvesting of veins is a useful method of achieving ease of approximation for vein reconstruction in a completely amputated digit. An attempt is made to repair two veins for each artery.

**Technical Steps**

- The technique of vein repair is similar to that for arterial repair with only a few exceptions.
- Generally fewer sutures are necessary at the anastomosis site because the blood flow through the venous system is not as strong as through the arterial system.
- Because the walls of the veins are more fragile than those of the arteries, minimize the application time of microclips.
- The distance from the needle insertion to the cut in the vessel should be two to three times the thickness of the wall.
- Use constant irrigation of the suture line with warm heparinized lactate solution to float the thin walls apart.
- Do not waste time repairing the very small veins; instead, connect only the largest veins. One large repaired vein is more reliable than two smaller repaired veins.

**Options When Dorsal Veins Are Absent** Occasionally in distal digital replantations it may be impossible to locate a suitable dorsal vein. Various available options are as follows:

- *Arteriovenous shunt.* If successful flow through a repaired digital artery is established, retrograde flow from the unrepaired distal contralateral artery may be seen. In the absence of a suitable vein in the distal part, connect this digital artery to a proximal vein (arteriovenous shunt). This procedure is successful in about half of the attempted cases in providing sufficient venous drainage (76,93).
- *Removal of the nail plate.* Removing the nail plate allows venous oozing from the nail bed. Every 1 or 2 h, have a physician, nurse, or family member stroke the nail bed with a cotton-tipped applicator to stimulate bleeding from the nail bed. In the interim, apply heparin-soaked pledgets to the exposed nail matrix.
- *Surgical leeches.* Surgical leeches have been successfully used when venous congestion is apparent. Place the leeches, which are readily available from various biological companies, on the failing part until they become engorged with blood; remove them and replace with fresh leeches every few hours (12,51).
- *Venocutaneous fistula.* The venocutaneous fistula technique involves the construction of a temporary venous return bypass using a venous graft (46). Anastomose the proximal side of the venous graft to a vein at the dorsum of the stump. Then suture the distal end of the graft to the skin around a punch wound on the volar side of the replanted fingertip (Fig. 34.10).

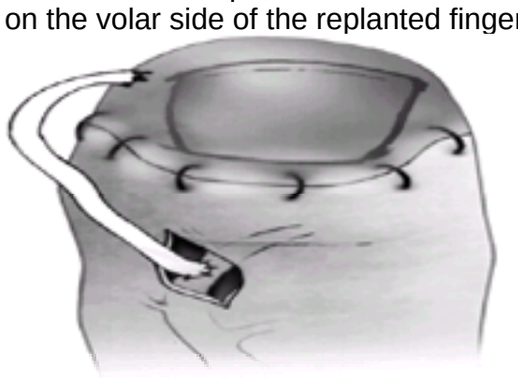

***Figure 34.10.*** The venous cutaneous fistula, a technique for reducing venous congestion in replanted fingertips when distal dorsal veins are not present. A cut is made in the volar pulp, and the vein graft extends from this bleeding fistula to an easily located dorsal vein on the proximal stump. (Modified from Kamai K, Sinokawa Y, Kishibe M. The Venocutaneous Fistula: A New Technique for Reducing Venous Congestion in Replantation Fingertips. *Plast Reconstruct Surg* 99:171;1997.)

- *Periodic massage.* Periodic massaging of the distal segment to enhance venous drainage improves the venous outflow temporarily but is usually not successful in achieving viability of the part if it must be continued more than a day or two.
- *Skin grafts.* When there is an absence of skin on the dorsum of the replanted digit, cover the anastomosed veins with a split-thickness or full-thickness graft.
- *Venous flaps.* If there is a deficit of veins in addition to subcutaneous tissue and skin, cover the defect by a venous flap (27,42,60,80). This flap may be based on a proximal pedicle from an adjacent digit or freely harvested from the dorsum of the hand or foot or volar forearm. A vein graft with its covering of subcutaneous tissue and skin serves as a conduit for venous return as well as skin coverage.

*All of these options to enhance venous drainage are inferior to a dorsal vein repair if it is feasible.*

### *Should the Arteries or Veins be Anastomosed First?*

Some surgeons prefer to repair the veins before the arteries to decrease blood loss and maintain a bloodless field for better vision (57,58). By judicious use of the tourniquet, however, the artery may be repaired first and a dry field maintained. This sequence provides the advantage of earlier revascularization and allows easier location of the most functional veins, detected by their spurting backflow. Additionally, if the veins are repaired first, and a subsequent arterial anastomosis fails to show adequate arterial inflow, the surgeon has wasted valuable time on a nonsalvageable part.

### *Variations of Repair*

In some difficult replantations, such as distal to the interphalangeal joint or deep in the thumb–index webspace, the back wall inside-out technique is favored over the conventional two-stage microanastomosis (1). Use this method in cases where limited exposure of the vessel ends may preclude the possibility of inverting the vessel for back wall repair.

Introduce the needle into one vessel end from the outside in, withdraw it, and pass it from inside out on the other vessel. Begin the repair with the back wall and, by alternating sutures, work the knots toward the front wall.

In some fingertip replantations, a reversed vein graft is sutured to the digital artery of the amputated fingertip before bone fixation. This sequence allows for better exposure and an easier anastomosis (40).

Various coupling devices, laser methods, and even tissue cements have been developed for small vessel repair, but none has proven as successful as interrupted suture methods (44,53,72).

## NERVE REPAIR

Nerve repair in replantation is usually not difficult because the bone has been shortened, and no tension should be present at the suture line.

### *Technical Steps*

- Attempt primary repair in all replantations, when feasible.
- If direct end-to-end repair is impossible, then use primary nerve grafts.
- The median antebrachial cutaneous nerve of the ipsilateral extremity is ideal for primary nerve grafting in the digital nerve (62).
- The nerves from a discarded segment such as a severely damaged digit may be used to bridge the gap.
- The Van Beek nerve approximator (Fig. 34.4) is extremely helpful in repair of nerves in difficult areas.

### *Using the Operating Microscope*

- Cut the nerve ends sharply until pouting fascicles are seen on each stump.
- Align the fascicles on the freshly cut nerve ends and approximate the ends without undue tension, using 8-0 to 10-0 monofilament nylon or polypropylene (prolene).
- Epineural repair after obtaining geographic fascicular alignment is the best method for the digital nerves.
- Only two or three epineural sutures are necessary; more sutures are used in proximal injuries, where the nerve is larger.
- Fibrin glue may be helpful but really does not save time in replantation (44).

## SKIN COVERAGE AND DRESSING

After all of these structures have been repaired and successful revascularization of the replanted part has been ensured, *meticulous hemostasis is essential.* Failure to obtain complete hemostasis can lead to multiple postoperative problems and failure of the replant.

- Loosely approximate the skin with a few interrupted nylon sutures. Usually the midlateral incisions are not closed to allow for decompression of the digital vessels. Excise all potentially necrotic skin, and place no tension on the skin during the closure. Cover the vessels without constriction from the overlying skin or sutures. A local flap or split-thickness graft may be necessary, even for digital vessel coverage. Large defects may be covered by “flow-through” arterialized venous flaps or pedicled venous flaps (27,42,60,80). Fasciotomies are indicated if the slightest pressure or constriction occurs.
- Cover the wounds with small strips of gauze impregnated with petrolatum or antibacterial grease. *Never place these strips in a continuous or circumferential manner around the replanted part.* Although it is preferable not to cover the replanted part with any dressing or splint, to allow free drainage and early active motion, this is usually not feasible because some type of protective dressing is necessary. The ideal dressing is bulky and uniformly compressive but not constrictive.
- Extend the plaster splints above the elbow to prevent proximal slippage while the hand is being elevated (Fig. 34.11). Apply plaster splints on one side of the hand (usually on the palmar aspect) so that the dorsum of the hand can be inspected if there is a postoperative problem. If flexor tendons have been repaired, however, place the splints dorsally to prevent unwanted pull of the flexors against the rigid plaster.

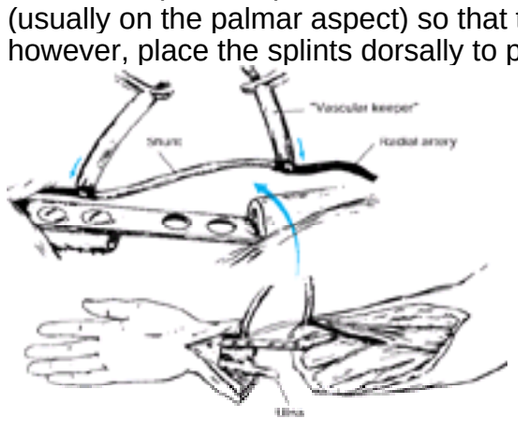


***Figure 34.11.*** Digital temperature is monitored with a telethermometer and small surface probes. These quantitative skin temperature measurements have proven to be the most reliable indicators of replantation status.

- Then elevate the extremity in the bulky compressive dressing by a soft (Styrofoam) cradle boot. Keep the fingertips exposed for application of temperature probes and frequent clinical observation. The environment of the bulky compressive dressing seems to be well suited to the replanted part: often, blood flow increases to the fingertips at the conclusion of the dressing application.
- Do not change the dressing for about 10 days (particularly in children) because anxiety and discomfort produced by the dressing change often incite potentially irreversible vasospasm in the replanted part (22). If there is excessive bleeding into the dressing, change the dressing immediately to prevent constriction from the blood-soaked dressings.

## MAJOR LIMB REPLANTATION

The amputation of major limbs (proximal to the wrist or lower extremity) is less common than amputation of digits or parts of the hand. In replantation of limbs amputated proximal to the wrist level or of amputations of a lower extremity below or above the knee, principles similar to those for digit replantation are used with minor modifications. The major difference is related to the increased amount of muscle tissue involved. Because more muscle mass is present in a major limb amputation, the duration of ischemia of the detached part is more critical. Whereas amputated digits that have been detached for 30 to 36 h may be replanted with a high degree of success, an amputated arm at the elbow area is in jeopardy if it has been avascular for 10 to 12 h, even with appropriate cooling. Rarely are major limbs cleanly severed; therefore, the muscle damage is usually quite severe. Extensive muscle debridement of both the detached part and the proximal stump is essential to prevent myonecrosis and subsequent infection. This problem, associated with major limb replantation, seldom occurs in digital reattachment (46).

### SHUNTING

- If the amputated part and the patient arrive in the operating room more than 4 h after injury, initiate immediate blood flow into the detached part. This is best accomplished by using some form of shunt, such as a Sundt (Huger Shulte Corporation, Galeta, CA) or ventriculoperitoneal shunt, to obtain rapid arterial inflow from the proximal vessel to the detached part (61) (Fig. 34.12).

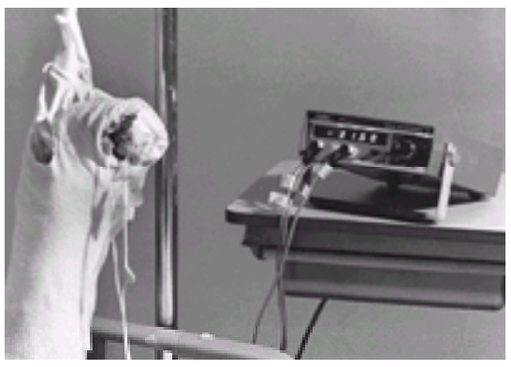

***Figure 34.12.*** A Sundt or ventriculoperitoneal shunt is used to obtain rapid arterial inflow from the proximal vessel to the amputated part. This is particularly useful for major limb amputations that arrive in the operating room more than 4 h after injury. (From Urbaniak JR. Replantation in Children. In Serafin D, Georgiade NG, eds. *Pediatric Plastic Surgery.* St. Louis: CV Mosby, 1984:1168.)

- Perform shunting before bone fixation unless the bone can be rapidly stabilized and early blood flow obtained. After establishing temporary blood flow, complete the debridement, stabilize the bone, remove the shunts, and perform a direct arterial repair or interposition vein grafting of the vessels.

### BONE FIXATION

- For major limb replantation, the best bone fixation is obtained with plates and screws. Cross-pin fixation of the joint is usually the best method for stabilizing the amputations at the joint level.
- Carefully plan adequate bone shortening relative to the type of injury, tissue damage, proximity of the epiphysis, and the particular limb involved. Usually the plate may be secured to the amputated part after the initial debridement and then fixed to the stump after blood flow has been established through the shunts (if the ischemia time has been longer than 10 to 12 h).

### DEBRIDEMENT

Because major limb amputations are usually severe injuries with extensive muscle and other soft-tissue damage, a great deal of soft tissue, including skin, muscle, tendon, and nerve, must be excised if the replanted part is to survive without infection. It is therefore prudent to shorten the bone considerably when possible.

### SEQUENCE OF VESSEL REPAIR

In major limb replantation, it is critical to *perform the arterial anastomosis before the venous anastomosis.* This sequence permits a physiologic washout of noxious agents, such as lactic acid, in the distal part. If this order is reversed, with venous repair first, the return of toxic metabolites to the systemic circulation can cause serious consequences, even death. Giving intravenous sodium bicarbonate before venous anastomosis is beneficial (23).

### FASCIOTOMIES

Fasciotomies are almost always necessary in major limb replantation. A common error is failure to decompress the replanted limb adequately, leading to myonecrosis with subsequent infection. Meshed split-thickness skin grafts provide some coverage of exposed vessels. Other areas may be closed primarily or grafted several days later.

### SECOND LOOK

- In replantations of major limbs, return the patient to the operating room within 48 to 72 h to evaluate the state of the muscle tissue.
- Change the dressing with the patient under general or regional block.
- Debride any necrotic tissue to prevent infection. In general, no anticoagulation is used for major limb replantations.

## POSTOPERATIVE MANAGEMENT AND REHABILITATION

Most patients with digital replantations are hospitalized for 7 to 8 days. Major limb replantations, of course, require longer periods, depending on the severity of the injury. Intelligent, careful postoperative management is essential to achieve a high success rate in replantation surgery (30).

### ENVIRONMENT

Keep the replanted part elevated in the bulky dressing, and keep it warm at all times. The patient should stay in a warm, comfortable room during the first week. If the recovery room is cooler than normal room temperature, place a patient heater or a warmer over the patient. Keep the patient's room at a minimum of 72°F (22°C) and prevent cool air drafts.

### ANTICOAGULATION AND ANTIBIOTICS

The use of anticoagulation therapy remains controversial. A few surgeons use none or perhaps only aspirin and di- pyridamole; some use all or various combinations of anticoagulants (11,52,57,104). We prefer some type of anticoagulation for all patients.

Heparin is generally not indicated in clean-cut amputations that are replanted or if the anastomosis was technically easy and the blood flow was immediately brisk. In these patients, we use aspirin, 300 mg, and dipyridamole, 50 mg, twice daily as well as 500 mg of intravenous low-molecular-weight dextran for 1 week. In addition, we give chlorpromazine, 25 mg three or four times daily, for a tranquilizing effect as well as to provide peripheral dilation. This drug is valuable in relieving vasospasms secondary to anxiety, which occurs particularly in children. In children, the dose is reduced to 10 mg three to four times daily by mouth.

If the injury is of the avulsing or crushing type, give intravenous heparin, 1,000 units every hour, in adults for 7 days. Adjust this dosage in children, giving about 100 U/kg for 4 h. Adjust this according to the activated partial thromboplastin time, which is maintained at 1.5 times normal. If bleeding occurs into the dressing, adjust the dosage and change the dressing immediately to prevent constriction. Do not use heparin prophylaxis in amputations proximal to the wrist level. Give appropriate antibiotics for 1 week.

### MONITORING

Capillary refill, pulp turgor, color, and warmth are all useful indicators in monitoring the replant (39), but quantitative skin temperature measurements have proved the most reliable indicators (28,38,49,65,74). Monitor digital temperature with a telethermometer and small surface probes (Fig. 34.11). The normal skin temperature of the digits is 31° to 35°C. Remember that ambient temperature may influence the interpretation of the recordings. Probes are usually placed on the replanted digits, on a normal digit for control, and on the dressing for measurement of the ambient temperature. An abrupt or even gradual change in temperature indicates that the replant may be failing, and steps must be taken to improve the blood flow. If the temperature drops below 30°C or shows more than a 2° drop when compared with the normal digit, appropriate methods of management must be undertaken immediately.

### ACTIVITY

Bed rest or ambulation is determined by the activity level or desire of the patient. If the patient is anxious and chooses to remain in bed or appears to be having difficulty with blood flow to the replanted part, then bed rest is advised for 3 to 5 days. If the patient is vigorous or energetic, however, allow activity a day or two after the replantation. Permit no smoking by the patient or in the patient's room, and all efforts should be made to keep the patient tranquil (15).

Relatively early active joint motion is encouraged in most replantations (17,18,69); because the dressing is not changed for at least 10 days, however, immediate early

motion is limited. In the patient who has had a replantation distal to the superficialis insertion, encourage movement of the digit the following day because there is really no stress on the flexor or extensor tendons. Otherwise, begin protective active motion against rubber bands and flexor and extensor outriggers, supervised by a hand therapist, 1 to 2 weeks after the replantation. Especially for replantation patients who live far from the treatment center, if more than one digit has been replanted or a major limb has been replanted, keep the patient in the hospital or in a nearby motel so that daily therapy can be supervised by hand therapists.

## PITFALLS AND COMPLICATIONS

### ACUTE COMPLICATIONS

Acute failures are secondary to inadequate perfusion (39). Often the surgeon can predict which replantation will have a postoperative problem with perfusion. Some examples include:

- Replantation in children under 10 years of age
- Crush and avulsion injuries
- Ring avulsion injuries
- Poor proximal flow observed before the arterial anastomosis
- Intermittent or inconsistent distal flow despite a technically good anastomosis

When these signs of jeopardy are present, extra postoperative efforts are necessary to enhance the chances of survival. Intravenous heparin is particularly beneficial in these difficult replantations.

#### *Regional Sympathetic Block*

The use of an indwelling silicone catheter to administer a regional sympathetic block is particularly helpful. Insert a #5 silicone urethral stent beside the median or ulnar nerve (depending on the digits revascularized or replanted) to permit regional block to be given in the postoperative course. The catheter exits from the dressing and has a stopcock attached so that a nurse can give 5 mL of 0.25% bupivacaine hydrochloride every 6 to 8 h. This drug provides regional block anesthesia to diminish vasospasm and alleviate pain. This procedure is particularly rewarding in children because it obviates the use of axillary or brachial block if postoperative spasm develops. In the postoperative period, we have rarely given an axillary or brachial block since the early 1980s.

#### *Management of the Failing Replant*

If the reattached part appears in jeopardy in the immediate postoperative period, as indicated by decreased skin temperature, loss of capillary refill, diminished pulp turgor, or abnormal color, immediately take the following steps:

- Inspect the dressing to rule out any type of constriction. Administer intramuscular narcotics prior to inspection.
- Depress or elevate the hand to improve the vascular status, depending on whether the problem is arterial or venous.
- Give an intravenous bolus of heparin (3,000 to 5,000 U), which often incites recovery.
- Give chlorpromazine to diminish anxiety and decrease vasospasm, if necessary.
- Ensure that the patient is adequately *hydrated* and that the *hematocrit* is normal or near normal.
- Alter the *environment* of the patient's room (for example, increase the temperature and remove smokers or other agitating factors), if necessary.
- Make all efforts to *calm* the patient, especially a child, as pain, fear, and anxiety may initiate peripheral vasospasm.

#### *Return to Operating Room*

If normal perfusion does not return after these management measures, return the patient to the operating room. Once this decision is made, do so within the first 4 to 6 h after the loss of adequate perfusion. Seldom have we found reexploration to benefit the patient if it occurs more than 1 to 2 days after replantation. If the patient is returned to the operating room within the first 12 to 48 h, however, many potential failures can be salvaged by redoing the vein graft, removing the thrombus, and usually grafting a previously unrecognized damaged vessel segment.

### SUBACUTE COMPLICATIONS

Although infections occur frequently in digital replantations, loss of a replanted digit is rare secondary to infection. The most common infections are pin tract infections, which usually occur more than 4 weeks after the replantation and are easily managed by removing the pins and putting the patient on antibiotics. We have seldom found it necessary to admit a patient to the hospital for pin tract infections.

Infection is more common and more serious in major limb replantations. The presence of large amounts of muscle that have been rendered ischemic increases the likelihood of infection. To ensure adequate muscle debridement, return all major limb replantations to the operating room in 48 h for a “second look” procedure. At this time, inspect the wounds thoroughly and debride any muscle necrosis that has progressed since the first procedure. Infections in major limb replantations may not become apparent until the second week (most commonly in 8 to 10 days); if the infection involves the vascular anastomosis, failure is almost inevitable.

### CHRONIC COMPLICATIONS

The most common chronic complications are cold intolerance, tendon adhesions, and malunion.

Cold intolerance is an almost universal complaint in patients who have undergone digital replantations. However, cold intolerance is not unique to digital replantation and occurs with almost equal incidence in other severe hand injuries, including amputations that are not replanted (29). Cold intolerance is related to the adequacy of digital reperfusion; for this reason, try to maximize the number of arterial repairs. Cold intolerance diminishes with time and usually resolves by 2 years (91). Pain is rare in successfully replanted limbs.

Because both the flexor and extensor tendons are usually repaired in replantations, tendon adhesions are common, with diminished motion. If this is severe, tenolysis may be performed as early as 3 months after replantation.

Malunion is most often seen after transmetacarpal replantation. These complex injuries require multiple tendon, vessel, and nerve repairs, and if care is not taken during bone fixation, rotational malunion may occur. Every effort should be made to properly align digits before replantation. Another form of malunion can occur in multiple digit replantations for which it is difficult to identify the various digits at the time of surgery. It may become apparent later that one digit has been exchanged for another. This is primarily a cosmetic problem and does not result in any diminished function.

Nonunion is not a common problem after replantation: it has been reported to occur in only 2% to 9% of digital replantations (86,87). Usually nonunions are asymptomatic, and I have yet to operate on a patient for a nonunion of a digital replantation.

## RESULTS

Most replantation centers can now achieve better than 80% viability in replantation of completely severed parts. Our team has achieved 77% viability in replantations and 92% in revascularizations of more than 1,800 amputations.

By applying the principles presented in this chapter, the experienced and proficient microsurgeon should be able to achieve at least an 80% overall viability rate in replantations. The results, based on our own long-term follow-up as well as reports from major replantation centers, should be as follows:

- The active range of joint motion should be about half of normal, depending on the level of injury.
- Cold intolerance is a definite problem that usually subsides within 2 years.
- Nerve recovery is comparable to the repair of an isolated, severed peripheral nerve (19).
- Cosmesis is usually better than any amputation revision or prosthesis (29).
- Near-normal growth may be anticipated in amputations through the diaphyseal region of children. If the injury involves the epiphyseal plate, growth will almost always be retarded, although excessive growth has been reported (24,35,67).

- The best results are obtained in replantations of the thumb, a finger distal to the insertion of the superficialis tendon, and the hand at the wrist level.

## CHAPTER REFERENCES

Each reference is categorized according to the following scheme: *, classic article; #, review article; !, basic research article; and +, clinical results/outcome study.


* 1. Acland RD. *Microsurgery Practice Manual.* St. Louis: CV Mosby, 1980.

+ 2. Ada S, Ozerkan F, Kaplan I. Heteroptic replantation. [German Original Title: Heterotope Replantationen.] *Handchir Mikrochir Plast Chir* 1995;27:315.

+ 3. Adani R, Castagneti C, Landi A. Degloving Injuries of the Hand and Fingers. *Research* 1995;314:19.

! 4. Allen DN, Chen LE, Seaber AV, Urbaniak JR. Pathophysiology and Related Studies of the No Reflow Phenomenon in Skeletal Muscle. *Clin Orthop* 1995;314:122.

+ 5. Arakaki A, Tsai TM. Thumb Replantation: Survival Factors and Reexploration in 122 Cases. *J Hand Surg* 1993;18B:152.

+ 6. Axelrod TS, Buchler U. Severe Complex Injuries to the Upper Extremity: Revascularization and Replantation. *J Hand Surg* 1991;16A:574.

+ 7. Baker GL, Kleinert JM. Digit Replantation in Infants and Young Children: Determinants of Survival. *Plast Reconstruct Surg* 1994;94:139.

+ 8. Belsky MR, Ruby LK. Double-Level Amputation: Should It Be Replanted? *J Reconstruct Microsurg* 1986;2:159.

+ 9. Beris AE, Soucacos PN, Malizos KN, Xenakis TA. Microsurgical Treatment of Ring Avulsion Injuries. *Microsurgery* 1994;15:459.

+ 10. Beris AE, Soucacos PN, Malizos KN, et al. Major Limb Replantation in Children. *Microsurgery* 1994;15:474.

# 11. Bright DS. *Techniques of Microsurgery. American Academy of Orthopaedic Surgeons Symposium: Microsurgery-–Practical Use in Orthopaedics.* St. Louis: CV Mosby, 1979:40.

# 12. Brody GA, Maloney WJ, Hentz VR. Digit Replantation Applying the Leech *Hirudo medicinalis. Clin Orthop* 1989;245:133.

# 13. Caffee HH. Improved Exposure for Arterial Repair in Thumb Replantation. *J Hand Surg* 1985;10-A:416.

+ 14. Camacho FJ, Wood MD. Polydigit Replantation. *Hand Clin* 1992;8:409.

+ 15. Chang LD, Buncke G, Slezak S, Buncke HC. Cigarette Smoking, Plastic Surgery, and Microsurgery. *J Reconstruct Surg* 1996;12:467.

* 16. Chen CT, Wei F, Chen H, et al. Distal Phalanx Replantation. *Microsurgery* 1994;15:77.

+ 17. Chiu H, Shieh S, Hsu H. Multivariate Analysis of Factors Influencing the Functional Recovery after Finger Replantation for Revascularization. *Microsurgery* 1995;16:713.

+ 18. Chiu HY, Lee JW. Influence of Joint Injury on Motor and Functional Recovery of Finger Replantation. *Microsurgery* 1994;15:848.

+ 19. Chu NS. Recovery of Finger Sensibility and Somatosensory Evoked Potentials following Digit-to-Digit Replantation in Man. *Scand J Rehab Med* 1996;28:125.

+ 20. Daigle P, Kleinert JM. Major Limb Replantation in Children. *Microsurgery* 1991;12:221.

+ 21. Daoutis NK, Gerostathopoulos N, Efstathopoulos D, et al. Major Amputation of the Upper Extremity. Functional Results after Replantation/Revascularization in 47 Cases. *Acta Orthop Scand [Suppl]* 1995;264:7.

! 22. Dell PC, Seaber AV, Urbaniak JR. Effect of Hypovolemia on Perfusion after Digit Replantation. *Surg Forum* 1980;31:503.

! 23. Dell PC, Seaber AV, Urbaniak JR. The Effect of Systemic Acidosis on Perfusion of Replanted Extremities. *J Hand Surg* 1980;5A:433.

+ 24. Demiri E, Bakhach J, Tsakoniatis N, et al. Bone Growth after Replantation in Children. *J Reconstruct Microsurg* 1995;11:113.

+ 25. Dubert T, Houimli S, Valenti P, Dinh A. Very Distal Finger Amputations: Replantation or “Reposition-flap” repair? *J Hand Surg* 1997;22B:353.

+ 26. Foucher G, Norris RW. Distal and Very Distal Digital Replantations. *Br J Plast Surg* 1992;45:199.

+ 27. Fukui A, Inada Y, Maeda M, et al. Pedicled and “Flow-Through” Venous Flaps: Clinical Applications. *J Reconstruct Microsurg* 1989;5:235.

+ 28. Gelberman RH, Urbaniak JR, Bright DS, Levin LS. Digital Sensibility Following Replantation. *J Hand Surg* 1978;3:313.

+ 29. Goel A, Navato-Dehning C, Varghese G, Hassanein K. Replantation and Amputation of Digits: User Analysis. *Am J Phys Med Rehabil* 1995;74:134.

* 30. Goldner RD. Postoperative Management. *Hand Clin* 1985;1:205.

* 31. Goldner RD, Howson MP, Nunley JA, et al. One Hundred Eleven Thumb Amputations: Replantation Versus Revision. *Microsurgery* 1990;11:243.

+ 32. Goldner RD, Nunley JA. Replantation Proximal to the Wrist. *Hand Clin* 1992;8:413.

* 33. Goldner RD, Stevanovic MV, Nunley JA, Urbaniak JR. Digital Replantation at the Level of the Distal Interphalangeal Joint and the Distal Phalanx. *J Hand Surg* 1989;14:214.

# 34. Hamilton RB, O'Brien BM, Morrison A, MacLeod AM. Survival Factors in Replantation and Revascularization of the Amputated Thumb—10 Years' Experience. *Scand J Plast Reconstruct Surg* 1984;18:163.

+ 35. Hertz H. Epiphyseal Growth after Replantation in Childhood. *Handchir Mikrochir Plast Chir* 1994;26:194.

+ 36. Hirase Y. Salvage of Fingertip Amputated at Nail Level: New Surgical Principles and Treatment. *Ann Plast Surg* 1997;38:151.

* 37. Hovgaard C, Angermann P, Hovgaard D. The Social and Economic Consequences of Finger Amputations. *Acta Orthop Scand* 1994;65:347.

+ 38. Hovius SER, Adrichem LNA, Mulder HD, et al. Comparison of Laster Doppler Flowmetry and Thermometry in the Postoperative Monitoring of Replantations. *J Hand Surg* 1997;38:151.

+ 39. Idler RS, Steichen JB. Complications of Replantation Surgery. *Microsurgery* 1992;8:427.

+ 40. Ikeda K, Morikawa S, Hashimoto F, Tomita K. Fingertip Replantation: Pre-osteosynthesis Vein Graft Technique. *Microsurgery* 1994;15:430.

+ 41. Ikuta Y. Method of Bone Fixation in Reattachment of Amputations in the Upper Extremities. *Clin Orthop* 1978;133:169.

+ 42. Inada Y, Fukui A, Tamai S, et al. An Experimental Study of the Venous Flap: Investigation of the Recipient Vein. *J Reconstruct Microsurg* 1990;6:123.

+ 43. Ishikura N, Tsukada S. An Easy Method of Vascular Anastomosis for Replantation of the Fingertips. *J Reconstruct Microsurg* 1995;11:141.

+ 44. Isogai N, Cooley BG, Kamiishi J. Clinical Outcome of Digital Replantation using the Fibrin Glue-Assisted Microvascular Anastomosis Technique. *J Hand Surg* 1996;21B:573.

* 45. Janezic TF, Arnex ZM, Solinc M, Zaletel-Kragelj L. One Hundred Sixty-Seven Thumb Replantations and Revascularisations: Early Microvascular Results. *Microsurgery* 1996;17:259.

+ 46. Kamai K, Sinokawa Y, Kishibe M. The Venocutaneous Fistula: A New Technique for Reducing Venous Congestion in Replantation Fingertips. *Plast Reconstruct Surg* 1997;99:171.

+ 47. Kim WK, Lee JM, Lim JH. Eight Cases of Nine-Digit and Ten-Digit Replantations. *Plast Reconstruct Surg* 1996;98:477.

* 48. Kim WK, Lee JM, Lim JH. Fingertip Replantations: Clinical Evaluations of 135 Digits. *Plast Reconstruct Surg* 1996;98:470.

+ 49. Kiyoshige Y, Tsuchida H, Watanabe Y. Color Monitoring after Replantation. *Plast Reconstruct Surg* 1996;97:463.

* 50. Komatsu S, Tamai S. Successful Replantation of a Completely Cut-off Thumb: Case Report. *Plast Reconstruct Surg* 1968;42:374.

# 51. Kraemer BA, Korber KE, Aquino TI, Engleman A. Use of Leeches in Plastic and Reconstructive Surgery: A Review. *J Reconstruct Microsurg* 1988;4:381.

+ 52. Kutz JE, Hanel D, Scheker L, et al. Upper Extremity Replantation. *Orthop Clin North Am* 1983;14:873.

# 53. Lanzetta M. Use of the 3-M Precise Microvascular Anastomotic System in Hand Surgery. *J Hand Surg* 1995;20:725.

+ 54. Malizos KN, Beris AE, Korombilias AB, et al. Distal Phalanx Microsurgical Replantation. *Microsurgery* 1994;15:464.

* 55. Malt RA, McKhann C. Replantation of Severed Arms. *JAMA* 1964;189:716.

* 56. Matsuda M, Chikamatsu E, Shimizu Y. Correlation Between Number of Anastomosed Vessels and Survival Rate in Finger Replantation. *J Reconstruct Microsurg* 1993;9:1.

+ 57. Morrison WA, O'Brien BM, McLeod AM. Digital Replantation and Revascularisation: A Long-Term Review of 100 Cases. *Hand* 1978;10:125.

+ 58. Morrison WA, O'Brien BM, McLeod AM. The Surgical Repair of Amputations of the Thumb. *Aust NZ J Surg* 1980;50:237.

+ 59. Nishi G, Shibata Y, Tago K, et al. Nail Regeneration in Digits Replanted after Amputation through the Distal Phalanx. *J Hand Surg* 1996;21A:229.

+ 60. Nishi G, Shibata Y, Kumabe Y, et al. Arterialized Venous Skin Flaps for the Injured Finger. *J Reconstruct Microsurg* 1989;5:357.

* 61. Nunley JA, Koman LA, Urbaniak JR. Arterial Shunting as an Adjunct to Major Limb Revascularization. *Ann Surg* 1981;193:271.

+ 62. Nunley JA, Ugino MR, Urbaniak JR, et al. Digital Nerve Grafts Utilizing the Median Antebrachial Cutaneous Nerve. *J Bone Joint Surg* 1989;71:563.

* 63. Polvsen B, Nylander G, Nylander E. Cold-Induced Vasospasm after Digital Replantation Does Not Improve with Time. *J Hand Surg* 1995;20B:237.

* 64. Polvsen B, Nylander G, Nylander E. Natural History of Digital Replantation: A 12-Year Prospective Study. *Microsurgery* 1995;16:138.

+ 65. Reagan DS, Grundberg AB, George MJ. Clinical Evaluations and Temperature Monitoring in Predicting Viability. I. Replantations. *J Reconstruct Microsurg* 1994;10:1.

+ 66. Russell RC, O'Brien BM, Morrison WA, et al. The Late Functional Results of Upper Limb Revascularization and Replantation. *J Hand Surg* 1984;9-A:623.

* 67. Saies AD, Urbaniak JR, Nunley JA, et al. Results after Replantation and Revascularization in the Upper Extremity in Children. *J Bone Joint Surg* 1994;76A:1766.

+ 68. Schlenker JD, Kleinert HE, Tsai T-M. Methods and Results of Replantation Following Traumatic Amputation of the Thumb in 64 Patients. *J Hand Surg* 1980;5:63.

+ 69. Silverman PM, Gordon L. Early Motion after Replantation. *Hand Clin* 1996;12:97.

* 70. Sixth People's Hospital, Shanghai. Replantation of Severed Fingers: Clinical Experience in 162 Cases Involving 270 Severed Fingers. Pamphlet July 1963.

* 71. Soucacos PN, Beris AE, Malizos KN, et al. Transposition Microsurgery in Multiple Digital Amputations. *Microsurgery* 1994;15:469.

# 72. Soucacos PN, Beris AE, Touliatos AS, et al. Current Indications for Single Digit Replantation. *Acta Orthop Scand [Suppl]* 1995;264:12.

+ 73. Stevanovic MV, Vucetic C, Bumbasirevic M, Vuckovic G. Avulsion Injuries of the Thumb. *Plast Reconstruct Surg* 1994;87:1099.

# 74. Stirrat CR, Seaber AV, Urbaniak JR, Bright DS. Temperature Monitoring in Digital Replantation. *J Hand Surg* 1978;3:342.

+ 75. Suzuki K, Matsuda M. Digital Replantations Distal to the Distal Interphalangeal Joint. *J Reconstruct Microsurg* 1987;3:291.

+ 76. Suzuki Y, Ishikawa K, Isshiki N, Takami S. Fingertip Replantation with an Efferent A-V Anastomosis for Venous Drainage: Clinical Reports. *Br J Plast Surg* 1993;46:187.

+ 77. Tamai S. 20 Years' Experience of Limb Replantation—Review of 293 Upper Extremity Replants. *J Hand Surg* 1982;7:549.

+ 78. Taras JS, Nunley JA, Urbaniak JR, et al. Replantation in Children. *Microsurgery* 1991;12:216.

+ 79. Touliatos AS, Soucacos PN, Beris A, et al. Alternative Techniques for Restoration of Bony Segments in Digital Replantation. *Acta Orthop Scand [Suppl]* 1995;264:19.

+ 80. Tsai T-M, Matiko JD, Breidenbach W, Kutz JE. Venous Flaps in Digital Revascularization and Replantation. *J Reconstruct Microsurg* 1987;3:113.

+ 81. Tsai T-M, McCabe SJ, Maki Y. A Technique for Replantation of the Finger Tip. *Microsurgery* 1989;10:1.

# 82. Urbaniak JR. Replantation of Amputated Parts—Technique, Results and Indications. In *American Academy of Orthopaedic Surgeons Symposium: Microsurgery—Practical Use in Orthopaedics.* St. Louis: CV Mosby, 1979:64.

* 83. Urbaniak JR. To Replant or Not to Replant? That Is Not the Question. *J Hand Surg* 1983;8-A:507.

# 84. Urbaniak JR. Replantation in Children. In: Serafin D, Georgiade NG, eds. *Pediatric Plastic Surgery.* St. Louis: CV Mosby, 1984.

* 85. Urbaniak JR, Evans JP, Bright DS. Microvascular Management of Ring Avulsion Injuries. *J Hand Surg* 1981;6:25.

# 86. Urbaniak JR, Hayes MG, Bright DS. Management of Bone in Digital Replantation: Free Vascularized and Composite Bone Grafts. *Clin Orthop* 1978;133:184.

* 87. Urbaniak JR, Roth JH, Nunley JA, et al. The Results of Replantation after Amputation of a Single Finger. *J Bone Joint Surg* 1985;67-A:611.

# 88. Urbaniak JR, Soucacos PN, Adelaar RS, et al. Experimental Evaluation of Microsurgical Techniques in Small Artery Anastomoses. *Orthop Clin North Am* 1977;8:249.

! 89. Urbaniak JR, Seaber AV, Chen LE. Assessment of Ischemia and Reperfusion Injury. *Clin Orthop* 1997;334:30.

+ 90. Urbaniak JR, Forester JS. Replantation in Children. In Meyer VE, Black MJM, eds. *Microsurgical Procedures. Hand and Upper Limb. Vol. 8.* Edinburgh: Churchill Livingstone, 1991:69.

# 91. Urbaniak JR, Goldner JR. Distal Digit Replantation. In Foucher G, ed. *Fingertip and Nailbed Injuries. Hand and Upper Limb. Vol. 7.* Edinburgh: Churchill Livingstone, 1991:40.

# 92. VanGiesen PJ, Seaber AV, Urbaniak JR. Storage of Amputated Parts Prior to Replantation. *J Hand Surg* 1985;8-A:60.

+ 93. Vesely J, Smrcka V. Replantation by Arteriolization of the Venous System of Amputated Parts. *Acta Chir Plast* 1995;37:67.

* 94. Wang S-H, Young K-F, Wei J-N. Replantation of Severed Limbs—Clinical Analysis of 91 Cases. *J Hand Surg* 1981;6:311.

+ 95. Ward WA, Tsai T, Breidenbach W. Per Primam Thumb Replantation for All Patients with Traumatic Amputations. *Clin Orthop* 1991;266:90.

+ 96. Weinzweig N, Sharzer LA, Starker I. Replantation and Revascularization at the Transmetacarpal Level: Long-Term Functional Results. *J Hand Surg* 1990;15A: 328.

+ 97. Whitney TM, Lineaweaver WC, Buncke HJ. Clinical Results of Bony Fixation Methods in Digital Replantation. *J Hand Surg* 1990;15:328.

+ 98. Yamano Y. Replantation of Fingertips. *J Hand Surg* 1993;18B:157.

+ 99. Yamauchi S, Nomura S, Yoshimura M, et al. A Clinical Study of the Order and Speed of Sensory Recovery after Digital Replantation. *J Hand Surg* 1983;8:45.

+ 100. Yoshizu T, Katsumi M, Tajima T. Replantation of Untidy Amputated Finger, Hand and Arm: Experience of 99 Replantations in 66 Cases. *J Trauma* 1978;18:194.

* 101. Zhong-Wei C, Meyer VE, Kleinert HE, Beasley RW. Present Indications and Contraindications for Replantations as Reflected by Long-term Functional Results. *Orthop Clin North Am* 1981;12:849.

* 102. Zhong-Wei C, Ch'ien Y-C, Lin CT. Further Experiences in the Restoration of Amputated Limbs. *Chin Med J* 1965;84:225.

+ 103. Zuker RM, Stevenson JH. Proximal Upper Limb Replantation in Children. *J Trauma* 1988;28:544.

# 104. Zumiotti A, Ferreira MC. Replantation of Digits: Factors Influencing Survival and Functional Results. *Microsurgery* 15:18;1994.

# CHAPTER 35

# FREE TISSUE TRANSFER

*Lior Heller, Reynaldo L. Aponte, and L. Scott Levin*

**L. Heller:** Fellow in Wound Healing and Plastic Surgery, Division of Plastic, Reconstructive, Maxillofacial, and Oral Surgery, Duke University Medical Center, Durham, NC, 27710.
**R. L. Aponte**: Physician Assistant, Division of Plastic, Reconstructive, Maxillofacial, and Oral Surgery, Duke University Medical Center, Durham, NC, 27710.
**L. S. Levin:** Associate Professor of Plastic and Orthopaedic Surgery, Chief—Division of Plastic, Reconstructive, Maxillofacial, and Oral Surgery, Duke University Medical Center, Durham, NC, 27710.

Debridement
- Debridement of the Acute Wound
- Chronic Wounds

Microsurgical Reconstruction
- Reconstructive Ladder

Free Tissue Transfer at the Upper Extremity
- Indications: Trauma, Sepsis, and Tumor
- Toe-to-Hand Transfer
- Microneural Reconstruction of the Upper Extremity
- Vascular Reconstruction of the Upper Extremity

Free Tissue Transfer in the Lower Extremity
- Indications
- Principles for the Foot and Ankle
- Plantar Skin Reconstruction
- Vascular and Diabetic Foot
- Stump Coverage

Preoperative Considerations
- Selection of Tissue Transplantation
- Recipient Vessels
- Timing of Free Tissue Transfer
- Patient Preparation

Specific Tissue Transfer
- Lateral Arm Flap
- Radial Forearm Flap
- Scapular and Parascapular Flaps
- Dorsalis Pedis Flap
- Groin Flap
- Temporoparietal Fascial Flap
- Muscle Flaps
- Fibula Flap
- Osteocutaneous Iliac Crest Flap
- Omental Flap

Postoperative Care
- Monitoring
- Flap Failure and Management
- Treatment of Failure

Aesthetic Considerations
Ilizarov Apparatus and Microsurgery
Future Technology
- Endoscopic Harvesting
- Flap Prefabrication

Microsurgery Cost and Outcomes
Chapter References

Autologous tissue transplantation describes the surgical technique used to transfer tissue from one location in the body to another using the operating microscope and techniques of microvascular surgery to perform small vessel anastomoses. Free flaps include isolated transfer, composite tissue transfer, and functioning free muscle transfer. Structural transfers such as vascularized bone grafts or toe transplantation for hand reconstruction are also included in this group of procedures. Specific tissue transfers such as vascular and neural grafts are also an integral part of the microsurgical reconstruction armamentarium. Although such “grafts” do not involve large amounts of tissue, they are considered tissue transplantation and thus are included here in the discussion of free tissue transfer.

Microsurgery for extremity reconstruction began more than three decades ago with the introduction of the operating microscope for anastomosis of blood vessels, described by Jacobson and Suarez (50). Microsurgical repair of digital arteries and digital replantation began in the 1960s (16,55), followed by microsurgical composite tissue transplantation in the 1970s. Microsurgeons expanded their efforts from achieving tissue survival to improving function as well as appearance in the 1980s. In the 1990s, the emphasis shifted to outcome. Today, composite transplantation or free tissue transfer routinely not only provides coverage but facilitates function.

The development of reconstructive microsurgery and the vital role it plays in orthopaedic surgery is credited to the efforts of many investigators who identified new donor sites, expanded indications for free tissue transfer, and constantly improved microsurgical techniques. In particular, the contributions of Mathes and Nahai (82) in summarizing the clinical application for muscle and musculocutaneous flap should be acknowledged, as well as the pioneering work of Ian Taylor (108), Harry Buncke (17), Harold Kleinert (55a), Robert Acland (2a), Bernard O'Brien (88a), and Fu Chan Wei (113a).

Orthopaedic surgeons perform reconstructive procedures in all fields of their practice. For example, the simultaneous management of fractures and associated soft-tissue injury—the so-called orthoplastic approach—is now accepted treatment for extremity trauma. It allows optimal repair processes to take place for bone and soft tissue while avoiding the adverse sequelae of failed fixation, sepsis, and ultimately, amputation. The orthopaedic trauma surgeon should appreciate the importance of anatomy, specifically being cognizant of intravenous planes and vascular territories (angiosomes) during dissection (108). Delicate soft-tissue handling and an awareness of the blood supply to muscle, fascia, and skin will prevent the orthopaedist from inadvertently damaging tissue, which may result in necrosis and exposure of either bone or implants that requires coverage with free flaps. Expeditious repair of soft tissue is important in the care of the injured extremities. It facilitates further reconstruction, such as bone grafting or tendon transfers.

A thorough understanding of free tissue transfer includes understanding the rationale for tissue transplantation, the timing of the transplant, and what transplant should be selected. The orthopaedic surgeon should have an understanding of the current techniques of reconstructive microsurgery and be able to obtain appropriate reconstructive consultation for patients.

## DEBRIDEMENT

The French word debridement implies the removing of soft tissues and bone that are nonviable, with hope of preventing infection. Before the era of free tissue transfer, debridement was often limited because removing tissue of questionable viability led to the exposure of vital structures such as bone. Surgeons were reluctant to make the traumatic defects larger by “radical debridement.” Now, in contrast, free tissue transfer of large, well-perfused flaps is readily available and allows radical debridement and necrectomy. Debridement is required both in acute trauma situations and for chronic wounds that have resulted from either the improper handling of soft tissue or infection.

### DEBRIDEMENT OF THE ACUTE WOUND

- In a fresh wound (such as a Gustilo 3B or 3C tibial fracture), perform the debridement with the tourniquet either up or down. Our preference is to begin the

debridement with the tourniquet up because hemorrahge and oozing can stain tissue, making it difficult to distinguish viable tissue from nonviable tissue that has been exposed to adjacent bleeding. Also see Chapter 12.

- Decide what should be debrided according to the appearance and consistency of the different tissues. Healthy tissue in the exanguinated extremity is bright and homogenous in color. Damaged tissue has foreign bodies, irregular tissue consistency, and an irregular distribution of dark red stains, indicating hematoma or contusion. Remove all nonviable tissue. The border of the debridement should include healthy tissue. Remove avulsed skin and muscle from the base of avulsed flaps.
- Let down the tourniquet and assess contractility, bleeding, color and consistency of tissue such as muscle tissue to determine viability of tissue.
- Wash exposed bone with antibiotic solution. Free bone fragments are usually removed.
- Ligate severed vessels and, if they are not vital, excise to normal appearing margins. If they are vital, restore continuity with interposition vein grafts.
- Nerves are the only structures in which the debridement is more conservative. The epineurium can be carefully removed, with fascicles remaining intact.

### CHRONIC WOUNDS

The treatment goal for the chronic wound is to treat the wound as a tumor and excise it in its entirety to the level of normal tissue planes (Fig. 35.1; see also Color Fig. 35.1). Excise all scar tissue. Bone debridement can be difficult, because it can be challenging to distinguish the viable bone and healthy callus from necrotic and inflamed areas. Techniques such as computed tomography (CT) scans, bone scans, and magnetic resonance imaging (MRI) may be helpful in preoperative planning for bone debridement.

***Figure 35.1.*** (See Color Fig. 35.1). Chronic wound following a tibial 3B injury. Proximal muscle is covered with granulation tissue. There is evidence of desiccated, infarcted tendon and chronic granulation tissue in the base of the wound. This wound required extensive debridement and free flap reconstruction.

At the conclusion of wound debridement, normal tissue planes should be visualized. If this is not possible, then a second-look procedure in which the debridement process is repeated is strongly advised. Re-debride no later than 48 hours, and preferably at 24 hours after the initial debridement (65).

## MICROSURGICAL RECONSTRUCTION

Sir Harold Gillies, considered as one of the fathers of modern reconstructive plastic surgery, used the motto “replace like with like.” The interpretation of this principle with regard to free tissue transfer is that the reconstructive microsurgeon transplants autogenously vascularized tissue into defects that are the result of trauma, tumor, infection, or congenital defects.

Consider free tissue transplantation for any tissue deficit that cannot be treated by an adjacent tissue rearrangement, skin grafting, or local pedicle flaps. Select free tissue transplantation in instances in which there are “composite deficiencies,” such as skin and bone or muscle and skin. Furthermore, free tissue transplantation may be considered for functional restoration that obviates the need for tendon transfer or nerve grafting, as in brachial plexus injuries, in which free muscle transplantation is performed for functional muscle restoration.

### RECONSTRUCTIVE LADDER

To understand the role of free tissue transfer in orthopaedic surgery, one must understand the concept of the “reconstructive ladder” (Fig. 35.2). It represents an increasingly complex solution for soft-tissue problems, with the ultimate goal being reconstitution of the soft-tissue envelope. The reconstructive algorithm, or ladder, is used to select treatment for damaged soft tissues. This algorithm should be used in the setting of acute or chronic soft tissue injury, with or without fractures. In addition, it can be applied to chronic conditions such as osteomyelitis, nonunion, or tumors (63).

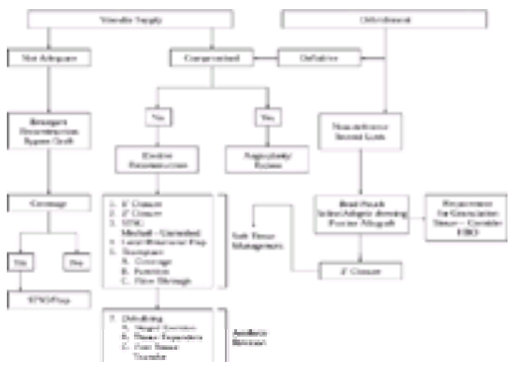

***Figure 35.2.*** Reconstructive Ladder. HBO, hyperbaric oxygen.

Coverage can be in the form of a skin graft, local tissue transfer, adjacent tissue transfer, regional tissue transfer, or free tissue transfer, which represents the most complex rung on the reconstructive ladder and is the subject of this chapter. As microvascular success rates have improved over the last three decades, the certainty in which tissue can be transplanted to provide coverage as well as function has been enhanced to an expected success rate of more than 95%. Free flaps facilitate solutions to complex soft-tissue problems, with the ultimate goal being reconstitution of the soft-tissue envelope.

Debridement is the first step in the process of the reconstructive ladder. After adequate debridement, it may be possible, such as in minor hand injuries, to close a wound primarily. This is known as primary closure (the first rung). This is rarely done in the treatment of open fractures because of associated soft-tissue loss, the degree of contamination, or the possible uncertainty as to the adequacy of debridement.

Delayed primary closure (the second rung) can be considered for reasons such as returning to the operating room in 24 to 48 hours after edema subsides, or if there is uncertainty about the safety of the wound closure (gunshot wounds or farmyard injuries). A wound may be left open to heal by epithelialization and wound contraction, as in the so-called secondary intention healing. This is the third rung of the reconstructive ladder. This may be applied to small donor areas, such as for skin grafts, or in abrasions over muscle compartments that have small areas that can rapidly epithelialize, obviating the need for skin grafts.

The next rung on the reconstructive ladder is the use of split or full-thickness skin grafts, either meshed or unmeshed. Skin grafting successfully closes many wounds in the extremities, particularly those that are beyond primary or delayed primary closure. The wound bed must be well vascularized with a smooth pink bed of granulation tissue for the graft to take. Grafts will work on fat, muscle fascia, and even intact periosteum. It is important that wound beds be cleaned before grafting to avoid flap loss by infection. Immobilization of the graft is crucial for a good “take of the graft.”

More complex wounds—for example, those that contain exposed vital structures such as nerves and arteries, bone that is devoid of periosteum, or those that have

insufficient vascularity and soft tissue to support skin grafts—require the importation of well-vascularized tissue to achieve wound closure. This may be accomplished by either local or distant flaps, which are the next rungs of the reconstructive ladder.

Rotational flaps, such as muscle, skin, fascia, or a combination of these types, can provide much-needed vascularized tissue and allow dead space to be obliterated and the wound to be closed without tension. These options may be limited because of the wound location or regional donor site deficiencies. In this instance, free tissue transplantation must be considered.

The highest rung on the reconstructive ladder uses free tissue transfer, possibly in combination with lower rungs of the ladder, such as skin closure, skin grafting, or rotational flaps. An example would be the use of a soleus myoplasty in the middle third of the tibia as well as requirements for distal third of the coverage. A muscle free flap, such as the latissimus dorsi, could be considered in such a case.

The reconstructive ladder has many rungs. The reconstructive surgeon may go from one level to another and, in many instances, may simultaneously use techniques from different levels of the ladder for different problems. Familiarity with options on the reconstructive ladder will help the reconstructive surgeon plan limb salvage and avoid the adverse sequelae that results from improper soft-tissue handling.

## FREE TISSUE TRANSFER AT THE UPPER EXTREMITY

### INDICATIONS: TRAUMA, SEPSIS, AND TUMOR

One of the main advantages of free flaps for hand reconstruction is that they allow early mobilization of the hand following injury. This feature decreases limb edema and postoperative stiffness. Free flaps allow the possibility of composite tissue reconstruction in one stage by transferring various combinations of nerve, bone, tendon, skin, and muscle at once. Free flaps can be contoured and cut to fit any defect precisely. Most important, microvascular free tissue transfers have enabled us to adhere more closely to one of the basic principles of any reconstruction effort, as set forth by Gillies—“replace losses in kind”—by allowing us to reconstruct these defects with tissue that is most similar to the lost tissue.

Patients who undergo mutilating upper extremity trauma often have the greatest need for free tissue transfers (Fig. 35.3; see also Color Fig. 35.3*A*). Trauma to the hand requires resurfacing using skin, muscle, or free fascial flaps. In the treatment of upper extremity trauma, patients who cannot be treated by conventional techniques such as skin grafting, local flaps, or distant flaps are candidates for free tissue transfer. When possible, it is desirable to import tissue rather than to use island pedicle flaps, which will further compromise upper extremity vascularity. For example, the radial forearm flap, if used for dorsal hand coverage, renders an already compromised limb more compromised. This method requires sacrifice of the radial artery. A fibula osteoseptocutaneous flap can also be used in cases of trauma of the upper extremity (Fig. 35.4; see also Color Fig. 35.4*C*).

***Figure 35.3.*** (See Color Fig. 35.3*A*.) (**A**) Gunshot wound to upper extremity with soft-tissue defect and exposure of tendons. (**B**) The patient required skin flap coverage. (**C**) An anterolateral thigh flap was selected for coverage. Donor site after skin grafting. (**D–F**) Function of extremity at 1 year.

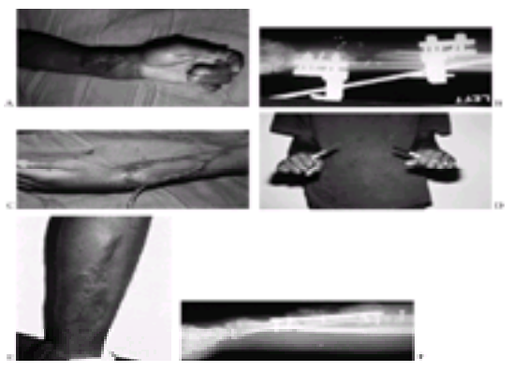

***Figure 35.4.*** **A:** (See Color Fig. 35.4*C*.) Gunshot wound to the distal forearm. The patient originally had debridement and skin graft coverage to the forearm. **B:** On the night of injury, the patient was treated with an external fixator. **C:** He subsequently had bony reconstruction with an osteocutaneous fibula transfer. **D:** Pronation. **E:** Donor defect is acceptable, with the skin graft covering the distal leg. **F:** Final radiograph with fibula in place.

Upper extremity tumors that involve compartment resections are best treated with free tissue transfer; specifically free muscle, skin, and free bone flaps (Fig. 35.5; see also Color Fig. 35.5*B*).

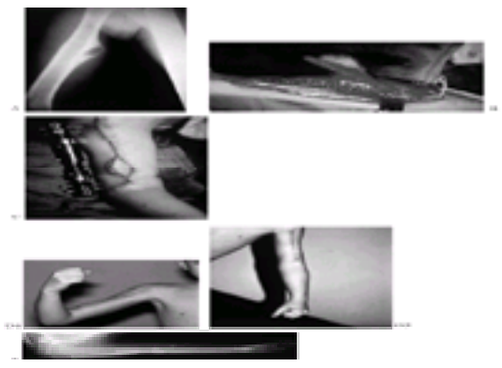

***Figure 35.5.*** Chondrosarcoma of the humeral shaft in a 9-year-old boy. **A:** A radiograph shows an eccentric lesion. **B:** An osteocutaneous fibula was taken with a small monitor paddle to ensure vascularity of the bone. **C:** An external fixator was used to hold the osteocutaneous fibula in place. **D:** Final function at 1 year. (See Color Fig. 35.5.) **E:** Radiographs at 1 year showing hypertrophy of the fibula graft and preservation of growth plates.

Upper extremity sepsis includes bone infection involving large intercalary segments either in the humerus or the forearm. The vascularized fibula transplant is an excellent method for reconstruction of such defects. Soft-tissue sepsis can usually be controlled and treated with local debridement and grafts, unless there is massive

necrosis requiring coverage, in which case select a free skin or muscle flap selected.

A large selection of free tissue transfers for hand reconstruction is available. One of the most commonly used flaps in hand reconstruction is the lateral arm flap; this is a fasciocutaneous flap that is a good choice for coverage of the dorsal or palmar defects. It is thin, easy to dissect, and associated with few complications (52).

Hand wounds resulting in palmar or dorsal defects can also be covered with a free temporoparietal fascia flap. This flap has a very low morbidity and a small scar because no skin is taken with the fascia. The flap can be taken as a double-layered flap, incorporating both the superficial and deep temporoparietal fascia on the superficial temporal vessels (47). The dorsalis pedis flap, scapular, parascapular, groin, and lateral thigh flaps can be used to cover defects on the palm and dorsum of the hand (14).

**TOE-TO-HAND TRANSFER**

Perhaps the best example of composite tissue transplantation is toe transplantation. Toe transfers include vascular, neural, osseous, tendinous, and nail components as part of the composite.

Microvascular toe transplants are believed to be superior to fingers or thumbs reconstructed by other techniques because the toe includes a sensate pulp with nail support, a near-normal appearance, and an active flexion mechanism of the transplanted toe (Fig. 35.6).

***Figure 35.6.*** (See Color Fig. 35.6.) **A:** Elective toe-to-hand transfer following amputation of a thumb. **B:** A trimmed toe transfer was selected. The first metatarsal phalangeal joint was preserved. **C:** Function shown at 1 year.

Both the great and the second toe have roles in toe-to-hand transplantation. Each transplant has advantages and disadvantages. The decision of which toe to transfer is based on several considerations: the patient's desire, donor morbidity, aesthetic aspects, as well as the part of the hand where the toe is needed. The patient should be informed that the donor morbidity from a great toe harvest (from a cosmetic and functional standpoint) would be greater than that of removing the second toe.

In a mutilated hand, where only a thumb is present, there is a need for an opposable post at the fourth and fifth digit so that the thumb and post can oppose each other. In such a case, it is more appropriate to take the second toe; bilateral second-toe transfers, or double-toe transfers, rather than the great toe (Fig. 35.7).

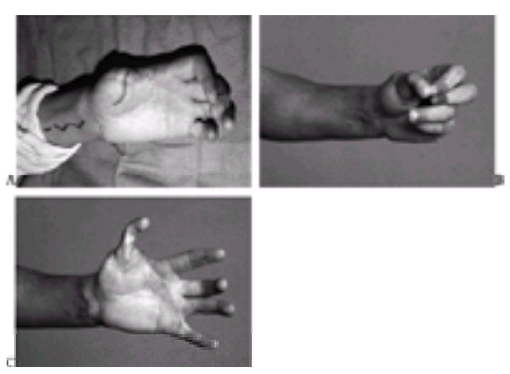

***Figure 35.7.*** **A:** Patient had replantation of multiple digits but unsuccessful replantation of his thumb. **B:** A second toe transfer was chosen to provide an opposable post. The patient made a conscious decision to have the second toe rather than the great toe taken because of his interest in athletics. **C:** Function of the hand postoperatively.

Thumb reconstruction by great-toe transplantation can be considered if at least one third of the proximal portion of the first metacarpal bone is present.

Second toe—to—thumb transplantation is indicated when a large discrepancy in size exists between the great toe and the thumb, when the loss of the great toe is not acceptable, or when the level of amputation is proximal to the proximal third of the first metacarpal and a considerable length of the metacarpal is necessary to provide adequate length. Second-toe or multiple-toe transfers also are indicated in a hand from which all fingers have been lost and there is no ulnar post against which the thumb can oppose. In this situation, two second-toe transfers may enhance the grip strength and the ability to manipulate fine objects. Partial toe transfer of the second toe can be used for reconstruction in cases of the amputation of a finger at the level of the distal interphalangeal (DIP) joint or even the nail itself. The distal aspect of the second toe can provide, in these cases, a pulp, sensibility, nail plate, and osseous length, which eases the patient's self-consciousness (15).

Microvascular reconstruction of the distal digits by partial toe transfer includes pulp flaps, which are used for volar thumb and finger resurfacing. There are three major indications for pulp transfer: (1) acute loss of the digital pulp, (2) unstable skin resulting from previous pulp reconstruction with skin graft or local flap, and (3) posttraumatic distal insensibility with pulp atrophy and distal neuroma with no possibility of nerve anastomosis (35).

If nail transfer is done, it should be based on at least one artery through one hemipulp and venous drainage through the dorsal skin proximal to the nail. A careful history as to whether there has been any damage to the foot in the lifetime of the patient will eliminate the need for an arteriogram. Doppler imaging can trace the pathway of the dorsalis pedis artery in cases in which the artery location needs to be found (32,67).

**MICRONEURAL RECONSTRUCTION OF THE UPPER EXTREMITY**

Peripheral nerve repair and brachial plexus reconstruction following injuries have evolved parallel to the development of microsurgery. In many cases of peripheral nerve injury, primary repair may not be possible for many reasons, including direct loss of nerve tissue from trauma, retraction of nerve stumps following delay in repair, or resection of the nerve for a primary nerve tumor or surrounding malignancies. Repair of the gap by primary closure with tension is avoided because tension hinders regeneration by encouraging gapping at the repair site with subsequent scar adhesion formation, as well as reducing blood flow in the repaired nerve (27). Nerve allografting is possible now owing to the advances in immunosupression, although clinical application of peripheral nerve allografting remains under experimental investigation (112).

Different procedures using microsurgical techniques have been described for brachial plexus reconstruction. Some of these techniques include nerve crossing procedures, free muscle transfer, and more recently, a combined technique of double free muscle and multiple nerve transfers. This procedure involves transferring the first free muscle neurotized by the spinal accessory nerve for elbow flexion and finger flexion, a second free muscle transfer reinnervated by the fifth and sixth intercostal nerves for finger flexion, and neurotization of the triceps brachi muscle via its motor nerve by the third and fourth intercostal motor nerves to extend and stabilize the elbow. Restoration of hand stability is obtained through the suturing of the sensory rami from the intercostal nerves to the median nerve (30). The

transferred muscles include latissimus dorsi, rectus abdominis, and gracilis. The gracilis muscle is considered to be the best option by many surgeons.

### VASCULAR RECONSTRUCTION OF THE UPPER EXTREMITY

The orthopaedic surgeon, in particular the hand surgeon, may encounter pathology that requires the understanding of free tissue transfer techniques. These transfers are not the classic transfers used in daily orthopaedic practice; thus, the subject will be mentioned briefly.

#### *Intimal Injuries*

Intimal injuries due to trauma from cannulation and indwelling devices are relatively common and can lead to thrombosis and resultant ischemia. The problem at the wrist is associated with arterial cannulation, especially in the 20% of the patients that have an incomplete vascular arch. Despite acceptable results with thrombolytic agents, we recommend prompt surgical exploration and resection of the thrombosed segment. Frequently, the gap needs to be reconstructed using reversed interpositional vein grafting (a form of tissue transfer) (68).

#### *Ulnar Artery Thrombosis*

Repetitive trauma to the hands may cause intimal damage and progress to thrombosis of the ulnar artery. Historically, management of ulnar artery thrombosis has been controversial. Treatments have included pharmacologic management, sympathectomy, thrombectomy, and arterial reconstruction. There has been a trend toward surgical management, and in the great majority of cases, we recommend this course of treatment (68). Resect the thrombosed segment of the artery and reconstruct the artery. This is best accomplished by means of a reverse interposition vein graft harvested from the forearm.

As the age of our population increases, the hand surgeon will care for more patients who experience the ravaging effects of diabetic angiopathy and peripheral vascular disease involving the upper extremities.

Together with improvements in conservative and pharmacologic treatments, the surgical approach to these diseases will evolve and will more frequently use techniques involving microsurgery and free tissue transfers such as free omental transfer to inosculate skin to provide vascularity to the hand (94).

## FREE TISSUE TRANSFER IN THE LOWER EXTREMITY

### INDICATIONS

#### *Trauma*

In recent years, increasing emphasis has been placed on open reduction and internal fixation in the management of fractures. The importance of good soft-tissue coverage to maintain the vascularity of bone fragments has also been emphasized. New methods of fracture fixation have evolved, such as indirect reduction and minimal internal fixation, that respect fracture biology and protect soft tissues.

The simultaneous management of soft-tissue injury and fractures, the so-called “orthoplastic approach,” coordinates repair processes for bone and soft tissue and avoids the adverse sequelae of exposed internal fixation, bone sepsis, and possible amputation.

The main indications for salvage of a severely damaged limb include any limb in a child, and in adults, those with potentially intact sensibility. Nerve injuries do not preclude salvage but should be distal enough to permit the return of some function (primarily sensory) within a reasonable amount of time. Conversely, complex lower limb injuries with nerve damage are frequently considered for amputation, because the return to a functional status with an appropriate prosthesis is usually more rapid (93).

Advanced age should not be a contraindication to the limb salvage. Careful preoperative patient evaluation and perioperative monitoring can reduce morbidity and mortality rates to be comparable to those of younger patients. Lower extremity microvascular reconstruction can be performed safely and successfully in the elderly patient (40).

Initially debride the devitalized and contaminated tissue and stabilize fractures. Patients with severe limb injury will often have sustained major vascular injury in the area of the trauma. Assess leg perfusion clinically and, if needed, consider an arteriogram if the zone of injury is large and it is in the region of potential microvascular anastomosis.

The timing of definitive wound management (such as free tissue transfer) in the injured extremity is usually determined by the general condition of the patient and the condition of the wound. The bacterial status of the wound, type of fracture, different types of tissues involved in the injury, and the exposed structures are factors that influence the timing of wound closure. In severe extremity trauma with soft-tissue loss and exposure of the underlying structures, cover the wound as early as possible. Acute coverage by day 5 to day 7 is generally accepted as having a good prognosis in terms of decreased risks of infection, flap survival, and healing of the fracture. If the wound can be radically debrided at the first setting, it can be covered immediately with a free flap (39) (Fig. 35.8; see Color Fig. 35.8*A*).

***Figure 35.8.*** (See Color Fig. 35.8*A*.) Trauma to the lower extremity emphasizing the importance of early coverage. **A:** Patient was treated with debridement and external fixator. **B, C:** At 48-hours, a one-stage reconstruction was performed with a nonvascularized iliac crest bone graft for the intercalary defect of the forefoot followed by a free scapular flap. **D:** One year after the reconstruction.

Base the choice of flap used for wound coverage on the size of the wound, type of tissue deficit, state of the wound (the colonization, amount of cavitation), location of the injury, and the length of the pedicle needed. Place the anastomosis in a “safe zone” where recipient vessels have not been damaged by the initial trauma. This is not always feasible. Therefore, plan to perform anastomosis outside the zone of injury, either proximally or distally.

The concept of “zone of injury” refers to the inflammatory response of the soft tissue of the traumatized lower limb, which extends beyond the gross wound and results in perivascular changes in the blood vessels. These changes include increased friability of the vessels and increased perivascular scar tissue. Both of these changes can contribute to a higher failure rate, especially in lower-limb free tissue transplantation, presumably due to a higher rate of microvascular thrombosis (5).

Most surgeons avoid the zone of injury by extensive proximal dissection of the recipient vascular pedicle, and some use vein grafts in lower limb reconstruction. Isenberg (49) demonstrated that clinical acceptability of the recipient pedicle (vessel wall pliability and the quality of blood from the transected end of the vessel) was more important than the distance from the wound.

Reconstruction of the traumatized leg can be challenging owing to the fact that both bony stabilization and soft-tissue coverage are required for a successful functional outcome. Free tissue transfer using microsurgical techniques has allowed surgeons to salvage traumatized extremities in patients who would formerly have required

amputation (42,48,59) (Fig. 35.9). See Chapter 8, Chapter 12, and Chapter 24.

***Figure 35.9.*** Gunshot wound involving both extremities. **A:** The right leg had a soft-tissue as well as an intercalary bone defect. The left leg had a distal wound with exposure of the tibia. **B:** External fixator and tobramycin spacer placed on the night of injury with anticipation of free vascularized fibula. **C:** Patient standing with right free myocutaneous rectus flap healed and left serratus flap healed. **D:** Vascularized fibula as a second stage for intercalary reconstruction.

***Orthopaedic Sepsis***

**Osteomyelitis and Infected Joint Prosthesis** Osteomyelitis is now a treatable disease. The Cierny-Mader classification guides treatment (26). The management of dead space after sequestrectomy relies heavily on the technique of free tissue transfer. Free muscle flaps provide coverage for the debrided bone and soft tissue, obliterate dead space, improve vascularity, and enhance leukocyte function (33,77,80).

Advances in skeletal reconstruction and fixation have improved the treatment of patients with osteomyelitis and large (greater than 6 cm) segmental bone defects. In the past, despite successful treatment of osteomyelitis, some patients have required amputation owing to chronic nonunions. Now, once the bone infection is treated, vascularized bone transplants (85,92) or bone lengthening with the Ilizarov device facilitates reconstruction and provides structural stability for limb function (3). See Chapter 32.

Local muscles traditionally had been used to treat chronic osteomyelitis, and free flaps have been described more recently for this use. Local gastrocnemius and soleus muscle flaps are still used for coverage of smaller wounds on the upper and middle thirds of the leg, respectively. However, local muscle flaps will not reliably cover defects greater than 25 $cm^2$ or those on the distal third of the leg, ankle, or foot. For these defects, free muscle transfers are preferred. The advantages of using the free muscle flaps such as latissimus dorsi (11), serratus anterior (44), and rectus abdominis (18) compared with the local pedicled muscle flaps such as the gastrocnemius muscle are that they provide greater bulk (filling larger wounds), have longer pedicles (increasing flexibility in muscle positioning), and carry larger diameter vessels (facilitating the microanastomoses).

**Infected Implants** Infection is the most serious potential complication in total joint arthroplasty, and the risk is increased with compromised wound healing. Clinical risk factors for compromised wound healing include diseases such as rheumatoid arthritis, peripheral vascular disease, chronic renal failure, and diabetes. Other risk factors include irradiation, steroids, immunosuppressive therapy, multiple previous surgeries, and malnutrition. When they are exposed, orthopaedic prosthetic materials become colonized with bacteria, and in the majority of these cases, rapid intervention is required to salvage the extremity and prevent osteomyelitis. Removal of the prosthesis, debridement, closure with a muscle flap and delayed insertion of a new prosthesis constitute the preferred treatment. Free muscle transfers not only provide coverage of the defect but also provide a well-vascularized tissue in close proximity to the new prosthesis (Fig. 35.10).

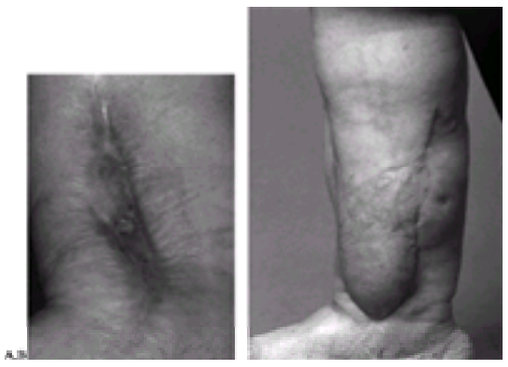

***Figure 35.10.*** **A:** Chronic osteomyelitis of the ankle. **B:** Patient underwent sequestrectomy and free latissimus flap for coverage of unstable skin as well as treatment of dead space following sequestrectomy.

Exposure of plates and screws may occur after open reduction and internal fixation of fractures. This occurs commonly when there is a significant tissue edema that creates difficulty in skin closure. It affects the medial pretibial surface of the distal leg more often than the lateral side. The treatment in this situation usually requires free flap coverage (51,73). See Chapter 135.

***Tumors***

The last decade has seen an increase in the use of microsurgical techniques in reconstruction for bone and soft-tissue tumors in the lower extremity. Specifically with the emphasis placed on limb salvage after compartment resection rather than amputation, microsurgical techniques have allowed the orthopaedic oncologist and reconstructive surgeon to work together to preserve limbs. In soft-tissue sarcoma, in which entire compartments are resected, microsurgical transplantation replaces components of both muscle and skin to maintain limb contour and aid in healing. For example, a large anterior compartment resection for a malignancy may expose the tibial cortex. Microsurgery is the only reconstructive option for wound closure. A flap such as the latissimus dorsi muscle could be used to cover the tumor defect. This muscle can also be innervated to assist in dorsiflexion of the foot.

The radiated wound, particularly following the treatment of soft-tissue sarcomas, has a high incidence of wound complications after attempted primary closure. Radiated wounds generally have a poor vascular supply, making surgery through these wounds difficult. Wounds tend to break down. Importing well-vascularized tissue into the wound results in more rapid wound healing and may improve local circulation in radiated areas. For this reason, many centers have adopted the policy that immediate microsurgical reconstruction be performed after tumor extirpation. The results of immediate microsurgical transfers in these cases have been well substantiated and have led to decreased hospital time, decreased costs, decreased morbidity, an increased rate of limb salvage, and a high-level of patient satisfaction (9).

Before the advent of free tissue transfer, the traditional treatment for high-grade sarcomas of bone, such as osteosarcomas, had been amputation. Limb salvage surgery has become a viable alternative for many patients due in part to the development of more effective perioperative chemotherapy. The success of limb salvage in these patients is primarily dependent on wide resection margins and the addition of perioperative chemotherapy. The current management of soft-tissue sarcomas or osteogenic sarcomas stresses more conservative resection and limb-sparing operations. See Chapter 126. These types of resections create complex composite defects of bone and soft tissue that require microsurgical reconstruction. Local flaps generally do not provide adequate coverage, and many times, the only option is a free tissue transfer.

Composite defects are often generated by tumor extirpation, and the use of composite flaps has been particularly advantageous in the reconstruction of tumor defects. Examples include a myocutaneous innervated latissimus dorsi for finger flexion or an osteocutaneous fibula flap for an intercalary bone defect that also has an

accompanying overlying skin defect (64) (Fig. 35.11).

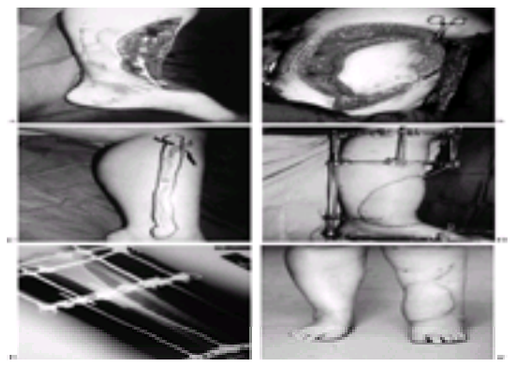

***Figure 35.11.*** **A:** Osteosarcoma of the tibia requiring resection of the anterior tibial compartment. Patient required (**B**) latissimus free flap (**C**) and a free fibula for reconstruction. (**D**) Final reconstruction with simultaneous Ilizarov, free latissimus dorsi myocutaneous flap, and free vascularized fibula flap. (**E**) Fibula in place as an intercalary graft compressed and held by an Ilizarov frame. (**F**) Final result at 1 year. The fibula hypertrophied, and fusion was performed into the talus with the fibula.

When the patient is to undergo adjuvant therapy, the appropriate window for the timing of the operation, which includes tumor resection and free tissue transfer, is determined by discussions with the oncologist and radiation therapist. Plan the operative details such as incisions, design of skin flaps, exposure, and preservation of the recipient site vessels with the oncology surgeon. It is usually possible to establish the requirements for soft-tissue and bone reconstruction early in the operation and begin the flap harvest concurrent with the tumor resection. If oncologic margins are not predictable, then it is best to complete the resection of the tumor before beginning dissection of the free flap (28) (Fig. 35.12; see also Color Fig. 35.12*B*).

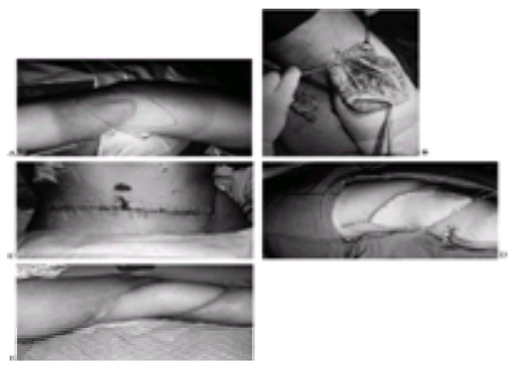

***Figure 35.12.*** Patient with popliteal mass presented with acute peroneal palsy. **A:** Diagnosis was neurosarcoma. **B:** Tumor defect after biopsy and local radiation. (See Color Fig. 35.12*B*). **C:** Harvest of free rectus abdominus myocutaneous muscle flap. **D:** Postoperative result with radiation catheters in place under the flap. **E:** Results at 1 year.

Flaps are indicated for the coverage of neurovascular structures (particularly if they are radiated), bone devoid of periosteum, and allografts or tumor prostheses that cannot be covered with local tissues. Sometimes blood supply to local flaps may be sacrificed during tumor resection.

Patients who undergo secondary reconstruction can be divided into two groups. The first are those who undergo resection of tumors and develop acute wound complications such as skin flap necrosis in the early postoperative period. These patients may require debridement and free flap coverage within the first or second postoperative week. It is safe to let questionable areas demarcate before surgery. Patients who present later with impending allograft or prosthesis exposure should undergo surgery as soon as possible to avoid infection of the implant or allograft.

The second group of patients are those who require reconstruction several months or years after primary tumor resection. Some of the patients in this group present with chronic unstable soft-tissue coverage, wound dehiscence, prosthesis infection, and prosthesis failure or limb growth that compromises soft tissue.

Although free tissue transfer adds extra time and technical complexity to the tumor operation, it may also lead to a decrease in amputation rates by decreasing wound complications. In addition, it allows the oncologic surgeon to obtain adequate margins of resection, which may favorably influence amputation rates by contributing to a decrease in local recurrence.

## PRINCIPLES FOR THE FOOT AND ANKLE

Despite advances in limb reconstruction in the last several years, resurfacing of the foot remains one of the most difficult reconstructive problems. Not only is it necessary to reestablish soft-tissue integrity but also the treatment plan must include attention to bony architecture and foot deformities that can be caused by muscle imbalance. Each anatomic region of the foot has certain characteristics that will influence selection of the free tissue transfer for reconstruction. The dorsum of the foot and the ankle require thin pliable soft-tissue coverage for exposed tendons that are devoid of paratenon, bones, or joints. The weight-bearing surface of the foot (the plantar skin) is unique with respect to its dermoepidermal histologic characteristics, the unique subcutaneous tissue in the heel pad, adherent dermal septae to the underlying plantar fascia, and the ability to withstand constant pressure and shear forces.

Providing coverage along with protective sensibility can be achieved with a free neurosensory flap such as the radial forearm flap (22). Free muscle flaps are used when bulk is necessary to obliterate dead space such as in osteomyelitis, severe crush injuries with extensive soft-tissue loss, and for weight-bearing surfaces (84). However, muscle flaps can often be bulky and, if they are not contoured properly, may prevent the use of normal shoes.

The radial forearm flap offers several potential advantages over other fasciocutaneous flaps and muscle flaps for resurfacing the foot and ankle. It meets most of the prerequisites for the “ideal” foot flap: It provides a large amount of well-vascularized, thin, and pliable soft tissue; it is easy to harvest; and it has large consistent vessels and a long pedicle. Furthermore, it facilitates the restoration of normal (original) foot contour by replacing “like-with-like,” allowing patients to wear normal shoes, and can provide a durable and stable weight-bearing plantar surface for walking. It also achieves an excellent aesthetic result without the need for debulking. Dryness and cracking of a hypertrophied skin graft, especially at the flap–foot skin interface, is less of a problem with skin flaps compared with free muscle flaps covered with split-thickness skin grafts. In addition, it has the potential for sensory reinnervation. Possible disadvantages include an unsightly donor site scar, especially in a young woman, and donor site skin graft breakdown with flexor tendon exposure.

## PLANTAR SKIN RECONSTRUCTION

The plantar skin has unique properties. It is thick and heavily keratinized, designed to resist high stress, and it is anchored to underlying bones and ligaments by thick fibrous connective tissue. The plantar surface acts as a shock-absorbing system for the foot, helping to minimize horizontal and vertical shear forces by its multidirectional fibrous septae (115). The plantar surface of the foot can be divided into three distinct areas, each with special requirements for replacement.

The instep skin in the normal foot is not subject to high stress and, in many cases, it has been used as a donor tissue for plantar resurfacing. Forefoot skin is the subject of significant forces during running and toe off in the normal gait cycle.

Base the decision to proceed with foot salvage on whether the foot will function better than a prosthesis after the reconstruction is complete. Achieving a normal gait cycle is possible only if the foot can fit into a regular or slightly modified shoe, is pain free, and ideally has some sensibility. Neurosensory flaps such as dorsalis pedis, lateral arm flap, tensor fascia lata flap, and radial forearm flap may be used to provide sensibility, but they may lack the bulk and thickness required for cavitary tissue

defects. Larger flaps such as muscle flaps that do contour better cannot be innervated. Thus, there is no ideal transfer. A review of flap options should be done for each patient. The specific complications include wound breakdown because of mechanical instability and excessive sheer forces, ulceration, formation of calluses, hyperthrophic scarring, and intrinsic muscle imbalance (62).

## VASCULAR AND DIABETIC FOOT

Nonhealing wounds of the extremities are common in patients with diabetes and peripheral vascular disease. The magnitude of the problem is enormous; statistics indicate that 14% of these patients are hospitalized an average of 6 weeks per year for foot problems, and more than 80% of amputations are performed on diabetics. The contralateral limb of one with an ulcer is at risk for further ulceration, and there is a 50% chance of loss of the opposite leg within 5 years (43). Care of these patients requires a close collaborative effort between the orthopaedist, the peripheral vascular surgical team, and the microsurgical team to optimize rapid and accurate assessment of the vascular problem, and to determine the most appropriate and timely plan for wound care and the most reliable method for revascularization. The results of macrovascular and microvascular anastomoses are comparable to those for nondiabetic patients undergoing the same procedure (58). Patients treated with cutaneous free flaps have less morbidity than patients treated with muscle free flaps (89). The radial forearm free flap is ideal for treatment of relatively small wounds of the foot and ankle. It provides cutaneous tissue with a lengthy vascular pedicle and a donor site that can often be closed primarily.

Despite the multiple medical problems of diabetic and dysvascular patients, surgical mortality has not been found to be higher in cases of microsurgical reconstruction procedures performed alone in these patients or in combination with macrovascular vascular reconstruction (13). Once the extremity has been revascularized, the most appropriate method of reconstruction can be carried out for defects of the foot in a well-vascularized limb. For those patients in whom the macrovascular blood supply is intact and without apparent compromise but who have large, unhealthy, colonized wounds, particularly if they involve tendon or bone, free flap coverage is indicated. Free tissue transfer techniques are ideal in these situations because (1) they are able to resurface any size defect; (2) they allow aggressive resection of the wound to eliminate colonized, fibrotic, unhealthy tissue; (3) the flap can help revascularize the foot; and (4) the defect is replaced with healthy nondamaged tissue (Fig. 35-13; see also Color Fig. 35.13*A*, Color Fig. 35.13*B*).

***Figure 35.13.*** (See Color Fig. 35.13*A*, Color Fig. 35.13*B*). A 64-year-old diabetic patient with a dysvascular foot. **A:** Necrotic foot preoperatively. **B:** After debridement of tissue. **C:** Preoperative planning of the scapula flap. **D:** The patient underwent free flap as well as femoral distal popliteal bypass. Final result at 1 year.

Diabetic and dysvascular patients require a high degree of vigilance to avoid problems both locally and systemically, with a much closer observation of the donor sites and recipient sites to preclude wound healing problems.

Because many diabetic and dysvascular patients are candidates for amputation before flap transfer (which was often offered as a last option before limb loss), these procedures do not increase the rate of limb loss, but can only increase the limb salvage rate (Fig 35-14; see also Color Fig. 35.14*A*). It is important to examine the result of lower extremity limb salvage as it relates to ambulatory function. Salvage of a useless limb in such patients is of little value in their overall management. Likewise, heroic attempts at salvaging a limb are not indicated if the operation subjects a patient to excessive morbidity.

***Figure 35.14.*** (See Color Fig. 35.14*A*). Diabetic foot infection. **A:** Dorsal view. **B:** Plantar view. **C:** Debridement. **D:** Reconstruction with a scapular free flap. The patient required debulking of the flap but was able to continue as a farmer with a special shoe.

The question of the cost/benefit ratio of such procedures has yet to be determined. Certainly in this era of cost-containment, the arguments against such “expensive” and sophisticated procedures versus straightforward amputation cannot be ignored. Although the exact cost of leg salvage in such a group of patients is difficult to determine, it may be less expensive than the combined cost of hospitalization, prosthesis fitting, rehabilitation, and disability payments.

A high degree of success can be achieved only by extremely careful patient selection. In the face of systemic complications, one must also exercise proper judgment and abort attempted reconstruction to ensure patient survival.

Chronic venous ulcers can also be treated with microsurgical tissue transfers. In the appropriate patient with localized disease, a dual surgical approach including wide excision of the ulcer and surrounding liposclerotic tissue bed, and coverage with a free flap containing multiple competent microvenous valves, may improve the underlying pathophysiology. In patients with complex ischemic or infected wounds from diabetes, free tissue transfer as an adjunct to lower extremity vascular reconstruction can help in obtaining a salvageable functional limb, thus presenting a viable alternative to amputation (41,75).

## STUMP COVERAGE

Despite the success achieved in limb-salvage procedures, a high number of amputations are performed as a result of major trauma, tumors, diabetic ulcers, and in cases when the patient is too ill to survive a lengthy operation. The level of amputation itself is an important factor for consideration. In cases of lower limb amputation, below-knee amputation is associated with faster rehabilitation compared with above-knee amputation. Below-knee amputees require less rehabilitation time, have a more natural gait, and can engage in more physical activities (6). The choice for the level of amputation is determined by the need to cover the stump with appropriate soft tissue stable enough to resist breakdown in a prosthesis. Skin grafting of amputation stumps, especially in lower limbs, provides only wound coverage, and usually does not meet the need for adequate padding. In cases for which a local flap is not available, free flaps should be considered. These flaps can provide coverage of the stump, and if microneural coaptation is performed, sensation of the stump can be achieved. That may assist proprioception within the prosthesis. An amputated limb may provide donor tissue, such as in traumatic below-knee amputations (Fig. 35.15).

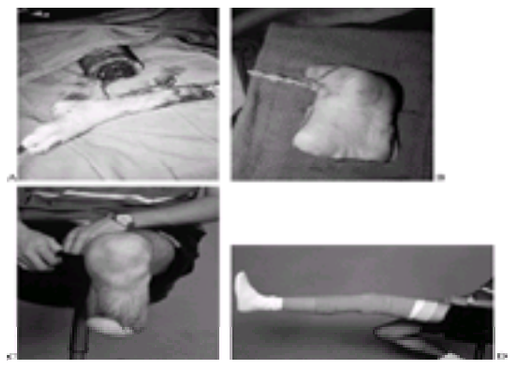

***Figure 35.15.*** Chronic infection of the tibia. **A:** Amputation level. **B:** Plantar fillet flap was harvested to preserve the length of the leg. **C:** Stump healed and (**D**) prosthetic device in place.

A free flap harvested from an amputated lower leg eliminates donor site morbidity (114). Fillet foot flaps are useful for salvage of below-knee level amputees.

## PREOPERATIVE CONSIDERATIONS

### SELECTION OF TISSUE TRANSPLANTATION

Free flaps can be categorized into two different types. Isolated tissue transplants include muscle, skin, fascia, bone, or flaps. The more common composite tissue transplant is a more complex flap that provides more than one function. Examples include myocutaneous, osteocutaneous, or innervated myocutaneous flaps.

The type of tissue deficiency and surface requirements will determine the type of flap to be selected. Tissue transplants are selected with respect to donor site morbidity, recipient site requirements, vascular pedicle length, and anticipated aesthetic result. For example, a myocutaneous latissimus dorsi flap should not be transplanted to the dorsum of the foot due to its bulk and the fact that the donor tissue does not match the dorsum of the foot. Other flaps, such as an isolated skin flap (radial forearm flap or lateral arm flap), are a better transplant. Similarly, to fill dead space after sequestrectomy of an infected tibia, a lateral arm flap, which is a small skin flap of approximately 5 × 7 cm is not appropriate owing to its lack of bulk and the fact that the muscle flaps, rather than skin flaps, are known to be more effective in the treatment of osteomyelitis. The use of a skin paddle with composite tissue transfers can be done for either contouring or as a monitor for perfusion of the flap.

The next consideration is whether dead space needs to be filled. If a flap were used purely for resurfacing, such as on the dorsum of the hand, so that secondary tendon reconstruction can be performed, a large bulky flap would not be required. However, if there is significant dead space, a large muscle flap such as a latissimus dorsi flap should be considered. Osseous flaps are selected for structural defects such as intercalary bone defects resulting from trauma, tumor, or infection. If a vascularized bone flap is to be selected, the cross section of the bone defect, available vascular supply, and fixation of the vascularized bone graft must be taken into consideration.

Not all flaps are selected to replace missing tissue. There are instances in which tissue coverage exists but it is insufficient in texture or quality. A soft-tissue envelope may need to be augmented, such as using a scapular flap to resurface a knee with unstable skin as a first stage before a total knee replacement. There are free flaps that are performed for purely aesthetic reasons, such as the resurfacing of extremities. This is an unusual use of free tissue transfer, and it is used only in special cases. A combination of the above-mentioned selection factors determines free flap selection.

### RECIPIENT VESSELS

Specific preoperative assessment in microsurgical procedures frequently includes angiography to evaluate the vasculature of the recipient site. The need for angiography, however, especially after trauma, is debatable. The vast experience gained in reconstructive microsurgery has enabled us to become familiar with the “vascular” anatomy in all regions of the body to optimize the selection of recipient site vessels. A meticulous clinical evaluation (with Doppler mapping) can provide valuable information without the need for recipient-site angiography (71).

The proper selection of recipient vessels is essential for the success of free tissue transfer, especially when the transfer is to the lower extremity. However, general agreement on which vessels to use has not yet been reached. Conflicting data have been reported on the survival and outcome of the transferred flaps, depending on the vessel used or the location of anastomosis proximal or distal to the zone of injury. For example, the anterior tibial vessels may be preferred for their easy accessibility, whereas the posterior tibial vessels are strongly advocated by others.

Park et al. (91) developed an algorithm for recipient vessel selection in free tissue transfer to the lower extremity. Based on their experience, the most important factors influencing the site of recipient vessel selection were the site of the injury and the vascular status of the lower extremity. The type of flap used, method, and site of microvascular anastomosis are less important factors in determining the recipient vessels.

### TIMING OF FREE TISSUE TRANSFER

The timing of the wound closure using microsurgical techniques is important. In severe injuries of the lower extremity with associated soft-tissue defects, early aggressive wound debridement and soft-tissue coverage with a free flap within 5 days has been found to reduce postoperative infection, as well as decrease flap failure, nonunion, and chronic osteomyelitis (19,20). Godina (39) emphasized the importance of radical debridement and early full-thickness soft-tissue coverage either acutely or within the first 72 hours.

Lister and Scheker (70) reported the first case of an emergency free flap transfer to the upper extremity in 1988; they defined the emergency free flap as a “flap transfer performed either at the end of primary debridement or within 24 hours after the injury.” Yaremchuk and colleagues (118) recommend that flaps be transferred between 7 and 14 days after injury after several debridements. The argument in favor of this approach is that the zone of injury, which often may not be apparent at presentation, can be determined by serial debridements performed in the operating room over several days.

When deciding to perform a primary closure with a free flap, two key factors should be considered: the presence of an exposed vital structure and the risk of infection. A vital structure is defined as “one that will rapidly necrose if not covered by adequate soft tissue” (21). The decision of what constitutes a vital structure depends on circumstances. Tissues such as vessels, nerves, joint surfaces, tendons, and bone denuded of periosteum may desiccate, die, and lead to infection when they are left exposed for long periods of time. When considering primary versus delayed coverage, take into account the risk of leaving the vital structure exposed and what functional deficit would occur if it were lost.

The risk of infection is the second important factor that should be considered because it may jeopardize the limb, the quality of the functional recovery, or the free flap. As the risk of infection increases, the wisdom of primary closure with a free flap is reduced. Debridement of the wound is the most powerful surgical tool to reduce the risk of infection of the wound. If radical debridement is not possible, then it is not safe to perform primary free flap transfer. Another perspective is that the capability to perform free tissue transfer allows the surgeon increased freedom to perform radical debridement and may actually reduce the risk of infection (86). The mechanism of injury, the elapsed time since injury, and the degree of contamination of the wound determine the risk of wound infection. In an acute, sharp noncontaminated injury, when closure would be routinely performed if there were no skin loss, there seems to be little reason not to consider an emergency free flap.

### PATIENT PREPARATION

Microsurgical procedures are major surgical procedures. Carefully evaluate the cardiovascular and pulmonary status. Nutritional assessment is of particular importance because this will influence healing, particularly in trauma and tumor patients. In elective cases, patients in a high-risk category may need preoperative nutritional supplements (7).

## SPECIFIC TISSUE TRANSFER

The commonly used fasciocutaneous free flaps are the lateral arm flap, radial forearm flap, scapular flaps, dorsalis pedis and groin flaps.

**LATERAL ARM FLAP**

The lateral arm flap (Fig. 35.16) can serve as an innervated fasciocutaneous flap or as a deepithelialized subcutaneous fascial flap. The lateral arm flap is based on the posterior radial collateral vessels (PRCA). The artery is a direct continuation of the deep brachial artery. The draining veins of this area are the venae comitantes of the PRCA. The pedicle length is approximately 7 cm. The external diameter of this artery is usually 1.5 to 2.0 mm but sometimes can be smaller, even 0.8 mm. The vein's diameter ranges from 2.0 to 2.5 mm. The anatomy of this vascular pedicle is constant, in contrast with the medial arm flap, which has a more variable vascular supply.

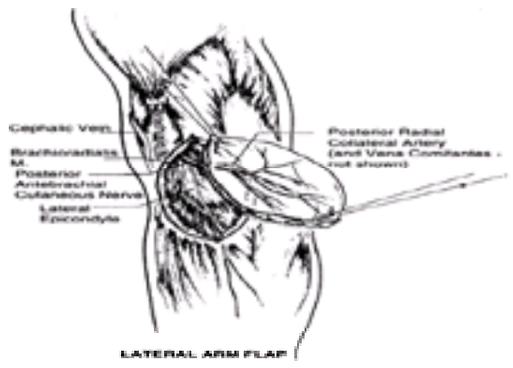


***Figure 35.16.*** Surgical anatomy of the lateral arm flap.

The lateral arm flap is innervated by the posterior brachial cutaneous nerve, a proximal branch of the radial nerve (C5—6), giving the flap potential as a sensate flap. Additional sensory supply comes from the posterior antebrachial cutaneous nerve, which divides at the distal upper arm, with the upper branch supplying the posterior inferior upper arm and the lower branch supplying the lateral side of the arm and elbow (82).

The dimensions of the skin flap is approximately 8 × 15 $cm^2$. The surface marking that is important in planning is a line that joins the deltoid insertion with the lateral epicondyle (this line marks the lateral intermuscular septum and the course of the PRCA). Design a flap with this line as the central vascular axis. Include the deep fascia in the flap. It also can be harvested based on the PRCA pedicle alone. This is advantageous in cases in which thin well-vascularized coverage is required and for coverage of areas where tendon gliding is required (119).

The distal territory is thin and is innervated by the lateral brachial cutaneous nerve of the arm; it is often hairless. In addition, vascularized bone (humerus) may be harvested with this flap for composite reconstruction (52).

The periostal blood supply from the PRCA will allow a vascularized bony segment 10 cm long and 1 cm wide to be included with the skin flap.

- Position the patient supine. Drape the arm to allow free movement; position the arm on an arm table or across the chest. A tourniquet is recommended but sometimes is difficult to maintain during proximal dissection.
- Begin dissection with a posterior incision to the triceps muscle fascia.
- Raise the flap subfascially and suture the skin to the fascia to prevent shearing.
- Elevate the posterior fascia to expose the lateral head of the triceps. Continue dissection to the anterior border of triceps muscle. Here, the fascia dives deep and inserts into the humerus. Perforators are now seen in the septum.
- Make an anterior incision down to fascia. Incise the anterior fascia over the brachialis and the brachioradialis muscle, following the level of the periosteum of the humerus.
- Ligate the distal continuation of the PRCA.
- Separate the fascial septum as close as possible to the periosteum. Follow the vascular pedicle proximally under the triceps muscle into the spiral groove. Separate the lower cutaneous nerve from the radial nerve.
- Modify the flap elevation technique when the fasciocutaneous flap is designed to include vascularized bone (humerus) and tendon (triceps).

**RADIAL FOREARM FLAP**

The radial forearm flap (Fig. 35.17)is a thin, well-vascularized fasciocutaneous flap on the ventral aspect of the arm. This flap was widely used in China before it was popularized in the Western literature (88,105). The flap is based on the radial artery, which can achieve a 20 cm pedicle and has a diameter of 2.5 mm. This pedicle length facilitates microsurgical anastomosis out of the zone of injury. The venous drainage is through the venae comitantes of the radial artery, but the flap can include the cephalic vein, the basilic vein, or both. The flap can contain the lateral antebrachial cutaneous nerve or the medial antebrachial cutaneous nerve and serve as a neurosensory flap. The size of the flap can be 10 × 40 $cm^2$. A portion of the radius can be included as a vascularized bone with this flap (29). The advantages of this flap are its long pedicle and potential sensory innervation. The quality of the bone from the radius is mainly cortical and not of any substantial volume (107). Including the bone in the radial forearm flap can lead to fracture of the radius.

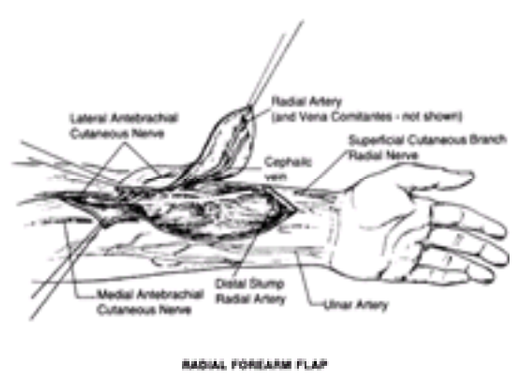


***Figure 35.17.*** Surgical anatomy of the radial forearm flap.

Preliminary tissue expansion will increase the flap dimensions; more important, it will allow direct closure of the donor defect (76).

- Position the patient supine, with the arm on a hand table. Preoperatively, evaluate the vascular supply to the hand by an Allen test and a Doppler scan, and confirm the circulation through the ulnar artery. A line drawn from the center of the antecubital fossa to the radial border of the wrist where the radial pulse is palpable represents the course of the radial artery. Center the flap over the course of the vessels. The more distal the flap design, the longer the pedicle.
- Make the skin incision and continue a subfascial dissection toward the vessels.
- On the distal part of the flap, identify the brachioradialis and flexor carpi radialis tendon. The radial artery and venae comitantes will lie along the ulnar side of the brachioradialis and along the radial side of the flexor carpi radialis tendon. The cephalic vein will lie radial to the brachioradialis.
- Dissect under the pedicle and isolate the pedicle distally.
- Raise flaps from distal to proximal and isolate the vessels proximally. Dissect deep to the deep fascia, elevating the flap from the underlying muscle. Combined flaps can include tendons and segments of the radius.

If the radius is harvested as vascularized bone, less than 40% of the cross section of the radius should be harvested, and the wrist and forearm should then be put in a

cast for 3 to 4 weeks. Avoid injury to the peritenon covering the tendons of the flexor carpi radialis, brachioradialis, and finger flexors because its loss can lead to skin graft failure and even loss of the tendons.

In most cases, the donor site requires a skin graft for closure, which leaves a scar in a visible place.

## SCAPULAR AND PARASCAPULAR FLAPS

The scapular flap (Fig. 35.18) is probably the workhorse of skin flaps. It is a thin, usually hairless skin flap from the posterior chest and can be deepithelialized and used as subcutaneous fascial, pedicled, or free flap.

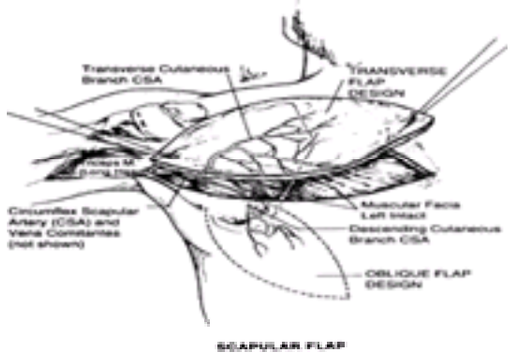


***Figure 35.18.*** Surgical anatomy of the scapular flap.

The flap is perfused by the cutaneous branches of the circumflex scapular artery (CSA) and drained by its venae comitantes. The CSA is a major tributary of the subscapular artery; it is the artery supplying blood to the scapula, the muscles that attach to the scapula, and the overlying skin. The length of the pedicle is 5 cm, and the diameter of the artery is 2.5 mm. The vascular pattern of this territory makes it possible to raise multiple skin flaps on a single vascular pedicle or to harvest the lateral border of the scapula as an osteocutaneous flap for a complex reconstruction.

The cutaneous territory can be 20 × 7 $cm^2$ and can be divided in two components: a horizontal territory (horizontal scapular flap) and a vertical territory (parascapular flap) based on the branches of the CSA after the vessel courses through the triangular space.

Innervated by the lateral posterior cutaneous branches of the intercostal nerves, this flap has no potential for being used as a sensate flap. Preliminary expansion of the territory of the scapular flap will increase the flap dimensions and permit direct donor site closure.

### *Parascapular Flap*

- Position the patient midlateral or in an oblique position. Elevate the flap retrograde.
- Start with a low medial incision. Identify the epifascial plane. Elevate the fascia cranially beneath the deep fascia, to the area of the triangular space.
- Complete the skin incision (the upper part). Carefully retract the flap medially. Identify the junction of the parascapular and horizontal branches of the circumflex scapula vessels.
- Divide the horizontal branches and dissect the circumflex scapular pedicle into the triangular space. Identify the thoracodorsal or scapular artery.

### *Scapular Flap*

- Use the same dissection strategy as for the parascapular flap.
- Start the dissection laterally and proceed toward the triangular space.
- As in the parascapular flap, the vascular pedicle can also be identified first in the course of the dissection.

Some surgeons favor the identification of the vascular pedicle as the first step of the dissection, especially in cases of microvascular transplant. Accomplish this with palpation of the triangular space and confirmation of pedicle location with a Doppler probe. Two approaches are available for scapular and parascapular flap elevation and preparation for the microvascular transplantation: lateral (initial pedicle identification) and medial (retrograde flap dissection). This flap can be combined with other flaps based on subscapular blood supply, and this may greatly facilitate certain complex reconstructions. These reconstructions include the latissimus dorsi and serratus anterior flaps, which can supply additional skin, muscle, and bone (rib), if necessary (31,98,109).

The primary indication for the scapular flap is a defect requiring a relatively thin, large cutaneous flap (10). These kinds of defects are often found in the foot (95). The osteoseptocutaneous free scapular flap reconstruction has been described in the lower extremity (100).

## DORSALIS PEDIS FLAP

The dorsalis pedis flap (Fig. 35.19) is a thin sensate fasciocutaneous flap from the dorsum of the foot. It is based on the dorsalis pedis artery, which originates from the anterior tibial artery and its venae comitantes (72). The length of the pedicle is 6 to 10 cm, and the diameter of the artery is 2 to 3 mm. The nerve supply comes from the branches of the deep and superficial peroneal nerves. The size of the flap is 6 × 10 $cm^2$, and it can be raised as a skin flap alone or in combination with the second metatarsal bone as an osteocutaneous flap or in combination with first- and second-toe transfer (83).

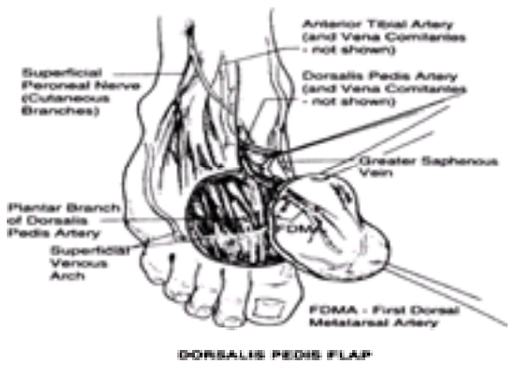


***Figure 35.19.*** Surgical anatomy of the dorsalis pedis flap.

- Position the patient supine with a tourniquet around the thigh.
- Make a distal incision for identification of the first dorsal metatarsal artery with subsequent retrograde dissection of the flap. Divide the first dorsal metatarsal artery and branches of the deep peroneal nerve to the first web space.
- Continue the dissection from distal to proximal in a plane just deep to the deep peroneal nerve and first dorsal metatarsal artery. This plane is just above the peritenon of all the extensor tendons.
- Then continue the dissection proximally up to the proximal head of the metatarsal. At that level, the deep perforating branch of the dorsalis pedis artery is encountered.
- Make the medial incision of the flap and elevate the medial part of the flap with the greater saphenous vein and the dorsal venous arch included in the flap.
- Over the tarsal bones, identify the dorsalis pedis artery. Divide the deep branch and incise the rest of the skin completely.

- With the upper incision completed, open the extensor retinaculum and identify the dorsalis pedis artery, its two venae comitantes, and nerve.
- Divide the extensor hallucis brevis muscle at the level of the extensor digitorum longus tendon to the second toe. Take care to preserve the paratenon on the remaining tendons to provide a bed for the skin graft.

The flap can be used in the upper extremity to cover joints and tendons, and in microvascular transplant of metatarsophalangeal joints in children (78).

The donor site morbidity is of concern with the use of this flap; it can include difficulties in primary healing with the need for skin grafts, and complications of lymphedema, and hypertrophic scarring of the foot (99).

**GROIN FLAP**

The groin flap (Fig. 35.20) provides a large skin and subcutaneous tissue territory based on the superficial circumflex iliac artery (SCIA) and vein (SCIV). The length of the pedicle is 2 cm, and the diameter is 1.5 mm. The dimension of the flap is approximately 10 × 25 $cm^2$.

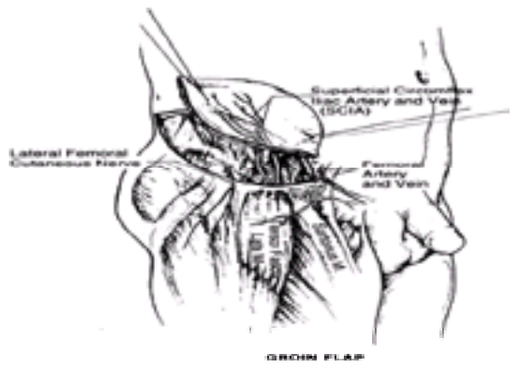


***Figure 35.20.*** Surgical anatomy of the groin flap.

Preliminary expansion of the lateral groin skin beneath the deep groin fascia expands flap dimensions and allows direct donor site closure.

- Position the patient supine with a beanbag or folded towel placed under the posterior iliac spine on the side of the planned flap. The medial approach is preferable for free flaps.
- Identify the SCIA 5 cm below the inguinal line before skin elevation.
- Incise medially and identify the superficial vein anterior to Scarpa's fascia. Identify the femoral artery and SCIV and SCIA.
- Start with a lateral skin incision. Leave the deep fascia intact.
- Next identify the lateral border of the sartorius muscle. Ligate the muscle branches of the SCIA branch. Divide the lateral cutaneous nerve.

The flap can be modified, including the sheets of external oblique aponeurosis for reconstruction of a tendon-like structure to replace the Achilles tendon or reconstruction of the calcaneus with a composite graft including the groin flap and iliac crest bone (113).

The complexity of the vascular anatomy and the small diameter of the superficial circumflex iliac artery make this flap less popular than other free skin flaps (25).

**TEMPOROPARIETAL FASCIAL FLAP**

The temporoparietal fascial flap (Fig. 35.21) can be used as a fascial or fasciocutaneous flap. The fascia covers the temporal muscle extending over the temporal fossa and lies superficial to the deep temporal fascia covering the temporalis muscle. It continues as the galea beyond the limits of the temporal fossa.

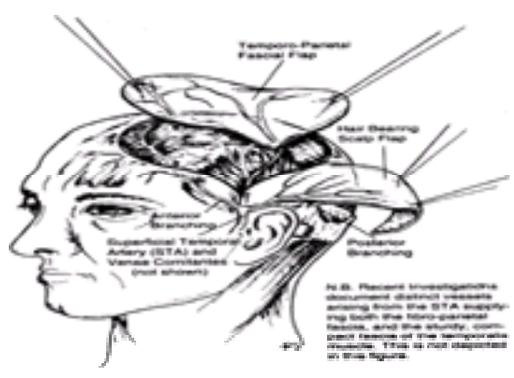


***Figure 35.21.*** Surgical anatomy of the temporoparietal fascial flap.

Vascular pedicle: The superficial temporal artery (STA) is the terminal branch of the carotid artery. The length of the artery is 4 cm, and the diameter of the artery is 2 mm. The course of the vessels is on the fascia from the preauricular area into the temporal fossa. The sensory nerve supply comes from the auriculotemporal nerve. The size of the flap is 12 × 9 $cm^2$ (1).

- Preoperatively, identify the course of the vessels with a Doppler probe and mark the incision lines parallel to hair follicles.
- Position the patient supine, with the head tilted slightly to the opposite side.
- Start the incision by raising a pretragal skin flap, extending the incision toward the vertex of the skull over the temporal fossa.
- Identify and spare the superficial temporal vein anterior and remain superficial to the STA. Identify the STA.
- Dissection proceeds cephalad deep to the hair follicles. Avoid damaging the superficial temporal vein and the frontal branch of the facial nerve.
- After cephalad completion of the dissection, incise the flap. Lift from the deep fascial plane toward the auricle.
- After complete dissection, leave the flap for observation of perfusion.

This flap is ideally suited for covering small defects of the foot, ankle, Achilles tendon, and hand. The minimal thickness of this well-vascularized flap prompts some authors to describe the technique as a “microvascular transplantation of a recipient bed” (12). This flap is useful for burns, particularly when joint spaces or tendons are exposed after debridement (23).

**MUSCLE FLAPS**

The following sections on each donor muscle flap include information on (1) the muscle's origin and insertion, function, vascular supply, innervation, and pedicle length; (2) the flaps size, functional loss on removal, and elevation; and (3) any special problems that may be encountered in their use.

The classification of muscle type is based on five patterns of muscle circulation (81). A muscle for free tissue transfer must be able to survive on one vascular pedicle that is dominant and that will support the entire muscle mass. Classification is as follows:

- Type 1: one vascular pedicle (extensor digitorum brevis, tensor fascia latae).
- Type 2: dominant pedicle and minor pedicles (abductor hallucis longus, gracilis).

- Type 3: two dominant pedicles (rectus abdominis, serratus anterior).
- Type 4: segmental vascular pedicles (none).
- Type 5: one dominant and secondary vascular pedicles (latissimus dorsi, pectoralis major, pectoralis minor).

Unclassified potential transfers include fillet flaps and combination flaps such as the latissimus dorsi–serratus anterior muscle flap based on one dominant pedicle (thoracodorsal artery).

***Latissimus Dorsi Flap***

The latissimus dorsi is a type 5 muscle (major pedicle and multiple segmental vessels) (Fig. 35.22). The dominant pedicle is the thoracodorsal artery and venae comitantes, which originate from the subscapular artery and vein. Secondary pedicles are two rows (lateral and medial) of four to six perforating arterial branches and venae comitantes taking origin from the posterior intercostal and lumbar arteries and veins. The length of the major pedicle can be as long as 8 cm and the arterial diameter as large as 2.5 mm. The artery enters the deep surface of the muscle in the posterior axilla, 10 cm inferior to the latissimus muscle insertion into the humerus (9).

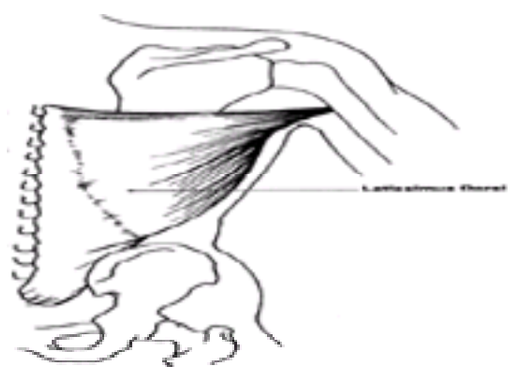

***Figure 35.22.*** Surgical anatomy of latissimus dorsi muscle flap.

The motor nerve supply is the thoracodorsal nerve (C6–C8), and the sensory innervation of the skin is supplied by multiple cutaneous branches of the intercostal nerves. Generally, this is not used as a sensate flap.

The latissimus dorsi is the largest transfer available, with a muscle surface area of 25 × 35 $cm^2$ and skin territory of 30 × 40 $cm^2$ (60).

The latissimus dorsi is an expandable muscle flap because function is preserved by the remaining synergistic shoulder girdle muscles.

- Position the patient midlateral, with the arm elevated 90°.
- Begin the dissection with an incision along the lateral muscle border.
- First, identify the muscle border and its relationship to the serratus muscle. Next, identify the pedicle and follow the pedicle to its origin in the axilla.
- Free the anterior border of the muscle and raise the flap from a ventral to dorsal direction to the spine. Take care to coagulate or ligate the perforating vessels.
- Next, divide the muscle distally as required. Raise the muscle in the cranial direction.
- Next, ligate the serratus branch of its artery.

For extensive wounds, the latissimus can be transplanted simultaneously with the serratus muscle, on a single vascular pedicle (36). The latissimus is commonly used in reconstruction in lower extremities for large defects (97,102). A combined flap including the ninth and tenth ribs as vascularized bone transplanted for simultaneous coverage and tibial bone reconstruction is possible but not commonly used (74).

***Serratus Anterior Flap***

The serratus anterior muscle is a thin, broad, multidigitated muscle on the lateral chest wall between the ribs and scapula. The muscle is supplied by two pedicles, the serratus anterior branch and the lateral thoracic artery. The length of each one of the pedicles is 6 to 8 cm, and the diameter of the artery is 2 to 3 mm (Fig. 35.23).

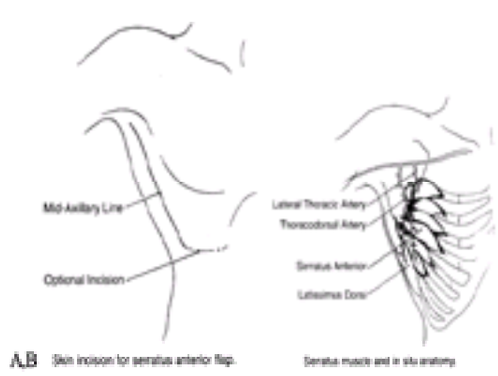


***Figure 35.23.*** **A:** Skin incision for a serratus anterior flap. **B:** Surgical anatomy of a serratus anterior flap.

The motor innervation is supplied by the C5–C7 roots of the long thoracic nerve and the T2–T4 segmental intercostal nerve supply for sensory innervation. The vascular pedicle as well as the motor nerve separates into fingers of muscles corresponding to the slips of the serratus. The size of the serratus anterior is 15 × 20 $cm^2$. A musculocutaneous flap of 5 × 15 $cm^2$ can be elevated (8).

- For a fascia flap, place the patient in a lateral position, and elevate the arm 90°.
- Make a slightly curved incision along the lateral border of the latissimus muscle.
- Next, identify the muscle border and the serratus arcade. Determine if the thoracodorsal pedicle is intact and find the entrance points of the motor fibers into the muscle. Outline the flap size on the muscle surface.
- Release the muscle from the thoracic wall. Preserve the three proximal slips to avoid winging of the scapula. The entire muscle is never taken because of the risk of winging of the scapula. Preservation of at least the upper five and preferably six slips and their innervation will decrease or totally eliminate winging of the scapula.
- Dissect the thoracodorsal pedicle to the length required.
- Transfer the flap.

Basing the serratus on its blood supply, and using the thoracodorsal artery makes it possible to elevate a combined latissimus dorsi and serratus anterior flap (44) (Fig. 35.24). The serratus is useful as a free flap for coverage or as an innervated functional muscle.

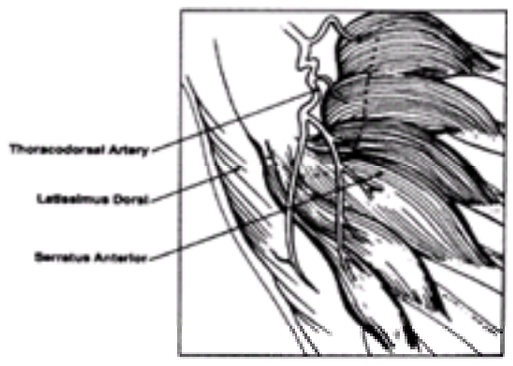


***Figure 35.24.*** Vascular pedicle to serratus anterior and latissimus dorsi muscle.

This flap is used particularly for hand reconstruction and for foot and ankle coverage.

***Rectus Abdominis Flap***

The vertically oriented rectus abdominis muscle extends between the costal margin and the pubic region and is enclosed by the anterior and posterior rectus sheaths. It is a type 3 muscle (two dominant pedicles) based on the superior epigastric artery and vein and inferior epigastric artery and vein. The pedicle length is 5 to 7 cm superiorly and 8 to 10 cm inferiorly.

Each of the dominant pedicles supplies just over one half of the muscle. There is an anastomosis between these vessels that is usually sufficient to support the nondominant half if one of the two pedicles is ligated. Because of the larger size and easier dissection of the inferior epigastric vessel, this is usually used for free tissue transfer.

The motor innervation is supplied by segmental motor nerves from the 7th through 12th intercostal nerves that enter the deep surface of the muscle at its mid to lateral aspects. The lateral cutaneous nerves from the 7th through 12th intercostal nerves provide sensation to the skin territory of the rectus abdominis muscle. The size of the muscle is approximately 25 × 6 $cm^2$. The skin territory that can be harvested is 21 × 14 $cm^2$ and is based on musculocutaneous perforators (82) (Fig. 35.25.).

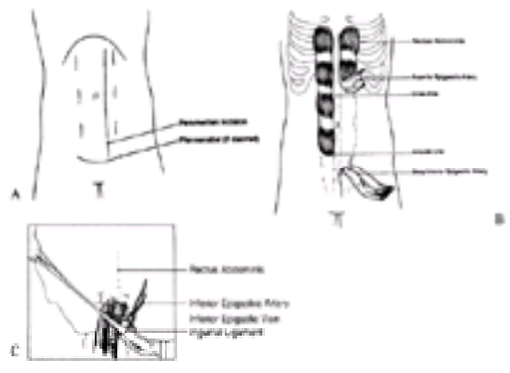

***Figure 35.25.*** **A:** Incision for the rectus abdominis flap. **B:** Rectus muscle harvesting. **C:** Vascular pedicle of the rectus abdominis muscle.

- Position the patient supine. For a muscle flap, make the initial incision vertically over the muscle. For a musculocutaneous flap, extend the incision around the skin island with an optional vertical incision extending to the muscle.
- Incise the anterior rectus sheath and dissect the sheath from the muscle surface. Avoid muscle injury or disruption of the anterior rectus sheath at the tendinous intersection. The tendinous intersection is located at the level of the xiphoid, the umbilicus, and midway between the xiphoid and umbilicus.
- When a skin island is used, it is preferable to expose the muscle proximal to the skin island for accurate location of the muscle position. Then the skin island can be incised and its edges elevated to the lateral and medial borders of the rectus sheath.
- Separate the muscle from the posterior sheath at the distal aspect of the flap and beyond the skin island if a musculocutaneous flap is planned. Take care to avoid disruption of the posterior sheath below the linea semi-circularis; below this line, the posterior sheath consists only of transversalis fascia.
- After the muscle has been divided from the posterior sheath, divide the distal muscle.

An advantage of this flap is the length of the pedicle and the ease of harvesting the flap with the patient in the supine position (96). One of the complications of using this flap is the abdominal defect, which may lead to weakness and, possibly, hernia formation.

***Gracilis Flap***

The gracilis muscle is a type 2 muscle (dominant pedicle and several minor pedicles.) It is a thin, flat muscle that lies between the adductor longus and sartorius muscle anteriorly and the semimembranosus muscle posteriorly. The dominant pedicle is the ascending branch of medial circumflex femoral artery and venae comitantes. The length of the pedicle is 6 cm, and the diameter of the artery is 1.6 mm. The minor pedicles are one or two branches of the superficial femoral artery and venae comitantes. Their length is 2 cm and diameter is 0.5 mm (38).

Motor innervation is by the anterior branch of the obturator nerve, which is located between the abductor longus and magnus muscles, and it usually enters the muscle above the level of the dominant vascular pedicle. The anterior femoral cutaneous nerve (L2–L3) provides sensory innervation to the majority of the anterior medial thigh.

This muscle functions as a thigh adductor. The presence of the abductor longus and magnus makes it an expendable muscle.

The size of the muscle is 6 × 24 $cm^2$. The skin territory is 16 × 18 $cm^2$, but the skin over the distal half of the muscle is not reliable when the flap is elevated, based on its dominant vascular pedicle with division of the minor vascular pedicles. In obese patients, the musculocutaneous flap may be too bulky, necessitating use of a skin graft placed on the muscle.

- Position the patient supine, with hip and knee flexed and leg abducted. Draw a line between the pubic tubercle and medial condyle of the femur.
- Because the muscle is 2 to 3 cm posterior to the line, make an incision 2 to 3 cm posterior parallel to this line. Identify and preserve the greater saphenous vein (anterior to the incision).
- Incise the fascia and identify the gracilis muscle medially and posterior to the adductor longus muscle.
- Divide the muscle distally.
- Ligate the minor pedicles.
- Proceed with dissection cephalad. Retract the adductor longus proximally. Expose the pedicle 6 to 12 cm distal to the pubic tubercle. Protect the medial cutaneous nerve on the surface of the adductor magnus.
- Clip or ligate small branches.
- Divide the muscle superiorly.
- If a skin island is included in the flap, it will be located over the middle or proximal portion. Make the incision down to the fascia, and include the fascia lata in the dissection.
- The rest of the dissection is similar to the dissection of the muscle alone.

### *Tensor Fascia Lata Flap*

The tensor fascia lata (TFL) is a type 1 muscle (one pedicle). The origin is anterior 5 to 8 cm of the outer edge of the anterior superior iliac spine, immediately behind the origin of the sartorius. The insertion is the iliotibial tract of the fascia lata. The dominant vascular pedicle is the ascending branch of the lateral circumflex femoral artery, which arises from the profunda femoris and venae comitantes. The length of the pedicle is approximately 7 cm, and the diameter of the artery is 2 to 3 mm. Motor innervation comes from the superior gluteal nerve, and sensory innervation comes from the cutaneous branches of T-12. The size of the muscle is approximately 5 × 15 $cm^2$, and the skin territory can be 7 × 22 $cm^2$ to 9 × 26 $cm^2$ (4).

- Position the patient supine and prep the entire lower extremity so that the hip can be adducted, abducted, and rotated during elevation. Make the initial incision for elevation of the flap along the anterior, posterior, or distal border of the flap.
- After the distal incision, identify the fascia lata below the skin. The TFL muscle can be identified after the dissection advances more proximally.
- Extend the anterior and posterior incision from below upward toward the anterior superior iliac spine and the border of the iliac crest.
- Identify the terminal branches of the lateral circumflex femoral artery 10 cm below the anterior superior iliac spine and continue to dissect deep to the rectus femoris to develop a long vascular pedicle.
- Continue the dissection above the pedicles to separate the TFL from the underlying gluteal muscle.
- Then complete the upper incision, transect the muscle, and prepare the flap for microvascular transplantation.

Communications between the origin of the muscle and the outer lip of the anterior iliac crest allow transplantation of the muscle with vascularized bone. The flap can be transferred as a functional unit and can be useful for foot and lower leg coverage (78).

## FIBULA FLAP

The fibula flap can be raised as an osteoseptocutaneous or isolated bone segment. The length of the bone can be up to 25 cm. The dominant pedicle is the peroneal artery and vein. The length of the pedicle is 2 cm; the diameter of the artery is up to 2.5 mm, and the vein diameter is 3 to 4 mm.

The course of the pedicle is posterior to the fibula through or beneath the flexor hallucis muscle. The sensory nerve supply is via the superficial peroneal nerve.

The skin territory is located on the lateral leg, and the size of the flap can be 8 × 15 $cm^2$. The skin blood supply is based on septocutaneous and musculocutaneous perforating vessels.

- Position the patient supine, with a tourniquet placed on the thigh. Center the skin island over the middle third of the fibula with the long vertical axis over the posterior edge of the fibula.
- Make the incision around the anterior part of the skin island through the crural fascia to the peroneus muscle.
- Dissect subfascially toward the posterior intermuscular septum.
- Make the incision through the posterior margins of the skin paddle and advance to subfascial dissection of the soleus muscle to the posterior intermuscular septum.
- Continue the dissection anteriorly to detach the anterior septum from the fibula.
- Posteriorly, continue the dissection toward the flexor hallucis muscle. At this point, it is important to identify the peroneal artery and vein and the motor nerve.
- Perform a distal osteotomy and proximally distract the distal end of the fibula with a clamp.
- Divide the interosseous membrane and expose the peroneal vessels.
- Perform a proximal osteotomy and dissect the vessels to their origin.
- Check the perfusion after releasing the tourniquet.

## OSTEOCUTANEOUS ILIAC CREST FLAP

A composite (osteomusculocutaneous, osseous muscle) transfer can include the superior anterior iliac crest with overlying skin, and a portion of contiguous muscle can be harvested.

The blood supply is the deep circumflex iliac artery (DCIA) and venae comitantes. The pedicle length is 6 to 8 cm, and the artery diameter is 2 to 2.5 mm. Skin territory can be 6 × 12 $cm^2$. A branch of T-12 supplies the skin portion of the flap.

- Place the patient in a supine position. Design the skin island along the iliac crest extending from the anterior superior iliac spine (ASIS) posteriorly for the desired length.
- Make the first skin incision in the upper margin of the flap, exposing the external oblique muscle fibers posteriorly along with the fascia. Dissect the skin in a loose areolar plane toward the iliac crest, taking care not to injure any musculocutaneous perforators.
- Incise the external oblique muscle approximately 2 to 3 cm parallel to the iliac crest.
- Identify the inguinal canal and retract the spermatic cord or round ligament medially and superiorly.
- Expose and incise the transversalis fascia and identify the deep circumflex iliac artery and vein. As the dissection approaches the ASIS, the ascending branch passes through the transversus abdominis muscle, coursing superiorly between this muscle and the internal oblique muscle.
- Resume the dissection cranially and laterally.
- Identify the vascular pedicle in the iliac groove lateral to the line of fusion between the iliacus fascia and transversalis fascia.
- After exposure of both medial and lateral cortices of the ileum, perform an osteotomy from a posterolateral to an inferomedial direction. A large segment of bone measuring 3.5 cm in height and 10 cm in length can be obtained.
- Close the donor site in layers to prevent abdominal herniation (101).

## OMENTAL FLAP

The omentum is a visceral structure containing fat and blood vessels within a thin membrane. It extends from the stomach to the transverse colon and beyond, covering the anterior peritoneal contents.

The omentum has two dominant pedicles: a right gastroepiploic artery and vein with a length of 6 cm and an artery diameter of 2 to 3 mm, and a left gastroepiploic artery and vein with a pedicle length of 4 cm and artery diameter of 2 mm. The omentum may be as large as 40 × 60 $cm^2$.

Prior intraabdominal surgery may preclude use of the omental flap because of extensive omental inflammatory adhesions.

The pliability and rich lymphatic network of the omentum make it ideal to fill cavities and fight infection. The omentum is particularly ideal for obliteration of irregular dead space cavities and thus has been effectively used in providing coverage after saucerization for chronic osteomyelitis (111).

- Place the patient supine.
- Make the incision at the abdominal midline.
- Release the areolar attachments of the omentum from the transverse colon so the omentum remains hanging on the greater curvature of the stomach. Return the omentum to the inferior abdominal cavity and expose the anterior paired layer attachments to the greater curvature of the stomach.
- Next, divide the short vascular branches between the gastroepiploic arch and the greater curvature of the stomach.
- At that point, make a decision whether to base the flap on the right or left gastroepiploic artery and vein.
- If the omentum will be based on the right gastroepiploic artery and vein, then ligate the left gastroepiploic artery and vein immediately distal to their junction with the splenic artery and vein. Mobilize the omentum within 3 cm of the gastric pylorus.
- If the omentum will be based on the left gastroepiploic artery and vein, then divide the right gastroepiploic vessels and ligate them along the greater curvature of the stomach immediately proximal to the pylorus. Mobilize the greater omentum from the greater curvature of the stomach to a point 5 to 7 cm proximal to the gastrosplenic ligament, where the standard flap elevation is completed.

Insert a nasogastric tube for 24 to 48 hours after the operation to decompress the stomach. This prevents gastric distention, which, among other things, might dislodge any of the vascular ligations along the greater curvature.

## POSTOPERATIVE CARE

Postoperative care of free tissue transfer patients requires that patients be adequately hydrated. Maintenance of proper body temperature and hematocrit is also important We do not routinely heparinize or use anticoagulation.

In addition to clinical observation, flaps are usually monitored with a laser Doppler for a minimum of 5 days. Although the immediate postoperative period of 24 to 48 hours is critical, there have been late occasional failures; thus, continue laser Doppler monitoring for 4 to 5 days.

Elevate the patient's extremities at all times to augment venous return. Do not allow patients who have undergone surgery of the lower extremity to ambulate postoperatively for a minimum of 3 weeks. The inosculation and healing of the flap to the wound bed, the selection of muscle or skin, and the “take” of the skin graft are factors that go into the timing to determine dependency of the lower extremity. Those patients who have reconstruction around the foot and ankle are most prone to increased venous pressure and resultant edema of the flaps. This edema can result in the dehiscence of the free flap from the surrounding tissue bed. For this reason, require patients who have undergone surgery on an extremity to keep their limbs elevated and use bed-to-chair transfers for a minimum of 3 weeks. Some experimental data suggest that this timing can be shortened. However, it is our experience that this is the amount of time it takes for the flap to mature and develop a sufficient venous return to withstand the hydrostatic pressure associated with standing.

Before proceeding with any other reconstruction such as bone grafting (such as in a case of open tibia fracture or tendon transfers), all wound surfaces must be epithelialized. There must be no edema, cellulitis, granulation tissue, or sinus tracts that could compromise the next stage of reconstruction. For example, in cases of a free muscle flap in the distal third of an open tibia fracture that ultimately requires bone grafting, it is essential that all skin grafts be totally epithelialized to decrease skin colonization of bacteria. Our preference is to remove the external fixator, clean the pin sites, and place the patient in a cast until the pin tracts heal. The flap can be then elevated, and an autogenous bone graft can be safely performed.

The donor site should be given the same attention as the recipient site during the postoperative period. Complications of the donor site include hematoma, seroma, and sensory nerve dysfunction and scar formation.

## MONITORING

Monitoring of free tissue transfer is essential to ensure transplant success. Many different monitoring devices and techniques have been used with varying levels of success.

An ideal flap monitoring should satisfy several criteria. It should be harmless to the patient and the flap, objective, reproducible, applicable to all types of flaps, and inexpensive. It is important that any monitor be capable of prolonged monitoring and respond rapidly to circulatory changes. Postoperative monitoring techniques can be grouped in four categories: (1) clinical evaluation, (2) direct vessel monitoring, (3) indicators of tissue circulation, and (4) metabolic parameters related to perfusion (17).

### *Clinical Evaluation*

Clinical evaluation remains the standard by which all methods of monitoring need to be measured. This process involves observation of skin color, temperature, capillary refill, and bleeding characteristics. Clinical observation fulfills many of the criteria of the ideal monitoring system. It is cheap, readily available, and can provide a dynamic picture. The disadvantages are the need for experienced personnel, and its use being confined to monitoring surface skin flaps and muscle flaps. Changes are often initially subtle, and by the time they are clinically apparent, salvage of the flap may be impossible because of irreversible tissue damage.

### *Direct Vessel Monitoring*

Direct vessel monitoring can be done by electromagnetic flowmeters. Readings are based on measuring the electric potential induced by blood flow. The ultrasonic Doppler measures sound waves reflected from columns of moving blood cells. Thermocouples measure the temperature difference between preanastomotic and postanastomotic sites on the vascular pedicle using two microthermocouples.

### *Circulation Monitoring*

Measurements based on monitoring the change in the temperature of the skin are used as indicators of the blood flow in skin. Photoplethysmography is based on the change of the amount of light reflected during change in the local cutaneous blood volume, and laser Doppler flowmetry is based in the same general principles as ultrasound Doppler but measures the frequency shift of light rather than sound waves reflected from moving red blood cells. Pulse oximetry continuously monitors both pulsatility and oxygen saturation. This measurement defines blood flow.

### *Metabolic Monitoring*

Transcutaneous oxygen monitoring and invasive measurements of $PO_2$ check the perfusion of tissue transplantations based on metabolic parameters. Levels of tissue oxygen tension have been monitored in flaps and have been shown to reflect the quality of capillary circulation (2).

Monitoring is usually performed in an intensive care unit setting or a step-down setting, depending on the condition of the patient. It is standard practice in our center to routinely monitor patients in an intensive care unit for the first 24 hours because this is when the problems most frequently occur following free tissue transfer.

Absolute values of laser Doppler measurements, patterns, and trends of flow can give valuable information about the dynamic perfusion range of blood flow over time. Low absolute values of perfusion, as well as relative change to the initial flow, are alarming signs, and require immediate clinical evaluation of the flap.

Based on our experience with laser Doppler monitoring we suggest classifying the perfusion in one of the following four groups with a corresponding diligence of observation.

1. If the perfusion is within or above the established range, maintain a normal degree of observation (46).
2. If the observed flow is somewhat low based on available tables of normal blood flow (46) for that flap, keep clinical evaluation at a modestly increased level (alert level 1).
3. If the relative flow falls to 50% of the initial flow of that flap and remains low for 30 minutes or more, maintain a more aggressive observation of the flap (alert level 2).
4. If the absolute flow is lower than 0.4 laser Doppler flow units (LDF) units for 30 minutes, institute a maximally aggressive clinical observation (alert level 3; “red alert”) and strongly consider exploration. This is typically inconsistent with viability of the flap regardless of flap type, recipient site, or blood flow history.

In cases of abnormal laser Doppler values, rule out artifact. Falsely low readings can occasionally be the result of a probe becoming detached from the flap. However, low readings can also be caused by hypovolemia, anemia, and hypothermia (46). Therefore, it is important to examine closely not only the laser Doppler equipment but also the general condition of the patient. Falsely elevated measurements can be caused by vibration, motion of the probe or tissue, location of the probe over a large vessel, or extreme variation in the hematocrit.

## FLAP FAILURE AND MANAGEMENT

Success of free tissue transfer should be on the order of 95% to 99%. Acute complications occur usually in the first 48 hours and include venous thrombosis, arterial thrombosis, hematoma, hemorrhage, and excessive flap edema.

Arterial insufficiency can be recognized by decreased capillary refill, pallor, reduced temperature, and the absence of bleeding after pin prick. This complication can be caused by arterial spasm, vessel plaque, torsion of the pedicle, pressure on the flap, technical error with injury to the pedicle, a flap harvested that is too large for its blood supply, or small vessel disease (due to smoking or diabetes). Management of arterial compromise requires prompt surgical intervention to restore the blood flow (110). Pharmacologic intervention includes vasodilators, calcium blockers, and anticoagulants for flap salvage presenting with arterial insufficiency (90).

Venous outflow obstruction can be suspected when the flap has a violaceous color, brisk capillary refill, and normal or elevated temperature, and produces dark blood

after pin prick. Venous insufficiency can occur due to torsion of the pedicle, flap edema, hematoma, or tight closure of the tissue over the pedicle. The venous outflow obstruction can result in extravasation of the red blood cells, endothelial breakdown, microvascular collapse, thrombosis in the microcirculation, and finally, flap death. Given the irreversible nature of the microcirculatory changes in venous congestion that occurs even after short periods of time, venous compromise must be recognized as early as possible.

These complications can occur alone or in any combination. The clinical observation and monitoring of the patient (such as with laser Doppler) should alert the surgeon, who has to decide between conservative and operative intervention. Conservative treatment may include drainage of the hematoma by the bedside release of a few sutures to decrease pressure. In cases of venous congesion, leeches may be helpful if insufficient venous outflow cannot be established despite a patent venous anastomosis (Fig. 35.26; see also Color Fig. 35.26). The leeches inject a salivary component (hirudin) that inhibits both platelet aggregation and the coagulation cascade. The flap is decongested initially as the leech extracts blood and is further decongested as the bite wound oozes after the leech detaches (110).



***Figure 35.26.*** (See Color Fig. 35.26). Venous congested flap treated with leeches.

**TREATMENT OF FAILURE**

Occasionally, free flaps, despite early return to the operating room for vascular compromise, do fail. Options for management include the performance of a second free tissue transfer, noting the technical or physiologic details that led to initial failure. Most of the time, free tissue transfers that fail are due to technical errors in judgment, whether they be flap harvest, compromise of the pedicle during the harvest, improper microvascular technique during anastomosis, improper insetting resulting in increased tissue tension and edema, or postoperative motion of the extremity resulting in pedicle avulsion. Although this is rare, it does occur.

The operating surgeon must then decide how to mannage this patient, based on several factors. Obviously, if a patient required a free flap in the first place, a second free flap should be considered. If a decision is made not to redo the flap, it could be left in place using the so-called “crane principle” in hope that underlying granulation will be sufficient such that skin grafting can be performed once the necrotic flap is removed.

The Crane principle can be applied to cases where a local flap or free tissue transfer fails in part or totally. The failed flap serves as a biologic dressing or eschar over the wound bed. If there is no infection, leave the eschar on the wound bed and observe for healing, evidenced by the formation of granulation tissue under the eschar. Ultimately, the eschar can be removed and, with an appropriate granulation bed, the wound can be skin grafted, obviating the need for another free tissue transfer. If a granulation bed is not produced, consider a second flap. Occasionally, failed free flaps are left in place, provided that there is no infection. With some wound contraction and granulation tissue taking place over time, the flap is removed and a skin graft can be performed to reepithelialize the wound.

Delayed debridement of unsalvageable free flaps can be considered for noncritical wounds and may obviate the need for a second free tissue transfer to obtain wound closure (116).

We believe that a necrotic flap can become a source of sepsis and further compromise local tissues. Remove necrotic nonviable flaps and apply a temporary wound dressing, such as a bead pouch or wound Vacuum Assisted closure device (KCI Company, San Antonio, Texas). Occasionally, when flaps fail in severely compromised extremities, consideration can be given to amputation in that the morbidity of a second free tissue transfer and perhaps the resultant extremity state renders the extremity less favorable for salvage and more favorable for amputation. If a second free flap is considered, avoid the errors that led to the initial flap compromise. It is prudent to obtain an arteriogram, evaluate the coagulation profile, and research other issues that led to failure.

## AESTHETIC CONSIDERATIONS

Providing patients ultimately with a functional limb after free tissue transfer is most important. Careful selection of the flap as well as consideration of donor scar management can result in a satisfactory aesthetic result (Fig. 35.27). The use of tissue expanders can help by decreasing donor site morbidity, as well as the need for debulking of flaps, which can result in an improved cosmetic result (24).

***Figure 35.27.*** Scapular flap for aesthetic reconstruction of the lower extremity. **A:** Defect on lower leg. **B:** Post-operative flap.

## ILIZAROV APPARATUS AND MICROSURGERY

There has been interest in combining free tissue transfer with the Ilizarov apparatus. The combination of Ilizarov and microsurgical techniques can be classified in four categories as follows.

Type 1 consists of the use of Ilizarov as an external fixator for bone stabilization in cases of open fractures. In these cases, adequate bone stock is present and will consolidate, usually without a bone graft, provided soft tissue coverage is achieved. Request for coverage may occur after the orthopaedic traumatologist places the Ilizarov frame and recognizes the need for augmentation of the soft-tissue envelope. Trends toward a multidisciplinary approach in lower extremity trauma care involve orthopaedic and plastic surgeons coordinating efforts at the time of the initial evaluation of the patient, which allows planning of emergent or early coverage (within 3 days) and proper pin and ring placement. If the procedure is planned properly, frames can be partially disassembled (for example, connecting rods removed) to allow access to wounds, pedicles, and space for hands to perform microsurgery. Free tissue transfer in these cases provides only coverage. The frame provides definitive fracture care, with options for progressive dynamization by frame disassembly, decreased rigidity, and increasing load to allow bone healing to occur. An example of a type 1 Ilizarov-microsurgery combination would be a comminuted distal third tibia fracture with an open wound.

The second combination of Ilizarov-microsurgery (type 2) is the application of the Ilizarov frame after placement of the flap for treatment of nonunion or malunion. Although the Ilizarov method can treat deformities or malunion without free tissue transfer, a large group of patients undergo initial stabilization with plates or conventional external fixators. These patients then undergo coverage with free flaps. The soft tissue heals, but the bone does not heal or develops deformity. If this is

recognized early, the Ilizarov frame can replace the external fixator and be used to align the nascent malunion acutely or gradually. If this occurs late, with bone healing in malalignment, the Ilizarov can be used to realign the limb after osteotomy (through the fracture) or through the summation plane (deformity is done at a different level).

Type 3 involves injuries that have soft tissue as well as bone defect, for which the Ilizarov frame can be used to treat the initial fracture by stabilization, followed by callous distraction after the soft tissue has healed. Two scenarios exist: (1) limb length and alignment are initially achieved the night of injury, and (2) corticotomy and free tissue transfer are performed at about 48 hours after the injury. The bone is transported through the maturing free flap, with the bone defect treatment spanning a few weeks to months, obviating the need for bone graft. The second option involves acute shortening of smaller defects, with primary bone healing under compression at the fracture site, in addition to performing the corticotomy at the time of flap coverage such that the initial fracture is compressed and the corticotomy is distracted ultimately to gain limb length with consolidation of the tibia at that time. Microsurgery is performed to reconstitute the soft tissue in these cases. The surface area in such cases and the volume of flaps are diminished so that morbidity of the donor site is decreased. For example, in a large soft-tissue injury in an open tibia fracture, the latissimus dorsi may have been previously selected for coverage. By acutely shortening the limb and decreasing the soft-tissue defect, a gracilis or slip of serratus may be adequate. This fulfills the need for soft-tissue coverage with an easier flap with less morbidity.

In type 4 reconstruction, the Ilizarov frame is used as a definitive fixation for vascularized bone grafts used for bone defects that exceed more than 6 cm. The osteoseptocutaneous fibula is our choice in such cases. Complications such as nonunion or delayed union, stress fractures, and prolonged time for bone remodeling have all been diminished using the Ilizarov technique.

In the instances of osteomyelitis, the soft tissue can be managed with free tissue transfer, and the Ilizarov frame can be used to bridge unstable defects requiring conventional or vascularized bone grafts. We have used the combination of a free vascularized fibular graft and the Ilizarov frame very successfully in instances of femur and tibia defects. Both microsurgical and Ilizarov technique have the capabilities to stand alone in solving limb reconstructive problems and should do so in specific cases. However, in patients considered for limb amputation, these combined techniques can be used to salvage extremities with good functional outcomes (66).

## FUTURE TECHNOLOGY

The search continues for new techniques that will result in faster and easier methods for microvascular anastomosis. Staplers may have a more important role in microsurgery in the future. They shorten the operating time and have proven to be safe (117). The vessels suitable for this technique must be chosen carefully, and the surgeons using this technique should also be experienced in conventional microsurgery.

It is expected that the time-consuming use of interrupted sutures will be replaced more and more by running sutures. Furthermore, refinements in laser welding and the development of new tissue glues may take over the role of sutures. The operating microscope itself may also vanish in time. Many microsurgeons prefer to use high-magnification loupes, in which they are able to achieve good results (103,104). Furthermore, advances in video technology now enable the surgeon to view a microsurgical field on a monitor in three dimensions without looking through microscope eyepieces (37).

### ENDOSCOPIC HARVESTING

Following the introduction of endoscopic techniques in almost every field of surgery, the application of endoscopic techniques for reconstructive microsurgery represents the natural evolution of this trend. Less postoperative pain, smaller scars in the donor area, better visualization of the operative field with the magnified video, and better hemostasis are only a few of the advantages of these techniques. These advantages have been reported in a recent series of patients in which latissimus dorsi harvesting was analyzed comparing endoscopic techniques and the traditional technique (69). Successful microvascular transplantation of gracilis muscle harvested with endoscopic guidance has been reported (34,106).

Prefabrication of flaps allows custom flaps to be constructed based on what is required for a specific defect. The exploration of this new frontier may increase the possibility of reconstructive capabilities and decrease the donor morbidity of classical reconstructions. Depending on the specific application of the prefabrication, one or more of the following advantages may be offered:

- Specific preferred blocks of tissue that are not naturally perfused by anatomically well-defined axial vessels or by a reliable pedicle that is easy to transfer may be used. One example is skin flaps that need to be very thin (the axial pedicles of all known flaps enter from the deep side, and a significant amount of subcutaneous tissue must be incorporated).
- A larger flap of specialized tissue may be transferred by manipulating the vascular territory of the flap. Examples include pretransfer delay of a cutaneous flap to include a larger skin island or pretransfer expansion of a flap to generate an additional amount of tissue. By extending the limits of perfusion, delay allows the transfer of a much larger amount of tissue than would be allowed by the original pedicle.
- The morbidity of a donor site can be reduced. Examples include pretransfer expansion of a flap to allow primary closure of the donor site and transfer of the lower abdominal skin based on an induced pedicle that spares the rectus muscles and the integrity of the abdominal wall.
- The satisfactory functional status of the replacement part may be ascertained before transfer. Thus, that which had been a lengthy multiple-stage posttransfer reconstruction can be converted into an elegant, single-step transfer of a finished functional part or organ.

### FLAP PREFABRICATION

Current clinical methods of flap prefabrication can be considered to be based on one or more of the following fundamental principles of reconstructive surgery:

- Delay or expansion (Fig. 35-28).

***Figure 35.28.*** **A:** A nine-year-old child with a crush injury to the right lateral distal thigh and knee resulting in a soft tissue defect. **B:** Scapular flap prior to transfer (pre-expansion). **C,D:** Postsurgical result following flap transfer and quadricepsplasty.

- Grafting: pretransfer grafting of flaps is necessary when complete graft take is mandatory to the success of the reconstruction, and when posttransfer grafting is neither feasible nor practical.
- Vascular induction using staged flap transfer. This method is based upon the well-established principle of staged flap transfer, for which the “vascular carrier” is the contemporary microvascular refinement of the old wrist carrier. The concept is that a small flap of muscle, fascia, intestine, omentum, or even an arteriovenous bundle or fistula can become a“vascular carrier” and can be induced to provide an alternative blood supply through neovascularization to a larger block of tissue after a relatively short staging period (87).

A fourth method of flap prefabrication makes use of recent advances in cell biology to induce the transformation of a flap from one tissue type to another. An application of these advancements can be found in bone and joint reconstruction, which is still most commonly performed with less than ideal alloplastic materials and remains a formidable challenge despite advances in free tissue transfer. With the possibility of inducing mesenchymal tissue to differentiate into bone, a simple muscle flap may be molded and transformed into a vascularized bone graft of desired shape and size (53,54).

## MICROSURGERY COST AND OUTCOMES

In this area of managed care and capitation, expensive procedures are often targeted by cost-containment efforts. Free flap procedures are costly, but they are also effective (45).

Because of the time-consuming and costly nature of microsurgery, appropriate indications and patient management are important. In this cost-conscious time, assessment of financial as well as functional outcomes are critical (56,61).

Clearly, a reduction in complication rates would reduce the cost of these procedures. At present, efforts are under way to reduce free flap costs at all stages of care by shortening the operating time with the use of new devices, shortening the monitoring time postoperatively, and even exploring in selected patients the possibility of using an outpatient monitoring system (57).

## CHAPTER REFERENCES

Each reference is categorized according to the following scheme: *, classic article; #, review article; !, basic research article; and +, clinical results/outcome study.


! 1. Abul-Hassan HS, von Drasek Ascher G, Acland RD. Surgical Anatomy and Blood Supply of the Fascial Layers of the Temporal Region. *Plast Reconstr Surg* 1986;77:17.

+ 2. Achauer BM, Black KS, Litke DK. Transcutaneous $PO_2$ in Flaps: A New Method of Survival Prediction. *Plast Reconstr Surg* 1980;65:738.

2a. Acland R, Smith P: Microvascular Surgical Techniques Used to Provide Skin Cover Over an Ununited Tibial Fracture. *J Bone Joint Surg* [Br] 1976; 58-B:471.

+ 3. Anthony JP, Mathes SJ, Alpert BS. The Muscle Flap in the Treatment of Chronic Lower Extremity Osteomyelitis: Results in Patients Over 5 Years After Treatment. *Plast Reconstr Surg* 1991;88:311.

+ 4. Armenta E, Fisher J. Vascular Pedicle of the Tensor Fascia Lata Myocutaneous Flap. *Ann Plast Surg* 1981;6:112.

# 5. Arnez ZM. Immediate Reconstruction of the Lower Extremity—an Update. *Clin Plast Surg* 1991;18:449.

+ 6. Arnez ZM, Valdatta L, Sassoon E, et al. Salvage of a Below Knee Amputation Stump with a Free Sensate Total Sole Flap Preserving Continuity of the Posterior Tibial Nerve. *Br J Plast Surg* 1998;51:470.

# 7. Azarow KS, Molloy M, Seyfer AE, Graeber GM. Preoperative Evaluation and General Preparation for Chest-wall Operations. *Surg Clin North Am* 1989;69:899.

! 8. Bartlett SP, May JW Jr, Yaremchuk MJ. The Latissimus Dorsi Muscle: A Fresh Cadaver Study of the Primary Neurovascular Pedicle. *Plast Reconstr Surg* 1981;67:631.

+ 9. Barwick WJ, Goldberg JA, Scully SP, Harrelson JM. Vascularized Tissue Transfer for Closure of Irradiated Wounds After Soft Tissue Sarcoma Resection. *Ann Surg* 1992;216:591.

+ 10. Barwick WJ, Goodkindt DJ, Serafin D. The Free Scapular Flap. *Plast Reconstr Surg* 1982;69:779.

+ 11. Bostwick JD, Nahai F, Wallace JG, Vasconez LO. Sixty Latissimus Dorsi Flaps. *Plast Reconstr Surg* 1979;63:31.

+ 12. Breot B, Upton J, Acland RD, et al. Experience with the Temporoparietal Fascial Free Flap. *Plast Reconstr Surg* 1985;76:177.

+ 13. Briggs SE, Banis JC Jr, Kaebnick H, et al. Distal Revascularization and Microvascular Free Tissue Transfer: An Alternative to Amputation in Ischemic Lesions of the Lower Extremity. *J Vasc Surg* 1985;2:806.

# 14. Brown DM, Upton J, Khouri RK. Free Flap Coverage of the Hand. *Clin Plast Surg* 1997;24:57.

# 15. Buncke GM, Buncke HJ, Oliva A, Lineweaker WC. In: Cohen M, ed. Toe to Hand Transplantation. *Mastery of Plastic and Reconstructive Surgery.* Little, Brown Company, 1994:1699.

! 16. Bunke HJ, Schultz WB. Experimental Digital Amputation and Replantation. *Plast Reconstr Surg* 1965;36:62.

# 17. Bunke H. *Monitoring in Microsurgery: Transplantation-Replantation.* Philadelphia: Lee & Febiger, 1991.

+ 18. Bunkis J, Walton RL, Mathes SJ. The Rectus Abdominis Free Flap for Lower Extremity Reconstruction. *Ann Plast Surg* 1983;11:373.

+ 19. Byrd HS, Cierny GD, Tebbetts JB. The Management of Open Tibial Fractures with Associated Soft-tissue Loss: External Pin Fixation with Early Flap Coverage. *Plast Reconstr Surg* 1981;68:73.

+ 20. Byrd HS, Spicer TE, Cierney GD. Management of Open Tibial Fractures. *Plast Reconstr Surg* 1985;76:719.

+ 21. Chen S, Tsai YC, Wei FC, Gau YL. Emergency Free Flaps to the Type IIIC Tibial Fracture. *Ann Plast Surg* 1990;25:223.

+ 22. Chicarilli ZN, Price GJ. Complete Plantar Foot Coverage with the Free Neurosensory Radial Forearm Flap. *Plast Reconstr Surg* 1986;78:94.

+ 23. Chowdary RP, Chernofsky MA, Okunski WJ. Free Temporoparietal Flap in Burn Reconstruction. *Ann Plast Surg* 1990;25:169.

+ 24. Chowdary RP, Murphy RX. Delayed Debulking of Free Muscle Flaps for Aesthetic Contouring Debulking of Free Muscle Flaps. *Br J Plast Surg* 1992;45:38.

+ 25. Chuang DC, Jeng SF, Chen HT, et al. Experience of 73 Free Groin Naps. *Br J Plast Surg* 1992;45:81.

# 26. Cierny GD, Mader JT. Approach to Adult Osteomyelitis. *Orthop Rev* 1987;16:259.

! 27. Clark WL, Trumble TE, Swiontkowski MF, Tencer AF. Nerve Tension and Blood Flow in a Rat Model of Immediate and Delayed Repairs. *J Hand Surg [Am]* 1992;17:677.

+ 28. Cordeiro PG, Neves RI, Hidalgo DA. The Role of Free Tissue Transfer Following Oncologic Resection in the Lower Extremity. *Ann Plast Surg* 1994;33:9.

! 29. Cormack GC, Duncan MJ, Lamberty BG. The Blood Supply of the Bone Component of the Compouod Osteo-cutaneous Radial Artery Forearm Flap—an Anatomical Study. *Br J Plast Surg* 1986;39:173.

# 30. Doi, K. New reconstructive procedure for brachial plexus injury. *Clin Plast Surg* 1997;24:75.

! 31. dos Santos LF. The Vascular Anatomy and Dissection of the Free Scapular Flap. *Plast Reconstr Surg* 1984;73:599.

+ 32. el-Gammal TA, Wei FC. Microvascular Reconstruction of the Distal Digits by Partial Toe Transfer. *Clin Plast Surg* 1997;24:49.

! 33. Eshima I, Mathes SJ, Paty P. Comparison of the Intracellular Bacterial Killing Activity of Leukocytes in Musculocutaneous and Random Pattern Flaps. *Plast Reconstr Surg* 1990;86:541.

+ 34. Fine NA, Orgill DP, Pribaz JJ. Early Clinical Experience in Endoscopic-assisted Muscle Flap Harvest. *Ann Plast Surg* 1994;33:465; discussion 469.

+ 35. Foucher G, Merle M, Maneaud M, Michon J. Microsurgical Free Partial Toe Transfer in Hand Reconstruction: A Report of 12 Cases. *Plast Reconstr Surg* 1980;65:61.

+ 36. Franceschi N, Yim KK, Lineaweaver WC, et al. Eleven Consecutive Combined Latissimus Dorsi and Serratus Anterior Free Muscle Transplantations. *Ann Plast Surg* 1991;27:121.

! 37. Franken RJ, Gupta SC, Banis JC Jr, et al. Microsurgery without a Microscope: Laboratory Evaluation of a Three-dimensional On-screen Microsurgery System. *Microsurgery* 1995;16:746.

+ 38. Giordano PA, Abbes M, Pequignot JP. Gracilis Blood Supply: Anatomical and Clinical Re-evaluation. *Br J Plast Surg* 1990;43:266.

+ 39. Godina M. Early Microsurgical Reconstruction of Complex Trauma of the Extremities. *Plast Reconstr Surg* 1986;78:285.

# 40. Goldberg JA, Alpert BS, Lineaweaver WC, Buncke HJ. Microvascular Reconstruction of the Lower Extremity in the Elderly. *Clin Plast Surg* 1991;18:459.

+ 41. Gooden MA, Gentile AT, Mills JL, et al. Free Tissue Transfer to Extend the Limits of Limb Salvage for Lower Extremity Tissue Loss. *Am J Surg* 1997;174:644; discussion 648.

+ 42. Gustilo RB, Mendoza RM, Williams DN. Problems in the Management of Type III (Severe) Open Fractures: A New Classification of Type III Open Fractures. *J Trauma* 1984;24:742.

+ 43. Gutman M, Kaplan O, Skornick Y, et al. Gangrene of the Lower Limbs in Diabetic Patients: A Malignant Complication. *Am J Surg* 1987;154:305.

+ 44. Harii K, Yamada A, Ishihara K, et al. A Free Transfer of Both Latissimus Dorsi and Serratus Anterior Naps with Thoracodorsal Vessel Anastomoses. *Plast Reconstr Surg* 1982;70:620.

# 45. Heinz TR, Cowper PR, Levin LS. Microsurgery Cost and Outcome. *Plast Reconstr Surg* 1999;89:89.

+ 46. Heller L, Levin LS, Klitzman B. Laser Doppler Flowmeter Monitoring of Free Tissue Transfers: Blood Flow in Normal and Complicated Cases. (Submitted.)

+ 47. Hirase Y, Kojima T. Use of the Double-layered Free Temporal Fascia Flap for Upper Extremity Coverage. *Am J Hand Surg* 1994;19:864.

+ 48. Howe HR Jr, Poole GV Jr, Hansen KJ, et al. Salvage of Lower Extremities Following Combined Orthopedic and Vascular Trauma. A Predictive Salvage Index. *Am Surg* 1987;53:205.

+ 49. Isenberg JS, Sherman R. Zone of Injury: A Valid Concept in Microvascular Reconstruction of the Traumatized Lower Limb? *Ann Plast Surg* 1996;36:270.

# 50. Jacobson JH, Suarez SE. Microsurgery and Anastomosis of Small Vessels. *Surg Forum* 1960;11:243.

# 51. Jones G, Nahai F. Management of Complex Wounds. *Curr Probl Surg* 1998;35:179.

+ 52. Katsaros J, Schusterman M, Beppu M, et al. The Lateral Upper Arm Flap: Anatomy and Clinical Applications. *Ann Plast Surg* 1984;12:489.

+ 53. Khouri RK, Koudsi B, Reddi H. Tissue Transformation into Bone In Vivo. A Potential Practical Application. *JAMA* 1991;266:1953.

# 54. Khouri RK, Upton J, Shaw WW. Principles of Flap Prefabrication. *Clin Plast Surg* 1992;19:763.

+ 55. Kleinert HE, Kasden M, Romero JL. Small Blood Vessels Anastomosis for Salvaged of Severely Injured Upper Extremity. J Bone Joint Surg (Am) 1963;45:788.

55a. Kleinert HE, Neale HW: Microsurgery in Hand Surgery. *Clin Orthop* 1974; 0:158.

+ 56. Kroll SS, Evans GR, Goldberg D, et al. A Comparison of Resource Costs for Head and Neck Reconstruction with Free and Pectoralis Major Flaps. *Plast Reconstr Surg* 1997;99:1282.

+ 57. Kutlu N. Out-patients' Upper Extremity Free Flaps. *J Reconstr Microsurg* 1998;14:269.

+ 58. Lai CS, Lin SD, Yang CC, et al. Limb Salvage of Infected Diabetic Foot Ulcers with Microsurgical Free-muscle Transfer. *Ann Plast Surg* 1991;26:212.

+ 59. Lange RH, Bach AW, Hansen ST Jr, Johansen KH. Open Tibial Fractures with Associated Vascular Injuries: Prognosis for Limb Salvage. *J Trauma* 1985;25:203.

+ 60. Lassen M, Krag C, Nielsen IM. The Latissimus Dorsi Flap. An Overview. *Scand J Plast Reconstr Surg* 1985;19:41.

+ 61. Laughlin RT, Smith KL, Russell RC, Hayes JM. Late Functional Outcome in Patients with Tibia Fractures Covered with Free Muscle Flaps. *J Orthop Trauma* 1993;7:123.

# 62. Levin L. Plantar Skin Coverage. *Problems in Plastic and Reconstructive Surgery* 1991;1:156.

# 63. Levin LS. The Reconstructive Ladder. An Orthoplastic Approach. *Orthop Clin North Am* 1993;24:393.

# 64. Levin L. Microsurgical Autologus Tissue Transplantation. *Techniques in Orthopaedics* 1995;10:134.

# 65. Levin L. Debridement. *Techniques in Orthopaedics* 1995;10:104.

+ 66. Levin L. Combined Free Tissue Transplantation and Ilizarov for Lower Extremity Salvage. Young Microsurgeon's Perspective. American Society for Reconstructive Microsurgery, January, 1996.

+ 67. Levin L. Great toe versus second toe to hand. *Techniques in Hand and Upper Extremity Surgery* October, 1997.

# 68. Levin LS, Moore RS Jr. Vascular Disorders of the Hand: Surgeons' Perspective. *J Hand Ther* 1999;12:152.

+ 69. Lin CH, Levin LS. Free Flap Expansion Using Balloon-assisted Endoscopic Technique. *Microsurgery* 1996;17:330.

+ 70. Lister G, Scheker L. Emergency Free Flaps to the Upper Extremity. *J Hand Surg [Am]* 1988;13:22.

+ 71. Lutz BS, Ng SH, Cabailo R, et al. Value of Routine Angiography Before Traumatic Lower-limb Reconstruction with Microvascular Free Tissue Transplantation. *J Trauma* 1998;44:682.

+ 72. Man D, Acland RD. The Microarterial Anatomy of the Dorsalis Pedis Flap and Its Clinical Applications. *Plast Reconstr Surg* 1980;65:419.

+ 73. Markovich GD, Dorr LD, Klein NE, et al. Muscle Naps in Total Knee Arthroplasty. *Clin Orthop* 1995;1:22.

+ 74. Maruyama Y, Okajima Y, Yoshida T, Motegi M. Tibial Reconstruction with Free Rib Latissimus Dorsi Osteomusculocutaneous Flap. *Acta Chir Plast* 1987;29:21.

# 75. Marzelle J, Trevidic P, Cormier F, et al. [New Trends in Limb Salvage. Vascularized Naps]. *J Mal Vasc* 1993;18:310.

+ 76. Masser MR. The Preexpanded Radial Free Flap [See Comments]. *Plast Reconstr Surg* 1990;86:295; discussion 302.

+ 77. Mathes SJ, Alpert BS, Chang N. Use of the Muscle Flap in Chronic Osteomyelitis: Experimental and Clinical Correlation. *Plast Reconstr Surg* 1982;69:815.

+ 78. Mathes SJ, Buchanan RT. Tensor Fascia Lata: Neurosensory Musculo-cutaneous Free Flap. *Br J Plast Surg* 1979;32:184.

+ 79. Mathes SJ, Buchannan R, Weeks PM. Microvascular Joint Transplantation with Epiphyseal Growth. *J Hand Surg [Am]* 1980;5:586.

+ 80. Mathes SJ, Feng LJ, Hunt TK. Coverage of the Infected Wound. *Ann Surg* 1983;198:420.

! 81. Mathes SJ, Nahai F. Classification of the Vascular Anatomy of Muscles: Experimental and Clinical Correlation. *Plast Reconstr Surg* 1981;67:177.

# 82. Mathes SJ, Nahai NF. *Reconstructive Surgery Principles, Anatomy & Techniques.* Churchill Livingston, 1997.

+ 83. May JW Jr, Chait LA, Cohen BE, O'Brien BM. Free Neurovascular Flap from the First Web of the Foot in Hand Reconstruction. *J Hand Surg [Am]* 1977;2:387.

+ 84. May JW Jr, Jupiter JB, Weiland AJ, Byrd HS. Clinical Classification of Post-traumatic Tibial Osteomyelitis. *J Bone Joint Surg [Am]* 1989;71:1422.

+ 85. May JW Jr, Rohrich RJ. Foot Reconstruction Using Free Microvascular Muscle Flaps with Skin Grafts. *Clin Plast Surg* 1986;13:681.

# 86. McCabe SJ, Breidenbach WC. The Role of Emergency Free Flaps for Hand Trauma. *Hand Clin* 1999;15:275, viii.

! 87. Morrison WA, Dvir E, Doi K, et al. Prefabrication of Thin Transferable Axial-pattern Skin Flaps: An Experimental Study in Rabbits. *Br J Plast Surg* 43:645 1990.

+ 88. Muhlbauer W, Herndl E, Stock W. The Forearm Flap. *Plast Reconstr Surg* 1982;70:336.

88a. O'Brien BM, MacLeod AM, Morrison WA: Microvascular Free Flap Transfer. *Orthop Clin North Am* 1977; 8:349.

+ 89. Oishi SN, Levin LS, Pederson WC. Microsurgical Management of Extremity Wounds in Diabetics with Peripheral Vascular Disease. *Plast Reconstr Surg* 1993;92:485.

+ 90. Pang CY, Forrest CR, Morris SF. Pharmacological Augmentation of Skin Flap Viability: A Hypothesis to Mimic the Surgical Delay Phenomenon or a Wishful Thought. *Ann Plast Surg* 1989;22:293.

+ 91. Park S, Han SH, Lee TJ. Algorithm for Recipient Vessel Selection in Free Tissue Transfer to the Lower Extremity. *Plast Reconstr Surg* 1999;103:1937.

+ 92. Peat BG, Liggins DF. Microvascular Soft Tissue Reconstruction for Acute Tibial Fractures—Late Complications and the Role of Bone Grafting. *Ann Plast Surg* 1990;24:517.

# 93. Pederson W. Limb Salvage. *Problems in Plastic and Reconstructive Surgery* 1991;1:125.

+ 94. Pederson WC, Pribaz JJ. Revascularization of the Upper Extremity with Microsurgical Omental Transfer: When Faced with End-stage Ischemia. *J Reconstr Microsurg* 1995;11:399.

+ 95. Rautio J, Asko-Seljavaara S, Laasonen L, Harma M. Suitability of the Scapular Flap for Reconstructions of the Foot. *Plast Reconstr Surg* 1990;85:922.

+ 96. Reath DB, Taylor JW. Free Rectus Abdominis Muscle Flap: Advantages in Lower Extremity Reconstruction. *South Med J* 1989;82:1143.

+ 97. Rosen HM. Double Island Latissimus Dorsi Muscle—Skin Flap for Through-and-through Defects of the Forefoot. *Plast Reconstr Surg* 1985;76:461.

+ 98. Roth JH, Urbaniak JR, Koman LA, Coldner JL. Free Flap Coverage of Deep Tissue Defects of the Foot. *Foot Ankle* 1982;3:50.

+ 99. Samson MC, Morris SF, Tweed AE. Dorsalis Pedis Flap Donor Site: Acceptable or Not? *Plast Reconstr Surg* 1998;102:1549.

+ 100. Sekiguchi J, Kobayashi S, Ohmori K. Use of the Osteocutaneous Free Scapular Flap on the Lower Extremities. *Plast Reconstr Surg* 1993;91:103.

+ 101. Serafin D, Sabatier RE, Morris RL, Georgiade NG. Reconstruction of the Lower Extremity with Vascularized Composite Tissue: Improved Tissue Survival and Specific Indications. *Plast Reconstr Surg* 1980;66:230.

# 102. Serafin D. The Groin-iliac Crest-deep Circumfex Iliac Artery Flap. In Serafin D: *Atlas of Microsurgical Composite Tissue Transplantation.* Philadelphia: W.B. Saunders, 1996:525.

+ 103. Serletti JM, Deuber MA, Guidera PM, et al. Comparison of the Operating Microscope and Loupes for Free Microvascular Tissue Transfer. *Plast Reconstr Surg* 1995;95:270.

+ 104. Shenaq SM, Klebuc MJ, Vargo D. Free-tissue Transfer with the Aid of Loupe Magnification: Experience with 251 Procedures. *Plast Reconstr Surg* 1995;95:261.

# 105. Song R, Gao Y, Song Y, Yu Y. The Forearm Flap. *Clin Plast Surg* 1982;9:21.

+ 106. Spiegel JH, Lee C, Trabulsy PP, Coughlin RR. Endoscopic Harvest of the Gracilis Muscle Flap. *Ann Plast Surg* 1998;41:384.

+ 107. Swanson E, Boyd JB, Mulholland RS. The Radial Forearm Flap: A Biomechanical Study of the Osteotomized Radius. Plast Reconstr Surg 1990;85:267.

+ 108. Taylor GI, Palmer JH. The Vascular Territories (Angiosomes) of the Body: Experimental Study and Clinical Applications. *Br J Plast Surg* 1987;40:113.

+ 109. Urbaniak JR, Koman LA, Goldner RD, et al. The Vascularized Cutaneous Scapular Flap. *Plast Reconstr Surg* 1982;69:772.

+ 110. Utley DS, Koch RJ, Goode RL. The Failing Flap in Facial Plastic and Reconstructive Surgery: Role of the Medicinal Leech. *Laryngoscope* 1998;108:1129.

+ 111. van Twisk R. Revascularised Omentum in Microvascular Surgery. *Netherlands Journal of Surgery* 1991;43:167.

# 112. Watchmaker GP, Mackinnon SE. Advances in Peripheral Nerve Repair. *Clin Plast Surg* 1997;24:63.

+ 113. Wei FC, Chen HC, Chuang CC, Noordhoff MS. Reconstruction of Achilles Tendon and Calcaneus Defects with Skin-aponeurosis-bone Composite Free Tissue from the Groin Region. *Plast Reconstr Surg* 1988;81:579.

113a. Wei FC, Epstein MD, Chen HC, Chuang CC, Chen HT: Microsurgical Reconstruction of Distal Digits Following Mutilating Hand Injuries: Results in 121 Patients. *Br J Plast Surg* 1993;46:181.

+ 114. Weinberg MJ, Al-Qattan MM, Mahoney J. “Spare Part” Forearm Free Flaps Harvested from the Amputated Limb for Coverage of Amputation Stumps. *J Hand Surg [Br]* 1997;22:615.

+ 115. Weinzweig N, Davies BW. Foot and Ankle Reconstruction Using the Radial Forearm Flap: A Review of 25 Cases. *Plast Reconstr Surg* 1998;102:1999.

+ 116. Wheatley MJ, Meltzer TR. The Management of Unsalvageable Free Flaps. *J Reconstr Microsurg* 1996;12:227.

+ 117. Yamamoto N, Nakai H, Satoh Y, Oshima Y. Clinical Application of a Nonpenetrating Microvascular Stapling Device for Vascularized Free Tissue Transfer. *Ann Plast Surg* 1999;42:49.

+ 118. Yaremchuk MJ, Brumback RJ, Manson PN, et al. Acute and Definitive Management of Traumatic Osteocutaneous Defects of the Lower Extremity. *Plast Reconstr Surg* 1987;80:1.

+ 119. Yousif NJ, Warren R, Matloub HS, Sanger JR. The Lateral Arm Fascial Free Flap: Its Anatomy and Use in Reconstruction. *Plast Reconstr Surg* 1990;86:1138; discussion 1146.

# CHAPTER 36

# VASCULARIZED BONE GRAFTS

*Kimberly K. Mezera and Andrew J. Weiland*

**K. K. Mezera:** Hand, Wrist, Elbow, Shoulder, and Microvascular Surgery, Department of Orthopaedic Surgery, Southwestern Medical School, Dallas, Texas 75235.
**A. J. Weiland:** Hospital for Special Surgery, New York, New York 10021.

History
Goals of Treatment
Indications
- Patient Assessment
- Defect Characteristics
- Donor Site Availability

Applications
- Trauma
- Tumor
- Osteomyelitis
- Nonunions
- Congenital Pseudarthrosis
- Avascular Necrosis (AVN)

Preoperative Planning
Surgical Techniques
- Vascularized Fibula
- Vascularized Iliac Crest
- Rib
- Dorsal Radial Grafts

Pitfalls and Complications
Authors' Perspective
Chapter References

Since first reported in the mid-1970s, the use of vascularized bone grafts has continued to be refined. Offering rapid bony union, increased stiffness and strength, less resorption, and more rapid hypertrophy than conventional bone grafts, they have distinct advantages in selected cases. They do, however, require specialized microsurgical skills and careful preoperative planning. With sources including the fibula, iliac crest, rib, radial styloid, and indications ranging from nonunion, tumor reconstruction, congenital pseudarthrosis, and radial club hand (52) to traumatic and infectious defects, the opportunities that can be afforded by vascularized bone grafts are vast and varied.

## HISTORY

Strauch, Bloomberg, and Lewin performed some of the first experiments on free tissue transposition in dogs in 1971 when they isolated a rib on the internal mammary pedicle and transposed it to the jaw (48). This was followed, again in the canine, with a free vascularized rib graft in 1973 by McCullough and Fredrickson (37). With the advent of microvascular techniques and development of microsurgical instruments, anastomosis of vessels as small as 1 mm was successfully accomplished by Buncke in 1965 in a rhesus monkey (11). Improvement on these techniques opened the door for the transfer of composite tissue. The first free skin flap was reported by Daniel and Taylor in 1973, involving the transfer of an iliofemoral island flap based on the superficial circumflex iliac artery to the right lower extremity (15). This was followed by a report in 1975 of the first free bone graft by Taylor et al., who transferred a fibula to a tibial defect (53). Buncke et al. (10) successfully transferred the first osteocutaneous flap utilizing a rib to the tibia in 1977 to treat a tibial pseudarthrosis, and this was followed shortly by Taylor's report of the first such graft using groin skin and iliac bone in 1978 (56).

## GOALS OF TREATMENT

The basic goals of treatment are:

1. To provide restoration of skeletal continuity
2. To achieve union rapidly, thus avoiding the slow process of creeping substitution as required for conventional grafts
3. To provide viable soft tissue coverage early
4. To restore and maintain the anatomy of the limb
5. To restore limb function including motion and strength

The surgeon should always strive to avoid complications and perform the procedures with the least morbidity and operative time necessary. For three-quarters of a century, conventional corticocancellous bone grafting, which has been shown to involve necrosis of the graft followed by a long process of revascularization, osteogenesis, and remodeling, has been the sole option in treatment of segmental bone defects. The living bone graft circumvents this prolonged process. With these goals in mind, the next step is the assessment of the patient and his or her expectations, the underlying pathology, and what is available to use as graft tissue. All of these points have to be considered in individualizing the treatment plan for each patient. Once this is determined, the surgical team can move to the next step in planning a vascularized bone graft.

## INDICATIONS

### PATIENT ASSESSMENT

Several issues regarding patient selection are crucial to planning a vascularized bone graft. Patient age and underlying medical condition play an important role in determining which patients are candidates. Although there is no age limit for vascularized bone grafts, elderly patients with underlying medical problems may present an unacceptably high surgical risk. Carefully weigh the risks of a long surgical procedure and requirement for prolonged limb protection against patient expectations. Those patients with evidence of peripheral vascular disease may also present risks that predispose to failure. Patients with multiple previous attempts at treatment may have altered local anatomy and limited availability for tissue coverage. Patients who smoke have been shown to have delayed bone healing. Those with hypercoagulable conditions or clotting abnormalities may also require special consideration.

### DEFECT CHARACTERISTICS

In patients with a history of trauma, irradiation, or infection, the condition of the recipient vessels in the defect must be carefully considered, as they may be at increased risk for failure of the graft because of poor arterial inflow and venous outflow. These procedures are often long and tedious, and the extensive dissection and long operative time required may exacerbate a previously quiescent infection and may increase the risk of graft failure.

### DONOR SITE AVAILABILITY

Several factors must be considered when choosing a bone for vascularized transfer. First, the donor bone must be of sufficient size to fill the defect. Free vascularized grafts offer advantages over conventional grafts in cases of defects greater than 6 to 8 cm. Lesser defects may not require as extensive a procedure, and a pedicled vascular graft may suit such a case well. Free vascularized iliac crest grafts are useful for defects no longer than 10 cm because of both the curvature and the structural characteristics of the bone. The nutrient vessels must be of adequate size for successful microvascular anastomoses. Arteriograms may aid in determining

the availability and status of vessels. Last, donor site morbidity must be minimized.

## APPLICATIONS

Current applications for vascularized bone grafts continue to expand. Well established are the uses of such grafts in patients with large defects secondary to trauma or after resection of locally aggressive or malignant bone tumors. Refractory nonunions, resection for osteomyelitis, and congenital pseudarthrosis of the tibia or forearm are other situations in which living grafts can be most useful. More recently, the use of vascularized bone grafts in the treatment of avascular necrosis of the femoral head has been reported with some mixed results. Avascular necrosis of the scaphoid (Priser's disease) and of the lunate (Kienbock's disease) has also been treated with vascularized bone grafts in hopes of arresting the underlying disease process.

### TRAUMA

Trauma is the most common cause of segmental bone loss in both upper and lower extremities. Perhaps the most frequent indication for vascularized bone grafts is the posttraumatic and often massive bone loss associated with severe trauma. Autogenous cancellous bone graft methods are not well suited for large defects of bone greater than 6 to 8 cm, as resorption of the graft may occur, and it does not provide structural support. In addition, scarring and relative avascularity of the recipient bed may not be conducive to graft incorporation. Defects in the tibia are most common; however, defects of the femur, ankle, and radius have also been treated with vascular bone grafts. An important concern in this setting is the condition of the recipient site, as often the bed has significant scarring. The arterial inflow to the area may be tenuous as well because of the “zone of injury,” which may extend a significant distance from the apparent bony defect. The fibular graft is most often utilized, as it nicely fits the longitudinal defect and is of sufficient length for most reconstructive settings. The rib graft was the first reported graft used clinically, but its usefulness in orthopaedics is somewhat limited because of its curved and malleable nature. It also has the potential for higher donor site morbidity if careful harvesting technique is not followed. The iliac crest is also useful; however, again the curvature of the bone often limits its application for defects less than 10 cm, and donor site morbidity is not insignificant.

### TUMOR

Much has been written about the use of vascularized bone grafts in the setting of tumor resection and reconstruction. Patients with locally aggressive or malignant tumors of bone often require *en bloc* resections that leave a large defect requiring reconstruction. Weiland et al. (61,62) have reported on a large series in which they used free fibula graft for the reconstruction of defects after massive tumor resections.

**Case Study 1** A 20-year-old college athlete presented with pain, swelling, and increased deformity of his wrist and forearm over several months' duration (Fig. 36.1).

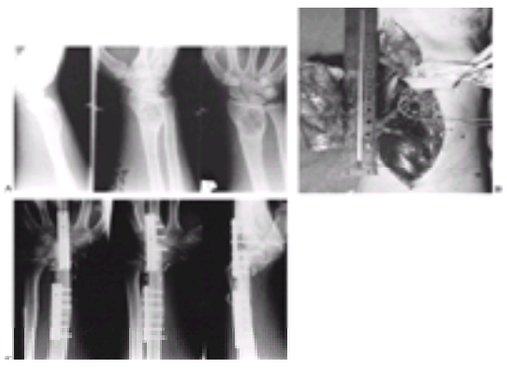

***Figure 36.1.*** **A:** Radiographs of a 20-year-old man demonstrate a lytic lesion in the distal radius that has thinned and expanded the cortex. **B:** Intraoperative photograph demonstrating a 7-cm *en bloc* resection of the distal radius from a dorsal approach. **C:** This 4-month postoperative radiograph demonstrates sound union proximally and distally.

A locally aggressive fibromyxoma was treated by *en bloc* resection and vascularized fibular grafting.

**Case Study 2** A 10-year-old girl presented with pain in her right hip of several months' duration (Fig. 36.2). A low-grade chondrosarcoma was treated by wide local excision, leaving a defect measuring 14 cm in the proximal femur. The defect was reconstructed using a vascularized fibula doweled into the recipient femur and external fixation to stabilize the graft. The graft healed uneventfully, but the patient later required a valgus intertrochanteric osteotomy to correct a resultant varus deformity of the proximal femur.

***Figure 36.2.*** **A:** Radiographs of a 10-year-old girl demonstrate a lucency and periosteal reaction in the right proximal femur. **B:** An MRI of the femur further delineates the lesion in the proximal shaft. **C:** Postoperative radiograph revealing the fibular graft and the external fixator in place. Note the doweling of the graft into the femur. **D:** Anteroposterior and lateral radiographs 3 years postoperatively reveal incorporation and hypertrophy of the graft but a varus deformity of the femoral neck. **E:** A 50° intertrochanteric valgus corrective osteotomy performed to improve neck shaft angle.

### OSTEOMYELITIS

A frequent problem faced by the orthopaedic surgeon, osteomyelitis can pose management and treatment problems for many reasons. The resection of soft tissue and bone is often too massive to obtain adequate debridement of the infected area. Often the patient has undergone multiple procedures including several irrigations and debridements. As many as 18 procedures were reported in a recent study (5) to have preceded presentation for the definitive grafting procedure. This leaves a significantly scarred and relatively avascular soft tissue bed to work with. The integrity of the surrounding vessels could also be potentially compromised, leading to high risk of graft failure. Furthermore, the potential of recurrence of the infection leading to almost certain graft failure is a foremost concern.

**Case Study 3** A 32-year-old patient sustained a bumper-type injury that resulted in a comminuted open fracture of the proximal tibia complicated by osteomyelitis (Fig. 36.3). Following debridement and application of an external fixator, the patient was left with a 13-cm bone defect, with interval healing after a vascular latissimus dorsi flap. A vascularized fibular graft was performed. The patient subsequently fractured at the proximal juncture site, however, and later required an open reduction, internal fixation, and plating before complete healing occurred.

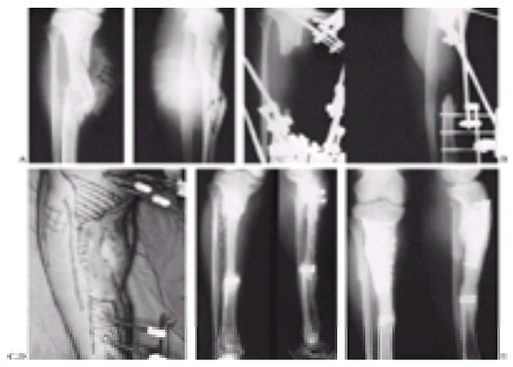

***Figure 36.3.*** **A:** Radiograph of a patient who sustained a bumper-type injury that resulted in a comminuted open fracture of the proximal tibia. **B:** Radiographic appearance following radical debridement demonstrates a 13-cm bone defect. **C:** Clinical appearance of leg following free soft-tissue transfer and coverage. **D:** A 6-month postoperative radiograph demonstrates sound union of vascularized fibular graft proximally and distally. **E:** Radiograph of patient 3 months following a repeated internal fixation performed because of a stress fracture of the proximal juncture site.

### NONUNIONS

Refractory nonunions can occur in many locations, but the well-known sites are the tibia and scaphoid. The tibia is often subjected to open injuries, and the blood supply to the area can be easily interrupted. The anatomy of the blood supply to the scaphoid lends itself to compromise, especially with proximal pole fractures. These situations may not often require the massive size grafts as seen in the previously discussed conditions; however, they still require a nutrient blood supply in which osteocytes and osteoblasts can survive, thus facilitating healing of the bone without the usual replacement of the graft with creeping substitution. In the case of scaphoid nonunions, a local pedicled vascularized bone graft will often be adequate to treat a nonunion. Zaidemberg et al. (72) described a vascularized graft to the scaphoid based on the radial styloid that offers promising results. Several other authors have reported on vascularized metacarpal bone grafts based on the branches of the radial and ulnar arteries.

### CONGENITAL PSEUDARTHROSIS

Congenital pseudarthrosis remains one of the most challenging problems facing the orthopaedic surgeon today. Conventional bone-grafting methods have failed to successfully treat these patients. Chen, Weiland, Hagan, and Bunke have all reported promising results using vascularized free fibular grafts in the treatment of this difficult problem. Congenial pseudarthrosis of the forearm is uncommon. Sellers (45) reported only 23 cases after a review of the literature. Conventional treatment has been fraught with poor results and recurrent nonunion. Allieu (1) and Sellers (45) both report improved results with the use of free vascularized graft for this condition.

**Case Study 4** An 11-year-old boy with von Recklinghausen's disease presented with a congenital pseudarthrosis of the right tibia and fibula that had defied several previous attempts at bone grafting and immobilization (Fig. 36.4). An extraperiosteal dissection and excision of the pseudarthrosis of the tibia and fibula were performed, resulting in an 8-cm tibial defect. A buttress plate was used to secure the graft to the tibia proximally and distally. Six months postoperatively there was good incorporation of the fibula graft proximally as well as distally. The patient subsequently required a contralateral epiphysiodesis to equalize a leg length discrepancy and an osteotomy of the tibia to correct valgus bowing.

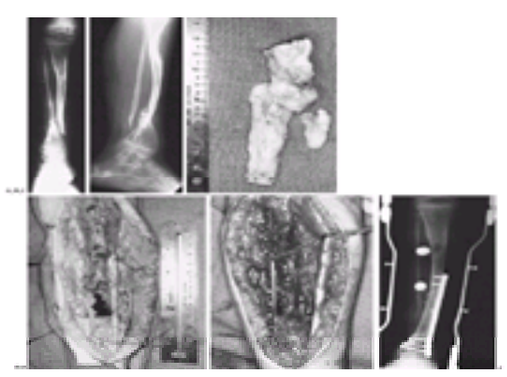

***Figure 36.4.*** **A:** Anteroposterior radiograph of an 11-year-old boy with von Recklinghausen's disease and congenital pseudarthrosis of the tibia. **B:** Lateral radiograph demonstrating a proximally as well as distally bowed tibia along with marked osteoporosis of the distal tibia and foot. **C:** Intraoperative photograph of resected specimen, including tibial and fibular pseudarthrosis. **D:** Intraoperative photograph demonstrating bony defect. Vessel loops are noted around the anterior neurovascular bundle as well as the saphenous vein. **E:** Intraoperative photograph demonstrating buttress plate. The vascular pedicle can be seen transversing the proximal portion of the plate into the graft. **F:** Radiograph of leg 6 months postoperatively, demonstrating sound union of the vascularized graft. However, tibial bowing was noted.

### AVASCULAR NECROSIS (AVN)

Several recent reports on the treatment of avascular necrosis of the femoral head have been published. This difficult problem often presents in the younger patient as a result of trauma, steroid use, or alcohol use or may be idiopathic. This group of patients is often too young for hip arthroplasty but is severely debilitated secondary to pain and stiffness. A vascularized bone graft may offer them a chance to retain their native hip as long as possible while restoring some of their quality of life. Both iliac crest and fibula have been reported in the literature as possible sites of donor bone graft. Results have been mixed, with some authors reporting good results and others saying that the results are no better than with simple core decompression. Scaphoid and lunate AVN have also been treated with vascularized bone grafts with promising results.

## PREOPERATIVE PLANNING

The surgeon should first be well trained and well versed in microvascular techniques and be able to perform multiple types of microvascular anastomoses that may be required in scarred or otherwise traumatized tissue. Assess the patient, the defect, and the possible donor sites as described elsewhere in this chapter well before the procedure. Obtain preoperative arteriograms of both the donor and recipient site to evaluate any vascular abnormalities that could preclude a successful graft transfer. Be aware that a normal arteriogram may not provide a true assessment of the arterial inflow. Scarred blood vessels or those easily prone to spasm may appear normal on an arteriogram. The surgeon will often be required to make intraoperative judgments of vascular viability and should be able to recognize vessel damage that would interfere with successful microvascular anastomoses.

## SURGICAL TECHNIQUES

### VASCULARIZED FIBULA

Studies have shown that the peroneal artery, which is intimately related to the undersurface of the bone, is the predominant blood supply to the fibula, supplying a nutrient artery and segmental musculoperiosteal vessels (53). Commonly an arteriogram of a normal leg exhibits a proximal anterior tibial artery takeoff followed by a bifurcation of posterior tibial and peroneal arteries. Occasionally, a separate peroneal artery does not exist, which may preclude use of the fibula as a donor.

- Although not essential, a two-team approach can save considerable operative time. The surgical technique for the donor fibula is rather constant, with the patient supine and the hip and the knee flexed.

- Use a lateral approach to the fibula, extending from the neck of the fibula in a distal direction.
- Identify the interval between the peroneus longus and the soleus muscles (Fig. 36.5). Incise the deep fascia the entire length of the incision.

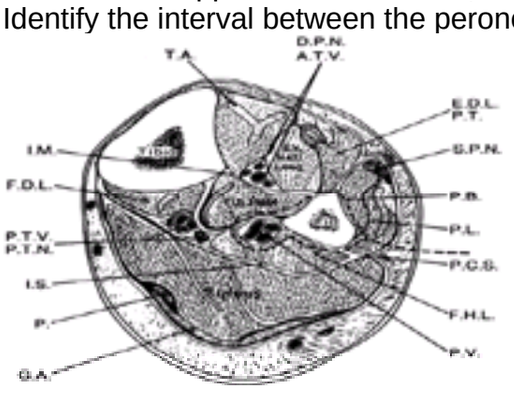


***Figure 36.5.*** Cross section of the middle third of the lower extremity, outlining the lateral approach for harvest of the fibula (*dotted line*). *T.A.*, tibialis anterior; *D.P.N.*, deep peroneal nerve; *A.T.V.*, anterior tibialis vessels; *E.D.L.*, extensor digitorum longus; *P.T.*, peroneus tertius, *S.P.N.*, superficial peroneal nerve; *P.B.*, peroneus brevis; *P.L.*, peroneus longus; *P.C.S.*, posterior crural septum; *F.H.L.*, flexor hallucis longus; *P.V.*, peroneal vessels; *G.A.*, gastrocnemius aponeurosis; *P.*, plantaris; *I.S.*, intermuscular septum; *P.T.V.*, posterior tibial vessels, *P.T.N.*, posterior tibial nerve; *F.D.L.*, flexor digitorium longus; *I.M.*, interosseous membrane. (From Weiland AJ. Vascularized Bone Transfers. In Murray JA, ed. *AAOS Instructional Course Lectures, Vol. 33.* St. Louis: CV Mosby, 1984:448.)

- Expose the lateral border of the fibula. Approach the fibula in a proximal-to-distal direction and elevate, with extraperiosteal dissection, the peroneus longus and brevis off the anterior border of the fibula.
- Divide the anterior crural septum along the length of the graft and identify and protect the deep peroneal nerve and anterior tibial artery and vein as the extensor group of muscles is dissected from the interosseous membrane.
- Divide the posterior crural septum the entire length of the graft and reflect the soleus as well as flexor hallucis muscles off the posterior border of the fibula. Preserve the nerve to the flexor hallucis longus while performing this dissection. Continue this dissection until the peroneal vessels are encountered.
- The nutrient artery is found in the middle half of the fibula, usually just proximal to the midpoint. The periosteal vessels pass circumferentially around the fibula. Preserve them with extraperiosteal dissection. The venous drainage is via paired venae comitantes of the peroneal artery and closely parallels it.
- Measure the length of the fibular graft needed and mark it, taking care to preserve at least the distal 6 cm of fibula to maintain stability of the ankle mortise. In children less than 10 years of age, we perform a synostosis between the fibula and tibia to prevent proximal migration of the distal fibula, which can cause valgus ankle deformity.
- Perform the proximal and distal osteotomies with a Gigli or power saw, taking care to place a bone retractor between the peroneal vessels and the fibula. Retract the bone graft posteriorly and laterally and divide the interosseous membrane along the entire length of the bone graft.
- Retract the graft anteriorly. Dissect the tibialis posterior muscle off the posterior aspect of the middle third of the fibula. At this point, the fibula graft will be isolated on the peroneal neurovascular bundle (Fig. 36.6). Dissect the pedicle proximally until the bifurcation of the posterior tibial artery and peroneal artery is identified. Before dividing the pedicle, deflate the tourniquet and allow circulation to the fibula for 10 to 15 min.

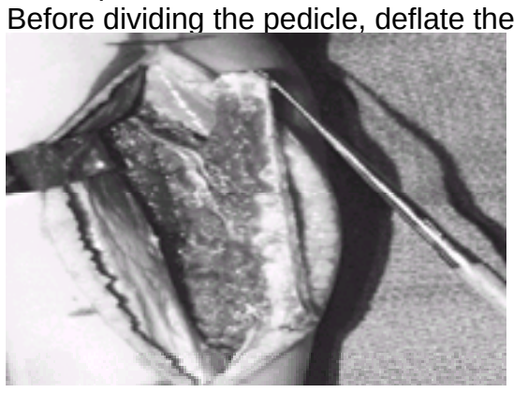

***Figure 36.6.*** The osteotomized fibula after the interosseous membrane has been divided. The vascular pedicle of the peroneal artery and vein is clearly visible in the proximal extent of the wound.

- The structure most at risk proximally is the peroneal nerve and its branches, which must be protected at all times.
- The technique for preparing the recipient site varies depending on the clinical condition being treated. In posttraumatic cases, focus initial attention at identification and protection of neurovascular structures. Failure to isolate a healthy level of recipient vessels is the most common cause for failure of free tissue transfer. The zone of injury often far exceeds the limits of the bone defect in posttraumatic and infected cases.
- Resect necrotic or nonviable bone ends.
- Rigidly fix the fibular graft into the defect. A variety of techniques may be used, including doweling of the end of the fibula inside the tibia, end-to-end apposition, or bayonet-type fixation. Regardless of the position of the fibular graft, rigid fixation is needed with external and/or internal fixation. Do not use medullary fixation through the vascularized fibular graft to avoid disrupting its blood supply. In most instances, pack cancellous bone graft in and around the juncture points of the recipient and donor bone to promote more rapid union.
- Perform the microvascular anastomoses. Usually one artery and one vein are anastomosed. Whenever possible, perform end-to-side arterial anastomosis so as not to compromise distal circulation to the extremity. End-to-end vein anastomosis is standard practice. The caliber of the recipient vein must be equal to or larger than that of the peroneal vein so that venous hypertension does not occur. Some authors recommend two venous anastomoses to assure adequate venous drainage. The recipient vein may be from either the superficial venous system or venae comitantes, as long as it is of sufficient caliber and scar-free.
- The fibular graft, because it is devoid of larger amounts of soft tissue or muscle, seems particularly tolerant of ischemia lasting up to 6 h. Do not rush attempts at achieving secure bony fixation to limit ischemia time, as secure fixation is of utmost importance.
- Adequate circulation is assessed by a patent and functioning anastomosis as well as by bleeding at the edges of the muscle cuff on the fibular graft. Before wound closure, ascertain that the vascular pedicle is not redundant, twisted, or kinked. It is preferable to resect and tailor a functioning anastomosis that is looped or kinked because of the potential danger of thrombosis.
- Although there is no universal agreement on the use of anticoagulants, some surgeons find it helpful to give intraoperative heparin before removing the vascular clamps from large lower extremity vessels.
- Pack cancellous bone chips harvested from the iliac crest about the proximal and distal juncture sites, insert deep drains, and close the skin.
- Close the donor site defect in two layers, the subcutaneous layer and the skin. Do not close the fascia, as this may lead to a compartment syndrome. Postoperatively, continue low-dose aspirin therapy and instruct patients not to smoke.

At present, there are no 100% reliable techniques for monitoring the vascularity to the bone graft in a noninvasive fashion. Overlying skin islands may be taken with the fibula; however, the presence or absence of the cutaneous circulation may not accurately reflect the osseous circulation. Bone scans have been used in the laboratory and clinically but are useful only for the first week after surgery and are impractical as a sequential monitoring system. If a scintiscan performed within the first week is negative, patent microvascular anastomosis is unlikely (65).

Immobilize and protect the grafted bone segment from weight bearing for at least 2.5 months or until incorporation and callus around the juncture sites are seen. In the adult, lower extremity graft incorporation usually occurs in 4 to 6 months, but it may be wise to protect the graft site with an orthosis throughout the first year.

Even experienced microsurgeons, if a novice at vascularized fibular grafting, should perform cadaveric dissections before surgery to refamiliarize themselves with the relationships of neurovascular structures to the interosseous membranes. With attention to meticulous technique, a very low incidence of donor-site morbidity can be expected.

**VASCULARIZED ILIAC CREST**

First described by Taylor as based on the superficial circumflex iliac artery (SCIA), this graft has undergone changes. In an elegant study combining cadaver dissection, angiography, and clinical trial, Taylor showed that the most reliable pedicle for the osteocutaneous iliac crest graft is the deep circumflex iliac artery, as it supplies a greater portion of the bone as well as an elliptical area of skin over the iliac crest and the iliacus, transversus, and internal oblique muscles as compared to the superficial system (54). In planning this graft, the incisions, orientation of the bone, and the choice of donor side should be carefully planned in advance. Use the

ipsilateral crest in the tibia if the recipient artery is to be the anterior tibial; however, use the contralateral crest for the recipient posterior tibial artery.

The iliac crest graft, based on the deep circumflex iliac artery (DCIA), can be harvested with or without a skin flap. If a skin graft is taken, place the incision in the long axis along the upper border of the anterior part of the iliac crest. The upper limit of area of skin that can be harvested is not known currently. Areas averaging 18 × 7.7 cm have been taken and closed primarily (55). Skin medial to the anterior superior iliac spine (ASIS) relies more on its blood supply from the anastomoses between the DCIA and the SCIA, and this means there may be temporary sluggish flow to this skin, but expect viability.

- Place the patient supine on the table with a small bump under the donor hip to help elevate the crest and aid in harvesting. If skin is to be harvested with the graft, mark the area on the skin.
- Make an incision from the femoral artery to a point about 10 cm posterior to the anterior superior iliac spine. A transinguinal approach to the vascular pedicle is preferred.
- Expose the external oblique muscle and incise it in line with its fibers, approximately 3 cm superior to the iliac crest. This edge of the muscle includes perforator branches of the DCIA. Then curve the incision toward the ASIS and parallel to the inguinal ligament to enter the inguinal canal. Next, identify the spermatic cord or round ligament and retract upward and medially. The external iliac artery can be palpated through the transversalis fascia.
- Incise the fascia and identify the DCIA and vein. They are most easily identified where they converge toward each other about 1 to 2 cm lateral to the external iliac artery. Trace the DCIA vessels laterally, dividing the transversalis fascia, internal oblique, and transversus abdominis from the inguinal ligament. As the ASIS is approached, it may become easier to identify the ascending branch lateral to the ASIS and then trace it medially to its origin from the SCIA by incising the internal oblique muscle 3 cm above and behind the ASIS.
- To isolate the bone, incise the transversus muscle parallel to the iliac crest, leaving a minimal rim of muscle on the bone. Incise the transversalis fascia, retract the extraperitoneal fat, and expose the line between the transversalis and the iliacus fascia. Incise the iliacus 1 cm medial to this line, thus exposing the periosteum of the iliac fossa. Bluntly dissect the iliacus muscle away from the remainder of the bone.
- Incise the lower skin border and cut the attachment of the tensor fasciae latae and glutei muscles sharply from the bone. Divide the inguinal ligament and the origin of the sartorius muscle just medial to the ASIS.
- Osteotomize the bone as measured to isolate the flap on its vascular pedicle. Allow the flap to sit for 20 min to assure viability before sectioning the pedicle.
- The lateral cutaneous nerve of the thigh will be encountered in close relation to the DCIA. The nerve may have to be sectioned to remove the graft, but attempt to preserve it.
- At the lateral margin of the iliac crest, use an oscillating saw to cut through the crest, creating a graft 2.5 cm in depth (wide). Then continue the cut medially with the osteocutaneous flap finally isolated on its vascular pedicle, consisting of the deep circumflex iliac artery and vein.
- Using sutures widely placed at the edges of the graft, carefully preserve the attachment of the overlying skin and subcutaneous tissue to the iliac crest to avoid accidental shearing of the small nutrient vessels supplying the skin.
- Because of the curvature of the ilium, grafts longer then 10 cm usually cannot be obtained. A portion of the iliacus must be retained on the inner table in order to preserve the nutrient blood supply to the bone. Close the donor site primarily. Harvest cancellous graft for use at the junction sites before closing the donor site. The hip may be flexed about 30° by flexing the table to facilitate closure of the defect.
- To avoid abdominal herniation, suture the iliacus fascia and muscle to the transversalis fascia and muscle. Next, suture the internal and external oblique muscles to the glutei, the fascia lata, and its muscle. Repair the inguinal canal and reattach the inguinal ligament laterally.
- Internally fix the graft into the recipient site; there is healthy bone on either end of the defect. Plates can often easily be used to fix the graft but should not lie on top of the nutrient artery. Fixation into the graft itself should be limited and avoid the nutrient artery and pedicle. Two plates can be used at either end or T-plates if a metaphysis is involved. Use no more than two screws in the graft. The use of Kirschner wires and screws alone has been reported (51) but is often associated with loss of position at the junction site.
- If adequate bone stock is not available for internal fixation, use external fixation (19,27,31). Almost any external fixator can be used, and the choice is dependent on the anatomic site, bone quality, and functional demands. Ilizarov-type frames offer multiplanar control and variation as to configuration, whereas the others offer ease of application. It has been used in many defects involving transfer of free vascularized grafts including the humerus, forearm, hand, femur, tibia, and foot for defects ranging from trauma and tumor to infection and congenital deformities (19).
- Regardless of the frame used, it must not block access to the microvascular anastomoses. The pins or wires can be carefully passed through the graft, always protecting the nutrient artery and pedicle. Pack cancellous graft around the junction sites and close the wound over drains.
- Healing of the graft can be expected in 8 to 12 weeks, roughly the same as healing rate for fractures at the same site.

### RIB

Östrup, Fredrickson, and Tam showed by injection studies that the posterior intercostal vessels give rise to the principal nutrient vessel of the ribs, whereas the anterior intercostal arteries supply mainly the periosteum of the rib. The graft, therefore, is based on the posterior vessels (10). The graft can survive on the anterior pedicle, but the bone may show some necrosis.

- Measure the pattern of the defect and trace out the pattern on the chest. Make a posterior transverse incision between two ribs (10).
- Identify the intercostal vessels posteriorly at the beginning of the dissection and develop the flap margins of the underlying rib in an anterior direction.
- Expose the rib and cut a segment sized to the bony defect. Dissect the vessels back to the pedicle and carefully ligate them. Then transpose the graft to the defect and secure it. Close the donor defect primarily over drains.

Complete survival of the rib as free living bone occurs only when the intramedullary blood supply is maintained via the nutrient artery, which is a branch of the posterior intercostal artery. Thus, the rib must be isolated on its nutrient artery. This requires a complicated posterior dissection within 3 cm of the costovertebral joint rather than a simple lateral segmental excision. This location will often obligate ligation of the adjacent dorsal branch of the intercostal artery, which risks transection of the artery of Adamkiewicz. This vessel arises between T-7 and L-1 and is the principal supply to the thoracolumbar segment of the spinal cord. Loss of this can result in permanent paraplegia. Preoperative angiography is recommended; however, the sixth rib should be selected when arteriography is not possible.

### DORSAL RADIAL GRAFTS

Nonunion and avascular necrosis of the scaphoid continue to be difficult to treat. Conventional methods of treatment including bone grafting and internal fixation have resulted in reports of successful union in 90% of patients (14,22,36,44,47,72). The period of immobilization is long, however, and the 10% of cases that are refractory despite conventional procedures present especially difficult treatment dilemmas. The vascularized bone graft offers the advantages of decreased times of immobilization and a high union rate for these refractory nonunions (12,32,33,72). Zaidemberg has most recently described a technique using a vascularized graft from the distal dorsoradial aspect of the radius based on a consistent retrograde branch from the radial artery that has shown good results and is technically straightforward (72).

- Perform a dorsal approach to the wrist by making an oblique incision on the radiodorsal aspect of the wrist. Take care to avoid injury to the dorsal sensory branch of the radial nerve.
- Divide the extensor retinaculum. Retract the first dorsal compartment containing the extensor pollicis brevis and abductor pollicis longus tendons palmarly. Reflect the extensor carpi radialis longus and finger extensor tendons ulnarly. The longitudinal course of the vessel is easily identified overlying the distal radius. Design a vascularized bone graft centering this perfusing periosteal blood vessel in the bone to be harvested.
- Visualize the nonunion of the scaphoid and freshen the sclerotic bone ends. Reduce the fracture. If adequate reduction of the scaphoid fracture cannot be achieved, then a combined palmar approach may be necessary to reduce the scaphoid fracture before bone grafting.
- Fashion a trough 15 to 20 mm in length running parallel to the long axis of the scaphoid.
- Harvest a bone graft corresponding in size to the cavity created in the scaphoid from the distal radius underlying the vascular pedicle. The bone graft is then easily transposed to the recipient scaphoid site. Secure the bone graft with Kirschner wires.
- If additional cancellous bone graft is needed, it can be harvested through the same distal radius site. A monitoring island of skin can be raised with the bone for postoperative documentation of vascularity if desired, as the periosteal vessel does continue into the skin overlying the bone.
- Close and apply a long arm cast with thumb spica for 1 month, followed by a short arm cast with thumb spica for 2 weeks. At 6 weeks, use radiographs to assess union. When stable bony union is certain, begin range-of-motion exercises.

## PITFALLS AND COMPLICATIONS

Microvascular surgery has the same complications as other surgery, such as infection, wound problems, and others. Use good surgical technique to minimize these.

Loss of function of the flexor hallucis longus (FHL) can occur when a fibula is harvested as a result of dissection of its origin off of the fibula, damage to its nerve, or postoperative scarring. Avoid loss of FHL function and peroneal nerve palsy by identifying and protecting these structures when necessary and avoiding unnecessary dissection into the muscles surrounding the fibula. When the fibula is harvested, a major vessel to the leg is sacrificed, but this rarely leads to any problems.

In harvesting the iliac crest, the lateral femoral cutaneous nerve to the thigh may need to be sacrificed. Advise patients about this ahead of time. Iliac grafts may be bulky. Minimize bulk by placing the grafts in the defect in the coronal plane. Secondary debulking may be necessary.

## AUTHORS' PERSPECTIVE

Vascularized bone grafts have expanded treatment options for multiple clinical situations where obtaining bone union has traditionally been difficult. However, the ability to perform such a procedure and the practical nature of doing this are two different situations. It is our opinion that the vascularized fibular graft is most useful for defects of the tibial and for avascular necrosis of the femoral head. The use of iliac crest grafts is somewhat more limited because of the more curved nature of the bone and the morbidity of the donor site. It should be considered if the fibular graft is not an option for a patient because of trauma or previous harvesting. Rib grafts have very limited use in orthopaedic surgery and are used only as a last resort to the other graft sites. Their curved nature makes them very amenable to use in the mandible. The dorsal/radial graft is useful for nonunions of the scaphoid, but we would recommend its use only for selected proximal pole nonunions and only after failed open reduction, internal fixation, and standard bone grafting, as it is more involved and requires greater dissection on the dorsal aspect of the wrist.

### CHAPTER REFERENCES

Each reference is categorized according to the following scheme: *, classic article; #, review article; !, basic research article; and +, clinical results/outcome study.


+ 1. Allieu Y, Gomis R, Yoshimura M, et al. Congenital Pseudarthrosis of the Forearm. Two Cases Treated by Free Vascularized Fibular Graft. *J Hand Surg* 1981;6:475.

+ 2. Berggren A, Weiland AJ, Dorfman HD. Free Vascularized Bone Grafts: Factors Affecting Their Survival and Ability to Heal to Recipient Bone Defects. *Plast Reconstruct Surg* 1982;69:19.

+ 3. Berggren A, Weiland AJ, Östrup LT, Dorfman H. Microvascular Free Bone Transfer with Revascularization of the Medullary and Periosteal Circulation or the Periosteal Circulation Alone. *J Bone Joint Surg* 1982;64A:73.

+ 4. Berggren A, Weiland AJ, Östrup LT. Bone Scintigraphy in Evaluating the Viability of Composite Bone Grafts Revascularized by Microvascular Anastomosis, Conventional Autogenous Bone Grafts and Free Nonrevascularized Periosteal Grafts. *J Bone Joint Surg* 1982;64A:799.

+ 5. Bishop AT, Wood MB, Sheetz KK. Arthrodesis of the Ankle with a Free Vascularized Autogenous Bone Graft. *J Bone Joint Surg* 1995;77A:1867.

+ 6. Bohay DR, Manoli A II. Clawtoe Deformity Following Vascularized Fibula Graft. *Foot Ankle Int* 1995;16:607.

* 7. Boyd HB. The Treatment of Difficult and Unusual Non-unions. *J Bone Joint Surg* 1943;25:535.

+ 8. Brookes M, Elkin AC, Harrison RG, Heald CB. A New Concept of Capillary Circulation in Bone Cortex. Some Clinical Applications. *Lancet* 1961;1:1078.

# 9. Brookes M. *The Blood Supply of Bone.* London: Butterworths, 1971.

+ 10. Buncke HJ, Furnas DW, Gordon L, Achauer BM. Free Osteocutaneous Flap from a Rib to the Tibia. *Plast Reconstruct Surg* 1977;59:799.

! 11. Buncke HJ, Schulz WP. Experimental Digital Amputation and Reimplantation. *Plast Reconstruct Surg* 1965;36:62.

+ 12. Chacha PB. Vascularised Pedicular Bone Grafts. *Int Orthop* 1984;8:117.

+ 13. Chew WYC, Low CK, Tan SK. Long Term Results of Free Vascularized Fibular Graft: A Clinical and Radiographic Evaluation. *Clin Orthop* 1995;311:258.

+ 14. Cooney WP, Linscheid RL, Dobyns JH, Wood MB. Scaphoid Nonunion: Role of Anterior Interpositional Bone Grafts. *J Hand Surg* 1988;13:635.

+ 15. Daniel RK, Taylor GI. Distant Transfer of an Island Flap by Microvascular Anastomoses: A Clinical Technique. *Plast ReconstrUct Surg* 1973;52:111.

+ 16. Daniel RK. Free Rib Transfer by Microvascular Anastomoses. *Plast Reconstruct Surg* 1977;59:737.

+ 17. Emery SE, Heller JG, Petersilge CA, et al. Tibial Stress Fracture after a Graft has been Obtained from the Fibula: A Report of Five Cases. *J Bone Joint Surg* 1996;78A:1248.

+ 18. Grishin IG, Golubev VG, Goncharenko IV, et al. Transfer of Free Vascularized Bone and Skin Bone Autografts: Experiences on the Application of External Fixation Apparatus. *J Reconstruct Microsurg* 1990;6:1.

+ 19. Grishin IG, Golubev VG, Goncharenko IV, et al. Transfer of Free Vascularized Bone and Skin-Bone Autografts: Experiences in the Application of External Fixation Apparatus. *J Reconstruct Microsurg* 1990;6:1.

* 20. Harmon PH. A Simplified Surgical Approach to the Posterior Tibia for Bone Grafting and Fibular Transference. *J Bone Joint Surg* 1945;27:496.

+ 21. Hasegawa Y, Iwata H, Torii S, et al. Vascularized Pedicle Bone-grafting for Nontraumatic Avascular Necrosis of the Femoral Head: A 5 to 11 Year Follow-up. *Arch Orthop Trauma Surg* 1997;116:251.

+ 22. Herbert TJ, Fisher WE. Management of the Fractured Scaphoid Using a New Bone Screw. *J Bone Joint Surg* 1984;66B:114.

+ 23. Hertel R, Pisan M, Jakob RP. Use of the Ipsilateral Vascularised Fibula for Tibial Reconstruction. *J Bone Joint Surg* 1995;77B:914.

+ 24. Hirayama T, Suematsu N, Inoue K, et al. Free Vascularised Bone Grafts in Reconstruction of the Upper Extremity. *J Hand Surg* 1985;10B:169.

+ 25. Hou SM, Hang YS, Liu TK. Ununited Femoral Neck Fractures by Open Reduction and Vascularized Iliac Bone Graft. *Clin Orthop* 1993;294:176.

! 26. Hurlbut PT, Van Heest AE, Lee KH. A Cadaveric Anatomic Study of Radial Artery Pedicle Grafts to the Scaphoid and Lunate. *J Hand Surg* 1997;22A:408.

+ 27. Ilizarov GA. The Tension-Stress Effect on the Genesis and Growth of Tissues. Part I. The Influence of Stability of Fixation and Soft Tissue Preservation. *Clin Orthop* 1989;238:249.

+ 28. Ishizaka M, Sofue M, Dohmae Y, et al. Vascularized Iliac Bone Graft for Avascular Necrosis of the Femoral Head. *Clin Orthop* 1997;337:140.

! 29. Iwata H, Torii S, Hasegawa Y, et al. Section III: Basic Science and Pathology: Indications and Results of Vascularized Pedicle Iliac Bone Graft in Avascular Necrosis of the Femoral Head. *Clin Orthop* 1993;295:281.

+ 30. Jupiter JB, Gerhard HJ, Guerrero J, et al. Treatment of Segmental Defects of the Radius with Use of the Vascularized Osteoseptocutaneous Fibular Autogenous Graft. *J Bone Joint Surg* 1997;79A:542.

+ 31. Jupiter JB, Kour AK. Reconstruction of the Humerus by Soft Tissue Distraction and Vascularized Fibula Transfer. *J Hand Surg* 1991;16A:940.

+ 32. Kawai H, Yamamoto K. Pronator Quadratus Pedicled Bone Graft for Old Scaphoid Fractures. *J Bone Joint Surg* 1988;70B:829.

+ 33. Kuhlmann JN, Mimoun M, Boabighi A, Baux S. Vascularized Bone Graft Pedicled on the Volar Carpal Artery for Non-union of the Scaphoid. *J Hand Surg* 1987;12B:203.

+ 34. Leung PC. Femoral Head Reconstruction and Revascularization: Treatment for Ischemic Necrosis. *Clin Orthop* 1996;323:139.

+ 35. Low CK, Pho RWH, Kour AK, et al. Infection of Vascularized Fibular Grafts. *Clin Orthop* 1996;323:163.

+ 36. Manske PR, McCarthy JA, Strecker WB. Use of the Herbert Bone Screw for Scaphoid Nonunions. *Orthopedics* 1988;11:1653.

+ 37. McCullough DW, Fredrickson JM. Neovascularized Rib Grafts to Reconstruct Mandibular Defects. *Can J Otolaryngol* 1973;2:96.

# 38. Moore JR, Weiland AJ. Vascularized Bone Grafts. In Chapman MW, ed. *Operative Orthopaedics, 2nd ed.* Philadelphia: JB Lippincott, 1993:1079.

+ 39. Ozaki T, Hillmann A, Wuisman P, Winkelmann W. Reconstruction of Tibia by Ipsilateral Vascularized Fibula and Allograft: 12 Cases with Malignant Bone Tumors. *Acta Orthop Scand* 1997;68:298.

+ 40. Parrish FF. Allograft Replacement of All or Part of the End of a Long Bone Following Excision of a Tumor. *J Bone Joint Surg* 1973;55A:1.

+ 41. Parrish FF. Treatment of Bone Tumors by Total Excision and Replacement with Massive Autologous and Homologous Grafts. *J Bone Joint Surg* 1966;48A:968.

+ 42. Pho RWH. Malignant Giant-cell Tumor of the Distal End of the Radius Treated by a Free Vascularized Fibular Transplant. *J Bone Joint Surg* 1981;63A:877.

+ 43. Riordan DC. Congenital Absence of the Radius. *J Bone Joint Surg* 1955;37A:1129.

+ 44. Schneider LH, Aulicino P. Nonunion of the Carpal Scaphoid: the Russe Procedure. *J Trauma* 1982;22:315.

+ 45. Sellers DS, Sowa DT, Moore JR, Weiland AJ. Congenital Pseudarthrosis of the Forearm. *J Hand Surg* 1988;13A:89.

+ 46. Sowa DT, Weiland AJ. Clinical Application of Vascularized Bone Autografts. *Orthop Clin North Am* 1987;18:257.

+ 47. Stark HH, Rickard TA, Zemel NP, Ashworth CR. Treatment of Ununited Fractures of the Scaphoid by Iliac Bone Grafts and Kirschner-Wire Fixation. *J Bone Joint Surg* 1988;70:982.

+ 48. Strauch B, Bloomberg AE, Lewin ML. An Experimental Approach to Mandibular Replacement: Island Vascular Composite Rib Grafts. *Br J Plast Surg* 1971;24:334.

+ 49. Swartz WM. Immediate Reconstruction of the Wrist and Dorsum of the Hand with a Free Osteocutaneous Groin Flap. *J Hand Surg* 1984;9A:18.

+ 50. Taguchi Y, Pereira BP, Kour AK, et al. Autoclaved Autograft Bone Combined with Vascularized Bone and Bone Marrow. *Clin Orthop* 1995;320:220.

+ 51. Takami H, Takahashi S, Ando M, Masuda A. Vascularized Fibular Grafts for the Reconstruction of Segmental Tibial Bone Defects. *Arch Orthop Trauma Surg* 1997;116:404.

+ 52. Tamai H, Gori Y, Tatsumi Y, et al. An Experience of Vascularized Fibula Head Transplantation in a Child with Radial Club Hand (in Japanese). *Seikeigeka* 1981;32:1645.

+ 53. Taylor GI, Miller GDH, Ham FJ. The Free Vascularized Bone Graft. *Plast Reconstruct Surg* 1975;55:533.

+ 54. Taylor GI, Townsend P, Corlett R. Superiority of the Deep Circumflex Iliac Vessels as the Supply for Free Groin Flaps: Experimental Work. *Plast Reconstruct Surg* 1979;64:595.

+ 55. Taylor GI, Townsend P, Corlett R. Superiority of the Deep Circumflex Iliac Vessels as the Supply for Free Groin Flaps: Clinical Work. *Plast Reconstruct Surg* 1979;64:745.

+ 56. Taylor GI, Watson N. One-stage Repair of Compound Leg Defects with Free, Revascularized Flaps of Groin Skin and Iliac Bone. *Plast Reconstruct Surg* 1978;61:494.

+ 57. Vail TP, Urbaniak JR. Donor-site Morbidity with Use of Vascularized Autogenous Fibular Grafts. *J Bone Joint Surg* 1996;78A:204.

+ 58. Weiland AJ, Berggren A, Jones L. The Acute Effects of Blocking Medullary Blood Supply on Regional Cortical Blood Flow in Canine Ribs as Measured by the Hydrogen Washout Technique. *Clin Orthop* 1982;165:265.

+ 59. Weiland AJ, Daniel RK. Microvascular Anastomoses for Bone Grafts in the Treatment of Massive Defects in Bone. *J Bone Joint Surg* 1979;61A:98.

# 60. Weiland AJ, Hotchkiss RN. Vascularized Bone Grafts. In *Operative Hand Surgery, 3rd ed.* New York: Churchill Livingstone, 1993:1179.

+ 61. Weiland AJ, Kleinert HE, Kutz JE, Daniel RK. Free Vascularized Bone Grafts in Surgery of the Upper Extremity. *J Hand Surg* 1979;4:129.

+ 62. Weiland AJ, Moore JR, Daniel RK. Vascularized Bone Autografts. Experience with 41 Cases. *Clin Orthop* 1983;174:87.

! 63. Weiland AJ, Phillips TW, Randolph MA. Bone Grafts: A Radiologic, Histologic, and Biomechanical Model Comparing Autografts, Allografts, and Free Vascularized Bone Grafts. *Plast Reconstruct Surg* 1984;74:368.

+ 64. Weiland AJ, Weiss APC, Moore JR, Tolo VT. Vascularized Fibular Grafts in the Treatment of Congenital Pseudarthrosis of the Tibia. *J Bone Joint Surg* 1990;72A:654.

# 65. Weiland AJ. Current Concepts Review: Vascularized Free Bone Transplants. *J Bone Joint Surg* 1981;63A:166.

# 66. Weiland AJ. Vascularized Bone Transfers. *AAOS ICL* 1984;33:446.

! 67. Weiss AP, Olmedo ML, Lin JC, Ballock RT. Growth Factor Modulation of the Formation of a Molded Vascularized Bone Graft *in vivo. J Hand Surg* 1995;20A:94.

+ 68. Wood MB. Free Vascularized Bone Transfers for Non-unions, Segmental Gaps, and Following Tumor Resection. *Orthopaedics* 1986;9:810.

+ 69. Wood MB. Upper Extremity Reconstruction by Vascularized Bone Transfers: Results and Complications. *J Hand Surg* 1987;12A:422.

+ 70. Yajima H, Tamai S, Mizumoto S, Ono H. Vascularised Fibular Grafts for Reconstruction of the Femur. *J Bone Joint Surg* 1993;75B:123.

+ 71. Yuceturk A, Isiklar ZU, Tuncay C, Tandogan R. Treatment of Scaphoid Nonunions with a Vascularized Bone Graft Based on the First Dorsal Metacarpal Artery. *J Hand Surg* 1997;22B:425;1997.

+ 72. Zaidemberg C, Siebert JW, Angrigiani C. A New Vascularized Bone Graft for Scaphoid Nonunion. *J Hand Surg* 16A:474;1991.

# CHAPTER 37

# PRINCIPLES OF HAND SURGERY AND SURGICAL APPROACHES TO THE HAND AND WRIST

*Michelle Gerwin Carlson, Robert M. Szabo, and Paul R. Lipscomb*

**M. Gerwin Carlson:** Department of Orthopaedics, The Hospital for Special Surgery, New York, NY, 10021.
**R. M. Szabo:** Professor of Orthopaedics, Professor of Surgery, Division of Plastic Surgery, Chief, Hand and Upper Extremity Service, University of California—Davis, School of Medicine, Sacramento, CA, 95817.
**P. R. Lipscomb:** Professor Emeritus of Orthopaedics, School of Medicine, University of California—Davis, Davis California, 95817.

A. Basic Principles of Hand Surgery
Preoperative Planning
Operating Room Setup
Tourniquets
Upper Arm Tourniquet
Forearm and Finger Tourniquets
Anesthesia
Digital Nerve Block
Wrist Block
Instruments
Magnification
Gloves, Skin Preparation, and Draping
Basic Surgical Technique
Postoperative Care
Dressings
General Care
Splinting
Conclusion
Chapter References
B. Surgical Approaches to the Hand and Wrist
Approaches to the Digits
Dorsal Approach
Midaxial Approach
Palmar Approach
Approaches to the Hand
Dorsal Approach
Palmar Approach
Approaches to the Wrist
Dorsal Approach
Palmar Approach
Chapter References

## A. BASIC PRINCIPLES OF HAND SURGERY

***Robert M. Szabo and Paul R. Lipscomb***

Sterling Bunnell (1882 to 1957), the father of modern hand surgery, said, “Next to the brain, the hand is man's greatest asset and to it is due the development of man's handiwork. The hand begins in the opposite cerebral cortex and extends from there to the tips of the nails” (5,6). He emphasized the importance of a detailed knowledge of structural and functional anatomy of the hand and a basic comprehension of the entire upper extremity (10). He also stressed the importance of atraumatic surgical technique in reconstructive hand surgery. Reconstruction of the hand is often a composite problem, requiring knowledge of orthopaedic, plastic, microvascular, and neurologic surgical techniques. The hand surgeon must be trained to handle all of the tissues in the extremity. Surgical reconstruction of the hand requires careful technique to minimize the formation of adhesions, which tend to bind together the nicely adjusted movable parts. Although cosmesis is important, the primary purpose of surgical reconstruction is to restore enough function to allow the patient to be self-sufficient (2,5,6,7,10,12,13,14,15 and 16).

### PREOPERATIVE PLANNING

Even in emergency surgery, the surgeon usually has time to examine the extremity carefully to determine the severity of involvement of the skin, vessels, nerves, tendons, and skeleton. He or she can then plan the anticipated surgical procedure, which, after cleansing and debridement, might call for a skin graft or repair of lacerated radial, ulnar, and digital arteries and nerves. Through clinical examination and radiographs, the physician can evaluate the skeletal structures and plan for reduction and internal fixation of subluxations, dislocations, and fractures.

For severe injuries, paralytic conditions, and some disease entities, staged surgical repair and reconstructive procedures may be indicated. In these cases, a sequence of surgical procedures can be planned and, in most cases, can be discussed with the patient and relatives before surgery.

The primary requirement in hand surgery is the restoration of the position of function, nutrition, sensibility, motion, and good skin cover. The ends of the digits should have noncicatricial touch surfaces. The thumb should oppose the fingers, and the hand should open and close for the functions of pinch, hook, and grasp. The wrist should usually be in an extended position or occasionally in a straight position, and the fingers should be flexed partially at the metacarpophalangeal, proximal interphalangeal, and distal interphalangeal joints. The priorities of reconstruction are, in order of their importance, artery, skin, bone and nerve, and tendon.

For elective surgical procedures, advise patients to discontinue any medications (aspirin, nonsteroidal antiinflammatory drugs) that may increase perioperative bleeding at least 4 days before surgery. Patients on warfarin should be under supervision by an internist, who should be consulted regarding management.

### OPERATING ROOM SETUP

Position a standard operating table so that a hand table can be attached to it. The distal end should have a stable, perpendicular appendage that extends to the floor. When fluoroscopy is needed, use a radiolucent table without legs that interfere with positioning of the fluoroscope. Always choose a table supported by legs when using a microscope, otherwise the operative field will drift out of focus as weight is placed on and taken off the table. With the patient in a comfortable supine position, abduct the extremity to 90° and place it on the table. Arrange the overhead lights opposite each other in line with the hand table so that neither surgeons' nor nurses' heads obstruct the focused light. The stools on which the surgeon and the assistant sit opposite from each other should be firm and stable, and their height should be adjustable. Both the surgeon and the assistant must be comfortably erect, with their forearms resting on the hand table.

### TOURNIQUETS

A tourniquet is mandatory for almost all hand surgery. As Bunnell said, “A jeweler can't repair a watch in a bottle of ink, and neither can we repair a hand in a pool of blood” (6). A bloodless field allows very small vessels and nerves to be seen and dissected with accuracy and minimal trauma.

Formerly, Esmarch bandages were used as tourniquets, and tourniquet palsy was not uncommon. Likewise, with the use of blood pressure cuffs that were not monitored by a mercury manometer or equipped with protective safety devices, false pressure readings, which sometimes masked extremely high pressures, remained undetected. The tourniquet gauge should, therefore, be checked and calibrated at least daily and the figures recorded (24). The calibration of many newer tourniquets is more stable and reliable. Become familiar with the one you are using and be confident that the pressure readings are accurate. Until a time of 2 hours was established by Wilgis as a safe period for a tourniquet to remain in place, tourniquet palsy was common (25).

### UPPER ARM TOURNIQUET

- Properly position the patient and the extremity, then smoothly wrap several layers of sheet wadding or Webril-type soft cast padding around the upper arm and into the lower axilla.
- Apply the pneumatic cuff snugly and as high as is comfortably possible over the padding.
- Securely attach the cuff to the tubing that leads from a nitrogen source, and inflate the tourniquet briefly to ensure that the system is operating properly.
- During skin preparation, take care to avoid seepage of solutions onto the cast padding and tourniquet cuff. Accomplish this by placing a vinyl drape around the tourniquet with an adhesive border sticking to the upper arm. Be careful that this drape is not completely circumferential because when the tourniquet is inflated, a shearing force is applied to the skin that could result in injury.
- After preparation and draping, mark the skin with a methylene blue pen to outline the proposed incisions.
- Elevate and exsanguinate the extremity with a snugly wrapped 4-inch rubber or elastic bandage. In most adults, inflate the tourniquet to a pressure of 250 mm Hg; occasionally, in patients with heavily muscled arms or significant hypertension, inflate the tourniquet to 300 mm Hg.

In children, the pressure generally need not exceed 200 mm Hg. Exsanguination is contraindicated in patients with infections or tumors. However, in these patients, elevate the extremity for a few minutes before inflating the tourniquet.

- In most surgical procedures requiring more than 2 hours of operating time, deflate the tourniquet for 10 to 15 minutes at the end of the first 1 to 1.5 hour. During this period, apply pressure to the wound with a soft pad for the first 5 minutes.
- Then gently remove the pad and secure hemostasis with electrocautery and ligatures. Elevate the extremity again and reinflate the tourniquet.
- Following application of the dressing, splint, or cast (if required), immediately remove the tourniquet and underlying padding to avoid venous congestion.

### FOREARM AND FINGER TOURNIQUETS

Forearm tourniquets are safe, effective, and well tolerated for surgery in the distal forearm, wrist, and hand (11). The optimal tourniquet pressure for this technique is 75 to 100 mm Hg above the patient's systolic pressure (11).

- Wrap several layers of Webril-type soft cast padding circumferentially around the proximal forearm and apply a pneumatic tourniquet approximately 5 cm below the medial epicondyle.
- Protect with a vinyl drape (as described under upper arm tourniquet) to keep the Webril dry.
- Exsanguinate with an Esmarch bandage before tourniquet inflation.

A relatively minor procedure on the digit can be performed using a digital tourniquet.

- Apply an encircling rubber tourniquet (Penrose drain 1.25 mm, or 1/2 inch, in diameter) at the base of the digit.
- Wrap the drain once around the base of the digit without tension, then mark and clamp with a hemostat the points at which the surfaces of the drain meet on the circumference.
- Remove the loop. Shorten the distance between the two marks by 20 mm.
- Reposition the Penrose drain around the base of the digit.
- As the assistant elevates and compresses the finger, stretch the drain around the finger so that the length is shortened by 20 mm. Then clamp the drain with the hemostat.

The pressure thus generated produces a bloodless field; the risk of digital nerve and arterial damage secondary to this pressure is minimal.

As an alternative, Salem described a method of simultaneous exsanguination of the finger and application of a digital tourniquet (21).

- Cut a finger from a sterile rubber glove and roll it onto the finger.
- Cut the tip from it and roll the remaining portion proximally to form a rubber ring at the base of the finger.

This technique is contraindicated in the presence of infection or tumors. There is no good way to standardize or measure pressure beneath a digital tourniquet, and there have been cases of ischemia from the surgeon forgetting to remove the digital tourniquet before applying the dressing. For these reasons, an arm or forearm tourniquet is preferable.

## ANESTHESIA

The choice of anesthesia for each procedure, other than a local block, is made by the anesthesiologist (17,23). Discuss with the anesthesiologist the patient's concerns and wishes, the estimated length of the operation, and the length of time the tourniquet will be in place. For most children, for apprehensive adults, and for extensive procedures and patients requiring surgery elsewhere on the body, general anesthesia is usually preferable. A general anesthetic may also be necessary because infection or neoplasm may contraindicate regional anesthesia.

Regional anesthesia in the form of supraclavicular, axillary, brachial, and peripheral nerve blocks is very satisfactory for many procedures involving the upper extremity. Preoperative and, if necessary, intraoperative sedation may be used to keep the patient from moving and to lessen discomfort from the tourniquet.

Intravenous anesthesia using 1% lidocaine solution and two tourniquets on the arm, when administered by a competent anesthesiologist, is satisfactory for many surgical procedures on the hand that take no longer than 1 ½ hours. The three main problems with this technique are tourniquet pain, oozing at the surgery site, and risk of systemic anesthetic toxicity from cuff failure. Re-exsanguination 15 to 20 minutes after injection of the local anesthetic by firm reapplication of a sterile Esmarch bandage, followed by complete release and immediate reinflation of the double cuff tourniquet provides a better surgical field with improved tourniquet tolerance (18).

With proper preoperative sedation and, if necessary, intravenous sedation, an arm tourniquet is generally well tolerated for half an hour or longer. Many procedures can be performed simply with local anesthesia or a digital block. Some clinical anesthesia is produced almost immediately with a 1% solution of plain lidocaine hydrochloride, but the full effect takes 3 to 7 minutes and lasts about an hour (20). Avoid local anesthetics with epinephrine for procedures on the hand. Injection in or close to an artery can result in ischemic necrosis of digits.

### DIGITAL NERVE BLOCK

- Keep the position of the neurovascular bundles in mind.
- Insert a 26-gauge needle dorsally between the metacarpal heads and just proximal to the finger web space.
- Make a small skin wheal and advance the needle to the palmar aspect of the web space.
- Aspirate to make sure that you are not in the digital artery or vein. Then inject 2 to 3 ml of 1% lidocaine.
- Rotate the needle 90° and advance it subcutaneously to the opposite side of the finger and repeat the injection of 2 to 3 ml lidocaine into the other web space.

When active movement of the patient's fingers is desirable during surgery, a block of the superficial branch of the radial nerve above the styloid process of the radius, as well as of the ulnar and median nerves on the palmar aspect of the wrist, is indicated

### WRIST BLOCK

- Block the median nerve between the palmaris longus and flexor carpi radialis tendon. In this interval at the proximal wrist crease, insert a 22-gauge needle directed 45° distally and 45° dorsally toward the floor of the carpal tunnel. If paresthesias are elicited, withdraw slightly and redirect the needle. Inject 5 ml of 1% lidocaine.

- Block the radial sensory nerve three fingerbreadths proximal to the radial styloid.
- Inject about 5 ml of 1% lidocaine evenly distributed dorsally and palmarly.
- Block the ulnar nerve at the level of the proximal wrist crease, just radial to the flexor carpi ulnaris.
- Using a 26-gauge needle, inject about 5 ml of 1% lidocaine after aspirating to be certain that you are not in the ulnar artery.
- Block the dorsal cutaneous branch of the ulnar nerve by injecting 5 ml of 1% lidocaine subcutaneously beginning at the intersection of the flexor carpi ulnaris and the proximal wrist flexion crease, and ending at the midpoint of the dorsal wrist.

## INSTRUMENTS

The hand surgeon requires special instruments that are often more delicate than those required for most other surgical procedures. Small knife blades, such as Bard-Parker #15 and #11; small Adson forceps; pointed, curved, and straight scissors; osteotomes and chisels; ronguers and small bone cutters; probes; hemostats; curets; gouges; tendon strippers; sharp hook and blade retractors; needles; sutures; and ligatures are indispensable for hand surgery. Other special instruments, various hand holders (including those made of malleable lead), hand and motorized drills, special sutures, and small needles should be available in the operating suite before starting a procedure.

## MAGNIFICATION

Many hand surgeons routinely use 2.5 × to 4.5 × magnifying glasses or loupes when dissecting. With magnification, the planes between diseased and normal tissue are immediately apparent. Likewise, the small branches of the digital nerves and arteries are seen and protected easily. Operating loupes have been designed on one of three basic types of magnification systems: simple, compound (galilean), and prismatic. For discussion of the fundamental optical principles and terminology, and a concise description of various loupes available on the market, the reader is referred to Baker and Meals' article (1).

Those who perform microvascular surgery need a variety of microsurgical instruments, as well as a double-headed or triple-headed binocular microscope with electric foot controls that allows 6 × to 15 × magnification. Learn, practice, and develop the technical skills of operating with microscopic magnification in the microsurgery laboratory; only after gaining this experience can the skill be applied to patients.

## GLOVES, SKIN PREPARATION, AND DRAPING

Although vaccination against hepatitis B virus is now available, there is no vaccination against either the hepatitis C virus or the human immunodeficiency virus (HIV). Take care to avoid injury to the surgical team by needle sticks (27). Although the incidence of glove puncture varies with the type of surgery, it is suggested that, on average, 5.6 injuries occur per 100 procedures (9). Double surgical gloves significantly protect the surgeon against needle perforations, but they impair comfort, sensitivity, and dexterity (instrument and tissue handling) during operations (26). Each surgeon must individually deliberate whether the price of perceived impairment of sensation and dexterity is worth the benefit of extra protection against injury.

Each hand surgeon and operating facility should establish a standardized routine for preparation of the skin and draping, thereby ensuring that each patient receives the same careful attention to detail that is necessary for successful hand surgery. If the surgical procedure is an elective one, caution the patient at the time of scheduling to avoid scratches and abrasions to the hand and the entire extremity for 2 weeks before surgery. Advise patients who are manual laborers and who are accustomed to having grease and dirt on their hands to scrub their hands with a detergent solution twice daily for several days before surgery.

Formerly, it was customary to shave the entire extremity, but it has been shown that this is unnecessary and, in fact, may do more harm than good. Shaving should be limited to the site of the proposed incisions and is done in the operating room immediately before final skin preparation. The nails should be cleansed and trimmed, and polish should be removed before the patient enters the operating room.

After the patient and the extremity are properly positioned, scrub the hand and forearm for 10 minutes with a sterile povidone-iodine solution from the tips of the nails to the upper arm, where the pneumatic tourniquet is in position. Then dry the extremity with sterile towels and paint it with povidone-iodine. Povidone-iodine stains the digits and obscures the evaluation of capillary flow in patients whom the vascular status must be assessed intraoperatively (e.g., replants, revascularizations). Consider an alternative scrub solution like chlorhexidine or hexachlorophene, particularly in these situations. Next, apply sterile drapes and stockinette to the hand and forearm. Cover the hand table with a waterproof drape to prevent contamination of the drapes should they become wet during the procedure. Then exsanguinate or elevate the extremity and request that the tourniquet be inflated. Take a seat, usually on the axillary side of the patient, and cut the stockinette to expose the hand.

## BASIC SURGICAL TECHNIQUE

The basic aim of hand surgery is to restore function and cosmesis to the greatest extent possible within the shortest, safest period of time. In acute injuries, this can often be done by thorough cleansing and debridement of the wound, followed by primary repair of nerve, bone, and tendon injuries. However, in some severe and mutilating injuries, the primary object of treatment is to obtain healing of the skin and subcutaneous tissues and skeletal stabilization without intercurrent wound infection. These injuries often mandate delayed wound closure and a further delay in the repair of tendons and nerves. For each injury or reconstructive procedure, formulate a basic plan, which may consist of one or more stages (12,13).

The time required for the induration of tissues that follows each injury and surgical procedure to subside is variable and must be anticipated. It is best to wait until all inflammatory signs have subsided, the danger of infection is past, the tissues are soft and supple, and the joints are flexible. During this waiting period, proper positioning, encouragement of active motion, and the use of corrective splinting help to prevent permanent stiffness.

Make surgical incisions so that they offer the best possible exposure, protection of important structures, and healing with minimal scar. For some conditions, they should parallel the flexion creases in the fingers, palm, and wrist. Zigzag incisions described by Bruner or the traditional Bunnell incision in a midlateral location are often most appropriate (4,5). On the dorsum, curved and **S**-shaped incisions are often appropriate for the fingers, metacarpal area, and wrist. Transverse incisions are often used at the level of the wrist. See Table 37.1 and Table 37.2 and the approaches described later in this chapter.

| *Desired exposure* | *Surgical approach* |
|---|---|
| Phalanges and PIP joins | Dorsal, palmar or midaxial |
| Digital neurovascular bundle and flexor tendons | Palmar and midaxial |
| Digital extensor tendon | Dorsal |
| Dorsal MP joint | Dorsal, midaxial on index and little finger |
| Palmar MP joint | Palmar hand |
| Metacarpal and digital extensors in hand | Dorsal hand |
| Flexor tendons and neurovascular bundles in hand | Palmar hand and carpal tunnel |
| Dorsal carpus and radiocarpal joint | Dorsal longitudinal or transverse |
| Dorsal ganglion | Transverse |
| Palmar carpus and radiocarpal joint wrist | Palmar carpal tunnel and palmar |
| Dorsal radius | Dorsal longitudinal |
| Palmar radius | Palmar radial approach to the radius |
| Scaphoid | Dorsal, palmar, or radial approach |
| Scapholunate joint | Dorsal transverse |
| Distal radioulnar joint | Dorsal, palmar, or ulnar approach |
| Distal ulna | Dorsal distal radius, ulnar approach to ulna |

***Table 37.1. Surgical Approaches in the Hand and Wrist***

| *Surgical approach* | *Structures at risk* |
|---|---|
| Dorsal digital | Dorsal sensory branch of the digital nerve |
| Mid-axial digital | Neurovascular bundle, dorsal sensory branch of the digital nerve, lateral band |
| Palmar digital | Neurovascular bundles |
| Dorsal hand | Superficial branches of the radial and ulnar nerves |
| Palmar hand | Common neurovascular bundles, superficial palmar arch, radial digital nerve at the thumb MP joint |
| Dorsal distal radius and extensor tendons | Superficial branches of the radial and ulnar nerves |
| Dorsal distal radioulnar joint | Superficial branches of the ulnar nerve |
| Dorsal radiocarpal joint | Superficial branches of the radial and ulnar nerves |
| Palmar distal radius and scaphoid | Palmar cutaneous branch of the median nerve and radial artery |
| Palmar carpal tunnel and Guyon's canal | Superficial palmar arch, palmar cutaneous and motor branch of the median nerve |
| Palmar distal radius, radiocarpal joint and flexor tendons | Palmar cutaneous branch of the median nerve, ulnar neurovascular bundle |
| Radial scaphoid | Superficial branches of the radial nerve and radial artery |
| Ulnar distal ulna | Dorsal sensory branch of the ulnar nerve |

***Table 37.2. Structures at Risk in Hand and Wrist Exposures***

Sharp dissection with the aid of loupes or magnifying glasses, Bard-Parker #15 and #11 blades, and small curved Littler scissors is essential for the atraumatic technique that has been championed by Bunnell and his disciples.

Obtain hemostasis with small hemostats and a bipolar cautery unit, both during the surgical procedure and just before wound closure, when the tourniquet is deflated. Then, irrigate the wound with Ringer's or normal saline solution before you close the skin. Injections of 0.25% bupivacaine (Marcaine) into the subcutaneous as well as deep tissues at this point decreases the amount of analgesics needed for immediate postoperative pain control.

Primary skin closure is appropriate for most surgical procedures and some sharp traumatic wounds. Interrupted 5-0 nylon sutures are usually used for closure of surgical wounds of the hand. An occasional subcutaneous absorbable suture allows removal of the skin sutures at the end of 1 week. If necessary, Steri-Strips can then be applied, thereby eliminating cross-hatch suture scars. For young children, always use small absorbable sutures to obviate the need for suture removal.

## POSTOPERATIVE CARE

### DRESSINGS

After most surgical procedures, the hand can be placed in the position of function in a large, bulky dressing (Fig. 37.1) (22). Plaster of Paris splints are incorporated in the well-padded dressing, which usually extends from the proximal level of the nails to above the elbow. Circumferential casting should be avoided, but in some situations (e.g., tendon transfers in a patient with cerebral palsy), strong rigid support is essential. If flexor tendons or nerves are repaired, the wrist and involved digit are immobilized in a semiflexed position to remove tension but are never positioned in full flexion. In extensor tendon injuries, the wrist and fingers are immobilized in extension.

***Figure 37.1.*** Bulky well-padded compression dressing. **A:** Use fourteen 4 × 4 inch fluffs; six 2 × 2 inch gauze; three combines; three rolls of 4-inch cast padding; two rolls of 6-inch bias stockinette; 1 yard of 4-inch stockinette; twenty-one 4 × 15 inch plaster splints; one ½ and one 1-inch tape; rope. **B:** Place three 2 × 2 inch gauze squares between the fingers. **C:** Distribute fluffs evenly about the hand. **D:** Place a combine dorsally and palmarly around the wrist, and wrap the hand with 4-inch cast padding. **E:** Place an additional combine around the elbow, which is maintained at 90°. **F:** Place plaster slabs (4 × 15 inches) dorsally and (**G**) around the elbow. **H:** Cover plaster with cast padding. **I:** Wrap the dressing with 6-inch bias. **J,K:** Place a tubular stocking and overwrap with 6-inch bias. **L:** Apply tape, and cut a slot posteriorly. **M:** Secure rope into the slot with tape. **N:** Elevate the extremity with the rope. (Reprinted with permission from Szabo RM.. Upper extremity emergency problems. In: Kravis TC, Warner CG, Jacobs LM, eds. *Emergency Medicine,* 3rd ed. New York: Raven Press, Ltd., 1993:164.)

In most cases, the dressing and splints should be applied with the forearm in slight supination. This is especially important if the splints or cast extend above the elbow. Sometimes, the forearm should be in a midposition, but rarely should it be immobilized in pronation.

### GENERAL CARE

On removal of the drapes and tourniquet, evaluate and record the status of circulation in the exposed fingertips. Keep the hand elevated on pillows that are appreciably higher than the shoulder. Evaluate the neurovascular status at regular intervals if the procedure was extensive enough to warrant hospitalization. If there is any question about adequacy of circulation, loosen the bandages and splints; if a cast has been applied, it should be split and spread along its full length.

When the patient becomes ambulatory, the extremity should be held in an elevated position at shoulder level or above. This position is often easiest to maintain if the patient places the operated hand on the opposite shoulder. Caution the patient not to place the hand in a dependent position. If the extremity is placed in a sling, more dependent edema and postoperative stiffness occurs than when cooperative patients keep the extremity elevated by use of their own muscles.

On discharge from the hospital or outpatient facility, patients and their relatives are instructed to check circulation in the fingertips by the blanch test and to observe for any numbness or tingling that was not previously present. Patients are advised to return immediately should there be any concern about changes in sensibility or the adequacy of circulation.

### SPLINTING

The correct use of splints is an important aspect of hand surgery. Splinting is used to prevent deformity, immobilize the operated part, protect joints and tendons, change or correct the position of joints, substitute for paralyzed muscles, and move joints passively.

The wrist is the key joint in the mechanics and function of the hand, whereas the metacarpophalangeal joint is of primary importance in the mechanical balance of a finger. Splinting the wrist in extension and the metacarpophalangeal joints in flexion is of fundamental importance unless specifically contraindicated.

Temporary splinting or immobilization is used before and after many surgical procedures. Splints may be made with plaster of Paris, fiberglass, plastic, or malleable metal. They are usually padded with sheet wadding, cotton, or felt, and are fastened to the extremity with web straps and buckles or Velcro fasteners.

Immobilization is used for treating infection, holding fractured bones in place, and facilitating healing after trauma or surgery. A limb is held in a certain position to protect against separation of newly repaired tissues, such as tendons, nerves, ligaments, and arteries; to keep paralyzed muscles in a relaxed position; and in some cases, to allow tissues to grow until they adapt to the desired position. Joints are gradually pulled into increased flexion or extension to correct deformities, to place the limb in the position of function, or to produce more motion in a joint.

Splints should not only maintain the position of function but should also allow function of all uninjured parts. Dynamic splinting is used to draw joints into flexion or extension gradually, as in changing the position from one of nonfunction to that of function. Rubber bands, spring wire, or flat blue spring steel produce tension that is controllable yet insufficient to injure the joints or to cause ischemia.

Internal splinting using K-wires, pins, screws, or plates is used to pin and immobilize fractured bones or joints. Special internal removable sutures can be used to pull the proximal ends of severed tendons distally, thereby eliminating or diminishing tension at the site of repair where individual sutures are used (3,8).

Various hand splints, fabricated for different purposes, are advertised in orthopaedic periodicals and can be obtained from surgical supply houses or manufacturers. Hospitals and outpatient facilities should maintain a supply of commonly used hand splints in several sizes.

## CONCLUSION

The following article, entitled “Who Should Do Surgery of the Hand?” was published as an editorial in 1961 and is as relevant today as it was then (14). It is reprinted by permission of *Surgery, Gynecology & Obstetrics.*

> Approximately one third of all injuries requiring the services of a physician or a surgeon, whether in the emergency department of a metropolitan hospital or the office of a rural practitioner, involve the hand. The physician administering the primary treatment for such injuries has a great responsibility, since his treatment determines, to a large extent, the final outcome.
>
> All physicians must be taught the basic principles that should govern the treatment of an injury to the hand. They must know that it is important to protect wounds from contamination and infection and that adequate help, facilities, and proper instruments must be available before one starts to care for the injured hand. The traumatized hand must be cleansed thoroughly but gently. When compared with injuries of the arm, leg, or abdomen, the involved tissue of the hand should be sparingly debrided. Whereas many wounds of the arms and legs should be treated by delayed closure, almost all wounds of the hand should be closed primarily and this closure must be without tension. In some instances, the use of skin grafts is necessary to avoid tension. When possible, fractures should be reduced and immobilized at the time of the primary treatment. However, if the physician is not trained to care adequately for the bone injury, less harm will be done if the skin is closed, the hand is placed in a position of moderate dorsiflexion of the wrist, moderate flexion of the fingers, and moderate abduction and opposition of the thumb, and a bulky dressing is applied to prevent edema. In such selected instances, the fractures can be dealt with after the cutaneous wound has healed. Even more important is the necessity to realize that severed nerves and tendons do not require primary repair; less harm will be done under unfavorable conditions by secondary repair of nerves and tendons after the initial wound has healed. A surgeon who attempts primary suture of a flexor tendon in its digital sheath should have had considerable education, training, and experience in reconstructive surgical treatment of the hand and should be capable of performing a tendon graft.
>
> Extensive, reparative, restorative, reconstructive, and rehabilitative surgery of the hand should be carried out in hospitals by surgeons well qualified and dedicated to this field of surgery. The surgeon interested in treatment of the severely injured hand must be educated to work in orthopedic surgery, plastic surgery, and neurosurgery. He should have knowledge of dermatologic, circulatory, paralytic and arthritic diseases which are prone to affect the hand. He must be well versed in the most minute details of the surgical and functional anatomy of the entire upper extremity. He must be versed in rehabilitative procedures and trained in splinting and bracing. He must be capable of teaching the patient how to prevent and overcome stiffness of joints and how to co-ordinate muscles which formerly had one function but after a tendon transfer have another function.
>
> Above all, the surgeon who devotes much of his time to surgery of the hand must teach medical students, interns, and residents how to care properly for injuries which affect the hand. Many of the principles established by such pioneers as Allen Kanavel, Sterling Bunnell, and Sumner Koch are still basic and pertinent. It is important that these principles be learned if crippling of the hand is to be minimized.
>
> Always think and strive to avoid being in the predicament that results in pondering to yourself “if there were only an operation that could undo the results of my last operation!”

### CHAPTER REFERENCES

Each reference is categorized according to the following scheme: *, classic article; #, review article; !, basic research article; and +, clinical results/outcome study.


# 1. Baker JM, Meals RA. A Practical Guide to Surgical Loupes. *J Hand Surg* 1997;22A:967.

* 2. Boyes J. *Bunnell's Surgery of the Hand,* 4th ed. Philadelphia: J.B. Lippincott, 1964.

+ 3. Brown C, McGrouther D. Excursion of the Tendon of Flexor Pollicis Longus and its Relation to Dynamic Splinting. *J Hand Surg* 1984;9A:787.

* 4. Bruner J. The Zig Zag Volar-digital Incision for Flexor Tendon Surgery. *Plast Reconstr Surg* 1967;40:571.

* 5. Bunnell S. *Surgery of the Hand,* 3rd ed. Philadelphia: J.B. Lippincott, 1948.

* 6. Bunnell S. Splinting the Hand. *Instr Course Lect* 1952;9:233.

# 7. Green D. General Principles. In: Green DP, Hotchkiss RN, Pederson WC, eds. *Green's Operative Hand Surgery,* 4th ed, Vol 1. New York: Churchill Livingstone, 1999:1.

+ 8. Hester RJ, Foad N.. Early Mobilization of Repaired Flexor Tendons within Digital Sheath Using an Internal Profundus Splint: Experimental and Clinical Data. *Ann Plastic Surg* 1984;12:187.

+ 9. Hussain S, Latif A, Choudhary A. Risk to Surgeons: A Survey of Accidental Injuries during Operations. *Br J Surg* 1988;75:314.

* 10. Kaplan E. Anatomy and Kinesiology of the Hand. In: Flynn J, ed. *Hand Surgery,* 3rd ed. Baltimore: Williams & Wilkins, 1982:33.

+ 11. Khuri S, Uhl RL, Martino J, Whipple R. Clinical Application of the Forearm Tourniquet. *J Hand Surg* 1994;19A:861.

# 12. Lipscomb P. Management of Recent Injuries of the Hand. *Minn Med* 1955;38:299.

# 13. Lipscomb P. Treatment of Acute Injuries of the Hand. *J Med Pharmacol* 1958;11:447.

* 14. Lipscomb P. Who Should do Surgery of the Hand? *Surg Gynecol Obstet* 1961;113:233.

# 15. Lynch A, Lipscomb P. Management of Fractures of the Hand. *Am Surg* 1963;29:277.

# 16. Milford L. The Hand. In Edmonson CA AS, ed. *Campbell's Operative Orthopaedics,* 6th ed. St. Louis: Mosby, 1980.

# 17. Ramamurthy S. Anesthesia. In G. DP, ed. *Operative Hand Surgery.* New York: Churchill-Livingstone, 1982.

+ 18. Rawal N, Hallén J, Amilon A, Hellstrand P. Improvement in I.V. Regional Anaesthesia by Re-exsanguination before Surgery. *Br J Anaesth* 1993;70:280.

# 19. Ritchie JM, Cohen PJ, Dripps RD. Cocaine, Procaine and Other Synthetic Local Anesthetics 388. In: Goodman LS, Gilman A, eds. *The Pharmacological Basis of Therapeutics,* 4th ed. New York: The Macmillan Company, 1970:388.

# 20. Rohrer TE, Leslie B, Grande DJ. Dermatologic Surgery of the Hand. General Principles and Avoiding Complications. *J Dermatol Surg Oncol* 1994;20:19; quiz 36.

+ 21. Salem M. Simple Finger Tourniquet. *Br Med J* 1973;1:779.

# 22. Szabo RM. Upper Extremity Emergency Problems. In: Kravis TC, Warner CG, Jacobs LM, eds. *Emergency Medicine,* 3rd ed. New York: Raven Press, Ltd, 1993:195.

# 23. Vandam L. Anesthesia for Hand Surgery. In: F. JE, ed. *Hand Surgery,* 3rd ed. Baltimore: Williams & Wilkins, 1982:74.

! 24. Wheeler D, PR L. A Safety Device for a Pneumatic Tourniquet. *J Bone Joint Surg* 1964;46:870.

+ 25. Wilgis E. Observations on the Effects of Tourniquet Ischemia. *J Bone Joint Surg* 1971;53A:1343.

+ 26. Wilson SJ, Sellu D, Uy A, Jaffer MA. Subjective Effects of Double Gloves on Surgical Performance. *Ann R Coll Surg Engl* 1996;78:20.

+ 27. Wright KU, Moran CG, Briggs PJ. Glove Perforation during Hip Arthroplasty. A Randomised Prospective Study of a New Taperpoint Needle. *J Bone Joint Surg Br* 1993;75B:918.


# B. SURGICAL APPROACHES TO THE HAND AND WRIST

***Michelle Gerwin Carlson***

There are several factors that are important to consider when choosing the surgical approach to the hand and wrist. An ideally planned incision will give the maximum exposure of the pathology with the minimum necessary length of incision and risk of injury to the surrounding structures. If possible, the incision should fall within Langer's lines to produce the most cosmetically pleasing scar and avoid hypertrophy (i.e., a transverse incision rather than a longitudinal one for excision of a dorsal ganglion). Injury to surrounding structures includes not only intraoperative injury but postoperative fibrosis that may limit range of motion. For instance, the dorsal approach to a metacarpal fracture avoids the dissection of the neurovascular bundles and flexor tendons necessary in a palmar approach. The dorsal approach is not only more facile but decreases the chance of postoperative fibrosis of the flexor tendons that may hamper rehabilitation and ultimately decrease range of motion. Cutaneous nerves should always be preserved whenever possible to decrease the risk of neuroma formation and painful scars. Loupe magnification is recommended for visualization of all the small structures of the wrist and hand. Microscope magnification is often necessary for repair of nerves and vessels.

## APPROACHES TO THE DIGITS

There are essentially three approaches to the digit: the dorsal approach, the midaxial approach, and the palmar approach. The midaxial approach and the midlateral approach are similar, except that the midaxial incision is dorsal to the midlateral. The midlateral incision is made at the anatomic midpoint of the finger. The midaxial incision is made at the connection of the centers of rotation of the respective joints and is slightly dorsal to the midlateral because the joints are dorsal to the rest of the soft tissues in the digit (flexor tendons). The midaxial incision is more often used because it is right over the bone and, on deep dissection, leaves the neurovascular structures safely in the palmar flap.

### DORSAL APPROACH

**Indications** The dorsal approach is effective for the exposure of the extensor mechanism and bone of the proximal and middle phalanx, proximal interphalangeal (PIP) joint and metacarpophalangeal (MP) joints.

**Contraindications** The dorsal approach does not allow for visualization of palmar articular fractures of the joints, for which a palmar approach is usually more effective. A transverse or H-type incision may be more appropriate for the exposure of the distal interphalangeal (DIP) joint for excision of a mucous cyst or arthrodesis. A longitudinal incision over the DIP joint may extend into the germinal matrix of the nail bed and cause nail deformity with growth.

**Technique (Fig. 37.2)**

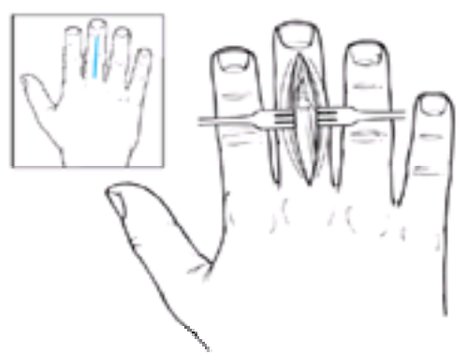

***Figure 37.2.*** The dorsal approach to the digit. The dorsal sensory branch of the digital nerve and the dorsal veins have been retracted.

- Make a longitudinal incision over the dorsum of the digit in the midline. Take care with deep dissection to protect the dorsal veins when possible and the dorsal sensory branches of the digital nerves.
- The extensor mechanism is well visualized. For exposure of the middle phalanx, incise the extensor mechanism between the two lateral bands. For exposure of the proximal phalanx, make an incision between the central slip and lateral band, being careful to preserve the insertion of the central slip on the base of the middle phalanx. If an arthrodesis of the PIP joint is to be performed, the central slip is divided longitudinally and is elevated off the base of the middle phalanx, along with subperiosteal dissection of the proximal and middle phalanx. In the thumb, make the exposure on one side of the extensor pollicis longus tendon. Expose the MP joint with proximal extension of the incision. Incise the dorsal hood 2 mm radial or ulnar to the extensor tendon, leaving a rim of hood attached to the extensor tendon for later repair.

### MIDAXIAL APPROACH

**Indications** The midaxial approach is indicated for exposure of the neurovascular bundle, the proximal, middle or distal phalanx, and the flexor sheath. Because the incision lies in the axis of the finger, it heals very well despite early mobilization and is often barely visible when healed. It provides excellent visualization of phalangeal fractures for placement of internal fixation (either screws or plates) on the radial or ulnar aspect of the bone. In this position, they are less likely to interfere with gliding of the adjacent tendon than in the dorsal or palmar position. The radial or ulnar midaxial incision may be favored based on the fracture anatomy, and this decision should be made preoperatively. Visualization of the neurovascular bundles is excellent through this incision, and it is ideal for isolated digital nerve repair. Visualization of the flexor tendons is sufficient to allow for debridement of tenosynovitis, but flexor tendon repair may be difficult.

**Contraindications** Visualization of the flexor tendons for repair is limited through this approach and is better accomplished through a palmar approach.

**Technique (Fig. 37.3)**

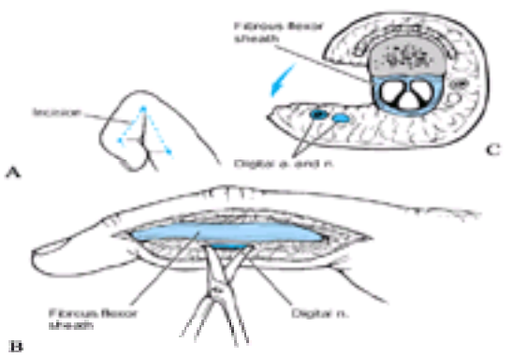


***Figure 37.3.*** The midaxial approach to the digit. **A:** The incision is made by connecting the flexion creases of the digits. **B:** The phalanges, fibrous sheath, and neurovascular bundles are visualized. The extensor hood is retracted or incised proximally, and the dorsal sensory branch is retracted dorsally. **C:** Axial schematic demonstrating midaxial approach.

- Flex the digit completely at the MP, PIP, and DIP joints. Mark the dorsal aspect of the flexion creases at these joints. Then extend the digit and connect these marks by a longitudinal line. It can be extended distally along the distal phalanx palmar to the nail. Proximally, it can be extended up dorsally over the MP joint except on the radial aspect of the index and ulnar aspect of the little finger, where it may be extended radially and ulnarly, respectively. Similarly, the incision can be extended palmarly proximal to the MP joint in a zigzag fashion to increase palmar exposure.

- Carry the incision down through the deep tissues dorsal to the neurovascular bundles. Divide Clelands' ligaments to expose the neurovascular bundle. With the neurovascular bundle in the palmar flap, the periosteum of the phalanges can be visualized. Palmarly, the flexor tendon sheath can be identified.
- Proximal dissection of the proximal phalanx will encounter two structures that limit exposure. The first is the dorsal branch of the digital nerve. This nerve lies dorsal over the middle phalanx but travels palmar to dorsal over the proximal phalanx and needs to be identified and protected. The second is the lateral band. This can be incised longitudinally to allow for excellent exposure of the proximal phalanx. Repair is optional if the contralateral lateral band is intact.
- Palmarly, the flexor sheath can be incised between the A2 and A4 pulleys for debridement of the flexor tendons.

### PALMAR APPROACH

**Indications** The palmar approach is ideal for exposure of the digital flexor tendons for repair, tenosynovectomy, or tumor excision. It is extensile into the hand. It also provides excellent visualization of the neurovascular bundles and is frequently used for the excision of Dupuytren's disease. It is the exposure of choice for a volar plate arthroplasty or the palmar articular fracture (2).

**Contraindications** The palmar approach is not ideal for the repair of phalangeal shaft fractures or the extensor mechanism.

**Technique (Fig. 37.4)**

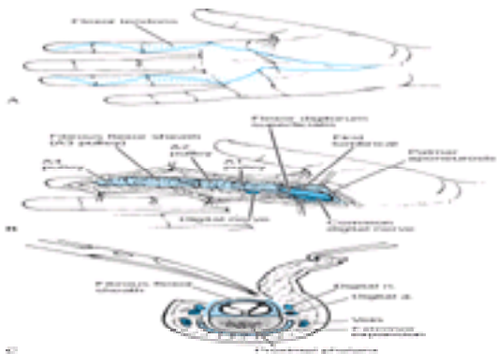

***Figure 37.4.*** **A and B:** The palmar approach to the digit and palm. With incision of the A3 or A1 and palmar pulley with retraction of the flexor tendons, the volar plate of the PIP and MP joints can be visualized respectively. **C:** Axial schematic demonstrating palmar approach.

- Plan a zigzag Brunner incision across the digit, extending from the distal phalanx into the palm. Cross the digital flexion creases at 45° angles to create a flap with a 90° corner. Any portion of this incision can be used.
- Dissect the subcutaneous tissue carefully to expose the flexor sheath and neurovascular bundles by division of Grayson's ligaments.
- Now incise the flexor sheath by creating an L with a radially or ulnarly based flap to allow access to the flexor tendons. This should be done between, proximal, or distal to the A2 and A4 pulleys. Take care to preserve these pulleys to prevent bowstringing of the flexor tendons postoperatively.
- If access to the PIP joint is desired, create a flap in the sheath over the joint, retract the flexor tendons, and expose the volar plate of the joint. Dissect the flexor plate from the middle phalanx to expose the joint.

## APPROACHES TO THE HAND

There are two approaches to the hand: dorsal and palmar. The dorsal approach exposes the extensor tendons, metacarpals (MP), and carpometacarpal (CMC) joints, and the intrinsic muscle compartments. The palmar approach exposes the flexor tendons and lumbricals, neurovascular bundles, and Dupuytren's disease.

### DORSAL APPROACH

**Indications** The dorsal approach exposes the extensor tendons, and the metacarpal, MP, and CMC joints.

**Contraindications** The dorsal approach is contraindicated for exposure of palmar articular fractures of the MP joint. It also does not provide visualization of the neurovascular bundles or flexor tendons.

**Technique (Fig. 37.5)**

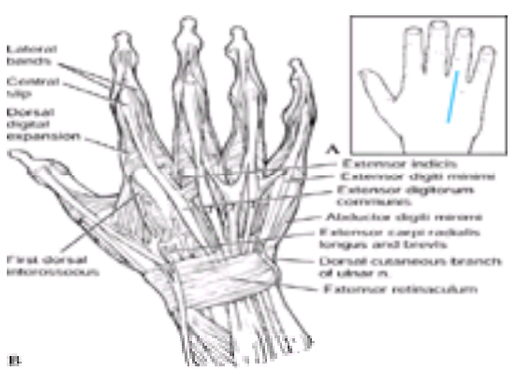


***Figure 37.5.*** The dorsal approach to the hand. **A:** The longitudinal incision is centered over the desired metacarpal. **B:** Deep dissection reveals the extensor tendon, which can be retracted, and the juncturae, which can be transected, to visualize the metacarpal.

- Make a longitudinal incision over the desired metacarpal. Extend it proximally or distally to expose the MP or CMC joint. Perform subcutaneous dissection to avoid injury to the cutaneous nerves, which are branches of the radial or ulnar nerve. The extensor tendons are visualized and may consist of multiple slips and multiple juncturae (8,11,12 and 13).
- If deeper exposure is desired, make an incision in the investing fascia of the extensor tendons and retract the extensor tendons. Occasionally, it will be necessary to divide the juncturae tendinae to provide exposure of the metacarpal or MP joint. These can be later repaired if desired.
- Subperiosteal dissection of the metacarpal is then possible to complete the exposure. The interosseous muscles are evident on either side of the metacarpal. In the thumb, the deep dissection is in the interval between the extensor pollicis longus and extensor pollicis brevis.
- Distal extension exposes the MP joint. Divide the extensor hood on either the radial or ulnar side, then incise the capsule to expose the MP joint. Proximal extension exposes the capsule of the CMC joint, which can be incised longitudinally and elevated subperiosteally.

Occasionally, when only a small incision is necessary, such as for repair of a lacerated extensor tendon or harvesting of the extensor indicis proprius tendon, make a transverse incision directly over the site of repair. This gives a more cosmetic scar because the incision falls within Langer's lines.

### PALMAR APPROACH

**Indications** The palmar approach to the hand is used for visualization of flexor tendons, neurovascular bundles, lumbricals, or Dupuytren's disease. It is also recommended for palmar articular fractures of the MP joint.

**Contraindications** The palmar approach is relatively contraindicated in the internal fixation of fractures of the metacarpals because it is more likely to cause adhesions between the flexor tendons and the bone.

**Technique (Fig. 37.4)**

- Make a zigzag Brunner incision in the palm over the desired area of exposure, usually over the flexor tendon. This can be extended to a Brunner incision of the digit and across the carpal tunnel.
- Incise the palmar fascia longitudinally. Careful dissection reveals the flexor tendon and common digital arteries and nerves on either side.
- The A1 pulley is visualized over the MP joint, and a palmar pulley can be identified proximally (7). The arteries can be traced proximally to the superficial palmar arch.
- Accomplish visualization of the MP joint with incision of the A1 pulley and detachment of the volar plate from the base of the proximal phalanx.
- In the thumb, care must be taken when dissecting over the flexor tendon because the radial neurovascular bundle originates ulnar to the flexor tendon and crosses to its radial side at the metacarpal level.
- For surgical release of trigger fingers, center a single longitudinal incision over the A1 pulley for the index through little fingers. A transverse incision for the thumb may be used (Fig. 37.6). Alternatively, the incision can be placed in the distal palmar crease transversely for the little, ring and long finger, and the proximal palmar crease for the index finger. If the longitudinal incision is used, do not cross any palmar creases or a scar contracture can form.

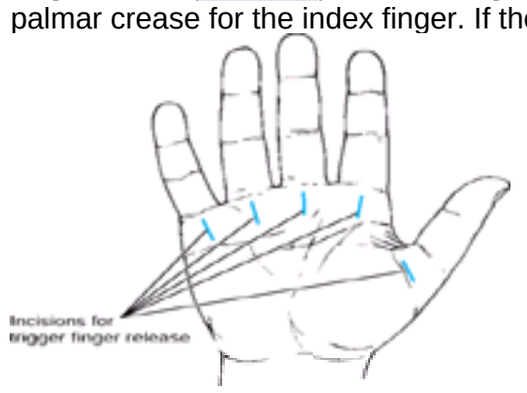


***Figure 37.6.*** Planned incision for release of trigger fingers (A1 pulleys).

## APPROACHES TO THE WRIST

### DORSAL APPROACH

The dorsal approach to the wrist is an extensile longitudinal incision with a few exceptions. It can be extended proximally to include the distal radius and ulna, and it can be extended distally into the hand as already described. Depending on the exposure desired, make the incision in the midline or displaced slightly radially or ulnarly. In certain situations, such as the approach to the scapholunate joint, the approach to the scaphoid, or for a proximal row carpectomy, a transverse incision may be used for a more cosmetic result.

#### *Approach to the Distal Radius and Extensor*

#### Tendons

**Indications** This approach is indicated to expose the distal radius for internal fixation of fractures or wrist fusion, or to expose the extensor tendons for tenosynovectomy.

**Contraindications** The dorsal approach to the distal radius is not effective in exposing the palmar aspect of the radius for fractures with palmar displacement or palmar articular fractures.

**Technique (Fig. 37.7)**

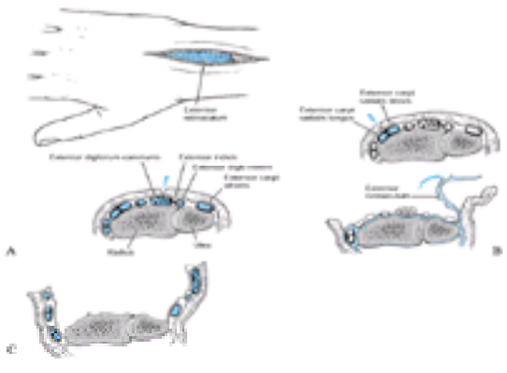

***Figure 37.7.*** The dorsal approach to the distal radius and extensor tendons. **A:** The incision is usually placed in the midline. **B:** Exposure of the extensor tendons. Axial schematic demonstrating incision of the dorsal retinaculum over the second dorsal compartment with radial and ulnar dissection of the extensor retinaculum. **C:** Exposure of the distal radius. Axial schematic demonstrating incision of the dorsal retinaculum over the third dorsal compartment with subperiosteal radial and ulnar dissection of the extensor tendons.

- Make a longitudinal incision over the digital extensor tendons. It may be midline or displaced slightly radially or ulnarly, depending on the location of the pathology.
- Use blunt dissection through the subcutaneous tissue to prevent injury to cutaneous nerves and the dorsal veins, when possible. Expose the extensor retinaculum and make deep skin flaps just superficial to the retinaculum if an extensor tenosynovectomy is planned. For the approach to the distal radius, skin flaps are not necessary.

*Exposure of the Extensor Tendons*

- Incise the dorsal retinaculum longitudinally over the index or fifth dorsal compartment. Then dissect radially and ulnarly cutting the intercompartmental septa to expose all six dorsal compartments as desired. Do not dissect the compartments superiosteally and avoid damage to the adjacent extensor tendons. This procedure can be aided by placing a small elevator in the next compartment to be exposed. This method easily identifies the intercompartmental septum for division.
- The retinaculum is particularly difficult to dissect between the second and third compartment. Here, subperiosteal dissection is necessary on Lister's tubercle to maintain continuity of the retinaculum. This approach is easily extensile into the hand and up the forearm.
- Often in closing the retinaculum after tenosynovectomy, it is split transversely, with half placed below the tendons and half above. Repair of the dorsal retinaculum is necessary to prevent bowstringing of the tendons.

*Exposure of the Distal Radius*

- Incise the dorsal retinaculum over the third dorsal compartment and retract the extensor pollicis longus tendon radially from the compartment.
- Perform *subperiosteal* dissection of the remaining compartments radially and ulnarly to expose the distal radius. Subperiosteal dissection of the fourth compartment decreases the likelihood of postoperative adhesion of the extensor digitorum communis tendons.
- This exposure can be extended distally to the carpus or proximally up the forearm to the extensor pollicis brevis muscles.
- After internal fixation of the radius, often the third dorsal compartment can be closed over the plate. The extensor pollicis longus tendon does not need to be replaced in its compartment.

***Approach to the Distal Radioulnar Joint***

- To include the distal radioulnar joint, continue ulnar dissection using the above-mentioned technique. If only the distal radioulnar joint needs to be approached, then a smaller skin incision can be made directly over the fifth dorsal compartment.
- Incise the extensor retinaculum over the fifth dorsal compartment and retract the extensor digitorum quinti tendon radially. The capsule of the distal radioulnar joint is immediately beneath this compartment and can be incised longitudinally. A synovectomy of the joint can then be performed, the distal ulna excised, or the triangular fibrocartilage complex (TFCC) repaired.
- After synovectomy or TFCC repair, repair the dorsal capsule primarily. After distal ulnar excision, reattach the dorsal capsule of the distal radioulnar joint to the palmar capsule over the end of the distal ulna with several nonabsorbable sutures to prevent subluxation of the distal ulna. Repair the extensor retinaculum with nonabsorbable sutures and close the skin as usual.

***Approach to the Radiocarpal Joint***

**Indications** The approach to the radiocarpal joint can be an extension of the previously described approach to the distal radius, with the dissection continued distally to dissect the carpal bones subperiosteally. This approach is useful for radiocarpal fusions. When a limited exposure of the wrist is known to be needed preoperatively, a transverse incision may be used with a more cosmetically appealing result. Often the scar, when healed, is barely visible within Langer's lines. If a later radiocarpal fusion is necessary, a longitudinal incision can be made at a right angle to this incision without complication. It is possible to excise the terminal branch of the posterior interosseous nerve through this transverse incision, if desired. Carry out the dissection proximally with incision of the third dorsal compartment under the proximal skin flap. The terminal branch of the posterior interosseous nerve is then evident between the third and fourth compartments and can be excised.

**Contraindications** A transverse incision is not extensile and should be avoided when exposure of the hand or distal radius is desired.

**Technique** Make a transverse incision over the proximal row approximately 1.5 cm distal to Lister's tubercle. The length of the incision is dependent on the pathology to be explored. (Fig. 37.8).

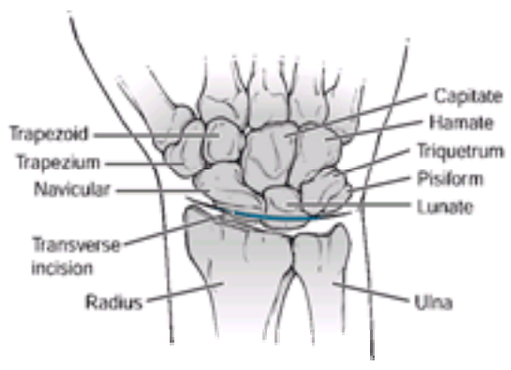


***Figure 37.8.*** The dorsal approach to the radiocarpal joint. A transverse incision is made over the radiocarpal joint distal to Lister's tubercle. After longitudinal incision of the extensor retinaculum and T-incision of the dorsal capsule, the radiocarpal joint is exposed.

*Proximal Row Carpectomy* The incision will need to be over the entire carpus, approximately 3 to 4 cm in length.

- Carry the incision down through the subcutaneous tissue, taking care to identify and protect the cutaneous branches of the radial and ulnar nerves.
- Incise transversely the capsule overlying the proximal row. Make a T over the lunate. Then expose the scaphoid, lunate, and triquetrum subperiosteally.
- After removal of the carpus, repair the capsule with nonabsorbable suture and close the skin.

*Scaphoid and Scapholunate Joint*

- Make a dorsal transverse incision 2 to 3 cm in length centered over the scaphoid or scapholunate joint, respectively. The scapholunate joint can be palpated 1 to 1.5 cm directly distal to Lister's tubercle.
- After the cutaneous nerves are dissected free, incise the capsule over the scapholunate joint, and dissect radially and ulnarly along the radiocarpal joint as necessary. Take care to avoid damage to the dorsal vessels entering the waist of the scaphoid.
- After repair of the scapholunate ligament or fixation of the scaphoid fracture, repair the capsule with nonabsorbable suture and close the wound with a subcuticular suture.

**PALMAR APPROACH**

The palmar approach to the wrist provides excellent visualization of the distal radius, carpal tunnel, digital flexor tendons, palmar aspect of the carpus, median and ulnar nerve, and the radial and ulnar arteries. One of two incisions can be used. The more radial incision centered over the flexor carpi radialis exposes the distal radius, radial artery, and scaphoid. The more midline incision exposes the carpal tunnel, median and ulnar nerve, ulnar artery, digital flexor tendons, carpus and distal radius, ulna, and palmar distal radioulnar joint. For the isolated exposure of the distal radius, the radial incision is preferred because it does not involve dissection around the digital flexor tendons and thereby decreases the chance of postoperative adhesions.

***Approach to the Distal Radius and Scaphoid***

**Indications** The palmar radial approach to the distal radius and scaphoid is indicated when the only structures that are necessary to be exposed are the distal radius, scaphoid, and radial artery. It has the advantage of not dissecting around the flexor tendons, therefore minimizing postoperative adhesions. It can be extended to include exposure of the scaphotrapezial joint distally and the palmar radius proximally.

**Contraindications** The carpal tunnel is not visualized through this incision but can be visualized through a separate incision. The flexor tendons, median and ulnar nerves, and ulnar artery, as well as the remainder of the carpus, are not visualized either and are better exposed through the midline palmar approach.

**Technique**

- Make a longitudinal incision over the flexor carpi radialis tendon, extending proximally as far as necessary (Fig. 37.9). Distally, end the incision at the proximal palmar wrist flexion crease if only the radius is to be exposed. If exposure of the scaphoid is necessary, the incision begins 2 cm proximal to and then extends just past the distal wrist flexion crease to the scaphoid tubercle. This approach is known as the Russe approach to the scaphoid. Carry the incision down through subcutaneous tissue in line with the flexor carpi radialis. It is important not to deviate ulnar to the flexor carpi radialis because injury to the palmar cutaneous branch of the median nerve can occur (6).

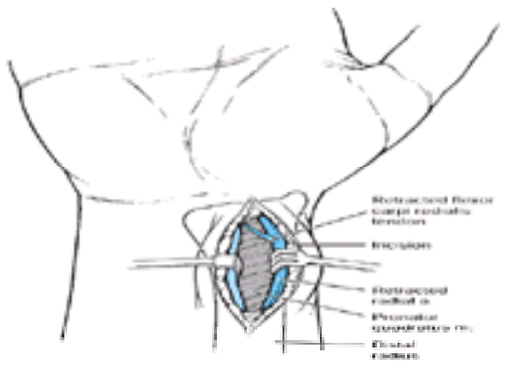

***Figure 37.9.*** The palmar approach to the distal radius and scaphoid. The incision is based over the flexor carpi radialis tendon and is curved radially distal to the distal wrist flexion crease.

- Incise the sheath overlying the flexor carpi radialis and retract the flexor carpi radialis ulnarly.
- Expose the radial artery along the radial border of the sheath and protect it.
- Incise the sheath deep to the flexor carpi radialis and retract the flexor tendons ulnarly. Identify the pronator quadratus on the palmar radius and incise it longitudinally on its radial aspect, leaving a small portion radially for reattachment.
- Then subperiosteally expose the radius ulnarly to the distal radioulnar joint.
- If exposure of the scaphoid is desired, incise the palmar capsule longitudinally to the scaphoid tubercle and expose the scaphoid.
- Close with repair of the palmar capsule and reattachment of the pronator, if possible. Then repair the skin with interrupted or running subcuticular sutures as desired.

***Approach to the Carpal Tunnel and Guyon's Canal***

**Indications** This approach is indicated for exposure of the median nerve in the carpal tunnel and ulnar nerve in Guyon's canal. Limited visualization of the flexor tendons and palmar aspect of the carpus is afforded (4,10).

**Contraindications** Exposure of the distal radius, and flexor tendons for rheumatoid flexor tenosynovectomy for rheumatoid arthritis requires proximal extension of this incision.

**Technique (Fig. 37.10)**

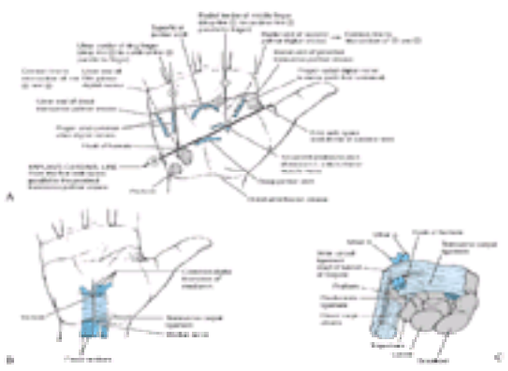

***Figure 37.10.*** Palmar approach to the carpal tunnel and Guyon's canal. **A:** The skin incision is made in line with the radial aspect of the fourth finger. Care should be taken not to stray radial to this line because injury of the palmar cutaneous branch of the median nerve may result. **B:** The palmar fascia fibers are noted to run longitudinally and are transected. After transection of the transverse carpal ligament, the median nerve and flexor tendons are identified within the wound and can be retracted for exposure of the palmar carpus. **C:** The location of Guyon's canal, which can be identified in the ulnar aspect of the wound.

- Make a longitudinal incision in the palm in line with the radial border of the ring finger. The distal extent of the incision intersects Kaplan's cardinal line (a line determined by abducting the thumb and drawing a horizontal line from the first web space parallel to the proximal transverse palmar crease). The proximal extent of the incision is the distal wrist flexion crease. Then incise sharply down through the subcutaneous tissue because the palmar cutaneous nerve is out of potential harm.
- Incise the palmar fascia longitudinally, and identify the ulnar nerve and artery beneath the palmar fascia in the ulnar aspect of the wound. Remember that the ulnar artery can be palmar to the palmaris brevis, and other anomalies have been reported as well (5,9). The ulnar artery and sensory branch of the ulnar nerve continue distally and may cross radial to the hook of the hamate (3).
- Then incise the transverse carpal ligament longitudinally, ensuring that the proximal aspect of the ligament is transected. Often, a tenotomy scissors is necessary to complete the proximal release. For further details, see Chapter 52 on compression neuropathies.

***Approach to the Digital Flexor Tendons, Radiocarpal Joint, and Distal Radius***

**Indications** This exposure provides the best access to the flexor tendons, median and ulnar nerves, and radiocarpal joint. The distal radius can also be exposed through this incision.

**Contraindications** If the distal radius alone is to be exposed, it is better to approach it through the radial palmar incision. This midline approach has an increased incidence of flexor tendon adherence owing to the dissection necessary around the tendons.

**Technique (Fig. 37.11)**

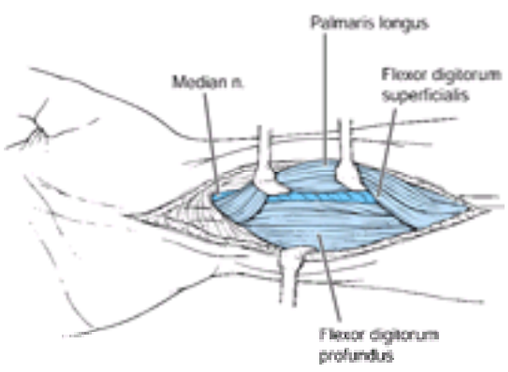


***Figure 37.11.*** Palmar approach to the digital flexor tendons, radiocarpal joint, and distal radius. Extension radial to the palmaris may produce injury to the palmar cutaneous branch of the median nerve. Deep dissection allows visualization of the digital flexor tendons, which may be retracted radially to expose the palmar distal radius and pronator. Subperiosteal dissection of the pronator exposes the distal radius. The radiocarpal joint is exposed through a longitudinal or T-incision.

- The incision is a proximal extension of the incision made for exposure of the carpal tunnel. Cross the wrist flexion creases at 45° angles. Proximal to the proximal wrist flexion crease, the incision can be a straight line, ulnar to the palmaris tendon.
- Divide the antebrachial fascia. Identify the median nerve and flexor tendons, and the ulnar nerve in the ulnar aspect of the wound.
- Retract the flexor tendons to expose the distal radius and distal radioulnar joint. To expose the distal radius, incise the pronator along its radial margin, leaving a small cuff of tissue to which to repair it. Expose the radius subperiosteally. The distal radioulnar joint can be visualized by longitudinal incision into the palmar capsule. Take care distally not to incise the triangular fibrocartilage complex (TFCC).
- Close the wound with repair of the pronator and the capsule. Close the skin with interrupted or subcuticular sutures.

***Radial Approach to the Scaphoid***

**Indications** The radial approach to the scaphoid provides excellent visualization of the proximal pole, waist, and distal pole of the scaphoid. It useful in procedures in which a dorsal extensile exposure of the scaphoid is desired, such as for vascularized bone grafting of the scaphoid, and provides excellent exposure of the radial styloid for radial styloidectomy.

**Contraindications** If the palmar aspect of the radius or flexor tendons need to be exposed, then the palmar approach to the scaphoid provides better visualization of the palmar wrist structures.

**Technique (Fig. 37.12)**

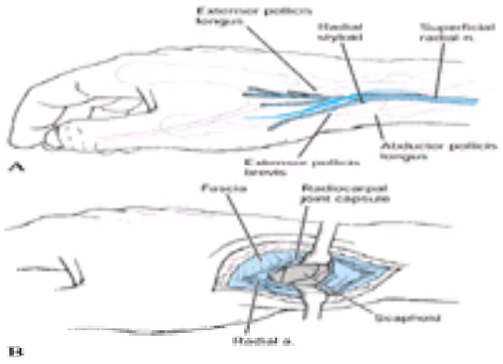


***Figure 37.12.*** The radial approach to the scaphoid. **A:** The curvilinear incision is made over the anatomic snuffbox, between the extensor pollicis longus and extensor pollicis brevis. **B:** A longitudinal incision is made in the radiocarpal joint capsule, and the radial artery is retracted distally. The scaphoid is visualized.

- Make a curvilinear incision over the anatomic snuffbox. Extend it proximally over the dorsal or radial aspect of the wrist as needed. Then proceed between the extensor pollicis longus dorsally and the extensor pollicis brevis palmarly. These tendons are easily identified because traction on the extensor pollicis longus produces extension of the thumb IP joint and traction on the extensor pollicis brevis produces extension and abduction of the thumb ray without extension of the IP joint.
- Take care to avoid injury to the superficial branches of the radial nerve, which may be multiple (1).
- Retraction of the tendons allows visualization of the radial artery and its dorsal branches, which must be preserved to maintain the vascularity of the scaphoid. Incise the joint capsule longitudinally and expose the scaphoid with distal and palmar retraction of the radial artery. It is important when exposing the scaphoid not to disrupt the dorsal blood supply to the bone by stripping the vessels that enter the scaphoid through the dorsal waist.

***Ulnar Approach to the Distal Ulna***

**Indications** The ulnar approach to the distal ulna is useful for distal ulnar excision or internal fixation, exposure of the extensor carpi ulnaris tendon, or open visualization of the TFCC.

**Contraindications** This exposure does not provide visualization of the distal radius, or the extensor or flexor tendons.

**Technique (Fig. 37.13)**

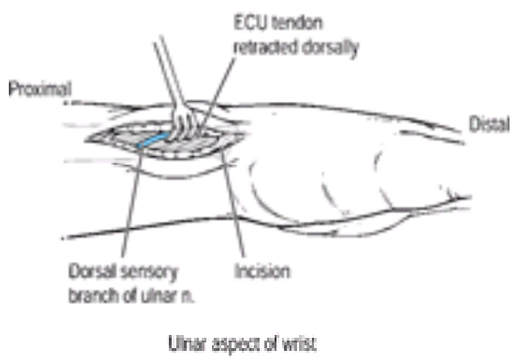


***Figure 37.13.*** The ulnar approach to the distal ulna. **A:** The longitudinal incision is made along the palmar aspect of the extensor carpi ulnaris tendon. **B:** The sheath over the extensor carpi ulnaris tendon is incised, and the extensor carpi ulnaris is retracted dorsally. Care must be taken to avoid injury to the dorsal sensory branch of the ulnar nerve, which travels from palmar to dorsal in this region. Subperiosteal dissection may be performed on the distal ulna and the ulnocarpal joint may be incised longitudinally to expose the TFCC.

- Make a longitudinal straight incision over the ulnar aspect of the distal ulna, just palmar to the extensor carpi ulnaris tendon. Center it over the ulnar head and extend it distally across the ulnocarpal joint and proximally as far as necessary.
- Perform deep dissection in a blunt fashion because the dorsal sensory branch of the ulnar nerve runs from palmar to dorsal across the distal ulna in this region.
- Incise the retinaculum over the extensor carpi ulnaris tendon longitudinally and retract the tendon dorsally.
- Incise the ulnocarpal joint capsule longitudinally along its ulnar aspect to visualize the TFCC. Start the incision distally and do not cut into the TFCC. Proximally, the distal radioulnar joint capsule and ulnar periosteum may similarly be elevated off the distal ulna to allow its exposure.
- Closure of the wound may include repair of the distal radioulnar joint capsule and the retinaculum over the extensor carpi ulnaris tendon if it is noted to sublux palmarly.

## CHAPTER REFERENCES

Each reference is categorized according to the following scheme: *, classic article; #, review article; !, basic research article; and +, clinical results/outcome study.


! 1. Abrams RA, Brown RA, Botte MJ. The Superficial Branch of the Radial Nerve: An Anatomic Study with Surgical Implications. *J Hand Surg* 1992;17:1037.

! 2. Bugbee WD, Botte MJ. Surface Anatomy of the Hand. The Relationships between Palmar Skin Creases and Osseous Anatomy. *Clin Orthop* 1993;296:122.

! 3. Cobb TK, Carmichael SW, Cooney WP. Guyon's Canal Revisited: An Anatomic Study of the Carpal Ulnar Neurovascular Space. *J Hand Surg* 1996;21:861.

! 4. Davlin LB, Aulicino PL, Bergfield TL. Anatomical Variations of the Median Nerve at the Wrist. [Review.] [29 refs.] *Orthop Rev* 1992;21:955.

! 5. Dodds GA 3d, Hale D, Jackson WT. Incidence of Anatomic Variants in Guyon's Canal. *J Hand Surg* 1990;15:352.

! 6. Dowdy PA, Richards RS, McFarlane RM. The Palmar Cutaneous Branch of the Median Nerve and the Palmaris Longus Tendon: A Cadaveric Study. *J Hand Surg* 1994;19:199.

! 7. Doyle JR. Anatomy and Function of the Palmar Aponeurosis Pulley. *J Hand Surg* 1990;15:78.

! 8. el-Badawi MG, Butt MM, al-Zuhair AG, Fadel RA. Extensor Tendons of the Fingers: Arrangement and Variations—II. *Clin Anat* 1995;8:391.

+ 9. Richards RS, Dowdy P, Roth JH. Ulnar Artery Palmar to Palmaris Brevis: Cadaveric Study and Three Case Reports. *J Hand Surg* 1993;18:888.

+ 10. Rotman MB, Manske PR. Anatomic Relationships of an Endoscopic Carpal Tunnel Device to Surrounding Structures. *J Hand Surg* 1993;18:442.

! 11. von Schroeder HP, Botte MJ. Anatomy of the Extensor Tendons of the Fingers: Variations and Multiplicity. *J Hand Surg* 1995;20:27.

# 12. von Schroeder HP, Botte MJ. Functional Anatomy of the Extensor Tendons of the Digits. [Review.][48 refs.] *Hand Clin* 1997;13:51.

! 13. Wehbe MA. Anatomy of the Extensor Mechanism of the Hand and Wrist. [Review.][13 refs.] *Hand Clin* 1995;11:361.

# CHAPTER 38

# FINGERTIP AND NAIL BED INJURIES

*Barry M. Katzman and David J. Bozentka*

**B. M. Katzman:** University of Pennsylvania, Department of Orthopaedics, Philadelphia, Pennsylvania, 19104.
**D. J. Bozentka:** Departmnt of Orthopaedics, University of Pennsylvania, Penn Hand Specialists, Philadelphia, Pennsylvania, 19104.

Fingertip Injuries
- Classification of Fingertip Injuries
- Healing by Secondary Intention
- Composite Grafts
- Revision Amputation
- Skin Grafts
- Local Flaps
- Regional Flaps
- Distant Flap Coverage
- Thumb Coverage
- Conclusions

Nail Bed Injuries
- Classification of Nail Bed Injuries
- Nail Bed Avulsions
- Nail Reconstruction
- Split Nail
- Linear Ridging
- Lateral Deviation
- Hooked Nail
- Total Nail Loss

Authors' Perspective
Chapter References

## FINGERTIP INJURIES

Fingertip injuries are defined as those injuries occurring distal to the insertion of the flexor and extensor tendons. They are the most common injuries of the hand and can lead to a significant functional and cosmetic deficit if they are not treated appropriately. The fingertip is the end organ for touch and is richly supplied with special sensory receptors that enable the hand to relay the shape, temperature, and texture of an object. The glabrous skin of the fingertip is specially adapted for pinch and grasp functions. Its volar surface consists of a fatty pulp covered by highly innervated skin. The skin of the fingertip is firmly anchored to the underlying terminal phalanx by multiple fibrous septa that traverse the fatty pulp.

After a fingertip injury, restoration of sensibility, stable skin coverage, and adequate padding are the goals of reconstruction. There are many treatment options, which range from allowing the wound to heal by secondary intention to flap coverage or revision amputation. No single procedure can be recommended, but each case must be individualized depending on the needs of the patient and the type of injury (19,32). Patient-related factors that should be considered include age, occupation, avocation, and general health. Injury-related factors include associated nail bed injuries, angle of injury, bone exposure, digit injured, and concomitant injuries.

This section reviews the common procedures performed for this injury. It discusses the indications, advantages, and disadvantages of each procedure, along with a treatment algorithm.

### CLASSIFICATION OF FINGERTIP INJURIES

Allen has classified fingertip injuries into four types based on the level of injury (1). Type 1 injuries involve only the pulp, and type 2 injuries involve the pulp and nail bed. Type 3 injuries include partial loss of the distal phalanx, whereas type 4 injuries are proximal to the lunula. This classification is useful because it allows the surgeon to help organize treatment options (Fig. 38.1). For example, type 1 injuries may heal quite well by secondary intention. In contrast, types 3 and 4 often require some type of flap coverage. Injuries must also be thought of in terms of whether bone is exposed and the angulation of injury. There are three general terms used to describe the angulation of injury—dorsal oblique, transverse, and volar oblique (Fig. 38.2). In general, dorsal oblique and transverse injuries are more suited to local flaps. Volar oblique flaps often require a regional flap. By considering all of these factors for each patient, a rational treatment plan can be initiated.

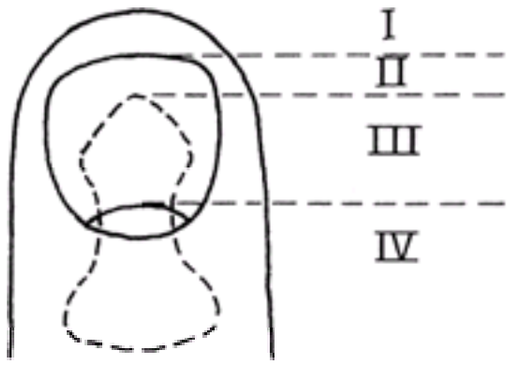


***Figure 38.1.*** The classification of injuries is illustrated.

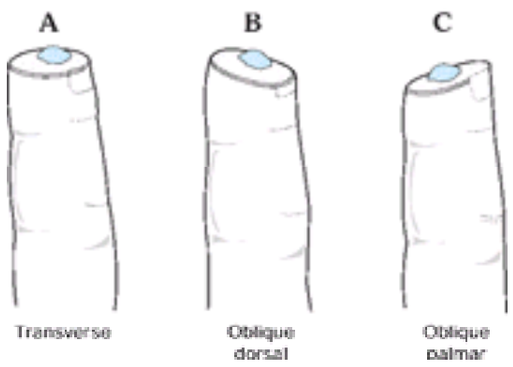


***Figure 38.2.*** The angles of injury are shown.

## HEALING BY SECONDARY INTENTION

The simplest treatment of fingertip injuries is to allow the wound to heal by secondary intention. This method relies on reepithelialization and contracture to provide wound closure. It is reserved for small defects (6 to 8 mm) without exposed bone and with minimal loss of pulp tissue. In young children this method provides good results even if bone is exposed.

- Begin treatment with a thorough debridement of the wound, which can be performed under local anesthesia in the emergency room.
- Perform local wound care two to three times daily with dressing changes. Healing is usually completed by 3 to 6 weeks depending on the size of the defect.

Chow and Ho reported good results in their series of patients treated in this manner (7). They noted that very few patients had pain or limited range of motion at 6 months from injury, although there was a 27% incidence of nail deformity. Other complications of this treatment method include delayed healing, pyogenic granuloma, cold intolerance, and stump tenderness. One should realize that the missing tissue is replaced by scar. Owing to the deficient tissue, the tip can become quite sensitive and therefore patients who use their fingertips repetitively during work are poor candidates for this technique.

## COMPOSITE GRAFTS

If the amputated part is clean and the tissue is of adequate integrity, use the part for soft-tissue coverage. If there is no exposed bone, defat the skin and suture it into the defect. The defatting is extremely important, because this piece will now act as a free skin graft. Minimize its thickness to enhance its chances of “taking.” This skin, however, may necrose and then would serve as a biologic dressing. The chance of success with this treatment is greater when used in children.

In children younger than 3 years old, we consider reattaching the amputated part as a composite graft (28). This is because children of this age have the extraordinary ability to heal these injuries. Elsahy reattached amputated fingertips without a microvascular anastomosis in 35 patients; subsequent survival was correlated with the level of injury (11). Tip amputations without nail bed involvement (Allen Type 1) survived in four of five patients. In contrast, only 2 of 10 amputations proximal to the lunula (Allen Type 4) survived. The major complication of this procedure is the necroses of the composite graft. If the finger is amputated 2 mm proximal to the lunula, then replantation can be considered. Microvascular anastomosis is difficult at this level. This procedure can give better cosmetic and functional results when compared with terminalization and revision amputation.

## REVISION AMPUTATION

A simpler course of action involves shortening of the digit or revision amputation. This procedure is indicated in situations in which minimal bone is exposed and the angle of the injury is such that other options are not appropriate. Take care to limit loss of length, particularly in treating the thumb. This procedure can be performed under local anesthesia in the emergency room if minimal bone shortening is required. Develop the flaps to cover the tip of the digit, preferably with volar skin. Use the volar skin rather than the dorsal skin to provide a more padded and durable soft tissue cover for the fingertip. Patients can return to their activities as tolerated when the soft tissues have healed.

## SKIN GRAFTS

Skin grafts can be used in injuries where there is skin loss but adequate subcutaneous tissue is present with no exposed bone. The lack of exposed bone is paramount, because skin grafts will not “take” on bone. Use this technique for injuries with skin loss of greater than 1 cm. In cases of smaller skin defects, allow the wound to heal by secondary intention, as previously described. Skin grafts can be divided into split thickness or full thickness. Full-thickness grafts provide better sensibility and durability, as well as a better cosmetic result. On the other hand, split-thickness skin grafts have a greater likelihood of “taking.” Idler and Strickland recommend split-thickness grafts because of their ability to contract and draw in normal tissue with a greatly reduced size of the defect (19). Take split-thickness skin grafts of 0.012 to 0.015 inches thick. Harvest smaller split thickness grafts free hand from the glabrous skin of the hypothenar eminence. Take larger grafts from the thigh or buttocks. Harvest full-thickness skin grafts locally from the palmar wrist crease or from the hypothenar area (Fig. 38.3A, Fig. 38.3B). The palmar wrist crease provides an area of approximately 2 × 6 cm, whereas the hypothenar skin provides an area of 2 to 2.5 cm in width by 6 to 8 cm in length. Harvest larger amounts of full-thickness skin grafts from distant sites such as the hairless area of the groin. The donor site in a full-thickness graft is typically closed primarily. Excellent hemostasis of the injury site must be obtained to avoid the postoperative complication of hematoma formation. Secure the graft with a bolus stent type of dressing that is left undisturbed for 5 to 7 days. Start therapy after the dressing is removed.

***Figure 38.3.*** **A:** The area to be taken for a hypothenar skin flap is shown. **B:** The skin that can be harvested from the palmar wrist crease is illustrated.

Complications from this procedure include hematoma, necrosis of the skin graft, and donor site complications.

## LOCAL FLAPS

Local flaps use adjacent local skin with its subcutaneous tissue and normal sensory end organs to cover defects. There are two common advancement flaps used for fingertip injuries. Both share similar principles in that a V incision is made adjacent to the defect. Atasoy and colleagues popularized the V-Y advancement flap in which the incision is made palmar, and Kutler described a similar flap in which the incisions are made laterally (2,22). The skin and subcutaneous tissues are advanced forward, and the proximal defect is closed end to end. After closure, the proximal portion of the wound forms the vertical line of the Y. Range of motion therapy is started 7 to 10 days following either local advancement flap as the wound permits. Another local flap is the homodigital triangular flap, which is dissected more proximally and the digital artery is included within the flap. Lanzetta et al. have recently described good results using this technique for volar oblique amputations (23).

### V-Y Advancement Flap

The V-Y advancement flap that was popularized by Atasoy et al. is used in fingertip injuries with dorsal angulation (2). It can be used for transverse amputations, although it is more difficult in this setting. The procedure is, however, contraindicated in palmarly angulated injuries.

- Make the incisions with the apex of the V at the midpalmar distal interphalangeal joint and the arms of the V extending to the widest portion of the amputation (Fig. 38.4B).

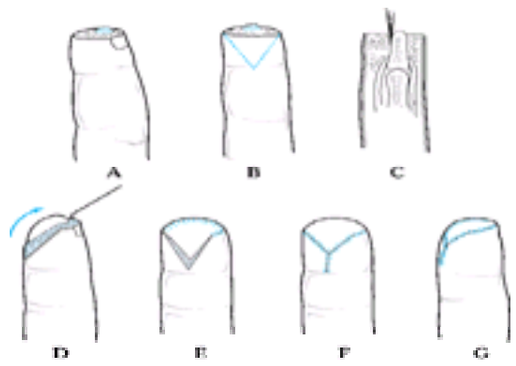


***Figure 38.4.*** **A:** A V-Y advancement flap, most useful in patients with a dorsal oblique type of injury, is shown. **B:** This is the approach for a planned incision. **C:** An incision to the fibrous septal attachments at the bony phalanx is shown. **D:** The septae are released; traction is placed distally. **E:** Tension is released. **F,G:** The wound is closed.

- Incise the skin, leaving the subcutaneous tissues intact.
- Release the fibrous septa connecting the flap to the underlying bone. This allows maximum mobilization and keeps the flap's blood and nerve supply intact.
- Use gentle traction with skin hooks to advance the flap into the defect.
- Release all tension so that suturing the distal margin of the flap is done without blanching (use small monofilament surture, 6-0 or 7-0). This avoids potential tip necrosis.
- Close the remaining donor defect side to side. This flap provides like tissue with good color and sensory characteristics.

Complications of this procedure include necrosis of the flap, hypesthesias, dysesthesias, impaired sensation, and cold intolerance.

V-Y Kutler Flap

The Kutler V-Y flap is also useful for transverse amputations (13,22,35). The design of this flap is similar to the V-Y advancement flap in that the apex is at the distal interphalangeal (DIP) joint and the base at the amputation site, although in this procedure the flap is placed laterally. The flaps can be elevated on one or both sides of the digit. Care again must be taken to divide the fibrous septa and preserve the neurovascular supply of the flap (Fig. 38.5).

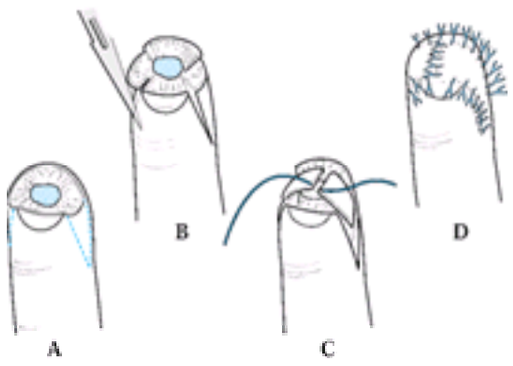


***Figure 38.5.*** Kutler flaps are shown. **A:** This is the method used for bilateral flaps. **B:** The incision with traction is illustrated. **C,D:** The wound is closed.

- Plan bilateral flaps with the apices of the triangles in the midlateral line of the distal interphalangeal flexion crease.
- Make the incisions to the level of the fibrous septal attachments at the bony phalanx, using traction distally with a skin hook to release proximal septa so flaps advance to the midline (Fig. 38.5B).
- Begin tension-free closure with small (6-0 or 7-0) nonabsorbable monofilament suture.
- Complete closure with several interrupted absorbable sutures at the amputated nail bed margin (Fig. 38.5D).

The disadvantage of this flap is the limited advancement and the resultant suture line lies over the pulp. This factor has likely led to the hypersensitivity noted by some patients. The two advancement flaps have similar complications including numbness, cold intolerance, and dysesthesias.

**REGIONAL FLAPS**

Regional flaps are defined as flaps taken from other parts of the hand that do not use tissue adjacent to the defect. This section discusses the cross-finger and thenar flap, which are considered for injuries not amenable to local flaps. They are well suited for volar oblique type injuries. The cross-finger flap can also be used in treating more proximal soft-tissue injuries of the finger. Owing to the postoperative immobilization required, the procedures are discouraged in patients predisposed to finger stiffness. This includes patients older than 50 years of age, patients with rheumatoid arthritis, and patients with multiple injured digits. These flaps are also not well suited for young children because of lack of compliance and simpler methods are usually adequate.

***Cross-Finger Flap***

The cross-finger flap is a random pattern flap taken from the dorsum of the adjacent finger to resurface a palmar defect. Do not use this flap in patients with vasospastic disorders including Buerger's disease and Raynaud's phenomenon (6,8,17).

- Create a template for the defect, drawing the pattern on the dorsum of the adjacent digit over the middle phalanx. Base the flap on the lateral aspect of the adjacent finger. The flap may be dissected from the midlateral line of the lateral aspect of the adjacent finger to the midlateral line medially as required to encompass the size of the defect.
- Carry down the dissection through the subcutaneous tissues, taking care not to disturb the paratenon of the extensor mechanism. Leave the paratenon intact to allow skin grafting of the donor site.
- Also leave undisturbed the dorsal veins within the flap.
- Cleland's ligaments, however, may need to be divided to provide full mobility. An innervated flap can be accomplished by including a dorsal cutaneous nerve branch, which is then sutured to the proper digital nerve.
- After the flap is raised, deflate the tourniquet. Obtain hemostasis to prevent hematoma formation.
- Inset the flap and trim appropriately (Fig. 38.6). Suture the flap into the recipient finger defect, using an interrupted half-buried mattress monofilament suture (6-0 or 7-0). Cover the donor site with a full-thickness skin graft that is sutured to the hinged portion of the flap. Secure the skin graft with a bolster dressing and immobilize the digits in a position that places the least tension on the flap. This is usually in the intrinsic plus position. Kirschner wires are rarely needed to maintain this position.

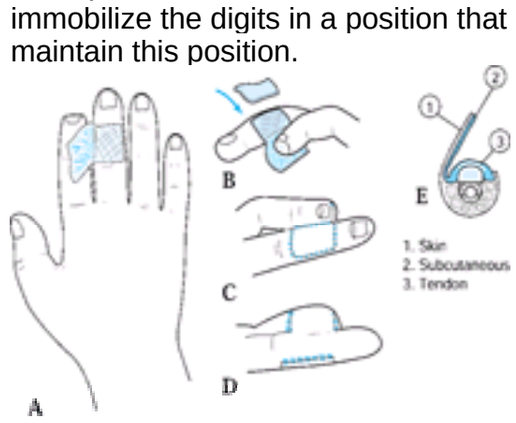

***Figure 38.6.*** A dorsal cross-finger flap is shown. **A:** This is the method for a planned incision. **B:** A full-thickness skin graft is sutured and secured. **C:** The flap is sutured. **D:** The palmar view of the repair is shown. **E:** A cross section of the donor finger is shown.

- Divide the flap and inset at 10 to 14 days postoperatively. Begin therapy soon after flap division. Be careful not to divide the flap too close to the recipient side in order to allow the flap to be inset more easily. This is a reliable flap, but there is usually a color mismatch at both the donor and recipient sites. One can expect protective sensation postoperatively, with two-point discrimination often twice normal.

***Reverse Cross-Finger Flap***

The reverse cross-finger flap is more commonly used for dorsal finger defects.

- Design the flap with its base at the midaxial line of the middle phalanx of the donor finger.
- Elevate the skin of the donor finger as a full-thickness skin graft and separate from the subcutaneous tissues. The base of this skin is opposite to the defect. Elevate the subcutaneous tissue on the dorsum of the donor finger as a flap, with its base hinged adjacent to the defect, leaving the paratenon again intact.
- Inset this flap into the defect and sew the skin back over the donor site. Then create a skin graft for the flap of subcutaneous tissue that has been transferred to the recipient finger defect.
- Apply a bolus stent-type dressing.
- Place the skin graft over the transferred subcutaneous tissue (Fig. 38.7).

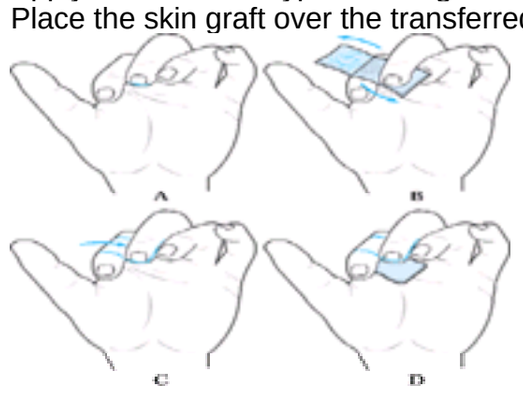


***Figure 38.7.*** A reverse cross-finger flap is shown. See the text for details. **A:** Design of the skin flap. **B:** Elevate the subcutaneous flap. **C:** Donor skin is sutured. **D:** The subcutaneous flap is sutured, and the skin is grafted.

To illustrate the use of a cross-finger or reverse cross-finger flap, a defect located on the palmar aspect of the long finger could be treated with a standard cross-finger flap. The donor finger would be the ring finger, and the flap would be hinged radially. The donor site would then be skin grafted. If the defect of the long finger was dorsal, a reverse cross-finger flap would be performed. The donor finger, however, would be the index finger and the flap would be hinged ulnarly. In this procedure, the recipient finger requires skin grafting.

***Thenar Flap***

The thenar flap has similar indications and contraindications as the cross-finger flap. The procedures are best suited for volar fingertip defects.

- Elevate this random pattern flap from the thenar eminence and hold the involved finger in flexion for insetting of the flap. Placing the flap ulnarly on the thenar eminence has been associated with scar tenderness. Base the flap proximally, distally, or radially dependent on the defect (Fig. 38.8A). The distal border should be parallel and adjacent to the metacarpophalangeal (MP) joint crease. The flap should be 1.5 times the width of the defect. This allows the soft tissue of the finger to assume a more rounded and normal appearance.

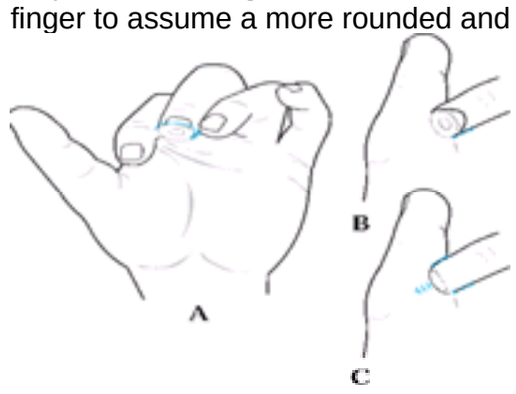


***Figure 38.8.*** A thenar flap is shown.

- Once the flap is outlined, dissect the skin and subcutaneous tissues off the thenar musculature.
- Take care not to injure the radial digital nerve or recurrent branch of the median nerve.
- Close the flap donor site primarily in a linear fashion with interrupted monofilament sutures, or cover with a full-thickness skin graft (Fig. 38.8B, Fig. 38.8C). Smith and Albin described an H-type thenar flap (40). In this procedure, fill the donor defect by advancing the remaining half of the H (Fig. 38.9). Approximate the raised flap to the amputation site by palmarly abducting the thumb and flexing the MP joint and the distal interphalangeal joint of the recipient finger. This minimizes the amount of proximal interphalangeal (PIP) flexion required for immobilization to less than 40° to 50° and decreases the risk of a PIP flexion contracture.

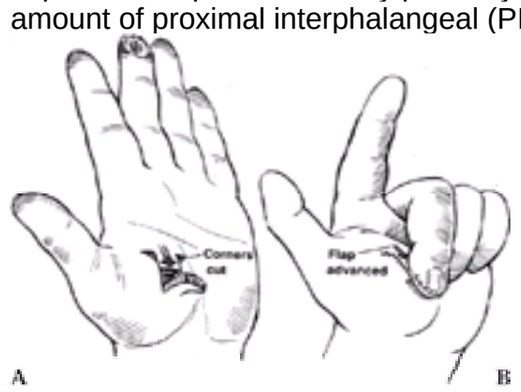


***Figure 38.9.*** **A:** A modification of the technique described by Smith and Albin is to incise two flaps in an H shape with small Burow's triangles cut at the base of the distal flap. **B:** The proximal flap is turned in a standard fashion to cover the fingertip, while the distal flap is advanced proximally to close the donor defect at one operation. (From Calkins ER, Smith DJ. The Cross Finger Flap. In: Blair WP. Techniques in Hand Surgery. Baltimore: Williams and Wilkins, 1996:58.

- Divide the flap at 10 to 14 days postoperatively. The base of the pedicle on the thenar eminence may be trimmed of excessive tissue, but usually neither the donor site nor the recipient finger requires further insetting.
- Start active flexion and extension exercises immediately.

The major criticism of this flap in the past has been a PIP flexion contracture and tenderness at the donor site. Melone et al. analyzed 150 cases and recommended

designing the flap high on the thenar eminence and not on the palmar aspect of the hand (26). In Melone's series, the average 2-point discrimination was 7 mm. In addition, the donor site was an infrequent source of pain. Only 4% of patients developed a flexion contracture, none of which were believed to be related to the procedure.

## DISTANT FLAP COVERAGE

Distant flaps are defined as flaps obtained from areas of the body other than the injured limb. These procedures are considered in hand injuries with large soft-tissue defects and provide thick, fatty coverage with little sensibility. The flaps can be developed from the chest, abdomen, groin, or opposite arm.

## THUMB COVERAGE

The thumb plays a crucial role in prehension and is involved in 50% of the function of the hand. Preservation of length of the thumb is more important functionally than in any other digit. Procedures used for thumb coverage described in this section include the Moberg advancement flap, cross-finger flap, palmar cross-finger flap, and neurovascular island flaps.

### *Moberg Advancement Flap*

The Moberg advancement flap involves advancement of the volar skin with its subcutaneous tissues and neurovascular bundles distally into a thumb tip defect (27,30). The unique anatomy of the thumb makes this flap more suitable for the thumb than the other digits. There is a risk of a flexion contracture postoperatively, but the thumb has only one interphalangeal joint, and a flexion deformity of this joint causes little functional deficit. The fingers, however, have two interphalangeal joints, and a flexion contracture of the proximal interphalangeal joint imparts a significant disability. Other differences between the thumb and fingers include their respective blood supplies. A component of the blood supply to the thumb arises from the first dorsal metacarpal artery. The thumb is less dependent on the volar blood supply. In contrast, the fingers rely more on the volar blood supply and, therefore, risk tip necrosis with this flap. The volar advancement flap has many advantages over other local, regional, and distant flaps. It provides immediate restoration of essentially normal sensation with preservation of length. It can be done in a single stage with low donor site morbidity. The pulp contour is restored, and the rehabilitation time is relatively short. In contrast to a neurovascular island flap, no cerebral cortical programming is needed.

- This flap is well suited to the volar oblique amputation of the thumb that is 1 to 1.5 cm in length. The surgical technique involves skin incisions on both the radial and ulnar midaxial lines. Make these incisions dorsal to the neurovascular bundles. Extend the incision proximally to the MP flexion crease or proximal phalanx (Fig. 38.10A). The incision can be extended further proximally to the thenar eminence for larger defects.




***Figure 38.10.*** A palmar advancement flap is shown. **A:** This is the method for a planned incision. **B:** Palmar soft tissue is advanced. **C:** Suture the flap into place distally, using a small (6-0 or 7-0) monofilament suture without tension. It may be necessary to flex the interphalangeal joints to achieve tension-free closure. Place a full-thickness skin graft over the donor defect.

- Elevate the flap from the flexor sheath and flex the thumb at the interphalangeal and MP joints to allow coverage of 1 cm defects (Fig. 38.10). Contour the flap when insetting it. The flap may be sutured to the nail. If the skin blanches, more proximal dissection is needed.
- Make a transverse incision at the base of the flap to allow further advancement to cover defects up to 1.5 cm. The resulting defect on the thenar eminence can then be covered with a skin graft.

Other variations of the procedure to gain length include a V-Y advancement at the base or bilateral Z-plasties along the longitudinal incisions (10). In addition, Dellon has described a modification that can be made up to 3 cm in length by using rotational flaps proximally (9). Results of the Moberg advancement flap have shown excellent return of sensitivity within two-point discrimination with 2 mm of the contralateral fingertips.

### *Cross-Finger Flap for Thumb Defects*

Cross-finger flaps for thumb injuries can be performed using a number of variations. This includes a standard cross-finger flap, a cross-finger flap including a branch of the superficial radial nerve with or without neurorrhaphy, and a palmar cross-finger flap. In treating thumb injuries, the index finger is used as the donor site for the standard cross finger flap and the long finger is used for the palmar cross finger flap (3,18,43,44). The importance of a sensate thumb tip has led to the use of innervated flaps. One option is a cross-finger flap that includes a branch of the superficial radial nerve.

- Raise the flap from the dorsal aspect of the proximal phalanx of the index finger. Dissect the superficial radial nerve branches and protect them proximally.
- Make a V-type incision with one limb along the radial midlateral line of the index finger and extending proximally along the second metacarpal.
- Make the other limb of the incision from the ulnar side of the defect of the thumb. Inset the flap and transfer the sensory nerve branches to the thumb incision.
- Use a full-thickness graft to resurface the donor site.
- Detach the flap at 3 weeks.

Walker et al. found that performing a first web space Z-plasty at the time of division can avoid a first web contracture (44). One can modify this procedure by transecting the dorsal radial sensory nerve branch more proximally and performing a neurorrhaphy with the ulnar digital nerve of the thumb. These procedures have the obvious advantage of bringing an innervated pedicle to the thumb. In Walker's series, all had cortical adaptation, but when carefully asked three of five patients had sensation referred to the dorsal index finger. They found that most patients had good sensation that may have been a combination of median and radial nerve sensation. They also found that the ulnar aspect of the flap had better sensory recovery than the radial aspect.

### *Palmar Cross-Finger Flap*

A palmar cross-finger flap has been described for injuries of the distal thumb. The surgical technique is similar to the standard cross-finger flap except the palmar skin is elevated for the flap. When used for the distal thumb, the long finger is often the donor site.

- Design the flap on the palmar surface of the middle phalanx. Its base should lie along the ulnar border in the midaxial line (Fig. 38.11A).

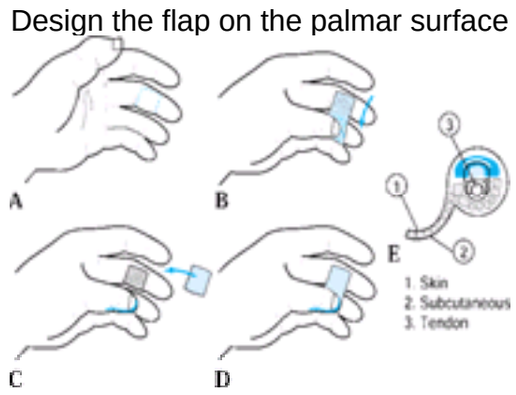


***Figure 38.11.*** A palmar cross-finger flap is shown. **A:** This is the flap design. **B:** The flap is elevated. **C:** The flap is inset, and the donor site skin is grafted. **D:**

The repair is completed. **E:** A schematic cross section of the donor finger illustrates the proper plane of dissection.

- Elevate the flap just superficial to the flexor sheath, taking care to preserve the ulnar neurovascular bundle and to not separate the flap from the radial neurovascular bundle (Fig. 38.11B).
- Suture the flap into place with a fine monofilament suture and suture a full-thickness skin graft over the donor middle phalanx. Apply a bolus dressing.
- Complete the repair.

Advantages of this procedure, as advocated by Vlastou et al., include better quality of skin because it is taken from the palmar surface (43). In addition, both digits are positioned in a more comfortable posture, which may decrease PIP joint stiffness. Cosmesis is also improved because the scar is on the palmar surface as compared with the more obvious dorsal surface of the donor digit. The risks of this procedure include exposing the tendon flexor sheath, stiffness, a painful donor site, and the potential for neurovascular injury. These complications have limited its use.

***Neurovascular Island Flaps***

The neurovascular island flap transfers the soft tissue of the border of a finger with its neurovascular bundle to the thumb. This technique sacrifices sensation in a finger of less importance to transfer sensate soft tissue to the thumb. It can be performed as a primary or reconstructive procedure. The donor site is often the ulnar border of the long finger, although one may also use the ulnar or radial aspect of the ring finger (24).

- Preoperatively, it is important to assess the arterial flow of the donor finger and the digit adjacent to the flap because the adjacent vessel is ligated. After the recipient site is prepared, dissect the digital nerves of the thumb to the muscle bellies of the flexor pollicis brevis and transect at this point. The deep location of the nerves helps prevent neuroma formation.
- Outline the donor site flap 3 to 4 mm proximal to the midline of the nail plate. The more distal the flap on the donor finger, the better the sensitivity in the recipient thumb. Carry the incision proximally along the midlateral line and palmar aspect of the hand. The distal margin of the flexor retinaculum marks the proximal portion of the incision. If the anatomy is normal, dissect from proximal to distal.
- Confirm that the common digital artery arises from the superficial arch and not the deep arch. Take care not to skeletonize the neurovascular bundle but, rather, take the neurovascular bundle as a unit with the subcutaneous tissue. This minimizes the risk of injury to the vessels.
- Ligate the digital artery branch to the adjacent finger and longitudinally separate the common digital nerve of the web space. Continue to dissect proximally to the superficial palmar arch. Then pass the neurovascular bundle beneath the digital nerve and transfer it to the thumb.
- Make a wide tunnel superficial to the palmar fascia. Then place a penrose drain from the thumb and passing into the palmar defect. Place the flap inside the penrose drain and transfer to the thumb.
- After suturing the flap into place, assess its viability. If flow is not adequate, ensure that there is no kinking of the vascular pedicle.
- Treat the donor site defect with a combination of primary closure and full-thickness skin graft (Fig. 38.12).

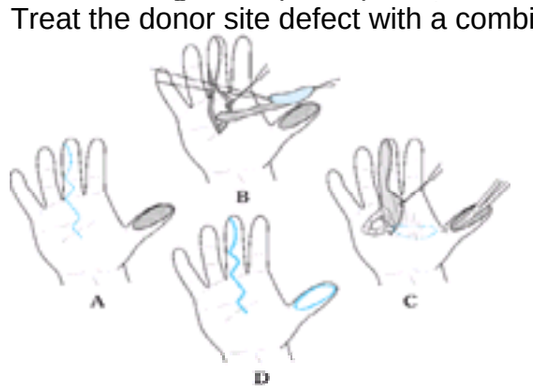


***Figure 38.12.*** An island flap is shown. **A:** Design the flap over the ulnar border of the long finger. It should be of the size necessary to match the recipient defect. Take care not to detach the neurovascular bundle from the undersurface of the flap. Use Brunner incisions to mobilize the donor vessels back to the palmar arch. **B:** Use sutures for traction as flap elevation and mobilization proceed. **C:** Make a generous tunnel beneath the palmar skin to allow the tension-free passage of the flap into the recipient defect. **D:** Complete the repair with a full-thickness skin graft placed onto the donor defect. Apply a bolus dressing.

The results of this operation have been mixed. Some authors have reported a deterioration of two-point discrimination with time. Others believed that this deterioration can be minimized with meticulous technique (41). The flap requires some cortical reorientation, which is not always complete.

***First Dorsal Metacarpal Artery Flap***

The first metacarpal artery flap restores sensate skin to the volar thumb in a one-stage procedure without the need for microvascular repair. Sherif has reviewed the anatomy of the first dorsal metacarpal artery (FDMA) and found the artery present in all cases (38) (Fig. 38.13). The artery originates from the radial artery, just distal to the extensor pollicis longus before the radial artery dips in between the two heads of the first dorsal interosseous muscle. He also found that the FDMA gave off three consistent branches: a radial branch, an ulnar branch, and an intermediate branch. Furthermore, a cutaneous branch was always present and originated from either the radial artery or the first dorsal metacarpal artery. The FDMA is superficial to the dorsal interosseous fascia and is covered by some fibers of this layer. Before making the incision, a Doppler scan may be used to identify the FDMA.

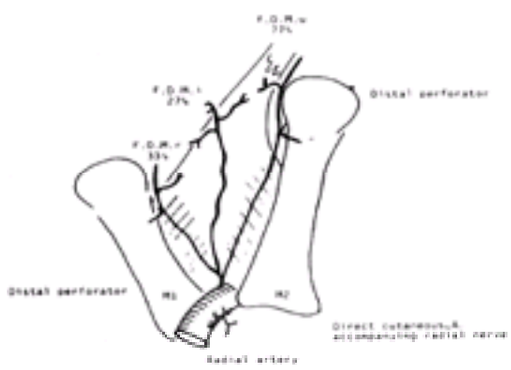


***Figure 38.13.*** The FDMA and its three fascial branches. The incidence of it being a large vessel is marked near each artery.

- Elevate the flap from the dorsal aspect at the base of the index finger. It can be extended to the PIP joint distally (14,31,38,39). If additional width of the flap is needed, expand it toward the third metacarpal to avoid a first web space contracture.
- Expose the FDMA distally to proximally and raise the aponeurosis with the perivascular fat as a pedicle (Fig. 38.14). The artery is usually superficial to the fascia, and a branch of the superficial radial nerve is included in the pedicle.

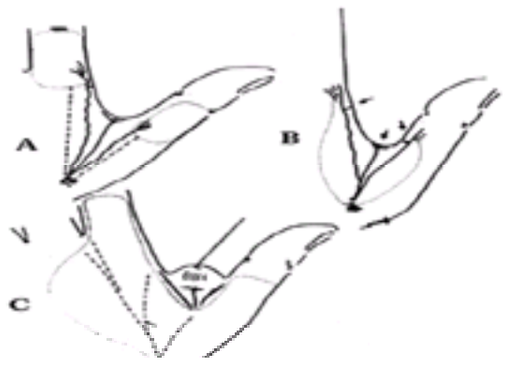


***Figure 38.14.*** The design of various flaps in the first web space is shown. **A:** Proximally based flaps are based on one of the FDMA branches. The island flap pedicle includes the FDMA and its branches, the first DIO fascia, subcutaneous tissue and veins, as well as the radial nerve branches and the accompanying artery. **B:** The distally based flap is based on one of the distal perforators (arrows). **C:** A double flap from the web space: The fascial flap is based on FDMA (marked in the drawing by a *hook*), and the cutaneous flap is based on the artery accompanying the radial nerve (dotted line).

- Take care to stay superficial to the extensor tendon paratenon. Rotate the proximally based flap around the point of origin of the artery at the base of the first interosseous space. During the dissection, there is often a large perforator near the second metacarpal neck that must be ligated.
- Once the pedicle is raised, tunnel it subcutaneously to the thumb without kinking. The flap can be used to cover thumb defects, either palmarly or dorsally, and can reach from the proximal portion of the thumb almost to its tip.

**CONCLUSIONS**

Our approach to fingertip injuries is the following: for adults, we assess the injury-related factors as well as patient-related factors such as age, occupation, general medical health, hand dominance, compliance, and associated injuries (Table 38.1). For small defects (less than 8 mm) with no exposed bone, we prefer to let these injuries heal by secondary intention. We have found that the cosmesis and sensitivity are adequate. If the defect is larger or has exposed bone, then we try to use a local flap. The flap required is dependent on the angulation of injury. For transverse or dorsal oblique injuries, we prefer a local V-Y advancement. We also use a lateral V-Y advancement for transverse defects. If the defect is oriented volarly, we perform a cross-finger flap or a thenar flap. Both require patient compliance, a second surgical procedure, and postoperative rehabilitation. For larger defects, we consider distant flaps and revision amputation. If there is a minimal portion of the nail bed remaining or no bone to support the nail bed, than a revision amputation is performed with ablation of the nail germinal matrix.

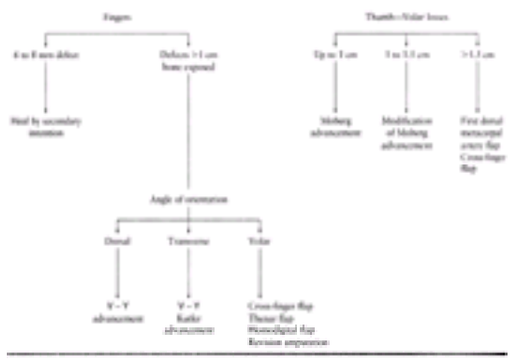

***Table 38.1. Management of Thumb and Fingertip Injuries in Adults***

We consider thumb injuries as a separate category. For volar injuries, we prefer the Moberg advancement flap. For larger defects, we use a first dorsal metacarpal or a cross finger flap.

For children younger than 3 years of age, we replace the amputated portion as a composite graft. In the 3- to 8-year-old age group, we defat the amputated part and use it as a free skin graft. Patients older than 8 years of age are treated as adults (Table 38.2).

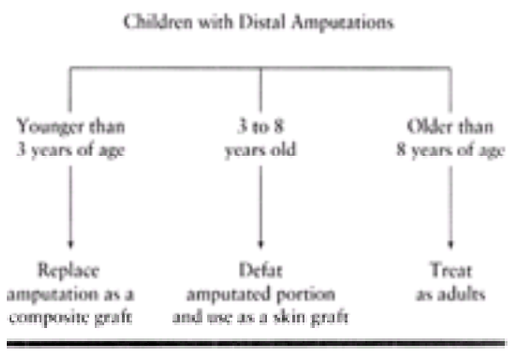


***Table 38.2. Children with Distal Amputations***

We agree with Louis (25), who believes that the deficit in sensitivity, hypesthesias, dysesthias, and cold intolerance in distal tip amputations may be primarily related to the injury and not to the treatment.

## NAIL BED INJURIES

The anatomy of the fingernail is highly specialized. It has four components: the nail plate, the nail bed, the perinail soft tissues, and the underlying bone and ligamentous support. The nail has multiple functions, including supporting and protecting the fingertip. It also plays a role in sensation of the digit in that if the nail is lost two-point discrimination of the finger decreases (45). Nail growth is dependent on several factors including age of the patient, injury pattern, and seasonal changes. On average, growth is approximately 0.1 mm per day. After loss of a nail, it takes approximately 3 to 6 months for a new nail to grow in completely, and nail growth is not normal for the first 100 days (5).

Optimal treatment of a nail bed injury requires an understanding of the anatomy and physiology of its components (Fig. 38.15). The nail fold is the most proximal portion of the nail complex. It consists of two parts, which include the dorsal roof and germinal matrix. The dorsal roof of the nail fold forms the cells that contribute to the shine of the dorsal nail surface. The nail bed also consists of two components. The most proximal portion is the germinal matrix. It is located along the proximal ventral floor of the nail fold and extends to the lunula. This is the area of the nail bed epithelium where nail plate production begins, and it is critical to nail growth (Fig. 38.16). The sterile matrix is the distal portion of the nail bed and extends from the lunula to the hyponychium. The sterile matrix acts as a road map for growth of the advancing nail and functions to keep the nail adherent to the underlying epithelium (Fig. 38.17). The eponychium is the distal portion of the nail fold that attaches to the dorsal surface of the nail. The lunula is the white arc just distal to the eponychium that parallels the natural distal shape of the nail. Distally, the hyponychium is the area of junction of the nail bed and the fingertip skin. It functions as a protective barrier and prevents bacteria from migrating beneath the nail.

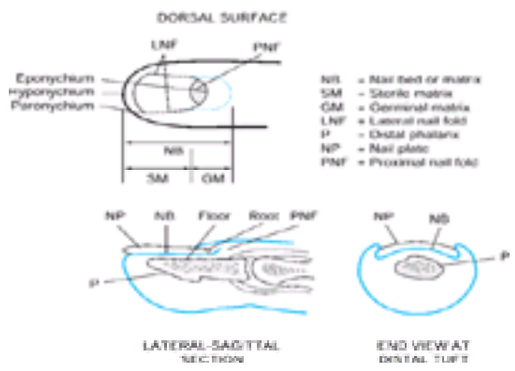


***Figure 38.15.*** The anatomy of and terminology for the distal segment of the fingernail are shown.

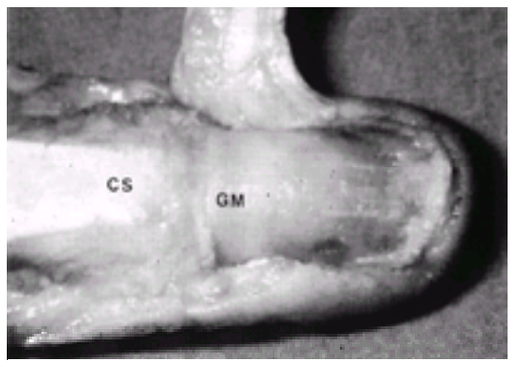


***Figure 38.16.*** With the eponychium reflected, the germinal matrix and complete extent of the nail are visible (*GM*). The central slip (*CS*) is inserting at the base of the nail matrix.

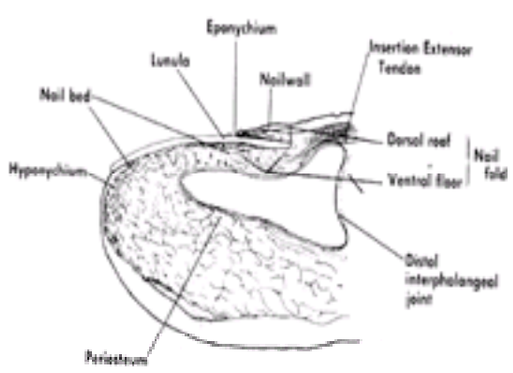


***Figure 38.17.*** Longitudinal drawing shows the terminology of the anatomy of the nail bed.

Both Zook et al. and Guy have reviewed the etiology of nail bed injuries and had very similar findings. The majority of these injuries occurred from a closing door, a machine injury, a saw injury, or by being crushed between two objects (Table 38.3) (16,48).

| | *Zook* | *Guy* |
|---|---|---|
| Closed in door | 71 | 3 |
| Smashed between objects | 63 | 5 |
| Machine | 36 | 8 |
| Saw | 24 | 7 |
| Lawnmower | 20 | 1 |
| Axe, knife, glass | 16 | 1 |
| Fan | 12 | 1 |
| Other | 38 | 4 |
| TOTAL | 280 | 30 |

***Table 38.3. Causes of Nail Bed Injuries***

The initial treatment of the injured nail bed is of utmost importance to prevent a nail deformity. Treatment of a nail deformity often requires a reconstructive procedure that is technically demanding, and the results are typically less than optimal. One problem facing the surgeon evaluating the injured nail is obscured visualization due to a subungual hematoma. In general, subungual hematomas encompassing greater than 50% of the nail have a higher likelihood of being associated with a displaced nail bed injury. In this situation, one should consider removing the nail and exploring the nail bed. Injuries with a subungual hematoma of less than 50% of the nail are less likely to have a repairable nail bed injury and should be treated nonoperatively. Patients may experience pain from the pressure related to a subungual hematoma. Making a small hole in the nail with a microophthalmic cautery can relieve the pressure. Drain the hematoma while taking care to not injure the underlying nail bed.

**CLASSIFICATION OF NAIL BED INJURIES**

Injuries of the nail bed can be divided into those that involve the germinal matrix or sterile matrix. In general germinal matrix injuries are more serious. Nail formation starts and is predominantly from the germinal matrix; therefore an injury in this region has a higher likelihood of permanently affecting nail growth. Van Beek et al. have further classified acute fingernail injuries, as outlined below (42).

***Germinal Matrix Injury:***

GI: Small subungual hematoma proximal nail (25%)

GII: Germinal matrix laceration, large subungual hematoma (50%)

GIII: Germinal matrix laceration and fracture

GIV: Germinal matrix fragmentation

GV: Germinal matrix avulsion

***Sterile Matrix Injury:***

SI: Small nail hematoma (50%)

SII: Sterile matrix laceration, large subungual hematoma (50%)

SIII: Sterile matrix laceration with tuft fracture

SIV: Sterile matrix fragmentation

SV: Sterile matrix avulsion

This classification system provides a framework for determining the appropriate treatment regimen (Table 38.4). Obtain radiographs to evaluate for a displaced distal phalanx fracture. Treat grade I injuries nonoperatively unless they are painful, for which decompression or nail removal can be performed.

- Type I—Often go untreated, decompression by drainage or nail removal
- Type II—Nail removal and suture repair of the nail bed
- Type III—Nail removal and suture repair of the nail bed, splint, and occasionally Kirschner-wire fixation of distal phalanx fracture
- Type IV—Remove the nail; meticulously repair the fragmented nail bed
- Type V—Repair nail bed, consider split-thickness nail graft for matrix loss

***Table 38.4. Treatment of Nail Bed Injuries***

***Repair of Grade II, III, and IV Injuries***

- Treat grade II, III, and IV injuries by first carefully removing the nail. An adherent nail may indicate a grade I injury with limited nail bed involvement.
- Facilitate nail removal with a freer elevator by exploiting the plane between the nail and the nail bed. Be careful when removing the nail so as not to injure the nail bed.
- Clean the nail and debride the nail bed if necessary. There is little advancement possible of the nail bed, so limit debridement to contaminated or devitalized tissues.
- Repair the nail bed under loupe magnification using 6-0 or 7-0 chromic suture.
- If the proximal germinal matrix is injured, visualization may be obscured by the nail fold. Make skin incisions at 90° to the nail fold along the lateral border of the nail. Then elevate the nail fold to evaluate the extent of injury fully.
- Most distal phalanx fractures are treated with a splint. A displaced fracture may cause displacement of the nail bed, and occasionally Kirschner wire fixation is required.
- After repair, replace the nail beneath the nail fold. Replacement of the nail has several important functions: (a) it serves as a template for the new growing nail; (b) it serves as a splint for fractures, (c) it provides a biologic dressing for the nail bed, and (d) it prevents scarring of the nail fold to the nail bed.
- Suture the nail in place with 4-0 or 5-0 nylon sutures. Place two horizontal mattress sutures proximally both radially and ulnarly to prevent injury to the germinal matrix. One or two simple sutures may be placed in the distal aspect of the nail and pulp to further secure the nail.
- If the nail is fragmented or not available, an artificial nail, Silastic sheet, or nonadherent gauze can be used.
- Bandage the finger to protect the digit and restrict motion for 7 to 10 days. Leave the replaced nail in place for 2 weeks.

**NAIL BED AVULSIONS**

The nail bed can avulse from either the germinal or sterile matrix. Similar to nail bed lacerations, the majority of avulsions occur in the distal aspect of the sterile matrix. Nail bed avulsions account for approximately 15% of all traumatic injuries to the nail (36). If the nail bed is allowed to heal by granulation, the resultant scar may cause a nail deformity or nonadherence.

***Avulsed Segment***

Ideally, the avulsed nail bed is sutured in an anatomic position (36). Often, the nail bed is attached to the nail plate. A decision must be made whether to separate the nail bed from the nail plate or suture the nail bed and plate as one unit. If the pieces are small, we tend to suture the nail bed and plate as one segment. If the fragment of the avulsed nail bed is large, it is carefully separated from the nail plate (Fig. 38.18). The nail bed can be sutured directly onto bone, as outlined by both Zook and Shepard (36,47).

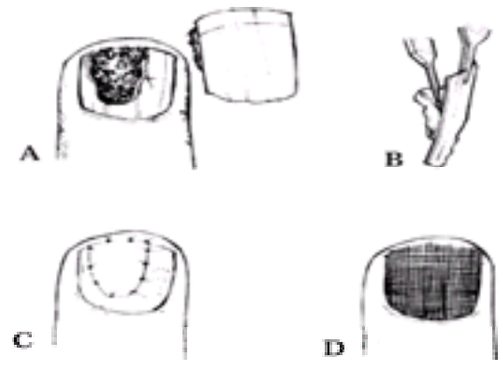


***Figure 38.18.*** **A:** A nail bed avulsion is shown. **B:** The matrix is attached to the plate. **C:** The avulsed segment is sutured. **D:** The nail plate is replaced.

- Many times, inspection in these situations reveals that the nail matrix is still attached to the avulsed nail plate. If the segment of nail matrix is large, shave it away for use as a free graft (Fig. 38.18B).
- Properly align the avulsed segment and suture it to the defect with 6-0 or 7-0 chromic suture.
- Replace the avulsed nail to cover the defect (Fig. 38.18D). If the nail plate is badly damaged, the dressing should be fine mesh gauze or other nail substitute.
- Use half-buried horizontal mattress sutures in conjunction with nail roof elevation to anchor a displaced nail plate or nail bed, or both, into the proximal nail fold (Fig. 38.19).

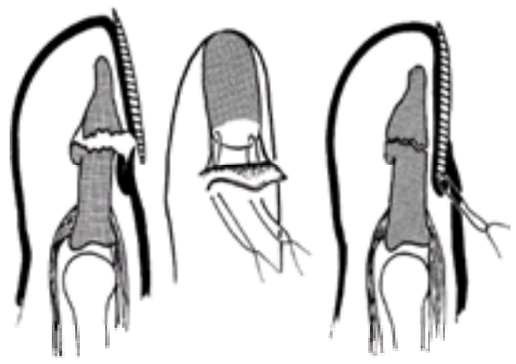

***Figure 38.19.*** The nail plate is sutured.

- The skin remnants can be sewn to the surrounding skin with 6-0 nylon suture.

***Incomplete Avulsions***

Incomplete avulsion of the nail bed often occurs at the germinal matrix. A bending force through the distal phalanx is transmitted proximally to avulse the germinal matrix and displace the nail from beneath the nail fold. In the past, the distal nail was left in place and the proximal avulsed nail bed was reapproximated (34). At present, elevation of the entire nail to ascertain the degree of injury and repair is recommended (Fig. 38.19) (36).

If the avulsed segment of nail bed is not available or amenable for repair, alternative treatment methods are necessary. In the past, treatment involved split-thickness skin grafts, dermal grafts, and healing by secondary intention. Zook and Shepard have used split-thickness nail bed grafts with good success (37,47). The preferred donor site is the injured nail, although grafts have been described from the great or second toe. Full-thickness grafts are discouraged due to the associated donor site morbidity.

- Harvest a split-thickness graft from adjacent tissue for coverage. A split-thickness nail matrix graft from a great toe can be used if insufficient tissue is presented on the digit of the avulsion.
- When taking a split-thickness nail graft, keep in mind that the thickness of the nail sterile matrix is only 240 to 990 µm (30 to 40 thousandths of an inch) and that the grafts are 165 to 240 µm (7 to 11 thousandths of an inch) (Fig. 38.20). Use a microscope to facilitate harvesting the graft.

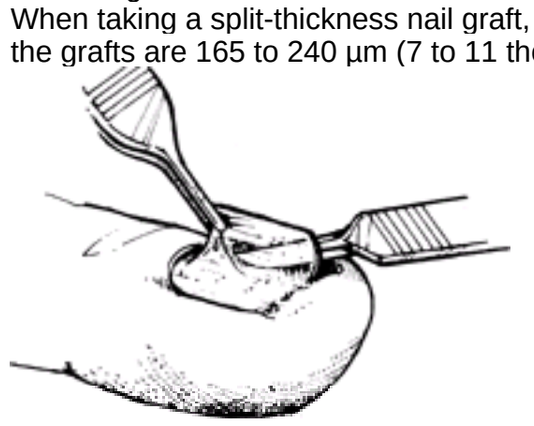

***Figure 38.20.*** In harvesting a split-thickness skin graft, an attempt is made to keep the graft so thin that the point of the knife can be seen through the graft. In practicality, the thickness of the graft varies from 7 to 10 thousandths of an inch.

- Create a template of the defect with a rubber glove and outline on the donor tissue. The tip of the scalpel should be seen at all times when harvesting the graft. Not visualizing the tip of the blade will likely lead to a graft that is too thick.
- Once the graft is procured, sew it into the defect with 7-0 chromic suture (Fig. 38-21). A linear avulsion may be treated with a bipedicle graft as an alternative. This technique fills the defect by advancing the nail bed from either side.

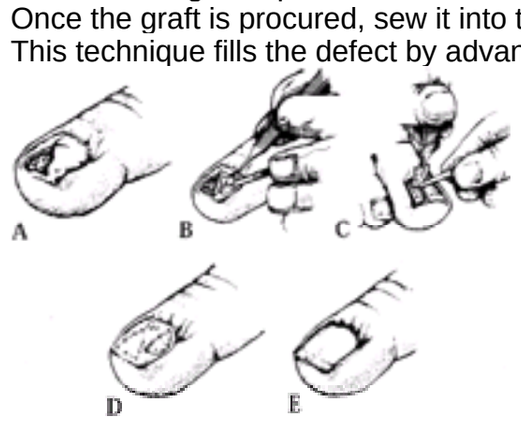


***Figure 38.21.*** **A:** A deep avulsion of the sterile matrix is shown. **B:** An adjacent matrix graft is harvested. **C:** A matrix graft from the great toe is shown. **D:** The graft is sutured. **E:** The graft is covered. (From Shepard GH. Treatment of Nail Bed Avulsions with Split-Thickness Nail Bed Grafts. *J Hand Surg* 1983;8:49.)

- The ideal dressing is the removed nail plate covered with a firm dressing.

**NAIL RECONSTRUCTION**

Nail bed injuries can lead to a variety of nail abnormalities. Typical deformities include nonadherence, split nails, linear ridging, crooked nails, and hooked nails. Nonadherence after trauma is the most common nail deformity. Distal nonadherence can be problematic due to dirt becoming lodged underneath the nail. Proximal nonadherence is more troublesome because the nail can become unstable and tear loose when picking up small objects. Nonadherence occurs when the nail does not adhere to the abnormal scar that has formed within the injured nail bed. Scar excision and primary repair has been performed. Although Zook and Russell believe that primary closure of the nail bed leads to excessive tension with resultant increased scar, they have recommended split-thickness nail grafting (20,37,47).

**SPLIT NAIL**

Split nails occur because of a longitudinal scar in the germinal or sterile matrix. The nail, therefore, grows on either side of the scar in the germinal matrix. The scar in the sterile matrix leads to nonadherence, and increased stresses in the nail causes the split or crack. Reconstructing a split nail is similar in principle to treating nonadherence. If the split is in the sterile matrix or distal germinal matrix region, the scar is excised and replaced with a split-thickness matrix graft. A split nail due to an abnormality in the germinal matrix requires a germinal matrix graft, which can be harvested from another finger or toe. Both have the complications of persistent deformity and donor site morbidity (Fig. 38-22).

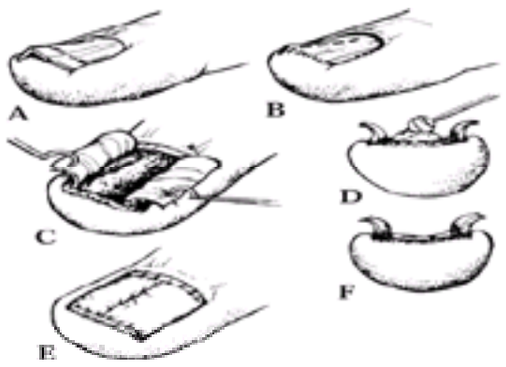


***Figure 38.22.*** **A:** A split nail following a 3 mm punch biopsy for the diagnosis of a ganglion. **B:** The defect at the base of the nail measures exactly 3 mm in diameter. **C:** After removal of the nail, the scar at the distal border of the germinal matrix is seen. **D:** A split-thickness nail graft is removed from the dorsum of the nail bed. **E:** The split-thickness nail bed graft is sutured in place with 7-0 chromic sutures. **F:** The patient's nail is shown 1 year later.

**LINEAR RIDGING**

Linear ridging is often secondary to a bony protuberance beneath the nail bed. As described by Kleinert, the treatment in this setting involves incising the nail bed over the involved area (20). An ostectomy is performed, and the nail bed reapproximated. Shepard has reported good results in six patients with this technique (Fig. 38.23) (37). If the etiology is due to scar from an injury to the sterile matrix, one can excise the scar and replace it with a split-thickness nail bed graft. For defects in the germinal matrix, one may be forced to use a full-thickness graft with its associated donor site complications. Linear ridging may be related to compression of the germinal matrix from a mucous cyst arising from the DIP. These cysts often arise in association with an osteophyte of the DIP related to degenerative joint disease. The deformity may progress from ridging to a split nail. Aspiration of the cyst often leads to recurrence. The surgical management involves excision of the osteophyte and cyst, including the stalk from the DIP. Gingrass et al. have reported a low rate of cyst recurrence with this technique (15). Progression of the nail deformity is prevented, but the deformity is likely to persist.

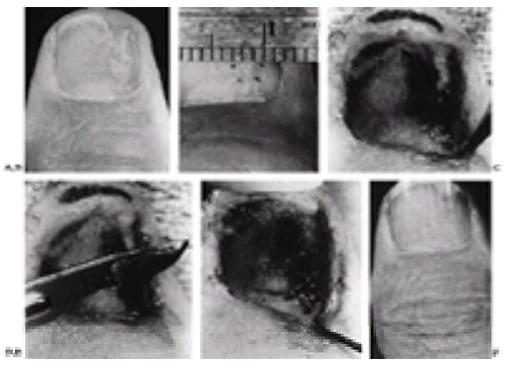

***Figure 38.23.*** **A:** A linear defect with nail ridging is shown. **B:** A linear incision was made over the bone protrusion. **C:** Matrix flaps are reflected away, revealing defect. **D:** Protruding bone is filed away. **E:** A slight overcorrection of the bony defect is encouraged to prevent thickening with callous formation. **F:** The nail matrix is sutured over the corrected bone.

**LATERAL DEVIATION**

Lateral deviation of the nail is due to a full-thickness avulsion of the lateral aspect of the nail bed with displacement (20). Rather than rotating a portion of the nail bed into the defect, the recommended management involves elevation of the entire nail bed and placing it in a straight position (Fig. 38.24).

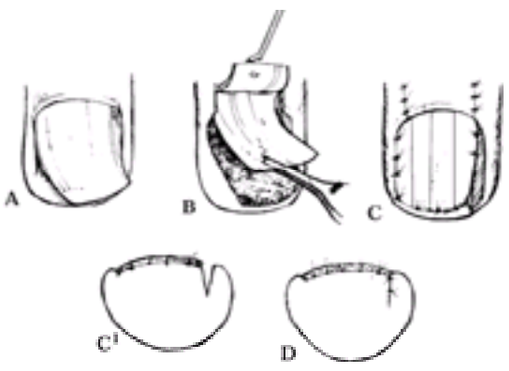


***Figure 38.24.*** **A:** Longitudinal curvature of nail is shown. **B:** A full thickness flap of matrix is illustrated. **C:** The epidermis is excised, and the flap is rotated. **D:** The wedge is sutured.

- After removal of the nail plate, create a full-thickness flap of sterile and germinal matrix down to the bone, with the only attachment being the proximal portion of the germinal matrix.
- Excise the epidermis between the nail bed and nail fold in the direction of rotation of the flap.
- Rotate the flap into the correct longitudinal position.
- Suture the wedge excision primarily, creating a straight nail.

**HOOKED NAIL**

A hooked nail involves volar displacement of the distal aspect of the nail. It can be due to a malunited fracture or a deficiency of skin of the digital pulp. Atasoy et al. have described an “antenna” procedure for correcting the deformity (Fig. 38-25) (4). The procedure involves freeing the tethered pulp and nail bed, splinting the freed nail bed, and reconstructing the soft-tissue defect of the pulp.

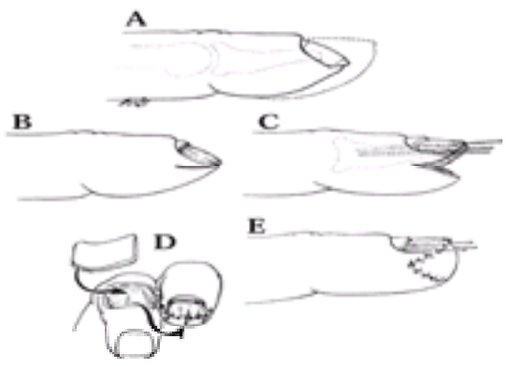


***Figure 38.25.*** **A:** A hook-nail deformity and normal contour of fingertip (dotted line) are shown. **B:** This is the procedure for removal of nail plate and skin marking. **C:** The pulp is reflected, the full-thickness of the nail matrix is elevated, and the nail matrix is splinted with three small Kirschner wires, like antennae. **D:** Coverage of the defect with a cross-finger flap is shown. **E:** Appearance after division of flap (2 weeks after surgery). (From Atasoy E, Godfrey A, Kalisman M. The "Antenna" Procedure for the Hook-Nail Deformity. *J Hand Surg* 1983;8:55.)

- Elevate the curved nail plate from the nail bed along its length and discard the portion of the nail plate distal to the lunula.
- Incise the pulp skin along the hyponychium and extend it on both sides of the pulp. Deepen the incision to reflect the pulp skin in a normal contour. Elevate the full-thickness nail bed to the level where the nail bed is straight.
- Insert two or three 0.028 Kirschner wires into the distal phalanx to splint the nail bed.
- Cover the pulp defect with a cross-finger flap. Shepard has recommended reconstructing the pulp defect with a lateral V-Y advancement flap and skin graft rather than a cross-finger flap (37). Bone grafting of the elevated portion of the distal phalanx has been discouraged by Zook due to the likelihood of bone graft resorption (46).
- An alternative treatment method involves shortening the nail bed, thereby allowing the nail to be supported by bone. A hook nail may be prevented while treating the initial injury by shortening the nail bed 2 mm greater than the distal phalanx (21). Both procedures are simple solutions but leave one with a shortened nail.

### TOTAL NAIL LOSS

Total nail loss can be treated by split-thickness skin grafting, nail prosthesis, or total nail reconstruction. Total nail reconstruction involves transfer of the nail bed as a free or vascularized nail graft. The free graft can be taken by elevating the nail plate and harvesting the nail bed and matrix as far as the proximal end of the nail matrix (29,33). In free nail grafts, Shepard notes the importance of taking the proximal nail fold. All patients in his series in which this was not incorporated would have failed. When the proximal nail fold was incorporated, he had a 50% success rate (37). The lateral edge of the great toe is often the donor site. The donor site is covered with a split-thickness skin graft.

Vascularized nail flaps have also been described. These flaps transfer a free nail with the advantage of better biologic adherence and viability. They are technically more difficult and take much longer to perform (12). Three types of vascularized grafts have been described. The first type is a long pedicle vascularized nail flap. This flap entails an 11 cm incision in which the digital artery and vein are used for anastomosis. A venous flap allows for a shorter incision, with the venous anastomosis proximal to the interphalangeal joint. The disadvantage of this flap is the concern of the existence of venous valves. The last flap is the short pedicle vascularized nail flap, which represents a combination of the above two flaps.

## AUTHORS' PERSPECTIVE

Nail bed injuries represent a very common injury in which the severity is often overlooked. It is imperative that these injuries be treated accurately initially to prevent a nail deformity. Nail bed injuries should be repaired anatomically and may require fixation of a displaced distal phalanx fracture. If it is available, the nail or substitute is replaced beneath the nail fold. Limiting a nail deformity may preclude the need for one of the technically demanding reconstructive procedures.

### CHAPTER REFERENCES

Each reference is categorized according to the following scheme: *, classic article; #, review article; !, basic research article; and +, clinical results/outcome study.


# 1 Allen M. Conservative Management of Fingertip Injuries In Adults. *The Hand* 1980;12:257.

+ 2 Arons MS. Fingertip Reconstruction with a Palmar Advancement Flap and Free Dermal Graft: A Report of Six Cases. *J Hand Surg* 1995;10A:230.

* 3 Atasoy E, Ioakimudis E, Kasdan ML, et al: Reconstruction of the Amputated Fingertip with a Triangular Volar Flap. *J Bone Joint Surg* 1970;52A:921.

* 4 Atasoy E, Godfrey A, Kalisman M. The "Antenna" Procedure for the Hook-Nail Deformity. *J Hand Surg* 1983;8A:55.

! 5 Baden H. Regeneration of the Nail. *Arch Dermatol* 1965;91:619.

# 6 Calkins ER, Smith DJ. *The Cross Finger Flap.* In: Blair WP. Techniques in Hand Surgery. Baltimore: Williams and Wilkins, 1996:48.

+ 7 Chow S, Ho E. Open Treatment of Fingertip Injuries in Adults. *J Hand Surg* 1982;7:470.

+ 8 Cohen B, Cronin E. An Innervated Cross-Finger Flap for Fingertip Reconstruction. *Plast Reconstr Surg* 1983;72:688.

+ 9 Dellon AL. The Extended Palmar Advancement Flap. *J Hand Surg* 1983;8:190.

+ 10 Elliot D, Wilson Y. V-Y Advancement of the Entire Volar Soft Tissue of the Thumb in Distal Reconstruction. *J Hand Surg* 1993;18B:399.

! 11 Elsahy NI. When To Replant a Fingertip After Its Complete Amputation. *Plast Reconstr Surg* 1977;60:14.

# 12 Endo T, Nakayama Y, Soeda S. Nail Transfer: Evolution of the Reconstructive Procedure. *Plast Reconstr Surg* 1997;100:907.

* 13 Fisher R. The Kutler Method of Repair for Fingertip Amputations. *J Bone Joint Surg* 1967;49A:317.

* 14 Foucher G, Braun J. A New Island Flap Transfer from the Dorsum of the Index to the Thumb. *Plast and Reconst Surg* 1979;63:344.

+ 15 Gingrass MK, Brown RE, Zook EG. Treatment of Fingernail Deformities Secondary to Ganglions of the Distal Interphalangeal Joint. *J Hand Surg* 1995;20A:502.

+ 16 Guy RJ. The Etiologies and Mechanisms of Nail Bed Injuries. *Hand Clin* 1990;6:9.

# 17 Hallock G. The Simple Cross-Finger Flap, Technique and Vascular Anatomy. *Orthop Rev* 1984;13:75.

+ 18 Holevich J. A New Method of Restoring Sensibility to the Thumb. *J Bone Joint Surg* 1963;45B:496.

# 19 Idler R, Strickland J. Management of Soft Tissue Injuries to the Fingertip. *Orthop Rev* 1982;10:25.

+ 20 Kleinert H, Putcha S, Ashbell T, Kutz JE. The Deformed Fingernail, a Frequent Result of Failure to Repair Nail Bed Injuries. *J Traumatol* 1967;7:177.

+ 21 Kumar VP, Satku K. Treatment and Prevention of "Hook Nail" Deformity with Anatomic Correlation. *J Hand Surg* 1993;18A:617.

* 22 Kutler W. A New Method for Fingertip Amputation. *JAMA* 1947;133:29.

+ 23 Lanzetta M, Mastropasqua B, Chollet A, Brisebois N. Versatility of the Homodigital Triangular Neurovascular Island Flap in Fingertip Reconstruction. *J Hand Surg* 1995;20B:824.

# 24 Lister GD: Skin Flaps. In: Green DP, ed. *Operative Hand Surgery.* New York: Churchill Livingstone, 1993:1741.

# 25 Louis DS: Amputations. In: Green DP, et al. *Operative Hand Surgery.* New York: Churchill Livingstone, 1993:53.

+ 26 Melone CP, Beasley RW, Carstens JH. The Thenar Flap—An Analysis of its Use in 150 Cases. *J Hand Surg* 1982;7:291.

* 27 Moberg E. Aspects of Sensation in Reconstructive Surgery of the Upper Extremity. *J Bone Joint Surg* 1964;46A:817.

+ 28 Moiemen NS, Elliot D, Composite Graft Replacement of Digital Tips 2. A Study in Children. *J Hand Surg* 1997;22B:346.

+ 29 Pessa JE, Tsai T, Li Y, Kleinert HE: The Repair of Nail Deformities with the Nonvascularized Nail Bed Graft: Indications and Results. *J Hand Surg* 1990;15A:466.

+ 30 Posner MA, Smith RJ: The Advancement Pedicle Flap for Thumb Injuries. *J Bone Joint Surg* 1971;53A:1618.

# 31 Russell RC, Van Beek AL, Wavak P, Zook EG: Alternative Hand Flaps for Amputations and Digital Defects. *J Hand Surg* 1981;6A:399.

# 32 Russell RC, Cases L.: *Management of Fingertip Injuries. Upper Extremity Trauma and Reconstruction* 1989;94:1298.

+ 33 Saito H, Suzuki Y, Fujino K, Tajima Y: Free Nail Bed Graft for Treatment of Nail Bed Injuries of the Hand. *J Hand Surg* 1983;8:171.

# 34 Schiller C: Nail Replacement in Fingertip Injuries. *Plast Reconstr Surg* 1957;19:521.

* 35 Shepard GH: The Use of Lateral V-Y Advancement Flaps for Fingertip Reconstruction. *J Hand Surg* 1983;8A:254.

# 36 Shepard GH. Management of Acute Nail Avulsions. *Hand Clin* 1990;6:39.

# 37 Shepard GH. Nail Grafts for Reconstruction. *Hand Clin* 1990;6:79.

! 38 Sherif MM. First Dorsal Metacarpal Artery Flap in Hand Reconstruction. I. Anatomical Study. *J Hand Surg* 1994;19A:26.

+ 39 Sherif MM. First Dorsal Metacarpal Artery Flap in Hand Reconstruction. II. Clinical Application. *J Hand Surg* 1994;19A:32.

+ 40 Smith RJ, Albin R: “H-Flap” for Finger Tip Injuries. *J Trauma* 1976;16:778;

# 41 Stice RC, Wood MB.: Neurovascular Island Skin Flaps in the Hand: Functional and Sensibility Evaluations. *Microsurgery* 1987;8:162.

# 42 Van Beek AL, Kassan MA, Adson MH, Dale V. Management of Acute Fingernail Injuries. *Hand Clin* 1990;6:23.

+ 43 Vlastou C, Earle AS, Blanchard JM. A Palmar Cross-Finger Flap for Coverage of Thumb Defects. *J Hand Surg* 1985;10A:566.

+ 44 Walker MA, Hurley CB, May JW. Radial Nerve Cross-Finger Flap Differential Nerve Contribution in Thumb Reconstruction. *J Hand Surg* 1986;11A:881.

# 45 Zook EG, Guy RJ, Russel RC. A Study of Nail Bed Injuries: Causes, Treatment, and Prognosis. *J Hand Surg* 1984;9A:247.

# 46 Zook EG. Anatomy and Physiology of the Perionychium. *Hand Clin* 1990;6:1.

# 47 Zook EG. Discussion of “Nail Grafts for Reconstruction.” *Hand Clin.* 1990;6:103.

# 48 Zook EG, Brown RE. The Perionchyium. In: Green DP, ed. *Operative Hand Surgery.* New York, Churchill Livingstone, 1990:1283

# CHAPTER 39

# DISLOCATIONS AND LIGAMENTOUS INJURIES OF THE DIGITS

*Donald H. Lee and Robert J. Neviaser*

**D. H. Lee:** Division of Orthopedic Surgery, University of Alabama at Birmingham, Birmingham, Alabama, 35294.
**R. J. Neviaser:** Department of Orthopedic Surgery, George Washington University, Washington, D.C., 20037.

Anatomy
Interphalangeal Joints
Metacarpophalangeal Joint
Carpometacarpal Joints
Pathophysiology
General Principles of Treatment
Classifications
Fingers
Distal Interphalangeal Joint
Proximal Interphalangeal Joint
Metacarpophalangeal Joint
Carpometacarpal Joint
Thumb
Anatomy
Thumb Metacarpophalangeal Joint
Trapeziometacarpal (Carpometacarpal) Joint
Chapter References

Through a unique combination of sensibility, stability, and mobility, the hand allows us to manipulate our environment. The thumb's mobile carpometacarpal joint and stable metacarpophalangeal (MP) and interphalangeal (IP) joints allow both precision pinch and power movements, including grasp. The stable carpometacarpal joints of the index and long fingers provide for stability along the central longitudinal axis of the hand, whereas the relatively mobile ring and little carpometacarpal joints provide mobility to allow cupping or flattening of the hand. The hingelike MP and especially the IP joints allow the ability to grasp objects of varying size.

Because of the constant exposure of the hand to external forces, dislocations and ligamentous injuries of the digital joints are quite common (396,397). Proximal interphalangeal (PIP) joint injuries are probably the most common joint injuries in the hand (68,128). Fortunately, in the acute phase, most digital dislocations and ligament injuries can be treated by closed or nonoperative means. This chapter discusses these topics by joint. The fingers are covered as one, except where a specific injury to a specific joint in a specific finger requires individual attention. The joints of the thumb are addressed separately. A general treatment algorithm is provided at the beginning of each section.

## ANATOMY

All the IP and MP joints of the fingers and thumb are similar in that their stability is provided by a series of ligaments. The major stabilizers of these joints include the volar plate and the collateral ligaments. The volar plate is a fibrocartilaginous structure firmly attached to bone distally, with a filmy proximal recess. On the sides of each joint are the collateral ligaments, which blend palmarly with the accessory collateral ligaments. The shape of these collateral ligaments varies from a slightly fanlike shape at the proximal IP level to very fan-shaped at the MP joint.

### INTERPHALANGEAL JOINTS

The proximal and distal interphalangeal joints are similar in configuration. The PIP joint is a hinge or ginglymus joint, consisting of a convex bicondylar proximal phalangeal head articulating with the biconcave middle phalangeal base. It allows approximately 100° to 110° of flexion. A centrally located proximal phalangeal notch articulates with a corresponding middle phalangeal median ridge (Fig. 39.1). Dorsally, the central slip attaches to a tubercle on the base of the middle phalanx. Palmarly, the volar plate forms the floor of the joint. The volar plate has a thickened distal fibrocartilagenous portion that is thicker along its lateral edges. The volar plate attaches along the volar base of the middle phalanx, blending with the volar periosteum of the middle phalanx centrally and the collateral ligaments laterally (Fig. 39.2) (12,14,15,20,28,38,76,77,82,95,137). The proximal portion of the volar plate tapers along its lateral edges to form two check-rein ligaments (Fig. 39.3) (12,14,15,82). Laterally, the collateral ligaments consist of a thicker dorsal cordlike collateral ligament proper, and a thinner volar accessory component (76,91,137). The collateral ligaments arise from a concavity along the lateral aspect of the proximal phalangeal head. The ligaments pass obliquely and palmarly to attach distally into a volar lateral tubercle on the base of the middle phalanx and along the distal lateral margin of the volar plate. The volar plate provides resistance to hyperextension injuries of the PIP joint. Resistance to lateral stresses are provided mostly by the collateral ligaments and secondarily, if at all, by the volar plate (68,114). Some stability is also afforded by the surrounding tendon and retinacular system (15,82,124). Disruption of at least two portions of the volar plate and two collateral ligaments must occur for displacement of the PIP joint (30).

***Figure 39.1.*** The fit of the articular surfaces of the metacarpophalangeal joint (*left*) and proximal interphalangeal joint (*right*). (From Green DP, Butler TE. Fractures and Dislocations in the Hand. In: Rockwood CA, Green DP, Bucholz RW, Heckman JD, eds. *Fractures in Adults, 4th ed.* Philadelphia: Lippincott-Raven, 1996:677, with permission.)

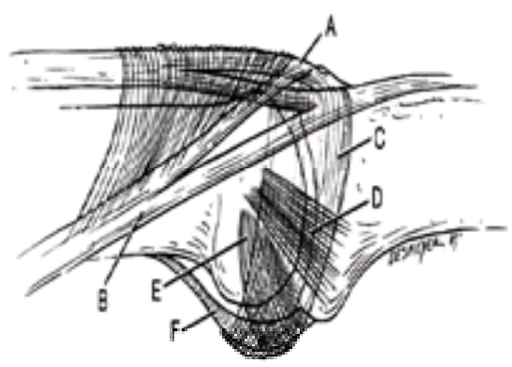

***Figure 39.2.*** Basic anatomy of the proximal interphalangeal joint. A, central extensor slip; B, intrinsic lateral band; C, transverse retinacular ligament; D, dorsal cord portion collateral ligament; E, accessory collateral ligament; F, volar plate. (From Vicar AJ. Proximal Interphalangeal Joint Dislocations without a Fracture. *Hand Clin* 1988;4:5, with permission.)

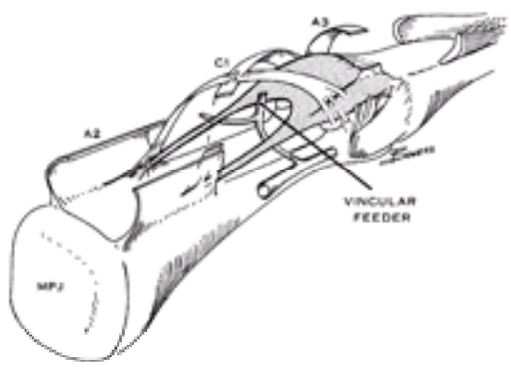


***Figure 39.3.*** The proximal portion of the volar plate tapers along its lateral edges to form two check-rein ligaments. (From Bowers WH, ed. *The Interphalangeal Joints*. Edinburgh: Churchill Livingstone, 1987, with permission.)

The distal interphalangeal (DIP) joint, in addition to the stability provided by the collateral ligaments and volar plate, has some dynamic stability provided by the insertions of the flexor digitorum profundus and the terminal tendon of the extensor mechanism on the base of the distal phalanx.

**METACARPOPHALANGEAL JOINT**

The MP joint of the fingers is a condyloid joint, consisting of a relatively ovoid metacarpal head articulating with an elliptical cavity at the base of the proximal phalanx. The metacarpal head is narrower dorsally than palmarly in the sagittal plane, and it has a proportionately larger anteroposterior diameter than that of the phalangeal head (Fig. 39.4). Joint motion is primarily in the sagittal (flexion–extension) plane, but both coronal (abduction–adduction) plane and small circumduction movements also occur (217).

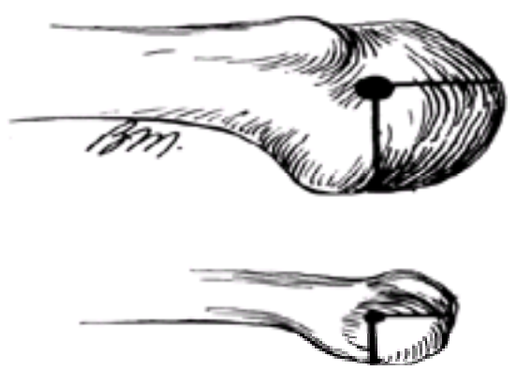

***Figure 39.4.*** Comparison of the metacarpal head (*top*), which is narrower dorsally than volarly in the sagittal plane and has a proportionately larger AP diameter than that of the phalangeal head (*bottom*). (From Green DP, Butler TE. Fractures and Dislocations in the Hand. In: Rockwood CA, Green DP, Bucholz RW, Heckman JD, eds. *Fractures in Adults, 4th ed.* Philadelphia: Lippincott-Raven, 1996:677, with permission.)

The MP joint capsule extends from the metacarpal neck to the base of the proximal phalanx. Volarly, the joint capsule blends with the volar plate, which consists of a thick fibrocartilagenous distal portion and a thin membranous proximal portion. The volar plate is more securely attached to the proximal phalanx than to the metacarpal neck. The volar plate is also continuous medially and laterally with the deep transverse metacarpal ligament (Fig. 39.5) (162,167,172,173,192,217). Dorsally, the MP joint capsule is thin, and it is reinforced by a loose insertion of the common extensor tendon. The collateral ligaments extend from the metacarpal head to the base of the proximal phalanx, and they also insert into the volar plate. In addition, the metacarpal origin of the collateral ligament is more dorsal than its counterpart at the PIP joint (207). These factors dictate that the collateral ligaments of the MP joint are at their longest or most taut in full flexion (Fig. 39.6), while those of the PIP are most taut at only a few degrees of flexion. It is important to remember this when testing for collateral ligament stability or when determining the tension appropriate for a repaired ligament, both during the repair and after surgery. Additionally, the sagittal bands and intrinsic muscle tendons provide secondary support to the MP joints (124).

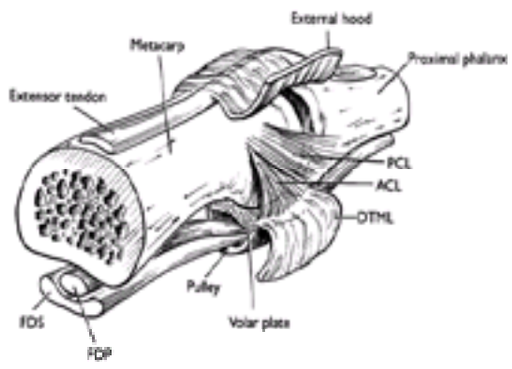


***Figure 39.5.*** Basic anatomy of the proximal interphalangeal joint. A, central extensor slip; B, intrinsic lateral band; C, transverse retinacular ligament; D, dorsal cord portion collateral ligament; E, accessory collateral ligament; F, volar plate. (From Vicar AJ. Proximal Interphalangeal Joint Dislocations without a Fracture. *Hand Clin* 1988;4:5, with permission.)

***Figure 39.6.*** The collateral ligaments of the metacarpophalangeal joint are taut with the joint in flexion and lax with the joint in extension.

## CARPOMETACARPAL JOINTS

The carpometacarpal (CMC) joints of the hand consist of a fixed, stable central unit that comprises the index and long CMC joints and the relatively mobile radial (thumb) and ulnar units (ring and little). Together they form the fixed transverse metacarpal arch of the hand (Fig. 39.7). The index and long finger metacarpals articulate with the trapezoid and capitate with strong CMC ligaments, providing relatively little motion (242,244,263,271). Stability of these joints is provided by tight joint articulations, thick dorsal capsular ligaments, volar ligaments, interosseous ligaments, and by some support of the transverse carpal ligament. Additionally, insertions of the flexor carpi radialis and extensor carpi radialis longus into the base of the index metacarpal, and of the extensor carpi radialis brevis into the base of the long metacarpal provide some dynamic stability to the these joints (Fig. 39.8).

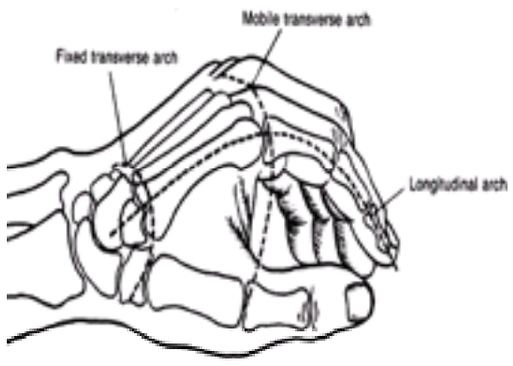


***Figure 39.7.*** The carpometacarpal joints of the index through little fingers form the fixed transverse arch of the hand.

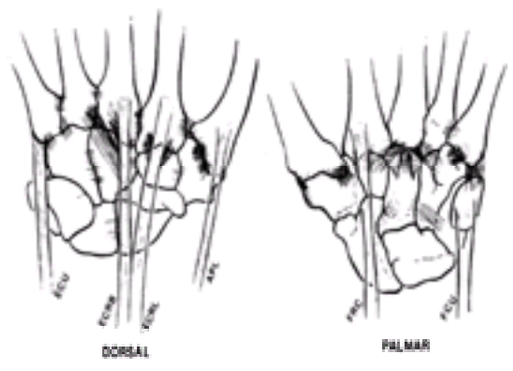


***Figure 39.8.*** The carpometacarpal joints with supporting ligaments and tendon insertions. (From Gunther SF. The Carpometacarpal Joints. *Orthop Clin North Am* 1984;15:25, with permission.)

The ulnar ring and little finger metacarpals are relatively mobile, providing approximately 10° to 30° of flexion and extension, respectively, as well as a few degrees of supination (212,244). They articulate with two separate hamate facets. A slightly convex fifth metacarpal base articulates with a slightly concave ulnar hamate facet, whereas a somewhat flatter fourth metacarpal articulates with the radial hamate facet. Stability to these joints is provided by the carpometacarpal and interosseous ligaments. Additionally, the hypothenar muscles and insertions of the extensor carpi ulnaris and flexor carpi ulnaris via the pisometacarpal ligament (a continuation of the flexor carpi ulnaris insertion) provide some dynamic stability to these joints.

## PATHOPHYSIOLOGY

Injuries to the digits and hand can occur from a variety of external forces. These forces can be direct (crush, burns, lacerations) and/or indirect forces (rotational, bending, axial loading). With indirect forces, the direction of the deforming force determines the type of joint injury, while the amount of force dictates whether the injury is a subluxation or a dislocation. For instance, dorsal PIP joint dislocations are often accompanied by a longitudinal compressive force; the magnitude of compression affects the complexity of the injury. When greater longitudinal compressive forces are combined with a hyperextension deforming force, dorsal PIP fracture–dislocations are produced. The mechanism of injury for a particular joint disorder is further discussed with each specific injury.

Secondary dynamic forces, provided by tendon insertions, frequently accentuate the deformity. For instance, insertion of the abductor pollicis longus on the base of the thumb metacarpal, and of the adductor pollicis on the metacarpal shaft, will accentuate a thumb CMC joint dislocation or fracture–dislocation.

Injuries of the soft tissues, usually through either direct forces or excessive indirect forces, can produce open wounds or neurovascular injuries. These injuries will ultimately affect the course of treatment. The treatment of an open dislocation with neurovascular compromise is different from that of a simple closed injury.

## GENERAL PRINCIPLES OF TREATMENT

The goal for any treatment of digital dislocations or ligament injuries is to restore functional, pain-free, and stable joint motion. To accomplish this goal requires an early, accurate evaluation and diagnosis of the injury and adequate treatment. The goal of treatment for injuries seen late is usually to provide pain relief.

Obtain a history of the mechanism of the injury (e.g., extension, flexion, lateral deviation force) and timing of the injury (acute versus chronic). Examine for active joint range of motion, neurovascular status, flexor and extensor tendon function, areas of localized tenderness, and, finally, passive joint stability.

Most dislocations or ligament injuries that are closed and simple can be treated by nonoperative means. Digital block or nerve block anesthesia can be helpful in evaluating joint stability or reducing dislocations, but this is often unnecessary. Determine and record the neurologic status prior to an anesthetic or treatment of the injury.

Dislocations are usually obvious from clinical examination, but good radiographs in at least two orthogonal planes (perpendicular to one another) are necessary. With a digital injury, radiographs of the digit (not of the hand) before and after treatment are needed to accurately assess any associated fractures, as well as the efficacy of treatment.

Use stress views to evaluate ligament injuries if clinical testing leads to a question about the integrity of a ligament (Fig. 39.9*A*). If used, anesthesia (usually a digital block or intraarticular injection) is helpful to reap the maximum benefit from a stress view. Similarly, stress views of the injured joint under fluoroscopy, when compared to the uninjured joint in the opposite hand, can be helpful in detecting ligament injuries (Fig. 39.9*B*).

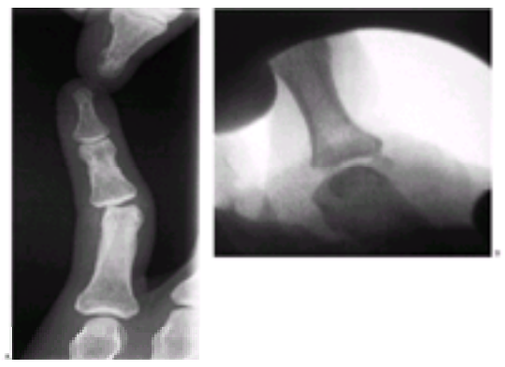

***Figure 39.9.*** **A:** AP radiograph with lateral stress applied to the proximal interphalangeal joint. Lateral deviation of more than 20° is indicative of a complete collateral ligament injury. **B:** Fluoroscopic stress view of the thumb MP joint showing lateral subluxation of the proximal phalanx.

Other specific radiographs may also be helpful in evaluating particular joint injuries. An oblique view (Brewerton view) of the metacarpal heads may be helpful in detecting small metacarpal head fractures (171,185,189,206). The Brewerton view is taken as an anteroposterior (AP) view of the hand with MP joints of the hand flexed approximately 65° and the x-ray beam tilted 15° from an ulnar to radial direction (185). Evaluation of the thumb CMC joint requires a true AP view and a lateral view of the joint (Robert view) (403). The AP radiograph is taken with the hand fully pronated and with the dorsum of the thumb lying flat on the x-ray plate. The x-ray beam is then centered over the thumb CMC joint. The lateral radiograph of the joint is taken with the radial side of the thumb lying on the x-ray plate (thumbnail lying perpendicular to the plate) and the x-ray beam centered over the joint. Evaluation of the finger CMC joints will frequently require oblique views of the hand. Occasionally, due to the difficulty in evaluating these joints, tomography or computed tomography (CT) may be needed.

After reduction of the joint, assess both active stability (full active range of motion) and passive stability (passively applied medial–lateral and anterior–posterior stress). If the injury is amenable to closed treatment, use a cast dressing that immobilizes the hand and wrist as well as all the fingers and, if necessary, the thumb. Take care when using a digital splint, as an acutely injured digit can be further harmed by immediately taping it to a digital splint. After surgical intervention, a similar cast dressing is applied.

In most cases with closed treatment, the dressing is changed within 5 days. Begin an appropriate active motion program, modifying for the specific injury. The same is recommended for many postoperative cases. The goal is to provide joint stability and adequate protection against reinjury or disruption of the repair while gaining maximal motion to prevent tendon adherence or joint stiffness.

## CLASSIFICATIONS

Dislocations and ligamentous injuries of the interphalangeal, metacarpophalangeal, and carpometacarpal joints can be classified similarly. Classification can be based on the status of the skin (closed versus open), the duration of injury (acute versus chronic), the degree of joint displacement (subluxation versus dislocation), the status of the joint surface (dislocation versus fracture–dislocation), and the ability to reduce the joint dislocation (simple versus complex).

Joint subluxations occur with disruption of some of the joint soft tissue supporting structures, but some contact remains between the articular surfaces. With dislocations, there is a loss of contact between the joint surfaces. Joint dislocations and subluxations can be further subclassified based on the direction of displacement of the distal portion of the injured digit relative to the proximal portion, that is, dorsal, lateral, or palmar (volar) dislocations.

Specific classifications of an injury pertaining to a particular joint will be discussed separately.

## FINGERS

### DISTAL INTERPHALANGEAL JOINT

#### *Assessment and Indications for Treatment*

In addition to an obvious DIP joint dislocation, flexor or extensor tendon avulsion injuries, nail bed injuries, and open injuries are common (Table 39.1). Assess these structures and obtain true AP and lateral radiographs of the digit and particularly of the DIP joint. Open dislocations require adequate debridement and antibiotics.

***Table 39.1. Algorithm for Assessment of Distal Interphalangeal (DIP) Joint Injuries***

Distal interphalangeal joint dislocations are uncommon. The more common injuries occur secondary to a hyperextension force (dorsal dislocation, dorsal lip fracture or fracture–dislocation), forced extension against resistance (flexor profundus tendon avulsion injury), flexion injury (extensor tendon avulsion injury), hyperflexion force (palmar dislocation), and lateral deviation force (collateral ligament injury). The addition of a longitudinal compression force usually adds some form of an intraarticular fracture.

#### *DIP Joint Dislocations*

Dislocations of the DIP joint are almost always dorsal and are rare (42,83). These injuries are usually produced by a longitudinal compression and hyperextension of the joint. Occasionally, a lateral, and even less commonly a palmar, dislocation can occur. Look for flexor (jersey finger) (Chapter 48) or extensor tendon (mallet finger) (Chapter 49) avulsion injuries, which are common. Simultaneous dislocation of the distal and proximal interphalangeal joints has been described and should be detectable by careful clinical examination and adequate radiographs of the injured digit (5,6,9,32,45,47,50,52,54,57,73,75,99,117,139,142).

- Perform a closed reduction, with or without digital block anesthesia, using longitudinal traction on the distal phalanx.
- Place direct pressure on the dorsal base of the distal phalanx, displacing it distally and palmarly.
- Postreduction radiographs should confirm congruous reduction of the joint.
- After joint reduction, assess joint stability and flexor and extensor tendon function. If joint instability is present after joint reduction, splint the joint for 2 to 3 weeks in 10° to 20° of flexion (for dorsal dislocations).
- With a palmar dislocation, dorsal lip fracture–dislocation, or terminal extensor tendon avulsion (mallet finger) injury, avoid splinting the DIP joint in hyperextension. This prevents dorsal skin wound problems. Splint, generally, for 6 weeks or more to promote healing (see Chapter 49). Fracture–dislocations of the joint can occur (46,51).
- If the flexor digitorum profundus is avulsed with the volar fragment, reattach the tendon.

- Open dislocations of the DIP joint are frequent and require irrigation, debridement, and antibiotics. Repair any associated nail bed injuries or nail plate avulsions.
- When the dislocation is chronic (greater than 3 weeks) or irreducible, perform an open reduction. Irreducible DIP joint dislocations may be secondary to interposed volar plate, flexor tendon, fracture fragment, or a sesamoid bone (32,44,53,58,67,70,98,103,107,108,112,118,122,123,130,133,150). Remove the interposed structure to reduce the joint.

#### *Open Reduction of an Irreducible DIP Joint Dislocation*

- Make a straight dorsal midline, transverse, or H-shaped incision and split the extensor tendon longitudinally in the midline. Alternatively, divide the tendon transversely and repair it at the time of closure.
- If the volar plate is interposed between the joint surfaces, incise as much of it as necessary to displace it palmarly.
- Release the collateral ligaments subperiosteally at their insertion into the middle phalanx and continue the dissection until the joint can be reduced. Test the joint for stability.
- If the joint is grossly unstable, transfix the joint with smooth 0.035–0.045 Kirschner (K-) wire(s) for 3 weeks. If the joint is fairly stable, immobilize it in a splint for a few days for comfort.
- Then apply a dorsal-block splint and allow active flexion. Remove the splint after 3 weeks.
- If the joint surface damage is extensive, perform a primary arthrodesis (see Chapter 72).

#### *Complications*

Complications in the treatment of DIP joint injuries will usually occur from a failure in diagnosis, from a delay in treatment, or from undertreatment. Failure to recognize a concomitant injury to soft tissues (e.g., flexor or extensor tendons) will result in a deformity (e.g., jersey finger or mallet finger) (186). Unrecognized dislocations generally require an open reduction and pin fixation, instead of a closed reduction. Delayed reduction of the joint may also result in significant articular damage, necessitating an arthrodesis. Redislocation of a dorsal DIP joint dislocation can occur if hyperextension is not prevented for at least 3 weeks.

#### *DIP Joint Ligament Injuries*

Unless they accompany a dislocation, nearly all ligament injuries of the DIP joint are partial tears or sprains at the DIP joint level and thus can be treated nonoperatively. Temporary splinting for a few days for comfort should be followed by an early, vigorous active motion program.

### PROXIMAL INTERPHALANGEAL JOINT

#### *Assessment and Indications for Treatment*

Proximal interphalangeal joint dislocations and subluxations are frequently associated with an injury to the volar plate, collateral ligament, extensor tendon (central slip), and joint articular surface (Table 39.2). Assess these structures and take true AP and lateral radiographs of the digit, particularly of the PIP joint. Stress views to assess collateral ligament injuries may be helpful. Open dislocations require adequate debridement and antibiotics.

***Table 39.2. Algorithm for Assessment of Proximal Interphalangeal (PIP) Joint Injuries***

Proximal interphalangeal joint injuries, especially dislocations, are among the most common hand injuries (23,38,42,98,104), ranging from a simple hyperextension injury, as seen in sporting injuries, to a severely comminuted fracture. The more common injuries occur secondary to a hyperextension force (dorsal subluxation or dislocation, volar plate rupture), longitudinal compression and hyperextension force (dorsal fracture–dislocation), lateral deviation force (collateral ligament injuries), and combined rotatory and longitudinal compression force (rotatory dislocations).

#### *PIP Joint Dorsal Dislocations*

There are several dorsal PIP joint dislocation classification systems (14,28,38,48,84,86,120). However, generally three types can be categorized depending on the degree of hyperextension force applied to the joint and any associated fractures (28,38).

- Type I is a hyperextension injury to the joint with subluxation but not dislocation.
- Type II is a dorsal dislocation.
- Type III is a shear fracture of the volar base of the middle phalanx, producing a fracture–dislocation (Fig. 39.10). Type I injuries are associated with avulsion of the volar plate, and a partial horizontal split occurs between the volar and dorsal portions of the collateral ligaments. Type II injuries are associated with a complete avulsion injury of the volar plate and a greater longitudinal tear of the collateral ligaments (12,18,28,38).

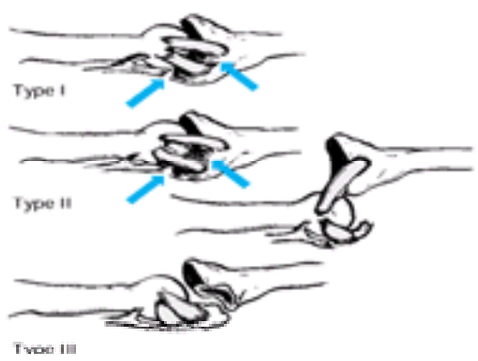


***Figure 39.10.*** Three types of dorsal PIP joint hyperextension injury (see text for description of injuries).

The acute dorsal injury without fracture can usually be reduced by closed means. A digital block is often unnecessary. The volar plate, by necessity, is ruptured, usually from the middle phalanx, but the collateral ligaments rarely are ruptured completely from their attachments (10,12). Perform reduction with longitudinal traction and direct pressure on the dorsal base of the middle phalanx, displacing it distally and palmarly. Confirm congruous reduction of the joint with postreduction radiographs. Assess both active and passive stability of the joint after reduction. With type I and II dorsal dislocations, the joint is usually stable after reduction (56,126). Type III injuries are discussed in the following section. Use a resting splint with the finger flexed to 20° to 30° for 7–10 days. Do not splint the digit in flexion for an extended period of time, and begin early active motion with protection against hyperextension. Alternatively, use an orthoplast figure-eight splint, preventing joint hyperextension (79). Protect the injured digit, especially during sporting activities, by taping it to the adjacent uninjured digit. Reassure the patient that persistent swelling and slow

resolution of stiffness is to be expected.

Treat open PIP joint dislocations with irrigation, debridement, and antibiotics (71,129).

Chronic dorsal dislocations are uncommon, as are irreducible dorsal dislocations (36,43,62,71,101), and require open reduction. An attempt at gentle closed reduction under adequate anesthesia is permissible but is best done in the operating room; if it is unsuccessful, the joint then can be approached surgically.

***Open Reduction of a Chronic, Irreducible, Dorsal PIP Joint Dislocation***

- Make a straight or slightly curvilinear dorsal longitudinal incision.
- Divide the central slip of the extensor mechanism in the midline but do not dissect distal to the base of the middle phalanx, as the attachments of the central slip to the middle phalanx and triangular ligament must remain intact.
- If the volar plate is interposed, split the interval between it and each accessory collateral ligament. Mobilize the volar plate and perform a trial reduction of the joint.
- If this fails, release the origins of the collateral ligaments from the proximal phalanx by sharp subperiosteal dissection. This should allow reduction if the joint is hyperextended and the volar plate is pushed palmarward.
- After reduction, test the joint for instability. If instability is present, transfix the joint with smooth 0.035–0.045 K-wire for 3 weeks.
- If the joint is fairly stable, close the extensor split and the skin separately with nonabsorbable sutures. Take postreduction radiographs to confirm congruous reduction of the joint.
- Immobilize the hand in a cast dressing with the PIP joints flexed no more than 10°. After 5–7 days, begin active flexion for an additional 2–4 weeks, using a dorsal extension-block splint to prevent hyperextension of the joint.

***Complications***

The most common complication following a dorsal PIP joint dislocation is stiffness secondary to prolonged splinting (146). Prolonged splinting of the joint in flexion can produce a joint flexion contracture, due to contracture of the volar plate (also referred to as a pseudoboutonnieére deformity) (90,91). A significant contracture can be treated with dynamic splinting, serial casting, or, eventually, surgical release of the contracture (25,38,80,88,140).

In contrast to prolonged splinting of the PIP joint, if joint hyperextension is not prevented for at least 3 weeks, either redislocation of the joint or a chronic swan-neck deformity may occur (104). A true lateral radiograph will help guard against persistent subluxation. With a chronic swan-neck deformity, painful snapping of the lateral bands over the phalangeal heads or inability to initiate joint flexion may occur. Treatment includes primary reattachment of the volar plate or sublimis tenodesis (see the section below on volar plate ruptures) (1,7,12,22,38,72,78,91,109,110,132,136,144,195).

***PIP Joint Palmar Dislocations***

Palmar PIP dislocations are rare and result from a longitudinal and rotatory force directed on a partially flexed PIP joint (39,127). The injury results in volar displacement of the middle phalanx relative to the proximal phalanx. There is a disruption of the extensor mechanism (central slip), creating a boutonnieére injury. One proximal phalangeal condyle may herniate between the central slip and the lateral band, producing a rotatory or irreducible PIP joint dislocation (see Rotatory Dislocations). There may be an injury to a collateral ligament and the volar plate (Fig. 39.11) (33,37).

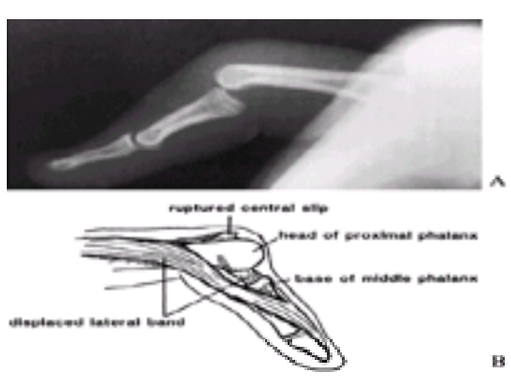


***Figure 39.11.*** **A:** Lateral radiograph of volar proximal interphalangeal dislocation. **B:** Diagram showing how the boutonnieére develops as the head of the proximal phalanx herniates through the extensor mechanism.

Usually, closed treatment will successfully reduce these dislocations:

- Reduce a palmar PIP joint dislocation with gentle traction on the middle phalanx with the MP and PIP joints flexed (134,146). Wrist extension may relax the extensor mechanism. In general, full passive extension of the joint is obtainable and postreduction radiographs should confirm congruous reduction of the joint.
- After reduction, test active PIP joint extension to determine the status of the central slip. With disruption of the central slip, the PIP joint should be splinted in extension for 4–6 weeks, either with smooth K-wire transfixing the joint or simply with an external splint.
- The DIP and MP joints should be permitted to move so that the extensor mechanism is less likely to become adherent. If the dislocation is irreducible or chronic (34,106,110,111), surgery is necessary.

**Open Reduction of a Chronic Palmar PIP Joint Dislocation**

- Make a straight dorsal or slightly curvilinear incision.
- Mobilize the lateral bands so that the head of the proximal phalanx is no longer caught between them.
- Reduce the joint, and transfix it in extension with smooth 0.035–0.045 K-wire.
- Reattach the central slip to the base of the middle phalanx with nonabsorbable sutures to remaining periosteum, through bone holes, or with miniature suture anchors. Repair the interval between each lateral band and the central slip with nonabsorbable sutures. Postreduction radiographs should confirm congruous reduction of the joint.
- Remove the pin after 6 weeks, having allowed active motion at the MP and DIP joints during that time.

**Complications** The results of open reduction of a chronic palmar PIP joint dislocation tend to be poor, emphasizing the need for early recognition of the injury (28,34,38,41,106,110,146). If any or too early PIP flexion is allowed during the immobilization period, a boutonnieére deformity will result. Treatment of the boutonnieére deformity varies depending on the duration of the deformity (35,89).

***PIP Joint Rotary (Irreducible) Dislocations***

Irreducible rotary dislocation of the PIP joint, a complex volar-lateral dislocation, is an uncommon injury in which the middle phalanx is displaced laterally and palmarly (8,21,24,30,36,39,59,61,63,65,69,93,98,100,102,106,110,111,122,127,135,143). The injury occurs secondary to a combined rotatory and compressive force applied to the PIP joint. Clinically, the PIP joint is swollen and tender. The digit may be deviated and flexed. In contrast to the palmar PIP joint dislocation, for which passive extension is possible after reduction, there is resistance to active and passive flexion and especially to passive extension.

On the injured side of the joint, the collateral ligament is ruptured and the condyle of the proximal phalanx usually penetrates through a longitudinal rent between the lateral band and the central slip (Fig. 39.12). The lateral band is looped through the joint around the condyle, preventing reduction.

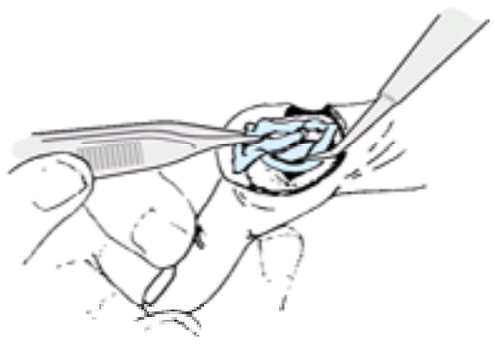

***Figure 39.12.*** A longitudinal rent in the extensor mechanism produced by the condyle of the proximal phalanx (*above probe*) splits the central slip (*held by forceps*) from the lateral band (*below probe*). The band then loops around the condyle and through the joint, preventing reduction.

Radiographically, the lateral and palmar dislocation can be improved by closed reduction, but there will be a persistent subluxation and widening of the joint space on the side of injury (Fig. 39.13). Due to the rotatory nature of the injury, on a true lateral radiograph of the digit, one phalanx may appear slightly rotated relative to the other. This persistent subluxation of the joint usually must be treated surgically. Attempt closed reduction following digital block anesthesia, with gentle longitudinal traction and finger rotation (20,28,38,134). Flex the MP and PIP joints to relax the lateral bands, and extend the wrist to relax the extensor mechanism. Confirm congruous reduction with radiographs and test for active motion and active and passive stability. With incomplete active PIP joint extension, splint the joint in full extension for 3–6 weeks.

***Figure 39.13.*** AP radiograph showing persistent subluxation or widening on one side of the PIP joint.

**Open Reduction of a Rotatory (Irreducible) PIP Joint Dislocation**

- Make a mid-axial or dorsal curvilinear incision angled toward the injured side of the PIP joint. The condyle protruding between the central slip and the lateral band will be seen at once (Fig. 39.14).

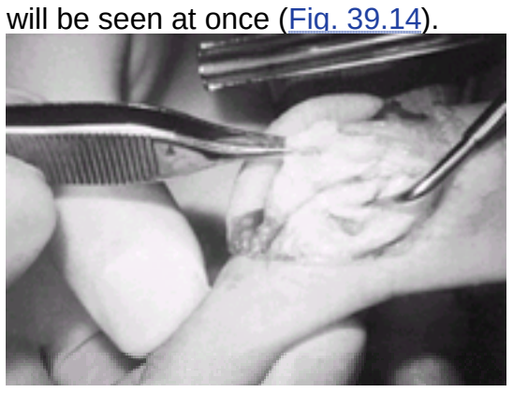

***Figure 39.14.*** Clinical photograph corresponding to Figure 39.12.

- Remove the lateral band from the joint with a blunt instrument. The joint will promptly reduce.
- Repair the collateral ligament if disruption of the collateral ligament results in persistent joint instability or subluxation. If the lateral band is not badly damaged, repair the longitudinal rent in the interval between the lateral band and the central slip. If the lateral band is severely damaged, excise it.
- The remaining intact central slip and lateral band are sufficient to provide full extension of the finger (100). Intraoperative postreduction radiographs should confirm congruous reduction of the joint.
- After 5–7 days of immobilization in a cast dressing, start active motion, with the finger strapped to the adjacent finger to protect against reinjury. Protect the finger for 4–6 weeks.

**Complications** Complications from treating rotatory PIP joint dislocations are usually due to failure to diagnose the dislocation, causing a delay in treatment that results in a fixed flexion deformity (146). Incomplete joint reduction results from incomplete removal of the lateral band. Joint instability results from inadequate collateral ligament repair. Failure to adequately reduce the joint will result in a fixed flexion deformity. Late treatment consists of volar plate and collateral ligament release, excision of the lateral band, and reduction of the joint (106).

***PIP Joint Fracture–Dislocations***

Fracture–dislocation of the PIP joint is probably the most difficult fracture–dislocation to treat in the hand. As the middle phalanx displaces proximally and dorsally, the head of the proximal phalanx is driven into the palmar lip of the base of the middle phalanx. A comminuted depressed fracture usually results and can involve 70% or more of the articular surface. These injuries can be divided into stable and unstable fracture–dislocations (28,38). In stable fracture–dislocations, the volar lip fracture usually involves less than 40% of the articular surface. The dorsal portions of the collateral ligaments remain attached to the middle phalanx. With unstable fracture–dislocations the volar lip fracture involves more than 40% of the articular surface. The collateral ligaments usually remain attached to the volar lip fracture. Dorsal joint subluxation, which is difficult to reduce and to maintain by closed means, tends to occur with PIP joint extension.

Whenever possible, treat this injury closed with the dorsal extension-block splinting technique (26,41,92,131). Dorsal subluxation associated with volar lip middle phalangeal fractures can occasionally be reduced with PIP joint flexion. Always try this technique first, since it yields the best results if applicable (Fig. 39.15). The key to its usefulness is restoration of the joint alignment, not reduction of the fracture. If the fracture reduces also, this is a bonus.

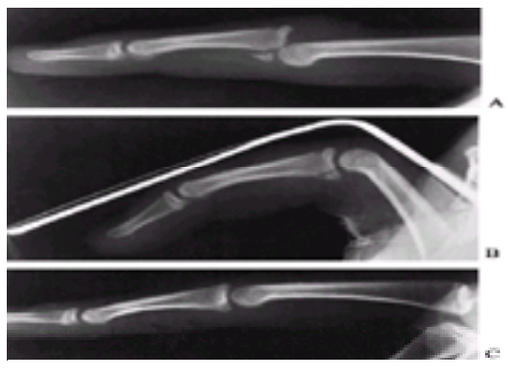

***Figure 39.15.*** Fracture–dislocation of the PIP joint. **B:** Joint reduced by flexion of the finger to 60° or more. The fracture reduction (anatomic here) is a bonus but is not necessary for a good result. **C:** Healed fracture–dislocation with good joint congruity.

**Dorsal Extension-Block Splinting**

- Use a padded hand-based aluminum splint or combine an aluminum splint with a short arm cast. With the latter technique, a padded aluminum splint loop is taped to a short arm cast over the top of the finger being tested (Fig. 39.16).

***Figure 39.16.*** Extension-block splint.

- The MP joint is splinted in flexion and the proximal phalanx is taped to the splint. Taping of the proximal portion of the digit ensures that finger flexion occurs at the PIP and not at the MP joint.
- Fashion the splint so that the PIP joint is flexed approximately 10° to 15° short of the unstable, dorsally subluxed position, which is generally between 30° to 40° of PIP joint flexion.
- A true lateral radiograph of the digit will confirm that the joint subluxation is corrected.
- Adjust the splint weekly by reducing the degree of PIP joint flexion by 25%, or approximately 10°. Take radiographs weekly to ensure that dorsal joint subluxation has not recurred.
- If joint alignment cannot be restored by closed means, extension-block splinting should be abandoned and an alternative procedure used. These measures include extension-block pinning (135,138), skeletal tractionor dynamic skeletal traction (2,3,17,22,55,97,105,115,119,121), dynamic hinged external fixation (48,49,66,74), open reduction and internal fixation (33,40,60,61,81,86,91,128,141,144,147,148 and 149), and vo-lar plate arthroplasty (11,29,31,60,61,87).

**Extension-Block Pinning**

- Place a smooth K-wire in the proximal phalangeal head and shaft from a distal to proximal direction at an angle, with the PIP joint partially flexed, which places it dorsal to the middle phalanx, and with the dorsal fracture–subluxation reduced.
- The wire prevents dorsal subluxation of the middle phalanx as seen on a lateral radiograph.

**Dynamic Skeletal Traction** Readers are advised to read the original articles for a detailed description of the skeletal traction techniques (2,3,17,55,97,105,119,121).

**Force-Couple Splint**

- Use a small needle to identify the joint line (Fig. 39.17A).



***Figure 39.17.*** Force-couple splint. See text for a description of each step in the technique. Agee JM. Unstable Fracture Dislocation of the Proximal Interphalangeal Joint: Treatment with the Force Couple Splint. *Clin Orthop* 1987;214:101.

- Insert smooth K-wires transversely into the middle phalangeal base (Fig. 39.17*B*) and into the center of the proximal phalangeal head (Fig. 39.17*C*), parallel to the PIP joint articular surface.
- Place a threaded K-wire in a dorsal to volar direction in the proximal half of the middle phalanx (Fig. 39.17*D*) and through the dorsal and volar cortices, being careful not to penetrate the flexor tendon.
- On both sides of the finger, bend the distal K-wire proximally at 90° and pass it proximal and palmar to the proximal wire (Fig. 39.17*E*). Make a second 90° bend in the distal wire, 5–10 mm proximal to the proximal wire, and direct the wire dorsally or vertically (Fig. 39.17*F*). Bend a hook into the ends of the K-wire to retain a rubber band.
- On both sides of the finger, bend the proximal K-wire at 90° in a palmar direction (Fig. 39.17*G*). Bend the proximal wire outside of the distal wire.
- Connect the vertically oriented, threaded K-wire and the vertical arms of the distal K-wire with a rubber band, producing linkage, or a force couple (Fig. 39.17*H*).
- Place adhesive tape around the ends of the proximal K-wire to prevent the two ends of the wire from spreading apart (Fig. 39.17*I*).
- The force couple allows joint range of motion and is used to palmarly displace the middle phalanx and dorsally displace the proximal phalanx and thereby reduce dorsal subluxation of the PIP joint fracture–dislocation (2,3) (Fig. 39.17*J*).

**Rubber Band Traction with an External Outrigger Device**

- Place a transosseous wire horizontally into the distal head of the middle phalanx and bend the wire distally on both sides of the finger at 90° angles.
- Place a loop into the ends of the wire and connect with rubber bands, the ends of the wire to a sliding U-shaped thermoplastic component.
- The U-shaped component is looped over a circular 3- or 6-inch-diameter hand/forearm outrigger hoop splint.

- The rubber band provides traction across the PIP joint. Use of the outrigger splint allows active finger flexion and extension (119,121) (Fig. 39.18).



***Figure 39.18.*** Outrigger splint. From Schenk RR. The Dynamic Traction Method. Combining Movement and Traction for Intra-Articular Fractures of the Phalanges. *Hand Clinic* 1994;10:187.

**Dynamic Hinged External Fixation**

- Under fluoroscopic guidance or open visualization, place a K-wire horizontally into the proximal phalangeal head center axis of rotation.
- Place the centering hole of a hinged external fixator [e.g., the Compass PIP Hinge (Smith and Nephew Richards, Memphis, TN)] over the central axis pin (Fig. 39.19).

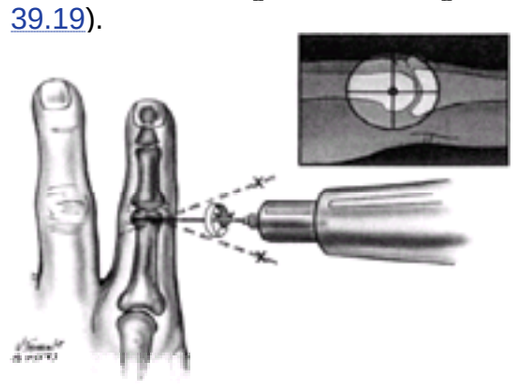

***Figure 39.19.*** Placement of the hinged external fixator. From Jones BF, Stern PJ. Interphalangeal Joint Arthrodesis. *Hand Clinic* 1994;10:267.

- Place smooth K-wires initially through the proximal and then through the distal pin blocks in the mid-axial line of the digit. Hold the middle phalanx reduced during K-wire placement in the distal pin block.
- Apply joint distraction or passive joint motion, as needed, using a built-in distraction screw or worm gear mechanism (Fig. 39.20).

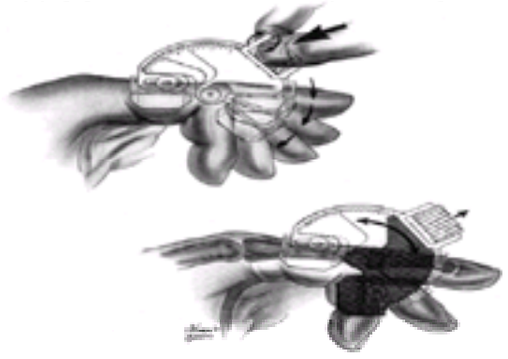

***Figure 39.20.*** Application of joint distraction. From Jones BF, Stern PJ. Interphalangeal Joint Arthrodesis. *Hand Clinic* 1994;10:267.

**Volar Plate Arthroplasty** *Open reduction and internal fixation* of the palmar lip fracture is a demanding and often frustrating technique. If the fragment is sufficiently large and the fracture fairly fresh, however, internal fixation may provide reasonably good joint motion. Methods of fixation include K-wires, screw fixation, and intraosseous wiring.

*Volar plate arthroplasty*, as described by Eaton and Malerich (31), is an alternative that can be used for acute as well as chronic injuries. Advancement of the volar plate attempts to restore the impacted volar articular surface.

- Make a palmar zigzag incision over the PIP joint.
- Elevate the flexor sheath from the distal edge of the $A_2$ to the proximal edge of the $A_4$ pulley, protecting the digital arteries and nerves at all times.
- Retract the flexor tendons without damaging the vincula.
- Mobilize the volar plate and accessory collateral ligaments with the attached palmar lip fragment from the middle phalanx, leaving it attached proximally.
- Excise the remaining collateral ligaments connecting the proximal and middle phalanges (especially in chronic cases), and then open the joint by hyperextending it (like a shotgun) (Fig. 39.21).

***Figure 39.21.*** PIP joint exposed by opening like a shotgun. *From the bottom:* Fracture fragment with attached volar plate, head of proximal phalanx, base of middle phalanx with defect from compression fracture.

- Debride small or loose fragments. If the fragment attached to the volar plate is large, fix it with fine smooth K-wire(s), screws, or an interosseous wire to the middle phalanx, being careful to establish a smooth articular surface and a congruous joint reduction.
- Confirm congruous reduction of the joint with postreduction radiographs.
- More commonly, the volar plate fragment cannot be used. Dissect it free subperiosteally from the volar plate, retaining all possible length of the plate. Mobilize the volar plate as much as possible, leaving its proximal attachment intact, by freeing any restraining bands in the recess.
- Create a transverse trough in the middle phalangeal defect at the dorsalmost part of the cancellous defect, near the palmar margin of the remaining dorsal articular cartilage. The trough must be perpendicular to the long axis of the middle phalanx. Place drill holes at the lateral margins of the trough.
- Place a criss-cross, nonabsorbable suture (2-0 or 3-0 Prolene) in the distal volar plate, and pass the ends through the drill holes. To prevent tethering of the distal

extensor mechanism, flex the DIP joint 30° when passing the sutures dorsally.

- Reduce the PIP joint, and pull the volar plate into the trough with the joint flexed no more than 30° (Fig. 39.22). Tie the suture over a protected button dorsally.

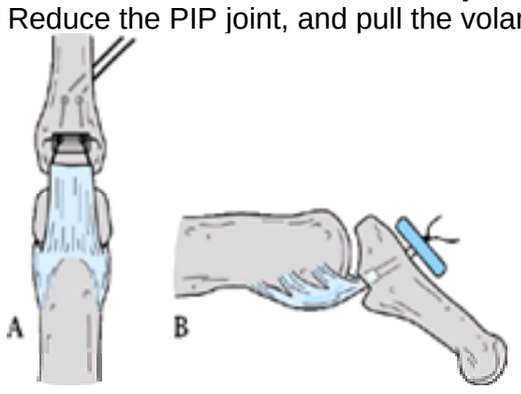


***Figure 39.22.*** **A:** View from palmar side of volar plate arthroplasty as sutures lead the distal edge of the volar plate into the trough at the base of the middle phalanx. **B:** Lateral view of volar plate arthroplasty, secured with the joint flexed.

- Confirm congruous reduction of the joint with intraoperative postreduction radiographs. Suture any remaining collateral ligament to the lateral margin of the volar plate.
- Transfix the joint with a smooth 0.035–0.045 K-wire with the joint in 20° to 30° of flexion.
- Immobilize the hand in a cast dressing. Remove the wire at 2 weeks, and encourage active flexion with use of an extension-block splint. Begin active extension at 4 weeks and extension splinting at 5 weeks if full extension is lacking. Motion may continue to improve for several months.

**Complications** Dorsal PIP joint fracture–dislocation complications are usually due to failure to treat the initial injury adequately or secondary to loss of reduction of the joint. Persistent joint dislocation can occur with closed treatment when the joint hinges instead of reducing congruously, or redislocation occurs with too rapid mobilization of the joint into extension. Redislocation can also result from inadequate reduction at surgery, or from failure of the pullout suture or of internal fixation. Angulation of the joint can occur secondary to asymmetrical impaction of the volar lip fragment or with oblique placement of the volar plate bone trough. Flexion contracture occurs with prolonged immobilization. Posttraumatic arthritis results from articular damage.

Treatment of complications includes joint contracture release, repeat open reduction and internal fixation, opening-wedge osteotomy and bone grafting, volar plate arthroplasty, and joint arthrodesis (27,28,31,38,64,140,146,149).

***PIP Joint Lateral Dislocations—Collateral Ligament Injuries***

**Acute Collateral Ligament Ruptures** Collateral ligament injuries are usually caused by an abduction or adduction force with the PIP joint in extension (91). The radial collateral ligament tends to be more commonly injured than the ulnar collateral ligament (42). Clinically, tenderness occurs over the site of injury, and joint laxity to lateral stress may be present. Most PIP joint collateral ligament injuries are incomplete and need only to be protected by strapping to an adjacent digit for 3–6 weeks (41,96). However, lateral dislocations of the PIP joint can result in complete, but uncommon, rupture of a collateral ligament and at least a portion of the volar plate (28,38). Angulation greater than 20° with lateral stress testing indicates a complete collateral ligament injury (34,68,95) (Fig. 39.9*A*).

Treatment of complete collateral ligament injuries is controversial. After closed reduction, assess stability of the joint by active motion and confirm joint congruency on radiographs. Acutely, use a temporary splint for comfort, followed by strapping to an adjacent digit for 3–4 weeks, encouraging full active motion. Repair of the collateral ligament has been described (4,13,16,41,60,61 and 62,91,94,113,116), but joint stiffness is a problem. The index radial collateral ligament is probably the only ligament that needs early surgery (41,62,94).

*Open Repair of Acute Collateral Ligament Ruptures*

- Make a radial mid-axial incision.
- Divide the transverse retinacular ligament, reflect it, and retract the radial lateral band dorsally.
- Identify and repair the torn collateral ligament. The stump usually is still attached at the middle phalanx and is repaired with nonabsorbable sutures.
- If no residual stump is present, roughen the bone and drill parallel holes obliquely across the phalanx. Pass a nonabsorbable suture, using a modified Bunnell suture technique, through the torn edge of the ligament. Pass the two suture ends through the holes in the bone and out through the skin. Tie the suture over a protected button with the joint reduced and the ligament pulled taut. Miniature suture anchors can be used instead of a transosseous pullout suture technique (Fig. 39.23).

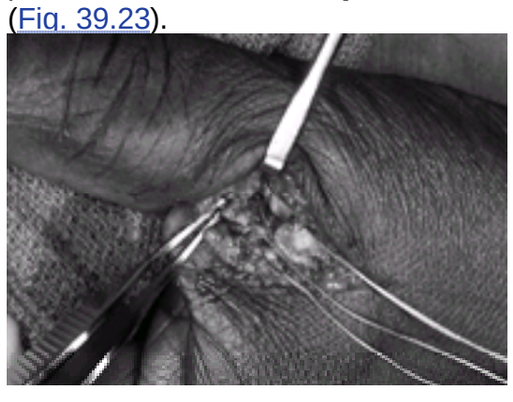

***Figure 39.23.*** Miniature suture anchors can be used instead of a pullout suture technique to repair the collateral ligament.

- Repair the accompanying partial tear of the volar plate as well.
- Repair the retinacular ligament, close the skin, and confirm congruous reduction of the joint with radiographs.
- Splint the digit in no more than 20° of PIP joint flexion for 5–7 days and then start active motion with adjacent finger-strapping for an additional 2–3 weeks.

**Chronic Collateral Ligament Ruptures** Chronic collateral ligament injuries are rarely sufficiently symptomatic to require reconstruction. Often, there are degenerative changes in the joint, and ligament reconstruction cannot be expected to alleviate symptoms due to arthritis. Once again, if reconstruction of a chronic PIP collateral ligament rupture is necessary, it is on the radial side of the index finger.

Reconstruction of the collateral ligament can be done by shortening or imbricating the remaining ligament or by augmenting the repair, usually with a slip of the superficialis (78,91,104,113).

*Open Repair of Chronic Collateral Ligament Ruptures*

- Make a surgical approach similar to that made for the acute collateral ligament injury.
- Identify the ligament and dissect it free. Imbricate it in its midportion, or shorten it and suture it with a nonabsorbable suture at the proper length.
- If further reinforcement is needed, separate the radial slip of the superficialis, leaving it attached distally detaching it proximally. Pass the tendon through a drill hole in the head of the proximal phalanx with a pullout suture and tie the suture over a protected button on the ulnar side of the proximal phalanx.
- Alternately, pass the superficialis through two holes drilled on the radial aspect of the proximal phalangeal head and suture the tendon to itself. Spread out the tendon dorsally and suture its radial (now dorsal) edge to the remaining fibers of the collateral ligament.
- Close the wound as previously described. After 10 days of immobilization in no more than 20° of flexion, encourage the patient to actively exercise with strapping to the adjacent long finger for an additional 4–5 weeks.

**Complications** Complications in the treatment of lateral PIP joint dislocations usually occur from inadequate initial treatment, and they are frequently an expected outcome of the injury, even with adequate treatment. Pain, instability, loss of motion, and arthrosis can occur from incomplete joint reduction, lateral translocation, or

uneven forces within the joint secondary to excessive scarring (146).

Late reconstruction cannot be expected to produce a perfectly stable joint. Potential problems of ligament reconstruction include joint stiffness or persistent laxity.

### *PIP Joint Volar Plate Ruptures (Swan-Neck or Hyperextension Deformity)*

Volar plate ruptures of the PIP joint can result from a dorsal PIP joint dislocation or hyperextension injury (type 1 dorsal PIP joint dislocation). The volar plate usually detaches distally from the middle phalanx, with or without a piece of bone. If the volar plate ruptures distally with a small fragment of bone (as seen on the lateral radiograph), the joint is inevitably congruous. This injury must be differentiated from the serious PIP joint fracture–dislocation. Treat the minor volar plate fracture as any other volar plate injury, with protection against hyperextension by either a temporary dorsal-block digital splint or by strapping to an adjacent finger for 3 weeks. Encourage full flexion.

Chronic volar plate ruptures can result in a swan-neck deformity with dorsal subluxation of the lateral bands. Painful flexion of the PIP joint can occur as the lateral bands sublux palmarly over the proximal phalangeal condyles. Distinguish this swan-neck deformity from the type of swan-neck deformity secondary to an extensor terminal tendon disruption (mallet finger). With volar plate insufficiency, the patient will be able to actively extend the DIP joint with the PIP joint held in full extension. Nonoperative treatment includes use of a orthoplast or silver (double-ring) splint to help prevent PIP joint hyperextension (Fig. 39.24). Symptomatic volar plate ruptures (Fig. 39.25) can be helped by surgical correction. Options include late reattachment or shortening of the volar plate, with or without some form of volar reinforcement (1,7,12,22,72,78,91,104,109,132,136,144).

***Figure 39.24.*** Silver ring (or double-ring) splint used for swan-neck deformity to prevent hyperextension at the PIP joint. The splint can be padded if it irritates the dorsum of the digit.

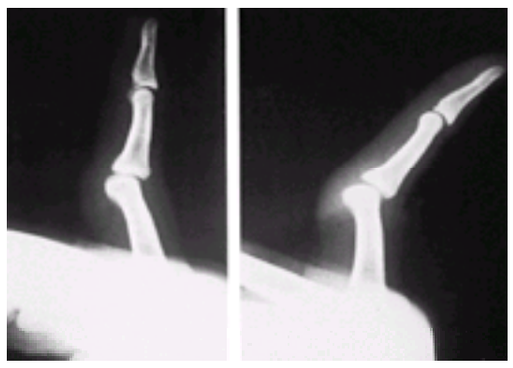

***Figure 39.25.*** Chronic volar plate rupture in a basketball player; it subluxated each time he caught the ball.

### Open Repair of Chronic Volar Plate Ruptures

- Make a palmar zigzag incision and release the flexor sheath between the $A_2$ and $_4$ pulleys.
- Protect the digital vessels and nerves while retracting the flexor tendons to expose the volar plate. If it has been ruptured in midsubstance and repair is possible, suture the edges directly.
- More often, it will be detached distally (Fig. 39.26*A*). In that case, roughen the base of the middle phalanx and create a transverse trough. Place a nonabsorbable suture in the distal end of the volar plate with a modified Bunnell suture technique. Place drill holes at the lateral margins of the trough in a distal but somewhat lateral direction so that the extensor mechanism will not be injured or trapped by the passing of the pullout suture. Pass the ends of the suture from the volar plate through the drill holes, and tie them over a protected button. To prevent tethering of the distal extensor mechanism, flex the DIP joint 30° when passing the sutures dorsally. As the suture is tied, flex the PIP joint. Apply gentle traction on the suture so the distal end of the volar plate is pulled snugly into the trough (Fig. 39.26*B*).

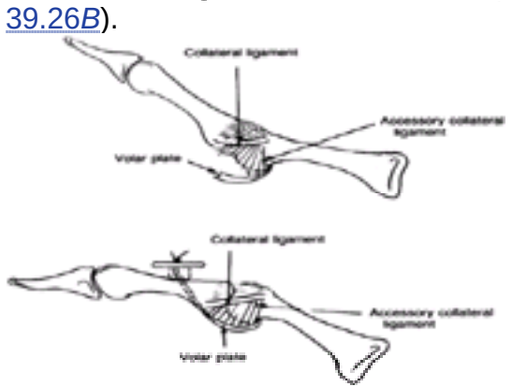


***Figure 39.26.*** **A:** Volar plate rupture usually occurs distal from the base of the middle phalanx. **B:** The distal margin of the volar plate is pulled snugly into a trough in the middle phalanx and secured through drill holes in the bone.

- If there is not enough of the volar plate left to advance or repair, a volar reinforcement procedure can be used. With this technique, isolate either slip of the superficialis. Leave it attached distally and detach it proximally under the $A_2$ pulley.
- Place a drill hole transversely in the neck of the proximal phalanx. Draw the proximal end of the detached superficialis slip into the hole, using a pullout nonabsorbable suture, and tie it over a protected button (Fig. 39.27). Take care to ensure that the superficialis slip is taut when the PIP joint is in 10° to 15° of flexion.

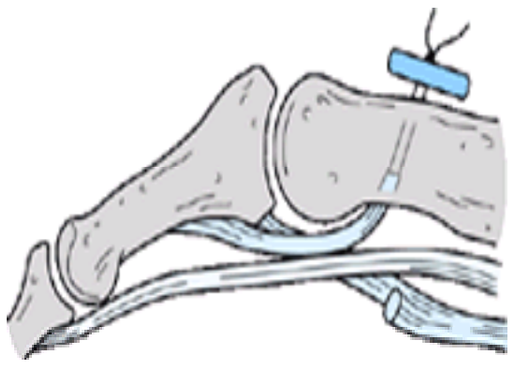

***Figure 39.27.*** One superficialis slip is fixed to the proximal phalanx, creating a tenodesis of the PIP joint.

- Temporarily fix the joint with a 0.035–0.045 smooth K-wire for 3 weeks, and then protect it with a dorsal-block splint for an additional 4 weeks.

### *Complications*

The complications associated with treating volar plate ruptures are the same as for dorsal PIP joint dislocations. Operative repair for chronic volar plate ruptures, as for any ligament repairs or reconstructions, can lead to some loss of motion and chronic thickening. A flexion deformity is common.

## METACARPOPHALANGEAL JOINT

### *Assessment and Indications for Treatment*

Metacarpophalangeal joint injuries are frequently associated with an injury to the volar plate, collateral ligament, and joint articular surface, which require adequate assessment and AP, lateral, and oblique radiographs of the hand (Table 39.3). A Brewerton view or oblique view of the metacarpal heads may be helpful to identify small fractures (see the section above on General Principles of Treatment) (171,185,189,206). Open dislocations require adequate debridement and antibiotics.

***Table 39.3. Algorithm for Assessment of Metacarpophalangeal (MP) Joint Injuries***

Injuries to the ligaments and dislocations of the MP joints are uncommon. Most of these occur with the fingers in some extension when the collateral ligaments are more lax. This provides some margin for protection so that complete ligament rupture is unusual. The most common mechanism of injury is hyperextension or ulnar deviation of the joint. The most commonly involved joint is the index finger, followed by the thumb and little finger. Central digit dislocations are usually associated with dislocation of either the adjacent index or little finger (42,151,153,154,156,170,177,180,182,187,188,195,200,202,211,212,216).

Metacarpophalangeal joint injuries are classified as dislocations or collateral ligament injuries. The dislocations are based on the direction of the dislocation (dorsal versus volar) and whether they are easily reducible (simple) or irreducible without surgical intervention (complex).

### *Dorsal MP Joint Dislocations*

With a hyperextension injury to the MP joint, the membranous portion of the volar plate usually ruptures off the metacarpal neck. Dorsal MP dislocations can be classified as simple (subluxation) or complex dislocations (165,172,174). Simple MP joint dislocations are easily treated by closed reduction. Take care not to converta simple dislocation into a complex dislocation (165,172,176,190,383). With simple MP joint dislocations, the proximal phalanx is hyperextended on the metacarpal head, but some contact remains between the MP joint articular surfaces. The proximal edge of the volar plate lies palmarward over the metacarpal head. Therefore, the base of the proximal phalanx should be pushed distally and palmarly. If hyperextension with traction is mistakenly used, the volar plate can slip dorsally over the metacarpal head and prevent reduction.

Interposition of the volar plate between the metacarpal head and the base of the proximal phalanx makes this complex dislocation irreducible (183). The lumbrical medially and the flexor tendon laterally around the metacarpal neck prevent reduction of the dislocation by longitudinal traction only (Fig. 39.28) (175). With a complex dislocation of the little finger, the structures preventing reduction include the abductor and flexor digiti minimi ulnarly and the lumbrical and flexor tendon radially (154).

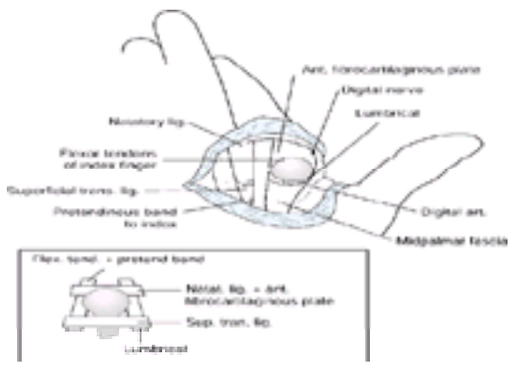

***Figure 39.28.*** The factors producing a complex dorsal MP joint dislocation (see text for details). (From Kaplan EB. Dorsal Dislocation of the Metacarpophalangeal Joint of the Index Finger. *J Bone Joint Surg* 1957;39A:1081, with permission.)

Clinically, the joint is slightly hyperextended, with the phalanx appearing parallel to the metacarpal with a tendency for the digit to overlap its neighbor (Fig. 39.29). On the palmar surface, the skin is puckered or dimpled. Radiographically, the joint space is widened, the joint surfaces are offset, and the sesamoid appears to lie within the joint (Fig. 39.30) (163,175,201,208).

***Figure 39.29.*** Complex MP dislocation with the finger parallel to the metacarpal.

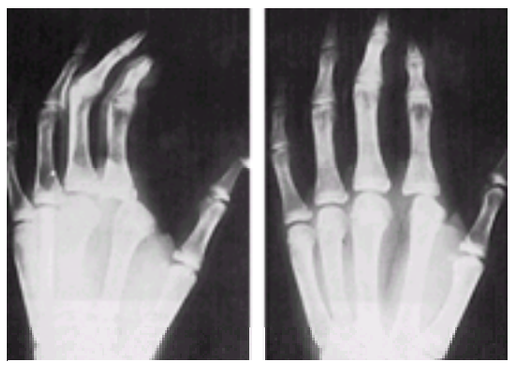

***Figure 39.30.*** The phalanx is offset at the MP joint, lying parallel to the metacarpal in a complex dislocation.

- Attempt a single effort at a closed reduction under a good anesthetic in the operating room with the wrist flexed to relax the flexor tendons.
- Apply pressure dorsally and distally to the base of the proximal phalanx while attempting to slide the proximal phalanx over the metacarpal head.
- Confirm reduction clinically and radiographically. Assess active and passive joint stability, splint the hand with the MP joints flexed for a few days for comfort, and start early active motion with an extension-block splint. If a closed joint reduction fails, perform an open reduction.

**Open Reduction of Complex Dorsal MP Joint Dislocations** Both the dorsal (158,160,177,183,187,199,201,204) and the palmar approaches (16,19,60,61,152,153,155,156 and 157,163,167,168 and 169,173,174,179,183,190,191,198,208,209 and 210,214,217) have strong advocates.

*Dorsal Approach*

- Make a straight or slightly curvilinear dorsal incision over the joint.
- Longitudinally release the extensor tendon or the sagittal band (usually on the ulnar side) and perform a dorsal midline capsulotomy.
- Identify and carefully incise longitudinally the volar plate in the midline; avoid damaging the metacarpal head articular surface. Flex the wrist to relax the flexor tendon and reduce the joint.
- If needed, push the separate halves of the volar plate over and around the metacarpal head.
- After the joint is reduced, separately repair the capsule, the extensor tendon or sagittal band, and the skin. Intraoperative postreduction radiographs should confirm congruous reduction of the joint.
- As with a closed reduction, splint the hand with the MP joints flexed for a few days and then begin active motion with an extension-block splint.

*Palmar Approach*

- Make an incision that connects the mid-axial line with the transverse mid-palmar crease. Take great care to avoid injury of the digital artery and nerve (especially the radial), which are pressed against the deep surface of the skin by the metacarpal head. Retract the nerves and arteries gently.
- Incise the $A_1$ pulley and retract the flexor tendons and lumbrical. The metacarpal head now dominates the field (Fig. 39.31*A*).

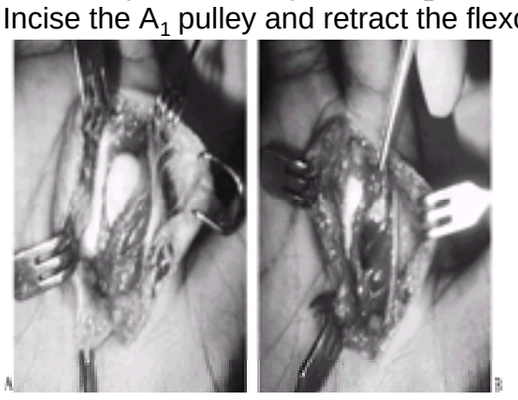

***Figure 39.31.*** **A:** When the skin is opened before reduction, the metacarpal head dominates the field. The flexor tendons lie ulnarly, the lumbrical and digital nerve radially, and the volar plate dorsally, blocking reduction. **B:** The volar plate (*held by the forceps*) has been extricated and the joint reduced.

- Carefully make a longitudinal incision between the sides of the volar plate and the deep transverse metacarpal ligament. Insert a sturdy but narrow-angled dental probe or skin hook around the volar plate to extricate it from between the phalangeal base and the metacarpal head. The joint will snap into the reduced position (Fig. 39.31*B*).
- Because the volar plate is still attached to the phalanx, no repair is needed.
- Repair the skin incision and splint the hand with the MP joints flexed for a few days. Then start active motion, preventing MP joint hyperextension with a dorsal-block splint for 3–4 weeks.

**Complications** Complications in treating dorsal MP joint dislocations may result either from a delay in treatment or from overly aggressive treatment. Damage to the articular surfaces can occur with repeated attempts at a closed reduction or secondary to a forceful open reduction. Traction and hyperextension of the digit can possibly convert a simple MP joint dislocation into a complex dislocation.

Loss of joint motion and degenerative arthritis may occur with delayed reduction. A combined volar and dorsal approach and collateral ligament release may be needed to openly reduce a longstanding dislocation (165,173,174,178,186,198,213). Injury to the neurovascular bundles can occur in the palmar approach with an inappropriate skin incision. Redislocation can occur if hyperextension is not prevented, and loss of joint motion can occur with prolonged immobilization.

***Palmar MP Joint Dislocations***

Palmar MP joint dislocations are rare (159,161,184,190,193,194,203,215,383). Avulsion of either the dorsal capsule from the metacarpal proximally or the volar plate from the proximal phalanx, or collateral ligament avulsion, can occur (159,197,203,215). Interposition of these structures between the metacarpal head and proximal phalanx can occur, producing a complex dislocation (174). If an attempt at a closed reduction under adequate anesthesia is unsuccessful, an open reduction is

warranted.

### *MP Joint Collateral Ligament Injuries*

Collateral ligament injuries of the MP joint often are missed. Since the collateral ligaments of the MP joint are at their longest or most taut in full flexion, testing for collateral ligament stability must be performed with the joint flexed maximally. The mechanism of injury usually consists of forced ulnar deviation of the digits. The injury seems to occur mostly in the ulnar three fingers and to the radial side (166,172). Clinically, tenderness is present over the injured ligament, and stress testing (passive radial/ulnar deviation) with the MP joint flexed produces pain. Obtain radiographs, including oblique and Brewerton views (171,185,189,206,213), to identify avulsion fractures. Stress views with the MP joint in full flexion may help confirm a ligament tear (213). Arthrography has been used to identify the location of the collateral ligament injury (164,181). The collateral ligament is avulsed off the metacarpal head most commonly but can also be torn distally or in midsubstance (195,196,213).

Initial treatment usually consists of immobilization with the MP joints flexed 30° to 50° for 3 weeks, followed by taping the finger to the adjacent digit for an additional 3 weeks (167,172,174). Surgery is advocated for gross instability of the joint (60,61,164,181,205,217), an associated displaced avulsion fracture (displaced 2 or 3 mm), or a displaced or rotated avulsion fracture involving 20% or more of the articular surface (174). With persistent joint instability, late reconstruction has been advocated (164,166,178).

#### Operative Repair of MP Joint Collateral Ligament Injuries

*Acute Collateral Ligament Ruptures*

- Make a longitudinal incision in the dorsum of the web space on the affected side of the digit.
- Incise and retract the transverse fibers of the extensor hood. Incise the joint capsule dorsal to the collateral ligament parallel to its dorsal margin. Dissect and mobilize the ligament.
- If there is an attached avulsion fracture of adequate size attached to the ligament, reduce and fix the bone fragment with one or two smooth 0.035 K-wires (Fig. 39.32).

***Figure 39.32.*** **A:** A displaced articular fracture usually is attached to the collateral ligament. **B:** K-wire fixation of the displaced fracture often must be done by placing the wire in the phalanx first.

- If the fragment is too small, place a pullout suture around it. Place a drill hole obliquely connecting the cortex on the opposite side of the phalanx to the site of the intended ligament attachment. Place the pullout suture through this hole and over a protected button.
- Close the transverse fibers of the hood and skin in layers and check for congruous reduction of the joint and adequate alignment of the fracture fragment with radiographs.
- Immobilize the hand with the MP joints flexed to 45° for 3 weeks and protected by taping the finger to the adjacent digit for another 3 weeks.

*Chronic Collateral Ligament Ruptures* When chronic, these ligament tears often are only minimally symptomatic. If they prove disabling, surgical treatment can be difficult. The same approach as previously described is used. Carefully tease out the collateral ligament, and mobilize it to its maximum length. Repair the ligament to the phalanx by the pullout suture technique. Perform closure as previously described.

**Complications** Complications in treating MP joint collateral ligament ruptures are usually due to undertreatment of the injury. They include residual pain, joint swelling, instability (index finger with pinch), and deviated digit (abducted little finger) (166,179,186,213).

Repairing or reconstructing the collateral ligament too tightly (i.e., collateral ligament repair with the joint held in extension) will result in a loss of joint motion.

## CARPOMETACARPAL JOINT

### *Assessment and Indications for Treatment*

Carpometacarpal joint dislocations are frequently associated with intraarticular fractures, so adequate assessment of the articular surfaces is needed with true AP, lateral, and oblique pronated radiographs of the hand (Table 39.4). Occasionally, tomography or a CT scan may be helpful to identify small fractures. Open dislocations require adequate debridement and antibiotics.

***Table 39.4. Algorithm for Assessment of Carpometacarpal (CMC) Joint Injuries***

### *Dislocations and Ligamentous Injuries*

Dislocations and ligamentous injuries of the CMC joints are virtually synonymous and will be considered together. Due to the inherent stability of the CMC joints, which are further strengthened by strong surrounding ligaments, pure CMC joint dislocations are uncommon; fracture–dislocations of the CMC joints are much more common.

The most common site for subluxation or dislocation is at the base of the fifth metacarpal (221). The fifth and fourth metacarpals may dislocate together, or all four may do so (251). Often, an intraarticular fracture is associated with dislocation of the CMC joint (60,61,221,224,227,228,230,231,243,251,252 and 253,256,259,260,261 and 262,266,270,271 and 272,281). Isolated dorsal CMC dislocations or fracture–dislocations generally occur when a longitudinal compressive force is applied to the dorsal aspect of the metacarpal head. This force produces a longitudinal compressive and flexion moment to the metacarpal. Occasionally, volar CMC dislocations can occur (218,224,228,257,265,267,277). Multiple CMC dislocations or dislocations of the index and long CMC joints generally occur when larger forces produce the injury. These injuries are frequently associated with metacarpal shaft fractures and soft-tissue injuries (219,222,227,230,231,235,237,238,242 and 243,245,246,247,248 and 249,251,252 and 253,254,257,264,268,269,273,274,275 and 276,278,279 and 280).

Careful evaluation of AP, lateral, and oblique radiographs reveals the injury (240). A 30° pronated lateral view, which places the fourth and fifth CMC joints in profile, will help in diagnosing dislocations or fracture–dislocations of these joints (221,232,233,250). Tomography or CT scan can be used to further delineate the injury or help diagnose occult fractures (250).

For dislocations without fracture, treatment options include a closed reduction, closed reduction and percutaneous K-wire fixation, and open reduction internal fixation of the dislocation (229,236,239,244). Closed reduction is usually possible.

- With adequate analgesia, apply longitudinal traction to the involved digit(s). Apply pressure over the dorsal base of the dislocated metacarpal in a distal and volar direction, then extend the metacarpal to help reduce the dislocated joint. Occasionally, closed reduction will fail because of interposed soft tissues or chondral fragments.
- If the reduction is successful, immobilize the hand with the wrist extended, the MP joints flexed, and the IP joints extended for 3–4 weeks.
- The CMC joint(s) must be frequently evaluated for redislocation. Because of the possibility of redislocation, closed reduction with percutaneous pinning is preferable (227,228 and 229,235,236,238,247,259,271).
- Transfix the metacarpal to the appropriate carpal or an adjacent stable metacarpal. Small associated fractures with some articular incongruity are unimportant (270).

If redislocation occurs, closed reduction fails, or a substantial intraarticular fracture is present and remains significantly displaced after a closed reduction, do an open reduction. Chronic dislocations usually require open reduction and internal fixation. Extensive dissection with excision of scar tissue may be necessary to achieve reduction. If symptomatic posttraumatic arthrosis is present, a resection or resection–interposition arthroplasty is useful, and an arthrodesis remains an option (220,221,223,225,226,229,234,236,241,245,246,254,255,258,260).

**Open Reduction of a CMC Dislocation**

*Acute CMC Dislocation*

- Make a dorsal longitudinal or oblique incision over the affected joint. Protect the dorsal sensory nerve branches and veins.
- Retract the extensor tendons and visualize the injured joint. Retract the ruptured ligaments and debride any small loose fragments about the joint. Gently reduce the joint.
- Reduce any intraarticular fractures and transfix them with one or two smooth 0.035–0.045 K-wires. If no fracture is present, reduce the dislocation and secure it with a 0.035–0.045 smooth wire placed obliquely from the metacarpal across the joint into the appropriate carpal bone or to an adjacent stable metacarpal.
- Ligament repair is unnecessary, although capsular closure can be performed. Confirm reduction of the joint with radiographs.
- Close the skin and splint the hand for 3–4 weeks, allowing full finger motion after the first few days. Remove the pins at 6 weeks.

*Chronic CMC Dislocation*

- Use the same approach as described for an open reduction of an acute dislocation.
- Incise and reflect the scarred ligaments by subperiosteal dissection. Perform an open reduction of the joint if the joint surfaces are preserved. Confirm proper position with radiographs.
- If arthrosis is present, resect the proximal 1 cm of the base of the metacarpal. A tendon anchovy or a portion of the joint capsule may be interposed in the area of the resected metacarpal. Repair the dorsal ligaments and close the skin. Use K-wire fixation if the joint is unstable. Splint the hand for 3–4 weeks, but permit early finger motion.

If a CMC arthrodesis is used instead of arthroplasty, take care to preserve the transverse metacarpal arch by fusing the fourth and fifth metacarpals in some flexion.

**Complications** A delay in diagnosis or treatment of CMC dislocations may result in chronic CMC dislocation and subsequent arthrosis (281). Undertreatment may result in a redislocation of the CMC joint following closed reduction alone or secondary to premature removal of fixation wires.

Injury of sensory nerves is common, so care in protecting them is imperative. Improper pinning of metacarpals to adjacent metacarpals can lead to a “pancake” hand from flattening of the transverse metacarpal arch. Posttraumatic arthritis can occur with poor surgical alignment of the carpometacarpal or intermetacarpal joints.

## THUMB

### ANATOMY

The anatomy of the joints of the thumb is somewhat different from that of the other digits. Like the finger MP joint, the thumb MP joint is a condyloid joint allowing for flexion–extension and abduction–adduction. The amount of thumb MP joint flexion varies widely, ranging from 5° to 115° (356). Variable amounts of MP joint hyperextension can also occur, ranging up to 45° (average 8°) (285). The amount of MP joint abduction–adduction is less in the thumb than in the fingers (0° to 20°, average 10°) (296). A slight difference in the shape between the proximal phalangeal condyles produces a slight amount of pronation of the thumb with MP flexion (285,308,373).

Like the finger PIP joint, the thumb MP joint is supported by strong collateral and accessory collateral ligaments as well as a volar plate. The adductor pollicis inserts into the ulnar sesamoid located within the volar plate, as well as the proximal phalanx. The abductor pollicis brevis and flexor pollicis brevis insert into the radial sesamoid, also located within the volar plate. Additionally, the adductor and abductor pollicis brevis tendons have an insertion or expansion into the extensor aponeurosis (328,370,371,376). Further support to the MP joint is provided by extensor pollicis longus and brevis tendons associated with the dorsal MP joint capsule and the flexor pollicis longus tendon, overlying the volar plate and sesamoids, volarly. Stability is therefore provided by both static and dynamic restraints.

The trapeziometacarpal joint consists of two saddle surfaces in apposition (Fig. 39.33) (287,389,391,392,393 and 394,406). The longitudinal axes of each joint surface are oriented perpendicular to one another, allowing flexion–extension, abduction–adduction, and some pronation–supination (389,390,395). An elongated volar lip of the thumb metacarpal provides an attachment site for the volar metacarpal ligament to the tubercle of the trapezium. Although it has a relatively loose capsular support, thickenings in the joint capsule help provide joint stability. Four ligaments have been frequently cited as the main stabilizers of the CMC joint: the volar or anterior oblique (palmar trapeziometacarpal) ligament, the dorsal (posterior) oblique ligament, the dorsoradial ligament, and the intermetacarpal ligament (386,387,389,392,399,402,404,406,408,409,411). Tubercles on both the metacarpal and trapezium serve as attachment sites for these ligaments (Fig. 39.33).

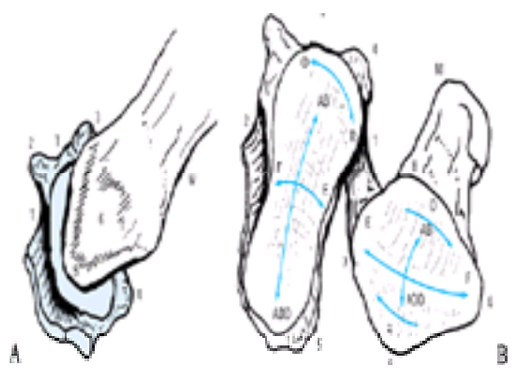


***Figure 39.33.*** **A:** Trapeziometacarpal joint seen from the volar side. *T,* trapezium; *M,* base of first metacarpal; *1,* FCR tunnel; *2,* radiovolar tubercle and ridge; *3,* dorsoradial tubercle; *4,* dorsoulnar tubercle; *5,* volar metacarpal beak; *6,* volar tubercle. **B:** Articular facets of the trapezium (*T*) and first metacarpal (*M*). *1,* dorsal ligament; *2,* FCR tunnel; *3,* volar radial tubercle; *4,* dorsoradial tubercle; *5,* dorsoulnar tubercle; *6,* volar metacarpal beak; *7,* dorsal beak; *8,* radial or lateral tubercle; *8,* ulnar or medial tubercle. (From Zancolli EA, Cozzi EP. *Atlas of Surgical Anatomy of the Hand*. New York: Churchill-Livingstone, 1992, with permission.)

## THUMB METACARPOPHALANGEAL JOINT

### *Assessment and Indications for Treatment*

The assessment and indications for treatment are similar to those of the MP joint of the fingers. Thumb MP joint injuries are frequently associated with collateral ligament and volar plate injuries, as well as an occasional intraarticular fracture.

Injuries to the ligaments and dislocations of the thumb MP joint are common and consist of dislocations, collateral ligament injuries, and volar plate ruptures. The dislocations are based on the direction of dislocation of the phalanx (dorsal versus volar) and whether they are easily reducible (simple versus complex).

### *Thumb MP Joint Dislocations*

Dislocations of the MP joint usually are dorsal, resulting from hyperextension, and can be treated closed (296,299,308,309). The dislocation results in a complete tear of the volar plate proximally and usually of a portion of the collateral ligaments (377). Dorsal subluxation of the MP joint can occur with less severe hyperextension injuries (324). Volar MP dislocations are not as common (313,322,344,348,349,383). Clinically and radiographically, hyperextension of the MP joint is noted. Widening of the joint space is suggestive of soft-tissue interposition. Interposition of the sesamoids between the metacarpal head and the base of the proximal phalanx is highly suggestive of a complex MP joint dislocation.

- Perform closed reduction of the dislocated joint under adequate analgesia with the wrist and IP joint flexed to relax the flexor tendon.
- Avoid longitudinal traction and hyperextension of the thumb MP joint, and push the base of the proximal phalanx distally and palmarly.
- Confirm congruous reduction of the joint on radiographs and test for active and passive joint stability. Test for collateral ligament stability and treat accordingly (see sections below on collateral ligament ruptures).
- Occasionally, dorsal dislocations may prove to be irreducible because of interposition of the volar plate or other structures (e.g., sesamoid, flexor pollicis longus) between the base of the proximal phalanx and the head of the metacarpal (296,301,310,312,323,329,341,343,354). When this situation is present, do an open reduction. Volar (323,341), dorsal (160,301), and lateral (354) approaches to the MP joint have been advocated.

#### Open Reduction of an Irreducible Thumb MP Joint Dislocation

- Make a chevron-shaped incision on the radial aspect of the joint, bringing the apex of the incision somewhat palmarly. Take care to not injure the digital nerves, especially the radial.
- Partially release the proximal flexor tendon pulley and retract the flexor pollicis longus.
- Make a longitudinal incision between the radial collateral ligament and the edge of the volar plate. Place a stiff-angled probe or a skin hook behind the volar plate, extricate it from the joint, and allow the joint to reduce.
- Repair the ligament, if needed, either directly or using pullout suture technique.
- Close the skin. Confirm congruous reduction of the joint with radiographs. After initial immobilization for comfort for a few days, begin motion using an extension-block splint for 3–4 weeks.

### *Thumb MP Joint Ulnar Collateral Ligament Ruptures*

Ulnar collateral ligament ruptures of the MP joint, also referred to as gamekeeper's thumb and skier's thumb, are common injuries (289,295,296,304,305,325,343,345,346,351,368,371,385). The mechanism of injury includes forceful abduction or radial deviation of the thumb proximal phalanx. Other injured structures may include the volar plate, the dorsal MP joint capsule, and the adductor aponeurosis, or there may be an avulsion fracture of the proximal phalanx (289,293,296,297,304,305 and 306,322,327,329,333,340,343,347,357,362,371,376,378,379).

A Stener lesion (376) occurs when there is interposition of the adductor aponeurosis between a completely avulsed ulnar collateral ligament (avulsed from the proximal phalanx) and the proximal phalanx ligament insertion site, or between two ends of a midsubstance ligament tear (Fig. 39.34). Interposition of the adductor aponeurosis interferes with healing of the ulnar collateral ligament. Complete ligament avulsion is needed to produce a Stener lesion; therefore, differentiating the complete from partial ligament avulsion injury is necessary to diagnose a Stener lesion. The reported incidence of a Stener lesion occurring with an acute ulnar collateral ligament rupture varies with different series, but it ranges from 14% to 83% (311).

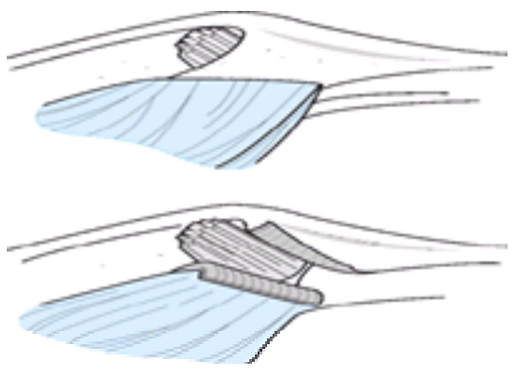

***Figure 39.34.*** The ulnar aspect of the metacarpophalangeal joint of the right thumb. After distal rupture, the ulnar collateral ligament has been folded right over. The torn end sticks out proximal to the adductor aponeurosis (shown divided in the *lower picture*). (From Stener B. Displacement of the Ruptured Ulnar Collateral Ligament of the Metacarpophalangeal Joint of the Thumb. A Clinical and Anatomic Study. *J Bone Joint Surg* 1962;44B:869, with permission.)

There is painful swelling of the MP joint with localized tenderness over the region of the ulnar collateral ligament, with instability when gently applying radial stress to the thumb MP joint (289,295,296,304,311,356,371,376). If there is no end point of resistance and angular deformation is more than 30° compared to the uninjured thumb (Fig. 39.35), a complete ulnar collateral ligament rupture is likely (289,304,318,355,356,372). Perform the test with the MP joint in full extension and at 30° of flexion. Palpation of the end of the ruptured collateral ligament is difficult, but it confirms a complete ligament rupture (282). Local or nerve-block anesthesia may be helpful in testing the collateral ligament if there is significantpain or muscle spasm (289,304,311,329,340,347,356,357,368).

***Figure 39.35.*** Complete instability to radial stress of the MP joint of the thumb. (From Neviaser RJ, Wilson JN, Lievano A. Rupture of the Ulnar Collateral Ligament of the Thumb—Correction by Dynamic Repair. *J Bone Joint Surg* 1971;53A:1357, with permission.)

Take radiographs to identify an avulsion fracture. In questionable cases, stress radiographs can be helpful (61,289,298,311,338,355) (Fig. 39.36). These tests should not be done in the presence of a significant articular fracture but can be of value with a small avulsion fracture. The fracture is not always attached to the ligament (Fig. 39.37), so the position of the fracture fragment does not always identify the location of the ruptured ligament end (320,338).

***Figure 39.36.*** Comparative stress radiographs showing instability of the left thumb.

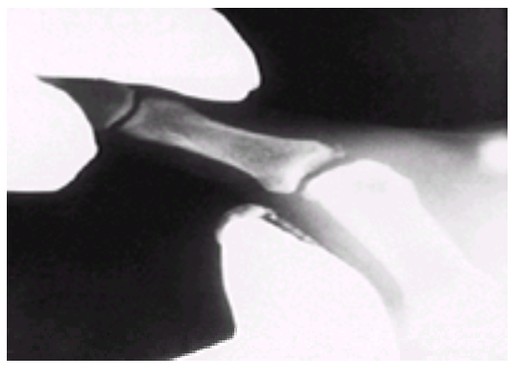

***Figure 39.37.*** Stress radiograph in which “avulsion” fracture follows phalanx, suggesting it is not attached to the ligament.

Arthrography, magnetic resonance imaging, and ultrasonography have been used to identify ulnar collateral ligament injuries (289,292,303,316,317,319,321,336,352,353,364,365,375), but in the majority of cases, the diagnosis can be made with the clinical examination and stress radiographs.

***Acute Thumb MP Joint Ulnar Collateral Ligament Injury***

Treat partial ruptures with immobilization in a thumb spica cast for 4 weeks (311). Alternatively, in a compliant patient, an orthoplast splint can be used (374).

When an acute complete rupture is present, operative repair provides the greatest security that a stable joint will result. Theoretically, a complete ligament rupture without a Stener lesion can be treated nonoperatively (296,360,376). Because this lesion frequently cannot be determined by physical examination, stress or plain radiographs, or arthrography, surgical repair is usually recommended (30,60,61,296,304,306,310,322,329,337,340,343,344 and 345,349,352,355,371,376,379,382). The ulnar collateral ligament can be directly repaired (midsubstance tears) or reattached to bone by pullout suture technique, mini-suture anchor, or absorbable tack, and by K-wires or tension-band wiring for small avulsion fractures (286,288,308,326,332,363,366,381).

**Repair of an Acute Thumb MP Joint Ulnar Collateral Ligament Injury**

- Make a chevron-shaped or curvilinear incision on the ulnar side of the MP joint. Take care not to extend the incision across the web space, which produces a contracting scar. Carefully elevate the skin flaps, protecting the branches of the dorsal radial sensory nerve. The torn ligament is usually seen at the proximal edge of the adductor aponeurosis.
- Divide the adductor pollicis aponeurosis just ulnar to its insertion into the extensor tendon and reflect it for later repair. Remove loose bone fragments from the MP joint.
- Note the level of injury to the ulnar collateral ligament. The ligament is typically avulsed distally from its insertion into the proximal phalanx. A midsubstance ligament tear may be directly repaired. Usually, the ulnar collateral ligament needs to be mobilized. Place a 4-0 nonabsorbable suture in its distal end using a modified Bunnell suture technique.
- Roughen the base of the proximal phalanx where the ligament is to be attached. Place one or two drill holes obliquely and through the opposite cortex. Place the ends of the sutures through the drill hole(s) and through the skin. Reduce the MP joint and tie the suture over a protected button. Alternatively, repair the ligament using miniature suture anchors placed within the bone trough (Fig. 39.23).
- Repair any rent in the dorsal capsule. Place a suture in the volar ulnar corner of the volar plate–collateral ligament complex to repair any tears in this region.
- If a small avulsed bone fragment is present, excise the fragment and repair the ligament; or, if the fragment is sufficiently large, repair it using K-wires or pullout suture technique.
- Repair the adductor aponeurosis to the extensor mechanism and close the skin.
- A K-wire can be used to transfix the MP joint, but it is usually not needed.
- Immobilize the thumb in a spica cast for 4 weeks and then begin protected motion in a removable custom splint for another 2–3 weeks. IP joint motion can be started earlier. Avoid forceful stressing of the ligament repair for 3 months.

***Chronic Thumb MP Joint Ulnar Collateral Ligament Instability***

When chronic MP joint instability is present, it usually results in weakness of thumb function (342). Treatment options include reefing or imbrication of the scarred collateral ligament or reattaching a remnant of scarred tissue to the proximal phalanx (60,61,346,348,357,379), dynamic tendon transfers (283,310,311,327,340,351,367,368), static tendon transfers (305,334,357,379), free tendon grafting (284,290,305,308,309,339,344,355,369,371,379), or MP fusion (304,333,337,343,352,357,371). Joint arthrodesis is generally recommended if posttraumatic arthritis is present (296,304,314,317,345,352) (see Chapter 72). If the joint is not arthritic, the following reconstructive procedures are valuable. There are, however, many other techniques using tendon grafts (284,308,335,339,350,371,379).

**Repair of a Chronic Thumb Ulnar Collateral Ligament Injury**

*Adductor Pollicis Advancement for Chronic Thumb Ulnar Collateral Ligament Injury (Neviaser Technique)*

- Use the approach for the acute collateral ligament injury. Protect the digital nerves dorsally and palmarly (Fig. 39.38).

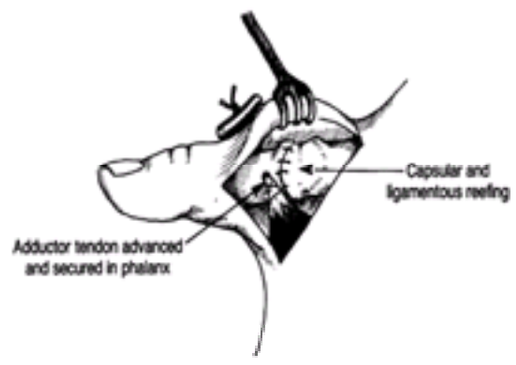


***Figure 39.38.*** Adductor pollicis advancement technique for chronic thumb ulnar collateral ligament injury. Capsuloligamentous complex is reefed, and the tendon of the adductor pollicis is advanced and inserted into a drill hole in the mid-axial region of the proximal phalanx.

- Isolate and detach the major tendon of insertion of the adductor pollicis. Leave enough tendinous tissue to accept a pullout suture.
- Mobilize a broad, proximally based, U-shaped flap on the metacarpal. Drill a bicortical hole in the ulnar mid-axial line of the proximal phalanx, 10–12 mm distal to the joint. Enlarge the opening on the ulnar side of the proximal phalanx to accept the adductor tendon.
- With the joint reduced, imbricate or advance the flap of scarred collateral ligament and suture it to the residual soft tissue at the phalangeal base with a nonabsorbable suture.
- Place a nonabsorbable modified Bunnell suture in the adductor tendon and pass it through the proximal phalanx to exit percutaneously on the radial side. With the thumb adducted, tie the suture over a protected button, making sure the adductor tendon is pulled well into the ulnar hole of the phalanx.
- Repair the aponeurosis and skin separately and immobilize the thumb in a spica cast for 4 weeks. Then begin protected motion in a removable custom splint for another 2–3 weeks. Remove the button and pullout suture at 5–6 weeks. Avoid forceful stressing of the ligament reconstruction for 3 months (351).

*Free Tendon Graft for Chronic Thumb Ulnar Collateral Ligament Injury (Smith Technique)*

- Use the approach for the acute collateral ligament injury (Fig. 39.39).

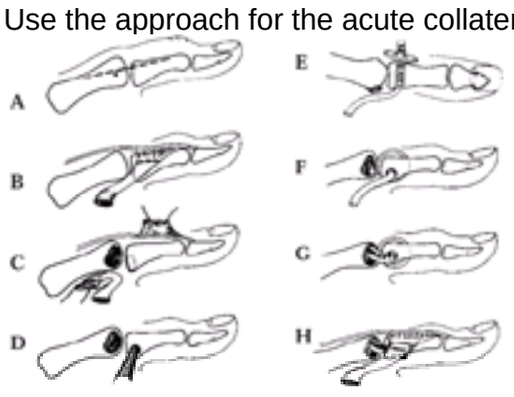


***Figure 39.39.*** Free tendon graft technique for chronic thumb ulnar collateral ligament injury. See text for details. (From Smith RJ. Posttraumatic Instability of the Metacarpophalangeal Joint of the Thumb. *J Bone Joint Surg* 1977;59A:14, with permission.)

- Drill a hole transversely, in a radial to ulnar direction, along the base of the proximal phalanx just distal to the articular surface.
- Place the hole volar to the axis of joint motion. Place a suture in the end of the free tendon graft and pass it through the proximal phalanx to exit percutaneously on the radial side, pulling the tendon through the ulnar hole. Tie the suture over a protected button.
- Alternatively, create two holes on the ulnar side of the base of the proximal phalanx, one dorsally and one volar to the axis of motion. Connect the holes within the medullary canal and enlarge them so that a free tendon graft (palmaris or long toe extensor) can be placed through them.
- Pull the remaining portion of the free tendon graft to the metacarpal head. Make parallel longitudinal incisions in the remnant of the collateral ligament. Secure the tendon graft, with nonabsorbable sutures, to the metacarpal head by weaving the graft through the ligament.
- Alternatively, place two holes in the ulnar side of the metacarpal head, one dorsal and one volar. Pass the tendon graft between the two holes and through an intramedullary tunnel. Pass the remaining portion of the tendon graft distally back on itself, parallel and volar to the other limb of the tendon graft. Suture the two limbs of the tendon graft to one another. Repair and imbricate, if needed, the adductor aponeurosis to the extensor mechanism and then close the skin (371).

*Extensor Pollicis Brevis Tendon Transfer for Chronic Thumb Ulnar Collateral Ligament Injury (Sakellarides Technique)*

- Use the approach for the acute collateral ligament injury (Fig. 39.40).

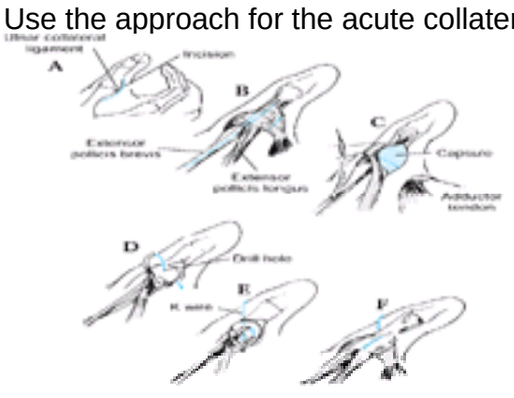


***Figure 39.40.*** Extensor pollicis brevis tendon transfer technique for chronic thumb ulnar collateral ligament injury. See text for details. (From Sakellarides HT, DeWeese JW. Instability of the Metacarpophalangeal Joint of the Thumb. Reconstruction of the Collateral Ligament Using the Extensor Pollicis Brevis. *J Bone Joint Surg* 1976;58A:106, with permission.)

- Transversely incise the scarred collateral ligament and create proximal and distal flaps.
- Dissect and mobilize the extensor pollicis brevis. Detach either half or all of the tendon distal to the MP joint, leaving it proximally based.
- Drill two holes, one dorsally and one medially, in the base of the proximal phalanx. Place a nonabsorbable modified Bunnell suture in the extensor pollicis brevis tendon and pass it through the dorsal hole, exiting medially. Suture the end of the tendon to the remaining proximal stump of collateral ligament. If no proximal metacarpal ligament stump is available, use a pullout suture technique. Repair and imbricate any remaining portion of the collateral ligament.
- Repair the adductor aponeurosis to the extensor mechanism and close the skin. Stabilize the MP joint with a K-wire, if needed (368).

**Complications** A delay in diagnosis or treatment of thumb MP joint ulnar collateral ligament injuries can result in chronic MP joint instability with pain, loss of pinch strength, and, with time, arthrosis (335,382).

With surgical repair or reconstruction, sensory nerve injury and web space contractures can occur. A loose ligament repair may leave a lax joint. Loss of joint motion is common following ligament repair or reconstruction. Residual pain can persist from unappreciated joint arthritis.

***Thumb MP Joint Radial Collateral Ligament Ruptures***

Injury to the radial collateral ligament of the MP joint is less common than its ulnar counterpart (294,331,333,346,371) and is usually caused by forceful adduction, ulnar deviation, or torsion of the thumb proximal phalanx. The radial collateral ligament can be avulsed from either the base of the proximal phalanx or the metacarpal head, or it can be attenuated in its midportion (294,300,371). The dorsal joint capsule may also be torn. The thumb often lies in ulnar deviation and slight pronation, a finding confirmed by radiographs (Fig. 39.41). Without a radial collateral ligament to provide stability, the proximal phalanx is deviated ulnarly by the strong pull of the adductor

pollicis. The patient will have localized tenderness over the area of injury. The metacarpal head may be prominent dorsoradially. Check with passive ulnar stress of the MP joint with the joint in extension and at 30° of flexion. Instability of greater than 30° as compared to the opposite thumb, without a firm end point, is indicative of a complete tear of the radial collateral ligament. Stress views of the MP joint may also be helpful to determine the integrity of the ligament.

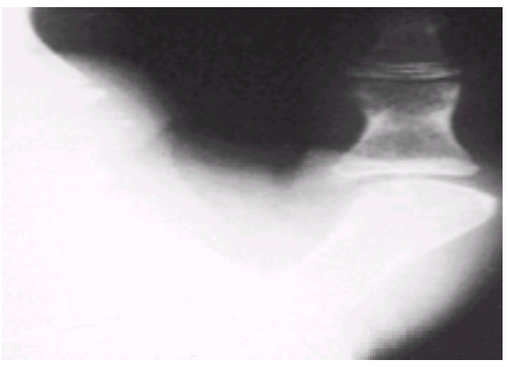

***Figure 39.41.*** Radial collateral ligament rupture leaves the phalanx subluxated ulnarly by the strong pull of the adductor pollicis.

Treat partial radial collateral ligament injuries in a thumb spica cast with the thumb in a reduced position for 4 weeks.

Unfortunately, these injuries usually are not recognized until found in the chronic state. As with the ulnar collateral ligament, treatment options include direct ligament repair (304,343,371), reefing or imbrication of the scarred collateral ligament or reattaching a remnant of scarred tissue to the proximal phalanx (294,310), dynamic tendon transfers (294,310,350,351), free tendon grafting (291,307,371), or MP fusion. If there is posttraumatic arthritis, do an arthrodesis. If the joint is not arthritic, use the following reconstruction (350,351).

**Repair of a Tear of the Thumb Radial Collateral Ligament**

*Acute Thumb MP Joint Radial Collateral Ligament Injury*

- Make a chevron incision on the radial side of the MP joint, protecting the dorsal radial sensory nerve.
- Divide the abductor pollicis brevis aponeurosis just radial to its insertion into the extensor tendon, and reflect it for later repair. Repair the ligament either in midsubstance or to either the proximal phalanx or metacarpal head, depending on the area of injury. If the ends of the torn ligament are identifiable, divide the capsule and ligament transversely and imbricate them. Repair any capsular and extensor mechanism tears.
- Close the skin separately. Stabilize the joint with a K-wire fixation if there is residual joint instability. Postoperative treatment is similar to that for ulnar collateral ligament tears.

*Chronic Thumb MP Joint Radial Collateral Ligament Injury*

- Use the approach for the acute collateral ligament injury. Detach the tendon of the abductor pollicis brevis with sufficient length to hold a suture.
- Create a proximally based, U-shaped flap of scarred radial collateral ligament mass.
- Drill a bicortical hole about 10–12 mm distal to the joint. Enlarge the radial hole with a curet.
- Imbricate or reef the ligament flap with the joint reduced. Pass a nonabsorbable suture through the abductor pollicis brevis tendon using a modified Bunnell suture technique. Pass both ends of the suture through the drill hole in the proximal phalanx and out through the skin on the ulnar side. Tie the suture over a protected button, making sure the tendon fits snugly in the radial hole (Fig. 39.42).




***Figure 39.42.*** Capsuloligamentous complex is reefed, and the tendon of the abductor pollicis brevis is advanced to a drill hole on the radial side of the phalanx in the mid-axial plane.

- Close the skin. Immobilize the thumb in a spica cast for 4 weeks and then begin protected motion in a removable custom splint for another 2–3 weeks. Remove the button and pullout suture at 5–6 weeks. Avoid forceful stress on the ligament repair for 3 months.

**Complications** Complications in treating thumb MP joint radial collateral ligament injuries are the same as those listed under ulnar collateral ligament tears described earlier.

***Volar Plate Ruptures***

Acute hyperextension injuries of the thumb MP joint are common and can be diagnosed by eliciting tenderness over the volar plate and detecting hyperextensibility of this joint (with the IP joint flexed) compared to the opposite thumb (311,377). Unlike the finger PIP joints, the volar plate detachment occurs proximally from the metacarpal. Treat with dorsal-block splinting (restricting the last 20° of extension) for 4 weeks.

For patients with chronic hyperextensibility at the MP joint, pain and weakness can occur with grasping or pinching (311,361,362). For patients failing nonoperative measures, the operative options for chronic MP joint instability include a volar plate capsulodesis (343,384), tenodesis (302,330), dynamic tendon transfer (361), or arthrodesis if arthritic changes are present.

**Volar Plate Capsulodesis for a Thumb MP Joint Hyperextension Injury**

- Make a palmar zigzag incision and retract the digital arteries and nerves.
- Incise the $A_1$ pulley in its proximal portion and retract the flexor pollicis longus. Incise the intervals between the sides of the volar plate and the accessory collateral ligaments. Release the distally based volar plate proximally and excise the sesamoids subperiosteally.
- Using an osteotome or a dental chisel, create a transverse trough in the metacarpal neck. Drill a hole through each edge of the trough obliquely through the metacarpal. Perform a trial reduction of the proximal edge of the volar plate into the trough. When the plate is properly seated, passive extension of the MP joint should be limited to 15° of flexion. If less flexion is evident, trim a portion of the free edge of the volar plate and recheck the position of the MP joint.
- Weave a nonabsorbable suture through the free proximal edge of the plate, using a modified Bunnell technique. Pass the suture ends through the drill holes and the skin and tie over a protected button, thereby drawing the volar plate securely into the trough.
- An alternative, but more difficult, method includes creating a synostosis between the sesamoids and metacarpal neck to produce a 15° to 20° flexion deformity of the MP joint. Transfix the joint with a smooth K-wire to maintain the joint position.
- Suture the accessory collateral ligaments to the edges of the volar plate with 5-0 nonabsorbable suture and close the skin.
- Use a plaster thumb spica splint for 4 weeks, allowing IP joint flexion at 1 week. Remove the splint and pin at 4 weeks. Begin exercises with an extension-block

splint for 2 more weeks, followed by removal of the button, suture, and splint.

**Complications** Complications in treating thumb MP joint hyperextension injury include joint stiffness with prolonged joint immobilization (278). Chronic instability can occur if hyperextension is not prevented for a sufficient amount of time. Degenerative arthritis can occur after chronic instability has developed (314).

Following surgical correction for chronic instability, a permanent flexion contracture is common. Recurrent hyperextensibility is the result of a loose capsulodesis, insecure fixation of the volar plate to the proximal phalanx, or insufficient immobilization.

Posttraumatic sesamoid arthritis of the MP joint can occur. The radial sesamoid appears to be more frequently involved (380). Acute injuries should be treated with the immobilization of the MP joint, usually in slight flexion (315,359). Chronic injuries, refractory to nonoperative treatment, are usually successfully treated with sesamoid excision (358,380). Sesamoid excision is performed through a volar approach to the MP joint volar plate, with enucleation of the sesamoid through a longitudinal incision in the volar plate (380).

## TRAPEZIOMETACARPAL (CARPOMETACARPAL) JOINT

### *Assessment and Indications for Treatment*

Thumb CMC joint dislocations are frequently associated with intraarticular fractures. To assess, take true AP and lateral radiographs of the thumb CMC joint (Robert view) (403). Dorsoradial subluxation of the CMC joint may indicate ligament injury. Stress radiographs may be helpful in diagnosing instability of the joint (392,393,395).

The most common dislocation or ligament injury at this joint is the Bennett's fracture–dislocation (see Chapter 40). Trapeziometacarpal dislocation without fracture is far less common but quite difficult to treat because of persistent instability (243).

### *Acute Trapeziometacarpal Dislocations*

Trapeziometacarpal dislocations without a concomitant fracture are rare. Most dislocations occur dorsally. The mechanism of injury is thought to be axial compression with a load on the metacarpal in flexion (405,411). Disruption of the dorsal ligaments probably occurs to allow the joint to dislocate (398,410,411), but the volar ligament is intact and is subperiosteally stripped off the base of the metacarpal (388,413). Clinically, a prominence is noted dorsoradially at the base of the thumb metacarpal with the thumb held is an adducted position, similar to that seen with a fracture–dislocation at the CMC joint.

Treatment options include a closed reduction or open reduction, with or without K-wire fixation, and thumb spica cast immobilization (252,400,401,410,412).

- Perform a closed reduction under adequate analgesia using longitudinal traction, abduction, and extension of the thumb. Place direct pressure on the base of the thumb metacarpal base, displacing it distally, volarly, and ulnarly.
- Postreduction radiographs should confirm congruous reduction of the joint.
- Immobilize in a thumb spica cast with the thumb held in abduction and extension and pressure placed on the dorsoradial aspect of the metacarpal base. With joint instability or radiographic signs of persistent subluxation, add percutaneous transarticular K-wire pinning. Remove the wires and cast at 6 weeks and begin exercises.

Despite successful reduction of acute dislocations of the thumb CMC joint, instability and redislocation are common, and early ligament reconstruction may be necessary. It is important to monitor the patient radiographically after K-wire removal at frequent intervals until it is certain that stability has been achieved.

### *Chronic Trapeziometacarpal Dislocations*

For chronic dislocations or for recurrent instability with posttraumatic arthritis, arthroplasty or arthrodesis is preferred (see Chapter 71, Chapter 72). If there is no significant arthritic change, do a ligamentous reconstruction. The most widely accepted technique uses the flexor carpi radialis as described by Eaton (390,392,395).

#### Thumb Trapeziometacarpal Ligamentous Reconstruction (Eaton)

- Make an incision along the dorsoradial margin of the thumb metacarpal and curve it palmarward as it approaches the wrist flexor crease, ending over the flexor carpi radialis. Take care to protect the sensory nerves (Fig. 39.43 and Fig. 39.44).

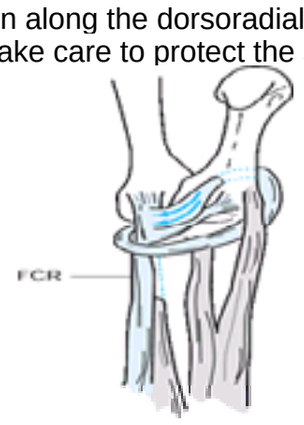


***Figure 39.43.*** Stabilization of the trapeziometacarpal joint by half of the flexor carpi radialis (*FCR*).

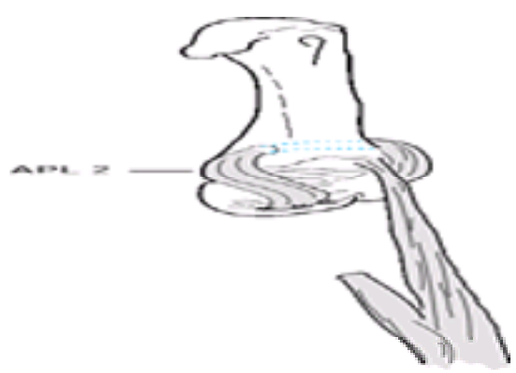

***Figure 39.44.*** Using the accessory slip of the abductor pollicis longus (*APL*) to stabilize the trapeziometacarpal joint.

- Extraperiosteally elevate the thenar muscle origin from the trapezium and metacarpal and retract it distally. Incise the roof of the flexor carpi radialis tunnel and any remaining volar radial CMC joint capsule.
- Use a drill or gouge to create a tunnel in the metacarpal base dorsally between the extensor pollicis longus and brevis and exiting at the palmar beak of the metacarpal. Take care not to enter the trapeziometacarpal joint.
- Longitudinally split half of the flexor carpi radialis for 6 cm, leaving it distally based. Expose the proximal portion of the tendon through transverse incisions over the tendon.
- Pass the tendon through the bone trough, in a volar to dorsal direction, using a suture or wire to guide the tendon through the trough. Reduce and pin the joint with a smooth K-wire, avoiding the tendon slip.
- Pull the tendon slip taut and suture it to the dorsal periosteum of the metacarpal.
- Redirect the tendon slip beneath the extensor pollicis brevis and abductor pollicis longus proximally across the joint and back under the remaining intact portion of the flexor carpi radialis. Turn the tendon slip back to the palmar periosteum of the metacarpal, and suture it there. Place additional sutures wherever the tendon slip changes direction.

- Close the skin and immobilize the thumb in a thumb spica cast for 4 weeks. Remove the K-wire and protect the thumb for an additional 2 weeks with a removable thumb spica splint. Start active exercises, but do not expect maximal return of motion for up to 4–6 months.
- An alternative to using the flexor carpi radialis tendon is to use one of the slips of the abductor pollicis longus. The most common insertion for the commonly present second slip is into the trapezium (407). This natural anchor can be used to advantage.
- Make a longitudinal incision starting along the dorsal ulnar side of the proximal third of the first metacarpal, curve it palmarward over the trapezium, and continue it along the anterior border of the first dorsal compartment.
- Dissect free an 8 cm distally based slip of the abductor pollicis longus attached to the trapezium.
- Use a drill or gouge to make a dorsal-to-palmar hole in the metacarpal parallel but distal to the trapeziometacarpal joint. Pass the slip of abductor pollicis longus tendon through the hole using a suture attached to the end of the tendon slip.
- Reduce the joint and tighten the tendon. Loop the tendon back on itself and suture to its trapezial insertion.
- Reinforce the new “ligament” by spreading it out and suturing it to the capsule on each side of the tendon wherever it crosses the joint.
- Pin the joint with a smooth K-wire if necessary. Immobilize the thumb in a thumb spica splint or cast for 6 weeks. When the cast and pin are removed, begin exercises (392).

**Complications** Complications in treating thumb trapeziometacarpal dislocations are usually the result of failing to identify the injury. Failing to immobilize an incomplete ligament injury can lead to persistent joint instability, requiring ligament reconstruction (391,392). Failingto recognize a complete dislocation will require an open reduction and ligament reconstruction (391,392,414). Persistent instability may lead to symptomatic joint arthritis requiring arthrodesis or arthroplasty (see Chapter 71, Chapter 72). Persistent subluxation can result if the new ligament is not tightened sufficiently with the joint reduced.

## CHAPTER REFERENCES

Each reference is categorized according to the following scheme: *, classic article; #, review article; !, basic research article; and +, clinical results/outcome study.

## INTERPHALANGEAL JOINTS (FINGERS AND THUMB)


+ 1. Adams JP. Correction of Chronic Dorsal Subluxation of the Proximal Interphalangeal Joint by Means of a Criss-Cross Volar Graft. *J Bone Joint Surg* 1959;41A:111.

+ 2. Agee JM. Unstable Fracture Dislocations of the Proximal Interphalangeal Joints of the Fingers: A Preliminary Report of a New Treatment Technique.*J Hand Surg* 1978;3:386.

+ 3. Agee JM. Unstable Fracture Dislocations of the Proximal Interphalangeal Joint: Treatment with the Force Couple Splint. *Clin Orthop* 1987;214:101.

+ 4. Ali MS. Complete Disruption of the Collateral Mechanism of Proximal Interphalangeal Joints of Fingers.*J Hand Surg* 1984;9B:191.

# 5. Ambrosia JM, Linscheid RL. Simultaneous Dorsal Dislocation of the Interphalangeal Joints in a Finger. Case Report and Review of the Literature. *Orthopedics* 1988;11:1079.

# 6. Andersen MB, Johannsen H. Double Dislocation of the Interphalangeal Joints in the Finger. Case Report and Review of Publications. *Scand J Plast Reconstr Hand Surg* 1993;27:233.

+ 7. Bate JT. An Operation for the Correction of Locking of the Proximal Interphalangeal Joint of a Finger in Hyperextension. *J Bone Joint Surg* 1945;27:142.

+ 8. Baugher WH, McCue FC. Anterior Fracture-dislocation of the Proximal Interphalangeal Joint. *J Bone Joint Surg* 1979;61A:779.

+ 9. Bayne O, Chabot JM, Carr JP, Evans EF. Simultaneous Dorsal Dislocation of Interphalangeal Joints in a Finger. *Clin Orthop* 1990;257:104.

+ 10. Benke GJ, Stableforth PG. Injuries of the Proximal Interphalangeal Joint of the Fingers. *Hand* 1979;3:263.

+ 11. Bilos ZJ, Vender MI, Bonavolonta M, Knutson K. Fracture Subluxation of Proximal Interphalangeal Joint Treated by Palmar Plate Advancement. *J Hand Surg* 1994;19A:189.

* 12. Bowers WH. The Proximal Interphalangeal Joint Volar Plate. II: A Clinical Study of Hyperextension Injury. *J Hand Surg* 1981;6:77.

# 13. Bowers WH. Management of Small Joint Injuries in the Hand. *Orthop Clin North Am* 1983;14:793.

# 14. Bowers WH, ed. *The Interphalangeal Joints*. Edinburgh: Churchill Livingstone, 1987.

* 15. Bowers WH, Wolf JW Jr, Nehil J, Bittinger S. The Proximal Interphalangeal Joint Volar Plate. I. An Anatomical and Biomechanical Study.*J Hand Surg* 1980;5:79.

# 16. Brunet ME, Haddad RJ. Fractures and Dislocations of the Metacarpals and Phalanges. *Clin Sports Med* 1986;5:773.

# 17. Buchanan RT. Mechanical Requirements for Application and Modification of the Dynamic Force Couple Method.*Hand Clin* 1994;10:221.

# 18. Burton RI, Eaton RG. Common Hand Injuries in the Athlete. *Orthop Clin North Am* 1973;4:809.

# 19. Campbell RM Jr. Operative Treatment of Fractures and Dislocations of the Hand and Wrist Region in Children. *Orthop Clin North Am* 1990;21:217.

# 20. Craig SM. Anatomy of the Joints of the Fingers. *Hand Clin* 1992;8:693.

+ 21. Crick JC, Conners JJ, Franco RS. Irreducible Palmar Dislocation of the Proximal Interphalangeal Joint with Bilateral Avulsion Fractures.*J Hand Surg* 1990;15A:460.

+ 22. Curtis RM. Treatment of Injuries of the Proximal Interphalangeal Joints of the Fingers. *Curr Pract Orthop Surg* 1964;2:125.

+ 23. Dawson WJ. The Spectrum of Sports-Related Interphalangeal Joint Injuries. *Hand Clin* 1994;19:315.

+ 24. De Smet L, Vercauteren M. Palmar Dislocation of the Proximal Interphalangeal Joint Requiring Open Reduction: A Case Report.*J Hand Surg* 1984;9A:717.

+ 25. Diao E, Eaton RG. Total Collateral Ligament Excision for Contractures of the Proximal Interphalangeal Joint. *J Hand Surg* 1993;18A:393.

+ 26. Dobyns JH, McElfresh EC. Extension Block Splinting. *Hand Clin* 1994;10:229.

+ 27. Donaldson WR, Millender LH. Chronic Fracture-Subluxation of the Proximal Interphalangeal Joint.*J Hand Surg* 1978;3:149.

# 28. Dray GJ, Eaton RG. Dislocations and Ligament Injuries in the Digits. In: Green DP, ed. *Operative Hand Surgery*, 3rd ed. New York: Churchill-Livingstone, 1993:767.

+ 29. Durham-Smith G, McCarten GM. Volar Plate Arthroplasty for Closed Proximal Interphalangeal Joint Injuries.*J Hand Surg* 1992;17B:422.

# 30. Eaton RG. *Joint Injuries of the Hand*. Springfield, IL: Charles C. Thomas, 1971.

* 31. Eaton RG, Malerich MM. Volar Plate Arthroplasty of the Proximal Interphalangeal Joint: A Review of 10 Years' Experience.*J Hand Surg* 1980;5:260.

+ 32. Espinosa RH, Renart IP. Simultaneous Dislocation of the Interphalangeal Joints in a Finger—Case Report.*J Hand Surg* 1980;5:617.

# 33. Freeland AE, Benoist LA. Open Reduction and Internal Fixation Method for Fractures at the Proximal Interphalangeal Joint. *Hand Clin* 1994;10:239.

+ 34. Freeman BH, Haskin JS Jr, Hay EL. Chronic Anterior Dislocation of the Proximal Interphalangeal Joint. *Orthopedics* 1985;8:385.

# 35. Froehlich JA, Akelman E, Herndon JH. Extensor Tendon Injuries at the Proximal Interphalangeal Joint. *Hand Clin* 1988;4:25.

# 36. Garroway RY, Hurst LC, Leppard J, Dick HM. Complex Dislocations of the Proximal Interphalangeal Joint. A Pathoanatomic Classification of the Injury. *Orthop Rev* 1984;13:21.

+ 37. Ghobadi F, Anapolle DM. Irreducible Distal Interphalangeal Joint Dislocation of the Finger: A New Cause. *J Hand Surg* 1994;19A:196.

# 38. Glickel SZ, Barron A, Eaton RG. Dislocations and Ligament Injuries in the Digits. In: Green DP, ed. *Operative Hand Surgery*, 4th ed. New York: Churchill-Livingstone, 1999:772.

+ 39. Grant IR. Irreducible Rotational Anterior Dislocation of the Proximal Interphalangeal Joint. A Spin Drier Injury. *J Hand Surg* 1993;18B:648.

+ 40. Green A, Smith J, Redding M, Akelman E. Acute Open Reduction and Rigid Internal Fixation of Proximal Interphalangeal Joint Fracture Dislocation. *J Hand Surg* 1992;17A:512.

# 41. Green DP. Dislocations and Ligamentous Injuries in the Hand. In: Evarts CM, ed. *Surgery of the Musculoskeletal System, 2nd ed.* New York: Churchill-Livingstone, 1990:385.

# 42. Green DP, Butler TE. Fractures and Dislocations in the Hand. In: Rockwood CA, Green DP, Bucholz RW, Heckman JD, eds. *Fractures in Adults*, 4th ed. Philadelphia: Lippincott-Raven, 1996:607.

+ 43. Green SM, Posner MA. Irreducible Dorsal Dislocation of the Proximal Interphalangeal Joint. *J Hand Surg* 1985;10A:85.

+ 44. Greenfield GQ. Dislocation of the Interphalangeal Joint of the Thumb.*J Trauma* 1981;21:901.

+ 45. Hage JJ, Reinders JFM, Schuwirth L. Simultaneous Dislocation of Both Interphalangeal Joints in a Finger. *Arch Orthop Trauma Surg* 1990;109:179.

+ 46. Hamer DW, Quinton DN. Dorsal Fracture Subluxation of the Distal Interphalangeal Joint of the Finger and the Interphalangeal Joint of the Thumb Treated by Extension Block Splintage.*J Hand Surg* 1992;17B:591.

+ 47. Hardy I, Russell J, McFarlane I. Simultaneous Dislocation of the Interphalangeal Joints in a Finger.*J Trauma* 1985;25:450.

# 48. Hastings H, Carroll C. Treatment of Closed Articular Fractures of the Metacarpophalangeal and Proximal Interphalangeal Joints. *Hand Clin* 1988;4:503.

# 49. Hastings H, Ernst JM. Dynamic External Fixation for Fractures of the Proximal Interphalangeal Joint. *Hand Clin* 1993;9:659.

+ 50. Hindley CJ. Triple Dislocations in the Index Finger.*J Trauma* 1989;25:122.

+ 51. Horiuchi Y, Itoh Y, Sasaki T, et al. Dorsal Dislocation of the DIP Joint with Fracture of the Volar Base of the Distal Phalanx. *J Hand Surg* 1989;14B:177.

+ 52. Hutchinson JD, Hooper G, Robb JE. Double Dislocations of Digits. *J Hand Surg* 1991;16B:114.

+ 53. Iftikhar TB. Long Flexor Tendon Entrapment Causing Open Irreducible Dorsoradial Dislocation of the Distal Interphalangeal Joint of the Finger.*Orthop Rev* 1982;11:117.

+ 54. Ikpeme JO. Dislocation of Both Interphalangeal Joints of One Finger.*Injury* 1977;9:68.

+ 55. Inanami H, Ninomiya S, Okutsu I, et al. Dynamic External Finger Fixator for Fracture Dislocation of the Proximal Interphalangeal Joint. *J Hand Surg* 1993;18A:160.

+ 56. Incavo SJ, Mogan JV, Hilfrank BC. Extension Splinting of Palmar Plate Avulsion Injuries of the Proximal Interphalangeal Joint.*J Hand Surg* 1989;14A:659.

+ 57. Inoue G, Kino Y, Kondo K. Simultaneous Dorsal Dislocation of Both Interphalangeal Joints in a Finger. *Am J Sports Med* 1993;21:323.

+ 58. Inoue G, Maeda N. Irreducible Palmar Dislocation of the Distal Interphalangeal Joint of the Finger. *J Hand Surg* 1987;12A:1077.

+ 59. Inoue G, Maeda N. Irreducible Palmar Dislocation of the Proximal Interphalangeal Joint of the Finger. *J Hand Surg* 1990;15A:301.

# 60. Isani A. Small Joint Injuries Requiring Surgical Treatment. *Orthop Clin North Am* 1986;17:407.

# 61. Isani A, Melone CP. Ligamentous Injuries of the Hand in Athletes. *Clin Sports Med* 1986;5:757.

# 62. Jobe MT. The Hand. In: Canale ST, ed. *Campbell's Operative Orthopaedics, 9th ed.* St. Louis: Mosby, 1998:3377.

+ 63. Johnson FG, Greene MH. Another Cause of Irreducible Dislocation of the Proximal Interphalangeal Joint of a Finger: A Case Report. *J Bone Joint Surg* 1966;48A:542.

# 64. Jones BF, Stern PJ. Interphalangeal Joint Arthrodesis. *Hand Clin* 1994;10:267.

+ 65. Jones NF, Jupiter JB. Irreducible Palmar Dislocation of the Proximal Interphalangeal Joint Associated with an Epiphyseal Fracture of the Middle Phalanx.*J Hand Surg* 1985;10A:261.

# 66. Kasparyan NG, Hotchkiss RN. Dynamic Skeletal Fixation in the Upper Extremity. *Hand Clin* 1997;13:643.

+ 67. Khuri SM. Irreducible Dorsal Dislocation of the Distal Interphalangeal Joint of the Finger. *J Trauma* 1984;24:456.

! 68. Kiefhaber TR, Stern PJ, Grood ES. Lateral Stability of the Proximal Interphalangeal Joint. *J Hand Surg* 1986;11A:661.

+ 69. Kilgore ES, Newmeyer WL, Brawn LG. Post-traumatic Trapped Dislocations of the Proximal Interphalangeal Joint. *J Trauma* 1976;16:481.

+ 70. Kitagawa H, Kashimoto T. Locking of the Thumb at the Interphalangeal Joint by One of the Sesamoid Bones. A Case Report. *J Bone Joint Surg* 1984;66A:1300.

+ 71. Kjeldal I. Irreducible Compound Dorsal Dislocations of the Proximal Interphalangeal Joint of the Finger.*J Hand Surg* 1986;11B:49.

+ 72. Kleinert HE, Kasdan ML. Reconstruction of Chronically Subluxated Proximal Interphalangeal Finger Joint. *J Bone Joint Surg* 1965;47A:958.

+ 73. Konsens RM, Cohn BT, Froimson AI. Double Dislocation of the Fifth Finger. *Orthopedics* 1987;10:1061.

+ 74. Krakauer JD, Stern PJ. Hinged Device for Fractures Involving the Proximal Interphalangeal Joint. *Clin Orthop* 1996;327:29.

+ 75. Krishnan SG. Double Dislocation of a Finger. A Case Report. *Am J Sports Med* 1979;7:204.

# 76. Kuczynski K. The PIP Joint, Anatomy and Causes of Stiffness in Fingers.*J Bone Joint Surg* 1968;50B:656.

# 77. Landsmeer JMF. Anatomical and Functional Investigations of the Human Finger, and Its Functional Significance. *Acta Anat* 1955;24(suppl):1.

+ 78. Lane CS. Reconstruction of the Unstable PIP Joint: The Double Superficialis Tenodesis.*J Hand Surg* 1978;3:368.

+ 79. Laporte JM, Berrettoni BA, Seitz WH Jr, et al. The Figure-of-Eight Splint for Proximal Interphalangeal Joint Volar Plate Injuries. *Orthop Rev* 1992;21:457.

# 80. Lee DH, Neviaser RJ. Complications of Trauma Surgery and Reconstructive Surgery of the Hand. In: Epps CH Jr, ed. *Complications in Orthopedic Surgery*, 3rd ed. Philadelphia: JB Lippincott, 1994:403.

+ 81. Lee MLH. Intra-articular and Peri-articular Fractures of the Phalanges.*J Bone Joint Surg* 1963;45B:103.

# 82. Leibovic SJ, Bowers WH. Anatomy of the Proximal Interphalangeal Joint. *Hand Clin* 1994;10:169.

# 83. Lenzo SR. Distal Joint Injuries of the Thumb and Fingers. *Hand Clin* 1992;8:769.

# 84. Liss FE, Green SM. Capsular Injuries of the Interphalangeal Joint. *Hand Clin* 1992;8:755.

+ 85. Lister G. Intraosseous Wiring of the Digital Skeleton. *J Hand Surg* 1978;3:427.

# 86. Lubahn JD. Dorsal Fracture Dislocations of the Proximal Interphalangeal Joint. *Hand Clin* 1988;4:15.

# 87. Malerich MM, Eaton RG. The Volar Plate Reconstruction for Fracture-dislocation of the Proximal Interphalangeal Joint. *Hand Clin* 1994;10:251.

# 88. Mansat M, Delprat J. Contractures of the Proximal Interphalangeal Joint.*Hand Clin* 1992;8:777.

# 89. Massengill JB. The Boutonnière Deformity. *Hand Clin* 1992;8:787.

+ 90. McCue FC, Honner R, Gleck JH, et al. A Pseudoboutonnière Deformity. *Hand* 1975;7:166.

* 91. McCue FC, Honner R, Johnson MC, Gieck GH. Athletic Injuries in the Proximal Interphalangeal Joint Requiring Surgical Treatment. *J Bone Joint Surg* 1970;52A:937.

* 92. McElfresh EC, Dobyns JH, O'Brien ET. Management of Fracture-Dislocation of the Proximal Interphalangeal Joints by Extension-Block Splinting.*J Bone Joint Surg* 1972;54A:1705.

+ 93. Meyn MA. Irreducible Volar Dislocation of the Proximal Interphalangeal Joint. *Clin Orthop* 1981;158:215.

# 94. Milford L. The Hand. In: Crenshaw AH, ed. *Campbell's Operative Orthopaedics, 7th ed.* St. Louis: CV Mosby, 1987:241.

! 95. Minamikawa Y, Horii E, Amadio PC, et al. Stability and Constraint of the Proximal Interphalangeal Joint. *J Hand Surg* 1993;18A:198.

# 96. Moberg E. Fractures and Ligamentous Injuries of the Thumb and Fingers. *Surg Clin North Am* 1960;40:297.

+ 97. Morgan JP, Gordon DA, King MS, et al. Dynamic Digital Traction for Unstable Communited Intra-articular Fracture-Dislocations of the Proximal Interphalangeal Joint. *J Hand Surg* 1995;20A:565.

+ 98. Murakami Y. Irreducible Dislocation of the Distal Interphalangeal Joint.*J Hand Surg* 1985;10B:231.

+ 99. Nathan FF, Schlein AP. Multiple Dislocations of a Single Finger. *Hand* 1973;5:52.

+ 100. Neviaser RJ, Wilson JN. Interposition of the Extensor Tendon Resulting in Persistent Subluxation of the Proximal Interphalangeal Joint of the Finger. *Clin Orthop* 1972;83:118.

+ 101. Oni OOA. Irreducible Buttonhole Dislocation of the Proximal Interphalangeal Joint of the Finger (A Case Report). *J Hand Surg* 1985;10B:100.

+ 102. Ostrowski DM, Neimkin RJ. Irreducible Palmar Dislocation of the Proximal Interphalangeal Joint. A Case Report. *Orthopedics* 1985;8:84.

+ 103. Palmer AK, Linscheid RL. Irreducible Dorsal Dislocation of the Distal Interphalangeal Joint of the Finger.*J Hand Surg* 1977;2:406.

+ 104. Palmer AK, Linscheid RL. Chronic Recurrent Dislocation of the Proximal Interphalangeal Joint of the Finger. *J Hand Surg* 1978;3:95.

# 105. Patel MR, Joshi BB. Distraction Method for Chronic Dorsal Fracture Dislocation of the Proximal Interphalangeal Joint. *Hand Clin* 1994;10:327.

+ 106. Peimer CA, Sullivan DJ, Wild DR. Palmar Dislocation of the Proximal Interphalangeal Joint. *J Hand Surg* 1984;9A:39.

# 107. Phillips JH. Irreducible Dislocation of a Distal Interphalangeal Joint. Case report and Review of Literature. *Clin Orthop* 1981;154:188.

+ 108. Pohl AL. Irreducible Dislocation of a Distal Interphalangeal Joint. *Br J Plast Surg* 1976;29:227.

+ 109. Portis RB. Hyperextensibility of the Proximal Interphalangeal Joint of the Finger Following Trauma. *J Bone Joint Surg* 1954;36A:1141.

+ 110. Posner MA, Kapila D. Chronic Palmar Dislocation of Proximal Interphalangeal Joints. *J Hand Surg* 1986;11A:253.

+ 111. Posner MA, Wilenski M. Irreducible Volar Dislocation of the Proximal Interphalangeal Joint of a Finger Caused by Interposition of an Intact Central Slip.*J Bone Joint Surg* 1978;60A:133.

+ 112. Rayan GM, Elias LS. Irreducible Dislocation of the Distal Interphalangeal Joint Caused by Long Flexor Tendon Entrapment. *Orthopedics* 1981;4:35.

+ 113. Redler I, Williams JT. Rupture of a Collateral Ligament of the Proximal Interphalangeal Joint of the Finger: Analysis of 18 Cases.*J Bone Joint Surg* 1967;49A:322.

! 114. Rhee RY, Reading G, Wray RC. A Biomechanical Study of the Collateral Ligaments of the Proximal Interphalangeal Joint.*J Hand Surg* 1992;17A:157.

+ 115. Robertson RC, Cowley JJ, Faris AM. Treatment of Fracture-Dislocation of the Interphalangeal Joints of the Hand. *J Bone Joint Surg* 1946;28:680.

+ 116. Rodriquez AL. Injuries to the Collateral Ligaments of the Proximal Interphalangeal Joints. *Hand* 1973;5:55.

+ 117. Ron D, Alkalay D, Torok G. Simultaneous Closed Dislocation of Both Interphalangeal Joints in One Finger.*J Trauma* 1983;23:66.

+ 118. Salamon PB, Gelberman RH. Irreducible Dislocation of the Interphalangeal Joint of the Thumb. Report of Three Cases.*J Bone Joint Surg* 1978;60A:400.

+ 119. Schenck RR. Dynamic Traction and Early Passive Movement for Fractures of the PIP Joint.*J Hand Surg* 1986;11A:850.

# 120. Schenck RR. Classification of Fractures and Dislocations of the Proximal Interphalangeal Joint. *Hand Clin* 1994;10:179.

# 121. Schenck RR. The Dynamic Traction Method. Combining Movement and Traction for Intra-Articular Fractures of the Phalanges. *Hand Clin* 1994;10:187.

+ 122. Selig S, Schein A. Irreducible Buttonhole Dislocations of the Fingers. *J Bone Joint Surg* 1940;22A:436.

+ 123. Simpson MB, Greenfield GQ. Irreducible Dorsal Dislocation of the Small Finger Distal Interphalangeal Joint: The Importance of Roentgenograms—Case Report.*J Trauma* 1991;31:1450.

! 124. Slattery PG. The Dorsal Plate of the Proximal Interphalangeal Joint. *J Hand Surg* 1990;15B:68.

* 125. Smith RJ. Intrinsic Muscles of the Finger. Function, Dysfunction, and Surgical Reconstruction. *Instr Course Lect* 1975;24:200.

+ 126. Soelberg M, Gebuhr P, Klareskov B. Interphalangeal Dislocations of the Fingers Treated by an Elastic Double-Finger Bandage. *J Hand Surg* 1990;15B:66.

+ 127. Spinner M, Choi BY. Anterior Dislocation of the Proximal Interphalangeal Joint: A Cause of Rupture of the Central Slip of the Extensor Mechanism. *J Bone Joint Surg* 1970;52A:1329.

+ 128. Sprague BL. Proximal Interphalangeal Joint Injuries and Their Initial Treatment. *J Trauma* 1975;15:380.

+ 129. Stern PJ, Lee AF. Open Dorsal Dislocations of the Proximal Interphalangeal Joint—Indication for Open Reduction. *J Hand Surg* 1985;10A:364.

+ 130. Stripling WD. Displaced Intra-articular Osteochondral Fracture—Cause for Irreducible Dislocation of the Distal Interphalangeal Joint. *J Hand Surg* 1982;7:77.

+ 131. Strong ML. A New Method of Extension-block Splinting for the Proximal Interphalangeal Joint—Preliminary Report.*J Hand Surg* 1980;5:606.

# 132. Swanson AB. Surgery of the Hand in Cerebral Palsy and Muscle Origin Release Procedures. *Surg Clin North Am* 1968;48:1129.

# 133. Thayer DT. Distal Interphalangeal Joint Injuries. *Hand Clin* 1988;4:1.

+ 134. Thompson JS, Eaton RG. Volar Dislocation of the Proximal Interphalangeal Joint (Abstract). *J Hand Surg* 1977;2:232.

+ 135. Twyman RS, David HG. The Doorstop Procedure. A Technique for Treating Unstable Fracture Dislocations of the Proximal Interphalangeal Joint. *J Hand Surg* 1993;18B:714.

+ 136. Van der Meulen JC. The Treatment of Prolapse and Collapse of the Proximal Interphalangeal Joint. *Hand* 1972;4:154.

# 137. Vicar AJ. Proximal Interphalangeal Joint Dislocations without a Fracture. *Hand Clin* 1988;4:5.

+ 138. Viegas SF. Extension Block Pinning for Proximal Interphalangeal Joint Fracture Dislocations: Preliminary Report of a New Technique. *J Hand Surg* 1992;17A:6.

+ 139. Watson FM. Simultaneous Interphalangeal Dislocation in One Finger. *J Trauma* 1983;23:65.

# 140. Watson HK, Weinzweig J. Stiff Joints. In: Green DP, ed.*Operative Hand Surgery, 4th ed.* New York: Churchill-Livingstone, 1999:552.

+ 141. Weiss AP. Cerclage Fixation for Fracture Dislocation of the Proximal Interphalangeal Joint. *Clin Orthop* 1996;327:21.

+ 142. Wesley MS, Barenfield PA, Eisenstein AL. Simultaneous Dorsal Dislocation of Both Interphalangeal Joints in a Finger. A Case Report. *J Bone Joint Surg* 1978;60A:1142.

+ 143. Whipple TL, Evans JP, Urbaniak JR. Irreducible Dislocation of a Finger Joint in a Child. A Case Report.*J Bone Joint Surg* 1980;62A:832.

+ 144. Wiley AM. Instability of the Proximal Interphalangeal Joint Following Dislocation and Fracture-Dislocation: Surgical Repair. *Hand* 1970;2:185.

+ 145. Wilson JN, Rowland SA. Fracture-dislocation of the Proximal Interphalangeal Joint of the Finger: Treatment by Open Reduction and Internal Fixation. *J Bone Joint Surg* 1966;48A:493.

# 146. Wilson RL, Liechty BW. Complications Following Small Joint Injuries.*Hand Clin* 1986;2:329.

+ 147. Wolfe SW, Katz LD. Intra-articular Impaction Fractures of the Phalanges. *J Hand Surg* 1995;20A:327.

# 148. Zemel NP, Stark HH. Problem Fractures and Dislocations of the Hand. *Instr Course Lect* 1988;37:235.

+ 149. Zemel NP, Stark HH, Ashworth CR, Boyes JH. Chronic Fracture Dislocations of the Proximal Interphalangeal Joint—Treated by Osteotomy and Bone Graft.*J Hand Surg* 1981;6:447.

+ 150. Zielinski CJ. Irreducible Fracture-dislocation of the Distal Interphalangeal Joint: A Case Report. *J Bone Joint Surg* 1983;65A:109.

## METACARPOPHALANGEAL JOINTS (FINGERS)

+ 151. Adler GA, Light TR. Simultaneous Complex Dislocation of the Metacarpophalangeal Joints of the Long and Index Fingers: A Case Report. *J Bone Joint Surg* 1981;63A:1007.

+ 152. Andersen JA, Gjerloff CC. Complex Dislocation of the Metacarpophalangeal Joint of the Little Finger. *J Hand Surg* 1987;12B:264.

+ 153. Araki S, Ohtani T, Tanaka T. Open Dorsal Metacarpophalangeal Dislocations of the Index, Long, and Ring Fingers. *J Hand Surg* 1987;12A:458.

+ 154. Baldwin LW, Miller DL, Lockhart D, Evans EB. Metacarpophalangeal Joint Dislocations of the Fingers. A Comparison of the Pathological Anatomy of the Index and Little Finger. *J Bone Joint Surg* 1967;49A:1587.

+ 155. Barash HL. An Unusual Case of Dorsal Dislocation of the Metacapophalangeal Joint of the Index Finger. *Clin Orthop* 1972;83:121.

+ 156. Barenfeld PA, Wesley MS. Dorsal Dislocation of the Metacarpophalangeal Joint of the Index Finger Treated by Late Open Reduction. *J Bone Joint Surg* 1972;54A:1311.

+ 157. Barry K, McGee H, Curtin J. Complex Dislocation of the Metacarpophalangeal Joint of the Index Finger. A Comparison of the Surgical Approaches. *J Hand Surg* 1988;13B:466.

+ 158. Becton JL, Christian JD Jr, Goodwin HN, Jackson JG. A Simplified Technique for Treating the Complex Dislocation of the Index Metacarpophalangeal Joint.*J Bone Joint Surg* 1975;57A:698.

# 159. Betz RR, Browne EZ, Perry GB, Resnick EJ. The Complex Volar Metacarpophalangeal Joint Dislocation. A Case Report and Review of the Literature. *J Bone Joint Surg* 1982;64A:1374.

+ 160. Bohart PG, Gelberman RH, Vandell RF, Salamon PB. Complex Dislocations of the Metacarpophalangeal Joint: Operative Reduction by Farabeuf's Dorsal Incision. *Clin Orthop* 1982;164:208.

+ 161. Boland D. Volar Dislocation of the Ring Finger Metacarpophalangeal Joint. *Orthop Rev* 1984;13:69.

# 162. Craig SM. Anatomy of the Joints of the Fingers. *Hand Clin* 1992;8:693.

+ 163. Cunningham DM, Schwarz G. Dorsal Dislocation of the Index Metacarpophalangeal Joint. *Plast Reconstr Surg* 1975;56:654.

+ 164. Doyle JR, Atkinson RE. Rupture of the Radial Collateral Ligament of the Metacarpo-phalangeal Joint of the Index Finger: A Report of Three Cases.*J Hand Surg* 1989;14B:248.

# 165. Dray GJ, Eaton RG. Dislocations and Ligament Injuries in the Digits. In: Green DP, ed. *Operative Hand Surgery*, 3rd ed. New York: Churchill-Livingstone, 1993:767.

+ 166. Dray G, Millender LH, Nalebuff EA. Rupture of the Radial Collateral Ligament of a Metacarpophalangeal Joint to One of the Ulnar Three Fingers.*J Hand Surg* 1979;4:346.

# 167. Eaton RG. *Joint Injuries of the Hand.* Springfield, IL: Charles C. Thomas, 1971.

+ 168. Flatt AE. Recurrent Locking of an Index Finger.*J Bone Joint Surg* 1958;40A:1128.

+ 169. Flatt AE. Fracture-dislocation of an Index Metacarpophalangeal Joint and an Ulnar Deviating Force in the Flexor Tendons. *J Bone Joint Surg* 1966;48A:100.

+ 170. Fraser KE, Stamer DT. Open Dorsal Dislocations of the Index, Long, Ring, and Small Finger Metacarpophalangeal Joints. *J Hand Surg* 1995;20:576.

+ 171. Gee TC, Pho RWH. Avulsion-Fracture at the Proximal Attachment of the Radial Collateral Ligament of the Fifth Metacarpophalangeal Joint—A Case Report.*J Hand Surg* 1982;7:526.

# 172. Glickel SZ, Barron A, Eaton RG. Dislocations and Ligament Injuries in the Digits. In: Green DP, ed. *Operative Hand Surgery*, 4th ed. New York: Churchill-Livingstone, 1999:772.

# 173. Green DP. Dislocations and Ligamentous Injuries in the Hand. In: Evarts CM, ed. *Surgery of the Musculoskeletal System, 2nd ed.* New York: Churchill-Livingstone, 1990:385.

# 174. Green DP, Butler TE. Fractures and Dislocations in the Hand. In: Rockwood CA, Green DP, Bucholz RW, Heckman JD, eds. *Fractures in Adults, 4th ed.* Philadelphia: Lippincott-Raven, 1996:607.

+ 175. Green DP, Terry GC. Complex Dislocation of the Metacarpophalangeal Joint. Correlative Pathological Anatomy. *J Bone Joint Surg* 1973;55A:1480.

+ 176. Guly HR, Azam MA. Locked Finger Treated by Manipulation. A Report of Three Cases. *J Bone Joint Surg* 1982;64B:73.

+ 177. Hall RE Jr, Gleason TF, Kasa RF. Simultaneous Closed Dislocations of the Metacarpophalangeal Joints of the Index, Long, and Ring Fingers: A Case Report. *J Hand Surg* 1985;10A:81.

# 178. Hubbard LF. Metacarpophalangeal Dislocations. *Hand Clin* 1988;4:39.

+ 179. Hunt JC, Watts HB, Glasgow JD. Dorsal Dislocation of the Metacarpophalangeal Joint of the Index Finger with Particular Reference to Open Dislocation. *J Bone Joint Surg* 1967;49A:1572.

+ 180. Imbriglia JE, Sciulli R. Open Complex Metacarpophalangeal Joint Dislocation. Two Cases: Index Finger and Long Fnger. *J Hand Surg* 1979;4:72.

+ 181. Ishizuki M. Injury to Collateral Ligament of the Metacarpophalangeal Joint of a Finger. *J Bone Joint Surg* 1988;13A:444.

# 182. Jobe MT. The Hand. In: Canale ST, ed. *Campbell's Operative Orthopaedics, 9th ed.* St. Louis: Mosby, 1998:3377.

+ 183. Kaplan EB. Dorsal Dislocation of the Metacarpophalangeal Joint of the Index Finger.*J Bone Joint Surg* 1957;39A:1081.

+ 184. Khuri SM, Fay JJ. Complete Volar Metacarpophalangeal Joint Dislocation of a Finger. *J Trauma* 1986;26:1058.

+ 185. Lane CS. Detecting Occult Fractures of the Metacarpal Head: The Brewerton View. *J Hand Surg* 1977;2:131.

#186. Lee DH, Neviaser RJ. Complications of Trauma Surgery and Reconstructive Surgery of the Hand. In: Epps CH Jr, ed. *Complications in Orthopedic Surgery, 3rd ed.* Philadelphia: JB Lippincott, 1994:403.

+ 187. May JW Jr, Rohrich RJ, Sheppard JS. Closed Complex Dorsal Dislocation of the Middle Finger Metacarpophalangeal Joint: Anatomic Dissection Considerations and Treatment. *Plast Reconstr Surg* 1988;82:690.

+ 188. McCarthy LJ. Open Metacarpophalangeal Dislocations of the Index, Middle, Ring, and Little Fingers. *J Trauma* 1980;20:183.

+ 189. McElfresh EC, Dobyns JH. Intra-articular Metacarpal Head Fractures. *J Hand Surg* 1983;8:383.

+ 190. McLaughlin HL. Complex “Locked” Dislocation of the Metacarpophalangeal Joints. *J Trauma* 1965;5:682.

+ 191. Milch H. Subluxation of the Index Metacarpophalangeal Joint. Case Report. *J Bone Joint Surg* 1965;47A:522.

! 192. Minami A, An K, Cooney WP, et al. Ligamentous Structures of the Metacarpophalangeal Joint: A Quantitative Study. *J Orthop Res* 1984;1:361.

! 193. Minami A, An K, Cooney WP, et al. Ligament Stability of the Metacarpophalangeal Joint. A Biomechanical Study. *J Hand Surgery* 1985;10A:255.

+ 194. Mlsna, J, Hanel DP, Kneeland B. Complex Volar Metacarpophalangeal Joint Dislocations: Pathological Anatomy as Viewed by MRI. *Orthopedics* 1993;16:1350.

# 195. Moberg E. Fractures and Ligamentous Injuries of the Thumb and Fingers. *Surg Clin North Am* 1960;40:297.

# 196. Moberg E, Stener B. Injuries to the Ligaments of the Thumb and Fingers. Diagnosis, Treatment, and Prognosis. *Acta Chir Scand* 1953;106:166.

+ 197. Moneim MS. Volar Dislocation of the Metacarpophalangeal Joint. Pathological Anatomy and Report of Two Cases. *Clin Orthop* 1983;176:186.

+ 198. Murphy AF, Stark HH. Closed Dislocations of the Metacarpophalangeal Joint of the Index Finger. *J Bone Joint Surg* 1967;49A:1579.

+ 199. Nachtigal M, Herndon WA, Yngave DA. Answer Please: Complex Dislocation of the Metacarpophalangeal Joint.*Orthopedics* 1987;10:509.

+ 200. Nussbaum R, Sadler AH. An Isolated, Closed, Complex Dislocation of the Metacarpophalangeal Joint of the Long Finger: A Unique Case.*J Hand Surg* 1986;11A:558.

+ 201. Nutter PD. Interposition of Sesamoids in Metacarpophalangeal Dislocations.*J Bone Joint Surg* 1940;22:730.

+ 202. Ramirez Ruiz G, Combolia Alue A, Valer Tito A, et al. Simultaneous Subluxation of the Metacarpophalangeal Joints of all Four Fingers: A Case Report. *J Hand Surg* 1985;10A:78.

+ 203. Renshaw TS, Louis DS. Complex Volar Dislocation of the Metacarpophalangeal Joint: A Case Report. *J Trauma* 1971;13:1086.

# 204. Robins RHC. Injuries of the Metacarpophalangeal Joints. *Hand* 1971;3:159.

+ 205. Schubiner JM, Mass DP. Operation for Collateral Ligament Ruptures of the Metacarpophalangeal Joints of the Fingers.*J Bone Joint Surg* 1989;71B:388.

+ 206. Schuind F. Locked Metacarpophalangeal Joint due to an Intraarticular Fracture of the Metacarpal Head. *J Hand Surg* 1992;17B:148.

! 207. Schultz RJ, Storace A, Krisnamurthy S. Metacarpophalangeal Joint Motion and the Role of the Collateral Ligaments. *Int Orthop* 1987;11:149.

+ 208. Sweterlitsch PR, Torg JS, Pollack H. Entrapment of a Sesamoid in the Index Metacarpophalangeal Joint. Report of Two Cases.*J Bone Joint Surg* 1969;51A:995.

# 209. Viegas SF, Heare TC, Calhoun JH. Complex Fracture Dislocation of a Fifth Metacarpophalangeal Joint: Case Report and Literature Review.*J Trauma* 1989;29:521.

+ 210. Von Raffler W. Irreducible Dislocations of the Metacarpophalangeal Joint of the Finger. *Clin Orthop* 1964;35:171.

+ 211. Wilhelmy J, Hay RL. Dual Dislocation of the Metacarpophalangeal Joints.*Hand* 1972;4:168.

# 212. Williams JS Jr, Kamionek S, Weiss AC, Akelman E. The Surgical Approach in Non-Border Digit Complex Dislocations of the Metacarpophalangeal Joint. *Orthop Rev* 1994;23:601.

# 213. Wilson RL, Liechty BW. Complications Following Small Joint Injuries. *Hand Clin* 1986;2:329.

# 214. Wolov RB. Complex Dislocations of the Metacarpophalangeal Joints. *Orthop Rev* 1988;17:770.

+ 215. Wood MB, Dobyns JH. Chronic Complex Volar Dislocation of the Metacarpophalangeal Joint.*J Hand Surg* 1981;6:73.

+ 216. Wright CS. Compound Dislocations of Four Metacarpophalangeal Joints. *J Hand Surg* 1985;10B:233.

# 217. Zemel NP. Metacarpophalangeal Joint Injuries in Fingers. *Hand Clin* 1992;8:745.

## CARPOMETACARPAL JOINTS (FINGERS)

+ 218. Berg EE, Murphy DF. Ulnopalmar Dislocation of the Fifth Carpometacarpal Joint—Successful Closed Reduction: Review of the Literature and Anatomic Reevaluation. *J Hand Surg* 1986;11A:521.

+ 219. Bergfield TG, Du Puy TE, Aulicino PL. Fracture-dislocations of All Five Carpometacarpal Joints. A Case Report. *J Hand Surg* 1985;10A:76.

+ 220. Black DM, Watson HK, Vender MI. Arthroplasty of the Ulnar Carpometacarpal Joints. *J Hand Surg* 1987;12A:1071.

+ 221. Bora FW Jr, Didizian NH. The Treatment of Injuries to the Carpometacarpal Joint of the Little Finger. *J Bone Joint Surg* 1974;56A:1459.

+ 222. Breitling V. Simultaneous Dislocation of the Bases of the Four Ulnar Metacarpals Upon the Last Row of Carpals. *Hand* 1983;15:28.

+ 223. Carroll RE, Carlson E. Diagnosis and Treatment of Injury to the Second and Third Carpometacarpal Joints. *J Hand Surg* 1989;14A:102.

+ 224. Chen VT. Dislocation of Carpometacarpal Joint of the Little Finger. *J Hand Surg* 1987;12B:260.

+ 225. Chmell S, Light TR, Blair SJ. Fracture and Fracture Dislocation of Ulnar Carpometacarpal Joint. *Orthop Rev* 1982;11:73.

+ 226. Clendenin MB, Smith RJ. Fifth Metacarpal/Hamate Arthrodesis for Posttraumatic Osteoarthritis. *J Hand Surg* 1984;9A:374.

+ 227. De Beer J De V, Maloon S, Anderson P, et al. Multiple Carpometacarpal Dislocations. *J Hand Surg* 1989;14B:105.

+ 228. Dennyson WG, Stother IG. Carpometacarpal Dislocation of the Little Finger. *Hand* 1976;8:161.

# 229. Dray GJ, Eaton RG. Dislocations and Ligament Injuries in the Digits. In: Green DP, ed. *Operative Hand Surgery, 3rd ed.* New York: Churchill-Livingstone, 1993:767.

+ 230. Fayman M, Hugo B, de Wet H. Simultaneous Dislocation of all Five Carpometacarpal Joints. *Plast Reconstr Surg* 1988;82:151.

+ 231. Fernyhough J, Trumble T. Late Posttraumatic Carpometacarpal Dislocation of the Ring and Little Finger. *J Orthop Trauma* 1990;4:200.

# 232. Fisher MR, Rogers LF, Hendrix RW. Systematic Approach to Identifying Fourth and Fifth Carpometacarpal Dislocations.*AJR Am J Roentgenol* 1983;140:319.

# 233. Fisher MR, Rogers LF, Hendrix RW, Gilula LA. Carpometacarpal Dislocations. *Crit Rev Diagn Imaging* 1984;22:95.

+ 234. Gainor BJ, Stark HH, Ashworth CR, et al. Tendon Interposition Arthroplasty of the Fifth Carpometacarpal Joint for Treatment of Posttraumatic Arthritis.*J Hand Surg* 1991;16A:520.

+ 235. Garcia-Elias M, Bishop AT, Dobyns JH, et al. Transcarpal Carpometacarpal Dislocations, Excluding the Thumb.*J Hand Surg* 1990;15A:531.

# 236. Glickel SZ, Barron A, Eaton RG. Dislocations and Ligament Injuries in the Digits. In: Green DP, ed. *Operative Hand Surgery, 4th ed.* New York: Churchill-Livingstone, 1999:772.

+ 237. Gore DR. Carpometacarpal Dislocation Producing Compression of the Deep Branch in the Ulnar Nerve. *J Bone Joint Surg* 1971;53A:1387.

# 238. Green DP. Dislocations and Ligamentous Injuries in the Hand. In: Evarts CM, ed. *Surgery of the Musculoskeletal System, 2nd ed.* New York: Churchill-Livingstone, 1990:385.

# 239. Green DP, Butler TE. Fractures and Dislocations in the Hand. In: Rockwood CA, Green DP, Bucholz RW, Heckman JD, eds. *Fractures in Adults, 4th ed.* Philadelphia: Lippincott-Raven, 1996:607.

# 240. Green DP, Rowland SA. Carpometacarpal Dislocations (Excluding the Thumb). In: Rockwood CA, Green DP, eds. *Fractures in Adults, 3rd ed.* Philadelphia: JB Lippincott, 1991:441.

+ 241. Green WL, Kilgore ES. Treatment of Fifth Digit Carpometacarpal Arthritis with Silastic Prosthesis. *J Hand Surg* 1981;6:510.

# 242. Gunther SF. The Carpometacarpal Joints. *Orthop Clin North Am* 1984;15:259.

+ 243. Gunther SF, Bruno PD. Divergent Dislocation of the Carpometacarpal Joints: A Case Report. *J Hand Surg* 1985;10A:197.

# 244. Gurland M. Carpometacarpal Joint Injuries of the Fingers. *Hand Clin* 1992;8:733.

+ 245. Hagstrom P. Fracture Dislocation in the Ulnar Carpometacarpal Joints. Open Reduction and Pinning. A Case Report. *Scand J Plast Reconstr Surg* 1975;9:249.

+ 246. Hartwig RH, Louis DS. Multiple Carpometacarpal Dislocations. A Review of Four Cases. *J Bone Joint Surg* 1979;61A:906.

+ 247. Harwin SF, Fox JM, Sedlin ED. Volar Dislocations of the Bases of the Second and Third Metacarpals.*J Bone Joint Surg* 1975;57A:849.

+ 248. Hazlett JW. Carpometacarpal Dislocations Other Than the Thumb. A Report of 11 Cases. *Can J Surg* 1968;11:315.

+ 249. Henderson JJ, Arafa MAM. Carpometacarpal Dislocation: An Easily Missed Diagnosis. *J Bone Joint Surg* 1987;69B:212.

+ 250. Hindman BW, Kulik WJ, Lee G, Avolio RE. Occult Fractures of the Carpals and Metacarpals: Demonstration by CT. *AJR Am J Roentgenol* 1989;153:529.

+ 251. Hsu JD, Curtis RM. Carpometacarpal Dislocations on the Ulnar Side of the Hand. *J Bone Joint Surg* 1970;52A:927.

# 252. Hurd M. Carpometacarpal Joint Injuries. *Hand Clin* 1992;8:733.

+ 253. Imbriglia JE. Chronic Dorsal Carpometacarpal Dislocation of the Index, Middle, Ring, and Little Fingers: A Case Report.*J Hand Surg* 1979;4:343.

# 254. Jobe MT. The Hand. In: Canale ST, ed. *Campbell's Operative Orthopaedics, 9th ed.* St. Louis, Mosby, 1998:3377.

+ 255. Joseph RB, Linscheid RL, Dobyns JH, Bryan RS. Chronic Sprains of the Carpometacarpal Joints. *J Hand Surg* 1981;6:172.

+ 256. Ker HR. Dislocation of the Fifth Carpometacarpal Joint. *J Bone Joint Surg* 1955;37B:254.

# 257. Kleinman WB, Grantham SA. Multiple Volar Carpometacarpal Joint Dislocations. Case Report of Traumatic Volar Dislocation of the Medial Four Carpometacarpal Joints in a Child and Review of the Literature. *J Hand Surg* 1978;3:377.

+ 258. Konsens RM, Seitz WH Jr. Post-traumatic Arthrosis of the Index Carpometacarpal Joint. A Rationale for Treatment and Report of Two Cases. *Orthopedics* 1987;10:1429.

+ 259. Laforgia R, Specchiulli F, Mariani A. Dorsal Dislocation of the Fifth Carpometacarpal. *J Hand Surg* 1990;15A:463.

+ 260. Lawlis JF, Gunther SF. Carpometacarpal Dislocations: Long-term Follow-up. *J Bone Joint Surg* 1991;73A:52.

+ 261. Lewis HH. Dislocation of the Second Metacarpal. Report of a Case. *Clin Orthop* 1953;93:253.

+ 262. Lilling M, Weinberg H. The Mechanism of Dorsal Fracture Dislocations of the Fifth Carpometacarpal Joint. *J Hand Surg* 1979;4:340.

# 263. Littler JW. Hand Structure and Function. In: Littler JW, Cramer LM, Smith JW, eds. *Symposium on Reconstructive Hand Surgery*, vol. 9. St. Louis: CV Mosby, 1974:3.

# 264. Mueller JJ. Carpometacapal Dislocations: Report of Five Cases and Review of the Literature.*J Hand Surg* 1986;11A:184.

+ 265. Nalebuff EA. Isolated Anterior Carpometacarpal Dislocation of the Fifth Finger. Classification and Case Report.*J Trauma* 1968;8:1119.

+ 266. Niechajev I. Dislocated Intra-articular Fracture of the Base of the Fifth Metacarpal: A Clinical Study of 23 patients. *Plast Reconstr Surg* 1985;75:406.

+ 267. North ER, Eaton RG. Volar Dislocation of the Fifth Metacarpal: Report of Two Cases. *J Bone Joint Surg* 1980;62A:657.

+ 268. Oni OOA, MacKenny RP. Multiple Dislocations of the Carpometacarpal Joints. *J Hand Surg* 1986;11B:47.

+ 269. O'Rourke PJ, Quinlin W. Fracture Dislocation of the Fifth Metacarpal Resulting in Compression of the Deep Branch of the Ulnar Nerve. *J Hand Surg* 1993;18B:190.

+ 270. Petrie PWR, Lamb DW. Fracture-Subluxation of Base of Fifth Metacarpal. *Hand* 1974;6:82.

# 271. Rawles JG Jr. Dislocations and Fracture-dislocations at the Carpometacarpal Joints of the fingers. *Hand Clin* 1988;4:103.

+ 272. Sandzen SC. Fracture of the Fifth Metacarpal Resembling Bennett's fracture. *Hand* 1973;5:49.

+ 273. Shephard E, Soloman DJ. Carpometacarpal Dislocation. Report of Four Cases. *J Bone Joint Surg* 1960;42B:772.

+ 274. Shorbe HB. Carpometacarpal Dislocations. Report of a Case. *J Bone Joint Surg* 1938;20:454.

+ 275. Stevanovic MV, Stark HH. Dorsal Dislocation of the Fourth and Fifth Carpometacarpal Joints and Simultaneous Dislocation of the Metacarpophalangeal Joint of the Small Finger: A Case Report.*J Hand Surg* 1984;9A:714.

+ 276. Storm JO. Traumatic Dislocation of the Fourth and Fifth Carpometacarpal Joints: A Case Report.*J Hand Surg* 1988;13B:210.

+ 277. Tountas AA, Kwok JMK. Isolated Volar Dislocation of the Fifth Carpometacarpal Joint. Case Report. *Clin Orthop* 1984;187:172.

+ 278. Waugh RL, Yancey AG. Carpometacarpal Dislocations, With Particular Reference to Simultaneous Dislocation of the Bases of the Fourth and Fifth Metacarpals. *J Bone Joint Surg* 1948;30A:397.

+ 279. Weiland AJ, Lister GD, Villarreal-Rios A. Volar Fracture Dislocations of the Second and Third Carpometacarpal Joints Associated with Acute Carpal Tunnel Syndrome.*J Trauma* 1976;16:672.

+ 280. Whitson RO. Carpometacarpal Dislocation. A Case Report. *Clin Orthop* 1955;6:189.

# 281. Wilson RL, Liechty BW. Complications Following Small Joint Injuries. *Hand Clin* 1986;2:329.

## METACARPOPHALANGEAL JOINT (THUMB)

+ 282. Abrahamsson S-O, Sollerman C, Lundborg C, et al. Diagnosis of Displaced Ulnar Collateral Ligament of the Metacarpophalangeal Joint of the Thumb.*J Hand Surg* 1990;15:457.

+ 283. Ahmad I, DePalma AF. Treatment of Gamekeeper's Thumb by a New Operation. *Clin Orthop* 1974;103:167.

+ 284. Alldred AJ. Rupture of the Collateral Ligament of the Metacarpophalangeal Joint of the Thumb*. J Bone Joint Surg* 1955;37B:443.

# 285. Barmakian JT. Anatomy of the Joints of the Thumb. *Hand Clin* 1992;8:683.

+ 286. Bischoff R, Buechler U, DeRoche R, Jupiter J. Clinical Results of Tension Band Fixation of Avulsion Fractures of the Hand. *J Hand Surg* 1994;19A:1019.

# 287. Bojsen-Moller F. Osteoligamentous Guidance of the Movements of the Human Thumb. *Am J Anat* 1976;147:71.

+ 288. Bovard RS, Derkash RS, Freeman JR. Grade III Avulsion Fracture Repair on the UCL of the Proximal Joint of the Thumb. *Orthop Rev* 1994;23:167.

+ 289. Bowers WH, Hurst LC. Gamekeeper's Thumb. Evaluation by Arthrography and Stress Roentgenography. *J Bone Joint Surg* 1977;59A:519.

+ 290. Breek JC, Tan AM, Van Thiel TPH, Daantje CRE. Free Tendon Grafting to Repair the Metacarpophalangeal Joint of the Thumb. Surgical Techniques and a Review of 70 Patients. *J Bone Joint Surg* 1989;71B:383.

+ 291. Brewood AFM, Menon TJ. Combined Reconstruction of Volar and Radial Instability of a Thumb Metacarpophalangeal Joint. *J Hand Surg* 1984;9B:333.

! 292. Bronstein AJ, Koniuch MP, van Holsbeeck M. Ultrasonographic Detection of Thumb Ulnar Collateral Ligament Injuries: A Cadaveric Study. *J Hand Surg* 1994;19A:304.

+ 293. Browne EZ, Dunn HK, Synder CC. Ski Pole Thumb Injury. *Plast Reconstr Surg* 1976;58:19.

+ 294. Camp RA, Weatherwax RJ, Miller EB. Chronic Posttraumatic Radial Instability of the Thumb Metacarpophalangeal Joint.*J Hand Surg* 1980;5:221.

+ 295. Campbell CS. Gamekeeper's Thumb. *J Bone Joint Surg* 1955;37B:148.

* 296. Coonrad RW, Goldner JL. A Study of the Pathological Findings and Treatment in Soft-Tissue Injury of the Thumb Metacarpophalangeal Joint. *J Bone Joint Surg* 1968;50A:439.

+ 297. Derkash RS, Matyas JR, Weaver JK, et al. Acute Surgical Repair of the Skier's Thumb. *Clin Orthop* 1987;216:29.

+ 298. Downey EF Jr, Curtis DJ. Patient-Induced Stress Test of the First Metacarpophalangeal Joint: A Radiographic Assessment of Collateral Ligament Injuries. *Radiology* 1986;158:679.

# 299. Dray GJ, Eaton RG. Dislocations and Ligament Injuries in the Digits. In: Green DP, ed. *Operative Hand Surgery, 3rd ed.* New York: Churchill-Livingstone, 1993:767.

+ 300. Durham JW, Khuri S, Kim MH. Acute and Late Radial Collateral Ligament Injuries of the Thumb Metacarpophalangeal Joint. *J Hand Surg* 1993;18A:232.

+ 301. Dutton RO, Meals RA. Complex Dorsal Dislocation of the Thumb Metacarpophalangeal Joint. *Clin Orthop* 1982;164:160.

+ 302. Eiken O. Palmaris Longus-tenodesis for Hyperextension of the Thumb Metacarpophalangeal Joint.*Scand J Plast Reconstr Surg* 1981;15:149.

+ 303. Engel J, Ganel A, Ditzian R, Militeanu J. Arthrography as a Method of Diagnosing Tear of the Ulnar Collateral Ligament of the Metacarpophalangeal Joint of the Thumb (“Gamekeeper's Thumb”). *J Trauma* 1979;19:106.

# 304. Frank WE, Dobyns JH. Surgical Pathology of Collateral Ligamentous Injuries of the Thumb. *Clin Orthop* 1972;83:101.

+ 305. Frykman G, Johansson O. Surgical Repair of Rupture of the Ulnar Collateral Ligament of the Metacarpophalangeal Joint of the Thumb. *Acta Chir Scand* 1956;112:58.

+ 306. Gerber C, Senn E, Matter P. Skier's Thumb. Surgical Treatment of Recent Injuries to the Ulnar Collateral Ligament of the Thumb's Metacarpophalangeal Joint. *Am J Sports Med* 1981;9:171.

# 307. Glickel SZ. Metacarpophalangeal and Interphalangeal Joint Injuries and Instabilities. In: Peimer CA, ed. *Surgery of the Hand and Upper Extremity*. New York: McGraw-Hill, 1996:1043.

# 308. Glickel SZ, Barron A, Eaton RR. Dislocations and Ligament Injuries in the Digits. In: Green DP, ed. *Operative Hand Surgery, 4th ed.* New York: Churchill-Livingstone, 1999:772.

+ 309. Glickel SZ, Malerich M, Pearce SM, Littler JW. Ligament Replacement for Chronic Instability of the Ulnar Collateral Ligament of the Metacarpophalangeal Joint of the Thumb.*J Hand Surg* 1993;18A:930.

# 310. Green DP. Dislocations and Ligamentous Injuries in the Hand. In: Evarts CM, ed. *Surgery of the Musculoskeletal System, 2nd ed.* New York: Churchill-Livingstone, 1990:385.

# 311. Green DP, Butler TE. Fractures and Dislocations in the Hand. In: Rockwood CA, Green DP, Bucholz RW, Heckman JD, eds. *Fractures in Adults, 4th ed.* Philadelphia: Lippincott-Raven, 1996:607.

+ 312. Green DP, Terry GC. Complex Dislocation of the Metacarpophalangeal Joint: Correlative Pathological Anatomy. *J Bone Joint Surg* 1973;55A:1480.

+ 313. Gunther SF, Zielinski CJ. Irreducible Palmar Dislocation of the Proximal Phalanx of the Thumb—Case Report. *J Hand Surg* 1982;7:515.

+ 314. Hagan HJ, Hastings H. Fusion of the Thumb Metacarpophalangeal Joint to Treat Posttraumatic Arthritis. *J Hand Surg* 1988;13A:750.

+ 315. Hansen CA, Peterson TH. Fracture of the Thumb Sesamoids. *J Hand Surg* 1987;12A:269.

+ 316. Harammati N, Hiller N, Dowdle J, et al. MRI of the Stener Lesion. *Skeletal Radiol* 1995;24:515.

+ 317. Hergan K, Mittler C, Oser W. Ulnar Collateral Ligament: Differentiation of Displaced and Nondisplaced Tears with US and MR Imaging. *Radiology* 1995;194:65.

! 318. Heyman P, Gelberman RH, Duncan K, Hipp JA. Injuries of the Ulnar Collateral Ligament of the Thumb Metacarpophalangeal Joint—Biomechanical and Prospective Clinical Studies on the Usefulness of Valgus Stress Testing. *Clin Orthop* 1993;292:165.

+ 319. Hinke DH, Erickson SJ, Chamoy L, Timins ME. Ulnar Collateral Ligament of the Thumb: MR Findings in Cadavers, Volunteers, and Patients with Ligamentous Injury (Gamekeeper's Thumb). *AJR Am J Roentgenol* 1994;163:1431.

+ 320. Hintermann B, Holzach PJ, Schultz M, Matter P. Skier's Thumb—The Significance of Bony Injuries. *Am J Sports Med* 1993;21:800.

+ 321. Hogland M, Tordai P, Muren C. Diagnosis by Ultrasound of Dislocated Ulnar Collateral Ligament of the Thumb. *Acta Radiol* 1995;36:620.

+ 322. Hooper GJ. An Unusual Variety of Skier's Thumb. *J Hand Surg* 1987;12A:627.

+ 323. Hughes LA, Frieberg A. Irreducible MP Joint Dislocation due to Entrapment of FPL.*J Hand Surg* 1993;18B:708.

+ 324. Inoue G, Miura T. Locked Metacarpophalangeal Joint of the Thumb.*J Hand Surg* 1988;13B:469.

# 325. Jobe MT. The Hand. In: Canale ST, ed. *Campbell's Operative Orthopaedics, 9th ed.* St. Louis: Mosby, 1998:3377.

# 326. Jupiter JB, Sheppard JE. Tension Wire Fixation of Avulsion Fractures in the Hand. *Clin Orthop* 1987;214:113.

+ 327. Kaplan EB. The Pathology and Treatment of Radial Subluxation of the Thumb with Ulnar Displacement of the Head of the First Metacarpal. *J Bone Joint Surg* 1961;43A:541.

# 328. Kaplan EB, Riordan DC. The Thumb. In: Spinner M, ed. *Kaplan's Functional and Surgical Anatomy of the Hand, 3rd. ed.* Philadelphia: JB Lippincott, 1984:116.

+ 329. Kessler I. Complete Avulsion of the Ulnar Collateral Ligament of the Metacarpophalangeal Joint of the Thumb. *Clin Orthop* 1961;29:196.

+ 330. Kessler I. A Simplified Technique to Correct Hyperextension Deformity of the Metacarpophalngeal Joint of the Thumb. *J Bone Joint Surg* 1979;61A:903.

+ 331. Kessler I, Heller J. Complete Avulsion of the Ligamentous Apparatus of the Metacarpophalangeal Joint of the Thumb.*Surg Gynecol Obstet* 1963;11:95.

+ 332. Kozin SH, Bishop AT. Tension Wire Fixation of Avulsion Fractures at the Thumb Metacarpophalangeal Joint. *J Hand Surg* 1994;19A:1027.

# 333. Lamb DW, Abernathy PJ, Fragiadakis E. Injuries of the Metacarpophalangeal Joint of the Thumb. *Hand* 1971;3:164.

+ 334. Lamb DW, Angarita G. Ulnar Instability of the Metacarpophalangeal Joint of the Thumb. *J Hand Surg* 1985;10B:113.

# 335. Lee DH, Neviaser RJ. Complications of Trauma Surgery and Reconstructive Surgery of the Hand. In: Epps CH Jr, ed. *Complications in Orthopedic Surgery, 3rd ed.* Philadelphia: JB Lippincott, 1994:403.

+ 336. Linscheid RL. Arthrography of the Metacarpophalangeal Joint. *Clin Orthop* 1974;103:91.

# 337. Linscheid RL, Grainger RW, Johnson EN. The Thumb Metacarpophalangeal Joint Injuries. *Minn Med* 1972;55:1037.

+ 338. Louis DS, Huebner JJ Jr, Hankin FM. Rupture and Displacement of the Ulnar Collateral Ligament of the Metacarpophalangeal Joint of the Thumb: Preoperative Diagnosis.*J Bone Joint Surg* 1986;68A:1320.

+ 339. Maneuaud M, Littler JW. Reconstruction of the Ulnar Metacarpophalangeal Ligament of the Thumb. *Ann Chir* 1978;32:605.

+ 340. McCue FC, Hakala MW, Andrews JR, Gieck JH. Ulnar Collateral Ligament Injuries of the Thumb in Atheletes.*J Sports Med* 1974;2:70.

* 341. McLaughlin HL. Complex “Locked” Dislocation of the Metacarpophalangeal Joints. *J Trauma* 1965;5:683.

+ 342. Milch H. Recurrent Dislocation of Thumb. Capsulorrhaphy. *Am J Surg* 1929;6:237.

# 343. Miller RJ. Dislocations and Fracture Dislocations of the Metacarpophalangeal Joint of the Thumb.*Hand Clin* 1988;4:45.

+ 344. Miyamoto M, Hirayama T, Uchida M. Volar Dislocation of the Metacarpophalangeal Joint of the Thumb—A Case Report. *J Hand Surg* 1986;11B:51.

# 345. Moberg F. Fractures and Ligamentous Injuries of the Thumb and Fingers.*Surg Clin North Am* 1960;40:297.

# 346. Moberg F, Stener B. Injuries to the Ligaments of the Thumb and Fingers. Diagnosis, Treatment, and Prognosis.*Acta Chir Scand* 1953;106:166.

+ 347. Mogensen BA, Mattsson HS. Post-traumatic Instability of the Metacarpophalangeal Joint of the Thumb. *Hand* 1980;12:85.

+ 348. Moneim MS. Volar Dislocation of the Metacarpophalangeal Joint. Pathologcial Anatomy and Report of Two Cases. *Clin Orthop* 1983;176:186.

+ 349. Moutet F, Guinard D, Lebrun CH, et al. Metacarpophalangeal Thumb Sprains Based on Experience with More Than 1000 Cases. *Ann Chir Main* 1989;8:99.

# 350. Neviaser RJ. Collateral Ligament Injuries of the Thumb Metacarpophalangeal Joint. In: Strickland JW, Rettig A, eds. *Hand Injuries in Athletes*. Philadelphia: WB Saunders, 1991:95.

* 351. Neviaser RJ, Wilson JN, Lievano A. Rupture of the Ulnar Collateral Ligament of the Thumb (Gamekeeper's Thumb).*J Bone Joint Surg* 1971;53A:1357.

+ 352. Noszian IM, Dinkhauser LM, Orthner E, et al. Ulnar Collateral Ligament: Differentiation of Displaced and Nondisplaced Tears with US. *Radiology* 1995;194:61.

+ 353. O'Callaghan BI, Kohut G, Hoogewoud HM. Gamekeeper Thumb: Identification of the Stener Lesion with US. *Radiology* 1994;192:477.

+ 354. Onuba O, Essiet A. Irreducible Dislocation of the Metacarpophalangeal Joint of the Thumb due to Tendon Interposition. *J Hand Surg* 1987;12B:60.

+ 355. Osterman AL, Hayken GD, Bora FW. A Quantitative Evaluation of Thumb Function after Ulnar Collateral Repair and Reconstruction.*J Trauma* 1981;21:854.

+ 356. Palmer AK, Louis DS. Assessing Ulnar Instability of the Metacarpophalangeal Joint of the Thumb. *J Hand Surg* 1978;3:542.

+ 357. Parikh M, Nahigan S, Froimson A. Gamekeeper's Thumb. *Plast Reconstr Surg* 1976;58:24.

+ 358. Parks BJ, Hamlin C. Chronic Sesamoiditis of the Thumb: Patthomechanics and Treatment. *J Hand Surg* 1986;11A:237.

+ 359. Patel MR, Pearlman HS, Bassini L. Fractures of the Sesamoid Bones of the Thumb. *J Hand Surg* 1990;15A:776.

+ 360. Pichora DR, McMurtry RY, Bell MJ. Gamekeepers Thumb: A Prospective Study of Functional Bracing.*J Hand Surg* 1989;14A:567.

+ 361. Posner MA, Langa V, Ambrose L. Intrinsic Muscle Advancement to Treat Chronic Palmar Instability of the Metacarpophalangeal Joint of the Thumb. *J Hand Surg* 1988;13A:110.

# 362. Posner MA, Retaillaud J. Metacarpophalangeal Joint Injuries of the Thumb. *Hand Clin* 1992;8:713.

+ 363. Rehak DC, Sotereanos DG, Bowman MW, Herndon JH. The Mitek Bone Anchor: Application to the Hand, Wrist, and Elbow. *J Hand Surg* 1994;19A:853.

+ 364. Resnick D, Danzig LA. Arthrographic Evaluation of Injuries of the First Metacarpophalangeal Joint: Gamekeeper's Thumb. *AJR Am J Roentgenol* 1976;126:1046.

+ 365. Rosenthal DI, Murray WT, Smith RJ. Finger Arthrography.*Radiology* 1980;137:647.

+ 366. Saetta JP, Phair IC, Quinton DN. Ulnar Collateral Ligament Repair of the Metacarpophalangeal Joint of the Thumb: A Study Comparing Two Methods of Repair. *J Hand Surg* 1992;17B:160.

+ 367. Sakellarides HT. The Surgical Treatment of Old Injuries of the Collateral Ligaments of the MP Joint of the Thumb Using the Extensor Pollicis Brevis Tendon (A Long Term Follow-up of 100 Cases). *Bull Hosp Joint Dis Orthop Inst* 1984;44:449.

* 368. Sakellarides HT, DeWeese JW. Instability of the Metacarpophalangeal Joint of the Thumb. Reconstruction of the Collateral Ligament Using the Extensor Pollicis Brevis. *J Bone Joint Surg* 1976;58A:106.

+ 369. Sennwald G, Segmuller G, Egli A. The Late Reconstruction of the Ligament of the Metacarpophalangeal Joint of the Thumb. *Ann Chir Main* 1987;6:15.

+ 370. Smith MA. The Mechanism of Acute Ulnar Instability of the Metacarpophalangeal Joint of the Thumb. *Hand* 1980;12:225.

* 371. Smith RJ. Posttraumatic Instability of the Metacarpophalangeal Joint of the Thumb. *J Bone Joint Surg* 1977;59A:14.

# 372. Smith RJ, Peimer CA. Injuries to the Metacarpal Bones and Joints. *Adv Surg* 1977;11:341.

# 373. Smith SA, Kuczynski K. Observations on the Joints of the Hand. *Hand* 1978;10:226.

+ 374. Sollerman C, Abrahamsson S, Lundborg G, Adalbert K. Functional Splinting Versus Plaster Cast for Ruptures of the Ulnar Collateral Ligament of the Thumb. A Prospective Randomized Study of 63 Cases. *Acta Orthop Scand* 1993;62:524.

+ 375. Spaeth HJ, Abrams RA, Bock GW, et al. Gamekeeper Thumb: Differentiation of Nondisplaced and Displaced Tears of the Ulnar Collateral Ligament with MR Imaging. *Radiology* 1993;188:553.

* 376. Stener B. Displacement of the Ruptured Ulnar Collateral Ligament of the Metacarpophalangeal Joint of the Thumb. A Clinical and Anatomic Study. *J Bone Joint Surg* 1962;44B:869.

+ 377. Stener B. Hyperextension Injuries to the Metacarpophalangeal Joint of the Thumb—Rupture of Ligaments, Fracture of Sesamoid Bones, Rupture of the Flexor Pollicis Brevis. An Anatomical and Clinical Study. *Acta Chir Scand* 1963;125:275.

+ 378. Stener B. Skeletal Injuries Associated with Rupture of the Ulnar Collateral Ligament of the Metacarpophalangeal Joint of the Thumb. A Clinical and Anatomic Study. *Acta Chir Scand* 1963;125:583.

+ 379. Strandell G. Total Rupture of the Ulnar Collateral Ligament of the Metacarpophalangeal Joint of the Thumb. Result of Surgery in 35 Cases. *Acta Chir Scand* 1959;118:72.

+ 380. Trumble TE, Watson HK. Posttraumatic Sesamoid Arthritis of the Metacarpophalangeal Joint of the Thumb. *J Hand Surg* 1985;10A:94.

+ 381. Vihtonen K, Juutilainen T, Patiala H, et al. Reinsertion of the Ruptured Ulnar Collateral Ligament of the Metacarpophalangeal Joint With an Absorbable Self-Reinforced Polylactide Tack. *J Hand Surg* 1993;18B:200.

# 382. Wilson RL, Liechty BW. Complications Following Small Joint Injuries. *Hand Clin* 1986;2:329.

+ 383. Wood MB, Dobyns JH. Chronic Complex Volar Dislocation of the Metacarpophalangeal Joint: Report of Three Cases. *J Hand Surg* 1981;6:73.

# 384. Zancolli E. *Structural and Dynamic Basis of Hand Surgery, 2nd ed.* Philadelphia: JB Lippincott, 1979:212.

+ 385. Zilberman Z, Rotschild E, Krauss L. Rupture of the Ulnar Collateral Ligament of the Thumb. *J Trauma* 1965;5:477.

## CARPOMETACARPAL JOINT (THUMB)

# 386. Barmakian JT. Anatomy of the Joints of the Thumb. *Hand Clin* 1992;8:683.

# 387. Bojsen-Moller F. Osteoligamentous Guidance of the Movements of the Human Thumb. *Am J Anat* 1976;147:71.

+ 388. Burkhalter WE. American Society for Surgery of the Hand Correspondence Newsletter, No. 18, 1981.

! 389. Cooney WP, Lucca MJ, Chao EY, et al. The Kinesiology of the Thumb Trapeziometacarpal Joint. *J Bone Joint Surg* 1981;63A:1371.

# 390. Dray GJ, Eaton RG. Dislocations and Ligament Injuries in the Digits. In: Green DP, ed. *Operative Hand Surgery, 3rd ed.* New York: Churchill-Livingstone, 1993:767.

+ 391. Eaton RG, Lane LB, Littler JW, et al. Ligament Reconstruction for the Painful Thumb Carpometacarpal Joint: A Long Term Assessment. *J Hand Surg* 1984;9A:692.

* 392. Eaton RG, Littler JW. Ligament Reconstruction for the Painful Thumb Carpometacarpal Joint. *J Bone Joint Surg* 1973;55A:1655.

+ 393. Eaton RG, Littler JW. A Study of the Basal Joint of the Thumb. Treatment of Its Disabilities by Fusion. *J Bone Joint Surg* 1984;51A:661.

+ 394. Eggars GWN. Chronic Dislocation of the Base of the Metacarpal of the Thumb. *J Bone Joint Surg* 1945;27:500.

# 395. Glickel SZ, Barron A, Eaton RG. Dislocations and Ligament Injuries in the Digits. In: Green DP, ed. *Operative Hand Surgery, 4th ed.* New York: Churchill-Livingstone, 1999:772.

# 396. Green DP. Dislocations and Ligamentous Injuries in the Hand. In: Evarts CM, ed. *Surgery of the Musculoskeletal System, 2nd ed.* New York: Churchill-Livingstone, 1990:385.

# 397. Green DP, Butler TE. Fractures and Dislocations in the Hand. In: Rockwood CA, Green DP, Bucholz RW, Heckman JD, eds. *Fractures in Adults, 4th ed.* Philadelphia: Lippincott-Raven, 1996:607.

+ 398. Hooper GJ. An Unusual Variety of Skier's Thumb. *J Hand Surg* 1987;12A:627.

! 399. Imaeda T, An K, Cooney WP III, Linscheid R. Anatomy of Trapeziometacarpal Ligaments.*J Hand Surg* 1993;18A:6.

+ 400. Jakobsen CW, Elberg JJ. Isolated Carpometacarpal Dislocation of the Thumb. Case Report. *Scand J Plast Reconstr Surg* 1988;22:185.

# 401. Jobe MT. The Hand. In: Canale ST, ed. *Campbell's Operative Orthopaedics, 9th ed.* St. Louis, Mosby, 1998.

# 402. Kuczynski K. Carpometacarpal Joint of the Human Thumb. *J Anat* 1974;118:119.

+ 403. Lasserre C, Pauzat D, Derennes R. Osteoarthritis of the Trapezio-metacarpal Joint. *J Bone Joint Surg* 1949;31B:534.

# 404. Littler JW. Trapeziometacarpal Joint Injuries. *Hand Clin* 1992;8:701.

+ 405. Moore JR, Webb CA. A Complete Dislocation of the Thumb Metacarpal. *J Hand Surg* 1978;3:547.

# 406. Napier JR. The Form and Function of the Carpometacarpal Joint of the Thumb. *J Anat* 1955;89:362.

+ 407. Neviaser RJ, Wilson JN, Gardner MM. Abductor Pollicis Longus Transfer for Replacement of the First Dorsal Interosseous.*J Hand Surg* 1980;5:53.

+ 408. Pagalidis T, Kuczynski K, Lamb DW. Ligamentous Stability of the Base of the Thumb. *Hand* 1981;13:29.

# 409. Pieron AP. The Mechanism of the First Carpometacarpal (CMC) Joint. *Acta Orthop Scand* 1973;148(suppl):1.

+ 410. Shah J, Patel M. Dislocation of the Carpometacarpal Joint of the Thumb. A Report of Four Cases. *Clin Orthop* 1983;175:166.

! 411. Strauch RJ, Behrman MJ, Rossenwasser MP. Acute Dislocation of the Carpometacarpal Joint of the Thumb: An Anatomic and Cadaver Study. *J Hand Surg* 1994;19A:93.

+ 412. Watt N, Hooper G. Dislocation of the Trapezio-metacarpal Joint. *J Hand Surg* 1987;12B:242.

+ 413. Wee JT, Chandra D, Satku K. Simultaneous Dislocations of the Interphalangeal and Carpometacarpal Joints of the Thumb: A Case Report. *J Hand Surg* 1988;13B:224.

# 414. Wilson RL, Liechty BW. Complications Following Small Joint Injuries. *Hand Clin* 1986;2:329.

# CHAPTER 40

# FRACTURES OF THE METACARPALS AND PHALANGES

*Jesse B. Jupiter and David A. Alessandro*

**J. B. Jupiter and D. A. Alessandro**: Massachusetts General Hospital, Boston, Massachusetts 02114.

Functional Anatomy
Principles of Treatment
Classification
Surgical Techniques
Metacarpals
Phalanges
Metacarpal Fractures
Epibasal Fractures
Pitfalls and Complications
Shaft Fractures
Pitfalls and Complications
Neck Fractures
Pitfalls and Complications
Head Fractures
Pitfalls and Complications
Thumb Metacarpal Fractures
Pitfalls and Complications
Phalangeal Fractures
Shaft Fractures
Pitfalls and Complications
Articular Fractures
Pitfalls and Complications
Authors' Perspective
Chapter References

Fractures involving the tubular bones of the hand are the most common of all skeletal injuries (17). The skeleton of the hand is inherently related to adjacent joints, overlying gliding tendon units, and deforming muscle forces. Although failure to gain union following a metacarpal or phalangeal fracture is rare, concomitant problems present a different story. Preventing angular or rotational deformity, articular stiffness, and tendon adhesion challenges even the most experienced surgeon (34). As Charnley recognized: “The reputation of a surgeon may stand as much in jeopardy from this injury [phalangeal fracture] as from any fracture of the femur” (13).

The vast majority of phalangeal and metacarpal fractures can be successfully treated without surgery. A nonanatomic outcome, however, can jeopardize overall hand function, leading at times to a prolonged and major disability (11). Therefore, it is important to identify the fractures that require operative treatment (Table 40.1), the surgical approaches that minimize soft tissue adhesions, and the postoperative management that best encourages joint mobilization and avoids soft tissue contracture (5).

| |
|---|
| Subcondylar proximal phalanx |
| Palmar base middle phalanx |
| T or intercondylar proximal/Middle phalanx |
| Displaced avulsion |
| Rotated spiral |
| Comminuted |
| Severely displaced |
| Extreme soft-tissue trauma |
| Bennett's/Reverse Bennett's |

***Table 40.1. Phalangeal and Metacarpal Fractures Often Requiring Internal Fixation***

## FUNCTIONAL ANATOMY

The longitudinal and transverse arches of the hand pass through the metacarpals, having a keystone in the metacarpophalangeal joints. The rigid central pillar of the hand passes through the second and third metacarpals, and the mobile carpometacarpal joints of the thumb, ring, and little rays permit mobility at the borders of the hand. The deep transverse metacarpal ligaments connect the four metacarpals of the hand and provide internal support, particularly for the long and ring metacarpals. The extrinsic flexor tendons exert a flexion and adduction force on the distal metacarpals that is enhanced by the short but powerful intrinsic tendons that pass on the palmar side of the midaxis of the metacarpophalangeal joint.

In contrast to the interconnected metacarpals, the phalanges are isolated skeletal units and are subject to the deforming muscle forces of both the extrinsic flexor and extensor tendons and the intrinsic tendons. The proximal parts of the proximal and middle phalanges are subject to strong flexor forces, whereas the more distal shafts and neck tend to go into hyperextension because of the pull of the extensor mechanism.

The thumb plays a unique role in all forms of prehensile hand function by the complex configuration of the carpometacarpal joint as well as the transmission of power through the numerous tendon insertions. When the integrity of the thumb skeleton has been disrupted or deformed secondary to fracture malunion, the balance of these forces is disturbed, leading to deformity.

## PRINCIPLES OF TREATMENT

Determine the fracture pattern by three radiographic views—anteroposterior, lateral, and oblique. Check rotational and angular alignment by evaluating the relationship of the fingernails to each other in both extension and flexion. It may be necessary, after careful assessment of the neurovascular status, to anesthetize the digit or hand to better assess rotational alignment and fracture stability.

If the fracture proves unstable, internal splintage is required. Kirschner wire fixation, particularly when placed percutaneously, is an excellent method in single or adjacent metacarpal or phalangeal fractures. Use of this technique requires expertise in wire placement and image intensification (2,4,24,37).

Open reduction and internal fixation are performed using various methods, including interosseous wire and tension band wire techniques as well as more stable miniscrews and plates (3,5,6 and 7,9,14,15,19,23,26,27,29,35,38,40,43,46,50). The greater the severity of the combined skeletal and soft tissue injury, the more important it becomes to achieve stable fixation that allows early mobilization.

The postoperative program is directed toward preserving joint motion and minimizing adhesions of the gliding structures, such as the tendons and joints. Under the supervision of a hand therapist, static and dynamic splints, antiedema measures such as Coban wraps, and active assisted range-of-motion exercises have proved an

effective means of regaining motion and avoiding joint contracture, even in severe combined skeletal and soft tissue injuries of the hand.

## CLASSIFICATION

Like fractures of long bones, phalangeal and metacarpal fractures call for specific methods of treatment depending on the fracture pattern and location. Features used to classify phalangeal and metacarpal fractures include location, fracture configuration, soft tissue integrity, and inherent stability (Table 40.2). These tubular bones are divided into base, shaft, neck, and articular heads (Fig. 40.1). In children, the epiphyseal zones are found at the bases of the phalanges and the head and neck of the metacarpals. The thumb metacarpal differs in that the epiphyseal center is found at the base.

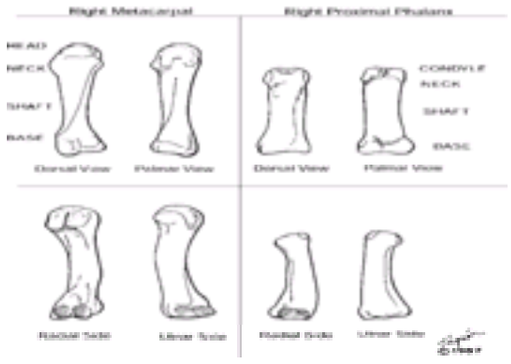


***Figure 40.1.*** Anatomy of the metacarpal and phalanx.

| *Location* | *Pattern* | *Skeleton* | *Soft tissue* | *Reaction to motion* |
|---|---|---|---|---|
| Base | Transverse | Simple | Closed | Stable |
| Shaft | Oblique | Impacted | Open | Unstable |
| Neck | Spiral | Comminuted | | |
| Condyle (head) | Avulsion | | | |
| Epiphysis | | | | |

***Table 40.2. Functional Fracture Classification***

## SURGICAL TECHNIQUES

### METACARPALS

In general, longitudinal incisions are preferred over transverse or serpentine approaches on the dorsum of the hand, as they limit trauma to the venous and lymphatic systems (Fig. 40.2).

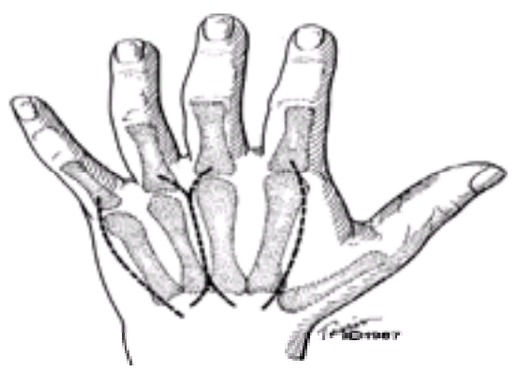

***Figure 40.2.*** Dorsal surgical approaches to the metacarpals.

- Approach the long and ring metacarpals through a longitudinal incision between the bones, using a Y-shaped extension if necessary to provide more proximal or distal exposure. Approach the border metacarpals individually through longitudinal incisions, with curving extensions as needed.
- Facilitate exposure of the distal metacarpal shafts, neck, or head by cutting through the juncturae tendinae linking the common extensor tendons. Tag these for later reapproximation with 5-0 nylon suture.
- Next, incise the junction of the sagittal band and extensor tendon to permit access to the metacarpophalangeal joint. Reapproximate it with fine nonabsorbable suture.
- At the shaft level, incise the periosteum carefully, leaving as much attached as possible and preserving the origins of the interosseous muscles. Gently expose the fracture site and remove the hematoma by irrigation with a small-bore needle and use of a dental pick.
- Surgical approaches to the thumb metacarpal are most often required for intraarticular fractures at the base. The palmar approach described by Gedda and Moberg starts proximally at the wrist crease and extends distally along the metacarpal shaft (Fig. 40.3) (22).

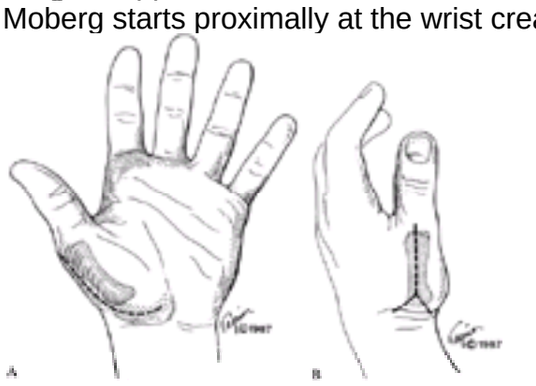

***Figure 40.3.*** Surgical approaches to the thumb metacarpal: palmar (**A**) and dorsal (**B**).

- Elevate the thenar muscles subperiosteally off the metacarpal shaft to give good exposure to the palmar aspect of the carpometacarpal joint. This approach is

particularly effective for Bennett fractures with small palmar fragments. The radiodorsal approach is preferred for fractures that extend onto the proximal metacarpal shaft.

- Make the incision along the radial edge of the metacarpal. Identify and preserve crossing branches of the radial sensory nerve as well as the insertion of the abductor pollicis longus tendon. Elevate the thenar muscles subperiosteally off the shaft, if necessary, to improve exposure of the base.

### PHALANGES

- Approach the proximal and middle phalanges through dorsolateral or midaxial incisions (Fig. 40.4).

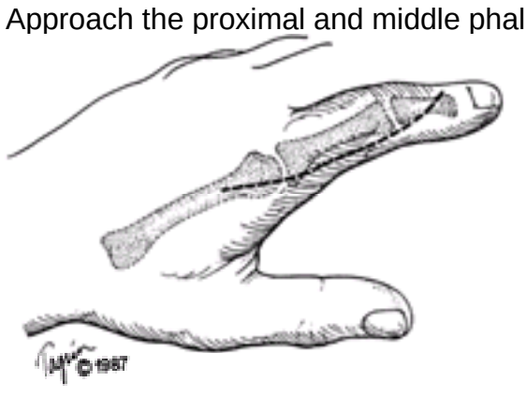

***Figure 40.4.*** Surgical approaches to the phalanges.

- Elevate the dorsal skin flap off the paratenon of the extensor tendon. Preserve the dorsal venous arcade whenever possible. Pay careful attention to preserving the paratenon and periosteum to avoid later adhesions between the phalanx and tendon.
- If more distal exposure of the shaft is necessary, incise the transverse retinacular ligament to allow further mobilization of the extensor mechanism. Mark this interval for later reapproximation.
- Approach the proximal interphalangeal joint straight dorsally between the central extensor tendon and the lateral band or between the lateral band and the collateral ligament. Occasionally, additional exposure can be obtained by osteotomizing the insertion of the central slip onto the base of the middle phalanx and reflecting the tendon proximally. The insertion can later be secured with a tension wire or small screw.
- Use a complete or partial H incision to gain access to the head of the middle phalanx or distal interphalangeal joint. Split the extensor tendon longitudinally or in a Z fashion to expose the joint.

## METACARPAL FRACTURES

### EPIBASAL FRACTURES

Fractures at the bases of the metacarpals, particularly the mobile ring and little, require a careful assessment of any intraarticular involvement. These fractures are often the result of crushing injuries and are associated with fracture-dislocations at the carpometacarpal joints. Accurate reduction may offset later posttraumatic arthrosis, particularly in the ulnar metacarpals. Achieve reduction with longitudinal traction and Kirschner wire fixation from little to ring metacarpal, metacarpal to hammate or capitate, or both. If comminution is extensive, surgical options are indirect reduction with a mini–external fixator or open reduction with a condylar plate. Approach the treatment of fractures at the base of the little metacarpal in a manner similar to that for fractures of the thumb carpometacarpal joint.

#### *Postoperative Management*

We recommend immobilization in a removable splint positioned with the wrist slightly extended, metacarpophalangeal joints flexed 80° to 90°, and interphalangeal joints free for movement. Start motion at the metacarpophalangeal and interphalangeal joints within the first week. Remove percutaneous pins after 4 weeks, and begin grip-strengthening exercises.

## PITFALLS AND COMPLICATIONS

Posttraumatic arthrosis can occur if accurate reduction is not achieved. It can be more symptomatic in the ulnar metacarpals because these carpometacarpal joints are so mobile. Arthrodesis may eventually be necessary.

### SHAFT FRACTURES

The treatment of metacarpal shaft fractures has progressed considerably since the 1930s, when virtually all metacarpal fractures were treated by bandaging over a roller bandage with little or no attempt to correct displacement. Angulation, shortening, or rotation that cannot be controlled by plaster support requires internal fixation. In addition, fractures associated with soft-tissue crush or open injuries are better managed with internal fixation (Table 40.3).

| |
|---|
| Multiple oblique or spiral fractures |
| Shortened fractures |
| Open fracture |
| Displaced border metacarpal (index/little finger) |

***Table 40.3. Indications for Internal Fixation—Metacarpal Shaft***

Percutaneous Kirschner wire fixation may be applicable for some transverse shaft fractures (37). Potential problems are inherent with the placement of the wire through the metacarpophalangeal joint capsule or the extensor tendon mechanism. For multiple transverse fractures or those associated with crushing injuries, we prefer dorsally placed tension band plates (Fig. 40.5), generally using four-hole one-quarter tubular plates with 2.0- or 2.7-mm screws. Some compression can be gained at the fracture line by drilling eccentrically in the farthest holes from the fracture line and placing both screws simultaneously (29). If comminution is noted at the fracture line, use a longer plate and place a small amount of cancellous bone graft—readily obtained from the distal radius—in the zones of comminution.

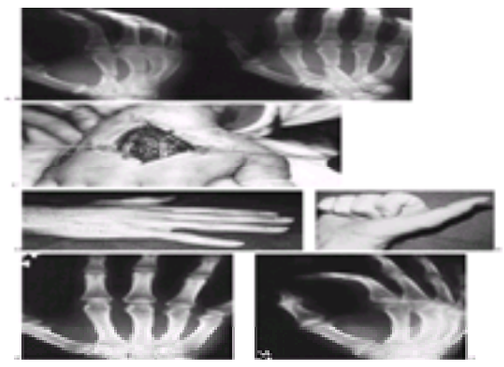

***Figure 40.5.*** A 24-year-old laborer's dominant right hand was crushed by a dumpster. There was extensive soft-tissue trauma associated with three metcarpal shaft fractures. **A,B:** Anteroposterior and oblique views revealed transverse metacarpal shaft fractures. **C:** Through two longitudinal incisions, one-quarter tubular plates and 2.7-mm screws were applied. **D,E:** Full flexion and extension were achieved within 6 weeks despite the extensive soft-tissue crush. **F,G:** Anteroposterior and oblique radiographs 6 months after plate removal.

Spiral and long oblique fractures provide a wide surface amenable to interfragmentary screw fixation (Fig. 40.6). The length of these fractures should be at least three times the diameter of the shaft at the level of the fracture to permit adequate fixation with screws alone. The screws should distribute interfragmentary compression evenly along the entire fracture length. Place one screw perpendicular to the fracture line and one perpendicular to the shaft to ensure distribution of compression and offset shear stresses on the implants. With short oblique fractures, a single screw cannot withstand the rotatory, shear, or bending stresses of normal activity. These stresses must be neutralized by a plate to allow early mobilization (Fig. 40.7).

***Figure 40.6.*** A 27-year-old surgical resident sustained spiral malrotated second and third metacarpal shaft fractures in a sporting event. **A:** Oblique radiograph shows the rotatory displacement of the metacarpal shaft fractures. **B:** Clinically, malrotation was readily apparent. **C:** The large fracture surfaces proved amenable to interfragmentary screw fixation using 2.7-mm and 2.0-mm screws. Note the arrangement of the screws to offset shear and rotational stresses. The patient made a full functional recovery.

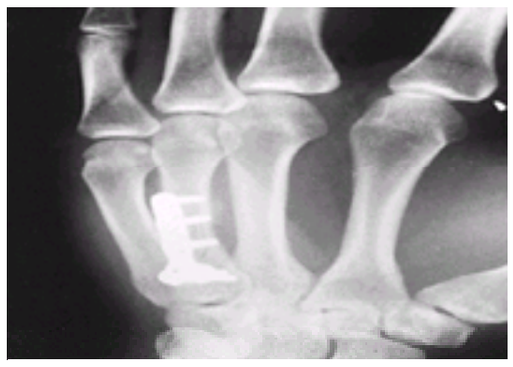

***Figure 40.7.*** A 35-year-old laborer sustained a severe crush injury to his left hand. In view of the massive soft-tissue trauma, rigid internal fixation was chosen to rapidly mobilize the hand. An interfragmentary screw was placed through a small T-plate.

The use of external fixation for closed, unstable metacarpal shaft fractures has been shown in recent studies to yield excellent results for union and total arc of hand motion (44,48). Traditionally, external fixation has been used for complex comminuted and open fractures, where the principles of indirect reduction and minimization of soft tissue stripping are advocated.

### *Postoperative Management*

Close incisions over a small vacuum drain, wrap the hand in Dacron batting dressing, and support it in a plaster splint. Begin active assisted range-of-motion exercises 48 to 72 h after surgery. Coban wraps around the digits and hand effectively control postoperative swelling. Take radiographs at 1, 3, and 6 weeks after surgery. The patient should be able to start light manual activities at 3 weeks and unrestricted activities by 6 to 8 weeks.

## PITFALLS AND COMPLICATIONS

The surgeon must be confident that the internal fixation is rigid enough to support the fracture during rehabilitation. Leaving the hand immobile until fracture union after an extensive surgical exposure can result in tendon adhesions or joint contracture. Unforeseen comminution or longitudinal fracture lines may cause the unwary surgeon to place the screws in unsound bone. Study the fracture pattern once the hematoma has been cleared and before the actual reduction. When a screw is loose because its threads have been stripped, achieve stable fixation by placing a larger screw, redirecting the screw, or using a longer plate. Converting to Kirschner wire fixation with tension loops of stainless-steel wire is also effective when rigid fixation is inadequate (18).

## NECK FRACTURES

Fractures of the metacarpal neck are almost always the result of direct impact. The deformity is generally palmar angulation of the distal fragment; rarely, malrotation may also be present. Excessive flexion of the distal fragment can lead to hyperextension at the metacarpophalangeal joint, interference with grip, and pain over the metacarpal head in the distal palm. Although most would agree that more than 10° of palmar angulation is unacceptable in the index and long metacarpals because of their immobile carpometacarpal joints, some controversy surrounds fractures of the metacarpal necks of the ring and little fingers. Several authors have reported acceptable functional results with flexion deformities of at least 70° in the little finger (16,30,31). We believe that reduction should be considered for angulation beyond 30° to 40° in the little finger and beyond 20° to 30° in the ring finger (49,53).

### *Treatment*

Closed reduction of metacarpal neck fractures is readily accomplished by the 90–90 method introduced by Jahss (33) of flexing the proximal interphalangeal joint and

using the proximal phalanx to push the metacarpal head into position. Reduction by direct pressure on the prominent palmar surface of the head with counterpressure on the dorsum of the shaft works equally well. Immobilization in this position is not acceptable to hold the reduction in place because of the risk of joint contracture or skin necrosis.

Percutaneous Kirschner wire fixation has proved most effective in stabilizing metacarpal neck fractures, particularly of the little and ring metacarpals. The wires, generally 0.035 in., can be introduced transversely, proximal and distal to the fracture and into the adjacent metacarpal, obliquely across the fracture, or longitudinally through the flexed MP joint. Place a 14-gauge hypodermic needle against the metacarpal to function as a pin guide. These methods of treatment carry a risk of permanent metacarpophalangeal joint stiffness when the pins transfix the extensor mechanism.

- We prefer to introduce the Kirschner wires from the base of the metacarpal. Using image intensification, make a small transverse incision over the dorsoulnar aspect of the base of the metacarpal. Create a small window in the metacarpal base. Bend a 0.045-in. Kirschner wire into a gentle arc and hammer it distally up the shaft while holding the fracture reduced in the 90–90 position. The pin should extend into the subchondral bone of the head (Fig. 40.8).

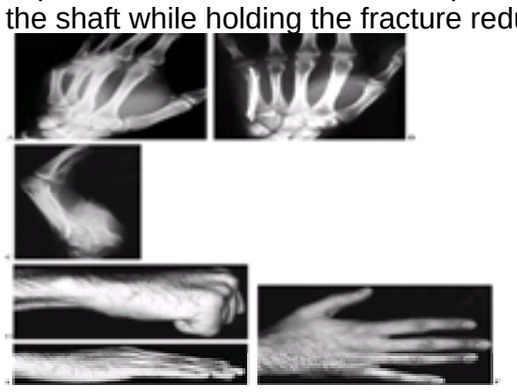

***Figure 40.8.*** **A:** A 21-year-old musician sustained a completely displaced metacarpal neck fracture of his dominant right hand. **B,C:** Three 0.045-mm Kirschner wires were inserted through a small opening in the base of the metacarpal. **D–F:** Motion exercises were started after 2 weeks, and full range of motion and healing were observed at 7 weeks. Pins were removed after 10 weeks.

- Introduce a second pin if motion is felt at the fracture. Cut the pin(s) just beneath the skin and apply an ulnar gutter splint with the metacarpophalangeal joint maintained in flexion. Gentle motion may be initiated 2 weeks after surgery.
- Percutaneous pins, placed sagittally from dorsal to palmar and bonded together by methylmethacrylate, have also been advocated as a reliable means of holding the reduction without opening the fracture site (45). The method, however, carries the risk of the extensor mechanism being transfixed by the pins or pin track sepsis. This technique is perhaps best reserved for fractures associated with soft tissue injury or bone loss.
- Reserve open reduction and internal fixation for grossly displaced fractures, fractures associated with extensive soft tissue trauma, or fractures seen too late for manipulative reduction. Because of the proximity of these fractures to the joint and extensor mechanism, we prefer crossed Kirschner wires looped with a stainless-steel wire as a tension band (Fig. 40.9).

***Figure 40.9.*** A 46-year-old woman was thrown from a horse, sustaining multiple injuries. Anteroposterior radiograph shows a fifth metacarpal neck fracture treated by two crossed Kirschner wires and a dorsal stainless-steel loop acting as a tension band.

- Place two 0.035-in. or 0.028-in. Kirschner wires, either criss-crossing the fracture or parallel to the fracture, dorsal to the midaxis of the bone. Place a 28-gauge stainless steel wire dorsally over the fracture and just under the points of the wires.
- Initiate motion 48 to 72 h after surgery. The Kirschner wires can be removed under local anesthesia in the office.

## PITFALLS AND COMPLICATIONS

The major difficulty associated with the treatment of metacarpal neck fractures lies in the potential for stiffness of the metacarpophalangeal joint. Avoid open reduction if possible; percutaneous techniques are preferable. We generally bury the Kirschner wires just under the skin to avoid pin track infections.

### HEAD FRACTURES

Less common than neck injuries, metacarpal head fractures are intraarticular fractures seen most often in young adults as a result of athletic injury (39). They vary from an osteochondral fracture to two- or three-part fractures in a sagittal or coronal plane to grossly comminuted fractures (28).

#### *Treatment*

Treatment planning should include anteroposterior and lateral tomography to determine the operability of the fracture as well as the location of the fragments. For nondisplaced as well as very comminuted fractures, splint support and protected motion are preferable.

Open reduction and internal fixation are indicated for the split or three-part fracture (28).

- Through a dorsal approach, open the joint capsule longitudinally. Meticulous handling of the small fracture fragments is imperative to avoid further fragmentation or devascularization. Preserve any soft tissue attachments.
- Provisionally stabilize the fracture with 0.028-in. Kirschner wires, verifying the reduction with anteroposterior, lateral, and oblique radiographs. As a general rule, if the fracture fragment is larger than two to three times the diameter of the screw head, internal fixation with 1.5-mm miniscrews is preferred.
- If secure fixation can be achieved, early mobilization of this joint injury can be started.
- With smaller fragments, Kirschner wire fixation is recommended. With impacted fragments, cautious elevation and support with cancellous bone graft obtained from the end of the radius can restore the anatomic profile of the metacarpal head (Fig. 40.10).

***Figure 40.10.*** A 22-year-old man suffered an open metacarpal head fracture. **A:** Anteroposterior radiograph shows a displaced split fracture. **B:** Irrigation,

debridement, open reduction, and internal fixation with two 1.5-mm screws were performed. This patient began early motion after 1 week to allow for wound healing.

### *Postoperative Management*

Postoperative management depends on the stability of the internal fixation. Screw fixation, if rigid, will permit protected motion 48 to 72 h after surgery. Kirschner wire fixation should be held in a splint with the metacarpophalangeal joint flexed 70° for 10 to 14 days before motion is started.

## PITFALLS AND COMPLICATIONS

Inability to fix the fracture fragment securely, increased fragmentation, or excessive soft-tissue stripping can lead to avascular necrosis, loss of reduction, metacarpophalangeal joint stiffness, or posttraumatic arthrosis. Proper preoperative assessment, particularly with tomography, may prevent the surgeon from entering into an unduly difficult reconstruction.

## THUMB METACARPAL FRACTURES

Most thumb metacarpal fractures occur at or near the base. The distinction between intraarticular and extraarticular fractures is important, particularly in that the thumb metacarpal will tolerate at least 30° angulation without noticeable deformity or altered function (25). The carpometacarpal joint of the thumb is critical for thumb and hand function, however, and inadequate treatment can lead to a substantial hand disability (12). Special radiographic views, including tomography or the Robert anteroposterior view taken with the hand in maximum pronation so that the dorsum of the thumb is against the radiographic plate, are often required to assess the fracture pattern accurately.

### *Treatment*

Several techniques, all with good reported results, have been advocated for treatment of Bennett's fracture-dislocation (8,21,51). The small palmar fragment remains attached to the trapezium and second metacarpal by the stout anterior oblique ligaments, while the shaft of the metacarpal is pulled proximally and radially, allowing the abductor pull to increase the deformity at the base.

Our approach has been directed toward regaining anatomic reduction of the intraarticular fracture.

- With image intensification, attempt closed reduction by longitudinal traction, pronation, and compression on the base of the metacarpal. If an anatomic reduction can be realized, percutaneous Kirschner wire fixation using 0.045 wires will guard against redislocation. The use of a 14-gauge hypodermic needle facilitates the placement of the Kirschner wires into the tubular shaft of the metacarpal.
- Direct one wire into the second metacarpal and a second into the trapezium. Cut the wires just under the skin and apply a thumb spica cast for 6 weeks (Fig. 40.11).

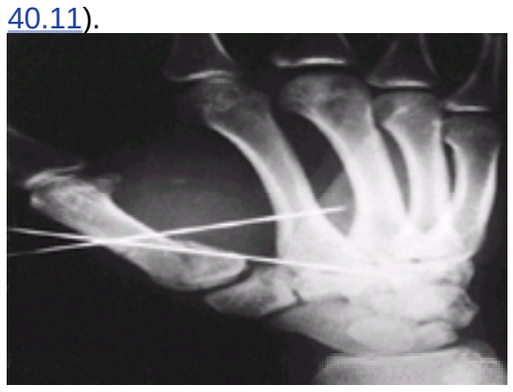

***Figure 40.11.*** A displaced Bennett's fracture was treated successfully by a closed reduction and percutaneous Kirschner wire fixation. Image intensification facilitated the pin placement.

- If an anatomic reduction cannot be obtained or maintained, open reduction and internal fixation are required. Through the palmar approach of Gedda and Moberg, reduce the fracture and gently hold it with a bone-reduction clamp while making provisional fixation with Kirschner wires.
- Introduce a 2.0- or 2.7-mm cortical screw from a dorsal direction into the fragment, placing the gliding hole in the metacarpal shaft. Use the half-threaded 4.0-mm cancellous screw only if adequate fixation cannot be achieved, as this type of screw may be difficult to remove.
- If small Kirschner wires are used, support the fixation by an additional Kirschner wire between the thumb metacarpal and second metacarpal as well as by a thumb spica cast for 4 to 6 weeks. With stable screw fixation, protected motion may be initiated 48 to 72 h after surgery.

Rolando (42) described a Y-shaped intraarticular fracture, but significant comminution is far more common. Preoperative tomography is exceedingly important to determine the operability of these fractures. Often they are impacted and require support with a cancellous bone graft. Place a small T or L plate on the dorsal surface of the metacarpal to support the reconstruction (Fig. 40.12) (19).

***Figure 40.12.*** A 42-year-old man fell and sustained a closed intraarticular Rolando fracture of the base of his right dominant thumb. **A:** Anteroposterior radiograph shows the fracture configuration. **B:** The fracture was openly reduced and internally fixed with a 2.0-mm interfragmentary screw as well as a small L plate. **C:** The fracture healed, and the functional recovery was excellent.

When the comminution is too extensive to allow screw-and-plate fixation, use Kirschner wire fixation with cancellous bone graft and mini–external fixation stabilizing the thumb metacarpal to the index metacarpal. This technique maintains distraction on the joint while healing occurs (Fig. 40.13) (10).



***Figure 40.13.*** A 30-year-old tool-and-die worker's dominant thumb was caught in a lathe, causing extensive skeletal and soft-tissue trauma. **A:** Anteroposterior radiograph shows a comminuted intraarticular fracture at the base of the metacarpal as well as a severe fracture of the proximal phalanx. **B:** Following repair of the flexor pollicis longus and the radial digital nerve and artery, an open reduction and internal fixation of the base of the metacarpal was accomplished. The impacted articular fragments were reduced, held with 0.035-mm Kirschner wires, and supported by distal radius cancellous bone graft. A mini-external fixation unit was placed to prevent settling of the joint reconstruction, to maintain the first webspace, and to maintain reduction of the proximal phalanx fracture. **C:** Rehabilitation of the hand progressed with the fixator in place.

## PITFALLS AND COMPLICATIONS

Failure to achieve or maintain anatomic reduction may result early in abduction deformity of the thumb metacarpal, leading to posttraumatic arthrosis. Miniscrew-and-plate fixation should be used only by a surgeon experienced in these techniques because inadequate fixation can lead to collapse of the articular restoration and to substantial later disability. When approaching this area, avoid prolonged intraoperative traction on the branches of the radial sensory nerve, which can result in a distressing neuritis.

## PHALANGEAL FRACTURES

### SHAFT FRACTURES

Phalangeal fractures are common. The associated complications are significant, and the functional disability can be profound (41). Certainly many are nondisplaced, stable, and readily treated by splintage or buddy straps, and others are easily reduced and held by external plaster support. Because of the intimate relationship of the tendons and joints to the phalangeal shaft, however, certain unstable phalangeal fractures—including displaced, comminuted, spiral, or short oblique—require internal fixation to ensure anatomic alignment and restore functional mobility.

#### *Treatment*

Many unstable phalangeal shaft fractures can be successfully treated by percutaneous wire fixation (Fig. 40.14).

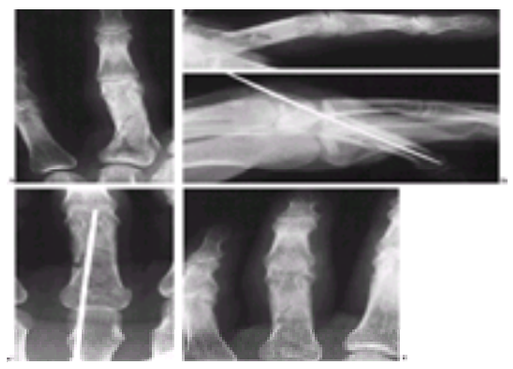

***Figure 40.14.*** A 37-year-old cardiologist sustained a closed fracture of his ring finger in a basketball game. **A,B:** Anteroposterior and lateral radiographs revealed a comminuted fracture with angular and rotatory malalignment. **C,D:** Treatment consisted of closed reduction, percutaneous longitudinal Kirschner wire placement, and plaster cast for 3 weeks. **E:** The fracture healed in near-anatomic position, and full function resulted.

- After appropriate anesthesia, apply longitudinal traction through the middle phalanx and flex the metacarpophalangeal joint 60° to 70° with the proximal phalanx flexed about 45° (4).
- Make angular and rotatory corrections at this juncture. If swelling is not profound, anatomic landmarks for insertion of Kirschner wires include the flare of the head of the proximal phalanx and the proximal palmar skin crease, which also lies under the flare (24). The size of the Kirschner wire is determined by the location of the fracture and the size of the bone.
- Stabilize fractures of the base, transverse shaft, and neck by one 0.045-in. or two 0.035-in. Kirschner wires placed longitudinally through the metacarpal head, preferably to one side of the extensor tendon and extended distally into the subchondral bone at the condylar levels. Verify the reduction and wire placement by image intensification, followed by standard radiographs in three views.
- Apply either dorsal and palmar splints or a plaster cast. Take care that the plaster does not come into contact with the pins, which are left protruding through the skin for ease of removal.
- Remove the cast at 3 weeks and the pins at that time or at 4 weeks, depending on the radiographic appearance. Initiate active assisted range-of-motion exercises under a therapist's supervision.

Spiral or short oblique fracture patterns can be satisfactorily stabilized with parallel Kirschner wires placed across the fracture site. For the index and little fingers, introduce the wires from the radial and ulnar sides, respectively, and leave them protruding through the skin for ease of removal. Open reduction and internal fixation are required for fractures that cannot be well reduced by manipulative reduction, those associated with soft tissue trauma, and those seen late.

- Approach the shaft through the interval between the lateral band and common extensor tendon. More distal exposure may require division of the transverse retinacular ligaments, which are marked for later reapproximation. Spiral fractures for the most part are amenable to interfragmentary screw fixation using 1.5-mm screws.
- Directing one screw perpendicular to the phalangeal shaft and a second perpendicular to the fracture line protects the fracture from shear and rotatory stresses. Countersink the holes to keep the screw heads from interfering with the overlying gliding structures. If the fracture is a short oblique pattern, the interfragmentary screw will require a neutralization plate to protect against shear or rotational forces, even though the plate may prove to be bulky.

The interosseous wire technique advocated by Lister is most effective for transverse fractures (Fig. 40.15) (38). Application is straightforward and requires little in the way of instrumentation, and the fixation is less bulky than plates. The disadvantages, however, include the failure to gain a tension band effect if the wire loop is placed in the midaxis of the shaft; also, the oblique Kirschner wire required to neutralize rotational forces may interfere with gliding of the lateral band. A wire loop placed on the dorsal aspect of the shaft in association with transverse or crossed Kirschner wires effectively functions as a tension band (23).

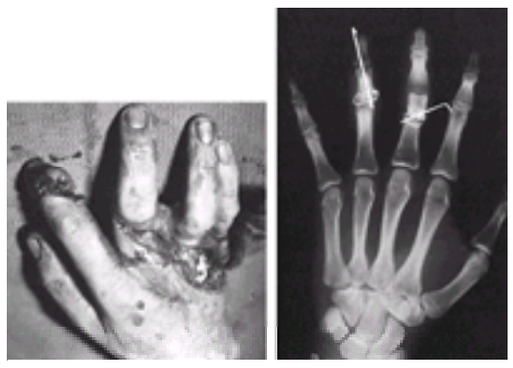

***Figure 40.15.*** A 19-year-old right-hand-dominant student caught his right hand in a table saw. Extensive soft-tissue and skeletal disruption resulted. The phalangeal fractures in the long and ring figers were fixed with an interosseous wire as well as an additional Kirschner wire for rotational control. Revascularization of the involved digits was also required.

- Start the technique of interosseous wire fixation with the placement of two parallel drill holes with a 0.035 Kirschner wire just dorsal to the midaxis of the shaft and just proximal and distal to the transverse fracture line. Pass a 20-gauge hypodermic needle into each drill hole to facilitate the passage of a 26-gauge stainless-steel wire through the drill holes, with the free ends facing the surgeon. Alternatively, with the hub cut off sharply, use the hypodermic needle to drill the holes.
- At this juncture, pass a 0.035-in. double-ended Kirschner wire obliquely from within the fracture site distally out through the skin. With the fracture held reduced, drive the Kirschner wire into the proximal fragment.
- Then firmly pull the interosseous wire, twist it manually for three or four turns, and then twist it with a needle holder until the twist is seen to bend gently. Stress the fracture manually to verify the stability of the fixation and cut the twist short and bend it either against the shaft or into a drill hole in the shaft (Fig. 40.15).

### *Postoperative Management*

Stable internal fixation permits the start of active motion 48 to 72 h after surgery. Coban wraps help reduce digital swelling, and static and dynamic splints help restore mobility while preventing potential joint contracture. Kirschner wires can usually be removed at 3 to 4 weeks. We prefer to leave interfragmentary screws in place unless they prove bothersome.

## PITFALLS AND COMPLICATIONS

Following external fixation, excessive soft tissue stripping, inadequate or loose internal fixation, and prolonged immobilization can cause loss of position or motion (20,47). Because of the inherent relationships of the tendons to the phalangeal skeleton, screws placed in the anteroposterior plane can risk tendon rupture if they protrude excessively from the bone (18).

### ARTICULAR FRACTURES

Nondisplaced fractures may be splinted, but frequent observation is required because of a high rate of displacement (52). Displaced phalangeal articular fractures, particularly basilar avulsion types and the condylar or bicondylar variants, often require open reduction and internal fixation, as the fragments are small and frequently are not only separated but also rotated (3). Obtain three radiographic views to visualize the fracture and degree of displacement adequately.

### *Treatment*

Avulsion fractures in the hand occur through a tension mechanism at the bases of the phalanges. If there is displacement or rotation, internal fixation is advised. Tension band fixation using a 28-gauge stainless-steel wire is effective for avulsion fractures such as bony gamekeeper's thumb fractures, lateral avulsion injuries, and dorsal avulsions of the middle phalanx (6,36).

In condylar fractures, the fracture must be sufficiently exposed to allow the fracture line and the joint to be visualized. Take care to avoid dissection of the soft tissue attachments to the condyles. We recommend either a dorsal or midaxial incision at the proximal interphalangeal joint level; use a modified H incision over the distal interphalangeal joint. For extremely displaced bicondylar fractures or those with associated impaction of the base of the middle phalanx, we have on occasion obtained added exposure by osteotomizing the insertion of the central slip, which is later replaced and secured with a tension band wire.

Fix unicondylar fractures with 1.5-mm lag screws. Small condylar fractures may be held by directing the screw from the opposite cortex, thereby avoiding devascularization of the collateral ligament or fragment by the relatively large screw head.

Bicondylar fractures, often the result of a more severe trauma, have a high risk of residual joint stiffness. For this reason, we try to obtain fixation rigid enough to permit early postoperative joint mobilization. Securely fix both condyles with a lag screw placed through a mini–condylar plate along the side of the shaft. This plate is designed to sit on the side of the shaft, thus avoiding interference with the glide of the extensor mechanism.

Unstable fracture-dislocations of the proximal interphalangeal joints are also difficult to treat and have a high incidence of residual stiffness or joint subluxation. The force-couple technique described by Agee (1) has the advantage of maintaining joint reduction while encouraging joint mobility. Not only does it help mold a new fibrocartilaginous joint surface on the base of the middle phalanx but it also avoids contracture of the soft tissues (Fig. 40.16) (1).

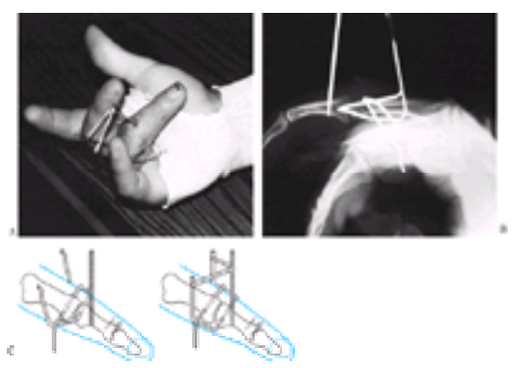

***Figure 40.16.*** A fracture-dislocation of the PIP joint was treated with a closed reduction and application of Agee tracture. **A:** Clincal appearance with traction in place. **B:** Radiographic appearance, showing reduction. **C:** Placement technique (**left**) before reduction and (**right**) after reduction, with rubber-band traction assembly in place.

- Place two parallel 0.045 Kirschner wires transversely just distal and proximal to the joint. Drill a 0.062 threaded Kirschner wire from dorsal to palmar in the proximal third of the middle phalanx.
- Bend the distal transverse Kirschner wire 90° on both sides to pass proximally and below the proximal Kirschner wire and bend it again 90° dorsally.
- Next, bend the proximal transverse wire 90° palmarly on either side of the finger extending palmarward and connect it beneath the digit by a strip of adhesive tape.
- Finally, connect the vertical threaded Kirschner wire with the vertical arms of the distal transverse Kirschner wire with a small rubber band, creating a “force couple” that reduces the dislocation.

- Encourage the patient to begin active motion and leave the device in place for at least 4 weeks and preferably for 6 weeks. A spring-loaded dynamic external fixator using the same principles of force coupling has been effective as well (32).

## PITFALLS AND COMPLICATIONS

Phalangeal articular fractures are among the most difficult hand injuries to treat because of their small size, precarious vascular supply, and propensity for associated soft-tissue contracture. Excessive exposure and soft tissue stripping, inadequate skeletal fixation, or fragmentation of the condylar fragments results in loss of joint mobility, arthrosis, or avascular necrosis. Careful preoperative planning is essential for proper operative management.

## AUTHORS' PERSPECTIVE

The proper treatment of fractures of the metacarpals and phalanges is a challenge because of the constant struggle between the achievement of skeletal union and the maintenance of soft tissue integrity and function. The techniques outlined seek to accomplish both goals. An underlying tenet is that the greater the soft tissue injury, the greater the need for stable fracture fixation to allow early motion. For best results, pay careful attention to edema control as well as the proper positioning and therapy of the uninjured portion of the hand.

### CHAPTER REFERENCES

Each reference is categorized according to the following scheme: *, classic article; #, review article; !, basic research article; and +, clinical results/outcome study.


* 1. Agee J. Unstable Fracture-Dislocations of the Proximal Interphalangeal Joint of the Fingers. *J Hand Surg* 1978;3:386.

+ 2. Barry P, Regnard PJ, Bensa P. Foucher's K-wire Technique for Fractures of the Neck of the Fifth Metacarpal–50 Cases. *Ann Chir Main* 1991;10:469.

# 3. Barton NJ. Intra-articular Fractures and Fracture-Dislocations. In Bowers W, ed. *The Interphalangeal Joints.* New York: Churchill-Livingstone, 1987.

* 4. Belsky MR, Eaton RG, Lane LB. Closed Reduction and Internal Fixation of Proximal Phalangeal Fractures. *J Hand Surg* 1984;9:725.

# 5. Belsole R. Physiologic Fixation of Displaced and Unstable Fractures of the Hand. *Orthop Clin North Am* 1980;111:393.

+ 6. Bischoff R, Buechler U, De Roche R, Jupiter J. Clinical Results of Tension Band Fixation of Avulsion Fractures of the Hand. *J Hand Surg* 1994;19A:1019.

+ 7. Bosscha K, Snellen JP. Internal Fixation of Metacarpal and Phalangeal Fractures with AO Minifragment Screws and Plates: A Prospective Study. *Injury* 1993;24:166.

# 8. Breen TF, Gelberman RH, Jupiter JB. Intra-articular Fractures of the Basilar Joint of the Thumb. *Hand Clin* 1988;4:491.

+ 9. Buchler U, Fischer T. Use of Mini–Condylar Plate for Metacarpal and Phalangeal Periarticular Injuries. *Clin Orthop* 1987;214:53.

+ 10. Buchler U, McCollam SM, Oppikofer C. Comminuted Fractures of the Basilar Joint of the Thumb: Combined Treatment by External Fixation, Limited Internal Fixation, and Bone Grafting. *J Hand Surg* 1991;16A:556.

# 11. Butt WD. Fractures of the Hand, II. Statistical Review. *Can Med Assoc J* 1962;86:775.

+ 12. Cannon S, Dowd G, Williams D. A Long-term Study Following Bennett's Fracture. *J Hand Surg* 1986;11B:426.

* 13. Charnley J. *The Closed Treatment of Common Fractures, 3rd ed.* Edinburgh: Churchill-Livingstone, 1974:150.

+ 14. Crawford GP. Screw Fixation for Certain Fractures of the Phalanges and Metacarpals. *J Bone Joint Surg* 1976;58A:487.

+ 15. Dabezies EJ, Schulte JP. Fixation of Metacarpal and Phalangeal Fractures with Miniature Plates and Screws. *J Hand Surg* 1986;11A:283.

# 16. Eichenholz SN, Rizzo PC. Fracture of the Neck of the Fifth Metacarpal—Is Overtreatment Justified? *JAMA* 1961;178:425.

+ 17. Emmett JE, Breck LW. A Review and Analysis of 11,000 Fractures Seen in a Private Practice of Orthopaedic Surgery. *J Bone Joint Surg* 1978;40-A:1169.

+ 18. Fambrough RA, Green DP. Tendon Rupture as a Complication of Screw Fixation in Fractures of the Hand. *J Bone Joint Surg* 1979;61-A:781.

# 19. Foster RJ, Hastings H II. Treatment of Bennett, Rolando, and Vertical Intra-articular Trapezial Fractures. *Clin Orthop* 1987;214:121.

# 20. Freeland AE. External Fixation for Skeletal Stabilization of Severe Open Fractures of the Hand. *Clin Orthop* 1987;214:93.

* 21. Gedda KO. Studies on Bennett's Fracture: Anatomy, Roentgenology, and Therapy. *Acta Chir Scand [Suppl]* 1954;193.

* 22. Gedda KO, Moberg E. Open Reduction and Osteosynthesis of the So-called Bennett's Fracture in the Carpometacarpal Joint of the Thumb. *Acta Orthop Scand* 1953;22:249.

! 23. Gould WL, Belsole RJ, Skelton WH. Tension Band Stabilization of Transverse Fractures: An Experimental Analysis. *Plast Reconstruct Surg* 1984;73:111.

* 24. Green DP, Anderson JR. Closed Reduction and Percutaneous Pin Fixation of Fractured Phalanges. *J Bone Joint Surg* 1973;55-A:1651.

# 25. Green DP, O'Brien ET. Fractures of the Thumb Metacarpal. *South Med J* 1972;65:807.

# 26. Greene TL, Noellart RC, Belsole RJ. Treatment of Unstable Metacarpal and Phalangeal Fractures with Tension Band Wiring Techniques. *Clin Orthop* 1987;214:78.

# 27. Hastings H II. Unstable Metacarpal and Phalangeal Fracture Treatment with Screws and Plates. *Clin Orthop* 1987;214:37.

+ 28. Hastings H II, Carroll C IV. Treatment of Closed Articular Fractures of the Metacarpophalangeal and Proximal Interphalangeal Joints. *Hand Clin* 1988;4:503.

! 29. Heim V, Pfieffer KM. *Small Fragment Set Manual: Technique Recommended by the ASIF Group, 2nd ed.* New York: Springer-Verlag, 1982.

# 30. Horst-Nielson F. Subcapital Fractures of the Four Ulnar Metacarpal Bones. *Hand* 1976;8:290.

+ 31. Hunter JM, Cowen NJ. Fifth Metacarpal Fractures in a Compensation Clinic Population. *J Bone Joint Surg* 1970;52-A:1159.

+ 32. Inanami H. Ninomiya S, Okutsu I, Tarui T. Dynamic External Finger Fixator for Fracture Dislocation of the Proximal Interphalangeal Joint. *J Hand Surg* 1993;18A:160.

* 33. Jahss SA. Fractures of the Metacarpals: A New Method of Reduction and Immobilization. *J Bone Joint Surg* 1938;20:178.

* 34. Jupiter JB, Koniuch M, Smith RJ. The Management of Delayed Unions and Nonunions of the Tubular Bones in the Hand. *J Hand Surg* 1985;4:457.

# 35. Jupiter JB, Sheppard JE. Tension Wire Fixation of Avulsion Fractures of the Hand. *Clin Orthop* 1987;214:113.

+ 36. Kozin SH, Bishop AT. Tension Wire Fixation of Avulsion Fractures at the Thumb Metacarpophalangeal Joint. *J Hand Surg* 1994;19A:1027.

+ 37. Lamb DW, Abernathy PA, Raine PA. Unstable Fractures of the Metacarpals: A Method of Treatment by Transverse Wired Fixation to Intact Metacarpals. *Hand* 1973;5:43.

* 38. Lister G. Intraosseous Wiring of the Digital Skeleton. *J Hand Surg* 1978;3:427.

# 39. McElfresh EC, Dobyns JH. Intra-articular Metacarpal Head Fractures. *J Hand Surg* 1983;8:383.

# 40. Melone CP Jr. Rigid Fixation of Phalangeal and Metacarpal Fractures. *Orthop Clin North Am* 1986;17:421.

+ 41. Pun WK, Chow SP, Luk KDK. A Prospective Study of 284 Digital Fractures of the Hand. *J Hand Surg* 1989;14-A:474.

* 42. Rolando S. Fracture de la base du premier metacarpien, et principalement sur une variété non encore écrite. *Presse Med* 19190;33:303.

# 43. Ruedi TP, Burri C, Pfeiffer KM. Stable Internal Fixation of Fractures of the Hand. *J Trauma* 1971;11:381.

+ 44. Schuind F, Donkerwolke M, Burney F. External Minifixation for Treatment of Closed Fractures of the Metacarpal Bones. *J Orthop Trauma* 1991;5:146.

+ 45. Scott MM, Mulligan PJ. Stabilizing Severe Phalangeal Fractures. *Hand* 1980;12:44.

# 46. Segmuller G. *Surgical Stabilization of the Skeleton of the Hand.* Baltimore: Williams & Wilkins, 1977.

+ 47. Seitz WH Jr. Management of Severe Hand Trauma with a Mini-External Fixator. *Orthopedics* 1987;10:601.

+ 48. Shehadi SI. External Fixation of Metacarpal and Phalangeal Fractures. *J Hand Surg* 1991;16A:544.

# 49. Smith RJ, Peimer CA. Injuries to the Metacarpal Bone and Joints. *Adv Surg* 1977;2:341.

# 50. Steel WM. The AO Small Fragment Set for Hand Fractures. *Hand* 1978;10:246.

+ 51. Surzur P, Rigault M, Charissoux JL, et al. Recent Fractures of the Base of the First Metacarpal: Study of a Series of 138 Cases. *Ann Chir Main* 1994;13:122.

+ 52. Weiss APC, Hastings H II. Distal Unicondylar Fractures of the Proximal Phalanx. *J Hand Surg* 1993;18A:594.

# 53. Workman CE. Metacarpal Fracture. *Mo Med* 1964;61:687.

# CHAPTER 41

# DISLOCATIONS OF THE CARPUS

*James H. Dobyns and Richard A. Berger*

**J. H. Dobyns, R. A. Berger:** Division of Hand Surgery, Department of Orthopaedic Surgery, Mayo Clinic, Rochester, Minnesota 55905.

Normal Anatomy of the Wrist
Kinematics of the Carpus
Terminology and Classification
Diagnosis and Patient Evaluation
History
Physical Examination
Imaging
Arthroscopy and Surgical Exploration of the Wrist
Presentation of Carpal Instability
Clinical Syndromes and Other Carpal Instabilities
Radiocarpal Level
Perilunate Level
Scapholunate Dissociation
Pitfalls and Complications
Other Carpal Instabilities
Carpal Instability Nondissociative (CIND)
Axial Instabilities
Chapter References

This chapter discusses many types of carpal instabilities and fracture–dislocations of the carpus. Chapter 42 reviews carpal bone fractures.

## NORMAL ANATOMY OF THE WRIST

In the normal wrist, there are eight carpal bones, anatomically divided into two rows. From radial to ulnar, the proximal carpal row is composed of the scaphoid, lunate, triquetrum, and pisiform (sometimes not classified as a carpal bone because it is a sesamoid bone within the tendon of the flexor carpi ulnaris). From radial to ulnar, the distal carpal row is composed of the trapezium, trapezoid, capitate, and hamate. Each bone has a unique shape, but each bone may be considered schematically to be cuboid. For the central bones--the capitate, trapezoid, and lunate—only the dorsal and palmar surfaces are available for capsular attachments. The remaining four sides are covered with articular cartilage. In contrast, the marginal carpal bones have an additional surface available for capsular attachments: the lateral (radial) surfaces of the trapezium and scaphoid and the medial (ulnar) surfaces of the hamate and triquetrum.

There are no predictable tendinous attachments to the carpal bones, with the exception of the pisiform. Occasionally, one of the multiple slips of the abductor pollicis longus inserts into the scaphoid or trapezium, and the tendon of the extensor carpi ulnaris may insert into the hamate. Only a few areas on the surfaces of the carpal bones are not covered by articular cartilage or capsular attachments, such as the neck of the capitate and the palmar surface of the proximal pole of the scaphoid. These areas are covered by the synovial layer of the joint capsule.

By Taleisnik's (35) definition, the carpal ligaments may be divided into extrinsic and intrinsic groups. Extrinsic ligaments are those with an attachment proximal or distal to the carpal bones, and intrinsic ligaments attach entirely to carpal bones. The carpal ligaments may also be classified anatomically as capsular or intraarticular. As a rule, intraarticular ligaments are intrinsic, but capsular ligaments may be intrinsic or extrinsic. Capsular ligaments are well organized structures that are thickenings of the joint capsule (4). They are composed of dense fascicles of collagen surrounded by loosely organized areolar tissue called the perifascicular space. This space transmits blood vessels supplying the carpal bones, the ligaments, and a surprising amount of nerve tissue. The nerve tissue in the ligaments may play a role in joint proprioception. Groups of fascicles, aligned in a roughly parallel fashion, form the thickening that is called a capsular ligament. It is covered on the joint surface by a continuous layer of synovial cells, the synovial stratum; on the superficial surface, it is covered by nonparallel fibrous elements called the fibrous stratum (4). The synovial and fibrous strata are direct extensions of the synovial and fibrous strata composing the joint capsule in regions where no ligamentous thickening is present. Morphologically, intraarticular ligaments are similar to capsular ligaments, but they are surrounded by synovial strata alone (8).

Ligaments insert into bone in much the same fashion that tendons do (4). The internal organization of the collagen fascicles is lost to form a zone of fibrocartilage. A “blue line” separates the fibrocartilage into mineralized and demineralized zones. The mineralized zone blends into the cortical bone in a fashion analogous to the formation of Sharpey's fibers of tendon insertion.

The palmar wrist joint capsule completely covers the carpal bones and joint spaces (Fig. 41.1) (9,35). After dissection of the synovial lining of the carpal tunnel, the remaining fibers appear to originate proximally from the radial and ulnar margins of the wrist and course obliquely distally toward the midline lunate and capitate. The individual ligaments can be more clearly defined when viewed from within the wrist (Fig. 41.2). Beginning radially, four distinct extrinsic palmar radiocarpal ligaments have been defined (8,9). Originating from the radial styloid process and the radialmost palmar lip of the radius is the radioscaphocapitate (RSC) ligament (9,35). It courses distally as a single ligament to insert into the radial aspect of the waist of the scaphoid and hemicircumferentially around the proximal half of the distal pole of the scaphoid. Palmar to the head of the capitate, it merges with fibers from the triangular fibrocartilage (TFC) complex and the triquetrum to form a supporting sling for the head of the capitate, sometimes referred to as the arcuate ligament. Only a small percentage of fibers from the RSC ligament join fibers from the scaphocapitate ligament, which is contiguous and distal to the RSC ligament, to insert into the body of the capitate. There is no discrete radial collateral ligament, but the fibers of the RSC ligament that insert into the waist of the scaphoid form a radial “wall” in the radiocarpal joint capsule and anatomically are well suited to behave as a radial collateral ligament.

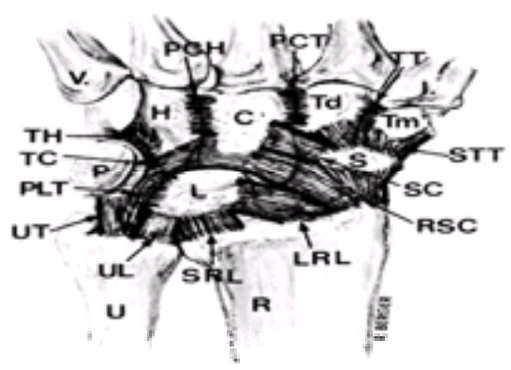


***Figure 41.1.*** The wrist region from a palmar perspective, showing the capsular extrinsic and intrinsic carpal ligaments. Bones: *R*, radius; *U*, ulna; *S*, scaphoid (distal pole); *L*, lunate; *P*, pisiform; *Tm*, trapezium; *Td*, trapezoid; *C*, capitate; *H*, hamate; *I*, first metacarpal; *V*, fifth metacarpal. Ligaments: *RSC*, radioscaphocapitate; *LRL*, long radiolunate; *SRL*, short radiolunate; *UL*, ulnolunate; *UT*, ulnotriquetral; *SC*, scaphocapitate; *PLT*, palmar lunotriquetral; *TC*, triquetrocapitate; *TH*, triquetrohamate; *STT*, scaphotrapeziotrapezoid; *TT*, trapeziotrapezoid; *PCT*, palmar capitotrapezoid; *PCH*, palmar capitohamate. Notice the interval between LRL and SRL, where the radioscapholunate neurovascular pedicle enters the radiocarpal joint.

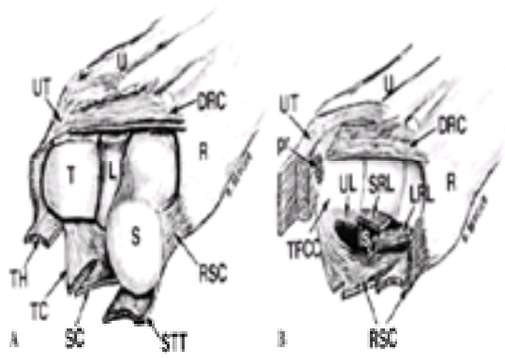


***Figure 41.2.*** **A:** A wrist from a distal and radial perspective with removal of the distal carpal row of bones. Bones: *R*, radius; *U*, ulna; *S*, scaphoid; *L*, lunate; *T*, triquetrum. Ligaments: *DRC*, dorsal radiocarpal; *UT*, ulnotriquetral; *TH*, triquetrohamate; *TC*, triquetrocapitate; *SC*, scaphocapitate; *STT*, scaphotrapeziotrapezoid. **B:** A wrist from a distal and radial perspective with the proximal and distal carpal rows of bones removed. Bones: *R*, radius; *U*, ulna. Ligaments: *RSC*, radioscaphocapitate; *LRL*, long radiolunate; *SRL*, short radiolunate; *UL*, ulnolunate; *TFCC*, triangular fibrocartilage complex; *pr*, prestyloid recess; *is*, interligamentous sulcus. The interligamentous sulcus is continuous with the space of Poirier at the tip of the palmar horn of the lunate. Notice the box-like arrangement of the extrinsic ligaments, which essentially envelop the proximal carpal row, resulting in a deepening of the radiocarpal joint.

Just ulnar to the origin of the RSC ligament, with a small amount of palmar overlap, the long radiolunate ligament takes origin (9). It is separated from the RSC ligament throughout its course by the intraligamentous sulcus. The long radiolunate ligament does not attach directly to the scaphoid but passes palmar to the proximal pole of the scaphoid and the palmar portion of the scapholunate interosseous ligament to insert entirely into the radial margin of the palmar horn of the lunate. Just ulnar to the origin of the long radiolunate ligament, the radioscapholunate (RSL) ligament enters the radiocarpal joint space through a defect in the palmar radiocarpal joint capsule. This structure is not a true ligament; it is a neurovascular bundle supplied by branches from the palmar carpal branch of the radial artery, the anterior interosseous artery, and the anterior interosseous nerve (8). It is covered by a thick synovial lining, readily appreciated with an arthroscope. The RSL ligament is continuous with the membranous proximal portion of the scapholunate interosseous ligament and attaches to the interfacet prominence, a fibrocartilaginous ridge separating the scaphoid and lunate fossae on the distal articular surface of the radius (4,8).

Ulnar to the penetration of the RSL ligament through the radiocarpal joint capsule, the short radiolunate ligament originates and courses distally to insert into the palmar horn of the lunate at the distal limit of the proximal articular surface of the lunate (9). The fibers of the short radiolunate ligament blend imperceptibly with fibers originating from the TFC complex, the ulnocarpal ligament complex. The radialmost aspect of this complex is the ulnolunate ligament, which attaches to the palmar horn of the lunate just ulnar to and in continuity with the short radiolunate ligament. More ulnarly, fibers course distally, deep to the palmar portion of the lunotriquetral ligament, where they curve radially to merge with fibers from the RSC ligament palmar to the head of the capitate. Forming the ulnar “wall” of the radiocarpal joint, the ulnotriquetral ligament inserts into the ulnar surface of the triquetrum, anatomically behaving as an ulnar collateral ligament, and continues distally to insert into the ulnar surface of the hamate. In 60% to 70% of normal adults, a small defect filled with synovial villi is found between the ulnolunate and ulnotriquetral ligaments. This defect marks the entrance to the pisotriquetral joint and is uniformly lined by tufts of synovial villi. A second defect in the TFC complex–ulnar collateral ligament complex is found more proximally and in the ulnar wall, which is also lined by synovial villi. This is the prestyloid recess, which sometimes communicates with the ulnar styloid process.

Dorsally, the radiocarpal joint capsule has only one thickened region, the dorsal radiocarpal ligament (Fig. 41.3). It originates from the dorsal margin of the distal radius, centered just distal to Lister's tubercle, and courses obliquely distally and ulnarly to insert partially into the dorsal horn of the lunate and more substantially into the dorsal surface of the triquetrum. It is separate from the dorsal portion of the lunotriquetral interosseous ligament and supports the fourth and fifth extensor tendon compartments at the level of the radiocarpal joint. Overlapping with the insertion of the dorsal radiocarpal ligament on the triquetrum, the dorsal intercarpal ligament originates to course distally and radially, passing just distal to the dorsal horn of the lunate to insert onto the dorsal surface of the waist and distal pole of the scaphoid. A few fibers also insert into the dorsal surface of the trapezoid. The dorsal intercarpal ligament also forms the floor of the fourth and fifth extensor tendon compartments as they cross the wrist region.

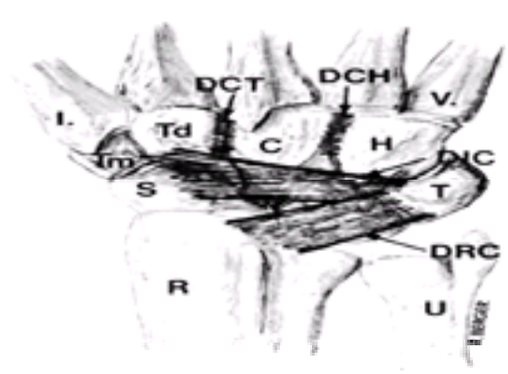


***Figure 41.3.*** The wrist region from a dorsal perspective, showing the capsular extrinsic and intrinsic carpal ligaments. Bones: *R*, radius; *U*, ulna; *S*, scaphoid; *T*, triquetrum; *H*, hamate; *C*, capitate; *Td*, trapezoid; *Tm*, trapezium; *I*, first metacarpal; *V*, fifth metacarpal. Ligaments: *DRC*, distal radiocarpal; *DIC*, dorsal intercarpal; *DCT*, dorsal capitotrapezoid; *DCH*, dorsal capitohamate.

Few ligaments span the midcarpal joint—an expected anatomic feature considering the relatively high range of motion between the proximal and distal carpal rows. However, stability of the midcarpal joint depends in part on the following intrinsic ligaments (Fig. 41.1 and Fig. 41.2). On the palmar surface of the carpus, beginning radially, the first midcarpal ligament is the palmar scaphotrapeziotrapezoidal (STT) ligament. These fibers originate from the distal half of the palmar surface of the distal pole of the scaphoid and diverge in a V pattern to insert onto the proximal surface of the palmar tubercle of the trapezium and the proximal palmar surface of the trapezoid. Ulnar to the origin of the STT ligament, the scaphocapitate ligament originates from the distal pole of the scaphoid (9). The proximal limit of the scaphocapitate ligament is continuous with the distal limit of the RSC ligament. The scaphocapitate ligament is a thick ligament that courses obliquely distally and ulnarly to insert onto the radial half of the palmar surface of the body of the capitate, carrying with it some of the distalmost fibers of the RSC ligament.

Ulnarly, the triquetrohamate ligament originates from the distal margin of the palmar surface of the triquetrum, just radial to the pisotriquetral joint capsule, to course distally and insert onto the palmar surface of the body of the hamate. A group of fibers from the origin of the triquetrohamate ligament diverge radially with fibers from the ulnar collateral ligament to insert into the ulnar half of the palmar surface of the body of the capitate as the triquetrocapitate ligament. Dorsally, there is a paucity of ligaments spanning the midcarpal joint. The distalmost fibers of the dorsal intercarpal ligament diverge to insert onto the dorsal surfaces of the trapezium and trapezoid, but there are no significant capsular ligaments connecting the proximal carpal row to the capitate or hamate dorsally.

Maintaining the integrity of each carpal row is a function of the intrinsic carpal ligaments. Within the proximal carpal row, there are two intrinsic ligament systems. The scapholunate ligament is composed of thick ligaments dorsally and palmarly, with a proximal and intermediate membranous region, which is continuous with the RSL ligament (2,4,8,23). The palmar region of the scapholunate ligament is longer than the dorsal region and has a more oblique orientation, perhaps allowing more rotation between the two bones. The dorsal region is a true capsular ligament, but the palmar region is entirely intraarticular, because the palmar surface of the scapholunate ligament is covered by, but is separate from, the long radiolunate ligament. Both the dorsal and palmar regions of the lunotriquetral ligament are capsular, connected proximally and intermediately by a membranous region (32). Both regions of the lunotriquetral ligament are quite thick and roughly equivalent in length. When intact, the membranous regions of the scapholunate and lunotriquetral ligaments isolate the midcarpal joint from the radiocarpal joint. In the distal carpal row, the intrinsic carpal ligaments form a nearly continuous sheet of fibers, spanning almost the entire palmar and dorsal surfaces of the trapezium and trapezoid and the bodies of the capitate and hamate (31).

Unlike the intrinsic ligaments of the proximal carpal row, there are no membranous components to the intrinsic ligaments of the distal carpal row (Fig. 41.4). The individual regions, although difficult to separate anatomically, are called the trapeziotrapezoid, capitotrapezoid, and capitohamate ligaments. There are two deep intrinsic ligaments in the distal carpal row that are not appreciated until the respective joints are opened. The deep capitohamate ligament is found in a nearly square recess in the contiguous articular surfaces of the capitate and hamate, near the palmar and distal extent of the surfaces. This ligament is thick and has an average

cross-sectional area of 25 $mm^2$. The deep capitotrapezoid ligament is situated in the mutual articular surfaces of the trapezoid and capitate, angling obliquely and dorsally toward the capitate. It is unclear what specific function these deep ligaments serve, but in addition to being mechanical constraints, they have an extremely high nerve content, suggesting some proprioceptive function.

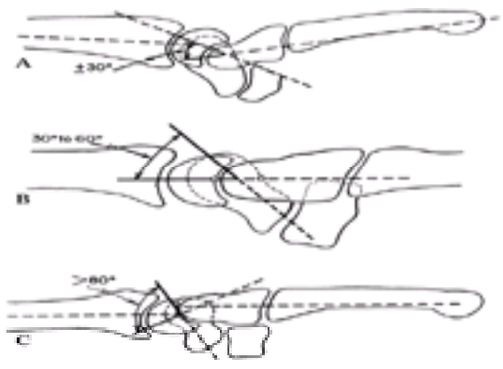


***Figure 41.4.*** These drawings of the forearm, carpus, and central metacarpal area show the alignment of (**B**) the balanced carpus and (**A,C**) the two common collapse positions—volar intercalated segment instability (VISI) and dorsal intercalated segment instability (DISI)—as they would be seen on a sagittal radiograph. **A:** Collapse in the VISI pattern is signified by a capitolunate angle of –30° or more. **B:** In the stable, normally balanced wrist, the radius, lunate, capitate, and third metacarpal form an almost colinear alignment. **C:** In the DISI pattern, a scapholunate angle of 80° or greater and lunate extension are typical.

## KINEMATICS OF THE CARPUS

Until 1982, the understanding of carpal kinematics had remained essentially unchanged from the time of the original radiographic visualization of the carpus in 1895 (12). It was thought that the two carpal rows behaved as separate units, with the scaphoid serving as a link between the rows. Navarro challenged the row concept by introducing a columnar concept, which is supported by Taleisnik (35). This view, however, has generally been accepted in terms of kinetic loading rather than kinematic behavior. With the development of sophisticated measurement techniques and the employment of rigid-body mechanical principles, such as instantaneous screw displacement axes and Eulerian angles, a new and still evolving understanding of the interrelationships of carpal bone kinematics began to unfold (5).

The carpus is capable of motion with six degrees of freedom:

Palmar flexion (60° to 80°)
Dorsiflexion (60° to 80°)
Radial deviation (15° to 25°)
Ulnar deviation (25° to 35°)
Pronation (5°)
Supination (5°)

Combinations of these planar motions result in circumduction. There is a functional direction of motion referred to as the “dart throw” axis, which moves the wrist from dorsiflexion and radial deviation to ulnar deviation and palmar flexion. The radiocarpal and midcarpal joints are thought to contribute equally to palmar flexion and dorsiflexion. The midcarpal joint contributes approximately 50% more motion than the radiocarpal joint to radial and ulnar deviation. The overall center of rotation of the wrist is in the head of the capitate for both major planes of motion (43).

Individual carpal bone motion studies support the row concept of integrated motion (5,15,33). Negligible translation of the carpal bones has been detected, compared with the magnitude of rotation. The bones of the distal carpal row behave very much as a single integrated unit, with minimal intercarpal motion. They move in the same plane as the metacarpals, mostly because of the strong ligamentous attachments between the bones of the distal carpal row. The bones of the proximal carpal row, although overall behaving as a functional unit, show significant differences of motion within the row. As the wrist is dorsiflexed, the scaphoid, triquetrum, and lunate show decreasing magnitudes of rotation in that order. Overall, the major direction of rotation is similar to that of the distal carpal row, but as dorsiflexion is achieved, the scaphoid supinates and the lunate pronates, resulting in a palmar separation of the two bones (23). The scaphoid also rotates through a greater arc relative to the lunate, further separating the palmar aspects of the two bones. The reverse phenomenon occurs in palmar flexion. There is little difference in the pronation or supination angles between the lunate and triquetrum. From ulnar deviation to radial deviation, the major axis of proximal row bone motion is palmar flexion. The relative pronation and supination tendencies of the scaphoid and lunate are similar to those found in palmar flexion of the wrist. The reverse phenomenon occurs in ulnar deviation, with relative separation of the palmar aspects of the scaphoid and lunate, as in dorsiflexion of the wrist. The additional degrees of freedom found in proximal row bone kinematics is probably due to the relative paucity of interosseous ligaments compared with those of the distal carpal row. This may explain the predisposition of the proximal carpal row to mechanical dissociation relative to the distal carpal row.

## TERMINOLOGY AND CLASSIFICATION

The term *instability* has been used for years in many different forms, and this has led to substantial confusion and misuse of the term. Recently, the Anatomy and Biomechanics Committee of the International Federation of Societies for Surgery of the Hand published a position statement dedicated to refining the definition of carpal instability (16). In the strictest terms, carpal instability is defined as a condition in which the wrist is unable to bear loads and does not exhibit normal kinematics throughout its arc of motion. This may include malalignment, but malalignment per se does not imply instability. Instability may be purely mechanical, or it may be clinical, as in a patient who has symptoms related to the instability. There are three categories of instability. A grade I or grade II (see Chapter 95) sprain of the soft-tissue restraint mechanisms of the carpus caused by a subluxation alters the natural relationships, but less than with a dislocation. A more severe sprain, perhaps a grade III with complete rupture, is usually caused by a dislocation (luxation). There is sufficient disruption of the soft-tissue restraints to cause two or more normally congruent joint surfaces to lose contact and congruency. A fracture–dislocation is similar to a dislocation, except that one or more major fracture fragments (i.e., at least 3–5 mm in greatest dimension) are produced by the force.

The most common carpal disruption is the perilunate dislocation pattern, which is a combination of radiocarpal and midcarpal disruption. The possible patterns, in proximal to distal progression, are radiocarpal, perilunate, midcarpal, axial, or combinations of these. Various degrees of sprain, dislocation, and fracture–dislocation can occur at any of the anatomic sites (Table 41.1). Fractures of a single or multiple carpal bones are often unstable and are therefore suitable for inclusion under the fracture–dislocation or subluxation categories, but they are discussed in Chapter 42 on fractures of the carpal bones.

| Injury type | Level | | | |
|---|---|---|---|---|
| | *Radiocarpal joint* | *Proximal carpal floor* | *Midcarpal joint* | *Distal carpal row* |
| Subluxation | Rotational (CIND)<br>VISI<br>DISI<br>Translational<br>Dorsal<br>Ulnar<br>Palmar<br>Combinations | Rotational (CIB)<br>DISI, scapholunate<br>VISI, lunotriquetral | Rotational (CIND)<br>VISI > DISI<br>Trapezoidotrapezoid<br>Scaphoscapotrapezoid<br>DISI > VISI<br>Capitolunate<br>Diffuse laxity | Axial |
| Dislocation | Dorsal<br>Palmar<br>Ulnar<br>Radial<br>Combinations | Perilunate (various stages)<br>Axial | Dorsal<br>Palmar | Axial |
| Fracture–dislocation | Barton's (palmar > dorsal)<br>Radial styloid with carpal translation<br>Lunate fossa<br>Avulsion<br>Die punch<br>With carpal translation<br>Combinations | Transverse<br>perilunate<br>Transradial styloid<br>Transscaphoid<br>Trans (other carpal bones of proximal carpal row)<br>Combinations | Transverse<br>Transcapitate<br>Transhamate<br>Trans (other carpal bones on distal carpal row)<br>Combinations | Axial<br>Ulnar<br>Radial<br>Combinations |

CIB, carpal instability dissociative; CIND, carpal instability nondissociative; Dislocation, loss of joint surface contact; DISI, dorsal intercalated segment instability; Fracture–dislocation, same as dislocation with fracture fragment >5 mm in greatest dimension; Subluxation, sprain with any degree of deformity but not dislocation; VISI, volar (palmar) intercalated segment instability.

***Table 41.1. Carpal Instability Categories***

Diagnosis and treatment are aided by classifying these complex injuries into certain patterns characterized by the mechanism of injury and resultant instability pattern

(Fig. 41.4):

- DISI is an acronym for dorsal intercalated segment instability.
- VISI is derived from volar intercalated segment instability.

The term *volar* is no longer used by hand surgeons to describe the ventral surface of the wrist; *palmar* is preferred, but VISI is a widely used term and therefore is used here. The intercalated segment in question is the proximal carpal row; usage does not differentiate between the entire row and any given portion of it (27). The position of the lunate, as visualized on a lateral radiographic view, whether facing dorsally or palmarly is the clue as to whether it is a DISI or VISI pattern. It is important to know whether the lunate is still bonded or linked with none, one, or both of its proximal carpal row neighbors, the scaphoid and triquetrum. If it is linked, it is termed *nondissociated* and, if unlinked, *dissociated.* DISI or VISI may therefore be coupled with the following acronyms: CID, CIND, and CIC (14):

- CID is an acronym for carpal instability dissociative.
- CIND stands for carpal instability nondissociative.
- CIC is an acronym for carpal instability combined or complex.

The term *dissociative* has been used for 20 years and was originally coined to describe the abnormal relationships occurring after injury at the scapholunate and triquetrolunate joints (27). Because the most obvious damage in scapholunate dissociation is to the intrinsic scapholunate and lunotriquetral ligaments in triquetrolunate dissociation, it seemed reasonable to use the term *nondissociative* for instabilities in which the initial damage appears to be to the extrinsic ligaments of the carpus. Another way of describing the difference is that dissociative lesions begin with damage to the intercarpal ligaments; nondissociative lesions begin with damage to the intracarpal or forearm–carpal ligaments.

It is appropriate to refer to a standard midcarpal instability as a CIND-VISI or CIND-DISI, depending on whether the collapse position is in flexion or extension. Because the proximal carpal row is deforming as a unit, this deformity is entirely different from the VISI deformity often seen with triquetrolunate dissociation, in which the deformity takes place within the proximal carpal row. If the intrinsic and extrinsic ligaments are damaged or if ligamentous elements at the radiocarpal and midcarpal levels are damaged, the carpal instability is combined or complex, and the abbreviation CIC is appropriate. This is often unnecessary because most instabilities eventually involve both intrinsic and extrinsic stabilizing structures. Staging of the condition implies various levels of damage to support structures. This theme is developed further as the specific instabilities are discussed.

The terms *dynamic* and *static* are also embedded in the literature and still serve a useful purpose, but they are susceptible to misunderstanding (36). Dynamic may mean progressive, and it is widely interpreted in that way in Europe. Applied to carpal instabilities, it was and is used to describe instabilities that do not appear obvious on the standard posteroanterior (PA) and lateral radiographs but require some stress or loading with the use of a provocative maneuver or a special imaging technique to display the instability. In this sense, dynamic has two different meanings. Static implies that the instability is obvious on standard radiographs taken without special loading maneuvers or techniques.

There is a progression of destabilization in carpal instability diagnoses. The spectrum of possibilities in a given instability varies from a barely noticeable sprain or contusion to a severe and seemingly fixed deformity, often with arthritic changes.

## DIAGNOSIS AND PATIENT EVALUATION

The current spectrum of clinically discrete, named pathologic entities includes those listed in Table 41.2.



***Table 41.2. Types of Carpal Injuries***

### HISTORY

Determine the nature of the trauma, the forces involved, and the position of the wrist and hand at impact (14,27,34,36). If it is possible, determine whether the injury was a single episode (with or without a particularly dramatic incident), multiple episodes, or not related to a memorable episode. Obtain any information relevant to a prior incident, diagnosis, or treatment involving the same area.

### PHYSICAL EXAMINATION

Deformity, swelling, abnormal positioning of the wrist, and difficulty in controlling wrist motions are the more common visible signs (14,26,36).

There are many soft-tissue problems, particularly tendon entrapments, that may result in audible or palpable crepitus at the wrist, but joint problems also produce noises. These are generally described as clicks, snaps, clunks, thuds, or creaks. Localize these, if possible, and relate them to the movement or stress that produces them. Try to reproduce the patient's pain and relate it to a particular sign or maneuver.

Several tests are useful, including the following:

- Localize the tenderness.
- Test for the presence, power, and excursion of the regional musculotendon units.
- Test for grip power, grip endurance, pinch power, and pinch endurance.
- Examine all neurovascular structures in the hand and wrist.
- Use various provocative maneuvers, which may be active or passive (see following sections). Include any maneuvers known by the patient to elicit symptoms.

The most common provocative maneuvers employed in examining the wrist are those directed at detecting disruptions in the interosseous ligaments between the scaphoid, lunate, and triquetrum. Many more maneuvers have been described in one form or another (6), but these form a core of examinations that can be built upon.

When conducting any of these tests, particularly provocative maneuvers, ask the patient about pain production and whether the symptoms produced are similar or identical to or different from the usual symptoms.

#### *Carpal Compression Test*

Compress the proximal carpal row by simultaneously applying convergent pressure to the scaphoid and triquetrum. A positive test is simply a complaint of pain and does not specifically identify an injury.

#### *Scaphoid Shift Test (Watson's Test)*

Place the thumb on the palmar skin over the distal pole of the scaphoid and the index finger on the dorsal skin over the scapholunate joint, and palpate the distal pole of the scaphoid at the point where the tendon of the flexor carpi radialis is no longer palpable. The scapholunate joint can be located just distal to the dorsal rim of the radius in line with Lister's tubercle. Beginning with the patient's wrist in ulnar deviation, apply a dorsally directed force to the distal pole of the scaphoid while passively deviating the wrist radially. Use the index finger to detect a dorsal shift of the proximal pole of the scaphoid. A positive test is one in which a subluxation is palpated or the patient complains of pain in the region of the dorsal scapholunate joint; it is relatively specific for scapholunate dissociation (38).

***Lunotriquetral Shuck Test (Kleinman's Test)***

Place one finger dorsally over the lunate and another palmar to the pisiform, and apply oppositely directed forces through the fingers while the patient's wrist is passively radially and ulnarly deviated. A positive test is a sense of subluxation through the lunotriquetral joint and pain with the maneuver (26).

***Lunotriquetral Ballottement Test (Reagan's Test)***

Stabilize the lunate with one hand and the pisiform–triquetrum column with the other hand. The pisiform–triquetrum column is passively shifted dorsally and palmarly. A positive test is one in which there is an excessive degree of motion compared to that in the contralateral wrist, and the patient complains of pain (30).

**IMAGING**

The examination should start with high-quality, unambiguous, standard-position PA and lateral radiographs of the wrist (Fig. 41.5) (19). In our practice, these are most often supplemented by stress views (usually grip-compression or arm-weight-traction views), motion studies (lateral extension–flexion or PA deviation views), or special projections, such as carpal tunnel views. If the diagnosis remains unclear, a technician scan, fine-cut computed tomography (CT) with reconstructions, or arthrography of the three carpal spaces may be helpful. Occasionally, ultrasound, magnetic resonance imaging (MRI) with and without gadolinium, or three-dimensional reconstruction may be indicated.

***Figure 41.5.*** Posteroanterior (**A**) and lateral (**B**) radiographs of a normal wrist. From the posteroanterior radiograph, one can easily assess the congruency of the carpal bone alignment using Gilula's lines (I,II,III) as well as assess ulnar variance. From the lateral radiograph, the scaphoid (dashed line) and lunate (solid line) are easily identified.

**ARTHROSCOPY AND SURGICAL EXPLORATION OF THE WRIST**

In skilled hands, arthroscopy yields information equivalent to and sometimes better than the combined imaging techniques. However, a thorough understanding of normal arthroscopic anatomy of the wrist is fundamental to making an accurate diagnosis and formulating a treatment plan (1).

An often overlooked value of arthroscopic surgery is that it provides the opportunity to examine the range-of-motion and perform provocative maneuvers before, during, and after surgical access to the wrist. It is fairly common that the information gained about the wrist in this way alters the treatment plan.

An improved surgical approach through the dorsal wrist joint capsule offers many theoretical and practical benefits (Fig. 41.6) (3) This approach is based on the anatomy of the dorsal radiocarpal and dorsal intercarpal ligaments. The dorsal radiocarpal ligament attaches to the dorsal rim of the radius between Lister's tubercle and the dorsal edge of the sigmoid notch, and distally to the dorsal lobe of the triquetrum. At this same level, the dorsal intercarpal ligament attaches to the triquetrum and spans the midcarpal joint to insert into the dorsal surface of the waist of the scaphoid, the lateral surface of the distal pole of the scaphoid, and the dorsal surface of the trapezoid.

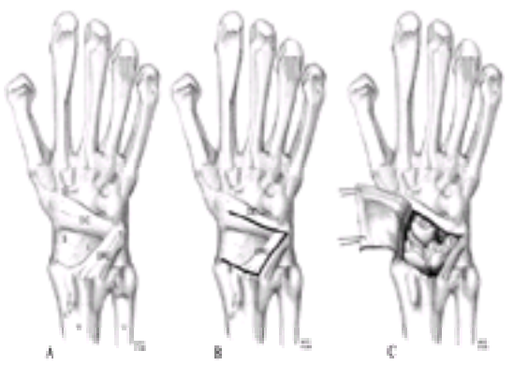

***Figure 41.6.*** **A:** The dorsal surface of the carpus defining the anatomy of the dorsal radiocarpal ligament (*DRC*) and the dorsal intercarpal ligament (*DIC*). (*S*, scaphoid; *L*, lunate; *T*, triquetrum; *Td*, trapezoid; *DRU*, distal radioulnar ligament; *R*, radius; *U*, ulna; *LT*, Lister's tubercle). **B:** The dorsal surface of the carpus outlining the landmarks used to create a fiber-splitting capsulotomy. The DRC attaches proximally along the dorsal rim of the radius between LT and the sigmoid notch and distally onto the dorsal lobe of the triquetrum. The DIC attaches ulnarly onto the dorsal lobe of the triquetrum and radially onto the scaphoid and trapezoid. The DRC is split by dividing the distance between LT and the sigmoid notch and connecting this point to the dorsal lobe of the triquetrum. The DIC is split by connecting the dorsal lobe of the triquetrum to the sulcus between the scaphoid and trapezoid. The capsulotomy can be reflected radially by incising the remaining attachment of the capsule along the dorsal rim of the radius to the tip of the radial styloid process. **C:** The completed fiber-splitting capsulotomy showing the reflected joint capsule. Exposed are the scaphoid, lunate, hamate, and capitate, as well as the radial two-thirds of the radiocarpal joint and the entire midcarpal joint. (From Berger RA, Bishop AT. A Fiber-splitting Capsulotomy Technique for Dorsal Exposure of the Wrist. *Tech Hand Upper Extremity Surg* 1997;1:2, with permission.)

- After performing a dorsal approach to the wrist capsule using the incision of your preference, identify the following landmarks by palpation: Lister's tubercle, sigmoid notch, dorsal lobe of the triquetrum, and sulcus of the STT joint.
- Make an incision from the central aspect of the dorsal lobe of the triquetrum proximally to the midpoint between Lister's tubercle and the sigmoid notch (splitting the dorsal radiocarpal ligament) and radially to the sulcus of the STT joint (splitting the dorsal intercarpal ligament).
- Release the dorsal radiocarpal joint capsule from the dorsal rim of the radius radially, until reaching the tip of the styloid process.
- Tangential to the dorsal cortices of the proximal carpal row, sharply elevate the radially based flap of capsule, exposing the entire midcarpal joint and the radial two-thirds of the radiocarpal joint.

This technique spares half of the normal course of the dorsal capsular ligaments, offers excellent exposure, and provides flexibility in performing capsular modifications, such as capsulodesis, without compromising exposure or stability.

### PRESENTATION OF CARPAL INSTABILITY

A survey of the diagnostic methods applied to carpal instability is incomplete without emphasizing that the condition has many presentations, which can be grouped roughly as follows:

1. Symptoms are present, but there is no or questionable deformity, even with imaging and provocative testing.
2. A condition, often referred to as a dynamic instability, may exist; this means that with appropriate stress—sometimes no more than wrist movement—a deformity occurs, but it spontaneously disappears after the stress is discontinued.
3. When a deformity is present on standard radiographs, even at rest, it is often referred to as a static deformity, for which there are three subdivisions: easily reducible, only reducible with difficulty, or not reducible at all by nonsurgical means.
4. The final stage of carpal instability is that of an almost fixed deformity with arthritic changes. The location and degree of the arthritic change are important.

## CLINICAL SYNDROMES AND OTHER CARPAL INSTABILITIES

### RADIOCARPAL LEVEL

Barton's fracture–dislocation is the most common carpal instability at the radiocarpal level and is usually discussed in the same manner as components of distal radial fractures (14,25,34,36,39) (see Chapter 44). Ulnar translation is the second most common instability at the radiocarpal level (29). It may occur as the residual of a full radiocarpal or perilunate dislocation, or it may develop after lesser degrees of trauma. Its manifestations may be subtle, or there may be a clinically visible ulnar displacement of the carpus and hand. Radiographs may show a gross ulnar displacement on the PA view, with the lunate directly distal to the TFC, or the displacement may be so mild that the lunate overlaps half on the radius and half over the TFC (a 50:50 lunate), rather than the usual 60% or more overlap on the radius. If there is a perilunate (i.e., scapholunate) disruption as well, the scaphoid may remain anatomic, permitting the lunate with the central and ulnar carpus to translate ulnarly (Fig. 41.7). Ulnar translation is a common end point of many carpal instabilities from either the initial injury itself or from chronic stress due to loading at the radiocarpal level, even after various reconstructions. If there is any evidence of ulnar translation instability, reconstructions that increase radiocarpal loading should be avoided.

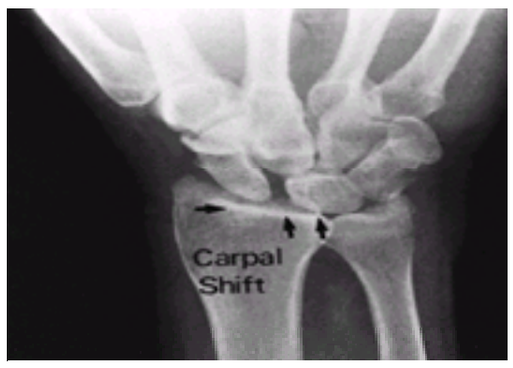


***Figure 41.7.*** PA view of a combined ulnar translation and perilunate disruption, demonstrating the ulnar shift of the lunate (*black arrows*), the increased scapholunate gap, and the 40:60 ratio (radial support to TFC support) position of the lunate.

For primary treatment, repair of freshly damaged ligaments dorsally and palmarly may be worthwhile, if done during the first 4–6 weeks and protected with percutaneous internal fixation for approximately 3 months. Even under these circumstances, the tendency toward ulnar slide is so great that many attempts fail. Decreasing the radial-to-ulnar angle by a closing wedge osteotomy of the radius added to the ligament repair or reconstruction has been considered, but experience with this approach is limited. The only procedure proven to halt ulnar translation is a limited radiolunate or RSL carpal fusion.

### PERILUNATE LEVEL

The greatest number of wrist instabilities occurs at the perilunate level (Fig. 41.8), reflecting a combination of radiocarpal and midcarpal disruption patterns (28). The disruption probably occurs in this manner because the lunate is strongly bound to the distal radius and weakly bound to the distal carpus; combined with the strut-like interference of the radially stabilizing scaphoid, which often fractures, this produces the most common of the full dislocations of the carpus: transscaphoid perilunate fracture–dislocation. This and other transosseous perilunate dislocations are often referred to as greater arc injuries, and the purely ligamentous perilunate disruptions are called lesser arc injuries (Fig. 41.9) (22).

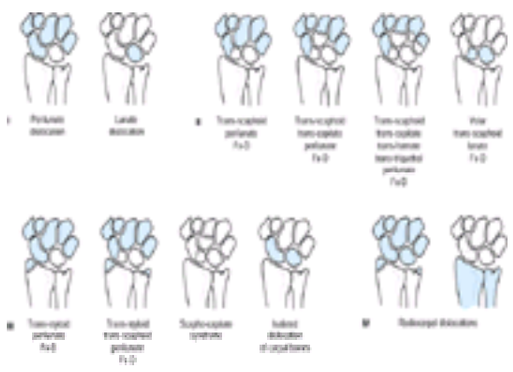

***Figure 41.8.*** The most common dislocations involving the carpus. Group I, perilunate and lunate dislocations, are usually only different stages of the same disruption pattern. Groups II and III are variations of the transosseous perilunate dislocations plus dislocations of single or paired carpal bones. Group IV includes the radiocarpal dislocations, both ligamentous and transosseous (i.e., fragments of the radius, ulna, or both bones).

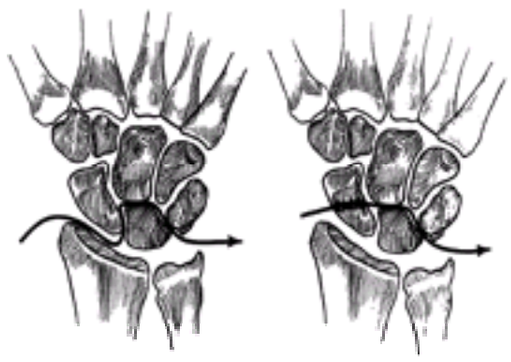

***Figure 41.9.*** Coronal-plane sketches of the wrist showing simplified versions of one of the disruption pathways for a lesser arc injury (**left**) and a greater arc injury (**right**). Several additional versions of the greater arc injuries are seen in groups II and III of Figure 41.7.

Most perilunate level injuries result from the application of a body-weight force on an outstretched hand, such as during a fall, a sports-related impact, or a motor vehicle accident. Certainly, injuries to the perilunate ligaments can occur with less impact under certain circumstances. Mayfield et al. (28) recreated a pattern of progressive perilunate instability by applying excessive axially directed loads to cadaver specimens positioned in maximum ulnar deviation, dorsiflexion, and supination. Ulnar-sided instability patterns are felt to result from similarly directed force in a radially deviated wrist, although this has not been reproduced in a laboratory environment. It is also conceivable that ligamentous injuries can occur with the wrist positioned in palmar flexion.

These fracture–dislocations and dislocations are fairly obvious clinically, resulting in a painful, tender, short, broad, and thick wrist. On radiographs, overlap of the carpal rows, an empty-cup lunate, and a displaced capitate are usually obvious (Fig. 41.10 and Fig. 41.11), but there is a remarkably high incidence of failure to diagnose this injury. There are many variants of this injury that do not reflect the full disruption pattern or that spontaneously reduce and therefore may be very difficult to diagnose. If the suspicion exists that a carpal injury may be greater than is obvious, one should investigate further with movement, traction, compression, and translational provocative maneuvers, as well as arthrography or arthroscopy. High-resolution tomography or CT will demonstrate the fracture details.

***Figure 41.10.*** PA (**A**) and lateral (**B**) radiographs show details of a complicated transosseous perilunate type of fracture–dislocation. It can be described as a transscaphoid, transulnar styloid, perilunotriquetral dislocation with an associated subluxation of the pisiform. The lunate and triquetrum are still in a relatively normal alignment with the forearm, and all physicians would be willing to call this a perilunate type of dislocation.

***Figure 41.11.*** PA (**A**) and lateral (**B**) radiographs of the same wrist show the lunate displaced palmarward and ulnarward, permitting the distal carpal row elements, particularly the capitate and hamate, to intrude toward the radius, displacing the scaphoid into flexion and the triquetrum ulnarward. Most physicians would call this a lunate dislocation because the carpal bones, other than the lunate, are fairly well aligned with the forearm. Nevertheless, the lunate is still in contact with a portion of its articular surface with the radius and still has intact ligament connections by its palmar radiolunate ligaments; therefore it is a stage of perilunate dislocation.

Treat early with closed reduction to minimize the risk of neurovascular or musculotendinous compromise (14,27,28,34,36). Longitudinal traction with the fingers in Chinese finger traps combined with manipulation usually results in reduction, especially if anesthesia is used. Sometimes, closed reduction can be maintained with the help of three-point molding in a thumb spica cast or splint (see Chapter 10). Apply dorsally directed pressure with pads and careful cast molding at the palmar projections of the scaphoid tuberosity and the pisiform, and palmarly directed pressure with pads and careful cast molding at the neck and dorsal sulcus of the capitate and Lister's tubercle. Monitor the patient closely after reduction to manage pain and swelling, assess sensory and motor functions, and ensure that the reduction is maintained. If the reduction is lost, open reduction and internal fixation, sometimes with a bone graft, is indicated. During open reduction and fixation, accomplish the following:

- Inspect and decompress the median and ulnar nerves, if compromised, and repair any extraarticular soft-tissue damage.
- Inspect and repair extrinsic and intrinsic ligament damage.
- Remove intraarticular debris and any interposed material.
- Survey and record the areas of joint cartilage damage and treat, if appropriate.
- Identify and treat fractures, restoring bone substance, position, and shape.
- Anatomically realign the carpal elements to each other and to the forearm.
- Internal fixation, percutaneous fixation, external fixation, or combinations of these are usually required to maintain position.

The postoperative routine depends on the specifics of the injury. Incorporate the hand and forearm in a well padded thumb spica splint, and elevate the hand. Start immediate motion of the fingers. Do not remove Kirschner wires (K-wires) for 8 weeks, unless they are loose or symptomatic. Splint the wrist and do not start range-of-motion exercises before 3 months.

## SCAPHOLUNATE DISSOCIATION

Scapholunate dissociation and rotary subluxation of the scaphoid are the same disorder, but the terms focus on differing aspects of the pathology. One directs attention to the linkage between the scaphoid and the rest of the proximal carpal row, and the other focuses on the scaphoid itself; both terms have been expanded to include the entire spectrum of injuries that disrupt the normal relationships of the scaphoid to the rest of the carpus. The pathomechanics of this condition are variable, but the classic mechanism is the same as that for perilunate dislocation. It is obvious that scapholunate dissociation as a residuum of perilunate dislocation is a more unstable variety than scapholunate dissociation as a solo entity.

It is entirely possible for scapholunate dissociation to occur independently of clinically significant perilunate injuries, although the entire spectrum of perilunate injuries must be considered with regard to treatment options. It has been hypothesized that even partial injuries of the scapholunate ligament may progress with cyclic loading to complete dissociation over time. In our experience, the palmar region of the scapholunate ligament is the most commonly disrupted site. This is probably related to the combined limited strength of the palmar region of the ligament and the phenomenon of mutual separation of the palmar regions of the scaphoid and lunate during wrist dorsiflexion and ulnar deviation.

Scapholunate dissociation tends to progress (27). Although some wrists are so inherently stable that a tear of the scapholunate interosseous membrane alone may have little clinical consequence, gradual attenuation of the regional extrinsic support system leads to increasing dissociation. This, plus the fact that none of the current treatments predictably restores normal stability and mobility, explains the continuing confusion about treatment.

### *Indications for Treatment*

Acute scapholunate dissociation requires treatment. Consider reconstruction of a large or chronic scapholunate dissociation that shows any of the following:

- Scapholunate gap of greater than 3 mm (Fig. 41.12)

***Figure 41.12.*** PA radiograph of the wrist showing a large scapholunate gap representing a static scapholunate dislocation. It also shows that the proximal pole of the scaphoid is trapped behind (i.e., dorsal or posterior to) the radial styloid. This is sometimes described as a scaphoid subluxation or dislocation, but the distal joint relationships of the scaphoid are still reasonably intact. After the scaphoid is reduced, treatment is carried out as for any other scapholunate dissociation.

- Scapholunate angle of greater than 60°
- A positive arthrogram or arthroscopic examination confirming a scapholunate ligament tear with increasing symptoms and minimal joint arthritis

The hope is to avoid the classic pattern of arthritic deterioration in progressive scapholunate dissociation.

***Principles of Treatment***

Several principles apply to the treatment of a scapholunate dissociation (13,14,34,36,40):

- Direct initial treatment of the fresh injury at protecting or repairing all the damaged ligaments and capsular structures.
- If repair is not possible or provides only questionable stability, reconstruction of or substitution for the damaged ligaments is appropriate. Bony stabilization by limited intercarpal fusion is one method of substituting for the damaged ligaments.
- Combinations of repair and reconstruction may be used.

***Surgical Techniques***

Although there are many operative procedures for treating scapholunate dissociation, only two are described here, in addition to the recommended management for the acute, reducible injury. Both surgical methods are best applied if the deformity is easily reducible. If the deformity is very difficult to reduce or if unexpectedly severe cartilage damage is found, a salvage procedure, such as a proximal row carpectomy or a more extensive fusion, may be indicated.

Treatment algorithms seem confusing and variable for scapholunate dissociation. These include cast immobilization, percutaneous pinning, direct ligament repair, capsulodesis, tenodesis, ligament reconstruction, and intercarpal arthrodesis.

A true scapholunate dissociation should not be treated closed because of the following paradox of reduction. In the normal wrist, the scaphoid and lunate will tend to separate at their anterior surfaces during dorsiflexion, while at the same time becoming more rotationally aligned to one another. In scapholunate dissociation, a diastasis develops between the scaphoid and lunate, and rotational displacement between the two bones increases. An attempt to close the scapholunate angle by dorsiflexing the wrist produces an increase in the diastasis, and an attempt to decrease the diastasis by palmar-flexing the wrist increases the scapholunate angle.

A grading scheme for dissociative carpal instability, based on the level of instability as defined by midcarpal arthroscopy, has been developed by Geissler and Freeland (18) (Table 41.3). On the basis of this scheme, we adopted the following treatment algorithm: If the injury is acute and the scapholunate relationship can easily be restored to normal, the scapholunate ligament should be allowed to heal primarily in accordance with the options listed in Table 41.4. For soft-tissue repairs alone to be successful, the reduction must easily be achieved and maintained, and the security of the soft-tissue repair must be high.

| | |
|---|---|
| Grade I | Partially torn or hemorrhagic scapholunate ligament<br>Normal alignment of distal edges of scapholunate joint<br>Standard arthroscopic probe not admitted into scapholunate joint cleft |
| Grade II | Torn or hemorrhagic scapholunate ligament<br>Minor malalignment of distal edges of scapholunate joint<br>Standard arthroscopic probe admitted into scapholunate joint cleft without rotation |
| Grade III | Torn scapholunate ligament<br>Marked malalignment of distal edges of scapholunate joint<br>Standard arthroscopic probe admitted into scapholunate joint cleft with rotation |
| Grade IV | Torn scapholunate ligament<br>Marked malalignment of distal edges of scapholunate joint<br>2.7 mm arthroscope may pass through scapholunate joint cleft between radiocarpal and midcarpal joints. |

From Geissler WB, Freeland AE. Arthroscopically Assisted Reduction of Intracarpular Distal Radius Fractures. Clin Orthop 1996;327:123, with permission.

***Table 41.3. Arthroscopically Based Grading of Dissociative Carpal Instability (Geissler and Freeland, 1996)***

| *Type* | *Recommended treatment* |
|---|---|
| I: acute injury, easily reduced | |
| Grade I | Percutaneous pinning |
| Grade II | Percutaneous pinning or direct repair |
| Grade III | Direct repair, ligament reconstruction (if inadequate ligament remnants), tenodesis or capsulodesis |
| Grade IV | Direct repair or ligament reconstruction (if inadequate ligament remnants), tenodesis or capsulodesis |
| II: chronic injury, easily reduced | Ligament reconstruction, tenodesis or capsulodesis |
| III: chronic injury, difficult reduction | Intercarpal arthrodesis |

***Table 41.4. Recommended Treatment for Scapholunate Dissociation Based on Arthroscopic Grades, Chronicity, and Ease of Reduction***

- Perform a dorsal fiber-splitting capsulotomy as described above. A palmar approach is occasionally indicated, which necessitates entering the carpal tunnel.

**Palmar Approach**

- Make a standard carpal tunnel incision with a curvilinear proximal extension, preserving the palmar cutaneous branches of the median nerve. Retract the flexor tendons after blunt dissection through the mesotenon radially or ulnarly. Take great care to protect the median nerve, which must be retracted radially, from excessive compression or tension.
- After visualizing the floor of the carpal tunnel, perform a synovectomy, using rongeurs; this reveals the fibrous lining of the palmar carpal ligaments. At this point, verify your orientation to the carpal anatomy; ligamentous tissue is seen converging on both the lunate and the capitate. It is easy to become confused about

which bone is which. If there is any question about a specific level, place a metallic instrument on the bone in question, and obtain a radiograph.

**Acute Scapholunate Dissociation** Closed reduction and prolonged support are appropriate if ideal alignment is obtained. However, ideal alignment is difficult to achieve in a true, complete scapholunate dissociation, for the reasons cited above. Therefore, closed management is best reserved for the treatment of incomplete scapholunate dissociation, or scapholunate "sprains," where the scapholunate rotational and diastatic relationships are normal.

- Cast support is similar to that described for perilunate dislocation. It may be necessary to percutaneously place temporary multiple K-wires across the scapholunate, radioscaphoid, or scaphocapitate joint intervals. If satisfactory anatomic alignment cannot be achieved, perform a dorsal approach to the carpus as described above.
- After the scaphoid and lunate are exposed, assess the damage to the scapholunate ligament. If the injury is acute, there is usually sufficient tissue to perform a direct repair. Place 0.047 mm K-wires, to be used as joysticks, into the dorsal aspects of the scaphoid and the lunate; these greatly enhance the ease of exposure and reduction.
- Reduce the scapholunate joint anatomically, stabilize it with two K-wires, and then remove the joysticks. Fully reflect the dorsal radiocarpal joint capsule to the level of the waist of the scaphoid. Do not completely strip the capsule from the scaphoid because it is the major source of blood supply to the bone.
- With the wrist maximally flexed toward the palm, use a small burr to "freshen" the attachment line of the scapholunate ligament that has been disrupted, usually along the ulnar margin of the scaphoid.
- With a $^{1}/_{32}$ inch (0.8 mm) drill point, drill four to six holes from this freshened margin distally and radially to exit just distal to the proximal articulating surface near the ridged waist of the scaphoid. Using Keith needles, pass a nonabsorbable suture (2-0 or 3-0 Mersilene) through the remnant of the scapholunate ligament and distally through the drill holes to exit at the waist of the scaphoid, where the sutures are tied securely (Fig. 41.13). Bring the radiocarpal joint to a neutral position, and take intraoperative radiographs to confirm the reduction.

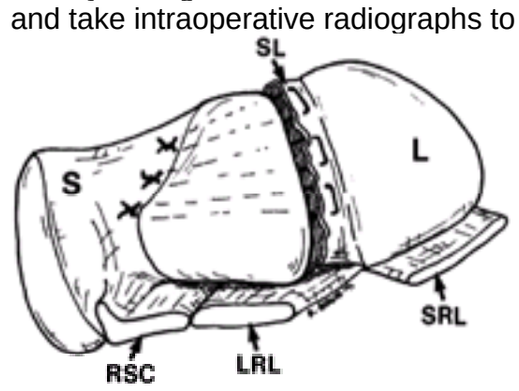


***Figure 41.13.*** Direct repair of the scapholunate ligament. An isolated scaphoid (*S*) and lunate (*L*) are viewed from a proximal and slightly radial perspective. The scapholunate ligament (*SL*) has been disrupted traumatically. In direct repair of the scapholunate ligament, suture material (2-0 or 3-0 Mersilene) is passed through the remnant of the ligament and drawn through drill holes in the scaphoid to exit near the waist of the scaphoid, where the suture is drawn tight and tied. This maneuver is accomplished after the scapholunate dissociation has been provisionally reduced and secured with a transosseous K-wire. (*RSC*, radioscaphocapitate ligament; *LRL*, long radiolunate ligament; *SRL*, short radiolunate ligament.

- Then close the wound, taking care to securely reattach the dorsal radiocarpal ligament and the dorsal radiocarpal capsule to the radius. If further reinforcement is indicated, use one or more capsulodesis techniques (described in the next section).

**Persistent Scapholunate Dissociation** Subacute and chronic scapholunate ligament tears are more difficult to treat than injuries. It may be difficult to anatomically reduce the subacutely or chronically disrupted scapholunate joint and obtain a repair that will withstand the demands that the patient will place on the wrist afterward. Degenerative changes will influence the choice of procedure. Two operative approaches are available: soft-tissue repair and augmentation or limited arthrodeses.

Proponents of limited arthrodeses to stabilize the malrotated scaphoid advocate STT fusion or scaphocapitate fusion. Radiocarpal or midcarpal degenerative changes detected radiographically are strong indications for intercarpal fusion. Important objectives with the STT or scaphocapitate fusion include reduction of the malrotated vertically displaced scaphoid, achieving parallelism and congruity of the proximal scaphoid and scaphoid sulcus, closure of the scapholunate interval, and maintenance of carpal height.

**Scaphotrapeziotrapezoidal Fusion**

- Approach the STT joint region through a transverse incision centered over the STT joint or through the longitudinal approach described previously, with a distal extension. If there is any question about the integrity of the articular surfaces of the midcarpal or radiocarpal joints, conduct a preliminary arthroscopic evaluation.
- With dorsal exposure of the STT joint region, adequately decorticate the distal articular surface of the scaphoid and the proximal articular surfaces of the trapezium and trapezoid.
- Position the scaphoid, with radiographic confirmation, so that the radioscaphoid angle is 40° to 45° and the carpal height is restored. Stabilize the three bones in this position with multiple K-wires, Herbert screws or AO screws, or staples, and pack autogenous bone graft from the iliac crest or ipsilateral radial metaphysis into the decorticated region.
- If scaphocapitate fusion is preferred, expose the scaphocapitate interval through the dorsal longitudinal approach. Decorticate the radial articulating surface of the capitate and the ulnar articulating surface of the distal one-half of the scaphoid. Mobilize, reduce, and bone-graft, as with the STT arthrodesis. Some surgeons advocate carrying out a radial styloidectomy to prevent radioscaphoid impingement, but this may lead to further destabilization due to disruption of the radiocarpal ligaments. Great care must be taken in performing a radial styloidectomy to preserve the origins of the palmar radiocarpal ligaments.
- After an STT or scaphocapitate fusion, we recommend postoperative immobilization with a thumb spica short-arm cast followed by a supporting splint for 4–6 weeks. Use radiographic evaluation on a regular basis to estimate consolidation of the fusion mass. This evaluation may be enhanced with the use of trispiral tomography.

**Soft-tissue Repair and Augmentation** If there is a subacute or chronic scapholunate dissociation with an essentially fixed deformity, which is difficult to reduce and tends to recur, or if there are periscaphoid degenerative changes or other special situations such as coexisting Kienböck's disease, the arthrodesis techniques described previously, including STT and scaphocapitate limited fusions, are preferable. If the deformity is relatively easy to reduce and there are no obvious signs of periscaphoid degenerative changes, soft-tissue repair and augmentation may be preferred. The basic prerequisite for soft-tissue repair and augmentation is the ability to reduce and maintain all relationships of the carpus, particularly the abnormal ones at the radioscaphoid, radiolunate, scapholunocapitate, scapholunate, and STT joints. Restoration of these relationships is achieved if the scapholunate gap is reduced to 3 mm or less, the scapholunate angle is about 40°, and the capitolunate angle is less than +15°. The soft-tissue procedures center on repair of the remnant of the scapholunate ligament, as described in the section on acute scapholunate injury, supplemented by a capsular flap or a tendon graft flap. The augmentation can be carried out with several capsulodesis techniques or by passing an extrinsic tendon graft through the scaphoid and lunate to enhance stability. The capsulodesis described by Blatt (10) uses the dorsal radiocarpal joint capsule with a proximal base; the distal edge of the flap is tethered to the dorsal aspect of the distal scaphoid. The tissue used for this procedure is relatively isotropic, and the resistance to chronic linear shear in tension is suspect.

A technique developed by Dobyns and Linscheid employing a capsuloligamentous flap theoretically promises greater resistance to deforming forces. This flap is based distally over the STT region and incorporates essentially the proximal one-half of the dorsal intercarpal ligament (Fig. 41.14).

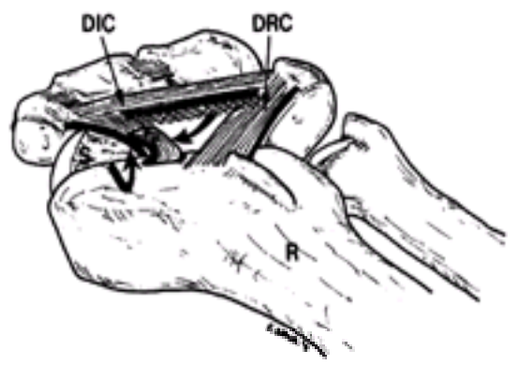

***Figure 41.14.*** Dobyns and Linscheid's capsulodesis for augmenting scapholunate ligament repair. The exposed carpal region is seen from a proximal, dorsal, and radial perspective, and the dorsal radiocarpal ligament (*DRC*) and dorsal intercarpal ligament (*DIC*) are outlined. After adequate exposure, detach the proximal half of the DIC from its insertion onto the dorsal aspect of the triquetrum. Very carefully, leaving the synovial lining of the joint capsule intact, elevate the DIC, leaving a distally based attachment onto the scaphoid, trapezium, and trapezoid. Rotate the free-flap proximally, passing over the scapholunate interosseous region, to which it may be sutured, and then through a small channel created in the dorsal lip of the distal radius, and suture it back onto itself. Provisional reduction of the scapholunate dissociation and primary repair of the scapholunate ligament, if possible, should be carried out before this maneuver (*R*, radius; *S*, scaphoid).

- Approach the carpus through the longitudinal incision described previously.
- Identify the insertion of the dorsal intercarpal ligament over the triquetrum and, with careful, sharp dissection, elevate the proximal one-half of the dorsal intercarpal ligament from the synovial lining of the joint capsule, beginning at the triquetrum and proceeding toward the STT region. Preserve the synovial lining of the joint capsule. The remaining dorsal intercarpal ligament spanning the distance between the triquetrum and the STT region should limit the risk of midcarpal destabilization.
- Reflect the distally based flap proximally over the proximal pole of the scaphoid and, if possible, over the scapholunate joint cleft dorsally. Then, attach it to the region of capsular attachment in the dorsal rim of the radius, or pull it through a channel drilled through the dorsal rim of the radius and suture it back onto itself.
- Adjust the tension to prevent the proximal pole of the scaphoid from translating dorsally. After this tension is set, pass several nonabsorbable sutures through the flap into the substance of the dorsal aspect of the scapholunate ligament.

If the remnant of the scapholunate ligament is inadequate for repair, particularly dorsally, a third capsulodesis technique may be considered. This technique uses the distal one-half of the dorsoradial carpal ligament in a fashion similar to that described previously employing the dorsal intercarpal ligament (Fig. 41.15).

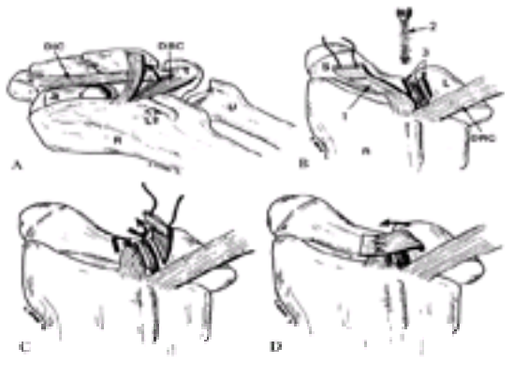

***Figure 41.15.*** Dorsal scapholunate ligament reconstruction and capsulodesis technique. **A:** The exposed carpus is seen from a proximal, dorsal, and radial perspective, with the dorsal radiocarpal (*DRC*) and dorsal intercarpal (*DIC*) ligaments also exposed (*S*, scaphoid; *R*, radius; *U*, ulna; *T*, triquetrum; *LT*, Lister's tubercle). In the same fashion by which the DIC flap was elevated in Dobyns and Linscheid's technique (Fig. 41.14), the radial half of the DRC is elevated by detaching its insertion onto the dorsal triquetrum, with the proximal flap left attached to the dorsal rim of the radius. **B:** Using a high-speed drill or burr, make channels in the dorsal cortices of the scaphoid and lunate adjacent to the scapholunate articulation. These vertical channels are connected to horizontal channels passing just on the dorsal margin of the mutual articular surfaces of the scaphoid and lunate within the joint cleft. **C:** Pass the proximally based DRC flap into the dorsal opening of the scaphoid channel and across the scapholunate articulation through the mutual articular channels to exit through the dorsal channel of the lunate. **D:** Draw the DRC flap over the dorsal aspect of the scapholunate ligament and suture it onto itself, after adjusting the tension. Before final suturing, provisionally reduce the scapholunate dissociation and repair the scapholunate ligament, if possible.

- Through a longitudinal approach, identify the triquetral insertion of the dorsal radiocarpal ligament. Elevate the distal and radial half of the dorsal radiocarpal ligament subperiosteally from the triquetrum, and separate it from the synovial lining of the radiocarpal joint capsule proximally to its attachment through the dorsal rim of the radius just distal to Lister's tubercle (Fig. 41.15*A*). Careful dissection allows elevation of this ligament without disruption of the synovial lining of the dorsal radiocarpal joint capsule.
- Using a small, high-speed burr, establish channels in the dorsal cortex of the scaphoid and lunate 2 mm away from the joint surface (Fig. 41.15*B*). Through the dorsal aspect of the mutual articulating surfaces within the joint cleft, create communicating channels perpendicular to these dorsal channels.
- Pass the free end of the ligament flap through the scaphoid channel, beginning dorsally and then out into the scapholunate joint cleft. Then, pass the ligament into the lunate channel in the joint cleft to exit through the dorsal channel of the lunate (Fig. 41.15*C*). Several options are now available, including suturing the flap back onto itself to enhance stability of the dorsal aspect of the scapholunate interosseous ligament, or passing it distally and suturing it into the capsule over the dorsal aspect of the capitate or base of the third metacarpal, if length permits (Fig. 41.15*D*). This provides a dorsal tether between the lunate and capitate to resist the tendency for a DISI deformity.

Using extrinsic wrist extensor or flexor tendons to augment intrinsic repair is technically demanding. This procedure requires a dorsal and palmar approach and uses a split, distally based strip of extensor carpi radialis longus or flexor carpi radialis, which is passed through drill holes in the scaphoid and lunate in a closed-loop fashion. The blood supply to the proximal pole of the scaphoid and lunate is fragile, and the drill holes do place these bones at risk for avascular necrosis; however, proponents of this technique think that it provides strong static control of the scaphoid.

A modification of this technique proposed by Brunelli and Brunelli (11) is a “tenodesis” procedure utilizing a distally based strip of flexor carpi radialis. A drill hole is created in a dorsopalmar orientation through the distal pole of the scaphoid, through which the tendon strip is passed. It is then passed proximally and secured to the dorsal rim of the radius. The rationale behind this procedure is the author's theory that advanced rotational subluxation of the scaphoid requires not only compromise of the scapholunate ligament but also instability at the STT joint. The tendon strip of the flexor carpi radialis stabilizes the STT joint and prevents excessive palmar flexion of the scaphoid.

Recently, interest has developed in substituting bone–ligament–bone autografts for the scapholunate ligament in patients with prearthritic scapholunate dissociation in whom inadequate ligament is present for direct repair. A recent laboratory study evaluating the strength and constraint properties of the subregions of the scapholunate ligament identified the dorsal region of the ligament as the strongest and the major constraint to translation and distraction (7). Proposed substitutes have included bone–ligament–bone complexes based on extensor retinaculum, intertarsal ligaments, and carpometacarpal ligaments. These carry significant promise, but clinical experience is very preliminary at this point. One should be cautioned that the strength of the transplanted tissue should approach that of the native scapholunate ligament and that care should be taken to avoid iatrogenic instability at the donor site (20,21,41).

**Postoperative Care and Rehabilitation** Postoperative care and rehabilitation are similar for both bony and soft-tissue repair techniques. Support the wrist in the neutral position for 8 weeks or more, removing K-wires between 8 and 12 weeks (sooner if required). Immediately initiate shoulder, elbow, and digit range-of-motion exercises; introduce forearm motion gradually if there is no associated ulnocarpal or forearm problem. Begin wrist motion between 8 and 12 weeks. Keep the exercise limited, light, and isokinetic until 20 weeks. Begin grip strengthening at 6 months. Wrist stress loading may begin at 1 year, contingent on comfort and a benign examination. Earlier rehabilitation may succeed, but the risk of overstressing the wrist is great and it pays to be cautious.

## PITFALLS AND COMPLICATIONS

The virtue of the limited fusion techniques is their relative simplicity. It is important to know that the radioscaphoid joint, which takes most of the loading for the carpus, is in good condition; it is vital that this joint be reduced and maintained at its most congruent fit. If these two conditions are not met, rapid radioscaphoid joint deterioration may occur. After STT fusions, impingement between the distal scaphoid and the radial styloid may occur, and it has been suggested that a small styloidectomy of the radius be performed at the time of the fusion. The long-term concern with radial column fusions is the effect of increased loading on one joint system over a prolonged period. There is not sufficient experience with these methods to respond to this concern. The virtue of the soft-tissue techniques is that, at their best, they restore a more normal distribution of stress across the carpal joints. The problems are the relative complexity of the repair techniques and the large forces that must be resisted by damaged and other questionable tissues. Because of these problems, partial or complete recurrence of deformity was common in the

early days of soft-tissue repair and reconstruction. The current techniques appear to be giving improved short-term results, but they must pass the test of time (24).

The problems described are the major pitfalls of these techniques, but as in all musculoskeletal procedures, other complications are seen, including pain dysfunction syndromes, neurovascular and compartment compromise, and infection. The last two are infrequent but serious and must be identified early and treated vigorously. Pain is so common that it should be assumed to be a likely occurrence. Plan on good pain control with particular attention to the control of swelling, autonomic dysfunction, and an early start of rehabilitation. Support with transcutaneous nerve stimulants, nerve blocks, and other measures.

## OTHER CARPAL INSTABILITIES

Space does not permit a full discussion of the less common types of carpal instability listed in “Terminology and Classification” above and in Table 41.1 and Table 41.2. See the references listed for triquetrolunate dissociation, CIND of the midcarpal and radiocarpal joints, combined types, and axial instabilities (17,25,30,37,42). The most salient features of each of these are discussed in the following sections.

### *Lunotriquetral Dissociation*

Triquetrolunate dissociation (i.e., lunotriquetral dissociation) may occur as an isolated injury, but it more commonly occurs as part of the spectrum of perilunate dislocations. Due to the extensive ligamentous insertion into the triquetrum on the dorsal, ulnar, and palmar surfaces, this injury is generally more stable than its counterpart in the scapholunate joint. Lunotriquetral dissociation is often associated with other ulnar wrist problems, including ulnocarpal impingement, TFC-complex tears, and distal radioulnar joint instabilities. Patients complain of pain localized to the ulnar half of the wrist that is often accompanied by a sensation of weakness. Examination reveals tenderness specific to the lunotriquetral articulation and exacerbation of discomfort with ballottement of the unstable triquetrum. Unless there is a significant static deformity resulting in a VISI pattern on lateral radiographs of the wrist, radiographic documentation of lunotriquetral dissociation may be difficult. Arthrography and MRI can demonstrate a defect in the lunotriquetral membrane suggesting triquetrolunate dissociation.

Treatment of triquetrolunate dissociation may not be necessary if symptoms are relieved after correction of the associated conditions. If an acute triquetrolunate dissociation with minimal deformity is discovered, external support with a cast or splint may be all that is necessary. Percutaneous K-wire fixation may be useful, particularly when the arthroscopic grading noted in Table 41.3 is followed.

In the more advanced or chronic stages, in which there is angular deformity, open surgical intervention may be indicated. Several options are available. Direct repair of the interosseous ligament in a fashion similar to that described for the scapholunate ligament may be carried out and augmented with capsular flaps similar to those described for scapholunate dissociation. If the direct repair cannot satisfactorily correct the deformity, two other options are available: augmentation of the ligament repair with a strip of distally based flexor carpi ulnaris passed through drill holes in the triquetrum and lunate, or a lunotriquetral arthrodesis, which is more successful in achieving union than scapholunate arthrodesis. Complications of lunotriquetral arthrodesis, including nonunion, persistent VISI deformity, and persistent subjective complaints, occur in 33% of patients undergoing this procedure. In patients with a fixed VISI deformity, a radiolunate arthrodesis may be necessary to counter the tendency for a VISI deformity to recur after appropriate treatment of lunotriquetral dissociation.

### *Direct Repair of the Lunotriquetral Ligament*

The technique of direct repair of the ligament is similar in sequence to that for the scapholunate ligament direct repair (Fig. 41.16).

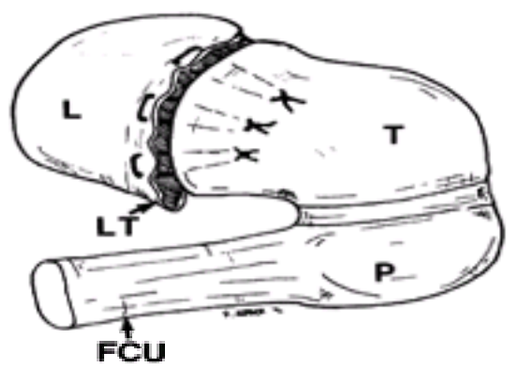


***Figure 41.16.*** Direct repair of the lunotriquetral ligament. The lunotriquetral complex is shown in an isolated fashion from a proximal and ulnar perspective. The lunotriquetral interosseous ligament (*LT*) has been traumatically disrupted, and strong suture (2-0 or 3-0 Mersilene) has been passed through the remnant of the ligament and into channels drilled through the substance of the triquetrum to exit ulnarly. After provisional reduction is achieved, these sutures are drawn tight and tied (*L*, lunate; *T*, triquetrum; *P*, pisiform; *FCU*, flexor carpi ulnaris tendon).

- After exposing the lunotriquetral joint dorsally by entering the radiocarpal joint through the interval between the fourth and fifth extensor compartments, freshen the triquetral insertion of the lunotriquetral ligament with a burr, and drill paired holes distally and ulnarly. It may be necessary to subperiosteally elevate the triquetral insertion of the TFC complex ulnarly to visualize the exit point of the drill holes. Do not perform this procedure without direct visualization because the extracapsular sutures may accidentally incorporate isolated cutaneous branches of the ulnar nerve.
- Pass the sutures through the remnant of the lunotriquetral ligament, which is usually attached to the lunate, and then through the drill holes, and tie them. Transarticular K-wire fixation is recommended. Postoperative care is similar to that outlined for reconstructions of the scapholunate ligament.

### *Palmar and Dorsal Exposures*

Palmar and dorsal exposures are required for augmentation of the lunotriquetral joint with a distally based slip of flexor carpi ulnaris. Refer patients requiring this procedure to surgeons who are experienced in this technique (Fig. 41.17). Through these incisions, test the supporting extrinsic ligaments (i.e., lunotriquetral portion of the dorsal radiolunotriquetral ligament and the overlapping portions of the palmar ulnolunate and ulnotriquetral ligaments), and tighten them, if needed. Lunotriquetral arthrodesis, carried out through a dorsal incision, consists of exposure of subchondral bone on both sides of the lunotriquetral articulation, insertion of a corticocancellous wedge of distal radius or iliac crest bone graft across the lunotriquetral joint, and fixation with K-wires or a transarticular compression screw (Fig. 41.18).

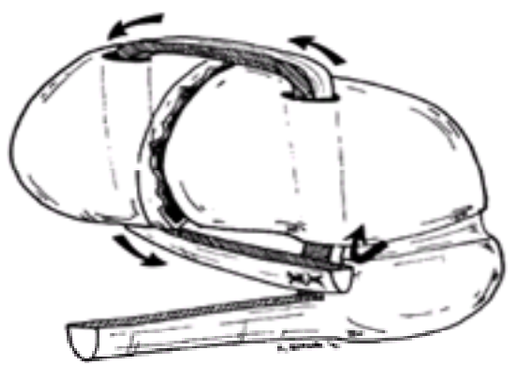

***Figure 41.17.*** Reconstruction of the lunotriquetral ligament using the flexor carpi ulnaris tendon (FCU). At least 6–8 mm of the dorsal half of the FCU tendon is elevated from a hemitranssection proximally and delivered distally, with maintenance of its attachment onto the pisiform. Preserve the ulnar artery and ulnar nerve, just lateral to this tendon. Vertically oriented drill holes, just larger than the diameter of the free tendon slip, are made through the triquetrum, exiting palmarly just proximal to the pisotriquetral articulation, and through the lunate. The distally based free slip of FCU is delivered dorsally through the triquetrum and across the lunotriquetral articulation. After provisional reduction is achieved, tension is adjusted in the slip, and it is sutured to itself near its attachment to the pisiform.

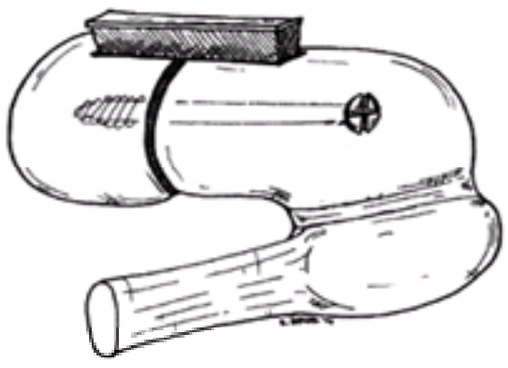

***Figure 41.18.*** Arthrodesis of the lunotriquetral articulation. After complete removal of articular cartilage from the mutual articulating surfaces of the lunate and triquetrum and after removal of subchondral bone until bleeding bone is apparent, the lunate and triquetrum are mutually aligned, with care taken to preserve the normal intercarpal space. A corticocancellous iliac crest bone graft is harvested. Some is fashioned to fit in a slot that is created on the dorsal surfaces of the lunate and triquetrum, spanning the lunotriquetral joint; the remainder of the graft is morcelized and packed into the lunotriquetral interval. Supplemental fixation may be achieved with a transosseous screw.

## CARPAL INSTABILITY NONDISSOCIATIVE (CIND)

CIND conditions are manifested by the same intercalated instability patterns (i.e., DISI and VISI) that indicate scapholunate dissociation and triquetrolunate dissociation, but no clear disruption of the connections between the bones of the proximal row and between the bones of the distal row is evident. In this condition, the instability is generated through an alteration in the restraints of the radiocarpal joint, the midcarpal joint, or both, although this condition is most often referred to as midcarpal instability in the literature. Common clinical presentations include a “loose jointed” individual, presentation with a snap or a clunk, a normal arthrogram, and an abnormal motion pattern of the entire proximal row on cineradiography or videotaped fluoroscopy. Radiocarpal and midcarpal arthroscopy can help determine the cause of the problem.

No universal procedure is available for the treatment of CIND because there are many causes. Treatment is directed at the abnormalities that are thought to generate the instability. Often, palmar and dorsal approaches are necessary if capsular repairs are anticipated. Each of the techniques described previously for the nondissociative type of carpal instabilities, including direct capsular repair of the space of Poirier, limited intercarpal fusions (e.g., STT, scaphocapitate, and other midcarpal arthrodeses and capsulodesis procedures to control proximal carpal row instability), and proximal row carpectomy are all viable options. In some circumstances, radiocarpal arthrodesis may provide a reasonable option. Clinical experience with this problem is limited. It is recommended that treatment be done by a surgeon who has accumulated experience with this condition.

In addition to the soft-tissue causes of CIND, there are also extraarticular abnormalities that generate similar conditions termed *carpal instability adaptive*. For example, a malunion of a distal radial fracture, with resultant dorsal angulation of the distal articular surface, can initiate a zigzag type of collapse that can simulate a DISI deformity. In this situation, treatment involves corrective osteotomy of the radius with an opening wedge osteotomy employing bone graft and plate fixation (see Chapter 44). Although not strictly a CIND, malunion of the scaphoid may also result in a DISI deformity. In this situation, operative treatment is an opening wedge osteotomy of the scaphoid with bone grafting and K-wire or screw fixation across the fracture site.

## AXIAL INSTABILITIES

Axial instabilities are disruptions in a columnar or longitudinal direction of the carpus, generally resulting from high-energy impact of the hand (17). They are often accompanied by tearing or avulsion of the individual components of the transverse carpal ligament system, frequently with separation of the metacarpal bases. A history of a high-energy impact with the involved hand raises suspicion of this injury. A high index of suspicion is required to diagnose this condition. Standard radiographs generally enable the diagnosis to be made, but because of the superimposition of the carpal bones, particularly on the lateral view, the findings may be subtle. If there are questions about the possibility of this injury and the standard radiographs do not resolve them, take stress radiographs or perform tomography, CT, or MRI. Coexisting soft-tissue injuries, such as stretching or tearing of contiguous vessels, nerves, or musculotendinous structures, often present a greater problem than the skeletal injury itself.

Direct initial treatment at preservation of the neurovascular and musculotendinous integrity of the affected extremity. Simple reduction of the dislocation may restore blood flow or nerve supply. Look for and decompress a compartment syndrome if it occurs. Repair of injured neurovascular and other soft tissues is often needed. Traction is often helpful in obtaining reduction, and the reduction can be maintained by K-wires and lag screws, as indicated. As a rule, transcarpal or transmetacarpal K-wire fixation is indicated to prevent redisplacement. Postoperatively, initiate early motion of the hand to prevent extrinsic tendon adhesions. The reduction must be stable enough to endure early motion.

## CHAPTER REFERENCES

Each reference is categorized according to the following scheme: *, classic article; #, review article; !, basic research article; and +, clinical results/outcome study.


# 1. Berger RA. Arthroscopic Anatomy of the Wrist and Distal Radioulnar Joint. *Hand Clinics* 1999;15:393.

! 2. Berger RA. The Gross and Histologic Anatomy of the Scapholunate Interosseous Ligament. *J Hand Surg [Am]* 1996;21:170.

+ 3. Berger RA, Bishop AT. A Fiber-splitting Capsulotomy Technique for Dorsal Exposure of the Wrist. *Tech Hand Upper Extremity Surg* 1997;1:2.

! 4. Berger RA, Blair WF. The Radioscapholunate Ligament: A Gross and Histologic Description. *Anat Rec* 1984;210:393.

+ 5. Berger RA, Crowninshield RD, Flatt AE. The Three-dimensional Rotational Behavior of the Carpal Bones. *Clin Orthop* 1982;167:303.

# 6. Berger RA, Dobyns JH. Physical Examination and Provocative Maneuvers of the Wrist. In: Gilula LA, Yin Y, eds. *Imaging of the Wrist and Hand.* Philadelphia: WB Saunders, 1996:23.

! 7. Berger RA, Imeada T, Berglund L, An KN. Constraint and Material Properties of the Subregions of the Scapholunate Interosseous Ligament. *J Hand Surg [Am]* 1999;24:953.

! 8. Berger RA, Kauer JMG, Landsmeer JMF. The Radioscapholunate Ligament: A Gross Anatomic and Histologic Study of Fetal and Adult Human Wrist Joints. *J Hand Surg [Am]* 1991;16:350.

! 9. Berger RA, Landsmeer JMF. The Palmar Radiocarpal Ligaments: A Study of Adult and Fetal Human Wrist Joints. *J Hand Surg [Am]* 1990;15:847.

+ 10. Blatt G. Capsulodesis in Reconstructive Hand Surgery: Dorsal Capsulodesis for the Unstable Scaphoid and Volar Capsulodesis following Excision of the Distal Ulna. *Hand Clin* 1987;3:81.

+ 11. Brunelli GA, Brunelli GR. Une Nouvelle Intervention pour la Dissociation Scapho-lunaire. Proposition d'Une Nouvelle Technique Chirurgicale pour l'Instabilite Carpienne avec Dissociation Scapho-lunaire. *Ann Chir Main Memb Super* 1995;14:207.

* 12. Bryce TH. On Certain Points in the Anatomy and Mechanism of the Wrist Joint Reviewed in Light of a Series of Roentgen Ray Photographs of the Living Hand. *J Anat Physiol* 1896;31:59.

+ 13. Conyers DJ. Scapholunate Interosseous Reconstruction and Imbrication of Palmar Ligaments. *J Hand Surg [Am]* 1990;15:690.

# 14. Cooney WP, Linscheid RL, Dobyns JH. Fractures and Dislocations of the Wrist. In Rockwood CA, and Green DP eds. *Fractures,* 3rd ed. Philadelphia: JB Lippincott Co, 1990:411.

! 15. deLange A, Kauer JMG, Huiskes R. Kinematic Behavior of the Human Wrist Joint: A Roentgen-Stereophotogrammatic Analysis. *J Orthop Res* 1985;3:56.

# 16. Garcia-Elias M, Berger RA, Horii E, et al. Position Statement: Definition of Carpal Instability. *J Hand Surg [Am]* 1999;24:866.

+ 17. Garcia-Elias M, Dobyns JH, Cooney WP, Linscheid RL. Traumatic Axial Dislocations of the Carpus. *J Hand Surg [Am]* 1989;14:446.

+ 18. Geissler WB, Freeland AE. Arthroscopically Assisted Reduction of Intraarticular Distal Radius Fractures. *Clin Orthop* 1996;327:125.

+ 19. Gilula LA, Destoutet JM, Weeks PM, et al. Roentgenographic Diagnosis of the Painful Wrist. *Clin Orthop* 1984;187:52.

! 20. Harvey EJ, Hanel D, Knight JB, Tencer AF. Autograft Replacements for the Scapholunate Ligament: A Biomechanical Comparison of Hand-based Autografts. *J Hand Surg [Am]* 1999;24:963.

+ 21. Hofstede DJ, Ritt MJPF, Bos KE. Tarsal Autografts for Reconstruction of the Scapholunate Interosseous Ligament: A Biomechanical Study. *J Hand Surg [Am]* 1999;24:968.

+ 22. Johnson RP. The Acutely Injured Wrist and Its Residuals. *Clin Orthop* 1980;149:33.

+ 23. Kauer JMG. The Interdependence of Carpal Articular Chains. *Acta Anat Scand* 1974;88:481.

+ 24. Lavernia CJ, Taleisnik J, Cohen M. Treatment of Subacute and Chronic Scapholunate Dissociation by Ligament Repair and Capsulodesis. Presented at the 45th Annual Meeting of the American Society for Surgery of the Hand, Toronto, Canada, September 24–27, 1990.

+ 25. Lichtman DM, Schneider JR, Swafford AR, Mack GR. Ulnar Midcarpal Instability: Clinical and Laboratory Analysis. *J Hand Surg [Am]* 1981;6:515.

# 26. Linscheid RL, Dobyns JH. Physical Examination of the Wrist. In: Post M, ed. *Physical Examination of the Musculo-Skeletal System.* Chicago: Year Book Medical Publishers, 1987:80.

* 27. Linscheid RL, Dobyns JH, Beabout JW, Bryan RS. Traumatic Instability of the Wrist: Diagnosis, Classification and Pathomechanics. *J Bone Joint Surg Am* 1972;54:1612.

+ 28. Mayfield JK, Johnson RP, Kilcoyne RK. Carpal Dislocations: Pathomechanics and Progressive Perilunar Instability. *J Hand Surg [Am]* 1980;5:226.

+ 29. Rayhack JM, Linscheid RL, Dobyns JH, Smith JH. Post-Traumatic Ulnar Translation of the Carpus. *J Hand Surg [Am]* 1987;12:180.

+ 30. Reagan DS, Linscheid RL, Dobyns JH. Lunotriquetral Sprains. *J Hand Surg [Am]* 1984;9:502.

! 31. Ritt MJ, Berger RA, Kauer JMG. The Gross and Histologic Anatomy of the Ligaments of the Capitohamate Joint. *J Hand Surg [Am]* 1996;21:1022.

! 32. Ritt MJ, Bishop AT, Berger RA, et al. Lunotriquetral Ligament Properties: A Comparison of Three Anatomic Subregions. *J Hand Surg [Am]* 1998;23:425.

! 33. Ruby LK, Cooney WP 3d, An KN, et al. Relative Motion of Selected Carpal Bones: A Kinematic Analysis of the Normal Wrist. *J Hand Surg [Am]* 1988;13:1.

# 34. Sennwald G. *The Wrist: An Anatomical and Pathophysiological Approach to Diagnosis and Treatment.* New York: Springer-Verlag, 1987.

+ 35. Taleisnik J. The Ligaments of the Wrist. *J Hand Surg [Am]* 1976;1:110.

# 36. Taleisnik J. *The Wrist.* New York: Churchill Livingstone, 1985.

+ 37. Taleisnik J, Watson HK. Midcarpal Instability Caused by Malunited Fractures of the Distal Radius. *J Hand Surg [Am]* 1984;9:350.

# 38. Watson HK, Ashmead D 4th, Makhlouf MV. Examination of the Scaphoid. *J Hand Surg [Am]* 1988:13;657

# 39. Watson HK, Black DM. Instabilities of the Wrist. *Hand Clin* 1987;3:103.

+ 40. Watson HK, Ryu J, Akelman E. Limited Triscaphoid Intercarpal Arthrodesis for Rotary Subluxation of the Scaphoid. *J Bone Joint Surg Am* 1986;68-:345.

+ 41. Weiss A. Scapholunate Ligament Reconstruction Using a Bone-Retinaculum-Bone Autograft. *J Hand Surg [Am]* 1998;23:205.

+ 42. Wright TW, Dobyns JH, Linscheid RL. Carpal Instability Non-dissociative. Presented at the 45th Annual Meeting of the American Society for Surgery of the Hand, Toronto, Canada, September 24–27, 1990.

! 43. Youm Y, McMurtry RT, Flatt A E, Gillespie TG. Kinematics of the Wrist. I. An Experimental Study of Radial-Ulnar Deviation and Flexion-Extension. *J Bone Joint Surg Am* 1978;60:423.

# CHAPTER 42

# FRACTURES OF THE CARPAL BONES

*Martin A. Posner*

**M. A. Posner:** Department of Orthopaedic Surgery, New York University School of Medicine, Hospital for Joint Diseases; Lenox Hill Hospital, New York, New York 10128.

Anatomy and Kinematics
Diagnostic Workup
Scaphoid
Acute Fractures
Chronic Fractures
Nonunions
Malunions
Idiopathic Avascular Necrosis
Fractures in Children
Triquetrum
Trapezium
Capitate
Inlay Bone Graft—Operative Technique
Lunate
Acute Fractures
Kienböck's Disease
Author's Perspective
Hamate
Fractures of the Body
Fractures of the Hook (Hamulus)
Pisiform
Trapezoid
Chapter References

Fractures of the carpal bones comprise a significant percentage of traumatic injuries to the upper extremity. Frequently, they are initially dismissed as being trivial, and medical attention is delayed. Their seriousness is often not recognized until months or even years later, when secondary arthritic changes appear. The diagnosis and treatment of carpal fractures require an understanding of the anatomy and mechanics of one of the most complex joints in the body.

## ANATOMY AND KINEMATICS

Our knowledge of the wrist dates back to the middle of the 16th century, when Versalius identified and numbered the carpal bones (29). For the next several centuries, the precise shape and articulation of each bone was known in detail, but little attention was paid to its ligaments and even less to its movements. Sir Charles Bell's description of the wrist in his classic treatise, *The Hand: Its Mechanism and Vital Endowments as Evincing Design*, published in 1813, was simply: “In the human hand, bones of the wrist are eight in number, and they are so closely connected that they form a sort of ball which moves on the end of the radius” (Fig. 42.1). It was not until the discovery of x-rays in 1895 that the study of wrist mechanics began. The following year, Bryce observed that the physiologic axis of the wrist was not fixed but shifted as the joint moved from flexion to extension (4). These studies were later enlarged by other investigators, who recognized the complex and synchronous movements of the carpal bones, movements that impart to the wrist both fluidity of motion and strength (60,61).

***Figure 42.1.*** Bones of the hand and wrist, from a 19th-century anatomy book by Charles Bell (7). The carpal bones at that time were referred to by numbers.

In 1919, Navarro introduced the concept of the vertical or columnar carpus (3). He described a *central column* for flexion and extension comprising the lunate, capitate, and hamate; and two side columns, a *medial column* and a *lateral column*. The medial column was for rotation and included the triquetrum and pisiform, and the lateral column was for mobility and included the scaphoid, trapezium, and trapezoid. In 1943, Gilford described wrist mechanics differently (37). He likened the wrist to a triple-link system with the radius, lunate, and capitate as the central link. The mechanical advantage of the system is that its two main joints, the radiolunate and lunate–capitate, move only half the excursion of the entire joint. The disadvantage of the system is instability of the central, intercalated mobile segment (i.e., lunate), which is dependent on its anatomic configurations and ligament attachments for stability. More than 50 years after Navarro published his initial account, Taleisnik modified his concept of the columnar carpus by including the entire distal carpal row with the lunate in the central column (92). Taleisnik also limited the medial (rotational) and lateral (mobile) columns to one bone each, the triquetrum and scaphoid respectively. In both the columnar and triple-link concepts of wrist mechanics, the scaphoid is the key bone for carpal stability. Although the scaphoid is anatomically located within the proximal carpal row, it functionally bridges both carpal rows.

## DIAGNOSTIC WORKUP

The evaluation of any carpal injury requires a careful physical examination, including the neurovascular status of the hand. Determining precise areas of tenderness aids in localizing the site of injury. Conventional radiographs are always necessary, and generally four views are obtained: posteroanterior (PA), anteroposterior (AP), lateral, and oblique (Fig. 42.2). The PA view in ulnar deviation visualizes the scaphoid, whereas the AP view (palm up or supinated view), usually taken with the fingers clenched and wrist ulnarly deviated, is useful for visualizing rotatory subluxation of the scaphoid. The lateral radiograph should be a true lateral view with the wrist in neutral position in order to evaluate carpal bone alignment (Fig. 42.3). Oblique views can be taken with the hand slightly pronated (posterior oblique) or slightly supinated (anterior oblique). The posterior-oblique view visualizes the carpal bones on the radial side of the wrist, particularly the scaphoid, and the anterior-oblique view visualizes the pisiform and, to a lesser extent, the hamate. Additional imaging techniques are sometimes required, including: carpal tunnel views; tomography, either computer assisted (CT) or polyaxial; arthrography; and magnetic resonance imaging (MRI). The CT is the most frequently used special imaging study for detecting carpal fractures and is obtained in at least two planes, using 2-mm slices. It has generally replaced polyaxial tomography (i.e., trispiral tomography) because of its wider availability and superior images. In addition to detecting occult fractures, CT is useful for assessing fracture healing and healing of bone grafts used for the treatment of nonunions. It also permits visualization of precise bony detail that aids in the evaluation of other conditions such as intraosseous tumors or cysts.

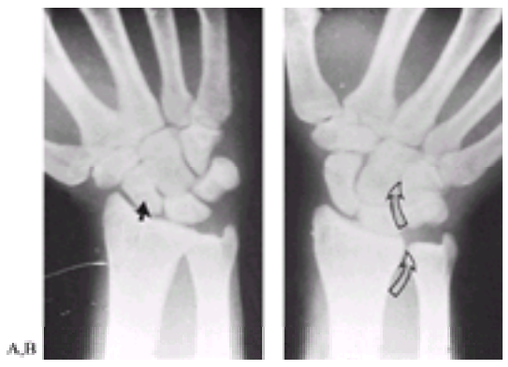

***Figure 42.2.*** Posteroanterior views of a normal wrist in radial and ulnar deviation. **A:** In radial deviation, the scaphoid is palmar flexed, and its shortened appearance is sometimes misinterpreted as a fracture (*closed arrow*). **B:** The outline of the scaphoid is best visualized with the wrist in ulnar deviation. This wrist position also demonstrates the relationships between the forearm and carpal bones. In ulnar deviation, the radioulnar, lunate-triquetral, and capitate-hamate joints (*open arrows*) line up to form a sinusoidal curve.

***Figure 42.3.*** **A,B:** Lateral radiographs of a normal wrist show the alignment of the radius, lunate, capitate, and metacarpals in neutral position and the movements of the radiocarpal and midcarpal joints with the wrist in slight and complete palmar flexion and dorsiflexion. Cineradiographic studies have shown that during the initial 30° of palmar flexion or dorsiflexion, motions at both radiocarpal and midcarpal joints are approximately equal. Further movements in either direction occur primarily at the midcarpal joint. The longitudinal axis of the scaphoid is at an angle of 45° to 60° to the longitudinal axis of the lunate with the wrist in neutral position.

## SCAPHOID

### ACUTE FRACTURES

Fractures of the scaphoid are the most common of carpal fractures. They usually occur in young adult men following falls on their outstretched palms. Experimental studies have shown that the force must be applied to the radial side of the palm, with the wrist extended a minimum of 95° (102). In that position, the scaphoid is the only carpal bone in contact with the radius. The proximal part of the scaphoid assumes a wedge-shaped configuration between the radius and capitate, where it is supported by the radial collateral and radiocapitate ligaments. The distal pole of the scaphoid, however, is unsupported and capsular structures in the area are lax. It is the distal pole that receives most of the applied force and the bone fractures at its most vulnerable area, its waist.

Suspect a scaphoid fracture when there is tenderness over the dorsal surface of the bone in the anatomic snuff box or over its tubercle on the palmar surface. Confirm the diagnosis with radiographs. The profile of the bone is best seen on PA and posterior-oblique views with the wrist in ulnar deviation (Fig. 42.4). Although radiographs taken immediately after the injury may be negative, the scaphoid should still be considered fractured until proven otherwise. Immobilize the wrist in a thumb spica splint or cast and repeat radiographs in 1 to 2 weeks. If there is a fracture, it should then be evident by the appearance of bone resorption at the fracture site. Occasionally, bone resorption does not appear until 3 weeks after the fracture, and even then radiographs may remain inconclusive. In these cases, radionuclide imaging with technetium-99m ($^{99m}$Tc) can be helpful (32). Although bone scans are highly sensitive and are generally positive within 24 h of a fracture, they are nonspecific. Therefore, although a fracture can be ruled out with a negative scan, a positive scan requires more specific imaging studies. Vibratory testing, using audible “intrasound” frequencies between 20 and 20,000 Hz (infrasound less than 20 Hz and ultrasound greater than 20,000 Hz are inaudible), has been shown to be effective in diagnosing occult scaphoid fractures (8). The test is considered positive when pain is sufficient to cause an immediate “positive retraction response.” The definitive test is a CT scan.

***Figure 42.4.*** Posterior oblique radiographs of a normal wrist in radial (**A**) and ulnar (**B**) deviation. The scaphoid (*shaded*) is best visualized with the wrist in ulnar deviation.

Fractures of the scaphoid have been classified using a variety of methods. The two most common are the relationship of the fracture to the longitudinal axis of the scaphoid (Russe's classification) and the site of fracture. Russe's classification comprises three types of fractures (Fig. 42.5) (80). Type I is a *transverse-oblique* fracture that is horizontal to the wrist joint and oblique to the longitudinal axis of the scaphoid. These fractures comprise approximately 35% of scaphoid fractures (90). Type II is a *transverse* fracture at right angles to the longitudinal axis of the scaphoid. It is the most common type of scaphoid fracture (60%). Type III is a *vertical-oblique* fracture that is vertical to the wrist joint and oblique to the scaphoid. Although vertical-oblique fractures are the rarest and occur in only 5% of scaphoid fractures, they are the most problematic with respect to healing because they are subject to high shear forces and tend to be unstable.

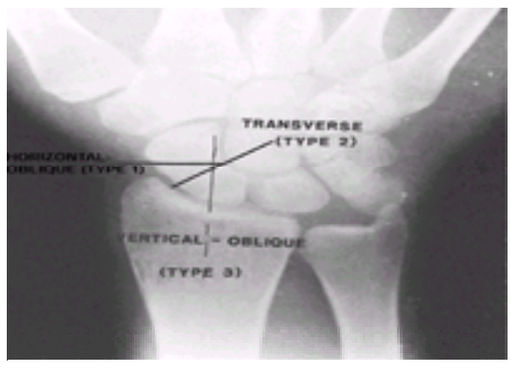


***Figure 42.5.*** Classification of scaphoid fractures according to Russe.

The second method of classification is based on the site of the fracture within the scaphoid, which is separated into *proximal, middle,* and *distal* thirds. Most fractures involve the middle third of the bone. They usually heal if they are not displaced, and there is no intercarpal instability. Fractures in the proximal third, sometimes referred to as the proximal pole of the scaphoid, have the highest incidence of nonunion and avascular necrosis because of the pattern of intraosseous circulation. The blood supply to the scaphoid enters dorsally and distally and traverses the bone in a proximal direction (36). Fractures in the distal third of the scaphoid are the rarest and tend to heal promptly because of the excellent blood supply in the area. Distal-third fractures include intraarticular fractures and fractures of the tubercle. Intraarticular fractures can cause articular incongruity when they are vertically oriented. They require operative reduction and internal fixation to avoid later arthritis at the scaphotrapezial joint. Fractures of the scaphoid tubercle usually result from direct trauma (Fig. 42.6). Treatment is directed primarily at relieving pain; this can be achieved by wearing a wrist splint for several weeks. There are few consequences of a tubercle fracture failing to heal because the bony prominence is extraarticular. Persistent pain is uncommon, but if it does occur the tubercle can be excised without compromising wrist function.

***Figure 42.6.*** **A:** Fracture of a scaphoid tubercle (*arrowhead*). **B:** The fracture healed after 6 weeks of immobilization.

Scaphoid fractures are also classified according to the time interval between injury and diagnosis. A scaphoid fracture is *acute* when diagnosed within 3 to 4 weeks of the injury. Healing can be expected in more than 95% of cases with thumb spica cast immobilization, provided the fracture is nondisplaced. When diagnosis is delayed more than 4 weeks, the prognosis is much worse, and failure to heal ranges from 40% to as high as 88% (49). The time period for what constitutes *delayed union* or *nonunion* is controversial because both terms have been applied to scaphoid fractures that have not healed after 4 to 6 months of immobilization (79,91). This is an arbitrary time period because it is impossible to state with certainty when delayed union begins. Although it is not unreasonable to label a scaphoid fracture that has not united in 4 to 6 months a “delayed union,” it is often premature to refer to a similar problem within that same time period as a “nonunion.” Unlike nonunions, delayed unions still have the capacity to heal with continued immobilization, which can sometimes take longer than 6 months. A nonunion is essentially a radiographic diagnosis that comprises specific criteria that are usually more obvious when the nonunion is hypertrophic rather than atrophic. Hypertrophic nonunions are characterized by sclerosis at the fracture site, which gives the appearance of a pseudarthrosis. Changes in atrophic nonunions tend to be less obvious; the fragments are osteoporotic, and the fracture margins irregular and cystic. The radiographic changes in both types of nonunions are most clearly seen with CT imaging.

The importance of fracture alignment was first recognized in 1943 by Gilford (37), who observed that when a scaphoid fracture is displaced, the proximal fragment flexes together with the adjacent lunate. This pattern results in a zig-zag deformity at the midcarpal joint, which has been likened to the bellows of a concertina and referred to as a “concertina collapse deformity” (9). Reducing the proximal fracture fragment restores normal tension to the palmar ligaments and corrects the abnormal rotation of the lunate (66). Carpal collapse associated with a displaced scaphoid fracture is generally described as *dorsal intercalated segment instability* or *DISI* (53). Unacceptable fracture displacement has been defined as 1 mm or more step-off on PA and/or oblique radiographs, greater than 15° angulation between lunate and capitate, and scapholunate angulation greater than 45° (8). In summary, the factors that have a negative impact on healing are obliquity of the fracture line, a fracture in the proximal pole of the scaphoid, displacement and/or angulation of the fracture, and a delay in diagnosis.

Treatment for nondisplaced scaphoid fractures is a well-molded thumb spica cast extending just distal to the interphalangeal joint, permitting only slight flexion of that joint. Because tension of the radial collateral ligament of the wrist can cause displacement at the fracture site, immobilize the wrist in slight flexion and radial deviation. Avoid forearm rotation by applying a Muenster cast, which permits elbow flexion and extension. After 8 weeks, use a below-elbow thumb spica cast until there is radiographic evidence of healing. It is critically important to document that radiographic healing is complete before immobilization is discontinued.

Conventional radiographs are usually sufficient to determine healing, but, if inconclusive, CT or tomography is necessary (Fig. 42.7), particularly when conventional radiographs appear to show a healed fracture but tenderness persists at the fracture site. If healing is incomplete, continue cast immobilization and obtain new radiographs in 6 to 8 weeks.

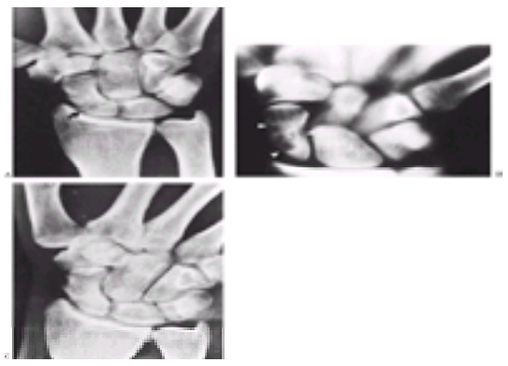

***Figure 42.7.*** **A:** Trispiral tomograph after 3 months of cast immobilization for a fracture in the proximal one-third of the scaphoid. Although there was no tenderness at the fracture site, healing was questionable because the fracture line was still visible (*arrow*). **B:** Tomographs confirmed the suspicion that the fracture had not healed, and a large area of radiolucency (*arrows*) was visualized that was not apparent on the conventional radiographs. **C:** After an additional 2 months of cast immobilization, the fracture healed.

Operative fixation of a nondisplaced scaphoid fracture may occasionally be indicated in patients (e.g., surgeons, dentists) who cannot work with their wrist in a cast and would face serious financial hardship if disabled for months. Bone screws are now available that provide stable fixation and compression of scaphoid fractures such as a cannulated AO/ASIF screw (Synthes, Paoli, PA) or Acutrak headless screw (Acumed, Beaverton, OR). Intraoperative radiographic imaging is essential to ensure

correct placement of the screw (Fig. 42.8).

***Figure 42.8.*** A nondisplaced scaphoid fracture (*arrow*) in a 40-year-old physician. The fracture healed in 2 months following insertion of an Acutrak headless, cannulated screw.

- Under direct radiographic imaging, drill a pin down the axis of the bone (Fig. 42.8*B*, arrow).
- Insert a second pin parallel to the first to prevent rotation and possible displacement of the fracture.
- Drill an Acutrak cannulated screw over the first wire; then, remove the second wire (Fig. 42.8*C*).

Postoperatively, apply a short-arm thumb spica splint for a week or two until there is soft-tissue healing and then convert to a well-molded thermoplastic thumb spica splint. The patient can then return to light work activities that do not require heavy lifting, pushing, or pulling. For surgeons, the splint can be removed while operating.

**CHRONIC FRACTURES**

Scaphoid fractures treated soon after the injury that have not healed after months of immobilization are different from fractures that were unrecognized until months after the injury. In the first situation, union is delayed but can still occur with continued immobilization, provided the fracture is stable and there are no radiographic signs of nonunion (i.e., sclerosis and/or cyst formation). Radiographic evidence of avascular necrosis is not an indication that the fracture will not heal, although it may take longer to heal. For scaphoid fractures unrecognized until months after the injury, the likelihood for healing with cast immobilization is poor.

**NONUNIONS**

Scaphoid nonunions require surgery, except in elderly or debilitated individuals. It is one of a few orthopaedic problems in which the indication for surgery depends on the radiographic appearance of the bone and not on the severity of patient's symptoms. Surgery is usually required even in patients who are asymptomatic and have excellent wrist mobility. Prospective studies have shown that without surgery, scaphoid nonunions are likely to lead to traumatic arthritis accompanied by pain, loss of wrist mobility, and weakness (54,57,78).

A wide variety of operative procedures have been recommended for scaphoid nonunions, including drilling the bone, excising the proximal fragment or even both fragments, excising the proximal carpal row, intercarpal and total wrist arthrodeses, prosthetic replacement of the scaphoid, radial styloidectomy, interposition of soft tissue into the nonunion site, and autogenous bone grafting (9,83). Drilling the bone is only of historic interest and has little relevance to contemporary hand surgery. Excising the proximal fracture fragment is a useful procedure provided the fragment is small, not exceeding 25% of the length of the bone (Fig. 42.9). The fragment can sometimes be removed arthroscopically. Avoid excising larger fragments because it can lead to abnormal shift of the other carpal bones, particularly the capitate. A coiled tendon graft can be inserted into the void as a plug, although it is not essential. Proximal row carpectomies and arthrodeses, whether they are partial or complete, are salvage procedures and are indicated when secondary arthritic changes have developed. Replacing the scaphoid with a silicone prosthesis is another salvage procedure that was popular until the mid-1980s. Since then, the procedure has been abandoned because of its high complication rate, including dislocation, breakage, and, most important, silicone synovitis (5,85). Titanium carpal implants are available, but they have not gained wide acceptance because they are inherently unstable and frequently cause bone erosion. Interposing a soft tissue flap between the fracture fragments was a procedure first recommended by Bentzon in 1940. It is still recommended by some when bone grafting is unsuccessful.

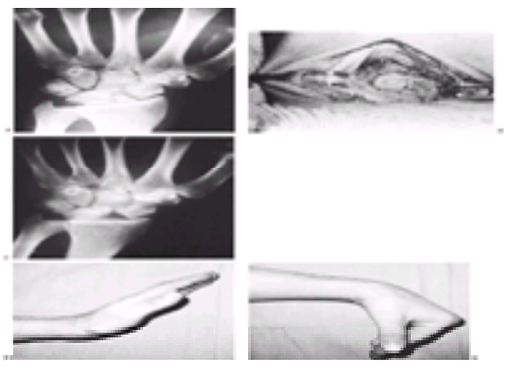

***Figure 42.9.*** **A:** Radiograph of a scaphoid nonunion in a 38-year-old accountant. The likelihood of achieving healing is minimal with a bone graft when there is a small proximal fracture fragment whose sclerotic appearance indicates avascular necrosis. **B:** The proximal fragment was excised, and a coiled piece of palmaris longus tendon (*arrows*) was inserted into the void. **C:** A radiograph 2 years later showed no secondary shifting of any carpal bone. **D,E:** The patient regained satisfactory pain-free wrist mobility.

Bone grafting is the procedure of choice for scaphoid nonunion when there are no arthritic changes (1,58,65). The concept of an inlay bone graft was introduced in 1937 by Matti, who used a dorsal surgical approach (58). Russe modified this to a palmar approach because it was less likely to damage the extrinsic blood supply to the scaphoid (80). A modification of his inlay bone graft remains the treatment of choice (9,64).

***Inlay Bone Graft—Operative Technique***

- Make a 3.0- to 4.0-cm longitudinal incision along the radial border of the flexor carpi radialis (FCR) tendon (Fig. 42.10). Curving the distal portion of the incision into the wrist flexion crease facilitates exposure.

***Figure 42.10.*** **A:** Radiograph of a nonunion of the scaphoid. **B:** At 3 months postoperatively, the fracture had healed and there was radiographic evidence of bone revascularization. **C:** A deep trough across the fracture site (arrows). **D:** Trough filled with an autogenous corticocancellous iliac bone graft. **E:** Radiograph

taken 4 months after surgery shows complete consolidation of the graft.

- Dissect the interval between the FCR and radial artery, and incise the joint capsule longitudinally.
- Identify the nonunion. The radial styloid serves as a guide to its location.
- Using a power burr, make a deep trough across the nonunion site (Fig. 42.10*C*, *arrows*). Curve the trough slightly to follow the contour of the scaphoid. Undercut its periphery to enhance stability of the bone graft.
- Harvest a corticocancellous graft from the outer surface of the ilium, just below the crest. Some prefer to harvest a graft from the distal radius; however, cancellous bone at that site is not nearly as dense as in the ilium. Shape the graft using a small bone cutter to be slightly larger than the trough so that it will fit snugly.
- Insert the graft with its thin cortical surface facing outward to be the covering of the trough. Only cancellous bone is in contact with the nonunion site (Fig. 42.10*D*). Fill any remaining defects with cancellous chips. With stable nonunions, the graft can be totally cancellous. Internal fixation with Kirschner wires is necessary only when there is movement at the nonunion site after the graft is inserted.
- Suture the joint capsule and skin, and apply an above-elbow cast for 6 to 8 weeks. After that period, continue immobilization with a below-thumb spica cast until healing occurs.

- Green (38) recommends that power instruments not be used when excavating the trough because of the risk of bone overheating. He uses two corticocancellous struts inserted into the trough with their cancellous surfaces together and cortical surfaces facing outward against the inner walls of the nonunion site to provide better stability.
- Green also reported that bone grafting is contraindicated in the presence of avascular necrosis of the proximal fragment, which is evident by the absence of punctate bleeding points in the bone.
- His recommendations differ from the experiences of most surgeons. A power burr facilitates preparation of the trough, which is the most important technical part of the operation, and the risk of bone damage is avoided by using irrigation.
- Cancellous bone rather than cortical bone should be positioned against the nonunion site.

**Other Techniques** In 1984, Herbert (41) introduced a double-threaded compression screw for the treatment of scaphoid nonunion. The procedure is technically demanding, and its benefits remain unproven. Newer and more effective screws are now available that are cannulated and provide greater compression (e.g., AO/ASIF screw, Acutrak tapered headless screw) (81).

#### *Malpositioned Nonunions—Operative Technique*

The scaphoid nonunion that is angulated is a difficult problem because it is frequently associated with subluxation of the lunate. The lunate, which is attached to the scaphoid by a strong interosseous ligament, follows the malpositioned proximal fragment, resulting in a “concertina” deformity or DISI deformity at the midcarpal joint. The nonunion site is flexed with apex dorsal angulation, and the bone has a “humpback” deformity. The degree of deformity may not be obvious on conventional radiographs, but it is clearly demonstrated on lateral CT.

- Measure the *intrascaphoid* angle that is formed by the intersection of lines drawn perpendicular to the proximal and distal articular surfaces of the scaphoid. The normal angle is 30° to 40°. An intrascaphoid angle greater than 45° generally should be corrected (5).
- Use a palmar operative approach. When lunate tilt is severe, a dorsal operative approach is preferable because it provides better visualization. Care must be taken with a dorsal approach to avoid damage to the radial artery and its dorsal branches to the scaphoid.
- Correct lunate alignment by flexing and ulnar deviating the wrist, and then stabilize the lunate with one or two Kirschner wires.
- Confirm normal radiocarpal and midcarpal alignment using intraoperative radiographic imaging.
- Bridge the defect in the scaphoid with an inlay wedge or trapezoidal-shaped bone graft harvested from the ilium. Stabilize the graft with Kirschner wires or a screw (20,27).

#### *Complications*

When bone grafting is unsuccessful, perform a second graft provided the criteria present when the first operation was performed still exist. The scaphoid should not be fragmented, and there should be no significant arthritic changes. Pulsed electromagnetic fields (PEMP) should also be considered (2,11). Although double-blind studies have not been performed to prove its efficacy, my experience is that it improves the chances for healing. Another surgical option is a vascularized bone graft. Several donor areas have been suggested, and probably the most effective is one suggested by Zaidemberg et al. (105). They recommended a graft harvested from the dorsoradial aspect of the distal radius, a site supplied by an ascending branch of the radial artery. Vascularized bone grafts have also been recommended for avascular necrosis of the scaphoid. The advantages of these procedures over conventional bone grafting have yet to be established by clinical studies.

### MALUNIONS

Treatment of a malunited scaphoid is controversial because of the risk that a corrective osteotomy may fail to unite and lead to an even greater problem, a nonunion. Surgery is not a difficult decision for the patient who has a significant disability from wrist pain, tenderness, and diminished grip strength. The decision is more difficult when there are a paucity of symptoms. However, malalignment of the midcarpal joint results in altered wrist kinematics that are likely to lead eventually to arthritic changes. Therefore, surgery is generally recommended for young patients. Careful preoperative planning is critically important and requires CT imaging.

- Use a dorsal operative approach.
- If the position of the lunate can not be corrected by wrist flexion and ulnar deviation, drill a Kirschner wire into the bone to serve as a joystick.

### HINTS AND TRICKS

- A radial styloidectomy should not be routinely performed as an adjunct to bone grafting. It is indicated for those rare cases of symptomatic arthritis confined to the area between the styloid process and the scaphoid.

- Use interoperative imaging to insure that carpal alignment has been restored.
- Osteotomize the scaphoid using a thin osteotome or a power saw.
- Insert a bone graft similar to the method used for grafting a malpositioned nonunion.

### IDIOPATHIC AVASCULAR NECROSIS

Idiopathic avascular necrosis of the scaphoid is a rare condition commonly referred to as “Preiser disease.” Actually, this is a misnomer because the patients Preiser described in his paper published in 1910 all had sustained prior injuries (25). When there are no apparent causes, it is more appropriate to refer to the condition as “idiopathic avascular necrosis of the scaphoid.” It may be similar to avascular necrosis of the lunate (Kienböck's disease) in that variations in the blood supply to the bone may predispose certain individuals to the condition. Trauma may be the main factor in disrupting the blood supply to the bone, but it may be so trivial that patients are unable to recall the episode(s) (74). Treatment depends on the condition of the scaphoid. In the absence of arthritic changes, a vascularized bone graft should be considered. When disease is chronic and pain is disabling, a salvage procedure would be required such as proximal row carpectomy, scaphoid excision combined with midcarpal arthrodesis, or total wrist arthrodesis.

### FRACTURES IN CHILDREN

The scaphoid begins to ossify at age 5 to 6 years, and ossification is completed by age 13 to 15 (85). Before ossification or in the early stages of ossification, scaphoid fractures are exceedingly rare because the bone is almost entirely cartilaginous, which cushions the effects of trauma. Even in the later stages of ossification, a considerable portion of the bone remains cartilaginous, and fractures are less likely to occur than when the bone is fully mature. Scaphoid fractures do occur in children, however; these fractures generally occur after the age of 9, unless there is precocious ossification. Most fractures involve the distal third of the bone or its tubercle (39). The incidence of fractures through the middle third of the bone is only 10% as compared to a 70% incidence in adults (97). Scaphoid fractures in children usually heal within 8 weeks. Nonunions are rare, but when they occur bone grafting is necessary (Fig. 42.11).

***Figure 42.11.*** **A:** Radiograph of the wrist of an 11-year-old child shows a nonunion of the scaphoid. There was a history of wrist injury more than 1 year earlier for which medical treatment was never obtained. At surgery, during preparation of the trough for the bone graft, there was minimal bleeding from either fracture fragment, consistent with the radiographic appearance of avascular necrosis. **B:** Healing was almost complete 3 months after surgery.

A fracture through the waist of the scaphoid in a child can pose a diagnostic dilemma, especially when there is separation of the fragments. Radiographs may show an actual fracture or what some believe is a developmental variation, a bipartite scaphoid arising from two ossification centers (101). Absence of a history of trauma, equal size and density of both bones with a clear space between them, and contiguous surfaces that are smooth have been cited as indications that a bipartite scaphoid is a developmental condition (69). These radiographic findings can also be associated with a fracture, however. Although some bipartite scaphoids can be developmental in origin, most result from trauma (56,69). More important than their etiology is their clinical course. Because they frequently are associated with later arthritis, treatment is warranted (82,101). Electrical stimulation has been suggested as a method of treatment, and little is lost by trying it. If it is not effective after 4 to 6 months, however, consider bone grafting.

## TRIQUETRUM

The incidence of fractures of the triquetrum has been reported to range from 3.5% to 31.6% of all carpal fractures (76). The incidence varies widely because most are chip fractures from the dorsal cortex of the bone that often go unnoticed. The mechanism of injury for these fractures is somewhat controversial. Initially, they were considered avulsion injuries caused by sudden wrist flexion; however, they almost always result from direct impact from the styloid process of the ulna (33,51). When the wrist is in maximum extension and ulnar deviation, the styloid process, which is often prominent in patients who sustain these injuries, functions as a chisel as it strikes the triquetrum and shears off a fragment from its dorsal aspect. Lateral radiographs frequently show the bone fragment to be at the level of the midcarpal joint, and it is sometimes misdiagnosed as a fracture fragment off the lunate. A posterior-oblique radiograph will usually demonstrate the defect in the triquetrum (2). To treat, immobilize the wrist for approximately 6 weeks, or until pain and tenderness have disappeared. Bone fragments that are nondisplaced or minimally displaced usually heal within several months. Displaced fragments that fail to unite are rarely symptomatic enough to warrant excision.

Fractures can also involve the body of the triquetrum and are either linear or comminuted. Comminuted fractures are commonly associated with dorsal chip fractures and probably occur by the same mechanism but are more severe. Treat with immobilization for 6 to 8 weeks. Although nonunions do occur, avascular necrosis has not been reported (3,23).

## TRAPEZIUM

Fractures of the trapezium account for 3% to 5% of all carpal fractures (76). These fractures are significant injuries when displaced because they affect the important trapeziometacarpal joint of the thumb. If not reduced, they may lead to pain, limitation of the thumb mobility, and weakness. Trapezial fractures fall into two categories: fractures involving the palmar ridge of the bone, and vertical fractures through the body of the bone.

Palmar ridge fractures account for 80% of trapezial fractures and result from falls on the outstretched palm. The ridge fractures either by direct contact or indirectly. An indirect fracture is an avulsion injury caused by a sudden tension force applied to the transverse carpal ligament as the thenar and hypothenar eminences diverge. Trapezial ridge fractures are subdivided into type I fractures, located at the base of the ridge, and type II fractures, located at the tip of the ridge (71). Both types of fractures are associated with local tenderness. Pain with resisted wrist flexion is common because of the close proximity of the FCR tendon to the fracture site.

Vertical fractures through the body of the bone account for the other 20% of trapezial fractures (Fig. 42.12). The mechanism of injury is unclear because they are difficult to reproduce experimentally (21). They probably result from sudden hyperextension–abduction of the thumb that forces the wrist into a position of maximum radial deviation. The trapezium is wedged between the first metacarpal and styloid process of the radius, and the styloid, functioning as an anvil, fractures the trapezium (30,46). The fracture is usually located in the middle of the bone. The lateral fragment remains tethered to the first metacarpal and is often displaced radially and proximally by the pull of the abductor pollicis longus, similar to the mechanism that contributes to a displaced Bennett's fracture. Horizontal fractures through the trapezium are rare (45).

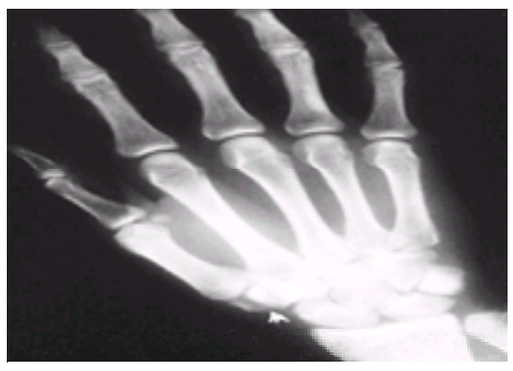

***Figure 42.12.*** Radiograph shows a vertical fracture through the body of the trapezium (*arrow*).

Trapezial fractures, regardless of location, are frequently overlooked because of inadequate radiographs. Posteroanterior and lateral views fail to show the entire body of the bone: the PA view because of superimposition by the trapezoid and base of the second metacarpal, and the lateral view because of superimposition by the hook of the hamate. In order to visualize the entire body of the trapezium, an oblique radiographic view is necessary. One such view is the Bett's view, which is obtained by placing the ulnar border of the hand on the cassette and directing the x-ray beam at the scaphoid–trapezium–trapezoid joints with the thumb abducted and extended (93). Visualizing the palmar ridge requires a carpal tunnel view.

Treat palmar ridge fractures with a thumb spica cast or splint for 6 to 8 weeks. Type I fractures through the base of the ridge tend to heal faster than type II fractures at the tip of the ridge. Occasionally, a type II fracture fails to unite and causes persistent pain and tenderness. Excision of the bony fragment is warranted in such cases. Treatment for nondisplaced fractures through the body is similar to that for type I and type II fractures of the palmar ridge. However, displaced fractures resulting in joint incongruity require operative reduction and internal fixation with Kirschner wires or a screw.

## CAPITATE

Fractures of the capitate are rare and account for only 1.3% of all carpal fractures (75). They occur as isolated injuries or in conjunction with other injuries, particularly fractures of the scaphoid. The combination of a scaphoid and capitate fracture was first reported by Fenton, who named the injury “naviculocapitate syndrome” (26). This is a complex injury that usually occurs following a fall on the outstretched hand with the wrist extended. Fenton believed that the scaphoid, buttressed medially by the capitate, was fractured by the styloid process of the radius, which functioned as a chisel. When the force was sufficiently violent, the capitate also fractured. The scaphoid can also fracture by striking the dorsal rim of the radius. When this occurs, the lunate extends, and the capitate migrates even further dorsally and fractures

as it impinges against the dorsal rim of the radius or against the dorsal rim of the lunate. Similar fractures have been reported following a blow to the dorsum of the flexed wrist, which causes the capitate to strike the volar lip of the radius (98). Regardless of mechanism of injury, the capitate usually fractures at its neck, and the proximal fragment rotates through an arc of 180° (89).

The blood supply to the capitate enters the distal, palmar aspect of the bone. Intraosseous circulation then proceeds in a distal-to-proximal direction, similar to the scaphoid (40). Therefore, a fracture through the neck of the capitate jeopardizes the blood supply to the proximal portion of the bone and can lead to avascular necrosis. Displaced capitate fractures require operative reduction and internal fixation (59). Nonunions, with or without avascular necrosis of the proximal fragment, require an inlay bone graft (31,62).

### INLAY BONE GRAFT—OPERATIVE TECHNIQUE

- Make a transverse incision over the dorsal aspect of the wrist. Curve the radial end of the incision distally for 1 to 2 cm. If additional exposure is required, curve the ulnar end of the incision proximally for the same distance. Mobilize the skin flaps taking care to protect the sensory branches of the radial nerve and the dorsal sensory branches of the ulnar nerve.
- Incise the extensor retinaculum longitudinally over the fourth tendon compartment and reflect it radially, exposing the second and third compartments. Retract the tendons in the fourth compartment ulnarly, and the tendons in the second and third compartments radially.
- Incise the underlying joint capsule transversely and reflect it proximally and distally. This surgical approach permits excellent visualization of the underlying carpal bones and is useful for a variety of other operations, including intercarpal arthrodeses.
- Make a deep trough across the nonunion site and pack it with a corticocancellous bone from the ilium.
- Close the joint capsule and extensor retinaculum. Immobilize the wrist in slight flexion to minimize the capsulodesis effect that follows any dorsal surgical approach to the wrist joint. Initially, apply volar and dorsal plaster splints; when soft tissue healing is complete, usually within 2 weeks, replace the splints with a circular cast or a well-molded plastic splint.

## LUNATE

The lunate has proportionally the largest surface area of cartilage (approximately 80%) of any carpal bone. Periosteum is confined to two small areas on the volar and dorsal surfaces of the bone through which nutrient vessels pass (95). Injection studies have shown that in more than 90% of specimens, the vessels form three distinct patterns of intraosseous circulation that resemble the letters Y, I, and X (Fig. 42.13) (35). The Y pattern is the most common (59%), followed by the I pattern (31%) and the X pattern (10%). Fewer than 10% of specimens had only volar nutrient vessels.

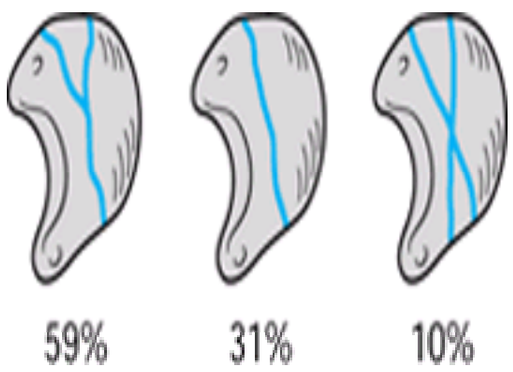


***Figure 42.13.*** The intraosseous vascular patterns in lunates.

### ACUTE FRACTURES

The incidence of acute fractures is generally reported to be less than 1.5% of carpal fractures (17,95). This low figure may reflect a failure to diagnose many lunate fractures. Fractures in bones that have a high proportion of cartilage and cancellous bone, such as the lunate, often go unrecognized because cancellous bone has a higher pain threshold than periosteum (12). Acute lunate fractures have been classified into five types (Fig. 42.14) (95):

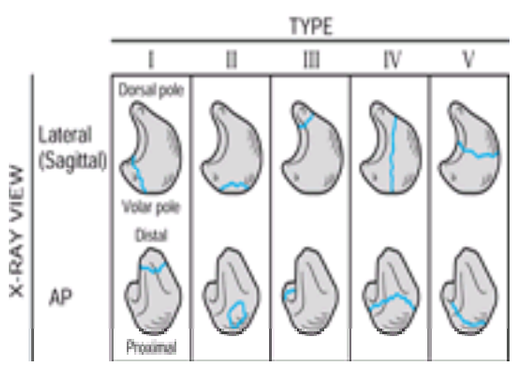


***Figure 42.14.*** Classification of lunate fractures. *Type I,* fracture of the volar pole; *type II,* chip fracture away from the nutrient vessels; *type III,* fracture of the dorsal pole; *type IV,* sagittal fracture through the bone; *type V,* transverse fracture through the waist of the bone

- I. Volar pole fractures at the entrance of the nutrient vessel.
- II. Chip fractures not in areas of nutrient vessels.
- III. Fractures of the dorsal pole at the entrance of the nutrient vessel.
- IV. Sagittal fractures through the bone.
- V. Transverse fractures through the waist of the bone.

Although acute lunate fractures almost always heal and there are no reports of late avascular necrosis (24), a type IV fracture proximal to any of the three vascular patterns could theoretically deprive the proximal portion of the bone of its blood supply (48). Compromise to the dorsal circulation could also occur following a type V fracture in a lunate having only a volar nutrient vessel.

### KIENBÖCK'S DISEASE

Kienböck's classic description of lunatomalacia in 1910 resulting from avascular necrosis remains valid to the present day, but the cause of the condition and the most effective treatment remain unresolved (48). In 1928, Hulten observed a correlation between Kienböck's disease and short ulnas and introduced the term “ulna minus variance” (43). The role that this anatomic variance plays in this condition remains unclear because its incidence varies in different races. Compared to the 87% incidence in Hulten's series, the average incidence in Japan is only 22% (94). In the United States, ulna variance is normally more positive in black than white Americans (+0.70 mm vs. +0.27 mm) (34). Accurate measurements are important because forearm rotation and grip affect ulna variance. Radiographs must be carried out with the wrist in neutral position, the forearm in neutral rotation (elbow flexed 90° and shoulder abducted 90°), and the fingers extended. Although ulna minus variance is not the primary etiologic factor in Kienböck's disease, it may increase the vulnerability of a lunate subjected to repetitive compressive forces. Kienböck's disease may therefore result from unrecognized and untreated minor fractures that disrupt the blood supply to the bone.

Since Kienböck's description of the condition, there has been general agreement about the radiographic appearance of the lunate in the later stages of the disease. For more that 30 years, however, opinions differed concerning the early radiographic appearance of the bone and the timing and sequence of subsequent changes. In

1947, Stahl attempted to bring order to a controversial subject by classifying changes he observed in wrist radiographs in a large series of patients with the condition (87). His classification system comprised five groups:

- Group I. A radiodense line that represented an acute compressive fracture of the lunate. This group of patients was the smallest of his five groups, comprising only 2% of the total number of cases.
- Group II. A line of rarefaction secondary to resorption at the fracture site. Stahl thought this occurred about 1 month after the original injury. The number of patients in this group was also small (5%).
- Group III. Sclerotic changes in close proximity to the fracture line or in the proximal portion of the bone. These changes occurred about 3 months after the injury. This was the largest group of patients in the series (47%).
- Group IV. Fragmentation and collapse of the lunate, the result of one or more vertical fractures through the area of rarefaction. This condition took at least 6 months to develop and was seen in 32% of the patients.
- Group V. End-stage disease with secondary arthritis. These patients were considerably older than those in the other groups, and the duration of their disease was the longest. They comprised 14% of the cases.

In 1977, Lichtman modified and improved Stahl's classification by correlating the radiographic appearance of the lunate with the clinical picture. Lichtman classified Kienböck's disease into four stages (52):

- Stage I. The earliest manifestation of the disease characterized by a linear compression fracture on conventional radiographs or CT. Since the introduction of MRI, it is now possible to diagnose early vascular injury to the bone. Clinically, patients complain of mild wrist pain.
- Stage II. Radiographically, the lunate becomes more dense. Initially, the size and shape of the bone remain the same, but later in this stage there is a decrease in the vertical height of the bone on its radial aspect. This is an ominous radiographic finding that usually indicates that further collapse can be anticipated. Patients typically complain of local pain and tenderness over the lunate. The wrist is sometimes swollen as a result of joint synovitis.
- Stage III. The entire lunate bone is collapsed in the frontal plane and elongated in the sagittal plane. Bony deformation is commonly associated with alterations in the architecture of other parts of the carpus; the capitate is shifted proximally, there is scapholunate dissociation with rotatory subluxation of the scaphoid, and the triquetrum is ulnarly deviated. Lichtman later subdivided this stage into III-A and III-B. In stage III-A, the rotatory subluxation of the scaphoid is not fixed, whereas in III-B it is fixed. The extent of lunate collapse can be quantified by the carpal height ratio. The ratio is the distance between the distal articular surface of the radius and the base of the third metacarpal, divided by the height of the third metacarpal. The normal ratio is 0.54 ± 0.03 (61). Conventional radiographs often fail to show the extent of bone damage, and tomography is required (Fig. 42.15). Patients' symptoms in this stage are similar to those with stage II disease, although they usually have greater wrist stiffness.

***Figure 42.15.*** **A,B:** Conventional lateral and posteroanterior views of the wrist in a patient with Kienböck's disease and an ulna minus deformity. The integrity of the lunate could not be determined by conventional radiographs. **C:** Lateral tomography clearly shows that the lunate had fragmented. This view also demonstrates the usefulness of tomography for visualizing the hamate bone and its hook (*arrow*).

- Stage IV is end-stage Kienböck's disease with generalized arthritic changes in the wrist. Clinical findings can range from mild discomfort to severe incapacitating pain, exacerbated by physical activities. There is usually a significant loss of wrist mobility.

Treatment of Kienböck's disease is variable, depending on the stage of the disease. Although opinions differ regarding the efficacy of a particular procedure, most agree that the objective of treatment for the early stages of the disease is to prevent further deterioration of the lunate and, if possible, reverse any changes that have already occurred. Immobilizing the wrist is a treatment option, but it is impractical because it must be prolonged, up to 1 year, and there is no assurance that it will be successful. Generally, surgery is the preferred treatment, and the procedures indicated for stages I and II can be divided into two groups: decompression of the lunate, and restoration of circulation to the bone.

Reducing compressive forces on the lunate can be achieved by a variety of techniques (72,96), including the following:

- Leveling the distal articular surfaces of the radius with the ulna when there is an ulna minus variance.
- Shortening both radius and ulna when they are of equal length to decrease muscle forces across the wrist.
- Changing the inclination of the articular surface of the radius by a lateral closing wedge osteotomy.
- Intercarpal arthrodesis to transfer some of the load to adjacent carpal bones (e.g., scaphoid–trapezial–trapezoid arthrodesis or scaphoid–capitate arthrodesis) (63,100).
- Capitate shortening to decrease the load on the central column (3,4).

Joint leveling is generally recommended and can be accomplished either by lengthening the ulna or by shortening the radius. Each method has its advantages and disadvantages. Ulna lengthening is less complicated but requires an iliac bone graft, which adds donor site morbidity to the procedure. A more serious potential problem is delayed or even nonunion at the interfaces of the ulna with the intercalated graft. In addition, the plate necessary for fixation of the graft is in a subcutaneous position and often must be removed later. Another disadvantage of the procedure is that the lengthened ulna may impinge against the sigmoid notch of the radius and cause pain with forearm rotation. With radial shortening, the primary disadvantage is that it requires a more extensive surgical exposure than ulna lengthening. Bone healing is more assured with radial shortening, however, and removal of the plate is usually unnecessary when it is placed on the volar aspect. Another advantage of radial shortening is that it produces relative lengthening of the extrinsic tendons, which results in additional reduction of force transmission across the wrist (103). Most surgeons recommend radial shortening using a volar operative approach.

Revascularization of the lunate was first proposed by Hori in 1979. He recommended curetting and bone grafting the lunate followed by implantation of the second or third dorsal metacarpal artery and vein. Inserting a pronator quadratus pedicle bone graft from the volar surface of the radius has also been suggested (47) as well as simple curettage and cancellous bone grafting combined with external skeletal traction (106).

## AUTHOR'S PERSPECTIVE

The lunate can also be revascularized with an autogenous cancellous inlay bone graft inserted into a trough fashioned between the lunate and triquetrum (Fig. 42.16). The triquetrum with its intact blood supply nourishes the bone graft, which serves as a scaffold for revascularization of the lunate. The technique for preparing the trough across the lunotriquetral joint is similar to preparing a trough across a scaphoid nonunion. The procedure is applicable for early stage I and stage II disease. It can occasionally be used for stage III-A disease, provided there is only a linear fracture line in the lunate and the bone has not fragmented. This can best be determined by CT imaging.

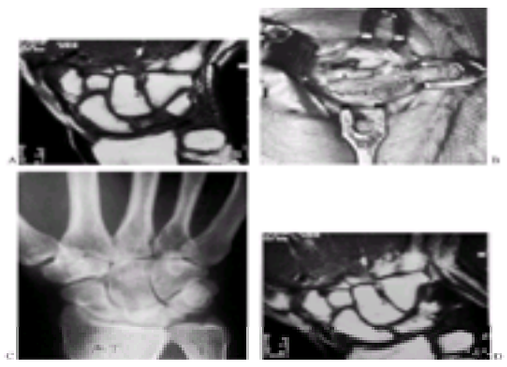

***Figure 42.16.*** An MRI showing avascular necrosis of the lunate. **B:** A trough was made across the lunate–triquetral joint, and an autogenous iliac bone graft was inserted (*arrows*). **C:** Radiograph 4 months after surgery showing consolidation of the graft. **D:** MRI showing revascularization of the lunate

Unfortunately, most patients with Kienböck's disease are not seen until the later stages of the condition, when the bone has fragmented and collapsed (stage III) and secondary arthritic changes have developed (stage IV). Unlike treatment for stage I and stage II disease, which is prophylactic and aims to prevent further deterioration, treatment for stage III and stage IV disease is palliative. The indication for surgery in patients with stage III and stage IV disease is determined not by the severity of the radiographic changes but rather by the magnitude of their symptoms. For stage III disease, lunate excision and replacement with a silicone prosthesis was a popular procedure before the mid-1980s. It is no longer recommended because of the high incidence of particulate synovitis. A more effective procedure with far fewer hazards is excision of the fragmented lunate and intercarpal fusion. Scaphoid–trapezial–trapezoid and scaphoid–capitate fusions used for reducing compressive forces on the lunate in the early stages of Kienböck's disease can also be used as salvage procedures for stage III disease when combined with lunate excision. With either type of intercarpal fusion, it is important to insure that after the lunate is excised, the normal width of the space previously occupied by the bone is maintained. An abnormally wide space between scaphoid and triquetrum indicates that the scaphoid has rotated, and if the scaphoid is arthrodesed in malposition it will result in later arthritis at the radioscaphoid joint. Normal congruency between scaphoid and capitate and between scaphoid and articular surface of the radius must be preserved.

In stage IV disease, when generalized arthritic changes have developed, proximal row carpectomy and total wrist arthrodesis are the most commonly performed salvage operations. Pain relief following proximal row carpectomy is usually effective, probably on the basis of denervation and decompression of the wrist joint (44). Wrist motions are limited, but generally they are in a functional arc. Grip strength is also reduced, but weakness can be minimized by postoperative exercises. Total arthrodesis is the most predictable operative procedure to provide a stable, pain-free wrist.

## HAMATE

### FRACTURES OF THE BODY

Fractures of the hamate involve the body of the bone or its hook (hamulus) with about equal frequency. Fractures through the body are either in the sagittal plane or in the coronal plane (55,68,77). Sagittal fractures can be divided according to which side of the hook they lie on. Coronal fractures, when located near the dorsal surface of the bone, are often associated with subluxations of the bases of the fourth and fifth metacarpals (Fig. 42.17). Regardless of direction, fractures through the body of the bone are intraarticular, and it is important to determine if articular congruity has been disrupted. Frequently, CT imaging is necessary. Displaced fractures require open reduction and internal fixation.

***Figure 42.17.*** **A,B:** Oblique and lateral radiographs show a coronal fracture through the dorsal aspect of the hamate (*arrows*) associated with dorsal subluxations of the bases of the fourth and fifth metacarpals.

### FRACTURES OF THE HOOK (HAMULUS)

The diagnosis and treatment of fractures of the hook of the hamate require a knowledge of the local anatomy. The hook serves as attachment for the transverse carpal and pisohamate ligaments and is the origin for two intrinsic muscles in the hypothenar eminence, the opponens digiti quinti and the flexor digiti quinti. The motor branch of the ulnar nerve passes close to the base of the hook on its ulnar side. Fractures may therefore injure this nerve branch and cause weakness of the ulnar innervated intrinsic muscles. Fractures may also produce a sensory deficit on the palmar surfaces of the ring and little fingers. Hook fractures are caused by direct or indirect trauma. Direct trauma is probably the more common mechanism of injury and is often associated with sports activities, such as baseball and tennis. When athletes grip a baseball bat or tennis racquet with the butt end of the handle resting on the hypothenar eminence, the force of the swing is transmitted to the bone, which causes it to fracture. Frequently, the athlete reports a painful “snap” or “crack” (8,88). Indirect trauma to the hook occurs as a result of a fall on the palm with the force transmitted to the bone through muscular and ligament attachments.

Symptoms include dull pain on the ulnar side of the wrist or in the hypothenar area of the palm. Tenderness directly over the hook should be considered a fracture until proven otherwise. Frequently, diagnosis is delayed because of inadequate radiographs. The profile of the hook can not be visualized on routine views, although on the PA view it can be seen as an oval density or “eye sign,” which represents its junction with the body of the bone (Fig. 42.18) (67). Absence of an “eye sign” should arouse suspicion of a fracture at the base of the hook. If the sign is present, however, it does not exclude a fracture through the middle of the hook or at its tip. Although carpal tunnel views show the hook in profile, they often fail to show its base, which is the usual location for most fractures. This is frequently the situation following acute fractures because pain prevents patients from extending their wrists sufficiently for the radiograph to profile the entire hook. For a carpal tunnel view to be diagnostic, it must visualize the flare at the base of the hook where it joins the body of the hamate. Incomplete carpal tunnel views are sometimes interpreted as “negative,” and only later is the correct diagnosis made. The radiographic technique that is most effective for visualizing the hook is CT in the lateral projection (Fig. 42.19).

***Figure 42.18.*** Posteroanterior radiograph of both hands. The oval density or “eye sign” representing the hook of the hamate (*small arrows*) is seen in the view of the left hand, but it is absent (*large arrow*) in the view of the right hand because it was fractured.

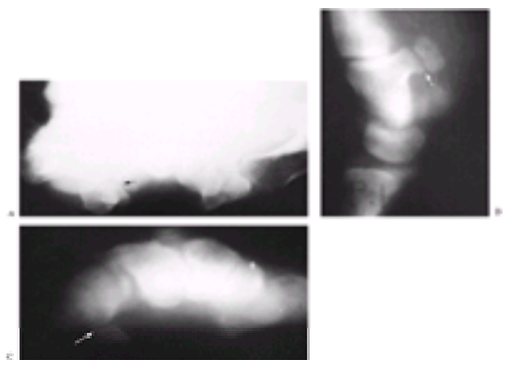

***Figure 42.19.*** **A:** Routine carpal tunnel view in a patient who complained of tenderness over the area of the hook of the hamate. Although there appears to be a disruption in the cortical outline of the hook of the hamate (*arrow*), the radiograph is not conclusive and was interpreted as negative. **B:** A lateral trispiral tomograph clearly demonstrates a fracture of the hook (*arrow*). **C:** The fracture was also evident on a carpal tunnel tomogram (*arrow*), but not with the same degree of clarity as was demonstrated on lateral tomography. Lateral tomography is the preferred imaging technique to visualize fractures of the hook of the hamate.

Acute fractures heal with immobilization, provided there is no displacement. When the parts are displaced, nonunion is likely because the blood supply to the fragment has been disrupted (73). Although bone grafting has been suggested as a method of treatment for nonunion (99), excision of the fragment is the preferred treatment (16,84).

***Fragment Excision—Operative Technique***

- Make an incision along the radial border of the hypothenar eminence and curve ulnarly into the wrist flexion crease (Fig. 42.20). This incision avoids a tender scar over the eminence, which is an important contact area for grasp.

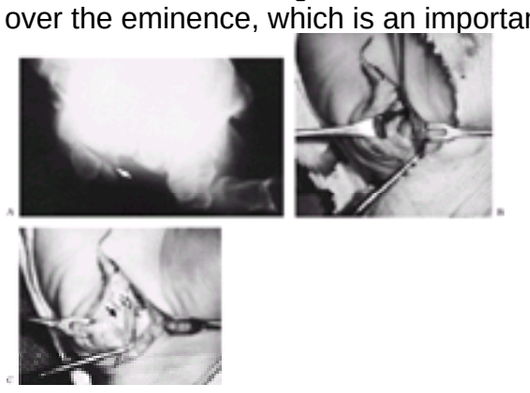

***Figure 42.20.*** **A:** Radiograph of a fracture of the hook of the hamate in a 35-year-old golfer (*arrow*). **B:** At surgery, the hook (*arrow*) was stripped of its periosteum and of the ligaments and intrinsic muscles attached to it. **C:** After excision of the bone fragment, the soft tissues were closed (*probe tip*). Care must be taken during the procedure to identify and protect the ulnar neurovascular bundle (*closed arrow,* nerve; *open arrow,* vessels).

- Identify the ulnar neurovascular bundle and carefully retract it.
- Excise the hook by sharply dividing its ligament and intrinsic muscle attachments.
- Repair the fibrous origin of the intrinsic muscles to preserve their power.
- Postoperatively, immobilize the wrist in slight flexion for 2 weeks. Patients can usually resume sports activities within 8 weeks, although there will usually be some discomfort with firm grasp for several months. Residual weakness is generally not a problem, even in professional athletes.

## PISIFORM

The pisiform is a sesamoid and is the only carpal bone into which a tendon, the flexor carpi ulnaris (FCU), inserts. The pisiform also serves as origin for the pisohamate and pisometacarpal ligaments, which secure it to the hamate and bases of the fourth and fifth metacarpals. The capsule between the pisiform and underlying triquetrum is tough but lax (70).

Pisiform fractures usually result from direct trauma following a fall on the palm. They also occur in individuals who use the heel of their hand as a hammer for striking objects. These fractures are best visualized by anterior-oblique and carpal tunnel radiographs (Fig. 42.21).

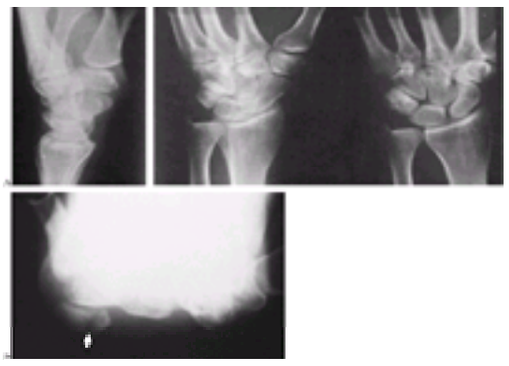

***Figure 42.21.*** **A:** A fracture of the pisiform was not evident on these three conventional radiographic views because of superimposition of other carpal bones. **B:** The fracture was obvious on a carpal tunnel view (*arrow*).

Most pisiform fractures are nondisplaced and heal with conservative splinting. However, fragmentation can occur, which requires excision of the bone. Chronic problems at the pisotriquetral joint can also occur as a consequence of damage to the articular cartilage resulting in chondromalacia. Occasionally, pain and local tenderness are so severe that excision of the pisiform is warranted (Fig. 42.22). Excise it subperiosteally, preserving the fibrous attachments of the ligaments and FCU, which are then resutured. Postoperatively, apply a dorsal splint with the wrist in slight flexion for 2 to 3 weeks.

***Figure 42.22.*** **A:** A 55-year-old woman complained of chronic pain over the pisiform area of her right palm. She reported falling on the heel of her hand approximately 1 year earlier. The oblique radiograph showed narrowing of the pisotriquetral joint (*black arrow*) with calcification in the area of the flexor carpi ulnaris (*white arrow*). **B:** At surgery, there was complete erosion of the cartilage over the contiguous articular surfaces of both bones (*small arrow,* triquetrum; *large arrow,* pisiform). An osteochondral body (*open arrow*) is seen at the distal end of the triquetrum. **C:** View after excision of the pisiform. The forceps is grasping the flexor carpi ulnaris tendon, and the ulnar neurovascular vesicle (*arrow*) is to the radial side of the triquetrum. **D:** The capsule of the pisotriquetral joint was sutured to the edge of the flexor carpi ulnaris (*arrows*) to preserve its function.

## TRAPEZOID

The trapezoid is the least likely carpal bone to be fractured, with a reported incidence of 0.2% (76). The low incidence is related to the anatomic position of the bone, which is surrounded and securely fixed to the trapezium, base of the second metacarpal, capitate, and scaphoid. Dislocations are more likely to occur than fractures, but they are also very rare.

### CHAPTER REFERENCES

Each reference is categorized according to the following scheme: *, classic article; #, review article; !, basic research article; and +, clinical results/outcome study.


* 1. Adams JD, Leonard RD. Fractures of the Carpal Scaphoid. A New Method of Treatment with a Report of One Case. *N Engl J Med* 1928;198:401.

+ 2. Adams BD, Frykman GK, Taleisnik J. Treatment of Scaphoid Nonunion with Cast and Pulsed Electromagnetic Fields. A Study Continuation. *J Hand Surg* 1982;17A:910.

+ 3. Almquist EE, Burns JF JR. Radial Shortening for the Treatment of Kienböck's Disease—A 5–10-year Follow-up. *J Hand Surg* 1982;7:348.

# 4. Almquist EE. Kienböck's Disease. *Hand Clin* 1987;3:141.

+ 5. Amadio PC, Berquist TH, Smith DK, et al. Scaphoid Nonunion. *J Hand Surg* 1989;14A:679.

+ 6. Barnard L, Stubbins SG. Styloidectomy of the Radius in the Surgical Treatment of Nonunion of the Carpal Navicular. *J Bone Joint Surg* 1948;30A:98.

* 7. Bell C. *The Hand: Its Mechanism and Vital Endowments as Evincing Design.* London: W Pickering, 1833.

# 8. Bishop AF, Beckenbaugh RD. Fractures of the Hamate Hook. *J Hand Surg* 1987;12A:149.

+ 9. Boeckstyns MEH, Kjaer L, Busch P, Holst-Nielson F. Soft Tissue Interposition Arthroplasty for Scaphoid Nonunion. *J Hand Surg* 1985;10A:109.

* 10. Bonin JG, Greening WP. Fractures of the Triquetrum. *Br J Surg* 1943;31:378.

+ 11. Bora FW, Osterman AL, Woodbury DF, Brighton CT. Treatment of Nonunion of the Scaphoid by Direct Current. *Orthop Clin North Am* 1984;15:107.

# 12. Brolin I. Post-Traumatic Lesions of the Lunate Bone. *Acta Orthop Scand* 1964;34:167.

# 13. Bryan RS, Dobyns JH. Fractures of the Carpal Bones Other Than the Lunate and Navicular. *Clin Orthop* 1986;149:107.

* 14. Bryce TH. Certain Points in the Anatomy and Mechanism of the Wrist Joint Reviewed in the Light of a Series of Roentgen Ray Photographs of the Living Hand. *J Anat Physiol* 1895;31:59.

+ 15. Carter PR, Benton LJ, Dysert PA. Silicone Rubber Carpal Implants: A Study of the Incidence of Late Osseous Complications. *J Hand Surg* 1986;11A:639.

+ 16. Carter PR, Eaton RG, Littler JW. Ununited Fracture of the Hook of the Hamate. *J Bone Joint Surg* 1977;59A:583.

+ 17. Cetti R, Christensen SE, Reuther U. Fracture of the Lunate Bone. *Hand* 1982;14:80.

# 18. Cooney WP, Dobyns JH, Linscheid RL. Fractures of the Scaphoid: A Rational Approach. *Clin Orthop* 1980;149:90.

+ 19. Cooney WP, Dobyns JH, Linscheid RL. Nonunion of the Scaphoid: Analysis of the Results of Bone Grafting. *J Hand Surg* 1980;5:343.

+ 20. Cooney WP, Dobyns JH, Linscheid RL, Wood MB. Scaphoid Nonunion: Role of Anterior Interpositional Bone Grafts. *J Hand Surg* 1988;13A:635.

# 21. Cordrey LJ, Ferrer-Torells M. Management of Fractures of the Greater Multangular. *J Bone Joint Surg* 1960;42A:1111.

# 22. DeBeer JDeV, Hudson DA. Fractures of the Triquetrum. *J Hand Surg* 1987;12B:52.

+ 23. Durbin FC. Nonunion of the Triquetrum. *J Bone Joint Surg* 1950;32B:388.

# 24. Eckenbaugh RD, Shives TC, Dobyns JH, Linscheid RL. Kienböck's Disease: The Natural History of Kienböck's Diseases and the Consideration of Lunate Fractures. *Clin Orthop* 1980;149:98.

# 25. Ferlic DC, Morin P. Idiopathic Avascular Necrosis of the Scaphoid: Preiser's Disease? *J Hand Surg* 1989;14A:13.

* 26. Fenton RL. The Naviculo-Capitate Fracture Syndrome. *J Bone Joint Surg* 1956;38A:681.

+ 27. Fernandez DL. A Technique for Anterior Wedge Shaped Grafts for Scaphoid Nonunions with Carpal Instability. *J Hand Surg* 1984;9A:733.

+ 28. Finkenberg JG, Hoffer E, Kelly C, Zinar DM. Diagnosis of Occult Scaphoid Fractures by Intrasound Vibration. *J Hand Surg* 1993;18A:4.

* 29. Fisk GR. An Overview of Injuries of the Wrist. *Clin Orthop* 1980;149:137.

+ 30. Freeland AE, Finley JS. Displaced Vertical Fracture of the Trapezium Treated with a Small Cancellous Lag Screw. *J Hand Surg* 1984;9A:843.

+ 31. Freeman BH, Hay EL. Nonunion of the Capitate: A Case Report. *J Hand Surg* 1985;10A:187.

# 32. Ganel A, Engel J, Oster Z, Farine I. Bone Scanning in the Assessment of Fractures of the Scaphoid. *J Hand Surg* 1979;4:540.

# 33. Garcia-Elias M. Dorsal Fractures in the Triquetrum—Avulsion or Compression Fractures? *J Hand Surg* 1987;12A:267.

# 34. Gelberman RH, Salamon PB, Jurist JM, Posch JL. Ulnar Variance in Kienböck's Disease. *J Bone Joint Surg* 1975;57A:674.

* 35. Gelberman RH, Bauman TD, Menon J, Akeson WH. The Vascularity of the Lunate Bone and Kienböck's Disease. *J Hand Surg* 1980;5:272.

* 36. Gelberman RH, Menon J. The Vascularity of the Scaphoid Bone. *J Hand Surg* 1980;5:508.

* 37. Gilford WW, Bolton RH, Lambrinudi C. The Mechanism of the Wrist Joint with Special Reference to Fractures of the Scaphoid. *Guy's Hosp Rep* 1943;92:52.

+ 38. Green DP. The Effect of Avascular Necrosis on Russe Bone Grafting for Scaphoid Nonunion. *J Hand Surg* 1985;10A:597.

# 39. Green MH, Hadied AM, LaMont RL. Scaphoid Fractures in Children. *J Hand Surg* 1984;9A:536.

* 40. Grend VR, Dell PC, Glowzewski BSF, et al. Interosseous Blood Supply of the Capitate and Its Correlation with Aseptic Necrosis. *J Hand Surg* 1984;9A:677.

+ 41. Herbert TJ, Fisher WE. Management of the Fractured Scaphoid Using a New Screw. *J Bone Joint Surg* 1984;66:114.

+ 42. Horii Y, Tamai S, Okuda H, et al. Blood Vessel Transplantation to Bone. *J Hand Surg* 1979;4:23.

* 43. Hulten O. Uber Anatomische Variationen den Handgelenkknochen. *Acta Radiol* 1928;9:155.

+ 44. Imbriglia JE, Broudy AS, Hagberg WC, McKernan D. Proximal Row Carpectomy: Clinical Evaluation. *J Hand Surg* 1990;15A:426.

+ 45. Jones JA, Pellegrini VD. Transverse Fracture-Dislocation of the Trapezium. *J Hand Surg* 1989;14A:481.

+ 46. Jones WA, Ghorbal MS. Fractures of the Trapezium—A Report on Three Cases. *J Hand Surg* 1985;10B:227.

# 47. Kawai H, Yamamoto K. Pronator Quadratus Pedicled Bone Graft for Old Scaphoid Fractures. *J Bone Joint Surg* 1988;70:829.

* 48. Kienböck R. Concerning Traumatic Malacia of the Lunate and the Consequences: Degeneration and Compressive Fractures. Peltier LF (trans). *Clin Orthop* 1980;149:4.

+ 49. Langhoff O, Andersen JL. Consequences of Later Immobilization of Scaphoid Fractures. *J Hand Surg* 1988;13B:77.

* 50. Lee MLH. The Intraosseous Arterial Pattern of the Carpal Lunate Bone and Its Relation to Avascular Necrosis. *Acta Orthop Scand* 1963;33:43.

# 51. Levy M, Fischel RE, Stern GM, Goldberg I. Chip Fractures of the Os Triquetrum. The Mechanism of Injury. *J Bone Joint Surg* 1979;61B:355.

+ 52. Lichtman DM, Mack GR, MacDonald RI, et al. Kienböck's Disease: The Role of Silicone Replacement Arthroplasty. *J Bone Joint Surg* 1977;59A:899.

* 53. Linscheid RL, Dobyns JH, Beabout JW, Bryan RS. Traumatic Instability of the Wrist. Diagnosis, Classification and Pathomechanics. *J Bone Joint Surg* 1972;54A:1612.

# 54. London PS. The Broken Scaphoid Bone. The Case Against Pessimism. *J Bone Joint Surg* 1961;43B:237.

# 55. Loth TS, McMillan MD. Coronal Dorsal Hamate Fractures. *J Hand Surg* 1988;13A:616.

* 56. Louis DS, Calhoun TP, Gan SM. Congenital Bipartite Scaphoid—Fact or Fiction? *J Bone Joint Surg* 1976;58A:1108.

* 57. Mack GR, Bosse MJ, Gelberman RH, Yu E. The Natural History of Scaphoid Nonunion. *J Bone Joint Surg* 1984;66A:504.

* 58. Matti H. Technik und Resultate Meiner Pseudarthrosenoperation. *Z Chir* 1936;63:1442.

# 59. Meyers MH, Wells R, Harvey JP Jr. Naviculo-Capitate Fracture Syndrome. A Review of the Literature and a Case Report. *J Bone Joint Surg* 1971;52A:1383.

* 60. McMurtay RL, Youm Y, Flatt AE. Kinematics of the Wrist. I. An Experimental Study of Radial-Ulnar Deviation and Flexion-Extension. *J Bone Joint Surg* 1978;60A:423.

* 61. McMurtay RL, Youm Y, Flatt AE. Kinematics of the Wrist. II. Clinical Applications. *J Bone Joint Surg* 1978;60A:955.

+ 62. Minami M, Yamazaki J, Chisaka N, et al. Nonunion of the Capitate. *J Hand Surg* 1987;12A:1089.

+ 63. Moy OJ, Peimer CA. Scaphocapitate Fusion in the Treatment of Kienböck's Disease. *Hand Clin* 1993;9:501.

+ 64. Mulder JD. The Results of 100 Cases of Pseudarthrosis in the Scaphoid Bone Treated by the Matti-Russe Operation. *J Bone Joint Surg* 1968;50:110.

+ 65. Murray G. End Results of Bone Grafting for Nonunion of the Carpal Navicular. *J Bone Joint Surg* 1946;28:749.

+ 66. Nakamura R, Hori M, Horii E, Miura T. Reduction of the Scaphoid Fracture with DISI Alignment. *J Hand Surg* 1987;12A:1000.

# 67. Norman A, Nelson JM, Green SM. Fractures of the Hook of the Hamate: Radiographic Signs. *Radiology* 1985;154:49.

# 68. Ogunro O. Fracture of the Body of the Hamate Bone. *J Hand Surg* 1983;8:353.

* 69. O'Rahilly R. A Survey of Carpal and Tarsal Anomalies. *J Bone Joint Surg* 1953;35A:626.

# 70. Paley D, McMurtay RY, Cruickshank B. Pathological Conditions of the Pisiform and Pisotriquetral Joint. *J Hand Surg* 1987;12A:110.

+ 71. Palmer AK. Trapezial Ridge Fractures. *J Hand Surg* 1981;6:561.

# 72. Palmer AK, Benoit MY. Lunate Fractures: Kienböck's Disease. In Cooney WP, Linscheid RL, Dobyns JH, eds. *The Wrist— Diagnosis and Operative Treatment.* St. Louis: CV Mosby, 1988:431.

* 73. Panagis JS, Gelberman RH, Taleisnik J, Baumgaertner M. The Arterial Anatomy of the Human Carpus. Part II: The Intraosseous Vascularity. *J Hand Surg* 1983;8A:375.

* 74. Preiser G. Zur Eine Typische Posttraumatische und zur Spontanfraktur Föhrende Ostitis des Naviculare carpi. *Fortschr Geb Roentgenstr* 1910;15:189.

# 75. Rand JA, Linscheid RL, Dobyns JH. Capitate Fractures. *Clin Orthop* 1982;165:209.

# 76. Razemon JP. Fractures of the Carpal Bones. In: Tubiana R, ed. *The Hand, Vol II.* Philadelphia: WB Saunders, 1985:821.

+ 77. Roth JH, deLorenzi C. Displaced Intra-articular Coronal Fracture of the Body of the Hamate Treated with a Herbert Screw. *J Hand Surg* 1988;13A:619.

# 78. Ruby LK, Stinson J, Belsky MR. The Natural History of Scaphoid Nonunion. A Review of 25 Cases. *J Bone Joint Surg* 1985;67A:428.

# 79. Ruby LK. Fractures and Dislocations of the Carpus. In: Browner BD, Levine AM, Jupiter JB, Trafton PG. Eds. *Skeletal Trauma* Philadelphia:WB Saunders, 1988:1343.

* 80. Russe O. Fracture of the Carpal Navicular: Diagnosis, Non-operative Treatment and Operative Treatment. *J Bone Joint Surg* 1960;42A:759.

# 81. Shaw JA. A Biomechanical Comparison of Scaphoid Screws. *J Hand Surg* 1987;12A:347.

# 82. Simmons BP. Injuries to and Developmental Deformities of the Wrist and Carpus. In: Bora W, ed. *The Pediatric Upper Extremity.* Philadelphia: WB Saunders, 1986:176.

+ 83. Smith L, Friedman B. Treatment of Ununited Fractures of the Carpal Scaphoid by Styloidectomy of the Radius. *J Bone Joint Surg* 1956;38A:368.

# 84. Smith P, Wright TW, Wallace PF, Dell PC. Excision of the Hook of the Hamate: A Retrosprective Survey and Review of the Literature. *J Hand Surg* 1988;13A:612.

# 85. Smith RJ, Atkinson RE, Jupiter JB. Silicone Synovitis of the Wrist. *J Hand Surg* 1985;10A:47.

# 86. Southcott R, Rosman MA. Nonunion of Carpal Scaphoid Fractures in Children. *J Bone Joint Surg* 1977;59B:20.

* 87. Stahl F. On Lunatomalacia (Kienböck's Disease): A Clinical and Roentgenological Study, Especially on Its Pathogenesis and the Late Results of Immobilization Treatment. *Acta Chir Scand [Suppl]* 1947;126:1.

# 88. Stark HH, Jobe FW, Boyes JH, Ashworth CR. Fractures of the Hook of the Hamate in Athletes. *J Bone Joint Surg* 1977;59A:575.

+ 89. Stein F, Siegel MW. Naviculocapitate Fracture Syndrome. A Case Report. *J Bone Joint Surg* 1969;51A:391.

# 90. Szabo RM, Manske D. Displaced Fractures of the Scaphoid. *Clin Orthop* 1988;230:31.

# 91. Szabo RM, Sutherland TB. Acute Carpal Fractures and Dislocations. In: Peimer CA, ed. *Surgery of the Hand and Upper Extremity.* New York McGraw-Hill, 1996:711.

# 92. Taleisnik J. Ligaments of the Wrist. *J Hand Surg* 1976;1:110.

# 93. Taleisnik J. *The Wrist.* New York: Churchill Livingston, 1985.

# 94. Tamai S, Yajima H, Ono H. Revascularization Procedures in the Treatment of Kienböck's Disease. *Hand Clin* 1993;9:455.

* 95. Tiesen H, Hjarbaek J. Classification of Fresh Fractures of the Lunate. *J Hand Surg* 1988;13B:458.

# 96. Trumble T, Glisson RR, Seaber AV, Urbaniak JR. A Biomechanical Comparison of the Methods for Treating Kienböck's Disease. *J Hand Surg* 1986;11A:88.

# 97. Vahvanen V, Westerlund M. Fractures of the Scaphoid in Children. *Acta Orthop Scand* 51:909;1980.

# 98. Vance RM, Gelberman RH, Evans EF. Scaphocapitate Fractures. Patterns of Dislocation, Mechanisms of Injury, and Primary Results of Treatment. *J Bone Joint Surg* 1980;62A:271.

+ 99. Watson HK, Rogers WD. Nonunion of the Hook of the Hamate: An Argument for Bone Grafting the Nonunion. *J Hand Surg* 1989;14A:486.

+ 100. Watson WK, Ryu J, DiBella A. An Approach to Kienböck's Disease. Triscaphe Arthrodesis. *J Hand Surg* 1985;10A:179.

# 101. Waugh RL, Sullivan RI. Anomalies of the Carpus With Particular Reference to the Bipartite Scaphoid (Navicular). *J Bone Joint Surg* 1950;32A:682.

# 102. Weber ER, Chao EY. An Experimental Approach to the Mechanism of Scaphoid Wrist Fractures. *J Hand Surg* 1978;3:142.

+ 103. Weiss APC. Radial Shortening. *Hand Clin* 1993;9:475.

# 104. Werner FW, Palmer AK. Biomechanical Evaluation of Operative Procedures to Treat Kienböck's Disease. *Hand Clin* 1993;9:431.

+ 105. Zaidemberg C, Siebert JW, Angrigiani C. A New Vascularized Bone Graft for Scaphoid Nonunion. *J Hand Surg* 1991;16A:474.

+ 106. Zelouf DS, Ruby LK. External Fixation and Cancellous Bone Grafting for Kienböck's Disease: A Preliminary Report. *J Hand Surg* 1996;21A:746.

# CHAPTER 43

# THE DISTAL RADIOULNAR JOINT

*Robert R. Slater, Jr.*

**R. R. Slater, Jr.:** Department of Orthopaedic Surgery, University of California, Davis, Sacramento, California 95817.
**H. Kirk Watson, M.D.,** of Hartford Orthopaedic, Plastic & Hand Surgeons, Inc., Hartford, Connecticut 06106, was a technical contributor to this chapter.

Anatomy
Biomechanics
Pathophysiology
Impingement
Instability
Incongruity
Principles of Treatment
Diagnostic Evaluations
History and Physical Examination
Plain Radiographs
Other Imaging Studies
Nonoperative Treatment
Surgical Techniques
Indications and Decision Making
Impingement Lesions
Instability
Incongruity Lesions
Special Conditions
A Word on Arthroscopy
Summary
Chapter References

The distal radioulnar joint (DRUJ) is a complex and important part of the wrist joint, providing several key functions to the articulation between the forearm and hand. Most important, the DRUJ acts in concert with the proximal radioulnar joint to allow the wrist and hand to rotate from pronation to supination and back again. The radioulnar joint appeared in evolution 36 million years ago (7), and the unique ability to transfer rotational force to the grasping hand is considered to have played a decisive role in human evolution. A forearm that can rotate while the hand grasps is a necessity in using spears, axes, and knives and in carrying infants and baskets, activities that allowed hominids to evolve from food gatherers to food producers.

The diagnosis of problems affecting the distal radioulnar joint can be difficult, and their management challenging. Although a wide variety of surgical procedures have been described to address DRUJ pathology, the best approach to these disorders remains controversial. This chapter summarizes current knowledge about the distal radioulnar joint and suggests treatment strategies for specific conditions. Before one considers the pathologic conditions that affect the DRUJ and options for their treatment, however, it is necessary to understand the anatomy and biomechanics of the joint (7,58).

## ANATOMY

The bony anatomy of the DRUJ has been well defined (17,77,78,108). The sigmoid notch of the distal radius is concave and hemicylindrical with three distinct margins: a sharp dorsal margin, a smoother palmar margin, and a distal margin, which is the junction between the lunate facet and the sigmoid notch (Fig. 43.1). The opposed ulnar head is also hemicylindrical but has a smaller radius of curvature than the sigmoid notch. Because of the mismatch in radii, there is some inherent laxity in the normal joint, and translatory motion parallel to the plane of the articular surfaces normally occurs during rotation of the hand. When the forearm is in neutral rotation, it is possible to translate the ulnar head passively approximately 3 mm dorsal and 5 mm palmar against the stabilized radius (79). In the extremes of forearm rotation, less than 10% of the ulnar head may be in contact with the notch. This relationship is important to consider when the normal shape and relative lengths of the radius and ulna are changed, either surgically, developmentally, or traumatically.

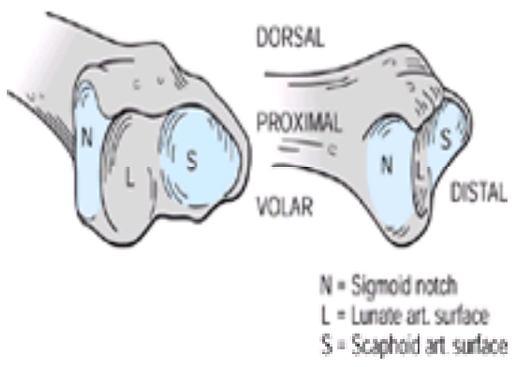


***Figure 43.1.*** Bony anatomy of the distal radius showing the confluence of the lunate facet and the sigmoid notch. Redrawn from an illustration by Elizabeth Roselius © 1993, with permission.

The ulnar styloid is another important element of the bony anatomy of the DRUJ. It is a continuation of the subcutaneous ridge of the ulnar shaft and stands as a strut on the end of the ulna to stabilize the ulnar soft tissues of the wrist. The sheath of the extensor carpi ulnaris, the ulnocarpal ligaments, and the triangular fibrocartilage all attach to the distal ulna and help maintain the congruency of the DRUJ; most of these attachments are at the base of the ulnar styloid (44,45,59,76,77,100).

The soft tissues and supporting structures around the DRUJ have been the focus of many studies. One of the most important structures is the triangular fibrocartilage complex (TFCC), a term coined by Palmer and Werner (Fig. 43.2) (77). It arises from the ulnar aspect of the lunate fossa of the radius and courses ulnarward to insert into the base of the ulnar styloid. It also flows distally, where it is joined by fibers arising from the ulnar aspect of the ulnar styloid and inserts distally into the triquetrum, hamate, and base of the fifth metacarpal. The prestyloid recess is a constant perforation found just distal to the level of the ulnar styloid and should not be confused with a traumatic disruption.

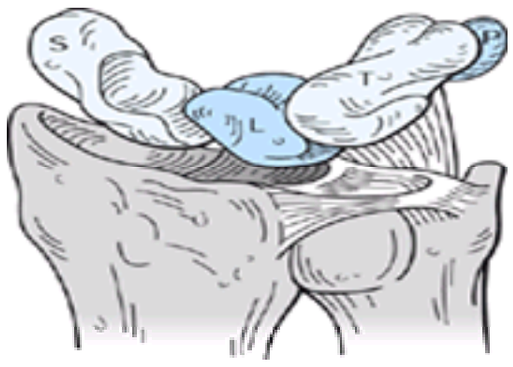


***Figure 43.2.*** Illustration of the triangular fibrocartilage and ulnotriquetral and ulnolunate ligaments, components of the triangular fibrocartilage complex (TFCC). S = scaphoid, L = lunate, T = triquetrum, P = pisiform. Redrawn from an illustration by Elizabeth Roselius © 1993, with permission.

In the center of the complex is the triangular fibrocartilage (TFC) proper. The periphery of the TFC is thickest, usually measuring 5 mm, and is the portion best suited to bear tensile loads. The rim is well vascularized and therefore has good healing potential (62). Tearing of the TFC along its peripheral margin allows DRUJ displacement and instability. In contrast, the central portion of the TFC is thin (usually only 1–2 mm thick) and has a disorganized, random collagen arrangement and little vascularity. This portion is better suited for force transmission and compressive loading.

Authors disagree about whether or not there may be congenital perforations of the TFC. That has implications for treatment because it would be important to know if a lesion discovered during evaluation of a patient's wrist were congenital or traumatic. Weigl and Spira (108) examined the TFC of 84 cadaver wrists with ages ranging from 1 day to 91 years and found that a congenital fenestration was sometimes present on the border between the radial and middle third of the disc. The frequency of the congenital lesions was not listed, but the authors found that 42% of specimens of all ages had fenestrations, usually without degenerative changes. Tan et al. (99) studied 120 fetal and infant wrists and found perforations in 27 (23%). Mikic found no perforations in untraumatized wrists younger than 20 years of age, including 38 fetal hands. Palmer and Werner found that 53% of their specimens had TFCC perforations, but all had associated erosions of the cartilage of the lunate and distal ulna. In most cases, the history and physical exam help clarify the etiology of the lesion.

The ulnotriquetral and ulnolunate ligaments also are considered part of the TFCC. They share a common origin from the region of the ulnar styloid base and fan out past the triangular fibrocartilage to insert on the triquetrum and lunate, respectively. The ligaments are important stabilizers of the ulnar corner of the wrist and resist palmar–ulnar displacement of the carpus, particularly in power grip. In rheumatoid arthritis the ligaments may become attenuated and allow such displacement (109), a problem that must be considered in planning treatment of DRUJ problems in patients with rheumatoid arthritis, as discussed below.

The other static stabilizers of the DRUJ are the joint capsule and the dorsal and palmar radioulnar ligaments. The DRUJ capsule is uniformly thin and contributes little in the way of stability. The characteristics and function of the dorsal and palmar radioulnar ligaments have been the subject of debate. Some authors (17,78,108) consider them nothing more than thickenings of the periphery of the TFCC. Other investigators (53) have studied them in cadaver models and have tried to assign specific biomechanical roles to them. The roles the ligaments may play in DRUJ biomechanics are discussed in the next session.

Two dynamic stabilizers of the distal ulna are the pronator quadratus and the extensor carpi ulnaris. The pronator quadratus has a superficial head, which is a prime mover for forearm pronation, and a deep head, which helps stabilize the DRUJ (92). The pronator quadratus actively stabilizes the joint by coapting the ulnar head in the sigmoid notch, particularly in pronation, and passively stabilizes the joint by viscoelastic forces in supination (17,50,78).

The ECU musculotendinous unit has unique features that lend additional stability to the DRUJ complex. Spinner and Kaplan (91) and Taleisnik et al. (98) demonstrated how the ECU is maintained in its position over the dorsal distal ulna by a separate fibroosseous tunnel deep to and separate from the extensor retinaculum (Fig. 43.3). The extensor retinaculum swings around and over the medial border of the ulna to insert primarily on the pisiform and triquetrum. This separate arrangement allows unrestricted rotation of the radius and ulna. Studies based on cadaver dissections have shown that an intact ECU and fibroosseous tunnel partially stabilize the DRUJ even after the TFC and other ligaments are sectioned (91).

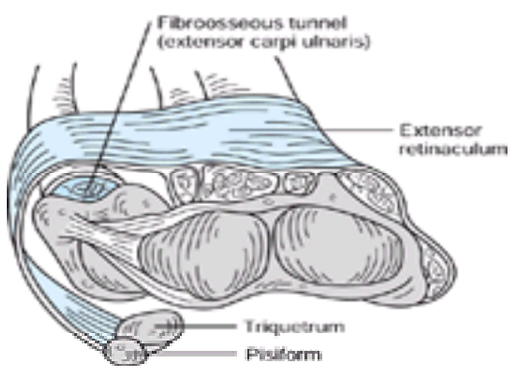


***Figure 43.3.*** The extensor carpi ulnaris lies in a fibroosseous tunnel separate from the extensor retinaculum; it is more superficial and passes around the medial border of the ulna to attach to the pisiform and triquetrum. Redrawn from an illustration by Elizabeth Roselius © 1993, with permission.

## BIOMECHANICS

Anatomically, the ulna is the stable axis of rotation of the forearm around which the radius moves. If there is a dislocation, it is technically the radius that is displaced dorsally or palmarly with respect to the ulna. In the orthopaedic literature and common usage, however, it is the convention to describe the position of the distal ulna with respect to the radius in describing DRUJ dislocations and instability. The conventional nomenclature is used in this chapter.

The distal radioulnar joint has both rotational and translational components of motion and does not have a single center of rotation. Many laboratory studies have been done to study the forces and structures that normally stabilize the joint as well as pathologic changes that occur after DRUJ injuries. In a recent study, Kihara et al. (53) used a cadaver model to assess the roles four structures play in stabilizing the DRUJ in different positions of forearm rotation: (a) the dorsal radioulnar ligaments; (b) the palmar radioulnar ligaments of the TFCC; (c) the pronator quadratus and the distal portion of the interosseous membrane underlying the muscle; and (d) the entire interosseous membrane. The authors showed that all four structures contribute to the stability of the DRUJ. Dislocation, and often diastasis, could occur only if all four structures were divided. It was not possible to define the roles of the dorsal radioulnar ligaments or palmar radioulnar ligaments while the interosseous membrane was intact.

Other investigators have shown that the stabilizing effects of the dorsal and palmar radioulnar ligaments are dependent on forearm rotation. Schuind et al. (88) and others (32,108) have demonstrated that the palmar radioulnar ligaments (RUL) become maximally tightened and thus stabilize the DRUJ in forearm supination, whereas the dorsal RUL becomes maximally tightened and stabilizes the DRUJ in forearm pronation (Fig. 43.4). Paradoxically, af Eckenstam and Hagert (5) concluded the opposite: sectioning studies on five cadavers showed that stability in supination was maintained by the dorsal fibers, and stability in pronation was maintained by the palmar fibers. A study by Adams and Holley (2) measured strain on the surface of the TFC articular disc and calculated the strain at the dorsal and palmar margins of the disc. In supination, strain increased dorsally; in pronation, strain increased palmarly. This apparent paradox can be rectified if one realizes that, in pronation, the dorsal radioulnar ligament tightens and tends to displace the ulna dorsally (Fig. 43.5). Left unchecked, this dynamic tensioning ultimately would lead to subluxation and dislocation of the joint. It is the palmar radioulnar ligaments that check that force and keep the joint reduced. If the interosseous membrane is disrupted and the palmar radioulnar ligament is sectioned, the DRUJ dislocates in pronation. The opposite is true in supination.

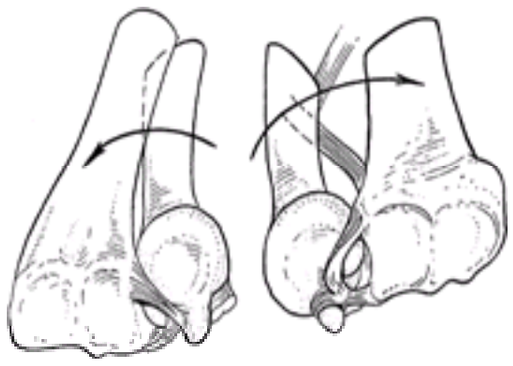

***Figure 43.4.*** When the wrist is pronated, as on the left, the dorsal radioulnar ligament is taut, seating the ulnar head against the dorsal rim of the sigmoid notch. In supination, on the right, the palmar radioulnar ligament displaces the ulnar head against the palmar radial rim. Reprinted with permission (59).

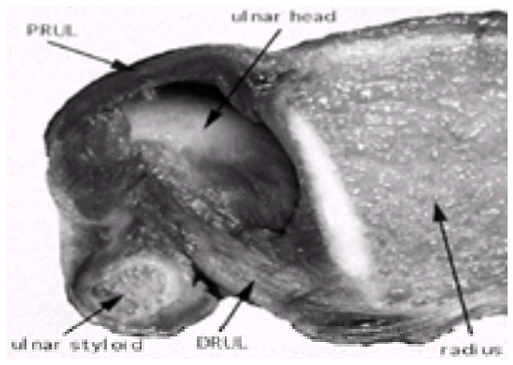


***Figure 43.5.*** Cross section through the DRUJ in a cadaver specimen. The central portion of the triangular fibrocartilage has been removed to expose the ulnar head. When the forearm is pronated, as shown here, the dorsal radioulnar ligament (DRUL) is tighter than the palmar radioulnar ligament (PRUL).

Fractures involving the distal radioulnar joint and the distal radius change the biomechanics of the TFC complex. In another study by Kihara et al. (52), dorsally angulated fractures of the distal radius were simulated in a cadaver model. The authors found that incongruency of the DRUJ occurred with increasing dorsal tilt of the distal radius, most pronounced with a change of more than 20° from the initial anatomic alignment. Also, with dorsal angulation, the intact interosseous membrane tightened and thus limited forearm rotation. The authors confirmed that DRUJ dislocation occurred only if both the TFCC and the interosseous membrane were sectioned.

The biomechanics and load bearing of the different components of the DRUJ also have been characterized. Compression and axial loading across the wrist are primarily transmitted to the distal radius, but the force is partially transmitted through the TFC to the ulnar head. Palmer et al. (78) showed that in a forearm with ulnar neutral variance, 80% of the static load is borne by the radius and 20% by the ulna. As ulnar length increases from -2.5 mm to + 2.5 mm, the load borne by the ulna increases from 4% to 42%. Removal of the TFCC decreased the load borne by the distal ulna by approximately 12%.

Biomechanical properties of the collagen arrangement and regional structural differences within the triangular fibrocartilage may explain the quality and location of the TFCC tears seen clinically. Chidgey et al. (24,25) found that the central disc of the TFC has undulating sheets of crisscrossed, poorly vascularized collagen fibers and that the origin of this disc from the radius is reinforced by collagen bundles projecting out from the radius for 1 to 2 mm. This corresponded with the clinical observation that central disc tears identified arthroscopically in 48 patients usually were oriented parallel to and 1 to 2 mm away from the radial origin of the TFCC at the junction between the short, radially oriented fibers and the remainder of the disc. It is postulated that high shear forces occur in this transition zone and account for the tear patterns seen. Tears were notably absent from the ulnar side of the central disc.

## PATHOPHYSIOLOGY

A complex scheme for categorizing and cataloguing the injuries and pathologies about the DRUJ has been proposed (17), but most conditions affecting the DRUJ fall into one of three categories: impingement, instability, or incongruity (Table 43.1).

| |
|---|
| IMPINGEMENT LESIONS |
| Ulnocarpal impaction syndrome |
| Ulna positive variant ("normal variant" long ulna with activity-related overuse) |
| Premature closure of radial epiphysis, secondary to trauma (acquired Madelung's deformity) or premature wrist fusion |
| Excision or settling of radial head secondary to trauma, tumor, or infection |
| Reconstruction of radial or ulnar shaft for trauma, tumor, or infection |
| INSTABILITY LESIONS |
| TFCC lesions with or without associated DRUJ instability |
| DRUJ subluxation or dislocation |
| With soft tissue disruptions |
| With forearm fractures (Galeazzi) |
| Ulnar styloid fractures or nonunions with disruption of the TFCC |
| Acute fractures including chondral fractures of the ulnar head or sigmoid notch |
| Radial head fractures with disruption of the DRUJ (Essex-Lopresti lesions) |
| Snapping or dislocating extensor carpi ulnaris tendon |
| INCONGRUITY LESIONS |
| Osteoarthritis |
| Post-traumatic arthritis |
| Rheumatoid arthritis |
| Other inflammatory or systemic arthritis |
| Fixed rotational deformity |

***Table 43.1. Classification of Distal Radioulnar Joint Disorders***

### IMPINGEMENT

Impingement disorders are characterized by ulnar-sided wrist pain made worse with ulnar wrist deviation. In ulnar impaction syndrome, ulnar deviation causes the lunate and triquetrum to abut against the ulnar head and TFCC. Radiographs show a long ulna relative to the radius and occasionally sclerotic or cystic changes in the ulnar head, lunate, or triquetrum. Tears of the lunotriquetral ligament and TFCC are common in this condition. Ulnar impingement syndrome is a special variant of impingement disorder. In that case, the distal ulnar shaft contacts the distal radius abnormally (usually the result of prior surgery) to cause pain, made worse with medial-lateral compression of the distal forearm and ulnar wrist deviation. A number of conditions may predispose a patient to an impingement syndrome (Table 43.1).

### INSTABILITY

Instability of the DRUJ may be acute or chronic and may relate to bony changes or soft tissue injuries or both. Fractures of the distal radius or distal ulna can alter the bony alignment of the DRUJ (52). Nonunion or malunion of these fractures may result in pain, weakness, and lost motion in addition to instability.

Ulnar styloid fractures have received renewed interest recently because of the importance of TFCC stability. Ulnar styloid fractures commonly occur together with fractures of the distal radius and are often overlooked while emphasis is placed on treating the radius fracture. Ulnar styloid fractures can be troublesome and painful, however, and can be a mark of TFCC instability. Symptomatic nonunions of the styloid do occur. Hauck et al. (44) recently classified these as type 1 with a stable DRUJ and type 2 with an unstable DRUJ. Type 1 fractures occur through the tip of the styloid and do not cause TFCC instability in and of themselves. Should nonunions of this type occur, they can be treated successfully by excision of the styloid fragment. Type 2 nonunions occur through the base of the styloid, are much

larger fragments, and imply TFCC instability if displaced.

Triangular fibrocartilage injuries can be seen alone or in association with instability of the DRUJ. The most common tear occurs within the articular disc of the TFC near its attachment to the radius. This tear does not seem to cause joint instability; however, the tear itself may be unstable and symptomatic (1,3,25,73,83). Despite the recognition of specific types of TFC lesions (Table 43.2) (74), the exact mechanisms of injury remain unclear. Adams et al. postulated that TFCC tears result from a distraction force during a violent axial load of the forearm; however, their cadaver study did not demonstrate the types of TFCC tears often seen clinically (3). Tears probably result from a combination of compression across the wrist, which traps the disc in the ulnocarpal joint, together with DRUJ distraction or twisting, which creates enough shear force to tear the disc. The regional differences in collagen arrangement also may play a role.

| *Subclass* | *Class I: Traumatic Findings* |
|---|---|
| A. | Central perforations |
| B. | Medial (ulnar attachment) avulsion with or without distal ulna fracture |
| C. | Distal avulsion (carpal attachment) |
| D. | Lateral (radial attachment) avulsion with or without sigmoid notch fracture |
| *Stage* | *Class II: Degenerative Findings* |
| 1 | TFCC wear |
| 2 | TFCC wear and lunate and/or ulnar chondromalacia |
| 3 | TFCC perforation and lunate and/or ulnar chondromalacia |
| 4 | TFCC perforation and lunate and/or ulnar chondromalacia and lunate-triquetral (L-T) ligament perforation |
| 5 | TFCC perforation and lunate and/or ulnar chondromalacia and L-T ligament perforation and ulnocarpal arthritis |

***Table 43.2. Palmer's Classification of TFCC Lesions***

**INCONGRUITY**

Incongruity of the DRUJ may result from a variety of conditions. Osteoarthritis is usually posttraumatic but is occasionally primary. In either case, the DRUJ becomes painful, and there is progressive loss of motion of the wrist and forearm and decreased grip strength (65). Rheumatoid arthritis also commonly affects the DRUJ (8,109). Incongruity may result from trauma such as radius fractures that extend into the DRUJ. Whatever the cause, when the distal ulna and sigmoid notch of the radius have incongruous surfaces, the result may be similar; symptoms include pain, swelling, lost motion, and catching or clicking at the DRUJ with forearm rotation.

## PRINCIPLES OF TREATMENT

The distal radioulnar joint provides several key functions to the articulation between the forearm and hand–wrist unit. The goal in treating any derangement of the DRUJ is to restore a pain-free, stable junction between the forearm and the rest of the wrist. That junction should allow forearm rotation, which occurs as the radius rotates around the distal ulna, and should restore or maintain as much stability as possible to the ulnar side of the wrist. Treatment options chosen for individual patients should be based on an understanding of the underlying pathology and specific pathoanatomic disorders (Table 43.3, Table 43.4 and Table 43.5). Three critical questions should be addressed and answered before any treatment is selected: (a) What is the duration of the disorder (acute or chronic)? (b) What is the principal cause of the disorder: ligamentous, cartilaginous, bony, or a combination thereof? And (c) what is the condition of the DRUJ articular surfaces: normal, incongruous, or arthritic?

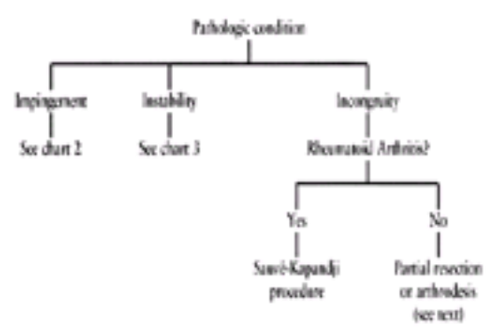


***Table 43.3. DRUJ Pathology General Treatment Algorithm***

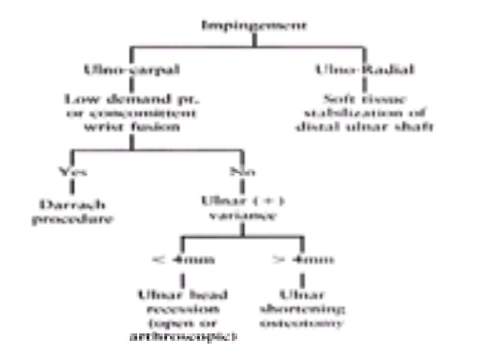


***Table 43.4. Impingement Lesions Treatment Algorithm***

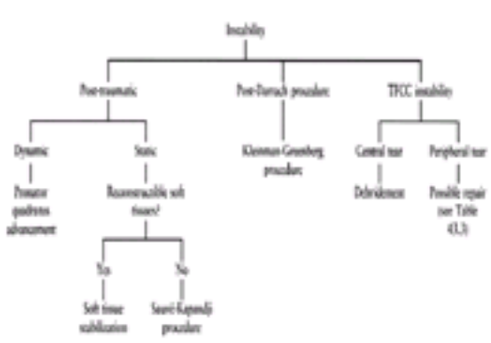


***Table 43.5. Instability Lesions Treatment Algorithm***

## DIAGNOSTIC EVALUATIONS

### HISTORY AND PHYSICAL EXAMINATION

Begin clinical evaluation of any of the disorders affecting the DRUJ with a detailed, accurate history. Knowing the mechanism of injury or symptom production can be helpful. For example, pain with ulnar wrist deviation that began insidiously or with chronic overuse suggests an impingement problem. Patients with traumatic lesions of the TFCC generally give a history of falling on the outstretched hand, which causes hyperextension of the wrist, or a history of the onset of ulnar-sided wrist pain after lifting a heavy object (80). A torque injury with axial load can also cause DRUJ instability. Specific activities that load the wrist during pronation and supination such as using a screwdriver or using a key may exacerbate the pain from a TFCC lesion. Patients often describe a sensation of catching or snapping in the wrist when there are problems in the DRUJ.

During the physical examination, measure the patient's wrist and forearm ranges of motion, both active and passive. A rigid endpoint with loss of motion suggests a bony problem such as fracture malunion, whereas a soft endpoint with limited motion implies scarring or soft tissue contractures. Look for subluxation of the ECU by watching the tendon while the patient actively supinates and pronates the forearm. Provocative maneuvers and applied stresses can be helpful. Pain with ulnar wrist deviation suggests an ulnar impaction syndrome. A TFCC tear should be suspected if the patient's pain is reproduced when torque is applied to the hand while axial load is applied across the wrist and the forearm is stabilized. Inflammatory changes of the DRUJ usually are associated with generalized conditions such as rheumatoid arthritis (18). Note the presence of any obvious deformity and unilateral grip weakness.

### PLAIN RADIOGRAPHS

Evaluate all patients' wrists radiographically. If there is a history of a specific traumatic event, include two views that show both the elbow and wrist because a dislocation of either the proximal or distal radioulnar joints may accompany any forearm fracture (Fig. 43.6). In the multiply traumatized patient, this is especially critical because other injuries may mask physical findings that would indicate injuries of the proximal or distal forearm joints. Standard posteroanterior (PA) and lateral views of the wrist can be used to rule out bony problems separate from the DRUJ; however, obtain ulnar variance view radiographs before any procedure on the DRUJ. The ulnar variance lateral view (Fig. 43.7*A*) is taken with the arm at the side (0° shoulder abduction), the elbow flexed 90°, the forearm in neutral rotation, and the wrist in neutral alignment (36). The ulnar variance PA view (Fig. 43.7*B*) is obtained with the patient's shoulder abducted 90°, the elbow flexed 90°, and the forearm in neutral rotation. For this view, there is disagreement about whether the wrist should be in ulnar deviation (36) to show the lunate centered over the lunate fossa of the radius or neutral deviation to show the lunate centered over the DRUJ (75). However, it should be evident that wrist position will not affect the relative lengths of the ulna and radius, and most patients are more relaxed with their wrist in neutral rather than extreme ulnar deviation. I prefer that patients keep their wrists in neutral for this x-ray.

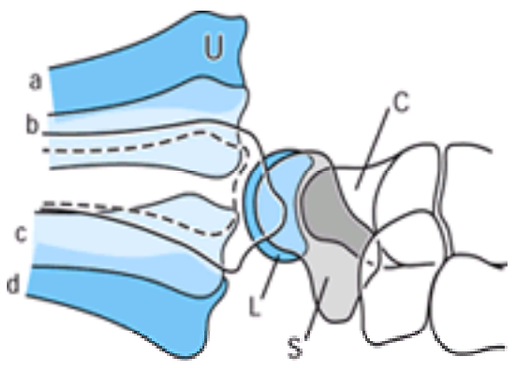


***Figure 43.6.*** Illustration of lateral radiographs of the wrist in neutral rotation with dorsal dislocation (*a*), dorsal subluxation (*b*), palmar subluxation (*c*), and palmar dislocation (*d*) of the ulna (*U*) on the radiocarpal mass. Complete superimposition of the proximal pole of the scaphoid (*S*) and the lunate (*L*) is seen. The radial styloid process is centered over the proximal part of the carpus. *C*, capitate. Redrawn from an illustration by Elizabeth Roselius © 1993, with permission.

***Figure 43.7.*** Forearm positioning for ulnar variance view x-rays: lateral view (**A**) and PA view (**B**).

### OTHER IMAGING STUDIES

Computed tomography (CT) scans can be useful for evaluating the DRUJ, particularly when there is a deformity related to the joint with associated pain and lost motion (22,26,54,66,67,90,91,108). Take three sets of scans, one each with the forearm in pronation, supination, and neutral rotation (Fig. 43.8), and compare to the uninjured wrist to assess joint instability accurately. The scan with the forearm in pronation is most sensitive for detecting palmar subluxation, whereas the neutral image is best for detecting dorsal subluxation and DRUJ diastasis. The supination view is best for confirming the degree of reduction or subluxation of the DRUJ (20). On any single CT image, one can gain clues about the position of the ulna relative to the radius by drawing a line through the dorsal radial and ulnar borders of the radius and a second line through the palmar radial and ulnar corners of the radius. An ulna that is adequately reduced must lie between those lines (66,67).

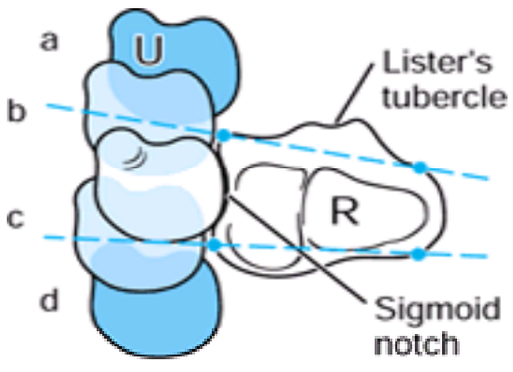


***Figure 43.8.*** Illustration of CT scans of a transverse section through the distal radioulnar joint. The sigmoid notch and Lister's tubercle of the radius are seen. The positions of the ulna (*U*) with (*a*) dorsal dislocation, (*b*) dorsal subluxation, (*c*) palmar subluxation, and (*d*) palmar dislocation are demonstrated. A *line* drawn through the dorsal ulnar and radial borders of the radius (*R*) shows the limit of dorsal congruity of the DRUJ, and a *line* drawn through the palmar ulnar and radial borders of the radius shows the limit of palmar congruity. Redrawn from an illustration by Elizabeth Roselius © 1993, with permission.

Magnetic resonance imaging scans are becoming more useful as better imaging coils and software are being developed and as investigators improve their abilities to interpret the images and correlate them with specific abnormalities (18,101). Arthrography remains a useful tool for evaluating the DRUJ, especially TFCC tears, and dynamic images of the arthrogram are most helpful. The images can be stored on videotape and studied in detail to detect subtle abnormalities and localize ligament and cartilage tears precisely.

## NONOPERATIVE TREATMENT

A trial of nonoperative management is helpful and warranted for patients with minor disorders of the DRUJ. Strains of the radioulnar or other ulnar-sided wrist ligaments may respond to rest, ice after activity, oral antiinflammatory medications, and splints to hold the wrist in neutral position. Tendonitis of the ECU may be treated with a steroid injection in the ECU tendon sheath, and then the wrist should be immobilized in pronation for 2 to 4 weeks, with the splint extending above the elbow.

Acute subluxations and dislocations of the DRUJ may be amenable to nonoperative treatment. Instability may be dorsal, palmar, or multidirectional. Dorsal dislocations are most common and may occur in conjunction with forearm fractures, such as the Galeazzi fracture-dislocation and its variants, or soft-tissue lesions without associated fractures (21,29). Simple, easily reducible dorsal dislocations can be treated by immobilizing the forearm and wrist in 20° supination in a rigid splint or cast for 4 to 6 weeks. Palmar dislocations are rare, usually chronic, and often result from rotatory malunions in the forearm (29). In that setting, immobilization usually fails. If the DRUJ has multidirectional instability, it suggests a severe injury of the joint structures and TFCC, and nonoperative management is difficult.

## SURGICAL TECHNIQUES

### INDICATIONS AND DECISION MAKING

Many surgical procedures have been described for treating disorders of the DRUJ. Tailor treatment choices to meet the goals and occupational and avocational demands of individual patients. For example, a resection arthroplasty may work well for a sedentary, low-demand elderly patient but may be a failure for a young laborer. It is helpful to consider treatment options in categories (Table 43.3, Table 43.4 and Table 43.5). Soft-tissue procedures are aimed at repairing, debriding, or replacing injured or destroyed soft tissues. Arthroplasties and arthrodeses are indicated to treat problems of bony malalignment, arthritis, and irreparable soft tissue injuries.

### IMPINGEMENT LESIONS

Treat impingement lesions with resection or realignment procedures. In the setting of an ulnar positive variant and ulnocarpal impaction syndrome, the ulnar column of the wrist must be unloaded (Fig. 43.9). This can be done by resecting a 2- to 4-mm wafer of distal ulna as described by Feldon et al. (38). The procedure retains the integrity of the TFCC to the base of the styloid process as well as the integrity of the DRUJ. It requires only a limited arthrotomy and allows direct inspection of the affected area. It is contraindicated in patients with DRUJ arthritis or more than 4 mm ulnar positive variance. More recently, this has been done arthroscopically, using a burr to remove the wafer of distal ulna (110).

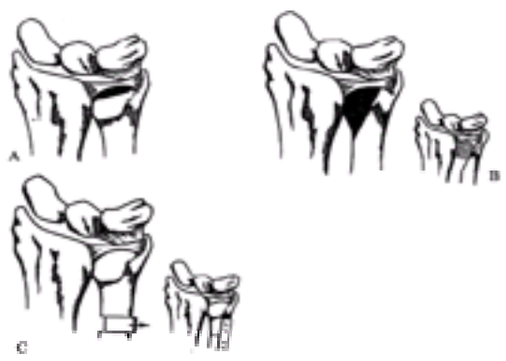

***Figure 43.9.*** Partial resection arthroplasty options. **A:** Feldon “wafer” resection. **B:** Bowers HIT resection. **C:** Ulnar shortening osteotomy. Redrawn from an illustration by Elizabeth Roselius © 1993, with permission.

In cases where there is greater than 4 mm ulnar positive variance, an ulnar shortening osteotomy is preferred. Several techniques have been described to accomplish this, and all work well (17,31,82,87,107). The integrity of the TFCC must be known before ulnar shortening. Assess indirectly by an arthrogram or, at the time of surgery, either arthroscopically or by open technique (Fig. 43.10). If the TFCC is torn or destabilized, it should be either repaired or debrided, depending on the characteristics and location of the tear, at the same time as the shortening is done.

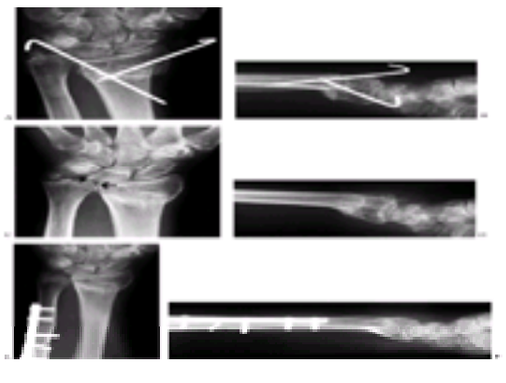

***Figure 43.10.*** Ulnar impaction syndrome. Posteroanterior (**A**) and lateral (**B**) radiographs showing attempted K-wire fixation of a radius fracture. This resulted in a malunion of the radius (**C,D**) and ulnar impaction syndrome from the ulnar positive variance (*arrows,* **C**), and the patient was referred for further treatment. An ulnar shortening osteotomy was performed (**E,F**), combined with arthroscopic debridement of a TFCC tear. The stable fibrous nonunion at the base of the ulnar styloid was left alone. The patient improved significantly and was pain-free at last follow-up.

Resection of the distal end of the ulna is another option for treating impingement disorders. This procedure is often credited to Darrach, who popularized it, although he was not the first to describe it (30). In a review of 24 cases of distal ulna resection, Dingman (34) discovered the best results were seen in those patients in whom the ulnar styloid process was left *in situ* to keep the TFCC intact, and he suggested that the resection should be subperiosteal because those patients in whom some bony regeneration occurred also had better results. Hartz and Beckenbaugh (43) reported the long-term results of the Darrach procedure in a group of 62 patients with posttraumatic DRUJ pathology. All patients improved. The authors found that the amount of ulna resected and whether or not the dissection was subperiosteal or regrowth of the distal ulna occurred had no effect on clinical outcome.

#### *Darrach Procedure—Nolan and Eaton Technique*

The Darrach procedure is best performed as described by Nolan and Eaton (Fig. 43.11) (72).

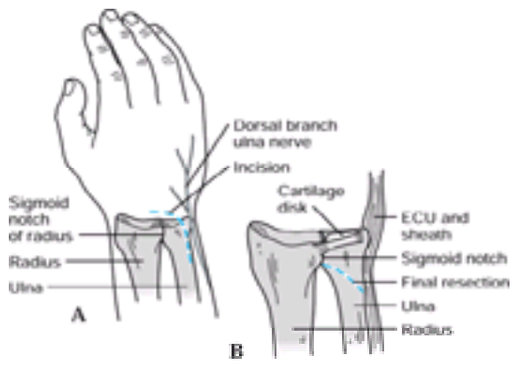


***Figure 43.11.*** The Darrach procedure. **A:** The skin incision; take care to avoid the dorsal cutaneous branch of the ulnar nerve. **B:** The DRUJ and TFCC are shown from a dorsal view. The distal ulna is resected at the radioulnar articulation just proximal to the sigmoid notch. The osteotomy angles obliquely proximalward to avoid a dorsal ulnar prominence. *ECU,* extensor carpi ulnaris. Redrawn from an illustration by Elizabeth Roselius © 1993, with permission.

- Make a dorsal ulnar incision over the distal ulna. Identify the dorsal cutaneous branch of the ulnar nerve and protect it throughout the case.
- Develop the interval between the extensor digiti quinti and the superficial extensor retinaculum and divide the retinaculum longitudinally, preserving it for subsequent closure. Expose the distal ulna through a longitudinal subperiosteal dissection. Leave the interosseous membrane and pronator quadratus undisturbed.
- The site of distal ulnar resection should be at the level of the radioulnar articulation; angle it 30° obliquely and proximally to avoid leaving a sharp dorsoulnar corner. The resected segment should be 4 to 6 mm on the radial border and 8 mm on the ulnar border.
- Dissect out and remove the distal segment, leaving the ligaments and triangular fibrocartilage intact.
- Close the periosteum meticulously and plicate the dorsal retinaculum. Drains are unnecessary.
- For the first 10 days postoperatively, use an above-elbow bulky dressing reinforced with plaster splints with the forearm maintained in neutral rotation. For the following 2 weeks, the patient should splint the wrist intermittently as symptoms allow and then begin progressive range-of-motion exercises.

Good results can be obtained with careful technique; however, several publications have pointed out many problems with the procedure. Failures have been attributed to excessive bony resection, distal ulnar instability with insufficient soft-tissue structures to tether the remaining ulna, extensor tendon rupture, ulnar deviation of the wrist, weakness, and wrist pain (10,11,13,33,39,43,60,70,71,103,105).

Another type of impingement lesion may result from a shortened distal ulna. The most common cause of that is a prior resection, but it may result from a growth disturbance of the distal ulnar physis (10). In such cases, the shortened ulna may impinge on the distal radius, causing a painful, disabling pseudarticulation. Bell et al. (10) first reported the condition in a series of 11 cases, 10 of which resulted from excision of the distal ulna after injury to the wrist. Further resection of the ulna is contraindicated in ulnar impingement syndrome. Instead, the ulnar stump should be stabilized by some means. Bell et al. recommended creation of a tenodesis using the ECU in the method of Goldner and Hayes (see below).

## INSTABILITY

Many techniques have been described to restore radioulnar stability via soft-tissue reconstructions using a sling of fascia lata or a slip of the overlying ECU and retinaculum (17). No large or long-term studies demonstrate any one specific technique to be superior over another. The techniques commonly used are described below.

### *Soft-Tissue Stabilization Using the FCU—Hui and Linscheid Technique*

Hui and Linscheid (47) described how to re-create a portion of the TFCC using the flexor carpi ulnaris (FCU) (Fig. 43.12).

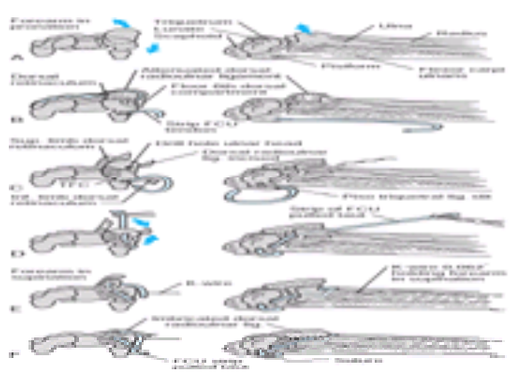

***Figure 43.12.*** The technique of ulnotriquetral augmentation tenodesis for stabilization of the DRUJ, as described by Hui and Linscheid. A: Starting pathologic position (ulnar head sits dorsal). B: Harvested strip of FCU. C: Drill hole in ulnar head. D: FCU strip passed through drill hole. E: K-wire to reduce DRUJ. F: FCU pulled taut and sutured (see text for details). *FCU,* flexor carpi ulnaris; *TFC,* triangular fibrocartilage. Redrawn from an illustration by Elizabeth Roselius © 1993, with permission.

- Make a slightly curving incision from the ulnar border of the small finger metacarpal to the middorsal forearm. Expose the extensor retinaculum and reflect it to its insertion into the pisiform.
- Incise the capsule radial to the ECU tendon and reflect it medially. Make a drill hole through the ulnar head angled from proximal-dorsal to distal-palmar (Fig. 43.12*A*, Fig. 43.12*B*).
- Expose the FCU through a separate longitudinal incision on the palmar aspect of the wrist. Split it longitudinally as far proximally as possible and then divide it proximally, leaving the medial half of the insertion intact distally (Fig. 43.12*C*).
- Make a hole in the pisotriquetral capsule and pass the tendon slip intracapsularly, through the drill hole in the distal ulna and through an enlargement of the prestyloid recess of the TFC (Fig. 43.12*D*).
- Supinate the forearm to reduce the ulnar head and transfix it to the distal radius with a K-wire. Pull the FCU tendon slip taught, double it back to the radioulnar capsule, and suture it securely to the pisotriquetral ligament (Fig. 43.12*E*).
- Imbricate the dorsal radioulnar ligament, replace the ECU in its sheath, and imbricate the extensor retinaculum (Fig. 43.12*F*).
- Postoperatively, immobilize the patient's wrist and forearm in a splint extending above the elbow for 6 weeks and then remove the K-wire and splint and institute physical therapy. After 3 months, the patient should begin vigorous exercises to regain pronation.

### *Alternative Soft-Tissue Stabilization Using the FCU—Tsai and Stilwell Technique*

The procedure described by Tsai and Stilwell (103) also uses the FCU tendon but relies on the interosseous membrane and ECU to aid in stabilization of the ulna (Fig. 43.13). The authors state that their operation is applicable both to the patient with an intact ulnar head and to the one with continuing instability of the ulnar stump after ulnar head excision.

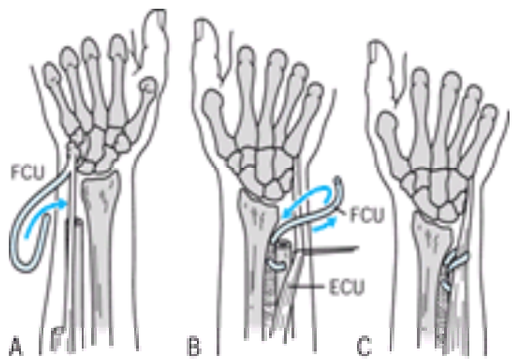


***Figure 43.13.*** The distal ulna can be stablized with a sling created from the flexor carpi ulnaris (FCU), as described by Tsai and Stilwell. A: Palmar view: harvested strip of FCU. B: Dorsal view: FCU strip passed through distal ulna. C: Dorsal view: FCU passed around extensor carpi ulnaris (ECU) and secured to interosseus membrane. Redrawn from an illustration by Elizabeth Roselius © 1993, with permission.

- Make an incision along the course of the FCU tendon. Expose the tendon from the musculotendinous junction to the pisiform and dissect out a strip from proximal to distal (Fig. 43.13*A*).
- Release Guyon's canal to avoid ulnar nerve compression with subsequent rerouting and tightening of the tendon.
- Make another incision dorsally, exposing the ulnar head or distal shaft in the case of previous ulnar head excision. Drill a hole from the medullary canal opening obliquely and proximally, emerging on the dorsal aspect of the ulna. Expose the interosseous membrane close to the ulna distally (Fig. 43.13*B*).
- Leave the FCU tendon slip attached to the pisiform and pass the free end dorsally, deep to the ulnar nerve and artery, into the medullary canal of the ulna and out the dorsal cortical hole.
- Make parallel incisions in the interosseous membrane perpendicular to the long axis of the forearm and pass the end of the slip of the FCU through these incisions, from proximal to distal.
- Supinate the forearm and pass the remaining tendon slip around the ECU to keep the soft-tissue leash positioned around the ECU; this helps keep the tendon stabilized dorsally on the distal ulna. Tighten the tendon slip, and suture it to the interosseous membrane.

  Postoperatively, maintain the forearm in supination for 6 weeks and then begin controlled motion and night splinting for an additional 2 to 4 weeks. The patient should avoid heavy stress on the ligament for 3 months after surgery (Fig. 43.13*C*).

Other procedures have been described that also attempt to create new “ligaments” out of adjacent tissue to stabilize the DRUJ. Blatt and Ashworth (15) designed a procedure to create a new distal-palmar to proximal-dorsal ligamentous structure using a distally based flap of palmar wrist capsule. Breen and Jupiter described another variation of a soft-tissue procedure designed to treat an unstable ulnar shaft after a Darrach procedure (19). They use strips of both the FCU and ECU. The ECU is passed from dorsal to palmar through a drill hole in the ulna and the FCU is pulled in the opposite direction, and then both tendon slips are pulled taught and sutured to each other with the forearm in supination.

All of the preceding procedures are based on the concept that a new ligament can be constructed to passively stabilize the ulna. Although there are insufficient data and large enough series to conclude that any one technique is definitely better than the others, it has been suggested (23) that the Hui-Linscheid procedure may be better than the Tsai-Stilwell procedure because the intraarticular course of the FCU in the latter results in more stiffness and loss of pronation. Another group of procedures that has been described relies on active muscle force to dynamically stabilize the distal ulna. These procedures are more applicable to an unstable distal ulna after the Darrach procedure than to a distal radioulnar joint that is unstable but still has an ulnar head.

### *Dynamic Stabilization—Goldner-Hayes Technique*

Goldner and Hayes (41) described a procedure that relies on the dynamic tethering action of a slip of the ECU (Fig. 43.14).

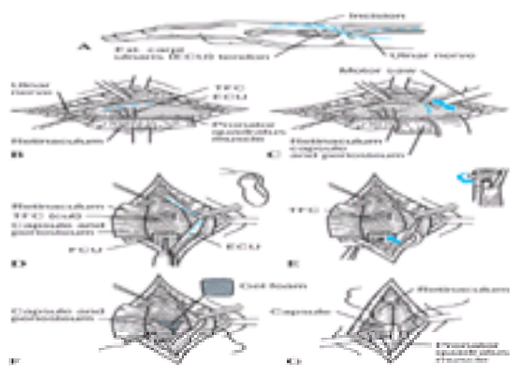

***Figure 43.14.*** Goldner-Hayes technique of stabilizing the distal ulna using half of the extensor carpi ulnaris. **A:** Incision. **B:** The dorsal retinaculum is reflected to expose the TFC and distal ulna. **C:** If not done previously, the ulnar head is removed as shown. **D:** Dorsal view, following ulnar head resection; a drill hole is made in the distal ulna in preparation for passing one half the ECU to be harvested (dotted line). **E:** The harvested ECU is passed through the tunnel in the distal ulna, wrapped 180° around the ulnar shaft, and sutured to itself (**inset**). **F:** Gel foam may be placed over the cut surface of the distal ulna (optional), and then the capsule and periosteum are closed. **G:** The retinaculum is carefully closed over the remaining ECU tendon. Redrawn from an illustration by Elizabeth Roselius © 1993, with permission.

- Make a longitudinal incision dorsally over the distal radioulnar joint. Identify and isolate the dorsal cutaneous branch of the ulnar nerve.
- Identify the ECU tendon and retract it, and identify and retract the extensor digitorum communis tendon to the little finger. Elevate the periosteum off the distal ulna by sharp dissection.
- If the ulnar head has been resected previously, shape the end of the ulna with a rongeur so that the dorsal edge is rounded, and trim the radial aspect so that there will be no impingement on the tendons to the little finger.
- Split the ECU from its insertion distally to a point 1 cm proximal to the newly shaped end of the ulna; the strip should be about one third of the width of the tendon and taken from the ulnar side of the tendon.
- While the forearm is held in supination, drill a 3-mm hole in the proximal ulna. The hole should enter the dorsal ulna 5 mm proximal to the end of the ulna and exit the medullary canal. Enlarge the tunnel slightly with curets if necessary.
- Pass the freed segment of the ECU through the hole from a dorsal to palmar position. Direct the tendon to the ulnar side of the remaining proximal ulna and suture it back on itself where the tendon entered the bone. This creates a cuff of tendon directly over the end of the ulna, which stabilizes the remaining ECU and tethers it toward the radial side of the ulna. Wrap the remaining tendon 180° around the ulnar stump. It should not be wrapped circumferentially, as this would cause impingement with forearm rotation.
- Close the soft tissues in routine fashion.

Postoperatively, immobilize the forearm in supination for 2 weeks and then begin gradual forearm rotation exercises. Protect the wrist for 3 months with a removable splint at night and intermittent splinting during the day. Goldner noted that snapping and popping of the soft tissues occasionally persist for 4 to 6 months postoperatively. Maximum improvement may take 1 year.

### *Transfer of the Pronator Quadratus Origin—Johnson Technique*

Johnson (49,50) described a technique of advancing the pronator quadratus so that it becomes a dynamic stabilizer of the DRUJ (Fig. 43.15). The procedure can be used for patients with an intact ulnar head as well as those who have had a previous Darrach procedure.

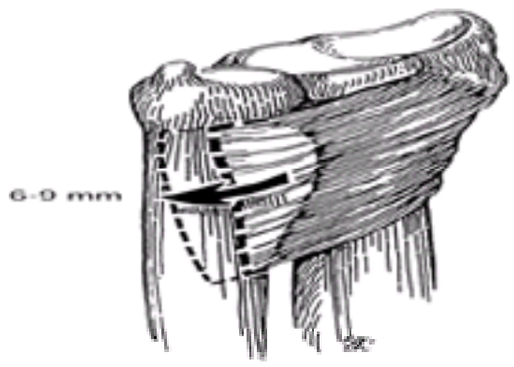


***Figure 43.15.*** The pronator quadratus advancement recommended by Johnson to treat dynamic instability of the DRUJ, seen from a palmar perspective. Redrawn from an illustration by Elizabeth Roselius © 1993, with permission.

- Make a dorsoulnar incision over the distal forearm. Identify and protect the dorsal cutaneous branch of the ulnar nerve.
- Identify the tendon of the ECU but do not unroof its sheath.
- Identify the pronator quadratus muscle distally and remove its origin from the ulna, working distally to proximally and including as much periosteum as possible with the tendon. By passively pronating the forearm, the muscle can be relaxed enough to allow for easy advancement dorsally.
- Advance the muscle 6 to 9 mm dorsally and secure it to the tendon sheath of the ECU with interrupted, nonabsorbable sutures.
- Rotate the forearm back to neutral position and cross-pin the radius and ulna with two 0.062-in. Kirschner wires (K-wires). Maintain the forearm in neutral for 4 weeks and then remove the pins and let the patient begin a supervised exercise program, including gentle range of motion and strengthening.

### *Treatment of a Failed Darrach Procedure*

A failed Darrach procedure with a painful, unstable distal ulnar shaft can be a difficult problem to treat. Ruby et al. (85) described a technique for transferring the pronator quadratus dorsally through the interosseous space to stabilize the distal ulna (Fig. 43.16). They suggested that this be used in combination with the Darrach procedure at the time of the original surgery or to treat Darrach procedure failures.

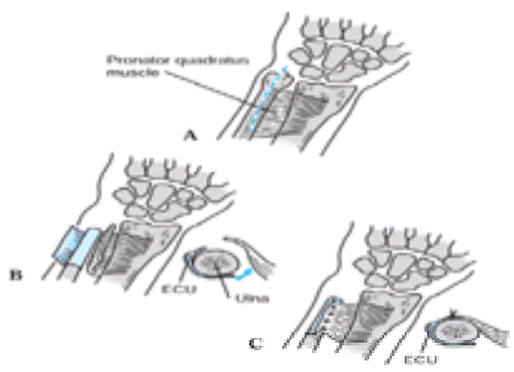


***Figure 43.16.*** Illustration of the pronator quadratus transfer described by Ruby et al. **A:** Incision of skin and periosteum. **B:** Periosteal flap is created, and pronator quadratus is delivered through the interosseous space. **C:** Pronator is sutured to the periosteal flap to stabilize the distal ulna. Redrawn from an illustration by Elizabeth Roselius © 1993, with permission.

### *Stabilization of the Ulna after Failed Darrach—Kleinman and Greenberg Technique*

Kleinman and Greenberg (56) described a procedure (Fig. 43.17) designed to solve the problem that combines the principles of stabilizing the ulnar stump with a strip of the ECU (as in the Goldner and Hayes procedure) with transfer of the pronator quadratus origin [as in the transfer described by Ruby et al. (85)]. Their original report described use of the procedure in six patients, and it was successful in all.

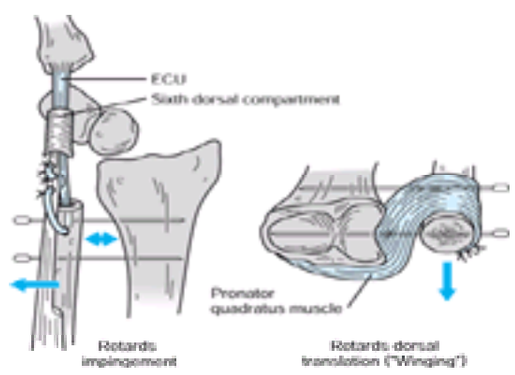


***Figure 43.17.*** Kleinman-Greenberg procedure for treating distal ulna instability resulting from a failed Darrach resection. The ECU tenodesis retards radioulnar impingement, and the pronator quadratus transfer limits dorsal translation. Temporary percutaneous pinning of the ulna to the radius adds additional stability. Redrawn with permission (56).

- Make a curvilinear dorsoulnar approach to the ulnar stump at the wrist level, extending the incision proximally along the distal ulnar diaphysis.
- Approach the ulna through the interval between the ECU and FCU, isolating the end of the previous Darrach resection. Smooth the contour of the remaining distal ulna if necessary.
- Dissect the pronator quadratus free of its palmar-medial insertion on the ulna and mobilize it radially to allow subsequent transfer from a palmar to a dorsal direction through the interosseous membrane.
- Use a burr to ream the intramedullary canal for later intramedullary passage of the ECU tendon. Harvest a slip of the ECU from proximal to distal, leaving its distal insertion intact. Make an exit hole 1.5 cm proximal to the end of the ulna. Pass the distally based 50% of the ECU through the canal and out the cortical drill hole in preparation for tenodesis.
- Drill two divergent K-wires (0.062 in.) percutaneously through the ulnar border into the radius using a lamina spreader to maintain the desired interosseous distance. The wires should diverge to prevent postoperative migration of the radius and ulna.
- Transfer the previously harvested pronator quadratus through the interosseous space and secure it to the dorsal-medial ulna. Tension the ECU to support the radioulnar space with the wrist in 10° ulnar deviation and suture it in place to complete the tenodesis.
- Postoperatively, immobilize the wrist and forearm in a bulky dressing reinforced with plaster splints extending above the elbow for 2 weeks, followed by a cylinder cast for 4 weeks. Remove the K-wires at 6 weeks, and then begin range-of-motion exercises.

### *The Sauvé-Kapandji Procedure*

None of the soft tissue procedures fully achieves the dual goals of restoring radioulnar stability while still allowing forearm rotation. Chronic instability that is deemed too

severe for a soft-tissue reconstruction or instability that persists despite other attempts at management is an indication for a salvage operation using a bony procedure. Arthrodesis of the distal radioulnar joint combined with a surgically created pseudarthrosis site proximally in the ulna is now commonly referred to as the Sauvé-Kapandji procedure. In many cases of painful instability of the DRUJ, it may be the most predictable treatment option.

Sauvé and Kapandji (87) described their procedure for the DRUJ in an article that was published in French in 1936. They were not the first to describe such a procedure (9,57) but have often been credited with its inception, and the association between their names and the procedure as it is now performed is deeply entrenched in the literature. In their description, Sauvé and Kapandji recommended resection of a 3-cm segment of distal ulna just proximal to the DRUJ, followed by decortication of the opposing joint surfaces and fixation with a single screw. They also advocated interposition of the pronator quadratus into the gap in the ulna to prevent reossification of the pseudarthrosis site.

Over the years, the technique has changed, and it continues to evolve. For example, the use of a single screw across the arthrodesis site as suggested by Sauvé and Kapandji has been supported by some authors (64,84,111), but a single screw does not provide rotational control of the distal ulnar segment. Therefore, other authors recommended the use of two screws (51) or two K-wires (96) to stabilize the distal fragment. Various uses have been proposed for the bone resected from the ulna. Goncalves (42) used it as a cortical strut wedged between the radius and ulna. Blanco and Blanco (14) used a 20 mm × 6 mm peg fashioned from the excised ulnar segment together with two K-wires to stabilize the arthrodesis construct.

Throughout its evolution the salient features of the Sauvé-Kapandji procedure have remained unchanged: one must stabilize the DRUJ, restore forearm rotation, prevent reformation of bone across the resected segment, and avoid painful instability of the residual ulnar shaft.

- Make a straight longitudinal incision, 6 to 8 cm long, along the ulnar border of the distal forearm (Fig. 43.18). Bluntly dissect and identify the dorsal cutaneous branch of the ulnar nerve; isolate and protect this nerve throughout the procedure. An alternative incision may be used for selected patients in whom additional procedures are planned at the same sitting. For example, in patients with rheumatoid arthritis, the Sauvé-Kapandji procedure may be combined with another soft-tissue procedure such as a dorsal wrist synovectomy, tenosynovectomy, or tendon transfer to treat extensor tendon ruptures that result from the caput ulnae syndrome. In such cases, start the incision more dorsally to facilitate exposure for the additional procedure, and then extended it proximally and obliquely to expose the distal ulna. Again, identify and protect the dorsal cutaneous branch of the ulnar nerve, which usually crosses the operative field.

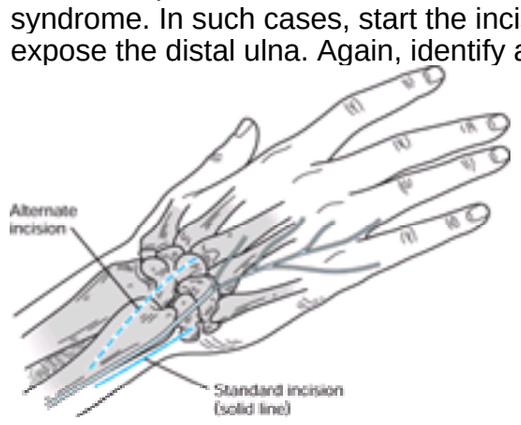


***Figure 43.18.*** The Sauvé-Kapandji procedure. The standard (*solid line*) and alternate (*dotted line*) incisions, emphasizing the position of the dorsal cutaneous branch of the ulnar nerve. The alternate incision courses more obliquely and dorsally than the standard incision and can be used if additional procedures are planned such as extensor tenosynovectomies in patients with rheumatoid arthritis. (Illustration by Birk Cox. Reprinted with permission from Slater RR, Szabo RM. The Sauvé-Kapandji Procedure. *Tech Hand Upper Extremity Surg* 1998;3:148.)

- Expose the distal 4 to 6 cm of the ulna extraperiosteally through the interval between the ECU and FCU. Next, select the appropriate level for an osteotomy of the ulnar diaphysis (Fig. 43.19).

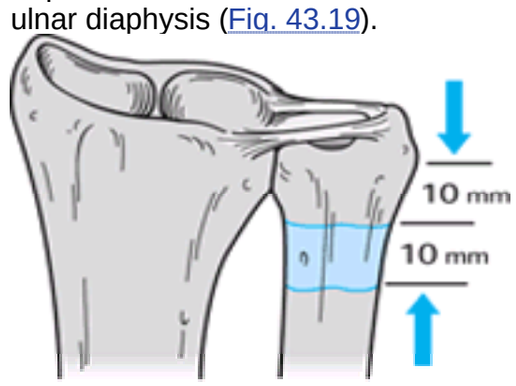


***Figure 43.19.*** The Sauvé-Kapandji procedure. Illustration of the ideal ulnar resection leaving approximately 1 cm of ulna distal to the osteotomy to allow fixation with two screws and resecting a 10- to 12-mm cuff of distal ulnar shaft. (Illustration by Birk Cox. Reprinted with permission from Slater RR, Szabo RM. The Sauvé-Kapandji Procedure. *Tech Hand Upper Extremity Surg* 1998;3:148.)

- Cut the bone just proximal to the flare of the ulnar head, which will leave enough of a distal ulnar segment to accommodate two fixation screws. It is helpful to use fluoroscopy to confirm that the proposed osteotomy site is appropriate. Make a second cut proximal and parallel to the first and remove a 10- to 12-mm segment of ulna. Save the removed bone for subsequent grafting into the DRUJ arthrodesis site.
- Next, expose the distal radioulnar joint. Make a dorsoulnar capsulotomy just radial to the ECU tendon. Alternatively, stay palmar to the ECU tendon and expose the joint by grasping the distal ulnar segment with a towel clip and reflecting it distally and medially, using the TFCC as a hinge (Fig. 43.20). Denude both the ulnar head and sigmoid fossa of the radius of all remaining cartilage and subchondral bone to create flush surfaces of cancellous bone on each side of the arthrodesis site.

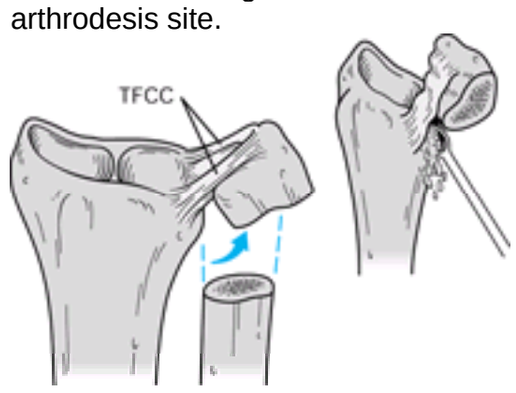


***Figure 43.20.*** The Sauvé-Kapandji procedure. The DRUJ can be exposed through a straight medial approach, reflecting the distal ulnar segment distally and medially, hinging it on the TFCC as illustrated. The joint then can be decorticated and prepared for fusion (**inset**). (Illustration by Birk Cox. Reprinted with permission from Slater RR, Szabo RM. The Sauvé-Kapandji Procedure. *Tech Hand Upper Extremity Surg* 1998;3:148.)

- Cannulated screws are ideal for fixation of the arthrodesis site and offer several advantages over K-wires and solid screws. Using cannulated screws over guide wires allows accurate screw placement and facilitates the alignment of the cortices of the distal ulna and radius. There is no need to remove hardware. Rehabilitation can begin sooner because of secure fixation. K-wires can be problematic because buried pins can irritate cutaneous nerves, and percutaneous pins can cause wound problems; both are avoided if screws are used.
- After selecting the desired fixation device and preparing the joint surfaces for fusion, the next step is to establish ulnar neutral variance. Move the ulnar head proximally or distally as required to bring its distal surface parallel with the distal radius surface (Fig. 43.21); confirm correct position fluoroscopically.

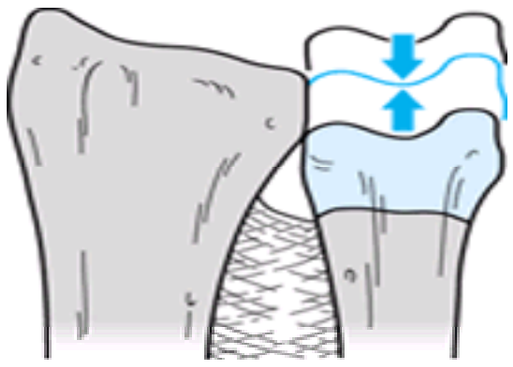

***Figure 43.21.*** The Sauvé-Kapandji procedure. Establish ulnar neutral variance by moving the distal ulnar segment proximally or distally as necessary to align the articular surface of the ulnar head even with the articular surface of the distal radius. Fluoroscopy is helpful for this step. (Illustration by Birk Cox. Reprinted with permission from Slater RR, Szabo RM. The Sauvé-Kapandji Procedure. *Tech Hand Upper Extremity Surg* 1998;3:148.)

- Select two appropriate guide wires from the chosen screw set and drill them into place to stabilize the ulnar head in proper position. Pass one wire through the radioulnar joint a few millimeters proximal to the subchondral bone; place the second wire proximal enough to allow room for seating of both screw heads without impingement on each other (Fig. 43.22). Confirm correct placement of the guide wires with fluoroscopy. It is important to do this while holding the forearm in neutral rotation. This is best accomplished with the patient's elbow resting on the operating table while the forearm is supported perpendicular to the table in neutral rotation. Avoid the tendency to rest the forearm in pronation on the operating table.

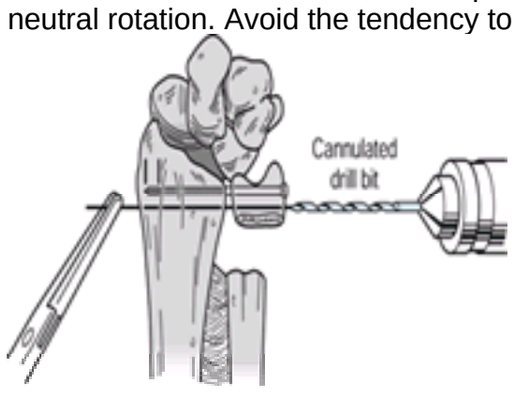


***Figure 43.22.*** The Sauvé-Kapandji procedure. Drill two guide wires for the selected cannulated screws parallel across the distal ulnar segment into the distal radius and across to the far cortex of the radius, and use a cannulated measuring guide to determine the appropriate screw lengths. After the screw lengths have been determined, advance the guide wires through the skin and hold them with a clamp to prevent displacement while the guide wires are overdrilled and the screws placed. (Illustration by Birk Cox. Reprinted with permission from Slater RR, Szabo RM. The Sauvé-Kapandji Procedure. *Tech Hand Upper Extremity Surg* 1998;3:148.)

- Advance the distal wire to the far (radial) cortex of the radius and measure for screw length. The proximal screw provides rotational control and needs only tricortical fixation; therefore, it should be 5 mm shorter than the distal screw. It also can be smaller in diameter if desired, which helps minimize the risk of fracturing the narrow ulnar diaphysis. After the guide wires are in proper alignment and the screw lengths have been measured, advance the wires through the skin to the radial side of the forearm with a mallet and grasp them with a clamp to avoid loss of position during the next steps (Fig. 43.22). Using a mallet minimizes the chance of wrapping up a radial sensory nerve branch with the power drive.
- Next, overdrill the guide wires with a cannulated drill bit. A tap is not usually necessary, but use it if the cortical bone is particularly dense. Before insertion of the screws, pack the cancellous bone harvested previously from the excised ulnar segment into the arthrodesis site as a graft (Fig. 43.23). In cases with severe bone loss, insert the resected ulnar piece as a corticocancellous bone graft into the DRUJ space. Then insert the selected screws over the guide wires while manually compressing the ulnar head against the radius. Tighten the distal screw first to avoid compressing the radial and ulnar shafts together and levering the ulnar head out of position.

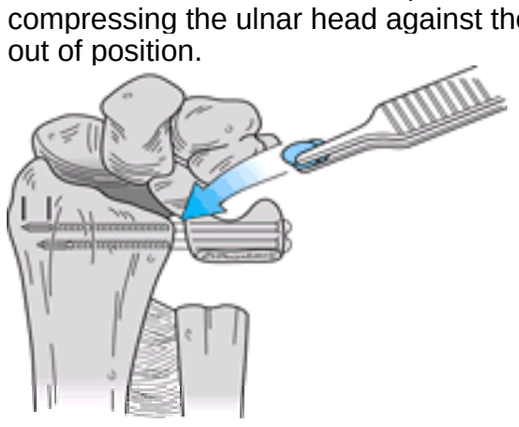

***Figure 43.23.*** The Sauvé-Kapandji procedure. Cancellous bone from the excised ulnar segment can be packed into the arthrodesis site before the screws are fully seated. The final position of the screws is illustrated. (Illustration by Birk Cox. Reprinted with permission from Slater RR, Szabo RM. The Sauvé-Kapandji Procedure. *Tech Hand Upper Extremity Surg* 1998;3:148.)

- Make a final adjustment of the proximal ulnar shaft length with another osteotomy (if necessary) so that there is a gap of 10 to 12 mm between the proximal and distal ulnar segments. Suture the fascia of the underlying pronator quadratus into the resultant gap to prevent reossification across the pseudarthrosis site (Fig. 43.24). This also helps stabilize the stump of the ulnar shaft. Repair the extensor compartments if they were disrupted, for example, to perform tenosynovectomies. Close the skin in routine fashion and obtain final radiographs.

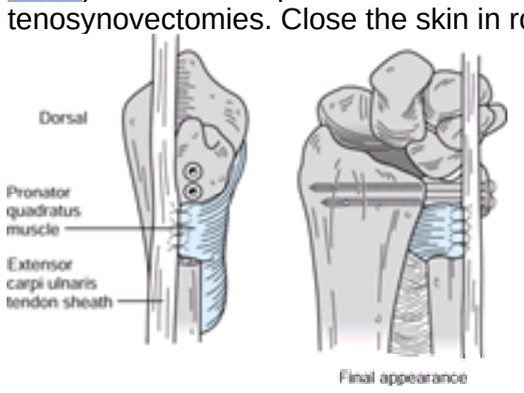


***Figure 43.24.*** The Sauvé-Kapandji procedure. Suture the pronator quadratus in place in the gap where the ulnar segment was excised (left). The final appearance of the construct is illustrated (right). (Illustration by Birk Cox. Reprinted with permission from Slater RR, Szabo RM. The Sauvé-Kapandji Procedure. *Tech Hand Upper Extremity Surg* 1998;3:148.)

### *Triangular Fibrocartilage Complex Instability*

Injury to the triangular fibrocartilage complex is diagnosed with increasing frequency as a cause of ulnar-sided wrist pain. Disruption of the TFC may be associated with instability of the distal radioulnar joint, or the lesions themselves may be unstable and symptomatic without causing instability of the entire joint. Treatment depends on location and characteristics of the injury (Table 43.6). Tears at the periphery of the TFC, along the well-vascularized medial insertion, are amenable to repair.

Increasingly, surgeons are making the repairs arthroscopically, as described in Chapter 75, but the procedure also may be done by open technique, as originally described.

| Tear Classification[1] | Lesion Location | Treatment |
|---|---|---|
| Traumatic | | |
| 1A | 2–3 mm from radial attachment | Debridement[2] |
| 1B | Base of ulnar styloid | Open/arthroscopic repair |
| 1C | Carpal attachment | Debridement |
| 1D | Radial attachment | Debridement/possible repair |
| Degenerative | | |
| II-1 | Central TFCC wear | Debridement |
| II-2 | Lunate/ulnar head chondromalacia | Debridement |
| II-3 | TFCC full thickness perforation, lunate/ulna chondromalacia | Debridement |
| II-4 | Stage II-3, and lunotriquetral ligament tear | Debridement/possible limited ulnocarpal fusion |
| II-5 | Ulnocarpal arthritis | Limited or total wrist arthrodesis |

[1] Classification according to Palmer et al.
[2] Debridement may be done open or arthroscopically.

***Table 43.6. Treatment of TFCC Tears***

### *TFCC Repair—Open Technique*

Hermansdorfer and Kleinman (46) described the following method of repairing the TFCC under direct visualization (Fig. 43.25).

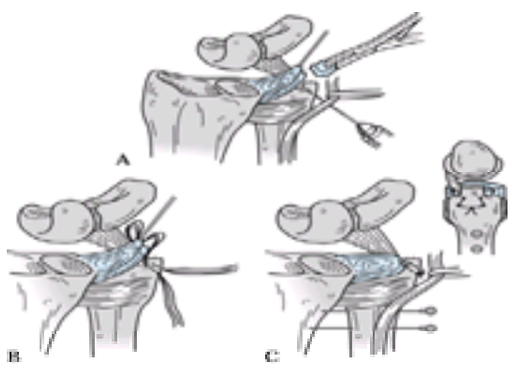


***Figure 43.25.*** Open repair of peripheral TFCC tears. **A:** Chronic granulation tissue is debrided from the site of injury, a cancellous bony trough is made at the base of the fovea, and drill holes are made across the ulnar cortex into the trough. **B:** 3-0 nonabsorbable sutures are placed through the prepared edge of the TFCC and passed through the drill holes. **C:** The distal ulna is percutaneously pinned to the radius with K-wires, and then the sutures are tied securely to reconstitute normal tension in the TFCC. Reprinted with permission (46).

- Make a dorsal skin incision paralleling the distal 3 cm of ulna and extending 3 cm distally and radially. Raise a radially based long retinacular flap to later support the ECU tendon dorsal to the flexion-extension axis of rotation. Retract the ECU tendon ulnarly and enter the ulnocarpal joint via a capsulotomy between the fifth and sixth dorsal compartments. Carefully avoid any further injury to the TFCC.
- Identify the traumatically separated TFCC and debride any granulation tissue from the fovea. Create a trough at the base of the fovea by curettage to cancellous bone.
- Place the forearm in neutral rotation and percutaneously pin the distal ulna and radius with two parallel 0.062-in. K-wires to maintain this alignment. Drill parallel small holes through the distal ulna, exiting at the base of fovea.
- Place 3-0 nonabsorbable sutures through the prepared edge of the TFCC and pass them through the drill holes. Tighten the sutures to bring the torn edge of the TFCC back to the fovea and tie them securely while trying to reconstitute the normal tension in the cartilage disc.
- Repair the dorsal capsule with inverted sutures and pass the previously designed flap of extensor retinaculum deep to the ECU and secure it distally to prevent ulnar subluxation of the tendon. That further enhances DRUJ stability as well.
- Postoperatively, immobilize the extremity in a plaster-reinforced bulky dressing extending above the elbow for 10 to 14 days, followed by an above-elbow cast for 4 weeks. Remove the K-wires after 4 weeks and immobilize the wrist in a below-elbow cast for an additional 6 weeks. Begin vigorous rehabilitation of the forearm and wrist at 12 weeks.

In their original series, Hermansdorfer and Kleinman (46) reported that 8 of 11 patients with follow-up greater than 1 year after this procedure returned to normal activities without pain. Measured grip strength averaged 87% of that of the uninjured hand, and measured wrist and forearm motion averaged between 96% and 99% of the contralateral side. Similar results have been reported by other authors after open and arthroscopic TFCC repairs (27,102).

Little attention in the literature has been given to palmar instability of the DRUJ. It has been my experience that the usual cause of this problem is a malunion of one or both forearm bones, and treatment with soft-tissue procedures is ineffective. If palmar instability is found (usually aggravated by supination), conduct a careful radiographic assessment of the forearm with comparative views of the normal extremity. Corrective osteotomy (angular, rotational, or both) is required to eliminate the instability.

## INCONGRUITY LESIONS

Incongruity of the DRUJ usually results in arthritis. A variety of surgical options have been proposed for treatment. Swanson recommended resection of the distal ulna and replacement with a silicone cap (94). Complications from silicone synovitis, particulate debris, and prosthesis failure led to the abandonment of this procedure and development of different techniques. Other forms of resection arthroplasty have gained more popularity.

### *Hemiresection Interposition Technique Arthroplasty—Bowers Technique*

The basic premise of the hemiresection interposition technique (HIT) arthroplasty operation described by Bowers (17) is that the portion of the distal ulna that articulates with the sigmoid notch of the distal radius is excised while the distal ulnar shaft and styloid process are preserved (Fig. 43.26). This preserves the triangular fibrocartilage complex, removes the damaged portion of the ulnar head, and maintains stability of the distal ulna.

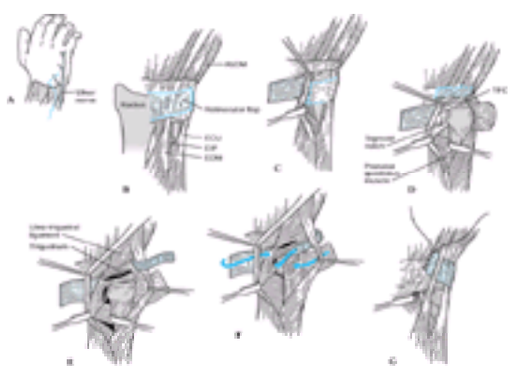

***Figure 43.26.*** Bowers' hemiresection interposition technique (HIT) of DRUJ arthroplasty. **A:** Incision, emphasizing the location of the dorsal cutaneous branch of the ulnar nerve. **B:** Outline of the dorsal retinacular flaps, proximal (1) and distal (2). **C:** The proximal flap has been reflected showing the proposed flap in the DRUJ

capsule (dotted line). **D:** The capsular flap has been reflected to expose the ulnar head and DRUJ. **E:** The second retinacular flap (*2*) has been reflected to expose the TFC and its carpal face. **F:** The ulnar head has been resected, and the capsular and retinacular flaps are set for repositioning. **G:** The first retinacular flap (*1*) is used to stabilize the ECU tendon. *EIP,* extensor indicis proprius, *EDM,* extensor digiti minimi. Redrawn from an illustration by Elizabeth Roselius © 1993, with permission.

- With the forearm in full pronation, open the interval between the extensor digiti quinti and ECU. Identify and protect the dorsal cutaneous branch of the ulnar nerve (Fig. 43.26*A*).
- Develop two flaps of the extensor retinaculum. The proximal flap, about one half the width of the retinaculum, is based radially; the distal flap is based ulnarly. Radial retraction of the extensor digiti quinti at this level places the surgeon immediately dorsal to the sigmoid notch of the radius (Fig. 43.26*B*, Fig. 43.26*C*).
- Open the capsule of the DRUJ close to the radius, allowing enough tissue to repair later. The entire triangular fibrocartilage can be seen through this interval. Remove the convexity of the ulnar head. The resection should preserve the shaft and ulnar styloid relationship (Fig. 43.26*F*).
- Suture the ulnarly based capsular flap over the raw bone of the distal ulna, with the sutures entering the palmar wrist capsule. Rotate the forearm to verify that there is no bony contact between the radius and ulna (Fig. 43.26*G*).
- If there is inadequate tissue to prevent radioulnar contact, place an “anchovy” of tendon from the palmaris longus tendon in the defect previously occupied by the ulnar head. If there is ulnar positive variance and impaction of the remaining ulnar styloid with the carpus on ulnar deviation of the wrist, the HIT may need to be combined with ulnar shortening to prevent translation and impingement of the residual ulna and ulnar styloid.
- After proper bony alignment is obtained, suture the distal, ulnarly based retinacular flap to the dorsal capsular structure remaining on the sigmoid notch. Pass the proximal, radially based flap around the ECU and suture it to the distal aspect of the retinaculum of the fourth compartment.
- Postoperatively, immobilize the forearm in neutral rotation for 3 weeks and then begin rehabilitation.

### *Matched Ulna Procedure–-Watson Technique*

Watson et al. (106) proposed that the distal ulna resection be performed with the intention of sculpting the distal ulna to carefully “match” the slope and shape of the distal radius throughout the arc of forearm pronation and supination. As Watson describes it, the operation should be performed as follows.

- Place the patient on the operating table with the affected extremity fully pronated on a hand table. The surgeon sits cephalad to the arm. Under tourniquet control, make a longitudinal incision dorsoulnarly over the distal ulna. Open the proximal edge of the extensor retinaculum over the ulnar head.
- Use Lexell rongeurs to begin the resection of the distal ulna approximately 5 to 6 cm proximal to the end of the ulna between the extensor digitorum communis and ECU. Resect the distal ulna in a long, sloping manner resembling an eccentrically sharpened pencil, not unlike the shape of a finger with the remaining ulnar cortex, representing the finger “nail,” facing ulnarward (Fig. 43.27). Rotate the forearm into full pronation and shape the ulna to match the surface and shape of the radius where they oppose each other. Similarly, rotate the forearm into full supination and shape the ulna to match the opposed surface of the radius. Inspect the flare of the radius at the sigmoid fossa. The dorsal rim of the fossa is usually more prominent than the palmar flare. If the flare protrudes ulnarward, it may impinge on a dorsal riding ulna. In that case, trim the radius to avoid that problem.

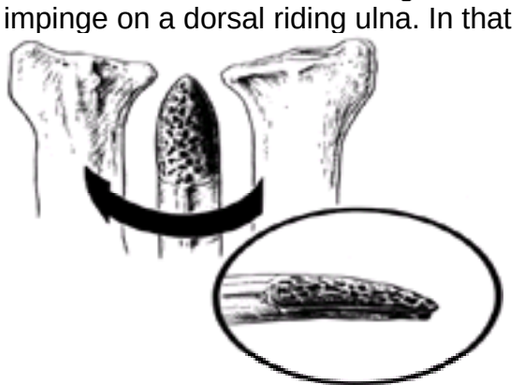

***Figure 43.27.*** Illustration of the matched ulna resection arthroplasty of the DRUJ. The distal ulna is shaped to resemble a finger (**inset**) with the finger “nail” facing ulnarward and contoured so there is no impingement against the distal radius through a full arc of forearm rotation.

- After removal of the ulnar head, the ulnar styloid will migrate radially and may impinge on the carpals. Check an x-ray and be sure the distalmost ulna lies at the level of the articular surface of the radius. Resection of the ulnar styloid is almost always necessary to achieve this. Then palpate between the radius and ulna to assure there are matching surfaces throughout the arc of forearm rotation. No interposition of soft tissue is necessary. The deep fascia of the ECU sheath may remain attached to the periosteum of the ulna, but this is not necessary. The raw bone of the distal ulna will become securely adherent to the ulnar sling mechanism without sutures or fixation.
- Occasionally the slope of the sulcus of the radius is reversed. When seen on a PA radiograph, the proximal portion of the radius sulcus joint protrudes more ulnarward than the distal portion; that is, the slope of the radius sulcus joint may be from proximal ulnar to distal radial. When the joint is shaped in this fashion, the proximal portion of the sulcus should be removed with a rongeur so that the radius and ulnar surfaces are again parallel to one another.
- Close the skin in routine fashion and apply a bulky hand dressing with a plaster splint that extends to the elbow but not above. The below-elbow dressing allows immediate forearm pronation and supination. Seven to 10 days postoperatively, patients should begin full mobilization out of the splint.

Uniform results and consistent pain relief do not follow the Bowers and Watson procedures. In a series in patients with posttraumatic DRUJ disorders reported by Saffar et al. (86), pain relief, wrist motion, and grip strength improved more after the Sauvé-Kapandji procedure than after the Bowers or Watson procedures. My own experience and observations are similar, and therefore I prefer the Sauvé-Kapandji procedure. It provides more predictable results in a variety of settings, including osteoarthritis. A recent study by Minami et al. (65) reported 15 patients with osteoarthritis of the DRUJ treated in this fashion, and all achieved good results. They suggested that this should not be done if the TFCC is intact or repairable but gave no supporting data for this statement. I do not consider an intact TFCC a contraindication to the Sauvé-Kapandji procedure. In fact, it seems logical to leave the distal ulna as a buttress for the intact TFCC. Taleisnik (97) considers retention of the distal ulna to help stabilize the TFCC, an advantage of the procedure.

## SPECIAL CONDITIONS

### *Rheumatoid Arthritis*

In evaluating patients with rheumatoid arthritis (RA), make an effort to distinguish the pain and instability of the DRUJ from radiocarpal and midcarpal joint symptoms. This is done by careful palpation, ballottement, and compression of the specific areas and a comparison of the degree of symptoms elicited by forearm rotation versus wrist flexion and extension. Despite advanced radiographic findings of radiocarpal and/or midcarpal arthritis, many arthiritis patients' complaints of “wrist pain” can be satisfied by addressing the DRUJ pathology.

The inflammatory changes and deforming forces acting on the hand and wrist in RA tend to cause palmar and ulnar displacement of the wrist, resulting in decreased mobility, strength, and function. Commonly, resection of the distal end of the ulna, the Darrach procedure, has been recommended for patients with RA and ulnar-sided wrist pain (48,69,81). However, removal of the distal ulna accelerates further palmar and ulnar translocation and ultimately dislocation of the carpus. This complication has been seen in patients with rheumatoid arthritis treated with the Darrach procedure (13,104). Black et al. (13) showed this to occur in 5 of 34 cases reviewed. Six other cases developed spontaneous radiocarpal ankylosis that stabilized the wrist and prevented the ulnar-palmar drift of the carpus.

In view of the limited success of total wrist arthroplasties and the alternative of wrist arthrodesis, the Sauvé-Kapandji procedure is an excellent choice for patients with rheumatoid arthritis and may obviate the need for further surgery on the radiocarpal joint (Fig. 43.28). With the Sauvé-Kapandji procedure, retention of the distal ulna provides a bony support for the ulnar side of the wrist and preserves the soft-tissue attachments of the ulnocarpal complex. The resulting stability at the wrist in rheumatoid patients may help prevent more distal joint deformity (104). The ulnar osteotomy allows as much shortening as necessary to match the length of the radius while retaining forearm rotation.

***Figure 43.28.*** Radiographic appearance of the wrist of a patient with rheumatoid arthritis before and after the Sauvé-Kapandji procedure. The preoperative PA (**A**) and lateral (**B**) and postoperative PA (**C**) and lateral (**D**) views are shown.

Results of the Sauvé-Kapandji procedure used to treat patients with rheumatoid arthritis have been generally good. In one series, 21 wrists in 17 patients were followed for an average of 39 months following the Sauvé-Kapandji procedure (104). All patients reported an increased ability to use their wrists in the functions of daily living after surgery when compared to before surgery and were pleased with the results. At an average of 39 months' follow-up, forearm pronation averaged 78°, and supination 86°. X-rays showed that ulnar and palmar translocations of the carpus were prevented.

In some cases of rheumatoid arthritis, wrist involvement is so severe that no radiocarpal motion is left, or the wrist is already dislocated. In that setting, a wrist arthrodesis or replacement arthroplasty is indicated. Then there is no benefit to the Sauvé-Kapandji procedure, and the Darrach procedure can be used to treat the DRUJ.

### *Essex-Lopresti Lesions*

In 1951, Essex-Lopresti (37) described two cases of comminuted fractures of the radial head associated with dislocations of the DRUJ. He speculated that the mechanism of injury was a violent longitudinal compression force along the long axis of the forearm that resulted in disruption of the DRUJ and the interosseous membrane and fracture of the radial head. Recognizing the extent of the injury to the forearm, Essex-Lopresti recommended not excising the radial head, or, if that were necessary, implanting a prosthesis in place of the radial head to hold the radius out to length while the interosseous membrane healed.

Since the original report, other authors (20,35) have shown that injuries of the Essex-Lopresti type can occur in conjunction with a variety of forearm fractures. The essential features of the injury are a disrupted DRUJ, a radial head fracture, and an associated forearm fracture. It is important to recognize this injury pattern so that it can be treated appropriately. Every effort should be made to preserve the radial head and perform open reduction with internal fixation of the fracture if a stable closed reduction is not obtainable. If the radial head must be excised for some reason, a prosthesis may be put in its place temporarily. A definitive procedure may be done later. One option for the symptomatic, established Essex-Lopresti lesion is replacement of the fragmented radial head or prosthesis with an allograft radial head. A preliminary report of that procedure in five patients followed for 2 to 7 years described good or excellent results in all patients (95).

### *Galeazzi Fracture-Dislocations*

A fracture of the shaft of the radius associated with dislocation of the DRUJ was reported by Cooper in the mid-19th century (28). Nearly 100 years later, in 1935, Galeazzi (40) described his experience with 18 cases. Since then, Galeazzi's name has come to be associated with a fracture of the distal radius in combination with a dislocated DRUJ. It is estimated (68) that these injuries account for nearly 7% of all fractures of the forearm in adults. The mechanism of injury is usually a fall on the outstretched hand with the forearm pronated. With the hand fixed to the ground, continued rotation of the patient's body causes hyperpronation, and the resultant forces cause the radial shaft to fracture. The radius then shortens, producing a disruption of the TFCC or an avulsion fracture of the ulnar styloid, which destabilizes the DRUJ.

Nonsurgical treatment of Galeazzi fracture-dislocations generally results in persistent symptoms, including recurrent or persistent dislocations of the DRUJ (63). Therefore, Galeazzi fracture-dislocations should be treated operatively whenever possible to maximize the chance for a good outcome. The fracture should be fixed rigidly, generally by open reduction and plating. The DRUJ should then be reduced. It should snap into place with a solid endpoint and is usually most stable in supination.

If the DRUJ can not be reduced or tends to spring back into subluxation or dislocation, it suggests soft tissue interposed in the joint. Most often, the ECU is the offending tissue. It may displace around the ulnar border of the dorsally dislocated ulna (6). Other structures that have been reported to block reduction include the extensor digitorum tendons, the extensor digiti minimi, the flexor pollicis longus, and the median nerve (12,93). In those cases where the joint cannot be reduced, make an incision over the dorsal aspect of the DRUJ, reflect the displaced soft tissues out of the way, and repair the sheath of the ECU to keep it centered over the distal ulna. Postoperatively, immobilize the forearm in approximately 20° to 30° supination for the first 4 weeks, followed by rehabilitation to gradually restore forearm rotation.

### *Capsular Release for Rotational Contracture*

Fixed pronation or supination contractures of the forearm may be the result of prior trauma to the forearm, interosseous membrane, or DRUJ. In selected cases, capsulotomy of the DRUJ may improve forearm rotation. This is particularly true in those patients who had a previous fracture of the distal radius with involvement of the DRUJ and are left with the sequelae of a contracted joint capsule. In a report of 18 patients, af Eckenstam noted 15 patients had improved forearm rotation following DRUJ capsulotomy (4). Other authors have made similar observations (17). A dorsal approach and capsulotomy should be used for patients with loss of pronation, and a palmar approach and release should be used for patients with loss of supination (5,55).

### A WORD ON ARTHROSCOPY

Arthroscopy of the wrist and DRUJ has become a useful way to diagnose and treat lesions of those joints, particularly the triangular fibrocartilage complex. Indications for this surgery are becoming better established. It is beyond the scope of this chapter, however, to address this in detail, and the reader is referred to Chapter 75.

## SUMMARY

In conclusion, in order to develop a satisfactory and successful treatment strategy for the multiple disorders of the distal radioulnar joint, one must first localize the pathology and be able to categorize it based on a good understanding of the anatomy and biomechanics of the region. For impingement problems, particularly ulnocarpal impingement, restoration of the length relationships between ulna and radius is required, frequently in the form of ulnar shortening. Instability often can be treated with an appropriate soft-tissue procedure. When the quality and condition of the soft tissues are inadequate, arthrodesis of the DRUJ in the form of the Sauvé-Kapandji procedure solves the instability problem. Injuries to the TFCC are an important source of problems related to the DRUJ. They should be assessed and treated either openly or arthroscopically, as the surgeon's capabilities allow. Incongruity of the DRUJ requires a bony procedure in the form of a resection arthroplasty or distal ulnar excision (rarely), or the Sauvé-Kapandji procedure.

## CHAPTER REFERENCES

Each reference is categorized according to the following scheme: *, classic article; #, review article; !, basic research article; and +, clinical results/outcome study.


! 1. Adams BD. Partial Excision of the Triangular Fibrocartilage Complex Articular Disk: A Biomechanical Study. *J Hand Surg* 1993;18A:334.

! 2. Adams BD, Holley KA. Strains in the Articular Disk of the Triangular Fibrocartilage Complex: A Biomechanical Study. *J Hand Surg* 1993;18A:919.

! 3. Adams BD, Samani JE, Holley KA. Triangular Fibrocartilage Injury: A Laboratory Model. *J Hand Surg* 1996;21A:189.

+ 4. af Ekenstam FW. Capsulotomy of the Distal Radioulnar Joint. *Scand J Plast Reconstruct Surg* 1988;22:169.

! 5. af Ekenstam F, Hagert CG. Anatomical Studies on the Geometry and Stability of the Distal Radio Ulnar Joint. *Scand J Plast Reconstruct Surg* 1985;19:17.

+ 6. Alexander AH, Lichtman DM. Irreducible Distal Radioulnar Joint Occurring in a Galeazzi Fracture: Case Report. *J Hand Surg* 1981;6A:258.

# 7. Almquist EE. Evolution of the Distal Raidoulnar Joint. *Clin Orthop* 1992;275:5.

* 8. Backdahl M. The Caput Ulnae Syndrome in Rheumatoid Arthritis: A Study of the Morphology, Abnormal Anatomy, and Clinical Picture. *Acta Rheumatol Scand [Suppl]* 1963;5:1.

* 9. Baldwin WI. Orthopaedic Surgery of the Hand and Wrist. In Jones SR, ed. *Orthopedic Surgery of Injuries. Vol. 1.* London: H. Frowde, Hodder and Stoughton, 1921:251–254.

+ 10. Bell MJ, Hill RJ, McMurtry RY. Ulnar Impingement Syndrome. *J Bone Joint Surg* 1985;67B:126.

+ 11. Bieber EJ, Linscheid RL, Dobyns JH, Beckenbaugh RD. Failed Distal Ulna Resections. *J Hand Surg* 1988;13A:193.

+ 12. Biyani A, Bhan S. Dual Extensor Tendon Entrapment in Galeazzi Fracture-Dislocation: A Case Report. *J Trauma* 1989;29:1295.

* 13. Black RM, Boswick JA, Wiedel J. Dislocation of the Wrist in Rheumatoid Arthritis. *Clin Orthop* 1977;124:184.

+ 14. Blanco R, Blanco F. The Use of a Bone Peg in the Sauvé-Kapandji Operation. *J Hand Surg* 1994;19B:221.

* 15. Blatt G, Ashworth CR. Palmar Capsule Transfer for Stabilization Following Resection of the Distal End of the Ulna. *Orthop Trans* 1979;3:13.

# 16. Bowers WH. Distal Radioulnar Joint Arthroplasty. *CORR* 1992;275:104.

# 17. Bowers WH. The Distal Radioulnar Joint. In Green DP, ed. *Operative Hand Surgery.* New York: Churchill Livingstone, 1993:973.

# 18. Braun RM. The Distal Joint of the Radius and Ulna: Diagnostic Studies and Treatment Rationale. *Clin Orthop* 1992;275:74.

+ 19. Breen T, Jupiter J. Extensor Carpi Ulnaris and Flexor Carpi Ulnaris Tenodesis of the Unstable Distal Ulna. *J Hand Surg* 1989;14A:612.

+ 20. Bruckner JD, Alexander AH, Lichtman DM. Acute Dislocations of the Distal Radioulnar Joint. In Pritchard DJ, ed. *Instructional Course Lectures.* Rosemont, IL: American Academy of Orthopaedic Surgeons, 1996:27.

# 21. Bruckner JD, Lichtman DM, Alexander AH. Complex Dislocations of the Distal Radioulnar Joint: Recognition and Management. *Clin Orthop* 1992;275:90.

# 22. Burk DL, Karasick D, Wechsler RJ. Imaging of the Distal Radioulnar Joint. *Hand Clin* 1991;7:263.

# 23. Burkhalter WE. Fractures and Dislocations of the Distal Radioulnar Joint. In Chapman MW, ed. *Operative Orthopaedics, 2d ed.* Philadelphia: JB Lippincott, 1993:1333.

! 24. Chidgey LK, Dell PC, Bittar E, et al. Tear Patterns and Collagen Arrangement in the Triangular Fibrocartilage (abstract). *J Hand Surg* 1990;15A:826.

! 25. Chidgey LK, Dell PC, Bittar ES, Spanier SS. Histologic Anatomy of the Triangular Fibrocartilage. *J Hand Surg* 1991;16A:1084.

! 26. Cone RO, Szabo R, Resnick D. Computed Tomography of the Normal Radioulnar Joints. *Invest Radiol* 1983;18:541.

+ 27. Cooney WP, Linscheid RL, Dobyns JH. Triangular Fibrocartilage Tears. *J Hand Surg* 1994;19A:143.

* 28. Cooper A. *A Treatise on Dislocations and Fractures of the Joints.* London: J Churchill, 1842.

* 29. Dameron TB. Traumatic Dislocation of the Distal Radioulnar Joint. *Clin Orthop* 1972;83:55.

* 30. Darrach W. Forward Dislocation at the Inferior Radio-Ulnar Joint, with Fracture of the Lower Third of the Shaft of the Radius. *Ann Surg* 1912:56:801.

+ 31. Darrow JC, Linscheid RL, Dobyns JH, et al. Distal Ulnar Recession for Disorders of the Distal Radioulnar Joint. *J Hand Surg* 1985;10A:482.

# 32. Davidson AJ, Horwitz MT. Recurrent or Habitual Dislocation of the Inferior Radio-Ulnar Articulation. *Am J Surg* 1938;41:115.

# 33. Dell PC. Distal Radioulnar Joint Dysfunction. *Hand Clin* 1987;3:563.

+ 34. Dingman PVC. Resection of the Distal End of the Ulna (Darrach Operation). An End Result Study of Twenty-four Cases. *J Bone Joint Surg* 1952;34A:893.

+ 35. Edwards GS, Jupiter JB. Radial Head Fractures with Acute Distal Radioulnar Dislocation. *Clin Orthop* 1988;234:61.

! 36. Epner RA, Bowers WH, Guilford WB. Ulna Variance: The Effect of Wrist Positioning and Roentgen Filming Technique. *J Hand Surg* 7:298;1982.

* 37. Essex-Lopresti P. Fractures of the Radial Head with Distal Radio-Ulnar Dislocation. *J Bone Joint Surg* 1951;33B:244.

+ 38. Feldon P, Belsky MR, Terrono AL. Partial (“Wafer”) Distal Ulna Resection for Triangular Fibrocartilage Tears and/or Ulnar Impaction Syndrome (abstract). *J Hand Surg* 1990;15A:826.

# 39. Gainor BJ, Schaberg J. The Rheumatoid Wrist after Resection of the Distal Ulna. *J Hand Surg* 1985;10A:837.

* 40. Galeazzi R. Uber ein besonderes Syndrom bei Verletzungen im Bereich der Unterarmknochen. *Arch Orthop Unfall-Chir* 1935;35:557.

+ 41. Goldner JL, Hayes MG. Stabilization of the Remaining Ulna Using One-Half of the Extensor Carpi Ulnaris Tendon after Reconstruction of the Distal Ulna. *Orthop Trans* 1979;3:330.

* 42. Goncalves D. Correction of Disorders of the Distal Radio-Ulnar Joint by Artificial Pseudarthrosis of the Ulna. *J Bone Joint Surg* 1974;56B:462.

# 43. Hartz CR, Beckenbaugh RD. Long-Term Results of Resection of the Distal Ulna for Post-traumatic Conditions. *J Trauma* 1979;19:219.

# 44. Hauck RM, Skahen J, Palmer AK. Classification and Treatment of Ulnar Styloid Nonunion. *J Hand Surg* 1996;21A:418.

+ 45. Heiple KG, Freehafer AA, Hof AV. Isolated Traumatic Dislocation of the Distal End of the Ulna or Distal Radioulnar Joint. *J Bone Joint Surg* 1962;44A:1387.

* 46. Hermansdorfer JD, Kleinman WB. Management of Chronic Peripheral Tears of the Triangular Fibrocartilage Complex. *J Hand Surg* 1991;16A:340.

* 47. Hui FC, Linscheid RL. Ulnotriquetral Augmentation Tenodesis: A Reconstructive Procedure for Dorsal Subluxation of the Distal Radioulnar Joint. *J Hand Surg* 1982;7:230.

# 48. Jackson IT, Milward TM, Lee P, Webb J. Ulnar Head Resection in Rheumatoid Arthritis. *Hand* 1974;6:172.

* 49. Johnson RK. Stabilization of the Distal Ulna by Transfer of the Pronator Quadratus Origin. *Clin Orthop* 1992;275:130.

! 50. Johnson RK, Shrewsbury MM. The Pronator Quadratus in Motions and in Stabilization of the Radius and Ulna at the Distal Radioulnar Joint. *J Hand Surg* 1976;1:205.

+ 51. Kapandji IA. The Kapandji-Sauvé Operation: Its Techniques and Indications in Non-rheumatoid Diseases. *Ann Chir Main* 1986;5:181.

! 52. Kihara H, Palmer AK, Werner FW, et al. The Effect of Dorsally Angulated Distal Radius Fractures on Distal Radioulnar Joint Congruency and Forearm Rotation. *J Hand Surg* 1996;21A:40.

! 53. Kihara H, Short WH, Werner FW, et al. The Stabilizing Mechanism of the Distal Radioulnar Joint During Pronation and Supination. *J Hand Surg* 1995;20A:930.

! 54. King GJ, McMurtry RY, Rubenstein JD, Ogston NG. Computerized Tomography of the Distal Radioulnar Joint: Correlation with Ligamentous Pathology in a Cadaveric Model. *J Hand Surg* 1986;11A:711.

+ 55. Kleinman WB, Graham TJ. The Distal Radioulnar Joint Capsule: Clinical Anatomy and Role in Postraumatic Limitation of Forearm Rotation. *J Hand Surg* 1998;23A:588.

+ 56. Kleinman WB, Greenberg JA. Salvage of the Failed Darrach Procedure. *J Hand Surg* 1995;20A:951–958.

* 57. Lauenstein C. Zur Behandlung der nach karpaler Vorderarmfraktur zuruckbleibenden Storung der Pro- und Supinationsbewegung. *Zentralbl Chir* 1987;1887:433.

# 58. Lewis OJ. Evoluntionary Change in the Primate Wrist and Inferior Radio-Ulnar Joints. *Anat Rec* 1965;151:275.

! 59. Linscheid RL. Biomechanics of the Distal Radioulnar Joint. *Clin Orthop* 1992;275:46.

+ 60. Mauer I. Reconstruction Following Posttraumatic Derangement of the Distal Radioulnar Joint. *Bull Hosp Joint Dis* 1961;22:95.

! 61. Mikic SDJ. Age Changes in the Triangular Fibrocartilage of the Wrist Joint. *J Anat* 1978;126:367.

! 62. Mikic Z, Somer L, Somer T. Histologic Structure of the Articular Disk of the Human Distal Radioulnar Joint. *Clin Orthop* 1992;275:29.

# 63. Mikic ZDJ. Galeazzi Fracture-Dislocations. *J Bone Joint Surg* 1975;57A:1071.

+ 64. Mikkelsen SS, Lindblad BE, Sommer J. Sauvé-Kapandji Operation for Disorders of the Distal Radioulnar Joint. *Contemp Orthop* 1993;26:151.

+ 65. Minami A, Suzuki K, Suenaga N, Ishikawa J. The Sauvé-Kapandji Procedure for Osteoarthritis of the Distal Radioulnar Joint. *J Hand Surg* 1995;20A:602.

! 66. Mino DE, Palmer AK, Levinsohn EM. The Role of Radiography and Computerized Tomography in the Diagnosis of Subluxation and Dislocation of the Distal Radioulnar Joint. *J Hand Surg* 1983;8:23.

+ 67. Mino DE, Palmer AK, Levinsohn EM. Radiography and Computerized Tomography in the Diagnosis of Incongruity of the Distal Radio-Ulnar Joint. A Prospective Study. *J Bone Joint Surg* 1985;67A:247.

+ 68. Moore TM, Klein JP, Patzakis MJ. Results of Compression-Plating of Closed Galeazzi Fractures. *J Bone Joint Surg* 1985;67A:1015.

+ 69. Newman RJ. Excision of the Distal Ulna in Patients with Rheumatoid Arthritis. *J Bone Joint Surg* 1987;69B:203.

+ 70. Newmeyer WL, Green DP. Rupture of Extensor Tendons Following Resection of the Distal Ulna. *J Bone Joint Surg* 1982;64A:178.

+ 71. Noble J, Arafa M. Stabilization of Distal Ulna after Excessive Darrach's Procedure. *Hand* 1983;15:70.

* 72. Nolan WB, Eaton RG. A Darrach Procedure for Distal Ulnar Pathology Derangements. *Clin Orthop* 1992;275:85.

+ 73. Osterman AL. Arthroscopic Debridement of Triangular Fibrocartilage Complex Tears. *Arthroscopy* 1990;6:120.

# 74. Palmer AK. Triangular Fibrocartilage Complex Lesions: A Classification. *J Hand Surg* 1989;14A:594.

! 75. Palmer AK, Glisson RR, Werner FW. Ulnar Variance Determination. *J Hand Surg* 1982;7:376.

# 76. Palmer AK, Linscheid RL, Fisk GR, Taleisnik J. Symposium: Distal Ulnar Injuries. *Contemp Orthop* 1983;7:81.

! 77. Palmer AK, Werner FW. The Triangular Fibrocartilage Complex of the Wrist: Anatomy and Function. *J Hand Surg* 1981;6:153.

! 78. Palmer AK, Werner FW. Biomechanics of the Distal Radioulnar Joint. *Clin Orthop* 1984;187:26.

! 79. Pirela-Cruz MA, Groll SR, Klug M, Windler D. Stress Computed Tomography Analysis of the Distal Radioulnar Joint: A Diagnostic Tool for Determining Translational Motion. *J Hand Surg* 1991;16A:75.

# 80. Poehling GG, Siegel DB, Koman LA, Chabon SJ. Arthroscopy of the Wrist and Elbow. In Green DP, ed. *Operative Hand Surgery, 3rd ed.* New York: Churchill Livingstone, 1993:189.

+ 81. Rana NA. Excision of the Distal End of the Ulna in Rheumatoid Arthritis. *J Bone Joint Surg* 1973;55B:96.

+ 82. Rayhack JM, Gasser SI, Latta LL, et al. Precision Oblique Osteotomy for Shortening of the Ulna. *J Hand Surg* 1993;18A:908.

+ 83. Reinus WR, Hardy DC, Totty WG, Gilula LA. Arthrographic Evaluation of the Carpal Triangular Fibrocartilage Complex. *J Hand Surg* 1987;12A:495.

+ 84. Rothwell AG, O'Neill L, Cragg K. Sauvé-Kapandji Procedure for Disorders of the Distal Radioulnar Joint: A Simplified Technique. *J Hand Surg* 1996;21A:771.

+ 85. Ruby LK, Ferenz CC, Dell PC. The Pronator Quadratus Interposition Transfer: An Adjunct to Resection Arthroplasty of the Distal Radioulnar Joint. *J Hand Surg* 1996;21A:60.

+ 86. Saffar P, Barbato B, Werther JR, Lenerle JP. Operative Treatment of Posttraumatic Distal Radio-Ulnar Joint Disorders. Comparative Study of Clinical Results between Four Procedures. (abstract). In *Proceedings of the American Society for Surgery of the Hand,* Nashville, TN, 1996.

* 87. Sauvé L, Kapandji M. Nouvelle Technique de Traitment Chirurgical des Luxations Recidivantes Isolées de l'Extremité Inferiéure du Cubitus. *J Chir* 1936;47:589.

! 88. Schuind F, An KN, Berglund L. The Distal Radioulnar Ligaments: A Biomechanical Study. *J Hand Surg* 1991;16A:1106.

# 89. Slater RR, Szabo RM. Disorders of the Distal Radioulnar Joint. *Semin Arthrop* 1997;8:156.

+ 90. Space TC, Louis DS, Francis I, Braunstein EM. CT Findings in Distal Radioulnar Dislocation. Case Report. *J Comput Assist Tomogr* 1986;10:689.

* 91. Spinner M, Kaplan EB. Extensor Carpi Ulnaris. Its Relationship to Stability of the Distal Radio-Ulnar Joint. *Clin Orthop* 1970;68:124.

! 92. Stuart PR. Pronator Quadratus Revisited. *J Hand Surg* 1996;21B:714.

+ 93. Sumner JM, Khuri SM. Entrapment of the Median Nerve and Flexor Pollicis Longus in an Epiphyseal Fracture-Dislocation of the Distal Radioulnar Joint: A Case Report. *J Hand Surg* 1984;9A:711.

# 94. Swanson AB. Implant Arthroplasty for Disabilities of the Distal Radioulnar Joint. Use of a Silicone Rubber Capping Implant Following Resection of the Ulnar Head. *Orthop Clin North Am* 1973;4:373.

+ 95. Szabo RM, Hotchkiss RN, Slater RR. The Use of Frozen-Allograft Radial Head Replacement for Treatment of Established Symptomatic Proximal Translation of the Radius: Preliminary Experience in Five Cases. *J Hand Surg* 1997;22A:269.

# 96. Taleisnik J. *The Wrist.* New York: Churchill Livingstone, 1985:429.

* 97. Taleisnik J. The Sauvé-Kapandji Procedure. *Clin Orthop* 1992;275:110.

! 98. Taleisnik J, Gelberman RH, Miller BW, Szabo RM. The Extensor Retinaculum of the Wrist. *J Hand Surg* 1984;9A:495.

! 99. Tan AB, Tan SK, Yung SW, et al. Congenital Perforations of the Triangular Fibrocartilage of the Wrist. *J Hand Surg* 1995;20B:342.

+ 100. Taylor GW, Parsons CL. The Role of the Discus Articularis in Colles' Fracture. *J Bone Joint Surg* 1938;20:149.

! 101. Totterman SM, Miller RJ, McCanci SE, Meyers SP. Lesions of the Triangular Fibrocartilage Complex: MR Findings with a Three Dimensional Gradient-Recalled-Echo Sequence. *Radiology* 1996;199:227.

+ 102. Trumble TE, Gilbert M, Vedder N. Isolated Tears of the Triangular Fibrocartilage: Management by Early Arthroscopic Repair. *J Hand Surg* 1997;22A:57.

* 103. Tsai TM, Stilwell JH. Repair of Chronic Subluxation of the Distal Radioulnar Joint (Ulnar Dorsal) Using Flexor Carpi Ulnaris Tendon. *J Hand Surg* 1984;9B:289.

* 104. Vincent KA, Szabo RM, Agee JM. The Sauvé-Kapandji Procedure for Reconstruction of the Rheumatoid Distal Radioulnar Joint. *J Hand Surg* 1993;18A:978.

+ 105. Watson HK, Brown RE. Ulnar Impingement Syndrome after Darrach Procedure: Treatment by Advancement Lengthening Osteotomy of the Ulna. *J Hand Surg* 1989;14A:302.

* 106. Watson HK, Ryu J, Burgess R. Matched Distal Ulnar Resection. *J Hand Surg* 1986;11A:612.

+ 107. Wehbe MA, Mawr B, Cautilli DA. Ulnar Shortening Using the AO Small Distractor. *J Hand Surg* 1995;20A:959.

! 108. Weigl K, Spira E. The Triangular Fibrocartilage of the Wrist Joint. *Reconstruct Surg Traumatol* 1969;11: 139.

! 109. Weiler PJ, Bogoch ER. Kinematics of the Distal Radioulnar Joint in Rheumatoid Arthritis: An *in Vivo* Study Using Centrode Analysis. *J Hand Surg* 1995;20A: 937.

+ 110. Wnorowski DD, Palmer AK, Werner FW, Fortino MD. Anatomic and Biomechanical Analysis of the Arthroscopic Wafer Procedure. *Arthroscopy* 1992;8:204.

+ 111. Zachee B, DeSmet L, Roosen P, Fabry G. The Sauvé-Kapandji Procedure for Nonrheumatic Disorders of the Distal Radioulnar Joint. *Acta Orthop Belg* 1994;60:225.

# CHAPTER 44

# FRACTURES OF THE DISTAL RADIUS

*Robert M. Szabo*

**R. M. Szabo:** Department of Orthopaedics and Surgery, Division of Plastic Surgery, Hand and Upper Extremity Service, University of California, Davis, School of Medicine, Sacramento, California 95817.

Anatomy
Definitions
Pathomechanics
Classifications
Frykman Classification of Colles' Fractures
Universal Classification of Distal Radius Fractures
Fernandez and Jupiter Classification of Distal Radius Fractures
Thomas Classification of Smith's Fractures
Treatment
Splint Application
Surgical Techniques
Percutaneous Pinning
Intrafocal (Kapandji) Pinning
External Fixation
Internal Fixation
Plate Fixation of the Distal Radius—Dorsal Approach
Arthroscopically Assisted Reduction
Rehabilitation
Outcomes
Pitfalls and Complications
Surgical Techniques— Reconstructive Surgery After Fractures of the Distal Radius
Chapter References

> The nature of this injury once ascertained, it will be a very easy matter to explain the different phenomena attendant on it, and to point out a method of treatment which will prove completely successful.
>
> Abraham Colles, 1814 (24)

Unfortunately, the result of the treatment of distal radius fractures often leaves much to be desired. The fracture that Abraham Colles described in 1814 was nonarticular and occurred during a fall on the outstretched hand in a somewhat osteoporotic patient. All distal radius fractures with dorsal displacement are commonly referred to as “Colles' fractures” regardless of the fracture configuration, degree of comminution, age of the patient, or mechanism of the injury. Because of their frequency, Colles' fractures are often regarded and treated casually. Controversy and confusion are found throughout the medical literature about the best way to treat a fracture of the distal radius. The fundamental principle of treatment is the restoration of anatomy with the hope of producing full, painless motion of the wrist. The method selected to achieve this objective can be determined only after careful study of the individual fracture pattern.

## ANATOMY

The distal radius is biconcave, triangular, and covered with hyaline cartilage. A smooth anteroposterior ridge divides the articular surface into two facets: a triangular lateral facet, which articulates with the scaphoid, and a quadrilateral medial facet, which articulates with the lunate (56). The medial surface of the distal radius forms a semicircular notch covered with hyaline cartilage, which articulates with the ulna head. This articulation enables the radius to swing around the ulna. The lateral surface elongates into a prominent styloid process, which gives attachment to the brachioradialis muscle (Fig. 44.1).

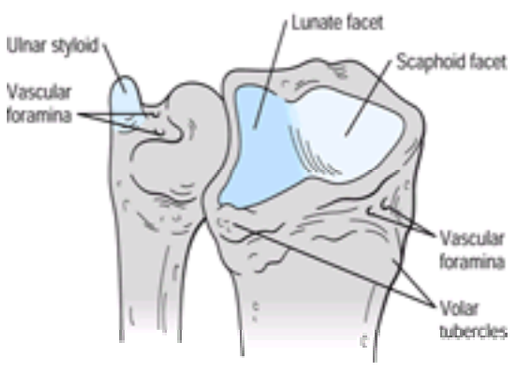


***Figure 44.1.*** Anterior distal end of the radius and ulna. (From Kaplan EB, Taleisnik J. The Wrist. In Spinner M, ed. *Kaplan's Functional and Surgical Anatomy of the Hand, 3rd ed.* Philadelphia: JB Lippincott, 1984. Reprinted with permission.)

The cortical bone in the area of the distal radial metaphysis is quite thin. There is normally an average of 23° of radial angulation in the anteroposterior plane (75). Average radial length from the tip of the radial styloid to the ulna head is 12 mm, although the variance can be considerable (Fig. 44.2) (31).

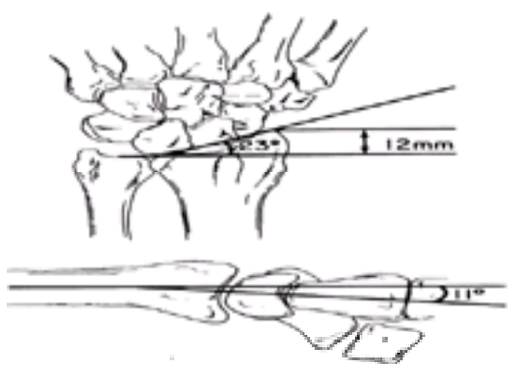


***Figure 44.2.*** Measurement of normal average radial angulation, radial length, and palmar angulation. (From Szabo RM, Weber SC. Comminuted Intra-Articular Fractures of the Distal Radius. *Clin Orthop*1988;230:40. Reprinted with permission.)

## DEFINITIONS

> Given an eponym, one may be sure (1) that the man so honored was not the first to describe the disease, the operation, or the instrument, or (2) that he misunderstood the situation, or (3) that he is generally misquoted, or (4) that (1), (2), and (3) are all simultaneously true. (78)

A*Colles' fracture* is defined as a complete fracture within the distal 2 cm of the radius with dorsal displacement of the distal fragment (9).

A*Smith's fracture* is a complete fracture within the distal 2 cm of the radius with palmar and proximal displacement of the distal fragment.

Confusion arises in trying to define a *Barton's fracture.* Barton, in his original article, describes a “subluxation of the wrist consequent to a fracture through the articular surface of the carpal extremity of the radius” (10). The controversy in his day was that this injury was frequently not recognized but instead was diagnosed and treated as a wrist “sprain.” Barton describes the mechanism of injury as a force met by the palm of the hand that drives the carpal bones against the dorsal edge of the articulating surface of the radius, creating a dorsal fracture and subluxation of the carpus. He said: “Rarely a fracture of similar character occurs on the *palmar* side of the radius from the application of force on the back of the hand” (10). It is therefore better to describe a dorsal Barton's fracture or a palmar Barton's fracture than to inaccurately use the term a *“reverse” Barton's fracture.* Until we drop eponyms from the scientific language, we need at least to agree on what we are describing with these terms.

## PATHOMECHANICS

The injury produced depends on the position of the wrist, the magnitude and direction of force, and the physical properties of the bone. A fall on the outstretched hand with the wrist in 40° to 90° of dorsiflexion produces a distal radius fracture with dorsal displacement (37). The radius probably first fractures in tension on its palmar surface, followed by compression on the dorsal surface, resulting in dorsal comminution. The lunate in particular can exert a compressive force on the distal radius, producing a so-called die-punch fracture (88). The ulnar styloid fracture component of the Colles' fracture results from a force transmitted through an intact triangular fibrocartilage complex.

Fractures of the distal radius with palmar displacement are attributed to more than one mechanism of injury. Smith claimed that this injury results from a fall on the back of the flexed hand (92). This mechanism of injury is not always implicated, and many of these fractures result from a fall on the outstretched extended hand. A fall with the forearm in supination followed by pronation around a fixed extended wrist may be the more common mechanism of injury (29,100).

Radial styloid fractures result from an avulsion (tensile) force generated through the palmar radiocarpal ligaments. Careful evaluation of other ligamentous injuries (e.g., perilunate dislocations with or without spontaneous reduction) should be given to the patient with a radial styloid fracture.

## CLASSIFICATIONS

Several classifications exist for distal radius fractures (26,37,39,51,72,74,86,100). Because there is such a great variation in the fracture types, however, no simple classification can be relied on to guide optimal treatment or be of prognostic value. Andersen et al. reported a low degree of interobserver and intraobserver agreement for the Frykman, Melone, Mayo, and AO classification systems for distal radius in a clinical setting using initial plain radiographs (5). Given the limitations of fracture classifications based solely on plain radiographs, their use as the sole means for determining the direction of treatment or for the direct comparison of results among different studies is not warranted (5).

### FRYKMAN CLASSIFICATION OF COLLES' FRACTURES

In 1967, Frykman introduced a comprehensive classification of Colles' fractures based on the extent of involvement of the articular surface of the radiocarpal and distal radioulnar joints (37).

| Type | Fracture |
|---|---|
| I | Extraarticular radial fracture |
| II | Extraarticular radial fracture with an ulna fracture |
| III | Intraarticular fracture of the radiocarpal joint without an ulna fracture |
| IV | Intraarticular radial fracture with an ulna fracture |
| V | Fracture of the radioulnar joint |
| VI | Fracture into the radioulnar joint with an ulnar fracture |
| VII | Intraarticular fracture involving radiocarpal and radioulnar joints |
| VIII | Intraarticular fracture involving radiocarpal and radioulnar joints with an ulnar fracture |

Frykman's classification fails to identify the direction and extent of fracture displacement (51).

### UNIVERSAL CLASSIFICATION OF DISTAL RADIUS FRACTURES

A symposium conference in 1990 led to a treatment-related “Universal Classification” based on the concept and principle of extraarticular versus intraarticular fractures and stable versus unstable fractures. This scheme is modeled after the classifications of Gartland and Werley and of Sarmiento (Table 44.1) (26,39,86).

| *Classification of fracture* | *Treatment preference* |
|---|---|
| I. Nonarticular, nondisplaced | Cast immobilization |
| II. Nonarticular, displaced | |
| A) Reducible, stable | Cast immobilization |
| B) Reducible, unstable | Percutaneous pins |
| C) Irreducible | Open reduction/external fixation |
| III. Articular, nondisplaced | Cast immobilization<br>Percutaneous pins |
| IV. Articular, displaced | |
| A) Reducible, stable | Closed reduction, Percutaneous pins (K-wires) |
| B) Reducible, unstable | Closed reduction, External fixation (± percutaneous pins) |
| C) Irreducible | Open reduction/external fixation + percutaneous pins |
| D) Complex | Open reduction/external fixation<br>Plate fixation + bone graft (± percutaneous pins) |

***Table 44.1. Universal Classification of Distal Radius Fractures (From Cooney, WP: Fractures of the Distal Radius. A Modern Treatment-Based Classification. Hand Clinics 24:213, 1993.)***

### FERNANDEZ AND JUPITER CLASSIFICATION OF DISTAL RADIUS FRACTURES

This is the most recent classification scheme developed to identify stable versus unstable patterns, to identify children's equivalent injuries, to include associated lesions, and to provide general recommendations for treatment (Table 44.2) (34,51).

***Table 44.2. A Practical, Treatment Oriented Classification of Fracrures of the Distal Radius and Associated Distal Radioulnar Joint Lessons. By Diego L. Fernandez, M.D. PD***

Many other classification systems exist that warrant consideration. The Melone (72,73) and Mayo (26,74) classifications draw attention to the intraarticular fracture components and fit into subdivisions of the Universal Classification type IV. The Comprehensive Classification of Fractures (AO/ASIF) (76) divides fractures into three types based on the presence or absence of articular involvement, with subdivisions into three groups that are further subdivided into three more groups, creating 27 categories.

**THOMAS CLASSIFICATION OF SMITH'S FRACTURES**

Thomas further classified Smith's fractures (100).

**TypeFracture**
I Transverse distal radial fracture with palmar and proximal displacement
II Palmar-lip fracture of the distal radius with dislocation of the carpus (palmar Barton's fracture)
III Oblique fracture of the distal radius, tilted palmarly

In evaluating results and recommendations for treatment, it is important to analyze which types of fractures are being discussed in any given series.

## TREATMENT

Treatment begins after careful examination of the patient. Sensibility is monitored in the alert patient, with particular attention given to the status of the median nerve. If decreased median nerve function is found in a patient with a swollen wrist, carpal canal pressures are measured and used to differentiate median nerve contusion from an acute compressive neuropathy. The patient with a median nerve contusion may be observed, but immediate operative decompression is recommended for acute carpal tunnel syndrome (42,95). The radiographs are analyzed, and the direction of displacement, degree of shortening and comminution, articular involvement, and ipsilateral carpal injuries are determined.

Because the best results are achieved with anatomic restoration and healing of the fracture, the goal of treatment is to obtain and maintain anatomic position. This goal must be met without compromising nerve function or digital motion.

Assessing stability of the initial fracture is critical in choosing treatment paths (Table 44.3) (96). What constitutes stability? Many distal radius fractures redislocate in a plaster cast. Despite early radiographic assessment followed by remanipulation within the first 2 weeks of treatment, malunion remains a common problem. Early redisplacement accounts for a small proportion of final displacements (about 5%) and is caused by movement at the fracture as a consequence of acute instability (50). The remaining displacements represent late deterioration in the fractures's position as a result of chronic instability (50). Intraarticular involvement and comminution are cited as the most sensitive indicators of stability (25,44,57). Both Jenkins (50) and Abbaszadegan (1) have found that malunion may be predicted by radial shortening and loss of radial angle on initial presentation independent of articular involvement. Shortening indicates initial metaphyseal comminution. Based on a study of 267 consecutively treated Colles' fractures, Abbaszadegan et al. (2) demonstrated that the probability of an acceptable anatomic result by closed treatment, if initial radial axial shortening is 5 mm or greater, was 20%.

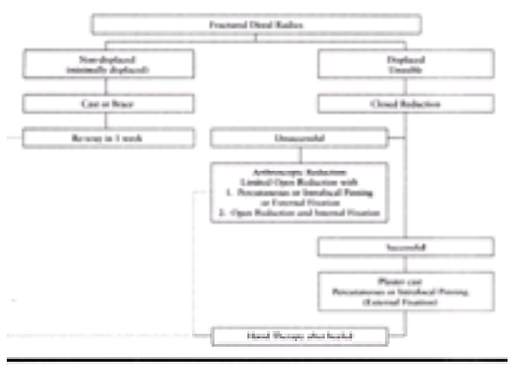

***Table 44.3. Treatment of Distal Radius Fractures***

**SPLINT APPLICATION**

Most minimally displaced, noncomminuted distal radius fractures are correctly managed with closed reduction and immobilization in mild flexion (10° to 20°) and ulnar deviation (15°), followed by early mobilization. This group includes Frykman type I and II and Smith's type I and III fractures. Immobilization in pronation and supination for Colles-type fractures has been advocated empirically, but no significance in results has been demonstrated in prospective trials comparing the two (18,31,69,86,87,102,104). Because the hand is more functional in a neutral or slightly pronated position, this is probably the preferred position for immobilization; however, careful examination of the distal radioulnar joint is warranted. Its injury should be considered in choosing a position of forearm immobilization. Smith fractures are more stable in supination. Reduction is performed by traction to the hand manually or with Chinese finger traps and countertraction to the humerus with the elbow flexed. The displacement is reduced gently after disimpaction of the fracture. Initial immobilization is maintained with above-elbow dorsal and palmar plaster slabs in the position previously mentioned.

Sarmiento et al. (86,87) reported improved early results with cast bracing for Colles' fractures, but others demonstrated no anatomic or functional advantage for this form of treatment (94). I have used plaster because it is readily available and easy to work with.

- Mold the plaster splints so that three-point pressure is applied to maintain reduction.
- Trim the plaster just proximal to the proximal palmar wrist crease and around the base of the thumb to allow full finger flexion and thumb opposition.
- Take radiographs after reduction and at frequent intervals over the next few weeks.
- After swelling decreases, the splints may become loose and need to be replaced.
- After 3 to 4 weeks, set the elbow free, and continue immobilization of the wrist for a total of 6 weeks.
- Begin gentle wrist exercises and have the patient wear a removable palmar splint for an additional few weeks.

See Chapter 10 for more technical details as well as a description of the cast technique.

The comminuted displaced distal radius fracture offers a greater treatment challenge. Most orthopaedic surgeons agree that the results of treatment correlate directly

with restoration of normal anatomy (4,6,8,9,22,25,32,37,39,43,44,45 and 46,48,77,88,97,98). Three techniques have been advocated to manage these injuries: percutaneous pinning, traction maintained by transfixing pins incorporated in plaster or with an external fixation device, and open reduction with internal fixation. For elderly patients (>75 years old) with an unstable extraarticular distal radius fracture, Kiyoshige has advocated open reduction and the use of bone cement to fill the void caused by osteoporotic bone loss (59). This technique has been used more often in Europe than in the United States but may be replaced by the introduction of newer materials such as injectable calcium phosphate.

## SURGICAL TECHNIQUES

### PERCUTANEOUS PINNING

Percutaneous pinning has been tried in many ways with a variety of implants (Fig. 44.3) (16,21,28,38,54,68,79,83,85,88,97,98). This technique is limited to the fractures in which anatomic reduction can be obtained by traction and in which there are no more than two intraarticular fragments. I prefer a technique similar to that described by Clancy (21).

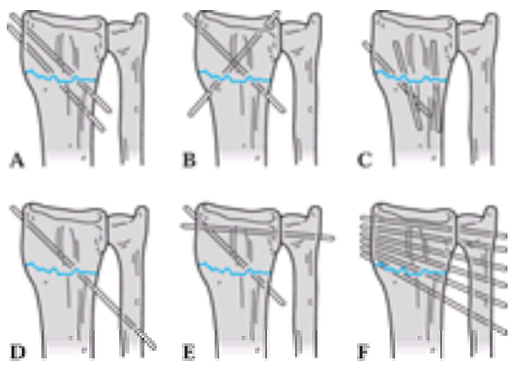


***Figure 44.3.*** Different techniques of percutaneous pinning. **A:** Pins placed through the radial styloid. **B:** Crossed pins. **C:** Kapandji intrafocal technique. **D:** Ulna-to-radius pinning without transfixation of the distal radioulnar joint. **E:** A radial styloid pin and transfixation of the distal radioulnar joint. **F:** Multiple pins from the ulna to the radius including transfixation of the distal radioulnar joint (Rahyack technique). (From Fernandez D, Jupiter J. *Fractures of the Distal Radius. A Practical Approach to Manangement.* New York: Springer-Verlag, 1995:129.)

- Obtain fracture reduction and check with a C-arm recorder
- Insert two crossed 0.062-in. smooth Kirschner wires percutaneously with a wire driver. Introduce the first wire at the radial styloid between the first and second dorsal wrist extensor compartments at a 45° angle with the long axis of the radius and 10° dorsally (Fig. 44.4).

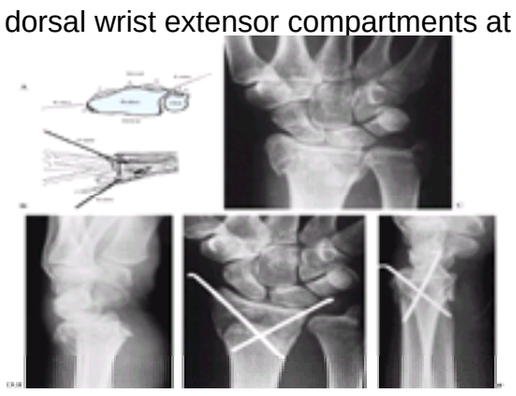

***Figure 44.4.*** Technique for percutaneous Kirschner wire fixation of Colles' fractures. **A:** Schematic cross section of the distal parts of the radius and ulna, demonstrating the extensor canals (numbered) and the starting points for both Kirschner wires. **B:** Dorsal view of the wrist, showing correct placement and orientation of both Kirschner wires for insertion into the distal part of the radius while avoiding the extensor tendons. **C,D:** Anteroposterior and lateral radiographs of distal radius fracture suitable for percutaneous pinning. **E,F:** Postoperative radiographs demonstrating anatomic reduction and proper fixation. (**A,B** from Clancy GJ. Percutaneous Kirschner Wire Fixation of Colles' Fractures. *J Bone Joint Surg*1984;66-A:1008. Reprinted with permission.)

- Engage the Kirschner wire into the ulnar cortex of the proximal radius and go no farther. Palpate the radial artery in the anatomic snuff box and avoid it.
- Introduce the second Kirschner wire between the fourth and fifth dorsal wrist extensor compartments, starting at the ulnar corner of the distal radius, avoiding the semicircular notch. Direct this wire 45° to the long axis of the radius and 30° palmarly and insert it into the radial cortex of the proximal radius, but go no farther.
- Under fluoroscopy, check the stability of the fracture, quality of reduction, and position of the Kirschner wires.
- Cut both Kirschner wires below the skin or bend the wires and leave them superficial to the skin.
- Place the extremity in well-padded, long-arm dorsal and palmar plaster splints with the forearm in slight supination.
- Four weeks after surgery, convert this form of immobilization into a below-elbow cast, maintaining the wrist in neutral position.
- Remove the pins at 6 to 8 weeks, and continue immobilization with a below-elbow cast for an additional 2 weeks.

Sometimes this technique produces distraction of the fracture fragments, and union is delayed. Late recurrence of deformity may be produced by early mobilization. Therefore, continue protection of the wrist until the fracture is clinically and radiographically healed.

### INTRAFOCAL (KAPANDJI) PINNING

This technique differs from percutaneous pinning in that the Kirschner wires are used to buttress the fracture fragments by being inserted into the fracture site dorsally, parallel to the fracture line. The indications for this technique are unstable extraarticular distal radius fractures in young patients (54,55).

- Insert a 0.062-in. smooth Kirschner wire percutaneously between the first and second extensor compartments parallel to the fracture line (use a small incision and blunt spreading to avoid placing any wires in tendons).
- Insert a second wire between the third and fourth dorsal extensor compartments, also parallel to the fracture line.
- Next, advance both wires with a power wire driver obliquely at a 45° angle to the long axis of the radius to engage the intact proximal cortex.
- Apply a plaster cast (my preference is to go above the elbow). Split the cast when dry.
- Remove pins and cast at 6 weeks.
- Start mobilization of the wrist when clinically and radiographically healed.

### EXTERNAL FIXATION

If the articular surface of the radius is comminuted into more than two fragments, I have adopted the use of external fixation (4,25,43,44,64,70,90,105). Although pins and plaster have been used successfully in the treatment of fractures that cannot be held reduced by plaster alone, external fixation has the advantage of being adjustable if fracture displacement occurs and avoids the complications of circumferential plaster (18,22,46,47,52,88). External fixation relies on the principle of “ligamentotaxis,” in which a distraction force applied to the carpus aligns the fracture fragments by means of intact ligaments. DePalma has shown in a Colles' fracture created in the laboratory that disruption to the carpal ligaments is rare. As investigators have gained experience with arthroscopy and open reduction of distal radius fractures, however, injury to these soft tissues has been reported (14,80,99). Distraction with external fixation frequently improves length and alignment, but intraarticular displacement may be increased and palmar tilt is often not restored (11). In selected cases in which traction restores length and intraarticular alignment, I use external fixation as the definitive treatment (Fig. 44.5).

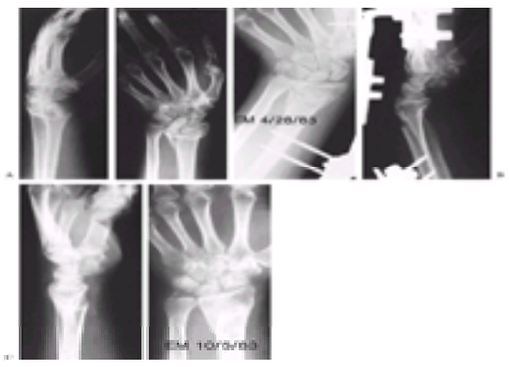

***Figure 44.5.*** A 37-year-old, right-hand-dominant woman sustained Frykman VII right distal radius fracture (anteroposterior and lateral views). **A:** Injury radiographs. **B:** Radiographs after application of an external fixation device. Notice anatomic restoration of an articular surface. **C:** Radiographs 5 months after original injury show preservation of the articular surface. (From Szabo RM, Weber SC. Comminuted Intraarticular Fractures of the Distal Radius. *Clin Orthop*1988;230:44. Reprinted with permission.)

If intraarticular fragments do not reduce with traction alone, I prefer to perform open reduction and internal fixation of the main fragments, most commonly through a dorsal approach to obtain restoration of the articular surface. The previously applied external fixator then functions as a neutralization device (Fig. 44.6). If a fracture requires open reduction, it usually requires supplemental iliac crest bone grafting. Autogenous cancellous bone can fill the gaps created by reducing the articular fragments. Leung demonstrated that bone grafting hastens healing of comminuted fractures of the distal radius and allows early removal of the external fixator without subsequent collapse (65). Many commercially available bone substitutes are being promoted that are made from allograft or synthetic materials. They have the advantage of avoiding donor site morbidity, but they are expensive. One product that stands out from the rest is injectable calcium phosphate; it is being evaluated in clinical trials (61). Calcium phophate is attractive because it is osteoconductive, has high compressive strength, and is gradually replaced by bone (36).

***Figure 44.6.*** Comminuted distal radius fracture sustained in car accident with metal particles imbedded in the skin. **A,B:** Preoperative radiographs, anteroposterior and lateral views. **C,D:** Postoperative radiographs, anteroposterior and lateral views, demonstrating application of external fixation with supplemental percutaneous pin fixation. The external fixation device used in this case was a WristJack.

Smooth Kirschner wires are used for supplemental fixation, avoiding the extensive dissection and periosteal stripping required to fix the fracture with a plate. External fixation is maintained for 8 to 10 weeks, after which protected range-of-motion exercises are started. If additional internal fixation has been used, I usually remove the pins a few weeks before removing the external fixation device. Axelrod and McMurty (8) reported 20 patients with comminuted distal radius fractures treated by open reduction and internal fixation without the addition of external fixation. Although articular congruency was restored in 88%, the overall complication rate was 50%. Half of all complications were directly related to the use of a plate and screws (8).

Several commercially available external fixation frames are available, each with small advantages over the others. In general, two threaded 3-mm half-pins are inserted distally and proximally.

- Make a longitudinal skin incision over the proximal half of the index metacarpal along its radial aspect. Dissect the subcutaneous tissues bluntly, and retract to avoid the small branches of the radial nerve.
- Elevate the portion of the first dorsal interosseous muscle over the metacarpal flare.
- Use a 2-mm drill to penetrate the proximal cortex of the index metacarpal at its metaphyseal flare.
- Insert the first pin with a power driver through this hole in the index metacarpal, and go into the base of the long finger metacarpal but not beyond this point.
- Insert a second pin parallel to the first in a similar fashion with the aid of a guide or the distal portion of the external fixation frame (the technique varies, depending on which external fixation frame is chosen). The depth of penetration of the second pin should be no farther than the ulnar cortex of the index metacarpal.
- Make a 3-cm longitudinal skin incision along the midradial aspect of the radius, beginning about 10 cm from the distal wrist crease. Dissect the subcutaneous tissues bluntly, and protect the sensory branch of the radial nerve. Retract the wrist extensors dorsally and the brachioradialis and sensory radial nerve palmarly.
- Use a 2-mm drill to penetrate the radial cortex of the radius at the level of the insertion of the pronator teres. Drill a 3-mm threaded half-pin into this hole while aiming at the ulnar shaft until it penetrates the ulna cortex of the radius.
- Insert a second pin distal and parallel to the first with the aid of a guide or the proximal portion of the external fixation frame.
- Close skin incisions loosely and apply sterile dressings to the wounds. Apply the external fixation frame.
- Perform fracture reduction with usual techniques or with the assistance of the fixator.
- Obtain anteroposterior and lateral radiographs to confirm proper positioning of the fixation pins and alignment of the fracture.

Final adjustments can be made with the fixator. If alignment cannot be obtained, however, open reduction and additional internal fixation should be considered. Additional incisions and pin placement are dictated by the fracture fragments that do not align with distraction alone.

Do not forget the distal radioulnar joint. If the distal radioulnar joint is severely comminuted, or the distal ulna is dorsally subluxed, a long-arm plaster splint maintaining the wrist in supination may be needed for additional immobilization. I routinely use this long-arm plaster immobilization postoperatively for the initial 4 weeks.

I now prefer to use an external fixation device called the WristJack (developed by Dr. John M. Agee, Sacramento, CA). Its mechanics permit independent adjustment of length, fracture alignment in the lateral and anteroposterior planes, and the position of the wrist in the flexion-extension plane. Distraction and flexion have a detrimental effect on the functional position of the hand, creating excess tension forces on the extensor tendons and resulting in a “clawing” of the hand (extrinsic extensor plus position). Clawing of the fingers is associated with hand stiffness. This observation and the difficulty in rehabilitating the hand when the wrist is in the flexed position led to the development of the WristJack, which allows for Colles' fracture fixation with the wrist in the extended position.

In a prospective study of 20 consecutive severely comminuted distal radius fractures, my colleagues and I demonstrated that anatomic reduction could be maintained despite a wrist neutral or extended position during external fixation. Most patients were performing active digital motion on the day of surgery, and 95% maintained functional finger motion during treatment (4). Dynamic external fixators have been used to allow for early motion of the wrist joint, but one study demonstrated a statistically significant loss of radial length compared with that in the static-fixator group (4 mm compared with 1 mm), with more frequent complications in the dynamic-fixator group (93). Another study showed increasing recurrent dorsal angulation with dynamic external fixation (58).

**INTERNAL FIXATION**

The technique of open reduction and plate fixation is necessary for managing the displaced intraarticular distal radius fracture with palmar dislocation of the carpus (Smith's fracture, type II) (Fig. 44.7). Experience has shown that this fracture seldom is stable. Although acceptable reduction can often be obtained by closed means, redisplacement of the fracture is common. Two surgical approaches to the distal radius are useful to apply a plate palmarly. They are described here as techniques A

and B.

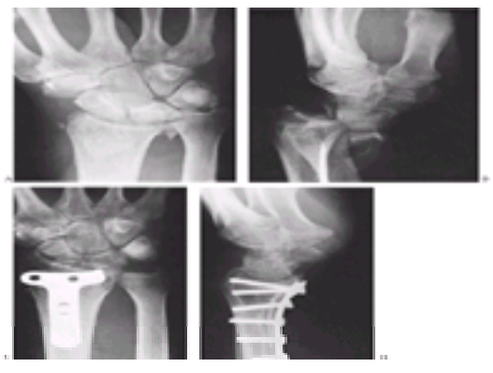

***Figure 44.7.*** **A,B:** Comminuted Smith type II distal radius fracture, anteroposterior and lateral preoperative radiographs. **C,D:** Anteroposterior and lateral radiographs demonstrate postoperative reduction and fixation with a palmar **T** -plate.

***Technique A: Palmar Radial Approach***

- Make an anterior incision, starting at the distal wrist crease along the radial border of the flexor carpi radialis tendon and extend it 6 to 8 cm proximally.
- Identify the flexor carpi radialis tendon and the radial artery. Incise the deep fascia between the flexor carpi radialis and radial artery. Divide the pronator quadratus at its radial insertion.
- Insert retractors on the ulnar and radial aspects of the radius and analyze the fracture pattern.
- Select a small fragment **T**-plate that will fit the width of the distal radius. Determine the length of the plate with respect to the proximal extension of the fracture so that the final result will provide stable internal fixation.
- Fix the plate first to the proximal fragment. The fracture is reduced by the buttress effect of the plate. If the distal fragments are large, obtain additional fixation with cancellous screws through the horizontal holes in the plate.
- Obtain radiographs to confirm the fracture reduction and the position of the internal fixation device.
- Reattach the pronator quadratus and close the tissues in layers.

***Technique B: Modified Carpal Tunnel Approach***

- Technique B uses a modified carpal tunnel incision. This incision allows extension into the carpal tunnel if release is necessary and avoids the palmar cutaneous branch of the median nerve and radial artery, which are vulnerable in technique A.
- Make an incision paralleling the ulnar crease, cross the distal wrist crease in an ulnar direction, and then curve back to the midline. Extend the incision 6 to 8 cm proximally from the distal wrist crease.
- Split the fascia proximal to the flexor retinaculum medial to the tendon of the palmaris longus.
- Identify and tag the median nerve. Incise the fascia and, if necessary, the flexor retinaculum (transverse carpal ligament) along the ulnar border of the median nerve.
- Retract the median nerve, palmaris longus, flexor pollicis longus, and flexor carpi radialis radially, and retract the flexor digitorum superficialis and flexor digitorum profundus ulnarly.
- Insert the **T**-plate and complete the procedure as described in technique A.
- After surgery, place the extremity in a bulky plaster-reinforced compression dressing until suture removal. Continue immobilization for a total of 5 to 6 weeks in a short-arm cast. Place the wrist in neutral to 15° of dorsiflexion, not in palmar flexion, particularly if the carpal tunnel is opened.

**PLATE FIXATION OF THE DISTAL RADIUS—DORSAL APPROACH**

Several authors have advocated open reduction and internal fixation of distal radius fractures when articular incongruities exceed 1 mm (33,101) to 2 mm (15,60). One of the problems in evaluating this approach is the unreliability of measuring displacement accurately. Cole et al. found a poor correlation between measurements made on images and plain radiographs with a gap or step displacement over 2 mm (23). Thirty percent of measurements from plain radiographs compared to computed tomography significantly underestimated or overestimated displacement. The authors concluded that computed tomography using an arc method of measurement that they describe, is more reliable for quantifying articular surface incongruities of the distal radius (23). They followed this study with an outcome study (20) (see below) that raised the question: Despite the well-established correlation between the development of posttraumatic osteoarthrosis of the radiocarpal joint and residual displacement of articular fragments, what amount of displacement of articular fragments is compatible with a good outcome?

Attempts to treat unstable intraarticular distal radius fractures with plates and screws have led to many problems, including nonrigid fixation, lack or loss of operative reduction, and tendon irritation or rupture, to mention a few (35). This has led surgeons to develop new implants to try to solve these problems (17,19,81,82). The surgical approach is similar except for the Forte plate, which requires a more elaborate exposure (17,19)]; the choice of implant is the surgeon's preference.

- Apply traction longitudinally either with temporary external fixation or finger trap traction. Apply a pneumatic tourniquet.
- Make a 10-cm dorsoradial incision parallel to the radius between the second and third dorsal extensor compartments in line with Lister's tubercle. Plan the incision so that the articular surface can be exposed through a dorsal capsulotomy and there is enough proximal exposure for the plate. Open the extensor retinaculum between the second and third dorsal extensor compartments and mobilize the extensor pollicis longus tendon after tagging it with an umbilical tape.
- Expose the radius subperiosteally between the extensor carpi radialis brevis and extensor digitorum communis tendons by elevating the fourth compartment. Do not enter the fourth dorsal compartment.
- Insert small Hohman retractors along the radial and ulnar cortices of the radius for retraction of the extensor tendons.
- Incise the dorsal wrist capsule and visualize the joint surface.
- Disimpact and manipulate the articular fragments into anatomic position. Accomplish this by inserting small elevators or curets into the metaphyseal fracture and pushing the fragments into place.
- Fill residual defects with autogenous cancellous bone graft from the iliac crest.
- Check the reduction with fluoroscopy.
- Obtain provisional fixation with one or two 0.062-in. Kirschner wires but avoid interference with placement of the plate.
- Contour the plate and apply it to the distal radius. Lister's tubercle can be removed to accommodate the plate.
- Drill, tap, and insert the screws according to the implant chosen.
- Confirm reduction and fixation device placement with radiographs in two planes.
- Close the extensor retinaculum and obtain complete coverage of the implant. Leave the extensor pollicis longus above the retinaculum.
- Close the skin and use a drain if deemed necessary.
- Immobilize the wrist in a long-arm bulky plaster-reinforced dressing for 2 weeks. At 2 weeks, remove the sutures and apply a cast (consider above-elbow immobilization) for an additional 4 weeks or until the fracture is clinically and radiographically healed (Fig. 44.8).

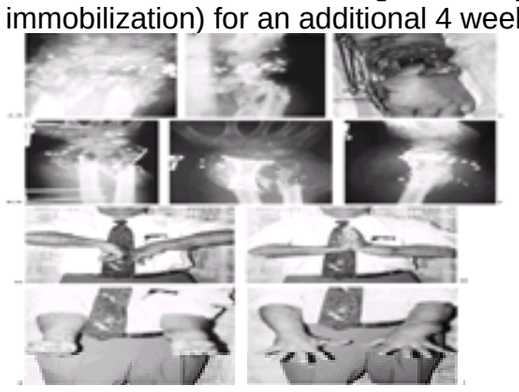

***Figure 44.8.*** Treatment of a severe comminuted distal radius fracture with massive soft tissue loss from a close-range shotgun injury. Initial management was irrigation and debridement followed by external fixation with limited Kirshner wire fixation. Definitive treatment consisted of obtaining soft tissue coverage with a microvascular free tissue transfer using a scapular flap. The articular surface was reconstructed with a p-plate and iliac crest bone graft at the same time as soft

tissue coverage. The distal ulna was allowed to form a pseudarthrosis. Preoperative (**A**) anteroposterior and (**B**) lateral radiograph. **C:** After initial incision and debridement and external fixation. **D:** Anteroposterior radiograph after external fixation. **E:** Anteroposterior radiograph after internal fixation. **F:** Lateral radiograph after internal fixation. **G:** Seven months postoperative wrist flexion. **H:** Seven months postoperative wrist extension. **I:** Seven months postoperative pronation with finger extension. **J:** Seven months postoperative supination with finger flexion.

### ARTHROSCOPICALLY ASSISTED REDUCTION

An alternative method to open reduction and internal fixation that allows for visualization of the articular surface is arthroscopically assisted reduction combined with either external or internal fixation (3,27,40,41,66,67,80,106). In one study, 49 of 50 patients had concomitant ligament injuries, and one third had chondral injuries (67). These additional injuries may explain different outcomes unrelated to radiographic findings, as no correlation could be established between x-ray findings and ligamentous injuries (80).

- Wait 2 to 4 days after the acute injury to avoid extravasation of fluid into the soft tissues.
- Wrap the forearm with an elastic bandage or Coban (3M, Minneapolis, MN) to prevent further extravasation. Apply 4 to 7 kg of traction to the index and long fingers and attempt a closed manipulative reduction.
- Use a traction tower, 2.7 mm 30° angle arthroscope, and standard arthroscopic techniques as described in Chapter 75.
- Place the arthroscope in the 3-4 portal and an outflow cannula in the 6-R portal.
- Lavage the joint thoroughly. Use a small-radius shaver to remove synovium and cartilage debris until the fracture is well visualized.
- Disimpact the fragments by prying between fracture lines with a hook or small osteotome inserted through the 4-5 portal.
- Insert 0.045-in. Kirschner wires percutaneously into the fracture fragments or into the fracture line (as described in the Kapandji technique above) and use these wires as joysticks to manipulate the fragments into anatomic positions.
- Advance the wires across the fracture into intact cortex to maintain reduction.
- Check reduction and position of pins under fluoroscopy.
- Apply a plaster cast (my preference is to go above the elbow). Split the cast when dry. Alternatively, use an external fixator as a neurtalization device.
- Remove pins and cast at 6 weeks.
- Start mobilization of the wrist when clinically and radiographically healed.
- Combined internal and external fixation is often needed for the treatment of severe distal radius fractures (12). With open fractures, this approach may be staged as illustrated.

### REHABILITATION

All patients regardless of treatment method are encouraged to move their fingers immediately. Patients are instructed to elevate the hand for the first week after treatment. Fractures are immobilized until clinically and radiographically healed. A recent study suggests that ultrasound signal may accelerate the healing of fractures of the distal radial metaphysis and decrease the loss of reduction during fracture healing (62). Further study of this technique is warranted before its value is assessed. When healed, patients are referred for supervised hand therapy to regain wrist motion and strength. Therapy is individually tailored for each patient, depending on severity of the fracture, age of the patient, functional demands, and postfracture problems.

## OUTCOMES

Does a poor anatomic result equate with an unacceptable functional result? Aro studied 146 patients with distal radius fractures (7). Ninety-six percent of the patients with radial shortening of less than 3 mm had a good functional result. Twenty-five percent of patients with radial shortening of 3 to 5 mm and 31% of patients with greater than 5 mm radial shortening had an unsatisfactory result, regardless of displacement or angular malalignment of the radial fragment. Even minor shortening of the radius significantly alters the load pattern across the wrist joint, causing functional limitation.

Malreduction with loss of palmar tilt alters the wrist mechanics, creating an alignment that permits the carpus to collapse dorsally, leading to dorsal midcarpal instability (98). Malreduction with loss of angulation toward the ulna leads to radial deviation of the hand and tends to palmar flex the scaphoid, which leads to increases in the scapholunate angle. Shortening, alone or in combination with angulation, disrupts the congruence of the distal radioulnar joint (DRUJ). This may cause pain in the distal radioulnar joint, interference with pronation/supination, and, because it results in an ulnar plus hand, may interfere with radial and ulnar deviation of the carpus from ulnar impingement and/or impaction.

Of 34 extraarticular Colles' fractures treated with plaster immobilization, Roth found that 27 remained symptomatic, and 16 had marked functional limitations at the end of treatment (84). Poor end results were associated with loss of radial angle, palmar tilt, and radial length.

Catalano et al. studied the long-term functional and radiographic outcomes in a series of young adults in whom an acute displaced intraarticular fracture of the distal aspect of the radius had been treated with operative reduction and stabilization (20). They found that at an average of 7.1 years, osteoarthrosis of the radiocarpal joint was evident on the plain radiographs and computerized tomography scans of 16 of 21 wrists (76%), and there was a strong association between the development of osteoarthrosis of the radiocarpal joint and residual displacement of articular fragments at the time of osseous union. The functional results, however, as determined by physical examinations and responses to questionnaires, did not correlate with the extent of the residual displacement at the time of fracture healing. Furthermore, all patients had a good or excellent functional outcome irrespective of radiographic evidence of osteoarthrosis of the radiocarpal or the distal radioulnar joint or nonunion of the ulnar styloid process (20).

## PITFALLS AND COMPLICATIONS

Failure to obtain anatomic reduction can result in secondary deformity of the distal radius, midcarpal instability, and arthritis (60,98). Median nerve damage may occur in the form of acute and late carpal tunnel syndrome, contusion, or stretch. Ulnar nerve damage has also been reported. Radial nerve damage occurs with the placement of external fixation pins percutaneously and can be avoided by a skin incision and proper identification of the sensory branch. A painful, stiff hand and reflex sympathetic dystrophy (49) are best prevented by minimizing swelling, starting digital motion immediately, not immobilizing in extreme positions, and avoiding constrictive dressings. The rate of complications related to fixation pins is as high as 60% in some series (105). Pin loosening is the most common problem, but metacarpal fractures, pin track infections, and intrinsic muscle tie-down have all been experienced.

Distal radioulnar joint dissociation or capsular contractures, TFC tears, and arthritis may require further reconstructive surgery to restore wrist motion (pronation–supination) and eliminate pain. Flexor tendon adhesions and tendon ruptures (particularly extensor pollicis longus ruptures) are known complications (13,30,107). The use of titanium distal radius plates has raised concern over increased tendon ruptures, with the use of internal fixation becoming more popular (53). Nonunion of the distal radius is extremely rare. Segalman and Clark recommend that if 12 mm of subchondral bone remains, union should be attempted with bone grafting and internal or external fixation (89).

Although this list is not complete, it represents most of the complications I have encountered.

## SURGICAL TECHNIQUES— RECONSTRUCTIVE SURGERY AFTER FRACTURES OF THE DISTAL RADIUS

Reconstructive surgery after fractures of the distal radius, including operations directed at correcting the distal radioulnar joint problem (Chapter 43), carpal tunnel release (Chapter 56), radiocarpal or limited intercarpal arthrodesis (Chapter 72), and tendon transfers or reconstructions (Chapter 48, Chapter 49 and Chapter 50), are described elsewhere in this book. Corrective osteotomy of the distal radius is the subject of this discussion.

Radial osteotomy is considered if the dorsal angulation of the distal radius is 25° greater than that in the normal wrist and if there is significant shortening (6 mm) of the radius. This amount of deformity usually results in a symptomatic patient. Besides restoring normal anatomy, a dorsal opening wedge reduces the traction and decompresses the median nerve, often making carpal tunnel release unnecessary in symptomatic patients with a distal radius malunion (63). Contraindications to osteotomy include advanced degenerative changes in the wrist, significant intraarticular incongruency, fixed carpal malalignment, or a stiff hand. The surgical technique used is that described by D. L. Fernandez (Fig. 44.9) (32). Viegas has described this procedure with minimal internal fixation combined with external fixation across the

carpus (103) and Meléndez uses direct rigid external fixation to the osteotomy thus maintaining correction while allowing early wrist exercises (71).

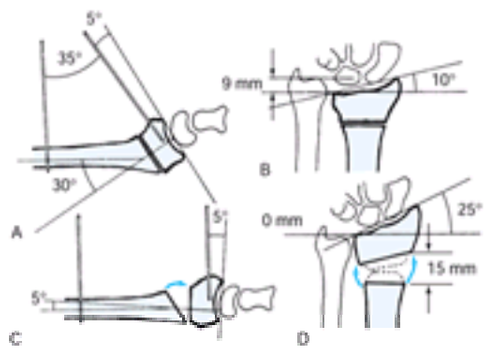


***Figure 44.9.*** Preoperative planning of the osteotomy. **A:** For correction in the sagittal plane, the dorsal tilt (30° in this patient) is measured between the perpendicular joint surface and the long axis of the radius on the lateral radiograph. The Kirschner wires are introduced so that they subtend the angle that corresponds to the dorsal tilt plus 5° of palmar tilt (30° + 5° = 35° in this patient). **B:** After opening the osteotomy by the correct amount, the Kirschner wires lie parallel to each other. **C:** For correction in the frontal plane, shortening (9 mm in this patient) is measured between the head of the ulna and the ulnar corner of the radius on the anteroposterior radiograph. The lines for the measurement are perpendicular to the long axis of the radius. The ulnar tilt is reduced to 10° in this patient. **D:** To restore the ulnar tilt to normal (average 25°), the osteotomy is opened more on the dorsoradial than on the dorsoulnar side. (From Fernandez DL. Correction of Post-Traumatic Wrist Deformity in Adults by Osteotomy, Bone Grafting, and Internal Fixation. *J Bone Joint Surg*64-1982;A:1169. Reprinted with permission.)

Careful preoperative planning includes examination of the radiographs of the affected and the normal wrist. Particular attention is directed at the ulnar variance to restore the normal anatomic relationship with the distal radioulnar joint. The osteotomy must correct the palmar tilt in the sagittal plane, the ulnar tilt in the frontal plane, and rotational deformities in the horizontal plane.

- Make a 10-cm dorsoradial incision parallel to the radius beginning 2 cm distal to Lister's tubercle.
- Expose the radius subperiosteally between the extensor carpi radialis brevis and extensor digitorum communis tendons. Do not enter the fourth dorsal compartment.
- Mark the osteotomy site with an osteotome (about 2.5 cm proximal to the wrist joint).
- Insert a 0.045-in. Kirschner wire perpendicular to the radius 4 cm proximal to the osteotomy site. Insert a second 0.045-in. Kirschner wire into the distal radius so that it subtends an angle with the first Kirschner wire that is 5° more than the amount of deformity (Fig. 44.8).
- Make the osteotomy parallel to the joint surface while protecting the soft tissues with subperiosteal retractors. This is facilitated by placing a fine Kirschner wire along the articular surface of the radius to act as a guide.
- Open the osteotomy dorsally until the two Kirschner wires are parallel to each other (a small Lamina spreader is useful for this maneuver).
- Open the osteotomy on the radial side to correct radial shortening. Rotate the distal fragment to correct any pronation or supination deformity.
- Shape a corticocancellous iliac crest graft into a trapezoid to fill the gap created by the osteotomy. Pack the area with cancellous graft material.
- Maintain the reduction with oblique, crossed Kirschner wires, and obtain anteroposterior and lateral radiographs.
- Obtain rigid fixation by applying a contoured **T**-plate to the dorsum of the radius. (I have preferred the 2.7-mm ASIF blade plate, which is easiest to cover with soft tissues.) An optional next step is to remove the Kirschner wires; it is acceptable to use only the Kirschner wires for fixation, but postoperative immobilization until union must be maintained. Lister's tubercle may be removed for better fit of the plate.
- Examine the distal radioulnar joint clinically and radiographically. If needed, perform a Sauvé-Kapandji or Darrach procedure (see Chapter 43).
- Close the tissues in layers, making certain that there is good coverage of the plate.
- After surgery, immobilize the wrist in a long-arm bulky plaster-reinforced dressing for 2 weeks. At 2 weeks, remove the sutures and begin protective active range-of-motion exercises.
- The osteotomy usually is healed in 8 to 12 weeks, at which time unrestricted activity is allowed.
- For correction of distal radius fractures with palmar tilt (Smith's fractures) a palmar opening wedge osteotomy is performed by an approach identical to that described for the acute care of Smith's type II fractures (technique B) (91).

## CHAPTER REFERENCES

Each reference is categorized according to the following scheme: *, classic article; #, review article; !, basic research article; and +, clinical results/outcome study.


+ 1. Abbaszadegan H, Jonsson U. External Fixation or Plaster Cast for Severely Displaced Colles' Fractures? Prospective 1-Year Study of 46 Patients. *Acta Orthop Scand*1990;61:528.

+ 2. Abbaszadegan H, Jonsson U, von Sivers K. Prediction of Instability of Colles' Fractures. *Acta Orthop Scand*1989;60:646.

+ 3. Adolfsson L, Jörgsholm P. Arthroscopically-Assisted Reduction of Intra-articular Fractures of the Distal Radius. *J Hand Surg [Br]*1998;23:391.

+ 4. Agee JM, Szabo RM, Chidgey LK, et al. Treatment of Comminuted Distal Radius Fractures: An Approach Based on Pathomechanics. *Orthopedics*1994;17:1115.

+ 5. Andersen DJ, Blair WF, Steyers CM Jr, et al. Classification of Distal Radius Fractures: An Analysis of Interobserver Reliability and Intraobserver Reproducibility. *J Hand Surg [Am]*1996;21A:574.

+ 6. Anderson R, O'Neil G. Comminuted Fractures of the Distal End of the Radius. *Surg Gynecol Obstet*1944;78:434.

+ 7. Aro HT, Koivunen T. Minor Axial Shortening of the Radius Affects Outcome of Colles' Fracture Treatment. *J Hand Surg [Am]*1991;16A:392.

+ 8. Axelrod T, McMurty R. Open Reduction and Internal Fixation of the Comminuted, Intra-articular Fractures of the Distal Radius. *J Hand Surg [Am]*1990;15A:1.

* 9. Bacorn R, Kurtzke J. Colles' Fracture. A Study of Two Thousand Cases from the New York State Workmen's Compensation Board. *J Bone Joint Surg*1953;35A:643.

* 10. Barton J. Views and Treatment of an Important Injury to the Wrist. *Med Examiner*1838;1:365.

! 11. Bartosh R, Saldana M. Intra-articular Fractures of the Distal Radius: A Cadaveric Study to Determine if Ligamentotaxis Restores Radiopalmar Tilt. *J Hand Surg [Am]*1990;15A:18.

+ 12. Bass RL, Blair WF, Hubbard PP. Results of Combined Internal and External Fixation for the Treatment of Severe AO-C3 Fractures of the Distal Radius. *J Hand Surg [Am]*1995;20A:373.

+ 13. Bell JS, Wollstein R, Citron ND. Rupture of Flexor Pollicis Longus Tendon: A Complication of Volar Plating of the Distal Radius. *J Bone Joint Surg [Br]*1998;80:225.

+ 14. Berger RA, Amadio PC. Predicting Palmar Radio-Carpal Ligament Disruption in Fractures of the Distal Articular Surface of the Radius Involving the Palmar Cortex. *J Hand Surgery [Br]*1994;19B:108.

+ 15. Bradway J, Amadio P, Cooney W III. Open Reduction and Internal Fixation of Displaced Comminuted Intra-articular Fractures of the Distal End of the Radius. *J Bone Joint Surg*1989;71A:839.

+ 16. Brennwald J, Pfeiffer K. Radiusfraktur Loco Classico. *Ther Umsch*1980;37:743.

+ 17. Brown CJH, Carter PR. Use of the Forte Plate in Unstable Dorsally Displaced Fractures of the Distal Radius. *Techniques Hand Upper Extremity Surg*1997;1:77.

+ 18. Carothers R, Boyd F. Thumb Traction Technic for Reduction of Colles' Fracture. *Arch Surg*1949;58:848.

+ 19. Carter PR, Frederick HA, Laseter GF. Open Reduction and Internal Fixation of Unstable Distal Radius Fractures with a Low-Profile Plate: A Multicenter Study of 73 Fractures. *J Hand Surg [Am]*1998;23A:300.

+ 20. Catalano LW 3rd, Cole RJ, Gelberman RH, et al. Displaced Intra-articular Fractures of the Distal Aspect of the Radius. Long-Term Results in Young Adults after Open Reduction and Internal Fixation. *J Bone Joint Surg*1997;79A:1290.

* 21. Clancy G. Percutaneous Kirschner Wire Fixation of Colles' Fractures. *J Bone Joint Surg*1984;66A:1008.

+ 22. Cole M, Obletz B. Comminuted Fractures of the Distal End of the Radius Treated by Skeletal Transfixion in Plaster Cast. *J Bone Joint Surg*1966;48A:931.

+ 23. Cole RJ, Bindra RR, Evanoff BA, et al. Radiographic Evaluation of Osseous Displacement Following Intra-articular Fractures of the Distal Radius: Reliability of Plain Radiography Versus Computed Tomography. *J Hand Surg [Am]*1997;22A:792.

* 24. Colles A. 1814. On the Fracture of the Carpal Extremity of the Radius. *Edinb Med Surg J*1814;10:181.

+ 25. Cooney R, Linscheid R, Dobyns J. External Pin Fixation for Unstable Colles' Fractures. *J Bone Joint Surg*1979;61A:840.

# 26. Cooney W. Fractures of the Distal Radius. A Modern Treatment-Based Classification. *Orthop Clin*1993;24:211.

+ 27. Culp R, Ostermann L. Arthroscopic Reduction and Internal Fixation of Distal Radius Fractures. *Orthop Clin North Am*1995;26:739.

* 28. DePalma A. Comminuted Fractures of the Distal End of the Radius Treated by Ulnar Pinning. *J Bone Joint Surg*1952;34A:651.

+ 29. Ellis J. Smith's and Barton's Fractures: A Method of Treatment. *J Bone Joint Surg*1965;47B:724.

+ 30. Engkvist O, Lundborg G. Rupture of the Extensor Pollicis Longus Tendon after Fracture of the Lower End of the Radius: A Clinical and Microangiographic Study. *Hand*1979;2:76.

# 31. Fahey J. Fractures and Dislocations about the Wrist. *Surg Clin North Am*1957;2:19.

* 32. Fernandez D. Correction of Post-traumatic Wrist Deformity in Adults by Osteotomy, Bone-grafting, and Internal Fixation. *J Bone Joint Surg*1982;64A:1164.

+ 33. Fernandez D, Geissler W. Treatment of Displaced Articular Fractures of the Radius. *J Hand Surg [Am]*1991;16A:375.

# 34. Fernandez D, Jupiter J. *Fractures of the Distal Radius. A Practical Approach to Manangement.* New York: Springer-Verlag, 1995.

+ 35. Fitoussi F, Ip WY, Chow SP. Treatment of Displaced Intra-articular Fractures of the Distal End of the Radius with Plates. *J Bone Joint Surg*1997;79:1303.

! 36. Frankenburg EP, Goldstein SA, Bauer TW, et al. Biochemical and Histological Evaluation of a Calcium Phosphate Cement. *J Bone Joint Surg*1998;80A:1112.

* 37. Frykman G. Fractures of the Distal End of the Radius, Including Sequelae—Shoulder, Hand, Finger Syndrome, Disturbance in the Distal Radioulnar Joint and Impairment of Nerve Function: A Clinical and Experimental Study. *Acta Orthop Scand [Suppl]*1967;108:1.

+ 38. Garner R, Grimes D. Percutaneous Pinning of Displaced Fractures of the Distal Radius. *Orthop Rev*1977;6:87.

* 39. Gartland J, Werley C. Evaluation of Healed Colles' Fractures. *J Bone Joint Surg*1951;33A:895.

+ 40. Geissler W. Arthroscopic Assisted Reduction of Intra-articular Fractures of the Distal Radius. *Hand Clin*1995;11:19.

+ 41. Geissler W. Arthroscopic Treatment of Intra-articular Distal Radius Fractures. *Atlas Hand Clin*1997;2:97.

* 42. Gelberman R, Szabo R, Mortensen W. Carpal Tunnel Pressures and Wrist Position in Patients with Colles' Fractures. *J Trauma*1984;24:747.

+ 43. Gjengedal E. Compound Fracture of the Distal End of the Radius Treated with Hoffman's Method of External Fixation. *Tidsskr Nor Laegeforen*1979;99:24.

+ 44. Grana W, Kopta J. The Roger Anderson Device in the Treatment of Fractures of the Distal End of the Radius. *J Bone Joint Surg*1979;61A:1234.

+ 45. Grana W, Randel R. Roger Anderson Device for Distal Radius Fractures. *AORN J*1978;28:1036.

* 46. Green D. Pins and Plaster Treatment of Comminuted Fractures of the Distal End of the Radius. *J Bone Joint Surg*1975;57A:304.

+ 47. Hammond G. Comminuted Colles' Fracture. *Am J Surg*1949;54:617.

+ 48. Hobart M, Kraft G. Malunited Colles' Fracture. *Am J Surg*1941;53:55.

+ 49. Hove LM. Nerve Entrapment and Reflex Sympathetic Dystrophy after Fractures of the Distal Radius. *Scand J Plast Reconstr Surg Hand Surg*1995;29:53.

+ 50. Jenkins NH. The Unstable Colles' Fracture. *J Hand Surg [Br]*1989;14B:149.

+ 51. Jupiter JB, Fernandez DL. Comparative Classification for Fractures of the Distal End of the Radius. *J Hand Surg [Am]*1997;22A:563.

+ 52. Kain T, Mandel R, Snedden H. Comminuted Distal Radius Fractures: Two Methods of Treatment. *Clin Orthop*1977;128:369.

+ 53. Kambouroglou GK, Axelrod TS. Complications of the AO/ASIF Titanium Distal Radius Plate System (Pi Plate) in Internal Fixation of the Distal Radius: A Brief Report. *J Hand Surg [Am]*1998;23A:737.

* 54. Kapandji A. L'Ostéosythése par Double Embrochage Intrafocal. Traitement Functionnel des Fractures Non Articulaires de l'Extremité Inférieure du Radius. *Ann Chir*1976;30:903.

+ 55. Kapandji A. Treatment of Articular Distal Radial Fractures by Intrafocal Pinning with Arum Pins. In Saffar P, Conney W III, eds. *Fractures of the Distal Radius.* London: Martin Dunitz, 1995:160.

# 56. Kaplan E, Taleisnik J. The Wrist. In Spinner M, ed. *Functional and Surgical Anatomy of the Hand, 3rd ed.* Philadelphia: JB Lippincott, 1984.

+ 57. Kaukonen JP, Karaharju EO, Porras M, et al. Functional Recovery after Fractures of the Distal Forearm. Analysis of Radiographic and Other Factors Affecting the Outcome. *Ann Chir Gynaecol*1988;77:27.

+ 58. Kawaguchi S, Sawada K, Nabeta Y, et al. Recurrent Dorsal Angulation of the Distal Radius Fracture During Dynamic External Fixation. *J Hand Surg [Am]*1998;23A:920.

+ 59. Kiyoshige Y. Intramedullary Bone-Cement Fixation for Colles Fracture in Elderly Patients. *Techniques Hand Upper Extremity Surg*1997;1:89.

* 60. Knirk J, Jupiter J. Intra-articular Fractures of the Distal End of the Radius in Young Adults. *J Bone Joint Surg*1986;68A:647.

+ 61. Kopylov P, Jonsson K, Thorngren KG, Aspenberg P. Injectable Calcium Phosphate in the Treatment of Distal Radial Fractures. *J Hand Surg [Br]*1996;21B:768.

+ 62. Kristiansen TK, Ryaby JP, McCabe J, et al. Accelerated Healing of Distal Radial Fractures with the Use of Specific, Low-Intensity Ultrasound. A Multicenter, Prospective, Randomized, Double-Blind, Placebo-Controlled Study. *J Bone Joint Surg [Am]*1997;79A:961.

+ 63. Kwasny O, Fuchs M, Schabus R. Opening Wedge Osteotomy for Malunion of the Distal Radius with Neuropathy. *Acta Orthop Scand*1994;65:207.

+ 64. Ledoux R, Teibaut A, Van der Ghist M. Bipolar Fixation of the Fractures of the Distal End of the Radius. *Int Orthop*1979;3:89.

+ 65. Leung J, Shen W, Tsang H, et al. An Effective Treatment of Comminuted Fractures of the Distal Radius. *J Hand Surg [Am]*1990;15A:11.

+ 66. Levy H, Glickel S. Arthroscopic Assisted Internal Fixation of Ulna Intra-articular Wrist Fractures. *Arthroscopy*1993;9:122.

+ 67. Lindau T, Arner M, Hagberg L. Intraarticular Lesions in Distal Fractures of the Radius in Young Adults. *J Hand Surg [Br]*1997;22B:638.

+ 68. Lucas G, Sachtjen K. An Analysis of Hand Function in Patients with Colles' Fractures Treated by Rush Rod Fixation. *Clin Orthop*1981;155:172.

+ 69. Mayer J. Colles' fracture. *Br J Surg*1940;27:629.

+ 70. Meléndez E, Mehue D, Posner M. Treatment of Unstable Colles' Fractures with a New Radius Mini-fixator. *J Hand Surg [Am]*1989;14A:807.

+ 71. Meléndez EM. Opening-Wedge Osteotomy, Bone Graft, and External Fixation for Correction of Radius Malunion. *J Hand Surg [Am]*1997;22A:785.

+ 72. Melone C. Articular Fractures of the Distal Radius. *Orthop Clin North Am*1984;15:217.

+ 73. Melone JCP. Distal Radius Fractures: Patterns of Articular Fragmentation. *Orthop Clin North Am*1993;24:239.

+ 74. Missakain M, Conney W III, Amadio P, Glidewell H. Open reduction and internal fixation for distal radius fractures. *J Hand Surg [Am]*1992;17A:745.

+ 75. Morissy R, Nalebuff E. Distal Radial Fracture with Tendon Entrapment: A Case Report. *Clin Orthop*1977;124:205.

# 76. Muller M, Nazarian S, Koch P, Schatzker J. *Comprehensive Classification of Fractures of Long Bone.* Berlin: Springer Verlag, 1990.

# 77. Nigst H. Fractures of the Distal Radius in the Adult: Anatomy, Trauma Mechanisms, Fracture Types, and Typical Associated Injuries. *Unfallheilkunde*1979;82:1.

* 78. Ravitch M. Dupuytren's Invention of the Mikulicz Enterotome with a Note on Eponyms. *Perspect Biol Med*1979;22:170.

+ 79. Rayhack J. The History and Evolution of Percutaneous Pinning of Displaced Distal Radius Fractures. *Orthop Clin*1993;24:287.

+ 80. Richards RS, Bennett JD, Roth JH, Milne K Jr. Arthroscopic Diagnosis of Intra-articular Soft Tissue Injuries Associated with Distal Radial Fractures. *J Hand Surg [Am]*1997;22A:772.

+ 81. Ring D, Jupiter JB. Operative Fixation of Fractures of the Distal Radius Using the pplate. *Techniques Hand Upper Extremity Surg*1997;1:125.

+ 82. Ring D, Jupiter JB, Brennwald J, et al. Prospective Multicenter Trial of a Plate for Dorsal Fixation of Distal Radius Fractures. *J Hand Surg [Am]*1997;22A:777.

+ 83. Roth B. Experience with Percutaneous K-Wire Osteosynthesis in Distal Radius Fractures. *Helv Chir Acta*1978;44:35.

+ 84. Roth JH, Miniaci A. Healing of Extra-articular Angulated Apex Volar Fractures of the Distal Radius. *Can J Surg*1988;31:39.

+ 85. Ruiz G. Percutaneous Pinning of Comminuted Colles' Fractures. *Clin Orthop*1975;108:174.

* 86. Sarmiento A, Pratt G, Berry N, Sinclair WF. Colles' Fractures: Functional Bracing in Supination. *J Bone Joint Surg*1975;57A:311.

+ 87. Sarmiento A, Zagorski J, Sinclair W. Functional Bracing of Colles' Fractures: A Prospective Study of Immobilization in Supination versus Pronation. *Clin Orthop*1980;146:175.

+ 88. Scheck M. Long-term Follow-up of Treatment of Comminuted Fractures of the Distal End of the Radius by Transfixation with Kirschner Wires and Cast. *J Bone Joint Surg*1962;44A:337.

+ 89. Segalman KA, Clark GL. Un-united Fractures of the Distal Radius: A Report of 12 Cases. *J Hand Surg [Am]*1998;23A:914.

+ 90. Seitz W Jr, Putna M, Dick H. Limited Open Surgical Approach for External Fixation of Distal Radius Fractures. *J Hand Surg*1990;15A:288.

+ 91. Shea K, Fernandez DL, Jupiter JB, Martin C Jr. Corrective osteotomy for malunited, volarly displaced fractures of the distal end of the radius. *J Bone Joint Surg [Am]*1997;79:1816.

* 92. Smith R. *A Treatise on Fractures in the Vicinity of Joints and on Certain Forms of Accidental and Congenital Dislocations.* Dublin: Hodges and Smith, 1854.

+ 93. Sommerkamp TG, Seeman M, Silliman J, et al. Dynamic external fixation of unstable fractures of the distal part of the radius. A prospective, randomized comparison with static external fixation. *J Bone Joint Surg [Am]*1994:76A:1149.

+ 94. Stewart H, Innes A, Burke F. Functional Cast-Bracing for Colles' Fractures: A Comparison between Cast-Bracing and Conventional Plaster Casts. *J Bone Joint Surg*1984:66B:749.

# 95. Szabo R. Acute carpal tunnel syndrome. *Hand Clin*1998;14:419.

# 96. Szabo R. Extra-articular Fractures of the Distal Radius. *Orthop Clin*1993;24:229.

# 97. Szabo R, Weber S. Comminuted Intra-articular Fractures of the Distal Radius. *Clin Orthop*1988;230:39.

+ 98. Taleisnik J, Watson H. Mid-carpal Instability Caused by Fractures of the Distal Radius. *J Hand Surg [Am]*1984;9A:350.

+ 99. Tang JB, Shi D, Gu YQ, Zhang QG. Can cast immobilization successfully treat scapholunate dissociation associated with distal radius fractures? *J Hand Surg [Am]*1996;21A:583.

* 100. Thomas F. Reduction of Smith's fracture. *J Bone Joint Surg*1957;39B:463.

+ 101. Trumble T, Schmitt S, Vedder N. Fractures Affecting Functional Outcome of Displaced Intra-articular Assisted Radius Fractures. *J Hand Surg [Am]*1994;19A:328.

+ 102. Van Der Linden W, Ericson R. Colles' Fracture: How Should Its Displacement Be Measured and How Should It Be Immobilized? *J Bone Joint Surg*1981;63A:1285.

# 103. Viegas S. A Minimally Invasive Distal Radial Osteotomy for Treatment of Distal Radius Fracture Malunion. *Techniques Hand Upper Extremity Surg*1997;1:70.

+ 104. Wahlstrom O. Treatment of Colles' Fracture. A Prospective Comparison of Three Different Positions of Immobilization. *Acta Orthop Scand*1982;53:225.

+ 105. Weber S, Szabo R. The Severely Comminuted Distal Radius Fracture as an Unsolved Problem. *J Hand Surg [Am]*1986;11A:157.

+ 106. Wolfe S, Easterling K, Yoo H. Arthroscopic Assisted Reduction of Distal Radius Fractures. *Arthroscopy*1995;11:706.

+ 107. Younger C, DeFiore J. Rupture of Flexor Tendons to the Fingers after a Colles' Fracture. *J Bone Joint Surg*1977;59A:828.

# CHAPTER 45

# GUNSHOT, CRUSH, INJECTION, AND FROSTBITE INJURIES OF THE HAND

*Beth A. Purdy and Robert Lee Wilson*

**B. A. Purdy and R. L. Wilson**: Children's Rehabilitative Services, Orthopaedic/Hand Surgery, Hand Surgery Associates, Phoenix, Arizona 85004.

Gunshot Wounds
- Ballistics and Wound Personality
- Epidemiology
- Classification
- Emergency Room Management
- Surgical Indications
- Principles of Operative Technique
- Rehabilitation
- Pitfalls and Complications
- Authors' Perspective

Crush Injuries
- Mechanism of Injury and Principles of Treatment and Evaluation
- Nonoperative Treatment
- Operative Technique
- Postoperative Care
- Pitfalls and Complications
- Author's Perspective

Injection Injuries
- Principles of Treatment
- Operative Technique
- Postoperative Care
- Pitfalls and Complications

Frostbite Injuries
- Epidemiology
- Physiology
- Classification
- Acute Management
- Operative Technique
- Pitfalls and Complications
- Authors' Perspective

Chapter References

Severe hand injuries, although rarely life threatening, are frequently life changing. Our hands define our vocations, avocations, pleasures, and even expression. Treatment of these injuries, then, must take into account the person whom the tragedy has struck and use all measures necessary to maximize the return toward normalcy.

The elegant anatomy of the hand has placed many different structures in efficient juxtaposition. Planning the treatment of injuries must take into account the rehabilitation of each structure. For example, a crushing injury at the metacarpal level with dorsal skin loss, extensor tendon injury, and fractures may require stable bony fixation for early mobilization, possible free tissue transfer for skin coverage and tendon gliding, and even possible combination flaps such as the dorsalis pedis flap to include extensor tendons. Isolated treatment of the bony injury may result in a favorable radiograph but would certainly compromise hand function. Treatment of the soft tissue defect without stable bony fixation would be equally disastrous.

Orthopaedic surgery has moved away from such principles as “go to the bone and stay there” to better appreciate the importance of soft tissue treatment and healing. Levin coined the term *orthoplastic* to emphasize the interplay between soft tissue management and bone reconstruction. Reconstruction of the soft tissue envelope demands definition of the layers deficient as well as the size of the defect before outlining a plan that will treat both the bone and soft tissue to the best advantage (38).

Godina, in a large study from Yugoslavia, reviewed 532 microsurgical reconstructions following extremity trauma (24). These were divided into three groups based on the timing of the free-flap transfer, ranging from less than 72 h to greater than 3 months. He showed that early coverage resulted in a lower rate of infection, fewer hospital days and operations, and earlier bone healing. Drawbacks of the study include the wide range of the middle group (72 h to 3 months). The study did emphasize the supreme importance of adequate initial debridement, which often will obviate later debridement and in some cases allow soft tissue coverage at the initial operation (24).

Hand injury treatment as it applies to gunshot, crush, paint injection, and frostbite is reviewed in this chapter, beginning with emergency room evaluation and treatment, surgical planning, staging, options, and, finally, postoperative rehabilitation.

## GUNSHOT WOUNDS

The treatment of penetrating trauma over the course of history has made its greatest advances in wartime. More than half of war wounds involve the extremities, and a fifth of these are hand wounds (11). Regrettably, injuries once commonplace only in times of war are now regular and expected occurrences in emergency rooms around the country. Specific injuries of the hands are seldom themselves life threatening but are frequently associated with other wounds and, as a result, are often complicated by delay in treatment. Maximal function and minimal long-term disability will be achieved only with thoughtful treatment, couched in a basic knowledge of ballistics and wound personality, appropriate emergency care, and reconstruction options.

### BALLISTICS AND WOUND PERSONALITY

Historically, gunshot wounds have been classified on the basis of the velocity of the bullet, with the difference between low and high velocity ranging from 1,100 to 3,000 ft/s (18,32). Velocity increases only the potential for increased tissue disruption; other factors determine the reality of that potential (fragmentation, yaw, missile shape, and deformation). Another popular reference is to the kinetic energy of the bullet, an immeasurable concept that reveals nothing of the magnitude, type, or location of tissue damage or the forces that cause tissue disruption and distracts from these crucial elements. Tissue damage from bullet projectiles occurs through two mechanisms: first, tissue crush by the projectile and any resultant secondary projectiles; and second, tissue stretch from temporary cavitation, which occurs in a radial fashion along the course of the bullet (19,20 and 21,32). Direct tissue damage from the projectile is increased by deformation of the bullet, fragmentation, and bullet yaw and tumble.

The final determination of wound severity is the tissue itself. Tissues such as skeletal muscle have a high level of elasticity and are therefore less affected by temporary cavity displacement pressure (4 atm) than less elastic tissue such as brain, liver, or spleen. Indeed, most injury to extremities is the result of structures directly hit by the intact bullet, bullet fragments, or secondary missiles (19,32,33). Since the Hague Conferences of 1899 and 1907, full metal jacketed bullets were adopted by the military of all major countries to limit unnecessary suffering of war (53). These standards are obviously not applied to civilian weapons. If a full metal jacketed bullet and a soft or hollow point bullet are fired from the same rifle, the latter will result in a much more dramatic wound from both increased yaw and deformation.

Shotgun wounds are classified on the basis of range (Table 45.1) (61). Round projectiles have poor ballistic properties, losing much of their energy in flight through the air. Their wounds are then reflective of the increased mass of the projectiles, not their high velocity. The greater the choke of the barrel, the less spread of pellets at

any given distance. Decreasing the choke (“sawed-off shotgun”) increases both the ability to conceal the weapon and the ability to hit multiple targets with one shot as a result of increased dispersion of the pellets.

| Type | Range | Clinical significance |
|---|---|---|
| I. Penetrating | >7 yards | Subcutaneous tissue or deep fascia penetration |
| II. Perforating | 3-7 yards | Perforates structures beneath deep fascia; wadding present if less than 5 yards |
| III. Massive | <3 yards | Extensive tissue destruction; wadding deep within wound, as well as any material the charge passed through before entry |

***Table 45.1. Classification of Shotgun Wounds***

The power associated with rifles is secondary to the increase in muzzle velocity possible with a longer barrel. The M-16 rifle represented a trend toward projectiles of lower weight and very high velocity (increasing the rounds that a soldier may carry). The resultant poor ballistic coefficient and high drag of the lighter bullet demands a closer target but results in greater tissue destruction, maximizing the wound channel from its high yaw angle after contact (3). It is possible to have both a small entrance and exit wound even in the setting of massive tissue destruction as the bullet yaws early and rights itself for exit. Damage by a military rifle before it yaws cannot be distinguished from that caused by a handgun, even by experts (18).

The majority of handgun shootings occur within 7 yards. The shorter barrel results in lower bullet velocity and less accuracy. A revolver is distinguished from a pistol by its cylinder versus the vertical magazine in the handle of the pistol. Innovation in the characteristics of the bullets has dramatically changed the level of tissue destruction even in the setting of decreased velocity. For example, a Glasser safety slug is a lightweight hollow copper bullet filled with number 12 birdshot pellets with a top sealed with a plastic cap. It ruptures on contact, releasing pellets in every direction, each of which rapidly decelerates, releasing its energy quickly (3).

**EPIDEMIOLOGY**

Firearms are present in 50% of American households according to 1994 estimates. This represents 200 million guns, 60 million handguns, and 3 million assault rifles (50). Washington and Lee reported in 1995 that 14 children younger than 19 years old will die in gun-related incidents each day in the United States (70). Ordog reported on 16,316 patients with 18,349 extremity gunshot wounds treated in Los Angeles from 1978 to 1992. The mean age was 24 years old, and 94% were male; 83% were from handguns, 6% rifles, and 6% shotguns. The majority of shots originated from a passing car. Thirteen percent of upper extremity wounds were associated with a vascular injury, and a vascular injury was four times more likely when the patient had a “major” fracture versus a “minor” or no fracture (50).

Hakanson et al., from the Carolinas Medical Center in Charlotte, NC, reviewed 218 gunshot fractures from 1985 to 1989. Male victims again predominated at 91%, 79% were uninsured, and 65% could be connected with the use of illicit drugs; medical charges averaged $13,108 (27). Another Los Angeles study reviewed gunshot wounds to the hands specifically, with 91 wounds representing 78 men and 13 women. Multiple injuries were present in 56 (58.2%), and 11% involved shotguns. The authors noted a greater injury with hollow point, fluid-filled, or partially jacketed bullets even in the setting of lower velocity (54). Further experience at the Martin Luther King, Jr., General Hospital in Los Angeles catalogued 387 children who sustained gunshot wounds, 117 of whom suffered extremity wounds (70). Finally, at Grady Memorial Hospital in Atlanta, of 72 gunshot wounds, the most consistent region involved was the hand and wrist (34).

**CLASSIFICATION**

Phillips et al. developed a classification of gunshot wounds (GSW) of the hand based on the experience at the Martin Luther King, Jr., General Hospital in Los Angeles (Table 45.2) (54).

| | |
|---|---|
| Zone I | Phalanges |
| Zone II | Metacarpals |
| Zone III | Carpal bones |
| Zone IV | Distal radius and ulna proximal to first carpal row |

***Table 45.2. Classification of GSWs to the Hand***

**EMERGENCY ROOM MANAGEMENT**

- Adhere to the principles of advanced trauma life support. More than half of gunshot wounds to the hand are associated with multiple gunshot injuries (54). In Ogden's study of extremity gunshot wounds, 6% of through-and-through extremity wounds were associated with missile penetration of another “major” body area. Do not allow the obvious hand injury to distract from diagnosing a possibly life-threatening occult wound. Disrobe the patient and inspect all surfaces, including the back.
- Begin specific examination of the wounded upper extremity with assessment of entrance and exit wounds, their size and character, swelling and deformity in the region between, and a mental note of vital structures potentially involved in the path of the bullet.
- Check pulses and circulation by Allen's test. With the high collateral flow in the distal upper extremity, the mere presence of pulses does not rule out a significant vascular injury proximally. Avoid tourniquets for control of brisk bleeding; rather, apply direct pressure. Resist the urge to clamp or coagulate blindly, as future vascular and nerve repair will likely be compromised by inadvertent injury to underlying structures. If an extremity wound is ever fatal, it is most likely related to initial blood loss (64).
- Perform a neurologic examination documenting the function in the radial, median, and ulnar nerves. Document profundus and superficialis tendon function as well as the bony architecture of the hand.
- Following examination, gently rinse with saline solution and apply a moist saline dressing and splint as appropriate.
- Administer intravenous first-generation cephalosporin or ceftriaxone.
- Give a tetanus booster in patients with known active immunity and tetanus toxoid plus human recombinant antitoxin to the nonimmunized, according to the guidelines of the Committee on Trauma of the American College of Surgeons.
- Bullet sterilization from the heat of firing was disproven in 1892 (18). The bullet will carry bacteria from the body surface and any other tissue through which it passes (such as colon). The most important cause of death from missile wounds on the battlefield in the preantibiotic era was streptococcal bacteremia, not clostridial myositis (19).
- Treatment of low-velocity gunshot wounds following emergency room treatment is controversial, with recommendations ranging from a minimum of 24 to 48 h coverage with IV cephalosporin to oral antibiotics given to outpatients only after manifestation of signs and symptoms of infection (29,34,50,70). Marcus advises that “the judgment of the physician performing the initial examination is the most important factor determining the appropriate treatment of a gunshot wound”(42). See the discussion that follows on surgical indications.
- Radiographically image the entire involved extremity and do a chest radiograph as well. Complex associated fractures may then be further imaged using CT, especially with involvement of the carpus.

- Do not overlook compartment syndrome, other associated gunshot wounds, and missile emboli. Suspect compartment syndrome of the hand when the hand is swollen. This presentation may be confused by associated skeletal and nerve injury. The hand will almost invariably be held in an intrinsics minus position. Naidu and Heppenstall find that excruciating pain with passive motion of the MCP joint of the involved digit is the most sensitive clinical indicator (49).
- Measure intracompartmental pressures. Recommendations for fasciotomy vary, ranging from intracompartmental pressures of over 30 mm Hg up to pressures within 30 mm Hg of the diastolic systemic pressure (26,52). There are 10 separate compartments in the hand (Table 45.3). Most frequently, release is necessary of one or two dorsal compartments, the hypothenar, and the thenar, with release of the transverse carpal ligament. The finger is enclosed in a tight investing fascia supported by unyielding volar skin. Occasionally midaxial finger incisions are also required to avoid tissue loss (49,52). The reader is referred to Chapter 13 and Chapter 65 for further discussion of compartment syndromes in the upper extremity.

| |
|---|
| Thenar |
| Hypothenar |
| Adductor |
| 4 Dorsal interosseous |
| 3 Volar interosseous |

***Table 45.3. Compartments of the Hand***

- Missile emboli most frequently occur with close-range shotgun injuries. They should be suspected when the primary wound cannot account for peripheral ischemia. Embolization has also been reported with 22-caliber missiles; the energy of the bullet is spent entering the vessel, and it is then swept along in the flow of blood until the lumen size limits further travel. Reported distant emboli sites include the posterior tibial artery, middle cerebral artery, popliteal artery, femoral artery, anterior tibial artery, and the ulnar artery (5,73).

Indications for formal vascular imaging are controversial. Ordog proposed a classification to aid in decision making (Table 45.4) (50). In addition, multiple wounds in the same extremity and potential arterial compromise may merit arteriography if the condition of the patient allows, to better plan the surgical approach and intervention.

| | | |
|---|---|---|
| Group 1 | Physical findings of vascular injury, unstable patient | Go directly to surgery |
| Group 2 | Physical findings of vascular injury, stable patient | Duplex Doppler ultrasonography, angiography, or both; surgery dependent on findings |
| Group 3 | Wound in proximity to vessel, no obvious compromise | Duplex Doppler ultrasonography; if negative, may treat as outpatient if injuries allow |
| Group 4 | Wound not in proximity to vessel, no signs or symptoms of vascular compromise | No investigation |

***Table 45.4. Ordog's Indications for Vascular Imaging***

## SURGICAL INDICATIONS

The need for formal debridement in the operating room is determined by the severity of the injury. Very often, little information is available regarding the type of weapon, the range at which the injury occurred, or the specific ammunition used. The treating physician must base a reasonable decision not on conjecture as to the velocity of the bullet but on the characteristics of the wound under examination. As previously mentioned, it is possible to have small entrance and exit wounds in the presence of massive underlying soft tissue and bony destruction. This is evidenced by massive swelling, loss of bone stability, and neurologic and vascular deficits, which require emergent surgery. Small entrance and exit wounds in the absence of these clinical signs may, in contrast, be treated with simple wound cleansing and dressing on an outpatient basis. Hampton's review of 368 bullet wounds of the extremities, more than half of which had associated fracture, showed that over 300 did not require debridement, and no sepsis resulted (28).

Marcus retrospectively reviewed low-velocity gunshot wounds of the extremities and grouped them on the basis of both debridement technique and presence or absence of fracture. Nonoperative treatment was defined as excision of wound margins under local anesthesia in the emergency room and wound irrigation with saline, with or without antibiotics. He found no difference in outcomes between those treated with surgical debridement and antibiotics and those without aggressive treatment (42).

Retained bullet fragments present a further dilemma. When they are lodged in the hand, their mere size may necessitate removal. When retained around joints or joint areas where exposure to synovial fluid and abrasion is possible, excision is also recommended to avoid mechanical damage as well as lead arthropathy (23). When they are lodged in the physis of a child, removal is mandatory. Washington and Lee reviewed their experience with gunshot wounds in children and reported that all physeal arrests were easily predicted on the admission radiographs (70). It was previously thought that the physis was highly susceptible to high-velocity injury if the track of the bullet was nearby.

Neurologic deficit is not sufficient reason for surgical exploration in and of itself, as many are neurapraxias. Phillips recommends no exploration before 3 months, then electrical studies to establish the need for repair or grafting (54).

## PRINCIPLES OF OPERATIVE TECHNIQUE

- Acute debridement serves two purposes: to remove nonviable tissue and foreign debris, and to decompress the wounded hand. With the close juxtaposition of many crucial structures in the hand, when there is any doubt about the viability of an important structure, delay excision until the second debridement.
- Debride skin conservatively with little or no excision of skin (31). Extend small wounds for adequate exposure of injured structures.
- Bony fragments may be retained, even if detached, unless grossly contaminated.
- There is rarely a good argument to be made for primary closure of wounds following the initial debridement. Sherman studied shotgun wounds and their complications and found that 31% of wounds primarily closed following debridement required further operative care for infection (61).
- Manage wounds open with moist dressings and splints.
- Carry out a second debridement 48 to 72 h following the first. Debridement is a learned art, as emphasized by Brown, who recommends: “Don't get wounded in the first 2 months of the war” (11).
- Complete or near amputations of the hand or digits rarely are appropriate for replantation. Salvage of skin, tendons, bone, nerve tissue, and even digits themselves may be valuable in reconstruction of the remainder of the injured limb. The viable skin covering near-amputations may be valuable in skin coverage.
- Skeletal stability is crucial for soft tissue healing as well as for mobilization of the hand to hasten rehabilitation. Restore both the longitudinal and transverse arches of the hand, even at the time of the initial debridement. In cases of bony loss, use Kirschner wire bayonet spacers, cross-pinning of metacarpals, or external fixation to achieve stability pending secondary bony reconstruction.
- Nerve repair in the hand may be carried out at the time of initial or secondary debridement, or the nerve ends may be marked for later repair or grafting. Stein and Strauss recommend primary repair only in cases of clean transection, whereas Hennessy advocates primary repair whenever possible, using nerves from nonviable parts of the injured hand when available (31,64).
- When vascular repair is necessary, gain control of the injured vessel both proximally and distally with adequate exposure. In the repair of the radial or ulnar artery in the distal forearm following a close-range shotgun wound, use caution to avoid peripheral embolization of pellets. Vascular repair almost always will require segmental resection, as the zone of injury often extends beyond the area visibly damaged. Vein grafting is usually necessary (5,26,32,50,61,64,73).

- Skin coverage options after the final debridement include delayed primary closure, healing by secondary intent, local flaps, or distant flaps.
- Postoperatively, support the wounded tissues with a dressing firm enough to eliminate dead spaces without inhibiting venous return. The dressing absorbs blood and exudates, provides a barrier to further contamination, increases patient comfort, and facilitates mobilization of uninjured parts. Place the hand in an intrinsics-plus position unless that compromises the repairs. Elevate the limb and begin early range-of-motion exercise for the shoulder and elbow to avoid stiffness.

### REHABILITATION

The success of rehabilitation requires a patient's understanding of his role and responsibility as an active member of the rehabilitation team. Begin patient education after application of the first postoperative dressing or in the emergency room for those treated nonoperatively. Mobilization of all parts possible, edema control, wound care, and splinting in functional positions are all elements of success in returning the injured limb to useful function.

### PITFALLS AND COMPLICATIONS

Pitfalls include compartment syndrome, overlooked associated gunshot wounds, underestimated vascular injury, and peri- or intraarticular lead particles. Lead near or in joints will be dissolved over time by acidic synovial fluid and incite a proliferative synovitis, which may result in focal articular cartilage erosion and degenerative arthritis. Radiographically, lead may resemble chondrocalcinosis, with metallic not calcific deposits. Remove intraarticular lead particles soon after injury. If lead arthropathy is suspected, measure serum lead levels. Delay surgical procedures until levels have been reduced with chelating agents such as D-penicillamine (23).

Duncan and Kettelkamp showed that the primary functional impairment following low-velocity gunshot wounds to the hand was loss of motion secondary to fractures and joint disruption, and this surpassed the disability from infection and tendon, nerve, or vascular injury. Most marked losses involved the proximal interphalangeal (PIP) joint. They strongly recommend stable internal fixation with early mobilization (16).

### AUTHORS' PERSPECTIVE

The key concept in the treatment of gunshot wounds to the hand is to treat individually each wound rather than mindlessly following protocols established for high- versus low-velocity weapons.

Often there is tremendous social and psychological impact associated with these injuries. Sensitivity to these issues and cooperation with counselors, social workers, and others can strongly influence the final outcome.

## CRUSH INJURIES

### MECHANISM OF INJURY AND PRINCIPLES OF TREATMENT AND EVALUATION

Compression of the hand and forearm between motor-driven rollers will produce a true crush injury. Such trauma usually occurs in the workplace from a printing press or with a home laundry machine—the classic “wringer arm” (43). The nature of the damage and the severity of the wound produced by these wringers or rollers are determined by a number of factors (17,60). Important ones include clearance between the rollers, the type of surface (steel or rubber), and the temperature of the crushing device. The speed of the roller partially determines the force applied; skin avulsion occurs at higher speeds.

Three forces are involved in roller or wringer injuries (1). A *compression force* is created when the large extremity is propelled into the small gap between the rollers. Compression results in tissue contusion. A *friction abrasion force* characteristically produces a distally based flap and often tears the skin. Last, a *shearing force* moves the soft tissues over deeper fixed structures, resulting in lacerations, subcutaneous hematomas, and disruption of musculotendinous junctions. The degree of injury is related to the roller size, clearance, duration of compression, and the method of extraction. The severity and depth of injury produced by the compression and shearing forces may not be readily evident. Skin that has been completely removed from its blood supply will undergo necrosis (67). Hemorrhage may further separate the subcutaneous tissues from the deep fascia and require drainage. Swelling or bleeding beneath the forearm fascia can produce increased pressure (see Chapter 13 and Chapter 65) and muscle ischemia and result in Volkmann's contracture. Although this is often described in the forearm, ischemic contracture involving the intrinsic muscles can occur in the hand (51). When examining the severely crushed, edematous hand, if pain is produced by the intrinsic stretch test and compartment pressures are significantly elevated, perform decompression of the interossei. If peripheral circulation is impaired and/or distal pulses are not palpable, evaluate further with a Doppler device and do an arteriogram if necessary. Test sensibility: two-point discrimination values greater than 10 mm are suggestive of nerve compression but may represent a traction injury to a nerve. Because fractures occur in 25% of roller injuries, obtain appropriate radiographs (43). An injury that is frequently unrecognized is dislocation of the metacarpal trapezial joint. This occurs when the transverse arch of the hand is flattened and compressed (Fig. 45.1) (71).

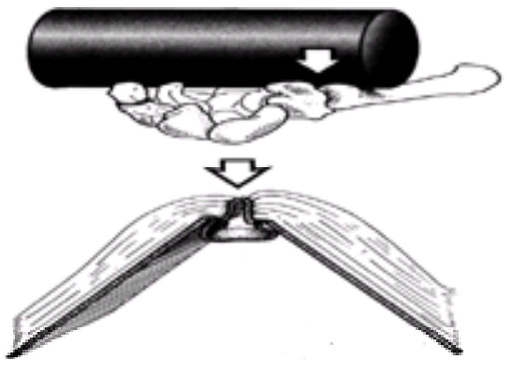

***Figure 45.1.*** Roller or crush injuries extending to the level of the wrist (**A**) can dislocate the basal (trapezial–metacarpal) joint and (**B**) are similar to breaking the binding of a book.

Crushing injuries of the upper extremity produced by a household laundry wringer were once common occurrences; fortunately, this device has almost disappeared with the advent of modern clothes dryers, and such injuries are now rare. Wringer injuries usually occur in children younger than 15 years of age and most often between ages 3 and 5 years. The maximal injury is usually located at the area most proximally involved (45). Damage usually occurs up to the level of the elbow, with more proximal trauma occurring in younger patients. The most frequent injuries encountered are friction burns from abrasion and soft tissue contusion, which can occasionally lead to tissue necrosis. Lacerations, joint injuries, and vascular trauma occur less frequently (65).

### NONOPERATIVE TREATMENT

- Cleanse the entire limb.
- Reduce dislocations and fractures.
- Suture lacerations.
- Open wound care may be appropriate, particularly with marginally perfused skin flaps.
- Apply a light nonconstrictive dressing and splint. The rare patient with a limb-threatening vascular injury or a major soft-tissue injury requires prompt surgical treatment. As with other crush injuries, the greatest difficulty is in assessing the initial depth of a wringer injury in a child. The most common surgical procedure required after a wringer injury is skin grafting. Antibiotics are indicated in patients with open fractures or obviously contaminated wounds (25).

### OPERATIVE TECHNIQUE

- Prepare and drape the entire extremity.
- Do not use a tourniquet.
- Do a methodical layer-by-layer debridement and irrigation of open wounds.
- If a compartment syndrome is present in the hand, wrist, or forearm, perform appropriate fasciotomies (15,49,51). Decompressions of the hand often require dorsal incisions for the interossei and separate incisions for the hypothenar and thenar compartments. For decompressions of the hand and/or forearm, include a

carpal tunnel release.

- Nerve injuries are difficult to assess, as loss of function most commonly results from a neuropraxia, but direct crushing and traction injury may be present (66). If the nerves are visible in wounds or fasciotomy incisions, inspect them; otherwise, simply observe them as they recover without surgical intervention.
- Stabilize fractures, as this enhances soft tissue management and facilitates rehabilitation.
- Repair tendon lacerations or avulsions.
- Leave all wounds open at the time of initial debridement. A common injury is a palmar laceration with a distally based skin flap and crush of the thenar and hypothenar muscles. Further necrosis may occur, requiring serial debridements.
- Cover the wounds with moist dressings and splint the extremity with the wrist in extension, the MP joints flexed, and the interphalangeal joints extended.
- Return to the operating room at 36- to 72-h intervals or as often as necessary to complete debridement of nonviable tissue.
- Skin loss will require resurfacing with either grafts or flaps (9,36,39).
- Crush injuries involving the dorsum of the hand usually have damage to skin, extensor tendons, and bone and joints. Conventional treatment of these injuries has been with staged reconstruction, first obtaining soft-tissue coverage and then performing bone repair and tendon grafts. Recent studies have suggested that immediate reconstruction with primary tendon and bone grafting along with skin closure results in faster return of motion and fewer surgical procedures.
- Injuries that involve both surfaces of the hand frequently result in amputation of some portion.

### POSTOPERATIVE CARE

Begin rehabilitation of these complex injuries immediately following surgery. While the surgical dressing immobilizes the injured tissues in the appropriate position, move the uninvolved portions of the hand. After the wound has stabilized, direct a more vigorous mobilization program at overcoming the most common problems of chronic edema and stiff joints (72).

The best way to limit or decrease edema is through elevation and active motion. Retrograde massage may prove helpful, and thermoelastic gloves can provide continual compression and warmth. To prevent joint stiffness and contractures, promptly mobilize all joints within the limits of pain tolerance. Try to move each joint through as great an arc of motion as possible at least three times a day, and preferably once each hour. With further healing, and when the patient has less pain, dynamic splinting may be added to the exercise program. Although splinting of the hand in metacarpophalangeal joint flexion and interphalangeal joint extension (safe position) prevents the most serious joint contractures, this attitude of the fingers increases the chance of developing contracture of the intrinsic muscles. Persistent dorsal edema of the hand predisposes to intrinsic muscle contracture even if these muscles have not been compromised initially. An intrinsic stretching exercise program can prevent contracture.

An active exercise program not only mobilizes joints but also restores the gliding of tendons and increases both tendon strength and wound healing. Motion begun too early may sometimes compromise soft-tissue healing; therefore, carefully monitor the patient. Persistent drainage from a wound indicates inadequate debridement with the presence of necrotic tissue or retained foreign material.

### PITFALLS AND COMPLICATIONS

After crush injuries, other problems that occur include scar contractures, tendon adherence, nerve compression, and chronic pain (12). The blood supply to skin flaps that have been markedly contused is usually poor and often distally based. Excise all obviously nonviable skin primarily. Suture borderline tissue flaps without tension and carefully observe them. By 3 to 5 days after injury, tissue viability should be clarified, and the wound can be debrided of all necrotic material.

Treat wounds with skin and soft-tissue loss with the simplest techniques that will provide a satisfactory result, such as a skin graft, either split thickness or full thickness. A local flap can be used to cover a small full-thickness defect resulting in exposed bone or tendon that requires vascularized tissue. More proximal flaps from the arm (posterior interosseous artery or radial forearm) can be employed for coverage of larger defects. More distant flaps (abdominal or groin) and free tissue transfers should also be considered. The latter may be composed of skin, muscle, fascia, or composite tissues. Although detached skin may be defatted and used as a full-thickness skin graft, if it is severely traumatized it will fail to heal. The decision as to which coverage is most appropriate depends on the requirements of future reconstructive surgery.

A scar contracture may be associated with an area of skin grafting or with a surgical incision required for a fasciotomy. Prevention of the latter can be achieved by application of the principles for incision placement (40). Contracted skin grafts can be resected and the defect treated with local soft-tissue mobilization or tissue expansion (47). A graft may be replaced by a flap if additional tissue is required after the contracture is released. This is important if the location is one that will receive considerable pressure with use or that will be subject to tissue breakdown. For example, split-thickness skin grafting on the palm may not withstand normal shearing forces, and primary closure of a wound involving a flexion crease ultimately worsens the contracture. Occasionally contractures can be released with a **Z**-plasty or a local flap.

Although a compartment syndrome should always be considered after a crush injury, direct muscle trauma with necrosis and fibrosis is more common. Selective muscle debridement is part of treating an open injury. Although adherence of injured muscles or tendons is common, prompt remobilization can limit the loss of motion in the hand. However, fractures and joint injuries will compound the problem. Tenolysis should be considered only after all the tissues in the extremity are well healed and the patient obtains full passive motion in the fingers. Adherence proximal to the musculotendinous junction will not respond to a lysis and should not be attempted, as it will not improve distal motion.

Nerve-related complaints may persist after a crush injury. External compression can occur at the site where a nerve passes adjacent to traumatized muscle or injured fixed tissues, that is, ligaments or bone. Crushing trauma is even more likely to produce an intraneural injury. The question is whether there is external nerve compression or internal fibrosis of the nerve. The production of paresthesias on percussion over a nerve may localize the injury but will not clarify the diagnosis. Electromyelograms and nerve conduction studies may help differentiate external or internal compression from traction.

The development of chronic pain after major trauma, particularly crushing injuries, is not rare (10). Several weeks after the initial trauma, the patient should be able to control pain with a nonnarcotic medication. If the patient still has considerable pain after this, a chronic problem must be acknowledged and will require the combined efforts of several specialties. If the patient is to participate actively in an exercise program, pain must be controlled. Supportive splinting and a variety of modalities including transcutaneous electrical nerve stimulator are indicated. The possibility of the patient developing a chronic pain syndrome must be recognized from the onset. Successful treatment requires early recognition and a rapid response.

### AUTHOR'S PERSPECTIVE

Although this section has dealt with crush injuries of the hand alone, they need to be considered in light of the broader classification of mutilating hand injuries. This is a topic too large to be included in this chapter, but a few principles need to be understood. Reconstructive surgery after a mutilating wound will be more effective if the primary treatment minimizes the amount of scar tissue. Soft-tissue coverage is critical. The preservation or sacrifice of tissue must be designed to gain the greatest function at the least risk. When the hand has been mutilated, normal function may be an unrealistic expectation in the setting of anatomic loss, but useful function may be created with what remains. Microsurgical techniques have expanded the repertoire of the reconstructive surgeon.

The major pitfall in a mutilating injury is failure to recognize the depth and significance of the original injury. The most critical element after such an injury is the correct timing of treatment. The judgment required to make these critical decisions arises from knowledge and experience.

## INJECTION INJURIES

### PRINCIPLES OF TREATMENT

High-pressure injection injuries of the hand (HPIIH) caused by grease, paint, or paint thinner occur frequently. Although the wound may initially appear innocuous, these injuries are surgical emergencies that require prompt exploration, decompression, and debridement (41).

Injection guns put out a fine stream of material under pressure that ranges from 600 to 4,000 lb/in$^2$. The substance fired at such velocity through a small nozzle enters the skin and spreads along fascial planes, tendon sheaths, or neurovascular bundles—the paths of least resistance (35). Tissue within the hand may be mechanically damaged by pressure and rendered ischemic. In addition, the material injected produces an acute chemical inflammation, which may be associated with additional soft tissue and vascular damage (14).

If the wound is not treated, or if the foreign material is not completely removed, chronic inflammation, fibrosis, foreign body granuloma (oleomas), and sinus formation with chronic tissue breakdown may occur. Paint produces an acute inflammatory response, whereas grease causes a delayed chemical reaction resulting in fibrosis and stiffness. The volume of material that enters the hand is directly proportional to the pressure produced by the gun. The greater the volume of material that has

been injected, the greater is the amount of soft tissue damage that occurs.

Following injection, symptoms are often initially minimal, with only a burning discomfort at the injection site. Within a short time, the finger usually becomes distended, pale, and numb with throbbing pain. Subsequently, greater pain and mottling of the skin appear. The pain may be related to ischemia, the injection having created a compartment syndrome of the digit. If a considerable volume of material has been injected, enlargement of the finger is immediate. The left hand is involved more frequently than the right, and the patients are usually men. Common injection sites include the distal segment of the index finger, thumb, or middle finger, which are usually used to check a presumed “plugged” injection tip. The palm and other digits are damaged less frequently.

Obtain radiographs of the hand and finger, which may demonstrate how deeply the grease or paint has extended. Many greases are radiopaque because of the lead that has been added as a lubricating agent. If routine x-rays do not yield enough information, xeroradiographs may provide useful information. Patients can develop systemic effects, which include fever, lymphangitis, and an elevated leukocyte count. These signs usually appear within 2 days after the injury and may last 4 to 5 days (13).

### OPERATIVE TECHNIQUE

- High-pressure injection injuries require immediate surgery.
- Local anesthetic blocks in the palm are usually contraindicated, and the extremities should obviously not be wrapped with a pressure bandage before application of the tourniquet (35).
- Use a modified midlateral incision to explore the finger. A zig-zag approach, although providing better exposure, is more likely to result in skin slough and may lead to further tissue compromise in wounds left open for subsequent debridement. If necessary, continue the incision into the palm in a curvilinear fashion, extending it past the wrist and into the forearm if needed.
- After surgical exposure, remove all the abnormal material such as grease or paint. Excise any fat or fascia that is involved. Resect tendon sheaths in part if they are involved, taking care to leave essential portions of the fibro-osseous sheath system. A small curet or rongeur may be helpful in removing the material.
- Nerves and arteries that are functional but have the foreign substance embedded in them should be left intact and not resected.
- Even after a meticulous dissection, some foreign material may remain. Solvents for grease or paint are inefficient and are not employed for fear of causing more tissue damage. Pack open the wounds with the intention of performing a secondary exploration and closure in 2 to 3 days.
- An alternative choice is to close the wounds loosely over drains.
- A third choice is to leave the wound completely open, allowing it to heal by secondary intention. Skin grafts may be required to close wounds if critical structures are exposed.
- Perform wound cultures at the time of all surgeries, as infections are not infrequent. Many surgeons recommend antibiotic coverage for 2 weeks, but the use of prophylactic antimicrobial drugs is not clearly indicated unless there is an active infection (41).
- Immobilize the hand in a safe position (MP flexion and interphalangeal joint extension).

### POSTOPERATIVE CARE

Treat wounds that are left open with the intent of healing by secondary intention with early motion and whirlpools as well as an intensive active exercise program. Patients whose wounds have been packed open should be considered for the same treatment or have their wounds reevaluated in the operating room for redebridement in 2 to 3 days. When it has been determined that all the foreign material has been removed, involve the patient promptly in the remobilization program as mentioned above. Make no attempt to close small defects with skin grafts. Except during exercise, place the patient's hand at rest in a position to prevent contractures, particularly flexion contractures at the PIP joint. Eventual impairment is related to the amount of tissue destroyed by foreign material. Paint gun injuries generally inflict greater damage than do grease guns, and injections into the palm have a better prognosis than injury to the digits.

### PITFALLS AND COMPLICATIONS

The most frequent complications from injection injuries result from failure to debride the wound sufficiently and premature wound closure. Although much has been written about the toxicity of both grease and paint, injected paint thinner is the most difficult to detect and completely remove (63). Injuries from paint thinner should never be closed primarily; multiple debridements and reexplorations can be anticipated.

Delay in initiating treatment leading to an adverse result often occurs because the patient or physician initially evaluating the injury is unaware of its significance (22). In one recent series, the only patients requiring amputation were those initially evaluated 3 to 8 days following injury. Although prompt surgery is recommended, this alone does not always ensure a good result. It is also possible to obtain a satisfactory result when surgical treatment has been delayed, particularly with grease gun injuries (62).

The question of amputation should be discussed with the patient initially and remain under consideration should delayed healing or complications arise. Retention of the tip of a digit that has required extensive soft-tissue and skin resection is not beneficial. The patient will be left with a painful atrophic finger with little function. The period of disability can be extensive, and it averaged 7 months in one study (22). In a more recent study where patients were treated with open wound management (wide debridement, drainage, open packing, and delayed closure), all the patients returned to work, 92% to their previous job (55). Because of the possible prolonged morbidity, several authors have recommended early amputation, especially after a paint gun injury (35,57). Prompt amputation often allows the patient to return to work within 6 to 8 weeks of the injury.

Late complications after injection injuries include skin breakdown, ulceration, and sinus formation with discharge of foreign material. Delayed infection rarely occurs if one can obtain wound healing within 2 weeks of the original injury. However, retention of foreign material, necrotic tissue, and chronically open wounds can produce sepsis.

## FROSTBITE INJURIES

### EPIDEMIOLOGY

Throughout history, frostbite has been closely associated with winter military campaigns. For example, 10% of all casualties in the 1982 Falkland Islands conflict were related to frostbite. Unfortunately, frostbite is also a civilian concern, even in urban, populated areas today. The human body is equipped with many mechanisms for the dissipation of heat but must rely on largely conscious measures for heat conservation. The strongest human defense against frostbite is the conscious decision to wear adequate clothing and seek shelter. Not surprisingly, then, urban frostbite most commonly occurs in those with altered mental states such as psychiatric illness and substance abuse. The homeless, elderly, and children are also at risk.

Both environmental and host factors predispose to cold injuries (Table 45.5). Wind velocity, ambient temperature, altitude, and duration of exposure set the environmental stage, acting on host factors such as protective clothing, systemic and vascular disease, previous cold injury, and ability to seek adequate shelter and treatment.

| | |
|---|---|
| Hypothermia | Lowering of body core temperature to less than 95°F |
| Frostnip | Pallor and numbness of affected tissue without epidermal or dermal damage following warming |
| Frostbite | Skin and subcutaneous tissues exposed to thermal stress freezing, resulting in ice formation in the skin or deep tissue |

***Table 45.5. Differentiation of Cold Injuries***

Valnicek, in a 12-year retrospective review of inpatient frostbite injuries in Saskatoon, Saskatchewan, concluded, “Fit, well-prepared people without cerebral impairment rarely present with significant frostbite injury” (69). In this series, 78% of victims were male and 46% associated with alcohol consumption, 17% with psychiatric illness, and 19% with trauma. The distribution of injury was 19% upper extremity, 31% upper and lower, and 47% lower extremity. Of the 63 patients with upper extremity frostbite, 13 required major amputation and 18 minor (69).

In a large review, 843 inpatient and 194 outpatient frostbite cases at Cook County Hospital in urban Chicago were reported over 10 winters. The mean age of the patients was 43 years, with over 76% between the ages of 30 and 60. Upper extremity involvement (47%) was slightly less than lower extremity (53%). Children showed almost exclusively upper extremity involvement, many with bilateral “glove-like” lesions. Hand amputations, when required, were most common at the finger MCP joint and the thumb IP joint (7).

Another review, from Edmonton, Alberta, sought predictors of poor outcome such as major tissue loss. Strong association was found with impaired cerebral function (alcohol, psychiatric illness), lower extremity involvement, infection on presentation, and delay in seeking medical attention (68). Inadequate protective clothing and exposure to metal or wetness was also correlated with severity of injury by Knize in a Denver, Colorado study (37).

## PHYSIOLOGY

The human body demonstrates predictable responses to a cold environment. The spinal cord signals the hypothalamus, resulting in increased muscle tone (shivering) and release of catecholamines and thyroxine. Increase in basal metabolic rate, vasoconstriction, and decreased sweating result. The most important organ in temperature regulation is the skin, specifically that of the extremities, which represents more than 50% of total body surface area. Blood flow to the skin during cold stress can virtually cease or can increase as much as 200-fold for heat loss (8). The “hunting reaction,” described by Sir Thomas Lewis in 1830, preserves both core temperature and extremity viability during cold exposure by cyclically alternating vasoconstriction and vasodilation to the limbs (8,48,56). This regulatory mechanism ceases when the core temperature drops, prioritizing preservation of core temperature over extremity viability.

Frostbite may occur with either slow or rapid freezing of tissue. Slow freezing results in extracellular ice crystal formation, which increases the osmotic pressure of the interstitium, pulling out intracellular water. Intracellular fluid does not crystallize, as it is continuously lost with a corresponding reduction of freezing point (48). Cell membrane damage, most marked in endothelium, occurs by mechanical damage from crystals and dramatic osmotic changes. Endothelial cell injury is seen microscopically with separation from the internal elastic lamina of the arterial wall. Ice crystal formation in plasma resulting in red cell sludging further compromises circulation. Cartilage cells, especially in epiphyseal cartilage, are very susceptible to even brief freezing. Muscle, blood vessels, and nerves are damaged more quickly than bone and connective tissue (8,48,56).

Rapid freezing is defined as cooling by more than 10°C/min. This results in immediate cell death by intra- and extracellular crystal formation. Exposure to cold metal or volatile liquids is the most common mechanism.

With rewarming, plasma and extracellular crystals melt, and damaged endothelial-lined capillaries dilate and leak fluid and protein into the interstitium. Intracellular swelling occurs in any viable cells, as they were previously dehydrated and regain water lost. Red and white blood cells and platelets aggregate, contributing to microcirculatory failure, a significant cause of tissue loss (8,48). Continued tissue injury following reperfusion may also be related to prostaglandin-induced vasoconstriction ($PGF_2a$, thromboxane $A_2$), similar to factors found in burn injury. These factors have been found in significant concentration in clear blisters associated with frostbite, leading some to recommend their debridement to limit further loss of viable tissue. Aloe vera is an inhibitor of thromboxane $A_2$, and aspirin or ibuprofen controls prostanoid production (30,44).

## CLASSIFICATION

The classification of frostbite injury parallels that of burn injury and indicates level of tissue loss. The prediction of level is often less than accurate, leading some to recommend a simplified version indicating only superficial and deep. Table 45.6 demonstrates both systems. Table 45.7 coordinates clinical presentation with degree of injury.

| *Frostbite* | *Degree* | *Level of injury* |
|---|---|---|
| Superficial | First | Partial thickness skin |
| | Second | Full thickness skin |
| Deep | Third | Skin and subcutaneous |
| | Fourth | Skin, subcutaneous tissue, muscle, tendon, bone |

***Table 45.6. Classification of Frostbite by Level of Tissue Loss***

| *Frostbite* | *Findings* | *Symptoms*[1] |
|---|---|---|
| First | Erythema, edema; no blisters or necrosis | Stinging, burning, aching; possible hyperhidrosis |
| Second | Erythema, edema, clear blisters that desquamate and form blackened eschar | Numbness, possible vasomotor disturbances |
| Third | Hemorrhagic blisters, skin necrosis, blue-gray discoloration | No sensation, tissue feels like “block of wood,” later shooting pains, burning, throbbing, aching |
| Fourth | Little edema, initially mottled, deep red or cyanotic; eventually dry, black, mummified | Possible joint discomfort |

***Table 45.7. Classification of Frostbite by Clinical Presentation***

## ACUTE MANAGEMENT

In the prehospital setting, the primary concern is protection of the injured part from mechanical trauma, avoiding pressure, rubbing, or exercise. If there exists any possibility of further cold exposure, rewarming is strongly contraindicated. Refreezing results in much greater tissue necrosis than the persistence of freezing until definitive and controlled rewarming can occur. Salimi, in a rabbit foot model, demonstrated that rapid rewarming was effective in limiting necrosis only when performed immediately after freezing. He recommends it only if it is performed immediately following removal from freezing (58). Unfortunately, most patients' injuries have already spontaneously thawed on presentation, 88% in the large Chicago Cook County Study (7).

Perform rewarming in a rapid, controlled fashion with 40°C to 42°C water containing a mild antibacterial agent until a flushed appearance to the part indicates reperfusion. Continuous monitoring of water temperature is imperative. Dry rewarming is contraindicated to avoid risk of burn injury. Narcotic analgesics will be required during rewarming. Give tetanus booster and antitoxin if not up to date. Obviously, if hypothermia exists, systemic treatment and measures take priority over rapid rewarming, although they often may be instituted simultaneously. Antibiotic prophylaxis is controversial and likely appropriate only in severe cases with delayed presentation.

Following rewarming, elevate involved limbs and control edema. Debride clear blisters but leave hemorrhagic blisters undisturbed. The goals of wound care are to preserve viable tissue and to prevent infection. Whirlpool treatment is recommended for open wounds. Escharotomy and fasciotomy may occasionally be required. Dressing wounds with topical agents such as aloe vera may be helpful in counteracting the vasoconstrictive effects of thromboxane $A_2$, and oral aspirin or ibuprofen counteracts the effects of prostanoids (30,44). Systemic vasoconstrictive agents such as nicotine are obviously prohibited. Multiple other treatments have been studied, but their usefulness has not been established; these include dextran, heparin, pluronic F-68, hyperbaric oxygen, phenformin ethylestrenol, streptokinase, urokinase, and reserpine. Hyperbaric oxygen is not helpful and may cause vasoconstriction and reduction in blood flow (56).

## OPERATIVE TECHNIQUE

“Frostbite in January, amputate in July,” and “hurry up and wait before you ablate” characterize the historical treatment of frostbite. Difficulty in prediction of tissue loss has led to a very conservative approach, often awaiting autoamputation. Earlier prediction is now possible through triple-phase bone scanning, radionuclide angiography, and magnetic resonance imaging/MRA (Table 45.8).

| Radiology | Timing | Advantage |
|---|---|---|
| Radionuclide angiography | Initial scan 24–48 h, repeat at 7 days | Evaluates microvascular blood flow |
| Triple-phase bone scan | >48 h after injury | Predicts three categories: no formal debridement, minor debridement, amputation |
| MRI/MRA | No timing recommendation as yet, preliminary report only | Direct visualization of occluded vessels, more specific imaging of surrounding tissue, clear-cut |

***Table 45.8. Imaging for Frostbite***

Amputation, when necessary, should be performed in a guillotine fashion, with delayed closure or coverage. Acute amputation is necessary only in the setting of infection, most common in patients with a delayed presentation.

Sympathectomy may be performed either medically or surgically. Reserpine infusion intraarterially into the affected limb causes depletion of arterial wall norepinephrine for up to 2 to 4 weeks (56); however, no difference has been shown in conservation of tissue, edema resolution, pain reduction, or improved function. Surgical sympathectomy plays a delayed role in treatment of vasospastic syndromes following a cold injury.

Severe cases of hand frostbite may result in either hands without digits or loss of all but the proximal thumb. Reconstruction of this difficult problem is possible through tissue transfers and free flaps. An excellent report of 25 digitless hand reconstructions by Borovikov demonstrated a reliable technique of toe-to-hand transfers to regain opposition (6).

## PITFALLS AND COMPLICATIONS

Many long-standing discomforts may result from a cold injury, many associated with vasomotor dysfunction (Table 45.9). Intrinsic injury affects strength and fine motor control in relation to both direct muscle freezing and neurologic injury. Arvesen studied 40 Norwegian soldiers following local cold injuries. Nerve conduction velocities were still markedly decreased 3 to 4 years following injury to the nerves in previously cold-injured limbs, even proximal to the level of injury (2).

| |
|---|
| Cold sensitivity |
| Hyperhidrosis |
| Color changes |
| Vasospastic attacks B |
| Raynaud's phenomenon |

***Table 45.9. Vasospastic Symptoms***

The particular sensitivity of cartilage to cold injury and the destruction of articular cartilage by ice crystal formation explain the arthritis that can occur as early as months following injury. In children, both the physis and the epiphysis are susceptible. Classic radiographic findings in the juvenile frostbite injury include total absence of the distal phalangeal epiphysis and damage to the middle phalangeal epiphyses. Distal metaphyses are frequently irregular even in the absence of clinical frostbite (56).

Squamous cell carcinoma has been reported in the regions of previous cold injuries, 20 to 30 years following injury, similar to burns or chronic osteomyelitis.

## AUTHORS' PERSPECTIVE

The only current proven and definitive method of improving the outcome of frostbite injury is its prevention. The important role of inflammatory mediators in perpetuating tissue damage following cold injury will be a future focus of research to modulate this effect. Acute management must focus on the basic principle of doing no further harm and protecting viable tissue. Rapid rewarming may be of great benefit only when a patient presents with frozen tissue. Later reconstruction must be tailored to the unique needs of the injured individual, often requiring tissue transfer.

## CHAPTER REFERENCES

Each reference is categorized according to the following scheme: *, classic article; #, review article; !, basic research article; and +, clinical results/outcome study.


* 1. Adams JP, Fowler FD. Observation in Wringer Injuries. *J Bone Joint Surg* 1961;43-A:1179.

! 2. Arvesen A, Wilson J, Rosen L. Nerve Conduction Velocity in Human Limbs with Late Sequelae after Local Cold Injury. *Eur J Clin Invest* 1996;26:443.

# 3. Barach E, Tomlanovich MT, Nowak R. Ballistics: A Pathophysiologic Examination of the Wounding Mechanisms of Firearms: Part II. *J Trauma* 1986;26:374.

+ 4. Barker JR, Haws MJ, Brown RE, et al. Magnetic Resonance Imaging of Severe Frostbite Injuries. *Ann Plast Surg* 1997;38:275.

+ 5. Bongard F, Johs SM, Leighton TA, Klein SR. Peripheral Arterial Shotgun Missile Emboli: Diagnostic and Therapeutic Management—Case Reports. *J Trauma* 1991;31:1426.

+ 6. Borovikov A. Toe-to-Hand Transfers in the Rehabilitation of Frostbite Injury. *Ann Plast Surg* 1993;31:245.

* 7. Boswick JA, Thompson JD, Jonas RA. The Epidemiology of Cold Injuries. *Surg Gynecol Obstet* 1979;149:326.

# 8. Britt LD, Dascombe WH, Rodriguez A. New Horizons in Management of Hypothermia and Frostbite Injury. *Surg Clin North Am* 1991;71:345.

# 9. Brown DM, Upton J, Khouri RK. Free Flap Coverage of the Hand. *Clin Plast Surg* 1997;24:57.

# 10. Brown H. Closed Crush Injuries of the Hand and Forearm. *Orthop Clin North Am* 1970;2:253.

* 11. Brown PW. War Wounds of the Hand Revisited. *J Hand Surg* 1995;20:61.

# 12. Carter PR. Crush Injury of the Upper Limb. *Orthop Clin North Am* 1984;14:719.

+ 13. Crabb DJM. The Value of Plain Radiographs in Treating Grease Gun Injuries. *Hand* 1981;13:39.

# 14. Craig EV. A New High-Pressure Injection of the Hand. *J Hand Surg* 1984;9-A:240.

! 15. DiFelice A, Seiler JG, Whitesides TE. The Compartments of the Hand: An Anatomic Study. *J Hand Surg* 1998;23A:682.

+ 16. Duncan J, Kettelkamp DB. Low-Velocity Gunshot Wounds of the Hand. *Arch Surg* 1974;109:395.

! 17. Entin MA. Roller and Wringer Injuries: Clinical and Experimental Studies. *Plast Reconstruct Surg* 1955;15:290.

# 18. Fackler ML. Gunshot Wound Review. *Ann Emerg Med* 1996;28:194.

# 19. Fackler ML. Wound Ballistics: A Review of Common Misconceptions. *JAMA* 1988;259:2730.

* 20. Fackler ML, Dougherty PJ. Theodor Kocher and the Scientific Foundation of Wound Ballistics. *Surg Gynecol Obstet* 1991;172:153.

! 21. Fackler MD, Malinowski JA. The Wound Profile: A Visual Method for Quantifying Gunshot Wound Components. *J Trauma* 1985;25:522.

# 22. Gelberman RH, Madison JLP, Jurist JM. High-Pressure Injection Injuries of the Hand. *J Bone Joint Surg* 1975;57-A:935.

+ 23. Giyanani R, Lomasney LM, Demos TC. Lead Arthropathy. *Orthopedics* 1996;19:629.

+ 24. Godina M. Early Microsurgical Reconstruction of Complex Trauma of the Extremities. *Plast Reconstruct Surg* 1986;78:285.

# 25. Golden GT, Fisher JC, Edgerton MT. “Wringer Arm” Re-evaluated: A Survey of Current Surgical Management of Upper Extremity Compression Injuries. *Ann Surg* 1973;177:362.

# 26. Hahn M, Strauss E, Yang EC. Gunshot Wounds to the Forearm. *Orthop Clin North Am* 1995;26:85.

+ 27. Hakanson R, Nussman D, Gorman RA, et al. Gunshot Fractures: A Medical, Social, and Economic Analysis. *Orthopedics* 1994;17:519.

* 28. Hampton OP Jr. The Indications for Debridement of Gun Shot (Bullet) Wounds of the Extremities in Civilian Practice. *J Trauma* 1961;1:368.

+ 29. Hansraj KK, Weaver LD, Todd AO, et al. Efficacy of Ceftriaxone versus Cefazolin in the Prophylactic Management of Extra-articular Cortical Violation of Bone Due to Low-Velocity Gunshot Wounds. *Orthop Clin North Am* 1995;26:9.

! 30. Heggers JP, Robson MC, Manavalen K, et al. Experimental and Clinical Observations on Frostbite. *Ann Emerg Med* 1987;16:1056.

* 31. Hennessy MJ, Banks HH, Leach RB, Quigley TB. Extremity Gunshot Wound and Gunshot Fracture in Civilian Practice. *Clin Orthop* 1976;114:296.

# 32. Hollerman JJ. Gunshot Wounds. *Ann Fam Pract* 1988;37:231.

# 33. Hollerman JJ, Fackler ML, Coldwell DM, Ben-Menachem Y. Gunshot Wounds: Bullets, Ballistics, and Mechanisms of Injury. *Am J Roetgenol* 1990;155:685.

* 34. Howland WS, Ritchey SJ. Gunshot Wounds in Civilian Practice. An Evaluation of the Results of Limited Surgical Treatment. *J Bone Joint Surg* 1971;53A:47.

# 35. Kaufman HD. High-Pressure Injection Injuries: The Problems, Pathogenesis and Management. *Hand* 1969;2:63.

+ 36. Kleinman WB, Dustman JA. Preservation of Functional Following Complete Degloving Injuries to the Hand: Use of Simultaneous Groin Flap. Random Abdominal Flap and Partial-Thickness Skin Graft. *J Hand Surg* 1981;6:82.

* 37. Knize DM, Weatherley-White RCA, Paton BC, Owens JC. Prognostic Factors in the Management of Frostbite. *J Trauma* 1969;9:749.

# 38. Levin SL. The Reconstructive Ladder: An Orthoplastic Approach. *Orthop Clin North Am* 1993;24:393.

# 39. Levin LS, Condit DP. Combined Injuries—Soft Tissue Management. *Clin Orthop* 1996;327:172.

* 40. Littler JW. Hand, Wrist and Forearm Incisions. In Littler JW, Cramer LM, Smith SW, eds. *Symposium on Reconstructive Hand Surgery.* St. Louis: CV Mosby, 1974:87.

* 41. Mann RJ. Paint and Grease-Gun Injuries of the Hand. *JAMA* 1975;231:933.

+ 42. Marcus NA, Blair WF, Shuck JM, Omer GE. Low-Velocity Gunshot Wounds to Extremities. *J Trauma* 1980;20:1061.

* 43. Matev I. Wringer Injuries of the Hand. *J Bone Joint Surg* 1967;49-B:722.

+ 44. McCauley RL, Hing DN, Robson MC, Heggers JP. Frostbite Injuries: A Rational Approach Based on the Pathophysiology. *J Trauma* 1983;23:143.

# 45. McCullough JH, Boswick JA Jr, Jonas RJ. Household Wringer Injuries: A Three-Year Review. *J Trauma* 1973;13:1.

+ 46. Mehta KC, Wilson MA. Frostbite Injury: Prediction of Tissue Viability with Triple-Phase Bone Scanning. *Radiology* 1989;170:511.

# 47. Meland NB, Smith AA, Craig JH. Tissue Expansion in the Upper Extremities. *Hand Clin* 1997;13:303.

# 48. Mills WJ, O'Malley J, Kappes B. Cold and Freezing: A Historical Chronology of Laboratory Investigation and Clinical Experience. *Alaska Med* 1993;35:89.

# 49. Naidu SH, Heppenstall RB. Compartment Syndrome of the Forearm and Hand. *Hand Clin* 1994;10:13.

+ 50. Ordog GJ, Balasubramanium S, Wasserberger J, et al. Extremity Gunshot Wounds: Part One—Identification and Treatment of Patients at High Risk of Vascular Injury. *J Trauma* 1994;36:358.

# 51. Ortiz JA, Berger RA. Compartment Syndrome of the Hand and Wrist. *Hand Clin* 1998;14:405.

+ 52. Ouellette EA, Kelly R. Compartment Syndromes of the Hand. *J Bone Joint Surg* 1996;78A:1515.

! 53. Padrta JC, Barone JE, Reed DM, Wheeler G. Expanding Handgun Bullets. *J Trauma* 1997;43:516.

+ 54. Phillips, P, Hansraj KK, Cox EE, Ashley EM. Gunshot Wounds to the Hand. The Martin Luther King, Jr., General Hospital Experience. *Orthop Clin North Am* 1995;26:95.

# 55. Pinto MR, Turkula-Pinto LD, Cooney WP, et al. High-Pressure Injection Injuries of the Hand: Review of 25 Patients Managed by Open Wound Technique. *J Hand Surg* 1993;18A:125.

# 56. Purdue GF, Hunt JL. Cold Injury: A Collective Review. *J Burn Care Rehabil* 1986;7:331.

+ 57. Ramos H, Posch JF, Lie KK. High-Pressure Injection Injuries of the Hand. *Plast Reconstruct Surg* 1970;45:221.

! 58. Salimi Z, Wolverson MK, Herbold DR. Frostbite: Experimental Assessment of Tissue Damage Using Tc-99m Pyrophosphate. *Radiology* 1986;161:227.

! 59. Salimi Z, Vas W, Tang-Burton P, et al. Assessment of Tissue Viability in Frostbite by 99mTc Tertechnetate Scintigraphy.*Am J Roentgenol* 1984;142:415.

# 60. Sangvinetti MV. Reconstructive Surgery of the Roller Injuries of the Hand. *J Hand Surg* 1974;2:134.

* 61. Sherman RT, Parrish RA. Management of Shotgun Injuries: A Review of 152 Cases. *J Trauma* 1963;3:76.

# 62. Stark HH, Wilson JN, Boyes JN. Grease-Gun Injuries of the Hand. *J Bone Joint Surg* 1961;43-A:485.

# 63. Stark HH, Ashworth CR, Boyes JH. Paint-Gun Injuries of the Hand. *J Bone Joint Surg* 1967;49-A:637.

# 64. Stein JS, Strauss E. Gunshot Wounds to the Upper Extremity: Evaluation and Management of Vascular Injuries. *Orthop Clin North Am* 1995;26:29.

# 65. Stone HH, Cantwell DV, Fullenwider JT. Wringer Arm Injuries. *J Pediatr Surg* 1976;2:375.

# 66. Szabo RM. Acute Carpal Tunnel Syndrome. *Hand Clin* 1998;14:419.

* 67. Tubiana R, Stack HG, Hakstian RW. Restoration of Prehension After Severe Mutilation of the Hand. *J Bone Joint Surg* 1966;48-B:455.

+ 68. Urschel JD. Frostbite: Predisposing Factors and Predictors of Poor Outcome. *J Trauma* 1990;30:340.

+ 69. Valnicek SM, Chasmar LR, Clapson JB. Frostbite in the Prairies: A 12-Year Review. *Plast Reconstruct Surg* 1993;92:633.

+ 70. Washington ER, Lee WA, Ross WAJ Jr. Gunshot Wounds to the Extremities in Children and Adolescents. *Orthop Clin North Am* 1995;26:19.

# 71. Wilson RL, Liechty BW. Complications Following Small Joint Injuries. *Hand Clin* 1986;2:329.

# 72. Wilson RL, Reynolds CC. Joint Stiffness. In McFarlane RM, ed. *Unsatisfactory Results in Hand Surgery.* Edinburgh: Churchill-Livingstone, 1987.

+ 73. Yoshioka H, Seibel RW, Pillai K, Luchette FA. Shotgun Wounds and Pellet Emboli: Case Reports and Review of the Literature. *J Trauma* 1995;39:596.

# CHAPTER 46

# AMPUTATIONS OF THE HAND

*Terry R. Light*

**T. R. Light:** Department of Orthopaedic Surgery and Rehabilitation, Loyola University Chicago Stritch School of Medicine, Maywood, Illinois, 60153.

Classification of Injury and Indications for Treatment
Emergent
Elective Amputation
Surgical Technique
Thumb Amputations
Digital Amputation
Wrist Disarticulation
Postoperative Care
Pitfalls And Complications
Author's Perspective
Chapter References

Amputating part of the hand is unpleasant for the patient and the surgeon. Nonetheless, a carefully planned and skillfully executed surgical procedure is essential for early restoration of pain-free, useful hand function. The ultimate goal of surgery is the restoration of a hand of acceptable appearance, capable of the highest degree of function consistent with its remaining musculoskeletal elements (1,27).

In general, optimal hand function is achieved through prompt wound healing and joint mobility in digits of maximal length. The surgeon must take care to preserve sensibility in retained elements and to prevent formation of painful neuromas.

Because the thumb is essential for both power and precision prehension, preservation or restoration of the thumb is of paramount importance. When the radial fingers are compromised, precision prehension is impaired, while loss of the ulnar digits reduces effective power grip (12). Preservation of length and sensibility is vital to radial digits, whereas preservation of joint mobility is more important to ulnar digits.

## CLASSIFICATION OF INJURY AND INDICATIONS FOR TREATMENT

Amputation procedures may be classified as emergent or elective, by the mechanism of injury or etiology, or by the anatomic region of the hand removed. Secondary revision of initially emergent amputations may be elected to address issues of appearance, function, or pain.

Partial hand amputation procedures may be carried out as either primary or secondary procedures.

### EMERGENT

Trauma is the most common indication for surgical amputation of portions of the hand. The management of acute traumatic amputation requires considerable judgment. The surgeon must often decide which parts should be retained by revascularization or replantation, which should be managed with direct wound closure, and which should be managed primarily by more proximal surgical amputation.

The mechanism of injury is important in understanding the likelihood of success with different treatment strategies. Sharp injuries preserve normal tissues in the proximal part and have a narrow zone of injury. Distal tissues that may be amenable to reattachment or revascularization are more likely to be preserved. Crush injuries often result in a wide zone of injury. Though the skin sleeve may have been preserved, the profound crushing of underlying bone, joint, and flexor and extensor tendons may preclude reestablishment of a supple, mobile digit. Avulsion injuries may result in substantial injury to neurovascular and tendinous structures proximal to the level of skin loss or disruption. Examination of amputated parts may aid in understanding the extent of injury to the residual parts of the hand or fingers.

In severe trauma affecting several digits, it often is easiest, initially, to preserve all viable tissue. Otherwise useless digits may be converted to fillet flaps for soft-tissue coverage or to supply digital nerve and bone for graft to be used in other digits. Although this approach is by design conservative, it will prove counterproductive if the decision to delete functionless digits is repeatedly postponed. Retained stiff, insensate, or unstable digits will compromise the rehabilitation of the remaining, less severely affected portions of the hand. Also, the original decision to delete the irreparably compromised digit may be questioned and additional futile surgeries performed in an attempt to avoid amputation. Early, appropriate decision making is often difficult: Less experienced surgeons should seek prompt consultation to establish realistic expectations for both themselves and their patients.

### ELECTIVE AMPUTATION

Digits may become ischemic and nonviable as a result of microvascular or macrovascular disease or a combination of the two. Microvascular disease, seen commonly in conditions such as scleroderma and diabetes mellitus, may result in digital ischemia. Irreversible digital ischemia may also result from macrovascular injury to the brachial artery after cardiac catheterization in the presence of systemic atherosclerotic macrovascular and microvascular disease.

Infection within the hand may necessitate partial hand amputation. The aim may be either to eliminate a refractory focus of infection, usually osteomyelitis, or to remove a part whose function has been irreparably compromised by infection. A painful, swollen finger rendered immobile after flexor sheath infection may occasionally be so impaired that the surgeon and patient elect digital amputation.

Malignant tumor may necessitate partial hand amputation. The histologic character of the tumor and its anatomic location should be the primary determinants of the level of amputation. The desire to preserve functional capability must be subservient to the need for appropriate tumor wound margins (see Chapter 74). Amputation may be confined to a single digit, a ray, or a more major segment of the hand—radial, central, or ulnar.

Congenitally anomalous hands may occasionally be improved functionally or aesthetically by the amputation of rudimentary digits. Small, floppy nubbins may be excised when they are insufficient for reconstruction. When macrodactyly distorts hand form and function, resection of one or two rays may be indicated. In cases of polydactyly, amputation of redundant elements must be carefully integrated with reconstruction of the remaining digits.

Various forms of thermal injury may lead to amputation. Frostbite injury characteristically affects the distal portions of the fingers. The thumb is less often involved since it is shorter than the fingers and is often protected by the fingers flexed around it against the palm. Patients who have experienced severe cold exposure may experience the effects of ischemia involving all the fingers, both thumbs, and all toes of both feet, profoundly limiting secondary reconstruction alternatives. The extent of remaining viable tissue is often uncertain for a number of days. In selected severe injury, bone scan or magnetic resonance imaging (MRI) may reveal preservation of osseous circulation in spite of overlying skin necrosis.

Heat may cause burns that primarily affect the dorsal structures, skin, and extensor mechanism without necessitating amputation. Electrical injury, by contrast, may have a more profound effect on deep tissues than on the skin. Early resection of the finger or ray that transmitted the electrical impulse is often necessary. Residual functional impairment after electrical injury may lead to secondary amputation.

Finally, it is occasionally wise to abandon local reconstructive surgical procedures in favor of prosthetic management. When a hand is painful, deformed, and without function, amputation may be the most effective reconstructive procedure (2).

## SURGICAL TECHNIQUE

- Design skin incisions and skin flaps to provide sensate skin over the palmar surface of the residual digit.
- Isolate each digital nerve in the involved digit. Apply modest traction to the nerve, and sharply divide the nerve, allowing it to retract proximally into soft tissue.
- Identify transected tendons and draw them distally into the wound. Sharply divide each tendon and allow it to retract proximally. Do not sew flexor or extensor tendons to one another over the end of the amputated digit. To do so will restrict motion in the residual portion of the digit and severely compromise tendon excursion and motion in adjacent fingers (see the discussion of the "quadriga" effect in the section below, Pitfalls and Complications).
- Ligate bleeding vessels at wound margins.
- Traumatic amputations that create oblique or jagged distal surfaces may result in a painful digit. Trim bone ends transversely and free them of palmar prominences.

### THUMB AMPUTATIONS

It is principally the attributes of position, stability, strength, and length that allow the thumb to carry out its unique range of activity (13). Motion, sensibility, and appearance are important but less vital attributes of normal thumb function.

Because of the thumb's unique position and essential role in prehension, preserving thumb length is a priority in the treatment of traumatic thumb injuries. A well-motored stiff thumb with basilar mobility and normal length is effective in most functions of the hand.

#### *Acute Management*

When traumatic amputation of the thumb occurs through the distal phalanx, local flap closure may be required. With disproportionate palmar skin loss, the Moberg palmar advancement flap allows preservation of thumb length with advancement of sensate skin distally (5). The radial nerve–innervated cross-finger flap from the dorsum of the index finger also brings sensate skin to the distal phalanx (see Chapter 38).

In the case of thumb amputation through the middle portion of the proximal phalanx or beyond, satisfactory function may be achieved if maximal length is preserved with local advancement flaps.

Amputation proximal to the metacarpophalangeal joints severely compromises prehension. Although thumb length may be sufficient for buttressing of objects in the palm in power grip, it is insufficient to reach the tips of adjacent fingers in precision prehensile activities. Secondary surgical reconstruction is usually advantageous when amputation occurs proximal to the middle of the proximal phalanx of the thumb. In such situations, the sacrifice of a few millimeters of skeletal length to allow direct soft-tissue closure over bone is usually preferable to extensive primary soft-tissue flap procedures. Once healing of the amputation has been achieved, reconstruction will be required to restore at least a portion of the lost thumb length.

#### *Secondary Thumb Reconstruction*

Late reconstruction procedures to improve the function of a thumb that has sustained amputation injury include phalangization, distraction lengthening, and pollicization, as well as toe-to-hand and wraparound flap microvascular transfers (see Chapter 34, Chapter 35 and Chapter 36 and Chapter 69).

**Phalangization** When ischemia or injury simultaneously shortens all other digits that could achieve pulp-to-pulp contact with the thumb, it makes little sense to lengthen the thumb beyond the arc of the remaining fingers. Phalangization restores primitive prehension to the hand. To be successful, it requires supple dorsal skin, normal thenar musculature, and a mobile carpometacarpal joint (24).

- Make a **Z**-shaped incision that provides generous web-space exposure and allows flap transposition, which shifts the web-space skin margin proximally (Fig. 46.1). Define the adductor pollicis and first dorsal interosseous muscles, and incise and release their investing fascia.

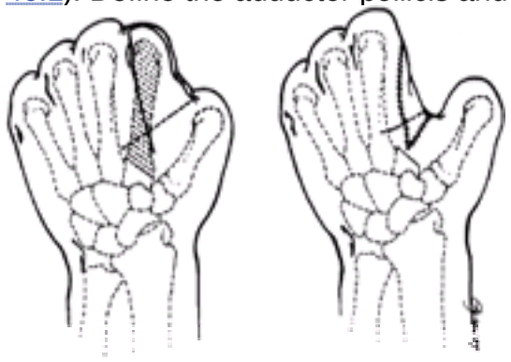

***Figure 46.1.*** Phalangization procedure. **A:** Resection of the index metacarpal is achieved through **Z**-plasty flap elevation. **B:** **Z**-plasty flap transposition increases the exposed prehensile surface of the thumb.

- Resect the index metacarpal, taking care to preserve the proximal attachment of extensor carpi radialis longus and flexor carpi radialis. Excise the first dorsal and first palmar interosseous muscles.
- Release the adductor pollicis insertion from the sesamoid at the metacarpophalangeal (MP) joint level and reinsert it more proximally on the thumb metacarpal. Transpose skin flaps. See Hints and Tricks box on the next page.

**Thumb Distraction Lengthening** When at least two thirds of the thumb metacarpal remains with good soft-tissue coverage, distraction lengthening is an effective technique for regaining useful thumb length (8,16). If proximal joint mobility and thenar musculature are preserved, the patient should be able to use the thumb effectively for prehensile activity, although it may be stiff.

**HINTS AND TRICKS**

- A simple three-digit prehension pattern may be recreated by the removal of the ring metacarpal. This procedure increases the mobility and independence of the little-finger metacarpal.
- Flexion and closing-wedge osteotomy with radial deviation of the base of the little-finger metacarpal may improve pinch between the little metacarpal and the thumb metacarpal (6).

- Make a longitudinal skin incision to expose the middle third of the thumb metacarpal (Fig. 46.2) and incise the periosteum. Bunch up the skin between the pin insertion sites such that distraction will not put undue pressure on the skin–pin interface. Insert two parallel groups of pins transversely through the collapsed distraction apparatus in close proximity to the intended osteotomy site.

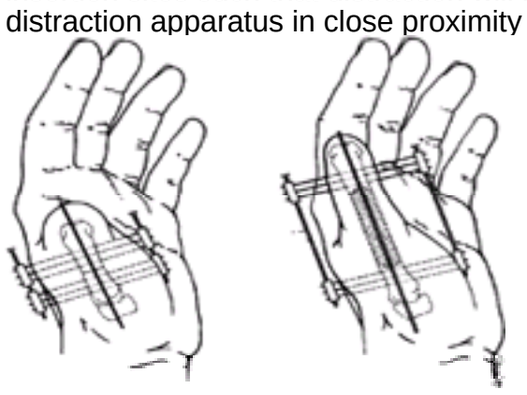

***Figure 46.2.*** Thumb distraction lengthening in an adult. **A:** Place pin groups adjacent to the mid-diaphyseal osteotomy site. **B:** Once the desired distraction has been achieved, lock the bone graft into the medullary canal of the distracted proximal segments.

- Make a transverse osteotomy through the middle third of the metacarpal.
- Place a longitudinal pin through the proximal and distal metacarpal segments and across the carpometacarpal joint. By transfixing the metacarpal to the trapezium, this pin provides resistance to the tendency of distraction to tighten the adductor and produce secondary adduction contracture. The longitudinal pin also prevents subluxation of the base of the thumb metacarpal on the trapezium with distraction.
- If bone grafting is planned as a second procedure, circumferentially incise the periosteum at the level of the osteotomy, and then turn the screws on the distraction device to create at least 5 mm of immediate distraction at the osteotomy site.
- If distraction osteogenesis is to be employed, repair the longitudinal incision of the metacarpal periosteum and then close the skin. Maintain osteotomy coaptation for 7 to 10 days, and then begin distraction of the osteotomy. Over the next 4 to 5 weeks, gradually lengthen the digit by advancing the distraction device about 1 mm per day; do this four times a day, in ¼ mm increments. The soft tissues will gradually stretch as the osteotomy gap is widened. Distraction takes place along the axis provided by the longitudinal pin. It is often possible to gain up to 3 to 3.5 cm of additional thumb length with distraction lengthening (8,17).
- Although bone consolidation may occur spontaneously in young patients, my custom in adults is to electively add iliac crest bone graft to span the gap between the proximal and distal metacarpal segments. Keep the device in place until graft incorporation is radiographically visible. Web-space deepening, as described above in the section on phalangization, is occasionally helpful as a secondary procedure.
- Alternatively, remove the distraction device after distraction, and stabilize the bone graft by plate fixation. Transfer the insertion of the adductor pollicis tendon more proximally to help diminish the tendency of the lengthened thumb to adduct. This allows web-space deepening without sacrificing adductor pollicis strength.

**Pollicization** Because pollicization allows restoration of both digital length and mobility, it is often recommended when traumatic thumb amputation results in basilar joint destruction (3,4,13). The index finger is usually the digit selected for pollicization. When the extent of trauma to the thumb has been severe enough to warrant pollicization, the adjacent index finger is often also compromised, but this is not necessarily a contraindication to pollicization. An injured digit with limited mobility may be a liability in the index position but may substantially enhance function when transposed to the thumb position.

Reconstruction of posttraumatic thumb injuries is similar to that of pollicization for the congenitally absent or hypoplastic thumb with individual modifications (see Chapter 69). If there is extensive scarring and soft-tissue loss over the radial border of the hand, preliminary flap coverage may be required.

- Skin incisions must be individualized when skin along the radial border of the hand is scarred. Design skin flaps to bring the best skin—palmar, dorsal, or a combination—into the web space created between the pollicized digit and the middle finger at the time of closure. Skin graft is often necessary dorsally and radially but should be avoided in the web space.
- Evaluate digital artery integrity of the index and middle fingers preoperatively by arteriography when there has been proximal injury. In some instances, the vascularity to the injured index finger may be insufficient to support disruption of collateral flow necessitated by pollicization. In such cases, plan to use a vein graft from the radial artery in the anatomic snuff box to the digital arteries of the transposed digit to effect microvascular revascularization of the digit.
- Identify and preserve the radial and ulnar index digital nerves and arteries. Preserve the digital nerves by splitting the common digital nerve to the index and middle fingers. Mobilize the ulnar proper digital artery to the index by ligating the radial proper digital artery to the middle finger.
- In adult pollicization, reestablish skeletal length by combining remaining thumb and index parts (Fig. 46.3). The goal is to achieve a reconstructed thumb whose tip extends to about 75% of the length of the proximal phalanx of the middle finger. If the index is of normal length and the thumb basilar joint is absent, use of the rotated index metacarpal head as a trapezium will prove most satisfactory.

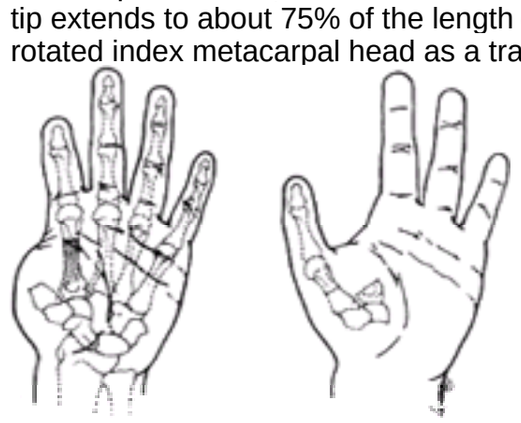

***Figure 46.3.*** Pollicization of a distally amputated index finger. **A:** The extent of index metacarpal resection depends on the residual length of both the thumb metacarpal and the index finger. **B:** Fix the transposed index metacarpal to the proximal thumb metacarpal remnant.

- When the trapezium and part of the thumb metacarpal remain, resect the entire index metacarpal and an appropriate portion of the proximal phalanx. Secure the proximal phalanx directly on top of the thumb metacarpal remnant. When the distal portion of the index has been damaged, retain an appropriate metacarpal length to achieve a composite digit of proper length. Retain the index metacarpophalangeal joint to provide thumb MP motion, while the proximal interphalangeal joint of the index will provide an interphalangeal joint for the reconstructed thumb.
- When the basilar joint and thenar musculature are absent, carry out a musculotendinous rearrangement as in pollicization for thumb aplasia. Advance the first dorsal and first palmar interossei insertions distally on the hood and shorten the extensor tendons. If the first dorsal interosseous muscle has been damaged, consider simultaneous opponensplasty tendon transfer. When the index digit is damaged distally and is merely being moved radialward without skeletal shortening, extensor tendon shortening may not be required.
- In adult pollicization, the flexor tendons to the pollicized digit will not spontaneously shorten and readapt their optimal resting length as occurs in pediatric pollicization. Make an incision in the distal forearm and resect a segment of index flexor tendon consistent with the extent of proximal transposition of the pollicized index finger.

## DIGITAL AMPUTATION

Fingertip and distal phalangeal injuries are discussed in Chapter 38. When amputation occurs at or proximal to the distal interphalangeal joint, distal flap coverage is rarely indicated. Modest bone shortening and contouring are usually preferable, unless the potentially sacrificed bone length is judged critical to preservation of the functional integrity of the affected finger.

In general, any digit that retains its superficialis insertion will continue to contribute effectively to grasp activity. When amputation occurs more proximally (e.g., proximal middle phalanx, proximal phalanx), the digit will have only limited value in the little-finger position and will probably be a nuisance in the index position. When amputation occurs proximal to the superficialis but distal to the midproximal phalanx, preservation of the digit in the middle or ring position may help prevent small objects from falling through the hand, although only limited MP joint flexion will occur through the pull of the intrinsic muscles.

When amputation or other severe mutilating injury has compromised multiple digits, it is best to preserve all available bone length. In multidigit degloving injuries, distant flap overage may be indicated.

Amputation through an interphalangeal joint requires attention to bone as well as to soft tissue to avoid a bulbous distal contour (Fig. 46.4).

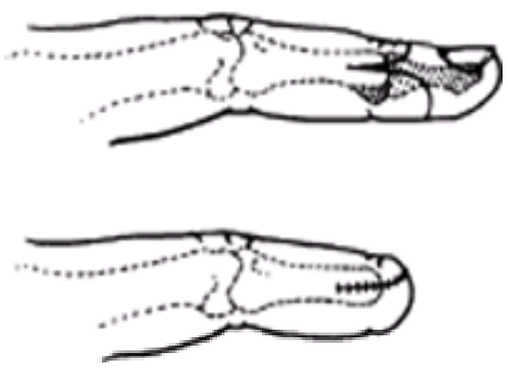

***Figure 46.4.*** Interphalangeal joint disarticulation amputation. **A:** Remove palmar condylar prominences. **B:** The greater length of the palmar flap brings the suture line away from the contact surface.

- Create palmar and dorsal tongue-shaped flaps by bilateral midlateral incisions. Make the palmar flap slightly longer, if possible, so that the scar will be dorsal. Pull tendons distally and divide them sharply.
- Gently divide digital nerves without applying undue traction, and allow them to retract into proximal soft tissues. Ligate digital arteries.
- Identify the palmar plate and excise it. Remove the cartilage from the exposed phalangeal articular surface to facilitate bone contouring. Resect the palmar condylar prominences in line with the palmar cortex of the diaphysis. Shape the remaining flat condylar surface with a rongeur and rasp to resemble a paddle. Palpate the bone through the overlying skin to ensure that all prominences have been relieved.
- Close the skin with interrupted sutures. Extensive contouring of skin margins is unnecessary, since the skin contour will gradually model to the underlying bony contour.
- Handle diaphyseal phalangeal amputations in a similar fashion.

### *Index Ray Resection*

The normal index finger is ideally situated to pinch and manipulate objects. Imperfections of the index finger are, however, poorly tolerated. When the index finger of an otherwise normal hand is compromised by loss of length, altered sensibility, or pain, many patients spontaneously shift to a prehension pattern that ignores the index finger in preference of a normal middle finger. The greater length of the middle finger allows it to meet the thumb easily for precision activity. When a short index finger is being ignored, it is often held in a hyperextended posture. Amputation of a short index finger is advised when patterns of disuse become fixed.

Amputation of the index finger may be accomplished by either MP joint disarticulation or index ray resection. MP joint disarticulation preserves the breadth of the palm, which is helpful in stabilizing objects held with a cylindrical grip but presents an obtrusive prominence in the web space (18). Ray resection narrows the palm and improves the appearance of the hand by achieving a broad, smooth web-space contour.

Design skin incisions to facilitate exposure and to provide a supple web space that will allow thumb mobility (Fig. 46.5). If the wedge of skin removed is too large, the distance from thumb to middle metacarpal will be diminished and thumb abduction may be limited. Dissect skin flaps from the index digit, taking care to preserve flap innervation.

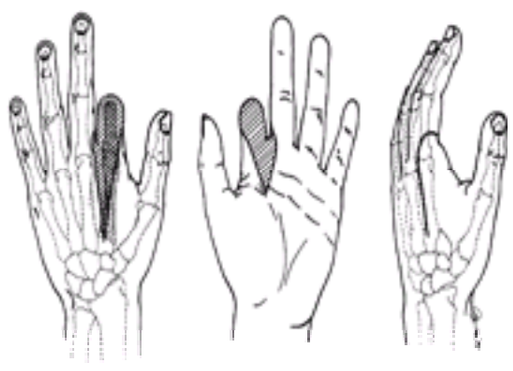

***Figure 46.5.*** Index ray resection. **A:** Dorsal view. **B:** Palmar skin resection. **C:** Wound closure preserves sensate skin throughout the widened web space.

- Divide the extensor indicis proprius tendon from its insertion ulnar to the index communis tendon and tag it. Apply traction to the extensor digitorum communis tendon, divide it, and allow it to retract.
- Osteotomize the index metacarpal obliquely through the proximal metaphysis, preserving the insertion of the extensor carpi radialis longus and flexor carpi radialis tendons.
- Although some authors advocate suturing the first dorsal interosseous tendon into the second dorsal interosseous insertion on the middle metacarpal to enhance the strength of lateral pinch, this transfer is occasionally too strong and may result in a fixed radial deviation and lumbrical plus (see Pitfalls and Complications, below) posture of the middle finger.
- Divide the deep transverse metacarpal ligament adjacent to the middle finger. Identify the index flexor tendons, pull them distally, divide them, and allow them to retract proximally. Take care in dealing with the digital nerves: The radial nerve to the index finger must not be extensively mobilized. Sharply divide digital nerves and allow them to retract into the soft tissue without tension. The ultimate neuroma end of the nerves must be distanced from further trauma.
- Remove the index finger. Sew the extensor indicis proprius into the middle finger extensor digitorum communis tendon at the level of its insertion to enhance independence of middle-finger extension. Trim the first dorsal and first palmar interosseous muscles as necessary to ensure a smooth web-space contour. Close the skin flaps with the thumb in palmar and radial abduction.

### *Central Ray Resection*

Amputation of the middle or ring finger at the MP joint level leaves an awkward space between the remaining digits (15). When the hand is in a dependent, supinated position, the gap between fingers makes it difficult to hold or cup small objects in the palm of the hand because of the tendency of such objects to escape from the grasp (Fig. 46.6) (4). Ray resection and reconstruction by either soft-tissue coaptation (Fig. 46.7) or ray transfer (Fig. 46.8) closes this gap and improves the aesthetic appearance of the hand (22,23). Both procedures narrow the palm and thus predictably weaken grasp and cylindrical grip palmar stabilization.

***Figure 46.6.*** Absence of either the middle or the ring finger impairs the ability to retain small objects in the palm.

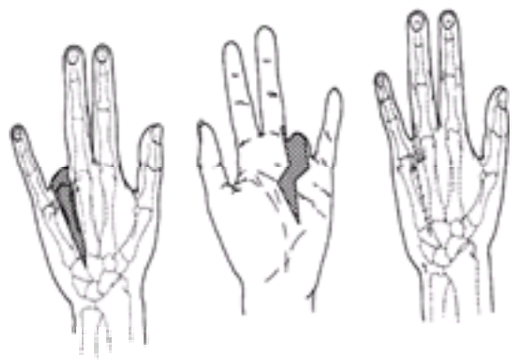

***Figure 46.7.*** Ring-finger ray resection with soft-tissue coaptation sling. **A:** Transverse intermetacarpal ligament and palmar plate continuity is preserved as the ring metacarpal is excised through a dorsal exposure. **B:** A palmar chevron incision allows resection of redundant palmar skin. **C:** Interweaving of the transverse intermetacarpal ligament brings the little metacarpal head toward the middle metacarpal, while dorsal skin closure stabilizes rotational alignment.

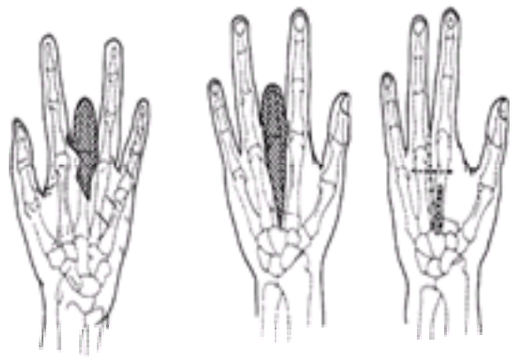

***Figure 46.8.*** Middle ray resection and index ray resection. **A:** Converging chevron incisions reduce palmar skin and soft-tissue redundancy. **B:** Corresponding step-cut osteotomies are fashioned in both the index and middle metacarpal proximal metaphyses. **C:** The transposed index finger is fixed to the middle finger with a plate and is further stabilized with Kirschner wire into the ring metacarpal.

Patients who have undergone index ray resection retain 80% of predicted grip strength (18). Pronation strength, a measure of grip stabilization by the breath of the metacarpal, is diminished to 50% of predicted values after index ray resection (18). Transposition of the index ray to the middle metacarpal position results in 75% of predicted grip strength, while transposition of the little-finger ray to the ring finger metacarpal position results in retention of 85% of predicted grip strength (7).

Soft-tissue coaptation, clearly the simpler procedure, effectively brings the relatively mobile little-finger ray into close approximation to the middle finger but is somewhat less successful in bringing the relatively fixed index metacarpal alongside the ring metacarpal (23).

***Central Ray Resection and Soft-tissue Coaptation***

- Make parallel zigzag incisions on the palmar surface overlying the metacarpal to be resected. Remove a generous wedge of dorsal skin. The dorsal skin resection will provide a dermodesis, which will stabilize the digit and prevent it from rotating into a position in which the fingers will scissor over one another in flexion.
- Resect the entire metacarpal subperiosteally. If the middle metacarpal is excised, preserve the proximal insertion of the extensor carpi radialis brevis within the periosteal sleeve, and take care to preserve the origin of the adductor pollicis muscle. When the ring metacarpal is resected, the entire metacarpal base may be removed, allowing radial shift of the little metacarpal on the hamate.
- Avoid injury to the deep motor branch of the ulnar nerve, which runs just palmar to the metacarpal and is vulnerable to injury when excising the metacarpal. Identify and ligate the proper digital arteries. Sharply divide the proper digital nerves distal to the common digital nerve bifurcation.
- Pull flexor and extensor tendons distally, divide them, and allow them to retract proximally. Divide the interosseous and lumbrical tendons.
- Retain a single continuous soft-tissue band, consisting of the palmar plate and the two adjacent deep transverse metacarpal ligaments, each of which is firmly attached to adjacent digits. Press the metacarpal heads together manually. Tightly secure the digits adjacent to the resected metacarpal to one another by dividing the ligament–palmar plate complex and weaving the two segments together. Then securely suture the shortened ligament–palmar plate complex with interrupted sutures.
- Close the palmar skin incision first. Observe the fingers with the wrist in both flexion and extension. Assess the extent of digital scissoring, if any, as the dorsal skin is approximated. If residual scissoring persists, excise further dorsal skin. Circumferential dressing and splinting maintains lateral metacarpal pressure and protects the ligament repair during the first 3 weeks after reconstruction.

***Central Ray Resection and Ray Transposition***

Re-creation of a normal web-space contour between the retained digits is facilitated if the skin of a single web space is preserved and shifted intact to the new web space (10,21). If possible, base the web-space flap on the digit that is not being transposed. For example, if the middle finger is being resected and the index finger is being transposed to the middle-finger position, the web-space skin of the middle–ring interval is retained based on the ring finger and is ultimately sewn to the ulnar border of the index finger.

- Create palmar zigzag incisions that converge over the middle third of the metacarpal to be resected. Resect a dorsal wedge of skin with its apex over the proximal third of the metacarpal.
- Identify the digital neurovascular structures. Sharply section the proper digital nerves, and ligate the proper digital arteries.
- Pull flexor and extensor tendons distally and divide them. Define the interosseous muscles inserting on the resected digit distally, dissect them free proximally, isolate them, and excise them. Divide the lumbrical tendon along the radial aspect of the digit being resected.
- When the middle metacarpal is resected, preserve the origin of the adductor pollicis on the middle metacarpal by subperiosteal dissection.
- Because nonunion of the bone-to-bone junction between transferred and recipient rays is a common complication of this procedure, careful planning of the bony osteotomy and secure internal fixation are essential (10). Transverse osteotomy through the proximal metaphysis rather than diaphysis provides maximal cancellous surface area and thus facilitates union. Alignment of the transferred digit is simplified by applying a **T** mini-fragment plate to the intact central metacarpal before osteotomy. Drill, tap, and secure the proximal screws, taking care to align the longitudinal limb of the plate with the long axis of the metacarpal to be removed. Then remove the screws and plate.
- Transversely osteotomize the metaphyseal base of both the recipient central metacarpal and the metacarpal to be transferred. Mobilize the transferred ray to allow transfer without tension. The interosseous muscle origins may need to be released. Suture the adductor pollicis origin to the ring metacarpal when the index ray is transposed to the middle position. Precisely fit the transferred ray onto the recipient base. Resecure the screws and plate proximally to the central metacarpal. Align the long axis of the transferred metacarpal to the longitudinal holes of the plate to reproduce the alignment of the excised metacarpal. Ensure that rotational alignment has been preserved, that the digit is clinically straight, and that the fingers do not overlap in flexion. Secure the shaft of the transferred metacarpal to the plate with additional screws.
- A distal transversely placed Kirschner wire may be helpful in further stabilizing the transferred digit during the first weeks following surgery. Approximate the deep transverse metacarpal ligaments from the adjacent sides of the resected metacarpal.
- Transpose the little-finger metacarpal to the ring position. The ultimate length discrepancy between the little and middle fingers may be minimized if the osteotomy is performed more proximally in the metaphysis of the little finger than in the metaphysis of the ring-finger metacarpal. This technique may add up to 1.5 cm in length to the shifted little-finger ray.

***Little-Finger Ray Resection***

When amputation of the little finger at the MP joint level is required, consider ray resection (Fig. 46.9). The hand that has undergone little-finger ray resection has an

excellent cosmetic appearance and acceptance. For this reason, ray resection is recommended in sedentary patients or those particularly concerned about cosmesis. In patients who depend on the breadth of the palm to stabilize a hammer, tennis racket, or other object with a cylindrical grip, removing the little-finger metacarpal will result in a significant loss of strength (11).

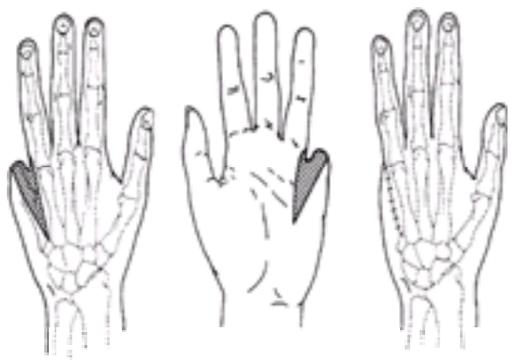

***Figure 46.9.*** Little finger ray resection. **A:** The extensor carpi ulnaris insertion into the proximal metacarpal is preserved. **B:** Palmar skin excision. **C:** Skin closure.

- Make a dorso-ulnar incision to expose the little-finger metacarpal. Isolate and divide the extensor communis and extensor quinti tendons. Because the extensor carpi ulnaris inserts on the base of the little-finger metacarpal, avoid disarticulating the carpometacarpal joint. Instead, divide the metacarpal obliquely through the tapering metaphysis.
- Divide the flexor tendons as well as the third palmar interosseous, lumbrical, and hypothenar muscle tendons. Trim the hypothenar muscles as necessary to create a smooth contour along the ulnar border of the hand.
- A third alternative, a compromise between MP disarticulation and ray resection, involves amputating the metacarpal head and neck and obliquely contouring the metacarpal through the distal diaphysis. Although this procedure improves the appearance of the hand and preserves most of the width of the palm, it eliminates the firm stabilizing contact surface over the palmar aspect of the little-finger metacarpal head.

### WRIST DISARTICULATION

When only the carpal bones remain, it is wisest to carry out wrist disarticulation by removing the carpal bones. When the entire length of the radius and ulna is preserved, forearm rotation is maximized within a prosthesis. Although fitting a prosthesis is somewhat simpler with diaphyseal forearm amputations, this advantage is modest and is outweighed by the advantage of preserving the integrity of the distal radio-ulnar articulation.

## POSTOPERATIVE CARE

The goal of partial hand amputation is the restitution of a pain-free, useful hand. This goal is usually best accomplished by early active movement of the injured hand. When internal fixation is used, a firm construct should be designed that will permit digital motion at the earliest possible time. The hand therapist may help guide the patient with a recent partial hand amputation to regain useful hand function. Emotional support should be provided by both the physician and the therapist to help the patient adapt to the altered body image.

## PITFALLS AND COMPLICATIONS

**Quadriga** Quadriga, or flexor digitorum profundus blockage, occurs when the free distal end of a transected profundus tendon becomes fixed distally and cannot move to the proximal extent of its normal excursion (19,26).

Because of the extensive side-to-side interconnections between the profundus tendons at the wrist and distal forearm level, limitation of motion of a single tendon may have an adverse effect on the motion of adjacent uninjured digits. Patients who have sustained amputation may experience limitation of active distal joint flexion in adjacent digits and may complain of palmar or flexor forearm pain with attempted forceful flexion. The condition is provoked by sewing the profundus tendon over the end of a digital amputation stump. It is best avoided by early active motion of both amputated and adjacent digits. When quadriga is diagnosed, release of the adherent profundus tendon in the palm proximal to the lumbrical origin will predictably relieve this condition.

**Lumbrical Plus** The lumbrical plus phenomenon may be precipitated by digital amputation (20). When amputation occurs through a finger proximal to the insertion of the profundus tendon but distal to the proximal interphalangeal joint, the proximal pull of the profundus is transmitted through the lumbrical into the dorsal hood apparatus, increasing the force of proximal interphalangeal joint extension. As the patient tries to grip forcefully, the proximal movement of the profundus results in a posture of proximal interphalangeal joint extension. This paradoxical digital motion may be eliminated either by sectioning the profundus proximal to the lumbrical origin or by releasing the radial lateral band.

**Neuroma** Because amputation implies the removal of innervated skin, all amputations inevitably require transection of sensory nerve branches. Neuromas occur whenever a nerve is transected and thus are an inevitable consequence of amputation. With proper surgical and postoperative management, however, neuromas need not be tender or painful. When a neuroma is caught in overlying scar or is adherent to a fixed structure, it often becomes symptomatic. The best approach is prevention. Many initially tender neuromas improve with local massage and desensitization activity under the guidance of a therapist. Do not consider surgical revision of tender neuromas until the wound has become supple and the skin is no longer adherent to underlying soft tissue and bone.

Other neuromas become symptomatic when they are fixed distally and tethered by proximal joint motion. In such situations, the nerve must be freed distally and allowed to migrate proximally. Early digital motion is encouraged (see Chapter 53).

## AUTHOR'S PERSPECTIVE

A properly planned and executed amputation procedure may simultaneously improve the function and the appearance of the residual hand. Simple procedures tend to be associated with less residual pain than complex reconstruction. Encourage early motion. Hand therapy may be invaluable in assisting patients to regain function.

## CHAPTER REFERENCES

Each reference is categorized according to the following scheme: *, classic article; #, review article; !, basic research article; and +, clinical results/outcome study.


# 1. Beasley RW. Surgery of the Hand and Finger Amputations. *Orthop Clin North Am* 1981;12:763.

* 2. Brown PW. Sacrifice of the Unsatisfactory Hand. *J Hand Surg* 1979;4(5):417.

# 3. Brunelli GA, Brunelli GR. Reconstruction of Traumatic Absence of the Thumb in the Adult by Pollicization. *Hand Clin* 1992;8(1):41.

# 4. Chase RA. *Atlas of Hand Surgery.* Philadelphia: WB Saunders, 1973.

# 5. Chase RA. *Atlas of Hand Surgery,* vol. 2. Philadelphia: WB Saunders, 1984.

# 6. Campbell Reid DA, Gosset J, eds.*Mutilating Injuries of the Hand.* Einburgh: Churchill-Livingstone, 1979.

+ 7. Cohen L, Bunkis J, Gordon L, Walton R. Functional Assessment of Ray Transfer for Central Digital Loss. *J Hand Surg* 1985;10A:232.

+ 8. Finsen V, Russwurm H. Metacarpal Lengthening after Traumatic Amputation of the Thumb. *J Bone Joint Surg* 1996;78:133.

+ 9. Gross SC, Watson HK. Revision of the Painful Tip Amputations. *Orthopaedics* 1989;12:1561.

* 10. Hanel D, Lederman ES. Index Finger Transposition after Resection of the Long Finger *J Hand Surg* 1993;18:271.

+ 11. Hogh J, Hooper G. Amputation of the Little Finger. *Acta Orthop Trauma Surg* 1988;107:269.

# 12. Light TR. Kinesiology of the Upper Limb. In: Bunch WH, Keagy R, Kritter AE, et al. eds. *AAOS Atlas of Orthotics,* 2nd ed. St Louis: CV Mosby, 1985:126.

# 13. Lister G. The Choice of Procedure Following Thumb Amputation. *Clin Orthop* 1985;195:45.

+ 14. Lyall H, Elliot D. Total Middle Ray Amputation. *J Hand Surg* 1996;21B(5):675.

+ 15. Massmejean E, Alnot J-Y, Coutier C, Cadot B. Résection du Quatrième Rayon pour Lésions de l'Annulaire les Amputations du Quatrième Rayon de la Main (Amputation of the fourth ray of the hand). *Rev Chir Orthop* 1997;83:324.

* 16. Matev IB. Thumb Lengthening through Metacarpal Bone Lengthening. *J Hand Surg* 1980;5:482.

+ 17. Moy OJ, Peimer CA, Sherwin FS. Reconstruction of Traumatic or Congenital Amputation of the Thumb by Distraction-Lengthening. *Hand Clin* 1992;8(1):57.

+ 18. Murray JF, Carman W, MacKenzie JK. Transmetacarpal Amputation of the Index Finger: A Clinical Assessment of Hand Strength and Complications. *J Hand Surg* 1977;2:471.

* 19. Neu BR, Murray JF, MacKenzie JK. Profundus Tendon Blockage: Quadriga in Finger Amputations. *J Hand Surg* 1985;10A:882.

* 20. Parkes A. The “Lumbrical Plus” Finger. *J Bone Joint Surg Br* 1971;53:236.

* 21. Plasschaert JM, Hage JJ. A Web-Saving Skin Incision for Amputation of the Third or Fourth Ray of the Hand. *J Hand Surg* 1988;13B:340.

+ 22. Posner MA. Ray Transposition for Central Digital Loss. *J Hand Surg* 1979;4:242.

* 23. Steichen JB, Idler RS. Results of Central Ray Resection without Bony Transposition. *J Hand Surg* 1986;11A:466.

* 24. Tubiana R, Roux JP. Phalangization of the First and Fifth Metacarpals: Indications, Operative Technique and Results. *J Bone Joint Surg Am* 1974;56:447.

+ 25. Van-Overstraeten L, Foucher G. Étude Comparative des Résections Metacarpiennes et des Translocations après Amputations des Doigts Medians (A comparative study of metacarpal resection and translocation after amputation of the middle finger). *Ann Chir Main Memb Super* 1995;14;74.

* 26. Verdan C. Syndrome of Quadriga. *Surg Clin North Am* 1960;40:425.

# 27. Zachary SV, Peimer CA. Salvaging the “Unsalvageable” Digit. *Hand Clin* 1997;13(2):239.

# CHAPTER 47

# PRINCIPLES OF TENDON REPAIR

*Paul R. Manske*

**P. R. Manske:** Department of Orthopaedic Surgery, Washington University, Barnes Jewish Hospital, St. Louis, Missouri, 63110.

Tendon Anatomy
Flexor Tendons
Extensor Tendons
Tendon Nutrition
Physiology of Tendon Healing
Principles of Management
Clinical Examination
Adequate Exposure
Associated Injuries
Atraumatic Technique
Surgical Technique
Suture Technique
Sheath Repair
Factors Affecting Tensile Strength
Increased Number of Suture Strands
Knot Location
Locking Versus Grasping Suture Configuration
Dorsal Versus Volar Suture Placement
Circumferential Suture
Postoperative Care
Author's Perspective
Chapter References

The frequency of injury to the functionally important flexor and extensor tendons is confirmed by review of the operative logs of orthopaedic operating rooms and emergency facilities. The techniques used to treat lacerated flexor and extensor tendons are reviewed in Chapter 48 and Chapter 49, while this chapter provides principles and basic concepts for addressing tendon injuries. Some principles are well accepted, but others are still in the development stages.

The principles of tendon repair are based on traditional practices, clinical experience, and interpretation of experimental animal studies. An understanding of the anatomic features of the tendon, the nutrient pathways to the tenndon, and the physiology of the healing process is essential to the formulation of a conceptual approach to tendon repair. Flexor and extensor tendons have distinguishing anatomic characteristics. Although there has been considerable experimental interest in the flexor tendon, there have been few investigations of the extensor tendon.

## TENDON ANATOMY

### FLEXOR TENDONS

The flexor tendons pass through several different anatomic environments or zones (Fig. 47.1). Nine flexor tendons pass through the synovium-lined carpal tunnel (zone IV) and enter the palm (zone III), where they are covered by a filmy paratenon. Two flexor tendons proceed to each finger (one to the thumb) and have an intricate arrangement within the digit (zone II). The superficialis tendon decussates into two tendon slips, which pass around the profundus tendon near the metacarpal phalangeal joint, and subsequently insert as a chiasma on the palmar surface of the middle phalanx. The profundus tendon passes through the decussation and inserts at the distal phalanx (zone I).

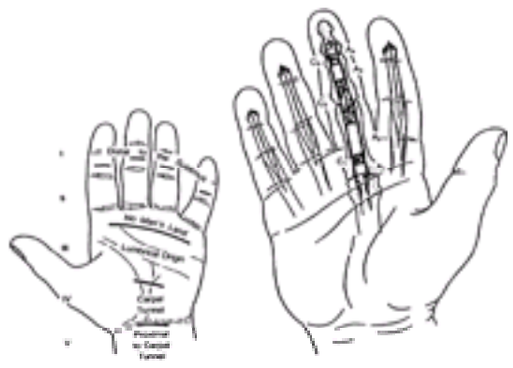

***Figure 47.1.*** Diagram of the flexor tendon zones and the location of the annular and cruciate fibro-osseous pulleys. (From Kleinert HE, Kutz JE, Cohn M. Primary Repair of Zone 2 Flexor Tendon Lacerations. In: Hunter J, Schneider L, eds. *American Academy of Orthopaedic Surgeons: Symposium on Tendon Surgery in the Hand.* St. Louis: CV Mosby, 1975.)

The superficialis tendon maintains independent muscle function to each finger, although the musculotendon unit to the small finger is frequently hypoplastic. The four profundus tendons have a common muscle belly. Consequently, the flexion of any individual distal phalanx by the profundus tendon usually results in movement at the distal joint of the other three. This has been referred to as the quadriga effect.

Within the digit (zone II), the flexor tendons are in a unique environment; they pass through a synovium-lined fibro-osseous sheath. The tendons are attached to the periphery solely by two filmy, vascularized mesenteric vincula (longum and breve), which are located near the midportion and at the insertion of both tendons, respectively. The vinculum breve is located at the insertion of the superficialis tendon and is intricately associated with the vinculum longum of the profundus tendon (Fig. 47.2); damage to the superficialis tendon insertion necessarily affects the blood supply to the midportion of the profundus tendon.

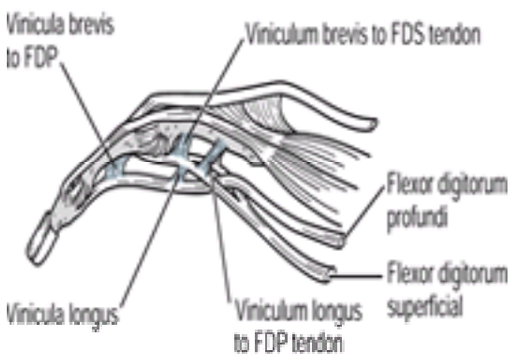

***Figure 47.2.*** The common origins of the vinculum breve to the superficialis tendon, and the vinculum longus to the profundus tendon.

The fibro-osseous sheath consists of a series of fibrous pulleys that are regularly interrupted longitudinally by a filmy synovium-lined membrane; together they form a continuous tunnel through which the tendons pass. The pulleys hold the gliding tendons against the phalanges and prevent tendon bow-stringing during finger motion. The pulleys are also thought to have a passive role in pumping fluid into the tendon during flexion and extension.

The microscopic anatomy of the tendon consists of a central core (the endotenon) that is composed primarily of acellular, longitudinal, collagenous fibers that are sparsely interspersed with fibroblasts. A thin epitenon layer of cells surrounds the central core. The epitenon cells are fibroblasts that may have different functional properties and characteristics from the internal fibroblasts of the endotenon. The epitenon cells are arranged in a matrix that is presumed to have a proteoglycan composition.

### EXTENSOR TENDONS

The extensor tendons also pass through several different environments or zones (Fig. 47.3). The extensor tendons enter the hand through a series of synovium-lined, retinacular compartments on the dorsum of the wrist. Unlike the flexor tendon, these tendons are attached to the retinacular compartments by long, mesotendinous, synovial sheets rather than by narrow, filamentous vincula. On the dorsum of the hand, the tendons emerge from the retinacular compartments and proceed individually to each digit. The extensor tendons are interconnected by tendinous bands known as juncturae tendinum. Distal to the metacarpophalangeal joint, the extensor mechanism forms an intricate arrangement of fibers that arise from the extrinsic extensor tendons and from the intrinsic musculotendinous units. This intricately arranged, digital, aponeurotic mechanism is essential to the synchronous movement of the three digit joints.

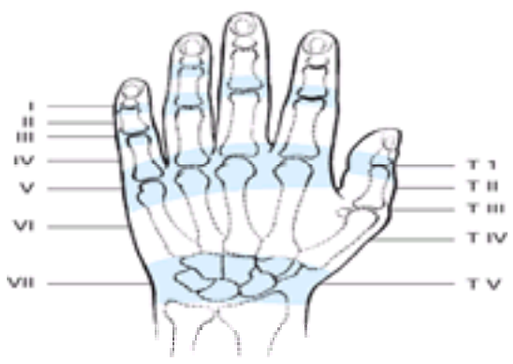


***Figure 47.3.*** Extensor tendon zones. (Redrawn with permission of WB Saunders Co. From Kleinert HE, Schepel S, Gill T. Flexor tendon injuries. *Surg Clin North Am* 1981;61:267.)

## TENDON NUTRITION

Although vascular perfusion by the mesenteric vincula to the tendon in zone II is an obvious nutrient pathway to the flexor tendon (11), diffusion of nutrients into the tendon is a more significant pathway within the digital sheath (41). Synovial fluid produced by the lining cells of the digital sheath is an obvious source of diffusible nutrients (47). Corporeal tissue fluid can also effectively diffuse into and maintain the viability of tendons, as shown by experiments in which tendon segments were placed in an abdominal wall diffusion chamber and in an *in vitro* tissue culture environment (27).

Proximal to the digital sheath, the tendon in the palm (zone VII) is surrounded by filmy paratenon. This vascularized connective tissue is thought to be the source of nutrients to the tendon. Within the carpal tunnel (zone IV), the tendons are surrounded by a synovial mesotenon that arises from the floor of the carpal tunnel. The nutrition of the flexor tendon within the carpal tunnel has not been investigated, but it is presumed to be derived from the synovium.

The extensor tendons within the retinacular compartments (zone III) receive nutrients from the mesotendinous synovial sheets arising from the floor of the compartments, with diffusion and perfusion serving as nutrient pathways (39). The filmy paratenon vascularizes the tendons on the dorsum of the hand and digit (zones I–VI).

## PHYSIOLOGY OF TENDON HEALING

The process by which flexor tendons heal is controversial (37). The traditional concept is that peripheral fibroblasts from the surrounding connective tissue invade the laceration site and serve as the source of reparative cells; the tendon itself is thought to have no intrinsic capacity for repair. However, *in vitro* studies of various experimental animals have shown that the epitenon cells migrate into and across the laceration site along a fibrin lattice, and collagen fibers formed by the epitenon and endotenon fibroblasts bridge the laceration sites (38,40,42,55). The repair site is vascularized by proliferation of vascular channels from within the proximal end of the tendon (18). These studies suggest that the tendon is a viable structure that possesses the intrinsic capacity for participating in the repair process.

The repair response of the tendon appears to be enhanced by the application of tension at the laceration site. Fibroblast migration, protein synthesis, and collagen deposition are increased by application of tensile forces to chicken tendons (5,61). Static tension applied to *in vitro* rabbit tendon segments showed increase in strength at the repair site (45), and intermittent cyclic tension enhanced the cellular response of lacerated chicken flexor tendon segments *in vitro* (65).

*In vivo* studies on experimental animals have demonstrated actual increase in tensile strength at the repair site. Kubota et al. (31) attributed this increase to both motion and tension in experiments on injured chicken flexor tendons. Hitchcock et al. (25) and Aoki et al. (1) demonstrated that the anticipated loss of tensile strength within the first 2 weeks following tendon repair can be avoided by actively mobilizing the tendon at the repair site.

The epitenon response is increased and a greater fibrous “callous” is produced if there is a large gap between the tendon ends (21).

Peripheral adhesions are known to attach to the healing tendon, potentially restricting tendon excursion during flexion and extension. Although the adhesions may contribute to the strength of the healing tendon, it is likely that the adhesions are not essential to the reparative process but only represent the response of the surrounding tissue to trauma (19). The concept of the tendon's intrinsic capacity for healing is attractive to surgeons, because it eliminates the need for fibrous adhesions at the repair site and encourages rehabilitation protocols that prevent their formation and attachment to the tendon. Nevertheless, restrictive adhesions following tendon repair continue to be the bane of surgeons who perform flexor tendon surgery.

Extensor tendons are thought to heal by invasion of fibroblasts from the periphery, but studies have not yet specifically defined this process.

## PRINCIPLES OF MANAGEMENT

There are basic operative principles that must be followed in caring for flexor or extensor tendon lacerations.

### CLINICAL EXAMINATION

The first principle is to diagnose the flexor or extensor tendon laceration by careful clinical examination. Begin the examination with a visual inspection of the hand. A disruption of the continuity of the tendon should be suspected by the location of the wound and the resting position of the digit. For example, a skin laceration immediately overlying a flexor tendon on the palm, in association with a digit whose resting position is not as flexed as the adjacent fingers, suggests a lacerated flexor tendon. However, remember that sharp, stiletto-type, penetrating objects can lacerate tendons through a small, inconspicuous skin wound at a distance from the

tendon.

Follow visual inspection with evaluation of the active motion of the joint mobilized by the tendon. The flexor profundus tendon to each digit can be examined by asking the patient to flex the distal joint of the involved digit (Fig. 47.4); inability to flex the distal interphalangeal joint indicates a lacerated profundus tendon. A laceration of both profundus and superficialis tendons is apparent when the patient is unable to actively flex the proximal and distal interphalangeal joints. Testing for a suspected superficialis tendon laceration in the presence of an intact profundus tendon is more difficult. The surgeon must eliminate the flexion force of the profundus tendon by making use of the quadriga effect (Fig. 47.5). To do this, manually hold the distal joints of the adjacent digits in full extension while the patient attempts to flex the involved finger. An inability to flex the involved digit actively at the proximal interphalangeal joint indicates a lacerated superficialis tendon.

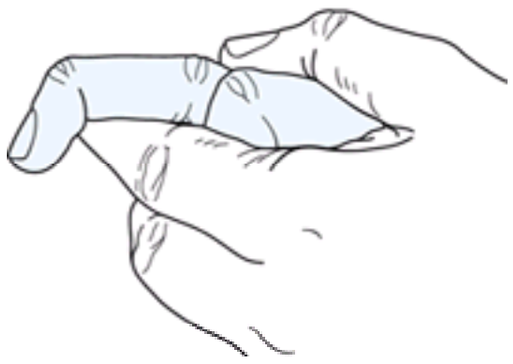

***Figure 47.4.*** Examination of an intact flexor profundus tendon.

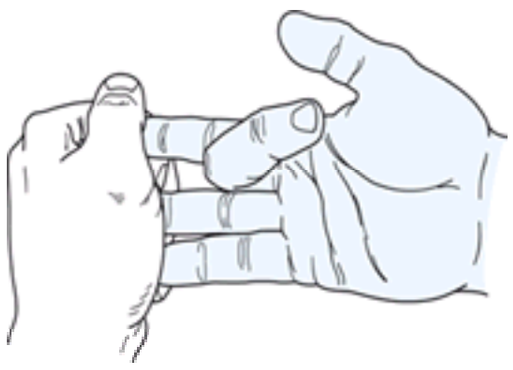

***Figure 47.5.*** Examination of an intact flexor superficialis tendon using the quadriga effect to eliminate the flexion force of the profundus tendon.

Test the extensor tendons to the fingers by asking the patient to extend each digit. Failure to achieve complete extension indicates a tendon laceration. The ability to obtain full extension may be misleading, however, because this may be accomplished in the presence of an extensor tendon laceration by the interconnecting junctura tendinum from an adjacent tendon. The examiner must test the comparative strength of digital extension against resistance; a digit that is being extended solely by an interconnecting junctura tendinum has a weaker extension force than the adjacent fingers with intact extensor tendons.

**ADEQUATE EXPOSURE**

A second principle involves adequate exposure of the wound site. In many instances, exposure is necessary to confirm the diagnosis of tendon laceration if the clinical examination of the tendon is not conclusive, or if the extent of injury to adjacent structures is not apparent. This occurs in patients who are not able to cooperate fully (children or incoherent patients, for example), as well as in those with partial or incomplete tendon lacerations when function of the digit is thought to be sustained by the adjacent intact structures, such as a junctura tendinum or intact vincula. The burden of proof about whether a flexor or extensor tendon laceration exists rests with the surgeon; if this cannot be determined by clinical examination, surgical exploration of the wound is indicated.

Adequate surgical exposure is also necessary to identify and expose the tendon ends. Generally speaking, proximal or distal extension of the original wound is achieved nthrough a zigzag approach, as described by Bruner (8), incorporating the original skin laceration (Fig. 47.6). Lacerated flexor tendons frequently retract into the palm or forearm unless prevented by an intact vinculum or lumbrical muscle. A second proximal incision may be necessary to retrieve the retracted tendon and pass it into the original wound site. Fortunately, proximal retraction of lacerated extensor tendons occurs infrequently because the tendon is usually held in place by the junctura tendinum or the synovial mesotendon beneath the retinaculum.

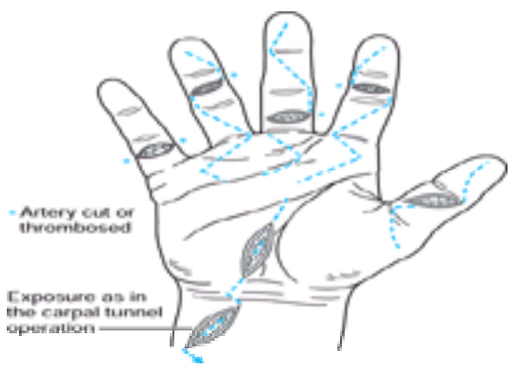


***Figure 47.6.*** Proximal and distal incisions extending from the laceration site to obtain exposure.

When it is necessary to incise the digital sheath to expose the flexor tendon ends, avoid cutting the fibro-osseous pulleys, particularly $A_2$ and $A_4$, and limit the incisional area to the intervening synovial portion of the sheath. This is best accomplished by an L-shaped (or hockey stick) incision, which facilitates closure of the digital sheath (34).

**ASSOCIATED INJURIES**

The third basic principle in the treatment of tendon injuries is to identify any associated injuries to the adjacent bones, nerves, or blood vessels. Before repairing the lacerated tendon, define the injuries to these associated structures. If possible, repair all the injured structures during the initial surgery. The sequence of repair is usually bone, ligament, tendon, nerve, and important blood vessels. Not all vessels require reanastomosis; only those that are essential to the viability of the injured part. Additionally, the surgeon may choose to perform a delayed repair of crushed or explosion-injured nerves. In replantation surgery, this sequence of repair may be altered in the interest of quickly restoring circulation to the digit.

Primary repair within 24 hours of injury is preferred. However, if appropriate facilities and skilled personnel are not available and the wound is properly irrigated and debrided, repair may be delayed up to 21 days with satisfactory clinical results (36,46,58).

### ATRAUMATIC TECHNIQUE

Handle the tendon in an atraumatic manner, because rough manipulation is associated with increased adhesions and the formation of restrictive scar tissue (9,48). This principle cannot be overemphasized. If possible, handle only the exposed, cut end of the tendon with the forceps. Do not apply crushing clamps to the tendon, and keep puncture holes made by suture needles or forceps inserted into the tendon substance to a minimum. Frequently, the surgeon draws the proximal and distal ends of the lacerated tendon into the wound site and holds them in position with straight taper needles placed transversely through the tendon and the adjacent soft tissue; this allows the repair to be accomplished without tension, minimizing repeated manipulation of the tendon ends.

## SURGICAL TECHNIQUE

### SUTURE TECHNIQUE

The basic objective of tendon surgery is to appose the lacerated tendon ends to allow the healing process to reestablish the continuity of the disrupted collagen bundles and the smooth gliding surface of the tendon. Restore the tubular form to the tendon, avoiding both gapping and bulging of tendon tissue at the repair site. This is particularly important for flexor tendon injuries within the digital sheath (zone II).

Numerous suture techniques have been described for flexor tendon repair. Most of them include a “core” suture, which passes through the endotenon substance of the tendon ends across the laceration site to provide strength and stability to the repair until healing takes place (Fig. 47.7). Additionally, a peripheral suture is placed circumferentially around the laceration site. Although this peripheral suture has been referred to as an *epitenon suture*, I prefer the term *circumferential* or *peripheral suture* because the technique of placing it includes more than the single layer of epitenon cells on the surface of the tendon. A properly placed circumferential suture coapts and invaginates the tendon ends, helping to prevent postoperative adhesions. This circumferential suture was once considered to be primarily of cosmetic importance to “tidy-up” the repair site; however, recent studies have noted the importance of this suture to improve tensile strength and gap resistance (31,33,53,68).

***Figure 47.7.*** A modified Bunnell core suture and circumferential running suture. (From Kleinert HE, Kutz JE, Cohen M. Primary Repair of Zone 2 Flexor Tendon Lacerations. In: Hunter J, Schneider L, eds. *American Academy of Orthopaedic Surgeons: Symposium on Tendon Surgery in the Hand.* St. Louis: CV Mosby, 1975.)

The suture technique for flexor tendons outside of zone II and for extensor tendons is not as critical, because the healed tendons do not have to glide in a confined sheath. Nevertheless, the surgeon is encouraged to use careful atraumatic techniques to minimize postoperative adhensions.

Various suture materials have been advocated. It is important that the suture be strong and nonreactive. Monofilament stainless steel is the strongest and least reactive of the available suture materials, but it is difficult to use without kinking or crimping the material, which potentially weakens the suture and leads to breakage. Most surngeons use one of several nonabsorbable synthetic materials: 3-0, 4-0, or 5-0 for core sutures, depending on the size of the tendon, and 5-0, 6-0, or 7-0 for the circumferential suture.

### SHEATH REPAIR

There is controversy about whether the digital sheath should be repaired at the time of tendon repair. Repair of the digital sheath at the time of zone II flexor tendon injuries has become popular on the premise that this enhances tendon nutrition by restoring the synovial environment (34). This concept is contradicted by studies that show that tendons heal in an extra–synovial fluid environment (27), as well as by studies that indicate that the integrity of the digital sheath does not affect the uptake of nutrients into the tendon (51). Experimental animal studies following tendon laceration and repair have produced conflicting results about whether sheath closure or reconstruction minimizes adhesions and improves tendon gliding (22,50,64). Sheath closure in the presence of an edematous swollen tendon may produce relative narrowing of the fibro-osseous tunnel and restrict tendon gliding. Be meticulous if you are performing sheath closure at the time of tendon repair, taking care not to compromise the cross-sectional diameter of the fibro-osseous tunnel.

## FACTORS AFFECTING TENSILE STRENGTH

The forces present at the flexor tendon repair site during passive digital motion, active digital motion, and active digital motion against resistance have been measured clinically in patients undergoing median nerve decompression at the carpal tunnel (59). Passive motion generates up to 0.9 kilograms force (kgf) in the digital flexor tendon. Active flexion against no resistance generates up to 3.9 kgf. Grasp against resistance generates up to 6.4 kgf, and tip pinch up to 12.0 kgf. Tendon repair rehabilitation protocols usually employ digital active or passive grasping activities. Consequently, 3.9–6.4 kgf is considered an appropriate approximation of the flexor tendon forces required to flex an uninjured finger. It should be noted that edema and increased tissue viscoelasticity associated with an injured digit probably result in increased resistance to flexion; therefore, the forces required to flex an injured digit following tendon laceration and repair are likely to be increased (23).

The tensile strength of standard two-strand suture techniques (e.g., Kessler, Bunnell) is approximately 2–3 kgf, as measured in human cadaveric tendons (2,6,66). These tensile strength values have been shown (44,67) to diminish more than 30% to 40% in experimental studies in immobilized tendons during the early (5–10 days) postoperative period; these values recover at approximately 2–3 weeks.

Several factors can impact the ultimate tensile strength and the resistance to gap formation at the repair site.

### INCREASED NUMBER OF SUTURE STRANDS

Increasing the number of core suture strands across the repair site can increase the tensile strength of the repair. Traditionally, suture techniques with two strands across the repair site were used (9,28). Increasing the suture strands to four nearly doubles the strength of two-strand repairs in human cadaver tendons (32,54). A six-strand suture technique described by Savage (57) has an ultimate tensile strength of 6.8 kgf.

Additionally, altering the standard core suture technique has been shown to increase the tensile strength. A longitudinal continuous running suture along both margins of the repaired tendon as described by Becker (Fig. 47.8) (4) increases the strength to 4.0 kgf, and a cross-stitch suture described by Silfverskiold and Anderson (Fig. 47.9) (60) increases strengths to 6.4 kgf in sheep cadaver tendons. The latter authors also reported tensile strength values of more than 10 kgf using a nylon mesh sleeve sutured to the tendon across the laceration site; again, the testing was performed in sheep cadaver tendons, and the values may not be comparable to studies using human cadavers.

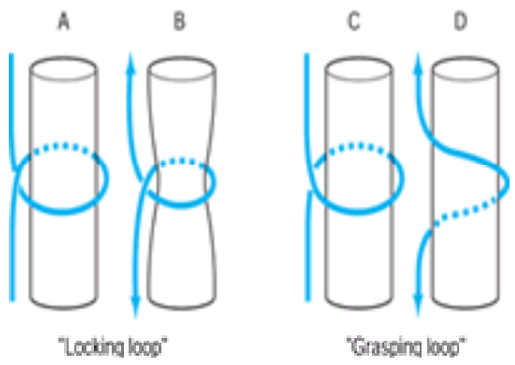


***Figure 47.8.*** Diagram of the Becker suture. (Redrawn with permission. From Becker H. Primary Repair of Flexor Tendons in the Hand without Immobilization. Preliminary Report. *Hand* 1978;10:37.)

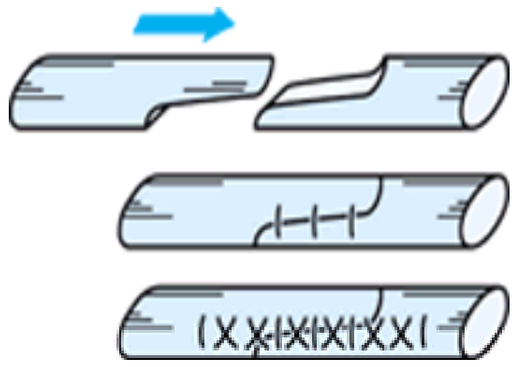

***Figure 47.9.*** Drawing of the criss-cross circumferential suture. (Redrawn with permission. From Silfverskiold KL, Anderson CH. Two New Methods of Tendon Repair. An *in Vitro* Evaluation of Tensile Strength and Gap Formation. *J Hand Surg* 1993;18A:58.)

**KNOT LOCATION**

The knot is the weak link in the suture strand (3,24). Therefore, a repair technique employing one knot is preferred to a technique using multiple knots.

Location of the knots within the repair site or outside the repair site also influences the tensile strength of the repair. Comparison of knot position in human cadavers showed that tendon repairs with knots located *within* the repair site had 60% to 80% of the strength of repairs having the knots located *outside* the repair site (3). Similar *in vivo* studies in canines (52) showed that four-strand suture repairs with the four knots located within the laceration site had 65% the tensile strength at 1 week after repair compared to tendon repaired with knots located away from the repair site. This increased to 75% at 3 weeks, and there was no significant difference in the tensile strength related to knot location by 6 weeks. The explanation for this difference is that knots located within the repair are subject to all the tensile forces applied at the laceration site. When the knots are placed outside the laceration site, the tensile forces are in part dissipated and absorbed by the friction between the suture material and tendon fibers; therefore, more tensile forces can be applied to the repair site before the suture fails. The four suture strands crossing the laceration site occupied 7% of the cross-sectional area of the tendon at the laceration site. Locating the four knots within the laceration site increased the occupied cross-sectional area to between 18% and 26%. The observation that there was no difference in the tensile strength at 6 weeks indicates that the knots within the repair site did not interfere with the healing process.

**LOCKING VERSUS GRASPING SUTURE CONFIGURATION**

There is debate over whether there is a difference in tensile strength related to the use of a locking or grasping suture configuration, as well as over whether more than one locking or grasping loop per suture strand increases the strength of the repair. The controversy is in part related to poorly defined terms: Unfortunately, the terms *locking* and *grasping* have often been used interchangeably. It is necessary to define a locking suture as originally defined by Pennington (49), who recognized the important relationship between the longitudinal and transverse components of the core suture (Fig. 47.10). When the transverse component is passed superficial (palmar) to the longitudi- nal component, it tightens around bundles of tendon fibers as tensile forces are applied; this is a *locking suture.* When the transverse component is passed deep (dorsal) to the longitudinal component, the suture does not tighten around the tendon bundles but rather pulls through the tendon fibers as tensile forces are applied; this is a grasping suture.

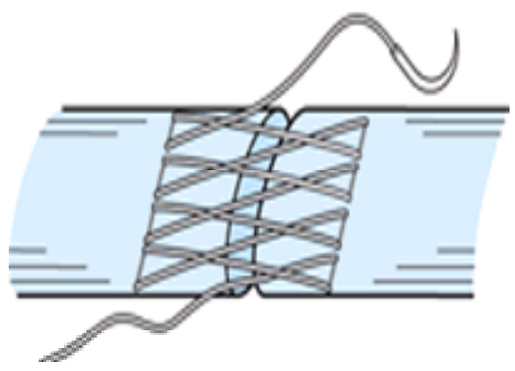

***Figure 47.10.*** Definitions of *locking loop* and *grasping loop*. In the locking loop configurations (**A**), the suture (**B**) tightens around the fiber bundles when tension is applied to the suture ends. In the grasping loop configuration (**C**), the suture (**D**) pulls through the fiber bundles without tightening around them when tension is applied to the suture ends. (Redrawn with permission of WB Saunders Co. From Hotokezaka S, Manske PR. Difference between Locking Loops and Grasping Loops: Effects on 2-Strand Core Suture. *J Hand Surg* 1997;22A:995.)

Mashadi and Amis (43) studied the effect of the locking suture configuration as defined by Pennington on tensile strength and gap formation using stainless steel suture material. They found no significant differences using one, two, or three locking loops per suture strand. In a subsequent study, Hotokezaka and Manske (26) compared locking and grasping loop suture configurations using polyester suture material. They confirmed the previous observation that additional locking loops do not contribute to increased strength or resistance to gap formation. One locking loop per suture strand had greater tensile strength than one grasping loop and was equal in tensile strength to two locking loops and two grasping loops. With respect to gap strength, one locking loop was equal to two locking loops and one grasping loop; however, gap formation was greatest using two grasping loops per suture strand as the added suture material pulled through the tendon allowing a larger gap. These authors conclude that a single locking loop per suture strand is preferred when using two-strand suture techniques.

**DORSAL VERSUS VOLAR SUTURE PLACEMENT**

Experimental studies (29,63) showed that placement of core sutures in the dorsal half of the tendon provided stronger repairs than core sutures placed in the volar half of human cadaver tendons. This was particularly evident using curvilinear testing techniques, whereby the tensile strength values were determined with the tendon in its native environment within the flexor sheath of the digit. It has not been conclusively established whether the improved tensile strength is related principally to the potential mechanical advantage of the dorsal placed suture during simulated digital flexion, or to a real biological difference between the dorsal and volar aspects of the

tendon.

**CIRCUMFERENTIAL SUTURE**

A continuous running suture is usually placed circumferentially around the periphery of the repair site. Formerly, it was thought that this circumferential suture served only to tidy-up the repair, but recent cadaver studies have shown that it also contributes to the tensile strength and gap resistance of the repair site (30,33,53,68). Tensile and gap strength values, in general, are increased according to the number of suture strands. Additionally, tensile strength is related to the suture configuration (30); simple sutures add approximately 1 kgf, mattress sutures add approximately 2 kgf, and the locking mattress suture described by Lin (33) (Fig. 47.11) and the cross-stitch suture (Fig. 47.10) (60) add approximately 3 kgf. Finally, increasing the depth of circumferential sutures has also been shown to increase the tensile strength and gap resistance (14).

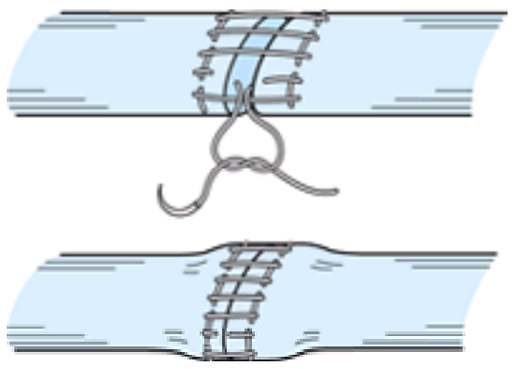

***Figure 47.11.*** Drawing of locking mattress circumferential suture. (Redrawn by permission. From Lin G-T, An K-N, Amadio PC, Cooney WP. Biomechanical Studies of Running Suture for Flexor Tendon Repair in Dogs. *J Hand Surg* 1988;13A:553.)

## POSTOPERATIVE CARE

The traditional postoperative management protocols following tendon repair have focused on minimizing tension at the repair site to allow the tendon to heal. Complete immobilization has been found to diminish the strength of the repair site, however, and to encourage attachment of fibrous adhesions from the peripheral tissue to the repaired tendon (32,67). Ideally, these peripheral adhesions will become long and filmy strands of scar tissue, which do not impede tendon excursion; however, they often are tight, dense bands that restrict tendon gliding. In experimental animals, a program of early passive motion effectively restored the gliding surface and increased the strength at the repair site of canine flexor tendons at 3 weeks after surgery (19,20). Consequently, carefully supervised and controlled passive range of motion of the digit has been advocated in the treatment of repaired flexor tendons in the early postoperative period (15,35). Early controlled mobilization has also been advocated following extensor tendon repair (7).

Active mobilization has been shown to increase the tensile strength of the repair site in experimental animals (1,25,31). Aoki et al. showed that the observed loss of tensile and gap strength at the repair site during the initial 2 weeks could be obviated by applying tension to the repaired tendon (1). Several authors have reported good results using active tendon mobilization protocols following flexor tendon repair (13,16,56,62). Active mobilization has also been advocated following extensor tendon repair (12,17).

## AUTHOR'S PERSPECTIVE

### *Flexor Tendons*

My preferred technique for flexor tendon repair within the digital sheath follows the previously noted principles, but it also takes into consideration the ease or difficulty of suture placement. The core consists of two two-strand locking sutures (3-0 braided polyester) as described by the Pennington (49) modification of the Kessler technique (28), resulting in four strands across the repair site. (If surgical exposure allows, a third locking suture can be placed, resulting in six strands.) The knots for each of the two sutures are tied within the repair site. The circumferential suture is a criss-cross suture (60) using 6-0 Prolene.

My postoperative rehabilitation protocols encourage protective active mobilization; the specific protocol utilized depends on the ability of the patient to understand and conform to the guidelines. Treat reliable patients with a removable splint as described by Cannon (10); this allows active digital flexion with wrist extension and active digital extension with wrist flexion. Between exercise sessions, hold the digit in full extension at the proximal interphalangeal joint (with the wrist and metacarpophalangeal joints flexed 30°) to prevent flexion contracture of that digital joint.

Treat less reliable patients with the passive motion (rubber band traction) similar to that originally described by Lister et al. (35); modifications include passing the rubber band through a pulley located at the distal palmar crease in the hand, as well as including all four digits in the traction device. Additionally, encourage patients to assist the passive flexion by actively flexing the digit during exercise periods.

### *Extensor Tendon*

My preferred technique for extensor tendons generally includes a core locking suture as described by Pennington (49), along with the circumferential criss-cross suture (60). An additional figure-eight can be added at the surgeon's discretion. Postoperatively, early motion is obtained using dynamic splinting (7).

The principles associated with tendon repair continue to evolve. Perhaps it is best to regard these principles as dynamic and ever-changing concepts that the surgeon must reconsider as they are modified and redefined. Only in that way will the objective of restoring the continuity of the collagenous fibers and reestablishing the gliding surface of the tendon be realized.

**CHAPTER REFERENCES**

Each reference is categorized according to the following scheme: *, classic article; #, review article; !, basic research article; and +, clinical results/outcome study.


! 1. Aoki M, Kubota H, Pruitt DL, Manske PR. Biomechanical and Histologic Characteristics of Canine Flexor Tendon Repair Using Early Postoperative Mobilization. *J Hand Surg* 1997;22A:107.

! 2. Aoki M, Manske PR, Pruitt DL, Larson B. Tendon Repair Using Flexor Tendon Splints: An Experimental Study. *J Hand Surg* 1994;19A:984.

! 3. Aoki M, Pruitt DL, Kubota H, Manske PR. Effect of Suture Knots on Tensile Strength of Repaired Canine Flexor Tendons. *J Hand Surg* 1995;20B(1):72.

+ 4. Becker H. Primary Repair of Flexor Tendons in the Hand Without Immobilization. Preliminary Report. *Hand* 1978;10:37.

! 5. Becker H, Diegelmann RF. The Influence of Tension on Intrinsic Tendon Fibroplasia. *Orthop Rev* 1984;13:153.

! 6. Bhatia D, Tanner K, Bonfield W, Citron N. Factors Affecting the Strength of Flexor Tendon Repair. *J Hand Surg* 1992;17B:550.

+ 7. Brown EZ, Ribik CA. Early Dynamic Splinting for Extensor Tendon Injuries. *J Hand Surg* 1989;14A:72.

+ 8. Bruner JM. The Zig-Zag Volar-Digital Incision for Flexor Tendon Surgery. *Plast Reconstr Surg* 1967;40:571.

+ 9. Bunnell S. Repair of Tendons in the Fingers and Description of Two New Instruments. *Surg Gynecol Obstet* 1918;16:103.

+ 10. Cannon NM. Post Flexor Tendon Repair Motion Protocol. *Indiana Center Newsletter* 1993;1:13.

! 11. Caplan HS, Hunter JM, Merklin RJ. Instrinsic Vascularization of Flexor Tendon. In: Hunter J, Schneider L, eds. *American Academy of Orthopaedic Surgeons: Symposium on Tendon Surgery in the Hand.* St. Louis: CV Mosby, 1975:48.

+ 12. Chow JA, Dovell S, Thomas J, et al. A Comparison of Results of Extensor Tendon Repair Followed by Early Controlled Mobilization Versus State Immobilization. *J Hand Surg* 1989;14B:18.

+ 13. Cullen KW, Tolhurst P, Land D, Page RE. Flexor Tendon Repair in Zone 2 Followed by Controlled Active Mobilization. *J Hand Surg* 1989;14B:392.

! 14. Diao E, Hariharan JS, Soejima O, Lotz JC. Effect of Peripheral Suture Depth on Strength of Tendon Repairs. *J Hand Surg* 1996;21A:235.

+ 15. Duran RE. Controlled Passive Motion Following Flexor Tendon Repair in Zones II and III. In: Hunter J, Schneider L, eds. *American Academy of Orthopaedic Surgeons: Symposium on Tendon Surgery in the Hand.* St. Louis: CV Mosby, 1975:105.

+ 16. Elliot D, Flemming AFS, Harris SB, Foster AJ. The Rupture Rate of Acute Flexor Tendon Repairs Mobilized by the Controlled Active Motion Regimen. *J Hand Surg* 1994;19B:607.

! 17. Evans RB. Immediate Active Short Arc Motion Following Extensor Tendon Repair. *Hand Clinics* 1995;11:483.

! 18. Gelberman RH, Khabie V, Cahill CJ. The Revascularization of Healing Flexor Tendons in the Digital Sheath. A Vascular Injection Study in Dogs. *J Bone Joint Surg Am* 1991;73:868.

# 19. Gelberman RH, Manske PR. Factors in Influencing Flexor Tendon Adhesions. *Hand Clin* 1985;1:35.

! 20. Gelberman RH, Vande Berg JS, Lunborg GN, Akeson WH. Flexor Tendon Healing and Restoration of the Gliding Surface. *J Bone Joint Surg Am* 1983;65:70.

! 21. Gelberman RH, Vande Berg JS, Manske PR, Akeson WH. The Early Stages of Flexor Tendon Healing: A Morphologic Study of the First Fourteen Days. *J Hand Surg* 1986;10:776.

! 22. Gelberman RH, Wood SL, Amiel D, et al. Influences of Flexor Sheath Continuity and Early Motion on Tendon Healing in Dogs. *J Hand Surg* 1990;15A:69.

! 23. Halikis MN, Manske PR, Kubota H, Aoki M. The Effect of Immobilization, Immediate Mobilization and Delayed Mobilization on the Resistance to Digital Flexion Using a Tendon Injury Model. *J Hand Surg* 1997;22A:464.

! 24. Herrmann JB. Tensile Strength and Knot Security of Surgical Suture Materials. *Am Surg* 1971;37:209.

! 25. Hitchcock TF, Light RR, Bunch WH, et al. The Effect of Immediate Constrained Digital Motion on the Strength of Flexor Tendon Repairs in Chickens. *J Hand Surg* 1987;2A:590.

! 26. Hotokezaka S, Manske PR. The Difference between Locking Loops and Grasping Loops: The Effect on 2-Strand Core Suture. *J Hand Surg* 1997;22A:995.

! 27. Katsumi M, Tajima T. Experimental Investigation of Healing Process of Tendons with or Without Synovial Coverage in or Outside of the Synovial Cavity. *J Niigata Med Asso* 1981;95:532.

+ 28. Kessler I. The “Grasping” Technique for Tendon Repair. *Hand* 1973;5:253.

! 29. Komanduri M, Phillips CS, Mass DP. Tensile Strength of Flexor Tendon Repairs in a Dynamic Cadaver Model. *J Hand Surg* 1996;21A:605.

! 30. Kubota H, Aoki M, Pruitt DL, Manske PR. Mechanical Properties of Various Circumferential Tendon Suture Techniques. *J Hand Surg* 1996;21B(4):474.

! 31. Kubota H, Manske PR, Aoki M, et al. Effect of Motion and Tension on Injured Flexor Tendons in Chickens. *J Hand Surg* 1996;21A:456.

! 32. Lee H. Double Loop Locking Suture: A Technique of Tendon Repair for Early Active Mobilization. Part I. Evolution of Technique and Experimental Study. *J Hand Surg* 1990;15A:945.

! 33. Lin G-T, An K-N, Amadio PC, Cooney WP. Biomechanical Studies of Running Suture for Flexor Tendon Repair in Dogs. *J Hand Surg* 1988;13A:553.

+ 34. Lister GD. Incision and Closure of the Flexor Sheath During Primary Tendon Repair. *Hand* 1983;15:123.

+ 35. Lister GD, Kleinert HE, Kutz JE. Primary Flexor Tendon Repair Followed by Immediate Controlled Mobilization. *J Hand Surg* 1977;2:441.

+ 36. Madsen E. Delayed Primary Suture of Flexor Tendons Cut in the Digital Sheath. *J Bone Joint Surg Br* 1970;52B:264.

# 37. Manske PR, Gelberman RH, Lesker PA. Flexor Tendon Healing. *Hand Clin* 1985;1:25.

! 38. Manske PR, Gelberman RH, Vande Berg JS, Lesker PA. Flexor Tendon Repair: Morphologic Evidence of Intrinsic Healing in Vitro. *J Bone Joint Surg Am* 1984;66:385.

! 39. Manske PR, Lesker PA. Nutrient Pathways to Extensor Tendons with the Extensor Retinacular Compartments. *Clin Orthop* 1983;181:234.

! 40. Manske PR, Lesker PA. Histological Evidence of Flexor Tendon Repair in Various Experimental Animals. An in Vitro Study. *Clin Orthop* 1984;182:353.

# 41. Manske PR, Lesker PA. Flexor Tendon Nutrition. *Hand Clin* 1985;1:13.

! 42. Manske PR, Lesker PA, Gelberman RH, Ruzinsky TE. Intrinsic Restoration of the Flexor Tendon Surface in the Nonhuman Primate. *J Hand Surg* 1985;10A:632.

! 43. Mashadi ZB, Amis AA. The Effect of Locking Loops on the Strength of Tendon Repair. *J Hand Surg* 1991;16B:1:35.

! 44. Mason ML, Allen HS. The Rate of Healing Tendons. An Experimental Study of Tensile Strength. *Ann Surg* 1941;113:424.

! 45. Mass DP, Tuel RJ, Labarbera M, Greenwald DP. Effects of Constant Mechanical Tension on the Healing of Rabbitt Flexor Tendons. *Clin Orthop* 1993;296:301.

+ 46. Matev I, Karagancheva S, Trichkova P, Tsekov P. Delayed Primary Suture of Flexor Tendons Cut in the Digital Theca. *Hand* 1980;12:158.

! 47. Matthews P. The Fate of Isolated Segments of Flexor Tendons within the Digital Sheath. *Br J Plast Surg* 1976;28:216.

! 48. Matthews P, Richards H. Factors in the Adherence of Flexor Tendons after Repair. An Experimental Study in the Rabbit. *J Bone Joint Surg Br* 1976;58:230.

! 49. Pennington DG. The Locking Loop Tendon Suture. *Plast Reconst Surg* 1979;63:648.

! 50. Peterson WW, Manske PR, Dunlap S, et al. Effect of Various Methods of Restoring Flexor Sheath Integrity on the Formation of Adhesions after Tendon Injury. *J Hand Surg* 1990;15A:48.

! 51. Peterson WW, Manske PR, Lesker PA. The Effect of Flexor Sheath Integrity on Nutrient Uptake in Chicken Flexor Tendons. *Clin Orthop* 1985;201:259.

! 52. Pruitt DL, Aoki M, Manske PR. Effect of Suture Knot Location on Tensile Strength After Flexor Tendon Repair. *J Hand Surg* 1996;21A:969.

! 53. Pruitt DL, Manske PR, Fink B. Cyclic Stress Analysis of Flexor Tendon Repair. *J Hand Surg* 1991;16A:701.

! 54. Robertson G, Al-Qattan M. A Biomechanical Analysis of a New Interlock Suture Technique for Flexor Tendon Repair. *J Hand Surg* 1992;17B:92.

! 55. Russell JE, Manske PR. Collagen Synthesis during Primate Flexor Tendon Repair in Vitro. *J Orthop Res* 1990;8:13.

+ 56. Sandow MJ, McMahon MM. Single-Cross Grasp Six-Strand Repair for Acute Flexor Tenorrhapy. *Atlas Hand Clin* 1996;1:41.

! 57. Savage R. In Vitro Studies of a New Method of Flexor Tendon Repair. *J Hand Surg* 1985;10B:135.

+ 58. Schneider LH, Hunter JM, Norris TR, Nadeau PO. Delayed Flexor Tendon Repair in No Man's Land. *J Hand Surg* 1977;2:452.

! 59. Schuind F, Garcia-Elias M, Cooney W III, An K. Flexor Tendon Forces: In Vivo Measurements. *J Hand Surg* 1992;17A:291.

! 60. Silfverskiold KL, Anderson CH. Two New Methods of Tendon Repair. An in Vitro Evaluation of Tensile Strength and Gap Formation. *J Hand Surg* 1993;18A:58.

! 61. Slack C, Flint MH, Tompson BM. The Effect of Tensional Load on Isolated Embryonic Chick Tendons in Organ Culture. *Connect Tissue Res* 1984;12:229.

+ 62. Small JO, Bennen MD, Colville J. Early Active Mobilization Following Flexor Tendon Repair in Zone 2. *J Hand Surg* 1989;14B:383.

! 63. Soejima O, Diao E, Lotz JC, Hariharan JS. Comparative Mechanical Analysis of Dorsal Versus Palmar Placement of Core Sutures for Flexor Tendon Repairs. *J Hand Surg* 1995;20:801.

! 64. Strauch B, DeMoura W, Ferder M, et al. The Fate of Tendon Healing after Restoration of the Integrity of the Tendon Sheath with Autogenous Vein Grafts. *J Hand Surg* 1985;10A:790.

! 65. Tanaka H, Manske PR, Pruitt DL, Larson BJ. Effect of Cyclic Tension on Lacerated Flexor Tendons in Vitro. *J Hand Surg* 1995;20A:467.

! 66. Trail I, Powell E, Noble J. The Mechanical Strength of Various Suture Techniques. *J Hand Surg* 1992;17B:89.

! 67. Urbaniak JR, Cahilll JD, Mortenson RA. Tendon Suturing Methods: Analysis of Tensile Strength. In: Hunter J, Schneider L, eds. *American Academy of Orthopaedic Surgeons: Symposium on Tendon Surgery in the Hand.* St. Louis: CV Mosby, 1975:70.

! 68. Wade P, Wetherell R, Amis A. Flexor Tendon Repair: Significant Gain in Strength from the Halsted Peripheral Suture Technique. *J Hand Surg* 1989;14B:232.

# CHAPTER 48

# FLEXOR TENDON INJURIES: ACUTE REPAIR AND LATE RECONSTRUCTION

*John S. Gould and Beth G. Nicholson*

**J. S. Gould and B. G. Nicholson:** Department of Orthopaedic Surgery, University of Virginia, and Alabama Sports Medicine and Orthopaedic Center, Health South Medical Center, Birmingham, Alabama 35205.

Terminology
Zones of Injury
- Zone 5
- Zone 4
- Zone 3
- Zone 2
- Zone 1

Surgical Techniques of Digital Flexor Tendon Repair
- Repairs in Each Zone
- Special Circumstances

Late Reconstruction
- One-Stage Tendon Grafting
- Two-Stage Tendon Grafting
- Tendon Grafting for the FDP with an Intact FDS
- Options for the Thumb

Tenolysis
Postoperative Care
- Primary Repairs
- Tenolysis
- Staged Flexor Tendon Reconstruction

Pitfalls and Complications
Chapter References

Although discussions of the anatomy, physiology, and biomechanics of human flexor tendons are beyond the scope of this chapter, the recent works of Gelberman and Manske (17,18), Manske and Lesker (19), and Brand (3) form the basis of present approaches to flexor tendon repair technique. Within the past 20 years, this knowledge has changed most of the principles and techniques of flexor tendon surgery and—with the enthusiasm for replantation—the timing as well. The importance that each surgeon attributes to the blood supply will determine the following:

- Whether a midlateral incision is used for exposure, which to some extent decreases blood supply to the tendon from that side (Fig. 48.1).

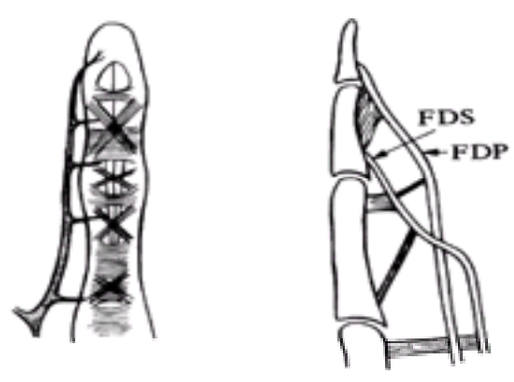


***Figure 48.1.*** Segmental blood supply to digital theca. FDS, flexor digitorum superficialis; FDP, flexor digitorum profundus. (Modified from Leddy JP. Flexor Tendons—Acute Injuries. In: Green DP, ed. *Operative Hand Surgery.* New York: Churchill-Livingstone, 1982;1350.)

- Whether a superficialis tendon, which has vascular interconnections with the profundus, is excised (Fig. 48.2).

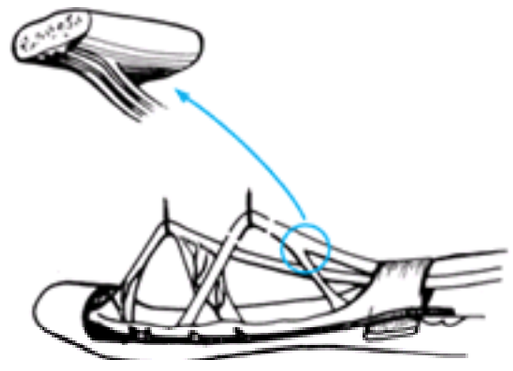

***Figure 48.2.*** Vinculae to digital flexors.

- Whether "strangulating" criss-cross suture techniques (e.g., Bunnell) are used or sutures are placed more palmarward to avoid disrupting the blood supply entering from and residing in the dorsal aspect of the tendon.
- Whether closure or reconstruction of the sheath is necessary to enhance intrinsic healing and the synovial fluid environment.
- Whether the effects of motion on tendon healing and strength determine the rehabilitation plan (8).

Acknowledged important principles include:

- A clean surgical wound is essential.
- One wound and one scar enhance outcomes.
- A poorer prognosis for function occurs with more damaged structures.
- A mature wound is better for tendon repair and reconstruction (2,22).
- Meticulous repair of all structures with stable bone fixation techniques permits immediate motion.
- In repair of the periosteum or the dorsal portion of the flexor sheath or pulley system, an interposing tissue minimizes adhesions.
- Repair of vessels is important to nerve regeneration.
- Repair of nerves is ideal for rehabilitation.
- Repair of tendons is necessary to prevent myostatic contracture and to allow rapid restoration of function, using a controlled rehabilitation plan.

## TERMINOLOGY

Definitions of the timing of tendon repair are imprecise in view of the conflicting opinions of many authorities (16,17,20,25).

*Primary repair* is repair of a tendon when the wound is initially debrided—during the “golden period” of the first 6 hours after injury, when it can be assumed that the wound has not been sufficiently colonized with bacteria to prevent closure. However, some fresh wounds are so grossly contaminated primarily that there is no golden period.

In wounds over 6 hours old, repair of flexor tendons might be deferred in favor of initial debridement only. If a digit is revascularized or replanted 6 hours after injury, and tendon repair is also carried out, this is also considered a primary repair.

*Delayed primary repair* occurs when the initial wound is washed and debrided but tendon repair is delayed for 2 to 14 days when the wound is not yet fully healed.

A repair performed after skin wound healing is considered a *secondary repair or reconstruction*. However, some authors consider repairs between 2 and 6 weeks to be late *delayed primary repair* because myostatic contracture is not well enough established to prevent “primary” end-to-end repair of the flexor tendon without having to resort to secondary reconstruction (i.e., grafting) (25).

## ZONES OF INJURY

Following Bunnell's (2) admonitions about problems with flexor tendon repairs in the pulley area of the digital theca (the “zone of the pulleys” or Bunnell's “no-man's land”), Verdan (32,33 and 34) classified flexor tendon injury sites into five zones, each with its peculiar anatomy and prognosis (Fig. 48.3). Doyle redefined the pulley zones of the digit and thumb (Fig. 48.4); this classification is now generally accepted (5,6).

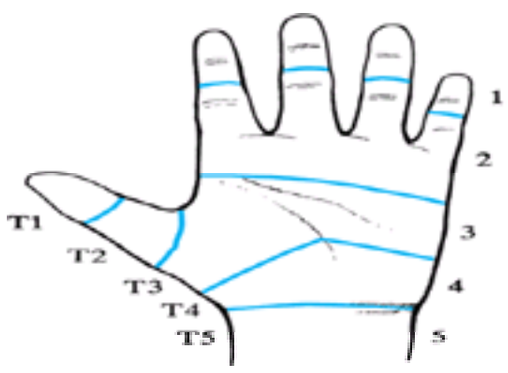


***Figure 48.3.*** Verdan's thumb and digital zones (modified).

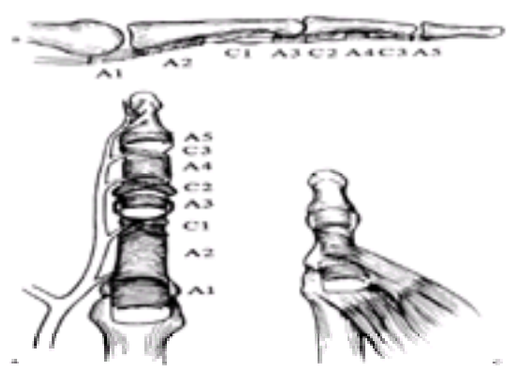

***Figure 48.4.*** Digital and thumb pulley systems as described by Doyle and Strauch. **A,B:** Digital. **C:** Thumb (note annular pulleys at the metacarpophalangeal and just proximal to the interphalangeal joint with oblique pulley over proximal phalanx). (**C** modified from Doyle JR, Blythe WF. Anatomy of the Flexor Tendon Sheath and Pulleys of the Thumb. *J Hand Surg* 1977;2:150.)

Flexor tendons to the digits may be injured in the wrist or forearm proximal to the carpal tunnel, which begins at the distal palmar wrist crease (surface marking) or the proximal edge of the deep transverse carpal ligament, extending from the trapezium to the hook of the hamate. The site of the tendon injury is what defines the zone, not the site of the skin lacerations. The tendon injury site is the position of the tendon with the wrist in neutral and the fingers in full extension, although more properly the fingers should be in their resting position of normal muscle tension or digital stance. As the fingers and wrist move into flexion, as the flexor muscles contract, the tendon moves proximally. Therefore, if the injury occurred at the wrist level but the finger or wrist or both were flexed, the tendon injury occurs more distally on the tendon (possibly in the carpal tunnel) when it resumes its neutral or more extended position.

### ZONE 5

A tendon injury in the wrist or distal forearm is in Verdan's zone 5. The musculotendinous junction area may be involved. Injuries can occur to the two wrist flexors, the palmaris longus, the median and ulnar nerves (and branches), the radial and ulnar arteries, and the nine flexor tendons of the digits and thumb. Multiple tendons and muscles may be injured. The prognosis for function, including individual function, in this area is good. Repairs need not be as meticulous as in other areas, but they still must be done well.

### ZONE 4

The carpal tunnel, Verdan's zone 4, extends from the distal palmar wrist crease or the proximal end of the deep transverse carpal ligament to its distal margin, as noted by the crossing of the proximal superficial palmar arch, formed from the ulnar side by the ulnar artery leaving the canal of Guyon. The surface determination of the distal extent of the tunnel is made by extending a line across the base of the palm from the palmar surface of the maximally extended thumb. In this zone, the nine flexors are tightly packed with the median nerve. Repairs must be meticulous, and results, especially for independent function, are more problematic than in any other area except the zone of the pulleys.

### ZONE 3

Zone 3 extends from the end of the carpal tunnel to the proximal end of the pulleys, which begin at the metacarpophalangeal (MP) joints. Surface markings in the palm are the proximal palmar crease for the index, about midway between the proximal and distal crease for the long finger, and the distal palmar crease for the ring and little fingers. In this zone, both the flexor digitorum superficialis (FDS) and the flexor digitorum profundus (FDP) are oval tendons, and the lumbrical muscle originates from the FDP. The lumbrical tendon runs in its own sheath or tunnel radial to the long flexor. Although repairs in zone 3 generally have a good prognosis, secondary reconstructive procedures originating here should allow for problems with intrinsic imbalance and excessive lumbrical action.

### ZONE 2

Zone 2, the zone of the pulleys, is the area of maximum concern and debate regarding aspects of tendon nutrition, healing, repair methods, and rehabilitation. Even the extent of the zone is argued. Investigators agree that the zone begins at the MP level [Bunnell's first pulley, Doyle's first annular (A1)], but the distal extent is not

defined. For prognostic purposes, the zone ends at the mid–middle phalanx, the site of Doyle's C3 (third cruciate) pulley but also the most distal extent of the superficialis slips' insertion (Fig. 48.4). Distal to this point only a one-tendon system, the profundus, exists, but Strauch has described the A5 (fifth annular) pulley at the distal interphalangeal (DIP) joint level (29). Zone 2 is peculiar in that actually three tendons (profundus and two slips of the superficialis) exist here in very close proximity; they are surrounded by the dense unyielding cover of a floor (dorsally) of bone, periosteum, and fibrous sheath and by sides and a roof (palmarly) of dense fibrous tissue, thicker even in the condensations of the annular and cruciate pulleys and dorsally at the palmar plates. Within the sheath and pulleys the tendons have an intrinsic blood supply as well as that from the parietal tenosynovium surrounding the tendons.

The superficialis tendon in this zone begins to split at the MP level to allow the profundus to pass through it. It then becomes two flat, slightly concave tendons that lie dorsal to the profundus and hug its sides and then join just proximal to the proximal interphalangeal joint to form the chiasm of Camper. The flat united tendinous structure then divides after the proximal interphalangeal (PIP) joint to form two flat slips, which insert along the middle phalanx to almost its midpoint.

Good results of surgical repair in this area depend on many of the surgical and rehabilitation techniques discussed in this chapter and are by no means routine.

**ZONE 1**

Zone 1 is the area between the FDS insertion (distal edge of C3 pulley) and the insertion of the profundus. Excellent technique is also required here, but with good conventional techniques the prognosis for function is good.

Five thumb flexor zones are described, but problems occur less often here with only one tendon of relatively uniform size and no intrinsics. These thumb flexor zones are listed below:

Zone 5 for the thumb flexor is also in the wrist, proximal to the carpal tunnel.
Zone 4 is the carpal tunnel.
Zone 3 is the relatively inaccessible thenar zone, extending from the distal edge of the tunnel to the MP joint.
Zone 2 is the pulley zone, consisting of an annular ligament at the MP joint and a long oblique pulley over three quarters of the proximal phalanx with a second annular pulley distally.
Zone 1 is distal to the pulley, just proximal to the interphalangeal joint, to the insertion of the flexor pollicis longus (FPL) just distal to the interphalangeal joint.

## SURGICAL TECHNIQUES OF DIGITAL FLEXOR TENDON REPAIR

Given the option, we prefer delayed primary repair of flexor tendons. This implies a thorough wash and debridement of the wound initially, with tendon repair at 48 to 96 hours. Initial care is done on an outpatient basis in an adequate facility (usually the operating room, but possibly an emergency department suite where tourniquet control, anesthesia, and good sterility are available). The patient is placed on the elective surgical schedule in a few days.

Several situations, both medically moderated and socially dictated, preempt this approach. An unreliable patient is likely to be admitted and operated on at the next available elective operating time after initial wound care. If the patient has been referred from out of town with a day-old injury, surgery is done at the next elective opportunity. Medical conditions indicating acute repair include a zone 5 injury requiring the repair of multiple damaged structures and the repair of muscle and tendons before muscle retraction makes the surgery technically more difficult. Digits with vascular impairment requiring revascularization or replantation are also repaired acutely, as delay may endanger the viability of the digit (see Chapter 34).

- Begin by increasing the exposure proximally and distally, converting the original laceration into part of the zigzag Bruner approach (Fig. 48.5) (4). The history of the injury suggests whether the actual site of tendon laceration will be at the skin level or more distally.

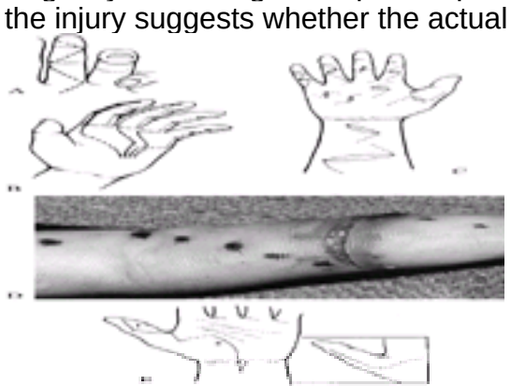

***Figure 48.5.*** Incision options. **A:** The zigzag Bruner incision. **B:** Midlateral incisions. **C:** Extensions of lacerations. **D:** Extension of incision in clinical photo. **E:** Incision options for the thumb. (**A,B** modified from Schneider LH, Hunter JM. Flexor Tendons—Late Reconstruction. In: Green DP, ed. *Operative Hand Surgery.* New York: Churchill-Livingstone, 1982;1379. **E** modified from Urbaniak JR. Flexor Pollicis Longus Repair. *Hand Clin* 1985;1:72.)

- Open the carpal tunnel area following the thenar crease, but 1 to 2 cm distal to the wrist crease, direct the incision ulnarly to the wrist crease, then change the direction sharply and curve the incision proximally back to the midline. From here, each zone is managed somewhat differently (see Chapter 37).

**REPAIRS IN EACH ZONE**

***Zone 5***

- After extending the exposure, check each structure to verify the findings at physical examination. Check each structure for continuity and function. The profundi are aligned at the same level just palmar to the pronator quadratus, with the index profundus frequently independent. The flexor pollicis is more radial yet and, although deeper, is just radial to the radial artery. The four superficialis tendons line up, with the long and ring finger tendons lying somewhat more superficially than the index and little finger tendons, which lie to either side and more dorsal. The little finger superficialis is closely associated with the ring finger tendon, although slightly more dorsal.
- If the profundi and flexor pollicis longus are intact, place an umbilical tape around them to avoid having to recheck their identity repeatedly. Similarly, mark the intact superficialis tendons and identify the more superficial wrist flexors—the flexor carpi radialis (FCR) and ulnaris (FCU)—and tag the median nerve with a vessel loop. Although any flexor motor can power any distal tendon, it is best to match the lacerated components because their lengths when repaired end to end should provide the appropriate tension. This is particularly important for the profundi. Because of their intimate interconnection, restoring tendon length is important to prevent the short tether syndrome (quadriga).

Tendons are identified based on their function, location, and appearance—that is, it does what it is supposed to do, lies where it is supposed to lie, and looks the way it is supposed to look. The preferred end-to-end tendon repair is the Tajima modification of the four-corner grabbing stitch of Kessler (Fig. 48.6) (30). Use two double-armed 3-0 or 4-0 monofilament polypropylene sutures with pointed tendon needles. (For a discussion of recently advocated multistrand techniques, see Chapter 47 by Manske, particularly zone 2 repairs.) The multistrand repairs, although more technically demanding, have experimentally demonstrated greater strength, allowing more active motion in postoperative rehabilitation, and may supersede the Kessler modifications in common usage (10,24,26,27,29,35,36 and 37).

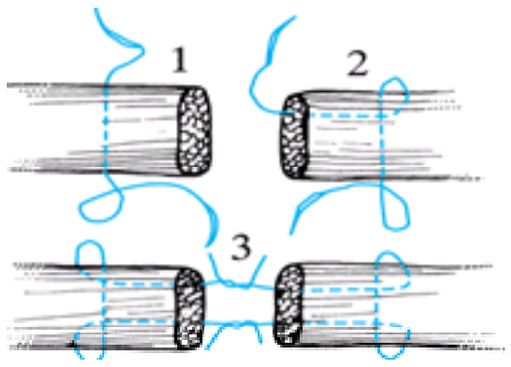


***Figure 48.6.*** The Tajima modification of the Kessler suture technique.

- Pass the suture transversely through the tendon about 1 cm behind the cut edge, which is minimally trimmed with curved Stephen scissors. Then reinsert each needle just behind the transverse suture and direct it on its side to the open end. Hold the tendon at its cut end with a Beasley-Babcock forceps. This technique is preferred to the conventional or modified Kessler, as the needles are not directed into the cut tendon ends, which seems to create fraying.
- Use a separate double-ended suture for each end. Once the sutures have been placed, cut the needles off, have the assistant hold tension on the two strands on that side, and tie the sutures on your side with a square knot, with a few additional ties.
- While the assistant holds the tied suture, take up the slack on the untied side, just bringing the ends together, and tie the second side. In zone 5, additional tidying sutures are usually not necessary. Occasionally, a horizontal mattress stitch with 6-0 nylon or polypropylene might be used to tuck in an irregular edge.
- Use a combination of horizontal mattress and locking horizontal mattress sutures for muscle repair. In the locking stitch, instead of tying the two ends of the suture in the conventional manner, make one or two throws on the needle end of the suture, then place the needle-holder tip through the loop end of the stitch, grasping the loose end on the far side and pulling it through the loop (Fig. 48.7). This maneuver not only creates the stitch tension away from the wound edge and everts the edges but also approximates the edges and prevents excessive eversion. This technique is also applicable in all tendon repairs where a horizontal mattress suture might be used (e.g., superficialis slips, chiasm of Camper), but excessive eversion is undesirable.



***Figure 48.7.*** The locking horizontal mattress stitch for “flat” tendons.

### *Zone 4*

More meticulous tendon repair is required in zone 4.

- After tying the Tajima sutures, do not cut the two tied suture ends. Leave them inside the tendon initially. Have the assistant hold the long ends and place a horizontal mattress or locking horizontal mattress stitch with 6-0 nylon in the outer layer of the tendon.
- Begin the circumferential running stitch away from your side with the tendon flipped over (i.e., on the dorsal or back side). Take the stitches toward yourself, return the tendon to the palmar side, and complete the suturing, tying finally to the initial stitch end.
- Although simple bites (1 mm or so from the cut edge) are often satisfactory, invert these edges or at least make them even. To invert, take each stitch just behind the cut edge (Fig. 48.8), which rolls in the edge, leaving a repair without pouting edges. Healing is not adversely affected.

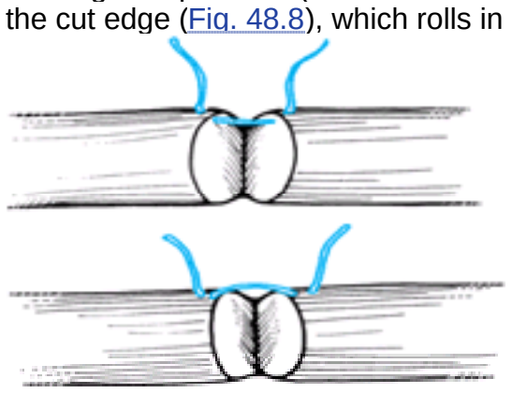

***Figure 48.8.*** Running stitch options at cut edge. The technique, depicted in the lower picture, slightly inverts the ends.

- After the repair of the structures in the carpal tunnel, begin rehabilitation, either with the wrist in neutral or dorsiflexion to prevent palmar subluxation of the contents of the tunnel.
- Because it is preferable to flex the wrist up to 30°, we prefer to repair the transverse carpal ligament. Direct suture is not usually feasible; zigzag cuts on opening the carpal ligament risk damage to the palmar cutaneous branch of the median nerve, which may run through the ligament, or to the motor branch of the median nerve. Consequently, we close the tunnel somewhat more loosely than its original ligament width by lacing it with a strip of tendon like a shoelace (usually using palmaris longus, but occasionally with a sagittal strip of FCR or an accessory tendon).

### *Zone 3*

Perform zone 3 repairs in a similar manner. The lumbrical may be repaired, but if it is damaged in its muscle substance, it is probably better to excise it rather than to risk an imbalance caused by intrinsic contracture. Repair both the superficialis and profundus if they are lacerated, and also repair a single tendon laceration. Restoration of digital strength and total function requires both tendons.

### *Zone 2*

In zone 2, the technique must be precise. Avoid scratching the tendon to avoid causing adhesions (27). Repair the bed, repair the tendon in a nonbulbous manner, and repair the sheath or pulley system.

- Extend the wound into a zigzag or Bruner incision (Fig. 48.5). Expose the sheath and open it along the side to create a funnel, as described by Lister (Fig. 48.9) (15).

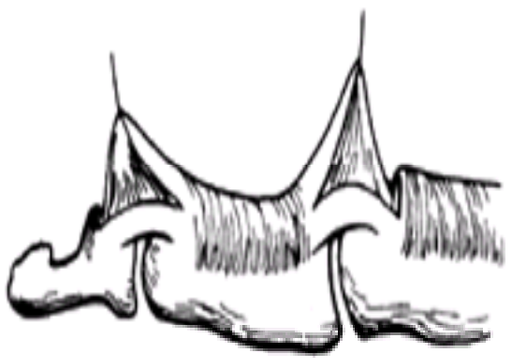

***Figure 48.9.*** Lister's technique of opening the sheath to form a funnel.

- The side cut joins the transverse wound in the sheath. If the tendon is sited proximally, make a second incision more proximally, a mirror image of the first. The distal tendon can usually be easily exposed in this manner, assisted by flexion of the distal joints. If the proximal end is not held by a vincula, or if the profundus alone is cut and not trapped at the MP level where it passes through the superficialis, it is in the palm, held by the lumbrical. Fishing for the proximal end with grasping-type instruments is dangerous to the tendon, the bed, and proximally to blood vessels and nerves. If the proximal end cannot be kneaded and milked into the wound and then grasped with a mosquito hemostat in its cut end, make a proximal incision and find it.
- Pass a pediatric rubber feeding tube or a silicone-dacron tendon rod distally to proximally through the sheath, suture the tendon with a single nylon suture through the cut end to the eyelet in the tubing or to the rod, and draw it back into the distal wound.
- When both tendons are cut, bring them together distally. Bring the profundus through the superficialis, in the normal anatomic position. If a problem arises passing it through the sheath, open the intervening skin bridge and create another sheath incision.
- Once the tendon (or tendons) is returned to the distal area, close the sheath opening with 6-0 nylon.
- When the tendons are brought into the distal wound, hold them in that position by skewering them with a milliner's needle that passes through the sheath and the tendons proximally. Avoid the neurovascular bundles by placing the needle more palmarly. Keith needles have a cutting edge and are less desirable than the pointed milliner's variety.
- Except at the open end, where the tendon may be handled with the Beasley-Babcock forceps, handle the tendon with the thumb and index fingers with an interposed moist sponge.
- Repair the superficialis slips or chiasm with horizontal mattress sutures or locking stitches, using 4-0 nylon. Collagen suture creates more reaction and is not advocated. Polypropylene is satisfactory; braided polyester sutures do not slide well and are no longer preferred by us. Braided nylon has also been satisfactory, but monofilament nylon and polypropylene are preferred.
- Repair the profundus tendon with the Tajima technique with 3-0 or 4-0 nylon or polypropylene, with the cut edge repaired with a running stitch. If there has been damage to the periosteum under the tendons, repair it with 6-0 nylon. If it cannot be repaired, a graft of antebrachial fascia may be sutured in place as an interposing membrane. Fractures are repaired before tendons, of course, but if neurovascular repairs are indicated, particularly with an intact skeleton, it may be technically easier to retrieve tendons into the wound and place the Tajima sutures into the tendon but not tie them so that the neurovascular repair under the microscope can be done on a flat (unflexed) digit.
- After the tendons are repaired, repair the sheath with 6-0 nylon (Fig. 48.10). Leaving a gap in the sheath may result in sagging of the edge of the sheath as the tendon attempts to pass through it, decreasing the vertical diameter and trapping the tendon (Fig. 48.11). Use simple or horizontal mattress sutures to repair the sheath. If a gap remains, fill it by sewing antebrachial fascia to and over the underlying sheath (Fig. 48.10). If a pulley is missing, reconstruct it, as described below.

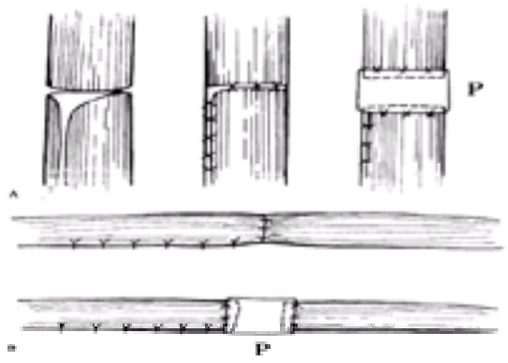


***Figure 48.10.*** Closure and reconstruction of the tendon sheath. **A:** Anteroposterior view of the sheath demonstrating direct repair and antebrachial fascial graft (P). **B:** Lateral view of repair and graft (P).

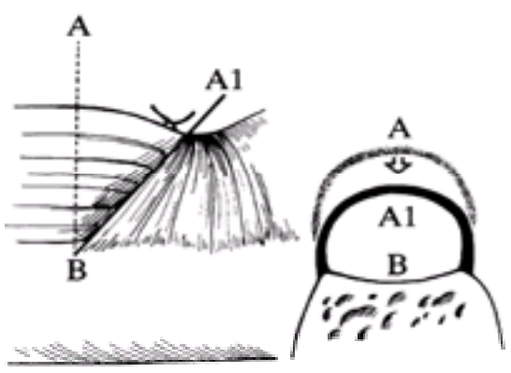


***Figure 48.11.*** Buckling of the unrepaired sheath as the tendon attempts to pass through. Note loss of height of pulley (A–B to A1–B).

### *Zone 1*

Repair the profundus in zone 1 as described for zone 2. Also reconstruct the sheath. Full flexion of the digit to the distal palmar crease usually requires A5 pulley preservation or reconstruction. When the sheath is cut away, a sagging effect occurs as the tendon moves proximally into the sheath, blocking full motion. Advancement of the profundus tendon under the distal stump for a reinsertion into bone rather than a tendon repair is not recommended: the short-tether or quadriga effect may occur with this maneuver, with loss of full flexion of the adjacent digits (33). This technique can generally be used safely with the index finger because of its usual independence from the other profundi. Advancement still creates slack in the lumbrical, however, which may weaken or unbalance its action.

- If the distal stump is short, take the Tajima stitch proximally, then pass needles longitudinally through the stump, then adjacent to the sides of the distal phalanx or through drill holes (with a 0.045-in. pin) in the phalanx from palmar to dorsal, emerging proximal to the germinal matrix of the nail bed.
- Tie the sutures over a dorsal button.
- Place horizontal mattress sutures at the cut edge.
- We have used small (or mini) suture anchors for avulsions and short stumps in preference to dorsal buttons in the last 3 years; 2-0 suture is used. We have had satisfactory results, but the series is too small to advocate their use as yet.

## SPECIAL CIRCUMSTANCES

### *Partial Lacerations*

Three concerns exist with partial lacerations (Fig. 48.12):



***Figure 48.12.*** A 90% partial tendon laceration.

- The tendon may rupture if it is not repaired.
- The tendon will be weakened if sutures are placed in it.
- The unrepaired portion may not fully heal and cause triggering [catching on the edge of the fibrous sheath system (A1)].

Based on the available studies, lacerations of 25% or less of the tendon's cross-sectional area in zones 3 and 5 are best left unrepaired. Repair lacerations of 50% with horizontal mattress or locking-type stitches; lacerations of 75% or greater require full repair. In zone 4, tidy up lacerations of 25% with debridement. In zones 1 and 2, repair all partial lacerations; lacerations of 25% are repaired with simple sutures. Use the “frayed tendon” rehabilitation protocol postoperatively.

***Segmental Injuries***

If a tendon is cut in several locations, as in lawn-mower-type injuries, repair it similarly in each location. If a segment is missing, replace it with a segmental tendon graft (Fig. 48.13), using palmaris or a segment of flexor carpi radialis.

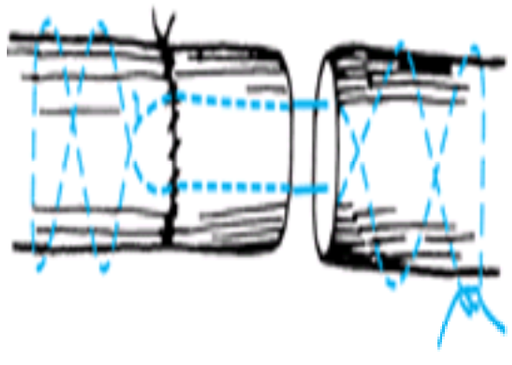

***Figure 48.13.*** An intercalary graft repaired with a modified Bunnell suture technique.

- Determine the length of graft needed by applying traction on the distal segment to place the digit in its normal stance position (Fig. 48.14). Then apply traction to the proximal end. Maximum traction determines the extent of the muscle's elasticity; no traction is the zero-tension position. Some 50% to 60% of the maximal elasticity is close to the resting tension of the muscle, which is the desired position.

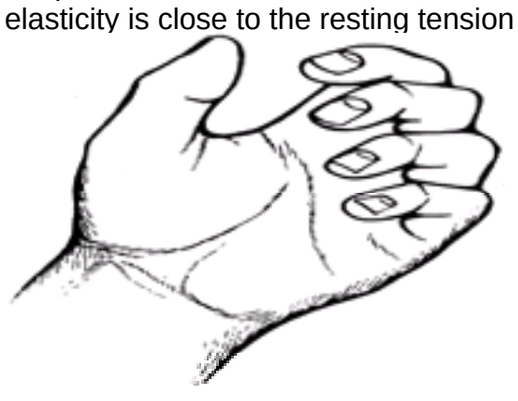

***Figure 48.14.*** The normal digital cascade or stance position.

- Take the amount of tendon graft and then a bit more, to achieve the normal stance position, suture it in tentatively, shorten it accordingly, and complete the suturing.
- This segmental interpositional graft technique, frequently used for extensor tendons, is most applicable in zone 5, is applicable with longer grafts in zone 4, and is possibly applicable in zone 3. In zones 1 and 2, grafting of the entire distal segment is more appropriate, as discussed below.

***Frayed Tendons***

Debridement and a special postoperative protocol may be adequate for the minimally frayed tendon that is for the most part intact. For severely “chewed-up” tendons, replacement is indicated. Use segmental grafts in zones 3, 4, and 5. In zones 1 and 2, if the tendon is badly damaged and hence irreparable but the bed is unharmed (not a common occurrence), perform a one-stage graft, either primarily or as a delayed procedure. Options are discussed in the section on grafting. If the bed and tendon are damaged, perform two-stage grafting. Placement of a tendon rod in the acute injury is questionable; we prefer to do this in the clean wound at 10 to 14 days.

***Muscle Damage***

If a profundus muscle is significantly damaged, perform tendon transfer using the long or ring superficialis. When a lone superficialis muscle is injured and is irreparable, we perform no reconstruction. For multiple or massive injuries of the flexor tendons, a transfer from the extensors may be indicated.

***Thumb Flexor Injuries***

Lacerations of the FPL may be repaired with direct suture, advancement, or grafting, depending on the zone and surgeon's preference (see Fig. 48.5) (31). Direct suture is used more often than not, but the usual independence of the muscle/tendon unit (it is occasionally associated with the profundus of the index) and the lack of lumbrical allow more repair options.

Urbaniak has shown that the FPL may be advanced to the bone insertion when the laceration has occurred within 1.2 cm from the insertion (31). Between the MP joint

and this point, he advocates advancement with equivalent Z-lengthening at the wrist, with and without reinforcing tendon grafting at the wrist (Fig. 48.15). Within the thenar zone, he prefers grafting. We have used these methods successfully but usually prefer direct suture methods (30). The technique and sheath repair methods are the same as in the digits. While access to the thenar zone is difficult, the injury that exposed and cut the tendon usually makes the access quite easy. If not, the pediatric feeding-tube method to retrieve the proximal end and grafting may be necessary. The carpal tunnel often must be opened to retrieve the proximal end of the flexor pollicis longus. Direct suture methods have been most successful in achieving full active motion, which is represented by full extension of the thumb into the plane of the digits and full flexion to the distal palmar crease of the little finger.

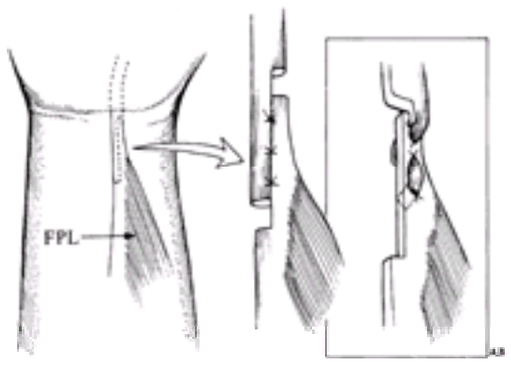


***Figure 48.15.*** Lengthening of the flexor pollicis longus at the wrist associated with distal advancement in thumb zone 2. Two methods of repair of the lengthening are depicted. (Modified from Urbaniak JR. Flexor Pollicis Longus Repair. *Hand Clin* 1985;1:73.)

## LATE RECONSTRUCTION

### ONE-STAGE TENDON GRAFTING

Although one-stage tendon grafting was once a common procedure, advocated for all injuries in zone 2, today it has only occasional indications (2,34). It is indicated when the damage to the tendons in zone 1 or 2 is irreparable but the tendon bed is uninjured or minimally injured (Fig. 48.16). Prerequisites include a soft, pliable hand and digit with full passive motion of the joints.

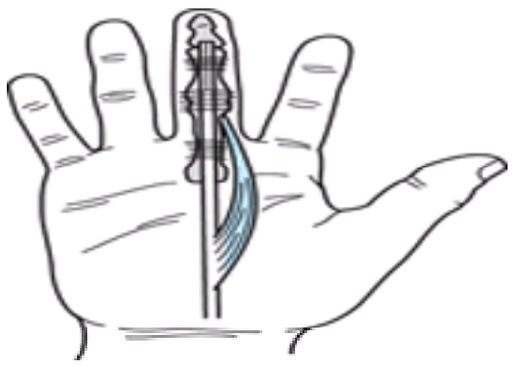

***Figure 48.16.*** One-stage tendon grafting from the palm. More extensive pulley preservation is more common than the minimal number depicted. These three (with the proximal one somewhat closer to the metacarpophalangeal joint) are the most critical.

- Expose from the profundus insertion to the palm, using a Bruner or midlateral incision, and extend into the palm as a zigzag or sequential transverse incision (Fig. 48.5B).
- Classically, the tendon sheath is partially excised, leaving only the three pulleys advocated by Bunnell. Today, however, most of the pulley and tendon sheath system is preserved, removing only enough to gain access to the remaining portions of tendon. Proximally, leave the profundus in the palm short enough so that it will not be drawn into the digital sheath when the digits are in full extension. Leave the lumbrical origin, along with an additional 1 to 2 cm.
- Distally, preserve a short stump of profundus. Leave the distal portion of the superficialis (the chiasm of Camper) and, if it is not already adhered, suture it to the sheath proximally as a tenodesis to prevent hyperextension of the PIP joint.
- The usual source of tendon graft is the palmaris longus. Take it through multiple transverse incisions in the forearm, starting just proximal to the distal palmar wrist crease, and remove it retrograde by passing a small hemostat from the proximal to the distal wound. Alternately, we use the short forearm Brand tendon stripper. Place it around the tendon distally and advance it into the forearm while tension is maintained with a hemostat on the distal divided tendon. The device then avulses the tendon at the musculotendinous junction. Whether to remove paratenon or not is a moot question. We remove all muscle and the bulk of the paratenon but do not compulsively remove all of it.
- Distally, just under the profundus stump and distal to the insertion of the palmar plate of the DIP joint, drill a hole with a $^{5}/_{64}$-in. bit just through the palmar cortex of the distal phalanx. This is distal to the epiphyseal plate in children.
- Make two drill holes with an 0.045-in. pin through the dorsal cortex on either side within the palmar cortical hole. Pull the tendon through the digit from the tip to the palm, after suturing it to either a reusable tendon rod or a pediatric feeding tube.
- Make a Bunnell-type weave through the end of the tendon with 3-0 polypropylene on milliner's needles (Fig. 48.17).

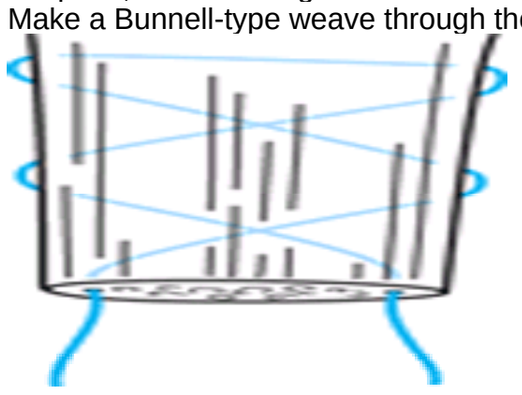

***Figure 48.17.*** The modified Bunnell suture, similar to that advocated by Kleinert.

- Pass the two needles through the bone and through dorsal skin proximal to the germinal matrix of the nail bed, through a rubber button pad (made from medicine-jar stoppers or the disposable irrigating syringe rubber bulb), and through the button. Pull the tendon end into the hole in the distal phalanx and tie the suture over the button (Fig. 48.18). When using a suture anchor, insert the anchor within the drill hole, to the side. Draw the tendon into the drill hole as described but secure it by the sutures from the suture anchor. Pull the polypropylene suture out distally.

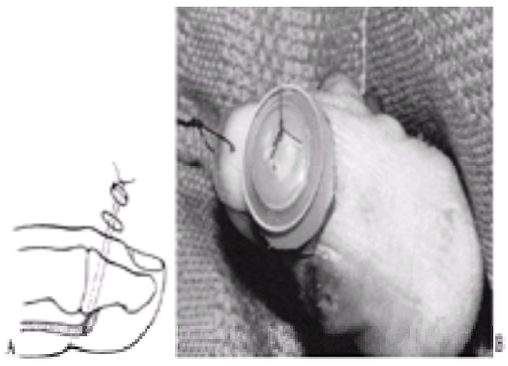

***Figure 48.18.*** The tendon graft is drawn into the palmar cortex with the suture tied over the dorsal button and button pad. Note that the button suture is placed proximal to the nail and germinal matrix. The graft is sutured to the profundus stump as well. **A:** Artist's drawing, lateral view. **B:** Clinical photograph of dorsal button. The suture has been placed through the nail for postoperative therapy.

- Suture the distal profundus stump down to the graft with two to four simple sutures using 4-0 braided polyester suture. Test the integrity of the button by gently attempting to lift it away from the skin, to ensure that the sutures to the profundus stump did not cut the polypropylene.
- Traction on the proximal tendon graft should flex the digit to the distal palmar crease. If bowstringing occurs, a pulley may need reconstruction. Then close the skin on the digit.
- Although each step is important, this next one is especially critical—setting the proper tension. Make a slit in the distal end of the profundus stump in preparation for a Pulvertaft interweave suture (Fig. 48.19). Pull the motor tendon distally to 60% of its maximum elasticity and pull the distal tendon graft through until the finger assumes a position slightly more flexed than its normal digital stance. Note that each finger, from radial to ulnar, is slightly more flexed (Fig. 48.14).

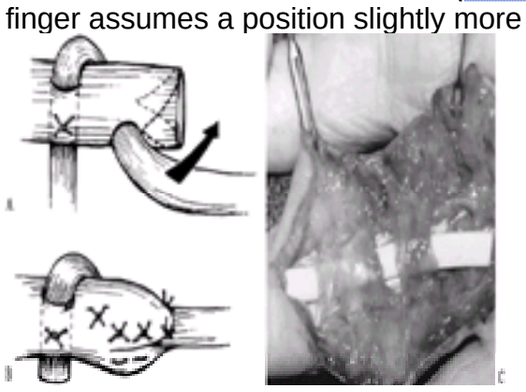

***Figure 48.19.*** The Pulvertaft proximal interweave. **A:** The initial pass of the graft through the motor tendon. **B:** The motor tendon end is split and sutured around the graft. Two additional passes are usually made through the motor tendon with the openings made 90° to each other. **C:** Clinical photograph of the proximal interweave. The motor end has not been sewn over. (Modified from Schneider LH, Hunter JM. Flexor Tendons—Late Reconstruction. In: Green DP, ed. *Operative Hand Surgery.* New York: Churchill-Livingstone, 1982;1387.)

- Using 4-0 braided polyester, suture the graft and motor tendon together with a simple or horizontal mattress suture. Then withdraw all support, place the wrist in neutral, and observe the stance of the digit. If it assumes the desired posture, a tenodesis effect is noted by flexing and extending the wrist. If the digit moves appropriately with the other fingers and returns to the proper position, the tension is correct; otherwise, tighten or loosen it.
- When properly adjusted, make two additional slits at 90° from each other and from the first slit and complete the weave and suturing. Fold the distal end of the stump around the graft (Fig. 48.19*B*). Making the slits can be facilitated with a “tendon-braiding” forceps. Otherwise, use a #11 blade or a #64 Beaver blade with a small hemostat placed through the slit to pull through the tendon. Some surgeons wrap the lumbrical muscle around this connection; we prefer not to disturb the lumbrical.
- Close the incisions in the palm. When the finger is sutured before the tension has been set, the zigzag wound is more easily closed, the corner stitches fit more readily, and you need not assume a contorted position to achieve closure.

Variations in method include other sources of tendon graft (the sagittal section of the FCR, the superficialis of the little finger, the proximal superficialis of the involved digit, and from the leg the plantaris or toe extensors). An interesting technique known as tenoplasty involves suturing the cut ends of the proximal profundus and superficialis together at the time of the initial injury (20). After a month, when this connection is healed, the proximal superficialis is divided in the wrist, drawn into the palm, threaded through the pulley system, and attached distally, thus requiring only one connection in the second stage. However, we prefer palmaris or plantaris as grafts because of their usual ease of harvesting and lack of bulk. When they are not present, the alternatives are considered.

Variations in distal insertions include suture to the profundus stump, through bone and back to tendon, and through bone onto nail or fingertip. When the tendon is brought through the tip of the finger, the tension may be readily set distally, with increased traction until the desired position is achieved. We prefer our method described above, which creates fewer problems with nail growth disturbance or irregularity in the digital pad contour.

**TWO-STAGE TENDON GRAFTING**

Two-stage tendon grafting is a salvage procedure based on the concept that the first stage reconstructs the bed and the pulley system, and the second replaces the tendon (11,25).

***Stage 1***

- Place a silicone tube (Carroll) (1) or a silicone or silicone-dacron rod (Hunter-Swanson or Hunter) (11), shaped like a tendon, into the digit, permitting a pseudosheath to form around the rod. Fix the rod distally and leave it unattached proximally, either at the palm or wrist level. We prefer the silicone-dacron Hunter rod and discuss this method below. The first stage of the procedure is usually performed under brachial plexus block anesthesia.
- Expose the digit through an extended Bruner incision from the profundus insertion to the palm and through a curvilinear incision in the wrist. The exposure in the hand is the same as in one-stage grafting.
- Preserve the distal profundus stump of about 1.5 cm as well as the tenodesis effect of the distal end of the superficialis. Preserve or rebuild the pulleys and carry exposure to the palm.
- Remove other residual bits of tendon by sharp excision with a Beaver blade (#64). Local scar tissue may be used to fashion a tunnel where the old pulley system was once located (Fig. 48.20). Preserve or create pulleys at the base of the proximal phalanx, over the PIP joint, and in the mid–middle phalanx.

***Figure 48.20.*** Clinical photograph of silicone-dacron tendon rod placed through original tendon sheath and pulley system. Tunneling is also done through healed scar.

- In the wrist, locate the profundus to the involved digit, leave it attached distally to the lumbrical to maintain its resting length, and tag it in the wrist with a colored

suture. The superficialis tendon is usually withdrawn into the wrist and excised; sagittal strips of it may be used for pulley reconstruction.

- Apply distal traction to the profundus at the wrist level to determine its elasticity, which should be equal to that of the uninvolved adjacent profundus tendons. If it has lost its elasticity because of severe myostatic contracture, the superficialis is left adhered in the palm, tested, and, if adequate, tagged as the future motor. If neither is adequate, choose and tag an adjacent superficialis.
- Select a tendon rod of appropriate width; usually a size 4 or 5 is correct for the digits, with the wider 5 needed for thumbs and the 3 for little fingers, smaller people, or children. The rod should fill the proposed sheath but move easily through it. It must also be large enough to create an adequate pseudosheath for the future tendon graft.
- Maintain the rod under saline or antibiotic solution in saline until usage to avoid lint accumulation. Handle primarily with smooth instruments or wet gloves. Pass the pointed end of the rod through the digital sheath from distal to proximal to the palm level. Then pass a long hemostat or Kelly clamp just palmar to the profundus and below the superficialis tendons (dorsal to them) through the carpal tunnel (usually on the proposed motor tendon) to the palm to the lumbrical level.
- Grasp the rod and draw it into the wrist. Distally, place the end of the rod snugly under the profundus stump and suture it securely with four simple or horizontal mattress stitches of braided polyester (Fig. 48.21). If a profundus stump is unavailable, alternatives include suture to periosteum or use of a special rod that has a screw attached that can be fixed to the distal phalanx.

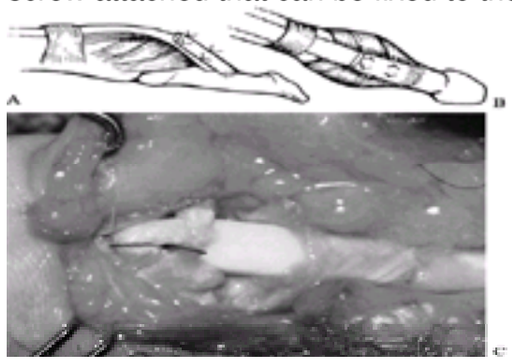

***Figure 48.21.*** The tendon rod is sutured under the old profundus stump. **A:** Lateral view. **B:** Anteroposterior view. **C:** Clinical photograph.

- With traction applied to the rod, the finger should flex to the distal palmar crease without bowstringing. Using a large hemostat, open the space palmar to the profundi at the distal forearm. The proximal end of the rod fits into this space (Fig. 48.22).

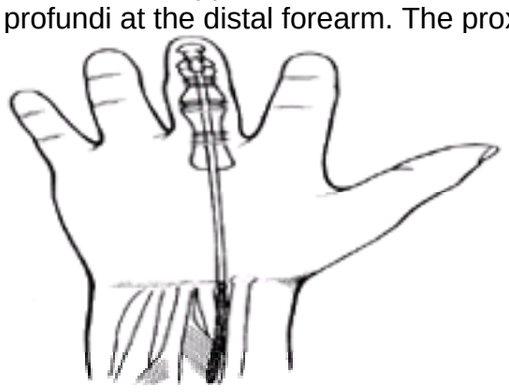

***Figure 48.22.*** Tendon rod in first stage of two-stage tendon grafting. The tendon rod is sewn under the profundus stump but lies free in the wrist, under the superficialis and on the profundi. The proximal pulley is drawn somewhat too distally.

- Test passive motion of the finger in full flexion and extension to determine if there is any buckling in the digit or the wrist. Extra length of rod in the wrist can be excised. In the palm, a bridge or pulley can be loosened to prevent buckling or a new pulley reconstructed. If buckling persists after skin closure, erosion of the rod through the skin can occur.

***Pulley Reconstruction***

Reconstruction is often required. It may also be needed during acute repair or one-stage grafting and in or after tenolysis. Our preferred technique is that described by Kleinert and attributed to Weilby (12). Other methods (for example, that of Lister) can also be used (14). Use the residual base of the annular ligaments and underlying periosteum, along with a long narrow strip of tendon. If superficialis is used, create a sagittal strip about one-eighth the width of the tendon, several inches long.

- Make a slit through the remnant of the annular ligament on either side of the rod using a #64 Beaver blade or a #11 blade, and place the tips of a cardiovascular hemostat through the slit to grasp the tendon. Draw the tendon over the rod and down through the opposite slit.
- Make several more pairs of slits distally. Criss-cross the tendon over the rod and through the slits, like a shoelace through eyelets.
- Finally, cinch the lacing (pulley) tight enough to eliminate bowstringing and yet loose enough to allow passage of the rod during passive range of motion.
- Pass the tendon ends through themselves or through proximal criss-crosses and suture them.

The technique is effective for immediate use without healing, owing to the friction of the interweave and passage through the slits (Fig. 48.23). A simple pulley reconstruction, particularly applicable to the A3 area, over the PIP joint, involves the use of one residual slip of superficialis left attached distally, with the proximal end woven through or sutured to the annular ligament remnant (Fig. 48.24).

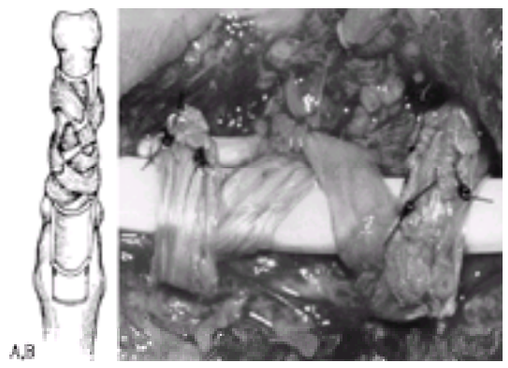

***Figure 48.23.*** Building the pulley using the remnant of the old annular ligament system and a strip of tendon; method described by Kleinert and attributed to Weilby. **A:** Artist's rendition. **B:** Clinical photograph of pulley built over a tendon rod.

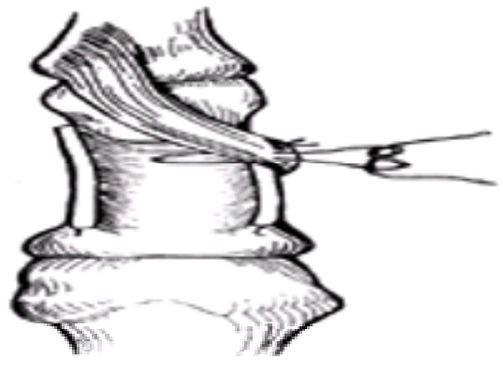

***Figure 48.24.*** Pulley built with remaining distal slip of superficialis, placed through and sutured to the remnant of the annular ligament. (Modified from Schneider LH, Hunter JM. Flexor Tendons—Late Reconstruction. In: Green DP, ed. *Operative Hand Surgery.* New York: Churchill-Livingstone, 1982;1425.)

### *Interval between Stages 1 and 2*

In the interval between stages, move the tendon rod back and forth with passive range of motion of the digit. This can be done with passive range using the opposite hand to move the digit through its range or by trapping the digit using adjacent fingers to draw it into flexion. The intact extensor mechanism extends the digit. If a capsulectomy or use of an artificial joint accompanied placement of the tendon rod, use dynamic splinting. This may include a low-profile extensor-assist splint alternating with flexor-assist rubber band or thread devices or individual spring-loaded assistive joint extensors, flexors, and adjustable static devices. The hand therapist plays a very significant role in helping the patient to achieve a maximum range at this point. The maximum attainable range, actively, after the second stage will be no more than that achieved passively at this time.

Leave the rod in place for about 2 months, possibly 3, to achieve a good pseudosheath, which is also soft, sheer, and flexible. Do not maintain the rod in place beyond this time as it may lead to a thicker, fibrous, less flexible pseudosheath with a poorer result.

Before proceeding with stage 2, take tendon rod films to be certain that the distal end of the rod is in place, buckling is absent, and the excursion of the rod is 1 cm or more. If these criteria are not met, stage 1 may need to be revised. It is not unheard of for the distal end of the rod to break loose and piston into the wrist (25). Obtain anteroposterior and lateral views of the hand and forearm (fingertips to midforearm) in full extension and full passive flexion of the involved digit. To determine excursion, measure the proximal tip of the rod from any fixed bony landmark. Assuming all is well, proceed to stage 2.

The most common problem in stage 1 is achieving good range of motion. This is essential, however, so do not proceed without it. Occasionally, an inflammatory reaction may occur because of the rod or lint, and so on. Prescribe rest, immobilization, and antibiotics and antiinflammatories for 10 to 14 days. If the problem resolves, resume therapy. If not, consider reexploration, rod removal, and debridement. If infection exists, use suction-irrigation and systemic antibiotics to clear the digit and attempt rerodding later. Most attempts at repeat tendon reconstruction are unsuccessful, however, and other approaches, such as fusions or amputation, may be indicated. If only inflammation occurs, it may be caused by lint contamination, and another attempt at rodding is warranted.

### *Stage 2*

The second stage of this procedure is relatively straightforward for the experienced surgeon. Add the free tendon graft, connecting it properly at either end. In fact, these steps are identical to those used in one-stage grafting. Unfortunately, there are pitfalls peculiar to this stage.

- Perform the procedure under general anesthesia with the arm and a leg prepped (usually the contralateral leg, so a second team can take the plantaris tendon graft unencumbered).
- Locate the plantaris with a short transverse incision made over the medial edge of the Achilles tendon, about four fingerbreadths above the tip of the medial malleolus. If you explore too distally, the tendon may have already fused with the Achilles tendon or it may be located behind it. It is generally absent or deficient about 14% of the time. Assuming it is present and not hypoplastic, make a second, more distal incision, divide the tendon, and withdraw it into the proximal wound.
- Split the fascia proximally and place the ring of a Brand tendon stripper over the tendon, which is grasped through the ring with a hemostat.
- With the leg straight and level (usually resting on two folded towels), advance the stripper slowly with a twisting motion of the fingertips while the tendon is held relatively taut. There is one interval, as the stripper passes between the gastrocnemius and the soleus, where progress is slow; be patient so that you do not prematurely cut the tendon.
- Advance the stripper to the musculotendinous junction, avulse the tendon, and deliver it. Debride muscle and paratenon, but do not remove paratenon compulsively.

If the plantaris is not present or adequate, we prefer to use a toe extensor. If one is grafting for a little finger, only to the superficialis insertion (see the discussion below on salvage), or to a thumb, a palmaris may be long enough. It is easy enough, in the absence of the plantaris, to take the palmaris, and measure it (on the surface) before proceeding with the toe extensor, which is more difficult to harvest and can result in more morbidity.

The advantage of the toe extensors is that they are always present and are long enough. The extensor brevis substitutes for the communis in the foot. The disadvantages are the interconnections between the tendons under the extensor retinaculum and proximally, which make it impossible to harvest a smooth, unblemished tendon, and it takes time to deliver the specimen.

- Begin with a transverse incision, just proximal to the level of the metatarsophalangeal joint over the prominent tendon. The fifth is not used, as there is no extensor brevis. We find that the third and fourth usually are easiest to harvest.
- Locate the extensor brevis tendon and suture it to the longus, which is then divided proximally. With traction on the cut end, identify the tendon proximally and make a second transverse incision.
- With the fascia divided, pass a hemostat distally over the exposed proximal tendon to the distal wound, where the cut end is grasped and the tendon delivered retrograde into the proximal wound. Continue proximally until an adequate length is obtained. The maneuver is easy distally, but proximally the tendon must be separated from its mates. This is done partly by peeling the tendon from the others and partly by cutting with a scissors. Closer-interval incisions proximally will facilitate this activity.
- Apply a bulky elastic dressing to the leg and foot for about 2 weeks.
- On the upper extremity, open the curvilinear incision on the wrist, exposing the tagged motor tendon and the proximal end of the rod. Again test the motor for elasticity; another motor can still be used.
- Remove the pseudosheath from the end of the rod and expose the incision over the distal end of the rod. We prefer to open the old zigzag, as a midlateral in a scarred finger at this point is more likely to injure digital nerve branches. Note the sutures taken through the profundus stump; locate the proximal extent of the stump and carefully lift the stump away from the underlying rod as the sutures are cut. Do not damage the pseudosheath under the rod or the palmar plate.
- A difference in the shade of the white palmar plate and the more opalescent pseudosheath distally over the bone should be apparent. Take the pseudosheath just distal to the plate off the bone with a #64 Beaver blade and drill a hole with a $^{5}/_{64}$-in. bit through the palmar cortex (as with the one-stage graft). Make two more holes on either side with 0.045-in. pins, from inside the hole through the dorsal cortex, to emerge proximal to the nail and the germinal matrix.
- Suture the tendon graft to the rod proximally and pull it through the pseudosheath (Fig. 48.25). If the tendon pulls free, simply reinsert the rod through the pseudosheath.




***Figure 48.25.*** Stage-2 tendon grafting. The tendon graft is attached to the rod, which is then drawn out of the hand distally, pulling the tendon through the pseudosheath. **A:** Clinical photograph of tendon graft sutured to the rod. **B:** Illustration of graft about to be drawn into the hand.

- Place a hemostat on the proximal tendon and place a weave stitch (usually a Bunnell type) through the distal end with 3-0 polypropylene on milliner's needles, which are then placed through the drill holes to be tied over the dorsal button and button pad (Fig. 48.18). Draw the tendon snugly into the bone before tying the suture.
- Secure the graft to the residual profundus stump with safety stitches of 4-0 braided polyester suture. With traction on the proximal tendon, the digit should fully flex or do so to the extent achieved with passive motion.

- Release the motor tendon from its distal attachment at the wrist crease level.
- Close the incision on the digit and attach the graft to the motor tendon at the proper tension, using the Pulvertaft interweave stitch (see one-stage graft technique above). Again, this is achieved by making a slit in the motor tendon, which has been pulled up to 60% of its elastic length, and pulling the graft through until the digit assumes a position of flexion slightly greater than the normal stance position relative to the other digits.
- After the first trial stitch, test the position with the tenodesis maneuver, flexing and extending the wrist. If the digit moves with the other fingers and then, with the wrist in neutral, achieves the proper digital stance, make two additional slits in the motor tendon and complete the interweave.
- Rehabilitation is described below. Immobilize in a bulky dressing with the wrist flexed 30°, the MP joints in 75° to 90° of flexion, and the interphalangeals toward extension (the intrinsic-plus position). Apply the bulky dressing with a posterior plaster splint above the elbow initially, to enforce elevation.

### TENDON GRAFTING FOR THE FDP WITH AN INTACT FDS

Ideally, of course, if a profundus is lacerated and the superficialis is intact, the cut tendon is repaired. If, however, the injury is unrecognized or the repair has ruptured, the surgeon may be faced with a finger that functions well with full mobility at the MP and PIP joints, but the tip of which is flail. The dilemma is whether to maintain this full functional PIP motion, sacrificing DIP motion, stabilizing the tip in some way, or to risk the excellent motion; that is, compromise the superficialis' full function for the sake of some DIP control. Nongrafting measures are tenodesis or arthrodesis of the DIP joint.

#### HINTS AND TRICKS

- The potential problems with this stage of the procedure include detachment of the graft proximally or distally or both, rupture of the graft, adherence of the graft to the sheath, and a flexion contracture of the DIP joint.
- To avoid rupture of the graft or pulling out of the suture distally, take an adequate graft; do not accept a graft of too-small diameter or one with iatrogenic defects. If the graft is damaged or hypoplastic, take the time to harvest the toe extensor. It is not worth the grief that results if this point is not heeded.
- To confirm the integrity of the distal polypropylene suture, test that the safety stitches have not cut it by gently lifting the button, making sure it is springy, and applying traction to the proximal tendon. Starting the polypropylene weave distally no more than 1.0 to 1.5 cm from the end of the graft is usually safe. The proximal attachment is usually safe with a three-slit interweave. Adhesion in the sheath should not be a problem if the motor muscle–tendon unit is elastic and has good excursion, the pseudosheath is not thick and fibrous, and rehabilitation is appropriate. If the proximal attachment is in the forearm and not the carpal tunnel, the adhesions at this site can be worked out with activity.
- A flexion contracture at the DIP joint remains an enigma. Avoiding iatrogenic damage to the palmar plate and attending to the problem with therapy are obvious. Pseudosheath contracture may be a factor. Two additional controllable factors may be preserving the A5 pulley and placing the tendon insertion just distal to the palmar plate, not further distal on the distal phalanx.
- With attention to all these factors, flexion contracture still occurs in some patients, and although the digit is functional, its appearance is compromised. An arthrodesis of the DIP joint is the solution in severe cases

The goal is to prevent giving way or hyperextension of the DIP joint during pinch or grasp. In some cases, a tenodesis may already exist from adherence of the distal profundus across the DIP joint. It may be accomplished surgically by suturing the profundus stump down to the sheath, residual annular ligament, and periosteum. Pin the joint for 1 month and then mobilize. The position of immobilization is in 5° to 10° of flexion for the digits and in 0° or neutral for the interphalangeal joint of the thumb. Theoretically, the digital interphalangeal joints should be increasingly flexed across the hand from radial to ulnar, allowing grip to the distal palmar crease. In reality, this is unnecessary for strength if the joint is stable. A flexed or a hooked finger is undesirable functionally and cosmetically.

Our problem with tenodesis is the stretching out of some and the further contraction of others. With these problems in mind, we prefer arthrodesis, which can be done in a variety of ways.

Tendon grafting is probably most indicated in the small digit, where the superficialis is often smaller than normal and may be deficient. It may also rupture if sufficient stress is placed on it (we once observed a rupture 30 years after the profundus injury). Otherwise, the decision to graft is made after considerable discussion with the patient concerning the potential benefits and risks. Grafting is most applicable in young patients. If the digit is mobile, a one-stage graft is a consideration. A two-stage procedure is more risky for the superficialis, but it is indicated if there is distal bed damage. Goldner has recommended that neither the graft nor the rod should be placed through the split in the superficialis but rather placed alongside in the sheath (9). Of course, the sheath may have contracted around a single tendon if the profundus has retracted significantly. It is reasonable to suggest to the patient that you will attempt to graft, but if the attempt appears more formidable once the finger is explored, then distal stabilization will be done instead.

### OPTIONS FOR THE THUMB

When the FPL injury is irreparable, unrecognized, or ruptured, options of one- or two-stage grafting may also be considered. If the muscle has lost its elasticity, a tendon transfer may also be performed, either as one stage, if the bed and pulley system are good, or two stages, through a pseudosheath. The usual motor is the superficialis to the ring finger, although the long finger tendon is equally acceptable. If two stages are planned, a large rod, either size 5 or 6, is needed and should be matched for size with the potential motor in the first stage. No graft supplement is needed, as the tendon reaches the distal phalanx easily. Also, with the flexor pollicis brevis, and the adductor and abductor pollicis all acting to flex the MP joint, arthrodesis of the interphalangeal joint can be considered. The strength and normal function of the thumb are significantly aided by a functioning FPL. The function of the intrinsics is not at significant risk with grafting or transfer as with an intact superficialis to a digit, so that interphalangeal fusion of the thumbs is far less indicated. It is, however, an option, particularly when there are multiple injuries and transfers and grafts are more important elsewhere.

## TENOLYSIS

Tenolysis is indicated when active motion fails to equal the passive range and it is determined that this is caused by tendon adhesion or block. The extent of full motion required for functional status depends on the patient's actual requirements and wishes and a realistic expectation of the results of surgery. A thumb, for example, that can pinch well to all the digits, particularly to the index and long fingers but does not flex to the distal palmar crease proximal to the little finger is not disabled by most criteria. However, a digit that does not flex to the palm and defunctionalizes all the others as well (quadriga) is very disabling. The musician, specifically a string player such as a violinist or cellist, may be significantly more disabled than a keyboard player with the same loss of range. Therefore, the decision to perform a tenolysis must be individualized.

Timing is also important. It takes time to maximally mobilize a digit and for the tendon to be revascularized. Two complications of tenolysis are failure to maintain gliding and rupture of the repair. Premature tenolysis may well be the cause of the latter. At least 4 months should elapse after repair before tenolysis to allow adequate revascularization of the tendon so that it can tolerate the procedure. The contraindication to tenolysis—too-extensive adhesions—is discussed below.

Tenolysis is a potentially formidable procedure. The results are directly proportional to the extent of the adhesions. If there is a small “spot weld,” subsequent full function (to the extent of the passive motion) may be anticipated. If the adhesions are extensive and there will be multiple healing or raw areas, the likelihood of success is nil. The amount of the initial trauma, particularly the number of tissues injured (bone, sheath, tendon, vessels, etc.) and the extent proximally and distally of damaged structures, determines the density of the adhesions in many cases. However, a simple tendon laceration, with or without infection, may result in multiple adhesions for a considerable distance.

Our approach is to tenolyze if the adhesions are limited or if there is a history of infection and to use two-stage tendon grafting (rod insertion) if the adhesions are extensive from trauma.

Many surgeons perform tenolysis under local anesthesia, preferring the patient to begin active mobilization immediately. We prefer to do the procedure under regional block. Therapy may be initiated with the block still in effect, and continuous passive motion seems to be helpful, particularly in controlling discomfort. Continuous passive motion is especially indicated if capsulectomy is also performed. Leaving an indwelling catheter in the palm around the digital nerves, or around the median or ulnar nerve (if this is adequate), for the injection of a long-acting anesthetic is a valuable adjunct postoperatively.

The surgical technique consists of sharply releasing the adherent scar through generous incisions, as needed. The more incisions needed, the more postoperative scarring, of course. If pulleys need to be removed, they must be rebuilt. Usually tenolysis is first performed, the digit rehabilitated, and then the pulley rebuilt to eliminate the unsightly, uncomfortable bowstringing in a later operation. Using the surgical technique described earlier for constructing pulleys, immediate construction can be undertaken.

- Investigate the site of the initial trauma or surgery, extending in either direction to open the sheath and determine whether the tendon is free. Remove adherent sheath, using a Beaver knife blade and Penfield elevators (usually #4) for the dissection.

- If the release seems sufficient, particularly if the digit only is involved, make an additional incision in the palm at the lumbrical level and apply traction to pull the tendons proximally. If motion is full with each tendon, apply traction distally to ensure the tendons glide well through the carpal tunnel.
- At the completion of the procedure, place an indwelling catheter in the hand or wrist for postoperative local anesthesia.

## POSTOPERATIVE CARE

Obstacles to successful rehabilitation following flexor tendon repair include the potential for rupture, adherence of the tendon to surrounding tissues, and joint contractures. Philosophies of postoperative management vary along a continuum from 3 to 4 weeks of complete immobilization, with the intent of minimizing the risk of rupture, to very early protected active mobilization, with emphasis on minimizing tendon adherence and joint contracture. Although controlled clinical studies are few, recent research definitely lends support to the concept of at least early passive mobilization (Fig. 48.26) (7,8,16).

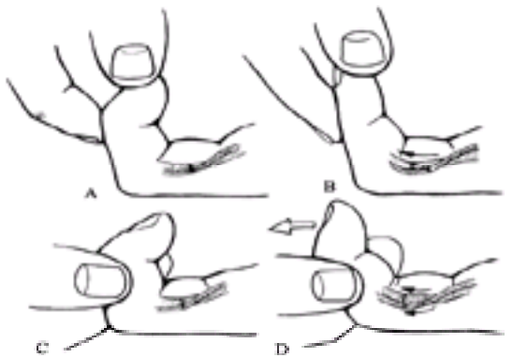


***Figure 48.26.*** Postoperative passive motion regimen described by Duran. **A,B:** With the proximal interphalangeal joint maintained in a flexed position, the distal interphalangeal joint is flexed and fully extended. **C,D:** With the distal interphalangeal joint maintained in flexed position, the proximal interphalangeal joint is carefully exercised. Both activities create gentle passive motion of tendons, promoting both strong healing and gliding.

Many variables must be considered in determining the best method of management for each patient. The degree of trauma and surgical technique will influence the strength of the repair and the degree of scarring. The experience and skill of the therapist are critical factors in the delicate balance between protection and mobilization during the early postoperative weeks. Consider the patient's behavior, attitude, and intelligence in terms of his or her ability to comprehend and implement instructions, degree of motivation, reliability, and availability for follow-up. Currently we use an early protected motion program.

### PRIMARY REPAIRS

Although the potential for dense tendon adherence is greater in zones 2 and 4, where there is less yielding adjacent tissue and more confined space, early protected motion management is used for all zones.

#### *Day 1*

Using a bulky dressing, position the wrist at 30° flexion and the MP joints in 70° to 90° flexion. Allow full active interphalangeal extension. Elevate the extremity to control edema.

Attach elastic traction to a nail suture inserted at the time of surgery and proximally about 8 cm proximal to the palmar wrist crease. Tension should be adjusted to maintain the involved digits in a flexed position at rest yet allow full active interphalangeal extension (Fig. 48.27).

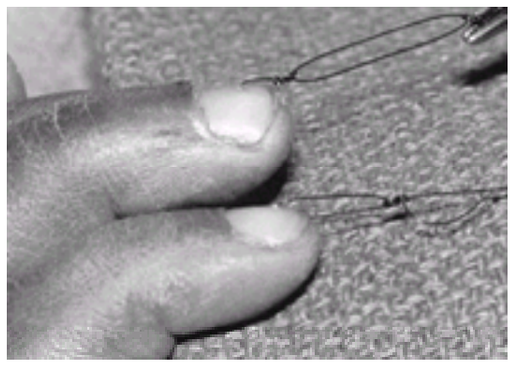

***Figure 48.27.*** Suture loops through nails for postoperative controlled passive motion method of Kleinert.

Instruct the patient to actively extend the interphalangeal joint fully 5 to 10 times every hour. If extension is difficult or painful, the patient may need to pull the traction distally with the other hand while extending to facilitate full active extension, then release slowly to return the finger passively to the flexed position.

**Problems and Variations** Among the problems that may occur are:

- No nail suture or loss of nail suture.
- Pain or apprehension limiting full, active interphalangeal extension.
- Inadequate fit of bulky dressing, allowing some MP extension as the patient attempts to extend the interphalangeals.
- Swelling, relieved by elevation and use of a compression wrap.
- Interphalangeal flexion contractures.

#### *Days 3 to 7*

Remove the bulky dressing and redress the hand in a light dressing. Place it in a thermoplastic splint with dorsal extension to the fingertips and joint positions maintained. Add a palmar piece to contour the palmar arch, ensuring stable positioning of the dorsum of the hand in the splint. Otherwise, the splint may tend to slip, and as the patient extends the interphalangeal joints, the dorsum of the hand may pull away from the splint, resulting in MP extension rather than full interphalangeal extension. Use Velfoam straps (2-inch) to the forearm and wrist, with a 1-inch strap across the palmar piece if necessary. Attach a pulley to the palmar piece. Attach nylon cord to the nail suture, run it through the pulley, and attach it to elastic traction. Attach the elastic to a safety pin on the proximal splint strap. The nylon should be just long enough so that the elastic does not catch on the pulley during active extension (Fig. 48.28).

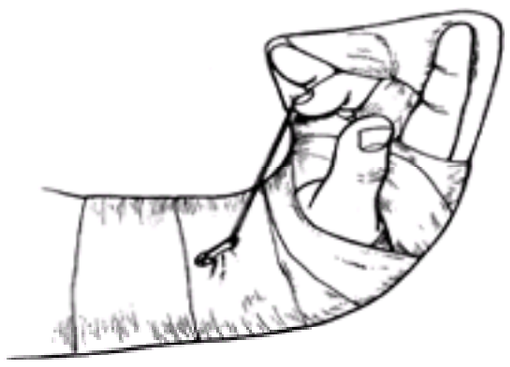

***Figure 48.28.*** Postoperative controlled passive motion thermoplastic splint with elastic traction. The splint maintains the metacarpophalangeal joint in flexion while allowing full extension of proximal interphalangeals against the elastic band.

Continue elevation of the hand as well as compression wraps for the hand and digits if necessary to control edema. Continue the same exercises, with emphasis on full interphalangeal extension. Manage early flexion contractures with careful, gentle assistive extension of the involved joint with the proximal and distal joints flexed. See the patient twice a week if possible to ensure maintenance of positioning and good progress. This stage may be delayed at the discretion of the surgeon if there is excessive trauma or a tenuous repair.

***Three Weeks***

At 3 weeks, change the wrist splint position to neutral. Continue traction and the exercise program, adding an active flexion hold after the digit is passively flexed fully five times per hour. This step requires maximum tendon excursion without maximum tensile loading that results with active flexion from the fully extended position.

**Problems and Variations** If impending flexion contractures of the interphalangeal joints are noted, discontinue elastic traction at night and use a static extension strap to the dorsal extension of the splint, extending the PIP only. A static aluminum splint may be used for the PIP or DIP, but it must be directed to one joint only to avoid tendon tension.

If soft-tissue contracture appears likely at the MP because of the level of injury, maintain the wrist at 30° flexion and increase MP extension to 40° to 45°.

Instruct the rehabilitation staff to discuss program changes with the surgeon if any question exists about the status of the patient. Very free joint mobility and tendon excursion may indicate minimal scarring, but the tendon may be more vulnerable to rupture.

***Five Weeks***

Discontinue the splint but continue traction to a wrist cuff. Allow full active wrist and digit motion, but with protection from full tendon tension because of a tenodesis effect. Begin joint blocking with the wrist and MP joints in neutral, along with full active flexion from the extended position, 10 times per hour. Dynamic flexion splinting can be added if necessary. Static individual joint extension splinting with the adjacent joints neutral or flexed may be indicated by lack of progress with active and assistive exercise alone.

**Problems and Variations** If wrist extension is limited significantly, or in the presence of MP or interphalangeal flexion contractures, continue neutral wrist splinting without traction. Remove the splint for exercise.

***Six Weeks***

Discontinue traction and continue exercise as at 5 weeks, but the wrist and digits may be extended simultaneously. Add individual dynamic joint extension splinting, if indicated, with the wrist neutral.

***Eight to 12 Weeks***

Full dynamic extension splinting may be added at 8 weeks if necessary. Add graded resistive exercise and activity at 10 weeks. By 12 weeks the patient may return to full activity.

***Care of the Thumb***

Postoperative management of primary flexor tendon repairs of the thumb is similar to that of the fingers, with the following exceptions:

- The wrist is flexed 30° to 35°.
- The thumb carpometacarpal joint is held in palmar abduction.
- The MP joint is in flexion, with elastic traction attached to the nail via a nylon cord run through the same type of palmar pulley as described for the fingers.

When full active flexion is initiated, in addition to joint blocking and opposition exercises, full tendon excursion is encouraged by full active extension of the carpometacarpal, MP, and interphalangeal, followed by flexion of the thumb toward the base of the little finger.

***Precautionsy***

Caution the patient during the first five postoperative weeks against attempted use of the uninvolved digits, as contraction of the FDS and FDP, particularly against resistance, may stress the repaired tendon. Close follow-up is essential for success. If positioning is lost, exercise techniques are incorrect, or adjustments are not made for impending contractures, the results will not be optimal.

**TENOLYSIS**

Postoperatively the primary goal is to maintain the degree of excursion of the lysed tendon achieved at surgery. Consider carefully all factors pertaining to each patient's clinical situation, including the patient's history, previous surgery, and preoperative status, the condition of the tendon, and the status of the pulley system. Excessive edema or pain, diminished vascularity from previous injury or surgery, previous infections, and poor tendon quality and pulley reconstruction are all factors that may require modification of postoperative care to achieve the maximum potential without complications.

***Twelve to 24 Hours***

Remove the bulky dressing and redress the wrist with Xeroform (Sherwood Medical, St. Louis, MO) and 4-inch stretch gauze bandages, using sterile technique. For pain control use TENS or an indwelling catheter with a 0.5% bupivacaine (Marcaine) injection before therapy. Control edema with elevation and a compression wrap if necessary.

With the wrist in neutral, perform joint blocking to isolate the flexor digitorum profundus and flexor digitorum superficialis 10 times each hour. Also with the wrist neutral, passively flex the involved digits, then ask the patient to actively maintain the position. Remove the passive force while the patient continues to hold. This is followed with active extension, and the patient repeats the exercise 10 times hourly. This requires maximum flexor and extensor excursion while reducing tensile loading of the lysed tendon.

See the patient three to five times per week to encourage exercise despite pain, with the goal of an active range of motion that is equal to the passive range. Achieving this goal within the first 2 weeks is critical. Measure joint range of motion, total active range of motion, and total passive motion twice weekly to monitor progress

objectively.

Splinting at night and between exercise sessions varies, depending on the tendency toward joint stiffness or the difficulty the patient has in initiating motion from either a flexed or extended position. Dynamic or static flexion is indicated if there is difficulty regaining preoperative passive flexion, or if active flexion is difficult and active extension is easily achieved. Gentle static individual joint extension splinting is helpful in the presence of impending flexion contractures. Discomfort may be minimized by using a static wrist support in neutral position. Delay full dynamic extension splints that fully stress the lysed tendon until 2 to 6 weeks, depending on tendon status.

#### *Two Weeks*

Remove sutures and begin skin debridement and lubrication and scar-remodeling techniques. Scar massage and elastomer molds help soften and flatten dense elevated or adherent scars. Continue to emphasize exercise, adding joint blocking and full flexion and extension of the digits with the wrist in a dorsiflexed position.

#### *Six to 12 Weeks*

Begin graded resistive exercise at 6 weeks. By 8 to 12 weeks the patient may return to full activity, including heavy work.

If the tendon is of poor quality after tenolysis, additional protection may be required. Fit the patient with a dorsal protective splint, maintaining the wrist and MP joints in flexion to protect the lysed tendon. Elastic traction, as described, with primary tendon repairs may be applied until 4 weeks postoperatively. Limit active exercise to passively flexing the involved digits; then ask the patient to actively maintain the position while the passive force is removed. This may be followed with full active extension within the protection of the splint, and will achieve the goal of maximum flexor excursion while reducing the potential risk of rupture.

Continuous passive motion devices and protocols, noted earlier, remain investigational. Their use following tenolysis, particularly when capsulectomy was also required, appears beneficial, but active motion with proximal blocking is also necessary, as with the standard technique.

### STAGED FLEXOR TENDON RECONSTRUCTION

#### *Postoperative Goals*

The goal in stage 1 is to maximize joint mobility and soft-tissue pliability during new sheath formation around the implant. In stage 2, the goal is to restore passive mobility and achieve a gliding graft within the pseudosheath for optimum active mobility.

#### *Precautions*

**Stage 1** Synovitis may occur, usually within 6 weeks postoperatively, as a result of implant surface contaminants, buckling of the implant, or overzealous therapy. This can usually be avoided with careful handling of the implant, appropriate pulley reconstruction at surgery, and careful postoperative management. Synovitis is characterized by discomfort in the operated digit and swelling with no signs of systemic illness. It is treated with immediate rest and immobilization. Concurrent procedures such as capsulectomy require specific management, but in harmony with the overall plan. Immediate postoperative dynamic splinting may be indicated if capsulectomies have been performed.

**Stage 2** Complications include adhesions along the graft or at the proximal attachment and rupture of the graft. If it is apparent that adhesions are limiting motion during the first 5 weeks after the second stage (as indicated by the absence of gradual improvement of active motion in the protected position at serial evaluations), earlier active motion and less protective splinting may be indicated.

Absence of a nail suture following stage 2 may be dealt with by gluing hook velcro or a dress hook to a nail or by constructing a moleskin sling 3 in. long and ½ in. wide with an eyelet midway. Apply tincture of benzoin to the lateral aspects of the finger to facilitate adherence and attach the two ends of the sling to the dorsolateral aspect of the distal phalanx. This is then attached to rubber-band traction.

**Either Stage** Pulley reconstruction may be a problem. Because stage 1 involved a passive gliding implant, there is no tension on the reconstructed pulleys. Pulley reconstruction at the time of tendon grafting may require protection of the pulleys for 6 weeks postoperatively, with either ½-in. paper tape or Orthoplast rings over the reconstructed pulley.

**Flexor Digitorum Superficialis Finger** Therapy is directed to the PIP joint with appropriate protection of the DIP, which will have been either tenodesed or fused.

*Stage 1 Postoperative Management*

**One to 2 Weeks** Remove the bulky dressing and redress with Xeroform and Kling bandages, using sterile technique. Splint the wrist in neutral if needed for comfort at night and between exercises. Control edema. Initiate active and assistive range-of-motion exercises for the uninvolved joints. Begin passive range of motion for individual involved joints and total flexion and extension with the wrist in neutral. Use buddy taping as well as static splinting for joint contractures.

**Two to 6 Weeks** Remove the protective splint and sutures. Soft-tissue management includes debridement, lubrication, and scar-remodeling techniques. Begin more aggressive range of motion and trapping and add dynamic or static splinting for joint or soft-tissue contractures. By 8 weeks the implant should glide without complication. Continue passive mobility techniques as indicated. The patient may return to work until stage 2 if the wrist is doing well.

*Stage 2 Postoperative Management*

Options include immobilization for 3 to 4 weeks, followed by protected active and passive flexion and extension until 6 weeks. Allow dynamic extension at 6 to 8 weeks and resistive exercise at 8 to 12 weeks. Early controlled passive motion can be initiated, as for primary flexor tendon repair.

## PITFALLS AND COMPLICATIONS

Muscle–tendon units exist to move joints through their full range of motion. If, after injury and repair or reconstruction, this basic function is not restored, the source of the problem must be determined. Simply put, the muscle must function, the motor–tendon unit must be intact, and the tendon must glide. At times, loss of the normal mechanical advantage is a potential problem, as in the rheumatoid with extensor tendon subluxation, or a pulley may be lost, lessening the effective motion.

Certainly, loss of muscle function may occur from denervation at the time of injury or from loss of vascularity leading to fibrosis and ischemic contracture. Myostatic contracture and atrophy of disuse may also occur. Surface palpation of muscle contracture, elasticity of the muscle–tendon unit, and electrical studies (EMG) will help in these determinations.

In most cases, however, failure of functional gliding results from adhesion formation, disruption of the repair, or both. The intact gliding tendon can be demonstrated with the tenodesis effect (flexing and extending the wrist, which produces the reciprocal motion in the digits) or with the forearm squeeze test to demonstrate digital flexion.

Dehiscence of the repair can occur when excessive muscle contraction is allowed during emergence from anesthesia or early in the postoperative course. All methods of postoperative rehabilitation attempt to avoid this. Even if the suture slips only a little, the resultant gap in a repair may result in flexor lag (the muscle contraction is used up before full motion is achieved, and active motion does not equal passive) and in excessive adhesion formation. This situation may be suspected if the resting posture or stance position of the digit is more extended than appropriate (Fig. 48.29). A complete rupture may actually be in continuity with pseudotendon in the gap. Some active motion is seen, fooling the surgeon into thinking that the problem is adhesion. At reexploration, an intact, even gliding tendon can be seen. It is easy to fail to note the opalescent appearance of the interposing pseudotendon and to appreciate that the extended position of the digit represents an old partial rupture with gap formation. In one-stage tendon grafting, gapping distal to the lumbrical leads to an overly long distal tendon, overpull of the lumbrical, and the “lumbrical syndrome” finger. In the latter, as the digit is flexed at the MP joints, the interphalangeals extend.

***Figure 48.29.*** Loss of normal digital stance (little finger) with a tendon repair rupture. Some active motion remained, but the repair was clearly attenuated.

Treatment of the ruptured repair or graft depends on how rapidly the problem is detected. With a repair, if the rupture is quickly detected, it is entirely appropriate to reenter the digit and redo the repair. The same is true for the graft. Late recognition of the ruptured tendon repair usually requires a graft, often with two stages, as scarring may be extensive.

The tendon graft may rupture in midsubstance or pull loose at either end. Proximal disruptions with the interweave are relatively rare, and midsubstance ruptures (discussed under the section on two-stage grafting) are often predictable, although uncommon. Pulling out of the insertion is the usual problem. Reinsertion is difficult, as there is no extra tendon to work with. If the pulley-sheath system can be easily reopened or was never closed (as demonstrated by passing a tendon rod), immediately repeat the second stage with a new graft. A transfer motor or an entire transfer unit of a superficialis for the thumb or little finger may now be appropriate. If the sheath cannot be readily opened, return to the beginning of stage 1. On one occasion, after a patient had suffered two successive distal pullouts, a new insertion technique was devised by drilling transversely across the distal phalanx and inserting the tendon through the bone before suturing it back to itself. This was successful but is not routinely needed.

Adherence of the tendon is determined by a gliding tendon with insufficient active excursion. This problem was discussed under tenolysis and two-stage grafting. It may be associated with partial rupture, as noted. Adherence of a tendon graft, particularly in two-stage grafting, seems to be more likely with thickened fibrous pseudosheaths after prolonging stage 1 but may occur related to inflammation or infection. Tenolysis of grafts, especially two-stage ones, has not provided good results for us. Redoing the entire two-stage procedure may be worth a try. Grafting only to the superficialis insertion (crossing two digital joints rather than three) has been a salvage maneuver used by Hunter and Schneider and by us and has been successful in such two-stage failures. Apparently, the lesser demands of moving only the PIP joint makes rehabilitation easier and improves the result in these cases.

An interesting additional complication of tendon repair in zone 2, observed by us and explained by Gilbert, involved trapping of the profundus dynamically in the superficialis division. When the patient slowly flexed his digit, he could do so to the distal palmar crease. When he attempted full flexion rapidly, the profundus was trapped, and the digit fully flexed at the PIP with the DIP extended. Removing one slip of the superficialis solved the problem.

The lumbrical syndrome, secondary to laxity of the one-stage graft or increased lumbrical activity with distal tendon adherence, is resolved by excision of the lumbrical or more simply by a Littler intrinsic release (removing the triangular area of the radial shroud ligament where the condensation of the oblique fibers meets the main portion of the extensor mechanism on the dorsoradial aspect of the digit) (21). This simple maneuver can be done under local anesthesia. If it does not resolve the problem, more anesthesia may be given if needed and tenolysis undertaken.

Infection is truly the most unsolvable complication of tendon surgery. The infection may be cleared, but reconstructive potential is extremely limited because after infection, scarring is extensive. A tendon rod (two-stage reconstruction) is needed but is contraindicated. Reflaring of the infection is all too common. Options include tenolysis (we will extend the tolerable limits of the procedure in this circumstance); one- and two-stage grafting; joint (PIP and DIP) arthrodesis in functional positions; and amputation. The sequence of attempted reconstructions is in the order cited.

## CHAPTER REFERENCES

Each reference is categorized according to the following scheme: *, classic article; #, review article; !, basic research article; and +, clinical results/outcome study.


* 1. Bassett AL, Carroll RE. Formation of Tendon Sheath by Silicone Rod Implants. *J Bone Joint Surg* 1963;45-A:884.

# 2. Boyes JH. *Bunnell's Surgery of the Hand, 5th ed.* Philadelphia: JB Lippincott, 1970.

# 3. Brand PW. *Clinical Mechanics of the Hand.* St. Louis: CV Mosby, 1985.

* 4. Bruner JM. The Zigzag Volar-Digital Incision for Flexor Tendon Surgery. *Plast Reconstruct Surg* 1967;40:571.

# 5. Doyle JR, Blythe WF. *The Finger Flexor Tendon Sheath and Pulleys: Anatomy and Reconstruction. AAOS Symposium on Tendon Surgery in the Hand.* St. Louis: CV Mosby, 1975.

! 6. Doyle JR, Blythe WF. Anatomy of the Flexor Tendon Sheath and Pulleys of the Thumb. *J Hand Surg* 1977;2:149.

# 7. Duran RJ, Houser RG. *Controlled Passive Motion Following Flexor Tendon Repair in Zones 2 and 3. AAOS Symposium on Tendon Surgery in the Hand.* St. Louis: CV Mosby, 1975.

! 8. Gelberman RH, Woo SL-Y, Lothringer K, et al. Effects of Early Intermittent Passive Mobilization on Healing Canine Flexor Tendons. *J Hand Surg* 1982;7:170.

+ 9. Goldner JL, Coonrad RW. Tendon Grafting of the Flexor Profundus in the Presence of a Completely or Partially Intact Flexor Sublimus. *J Bone Joint Surg* 1969;51-A:527.

! 10. Howard RF, Ondrovic L, Greenwald DP. Biomechanical Analysis of Four-Strand Extensor tendon repair techniques. *J Hand Surg [Am]* 1997;22(5):838.

* 11. Hunter JM, Salisbury RE. Flexor Tendon Reconstruction in Severely Damaged Hands: A Two-Stage Procedure Using a Silicone Dacron Reinforced Gliding Prosthesis Prior to Tendon Grafting. *J Bone Joint Surg* 1971;53-A:829.

+ 12. Kleinert HE, Bennett JB. Digital Pulley Reconstruction Employing the Always Present Rim of the Previous Pulley. *J Hand Surg* 1978;3:297.

* 13. Kleinert HE, Kutz JE, Ashbell TS, Martinez E. Primary Repair of Lacerated Flexor Tendon in “No Man's Land.” *J Bone Joint Surg* 1967;49-A:577.

+ 14. Lister GD. Reconstruction of Pulleys Employing Extensor Retinaculum. *J Hand Surg* 1979;4:461.

+ 15. Lister GD. Incision and Closure of the Flexor Sheath During Primary Tendon Repair. *Hand* 1983;15:123.

+ 16. Lister GD, Kleinert HE, Kutz JE, Atasoy E. Primary Flexor Tendon Repair Followed by Immediate Controlled Mobilization. *J Hand Surg* 1977;2:441.

# 17. Manske PR, Gelberman RH, Lesker PA. Flexor Tendon Healing. *Hand Clin* 1985;1:25.

! 18. Manske PR, Gelberman RH, Vande Berg J, et al. Flexor Tendon Repair: Morphological Evidence of Intrinsic Healing *in Vitro. J Bone Joint Surg* 1984;66-A:385.

! 19. Manske PR, Lesker PA. Biochemical Evidence of Flexor Tendon Participation in the Repair Process—An *in Vitro* Study. *J Hand Surg* 1984;9-B:117.

+ 20. Paneva-Holevich E. Two-Stage Tenoplasty in Injury of Flexor Tendons of the Hand. *J Bone Joint Surg* 1969;51-A:21.

* 21. Parkes A. The “Lumbrical Plus” Finger. *J Bone Joint Surg* 1971;53-B:236.

* 22. Peacock EE. Fundamental Aspect of Wound Healing Relating to the Restoration of Gliding Function after Tendon Repair. *Surg Gynecol Obstet* 1964;119:241.

* 23. Potenza AD. Tendon Healing within the Flexor Digital Sheath in the Dog. *J Bone Joint Surg* 1962;44-A:49.

\+ 24. Savage R, Risitano G. Flexor Tendon Repair Using a “Six Strand” Method of Repair and Early Active Mobilisation. *J Hand Surg [Br]* 1989;14(4):396.

\# 25. Schneider LH. Staged Tendon Reconstruction. *Hand Clin* 1985;1:109.

\+ 26. Silva MJ, Hollstein SB, Fayazi AH, et al. The Effects of Multiple-Strand Suture Techniques on the Tensile Properties of Repair of the Flexor Digitorum Profundus Tendon to Bone. *J Bone Joint Surg [Am]* 1998;80:1507.

\+ 27. Singer G, Ebramzadeh E, Jones NF, Meals R. Use of the Taguchi Method for Biomechanical Comparison of Flexor-Tendon-Repair Techniques to Allow Immediate Active Flexion. A New Method of Analysis and Optimization of Technique to Improve the Quality of the Repair. *J Bone Joint Surg [Am]* 1998;80:1498.

! 28. Strauch B, deMoura W. Digital Flexor Tendon Sheath: An Anatomic Study. *J Hand Surg* 1985;10-A:785.

! 29. Thurman RT, Trumble TE, Hanel DP, et al. Two-, Four-, and Six-Strand Zone II Flexor Tendon Repairs: An *in Situ* Biomechanical Comparison Using a Cadaver Model. *J Hand Surg [Am]* 1998;23(2):261.

\# 30. Urbaniak JR. Repair of the Flexor Pollicis Longus. *Hand Clin* 1985;1:69.

\+ 31. Urbaniak JR, Goldner JL. Laceration of the Flexor Pollicis Longus Tendon: Delayed Repair by Advancement, Free Graft or Direct Suture. A Clinical and Experimental Study. *J Bone Joint Surg* 1973;55-A:1123.

* 32. Verdan CE. *Chirurgie Reparatrice et Fonctionnelle des Tendons de la Main.* Paris: LExpansion Scientific Franátaise, 1952.

* 33. Verdan CE. Syndrome of the Quadriga. *Surg Clin North Am* 1960;40:425.

\+ 34. Verdan CE. Half a Century of Flexor Tendon Surgery. *J Bone Joint Surg* 1972;54-A:472.

! 35. Winters SC, Gelberman RH, Woo SL, et al. The Effects of Multiple-Strand Suture Methods on the Strength and Excursion of Repaired Intrasynovial Flexor Tendons: A Biomechanical Study in Dogs. *J Hand Surg [Am]* 1998;23:97.

\+ 36. Winters SC, Seiler JG 3rd, Woo SL, Gelberman RH. Suture Methods for Flexor Tendon Repair. A Biomechanical Analysis During the First Six Weeks Following Repair. *Ann Chir Main Memb Super* 1997;16:229.

\+ 37. Zatiti SC, Mazzer N, Barbieri CH. Mechanical Strengths of Tendon Sutures. An *in Vitro* Comparative Study of Six Techniques. *J Hand Surg [Br]* 1998;23:228.

# CHAPTER 49

# EXTENSOR TENDON INJURIES: ACUTE REPAIR AND LATE RECONSTRUCTION

*James S. Thompson and Clayton A. Peimer*

**J. S. Thompson:** Carolina Hand Surgery Associates; Mission-St. Joseph's Health System, Asheville, North Carolina, 28801.
**C. A. Peimer:** University at Buffalo School of Medicine and Biomedical Sciences, State University of New York; Millard Fillmore Health System, Buffalo, New York, 14209.

Functional Anatomy
- Finger Extensor Mechanism
- Thumb Extensor Mechanism

Clinical Signs
- Extensor Laceration or Rupture
- Extensor Component Tenodesis or Contracture

General Principles of Management
Acute Extensor Repair
- Forearm and Wrist
- Dorsum of the Hand
- Metacarpophalangeal Joint
- Proximal Phalanx
- Proximal Interphalangeal Joint
- Middle Phalanx and Distal Interphalangeal Joint

Late Reconstruction
- Forearm, Wrist, and Dorsum of the Hand
- Extensor Tenodesis of the Hand and Digits
- Late Boutonnière Deformity
- Late Swan-Neck and Mallet Deformities
- Thumb

Chapter References

"The hand," wrote Sterling Bunnell, "includes exact machinery of much refinement and tissues of great delicacy and specialization" (8). The extensor mechanism is a prime example of the "machinery" Bunnell was describing. Because of its subcutaneous vulnerability, it is one of the most frequently injured structures in the hand.

Many anatomists have appreciated the complexity of the extensor mechanism, among them Albinus, who presented the first detailed structural description in 1734 (46). Reconstructive surgeons who attempt surgical correction of hand dysfunction resulting from extensor tendon injury or imbalance quickly gain respect for the structure.

Intrinsic muscle abnormalities aside (see Chapter 63), the diagnosis of most extensor lesions (acute and chronic) is relatively simple. Likewise, the surgical exercise of tendon suture is not as technically demanding as it is for flexor tendons, because the extensors are primarily extrasynovial. The thin nature of the extensors within the digits, however, as well as the intimate proximity of the extensor mechanism to periosteum and bone (to which it readily adheres) and the influence of the digital extensors on the critical function of the interphalangeal joints (49,58), all contribute to potentially poor functional results following surgical treatment of extensor tendon injuries (19,20,22,23,25,36,45,51,74).

In the fingers, proximal interphalangeal (PIP) and distal interphalangeal (DIP) motion are interdependent, and lack of or excess of extension in either joint reciprocally affects the other. The swan-neck or boutonnière positions are the classic examples of this interphalangeal reciprocity (see Fig. 49.10). The entire extensor mechanism, the total digital deformity, and the lack of motion or presence of abnormal motion at each joint must be considered in planning reconstruction (13). Eaton has aptly described the extensor mechanism as a "sleeping giant which is not appreciated until it becomes disorderly or out of balance. When out of control it can create great disturbances" (17).

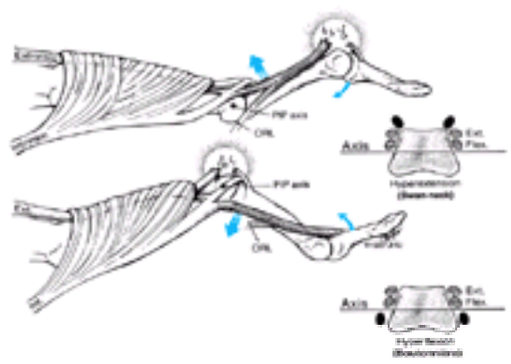

***Figure 49.10.*** The dorsopalmar translation of the conjoined lateral bands is demonstrated in the two classic reciprocal digital deformities: swan-neck (*top*) and boutonnière (*bottom*). The *insets* are transaxial representations of the condyles of the proximal phalanx, showing the normal positions of the conjoined lateral bands in extension and flexion of the PIP joint. The abnormal positions of the conjoined lateral bands in each deformity are represented in *black*.

Restoring a normally functioning extensor mechanism can be more difficult than reconstructing a flexor system. A surgeon contemplating such a restorative attempt must approach the problem with complete understanding and great care. Failure to comprehend the diverse and complex structure's functional anatomy and to appreciate the need for proper dressing and appropriate rehabilitation may contribute to poor results in extensor reconstruction, regardless of the anatomic level or the mechanism of injury (22).

This chapter is not meant to be a compendium of procedures but rather a description of principles and concepts useful for devising appropriate management for each case. The primary focus of the chapter is the finger extensor mechanism; the thumb extensor system and the wrist extensor will be discussed briefly. Table 49.1 lists abbreviations and terminology that will be used.

*Table 49.1. Abbreviations and Terminology*

## FUNCTIONAL ANATOMY

### FINGER EXTENSOR MECHANISM

The digital extensor system consists of three joints extended by a single confluent tendinous mechanism (Fig. 49.1, Fig. 49.2) formed by the interlinkage of two separate and neurologically independent components: tendons of the extrinsic, radial-nerve-innervated muscle and tendons of the intrinsic, ulnar/median-nerve-innervated muscles.

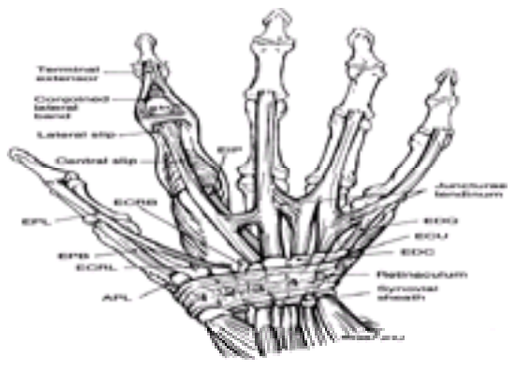


***Figure 49.1.*** The extensor mechanism of the wrist and dorsum of the hand. The six extensor compartments at the wrist contain (*1*) the abductor pollicis longus (*APL*) and extensor pollicis brevis (*EPB*); (*2*) the extensor carpi radialis longus (*ECRL*) and brevis (*ECRB*); (*3*) the extensor pollicis longus (*EPL*); (*4*) the extensor digitorum communis (*EDC*) II–V and extensor indicis proprius (*EIP*); (*5*) the extensor digiti quinti (*EDQ*); and (*6*) the extensor carpi ulnaris (*ECU*). An important anatomic detail is the presence of a synovial sheath around each tendon unit within each fibro-osseous canal. These sheaths are often involved in rheumatoid disease.

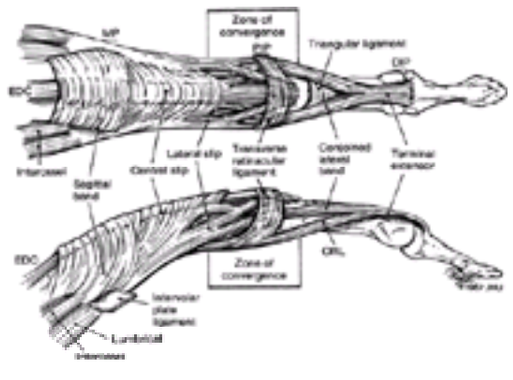


***Figure 49.2.*** Digital extensor mechanism. **A:** Dorsal view. **B:** Lateral view.

The radially innervated extrinsic extensors contributing to the extensor mechanism, and their fingers of action, are the extensor digiti communis (EDC) (all fingers), the extensor indicis propius (EIP) (index), and the extensor digiti quinti (EDQ) (little finger) (Fig. 49.1). While this arrangement is considered normal, subtle variations in extrinsic extensor tendon anatomy are fairly common (2,15,27,67,77,79,83), especially the presence or absence of a discrete separate EDC tendon to the little finger (60). After passing beneath the extensor retinaculum (69) (through synovial sheaths within each extensor compartment), the extrinsic extensor tendons are interconnected by juncturae tendinum on the dorsum of the hand (66,78,80). Laceration of individual extrinsic extensor tendons proximal to the juncturae may be masked by partial metacarpophalangeal (MP) extension transmitted through the juncturae by the adjacent tendons (15,66,78,80). The juncturae tendinum may act as force vectors in the dynamic stabilization of the MP joints during flexion (1).

At the MP level, the sagittal bands (Fig. 49.2, Fig. 49.3), which act to maintain centralization of the extensor tendons, form the most proximal insertion of the extensor mechanism (37). The sagittal bands surround the metacarpal heads and insert into the MP volar plate and intervolar plate ligaments (Fig. 49.3*B*). The sagittal bands also prevent dorsal prolapse of the extrinsic extensor tendons during MP hyperextension (Fig. 49.4).

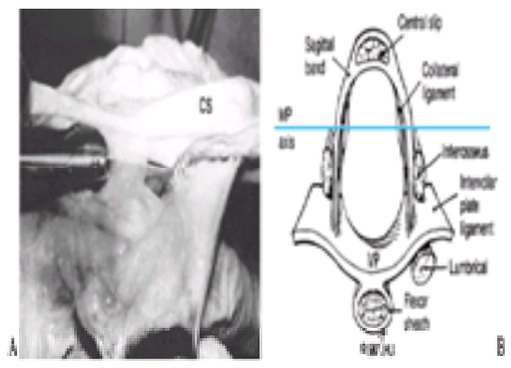


***Figure 49.3.*** **A:** Radial sagittal band of the middle finger. There is a natural cleavage plane (through which the scissors penetrate) between the transverse fibers of the sagittal band and the oblique fibers from the lateral slip (*arrows*) to the central slip (*CS*). **B:** Transaxial view at the MP level of the sagittal bands and their insertion into the periphery of the volar plate (*VP*) and intervolar plate ligament. Note the relationship of the interossei and lumbrical to the MP axis of rotation and intervolar plate ligament.

***Figure 49.4.*** Hand of a 39-year-old woman with systemic lupus erythematosus, treated for 20 years with oral steroids. All five extensor tendons subluxate with digital flexion. With extension, marked MP hyperextension/dorsal prolapse of the EDC tendons is present due to incompetence of the MP sagittal bands.

Attenuation or injury to the radial aspect of a sagittal band may allow subluxation of the extensor tendon into the ulnar intermetacarpal sulcus with MP flexion (36). If this subluxation is reducible, the physical finding may simply be painful snapping as the tendon moves to and fro with MP flexion or extension (Fig. 49.5) (30,33,34,58,59). If, however, the extensor tendon becomes permanently fixed palmar to the MP axis of rotation in the ulnar intermetacarpal sulcus (frequently seen in rheumatoid disease; see Chapter 70), it becomes a strong MP flexor and contributes significantly to ulnar deviation of the fingers (56).

***Figure 49.5.*** **A:** Ulnar subluxation of the EDC of the middle finger (*arrow*) with finger flexion in an elderly patient with extremely atrophic skin. **B:** Reduction of the subluxation occurs with finger extension.

Because the MP joint is proximal to the zone of convergence (Fig. 49.6) of the intrinsic and extrinsic contributions to the digital extensor mechanism, these two separate and distinct systems act as antagonists at this level. The intrinsics, being palmar to the MP rotational axis, act as MP flexors; the extrinsics, being dorsal, are MP extensors (Fig. 49.2*B*). This paradox of action at the MP joint is a primary factor contributing to difficulty in understanding the digital extensor mechanism (17,43).

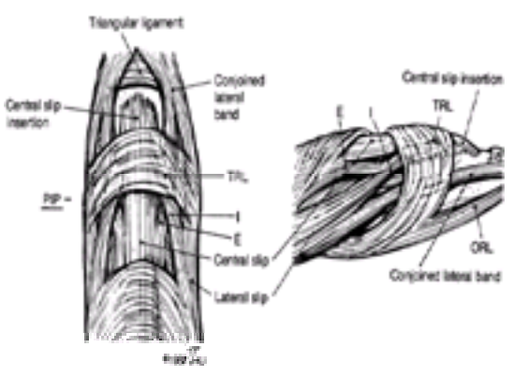


***Figure 49.6.*** The zone of convergence of the digital extensor mechanism, which begins at about the midportion of the proximal phalanx and ends at the level of the central slip insertion into the dorsal base of the middle phalanx. Proximal to the zone of convergence, the extrinsic and intrinsic components of the extensor mechanism are separate: The central slip is extrinsic, while the lateral slips are intrinsic. Within the zone of convergence there is complete reciprocal crossover of fibers from the central slip and lateral slips. The products of the completed convergence are the central slip insertion and the conjoined lateral bands, both of which have dual muscular activity (intrinsic and extrinsic) for extension of both interphalangeal joints. *PIP*, proximal interphalangeal joint; *TRL*, transverse retinacular ligament; *ORL*, oblique retinacular ligament; *E*, extrinsic contribution to conjoined lateral bands; *I*, intrinsic contribution to central slip insertion.

An insertion point of the extrinsic extensor is present in the dorsal MP capsule and dorsal base of the proximal phalanx (Fig. 49.7, Fig. 49.8). Although the insertion point has been described as indifferent (17) and variable (46), it is consistently present and represents the second of the insertion points of the extensor system, the first being the sagittal bands (Fig. 49.3) (75). These two insertion points are not firmly fixed bony insertions in the pure sense, as are those at the dorsal base of the middle and distal phalanges. In fact, these insertions have an excursion approximately equal to the excursion of the central slip at the PIP joint (Table 49.2) and therefore become taut only when the PIP joint is in full extension (18).

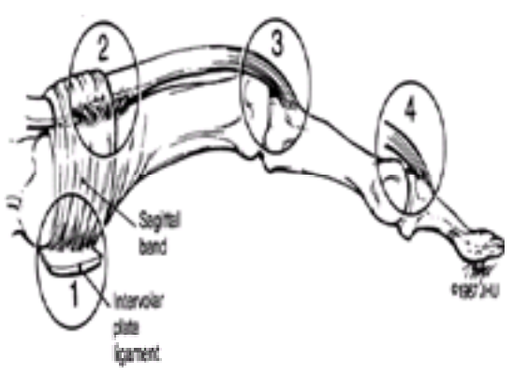


***Figure 49.7.*** Lateral aspect of a finger demonstrating the four insertion points of the extensor mechanism. (*1*) Insertion through the sagittal bands into the volar plate and intervolar plate ligament. (*2*) Extensor insertion into the dorsal MP joint capsule and base of the proximal phalanx. This is a loose or indifferent insertion. (*3*) Central slip insertion into dorsal base of middle phalanx. (*4*) Terminal extensor insertion into dorsal base of distal phalanx.

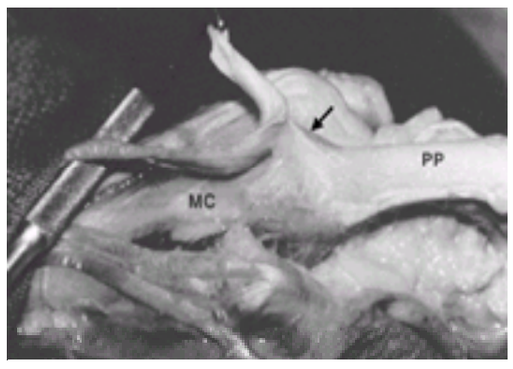


***Figure 49.8.*** Extensor insertion into the dorsal MP capsule and dorsal base of the proximal phalanx (*arrow*). This insertion is filmy and loose and has an excursion

equal to the extensor amplitude at the PIP joint. This “insertional excursion” allows PIP and DIP flexion while the MP joint is in maximum hyperextension. With PIP extension, however, this insertion becomes taut and assists extension of the proximal phalanx (*PP*). *MC*, metacarpal.

| Muscles | Amplitude (mm) | | | |
|---|---|---|---|---|
| | Wrist | MP | PIP | DIP |
| Wrist extensors | 35 | | | |
| Finger extensors | 50 | 16 | 10[b] | 5 |
| Intrinsics | | 8 | | |

[a] Measurements in mm are averages and will vary from individual to individual due to skeletal size and, therefore, arc length differences. A few mm alteration of normal excursion in a component of the extensor system may cause a significant functional loss.
[b] The proximal–distal excursion limit of the MP sagittal bands and the insertional excursion of the extensor insertion at the MP capsule and base of the proximal phalanx equal the extensor amplitude at the PIP joint, allowing full IP flexion/extension with the MP joints held in maximum hyperextension.

***Table 49.2. Extensor Tendon Excursion[a]***

This function can be easily demonstrated in a normal finger by maintaining the MP joint in maximum hyperextension and actively flexing and extending the interphalangeal (IP) joints. A fixed insertion of the extrinsic extensor at the MP level would obviate the possibility of this maneuver. If the entire extensor mechanism is lacerated at the proximal phalangeal level (rarely the case in isolated laceration of the tendon, because of its broad convex shape, but frequently seen in dorsal guillotine-type injuries with transection of the bone), the extensor mechanism retracts only a distance equal to or less than the available insertional excursion.

The intrinsic muscle group contributing to the extensor mechanism is composed of the interossei (all ulnar-innervated), the fourth and fifth lumbricals (ulnar-innervated), and the second and third lumbricals (median-innervated). Along the proximal phalangeal segment, the fibers of the intrinsic tendons (lateral slips) merge, winglike, into the central slip (Fig. 49.9*A*). This configuration explains the necessity of the triangular (wing) excision (Fig. 49.9*B*) in cases of intrinsic muscle contracture proposed by Littler for complete intrinsic release (41). A smaller excision or simple lateral slip tenotomy will not completely eliminate the influence of abnormal intrinsic muscle tension on the central slip and its attendant limitation of IP flexion.

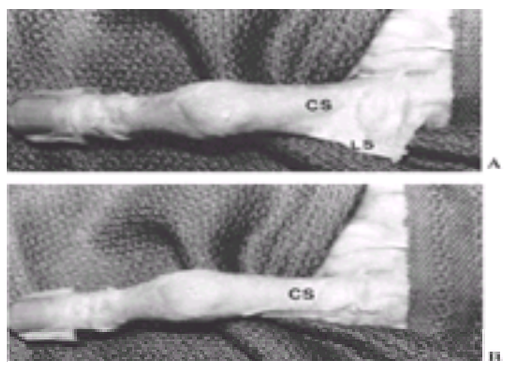


***Figure 49.9.*** **A:** Anatomic preparation demonstrating winglike configuration of intrinsic contribution to the digital extensor mechanism. **B:** The wing excision of Littler that is necessary for complete elimination of intrinsic influence on the digital extensor mechanism. *CS*, central slip; *LS*, lateral slip.

At about the midportion of the proximal phalanx, the central slip begins its trifurcation. Distal to this level of trifurcation, there is free exchange of fibers from the central slip to the lateral slips and from the lateral slips to the central slip (Fig. 49.6). Distal to the anatomic zone of convergence, the central slip and conjoined lateral bands are truly a dual extensor mechanism with both intrinsic and extrinsic contributions, either (or both) of which is capable of powering active IP extension.

Fowler recognized this dual nature of the extensor assembly in 1949 (24). Even Bunnell had held a different functional view of the extensor mechanism before Fowler's observations (D. C. Riordan, personal communication, 1987) (8,46). This duality of extensor motor power at the IP joint (29,54), plus the mechanical concept of a dynamic IP tenodesis [the oblique retinacular ligament (ORL)], forms the basis for many procedures involving redistribution of forces in IP joint extensor dysfunction (42,47,73,76).

At the PIP joint, the transverse retinacular ligaments (TRL) act to gently maintain the conjoined lateral bands within certain limits of dorsopalmar excursion (Fig. 49.2*B*). This dorsopalmar translation of the conjoined lateral bands (Fig. 49.10) was presented in 1923 by Hauck (31). Palmar displacement of the conjoined lateral bands occurs normally with PIP flexion, allowing synchronized distal interphalangeal (DIP) flexion (62). Smooth, unrestricted DIP flexion depends on normal PIP flexion, which allows relaxation of the conjoined lateral bands and oblique retinacular ligament.

Lax PIP volar plates (VP) in some people allow DIP flexion while the PIP joint is maintained in extension (usually slight hypertension). This maneuver is possible only in people with PIP-VP laxity and normal supple intrinsic muscles. Repeating this “trick” may result in further VP laxity, stretching of the TRL, allowing further dorsal migration of the conjoined lateral bands and development of painful locking of the PIP joint in hyperextension, a dynamic swan-neck deformity (Fig. 49.10, Fig. 49.11).

***Figure 49.11.*** Dynamic swan-neck deformity in a professional musician with PIP volar plate laxity. The conjoined lateral bands (*arrows*) bowstring dorsally as the transverse retinacular ligament stretches (see Fig. 49.10). The finger is locked in extension at the PIP joint, causing occupational disability. Successful surgical treatment was flexor superficialis tenodesis of the PIP joint blocking PIP hyperextension; this allowed complete DIP extension.

This phenomenon clearly illustrates the participation of the static VP in the normal and abnormal dynamics of extension. Littler has emphasized the importance of the VP as an adjunct to the dynamic process of normal digital extension (49). VP stretching or contracture also contributes to the fixed reciprocal deformities, including the swan-neck deformity (PIP hyperextension and DIP flexion) and the boutonnière deformity (PIP flexion and DIP hyperextension).

The central slip terminates in a broad, strong bony insertion at the dorsal base of the middle phalanx (Fig. 49.12). The conjoined lateral bands merge over the dorsum of the middle phalangeal segment to form the terminal extensor tendon (Fig. 49.2*A*), which inserts into the dorsal base of the distal phalanx (Fig. 49.13). The triangular

ligament is composed of transverse fibers between the conjoined lateral bands distal to the central slip insertion and proximal to the merging of the bands (Fig. 49.6) (37).

***Figure 49.12.*** Broad insertion of central slip (*CS*) into the dorsal base of the middle phalanx. The glistening, gliding layer is seen covering the dorsal aspect of the proximal phalanx.

***Figure 49.13.*** Bony insertion of the terminal extensor (*TE*) into the dorsal base of the distal phalanx. The proximal ends of the conjoined lateral bands (*arrows*) are visible at the PIP joint level.

The ORL may play a unique and integral role in the extensor system. The existence and biomechanical significance of the ORL in normal digits is controversial (53,55,65). Weitbrecht illustrated this structure in 1742 and named it the *retinaculum tendini longi* (82). The ORL (Fig. 49.14) originates palmar to the PIP axis of rotation from the periosteum of the proximal phalanx and flexor sheath and passes dorsally and distally to join the terminal extensor tendon (63). Walsh clearly demonstrated the ORL in a prize-winning monograph in 1897 (81). Landsmeer subjected the ligament to a sophisticated dynamic analysis, and the soundness of the mechanical basis of a “dynamic interphalangeal tenodesis” concept has induced procedures designed to augment DIP extension based on active PIP extension (38,39 and 40,42,73). ORL tightness may also contribute to pathologic conditions such as fixed DIP hyperextension in the boutonnière deformity and DIP extension contracture in digital Dupuytren's disease (see Chapter 62).

***Figure 49.14.*** The oblique retinacular ligament, elevated by the probe, originates along the proximal phalangeal periosteum and flexor sheath, passes volar to the PIP axis of rotation, and joins the terminal extensor tendon. The principle of “dynamic interphalangeal tenodesis” is based on the biomechanical fact that a structure of fixed length extending from the proximal phalanx to the distal phalanx, palmar to the PIP axis, and dorsal to the DIP axis will relax with PIP flexion and tighten with PIP extension.

Complete understanding of the extensor mechanism is elusive, but functional understanding requires only time and assimilation of many small bits of information. The complete mechanism (Table 49.3)—extrinsic and intrinsic motors, merging tendons, dynamic and static retaining ligaments, and other contributing components—when functioning normally has been described as a “fugue of motion” (J. W. Littler, personal communication, 1987).

| *Dynamic structures*[a] | *Static structures*[b] |
|---|---|
| Extrinsic muscles (EDC, EIP, EDQ, EPL, EPB, APL) | Retinaculum Juncturae |
| Intrinsic muscles (interossei, lumbricals, thenar intrinsics, hypothenar intrinsics) | Sagittal bands |
| | Oblique retinacular ligament |
| | Transverse retinacular ligament |
| | Triangular ligament |
| | Gliding layer |
| | Volar plates |

[a] Directly powered by muscle
[b] Although static, these structures all have important dynamic functions.

***Table 49.3. Components of the Digital Extensor System***

**THUMB EXTENSOR MECHANISM**

The abductor pollicis longus (APL) inserting on its dorsal base and into the fascia of the thenar intrinsic muscles provides extension and abduction of the first metacarpal (Fig. 49.1). The multiple slips of this muscle–tendon unit make it very useful in reconstructive procedures at the base of the thumb (70).

The variable extensor pollicis brevis (EPB) inserts into the dorsoradial base of the proximal phalanx and the extensor pollicis longus (EPL) into the dorsal base of the

distal phalanx (Fig. 49.1). These two muscle–tendon units exert extensor influence on multiple joints: the EPB on the trapeziometacarpal joint (extension/abduction) and MP joint (extension); and the EPL on the trapeziometacarpal joint (extension/abduction), MP joint (extension), and IP joint (extension).

The intrinsics of the thumb [abductor pollicis brevis (APB), flexor pollicis brevis (FPB), and adductor pollicis (AP)] contribute to IP extension through the extensor hood at the MP joint and frequently confuse the inexperienced examiner in cases of suspected EPL laceration (48). The intact thenar intrinsics will extend the IP joint to a near-neutral position, but the diagnosis of EPL rupture or laceration is obvious if the entire thumb ray is compared with that of the uninjured thumb.

## CLINICAL SIGNS

### EXTENSOR LACERATION OR RUPTURE

A “dropped joint” (lack of full extension with posture in flexion) at the site of extensor muscle tendon action is the simple sign of complete extensor functional deficit (43). An MP drop is seen with extrinsic extensor laceration or rupture, a PIP drop with complete central slip laceration or rupture, and a DIP drop (mallet) with terminal extensor tendon laceration or rupture.

In the thumb, laceration of the contents of the first extensor compartment (EPB, APL) will present as flexion/adduction of the first metacarpal and a lag in full extension of the MP joint. The EPL functions as both MP and IP extensor in this situation. Isolated laceration of the EPB is rare, and repair of this tendon is optional, depending on the functional deficit at the MP joint. This lesion is frequently undiagnosed in the emergency situation because of the presence of MP extension through the intact EPL. EPL extension of the MP joint, however, will usually be incomplete when compared with that of the opposite, uninjured side. The magnitude of the MP extensor lag secondary to EPB laceration is variable, and this factor determines whether EPB repair is warranted.

Two basic patterns of EPL laceration are seen, and the presentation depends on whether the laceration site is proximal or distal to the MP joint. Proximal to the MP joint, the entire thumb ray is affected and demonstrates metacarpal adduction, incomplete MP extension, and IP extension lag (some IP extension remains, by virtue of intact thumb intrinsics). The EPL retracts significantly when lacerated proximal to the MP extensor hood, and retrieval from the synovial extensor compartment or the distal forearm may be difficult and may require a proximal counterincision.

Extensor pollicis longus laceration distal to the MP joint is simpler, easily diagnosed by consideration of the injury location and loss of IP hyperextension. The tendon cannot retract more than a few millimeters because of its attachment to the MP extensor hood. It should be repaired and treated as a sharply lacerated terminal extensor tendon of a finger (discussed later).

### EXTENSOR COMPONENT TENODESIS OR CONTRACTURE

Several simple maneuvers will establish the location of restriction of gliding (tenodesis) of the extrinsics or contracture/fibrosis of the intrinsic components (Table 49.4). The level of extrinsic tenodesis is frequently made obvious by scars. Intrinsic contracture and contracture of the ORL, however, cannot be appreciated without the use of clinical tests (43).

| Name of test | Component tested | Positive test | Negative test | Interpretation of positive test |
|---|---|---|---|---|
| Extrinsic entrapment test | Extrinsic tendon proximal to PIP joint | With MP joint flexed, IP joints cannot flex completely[a] | With MP joint flexed, IP joints flex completely | Extrinsic mechanism tenodesed by scar or contracted proximal to PIP joint, distal to wrist[a] |
| Intrinsic test (Bunnell test) | Intrinsic muscle tendon units | With MP joint extended, IP joints cannot flex completely[b] | With MP joint extended, IP joints flex completely | Contracture, fibrosis, or adherence of intrinsic muscles reducing their amplitude (see Table 49.1) |
| ORL tightness test | Oblique retinacular ligament | With PIP joint fully extended, DIP joint cannot flex completely | With PIP joint fully extended, DIP joint can be flexed completely | Shortening contracture or scarring of the ORL, seen posttrauma, in digital Dupuytren's and some connective tissue disorders |

[a] The same test can be done at the wrist; reduction of passive IP flexion by wrist flexion indicates tenodesis by scar or contracture of the extrinsic extensors proximal to the wrist joint.
[b] Adding radial or ulnar deviation in addition to extension at the MP joint may reveal differential intrinsic tightness (i.e., ulnar intrinsics more contracted than radial, as frequently seen in rheumatoid disease).

***Table 49.4. Clinical Tests for Tightness or Entrapment of Extensor Mechanism Components***

## GENERAL PRINCIPLES OF MANAGEMENT

Bunnell in 1922 was the first surgeon to enumerate the reasons for poor results after tendon surgery (7). He was primarily discussing flexor tendons, and the reasons remain valid and apply equally well to extensor tendons (Table 49.5).

| |
|---|
| Traumatizing technique |
| Poor incisions |
| Damage to gliding surface |
| Too much or too little postoperative movement |
| Crude suturing technique |

Modified from Bunnell S. Repair of Tendons in Fingers. *Surg Gynecol Obstet* 1922;35:88.

***Table 49.5. Reasons for Poor Results after Extensor Tendon Surgery***

The integrity of the gliding layer between the extensor mechanism and the phalanges is important. This layer is often described as periosteum, and indeed the deep portion of the layer is phalangeal periosteum. The superficial cellular components of the gliding layer, however, are more areolar in nature and cannot be distinguished from paratenon. Absence of the gliding layer makes adherence to bone much more likely. Repair of a cleanly lacerated gliding layer, when possible, improves chances for more normal extensor excursion. Preserving the gliding layer in the exposure for reconstruction of phalangeal fractures improves the postoperative range of motion (14,58). Careful preservation of the gliding layer improves results after other elective procedures, and this specialized tissue should be considered an integral part of the extensor mechanism (71).

Surgical approaches that involve splitting the extensor tendon and gliding layer are unnecessary and should not be used. They do not facilitate bone reduction but rather create severe extensor mechanism trauma, resulting in adherence and loss of tendon amplitude. Incisions preserving the entire extensor mechanism allow access and reduction of all phalangeal fractures (14,52).

The major dualities in the digital extensor mechanism should be fixed in the surgeon's mind (Table 49.6). A knowledge of these redundancies in the system facilitates decision making in both acute repairs and late reconstructions. A common power-saw injury, for instance, results in an untidy laceration of a lateral slip and portion of the central slip over the proximal phalangeal segment with destruction of the underlying gliding layer and abrasion or cortical chipping of the phalanx. Such an injury is best treated by debridement of the shredded tendon followed by early initiation of motion.

| |
|---|
| Double extrinsic extensors for index finger (EDC, EIP) |
| Double extrinsic extensors for little finger (EDC, EDQ) |
| Double IP motor power sources (extrinsic, intrinsic) |
| Two lateral slips per finger |
| Two conjoined lateral bands per finger |

***Table 49.6. Extensor System Dualities***

Unnecessary repair of tendons in these circumstances is done when the surgeon does not realize that there is enough undamaged extensor mechanism to perform IP extension. Adequacy of the mechanism can be checked easily after digital anesthesia by asking the patient to straighten the finger. Recognizing the redundancy of the extensor mechanism, and therefore the expendability of certain elements, should prevent one of the complications of extensor repairs seen by hand surgeons—unnecessary suture of partial lacerations resulting in digits stiffly fixated in extension.

## ACUTE EXTENSOR REPAIR

### FOREARM AND WRIST

Little has been written about the repair of lacerated wrist extensor tendons, and the subject deserves mention. The wrist extensors maintain balanced alignment of the hand and provide stabilization of the hand during grip. They should be repaired when possible. Isolated laceration of a wrist extensor is rare, because of the intimate anatomic arrangement of the extensor complex in the forearm and wrist. Wrist extensor tendon lacerations are therefore usually associated with laceration of one or more of the digital extensors.

Careful physical examination to rule out associated neurovascular injuries is mandatory (stab wounds in the forearm with small entry wounds may be very misleading), followed by complete surgical exploration and repair. Dorsal laceration in the proximal forearm frequently involves branches of the radial nerve. Explore and repair them if feasible. Muscle bellies of the extensor muscles can be opposed with nonabsorbable or synthetic absorbable sutures (Table 49.7).

| *Tissue* | *Suture size*[a] |
|---|---|
| Muscle bellies | 2-0, 3-0 |
| Tendons of forearm and wrist: | |
| Core sutures | 2-0, 3-0 |
| Outer sutures | 3-0, 4-0 |
| Tendons of hand and fingers: | |
| Core sutures | 3-0, 4-0 |
| Outer sutures | 4-0, 5-0 |

[a] Use core sutures of nonabsorbable, synthetic, braided material in areas where the tendons are large enough to allow their use (i.e., dorsum of hand, wrist, forearm). All outer sutures used are synthetic, slowly absorbable, polyglycolic acid, polyglactin, or polydioxanone. Use of nonabsorbable sutures as outer sutures frequently results in irritation at the sites of unburied knots. Use fine, synthetic, absorbable sutures for repair of partial tendon and terminal extensor lacerations in the digits. Proper dressings, splints, patient education, and therapy are the keys to successful results.

***Table 49.7. Suture Materials for Extensor Tendon Repair[a]***

Fibrous septae within the substance of muscles, when identifiable, afford the most secure purchase for suture placement. Synthetic, slowly absorbed sutures are now preferred for peripheral sutures of muscle and tendon. The details of extensor repair—positioning after surgery, proper dressings and splints, patient education, and appropriate type and timing of therapy—are more important than the type of suture material used (72).

Because the brachoradialis (BR), extensor carpi radialis longus (ECRL), extensor carpi radialis brevis (ECRB), EDC, and EDQ have their origins from the lateral epicondyle, elbow flexion (in addition to wrist extension) facilitates repair (15). After surgery, use a long-arm dressing with elbow at 90° flexion, the forearm in neutral rotation, the wrist extended 45°, and the MP joints flexed about 15°. Allow the IP joints full, unrestricted motion throughout treatment of the injury. Allow active motion of the MP joints at 3 weeks, and of the elbow at 4 weeks (Table 49.8). At 5 weeks, gently institute wrist motion under the guidance of a hand therapist. Use a removable splint that maintains the neutral or slightly extended position between exercise sessions and at night for an additional 3 to 4 weeks. The development of sufficient tensile strength to allow application of significant stress across the repair requires at least 5 weeks (50). However, some motion at the juncture site is beneficial for the return of maximum postoperative tendon excursion.

| | | Immobilization | |
|---|---|---|---|
| *Joint* | *Position* | *Type* | *Duration* |
| Elbow | 90° flexion, neutral pronation/supination | Cast | 4 weeks |
| Wrist[b] | 45° extension<br>Neutral/slight extension | Cast<br>Removable splint[c] | 4–5 weeks<br>3–4 weeks |
| MP[d] | 15° flexion | Cast/splint | 3 weeks |
| PIP | Allow full ROM | None | |
| DIP | Allow full ROM | None | |

[a] Include the elbow only in proximal forearm injuries when flexion facilitates repair of muscles originating from the lateral epicondyle, which is proximal to the axis of rotation of the elbow.
[b] Wrist immobilization alone will extend approximately 60% of extrinsic extensor tendon amplitude.
[c] A removable splint is used for 3–4 weeks following the initial 4–5 weeks in a static cast at 45° extension.
[d] Immobilize the MP joints in slight flexion to maintain the collateral ligaments under tension around the metacarpal heads.
ROM, range of motion.

***Table 49.8. Postoperative Management of Extensor Tendon Repairs in the Forearm and Wrist[a]***

The keys to the best results, therefore, are protection that is adequate for the specific repair and some motion that is prompt enough to achieve early tendon gliding. The surgeon determines the immobilization method and mobilization sequence. Observe the juncture directly before wound closure and assess the effects of passive MP and IP flexion. Because about 60% of the digital extensor amplitude occurs at the wrist, immobilization of the wrist in extension affords significant protection for extensor repairs (45). Graduated institution of range of motion for each of the joints possibly affected by extensor injuries, rather than prolonged immobilization of all joints, contributes to improved results (6,21).

In addition to individualized mobilization of joints, frequent clinical evaluation by the surgeon and close supervision by an informed, experienced hand therapist are necessary to achieve optimum results following extensor repair or reconstruction (6,21,61).

### DORSUM OF THE HAND

Laceration of a single tendon of the EDC may be masked by juncturae tendini pull-through. Laceration of the EIP and EDQ results in loss of independent MP extension

of the index or little finger. Repair all of these tendons (3) using appropriate core and outer sutures (Table 49.7).

The method of immobilization (Table 49.9) is similar to that for lacerations in the forearm and wrist. Involvement of the EDC tendons necessitates inclusion of all fingers in the dressings and splints, but isolated lacerations of the EIP and EDQ may be treated with immobilization of only the involved digit and the wrist.

| Joint | Position | Immobilization | |
|---|---|---|---|
| | | Type | Duration |
| Wrist[a] | 45° extension | Cast | 4–5 weeks |
| | Neutral/slight extension | Removable splint[b] | 3–4 weeks |
| Affected MP[c] | Neutral | Cast | 3 weeks |
| Other MPs[d] | 15° flexion | Cast | 3 weeks |
| PIP | Allow full ROM | None | |
| DIP | Allow full ROM | None | |

[a] Wrist immobilization alone will retard approximately 60% of extrinsic extensor tendon amplitude.
[b] A removable splint is used for 3–4 weeks following the initial 4–5 weeks in a static cast at 45° extension.
[c] A neutral MP position of the affected digit coupled with MP flexion of digits with intact EDC tendons reduces possible tension at the anastomosis site.
[d] Immobilize the MP joints in slight flexion to maintain collateral ligaments under some tension around the metacarpal heads.
ROM, range of motion.

***Table 49.9. Postoperative Management of Extensor Tendon Repairs in the Dorsum of the Hand***

**METACARPOPHALANGEAL JOINT**

***Laceration***

Delayed repair of a lacerated extensor tendon and MP joint capsule is prudent. The rationale for wound irrigation, inspection, open wound treatment, splinting, and delayed repair after 5 to 10 days of antibiotic treatment is to minimize the risk of infection from human bites, which is increased by primary closure (16). Primary closure, an inappropriate treatment for a human bite, frequently leads to septic destruction of the MP joint (see Chapter 73). Perform primary closure of lacerations of the extensor tendon and MP joint only if you are confident of the history, and if the wound appears compatible with that history. The methods and duration of immobilization are the same as those described for extensor lacerations on the dorsum of the hand (Table 49.8).

***Extensor Subluxation***

Closed subluxation of the extensor tendon at the MP joint (Fig. 49.5) can frequently be managed successfully with extension splinting for 4 to 6 weeks (57). Repair acute sharp injuries to the radial sagittal band of the MP joint to prevent ulnar extensor tendon subluxation. Chronic subluxation that does not respond to MP extension splinting requires surgical treatment. Release the ulnar sagittal band and, if possible, reef the radial sagittal band. If adequate substance for repair is not present in the radial sagittal band, several surgical reconstructions have been described using juncturae or strips of the tendon secured to soft tissue on the radial side of the joint to prevent the ulnar subluxation (10).

**PROXIMAL PHALANX**

Complete laceration of the extensor mechanism at the proximal phalanx is very rare without transection of the digit. Therefore, lacerations over the proximal phalanx are usually partial and affect only the tendon over the convex portion of the phalanx. These tendon injuries do not retract significantly, do not result in loss of extension at the IP joints, and are usually diagnosed only through direct visual inspection of the wound.

Repair of the central slip is indicated, but lateral slip repair, especially if the gliding layer is disrupted, is optional. Treat untidy injuries of a single lateral slip with debridement of the crushed tendon ends. Initiate motion after 10 days of splinting. Remember the dualities of the system and the concept of expendability in crushing and abrading injuries. Fine, synthetic, slowly absorbable sutures are preferable for repair of the central slip.

After repair of partial laceration of the central slip, ask the patient to actively flex and extend the MP and PIP joints. This exercise provides some indication of whether early motion will jeopardize the repair. If no tension on the repair is demonstrated with active flexion/extension of the MP or PIP joints, consider early motion. If there is significant tension on the repair, follow the postoperative regimen for laceration of the extensor tendon at the PIP joint (Table 49.10).

| Joint | Position | Immobilization | |
|---|---|---|---|
| | | Type | Duration |
| MP | Allow ROM | None | |
| PIP | Full extension | Transarticular Kirschner wire and dorsal splint | 5 weeks constant, followed by splint weaning[a] |
| | Full extension | Removable thermoplastic splint | 3 weeks, night only[b] |
| DIP | Allow ROM, flexion encouraged[c] | None | |

[a] Splint weaning—Remove splint for 1 hour each morning and evening for 3 days, then 2 hours each morning and evening for 3 days. If no PIP extension lag develops and active and passive flexion gradually increase during the 6 days, splinting may be discontinued during the day. If PIP extension lag (>10°) develops, return to constant splinting in full extension for an additional week, then resume the weaning routine.
[b] Night splinting in full PIP extension is recommended for 3 weeks following 5 weeks of constant splint wear. If an extension lag develops during the splint weaning routine, consider prolonging the night splinting period.
[c] Maintain the amplitude of lateral slips and conjoined lateral bands.
ROM, range of motion.

***Table 49.10. Postoperative Management of Extensor Tendon Repairs of the PIP Joint (Acute Boutonnière Deformity)***

**PROXIMAL INTERPHALANGEAL JOINT**

Untreated laceration of the central slip at the PIP joint allows development of the buttonhole (boutonnière) deformity. The inevitable flexion of the middle phalangeal segment due to unopposed FDS pull encourages herniation of the proximal phalangeal condyles through the central slip defect. As the PIP flexion deformity progresses, the conjoined lateral bands slide palmar to the PIP axis, maintaining and increasing PIP flexion and tightening the terminal extensor, which produces DIP hyperextension (Fig. 49.10). The boutonnière deformity, when allowed to progress, is one of the most difficult reconstructive challenges to confront a hand surgeon (9,47,61,76).

The key to prevention, in sharp injuries, is careful exploration of all wounds over the PIP dorsum and extensor tendon repair. If there is a complete PIP extension deficit, the PIP joint should be maintained in full extension with a transarticular Kirschner wire before tendon repair. If the PIP extension deficit is not severe (less than 30° to 40°), tendon repair and external splinting will usually suffice. Careful postoperative management (Table 49.10) is necessary for optimum results.

Closed dorsal injury at the PIP level is the cause of many late-presenting, difficult, fixed boutonnière deformities. Prevention in these cases is simply based on an awareness of the potential problem and a high index of suspicion. Immobilize the PIP joint in extension and observe it with careful follow-up examinations. Unrestricted finger flexion after blunt trauma to the dorsum of the PIP region with central slip contusion/rupture may lead to severe deformity. PIP flexion, therefore, should be instituted gradually and only after follow up examinations reveal full active PIP extension. If there is significant periarticular swelling and pain with attempted flexion, a prudent assumption is that the injury is a closed boutonnière deformity until proven otherwise; adherence to the regimen presented in Table 49.10 is indicated.

**MIDDLE PHALANX AND DISTAL INTERPHALANGEAL JOINT**

At least seven classifications of classic mallet-finger deformity (dropped distal phalanx) exist.

- Closed rupture of the terminal extensor tendon
- Intraarticular avulsion fracture of the terminal extensor insertion (dorsal base of the distal phalanx) without palmar DIP subluxation
- Intraarticular avulsion fracture of the terminal extensor insertion (dorsal base of the distal phalanx) with palmar DIP subluxation
- Open laceration of the terminal extensor at the middle phalanx or DIP level
- Dorsal abrasion/degloving-type composite tissue injury with loss of tendon substance
- Extraarticular fracture at the base of the distal phalanx in adults with marked palmar angulation
- Transepiphyseal fracture of the distal phalanx in children with marked palmar angulation

Most mallet fingers fall into the first four groups, and it is these that are the basis for discussion of mallet fingers in this chapter. Fortunately, injuries in the fifth group are relatively rare; they often require flap or graft coverage (see Chapter 8, Chapter 38) before extensor tendon reconstruction can be considered. The last two groups of fractures, because of marked palmar angulation at the fracture site, are usually associated with nail-root avulsions and are treated relatively easily (see Chapter 38, Chapter 40).

All mallet fingers involving loss of terminal extensor contact with the distal phalanx (groups 1 through 5) may present with PIP recurvatum (swan-neck deformity), the magnitude of which depends on the ability of the PIP VP to resist the increased extensor force (central slip plus conjoined lateral bands) on the middle phalanx.

Mallet fingers in groups 1 and 2 can be managed satisfactorily by closed means in Stack splints (11,26,65). In group 2, the area of articular surface on the fracture fragment of the distal phalanx is not critical, as long as the DIP joint is not palmarly subluxated (11). Even though anatomic reduction may be impossible in a splint, results are good if joint alignment is maintained (11).

The presence of palmar subluxation of the distal phalanx indicates that enough of the DIP collateral ligament insertion is present on the fracture fragment to allow the unopposed FDP insertion to palmarly displace the distal phalanx. This circumstance usually does not occur until 50% or more of the articular surface of the distal phalanx is present on the fracture fragment (11).

If palmar subluxation of the distal phalanx is present, treat the injury surgically with reduction of the DIP joint, transarticular Kirschner wire fixation (Table 49.11), and open reduction of the fracture fragment. Methods for fragment fixation are diverse, and none have a clear advantage. The clear disadvantage of open treatment of any mallet deformity is loss of DIP flexion. A certain amount of flexion loss is the cost of accurate joint and fracture reduction in group 3 mallet deformities and tendon repair in group 4 mallet deformities. A patient who is advised about this problem in advance of surgery is usually satisfied with the surgeon's efforts, while the unprepared patient is often disappointed.

| *Joint* | *Size (mm)* |
|---|---|
| PIP | 0.35, 0.45 |
| DIP[a] | 0.28, 0.35 |

[a] Smooth wires only.

***Table 49.11. Transarticular Kirschner Wire Sizes[a]***

The postoperative management of mallet deformity (Table 49.12) is also used in the treatment of closed mallet injuries. Open mallet deformities (group 4) are also managed as shown in Table 49.12. Place fine, synthetic, absorbable sutures in the tendon after the DIP joint has been fixed in neutral extension with a transarticular Kirschner wire.

| | | Immobilization | |
|---|---|---|---|
| *Joint* | *Position* | *Type* | *Duration* |
| MP | Allow ROM | None | |
| PIP | Allow ROM[b] | None | |
| DIP | Full extension | Transarticular Kirschner wire and plastic splint | 5 weeks constant, followed by splint weaning[c] |
| | Full extension | Removable plastic splint | 3 weeks, night only[d] |

[a] The same regimen may be used in the treatment of closed mallet injuries.
[b] A few days of postoperative PIP immobilization is not detrimental, but prolonged PIP immobilization during the treatment of extensor tendon laceration over the middle phalanx or DIP joint will result in loss of total PIP flexion.
[c] Splint weaning—Remove splint for 1 hour each morning and evening for 3 days, then 2 hours each morning and evening for 3 days. If an DIP extension lag develops and active and passive flexion gradually increase during the 6 days, discontinue splinting during the day. If DIP extension lag (>10°) develops, return to constant splinting in full extension for an additional week, then resume the splint weaning.
[d] Night splinting in full DIP extension is recommended for 3 weeks following 5 weeks of constant extension splint wear. If an extension lag develops during the splint weaning, prolong night splinting.
ROM, range of motion.

***Table 49.12. Postoperative Management of Extensor Tendon Repair Over the Middle Phalanx or at the DIP Joint (Acute Mallet Deformity)[a]***

## LATE RECONSTRUCTION

Delayed extensor reconstruction is controversial, and many procedures have been described. The following are a few simple guidelines divided into general anatomic levels for the management of chronic extensor deficits.

### FOREARM, WRIST, AND DORSUM OF THE HAND

Wrist and MP extension are the functional losses accompanying disruption of wrist extensors and extrinsic digital extensors. Without wrist extensors, the grasp function of the hand is disabled. Loss of MP extension eliminates the placement arc of the fingers, while digital encompassment (IP flexion through FDP/FDS, and IP extension through intact intrinsic musculature) is maintained (49). Loss of either wrist extension or MP extension results in marked disability. Tenodesis and stiffened joints may also contribute to the clinical presentation.

Reconstructive goals are independent wrist or MP extension using a technique that provides satisfactory power and amplitude to meet functional requirements. Normal amplitude is rarely achieved, but adequate power for extensor function is a reasonable goal, since normal digital extensor strength is 10% of that of all the muscles below the elbow, and digital extensor work capacity is less than one third of that of the digital flexors (5). Indeed, according to Brand, the FDS and FDP of the middle finger alone are as strong as the extensors of all the other fingers (5).

The three options available for late reconstruction of extrinsic wrist and digital extensor loss are attempted delayed repair, interpositional tendon graft, and redistribution of power through tendon transfer. In general, tendon transfers are the most successful. Delayed repair and interpositional tendon graft suffer in comparison because the lacerated muscle–tendon unit is usually compromised by retraction, adherence, and weakness. There are multiple options for tendon transfers to restore wrist and MP extension; these methods are most fully described in treatises dealing with reconstruction following radial nerve palsy (see Chapter 55) (64). If composite tissue loss on the dorsum of the hand or forearm necessitates flap coverage, the use of silicone rods beneath the flap will facilitate later tendon transfer (61).

### EXTENSOR TENODESIS OF THE HAND AND DIGITS

Posttraumatic tenodesis of the extensor tendons over the metacarpals and phalanges is a relatively common clinical problem, presenting after extensor tendon injuries with or without fractures. The gliding layer has been disrupted in these cases and dense adhesions are present between the bone and extensor tendon. Extensor tenolysis in the hand or digit with or without use of synthetic interpositional material (silicone sheets, which eventually require removal) is a worthy surgical attempt to improve functional range of motion. The long-term results, however, are highly variable.

The gains in range of motion may be dramatically good in some patients and dismally poor in others. Adhesions may extend far beyond the level of injury; other factors, both objective (e.g., stiffened MP or IP joints, loss of muscle amplitude, altered tendon nutrition) and subjective (e.g., pain perception and tolerance, patient understanding and motivation), are as important as simply lysing tendon from bone. The gains in flexion will be more significant than the reduction in extensor lag, and the necessity for joint capsulotomy will decrease the overall benefit of extensor tenolysis (12). If the joints are supple, however, and a well-motivated patient understands the rigors of maintaining postoperative tendon excursion, tenolysis is an acceptable surgical option.

The PIP joint, which accounts for 85% of final interphalangeal encompassment, is most affected by extensor tenodesis of the central slip over the proximal phalanx (48,49). Consider the feasibility of separation of the extrinsic and intrinsic contributions to the extensor mechanism at the proximal phalangeal level. The extrinsics would then be isolated as MP extensors. Excise the area of tenodesis to eliminate the extensor tether of the PIP joint. If the lateral slips are normal and the area of tenodesis is proximal to the zone of convergence (Fig. 49.6), the intrinsic muscles then become the sole IP extensors. When possible, this solution to the problem can be very successful (44,45).

Few patients complain of loss of DIP flexion after extensor injury followed by tenodesis over the middle phalanx, even though DIP flexion is uniformly decreased after such injuries. Tenolysis at the middle phalangeal level could be considered in a patient with unique occupational demands (e.g., a professional musician, requiring maximum DIP range of motion).

## LATE BOUTONNIÈRE DEFORMITY

Reconstruction of the chronic boutonnière deformity is not easily accomplished and often frustrates the most experienced hand surgeons. The fixed or flexible nature of the PIP flexion deformity is extremely important in operative planning. All reconstructions in late boutonnière deformities depend on attainment of maximum passive PIP extension followed by appropriate distribution of the available extensor power (9,13,45,58,61,68,76).

## LATE SWAN-NECK AND MALLET DEFORMITIES

Many innovative reconstructive procedures have been proposed and used in restoration of swan-neck deformity. If the DIP joint assumes the extended position when PIP hyperextension is blocked at neutral or slight flexion, direct treatment simply at limiting PIP extension to a neutral or slightly flexed position.

A more challenging swan-neck deformity follows rupture of the terminal extensor in patients with lax PIP volar plates. The increased extensor pull on the middle phalanx (Fig. 49.10) causes progressive PIP hyperextension. In these cases, surgical management can be divided into two basic categories: procedures designed to shift extensor pull from the middle to the distal phalanx, and procedures using the dynamic interphalangeal tenodesis concept to limit PIP hyperextension and augment DIP extension.

The prime example of an extensor shift procedure is the Fowler central slip tenotomy (4,28,32). Tenotomy of the central slip reduces extensor tone on the PIP joint and allows proximal shift of the conjoined lateral bands, increasing DIP extensor tone. This procedure is simple and is usually effective in improving DIP extension and reducing PIP hyperextension. DIP extension will not be complete in most cases, however, and PIP extension lag is a potential problem following central slip tenotomy (71). Use this procedure exclusively in swan-neck deformities resulting from rupture and separation of the terminal extensor tendon.

Several procedures have been described that create a strong oblique retinacular ligament homologue; they have been reported to be effective (30,42,43,73). These procedures provide predictable methods for correcting loss of DIP extension and PIP hyperextension.

If the deformity is purely DIP extension loss (mallet finger) with no tendency toward PIP hyperextension, direct treatment toward reconstituting the terminal extensor tendon by excision of interposed scar and secondary repair, tendon graft, or tendodermadesis (34).

## THUMB

Late extensor deficits are less common in the thumb ray than in the fingers because of the thumb's recessed and palmar abducted position, which provides relative protection from longitudinal dorsal trauma. The thumb of the nondominant glove hand in baseball and softball is an exception to this rule, but athletes tend to sustain fractures and ligament injuries rather than extensor tendon deficits after thumb trauma.

Most late extensor deficits in the thumb occur secondary to the deformities of rheumatoid disease or attritional rupture of the EPL following a distal radial fracture. Reconstruction of the rheumatoid thumb is discussed in Chapter 70. Tendon transfer, especially EIP, provides the most satisfactory solution to late EPL deficit, if the joints are supple (70). All procedures discussed in this chapter regarding late mallet deformities are applicable, but rarely applied, to the thumb.

## CHAPTER REFERENCES

Each reference is categorized according to the following scheme: *, classic article; #, review article; !, basic research article; and +, clinical results/outcome study.


! 1. Agee J, Gudera M. The Functional Significance of the Juncturae Tendinae in Dynamic Stabilization of the Metacarpophalangeal Joints of the Fingers. *J Hand Surg* 1980;5:288.

! 2. Albright J, Linburg RM. Common Variations of the Radial Wrist Extensors. *J Hand Surg* 1978;3A:134.

+ 3. Aulicino PL. Acute Injuries of the Extensor Tendons Proximal to the Metacarpophalangeal Joint. *Hand Clin* 1995;11:403.

+ 4. Bowers WH, Hurst LC. Chronic Mallet Finger: The Use of Fowler's Central Slip Release. *J Hand Surg* 1978;3:373.

* 5. Brand PW. *Clinical Mechanics of the Hand*. St. Louis: CV Mosby, 1985:273.

+ 6. Brown EZ Jr, Ribik CA. Early Dynamic Splinting for Extensor Tendon Injuries. *J Hand Surg* 1989;14A:72.

* 7. Bunnell S. Repair of Tendons in the Fingers. *Surg Gynecol Obstet* 1922;35:38.

* 8. Bunnell S. Surgery of Intrinsic Muscles of the Hand. *J Bone Joint Surg* 1942;24:1.

# 9. Burton RI. Extensor Tendons—Late Reconstruction. In: Green DP, Hotchkiss RN, Pederson WC, eds. *Green's Operative Hand Surgery*, 4th ed. New York: Churchill Livingstone, 1999: 1988.

+ 10. Carroll C, Moore JR, Weiland AJ. Posttraumatic Ulnar Subluxation of the Extensor Tendon: A Reconstructive Technique. *J Hand Surg* 1987;12A:227.

+ 11. Crawford GP. The Molded Polythene Splint for Mallet Finger Deformities. *J Hand Surg* 1984;9A:231.

+ 12. Creighton JJ Jr, Steichen JB. Retrospective Statistical Analysis of Motion Following Extensor Tenolysis in the Hand and Digit. *J Hand Surg* 1986;11A:761.

+ 13. Curtis RM, Reid RL, Provost JM. A Staged Technique for Repair of the Traumatic Boutonnière Deformity. *J Hand Surg* 1983;8:167.

+ 14. Dabezies EJ, Schutte JP. Fixation of Metacarpal and Phalangeal Fractures with Miniature Plates and Screws. *J Hand Surg* 1986;11A:283.

# 15. Doyle JR. Extensor Tendons—Acute Injuries. In: Green DP, Hotchkiss RN, Pederson WC, eds. *Green's Operative Hand Surgery*. 4th ed. New York: Churchill Livingstone, 1999: 1950.

+ 16. Dreyfuss UY, Singer M. Human Bites of the Hand: A Study of One Hundred Six Patients. *J Hand Surg* 1985;10A:884.

* 17. Eaton RG. The Extensor Mechanism of the Fingers. *Bull Hosp Joint Dis* 1969;30:39.

! 18. Elliot D, McGrouther DA. The Excursions of the Long Extensor Tendons of the Hand. *J Hand Surg* 1986;11B:77.

+ 19. Elliott RA Jr. Injuries to the Extensor Mechanisms of the Hand. *Orthop Clin North Am* 1970;1:335.

+ 20. Entin MA. Repair of the Extensor Mechanism of the Hand. *Surg Clin North Am* 1960;40:275.

+ 21. Evans RB. Early Active Short Arc Motion for the Repaired Central Slip. *J Hand Surg* 1994;19A:991.

# 22. Eversman WW. Complications of Extensor Tendon Injuries. In: Boswick JA, ed. *Complications in Hand Surgery.* Philadelphia: WB Saunders, 1986:38.

* 23. Flatt AE. *The Care of Minor Hand Injuries*, 4th ed. St. Louis: CV Mosby, 1979.

* 24. Fowler SB. *Extensor Apparatus of the Digits. J Bone Joint Surg Br* 1949;31:477.

+ 25. Froehlich JA, Akelman E, Herndon JH. Extensor Tendon Injuries at the Proximal Interphalangeal Joint. *Hand Clin* 1988;4:25.

+ 26. Garberman SF, Diao E, Peimer CA. Mallet Finger: Results of Early versus Delayed Closed Treatment. *J Hand Surg* 1994;19A:850.

! 27. Gonzalez MH, Weinzweig N, Kay T, Grindel S. Anatomy of the Extensor Tendons to the Index. *J Hand Surg* 1996;21A:988.

+ 28. Grundberg AB, Reagan DS. Central Slip Tenotomy for Chronic Mallet Finger Deformity. *J Hand Surg* 1987;12A:545.

! 29. Harris C, Rutledge GL Jr. The Functional Anatomy of the Extensor Mechanism of the Finger. *J Bone Joint Surg Am* 1972;54:713.

+ 30. Harvey FJ, Hume KF. Spontaneous Recurrent Ulnar Dislocation of the Long Extensor Tendons of the Fingers. *J Hand Surg* 1980;5:492.

* 31. Hauck G. Die Ruptur der Dorsal Aponeuroe am ersten Interphalangeal Gelenk, zugleich eim Beitrag zur Anatomie and Physiologie der Dorsal Aponeurose. *Arch Klin Chir* 1923;123:197.

+ 32. Houpt P, Dijikstra R, Storm van Leeuwen JB. Fowler's Tenotomy for Mallet Finger Deformity. *J Hand Surg* 1993;18B:499.

+ 33. Inoue G, Tamura Y. Dislocation of the Extensor Tendons over the Metacarpophalangeal Joints. *J Hand Surg* 1996;21A:464.

+ 34. Iselin F, Levame J, Godoy J. A Simplified Technique for Treating Mallet Fingers: Tenodemadesis. *J Hand Surg* 1977;5:214.

+ 35. Ishizuki M. Traumatic and Spontaneous Dislocation of Extensor Tendon of the Long Finger. *J Hand Surg* 1990;15A:967.

* 36. Kaplan EB. Anatomy, Injuries and Treatment of the Extensor Apparatus of the Hand and Fingers. *Clin Orthop* 1959;13:24.

* 37. Kaplan EB. *Functional and Surgical Anatomy of the Hand,* 2nd ed. Philadelphia: JB Lippincott, 1965.

+ 38. Kleinman WB, Peterson DP. Oblique Retinacular Ligament Reconstruction for Chronic Mallet Finger Deformity. *J Hand Surg* 1984;9A:399.

* 39. Landsmeer JMF. Anatomy of the Dorsal Aponeurosis of the Human Finger and Its Functional Significance. *Anat Rec* 1949;104:31.

* 40. Landsmeer JMF. The Coordination of Finger Joint Motions. *J Bone Joint Surg Am* 1963;45:1654.

* 41. Littler JW. Tendon Transfers and Arthrodesis in Combined Median and Ulnar Nerve Paralysis. *J Bone Joint Surg Am* 1949;31:225.

* 42. Littler JW. Restoration of the Oblique Retinacular Ligament for Correcting Hyperextension Deformity of the Proximal Interphalangeal Joint. Groupe d'Éaatudes de la Main L'Expansion Editeur. 1966;1:39.

* 43. Littler JW. The Finger Extensor Mechanism. *Surg Clin North Am* 1967;47:415.

* 44. Littler JW. Principles of Reconstructive Surgery of the hand. In: Converse JM, ed. *Reconstructive Plastic Surgery,* 2nd ed., vol. VI. Philadelphia: WB Saunders, 1977:3127.

* 45. Littler JW. The Digital Extensor-Flexor System. In: Converse JM, ed. *Reconstructive Plastic Surgery,* 2nd ed., vol. VI. Philadelphia: WB Saunders, 1977:3173.

* 46. Littler JW. The Finger Extensor System. *Orthop Clin North Am* 1986;17:483.

* 47. Littler JW, Eaton RG. Redistribution of Forces in Correction of Boutonnière Deformity. *J Bone Joint Surg Am* 1967;49:1267.

* 48. Littler JW, Herndon JH, Thompson JS. Examination of the Hand. In: Converse JM, ed. *Reconstructive Plastic Surgery,* 2nd ed., vol. VI. Philadelphia: WB Saunders, 1977:2964.

* 49. Littler JW, Thompson JS. Surgical and Functional Anatomy. In: Bowers WH, ed. *The Interphalangeal Joints*. New York: Churchill Livingstone, 1987:14.

* 50. Mason ML, Shearon CG. The Process of Tendon Repair: An Experimental Study of Tendon Suture and Tendon Graft. *Arch Surg* 1932;25:616.

+ 51. McFarlane RM, Hampole MK. Treatment of Extensor Tendon Injuries of the Hand. *Can J Surg* 1973;16:366.

+ 52. Melone CP Jr. Rigid Fixation of Phalangeal and Metacarpal Fractures. *Orthop Clin North Am* 1986;17:421.

! 53. Micks JE, Hager D. Role of the Controversial Parts of the Extensor of the Finger. *J Bone Joint Surg Am* 1973;55:884.

! 54. Micks JE, Reswick JB. Confirmation of Differential Loading of Lateral and Central Fibers of the Extensor Tendon. *J Hand Surg* 1981;6:462.

* 55. Milford LW.*Retaining Ligaments of the Digits of the Hand.* Philadelphia: WB Saunders, 1968.

+ 56. Rayan GM, Murray D. Classification and Treatment of Closed Sagittal Band Injuries. *J Hand Surg* 1994;19A:590.

+ 57. Ritts GD, Wood MB, Engber WD. Nonoperative Treatment of Traumatic Dislocations of the Extensor Digitorum Tendons in Patients Without Rheumatoid Disorders. *J Hand Surg* 1985;10A:714.

# 58. Rosenthal EA. Extensor Surface Injuries at the Proximal Interphalangeal Joint. In: Bowers WH, ed. *The Interphalangeal Joints*. New York: Churchill Livingstone, 1987:94.

+ 59. Saldana MJ, McGuire RA. Chronic Painful Subluxation of the Metacarpal Phalangeal Joint Extensor Tendons. *J Hand Surg* 1986;11A:420.

! 60. Schneck RR. Variations of the Extensor Tendons of the Fingers. Surgical Significance. *J Bone Joint Surg Am* 1964;46:103.

! 61. Schneider LH. Reconstruction in Chronic Extensor Tendon Problems. In: Strickland JW, Steichen JB, eds. *Difficult Problems in Hand Surgery.* St. Louis: CV Mosby, 1982:47.

! 62. Schultz RJ, Furlong J, Storace A. Detailed Anatomy of the Extensor Mechanism at the Proximal Aspect of the Finger. *J Hand Surg* 1981;6:493.

* 63. Shrewsbury MM, Johnson RK. A Systematic Study of the Oblique Retinacular Ligament of the Human Finger: Its Structure and Function. *J Hand Surg* 1977;2:194.

# 64. Smith RJ.*Tendon Transfers in the Hand and Forearm.* Boston: Little, Brown, 1987.

+ 65. Stack HG. Mallet Finger. *Hand* 1969;1:83.

+ 66. Stack HG. Bottonhole Deformity. *Hand* 1971;3:152.

! 67. Steichen JB, Petersen DP. Junctura Tendinum between Extensor Digitorum Communis and Extensor Pollicis Longus. *J Hand Surg* 1984;9A:674.

+ 68. Stern PJ. Extensor Tenotomy: A Technique for Correction of Posttraumatic Distal Interphalangeal Joint Hyperextension Deformity. *J Hand Surg* 1989;14A:546.

! 69. Taleisnik J, Gelberman RH, Miller BW, Szabo RM. The Extensor Retinaculum at the Wrist. *J Hand Surg* 1984;9A:495.

# 70. Thompson JS. Surgical Treatment of Trapeziometacarpal Anthrosis. *Adv Orthop Surg* 1986;10:105.

# 71. Thompson JS. Interphalangeal Arthroplasties. In: Bowers WH, ed.*The Interphalangeal Joints.* New York: Churchill Livingstone, 1987:156.

* 72. Thompson JS, Littler JW. Dressings and Splints. In: Converse JM, ed. *Reconstructive Plastic Surgery,* 2nd ed., vol. VI. Philadelphia: WB Saunders, 1977:2991.

* 73. Thompson JS, Littler JW, Upton J. The Spiral Oblique Retinacular Ligament (SORL). *J Hand Surg* 1978;3:482.

+ 74. Tubiana R. Surgical Repair of the Extensor Apparatus of the Fingers. *Surg Clin North Am* 1968;48:1015.

! 75. Tubiana R, Valentin P. Anatomy of the Extensor Apparatus and the Physiology of Finger Extension. *Surg Clin North Am* 1964;44:897.

+ 76. Urbaniak JR, Hayes MG. Chronic Boutonnière Deformity—An Anatomic Reconstruction. *J Hand Surg* 1981;6:379.

! 77. von Schroeder HP, Botte MJ. The Extensor Medii Proprius and Anomalous Extensor Tendons to the Long Finger. *J Bone Joint Surg Am* 1991;16:1141.

! 78. von Schroeder HP, Botte MJ. The Functional Significance of the Long Extensors and Juncturae Tendium in Finger Extension. *J Hand Surg* 1993;18:641.

! 79. von Schroeder HP, Botte MJ. Anatomy of the Extensor Tendons of the Fingers: Variations and Multiplicity. *J Hand Surg* 1995;20A:27.

! 80. von Schroeder HP, Botte MJ, Gellman H. Anatomy of the Juncturae Tendinum of the Hand. *J Hand Surg* 1990;15A:595.

* 81. Walsh JF.*The Anatomy and Functions of the Muscles of the Hand.* Philadelphia: Charles H. Walsh, 1987.

* 82. Weitbrecht J. *Syndesmology (Historia Ligamentum Corporis Humani)*, 1742. Translated by Kaplan EB. Philadelphia: WB Saunders, 1969.

! 83. Wood VE. The Extensor Carpi Radialis Intermedius Tendon. *J Hand Surg* 1988;13A:242.

# CHAPTER 50

# STENOSING TENOSYNOVITIS AND EPICONDYLITIS

*Mark E. Pruzansky*

**M. E. Pruzansky:** Department of Orthopaedic Surgery, Mt. Sinai School of Medicine, New York, New York, 10028.

Trigger Digit
Percutaneous Release
Pitfalls and Complications
De Quervain's Disease
Decompression of First Dorsal Compartment of the Wrist
Pitfalls and Complications
Lateral Epicondylitis
Repair of Extensor Tendon Origin
Pitfalls and Complications
Medial Epicondylitis
Repair of Flexor Tendon Origin
Pitfalls and Complications
Tendinitis About the Wrist
Finger Flexor Tendinitis In the Carpal Tunnel
Flexor Tenosynovectomy
Wrist Flexor Tendinitis
Decompression of Wrist Flexor Tendons
Pitfalls and Complications
Finger Extensor Tendinitis At the Wrist
Decompression of Finger Extensor Tendons
Pitfalls and Complications
Radial Wrist Extensor Tendinitis
Decompression of Wrist Extensors
Pitfalls and Complications
Ulnar Wrist Extensor Tendinitis
Reconstruction of the Sixth Dorsal Compartment Retinaculum
Pitfalls and Complications
Chapter References

Normal function of the hand requires the smooth and almost frictionless gliding of flexor and extensor tendons. Inflammation of the tenosynovium, especially at points where a tendon changes direction, can lead to stenosis of the tendon sheath, which interferes with the action of the enclosed tendon. Symptoms include pain and limitation or irregularity of joint motion. Stenosing tenosynovitis may affect any of the flexor or extensor tendons, alone or in combination.

Causes of stenosing tenosynovitis include acute trauma, repetitive trauma related to occupation or sports, tumor, infection, gout, rheumatoid arthritis, and metabolic disorders. The principles of treatment include cessation or modification of the activities contributing to pain, hand therapy, use of antiinflammatory agents, and surgical correction of the impediments to tendon motion.

## TRIGGER DIGIT

Trigger digit is usually the result of constriction of the first annular pulley of the flexor tendon sheath, which causes pain and difficulty in extending or flexing the proximal interphalangeal joint (44,66,94). In the case of trigger thumb, the patient has difficulty extending or flexing the interphalangeal joint (45,98). It appears that fibrocartilaginous metaplasia of the $A_1$ pulley is the cause of the crepitus (82). Repetitive flexion and direct trauma may also cause stenosing tenosynovitis of the flexor tendon of the finger (9,10,25,48,64,88). The patient feels pain when the digit is forcibly straightened or flexed. Extending the distal interphalangeal joint before straightening the proximal interphalangeal joint often avoids the characteristic painful snap. On palpation, there is usually tenderness just proximal to the metacarpophalangeal joint on the palmar side.

Traumatic flexor tenosynovitis is a reactive swelling in the flexor digitorum profundus or flexor pollicis longus tendon, which is proximal or distal to the $A_1$ pulley. A ganglion within the substance of the first or second annular pulleys may be found in cases of stenosing tenosynovitis of the flexor tendons of the digits.

Not all joint “catching” is due to stenosing tenosynovitis. Interphalangeal joint locking may be caused by interference with the normal gliding mechanism of the lateral bands or by irregularities within the interphalangeal joints. Osteophytes and malunited fractures of the proximal interphalangeal joints can block extensor hood function and the normal motion of the collateral ligaments, and joint “mice” can restrict proximal interphalangeal joint mobility.

Trigger digit occurs most commonly in healthy women who are in their sixth decade of life (17,24,54,58,64,80,81,83). It is associated with de Quervain's disease, with carpal tunnel syndrome, and with triggering of any of the other nine digits of the hand (1,6,8,38,54,58,80,81). It occurs more commonly in de Quervain's disease than in carpal tunnel syndrome.

The incidence of trigger finger is increased in patients with Dupuytren's disease, rheumatoid arthritis, or diabetes mellitus (15). It is associated with another type of tenosynovitis in more than two thirds of patients, and it is bilateral in 25% (78,80). Congenital trigger digit is the most common form of digital flexion contracture in infants (22). Trigger thumb is sometimes hereditary, and it occurs more commonly than trigger finger (16,21,22,45,86,93). Surgical correction can be deferred until 1 year of age without permanent loss of motion. Thirty percent of congenital cases correct themselves spontaneously before 1 year of age. Splint immobilization and steroid injection in the flexor tendon sheath may be curative (69).

Surgery is warranted if symptoms persist despite conservative management. Percutaneous release is less reliable than other surgical techniques and offers little advantage in the middle and ring fingers (3,79). For nonrheumatoid patients, percutaneous release is an available but less reliable form of treatment than others (3,79). It is indicated in the middle and ring fingers where the risk of nerve damage is less than in other digits. It may be indicated in the elderly patient with Dupuytren's disease. The best cure rates are obtained when the patient is actively locking. The technique involves the use of a 19-gauge needle to cut the $A_1$ pulley distal to proximal over the hyperextended metacarpophalangeal joint. Partial laceration of the superficialis tendon is common but generally does not result in clinical sequelae.

### PERCUTANEOUS RELEASE

- Infiltrate the area of the proposed skin incision with local anesthetic. In the case of stenosing tenosynovitis of the index finger, incise the proximal flexor crease of the palm. In treating triggering of the middle, ring, or little fingers, make a 15 mm incision in the distal flexion crease. In the thumb, incise the proximal flexion crease in the area between the two sesamoids (Fig. 50.1).

***Figure 50.1.*** Skin incision for correction of trigger thumb.

- With pneumatic tourniquet control, clear fat from the palmar surface of the flexor tendon sheath by blunt dissection. Use medial and lateral Ragnel retractors to protect the neurovascular bundles (Fig. 50.2).

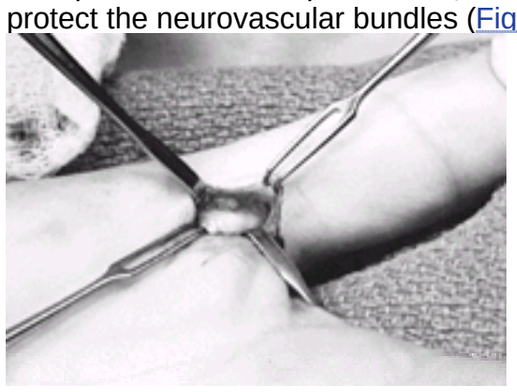

***Figure 50.2.*** Exposure of the thickened proximal pulley in a trigger thumb.

- Identify the proximal edge of the first annular band by its thickened transverse collagen bundles, which contrast with the longitudinal striations of the paratenon proximally.
- Incise the radial half of the proximal pulley and resect the redundant tenosynovium from the flexor tendons (Fig. 50.3). Withdraw both flexor tendons from the wound to examine them for thickening.

***Figure 50.3.*** Division of the proximal pulley of the thumb.

- If there are tendon nodules and triggering persists, perform a mid-lateral partial wedge resection of the tendon substance and primary closure.
- Evaluate the reconstruction by having the patient move the affected finger. If triggering still persists, partially section no more than 5 mm of the second annular band by gentle pressure with open blunt dissecting scissors.
- Fingers caught in extension may have nodular thickening of the flexor digitorum profundus tendon distal to the $A_2$ pulley or constriction of the sheath. Consider performing a partial sectioning of the distal edge of the $A_2$ pulley through an oblique incision near the proximal flexion crease of the finger, or perform an elliptical resection of tendon substance, followed by primary tendon closure.
- In patients with rheumatoid arthritis, strip the flexor tendons at their nodules and tenosynovium through a zigzag incision from the distal flexor crease at the palm to the volar distal interphalangeal joint crease. Preserve annular pulleys when the flexor sheath is opened. Repair them afterwards if their release is necessary. Resistance to ulnar drift is thereby improved.
- Occasionally, resection of the ulnar slip of the sublimis tendon is necessary to achieve adequate active and passive range of motion during the procedure.
- Achieve hemostasis after the tourniquet is released. Close the skin using nonabsorbable, interrupted sutures. Apply soft compression dressing to maximize finger mobility. Occupational therapy may be necessary to reduce residual soft-tissue contractures in chronic cases.

## PITFALLS AND COMPLICATIONS

Patients whose ethnic origins are associated with an increased propensity for Dupuytren's disease (i.e., those of Irish, English, and northern German extraction) may develop localized thickening of the palmar fascia as a complication of surgery for transverse bands of the trigger digit. Excise the palmar fascia that is visible around the edges of the skin incision to prevent this complication. In patients with demonstrable Dupuytren's disease, surgical correction of trigger digit may stimulate progression of fascial thickening, and the value of surgery should be weighed carefully against this risk. If neurovascular injury occurs during surgery, immediate microsurgical repair is indicated. Avoid resecting more than 25% of the second annular band to prevent PIP joint contraction and reduction of total active range of motion of the digit. Palpating the sesamoids overlying the first metacarpophalangeal joint prevents excessive radial placement of the skin incision and potential digital nerve damage.

## DE QUERVAIN'S DISEASE

In 1895, de Quervain described stenosing tenosynovitis of the abductor pollicis longus and extensor pollicis brevis within the first dorsal compartment of the wrist (21,27,42). Pain that often radiates up the forearm or down to the thumb and swelling over the radial styloid characterize the disorder (Fig. 50.4). Wringing motions of the hand and wrist, and repetitive flexion and extension of the thumb, especially the basal joint, magnify the symptoms (47,74). Finkelstein's maneuver (hyperflexion of the entire first ray with ulnar deviation of the wrist) reproduces the pain during physical examination (27). Tenderness on palpation of the radial styloid process and crepitus on motion of the first ray may be evident (13,42). The inflammatory process may involve either or both the long abductor and short extensor tendons of the thumb. The abductor pollicis longus is made up of two or more tendons in 80% of patients (27,61,90). Ganglionic degeneration of the roof of the first extensor compartment is sometimes found.

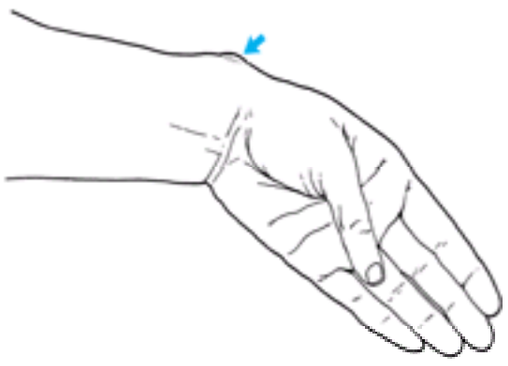

***Figure 50.4.*** Nodular thickening of the first dorsal compartment in de Quervain's disease.

De Quervain's disease occurs most commonly in healthy women in their sixth decade of life (19,53,56,59,68,89,96). An increased incidence of de Quervain's disease has been found in patients with Dupuytren's disease, rheumatoid arthritis, gout, or diabetes mellitus. Many patients with de Quervain's disease develop trigger finger or

carpal tunnel syndrome, or both, although the reverse is not true (1,25,38,54,63,80,81). Bilateral involvement eventually occurs in 30% of patients with de Quervain's disease (80,81).

Osseous malformations, fracture nonunions, and arthritis of the radiocarpal and carpometacarpal joints must be identified before treatment. Try brief periods of splint immobilization of the wrist, including the first metacarpal, and glucocorticoid injections of the first dorsal compartment; these are, however, less successful in treating de Quervain's disease than other forms of stenosing tenosynovitis. Avoid prolonged splinting. Instead, initiate active and passive stretching exercises early to promote tendon gliding. Surgery is indicated if the symptoms persist despite conservative treatment.

**DECOMPRESSION OF FIRST DORSAL COMPARTMENT OF THE WRIST**

- Infiltrate the area of the proposed skin incision with local anesthetic before inflating the pneumatic tourniquet (Fig. 50.5). Make the dorsal half of the incision along a transverse extensor crease of the wrist about 10 mm proximal to the tip of the radial styloid (Fig. 50.6). Follow Langer's lines in a palmar direction, making a 30 mm incision centered over the radial styloid. Radial sensory nerve branches are encountered just deep to the dermis; protect them by gentle retraction (Fig. 50.7).

***Figure 50.5.*** Infiltration of the skin in surgery for de Quervain's disease.

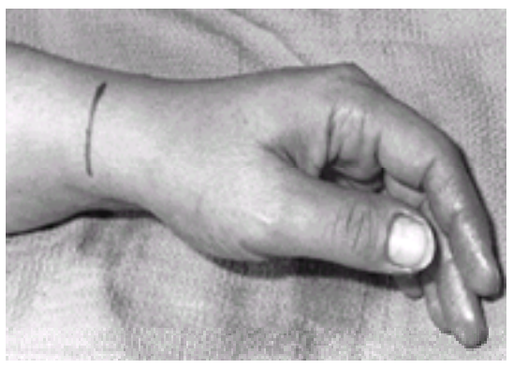

***Figure 50.6.*** Skin incision for surgical treatment of de Quervain's disease.

***Figure 50.7.*** Exposure of the thickened roof of the first dorsal compartment.

- With a scalpel, incise the thickened sheath of the first dorsal compartment distally and proximally (Fig. 50.8). There may be more than one septum separating the numerous slips of the abductor pollicis longus or the extensor pollicis brevis; carefully identify each tendon.

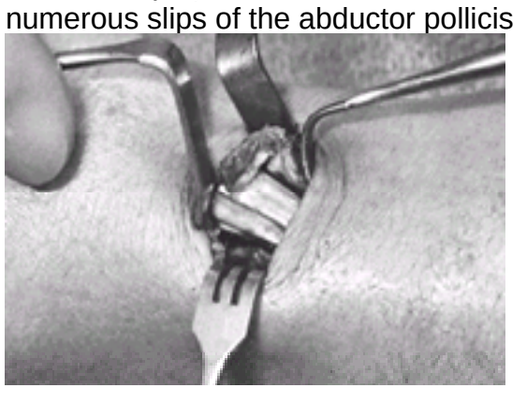

***Figure 50.8.*** Elevation of the roof of the first dorsal compartment.

- Excise thickened tenosynovium and retinacular ganglia. Examine the floor of the first dorsal compartment for bony, neoplastic, and calcific irregularities or anomalous tunnels containing aberrant tendons. These must be unroofed. Ask the patient to flex and extend the thumb to demonstrate unimpeded motion.
- After the tourniquet is released, achieve hemostasis. Close the skin with a nonabsorbable intracuticular suture (Fig. 50.9). To prevent palmar subluxation of the tendons, apply a palmar spica splint for 2 weeks until the skin suture is removed.

***Figure 50.9.*** Running intracuticular 5-0 monofilament steel suture is tied over a 4×4 cm gauze dressing.

## PITFALLS AND COMPLICATIONS

Failure to free the extensor pollicis brevis completely from thick adhesions to the abductor pollicis longus or failure to identify and to incise its separate sheath may cause symptoms to persist. The abductor pollicis longus may have multiple slips inserting into the first metacarpal and into the trapezium, carpometacarpal joint capsule, fascia of the opponens or abductor pollicis brevis, or flexor retinaculum. Failure to identify and separate all of the tendons may result in incomplete resolution of symptoms.

Laceration of the radial sensory nerve branches warrants immediate microsurgical repair to reduce the likelihood of painful neuroma formation. Compression of the terminal branches of the radial nerve may also produce pain in the area of the first dorsal compartment. Symptoms include numbness and tingling over the dorsal surface of the thumb and index finger. Paresthesias are accentuated by percussion in this area. In making a diagnosis, be careful to differentiate this nerve compression syndrome (Wartenberg's disease) from de Quervain's disease.

## LATERAL EPICONDYLITIS

Lateral epicondylitis is inflammation of the common extensor origin of the elbow. It is often referred to as “tennis elbow” (8,18,33,34,36,60,70,71 and 72). Usually, there are small tears of the tendon of origin of the extensor carpi radialis brevis, although the extensor digitorum communis may be involved as well (70,72). The pathology ranges from angiofibroblastic proliferation to complete tendon rupture (24,71). Pain over the lateral epicondyle and extensor muscle mass when lifting objects palm down and when playing racket sports is characteristic. Throwing and wringing motions may also be painful. Grip strength is decreased as a result of pain on attempts to stabilize the wrist in extension. Tenderness to palpation occurs over the lateral epicondyle of the elbow and radial collateral ligament. Wrist extension against resistance causes pain at the lateral epicondyle. Radiographic evaluation of the elbow may demonstrate a lateral exostosis, bone fragments, or calcific deposits over the lateral epicondyle.

Lateral epicondylitis must be differentiated from radial tunnel syndrome, in which the posterior interosseous nerve is compressed under the fibrous arch of the supinator muscle (60). Radial tunnel syndrome is characterized by tenderness over the supinator, just distal to the radial head. Pain is reproduced by the patient resisting forearm pronation, or by resisting middle finger extension with the wrist supported. A lidocaine injection at the arcade may help to distinguish them. The two entities may coexist.

Treat lateral epicondylitis with rest, local application of ice, and nonsteroidal antiinflammatory drugs (49,72). A 90° long-arm splint with the wrist slightly extended and supinated may be used in recalcitrant cases, although it rarely affects the outcome. Local injections of glucocorticoids are helpful in severe cases; repeated injections, however, may cause delayed tendon rupture resulting from their catabolic effects. Advise patients to change to “palm-up” lifting and analyze their sport technique and form to prevent relapse.

A proximal forearm counterforce brace may help to prevent relapses. Because the condition is attributable to overuse, gentle and then progressive wrist curls to strengthen forearm extensors, and proper stretching exercises are indicated after the initial recovery is well under way (32). Surgery is indicated in the few cases that do not respond to conservative therapy. Endoscopic and arthroscopic releases do not have the outcome studies yet to justify their use (2,37).

### REPAIR OF EXTENSOR TENDON ORIGIN

- After administration of regional or general anesthesia, make a 5 cm longitudinal incision centered over the radial head (Fig. 50.10).

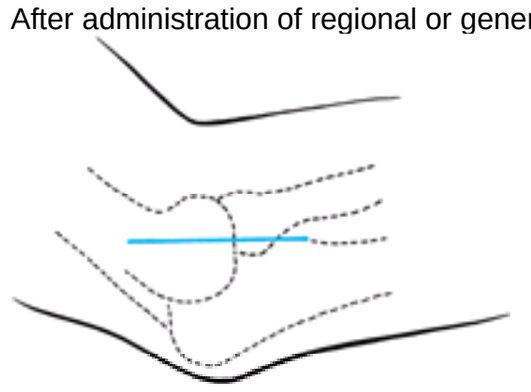

***Figure 50.10.*** Skin incision used in the surgical treatment of lateral epicondylitis.

- Retract and incise the antebrachial fascia over the extensor carpi radialis brevis, and identify the common extensor origin (Fig. 50.11). Gross disruption may be visible. Chronic inflammatory changes may be seen in the proximal margin of the extensor tendon, but angiofibroblastic changes become apparent after exposing the deep surface of the tendon of origin.

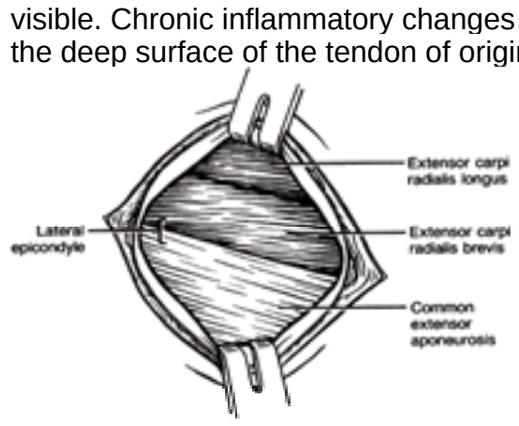


***Figure 50.11.*** Exposure of the common extensor muscle group with their tendons of origin after retraction of the antebrachial fascia.

- Incise the extensor aponeurosis longitudinally, where the damage is most accessible. You may need to elevate the extensor carpi radialis brevis completely as a flap (Fig. 50.12). Do not damage the radial or lateral ulnar collateral ligaments.

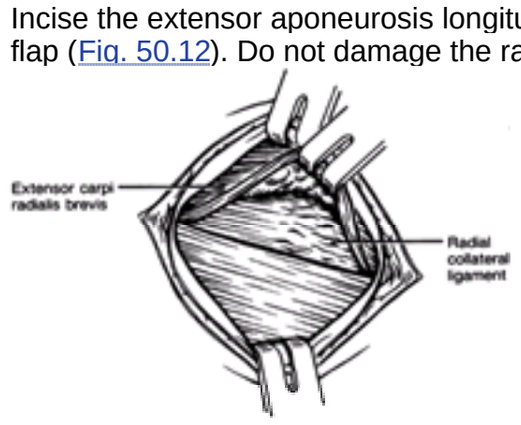


***Figure 50.12.*** Partial elevation of the tendon of origin of the extensor carpi radialis brevis, demonstrating tendinous degeneration on its undersurface where it is

attached to the lateral epicondyle and radial collateral ligament of the elbow.

- Remove proliferative synovium from the anterolateral joint if crepitus was felt preoperatively. Excise granulation tissue from beneath the extensor carpi radialis tendon (Fig. 50.13) and the extensor digitorum communis, if necessary. Debride degenerated tendon to healthy tissue. The deep surface of the tendon should be free of all granulation tissue (Fig. 50.14).

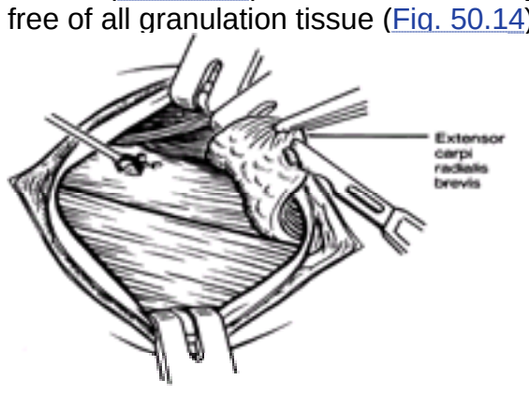


***Figure 50.13.*** Excision of granulations from the deep surface of the extensor carpi radialis brevis tendon and decortication of the lateral epicondyle.

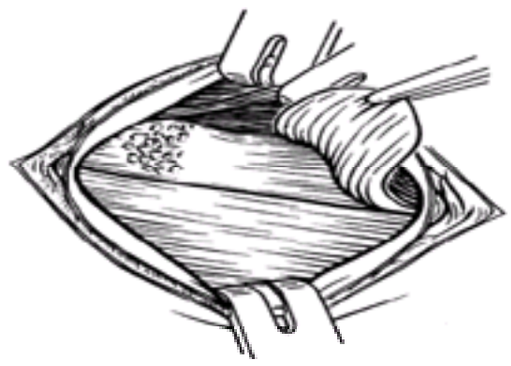

***Figure 50.14.*** Well-debrided tendon of origin of the extensor carpi radialis brevis and lateral epicondyle, which are decorticated and prepared for tendon reattachment.

- Decorticate the lateral epicondyle to punctate bleeding corticocancellous bone. Remove exostoses and calcifications.
- Suture the extensor carpi radialis brevis tendon to the surrounding periosteum and to the extensor digitorum communis tendon (Fig. 50.15). If adequate tendon length remains, suture it through connecting drill holes in the epicondylar ridge. When inadequate tissue remains for a repair, I use a tendon graft figure-of-eight. Place a bone tunnel or two suture anchors across the ridge. Capture the fascia and septa of the affected muscles distally (Fig. 50.16).

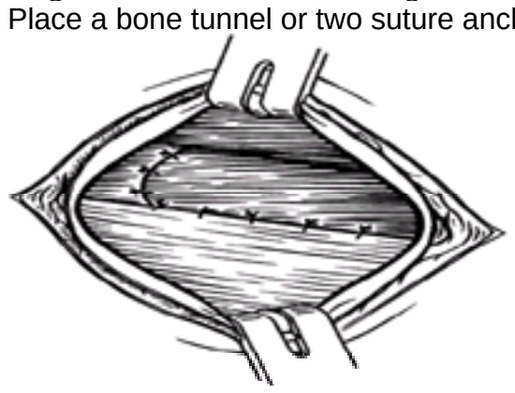

***Figure 50.15.*** Reattachment of the extensor carpi radialis brevis tendon of origin to the extensor aponeurosis and periosteum of the lateral epicondyle.

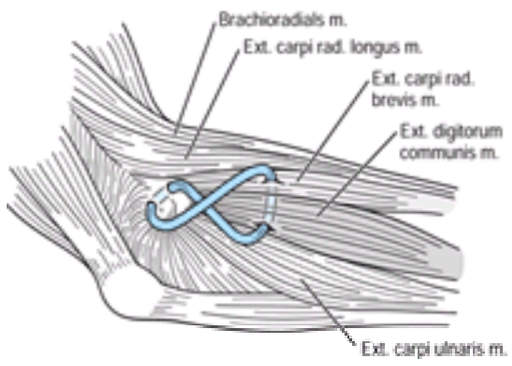


***Figure 50.16.*** Figure-of-eight tendon graft. See text for details.

- Suture the common extensor aponeurosis closed, and then close the skin. Immobilize the forearm in a long-arm splint in neutral rotation with the elbow flexed 90° and the wrist extended 20°. Remove the splint in 2 to 3 weeks, depending on the degree of extensor tendon repair. Encourage patients to begin gentle range-of-motion exercises, but they should avoid stress for 5 weeks. After that time, gradually initiate progressive, resistive exercises. Advise patients with complete tears to forego vigorous sports for 6 months.

## PITFALLS AND COMPLICATIONS

Lateral epicondylitis must be differentiated from other causes of lateral elbow pain. Rheumatoid arthritis, gout, radial tunnel nerve syndrome, osteochondritis dissecans, and loose bodies may cause lateral elbow pain alone or in concert with lateral epicondylitis.

## MEDIAL EPICONDYLITIS

The symptoms of medial epicondylitis include pain at the tendons of origin of the flexor pronator muscle group, most commonly the pronator teres and the flexor carpi radialis (30,32). Overuse in golf and throwing are common causes of microtearing in this near mirror-image of its lateral counterpart. During physical examination, pain on resisted pronation or wrist flexion helps to make the diagnosis.

Advise the patient to avoid provocative activities, as well as forceful gripping and twisting. Counterforce bracing over the proximal muscles of the pronator and flexor radialis may be useful; be careful to avoid ulnar nerve compression. Injection of a corticosteroid usually provides fast relief but no long-term benefit (87). Begin flexor

and pronator strengthening exercises when symptoms persist. Encourage sports technique training since medial epicondylitis is usually an overuse syndrome. Reserve surgery for at least 6 months in cases unresponsive to conservative care.

### REPAIR OF FLEXOR TENDON ORIGIN

- Make a skin incision 4 cm long, parallel and 1 cm proximal to the course of the ulnar nerve, beginning at the medial epicondyle. Take care to avoid branches of the medial antebrachial cutaneous nerve. Reflect the affected tendons—the pronator teres and flexor carpi radialis—off the medial epicondylar ridge. Reflect them as far posteriorly as the septum between the flexor carpi radialis and the palmaris longus (when present) or the humeral head of the flexor carpi ulnaris. While undermining distally, carefully consider the depth of dissection to avoid the anterior band of the medial collateral ligament.
- Roughen the epicondyle before reattaching the tendons to surrounding tendon and fascia. Use a suture if necessary through connecting drill holes, or one attached to an anchor, to affix the common tendon of origin more securely to the medial ridge.
- Place the arm into a long-arm splint for 3 weeks with the elbow flexed 90°, the forearm in neutral rotation, and the wrist at 0°. Begin strengthening exercises at 4 to 6 weeks and sports at 4 to 6 months.

## PITFALLS AND COMPLICATIONS

Medial epicondylar pain can be mimicked by nonunion, valgus instability, and medial antebrachial cutaneous or ulnar neuropathy. Plain and stress radiographic views may demonstrate nonunion of the medial epicondyle and laxity of the medial collateral ligament of the elbow. Tenderness to palpation and Tinel's sign may demonstrate more distal ligamentous laxity, superficial medial antebrachial cutaneous neuropathy, or posterior ulnar neuritis. Cubital tunnel syndrome and its subtle variations must be completely treated because they may coexist with medial epicondylitis (31,52). In such cases, even the additional release of the transverse humeral ligament will fail. Submuscular, ulnar nerve transposition must be added to the reconstruction to achieve a high level of success.

## TENDINITIS ABOUT THE WRIST

### FINGER FLEXOR TENDINITIS IN THE CARPAL TUNNEL

Thickening and fibrosis of the digital flexor tendons can occur in the carpal tunnel (51). Usually, it is idiopathic in origin, causing compression of the median nerve (see Chapter 52) (4,9,13,59). Repetitive motions of the digits and wrist and direct trauma may cause or exacerbate flexor tendonitis. Many conditions may precipitate symptomatic digital flexor tenosynovitis at the wrist. These include rheumatoid arthritis; gout; collagen vascular disease; anomalous muscles, tendons, and arteries; tumors; congenital dysplasias; fungus; tubercle bacillus; and atypical bacteria (1,4,10,39,41,50,58,62,63,67,78,83,97). Occasionally, local steroid injections or flexor tenosynovectomy are necessary in recalcitrant cases. Cases involving infection require surgical decompression and intravenous antibiotics. The treatment of dysplastic, neoplastic, toxic, and metabolic sources of flexor tendinitis usually requires surgical decompression and tenosynovectomy of the flexors or the carpal tunnel and pharmacologic therapy to protect the contents of the carpal tunnel from irreparable damage and to eradicate the underlying disease process.

Splinting of the wrist, application of ice, and administration of oral antiinflammatory agents are usually successful in treating noninfectious causes of this condition.

Flexor tenosynovectomy at the wrist can be performed through a limited incision distal to the transverse flexor crease of the wrist, or through a more extensive exposure involving a 4 cm zigzag proximal extension of the original thenar crease incision to include the distal forearm (see Chapter 52); the latter is more commonly used in patients with rheumatoid arthritis. Bone spurs need to be excised and large areas of raw bone covered with ligamentous rotation flaps or patch grafts of transverse retinacular origin.

### FLEXOR TENOSYNOVECTOMY

- In performing tenosynovectomy of the flexors of the carpal tunnel, be careful to avoid lacerating the large, aberrant sensory branches of the ulnar and median nerves in the subcutaneous fat, or those penetrating the transverse carpal ligament, or damaging the median nerve.
- Splint the dorsiflexed wrist for 2 weeks after surgery to allow a new, loose retinacular “ligament” to form, preventing painful recurrent subluxation of the finger flexors from the carpal tunnel when the hand is used to grip in the flexed wrist position. If subluxing flexor tendinitis occurs at the carpal tunnel, do a reconstruction of the transverse retinacular ligament using ligamentous remnants or the adjacent fascia.
- Fashion the new ligament at the distal margin of the carpal canal to prevent compression of the median nerve (Fig. 50.17, Fig. 50.18). Because Dupuytren's disease or its diathesis is exacerbated by this procedure, weigh the pros and cons of surgical management of flexor tendinitis carefully for patients with coexistent Dupuytren's disease.

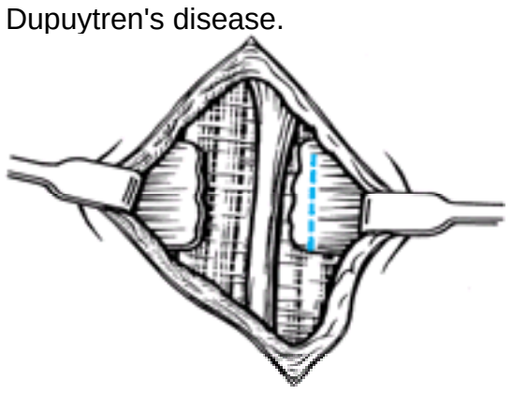

***Figure 50.17.*** Formation of a distally based “ligament” that is 5 mm in diameter.

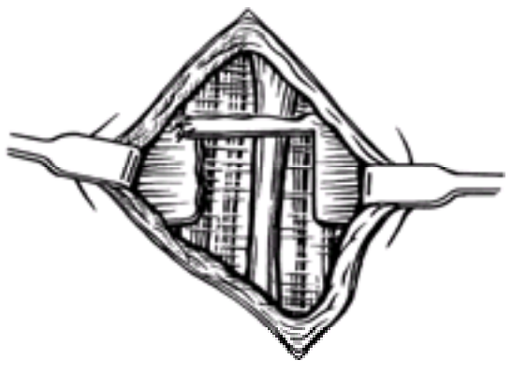

***Figure 50.18.*** A new transverse carpal ligament is sutured to the old ligamentous stump on the opposite side of the carpal tunnel.

## WRIST FLEXOR TENDINITIS

Inflammation of the tendons of the flexor carpi radialis and that of the flexor carpi ulnaris occur independently and are usually related to repetitive flexion, direct trauma, wrist fracture, cysts, or excessive wrist extension (28). Calcifications may exist within the tenosynovium (Fig. 50.19). Rheumatic, metabolic, infectious, and neoplastic diseases may also involve these tendons. Inflammation of the flexor carpi radialis tendon occurs in its fibroosseous tunnel within the transverse carpal ligament (28). The flexor carpi ulnaris tendon may become inflamed just proximal to the pisiform (77). The latter may also be involved in an arthritic process at its articulation with the triquetrum. Ulnar neuritis at Guyon's canal may be secondary to flexor carpi ulnaris tendinitis (77).

***Figure 50.19.*** Calcification of a portion of the tenosynovium of the flexor carpi ulnaris tendon.

When overuse is the cause, treatment includes volar splinting in neutral flexion, administration of oral antiinflammatory drugs, and local application of ice.

**DECOMPRESSION OF WRIST FLEXOR TENDONS**

- Decompress the flexor carpi radialis tendon using a 4 cm zigzag incision that begins at the tuberosity of the scaphoid and extends proximally.
- Open the fibro-osseous tunnel of the flexor carpi radialis and release adhesions and attachments to the trapezium (7,30). Look for and remove space-occupying lesions and exostoses.
- Repair or **Z**-lengthen a contracted flexor carpi radialis tendon.
- Close the skin with interrupted sutures and apply a dorsal splint in 20° flexion, which the patient must wear for 2 weeks.
- Advise the patient to begin active exercises after the sutures are removed.
- For surgical treatment of chronic flexor carpi ulnaris tendinitis, use a palmar-ulnar zigzag incision (Fig. 50.20).

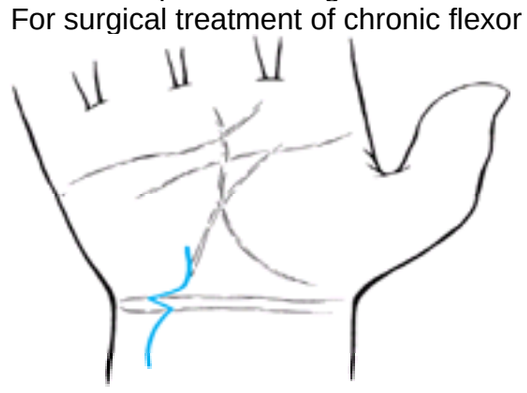

***Figure 50.20.*** The incision used to expose Guyon's canal and the distal portion of the flexor carpi ulnaris tendon.

- When signs of ulnar nerve compression are present, section the palmar fascia and the origin of the abductor digiti minimi muscle; also divide the pisohamate ligament, decompressing Guyon's canal (Fig. 50.21). Protect the ulnar nerve and artery proximally and distally, and preserve the pisiform metacarpal ligaments. When pisotriquetral arthritis is present, enucleate the pisiform subperiosteally from its capsule through a palmar longitudinal incision (Fig. 50.22, Fig. 50.23) (77).

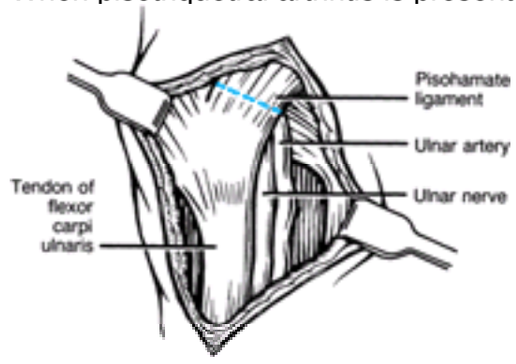


***Figure 50.21.*** Incision of the pisohamate ligament.

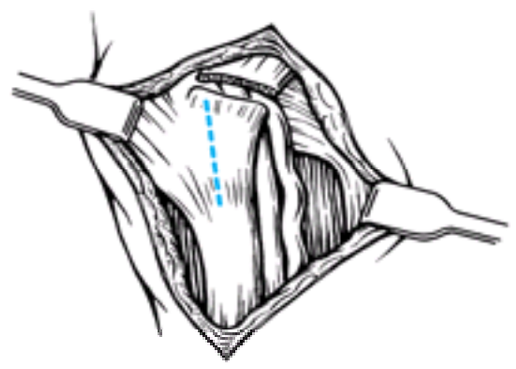

***Figure 50.22.*** Incision of the capsule of the pisiform.

***Figure 50.23.*** Removal of the pisiform.

- Just proximal to the pisiform, perform a **Z**-plasty of the flexor carpi ulnaris tendon to allow 5 mm of tendon lengthening (Fig. 50.24, Fig. 50.25) (77). Suture the

capsule of the pisiform closed.

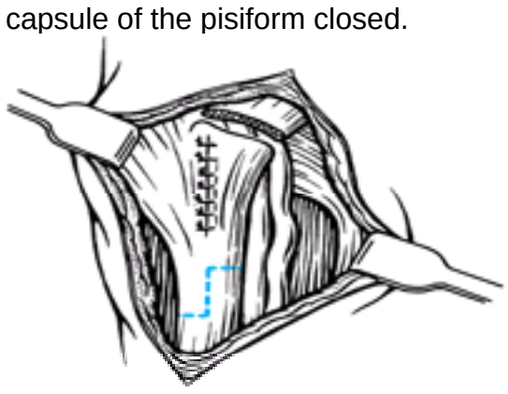

***Figure 50.24.*** Incision used to **Z**-lengthen the flexor carpi ulnaris tendon, with subsequent closure of the capsule of the pisiform.

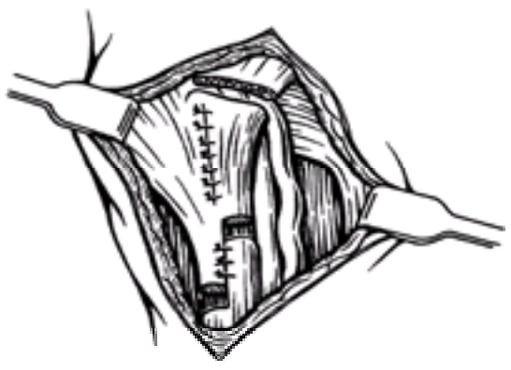

***Figure 50.25.*** Lengthening of the flexor carpi ulnaris tendon by 5 mm using a **Z**-plasty.

- After the tourniquet is released and hemostasis is achieved, close the skin. Immobilize the wrist for 2 weeks in a dorsal splint in 20° of palmar flexion until the sutures are removed.

## PITFALLS AND COMPLICATIONS

The palmar cutaneous branch of the median nerve must be carefully protected in the radial wrist exposure. The ulnar nerve and artery are in proximity to the flexor carpi ulnaris and can be injured by laceration or too-vigorous traction. The pisiform metacarpal ligament should be kept intact to avoid weakening wrist flexion in a palmar-ulnar direction.

## FINGER EXTENSOR TENDINITIS AT THE WRIST

Inflammation of the finger extensor tenosynovium can occur over the dorsum of the wrist, distal to and including the extensor retinaculum. Extension of the fingers causes heaping of the tenosynovium at the distal margin of the extensor retinaculum (Fig. 50.26). It is usually attributable to repetitive extension of the fingers and wrist or to direct trauma (9,10,64).

***Figure 50.26.*** Heaping up of the extensor tenosynovium distal to the extensor retinaculum during finger extension.

Rheumatoid arthritis, collagen vascular disease, gout, tumors, fungus, congenital dysplasias, and typical or atypical bacterial infections may also cause symptomatic extensor tenosynovitis of the wrist (4,5,10,39,41,50,57,58,62,63,67,78,83,97). Palmar splinting of the wrist in 20° extension, local application of ice, and dorsal administration of antiinflammatory drugs are usually successful in treating the condition. Local injections of steroids around the inflamed tenosynovium or extensor tenosynovectomy may be necessary in severe cases.

Isolated tenosynovitis of the extensor pollicis longus, known as “drummer boy” palsy (29,65), is caused by repetitive flexion and extension of the thumb with ulnar and radial deviation of the wrist. Treatment includes splinting, application of ice, and oral administration of nonsteroidal antiinflammatory drugs. Local instillation of steroid preparations or surgery is occasionally warranted.

### DECOMPRESSION OF FINGER EXTENSOR TENDONS

- After administering regional or general anesthesia, make an oblique incision from the base of the second metacarpal to the metaphysis of the distal ulna (Fig. 50.27). Identify and protect the sensory branches of the radial and ulnar nerves. If possible, retract rather than transect large veins while exposing the tendons in the distal part of the wound (Fig. 50.28).

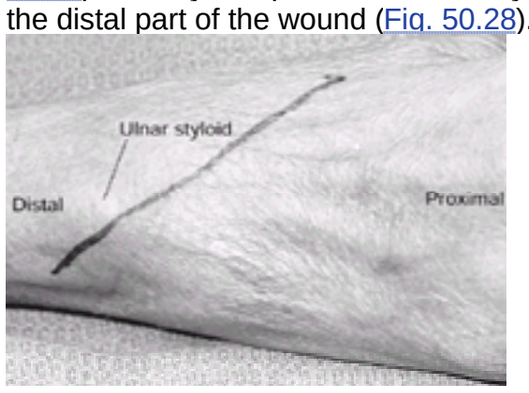


***Figure 50.27.*** The incision used to expose the extensor retinaculum.

***Figure 50.28.*** Tenosynovitis of the extensors at the wrist

- Incise the extensor retinaculum at the septum between the first and second dorsal compartments. Preserve the proximal 20% of the extensor retinaculum to prevent bow-stringing of the extensor tendons, and raise the extensor retinaculum as an ulnar-based flap until the sixth compartment is decompressed (Fig. 50.29). Remove Lister's tubercule using a rongeur.

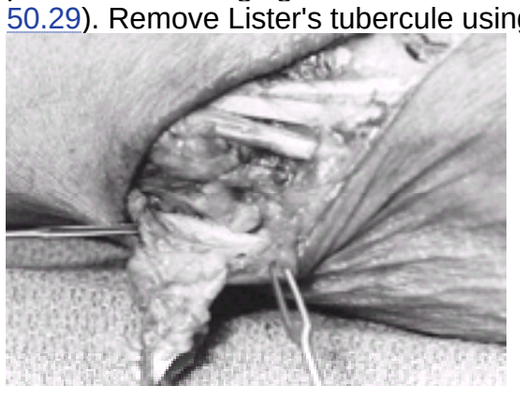

***Figure 50.29.*** The extensor retinaculum is raised as an ulnar-based flap.

- Excise the tenosynovium from all of the finger and wrist extensors (Fig. 50.30). Pass the flap of extensor retinaculum deep to the finger and wrist extensor, and sew it back to adjacent soft tissues in the area of the first dorsal compartment of the wrist (Fig. 50.31).

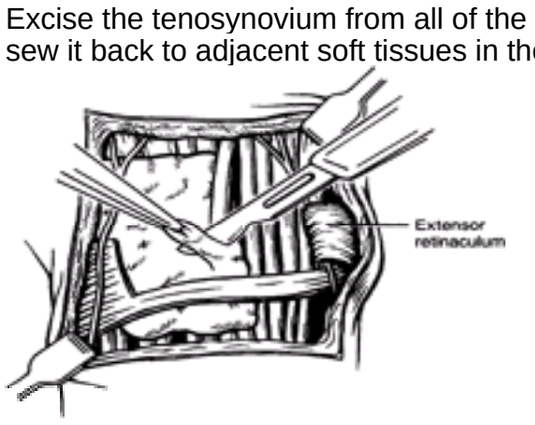


***Figure 50.30.*** Extensor tenosynovectomy.

***Figure 50.31.*** The extensor retinacular flap is laid deep to the extensor tendons and sewn to the roof of the first dorsal compartment and to the adjacent wrist capsule.

- After the tourniquet is released and hemostasis is achieved, close the wound. Drainage may be continued for 2 days, if necessary. Have the patient wear a 20° dorsiflexed palmar splint until the skin sutures are removed; then begin gentle active range-of-motion exercise.
- Treat isolated tenosynovitis of the extensor pollicis longus by incising the third dorsal compartment and by removing Lister's tubercle. Do this through a 2 cm transverse incision extending in an ulnar direction from Lister's tubercle.
- Protect the sensory branches of the radial nerve.
- Transpose the extensor pollicis longus tendon radially, away from Lister's tubercle, which has been removed. Suture the tendon sheath closed, and then close the skin. Have the patient wear a palmar splint for 2 weeks until the skin sutures are removed.

## PITFALLS AND COMPLICATIONS

The sensory branches of the superficial radial nerve and dorsal cutaneous branch of the ulnar nerve can be lacerated during surgery; take care to avoid them, and repair them if injured. The extensor pollicis longus tendon can also be lacerated as it crosses the radial wrist extensors obliquely. Immediate tenorrhaphy is necessary.

Extensor pollicis longus tendinitis can be differentiated from de Quervain's disease, as different points of maximal tenderness are evident with palpation.

## RADIAL WRIST EXTENSOR TENDINITIS

Radial wrist extensor tendinitis (intersection syndrome) is caused by inflammation of the tenosynovium of the extensor carpi radialis longus and brevis within the second dorsal extensor compartment of the wrist (40). Pain and swelling are elicited on palpation where the two wrist extensors cross the abductor pollicis longus and extensor pollicis brevis (6,40,43,92). The condition may be attributable to repetitive extension and flexion of the wrist or to direct trauma. It is known as “bugaboo forearm” in helicopter skiers (76).

Conservative therapy includes a palmar wrist splint in 20° extension, application of ice, administration of oral nonsteroidal antiinflammatory agents, and local injections of steroid preparations. Changing sports techniques and equipment is helpful. Surgery is reserved for recalcitrant cases that are unresponsive to prolonged conservative therapy, including steroid injections around the tendons just proximal to the extensor retinaculum.

### DECOMPRESSION OF WRIST EXTENSORS

- Using regional or general anesthesia, make an ulnar-based chevron incision over the second dorsal compartment, crossing the wrist creases diagonally. Protect the branches of the radial nerve.
- Incise the second dorsal extensor compartment and remove exuberant tenosynovium from the two radial wrist extensors back to their junction with the tendons of the abductor pollicis longus and extensor pollicis brevis (40). Attempt to leave intact a portion of the distal extensor retinaculum. Examine the tendons, and remove their tenosynovium. Achieve hemostasis after the tourniquet is released.
- Close the skin and apply a palmar splint in 20° dorsiflexion. Remove skin sutures 2 weeks later, and discard the splint.

## PITFALLS AND COMPLICATIONS

Intersection syndrome can be differentiated from de Quervain's disease on the basis of their different points of maximal tenderness. Sensory branches of the radial nerve should be repaired if lacerated.

## ULNAR WRIST EXTENSOR TENDINITIS

Ulnar wrist extensor tendinitis (i.e., chronic or recurrent subluxation of the extensor carpi ulnaris tendon) may result in painful tenosynovitis. This condition is usually attributable to a single forceful or repetitive hypersupination motion of the wrist with ulnar deviation (14). The infratendinous retinaculum of the wrist is stretched or ruptured, allowing palmar subluxation of the extensor carpi ulnaris tendon (14,35). Conservative management consists of splint immobilization in a dorsiflexed position, pronation, and radial deviation of the wrist. Administration of oral antiinflammatory agents and local injection of steroids may alleviate symptoms. Surgical reconstruction is indicated in selected individuals in whom conservative therapy fails to resolve symptoms (20).

### RECONSTRUCTION OF THE SIXTH DORSAL COMPARTMENT RETINACULUM

- After administration of general or regional anesthesia, pronate the wrist and make a hockey-stick incision from the base of the fifth metacarpal; extend it 2 cm radially and 4 cm proximally (Fig. 50.32). Protect the sensory branches of the ulnar nerve as they cross the distal portion of the wound. Expose the supratendinous portion of the retinaculum, and identify the sixth dorsal extensor compartment.

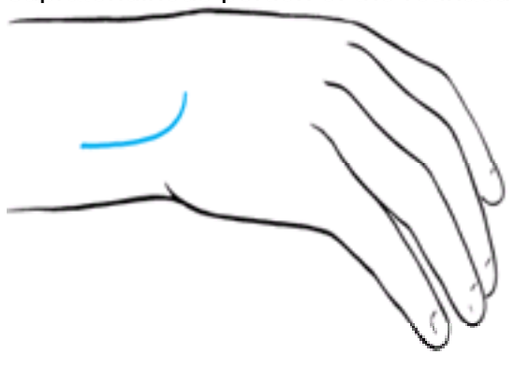

***Figure 50.32.*** Incision to reconstruct the sixth dorsal compartment of the wrist.

- Make a radially based flap about 1 cm wide and about 5 mm proximal to the distal margin of the retinaculum through the supratendinous extensor retinaculum. Make the window palmar enough to view the extensor carpi ulnaris tendon, which is subluxed into the depths of the wound (Fig. 50.33) (11).

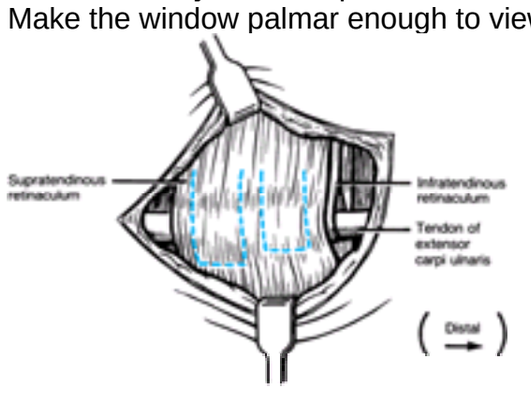


***Figure 50.33.*** Preparation of the flaps in the supratendinous portion of the extensor retinaculum.

- Locate the stretched or torn infratendinous retinaculum, which normally creates a medial wall against palmar subluxation of the extensor carpi ulnaris tendon.
- After assessing the proper dorsal replacement position for the extensor carpi ulnaris tendon, create a second radially based flap, about 1 cm wide, from the proximal portion of the extensor retinaculum. Make it long enough in a palmar-ulnar direction to allow creation of a sling around the tendon of the extensor carpi ulnaris (35). After the proximal flap has been wrapped around the extensor carpi ulnaris tendon and sutured to itself with two horizontal mattress sutures, repair the infratendinous retinacular leash around the same tendon, using a pull-out wire suture (Fig. 50.34) (14).

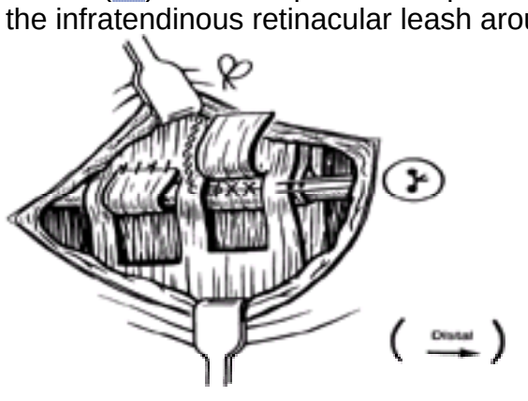


***Figure 50.34.*** Creation of an extensor carpi ulnaris sling and repair of the infratendinous retinaculum using a pull-out wire technique.

- If the septal tissues are irreparable, use the distal flap portion of the extensor retinaculum as a free fascial graft. A portion of the extensor carpi ulnaris tendon proximal to the extensor retinaculum may also be used as a free graft (14). Close the retinaculum (Fig. 50.35).

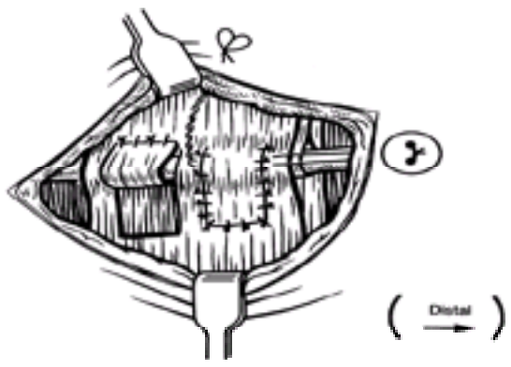


***Figure 50.35.*** Closure of the retinacular window and placement of the pull-out wire.

- After the tourniquet is released, achieve hemostasis and close the skin. Place the extremity in a long-arm splint for 6 weeks with the wrist dorsiflexed at 25° with the forearm in neutral rotation. Remove the splint and encourage the patient to engage in active motion of increasing intensity over the next 6 weeks.

## PITFALLS AND COMPLICATIONS

The dorsal cutaneous branch of the ulnar nerve may be lacerated; if it is, repair it microscopically. Use a free graft to repair a deficient infratendinous retinaculum, because swinging a fascial flap toward the deficient medial wall may tether wrist rotation.

## CHAPTER REFERENCES

Each reference is categorized according to the following scheme: *, classic article; #, review article; !, basic research article; and +, clinical results/outcome study.


* 1. Aitken A. Stenosing Tendovaginitis at the Radial Styloid Process. *N Engl J Med* 1945;232:105.

# 2. Baker CL, Brooks AA. Arthroscopy of the Elbow. *Clin Sports Med* 1996;15:261.

! 3. Bain GI, Turnbull J, Charles MN, et al. Percutaneous $A_1$ Pulley Release: A Cadaveric Study. *J Hand Surg [Am]* 1995;20:781.

+ 4. Barfred T, Ipsa T. Congenital Carpal Tunnel Syndrome. *J Hand Surg* 1985;10:246.

+ 5. Barfred T, Hojlund AP, Bertheussen K. Median Artery in Carpal Tunnel Syndrome. *J Hand Surg* 1985;10A:854.

+ 6. Berman M. Stenosing Tenovaginitis of the Dorsal and Volar Compartments of the Wrist. *Arch Surg* 1952;55:752.

! 7. Bishop AT, Gabel G, Carmichael SW. Flexor Carpi Radialis Tendonitis. Part I: Operative Anatomy. *J Bone Joint Surg* 1994;76:1009.

* 8. Boyd N. Tennis Elbow. *J Bone Joint Surg Am* 1973;55:1183.

* 9. Boyes J, ed. *Bunnel's Surgery of the Hand,* 4th ed. Philadelphia: JB Lippincott, 1970.

* 10. Boyes J, ed. *Bunnell's Surgery of the Hand,* 5th ed. Philadelphia: JB Lippincott, 1984.

# 11. Broker AS. Extensor Carpi Radialis Tenosynovitis. *Orthop Rev* 1977;6:99.

+ 12. Browne EZ. Carpal Tunnel Syndrome Caused by Hand Injuries. *Plast Reconstr Surg* 1975;56:41.

# 13. Bunnel S. *Surgery of the Hand.* Philadelphia: JB Lippincott, 1944.

+ 14. Burkhart S, Wood MB, Linscheid RL. Post-traumatic Recurrent Subluxation of the Extensor Carpi Ulnaris Tendon. *J Hand Surg* 1982;7:1.

+ 15. Chammas M, Bousquet P, Renard E, et al. Dupuytren's Disease, Carpal Tunnel Syndrome, Trigger Finger, and Diabetes Mellitus. *J Hand Surg [Am]* 1995;20:109.

+ 16. Compere E. Bilateral Snappy Thumbs. *Am Surg* 1933;97:773.

+ 17. Conklin J, et al. Stenosing Tenosynovitis. *Surg Clin North Am* 1960;40:531.

* 18. Coonrad RW. Tennis Elbow—Its Course, Natural History. Conservative and Surgical Management. *J Bone Joint Surg Am* 1973;55:1177.

* 19. Cotton F, et al. De Quervain's Disease. *N Engl J Med* 1938;219:120.

+ 20. Crimmins CA, Jones NF. Stenosing Tenosynovitis of the Extensor Carpi Ulnaris. *Ann Plast Surg* 1995;35:105.

+ 21. Dellon A, Hansen FC. Bilateral Inability to Grasp Due to Multiple (Ten) Congenital Trigger Fingers. *J Hand Surg* 1980;5:470.

* 22. Dinham J, Maggett D. Trigger Thumbs in Children. *J Bone Joint Surg Br* 1974;56:153.

* 24. Fahey J, Hrivnakova J, Dobias J. Trigger Finger in Adults and Children. *J Bone Joint Surg Am* 1954;36:1200.

+ 25. Fara M, Hrivnakova J, Dobias J. Stenosing Tendovaginitis of the Radial, Dorsal and Volar Compartments of the Hand. *Acta Chir Plast* 1973;15:93.

+ 26. Fenton R. Stenosing Tenosynovitis at the Radial Styloid Process Involving an Accessory Tendon Sheath. *Bull Hosp Joint Dis* 1952;11:90.

* 27. Finkelstein H. Stenosing Tendovaginitis of the Radial Styloid Process. *J Bone Joint Surg* 1930;12:509.

* 28. Fitton J, Doldie W. Lesions of the Flexor Carpi Radialis Tendon and Sheath Causing Pain at the Wrist. *J Bone Joint Surg* 1968;50B:359.

# 29. Froimson A. Stenosing Tenosynovitis. In: Green D, ed.*Operative Hand Surgery.* New York: Churchill Livingstone, 1982.

+ 30. Gabel G, Bishop AT, Wood MB. Flexor Carpi Radialis Tendinitis. Part II: Results of Operative Treatment. *J Bone Joint Surg* 1994;76:1015.

+ 31. Gabel GT, Morrey BF. Operative Treatment of Medial Epicondylitis. *J Bone Joint Surg* 1995;77:1065.

# 32. Gabel GT, Morrey BF. Tennis Elbow. *Instr Course Lect* 1998;47:165.

* 33. Goldie I. Upper Condylitis Lateralis Humeri. *Acta Chir Scand* 1964;339(suppl):1.

+ 34. Goldberg E, Abraham E, Siegel I. The Surgical Treatment of Chronic Lateral Humeral Epicondylitis by Common Extensor Release. *Clin Orthop* 1988;233:208.

# 35. Green D. The Sore Wrist Without a Fracture. *Instr Course Lect* 1985;34:311.

+ 36. Gregg J, Torg E. Upper Extremity Injuries in Adolescent Tennis Players. *Clin Sports Med* 1988;7:371.

+ 37. Grifka J, Boenke S, Kramer J. Endoscopic Therapy in Epicondylitis Radialis Humeri. *Arthroscopy* 1995;11:743.

+ 38. Grimes H. Stenosing Tenosynovitis. *J Ark Med Soc* 1981;77:499k.

+ 39. Gropper P, Pizesky WA, Bowen V, Clement PB. Flexor Tenosynovitis Caused by *Coccidioides immitis. J Hand Surg* 1983;8:344.

+ 40. Grundberg A, Reagan D. Pathologic Anatomy of the Forearm: Intersection Syndrome. *J Hand Surg* 1985;10A:299.

+ 41. Gumther S, Elliot R. *Mycobacterium kansasii* Infection in the Deep Structures of the Hand. *J Bone Joint Surg Am* 1976;59:140.

* 42. Hall CL, Berg C. Chronic Stenosing Tenosynovitis of the Wrist. *J Int Coll Surg* 1930;12:509.

* 43. Howard N. Peritendinitis crepitans. *J Bone Joint Surg Am* 1976;19:447.

! 44. Hueston J, et al. The Etiology of Trigger Finger. *Hand* 1973;4:257.

+ 45. Hueston JT, Wilson WF, Soin K. Trigger Thumb. *Med J Aust* 1973;2:1044.

* 46. Jahs SA. Trigger Finger in Children. *JAMA* 1936;107:1463.

+ 47. Janssen J, Teasley JL. De Quervain's Disease. Stenosing Tenosynovitis of the First Dorsal Extensor Compartment. *Wis Med J* 1970;69:95.

+ 48. Jozsa L, Reffy A, Demel S, Balint JB. Foreign Bodies in Tendons. *J Hand Surg* 1989;14B:84.

+ 50. Kamien M. A rational management of tennis elbow. *Sports Med* 1990;9:173.

+ 50. Kelly PJ, et al. Infections of Tendon Sheaths, Bursae, Joints, and Soft Tissues by Acid-fast Bacilli and Tubercle Bacilli. *J Bone Joint Surg* 1963;45A:326.

! 51. Kerr C, Syber TD, Albarracin N. An Analysis of the Flexor Synovium in Ideopathic Carpal Tunnel Syndrome: Report of 625 Cases. *J Hand Surg* 1992;17A:1028.

+ 52. Kurvers H, Verhaar J. The Results of Operative Treatment of Medial Epicondylitis. *J Bone Joint Surg* 1995;77:1374.

+ 53. Lamphier T, et al. De Quervain's Disease. *Ann Surg* 1953;138:832.

+ 54. Lapidus P, et al. Stenosing Tendovaginitis of the Wrists and Fingers. *Arch Surg* 1952;64:475.

# 55. Lapidus P, Guidotti FP. Stenosing Tendovaginitis of the Wrists and Fingers. *Clin Orthop* 1972;83:87.

! 56. Leao L. De Quervain's Disease: A Clinical and Anatomic Study. *J Bone Joint Surg Am* 1958;40:1063.

+ 57. Lee K. Tuberculosis Representing a Carpal Tunnel Syndrome. *J Hand Surg* 1985;10A:242.

# 58. Lipscomb P. Tenosynovitis of the Hand and the Wrist: Carpal Tunnel Syndrome, de Quervain's Disease, and Trigger Digit. *Clin Orthop* 1959;13:164.

# 59. Lipscomb P. Non-suppurative Tenosynovitis and Paratendinitis. *Instr Course Lect* 1950;7.

+ 60. Lister G, et al. The Radial Tunnel Syndrome. *J Hand Surg* 1959;4:52.

+ 61. Loomis L. Variations of Stenosing Tenosynovitis of the Radial Styloid Process. *J Bone Joint Surg Am* 1951;33:220.

+ 62. Louis D, Hankin FM, Greene TL, Dick HM. Lipofibromas of the Median Nerve: Long-term Follow-up of 4 cases. *J Hand Surg* 1985;10A:403.

+ 63. Love G, Melchior E. *Mycobacterium terrae* Tenosynovitis. *J Hand Surg* 1985;10A:730.

# 64. McCue F, Miller G. Soft Tissue Injuries in the Hand. In: *American Academy of Orthopedic Surgeons: Symposium on Upper Extremity Injuries in Athletes.* St. Louis: CV Mosby, 1986.

+ 65. McMahon MS, Posner MA. Triggering of the Thumb Due to Stenosing Tenosynovitis of the Extensor Pollicis Longus: A Case Report. *J Hand Surg* 1994;19:623.

! 66. Meachim G, Roberts C. The Histopathology of Stenosing Tendovaginitis. *J Pathol* 1969;98:187.

+ 67. Moore J, Weiland A. Gouty Tenosynovitis in the Hand. *J Hand Surg* 1985;10A:291.

# 68. Muckart R. Stenosing Tendovaginitis of the Abductor Pollicis Longus and Extensor Pollicis Brevis at the Radial Styloid. *Clin Orthop* 1954;33:201.

! 69. Murphy D, Failla JM, Koniuch MP. Steroid versus Placebo Injection for Trigger Finger. *J Hand Surg [Am]* 1995;20:628.

+ 70. Neviaser T, et al. Lateral Epicondylitis: Results of Outpatient Surgery and Immediate Motion. *Contemp Orthop* 1985;22:43.

+ 71. Nirschl R. Mesenchymal Syndrome. *Va Med* 1969;96:659.

+ 72. Nirschl R, Pettrone S. Tennis Elbow: The Surgical Treatment of Lateral Epicondylitis. *J Bone Joint Surg Am* 1979;61:832.

# 73. Nirschl R. Prevention and Treatment of Elbow and Shoulder Injuries in the Tennis Player. *Clin Sports Med* 1988;7:289.

+ 74. Oldberg S. A New Fact in the Etiology of Chronic Nonspecific Tendovaginitis in the Wrist. *Upsala J Med Sci* 1973;78:160.

+ 75. Ollivierre CO, Nirshcl RP, Pettrone FA. Resection and Repair for Medial Tennis Elbow: A Prospective Analysis. *J Sports Med* 1995;23:214.

+ 76. Palmer DH, Lane-Larsen CL. Helicopter Skiing Wrist Injuries: A Case Report of “Bugaboo Forearm.” *J Sports Med* 1994;22:148.

+ 77. Palmieri T. Pisiform Area Pain Treated by Pisiform Excision. *J Hand Surg* 1982;7:477.

* 78. Phalen G. Carpal Tunnel Syndrome. *Clin Orthop* 1972;83:29.

+ 79. Pope DF, Wolfe SW. Safety and Efficacy of Percutaneous Trigger Finger Release. *J Hand Surg [Am]* 1995;20:280.

! 80. Pruzansky M, Riordan D. Trigger Finger, Carpal Tunnel Syndrome and de Quervain's Disease: Tardive Manifestation of Deficient Connective Tissue (1993, unpublished data).

+ 81. Pruzansky M, Riordan D. The Association of Trigger Finger, Carpal Tunnel Syndrome and de Quervain's Disease with Dupuytren's Disease (1993, unpublished data).

! 82. Sampson SP, Badamente MA, Hurst LJ, et al. Pathology of the Human $A_1$ Pulley in the Trigger Finger. *J Hand Surg* 1991;16A:714.

+ 83. Schneider LH, Bush DC. Tuberculosis of the Hand and Wrist. *J Hand Surg* 1984;9A:391.

+ 84. Seradje H, Kleinert H. Reduction Flexor Tenoplasty. *J Hand Surg* 6:543,1981.

+ 85. Sorensen V. Treatment of Trigger Fingers. *Acta Orthop Scand* 1970;41:428.

* 86. Sprecher E. Trigger Finger in Infants. *J Bone Joint Surg Am* 1949;31:672.

+ 87. Stahl S, Kaufman T. The Efficacy of an Injection of Steroids for Medial Epicondylitis: A Prospective Study of Sixty Elbows. *J Bone Joint Surg* 1997;79:1648.

+ 88. Stefanich R, Peimer CA. Longitudinal Incision for Trigger Finger Release. *J Hand Surg* 1989;14:316.

+ 89. Stern A, et al. Stenosing Tendovaginitis at the Radial Styloid Process. *Arch Surg* 1951;63:215.

+ 90. Strandess G. Variations in the Anatomy in Stenosing Tenosynovitis at the Radial Styloid Process. *Acta Chir Scand* 1957;113:234.

+ 91. Taleisnik J, Gelberman RH, Miller BW, Szabo RM. The Extensor Retinaculum of the Wrist. *J Hand Surg* 1984;9A:495.

+ 92. Thompson AR, et al. Peritendinits Crepitans and Simple Tenosynovitis: A Clinical Study of 544 Cases in Industry. *Br J Ind Med* 1951;8:150.

+ 93. Van Gemechten F. Familial Trigger Thumb in Children. *Hand* 1982;14:1.

+ 94. Weildy A. Trigger Finger. *Acta Orthop Scand* 1970;41:419.

# 95. Wilgis ES. Compression Neuropathies. In: *American Academy of Orthopedic Surgeons: Symposium on Microsurgery.* St. Louis: CV Mosby, 1979.

+ 96. Younghusband O, et al. De Quervain's Disease: Stenosing Tenovaginitis at the Radial Styloid Process. *Can Med Assoc J* 1963;89:508.

+ 97. Yuan RN. *Candida ablicans* Tenosynovitis of the Hand. *J Hand Surg* 1985;10A:719.

* 98. Zelle O, et al. Snapping Thumb: Tendovaginitis Stenosans. *Am J Surg* 1936;33:31.

# CHAPTER 51

# PRINCIPLES OF NERVE REPAIR

*Robert M. Szabo*

**R. M. Szabo:** Professor of Orthopaedics, Professor of Surgery, Division of Plastic Surgery; Chief, Hand and Upper Extremity Service, University of California, Davis, School of Medicine, Sacramento, California, 95817.

Natural History of Nerve Injury
Clinical Assessment of Peripheral Nerve Injury
Nerve Repair
- Indications for Surgery
- Anatomic Basis of Nerve Repair
- Types of Neurorrhaphy
- Nerve Grafting
- Operative Techniques

Postoperative Care
Rehabilitation
Newer (Future) Techniques
Chapter References

Acute traumatic damage to a peripheral nerve may occur as a result of traction, contusion, compression, or laceration. The mechanism of injury determines the nature of the lesion, its management, and its prognosis.

A nerve trunk can be stretched by as much as 15% of its length without injury. Much of this elasticity derives from the geometry of the nerve. The nerve trunk runs an undulating course in its bed; the funiculi run an undulating course in the epineurium; and the nerve fibers run an undulating course inside the funiculi (26). The straightening of these undulations provides elasticity in the physiologic range of stretching. As the nerve is stretched beyond this limit, the axons (efferent) and dendrites (afferent), which have little tensile strength, fail before the surrounding connective tissues (epineurium and perineurium), which are stronger. When the tensile strength of the perineurium is exceeded, which occurs at about 20% of stretching, the nerve tears in two. In the region between the elastic limit and the mechanical limit, the nerve fibers are damaged to various degrees without gross disruption of the nerve trunk. Traction injuries may be associated with fractures, at the time of injury or during reduction or fixation; with dislocations and stretch injuries; and with gunshot wounds. Although spontaneous recovery is typical of most of these injuries, complete nerve loss can also occur.

Contusion injuries from a blunt blow to the nerve carry a similar prognosis to traction injuries, with spontaneous functional recovery the normal prognosis. Recovery from compression injuries depends on how long the nerve has been compressed and the degree of compression.

A lacerated nerve has no chance of spontaneous recovery, and the discontinuity must be surgically repaired. If the wound is a clean one from a sharp object such as a knife or glass, the damage to the nerve is likely to be local; this is unlike a crush, traction, or missile wound, in which damage may extend a considerable distance proximally and distally. The likelihood of functional recovery after accurate surgical repair depends on which nerve is involved, the level of the injury, the condition of the wound, and, most important, the age of the patient. Results of nerve repair in children are always better than those in adults. More distal injuries have a better prognosis for recovery than proximal ones, and a pure motor or sensory nerve has a better prognosis than a mixed nerve.

Seddon proposed a simple classification of nerve injuries based on degree of damage rather than on mechanism of injury (25,26). Neurapraxia is a minor injury resulting from traction or compression in which ischemia or local demyelination interfere with nerve function. Damage to motor function is usually greater than to sensation, and recovery is within hours or days. Axonotmesis is a moderate injury in which continuity of axons is disrupted with wallerian degeneration distal to the lesion. The endoneurial tubes remain intact, and regenerating axons can reestablish their functional connections. Good recovery, usually within a year, is likely. Neurotmesis is a severe injury with disruption of axons and connective tissues of the nerve. Fibrosis, loss of coaptation, and loss of continuity mitigate against spontaneous recovery. Surgical repair is indicated.

Sunderland classified peripheral nerve lesions into five types, representing increasing degrees of damage (Table 51.1) (26). Millesi has added a second variable, the degree of fibrosis, to Sunderland's classification (see Chapter 60).

| Injury | Anatomy | Functional loss | Recovery |
|---|---|---|---|
| First-degree | No disruption of axon; no wallerian degeneration | Variable, usually more motor than sensory | Spontaneous, in hours to weeks; simultaneous distal and proximal recovery |
| Second-degree | Disruption of axon with wallerian degeneration; endoneurial tubules intact | Complete sensory, motor and sympathetic loss | Spontaneous, proximal to distal motor recovery up to 1 year |
| Third-degree | Disruption of endoneurium, fascicles, and axons; perineurium intact; fibrosis and neuroma common | Complete | Spontaneous, proximal to distal motor recovery slower with some permanent motor and sensory loss likely |
| Fourth-degree | Extensive disruption with only some connective tissue continuity; fibrosis and neuroma common | Complete | Little spontaneous recovery without surgery |
| Fifth-degree | Complete disruption | Complete | No recovery without surgery |

Adapted from Sunderland S: *Nerves and Nerve Injuries*, 2nd ed. Edinburgh: Churchill Livingstone, 1978.

***Table 51.1. Classification of Nerve Injuries***

## NATURAL HISTORY OF NERVE INJURY

Experimentally, a sharp surgical division of a peripheral nerve is the model that has been best studied; traction and crush injuries are less well understood. Within a month after laceration, the distal portion of the nerve, cut off from trophic support of proximal cell bodies, undergoes wallerian degeneration. This process involves disintegration of the axon and myelin sheath, which are absorbed by macrophages and Schwann cells, leaving a tubule along the pathway of the former axon. Proximal to the lesion, some retrograde degeneration occurs, which is likely to be greater in more proximal lesions.

Within about 96 hours, the cell bodies whose axons or dendrites have been severed enlarge and their metabolic activity greatly increases. At the same time, axons sprout at the proximal stumps (3). If the two severed ends are still congruently opposed, axon sprouts grow at a rate as much as 1 mm each day down the endoneurial tubules of the degenerating distal axons to eventually reestablish connection with the sensory, motor, and sympathetic nerve end points. The actual rate of recovery is affected by age. In an animal model, Choi showed that the speed of wallerian degeneration, axonal regeneration, and myelin regeneration was greater in 2-month-old rats than in 10-month-old rats (5). Spontaneous recovery from mild axonotmesis may take from 1 to 6 months, with more proximal lesions requiring more time to heal.

In more severe lesions, several factors mitigate against successful natural recovery. The chief of these is loss of coaptation. If the nerve is completely transected, retraction of the severed ends and motions of the extremity destroy coaptation, and axon sprouts do not grow into the distal endoneurial tubules. After a noncongruent repair, malaligned axon sprouts grow into epineurial tissues and reach a blind end or grow into inappropriate tubules to establish connections that are nonfunctional. A second obstruction to successful natural repair is the development of fibrosis in the vicinity of the lesion. Fibrosis may distort the nerve architecture and destroy coaptation; it may create a barrier at the lesion that is difficult for the axon sprouts to traverse; and it may tether the nerve to surrounding tissues, impairing its mobility. In general, extensive soft-tissue injuries with a major inflammatory response lead to a greater degree of fibrosis. In traction, crush, and missile injuries, fibrosis may

extend a considerable distance proximally and distally.

The management of peripheral nerve lesions must be designed to enhance the natural pathways of repair. This involves the reestablishment and maintenance of coaptation, avoidance of traction, and excision of excessive fibrosis.

## CLINICAL ASSESSMENT OF PERIPHERAL NERVE INJURY

Severance of a peripheral nerve causes acute loss of sensory, motor, and sympathetic functions of that nerve distal to the lesion. Clinically, the acute picture is often confused by associated injuries. Fractures and dislocations; damage to muscles, tendons, or vascular structures; and head injury or altered psychological state can mask or mimic a peripheral nerve injury. Assessment of peripheral neuropathy should be done as early as possible after stabilization of the patient's other injuries so that proper therapy can be planned (Fig. 51.1).

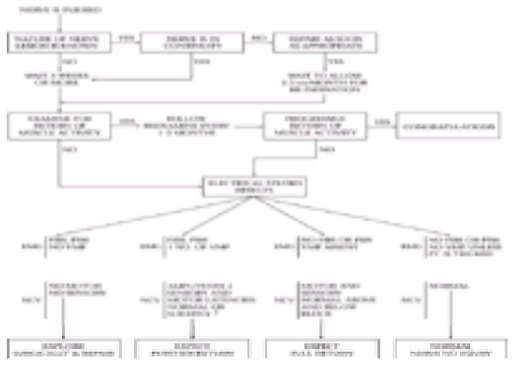

***Figure 51.1.*** Algorithm for management of peripheral nerve injuries. *EMG,* electromyograms; *FIBS,* fibrilation potentials; *NCV,* nerve conduction study; *PSW,* posititive sharp waves; *VMP,* voluntary motor unit potetials (interference pattern). (From Frykman G, Wolf A, Coyle T. An Algorithm for Management of Peripheral Nerve Injuries. *Orthop Clin North Am* 1981;12:240, with permission.)

A number of diagnostic tests have been devised to evaluate the function of a peripheral nerve (Table 51.2); these are reviewed by Omer (22). Accuracy and consistency in performing the initial diagnostic tests is critical, because these are the standards by which spontaneous recovery and the need for surgery are judged. Sometimes assessment can be made only by surgical exploration, as in young children or in head trauma victims.

| Test | Effect of measurements | Comment |
|---|---|---|
| Subjective activity | Loss of sensing in affected distribution | Test by touch/pallor. Nociceptive, or palpitation, correlates loosely with sensory loss. |
| Wrinkle test | Denervated skin immersed in warm water for 30 min will not wrinkle | |
| Volitional muscle action | Lost distal to lesion | Palpate the muscle belly rather than simply looking at distal tendon. Test all muscles (distal to proximal) to localize lesion. Nerve block of parallel nerves may be useful. |
| Electromyography | Fibrillation action potentials in denervated muscle | Seen several weeks after neurotmesis |
| Nerve conduction velocity | Stimulus distal to lesion is not seen proximally, or velocity is reduced in partial lesion. | A true sensory test independent of central integration |
| Static and moving two-point discrimination | Loss, recovery shows increasing acuity | May be confused by overlapping receptive fields, difficult to administer consistently |
| Semmes-Weinstein monofilaments | Loss, recovery shows increasing acuity. | This and the tuning fork test are threshold tests, best suited to follow nerve status after compression injury when nerve is intact |
| Tuning fork or vibrometer | Loss, recovery shows increasing acuity. | |
| Tinel's sign | In recovery, percussion over regenerating fiber produces tingling in area of distribution | Failure to progress distally is indicative for surgery |
| Pick up test | Loss, with recovery, speed and accuracy improve. | Reflects functionality of the motor (combined sensory, motor, and central function) |

***Table 51.2. Tests of Peripheral Nerve Function***

## NERVE REPAIR

### INDICATIONS FOR SURGERY

If nerve damage is suspected in the context of an open wound, direct inspection of the nerve at the time of irrigation and debridement is indicated. An acute primary repair may be undertaken if the wound is clean, the mechanism of injury is a sharp laceration, the patient's condition is stable, and the surgical team and its facilities are available (8). If this constellation of circumstances is not encountered, perform a delayed primary repair within 8 to 15 days. If repair is to be delayed, the nerve ends can be tagged with wire suture to facilitate later identification at the time of acute exploration of the wound. Tagging is not critical, because later surgery is based on identifying normal nerve proximal and distal to the lesion and dissecting toward the injury, rather than on searching for suture tags in a bed of scar. The wire is useful for locating nerve ends on radiographs, however. If the severed ends can be easily approximated, they may be loosely sutured together to resist retraction during the interval before the delayed repairs.

Early repair is preferable in a clean wound, because extensive nerve retraction has not yet occurred and less mobilization is required. The delay of 1 or 2 weeks after injury may offer some advantages, however, besides allowing the surgical team opportunity to prepare. The posttraumatic edema of the cut ends has time to resolve, and the nerve cell bodies greatly increase their anabolic activity in association with axon sprouting. The extent of proximal and distal damage to the nerve is easier to assess. The location of early axon sprouts can help define the necrotic terminus of the proximal stump.

In a closed injury with suspected neuropathy, after an acute compartment syndrome is ruled out, quantitative diagnostic tests should be performed (Table 51.2) to serve as a standard by which the recovery of the deficit may be measured. These tests must be performed in a meticulous and consistent way so that comparisons are valid. Although no single test is infallible, the combined weight of several tests with similar results allows a reasonably secure diagnosis. The patient should be reevaluated at intervals of 4 to 6 weeks.

Secondary repair (>2 weeks after injury) is indicated in heavily contaminated wounds, if soft-tissue coverage is poor and requires flaps, if the amount of nerve damage cannot be assessed early (e.g., in patients with gunshot wounds, head injuries), or if the diagnosis is initially missed. Some motor recovery may be expected after repairs as late as 1 year after injury; partial sensory recovery may result from repairs as late as 2 years after injury. Success diminishes with delay, however, because muscle atrophies and endoneurial tubules undergo fibrosis.

### ANATOMIC BASIS OF NERVE REPAIR

The anatomic goal of neurorrhaphy is, simply, to exactly realign the axons so that regenerating axon sprouts will reconnect to their preinjury end points. A number of factors frustrates the surgeon's attempt to achieve this. Edema in the proximal stump and shrinkage of the distal stump prohibit exact coaptation of formerly congruent ends, as will any distortion caused by less-than-perfect suture technique. A greater problem is segmental loss of even a few millimeters of nerve due to necrosis resulting from the injury. The pioneering studies of Sunderland in mapping the topography of the fasciculi in the peripheral nerves reveal a complex arrangement of branching, joining, and wandering pathways. Consequently, the number, size, arrangement, and neurologic content of the fascicles as seen in cross section vary along the nerve. With greater segmental loss, the cross-sectional arrangements of the two ends are increasingly dissimilar and the possibility of excellent coaptation diminishes accordingly.

Sunderland's diagram of the fascicular topography of a segment of the musculocutaneous nerve (Fig. 51.2) has been often reproduced and stands as a graphic display of the impossibility of obtaining perfect coaptation after segmental loss. Jabaley et al. (14,32) have found that in several regions of the median and radial nerves, the fascicular topography is considerably less variable than in Sunderland's diagram and that precise coaptation of most fascicles is theoretically possible despite segmental loss. Even over a longer distance encompassing various fascicular plexi, a bundle of axons tends to remain in the same quadrant of the nerve.

***Figure 51.2.*** Fascicular topography of a segment of the musculocutaneous nerve. (From Sunderland S: *Nerves and Nerve Injuries, 2nd ed.* Edinburgh: Churchill-Livingstone, 1978:32, with permission.)

If segmental loss is minimal, aligning epineurial features (vessels) at the two stumps and by sketching the cross-sectional appearance of the two ends and approximating them accordingly can ensure correct rotational alignment. When segmental loss is greater, a sketch of the cross-sectional fascicular arrangement can be compared with published maps, which may facilitate alignment. Finally, intraoperative electrical stimulation can be used to distinguish predominantly motor from sensory fascicles. With the patient awake and the tourniquet released, stimulation of the distal stump may identify motor fascicles, and stimulation of the proximal stump may identify sensory fascicles. Silent fascicles proximally are presumed to be motor, and silent fascicles distally are presumed to be sensory (10).

A staining technique based on acetylcholinesterase has been shown to help differentiate motor from sensory fascicles within a nerve. Because it requires 24 hours of incubation time, it is not usually suitable for intraoperative use, although it has provided confirmation of mapping of fascicles done by other means. Similar histochemical techniques with shorter development times show promise, but they are not now in general use (24).

**TYPES OF NEURORRHAPHY**

Three surgical techniques of neurorrhaphy are in current use: epineurial repair, fascicular repair, and group fascicular repair. Each technique is appropriate to certain circumstances. Appreciation of microneuroanatomy is essential to understanding the techniques of nerve repair (Fig. 51.3). At present, all repairs are done with microsutures. In countries other than the United States, commercially available fibrin glue is often used in combination with a limited number of sutures. This glue is made from donated blood products. It is possible to make fibrin glue from the patient's own donated plasma by mixing it with thrombin, but the cost, time, and effort need to be weighed against the benefits. Experimentally, there is some evidence that fibrin seals are efficacious (23), but the true value has not been established.

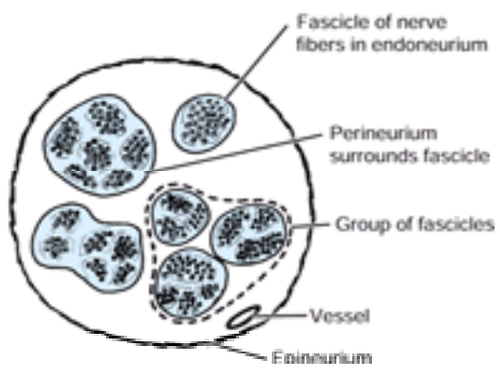


***Figure 51.3.*** Cross section of a peripheral nerve, indicating principal structures.

Epineurial repair is the standard method of nerve repair carried out by placing several sutures peripherally in the epineurium after aligning the nerve ends according to fascicular pattern and epineurial landmarks. This technique has the advantage of being less technically demanding, being less traumatic to the nerve ends, and placing less suture material in the repair site. Epineurial repair is indicated for small nerves, for nerves with only one or two fascicles, and for primary repair of a clean laceration in a larger nerve.

In fascicular (also called funicular) repair, individual fascicles are dissected free of enveloping epineurium and sutured fascicle to fascicle through the perineurium. In principle, this method should lead to a more precise coaptation and better recovery. In practice, fascicular repair is technically demanding, inevitably causes some trauma to the nerve ends, and leaves suture material within the nerve, which may stimulate a fibrotic response. Nonetheless, in the hands of those skilled in the technique, fascicular repair produces good results, especially in nerves with two to five large fascicles or if epineurium constitutes a large part of the cross-sectional area of the nerve.

Group fascicular repair is similar in principle to fascicular repair except that recognizable groups of fascicles are joined instead of individual fascicles. The repair of more than five fascicles or groups is impractical, because it excessively injures the nerve end and leaves too much suture material within the wound. Group fascicular repair is the technique employed in nerve grafting.

Epineurial and fascicular repair may be combined, as in repair of a laceration of the median nerve at the wrist, where fascicular repair of the motor component may be combined with epineurial repair to approximate sensory elements. The choice of technique depends on the topography of the nerve at the site of the lesion. The superiority of fascicular or group fascicular repair over epineurial repair has not been clearly demonstrated clinically or experimentally. The immediate environment of wound healing, the condition and age of the patient, and the skill of the surgeon are probably more important than the type of neurorrhaphy.

**NERVE GRAFTING**

If segmental loss prohibits end-to-end repair without excessive tension, interfascicular nerve grafting is indicated. This technique was developed and refined by Millesi, whose series shows a high percentage of good or excellent results (20,21). The nerve stumps are stepcut, and the fascicles are debrided of enveloping epineurial tissues. Corresponding fascicles or groups of fascicles are identified by geometry or electrodiagnostic tests. Graft segments long enough to bridge the gap without tension are sutured through the perineurium to connect appropriate fascicles or groups of fascicles in the proximal and distal stumps. Although the regenerating axons must cross two suture lines, it is thought that the prognosis is better for crossing two suture lines without tension than one suture line under tension. The sural nerve is typically used as the graft; this can yield a usable graft segment as long as 40 cm. The lateral antebrachial cutaneous nerve can also be used (27).

Although nerve repair under tension has a poor prognosis, what constitutes excessive tension (and thus an indication for grafting) is not universally agreed. Wilgis suggests that if an 8-0 suture cannot close the gap, tension is too great (31). Millesi recommends grafting gaps greater than 2.5 cm with the extremity in a functional position (20). By mobilizing the nerve proximally and distally and flexing the joints it crosses, gaps of several centimeters may easily be closed. Flexion of the elbow more than 90° or the wrist beyond 40° to close a gap is contraindicated. The surgeon must judge the potential morbidity of postoperative immobilization of the joints in a flexed position against the morbidity of nerve grafting in light of his or her own skills and experience.

**OPERATIVE TECHNIQUES**

- Prepare and drape the entire extremity into the operative field, because it is often necessary to mobilize the nerve proximally and distally for considerable distances.
- Prepare and drape one or both lower extremities if nerve grafting is a possibility.
- Apply a tourniquet to each extremity being draped.

- Use a generous, extensile incision.
- In freeing the nerve, work from normal nerve toward the lesion: distalward in the proximal portion and proximalward in the distal portion. Keep exposed portions of the nerve moist with saline-soaked sponges.
- Handle the nerves very gently using a jeweler's forceps to grasp only the epineurium.
- Avoid applying any pressure to the fascicles, which may result in further injury.

Use magnifying loupes in the initial identification of the nerve and its dissection. Final preparation of the nerve ends and suturing are facilitated by an operating room microscope, enabling proper grouping of similar nerve fascicles, aligning of epineurial landmarks with proper orientation, and more accurate placement of sutures. Use microsurgical instruments to perform nerve repair and nerve grafts.

***Epineurial and Group Fascicular Repairs***

- Place a moist wooden tongue depressor beneath the end of the nerve.
- While an assistant applies gentle traction on the nerve end with a jeweler's forceps, use a Weck blade to cut back the nerve ends sharply until noninjured tissue is reached.
- Inspect the proximal portion of the cut ends under the microscope to look for bulging axons.
- Repeat these steps on the opposite nerve end.
- After both ends have been resected until normal-looking structures are seen, the repair can begin.
- Inspect the epineurium for longitudinal blood vessels as a landmark to orient the nerve. Inspect the fascicular pattern of the proximal and distal stumps for orientation.
- Have the assistant take the tension off the nerve by grasping the proximal and distal segments of the nerve about 1 cm away from the repair and approximating the nerve ends. If the tension is observed to be great or approximation is not possible, consider further mobilization of the nerve or grafting.
- In an epineurial repair, after alignment of the nerve, pass the appropriate suture proximally and distally in the epineurium only, and tie the knot firmly. Pass a second suture 180° opposite to the first suture in a similar fashion. Leaving the strands of these two initial knots long may assist in turning the nerve. Use the minimal amount of sutures necessary to close the entire epineurium on the anterior side, and repeat this, having turned the nerve around, on the posterior side. Use a nonabsorbable 9-0 suture (nylon) for larger nerves, and a 10-0 nonabsorbable suture for smaller nerves (Fig. 51.4).

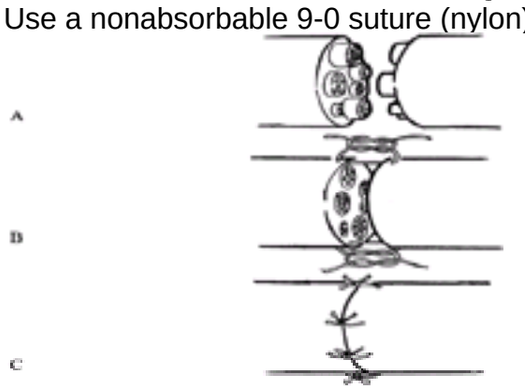


***Figure 51.4.*** Epineurial repair. **A:** Nerve ends are freshly cut back to well-visualized fascicles. **B:** Two sutures are placed into the epineurium at 180° from each other, maintaining alignment of the fascicles in the proximal and distal stumps. **C:** The remainder of the epineurium is approximated using the minimal number of simple sutures necessary to complete the closure.

In a fascicular repair:

- Identify the fascicles proximally and distally by observing the cross-sectional anatomy under the microscope.
- Coapt the ends of the matching funiculi, placing 10-0 nylon interrupted sutures through the interfascicular epineurium and the perineurium of the individual fascicles. Avoid all tension (Fig. 51.5).

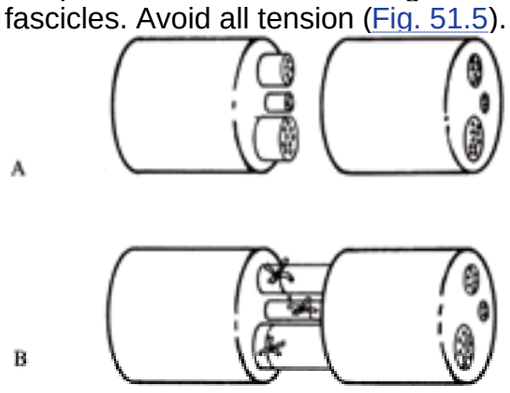


***Figure 51.5.*** Fascicular repair. **A:** Individual fascicles are identified proximally and lined up with their distal counterpart. **B:** These individual fascicles are then approximated with minimal sutures. The epineurial layer is then repaired as shown in Figure 51.4*B* and Figure 51.4*C*.

In a grouped fascicular repair:

- Identify groups of fascicles by observing proximal and distal cross-sectional anatomy, and join these groups with interrupted 10-0 nylon suture placed in the interfascicular epineurium.

In mixed fascicular and epineural repair:

- Line up the major group of fascicles that can be identified, and perform a grouped fascicular repair.
- Then repair the epineurium circumferentially around the entire nerve as described under epineurial repair.

***Nerve Grafting***

- Explore and prepare the nerve stumps, as described previously.
- Examine the cross-sectional anatomy, and isolate the fascicle groups.
- Measure the distance between the two stumps, with the elbow and wrist joints extended.
- Pass a 10-0 nylon stitch between the fascicles of the graft, catching the interfascicular epineurium, and pass this stitch into the proximal stump of one group of fascicles.
- Approximate the distal end of the graft to the stump of the corresponding distal fascicle group in a similar fashion.

The usual donor site for nerve graft material is the sural nerve. The use of this nerve creates a sensory loss at the lateral side of the foot below the lateral malleolus, which causes no problem in the vast majority of patients.

- Locate the nerve behind the lateral malleolus with a 1 cm longitudinal incision.
- Tag the nerve with umbilical tape. A few centimeters proximal to this incision, make a small transverse incision over the nerve.
- Pull on the nerve distally with slight tension so that it can be easily palpated in the proximal incision.
- Place two to three more incisions proximally over the nerve at equal intervals to identify its full length. Then transect the nerve through the most proximal incision to harvest the entire segment of the sural nerve.

- Close the wounds as usual and drain if appropriate. *Avoid suction drains placed close to a nerve repair or nerve graft, because they may disrupt the suture line.*

A tendon stripper can be used to harvest the nerve through a single distal incision, but great care must be taken not to cut the nerve too short. Other sources of donor nerve include the lateral and medial antebrachial cutaneous nerves and the terminal articular branches of the posterior interosseous nerve, but the sural nerve provides the longest nerve segment with the least morbidity.

It is essential to document in the operative notes exactly where the location of repair is in relation to surface anatomy. Each juncture should be measured and noted so that after surgery it is possible to follow the progression of Tinel's sign (i.e., distal tingling on percussion). If using a long interfascicular graft, progression may cease at the distal nerve juncture. The surgeon knows that this is happening if the progression of Tinel's sign ceases at the same point noted for the distal juncture.

## POSTOPERATIVE CARE

Immobilize the extremity in the same position it is in during the operation for 10 to 14 days. After wound sutures are removed, place the extremity in a plaster cast in a position to relax all suture lines. For example, a median nerve repair in the forearm requires the wrist to be in slight flexion and the elbow placed at 90° of flexion. Continue immobilization for a total of 6 weeks, but at 4 weeks start to straighten out the joints that have been splinted in a position to avoid tension on the nerve suture line.

## REHABILITATION

Preoccupation with the technical intricacies of nerve repair should not cause the surgeon to lose sight of the goal, which is a functional patient. Although nerve repair is feasible, the patient may be better served by other procedures, such as tendon transfers. If an older patient is well adapted to the disability, it may be better not to intervene despite the possibility of improved function.

It is inevitable that after nerve repair, some regenerating neurons will make connections to sensory or motor end points different from those to which they were formerly connected (7). Although they recover sensory function and transmit signals to the brain, the meaning of these signals is garbled if they are evaluated in the cortex according to preinjury habits of interpretation. The patient must be reeducated to correlate sensory input with external reality. In children, this is readily accomplished. Hudson et al. reported their results on 18 children with lacerations of the median nerve treated by primary epineurial repair (13). The mean return of motor power to the opponens pollicis was 4.5 and the mean static two-point discrimination was 5 mm (13). Older patients are less flexible and may ignore sensory information supplied by heterotopically regenerated nerves. In this case, the anatomically successful nerve repair is in vain. An aggressive program of therapy aimed at sensory reeducation may considerably improve the clinical results of nerve repair by training the patient to adapt to the altered arrangement of the peripheral axons.

## NEWER (FUTURE) TECHNIQUES

There has been some interest in allograft sural nerve grafting. Experimentally, nerve regeneration across peripheralnerve allografts compared favorably with control autografts in primates when they were immunosuppressed with Cyclosporin A (1). It does not seem worthwhile, however, to run the risks of immunosuppressing patients for this purpose. Others have experimented with various biologic materials to act as nerve conduits (4,6,9,11,29,33).

Injury to a peripheral nerve is followed by local synthesis and release of neurotrophic factors, which play a role in the regeneration process. There has been significant interest in using silicone tubes for nerve repair both to handle a small gap and to capitalize on these neurotrophic factors (12,30) to increase the specificity of neural connections (motor to motor and sensory to sensory). Animal studies have shown some conflicting results. Some have demonstrated that there is merit to this technique(12,19); Brushart's experiments demonstrated no evidence for neurotropic interactions promoting correct fascicular reinnervation in a mixed nerve (2). Using a silicone tube, he could not find any neurotropic factors that promote fascicular specificity and thus stated that an “enclosed gap is not an acceptable substitute for nerve graft when reconstructing a nerve that serves multiple functions” (2).

Lundborg et al. adopted this concept for repair of transected human median and ulnar nerves in the forearm (17). Lundborg used silicone tubes of appropriate size to enclose the injury zone, intentionally leaving a gap measuring 3 to 4 mm between the nerve ends inside the tube. His early results from a prospective, randomized, clinical study comparing this technique with conventional microsurgical technique for repair of human median and ulnar nerves showed no difference between both techniques, with the exception of perception of touch, which showed a significant difference at the 3-month checkup in favor of the tubulization technique. Furthermore, at reexploration 11 months after the initial procedure Lundborg reported that the former gap was replaced by regenerated nerve tissue in direct continuity with the proximal and distal parts of the nerve trunk, with the exact level of the former injury being impossible to identify (17). I witnessed this reexploration while I visited Lundborg and confirmed that this finding was quite accurate.

Lundborg et al. have also developed a bioartificial nerve graft in which multiple polyamide (nylon) filaments were placed inside silicone tubes to make an intrinsic and extrinsic framework, respectively, for regenerating axons. Early animal experiments have shown that the new artificial nerve graft can be used to support regeneration across extended gaps in nerves (15,16,28).

Another future avenue for nerve repair uses the concept of end-to-side repair. The possibility that collateral sprouting can occur from intact axons in an undamaged nerve, induced by factors from the attached nerve segment, and subsequently can make functional peripheral connections may permit damaged nerves to be sutured to nearby normal nerves. Lundborg et al. studied this concept in the rat by suturing either a 7-day predegenerated or a fresh nerve segment in an end-to-side fashion to the sciatic nerve proper (18). Allowing time for recovery, the pinch reflex test was present in the majority of cases using a predegenerated nerve segment but not in those using a fresh segment, and neurofilament staining and histologic examination confirmed the presence of axons in the attached nerve segment(18).

## CHAPTER REFERENCES

Each reference is categorized according to the following scheme: *, classic artice; #, review article; !, basic research article; and +, clinical results/outcome study.


! 1. Bain JR, Mackinnon SE, Hudson AR, et al. The Peripheral Nerve Allograft in the Primate Immunosuppressed with Cyclosporin A: I. Histologic and Electrophysiologic Assessment. *Plast Reconstr Surg* 1992;90:1036.

! 2. Brushart TM, Mathur V, Sood R, Koschorke **GM**. Joseph H. Boyes Award. Dispersion of Regenerating Axons Across Enclosed Neural Gaps. *J Hand Surg [Am]* 1995;20A:557.

* 3. Cabaud H, Rodkey W, Nemeth T. Progressive Ultrastructural Changes after Peripheral Nerve Transection and Repair. *J Hand Surg [Am]* 1982;7A:353.

! 4. Calder JS, Green CJ. Nerve-muscle Sandwich Grafts: The Importance of Schwann Cells in Peripheral Nerve Regeneration Through Muscle Basal Lamina Conduits. *J Hand Surg [Br]* 1995;20B:423.

! 5. Choi SJ, Harii K, Lee FM, et al. Electrophysiological, Morphological, and Morphometric Effects of Aging on Nerve Regeneration in Rats. *Scand J Plast Reconstr Surg Hand Surg* 1995;29:133.

! 6. Delaere O, Guerit JM, Van Wijck R. Sciatic Nerve Regeneration in the Rat after Frozen Muscle Grafting. A Comparative Study Using Somatosensory Evoked Potentials. *J Hand Surg [Br]* 1996;21B:53.

! 7. Dellon A, Munger B. Correlation of Histology and Sensibility after Nerve Repair. *J Hand Surg [Am]* 1983;8A:871.

# 8. Frykman G, Wolf A, Coyle T. An Algorithm for Management of Peripheral Nerve Injuries. *Orthop Clin North Am* 1981;12:239.

! 9. Fullarton AC, Glasby MA, Lawson GM. Immediate and Delayed Nerve Repair Using Freeze-thawed Muscle Allografts. Associated Long-bone Fracture. *J Hand Surg [Br]* 1998;23B:360.

+ 10. Gaul JJ. Electrical Fascicle Identification as an Adjunct to Nerve Repair. *Hand Clin* 1986;2:709.

! 11. Hall SM, Enver K. Axonal Regeneration Through Heat Pretreated Muscle Autografts. An Immunohistochemical and Electron Microscopic Study. *J Hand Surg [Br]* 1994;19B:444.

! 12. Hansson T, Povlsen B. Functional Regeneration of C-fibres Inside a Silicone Tube after Sciatic Neurotomy in Rats. *Scand J Plast Reconstr Surg Hand Surg* 1997;31:7.

+ 13. Hudson DA, Bolitho DG, Hodgetts K. Primary Epineural Repair of the Median Nerve in Children. *J Hand Surg [Br]* 1997;22B:54.

+ 14. Jabaley M, Wallace W, Heckler F. Internal Topography of Major Nerves of the Forearm and Hand. *J Hand Surg [Am]* 1980;5A:1.

! 15. Lundborg G, Dahlin L, Dohi D, et al. A New Type of “Bioartificial” Nerve Graft for Bridging Extended Defects in Nerves. *J Hand Surg [Br]* 1997;22B:299.

! 16. Lundborg G, Kanje M. Bioartificial Nerve Grafts. A Prototype. *Scand J Plast Reconstr Surg Hand Surg* 1996;30:105.

+ 17. Lundborg G, Rosén B, Dahlin L, et al. Tubular Versus Conventional Repair of Median and Ulnar Nerves in the Human Forearm: Early Results from a Prospective, Randomized, Clinical Study. *J Hand Surg [Am]* 1997;22A:99.

! 18. Lundborg G, Zhao Q, Kanje M, et al. Can Sensory and Motor Collateral Sprouting Be Induced from Intact Peripheral Nerve by End-to-side Anastomosis? *J Hand Surg [Br]* 1994;19B:277.

! 19. Luo ZJ, Lu SB. Selective Reinnervation of Regenerating Mixed Nerve Fibres Across a Silicone Tube Gap. Further Experimental Evidence of Neurotropism. *J Hand Surg [Br]* 1996;21B:660.

# 20. Millesi H. Interfascicular Nerve Grafting. *Orthop Clin North Am* 1981;12:287.

+ 21. Millesi H, Meissl G, Berger A. The Interfascicular Nerve Grafting of the Median and Ulnar Nerves. *J Bone Joint Surg[Am]* 1972;54A:727.

# 22. Omer GJ. Evaluation of the Extremity with Peripheral Nerve Injury and Timing for Nerve Suture. *Instr Course Lect* 1984;33:463.

! 23. Povlsen B. A New Fibrin Seal: Functional Evaluation of Sensory Regeneration Following Primary Repair of Peripheral Nerves. *J Hand Surg [Br]* 1994:19B:250.

! 24. Riley D, Lang D. Carbonic Anhydrase Activity of Human Peripheral Nerves: A Possible Histochemical Aid to Nerve Repair. *J Hand Surg [Am]* 1984;9A:112.

# 25. Sunderland S. The Anatomic Foundation of Peripheral Nerve Repair Techniques. *Orthop Clin* 1981;12:245.

# 26. Sunderland S. *Nerves and Nerve Injuries,* 2nd ed. Edinburgh: Churchill Livingstone, 1978:41.

+ 27. Tank M, Royce CJ, Coates P. The Lateral Antebrachial Cutaneous Nerve as a Highly Suitable Autograft Donor for the Digital Nerve. *J Hand Surg [Am]* 1983;8A:942.

! 28. Terada N, Bjursten LM, Dohi D, Lundborg G. Bioartificial Nerve Grafts Based on Absorbable Guiding Filament Structures—Early Observations. *Scand J Plast Reconstr Surg Hand Surg* 1997;31:1.

! 29. Whitworth IH, Brown RA, Doré C, et al. Orientated Mats of Fibronectin as a Conduit Material for Use in Peripheral Nerve Repair. *J Hand Surg [Br]* 1995;20B:429.

! 30. Whitworth IH, Brown RA, Doré CJ, et al. Nerve Growth Factor Enhances Nerve Regeneration Through Fibronectin Grafts. *J Hand Surg [Br]* 1996;21B:514.

# 31. Wilgis E. Nerve Repair and Grafting. In: Green DP, ed. *Operative Hand Surgery*, Vol. 2. Edinburgh: Churchill Livingstone, 1982:1381.

# 32. Williams H, Jabley M. The Importance of Internal Anatomy of the Peripheral Nerves to Nerve Repair in the Forearem and Hand. *Hand Clin* 1986;2:689.

! 33. Zeng L, Huck S, Redl H, Schlag G. Fibrin Sealant Matrix Supports Outgrowth of Peripheral Sensory Axons. *Scand J Plast Reconstr Surg Hand Surg* 1995;29:199.

# CHAPTER 52

# COMPRESSION NEUROPATHIES OF THE UPPER EXTREMITY

*Mark N. Halikis, Julio Taleisnik, and Robert M. Szabo*

**M. N. Halikis:** Department of Orthopaedic Surgery, Uiversity of California, Irvine, Orange, California, 92868.
**J. Taleisnik:** Department of Orthopaedic Surgery, Uiversity of California, Irvine, Orange, California, 92868.
**R. M. Szabo:** Departments of Orthopaedics and Plastic Surgery, University of California, Davis Health System, Sacramento, California, 95817.

Pathophysiology
Assessment
Diagnostic Studies
Principles of Treatment
Compression Neuropathies of the Median Nerve
Carpal Tunnel Syndrome
Pronator Syndrome
Anterior Interosseous Nerve Syndrome
Compression Neuropathies of the Ulnar Nerve
Cubital Tunnel Syndrome
Ulnar Tunnel Syndrome
Compression Neuropathies of the Radial Nerve
Posterior Interosseous Nerve Syndrome
Radial Tunnel Syndrome
Superficial Radial Nerve Compression Syndrome (Cheiralgia Paresthetica)
Lateral Antebrachial Cutaneous Nerve Compression
Chapter References

## PATHOPHYSIOLOGY

Whenever A Nerve Is Contained In A Space That Has Limited Compliance, Such As The Carpal, Cubital, Or Ulnar Tunnels, or It Lies Deep To Fibrous Bands And Tendinous Arches Of Origin, It Is Vulnerable To Compression. An Increase In The Volume Of Material Within One Of These Limited Spaces Or A Decrease In Size Of The Space Can Lead To Increased Pressures, Which In Turn Can Compress The Nerve. Other Factors That May Lead To A Mechanical Peripheral Neuropathy Include Stretching Of The Nerve And Abnormal Nerve Motion About Or Adherence To Fibrous Bands Or Fascial Edges. The Intrinsic Response Of The Nerve To This Mechanical Insult Varies Little Regardless Of The Location Of The Injury Or The nature of the offending agent. The sequence of pathologic changes within the median nerve and the resulting clinical progression are the same whether the entrapment is secondary to synovitis within the carpal tunnel or secondary to a bone fragment from a fracture of the distal radius. Relief of the compression, generally accomplished by releasing the confining tunnel or compressive fibrous band, reverses these changes partially or completely. If damage to the nerves is irreversible (i.e., if entrapment is chronic), release can halt progression. All three major nerves of the upper extremity, the median, ulnar, and radial, may be injured by compression in locations where they are anatomically vulnerable.

Compression of a nerve has an effect on its structure and function. The severity of the resulting lesion depends on the magnitude of the compression as well as its duration. Both direct mechanical factors causing myelin damage and alterations in blood flow to and within the nerve likely play roles of varying degrees in causing the nerve changes seen in compression neuropathies. Ischemic changes caused by blood-flow alterations play a part in acute, easily reversible nerve-function alterations (72). Experiments have shown that elevation of pressure in and about the nerve to within 40 mm Hg of diastolic blood pressure cause profound changes in sensory nerve function of the median nerve, which are reversible with restoration of blood flow. Motor dysfunction of the nerve requires higher and more sustained elevations in pressure. These changes in function are not associated with structural changes in the nerve (132). Ischemia also plays a role in chronic compression. It is believed to contribute to intraneural scarring as well as edema from prolonged loss of blood supply to the nerve. Structural changes, particularly alterations in or loss of the myelin coatings of nerve fibers, are seen in chronic, higher-pressure compressions, especially those involving an edge such as a fibrous band or tendon. These changes resolve only in some cases, after enough time has elapsed for repair of damaged myelin. Compression of the nerve has also been shown to inhibit axoplasmic flow, both antegrade and retrograde, diminishing nerve function and contributing to the bulging appearance of the nerve proximal and distal to the site of compression (72).

The mechanism whereby surgical decompression works is not entirely understood. The frequently dramatic response to treatment can be explained only by the reversal of a vascular lesion (33,34). According to this theory, the mechanical factor responsible for producing the compression obstructs venous return, followed by segmental anoxia, capillary vasodilatation, and edema (33,125). The nerve edema aggravates the compression and leads to abnormal axonal and cellular exchange (34,124,131). Surgical release at this stage is a rewarding procedure. Prolonged compression results in intraneural fibrosis, after which nerve recovery is less likely to occur despite decompression.

### ASSESSMENT

Clinical evaluation of an entrapment syndrome and determination of the site of compression are greatly aided by a knowledge of the anatomic distribution of a nerve and its function. Clinical evaluation of nerve compression neuropathies includes sensory threshold testing, provocative testing, and evaluation of muscle weakness or atrophy. The most consistent and reliable way to evaluate sensibility in nerve compression is to use threshold testing (126,127,132,133,134). Threshold tests evaluate *how well* a single nerve fiber innervating a receptor or group of receptor cells *is functioning*. These include vibrometry, Semmes–Weinstein monofilaments, and vibration testing. To test with Semmes–Weinstein monofilaments, apply pressure to the fingertip with the filament until the filament bends (Fig. 52.1). The pressure required to bend the filament is directly related to its diameter. Apply filaments of successively increasing diameter to determine the sensory threshold of slowly adapting nerve fibers. Perform vibration testing with a 256 cycles-per-second (cps) tuning fork to evaluate the sensory threshold of quickly adapting nerve fibers (Fig. 52.2).

***Figure 52.1.*** Threshold testing with Semmes–Weinstein monofilaments.



***Figure 52.2.*** Vibration sensation testing with a 256 cps tuning fork.

Innervation density tests (i.e., two-point and moving two-point discrimination) (Fig. 52.3) measure multiple overlapping peripheral receptor fields and the density of innervation—*how many* nerve fibers *are present* and correctly represented in the cerebral cortex. Early in compression neuropathies, nerve fibers are not lost; rather, the nerve fibers that are present are not functioning well. In nerve laceration, in contrast, nerve fibers to the innervated area are lost. Innervation density tests are more useful for evaluating nerve laceration and recovery after repair than for evaluating compression neuropathies. These tests are abnormal in only 20% of patients with electrically proven carpal tunnel syndrome (CTS), whereas threshold tests detect more than 80% of electrically proven CTS patients (133).



***Figure 52.3.*** Two-point discrimination testing.

Provocative tests compress, stretch, or percuss the nerve to elicit numbness and paresthesias in its sensory distribution. Provocative tests are especially important in patients with exertional compression neuropathies, where symptoms and signs may be minimal or absent at rest. [For this reason, it may also be advisable to perform sensory testing before and after activity (12).] The examiner evaluates weakness and atrophy subjectively. Muscles innervated by the nerve suspected of compression are tested for bulk and strength. Comparison to the uninvolved extremity is especially helpful.

**DIAGNOSTIC STUDIES**

Although not a substitute for a thorough clinical examination, electrodiagnostic studies may help to corroborate clinical impressions. They truly are the only objective test of nerve compression. Additionally, they may indicate a level of severity of nerve damage that may have prognostic implications for treatment. A detailed explanation of neurodiagnostics of the upper extremity is beyond the scope of this chapter. Here we offer a brief, basic description of methods and definitions of terms. For a more complete understanding, read review articles and book chapters published on this subject (49,51,56). The neurodiagnostic study, when used for the majority of upper extremity compression injuries, is composed of two parts: the nerve conduction or velocity (NCV) and the electromyography (EMG) needle examination. The NCV measures the speed of conduction of an impulse along a segment of nerve. The EMG measures the response of muscle fibers to conducted nerve impulses.

When stimulated, a segment of nerve conducts or propagates an electrical impulse. This impulse can be detected by a surface electrode on the skin overlying a nerve or a muscle innervated by a nerve. In an NCV test, the nerve is stimulated electrically at one point and the impulse measured at another point along its length. When the study measures an impulse traveling in a physiologic direction, it is called an orthodromic study; when it measures an impulse traveling in the opposite direction, it is called antidromic. Impulses propagated by sensory nerves or the sensory fibers of a mixed nerve are measured by surface electrodes as a waveform called the sensory nerve action potential. Motor nerves or the motor fibers of mixed nerves are measured by the electrical response of multiple muscle fibers, which produce a waveform known as the composite muscle action potential.

The interval from stimulation of the nerve to the time at which the sensing electrode detects the waveform is known as the latency. In motor nerves, latency also encompasses the time it takes the nerve impulse to be transmitted across the neuromuscular junction and to activate the muscle fibers. Neurodiagnosticians often report latencies, especially when evaluating nerve conduction across short nerve segments at the wrist. Latencies are reported in units of time (msec). Conduction velocities are reported in units of meters per second and can be calculated from the measured latency and knowledge of the length of the nerve segment over which the latency was measured. Velocities are reported for longer lengths of nerve segments tested, such as from the midforearm to the hand. Additional measurements can be obtained by evaluating the waveforms. These include the amplitude, duration, and area of the waveform (Fig. 52.4). These parameters can aid the electromyographer in characterizing the conduction of the nerve. The amplitude and duration depend on the number of nerve fibers and the speed of conduction of the different nerve fibers transmitting the stimulated impulse, respectively.

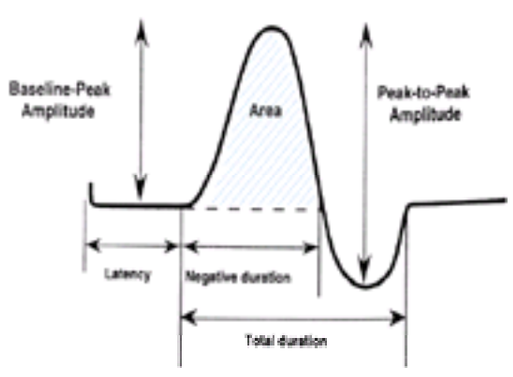


***Figure 52.4.*** A waveform obtained from nerve conduction testing. (From Holmlund T. Electrodiagnosis and Neurologic Evaluation. In: Peimer CA, ed. *Surgery of the Hand and Upper Extremity.* New York: McGraw-Hill, 1996:1277, with permission.)

Electromyography employs needle electrodes placed within muscle to evaluate the activity of a single motor unit consisting of the nerve cell, its fibers, and the group of muscle fibers it innervates (Fig. 52.5). Normally, a muscle fiber at rest is essentially electrically silent. After a brief burst of electrical activity that occurs while the electrode is inserted, the needle measures only occasional background impulses. When the muscle is voluntarily contracted, the electrode senses the electrical activity of the motor unit, which is a waveform called the motor unit potential (MUP). In the pathologic state, different waveforms may be detected that give insight into the disease process affecting the muscle as well as the chronicity of the condition and whether recovery or further loss is occurring. (Some names of these waveforms and their general implications are offered here, but this information should not be considered a definitive reference.)

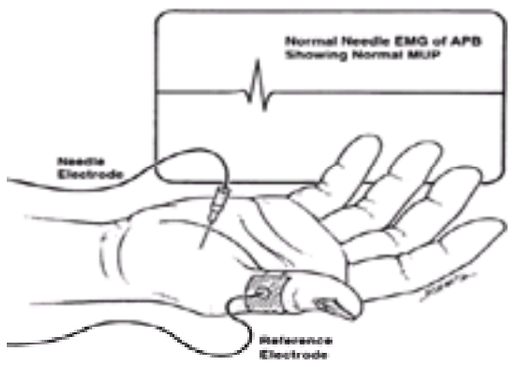


***Figure 52.5.*** Electromyography (EMG). APB, abductor pollicis brevis; MUP, motor unit potential. (From Hillburn JW. General Principles and Use of Electrodiagnostic Studies in Carpal and Cubital Tunnel Syndromes. *Hand Clin* 1996;12:205, with permission.)

Positive sharp waves and fibrillation potentials commonly indicate recent muscle denervation (Fig. 52.6*A*). The development of small highly polyphasic MUPs (Fig. 52.6*B*) and decreased fibrillations is considered evidence of early reinnervation of muscle. MUPs that are of great duration and amplitude are considered evidence of chronic denervation with collateral reinnervation resulting from adjacent nerve sprouting. Many waveforms are characteristic of neuropathies, and others of myopathies. The significance of the different electrical events is subject to the clinical setting and the interpretation of the electromyographer.

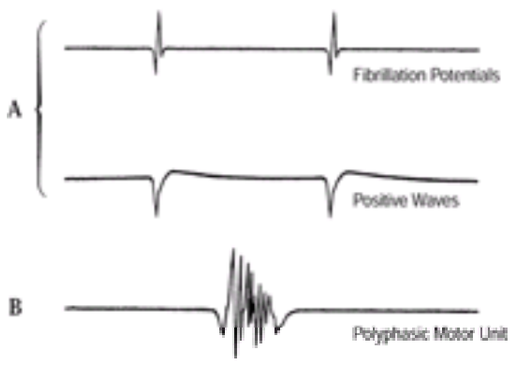


***Figure 52.6.*** Abnormal EMG motor unit potentials. **A:** Fibrillation potentials and positive sharp waves indicate recent muscle denervation. **B:** Polyphasic MUPs indicate early reinnervation of muscle. (From Hillburn JW. General Principles and Use of Electrodiagnostic Studies in Carpal and Cubital Tunnel Syndromes. *Hand Clin* 1996;12:205, with permission.)

When evaluating the electrodiagnostic report, it is important to understand that “normals” for particular tests are laboratory, machine, and operator dependent because of variations in how measurements are calculated, technique, and environmental factors such as skin temperature. However, rule-of-thumb normals may be useful. For the median nerve at the wrist, distal motor latencies of more than 4.5 msec and distal sensory latencies of more than 3.5 msec are considered abnormal. In a patient with unilateral involvement, a difference from one hand to the other of more than 1.0 msec for motor latency and 0.5 msec for sensory latency is also considered abnormal (Table 52.1) (126). It is helpful to develop a relationship with an electromyographer who produces reliable and consistent results and whose interpretations of these studies are useful in your evaluation and treatment of patients.

| Test | How performed | Condition measured | Positive result | Interpretation of positive result |
|---|---|---|---|---|
| Distal sensory latency and conduction velocity | Orthodromic stimulus and recording across wrist | Latency, conduction velocity of sensory fibers of median nerve | Latency greater than 3.5 msec or asymmetry of latency greater than 0.5 msec vs. contralateral hand | Probable CTS |
| Distal motor latency and conduction velocity | Orthodromic stimulus and recording across wrist | Latency, conduction velocity of motor fibers of median nerve | Latency greater than 4.5 msec or asymmetry of latency greater than 1.0 msec vs. contralateral hand | Probable CTS |
| EMGs | Needle electrodes placed in muscle record activity at rest and with active contraction | Denervation of thenar muscles | Fibrillation potentials, sharp waves, increased insertional activity | Very advanced motor median nerve compression |

CTS, carpal tunnel syndrome; EMG, electromyogram.
Adapted from Szabo RM: Nerve Compression Syndrome. In: Mandle PR, ed. *Hand Surgery Update*. Rosemont, IL: American Academy of Orthopaedic Surgeons, 1996, with permission.

***Table 52.1. Electrodiagnostic Tests for Carpal Tunnel Syndrome***

Certain clinical and metabolic disorders can affect nerve function. Conditions commonly associated with nerve dysfunction include hypothyroidism with myxedema (98), obesity (84,85), cervical radiculopathy, diabetes mellitus, alcoholism (83), and exposure to neurotoxic chemicals or chemotherapeutic agents. These disorders in and of themselves can cause polyneuropathy, independent of compression neuropathy; they may increase the susceptibility of nerves to compression; or they may negatively affect recovery of nerves after adequate treatment. When suspected, these disorders should be investigated and managed. They are not, however, contraindications to treatment of coexisting compression neuropathies.

Recently, some members of the medical community, of the popular media, and in the medicolegal and workers' compensation arena have included certain compressive neuropathies, most notably CTS, in a category of disorders known as cumulative trauma disorders or repetitive stress injuries. The association between repetitive stress or activity, and compression neuropathies has been described (41). It is fairly well accepted that certain activities or prolonged positioning of the extremities can incite the symptoms of compression neuropathies, but controversy exists about whether certain activities or occupations can cause them (129).

## PRINCIPLES OF TREATMENT

The critical component of effective treatment of compression neuropathies of the upper extremity is an accurate diagnosis. A perfectly performed surgical procedure is likely to provide no benefit to the patient if it is not indicated for the condition causing the symptoms. Remember that each of the compression neuropathies is related to a syndrome, which is a constellation of symptoms and signs (123). Positive neurodiagnostic studies in the absence of symptoms and signs cannot make the diagnosis of any of the compression neuropathy syndromes.

Categorizing patients based on the relative severity of their compression neuropathies may be helpful in determining treatment options. Mild cases are those with a short history of symptoms that are intermittent rather than continuous, and with negative or minimally abnormal electrodiagnostic findings. Severe cases are those with histories of symptoms for more than a year, profound and persistent numbness with atrophy of involved musculature, and both very prolonged (or absent) conduction velocities and advanced EMG findings. Mild cases are likely to respond to nonoperative measures (40), whereas severe cases do not, and therefore initial treatment should be operative.

Nonoperative treatment includes splinting, medications, physiotherapy, corticosteroid injections, and correction of metabolic abnormalities. The nerve may be protected through avoidance of positions that are deleterious to nerve function. For instance, prolonged extreme positioning of the wrist in flexion in patients with CTS or of the elbow in flexion in patients with cubital tunnel syndrome aggravates symptoms and should be avoided. Splinting is employed, usually at night, to prevent this type of positioning. Therefore, nerve protection involves educating the patient about activities and postures that may lead to compression of nerves at vulnerable sites, and

how to avoid them.

Oral medications, most commonly nonsteroidal anti-inflammatory drugs (NSAIDs) and diuretics, have been used in treating compression neuropathies. No medications, however, have any documented efficacy. Physiotherapy may be helpful in treating certain types of nerve compression but is most helpful in postoperative rehabilitation. Corticosteroid injection is usually employed after failure of the previously described nonoperative treatments. A powerful anti-inflammatory agent is delivered directly to the tissues about the nerve, at a specific location. Since few cases of CTS are the result of acute or chronic inflammation in the flexor tenosynovium (62,82), the mechanism whereby steroid injections relieve symptoms is unknown. In addition to their therapeutic value, injections may help in confirming a diagnosis, providing a prognostic indicator of the potential effectiveness of operative treatment (45).

Treat CTS induced by pregnancy with splints and elastic gloves at night until delivery of the child, when it will likely resolve spontaneously. For severe symptoms, local injections of steroids may help. If symptoms persist thereafter, operation may be necessary.

Indications for surgery include failure of nonsurgical management; acute, rapidly progressive involvement; severe cases; and symptom recurrence. Tourniquet control during surgery is preferred unless the site of compression is too proximal or unless specific contraindications exist. Meticulous hemostasis is imperative during the exposure, especially in patients with a coagulopathy and in those who are taking aspirin or are on anticoagulation treatment to reduce postoperative bleeding and swelling. Facilitate this by exsanguinating the extremity through elevation rather than by elastic wrapping, so that vessels remain partially filled and are easier to identify and coagulate or tie off.

Decompression is generally an outpatient procedure and may be performed under general, regional, or local anesthesia. Local anesthesia is reserved for less involved cases and can be used with tourniquet control, which is well tolerated for brief procedures. Make the incision to allow adequate visualization of the nerve and all suspected sites of compression. The choice of treatment of the nerve depends on its appearance under direct visualization, the location of the entrapment, and the clinical findings. If the bed in which the nerve lies is scarified or makes the nerve vulnerable to potential mechanical trauma, consider nerve transposition or flap coverage.

## COMPRESSION NEUROPATHIES OF THE MEDIAN NERVE

Compression of the median nerve typically occurs within the carpal tunnel or deep to the origin of the pronator teres (PT). A third form of median nerve entrapment is isolated compression of the anterior interosseous nerve (AIN).

### CARPAL TUNNEL SYNDROME

#### *Pathophysiology and Anatomy*

At the level of the wrist, the median nerve lies within the confined space of the carpal tunnel along with the long flexor tendons to the fingers and thumb. The tunnel is bounded on three sides by the bones of the carpus, which make up the floor of the canal, and on the fourth by the transverse carpal ligament (TCL), which forms the roof (Fig. 52.7). Compressive neuropathy of the median nerve within the carpal tunnel may result from any space-occupying lesion under the TCL (19,67,145). A frequent cause is flexor tenosynovitis; other causes are fractures and dislocations of the floor of the canal and distal radius, and other space-occupying lesions such as tumors and ganglia. These space-occupying lesions increase the volume of the contents of the noncompliant carpal tunnel, raising the pressure on its contents, which include the median nerve. In many cases, there are no particular identifiable causes even though the nerve is clearly compressed. Although many of these cases are attributed to “nonspecific synovitis,” pathologic examination of the synovium obtained from the carpal canal in these cases usually fails to reveal signs of inflammation. Rather, fibrosis and/or edema changes are seen, which may themselves be secondary to compression rather than the primary cause of the entrapment neuropathy (62,82).

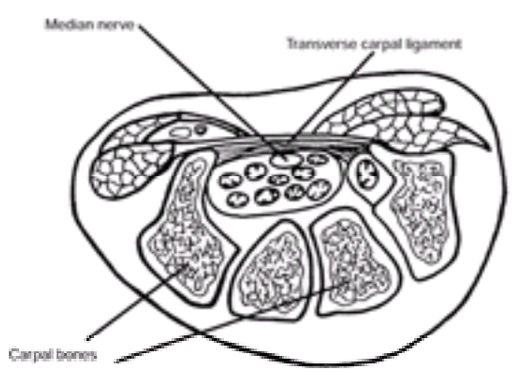


***Figure 52.7.*** Cross section of a wrist through the carpal canal. The median nerve and digital flexor tendons lie in the space formed by the bony carpal arch and transverse carpal ligament. (Adapted from North ER, Kaul MP. Compression Neuropathies: Median. In: Peimer CA, ed. *Surgery of the Hand and Upper Extremity.* New York: McGraw-Hill, 1996:1307, with permission.)

#### *Assessment*

The diagnosis of CTS is strongly suggested by the patient's history. Typically, he complains of aching or burning pain along the median nerve distribution and of numbness and tingling in the median-nerve-innervated digits (Fig. 52.8*A*) during the night and early morning as well as during activities. Numbness may extend into the ulnar digits in some patients. These symptoms are aggravated by elevation, repetitive activities, and prolonged flexion positioning of the wrist (130). Radiation of symptoms proximal to the wrist is not unusual. Complaints of the hand feeling fat, clumsiness in manipulation, and dropping items are also frequent. The incidence is greater in women than in men, although the difference is decreasing. In the past, postmenopausal women were the most common patients; commonly associated diagnoses were rheumatoid arthritis and distal radius malunion. Recently, a large, younger group of patients with essentially equal distribution of women and men has emerged. In this group the carpal tunnel disease has been labeled idiopathic (62).

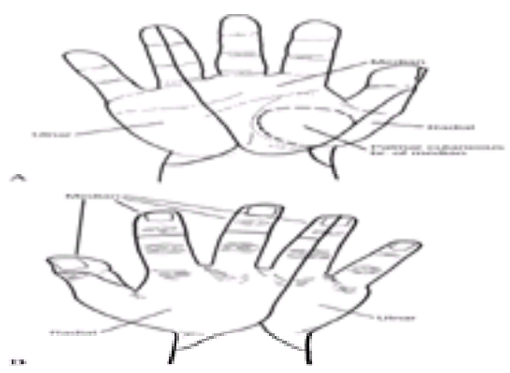

***Figure 52.8.*** **A:** Palmar sensory distributions of ulnar, median, palmar cutaneous, and radial nerves. **B:** Dorsal sensory distributions of radial, median, and ulnar nerves.

Examination includes sensory, provocative, sudomotor, and strength testing. Sensibility may be reduced throughout the area normally supplied by the median nerve except for the thenar eminence, the distribution of the palmar cutaneous branch (Fig. 52.8*A*), which does not enter the carpal canal (135). As noted previously, the most consistent and reliable way to evaluate sensibility in nerve compression is to use threshold testing (Semmes–Weinstein monofilaments, vibrometry, and 256 cps vibration testing) (126,127,132,133,134). Provocative tests compress or percuss the median nerve to elicit numbness and paresthesias in the distribution of the median

nerve in patients with CTS. Phalen's wrist flexion test, in which the wrist is maximally flexed with the fingers slightly curled, is sensitive (Fig. 52.9) (43). A positive test for CTS is reproduction of symptoms within 60 sec. Tinel's nerve percussion test, in which the median nerve is percussed as it enters the carpal canal to elicit symptoms (Fig. 52.10), is specific and indicates CTS in cases in which Phalen's test is also positive (65). Another useful test is the direct compression test, which is sensitive *and* specific. The examiner's thumbs apply direct pressure to the median nerve as it enters the carpal tunnel (Fig. 52.11) (29). A positive test is reproduction of symptoms, which appear within 30 sec and disappear with release of compression. Together, these tests provide added clinical evidence of median nerve compression at the wrist (Table 52.2).

***Figure 52.9.*** Phalen's wrist flexion test.

***Figure 52.10.*** Tinel's nerve percussion test.

***Figure 52.11.*** Durkan's median nerve compression test.

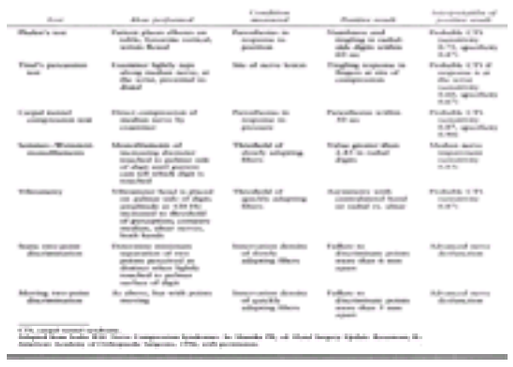

***Table 52.2. Diagnostic Tests for Carpal Tunnel Syndrome***

Sudomotor activity (sweating) may be diminished. This is easy to detect clinically by sliding a metal object (e.g., a pen) between the patient's fingers, which are held together. The object slides much more easily on dry skin than on skin with normal perspiration. Strength testing is difficult and somewhat subjective. The most easily evaluated muscle of the thenar eminence is the abductor pollicis brevis (APB) muscle. Most often, this muscle is innervated solely by the median nerve, but it can also have a contribution from the radial nerve. It is the most superficial of the thenar muscles and can be palpated during active opposition or resisted palmar abduction of the thumb. Relative weakness of palmar abduction of the thumb against resistance or muscle atrophy occurs in more advanced cases. Flattening or concavity of the normally bulging thenar eminence indicates atrophy of the APB (Fig. 52.12*A*). A weak, soft, or small APB is seen in severe cases of CTS and indicates denervation of the muscle.

***Figure 52.12.*** **A:** A flattened thenar eminence indicates atrophy of the abductor pollicis brevis. **B:** Abductor pollicis brevis (*arrow*). (From North ER, Kaul MP.

Compression Neuropathies: Median. In: Peimer CA, ed. *Surgery of the Hand and Upper Extremity.* New York: McGraw-Hill, 1996:1307, with permission.)

Radiographic examination is not indicated in all cases because there is a low yield of findings (9); it should be restricted to patients with a history of trauma or arthritis and those with decreased wrist range of motion on examination. One of us (JT) obtains radiographs to rule out Kienböck's disease in younger patients and peritrapezial arthritis in older ones. Additional diagnoses uncovered by preoperative radiographs include scapholunate advanced collapse (SLAC) wrists, ununited fractures of the scaphoid, and radiopaque masses within the carpal tunnel (136). The views recommended include posteroanterior (PA), lateral, and carpal tunnel views.

Additional examinations include electrodiagnostic studies and laboratory tests. Positive nerve conduction velocities show increased latencies. In severe cases, EMG exams may show abnormalities and may give information regarding treatment prognosis. In mild or exertion-related cases, electrodiagnostic studies may be negative. This negative finding does not rule out CTS in the presence of typical signs and symptoms. Provocative nerve conduction evaluation may help to uncover these dynamic forms of CTS (14). EMG examination may be helpful when a cervical radiculopathy is suspected. Order laboratory testing to screen for metabolic disorders that may contribute to or cause CTS, (a) when there is suspicion of these disorders, (b) when there is bilateral presentation, and (c) in children who may have rare mucopolysaccharidosis or mucopolylipidosis (139). Tests include erythrocyte sedimentation rate, rheumatoid factor, serum glucose level, uric acid, thyroid panel, and renal indices. Liver function tests may be indicated if alcohol-related peripheral neuropathy is suspected. If doubt persists about the correct diagnosis, an injection of a small amount of a steroid preparation mixed with local anesthetic into the carpal tunnel (not into the nerve) can be a therapeutic and diagnostic aid (Fig. 52.13) (Table 52.3) (45). The entry site for the needle is slightly proximal to the distal wrist crease, ulnar to the palmaris longus (PL) to avoid impaling the median nerve, and approximately 1 cm radial to the flexor carpi ulnaris (FCU) to avoid entrance into the canal of Guyon. Insert the needle at a 45° angle, beneath the proximal margin of the TCL and directed in line with the ring finger ray. Palpation in the midpalm just distal to the TCL while injecting can help confirm proper needle placement by enabling you to feel the flush of fluid into the canal.

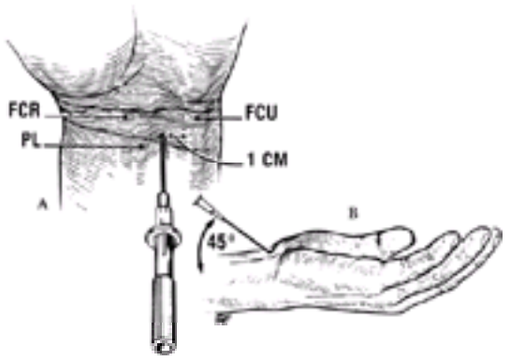


***Figure 52.13.*** Injection into the carpal tunnel. **A:** The entry site for the needle. PL, palmaris; FCU, flexor carpi ulnaris. **B:** Insertion of the needle. (From Gelberman RH, Rydevik BL, Pess GM, et al. Carpal Tunnel Syndrome: A Scientific Basis for Clinical Care. *Orthop Clin North Am* 1988;19:117, with permission.)



***Table 52.3. Carpal Tunnel Syndrome Summary***

### *Classification*

Patients with CTS may be classified into three categories. The mild group consists of patients with intermittent symptoms that have been present less than 1 year, who have normal two-point discrimination, no thenar weakness or atrophy, no denervation potentials on EMG, and mildly elevated NCV. With conservative treatment and steroid injection, 40% will be free of symptoms at 12 months. The severe group consists of those with profound, persistent symptoms that have been present longer than 1 year, thenar weakness or atrophy, and marked abnormalities on electrodiagnostic studies (40). Patients in the severe group fail to respond adequately to conservative therapy and should receive operative treatment, which may include tendon transfers concurrent with carpal tunnel release. In the moderate group, conservative treatment shows findings and gives results intermediate between those of the mild and severe groups. The presence of underlying disorders or advanced age in any of these patients diminishes the response to conservative (and possibly operative) care.

### *Nonoperative Treatment*

Initially, institute nonoperative treatment in all patients except those with severe disease. Splint the wrist in neutral to slight extension at night and during activities that exacerbate symptoms. In exertional or dynamic cases, modification of activities that exacerbate symptoms may be helpful. Vitamin $B_6$ has no effect on the natural history of CTS (3,4). Steroid injection offers transitory relief in 80% of patients, with only 22% being free of symptoms at 12 months. The patients in the mild group fare better than others with steroid injection (40). Treat or correct underlying disorders if possible.

### *Surgical Indications and Relative Results*

Indications for surgery include failure of nonoperative treatment, persistent or progressive symptoms, acute onset with profound sensory loss associated with trauma, and weakness or atrophy of thenar muscles. Results of surgery vary according to severity of disease, choice of surgical treatment, and individual patient physiology and social issues. As a general rule, we believe that with adequate release of the carpal tunnel, major or complete relief of discomfort associated with CTS is likely, as is relief of transient numbness. Persistent or profound numbness may not disappear with release if it has been present for a prolonged period (over 12 months). Weak or atrophied muscle is not expected to recover with release, but if it is not complicated by underlying disease, its progression will likely be halted. Nolan et al. (87) showed that patients with severe disease, followed for more than 2 years after carpal tunnel release, show improvement. Therefore, surgery is indicated in these patients, especially if symptoms of discomfort are present.

### *Preoperative Planning*

Make the decision to perform surgical release in a patient with CTS in the context of the patient's general condition. You must be certain of the diagnosis of CTS and that its cause is compression of the median nerve at the wrist. Within reason, exclude other potential sources of the symptoms and maximally correct any contributing conditions. With these issues resolved, you must include the particular considerations of the patient in the surgical care. If malunions and carpal instabilities are severe enough to compromise results, treat them prior to or concurrently with release. In patients with severe atrophy of the thenar musculature, perform opponensplasty at the time of release. A particularly suitable procedure for restoration of thumb palmar abduction in the patient with severe CTS is the Camitz opponensplasty, in which the PL is harvested and extended with a strip of palmar fascia, then routed subcutaneously and sutured into the thumb at the level of the metacarpophalangeal (MP) joint along the APB tendon (Fig. 52.14).

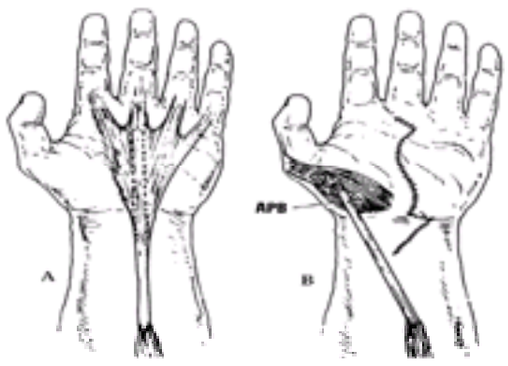

***Figure 52.14.*** The Camitz transfer for restoration of thumb palmar abduction in patients with severe atrophy of the thenar musculature. **A:** Harvesting of the palmaris longus. **B:** Rerouting of the PL. (From Imbriglia JE, Hagberg WC, Baratz ME. Median Nerve Reconstruction. In: Peimer CA, ed. *Surgery of the Hand and Upper Extremity.* New York: McGraw-Hill, 1996:1381, with permission.)

***Open Carpal Tunnel Release***

- Start the incision at the junction of the proximal and middle thirds of the palm (at the level of Kaplan's Cardinal Line) on the radial aspect of the ring finger ray and continue it proximally to a point where the interthenar crease intersects the distal wrist crease, just ulnar to the PL tendon (Fig. 52.15).



***Figure 52.15.*** Approach to the carpal tunnel. The more proximal porton (*dashed and dotted lines*) is used when a more extensive exposure is required.

- To extend this incision for increased exposure, as is needed in flexor tenosynovectomy, carry the incision along the wrist crease ulnarly to a point just radial to the flexor carpi ulnaris tendon and, if necessary, gently curve it proximally and radially to the ulnar aspect of the PL tendon.
- Divide the subcutaneous fat to expose the palmar fascia and divide the palmar fascia in line with the incision, which exposes the TCL. Take care to avoid injury to the ulnar nerve and artery that lie nearby, on the ulnar aspect of the field in the canal of Guyon.
- Divide the TCL longitudinally, close to its ulnar attachments and extending distally until you reach the fatty envelope surrounding the vessels of the superficial palmar arch.
- Proximally, with the median nerve under direct vision, elevate the skin off of the TCL where it blends into the antebrachial fascia.
- Divide the proximal portion of the TCL and the antebrachial fascia with scissors 3–5 cm proximal to the carpal canal.
- Elevate the entire radial flap of skin, including subcutaneous tissue, ligament, and intact palmar cutaneous branch of the median nerve and its divisions, to expose the median nerve in the canal.
- Use blunt dissection to free the median nerve from the radial wall of the canal, where it is often tethered by synovium.
- Sweep the contents of the canal away from first the radial and then the ulnar aspects of the canal, inspecting the floor for masses or irregularities. Also examine the digital flexor tendons for fraying and other damage.
- Perform synovectomy (e.g., in rheumatoid patients), and reduce and fix fractures or dislocations if indicated.
- Release the tourniquet and obtain hemostasis. Close only the skin with 5-0 nylon suture.
- Apply a well-padded dressing with plaster reinforcement as desired to immobilize the wrist in neutral and the thumb in palmar abduction. Be sure not to splint the thumb in radial abduction because this position encourages lengthening of the thenar muscles, which results in prolonged pinch weakness.

There have been significant differences of opinion about whether internal neurolysis improves the results of carpal tunnel release in patients with severe CTS manifested by thenar atrophy or fixed sensory deficit (33,34,42,71,73). In a combined series of patients (69 hands) from San Diego and Sacramento, added benefit from internal neurolysis in the treatment of severe CTS could not be demonstrated (42). Lowry and Follender (71) confirmed this finding with a prospective, randomized, double-blind, controlled study. We therefore no longer perform or recommend internal neurolysis in the treatment of CTS. Concomitant release of the canal of Guyon in patients with evidence of compression of the ulnar nerve at the level of the wrist in conjunction with CTS is not recommended (117). Transection of the TCL during carpal tunnel release alone results in an increase in the volume of the carpal tunnel of approximately 24% and a change in the orientation and shape of the canal of Guyon (102). Clinically, this results in resolution of the symptoms referable to ulnar nerve compression at the wrist in these patients.

***Endoscopic Carpal Tunnel Release***

Open carpal tunnel release is considered the preferred surgical technique, especially for surgeons not doing a large volume of these surgeries, because it offers good visualization of the TCL, the superficial arch, and the carpal canal contents. It is a proven, reliable method. Nonetheless, some herald endoscopic carpal tunnel release as a step forward in the treatment of CTS (15,21,94). Proponents of the latter technique claim decreased morbidity as a result of the smaller scar, which occurs away from the base of the palm, and more rapid rehabilitation (35,142). Several systems exist for the purpose of endoscopic release; they have in common visualization of the undersurface of the TCL with an arthroscope as the ligament is divided from within the canal using special knives or a blade mechanism. Agee et al. (2) and Chow (21) developed independent systems that are available commercially.

In a multicenter prospective randomized study, Agee et al. (2) demonstrated a decrease in early postoperative pain and morbidity using his device, but by 6 weeks, results were comparable to those of standard carpal tunnel release.

Additional studies have evaluated endoscopic release (15,35). Although scar pain has been reduced and time to recovery of preoperative grip and pinch strength minimally shortened, pillar pain and palmar tenderness have not been eliminated. In cadaver studies, incomplete release of the TCL has been demonstrated to occur in up to 50% of the specimens (111). Clinically, however, patients do obtain symptomatic relief from the endoscopic technique. As endoscopic release systems have been refined and experience with the technique gained, results have improved. The procedure remains hazardous in inexperienced hands and requires specialized training. A risk of cutting neurovascular structures or tendons exists because of limited visualization and deviations from proper technique (81,110). Recurrent or incomplete relief of symptoms from endoscopic release has been shown to be related to incomplete release of the TCL. This improves after subsequent open carpal tunnel release (36,53).

Endoscopic carpal tunnel release remains a controversial method for treatment of CTS. However, with a thorough knowledge of the pertinent anatomy and with experience, it can be a safe and effective treatment in appropriate patients if the surgeon adheres to several tenets. The surgical consent form must specify both an endoscopic and an open carpal tunnel release, because several conditions may necessitate aborting the former and proceeding with the latter. These include (a) difficulty in visualization that results from equipment problems, fogging, or the inability to clear synovium from the undersurface of the ligament, (b) presentation of atypical anatomy, and (c) difficulty in manipulating the endoscope. The surgeon must place the endoscope in the ulnar aspect of the carpal tunnel and keep it aligned with the ring finger ray to prevent injury to the median nerve and the superficial vascular arch (108). (Specific techniques are not discussed here; refer to the manufacturer's technique manual for each system.) The surgeon must verify absolutely that the endoscope is within the carpal tunnel and not in the canal of Guyon before making any cuts. Endoscopic carpal tunnel release is inappropriate in patients with bony deformity caused by fracture or dislocation and in those with inflammatory synovitis who require synovectomy or whose synovitis may make visualization difficult. If endoscopic tunnel release is considered, preoperative radiographs are necessary to evaluate these issues.

Multiple limited- and minimal-incision methods and systems have been developed for carpal tunnel release and are commercially available (13,68,86). These differ from

endoscopic techniques in that the TCL is divided by a relatively blind method rather than being visualized with an arthroscope. The benefits of this technique over open carpal tunnel release are similar to those of the endoscopic methods, as are the risks.

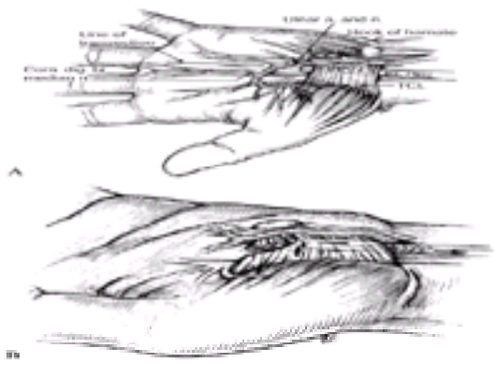

***Figure 52.16.*** Endoscopic carpal tunnel release with the system developed by John M. Agee. **A:** Insertion of the blade assembly beneath the transverse carpal ligament. **B:** Division of the transverse carpal ligament. (From Gelberman RH, North ER. Carpal Tunnel Release. In: Gelberman RH, ed. *Operative Nerve Repair and Reconstruction.* Philadelphia: Lippincott, 1991:899, with permission.)

### *Postoperative Care and Rehabilitation*

Immediately postoperatively, encourage active, gentle finger range-of-motion exercises. Patients should also maintain mobility of the elbow and shoulder. Elevation is crucial, especially during sleep, to reduce edema. Remove bulky dressings and splints 5 days postoperatively. The patient then wears a removable prefabricated wrist splint for comfort only. [One of us (MNH) instructs the patient to wear the splint full time.] The wrist is put through gentle range-of-motion excercises several times a day, independently of finger motion. Continue the splint for 2–3 weeks for patient comfort only, during which time encourage progressive use of the hand. Then discontinue daytime splinting. Continue nighttime wear for an additional 3–4 weeks if desired (96). Use physiotherapy selectively for patients who are progressing poorly. Recovery takes months, so patients who are told that the carpal tunnel release is a minor operation and full recovery can be anticipated in 2 weeks are grossly misled and usually unhappy.

The patient's return to work depends largely on the demands of his occupation. Gellman et al. (44) have shown that grip strength returns to preoperative levels 3 months after surgery, and pinch strength returns at 6 weeks. Their work provides us with an indication of when patients ought to be able to return to their previous levels of occupational activity. Many studies employ “return to work” as a measure of outcome without clearly delineating what criteria are to be met to determine when a patient should return to work. Many factors influence the actual return-to-work time. Palmar tenderness, a particularly important consideration in manual laborers, may persist for longer than 6 months. Full recovery of nerve function may not occur, depending on the severity of nerve damage. Persistent palmar pain and early recurrent symptoms in workers' compensation cases are increasing, unsolved problems for patients, physicians, and industry. Without job modification for these patients, carpal tunnel release alone may lead to failure in returning the patient to gainful employment.

### *Complications*

Complications are caused by misdiagnosis or technical factors. Conditions associated with peripheral neuropathies must be suspected, recognized, and treated before surgery, or concurrently with the surgical release. Upton and McComas (137) proposed a “double crush” syndrome as a hypothesis to explain the failure of distal decompressions in nerves subject to compression in multiple sites. Many patients with CTS have a cervical radiculopathy. Others may have concomitant compression at the carpal tunnel as well as under the PT. Release of the carpal tunnel in these cases may not relieve symptoms because the more proximal compression remains. Hypertrophic synovium, if not removed at the time of surgery, may cause persistent compression despite ligament release.

Complicating technical factors include improper placement of the incision (i.e., usually too far radially), which jeopardizes the median nerve and its motor branch, as well as leading to injury or entrapment of the palmar cutaneous nerve or its branches (Fig. 52.17). Poor exposure may result in incomplete division of the TCL or in injury to the superficial palmar arch. Do not use transverse incisions at the wrist crease for blind decompression of the carpal tunnel.



***Figure 52.17.*** The palmar cutaneous branch of the median nerve and its divisions crossing a carpal tunnel incision placed too far radially.

A rare complication is a tendency of the flexor tendons to the little finger to sublux during strong gripping. This is often only a transitory problem. Bowstringing of the flexor tendons with flexion of the wrist has been noted. This complication is easily prevented by postoperatively immobilizing the wrist in slight dorsiflexion for 2–3 days (138), which additionally may prevent adherence of the nerve and tendons to palmar structures and improve grip strength (88). Reserve reconstruction of the TCL for instances where immobilization of the wrist in flexion is necessary after carpal tunnel release. Complications from deficient postoperative management usually result from swelling and edema or poor control of pain, leading to loss of finger or wrist motion (particularly if a synovectomy was performed) and to reflex sympathetic dystrophy. The benefits of a good postoperative dressing, an aggressive exercise program, and elevation cannot be emphasized enough.

Pillar pain—pain at the base of the thenar and hypothenar eminences after carpal tunnel release—is a common finding in patients. It varies greatly from case to case in both severity and duration of its symptoms. Its etiology is poorly understood, although many theories have been proposed. It generally subsides and resolves over time. Seradge and Seradge (113) noted ulnar-sided wrist pain in 1% of their patients after carpal tunnel release. They attributed this pain to the pisotriquetral joint, whose mechanics are altered by division of the TCL. Treatment consisted of excision of the pisiform in cases with transient response to steroid injection of the joint. We have no evidence to substantiate this theory or to recommend this approach.

## PRONATOR SYNDROME

The term *pronator syndrome* was initially coined to describe compression of the median nerve in the proximal forearm beneath the pronator teres muscle. Since then, common usage has evolved so that it now denotes compression of the median nerve in the proximal forearm and about the elbow (59).

### *Pathophysiology and Anatomy*

The median nerve lies anterior to the brachial artery and medial to the biceps muscle in the midarm. In the distal arm, it crosses the brachial artery to lie medial to it, coursing on the brachialis muscle. The supracondylar process is an anomalous spur arising on the anteromedial aspect of the distal humerus, 5 cm proximal to the medial epicondyle, in as many as 3% of individuals. The ligament of Struthers is a fibrous band that may arise from the supracondylar process (spur) of the humerus (7) and attaches to the medial epicondyle, forming a fibro-osseous tunnel through which the median nerve and, at times, the brachial artery pass (Fig. 52.18) (66). The median nerve enters the antecubital fossa coursing beneath the lacertus fibrosus (bicipital aponeurosis), then travels between the superficial (humeral) and deep

(ulnar) heads of the PT muscle. It continues distally beneath the arch of origin of the flexor digitorum superficialis (FDS), coming to lie between it and the flexor digitorum profundus (FDP). The median nerve maintains this relationship throughout its course to the wrist. Potential sites of compression include the supracondylar process and the ligament of Struthers, the lacertus fibrosus, the arch of the origin of the PT, and the arch of the origin of the FDS (Fig. 52.26, Table 52.4).

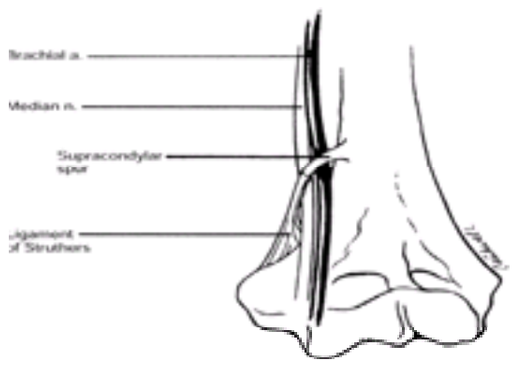


***Figure 52.18.*** The ligament of Struthers. (From Stern PJ, Fassler PR. Pronator Syndrome. In: Gelberman RH, ed. *Operative Nerve Repair and Reconstruction.* Philadelphia: Lippincott, 1991:995, with permission.)

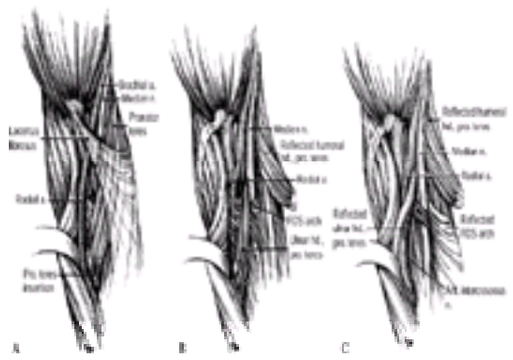

***Figure 52.26.*** **A:** Division of the lacertus fibrosus. **B:** Exposure of the median and anterior interosseous nerves and the arch of the superficialis. **C:** The radial origin of the superficialis muscle elevated by subperiosteal dissection to expose the deep volar compartment and the AIN. (From Eversmann WW Jr. Entrapment and Compression Neuropathies. In: Green DP, ed. *Operative Hand Surgery.* New York: Churchill Livingstone, 1982:1341, with permission.)

| |
|---|
| Supracondylar process of the humerus and ligament of Struthers |
| Bicipital aponeurosis (lacertus fibrosus) |
| Arch of the origin of the pronator teres |
| Arch of the origin of the flexor digitorum superficialis |

***Table 52.4. Potential Compression Sites of the Median Nerve in Pronator Syndrome***

### *Assessment*

The symptoms arising from compression of the median nerve at this level, including numbness in the radial three and one-half digits and thenar weakness, may be attributed to CTS. In pronator syndrome, unlike in CTS, paresthesias are typically absent at night. Important additional symptoms that may help differentiate this condition from CTS are pain in the anterior aspect of the proximal forearm and numbness in the thenar region—the territory of the palmar branch of the median nerve that does not travel through the carpal tunnel, having branched from the median nerve several centimeters proximal to the wrist. Sensory threshold testing detects decreased sensation in the radial three and one-half digits, as in CTS, with the addition of numbness in the thenar eminence, the area innervated by the palmar cutaneous branch (Fig. 52.8*A*). The findings of weakness and atrophy in the thenar musculature may be indistinguishable from those seen in CTS, although they are less severe and are most often absent.

The portion of the physical examination that will further differentiate pronator syndrome from CTS is provocative testing. Phalen's test should be negative, but it may be positive (47,95). Tinel's percussion test, in which the median nerve is percussed at the level of the pronator muscle, elicits paresthesias in the distribution of the median nerve in the proximal forearm rather than at the carpal tunnel (Fig. 52.19). To perform the pronator compression test, place direct thumb pressure just proximal and lateral to the proximal edge of the PT muscle belly (Fig. 52.20). (The brachial pulse will be palpable lateral to the nerve.) A positive test is reproduction of paresthesias in the median-nerve-innervated digits within 30 seconds, and it supports the diagnosis of pronator syndrome (38). According to Olehnik et al. (95), the pronator compression test is the most accurate diagnostic test. Several tests have been designed to give clues to the specific site of compression of the median nerve in pronator syndrome. The production of pain or aggravation of paresthesias with simultaneous resisted forearm supination and resisted elbow flexion beyond 120° indicates probable entrapment of the median nerve at the lacertus fibrosus (Fig. 52.21) (7,33,58,115,122). Entrapment of the nerve between the two heads of the PT muscle is indicated by elicitation of paresthesias in the median nerve sensory distribution with resisted forearm pronation while the elbow is slowly extended from full flexion (Fig. 52.22) (33,58,121,122). Paresthesias elicited in the radial three and one-half digits with resisted independent flexion of the proximal interphalangeal (PIP) joint of the long finger suggest entrapment beneath the superficialis arch of origin (Fig. 52.23, Table 52.5) (33,122).

***Figure 52.19.*** Tinel's percussion test in the proximal forearm for evaluation of pronator syndrome.

***Figure 52.20.*** The pronator compression test.

***Figure 52.21.*** Testing for entrapment of the median nerve at the lacertus fibrosus in pronator syndrome.

***Figure 52.22.*** Testing for entrapment of the median nerve at the pronator in pronator syndrome.

***Figure 52.23.*** Testing for entrapment of the median nerve at the arch of the flexor digitorum superficialis in pronator syndrome.

| *Symptoms, signs, findings* | *Carpal tunnel syndrome* | *Pronator syndrome* |
|---|---|---|
| Nocturnal symptoms | Common | Uncommon |
| Numbness in palm at thenar eminence | Not present | Present |
| Tinel's percussion sign | Positive at wrist<br>Negative in forearm | Negative at wrist<br>Positive in forearm |
| Median nerve compression sign | Positive at wrist<br>Negative in forearm[a] | Negative at wrist<br>Positive in forearm |
| Phalen's test | Positive | Negative[b] |
| Pronator signs | Negative | Positive |
| Electrodiagnostic studies | NCV positive at wrist | NCV negative at wrist |

[a] May be positive (95).
[b] Commonly positive (47,95).
NCV, nerve conduction velocity.

***Table 52.5. Carpal Tunnel versus Pronator Syndrome***

Special diagnostic procedures include electrodiagnostic studies and radiographs of the elbow. Median nerve conduction velocities from the elbow to the wrist are decreased in less than one third of cases (16,47,95). The value of obtaining these studies is to evaluate for the presence of CTS. A normal conduction velocity at the level of the wrist supports proximal compression of the median nerve in the presence of symptoms and signs of pronator syndrome. A study consistent with CTS indicates the necessity of treatment directed at the wrist but does not rule out a double crush phenomenon, with compression both at the carpal tunnel and in the proximal forearm. Failed carpal tunnel releases that respond to subsequent operative release in the proximal forearm support the occurrence of simultaneous compression of the nerve at these two sites (95). Four views of the elbow—anteroposterior (AP), lateral, and two obliques—are obtained to evaluate the presence of a supracondylar process. Although its presence is suggestive of compression of the median nerve beneath the ligament of Struthers, it is not pathognomonic; this is a very rare site of entrapment. The absence of a supracondylar process does not rule out the presence of a ligament of Struthers and entrapment at this site (Table 52.6).

| | |
|---|---|
| Pathology | |
| 1. Compression of the median nerve in the proximal forearm | |
| 2. Spasm of muscles | |
| 3. Lacertus fibrosus | |
| Pronator teres | |
| Arch of the FDS | |
| History | |
| Associated with activities requiring repetitive forearm pronation and elbow flexion—exacerbation | |
| Symptoms | |
| Numbness and tingling in radial digits | |
| Numbness in palm or dorsal sensory | |
| Pain in proximal forearm | |
| Feeling of fatigue or cramping in forearm with use | |
| Sensory exam | |
| Diminished sensation in radial digits | |
| Diminished sensation in palm at thenar eminence | |
| Threshold does more sensitive (Semmes–Weinstein, or biometer) | |
| Motor exam | |
| Hand weakness and atrophy uncommon | |
| Provocative tests | |
| Resisted elbow flexion and forearm supination—exacerbation of symptoms at lacertus fibrosus | |
| Resisted pronation with elbow in extension—exacerbation of pain at proximal forearm | |
| Resisted flexion of PIP joint of long finger—exacerbation at FDS arch | |
| Provocative compression test—compression of median nerve at proximal forearm | |
| Percussion of median nerve in proximal forearm (Tinel's sign) | |
| Diagnostic studies | |
| EMG positive in only 50% of cases | |
| NCV or EMG and radiography | |
| Radiography of elbow in evaluation for supracondylar process | |
| Differential diagnosis | |
| Carpal tunnel syndrome | |
| Cervical radiculopathy | |
| Note: These diagnoses especially (50%) more common than PRS. Carpal tunnel syndrome. | |

***Table 52.6. Pronator Syndrome Summary***

### *Preoperative or Nonoperative Management*

Nonoperative treatment consists of anti-inflammatory medications, splinting, and rest for 4–6 weeks. Modification of activities is particularly important because symptoms are often related to repetitive elbow flexion and extension and to forearm pronation and supination. Physiotherapy in the form of massage, stretching, and iontophoresis to mobilize and relax potentially tight structures may be helpful. Carefully placed steroid injections in the site of maximal tenderness and pain (but not into the nerve) may be useful for diagnostic and therapeutic purposes.

### *Surgical Indications and Relative Results*

Surgery generally is not necessary because most patients respond to nonoperative care. Surgery is indicated in those cases where symptoms persist longer than 6 weeks to 3 months following adequate conservative management.

Improvement after surgical release is reported in approximately 80% to 90% of cases (38,47,59,95). Complete relief of symptoms occurs in only about one third of those who improve. There appears to be no preoperative indicator of which patients will have the better results (95). As in CTS, return to work will depend in part on the demands of the patient's particular vocation. Of the 36 patients in the series reported by Olehnik et al. (95), 25 returned to their preoperative or similar occupations and eight returned to work but had to change jobs. The final work status of the remaining three patients was unknown.

### *Preoperative Planning*

To plan the surgical incision, you must determine whether the site of compression is above or below the elbow. If there is evidence of compression under an arcade of Struthers, center the surgical exposure at the radiographic projection of the supracondylar process. If the compression is below the elbow, extend the incision distal to the elbow flexion crease onto the forearm to expose the pronator and the arch of the FDS.

### *Technique for Release of Compression at the Ligament of Struthers*

- Center the incision over the supracondylar process and make it in line with the medial neurovascular bundle anterior to the medial intermuscular septum (Fig. 52.24).

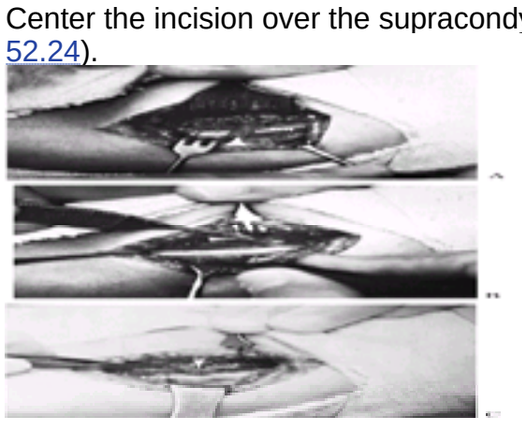

***Figure 52.24.*** Entrapment of the median nerve (MN) under a ligament of Struthers. **A:** Initial appearance. **B:** The ligament divided and elevated (*arrow*). **C:** Supracondylar process (*arrow*).

- Palpate the supracondylar process and expose the ligament of Struthers.
- The median nerve, brachial artery, and sometimes the ulnar nerve lie within the proximity of the supracondylar process; therefore, proceed; cautiously with dissection.
- Divide the ligament of Struthers and excise the supracondylar process.
- Continue distally and divide the lacertus fibrosus. This is done routinely in decompression of the median nerve for these cases and for others that do not involve compression at the supracondylar process. The lacertus fibrosus may act as a compressive band across the flexor muscle mass in supination and hence should be divided with any exploration of the median nerve.
- If you do not find a ligament of Struthers, you must discover the area of compression by additional dissection distally.

### *Technique for Release of Compression Distal to the Ligament of Struthers*

- Begin the incision along the projection of the medial neurovascular bundle, 5 cm proximal to the elbow flexion crease.
- Continue it in a gentle curve along the elbow flexure, and extend it distally past the superficialis arch (Fig. 52.25).

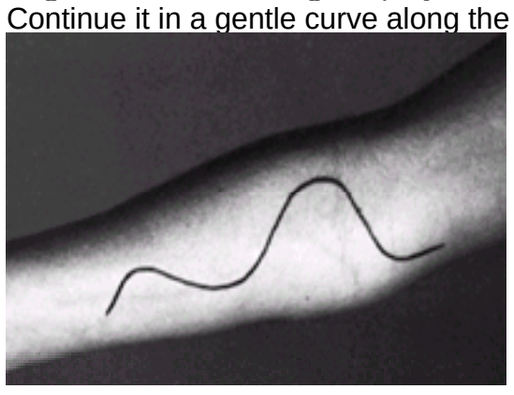

***Figure 52.25.*** Extensile approach for the exposure of the median nerve at the elbow and proximal forearm.

- Protect the medial antebrachial cutaneous nerve from injury.
- Raise full-thickness flaps radially and ulnarly off the forearm muscle fascia.
- Identify the median nerve proximal to the lacertus fibrosus and the PT (Fig. 52.26*A*).
- The lacertus fibrosus originates from the anteromedial aspect of the musculotendinous junction of the biceps and travels distally and medially, crossing the median nerve and brachial artery to blend into the fascia of the flexor pronator muscle mass. Divide it in line with the course of the median nerve.
- Follow the median nerve distally as it passes between the two heads of the PT.
- Detach the superficial head of the pronator from its distal conjoined tendon with the deep head, using a stepcut or long oblique incision designed to allow

reattachment of the superficial head with relative lengthening (122). This requires dissection distal to the midforearm level.

- Reflect the superficial head ulnarly (Fig. 52.26*B*).
- Identify the arch of the FDS, which lies in the distal portion of the wound, deep to the pronator. Expose the FDS by reflection of the superficial head of the pronator.
- Follow the median nerve as it courses deep to the arch of the FDS.
- Detach the radial origin of the FDS (Fig. 52.26*C*) or, alternatively, divide it in line with its fibers between its radial and ulnar halves to expose and decompress the median nerve.
- Reattach the superficial pronator at a point proximal to its original insertion or in a lengthened position, using the stepcut.
- Close the skin.

Alternative incisions that are oriented fairly transversely, with a goal of minimizing unsightly scarring, have been described (38). These have been criticized for not providing adequate exposure of the nerve and the sites of compression (58). Olehnik et al. (95) described an oblique incision centered over the point of maximal tenderness in the proximal forearm (Fig. 52.27). The fascia was then split longitudinally to allow adequate access to the soft-tissue structures in the antecubital fossa to the midforearm. Deep digital palpation and dissection were used to evaluate for compression of the nerve proximally by a ligament of Struthers. They additionally released intramuscular fascial bands of the PT and FDS that crossed the nerve. The authors of this study point out the importance of tracing the nerve along its course, releasing all fibrous bands and vascular structures that are potential sites of compression.

***Figure 52.27.*** An oblique incision 3 months after surgery for decompression of the median nerve in pronator syndrome. (From Olehnik WK, Manske PR, Szerzinski J. Median Nerve Compression in the Proximal Forearm. *J Hand Surg [Am]* 1994;19:121, with permission.)

### *Postoperative Care and Rehabilitation*

After skin closure, apply a well-padded compression dressing and a posterior plaster splint with the elbow flexed at right angles and the forearm in semipronation. Encourage shoulder and finger motion immediately after the operation. After 5 days, discontinue immobilization; allow the patient to resume elbow flexion and extension and forearm rotation and to gradually return to full activities as tolerated.

### *Complications*

As for CTS, misdiagnosis and technical factors are responsible for most complications. The most important is failure to release constriction at one of the four sites of possible entrapment. You must also address all other potential sources of compression by visualizing the nerve along its course. Avoid accidental damage to branches of the median nerve by initially exposing and dissecting the nerve along its lateral aspect, which is free of branches.

## ANTERIOR INTEROSSEOUS NERVE SYNDROME

### *Pathophysiology and Anatomy*

The anterior interosseous nerve (AIN) is a branch of the median nerve that is essentially entirely motor except for a few terminal branches that are sensory to a portion of the carpus. The most common pattern of muscles innervated by the AIN includes the FDP to the index finger, the flexor pollicis longus (FPL), and the pronator quadratus (PQ). This innervation pattern varies significantly, which can cause confusion during clinical examination. The nerve arises from the dorsal aspect of the median nerve as it passes between the two heads of the PT. In some cases, it passes deep to the deep head of the PT. It passes beneath the arcade of the FDS and courses distally along the anterior surface of the interosseous membrane between the FDP and the FPL, accompanied by the anterior interosseous artery. The AIN gives branches to the FPL and the radial aspect of the FDP muscles approximately 4 cm distal to its origin from the median nerve (Fig. 52.28). Compression may be caused by one of many structures, including the deep head of the PT, the FDS, accessory muscles (e.g., Gantzer's muscle, and an accessory FPL) (28,74), aberrant vessels (e.g., anomalous radial artery), and tendinous bands along the course of the nerve.

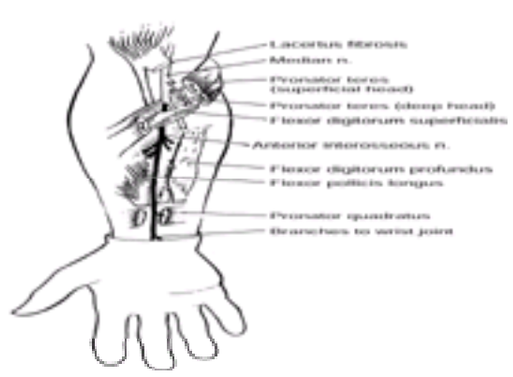


***Figure 52.28.*** The course and innervations of the anterior interosseous nerve. (From Chidgey LK, Szabo RM. Anterior Interosseous Nerve Palsy. In: Szabo RM, ed. *Nerve Compression Syndromes: Diagnosis and Treatment.* Thorofare, NJ: Slack, 1989:153, with permission.)

### *Assessment*

Patients initially complain of vague, aching pain in the proximal forearm and sometimes in the wrist. This occurs at rest and is exacerbated by activities. There is no sensory deficit with AIN syndrome, which is different from carpal tunnel and pronator syndromes. Patients may note difficulty with activities such as writing, or weakness in tip pinch. Frequently, there is a history of a single episode of strong contraction of elbow, wrist, and finger flexors accompanied by pain and followed shortly thereafter by motor loss.

Findings on clinical examination include weakness or paralysis of the muscles innervated by the AIN (18). Weakness of the FPL and of the radial half of the FDP makes it difficult or impossible for the patient to tip pinch with the index finger and thumb (i.e., to make the so-called OK sign). The lack of long flexors results in a hyperextension attitude of the distal joints of these two digits (Fig. 52.29) (119). You can test the weakness of the PQ by asking the patient to pronate against resistance, with the elbow flexed to neutralize the stronger PT. However, isolated paralysis of any one or a combination of these muscles has been reported (50).

***Figure 52.29.*** Incomplete anterior interosseous nerve syndrome. **A:** Preoperative loss of flexion of the right thumb. **B:** Postoperative result.

It is important to differentiate between an FDP or FPL rupture and AIN syndrome in the patient with acute presentation. This is done best by looking for the tenodesis effect of the FPL and index FDP (79). Innervation anomalies add variability to the classic examination findings. Martin-Gruber connection (median to ulnar motor nerve connection in the forearm) occurs in 15% of individuals; 50% of these arise from the AIN. The presence of this anomaly may cause weakness of additional intrinsic muscles of the hand in patients with AIN syndrome. Additionally, in 50% of individuals, the FDP to the index is innervated by branches from the median nerve, not the AIN (50). The diagnosis is usually confirmed by EMG studies. Nerve conduction studies are usually not affected, although side-to-side differences may be noted (Table 52.7).

| |
|---|
| Pathology |
| Compression of AIN in proximal forearm |
| History |
| Injury from single episode of strong contraction of elbow, wrist, and finger flexors |
| Associated with activity |
| Symptoms |
| Vague aching pain in proximal forearm, and wrist |
| Difficulty with activities requiring tip pinch (e.g., writing) |
| No numbness or tingling |
| Sensory exam |
| Normal |
| Motor exam |
| Weakness or paralysis of FPL and/or FDP to index |
| Weakness of forearm pronation with elbow flexed |
| Hyperextension of DIP of index and IP of thumb with forceful tip pinch "OK sign" |
| Provocative tests |
| None |
| Diagnostic studies |
| EMG of FPL, radial FDP, and pronator quadratus is diagnostic |
| NCV occasionally abnormal |
| Radiographs not helpful |
| Alternative diagnoses |
| Avulsion injury or rupture of FDP and/or FPL |
| Parsonage–Turner syndrome |

AIN, anterior interosseous nerve; FPL, flexor pollicis longus; FDP, flexor digitorum profundus; EMG, electromyography; NCV, nerve conduction velocity.

***Table 52.7. Anterior Interosseous Nerve Syndrome Summary***

### *Preoperative or Nonoperative Management*

In a patient who presents acutely, obtain neurodiagnostic studies 2–3 weeks after injury, and again at 6 and 12 weeks if no clinical improvement is noted. Chronic cases, presenting after 6 weeks, should have neurodiagnostic examination performed initially and the patient should be followed clinically; if no improvement is noted, perform another study at 12 weeks after the injury. Although no specific protocols have been evaluated, nonoperative treatment may consist of avoidance of exacerbating activities, immobilization of the elbow in flexion and the forearm in pronation, and the use of NSAIDs.

### *Surgical Indications and Relative Results*

Essentially all reported cases have gone on to spontaneous recovery, although in some instances this has taken up to 2 years. Most authors agree that recovery can be enhanced by surgical exploration when spontaneous recovery is not apparent or is slow (50). Recovery is generally complete within 6 months after surgery. Persistence of the motor symptoms without signs of significant improvement for 8–12 weeks is an indication for surgical exploration and decompression (122). Evidence of clinical motor recovery or signs of reinnervation on EMG would call for further observation.

### *Operative Technique*

The surgical technique and postoperative management are very similar to those used in the pronator syndrome.

- Use the same incision as for pronator syndrome.
- Divide the lacertus fibrosus to allow access to the median nerve as it passes beneath the superficial head of the PT (Fig. 52.26*A*).
- The AIN branches from the median nerve just distal to the proximal border of the superficial head of the pronator. Trace it beneath this muscle. This is a common site of entrapment.
- If necessary for exposure, you may detach the superficial head of the pronator (Fig. 52.26*B*).
- Trace the nerve distally as it passes beneath the FDS. If necessary, detach the origin of this muscle or divide its fibrous arch, as in pronator syndrome exploration, to trace the nerve distally (Fig. 52.26*C*).
- Trace the nerve as it travels along the anterior interosseous membrane between the FPL and FDP muscles.
- Terminate the distal dissection when you visualize the branches to the deep flexors.
- Reattach the FDS muscle. (This may be done posterior to the median nerve if you feel that anterior transposition is necessary.)
- Reattach the PT superficial head deep to the median nerve and AIN.
- Close the skin and place a long-arm splint.

As in pronator syndrome, it is important to visualize the entire nerve and divide all suspected offending structures. The postoperative management is essentially identical to that after treatment of the pronator syndrome.

### *Complications*

Possible complications are similar to those described for the carpal tunnel and PT syndromes. The main problem is an error in diagnosis, particularly for the patient with an incomplete syndrome involving either the thumb or the index long flexors, but not both (Fig. 52.29) (50). Such a presentation may lead to the erroneous diagnosis of tendon rupture and to a negative tendon exploration. Perform the tenodesis test with the wrist in maximal extension along with MP joint and PIP joint extension. This should produce slight flexion at the distal interphalangeal (DIP) joint of the index and the IP joint of the thumb with AIN syndrome but not with tendon rupture (79).

Suspect Parsonage–Turner syndrome (brachial neuritis) in cases with an acute onset of pain in the forearm followed by weakness in the muscles normally affected in AIN syndrome a few days to weeks later (at times associated with a febrile illness, vaccination, or unrelated surgery), especially in bilateral cases (149). In Parsonage–Turner syndrome, there will also be shoulder pain and involvement of the shoulder muscles at times. AIN compression syndrome generally presents after an acute injury or in conjunction with repetitive activity, whereas brachial neuritis is insidious in nature. In Parsonage–Turner syndrome there is pain not associated with an injury, which may involve more proximal areas of the upper extremity than that seen in AIN syndrome. Parsonage–Turner syndrome often produces EMG results similar to those of AIN syndrome in the FPL, FDP, and PQ. Sampling of more proximal muscles innervated by the brachial plexus, such as the deltoid, may also demonstrate EMG abnormalities, which is different from AIN entrapment (Table 52.8).

| Symptom, finding | AIN syndrome | Parsonage–Turner syndrome |
|---|---|---|
| Pain preceding onset of motor dysfunction not associated with trauma | No | Yes |
| Acute traumatic event or repetitive injury | Yes | No |
| EMG abnormalities in AIN-innervated muscles (FPL, FDPI, PQ) | Yes | Yes |
| EMG abnormalities in more proximal musculature (e.g., deltoid, triceps, biceps) | No | Maybe |

AIN, anterior interosseous nerve; EMG, electromyography; FPL, flexor pollicis longus; FDPI, flexor digitorum profundus to the index finger; PQ, pronator quadratus.

***Table 52.8. AIN Syndrome versus Parsonage–Turner Syndrome***

Complete recovery is seen in 90% of cases treated surgically or nonoperatively. Surgical exploration and decompression are reserved for cases associated with trauma.

## COMPRESSION NEUROPATHIES OF THE ULNAR NERVE

### CUBITAL TUNNEL SYNDROME

#### *Pathophysiology and Anatomy*

The most common location for entrapment of the ulnar nerve is about the elbow; this condition is known as cubital tunnel syndrome. There are five potential compression sites of the nerve that occur along its course. At the midarm level, the ulnar nerve pierces the medial intermuscular septum and runs distally posterior to it. Approximately 8 cm proximal to the medial epicondyle, the nerve may pass through an inconstant fibrous tunnel, the arcade of Struthers, formed by a band connecting the medial intermuscular septum to the tendon of the medial head of the triceps. This is the first potential site of compression (Fig. 52.30). The nerve continues posterior to the intermuscular septum. The edge of the septum becomes a second potential site of compression, usually after failed anterior transposition. The nerve then comes to lie in the retrocondylar groove of the medial epicondyle, the third potential site of compression, where it gives off a few articular sensory branches to the elbow joint; it then enters the cubital tunnel, the fourth potential site of compression. The cubital tunnel is a fibro-osseous canal formed by the medial epicondyle anteriorly, the ulnohumeral ligament posterolaterally, and a structure termed the cubital tunnel retinaculum (92), which is superficial and forms the roof of the tunnel. The fifth potential site of compression occurs as the nerve passes under Osborne's fascia, a thick fascial layer that connects the heads of the FCU to the medial epicondyle and olecranon in nearly 80% of individuals and is often confluent with the cubital tunnel retinaculum (24). The nerve then courses to enter the forearm between the two heads of the FCU. At this level, it gives off several motor branches to the FCU. It comes to lie medial to the FDP, piercing the deep flexor pronator aponeurosis—a fascial structure serving as a common origin and aponeurosis of the humeral head of the FDS and the FCU—as it exits the cubital tunnel (61). This aponeurosis is the sixth and most distal potential compression site, and it, like the medial intermuscular septum, is usually a site of secondary compression after anterior transposition (Fig. 52.31, Table 52.9).

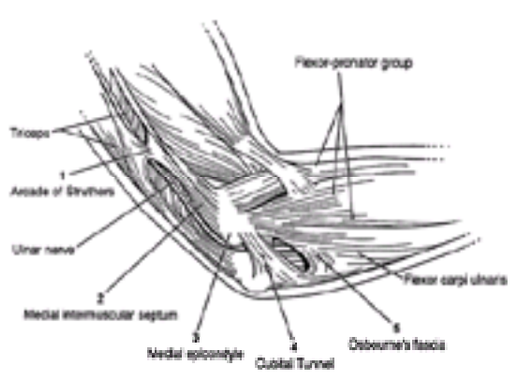


***Figure 52.30.*** The first five potential compression sites of the ulnar nerve in cubital tunnel syndrome: (*a*) arcade of Struthers, (*b*) medial intermuscular septum (considered a secondary site of compression), (*c*) medial epicondyle, (*d*) cubital tunnel, (*e*) Osborne's fascia. (From Osterman AL, Davis CA. Subcutaneous Transposition of the Ulnar Nerve for Treatment of Cubital Tunnel Syndrome. *Hand Clin* 1996;12:421, with permission.)

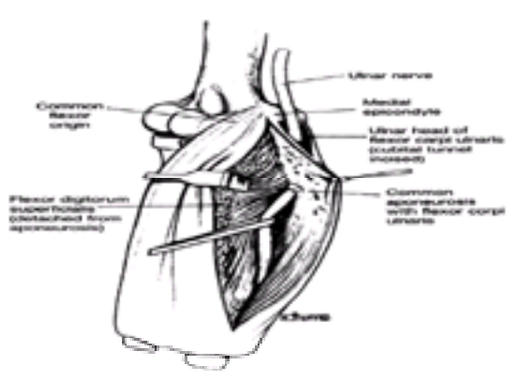


***Figure 52.31.*** The sixth potential site of compression of the ulnar nerve in cubital tunnel syndrome, the flexor pronator aponeurosis.

| |
|---|
| Arcade of Struthers |
| Medial intermuscular septum* |
| Medial epicondyle |
| Cubital tunnel |
| Proximal edge of the FCU muscle (Osborne's fascia) |
| Deep flexor pronator aponeurosis* |

* Usually implicated as secondary sites of compression after anterior transposition.
FCU, flexor carpi ulnaris.

***Table 52.9. Potential Compression Sites of the Ulnar Nerve in Cubital Tunnel Syndrome***

Compression of the nerve is often of a dynamic nature. Both constriction of the nerve and traction are implicated in its dysfunction. Flexion of the elbow has been shown to cause increased intraneural pressure in the ulnar nerve at the cubital tunnel and decreased volume in the cubital tunnel itself (92). The ulnar nerve at the

elbow normally glides to accommodate elbow flexion (6). When tethered by scar or fibrosis, the ulnar nerve experiences traction forces, which affect nerve function.

Additional causes of compression include trauma, deformity (e.g., cubitus valgus), malunion or nonunion of the medial epicondyle, elbow instability, spurs or bone fragments within the floor of the cubital tunnel (Fig. 52.32), tumors, abnormal muscles (e.g., anconeus epitrochlearis), and a nerve that subluxates or dislocates repeatedly over the medial epicondyle.

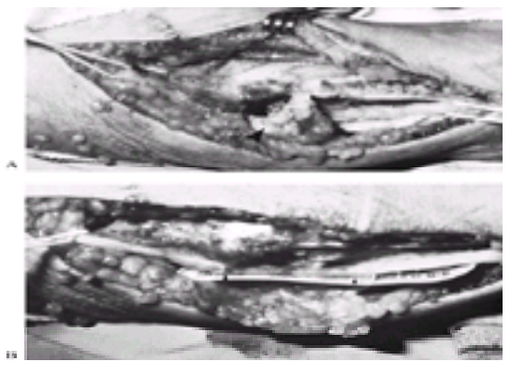

***Figure 52.32.*** **A:** Compression of the ulnar nerve at the elbow by a large osteochondral body (*arrow*). **B:** Severe nerve constriction (*between arrows*) after removal of the osteochondral fragment.

***Assessment***

The presenting complaint is usually numbness and paresthesias along the ulnar nerve distribution, the small finger, the ulnar half of the ring finger, and the ulnar aspect of the hand (Fig. 52.8). This is exacerbated by leaning on the elbow or positioning it in flexion. Aching pain may be referred to the medial aspect of the elbow. Numbness on the medial half of the forearm is not usually present. Weakness of grip or loss of dexterity in the fingers may accompany these symptoms.

Physical examination includes sensory evaluation, provocative testing, and motor examination. Threshold sensory evaluation, including Semmes–Weinstein monofilaments and vibratory testing, is most sensitive and is recommended. Two-point discrimination yields abnormal results in more advanced cases. Sensation is decreased in the ring and small fingers as well as in the ulnar half of the dorsum of the hand, which indicates compression proximal to the origin of the dorsal cutaneous branch of the ulnar nerve and therefore proximal to the wrist.

Employ provocative testing to help localize the site of compression, as well as uncover dynamic forms of the disorder. Tinel's test is positive if paresthesias are elicited in the distribution of the nerve when it is gently percussed. The location of percussion with maximal elicitation of symptoms may indicate the site of compression. Tinel's test is sensitive but not specific, giving a high rate of false positive results at the cubital tunnel (23). The elbow flexion test described by Buehler and Thayer (17) and others (101), which is flexion of the elbow beyond 90° with the forearm in supination and the wrist in extension, is positive when symptoms are produced within 1 minute, and it may localize compression to the level of the elbow. Novak et al. (90) modified this test to include direct compression of the ulnar nerve with the examiner's finger just proximal to the cubital tunnel while the elbow is flexed maximally (Fig. 52.33). The test is considered positive when paresthesia symptoms are produced in the ulnar nerve distribution within 30 seconds. This test is reported to have 0.91 sensitivity and 0.97 specificity. Evaluate potential subluxation of the ulnar nerve over the medial epicondyle by direct palpation while the elbow is brought from full extension to full flexion. Ulnar nerve subluxation is seen in 16% of normal individuals (20) and therefore is not considered pathologic per se. If associated with neuritic symptoms, it may be the cause of injury to the nerve. Palpation may also elicit tenderness and disclose an enlarged, sensitive nerve.

***Figure 52.33.*** The flexion compression test for cubital tunnel syndrome.

Motor examination is helpful in patients with more advanced disease. Atrophy may be seen most commonly in the hypothenar musculature and in the first dorsal interosseous muscle. When weakness is present, it involves not only the ulnar innervated intrinsic muscles but typically the FDP to the ring and small fingers. When both ulnar innervated intrinsic and extrinsic muscles are involved, the ulnar claw hand, a sign of intrinsic–extrinsic imbalance, does not appear as severe. Grip strength testing is often normal unless there is significant loss of power to the long flexors of the ring and small finger. Pinch strength, especially key position, is decreased as a result of loss of strength to the flexor pollicis brevis (FPB), the adductor pollicis, and the first dorsal interosseous muscle. Froment's sign (hyperflexion of the IP joint) and Jeanne's sign (hyperextension of the MP joint of the thumb) are elicited during key pinch (Fig. 52.34). Weakness or paralysis of the FPB concentrates the flexion force of the FPL at the IP joint, causing hyperflexion of this joint (11). The EPL compensates for the adductor pollicis and enhances hyperextension of the MP joint of the thumb because it is unopposed by the intrinsic flexor of the thumb (the EPB).

***Figure 52.34.*** Froment's sign and Jeanne's sign, seen with intrinsic muscle weakness in ulnar nerve palsy.

For subjective evaluation, directly test the strength of the first dorsal interosseous muscle against resistance, and measure it by side-to-side comparison in unilateral cases. In some individuals, contribution of innervation to this muscle from the median nerve can occur (109), and therefore this test is not specific. Evaluation of the abductor digiti quinti is also subjective. Side-to-side comparison is facilitated by a confrontation test. Ask the patient to maximally abduct her fingers while holding her hands out in front, palms facing her. She brings the tips of her small fingers together and, while she resists collapse of the abducted small fingers, she brings her hands

together. In unilateral cases with abductor weakness, the weak hand's small finger collapses to the side of the ring finger (Fig. 52.35).

***Figure 52.35.*** The confrontation test.

Wartenberg's sign is abduction of the small finger with extension of the fingers at the MP joint level. It indicates interosseous dysfunction. The cross finger test (30) is very useful and also evaluates function of the interossei. Ask the patient to cross his index and long fingers. Patients with ulnar nerve dysfunction often have trouble performing this task. Atrophy and weakness of intrinsic muscles innervated by the ulnar nerve indicate a moderate to severe lesion of the nerve (Table 52.10).

| Test | How performed | Condition measured | Positive result | Interpretation of positive result |
|---|---|---|---|---|
| Tinel's sign | Ulnar nerve gently tapped along its course about the elbow | Presence of regenerating neurons in nerve at site of compression | Paresthesia in small and ring fingers | 0.70 sensitivity and 0.98 specificity |
| Elbow flexion | Elbow flexed greater than 90° with forearm supinated and wrist extended | Compression of ulnar nerve at cubital tunnel due to positioning | Paresthesia in small and ring fingers within 60 sec | 0.71 sensitivity and 0.99 specificity |
| Flexion-compression | Elbow flexed maximally with simultaneous finger compression of ulnar nerve just proximal to cubital tunnel | Compression of ulnar nerve at cubital tunnel due to positioning, and direct pressure | Paresthesia in small and ring fingers within 30 sec and within 60 sec | 0.91 sensitivity and 0.97 specificity at 30 sec, 0.98 sensitivity and 0.95 specificity at 60 sec |
| Confrontation | Hands held with palms toward face in front of patient, small fingertips brought together, small fingers exist collapse into adduction as hands brought together | Relative weakness of abductor digiti minimi or unilateral ulnar nerve compression | Asymmetrical collapse of weak hand's small finger to side of ring finger | Not specific for ulnar nerve compression neuropathy, may detect digiti weakness of ADM or ulnar nerve compression neuropathy |
| Cross finger | Patient asked to cross index and long fingers | Weakness of interosseous muscles of hand | Inability to completely cross fingers | Not specific for ulnar nerve compression neuropathy, seen in relatively advanced cases |

ADM, abductor digiti minimi.

***Table 52.10. Provocative Tests for Cubital Tunnel Syndrome***

Radiographs are indicated in cases of previous trauma, deformity, and suspected arthritis, and where there is incomplete range of motion. AP, lateral, and oblique views are obtained, as well as axial views of the distal humerus and olecranon for evaluation of the ulnar groove.

Neurodiagnostic studies include NCV and EMG evaluation. These are helpful in confirming the diagnosis and in classifying the case for treatment and prognostic purposes. NCV evaluations of the segment of the ulnar nerve across the elbow are considered significant if conduction values are reduced by 33% (33). Segmental “inching” studies may be helpful in localizing the site of compression, especially in previously operated cases with recurrence of symptoms. EMG evaluation of the ulnar innervated muscles can provide information on chronicity and progression as well as severity, and it may indicate the approximate site of compression. More importantly, EMG needle examination coupled with somatosensory evoked potential (SSEP) evaluates for radiculopathies and more proximal lesions, including thoracic outlet syndrome (TOS), which is suspected especially in cases of bilateral ulnar nerve symptoms (Table 52.11).

| |
|---|
| Pathology |
| A compression of the ulnar nerve at the level of the elbow |
| History |
| Usually insidious onset, associated with prolonged or repetitive flexion of the elbow |
| Delay for years after elbow fracture |
| Symptoms |
| Numbness and tingling in the ulnar digits and hand |
| Weakness of grip and key pinch |
| A nuisance to the manipulation |
| Sensory exam |
| Decreased sensation in ulnar pattern and dorsal hand, ulnar half of ring and entire small finger |
| Threshold testing is more sensitive (Semmes–Weinstein, calibrated monofilaments) |
| Two-point discrimination is affected in severe cases |
| Motor exam |
| Froment's sign with key pinch |
| Decreased ability to cross fingers |
| Asymmetry in contemporaneous testing of hypothenar, ADM, and dorsal interosseous muscles |
| Abduction of the small finger with extension of the fingers (Wartenberg's sign) |
| Weakness of the FDP to the small and ring fingers |
| Functional pinch and grip strength can be seen |
| Atrophy of hypothenars, interossei, and adductor pollicis |
| Provocative tests |
| Elbow flexion test positive in 60 sec |
| Flexion–compression test is positive in 30 sec |
| Tinel's sign positive about elbow |
| Diagnostic studies |
| Radiographs of the elbow in cases of trauma, arthritis and deformity |
| NCV: sensitivity of almost by 33%, may be done with the elbow flexed |
| Alternative diagnoses |
| Ulnar tunnel syndrome |
| TOS, especially in bilateral cases |
| Cervical radiculopathy |

FDP, flexor digitorum profundus; NCV, nerve conduction velocity; TOS, thoracic outlet syndrome.

***Table 52.11. Cubital Tunnel Syndrome Summary***

### *Classification*

Dellon (26) developed a useful classification system for cubital tunnel syndrome (Table 52.12). He classified patients into mild, moderate, and severe categories depending on physical and electrodiagnostic findings. Surgical treatment options and the relative results with respect to the patient classification will be discussed.

| |
|---|
| Mild |
| Sensory |
| Paresthesias come and go |
| Vibratory perception increased |
| Motor |
| Subjective weakness, clumsiness or loss of coordination |
| Tests |
| Elbow flexion test and/or Tinel's sign may be positive |
| Moderate |
| Sensory |
| Paresthesias come and go |
| Vibratory perception normal or decreased |
| Motor |
| Measurable weakness in pinch and/or grip strength |
| Tests |
| Elbow flexion test and/or Tinel's sign positive |
| Finger crossing may be abnormal |
| Severe |
| Sensory |
| Paresthesias are persistent |
| Vibratory perception decreased |
| Abnormal two-point discrimination (static > 6 mm, moving > 4 mm) |
| Motor |
| Measurable weakness in pinch and grip, plus muscle atrophy |
| Test |
| Positive elbow flexion test and/or positive Tinel's sign may be present |
| Finger crossing usually abnormal |

From Dellon AL: Review of Treatment Results for Ulnar Nerve Entrapment at the Elbow. J Hand Surg [Am] 1989;14:688.

***Table 52.12. Staging of Ulnar Nerve Compression at the Elbow***

### *Preoperative or Nonoperative Management*

Neither vitamin $B_6$ nor NSAIDs have been shown to have an effect on cubital tunnel syndrome. Injections are advocated by some. Two of us (MNH and JT)

occasionally use them. Water-soluble steroid is injected at the proximal aspect of the cubital tunnel, not into the tunnel. Take great care to avoid injury to the ulnar nerve, which is at risk. Most agree, though, that injection is to be avoided because of the great risk of injury to the nerve, especially if injection is made into the cubital tunnel where the nerve is tightly confined.

The most effective nonsurgical management of cubital tunnel syndrome includes patient education and splinting. The occupational or physical therapist instructs the patient in nerve protection. This includes avoidance of repetitive flexion and extension of the elbow, of prolonged positioning of the elbow in the flexed position, and of leaning on the medial aspect of the elbow. Adjustments are made in the height of work stations and seats when indicated, so that the elbow is flexed no more than 30° during work. Elbow pads may be worn to prevent direct pressure on the nerve in its subcutaneous position (Fig. 52.36). Hand therapists can provide Thermoplast or pillow extension splints that hold the elbow in 30° to 45° of flexion during sleep to prevent hyperflexion (Fig. 52.37). Recheck the patient after 3 months of treatment. In mild cases and some moderate ones, patients who comply with these instructions may have a good response and be able to avoid surgery.

***Figure 52.36.*** Commercially available elbow pads worn to protect the ulnar nerve from mechanical irritation.

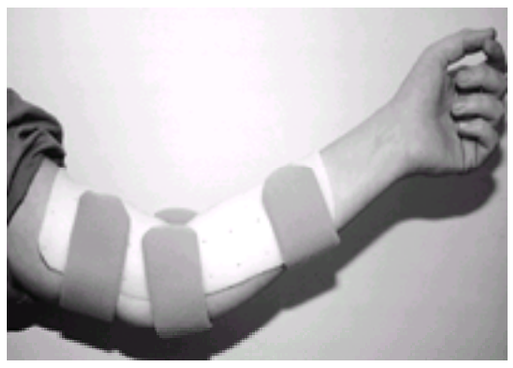

***Figure 52.37.*** Thermoplast night splints custom fabricated by a hand therapist.

### *Surgical Indications and Relative Results*

Progression or inadequate amelioration of symptoms with nonoperative care is an indication for surgery. Inability of the patient to comply with nonsurgical care in mild or moderate cases is a relative indication. Severe involvement, including motor dysfunction, requires surgical intervention. Ulnar neuropathies associated with deformity, bony lesions, tumors, and elbow instabilities, among others, require attention to the pathology contributing to the nerve compression as well as the nerve itself.

The severity of disease, its chronicity, and the general condition of the patient all influence the outcome of treatment. Patients with intermittent symptoms, no atrophy, and mild electrodiagnostic findings respond well to nonoperative treatment (32). The choice of surgical procedure in some instances may also have an effect. In most uncomplicated cases, return of sensation and motor function occurs within 6 months. Nouhan and Kleinert (89) evaluated 33 limbs that had been followed for an average of 49 months. Preoperative nerve compression was classified as mild in 6, moderate in 7, and severe in 20. Surgical treatment consisted of submuscular transposition with **Z**-lengthening of the flexor pronator mass. There were 97% good to excellent results overall; the preoperative classification did not influence the final result.

Seradge and Willis (114) evaluated the results of 160 cases undergoing cubital tunnel release and medial epicondylectomy. Preoperative severity of compression was mild in 7%, moderate in 86%, and severe in 7%. There were 87% good, 12% fair, and 1% poor results (failure of treatment). Factors that increased the rates of symptom recurrence in their patients included female sex, the presence of concomitant CTS or TOS in the same extremity, age in the third or fourth decade, and patients who did not return to work within 3 months after surgery. Limb dominance, length of preoperative conservative care, and EMG results did not have a relationship to recurrence rate.

In a literature review by Dellon (26), patients in the mild group had excellent results from surgery no matter what technique was used. Patients in the moderate group did not improve without surgery, and decompression *in situ* was not effective. Medial epicondylectomy produced 50% excellent results with a high recurrence rate, whereas submuscular transposition gave 80% excellent results with the lowest recurrence rate. In severe patients, surgery resulted in less than 50% excellent results for sensory recovery and up to 25% for motor recovery. Recurrence developed in 30% of these patients. In this group, the poorest results were in those undergoing intramuscular transposition, and the best were in those receiving submuscular transposition and internal neurolysis.

### *Preoperative Planning*

When a particular condition contributes to compression of the ulnar nerve, consider additional diagnostic studies to further delineate the pathology. Computed tomography (CT) scans can further characterize suspected bony abnormalities, including space-occupying spicules or fragments, fracture callus, and malunions or nonunions. Suspected tumors are best visualized by magnetic resonance imaging (MRI) evaluation. Progressive deformities (e.g., cubitus valgus due to nonunion of the lateral condyle) must be stabilized at the time of decompression and transposition of the nerve, or in a staged fashion. Patients with previously failed decompressions should undergo inching nerve conduction velocities to better localize the site of compression, most often in the most proximal or distal portion of the previous surgical exposure.

Better than 80% to 90% good results are obtainable with any of the commonly employed operative methods. The choice of operative technique is greatly influenced by the cause of the compression, the patient's age, and systemic conditions such as diabetes or alcoholism. Operative techniques include simple decompression, medial epicondylectomy, subcutaneous transposition, intramuscular transposition, and submuscular transposition. The nerve may be decompressed by simple division of the arch of origin of the FCU (or the cubital tunnel) in the following cases: (a) if clinical findings (e.g., a localized nerve percussion sign) suggest isolated entrapment of the nerve beneath the arch (or cubital tunnel retinaculum), (b) if the nerve presents a constricting groove caused by this arch (or retinaculum), as visualized during operation (Fig. 52.38), or (c) if the nerve is vulnerable to manipulation (e.g., in older patients or patients with diabetic or alcoholic neuropathy) (148).

***Figure 52.38.*** Well-defined constriction of the ulnar nerve (*arrow*), seen after division of the arch of origin of the flexor carpi ulnaris.

Anterior submuscular transposition is best suited for neuropathies associated with elbow deformity, abnormalities of the cubital canal, and the subluxing or dislocating ulnar nerve, particularly in the younger population and in the more severe cases with evidence of motor involvement (66,69). A particular indication for medial epicondylectomy is the ulnar neuropathy associated with nonunion of a fracture of the medial epicondyle. Routine use of this technique has been shown to be effective (48,60). Some prefer anterior subcutaneous transposition over submuscular transposition (1,31,99,104). Subcutaneous transposition is commonly employed as part of other operative procedures about the elbow, including fracture reduction, elbow arthroplasty, and neurorrhaphy of the ulnar nerve in cases where there is loss of nerve length.

Dissection of the ulnar nerve is delicate and requires patience and diligence to prevent damage to the nerve, its branches, and its accompanying blood supply. This is aided by use of magnification, fine instruments, and bipolar cautery. A trained surgical assistant is invaluable in facilitating these procedures and in adding a level of safety to prevent potential complications related to nerve injury.

In Situ *Decompression*

- Start the skin incision equidistant between the olecranon and the medial epicondyle; extend it 3–4 cm proximally and 6–8 cm distally (Fig. 52.39*A*).

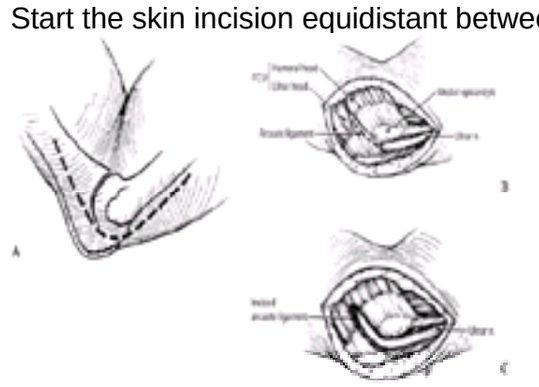

***Figure 52.39.*** *In situ* decompression of the ulnar nerve at the cubital tunnel. **A:** Skin incision. **B:** Division of the arcuate ligament (cubital tunnel retinaculum). **C:** Extension of the incision into the interval between the two heads of the flexor carpi ulnaris to ensure distal decompression. (From Ferlic DC. *In Situ* Decompression of the Ulnar Nerve at the Elbow. In: Gelberman RH, ed. *Operative Nerve Repair and Reconstruction.* Philadelphia: Lippincott, 1991;1063, with permission.)

- Isolate the ulnar nerve before it enters the cubital canal.
- Delineate the arch of origin of the FCU, elevate it from the nerve, and divide both it and Osborne's fascia while protecting the nerve under direct visualization (Fig. 52.39*B*).
- Extend this division distally between the two heads of the FCU to allow room for the nerve (Fig. 52.39*C*).
- Flex and extend the elbow, and make sure the nerve does not sublux. If subluxation occurs, be prepared to transpose the nerve or perform a medial epicondylectomy.
- Release the tourniquet for careful hemostasis.
- Do not close the FCU heads beneath the ulnar nerve.
- Close only the skin.
- Apply a well-padded dressing.

Support the arm in a sling for a few days. Encourage immediate active flexion and extension of the elbow. Subluxation of the nerve after decompression is rare. On the contrary, nerves that are as tense as bow strings proximal to the constricting tendinous arch, snapping over the medial epicondyle during elbow flexion and extension, recover a normal excursion after decompression.

***Medial Epicondylectomy***

- Center the incision over the medial epicondyle, and extend it proximally and distally far enough to expose all potential compression sites (Fig. 52.40).

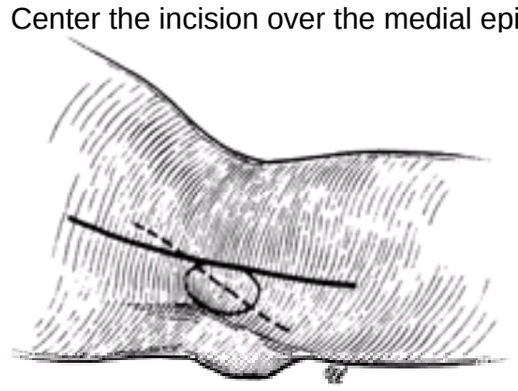

***Figure 52.40.*** Skin incision for medial epicondylectomy (*dark line*). The *dashed line* represents a common position of a cutaneous nerve branch (usually from the medial antebrachial cutaneous), which must be protected during exposure. (From Heithoff SJ, Millender LH. Medial Epicondylectomy. In: Gelberman RH, ed. *Operative Nerve Repair and Reconstruction.* Philadelphia: Lippincott, 1991:1088, with permission.)

- Isolate the ulnar nerve as it enters the cubital tunnel.
- Decompress the nerve in the cubital tunnel; lift the retinaculum off the nerve; protect the nerve and directly visualize it to prevent formation of a painful neuroma. Divide the retinaculum.
- Trace the nerve into the FCU muscle. Divide the origin of the arch of the FCU.
- Continue decompression of the nerve between the heads of the FCU; do not damage the multiple muscular branches in this area.
- Divide the deep flexor pronator aponeurosis until the nerve has been dissected 8 cm distal to the medial epicondyle.
- Trace the nerve approximately 8 cm proximally.
- Release the arcade of Struthers.
- Excise the distal 8 cm of the intermuscular septum in the arm, taking care not to damage any of the vessels associated with the nerve. (Multiple vascular leashes exist near the insertion of the septum into the medial epicondyle.)
- Make an incision directly over the medial epicondyle. Elevate the flexor pronator mass subperiosteally, both radially and ulnarly, while preserving the proximal attachments of the muscle mass (Fig. 52.41*A*).

***Figure 52.41.*** Medial epicondylectomy. **A:** Elevation of the flexor pronator mass. **B:** Removal of the medial epicondyle with an osteotome. **C:** Closure of the flexor pronator origin. (From Eversmann WW Jr. Entrapment and Compression Neuropathies. In: Green DP, ed. *Operative Hand Surgery*, 3rd ed. New York: Churchill Livingstone, 1993:1341, with permission.)

- Perforate the base of the epicondyle where you will make the osteotomy with a small drill, Kirschner wire (K-wire), or osteotome.
- Preserve the medial collateral ligament, which arises from the distal, inferior portion of the epicondyle.
- Remove the epicondyle, cutting it in line with the medial cortex of the distal humerus (Fig. 52.41*B*). Perforating the planned osteotomy line with drill holes may be helpful.
- Cover the raw bone surface with bone wax, and close the tendon of the flexor pronator mass (Fig. 52.41*C*). We recommend decompression of the nerve proximally and distally at all sites of potential compression.
- Check that the ulnar nerve glides unimpeded during flexion–extension of the elbow.
- Release the tourniquet and obtain hemostasis.
- Close only the skin after this.
- Apply a well-padded dressing and a long arm posterior splint.

Postoperatively, leave the splint in place for 3–5 days. Then remove it and begin active range-of-motion exercises. Use a sling to protect the arm when it is not engaged in therapy. Full range of the elbow should be achieved by 3–4 weeks. At that time, begin progressive, gentle strengthening. Theoretically, the nerve will slowly transpose itself anteriorly and come to rest in a position without tension, anterior to or on the flexion–extension axis of the elbow. Seradge (112) demonstrated a decreased incidence of elbow contracture and a decrease in return-to-work time of 50% in patients who had mobilization of their elbows within 3 days of surgery following medial epicondylectomy versus those who were immobilized for 14 days postoperatively.

### *Anterior Transposition*

The three methods of anterior transposition—subcutaneous, intramuscular, and submuscular—are essentially similar in their means of initial decompression and mobilization of the nerve, and this is described here. Both the way the transposition is maintained and the rehabilitation vary with the method, however, so they will be described under separate headings.

- Center the incision between the olecranon and the medial epicondyle, and extend it along the axes of the humerus and ulna 8–10 cm proximally and distally.
- Expose the deep fascia, and elevate the radial flap along this plane over the origin of the flexor–pronator muscles. Extend the exposure to adequately visualize the ulnar nerve along its course from the arcade of Struthers to well into the interval between the heads of the FCU and, laterally, to visualize the median nerve.
- Isolate the ulnar nerve as it enters the cubital tunnel.
- Decompress the nerve in the cubital tunnel; lift the retinaculum off the nerve, protect the nerve and directly visualize it, then divide the retinaculum.
- Trace the nerve into the FCU muscle. Divide the origin of the arch of the FCU (Fig. 52.42*A*).

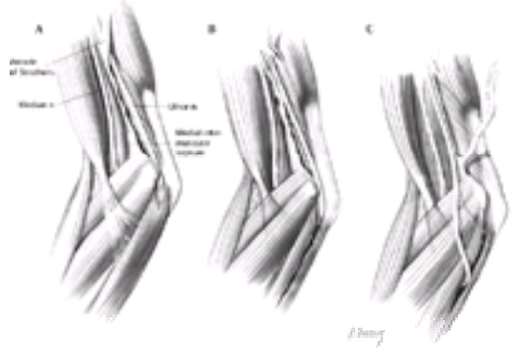

***Figure 52.42.*** Anterior transposition. **A:** Exposure of the ulnar nerve. **B:** Decompression carried distally and proximally. **C:** Excision of the distal 8 cm of the intermuscular septum. (From Spinner M, Linscheid RL. Nerve Entrapment Syndromes. In: Morrey BF, ed. *The Elbow and Its Disorders*, 2nd ed. Philadelphia: Saunders, 1993:813; and from Spinner M. *Injuries to the Major Branches of the Forearm*, 2nd ed. Philadelphia: Saunders, 1978, with permission.)

- Continue decompression of the nerve between the heads of the FCU (do not damage the multiple muscular branches in this area), releasing Osborne's fascia, the fascia of the two heads of the FCU, and the pronator aponeurosis.
- Divide the deep flexor pronator aponeurosis 8 cm distal to the medial epicondyle.
- Trace the nerve approximately 8 cm proximally.
- Release the arcade of Struthers (Fig. 52.42*B*).
- Excise the distal 8 cm of the intermuscular septum of the arm to prevent secondary impingement on the nerve after anterior transposition. Take care not to damage any of the vessels associated with the nerve. Multiple vascular leashes exist near the insertion of the septum into the medial epicondyle (Fig. 52.42*C*).
- Mobilize the nerve from the cubital tunnel, preserving the small longitudinal vessels accompanying it.
- You may need to divide small branches arising from the nerve to the joint; branches to the ulnar head of the FCU must be preserved. Carefully separate them proximally from the main trunk by interfascicular dissection, to allow mobilization of the nerve.
- Make sure the nerve can be brought anterior to the medial epicondyle so that it lies in a relaxed course anterior to the flexion–extension axis of the elbow, none of the muscular branches to the FCU are under tension, and there is no kinking of the nerve proximally or distally.

### *Subcutaneous Transposition*

Eaton et al. (31) described a technique (described next) that employs a fasciodermal sling fashioned from the fascia of the medial epicondyle and sutured into the dermis of the anterior skin flap (Fig. 52.43). The nerve comes to lie in the plane between the dermis and fat of the anterior flap, and the fascia of the flexor–pronator muscles, and it is maintained there by the sling. An alternative method for creation of a sling to maintain the anterior position of the nerve employs the medial intermuscular septum as described by Pribyl and Robinson (99). One of us (RMS) avoids the use of fascial slings and prefers to suture the fat of the lateral skin flap to the medial fascia to create a broad-based tunnel.

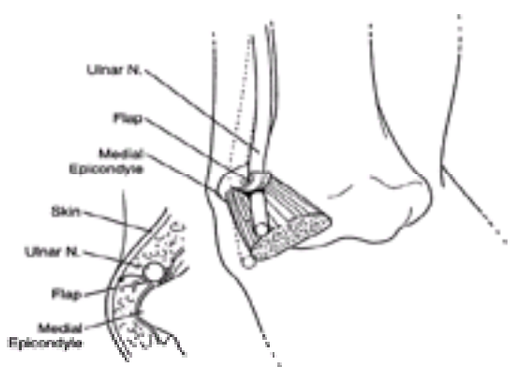

***Figure 52.43.*** The fasciodermal sling for maintaining the ulnar nerve in its transposed position. (From Osterman AL, Davis CA. Subcutaneous Transposition of the Ulnar Nerve for Treatment of Cubital Tunnel Syndrome. *Hand Clin* 1996;12:421, with permission.)

- Make a mark on the dermis of the anterior (radial) skin flap, approximately 1 cm anterior to the medial epicondyle, to indicate the site of attachment of the dermal sling.
- Raise a strip of fascia from the flexor pronator muscles at least 1.5 cm in length, detaching it distally so that it hinges proximally from the medial epicondyle.
- Transpose the nerve anterior to the hinge of the fascial flap.
- Suture the fascial flap into the dermis of the anterior skin flap with nonabsorbable suture, at the mark. Take care to not damage cutaneous branches in the flap arising largely from the medial antebrachial cutaneous nerve.
- Inspect the nerve in its position anterior to the fasciodermal sling. The nerve must not bend at the sling and may only bend at a 45° angle at the FCU hiatus with the elbow in flexion and extension. It must glide without tethering, and there must be enough space for a hemostat to be passed alongside it without difficulty.
- Release the tourniquet and obtain hemostasis.
- Close the skin.

Postoperative care consists of a splint and sling for approximately 5 days, followed by early active range-of-motion exercises. Weirich et al. (144) demonstrated average return to work and activities of daily living by 1 month in patients immediately mobilized after subcutaneous transposition, versus 2.75 months in those mobilized later than 7 days. By 2–3 weeks, the patient should regain nearly full range of motion of the elbow. Progress with strengthening thereafter, with a return to most activities by 6 weeks postoperatively.

***Intramuscular Transposition***

This technique was described by Adson at the turn of the century, and it was evaluated in a series published by Kleinman and Bishop in 1989 (63), from which the following description is derived. We do not use this technique as part of routine treatment for cubital tunnel syndrome.

- Decompress and mobilize the ulnar nerve (Fig. 52.44*A*). Transpose it anteriorly to a position where it will lie without kinking or tension, and mark or note its position on the fascia of the flexor–pronator mass (Fig. 52.44*B*).

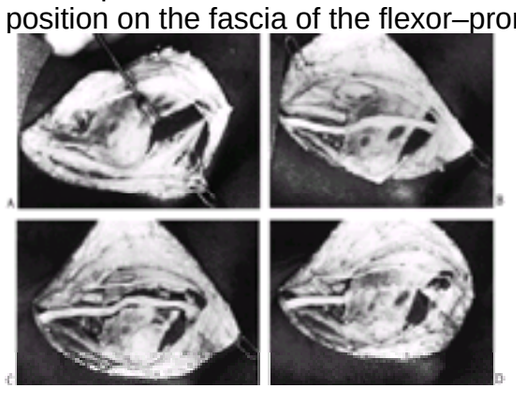

***Figure 52.44.*** Intramuscular transposition. **A:** Decompression and mobilization of the ulnar nerve. **B:** Transposition of the nerve to the flexor pronator fascia. **C:** Laying the nerve in a trough. **D:** Closing the fascia over the nerve. (From Kleinman WB. Anterior Intramuscular Transposition. In: Gelberman RH, ed. *Operative Nerve Repair and Reconstruction.* Philadelphia: Lippincott, 1991:1069, with permission.)

- Return the nerve to the ulnar groove, and make an incision in the fascia of the flexor–pronator musculature where the nerve lay in the previous step.
- Along this incision, create a 5- to 10-mm-deep trough in the substance of the muscles. Sharply excise portions of the fibrous septae that cross the trough from within the bellies of the muscles so that the tissue contacted by the nerve will be muscle.
- Lay the nerve in the trough. Ensure that its course is without sharp angles at the proximal and distal extents of the trough, and that it rests easily in the trough, beneath the level of the fascia (Fig. 52.44*C*).
- Close the fascia over the nerve, and test the excursion of the nerve under the closure; it should glide without hindrance. Fascial closure is facilitated by placing the forearm in full pronation and the elbow in 90° of flexion (Fig. 52.44*D*).
- Release the tourniquet and obtain hemostasis.
- Close the skin.
- Place the arm in a bulky splint that holds the forearm in 45° of pronation and the elbow in 90° of flexion.

Postoperatively, hold the forearm in the semipronated position and the elbow in flexion for 3 weeks, then institute progressive range of motion exercises. Permit unrestricted use by 6 weeks.

***Submuscular Transposition***

Learmonth (66,69) provided the classical description of the technique of submuscular transposition of the ulnar nerve. He lengthened the flexor–pronator muscle mass by a stepcut, or **Z**-lengthening, of the common tendinous origin from the medial epicondyle to decrease the tension on the nerve in its anterior position on the fascia of the brachialis muscle and anterior capsule of the elbow (89).

- Identify the lateral border of the flexor–pronator origin, and raise the anterior skin flap adequately to visualize it.
- Identify the median nerve, which lies lateral to the flexor–pronator origin. The goal of the procedure is to place the ulnar nerve alongside the median nerve.
- To gain access to the lateral margin of the muscles, cut the fascial reflection at this margin.
- Using blunt dissection, elevate the flexor–pronator muscles from lateral to medial. This dissection begins distal to the flexor–pronator origin and proceeds between the flexor–pronator muscle group and the brachialis muscle and anterior elbow capsule.
- The appropriate medial exit of this dissection is in the interval between the humeral and ulnar heads of the FCU. To facilitate completion of the lateral-to-medial dissection in this plane, identify the interval medially.
- After the entire muscle mass is raised, detach it from its origin by creating a 90° stepcut in the common tendon, and turn it distally (Fig. 52.45*A*). Leave the posterior limb of the stepcut long and based on the epicondyle. To avoid damage to the medial collateral ligament complex of the elbow, you may use an elevator to dissect the muscle off the anterior elbow capsule. At this stage, ensure that the deep pronator aponeurosis, which forms a common intermuscular septum between the FCU and the humeral head of the FDS (Fig. 52.31), is divided adequately to avoid kinking of the nerve distally when it is transposed.

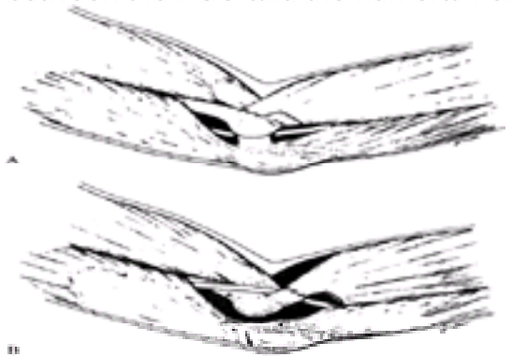

***Figure 52.45.*** Detachment of the flexor pronator mass from the medial epicondyle using a stepcut. **A:** Making the stepcut. **B:** Reattachment of the flexor pronator mass after transposition of the nerve. (From Rayan GM. Proximal Ulnar Nerve Compression: Cubital Tunnel Syndrome. *Hand Clin* 1992;8:325, with permission.)

- Transpose the nerve anteriorly so that it lies next to the median nerve on the anterior surface of the brachialis muscle and tendon and the anterior joint capsule,

where it will be deep to the flexor pronator mass.

- Make certain there is no kinking of the nerve proximally at the arcade of Struthers (or the medial intermuscular septum) or distally at the deep pronator aponeurosis, and that the muscular branches of the nerve are not under tension (Fig. 52.46). Protect the posterior branch of the medial antebrachial cutaneous nerve.

***Figure 52.46.*** Anterior submuscular transposition. **A:** Extensile incision, allowing visualization of all potential compression sites. Note the proximity of the posterior branch of the medial antebrachial cutaneous nerve. **B:** Transposition of the nerve and reattachment of the muscles to the epicondyle. (From Spinner M, Linscheid RL. Nerve Entrapment Syndromes. In: Morrey BF, ed. *The Elbow and Its Disorders*, 2nd ed. Philadelphia: Saunders, 1993:813; and from Spinner M. *Injuries to the Major Branches of the Forearm*, 2nd ed. Philadelphia: Saunders, 1978, with permission.)

- Release the tourniquet and carefully secure hemostasis.
- Reattach the stepcut flexor–pronator origin in a lengthened position over the ulnar nerve with nonabsorbable suture, and reapproximate the heads of the FCU with absorbable suture (Fig. 52.45*B*) (25).
- Close the skin.
- Apply a well-padded dressing from the hand to the upper arm, with a posterior plaster splint.

Postoperatively, maintain the arm in plaster immobilization for 7–12 days. Then remove the immobilization, place the arm in a sling, and institute active range-of-motion exercises. The wrist can be protected from extending with a removable Velcro splint. Full elbow range is expected by 3 weeks, when the sling is removed. Restrict the patient from forceful gripping with the hand for an additional 1–3 weeks, but encourage light activities. Begin strengthening 4–6 weeks postoperatively, and have the patient return to nearly full activities at 6–9 weeks, with unrestricted use at 9–12 weeks depending on individual progress and demands.

### *Complications*

The most common causes of recurrent cubital tunnel syndrome are incomplete decompression and inadequate mobilization of the nerve at the time of transposition. Failure to decompress the nerve at the site of entrapment often results in failure to relieve symptoms, and this can be avoided by carefully evaluating all potential sites of compression. When initial relief of symptoms is followed by recurrence, common causes are kinking of the nerve proximally at the arcade of Struthers or on the margin of the intermuscular septum, and distally at the deep pronator aponeurosis. You can avoid this by making the incisions adequate for exposure and by examining the nerve at surgery, before closing the wound, to ensure that it is not entrapped by the procedure anywhere along its length.

Reoperation should be preceded by nonoperative care and repeat neurodiagnostics, including the inching studies previously mentioned, to evaluate for the potential site of secondary compression. When revision surgery is appropriate, the procedure of choice is submuscular transposition (26) unless this was the initial procedure. In that case, the choice of revision surgical technique is often determined at surgery, at which time the status of the nerve and its bed can be evaluated. The results of repeat decompression are poor in comparison to those of initial decompression (5,106). The medial antebrachial cutaneous nerve (particularly the posterior branch) is at risk for injury during the dissection. This injury commonly results in pain and an unhappy patient.

## ULNAR TUNNEL SYNDROME

### *Pathophysiology and Anatomy*

Ulnar tunnel syndrome is caused by the compression of the motor, sensory, or motor and sensory portions of the ulnar nerve in the canal of Guyon. The canal of Guyon is a confined fibro-osseous triangular space on the ulnar aspect of the volar wrist (Fig. 52.47). The roof of this space is formed by the volar carpal ligament proximally (the thickened distal extension of the antebrachial fascia, which becomes confluent with the tendinous insertion of the FCU onto the pisiform) and the pisohamate ligament distally (which is the extension of the FCU from the pisiform onto the hook of the hamate). The lateral wall is formed by the TCL proximally and the hook of the hamate distally. The medial wall is formed by the pisiform and its associated fibrous structures, and the abductor digiti minimi. The ulnar artery and nerve enter the canal of Guyon at the wrist, deep and radial to the FCU tendon, the artery lying radial to the nerve. In the proximal portion of the canal, the motor and sensory bundles of the nerve lie side by side as one nerve. Just at the distal margin of the pisiform, the nerve divides into deep and superficial branches. The deep branch, which is the motor division, dives through a fibrous arch formed by the origins of the abductor digiti minimi and flexor digiti minimi at the base of the hypothenar muscle group. It continues on to innervate the intrinsic muscles of the hand. The superficial branch continues on through the canal, beneath the pisohamate ligament, to course along the palmar surface of the hypothenar musculature and become, in its terminal branches, the proper digital nerves of the ulnar and radial small finger and the ulnar ring finger.

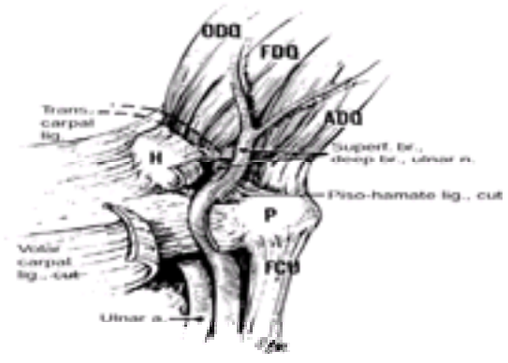


***Figure 52.47.*** The anatomy of the ulnar tunnel and the course of the ulnar nerve from the forearm into the wrist as seen in a palmar view of the medial side of the wrist. ODQ, opponens digiti quinti muscle; FDQ, flexor digiti quinti muscle; ADQ, abductor digiti quinti muscle; H, hook of hamate; P, pisiform; FCU, flexor carpi ulnaris tendon. (From Eversmann WW Jr. Entrapment and Compression Neuropathies. In: Green DP, ed. *Operative Hand Surgery*, 3rd ed. New York: Churchill Livingstone, 1993:1341, with permission.)

Gross and Gelberman (46) described the ulnar tunnel and divided it into clinically relevant zones (Fig. 52.48). Zone I is the area of the canal from the proximal margin of the volar carpal ligament to the distal margin of the pisiform—more specifically, where the nerve bifurcates. It is defined by the presence of both the motor and the sensory divisions of the ulnar nerve. With division of the nerve into motor and sensory branches, zones II and III are defined; the former is associated with the motor and the latter with the sensory division. These last two divisions run side by side in the canal up to the level of the hypothenar fibrous arch.

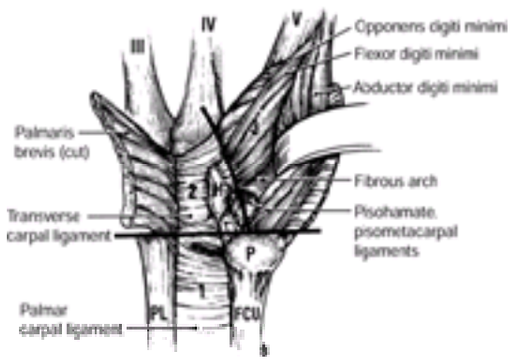


***Figure 52.48.*** Zones of the ulnar tunnel. Zone 1 is defined by the presence of both the sensory and motor divisions of the ulnar nerve, prior to the bifurcation at the level of the pisiform. Zone 2 is the zone of the motor branch only. Zone 3 is the region of the sensory branch only. H, hook of hamate; P, pisiform; FCU, flexor carpi ulnaris tendon; PL, palmaris longus tendon. (From Gelberman RH. Ulnar Tunnel Syndrome. In: Gelberman RH, ed. *Operative Nerve Repair and Reconstruction.* Philadelphia: Lippincott, 1991:1131, with permission.)

Entrapment of the ulnar nerve in the ulnar tunnel may be a result of space-occupying lesions. Ganglions arising from the triquetrohamate joint are the most common cause. Others include aneurysms (Fig. 52.49), lipomas, fractures of the bony walls (particularly the hook of the hamate) of the canal of Guyon, anatomic variations of the canal, and accessory or aberrant muscles. Repeated blunt trauma to the hypothenar region is the second most common cause (10,116). Compression in zones I and II is most often caused by ganglions and fractures of the hook of the hamate. Zone III is most often affected by a vascular lesion of the ulnar artery (116,128).

***Figure 52.49.*** Aneurysm of the ulnar artery within the canal of Guyon (ulnar tunnel), producing an ulnar tunnel syndrome.

### *Classification*

Entrapment at the wrist may produce pure motor, sensory, or mixed symptoms (10). Shea and McClain (116) described three ulnar nerve compression syndromes at and distal to the wrist. These correspond to the three anatomic areas of the canal. In type I, the entrapment takes place in the proximal zone, resulting in mixed motor and sensory deficit. Type II is purely motor, secondary to compression in the canal of Guyon or at the hook of the hamate in association with the origins of the abductor digiti minimi and the flexor digiti minimi and within the substrate of the opponens digiti quinti. Type III is caused by pressure on the superficial branch of the ulnar nerve, producing a sensory deficit in the ring and small fingers without associated muscle weakness or atrophy (Table 52.13).

| Type | Anatomic zone | Symptoms/signs | Most common cause(s)[a] |
|---|---|---|---|
| I | I<br>Motor and sensory components | Intrinsic muscle weakness, decreased sensation of ring and small fingers | Ganglion from triquetrohamate joint,[b] hook of hamate fracture |
| II | II<br>Motor component | Intrinsic muscle weakness | Ganglion from triquetrohamate joint, hook of hamate fracture |
| III | III<br>Sensory component | Decreased sensation of ring and small fingers | Vascular injury, anomalous muscle |

[a] Gelberman RH. Ulnar Tunnel Syndrome. In: Gelberman RH, ed. Operative Nerve Repair and Reconstruction. Philadelphia: Lippincott, 1991:1131.
[b] 36% of traumatic cases.
[c] 18% of traumatic cases.

***Table 52.13. Classification of Ulnar Tunnel Syndrome***

### *Assessment*

Ulnar tunnel syndrome may be difficult to distinguish from cubital tunnel syndrome. One difference is the sparing of sensation of the dorsal ulnar half of the hand in ulnar tunnel syndrome. This area is innervated by the dorsal branch of the ulnar nerve, which arises variably from the ulnar nerve, but always proximal to the wrist crease, and does not enter the canal. Another difference is sparing of the long flexors of the ring and small fingers, leading to a more pronounced ulnar claw deformity in patients with ulnar tunnel versus cubital tunnel syndrome. Additionally, a history of repeated trauma to the hypothenar region may direct special attention to evaluation of this area in patients who present with ulnar-nerve-related symptoms (Table 52.14).

| *History, signs, findings* | *Cubital tunnel syndrome* | *Ulnar tunnel syndrome* |
|---|---|---|
| History | Insidious onset<br>Elbow trauma, fracture<br>Prolonged elbow flexion | Insidious onset<br>Wrist trauma, carpal fracture<br>Exposure to vibrational tools, repeated pounding of hypothenar eminence |
| Diminished sensation dorsal-ulnar hand | Yes | No |
| Tinel's sign | Positive at elbow<br>Negative at wrist | Negative at elbow[a]<br>Positive at wrist |
| Provocative tests | Elbow flexion test positive<br>Phalen's test negative | Elbow flexion test negative<br>Phalen's test may be positive |
| Weakness of FDP to ring and small fingers | Yes | No |
| "Claw" deformity[b] | Mild | Moderate to severe |
| Froment's sign | Positive | Positive |
| NCV | Slowing at elbow | Slowing at wrist |
| EMG changes in FDP | Yes | No |
| Mass lesion is a common cause of compression | No | Yes |

[a] Tinel's sign positive in 16% of normal individuals. (Dellon AL. Tinel or Not Tinel? J Hand Surg [Am] 1998;23:216.)
[b] In advanced cases.
FDP, flexor digitorum profundus; NCV, nerve conduction velocity; EMG, electromyography.

***Table 52.14. Cubital versus Ulnar Tunnel***

A careful examination is extremely helpful in precisely localizing the site of compression. Palpation of the deep structures within the hypothenar region may suggest a mass, not infrequently a ganglion within the canal. Allen's test (an evaluation of the contributions made by the radial and ulnar arteries to the blood supply of the hand)

is performed because thrombosis or aneurysm of the ulnar artery may be the cause of the neuropathy. Tinel's test over the ulnar nerve at the level of the wrist and compression of the nerve over zone I may be helpful in distinguishing ulnar tunnel from cubital tunnel syndrome, although this has not been verified by studies. Phalen's test may also be positive in ulnar tunnel syndrome.

Because of the high incidence of space-occupying lesions and fractures associated with compression of the ulnar nerve in the canal of Guyon, obtain radiographs. Plain radiographs, including PA, lateral, and carpal tunnel (ulnar tunnel) views, can be used to screen for fractures, dislocations, and arthritis. If a hook-of-the-hamate fracture is suspected but not proven in plain radiographs, a CT scan is the diagnostic study of choice. Mass lesions include ganglia and aneurysms and are best evaluated by MRI. In some cases of vascular lesions, arteriograms may be of additional help. Electrodiagnostic studies show slowing of the NCV across the wrist of the sensory and/or motor portions of the nerve. In theory, isolated slowing in the sensory portion is not diagnostic of isolated sensory division compression because the sensory fibers of the nerve are more susceptible to compression than are the motor fibers. If EMG evaluation shows abnormalities in the FCU and FDP muscles in addition to the intrinsics, compression of the ulnar nerve is present proximally (Table 52.15).



***Table 52.15. Ulnar Tunnel Syndrome Summary***

### *Preoperative or Nonoperative Management*

Except for cases resulting from repeated blunt trauma, in which cessation of trauma may lead to complete resolution of symptoms, and for the mild type II neuropathy, the ulnar tunnel syndrome is best treated surgically. In the absence of identifiable lesions causing compression of the nerve in the ulnar tunnel, nonoperative treatment consists of splinting, NSAIDs, and avoidance of activities that aggravate or precipitate symptoms. Failure to adequately improve symptoms is an indication for surgery.

### *Surgical Indications and Relative Results*

As noted in the preceding section, most cases of ulnar tunnel syndrome are treated operatively because there is often a mass lesion or a vascular injury or anomaly causing compression of the nerve. In cases of acute onset of ulnar tunnel syndrome in association with wrist trauma and swelling, Vance and Gelberman (140) recommend operative release and exploration if no improvement is noted within 48 hours. Alternatively, Howard (52) suggests observation for 6–8 weeks after the injury before exploration. It is reasonable to treat acute, traumatic ulnar tunnel syndrome expectantly in cases of incomplete or mild neurologic deficit, and to reserve urgent operative decompression for those cases with dense sensory deficits and/or paralysis of intrinsic muscles. Results of operative management are generally good, and recurrence is rare. Return of muscle function is adequate to avoid the need for tendon transfer. The rate and extent of recovery are likely related to the preoperative duration and severity of symptoms.

### *Preoperative Planning*

Identification of the cause and site of compression is essential to treat the offending lesion at surgery. Plan for and inform the patient of excision of a fractured hook of the hamate or arthritic pisiform. Vascular reconstruction may be necessary in ulnar artery aneurysms and thrombosis. Ganglia must be identified and excised. If no particular lesion is identifiable, suspicion of a particular zone of compression will help direct particular attention to the segment of the nerve corresponding to that zone.

### *Operative Technique*

The choice of incision and extent of exposure vary according to the particular pathology suspected as the cause of compression. The technique of exploration and decompression of the nerve through its course in the ulnar tunnel is described here.

- Center a zigzag incision over the canal of Guyon, beginning just proximal to the proximal wrist crease at the radial border of the FCU tendon (Fig. 52.50). Or, in the case of concomitant CTS, use the incision for carpal tunnel release described earlier in this chapter and carry the dissection ulnarly to expose the canal of Guyon.

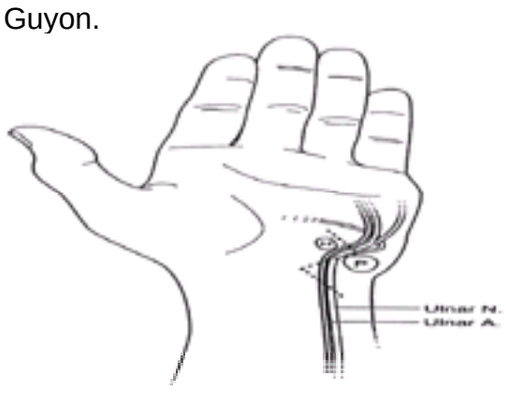


***Figure 52.50.*** Incision for exposure of the ulnar tunnel. H, hook of hamate; P, pisiform. (From Osterman AL, Kitay GS. Compression Neuropathies: Ulnar. In: Peimer CA, ed. *Surgery of the Hand and Upper Extremity.* New York: McGraw-Hill, 1996:1339, with permission.)

- Begin dissection proximally. Incise the fascia along the lateral border of the FCU.
- Identify the ulnar artery and nerve after retracting the FCU medially; the artery lies lateral to the nerve.
- Trace the ulnar nerve and artery distally, and incise (in order) the overlying palmaris brevis muscle, the hypothenar fat, any fibrous bands, and the palmar carpal ligament.
- Identify the pisiform. The ulnar nerve bifurcates as it passes by the pisiform; the sensory branch continues distally, and the motor branch dives toward the origin of the hypothenar muscles.
- Trace the sensory branch onto the hypothenar muscles, dividing any crossing and potentially constrictive structures.
- Trace the motor branch into the fibrous arch of the hypothenars and several millimeters distally, again dividing any potentially constricting fibrous structures.
- Inspect the floor, walls, and contents of the canal, and identify any masses, aberrant muscles, fractures, or offending structures.
- Identify and inspect the ulnar artery for any abnormalities.
- One of us (JT) performs release of the carpal tunnel routinely at this time.
- Close the skin.
- Apply a padded hand dressing similar to that for carpal tunnel release.

Postoperative care is as for carpal tunnel release. If you treated other pathology simultaneously, institute specific rehabilitation and advise precautions as indicated.

### *Complications*

Complications are similar to those associated with CTS. Incomplete release is potentially a problem if the nerve is not traced distally enough into zone III, between the

pisohamate and pisometacarpal ligaments. An additional pitfall is failure to recognize the existence of a vascular component within this syndrome.

## COMPRESSION NEUROPATHIES OF THE RADIAL NERVE

The radial nerve can be entrapped as it crosses the lateral intermuscular septum in the arm (most frequently in conjunction with displaced fractures of the humerus) or compressed proximal to the elbow in association with a fibrous arch from the lateral head of the triceps (a rare form of compression) (75). Evaluation of these two conditions reveals involvement of the muscles innervated by the posterior interosseous nerve as well as those by the radial nerve prior to its branching into motor and sensory divisions—typically the brachioradialis and extensor carpi radialis longus (ECRL) muscles. Additionally, sensory disturbances in the radial nerve distribution are common with these disorders. EMG evaluation is often diagnostic, and observation is the treatment of choice. If recovery is not spontaneous within 3 months, exploration and decompression are warranted.

The two more distal compressions are the posterior interosseous nerve (PIN) syndrome and the radial tunnel syndrome (RTS) (143). Additionally, the superficial, sensory branch of the radial nerve (SBR) can be compressed in the distal forearm, causing pain and sensory disturbances in the radial nerve sensory distribution.

### POSTERIOR INTEROSSEOUS NERVE SYNDROME

#### *Pathophysiology and Anatomy*

The radial nerve travels along the posterior aspect of the middle third of the humerus in a diagonal course between the lateral and medial heads of the triceps. At the distal third of the humerus, the nerve pierces the lateral intermuscular septum and then travels anteriorly and distally between the brachialis and brachioradialis muscles. Just proximal to the elbow, the nerve bifurcates into superficial and deep branches. The superficial branch, the sensory division, continues distally, traveling between the brachioradialis and supinator muscles. The posterior interosseous (deep) branch, essentially a purely motor nerve, passes between the two heads of the supinator muscle under an inverted fibrous arch, the arcade of Frohse, which is formed by the thickened edge of origin of the superficial head and is seen readily (Fig. 52.51) (55). It continues beneath the supinator muscle, exiting under its distal edge. The PIN innervates the muscles of the posterior forearm (Fig. 52.52).

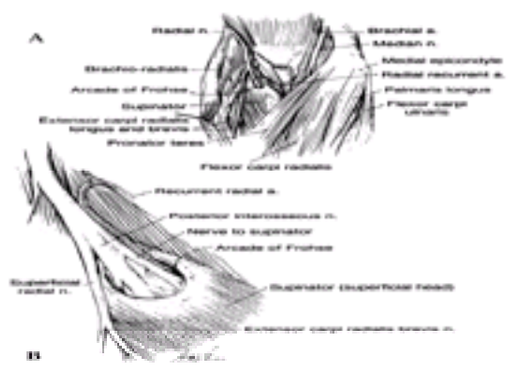

***Figure 52.51.*** **A:** Composite drawing of dissections of the forearm at the level of the elbow. **B:** Enlarged view of the posterior interosseous nerve and its relationship to the supinator muscle. The motor supply to the extensor carpi radialis brevis arises most frequently from the superficial radial nerve. (From Spinner M. *Injuries to the Major Branches of Peripheral Nerves of the Forearm.* Philadelphia: Saunders, 1972, with permission.)

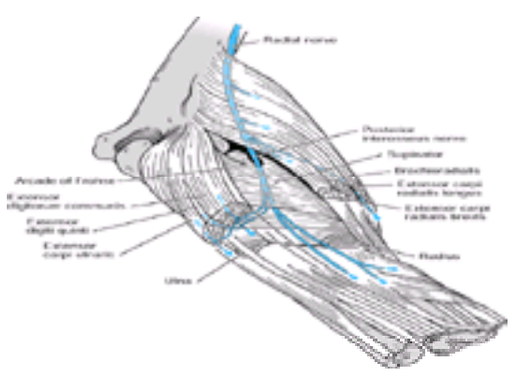

***Figure 52.52.*** Innervations of the posterior interosseous nerve. Not labeled in the diagram are the distal innervations, from radial to ulnar: abductor pollicis longus, extensor pollicis brevis, extensor pollicis longus, and terminal sensory branches to the dorsal carpus. (From Spinner M, Linscheid RL. Nerve Entrapment Syndromes. In: Morrey BF, ed. *The Elbow and Its Disorders*, 2nd ed. Philadelphia: Saunders, 1993:813; and from Spinner M. *Injuries to the Major Branches of the Forearm*, 2nd ed. Philadelphia: Saunders, 1978, with permission.)

There are five classic potential compression sites of the PIN (Fig. 52.53). Just proximal to the radiocapitellar joint, after branching from the radial nerve, the PIN travels through fibrous tissue that is associated with the anterior capsule of the radiocapitellar joint. This fibrous tissue may form bands that can cause constriction of the nerve (37). The nerve continues distally and is crossed by the leash of Henry, small radial recurrent vessels that have been reported to be a source of compression (70). The fibrous leading edge of the extensor carpi radialis brevis (ECRB) muscle travels diagonally across the proximal edge of the supinator muscle and can cause compression of the PIN just prior to its entrance under the arcade of Frohse (70,107,118). The edge of the ECRB and the fibrous arcade of Frohse, the thickened proximal edge of the supinator muscle, are the most common sites of compression in PIN syndrome (Table 52.16). The nerve wraps around the proximal radius between the two heads of the supinator and may also be compressed as it exits from beneath the superficial head on its distal margin of this muscle.

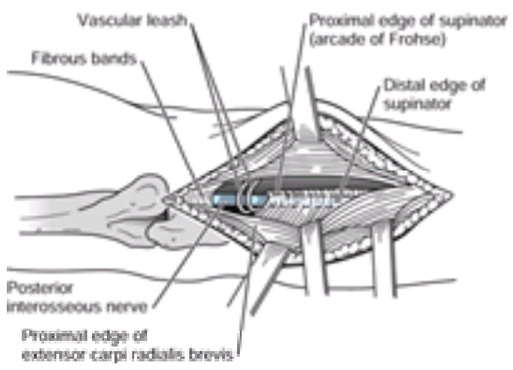


***Figure 52.53.*** The five potential compression sites of the posterior interosseous nerve: fibrous bands on the anterior radiocapitellar joint capsule, the vascular leash of Henry (radial recurrent vessels), the proximal edge of the extensor carpi radialis brevis, the arcade of Frohse (proximal edge of the supinator), and the distal edge of the supinator. (From Hynes DE, Peimer CA. Compression Neuropathies: Radial. In: Peimer CA, ed. *Surgery of the Hand and Upper Extremity.* New York: McGraw-Hill, 1996:1291, with permission.)

| |
|---|
| Fibrous bands |
| Recurrent leash of vessels; "leash of Henry" |
| Extensor carpi radialis brevis |
| Arcade of Frohse (proximal edge of superficial head of supinator) |
| Supinator muscle distal margin |

The sites of compression can be remembered by the acronym FREAS.
PIN, posterior interosseous nerve.

***Table 52.16. The Five Potential Compression Sites of the PIN from Proximal to Distal***

Other causes of PIN compression include space-occupying lesions such as lipomas (103) and ganglions (77,93), radiocapitellar synovitis in patients with rheumatoid arthritis (78,147), fractures of the radial neck, and dislocations of the radial head (80). PIN compression may also be iatrogenic, as after internal fixation of fractures of the proximal radius, in which the nerve is extremely vulnerable because it may lie directly on the periosteum opposite the tuberosity of the radius (Fig. 52.54) (120).

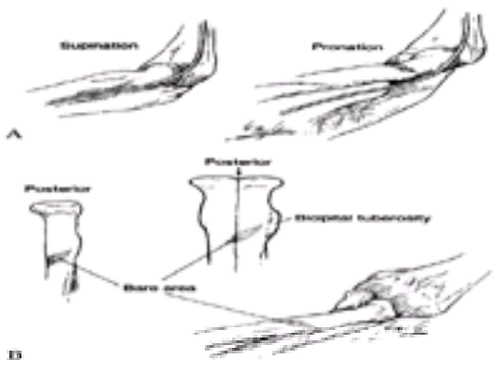


***Figure 52.54.*** **A:** In supination with a bare area of the proximal radius, the posterior interosseous nerve comes to lie against the periosteum of the radius. **B:** Details of the bare area. (From Spinner M. *Injuries to the Major Branches of Peripheral Nerves of the Forearm.* Philadelphia: Saunders, 1972, with permission.)

### *Assessment*

The PIN syndrome is purely motor. Onset is usually insidious. There may be a history of trauma to the radial head or neck. Symptoms include weakness of the PIN-innervated muscles, and pain but not sensory dysfunction. The bra-chioradialis and the ECRL are not involved because they are innervated by the radial nerve. The ECRB may be spared because its innervation may originate more proximally, or it may appear to arise from the superficial bifurcation of the radial nerve (Fig. 52.51). The complete syndrome involves loss of extension of all digits and of the extensor carpi ulnaris. The patient can dorsiflex the wrist but with radial deviation. Middle and distal digital joints may still be extended through their intact intrinsics. Partial syndromes may involve just the extensor digitorum communis (EDC), with extension of the thumb and index finger preserved (Fig. 52.55). Early in the compression syndrome, a less striking clinical picture may exist, with paresis or paralysis of isolated digits. Patients with rheumatoid arthritis may present the same attitude of the hand whether the cause is a PIN compression or rupture or dislocation of the EDC tendons. A careful examination assists the clinician in differentiating between these two entities (76,78).

***Figure 52.55.*** Incomplete dorsal interosseous nerve syndrome.

Diagnostic studies include routine radiographs of the elbow, especially in cases of trauma or arthritis. Soft-tissue masses may stretch or compress the PIN near the proximal radius. Functional loss of finger extension may be present, even though the patient is completely unaware of the presence of a mass. MRI examinations are extremely helpful in these patients, for preoperative evaluation of the size, shape, and location of the mass. Electrodiagnostic studies are imperative. The EMG portion of the examination is usually diagnostic (Table 52.17).

| |
|---|
| Compression of PIN in proximal forearm most commonly in arcade of Frohse or ECRB tendon |
| Tumors, ganglia, or synovitis of radiocapitellar joint compress PIN in proximal forearm |
| **History** |
| Incidence unclear |
| Fracture or dislocation of radial head |
| Rheumatoid arthritis with radiocapitellar synovitis |
| **Symptoms** |
| Pain in proximal, lateral forearm |
| Weakness or paralysis of all or some of PIN-innervated muscles |
| **Sensory exam** |
| Normal |
| **Motor exam** |
| Extension of wrist with radial deviation |
| Loss of extension of all digits or loss of extension of long, ring, and small fingers at MP joints |
| **Provocative tests** |
| None |
| **Diagnostic studies** |
| EMG exam diagnostic |
| In cases where mass compression is suspected, MRI examination |
| Radiographs of the elbow for evaluation of fracture or arthritis when indicated |
| **Alternative diagnoses** |
| Most proximal injury of radial nerve indicated by sensory disturbance or motor involvement of ECRB and brachioradialis muscles |
| Diagnosis or dislocation of external tendons often seen in rheumatoid arthritis |

PIN, posterior interosseous nerve; EMG, electromyography; MRI, magnetic resonance imaging; ECRB, extensor carpi radialis brevis.

***Table 52.17. Posterior Interosseous Nerve (PIN) Syndrome***

### *Preoperative or Nonoperative Management*

Patients rarely present with acute PIN syndrome except in cases of trauma. In cases of fracture or dislocation, follow management algorithms for treatment of such injuries complicated by nerve dysfunction. In the rare case of acute onset of PIN without injury, rule out the presence of a mass. In the absence of fracture, dislocation, or tumor, the patient can be evaluated with EMG studies and observed for 6–8 weeks. During this time, we recommend NSAIDs, maintaining joint mobility to prevent

contracture, and avoidance of activities requiring repetitive or forceful elbow or wrist flexion and extension and forearm pronosupination. Splinting of the wrist in slight extension alone will often improve function of the hand markedly. Additional dynamic splinting for MP joint extension aids in opening the hand for grasp, but the splint itself may be cumbersome and interfere with activities. Failure to improve clinically or electromyographically in 6–8 weeks is an indication for operative treatment.

### *Results*

Surgical decompression for the treatment of PIN syndrome produces good to excellent results in 85% of patients (54). Patients generally recover motor function, although improvement may take 18 months to complete. If the paralysis has been longstanding (more than 12–18 months), so that end organ innervation of the muscle has atrophied, there will be residual loss or inadequate recovery. These patients can be treated with appropriate tendon transfers (see Chapter 55 on radial nerve palsy) (54).

### *Preoperative Planning*

Be prepared to address concomitant fractures and dislocations. You must delineate the sizes and locations of masses to optimize the choice of approach. This requires a preoperative MRI. In cases of suspected malignancy, perform a metastatic workup and choose a treatment appropriate for the neoplasm. In patients with rheumatoid arthritis and radiocapitellar disease, radial head excision may be indicated.

There are several approaches to the radial nerve in the proximal forearm. Use the one that allows complete visualization of the potential compression sites of the nerve and that allows treatment of any associated conditions. Three popular approaches are the anterolateral extensile, posterior, and brachioradialis muscle–splitting approaches. Perform the surgery under tourniquet control and regional or general anesthetic.

### *Anterolateral Approach*

- Begin the incision 5 cm above the flexor crease on the lateral aspect of the arm, over the interval of the brachioradialis and biceps. Extend it distally, across the flexor crease, along the ulnar border of the brachioradialis muscle (Fig. 52.56).

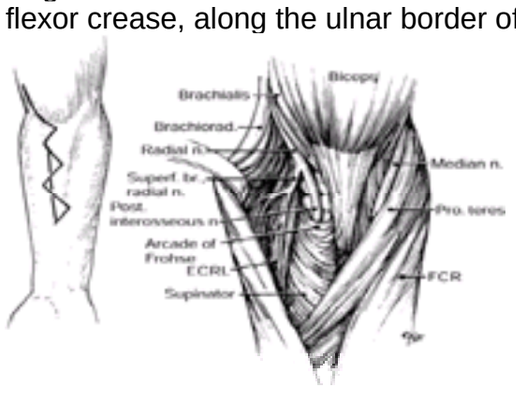


***Figure 52.56.*** The anterolateral approach to the radial nerve. (From Eversmann WW Jr. Entrapment and Compression Neuropathies. In: Green DP, ed. *Operative Hand Surgery*, 3rd ed. New York: Churchill Livingstone, 1993:1341, with permission.)

- Develop the skin flaps to the level of the muscle fascia. Protect the lateral brachial and lateral antebrachial cutaneous (LABC) nerves as well as the cephalic vein in the subcutaneous tissues.
- Deepen the dissection proximally and identify the radial nerve in the interval between the brachialis and brachioradialis just proximal to the flexion crease of the elbow.
- Trace the nerve distally onto the anterior capsule of the radiocapitellar joint, the first site of potential compression, where fibrous bands may compress the nerve. Release all substantial structures crossing the nerve.
- Continue tracing the nerve distally. The fan-shaped leash of vessels from the radial recurrent artery cross the nerve as they travel to the brachioradialis. With bipolar cautery, coagulate the vessels and divide them.
- While visualizing the nerve, pronate the forearm and flex the wrist. This will tighten the leading edge of the ECRB and may demonstrate its compression of the PIN. Remove a portion of the fibrous edge of the muscle in the region of the nerve.
- Continue following the nerve as it enters the arcade of Frohse. Divide the fibrous arch while protecting the underlying PIN.
- The superficial head of the supinator often has a tough fascial envelope. Because of this and for the benefit of exploration of the nerve as it travels through the supinator, it may be preferable to divide the superficial head of the supinator as it crosses the PIN.
- Trace the nerve as it branches and exits the supinator. Divide the distal margin of the superficial head of the supinator.

### *Posterior Approach of Thompson*

- Make an incision along the line connecting the lateral epicondyle and Lister's tubercle with the forearm in pronation. Begin it 2 cm distal to the lateral epicondyle, and extend it 8 cm.
- Locate the interval between the ECRB and EDC muscles in the distal portion of the wound. Develop this interval and extend it proximally.
- Identify the transverse-oblique fibers of the supinator muscle (Fig. 52.57).

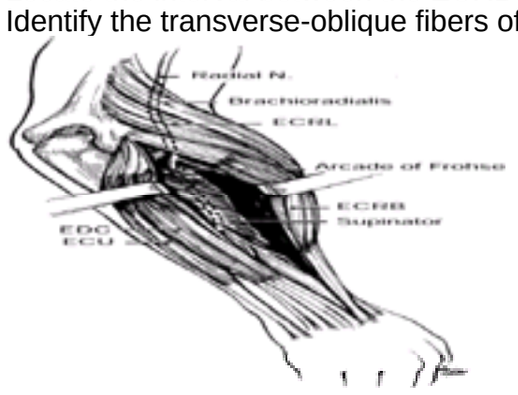


***Figure 52.57.*** The posterior muscle-splitting approach to the radial tunnel and the arcade of Frohse. ECU, extensor carpi ulnaris; ECRB, extensor carpi radialis brevis; ECRL, extensor carpi radialis longus; EDC, extensor digitorum communis. (From Eversmann WW Jr. Entrapment and Compression Neuropathies. In: Green DP, ed. *Operative Hand Surgery.* New York: Churchill Livingstone, 1982:1341, with permission.)

- Increase exposure by developing the interval between the ECRB and the supinator. Avoid dissection between the EDC and the supinator, which would place the motor innervation of the EDC at risk (120).
- Explore the nerve as previously described, beginning proximally. It may be difficult to isolate the fibrous bands of the first site of compression, which is a disadvantage of this approach. (One can extend this approach proximally by developing the interval on the medial and lateral aspects of the brachioradialis muscle.)

### *Brachioradialis Muscle–Splitting Approach*

- Make an incision centered over the mobile wad at the level of the radiocapitellar joint (Fig. 52.58).

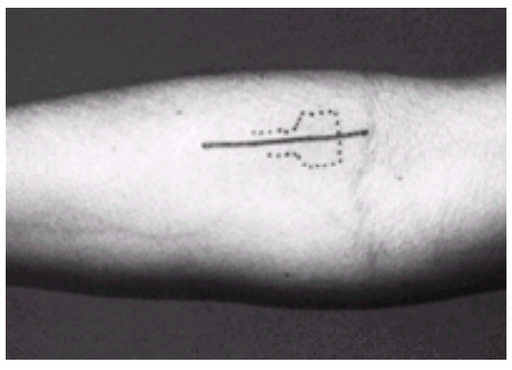

***Figure 52.58.*** Incision for the muscle-splitting approach to the radial tunnel.

- Develop the skin flaps to the level of the muscle fascia. Protect the lateral brachial and LABC nerves in the subcutaneous tissues.
- Make an incision in the brachioradialis fascia in line with the muscle fibers.
- Palpate the radial head.
- Bluntly dissect through the substance of the muscle, separating its fibers and heading toward the radial head. Continually locate the radial head by palpation.
- Identify the transverse-oblique fibers of the supinator. The superficial branch of the radial nerve will be on the underside of the brachioradialis (Fig. 52.59).

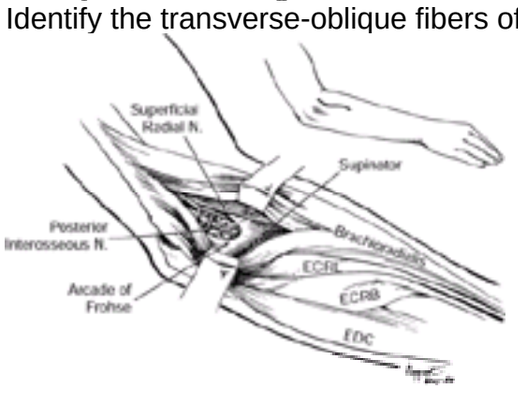


***Figure 52.59.*** The muscle-splitting approach to the radial tunnel. (From Peimer CA, Wheeler DR. Radial Tunnel Syndrome/Posterior Interosseous Nerve Compression. In: Szabo RM, ed. *Nerve Compression Syndromes: Diagnosis and Treatment.* Thorofare, NJ: Slack, 1989:177, with permission.)

- Identify the PIN as it enters the arcade of Frohse.
- Dissect the nerve, evaluating the five potential sites of compression and dividing all potential offending structures. (Pronate the forearm and flex the wrist to evaluate ECRB compression of the nerve.) Carry decompression out to the distal margin of the supinator.
- If more proximal exposure is desired, extend the skin incision along the interval between the brachioradialis and the biceps on the arm. Proceed with deeper exposure as described in the anterolateral approach.
- If more distal exposure is desired, extend the incision so that you can reach the interval between the ECRB and EDC muscles. Proceed with deeper dissection as described in the posterior approach.
- Loosely approximate the fascia of the brachioradialis before closing the skin.

### *Authors' Preferred Method*

- Start the incision 4–5 cm proximal to the elbow flexion crease, at the interval between the brachioradialis laterally and the brachialis medially.
- Distally, continue the incision to the interval between the ECRB and the ECRL laterally and to the EDC medially (Fig. 52.60).

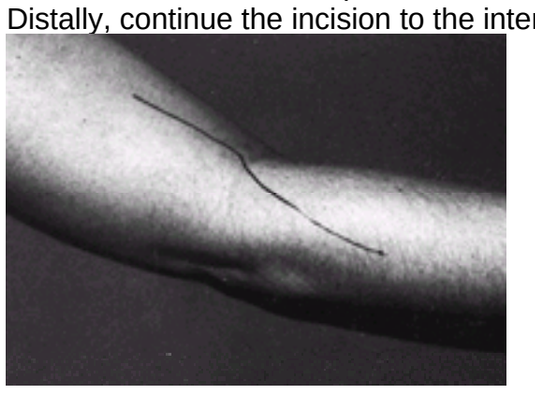

***Figure 52.60.*** Approach for the radial nerve and its bifurcation at the elbow and proximal forearm.

- Begin deep dissection at the proximal end of the incision.
- Identify the radial nerve and tag it with a moist, wide Penrose drain.
- At the distal end of the incision, develop the plane between the ECRB and the EDC, exposing the oblique fibers of the supinator muscle (Fig. 52.57).
- Accomplish wider exposure by partially detaching the ECRB from the lateral epicondyle.
- Dissection to increase exposure is between the ECRB and the supinator, as in the posterior approach. (Do not dissect between the EDC and the supinator.)
- Trace the nerve from proximal to distal, using the proximal and distal intervals for exposure.
- Divide all potential compressing structures as previously noted.

After decompression of the nerve, release the tourniquet and obtain hemostasis. Do not close any deep structures except as noted for the brachioradialis-splitting technique. Suture the skin in layers. Apply a padded dressing and a long-arm splint with the forearm in supination and with the elbow flexed 90°.

### *Postoperative Care and Rehabilitation*

Immediately postoperatively, encourage shoulder and finger range-of-motion exercises. Because these approaches are carried out between anatomic planes, you may discontinue immobilization as early as 3–5 days and no later than 7–10 days. Depending on individual patient recovery, slings or wrist splints may be used for up to 3 weeks for comfort. Formal therapy for strengthening and range of motion is not routinely implemented but should be used when the patient is slow to progress. Return-to-work time is influenced by the severity of the syndrome and the particular job demands.

### *Complications*

In addition to the pitfalls common to other entrapment syndromes, differentiation of the PIN syndrome from extensor tendon ruptures or dislocations in the patient with rheumatoid arthritis is important. Make this distinction by performing a tenodesis test. When the wrist is passively flexed, the fingers will not extend at the MP joints if the tendons are ruptured. If the tendons are intact, as in PIN syndrome, extension of the MP joints will occur as the wrist falls into flexion.

Avoid forceful dissection between the supinator muscle and the extensor digitorum, because this will jeopardize the innervation of the EDC muscle. Identification and resection of a portion of the fibrous leading edge of the ECRB where it crosses the PIN, as well as separate division of the arcade of Frohse, are critical because these are the common sites of compression of the nerve. “Recurrence,” or rather failure of operative treatment, is caused by incomplete decompression of the nerve at all the potential sites of entrapment.

## RADIAL TUNNEL SYNDROME

### *Pathophysiology and Anatomy*

The radial tunnel is the region along the course of the radial nerve and its posterior interosseous (deep) branch, beginning proximally where the radial nerve lies deep between the brachioradialis and the brachialis, and extending distally to the distal border of the supinator muscle (107). The five sites of compression are the same as those for PIN syndrome (97,107), easily remembered by the mnemonic FREAS (Table 52.16). Unlike in PIN syndrome, the compression of the PIN in RTS is not caused by masses, fractures, and disturbances of the radiocapitellar joint. It is associated with repetitive elbow flexion and extension and forearm rotation. It is likely a dynamic form of compression of the PIN (57).

### *Assessment*

Radial tunnel syndrome is a painful condition, without motor deficit and usually without sensory changes. Patients present with a dull, aching or burning pain over the lateral aspect of the elbow in the region of the proximal extensor–supinator muscle mass. Symptoms may radiate distally along the course of the extensor muscles to the radial aspect of the hand or proximally to the shoulder. In some cases, there may be paresthesias in the radial nerve distribution. Symptoms are worsened by activities, especially those requiring forceful and repetitive elbow motion or wrist flexion and extension and forearm pronosupination, and are relieved by rest. The association between lateral epicondylitis, or “tennis elbow,” and RTS has been noted (107,141). Patients may present with tennis elbow symptoms and evidence of lateral epicondylitis, which may respond to local steroid injections followed by localization of discomfort several centimeters distal to the lateral epicondyle over the radial tunnel. The resultant RTS can then exist solely or concurrently with the tennis elbow; 5% of patients with lateral epicondylitis also have RTS (128). The diagnosis of RTS is differentiated from tennis elbow by examination.

Physical examination will reveal tenderness centered over the radial head and neck along the course of the radial nerve. Comparison of the opposite, unaffected side is recommended because many normal individuals find this area exquisitely tender to deep palpation. Distal radiation of symptoms can occur with manual compression of the nerve in this region. Limitation of elbow extension and weakness of grip further suggest RTS. Sensory deficits in the distribution of the superficial radial branch may be seen in RTS and suggest compression of the nerve in the proximal aspect of the tunnel at a point where both divisions of the main trunk are simultaneously vulnerable, such as beneath the fibrous bands proximal to the arcade of Frohse. Because of its dynamic or exertional nature, provocative testing is invaluable in detecting RTS and may give clues to the site of compression of the nerve within the radial tunnel. Described provocative tests for RTS include the elbow flexion test, the middle finger extension test (107), passive pronation of the forearm (33), and the supination test (70) (Table 52.18). In the elbow flexion test (Fig. 52.61), ask the patient to flex his elbow against resistance. Reproduction of pain with this maneuver indicates compression of the nerve by fibrous bands on the capsule of the radiocapitellar joint. In the middle finger extension test (Fig. 52.62), ask the patient to extend his middle finger against resistance applied by you over the proximal phalanx. Hold his forearm in full pronation and his elbow extended. Reproduction of pain in the radial tunnel region with this maneuver indicates entrapment of the PIN at the ECRB tendon.

| Test | How performed | Positive result | Interpretation |
|---|---|---|---|
| Elbow flexion test | Active full flexion of elbow with forearm supinated and wrist in neutral | Reproduction or aggravation of RTS symptoms; pain in radial tunnel region | Compression of radial nerve by fibrous bands proximal to the radial neck |
| Supination test | Isometric, resisted supination of forearm from fully pronated position with elbow in extension | Reproduction or aggravation of RTS symptoms; pain in radial tunnel region | Compression of posterior interosseous nerve beneath the arcade of Frohse |
| Middle finger extension test | Isometric extension of middle finger MP joint against pressure placed by examiner over proximal phalanx, resisted wrist, pronated forearm, extended elbow | Reproduction or aggravation of RTS symptoms; pain in radial tunnel region | Compression of posterior interosseous nerve by fibrous edge of ECRB* |
| Passive pronation of the forearm | Passive pronation of forearm with the elbow in 45° to 90° of flexion and the wrist in full flexion followed by extension of the wrist | Reproduction or aggravation of RTS symptoms; pain in radial tunnel region with pronation followed by relief of symptoms with wrist extension | Compression of posterior interosseous nerve beneath the arcade of Frohse if symptoms produced with pronation, compression by ECRB if symptoms relieved by wrist extension |

*The middle finger extension test may not be reliable in localizing compression to the ECRB medial fibrous extension and may also aggravate symptoms of lateral epicondylitis (Werner C-O: Lateral Elbow Pain and Posterior Interosseous Nerve Entrapment. Acta Orthop Scand Suppl 1979;174:1) but is supportive of the diagnosis of RTS if pain is increased in the area of the radial tunnel.
ECRB, extensor carpi radialis brevis.

***Table 52.18. Provocative Tests for Radial Tunnel Syndrome (RTS)***

***Figure 52.61.*** The elbow flexion test for radial tunnel syndrome.

***Figure 52.62.*** The middle finger extension test for radial tunnel syndrome.

Electrodiagnostic studies are not generally helpful in diagnosis of RTS. Conduction velocities are often normal, and EMG changes are present in patients with clinically evident weakness or atrophy and therefore carry the diagnosis of PIN syndrome. There may be a place for dynamic electrodiagnostic studies to detect subtle changes in nerve function (64,100). We believe that a localized injection of anesthetic, with or without steroid, into the radial tunnel, which produces a PIN palsy and relieves symptoms, is diagnostic for RTS. Localized steroid injection may also assist in differentiating RTS from tennis elbow (Table 52.19).

| |
|---|
| Pathology |
| Compression of PIN in proximal forearm most commonly at arcade of Frohse or ECRB tendon |
| History |
| Association with repetitive elbow flexion–extension and forearm pronosupination |
| Symptoms |
| Pain in proximal, lateral forearm |
| Sensory exam |
| Normal |
| Motor exam |
| Normal |
| Provocative tests |
| Elbow flexion test; positive test indicates compression proximal to arcade of Frohse |
| Supination test; positive test indicates compression at proximal margin of arcade of Frohse |
| Middle finger extension test; may indicate compression by edge of ECRB muscle |
| Passive forearm pronation, wrist extension test; compression at arcade of Frohse or ECRB |
| Diagnostic studies |
| Routine neurodiagnostic studies often not helpful, dynamic studies may be of diagnostic value |
| Radiographs of the elbow for evaluation of fracture or arthritis when indicated |
| Alternative diagnosis |
| Lateral epicondylitis (tennis elbow) |

ECRB, external carpi radialis brevis.

***Table 52.19. Radial Tunnel Syndrome Summary***

### *Preoperative or Nonoperative Management*

Nonoperative management of RTS includes initially reducing inflammation in the area of the radial tunnel with wrist splinting, administration of NSAIDs, and avoidance of activities that involve forearm pronosupination. Prescribe formal hand therapy. Administer steroid iontophoresis over the radial tunnel three times per week for 2–3 weeks. After significant reduction in inflammation, begin soft-tissue mobilization, gentle progressive stretching, and nerve gliding exercises. Institute strengthening later, tailoring it so that it does not exacerbate symptoms.

### *Surgical Indications and Relative Results*

Failure to improve after 2–4 months of adequate treatment, progressive symptoms, and the impracticality of permanent activity modification are all indications for surgical intervention.

The relief of aching pain in the proximal forearm often occurs within the first few weeks after surgery, although complete resolution of pain may take several months to a year. Lister et al. (70) noted approximately 92% good to excellent results in a review of the combined cases of three series, including their own. Jebson and Engber (57) reported 71% good results and 29% fair/poor results in their 8-year follow-up of 33 extremities in 31 patients. Ritts et al. (105) reviewed the results of 34 cases performed over the span of 10 years. They noted only 51% good results with surgery, and workers' compensation cases often had an unsatisfactory result. There is no difference in the operative results of patients with normal preoperative electrodiagnostic studies and those with abnormal ones. Peimer and Wheeler (97) noted that the best results were in patients whose nerves appeared normal at surgery. Ritts et al. (105) noted that the best prognostic factor for operative treatment was a good response to a preoperative injection.

### *Operative Technique—Authors' Preferred Method*

The technique for decompression of the PIN in RTS is the same as that described for PIN syndrome. Because of its simplicity and sufficient exposure, the brachioradialis–splitting technique (107) is preferred. If the site of compression has been well localized by clinical methods to the arcade of Frohse, a limited skin incision may be employed.

- Make an incision approximately 6 cm long, starting at the elbow crease and projected longitudinally over the radial head (Fig. 52.58).
- Expose the brachioradialis and split its fibers by blunt dissection. Take care to not injure branches of the lateral brachial and antebrachial nerves.
- After traversing the brachioradialis, retract the superficial branch of the radial nerve and the ECRL laterally to expose the deep branch of the radial nerve and the oblique fibers of the supinator (Fig. 52.59, Fig. 52.63).

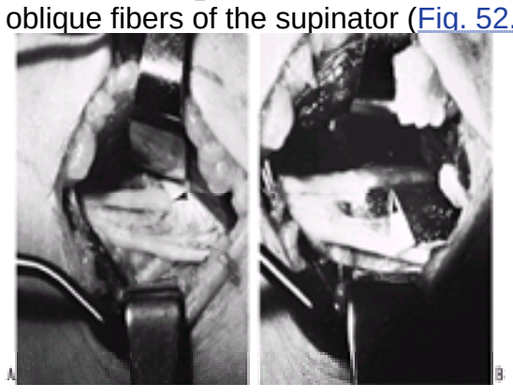

***Figure 52.63.*** Superficial and deep branches of the radial nerve. **A:** The deep branch is seen as it passes under the arcade of Frohse (*arrow*). **B:** Compression of the deep branch (*arrow*) after division of the superficial head of the supinator.

- Divide the structures at the five potential sites of compression to fully expose the PIN.
- Loosely approximate the deep fascia.
- Close the skin.

Apply a well-padded compression dressing from above the elbow to beyond the wrist, with the forearm and wrist in neutral.

### *Postoperative Care and Rehabilitation*

Encourage immediate postoperative finger and shoulder range-of-motion exercises. Remove the postoperative dressing at 5 days. Place the arm in a sling and the wrist in a cock-up splint. Encourage active range-of-motion exercises of the elbow and wrist so that full range is achieved by 3 weeks postoperative. Remove the wrist splint and sling at 3 weeks and institute therapy for elbow and wrist range of motion if the patient is progressing slowly. If the patient is progressing well, encourage progressive use of the upper extremity in daily activities, but caution against forceful activities until 6 weeks after surgery. If job demands are fairly strenuous, a strengthening program may be prescribed under a therapist's supervision. Return to work is allowed at 6–8 weeks but may not be realized until up to 3–4 months for patients who are manual laborers. Complete recovery can take up to a year. Job modification in conjunction with surgery may be indicated, especially in workers' compensation cases.

### *Complications*

Radial tunnel syndrome is identified solely by clinical examination and must not be overdiagnosed. Overdiagnosis leading to incorrect treatment or overtreatment is the main cause of failure. Lateral epicondylitis is far more common. Injections of local anesthetic over the lateral epicondyle and more distally over the radial tunnel are helpful in differentiating between these two entities and in establishing the diagnosis. When the two conditions coexist and are unresponsive to nonoperative management, treatment of the lateral epicondylitis at the time of radial tunnel release is requisite for maximal postoperative relief of symptoms. Postoperatively, transitory but distressing partial paresis of the finger extensors may occur, but it resolves spontaneously in 6–12 weeks.

## SUPERFICIAL RADIAL NERVE COMPRESSION SYNDROME (CHEIRALGIA PARESTHETICA)

Compression neuropathy of the SBR was first described by Wartenberg in 1932 (143). He suggested that the condition be named cheiralgia paresthetica because of its similarity to the isolated involvement of the lateral cutaneous nerve of the thigh, which is called meralgia paresthetica.

### *Pathophysiology and Anatomy*

The radial nerve bifurcates just proximal to the elbow, in the interval between the brachioradialis and brachialis muscles. The superficial sensory branch continues toward the wrist under cover of the brachioradialis and medial to the ECRL muscle. It courses superficially to the supinator in the proximal forearm, and then to the PT insertion in the midforearm. In the distal third of the forearm, the nerve pierces the antebrachial fascia between the tendons of the brachioradialis and ECRL muscles. The nerve passes superficially to the extensor retinaculum and divides into terminal branches to provide cutaneous innervation to the dorsoradial aspect of the hand (Fig. 52.8).

When the forearm is in supination, the sensory branch lies deep to the fascia, without compression from the tendons of the brachioradialis and ECRL muscles. As the forearm pronates, the ECRL tendon crosses beneath the brachioradialis tendon in a scissors-like fashion, pinching or compressing the nerve (Fig. 52.64*A*). Palmar–ulnar deviation of the wrist places traction on the nerve (Fig. 52.64*B*). Repetitive traumatization of the nerve causes swelling, which inhibits its normal gliding through the fascia, leading to a traction injury (27).

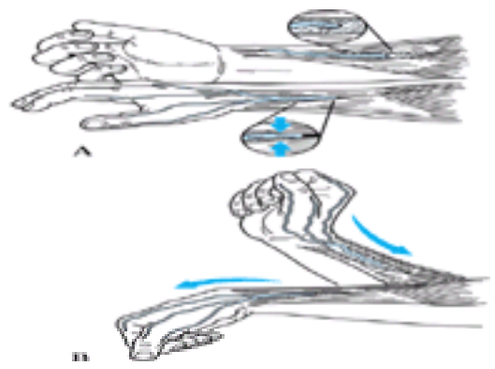

***Figure 52.64.*** **A:** Pronation of the forearm causes a pinching of the superficial branch of the radial nerve. **B:** Palmar–ulnar flexion of the wrist puts the superficial radial nerve in maximal traction. (From Dellon AL, MacKinnon SE. Radial Sensory Nerve Entrapment in the Forearm. *J Hand Surg [Am]* 1989;11:199, with permission.)

### *Assessment*

Usually, a history of repeated, job-related forearm pronosupination is given. Affected patients complain of pain, numbness, tingling, and dysesthesias over the dorsoradial aspect of the hand. Symptoms are brought on by wrist movement and are intensified when the patient makes a tight grip with the thumb and index finger. Nighttime awakening caused by symptoms is not common. Sensory examination reveals alterations in moving two-point and vibratory sensation. There is no motor dysfunction of radially innervated muscles, although grip and pinch strength may be decreased secondary to pain. Percussion along the course of the nerve, particularly as it emerges between the brachioradialis and ECRL tendons, produces paresthesias. Dellon and MacKinnon (27) described a provocative test for eliciting symptoms in which the patient is instructed to pronate the forearm with the elbow in extension. If within 30–60 seconds the symptoms of paresthesias or dysesthesias are evoked or exacerbated over the dorsal radial aspect of the hand, entrapment is confirmed (Fig. 52.65).

***Figure 52.65.*** The provocative test for entrapment of the superficial branch of the radial nerve, consisting of forced pronation of the forearm. (From Dellon AL, MacKinnon SE. Radial Sensory Nerve Entrapment in the Forearm. *J Hand Surg [Am]* 1989;11:199, with permission.)

The entity most commonly confused with superficial radial nerve entrapment is de Quervain's stenosing tendovaginitis of the first dorsal wrist compartment. Finklestein's test (i.e., pain on quick ulnar deviation of the hand with the patient's thumb grasped in the palm) is positive in both entities. The presence or absence of swelling over the first dorsal compartment, a nerve compression test over the course of the superficial radial nerve, and careful sensory testing are used to differentiate these two entities. Electrodiagnostic testing is rarely useful, although it often shows abnormalities in conduction velocity or amplitude (27). Injury to the LABC nerve as a source of the patient's symptoms must also be excluded because there is overlap in the innervation of the LABC and the SBR nerves in the mid and distal forearm in 75% of patients (27). Exclude it by performing serial blocks with local anesthetic. First block the LABC nerve at the lateral arm, then block the SBR at the site of suspected entrapment. Improvement in symptoms subsequent to the second injection but not the first implicates the SBR as the cause (Table 52.20).



***Table 52.20. Cheiralgia Paresthetica Summary***

### *Preoperative or Nonoperative Treatment*

Nonoperative treatment includes avoidance of pronosupination and radioulnar deviation of the wrist, splinting of the wrist with or without inclusion of the thumb and forearm, and NSAIDs. Physiotherapy, including tissue mobilization and nerve gliding exercises, steroid iontophoresis, and progressive gentle stretching, may be helpful. Administer steroid injections subfascially, and use them judiciously because of the potential for depigmentation of the skin and subcutaneous fat atrophy. Patients with long-term symptoms or onset of symptoms associated with a fracture or crush injury tend not to improve with nonoperative treatment.

### *Surgical Indications and Relative Results*

Failure to improve, or inadequate improvement, after prolonged nonoperative treatment is an indication for surgery.

In the series reported by Dellon and MacKinnon (27), pain relief was good or excellent in 86% of patients undergoing surgery. Of these patients, 43% returned to their regular jobs, 22% returned to modified work, and 35% remained disabled because of associated injuries. Objectively, marked improvement was noted in grip and pinch strength.

### *Operative Technique*

- Make an 8 cm curvilinear incision just volar to the mid-radial aspect of the radius, centered in relation to the point where the nerve pierces the antebrachial fascia (Fig. 52.66*A*). (The location of the positive Tinel's sign may also be used.) To prevent scarring about the nerve, avoid placing the incision directly over the nerve.

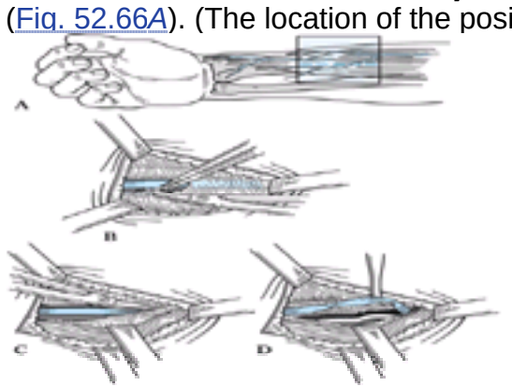

***Figure 52.66.*** Decompression of the superficial branch of the radial nerve. The incision (**A**) is represented by the *dashed line*. The fascia joining the brachioradialis and extensor carpi radialis longus (**B**) is divided distally (**C**) and proximally (**D**). The nerve is lying loosely in its bed, and the brachioradialis and ECRL are gliding independently. (From Dellon AL, MacKinnon SE. Radial Sensory Nerve Entrapment in the Forearm. *J Hand Surg [Am]* 1989;11:199, with permission.)

- Identify and protect cutaneous branches of the LABC nerve.
- Identify the SBR and the fascia between the BR and ECRL.
- Release the fascia joining the BR and ECRL distally out to the insertion of the BR (Fig. 52.66*B*).
- Release the fascia at least 6 cm proximal to the nerve (Fig. 52.66*C*).
- Ensure that the nerve lies loosely in the subcutaneous tissue and that the BR and ECRL glide independently without constriction of the SBR (Fig. 52.66*D*).
- Close the wound, and apply a bulky compression dressing with a volar splint.

### *Postoperative Care and Rehabilitation*

Remove the postoperative dressing after 7–10 days. We discourage splinting. Begin a home program of scar therapy and tissue mobilization. Encourage the patient to use the hand progressively in regular activities.

### *Complications*

As with the majority of compression neuropathies, accurate diagnosis and good surgical technique will prevent complications. You must differentiate between SBR entrapment and de Quervain's tendovaginitis by physical examination. If concomitant de Quervain's exists, treat it appropriately. Exclusion of entrapment of the LABC nerve by differential anesthetic blocks is also imperative. Avoid excessive handling of the nerve at surgery to prevent neuroma formation.

## LATERAL ANTEBRACHIAL CUTANEOUS NERVE COMPRESSION

### *Pathophysiology and Anatomy*

The LABC nerve is the terminal, sensory portion of the musculocutaneous nerve. Arising from the musculocutaneous nerve in the interval between the biceps and brachialis muscles, it continues distally under cover of the biceps muscle and then the lateral border of the biceps tendon to the elbow flexion crease. At this level, the nerve lies on top of the brachialis, lateral to the biceps and medial to the brachioradialis. It pierces the brachial fascia lateral to the biceps tendon. It divides into an anterior branch and a posterior branch, the former traveling with the cephalic vein to innervate the anterior surface of the radial forearm to the thenar eminence, and the latter continuing to innervate the radial and posterior aspect of the distal forearm to the wrist (Fig. 52.67). The anterior branch of the LABC nerve communicates with the superficial radial nerve above the wrist (8). Compression of the LABC nerve is rare but can occur where it emerges from beneath the lateral border of the biceps tendon just medial to the brachioradialis. The nerve is compressed between the brachialis fascia and the tendon of the biceps when the elbow is extended. Compression of the nerve can be further accentuated with pronation of the forearm (8,91).

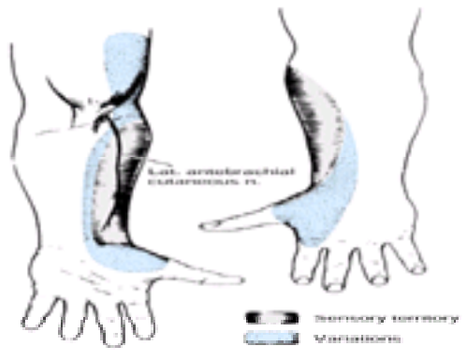


***Figure 52.67.*** Palmar and dorsal sensory innervation of the lateral antebrachial cutaneous (musculocutaneous) nerve. (From Nunley JA, Howson P. Lateral Antebrachial Nerve Compression. In: Szabo RM, ed. *Nerve Compression Syndromes: Diagnosis and Treatment.* Thorofare, NJ: Slack, 1989:201, with permission.)

### *Assessment*

Characteristically, the history includes repetitive, forceful exercise of the elbow in a position of extension. Patients complain of pain over the lateral aspect of the elbow on active motion of the elbow, with accompanying burning or numbness in the radial forearm. Examination reveals decreased sensibility distally along the radial aspect of the forearm. Elbow extension is limited with the forearm fully pronated. Point tenderness is found lateral to the biceps tendon at the elbow crease. Compression may be confirmed with sensory NCV studies measured between the elbow flexion crease and the axilla. A nerve block with local anesthetic that produces numbness along the nerve's cutaneous distribution and eliminates symptoms aids in the diagnosis. The nerve lies between the cephalic and median cubital veins 1.5 cm lateral to the biceps tendon, and the injection is best placed just distal to the cubital crease (Table 52.21).

| | |
|---|---|
| **Pathology** | |
| Compression of the LABC nerve between the brachioradialis and brachialis at the elbow | |
| **History** | |
| Repetitive forceful pronupination of the forearm and cocking of the elbow in a position of extension | |
| Acute hyperextension of elbow with forearm pronated | |
| **Symptoms** | |
| Burning pain at the lateral elbow, radiating proximally and distally | |
| Numbness along the volar radial border of the forearm | |
| Symptoms aggravated or induced by active motion of elbow | |
| Mild elbow flexion contracture | |
| **Sensory exam** | |
| Decreased sensibility along radial aspect of the forearm | |
| **Motor exam** | |
| No deficits | |
| **Provocative tests** | |
| Pain on repeated pronupination of the forearm | |
| Pain on passive extension of the elbow with full forearm pronation | |
| **Diagnostic studies** | |
| Sensory nerve conduction velocities slowed from axilla to elbow | |
| Diagnostic block of LABC results in numbness of radial forearm and achieves improvement of symptoms | |
| Radiographs of the elbow to evaluate articular pathology | |
| **Alternative diagnoses** | |
| Lateral epicondylitis | |
| Radial tunnel syndrome | |
| Entrapment of the sensory branch of the radial nerve | |
| Brachial neuritis | |
| Intracapitular elbow pathology | |

***Table 52.21. Lateral Antebrachial Cutaneous (LABC) Nerve Compression***

### *Preoperative or Nonoperative Management*

Conservative treatment initially consists of splinting and anti-inflammatory medication. If symptoms persist or worsen over the first few weeks, administer a local injection of corticosteroids around the nerve. Nonoperative treatment has limited success.

### *Surgical Indications and Relative Results*

Consider surgical decompression if symptoms do not resolve within 3 months.

Davidson et al. (22) reviewed 15 patients with a diagnosis of LABC nerve entrapment. Average follow-up was 13.4 years, with a minimum of 2 years. Eleven of these patients underwent surgical decompression. Of these, none had recurrence of hypesthesia, and all had complete relief of pain and full range of motion. One patient subsequently underwent release of the lateral epicondyle. Of the four patients who were treated nonoperatively, one had persistent hypesthesia but full range of motion and complete pain relief.

### *Preoperative Planning*

If surgery is planned, obtain radiographs of the elbow to rule out bony pathology. Examine the patient on more than one occasion to confirm consistent findings. Consider all extraarticular and intraarticular elbow conditions when evaluating the patient.

### *Operative Technique*

- Begin the incision proximal to the elbow flexion crease along the lateral border of the biceps muscle. Curve it laterally at the elbow flexion crease to head toward the radial tunnel. Do not cross the cubital flexion crease at right angles.
- Identify the LABC nerve 1.5 cm lateral to the tendon at the level of the medial condyle (Fig. 52.68*A*).

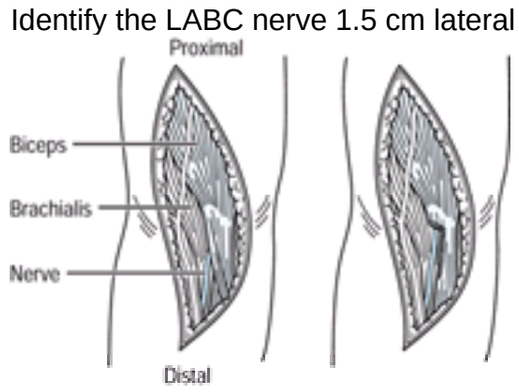


***Figure 52.68.*** **A:** The lateral antebrachial nerve emerging from beneath the lateral border of the biceps tendon. **B:** A wedge-shaped section taken out of the overlying biceps tendon to decompress the nerve. (From Nunley JA, Howson P. Lateral Antebrachial Nerve Compression. In: Szabo RM, ed. *Nerve Compression Syndromes: Diagnosis and Treatment.* Thorofare, NJ: Slack, 1989:201, with permission.)

- Trace the nerve proximally several centimeters.
- Demonstrate the area of entrapment by pronating the arm in extension. Look for flattening of the nerve and loss of vascular markings.
- Excise a triangular wedge of biceps tendon (1×3 cm) where the nerve is compressed by the edge of the biceps and the brachialis (Fig. 52.68*B*).
- Ensure that the decompression is complete by pronating and supinating the elbow while it is in extension.
- Apply a bulky dressing, and splint the elbow at 90° in neutral rotation.

### *Postoperative Care and Rehabilitation*

At 2–3 weeks postoperatively, remove the splint and allow full, unrestricted activity to tolerance.

## CHAPTER REFERENCES

Each reference is categorized according to the following scheme: *, classic article; #, review article; !, basic research article; and +, clinical results/outcome study.


+ 1. Adelaar R, Foster W, McDowell C. The Treatment of the Cubital Tunnel Syndrome. *J Hand Surg [Am]* 1984;9:90.

+ 2. Agee JM, McCarroll HR, Jr., Tortosa RD, et al. Endoscopic Release of the Carpal Tunnel: A Randomized Prospective Multicenter Study. *J Hand Surg [Am]* 1992;17:987.

+ 3. Amadio PC. Pyridoxine as an Adjunct in the Treatment of Carpal Tunnel Syndrome. *J Hand Surg [Am]* 1985;10:237.

# 4. Amadio PC. Carpal Tunnel Syndrome, Pyridoxine, and the Work Place. *J Hand Surg [Am]* 1987;12:875.

# 5. Amadio PC, Gabel GT. Treatment and Complications of Failed Decompression of the Ulnar Nerve at the Elbow. In: Gelberman RH, ed. *Operative Nerve Repair and Reconstruction.* Philadelphia: Lippincott, 1991:1107.

! 6. Apfelberg DB, Larson SJ. Dynamic Anatomy of the Ulnar Nerve at the Elbow. *Plast Reconstr Surg* 1973;51:76.

+ 7. Barnard LB, McCoy SM. The Supracondyloid Process of the Humerus. *J Bone Joint Surg* 1946;28:845.

+ 8. Bassett RH III, Nunley JA. Compression of the Musculocutaneous Nerve at the Elbow. *J Bone Joint Surg Am* 1982;64:1050.

+ 9. Bindra RR, Evanoff BA, Chough LY, et al. The Use of Routine Wrist Radiography in the Evaluation of Patients with Carpal Tunnel Syndrome. *J Hand Surg [Am]* 1997;22:115.

# 10. Botte MJ, Gelberman RH. Ulnar Nerve Compression at the Wrist. In: Szabo RM, ed. *Nerve Compression Syndromes—Diagnosis and Treatment.* Thorofare, NJ: Slack, 1989.

# 11. Brand PW, Hollister A. Transmission. In: Brand PW, Hollister A, eds. *Clinical Mechanics of the Hand*, 2nd ed. St. Louis, MO: Mosby Year Book, 1993:60.

+ 12. Braun R, Davidson K, Doehr S. Provocative Testing in the Diagnosis of Dynamic Carpal Tunnel Syndrome. *J Hand Surg [Am]* 1985;14:195.

! 13. Bromley GS. Minimal-incision Open Carpal Tunnel Decompression. *J Hand Surg [Am]* 1994;19:119.

+ 14. Bronson J, Beck J, Gillet J. Provocative Motor Nerve Conduction Testing in Presumptive Carpal Tunnel Syndrome Unconfirmed by Traditional Electrodiagnostic Testing. *J Hand Surg [Am]* 1997;22:1045.

+ 15. Brown MG, Keyser B, Rothenberg ES. Endoscopic Carpal Tunnel Release. *J Hand Surg [Am]* 1992;17:1009.

+ 16. Buchthal F, Rosenflack A, Trojaborg W. Electrophysiological Findings in Entrapment of the Median Nerve at Wrist and Elbow. *J Neurol Neurosurg Psychiatry* 1974;37:340.

+ 17. Buehler MJ, Thayer DT. The Elbow Flexion Test. *Clin Orthop* 1988;233:213.

# 18. Chidgey LK, Szabo RM. Anterior Interosseous Nerve Palsy. In: Szabo RM, ed. *Nerve Compression Syndromes: Diagnosis and Treatment.* Thorofare, NJ: Slack, 1989.

+ 19. Chidgey LK, Szabo RM, Wiese DA. Acute Carpal Tunnel Syndrome Caused by Pigmented Villonodular Synovitis of the Wrist. *Clin Orthop* 228:254-7, 1988.

+ 20. Childress HM. Recurrent Ulnar-nerve Dislocation at the Elbow. *Clin Orthop* 1975;108:168.

+ 21. Chow JCY. Endoscopic Release of the Carpal Ligament: A New Technique for Carpal Tunnel Syndrome. *Arthroscopy* 1989;5:19.

+ 22. Davidson JJ, Bassett FH, Nunley JA II. Musculocutaneous Nerve Entrapment Revisited. *J Shoulder Elbow Surg* 1998;7:250.

+ 23. Dellon AL. Tinel or Not Tinel? *J Hand Surg [Am]* 1984;9:216.

! 24. Dellon AL. Musculotendinous Variations about the Medial Humeral Epicondyle. *J Hand Surg [Br]* 1986;11:175.

+ 25. Dellon AL. Operative Technique for Submuscular Transposition of the Ulnar Nerve. *Contemp Orthop* 1988;16:17.

* 26. Dellon AL. Review of Treatment Results for Ulnar Nerve Entrapment at the Elbow. *J Hand Surg [Am]* 1989;14:689.

* 27. Dellon AL, MacKinnon SE. Radial Sensory Nerve Entrapment in the forearm. *J Hand Surg [Am]* 1986;11:199.

! 28. Dellon AL, MacKinnon SE. Musculoaponeurotic Variations along the Course of the Median Nerve in the Proximal Forearm. *J Hand Surg [Br]* 1987;12:359.

* 29. Durkan JA. A New Diagnostic Test for Carpal Tunnel Syndrome. *J Bone Joint Surg Am* 1991;73:535.

+ 30. Earl AS, Vlastou C. Crossed Fingers and Other Tests of Ulnar Nerve Motor Functions. *J Hand Surg* 1980;5:560.

* 31. Eaton RJ, Crowe JF, Parkes JC III. Anterior Transposition of the Ulnar Nerve with a Non-compressing Fasciodermal Sling. *J Bone Joint Surg Am* 1980;62:820.

+ 32. Eisen A, Danon J. The Mild Cubital Tunnel Syndrome. *Neurology* 1974;24:608.

# 33. Eversmann WW Jr. Entrapment and Compression Neuropathies. In: Green DP, ed. *Operative Hand Surgery.* New York: Churchill Livingstone, 1982.

! 34. Eversmann WW Jr, Ritsick JA. Intraoperative Changes in Motor Nerve Conduction Latency in Carpal Tunnel Syndrome. *J Hand Surg* 1978;3:77.

+ 35. Feinstein PA. Endoscopic Carpal Tunnel Release in a Community-based Series. *J Hand Surg [Am]* 1993;18:451.

+ 36. Forman DL, Watson HK, Caulfield KA, et al. Persistent or Recurrent Carpal Tunnel Syndrome Following Prior Endoscopic Carpal Tunnel Release. *J Hand Surg [Am]* 1998;23:1010.

! 37. Fuss FK, Wurzl GH. Radial Nerve Entrapment at the Elbow: Surgical Anatomy. *J Hand Surg* 1991;16:742.

* 38. Gainor BJ. The Pronator Compression Test Revisited: A Forgotten Physical Sign. *Orthop Rev* 1990;19:888.

# 39. Gelberman RH. Ulnar Tunnel Syndrome. In: Gelberman RH, ed. *Operative Nerve Repair and Reconstruction.* Philadelphia: Lippincott, 1991:1131.

+ 40. Gelberman R, Aronson D, Weisman M. Carpal Tunnel Syndrome: Results of a Prospective Trial of Steroid Injection and Splinting. *J Bone Joint Surg Am* 1980;62:1181.

! 41. Gelberman RH, Hergenroeder PT, Hargens AR, et al. The Carpal Tunnel Syndrome: A Study of Carpal Canal Pressures. *J Bone Joint Surg Am* 1981;63:380.

+ 42. Gelberman RH, Pfeffer GB, Galbraith RT, et al. Results of Treatment of Severe Carpal Tunnel Syndrome without Internal Neurolysis of the Median Nerve. *J Bone Joint Surg Am* 1987;69:896.

+ 43. Gellman H, Gelberman RH, Tan AM, Botte MJ. Carpal Tunnel Syndrome: An Evaluation of the Provocative Diagnostic Tests. *J Bone Joint Surg Am* 1986;68:735.

* 44. Gellman H, Kan D, Gee V, et al. Analysis of Pinch and Grip Strength after Carpal Tunnel Release. *J Hand Surg [Am]* 1989;14:863.

* 45. Green DP. Diagnostic and Therapeutic Value of Carpal Tunnel Injection. *J Hand Surg [Am]* 1984;9:850.

* 46. Gross MS, Gelberman RH. The Anatomy of the Distal Ulnar Tunnel. *Clin Orthop* 1985;196:238.

+ 47. Hartz CR, Linscheid RL, Gramse RR, Daube JR. The Pronator Teres Syndrome: Compressive Neuropathy of the Median Nerve. *J Bone Joint Surg Am* 1981;63:885.

+ 48. Heithoff SJ, Millender LH, Nalebuff EA, et al. Medial Epicondylectomy for the Treatment of Ulnar Nerve Compression at the Elbow. *J Hand Surg [Am]* 1990;15:22.

# 49. Hilburn JW. General Principles and Use of Electrodiagnostic Studies in Carpal and Cubital Tunnel Syndromes: With Special Attention to Pitfalls and Interpretation. *Hand Clin* 1996;12:205.

+ 50. Hill NA, Howard FM, Huffern BR. The Incomplete Anterior Interosseous Syndrome. *J Hand Surg [Am]* 1985;10:4.

# 51. Holmlund T. Electrodiagnosis and Neurologic Evaluation. In: Peimer CA, ed. *Surgery of the Hand and Upper Extremity.* New York: McGraw-Hill, 1996:1277.

+ 52. Howard FM. Ulnar Nerve Palsy in Wrist Fractures. *J Bone Joint Surg Am* 1961;43:1197.

+ 53. Hulsizer DL, Staebler MP, Weiss A-PC, Akelman E. The Results of Revision Carpal Tunnel Release Following Previous Open versus Endoscopic Surgery. *J Hand Surg [Am]* 1998;23:865.

# 54. Hynes DE, Peimer CA. Compression Neuropathies: Radial. In: Peimer CA, ed. *Surgery of the Hand and Upper Extremity.* New York: McGraw-Hill, 1996:1291.

! 55. Inserra S, Spinner M. An Anatomic Factor Significant in Transposition of the Ulnar Nerve. *J Hand Surg [Am]* 1986;11:80.

# 56. Iyer VG. Understanding Nerve Conduction and Electromyographic Studies. *Hand Clin* 1993;9:273.

# 57. Jebson PJL, Engber WD. Radial Tunnel Syndrome: Long-term Results of Surgical Decompression. *J Hand Surg [Am]* 1997;22:889.

# 58. Johnson RK, Spinner M. Median Nerve Compression in the Forearm: The Pronator Tunnel Syndrome. In: Szabo RM, ed. *Nerve Compression Syndromes: Diagnosis and Treatment.* Thorofare, NJ: Slack, 1989.

* 59. Johnson RK, Spinner M, Shrewsbury MM. Median Nerve Entrapment Syndrome in the Proximal Forearm. *J Hand Surg* 1979;4:48.

+ 60. Kaempffe FA, Farbach BA. A Modified Surgical Procedure for Cubital Tunnel Syndrome: Partial Medial Epicondylectomy. *J Hand Surg [Am]* 1998;23:492.

! 61. Kane E, Kaplan EB, Spinner M. Observations of the Course of the Ulnar Nerve in the Arm. *Ann Chir* 1973;27:487.

! 62. Kerr CD, Sybert DO, Albarracin NS. An Analysis of the Flexor Synovium in Idiopathic Carpal Tunnel Syndrome: Report of 625 Cases. *J Hand Surg [Am]* 1992;17:1028.

+ 63. Kleinman WB, Bishop AT. Anterior Intramuscular Transposition of the Ulnar Nerve. *J Hand Surg [Am]* 1989;14:972.

+ 64. Kupfer DM, Bronson J, Lee GW, et al. Differential Latency Testing: A More Sensitive Test for Radial Tunnel Syndrome. *J Hand Surg [Am]* 1998;23:859.

# 65. Kuschner S, Ebramzadeh E, Johnson D, et al. Tinel's Sign and Phalen's Test in Carpal Tunnel Syndrome. *Orthopedics* 1992;15:1297.

* 66. Learmonth JR. A Technique for Transplanting the Ulnar Nerve. *Surg Gynecol Obstet* 1942;75:792.

+ 67. Lee KE. Tuberculosis Presenting as Carpal Tunnel Syndrome. *J Hand Surg [Am]* 1985;10:242.

+ 68. Lee WPA, Plancher KD, Strickland JW. Carpal Tunnel Release with a Small Palmar Incision. *Hand Clin* 1996;12:271.

+ 69. Leffert RD. Anterior Submuscular Transposition of the Ulnar Nerve by the Learmonth Technique. *J Hand Surg* 1982;7:147.

+ 70. Lister GD, Belsole RB, Kleinert HE. The Radial Tunnel Syndrome. *J Hand Surg [Am]* 1979;4:52.

+ 71. Lowry WE, Follender AB. Interfascicular Neurolysis in the Severe Carpal Tunnel Syndrome. A Prospective, Randomized, Double-blind, Controlled Study. *Clin Orthop* 1988;227:251.

# 72. Lundborg G, Dahlin LB. Pathophysiology of Nerve Compression. In: Szabo RM, ed. *Nerve Compression Syndromes: Diagnosis and Treatment.* Slack, NJ: Thorofare, 1989.

+ 73. MacKinnon SE, McCabe S, Murray JF, et al. Internal Neurolysis Fails to Improve the Results of Primary Carpal Tunnel Decompression. *J Hand Surg [Am]* 1991;16:211.

+ 74. Mangini U. Flexor Pollicis Longus Muscle: Its Morphology and Clinical Significance. *J Bone Joint Surg Am* 1960;42:467.

+ 75. Manske PR. Compression of the Radial Nerve by the Triceps Muscle. Case Report. *J Bone Joint Surg Am* 1977;59:835.

+ 76. Marmor L, Lawrence JF, Dubois EL. Posterior Interosseous Nerve Palsy Due to Rheumatoid Arthritis. *J Bone Joint Surg Am* 1967;49:381.

+ 77. Mass DP, Tortosa R, Newmeyer W, et al. Compression of Posterior Interosseous Nerve by a Ganglion—A Case Report. *J Hand Surg [Am]* 1982;7:92.

+ 78. Millender LH, Nalebuff EA, Holdsworth DE. Posterior Interosseous Nerve Syndrome Secondary to Rheumatoid Synovitis. *J Bone Joint Surg Am* 1973;55:375.

+ 79. Mody BS. A Simple Clinical Test to Differentiate Rupture of Flexor Pollicis Longus and Incomplete Anterior Interosseous Paralysis. *J Hand Surg [Br]* 1992;17:510.

+ 80. Morris AH. Irreducible Monteggia Lesion with Radial-nerve Entrapment. A Case Report. *J Bone Joint Surg Am* 1974;56:1744.

+ 81. Murphy Jr RX, Allentown PA, Jennings JF, et al. Major Neurovascular Complications of Endoscopic Carpal Tunnel Release. *J Hand Surg [Am]* 1994;19:114.

! 82. Nakamichi K, Shinatro T. Histology of the Transverse Carpal Ligament and Flexor Tenosynovium in Idiopathic Carpal Tunnel Syndrome. *J Hand Surg [Am]* 1998;23:1015.

! 83. Nathan PA, Keniston RC, Lockwood RS, Meadows KD. Tobacco, Caffeine, Alcohol and CTS in American Industry. A Cross Sectional Study of 1464 Workers. *J Occup Environ Med* 1996;38:290.

! 84. Nathan P, Keniston R, Myers L, et al. Obesity as a Risk Factor for Impaired Sensory Conduction of the Median Nerve in Industry: A Cross-sectional and Longitudinal Study Involving 429 Workers. *J Occup Med* 1992;34:117.

! 85. Nathan PA, Keniston RC, Myers LD, Meadows KO. Obesity as a Risk Factor for Slowing of Sensory Conduction of the Median Nerve in Industry. A Cross Sectional and Longitudinal Study Involving 429 Workers. *J Occup Med* 1992;34:379.

+ 86. Nathan P, Meadows K, Keniston R. Rehabilitation of Carpal Tunnel Surgery Patients Using a Short Surgical Incision and an Early Program of Physical Therapy. *J Hand Surg [Am]* 1993;18:1044.

+ 87. Nolan III WB, Alkaitis D, Glickel SZ, Snow S. Results of Treatment of Severe Carpal Tunnel Syndrome. *J Hand Surg [Am]* 1992;17:1020.

# 88. North ER, Kaul MP. Compression Neuropathies: Median. In: Peimer CA, ed. *Surgery of the Hand and Upper Extremity.* New York: McGraw-Hill, 1996:1307.

+ 89. Nouhan R, Kleinert JM. Ulnar Nerve Decompression by Transposing the Nerve and Z-Lengthening the Flexor-Pronator Mass: Clinical Outcome. *J Hand Surg [Am]* 1997;22;127.

! 90. Novak CB, Lee GW, Mackinnon SE, et al. Provocative Testing for Cubital Tunnel Syndrome. *J Hand Surg [Am]* 1994;19:817.

# 91. Nunley JA, Howson P. Lateral Antebrachial Nerve Compression. In: Szabo RM, ed. *Nerve Compression Syndromes: Diagnosis and Treatment.* Thorofare, NJ: Slack, 1989:201.

! 92. O'Driscoll SW, Horii E, Carmichael SW, Morrey BF. The Cubital Tunnel and Ulnar Neuropathy. *J Bone Joint Surg Br* 1991;73:613.

+ 93. Ogino T, Minami A, Kato H. Diagnosis of Radial Nerve Palsy Caused by Ganglion with Use of Different Imaging Techniques. *J Hand Surg [Am]* 1991;16:230.

+ 94. Okutsu I, Niromiya S, Takatori Y, Ugawa Y. Endoscopic Management of Carpal Tunnel Syndrome. *Arthroscopy* 1989;5:11.

+ 95. Olehnik WK, Manske PR, Szerzinski J. Median Nerve Compression in the Proximal Forearm. *J Hand Surg [Am]* 1994;19:121.

+ 96. Omer GE. Median Nerve Compression at the Wrist. *Hand Clin* 1992;8:317.

# 97. Peimer CA, Wheeler DR. Radial Tunnel Syndrome/Posterior Interosseous Nerve Compression. In: Szabo RM, ed. *Nerve Compression Syndromes: Diagnosis and Treatment.* Thorofare, NJ: Slack, 1989:177.

+ 98. Purnell D, Daly D, Lipscomb P. Carpal Tunnel Syndrome Associated with Myxedema. *Arch Intern Med* 1961;108:751.

+ 99. Pribyl CR, Robinson B. Use of the Medial Intermuscular Septum as a Fascial Sling During Anterior Transposition of the Ulnar Nerve. *J Hand Surg [Am]* 1998;23:500.

+ 100. Raimbeau G, Saint-Cast Y, Pelier-Cady MC. Syndrome du Tunnel Radial: Etude d'une Série Homogène et Continue de 35 Cas. *Rev Chir Orthop* 1990;76:177.

! 101. Rayan GM, Jensen C, Duke J. Elbow Flexion Test in the Normal Population. *J Hand Surg [Am]* 1992;17:86.

! 102. Richman J, Gelberman R, Rydevik B, et al. Morphologic Changes after Release of the Transverse Carpal Ligament. *J Hand Surg [Am]* 1989;14:852.

+ 103. Richmond DA. Lipoma Causing a Posterior Interosseous Branch of the Radial Nerve Lesion. *J Bone Joint Surg Br* 1953;35:83.

+ 104. Richmond J, Southmayd W. Superficial Anterior Transposition of the Ulnar Nerve at the Elbow for Ulnar Neuritis. *Clin Orthop* 1982;164:42.

+ 105. Ritts GD, Wood MB, Linscheid RL. Radial Tunnel Syndrome: A 10 Year Surgical Experience. *Clin Orthop* 1987;219:201.

+ 106. Rogers MR, Bergfield TG, Aulicino PL. The Failed Ulnar Nerve Transposition: Etiology and Treatment. *Clin Orthop* 1991;269:193.

* 107. Roles NC, Maudsley RH. Radial Tunnel Syndrome: Resistant Tennis Elbow as a Nerve Entrapment. *J Bone Joint Surg Br* 1972;54:499.

! 108. Rotman MB, Manske PR. Anatomic Relationships of an Endoscopic Carpal Tunnel Device to Surrounding Structures. *J Hand Surg [Am]* 1993;18:442.

! 109. Rowntree T. Anomalous Innervation of the Hand Muscles. *J Bone Joint Surg Br* 1949;31:505.

! 110. Scroggin JF, Whipple TL. A Potential Complication of Endoscopic Carpal Tunnel Release. *Arthroscopy* 1992;8:363.

! 111. Seiler JG, Barnes K, Gelberman RH, Chalidapong P. Endoscopic Carpal Tunnel Release: An Anatomic Study of the Two-Incision Method in Human Cadavers. *J Hand Surg [Am]* 1992;17:996.

+ 112. Seradge H. Cubital Tunnel Release and Medial Epicondylectomy: Effect of Timing of Mobilization. *J Hand Surg [Am]* 1997;22:863.

+ 113. Seradge H, Seradge E. Piso-Triquetral Pain Syndrome after Carpal Tunnel Release. *J Hand Surg [Am]* 1989;14:858.

+ 114. Seradge H, Willis O. Cubital Tunnel Release with Medial Epicondylectomy Factors Influencing the Outcome. *J Hand Surg [Am]* 1998;23;483.

+ 115. Seyffarth H. Primary Myoses in the M. Pronator Teres as Cause of Lesion of the N. Medianus (the Pronator Syndrome). *Acta Psychiatr Neurol* 1951;74(suppl):251.

+ 116. Shea JD, McClain EJ. Ulnar-Nerve Compression Syndromes at and Below the Wrist. *J Bone Joint Surg Am* 1969;51:1095.

+ 117. Silver MA, Gelberman RH, Gellman H, Rhoades CE. Carpal Tunnel Syndrome: Associated Abnormalities and Ulnar Nerve Function and the Effect of Carpal Tunnel Release on These Abnormalities. *J Hand Surg [Am]* 1985;10:710.

+ 118. Spinner M. The Arcade of Frohse and Its Relationship to Posterior Interosseous Nerve Paralysis. *J Bone Joint Surg Br* 1968;50:809.

+ 119. Spinner M. The Functional Attitude of the Hand Afflicted with an Anterior Interosseous Nerve Paralysis. *Bull Hosp Joint Dis* 1969;30:21.

# 120. Spinner M. Injuries to the Major Branches of Peripheral Nerves of the Forearm. Philadelphia: Saunders, 1972.

# 121. Spinner M. Injuries to the Major Branches of Peripheral Nerves of the Forearm, 2nd ed. Philadelphia: Saunders, 1978.

# 122. Spinner M. Management of Nerve Compression Lesions of the Upper Extremity. In: Omer GE, Spinner M, eds. *Management of Peripheral Nerve Problems.* Philadelphia: Saunders, 1980:562.

123. Stedman's Medical Dictionary, 24th ed. Baltimore: Williams & Wilkins, 1982:1382.

# 124. Sunderland S. *Nerves and Nerve Injuries.* Baltimore: Williams & Wilkins, 1968.

# 125. Sunderland S. The Nerve Lesion in the Carpal Tunnel Syndrome. *J Neurol Neurosurg Psychiatry* 1976;39:615.

# 126. Szabo RM. Carpal Tunnel Syndrome. In: Szabo RM, ed. *Nerve Compression Syndromes: Diagnosis and Treatment.* Thorofare, NJ: Slack, 1989:101.

# 127. Szabo RM. Median Nerve Compression: Distal. In: Gelberman RH, ed. *Operative Nerve Surgery*. Philadelphia: Lippincott, 1991.

# 128. Szabo RM. Nerve Compression Syndromes. In: Manske PR, ed. *Hand Surgery Update.* Rosemont, IL: American Academy of Orthopaedic Surgeons, 1996.

# 129. Szabo RM. Occupational Carpal Tunnel Syndrome. In: Kasdan ML, ed. *Occupational Hand and Upper Extremity Injuries and Diseases*, 2nd ed. Philadelphia: Hanley and Belfus, 1998:113.

! 130. Szabo R, Chidgey L. Stress Carpal Tunnel Pressures in Patients with Carpal Tunnel Syndrome and Normal Patients. *J Hand Surg [Am]* 1989;14:624.

! 131. Szabo RM, Gelberman RH. Peripheral Nerve Compression—Etiology, Critical Pressure Threshold and Clinical Assessment. *Orthopedics* 1984;7:1461.

# 132. Szabo RM, Gelberman RH. The Pathophysiology of Nerve Entrapment Syndromes. *J Hand Surg [Am]* 1987;12:880.

+ 133. Szabo RM, Gelberman RH, Dimick MP. Sensibility Testing in Patients with Carpal Tunnel Syndrome. *J Bone Joint Surg Am* 1984;66:60.

! 134. Szabo RM, Gelberman RH, Williamson RV, et al. Vibratory Sensory Testing in Acute Peripheral Nerve Compression. *J Hand Surg [Am]* 1984;9:104.

! 135. Taleisnik J. The Palmar Cutaneous Branch of the Median Nerve and the Approach to the Carpal Tunnel. An Anatomical Study. *J Bone Joint Surg Am* 1973;55:1212.

# 136. Taleisnik J. *ASSH Newsletter 1998-128*. American Society for Surgery of the Hand, 1998; June 8.

* 137. Upton ARM, McComas AJ. The Double Crush in Nerve Entrapment Syndromes. *Lancet* 1973;1:359.

+ 138. Urbaniak JR, Desai SS. Complications of Nonoperative and Operative Treatment of Carpal Tunnel Syndrome. *Hand Clinics* 1996;12:325.

+ 139. Van Heest AE, House J, Krivit W, Walker K. Surgical Treatment of Carpal Tunnel Syndrome and Trigger Digits in Children with Mucopolysaccharide Storage Disorders. *J Hand Surg [Am]* 1998;23:236.

+ 140. Vance RM, Gelberman RH. Acute Ulnar Neuropathy with Fractures at the Wrist. *J Bone Joint Surg Am* 1978;60:962.

+ 141. Verhaar J, Spaans F. Radial Tunnel Syndrome: An Investigation of Compression Neuropathy as a Possible Cause. *J Bone Joint Surg Am* 1991;73:539.

+ 142. Viegas SF, Pollard A, Kaminski K. Carpal Arch Alteration and Related Clinical Status after Carpal Tunnel Release. *J Hand Surg [Am]* 1992;17:1012.

* 143. Wartenberg R. Cheiralgia Paresthetica (Isolierte Neuritis des Ramus Superficialis Nervi Radialis). *Z Gesamte Neurol Psychiatr* 1932;141:145.

+ 144. Weirich SD, Gelberman RH, Best SA, et al. Rehabilitation after Subcutaneous Transposition of the Ulnar Nerve: Immediate Versus Delayed Mobilization. *J Shoulder Elbow Surg* 1998;7:244.

+ 145. Weiss A-PC. Synovial Sarcoma Causing Carpal Tunnel Syndrome. *J Hand Surg [Am]* 1992;17:1024.

+ 146. Werner C-O. Lateral Elbow Pain and Posterior Interosseous Nerve Entrapment. *Acta Orthop Scand Suppl* 1979;174:1.

! 147. White SH, Goodfellow JW, Mowat A. Posterior Interosseous Nerve Palsy in Rheumatoid Arthritis. *J Bone Joint Surg Br* 1988;70:468.

+ 148. Wilson DH, Krout R. Surgery of Ulnar Neuropathy at the Elbow: 16 Cases Treated by Decompression without Transposition. Technical Note. *J Neurosurg* 1973;38:780.

+ 149. Wong L, Dellon AL. Brachial Neuritis Presenting as Anterior Interosseous Nerve Compression—Implications for Diagnosis and Treatment: A Case Report. *J Hand Surg [Am]* 1997;22:536.

# CHAPTER 53

# NEUROMAS

*Alan E. Freeland*

**A. E. Freeland:** Department of Orthopaedic Surgery and Rehabilitation, University of Mississippi Medical Center, Jackson, Mississippi, 39216.

Histology
Classification (Sunderland)
Pathophysiology of Neuroma Pain
Diagnosis
Treatment
Nonsurgical Treatment
Surgical Techniques
Postoperative Care and Rehabilitation
Outcomes
Pitfalls and Complications
Chapter References

After nerve injury, the regenerating axons proximal to the injury site seek to grow and reestablish contact with their respective end organs. Continuity or repair of the Schwann cell endoneurial tube aids this process. Regenerating axons that do not grow through the zone of injury and into the distal segment of endoneurial tube become encased in scar and constitute a *forme frustre* of peripheral nerve regeneration.

The resulting nodule formed within the zone of injury in an intact crushed or stretched nerve, or in the terminal end of the proximal segment of a lacerated nerve, is called a *neuroma.* The neuroma is usually well circumscribed, white, and rubbery or firm in consistency. It may adhere to adjacent scar, skin, muscle, fascia, tendon, periosteum, or bone.

All peripheral nerves form neuromas in response to injury, but only neuromas containing sensory nerve fibers can be symptomatic. The digital nerves of the hand, the palmar and ulnar cutaneous nerves, and the dorsal sensory branches of the radial and ulnar nerves are pure sensory nerves and are especially prone to form painful neuromas. As many as 30% of neuromas formed by these nerves become symptomatic (7). Common digital nerves in ray amputations appear more inclined to be painful than those of digital amputations, possibly because the former contain more sensory fibers.

## HISTOLOGY

Microscopically, a neuroma is a neural swelling consisting of randomly directed axons in a matrix of proliferative mesothelial elements, primarily epineurium and endoneurium. There is a disorganized mixture of axons with a predominance of small-diameter unmyelinated fibers, frequently in whorl-type patterns surrounded by Schwann cells, fibroblasts, collagen, macrophages, and capillaries. Myofibroblasts have been consistently identified by electron microscopy in painful neuromas. These cells may serve as histologic markers of a symptomatic neuroma, but their pathophysiologic role remains undetermined (1,5).

## CLASSIFICATION (SUNDERLAND)

Sunderland classified neuromas into three major categories (Table 53.1): neuroma-in-continuity; neuromas in completely severed, unrepaired nerves; and amputation stump neuromas (28). Neuromas-in-continuity include those with intact perineurium, those with partial nerve division, and those that form after nerve repair or grafting.

I. Neuroma-in-continuity
   A. Perineurium intact
   B. Partial nerve division
   C. After nerve repair or grafting
II. Neuromas in completely severed and unrepaired nerves
III. Amputation stump neuromas

From Sunderland S. *Nerves and Nerve Injuries*, 2nd ed. New York: Churchill Livingstone, 1978:188, with permission.

***Table 53.1. Classification (Sunderland)***

## PATHOPHYSIOLOGY OF NEUROMA PAIN

The central perception of pain from neuromas is transmitted by afferent small unmyelinated C and A delta fibers. This picture is sometimes confounded by the involvement of additional adjacent afferent axons contained within the same sensory nerve (Table 53.2). Afferent impulses are biochemically mediated and may occur spontaneously or be triggered physically (Table 53.3). In the gate theory of pain, nociceptors do not appear to override other nociceptors, whereas touch or pressure may do so. Proximity of a neuroma to skin, to bony prominences, and to the working surface (palm) of the hand renders it more vulnerable to mechanical impulses (19,26,31).

| *Central pain perception* | |
|---|---|
| *Nociceptors* | *Type of Pain Mediated* |
| Small unmyelinated C fibers | Neuroma |
| Small unmyelinated A delta fibers | Neuroma |
| Sympathetic fibers | Sympathetic-mediated chronic pain |
| Larger unmyelinated A beta fibers | Hyperpathic pain |
| Various | Other sympathetically independent chronic pain |

From Mackinnon SE, Evaluation and Treatment of the Painful Neuroma. *Tech Hand Upper Extrem Surg* 1997;1:198; Meyer RA, Raja SN, Campbell JN, et al. Neural Activity Originating from a Neuroma in the Baboon. *Brain Res* 1983;312:335; Sunil M. Centrocentral Anastomosis of Peripheral Nerves. A Neurosurgical Treatment of Amputation Neuromas. In: Siegfried J, Zimmerman M, eds. *Phantom and Stump Pain*. New York: Springer-Verlag, 1981:121; and Wall PD, Gecik M. Properties of Afferent Nerve Impulses Originating from a Neuroma. *Nature* 1974;248:740, with permission.

***Table 53.2. Pathophysiology of Neuroma Pain***

| |
|---|
| Spontaneous impulses |
| Neurohormonal influences on sensory end organs |
| Mechanical impulses (touch and pressure) |
| Stretch |
| Impact |
| Compression |
| Temperature |
| Cold/damp |
| Ephaptic impulses (cross-talk) |
| Sympathetic (epinephrine/norepinephrine) |

From Mackinnon SE. Evaluation and Treatment of the Painful Neuroma. *Tech Hand Upper Extrem Surg* 1997;1:195; Meyer RA, Raja SN, Campbell JN, et al. Neural Activity Originating from a Neuroma in the Baboon. *Brain Res* 1985;325:255; Sunii M. Centrocentral Anastomosis of Peripheral Nerves. A Neurosurgical Treatment of Amputation Neuromas. In: Siegfried J, Zimmerman M, eds. *Phantom and Stump Pain*. New York: Springer-Verlag, 1981:123; and Wall PD, Gutnik M. Properties of Afferent Nerve Impulses Originating from a Neuroma. *Nature* 1974;248:740, with permission.

***Table 53.3. Biochemically Mediated Afferent Impulses***

There may be a genetic or sex-related (hormonal) predisposition to heightened pain sensitivity and perception. Psychosocial factors may also play a variable role in the perception and expression of pain. Such factors include individual personality, pain tolerance, and secondary gain. These elements may be difficult to sort out and may confound diagnosis, treatment, and outcome.

Although symptomatic neuromas alone can be dis-abling, a diathesis similar to that seen in patients who develop chronic regional complex pain occurs more frequently than expected by chance alone. Symptomatic neuromas of the hand may be complicated by sympathetically or independently mediated pain. There may be combinations of pain involvement (see Table 53.2, Table 53.6). Pain patterns are often refractory to treatment until the noxious stimulation of the nociceptors is eliminated. Chronicity may lead to dystrophic tissue changes. The impairment and consequent outcome of a symptomatic neuroma are worsened by the complexity of such additional afferent nerve fiber involvement.

| *Discriminator* | *Neuroma* | *Complex Regional Chronic Pain* | |
|---|---|---|---|
| | | *SMCP* | *SICP* |
| Tinel's sign | Localized | Nonlocalized | Nonlocalized |
| Pain distribution | Anatomic (peripheral nerve) | Nonanatomic (global) | Nonanatomic (global) |
| Pain characterization* | Well characterized (< 3 descriptors) | Poorly characterized (> 3 descriptors) | |
| Sympathetic block | No effect | Pain relief | No effect |
| Peripheral nerve block | Pain relief | Pain relief | No effect or worse |
| Pain rating scale* | < 15 | > 15 | > 15 |
| MMPI* | Normal | Abnormal | Abnormal |

SMCP, sympathetically mediated chronic pain; SICP, sympathetically independent chronic pain; MMPI, Minnesota Multiphasic Personality Inventory.
* From Mackinnon SE. Evaluation and Treatment of the Painful Neuroma. *Tech Hand Upper Extrem Surg* 1997;1:195, with permission.

***Table 53.6. Relating Diagnostic Discriminators to Pain Type, Etiology, and Pathophysiology***

## DIAGNOSIS

Patients who form symptomatic neuromas have a focus of burning, aching pain, strongest at the site of the nerve injury (Table 53.4). The pain may radiate peripherally in the sensory distribution of the injured nerve, or proximally in the distribution of the nerve trunk. A dysesthetic “trigger area” found in the same site may radiate pain peripherally in the distribution of the injured nerve on percussion. This pain is equivalent to a nonadvancing Tinel's sign and may be called a *neuroma sign.*

| |
|---|
| Pain (neuroma sign—nonadvancing dysesthetic “trigger area” to percussion) |
| Pain well localized in the distribution of the involved peripheral nerve |
| Burning/aching pain is highly characteristic. |
| Pain is relieved by peripheral nerve block. |

***Table 53.4. Diagnosis of Neuroma***

Relief of these symptoms with an injection of a local anesthetic helps to confirm the diagnosis. Often there is corresponding sensory deficiency or loss. The history, physical examination, peripheral and sympathetic nerve blocks, and standardized pain and psychosocial analysis in various combinations aid in establishing the diagnosis, sorting out confounding factors, and predicting outcome.

## TREATMENT

Iatrogenic sensory nerve injury may be unavoidable. Knowledge of sensory nerve anatomy in the hand and digits helps to minimize such injuries. In both traumatic and iatrogenic lacerations, careful identification of transected nerve ends and their repair at the time of primary wound treatment improves the likelihood of functional nerve recovery and decreases the risk of symptomatic neuroma formation. In cases of segmental nerve injury with an identifiable and reparable distal end, and in a clean and adequately vascularized bed, nerve grafting accomplishes the same goals. In instances where nerve repair or reconstruction is not possible and in some amputations, painful neuromas may develop. The signs are identifiable early, and prompt treatment is usually more effective than later measures.

### NONSURGICAL TREATMENT

Nonsurgical measures are more likely to succeed when a painful neuroma is mild and is treated early. Medications, therapy, physical modalities, and consultation with a pain management specialist may be helpful (Table 53.5). If injections of the neuroma are used, adding triamcinolone acetate to the injection solution may produce a collagenase effect and soften adjacent scar sufficiently to be curative or palliative in some cases (23). Use as much as 10 mg of triamcinolone acetate (i.e., a 10 mg/ml concentration diluted 1:1 or more with 1% lidocaine) and repeat three times at 1- to 3-week intervals as needed. Advise patients that depigmentation of the skin and atrophy of the subcutaneous fat may accompany triamcinolone injection (15).

| |
|---|
| These treatments can be used individually, in sequence, or in combination: |
| Desensitization |
| Steroids |
| Oral (Medrol dose pak) |
| Injection (steroid diluted 1 : 1 or more with local anesthetic; up to 3 times at 1–3-week intervals)[a] |
| Oral medications for neuropathic pain |
| Neurontin |
| Elavil |
| Tegretol |
| TENS unit |
| Bretylium + steroid regional Bier block[b] |

Note: Consultation with a pain specialist may be necessary.
TENS, transcutaneous electrical nerve stimulation.
[a] From Tada K, Nakashima H, Yoshida T, Kitano K. A New Treatment of Painful Amputation Neuroma. A Preliminary Report. *J Hand Surg* 1987;12B:273, with permission.
[b] From Karvela O, Niemmen S. Treatment of Painful Neuromas with Neurolytic Blockade. *Pain* 1990;41:161, with permission.

***Table 53.5. Nonoperative Treatment***

Although inhibition of neuroma formation has been demonstrated histologically after application of triamcinolone on a freshly severed nerve, there is no histologic response to the application of this steroid in the chronic neuroma. The reason for improvement or resolution of neuroma pain after steroid injection in the chronic neuroma remains unclear. The use of collagenase inhibitors and gangliocidal agents on freshly cut nerve ends is an area of ongoing investigation that may have future clinical impact (3).

## SURGICAL TECHNIQUES

Operative intervention for symptomatic neuromas is indicated after confirmation of the diagnosis by injection of local anesthetic and when physical measures such as desensitization and injection with triamcinolone acetate fail to provide relief. The more clearly the diagnostic discriminators demonstrate a pure neuroma pain picture, the better are the outcome expectations following surgery (Table 53.6).

### *Neurorrhaphy and Nerve Grafting*

It is easier to prevent symptomatic neuromas than to heal them. Take particular care when operating in the vicinity of the major sensory nerves of the hand, in excision of ganglions. Other tricky surgeries include decompression of de Quervain's stenosing tenosynovitis of the first dorsal compartment, carpal tunnel decompression, palmar fasciotomy or fasciectomy for Dupuytren's disease, $A_1$ pulley release for trigger digits, and tendon repair and reconstruction.

For optimal recovery, posttraumatic and iatrogenic transections of the nerves should be identified and repaired early whenever possible. Secondarily identified lacerations may merit nerve grafting if direct suture cannot be performed (6). In either instance, the preferred treatment for prevention of painful neuromas is to restore the continuity of the nerve, allowing successful axonal regeneration across the injury site.

Current investigations with neurotrophic hormones, electric current, a variety of artificial (e.g., polyglycolic acid, collagen-filled) and autogenous (e.g., vein and muscle) conduits, and the use of nerve allografts with immunosuppressors may soon play a larger, more definitive role in secondary neuroma treatment by means of nerve reconstruction (19,20). Neurovascular island flaps and toe–hand transfers have been successful for management of refractory digital neuromas when the distal portion of the involved nerve is not available, when sensory restoration is important, and in the reconstruction of an amputated digit (17,27).

### *Decompression and Translocation*

Consider decompression of the nerve if a neuroma-in-continuity forms with the intact perineurium as a result of repetitive or cumulative trauma (e.g., bowler's, jeweler's, or surgeon's thumb) and does not respond to nonsurgical measures. A neurolysis may be performed and the perineural sleeve of scar removed. In some instances, the nerve may be translocated intact, deep to muscle such as the thumb abductor or a lumbrical muscle in the palm (Fig. 53.1) (14).

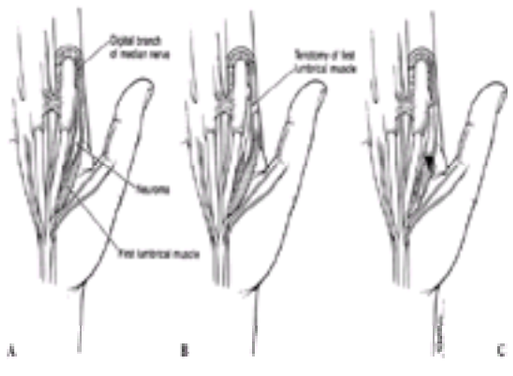


***Figure 53.1.*** Submuscular transposition. **A:** Exposing the radial digital neuroma. **B:** Division of the lumbrical muscle. **C:** Mobilization of the lumbrical muscle and digital nerve.

- Expose the radial digital neuroma at the base of the index fingers adjacent to the lumbrical muscle.
- Divide the lumbrical muscle near its insertion.
- Mobilize the lumbrical muscle and digital nerve.
- Translocate the digital nerve beneath the muscle.
- Reapproximate the muscle insertion by suture.
- The lumbrical muscle now overlies and protects the neuroma-in-continuity.

Translocation methods may also have merit in the treatment of chronic symptomatic Sunderland type II neuromas.

### *Simple Excisional Neurectomy*

After digital amputation, traditional recommendations are that each digital nerve end be identified, mobilized, and placed under gentle tension, and that the sharply divided end be allowed to retract 6–10 mm into healthy tissue proximal to the amputation stump (Fig. 53.2) (30).

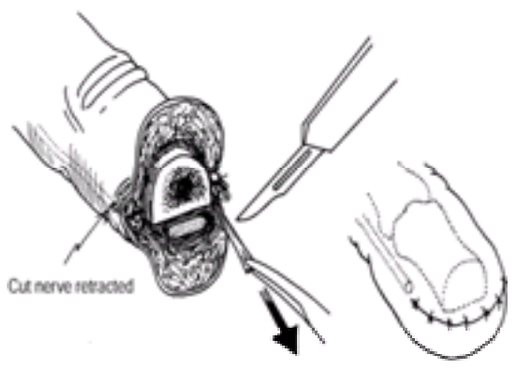

***Figure 53.2.*** Simple immediate or early primary excisional neurectomy.

- Identify and ligate the digital arteries.
- Place the digital nerve under gentle tension.
- Cut the digital nerve as far proximal as possible.
- Allow the cut nerve end to retract 6–10 mm proximal to the amputated bone end.

Crushing, coagulation, freezing, chemical injections, nerve ligation, and capping of the nerve end have been tried with varying success and are not recommended.

Surgery may be indicated if a symptomatic neuroma forms and does not respond satisfactorily to triamcinolone acetate injection, desensitization, transcutaneous electrical nerve stimulation, or other nonoperative measures. For excisional neurectomy to be successful in the treatment of amputation neuromas, a stump revision must be performed if there is a bony prominence representing a potential source of trauma to the nerve end. Simple neuroma resection has become a benchmark by which other measures may be gauged (Fig. 53.3).

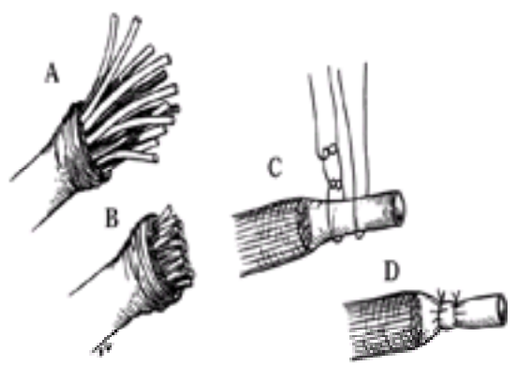


***Figure 53.3.*** Funicular excision with epineural ligation. **A:** Mobilization of the epineurium. **B:** Cutting the funicular ends. **C,D:** Restoration and suturing of the epineurium.

- Dissect the digital nerve and its neuroma away from the digital artery.
- Place the digital nerve and its neuroma under gentle tension.
- Resect the neuroma by cutting the digital nerve as far proximal as possible.
- Allow the cut nerve end to retract into unscarred soft tissue 6–10 mm from the amputated bone end.

In some patients treated by this method, the course after simple excisional neurectomy is one of initial improvement followed by recurrent symptoms as the anatomic neuroma reforms in its new position. A second excisional neurectomy may occasionally be helpful after a failed initial procedure, but subsequent procedures offer diminishing returns (30).

***Transposition***

Neuroma formation has been linked to the neurohormonal influences of sensory end organs, particularly those of the skin. Transposition may remove the nerve end from local neurohormonal influences at the site of injury. Transposition of a severed nerve end to a protected environment away from skin, bony prominences, and the working surface of the hand and avoidance of tension on the nerve may provide the best physical protection of the severed proximal nerve end. It may prevent, improve, or eliminate symptoms.

Although cut nerve ends or symptomatic neuromas with poor full-thickness skin coverage may often be protected by submuscular translocation or by local or distal flap coverage, it may be easier and more practical to transpose the nerve to a protected environment. An area with better blood supply, less scar, and less tension seems to have a salutary effect on a painful neuroma. Transposition has the additional benefits of physically removing the nerve end from areas of direct trauma, such as the working surface of the hand, bony prominences (especially amputated bone ends), severely scarred areas, and local neurohormonal influences. There are three types of translocation procedures for cut nerve ends: subcutaneous, intramuscular, and intraosseous.

- To protect the nerve end or the neuroma from direct trauma in the area to which it is transposed, place a resorbable suture through the epineurium without violating the nerve, or through the capsule without violating the neuroma (Fig. 53.4, Fig. 53.5) (4).

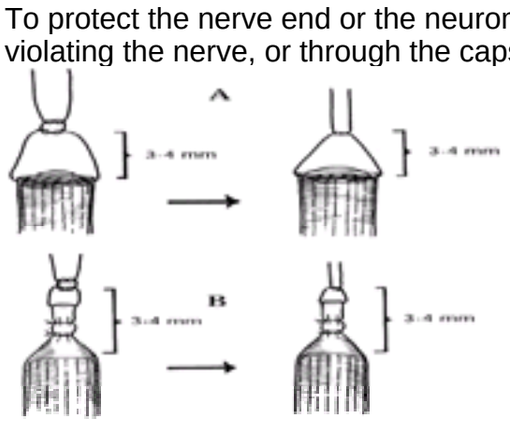


***Figure 53.4.*** Suture techniques for nerve transposition. **A:** Unligated nerve end. **B:** Ligated nerve end.

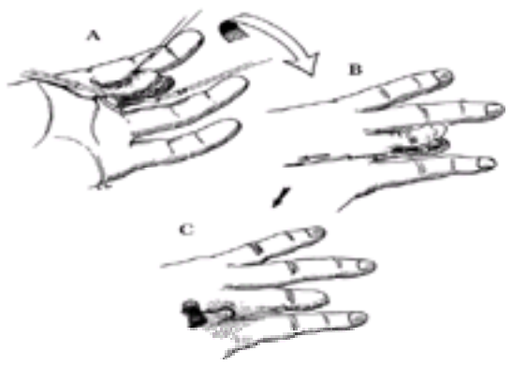


***Figure 53.5.*** Subcutaneous dorsal web space transposition. **A:** Dissection and mobilization of the digital nerve and its neuroma. **B:** Suturing the perineurium. **C:** Tying the suture over a dental roll.

- Tie a knot 3–4 mm distal to the freshly cut nerve end or neuroma to prevent its direct contact with the structures to which it is transposed.
- After transposition of any type, inspect the nerve trunk to be certain it is neither under tension nor kinked.

- In diffusely dysesthetic digital amputation stumps with one palpable sensitive digital neuroma and one nonpalpable insensitive neuroma, consider transposing both nerves. If transposition is not done, the remaining digital neuroma sometimes becomes significantly more painful, even though the transposed neuroma becomes asymptomatic.

The following three procedures are optional for neurectomy or transposition.

- Mobilize the epineurium proximally exposing the fu-nicular ends.
- Cut the funicular ends proximally.
- Restore and suture the epineurium over the cut funicular ends without injuring them.

**Dorsal Subcutaneous Transposition**

- Dissect and mobilize the digital nerve and its neuroma. Dissect the neuroma and its fibrous capsule in continuity with its nerve proximally and mobilize it so that it can be translocated without tension.
- Protect the digital artery.
- Ensure hemostasis.
- Resect the neuroma. Select a dorsal, scar-free site away from bony prominences and local pressure or trauma. The area chosen should place the neuroma dorsal to muscle, positioning the muscle between the neuroma and the surface of the hand (13,18). The web space is preferred for neuromas of the digital stumps and the area between or adjacent to the metacarpals for those involving the common digital nerves of the palm (Fig. 53.4, Fig. 53.5 and Fig. 53.6).

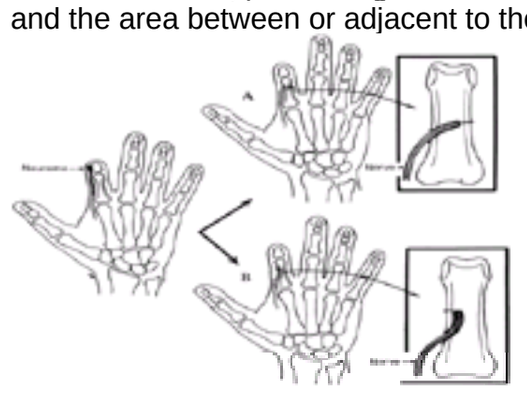

***Figure 53.6.*** Intraosseous transposition. **A:** Drilling of two small holes in the far cortex opposite the initial drill hole. **B:** Drill two small holes in the near cortex distal to the initial drill hole.

- Attach two fine sutures to the perineurium only, on opposite sides of the resected distal tip of the nerve.
- Tunnel under or into the subcutaneous fat in the adjacent dorsal web space.
- Tie a knot 3–4 mm distal to the nerve fascicles to prevent them from directly abutting soft tissues, muscle, or bone after transposition.
- Bring the needles out through the skin in the proximal portion of the dorsal web space.
- Transpose the nerve into the depths of the subcutaneous tunnel in the dorsal web space.
- Be sure the nerve is not kinked.
- Be sure the nerve is not under excessive tension.
- Tie the suture over a dental roll.

**Intramuscular Transposition** Although intramuscular transposition has long been advocated, there is now evidence from both laboratory and clinical studies that neuroma formation is suppressed by placing the transected proximal nerve end directly into muscle substance (19). The operative technique is similar to that of dorsal subcutaneous transposition. Although the procedure of neuroma excision and implantation of the transected nerve end into the brachioradialis has been a successful method of treating symptomatic neuromas of the superficial radial nerve, similar procedures placing the digital nerves into the intrinsic muscles of the hand have been disappointing. Perhaps muscle contracture, a relatively large muscle excursion in relation to muscle size, pressure, traction on the nerve during use, or some combination of these is at fault. Therefore, this procedure is not currently recommended.

**Intraosseous Transposition** Intraosseous transposition of the cut proximal end of a sensory nerve or of a neuroma with sensory neuroma resection produces results at least comparable to those of subcutaneous transposition (2,9,12,21,22). Either of two techniques for intraosseous transposition may be used (Fig. 53.7).

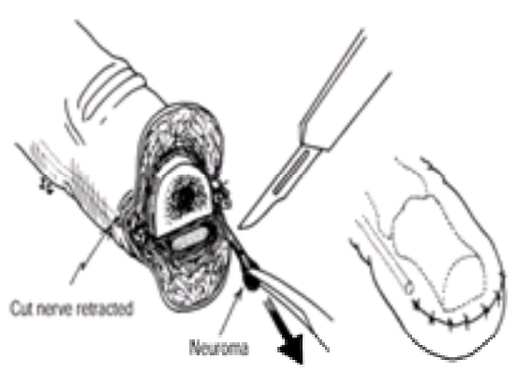


***Figure 53.7.*** Simple late excisional neurectomy.

- Dissect and mobilize the digital nerve and its neuroma.
- Protect the digital artery.
- Ensure hemostasis.
- Resect the neuroma.
- Attach two fine sutures to the perineurium only, on opposite sides of the resected tip of the nerve.
- Drill a hole in the adjacent phalanx large enough to accommodate the nerve without constriction and proximal enough to avoid excessive nerve tension.
- Drill two small holes in the far cortex opposite the initial drill hole using a small Kirschner wire or drill. Pass the needles and suture ends through these holes. Tie the suture over a dental roll or make a small skin incision prior to passing the suture ends and tie them directly on the bone. Two alternative methods follow:
- Alternative A: Drill two small holes in the near cortex distal to the initial drill hole using a small Kirschner wire or drill. Pass the needles and suture ends through these holes. Tie the sutures directly on the bone.
- Alternative B: Suture the epineurium to the periosteum adjacent to the initial hole and leave the nerve end free within the bone.
- Be sure the nerve is not kinked.
- Be sure the nerve is not under excessive tension.

An obstructing knot prevents compression of the proximal nerve end against intramedullary bone. The epineurium may also be sutured to the periosteum or to the bone at the site of its entry into the intramedullary canal. In either technique, there should be no tension on the nerve at any point. The angle that the transposed nerve makes as it enters and courses through the bone should not be too acute. In transposing a transected nerve into bone, it is important to avoid tension on the proximal stump in any position in the arc of motion of adjacent joints.

***Centrocentral Coaptation***

Centrocentral coaptation is the joining of two nerves or fascicles of the same diameter to either end of an autologous nerve or fascicle transplant, artificially created by sharply dividing and then resuturing one of the nerves or fascicles 5–10 mm from its cut end (Fig. 53.8).

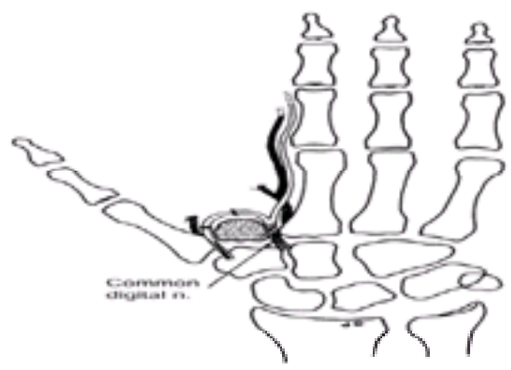


***Figure 53.8.*** Centrocentral coaptation for index finger ray amputation.

- Ligate the digital arteries.
- When done as a secondary procedure, resect the neuromas.
- Intercalate a section of digital nerve graft (from the amputated finger or other donor site) between the digital nerves of the index finger.
- The nerve graft should be at least 5–10 mm in length and of similar diameter to the digital nerves.
- Allow no tension at the suture lines.
- Protect with adequate cover.
- Keep away from skin suture lines.
- Primary centrocentral coaptation is preferred, although secondary centrocentral coaptation can be done.

The junctures should be performed between the central nerve or fascicle and the transplant, so that the physiologic regeneration of the central axons course past the suture lines and bypass each other at the midportion of the transplant (Fig. 53.9).

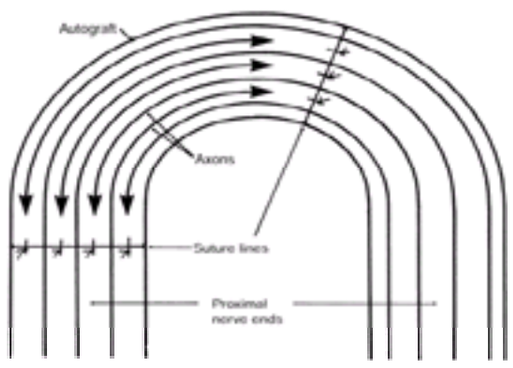


***Figure 53.9.*** Close-up of the centrocentral coaptation. The axons (*arrows*) course past the suture lines and interdigitate at the midportion of the intercalated nerve graft.

- The axons recognize each other as “nontarget structures.” Therefore, the neuroma is small and nonsensitive.
- Increased intraneural pressure reduces axoplasmic flow, centrally inhibiting neural protein synthesis and stopping axonal growth after 3–5 mm of axonal overlap.
- The nerve fascicles' insulation from neurotrophic growth factors also inhibits neuroma formation.

If more than one centrocentral fascicular junction is performed at the same area, the suture lines may be offset stepwise to minimize the chances of axonal compression by interfascicular connective tissue proliferation. Protect the centrocentral junction by adequate full-thickness cover and place it as far from the skin suture lines as possible. This procedure is excellent for cases of digital or ray amputation. It can be performed as a primary or secondary procedure (8,10,11,16,26,27,29).

Axonal regeneration appears to cease after an overlap of 2–5 mm within the midportion of the transplant, as the increased intraneural pressure created by this juncture mechanically reduces its axoplasmic flow; this centrally inhibits neural protein synthesis. This mechanism also minimizes the size of the intraneural neuroma within the transplant.

Another theory explaining the inhibition of symptomatic neuroma formation by centrocentral union is that macromolecular proteins in the distal nerve stump and sensory receptors (i.e., target-derived neurotrophic factors) stimulate axonal regeneration locally at the site of injury and centrally at the nerve cell body by retrograde axoplasmic transport. They may also guide the regenerating axons to their target end organs after nerve repair or grafting is performed. In the case of an unsatisfied proximal nerve end, these neurotrophic factors may contribute to neuroma formation and its symptoms. Centrocentral coaptation may insulate the central nerve segment or the fascicle stumps from neurotrophic influences and confine the regenerating axons to a nontarget environment, allowing the regenerative process to cease.

## POSTOPERATIVE CARE AND REHABILITATION

After skin closure, provide a supportive and protective dressing until pain at the operative site is minimal. In the case of a successful operation, it takes 3 to 6 weeks for the pain to subside. Thereafter, have the patient remove the protective dressing or splint 3 to 4 times each day for therapy. Therapy includes joint motion and tendon excursion exercises, as well as scar softening, mobilization, and desensitizing measures. Use warm water soaks, massage, and active range-of-motion exercises.

It is becoming apparent that nerves, much like tendons, are capable of gliding a limited distance in the tissue that surrounds them. To the extent that this gliding is impaired by scar adhesion, traction on the nerve may occur and may produce symptoms. We attempt to restore gliding by early motion, scar massage, softening, mobilization, and desensitization after neuroma surgery. Aerobic conditioning has proven helpful to some patients (Table 53.7).

| |
|---|
| Scar management therapy (soften, mobilize, desensitize scar tissue) |
| Massage |
| Vibration |
| Desensitization program |
| Active range-of-motion exercises (minimize nerve-to-scar tethering) |
| Edema control |
| Compression garments |
| Isotoner gloves |
| Digital stump sock |
| Compression pump |
| Retrograde massage |
| Elastic wrappings |
| Aerobic conditioning (endorphin/enterokinin generation) |

***Table 53.7. Postoperative Care and Rehabilitation***

The Jobst pump (Jobst Institute, Toledo, OH) or an Isotoner glove (Aris Isotoner, New York, NY) may be used to diminish swelling. The Isotoner glove is worn at night. Vibration may be soothing and softens, mobilizes, and desensitizes the scar area. Other physical measures to soften and desensitize the scar include Silastic

elastomer (Smith & Nephew, Menomonee Falls, WI), maintained in place with Coban (Medical Products Division of 3M, St. Paul, MN), which may be worn at night. Paraffin wax bath and phonophoresis deliver deep heat and may be soothing. Carefully combined with massage, they may help to stretch and soften scar. Continue these methods until the patient's pain is well within tolerance, resolved, or has reached a point of maximum medical improvement.

A positive supportive attitude by the therapist and the physician and a program directed at functional recovery, desensitization of the stump and scar, and early return to manual activities (including work and recreation) play a very important role in patient recovery.

## OUTCOMES

Primary or early neurorrhaphy is probably the best single measure to prevent a symptomatic neuroma. Nerve grafting and neurotized tissue transfer are a close second. These methods may also restore sensory loss. Decompression and translocation of an intact neuroma in continuity is also a highly reliable procedure. Each of these procedures reestablishes nerve continuity. They are at least 80% to 90% successful in avoiding or eliminating symptoms or making them tolerable.

Simple excisional neurectomy is about 65% reliable. Repetition of this procedure for initial failure is also about 65% effective. After two unsuccessful attempts at simple excisional neurectomy, there is little yield from repeating the procedure again.

Nerve transposition and centrocentral coaptation are usually used as salvage procedures for symptomatic neuromas in which the distal nerve segment is not available and in which the reestablishment of sensation is not critical. These procedures are 80% to 90% successful.

Patients with pure neuroma pain fare better than those with complex pain. Patients who do not have adverse psychosocial factors fare better than those who have them (25).

## PITFALLS AND COMPLICATIONS

Prevention of a symptomatic neuroma in cases of nerve division can be achieved by repair using direct suture in freshly lacerated lesions and by nerve grafting, primarily or secondarily, in cases with nerve loss and those in which direct suture cannot be accomplished without tension. In elective digital amputations or ray resection, centrocentral coaptation or transposition may be selected for digital nerve management. For traumatic amputations, the condition of the wound at the time of surgery may dictate whether the transected nerves are managed by simple excision or by a nerve-manipulating procedure. If the wound is contaminated or if additional dissection would jeopardize tissue viability, the transected nerve ends should be managed by simple excision. Centrocentral coaptation or transposition of the neuroma may be deferred and performed as a delayed primary procedure when wound conditions permit or secondarily if a symptomatic neuroma develops. Naturally, prevention of a symptomatic neuroma is preferable to treatment of one.

Treatment possibilities for a symptomatic neuroma include nerve grafting if a distal nerve end is available. Decompression and submuscular translocation are quite reliable in managing neuromas caused by repetitive or cumulative trauma that form in continuity with the perineurium intact. Dorsal subcutaneous or intraosseous transposition is effective in treating symptomatic neuromas when no suitable distal nerve exists. Centrocentral coaptation is an excellent method of managing transected digital nerves. Although setting the standard for comparison, simple excision does not provide as good or as reliable results for established neuromas as do the other procedures described in this chapter.

The principles of nerve transposition in instances of symptomatic neuromas include removing the free nerve end from areas of scarring, bony prominences, and the working surface of the hand. Translocation or transposition can also remove a freshly cut nerve end from local neurohormonal influences arising from denervated cutaneous sensory end organs. The free nerve end must be under no tension and should lie in or adjacent to well-vascularized tissues. There must be no kinking of the translocated nerves.

In the case of nerve transposition failure, the reason may be excessive nerve tension, pullout, or kinking. Consider performing a second surgical procedure to investigate the causes and redo the transposition or relocate the nerve. The same is true in failure of centrocentral coaptation.

Although neuroma formation elsewhere in the body is suppressed by intramuscular transposition of the proximally transected nerve, this method has proved ineffective for controlling neuroma pain in the hand. Intrinsic muscle contracture causes a relatively large excursion in relation to muscle size; pressure and traction have been implicated.

Successful intervention for a symptomatic neuroma correlates with the time from its formation. Chronic pain syndromes and the establishment of central pain are time related and often involve psychosocial and economic factors. The longer a painful neuroma goes untreated, the less likely it is that any modality can be effective. Treatment should be completed expeditiously, and the patient should return to work, even if performing only light duty, as soon as possible.

Reoperation after a failure of initial surgical treatment of a painful neuroma may be successful and is indicated. If a second operation does not solve the problem, additional surgery produces sharply diminished returns. Although another operation is sometimes indicated, the physician should also consider alternatives. The patient can, for example, be referred to a multidisciplinary pain clinic as an alternative to additional surgery. These clinics provide diagnostic and therapeutic nerve blocks. They are particularly helpful with complex regional independent and sympathetically mediated pain.

Regional and stellate ganglion sympathetic blocks have moderated symptoms in some patients with complex pain components. There has also been some success with both peripheral nerve and central spinal cord stimulators. Although these methods for managing chronic pain are not a panacea, some otherwise refractory problems have responded favorably.

## CHAPTER REFERENCES

Each reference is categorized according to the following scheme: *, classic article; #, review article; !, basic research article; and +, clinical results/outcome study.


! 1. Badalamente MA, Hurst LC, Ellstein J, McDevitt CA. The Pathobiology of Human Neuromas. An Electron Microscope and Biomechanical Study. *J Hand Surg* 1985;10B:49.

* 2. Boldrey E. Amputation Neuroma in Nerves Implanted into Bone. *Ann Surg* 1943;118:1052.

! 3. Brandner MD, Bunke JH, Campagna-Pinto D. Experimental Treatment of Neuromas in the Rat by Retrograde Axioplasmic Transport of Ricin with Selective Destruction of Ganglion Cells. *J Hand Surg* 1989;14A:710.

+ 4. Braun RM. Epineural Nerve Suture. *Clin Orthop* 1982;163:50.

! 5. Cravioto H, Battista A. Clinical and Ultrastructure Study of Painful Neuroma. *Neurosurgery* 1981;8:181.

# 6. Dellon AL, Mackinnon SE. Pain after Radial Sensory Nerve Grafting. *J Hand Surg* 1986;11:341.

+ 7. Fisher GT, Boswick JA Jr. Neuroma Formation Following Digital Amputations. *J Trauma* 1983;23:136.

+ 8. Fournier P, Papot G, Cayrol M. Value of Samii's Method in the Treatment of Digital Neuroma. *Ann Surg* 1986;5:253.

+ 9. Goldstein SA, Sturim HS. Intraosseous Nerve Transposition for Treatment of Painful Neuromas. *J Hand Surg* 1985;10A:270.

+ 10. Gonzalez-Darder J, Barbera J, Abellan MJ, et al. Centro-central Anastomosis in the Prevention and Treatment of Painful Terminal Neuroma. *J Neurosurg* 1985;63:754.

# 11. Gorkisch K, Boese-Landgraf J, Vaubel E. Treatment and Prevention of Amputation Neuromas in Hand Surgery. *Plast Reconstr Surg* 1984;73:293.

+ 12. Hemmy DC. Intramedullary Nerve Implantation in Amputation and Other Traumatic Neuromas. *J Neurosurg* 1981;54:842.

# 13. Herndon JH, Eaton RG, Littler JW. Management of Painful Neuromas in the Hand. *J Bone Joint Surg Am* 1976;58:369.

+ 14. Karev A, Stahl S. Treatment of Painful Nerve Lesions in the Palm by “Rerouting” of the Digital Nerve. *J Hand Surg* 1986;11A:539.

+ 15. Kirvela O, Nieminen S. Treatment of Painful Neuromas with Neurolytic Blockade. *Pain* 1990;41:161.

+ 16. Kon M, Bloem JJA. The Treatment of Amputation Neuromas with a Centrocentral Nerve Union. *Ann Plast Surg* 1987;18:506.

+ 17. Kumar N, Stevenson JH. Intractable Digital Neuroma Pain. The Ultimate Solution. *Br J Plast Surg* 1990;43:122.

+ 18. Laborde KJ, Kalisman M, Tsai TM. Results of Surgical Treatment of Painful Neuromas of the Hand. *J Hand Surg* 1982;7:190.

# 19. Mackinnon SE. Evaluation and Treatment of the Painful Neuroma. *Tech Hand Upper Extrem Surg* 1997;1:195.

+ 20. Manzos RN, Damana ZH, Anastasiou EA, et al. Neuromas and Gaps in Sensory Nerves of the Hands. *Am J Orthop* 1997;26:481.

+ 21. Masquelet AC, Beliver C, Nordin JY. Treatment of Painful Neuromas of the Hand by Intraosseous Nerve Implantation. *Ann Chir Main* 1987;6:64.

+ 22. Mass DP, Ciano MC, Tortosa R, et al. Treatment of Painful Hand Neuromas by Their Transfer into Bone. 20 Cases. *Plast Reconstr Surg* 1984;74:182.

* 23. McGrath M. Local Steroid Therapy in the Hand. *J Hand Surg* 1984;9A:918.

! 24. Meyer RA, Raja SN, Campbell JN, et al. Neural Activity Originating from a Neuroma in the Baboon. *Brain Res* 1985;325:255.

+ 25. Novak CB, Van Vhet D, Mackinnon SE. Subjective Outcome following Surgical Management of Upper Extremity Neuromas. *J Hand Surg* 1995;20A:221.

* 26. Samii M. Centrocentral Anastomosis of Peripheral Nerves. A Neurosurgical Treatment of Amputation Neuromas. In: Siegfried J, Zimmerman M, eds. *Phantom and Stump Pain.* New York: Springer-Verlag, 1981:123.

+ 27. Seckel BR. Discussion of “Treatment and Prevention of Amputation Neuromas in Hand Surgery.” *Plast Reconstr Surg* 1984;73:297.

* 28. Sunderland S. *Nerves and Nerve Injurires*, 2nd ed. New York: Churchill Livingstone, 1978:188.

+ 29. Tada K, Nakashima H, Yoshida T, Kitano K. A New Treatment of Painful Amputation Neuroma. A Preliminary Report. *J Hand Surg* 1987;12B:273.

+ 30. Tupper JW, Booth DM. Treatment of Painful Neuromas of Sensory Nerves in the Hand: A Comparison of Traditional and Newer Methods. *J Hand Surg* 1976;1:144.

! 31. Wall PD, Gutnick M. Properties of Afferent Nerve Impulses Originating from a Neuroma. *Nature* 1974;248:740.

# CHAPTER 54

# PRINCIPLES FOR RESTORATION OF MUSCLE BALANCE AFTER FOREARM AND HAND PARALYSIS

*Paul W. Brand and Anne Hollister*

**P. W. Brand:** Clinical Professor Orthopaedics Emeritus, University of Washington, Seattle, Washington, 98116.
**A. Hollister:** Department of Orthopaedic Surgery, LSUMC, Shreveport, Louisiana, 71130.

Work and Attitude of the Patient
Quantitative Evaluation of Muscles
Changes in Muscle Strength After Transfer
Changes in Excursion of Muscle After Transfer
Mechanical Balance at Each Joint
Changes in Passive Structures After Paralysis
Trick Movements Developed After Paralysis
Timing of Tendon Transfers
Chapter References

## WORK AND ATTITUDE OF THE PATIENT

A surgeon can move muscles around and attach tendons to new insertions. Therapists can help the patient to understand new patterns of control of the hand. Only the patient can heal the wound and make the hand work. In this process, one of the most important variables is the attitude of the patient and her willingness to accept the disciplines of recovery.

The very best results occur when the patient is self-employed, has no one to blame but himself for the injury, and has everything to gain by a speedy return to work. The poorest results occur when a patient blames someone else for the injury, and is angry and resentful. This problem is compounded when the patient expects to obtain a larger financial reward if she has residual disability. The outlook is still worse if the patient already has a poor self-image, has been a failure, and now views the injury as a lasting excuse for continued dependency.

No plan for reconstructive surgery should be finalized until the patient's own attitudes and personality have been evaluated and until he has been brought fully into the picture. Before outlining any program, the surgeon must encourage patients to talk and present their own ideas about the future. It is important to know how the patient has been influenced by others, including family, employer, and attorney. If the patient has been fortunate enough to see a surgeon before talking to a lawyer, it may be possible for the surgeon to recommend a legal advisor who works for a fee rather than for a proportion of any potential award and who understands the harm that is done to the process of recovery by delays in the financial settlement and by suggestions that it may be financially beneficial to the patient to maximize the disability.

If a patient is angry, it is worthwhile to spend time with the patient or to get help for the patient to come to terms with these emotions, enabling the process of rehabilitation to start with a single-minded and uncomplicated determination to do well.

The physician must also determine the patient's attitude about the worth of any complex procedure. An operation that would be obviously indicated for a young manual worker may be inappropriate for a retired person who can manage what he needs to do with the ranges of useful motion that remain.

In planning tendon transfers, there is often a choice between a simple procedure, using synergistic transfers, and one that is more complex, requiring the retraining of nonsynergists. Age must be taken into account. Children and young people can easily bring back into their consciousness the mechanisms of control of any muscle in the upper limb and can reprogram their nervous system to make it fit a different pattern. This may, however, be almost impossible for some elderly people of even the highest intelligence. Their neuronal pathways have created “ruts” that have deepened over years of efficient use. The ruts remain even when new pathways are established, and it is not good use of mental concentration to direct it constantly away from useful activity to control the new pathways. For these patients, synergistic muscles should be used, and only one movement should be restored at a time.

## QUANTITATIVE EVALUATION OF MUSCLES

Every muscle has two major variables that identify its potential. The first is its capability for creating tension, and the second is the distance, or excursion, through which its tension may be sustained.

No surgeon who is unable to work out the mechanical effect of her proposed actions should move muscles or tendons. I do not suggest that a mathematical equation needs to be worked out in each case. However, the surgeon and therapist should use approximate figures that can inform them whether any given tendon transfer can provide enough but not too much tension to restore balance and whether a given muscle is capable of providing the range of motion needed by the joints.

Accounts of the way in which muscles can be evaluated are available elsewhere (1,2). A summary is provided in Table 54-1, and a composite graph of all the muscles of the forearm and hand is given in Fig. 54.1 Figure 54.1 shows the tension capability on the vertical scale and the potential range of excursion on the horizontal scale. Both of these scales are relative. The numbers for tension represent each muscle as a percentage of the combined tensions of all muscles below the elbow. The excursions are the average of the fiber lengths of each muscle in a medium-sized forearm or hand, measured while all muscles are in their position of physiologic rest.



***Table 54.1. Normal Mean Fiber Lengths, Mass Fractions, and Tension Fractions for Adult Muscles***



***Figure 54.1.*** Using values from Table 54.1, this diagram shows the relationship between fiber length and tension-producing capability. Some muscle groups are circled for clarity. (See Table 54.1 for a key to abbreviations.) (From data in Brand PW, Beach RB, Thompson DE. Relative Tension and Potential Excursion of Muscles in the Forearm and Hand. *J Hand Surg* 1981;6:209.)

Most muscles whose tendons cross only one joint actually use only one half to two thirds of the excursions that are calculated from the fiber lengths. Muscles whose tendons cross several joints more often use their whole potential excursion, but even these muscles manage to work within the central half to two thirds of their potential most of the time by means of extending one of the joints while allowing others to flex.

No surgeon should assume that a given nerve injury must result in the classic pattern of muscle loss for that injury. There are many patterns of innervation and of injury and disease, and the only reliable way to evaluate patterns of paralysis is to have a hands-on clinical test of every movement while the examiner's fingers feel for the tightening of the tendons. During surgery, some clinical testing can be repeated while the tendons are exposed if the patient is awake, or at least a needle electrode should be used to stimulate the muscles that are about to be used to confirm their vitality, strength, and potential for excursion.

**CHANGES IN MUSCLE STRENGTH AFTER TRANSFER**

It has been commonly taught that muscles can be expected to lose one grade of strength after transfer. This rule is based on the Medical Research Council (MRC) system of grading of muscle tension, which was developed in Britain during World War II and has been widely used ever since. The grades are 0 to 5; 5 is normal, and 1 is a twitch without movement of a joint. Three of the grades refer to the ability of a muscle to oppose gravity: unable to move against gravity, able to move against gravity, and able to move against gravity and resistance. Because the effect of gravity on muscle varies depending on what limb segment has to be moved, and because movement against gravity is a very small part of the work of muscles in the upper limb, the MRC scale gives a much wider spread at the lower end of the scale. For this and other reasons, Yahr and Beebe suggested that it would be more reasonable to use a simple percentage scale in which 100% is normal (3). Some may prefer to use a scale of 0 to 10, in which 10 is equal to 100%. Grade 1 on the MRC scale is about 5%; 2 is perhaps 10%; 3 is approximately 25%; 4 is 60% to 70%; and 5 is 100%.

The old “rule” that said a muscle would lose 1 grade of strength (MRC scale) on transfer was never a quantitative statement but, rather, a warning to expect less tension out of a muscle after it has been transferred than it had before. However, the basic concept of loss of strength is wrong. A muscle has the same nerve supply, the same blood supply, and the same number of sarcomeres after it has been rerouted as it had before.

There is a change in the effectiveness of a muscle after transfer. This change is due not to loss of active muscle tension but to the increased passive drag on the muscle caused by the changed elastic properties of passive soft tissue. All the soft tissue in and around a muscle must be lengthened with the muscle as it moves and exerts an elastic restraint. In the normal situation of a muscle, the length-tension curve of this tissue is low (Fig. 54.2) and becomes steep only toward extremes of movement. After a muscle is moved to another part of the limb, it becomes surrounded by scar tissue that binds it to the tissues along the new pathway. Scar tissue has a short, steep length-tension curve and may severely limit the excursion of a muscle after transfer. If great care is taken to pass the tendon through yielding fatty tissue only, without using a large wound of access, the postoperative scar will bind the tendon only to tissues that can be easily moved and stretched and will have a low length-tension curve. If an open wound of access cuts through fascia or retinaculum, or if bone is scratched or periosteum is cut, the scar may bind the tendon directly to an immovable structure and the postoperative range of excursion will be very short. In either case, the actual tension produced by the muscle is the same as it was before repositioning. The change is that the tension will be useful only for a shorter distance on either side of the position in which the muscle and tendon rested while the wound was healing. When wider excursion is attempted, part of the energy of the muscle is used in stretching or attempting to stretch scar tissue.

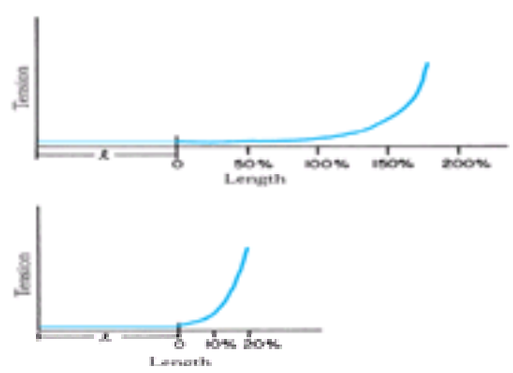


***Figure 54.2.*** **A:** Normal paratendinous material is shown. Resting length l requires almost no tension to lengthen up to 100% and then gradual increase until elastic limit, in this case at about 160%. **B:** Scar tissue replacing the paratendon. Resting length (l) requires tension to lengthen from the start. Elastic limit is between 10% and 20%. If the scar is short, the percentage of lengthening must also be short.

Whenever possible, no fascia or other immobile tissue should be cut in the same wound as a transferred tendon. This is why it is wise to use only a small wound proximally where the muscle or tendon is to change direction and only a small wound distally where the tendon is to be attached. The tendon should be tunneled between the two incisions with no open wound. First detach the tendon from its original site of insertion. After the tendon has been freed from other tissues, if necessary, pull it out through the proximal incision. Then pass tendon-tunneling forceps from the incision of proposed insertion to the proximal incision. Open the jaws to receive the tendon end, and withdraw the forceps distally with the tendon following.

Several factors help ensure success. The tendon-tunneling forceps should have a smooth, rounded nose, widening to a viper head, quite close to the nose, and then narrowing back to a straight shaft as far as the handles. This ensures that any resistance that is felt during passage will be at or near the advancing end (Fig. 54.3). It should be possible to open the jaws of the tunneling forceps without increasing the width of the tunnel. It is essential that the surgeon know the anatomy of the pathway, having passed forceps of the same pattern along the chosen path previously, at least in a fresh cadaver arm, so the feel of the structures is familiar.

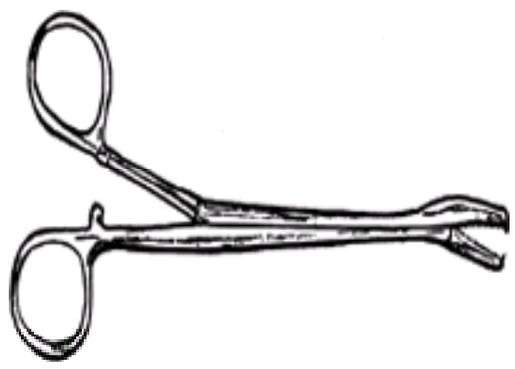

***Figure 54.3.*** A tendon tunneler is illustrated. A tendon tunneler must have a smooth blunt nose; its thickest point should be just behind the nose (the “viper” head); and it should be possible to open the jaws and the handles without stretching or tearing the tissues of the tunnel. (From Brand PW. Muscles—The Motors of the Hand. In: Rob C, Smith R, eds. *Operative Surgery,* 3rd ed. Stoneham, MA: Butterworth Publishers, 1977, with permission.)

The forceps must never be forced through if resistance is felt. It must be withdrawn a little and probed until yielding tissue is found. If a tendon or graft is to be passed through the carpal tunnel (often a good path), the nose of the tunneler must be deep to all tendons and sheaths. The feel of the floor of the tunnel is hard, irregular, and quite unmistakable; it is safe for the tunneler to press on the floor. If passage of the tunneler pulls the fingers into flexion, it means that the tunneler is in among the tendons. It must be pulled back and rerouted more deeply on the floor. I have never known adhesions to be a problem in this uninjured skeletal plane; this plane also is clear of the median nerve.

If a muscle is used for transfer that is weaker than the original muscle it is to replace and if it is not blocked by adhesions, it may eventually become stronger until it is able to match the requirements of its new responsibilities.

It is true that all muscles, with or without surgical interference, respond to repeated strong contractions by becoming stronger. This is accomplished by the addition of sarcomeres in new muscle fibrils in parallel with the old. The condition for this hypertrophy is that the weak muscle must actually contract as strongly as it is able, in phase with its new task. I have seen many transferred muscles that have become progressively weaker after surgery and have been regarded as failures. In a few cases, this has been because it has become rigidly adherent in its new pathway; however, this has often been because the muscle was never reeducated to contract in phase with its new action. The hand therapist must not be content to see the transferred muscle contracting on command or in the sequence of postoperative exercises that are planned to involve contraction of that muscle. The muscle must be seen to contract during activities of daily living or at a work bench where the patient is thinking of work rather than of the hand.

**CHANGES IN EXCURSION OF MUSCLE AFTER TRANSFER**

Surgeons often wonder what happens if they transfer a muscle that has short fibers to replace a muscle that had long fibers. Assuming that the new muscle will have a shorter excursion, will it eventually develop longer fibers to match the requirement of its new task?

The answer is that it will not. If the patient exercises well and uses the muscle effectively, the result is gradual lengthening of the paratendinous soft tissues to maximize available excursion. However, the number of sarcomeres in series in each fiber remain the same. The only way to lengthen a muscle fiber is to keep it on stretch at rest. The only way to do this without shortening the fibers on the opposite side of the limb is to operate and attach the tendon at a higher relative tension. Muscle fibers respond to constant tension by adding sarcomeres in series until normal resting tension is reestablished.

There is a danger in attaching transferred muscles at high tension, because the muscle may respond by involuntary contractions that cause avulsion at the suture line. The best way to handle the problem is to make the attachment of a transferred tendon at a tension just above normal resting tension (for a wrist-moving muscle, this may be 1 cm of distal pulling of tendon from its relaxed position), and to place the limb in the postoperative cast in a posture to relax that tension until the wound has healed, usually in 3 to 4 weeks. After the posture is allowed to return to normal, the transferred muscle tends to give electromyographic discharges for 1 or 2 weeks until new sarcomeres have grown and relaxed the tension. This whole process brings the new muscle enough into consciousness to be of some assistance in the process of reeducation.

**MECHANICAL BALANCE AT EACH JOINT**

The calculation that is needed for balance involves moment or torque at a joint. This is the product of the tension of the muscle and the lever arm or moment arm at the joint. A weak muscle may produce a high torque at a joint if it crosses the joint far enough from its axis to have a long lever. In so doing, however, it uses a lot of excursion and may be able to produce only a limited range of motion of the joint. A stronger muscle may produce the same torque by crossing the joint nearer to the axis; it requires less excursion, thus allowing a wider range of joint motion.

If one knows the leverage or moment arm of a tendon at each joint that it crosses, the excursion needed at that joint may be calculated by multiplying the moment arm in centimeters by the number of degrees of required motion of the joint measured in radians (1 radian = 57.3°) (Fig. 54.4). This also may be checked at surgery when a tendon is transferred. The joint is moved through some multiple of 60° (approximately 1 radian), checked by a geometric triangle (Fig. 54.5), and the resulting motion of the tendon is measured on a millimeter scale. For example, after performing a tendon transfer for intrinsic muscle function at the metacarpophalangeal joint of the middle finger, the surgeon may hold the proximal part of the tendon, pulling it gently, while he flexes the metacarpophalangeal joint through 90° (1.5 radians). If the tendon moves 15 mm, it is lying 10 mm in front of the axis of the metacarpophalangeal joint. By doing this, the surgeon is able to make sure that the tendon is positioned correctly. If, with the same metacarpophalangeal angular motion, the tendon moves only 8 mm, the surgeon has inadvertently passed the tendon behind the metacarpal ligament rather than in front of it; in that case, the tendon will be a weak metacarpophalangeal flexor unless it is rerouted (Fig. 54.6).

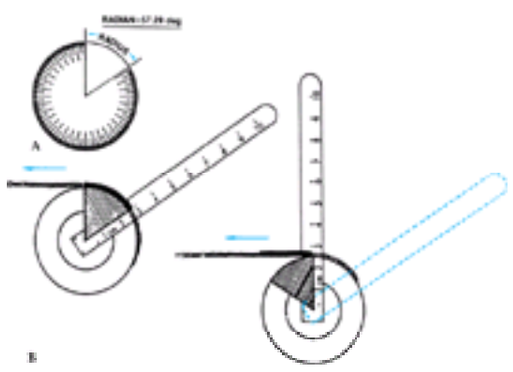

***Figure 54.4.*** **A:** A radian is shown. The length of a radius, measured on the circumference, is joined to the center by two radii. **B:** The way in which the lengthwise movement of a tendon may be used to measure the moment arm of a joint. If the joint moves 57.29°, the length of rope that runs off the pulley must be equal to its moment arm at the joint (i.e., radius of pulley). (From Brand PW. *Clinical Mechanics of the Hand.* St. Louis: CV Mosby, 1985, with permission.)

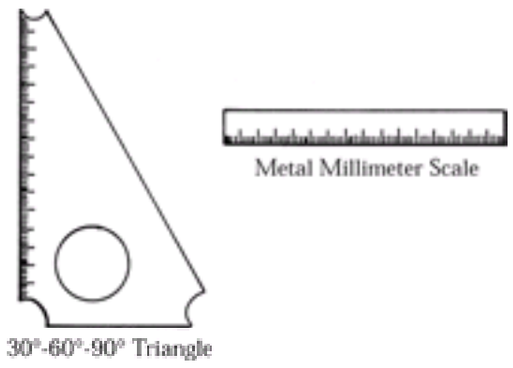


***Figure 54.5.*** A 30° to 60° to 90° triangle. The corners are cut off to allow the triangle to be tucked into web spaces, where the actual joint axis is deep in tissue. (From Brand PW. *Clinical Mechanics of the Hand.* St. Louis: CV Mosby, 1985, with permission.)

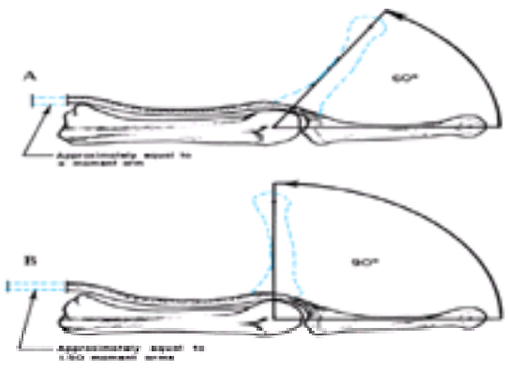

***Figure 54.6.*** **A:** For 60° of joint movement, tendon movement is approximately equal to a moment arm. **B:** For 90° of joint movement, the tendon moves a distance approximately equal to 1.5 moment arms. (From Brand PW. *Clinical Mechanics of the Hand.* St. Louis: CV Mosby, 1985, with permission.)

Figure 54.7 shows a cross section of the wrist, based on mechanics rather than anatomy. It shows the relation of each tendon to the axes of flexion and extension, and of radioulnar deviation of the wrist. The number of dots marking each tendon indicates the tension fraction of the muscle. It is possible to calculate the torque available for each movement of the wrist by multiplying the available tension by the measured distance from the relevant axis. While planning tendon transfers, it may be good to sketch diagrams like Fig. 54.7 and Fig. 54.8 to demonstrate the new balance that will be achieved after paralysis and after tendon transfers.

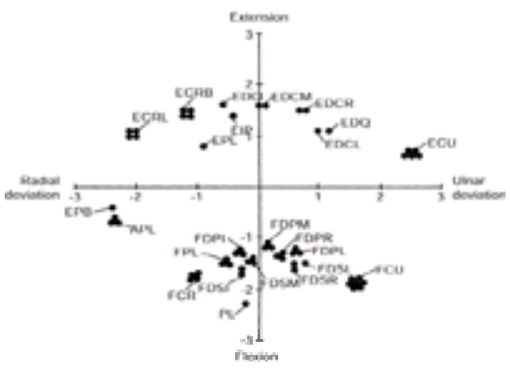


***Figure 54.7.*** This is not an anatomic diagram; it is a simplified mechanical statement of the capability of each muscle to affect the wrist joint. The positions of the tendons in relation to the axes of flexion and extension and of radioulnar deviation represent their moment arms at the wrist. The number of dots in each cluster is an indication of the tension capability of that muscle-tendon unit rounded off to the nearest whole number. (See Table 54.1 for a key to abbreviations.) (From Brand PW. *Clinical Mechanics of the Hand.* St. Louis: CV Mosby, 1985, with permisson.)

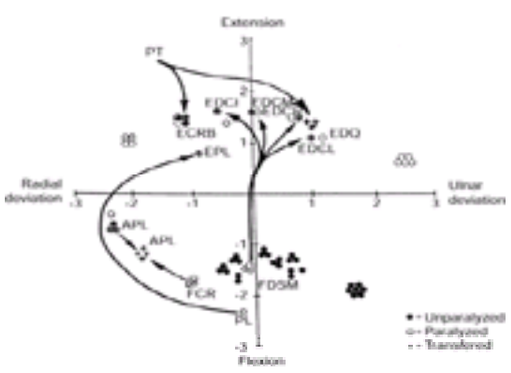


***Figure 54.8.*** My preferred pattern of transfer for radial palsy. When normal muscle Ÿ is transferred to a site of paralyzed muscle ¡, the symbol Å indicates activation of paralyzed tendon, while the original tendon becomes ¡. (See Table 54.1 for a key to abbreviations.) (From Brand PW. *Clinical Mechanics of the Hand.* St. Louis: CV Mosby, 1985, with permission)

If one muscle is used to provide tension to two different tendon insertions, the surgeon must make sure that the excursion required of each tendon is the same for each range of motion. Otherwise, the tendon with the bigger moment arm will fall slack and exert no tension, because it is linked to a tendon that moves less, having a smaller moment arm. For example, in radial palsy, a pronator teres attached to both extensor carpi radialis longus and extensor carpi radialis brevis is effective for extension only through the extensor carpi radialis longus insertion, which is the least effective extensor. The pronator should be attached only to the extensor carpi radialis brevis or to a better balanced pair of insertions.

## CHANGES IN PASSIVE STRUCTURES AFTER PARALYSIS

One of the remarkable features of the hand is that tissues in close proximity to each other exhibit sharply contrasting responses to imposed mechanical stress. Tendons, tendon sheaths, and ligaments respond to repetitive tensile stress by a steep elastic curve of resistance before 10% of elongation has occurred. Paratenon and areolar tissue between tendons respond to repetitive tensile stress by allowing more than 100% lengthening with minimal elastic resistance. Skin occupies an intermediate position, and muscle allows about 100% of passive lengthening from its fully relaxed position. The last 50% of muscle lengthening requires significant tension, the energy of which is stored and used to supplement the active contraction of the stretched muscle.

In contrast to the highly variable responses to repetitive stress, all of these tissues have a rather constant response to long-term changes in their resting tension.

If muscle, ligament, or skin is held in a slightly stretched position for several days at a time, the tissue begins to undergo structural change to adapt to the new length and to restore the resting tension that was characteristic of the tissue before the change. A continuously stretched muscle fiber begins to add sarcomeres to increase its resting length and reduce tension. Collagen bands become progressively absorbed and are replaced by new collagen that is no longer under tension. Skin cells in the germinal layer show many mitotic figures, and growth reduces the slight tension that had been imposed on it.

Conversely, if any of these tissues are allowed to rest in a totally slack and loose position, the tissue elements begin to be absorbed and reoriented in a shortened position. Muscle fibers lose sarcomeres until normal physiologic resting tension is restored in the new posture.

The normal physiology of muscle-joint interaction largely depends on the harmony between active muscle contraction and the viscoelastic changes in the passive soft tissues. For example, a stretched muscle uses elastic recoil to provide most of the force when it begins to contract; most of the active contractile force of a muscle, as it nears its limit of shortening, is consumed in stretching out its opposing muscles and is not available for its primary function of moving the joints. Similarly, the elastic stretching and recoil of skin and connective tissue participates in all joint motion, and the feedback of its sensory nerves provides the best monitor of joint position and pro- prioception.

One of the first effects of paralysis is to unbalance the hand. This results in a collapse of joints toward the posture in which the unparalyzed muscles are shortened and in which the soft tissues on the paralyzed side are stretched to the point at which their elastic tension equals the diminished tonus of the shortened unparalyzed muscles.

This new position of equilibrium is unstable. The unparalyzed muscles rest at a tension below their normal resting tension and begin losing sarcomeres to restore tension in the shortened position. The stretched skin and other soft tissues begin to grow to reduce their unnatural state of tension.

These initial compensations result in further destabilization of the equilibrium until some joints reach a point beyond which they cannot move. This process is seen in ulnar palsy, in which there may be minimal clawing soon after injury but severe deformity after several months. It is also seen in radial palsy if the wrist is not supported night and day. And this process is seen in the thumb in median palsy, in which the dorsal tissues of the thumb web become progressively narrower and the ligaments at the base of the thumb change their length and density; after 1 or 2 years it may become impossible to oppose the thumb fully even after effective tendon transfers.

Muscle balance has been emphasized here because it is often neglected. A recognition of its importance results in a greater insistence on maintaining a normal functional position of the hand at rest as well as during activity until muscle balance is restored. This discussion should also stimulate the surgeon to operate earlier to restore muscle balance.

## TRICK MOVEMENTS DEVELOPED AFTER PARALYSIS

So-called trick movements are the various attempts by an active person to get things done despite the limitations of paralysis. It is the good patient who finds a way around her disability, and it is only a foolish surgeon or therapist who decries these efforts unless there is a serious reason for preventing their use.

A trick movement is a way of using the hand that would never be done if the hand were normal. When the normal way to hold an object or to perform an action is no longer possible, some people react passively and wait for the doctor to do something. Others are determined to move ahead and find a way to do the job with whatever resources remain in the hand. These unorthodox patterns of movement indicate that the will to work is maintained. When patients succeed in accomplishing objectives, they gain confidence and maintain personal pride. These are assets beyond price. The quality of muscles, skin, and joint motion are maintained in better condition than if the limb is passive in a splint.

Two possible problems may result from trick movements. The tissues may become stretched or contracted as a result, and the trick may persist after tendons have been transferred. Tissue changes have already been mentioned, and examples have been given from paralysis of each of the three main nerve paralyses. Of the trick movements that may be troublesome as a habit after tendon transfer, one of the worst is the lateral squeeze pinch that is developed by almost every patient who has a low ulnar median palsy (Fig. 54.9). These patients cannot easily use their thumbs except by simultaneous contraction of the extensor pollicis longus and flexor pollicis longus. Each of these muscles, although opposing each other at the interphalangeal and metacarpophalangeal joints, has a common vector for adduction at the carpometacarpal joint of the thumb. To make this work, the two muscles must contract together. The flexor pollicis longus overcomes the extensor pollicis longus at the two distal joints where its moment arms are greater, and the extensor pollicis longus keeps the carpometacarpal joint in extension for which it has a better leverage than the flexor pollicis longus has for flexion. The resulting ugly pinch is strong and becomes frequently used.

***Figure 54.9.*** The lateral squeeze pinch, which is used by patients who have low median and ulnar paralysis of the thumb. The thumb squeezes with all joints in flexion except the carpometacarpal joint, which is in extension and supination. (From Brand PW. *Clinical Mechanics of the Hand.* St. Louis: CV Mosby, 1985, with permission.)

The late deformities are flexion contracture of the interphalangeal joint and shortening of the dorsal skin and fascia of the web. Even if these deformities are corrected by surgery, the habit of using the extensor pollicis longus for pinch tends to persist. It is most difficult to get rid of if it has been used for many months or years and by older patients. The problem of this abnormal pinch is that it is the opposite of the new pattern that the surgeon uses to restore normal pinch. The newly transferred abductor-opponens transfer may be hard to reeducate, but the extensor pollicis longus is easy to use by force of habit. The extensor pollicis longus also has a better moment arm to pull into supination than the new transfer has for pronation. The patient's instinctive tendency to contract the extensor pollicis longus on attempted pinch is the cause of many failures of opponens transfers.

To prevent the development of this habit pattern, the thumb may be splinted forward or held out by a C-splint. If a tendon transfer is to be delayed many months, however, it is not likely that a patient will agree to remain restrained. If the pattern is already firmly established at the time surgery is planned, consider using the habit, rather than fighting it, by transferring the extensor pollicis longus through the distal forearm between radius and ulna to be attached to the stump of its own tendon to serve as an abductor-extensor of the thumb. The attempt to use the trick movement then enhances the true opponens action. This transfer leaves the thumb with inadequate thumb supination and should be used only in older patients or if there is likelihood of failure of regular transfers.

## TIMING OF TENDON TRANSFERS

There is no doubt that the best time for a muscle balance operation in any case of irreparable nerve loss is as soon as possible after wounds have healed and after there is tissue homeostasis. This approach allows no time for harmful secondary stretching or contractures or for the development of trick movements or habitual patterns.

Tissue homeostasis may be judged by a return of normal skin mobility, joint mobility, hand volume, and skin temperature. I suggest the use of a skin thermometer for comparing the affected side with the normal side. A hand volumeter is also a useful instrument for monitoring the resolution of any inflammatory state in the tissues of the hand. The patient should notice the progress in the graph of these records, which can also be used after surgery to mark progress in recovery from the operation and the mobilizing of joints and tendons. The patient learns to associate raised temperatures with inflammation and notices how his hand volume increases when the hand is hanging down and how it decreases after a period of elevation and moderate exercise.

If tendon transfers are performed while there is still tissue inflammation as marked by lack of free skin mobility, elevated local temperature, and hand volume, the postoperative inflammation is likely to be more severe and the adhesions around transferred tendons more difficult to resolve.

The patient must have time before surgery to learn about and understand the implications of the operation and to identify the muscle and tendon to be transferred, so that there may be no loss of time in the critical period after the postoperative cast is removed.

Timing of surgical intervention is more difficult if the nerve has been repaired and is in process of recovery. Too many surgeons assume that they have to wait until they are absolutely certain that no recovery is possible before they decide to operate for restoration of muscle balance. They are afraid of some recovery occurring after they have performed a tendon transfer and of being told that their operation was unnecessary and possibly harmful.

The treatment plan is dominated more by the fear of lawsuits than by the good of the patient. The correct approach to this problem is first to make a realistic estimate of the probability of good recovery of the involved muscles, recognizing that muscle recovery is good if the nerve repair is accurate and without tension, and is in the same limb segment as the affected muscle. The likelihood of good recovery is fair if the nerve injury and repair is in the limb segment proximal to the muscle, and it is poor if the injury is two segments proximal. An ulnar nerve division above the elbow, for example, rarely results in good recovery of the intrinsic muscles in the hand. A median nerve above the elbow has a slightly better likelihood of recovery, but the secondary stiffness and contracture that results from the necessary 1- to 2-year wait to make sure is more harmful than any disability that may result from an early transfer followed 1 or 2 years later by recovery of the thenar muscles.

If an operation is to be performed early although later recovery is possible, it is wise to select a tendon for transfer that will not leave a significant defect by its loss from the donor site. For example, in a high median palsy, although the thumb is fully mobile passively, it is appropriate to use the extensor indicus proprius around the ulnar

border of the wrist to restore abduction to the thumb. This muscle might be inadequate if it had to oppose contracted tissues and a negative pattern of use after 1 or 2 years. Similarly, a palmaris longus, extended by free grafts through the carpal tunnel, is appropriate for a new case of intrinsic palsy of the fingers before the support of the volar plates and other tissues is lost by being stretched and before the interphalangeal joints become stiff in flexion.

The whole situation must be fully explained to the patient and the pros and cons offered in writing so that the patient may understand and choose between the possible harm of operating early and the more probable harm of waiting until much later.

## CHAPTER REFERENCES

Each reference is categorized according to the following scheme: *, classic article; #, review article; !, basic research article; and +, clinical results/outcome study.


# 1. Brand PW. *Clinical Mechanics of the Hand.* St. Louis: CV Mosby, 1985.

! 2. Brand PW, Beach RB, Thompson DE. Relative Tension and Potential Excursion of Muscles in the Forearm and Hand. *J Hand Surg* 1981;6:209.

+ 3. Yahr MD, Beebe GW. Recovery of Motor Function. In: Woodhall B, Beebe GW, eds. *Peripheral Nerve Regeneration: A Follow-up Study of 3656 World War II Injuries (V.A. Medical Monograph).* Washington, D.C.: U.S. Government Printing Office, 1956:13.

# CHAPTER 55

# RADIAL NERVE PALSY

*Larry K. Chidgey and Robert M. Szabo*

**L. K. Chidgey:** Orthopaedic Department, University of Florida, Gainesville, Florida, 32610.
**R. M. Szabo:** Department of Orthopaedics and Plastic Surgery, University of California, Davis Health System, Sacramento, California, 95817.

Anatomy
Principles of Treatment
Surgical Techniques
Standard or Flexor Carpi Ulnaris Transfer
Flexor Carpi Radialis Transfer
Modified Boyes Transfer
Posterior Interosseous Nerve Palsy
Early Tendon Transfers
Postoperative Care
Pitfalls and Complications
Chapter References

Radial nerve palsy most frequently results from penetrating injuries to the lower arm and the upper forearm and from fractures of the middle to distal third of the humerus. The major functional impairment is an alteration in the ability to grasp and release.

Riordan separated grasp into three phases (28):

- Phase 1 constitutes opening the hand widely and requires the long extensors of the fingers and the thumb, abduction of the first metacarpal, and intrinsic muscle action.
- Phase 2 involves surrounding the object and requires combined long flexors and intrinsic action.
- Phase 3 is gripping the object between the fingers and the palm or between the fingers and the thumb and requires strong action of the long flexors. Phase 3 also requires stabilization of the wrist by the wrist extensors to prevent the strong finger flexors from pulling the wrist into flexion, causing a loss in power grip strength. Opening the hand for release requires the long extensors and the intrinsic muscles to perform as in phase 1 of grasp. In high radial nerve palsy, grasp phases 1 and 3 and the ability to release are severely impaired. In posterior interosseous nerve palsy, at least one of the radial wrist extensors is intact for wrist stability during phase 3 of grasp, and only grasp phase 1 and release are affected. Reconstruction for radial nerve palsy is directed at rebalancing the grasp-release mechanism necessary for normal hand function.

## ANATOMY

The radial nerve (Fig. 55.1) originates from the posterior cord of the brachial plexus. Contributing nerve fibers can be traced from the fifth through the eighth cervical roots, with the largest contribution usually from the seventh. The nerve enters the upper arm posteriorly, accompanying the deep brachial artery between the long and medial heads of the triceps. The radial nerve does not travel in the spiral groove of the humerus but lies instead on the upper part of the medial triceps, separated from the underlying bone by a layer of muscle approximately 3.4 mm thick (40). The nerve is in direct contact with the humerus only in the distal arm, where it pierces the lateral intermuscular septum.

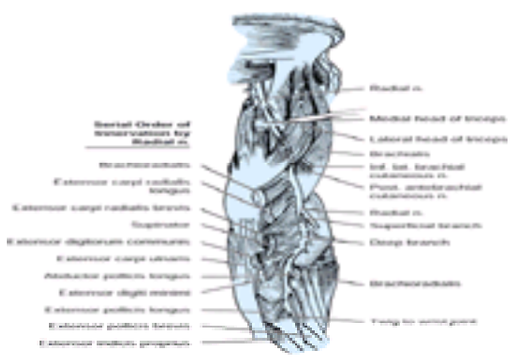

***Figure 55.1.*** The radial nerve is shown as it courses through the arm and forearm. (Modified from Hollinshead WH. *Anatomy for Surgeons,* Vol 3. The Back and Limbs, 3rd ed. New York; Harper & Row, 1982, with permission)

Innervation of the triceps varies. Linell suggested four branches to the triceps: a branch to the long head arising about 7.1 cm below the tip of the acromion, a branch to the medial head arising about 9.5 cm below the acromial tip, the nerve to the lateral head arising about 10.1 cm, and another larger branch to the medial head about 11.2 cm below the acromial tip (19). Sunderland reported more variability, with 5 to 10 branches typically found (36). Because the branches to the triceps arise high in the arm, paralysis of the triceps from a fracture of the humerus is unlikely.

The radial nerve pierces the lateral intermuscular septum about 10 cm proximal to the lateral epicondyle and enters the anterior arm between the brachialis and the brachioradialis. The motor branches to the brachioradialis and the extensor carpi radialis longus are given off in this area above the elbow. A branch is often extended to the brachialis, but the predominant innervation of this muscle is the musculocutaneous nerve (29).

The radial nerve divides into a superficial and deep branch at about the level of the lateral epicondyle. The level of bifurcation varies from 4.5 cm above the lateral epicondyle to 4 cm below, with division at or below the epicondyle more common (19). At about this same level, the radial nerve gives a branch to the extensor carpi radialis brevis. Salsbury found this branch to arise from the superficial branch of the radial nerve in 56% of specimens, from the deep branch in 36%, and from the angle formed by the two in 8% (29). With the exception of the frequent branch to the extensor carpi radialis brevis, the superficial branch of the radial nerve is purely sensory.

After the bifurcation of the superficial and deep branches, the superficial branch continues distally and dorsally under the cover of the brachioradialis. It emerges from under this muscle at the junction of the middle and distal thirds of the forearm to continue subcutaneously along the dorsoradial aspect of the forearm to supply skin on the lateral part of the dorsum of the wrist and hand.

The deep branch of the radial nerve is often referred to as the posterior interosseous nerve. Its function is purely motor, except for several branches to the wrist joint at its most terminal extent, which are sensory. The posterior interosseous nerve passes from the proximal anterior forearm to the posterior forearm through the supinator muscle, which it innervates. The proximal margin of the supinator forms a fibrous arch, referred to as the arcade of Frohse, through which the nerve passes (12).

The posterior interosseous nerve exits the supinator approximately 8 cm below the elbow joint, and it immediately divides into multiple branches. Spinner observed that the branches seem to be arranged into two major groups (34). The first group supplies the superficial layer of extensor muscles (the extensor digitorum communis, extensor digiti minimi, and extensor carpi ulnaris), and the second group supplies the deep layer (the abductor pollicis longus, extensor pollicis longus and brevis, and

extensor indicis proprius). The serial order of innervation varies, but it usually follows a proximal to distal pattern (Fig. 55.1).

## PRINCIPLES OF TREATMENT

Tendon transfers for radial nerve palsy have been considered relatively predictable and reproducible. Some surgeons have advocated early definitive tendon transfers to the exclusion of neurolysis or neurorrhaphy for a high radial nerve lesion or a segmental nerve defect (2,7). We think this approach denies the patient a potentially superior result.

Civilian nerve injuries resulting in neurapraxia or axonotmesis have a high recovery rate (1). If recovery is delayed, neurolysis becomes extremely valuable. Functional return after neurolysis in neurapraxia or axonotmesis can be excellent. The myelin sheaths are still intact or at least properly aligned, allowing selective reinnervation of the muscles by the same regenerating axons as before injury. This reinnervation restores independent control of the individual muscles, a characteristic that is never achieved with primary nerve repair, nerve graft, or tendon transfers.

After neurotmesis, return of at least some muscle function after primary radial nerve repair or nerve grafting can be expected in 77% of patients (21). Even if the return in muscle function is limited, the result is often superior to that achieved by tendon transfers alone when combined with definitive tendon transfers. Therefore, initial emphasis should be placed on the nerve injury.

Initial treatment of radial nerve palsy depends on the nature and severity of the inciting injury. Closed injuries, such as crush injuries, low-velocity gunshot wounds, and closed fractures, result in neurapraxia or axonotmesis, and they should simply be observed initially. In open injuries, such as open fractures and lacerations, the nerve should be explored during the initial irrigation and debridement of the wound.

The reported incidence of high radial nerve palsy associated with humeral shaft fractures is 2% to 15% (8,13,14,17,18,20,23,25,31,33). Several factors influence prognosis for patients with such fractures. Partial paralysis indicates continuity of the nerve and is a good prognostic sign. Functional recovery can be expected. Kaiser et al. believe that a comminuted, middle-third fracture of the humerus with immediate onset radial nerve palsy offers the poorest prognosis for nerve recovery (17). This poor prognosis is related to the high energy involved in this fracture. They suggest early exploration of nerves with this fracture pattern.

Holstein and Lewis suggested that a spiral oblique fracture of the distal humerus places the radial nerve at particular risk for entrapment in the fracture site (14). They think early exploration is indicated if this fracture pattern is associated with a radial nerve palsy. In contrast, Pollock and colleagues, who noted a 92% spontaneous recovery rate irrespective of the fracture pattern, recommend initial observation in all closed humerus fractures with associated radial nerve palsy (25). If nerve function shows no signs of improvement in 3 to 4 months, explore the nerve with neurolysis or neurorrhaphy. In a more recent study, Foster et al. examined a series of 14 patients with radial nerve palsy caused by open humeral shaft fractures. The nerve was either lacerated or interposed in the fracture in 64% of patients (11).

Our experience suggests spontaneous recovery in most fractures. For all closed fractures of the humerus associated with a radial nerve palsy, we treat the nerve injury expectantly if the fracture can be reduced closed. Most patients can be expected to recover in 1 to 4 months. In 3 to 4 weeks, if recovery has not begun, assess the extent of the nerve damage by electromyography. If no neurologic recovery is observed in 3 to 4 months, we explore the nerve with neurolysis or neurorrhaphy. If reduction is blocked by any soft-tissue interposition, especially if the fracture is of the distal spiral oblique type, we explore the nerve and reduce and internally fix the fracture.

If manipulation results in an acute radial nerve palsy of immediate onset, early exploration should be considered. Radial nerve palsies that are delayed in onset, even after manipulation, may be observed. In open fractures, the nerve should be explored during irrigation and debridement of the fracture. Repair nerves and fix rigid fractures. Repair segmental defects with interfascicular grafts. Functional nerve return can be expected in as many as 77% of patients (21).

We have observed return of muscle function, even after grafting defects as large as 15 cm. As a general rule, nerve regeneration progresses at a rate of 1 mm per day (32). Lesions above the elbow may progress at a slower rate. After giving up on a nerve repair, we have occasionally been surprised to find some muscle function return several months after that predicted by the 1-mm-per-day formula.

The importance of maintaining supple joints free of deformity cannot be overemphasized. Use splints and physical therapy while awaiting nerve recovery and before considering tendon transfers. Splinting must be individualized. A simple palmar cock-up splint may increase the grip strength 3 to 5 times (9). Most patients are well served by such a splint. A patient requiring greater excursion of the fingers may prefer a dynamic splint with extension assists for the wrist and metacarpophalangeal joints (Fig. 55.2) (24,37,38).

***Figure 55.2.*** A dynamic splint with an extension assist for the wrist metacarpophalangeal joints of the fingers and abduction or extension assist for the thumb are shown.

## SURGICAL TECHNIQUES

The surgeon considering the operative treatment of a patient with radial nerve palsy should be familiar with the fundamental principles of tendon transfers and biomechanics (see Chapter 54). In selecting radial nerve transfers, approach each patient individually, with attention to age, occupation, and recreational goals. Become familiar with the limitations and uses of the different available transfers (Table 55.1). The transfers discussed here assume an isolated radial nerve palsy.

| | Transfer | Advantages | Disadvantages |
|---|---|---|---|
| "Standard" transfer | PT → ECRB<br>FCU → EDC<br>PL → reinserted EPL | Requires little retraining<br>Predictable | Unable to extend fingers and wrist simultaneously<br>Dominance of radial forces across the wrist |
| FCR transfer | PT → ECRB<br>FCR → EDC<br>PL → reinserted EPL | Maintains FCU as an ulnar wrist flexor—important in heavy labourer | Unable to fully extend fingers & wrist simultaneously |
| Modified Boyes transfer | PT → ECRB<br>FDS III → EDC<br>FDS IV → EIP & EPL<br>FCR → APL & EPB | Able to extend wrist and fingers simultaneously; independent control of index and thumb from other fingers for pinch | Potential flexion or extension deformities of the donor finger PIP joints<br>Transfer not synergistic with potential for difficult rehabilitation<br>Potential for adhesions at interosseous membrane |

ECRB, extensor carpi radialis brevis; PT, pronator teres; EDC, extensor digitorum communis; FCU, flexor carpi ulnaris; PL, palmaris longus; EPL, extensor pollicis longus; FCR, flexor carpi radialis; APL, abductor pollicis longus; EPB, extensor pollicis brevis; EIP, extensor indicis proprius; FDS III, flexor digitorum superficialis to the long/ring/ring; FDS IV, flexor digitorum superficialis to the ring/ring/ring

***Table 55.1. Transfers for Radial Nerve Palsy***

In planning incisions for tendon transfers, consider the resulting effects on tendon gliding from the adhesions that inevitably form. Avoid longitudinal incisions along the

path of the transfer, which tend to form adhesions through their entire length between the transferred tendon and the overlying fascia and skin. Incisions passing directly over tendon junctures are especially troublesome and may inhibit the transferred tendon from gliding. Make small transverse incisions to mobilize muscle-tendon units if the unit is freely dissectible from its surrounding structures. If the muscle to be transferred requires significant dissection, avoid incisions that run in a direct line with the proposed path of the transfer. The skin is fairly mobile in the forearm, and adequate exposure can often be obtained by simple retraction without extensive skin incisions.

Little controversy exists in regard to choosing the motor tendons to restore wrist extension. Transfer the insertion of the pronator teres to the extensor carpi radialis brevis at its musculotendinous junction. Avoid the dual insertion of the pronator teres to the extensor carpi radialis brevis and extensor carpi radialis longus (3,4,9). Brand described the biomechanical reasons for avoiding dual insertion (6).

Consider both radial wrist extensors as ropes attached to two different-sized pulleys on the same shaft (Fig. 55.3). If each rope is wrapped around its respective pulley and pulled separately, more rope unwraps from the larger pulley, which has a larger moment arm. If the two ropes are tied together and tension is placed on the knot, the rope around the larger pulley (larger moment arm) becomes loose because a longer length of rope is pulled off the larger pulley than the smaller one. The rope to the smaller pulley remains tight and is therefore the only one effective in turning the shaft. The extensor carpi radialis longus has a smaller moment arm for wrist extension than does the extensor carpi radialis brevis. With insertion of the pronator teres into both radial wrist extensors, as the pronator teres begins to contract, the extensor carpi radialis brevis with its larger moment arm for wrist extension becomes slack, and the extensor carpi radialis longus provides the only effective wrist extensor.

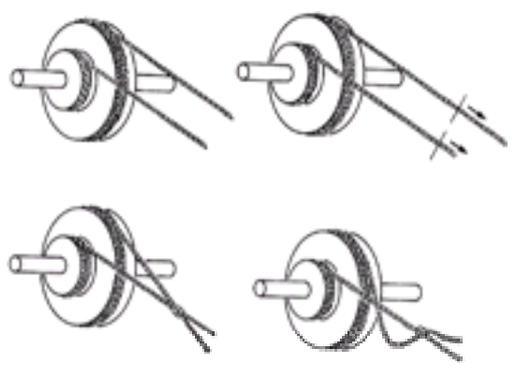

***Figure 55.3.*** **A:** Two ropes are attached to two different-sized pulleys on the same shaft. **B:** If each rope is pulled separately, more rope unwraps from the larger pulley. If the two ropes are tied together (**C**) and tension is placed on the knot (**D**), the rope around the larger pulley will become loose because a longer length of rope is pulled off the larger pulley than the smaller one. The rope to the smaller pulley remains tight and is the only one effective in turning the shaft. (From Brand PW: *Clinical Mechanics of the Hand.* St. Louis: C.V. Mosby, 1985, with permission.)

Wrist extension will be weaker than if the pronator teres had only been transferred to the extensor carpi radialis brevis. The extensor carpi radialis longus has a larger moment arm for radial deviation of the wrist than for wrist extension, and with a dual insertion of the pronator teres, attempted wrist extension results in significant radial deviation.

**STANDARD OR FLEXOR CARPI ULNARIS TRANSFER**

In older patients and in those who are difficult to rehabilitate or have less need for independent digital control, use what is known as the standard or flexor carpi ulnaris (FCU) transfer (15,16,28,30). Transfer the pronator teres to the extensor carpi radialis brevis for restoration of wrist extension; the flexor carpi ulnaris around the ulnar side of the forearm to the extensor digitorum communis for finger extension; and the palmaris longus to the rerouted extensor pollicis longus for thumb extension and abduction. One disadvantage of this set of transfers is the inadequate excursion of the flexor carpi ulnaris to accommodate wrist and finger extension. The patient is unable to extend the wrist fully and the fingers at the same time. Brand also pointed out the dominance of radial forces after this transfer (6). We have not found this a significant problem among carefully selected patients. The flexor carpi ulnaris transfer for finger extension has been the most reproducible of such transfers. A recent report from Roslein and Wilgis demonstrated that six patients were doing well at an average of 8 years after an FCU transfer (27). If the palmaris longus is not available, use the flexor digitorum superficialis to the ring finger, which is divided between the $A_1$ and $A_2$ pulleys.

- The incisions for the flexor carpi ulnaris transfer are shown in Figure 55.4. Under tourniquet control, expose the pronator teres insertion through a 7 cm longitudinal midaxial incision (incision 1) over the middle third of the radius while the forearm is held in neutral rotation.

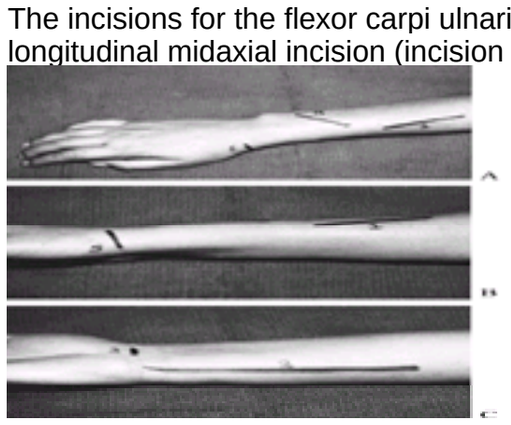

***Figure 55.4.*** Incisions for the flexor carpi ulnaris (standard) transfer are shown. **A:** Dorsal incision. **B:** View of ulnar side. **C:** Palmar view.

- Identify the insertion of the pronator teres by developing the interval between the brachioradialis and the extensor carpi radialis longus, carefully protecting the sensory branch of the radial nerve. Even in radial nerve palsy, trauma to the sensory branch may produce a painful neuroma. The insertion of the pronator teres is predominantly muscular, with very little tendinous component.
- To gain sufficient tendon length, elevate the pronator teres off the radius with a 3 cm strip of periosteum (Fig. 55.5). The periosteum in adults is thin, and this strip is usually small; handle it with care (Fig. 55.6).

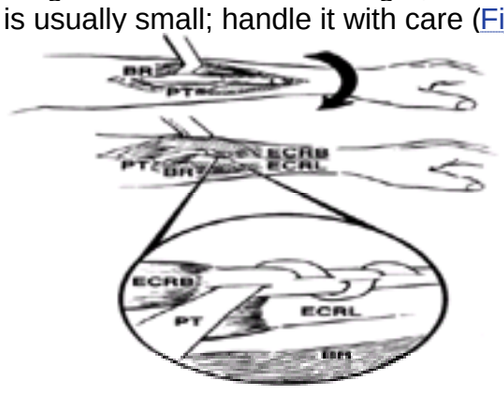


***Figure 55.5.*** Pronator teres (PT) to extensor carpi radialis brevis (ECRB) transfer is illustrated. The pronator teres is elevated off its radius insertion with a 3 cm strip of periosteum and then passed superficial to the brachioradialis (BR) and the extensor carpi radialis longus (ECRL).

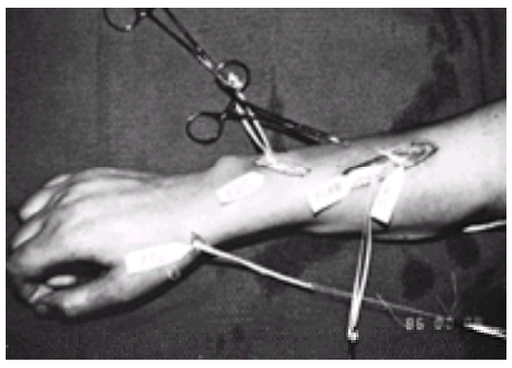

***Figure 55.6.*** In adults, the strip of periosteum elevated off of the radius with the pronator teres (PT) is thin and should be handled with care.

- Bring the pronator teres out proximally from underneath the rachioradialis, and pass it superficially over the brachioradialis and extensor carpi radialis longus to the extensor carpi radialis brevis. Simply pronate the forearm to expose the extensor carpi radialis brevis. The periosteal strip of the pronator teres will later be woven through the extensor carpi radialis brevis tendon just distal to the musculotendinous junction. Mobilize all the muscle-tendon units, however, before completing any junctures.
- To expose the flexor carpi ulnaris (Fig. 55.7*A*), make a longitudinal incision (incision 2) along the palmar ulnar forearm directly overlying the flexor carpi ulnaris muscle belly. Distally, start the incision at the proximal wrist crease just proximal to the pisiform. Continue the incision proximally to the junction of the middle and proximal thirds of the forearm.

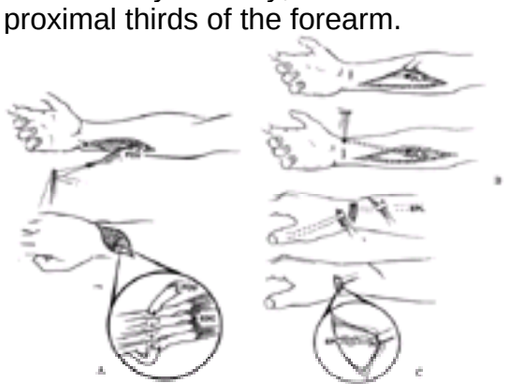

***Figure 55.7.*** The flexor carpi ulnaris transfer is shown. **A:** The flexor carpi ulnaris (FCU) is mobilized and tunneled subcutaneously around the ulnar border of the forearm. The flexor carpi ulnaris tendon is passed through a slit in each of the extensor digitorum communis (EDC) tendons in a proximal-ulnar to distal-radial direction at a 45° angle proximal to the dorsal retinaculum. The palmaris longus (PL) is mobilized (**B**) and tunneled subcutaneously to meet the rerouted extensor pollicis longus (EPL)(**C**), providing simultaneous extension and radial abduction to the thumb. The pronator teres is transferred to the extensor carpi radialis brevis for wrist extension.

- Place a tag suture in the flexor carpi ulnaris tendon, and detach it from its insertion on the pisiform. Use the tag suture to provide traction on the tendon and to mobilize the flexor carpi ulnaris from its underlying extensive origin from the ulna and its overlying origin from the fascia. Stop this mobilization 5 cm distal to the flexor carpi ulnaris origin to avoid damaging its innervation from the ulnar nerve.
- Expose the extensor digitorum communis tendons through a 3 cm oblique incision (incision 4) in the distal forearm, cutting in a proximal–radial to distal–ulnar direction. Tunnel a tendon passer subcutaneously from the ulnar margin of incision 4 to the proximal extent of incision 2. With this tendon passer, bring the flexor carpi ulnaris subcutaneously around the ulnar side of the forearm to lie along the ulnar aspect of the extensor digitorum communis. If the bulk of the distal muscle belly of the flexor carpi ulnaris in its new position seems excessive, bring it out of its tunnel and trim it from its tendon.
- If a palmaris longus exists, transfer it to the rerouted extensor pollicis longus (see Fig. 55.7*B*). Reroute the extensor pollicis longus tendon subcutaneously along the radial border of the wrist, enabling the transfer to extend and radially abduct the thumb.
- Expose the palmaris longus distal insertion into the palmar fascia through a 1 cm transverse incision (incision 3) at the proximal wrist crease. Expose the proximal tendon and muscle belly of the palmaris longus through the proximal portion of incision 2. Divide the palmaris longus tendon distally, and deliver it into the proximal portion of incision 2.
- Make a 2 cm transverse incision (incision 5) over the radial aspect of the wrist just distal to the radial styloid, and expose the extensor pollicis longus tendon in the dorsal extent of this incision.
- Identify and divide the extensor pollicis longus tendon proximal to the dorsal retinaculum (incision 4), and deliver this tendon from its dorsal compartment into incision 5.
- Tunnel a tendon passer subcutaneously from incision 5 to the proximal extent of incision 2, and deliver the palmaris longus tendon across the palmar aspect of the forearm into incision 5 to meet the rerouted extensor pollicis longus. Deflate the tourniquet, achieve hemostasis, and close incisions 2 and 3.
- Make the junction between the pronator teres and the extensor carpi radialis brevis last, because the tenodesis effect caused by flexing and extending the wrist is used to make sure the tension of the finger and thumb transfers are appropriate and produce synchronous motion. The juncture of the periosteal strip of the pronator teres to the extensor carpi radialis brevis may be tenuous and intolerant of the repeated wrist manipulations involved with setting the tension of the finger and thumb transfers.
- For the flexor carpi ulnaris to extensor digitorum communis transfer, we prefer an end-to-side juncture rather than an end-to-end juncture. Some patients have demonstrated improved motor function return even a few years after injury. Dividing the extensor digitorum communis tendons for an end-to-end juncture deprives the patient of a potentially superior result if any motor function returns after the transfers have been completed.
- Pass the flexor carpi ulnaris tendon through a slit in each of the extensor digitorum communis tendons in a proximal–ulnar to distal–radial direction at a 45° angle (Fig. 55.7*A*). Determine the site where the flexor carpi ulnaris is passed through the extensor digitorum communis tendons by fully flexing the wrist and fingers to make sure the juncture is proximal enough to remain unrestricted by the dorsal retinaculum. Suture each extensor digitorum communis tendon individually to the flexor carpi ulnaris with 4-0 nonabsorbable braided Dacron.
- The tension under which the transfers are sutured is critical. Set the tension by placing the metacarpophalangeal joints and the wrist joint in full extension, and suture the flexor carpi ulnaris tendon under slight tension.
- For the palmaris longus to extensor pollicis longus transfer, place the thumb, interphalangeal, and metacarpophalangeal joints in full extension and the carpometacarpal joint in full radial abduction. Weave the palmaris longus tendon three times through the extensor pollicis longus tendon and suture it with 4-0 nonabsorbable braided Dacron, as described by Pulvertaft (Fig. 55.7*C*) (26). Pull the palmaris longus tendon distally under mild tension while completing this juncture. Move the wrist, fingers, and thumb through a full range of motion to ensure that motion is synchronous and no restrictions are caused by the junctures.
- Set the tension for the wrist transfer by placing the wrist joint in maximal extension. Pull the pronator teres under slight tension to the extensor carpi radialis brevis tendon just distal to the musculocutaneous junction. Weave the pronator teres through the extensor carpi radialis brevis tendon, and suture it in place (Fig. 55.5).
- Assess the tension of all the transfers again by rotating the wrist through a range of motion. With the fingers fully extended with flexion of the wrist and with the fingers flexed into the palm with extension of the wrist, a synchronous tenodesis effect should be observed.
- In older patients or in patients who may be difficult to reeducate, suture the musculotendinous units under moderate tension to provide an extra component of sensory feedback through the stretch reflex.
- Close the remainder of the wounds while maintaining the wrist and fingers in maximal extension and the thumb in maximal extension and radial abduction. Apply dressings and splints as described under “Postoperative Care.”
- If the palmaris longus is not available, use the flexor digitorum superficialis tendon to the ring finger to the rerouted extensor pollicis longus for thumb extension and abduction. Make a 1 cm transverse incision in the distal palm over the fourth metacarpophalangeal joint, and divide the flexor digitorum superficialis tendon between the $A_1$ and $A_2$ pulleys. Deliver the tendon into the middle forearm through incision 2, and tunnel it subcutaneously into incision 5 to meet the rerouted extensor pollicis longus. The juncture and tension are identical to those described for the palmaris longus transfer.

## FLEXOR CARPI RADIALIS TRANSFER

Patients who wish to return to heavy labor may have difficulty if the flexor carpi ulnaris is sacrificed for transfer. The flexor carpi ulnaris is a strong ulnar deviator and an important wrist stabilizer, and it is necessary for activities like hammering. In these patients, select the flexor carpi radialis to provide finger extension (5,35,39). The flexor carpi radialis also has a greater excursion than the flexor carpi ulnaris (6). This allows more extension of the fingers with wrist extension.

- For wrist extension, use the pronator teres to extensor carpi radialis brevis, which is exposed through a 7 cm longitudinal midaxial incision (incision 1) (Fig. 55.8) along the middle third of the forearm, as previously described.

***Figure 55.8.*** **A, B:** Incisions for the flexor carpi radialis transfer.

- Expose the insertion of the flexor carpi radialis and palmaris longus through a 1 cm transverse incision (incision 2) at the proximal wrist crease, extending from the radial side of the flexor carpi radialis tendon to the radial side of the palmaris longus. Avoid damaging the palmar cutaneous branch of the median nerve with this incision.
- Expose the proximal muscle bellies of the flexor carpi radialis and palmaris longus through a 3 cm transverse palmar incision (incision 3) at the level of the junction of the proximal and middle thirds of the forearm. Divide the tendons of the flexor carpi radialis and palmaris longus distally, free both of these muscle–tendon units of their fascial attachments by blunt dissection, and deliver both into incision 3 (Fig. 55.9*A*).

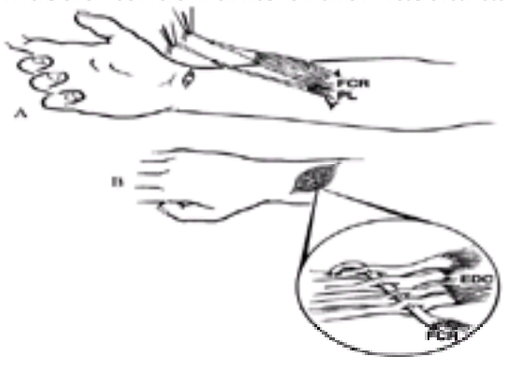


***Figure 55.9.*** The flexor carpi radialis transfer. **A:** The flexor carpi radialis (FCR) and the palmaris longus (PL) are mobilized through the same forearm incision. **B:** The flexor carpi radialis is tunneled around the radial border of the forearm and passed through a slit in each of the extensor digitorum communis (EDC) tendons to provide finger extension. The palmaris longus is transferred to the rerouted extensor pollicis longus for thumb abduction and extension, and the pronator teres is transferred to the extensor carpi radialis brevis for wrist extension.

- Expose the extensor digitorum communis tendons through a 3 cm oblique incision (incision 4) in the distal forearm, moving in a proximal–ulnar to distal–radial direction. Into this incision, tunnel the flexor carpi radialis subcutaneously around the radial side of the forearm superficial to the brachioradialis, extensor carpi radialis longus, and extensor carpi radialis brevis. Make a 2 cm transverse incision (incision 5) over the radial aspect of the wrist just distal to the radial styloid, and expose the extensor pollicis longus tendon in the dorsal extent of this incision.
- Return to incision 4, and identify and divide the extensor pollicis longus tendon at its musculotendinous junction.
- Deliver the extensor pollicis longus from its dorsal compartment into incision 5. Tunnel the palmaris longus subcutaneously from incision 3 to meet the rerouted extensor pollicis longus tendon in incision 5.
- Deflate the tourniquet, achieve hemostasis, and close incisions 2 and 3. Make the junction between the pronator teres and the extensor carpi radialis brevis last (see earlier section on standard transfer).
- Pass the flexor carpi radialis tendon through a slit in each of the extensor digitorum communis tendons in a proximal–radial to distal–ulnar direction at a 45° angle (Fig. 55.9*B*). Determine the site at which the flexor carpi radialis is passed through the extensor digitorum communis tendons by fully flexing the wrist and fingers to confirm that the juncture is proximal enough to be unrestricted by the dorsal retinaculum. Suture each extensor digitorum communis tendon individually to the flexor carpi radialis with 4-0 nonabsorbable braided Dacron. Set the tension in the flexor carpi radialis to extensor digitorum communis transfer by placing the metacarpophalangeal joints and the wrist joint in full extension. Suture the flexor carpi radialis tendon under slight tension.
- For transfers of the palmaris longus to the extensor pollicis longus and of the pronator teres to the extensor carpi radialis brevis, do exactly as described earlier under standard transfer.
- Close the remaining wounds while maintaining the wrist and fingers in maximal extension and the thumb in maximal extension and radial abduction.
- Apply dressings and splints as described under “Postoperative Care”. If the palmaris longus is not available, use the flexor digitorum superficialis tendon to the ring finger to the rerouted extensor pollicis longus for thumb extension and abduction (see description under “Standard or Flexor Carpi Ulnaris Transfer”).

**MODIFIED BOYES TRANSFER**

For young patients who may require a greater range of motion in the fingers independent of wrist motion and who are cooperative rehabilitation candidates, use a modification of the transfer described by Boyes (4,10). The flexor digitorum superficialis of the middle and ring fingers are passed through windows in the interosseous membrane to act as finger extensors. The flexor digitorum superficialis tendon of the middle finger is sutured to the extensor digitorum communis of all four fingers, and the flexor digitorum superficialis tendon of the ring finger is sutured to the extensor indicis proprius and the extensor pollicis longus.

This method provides independent control of the index finger and thumb from the other fingers for the pinch function. The flexor carpi radialis is brought around the radial side of the forearm to the abductor pollicis longus to provide thumb abduction. Boyes describes insertion of the pronator teres into the extensor carpi radialis longus and extensor carpi radialis brevis for wrist extension. We insert the pronator teres only into the extensor carpi radialis brevis for the reasons described earlier. In young patients, retraining the out-of-phase flexor digitorum superficialis to act as a finger extensor has not been a major problem.

- Under tourniquet control, expose the pronator teres insertion through a 7 cm longitudinal midaxial incision (incision 1) (Fig. 55.10) over the middle third of the radius while the forearm is held in neutral rotation.

***Figure 55.10.*** Incisions for the flexor digitorum superficialis (modified Boyes) transfer are shown. **A:** Dorsal incisions. **B:** Palmar incisions.

- Isolate and mobilize the pronator teres with a 3 cm strip of periosteum, as previously described.
- Make a 2 cm transverse incision (incision 2) in the distal palm over the third and fourth metacarpophalangeal joints, and identify the flexor digitorum superficialis tendons of the middle and ring fingers between the $A_1$ and $A_2$ pulleys (Fig. 55.11*A*).

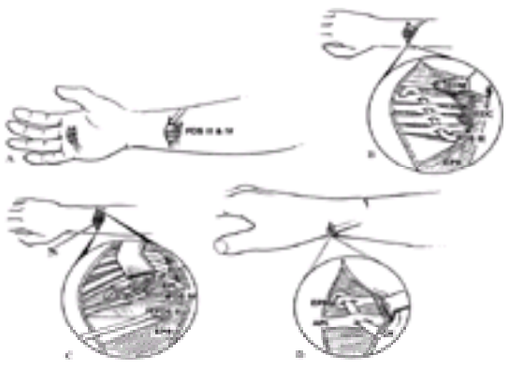

***Figure 55.11.*** The flexor digitorum superficialis (modified Boyes) transfer is shown. **A:** The flexor digitorum superficialis tendons to the long and ring fingers (FDS III and IV) are divided distally between the $A_1$ and $A_2$ pulley and delivered into the midforearm. **B:** The two flexor digitorum superficialis tendons are passed through windows in the interosseous membrane to the dorsal forearm. The flexor digitorum superficialis to the ring finger is transferred to the extensor pollicis longus (EPL) and extensor indicis proprius (EIP) to provide index and thumb extension independent of finger extension. **C:** The flexor digitorum superficialis to the long finger is passed through a slit in each of the extensor digitorum communis (EDC) tendons in a radial to ulnar direction to provide finger extension. The extensor digiti minimi (EDM) is not included in this transfer if the extensor digitorum communis tendon to the little finger is present. **D:** The flexor carpi radialis (FCR) is transferred to the abductor pollicis longus (APL) and extensor pollicis breves (EPB) to provide thumb abduction. The juncture is made distal to the dorsal retinaculum. The pronator teres to extensor carpi radialis brevis transfer provides wrist extension.

- Identify the proximal flexor digitorum superficialis muscle–tendon units through a 3 cm transverse palmar incision (incision 3) at the junction between the middle and distal forearm. Divide the flexor digitorum superficialis tendons between the $A_1$ and $A_2$ pulleys, and deliver the tendons into incision 3.
- At a level just proximal to the pronator quadratus through incision 3, excise two 1 × 2 cm openings from the interosseous membrane, one on each side of the anterior interosseous artery, taking care to protect it and the posterior interosseous artery on the dorsal side of the membrane.
- Expose the extensor digitorum communis, extensor indicis proprius, and extensor pollicis longus tendons through a 3 cm transverse incision (incision 4) just proximal to the wrist.
- Pass the divided flexor digitorum superficialis tendons through the interosseous membrane, with the superficialis tendon of the long finger passing radially between the profundus tendons and the flexor pollicis longus tendon and the superficialis tendon of the ring finger passing to the ulnar side of the profundus tendons.
- Through a 2 cm transverse incision (incision 5) at the base of the thumb, divide the flexor carpi radialis tendon just proximal to the flexor retinaculum. Through this same incision, expose the abductor pollicis longus and the extensor pollicis brevis in the first compartment.
- Deflate the tourniquet, achieve hemostasis, and close incisions 2 and 3.
- Retract the extensor digitorum communis tendons ulnarly, and weave the ring finger superficialis tendon first through the extensor pollicis longus and then through the extensor indicis proprius tendon while maintaining the index metacarpophalangeal, thumb, and wrist in extension and pulling the superficialis tendon distally under moderate tension (Fig. 55.11*B*). Make the juncture near enough to the extensor retinaculum to avoid impingement when the wrist and fingers are flexed simultaneously.
- In bringing the superficialis through the interosseous membrane, pull the tendon distal enough to present the muscle belly into the interosseous window to prevent adhesions. Pass the superficialis of the long finger through a slit in each of the extensor digitorum communis tendons in a proximal–radial to distal–ulnar direction at a 45° angle (Fig. 55.11*C*).
- Suture each extensor digitorum communis tendon individually while you bring the superficialis tendon under moderate tension distally and hold the finger metacarpophalangeal joints and wrist joint in extension.
- Weave the flexor carpi radialis through the abductor pollicis longus and extensor pollicis brevis with the thumb in full radial abduction and the flexor carpi radialis under mild tension (Fig. 55.11*D*). Rotate the thumb through a range of motion to ensure that there is no impingement of this latter juncture with the first dorsal compartment tunnel.
- Complete the pronator teres to extensor carpi radialis brevis juncture, as previously described. Close the remainder of the incisions, and apply dressings and splints as described under "Postoperative Care."

### POSTERIOR INTEROSSEOUS NERVE PALSY

In isolated posterior interosseous nerve palsy, the brachioradialis, extensor carpi radialis longus, and in most cases, the extensor carpi radialis brevis innervations are intact. A wrist extensor need not be replaced in these patients. Because all of the radial wrist extensors are intact, a significant amount of radial deviation may occur with wrist extension. In this group of patients, use the flexor carpi radialis for finger extension.

The palmaris longus or flexor digitorum superficialis of the ring finger may be transferred to the rerouted extensor pollicis longus to restore thumb extension and abduction. For patients requiring a greater range of finger motion, pass the flexor digitorum superficialis of the middle and ring fingers through windows in the interosseous membrane, to act as finger and thumb extensors. Use the flexor carpi radialis to provide thumb abduction. Sacrificing the ulnar deviating force of the flexor carpi ulnaris exaggerates radial deviation caused by the radial wrist extensors. Therefore, we do not use the flexor carpi ulnaris to obtain finger extension in posterior interosseous nerve palsy.

### EARLY TENDON TRANSFERS

Burkhalter suggests transfer of the pronator teres to the extensor carpi radialis brevis as an "internal splint" while awaiting nerve recovery (9). This transfer allows the patient to remain brace free. If neurologic return does not occur, nothing has been lost and the remainder of the definitive transfers can be completed. This transfer is useful in selected cases. Patients with a poor prognosis for relatively early nerve recovery because of a high radial nerve laceration, a large defect requiring a long graft, or a nerve graft or nerve repair performed in a less than optimal tissue bed are all considered candidates.

Some patients do not tolerate bracing because of noncompliance or job-related conditions. We also consider early pronator teres to extensor carpi radialis brevis transfer in these patients. As with any tendon transfer, early transfers cannot be considered until a full or near-full passive range of motion has been achieved and tissue equilibrium exists (3).

## POSTOPERATIVE CARE

- Immediate postoperative care is similar in each of the transfers. After the incisions have been closed, apply a bulky plaster-reinforced compression dressing that maintains the elbow at 90° of flexion, forearm in neutral, the wrist at 45° of dorsiflexion, the metacarpophalangeal, the proximal interphalangeal, and distal interphalangeal joints of the fingers at 0°, and the thumb at maximal extension and abduction. No immobilization of the fingers or thumb is required for the early transfer of the isolated pronator teres to extensor carpi radialis brevis.
- Remove the dressing 10 days postoperatively for suture removal. Apply a long arm cast, maintaining forearm, wrist, and fingers in the same position. The patient wears this cast for approximately 3 more weeks. Then change to a removable short arm splint, maintaining the wrist in 45° of dorsiflexion and metacarpophalangeal joints in 20° of flexion, and leaving the proximal and distal interphalangeal joints free. Supervised physical therapy is started at this time.
- Discontinue use of the splint 2 to 3 weeks later, unless an extensor lag at the metacarpophalangeal joints or the wrist occurs, for which nighttime splinting is continued until it resolves.

## PITFALLS AND COMPLICATIONS

Use of the flexor digitorum superficialis may produce a flexion contracture or hyperextension deformity at the proximal interphalangeal joint. Littler suggested that these deformities can be eliminated, at least to the point where no functional impairment occurs, by dividing the flexor digitorum superficialis tendon proximally between the A1 and A2 pulleys instead of at its insertion (22).

The importance of synergistic transfers becomes an issue when the flexor digitorum superficialis (a finger flexor) is transferred to the extensor digitorum communis or the extensor pollicis longus (finger extensors). Many surgeons believe that the flexor digitorum superficialis is an easy muscle to retrain, and in young patients, this seems to be true (6,10). We avoid this transfer in older patients who may have difficulty with reeducation.

## CHAPTER REFERENCES

Each reference is categorized according to the following scheme: *, classic article; #, review article; !, basic research article; and +, clinical results/outcome study.


* 1. Bateman JE. *Trauma to Nerves in Limbs.* Philadelphia: W.B. Saunders, 1982.

+ 2. Bevin AG. Early Tendon Transfer for Radial Nerve Transection. *Hand* 1976;8:134.

* 3. Boyes JH. Tendon Transfers in the Hand. Proceedings of the 15th General Assembly of the Japan Medical Congress. Medicine in Japan in 1959. 1959;5:958.

* 4. Boyes JH. Tendon Transfers for Radial Nerve Palsy. *Bull Hosp Jt Dis* 1960;21:97.

# 5. Brand PW. Tendon Transfers in the Forearm. In: Flynn JE, ed. *Hand Surgery,* 2nd ed. Baltimore: Williams & Wilkins, 1975.

# 6. Brand PW. *Clinical Mechanics of the Hand.* New York: The C.V. Mosby Company, 1985.

+ 7. Brown PW. The Time Factor in Surgery of Upper-extremity Peripheral Nerve Injury. *Clin Orthop* 1970;68:14.

+ 8. Bryer BF. Management of Humeral Shaft Fractures. *Arch Surg* 1960;81:914.

+ 9. Burkhalter WE: Early Tendon Transfer in Upper Extremity Peripheral Nerve Injury. *Clin Orthop* 1974;104:68.

* 10. Chuinard RG, Boyes JH, Stark HH, Ashworth CR. Tendon Transfers for Radial Nerve Palsy: Use of Superficialis Tendons for Digital Extension. *J Hand Surg* 1978;3:560.

+ 11. Foster RJ, Swiontkowski MF, Bach AW, Sack JT. Radial Nerve Palsy Caused by Open Humeral Shaft Fractures. *J Hand Surg* 1993;18A:121.

* 12. Frohse F, Frankel M. Die Muskeln des Menschlichen Armes. In: von Bardeleben K, ed. *Handbuch der Anatomie des Menschen,* Vol. 2. Jena: Fischer, 1908.

+ 13. Garcia A, Maeck BH. Radial Nerve Injuries in Fractures of the Shaft of the Humerus. *Am J Surg* 1960;99:625.

* 14. Holstein A, Lewis GB. Fractures of the Humerus with Radial-nerve Paralysis. *J Bone Joint Surg* 1963;45-A:1382.

* 15. Jones R. On Suture on Nerves, and Alternative Methods of Treatment by Transplantation of Tendon. *Br Med J* 1916;1:641.

* 16. Jones R. Tendon Transplantation in Cases of Musculospiral Injuries not Amenable to Suture. *Am J Surg* 1921;35:333.

+ 17. Kaiser TE, Franklin HS, Kelly PJ. Radial Nerve Palsy Associated with Humeral Shaft Fractures. *Orthopedics* 1981;4:1245.

+ 18. Klenerman L. Fractures of the Shaft of the Humerus. *J Bone Joint Surg* 1966;48-B:105.

* 19. Linell EA. The Distribution of Nerves in the Upper Limb with Reference to Variabilities and Their Clinical Significance. *J Anat* 1921;55:79.

* 20. Mast JW, Spiegel PG, Harvey JP, Harrison C. A retrospective study of 240 adult fractures. *Clin Orthop* 1975;112;254.

* 21. Millesi H, Messil G, Berger A. Further Experience with Interfascicular Grafting of the Median, Ulnar, and Radial Nerves. *J Bone Joint Surg* 1976;58-A:209.

+ 22. North ER, Littler JW. Transferring the Flexor Superficialis Tendon: Technical Considerations in the Prevention of Proximal Interphalangeal Joint Disability. *J Hand Surg* 1980;5:498.

+ 23. Packer JW, Foster RR, Garcia A, Grantham SA. The Humeral Fracture with Radial Nerve Palsy: Is Exploration Warranted? *Clin Orthop* 1972;88:34.

+ 24. Penner DA. Dorsal Splint for Radial Palsy. *Am J Occup Ther* 1972;26:46.

+ 25. Pollock FH, Drake D, Bovill EG, et al. Treatment of Radial Neuropathy Associated with Fractures of the Humerus. *J Bone Joint Surg* 1981;63-A:239.

* 26. Pulvertaft RG. Tendon Grafts for Flexor Tendon Injuries in the Fingers and Thumb. A Study of Technique and Results. *J Bone Joint Surg* 1956;38-B:175.

+ 27. Raskin KB, Wilgis EFS. Flexor Carpi Ulnaris Transfer for Radial Nerve Palsy: Functional Testing of Long-term Results. *J Hand Surg* 1995;20A:737.

# 28. Riordan DC. Tendon Transfers in Hand Surgery. *J Hand Surg* 1983;8:748.

+ 29. Salsbury CR. The Nerve to the Extensor Carpi Radialis Brevis. *Br J Surg* 1938;26:95.

+ 30. Scuderi C. Tendon Transplants for Irreparable Radial Nerve Paralysis. *Surg Gynecol Obstet* 1949;88:643.

+ 31. Seddon HJ. The Practical Value of Peripheral Nerve Repair. *Proc R Soc Med* 1949;42:427.

+ 32. Seddon HJ. *Surgical Disorders of the Peripheral Nerves,* 2nd ed. Edinburgh: Churchill-Livingstone, 1975.

+ 33. Shaw JL, Sakellarides H. Radial Nerve Paralysis Associated with Fractures of the Humerus. A Review of Forty-five Cases. *J Bone Joint Surg* 1967;49-A:899.

+ 34. Spinner M. The Radial Nerve. In: *Injuries to the Major Branches of Peripheral Nerves of the Forearm.* Philadelphia: W.B. Saunders, 1972.

* 35. Starr CL. Army Experience with Tendon Transference. *J Bone Joint Surg* 1922;4:3.

+ 36. Sunderland S. Metrical and Non-metrical Features of the Muscular Branches of the Radial Nerve. *J Comp Neurol* 1946;85:93.

* 37. Thomas FB. A Splint for Radial (Musculospiral) Nerve Palsy. *J Bone Joint Surg* 1944;26:602.

+ 38. Thomas FB. An Improved Splint for Radial (Musculospiral) Nerve Paralysis. *J Bone Joint Surg* 1951;33-B:272.

+ 39. Tsuge K, Adachi N: Tendon Transfer for Extensor Palsy of the Forearm. *Hiroshima J Med Sci* 1969;18:219.

+ 40. Whitson RO. Relation of the Radial Nerve to the Shaft of the Humerus. *J Bone Joint Surg* 1954;36-A:85.

# CHAPTER 56

# MEDIAN NERVE PALSY

*Steven M. Green*

**S. M. Green:** Orthopaedic Surgery, New York University and Mt. Sinai Medical Schools, New York, New York, 10128.

Introduction
Nonsurgical Treatment
Surgical Concepts
Tendon Transfers for Intrinsic Palsy
Flexor Digitorum Superficialis
Extensor Indicis Proprius
Extensor Digiti Quinti
Extensor Carpi Ulnaris
Palmaris Longus
Abductor Digiti Quinti (Huber Transfer)
Flexor Pollicis Longus
Tendon Transfers for Flexor Pollicis Longus Palsy
Flexor Digitorum Superficialis
Brachioradialis
Tendon Transfers for Flexor Profundus Palsy
Flexor Profundus Transfers
Extensor Carpi Radialis Brevis
Postoperative Rehabilitation
Pitfalls and Complications
Chapter References

## INTRODUCTION

Despite advances in the understanding, evaluation, and treatment of peripheral nerve disorders, surgical reconstruction for paralysis of median innervated muscles remains a common procedure. This chapter discusses the analysis of such problems and the concepts and techniques of rehabilitation.

The median nerve innervates muscles that originate within the hand (intrinsic) and those whose origin is more proximal (extrinsic). Table 56.1 lists these muscles and their primary functions. The ulnar and radial nerve may activate muscles usually innervated by the median nerve (21). These variations can lead to diagnostic confusion (11). The pronator teres and quadratus both pronate the forearm. Because the pronator teres is more effective if the elbow is extended, the individual force of these two muscles can be determined by testing the strength of pronation with the elbow in extension and then in flexion.

| Muscle | Function |
|---|---|
| Flexor Carpi Radialis (FCR) | Wrist Flexion |
| Palmaris Longus (PL) | Wrist Flexion |
| Pronator Teres (PT) | Forearm Pronation |
| Pronator Quadratus (PQ) | Forearm Pronation |
| Flexor Digitorum Superficialis (FDS) | PIP Flexion |
| Flexor Digitorum Profundus (FDP) | PIP and DIP Flexion |
| Flexor Pollicis Longus (FPL) | IP Thumb Flexion |
| Abductor Pollicis Brevis (APB) | Thumb Palmar Abduction, Pronation |
| Opponens Pollicis (OP) | Thumb Pronation |
| Flexor Pollicis Brevis (FPB) | Thumb MP Flexion |

***Table 56.1. Muscles Innervated by the Median Nerve***

The ability of the flexor digitorum superficialis (FDS) to flex the proximal interphalangeal joint of a finger is examined by holding the other digits in extension, thereby inhibiting flexor digitorum profundus function. Because the ring and small fingers often share a common muscle belly, the power of proximal interphalangeal joint flexion of these two digits should be tested both individually and simultaneously. In testing the strength of distal joint flexion, one evaluates the function of the flexor pollicis longus (FPL) and the flexor digitorum profundus. Thumb opposition is a combined motion of palmar abduction, pronation, and flexion (7). This essential thumb motion brings the thumb pulp in contact with that of one or more fingers. Although prehension is achieved by the three thenar intrinsic muscles, the abductor pollicis brevis is the most important (8,10).

Median nerve palsy is most often a result of trauma such as laceration, traction, fracture, gunshot wound, or chronic compression neuropathy. Diabetic peripheral neuropathy and viral and lepromatous infection are less common etiologies.

Median nerve palsy is frequently a rather disabling condition. Loss of active pronation adversely affects a person's ability to use a computer keyboard or a tool such as a screwdriver. Weakness of the flexor carpi radialis is rarely a problem because the flexor carpi ulnaris is innervated by the ulnar nerve and can adequately perform wrist flexion. Of greater functional importance is the loss of digital flexion of the thumb, index, and middle fingers. The ring and small fingers are less affected because their profundi are usually innervated by the ulnar nerve. Loss of opposition severely affects one's ability to grasp as well as engage in fine manipulation.

## NONSURGICAL TREATMENT

In situations in which a median palsy is expected to resolve, make efforts to maintain joint flexibility to prevent contractures. Teach the patient to perform frequent range-of-motion exercises primarily to prevent extension deformity of the finger joints and fixed adduction of the thumb. Using Velcro loop straps to tie the affected finger and a normal finger together preserves joint motion and enhances hand function as well. An opposition splint maintains the thumb–index web space and places the thumb in a more useful position. If contractures have developed, a hand therapy program is required to restore digital flexibility. Avoid dynamic traction on the thumb, which can cause stretching of the ulnar collateral ligament rather than improvement of the adduction contracture. A better method uses a static thumb–index web space splint, which is modified as abduction is obtained.

## SURGICAL CONCEPTS

A frequent etiology of median nerve palsy is chronic carpal tunnel syndrome that has caused thenar atrophy. In spite of modern microsurgical techniques, recovery of motor function after median nerve neurorrhaphy is frequently poor. Performing a tendon transfer as an internal splint simultaneous with repair of proximal median nerve injuries is useful, because permanent thenar palsy is common. An opposition tendon transfer provides early functional recovery, avoids adduction contracture, and eliminates the need for splinting. Even if the intrinsic muscles are reinnervated, the recovered strength is rarely normal.

A thumb–index web space contracture that is resistant to splinting can be corrected by release of the deformity with skin plasties or skin grafts and release of the adductor and the first dorsal interosseous muscles and, if necessary, the trapeziometacarpal joint capsule. Joint fusion places a digit in a more functional position and

is especially useful in treating palsy of the flexor digitorum profundus (provided that the FDS is of normal strength) and for weakness of the FPL. Although joint fusions are technically simple, improve dexterity, and do not require postoperative rehabilitation, they neither restore mobility nor improve weakness. Tendon transfers require more surgical skill and patient cooperation than does joint fusion, but they have the potential of providing active joint motion and regaining strength.

Although tendon transfers to restore opposition are commonplace today, it was not until 1918 that Steindler (24) suggested rerouting the FPL to restore thumb mobility. Bunnell (4), in his classic article of 1938, outlined the basic principles of opposition reconstruction and emphasized that surgery must be individualized to meet the patient's needs, because “each hand is a problem in itself.” He wrote that candidates for tendon transfer surgery must have adequate sensibility, the thumb joints should be stable, and the skin and joints must be supple.

In restoring opposition, consider the excursion and force of the tendon to be transferred, the direction of its pull, and the axis of insertion into the thumb (6) (see Chapter 54). Although it may not be possible to replace the function of several weakened intrinsic muscles fully with one tendon transfer, the replacement should match as closely as possible the normal force and excursion of the paralyzed muscles. The force generated by a muscle is proportional to its cross-sectional area, which is 6.0 $cm^2$ for the median innervated thenar intrinsics (3).

The long finger superficialis (cross section of 5.8 $cm^2$) and the extensor carpi ulnaris (ECU) (6.2 $cm^2$) most closely match the thenar forces. Although the ring finger superficialis (3.2 $cm^2$), the extensor indicis proprius (EIP) (1.7 $cm^2$), the palmaris longus (PL) (1.8 $cm^2$), and the abductor digiti quinti (2.1 $cm^2$) are frequently used for tendon transfers, their potential force of contraction is significantly less. Excursion, or the change in length between full relaxation and contraction, depends on mean fiber length, which averages 3.5 cm for the thenar muscles. This figure is surpassed by all the commonly used transfers.

In selecting a tendon for transfer, the surgeon must not substitute one imbalance for another. Choosing a strong motor may improve thumb function, but if a finger flexor is used, the improvement occurs at the expense of power grip. To produce the motion of opposition, the transfer must pull from the direction of the pisiform, paralleling the fibers of the abductor pollicis brevis (7). Transfers that use a pulley distal to the pisiform encourage metacarpal flexion at the expense of palmar abduction. The reverse is true for transfers that pull more proximal and radial to the pisiform. Unless there exists a supple subcutaneous bed through which the transfer is to be passed, the motor will not be able to transmit its force of contraction. Therefore, skin resurfacing may be required before a tendon transfer is performed. Although free skin grafts can be used in some areas, flaps are frequently necessary to provide adequate subcutaneous tissue to allow tendon excursion. Alternatively, a Silastic tendon prosthesis can be used to form an adequate pathway for eventual tendon transfer at a second stage.

The most predictable insertion is made into the tendon of the abductor pollicis brevis (13). Insertions into the ulnar base of the proximal phalanx do not produce greater rotation during opposition, and these insertions may slip about the metacarpophalangeal (MP) joint, causing unwanted extension or flexion of the proximal phalanx. Insertions into the extensor mechanism or the MP joint capsule increase thumb extension and stability, but they are recommended only for patients with combined nerve palsies in which a single insertion may result in stretching out of the thumb ulnar collateral ligament (1,2,20).

## TENDON TRANSFERS FOR INTRINSIC PALSY

### FLEXOR DIGITORUM SUPERFICIALIS (4,12,22,26)

- Incise the proximal flexor sheath, and divide the FDS (Fig. 56.1, Fig. 56.2, Fig. 56.3, Fig. 56.4, Fig. 56.5, Fig. 56.6 and Fig. 56.7). Be careful not to divide the FDS too distally, or hyperextension of the proximal interphalangeal (PIP) joint may occur.

***Figure 56.1.*** The three incisions required for an opposition transfer using the ring finger superficialis are shown.

***Figure 56.2.*** The flexor carpi ulnaris tendon stump has been created, the superficialis passed beneath the intact portion of the wrist flexor, and a subcutaneous pathway produced with the tendon passer.

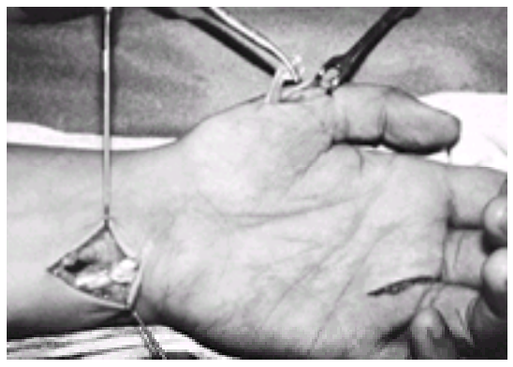

***Figure 56.3.*** The superficialis has been transferred and the tendon loop formed.

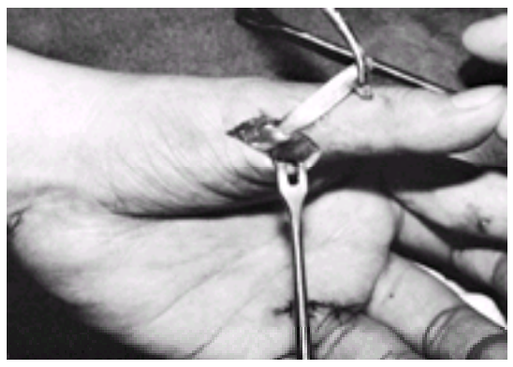

***Figure 56.4.*** The superficialis has been passed through the substance of the thenar intrinsic tendon.

***Figure 56.5.*** Lack of active opposition as a result of median nerve palsy.

***Figure 56.6.*** Same patient is shown as in Figure 56.5 after superficialis transfer (palmar abduction).

***Figure 56.7.*** The same patient is shown (opposition).

- At a point 2 cm proximal to the wrist, expose and withdraw the FDS.
- Transect the radial half of the FCU 2 cm from its insertion, leaving a distally based stump that is sutured to itself, forming a loop.
- Pass the FDS dorsal to the FCU, then through the loop of the FCU.
- Expose the intrinsic tendon on the radial side of the thumb metacarpal-phalangeal (MP) joint.
- Pass a large clamp from the thumb incision to retrieve the FDS.
- Place the thumb in opposition to the ring finger.
- Interweave the FDS into the intrinsic at half the potential excursion of the transfer.

**EXTENSOR INDICIS PROPRIUS (27)**

- Expose and divide the extensor indicis proprius (EIP) with a thin strip of radial MP extensor hood. Suture the defect in the hood.
- Withdraw the EIP just proximal to the retinaculum.
- Place a large clamp into a 2 cm incision at the distal ulnar aspect of wrist.
- Retrieve the EIP and continue as for a FDS transfer.

If the MP hood is not closed, a loss of extension is possible. This transfer is not as powerful as a FDS transfer, but it has the advantage that it does not weaken the patient's grip (6).

**EXTENSOR DIGITI QUINTI (23,25)**

- Make sure that before the extensor digiti quinti (EDQ) is divided that there is a ring—to—small communis slip (Fig. 56.8).

***Figure 56.8.*** The EDQ has been divided, and a clamp has been used to form a subcutaneous passage between the distal forearm and the thenar eminence.

- Divide the EDQ at the small finger MP and withdraw it via an additional incision proximal to the rentinaculum.
- Complete the procedure as for an EIP transfer.

**EXTENSOR CARPI ULNARIS (19)**

- Expose the distal ECU and divide it at its insertion (Fig. 56.9, Fig. 56.10, Fig. 56.11 and Fig. 56.12).



***Figure 56.9.*** The insertion of the ECU has been transsected.

***Figure 56.10.*** The extensor pollicis brevis has been divided at its musculotendinous junction and its insertion exposed.

***Figure 56.11.*** The transposed extensor pollicis brevis, without traction.

***Figure 56.12.*** The extensor pollicis brevis, with traction.

- Divide the extensor pollicis brevis at the musculotendinous juncture and bring it out at the thumb MP.
- Transfer the EPB subcutaneously across the palm and suture it into the ECU.

Insufficient ECU excursion and less-than-optimal insertion of the EPB precludes full recovery of opposition.

**PALMARIS LONGUS (5,16)**

- Through a palmar incision, dissect the PL and elongate it with palmar fascia.

- Pass the tendon subcutaneously and suture it into the APB tendon.

Although it is a useful adjunct to carpal tunnel release, PL transfer is a weak transfer that provides good abduction but poor pronation (Fig. 56.13).

***Figure 56.13.*** The palmeris longus has been exposed and prolonged with a strip of palmar fascia.

**ABDUCTOR DIGITI QUINTI (HUBER TRANSFER) (14,17)**

- Expose the entire muscle and tendon to the ADQ.
- Identify the ulnar artery or nerve and neurovascular pedicle to the ADQ.
- Divide the insertion and attachments to the FCU and pisiform.
- Turn the muscle like the page of a book, and pass it through a generous tunnel toward the thumb. Suture it into the abductor pollicis brevis (APB).

This difficult operation will be ineffective if the neurovascular pedicle is damaged or kinked (Fig. 56.14, Fig. 56.15 and Fig. 56.16).

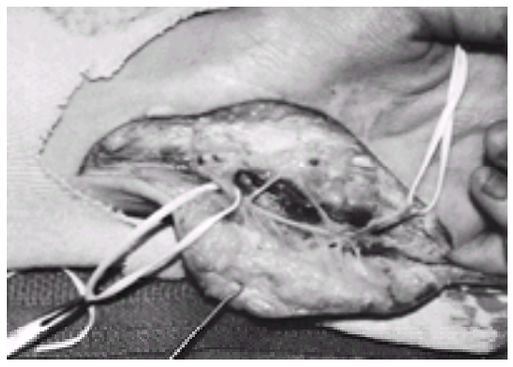

***Figure 56.14.*** The ADQ muscle has been exposed and the ulnar nerve and artery carefully dissected and retracted with vessel loops.

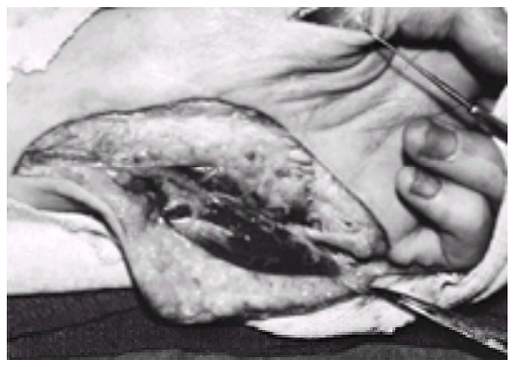

***Figure 56.15.*** The origin and insertion of the ADQ have been divided and the conjoined thenar intrinsic tendon exposed.

***Figure 56.16.*** Active palmar abduction regained after ADQ transfer.

**FLEXOR POLLICIS LONGUS (15,18,24)**

- Reroute the FPL after osteotomy of the proximal phalanx or before interphalangeal joint fusion.

Although this procedure avoids division of the FPL, palmar abduction rather than true opposition is obtained. Better results occur with FPL transfer using the FDS technique.

## TENDON TRANSFERS FOR FLEXOR POLLICIS LONGUS PALSY

**FLEXOR DIGITORUM SUPERFICIALIS**

- Expose the FPL and the FDS through a midvolar forearm incision.

- Divide the FDS and interweave it into the FPL so that the interphalangeal joint of the thumb rests in 30° of flexion.

Usually with high median palsy, the FDS is weakened and not available for transfer. Interphanlangeal fusion is more reliable.

### BRACHIORADIALIS

- Release the extensive insertion and fully mobilize the brachioradialis (BR) well up the forearm. The BR does not have equivalent excursion to the FPL and requires a large incision to release the insertion fully.
- Attach the BR tendon to the FPL with an interweave technique.

## TENDON TRANSFERS FOR FLEXOR PROFUNDUS PALSY

### FLEXOR PROFUNDUS TRANSFERS

- Expose all of the FDP tendons in the distal forearm.
- Suture side to side the weakened tendons to the active ones.

This procedure will increase distal joint mobility, but not strength. If the FDS are functioning, distal interphalangeal (DIP) joint fusions are preferable.

### EXTENSOR CARPI RADIALIS BREVIS

- Divide the extensor carpi radialis brevis (ECRB) at the 3rd metacarpal.
- Pass it through a large window in the interosseous membrane.
- Interweave into the paralyzed FDP.

A wrist extensor has significantly less excursion than the profundi, so only incomplete digital mobility is achievable.

## POSTOPERATIVE REHABILITATION

Tendon transfers require 4 weeks of constant postoperative immobilization. If the purpose of the surgery is to regain digital flexion, place the wrist in 30° of palmar flexion, the MP joint in maximal flexion, and the interphalangeal joint flexed approximately 20°. Protect opposition transfers for 1 month by immobilizing the thumb in maximal palmar abduction with the wrist in a neutral position unless an extensor was transferred. Extensor transfer requires mild wrist flexion to relieve suture line tension.

After 4 weeks, the splint can be removed and the reeducation process begun. The patient should exercise for 5 to 10 minutes every 1 to 2 hours. More prolonged activity may fatigue the transfer. Encourage active motion to activate the transfer and permit passive motion, which does not stress the tendon juncture. Gentle resistance, such as squeezing a wet sponge or crumpling a newspaper, is permitted at postoperative week 6. Muscle reeducation can be encouraged by having the patient activate both hands simultaneously. Muscle massage and biofeedback may be helpful. If after 6 weeks adequate digital motion has not been achieved, splint the MP joint in extension in order to generate more power at the interphalangeal joint.

Subsequent to opposition transfer, some patients continue to flex rather than abduct the thumb. Inhibit this tendency by splinting the interphalangeal joint in extension. Eight weeks after tendon transfer surgery, encourage the strengthening process using putty and free weights. At this time, passive stretching of the transfer can be prescribed if the resting tension of the transfer is too high or if contractures are developing.

## PITFALLS AND COMPLICATIONS

Poor functional recovery after tendon transfer usually occurs because of uncorrected preoperative joint stiffness, errors in surgical technique, or inability of the muscle to be reeducated. If adequate mobility is caused by either excessive or inadequate tension of the transfer, revision surgery can be done to alter the tension. Occasionally, disruption of the transfer occurs, which is usually the consequence of excessive loading in the first few months after surgery. If you recognize this condition, perform an expeditious repair.

Deformity of the PIP joint can occur subsequent to transfer of the FDS. If this tendon is divided close to its insertion and the volar plate is or becomes lax, a swan-neck deformity can ensue. Minimize this problem by dividing the tendon in the palm, thereby retaining the distal portion of the superficialis tendon. Although this technique minimizes PIP hypertension, the reverse complication, i.e., PIP joint flexion contracture, can occur if the patient was not instructed to extend the joint fully subsequent to transfer injury.

If the PIP joint begins to hyperextend soon after FDS is divided, use an extension block splint. Conversely, if the finger develops a flexion contracture, apply a dynamic extension splint. Loss of index MP joint extension and radial subluxation of the extensor digitorum communis are known complications of the extensor digiti propius (EIP) opposition transfer. Avoid these problems by careful closure of the extensor hood. Positioning the wrist in marked flexion after a simultaneous carpal tunnel release and tendon transfer to restore opposition can result in palmar subluxation of the median nerve and flexor tendons. Subluxation can produce scar entrapment of the nerve, bow-stringing of the flexor tendons, and a wrist flexion contracture. Excessive loss of finger extension may result after transfer of the extensor carpi radialis to the digital flexors because the excursion of a wrist motor is significantly less than that of a digital flexor. Avoid this problem by making sure that at the time of transfer, the fingers can be passively extended fully with the wrist in no more than 20° of flexion.

## CHAPTER REFERENCES

Each reference is categorized according to the following scheme: *, classic article; #, review article; !, basic research article; and +, clinical results/outcome study.


* 1. Brand PW. Tendon Grafting Illustrated by a New Operation for Intrinsic Paralysis of the Fingers. *J Bone Joint Surg* 1961;34-B:444.

+ 2. Brand PW. The Hand in Leprosy. In: Pulvertaft RG, ed. *Clinical Surgery.* Washington, D.C.: Butterworth, 1966.

* 3. Brand PW, Beach MA, Thompson DE. Relative Tension and Potential Excursion of Muscles in the Forearm and Hand. *J Hand Surg* 1981;6:209.

* 4. Bunnell S. Opposition of the Thumb. *J Bone Joint Surg* 1938;20:269.

+ 5. Camitz H. Uber die Behandlung Oppositionslahmung. *Acta Chir Scand* 1929;65:77.

+ 6. Cooney PW, Linscheid RL, Kai-Nan AN. Opposition of the Thumb: An Anatomic and Bio-mechanical Study of Tendon Transfers. *J Hand Surg* 1984;9-A:777.

# 7. Curtis RM. Opposition of the Thumb. *Orthop Clin North Am* 1974;5:305.

* 8. Duchenne GBA. Physiology of Motion (Trans. Kaplan EB.) Philadelphia: W.B. Saunders, 1959.

* 9. Huber E. Hilfsoperation bei Medianaulahmung. *Dtsch Z Chir* 1921;162:271.

# 10. Kaplan EB. *Functional and Surgical Anatomy of the Hand,* 2nd ed. Philadelphia, JB Lippincott, 1961.

# 11. Kirklin JW, Thomas CG. Opponens Transplant: An Analysis of the Methods Employed and Results Obtained in Twenty-Five Cases. *Surg Gynecol Obstet* 1948;86:213.

# 12. Krukenberg H. Lieber Ersatz des M. Oppens Pollicis. *Z Orthop Chir* 1921;42:178.

# 13. Littler JW. Tendon Transfers and Arthrodesis in Combined Median and Ulnar Nerve Paralysis. *J Bone Joint Surg* 1949;31-A:225.

* 14. Littler JW, Cooley SGS. Opposition of the Thumb and Its Restoration by Abductor Digiti Quinti Transfer. *J Bone Joint Surg* 1963;45-A:1389.

# 15. Makin M. Translocation of the Flexor Pollicis Longus Tendon to Restore Opposition. *J Bone Joint Surg* 1967;49-B:458.

# 16. Ney KW. A Tendon Transplant for Intrinsic Hand Muscle Paralysis. *Surg Gynecol Obstet* 1921;33:342.

# 17. Nicolaysen J. Transplantation Des M. Abductor Dig V bei Fehlender Oppositions—Fahigkeit des Daumens. *Dtsch Z Chir* 1922;168:133.

# 18. Oberlin C, Alnot JY. Opponensplasty through translocation of the flexor pollicis longus technique and indications. *Ann Chir Main* 1988;7:25–n31.

# 19. Phalen GS, Miller RC. The Transfer of Wrist Extensor Muscles to Restore or Reinforce Flexion Power of the Fingers and Opposition of the Thumb. *J Bone Joint Surg* 1947;29:993.

# 20. Riordan D. Tendon Transfers for Nerve Paralysis of the Hand and Wrist. In: Adams JP (ed): *Current Practice of Orthopaedic Surgery.* St. Louis: C.V. Mosby, 1964.

* 21. Rowntree T. Anomalous Innervation of the Hand Muscles. *J Bone Joint Surg* 1949;31-B:505.

* 22. Royle ND. An Operation for Paralysis of the Intrinsic Muscles of the Thumb. *JAMA* 1938;111:612.

# 23. Schneider L. Opponensplasty using the Extensor Digiti Minimi. *J Bone Joint Surg* 1969;1-A:1297.

# 24. Steindler A. Orthopaedic Operations of the Hand. *JAMA* 1918;71:1288.

# 25. Taylor R. Reconstruction of the Hand, a New Technique in Tenoplasty. *Surg Gynecol Obstet* 1921;32:237.

# 26. Thompson TC. A Modified Operation for Opponens Paralysis. *J Bone Joint Surg* 1942;24:632.

# 27. Zancolli EA. Structural and Dynamic Bases of Hand Surgery, 2nd ed. Philadelphia: J.B. Lippincott, 1979:3,11,15.

# CHAPTER 57

# ULNAR NERVE PARALYSIS

*Paul W. Brand and Anne Hollister*

**P. W. Brand:** Department of Orthopaedics, University of Washington, Seattle, Washington, 98116.
**A. Hollister:** Department of Orthopaedic Surgery, LSUMC, Shreveport, Louisiana, 71130.

Flexion and Ulnar Deviation of the Wrist
Flexion of the Ring Finger and Little Finger
Independent Flexion at the Metacarpal Joints of all Fingers
Interphalangeal Extension of all Fingers
Adduction–Abduction of all Fingers
Choice of Motor for Intrinsic Transfers
Strength
Pathway of Transferred Tendons
Fowler's or Modified Fowler's Operation
ECRL or PL Transfer
Reversal of the Metacarpal Arch
The Thumb in Ulnar Nerve Palsy
Flexor Digitorum Superficialis Transfer
FDS Transfer (Technique of Sozen)
Postoperative Care
Chapter References

Damage to the ulnar nerve can affect the following motor functions:

- Flexion and ulnar deviation of the wrist
- Flexion of the ring and little fingers
- Independent flexion at the metacarpal (MP) joints of all fingers
- Interphalangeal (IP) extension of all fingers
- Abduction–adduction of all fingers
- Adduction–flexion of the carpometacarpal joint
- Adduction–flexion of the MP joint of the thumb

## FLEXION AND ULNAR DEVIATION OF THE WRIST

High ulnar nerve palsy can result in paralysis of the flexor carpi ulnaris (FCU), the strongest muscle in the forearm. The FCU is an important element in many physical actions such as swinging an ax, hammer, or club; cutting with a knife; and pounding on a desk. Paralysis results in a general sense of weakness in a variety of actions, but there is no total loss of any action, nor is there a deformity at rest.

For this reason, most surgeons do not feel justified in performing tendon transfers to balance the wrist following high ulnar nerve palsy. For some manual workers, however, the loss of this powerful muscle is a handicap. For a carpenter, who might feel disabled by an ulnar-flexor quadrant weakness at the wrist, for example, it might be practical for the surgeon to transfer the flexor carpi radialis (FCR) to the insertion of the FCU, inasmuch as the radial-flexor quadrant is unaffected in ulnar palsy.

## FLEXION OF THE RING FINGER AND LITTLE FINGER

Flexion of the ring finger and little finger is severely weakened in high ulnar palsy, with loss of flexor profundus function in both fingers, in particular because the strength of the surviving median-supplied flexor digitorum superficialis (FDS) to the little finger is less than one-third the strength of the profundus. In the ring finger, the FDS is two-thirds the strength of the profundus, so that only two fifths of the flexor strength of the ring finger survives. The flexor weakness of the ring finger, however, is partially masked by the fact that the paralyzed ulnar-supplied part of the profundus moves to some extent with the median-supplied profundus to the middle finger. This cross-finger support is variable and only partial, because the actual muscle fibers are not shared but are linked by connective tissue, which allows some independence.

Some extrinsic flexor power remains in the ulnar two fingers; for this reason, no deformity is caused by paralysis of the long flexors. Because deformity is more obvious than functional disability, substitution is rarely offered for the paralyzed long flexors. If the weakness seems really disabling, the profundus tendons of the ring finger and little finger may be sutured side-to-side to the profundus of the middle finger in the forearm so that they move fully together. This technique does not really add strength; it merely “shares” the weakness more evenly. If one adds the tension fractions (see Chapter 54, Fig. 54.1, Fig. 54.2) of all the muscles that normally combine to flex the little finger and ring finger, including the intrinsic muscles, the total is 14.6. Of these, only 2.9—about one fifth—survive in high ulnar palsy.

Even when the deformity of claw hand has been corrected by replacing the intrinsic muscles by transfers, the total tension fraction is commonly 1.0 to 3.0, shared between four fingers. The result is a gross weakness of ulnar-side grip, only about 25% of normal strength. Yet most forearm muscles remain unparalyzed, and the forearm and hand retain at least 70% of their total tension capability.

Even when grip strength as a whole is acceptable, a specific weakness of ulnar-side grip results in a significant disability for all actions that use the width of the hand to control radial-ulnar torque. One of the most common of these actions of the hand is the use of a hammer (Fig. 57.1). All hand movements that require a twist or turn, either in a pronation-to-supination direction or in ulnar deviation, require that the object be held in such a way as to transmit a torque, by means of a *force couple.* The handle of a hammer is moved by a force couple when one force (F2) pulls upward and a simultaneous force (F1) pushes downward, with a distance between them, along the handle. The hammer head is forced down while the end of the handle may move up, or the whole hammer may move, with F1 moving more than F2. This produces a torque on the hammer proportional to the magnitude of the forces multiplied by the perpendicular distance between them.

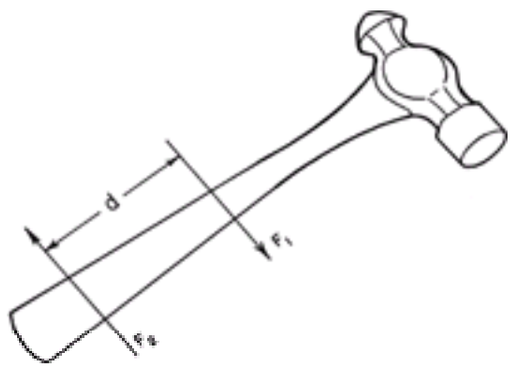


***Figure 57.1.*** To strike with a hammer, it is necessary to produce a “force couple”: Two forces move in opposite directions.

As with all forms of torque, the length of the lever arm is just as important as the amount of force. In the case of a couple, twice as much total force is needed to produce the same torque if the two components are moved 50% closer together. In a medium-sized hand, the width of an effective grip is about 10 cm (Fig. 57.2). In the same hand, if only the index and middle fingers are strong, the effective width of the hand is reduced to about 5 cm (Fig. 57.3).

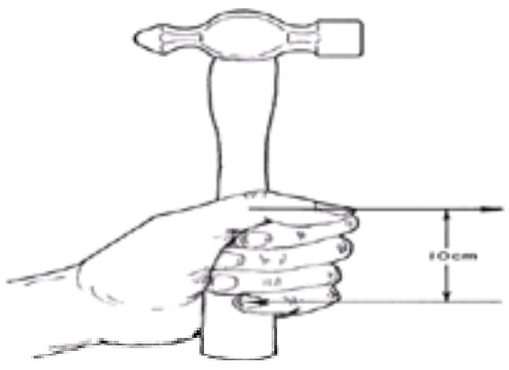


***Figure 57.2.*** A normal hand may be about 10 cm wide where it holds a hammer. In the force stroke, the thumb web pushes while the little and ring fingers pull. In retracting the hammer, the hypothenar mass pushes, and the index and middle fingers pull.

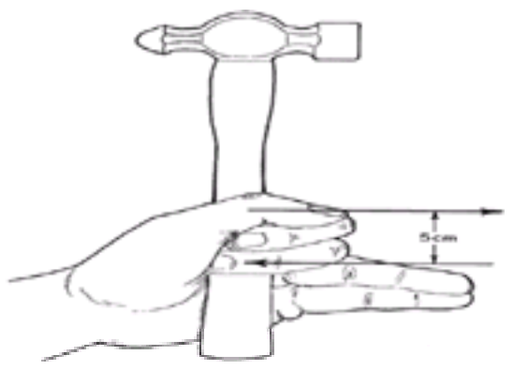

***Figure 57.3.*** In high ulnar palsy, the little and ring fingers may be so weak that only the middle finger can pull firmly enough to complete the couple. This is only half as wide as in a normal hand. The hammer is unstable and its action is weak. For many tasks involving torque, it is better to have strong index and little fingers, even if the middle finger is weak.

Even though such a hand may retain 50% of its power to grip an object, it will have only 25% of its power to turn, twist, or swing an object. The patient has difficulty describing the weakness, saying only, “I feel my hand is weak.” The dynamometer is not a measure of the dexterity strength of a hand, but only of squeeze power. Most manual tasks demand multidirectional torque, which requires a broad hand with strength at each of its borders.

A further problem associated with paralysis of the finger flexors is the reversal of the metacarpal arch, usually thought of as being caused by paralysis of the intrinsic muscles. The best muscles to control the arch, however, are those that cross the fifth carpometacarpal joint on the palmar side, thus serving as carpometacarpal flexors. These are the hypothenar muscles and the long flexors to the ring and little fingers. Brandsma has noted that patients with ulnar palsy who retain ulnar-supplied profundus rarely have severe arch reversal (W. Brandsma, Carville, Louisiana, personal communication, 1984).

Recognition of the importance of the loss of profundus in the ulnar-paralyzed hand should suggest rethinking the patterns of correction. An obvious method to increase ulnar-side grip strength is to use the extensor carpi radialis longus (ECRL) to reactivate the flexor profundus tendons to the ring finger and little finger. The muscle fibers of the ECRL are long enough to allow a good range of finger flexion with a little synergistic extension of the wrist. The ECRL is also strong enough to compensate for the ulnar profundus loss and helps to rebalance the wrist, which is relatively overpowered by the dorsal and radial side in high ulnar palsy.

## INDEPENDENT FLEXION AT THE METACARPAL JOINTS OF ALL FINGERS

The most significant functional loss in ulnar nerve palsy is independent flexion at the MP joints. This loss of flexion is important because it is the basis for the deformity of claw hand. Uncontrolled extension of the MP joints results in failure of the long extensor tendons to extend the IP joints. It also changes the sequence of flexion of the fingers, making it impossible to flex the proximal segment ahead of the distal segments. Therefore, when the hand closes on an object, the force of grasp is transmitted only through the fingertips rather than through the whole palmar surface of the fingers. High localized tip pressure results, leading to inhibition of the use of strength in sensitive fingers, or to pressure sores and injuries to fingertips in insensitive fingers (Fig. 57.4 and Fig. 57.5).

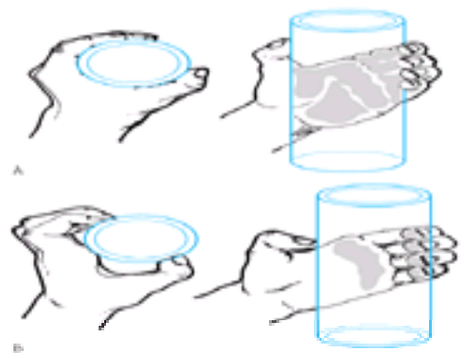

***Figure 57.4.*** **A:** Normal hand grasping a cylinder. The area of skin contact is shaded. **B:** Claw hand grasping a cylinder. The area of contact is limited to the fingertips and the metacarpal heads. (From Brand PW. *Clinical Mechanics of the Hand,* 3rd ed. St. Louis: CV Mosby, 1999:215–216.)

***Figure 57.5.*** This patient had loss of sensation from Hansen's disease. The little ulcers and scars are in the most characteristic position for a patient with functional

clawing. The high stress occurs just in front of the fingernail at the end of the phalanx. (From Brand PW. *Clinical Mechanics of the Hand,* 3rd ed. St. Louis: CV Mosby, 1999:290.)

Ulnar palsy results in MP flexion weakness in all fingers, not just in the ring and little fingers. Clawing may occur earliest and most obviously in the ulnar-side fingers, because they lose all intrinsic muscles in ulnar palsy, whereas the index and middle fingers usually have median-supplied lumbricals. The lumbricals, however, can exert only about one tenth the tension of the combined interossei. The presence of intact lumbricals may delay the onset of clawing or make it less severe; however, when the end of the finger is pushed backward, as when pinching against the thumb, the MP joint retreats into extension and the proximal interphalangeal (PIP) joints hyperflex.

This mechanism is similar to Froment's sign in the thumb. It can be tested in a patient who has no clawing of the index and middle fingers by asking her to hold the intrinsic-plus position (MP joint flexed and IP joints extended) while the examiner pushes backward with a finger against the middle of the front of the proximal phalanx of the patient's finger. If this test causes the finger to buckle into PIP flexion, weakness of the intrinsic muscles is indicated, as is a need to rebalance the finger to compensate for present weakness and to prevent clawing later.

Operations to restore MP flexion will be considered in the next section, but first let us emphasize that we are recommending the restoration of active flexion, not just the provision of a block to limit extension of the MP joints.

The *deformity* of claw hand may be easily corrected simply by providing a passive block to prevent hyperextension, thus allowing the long extensors to extend the IP joints. Surgery proposed to provide a passive block includes tenodesis, capsulodesis, bone block, or even an extensive scar on the palmar side of the MP joint. The result in each case is a beautiful, straight hand.

The real problem with ulnar palsy is *functional*, not cosmetic, in that as the hand begins to close on an object the sequence of closure is reversed. The proximal segment should flex first, followed by the distal segments, each making contact with the object and accepting a share of the load and the pressure; in ulnar palsy, the tips flex first, and the fingers curl down into the fist, tips first. Thus the object is grasped with all the pressure on the fingertips (Fig. 57.4).

## INTERPHALANGEAL EXTENSION OF ALL FINGERS

In the normal hand, the intrinsic muscles extend or help to extend the IP joints by three mechanisms:

1. Direct action of the lumbricals together with those interosseus muscles that insert into the lateral band create direct extension of the PIP and distal interphalangeal (DIP) joints. This mechanism is effective even in radial nerve palsy, which inactivates the long extensors.
2. The intrinsic muscles hold the MP joint flexed without flexing the IP joints. Thus the long extensors can be prevented from extending the MP joints, while they remain effective on the IP joints.
3. The unique action of the lumbricals pulls the profundus tendons distally (by their origins on profundus tendons), while pulling the lateral bands proximally to facilitate IP extension with MP flexion.

This third action, the weakest of the three, cannot be reproduced by tendon transfer, so we shall consider only the other two mechanisms. By bringing the tendon of any muscle across the palmar side of the intermetacarpal ligament and attaching it to the lateral band, both extension mechanisms are accomplished. Such a transfer, which flexes the MP joints and extends the IP joints, corrects both elements of the claw hand deformity (Fig. 57.6). We have found this pattern most successful.

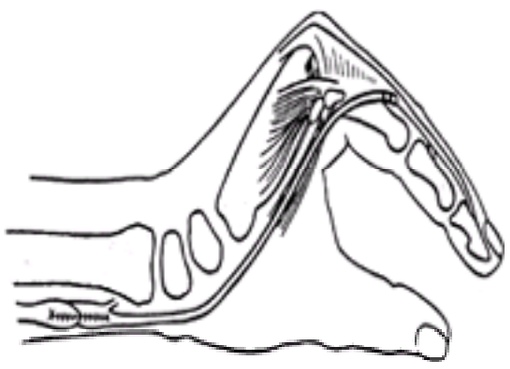

***Figure 57.6.*** Tendon transfer to correct intrinsic-minus hand. The transferred tendon or graft passes in front of the transverse intermetacarpal ligament and into the lateral band. (From Milford L. *The Hand*, 2nd ed. St. Louis: CV Mosby, 1982.)

In the normal hand, however, only part of the force of the intrinsic muscles is transferred into the lateral bands. The greater part moves directly into bone and flexes only the MP joint. Thus the fingers are free to flex at the MP joint with or without IP extension. Following tendon transfer into the lateral band, with no intrinsic transfer into the proximal phalanx, the total force of the transfer for MP flexion must also provide tension for IP extension. In hypermobile fingers, this constant pull on the lateral bands may result in a degree of progressive hyperextension of the PIP joints that can become a true swan-neck deformity—most common in cases where the FDS tendon has been removed and used for transfer to the lateral band (1). The PIP joint is thus deprived of its prime flexor, which has then become an uncontrolled extensor.

Because of this complication, we have given up using the Stiles–Bunnell transfer of the superficialis tendons for claw hand correction except in cases where the PIP joints have become so stiff in flexion, even after preoperative therapy, that hyperextension is very unlikely to develop. Do not perform attachment of any transfer for intrinsic replacement to the lateral band in fingers that have hypermobile PIP joints. In such cases, and especially in those deprived of their FDS, it is better to attach the tendon transfer to the flexor tendon sheath, as suggested by Brooks (4) and Zancolli (13,14). In such cases, the long extensors hold the IP joints in extension in the first stage of total finger flexion, although at a higher total cost of energy (because the intrinsic MP flexors must work against and overcome the MP extension moment from the extrinsic extensors).

## ADDUCTION–ABDUCTION OF ALL FINGERS

Adduction–abduction of all fingers is a function of the intrinsic muscles supplied by the ulnar nerve. The median-supplied lumbricals are weak enough and are near enough to the abduction–adduction axis of the MP joints that they have only a small active abduction capability.

Fingers should not be provided with an effective abductor (away from the midline of the hand) unless there is an effective adductor to restore the side-by-side position of all fingers. Most tasks can be accomplished by side-by-side fingers, as long as they have independent flexion and extension. Fingers that can abduct but not adduct look strange, and the projecting fingers become caught on the edges of pockets or bags and are subject to injury in the workplace.

To control both adduction and abduction, eight separate tendons are needed, one to each side of each finger. The first editions of Bunnell's famous book on hand surgery (5) described how all superficialis tendons should be split to give the required eight tendon insertions, and instructed us to transfer both slips of any one tendon to the same side of adjacent fingers.

[On a personal note (P.W.B.), while I was working in India in 1948, the first edition of Bunnell was my “bible” and I faithfully did as instructed, and my therapists struggled without success to teach my leprosy patients how to spread and adduct their fingers after surgery. Years later, I visited Bunnell and asked if I could see his results. He confessed that he had never succeeded in getting any patient to control abduction and adduction with the split-superficialis operation that formed the frontispiece of the first edition of his book. It had just seemed a sensible pattern to use. Nevertheless, I am grateful for the book.]

Unless there is an unusual need for individual control of lateral movement of fingers, we now recommend that all intrinsic replacement tendons or grafts should be

attached on the side of the finger that will pull it toward the line between the index and middle fingers. Thus, the middle, ring, and little fingers are moved radially by the insertions on their radial sides, and the index finger is moved toward the ulna by its ulnar-side insertion. The result will be that all fingers will ordinarily be held side by side. In addition, a replacement for the first dorsal interosseous muscle may be added to the radial side of the index finger, if deemed necessary (Fig. 57.7).

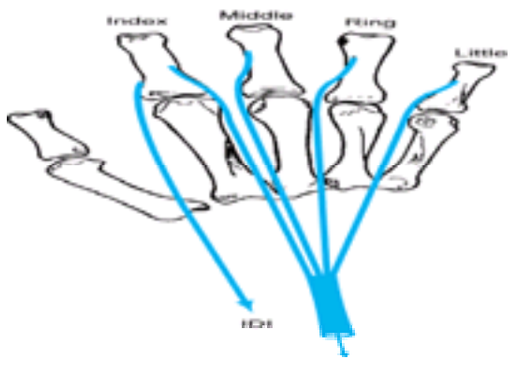


***Figure 57.7.*** For correction of ulnar paralysis, a single motor may be used for the radial side of the middle, ring, and little fingers and the ulnar side of the index finger. A separate motor may be used for the radial side of the index finger if necessary. (From Brand PW. *Clinical Mechanics of the Hand,* 3rd ed. St. Louis: CV Mosby, 1999:291.)

There are two reasons for adding an index finger abductor. The first is to facilitate spreading of the fingers, as a piano player or typist might require. This motion does not need a strong muscle, and even the extensor indicis proprius (EIP), properly rerouted, might be adequate. The second is to stabilize the index finger against the thrust of the thumb in pinch. A normal pinch is not “square,” pulp to pulp. There is at least a 30° angle between the thumbnail and the fingernail, so the transverse vector of the thumb force that pushes the finger across the palm is perhaps half as great as the vector that pushes the finger dorsalward from palmarly (Fig. 57.8*A*).

***Figure 57.8.*** **A:** Normal pinch angle of about 30° between markers on thumbnail and fingernail. Pinch is stable by action of intrinsic muscles. **B:** With index finger abducted, the angle between thumbnail and fingernail is greater, making an unstable pinch. **C:** Desirable pinch in an ulnar palsy patient. An ulnar-side intrinsic transfer to the index finger acts like a first palmar interosseous and circumducts the index MP joint so as to oppose the thumb pulp. This results in a true square pinch that needs no other intrinsic muscle support. **D:** Key pinch does not demand much intrinsic muscle support of the index finger, providing it is supported by all the fingers flexed together.

It would seem necessary, therefore, to have an index finger abductor about half as strong as the flexors. The first dorsal interosseous muscle, at a tension fraction of 3.2, is about right. The index finger has no true adduction–abduction axis, however, but moves around a variable cone (2). There is also a link between abduction and rotation. Thus, a replacement for the first dorsal interosseous will twist the finger while it abducts, so that it faces more across the palm than before, providing a pinch that is less square.

The more the first dorsal interosseous pulls, the more it increases the angle between the line of thrust of the thumb and that of the index finger (Fig. 57.8*B*). This configuration makes the pinch more unstable, requiring support by a force vector that opposes the result of the two major flexion forces of the thumb and index finger. In effect, the first dorsal interosseous muscle, by being a rotator, increases the need for itself as an abductor.

The converse of this fact is that if no replacement is made for the first dorsal interosseous muscle, but one is provided for the first palmar interosseous on the ulnar side of the finger, the result will be to twist the finger into external rotation and diminish the angle by which the index finger meets the thumb. The result of an “ulnar-side only” attachment of an intrinsic replacement to the index finger is that the thumb and index finger meet in a true square pinch, with fingernail and thumbnail parallel and with thumb flexors opposing finger flexors squarely, so that no lateral stabilization is necessary (Fig. 57.8*C*).

For these reasons, routine replacement for the first dorsal interosseous is not advised, except as a device for spreading the fingers apart. For the purposes of pinch, the first palmar interosseous (we may call it “the opponens indicis”) is all that is needed.

If the patient uses key pinch a lot, rather than a tip or pulp pinch, then there is more reason for a first dorsal interosseous replacement, since it directly supports the side of the index finger against the thumb. Even in key pinch, however, this is unnecessary if the patient usually pinches against an index finger, which is supported by all four fingers flexed together (Fig. 57.8*D*).

In most cases of paralysis of the intrinsic muscles of the hand, therefore, it is best to use one muscle only as a replacement for the intrinsics to all four fingers, and to extend it by four strands of tendon or tendon graft. Attach the tendon to the lateral band on the radial side of the middle, ring, and little fingers, and to the ulnar-side lateral band of the index finger.

## CHOICE OF MOTOR FOR INTRINSIC TRANSFERS

The total tension capability of all the intrinsic muscles to the fingers is greater than the total of the flexor profundus. Thus, it would seem that a powerful muscle would be required for each finger to replace the lost tension. In the normal hand, however, the total intrinsic tension to any finger is divided between multiple insertions, and it would lead to gross imbalance to apply that total tension to any one insertion on only one side of a finger.

Most surgeons use much less total tension, and use only one muscle, such as a single superficialis tendon, split into four strands in the proximal palm and taken to one lateral band of each finger. The ECRL (tension fraction, 3.5) is our favorite. It may be used, with a free graft split into four insertions; or two weaker muscles, such as the EIP and the extensor digiti quinti (EDQ) may be used, with two insertions each (5).

Following the experience of Fritschi (6,7), we have sometimes used the palmaris longus (PL) (average tension fraction, 1.2) with grafts to all four fingers; we have found that it does correct the claw deformity in cases that are operated on early, before bad habit patterns have developed and before the palmar plate has become grossly stretched. The advantage of using the PL is that the operation may be done immediately after any ulnar nerve injury in the arm or upper forearm with the confidence that nothing has been lost, even if the intrinsic muscles recover later. This is an important advantage. Early surgery prevents the development of any deformity and leaves the option of adding a stronger muscle a year or two later, if the intrinsic muscles have not recovered and if the patient needs more grasp strength.

Zancolli (13,14) popularized a technique for moving the FDS tendons from their insertion on the middle phalanx to be attached to the flexor sheath in front of the MP joint. This “lasso” operation deprives the PIP joint of its prime flexor, but it leaves the muscle as a flexor of the MP joint. This is similar to the old Stiles operation, except that the insertion is central rather than to the lateral band (12). It is also rather simple to perform, but it may create long-term problems because the PIP joint is deprived

of a flexor except by contraction of the profundus, which is more effective at the DIP joint than at the PIP joint when working against resistance (2).

The same problem results in hyperflexion of the IP joint of the thumb in Froment's sign of ulnar palsy. In the fingers, the deformity develops slowly, but finally a hyperflexed DIP joint and a hyperextended PIP joint give rise to a swan-neck deformity. The lasso operation should be reserved for the late correction of clawed fingers that have become somewhat stiff in PIP joint flexion and therefore are unlikely to become fully corrected or hyperextended.

If a lasso operation has been performed (or a Stiles–Bunnell with transfer of superficialis tendons) and the DIP joints begin to show signs of persistent flexion, it is best to intervene early with a profundus tenodesis in the middle segment with the DIP joint just short of full extension. This technique transfers profundus power from DIP joints to PIP joints and provides a more satisfactory hand, even though active flexion of the DIP joints is lost (Fig. 57.9).

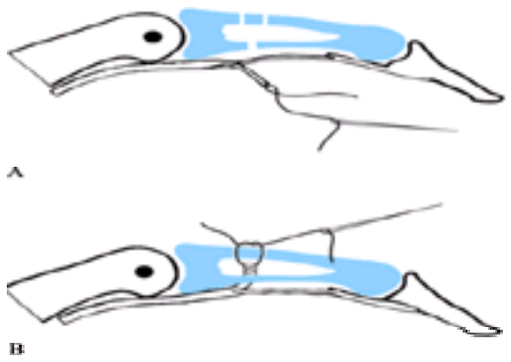


***Figure 57.9.*** Profundus tenodesis in the middle segment. **A:** The profundus tendon is split, and half divided distally. The proximal end of the middle phalanx has a 2 mm drill hole in the anterior cortex and two 1 mm holes in the dorsal cortex. **B:** The cut end of the profundus slip is drawn into bone, leaving half of the profundus in continuity.

### STRENGTH

Various muscles have been used with success for the correction of claw hand. It is easy to misunderstand the relative usefulness of each. Since surgeons and patients are so often concerned about deformity, procedures such as the Stiles–Bunnell (12) or the lasso of Zancolli (13) are often preferred because they are “strong” correctors of deformity. They do not really add strength to the fingers, however; they take strength away from PIP flexion and move it proximally to the MP joint.

Even a weak tendon transfer such as a PL from the wrist area is relatively stronger, because it adds something to the fingers from an area that is unaffected by paralysis. From the point of view of added strength, Fowler's operation using the EIP and EDQ (tension fractions 1 plus 1 equal 2) is better, and the transfer of the ECRL or the extensor carpi radialis brevis (ECRB) (tension, 3.5 or 4.2) may be the best of all (11).

In the immediate postoperative phase, both surgeon and patient appreciate quick correction of deformity. It is in the long term, however, that the patient realizes the extent of the weakness and how the removal of a strong flexor from the PIP joint is a high price to pay for the flexion of the MP joint.

## PATHWAY OF TRANSFERRED TENDONS

An advantage of the Stiles–Bunnell (5,12), Fowler (11), and lasso (13) operations is that the tendons are all long enough for direct transfer without grafts. If a single superficialis tendon is to be used for four fingers (modified Stiles–Bunnell), the tendon should be withdrawn in the proximal palm, just distal to the roof of the carpal tunnel, so that each tendon strand can be passed to its own finger without having to cross a palmar septum (5).

### FOWLER'S OR MODIFIED FOWLER'S OPERATION

- Divide the tendons of the EIP or EDQ over the back of the MP joints, and withdraw them back to the carpal area. Split each into two strands.
- Pick up each strand by its tip, using a curved tunneler that has been passed from the base of one side of each finger, *in front of the transverse metacarpal ligament*, through an intermetacarpal space, appearing in the dorsal incision to pick up its tendon and withdraw it to its point of insertion. Accomplish this tunneling without penetrating the dorsal fascia that overlies the extensor tendons. Some strands of fascia that lie on the palmar and dorsal surfaces of the interosseous muscles in each space may have to be penetrated. Most, however, may be avoided by gentle and sensitive passage of the rounded nose of the tendon tunneler; feel for weak areas or gaps in the fascia.
- It is best to pass the tendon strands to the index and middle fingers through the second intermetacarpal space, and the two strands to the ring and little fingers through the third space. The strand to the little finger crosses the neck of the fourth metacarpal on the palmar side on its way to the proximal phalanx of the little finger.
- This route to the little finger sounds complex, and there may be concern that adhesions will occur as the tendon hugs the neck of the fourth metacarpal bone. It is not difficult, however, if a curved, blunt-nosed tunneler is passed empty from the little finger and angled across until the bone of the fourth metacarpal neck is felt. Then slip the tunneler between the bone and the flexor tendons, and turn immediately dorsally, through the intermetacarpal space, and then proximally to the rerouting incision over the wrist where the tendon strand is grasped and pulled through, back to the finger.

This pathway is less likely to result in two deformities that are common in the original Fowler's operation: reversal of the metacarpal arch and continued abduction of the little finger. If adhesions form in this modification of Fowler's operation, they occur at the point of perforation of the fascia in the interosseous space, not to the bone.

### ECRL OR PL TRANSFER

For most cases that need a transfer for intrinsic palsy, we prefer to use a wrist-moving muscle, such as the ECRL or the PL, extended by grafts. The fingers are approached through the carpal tunnel and along the lumbrical canals. The junction between the tendon and the grafts is made in the distal forearm, proximal to the carpal tunnel.

- Divide the ECRL tendon near its insertion and withdraw it proximally about midforearm through a transverse incision. Make a second transverse incision in the anterior distal forearm about 5 cm proximal to the wrist crease, centered over the PL.
- Pass a blunt-nosed tunneler into this incision and direct it proximally beneath the tendons of PL, FCR, and brachioradialis (BR) to appear in the proximal incision over the ECRL.
- Grasp the end of the tendon and pull it through to the distal incision, where it is joined to a four-tailed graft, either of a plantaris tendon (folded in two and each limb split in two) or to a 12 mm wide strip of fascia lata, taken from the lateral thigh and split into four tails in its distal two thirds.
- Make a rerouting incision in the center of the proximal palm, just distal to the carpal tunnel. Pass a curved tunneler through a split in the palmar fascia, deep and proximally, until the bony-ligamentous floor of the carpal tunnel is felt, deep to all tendons and sheaths. Then direct the tunneler toward the distal forearm incision, between the FCU and the flexor tendons to the fingers, until it appears in the wound.
- Grasp all the ends of the four tendon strands with the tunneler and pull them into the palm. From here, pull each strand separately to each finger, and attach it to the lateral band (Fig. 57.6), or else to the flexor sheath in front of the MP joint, as suggested by Brooks (4).
- If the ECRB is to be used as a motor, divide it at its insertion and withdraw it 10 cm up the forearm, pulling a black thread behind it to identify its sheath. Remove the distal 1–2 cm if required and attach a four-tailed graft to the stump.
- Grasp the four graft tails with tunneling forceps and pull them back through the sheath, following the thread marker. From there, tunnel each graft through an interosseous space to its own finger. Grafts to the index and middle fingers pass through the second intermetacarpal space, and grafts to the ring and little fingers pass through the third space, using the same technique described for the modified Fowler's operation.
- Suture all grafts into position with the wrist flexed (for tendons that pass through the carpal tunnel) or extended (for the ECRB and the dorsal route). The MP joints are flexed and the IP joints extended (Fig. 57.6). In this position, tendon tension should be minimal or even zero.
- In the postoperative splint, position the wrist straight and the fingers in full MP flexion and IP extension.

### REVERSAL OF THE METACARPAL ARCH

A real disadvantage of Fowler's operation and of the use of the ECRB as a motor is that both the tendon or the tendon grafts cross the carpometacarpal joints on the dorsal side. The result is an increase of extensor torque on these joints for the ring and little fingers, where there is already severe loss of flexor torque due to high ulnar paralysis.

The result is often a constant extensor posture at these joints, especially in the fifth ray, producing a marked reversal of the metacarpal arch. This is one more reason we prefer to route transfers for intrinsic replacement across the palmar side of the hand, where, in addition to their effect on the fingers, they can help stabilize the mobile metacarpals and may even make it possible to cup the palm.

**THE THUMB IN ULNAR NERVE PALSY**

Ulnar palsy results in thumb weakness in pinch and grip and usually results in deformities with hyperextension of the metacarpophalangeal (MCP) joint (Jeanne's sign) and hyperflexion of the IP joint (Froment's sign). These deformities result from loss of the intrinsic muscles, which are strong MCP and carpometacarpal (CMC) flexors (Fig. 57.10). The basic imbalance producing these deformities is loss of flexion power at the proximal and middle joints in the chain. There is also a loss of adduction power at the CMC and MCP joints.

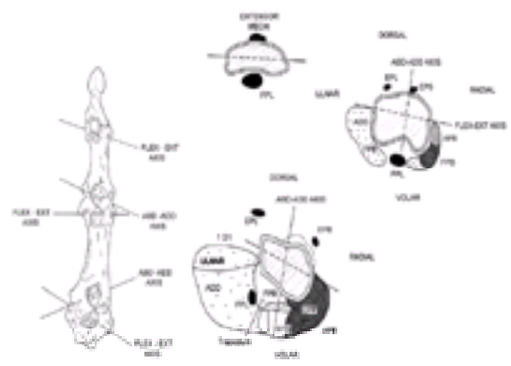

***Figure 57.10.*** The mechanics of the thumb in ulnar palsy. The thumb is comprised of four bones linked by three joints. Each joint moves about one or more axes of rotation. The carpometacarpal joint has two axes, a flexion–extension axis in the trapezium and an abduction–adduction axis in the metacarpal. The metacarpophalangeal joint has two axes of rotation, a flexion–extension (*FE*) axis in the metacarpal head and an abduction–adduction (*AA*) axis in the proximal phalanx. The interphalangeal joint has one axis in the distal proximal phalanx. The muscles of the thumb and the external loads act across these axes, and the balance of the thumb depends on the balance of the torques about all of the axes of rotation of the thumb.
The force the muscles can generate is determined by their cross-sectional area. The mechanical advantage of the muscles is determined by their distances from, and directions of pull relative to, the axes. Cross sections of each thumb joint showing the bones, muscles, and axes of rotation are a good way to conceptualize the actions of the muscles on each axis. We can see that the FPL crosses the CMC joint palmar to the FE axis and just ulnar to the AA axis. It is a flexor and an adductor, but it has a small mechanical advantage at either axis. At the MCP joint, it lies palmar to the FE axis, and the AA axis passes through the tendon. The FPL has a good mechanical advantage for flexion of the MCP joint, but it does not have any effect on AA motions or torques since the axis passes though it. It is a flexor of the IP joint. In these cross sections, the ulnar-innervated muscles are *stippled* and the median and radial innervated muscles are *shaded* or black to illustrate the effect of ulnar palsy on the thumb mechanism. The deficit is the paralysis of the first dorsal interosseus, adductor pollicis, and flexor pollicis brevis. This leads to loss of flexor torques at the MCP and CMC joints, loss of adductor torques at the CMC and MCP joints, and weakness of IP extension. (From Brand PW, Hollister AM. *Clinical Mechanics of the Hand*, 2nd ed. Chicago: Mosby, 1982:85.)

There are three joints at which the thumb may be flexed: the CMC, MCP, and IP joints. The moment arms of the flexor pollicis longus (FPL) at the IP and the MCP joints are 0.75 and 1.0, respectively (Fig. 57.11). For equilibrium at the IP joint, a 2 kg load on the thumb pulp may require 5.33 kg of tension in the FPL tendon. At the MCP joint, the added moments of the adductor pollicis (AP) and the flexor pollicis brevis (FPB) maintain equilibrium. For equilibrium at the MCP joint, a 2 kg load on the thumb pulp needs a 12.0 kg tension in the FPL tendon if other muscles are paralyzed. The 12.0 kg tension that is needed to stabilize the MCP joint is much too great at the IP joint. The latter goes into sharp flexion. Once the IP joint goes into flexion, the moment arm of the load is shortened and may even run through the axis. This is the mechanics of Froment's sign for ulnar palsy.

The shortage of flexor power at the MCP joint allows the external load to push it to the limits of MCP extension. This is the mechanics of Jeanne's sign.

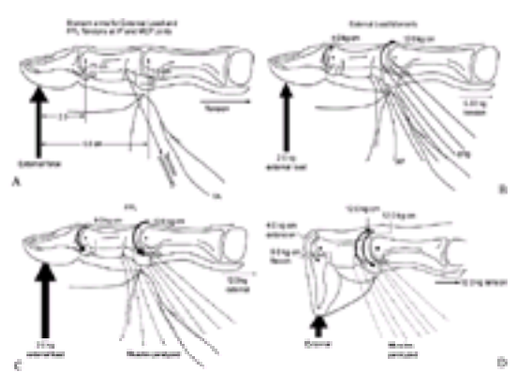

***Figure 57.11.*** The mechanics of Froment's sign. The ulnar-palsied thumb will collapse with IP joint hyperflexion (Froment's sign) and MCP hyperextension when lateral pinch is attempted. The loss of flexor torque at the MCP joint is particularly pronounced since the short flexor and adductor have the largest tension fractions and mechanical advantages for flexion of the MCP joint.
The balance of torques about each joint of the thumb is dependent on the magnitude of the force and its distance from the axis of rotation (A). We can see that both the external load and the tendons act across multiple joints simultaneously. The moment arms for the FPL increase only slightly as one moves from the IP (0.75 cm) to the MCP joint (1.0 cm), but the moment arm for the external load applied at the tip increase from 2 cm at the IP joint to 6 cm at the MCP joint (B,C). The flexor moments needed to stabilize the MCP joints are three times greater than those needed to stabilize the IP joints. If the FPL is the only flexor for the two joints, there will be an excessive flexor torque at the IP joint and insufficient flexor torque at the MCP joint, resulting in hyperflexion of the IP joint and hyperextension of the MCP joint (D). The imbalance can be treated by fusion of the MCP joint, by tendon transfers to increase the flexion torque at the MCP joint, or by a combination of these procedures.

The thumb imbalance for a patient with ulnar palsy can be analyzed by considering the mechanics of the thumb joints individually and as a chain. Any muscle or tendon transfer acts on the axes of rotation of the joints of the thumb (Fig. 57.11) with the muscles crossing them, showing ulnar palsy. The CMC and the MCP joints have two axes of rotation each, one for flexion–extension (FE) movements and one for abduction–adduction (AA) movements (8).

In each joint, the axis for AA movements is not perpendicular to the FE axis or the bones. As a result, the path of the bones when they move is cone shaped, producing combined AA and pronation and supination movements. The IP joint has only one axis. The effects of a generic ulnar nerve palsy on the joints of the thumb can be seen in Fig. 57.10. In this specific case, there is loss of flexion and adduction at the proximal thumb joints.

There is a great deal of variation in the pattern of innervation of the short flexor and adductor muscles of the thumb. Sometimes, the median nerve supplies enough of the short flexor muscles so that ulnar palsy does not leave much deficit. In other cases, the FPL is the only thumb flexor that survives ulnar palsy. More commonly, enough of the short flexor is paralyzed to produce weakness in flexion of the proximal joints. In the latter two instances, any attempt at firm pinch results in flexion of the IP joint and extension of the MP joint. This functional test may be used to determine the need for tendon transfer. If the patient can pinch strongly without IP flexion, there is probably no need for a transfer.

### FLEXOR DIGITORUM SUPERFICIALIS TRANSFER

- If a transfer is needed, the best tendon to use is the FDS of the middle finger. Divide it in the middle of the proximal segment of the finger and withdraw it into the palm through an incision parallel to, and just to the ulnar side of, the thenar crease, just distal to the midpalm. The palmar fascia must be split (not cut), leaving a significant strand to the radial side of the split.
- In the middle segment of the thumb, through an incision on its dorsiradial aspect, expose the edge of the dorsal expansion. Insert tendon-tunneling forceps halfway between the MP and IP joints and direct them subcutaneously to the palmar incision. The nose of the forceps must appear in the palmar incision superficial to the palmar fascia. Thus, when the tendon is pulled into the thumb, the radial strand of palmar fascia serves as a pulley, preventing the tendon from losing its angle of approach to the thumb (Fig. 57.12).

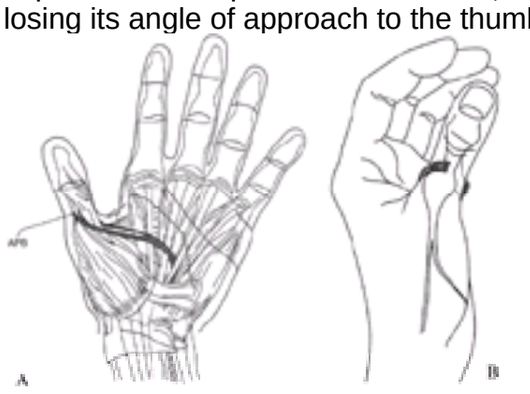

***Figure 57.12.*** The flexor digitorum superficialis tendon is divided through the finger incision and withdrawn in the palmar incision. The tunneling forceps picks it up there and takes it to the thumb. Note that in the palmar incision (**A**), the tunneling forceps lies superficial to the palmar fascia. The tendon comes from deep to the fascia but turns around the fascia edge and uses that edge as a pulley. (**B**) Insertion points of the transferred tendon.

Of the thumb's three joints, the CMC-1 and the MCP-2 joints both have two axes of rotation. The IP-2 joint has one axis or hinge. None of the hinges are perpendicular to the bones or to one another, so there are conjunct rotations with flexion–extension at all of the joints and with abduction–adduction at the CMC and MCP joints. The mechanical advantage of the muscles is determined by their distance from, and angle of pull relative to, the axes of rotation. For instance, the FPL is a flexor and adductor of the CMC joint, and a pure flexor of the MCP and IP joints (3).

Ulnar palsy produces paralysis of the first dorsal interosseus, the adductor, and a variable portion of the short flexor. This results in a loss of power for CMC and MCP flexion and adduction.

The tendon transfer may be passed ulnar to the MCP joint and attached to the extensor pollicis longus (EPL) tendon while the IP joint is fully extended. Alternatively, half the tendon transfer may be attached to the EPL and the other half closer to the MP joint, to the tendon of attachment of the abductor pollicis brevis. This double insertion (or yoke) (Fig. 57.12*B*) serves as a check to prevent excessive MP flexion and abduction or adduction.

If the paralysis involves most of the short flexors or if the MCP joint is hypermobile, the double insertion should be used or it may be better to fuse the MCP joint just short of extension and with some medial rotation of the phalanx on the metacarpal. The transfer will still act as a flexor and adductor of the CMC joint, allowing good lateral and tip pinch.

In those cases with extensive paralysis of the short flexors in which only the FPL is left for CMC and MCP flexion, the transfer may not be able to add sufficient flexor force to the CMC joint to prevent IP joint hyperflexion, even when the MCP joint has been fused. In these cases, tenodesis of the IP joint with suture of the FPL to the $A_1$ pulley will give a stable IP joint in a useful position as well as preserving the FPL as a CMC flexor and adductor.

- Immobilize the hand with the IP joint extended, the MP joint slightly flexed, and the thumb in a pinching position. The middle (or donor) finger should be splinted in IP extension to discourage proximal attachment of the stump of the superficialis tendon.

### FDS TRANSFER (TECHNIQUE OF SOZEN)

If a transfer is needed, the best tendon to use is the FDS of the middle finger. We always regret having to deprive any finger of its superficialis tendon, for reasons already discussed. Dr. Selcuc Sozen (11a) has demonstrated a way to avoid the development of a swan-neck deformity in a finger after removal of its superficialis tendon.

- Divide the tendon only halfway through, just proximal to the PIP joint, and then split it back to the level of the $A_1$ pulley, at which level the other half of the tendon is divided. Now attach the half-thickness tendon that remains in the finger to the $A_1$ pulley at a tension just enough to hold the PIP joint short of full extension. This tenodesis prevents any hyperextension of the PIP joint and thus of any gross deformity (3).
- Now withdraw the main tendon proximally through a longitudinal incision parallel to and just to the ulnar side of the thenar crease, just distal to the midpalm. Split the palmar fascia (do not cut it), leaving a good strand of palmar fascia radial to the split.
- Using an incision on the dorsiradial aspect of the middle segment of the thumb, expose the edge of the dorsal expansion. Insert the tendon-tunneling forceps halfway between the MP and IP joints and direct them subcutaneously to the palmar incision. The nose of the forceps must appear in the palmar incision *superficial* to the palmar fascia. Thus, when the tendon is pulled into the thumb, the radial strand of palmar fascia serves as a pulley, preventing the tendon from losing its angle of approach to the thumb (Fig. 57.10).

The tendon transfer may be attached to the EPL tendon while the IP joint is fully extended. Alternatively, half the tendon transfer may be attached to the EPL and the other half closer to the MP joint, to the tendon of attachment of the abductor pollicis brevis. This double insertion (or yoke) serves as a check to prevent excessive MP flexion.

- Immobilize the hand with the IP joint extended, the MP joint flexed, and the thumb in a pinching position. Splint the middle (or donor) finger just short of IP extension.

## POSTOPERATIVE CARE

In the early postoperative reeducation phase of all these operations, exercise only one of the two joints in each digit. Apply cylindrical plaster casts to the IP joints (finger and thumb) in the corrected position, while encouraging the MP joints to move. After a few days, free up the IP joints, and prevent the MP joints from extending with a knuckle-bender splint.

Only when reeducation is proceeding well should both MP and IP joints be released at the same time. Even then, if there is a tendency to MP hyperextension or clawing, reimpose the alternating restrictions. In the thumb, the MP joint is difficult to immobilize, and IP extension may be continued longer if needed.

### CHAPTER REFERENCES

Each reference is categorized according to the following scheme: *, classic article; #, review article; !, basic research article; and +, clinical results/outcome study.


* 1. Brand PW. Reconstruction of the Hand in Leprosy. *Ann R Coll Surg Engl* 1952;2:350.

* 2. Brand PW. Mechanics of Individual Muscles at Individual Joints. In: Brand PW, ed. *Clinical Mechanics of the Hand*, 3rd ed. St. Louis: CV Mosby, 1999:100.

\# 3. Brand PW, Hollister AM. *Clinical Mechanics of the Hand*, 2nd ed. Chicago: Mosby, 1982:84.

+ 4. Brooks A, Jones D. A New Intrinsic Tendon Transfer. Presented at the *American Society for Surgery of the Hand Annual Meeting,* San Francisco, 1975.

* 5. Bunnell S. Surgery of the Intrinsic Muscles of the Hand Other Than Those Producing Opposition of the Thumb. *J Bone Joint Surg* 1942;24:1.

# 6. Fritschi EP. *Reconstructive Surgery in Leprosy.* Bristol, UK: John Wright & Sons, 1971.

# 7. Fritschi EP. *Surgical Reconstruction and Rehabilitation in Leprosy.* New Delhi: The Leprosy Mission, 1984.

+ 8. Hollister A, Buford W, Myers L. Axes of Rotation of the Thumb Carpometacarpal Joint. *J Orthop Res* 1992;10:454.

+ 9. Hollister A, Buford W, Giurintano DG, Myers L. The Axes of Rotation of the Thumb Interphalangeal and Metacarpophalangeal Joints. *Clin Orthop* 1995;320:188.

+ 10. Hollister AM, Giurintano DG. Thumb Movements, Motions and Moments. *J Hand Ther* 1995;7:106.

* 11. Riordan DC. Tendon Transplantations in Median-Nerve and Ulnar-Nerve Paralysis. *J Bone Joint Surg Am* 1953;35:312.

# 11a. Sozen S. Opponens plasty. Videotape presented at the annual meeting of the American Society for Surgery of the Hand, September 1987.

* 12. Stiles HJ, Forrester-Brown MF. *Treatment of Injuries of the Spinal Peripheral Nerves.* London: Frowde and Hodder & Stoughton, 1922:166.

* 13. Zancolli EA. Correccion de la Garra Digital por Paralisis Intrinseca. La Operacion del “Lazo.” *Acta Orthop Latino Americana* 1974;1:65.

* 14. Zancolli E. *Structural and Dynamic Bases of Hand Surgery*, 2nd ed. Philadelphia: JB Lippincott, 1979.

# CHAPTER 58

# TENDON TRANSFERS IN COMBINED NERVE PALSIES OF THE FOREARM AND HAND

*George E. Omer, Jr. and William F. Blair*

**G. E. Omer, Jr.:** Department of Orthopaedics and Rehabilitation, The University of New Mexico Health Sciences Center, Albuquerque, New Mexico, 87131-5296.
**W. F. Blair:** Steindler Orthopaedic Clinic, Iowa City, Iowa 52230.

Principles
Patient Evaluation
Preoperative Management
Surgical Techniques
General
Combined Low (Distal) Median and Ulnar Palsy
Combined High (Proximal) Median and Ulnar Palsy
Combined High (Proximal) Ulnar and Radial Palsy
Combined High (Proximal) Median and Radial Palsy
Rehabilitation
Authors' Perspective
Chapter References

## PRINCIPLES

Combined nerve palsies in the forearm and hand result in severe functional loss. Multiple nerve palsies usually result from extensive trauma. There may be skeletal instability with loss of normal motion. Circulation is usually impaired, and the result is ischemic pain and increased fibrosis. Muscle–tendon units are often lacerated and sometimes avulsed; consequently, neuromotor function is impaired, and the resulting fibrotic infiltration complicates normal muscle function.

Combined nerve palsies impose not only complex muscle weakness and diminished sensibility but also poor proprioception on the forearm and hand, with a loss of position sense and other normal feedback mechanisms. As joints stiffen and muscles atrophy, maintaining a mobile extremity without deforming contracture demands persistent rehabilitation and meticulous splinting. The most important aspect of a rehabilitation program is the patient's acceptance of the responsibility and initiative for recovery. Reconstructive surgical procedures should not be undertaken until appropriate joint motion returns and skeletal alignment is stable (18,25,29,31,33).

Abnormal patterns of motor activity enhance the distortion of sensibility that accompanies a peripheral nerve deficit (24). Sensibility loss is more profound in combined nerve palsies, and motor return rarely passes two major joints distal to the injury (19). Make nerve repairs as soon as clinically appropriate, but delay surgical reconstruction to restore sensibility until all indicated tendon transfers have been performed and the patient has supple tissues with an established range of motion. Precise sensibility first requires precise motion (24,26,29), which may be obtained through surgical reconstruction and focused rehabilitation. The motion expected after tendon transfer cannot exceed the passive motion present preoperatively.

The preoperative action of the selected motor muscle should be synergistic with the anticipated postoperative action, or at least retrainable by conscious control. Electromyographic studies indicate that a new activity pattern can be developed to correspond with a new mechanical function, but the old activity pattern is not lost (42). Furthermore, the longer the surgeon waits for clinical nerve recovery, the more difficult it is to prevent gradual deformity.

Muscles with only temporary loss of function, such as those with neurapraxic lesions, may not regain normal strength for elective transfer procedures (15). Previously repaired tendons may be used for transfer only under optimal conditions (7). Reconstruction for combined nerve palsies is made more difficult by the smaller number of motor tendons that are available to stabilize residual function (9) or to provide additional function while awaiting potential nerve recovery following neurorrhaphy (5). It is usually inappropriate, therefore, to use intact muscle–tendon units as internal splints to enhance patterns of motion in combined nerve palsies (20). Use as few transfers as necessary. The objective of reconstructive surgery in the extremity with combined nerve injuries is limited. Strive for a balanced, functional hand, because tendon transfers redistribute existing assets rather than create new ones (43). The motor muscle for transfer is selected on the basis of its current clinical function.

Tendon transfers in combined nerve palsies are more complicated than those in isolated nerve palsy for a number of reasons: Extremity injuries are often complex; the patient has poor proprioception and distorted sensibility; fewer muscles are available for transfer and the ones that are available for potential transfer are weak. In addition, combined palsies require multiple operations, and longer follow-up time is required to make valid outcome-based decisions regarding tissue or tendon transfer than in isolated palsies (24,26). (Principles for tendon transfers are presented in Chapter 54.)

## PATIENT EVALUATION

Evaluate the involved extremity for the level and extent of injury. Return of good muscle power across two joints distal to the nerve injury is rare (24). Ongoing assessment requires multiple quantitative tests that are repeated at regular intervals of 3 to 4 weeks. They include the following:

- A voluntary muscle test with recorded range of motion
- A test for light-touch two-point discrimination distance over autonomous zones for pertinent peripheral nerves
- A wrinkle test for sudomotor function
- Gross grip and finger-pinch strength tests
- Timed pick-up test for median or ulnar nerve lesions (24,33)

In high (proximal) nerve palsy, the motor function potential is better than the sensibility potential.

Age and intelligence are pertinent because the patient must have developed the cerebral imprint for the proposed neuromuscular function to be reconstructed, and he must comprehend what is to be done and accept the postoperative discipline for rehabilitation. If the patient is an adult, it is relevant to determine whether he desires an increase in functional performance or only cosmetic improvement.

Combined nerve palsies, almost always combinations of either high or low injuries, can present at mixed levels, as in, for example, a low ulnar and high radial palsy. A combined nerve palsy that presents at mixed levels requires a systematic but individualized approach. These unusual combinations are not discussed in this chapter. Surgeons reconstructing extremities with multiple nerve injuries should be experienced enough to select the appropriate procedures for each individual case.

## PREOPERATIVE MANAGEMENT

Immobilize the extremity in an appropriate position to maintain the desired result. After either median or ulnar palsy, the thumb–index web must be maintained to prevent thumb adduction and supination contracture. Wrist extension is a priority in radial palsy (23). Maintaining a mobile extremity without deforming contracture demands a vigorous rehabilitation program. Use progressive static splints or dynamic splints when full passive range of motion is not present. As stated, the functional range of motion achievable after tendon transfer depends on passive movement present before surgery.

Do elective tendon transfers only when tissue homeostasis and equilibrium are present. Chronic wounds are contraindications to elective surgery. Soft tissues should be free of scar contracture. The timing of tendon transfers varies with the level of the nerve injuries, as well as with the severity of the extremity injury.

## SURGICAL TECHNIQUES

### GENERAL

- Position the patient supine with the involved extremity on an arm table.
- Using tourniquet control, place the incision so that the tendon junctures are beneath skin flaps and away from subcutaneous scars. Make the incisions transverse to the subcutaneous path of the transferred tendon. The subcutaneous pathway must glide with the transferred tendon.
- Mobilize the motor muscle to protect its neurovascular bundle, which usually enters the proximal third of the muscle. The selected muscle–tendon unit should have amplitude adequate for the anticipated motion (2). Reevaluate the texture, vascularity, and excursion of the selected muscle under direct vision at the operating table (28).
- Do not cross bare bone with the transferred tendon. Muscle–tendon units that must move through fascial planes, such as an interosseous membrane, must have as large an opening in the fascia as practical. Place the muscle in the fascial window, as the exterior muscle fibers will adhere to the edges of the window while the interior muscle fibers will retain motion. If the tendon is placed in the fascial window, it will bind fast and motion will be lost (17). The motor muscle selected must be strong enough for its new task, because it will have to pull itself free of the healing fibrosis after surgery and will usually lose one grade of strength on Lovett's clinical scale (17).
- Select an appropriate moment arm for the direction of muscle–tendon action (8). Most muscles are parallel to bone, and the angle of approach between the transferred tendon and its insertion should be small. The greater the angle of approach that the tendon takes to its insertion point, the greater the force the muscle can exert, but the result is a “bowstring.” When a pulley is required to increase the approach angle to more than 45°, a loss of force secondary to friction occurs. Eventually, a bowstrung tendon will shift to a straight line and then become too slack for effective action. The more distal to the joint's axis of motion the transfer is anchored, the more force the muscle can exert on the joint, but also the more excursion is required of the tendon to provide a normal range of motion in the joint. If the insertion of a transferred tendon is split, the motor will act primarily on the slip under greater tension.
- A tendon transfer is more effective when it crosses only one joint. If the tendon bowstrings across a proximal joint, its mechanical advantage at that joint will be so great that it may force that joint into unwanted movement or use up all its amplitude so that it cannot move the distal joint. An example is the transfer of the brachioradialis (BR) into the flexor pollicis longus (FPL): When the elbow and wrist are extended, the patient can hold an object tightly, but when the elbow is fully flexed, the muscle–tendon power is dissipated at the elbow, and the patient drops the object. A second example is an unstable bony nonunion where tendon transfers fail because the telescoping skeleton prevents the development of adequate amplitude for functional power.
- Use synthetic sutures for tendon fixation to minimize tissue reaction. The suture can be relatively large, such as 2-0 for forearm transfers. Some tendon ischemia is prevented by inserting the suture through the center of the tendon and then circling only half the tendon; when suturing along the length of the tendon, protect circulation further by alternating these half-tendon circles from side to side. Avoid “lacing” a transferred tendon into a group of paralyzed muscle–tendon units; lacing creates bulk, with twist and scar, and increases friction. Select a precise insertion point, and at that point, suture a short length of the mobile paralyzed tendons and the transferred tendons side to side to prevent a shifting moment-arm, or “whipsawing,” of the tendons. Alternatively, leave the paralyzed tendon in its bed and pass the transferred tendon across it, as can be done with the flexor carpi ulnaris (FCU) to the extensor digitorum communis (EDC). This is an oblique transfer, and there should be a double line of nonabsorbable sutures to prevent shifting of the four slips of the EDC. You can disconnect the paralyzed tendon from its fibrotic muscle and connect it directly to the transferred muscle. Complete excision of the paralyzed muscle mass, however, may bring unwelcome hemorrhage and should not be done unless the paralyzed muscle belly is causing deformity.
- Deflate the tourniquet when final tension is set for the transfer so that muscle ischemia does not contract the muscle to such a degree that the tension is set too loose. The tension of a tendon transfer is best judged when the hand is in the position it will assume when the transferred tendon contracts. For extensor transfers, resting tension should be strong enough to passively hold the extremity in functional position against gravity; at the same time, be sure that the wrist has the potential for a normal arc of flexion. Flexor tendons often cross more than one joint and should be fixed at somewhat greater than normal tension against gravity. Appropriate tension brings perception of the new muscle more readily into consciousness, because stretch reflexes and other feedback mechanisms are stimulated when opposing muscles work to restore the neutral position of the extremity (4).

### COMBINED LOW (DISTAL) MEDIAN AND ULNAR PALSY

Low (distal) median–ulnar palsy is the most common combined nerve palsy. The complete loss of palmar sensibility and intrinsic motor muscles produce an almost useless claw hand (Table 58.1). Examination demonstrates a flat transverse palmar or metacarpal arch, with hyperextension at the metacarpophalangeal (MP) joints and hyperflexion at the proximal interphalangeal (PIP) joints. An abducted little finger may be associated with the flat transverse metacarpal arch. The patient flexes the wrist to obtain greater finger extension, a functional tenodesis, but with prolonged use the result is often a fixed flexion contracture of the wrist. Do not attempt tendon transfers until contractures have been corrected and the hand is mobile.

| Needed function | Preferred transfer | Alternative transfer |
|---|---|---|
| Thumb adduction—key pinch | ECRB with free tendon graft between 1st and 4th metacarpals, to adductor tubercle of thumb (APB tendon) | FDS (long) to adductor tubercle of the thumb with palmar fascia and flexor tendons as pulleys |
| Thumb abduction—opposition | FDP around pisiform pulley through thenar muscle tunnel to APB tendon insertion and EPL tendon | PL to APB tendon insertion or FDS (ring) to APB tendon |
| Thumb-index tip pinch | APL slip with free tendon graft to first dorsal interosseous tendon and arthrodesis of the thumb MP joint | EPB or PL to first dorsal interosseous tendon (if thumb MP joint has undergone arthrodesis) |
| Metacarpal (palmar) transverse arch and adduction for little finger | FDM tendon split and about half is passed volar to deep transverse metacarpal ligament to radial collateral ligament of MP joint of little finger or the $A_2$ pulley of the flexor sheath | FDS (little) to deep transverse metacarpal ligament between fourth and fifth metacarpals or FDS (long or ring) combined as single transfer for thumb adduction and metacarpal arch |
| Power flexion for proximal phalanges and integration of MP and interphalangeal motion (classical fingers) | ECRL or BR to all four fingers using four radial free tendon grafts and flexor sheath insertion ($A_2$ pulley) or lateral bands of dorsal apparatus | FCR (if wrist flexion contracture) with four radial free tendon grafts to either flexor sheath ($A_2$ pulley) or dorsal apparatus |
| Radial and ulnar volar sensibility | Superficial radial nerve transfascicular or cutaneous neurovascular island | Cross-finger index-to-thumb fillet flap (superficial radial nerve) |

APL, abductor pollicis brevis; APL, abductor pollicis longus; BR, brachioradialis; ECRB, extensor carpi radialis brevis; ECRL, extensor carpi radialis longus; EDM, extensor digiti minimi; EIP, extensor indicis proprius; EPB, extensor pollicis brevis; EPL, extensor pollicis longus; FCR, flexor carpi radialis; FDS, flexor digitorum superficialis; MP, metacarpophalangeal; PL, palmaris longus.

***Table 58.1. Combined Low (Distal) Median and Ulnar Palsy***

Adduction deformity of the thumb can be prevented by immobilizing it in radiopalmar abduction. If possible, abduct the thumb on a swivel splint (C-bar), which will add rotation to abduction and prevent carpometacarpal joint contracture (27).

- An inadvertent contracture can be relieved by a Z-plasty of the skin web. A local dorsal free skin flap may be necessary. If Z-plasty release is necessary, identify the superficial radial nerve and preserve it for possible sensory reconstruction.
- Excise tightened fascia over the thenar intrinsic muscles. It may be necessary to strip the adductor pollicis from the third metacarpal in fixed contractures.
- Additional strength in a palsied power train requires a new muscle–tendon unit, and in median–ulnar palsy, additional strength must be added by radial-innervated muscle–tendon units (18,21,24,33). This is most important for the thumb.
- Use the extensor carpi radialis brevis (ECRB) to enhance thumb adduction for key pinch (Fig. 58.1) (38). Through a dorsal longitudinal zigzag incision (1.5 cm) that extends from the base of the third metacarpal to the dorsal retinaculum, identify the ECRB and transect it at its insertion.

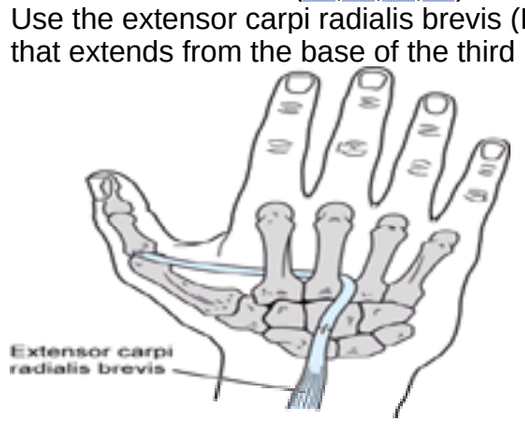


***Figure 58.1.*** Transfer of the extensor carpi radialis brevis extended with a free tendon graft to add power to key pinch, as well as to align and provide power to wrist extension.

- Through a longitudinal incision between the distal thirds of the third and fourth metacarpals, expose the dorsal interosseous fascia and make a small window

between the paralyzed interosseous muscles.

- Harvest a tendon graft (palmaris longus or plantaris). Attach this graft to the distal end of the ECRB and pass it volarly between the third and fourth metacarpals into the palmar space. A short incision in the palmar crease will identify the free graft and the adductor pollicis muscle. Then tunnel the tendon graft radialward just superficial (volar) to the adductor pollicis and deep (dorsal) to the flexor tendons and neurovascular structures. Make a short incision over the abductor tubercle of the first metacarpal. Attach the graft to the fascia over the abductor tubercle of the first metacarpal, and to the tendon of the abductor pollicis brevis, which improves pronation.
- Test the length of the transfer graft. With the wrist in dorsiflexion, the thumb should be against the palm; with the wrist in palmar flexion, the thumb should fall into abduction.
- Postoperatively, immobilize the hand with the thumb in neutral position (not adducted) and the wrist in 40° of dorsiflexion (38). The average strength of key pinch is doubled by this operation (11,38).
- Use the extensor indicis proprius (EIP) to increase thumb abduction and opposition (Fig. 58.2) (6,22). Identify the EIP through a short dorsal longitudinal or small zigzag incision over the MP joint of the index finger. If identified, preserve the superficial radial nerve for sensory reconstruction.

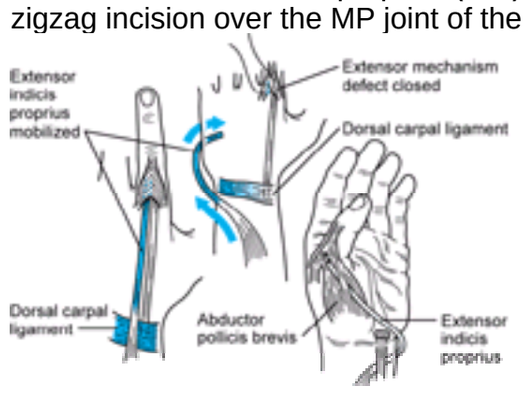


***Figure 58.2.*** Transfer of the extensor indicis proprius to add power for abduction of the thumb.

- Extend the EIP tendon by removing a slice of the extensor apparatus in line with the tendon, and then meticulously repair the extensor apparatus with nonabsorbable sutures.
- Make a short incision over the dorsum of the hand distal to the dorsal retinaculum in line with the EIP tendon. Free the EIP from the EDC to the index and deliver it into the forearm longitudinal incision. Free the muscle bluntly from surrounding soft tissues.
- Make a short transverse incision just distal to the pisiform. Use a tendon passer to tunnel the EIP tendon subcutaneously around the ulnar border of the forearm, using the pisiform and its ligaments as a pulley. Apply intermittent tension on the EIP tendon to assess the range of functional motion.
- Make a short incision along the radial border of the thumb MP joint, and identify the tendon of the abductor pollicis brevis (APB). Use a tendon passer to develop a subcutaneous tunnel across the palm from the pisiform to the thumb MP joint. For the patient anticipating considerable palmar pressure in daily activities, make a short incision over the thenar muscle area and create an intramuscular tunnel for the EIP tendon. The tunnel results in less bowstringing across the base of the palm (17,21,22,27). Attach the transfer to the APB tendon, the joint capsule, and the extensor pollicis longus (EPL) over the proximal phalanx of the thumb. Set the tension with the wrist in neutral flexion–extension and the thumb in maximal abduction.
- The abductor pollicis longus (APL) can provide additional second-MP-joint stability for thumb–index tip pinch (Fig. 58.3) (16,20). Identify the slips of the APL at the radial styloid of the radius through a short incision. Identify and protect the sensory branches of the radial nerve. Distal to the dorsal retinaculum, identify the extensor pollicis brevis (EPB). Then apply traction to each abductor tendon to determine which one inserts on the metacarpal. Preserve this slip and detach one of the remaining slips at its insertion. Obtain a tendon graft from the palmaris longus or plantaris. Make a short incision over the insertion of the first dorsal interosseous tendon at the level of the second MP joint. Suture the graft to the tendon of the first dorsal interosseous muscle and pass it subcutaneously to the radial styloid and suture it to the previously selected slip of the APL tendon. Tension is proper when the index finger and the wrist are in neutral position (16). Follow-up studies indicate that tendon transfers to the first dorsal interosseous muscle tendon do not add significant strength to pinch (31).

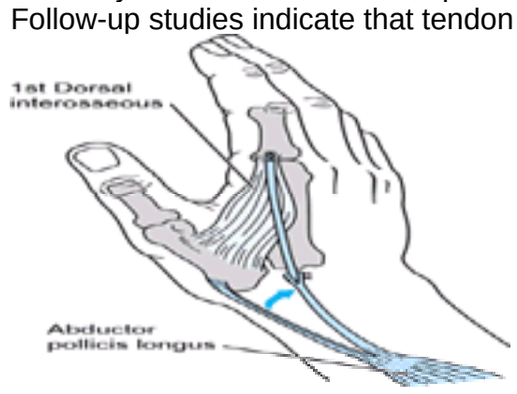


***Figure 58.3.*** Transfer of the abductor pollicis longus extended with a free tendon graft to improve stability for thumb–index tip pinch.

- Arthrodesis of the MP joint of the thumb will strengthen both key and tip pinch (13). The chevron arthrodesis is the most effective procedure for fusion of the MP and PIP joints (Fig. 58.4) (17,35). Through a dorsal longitudinal incision, widely expose the joint. Point the apex of the chevron proximally. The apex of the distal bone is perpendicular to the coronal plane of the bone. Angle the cuts of the apex of the proximal bone to the desired degree of flexion at the arthrodesis site. An appropriate position is 15° of flexion, 5° of abduction, and some pronation so that the pulp of the thumb faces the pulp of the index finger. Immobilize for approximately 8 weeks (35).

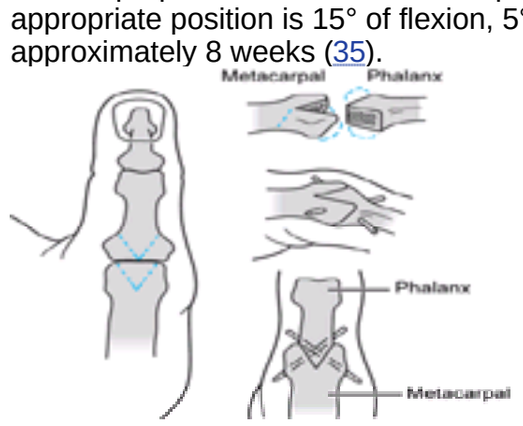


***Figure 58.4.*** Arthrodesis of the metacarpophalangeal joint of the thumb utilizing a chevron-shaped mortise cut.

Patients with a persistently abducted little finger usually have a flat transverse (palmar) arch. The extensor digiti minimi (EDM) has the potential to abduct the little finger through its indirect insertion into the abductor tubercle on the proximal phalanx (Fig. 58.5) (1). The EDM, however, should not be transferred unless there is an active EDC to the little finger.

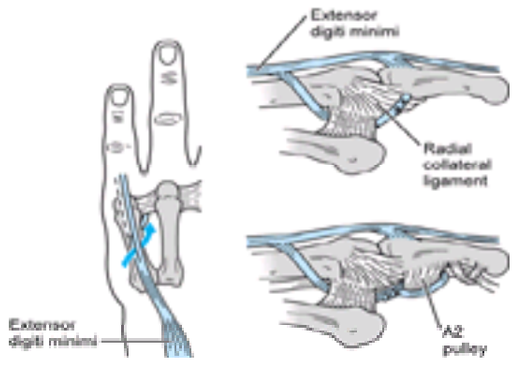


***Figure 58.5.*** Transfer of the ulnar half of the extensor digiti minimi to correct abduction of the little finger.

- Make a longitudinal incision over the dorsal aspect of the MP joint of the little finger. Detach the ulnar half of the EDM from the dorsal apparatus and dissect proximally to the distal edge of the extensor retinaculum (the dorsal carpal ligament). Make a palmar incision obliquely from the distal palmar crease to the proximal digital crease to expose the deep transverse metacarpal ligament and the flexor sheath of the little finger. Pass the ulnar half of the EDM between the fourth and fifth metacarpals into the palmar wound. If the little finger is clawed as well as abducted, insert the tendon slip into the radial aspect of the $A_1$ pulley, or a radially based flap of the flexor tendon sheath just distal to the proximal pulley.
- If the little finger is not clawed, pass the tendon slip beneath the deep transverse metacarpal ligament and suture it into the phalangeal attachment of the radial collateral ligament of the MP joint of the little finger. Set the tension with the wrist in neutral flexion–extension and the MP joint in 20° of flexion. Splint the ring and little fingers for 4 weeks with the wrist extended and the MP joint flexed; leave the interphalangeal joints free to prevent adhesions of the flexor tendons.
- The most reliable method for increasing power for gross grasp is to add an extra muscle–tendon unit to the power train for flexion of the proximal phalanges. Prolong the extensor carpi radialis longus (ECRL) or the brachioradialis (BR) with palmaris longus, plantaris, or toe extensor tendon slips (29,31) (Fig. 58.6) (see Chapter 58). The junction between the ECRL and the tendon slip must be proximal enough so that the suture site will not bind on the metacarpal shafts. Pass the tendon slips superficial to the dorsal carpal ligament, through the lumbrical space, and radial to the fifth, fourth, and third metacarpal, but ulnar to the second metacarpal. Tunnel the free tendon slips volar to the deep transverse metacarpal ligament (intervolar plate ligament). If not passed correctly, the transfer will act only as a radial deviator and will not control the hyperextension of the MP joint. The slip insertion should be into the $A_2$ pulley of the flexor sheath (Fig. 58.6*D*) or into the bone of the proximal phalanx (Fig. 58.6*C*) for power flexion. If coordination of finger extension and flexion is more important than flexion power, the insertion can be the lateral band of the dorsal apparatus (Fig. 58.6*B*) (24). Identify the lateral bands of the dorsal apparatus or the $A_2$ pulley of the flexor sheath with short longitudinal incisions. Suture the tendons with the wrist dorsiflexed 45° and the MP joints flexed 60° to 80°.

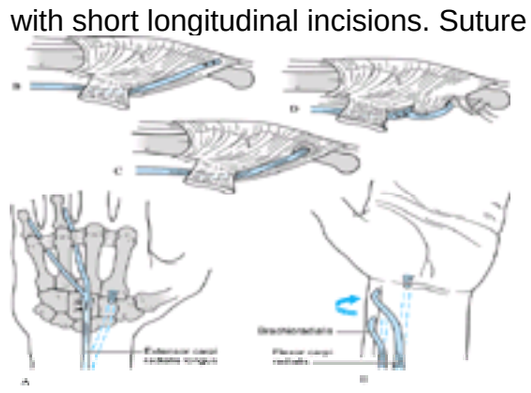

***Figure 58.6.*** Transfer of the extensor carpi radialis longus with free tendon grafts for power flexion of the proximal phalanx. Additional free tendon grafts for the index and long finger (**A**) should be added between the second and third metacarpals to achieve full power of the transfer. (This addition is not illustrated.)

There are no standard recommendations for restoring sensation. Motor reconstruction is concentrated on the thumb, but few patients gain enough precise motor function to have good sensibility. Methods for restoration of sensation include free nerve grafts, free vascularized nerve grafts, digital nerve translocation, neurocutaneous flaps, neurovascular cutaneous island pedicles, and free neurovascular cutaneous islands. We prefer microsurgical digital nerve translocation and creation of a neurovascular cutaneous island pedicle (10,28,31,40,41).

- The brachioradialis (BR) also may be used to motor thumb adduction.
- The most practical procedure in median–ulnar palsy is translocation of the superficial radial nerve. Expose the superficial radial nerve through a longitudinal zigzag incision over the radial dorsal aspect of the index phalanx and dorsum of the hand. Expose the nerve to the base of the thumb–index web, if a Z-plasty of the web has not been done. Expose the ulnar proper volar digital nerve of the thumb through a longitudinal incision. Translocate the superficial radial nerve to the ulnar proper volar digital nerve of the thumb using microsurgical techniques. A major advantage is that the nerve translocation procedure may be done at the same time as the tendon transfers for median–ulnar palsy.
- An alternative procedure to a nerve translocation is to create a neurovascular cutaneous island pedicle. Raise an island of skin over the distal third of the proximal phalanx of the index finger (Fig. 58.7). The superficial radial nerve and dorsal digital vessels form a neurovascular bundle that is dissected proximally to the digital artery. It may be necessary to ligate several anastomosing branches to the volar digital artery (12,32). Make an incision along the ulnar aspect of the thumb; elevate the island with the neurovascular pedicle, and place it on the ulnar palmar surface of the thumb. Many adult patients will perceive sensation as coming from the donor site, but they will also make a cortical adjustment and effectively use the miscued sensibility (29). Delay this procedure until tendon transfers have healed and initial rehabilitation is under way.

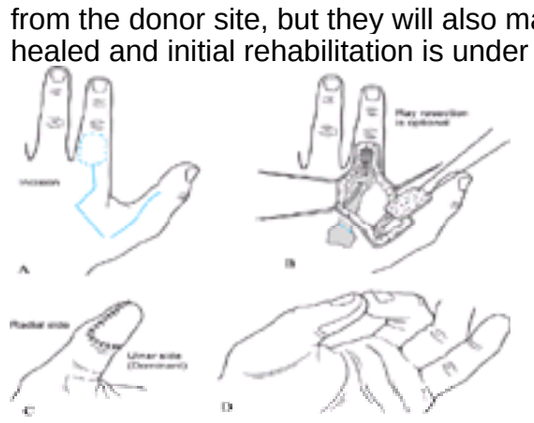

***Figure 58.7.*** Neurovascular cutaneous island pedicle.

## COMBINED HIGH (PROXIMAL) MEDIAN AND ULNAR PALSY

The involved hand will rarely be used for precision activities after such a severe injury as high median–ulnar palsy (Table 58.2). The most important clinical problem is the total loss of volar sensibility, while atrophy of the finger pulps will discourage both precision and power grip. If the other hand is normal, focus on improving key pinch and simple grasp.

| Needed function | Preferred transfer | Alternative transfer |
|---|---|---|
| Thumb adduction—(AP) key pinch | ECRB with free tendon graft between 2nd and 3rd metacarpals to adductor tubercle of the thumb | BR or EIP with free tendon graft between 2nd and 3rd metacarpals to adductor tubercle of thumb (APB tendon) |
| Thumb flexion (IP joint) | BR to FPL to tendon | Tenodesis of FPL distal to MP joint of thumb |
| Thumb abduction (APB) | EIP around pisiform pulley to insertion of APB (plus FPL tendon) | EPL or ECU with graft transferred around pisiform pulley to APB tendon (thumb MP joint is fused and no active motion at IP) |
| Thumb–index (or long) pinch (tip pinch) | A tenodesis of thumb MP joint; APL slip with free tendon graft to free distal interosseous tendon | EPB or FPL to distal interosseous tendon, fusion of thumb MP joint |
| Finger flexion (FDP) | ECRL to all four tendons of FDP with possible transfer of distal IP of about three fingers | Biceps brachii extended with ECR tendon to tendons of FDP |
| Clawed fingers—power for flexion of proximal phalanx, integration of MP and IP motion | Transfers of all four digits with free tendon graft from distal carpal ligament (after a deep transverse metacarpal ligament to lateral bands of extensor apparatus) or from deep transverse metacarpal ligament to extensor apparatus | Capsulodesis of MP volar capsule, or arthrodesis of PIP joints, or arthrodesis of MP joints |
| Metacarpal (palmar) arch and adduction for little finger | FDM to deep transverse metacarpal ligament (DTM), of little finger (hand by native) | FDM to radial lateral bands (extensor hood) of the ring and little finger (Fowler–Brunelli) |
| Wrist flexion | — | ECU to insertion of FCU |
| Radial and ulnar volar sensibility | Superficial radial neurovascular island flap to palm or first dorsal metacarpal artery neurovascular island pedicle flap | Superficial radial nerve transferred to free vascularized nerve graft |

AP, adductor pollicis; APB, abductor pollicis brevis; APL, abductor pollicis longus; BR, brachioradialis; ECRB, extensor carpi radialis brevis; ECRL, extensor carpi radialis longus; ECU, extensor carpi ulnaris; EIP, extensor indicis proprius; EPB, extensor pollicis brevis; EPL, extensor pollicis longus; FCR, flexor carpi radialis; FCU, flexor carpi ulnaris; FDM, flexor digitorum minimi; FDP, flexor digitorum profundus; FDS, flexor digitorum superficialis; FPL, flexor pollicis longus; FR, lumbricalis; LUM, lumbricalis; MP, metacarpophalangeal; PL, palmaris longus.

***Table 58.2. Combined High (Proximal) Median and Ulnar Palsy***

Use the ECRB to retain wrist extension and to restore thumb adduction power for key pinch (Fig. 58.1), and the EIP to improve thumb abduction (Fig. 58.2). Extend a slip of the APL to the tendon of the first dorsal interosseous (Fig. 58.3), and employ arthrodesis of the MP joint of the thumb to strengthen thumb–index tip pinch. The surgical techniques are similar to those used in low combined median and ulnar palsy.

- Use the ECRL for finger flexion (Fig. 58.8). Make a midline longitudinal, slightly zigzag incision from a point approximately 2.5 cm above the volar wrist crease to the proximal third of the forearm. With traction, identify the tendon of the flexor carpi radialis (FCR). On the radial aspect of this tendon is the radial artery and the tendon of the BR. On the dorsal aspect of the FCR is the flexor digitorum superficialis (FDS) and the flexor pollicis longus (FPL). Tag the FPL, and displace the FDS ulnarward to reveal the flexor digitorum profundus (FDP). Detach the ECRL at its insertion and release it halfway or more up the forearm to obtain maximal muscle–tendon motion. Tunnel the ECRL around the radial side of the forearm across all four tendons of the FDP, which is left in its usual position. Flex the fingers and align them more transversely than obliquely to ensure equal tension for gross grasp. The change in resting position is approximately 2 cm for the index and long finger tendons. Suture the transfer well proximal to the transverse carpal ligament to allow adequate and free excursion. Each transfer junction has a proximal and distal suture to prevent whipsawing under tension. Align tension so that there is functional extension of the fingers with the wrist in 15° to 20° of flexion.

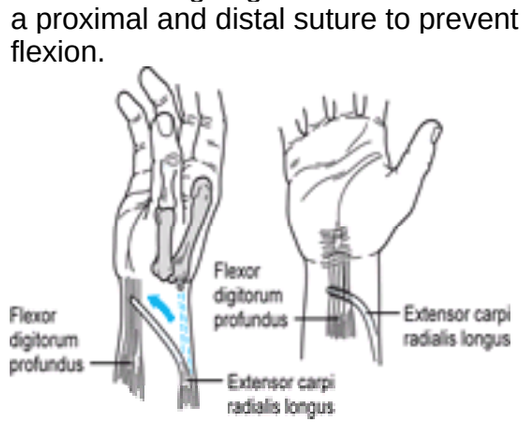


***Figure 58.8.*** Transfer of the extensor carpi radialis longus to the flexor digitorum profundus for finger flexion.

- Use the BR tendon to enhance thumb flexion (Fig. 58.9). Identify the BR in the volar forearm incision and release it near its insertion. Free it extensively from all tissue attachments so that it has approximately 5 cm of passive mobility (28). Also free the FPL so that it glides both proximally and distally to the wrist. Weave the BR tendon into the tendon of the FPL, and secure it with nonabsorbable sutures. Adjust tension so that there is full extension of the thumb when the wrist is in 20° of flexion and the thumb in full abduction (39). If thumb–index tip pinch is unstable with MP joint extension and IP joint flexion (the “crank-handle” effect), then thumb MP arthrodesis is indicated (3). As indicated previously, we routinely use arthrodesis of the MP joint of the thumb for the initial surgical reconstruction.

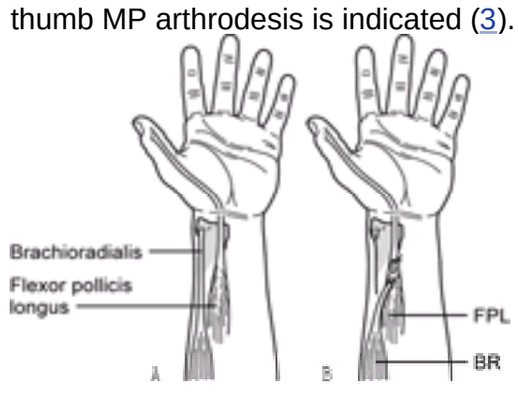


***Figure 58.9.*** Transfer of the brachioradialis (*BR*) to the flexor pollicis longus (*FPL*) for thumb flexion. Both muscle–tendon units must glide freely before the anastomosis.

Before reconstruction, it may appear that restoration of the intrinsic function will not be necessary, but when flexion is restored to the IP joints, the fingers will gradually assume a clawed position. Static techniques are used in most cases. Riordan (36) credits Fowler for developing a tenodesis of all four fingers utilizing free tendon grafts from the dorsal carpal ligament passed volar to the deep transverse metacarpal ligament to the lateral bands of the extensor apparatus (Fig. 58.10*A*). Wrist flexion increases the tension on the tenodesis so that the function is semiactive. Parkes (34) placed a free tendon graft between the radial lateral band of the dorsal apparatus of the finger and the deep transverse metacarpal ligament (Fig. 58.10*B*). Riordan (37) split the FDS of the long finger into four slips; one slip is passed through the lumbrical canal of each finger and inserted into the lateral band of the dorsal apparatus. Zancolli (44) opened the proximal ($A_1$) pulley of the flexor sheath and excised a flap from the volar plate (Fig. 58.10*C*).

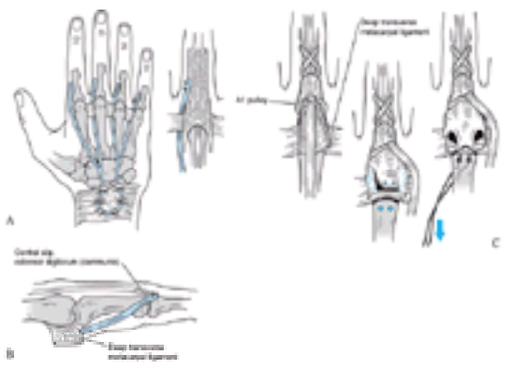

***Figure 58.10.*** **A:** Dynamic dorsal tenodesis to control claw finger deformity. The free tendon to the index finger may be inserted on the ulnar side when increased index and long finger adduction for pinch is important. **B:** Static tenodesis to control claw finger can be obtained by using a free tendon graft or slip between the radial lateral band of the dorsal apparatus of the finger and the flexor retinaculum (deep transverse metacarpal ligament) in the palm. The grafts function independently in each finger. **C:** A Zancolli capsulodesis of the metacarpophalangeal (*MP*) joint to correct finger clawing.

There are not consistent recommendations for reconstruction of sensibility in this lesion. Two procedures to transfer sensibility to the thumb are described in the section on low median–ulnar nerve palsy. Sensibility can be transferred to the radial volar aspect of the hand (Fig. 58.11). Careful testing of the superficial radial nerve will demonstrate the distal level of sensibility on the dorsum of the index finger.

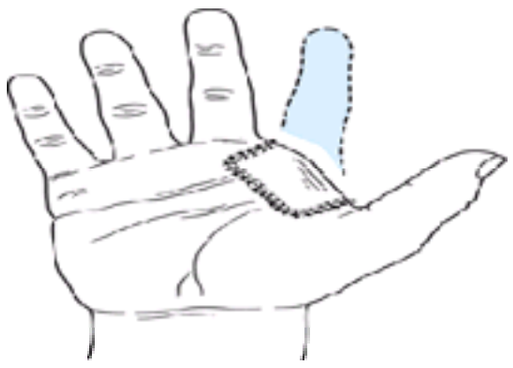

***Figure 58.11.*** Fillet of index finger, with larger radial-innervated cutaneous island.

- Remove the skeleton of the index finger distal to the proximal third of the second metacarpal. Discard the insensitive distal skin. Then fit the filleted index finger flap into an additional volar defect created for it in the insensitive palmar skin (29,31,32). This procedure will provide protective sensibility within the thumb–middle web space.

In time, the wrist will translocate ulnarward on the radius secondary to the concentration of extrinsic forces to the radial side of the hand (26,29). A sequela of the carpal change is a decrease in the thumb–index web space, with loss of ability to grasp larger objects.

## COMBINED HIGH (PROXIMAL) ULNAR AND RADIAL PALSY

Patients with high ulnar–radial palsy retain radiovolar sensibility, and reconstruction is useful to improve function. Surgery is often staged, however, and rehabilitation is difficult because surgical procedures need to be performed both for finger extension and flexion and for thumb adduction and abduction (Table 58.3).

| Needed function | Preferred transfer | Alternative transfer |
|---|---|---|
| Wrist extension | PT to ECRB | — |
| Thumb adduction—key pinch | One-half FDS (long) as split transfer, to abductor tubercle of thumb, and, one-half FDS (long) in two slips to $A_1$ pulley of flexor sheath for ring and little fingers, and, later, tenodesis of proximal IP joints, ring and little fingers if unable to fully extend | Tenodesis with free tendon graft from radial lateral band of distal epiphysis to deep transverse metacarpal ligament, or capsulodesis of MP volar capsule |
| Clawed fingers: metacarpal (palmar transverse arch), and power flexion of proximal phalanx and integration of MP and IP motion | | |
| Thumb-index tip pinch | Arthrodesis of thumb MP joint | — |
| Proximal thumb stability for abduction and wrist flexion (radial aspect) | Tenodesis of APL to radius | FCR (yoke insertion) to APL and OPB |
| Wrist flexion (ulnar aspect) | — | PL to insertion of FCU |
| Finger and thumb extension | FDS (index and ring) through interosseous membrane to EDC and EPL | PL to EDC and EPL |
| Finger flexion (ring and little) | Tenodesis of FDP (long) as active tenodesis to ring and little FDP with double suture line, and tenodesis of DIP joint of ring and little fingers, using FDP tendons | — |
| Volar sensibility—ring and little fingers | Median digital nerve transfer | Free vascularized nerve grafts, or neurovascular cutaneous island pedicle |

APL, abductor pollicis longus; ECRB, extensor carpi radialis brevis; EDC, extensor digitorum communis; EPB, extensor pollicis brevis; EPL, extensor pollicis longus; FCR, flexor carpi radialis; FCU, flexor carpi ulnaris; FDP, flexor digitorum profundus; FDS, flexor digitorum superficialis; PL, palmaris longus; PT, pronator teres; IP, interphalangeal; DIP, distal interphalangeal; MP, metacarpophalangeal; PIP, proximal interphalangeal.

***Table 58.3. Combined High (Proximal) Ulnar and Radial Palsy***

Use the pronator teres (PT) for wrist extension (Fig. 58.12). A major function of the PT transfer to the ECRB is stabilization of the wrist. Increasing dorsal extension power of the wrist by an increment of one may increase power grip three to five times (5).

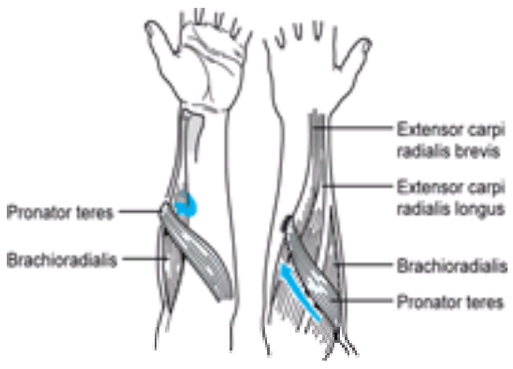


***Figure 58.12.*** Transfer of the pronator teres to the extensor carpi radialis brevis for wrist extension and stabilization.

- Through a longitudinal incision on the volar side of the radial aspect of the middle third of the forearm, expose the tendons of the PT, ECRB, and ECRL. Free the PT with a generous tongue of periosteum from the radius. Bluntly free the PT muscle belly, avoiding neurovascular injury. Pronate the forearm, and pass the PT subcutaneously and superficial to the BR and the ECRL muscle for attachment to the tendon of the ECRB. The wrist should rest in 30° of extension against gravity.
- Utilize the long FDS to improve the integration of MP and interphalangeal joint flexion, key pinch for the thumb, and the flattened metacarpal arch (Fig. 58.13) (22,24,30). The ring finger FDS cannot be used when the ulnar-innervated portion of the FDP is paralyzed. Expose the long finger FDS through a volar zigzag incision that extends from the PIP crease to the distal palmar crease. Release of the long FDS may result in a residual hyperextension deformity of the PIP joint. To prevent this problem, release the distal radial insertion of the FDS proximal to the PIP joint and perform tenodesis to prevent hyperextension of the joint after completion of the transfer. Release the ulnar half of the FDS at its terminal insertion. Retain the flexor sheath, especially the proximal $A_1$ and $A_2$ pulleys. The ulnar half of the long FDS tendon is split longitudinally again into two slips.

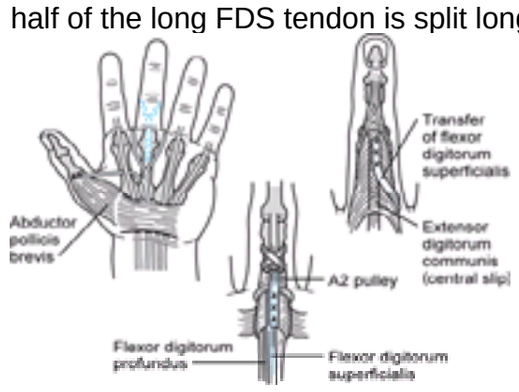

***Figure 58.13.*** Transfer of the long flexor digitorum superficialis (*FDS*) for thumb adduction and opposition, and to prevent clawing of the ring and little fingers.

- When increased power for grip is desired and the EDC will extend the PIP joint with the MP joint stabilized in flexion, insert a long FDS ulnar slip into each $A_2$ pulley of the ring and little fingers (Fig. 58.13). Make a longitudinal zigzag incision on the volar side of the little and ring fingers. Expose the proximal edges of the flexor sheaths and pass the FDS ulnar slips distally through the flexor sheaths and volarly around the distal edge of the $A_2$ pulley and suture them in place. The $A_2$ pulley insertion does not extend the PIP joint, while active flexion returns to the MP joint of the ring and little fingers.
- Extension of the fingers is usually weak, however, or absent in high combined ulnar and radial palsy. If preoperative testing indicates that the interphalangeal joints cannot be actively extended by the EDC when the MP joint is flexed, then insert the FDS slips into the dorsal apparatus (24,30). Make short longitudinal incisions over the dorsal aspect of the PIP joints of the right and little fingers. Direct the FDS ulnar slips radial to the ring and little fingers and volar to the deep transverse metacarpal ligament and then dorsally to be sutured at the insertion of the central slip of the dorsal apparatus on the middle phalanx (Fig. 58.13). Traction on the transferred FDS slips should flex the MP joints and extend the PIP joints.
- Expose the abductor tubercle of the thumb through either a short longitudinal incision over the tendon of the APB, or a midline dorsal longitudinal incision for arthrodesis of the MP joint. Arthrodesis of the thumb MP joint gives improved strength for grip. Direct the radial half of the long FDS transversely over the volar surface of the adductor pollicis, but dorsal to the flexor tendons and neurovascular structures. Suture it into the insertion of the pollicis brevis (PB) tendon. The functional mechanism of this tendon transfer is similar to that of the Bunnell “tendon T” operation (20), except that the pulley for this transfer is the distal edge of the palmar fascia inserted into the third metacarpal rather than a free tendon graft between the first and fifth metacarpals. Traction of the transferred long FDS tendon should adduct and pronate the first metacarpal, as well as increase the metacarpal (palmar) arch and depress the clawed fingers (30).
- Use the index and ring FDS tendons to extend the fingers and the thumb (2,26) (Fig. 58.14). Expose the FDS tendons through volar zigzag incisions that extend from the PIP crease to the transverse palmar crease. Release the distal radial insertion of the FDS tendon proximal to the PIP joint and perform tenodesis to prevent hyperextension, or divide the FDS tendon proximal to the chiasma tendinum and deliver it into the longitudinal incision on the volar side of the radial aspect of the forearm. Proximal to the pronator quadratus, excise two windows from the interosseous membrane, one on each side of the anterior interosseous artery. The windows should be as large as possible for the patient's anatomy. If there is any indication of injury to either the anterior or posterior interosseous vessels, deflate the tourniquet and control hemorrhage. It is very difficult to establish hemostasis after the two FDS tendons are placed through the interosseous membrane.

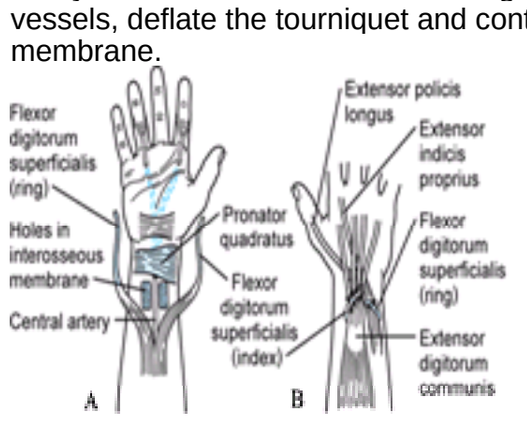


***Figure 58.14.*** Transfer of the index and ring flexor digitorum superficialis tendons through the interosseous membrane for finger and thumb extension.

- Make a J-shaped incision on the dorsum of the forearm. The transverse arm passes from the radial styloid to the ulnar styloid, with the longitudinal arm extending proximally on the ulnar aspect of the dorsum of the forearm. Pass the two FDS tendons to the dorsum of the forearm through the openings in the interosseous membrane, with the index FDS to the radial side of the profundus muscle group and the ring FDS to the ulnar side of the profundus group. Place the muscle of both FDS units in the interosseous membrane windows, because bare tendon will adhere with resulting loss of motion. If it is not technically feasible to do so, route the FDS units subcutaneously around both sides of the forearm.
- Attach the ring FDS to the EPL and the EIP tendons. Suture the index FDS to the EDC tendons. Place the junction well proximal to the dorsal retinaculum. If there is blocking of the sutures against the dorsal retinaculum, narrow this fascial band. Suture the index FDS obliquely across the tendons of the EDC tendons with a double suture line to provide stability. The recipient tendons are not divided proximal to the junction. Form a fist passively with the wrist held in 45° of extension; then suture the tendons at normal tension. With release of the fist, the digits should splay into functional extension against gravity. The transfers must be tight enough to provide extension, but not so tight that they limit functional flexion of the fingers and wrist. Full flexion of the wrist is uncommon.

The loss of balanced power across the PIP joints caused by removing the FDS may ultimately result in either a flexion contracture or a swan-neck deformity of these joints. Because it is not possible to accurately predict which of these deformities will occur in a given patient, we believe that it is preferable to wait for the onset of deformity before treating it. The most predictable corrective procedure may be arthrodesis of the PIP joint (13,25).

It is desirable to repower the APL, because incomplete abduction of the first metacarpal may cause awkwardness and loss of strong pinch. The FCR tendon can be split and inserted into the tendons of the APL and the EPB and still retain wrist flexion (Fig. 58.15) (33). We have seen this “yoke” insertion produce local irritation, however, and we usually join the APL to the radius to provide a simple tether for stability.

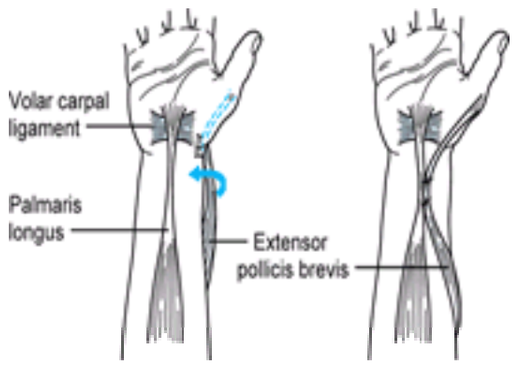


***Figure 58.15.*** Tenodesis of the palmaris longus and the extensor pollicis brevis to provide proximal stability of the thumb.

- Increased flexion of the distal interphalangeal (DIP) joints of the ring and little fingers may be achieved by side-to-side tenodesis with the FDP of the long finger (Fig. 58.16). Utilize a longitudinal incision on the radial volar aspect of the forearm. Identify the tendons of the FDP; apply tension to the ring and little finger tendons of the FDP until the finger pulps of all four digits are in transverse alignment instead of the usual oblique alignment. To maintain the transverse alignment, suture the tendons of the inactive ring and little FDP tendons with nonabsorbable sutures to the active long tendon of the FDP. The active index FDP is allowed independent motion. A double line of sutures at the tendon junction site is important to prevent whipsawing of the tendons during the power grip. It may be appropriate to join the ring and little FDP tendons across their DIP joints to eliminate one joint in the motion train.

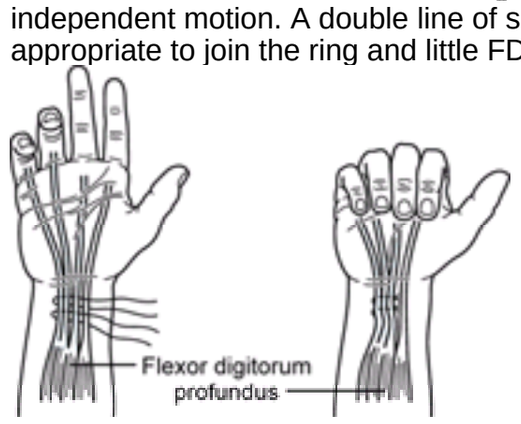

***Figure 58.16.*** Tenodesis of the denervated long and little flexor digitorum profundus (*FDP*) tendons to the innervated index and long FDP tendons for active flexion of all four fingers.

Restoration of sensation is the final stage of surgical reconstruction. In high ulnar–radial palsy, patients have median sensation and lack the precise ulnar motor function required for precise sensibility. Delay any procedure until all tendon transfers have healed and initial rehabilitation has been initiated.

**COMBINED HIGH (PROXIMAL) MEDIAN AND RADIAL PALSY**

Tendon transfers in patients with combined high median and radial palsy will result in a hand that functions only slightly more effectively than a prosthesis (24,25,31). All wrist motors are lost except the FCU. Radiocarpal (wrist) arthrodesis is indicated. When arthrodesis is performed on the wrist, finger flexion is not enhanced by wrist extension, and the total range of finger motion is limited (Table 58.4).

| *Needed function* | *Preferred transfer* | *Alternative transfer* |
|---|---|---|
| Forearm pronation | Biceps brachii tendon retouring around the radius | — |
| Wrist extension and flexion | Radiocarpal arthrodesis | — |
| Finger flexion | Tenodesis of FDP ring and little fingers (active motors) to FDP index and long fingers | — |
| Finger and thumb extension | FCU to tendons of EDC and EPL | — |
| Proximal thumb stability for abduction | Arthrodesis of thumb MP joint, and, tenodesis of APL tendon to radius | — |
| Thumb abduction (opposition) | | ADQ to the insertion of the APB, or AP tendon insertion from adductor tubercle to abductor tubercle |
| Thumb flexion | Tenodesis of EPL across thumb IP joint | Biceps brachii extended with FCR tendon to tendon of EPL |
| Radioulnar sensibility | Ulnar digital nerve transfascicular | Neurovascular cutaneous island pedicle from ring finger, or free vascularized nerve graft |

ADQ, abductor digiti quinti; AP, abductor pollicis; APB, abductor pollicis brevis; APL, abductor pollicis longus; EDC, extensor digitorum communis; EPL, extensor pollicis longus; FCR, flexor carpi radialis; FCU, flexor carpi ulnaris; FDP, flexor digitorum profundus; FPL, flexor pollicis longus; IP, interphalangeal; MP, metacarpophalangeal.

***Table 58.4. Combined High (Proximal) Median and Radial Palsy***

- The first priority in treatment is arthrodesis of the wrist, preferably using a low-profile plating technique.
- Utilize the ulnar innervated portion of the FDP for flexion of the fingers and thumb (Fig. 58.17). Approach the FDP through a longitudinal volar incision on the ulnar aspect of the forearm. Because the radial portion of the FDP is denervated, the FDP tendons to the index and long fingers must be under greater tension than those to the ring and little fingers. A double line of proximal and distal sutures at the tendon junction is important to prevent shifting, or whipsawing, of the tendons when a power grip is applied. After suture, the finger pulps of all four digits are in transverse alignment instead of the usual oblique alignment.

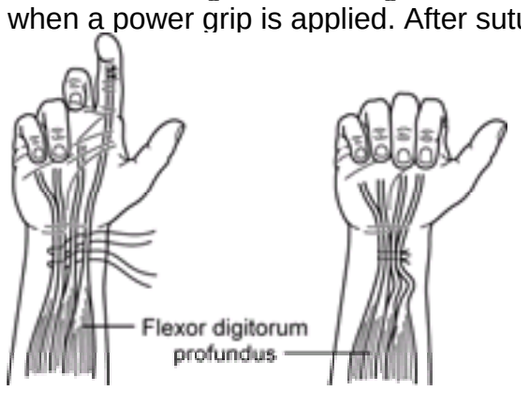


***Figure 58.17.*** Tenodesis of the denervated index and long flexor digitorum profundus (*FDP*) tendons to the innervated ring and little FDP tendons for active flexion of all four fingers.

To obtain maximal finger flexion and finger extension, we have usually done the FDP “group suture” before tendon transfers for finger extension. It is useful, however, to use dynamic finger extension splits with intrinsic stops for appropriate positioning in preparation for the surgical reconstruction of finger extension.

- Utilize the FCU for finger and thumb extension (Fig. 58.18). The oldest surgical procedure for digital extension used the FCU (2). Through the incision described for the FDP modification, transect the FCU just proximal to the pisiform and free it up proximally to obtain appropriate passive motion. A second longitudinal incision, 5–7 cm distal to the medial epicondyle, will facilitate the release of the muscle. The limiting factor in the dissection is the innervation of the FCU, which enters the muscle in its proximal 5 cm.

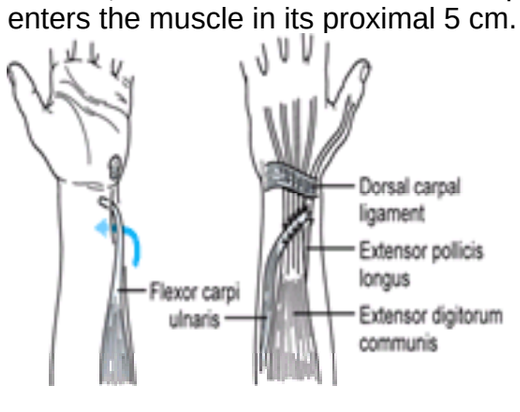


***Figure 58.18.*** Transfer of the flexor carpi ulnaris (*FCU*) to the extensor digitorum communis (*EDC*) and extensor pollicis longus (*EPL*) for finger and thumb extension.

- Make a dorsal longitudinal incision in the midline of the forearm. Pass a tendon passer from the dorsal incision subcutaneously around the ulnar border of the forearm, and pull the tendon of the FCU into the dorsal incision. The FCU may need to be passed back and forth, with careful observation and additional dissection, plus release of subcutaneous tissues, to obtain a straight pull from the medial epicondyle to the central portion of the dorsal retinaculum. If there is excessive muscle bulk, the FCU muscle belly can be trimmed distally; a bulky appearance, however, may be preferable to excessive bleeding when the tourniquet is released.
- For finger and thumb extension, bring the FCU well proximal to the dorsal retinaculum and suture it obliquely across the tendons of the EDC and the EPL. Leave the extensor tendons in their normal compartments, and place the FCU superficially across each tendon with a double suture line for stability. When the EDC slip to the little finger is absent, include the EDM in the tendon transfer. The junction increases tension on the EDC tendon slips until the fingers are held in a functional extension splay against gravity.
- After the tension is set for the EDC tendon slips, add the EPL tendon as the final insertion of the FCU transfer. Adjust tension against gravity so that the thumb fits into the extension splay demonstrated by the digits. In high median–radial palsy, however, finger flexion is inadequate, and the range of digit extension should be more modest to fit the potential range of flexion. Over time, and with balanced flexor tension, the patient can usually extend all fingers, or only the thumb. The occasional patient learns to show individual digits in extension through selective flexion (26). These FCU transfer functional activities are much more specific in isolated radial palsy, with normal wrist mobility and individual FDP flexor motion (23). The fused wrist, however, prevents radial deviation of the wrist, which is the most common long-term problem in isolated radial palsy with an FCU transfer.

Muscle–tendon procedures for abduction of the thumb are indicated only in special circumstances of functional need. Transfer of the abductor digiti quinti for thumb abduction (the Huber operation) (14) results in inadequate excursion, and it is questionable that total hand function is improved, inasmuch as the little finger, with sensation intact, has lost its ability to oppose. Transfer of the insertion of the adductor pollicis from the adductor tubercle of the first metacarpal to the abductor tubercle is almost as effective (the de Vecchi operation) (25,31).

Complex procedures to restore sensation, such as neurovascular islands, are not usually indicated in high median–radial palsy. Patients with high median–radial palsy do not regain precise sensibility, because there are so few remaining precision muscle motors and it is difficult to balance the advantages and disadvantages of digital nerve translocations. Finally, many adult patients do not have cortical reorientation following surgical procedures to restore sensation.

## REHABILITATION

The preoperative evaluation provides objective data to determine how much function has been lost and how much retained. Interview the patient to determine whether she desires an increase in function or in cosmesis. Document passive range of motion and initiate therapy before surgery if there are limitations in motion. Static and dynamic splints are useful to maintain or increase joint range of motion. For example, if the thumb–index web space is narrowed, a static thumb web spacer may be fabricated and adjusted serially until full range of motion is obtained with a web space equal to the contralateral extremity. Sensibility evaluation is important because defects influence how the patients uses her hand. Conduct a functional assessment to document sensibility loss.

Preoperative training is valuable in the combined nerve palsies. It is important that the patient comprehend what is to be done and be ready to accept the postoperative discipline. Biofeedback is effective, and if possible, the patient should be able to palpate the major muscles to be transferred. The preoperative goals of rehabilitation are to maintain or achieve a supple hand and to enhance remaining hand function.

The pertinent consideration in postoperative splinting of the hand that has undergone tendon transfer procedures is identification of the points at which the relocated musculotendinous unit crosses the wrist and the digital joints. During the early postoperative period, direct splinting toward protection of the transfer, correction of stiffness secondary to postoperative immobilization, and controlled tension on the musculotendinous transfer. Brand (3) has recommended placing the hand in a volar slab cast with a very light unpadded cylindrical wrap to make a circular support that holds the fingers in the appropriate position during the postoperative period. A soft bulky dressing may be added.

Surgical procedures in low median–ulnar palsy emphasize transfers to improve intrinsic muscle function. All indicated surgery can be done at the same time. Immobilize the forearm in a light, compressive, bulky dressing with a volar plaster splint. Hold the wrist in 45° of extension, the MP joints (except the thumb) in full flexion, and the IP joints in full extension.

Change dressings in 14 days for suture removal and reapply a molded splint to hold the position of the joints. Initiate light strengthening at 8 weeks postoperatively. The MP arthrodesis of the thumb is immobilized for at least 8 weeks (35). Allow unrestricted use at 12–14 weeks postoperatively.

High median–ulnar palsy involves the elbow joint as well as more distal joints. Postoperatively, hold the hand and forearm in light, well-padded splints within a bulky dressing, with the wrist in 10° to 15° of extension, the thumb in opposition, the fingers supported in a “straight-line” position of full MP flexion, and the IP joints in 10° of flexion. Support the elbow in 90° of flexion (Munster level) (28). Start gentle active motion under supervision at 6 weeks postoperatively. Initiate strengthening at 8 weeks postoperatively. Elastic splinting can be used to support finger flexion, and static splints can be used to support thumb opposition. Gradually, change emphasis to functional use of the hand.

Some patients can benefit from multiple stages in reconstruction: First, do thumb and little-finger intrinsic procedures; second, do finger and thumb flexion procedures; third, correct residual claw fingers. These steps can be done at 3-month intervals, followed by any elective procedure for sensibility.

High ulnar–radial palsy is a rehabilitation problem. It is difficult to retrain flexion and extension simultaneously; consider staging the surgery for these cases. The first stage might include wrist and digit extension procedures, plus thumb abduction. The second stage might include digit flexion and thumb adduction. Arthrodesis of MP or IP joints can be done in either surgical stage, or the surgical stages could be reversed in order.

Sensibility procedures are the final stage of these surgical reconstructions. If done in the order just mentioned, the first phase is a radial nerve correction, and the wrist is immobilized in 45° of extension, the MP joints in 15° of flexion, and the thumb in maximal extension and abduction. Immobilize the elbow in a Munster-type above-elbow cast with 15° to 30° of pronation, leaving the PIP joints free. Remove the sutures at 14 days, but do not remove the long-arm cast until 6 weeks postoperatively. Use removable short-arm splints to hold the wrist, fingers, and thumb in extension.

Do the second phase, which involves finger flexion and intrinsic balance for the thumb, 12 weeks after the first phase. Hold the wrist in 45° of extension, the MP joints in full flexion, and the IP joints in extension (10° of flexion if tenodesis is done). Adduct the first metacarpal so that it is parallel with the plane of the second metacarpal. Maintain this intrinsic-plus position by immobilizing in plaster for 4 weeks before resuming active extension.

High median–radial palsy is also difficult for appropriate rehabilitation and can be done in two stages. The first stage might include arthrodesis of the wrist and the MP joint of the thumb, as well as tenodesis of the APL tendon to the radius. The second stage could be limited to finger and thumb extension, plus any elbow surgery. Finally, the flexors could undergo tenodesis. Tenodesis of the finger FDP flexor and the thumb FPL flexor requires protective support against a stronger FCU extensor.

## AUTHORS' PERSPECTIVE

Surgeons concerned with reconstruction of the upper extremity after combined nerve palsies have occurred should be experienced enough to select appropriate procedures based on the individual case. The appropriate donor muscles will change with the combination of nerve palsies and tissue equilibrium. Perform surgical procedures to restore motor function before doing procedures to improve sensibility, because precise sensibility requires precise motion. To add strength, a new muscle–tendon unit must be placed in the power train. The anticipated result should be a balanced simplification of functional performance, because surgery and rehabilitation will redistribute the few remaining assets rather than create new ones. Motivated patients create successful surgeons, and the key to success for these surgical problems is simplicity. Complexity invites failure.

### CHAPTER REFERENCES

Each reference is categorized according to the following scheme: *, classic article; #, review article; !, basic research article; and +, clinical results/outcome study.


+ 1. Blacker GJ, Lister GD, Kleinert HE. The Abducted Little Finger in Low Ulnar Nerve Palsy. *J Hand Surg* 1976;1:190.

* 2. Boyes JW. Tendon Transfers for Radial Palsy. *Bull Hosp Joint Dis* 1960;21:97.

* 3. Brand PW. Tendon Transfers for Median and Ulnar Nerve Paralysis. *Orthop Clin North Am* 1970;1:447.

# 4. Brand PW. Tendon Transfers in the Forearm. In: Jupiter JB, ed. *Flynn's Hand Surgery*, 4th ed. Baltimore: Williams and Wilkins, 1991:490.

* 5. Burkhalter WE. Early Tendon Transfer in Upper Extremity Peripheral Nerve Injury. *Clin Orthop* 1974;104:68.

* 6. Burkhalter WE, Christensen RC, Brown PW. Extensor Indicis Proprius Opponensplasty. *J Bone Joint Surg Am* 1973;55:725.

+ 7. Chiu H-Y. Use of a Previously Repaired Tendon for Tendon Transfer. *J Hand Surg [Br]* 1987;12:185.

# 8. Cooney WP. Tendon Transfers for Median Nerve Palsy. *Hand Clin* 1988;4:155.

# 9. Eversmann WW Jr. Tendon Transfers for Combined Nerve Injuries. *Hand Clin* 1988;4:187.

! 10. Haran T, Tsuyama N, Furusawa S. An Attempt to Regain Sensations in the Median Nerve by Transferring the Superficial Radial Nerve to the Median Nerve. *Operation* 1973;27:551.

+ 11. Hastings HH, Davidson S. Tendon Transfers for Ulnar Nerve Palsy. Evaluation of Results and Practical Treatment Considerations. *Hand Clin* 1988;4:167.

! 12. Holevich J. A New Method of Restoring Sensibility to the Thumb. *J Bone Joint Surg Br* 1963;45:496.

* 13. Littler JW. Tendon Transfers and Arthrodesis in Combined Median and Ulnar Nerve Paralysis. *J Bone Joint Surg Am* 1949;31:224.

+ 14. Littler JW, Colley SGE. Opposition of the thumb and Its Restoration by Abductor Digit Quinti Transer. *J Bone Joint Surg Am* 1963;45:1389.

+ 15. Moneim MS, Omer GE Jr. Latissimus Dorsi Muscle Transfer for Restoration of Elbow Flexion after Brachial Plexus Disruption. *J Hand Surg [Am]* 1986;11:135.

! 16. Neviaser RJ, Wilson JN, Gardner MM. Abductor Pollicis Longus Transfer for Replacement of First Dorsal Interosseous. *J Hand Surg* 1980;5:53.

* 17. Omer GE Jr. Evaluation and Reconstruction of the Forearm and Hand after Traumatic Peripheral Nerve Injuries. *J Bone Joint Surg Am* 1968;50:1454.

# 18. Omer GE Jr. Tendon Transfers in Combined Nerve Lesions. *Orthop Clin North Am* 1974;5:337.

+ 19. Omer GE Jr. Injuries to Nerves of the Upper Extremity. *J Bone Joint Surg Am* 1974;56:1615.

+ 20. Omer GE Jr. Early Tendon Transfers in the Rehabilitation of Median, Radial, and Ulnar Palsies. *Ann Chir Main* 1982;1:187.

+ 21. Omer GE Jr. Reconstruction of a Balanced Thumb through Tendon Transfers. *Clin Orthop* 1985;195:104.

# 22. Omer GE Jr. Early Tendon Transfers as Internal Splints after Nerve Injury. In: Hunter JM, Schneider LH, Mackin EJ, eds. *Tendon Surgery in the Hand.* St. Louis, MO: CV Mosby, 1987;413.

# 23. Omer GE Jr. Tendon Transfers in Radial Nerve Paralysis. In: Hunter JM, Schneider LH, Mackin EJ, eds. *Tendon Surgery in the Hand.* St. Louis, MO: CV Mosby, 1987;425.

# 24. Omer GE Jr. The Palsied Hand. In: Evars CM, ed. *Surgery of the Musculoskeletal System*, 2nd ed. New York: Churchill Livingstone, 1990:849.

# 25. Omer GE Jr. Tendon Transfers for Combined Nerve Injuries. In: Gelberman RH, ed. *Operative Nerve Repair and Reconstruction.* Philadelphia: Lippincott, 1991:747.

+ 26. Omer GE Jr. Tendon Transfers for Combined Traumatic Nerve Lesions of the Forearm and Hand. *J Hand Surg [Br]* 1992;17:603.

# 27. Omer GE Jr. Intrinsic Transfers with the Extensor Indicis Proprius and the Extensor Digiti Minimi Tendons. In: Blair WF, ed. *Techniques in Hand Surgery.* Baltimore: Williams and Wilkins, 1996;688.

+ 28. Omer GE Jr. Tendon Transfers for Median Nerve Paralysis. In: Strickland JW, ed. *The Hand.* In: Thompson R, Jr., ed. *Master Techniques in Orthopaedic Surgery.* Philadelphia: Lippincott-Raven, 1998:319.

# 29. Omer GE Jr. Reconstruction of the Forearm and Hand after Peripheral Nerve Injuries. In: Omer GE Jr, Spinner M, Van Beek AL, eds. *Management of Peripheral Nerve Problems*, 2nd ed. Philadelphia: Saunders, 1998:675.

+ 30. Omer GE Jr. Ulnar Nerve Palsy. In: Green DP, Hotchkiss RN, Pederson WC, eds. *Green's Operative Hand Surgery*, 4th ed. New York: Churchill Livingstone, 1999:1526.

+ 31. Omer GE Jr. Combined Nerve Palsies. In: Green DP, Hotchkiss RN, Pederson WC, eds. *Green's Operative Hand Surgery*, 4th ed. New York: Churchill Livingstone, 1999:1542.

! 32. Omer GE Jr, Day DJ, Ratcliff H, Lambert P. Neurovascular Cutaneous Island Pedicles for Deficient Median Nerve Sensibility. *J Bone Joint Surg Am* 1970;52:1181.

# 33. Omer GE Jr, Pierla-Cruz M. Complications of Peripheral Nerve Injuries. In: Epps CH Jr, ed. *Complications in Orthopaedic Surgery*, 3rd ed. Philadelphia: Lippincott, 1994:811.

! 34. Parkes A. Paralytic Claw Fingers—A Graft Tenodesis Operation. *Hand* 1973;5:192.

# 35. Pribyl CR, Omer GE Jr, McGinty L. Effectiveness of the Chevron Arthrodesis in Small Joints of the Hand. *J Hand Surg [Am]* 1996;21:1052.

# 36. Riordan DC. Tendon Transfers for Nerve Paralysis of the Hand and Wrist. In: Adams JP, ed. *Current Practice in Orthopaedic Surgery,* Vol. 2. St. Louis, MO: CV Mosby, 1964:17.

# 37. Riordan DC. Tendon Transfers in Hand Surgery. *J Hand Surg* 1983;8:748.

* 38. Smith RJ. Extensor Carpi Radialis Brevis Tendon Transfer for Thumb Adduction—A Study of Power Pinch. *J Hand Surg* 1983;8:4.

# 39. Smith RJ. Tendon Transfers of the Hand and Forearm. Boston: Little, Brown, 1987.

! 40. Stocks GW, Cobb T, Lewis RC. Transfer of Sensibility in the Hand: A New Method to Restore Sensibility in Ulnar Nerve Palsy with Use of Microsurgical Digital Nerve Translocation. *J Hand Surg* 1991;16:219.

! 41. Turnbull F. Radial-medial Anastomosis. *J Neurosurg* 1949;5:562.

! 42. Waters RL, Stark IZ, Gubernick I, et al. Electromyographic Analysis of Brachioradialis to Flexor Pollicis Longus Tendon Transfer in Quadriplegia. *J Hand Surg [Am]* 1990;15:335.

* 43. White WL. Restoration of Function and Balance of the Wrist and Hand by Tendon Transfers. *Surg Clin North Am* 1960;40:427.

* 44. Zancolli EA. Claw-hand Caused by Paralysis of the Intrinsic Muscles. A Simple Surgical Procedure for Its Correction. *J Bone Joint Surg Am* 1975;39:1076.

# CHAPTER 59

# NEUROLOGIC CONDITIONS ABOUT THE SHOULDER

*Robert M. Szabo*

**R. M. Szabo:** Departments of Orthopaedic Surgery, and Hand and Upper Extremity Service, University of California, Davis, School of Medicine, Sacramento, California, 95817.

Evaluation of the Patient
Parsonage-Turner Syndrome
Suprascapular Nerve Entrapment
Surgical Techniques
Posterior Approach
Superior Approach for Decompression of the Suprascapular Nerve
Zachary Procedure for Restoration of Shoulder External Rotation
Axillary Nerve Compression (Quadrilateral Space Syndrome) and Injury
Decompression of the Axillary Nerve
Approach for Axillary Nerve Repair or Grafting
Long Thoracic Nerve (Serratus Anterior) Palsy
Treatment
Teres Major Transfer
Spinal Accessory Nerve Palsy
Rhomboid and Levator Scapulae Muscle Transfer for Accessory Nerve Palsy
Upper Brachial Plexus Palsy
Chapter References

## EVALUATION OF THE PATIENT

Symptoms of neurologic conditions of the shoulder include pain, weakness, or both. Obtain a complete history and perform a thorough physical examination; pay particular attention to testing and grading each muscle about the shoulder girdle and examining for specific local areas of tenderness. Then decide to what extent the pain is related to organic pathology. This decision making takes into consideration the patient's credibility, whether worker's compensation is a factor, and whether litigation is pending.

The diagnosis of shoulder pain is difficult, analogous to evaluating the source of low back pain. Most often, pathology resides in the rotator cuff or with intraarticular problems; take care not to fall into the trap of missing some of the less common diagnostic entities. The shoulder often is implicated in pain arising from the neck (1,8). This chapter does not discuss the qualities of cervical radiculopathy and arthritic changes about the neck, but I mention them here to remind you not to have tunnel vision when evaluating the shoulder.

Pain secondary to nerve compression can be caused by thoracic outlet syndrome, suprascapular nerve compression syndrome, and quadrilateral space syndrome. See Chapter 61 for a complete discussion of thoracic outlet syndrome.

Pain can also be secondary to weakness or instability about the shoulder, due to palsies of the suprascapular, axillary, long thoracic, and spinal accessory nerves, as well as palsy of the upper brachial plexus. Vague shoulder pain and weakness of the involved muscle groups are the main symptoms of isolated nerve injuries about the shoulder (44).

The purpose of this chapter is to review the diagnosis and treatment of specific nerve entrapments or palsies about the shoulder that result in pain, weakness, or both. Systemic conditions, such as arthrogryposis, muscular dystrophies, polio, and stroke, will not be discussed; instead, see the works of Saha (58) and Scholtstaedt et al. (60). Also see Chapter 67, Chapter 68, and Chapter 178.

## PARSONAGE-TURNER SYNDROME

Before addressing specific conditions that can be traced to an isolated nerve insult, one must be aware of a syndrome comprising pain and flaccid paralysis of the muscles about the shoulder girdle. Parsonage and Turner first described it in 1948 (50), calling it *neuralgic amyotrophy.* The syndrome today is more often referred to by their names.

> The essential clinical picture is simple: Without any constitutional disturbance, pain starts suddenly across the top of the shoulder blade and may radiate down the outer side of the upper arm or into the neck. This pain lasts from a few hours to a fortnight or more, and then a flaccid paralysis, of some of the muscles of the shoulder girdle and often of the arm, develops, and in some cases there is a patch of numbness over the outer side of the upper arm. When the paralysis appears, the severe pain usually stops, but a dull ache may persist considerably longer. This clinical picture is subject to modifications. (50)

In their series of 136 patients, Parsonage and Turner were able to identify a precipitating cause in 66 patients. Some of the causes cited were infection, trauma, or previous vaccination. They noted that local pain was almost always the presenting symptom, generally a constant severe ache that lasted for a few hours to a week or two and then stopped fairly suddenly as muscle paralysis appeared. Involvement of the long thoracic nerve leading to paralysis of the serratus anterior was the most common finding. The authors also reported cases in which the suprascapular nerve, the axillary nerve, and C-5 and C-6 nerve root were involved. The prognosis for recovery was related to the amount of initial paralysis. Muscles not completely paralyzed or those showing some return during the first few weeks usually recovered completely in 6 months or less. With severe wasting occurring early and rapidly, the prognosis for useful return of function was poor. Recovery of voluntary power in completely paralyzed muscles was found 9 to 12 months after the onset, and recovery continued up to 2 years or longer. The only treatment recommended was to move the shoulder joint through its full range of motion on a regular basis to prevent stiffness.

The pathophysiology of this syndrome is not any better understood today than it was by Parsonage and Turner in 1948. It is important to keep this fact in mind when evaluating any nerve palsy about the shoulder, because early surgical treatment is not indicated (17). A history of severe pain preceding muscle paralysis or the close timing of a vaccination forms the basis for this diagnosis. Other than symptomatic therapy, no specific treatment is available.

## SUPRASCAPULAR NERVE ENTRAPMENT

The suprascapular nerve may be compressed in the suprascapular notch, resulting in little more than pain about the medial aspect of the scapula. The pain is usually diffuse, deep aching and may be localized to the posterior aspect of the shoulder. Adduction of the forward-flexed arm across the body produces traction on the nerve and may increase this pain (53). Deep palpation over the suprascapular notch may show marked tenderness. With further compression or traction on this nerve, atrophy and loss of external rotator function will ensue (Fig. 59.1). The external rotation deficit limits the patient's ability to perform activities with the arm in an overhead position. With prolonged compression and loss of all external rotator function, posterior shoulder instability may also result.

***Figure 59.1.*** A 27-year-old body-builder noticed asymmetry of his shoulder muscles. The *arrow* points to atrophy of the infraspinatus muscle. Some decrease in supraspinatus muscle mass is evident but is masked by the well-developed trapezius muscle. Electrodiagnostic studies confirmed suprascapular nerve palsy.

The suprascapular nerve is a mixed peripheral nerve that arises from the upper trunk of the brachial plexus (C-4 to C-6) (Fig. 59.2). It courses laterally, deep to the trapezius and omohyoid muscles, and enters the supraspinous fossa passing under the transverse suprascapular ligament. The suprascapular artery and vein course with the nerve, but they pass above the transverse suprascapular ligament. The sensory component supplies the posterior capsule of the shoulder joint and has no cutaneous distribution (57). The suprascapular nerve courses deep to the supraspinatus muscle, innervating this muscle with two branches. The nerve continues to the lateral edge of the spine of the scapula, curving around it medially into the infraspinous fossa, deep to the infraspinatus muscle. As the nerve courses under the edge of the spine of the scapula, it commonly passes through an inferior transverse scapula ligament (the spinoglenoid ligament) that inserts at the lateral border of the scapular spine and the scapular neck.

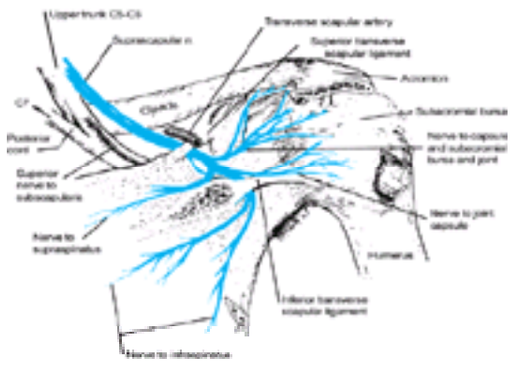

***Figure 59.2.*** The course and distribution of the suprascapular nerve originating from the upper trunk, passing under the superior transverse scapular ligament and innervating the supraspinatus, then passing under the inferior transverse scapular ligament and innervating the infraspinatus. (From Narakas A. Compression Syndromes about the Shoulder Including Brachial Plexus. In: Szabo RM, ed. *Nerve Compression Syndromes—Diagnosis and Treatment.* Thorofare, NJ: Slack, 1989, with permission.)

More commonly, the site of entrapment is found to be underneath the transverse suprascapular ligament; isolated atrophy and weakness of the infraspinatus muscle, however, have been attributed to compressions underneath the inferior transverse scapular ligament (63,65). Dermirhan et al. studied the anatomy and morphology in cadavers to determine the role of entrapment in the suprascapular nerve. They found the spinoglenoid ligament to be present in 60.8% of shoulders, and that it was wider at the superior entrance of the tunnel and fanned and twisted toward the inferior aspect (9). In all their specimens, the fibers inserted into the posterior shoulder capsule. During cross-body adduction and internal rotation of the glenohumeral joint, the suprascapular nerve moved laterally and stretched underneath the spinoglenoid ligament. In this position, the interaction of the spinoglenoid ligament and the posterior capsule resulted in stretching of the nerve (9).

Electromyography is critical for the diagnosis of compression of the suprascapular nerve. Diagnostic are denervation potentials in the supraspinatus and infraspinatus muscles and prolonged conduction time from Erb's point to the supraspinatus and infraspinatus muscles in the absence of involvement of other peripheral nerves (37). Root compression at the C-5 level can mimic suprascapular nerve entrapment syndrome; if C-5 root compression is the cause, however, electrodiagnostic studies of the deltoid and rhomboids will demonstrate abnormalities in these muscles. Magnetic resonance imaging is also useful not only for the detection of ganglion cysts but also for assessing the stage of paralysis (26).

Suprascapular nerve palsy can result from direct trauma such as fracture of the scapula or a blow to the shoulder region (70). It has been reported as well to result from compression by a ganglion cyst (26,47,54,62,65) or from a bone cyst (61). Rengachary et al. studied the anatomy of the suprascapular notch in cadavers and concluded that certain configurations might contribute to nerve entrapment (56). Ticker et al. found the ligament to be partially ossified in 18% of cadavers (66). It is debatable whether this entity is an actual nerve entrapment syndrome or a situation in which the nerve is fixed at a given point and the dysfunction is actually caused by traction.

Ferretti et al. studied 96 top-level volleyball players and in 12 found isolated paralysis of the infraspinatus on the dominant side (16). They attributed this denervation to the athlete's repeated stressing and stretching of the nerve when serving (with the arm cocked) and following through. Sandow and Ilic proposed that the infraspinatus branch of the suprascapular nerve can be directly compressed between the lateral border of the scapular spine and the medial margin of the rotator cuff during the extremes of shoulder motion during sports such as volleyball and baseball; they treat these athletes with a “notchplasty” in addition to release of both the superior and inferior suprascapular ligaments (59).

Most authors recommend decompression of the suprascapular nerve for severe pain or atrophy. Martin et al., however, reviewed their experience with nonsurgical treatment and concluded that “in the absence of a well-defined lesion producing mechanical compression of the suprascapular nerve, suprascapular neuropathy should be treated non-operatively” (43). Twenty percent of the patients in their study failed conservative treatment, however, and no predictors were found that would indicate the need for operative versus nonoperative care. For exposure of the nerve, posterior, anterior, and superior approaches have all been described (45,48,53,64). Most authors have abandoned the anterior approach because it is a more difficult dissection and has a higher risk of complications.

## SURGICAL TECHNIQUES

### POSTERIOR APPROACH

- Place the patient either prone or in the lateral decubitus position, with the involved side uppermost.
- Make the skin incision parallel to and 1 inch superior to the scapular spine, along its entire length.
- Elevate the trapezius muscle from the spine and reflect it superiorly, exposing the supraspinatus muscle. Palpate the suprascapular ligament overlying the suprascapular notch.
- Clean the suprascapular ligament with a blunt elevator. Protect the suprascapular artery and vein, which are superficial to the ligament. Protect the suprascapular nerve and sharply excise (not just release) the transverse suprascapular ligament.
- Enlarge the suprascapular notch only if you find that the nerve is not completely free of impingement or traction. Inspect and palpate the surrounding region for any abnormal masses.
- Reattach the trapezius muscle to the spine of the scapula using nonabsorbable sutures placed through drill holes in the bone.
- Close the wound in routine fashion.
- Following surgery, immobilize the patient in a sling for 10 days. Then remove the sutures and initiate gradual progressive range-of-motion and shoulder-strengthening exercises.

## SUPERIOR APPROACH FOR DECOMPRESSION OF THE SUPRASCAPULAR NERVE

Menon described the superior approach and claims that it offers ease of access to the suprascapular ligament while avoiding detachment of the trapezius muscle (Fig. 59.3) (45). I prefer this approach, as long as access to the spinoglenoid ligament is not required. It leaves a very cosmetically acceptable scar. This approach is, however, too limited to excise ganglions that originate from the glenohumeral joint. It may be combined with the posterior approach if a more extensile exposure is needed.

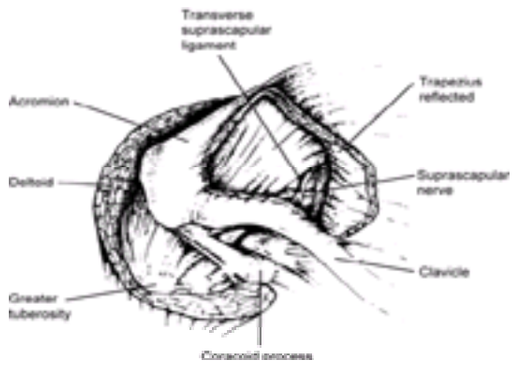


***Figure 59.3.*** Superior surgical approach to the transverse suprascapular ligament. The trapezius is reflected medially to expose the suprascapular ligament and nerve. (Illustration courtesy of J. Menon.)

- Place the patient in a semi-sitting beach chair or a lateral position held by a vacuum bean bag.
- Start the incision over the distal third of the clavicle, extending it over the acromioclavicular joint to the lateral border of the spine of the scapula.
- Incise the subcutaneous tissue along the line of the incision.
- Detach the trapezius muscle from the distal third of the clavicle and the acromion process and reflect it medially.
- Palpate the superior border of the scapula, directing a finger toward the coracoid process. Move the fat pad underneath the trapezius to one side to expose the superior border of the scapula.
- Pass a right-angle clamp beneath the ligament and through the foramen, and then transect the ligament.
- Remove the ends of the ligament with a rongeur.
- Reattach the trapezius muscle to the lateral end of the acromion and the clavicle by passing sutures through drill holes; then close the skin.

## ZACHARY PROCEDURE FOR RESTORATION OF SHOULDER EXTERNAL ROTATION

If the patient has longstanding weakness and irreparable damage of the supraspinatus and infraspinatus muscles, consider reconstructive substitution for the external rotators. The operation that I have found works best is the one described by Zachary and Leeds (73) [a modification of L'Episcopo's (34) procedure], which is a transfer of the teres major and the latissimus dorsi to the lateral aspect of the humerus (Fig. 59.4).

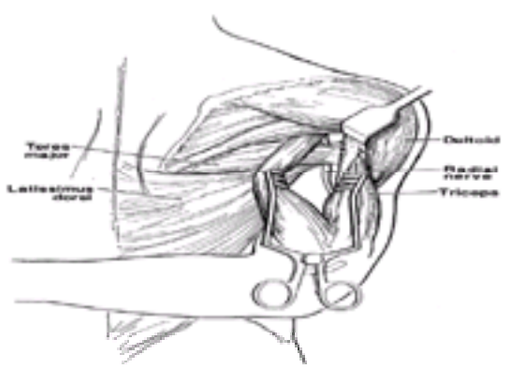


***Figure 59.4.*** Posterior view right shoulder. Transplantation of the teres major and latissimus dorsi muscles for restoration of external rotation at the shoulder. Retraction of the deltoid muscle superiorly and separation of the long and lateral heads of the triceps muscle expose the insertion of the teres major and latissimus dorsi. The tendons of the teres major and latissimus dorsi are passed through slots in the lateral head of the triceps muscle and fixed to the posterolateral aspect of the humerus through drill holes in the bone. (Adapted from Zachary RB, Leeds MB. Transplantation of Teres Major and Latissimus Dorsi for Loss of External Rotation at the Shoulder. *Lancet* 1947;253:758, with permission.)

- Place the patient prone with the arm in full internal rotation.
- Make a curvilinear incision over the posterior aspect of the upper third of the arm.
- Expose the insertion of the teres major and latissimus dorsi muscles by retracting the posterior border of the deltoid muscle superiorly; separate the long and lateral heads of the triceps muscle.
- Identify the radial nerve at the lower border of the teres major muscle. Detach the teres major and latissimus dorsi muscles together from their insertion on the humerus.
- Fully externally rotate the arm and pass the tendinous insertions of the teres major and latissimus dorsi muscles through a slit in the upper part of the lateral head of the triceps.
- Attach the latissimus dorsi and teres major muscles to the posterior lateral aspect of the humerus with mattress sutures passed through drill holes in the bone.
- Close the wound, and use a shoulder abduction splint to immobilize the patient in 90° of forward flexion and external rotation.
- Continue immobilization for 4 weeks, and then begin range-of-motion exercises.

## AXILLARY NERVE COMPRESSION (QUADRILATERAL SPACE SYNDROME) AND INJURY

The axillary nerve contains fibers from C-5 and C-6 and is a terminal branch of the posterior cord. It lies on the subscapularis muscle behind the axillary artery and dips posteriorly just inferior to the glenohumeral joint before emerging in the quadrilateral space (Fig. 59.5). It innervates the teres minor and the deltoid muscles. The axillary nerve enters the quadrilateral space together with the posterior humeral circumflex artery.

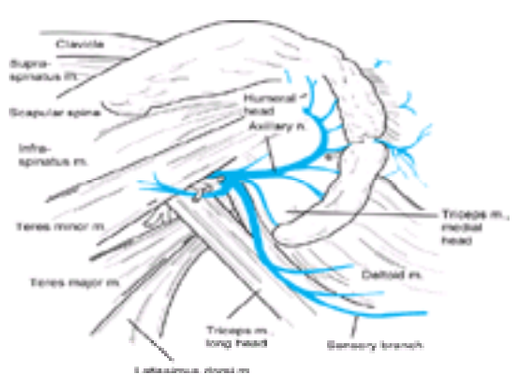


***Figure 59.5.*** Posterior view of the axillary nerve and posterior circumflex humeral vessels as they course through the quadrilateral space. (From Narakas A.

Compression Syndromes about the Shoulder Including Brachial Plexus. In: Szabo RM, ed. *Nerve Compression Syndromes—Diagnosis and Treatment.* Thorofare, NJ: Slack, 1989, with permission.)

The quadrilateral space is bounded anteriorly by the subscapularis fascia, superiorly by the teres minor, inferiorly by the teres major, laterally by the humerus and joint capsule, and medially by the long head of the triceps (49). The axillary nerve is tethered in this space by muscular fascia, joint capsule, and periosteum. At the time of surgery, normally this space will admit an index finger along the neurovascular pedicle; the arm is in a relaxed position at the side. In abduction, this space is narrowed by the scissorlike effect of the triceps and the teres major, and the nerve is placed under tension by its distal site of innervation. Full forward flexion of the arm puts the subscapularis, teres major, and triceps muscles under tension, and it causes the humeral head to impinge on the axillary nerve. Abduction and external rotation further narrow the tunnel (49).

Idiopathic axillary nerve compression (the quadrilateral space syndrome) is a rare condition, and the diagnosis is often delayed (7). One case caused by a ganglion has been reported (27). Pain usually is described as being diffuse and anterior; extreme movements of the shoulder involving abduction and external rotation, however, exacerbate the symptoms. Typically, examination reveals tenderness over the posterior aspect of the quadrilateral space. Rarely is there any weakness of the deltoid or sensory deficit over the distribution of the axillary nerve. Electromyographic examinations are often normal and patients are often labeled neurotic.

Arteriography was once deemed necessary to confirm the diagnosis (3,4). This invasive procedure should be performed to document this syndrome only if surgery is contemplated. Perform a subclavian arteriogram by using the Seldinger technique with the humerus at the side and in abduction and external rotation (Fig. 59.6). Follow the dye distally to visualize the posterior humeral circumflex artery. In a positive arteriogram, the posterior humeral circumflex artery is patent with the arm at the side and occludes with the arm in external rotation and abduction. In normal extremities, the posterior humeral artery does not occlude in this position.

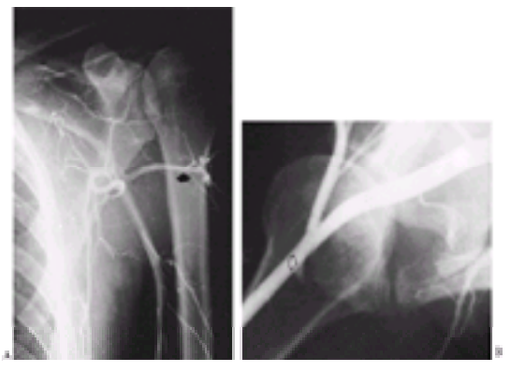

***Figure 59.6.*** Subclavian arteriogram of a patient with quadrilateral space syndrome. **A:** With the arm at the side, the posterior humeral circumflex artery is patent (*arrow*). **B:** With the arm in abduction and external rotation, occlusion of the posterior humeral circumflex artery is seen near its origin (*arrow*).

Francel et al. have found that arteriography is unnecessary and make the diagnosis on the basis of tenderness over the quadrilateral space, paresthesia over the lateral shoulder and upper posterior arm, and deltoid weakness associated with decreased shoulder abduction in the presence of a history of trauma (18). In addition, I have found that a diagnostic nerve block is more valuable in confirming the diagnosis than are any radiologic or electrodiagnostic studies. I inject 10 ml of 1% plain lidocaine into the quadrilateral space. If the injection produces numbness in the distribution of the axillary nerve, and the shoulder pain resolves in spite of provocative maneuvers, the diagnosis is more likely.

Conservative therapy consists of avoiding aggravating movements, administration of antiinflammatory medication, steroid injections, and range-of-motion exercises. When this therapy has failed and diagnosis is confirmed, surgical decompression is recommended.

**DECOMPRESSION OF THE AXILLARY NERVE**

***Classic Approach***

- Make a skin incision parallel to and one fingerbreadth inferior to the scapular spine, and curve it along the posterior border of the deltoid muscle (Fig. 59.7).

***Figure 59.7.*** Skin incision for decompression of the quadrilateral space. The incision parallels and is just inferior to the spine of the scapula and curves inferiorly over the posterior humerus. The *x* marks the location of the quadrilateral space.

- Dissect the fascia at the inferior border of the deltoid muscle starting inferior and laterally and proceeding superiorly and medially. Detach the deltoid muscle from the spine of the scapula, leaving a musculotendinous border for reattachment (Fig. 59.8).

***Figure 59.8.*** The deltoid muscle is dissected from the spine of the scapula and reflected laterally. The axillary nerve exits the quadrilateral space and is seen entering the deltoid (*arrow*).

- Elevate the teres minor muscle superiorly. Cahill (3,4) recommends detaching the teres minor muscle from the humerus at this point, but I have never found it necessary to do so.
- Insert your index finger into the quadrilateral space, directing it anteriorly, and palpate the posterior humeral circumflex artery.
- Move the arm to extreme ranges of motion and feel for any compressing structures. You may find a scarred inferior glenohumeral ligament; tight teres minor, triceps, or teres major tendons; or tight subscapularis fascia. I have been impressed by the sharp scissorlike effect of the lateral head of the triceps tendon on the

axillary nerve and posterior humeral circumflex vessel; therefore, I incise part of this tendinous insertion to create more space in the tunnel.
- Reattach the deltoid muscle to the scapular spine with nonabsorbable sutures through drill holes in the bone.
- Close the rest of the wound in the usual fashion. After surgery, place the arm in a sling for 7 to 10 days, then encourage gentle mobilization.
- Begin active deltoid muscle exercises at 6 weeks. Do not start resistive exercises requiring full abduction and external rotation for 3 months.

#### *Limited Incision Approach for Decompression of the Axillary Nerve*

Francel et al. described a technique that does not require division of the deltoid muscle and uses a smaller incision (18). I now routinely use this approach and have found exposure to be adequate and postoperative rehabilitation to be faster.

- Position the patient prone with the arm extended on an arm board.
- With the patient standing before induction of general anesthesia, determine the point of maximum tenderness over the quadrilateral space. Make a vertical or an S-shaped incision over this point.
- Raise skin flaps to expose the inferior border of the deltoid.
- Incise the deltoid fascia along the inferior border of the muscle and retract the deltoid superiorly to expose the teres major and minor muscles.
- Dissect laterally and identify the tendon of the long head of the triceps.
- Open the fascia between the teres muscle bellies and explore the quadrilateral space.
- Identify the axillary nerve and the posterior circumflex humeral vascular bundle and tag them with rubber drains.
- Sharply divide any fibrous bands to decompress the space. (Although the authors do not mention this method, I incise the part of the tendinous insertion of the lateral head of the triceps if I find it compressing the axillary nerve and posterior humeral circumflex vessel when the arm is placed in abduction and external rotation.)
- Perform neurolysis if you find nerve fibrosis.
- Close the wound in layers. No drain is usually necessary.
- After surgery, place the arm in a sling for 7 to 10 days, then encourage gentle mobilization and progress to resistive exercises as tolerated.

The axillary nerve's relationship to the glenohumeral joint makes it particularly susceptible to injury from trauma to the shoulder joint. Coene and Narakas have reported that when diagnosed by electromyography, the incidence of axillary nerve injury in glenohumeral dislocations and humeral neck fractures is as high as 30% (6). These lesions, which are often overlooked, frequently are neurapraxias that resolve spontaneously. Persistent deltoid muscle palsy due to lesions of the axillary nerve is rare, but when present it greatly affects the function of the upper limb. Atrophy of the deltoid muscle and loss of shoulder abduction strength are evident on examination. Tinel's sign may be positive in the infraclavicular region, but this test is not reliable. Sensibility may be decreased over the lateral aspect of the upper arm. Deltoid insufficiency may be masked by a strong rotator cuff.

Hertel et al. describe a more objective and reproducible method for assessing deltoid function, which they have called the *deltoid extension lag sign* (23). This test, which is based on the fact that no other muscle can compensate for insufficiency of the posterior part of the deltoid, is performed with the following steps (23):

- Have the patient sit on an exam table, facing away from you.
- Grasp both wrists and elevate the upper extremities into full passive shoulder extension.
- Allow the shoulders to relax to submaximal extension to avoid elastic recoil in the shoulder.
- Ask the patient to maintain this position as you let go.
- The sign is positive when a lag or angular drop occurs when you let go. Changes may be subtle, with a lag drop as little as 5°.

Electromyographic testing is diagnostic. If signs of reinnervation are absent by 6 months following injury, then surgical exploration is indicated (6,52).

#### APPROACH FOR AXILLARY NERVE REPAIR OR GRAFTING

- Place the patient in the lateral position. Prepare and drape the shoulder widely to provide access both anteriorly and posteriorly.
- Make a skin incision along the anterior inferior border of the clavicle and extend it along the deltopectoral groove. Open the deltopectoral interval while protecting the cephalic vein.
- Detach the pectoralis minor muscle from the coracoid process and expose the branches of the brachial plexus. Leave a tendinous tag on the muscle for repair at closure.
- Isolate the posterior cord and identify the axillary nerve.
- Abduct and externally rotate the arm, and identify the inferior margin of the pectoralis major muscle insertion. Totally or partially release the tendinous portion of the pectoralis major muscle if necessary to better visualize the axillary nerve.
- The lesion usually cannot be addressed with only an anterior approach. Therefore, at this point perform a posterior approach, detaching the deltoid as previously described for quadrilateral space syndrome.
- If a neuroma-in-continuity is found, resect the neuroma back to normal-appearing neural tissue.
- Because repair of the nerve by direct apposition is usually not technically possible, obtain a sural nerve graft to bridge the gap.
- First, suture the sural nerve to the distal stump of the axillary nerve, and pass the nerve graft through the quadrilateral space and then suture to the proximal stump.
- Put the shoulder through a range of motion to demonstrate that there is no tension on the repair.
- Reattach the pectoralis major (if detached), the pectoralis minor, and the deltoid muscles.
- Close the subcutaneous tissues and skin in the usual fashion.
- Postoperatively, immobilize the upper extremity for 3–4 weeks in a shoulder immobilizer. Initiate physical therapy as described for decompression of the quadrilateral space.

In cases of isolated deltoid muscle palsy, either longstanding or with irreparable axillary nerve damage, consider a tendon transfer. Deltoid muscle palsy is often associated with paralyzed rotator cuff muscles, and shoulder arthrodesis becomes the best option. If at least one of the rotator cuff muscles is active and the usual prerequisites for tendon transfer are fulfilled (good passive range of motion of the shoulder joint, normal articular surfaces, and a strong muscle that is available for transfer), then consider restoring deltoid function by tendon transfer. The trapezius transfer is most commonly used (31). Recently, the latissimus dorsi muscle, raised on its neurovascular pedicle and completely rotated, has been used to replace the anterior part of the deltoid (28). Study the original description of the technique in detail if you plan to perform this operation (28).

The anterior deltoid muscle can be damaged iatrogenically during operations about the shoulder where it is either detached from its origin or split. If the muscle is denervated, pain and weakness result. The posterior deltoid muscle can be mobilized and advanced to assume the function of the anterior portion (38).

### LONG THORACIC NERVE (SERRATUS ANTERIOR) PALSY

The long thoracic nerve is formed from the roots of C-5 to C-7. It passes posterior to the brachial plexus and lies on or penetrates the anterior surfaces of the scalenus medius, then angulates over the first or second ribs as it courses along the lateral thoracic wall downward and branches to supply the digitations of the serratus anterior muscle (30).

To avoid injury to the long thoracic nerve, it is important to be aware that it courses obliquely in an anterosuperior to posteroinferior direction as it progresses to the posterior angle of the second rib (14). Traction on the nerve is exerted when the shoulder is depressed or when the cervical spine is bent in a contralateral direction. Kauppila's autopsy study suggests that the potential site for damage is anterior to the lower part of the scapula, where the nerve may be exposed to both compression and traction (32).

Isolated serratus anterior palsy may follow an injury such as a direct blow to the shoulder or a sudden jerk of the arm forward or backward (68). The nerve can be injured between the coracoid process and the first or second ribs. Injury to the nerve during surgery has been reported following axillary approaches for thoracotomy, radical mastectomy, and axillary node dissection (12,40,51). Repetitive trauma can also cause loss of serratus anterior function, particularly in laborers who carry heavy objects on their shoulders. Sustained compression has been described from the downward strain on the shoulder produced by carrying heavy knapsacks. A sudden forceful muscular exertion such as lifting a heavy box or pushing with arms stretched overhead to support a ladder has also been reported as a cause. The prognosis is favorable if the nerve injury is from chronic minor trauma, but it seems to be less favorable if the nerve is injured by a single major episode (67). Gozna and Harris studied cadavers and showed that, when the underside of the scapula was coated with graphite and depressed forcefully downward against the thorax, a graphite imprint was found on the long thoracic nerve at the level of the second rib (19). They concluded that this is the site of the nerve injury. Successful repair of this nerve is hampered by its surgically inaccessible location. Generally, one should wait for 1 or 2 years before considering operative treatment, as most patients improve slowly with time (17,19).

Nerve injury must be differentiated from traumatic avulsion of the serratus anterior muscle, which also causes winging of the scapula (21); the latter injury is rare. Electromyography and radiographs are diagnostic.

Paralysis of the serratus anterior muscle causes scapular instability with attempts to elevate the shoulder. The scapula pulls away from the chest wall as the extremity moves into forward flexion or abduction. Normally, to elevate the shoulder fully, the scapula must remain stable and close to the chest wall; at the same time, the medial angle must depress and the inferior angle must rotate laterally and upward. Patients who have serratus anterior muscle palsy may be able to attain full shoulder motion in a supine position where the weight of the body supports and stabilizes the scapula; when they are standing upright, however, they cannot complete full shoulder flexion and abduction.

The serratus anterior muscle has two functions: Statically, it stabilizes the scapula to the thorax so that scapulohumeral muscles can work against a fixed point to achieve arm elevation; dynamically, it actively rotates the scapula anteriorly and dorsally to contribute to full arm elevation.

Examine the patient standing, at rest. If he has serratus anterior muscle paralysis, the medial rim of the scapula protrudes from the thoracic wall, and the inferior border of the scapula “wings.” The winging of the scapula is more distinct if the patient lifts his arm into forward flexion and uses it for some sort of exertion, such as in doing a pushup against a wall (Fig. 59.9).



***Figure 59.9.*** This patient demonstrates inferior scapula winging while doing a pushup against the wall. She has a longstanding serratus anterior palsy from a traction injury.

Nerve conduction studies and electromyography are both valuable in determining whether the lesion is partial or complete and whether regeneration is occurring after Wallerian degeneration. The rest of the upper brachial plexus requires electrodiagnostic study to confirm the diagnosis of isolated long thoracic nerve palsy.

**TREATMENT**

Conservative therapy consists of strengthening the remaining muscles around the shoulder girdle and avoiding activities that cause winging of the scapula. All exercises to strengthen the muscles should be performed with the scapula stabilized. Have the patient lie supine or stand upright with her back placed firmly against a wall. Patients can be taught to substitute movements to stabilize the scapula using a combination of trapezius and rhomboid muscle function. In addition, a custom-fabricated shoulder brace can be used to stabilize the scapula. Although these jacket-braces are usually not well tolerated, they are often appreciated by self-employed laborers who are highly motivated to use them in order to keep working.

When it is determined that recovery has ceased and the patient is sufficiently handicapped, consider surgical stabilization. There are two general approaches to scapular stabilization: static and dynamic. Static procedures have been described using various ligaments, fascia, or even bony scapulopexy with fixation of the scapula to the ribs (11,20,33). Although these procedures improve the winging of the scapula and allow the humeroscapular muscles to function against a fixed point during movement of the shoulder joint, they hinder motion of the scapular thoracic joint and make it impossible to obtain a full range of motion. Therefore, I prefer dynamic muscle stabilization if at all possible.

Muscles used for substitution of the serratus anterior muscle include the pectoralis major, pectoralis minor, and teres major muscles (5,25,39,42,55,67,74). The rhomboids and latissimus dorsi muscles have also been used, but few authors advocate transferring them to remediate serratus anterior muscle palsy (24). Pectoralis major transfer is probably the most common procedure, but it takes away a very strong axiohumeral muscle and thereby limits forward flexion, adduction, and internal rotation—functions already compromised by the absence of the serratus anterior muscle. Moreover, the pectoralis major tendon is too short to be directly sutured to the inferior tip of the scapula unless you use fascia to elongate it.

Similarly, the pectoralis minor tendon is too short to be directly attached to the tip of the scapula without the addition of fascia. Another reason not to choose the pectoralis minor muscle is that it serves as an antagonist to the serratus anterior muscle; it pulls the coracoid process down and forward and thus causes backward rotation of the scapula. The pectoralis minor muscle is active in downward movement of the arm, whereas the serratus anterior muscle acts in lifting the arm. Furthermore, the pectoralis minor muscle is relatively weak.

The teres major muscle is a good substitute for the serratus anterior muscle for the following reasons:

- Its strength is equal to that of the serratus anterior.
- Its function as a depressor and internal rotator of the humerus is taken over by the latissimus dorsi.
- Its use does not further weaken the axioscapular muscle group.
- The course of its fibers corresponds to that of the serratus anterior muscle.
- It does not need to be elongated with fascia.
- The surgical scars are inconspicuous (67).

**TERES MAJOR TRANSFER**

Refer to Figure 59.10.

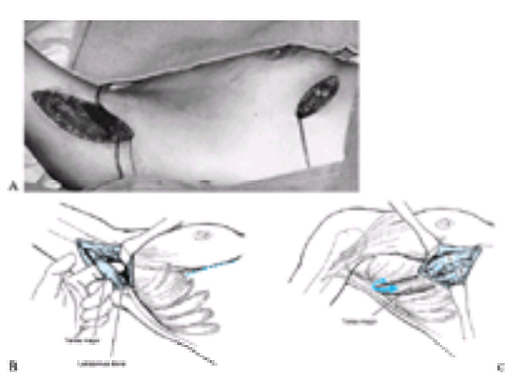

***Figure 59.10.*** Surgical technique for teres major muscle transposition. **A:** An incision is made in the axilla parallel to the posterior fold, and the insertion of the teres major tendon on the humerus is exposed. Then a curved incision is made in the inframammary crease. **B:** The teres major tendon is dissected off the humerus and fed subperiosteally from its humeral insertion and tagged with a suture. **C:** The teres major tendon is passed deep to the latissimus dorsi into the inframammary incision and attached subperiosteally to the fifth and sixth ribs (5,6).

- Place the patient in a lateral position.
- Make a skin incision parallel to the posterior axillary fold to expose the insertion of the teres major and the latissimus dorsi muscle. The insertion of the teres major tendon is more distal than that of the latissimus dorsi.
- Identify the teres major tendon and detach it from the humerus while carefully retracting the neurovascular bundle laterally.
- Insert two heavy nonabsorbable sutures into the teres major tendon and bluntly dissect its muscle from the latissimus dorsi tendon.
- Make an incision, concave side up, below the breast in the inframammary fold.
- Create a blunt tunnel from the posterior to the anterior incision, using a finger to dissect deep to the latissimus dorsi muscle.
- Pass the sutures and the teres major tendon deep to the latissimus dorsi muscle into the anterior wound. Make sure that fascia is not binding the muscle and that the muscle is neither kinked nor twisted in the axillary wound.
- Expose the fifth and sixth ribs subperiosteally through the inframammary incision.
- Divide the teres major tendon into two slips and insert the superior slip into the fifth rib and the inferior slip into the sixth rib through drill holes in the bone. Determine tension by placing the arm in abduction and forward flexion with external rotation. In this position, the transferred teres major tendon should feel snug and draw the inferior pole of the scapula toward the chest wall. Secure this insertion with further nonabsorbable sutures into the periosteum and the teres major tendon.
- Close the wounds in routine fashion.
- After surgery, place the patient in a shoulder abduction splint, maintaining the arm in abduction, forward flexion, and external rotation for 6 weeks.
- Encourage motion of the elbow, wrist, and digits during the period of shoulder immobilization.
- After 6 weeks, initiate physical therapy to regain full range of motion in the shoulder along with gradual strengthening exercises.

## SPINAL ACCESSORY NERVE PALSY

Spinal accessory nerve injury leads to trapezius muscle dysfunction. The trapezius muscle is important in stabilizing the scapula during forward elevation of the arm, and paralysis of it results in drooping, lateral displacement, and winging of the scapula, with weakness of forward elevation and abduction. Patients complain of pain in the shoulder and axilla. Pain and weakness increase with exertion of the arm. The pain may result from traction on the brachial plexus, causing a radiculitis; it has even been demonstrated that traction on the suprascapular nerve alone can be the cause of pain in trapezius palsy (46). The pain also may result from a neuroma (see Chapter 53), which is demonstrated by eliciting Tinel's sign in the posterior cervical triangle.

The accessory nerve exits the skull through the jugular foramen and passes inferior to the surface of the sternocleidomastoid muscle, which it innervates. As it passes underneath or penetrates the deep head of that muscle, it reappears under its posterior edge between the upper and middle thirds. It then enters the posterior cervical triangle, where it lies superficially. The nerve passes beneath the trapezius and forms a plexus with fibers from the third and fourth cervical nerves while innervating the trapezius muscle (72). To delineate the safe limits for muscle-splitting incisions of the trapezius, Jobe et al. dissected the shoulders of 25 cadavers and found that the spinal accessory nerve runs a vertical course medial and parallel to the vertebral border of the scapula (29). They also found that three to six nerve branches also run a vertical course lying 33% to 50% of the distance from the tips of the vertebral spinous processes to the lateral tip of the acromion. They concluded that muscle-splitting incisions are relatively safe in the lateral half of the muscle (29).

The spinal accessory nerve's superficial position in the floor of the posterior cervical triangle renders it vulnerable to injury. Most commonly, the injury occurs during a surgical procedure such as surgical lymph node biopsy or removal of a benign tumor (13,71). It used to be that the nerve was frequently excised during radical neck dissection for malignant tumor, but more recently it is being spared when this operation is performed. The nerve may also be injured by penetrating or blunt trauma to the neck; I explored and grafted one patient's nerve that had been divided from a bite in the neck during a lovers' quarrel. Spontaneous palsy of the accessory nerve has been reported, but all known cases were due to heavy, repetitive work or were related to a particular incident of strenuous activity (41).

On examination, look for signs of surgical scars, and percuss to elicit Tinel's sign in the posterior cervical triangle. The patient may be unable to abduct the shoulder above 80°, and shrugging of the shoulder produces winging of the superior border of the scapula. An abduction test has been devised to further demonstrate the flaring of the vertebral border of the scapula: Hold the patient's wrist firmly at his side and ask him to attempt abduction against resistance. The test is considered positive if there is flaring of the entire vertebral border of the scapula (69).

Electrodiagnostic testing will confirm trapezius muscle palsy, help localize the lesion, and rule out other forms of neuropathy. Initially and up to 1 year, perform exploration of the nerve with neurolysis, repair, or grafting as necessary. After 1 year, consider reconstructive substitutions for the trapezius.

Conservative treatment is usually unsuccessful. Before surgery, however, I give the patient a trial of shoulder immobilization to see if removing the pull of the weight of the extremity on the brachial plexus will decrease the pain. If Tinel's sign is positive in the posterior cervical triangle, I usually inject 3 or 4 ml of 1% lidocaine at the site of Tinel's sign to see if this injection eliminates the pain. If the pain is diminished by a trial unweighing of the arm, I find that trapezius muscle substitution reconstruction will be predictably successful.

Reconstructive options take the form of static or dynamic scapular stabilizations. Static stabilization procedures using fascia tend to stretch in time and are more often used in patients who have neuromuscular disorders and widespread weakness (10,22). The procedure of choice is an operation first described by Eden (15) in 1924, and later by Lange (35) in 1951. The Eden-Lange procedure is a lateral transfer of the levator scapulae and rhomboid major and minor muscles (36). The trapezius muscle has upper, middle, and lower components: The upper portion rotates and elevates the scapula, the middle portion stabilizes and adducts the scapula, and the lower portion downwardly rotates and depresses the scapula. The lateral transfer of the levator scapulae and rhomboid muscles allows them to approximate the function of the three portions of the trapezius muscle by changing the direction of their pull. The operation is well described by Bigliani et al., whose technique follows (2).

### RHOMBOID AND LEVATOR SCAPULAE MUSCLE TRANSFER FOR ACCESSORY NERVE PALSY

- Place the patient in a lateral decubitus position, and elevate the head of the table 15°.
- Make an incision midway between the spinous processes and the medial scapular border, parallel to and along the length of the medial scapular border (Fig. 59.11).

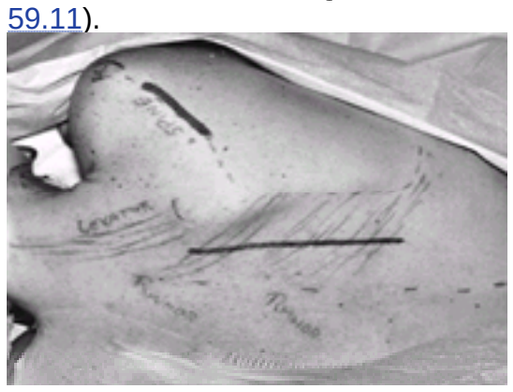

***Figure 59.11.*** Incisions for the transfer of the rhomboids and levator scapulae in the treatment of trapezius paralysis.

- Transect the trapezius muscle close to the scapula border.
- Identify the levator scapulae and the rhomboid minor and major muscles, and carefully separate them from each other.
- Use a narrow osteotome to detach the three muscles to be transferred from the medial border of the scapula (Fig. 59.12).

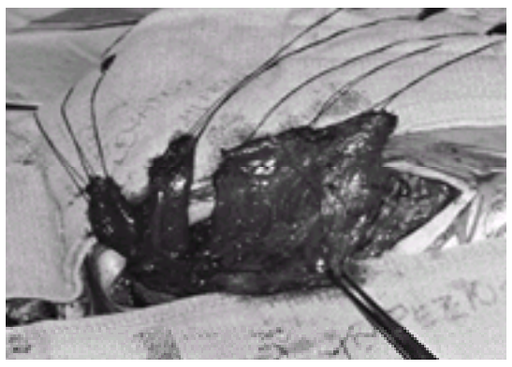

***Figure 59.12.*** The levator scapulae, rhomboid minor and rhomboid major tendon are detached from their insertion on the medial border of the scapula and then transferred laterally.

- Separate the three individual muscles and dissect them proximally and medially, taking care to avoid injury to the dorsal scapular nerve. Tag the ends of each muscle with nonabsorbable sutures.
- Elevate the infraspinatus muscle from the inferior fossa of the scapula.
- Place six drill holes in the scapula, 1.5–2 cm apart, starting 4–5 cm lateral to the medial border of the scapula and 1 cm below its spine.
- Attach the rhomboid major and minor muscles to these drill holes with nonabsorbable heavy suture material.
- Tie the sutures with the scapula in the reduced position and the arm abducted 90°, and imbricate the infraspinatus muscle over the repair.
- Make a 4 cm incision over the scapular spine, starting 3 cm medial to the acromion process and extending medially.
- Dissect the trapezius, deltoid, and supraspinatus muscles subperiosteally and drill three holes through the spine of the scapula. Make a tunnel through the atrophied trapezius muscle, connecting the medial and lateral wounds in the line of the fibers of the upper trapezius.
- Pass the levator scapulae muscle through the tunnel and secure it to the spine of the scapula using nonabsorbable heavy suture material.
- Close the incisions in routine fashion and apply an abduction brace.
- Keep the patient in an abduction brace for 6 weeks after surgery. Allow her to perform passive assistive exercises.
- At 6 weeks, start her on a rehabilitation program to strengthen the shoulder.

## UPPER BRACHIAL PLEXUS PALSY

With C5–C6 brachial plexus palsy, a patient will develop a flail shoulder. In time, the weight of the shoulder will cause inferior glenohumeral subluxation and pain. The pain may be secondary to traction on the brachial plexus or joint incongruity. In general, the treatment is reconstruction of the brachial plexus or a shoulder arthrodesis (see Chapter 60 and Chapter 103).

In a C5–C6 brachial plexus palsy, the function of elbow flexion is also absent. While constructing elbow flexion with either pectoralis major or latissimus dorsi tendon transfer, the shoulder may be stabilized if the transfer is performed by rotating the muscle completely on its neurovascular pedicle. Since the primary function of these muscle transfers is elbow reconstruction, they will not be described in this chapter (see Chapter 58 and Chapter 60).

### CHAPTER REFERENCES

Each reference is categorized according to the following scheme: *, classic article; #, review article; !, basic research article; +, clinical results/outcome study


# 1. Bateman J. Neurologic Painful Conditions Affecting the Shoulder. *Clin Orthop* 1983;173:44.

+ 2. Bigliani J, Perez-Sana J, Wolfe I. Treatment of Trapezius Paralysis. *J Bone Joint Surg Am* 1985;67A:871.

# 3. Cahill B. Quadrilateral Space Syndrome. In: Omer G, Spinner M, eds. *Management of Peripheral Nerve Problems*. Philadelphia: WB Saunders, 1980.

+ 4. Cahill B, Palmer R. Quadrilateral Space Syndrome. *J Hand Surg Am* 1983;8:65.

+ 5. Chaves J. Pectoralis Minor Transplant for Paralysis of the Serratus Anterior. *J Bone Joint Surg Br* 1951;33:228.

+ 6. Coene L, Narakas A. Surgical management of axillary nerve lesions, isolated or combined with other infraclavicular nerve lesions. *Periph Nerve Repair Regener* 1986;3:47.

+ 7. Cormier P, Matalon T, Wolin P. Quadrilateral Space Syndrome: A Rare Cause of Shoulder Pain. *Radiology* 1988;167:797.

# 8. Date ES, Gray LA. Electrodiagnostic Evidence for Cervical Radiculopathy and Suprascapular Neuropathy in Shoulder Pain. *Electromyogr Clin Neurophysiol* 1996;36:333.

! 9. Demirhan M, Imhoff AB, Debski RE, et al. The Spinoglenoid Ligament and Its Relationship to the Suprascapular Nerve. *J Shoulder Elbow Surg* 1998;7:238.

+ 10. Dewar F, Harris M. Restoration of Function of the Shoulder following Paralysis of the Trapezius by Fascial Sling Fixation and Transplantation of the Levator Scapulae. *Ann Surg* 1950;132:1111.

+ 11. Dickson F. Fascial Transplants in Paralytic and Other Conditions. *J Bone Joint Surg* 1937;19:405.

+ 12. Duncan M, Lotze M, Gerber L, Rosenbury S. Incidence, Recovery and Management of Serratus Anterior Muscle Palsy after Axillary Node Dissection. *Phys Ther* 1983;63:1243.

+ 13. Dunn A. Trapezius Paralysis after Minor Surgical Procedures in the Posterior Cervical Triangle. *South Med J* 1974;67:312.

! 14. Ebraheim NA, Lu J, Porshinsky B, et al. Vulnerability of Long Thoracic Nerve: An Anatomic Study. *J Shoulder Elbow Surg* 1998;7:458.

* 15. Eden R. Zur Behandlung der Trapeziuslahmung Mittelst Muskelplastick. *Deutsche Zeit Chir* 1924;184:387.

+ 16. Ferretti A, Cerullo G, Russo G. Suprascapular Neuropathy in Volleyball Players. *J Bone Joint Surg Am* 1987;69:260.

+ 17. Foo C, Swann M. Isolated Paralysis of the Serratus Anterior: A Report of 20 Cases. *J Bone Joint Surg Br* 1983;65:552.

+ 18. Francel TJ, Dellon AL, Campbell JN. Quadrilateral Space Syndrome: Diagnosis and Operative Decompression Technique. *Plast Reconstr Surg* 1991;87:911.

+ 19. Gozna E, Harris R. Traumatic Winging of the Scapula. *J Bone Joint Surg Am* 1979;61:1230.

+ 20. Harmon P. Surgical Reconstruction of the Paralytic Shoulder by Multiple Muscle Transplantations. *J Bone Joint Surg Am* 1950;32:583.

+ 21. Hayes J, Zehr D. Traumatic Muscle Avulsion Causing Winging of the Scapula. *J Bone Joint Surg Am* 1981;63:495.

+ 22. Henry A. An Operation for Slinging a Dropped Shoulder. *Br J Surg* 1926;15:95.

+ 23. Hertel R, Lambert SM, Ballmer FT. The Deltoid Extension Lag Sign for Diagnosis and Grading of Axillary Nerve Palsy. *J Shoulder Elbow Surg* 1998;7:97.

+ 24. Herzmark M. Traumatic Paralysis of the Serratus Anterior Relieved by Transplantation of the Rhomboidei. *J Bone Joint Surg Am* 1951;33:235.

+ 25. Iceton J, Harris E. Treatment of Winged Scapula by Pectoralis Major Transfer. *J Bone Joint Surg Br* 1987;69:108.

+ 26. Inokuchi W, Ogawa K, Horiuchi Y. Magnetic Resonance Imaging of Suprascapular Nerve Palsy. *J Shoulder Elbow Surg* 1998;7:223.

+ 27. Ishima T, Usui M, Satoh E, et al. Quadrilateral Space Syndrome Caused by a Ganglion. *J Shoulder Elbow Surg* 1998;7:80.

+ 28. Itoh Y, Saski T, Ishiguro T, et al. Transfer of Latissimus Dorsi to Replace a Paralysed Anterior Deltoid. *J Bone Joint Surg Br* 1987;69:647.

! 29. Jobe CM, Kropp WE, Wood VE. Spinal Accessory Nerve in a Trapezius-splitting Surgical Approach. *J Shoulder Elbow Surg* 1996;5:206.

+ 30. Kaplan P. Electrodiagnostic Confirmatinon of Long Thoracic Nerve Palsy. *J Neruol Neurosurg Psych* 1980;43:50.

+ 31. Karev A. Trapezius Transfer for Paralysis of the Deltoid. *J Hand Surg Br* 1986;11B:81.

! 32. Kauppila LI. The Long Thoracic Nerve: Possible Mechanisms of Injury Based on Autopsy Study. *J Shoulder Elbow Surg* 1993;2:244.

+ 33. Ketenjian A. Scapulocostal Stabilization for Scapular Winging in Facioscapulohumeral Muscular Dystrophy. *J Bone Joint Surg Am* 1978;60:476.

* 34. L'Episcopo J. Restoration of Muscle Balance in the Treatment of Obstetrical Paralysis. *N Y State J Med* 1939;39:369.

* 35. Lange M. Die Behandlung der Irreparablem Trapeziuslahmung. *Langenbechs Arch Klin Chir* 1951;270:437.

* 36. Langenskoild A, Pyoppy S. Treatment of Paralysis of the Trapezius Muscle by the Eden-Lange Operation. *Acta Orthop Scand* 1973;44:383.

+ 37. Laulund T, Fedders O, Sogaard I, Kornum M. Suprascapular Nerve Compression Syndrome. *Surg Neurol* 1984;22:308.

# 38. Leffert R. Neurological Problems. In: Rockwood C, Matsen FA, eds. *The Shoulder.* Philadelphia: WB Saunders, 1990:750–773.

+ 39. Lindstrom N, Danielsson L. Muscle Transposition in Serratus Anterior Paralysis. *Acta Orthop Scand* 1962;32:369.

+ 40. Makin G, Brown W, Ebers G. C7 Radiculopathy: Importance of Scapular Winging in Clinical Diagnosis. *J Neurol Neurosurg Psych* 1986;49:640.

+ 41. Mariani PP, Santoriello P, Maresca G. Spontaneous Accessory Nerve Palsy. *J Shoulder Elbow Surg* 1998;7:545.

+ 42. Marmor L, Bechtol C. Paralysis of the Serratus Anterior Due to Electric Shock Relieved by Transplantation of the Pectoralis Major Muscle: A Case Report. *J Bone Joint Surg Am* 1963;45:156.

+ 43. Martin SD, Warren RF, Martin TL, et al. Suprascapular Neuropathy. Results of Non-operative Treatment. *J Bone Joint Surg Am* 1997;79:1159.

+ 44. McIlveen SJ, Duralde XA, D'Alessandro DF, Bigliani DU. Isolated Nerve Injuries about the Shoulder. *Clin Orthop* 1994;18:54.

# 45. Menon J. Suprascapular Entrapment Neuropathy: A New Surgical Exposure. *Contemp Orthop* 1990;21:247.

+ 46. Mizuno K, Muratso H, Kurosaka M, et al. Compression Neuropathy of the Suprascapular Nerve as a Cause of Pain in Palsy of the Accessory Nerve: A Case Report. *J Bone Joint Surg Am* 1990;72:938.

+ 47. Moore TP, Fritts HM, Quick DC, Buss DD. Suprascapular Nerve Entrapment Caused by Supraglenoid Cyst Compression. *J Shoulder Elbow Surg* 1997;6:455.

# 48. Murray J. Surgical Approach for Entrapment Neuropathy of the Suprascapuar Nerve. *Orthop Rev* 1974;3:33.

# 49. Narakas A. Compression Syndromes about the Shoulder Including Brachial Plexus. In: Szabo R, ed. *Nerve Compression Syndromes—Diagnosis and Treatment*. Thorofare, NJ: Slack, 1989.

* 50. Parsonage M, Turner J. Neuralgic Amyotrophy: The Shoulder-Girdle Syndrome. *Lancet* 1948;973.

+ 51. Petrera J, Trojaborg W. Conduction Studies of the Long Thoracic Nerve in Serratus Anterior Palsy of Different Etiology. *Neurology* 1984;34:1033.

+ 52. Petrucci F, Morelli A, Raimondi P. Axillary Nerve Injuries: 21 Cases Treated by Nerve graft and Neurolysis. *J Hand Surg Am* 1982;7:271.

+ 53. Post M, Mayer J. Suprascapular Nerve Entrapment Diagnosis and Treatment. *Clin Orthop* 1987;223:126.

+ 54. Rachbauer F, Sterzinger W, Frischhut B. Suprascapular Nerve Entrapment at the Spinoglenoid Notch Caused by a Ganglion Cyst. *J Shoulder Elbow Surg* 1996;5:150.

+ 55. Rapp I. Serratus Anterior Paralysis Treated by Transplantation of the Pectoralis Minor. *J Bone Joint Surg Am* 1954;336:852.

! 56. Rengachary S, Burr D, Lucas S, et al. Suprascapular Entrapment Neuropathy: A Clinical Anatomical and Comparative Study. Part 2: Anatomical Study. *Neurosurgery* 1979;5:447.

+ 57. Rengachary S, Nelt J, Singer P, Brackett C. Suprascapular Entrapment Neuropathy: A Clinical Anatomical and Comparative Study. Part 1: Clincial Study. *Neurosurgery* 1979;5:441.

* 58. Saha S. Surgery of the Paralysed and Flail Shoulder. *Acta Orthop Scand* 1967;suppl 97:9.

+ 59. Sandow MJ, Ilic J. Suprascapular Nerve Rotator Cuff Compression Syndrome in Volleyball Players. *J Shoulder Elbow Surg* 1998;7(5):516.

* 60. Scholtstaedt E, Larsen L, Bost F. The Surgical Reconstruction of the Upper Extremity Paralyzed by Poliomyelitis. *J Bone Joint Surg Am* 1958;40:633.

+ 61. Sjödén GO, Movin T, Güntner P, Ingelman-Sundberg H. Spinoglenoid Bone Cyst Causing Suprascapular Nerve Compression. *J Shoulder Elbow Surg* 1996;5:147.

+ 62. Skirving AP, Kozak TK, Davis SJ. Infraspinatus Paralysis Due to Spinoglenoid Notch Ganglion. *J Bone Joint Surg Br* 1994;76:588.

+ 63. Steiman I. Painless infraspinatus Atrophy Due to Suprascapular Nerve Entrapment. *Arch Phys Med Rehabil* 1988;69:641.

+ 64. Swafford A, Lichtman D. Suprascapular Nerve Entrapment: Case Report. *J Hand Surg Am* 1982;7:57.

+ 65. Thompson R, Schneider W, Kennedy T. Entrapment Neuropathy of the Inferior Branch of the Suprascapular Nerve by Ganglion. *Clin Orthop* 1982;166:185.

+ 66. Ticker JB, Djurasovic M, Strauch RJ, et al. The Incidence of Ganglion Cysts and Other Variations in Anatomy along the Course of the Suprascapular Nerve. *J Shoulder Elbow Surg* 1998;7:472.

* 67. VanNes C, VanNes J. Serratus Paralysis. *Arch Chir Neerlandicum* 1969;21:296.

+ 68. Vastamäki M, Kauppila LI. Etiologic Factors in Isolated Paralysis of the Serratus Anterior Muscle: A Report of 197 Cases. *J Shoulder Elbow Surg* 1993;2:240.

+ 69. Vastamäki M, Solonen K. Accessory Nerve Injury. *Acta Orthop Scand* 1984;55:296.

+ 70. Weaver H. Isolated Suprascapular Nerve Lesions. *Injury* 1983;15:117.

+ 71. Woodhall B. Trapezius Paralysis following Minor Surgical Procedures in the Posterior Cervical Triangle. *Ann Surg* 1952;136:375.

+ 72. Wright T. Accessory Spinal Nerve Injury. *Clin Orthop* 1975;108:15.

* 73. Zachary R, Leeds M. Transplantation of Teres Major and Latissimus Dorsi for Loss of External Rotation at Shoulder. *Lancet* 1947:757.

+ 74. Zeier F. The Treatment of Winged Scapula. *Clin Orthop* 1973;91:128.

# CHAPTER 60

# BRACHIAL PLEXUS INJURIES

*Hanno Millesi*

**H. Millesi:** Professor Emeritus, University of Vienna Medical School; Vienna Private Hospital; and Ludwig-Boltzmann Institute for Experimental Plastic Surgery, Vienna, Austria.

Types of Lesions
Open Injury
Closed Injury
Diagnosis
Location of Injury
Extent of Lesions
Degree of Damage
Indications for Surgery and Expected Results
Basic Approaches to Brachial Plexus Lesions
Treatment of Root Avulsions by Intercostal Nerve Transfer
Combined Approach to Treat Brachial Plexus Lesions
Reimplantation of Avulsed Roots
Laminectomy for Verification of Root Avulsions
Immediate Free Muscle Grafting
Techniques for Exploration (Combined Approach)
Brachial Plexus Surgery in the Beach-Chair Position
Anterior Approach in the Supine Position
Exposure of the Cervical Plexus and the Accessory Nerve
Exploration and Transfer of Intercostal Nerves
Techniques for Surgical Repair
Neurolysis
Neurorrhaphy
End-to-Side Coaptation
Nerve Grafting
Nerve Transfer
Selection of Surgical Techniques According to the Severity of the Nerve Lesion
Postoperative Care
Secondary Reconstructive Surgery
Chapter References

## TYPES OF LESIONS

The typical patient with a brachial plexus injury has been injured in a motorcycle accident (Table 60.1). Other traffic accidents or sports accidents are less frequently the cause of a brachial plexus injury, and the resultant lesions are generally less severe. Open injuries to the brachial plexus may result from stabbing, but these lesions are rather rare. Gunshot wounds usually lead to only partial lesions.

| *Cause* | *Number of cases* |
|---|---|
| Motorcycle accidents | 176 |
| Car accidents | 26 |
| Other traffic accidents | 22 |
| Other accidents | 19 |
| Gunshots | 3 |
| Cuts | 1 |
| Total | 247 |

***Table 60.1. Causes of Brachial Plexus Injuries***

A common mechanism of injury is compression trauma to the shoulder with fixation of the brachial plexus between the clavicle and the first rib. In such cases, the patient's head continues to move away from the shoulder, and a traction lesion results. The position of the arm at the time of injury influences which roots are most exposed to traction. The plexus may be compressed. If the humerus is fractured, the plexus is exposed to uncontrolled traction.

### OPEN INJURY

In an open injury with clean transection of parts of the brachial plexus, primary repair is indicated. A blunt injury must be treated according to the rules of peripheral nerve surgery; in such cases, the brachial plexus should be repaired in a second stage.

### CLOSED INJURY

In a fracture of the clavicle, compression of the brachial plexus by the fragments of the clavicle is possible. Repositioning and osteosynthesis are indicated if there is an ipsilateral plexus injury. A fracture of the transverse processes of the cervical vertebrae may also cause external compression of parts of the brachial plexus. Operative decompression is indicated.

With concomitant rupture of the subclavian artery and subclavian vein, a huge hematoma forms that compresses the brachial plexus. Vascular surgery to repair the artery or the vein is indicated as an emergency procedure. The question arises whether immediate repair of the brachial plexus should be performed. Usually, these patients have suffered severe trauma and severe loss of blood. Because a surgeon with experience in brachial plexus surgery might not be available, vascular repair should be performed, and the vascular surgeon should use an incision that will allow for later brachial plexus repair. Do not attempt to identify the individual parts of the brachial plexus other than what is necessary for the vascular repair, because this will increase the fibrosis and make the secondary operation more difficult.

In recent years in a few centers, primary repair of the brachial plexus lesion by a competent brachial plexus surgeon has been undertaken. I have had the opportunity to see the results of some of these cases. My impression is that the repair performed under these acute circumstances tends to be less fastidious than early elective secondary repair and, consequently, the results are not as good.

Most patients with brachial plexus lesions have suffered a closed injury; however, they may also have suffered craniocerebral trauma or other injuries of the extremities that require more immediate attention. Although there is no indication for emergency surgery for a brachial plexus injury, the question arises as to whether early exploration is indicated (3,4). An advantage of early surgery is that the lack of fibrous tissue makes exploration easier. On the other hand, the extent of the damage is much more difficult to assess because the damaged parts have not yet developed the inevitable fibrosis, making it more difficult to identify those lesions that may have

a chance for spontaneous recovery.

## DIAGNOSIS

Lesions differ according to the location of the injury, the extension throughout the plexus, and the degree of damage.

### LOCATION OF INJURY

#### *Supraganglionic Lesions*

In an avulsion of the nerve roots, the lesion is between the spinal ganglion and the medulla (a supraganglionic lesion). There is no proximal stump and no neuroma formation. The characteristics of these lesions are summarized in Table 60.2.

| Anatomic pathology | Sequela | Clinical findings |
|---|---|---|
| No proximal stump | No neuroma | No sign of Tinel's sign |
| Dural and arachnoid lesion with avulsed roots | Meningocele | Myelographic leak<br>Roots not visible on CT |
| Dorsal roots interrupted | Denervation of dorsal neck muscles | Changes in EMG of these muscles |
| Nerve fibers to skin in continuity with their neurons in the spinal ganglion | No wallerian degeneration of sensory nerve fibers | Nerve conduction positive despite loss of sensation |

CT, computed tomography; EMG, electromyogram.

***Table 60.2. Characteristics of Supraganglionic Brachial Plexus Injury with Avulsion of Roots***

If the avulsed root can be extracted from the intervertebral canal and is situated outside, then the avulsion is recognized easily during surgical exploration. If, after a root avulsion, the spinal nerve remains within the intervertebral canal, the situation is not as clear. If such a spinal nerve is transected, part of the cross section may show fibrosis and degeneration but with the sensory fibers still intact. Measurement of evoked potentials can establish whether conduction to the central nervous system is possible.

#### *Infraganglionic Lesions*

With rupture, the spinal nerve is interrupted and the roots remain intact (an infraganglionic lesion). There is a proximal stump with neuroma formation. The characteristics of such lesions are summarized in Table 60.3.

| Anatomic pathology | Sequela | Clinical findings |
|---|---|---|
| Spinal nerve interrupted, proximal stump in continuity with the respective neurons | Formation of neuroma | Tinel's sign positive |
| No lesion of dura and arachnoid | No meningocele | Myelography negative |
| Roots in continuity | | Roots visible on CT and myelography |
| Dorsal roots of spinal nerve in continuity | Deep dorsal neck muscles intact | EMG normal |
| Nerve fibers to skin not in continuity with their neurons in the spinal ganglion | Sensory nerve fibers undergo wallerian degeneration | Nerve conduction abnormal |

CT, computed tomography; EMG, electromyogram.

***Table 60.3. Characteristics of Rupture of Spinal Nerves with Roots Intact***

#### *Trunk Lesions*

At the trunk level, a lesion may be proximal or distal. The long thoracic nerve, which exits the individual spinal nerves at a very proximal level, remains intact in these cases. The suprascapular nerve is usually involved. The pectoral nerves may or may not be damaged, depending on the level of injury (Table 60.4).

| *Lesion* | *Function* |
|---|---|
| Long thoracic nerve intact | Serratus anterior muscle functioning |
| Suprascapular nerve involved | Supraspinatus and infraspinatus muscles paralyzed |
| Upper trunk lesion | Paralysis of shoulder muscles<br>Paralysis of biceps brachii |
| Middle trunk lesion | Paralysis of muscles innervated by radial nerve |
| Lower trunk lesion | Paralysis of ulnar-innervated and most median-innervated muscles |

***Table 60.4. Characteristics of Trunk Lesions in Brachial Plexus Injuries***

#### *Cord Lesions*

When the lesion is at the level of the cords in the plexus, the long thoracic nerve, the suprascapular nerve, and the pectoral nerves are intact (Table 60.5). A cord lesion may be suspected if a Tinel Hoffmann sign is located in the infraclavicular fossa.

| Lesion | Function |
|---|---|
| Long thoracic nerve intact | Serratus anterior muscle functioning |
| Pectoral nerves intact | Pectoral muscles functioning |
| Suprascapular nerve intact | Supraspinatus and infraspinatus muscles functioning |
| Posterior cord lesion | Paralysis of muscles innervated by axillary and radial nerves |
| | Paralysis of latissimus dorsi, teres major, teres minor, and subscapularis muscles |
| Lateral cord lesion | Paralysis of biceps and pronator teres; partial paralysis of forearm muscles innervated by median nerve |
| Medial cord lesion | Paralysis of forearm muscles innervated by ulnar nerve and intrinsic muscles of the hand; partial paralysis of forearm muscles innervated by median nerve |

***Table 60.5. Characteristics of Cord Lesions in Brachial Plexus Injuries***

## EXTENT OF LESIONS

Brachial plexus injuries often involve more than one specific lesion. For example, a single spinal nerve may have both a supraganglionic lesion and an infraganglionic lesion. One nerve root may have suffered an avulsion, and a neighboring one may have suffered a rupture. A common occurrence is the combination of a trunk lesion with a cord lesion. Such combinations lead to difficulties in diagnosis. Both false-positive and false-negative results occur with myelography and computed tomography.

A complete brachial plexus lesion involves all five roots (C-5, C-6, C-7, C-8, and T-1). The brachial plexus may receive a major additional source from C-4 or T-2. In the case of a prefixed plexus, the brachial plexus consists of roots C-4 to C-8; in the case of a postfixed plexus, it includes roots C-6 to T-2 (Table 60.6).

| | *C4* | *C5* | *C6* | *C7* | *C8* | *T1* | *Total* |
|---|---|---|---|---|---|---|---|
| Avulsion | 1 | 22 | 39 | 68 | 53 | 43 | 226 |
| Interruption | 5 | 58 | 41 | 10 | 6 | 9 | 129 |
| Lesion in continuity | 0 | 3 | 3 | 5 | 24 | 29 | 64 |
| Total | | | | | | | 419 |

* Brachial plexus configurations: *normal* (C5–T1), 77 patients; 385 affected nerve roots; *prefixation of C4* (C4–T1), 2 patients, 10 affected nerve roots; *strong contribution of C4* (C4–T1), 4 patients, 24 affected nerve roots.

***Table 60.6. Involvement of Individual Nerve Roots in 83 Patients with Complete Brachial Plexus Palsies****

Partial brachial plexus lesions are of two types. Type 1 lesions involve all roots but to different degrees. Initially there might be a complete brachial plexus lesion with partial recovery. Regard recovered muscles as weaker than normal muscles; this may be important if palliative surgery is being considered. In type 2 lesions, some roots are damaged whereas others are completely intact. In this case, perform palliative surgery according to the usual indications.

The following specific lesions are differentiated according to the extent of the injury:

- Upper brachial plexus lesion (C-5, C-6)
- Extended upper brachial plexus lesion (C-5, C-6, C-7)
- C-7 lesion
- Lower brachial plexus lesion (C-8, T-1)
- Peripheral lesion involving the suprascapular, the axillary, and the musculocutaneous nerves; this lesion simulates an upper brachial plexus lesion.

## DEGREE OF DAMAGE

The extent of damage caused by a brachial plexus injury has been classified by Sunderland (33) into five degrees:

- *First-degree lesions* involve a conduction block without morphologic changes, which can be recognized by electrophysiologic examination. If after several days the conductivity of motor nerve fibers distal to the lesion remains intact despite paralysis, assume a first-degree lesion. Complete spontaneous recovery is possible.
- *Second-degree lesions* are typified by a loss of continuity of axons with other structures intact. This lesion cannot be recognized as easily as a first-degree lesion. Complete spontaneous recovery is still possible. There is no indication for surgery, but the occurrence of external compression and the development of fibrosis may hinder spontaneous recovery.
- *The amount of fibrosis,* not considered in Sunderland's original scheme, may be classified as follows (19,21):

  Type A fibrosis, in which the epifascicular epineurium has become fibrotic and the whole nerve is compressed like a tight stocking;
  Type B fibrosis, in which the interfascicular epineurium has also become fibrotic;
  Type C fibrosis, in which the content of the fascicles of the endoneurium has become completely fibrotic. If type A or type B fibrosis is combined with a first- or second-degree lesion, spontaneous recovery will be impeded and neurolysis is indicated.
- *Third-degree lesions* are marked by a loss of continuity of axons and endoneural structures with intact perineurium. Type A or B fibrosis is possible; the content of the fascicles may have become completely fibrotic (type C) if the lesion is very severe or if a long time has elapsed since the injury. With type A or B fibrosis, neurolysis is indicated. With type C fibrosis, neurolysis cannot effect regeneration, and resection with replacement of the involved fascicles by nerve grafts is indicated.
- In *fourth-degree lesions*, continuity is preserved only by connective tissue. This connective tissue can become completely fibrotic, in which case there is no chance for nerve fibers to grow beyond the lesion (type 4S; S = scar). In other cases, a neuroma may grow into the connective tissue that still unites the two stumps; in such instances, some nerve fibers may reach the distal stump, and therefore some conduction may be elicited during intraoperative stimulation (type 4N; N = neuroma). However, there is no chance for functional recovery. All fourth-degree lesions necessitate resection and repair by nerve grafts.
- In *fifth-degree lesions*, there is a complete loss of continuity.

Different degrees of involvement are possible in combined lesions. The differentiation between these degrees is made during intraoperative dissection with or without nerve stimulation (Table 60.7).

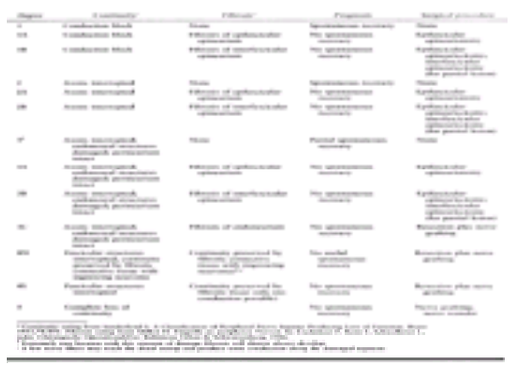

*Table 60.7. Combined Evaluation System for Extent of Brachial Plexus Injuries*

## INDICATIONS FOR SURGERY AND EXPECTED RESULTS

Simple first- or second-degree brachial plexus lesions have good chances for spontaneous recovery, and no surgery is indicated. However, first- or second-degree lesions with epifascicular fibrosis (type 1A or 2A, respectively) usually have initial signs of recovery with subsequent failure to improve, or even some deterioration. Exploration is indicated, and after neurolysis a complete return of function is possible. The same is true for first- or second-degree lesions with interfascicular fibrosis (type 1B or 2B, respectively).

Third-degree lesions have some chance of spontaneous recovery, but this takes longer and the recovery will always be less than complete. Pure third-degree lesions without fibrosis are rare; usually there is a type A or B fibrosis. Such lesions can be converted into pure third-degree lesions by internal neurolysis, after which recovery may occur. If the endoneural space has become completely fibrotic (type 3C), however, there is no chance of spontaneous recovery. In such cases, resect the fascicles and repair continuity by nerve grafts.

In type 4N lesions with neuroma formation, some nerve fibers may get into the distal stump. Usually, regeneration takes a long time and the muscles may have already atrophied and fibrosed before regeneration can occur. Therefore, spontaneous recovery cannot be expected in these lesions, and surgical repair is indicated. This is also the case for fourth-degree lesions without neuroma formation (type 4S). Likewise, if there is a loss of continuity (type 5), there is no chance for spontaneous recovery.

In patients with complete loss of continuity, or type 3C, 4N, or 4S lesions, continuity must be restored. Because of the complexity of the structure of the brachial plexus and the long distance between the site of the lesion and the target organs, expect only partial recovery. Except in infants, the return of intrinsic hand function has not been observed.

The main goal of surgery is the return of active elbow flexion. If this occurs, the result can be regarded as satisfactory. In addition, some control of the shoulder joint, with the correction of subluxation, and the return of some protective sensation can be expected. If some forearm muscles become active, the result can be regarded as good. It is the experience of surgeons involved with brachial plexus surgery that the development of pain syndromes is less common in patients treated operatively than in those who are not treated. In some instances, pain is relieved by surgery.

## BASIC APPROACHES TO BRACHIAL PLEXUS LESIONS

Strategies to deal with brachial plexus lesions are based in part on the historical development of brachial plexus surgery since the 1960s. In 1966, a roundtable discussion on brachial plexus surgery was held on the occasion of the tenth Sociéaate Internationale de Chirugie Orthopédique et Traumatologie (SICOT) congress in Paris. All roundtable members agreed that surgery has nothing to offer in the case of panplexus root lesions, except to verify the diagnosis. With the diagnosis of a root lesion, their recommendation was to not waste time with physiotherapy, and to perform early above-elbow amputation with arthrodesis of the shoulder joint, provided that there is a strong serratus anterior and trapezius muscle (31).

Advances have occurred since that recommendation, however. Yeoman and Seddon (31,39) have performed an intercostal nerve transfer linking the third and fourth intercostal nerves with the musculocutaneous nerve via a nerve graft. This experience was furthered by Tsuyama et al. (35). The percentage of good functional recovery of the biceps muscle has constantly improved and has reached a very high standard in recent years (29,34). In the early 1960s, Millesi developed the combined approach to brachial plexus surgery based on the new, reliable technique of interfascicular nerve grafting. In recent years, two new trends have developed: the reimplantation of avulsed roots by Carlstedt et al. (9) and immediate free muscle grafting by Doi (13). These new trends are listed in more detail in the following paragraphs.

### TREATMENT OF ROOT AVULSIONS BY INTERCOSTAL NERVE TRANSFER

In contrast to Seddon (31), who recommended intercostal nerve transfer only “if there is no shadow of doubt that the plexus is completely destroyed,” Tsuyama et al. (35) applied this technique in all cases that showed signs of root avulsion (e.g., one or two meningocelias in the myelogram), without convincing himself that really all roots were avulsed. The advantages of this strategy are that it is simple and the brachial plexus need not be explored. The disadvantage is that it neglects other possibilities to gain additional functions for the patient.

### COMBINED APPROACH TO TREAT BRACHIAL PLEXUS LESIONS

When a reliable nerve grafting technique was available (18,19,22,23,24 and 25), the combined approach to treatment was immediately applied to brachial plexus lesions. This approach proved to be very helpful because brachial plexus lesions usually involve very long defects that cannot be treated by end-to-end coaptation. From the beginning, the goal was to restore the continuity of as many structures as possible in peripheral lesions, and to exploit not only the intercostal nerve transfer but also all other available nerve transfers, such as accessory nerve, cervical plexus, and so on. In these concepts, reconstructive procedures at a later stage are included (26). Early results of this approach were presented in February 1969 at a meeting in Lausanne, Switzerland (20).

### REIMPLANTATION OF AVULSED ROOTS

In recent years, attempts have been made to reimplant avulsed roots, and considerable experimental successes have been presented by Carlstedt et al. (9). He applied this technique also in human cases with some success.

### LAMINECTOMY FOR VERIFICATION OF ROOT AVULSIONS

Rootlets were explored within the vertebral canal by dorsal laminectomy to prove avulsion. After clarifying the diagnosis, the wound would be closed and the brachial plexus explored from an anterior approach. Information about the continuity for the dorsal roots but not for the ventral roots can be obtained more easily through intraoperative studies of evoked potentials.

Today, continuity of the ventral rootlets can be proven by the technique of central stimulation (36,37). With stimulation of the precentral gyrus of the cerebrum, action potentials reach all the peripheral nerves. Lack of a peripherally recorded potential indicates that the rootlets are avulsed. This is a reliable technique and it makes surgical exploration to verify root avulsion obsolete.

### IMMEDIATE FREE MUSCLE GRAFTING

Doi (13) has treated fresh brachial plexus lesions by immediate free muscle grafting. In a first stage, the gracilis muscle was connected to the accessory nerve and used to activate the extensor digitorum communis tendons. At the same time, sensory fibers from the cervical plexus were transferred to the median nerve. In a second stage, a free muscle graft of the contralateral gracilis muscle was used to activate the flexor muscles of the fingers and also to produce flexion of the elbow joint. This muscle was connected to intercostal nerves II, III, and IV, for motor function. The sensory components of the intercostal nerves were transferred to the ulnar nerve. At the same stage, the motor components of intercostal nerves V and VI were transferred to the triceps muscle to achieve elbow extension. With this technique, elbow flexion and extension as well as finger flexion and extension were achieved.

In my opinion, this technique is very useful for older cases in which the original muscles of the arm are atrophic, but it may lead to a waste of muscle and nerves in cases less than 4 to 6 months old if no attempt is made to reinnervate them. In addition, nothing is done for shoulder abduction and external rotation. I feel that function of the shoulder joint is key to positioning the forearm and hand for function.

## TECHNIQUES FOR EXPLORATION (COMBINED APPROACH)

### BRACHIAL PLEXUS SURGERY IN THE BEACH-CHAIR POSITION

Many surgeons approach the brachial plexus anteriorly with the patient in a beach-chair position. This has the advantage that the surgeon sees all anatomic structures as they are depicted in the textbooks. The primary disadvantage, however, is that the clavicle is an obstacle for the exposure, and it is understandable that many surgeons do an osteotomy of the clavicle to facilitate the exposure. After the brachial plexus surgery, the clavicle is fixed with plate and screws (27,28).

**ANTERIOR APPROACH IN THE SUPINE POSITION**

- I prefer the supine position and an anterior approach for exploration. Place the patient supine with some support beneath the scapula to elevate the shoulder joint slightly. Turn the head to the contralateral side, prep the arm, and drape it free.
- For exploration of the supra- and infraclavicular fossas, sit between the head of the patient and the abducted arm. For exploration of the axilla and the upper arm, move into the angle between the trunk and the upper arm.

The advantages of this approach are that the supra- and infraclavicular fossae are approached from the cranial direction. The clavicle can be lifted and does not form an obstacle, and an osteotomy of the clavicle is never necessary. Also, the roots can be visualized from both the dorsal and anterior aspects. This is further facilitated by a sagittal incision, as outlined below. The only disadvantage is that the anatomy is seen upside down in relation to the usual anatomic illustrations.

- Make a *sagittal incision* directly across the supraclavicular fossa, crossing the clavicle at an oblique angle (Fig. 60.1). This incision has the advantage that it can be extended dorsally to the border of the trapezius muscle, and the supraclavicular fossa can be explored very dorsally. This also provides a good approach to the spinal nerves from a dorsal aspect (Fig. 60.2 and Fig. 60.3).

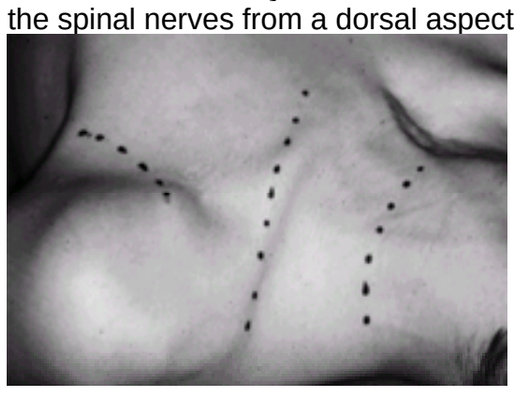

***Figure 60.1.*** Approach to the brachial plexus by a sagittal incision. The figure shows the patient on his back. His head is on the right, the shoulder on the left side in the position of surgery.

***Figure 60.2.*** The exploration of the upper, middle, and lower trunks through a sagittal incision in a patient with a lesion in continuity. The lesion is on the right side. *Left* is proximal and *right* distal.

***Figure 60.3.*** The remaining scar of the patient from Figure 60.1.

- Always use a *second curved incision*, starting at the coracoid process and following the lines of tension to reach the anterior axillary fold. Where it turns to follow the anterior axillary fold, it can be continued to the middle aspect of the medial surface of the upper arm.
- Elevate the skin between these two incisions to unite the two fields. The only drawback to this approach is that the pedicled skin flap between these two incisions has to be moved in a medial or lateral direction to provide a proper field of vision.
- If spinal nerves C-5 and C-6 have to be explored, make a *third incision* in the transverse direction, again following the tension lines in the caudal third of the neck.
- In very rare instances, a fourth transverse incision far more cranially on the neck is necessary to provide access to the cervical plexus and the accessory nerve.
- Begin the exploration of the brachial plexus in the deltopectoral groove, sparing the cephalic vein. Transect the fascia beneath the muscle and find the lateral cord. Cranially, the posterior cord is seen; inferiorly, the artery is encountered. Medial to the artery, expose the medial cord. Proceeding in a lateral direction, the division of the lateral cord into the musculocutaneous nerve and the lateral root of the median nerve is seen. Follow the posterior cord, dorsal to the artery, to explore the division into the radial, axillary, and thoracodorsal nerves. Follow the medial cord distally to expose the ulnar nerve and the medial origin of the median nerve as well as the medial antebrachial cutaneous nerve. Usually, this area is free of scar and the dissection is easy.
- If this part of the brachial plexus is damaged, it will be fibrotic. If it is scarred in, I do not dissect at this level. Lengthen the incision to the medial aspect of the upper arm and explore the nerves where they are normal, following them proximally into the area of injury.
- Having defined the aforementioned structures in the deltopectoral sulcus, dissect in a medial direction.
- Isolate and retract the pectoralis minor muscle to expose the plexus along its medial border.
- Continue the dissection to the area beneath the clavicle. This level is usually fibrotic.
- Next, enter the supraclavicular fossa by transecting the superficial cervical fascia. The external jugular vein is seen and spared, and the omohyoid muscle is identified.
- Dissect bluntly from both sides beneath the clavicle. Partially detach the clavicular origin of the pectoralis major muscle and isolate the subclavius muscle to facilitate this procedure.
- Follow the cords to define the divisions and to isolate the upper, middle, and lower trunks. Follow them up to the spinal nerves.
- The brachial plexus is now exposed in its full length and access is available through several windows:
  - The supraclavicular fossa cranial to the omohyoideus muscle.
  - The space between the omohyoid muscle and the clavicle.
  - The space between the clavicle and the subclavian muscle.
  - The space between subclavian muscle and the pectoralis major muscle proximal to the pectoralis minor muscle.
  - The space between the pectoralis major and the deltoid muscle distal to the pectoralis minor muscle.

- The axillary groove and the medial aspect of the arm.

To achieve this approach, no traversing structures need to be transected.

During the dissection, the minor structures of the brachial plexus are defined as well. This includes the suprascapular nerve in the supraclavicular fossa, originating from the superior trunk at its division into the anterior and posterior division, the medial and the lateral pectoral nerves, going to the major pectoralis muscles. The long thoracic nerve and the dorsal scapular nerve are met where they emerge from the scalenus medius muscle. The phrenic nerve is seen on the anterior aspect of the scalenus anterior muscle.

### EXPOSURE OF THE CERVICAL PLEXUS AND THE ACCESSORY NERVE

- Using the third transverse incision in the lower part of the neck just described to approach the roots of C-5 and C-6, explore the plexus and the accessory nerve. In exceptional cases, make another more cranially located transverse incision to facilitate the exposure, again undermining the skin between the two incisions.
- On the dorsal border of the sternocleidomastoid, define the nerves ascending around the border of this muscle. Here are found the transversus colli nerve, the major auricular nerve, and the minor occipital nerve. Follow these nerves in a central direction to reach the roots of C-4 and C-3. The C-4 root can also be reached by following the phrenic nerve after its exposure on the anterior surface of the scalenus anterior muscle. The different branches of the supraclavicular nerves, followed in a central direction, lead to C-4. Use electric stimulation to recognize motor branches.
- Following the technique of Brunelli and Monini (8), expose the anterior motor branches of the cervical plexus.
- Slightly lateral and deep to the punctum nervosum, a group of lymph nodes is encountered. Deeper to these structures is the accessory nerve, emerging from a layer beneath the sternocleidomastoid muscle. Farther distally, the accessory nerve becomes more superficial. Before it enters the trapezius muscle, it gives off one branch to the muscle, which is able to maintain the function of the muscle even if the accessory nerve is transected distally to it. In this way, the function of the trapezius muscle can be preserved. Frequently, the trapezius muscle gets an additional innervation by a branch from the cervical plexus.

## EXPLORATION AND TRANSFER OF INTERCOSTAL NERVES

The intercostal nerves I to VI consist of a motor component that innervates in its dorsal segment the serratus posterior superior and serratus posterior inferior muscles. Along their course, they give off branches to the intercostal muscles, and finally they innervate the transversus thoracis muscle. The sensory component leaves the nerve at the anterior border of the serratus anterior muscle, as lateral cutaneous rami, which reach the subcutaneous tissue and divide into a ventral and a dorsal branch. Close to the sternum, the anterior cutaneous branches leave the nerves and again divide into a ventral and a lateral branch. It is therefore obvious that these nerves contain a decreasing number of motor fibers as they progress distally. In the proximal segment before the lateral cutaneous branches leave the nerve, they contain more sensory fibers than after the departure of these nerves. Intercostal nerves VII to XII contain more motor fibers because they innervate the muscles of the abdominal wall.

Intercostal nerves III and IV, and sometimes also V, can be exposed to a very distal level, by the following technique:

- Make an incision that runs parallel to the ribs. The nerves can be transected far distally, isolated to a more proximal level, turned in the direction of the nerve to be neurotized (mainly the musculocutaneous nerve), and connected directly with this nerve. The advantage of this procedure is that only one coaptation is necessary. The disadvantage is that the incision has to be performed far in an anterior direction and the number of motor fibers is lower than in the midaxillary line, for example.

  An alternative to this technique is the following:

- Perform a longitudinal incision in the lateral thoracic wall between the pectoralis major and the latissimus dorsi muscle.
- Split the fibers of the serratus anterior longitudinally along each rib; expose the ribs for a distance of 8–10 cm.
- Isolate the intercostal nerves after dissecting off the external intercostal muscles, elevating the periosteum of the rib, and lifting the rib to gain access to the space beneath the lower border of the rib.
- Define the intercostal nerves here. Sometimes there are separate motor and sensory components.
- Use electric stimulation to identify the motor component for transfer to muscles and eventually the sensory component for transfer of sensory fibers.

If this is done in the midaxillary level, even if 5 or 6 cm of the nerve are isolated, the target nerve is not reached and a nerve graft has to be used in all cases. The disadvantage of this technique is that two lines of coaptation must be crossed by the nerve fibers. The advantage is that the incision is less conspicuous and the nerves contain relatively more motor fibers. It is obvious that from intercostal nerve V onwards, all further intercostal nerve transfers would need a graft because the distance between the thoracic wall and the proximal arm is too long. Because the motor fibers in general are small in number, three intercostal nerves are needed to neuroticize a nerve of the caliber of the musculocutaneous nerve. Considering the high success rate of Tetsuya et al. (34) and Ogino and Naito (29), a transfer with end-to-end coaptation seems safer than a transfer by nerve graft. I recommend using intercostal nerves III and IV as nerve transfers by end-to-end repair; use intercostal nerves V, VI, and so forth via nerve grafts.

Another technique (10), which has not become popular, involves the following steps:

- Explore the intercostal nerves dorsally with the patient in a prone position.
- Bring the intercostal nerves above the pleura to the anterior side.
- Continue the operation after turning the patient on his or her back.

## TECHNIQUES FOR SURGICAL REPAIR

### NEUROLYSIS

External neurolysis isolates the nerve trunks from adhesions to the surrounding tissues. An epifascicular epineuriotomy (single or multiple) is indicated to decompress the nerve trunk with type A fibrosis. If there is a moderate degree of interfascicular fibrosis (type B), epineuriotomy will not be sufficient. An epifascicular epineuriectomy (dissecting the epifascicular tissue) is then indicated. With more extensive interfascicular fibrosis (type C), the interfascicular tissue must be partially excised to achieve decompression (interfascicular epineuriectomy).

### NEURORRHAPHY

A neurorrhaphy with end-to-end coaptation of nerve stumps is rarely possible with brachial plexus lesions. It is most appropriate in cases of clean transection (e.g., stab injuries) and follows the usual techniques.

### END-TO-SIDE COAPTATION

Viterbo (38) discovered that a denervated nerve brought with its cross section end-to-side in contact with an innervated nerve may be neurotized from the innervated nerve. The neurotization occurs across the perineurium if an epineurial window is created, and the neurotization is even better, of course, when a perineurial window is also made. The possibility of end-to-side coaptation offers many opportunities in brachial plexus surgery. I have successfully performed an end-to-side coaptation between a functioning dorsal scapular nerve and the denervated long thoracic nerve. Before that, my colleagues and I had transected the dorsal scapular nerve and sacrificed its function to achieve neurotization of a serratus anterior muscle, which is extremely important. By using end-to-side coaptation, we not only preserve the dorsal scapular function but also innervate the serratus anterior muscle. In a similar way, we have used nerve grafts that were coapted end-to-side to the phrenic nerve with its proximal end, and end-to-end to the lateral and medial pectoral nerves. In this way, the phrenic nerve could be used as an axon donor without sacrificing its function. Our results with end-to-side coaptation have been excellent in small nerves with one function. Whether it works in major nerves with multiple functions is not yet known (see the following discussion).

So far, we have made only epineurial windows. A perineurial window does not seem to be necessary. It is obvious that this method offers a vast amplification of the possibilities in brachial plexus surgery. Its full value has yet to be shown in sufficient clinical cases.

### NERVE GRAFTING

Restoration of continuity by free nerve grafting is performed using the sural nerve, the medial antebrachial cutaneous nerve, and occasionally the superficial branch of

the radial nerve. The use of cutaneous nerve segments for nerve grafting has the great advantage that well-defined points of the proximal stump can be coapted to well-defined points of the distal stump. Place the grafts individually to increase the spontaneous revascularization and to avoid central fibrosis. The grafts must be long enough to avoid longitudinal tension. Very few stitches are necessary to approximate the graft to the proximal and distal stumps. In recent years, the use of fibrin glues has been recommended to shorten the operative time considerably (27,28). If the grafts are long enough and the coaptations are absolutely tensionless, only a few sutures between the stumps and the grafts are necessary. In this case, the decrease of operative time by using tissue glue is minimal (Table 60.8).

| |
|---|
| Sural nerve (bilateral) |
| Antebrachial medial cutaneous nerve (bilateral) |
| Superficial branch of the radial nerve |
| Femoral lateral cutaneous nerve (bilateral) |
| Saphenous nerve (bilateral) |
| Lateral antebrachial cutaneous nerve |
| Segments of the ulnar nerve after splitting by microsurgical dissection |

***Table 60.8. Donor Nerves for Free Nerve Grafts***

In a root avulsion at C-8 and T-1, the ulnar nerve is available for use as a nerve graft. Bonney and Birch (4) have transplanted the ulnar nerve as a free vascularized graft based on the ulnar artery. Breidenbach and Terzis (6,7) have demonstrated that a free microvascular transfer is possible by using the superior ulnar collateral artery as the nutritive vessel without sacrificing the ulnar artery (Table 60.9).

| |
|---|
| Ulnar nerve in case of root avulsion C8 and T1 |
| Saphenous nerve (bilateral) |

***Table 60.9. Donor Nerves for Vascularized Nerve Grafts***

If there is a long superior collateral ulnar artery, the ulnar nerve can be transferred as an island flap without interrupting the blood supply. If the blood supply is not interrupted by a complication, this type of nerve graft offers the advantage that it is not dependent on the vascularity of the recipient bed. Achieving connections of well-defined spots on the proximal and the distal stumps is more difficult. Initial expectations that the qualitative result of regeneration would be significantly improved by this method have not been fulfilled. Most authors agree that the first signs of recovery might occur somewhat earlier but the final result is the same as with free nerve grafting with spontaneous revascularization (1,2,5,16,17,19).

The ulnar nerve can also be used as a donor of free graft after the epifascicular epineurium has been removed and the nerve trunk has been split into minor units by interfascicular dissection (19).

**NERVE TRANSFER**

By connecting the proximal stump of a normal nerve to the distal stump of a denervated nerve, nerve fibers can be transferred to the denervated nerve and will neurotize this denervated nerve. After reaching the target organ, functional recovery can be achieved; however, the patient must learn to use the stimuli from the donor nerve to perform a different movement with the newly reinnervated muscles. In the vast majority of cases, patients learn this quite easily. A correct term for this procedure would be *nerve-fiber transfer*. The term *neurotization* is widely used for this procedure, but this is incorrect because neurotization means to bring nerve fibers into a denervated area. Regardless of what type of transfer I do—end-to-end, end-to-side repair, or nerve grafting—I always neurotize a denervated nerve from an innervated proximal stump.

Another frequently used axon donor is the accessory nerve, especially after the first branch has left the nerve. The superior part of the trapezius muscle remains innervated by this branch and can even be used for a muscle transfer at a later stage. The trapezius muscle frequently has an additional innervation from the cervical plexus (ramus trapezius) and does not become totally denervated, even if the whole accessory nerve has been transected.

Brunelli and Monini (8) described the use of the anterior nerves of the cervical plexus.

The dorsal scapular nerve is used now mainly in an end-to-side fashion.

The phrenic nerve has also been suggested as an axon donor. The consequence of transecting the nerve would be the loss of function of the ipsilateral diaphragm. In a young patient, this might not do much harm if the thoracic muscles are intact. It should, however, never be combined with an intercostal nerve transfer. The phrenic nerve, of course, may easily be used if there is an accessory phrenic nerve available. Today, we use it in an end-to-side fashion.

The hypoglossus nerve has also been suggested as a source for the brachial plexus; however, this may cause some problems with tongue function.

Gu et al. (14) observed that a clean transection of C-7 does not create many adverse consequences, and contralateral transfers can be done. Usually after transection of C-7, the patient notes some weakness in the triceps as well as wrist and finger extensors. This weakness, however, disappears within a few weeks by compensatory hypertrophy of the remaining innervated fibers. The patient experiences some minimal sensory loss in the thumb and index finger, which does not create a long-term problem. Gu et al. (14) and Chuang et al. (11) performed a series of C-7 transfers that provided additional useful function. The only problem, however, is that the patient has to consciously use the nonparalyzed side to have an effect on the contralateral paralyzed side.

The problem with contralateral C-7 transfer is a major loss of function caused by a variation in the distribution of the nerve fibers. Intraoperative electric stimulation studies may avoid this, but in my opinion they are not reliable enough. Therefore, before a C-7 transfer, I perform an exposure of the contralateral root C-7 and place a ligature on the divisions. On the day after the operation, the real loss of function can be estimated very well and the patient can decide whether this functional loss, which decreases with time, is acceptable. If the patient accepts this condition, the C-7 transfer is performed at a second stage.

I performed my first C-7 transfer in 1993; after evaluating the functional result of the first three cases several years thereafter, I started to do it as a routine procedure. A C-7 transfer is appropriate in patients with avulsions of all five roots, or in patients with avulsion of several roots who have had the usual reconstructive procedures (restoration of continuity and ipsilateral nerve transfers) and who desire additional strength (Fig. 60.4).

***Figure 60.4.*** This 26-year-old patient suffered a complete brachial plexus lesion in a skiing accident. The first operation was performed in May 1996. There was a peripheral lesion of C-5 and C-6 and an avulsion of C-7, C-8, and T-1. At the first operation, nerve grafts were used to establish continuity from the accessory nerve to the musculocutaneous nerve. From a motor branch of the cervical plexus, the pectoralis nerve was neurotized. From C-5, nerve grafts were used to establish the continuity with the suprascapular, axillary, and radial nerves. C-6 was used to innervate the median nerve. **A:** From the neurotization of the median nerve, the patient achieved very little flexion activity of the finger flexors. **B:** The patient developed quite good shoulder control and external rotation, and good function of the triceps but weak function of the biceps muscle. A triceps transfer had to be performed to achieve sufficient elbow flexion. To improve the hand function, a C-7 transfer was performed in November 1996, connecting the dorsal division of C-7 by two saphenous nerve grafts with the ulnar nerve. **C:** This operation led to a significant improvement in the finger flexors with useful flexion of the fingers including the flexor pollicis longus, providing a key grip function between thumb and index finger (see Table 60.11).

| Transfer of nerve fibers from |
|---|
| *1st stage* |
| Accessory nerve to musculocutaneous nerve |
| Cervical plexus motor branch to suprascapular nerve |
| Cervical plexus motor branch to axillary nerve |
| Cervical plexus motor branch to lateral pectoral nerve |
| Phrenic nerve end-to-side by graft to medial pectoral nerve |
| Dorsal scapular end-to-side to long thoracic nerve |
| Intercostal II to thoracodorsal nerve by end-to-end |
| Intercostal III to V to radial nerve |
| Intercostal VI to VIII to median nerve |
| *2nd stage* |
| Contralateral C7 via a saphenous nerve graft to ulnar nerve |

***Table 60.11. Avulsion of All Five Roots (1st Alternative)***

For patients with avulsions of all five roots, initially perform nerve transfers to improve shoulder and elbow function. In a second stage, do a C-7 transfer to provide additional functional recovery in the forearm and finger flexors. With recovery of these muscles, reconstruct a gripping function of the hand.

In an initial series, we used the ulnar nerve as a vascularized graft to connect C-7 with the median nerve. In a follow-up series, we used the ulnar nerve as a vascularized graft to connect the anterior division of C-7 with the median nerve, and free nerve grafts to connect the posterior division of C-7 with the radial nerve distal to the branches to the triceps muscle.

In other cases when the radial nerve was neurotized by other donors, the anterior division was connected via a saphenous nerve graft with the median nerve, and the posterior division via a saphenous nerve graft with the ulnar nerve, attempting to restore the function of both the median and the ulnar nerves. So far, the results are encouraging, and late results will be available in a few years.

Complications were encountered in two cases. In one case, the biceps muscle became paralyzed after the ligature, in spite of the fact that this was not recognized during intraoperative electrostimulation. In this case, we opened the ligature and performed the C-7 transfer as an end-to-side coaptation between the now-preserved anterior and posterior division of C-7 and the grafts. This case is

***Figure 60.5.*** This 7-year-old boy suffered a skiing accident that caused a complete lesion of the right brachial plexus, along with a lesion of the subclavian artery and a fracture of the clavicle. The artery was reconstructed by a vein graft and the brachial plexus was operated on in the boy's home town, but there was no recovery. I saw the patient for the first time 11 months after the accident. Avulsion of the C-7, C-8, and T-1 roots was diagnosed, and a reexploration with a C-7 transfer from the contralateral side was planned.
The left root C-7 was ligated, and there was no unexpected loss of function. Six days later, the right brachial plexus was explored, and the avulsion of C-7, C-8, and T-1 was confirmed. Only the right C-6 root could be used as a proximal stump. It was connected with the musculocutaneous nerve by a graft 18 cm long, with good success (biceps now M-4). Another graft was used to neurotize the axillary nerve (abduction with the shoulder joint now 30°), and two nerve grafts were interposed between C-6 and the radial nerve (with no recovery). A vascularized ulnar nerve segment 30 cm long was used to connect the contralateral C-7 and the ipsilateral median nerve.
These images represent the patient's hand at a follow-up examination 6 years after the initial surgery. **A:** On the patient's right side, note the scar of the sagittal incision and the somewhat broadened scar from the curved incision over the deltopectoral sulcus. On the patient's left, note a sagittal scar from the exploration of the C-7 contralateral. **B,C,D:** There is good functional return in the flexor digitorum superficialis and profundus, the flexor pollicis longus, the flexor carpi radialis, and the palmaris longus.
A tendon transfer for finger extension is scheduled.

especially interesting and we presently are awaiting the final result. If this end-to-side coaptation would work also with major nerve trunks, new possibilities would be available.

In the second case, the sensory loss of the thumb and the index finger was more than had been expected. In this case, the C-7 transfer was performed with only the dorsal division, and the anterior division was preserved. The area of loss of sensibility was reduced significantly.

## SELECTION OF SURGICAL TECHNIQUES ACCORDING TO THE SEVERITY OF THE NERVE LESION

If nerve continuity is present, do a progressive intraneural neurolysis to define the degree of damage. If it becomes clear that the fascicular structure remains intact and decompression has been achieved, end the surgery. If not, the next step must be carried out until you are convinced that the damage makes spontaneous recovery

impossible. In this case, resect the damaged part and restore continuity by nerve grafting.

If nerve continuity is not present, prepare the proximal and distal stumps by resection or by interfascicular dissection until normal tissue is found. Then restore continuity by nerve grafts. In short defects (5–6 cm), direct end-to-end repair can be done. If, however, the defect is very large and extends, for example, from the trunk to the distal cord level, we prefer to do nerve grafts directly to the peripheral nerves (e.g., from C-5 directly to the axillary nerve, or from C-6 directly to the musculocutaneous nerve).

If a lesion is at the level of the spinal nerves, restoring continuity of all structures is usually impossible; you must then decide which parts are to be repaired. The highest priority is to restore elbow flexion. If possible, C-6 is united with distal structures leading to that part of the lateral cord that forms the musculocutaneous nerve, or in longer lesions we unite C-6 directly with the musculocutaneous nerve. The next important function is the control of the shoulder joint. Thus we try to neurotize the suprascapular nerve with fibers coming from C-5 or even C-4. Nerve fibers of the dorsal aspect of C-5, C-6, and C-7 are united with the posterior cord to provide nerve fibers to the axillary and radial nerves or in long defects with the nerves directly. C-8 and T-1 have a poor prognosis and therefore are the last priority.

In cases of root avulsion, an individual plan must be made for each patient. If the avulsion involves C-8 and T-1, the ulnar nerve can be used as a nerve graft. No attempt is made to neurotize the medial cord because of the low success rate (27), but this does not exclude neurotization of the ulnar nerve if a sufficient number of axon donors are available.

If C-6 is avulsed, C-5 can be used for the musculocutaneous nerve; in addition, it is connected with the scapular nerve. If C-7 is avulsed, the accessory nerve may be the donor for neurotization of the radial nerve.

If C-5 and C-6 are both avulsed, the accessory nerve may neurotize the suprascapular, and the axillary nerve and intercostal nerves are used for the musculocutaneous nerve. The musculocutaneous, however, can also be neuroticized successfully by the accessory nerve (15). A similar approach is used in avulsion of C-5, C-6, and C-7. If all roots are avulsed, we prefer transfers at present, as suggested in Table 60.10, Table 60.11, Table 60.12 and Table 60.13.

| Transfer of nerve fibers from |
|---|
| *1st stage* |
| C5 to lateral cord |
| Accessory nerve to suprascapular nerve |
| Motor branch of cervical plexus to axillary nerve |
| Motor branch from cervical plexus to medial pectoral nerve |
| Phrenic nerve end-to-side to lateral pectoral nerve |
| Dorsal scapular end-to-side to long thoracic nerve |
| The intercostal II end-to-end to thoracodorsal nerve |
| Intercostal III, IV, V, and VI to radial nerve |
| *2nd stage* |
| Contralateral C7, anterior division via vascularized ulnar nerve graft to median nerve (if no motor recovery in the median nerve innervated muscles) |

***Table 60.10. Avulsion of Four Roots Except C5***

| Transfer of nerve fibers from |
|---|
| *1st stage* |
| Accessory nerve to suprascapular nerve end-to-end |
| Cervical plexus to axillary nerve |
| Phrenic nerve to medial and lateral pectoral nerve end-to-end by nerve graft |
| Dorsal scapular to long thoracic nerve end-to-side |
| Intercostal nerve II to thoracodorsal nerve end-to-end |
| Intercostal nerve III, IV, and V to musculocutaneous nerve end-to-end or via nerve graft |
| *2nd stage* |
| Contralateral C7 anterior division to median nerve by vascularized ulnar nerve graft |
| Contralateral C7 posterior to radial nerve by free split ulnar nerve graft |

***Table 60.12. Avulsion of All Five Roots (2nd Alternative)***

| Transfer of nerve fibers from |
|---|
| *1st stage* |
| C4 to radial nerve |
| C4 to axillary nerve |
| Accessory nerve to suprascapular nerve end-to-end |
| Dorsal scapular to long thoracic nerve end-to-side |
| Phrenic nerve to medial and lateral pectoral nerve end-to-side via nerve graft |
| Intercostal II to thoracodorsal nerve end-to-end |
| Intercostal III, IV, and V to musculocutaneous nerve end-to-end or via nerve graft |
| *2nd stage* |
| C7 anterior division to median nerve by saphenous and superficial radial nerve graft |
| C7 posterior division to ulnar nerve by saphenous nerve graft |

***Table 60.13. Avulsion of All Five Roots (3rd Alternative) (Source from C4 to C5 Available)***

## POSTOPERATIVE CARE

After wound closure, immobilize the patient for 10 days in the intraoperative position by a plaster cast that includes the head, the trunk, and the arm. After this time, initiate passive and active mobilization for as wide a range of motion as possible. Electrotherapy of the denervated muscles is useful. Splinting should avoid overstretch of muscles, especially the biceps. There is still some question as to whether the shoulder joint should be immobilized in abduction to maintain full range of motion. In my experience, return of active motion in the shoulder joint is always limited; therefore, it is unnecessary to maintain a wide range of passive motion. The use of a custom orthosis is recommended.

## SECONDARY RECONSTRUCTIVE SURGERY

In partial type II lesions with intact muscles, perform procedures to replace lost elbow flexion. Such procedures include the following:

- Transfer of the lateral segment of the pectoralis major muscle (12);
- Transfer of the latissimus dorsi muscle (40);
- Transfer of the common forearm flexor muscles from the medial epicondyle of the humerus to the shaft of the humerus (32).

In partial type I lesions, carefully evaluate the available muscle force. To improve the functional result in a regenerating biceps, a shortening of the biceps tendon some times helps. The biceps tendon can also be transferred 1 or 2 cm distally to provide a better lever arm and better flexion power by sacrificing supination. Simultaneous innervation of the biceps and triceps occurs quite often, and usually the triceps is the stronger muscle. In this case, mobilize the triceps, transfer its tendon to the anterior aspect, and unite it with the biceps tendon so that both muscles act as flexors. Sometimes the triceps has successfully replaced a nonfunctioning biceps, and

in some cases we have initially restored the function of the triceps by nerve transfer, planning a later muscle transfer. The control of shoulder function can be achieved by transferring the horizontal part of the trapezius muscle, including the bony insertion at the acromion, to the humerus, as described by Saha (30). Active gain of abduction is limited, but usually subluxation can be avoided and some control achieved. In some cases, after tenolysis and mobilization of the supraspinatus muscle and tendon, the horizontal part of the trapezius muscle was directly transferred to the supraspinatus tendon, proximal or in other cases distal to the acromion, passing beneath the acromion. There are cases in which the clavicular and posterior heads of the deltoid muscle recover but the acromial component does not. The clavicular head and the posterior third then act as adductors. In such cases, we have transferred successfully the clavicular and the posterior heads toward the median line of the shoulder joint (medianization) to make both parts abductors.

Forceful recovery of elbow flexion does not help if the patient cannot externally rotate the shoulder. External rotation is a crucial function and must be considered from the beginning. We feel it is extremely important to achieve a strong pectoralis major muscle. We transfer the pectoralis major muscle around the humerus shaft to the dorsal side along with the latissimus dorsi muscle, to act as an external rotator. If there is an internal rotation contracture, perform an osteotomy of the humerus at the same time to derotate the humerus by about 60°. The osteotomy is immobilized by plate and screws, and the pectoralis and the latissimus dorsi, if recovered, are transferred to the lateral aspect of the humeral shaft. Some patients develop a supination contracture, which has to be treated by mobilizing the radius and ulna with transection of the interosseus membrane, ensuring that the radial tuberosity clears the ulna during pronation. The biceps tendon can be inserted into the coronoid process to avoid supination and pronation contracture.

If elbow flexion has returned but wrist and finger flexion are still paralyzed, we perform an arthrodesis or a tenodesis of the wrist joint. If one or two forearm muscles have returned, it is possible to restore simple gripping function (key grip) by tendon transfers. If all these procedures fail, and the local muscles are degenerated, a free muscle graft can still replace one or two important functions (13).

**CHAPTER REFERENCES**

Each reference is categorized according to the following scheme: *, classic article; #, review article; !, basic research article; and +, clinical results/outcome study.


+ 1. Alnot JY, Oberlin C, Bellaicke H. Vascularized Ulnar Nerve Transfer in Total Palsy of the Brachial Plexus. Presented at the joint meeting of the *Groupe pour l'Avancement de la Microchirurgie* and the *Deutschsprachige Arbeitsgemeinschaft für Mikrochirurgie der peripheren Nerven und Gefäbe* , Strasbourg, France, May 1984.

+ 2. Anderl H, Hussl H. Erfahrungen mit Vaskularisierten Nerventransplantaten. Presented at the *Deutschsprachige Arbeitsgemeinschaft für Mikrochirurgie der peripheren Nerven und Gefäbe* , Bern, Switzerland, December 1986.

# 3. Bonney G. The Case for Early Surgery. Presented at the *Symposium on Brachial Plexus Injuries* at the St. Mary's Hospital, London, Great Britain, January 1983.

# 4. Bonney G, Birch R. Surgical Aspects. Presented at the *Symposium on Brachial Plexus Injuries* by the British Society for Surgery of the Hand, Barbicane Center, London, Great Britain, November 1982.

+ 5. Bonney G, Birch R, Jamieson AM, Eames RA. Experience with Vascularized Nerve Grafts. *Clin Plast Surg* 1984;11:137.

# 6. Breidenbach W, Terzis JK. The Anatomy of Free Vascularized Nerve Grafts. *Clin Plast Surg* 1984;11:65.

! 7. Breidenbach W, Terzis JF. The Blood Supply of Vascularized Nerve Grafts. *J Reconstr Microsurg* 1986;3:43.

+ 8. Brunelli G, Monini L. Neurotization of Avulsed Roots of Brachial Plexus by Means of Anterior Nerves of Cervical Plexus. *Clin Plast Surg* 1984;11:148.

+ 9. Carlstedt T, Grane P, Hallén R, Noren G. Spinal Cord Implantation of Avulsed Central Roots: Human Application. *J Hand Surg* 1996;21B.

+ 10. Celli L, Mingione A, Landi A. New Technical Acquisitions in the Surgery of Brachial Plexus Lesions. Nuove Acquisizioni di Tecnica Chirurgica Nelle Lesioni della Plesso Brachiale. Indicazioni alla Neurolisi, Autoinneste e Trapianti Nervosi. Atti *XIX Congr della Soc Italiana di Ortopedia e Traumatologia*, Cagliari, 1974.

+ 11. Chuang ChD, Wei FC, Noordhoff MS. Cross-Chest C7 Nerve Grafting Followed by Free Muscle Transplantation for the Treatment of Avulsed Brachial Plexus Injuries. *Plast Reconstr Surg* 1993;92:717.

+ 12. Clark JPM. Reconstruction of Biceps Brachii by Pectoral Muscle Transplantation. *Br J Surg* 1946;34:180.

+ 13. Doi K. Double Free Muscle Transfer to Reconstruct Prehension Following Complete Avulsion of Brachial Plexus. Video presentation at *11th Congress of the International Society of Plastic, Reconstructive and Aesthetic Surgery*, Yokohama, Japan, April 16–22, 1995.

+ 14. Gu YD, Zang GM, Yan JG, et al. Seventh Cervical Root Transfer from the Lateral Healthy Side for Treatment of the Brachial Plexus. *J Hand Surg* 1992;17B:518.

+ 15. Merle M. Neurotization of Brachial Plexus Lesions with the Spinal Accessory Nerve—Functional Results. Presented at the 2nd annual meeting of the *American Society of Reconstructive Microsurgery*, New Orleans, United States, February 1986.

+ 16. Merle M. Vascularization of Nerve Grafts. Presented at 9th meeting of the *International Microsurgical Society*, Brescia, Italy, 1986.

+ 17. Merle M, Lebreton E, Bour C, et al. Free Vascularized Nerve Transfer in Brachial Plexus Injuries. Presented at joint meeting of the *Groupe pour l'Avancement de la Microchirurgie* and the *Deutschsprachige Arbeitsgemeinschaft für Mikrochirurgie der peripheren Nerven und Gefäbe* , Strasbourg, France, May 1984.

+ 18. Millesi H. Zum Problem der überbrückung von Defekten peripherer Nerven. *Wien Med Wschr* 1968;118:182.

+ 19. Millesi H. Das Problem der Defektbehebung peripherer Nerven. Presented at the 9th meeting of *Deutschsprachige Arbeitsgemeinschaft für Mikrochirurgie der peripheren Nerven und Gefäbe*, Berne, Switzerland, December 1968.

+ 20. Millesi H. Résultats Tardifs de la Greffe Nerveuse Interfasciculaire: Chirurgie Réparatrice de Lésions du Plexus Brachial. Presented at the *Symposium at the Clinique Longeraie* (Dir Prof Claude Verdan), Lausanne, Switzerland, February, 1969.

# 21. Millesi H. Eingriffe an peripheren Nerven. In: Gschnitzer F, Kern E, Schweiberer L, eds. *Chirurgische Operationslehre.* Baltimore: Urban & Schwarzenberg, 1986:1.

+ 22. Millesi H, Ganglberger J, Berger A. Interfasciculäre Nerventransplantation mit Hilfe der Mikrochirurgischen Technik. Transactions of the 43th Congress of Plastic and Reconstructive Surgery, Rome, Italy, October 1967. *Excerpta Medica Int Corp Ser* 174,56.

+ 23. Millesi H, Ganglberger J, Berger A. Erfahrungen mit der Mikrochirurgie peripherer Nerven. *Chir Plastica* 1967;3:47.

+ 24. Millesi H, Meissl G, Berger A. The Interfascicular Nerve Grafting of the Median and Ulnar Nerves. *J Bone Joint Surg Am* 1972;54:727.

+ 25. Millesi H, Meissl G, Berger A. Further Experience with Interfascicular Grafting of the Median, Ulnar and Radial Nerves. *J Bone Joint Surg Am* 1976;58:209.

# 26. Millesi H, Meissl G, Katzer H. Zur Behandlung der Verletzungen des Plexus brachialis—Vorschlag einer integrierten Therapie. *Brun's Beiträge Klin Chir* 1973;221:429.

+ 27. Narakas AO. Thoughts on Neurotization of Nerve Transfers In Irreparable Nerve Lesions. *Clin Plast Surg* 1984;11:153.

# 28. Narakas A. Brachial Plexus Injury. Presented at 3rd *Congress of International Federation of Societies for Surgery of the Hand*, Tokyo, Japan, November 1986.

+ 29. Ogino T, Naito T. Intercostal Nerve Crossing to Restore Elbow Flexion and Sensibility of the Hand for a Root Avulsion Type of Brachial Plexus Surgery. *Microsurgery* 1995;16:571.

# 30. Saha AK. Surgery of the Paralyzed and Flail Shoulder. *Acta Orthop Scand* 1967;97(suppl):1.

# 31. Seddon HJ. Surgical Disorders of the Peripheral Nerves, 2nd ed. New York: Churchill Livingstone, 1975:196.

# 32. Steindler A. Reconstruction Work on Hand and Forearm. *NY Med J* 1918;108:117.

* 33. Sunderland S. A Classification of Peripheral Nerve Injuries Producing Loss of Function. *Brain* 1951;74:491 .

+ 34. Tetsuya H, Nagano A, Yoshihisa A, et al. The Present and Future of the Intercostal Nerve Crossing as a Treatment of Brachial Plexus Injuries. In: Vastamäki M, ed. *Curr Trends Hand Surg* 1995;289.

# 35. Tsuyama N, Sagakuchi R, Hara T, et al. Reconstructive Surgery in Brachial Plexus Injuries. In: Proceedings of the 11th annual meeting of the *Japanese Society of the Hand.* Hiroshima, Japan, 1968:39.

+ 36. Turkof E, Millesi H, Turkof R, et al. Intraoperative Electroneurodiagnostics (Transcranial Electrical Motor Evoked Potentials) to Evaluate the Functional Status of Anterior Spinal Roots and Spinal Nerves during Brachial Plexus Surgery. *Plast Reconstruct Surg* 1997;99:1632.

+ 37. Turkof E, Monsivais J, Dechtyar I, et al. Motor Evoked Potential as a Reliable Method to Verify the Conductivity of Anterior Spinal Roots in Brachial Plexus Surgery: An Experimental Study on Goats. *J Reconstr Microsurg* 1995;11:357.

+ 38. Viterbo F. Two End-to-side Neurorrhaphies and Nerve Graft Removal of the Epineural Sheath: Experimental Study in Rats. *Br J Plast Surg* 1994;47:75.

+ 39. Yeoman PM, Seddon HJ. Brachial Plexus Injuries: Treatment of the Flail Arm. *J Bone Joint Surg Br* 1961;43:493.

+ 40. Zancolli E, Mitre H. Latissimus Dorsi Transfer to Restore Elbow Flexion. An Appraisal of Eight Cases. *J Bone Joint Surg Am* 1973;55:1265.

# CHAPTER 61

# SURGERY OF THE THORACIC OUTLET

*Robert D. Leffert*

**R. D. Leffert:** Massachusetts General Hospital, Boston, Massachusetts, 02114.

Clinical Presentation of Thoracic Outlet Syndrome
Diagnosis of Thoracic Outlet Syndrome
Conservative Therapy
Indications for Surgery
Surgical Techniques
The Transaxillary Approach
Anterior Approaches to the Thoracic Outlet
Posterior Approach
Postoperative Care and Rehabilitation
Pitfalls and Complications
Inadequate Resection
Pneumothorax
Intercostobrachial Neuralgia
Brachial Plexus Injury
Long Thoracic Nerve Injury
Vascular Injury
Conclusions
Chapter References

The signs and symptoms of thoracic outlet syndrome (TOS) result from compression of the neurovascular structures as they exit the chest and neck and pass through the costoclavicular interval and down into the axilla. The clinical presentation in each patient reflects the degree of compression of the brachial plexus and of the subclavian artery and vein. Historically, the interscalene area was considered the primary site of compression, but subsequent experience has shown that treatment of this disorder requires understanding the dynamic anatomy of the entire region of the neck and shoulder region.

Changes in the alignment of the shoulder girdle with normal development, age, and disease complicate the problem considerably but also provide a way to understand how signs and symptoms are produced (39). Specifically, exaggeration of the normal caudad descent of the shoulder girdle produced by poor posture or local injury can cause compression of the lower trunk of the brachial plexus and of the subclavian artery and vein (Fig. 61.1). This mechanism can explain the emergence of symptoms of TOS in patients who are asymptomatic before motor vehicle accidents (6,20,26). Congenital anatomic abnormalities such as cervical ribs, long transverse processes, or congenital bands can increase the severity of the effect.

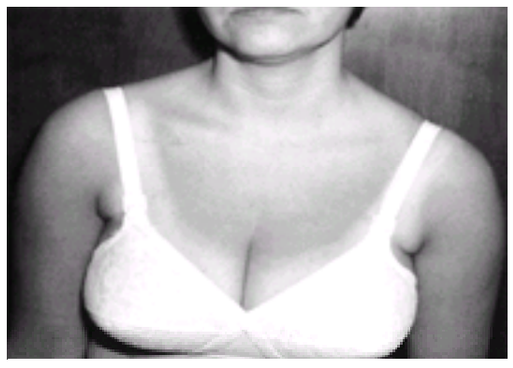

***Figure 61.1.*** This patient was asymptomatic before a motor vehicle accident in which she sustained what was termed a whiplash injury. This caused pain in the shoulder girdle, which led to a postural droop of her scapula and subsequent thoracic outlet compression. She was overweight with large breasts, which added to the downward pull on her shoulder girdle. Ultimately, after failure of conservative treatment, she underwent first rib resection with relief of her symptoms but required extensive postoperative muscle reeducation to correct her posture.

Although the incidence of cervical ribs in the general population has been reported in different studies to range from 0.056% to l.5% (35), nine types of congenital fibrous bands have been described that can cause neurovascular compression within the thoracic outlet (30). Malunions and nonunions of the clavicle can also lead to thoracic outlet compression (14). Instability of the glenohumeral joint (33) can be associated with numbness and tingling within the limb or with secondary TOS (17).

For reasons that are discussed further later, females with TOS outnumber males by about four to one. The disorder is seen most commonly between puberty and the fourth decade of life. Although there are scattered case reports of girls who have developed TOS in childhood, the authors do not report whether the patients had attained menarche. A postmenopausal woman who develops symptoms thought to be due to thoracic outlet compression should be carefully examined to be certain that the symptoms are not due to another condition.

## CLINICAL PRESENTATION OF THORACIC OUTLET SYNDROME

For reasons that will become much clearer later in this chapter, I believe that the diagnosis of TOS is primarily clinical. Although some laboratory examinations are helpful, diagnosis is usually made on the basis of a careful history and physical examination.

The symptoms of TOS are quite variable, depending on which structures are being compressed. The majority of patients complain of pain and paresthesias that radiate from the neck, upper chest, or shoulder region, down the medial aspect of the arm and into the little and ring fingers, although some experience numbness of the entire upper limb. Much less commonly, it is the radial aspect of the arm and hand that is numb. Symptoms are often nocturnal; elevation of the arm in sleep or during activities aggravates them. Complaints such as the inability to hold a hair dryer or to work with the arms above the head are common. Some patients have numbness when driving or when carrying heavy objects. These symptoms are caused by compression of the lower trunk of the brachial plexus.

The signs are usually subtle and may be confined to weakness of the ulnar-innervated intrinsic muscles unless compression is severe. There may be weakness of all the intrinsic musculature and loss of power of the long flexors of the little and ring fingers. When the upper trunk of the brachial plexus is involved, differential diagnosis becomes more difficult, and there may be confusion with cervical radiculopathy or carpal tunnel syndrome.

Signs and symptoms of TOS may include acute arterial insufficiency or gangrene in the hand, but such severe symptoms are rarely seen in an orthopaedic practice. Such patients usually have acute occlusion of the subclavian or axillary arteries and often have aneurysms caused by compression by significant cervical ribs (13,27). This complication is more often found in older patients with long histories of often undiagnosed symptoms.

Venous compression can cause swelling of the hand and upper limb, which, if intermittent, is difficult to document until its severity motivates the patient to have it examined. Intermittent venous compression in the absence of thrombosis produces cyanosis as well as swelling in the limb.

Occasionally, a patient exhibits acute venous thrombosis, the so-called Paget-Schroetter syndrome (11,13,34). This “effort thrombosis” of the subclavian and axillary veins results from underlying subclinical thoracic outlet compression and repetitive or strenuous use of the arms, particularly in the overhead position. The symptoms are acute pain and swelling of the limb and ipsilateral chest wall. Prompt recognition of the condition is imperative—delay may result in considerable disability due to chronic pain and swelling. Acute therapy consists of administration of intravenous thrombolytics by catheter, with mechanical dilatation, if needed. Maintain the patient on anticoagulants for 3 or 4 months, and follow up with elective first rib resection to diminish the likelihood of recurrent thrombosis (35).

Unilateral Raynaud's phenomenon has been occasionally diagnosed as being consistent with TOS. In this case, it is attributed to selective compression of the sympathetic innervation of the limb within the lower trunk of the brachial plexus. The etiology of unilateral Raynaud's phenomenon is not collagen disease. More likely, this phenomenon represents episodes of distal embolization from an aneurysm located within the subclavian artery (13).

Patients with TOS may have significant neck or chest pain. When TOS is in the left hemithorax, such pain may mimic angina or myocardial infarction and bring the patient repeatedly to the emergency room or cardiac care unit (42).

## DIAGNOSIS OF THORACIC OUTLET SYNDROME

The physical examination is most important, not only to achieve a positive diagnosis but also to rule out other conditions that may be confused with TOS or that may coexist with it. Cervical radiculopathy is unusual in the C8—T1 distribution in the arm and hand (5). Nevertheless, when the symptoms are difficult to interpret, the cervical spine must be ruled out as a site of disease. There may be tenderness over the brachial plexus in the supraclavicular fossa, but this nonspecific finding may accompany either thoracic outlet compression or cervical radiculopathy.

Of the various provocative maneuvers used to elicit thoracic outlet compression, the overhead exercise test and Wright's maneuver (49) are the most consistently positive. The first test is performed by having the patient, in the “hands-up” position, rapidly flex and extend the fingers. In susceptible patients, this exercise produces cramping on the affected side within 30 seconds. In addition, placing the arm in the abducted and laterally rotated position not only obliterates the pulse at the wrist but also reproduces the symptoms. Lowering the arm to the side restores the pulse and alleviates the symptoms.

The mere obliteration of a distal pulse with any of the provocative positions is not diagnostic of TOS, because in many young women, some position of the arm can obliterate a pulse. The reproduction of the symptoms is crucial! Sometimes they can be elicited by rotating the neck to the opposite side or by having the patient take a deep breath, particularly while the affected extremity is abducted and externally rotated at the shoulder.

The costoclavicular maneuver or military brace position reproduces symptoms in patients whose costoclavicular interval has been narrowed, particularly by a clavicular fracture. The classic Adson's maneuver is performed by having the patient, with the arm dependent, rotate and hyperextend the neck to the affected side and take a deep breath. In my experience, this has been the least rewarding of the provocative tests.

It is important to examine the shoulder girdle carefully to verify the stability of the glenohumeral joint, because patients with instability may complain that the arm “feels dead” (33). In addition, finding an increased venous pattern on the side of the lesion is presumptive evidence of venous hypertension and possible compression or thrombosis.

Manual muscle testing must include the intrinsic muscles of the hand. The only motor deficit may be just-perceptible atrophy of the hypothenar muscles and weakness of adduction of the little finger to the ring finger. Rarely, all of the intrinsics are weak or atrophic. The cutaneous distribution of the first thoracic nerve is the medial aspect of the forearm, thus it is differentiated from the distribution of the ulnar nerve.

Adequate radiographs are essential. It may be difficult to assess the lower cervical spine for the presence of adventitious ribs or long transverse processes at C7 because the patient's identification plate may have been placed there. Hypoplastic, true first ribs may be present, and sometimes, a cervical rib can be confused with a hypoplastic rib unless you are sure of the vertebral level. Count from the atlas caudalward to establish that there is, in fact, a cervical rib. Look carefully at the disc spaces and the intervertebral foramina, and note abnormalities. In the lateral view of patients with droopy shoulders, the physician may be able to clearly define the second dorsal vertebra. Such patients may resemble those with TOS but may have no peripheral neural deficits in the limbs (37).

Apical lordotic radiographs of the chest can rule out lung tumors, which can mimic TOS in their presentation. Adequate radiographs of the shoulder are also necessary. When there is significant concern about possible cervical radiculopathy, magnetic resonance imaging (MRI) or myelography may be indicated. They are not needed in most cases.

Noninvasive vascular studies have been advocated as a reliable diagnostic test for TOS. In my experience, however, because pulses can be positionally obliterated in many normal people, the incidence of false-positive results is substantial. Interpret such studies with caution. For patients with intrinsic vascular disease, noninvasive studies can be extremely useful.

Arteriography and venography have limited application in the general diagnosis of TOS, and I do not routinely use them. Because the occlusion of arterial outflow with the position of the arm may be observed in asymptomatic patients, an arteriogram would provide little information unless there is serious consideration of the presence of an aneurysm in the subclavian artery or intrinsic vascular disease. Patients with complete cervical ribs may have an increased incidence of such aneurysms (13,27). Therefore, in such patients, it is prudent to obtain arteriographic studies if the surgeon intends to explore the thoracic outlet through the axilla. Venography is useful in demonstrating thrombosis of the axillary or subclavian vein and in following the process of recanalization, should it occur. Noninvasive testing may be of value in this situation as well.

Although some have claimed success using measurement of the velocity of conduction of the ulnar nerve through the thoracic outlet to diagnose TOS, the experience of many workers has failed to substantiate this claim (40,42,44). Reports from electrodiagnostic laboratories may say, “There is no evidence of TOS”; interpret such statements based on nerve conduction velocity (NCV) with caution, however, because the test is not of value in this situation.

Where NCV is very useful is in differential diagnosis. Conditions such as ulnar neuropathy at the elbow and carpal tunnel syndrome are readily identified by means of NCV determinations. Because NCV determination is not a reliable means of assessing the plexus within the thoracic outlet, the use of somatosensory evoked potentials and F responses has received attention as a means of obtaining further objective evidence of neural dysfunction to diagnose TOS (10,23). Some workers have found the measurement of the amplitude of the evoked response of the medial cutaneous nerve of the forearm and C8 root stimulation to be of value in making the diagnosis (24). In my opinion, the diagnostic value of such measurements has not yet been firmly established, and the diagnosis remains clinical (4,44).

Electromyographic examination of patients with TOS is usually not markedly abnormal unless there has been sufficient compression to cause denervation. In such cases, it is often possible clinically to detect atrophy and weakness of the ulnar-innervated interosseous and hypothenar muscles. In other patients, however, these muscles may show fibrillation potentials at rest that appear to be clinically normal (36).

The question of double-crush syndrome and TOS is controversial. Although Carroll and Hurst (7) have written that the coexistence of TOS and carpal tunnel syndrome is rare if it exists at all, patients are seen nonetheless with well-demonstrated signs of both entities (47). Ulnar neuropathy may coexist with TOS (16). Patients may have hard-to-define combinations of signs and symptoms that appear to be the result of more than TOS. I these cases, look for additional lesions to explain the entire picture; otherwise treatment will fail.

## CONSERVATIVE THERAPY

The general condition of patients with TOS varies enormously, and in many cases, the symptoms have been present for months or years. Not uncommonly, such patients have been told that their symptoms are of emotional origin, or they have been subjected to unsuccessful conservative or operative treatment. Such patients require objective, sympathetic evaluation and sometimes psychological consultation. Some patients with TOS are clinically depressed. The very deleterious effect depression has on their posture aggravates the anatomic problem. If such is the case, the surgeon may, according to training and inclination, treat the patient with antidepressants or refer him or her for psychotherapy. It is not rare to see patients whose symptoms of TOS can be lessened by such measures, even though some may ultimately require surgery.

The general level of fitness of patients with TOS is often poor. It is worthwhile to inquire about their level of physical activity; often, it is quite limited. Sometimes, patients are afraid to exercise for fear of worsening the condition, or they have been so advised by their physicians. If the patients have no other serious medical problems, make an effort to mobilize them with aerobic exercises. Probably the easiest generalized exercise for such patients is walking, because it does not usually cause much discomfort. Some patients may experience increased symptoms with walking, and in these cases, the use of a shoulder support such as the Biomet Hook

Hemi-Harness (Biomet, Warsaw, IN) (Fig. 61.2) or the Roylan sling (Smith & Nephew, Germantown, WI) (Fig. 61.3) may help. Also, such patients may be able to benefit from use of a stationary bicycle.

***Figure 61.2.*** The Biomet Hook Hemi-Harness as seen from behind is shown. It consists of two cloth sleeves with Velcro closures and an adjustable strap that can be tightened or loosened as needed to support the shoulder girdles. In addition to the height of the shoulders, the degree of retropulsion is determined by where the strap is attached to the sleeves, and this, too, may be varied according to the correction required.

***Figure 61.3.*** The Roylan sling as seen from the back (**A**) and the front (**B**).

The problem of obesity can be extremely difficult to manage; patients do not like to be told that they are overweight. Yet, excess soft tissue can place additional strain on the shoulders, particularly in women who have large breasts, which can aggravate TOS by increasing traction on the structures crossing the first rib. In cases of gigantomastia, reduction mammoplasty as a first step in the treatment of very debilitating TOS may be successful. Kay has reported on neurologic deficits in women with large breasts (15). The mechanism of thoracic outlet compression makes it likely that this is the locus of the problem. Even if weight reduction does not produce the desired alleviation of compression, the patient who is thinner will be easier and safer to operate on, especially through the axilla.

The most important part of the conservative management of TOS involves correcting postural abnormalities that can be identified as contributing to the compression, and exercises to strengthen the shoulder girdle when it is determined that weakened muscles are a significant factor (Fig. 61.4). Unfortunately, when the physician refers patients with TOS to a physical therapy department, it is not always guaranteed that the therapist caring for the patient will understand the genesis of the problem and apply appropriate therapy. Very often, stereotyped routines (25) such as stretching, soft-tissue massage, “nerve mobilization,” and cervical traction are used, and these methods will actually worsen the symptoms in many patients. The TOS patient must have a thorough analysis by a knowledgeable therapist, and an individual therapy program should be designed, implemented, and monitored to avoid provocative maneuvers (25).

***Figure 61.4.*** **A:** The therapist is instructing the patient in the correct way to exercise. Note that the arms are held in front of the plane of the body and that they are below shoulder height. The trapezius, rhomboids, and levator scapulae can be strengthened in this way without bracing the shoulders back or provoking symptoms. The therapeutic plan must be individualized to the specific patient's needs, and most often it can be carried out as a home program with occasional visits to the therapist. **B:** Exercises for the upper trapezius that are tolerated by most patients with TOS.

Patients with significant shoulder girdle disorders may not tolerate even the most gentle conservative program. Particularly in the case of anterior glenohumeral instability, the exercises often prove provocative because they tend to reproduce the subluxations. Such patients may be differentiated from those with dead arm syndrome. In all likelihood, many patients with the diagnosis of dead arm syndrome owing to glenohumeral instability really have TOS. If the condition goes unrecognized, the patients will continue to be symptomatic even after shoulder repair. Leffert and Gumley studied an interesting series of patients in whom these two entities coexisted (17).

If an activity of daily living or employment seems to be related to symptoms of TOS, modify such activities, if possible. Overhead activities, the carrying of heavy loads, or the use of backpacks can be quite provocative to patients with compression within the thoracic outlet.

Use conservative measures and review progress periodically so that the condition does not drag on interminably. The conservative approach with periodic review is particularly important in patients whose cases are complicated by litigation, insurance, or open workers' compensation cases. Caregivers must try to be objective in interpreting symptoms so that patients are not unfairly deprived of the benefits of treatment. In addition to periodic reviews, set a time limit beyond which conservative therapy should be viewed as having failed. If there is no positive response, the clinician must decide whether to advise surgery or to accept the status quo with hopes that the condition may improve with time.

## INDICATIONS FOR SURGERY

Failure of a carefully supervised program that includes the previously described treatment measures is the usual indication for surgery.

Patients with significant neurologic deficits—usually of the intrinsic muscles of the hand but sometimes in the long flexors as well—almost never respond positively to conservative therapy. If they are subjected to surgery, however, they should know preoperatively that postoperative improvement in the power of the long flexors may actually increase the muscle imbalance in the fingers and cause clawing or make it worse. Advise such patients that they may require secondary hand reconstruction

for the muscle imbalance if it occurs. For those who have significant sensory loss, the outlook is somewhat unpredictable but generally favorable.

Patients with impending or established gangrene in the hand are candidates for immediate surgery. Fortunately, they are rare and usually are not seen primarily by the orthopaedic surgeon but more likely by vascular surgeons.

The most problematic indication for surgery in the thoracic outlet is intractable pain. Only the patient can feel and describe the pain; the surgeon must be able to interpret these reports appropriately. Constraints of daily routine, vocational or avocational adjustments, sleep disturbance, and history of analgesic use are all important avenues of inquiry necessary to formulate a decision for surgery. A complete and in-depth review of what was done in prior physical therapy sessions is most important, because the patient may not have had optimal care, or may actually have gotten worse because of provocative positioning the exercises require (25).

Patients with TOS often have very complicated medical records. Review the differential diagnosis very carefully before proceeding. Discuss with the patient and family the mechanics and objectives of surgery. Explain all possible complications in detail so that the patient can give an informed consent. If you believe that a second opinion would be useful, made certain that the surgeon or physician rendering this opinion has sufficient experience in the area to provide a valid opinion. Too often that opinion may be rendered on the basis of little personal experience or knowledge.

An obese patient who has made little genuine attempt to lose weight despite specific evaluation for the cause of obesity and instructions to correct it evinces poor cooperation. I have found it prudent to inform such patients that their surgery is elective and will not be done until they demonstrate genuine evidence of being willing or able to participate in their own rehabilitation.

Because of the possibility of significant intraoperative hemorrhage, the patient's blood should be typed and cross-matched before surgery. Whether to operate on a patient who will not accept blood transfusion or blood products, should they be needed intraoperatively, is a difficult and individual decision for which I do not have a confident answer.

Depending on the surgeon's training and inclinations and local custom, as well as the nature of the surgery to be performed, either a vascular or general thoracic surgeon may be part of the operating team. Although I have performed the vast majority of my surgeries without need for such assistance, it is valuable to ensure that such help is available on an if-needed basis. For patients who have particular problems such as successive surgeries in which complications can be anticipated, consultants may be invited to participate at the beginning of the case. In addition, the operating team should be experienced and adequate in number. I require three scrubbed assistants for surgery by the axillary route. Do not use overhead arm traction with weights, as is used in shoulder arthroscopy; it carries a risk of inducing an intraoperative traction injury of the brachial plexus.

Finally, make sure proper instruments are available and in working order before you make the skin incision. Have vascular and thoracic surgical instrument packs in the operating room should they be needed.

General anesthesia for surgery of the thoracic outlet by the transaxillary route requires that the patient be profoundly relaxed. The newer, short-acting muscle relaxants are particularly well suited to this situation. Discuss the time frame for the surgery with the anesthesiologist before commencing surgery so that muscular relaxation may be reversed by the time the incision is closed, thus allowing extubation without delay.

Surgeons with inadequate training or experience should not undertake thoracic outlet surgery because it has the potential for very serious complications. However, with proper identification of patients suffering from significant compression and technically adequate surgery, the results are very gratifying in most cases.

## SURGICAL TECHNIQUES

There is no universal agreement as to which surgical procedure is best for the treatment of TOS. Scalenotomy was the first procedure to gain favor. If the pathology resided entirely between the scalene muscles (1,2 and 3), as was theorized, release of the anterior scalene should have permanently cured the condition. Unfortunately, the incidence of recurrence following scalenotomy was sufficiently high that surgeons had to develop other procedures.

Many workers have considered the first rib to be the common denominator of compression and have concentrated their efforts on eliminating it as well as adventitious ribs or congenital bands that might be encountered in the course of exploration (9). Since Roos reported his experience with the transaxillary first rib resection in 1966, this approach has been the procedure most often performed, and as the mainstay of the surgical approach to the problem, it is described in detail (28,29,30,31 and 32). A variety of anatomic approaches, however, may be used for exploration of the thoracic outlet and removal of the first rib.

Significant reduction in the costoclavicular interval due to fracture angulation or hypertrophic subclavicular callus may occasionally necessitate claviculectomy. It is worth considerable effort to retain the clavicle if to do so does not materially increase the surgical risks (14). Removal of the strut function of the intact clavicle from a shoulder girdle with poor muscular support can markedly increase symptoms because of the superimposed traction effect of the ptotic shoulder. Patients with a good trapezius may function well following claviculectomy, but they experience weakness in overhead use of the arm. The enthusiasm for claviculectomy for uncomplicated thoracic outlet compression has been very limited. The procedure is not recommended (19).

The use of scalenectomy to treat TOS depends on the local pathology. Some authors consider it the preferred method of surgical treatment in certain cases (31). Although it is desirable to avoid reattachment of the scalenes to the bed of the first rib after it has been resected, I do not routinely resect a portion of the anterior and middle scalenes because of the possibility of injury to branches of the brachial plexus, which may actually pass through the middle scalene. The phrenic nerve must be out of harm's way if you elect to resect part of the anterior scalene.

Scalenectomy may be indicated in patients in whom a recurrence has been deemed due to scarring within the scalene muscles themselves. An anterior approach is best. In addition to obvious branches of the brachial plexus and phrenic nerve, the long thoracic nerve is particularly vulnerable, because it may not always be located lateral to the middle scalene. It may pierce the muscle or even present as two branches, each of which must be gently retracted and preserved.

In the next section, I describe in detail three operative approaches to the thoracic outlet specifically for resection of the first rib and then will comment briefly on the others.

### THE TRANSAXILLARY APPROACH (28,29,31,32)

Refer to Figure 61.5.

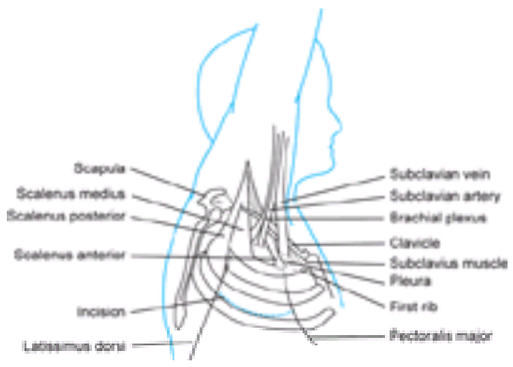


***Figure 61.5.*** Anatomy of the right thoracic outlet from the axillary view with the upper extremity and shoulder elevated. (From Roos DB. Experience with First Rib Resection for Thoracic Outlet Syndrome. *Ann Surg* 1971;173:429, with permission.)

- Place the patient, under general endotracheal anesthesia, on the operating table in the lateral decubitus position with the head tilted up. Face the patient's back. I place a high standing stool obliquely toward the head of the table near me so that a sterilely gowned assistant can maintain the arm abducted during the

procedure. This assistant can lower the arm or change its position as required lest a brachial plexus injury occur from excessive traction, such as might occur if the arm were suspended from the ceiling. Two other scrubbed assistants are necessary, one on either side of the table, to retract the latissimus dorsi and pectoralis major muscles during the procedure.

- Drape to permit movement of the arm as well as access to the upper hemithorax, axilla, shoulder area, and neck.
- Make a transverse skin incision between the pectoralis major and latissimus dorsi muscles over the third interspace, just below the axillary hairline. If the incision is prolonged into the tail or body of the female breast, it can cause a hypertrophic scar. I spread self-retaining retractors horizontally in the wound to dissect the fat and render the tissues temporarily ischemic, thus eliminating the need to ligate superficial vessels.
- Incise the fascia longitudinally in the midline and bluntly spread the tissues with your fingers. Dissect through the subcutaneous tissues to the level of the rib cage. Retract the latissimus and pectoralis muscles.
- Overhead lights will not provide sufficient illumination to perform the surgery safely. Use a headlight or lighted retractors.

The intercostobrachial nerve arises from the second intercostal nerve and crosses the axilla embedded in fat to ultimately reach the medial aspect of the arm. If possible, mobilize and retract it, because trauma to the nerve can result in annoying dysesthesia on the posteromedial aspect of the upper arm and axilla.

- Bluntly dissect with the fingers by touch until the surface of the first rib can be palpated. Have the assistant elevate the arm obliquely to open the outlet.
- Ligate the supreme thoracic arterial branch to allow mobilization of the artery, which is done under direct vision with nonabsorbable sutures or malleable clips.
- Now identify the important structures in the field. The anterior scalene muscle attaches to the scalene tubercle, which is located toward the inner border of the first rib rather than extensively on its cephalic surface, although occasionally the muscle may extend over it. Use a small wad or “palm” of gauze and blunt dissection to delineate the muscle from the adjacent subclavian artery and vein.
- Have assistants on each side of the table retract the muscles using Deaver or similar retractors. If the muscle relaxant wears off, the surgeon and assistants will become aware that the muscles are getting tighter and the operative field is collapsing. Close cooperation with the anesthesiologist is vital to the success of the surgery.
- The most anterior structure in the wound is the subclavius muscle with the costoclavicular ligaments and their insertion into the superior surface of the first rib. Just behind and adjacent to them is the subclavian vein. Use a blunt periosteal elevator (Fig. 61.6) and dissecting sponges to clear the surface of the first rib of its soft tissues anterior to the middle scalene.

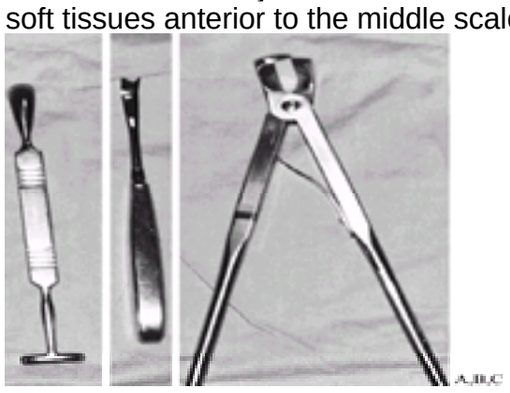


***Figure 61.6.*** Instruments for transaxillary first rib resection are shown. Penosteal elevator (**A**), rasp for first rib (**B**), and Roos rib cutter (**C**) are illustrated.

- Turn attention to the superior surface of the first rib. Define and detach the anterior scalene. The phrenic nerve is not usually at risk with this approach, because it is located at least 2 cm cephalad to the tubercle. Using gentle, blunt dissection, tease the subclavian artery and vein away from the anterior scalene. Because the pleura may rise posteriorly and be adherent to the posterior surface of the muscle, it is helpful to use a long right-angled clamp to dissect behind the muscle and to shield each vessel in turn as, alternately, half of the muscle is cut sharply at its insertion to the bone. Obviously, all of this must be done very carefully under direct vision. When the muscle has been cut, it retracts.
- At this stage, visualization is limited by the middle scalene, which can be elevated off the first rib with the elevator. It is tempting to sharply divide this muscle at its insertion, but the possibility of injury to the nerve to the serratus anterior makes penetration inadvisable. As the muscle is elevated, it can also be partially retracted with the blunt retractor.
- Using a rasp with a cutting edge that conforms to the outer curvature of the first rib, separate the soft tissues from the bone. Often, the first digitation of the serratus anterior muscle may overlap the insertion of the middle scalene on the first rib, and it must be bluntly separated. Alternate the rasp, the periosteal elevator, and gauze sponges to clear the surface of the rib of its muscle attachments. The undersurface should be similarly cleared, although it is not desirable to perform the entire dissection subperiosteally because of the possibility of later regeneration of the rib, particularly in young patients.
- The periosteum of the first rib must be disrupted and as much of it removed as possible. This procedure may result in a tear in the adjacent pleura, causing a pneumothorax. During this maneuver, ask the anesthesiologist to control respiration so that the lung is retracted from the pleura in exhalation. About 30 seconds of apnea should be required. Then controlled respiration may be resumed.
- Flood the wound with normal saline to demonstrate the integrity of the pleura. If the pleura has been breached, there will be air bubbles with respiration, or the fluid will simply funnel down into the pleural cavity. If there is a pneumothorax, drain it with a soft rubber catheter at wound closure or insert a chest tube. Usually, a #26 tube can be inserted below the incision and into the rent in the pleura without difficulty. Connect it to underwater seal and suction. A pneumothorax does not significantly prejudice the remainder of the operative procedure, and the tube can be placed just before closure. It usually needs to be retained for 24 hours.
- Next, address the tendon of the subclavius muscle and costoclavicular ligament. Make an incision at the insertion onto the bone, which covers the superior surface of the rib. Keep the subclavian vein constantly under direct vision because it is immediately adjacent to the tendon and at significant risk. Once the plane of dissection has been established, however, it is possible to use the periosteal elevator and direct it away from the vein as the tendon is elevated from the rib. Failure to perform this part of the procedure properly will cause the line of section of the rib to lie at the level of the subclavian vein, where a sharp edge of bone will adhere to it.
- Having detached all the important soft tissue from the first rib, thoroughly explore the outlet for the presence of fibrous bands that are radiographically invisible but that may be quite significant in causing compression of the neurovascular structures. Never retract the neurovascular structures themselves with any considerable tension because of the very real possibility of injury. By positioning the arm appropriately, it is possible to lift the structures off the surface of the rib so that a retractor is usually not necessary.
- In addition to fibrous bands of various types, other important variations in the local anatomy can be observed (30). For example, the anterior scalene may actually be overlapped in its insertion by the middle scalene. There may be additional vascular branches, or a cervical rib. A complete cervical rib may actually attach to the manubrium, but a lesser one may reach to the scalene tubercle. The attachment of the two ribs, which can be fibrous or actually fused, can create significant problems, especially if the subclavian artery is located at the juncture.

I recently encountered such a situation that had resulted in a symptomatic aneurysm with emboli in the arm of a 24-year-old woman. After the bone had been removed, I had the valuable assistance of a vascular surgeon (prearranged) who did a vein graft to the thrombosed aneurysm, with an excellent clinical result. This dissection required both a supraclavicular and an infraclavicular exposure—which is usually not necessary, because most cervical ribs can be removed without having to make a supraclavicular incision. I always obtain preoperative permission to make one, however, should it be necessary. The rib may have to be removed piecemeal with rongeurs rather than being resectable by means of two neat cuts of a rib cutter. Piecemeal removal, of course, adds to the time necessary for the procedure, as well as its difficulty.

- Once the anatomy is clear, decide which instruments will be used to remove the rib. Ideally, a rib cutter can be placed posterior to the lower trunk of the brachial plexus, almost to the level of the transverse process, and the rib can be cut at that level. If a straight rib cutter is used, however, the resulting osteotomy will be oblique, leaving a very sharp point on the posterior portion of rib, a most undesirable situation. For that reason, I have used the rib cutter designed by Roos (see Fig. 61.6), which produces a transverse cut, owing to the inclination of its cutting surfaces.

When used on the left side, introduce the rib cutter with its point facing upward, hooking it beneath the rib and closing the jaws before sliding it posteriorly. For a rib on the right side, the point will face caudad, placing the pleura at risk. In either case, the jaws should be almost closed and under direct vision so that they will be safely beneath the neurovascular structures and posterior to them. During this period, the anesthesiologist should maintain apnea in expiration.

- After verifying that nothing has been caught in the jaws of the rib cutter, firmly close the blades and cut the rib. Then gently slide the instrument forward and open it in the reverse manner in which it was inserted. Grasp the rib with a Kocher forceps and visualize the anterior attachment to cartilage. Using a standard rib cutter with its blades pointed away from the subclavian vein, divide the rib and gently remove it from the wound. Complete as close to total rib resection as possible. There should be at least 1.5 cm of space behind the lower trunk of the brachial plexus; in most patients there will be 2 cm or less of posterior rib fragment (measuring from the transverse process). Anteriorly, the line of resection should be medial to the subclavian vein and disarticulation is optimal.
- At this point, retest the integrity of the pleura. Achieve complete hemostasis. Digitally explore the outlet and place the patient's arm in all positions to assess whether there is any compression of the neurovascular structures. Usually there is not, although if the second rib is very prominent, it could cause compression. Relieve it by removing the middle third of the rib.

If there is a pneumothorax, insert a chest tube at this point and then prepare for closure. Give antibiotics if there has been a pleural leak but not in an otherwise uncomplicated case.

Return the arm, which the assistant has intermittently raised and lowered, to the side. Drains are not used, nor should they be needed.

Complete a subcutaneous closure, followed by a subcuticular closure using nonabsorbable suture, which is removed at 2 weeks postoperatively. Apply a small dressing. A sling is not needed.

### ANTERIOR APPROACHES TO THE THORACIC OUTLET

Anterior approaches to the structures within the thoracic outlet have been advised for resection of cervical ribs and resection of the first thoracic rib as well as for scalenectomy (3,9,21,22). In my experience, the exposure obtained for subtotal resection of the first rib is less satisfactory than that gained with the axillary approach, although this is not a universally held opinion.

Adson advocated the supraclavicular approach for scalenotomy and resection of cervical ribs (1,3). It has the advantage of allowing relatively easy access to the anterior scalene muscle and the vessels.

- Make a 7 to 9 cm incision 1 to 2 cm above and parallel to the clavicle, extending from the midpoint of the clavicular attachment of the sternomastoid muscle to the anterior edge of the trapezius. Identify the platysma muscle for later careful reapproximation.
- The external jugular vein must usually be ligated. To facilitate exposure, divide about half of the sternomastoid anteriorly, just above its insertion; 1 to 2 cm of trapezius may be similarly cut. Divide the omohyoid muscle at its midpoint. The suprascapular and transverse cervical vessels run horizontally and must usually be ligated.
- Identify the phrenic nerve on the surface of the anterior scalene muscle as it proceeds distally. Carefully retract and preserve it. Detach the anterior scalene muscle and allow it to retract. The belly of the muscle may then be safely resected. To detach the muscle safely, carefully dissect the subclavian artery and vein away from it and the pleura posteriorly. The internal jugular vein is on the medial side of the muscle. Mobilize the subclavian artery in its extraadventitial plane and retract it medially, while retracting the brachial plexus laterally.
- If a cervical rib is present, remove it from its periosteal envelope and resect it. Remove as much of the periosteum as possible. Elevate the middle scalene off the first rib, and then remove the rib.
- Reserve the transclavicular approach for postoperative recurrences of thoracic outlet compression in which adherence of the subclavian artery or vein to the anterior edge of the resected rib is strongly suspected.
- In the subclavicular approach, make a 7 cm skin incision over the cartilage of the first rib, midway between the clavicle and second rib (12). Split the pectoralis major in the line of its fibers, exposing the cartilage of the first rib. Open the periosteum of the anterior portion of the first rib with a scissors, and carry out further dissection with a finger or gauze.
- After the costochondral junction is divided, remove the cartilage with a rongeur. The rib may then be grasped and levered, either caudally or cephalad, for stripping of the anterior and middle scalene muscles. Use a rasp, if necessary, to denude the rib further, then cut the rib posteriorly with Sauerbruch rib shears.

The significant disadvantage of this exposure is that any abnormalities of the first rib encountered, including abnormal width or a cervical rib, are difficult to manage because of limited access. The presence of anomalous bands cannot be easily verified or dealt with, and the vessels must be constantly retracted and are at risk in an extremely confined space. Other than for access to the anterior portion of the first rib, this is not a useful incision and is not recommended.

### POSTERIOR APPROACH

The posterior approach (Fig. 61.7) is identical to that used for thoracoplasty (8). Although it is considered a technique that does not involve any disability or disfigurement, it is an extensive approach that traverses the trapezius muscle, the levator scapulae, and rhomboids. For this reason, I believe that it should be used infrequently; it should particularly be avoided in patients who already have weakness of these muscles and sagging shoulders, as well as those who must do heavy labor following their convalescence.

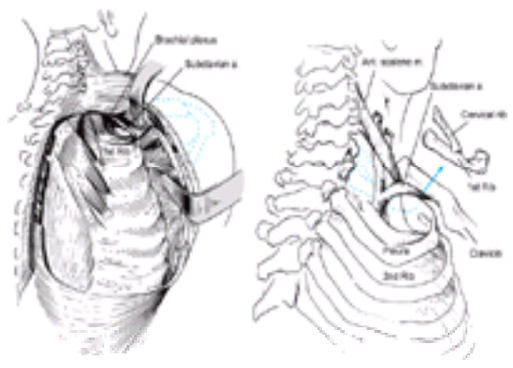

***Figure 61.7.*** **A:** Posterior approach for resection of the first thoracic rib is shown. **B:** A cervical rib has been removed with the first thoracic rib. (From Clagett OT. Presidential Address: Research and Prosearch. *J Thorac Cardiovasc Surg* 1962;44:153, with permission.)

However, the posterior approach is useful for decompression of the thoracic outlet in patients who are extremely muscular or obese and in whom the axillary approach would be technically difficult. It is the preferred approach for reoperations in which a retained posterior segment of rib has become adherent to the brachial plexus and is causing symptoms.

- Place the patient in the lateral decubitus position, with the affected side up. Prep and drape the arm free. Drape the entire hemithorax posteriorly past the midline, including the neck to the hairline.
- Make a long incision from the superior angle of the scapula, 2 cm medial to its vertebral border, for the length of the bone. An incision too close to the scapula will encounter the anastomotic scapular vessels, causing annoying bleeding.
- Section the trapezius, levator scapulae, and both rhomboids, taking care to avoid the spinal accessory nerve and dorsal scapular nerve.
- Introduce a scapular retractor beneath the scapula, which can then be retracted anteriorly and laterally (see Fig. 61.7).
- The first rib must be identified from the level of its transverse process; the rib is not horizontal in most patients, and the second rib may partially obscure it. The posterior scalene may blend with the middle scalene and is attached to the outer surface of the second rib. It is easily detached. Identify and carefully section the middle scalene, which inserts onto the superior surface of the first rib. Anterior to it, the lower trunk of the brachial plexus lies in contact with the rib, with the subclavian artery immediately anterior to it, restrained by the insertion of the anterior scalene to the scalene tubercle. The first digitation of the serratus anterior originates from the outer aspect of the first rib and can be freed with a rasp. The subclavian vein is, of course, anterior to the anterior scalene and must be carefully protected.
- Remove the first rib. If a cervical rib is present, it can be easily removed through the same incision. It is impossible, however, to deal with a subclavian aneurysm through this approach. Although the rib is resected subperiosteally to protect the adjacent structures, remove as much of the periosteum as possible to prevent regeneration of the bone.
- If a pneumothorax has been produced, insert a chest tube.
- Perform closure in layers, taking care to approximate anatomically the very important suspensory muscles of the scapula, including the levator scapulae, rhomboids, and trapezius. Place the patient in a sling for 3 weeks postoperatively and then begin exercises to strengthen shoulder girdle muscles.

## POSTOPERATIVE CARE AND REHABILITATION

In uncomplicated exploration and decompression of the thoracic outlet by the axillary route, there is minimal blood loss and physiologic disturbance. Although there may be moderate postoperative pain, within a day most patients are sufficiently comfortable to move about without the support of a sling. If a pleural tear has occurred intraoperatively, then a chest tube is used for 24 hours. Most patients are discharged from the hospital on the second or third day after surgery.

Within 48 hours of surgery, the dressing may be reduced to a single layer of gauze or removed altogether. Patients may shower as long as the wound is kept dry; underarm deodorants and powders are prohibited until the sutures are removed. Patients may be ambulatory at home but are cautioned against heavy lifting or any strenuous activities for 4 weeks after surgery. Then they may resume their preoperative exercise program, if there is no significant postural abnormality or weakness of the scapular muscles. It is most important that these exercises do not involve either overhead use of the arms or shoulder bracing, because both of these types of exercises essentially duplicate the provocative maneuvers that are used in diagnosis. Unfortunately, they are still prescribed and used in many physical therapy facilities (25).

## PITFALLS AND COMPLICATIONS

### INADEQUATE RESECTION

Inadequate resection of the first rib usually results from the surgeon's inexperience or timidity. Failure to resect the subclavius tendon anteriorly produces a line of resection of the first rib at the level of the subclavian vein that will then adhere and cause symptoms of venous compression. Because the vein has a thin wall and is easily torn, reoperation is hazardous. It is best performed, if necessary, by the transclavicular route.

Failure to resect sufficient rib posteriorly to clear the lower trunk of the brachial plexus by 2 cm is most common with an anterior approach, but it may also occur with a transaxillary procedure. In most cases, less than 2 cm of rib should remain from the level of the transverse process, but it is unnecessary to disarticulate the rib. If recurrence is believed to be due to adherence of the lower trunk of the plexus to the rib remnant, this problem is best approached through a posterior, high thoracoplasty approach (8,41). The hazards of this procedure stem from the difficulty of separating the periosteum and scar from the nerves, which must be carefully defined and lysed while the rib remnant is removed. Preliminary resection of the second rib is an aid to the dissection, which then proceeds to the bed of the first rib with a wider and clearer field.

### PNEUMOTHORAX

Because an intact periosteal sleeve can result in regeneration of a resected rib, particularly in a young patient, it is advantageous to remove or displace as much of the periosteum as possible. The close adherence of the pleura, however, makes rents in this filmy structure common during the course of the dissection. Because the pleura cannot be directly repaired, either a rubber catheter may be used to drain the pleural cavity during closure and then withdrawn, or a chest tube may be placed through a separate stab wound and connected to underwater suction for 24 hours. Then, after a radiograph confirms the absence of a pneumothorax, the tube may be removed. If a patient has sustained an intraoperative pneumothorax, he or she should be restricted from air travel for 7 to 10 days.

### INTERCOSTOBRACHIAL NEURALGIA

The intercostobrachial nerve passes from the chest into the subcutaneous tissues of the arm and innervates the posterior brachium, in many patients, down to the level of the olecranon. Because it is located at the midpoint of the axillary incision made over the third interspace, it is liable to injury, either by laceration or traction. Even if care is taken to protect it, in many cases, there is some transient numbness along the posterior aspect of the arm, which gradually fades with time. If the nerve is cut, however, the patient may experience very annoying dysesthesia that can be permanent. Prevention is the best means of dealing with the problem. If there is a neuroma, local nerve blocks are of occasional value.

### BRACHIAL PLEXUS INJURY

The most serious non-life-threatening complication of thoracic outlet surgery is injury to the brachial plexus (45). Occasionally, patients have varying degrees of neural dysfunction in excess of what was present preoperatively. The patient with increased postoperative loss of intrinsic function in the hand and numbness of the little and ring fingers may have sustained either a direct laceration of the lower trunk or a traction injury. In the first situation, repair is impossible, and no improvement is expected. In the second situation, often there is little spontaneous recovery, although it may occur. This complication can be avoided by gentle handling of the nerves with minimal or no direct retraction.

The patient who awakens from surgery with numbness of the entire arm and significant motor weakness that was not present preoperatively has sustained a traction injury to the brachial plexus, which usually results from excessive pull on the arm during surgery. This complication can result in permanent neurologic loss and pain, and can largely be avoided by carefully monitoring the amount of intraoperative traction. During the procedure, arm traction must be periodically lessened so that a constant pull is not maintained.

### LONG THORACIC NERVE INJURY

Local injury to the nerve on the chest wall or as it comes around or through the middle scalene can result in permanent winging of the scapula owing to paralysis of the serratus anterior (48). The nerve should be sought and carefully protected. Sometimes, separate branches to the digitations of the serratus anterior are seen, in which case these must be preserved. This complication weakens the patient's ability to lift the arm in front of the plane of the body.

### VASCULAR INJURY

The subclavian artery and vein are clearly at risk in any procedure performed within the thoracic outlet. The surgeon must have available appropriate technical ability or surgical assistance for all eventualities. As stated earlier, appropriate instruments must be present in the room, and the sterile field should be draped to allow for additional procedures, including thoracotomy, if necessary.

### CONCLUSIONS

The diagnosis and treatment of patients with TOS is demanding, sometimes frustrating, and technically challenging. However, many carefully selected patients get good results from surgical treatment when conservative therapy has been strenuously employed and failed. The nature of the patient population is such that attempting to compare the results of different series of surgically treated patients can lead to markedly divergent impressions of the effectiveness of surgery. In my own experience, about three quarters of the patients that I have operated on have had good to excellent results. Despite the fact that these surgical patients represent less than 20% of all the patients I have seen with this entity, I believe that the surgery of TOS has a rightful place in the armamentarium of orthopaedics.

### CHAPTER REFERENCES

Each reference is categorized according to the following scheme: *, classic article; #, review article; !, basic research article; and +, clinical results/outcome study.


* 1. Adson AW. Surgical Treatment for Symptoms Produced by Cervical Ribs and the Scalenus Anticus Muscle. *Surg Gynecol Obstet* 1947;85:687

* 2. Adson AW. Cervical Ribs: Symptoms, Differential Diagnosis and Indications for Section of the Insertion of the Scalenus Anticus Muscle. *J Internat Coll* Surg 1951;16:546.

* 3. Adson AW, Caffey JR. Cervical Rib: A Method of Anterior Approach for Relief of Symptoms by Division of the Scalenus Anterior. *Ann Surg* 1927;85:839.

+ 4. Aminoff MJ, Olney RK, Parry GJ, et al. Relative Utility of Different Electrophysiologic Techniques in the Evaluation of Brachial Plexopathies. *Neurology* 1988;38:546.

+ 5. Brain, Lord, Wilkinson, M, eds. *Cervical Spondylosis and Other Disorders of the Cervical Spine.* W.B. Saunders Co.: Philadelphia, 1967.

+ 6. Capistrant TD. Thoracic Outlet Syndrome in Whiplash Injury. *Ann Surg* 1977;185:175.

+ 7. Carroll RE, Hurst LC. The Relationship of Thoracic Outlet Syndrome and Carpal Tunnel Syndrome. *Clin Orthop Rel Res* 1982;164:149.

+ 8. Clagett OT. Presidential Address: Research and Prosearch. *J Thorac Cardiovasc Surg* 1962;44:153.

+ 9. Falconer MA, Li FWP. Resection of the First Rib in Costoclavicular Compression of the Brachial Plexus. *Lancet* 1962;1:59.

+ 10. Glover JL, Worth RM, Bendick PJ. Evoked Responses in the Diagnosis of Thoracic Outlet Syndrome. *Surgery* 1981;89:86.

+ 11. Gloviczki P, Kazmier FJ, Hollier LH. Axillary-Subclavian Venous Occlusion: The Morbidity of a Non-Lethal Disease. J Vasc Surg 1986;4:333.

+ 12. Hamlin H, Pecora D. Subclavicular Segmental Resection of First Rib for Correction of Subjacent Neurovascular Compression. *Am J Surg* 1969;117:757.

+ 13. Judy KL, Heymann RL. Vascular Complications of Thoracic Outlet Syndrome. *Am J Surg* 1972;123:521.

+ 14. Jupiter JB, Leffert RD. Non-Union of the Clavicle: Associated Complications and Surgical Management. *Am J Bone Joint Surg* 69:753-760,1987

+ 15. Kay BL. Neurological Changes with Excessively Large Breasts. *South Med J* 1972;65:177.

+ 16. Leffert RD. Anterior Transposition of the Ulnar Nerves by the Learmonth Technique. *J Hand Surg* 1982;7:147.

+ 17. Leffert RD, Gumley G. Dead Arm Syndrome and Thoracic Outlet Syndrome. *Orthop Trans J Bone Joint Surg* 1985;9:44

+ 18. Le Forestier N, Moulonguet A, Maisonobe T, et al. True Neurogenic Thoracic Outlet Syndrome: Electrophysiological Diagnosis in Six Cases. *Muscle Nerve* 1998;21:1129.

+ 19. Lord JW. Thoracic Outlet Syndromes: Current Management. *Ann Surg* 1971;173:700.

+ 20. Mailis A, Papagapiou M, Vanderlinden RG, et al. Thoracic Outlet Syndrome after Motor Vehicle Accidents in a Canadian Pain Clinic Population. *Clin J Pain* 1995;11:316.

+ 21. Nelson RM, Jenson CB. Anterior Approach for Excision of the First Rib. *Ann Thorac Surg* 1970;9:1.

# 22. Novak CB, Mackinnon SE. Thoracic Outlet Syndrome. *Orthop Clin North Am* 1996;27:747.

+ 23. Passero S, Paradiso C, Giannini F, et al. Diagnosis of Thoracic Outlet Syndrome. Relative Value of Electrophysiological Studies [see comments]. *Acta Neurol Scand* 1994;90:179.

+ 24. Pavot AP, Ignacio DR, Gargour GW, et al. Assessment of Conduction from C8 Nerve Root Exit to Supraclavicular Fossa—Its Value in the Diagnosis of Thoracic Outlet Syndrome. *Electromyog Clin Neurophysiol* 1989;29:445.

+ 25. Peet RM, Hendricksen JD, Guderson TP, Martin GM: Thoracic Outlet Syndrome: Evaluation of a Therapeutic Exercise Program. *Proc Mayo Clin* 1956;31:281.

+ 26. Razi DM, Wassel HD. Traffic Accident Induced Thoracic Outlet Syndrome: Decompression without Rib Resection, Correction of Associated Recurrent Thoracic Aneurysm. *Int Surg* 1993;78:25.

* 27. Rob CG, Standeven A. Arterial Occlusion Complicating Thoracic Outlet Syndrome. *Br Med J* 1958;2:709.

* 28. Roos DB. Transaxillary Approach to the First Rib to Relieve Thoracic Outlet Syndrome. *Ann Surg* 1966;163:354.

* 29. Roos DB. Experience with First Rib Resection for Thoracic Outlet Syndrome. *Ann Surg* 1971;173:429.

* 30. Roos DB. Pathophysiology of Congenital Anomalies in Thoracic Outlet Syndrome. *Acta Chir Belg* 1980;5:353.

* 31. Roos DB. The Place for Scalenectomy and First Rib Resection in Thoracic Outlet Syndrome. *Surgery* 1982;92:1077.

* 32. Roos DB, Owens JC. Thoracic Outlet Syndrome. *Arch Surg* 1966;93:71.

+ 33. Rowe CR, Zarins B. Recurrent Transient Subluxation of the Shoulder. *Am J Bone Joint Surg* 1981;63A:863.

+ 34. Shuttleworth RD, van der Merwe DM, Mitchell WL. Subclavian Vein Stenosis and Axillary Vein “Effort Thrombosis.” Age and the First Rib Bypass Collateral, Thrombolytic Therapy and First Rib Resection. *S Afr Med J* 1987;71:564.

+ 35. Singh HK. Incidence of Congenital Rib Anomalies. *Indian J Chest Dis Allied Sci* 1973;15:157.

+ 36. Smith T, Trojaborg W. Diagnosis of Thoracic Outlet Syndrome. Value of Sensory and Motor Conduction Studies and Quantitative Electromyography. *Arch Neurol* 1987;44:1161.

+ 37. Swift TR, Nichols FT. The Droopy Shoulder Syndrome. *Neurology* 1984;34:212.

* 38. Telford ED, Stopford JSB: The Vascular Complications of Cervical Rib. *Br J Surg* 1931;18:57.

* 39. Todd TW. The Descent of the Shoulder After Birth. *Anat Anz* 1912;14:385.

+ 40. Urschel HC, Paulson DL, MacNamara JJ. Thoracic Outlet Syndrome. *Ann Thorac Surg* 1968;6:1.

+ 41. Urschel HC Jr, Razzuk MA, Hyland JW, et al. Thoracic Outlet Syndrome Masquerading as Coronary Artery Disease (Pseudoangina). *Ann Thorac Surg* 1973;16:239.

+ 42. Urschel HC Jr, Razzuk MA. The Failed Operation for Thoracic Outlet Syndrome: The Difficulty of Diagnosis and Management. *Ann Thorac Surg* 1986;42:523.

* 43. Urschel HC, Razzuk M. Management of Thoracic Outlet Syndrome. *N Engl J Med* 1972;286:1140.

+ 44. Veilleux M, Stevens JC, Campbell JK. Somatosensory Evoked Potentials: Lack of Value for Diagnosis of Thoracic Outlet Syndrome. *Muscle Nerve* 1988;11:571.

+ 45. Wilbourn AJ. Thoracic Outlet Syndrome Surgery Causing Severe Brachial Plexopathy. *Muscle Nerve* 1988;11:66.

* 46. Wilbourn AJ, Lederman RJ. Evidence for Conduction Delay in Thoracic Outlet Syndrome Is Challenged. *N Engl J Med* 1984;310:1052.

+ 47. Wood VE, Frykman GK. Winging of the Scapula as a Complication of First Rib Resection: A Report of 6 Cases. *Clin Orthop* 1980;149:160.

+ 48. Wood VE, Biondi J. Double Crush Nerve Compression in Thoracic Outlet Syndrome. *Am J Bone Joint Surg* 1990;72:85.

* 49. Wright IS. The Neurovaascular Syndrome Produced by Hyperabduction of the Arms. *Am Heart J* 1945;29;1.

# CHAPTER 62

# DUPUYTREN'S DISEASE

*John D. Lubahn*

**J. D. Lubahn:** Departments of Orthopaedic Surgery and Orthopaedics, Hamot Medical Center, Erie, Pennsylvania 16550.

History
Etiology and Pathophysiology
Trauma
Free Radicals
Myofibroblasts and Fibroblasts
Collagen
Glycosaminoglycans
Fibrofatty Tissue
Growth Factors
Principles of Treatment
Concomitant Disease
Anatomy
Diseased Fascia
Surgical Indications
Surgical Techniques
Open-Palm Technique
Alternative Surgical Treatments
Skin Grafting
Pitfalls and Complications
Chapter References

## HISTORY

As early as 1614, Felix Plater described what may have been Dupuytren's contracture in the hands of a stone mason working in a quarry near Basel, Switzerland (41). He identified the disease in the flexor tendons and in fact could have been describing a rupture of the $A_1$ pulley. Other well-known surgeons, such as Henry Cline and Sir Astley Cooper, described the condition during the next century and correctly located the disease in the palmar fascia.

In 1832, however, Baron Guillaume Dupuytren not only located the disease in the palmar fascia but also speculated that the etiology might be traumatic. He recommended surgical treatment of the diseased fascia through transverse incisions and postoperative splinting with the fingers held in extension. In addition to reporting the condition, he also lectured extensively on it (8,9). Thus, the choice of “Dupuytren” as an eponym, instead of a descriptive term such as “palmar fibromatosis,” is justifiable.

Recent research has focused on several aspects of the disease, including the potential role of heredity, trauma, myofibroblasts, collagen, growth factors, and smooth muscle (which contributes to the contractile nature of the condition).

Surgical treatment is generally successful and rewarding, but careful consideration must be given to patient selection, history, physical findings, and the patient's ultimate goals from both functional and cosmetic perspectives.

For readers interested in a more in-depth history of the disease, the Groupe d'Etude de la Main (GEM) monograph edited by Hueston and Tubiana (22), an article by Whaley and Elliot in the *British Journal of Hand Surgery* (52), and *Dupuytren's Disease: Biology and Treatment* by McFarlane, McGrouther, and Flint (11) provide the complete history.

## ETIOLOGY AND PATHOPHYSIOLOGY

### TRAUMA

Larsen experimentally explored the role of trauma and believed that microhemorrhages and hemosiderin were part of the pathophysiology of Dupuytren's disease (27). He was able to produce similar histologic lesions in monkeys, but the animals never developed flexion contractures. Although trauma is often implicated in the etiology, studies have also shown that the disease occurs in almost equal frequency in manual and nonmanual workers (17,18).

### FREE RADICALS

Free radicals may also play a role in “microtraumatizing” tissue and causing secondary contracture (10,38). Low levels of superoxide may stimulate fibroblast growth, which may also be important in wound healing and the evolution of scar.

### MYOFIBROBLASTS AND FIBROBLASTS

In recent years, one of the most intriguing explanations regarding the pathophysiology of Dupuytren's contracture involves the myofibroblast. Gabbiani and Majno called attention to this cell in 1972 (13). They were able to measure the contractile forces of myofibroblasts grown in tissue culture and found them comparable with that of rabbit skeletal muscle. They believed the myofibroblast was the driving force behind the palmar fascial contraction.

Chiu and McFarlane (6) further elaborated on the pathophysiology, believing that the myofibroblasts contained elements of smooth muscle as well as collagen-producing fibroblasts. As the disease progressed, the contractile elements shortened the collagen. Concurrently, intercellular adhesion occurred in areas known as desmosomes, which contained fibronectin, a gluelike material that promotes intercellular adherence. Burch believed that proliferating fibroblasts were the consequence of an autoimmune response to collagen by “forbidden” lymphocytes (4).

Chiu and McFarlane further subclassified the disease into three stages: stage I, early disease with proliferation of perivascular fibroblasts; stage II, active disease, with nodular thickening of the palmar fascia, associated joint contracture, and hypertrophied fibroblasts as well as orderly deposition of collagen fibers; and stage III, advanced disease, with progressive joint contracture and diffuse fibrotic thickening of the palmar fascia. Histologically, wavy bundles of collagen fibers separating a sparse number of fibroblasts become apparent (6).

### COLLAGEN

In addition to the abnormal array of fibroblasts and myofibroblasts with their contractile elements, the collagen found in Dupuytren's disease is identical to that which predominates in scar tissue. For example, normal palmar fascia contains almost no type III collagen. Approximately 30% of the collagen in Dupuytren's nodules is type III; in uninvolved regions of the palmar fascia in patients with Dupuytren's disease, 10% to 15% of the collagen is type III (14).

### GLYCOSAMINOGLYCANS

The collagen in normal or abnormal tissue is embedded in a ground substance composed of proteoglycans, proteins, and hyaluronate. The exact molecular structure of

proteoglycans in palmar fascia has not yet been described, but basic knowledge of proteoglycans isolated from similar tissue can be extrapolated. Large proteoglycans primarily contain chondroitin sulfate; smaller proteoglycans contain dermatan sulfate. They bind to a hyaluronate similar to proteoglycans in collagen.

Proteoglycans in the skin, however, contain chondroitin sulfate but do not bind to hyaluronate. In the palmar fascia, the matrix is produced by local cells that synthesize the components from basic substrates, such as glucose and amino acids. In Dupuytren's disease, certain factors may inhibit or activate these metabolic pathways. Generally, a total increase in the amount of glycosaminoglycan occurs.

### FIBROFATTY TISSUE

The potential role of the layer of fat between skin and fascia has been the subject of speculation and investigation in the development of Dupuytren's disease. Its teleologic role seems to be to cushion forces transmitted through the skin to the fascia. As a response to micro- (and macro-) trauma, it becomes involved in increased vascular proliferation. Rabinowitz et al. (42) have shown that various enzymatic changes may play a role in the etiology of Dupuytren's disease.

### GROWTH FACTORS

In recent years, numerous growth factors have been implicated in the pathophysiology of Dupuytren's disease. For example, transforming growth factor-b plays a possible role, as does epidermal growth factor (24). In 1992, Badalamente et al. (1) focused on the role of platelet-derived growth factor as a cellular signal for myofibroblast proliferation in the formation of Dupuytren's nodules. Finally, Tomasek and Rayan in 1995 (48) correlated the smooth-muscle-like phenotype of fibroblasts in Dupuytren's disease with increased contractility.

## PRINCIPLES OF TREATMENT

A genetic predisposition to Dupuytren's disease appears to exist, but the exact genetic pattern is unknown. Controversy surrounds the theory that the pattern is autosomal dominant with high penetrance. The disease is 6- to 10-fold more prevalent in men than in women (51). When Ling interviewed his patients, they reported that 16% of their relatives had Dupuytren's disease. Careful examination of the relatives, however, revealed the incidence was 68%! Despite this finding, Ling was unable to prove a clear mode of genetic transmission (28).

Certain factors have been shown to predispose people to a more virulent form of Dupuytren's disease. For example, in patients in their teens or 20s, Hueston has referred to the disease as a “Dupuytren's diathesis” (21). This may include plantar fibromatosis (Ledderhose's disease), penile fibromatosis (Peyronie's disease), and knuckle pads. These conditions should be sought out during the history and physical examination of the patient because it has been found that they are predictive of a poorer prognosis.

Arguably, in these aggressive forms, the clinical course resembles that of an aggressive fibromatosis. When seen in children, this condition may resemble Dupuytren's disease histologically but predictably will have an extremely virulent clinical course. A similar condition, juvenile aponeurotic fibroma (31,49), has been noted to recur as fibrosarcoma with metastatic disease and death. Certainly, the combination of a young boy with a strong family history and an early onset of contracture carries a poor prognosis. Likewise, when the disease appears in young women, it tends to be more virulent and recurrent. Although this is generally true in younger women, in my experience older women do not fare much differently from men in terms of natural history. The presence of osteoarthritis in the proximal interphalangeal (PIP) or metacarpophalangeal (MP) joints compromises the final result by limiting the eventual range of motion (Fig. 62.1).

***Figure 62.1.*** Persistent PIP flexion contracture in the right small finger with previous amputation of the left small finger in a 27-year-old man with seizure disorder.

### CONCOMITANT DISEASE

Many diseases have been found in association with Dupuytren's disease—acquired immune deficiency syndrome (AIDS), for example. Free radicals have been linked to the apparent relationship between Dupuytren's disease and human immunodeficiency virus (HIV)–infected patients (3). Other frequently associated diseases include diabetes mellitus, tuberculosis, epilepsy, and alcoholism. Dupuytren's disease has been associated with many other diseases, with no clear causal relationship. It is particularly important to document these associated conditions in obtaining a patient history because some of these conditions may ultimately affect the prognosis (39).

Nissenbaum and Kleinert (39) were concerned that the coexistence of Dupuytren's disease with carpal tunnel syndrome might predispose to postoperative complications, such as increased swelling and complex regional pain syndrome. For this reason, they suggested minimizing complications by treating the more significant clinical problem—carpal tunnel syndrome or Dupuytren's disease—first. Michon (36) believed that carpal tunnel in Dupuytren's disease could safely be released concomitantly, as did Gonzalez and Watson (16).

Carefully evaluate the patient for coexistent boutonniere deformity (26), which would affect postoperative management. Hyperextension of the distal interphalangeal (DIP) joint with associated PIP joint contracture in Dupuytren's disease should alert the examiner to the possibility of boutonniere. If the DIP joint can be passively flexed following PIP joint release, then a PIP extension splint and a program of passive flexion should correct the boutonniere (Fig. 62.2). Postoperative management should focus on maintaining the PIP joint in full extension as well as concomitant passive flexion of the DIP joint to pull the lateral bands to their more anatomic position dorsal to the axis of PIP joint motion.

***Figure 62.2.*** **A:** Persistent Dupuytren's contracture in the palm of a 71-year-old woman with severe arteriosclerotic cardiovascular disease. **B: Z**-plasty of skin contracture with subcutaneous fasciotomy while the patient was under local anesthesia. **C:** Improved extension postoperatively.

Coexistent trigger finger should be addressed surgically, with the Dupuytren's contracture removed if present. Conversely, Dupuytren's nodules need not be excised at

the time of $A_1$ pulley release (5).

Finally, patients with significant coexisting diseases, such as coronary artery disease or history of cerebral vascular accident, need not cancel surgery but rather should have it done under local anesthesia, with appropriate sedation. The fasciotomy may be limited, if necessary, and only the affected digits released. Limited fasciotomy has occasionally been helpful for such patients (Fig. 62.3) (16,37).

***Figure 62.3.*** A 27-year-old man with seizure disorder and recurrent Dupuytren's disease in both hands. Note previous amputation of the left small finger at the PIP joint level and recurrent flexion contracture of the PIP joint in the right small finger after two previous open fasciectomies. This patient was counseled to continue stretching his right hand and advised to use nonsteroidal medication. No further surgery has yet been required.

Diabetes concurrent with Dupuytren's disease may present problems of insulin management as well as a slight increased risk of postoperative wound infection. In the patient with diabetes, distinguishing between Dupuytren's disease and trigger finger is important. Finally, patients with seizure disorder have a high likelihood of recurrence and a tendency toward a more aggressive form of the disease (Fig. 62.4) (45).

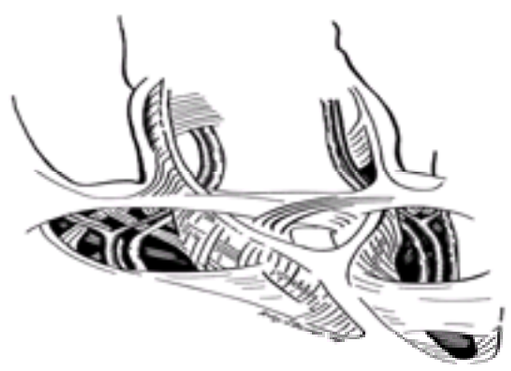

***Figure 62.4.*** Normal anatomy of the palm showing lattice-like arrangement of fascial bands surrounding the common digital nerve and artery at the level of bifurcation.

## ANATOMY

The palmar fascia is a triangular-shaped structure on the volar surface of the hand, with four longitudinal thickened fascial segments corresponding to the individual finger metacarpals. There is a separate extension toward the thumb and thenar musculature. The fascia is attached to the skin of the palm by vertical septae and to the deeper structures of the hand, the flexor sheath, and intrinsic musculature through similar longitudinal septae, the ligaments of Legueu and Juvara.

The longitudinal fasciculi of the palmar fascia terminate at the proximal finger crease of the skin. The superficial transverse fasciculi, as well as a discrete deep transverse fiber layer, are proximal to the termination and perpendicular to the longitudinal fasciculi.

Between the superficial transverse metacarpal ligament distally and the finger flexion crease, the palmar fascia divides into smaller fascial elements extending onto the finger to join Cleland's ligament, Grayson's ligament, and the lateral digital sheath of Gosset (43) (Fig. 62.5). The fascia “spirals” around the neurovascular bundle in this region, and some authors refer to this normal fascial tissue as a “spiral band.” Located more transversely in the web space, the “natatory ligament” runs from the deeper palmar fascia across the skin of the web and becomes adherent to the skin within the web space.

***Figure 62.5.*** Pathologic anatomy in which fascial bands have coalesced into fascial cords surrounding the neurovascular bundle. Depending on which bands are involved and to what extent, the neurovascular bundle may be drawn toward the midline in a subcutaneous position, making it vulnerable to surgical dissection.

I and others believe that no true spiral band exists (50; D. A. McGrouther, personal communication). Rather, the fascia reaches the finger through a confluence of attachments to tendon sheath, intrinsic muscle fascia, and skin. McGrouther has drawn the analogy between these fascial structures and a wooden lattice configuration that can flex and extend with the fingers, thereby becoming longer or shorter with normal function.

## DISEASED FASCIA

In 1959, Luck suggested the term *band* for normal fascial structures and *cord* for those afflicted with Dupuytren's disease. These terms have endured (30). The central part of the finger is not covered by a fascial band but rather by a fibrofatty tissue that may become involved with Dupuytren's disease. Gosset described the continuation of the vertical septae of Legueu and Juvara and described them blending with the capsule and the MP joint and extending along the side of the finger to the lateral digital sheet. Continuations of the natatory ligament are confluent with this from the web space. Each of these structures can become involved in the contracture.

McFarlane's (33) description of the diseased fascia in Dupuytren's disease does not explain how a nodule becomes a cord but does quite clearly define the anatomy of the central cord, which is the diseased longitudinal band of the normal palmar fascia, known as the pretendinous band. This cord may extend to the finger, involving the fibrofatty tissue, with the volar surface of the finger becoming confluent with the central cord. This cord usually passes distally in the midline of the finger and may be

adherent to the Grayson's ligament, tendon sheaths, the lateral digital sheet, or the skin of the middle phalanx, potentially resulting in MP or PIP flexion deformity or both (Fig. 62.6).

***Figure 62.6.*** Severe PIP contracture and MP contracture of the left small finger. A longitudinal incision is directed distally on the finger and broken up into **Z**-plasty at the level of the PIP joint to facilitate release of the skin contracture.

The natatory ligament becomes the natatory cord, causing contracture of the web space and thus making spreading of the fingers difficult. This is common in Dupuytren's disease. On the finger, the lateral digital sheet and Grayson's ligament become the lateral cord. This cord is proximally adherent to the diseased palmar fascia via a *spiral cord.* This term describes the path of the diseased fascia as it surrounds the neurovascular bundle, pulling it toward the midline of the finger and often leaving it in a vulnerable subcutaneous position. This spiral cord more often affects the neurovascular bundle when a PIP contracture greater than 30° exists (33).

## SURGICAL INDICATIONS

Many patients function with mild contractures. Early complaints may be of the presence of a tender nodule. Later, patients may have difficulty retrieving objects from their pockets, wearing gloves, or shaking hands. A tender nodule alone is a relative contraindication to surgery, as removal may result in recurrence and a tender scar. Once the patient is no longer able to place her hand flat on a table top (Hueston's positive table-top test), consider surgery. This sign is usually associated with an MP joint contracture of 30° or more.

Consider any contracture of the PIP joint an indication for surgery, particularly in young patients. It is quite difficult to obtain good PIP joint function if the condition is left untreated and allowed to progress. The patient must understand, however, that surgery is palliative, and eventual recurrence is probable. In younger patients with a positive family history, the disease is almost certain to recur. Careful splinting (particularly at night) for 6 to 12 weeks after surgery may help prevent recurrent contracture even in the face of recurrent disease.

Generally, the first patient–doctor visit should be used to explore the goals and expectations of both the patient and surgeon as to the eventual outcome of treatment. Although surgical treatment is available and may have a limited role in some patients, uniform success has not been reported (12,20,47,53,54). I have found that cortisone injection in the isolated painful palmar nodule is somewhat helpful in relieving local symptoms. In the natural course of the disease, the pain in the nodule disappears. Whether contracture occurs is not predictable.

## SURGICAL TECHNIQUES

Depending on the extent of the disease, the patient's general health, and whether previous surgery has been performed, the choice of anesthesia may vary. Anesthesia may be an axillary block, general endotracheal, or monitored anesthesia care in which the surgeon places a wrist block or a digital block plus local anesthesia. Sedation with Diprovan (propothol) or Versed (midazolam hydrochloride) may be used. Bier block may be suitable in certain circumstances, but in my experience the intravenous fluid from the anesthetic often compromises the surgical field. The patient rarely tolerates the tourniquet for more than 30 to 60 min, making Bier block comparable to wrist block, digital block, or local anesthesia with monitored anesthesia care. Regardless of the choice of anesthetic, if the procedure is not completed within 2 hours and the tourniquet must be deflated, dissection becomes increasingly difficult.

### OPEN-PALM TECHNIQUE

Although numerous surgical procedures have been described, I prefer the open-palm technique described by McCash (32).

- Make a transverse incision over the diseased ray or rays in or immediately adjacent to the distal palmar crease. Extensions of the incision toward the involved digit and proximally in the palm may be through either zigzag or straight-line incisions, with the straight-line incisions designed for later **Z**-plasty (Fig. 62.7).

***Figure 62.7.*** **A:** Dissection from proximal to distal, with the diseased fascia held with an Allis clamp. **B:** Underlying preserved common digital nerve at the level of bifurcation. Note intimate involvement between diseased fascia still held by Kocher and underlying digital nerve. A relatively large pacinian corpuscle is located just proximal to the bifurcation. Pacinian corpuscles, usually visible to the naked eye and under 3.5- or 2.5-power loupe magnification, are ideal landmarks to alert the surgeon to the near proximity of the digital nerve.

- Bruner-type incisions may be used when the PIP joint is not involved. When the incision must be extended distally on the finger to the PIP joint or further, use a straight, longitudinal incision broken into the appropriate number of **Z**-plasties. In the palm the Bruner-type incision lends itself well to the **V-Y** closure (23).
- When the longitudinal incision is used, and a PIP contracture is involved in Dupuytren's disease, employ a classic 60° **Z**-plasty at the level of the PIP joint. This technique theoretically allows a 75% gain in length when the joint is mobilized. Once the joint has been mobilized, the transverse line of the **Z**-plasty should lie at or close to the level of the PIP joint.
- Leave the wound open, like the distal palmar wound, to facilitate drainage and avoid tension on the wound closure. Normal skin has the potential for plastic deformation, but diseased skin of Dupuytren's disease rarely does.
- Begin exposing the diseased fascia through the proximal incision at the base of the palm, which should be extended to include normal fascia. Using the basic, general surgical principle of dissecting from normal toward abnormal tissue, identify the distal margin of the transverse carpal ligament, superficial palmar arch, and associated common digital arteries and nerves and trace them distally through the lumbrical canals.
- As you encounter diseased fascia, carefully separate it from the skin and underlying tissues, dividing the diseased superficial fibrous sepae as well as the diseased tissue deep within the palm.
- It is frequently possible to identify the ligaments of Legueu and Juvara. Divide them close to intrinsic muscle or tendon sheath, removing a small segment of normal tissue, particularly when dense adherence exists between the diseased tissue and the flexor sheath.
- Perform the majority of the dissection with a #15 blade, beaver blade, or sharp tenotomy scissors. Maintain tension on the diseased fascia, holding it superficially with a single-tooth forceps, a Kocher clamp, or an Allis clamp (Fig. 62.7).
- Maintain traction on the skin flaps using single- or double-hook retraction and with the aid of a specialized surgical hand table if an assistant is unavailable.

- Place sterile rubber bands or vessel loops around the neurovascular bundles to protect them and mark their location. At the level of the transverse incision and approaching the MP joint, be particularly alert for the possibility of a “spiral cord” that displaces the common digital nerve to the involved digits in a superficial position. Clinically, a “soft pulpy mass” as described by Short and Watson should alert the surgeon to the presence of this structure (44). Often, the neurovascular bundle will appear to pass directly through the diseased tissue; in fact, in a recurrence, it often does.
- Use magnification, a 3.5-power loupe, or an operating microscope to better visualize the neurovascular bundle. Carefully protect the nerve and sharply dissect it longitudinally from the surrounding tissue. The nerve frequently turns acutely 45° or 90° as it is deformed by the diseased collagen, making dissection tedious.
- As the dissection is carried onto the finger, mobilize the **Z**-plasty incisions, which should have been outlined before the surgical dissection. In general, cuts between 5 mm and 10 mm in length are sufficient and designed such that with closure of the **Z**-plasty the transverse limb lies at or near the PIP flexion crease.
- Ideally, the entire segment of diseased fascia with the involved ray is removed in one segment from proximal to distal. The distal diseased fascia may adhere to the flexor sheath, collateral ligaments of the PIP joint, lateral digital sheet of Gosset, or Grayson's ligaments. It rarely extends dorsally and should not involve Cleland's ligaments.
- Depending on the length of the procedure and your confidence in having maintained adequate hemostasis with bipolar electrocautery through the course of the procedure, you may elect to close a portion of the wound before deflating the tourniquet.
- With the open-palm technique, leave the entire transverse incision open. With this technique, hematoma accumulation in the palm is unlikely; likewise with the fingers in the case of distal **Z**-plasty, where the transverse limb is left open. With a tighter closure, meticulous hemostasis following tourniquet deflation and before wound closure is more important.
- I prefer to close the wound with 5-0 nylon sutures placed in a horizontal or vertical mattress fashion.
- Apply a bulky dressing loosely with a dorsal splint and encourage the patient to flex and extend the fingers when he awakens in the recovery room or when the axillary block wears off.
- Change the dressing within 24 to 48 hours. Provide the patient detailed instructions for wound care and for a home exercise program. Remove sutures in 7 to 10 days. An outpatient hand therapy program is crucial in obtaining good results.

**ALTERNATIVE SURGICAL TREATMENTS**

The arterial supply of blood to the palm, combined with the dense fascial attachments between the skin and the palm that may be involved in Dupuytren's disease, make rotation flaps difficult if not impossible. The central palmar skin has been shown by microangiography to have limited circulation (7). Any surgical procedure, therefore, should limit the amount of undermining of the skin in this region and avoid straight longitudinal incisions that may predispose to later contracture.

Many more surgical techniques and variations of surgical incisions to treat Dupuytren's disease are described than are detailed here. In a recent textbook, McGrouther lists more than 40 surgical techniques that have been published since Dupuytren's original description (34). All involve variations on zig-zag incisions, **Z**-plasties, local rotation flaps, and **V-Y**–plasty. This latter procedure, originally described by Palmen (40), has been more recently popularized by King et al. (23). The goal of this and any wound closure in Dupuytren's disease should be to avoid tension while maintaining circulation to and viability of the flap.

Bedeschi (2) has modified the **V-Y** technique to the shape of a “honeycomb,” which is comparable to the **V-Y**–plasty. I have found that it works well for single-digit involvement, particularly at the MP joint.

- Outline an incision from an area just proximal to the involved fascia in the involved finger and zig-zag distally at angles between 90° and 110° onto the finger and distal to the diseased fascia. Transverse incisions extend off the apex of the zig-zag incision (Fig. 62.8).

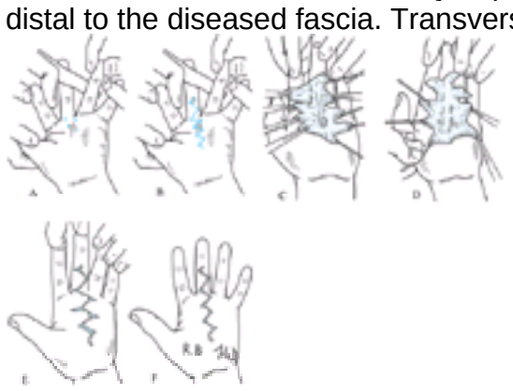

***Figure 62.8.*** “Honeycomb incision” allowing skin closure with V-Y-plasty. **A:** First four basic markers for the top angles of the zig-zag incision at the palmodigital level. **B:** The incision design. **C,D:** The wide exposure allowed by this technique enables extensive and safe palmar and digital fasciectomy. **E:** At the end of the operation, note the complete correction of the contracture; only the zig-zag incision is sutured. Transverse incisions become small open areas, avoiding tension on wounds and preventing hematomas. **F:** The same patient after 14 days. (Redrawn from Bedeschi P. Various Views and Techniques. Management of the Skin. Part 1. Honeycomb Technique. In. McFarlane RM, McGrouther DA, Flint MH, eds. *Dupuytren's Disease. Biology and Treatment. The Hand and Upper Limb Series, Vol 5.* Edinburgh: Churchill Livingstone, 1990:311.)

- Protect the neurovascular structures throughout and remove all the diseased fascia.
- Suture the zig-zag incisions and leave the transverse incisions open.
- Do not use postoperative splinting; initiate therapy immediately.

In the late 1950s and early 1960s, Sir Archibald McIndoe (35) believed that the only form of surgical treatment that could potentially cure Dupuytren's disease was radical fasciectomy. It initially appeared to yield satisfactory results in more than 200 cases; however, Skoog (46) noted that, following radical fasciectomy, some patients had pain when gripping objects and a general feeling of the palm's being “unprotected.” Skoog proposed a selective aponeurosectomy. He also reported that the transverse elements of the palmar aponeurosis seemed to be spared the changes of Dupuytren's disease. In the selective aponeurosectomy (commonly referred to as *partial fasciectomy*), only the diseased palmar fascia is removed, and the transverse elements are left intact.

**SKIN GRAFTING**

Hueston (19) and Gonzales (15) have popularized skin grafting in Dupuytren's disease. In addition to providing wound coverage, the technique prevents recurrent disease from forming beneath the graft. A short period of immobilization is required, and there may be morbidity associated with a donor site. As with open-palm technique, full-thickness skin grafting at the site of Dupuytren's resection allows the fingers to be brought into full extension with no tension, particularly at the level of the proximal interphalangeal joint. A skin graft here not only prevents recurrent disease but may also minimize tension on the incisional scar and further prevent contracture of the scar.

Gonzales' choice for donor site is either the instep of the foot or the groin. The instep of the foot better resembles palmar skin, but local size constraints permit only small amounts of graft to be harvested. The groin has the added risk that the graft may bear hair, an equally undesirable outome. The constraints have led me to use the upper inner portion of the arm or the lateral side of the leg (Fig. 62.9). Although it controls local recurrence in the area immediately beneath the flap, skin grafting does not prevent Dupuytren's disease from occurring in other areas of the palm. Always consider skin grafting in recurrent disease where the skin is scarred from previous surgery in addition to being diseased.

***Figure 62.9.*** **A:** Recurrent contracture (third time) in the palm of a 67-year-old retired avid golfer. Severe contralateral disease was present as well. This longitudinal

skin and fascial contracture caused pain when the patient was gripping a club. **B:** The site of excised skin and diseased fascia was covered by a full-thickness skin graft harvested from the lateral thigh with the donor defect closed primarily. **C:** Six months postoperatively, the hand in full extension. **D:** Full flexion. Note severe PIP flexion contracture in the contralateral hand in **C.** This hand was asymptomatic and, in fact, enabled the patient to grip a golf club better.

Although it requires some additional donor site morbidity, free-tissue transfer (25) may also have a role for some patients.

Postoperative rehabilitation following full-thickness skin grafting requires a 7- to 10-day period of splint immobilization to ensure graft adherence. During this time, the patient may remove the splint four or five times per day to gently flex and extend the involved fingers. Patients must be watched closely for signs of increasing edema, disproportionate pain, stiffness, infection, and signs of complex regional pain syndrome. Once the wound has healed, sutures are removed, and the skin graft has taken, have the patient begin a more active range-of-motion program. Some patients progress rapidly on their own but require the services of a trained hand physiotherapist. Many scars are erythematous, thick, hard, and painful. Elastomer supported by Coban helps to minimize the amount of redness and swelling that develops. Cortisone injection of the scar and regular use of nonsteroidal antiinflammatory drugs have also been beneficial in reducing edema and scar formation.

## PITFALLS AND COMPLICATIONS

In preparing a surgical consent form for Dupuytren's disease, the most important complications to include are digital nerve injury, infection, and recurrence. The patient may be at greater risk for each of these complications, depending on certain preexisting conditions. For example, severe contractures or dimpling of the skin may increase the risk of digital nerve injury or digital nerve dysesthesia following fasciectomy. A strong family history of Dupuytren's disease, surgery at an early age in men or women, or surgery in women may predispose to recurrence. Tender scars, chronic edema, reflex sympathetic dystrophy (more appropriately now called complex regional pain syndrome), and limited range of motion are less common with the open-palm technique (30).

Hematoma (Fig. 62.10), a fairly devastating complication, is more common when the palm is closed. The surgeon needs to remember that the central portion of the palm is a relatively disvascular area (7). The creation of large flaps in the palm of the hand or significant dissection that undermines the wound margins may compromise the circulation temporarily or permanently, leading to skin slough and secondary contracture.

***Figure 62.10.*** Postoperative hematoma in the hand of a 42-year-old man whose fasciotomy was performed using the closed-palm technique. Although his ultimate result was satisfactory, additional therapy was required for PIP and MP joint stiffness secondary to hematoma resolution.

Severe edema, erythema, pain, swelling, and limited range of motion may occasionally occur after open palmar fasciectomy and have been referred to as a flare reaction. It occurs more often when a fairly acute presentation of palmar fibromatosis with a painful nodule initially exists. Should it develop, I recommend treatment with nonsteroidal antiinflammatory medication. In combination with compressive elastomer (otoform and Coban) to the wound, elevation, and an occasional steroid injection in the latter stages of the disease, it may calm the process. Six to 12 months later, if a contracture persists, surgical release may once again be considered (Fig. 62.11). Treatment of severe recurrence includes the possibility of skin grafting (Fig. 62.9).

***Figure 62.11.*** **A:** Inflamed palm of a 57-year-old man who was seen 3 months following fasciectomy for Dupuytren's disease in which the palmar skin was closed. He developed a local wound dehiscence and secondary infection. He also developed a secondary “flare” reaction and had been scheduled for revision surgery. Instead, he was treated with nonsteroidal antiinflammatory medication and therapy in the form of elastomer and edema control, intermittent protective splinting, and a general range-of-motion program. **B:** One year later, he underwent revision fasciectomy using the open-palm technique. **C,D:** Three months postoperatively, full extension and flexion. (Amputation of the contralateral small finger was from an industrial accident.)

In severe recurrent contracture, amputation is occasionally indicated. It is usually performed at the request of the patient who, for some reason, cannot tolerate an additional procedure on the involved finger. Amputation should be done with a caveat: Spread of the disease to other digits should not involve amputation of each of the fingers. Instead, resection of the contracture should be performed along with PIP joint arthrodesis, with shortening of the bone to correct the deformity and allow extension of the finger without severe damage to the neurovascular bundle. This is an excellent salvage procedure. In certain individuals, for whom motion is extremely important (a musician, for example), PIP joint replacement arthro-plasty, with a silicone-type prosthesis, may afford enough improved motion to alter the functional course.

## CHAPTER REFERENCES

Each reference is categorized according to the following scheme: *, classic article; #, review article; !, basic research article; and +, clinical results/outcome study.


! 1. Badalamente MA, Hurst LC, Grandia SK, Sampson SP. Platelet-Derived Growth Factor in Dupuytren's Disease. *J Hand Surg* 1992;17A:317.

+ 2. Bedeschi P. Various Views and Techniques. Management of the Skin. Part 1: Honeycomb Technique. In: McFarlane RM, McGrouther DA, Flint MH, eds. *Dupuytren's Disease: Biology and Treatment. The Hand and Upper Limb Series, Vol 5.* Edinburgh: Churchill Livingstone, 1990;311.

# 3. Bower M, Nelson M, Gazzard BG. Dupuytren's Contractures in Patients Infected with HIV. *Br Med J* 1990;300:164.

! 4. Burch PR. Dupuytren's Contracture: An Auto-immune Disease? *J Bone Joint Surg* 1966;48B:312.

# 5. Burgess RC, Watson HK. Stenosing Tenosynovitis in Dupuytren's Contracture. *J Hand Surg* 1987;12A:89.

* 6. Chiu HF, McFarlane RM. Pathogenesis of Dupuytren's Contracture: A Correlative Clinical-Pathological Study. *J Hand Surg* 1978;3A:1.

* 7. Conway H, Stark RB. Arterial Vascularization of the Soft Tissues of the Hand. *J Bone Joint Surg* 1954;36A:1238.

* 8. Dupuytren G. *Leéons* Orales de Clinique de Chirugicale, Vol1. Paris: G. Ballière, 1832.

* 9. Dupuytren G. Permanent Retraction of the Fingers Produced by an Affection of the Palmar Fascia. *Lancet* 1834;2:222.

# 10. Duthie RB, Francis MJ. Free Radicals and Dupuytren's Contracture. *J Bone Joint Surg* 1988;70B:689.

* 11. Elliot D. The Early History of Contracture of the Palmar Fascia. In: McFarlane RM, McGrouther DA, Flint MH, eds. *Dupuytren's Disease: Biology and Treatment.* Edinburgh: Churchill Livingstone, 1990:1.

* 12. Finney R. Dupuytren's Contracture—A Radiotherapeutic Approach. *Lancet* 1953;2:1064.

!* 13. Gabbiani G, Majno G. Dupuytren's Contracture. Fibroblast Contraction? An Ultra-structural Study. *Am J Pathol* 1972;66:131.

! 14. Glimcher MF, Pebody HM. Collagen organization. In: McFarlane RM, McGrouther DA, Flint MH, eds. *Dupuytren's Disease: Biology and Treatment.* Edinburgh: Churchill Livingstone, 1990:72.

* 15. Gonzales RI. Open Fasciectomy in Full Thickness Skin Graft in a Correction of Digital Flexion Deformity. In: Hueston JT, Tubiana R, eds. *Dupuytren's Disease, 2nd ed.* Edinburgh: Churchill Livingstone, GEM Monograph, 1985:158.

+ 16. Gonzalez F, Watson HK. Simultaneous Carpal Tunnel Release and Dupuytren's Fasciectomy. *J Hand Surg* 1991;16B:175.

* 17. Herzog EG. The Etiology of Dupuytren's Contracture. *Lancet* 1951;1:1305.

* 18. Hueston JT. The Incidence of Dupuytren's Contracture. *Med J Aust* 1960;47:999.

* 19. Hueston JT. The Control of Recurrent Dupuytren's Contracture by Skin Replacement. *Br J Plast Surg* 1969;22:152.

* 20. Hueston JT. Enzymatic Fasciotomy. *J Hand Surg* 1971;3B:38.

* 21. Hueston JT. Diathesis as a Guide to the Timing and Extent of Surgery in Dupuytren's Disease. In: Hueston JT, Tubiana R, eds. *Dupuytren's Disease, 2nd ed.* Edinburgh: Churchill Livingstone, GEM Monograph, 1985:134.

* 22. Hueston JT, Tubiana R, eds. *Dupuytren's Disease, 2nd ed.* Edinburgh: Churchill Livingstone, GEM Monograph, 1985.

+ 23. King EW, Bass DM, Watson HK. Treatment of Dupuytren's contracture by extensive fasciectomy through multiple **Y-V**–plasty incisions: short-term evaluation of 170 consecutive operations. *J Hand Surg* 1979;4:234.

! 24. Kloen P, Jennings CL, Gebhardt MC, et al. Transforming Growth Factor-Beta: Possible Role in Dupuytren's Contracture. *J Hand Surg* 1995;20A:101.

+ 25. Kouri RK. *Innovations in Flap Design.* Paper Presented at the 11th Annual Meeting of the American Society for Reconstructive Microsurgery, Tucson, AZ, January 1996.

# 26. Kuhlmann JN, Boabighi A, Guero S, et al. Boutonniere Deformity in Dupuytren's Disease. *J Hand Surg* 1988;13B:379.

! 27. Larsen RD, Takagishi N, Posch JL. The Pathogenesis of Dupuytren's Contracture. Experimental and Further Clinical Observations. *J Bone Joint Surg* 1960;42A:993.

! 28. Ling RS. The Genetic Factor in Dupuytren's Disease. *J Bone Joint Surg* 1963;45B:709.

+ 29. Lubahn JD, Lister GD, Wolfe T. Fasciectomy and Dupuytren's Disease: A Comparison between the Open-Palm Technique and Wound Closure. *J Hand Surg* 1984;9A:53.

+ 30. Luck JV. Dupuytren's Contracture: A New Concept of the Pathogenesis Correlated with Surgical Management. *J Bone Joint Surg* 1959;41A:635.

+ 31. Marty-Double C, Balmes P, Mary H, et al. Juvenile Fibromatosis Resembling Aponeurotic Fibroma and Congenital Multiple Fibromatosis. One Case with Pleuropulmonary Involvement. *Cancer* 1988;61:146.

+ 32. McCash CR. The Open Palm Technique in Dupuytren's Contracture. *Br J Plast Surg* 1964;17:271.

* 33. McFarlane RM. Patterns of the Diseased Fascia in the Fingers in Dupuytren's Contracture. Displacement of the Neurovascular Bundle. *Plast Reconstr Surg* 1974;51:31.

+ 34. McGrouther DA, Flint MH. Various Views and Techniques. In: McFarlane RM, McGrouther DA, Flint MH, eds. *Dupuytren's Disease: Biology and Treatment.* Edinburgh: Churchill Livingstone, 1990;311.

+ 35. McIndoe A, Beare RLB. The Surgical Management of Dupuytren's Contracture. *Am J Surg* 1958;95:197.

+ 36. Michon J. Serious Postoperative Complications in Dupuytren's Disease (Abstract). *J Hand Surg* 1977;2A:238.

+ 37. Moermans JP. Segmental Aponeurectomy in Dupuytren's Contracture. *J Hand Surg* 1991;16B:243.

! 38. Murrell GA, Francis MJ, Bromley L. Free Radicals and Dupuytren's Contracture. *Br Med J* 1987;295:1373.

+ 39. Nissenbaum M, Kleinert HE. Treatment Considerations in Carpal Tunnel Syndrome with Coexistent Dupuytren's Disease. *J Hand Surg* 1980;5A:544.

* 40. Palmen AJ. Die sägeplastik, eine unter anderen für Dupuytrensche fingerkontraktur und syndaktylie geeignete Schnittführung. *Zentralbl Chir* 1932;59:1377.

* 41. Plater F. Hominis Affectibus. In: König JL, Brandmyller J, Basel LI, eds. *Observationum*, Vol 3. Basel: Köenig, 1614:140.

! 42. Rabinowitz JL, Ostermann L Jr, Bora FW, Staeffen J. Lipid Composition and *de Novo* Lipid Biosynthesis of Human Palmar Fat in Dupuytren's Disease. *Lipids* 1983;18:371.

+ 43. Ritter MA. The Anatomy and Function of the Palmar Fascia. *Hand* 1973;5:263.

+ 44. Short WH, Watson HK. Prediction of the spiral nerve in Dupuytren's contracture. *J Hand Surg* 1982;7A:84.

+ 45. Skoog T. Dupuytren's Contracture with Special Reference to Aetiology and Improved Surgical Treatment. Its Occurrence in Epileptics. Notes on Knuckle-Pads. *Acta Chir Scand [Suppl]* 1948;139:27.

# 46. Skoog T. The Transverse Elements of the Palmar Aponeurosis in Dupuytren's Contracture. Their Pathological and Surgical Significance. *Scand J Reconstruct Surg* 1967;1:51.

+ 47. Steinberg CL. Tocopherols in Treatment of Primary Fibrositis.*AMA Archives of Surgery* 1951;63:824.

! 48. Tomasek J, Rayan GM. Correlation of Alpha-Smooth Muscle Actin Expression and Contraction in Dupuytren's Disease Fibroblasts. *J Hand Surg* 1995;20A:450.

+ 49. Urban M, Feldberg L, Janssen A, Elliot D. Dupuytren's Disease in Children. *J Hand Surg* 1996;21B:112.

# 50. Watson HK, Paul H Jr. Pathologic Anatomy. *Hand Clin* 1991;7:661.

! 51. Welsh KI, Spencer JD. Immunology and Genetics. In: McFarlane RM, McGrouther DA, Flint MH, eds. *Dupuytren's Disease: Biology and Treatment.* Edinburgh: Churchill Livingstone, 1990:99.

# 52. Whaley DC, Elliot D. Dupuytren's Disease. A Legacy of the North? *J Hand Surg* 1993;18B:363.

+ 53. Zachariae L, Clemmensen T, Oleson E, Ulfeldt M. The Effect of a Diuretic (Centyl, Leo) on the Oedema of the Hand Following Surgical Treatment of duPuytren's Contracture. *Acta Orthop Scand* 1970;41:411.

+ 54. Zachariae L, Zachariae F. Hydrocortisone Acetate in Treatment of Dupuytren's Contraction and Allied Conditions. *Acta Orthop Scand* 1954;26:50.

# CHAPTER 63

# INTRINSIC MUSCLE CONTRACTURES

*Clayton A. Peimer*

**C. A. Peimer:** Departments of Orthopaedic Surgery and Anatomic Sciences, University at Buffalo School of Medicine and Biomedical Sciences, State University of New York; Department of Hand and Microsurgery, Millard Fillmore Health System; and The Hand Center, University of Buffalo, Buffalo, New York, 14209.

Anatomy
Diagnosis of Contracture
Mild Intrinsic Contracture
Nonsurgical Treatment Immediately After Injury
Acute Posttraumatic Edema: Fascial Release
Moderate Intrinsic Contracture
Distal Intrinsic Release
Severe Posttraumatic Intrinsic Contracture
Proximal Intrinsic Release
Spastic Contracture
Intrinsic Muscle Slide
Ulnar Motor Neurectomy
Contracture Following Terminal Tendon Injury: Mallet Finger
Lumbrical Contracture
Intrinsic Contracture and Connective Tissue Disease
Swan-Neck Deformities
Pitfalls and Complications
Acknowledgments
Chapter References

A balanced interaction of the intrinsic and extrinsic muscles provides the normal dexterity and power of the hand (4,16,17,21,22,38). If an injury or pathologic condition affects one set of these muscles, the hand may become dysfunctional. Intrinsic muscle imbalance may be attributable to weakness, paralysis, loss of compliance, stiffness, or contracture (18,36,39). Contracture or stiffness of the hypothenar, lumbrical, or interosseous muscles leads to digital imbalance that disables the hand. This chapter focuses on the correction of hand problems caused by contracture of the intrinsic muscles. An understanding of the anatomy, as well as of the specific pathophysiology, is essential if the operating surgeon is to correct these problems (1,13,28). Although the causes of intrinsic contractures may vary, there are a number of typical pathologic patterns based on the common mechanisms of trauma, spasticity, and connective tissue diseases.

## ANATOMY

The mid-axis of the hand, as viewed from the dorsum, is defined as the central axis of the third metacarpal. The dorsal interosseous muscles abduct the fingers from this axis, whereas the palmar interosseous muscles adduct them. There are four dorsal and three palmar interosseous muscles. In addition, there are three hypothenar muscles that function like dorsal interosseous muscles. Dorsal interosseous muscles arise from the metacarpal shafts and insert so as to achieve digital abduction; the designation of first dorsal interosseous muscle thus belongs to that muscle on the radial side of the index finger, and so on, in an ulnar direction. The little finger is actually abducted by the abductor digiti quinti; the middle finger is abducted in both a radial and an ulnar direction and, therefore, has two dorsal interosseous muscles (2,3,6,15,20).

Except for the third, the dorsal interosseous muscles have two muscle bellies and therefore two (tendon) insertions—one into the base of the proximal phalanx and the other via the dorsal (tendon) mechanism (Fig. 63.1). The bony insertion deviates the digit and has a mild effect on proximal phalangeal [metacarpophalangeal (MP) joint] flexion. The tendon insertion produces MP joint flexion via the transverse fibers over the dorsum of the proximal phalanx. The tendon insertion also assists with proximal interphalangeal (PIP) and distal interphalangeal (DIP) extension via the oblique fibers that continue distally to join the lateral slips of the extensor tendon, forming the conjoined lateral band. The (radial and ulnar) lateral bands unite over the dorsum of the middle phalanx to become the terminal tendon. The abductor digiti quinti inserts into bone on the ulnar side of the proximal phalanx of the little finger, and the flexor digiti quinti brevis forms the ulnar lateral band in the little finger. The palmar interosseous muscles also arise from the metacarpal shafts, but each has only one muscle belly. None has a bone insertion into the proximal phalanx, but each functions as do the lateral bands from the dorsal interossei (via the transverse fibers, conjoined lateral band, and terminal tendon). The opponens digiti quinti, the most dorsal of the three hypothenar muscles, has an unusual insertion into the ulnopalmar shaft of the fifth metacarpal, producing carpometacarpal flexion and supination when it contracts.

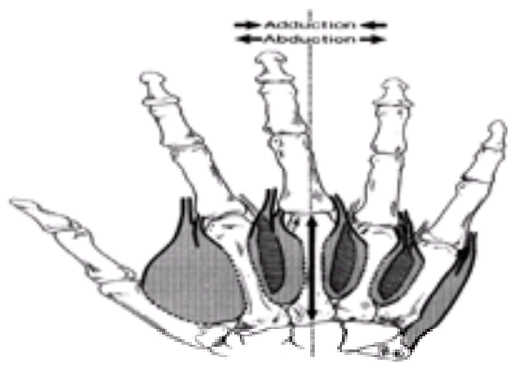


***Figure 63.1.*** Dorsal view of the anatomy of the interosseous muscles. Except for the third, all dorsal interossei have two muscle bellies and two tendon insertions. The dorsal interossei act as digital abductors. The hypothenar muscles function as dorsal interossei. Without exception, the palmar interosseous muscles, which have only one muscle belly, insert into the lateral band and oblique fibers.

The lumbricals extend the PIP and DIP joints but also assist in flexing the MP joints. The lumbricals are unique in that they arise on their antagonist, originating from the tendons of the flexor digitorum profundus in the mid palm (Fig. 63.2). Lumbricals of the index and middle fingers originate from the radial side of the respective flexor digitorum profundus tendons. Lumbricals of the ring and little fingers originate from bipennate muscle bellies on the adjacent surfaces of the flexor digitorum profundus tendons. Lumbrical tendons course distally palmar to the deep transverse intermetacarpal ligaments, becoming part of the radial lateral bands at the midportion of the proximal phalanges. When the lumbrical muscles contract, they pull the flexor digitorum profundus tendon distally, decreasing its flexion effect (relaxing the antagonist), as well as pulling proximally on the lateral band and terminal tendon, thereby extending the PIP and DIP joints.

***Figure 63.2.*** Lumbrical anatomy. The lumbrical is unique in that it both arises from and inserts into a tendon, relaxing its antagonist when functioning. Normal lumbrical contraction tightens the lateral band (interphalangeal extensor fibers); it also pulls the flexor digitorum profundus tendon distally, diminishing flexor tone.

The extrinsic extensor tendons are the only extensors of the proximal phalanges (MP joints), lying in the dorsal midline and inserting via the sagittal bands (Fig. 63.3). These aponeuroses pass in a palmar direction, attaching into the palmar plate and base of the proximal phalanges. The sagittal bands (extrinsic extensor fibers) are proximal and medial to the transverse fibers (intrinsic flexor fibers). It is important not to confuse the sagittal bands with the transverse fibers, since the sagittal bands arise from the extensor tendon, pass in a palmar direction, and extend the finger, whereas the more distal transverse fibers arise from the lateral band and pass dorsally, insert into the dorsal tendon mechanism (not bone), and flex the proximal phalanx (Fig. 63.4) (9,18,20,31,36).

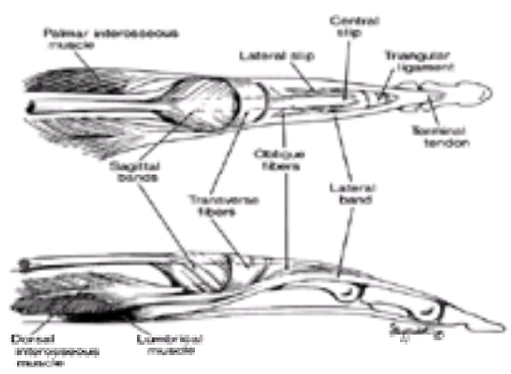


***Figure 63.3.*** Anatomy of the extrinsic extensor tendons. The dorsal tendon mechanism at the metacarpophalangeal (MP) and proximal interphalangeal joint is composed of MP joint extensor fibers from the sagittal bands and intrinsic flexor fibers via the transverse fibers. More distally, the interphalangeal extensor tendons are formed from both the intrinsic and extrinsic tendons.

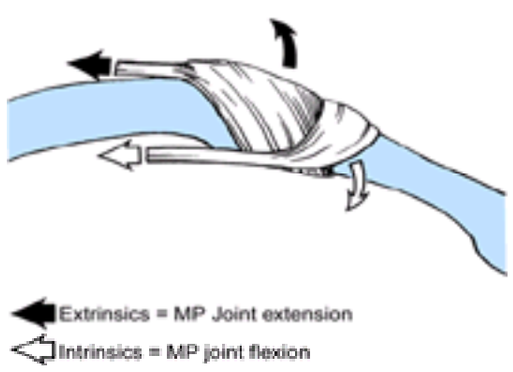


***Figure 63.4.*** Functional slings. At the metacarpophalangeal (MP) joint, the more proximal extrinsic extensor tendon extends the joint via the sagittal fibers, which course distally and in a palmar direction to insert on the palmar plate and flexor sheath. The intrinsic tendons act as flexors via the transverse fibers, coursing distally and dorsally over the base of the proximal phalanx. (From Smith RJ. Intrinsic Muscles of the Fingers: Function, Dysfunction and Surgical Reconstruction. *Instr Course Lect* 1975;24:200, with permission.)

## DIAGNOSIS OF CONTRACTURE

Intrinsic muscles flex the MP joints, extend the interphalangeal joints, and deviate the fingers. Therefore, intrinsic contractures, with concomitant loss of compliance or elasticity, would be expected to interfere with interphalangeal joint flexion and MP joint extension. Less severe contractures tend to affect the interphalangeal joints, whereas more severe contractures produce deformity at both levels.

Intrinsic muscle tightness, or an intrinsic contracture, should be suspected when active PIP flexion is limited (Fig. 63.5). A simple physical test will usually confirm the diagnosis. Passive PIP flexion is tested by the examiner while the MP joint is held flexed; it is then tested again while the MP joint is held extended. A test of intrinsic tightness is positive if there is significantly less passive PIP flexion with the MP joint extended than with it flexed. Many authors have described this test, and it is often (confusingly) recorded eponymically (7,10,30,34). In contrast, extrinsic tightness (contracture of the extensor tendons) is present if passive PIP flexion is more limited when the MP joint is flexed than when it is held in extension. It may be impossible to perform these tests effectively if there are contractures in the MP or PIP joints, or if a joint is dislocated. If there are both intrinsic and extrinsic contractures simultaneously, one may obscure the other.

***Figure 63.5.*** Intrinsic muscle tightness is tested by passively flexing the proximal interphalangeal joint while the metacarpophalangeal (MP) joint is held flexed; it is then tested again while the MP joint is held extended. The intrinsic tightness test is positive if there is significantly less passive proximal interphalangeal flexion with the MP joint extended than with it flexed.

The most common presentation of a functionally significant intrinsic contracture follows trauma, probably caused by muscle changes as a consequence of edema, anoxia, and immobilization. For example, a patient may complain that she cannot grasp objects; sometimes patients report weakness. A careful history and examination will reveal the intrinsic muscle pathology. When examined in the office, the patient may be almost able or fully able to make a fist with unrestricted simultaneous MP and PIP flexion. In attempting to grasp a hammer, however, the flexion of the MP joints is blocked by the hammer, and active flexion of the PIP joints is decreased. This activity is a functional test of intrinsic tightness.

## MILD INTRINSIC CONTRACTURE

### NONSURGICAL TREATMENT IMMEDIATELY AFTER INJURY

If a diagnosis of mild intrinsic tightness or of contracture is made soon after injury (after a Colles' fracture, for example), significant dysfunction may be avoided. Treat to reduce swelling, mobilize the intrinsic tendons, and stretch the muscle bellies. Institute elevation, fluid-flushing massage, and intrinsic muscle-stretching exercises. Stretch the intrinsic muscles by gradually and repetitively performing an intrinsic tightness test, which involves simultaneous passive extension of the MP joints and passive flexion of the PIP joints. This home and supervised outpatient therapy program must be continued for several weeks to be fully effective.

### ACUTE POSTTRAUMATIC EDEMA: FASCIAL RELEASE

During the immediate posttraumatic phase, if the hand is severely swollen, measure the pressure of the intrinsic muscle compartments. (See Chapter 13 and Chapter 65 for information on compartment syndromes.) In acute cases, surgical release of the fascial envelope about the intrinsic muscles, in addition to the adductor pollicis, and release of the carpal tunnel may be required (23,29).

- After applying a tourniquet, approach the intrinsic compartments of the swollen hand through longitudinal incisions about 5 cm long, centered over the mid shafts of the second and fourth metacarpals. Avoid injury to the dorsal veins and sensory nerves.
- Retract the extensor tendons and incise the interosseous fascia longitudinally at each intermetacarpal space. If the second metacarpal incision does not afford adequate access to the adductor pollicis in the first web, once the first dorsal interosseous muscle fascia has been released, make an additional 3 cm longitudinal incision just ulnar to the thumb MP joint, extending it proximally. Incise the fascia dorsal and palmar to the adductor.
- In severe injuries, it may be necessary to perform decompression of the hypothenar muscle via a longitudinal 3 cm incision at the ulnopalmar aspect of the hand and another incision over the thenar muscles, as well as carpal tunnel release.
- Pin the MP joints of severely swollen hands at about 70° of flexion with smooth 0.045 Kirschner wires (K-wires); pin the thumb metacarpal in wide palmar abduction and pronation. Do not close these longitudinal wounds while the hand remains swollen; they may be closed secondarily after several days, or by skin grafting.
- Keep the hand elevated and closely observe circulation. Begin hand therapy with bedside visits to encourage tendon gliding and small joint motion, except in those joints that are transfixed. Continue active exercises during the period of healing and maturation of skin grafts, if grafting has been required. Dynamic splints and closely supervised active exercises may be necessary. Remove the transfixion K-wires when the swelling has subsided adequately; in any event, remove wires within 21 to 28 days following insertion.

## MODERATE INTRINSIC CONTRACTURE

After trauma, the moderately edematous hand is likely to develop intrinsic tightness that affects the PIP joints exclusively. When the hand is unprotected and swollen, MP joint flexion also becomes difficult. The intrinsic muscles, however, can achieve relatively unresisted PIP extension because the capsule and collateral ligaments are initially more lax in that position. Continued PIP extension via tight intrinsic muscles results in limited PIP flexion; in severe cases, it may also be associated with actual capsular tightness at the PIP level. The intrinsic tightness test is positive in such cases.

### DISTAL INTRINSIC RELEASE

To relieve the tightness—assuming that a program of intrinsic stretching exercises has failed—a distal intrinsic release is needed. The entire intrinsic mechanism need not be sacrificed, since only PIP flexion is impaired. This release of the oblique fibers of the lateral bands is known as a distal intrinsic release (i.e., it is distal to the transverse fibers) (2,3,10,18,36).

- Approach the lateral bands in the affected fingers through a dorsal, longitudinal incision 2–3 cm long over the middle third of the proximal phalanx. Carry the incision down to the dorsal mechanism, then elevate the skin flaps, first to the radial side and then to the ulnar side, exposing the lateral bands, the oblique fibers, and the central and lateral slips of the tendon mechanism.
- Divide the lateral bands and their oblique fibers near the distal edge of the wound as they insert into the central slip of the extensor mechanism (Fig. 63.6). Do not divide the lateral slip or the central slip of the extensor tendon; preserve the transverse fibers of the intrinsic tendon as well. Resect a 1 cm piece of the lateral band and its oblique fibers to correct the contracture completely.

***Figure 63.6.*** Distal intrinsic release. For moderate intrinsic contracture that limits proximal interphalangeal flexion, resection of the oblique fibers and contiguous lateral bands is performed on both the radial and ulnar sides of the finger through a dorsal incision.

- Repeat the intrinsic tightness test after both radial and ulnar lateral bands have been resected to verify the completeness of the procedure (Fig. 63.7). Close the wounds and splint the MP joints in extension, taping the PIP joints into flexion.

***Figure 63.7.*** **A,B:** A 56-year-old woman had limited active proximal interphalangeal flexion 6 months after a Colles' wrist fracture. **C,D:** The intrinsic tightness test was positive. **E:** A distal intrinsic release was performed. **F:** Immediately after the surgical release of the intrinsic, the tightness test was negative. **G,H:** At 2 years after surgery, marked improvement in active proximal interphalangeal flexion continues, although motion is still imperfect.

- Begin active and passive PIP flexion exercises within a day or two of surgery. The MP flexion-block splint can generally be discontinued after 14 days, although intrinsic stretching and exercises should be continued for several weeks.

## SEVERE POSTTRAUMATIC INTRINSIC CONTRACTURE

An extended anoxic injury, severe swelling, and prolonged elevated compartment pressure will produce intrinsic myonecrosis with secondary fibrosis, causing deformities at both the MP and the interphalangeal joints (2,3,18,19,34,36). These MP flexion contractures result only from marked and severe intrinsic fibrosis, as evidenced by the fact that most significant posttraumatic MP joint deformities are extension contractures resulting from tight collateral ligaments and secondary capsular scarring. The swollen MP joints strongly resist being flexed, and only in the presence of marked intrinsic muscle scarring will a contracture be severe enough to force the already tight, extended MP joints into a flexed position. Severe PIP extension or hyperextension may also be a part of this often static deformity. Secondary changes at both joints, with pericapsular fibrosis in the deformed position, are not uncommon. Often the first web is also limited because of contracture of the adductor pollicis and the first dorsal interosseous muscles. A significant degree of hand dysfunction results from these contractures.

### PROXIMAL INTRINSIC RELEASE

Correction of severe contracture requires release of not only the distal intrinsic fibers, but also the transverse fibers of the dorsal tendon mechanism that normally flex the MP joints (Fig. 63.8). It is unlikely that these scarred intrinsic muscles will be functional to any extent; therefore, they are best handled by removing the tendons altogether, thus eliminating the deforming force. Overcorrection is rarely a problem, even with an aggressive and complete release. Indeed, full correction may be difficult to achieve.

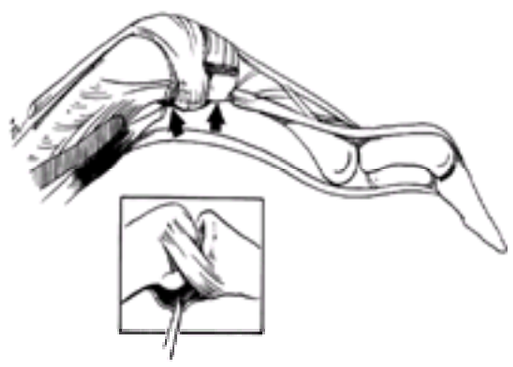

***Figure 63.8.*** Proximal intrinsic release. For severe intrinsic contracture causing fixed metacarpophalangeal (MP) flexion and proximal interphalangeal extension deformities, transverse fibers of the dorsal mechanism, intrinsic insertions into bone, and contiguous oblique fibers are resected on both sides of the affected digits. MP joint release may also be needed.

- Make a dorsal transverse incision that extends from the radial mid-axis of the second metacarpal to the ulnar mid-axis of the fifth, just proximal to the MP joints at the metaphyseal flare of the metacarpals.
- Divide the tendons of all interossei and of the abductor digiti quinti muscles at the MP joints. If MP flexion persists even after the tendons have been removed, free the accessory collateral ligaments and palmar plate from their attachments to the base of the proximal phalanx, and with a dental probe release any scarring between the plate and the metacarpal head.
- Verify relief of the combined MP flexion and PIP extension contractures by repeating the intrinsic tightness test.
- When residual capsular inelasticity hinders positioning of the MP joints in extension, it may be necessary to pin them in that position with obliquely placed, smooth K-wires for about 2 weeks. To correct PIP extension, it may also be necessary to release the lateral bands separately—in much the same manner as the distal intrinsic release was performed—at the time of the proximal intrinsic release. In such cases, individual dorsal incisions may also be required to relieve the PIP contractures completely.
- Postoperative care is essentially the same as it is for a distal intrinsic release, as described earlier.

With severe contractures, a release of the adductor pollicis muscle is also necessary (12,19). Since the skin is often tight, I have found that the most dependable way to relieve the first web contracture is by approaching the adductor via a standard Z-plasty or a Wolff four-flap Z-plasty in which the dorsal longitudinal limb can be extended as far proximally as necessary (6). The dorsal approach prevents injury to the palmar neurovascular and tendon structures.

- Use a small chisel or elevator to free the adductor from its third metacarpal origin.
- If necessary, pin the first metacarpal in wide palmar abduction and pronation for up to 3 weeks, depending on the ease of maintaining the corrected position with splints and dressings alone.

## SPASTIC CONTRACTURE

Intrinsic spasticity may cause dysfunctional deformities in patients with cerebral palsy; it may also occur following cerebrovascular accidents, and it may also affect patients with central nervous system diseases (11,19,24,26,27,33). At times, the intrinsic spasticity is not clinically evident until after the tighter and stronger finger and wrist flexors have been released surgically. Weeks or months after a flexor release or slide, the previously corrected digits may begin to assume an intrinsic-plus posture, with combined MP flexion and PIP extension or hyperextension, often appearing unexpectedly. Although this deformity is similar to that associated with severe posttraumatic contracture, the cause and treatment are different. This condition is attributable to overactive muscles, not scarred and necrotic tissue. The purpose of a surgical release is ideally to decrease the spasticity, and to lengthen the intrinsic muscle–tendon unit to correct the deformity and preserve function. Strictly speaking, the intrinsic muscle cannot be lengthened; however, such an effect is attainable via a muscle slide (31,32).

### INTRINSIC MUSCLE SLIDE

- Make dorsal longitudinal incisions. Generally, incisions over the second and fourth metacarpals are sufficient. Avoid injury to sensory nerves, dorsal veins, and extensor tendons.
- After incising the interosseous fascia longitudinally, completely release the metacarpal origins of the interossei subperiosteally with an elevator. Place the fingers in the intrinsic-minus (claw) position, and slide the released muscles distally (Fig. 63.9).

***Figure 63.9.*** Intrinsic muscle slide. The metacarpal origins of the interossei are completely released subperiosteally with an elevator. Placing the fingers in an intrinsic-minus (claw) position causes the released muscles to slide distally.

- Make separate incisions over the ulnar portion of the first metacarpal for the superficial head of the first dorsal interosseus, avoiding trauma to the princeps pollicis artery, and at the ulnar aspect of the little-finger MP joint to transect the tendons of the flexor digiti quinti.
- Transection of the abductor digiti quinti may also be necessary. In this situation, maintain splinting in the intrinsic-minus (claw) position of combined MP extension and PIP flexion for 2–3 weeks before initiating therapy and exercises, so as to encourage the released muscles to reattach more distally.

### ULNAR MOTOR NEURECTOMY

Certain spastic deformities are so severe that salvage by intrinsic muscle slide is precluded. Patients with such deformities may have associated capsular contractures and PIP hyperextension. The best operation in these cases is an ulnar motor neurectomy.

- Make a curvilinear, longitudinal, ulnopalmar incision extending distally from a point just proximal and radial to the pisiform, to a position distal and radial to the hamulus (hook) of the hamate.
- Identify the deep motor branch of the ulnar nerve as it courses dorsally and in a radial direction around (distal to) the hamulus. Excise a 1 cm segment of nerve. Do not cut the sensory branches of the nerve. Contractures, if present, may be addressed appropriately at the same time.

Secondary small joint deformities necessitating ligament reconstruction or replacement may occur in the chronically spastic hand. For a discussion of the sublimis tenodesis and other similar procedures, see Chapter 68.

## CONTRACTURE FOLLOWING TERMINAL TENDON INJURY: MALLET FINGER

When the terminal extensor tendon is divided or avulsed, the proximal part of the terminal tendon and contiguous conjoined lateral bands retract proximally, unbalancing the extensor forces at the PIP joint. A hyperextension deformity of the PIP joint may gradually develop, or the joint may merely become more difficult to flex actively (14,27). The intrinsic tightness test is typically positive.

Repair of the terminal tendon as well as intrinsic stretching exercises may be required to correct this problem. Digital rebalancing may have to be undertaken in resistant cases. The need for tendon transfer release or capsulodesis is determined by a careful assessment of the combined effects of the intrinsic and extrinsic tendon contributions to the PIP overpull.

## LUMBRICAL CONTRACTURE

The lumbrical is a unique muscle that both arises from and inserts into a tendon, relaxing its antagonist when functioning. Normal PIP flexion depends on balanced flexor digitorum profundus contraction and lumbrical relaxation. Lumbrical scarring (shortening) and loss of elasticity cause transmission of flexor digitorum profundus traction into the lumbrical tendon, to which it has become tethered, rather than through the more distal portion of the flexor digitorum profundus tendon (Fig. 63.10*A*). Active pull on the flexor digitorum profundus tendon then causes PIP and DIP extension via the contracted lumbrical, rather than flexion, a situation Parkes termed the “paradoxical lumbrical-plus finger” (25).

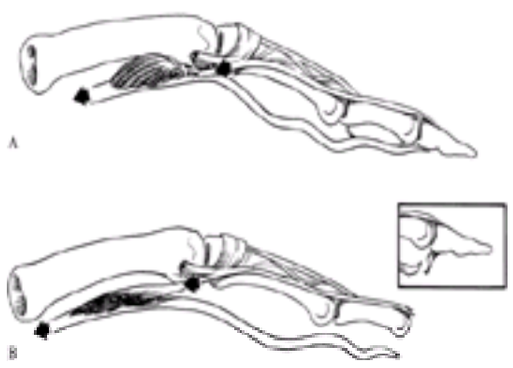


***Figure 63.10.*** Lumbrical contracture. **A:** Lumbrical scarring to the flexor digitorum profundus causes transmission of flexor force into the lumbrical tendon rather than through the more distal portion of the flexor digitorum profundus tendon. **B:** When the normal flexor digitorum profundus insertion is lost (as in an untreated flexor digitorum profundus laceration or a distal joint amputation), contraction of the flexor digitorum profundus muscle is transmitted distally only via the intact lumbrical, thereby producing a paradoxical extensor effect.

Paradoxical lumbrical transmission of flexor forces may also be seen when the normal flexor digitorum profundus insertion is lost, as may occur in untreated distal tendon lacerations or distal joint amputations (Fig. 63.10*B*). The then-lax profundus tendon retracts proximally, and contraction of the flexor digitorum profundus muscle is transmitted to the dorsum of the PIP joint via the lumbrical tendon, producing paradoxical extension or limited active flexion. A loosely inserted tendon graft would have the same effect. The intrinsic tightness test is positive in such cases.

Resection of the radial lateral band will cure this problem. Indeed, I am careful to test patients with DIP amputations for intrinsic tightness, and I often perform an acute radial lateral band release. Intrinsic stretching exercises become a regular part of the rehabilitation program.

## INTRINSIC CONTRACTURE AND CONNECTIVE TISSUE DISEASE

Interosseous contracture is common in the patient with rheumatoid arthritis. Unlike posttraumatic deformities, contracture may be associated with painful synovitis, ulnar digital drift, joint subluxation, and joint destruction. Secondary deformities are common and may require a combination of joint and tendon reconstruction and releases (5,8,35,37). It is beyond the scope of this chapter to discuss correction of rheumatoid ulnar drift, intrinsic tenodesis, and spiral oblique retinacular ligament reconstruction (see Chapter 70).

### SWAN-NECK DEFORMITIES

Swan-neck deformities are more common in the arthritic hand but may develop after trauma, with severe intrinsic tightness. In general, there must be a physiologic predisposition to (passive) PIP joint hyperextension (present in many patients with connective tissue inflammatory diseases). In addition, intrinsic tightness, whether clinical or subclinical, is a requirement for this deformity, characterized by the combination of PIP joint hyperextension and DIP joint flexion. At the PIP joint, there is (secondary) laxity of the volar plate, dorsal subluxation of the lateral bands, and contracture of the collateral ligaments, which makes it difficult for the patient to initiate PIP flexion, at first. With time, the deformities may become fixed.

In addition to intrinsic muscle imbalance, there are other causes of swan-neck deformity in patients with systemic arthritis. Extrinsic tightness in a patient with palmar subluxation of the proximal phalanx but no ulnar drift increases tension in the extrinsic extensor central slip, producing PIP hyperextension. In such a case, the intrinsic tightness test will be negative, but the extrinsic tightness test is positive. Further, there are patients who have coexisting intrinsic and extrinsic tightness. Such individuals demonstrate marked resistance or inhibition of passive PIP joint flexion at the extremes of both the intrinsic and extrinsic tightness tests. In these, the PIP joint is “least tight” when the MP joint is held at about 30° to 40° of flexion; and it is “most tight” at maximal MP flexion and also at maximal MP extension. Flexor tendon rupture (especially of the flexor superficialis), PIP joint volar plate laxity, and DIP joint destruction resulting in terminal extensor tendon rupture all may produce swan-neck deformities. In such problems, testing for intrinsic and extrinsic tightness will not necessarily limit passive PIP joint flexion until and unless the PIP deformity becomes fixed.

#### *Operative Technique*

Static swan-neck deformity results from secondary contracture of the PIP joint collateral ligaments and fixed dorsal luxation of the lateral bands. Release of the intrinsics alone will not restore normal balance and physiologic tendon function. Such fingers need intrinsic release (proximal or distal release, as appropriate), restoration of DIP joint extension—or tenodesis in an extended position—and correction of the volar plate–ligament incompetence at the PIP joint. If the PIP joint extension contracture is fixed, perform dorsal capsulectomy and serial sectioning of some, or the majority, of the collateral ligaments. To achieve treatment goals, combine the PIP joint and intrinsic releases with an intrinsic tenodesis (Fig. 63.11).

***Figure 63.11.*** Intrinsic tenodesis is performed when tightness is associated with proximal interphalangeal (PIP) joint palmar plate laxity. Proximal intrinsic release is done on one side of the finger (typically the ulnar side). The other intrinsic tendon is detached proximally, but its lateral band is kept attached to its normal distal phalangeal insertion and then passed proximally, palmar to Cleland's ligament. The tendon is inserted into bone by suture or anchor with the PIP joint held flexed about 30° to 40°. (From Peimer CA. Intrinsic Muscle Dysfunction and Contractures. In: *Surgery of the Hand and Upper Extremity.* Peimer CA, ed. New York: McGraw-Hill, 1996:1559, with permission.)

- Approach fingers dorsally, through a curvilinear longitudinal incision centered at the PIP joint, producing the releasing incision described earlier.
- Divide the ulnar lateral band as for a standard (proximal or distal) intrinsic release. Then detach the radial lateral band proximally, and dissect distally over the middle phalanx, carefully separating it from the intact central slip, and continuing dissection to the middle third of the middle phalanx. Keep the terminal tendon attached distally.
- Pass the dissected tendon slip in a proximal direction, keeping it palmar to the axis of the PIP joint motion and palmar to Cleland's ligament, with gentle dissection via a small curved clamp.
- In the majority, anchor the tendon into bone with the PIP joint flexed about 30°; the joint may be pinned temporarily.

This operation reverses intrinsic tightness, releases the PIP joint, creates a volar check-rein (ligament) at the PIP joint, and increases extensor tenodesis in the terminal tendon to improve DIP joint extension.

In a particular case, the tissue condition (or surgeon preference) may dictate using the ulnar lateral band rather than the radial one, and there is not a significant technical difference. The goal of the operation is to tenodese the PIP joint in about 30° flexion. Postoperative dressings protect this position.

Begin a therapy program within a very few days of operation—this is critical to prevent fixed PIP joint contracture and tendon adhesions. Hand therapists can fabricate a custom digital extension-block splint that allows active PIP flexion and extension to about 30° to 35° during active and passive exercises. Beginning at about 4–5 weeks after surgery, allow active PIP joint extension *out* of the splint, but continue splint protection for 6–8 weeks after surgery.

***Alternative Operative Technique***

An alternative to intrinsic tenodesis is the creation of a spiral oblique retinacular ligament (SORL), but this requires a free tendon graft.

- Suture the graft into the normal insertion of the terminal extensor tendon at the distal phalanx, and then pass proximally, but diagonally, across the palmar surface of the fibro-osseous canal, staying dorsal to the neurovascular bundles.
- Suture it into the proximal phalanx, volar and proximal to the PIP joint (Fig. 63.12).

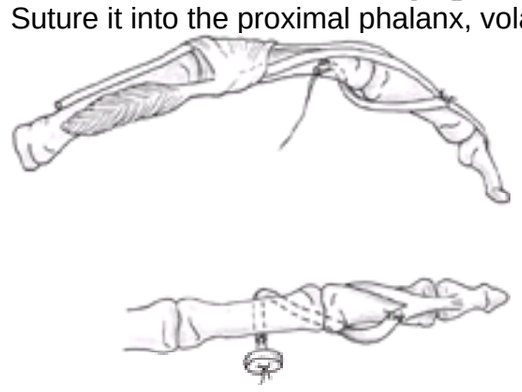

***Figure 63.12.*** Spiral oblique retinacular ligament (SORL) reconstruction follows the principles of intrinsic tenodesis but is utilized when Cleland's ligament is inadequate or the dorsal tendons unsuitable. A tendon graft is needed and is passed from distal to proximal across the fibro-osseous canal, but dorsal to the neurovascular bundles. It is inserted into bone with the PIP joint flexed 30° to 40°. (From Peimer CA. Intrinsic Muscle Dysfunction and Contractures. In: *Surgery of the Hand and Upper Extremity.* Peimer CA, ed. New York: McGraw-Hill, 1996:1559, with permission.)

This reconstruction needs a more extensive dissection than intrinsic tenodesis, in addition to the need for a tendon graft, and probably should be reserved for patients who do not otherwise have adequate stability of Cleland's ligament to act as a check to retain an intrinsic tendon palmar to the axis of PIP motion. Alternatively, one can reasonably consider passing the native intrinsic tendon, if available (as described earlier), across the flexor surface, as with the SORL, to avoid tendon graft where dorsal tissues allow native correction but Cleland's ligament still does not provide a useful check-rein.

## PITFALLS AND COMPLICATIONS

The most common problem accompanying intrinsic tightness and contractures is failure to recognize the underlying cause of limited PIP motion following injury. Intrinsic contractures are far more common than generally appreciated. Adequate correction requires accurate diagnosis. When active PIP flexion is limited as a result of posttraumatic hand edema, suspect intrinsic tightness and impending contractures and perform an intrinsic tightness test. Prompt institution of intrinsic muscle-stretching exercises and regular supervised therapy will often prevent the development of deformity and fixed contractures.

Surgical release of the intrinsic muscles, when required, should not be considered an end in itself, but rather a means to an end—a second chance at therapy. Intrinsic contracture destroys the delicate balance of the hand. Intrinsic release will not achieve functional improvement unless these very demanding and unforgiving small joints and tendons are made to glide in order to regain the full range of motion in the postoperative interval. Select patients carefully, and make every effort to help them understand the crucial role they will play in their own recovery. Patients who are not intellectually and emotionally committed to a recovery that requires tediously repetitive therapeutic exercises, including frequent hand therapy and office visits, should not undergo the procedure.

## ACKNOWLEDGMENTS

The author wishes to acknowledge John A. Nyquist for the illustrations in this chapter, and Frances S. Sherwin for editorial assistance.

### CHAPTER REFERENCES

Each reference is categorized according to the following scheme: *, classic article; #, review article; !, basic research article; and +, clinical results/outcome study.

+ 1. Brandsma JW, Schreuders TA, Birke JA, et al. Manual Muscle Strength Testing: Intraobserver and Interobserver Reliabilities for the Intrinsic Muscles of the Hand. *J Hand Ther* 1995;8A:185.

* 2. Bunnell S. Ischemic Contracture, Local, in the Hand. *J Bone Joint Surg Am* 1953;35:88.

* 3. Bunnell S, Doherty EW, Curtis RM. Ischemic Contracture, Local in the Hand. *Plast Reconstr Surg* 1948;3:424.

+ 4. Buschbacher R. Side-to-side Confrontational Strength Testing for Weakness of the Intrinsic Muscles of the Hand. *J Bone Joint Surg Am* 1997;793:401.

+ 5. Ellison MR, Flatt AE, Kelly RJ. Ulnar Drift of the Fingers in Rheumatoid Disease. *J Bone Joint Surg Am* 1971;53:1061.

! 6. Eyler DL, Markee JE. The Anatomy and Function of the Intrinsic Musculature of the Fingers. *J Bone Joint Surg Am* 1954;36:1.

+ 7. Finocohietto R. Retraction de Volkmann de los Musculos Intrinsicos de las Manos. *Bol Trab Soc Chir* 1920;4:31.

+ 8. Flatt AE. Some Pathomechanics of Ulnar Drift. *Plast Reconstr Surg* 1966;37:295.

# 9. Flatt AE. *The Care of Congenital Anomalies.* St. Louis, MO: CV Mosby, 1977:64.

+ 10. Harris C Jr, Riordan DC. Intrinsic Contracture in the Hand and Its Surgical Treatment. *J Bone Joint Surg Am* 1954;36:10.

+ 11. Honing ML, Kon M. Dysfunctional Postures of the Hand as Part of a Conversion Reaction. *J Hand Surg* 1996;21B:271.

+ 12. Jensen CB, Rayan GM, Davidson R. First Web Space Contracture and Hand Function. *J Hand Surg* 1993;18A:516.

+ 13. Johanson ME, Skinner SR, Lamoreuz LW. Phasic Relationships of the Intrinsic and Extrinsic Thumb Musculature. *Clin Orthop* 1996;322A:120.

* 14. Kaplan EB. Anatomy, Injuries and Treatment of the Extensor Apparatus of the Hands and the Digits. *Clin Orthop* 1959;13:24.

# 15. Kaplan EB, Smith RJ. Kinesiology of the Hand and Wrist and Muscular Variations of the Hand and Forearm. In: Spinner MB, ed. *Kaplan's Functional and Surgical Anatomy of the Hand*, 3rd ed. Philadelphia: JB Lippincott, 1984:283.

+ 16. Kozin SH, Porter S, Clark P, Thoder JJ. The Contribution of the Intrinsic Muscles to the Grip and Pinch Strength. *J Hand Surg* 1999;24A:64.

+ 17. Krylow AM, Rymer WZ. Role of Intrinsic Muscle Properties in Producing Smooth Movements. *INT ENA Trans Biomed Eng* 1997;44:165.

+ 18. Lee FS, Gellman H. Reconstruction of Intrinsic Hand Deformities. *Hand Clin* 1998;14:499.

+ 19. Lees VC, Wren C, Elliot D. Internal Splints for Prevention of First Web Contracture Following Severe Disruption of the First Web Space. *J Hand Surg* 1994;19:560.

! 20. Linscheid RL, An KN, Gross RM. Quantitive Analysis of the Intrinsic Muscles of the Hand. *Clin Anat* 1991;4:265.

+ 21. Mahaffey P. The Contribution of the Intrinsic Muscles to Grip and Pinch (letter). *J Hand Surg* 1999;24:870.

! 22. Marzke MW, Toth N, Schick K, et al. EMG Study of Hand Muscle Recruitment during Hard Hammer Percussion Manufacture of Oldowan Tools. *Am J Anthropol* 1998;105:315.

+ 23. Ortiz JA, Berger RA. Compartment Syndrome of the Hand and Wrist. *Hand Clin* 1998;14:405.

+ 24. Palmer DT, Horn LJ, Harmon RL. Botulinum Toxin Treatment of Lumbrical Spasticity: A Brief Report. *Am J Phys Med Rehabil* 1998;77:348.

+ 25. Parkes A. The Lumbrical-Plus Finger. *J Bone Joint Surg Br* 1971;53:236.

+ 26. Pomerance JF, Keenan MA. Correction of Severe Spastic Flexion Contractures in the Nonfunctional Hand. *J Hand Surg* 1996;21:828.

+ 27. Pratt DR, Bunnell S, Howard LD Jr. Mallett Finger: Classification and Methods of Treatment. *Am J Surg* 1977;93:573.

+ 28. Schrueders TA, Stam HJ. Strength Measurements of the Lumbrical Muscles. *J Hand Ther* 1996;9:303.

+ 29. Shin AY, Chambers H, Wilkins KE, Bucknell A. Suction Injuries in Children Leading to Acute Compartment Syndrome of the Interosseous Muscles of the Hand: Case Reports. *J Hand Surg* 1996;21:675.

+ 30. Smith RJ. Nonischemic Contractures of the Intrinsic Muscles of the Hand. *J Bone Joint Surg Am* 1971;53:1313.

+ 31. Smith RJ. Balance and Kinetics of the Fingers under Normal and Pathalogical Conditions. *Clin Orthop* 1974;104:92.

* 32. Smith RJ. Intrinsic Muscles of the Fingers: Function, Dysfunction and Surgical Reconstruction. *Instr Course Lect* 1975;24:200.

# 33. Smith RJ. Surgery of the Hand in Cerebral Palsy. In: Pulvertaft RG, ed. *Operative Surgery, The Hand*, 3rd ed. London: Butterworth, 1977:215.

# 34. Smith RJ. Intrinsic Contracture. In: Green DP, ed. *Operative Hand Surgery*. New York: Churchill Livingstone, 1988:609.

+ 35. Smith RJ, Kaplan EB. Rheumatoid Deformities at the Metacarpophalangeal Joints of the Fingers: A Correlated Study of Anatomy and Pathology. *J Bone Joint Surg Am* 1967;49:31.

+ 36. Tajima T. Treatment of Post-Traumatic Contracture of the Hand. *J Hand Surg* 1988;13B:118.

+ 37. Thompson JS, Littler JW, Upton J. The Spiral Oblique Retinacular Ligament (SORL). *J Hand Surg* 1978;3:482.

! 38. Van Sint Jan S, Rooze M. Anatomical Variations of the Intrinsic Muscles of the Thumb. *Anat Rec* 1996;238:120.

+ 39. von Schroeder HP, Botte MJ. Definitions and Terminology of Compartment Syndrome and Volkmann's Ischemic Contracture of the Upper Extremity. *Hand Clin* 1998;14:331.

# CHAPTER 64

# BURN CONTRACTURES

*Peter J. Stern and Kevin P. Yakuboff*

**P. J. Stern:** Department of Orthopaedic Surgery, University of Cincinnati College of Medicine, Cincinnati, Ohio 45267.
**K. P. Yakuboff:** Department of Surgery, Division of Plastic, Reconstructive and Hand Surgery, Shriners Burns Institute, Cincinnati, Ohio 45267.

Principles of Soft-Tissue Coverage
Thumb Reconstruction
Adduction Contracture
Opposition, Extension, and Flexion Contractures
Inadequate Thumb Length
Pollicization of the Index Finger
The Proximal Interphalangeal Joint
Release of Contractures
Burn Syndactyly
Extension Contractures of the Wrist and Metacarpophalangeal Joints
Release of Extensor Contractures
Elbow Contractures
Resection of Heterotopic Bone
Axillary Contractures
Free-Tissue Transfer
Chapter References

Burns are a major health hazard, second only to motor vehicle accidents as the leading cause of accidental death in the United States (10). Despite aggressive techniques of acute burn wound management, crippling hand deformities occur. In a severe burn, the hand, which accounts for 5% of the total body surface area, is often neglected as attention is focused on helping the burn victim to survive. By the time it has been ascertained that the patient will survive, fixed contractures that are functionally disabling and aesthetically displeasing often have developed, and surgical reconstruction may be indicated (1,12,22,24).

First-degree and superficial second-degree burns heal satisfactorily without tissue replacement. Deep second-degree (i.e., partial-skin-thickness), third-degree (i.e., full-skin-thickness), and fourth-degree (i.e., tendon, bone, nerve, or joint) burns that are not debrided and covered with skin grafts or flaps heal by granulation tissue, producing scar and contractures. Early wound closure and splinting are essential to prevent contractures during the acute burn period and to minimize the necessity for secondary reconstruction. Beasley observed that the triad of edema, inflammation, and especially immobility is responsible for the deformities produced by thermal injuries (7). He further pointed out that the severity of the deformities is directly proportional to the amount of time a wound remains open.

Before undertaking upper extremity burn reconstruction, several factors require consideration. First, the surgeon must assess the functional needs of the patient. There is no reason to launch a series of reconstructive procedures if a patient has fully adjusted to his condition and is able to carry out the activities of daily living as easily as before the burn (17). Having decided to proceed with reconstruction, remember that other priority areas, particularly the head and neck, may require surgical correction; if a large area of body surface has been burned, unscarred skin may be at a premium. Therefore, the surgeon must plan for the appropriate allocation of skin. Preoperative radiographs are mandatory before any procedure involving the mobilization of joints.

Complete restoration of joint motion may not be possible with a soft-tissue release, because the articular surfaces may be incongruous on account of sepsis, dislocation, or heterotopic ossification. Although both extremities may be burned and require reconstruction, it may be practical to reconstruct only one extremity because of limited skin availability, leaving the other as an assistive appendage. If the entire extremity including the axilla is burned, reconstruction should proceed in a proximal to distal fashion; shoulder and elbow mobility should be restored before hand procedures are performed. Full hand motion is useless if elbow and axillary contractures preclude positioning the hand in space (23). Reconstructive procedures should preferably not be performed through scar that is hypertrophic and red. Wait until the scar has matured, a process that can be accelerated with the use of elastic pressure garments.

## PRINCIPLES OF SOFT-TISSUE COVERAGE

The surgeon must understand certain principles of soft-tissue coverage before reconstruction of specific anatomic locations can be accomplished (Fig. 64.1). Burn contractures are corrected by scar incision, excision, or a combination of both procedures. Afterward, a soft-tissue defect exists.

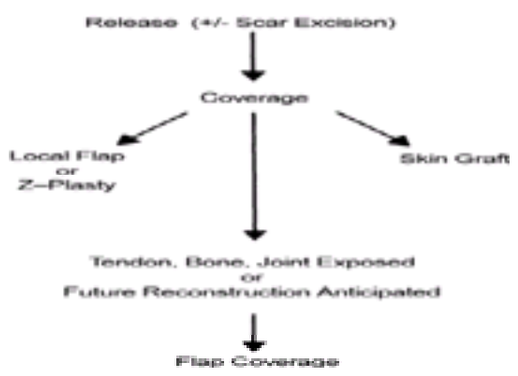


***Figure 64.1.*** Outline of the surgical treatment of burn contractures.

Most defects in the hand can be covered by a skin graft, a local flap, or a combination of the two. After a burn release, local flaps, such as Z-plasties, have limited application and should be considered for coverage only if the flap consists of pliable, unburned skin. Scarred skin usually does not tolerate the stress of being rotated as a local flap, and a significant portion of the flap may become necrotic. Local flaps, however, have the advantages of providing a good color match and usually obviate the need for a skin graft.

Skin grafting is the mainstay of treatment after contracture release or excision. Skin grafts adhere only to a well-vascularized surface. A tendon denuded of paratenon, bone without periosteum, and articular cartilage do not accept a skin graft; they require flap coverage. If simultaneous or future bone, nerve, or tendon reconstruction is being considered, a skin graft alone provides insufficient coverage.

After deciding to use a skin graft, the next choices depend on the size and location of the defect and the availability of unburned donor skin. A donor site should be inconspicuous and should match the recipient defect as closely as possible. For example, a defect on the palm would ideally be covered with adjacent, unscarred palmar skin, but transfer is rarely possible because of the limited availability of palmar skin. Unscarred skin is usually available from the lateral, hair-free portion of the groin or from the buttocks, or even from the instep of the foot. After selecting a donor site, the physician must next choose between a split-thickness skin graft and a full-thickness skin graft.

A full-thickness skin graft has several advantages in burned hand reconstruction. It is durable and is particularly suited for contact areas, such as the palm and the mobile palmar surface of the fingers. It contracts less than a split-thickness skin graft and is less conspicuous. The donor site for a full-thickness skin graft is closed primarily, so there is considerably less postoperative pain than occurs after a split-thickness skin graft, in which the reepithelializing donor site may be painful for

several days after graft harvesting.

Two circumstances in burn reconstruction make a split-thickness graft a more practical choice for coverage than a full-thickness skin graft. If the area to be covered is large, a split-thickness skin graft is indicated. The donor site for a split-thickness skin graft does not require primary closure, and more skin is available for grafting. The split-thickness skin graft can be expanded by meshing, although meshed skin is aesthetically displeasing and it tends to contract more than a nonmeshed graft. A split-thickness graft is also indicated if the recipient bed has poor vascularity, as occurs following radiation burns or with burns in which there is residual skin ulceration and low-grade sepsis.

Under certain conditions, skin grafting is not applicable. Fourth-degree burns, particularly if untreated during the acute burn period, tend to leave the extremity in a contracted, fibrotic condition (21). After the scar has been excised, there is often exposed bone, tendon, or joint, and these structures will not accept skin grafting of any kind. Furthermore, with deep fourth-degree burns, it is often necessary to perform reconstructive procedures involving the tendons (e.g., tenolysis or tendon graft) or joints (e.g., capsulotomy); coverage with a skin graft is not appropriate because the graft, even if it does take, adheres tightly to the tendon or joint, limiting mobility. Always perform scar release or scar excision before elevation of a flap. After excision of the burn cicatrix, the recipient bed may be three to four times larger than it was before. Knowing the dimensions of the recipient bed, the surgeon can better design an appropriate-size flap.

In most cases, skin flaps are unnecessary. Most burns involve injury to the skin alone, and a flap is usually not indicated. If mobile structures are exposed, however, or if future reconstruction is anticipated, do not hesitate to apply a flap.

## THUMB RECONSTRUCTION

Because the thumb contributes 40% to 50% of the function of the hand, its functional restoration is a primary goal in upper-extremity reconstruction after burns. For normal thumb function, there must be adequate length, sensibility, mobility, stability, and strength, and a satisfactory appearance. Most thermal injuries produce skin contractures that limit thumb mobility and use. In severe burns, loss of thumb length is usually secondary to a fourth-degree injury in which the distal portion or more of the thumb becomes necrotic, necessitating amputation. In children, longitudinal growth may be restricted because of a dermal contracture or direct thermal injury to the growth plates.

### ADDUCTION CONTRACTURE

Adduction contracture of the thumb, in which the thumb metacarpal is adducted toward the index finger metacarpal in a plane perpendicular to the palm, is the most common contracture of the burned thumb (26). In its mildest form, it is produced by dorsal scarring over the thumb–index web, and the palmar skin is usually not burned. Reconstruction of the thumb–index cleft can be accomplished by several techniques.

Z-Plasty

Z-plasty is indicated in circumstances where the flaps to be rotated are not severely scarred (33).

- Design it so that the palmar limb generally follows the thenar crease, the middle limb parallels the leading edge of the thumb–index cleft, and the dorsal limb parallels the ulnar aspect of the thumb metacarpal. All limbs should be of equal length.
- After incision, elevate the flaps, making them as thick as possible, and preserve any blood vessels that penetrate the base of the flap.
- Take care to avoid dividing the radial neurovascular bundle to the index finger that lies immediately beneath the palmar flap.
- After the flaps have been raised, release the previously inflated tourniquet and secure meticulous hemostasis.
- Rotate the flaps and sew them into position. Be sure that the flaps are vascularized. A flap that is dark and congested (e.g., in venous insufficiency) or one that is pale and white (e.g., in arterial insufficiency) invariably becomes necrotic. If not vascularized, return the flap to its original position and consider an alternative form of coverage, such as skin grafting.

A Z-plasty is indicated for the correction of mild linear contractures and can be performed only when the skin being rotated is relatively pliable and unburned. If the skin is scarred and fibrotic, seek alternative techniques of coverage.

#### *Skin Grafting*

- If contracture is severe, it is best to divide the contracture band sharply by incising perpendicular to it (Fig. 64.2). Carry the incision down to the fascia overlying the first dorsal interosseous muscle and to the leading edge of the adductor pollicis muscle.

***Figure 64.2.*** **A:** Thumb adduction contracture of moderate severity. **B:** A transverse release down to the adductor pollicis and first dorsal interosseous muscles (*left*), followed by application of a full-thickness skin graft (*right*). **C:** The final result 13 months after release. (From Stern PJ, Neale HE, Carter W, and MacMillan BG. Classification and Management of Burned Thumb Contractures in Children. *Burns* 1985;11:168, with permission.)

- Cover the resultant defect, which is elliptical, with a skin graft.

#### *Adductor Release and Trapezial Excision*

- If the patient has sustained a deep burn, a severe adduction contracture may result. This type of contracture involves more than skin and necessitates release of deep structures.
- Release the dermal contracture and the fascia overlying the first dorsal interosseous and adductor as outlined earlier.
- If the thumb remains tightly adducted, consider releasing the insertion of the adductor pollicis muscle from the base of the proximal phalanx of the thumb. The adductor muscle in a severe burn is often fibrotic but rarely nonfunctional; therefore, it is advisable to reinsert the muscle more proximally on the neck or shaft of the thumb metacarpal through a pull-out wire or suture anchor.
- Rarely, even after the skin and adductor muscle have been released, an adduction contraction may persist. In these instances, carry the incision down over the trapeziometacarpal joint and release the joint capsule.
- If the contracture still persists, excision of the trapezium is indicated.
- It is usually necessary to pass a temporary Kirschner pin from the thumb metacarpal into the carpus to hold the thumb in its newly released position.
- After such an extensive release, coverage with a skin graft is usually inadequate. Plan on using a distant flap, such as one from the hair-free inner aspect of the contralateral forearm, to resurface and maintain breadth of the thumb–index cleft.
- After release of any adduction contracture, postoperative splinting is mandatory. Although there are several causes of a persistent contracture—including inadequate surgical release, loss of skin graft, or the inappropriate use of burned skin or flap coverage—one of the most common causes is failure to splint the thumb metacarpal midway between palmar and radial abduction. A splint can be fabricated from thermoplastic material and lined with silicone to maintain satisfactory breadth between the thumb and index finger. Have the patient wear the splint until the wound has matured, usually 3 to 9 months. It is often helpful to alternate splinting with use of an elastic compressive glove, which also accelerates the scar maturity.

### OPPOSITION, EXTENSION, AND FLEXION CONTRACTURES

Less commonly, the thumb metacarpal may be drawn into a position of *opposition* (i.e., pronation and palmar abduction of the thumb), *extension* (i.e., when the index finger is drawn away from by a scar band between the distal radius and the thumb metacarpal), or *flexion* (i.e., when scarring over the palmar aspect of the thumb

produces flexion of the interphalangeal or metacarpophalangeal joint) (26). As in adduction contractures, all of these contractures require surgical incision with or without a scar excision, followed by appropriate soft-tissue coverage and splinting.

With opposition and extension contractures, severe flexion or hyperextension contractures of the interphalangeal or metacarpophalangeal joint of the thumb often coexist, producing articular incongruity and joint subluxation or dislocation. In such cases, particularly if there is satisfactory mobility of two of the three thumb joints, an arthrodesis of the dislocated joint in a functional position is indicated.

## INADEQUATE THUMB LENGTH

Severe burn injuries often result in loss of thumb length (20). Restoration of length can be accomplished by a number of surgical techniques. These include toe-to-hand transfer and osteoplastic reconstruction, consisting of a tube pedicle flap placed around a bone graft, followed by neurovascular island transfer for restoration of sensibility. Also possible are metacarpal osteotomy and progressive distraction and pollicization with movement of an adjacent digit, usually the index finger, on its neurovascular pedicle to the thumb position. If only a small amount of thumb length has been lost, use phalangization to increase thumb length. Release the thumb-web contracture, and proximally transpose the adductor muscle to the thumb metacarpal, making the thumb–index cleft deeper and giving the thumb more apparent length (28).

The burn may be so severe that thumb reconstruction is not feasible. The phalanges may have been amputated, and various lengths of metacarpals may be encased in a cocoon of burned skin. If thenar muscle contraction can be appreciated by manual palpation, a “mitten hand” can be created by excising the index finger metacarpal (leaving the base where the wrist flexor and extensor tendons attach). Thereby a cleft is created between the thumb and ulnar digits so that the patient can accomplish a pinch maneuver of a crude side-to-side type (Fig. 64.3).

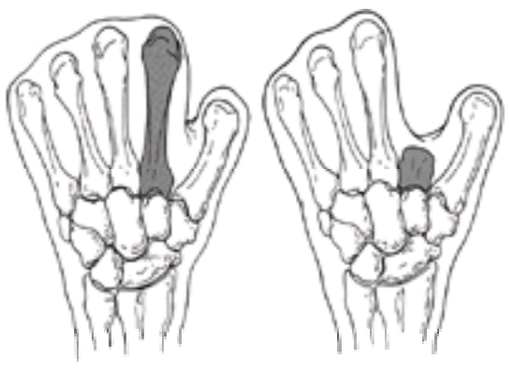

***Figure 64.3.*** **A:** “mitten hand” is created by excising the index metacarpal. A crude pinch maneuver is possible if the thenar motors are intact.

The pollicization procedure involves placing a digit (usually the index finger) on top of the remains of the thumb (20,31). Pollicization is more likely to be successful if there is an intact thumb trapeziometacarpal joint, functioning thenar musculature, and relatively good sensibility of the digit to be pollicized.

Before performing the procedure, it is advisable to excise scarred tissue in the thumb–index cleft and replace it with a skin flap from the groin or abdomen, which can later be used to resurface the cleft between the pollicized thumb and the remaining ulnar digits. After flap tissue has been transferred, perform the pollicization procedure. It is preferable to transfer the index ray, particularly if it has been damaged and is already short (Fig. 64.4). If it is absent, any other digit can be transferred.

***Figure 64.4.*** **A:** Preoperative photograph of a hand that is ideally suited for pollicization of the index finger. Neither the thumb nor the index remnant is functional. **B:** Index pollicization and application of the distal flap have resulted in creation of a useful thumb.

For conventional pollicization (e.g., aplasia of the thumb), design the incisions so that the pollicized digit can be transposed and rotated to provide skin flaps for a cleft between the thumb and the remainder of the hand. When pollicizing a burned index finger, make the incisions along the border of areas that have previously been scarred, exposing the index metacarpal shaft and the tip of the thumb.

### POLLICIZATION OF THE INDEX FINGER

- Reflect the interosseous muscles from the index metacarpal shaft. They are often fibrotic and are not useful for future motor function, as in conventional pollicizations.
- Ligate the proper digital artery to the radial side of the middle finger, and split the common digital nerve to the index and middle finger proximally as far as possible.
- Osteotomize the index finger metacarpal through its base, and remove a segment of metacarpal shaft, being careful to preserve the index metacarpophalangeal joint.
- Leave the flexor tendons to the index finger intact. If necessary, Z-lengthen the extensor tendons, which often are scarred.
- Rotate the index finger so that it can be put on top of the thumb remnant with the pulp of the pollicized digit directly facing the ulnar digits. Turn the pollicized digit so that it is 120° to 140° from the plane of the palm. It is easiest to stabilize the skeletal structure of the pollicized digit with one or two longitudinal Kirschner pins.
- Deflate the tourniquet to ensure that the pollicized digit is viable and that its vascular pedicle has not been stretched or twisted.
- Close the wound, being careful to line the thumb–index cleft with soft, pliable skin.
- Maintain skeletal pin fixation for 6–8 weeks, and maintain splinting of the thumb in wide palmar abduction for 6–9 months.

Errors in positioning of the transferred digit, inadequate bony fixation, or contracture of the thumb cleft cause the most common complications of pollicization. These can usually be prevented by careful preoperative planning and attention to intraoperative technique.

Pollicization for the severely burned hand has the advantage of being a one-stage procedure that does not require microvascular techniques. It converts two relatively useless digits into a single, functional, opposable thumb, making activities requiring opposition and prehension possible.

## THE PROXIMAL INTERPHALANGEAL JOINT

Burns of the proximal interphalangeal joint can produce flexion or extension contractures. If surgical intervention is necessary, take preoperative radiographs of the proximal interphalangeal joint to confirm that a cartilaginous space is present and that the joint is not subluxed or dislocated (8).

Burn flexion contractures may arise from scarring of the palmar skin of the proximal interphalangeal joint or from dorsal burns in which the central tendon over the

proximal interphalangeal joint is disrupted, resulting in a “burn boutonnière” deformity. They may also come from a dorsal burn over the metacarpophalangeal joint, producing a metacarpophalangeal hyperextension deformity and a proximal interphalangeal flexion deformity secondary to the tenodesis effect of the tightened flexor tendons (27). To treat these contractures successfully, determine the cause and then select an appropriate technique for surgical correction.

Mild digital flexion contractures produced by a linear scar band across the interphalangeal or metacarpophalangeal joints, with pliable skin on either side of the band, can be corrected by a single Z-plasty or a series of Z-plasties (Fig. 64.5). If there is extensive scarring of the palmar skin, incision and possible excision of the scar band will be necessary (Fig. 64.6).

***Figure 64.5.*** **A:** A linear contracture of the index finger (*left*) with pliable skin on each side of the scar band. A series of multiple Z-plasties is designed (*right*). **B:** The Z-plasties are rotated into position (*left*), and there is full digital extension after surgery.

***Figure 64.6.*** **A:** Moderately severe contracture of all digits as a result of a palmar contact burn. **B:** The burn scar was excised, the digits were pinned temporarily in extension, and a full-thickness autograft was applied. **C:** After surgery, nearly full digital extension is possible.

### RELEASE OF CONTRACTURES

- If a contracture of only the proximal interphalangeal joint exists, incise the scar transversely across the anterior aspect of the joint, extending the incision from the radial to the ulnar midaxial line (4). It is usually unnecessary to excise the contracture band completely. Carry the incision down to the flexor tendon sheath, taking care not to sever the digital nerves. They are always deep to the burn scar and are usually covered by a thin layer of fat.
- If a proximal interphalangeal flexion contracture persists after dermal release, decide whether to perform a proximal interphalangeal capsular release. If so, the flexor tendons will be exposed, and flap coverage, using an adjacent cross-finger flap or a distant flap, will be necessary to prevent tendon desiccation (15).
- If the flap procedure is not feasible, do not perform a capsular release. Accomplish coverage with a skin graft.
- Regardless of the coverage technique, deflate the tourniquet and secure meticulous hemostasis. Assess the newly extended finger for vascular integrity, because arterial inflow may be compromised by the sudden digital extension. If the digit is pale, flex it until circulation has been restored.
- Temporary proximal interphalangeal joint immobilization with an oblique transarticular Kirschner pin is often helpful.
- Cover the defect with a full-thickness skin graft that is stented with a tie over a bolus dressing.
- After the graft has taken, extension splinting at night with a silicone-lined, static splint is recommended until the graft matures.

Flexion deformities secondary to destruction of the central tendon over the dorsum of the proximal interphalangeal joint are difficult to reconstruct, because the skin over the dorsum of the joint is scarred, the central tendon has been destroyed, and usually there is a fixed contracture of the palmar plate and collateral ligaments. Consider restitution of proximal interphalangeal extension only if the joint can be passively extended and radiographs show joint congruity. If these requirements are met, excise the scarred tendon over the proximal interphalangeal joint, and advance the more proximal, unscarred, central tendon into the dorsal base of the middle phalanx.

Occasionally, elongation of the central tendon with a free graft is necessary. After the central slip has been reconstructed, pin the proximal interphalangeal joint in extension for 3 weeks; then initiate active flexion. The results of this surgery are unpredictable and often unsatisfactory. If a fixed flexion contracture exists, arthrodesis of the joint in a functional position can provide a more reliable result.

Like the boutonnière deformity, proximal interphalangeal extension contractures are difficult to treat successfully. They are caused by skin fibrosis over the dorsum of the joint or by ischemic contractures of the interosseous muscles. When the contracture is secondary to a dorsal skin burn, a simple transverse release of tightened skin and skin graft is adequate. Often, however, it is necessary to perform a tenolysis of the extensor apparatus, divide the dorsal capsule, and partially divide the dorsal, cordlike portion of the collateral ligaments. At this point, the extensor tendon over the dorsum of the proximal interphalangeal joint is usually exposed, and coverage with a local flap must be performed.

Extension contractures resulting from intrinsic tightness often can be successfully corrected. To make the diagnosis, passively extend the metacarpophalangeal joint and then passively flex the proximal interphalangeal joint; shortened, scarred, intrinsic muscles resist passive flexion. Conversely, if the metacarpophalangeal joint is passively flexed, the intrinsic muscles, whose axis of motion is palmar to the metacarpophalangeal joint and dorsal to the proximal interphalangeal joint, are relaxed, and passive proximal interphalangeal flexion is unresisted. An intrinsic release can usually be performed by excising the distal fibers of the lateral bands at the level of the neck of the proximal phalanx.

## BURN SYNDACTYLY

Dorsal burns often extend into the distally sloping interdigital clefts. During the acute burn period, it may be difficult to gain access to this area, particularly if the metacarpophalangeal joints are immobilized in the “safe” position of metacarpophalangeal flexion. Syndactyly, usually of the dorsal skin, results. The degree of syndactyly varies; in severe cases, it may extend beyond the proximal interphalangeal joint.

Indications for correction of postburn syndactyly vary. Syndactyly of any degree restricts digital abduction and makes the grasping of large, cylindrical objects difficult. The syndactylized digits are often subjected to a sudden abduction force that can lead to traumatic breakdown of the scar contracture, bleeding, and additional fibrosis. Some patients complain that they are unable to wear gloves, and others have problems with hygiene because particles of dirt collect in a pocket formed by dorsally syndactylized skin and the normal distal edge of the palmar skin.

The principles of successful treatment of burn syndactyly listed by Upton (29) are as follows:

- Use skin grafts.
- Use flaps to line the depth of the web space.
- Make certain release is adequate with slight overcorrection.

- Avoid straight-line incisions in the depth of the palmar aspect of the commissure.
- Initiate proper stent fixation of skin grafts and postoperative immobilization of the extremity.

Base your choice of technique for the release of web syndactyly on the severity of the syndactyly and the condition of the adjacent skin (3,16,19). Mild or moderate syndactyly can be treated by a Z-plasty or a local rotation flap. The lateral palmar rotation flap is particularly appealing, because it allows the surgeon to create a new interdigital cleft with supple, local, full-thickness skin that is unlikely to recontract (Fig. 64.7). Close the donor defect for rotation flaps, primarily if it is small, or cover it with a skin graft.

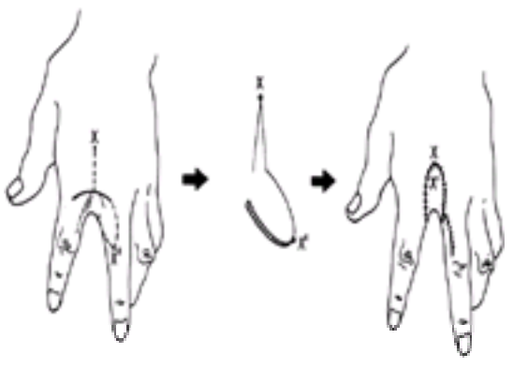

***Figure 64.7.*** A dorsal web syndactyly exists between the index and middle fingers. A lateral volar flap (*apex X'*) is designed to rotate 180° so that points *X* and *X'pr* can be opposed. In this example, the donor defect was closed primarily; however, if tension exists, a skin graft should be applied.

In severe cases of burn syndactyly, it is necessary to make a longitudinal incision of the burn cicatrix (Fig. 64.8). The incisions on the palmar and dorsal sides should extend to the bifurcation of the common digital artery. After the release has been accomplished, cover it with a thick split– or full-thickness autograft. Because the graft is placed on a concave surface, make sure that there is good contact between the graft and its recipient bed. Stent the graft into place. When you are certain the graft has taken, use night extension splinting with the digits abducted for 6–9 months.

***Figure 64.8.*** **A:** Severe dorsal burn syndactyly (*left*). Scar excision (*center*) is followed by application of a full-thickness graft (*right*). **B:** Postoperative extension (*left*) and flexion (*right*) views.

## EXTENSION CONTRACTURES OF THE WRIST AND METACARPOPHALANGEAL JOINTS

Extension contractures of the wrist and metacarpophalangeal joints occur simultaneously. These contractures usually are the result of flame burns in which the victim tightly clenches her fist or protects her face from thermal injury. Metacarpophalangeal extension contractures arise from scarred skin over the dorsum of these joints or from immobilization of the metacarpophalangeal joints in extension during the acute burn period, allowing the collateral ligaments and soft tissues around the metacarpophalangeal joints to contract (13).

Contracture severity at the level of metacarpophalangeal joints varies (13). In mild metacarpophalangeal contractures, if the wrist is dorsiflexed (i.e., the skin over the dorsum of the hand is relaxed), full, active, metacarpophalangeal flexion can be accomplished. If the wrist is passively flexed, however, metacarpophalangeal flexion is limited by tight skin over the dorsum of the wrist and hand. A dorsal transverse incision of the contracted skin at the level of the metacarpal necks is often sufficient to release the contracture. If the scar tissue of the dorsum of the metacarpophalangeal joints is thick or has been previously grafted with meshed autograft, giving the skin a corrugated appearance, it may be preferable to excise, rather than incise, the burn scar. In such instances, carry the excision down to the subcutaneous fat, taking care to preserve the dorsal veins that are nearly always deep to the burn scar.

Sometimes, metacarpophalangeal extension contractures are produced by linear bands of scar that mimic the extensor tendons. In such cases, the surgeon may make the error of not performing a deep enough release for fear of severing a tendon that is mistakenly thought to be within the burn cicatrix. This is virtually never the case. The extensor tendons lie deep to the scar in a bed of loose, areolar, connective tissue. After the release has been accomplished by incision, excision, or a combination of both, soft-tissue coverage can usually be accomplished with a skin graft.

In the case of moderate or severe metacarpophalangeal contracture, a more aggressive surgical release is necessary. The position of the metacarpophalangeal joint is fixed, regardless of wrist position, and the metacarpal heads are prominent in the palm. Metacarpophalangeal hyperextension may be so severe that the dorsal surface of the proximal phalanx may lie on top of the dorsal surface of the metacarpal. In such cases, associated flexion contractures of the proximal interphalangeal joints, caused by the flexor tenodesis effect, occur, as does destruction of the central tendon overlying the proximal interphalangeal joint. Grasping objects of any size is difficult or impossible, and often only a crude pinch maneuver between the index finger and the thumb is possible.

Release of these fixed extension contractures requires careful preoperative planning (Fig. 64.9). Contractures of the metacarpophalangeal capsule and collateral ligaments are to be expected.

***Figure 64.9.*** **A:** A dorsal burn caused combined wrist and metacarpophalangeal fixed extension contractures. **B:** Dorsal view (*left*) with outline of the proposed excision. The linear bands over the metacarpophalangeal joints contain scar, not extensor tendons. After dermal release (*right*), metacarpophalangeal capsulotomies, and temporary pinning in flexion, a large dorsal area requires skin grafting. **C:** The functional result (both hands), demonstrating excellent metacarpophalangeal flexion.

**RELEASE OF EXTENSOR CONTRACTURES**

- Release the metacarpophalangeal capsular contractures by splitting the extensor tendon longitudinally over the joint in its midportion and incising the dorsal capsule transversely.
- Release the collateral ligaments by sharply dividing the origin of the ligament from the metacarpal head, preserving the most inferior and proximal fibers to prevent lateral joint instability.
- After the collateral ligaments and dorsal capsule have been released, position the metacarpophalangeal joint in 70° of flexion by passing a pin from the metacarpal head into the proximal phalanx.
- Sometimes after metacarpophalangeal capsulotomies, the metacarpophalangeal joints and extensor tendons are exposed, and they must be covered with a distant flap. Plan ahead for such an eventuality to make sure that flap tissue is available.
- Initiate postoperative range-of-motion exercises after the skin graft has taken. Begin a program of active and passive metacarpophalangeal flexion exercises and night splinting with the metacarpophalangeal joints in flexion to prevent recontracture.

## ELBOW CONTRACTURES

Postburn elbow contractures occur frequently, and surgical correction is often necessary because limited elbow mobility directly affects the efficiency of hand, wrist, and shoulder function (25). These contractures are often subjected to the stress of sudden elbow extension, resulting in recurrent tearing of antecubital burn scars, pain, and additional fibrosis. Occasionally, burn scarring forms deep pockets that collect debris and cause hygiene problems.

Elbow flexion contractures, particularly in children, usually can be corrected by complete division of the dermal scar in the antecubital fossa. The amount of scar varies from a longitudinal band (correctable by Z-plasty, local flap, or skin graft) to diffuse scarring (Fig. 64.10 and Fig. 64.11). Regardless of technique, take care to extend the release to subcutaneous tissue and avoid injuring anterior neurovascular structures. For severe contractures, consider division of deeper structures, which may include lengthening the biceps tendon, dividing the brachialis fascia, and anterior elbow capsulotomy. When such structures are divided, plan for flap coverage.

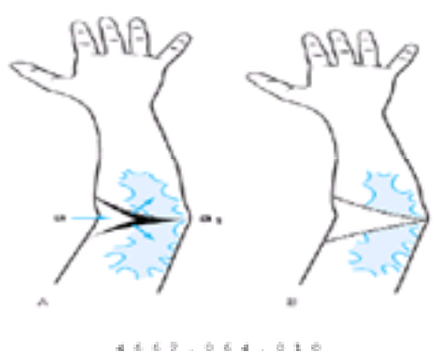

***Figure 64.10.*** Y–V flap. **A:** Scaring of the ulnar aspect of the antecubital fossa treated with a Y–V advancement flap (*a* is advanced to *a1*). **B:** Flap sewn into position. (From Kurtzman LC, Stern PJ. Upper Extremity Burn Contractures. *Hand Clin* 1990;6:261, with permission.)

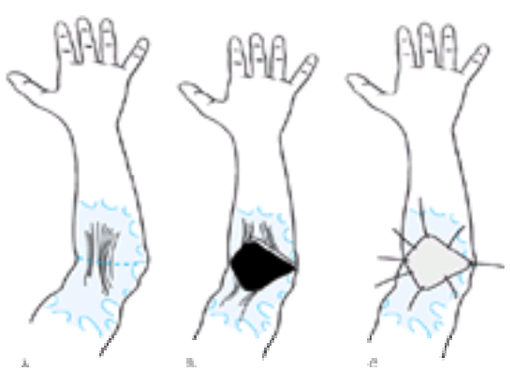

***Figure 64.11.*** Full-thickness skin graft. **A:** *Dotted line* indicates incision for release of eschar, and the incision must extend to normal skin on the radial and ulnar sides. **B:** Diamond-shaped defect after release. **C:** Full-thickness skin graft applied for coverage. (From Kurtzman LC, Stern PJ. Upper Extremity Burn Contractures. *Hand Clin* 1990;6:261, with permission.)

One of the most devastating problems affecting function in the burn patient is heterotopic ossification bridging the elbow joint (Fig. 64.12) (14). The ossification forms in the acute burn period, is usually associated with a concomitant deep burn to the elbow, and is found in approximately 2% of patients with elbow burns. The first clinical signs of heterotopic ossification appear 4–6 weeks after the burn injury and are usually heralded by complaints of increasing elbow pain and a rather rapid decrease in range of motion. Initial radiographs may be unremarkable except for soft-tissue swelling, but follow-up radiographs (within 3 months) show ossification bridging the elbow joint. If heterotopic bone forms bilaterally, functional impairment is severe, and the patient will have difficulty performing even simple activities of daily living.

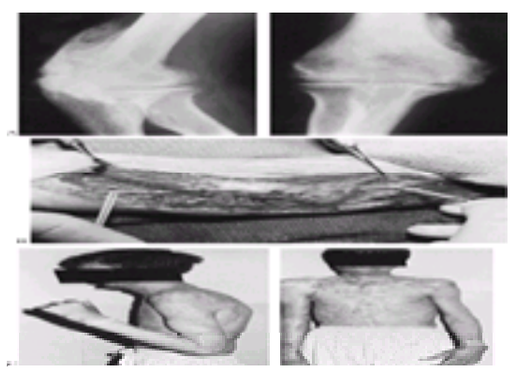

***Figure 64.12.*** **A:** Radiographs demonstrate heterotopic ossification bridging the posteromedial surface of the elbow. The patient's elbow was rigidly fixed in extension. **B:** An operative photograph shows that the ulnar nerve (marked by *loops*) proximal and distal to the elbow joint is encased by heterotopic ossification. It was unroofed and transposed anteriorly. **C:** After heterotopic bone excision, elbow flexion and extension were restored.

Surgical treatment of heterotopic bone must be timed appropriately. If the bone is excised when it is immature, it may reform, making a second surgical excision even more difficult. Usually, it takes 8–16 months for the bone to mature. Diagnostic studies used to assess bone maturity such as serial technetium phosphate bone scans and measurement of serum alkaline phosphatase levels may be misleading. Despite the potential for bone reformation, we prefer early excision (8–12 months), particularly if there is ulnar nerve compromise.

The new bone usually forms posteromedially, and the ulnar nerve may be encased in it (30). Test motor and sensory function of the ulnar nerve before surgery. If function is impaired, an electromyogram and nerve conduction studies are recommended. Ulnar nerve function can be anticipated to improve following decompression

(11).

**RESECTION OF HETEROTOPIC BONE**

- Perform surgical excision of the bone through a long, posteromedial elbow incision.
- Identify the ulnar nerve, proximal and distal to the new bone. If bone encases the nerve, it is helpful to unroof and transpose it anteriorly.
- After the nerve has been mobilized, it is usually necessary to perform an elbow arthrotomy, because there are often intraarticular adhesions that must be lysed.
- Detach and reinsert the medial collateral ligament complex. After the skin has been closed, record the range of motion, and splint the elbow for 3–5 days in 90° of flexion. Then begin active and assisted passive range-of-motion exercises.

Results of surgical excision of heterotopic ossification about the elbow have shown significant improvement in range of motion in most cases (11). The worst results usually occur when there is complete ankylosis preoperatively.

Diphosphonates, which are potent inhibitors of mineralization and bone resorption, have been shown to be of some benefit in the prevention of heterotopic bone formation in patients undergoing total hip arthroplasty. There is, however, no evidence that these compounds are effective in preventing bone from reforming after excision in the burn victim. Other ancillary treatment modalities include low-dose irradiation or oral indomethacin.

## AXILLARY CONTRACTURES

Axillary contractures restrict shoulder motion, particularly abduction and forward flexion (6,18). If surgical procedures are planned for more distal portions of the extremity, correct the axillary contracture first to facilitate access to these areas.

The extent of an axillary contracture varies. Most commonly, a band extends anteriorly from the chest to the upper arm, parallel to the inferior edge of the pectoralis major muscle. There may also be a posterior band from the chest to the brachium that follows the inferior and lateral edge of the latissimus dorsi. Often, the deep axillary skin in the apex of the axilla is unburned; in severe burns, however, the axillary fossa may be obliterated completely.

Surgical release of an axillary contracture involves the same principles discussed earlier in this chapter. In most cases, the treatment of choice is incision (often combined with excision) of the scar. Carry the dissection down to the axillary fat. It is often helpful to divide the fascia over the latissimus dorsi or pectoralis major muscles. After the release, obtain coverage with a thick split-thickness skin graft.

Although most axillary contractures can be successfully managed by release and skin grafting, this technique has the disadvantage of prolonged postoperative splinting, occasional graft loss, and linear contracture along the graft edges. To avoid these problems, thin regional fasciocutaneous flaps have been successfully used (2).

## FREE-TISSUE TRANSFER

The majority of acute and reconstructive problems encountered in the thermally injured upper extremity can be solved with the previously described skin grafting techniques. Complex wounds, however, that have exposed joints, bone, or tendons resulting from thermal injury or extensive scar release require flap coverage. Before microsurgical free-tissue transfer, these wounds were covered with distant pedicled flaps. The groin flap was commonly used for complex hand wounds (Fig. 64.13).

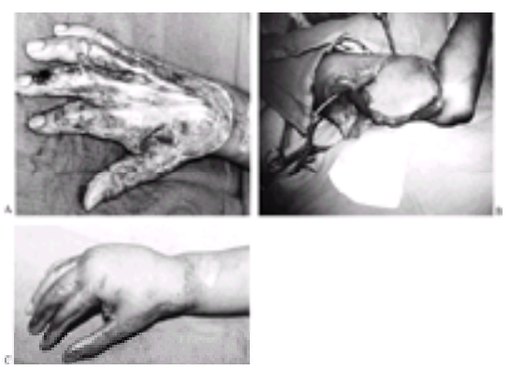

***Figure 64.13.*** **A:** Deep contact burn with exposed tendons. **B:** Free microvascular lateral arm flap elevated from injured extremity for transfer to hand. **C:** Late follow-up showing excellent resurfacing.

Pedicle flaps remain a valuable tool but have limitations. Immobility and dependent positioning of the involved extremity required for use of a groin flap are liabilities in the rehabilitation of the acutely burned patient. In addition, in large burns, availability of pedicled skin flaps may be severely limited. Early wound coverage using free-tissue transfer techniques is a single-stage procedure that allows for earlier rehabilitation and salvage of the extremity (5). Free muscle flaps are more likely to be available even after extensive burns. They are particularly useful in reconstructive cases after patients have finished the acute phase of their burn care.

In the acute burn setting, free-tissue transfer is a valuable tool when growth plates, joints, tendons, and bone become exposed, as usually occurs in deep contact burns and high-voltage electrical injuries. Deep contact burns usually are the result of contacting mufflers, printing presses, or roller presses (Fig. 64.13). When such a burn occurs on the dorsum of the hand, the entire extensor mechanism is at risk. Early debridement and coverage with a free flap will prevent loss of the extensor mechanism. The flaps chosen for this problem depend on the size of the wound and the availability of donor sites. The lateral arm flap and temporalis fascia flap are useful choices in this situation.

Electrical injuries (high voltage) to the upper extremity are devastating. They frequently result in massive skin and muscle loss. The amputation rate for high-voltage injury approaches 50% (32). Preservation of vital structures remaining after radical debridement and limb salvage requires early coverage with large free flaps (9). Usually, latissimus dorsi or rectus abdominal muscle flaps are required to cover the entire defect. In addition, free-muscle transfer may be used to restore function in extremities severely damaged by high-voltage electrical injuries. Most commonly, a free gracilis muscle transfer is used to restore finger flexion.

Restoration of basic prehensile function in hands with established severe burn scar deformity is a formidable challenge (Fig. 64.14). To correct this mitten hand deformity, multiple problems need to be addressed: A basic thumb must be created, as well as a first web space. Additionally, established contractures in the digits and wrist must be released. Ideally, a toe transfer offers the best result in thumb reconstruction. Both the great toe and the second toe are acceptable choices in restoring prehensile ability in this deformity. We prefer the second toe in reconstructing the mitten hand and reserve the great toe for isolated thumb reconstruction.

***Figure 64.14.*** **A:** Mitten hand deformity after a burn. **B:** Second toe prepared for microvascular transfer to thumb. **C:** Five-year follow-up showing thumb extension. **D:**

Thumb flexion allowing prehension.

## CHAPTER REFERENCES

Each reference is categorized according to the following scheme: *, classic article; #, review article; !, basic research article; and +, clinical results/outcome study.


# 1. Achauer BM. The Burned Hand. In: Green DP, Hotchkiss RN, Pederson WC, eds. *Operative Hand Surgery*, 4th ed. Philadelphia: Churchill Livingstone, 1999:2045.

+ 2. Achauer BM, Spenler CW, Gold ME. Reconstruction of Axillary Burn Contractures with the Latissimus Dorsi Fasciocutaneous Flap. *J Trauma* 1988;28:211.

+ 3. Alexander JW, MacMillan BG, Martel L. Correction of Postburn Syndactyly: An Analysis of Children with Introduction of the VM-plasty and Postoperative Pressure Inserts. *Plast Reconstr Surg* 1982;70:345.

+ 4. Alexander JW, MacMillan BG, Martel L, Krummel R. Surgical Correction of Postburn Flexion Contractures of the Fingers in Children. *Plast Reconstr Surg* 1981;68:218.

+ 5. Asko-Seljavaara S, Pitkanen J, Sundell B. Microvascular Free Flaps in Early Reconstruction of Burns in the Hand and Forearm. Case Reports. *Scand J Plast Reconstr Surg* 1984;18:139.

# 6. Beasley RW. Burns of the Axilla and Elbow. In: Converse JM, ed. *Plastic Reconstructive Surgery* Philadelphia: WB Saunders, 1977:3391.

* 7. Beasley RW. Secondary Repair of Burned Hands. 1981 [classical article]. *Hand Clin* 1990;6:319.

# 8. Belliappa PP, McCabe SJ. The Burned Hand. *Hand Clin* 1993;9:313.

+ 9. Chick LR, Lister GD, Sowder L. Early Free-flap Coverage of Electrical and Thermal Burns [comments]. *Plast Reconstr Surg* 1992;89:1013.

* 10. Demling RH. Burns. *N Engl J Med* 1985;313:1389.

+ 11. Djurickovic S, Meek RN, Snelling CF, et al. Range of Motion and Complications after Postburn Heterotopic Bone Excision about the Elbow. *J Trauma* 1996;41:825.

+ 12. Fleegler EJ, Yetman RJ. Rehabilitation after Upper Extremity Burns. *Orthop Clin North Am* 1983;14:699.

+ 13. Graham TJ, Stern PJ, True MS. Classification and Treatment of Postburn Metacarpophalangeal Joint Extension Contractures in Children. *J Hand Surg [Am]* 1990;15:450.

+ 14. Hoffer MM, Brody G, Ferlic F. Excision of Heterotopic Ossification about Elbows in Patients with Thermal Injury. *J Trauma* 1978;18:667.

+ 15. Jackson IT, Brown GE. A Method of Treating Chronic Flexion Contractures of the Fingers. *Br J Plast Surg* 1970;23:373.

+ 16. Krizek TJ, Robson MC, Flagg SV. Management of Burn Syndactyly. *J Trauma* 1974;14:587.

# 17. Kurtzman LC, Stern PJ. Upper Extremity Burn Contractures. *Hand Clin* 1990;6:261.

+ 18. Law EJ, Hoefer RW, MacMillan BG. Clinical Experience with Axillary Burns in Children. *J Trauma* 1972;12:34.

+ 19. MacDougal B, Wray RCJ, Weeks PM. Lateral-Volar Finger Flap for the Treatment of Burn Syndactyly. *Plast Reconstr Surg* 1976;57:167.

+ 20. May JWJ, Donelan MB, Toth BA, Wall J. Thumb Reconstruction in the Burned Hand by Advancement Pollicization of the Second Ray Remnant. *J Hand Surg [Am]* 1984;9:484.

+ 21. Nuchtern JG, Engrav LH, Nakamura DY, et al. Treatment of Fourth-degree Hand Burns. *J Burn Care Rehabil* 1995;16:36.

# 22. Peterson HD, Elton R. Reconstruction of the Thermally Injured Upper Extremity. *Major Probl Clin Surg* 1976;19:148.

+ 23. Robson MC, Smith DJJ, Vander ZA, Roberts L. Making the Burned Hand Functional. *Clin Plast Surg* 1992;19:663.

# 24. Salisbury RE, Bevin AG. *Atlas of Reconstructive Burn Surgery.* Philadelphia: WB Saunders, 1981:108.

+ 25. Stern PJ, Law EJ, Benedict FE, MacMillan BG. Surgical Treatment of Elbow Contractures in Postburn Children. *Plast Reconstr Surg* 1985;76:441.

+ 26. Stern PJ, Neale HW, Carter W, MacMillan BG. Classification and Management of Burned Thumb Contractures in Children. *Burns Incl Therm Inj* 1985;11:168.

+ 27. Stern PJ, Neale HW, Graham TJ, Warden GD. Classification and Treatment of Postburn Proximal Interphalangeal Joint Flexion Contractures in Children. *J Hand Surg [Am]* 1987;12:450.

+ 28. Tubiana R, Roux JP. Phalangization of the First and Fifth Metacarpals. Indications, Operative Technique, and Results. *J Bone Joint Surg Am* 1974;56:447.

+ 29. Upton J. Discussion of Correction of Postburn Syndactyly: An Analysis of Children with Introduction of the V-M Plasty and Postoperative Pressure Inserts. *Plast Reconstr Surg* 1982;70:353.

+ 30. Vorenkamp SE, Nelson TL. Ulnar Nerve Entrapment due to Heterotopic Bone Formation after a Severe Burn. *J Hand Surg [Am]* 1987;12:378.

+ 31. Ward JW, Pensler JM, Parry SW. Pollicization for thumb reconstruction in severe pediatric hand burns. *Plast Reconstr Surg* 1985;76:927.

# 32. Yakuboff KP, Kleinert H. *Electrical Injuries in Occupational Hand and Upper Extremity Injuries and Diseases.* Philadelphia: Hanley & Belfus, 1991:249.

# 33. Yakuboff KP, Kurtzman LC, Stern PJ. Acute Management of Thermal and Electrical Burns of the Upper Extremity. *Orthop Clin North Am* 1992;23:161.

# CHAPTER 65

# MANAGEMENT OF VOLKMANN'S CONTRACTURE

*Richard H. Gelberman and Michael J. Botte*

**R. H. Gelberman:** Department of Orthopaedic Surgery, Barnes Hospital, St. Louis, Missouri, 63110.
**M. J. Botte:** Division of Orthopaedic Surgery, Scripps Clinic, La Jolla, California, 92037.

Historical Aspects
Pathogenesis of Ischemic Contracture
Classification of Contractures
Mild Contractures
Moderate Contractures
Severe Contractures
Treatment
Mild Contractures
Moderate to Severe Contractures
Reconstruction of Hand Deformities
Free Vascularized Tissue Transfers
Chapter References

## HISTORICAL ASPECTS

Acute compartment syndrome produces high interstitial tissue fluid pressures that can reduce capillary perfusion below the level necessary for tissue viability (1,3,7,8 and 9,11,22,26,29,35,36,58,59,68,81,93,97,98 and 99). If the compartment syndrome is sustained or untreated, ischemia results in irreversible muscle and nerve damage (12,19,23,25,28,33,34,35 and 36,40,64,70,74,77,79,86,87,96). Muscle then undergoes necrosis, fibrosis, and contracture. Concomitant nerve injury results in further muscle dysfunction, sensibility deficits, or chronic pain. The result is a dysfunctional limb with varying amounts of deformity, stiffness, or paralysis, known as Volkmann's ischemic contracture (4,5,10,13,25,30,31 and 32,37,39,40 and 41,44,45,46,47 and 48,50,51,56,61,62,63,64,65,66,67 and 68,71,72,74,75,76,77 and 78,80,81,84,85,90,91,92 and 93,97,100,101). See Chapter 13 on Compartment Syndrome.

In 1881, Richard von Volkmann first described this condition, noting paralysis and subsequent limb contracture that followed the application of tight, constricting bandages to an injured limb (93). In 1922, Brooks described a similar condition and believed venous obstruction was a factor in the contracture formation (12). Arterial spasm or injury were subsequently indicated as causes by Leriche and Griffiths (32,49). In an attempt to prevent the contracture described by Volkmann, Bardenheur in 1911 discussed the use of forearm fasciotomy (2). His “aponeurectomy” consisted of division of the deep antecubital and forearm fascia. In 1922, Murphy also suggested fasciotomy as a means of prevention of paralysis and contracture when pressure was increased within a fascia-enclosed muscle space following hemorrhage or edema (65). Although the pathogenesis was not clearly understood, in 1926 Jepson objectively demonstrated the beneficial effects of early fascial decompression of injured muscle (44).

Since these early reports, several investigators have discussed the various aspects of ischemic contracture formation and prevention, including the need for immediate fasciotomy, and the role of median and ulnar nerve decompression and brachial artery exploration. The operative technique and appreciation of surgical anatomy evolved from reports by Benjamin (3), Eichler and Lipscomb (22), Henry (38), Eaton and Green (21), Whitesides et al. (98), Newmeyer and Kilgore (66), and Gelberman (24,25,26,27 and 28). The relationships between increased tissue fluid pressure and myoneural dysfunction, as well as the use of fasciotomy to prevent ischemic contracture, are now well established (1,2,3,4 and 5,7,8,9,10,11,12 and 13,19,20,21,22,23,24,25,26,27,28 and 29,33,34,35 and 36,40,41,46,50,51 and 52,58,59,63,64,78,84,86,94,98,99).

Despite the current appreciation for urgency in the management of acute compartment syndrome, delays in treatment still occur; these result in patients developing the full sequelae of Volkmann's ischemic contracture. The deficits can be devastating, and management is challenging. Treatment can require a prolonged rehabilitation program and/or operative management. A comprehensive rehabilitation program includes active and passive exercises, strengthening, splinting, desensitization, and pain management. Operative management includes nerve decompression, infarct excision, contracture release, myotendon lengthening, tendon transfers, or free tissue transfers (4,5,10,13,14,15,16,17 and 18,21,22 and 23,25,30,31 and 32,37,39,40,41,42,43,44,45,46,47 and 48,50,51,53,54,55,56 and 57,60,61,62,63,64,65,66,67,68 and 69,73,74,75,76,77 and 78,80,81,82,83,84 and 85,88,89,90,91,92 and 93,95,97,100,101). The following discussion reviews the general features of Volkmann's ischemic contracture, the classification of deformities, and the methods of management.

## PATHOGENESIS OF ISCHEMIC CONTRACTURE

Muscles and nerves are vulnerable to changes in oxygen tension. Muscle undergoes necrosis after 4 hours of ischemia produced experimentally by application of a tourniquet (33,34). With prolonged ischemia, muscle necrosis leads to fibroblastic proliferation within the muscle infarct. A variable amount of longitudinal and horizontal contraction may progress over a 6- to 12-month period following the ischemic insult. The necrotic muscle adheres to surrounding structures, fixes muscle position, and reduces excursion and mobility. Limitation of muscle excursion may lead to loss of joint motion with subsequent joint contracture.

Peripheral nerves in the vicinity can also be injured from the original ischemic insult, as well as from subsequent compression resulting from muscle fibrosis, or from the chronic stretch of limb deformity. The developing fibrosis may surround, tether, or impinge on adjacent peripheral nerves, leading to local compression. Hyperflexion at the elbow or wrist can lead to secondary neuropathy of the ulnar nerve or the median nerve, respectively. In addition to the associated motor loss, neuropathy following ischemic contracture can lead to paresthesias, loss of limb sensibility, and chronic pain.

The deepest compartments, especially those adjacent to bone on the volar forearm, usually have the highest interstitial pressure during an acute compartment syndrome (7,8,9 and 10,91,92). Subsequent injury that leads to ischemic necrosis is most marked in these deep compartments, more commonly involving the flexor digitorum profundus and flexor pollicis longus (Fig. 65.1 and Fig. 65.2). In the mildest contractures, only part of the flexor digitorum profundus undergoes necrosis, usually to the ring and long fingers. In severe contractures, all four digits are involved. The flexor digitorum superficialis and pronator teres are generally less severely affected. In the most severe cases, the wrist flexors, the wrist and digital extensors, and the compartments proximal to the elbow may also undergo varying degrees of fibrosis and contracture.



***Figure 65.1.*** The muscles affected in 16 cases of Volkmann's contracture of the forearm. (Adapted from Seddon HJ. Volkmann's Contracture: Treatment by Incision of the Infarct. *J Bone Joint Surg Br* 1956;38:152, with permission.)

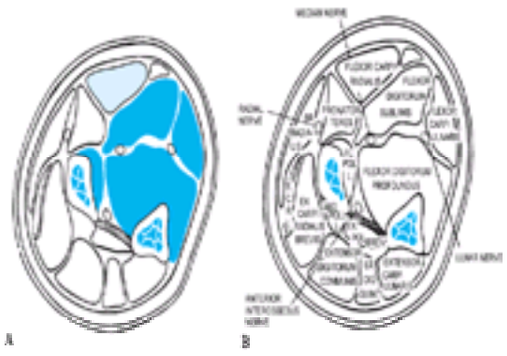

***Figure 65.2.*** Cross section of Volkmann's contracture of the forearm. **A:** The *shading* represents the degree of involvement of the various muscles. The diagram is based on the data provided in Figure 65.1. **B:** Key to muscles. The plane of section is through the upper third of the forearm. *E, EX,* extensor; *DIG,* digiti; *FL,* flexor; *POL, POLL,* pollicis; *L,* longus; *BREV,* brevis; *BR,* brachio; *ABD,* abductor; *C,* carpi; *R,* radialis. (Adapted from Seddon HJ. Volkmann's Contracture: Treatment by Incision of the Infarct. *J Bone Joint Surg Br* 1956;38:152, with permission.)

The frequent involvement of the deep flexors of the forearm is attributed to their deep location, a factor that increases their vulnerability to ischemia (79). These deep compartments, particularly the regions adjacent to bone, usually have the highest interstitial pressures (34). With compression from within the compartment, the circulation to the deep portions of the muscle belly are compromised, whereas collateral circulation to the more superficial parts of the muscle is retained. In the forearm, the most severe muscle damage usually occurs in the middle third of the muscle belly, with more injury closer to bone, and less injury toward the proximal and distal surfaces. When a compartment syndrome remains untreated, swelling may eventually resolve, but the injured, necrotic muscle becomes fibrotic. An ellipsoid section or cord of cicatrix can develop within the muscle or group of muscles. The characteristic deformity of ischemic contracture may take weeks or months to completely develop. When the forearm, hand, and arm are significantly involved, the deformity in the upper extremity often consists of varying amounts of elbow flexion, forearm pronation, wrist flexion, thumb flexion and adduction, digital metacarpophalangeal (MP) joint extension, and interphalangeal joint flexion (Fig. 65.3). The MP joint extension and proximal interphalangeal joint flexion give rise to a “claw hand” deformity. The extremity may initially be flexible, especially in milder cases. Chronic muscle imbalance and lack of joint motion may ultimately lead to fixed deformity from secondary joint capsule, ligament, and skin contracture.

***Figure 65.3.*** **A,B,C:** Upper extremity of a patient with severe ischemic contracture. Unrecognized compartment syndrome developed after revascularization of the extremity for a brachial artery injury. The deformity includes hyperextension at the metacarpophalangeal joints and flexion at the interphalangeal joints. The forearm muscle mass is fibrotic, with a firm, “woody” consistency. Fixed myotendinous contractures exist that involve the extrinsic flexor and extensor muscles. The elbow flexors are also involved, with a fixed flexion deformity at the elbow and associated fibrosis of the brachium. Patients with established ischemic contracture often also show wrist flexion, forearm pronation, and adduction or flexion of the thumb.

The pathomechanics of the ischemic claw-hand deformity are complex. Although there may be an apparent similarity between the ischemic contracture and the intrinsic muscle contracture in some patients, the actual deformities are considerably different. Intrinsic muscle contracture results in an intrinsic-plus deformity, with flexion at the MP joints and extension at the proximal interphalangeal joints. Volkmann's contracture often leads to an intrinsic-minus deformity, with hyperextension at the MP joints and flexion at the interphalangeal joints. Although the two entities are associated and may occur simultaneously, the resultant claw-hand deformity is determined by contracture of the more powerful extrinsic finger flexors. A paradoxical situation of a claw-hand deformity with intrinsic tightness can exist (82). The intrinsic contracture may not become apparent until the extrinsic flexors have been released by a muscle slide, tendon lengthening, or tenotomy. Only then does intrinsic tightness become evident.

An additional factor in the pathomechanics of upper extremity deformity is the amount of peripheral nerve injury superimposed on the muscle. Ischemic injury to the muscle usually results in muscle contracture (from fibrosis of the necrotic muscle). Nerve injury, conversely, results in muscle paralysis. Concomitant median and ulnar neuropathy in the forearm or wrist therefore contribute to intrinsic muscle weakness and, in turn, to an intrinsic-minus deformity. The final clinical outcome is dependent on the relative amount of extrinsic and intrinsic muscle contracture (from muscle ischemia) and on the amount of extrinsic and intrinsic muscle paralysis (from nerve injury) (9,10).

## CLASSIFICATION OF CONTRACTURES

Several authors have classified contractures according to severity of involvement (4,50,63,80,91,100). The simplest classification, popularized by Seddon and Tsuge (80,91), describes mild, moderate, and severe involvement. This classification is useful for determining treatment options.

### MILD CONTRACTURES

A mild or localized contracture is limited to a portion of the deep extrinsic finger flexors, usually involving only two or three fingers. Hand sensibility and strength are normal. The intrinsic muscles are not involved, and fixed joint contractures are not present. Most mild types of ischemic contracture are caused by fractures or crush injuries to the forearm or elbow, and they usually occur in young adults (40,91).

### MODERATE CONTRACTURES

Moderate contracture, the classic type, primarily involves the flexor digitorum profundus and flexor pollicis longus muscles. Less frequently, the flexor digitorum superficialis, flexor carpi radialis, and flexor carpi ulnaris are involved. The wrist and thumb become flexed and the hand assumes a claw-hand deformity from contracture of the long finger flexors.

Secondary compression neuropathies may develop at specific locations where nerves pass beneath ligaments or fibrous arcades or through contracted muscles. The median nerve is most frequently compressed, usually at the lacertus fibrosus, pronator teres, or flexor digitorum superficialis, or within the carpal tunnel. The ulnar nerve may be compressed within the cubital tunnel or between the two heads of the flexor carpi ulnaris. The radial nerve is rarely involved, but it may be compressed at the arcade of Frohse or within the supinator muscle.

Most moderate contractures are caused by a supracondylar fracture of the humerus. These fractures occur most commonly at 5 to 10 years of age (40,62,63,91).

### SEVERE CONTRACTURES

Severe contractures affect forearm extensors as well as flexors (Fig. 65.3). Complications, including loss of nerve function, malunion or nonunion of forearm fractures, and cutaneous scarring and contracture, are often encountered. The most common causes of severe contracture are prolonged ischemia secondary to brachial artery injury, and prolonged external compression secondary to drug overdose.

## TREATMENT

### MILD CONTRACTURES

The treatment of mild contractures depends on the severity of the deformity and the time interval between injury and initiation of treatment. Contractures of the deep forearm flexors, with normal hand sensibility and strength, may be treated conservatively. Occupational therapy, including passive and dynamic extension splinting, is designed to maintain wrist and interphalangeal joint extension, to maintain or improve thumb web-space width, and to strengthen weak thumb intrinsic muscles. Alternate the use of bivalved pancake plaster casts or custom-molded synthetic orthoses with low-profile digital extension, and thumb opposition splints. A C-bar may be incorporated into the splint to maintain thumb position. In the early stages, have the patient alternate passive and dynamic splints at 2-hour intervals during the day and, at night, wear extension splints. Splinting techniques for Volkmann's contracture have been described in detail by Goldner (30). A satisfactory outcome can be expected when mild contractures are treated soon after their development using these techniques.

Tsuge recommends operative treatment for mild contractures that are encountered late (91,92). If the contracture is limited to one or two digits and a cordlike area is palpable, simple excision of the infarcted muscle or lengthening of the involved flexor tendons is recommended.

- Perform excision of the infarcted muscle through a curved, longitudinal incision on the palmar forearm.
- Identify and protect the radial artery, median nerve, and ulnar artery and nerve.
- Retract the flexor digitorum superficialis and flexor carpi radialis radially, and the flexor carpi ulnaris ulnarly, to expose the flexor digitorum profundus.
- Isolate and excise the palpable, cordlike areas of indurated muscle. The flexor digitorum profundus of the ring and long fingers is most commonly affected.
- If the contracture is localized to the pronator teres, this muscle may be excised. If the contracture and induration involve three or four digits, flexor tendon lengthening may be required.
- Perform Z-lengthening of the involved tendons in the distal two thirds of the forearm.
- Begin the Z-lengthening incisions proximally, near the musculotendinous junctions, to ensure adequate tendon length for satisfactory correction. Repair the tendons using 4-0 nonabsorbable suture.
- Following the surgery, immobilize the forearm in supination, the wrist in extension, and the digits in the corrected amount of extension.

### MODERATE TO SEVERE CONTRACTURES

The treatment of moderate to severe Volkmann's contracture may be divided into four phases (25):

1. Release of secondary nerve compression
2. Treatment of contractures
3. Tendon transfers for substitution and reinforcement
4. Salvage procedures for the severely contracted or neglected forearm

#### *Phase 1: Release of Secondary Nerve Compression*

Following muscle infarct, nerves may become compressed within a constricting cicatrix, or at specific anatomic locations where space is minimal. Secondary compressive neuropathies require attention in the earliest stages of treatment. Improvement of nerve function is related to the severity and duration of compression, as nerves may sustain compression for longer periods than muscle and still show some reversibility, particularly in sensory function (11,79). When continuity is maintained, nerves may show signs of gradual recovery over a 12-month period (80,85). If both fibrosis and contracture are severe, all three major forearm nerves may become constricted. Careful clinical assessment is essential before the first phase of treatment.

**Median Nerve Decompression** Return of median nerve function is essential for restoring a useful functional extremity. This nerve lies in the center of the constricting cicatrix and may become compressed in four anatomic regions: the lacertus fibrosus, the pronator teres, the proximal arch of the flexor digitorum superficialis, and the carpal tunnel. Sensory and motor loss consistent with median neuropathy warrant aggressive management for decompression.

- Use an incision similar to that used for decompression of an acute forearm compartment syndrome (24) (Fig. 65.4). Begin the incision on the palmar aspect of the medial arm, about 2 cm proximal to the medial epicondyle. Extend it obliquely across the antecubital fossa to the mobile wad. Continue the incision longitudinally, curving slightly ulnarly to reach the palmar distal forearm. Extend the incision into the palm for carpal tunnel release. Locate the distal portion of the incision ulnar to the palmaris longus to avoid injury to the palmar cutaneous branch of the median nerve.

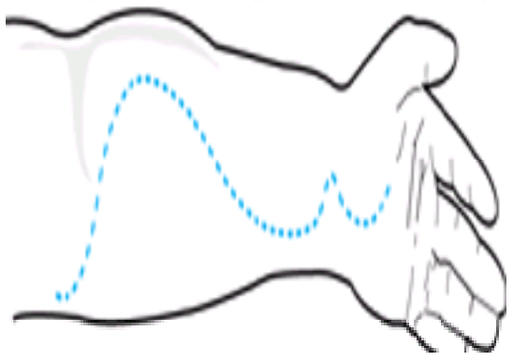

***Figure 65.4.*** The incision used for decompression of the median nerve in the forearm and hand. (Adapted from Gelberman RH, et al. Decompression of Forearm Compartment Syndromes. *Clin Orthop* 1978;134:225, with permission.)

- Identify the median nerve in the proximal portion of the incision and trace it distally to the lacertus fibrosus. The lacertus fibrosus is a fascial extension of the biceps tendon and lies anterior to the median nerve at the elbow. Nerve compression occurs frequently in this area in the acute stages of a forearm compartment syndrome, and it may also occur in the later stages of contracture.
- If signs of proximal median nerve compression are present, release the lacertus fibrosus. Incise the fascia of the lacertus fibrosus in a longitudinal fashion along the course of the median nerve to allow complete decompression and exposure of the nerve.
- Continuing distally, the median nerve will pass between the two heads of the pronator teres muscle. Nerve compression can occur between these two heads. The ulnar head lies deep to the nerve, and the humeral head is superficial to the nerve. A tendinous band, which often lies along the deep head, may contribute to compression.
- Completely release the nerve throughout the entire length of its passage through the pronator teres. This often requires division of the humeral head of the pronator teres and division of any tendinous bands, deep or superficial, that may impinge on the nerve.
- Distal to the pronator teres, the median nerve continues beneath and within the fascia of the flexor digitorum superficialis muscle, passing deep to the arch formed by the ulnar and radial origins. The nerve is most frequently compressed beneath the fibrous origin of this muscle (72).
- Decompress the nerve by either incising the investing fascia or by dissecting the flexor digitorum superficialis from the underlying flexor digitorum profundus. Completely release the nerve from the investing fascia (72).
- Despite the proximal location of muscle necrosis in Volkmann's contracture, the incidence of median nerve compression in the carpal tunnel is high. Extend the incision for forearm decompression and expose the palmar fascia and transverse carpal ligament (24,87).
- Incise these structures to decompress the median nerve decompression from the distal arm to the midpalm.

**Ulnar Nerve Decompression** The incidence of ulnar nerve compression is much lower than that of median nerve compression. It is often compressed at the elbow as it passes between the ulnar and humeral heads of the flexor carpi ulnaris. Decompress it if there are signs of ulnar neuropathy.

**Radial Nerve Decompression** The radial nerve is rarely involved in compression neuropathies following Volkmann's contracture. Occasionally, however, it may require decompression as it passes under the tendinous origin of the supinator muscle (arcade of Frohse) or within the muscle itself. Nerve compression is manifested

by motor loss of the digital and thumb extensors and the ulnar wrist extensors. Radial wrist extensor strength and radial nerve sensibility remain intact, as these neural branches arise proximal to the area of compression (10).

- To decompress the radial nerve, make a straight, longitudinal incision on the proximal half of the posterior forearm along an imaginary line extending between the lateral epicondyle and the radial styloid.
- Develop the interval between the extensor carpi radialis brevis and the extensor digitorum communis. This interval is most easily defined in the distal portion of the incision and should be developed here first and traced proximally.
- Retract the extensor carpi radialis brevis radially and the extensor digitorum communis ulnarly.
- Identify the supinator.
- Identify the radial nerve proximally where it enters the supinator. The nerve may be found to be compressed by the tendinous bands of the arcade of Frohse, by a vascular leash that crosses the nerve transversely in this region, or by the supinator muscle itself. Carefully divide the appropriate structures to decompress the nerve (10).

Forearm nerve decompression should be undertaken as soon as the patient's condition permits. A nerve stimulator may be helpful for verification of conductivity, especially in heavily scarred areas. Early return of sensibility and a decrease in pain may be expected when decompression is undertaken in a timely manner. Motor function return, although variable, can progress over several days or weeks, depending on whether neuropraxia or axontemesis is present. If nerves are irreparably damaged or have lost continuity (neurotemesis), secondary excision of damaged segments and microsurgical repair or reconstruction may offer some return of nerve function. Alternatively, reconstruction may be accomplished with appropriate tendon transfers.

### *Phase 2: Treatment of Contractures*

Elbow flexion, forearm pronation, wrist flexion, digital clawing, and thumb adduction are fixed deformities that develop over time. Procedures used to help correct established forearm contractures include infarct incision, flexor tendon lengthening or excision, and flexor pronator slide. These procedures should be performed at the time of, or subsequent to, nerve decompression.

**Infarct Excision** Perform infarct excision 1 to 6 months after injury (Fig. 65.5) (52,80,91,92). Seddon recommends at least 6 months of preliminary splinting before contracture release (80).

***Figure 65.5.*** Excision of an infarct in the forearm, with preservation of the flexor carpi ulnaris and ulnar neurovascular bundle. (Adapted from Seddon HJ. *Rev Chir Orthop Reparatrice Appar Mot* 1960;46:149, with permission.)

- Excise the frequently encountered ellipsoid infarct through a long palmar forearm incision (80).
- Excise fibrotic muscle and contracted scar tissue. The deep digital flexors and thumb flexor are usually most extensively involved. The pronator teres and pronator quadratus may be released or, if they are fibrotic, excised.
- Gently manipulate the forearm and wrist into supination and extension, respectively, and immobilize in this corrected position following surgery.

**Flexor Tendon Lengthening** Goldner has noted that infarct excision may not be necessary and advocates Z-lengthening of the forearm flexors proximal to the wrist (30). The flexor digitorum profundus, flexor digitorum superficialis, flexor pollicis longus, and pronator teres may be lengthened to accomplish digital and thumb extension, and forearm supination (6,30). If severe forearm fibrosis is encountered and digital contracture is severe, excise the flexor digitorum superficialis.

The chief disadvantage of flexor tendon lengthening in the forearm is further weakening of an already weakened muscle. However, contracture release is usually functionally advantageous to the maintenance of maximal strength. Tendon transfers, if needed, may be performed at a later date.

**Flexor Pronator Slide** The flexor pronator slide, first described by Page in 1923 (69), has gained wide acceptance (22,50,91,92). It has been shown to be more effective than infarct excision alone in obtaining a lasting correction (22).

- Make a skin incision on the medial side of the elbow, 6 cm proximal to the medial humeral condyle and extending to the junction of the middle and distal thirds of the forearm. Separate the subcutaneous tissue from the deep fascia on the ulnar and radial sides of the incision.
- Isolate the ulnar nerve at the level of the elbow and transpose it anteriorly.
- Proceed with systematic, complete operative detachment of the origins of the flexor muscles of the forearm. Dissect the muscles subperiosteally using a scalpel.
- Release the origins of the pronator teres, flexor carpi radialis, palmaris longus, and the humeral head of the flexor carpi ulnaris, and then detach the flexor digitorum superficialis.
- Detach the ulnar head of the flexor carpi ulnaris and the broad origin of the flexor digitorum profundus from the anterior aspect of the ulna.
- Carry the dissection across the interosseous membrane and release the origin of the flexor pollicis longus from the anterior aspect of the radius.
- Take care to avoid injury to the interosseous artery, vein, and nerves when detaching the flexors from the interosseous membrane.
- Allow the muscles to slide distally 2–3 cm.
- The incision may be extended distally and the palmar wrist capsule and pronator quadratus released. Although excision of the infarct and neural releases may be performed at the time of the flexor pronator slide, tendon transfers are performed secondarily (91,92).
- Postoperatively, immobilize the extremity for 2–3 weeks with the elbow at 90° flexion, the forearm supinated, and the wrist and digits extended.

The flexor pronator slide has been criticized for the unpredictability of correction achieved, the risk of recurrence of deformity with growth, and the resultant decrease in grip strength, particularly at the distal interphalangeal joint (52,91,92). Despite these criticisms, the procedure has gained popularity and has been shown to be effective in achieving satisfactory to excellent results in a large group of patients with moderate to severe contractures (91,92).

### *Phase 3: Tendon Transfers for Substitution and Reinforcement*

Among the most desirable functions to restore in patients with Volkmann's contracture are finger and thumb flexion and thumb opposition. Tendon transfers are usually delayed until nerve recovery has plateaued and the contractures have been corrected maximally with mobilization and splinting, or with operative releases. In 1947, Phalen and Miller described a series of tendon transfers designed to provide digital flexion and thumb opposition (73).

#### Tendon Transfers

- Transfer the extensor carpi radialis longus to the flexor digitorum profundus, and transfer the extensor carpi ulnaris, lengthened by tendon graft, to the thumb for opposition (71,73).
- Excise the tendons of the flexor digitorum superficialis if they are nonfunctional. The extensor pollicis brevis may be used to reinforce the extensor carpi ulnaris–opponens transfer.
- Alternative transfers to augment thumb opposition include the abductor digiti quinti opponensplasty described by Huber (42,52) and the extensor indicis proprius opponensplasty described by Zancolli (100) and Burkhalter et al. (14).
- To reinforce thumb flexion, the brachioradialis may be transferred to the flexor pollicis longus (91,92).
- When flexor tendons have been weakened severely by previous Z-lengthening, reinforcement by transfer of the extensor carpi radialis longus to the flexor

digitorum profundus, and transfer of the extensor carpi ulnaris to the flexor pollicis longus, can be performed (30).

### *Phase 4: Salvage of the Severely Contracted or Neglected Forearm*

The procedures of Phases 2 and 3 usually provide satisfactory results, and further procedures are seldom necessary. Occasionally, however, additional measures may be required for satisfactory correction of the severely contracted or neglected forearm. Operations that have proved useful include proximal or distal row carpectomy, radial and ulnar shortening, wrist fusion, and digital joint fusion.

Proximal or distal row carpectomy results in limb shortening that allows wrist extension while maintaining flexibility. In severe deformities, carpectomy may be performed before tendon transfer. If adequate donor muscles are not available for transfer, interphalangeal joint fusion can be performed. The stabilized limb can then function as a hook, which is generally superior to a prosthesis, especially if some sensibility is retained (30). Radial and ulnar shortening and wrist fusion are rarely indicated for the treatment or salvage of Volkmann's contracture.

## RECONSTRUCTION OF HAND DEFORMITIES

The hand deformity associated with Volkmann's contracture is complex, requiring a systematic approach. Intrinsic contractures should be addressed only after extrinsic finger flexors have been released. Fixed extrinsic contractures create a claw-hand deformity (hyperextension of the MP joints and flexion of the interphalangeal joints). Following extrinsic muscle release, intrinsic tightness may become apparent. Complete release of intrinsic contractures may not be desirable, since preservation of some MP joint flexion will prevent recurrence of the claw-hand deformity. If the intrinsic contracture is severe, the oblique fibers of the extensor hood may be released to permit flexion of the interphalangeal joints (82).

Thumb-in-palm deformity often accompanies the claw hand in Volkmann's contracture. The deformity may be caused by both intrinsic and extrinsic contractures. Flexion contracture at the interphalangeal joint may be corrected with flexor pollicis longus lengthening. Residual deformity following tendon lengthening is attributable to intrinsic muscle contracture, joint contracture, or skin contracture of the first web. Recommended procedures for correction of a severe thumb-in-palm deformity include release of the adductor pollicis, deepening of the thumb web space, fusion of the MP joint or interphalangeal joint, or excision of the trapezium (6,30). Thenar origin release (recession) and release of the first dorsal interosseous muscle may also be necessary for additional correction (6,57).

The most significant hand disabilities may not be caused by intrinsic contractures but rather by secondary problems from sequela of extrinsic muscle contractures in the forearm or by associated neuropathy. Loss of median and ulnar nerve sensibility, intrinsic paralysis secondary to median and ulnar motor nerve paralysis, and interphalangeal joint flexion deformity secondary to contracture of the extrinsic flexors cause severe functional deficits. Proper management of these problems, as described in Phase 1 and Phase 2, should significantly improve hand function.

## FREE VASCULARIZED TISSUE TRANSFERS

The deformity of established Volkmann's ischemic contracture remains a challenging problem despite the available methods of management. Advances in the free transfer of vascularized muscle, nerve, and skin have offered potential additional methods of reconstruction (15,16,17 and 18,43,88). One of the early uses of these techniques for reconstruction of Volkmann's contracture was the transfer of the lateral head of the pectoralis major to the flexor forearm, reported by Chien et al. in 1977 (15). Subsequently, Taylor and Daniel achieved satisfactory results with a free vascularized superficial radial nerve graft transfer to an irreparably damaged median nerve (89). Chuang et al. have obtained an 80% success rate in free muscle transfer in nine patients undergoing 10 transfers for Volkmann's contracture (16,17 and 18). As free tissue transfer has become more popular, reconstruction of forearm muscles has now included the use of the gracilis, rectus femorus, latissimus dorsi, or pectoralis muscles (15,16,17,18,43,53,54 and 55,60). The early results of these procedures are promising, especially in their role in the reconstruction of severe or neglected Volkmann's contracture in which few adequate donor muscles are available for tendon transfer.

## CHAPTER REFERENCES

Each reference is categorized according to the following scheme: *, classic article; #, review article; !, basic research article; and +, clinical results/outcome study.


! 1. Ashton H. The Effect of Increased Tissue Pressure on Blood Flow. *Clin Orthop* 1975;113:15.

+ 2. Bardenheuer L. Die Entstehung und Behandlung der ischamischen Muskelkontractur und Gangran. *Dtsch Z Chir* 1911;108:44.

+ 3. Benjamin A. The Relief of Traumatic Arterial Spasm in Threatened Volkmann's Contracture. *J Bone Joint Surg Br* 1959;39:711.

# 4. Benkeddache Y, Gottesman H, Hamdani M. Proposal of a New Classification for Established Volkmann's Contracture. *Ann Chir* 1985;4:134.

+ 5. Blout WP. Volkmann's Ischaemic Contracture. *Surg Gynecol Obstet* 1950;90:244.

+ 6. Botte MJ, Keenan MA, Gellman H, et al: Surgical Management of Spastic Thumb-in-palm Deformity in Adults with Brain Injury. *J Hand Surg* 1989;14A:174.

# 7. Botte MJ, Gelberman RH. Compartment Syndrome and Ischemic Contracture. In: Nickel VL, Botte MJ, eds. *Orthopaedic Rehabilitation*, 2nd ed. New York: Churchill Livingstone, 1992.

# 8. Botte MJ, Gelberman RH. Compartment Syndrome and Volkmann's Contracture. In: Peimer CA, ed. *Surgery of the Hand and Upper Extremity*. New York: McGraw-Hill, 1996:1539.

# 9. Botte MJ, Gelberman RH. Acute Compartment Syndrome of the Forearm. *Hand Clin* 1998;14:391.

# 10. Botte MJ, Keenan MAE, Gelberman RH. Volkmann's Ischemic Contracture of the Upper Extremity. *Hand Clin* 1998;14:483.

# 11. Boyes JH. *Bunnell's Surgery of the Hand*. Philadelphia: JB Lippincott, 1970.

! 12. Brooks B. Pathological Changes in Muscle as a Result of Disturbances of Circulation: An Experimental Study of Volkmann's Ischemic Paralysis. *Arch Surg* 1922;5:188.

+ 13. Bunnel S. Ischemic Contracture Local in the Hand. *J Bone Joint Surg Am* 1953;35:88.

+ 14. Burkhalter WE, Christensen RC, Brown P. The Extensor Indicis Proprius Opponensplasty. *J Bone Joint Surg Am* 1973;55:725.

# 15. Chien CW, Daniel RK, Terzis JK. *Reconstructive Microsurgery.* Boston: Little, Brown, 1977.

# 16. Chuang DCC. Function Free Muscle Transplantation. In: Peimer CA, ed. *Surgery of the Hand and Upper Extremity*. New York: McGraw-Hill, 1996:1901.

+ 17. Chuang DCC, Chen HC, Wei FC, et al. Compound Functioning Free Muscle Flap Transplantation (Lateral Half of Soleus, Fibula and Skin Flap). *Plast Reconstr Surg* 1992;89:335.

+ 18. Chuang DCC, Strauch RJ, Wei FC. Technical Consideration in Two-stage Function Free Muscle Transplantation (FFMT) Reconstruction of Both Flexor and Extensor Function of the Forearm. *Microsurgery* 1994;15:338.

! 19. Dann I, Lassen A, Westing H. Blood Flow in Human Muscles during External Pressure on Venous Stasis. *Clin Sci* 1967;32:467.

# 20. Doyle JR. Anatomy of the Upper Extremity Muscle Compartments. *Hand Clin* 1998;14:343.

+ 21. Eaton RG, Green WT. Epimysiotomy and Fasciotomy in Treatment of Volkmann's Ischemic Contracture. *Orthop Clin North Am* 1972;3:175.

# 22. Eichler GR, Lipscomb PR. The Changing Treatment of Volkmann's Ischemic Contractures from 1955 to 1965 at the Mayo Clinic. *Clin Orthop* 1967;50:215.

* 23. Finochietto R. Volkmann's Contracture of the Intrinsic Muscles of the Hand. *Bol y Trab Soc Cir* (Buenos Aires) 1920;4:31.

+ 24. Gelberman RH, Zakaib GS, Mubarak SJ, et al. Decompression of Forearm Compartment Syndromes. *Clin Orthop* 1978;134:225.

# 25. Gelberman RH. Volkmann's Contracture of the Upper Extremity: Pathology and Reconstruction. In: Mubarak SJ, Hargens AR, eds. *The Compartment Syndrome and Volkmann's Contracture*. Philadelphia: WB Saunders, 1981.

# 26. Gelberman RH, Garfin SR, Hergenroeder PT, et al. Compartment Syndromes of the Forearm: Diagnosis and Treatment. *Clin Orthop* 1981;161:252.

+ 27. Gelberman RH, Szabo RM, Mortensen WW. Carpal Tunnel Pressures and Wrist Position in Patients with Colle's Fractures. *J Trauma* 1984;8:747.

# 28. Gelberman RH. Acute Carpal Tunnel Syndrome. In: Gelberman RH, ed. *Operative Nerve Repair and Reconstruction*. Philadelphia: JB Lippincott, 1991:939.

# 29. Gellman H, Buch K. Acute Compartment Syndrome of the Arm. *Hand Clin* 1998;14:385.

# 30. Goldner JL. Volkmann's Ischemic Contracture. In: Flynn JE, ed. *Hand Surgery*. Baltimore: Williams & Wilkins, 1975.

# 31. Goldner L. Intrinsic and Extrinsic Contractures of the Hand Due to Ischemic and Nonischemic Causes. In: Jupiter J, ed. *Flynn's Hand Surgery*. Baltimore: Williams & Wilkins, 1991:913.

+ 32. Griffiths DV. Volkmann's Ischemic Contracture. *Br J Surg* 1940;28:239.

! 33. Hargens AR, Romine JS, Sipe JC, et al. Peripheral Nerve Conduction Block by High Muscle Compartment Pressure. *J Bone Joint Surg Am* 1979;61:192.

! 34. Hargens AR, Evans KL, Hagen PL, et al. Quantitation of Skeletal-Muscle Necrosis in a Model Compartment Syndrome. Presented at a meeting of the Orthopedic Research Society, Dallas, TX, February 1978.

! 35. Hargens AR, Akeson WH, Mubarak SJ, et al. Kappa Delta Award Paper. Tissue Fluid Pressures: From Basic Research Tools to Clinical Applications. *J Orthop Res* 1989;7:902.

# 36. Hargens AR, Mubarak SJ. Current Concepts in Pathophysiology, Evaluation, and Diagnosis of Compartment Syndrome. *Hand Clin* 1998;14:371.

+ 37. Harris CJ, Riordan DC. Intrinsic Contracture in the Hand and Its Surgical Treatment. *J Bone Joint Surg Am* 1954;36:10.

# 38. Henry AK. *Extensile Exposure, 2nd ed.* London: Churchill Livingstone, 1973.

+ 39. Hill RL, Bortrkes B. Volkmann's Ischemic Contracture in Hemophilia. *Am Surg* 1936;103:444.

+ 40. Holden CE. The Pathology and Prevention of Volkmann's Ischemic Contracture. *J Bone Joint Surg Br* 1979;61:296.

# 41. Hofmeister EP, Shin AY. The Role of Prophylactic Fasciotomy and Medical Treatment in Limb Ischemia and Revascularization. *Hand Clin* 1998;14:457.

# 42. Huber E. Hiltsoperation ber Medianers-lahmung. *Dtsch Z Chir* 1921;162:271.

+ 43. Ikuta Y, Kubo T, Tsuge K. Free Muscle Transplantation by Microsurgical Technique to Treat Severe Volkmann's Contracture. *Plast Reconstr Surg* 1976;58:407.

! 44. Jepson PN. Ischemic Contracture. Experimental Study. *Am Surg* 1926;84:785.

+ 45. Jorge J. Retraction Ischejique de Volkmann. Rapport d'Albert Monchet. *Bull Mem Soc Nat Chir* 1925;51:884.

# 46. Kadiyala RK, Waters PM. Upper Extremity Pediatric Compartment Syndromes. *Hand Clin* 1998;14:467.

+ 47. Landi A, DeSantis G, Torricelli P, et al. CT in Established Volkmann's Contracture in Forearm Muscles. *J Hand Surg* 1989;14B:49.

# 48. Lee FS, Gellman H. Reconstruction of Intrinsic Hand Deformities. *Hand Clin* 1998;14:499.

+ 49. Leriche R. Surgery of the Sympathetic System: Indicators and Results. *Ann Surg* 1928;88:449.

+ 50. Lipscomb PR. The Etiology and Prevention of Volkmann's Ischemic Contracture. *Surg Gynecol Obstet* 1956;103:353.

# 51. Lister G. *The Hand: Diagnosis and Indications*. Edinburgh: Churchill-Livingstone, 1977.

# 52. Littler JW. The Hand and Upper Extremity. In: Converse JM, ed. *Reconstructive Plastic Surgery.* Philadelphia: WB Saunders, 1977.

+ 53. Manktelow RT, Mckeen NH. Free Muscle Transplantation to Provide Active Finger Flexion. *J Hand Surg* 1978;3:416.

+ 54. Manktelow RT, Zuker RM, Mckee NH. Functioning Free Muscle Transplantation. *J Hand Surg* 1984;9A:32.

+ 55. Manktelow RT, Zuker RM. The Principles of Functioning Muscle Transplantation: Applications to the Upper Arm. *Ann Plast Surg* 1989;22:1275.

# 56. Massart R. La Maladie de Volkmann. *Rev Orthop* 1935;22:385.

* 57. Matev I. Surgical Treatment of Spastic “Thumb-in-palm” Deformity. *J Bone Joint Surg Br* 1963;45:703.

* 58. Matsen FA III, Winquist RA, Drugmire RB Jr. Diagnosis and management of Compartmental Syndromes. *J Bone Joint Surg Am* 1980;62:286.

+ 59. Matsen FA III, Wyss CR, Drugmire RB Jr, et al. The Effects of Limb Elevation and Dependency on Local Arteriovenous Gradients in Normal Human Limbs with Particular Reference to Limbs with Increased Tissue Pressure. *Clin Orthop* 1980;150:187.

# 60. Mckee NH, Kuzon WM Jr. Functioning Free Muscle Transplantation: Making It Work. What Is Known? *Ann Plast Surg* 1989;23:249.

+ 61. Meyerding HW. Volkmann's Ischemic Contracture. *JAMA* 1930;94:394.

+ 62. Meyerding HW. Volkmann's Ischemic Contracture Associated with Supracondylar Fracture of Humerus. *JAMA* 1936;106:1139.

+ 63. Mubarak SJ, Carroll NC. Volkmann's Contracture in Children: Etiology and Prevention. *J Bone Joint Surg Br* 1979;61:285.

# 64. Mubarak SJ, Hargens AR, eds. *Compartment Syndromes and Volkmann's Ischemic Contracture*. *Monographs in Clinical Orthopaedics,* vol. III. Philadelphia: WB Saunders, 1981.

+ 65. Murphy JB. Myositis. *JAMA* 1914;63:1249.

+ 66. Newmeyer WL, Kilgore ES Jr. Volkmann's Ischemic Contracture Due to Soft-tissue Injury Alone. *J Hand Surg* 1976;1A:221.

# 67. Ortiz JA, Berger RA. Compartment Syndrome of the Hand and Wrist. *Hand Clin* 1998;14:405.

# 68. Ouellette EA. Compartment Syndromes in Obtunded Patients. *Hand Clin* 1998;14:431.

+ 69. Page CM. An Operation for the Relief of Flexion-Contracture in the Forearm. *J Bone Joint Surg* 1923;5:233.

# 70. Parks A. Ischemic Effects of External and Internal Pressure on the Upper Limb. *Hand* 1973;5:105.

+ 71. Parks A. The Treatment of Established Volkmann's Contracture by Tendon Transplantation. *J Bone Joint Surg Br* 1951;33:359.

+ 72. Peacock EE, Madden JW, Trier WC. Transfer of Median and Ulnar Nerves During Early Treatment of Forearm Ischemia. *Ann Surg* 1969;169:748.

+ 73. Phalen GS, Miller RC. The Transfer of Wrist and Extensor Muscles to Restore or Reinforce Flexion Power of the Fingers and Opposition of the Thumb. *J Bone Joint Surg* 1947;29:993.

+ 74. Reid RL, Travis RT. Acute Necrosis of the Second Interosseous Compartment of the Hand. *J Bone Joint Surg Am* 1973;55:1095.

+ 75. Rergstad A, Hellum C. Volkmann's Ischemic Contracture of the Forearm. *Injury* 1980;12:148.

+ 76. Rolands RP. A Case of Volkmann's Contracture Treated by Shortening the Radius and Ulna. *Lancet* 1905;2:1168.

+ 77. Salisbury RE, McKeel DW, Matson AD. Ischemic Necrosis of the Intrinsic Muscles of the Hand after Thermal Injuries. *J Bone Joint Surg Am* 1974;56:1701.

+ 78. Sarokhan AJ, Eaton RG. Volkmann's Ischemia. *J Hand Surg* 1983;8:806.

# 79. Seddon HJ. *Surgical Disorders of the Peripheral Nerves*. Baltimore: Williams & Wilkins, 1973.

+ 80. Seddon HJ. Volkmann's Contracture: Treatment by Incision of the Infarct. *J Bone Joint Surg Br* 1956;38:152.

+ 81. Seddon HJ. Volkmann's Ischemia. *Br Med J* 1964;1:1587.

* 82. Smith RJ. Intrinsic Muscles of the Fingers: Function, Dysfunction and Surgical Reconstruction. *Instr Course Lect* 1975;5:24.

# 83. Smith R. Intrinsic Contracture. In: Green DP, Hotchkiss RN, Pederson WC, eds. *Operative Hand Surgery*, 4th ed. New York: Churchill Livingston, 1999:604.

+ 84. Spinner M, Aiache A, Silver L, et al. Impending Ischemic Contracture of the Hand. Early Diagnosis and Management. *Plast Reconstr Surg* 1972;50:341.

+ 85. Sundoraraj GD, Mani K. Pattern of Contracture and Recovery Following Ischemia of the Upper Limb. *J Hand Surg* 1985;10B:155.

! 86. Szabo RM, Gelberman RH, Williamson RV, et al. Effects of Increased Systemic Blood Pressure on Tissue Fluid Pressure Threshold of Peripheral Nerve. *J Orthop Res* 1983;1:172.

# 87. Szabo RM. Acute Carpal Tunnel Syndrome. *Hand Clin* 1998;14(3):419.

! 88. Tamai S, Komatsu S, Sakamoto H, et al. Free Muscle Transplants in Dogs with Microsurgical, Neurovascular Anastomoses. *Plast Reconstr Surg* 1970;46:219.

+ 89. Taylor GI, Daniel RK. The Free Flap: Composite Tissue Transfer by Vascular Anastomoses. *Aust N Z J Surg* 1973;43:1.

# 90. Trice M, Colwell CW. A Historical Review of Compartment Syndrome and Volkmann's Ischemic Contracture. *Hand Clin* 1998;14:335.

* 91. Tsuge K. Treatment of Established Volkmann's Contracture. *J Bone Joint Surg Am* 1975;57:925.

# 92. Tsuge K. Management of Established Volkmann's Contracture. In: Green DP, Hotchkiss RN, Pederson WC, eds. *Operative Hand Surgery*, *4th ed.* New York: Churchill Livingstone, 1999:592.

* 93. Volkmann R von. Die Ischaemischen Muskellahmungen und Kontrakturen. *Zentralbl Chir* 1881;8:801.

+ 94. Vukanovic S, Hauser H, Wrttstein P. CT Localization of Myonecrosis for Surgical Decompression. *Am J Radiol* 1980;135:1298.

! 95. von Schroeder H, Botte M. Functional Anatomy of the Extensor Tendons of the Digits. *Hand Clin* 1997;13:51.

# 96. von Schroeder HP, Botte MJ. Crush Syndrome of the Upper Extremity. *Hand Clin* 1998;14:451.

# 97. von Schroeder HP, Botte MJ. Definitions and Terminology of Compartment Syndrome and Volkmann's Ischemic Contracture of the Upper Extremity. *Hand Clin* 1998;14:331.

* 98. Whitesides TE Jr, Heney TC, Morimoto K, et al. Tissue Pressure Measurements as a Determinant for the Need of Fasciotomy. *Clin Orthop* 1975;113:43.

+ 99. Yamaguchi S, Viegas SF. Causes of Upper Extremity Compartment Syndrome. *Hand Clin* 1998;14:365.

+ 100. Zancolli E. Tendon Transfers after Ischemic Contracture of the Forearm: Classification in Relation to Intrinsic Muscle Disorders. *Am J Surg* 1965;109:356.

# 101. Zancolli E. Classification of Established Volkmann's Ischemic Contracture and the Program for Its Treatment. In: *Structural and Dynamic Bases of Hand Surgery*, *2nd ed.* Philadelphia: JB Lippincott, 1979:314.

# CHAPTER 66

# SURGICAL TREATMENT OF THE UPPER EXTREMITY IN CEREBRAL PALSY

*Gary A. Miller and F. William Bora, Jr.*

**G. A. Miller:** Department of Orthopaedic Surgery, Washington University School of Medicine; and St. Louis Veterans Affairs Medical Center, St. Louis, Missouri, 63110.
**F. W. Bora, Jr.:** Penn Medicine at Radnor, Radnor, Pennsylvania, 19087.

Evaluation
Diagnosis
Cognition
Sensibility
Motor Examination
Overall Assessment
Aims of Treatment
Patient Age and Timing of Surgery
Surgical Techniques
Shoulder
Elbow
Forearm
Wrist
Hand
Chapter References

Cerebral palsy (CP) is a nonprogressive perinatal encephalopathy characterized by cognitive, sensory, and motor problems. The condition is highly prevalent, some 300,000 children in the United States being affected (2). The disease is classified on the basis of the observed motor deficit, be it manifest as abnormal tone, motion disorders, or some combination.

Spasticity (paraplegia, hemiplegia, and monoplegia) refers to abnormally heightened tone and is the predominant motor manifestation of the affliction. Spastic hemiplegia accounts for about one third of cerebral palsy patients (26). Motion disorders feature deviations in tone markedly affected by position and activity and include extrapyramidal (athetosis, dystonia) and atonic variants. Spasticity and motion disorders often occur together. Those patients with predominantly spastic manifestations have the best prognosis for improvement from surgery and orthotics. A strong element of motion disturbance often renders the results of surgery unpredictable, and a conservative attitude toward surgical reconstruction may be most appropriate in such settings (4,29).

## EVALUATION

Multiple factors must be weighed in planning upper extremity management. These include the patient's cognitive capacity, sensibility, motor disorders, emotional status, age, and social orientation. Only carefully selected children with cerebral palsy become candidates for upper extremity surgery (19). If a child denies the limb, it is unlikely he or she will ever use it despite improvements gained through surgical reconstruction (29).

## DIAGNOSIS

Diagnosis is difficult in the newborn, as the full picture of motor disturbance may take the first several years of life to emerge. Developmental milestones and disturbances in tone and symmetry should be monitored. Milestones may appear late in children with cerebral palsy. By 6 months of age, the Moro, grasp, and tonic neck reflexes have disappeared in normal children but may persist in patients with cerebral palsy. Limited spontaneous movement of one or more limbs in the neonate may suggest the diagnosis. Increased resistance or lack of resistance to passive motion of the upper limb should also cause concern, particularly if asymmetric. Affected infants are slow to develop balance and tend to show persistence of primitive tone reflexes.

Handedness in children develops normally at about 18 to 24 months; infants with cerebral palsy may display hand preference early (9). This results from poor function in the nondominant limb.

By 1 year, the normal child has developed pinch and hand placement through shoulder and elbow movement. Such selective muscle control develops slowly in the child with cerebral palsy. Thumb opposition develops only in mildly affected cases. Hand placement may be limited by motion disturbances. As the child grows, sensory and cognitive defects emerge—helping to establish the diagnosis.

## COGNITION

Cognition includes processes that indicate intelligence: perception, abstract thinking, and communication. Learning problems are profound in many patients with cerebral palsy, and at least half such patients are mentally retarded (2). A specific intelligence level has not been established as a prerequisite for operative treatment of the upper extremity. In general, however, only those patients with educable (IQ of 50 to 70) or higher cognitive ability can expect functional results from upper extremity surgery (9). Some surgeons maintain that surgery should not be considered in patients whose IQ is below 70, as such patients often do poorly (4,8). However, Samilson and Morris noted that standard tests of intelligence may be misleading due to the patient's significant motor impairment (28). A consensus is that the IQ should be considered in planning surgical treatment but should not constitute the sole determining factor (2).

## SENSIBILITY

Surgical success depends greatly on sensibility. Tachdjian and Minear report sensory defects in about 50% of patients with average intelligence (34). Sensation mediated by thalamic activity, such as light touch and temperature, is usually normal in the patient with spastic hemiparesis. Sensory defects most often affect the cortical functions of stereognosis, position sense, and two-point discrimination (24). These deficits stem from parietal lobe lesions.

Sensory examination is very difficult in children under age 3 or 4 years. Information may be gathered by observing the child at play. Stereognosis is assessed by having the child close his eyes and raise his hands over his head while identifying and describing the characteristics of objects placed in each hand (6). If appropriate, two-point discrimination and proprioception may be determined.

Hoffer considers sensibility to be normal when five of five objects are identified correctly, graphesthesia is accurate, or two-point discrimination is less than 5 mm (9). Sensibility is graded as mildly impaired when only three of five objects are identified, or two-point discrimination is 5–10 mm. Moderate to severe impairment applies to hands with greater limitations.

Patients with abnormal sensibility usually gain little from surgery. Prehension requires good proprioception and stereognosis, and it may not be an appropriate goal for the hand with poor sensibility. Green and Banks have shown that the results of surgery correlate with stereognosis (8). The patient who exhibits poor stereognosis may exclude the abnormal extremity from use. Such children often have a distorted body image. These patients generally do not benefit from reconstructive surgery.

## MOTOR EXAMINATION

Examine the child on several occasions and in different settings to evaluate her abilities to grasp and release and to reach for and transfer objects. Observe her at play, at specific tasks, while performing activities of daily living, and after periods of stretching (29). Study functional tasks, including dressing, toileting, feeding, and key pinch. Activity should be assessed in different settings and at varied table levels because the position of the shoulder and trunk may greatly affect hand function (29). Hoffer has emphasized the importance of hand placement in planning treatment (9). Ask her to touch her head and then the opposite knee. Performing this exercise

within 5 seconds demonstrates good function and according to Hoffer is a favorable prognostic sign.

If the patient can cooperate, perform voluntary muscle testing and grade the individual muscles. Judge whether a deficit in muscle function is due to paresis or to overactivity of antagonist muscles. Observe the patient's use of the more normal hand to position and open the fingers of the other hand for grasp. Spasticity and increased tone are determined by passive testing. Contracture of the flexor digitorum superficialis, for example, may explain the patient's need to flex the wrist before release (4). Excess finger flexor tone can be distinguished from wrist flexor tone by testing wrist extension with the fingers passively flexed.

Nerve and neuromuscular blocks may aid in distinguishing tone from contracture. For example, it may be difficult to assess the strength of wrist and finger extensors with the wrist held in flexion. Blocking the median and ulnar nerves at the elbow will identify joint contractures, permit evaluation of extensors, and determine if deformity is secondary to increased tone or fixed muscle/tendon contractures (9). Measuring the range of motion before and after nerve block determines the need for release of soft tissue and contracture.

Preferred motors for tendon transfer are those strong muscles under good voluntary control that are phasic with the activity for which transfer is planned (2). Goldner suggests that repeated observation of the patient's hand in grasp and release permits determination of phasic activity (4). Hoffer and others have advocated dynamic electromyography for this purpose (9,11). Hoffer contends that a muscle will not change in phasic activity following transfer (9). Muscles in phase for specific activities will be functional. Muscles active only in release and not in grasp, for example, will be effective if transferred to finger extensors. Those muscles active only during grasp are good transfers for wrist extension. Muscles that fire continuously are not candidates for transfer, according to Hoffer (9). Other authors have observed such muscles becoming phasic after transfer (28). This issue is not yet resolved, and the role of dynamic electromyography remains controversial. Although acknowledging its potential, we do not rely on this technique in planning treatment.

## OVERALL ASSESSMENT

Assess cognitive, sensory, motor, and psychosocial elements in planning management, and recognize the overall severity of involvement. Green and Banks (8) have devised a grading system for evaluating patients, and this has been modified by Samilson and Morris (28):

- Excellent: good function in activities of daily living, effective grasp and release, excellent control, wrist extension of 45° or more, full active finger extension, active supination of 50° or more
- Good: hands used as helpers in activities of daily living, effective grasp and release with good control, wrist extension of 15° to 45°, can actively extend the fingers with the wrist extended
- Fair: hands used as helpers but not effective in dressing, moderate grasp and release, fair control
- Poor: hands used only as weights, poor or absent grasp and release, poor control, no finger extension unless the wrist is in maximum flexion

It is very important to assess the patient's and the family's motivation. Surgery is of value only when the patient and parents are committed to attaining realistic goals. Make clear to the parents that a normal extremity will not be the outcome, but that worthwhile improvements in function and cosmesis may result (29).

## AIMS OF TREATMENT

Cerebral palsy patients have deficits in function, cosmesis, and hygiene. The spastic hemiparetic patient with reasonable intelligence, good sensibility, motivation, and appropriate parental support should have a good functional extremity as the goal. Planned procedures in such patients have predictable results (3). Mentally retarded patients with poor sensibility should instead undergo procedures directed toward improvement of hygiene and prevention of skin maceration (24). Improvement of cosmesis and hygiene are goals for patients with reasonable intelligence but other limiting factors. Diminished sensibility and voluntary control are not contraindications to surgical treatment, although expectations are lower in such patients (4).

## PATIENT AGE AND TIMING OF SURGERY

Patterns of deformity may change during the first several years of life. While the patient's age is only one of the factors to be considered, surgery generally should not be performed before the motor pattern becomes established, and not until central nervous system maturation permits compliance with the postoperative regimen (33). To prevent deformity and rejection of the extremity, however, surgery should not be overly delayed.

During the first few years, thumb abduction, wrist and digital extension, and forearm supination should be preserved through use of resting and/or night splints. By age 4, the pattern of persistent deformity becomes evident, and children may become candidates for operative treatment. The optimal time for tendon transfers is between ages 5 and 12 years (2).

## SURGICAL TECHNIQUES

The most common deformities of the upper extremity are listed in Table 66.1. Treatment of the proximal part of the extremity should be done before treatment of the hand. In general, begin with capsulotomies (rarely needed in children), tenotomies, and tendon lengthenings to correct deformities; proceed to tendon transfers; and conclude with arthrodesis of joints where necessary.

| | Deformity | Procedure |
|---|---|---|
| Shoulder | Adduction–internal rotation<br>Abduction–internal rotation | Subscapularis lengthening<br>Rotational humeral osteotomy<br>Deltoid recession<br>Teres minor lengthening<br>Infraspinatus lengthening |
| Elbow | Flexion | Flexor release |
| Forearm | Pronation | Flexor-pronator release (pronator tenotomy, pronator rerouting) |
| Wrist | Flexion<br>Inadequate extension | Flexor-pronator release<br>Transfer FCU to ECRB<br>Arthrodesis |
| Hand | Digital flexion<br>Inadequate MCP extension<br>Scissorsick<br>Thumb-in-palm | Z-lengthening<br>Transfer FCU to EDC<br><br>Superficialis tenodesis<br>PIP capsulotomy<br>Adductor pollicis tenotomy<br>Transfer BR to APL<br>MCP capsulotomy<br>MCP arthrodesis<br>Web Z-plasty<br>FPL abductor plasty |

MCP, metacarpophalangeal; FCU, flexor carpi ulnaris; ECRB, extensor carpi radialis brevis; EDC, extensor digitorum communis; BR, brachioradialis; APL, abductor pollicis longus; FPL, flexor pollicis longus.

***Table 66.1. Common Deformities of the Upper Extremity***

### SHOULDER

#### *Adduction–Internal Rotation*

Adduction–internal rotation is the most common shoulder deformity. It results from spasticity and contracture of the subscapularis and pectoralis major. Internal rotation contracture limits the positioning of the upper extremity and may be managed by passive stretching exercises. For resistant deformity, subscapularis and pectoralis major lengthening or release is recommended (4). If the deformity persists, humeral osteotomy may be necessary.

#### Subscapularis and Pectoralis Major Lengthening Technique

- We prefer a deltopectoral approach, although the procedure may be performed through an axillary incision. Make a longitudinal incision from the coracoid to the border of the pectoralis major insertion (Fig. 66.1*A*).

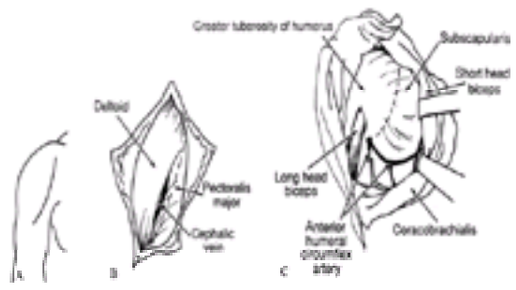


***Figure 66.1.*** **A:** Incision for subscapularis–pectoralis major lengthening. **B:** Interval between deltoid and pectoralis major. **C:** Lengthening of subscapularis. Take care to avoid the anterior humeral circumflex vessels.

- Identify the deltopectoral groove and develop the interval between the deltoid and the pectoralis major (Fig. 66.1*B*). Protect the cephalic vein.
- The scapularis, bordered inferiorly by the anterior humeral circumflex veins, is lengthened medially to the glenohumeral joint (Fig. 66.1*C*). For persistent deformity, release the subscapularis at its insertion into the humerus.
- If the tendon of the pectoralis major is tight, lengthen it by a stepcut incision.
- Postoperatively, immobilize the limb in 25° to 30° of abduction and 20° of external rotation for 4 to 6 weeks. Begin active assisted exercises to retain shoulder range of motion at 2 weeks.
- More resistant deformities may require an external rotational osteotomy of the proximal humerus. The osteotomy is performed via an anterior approach and is held with crossed pins or with plate fixation.

### *Abduction–External Rotation*

Abduction–external rotation is uncommon (9).

- Perform surgical release, when it is indicated, through a “strap” incision, permitting access to the deltoid and the spine of the scapula.
- Detach the fibers of the anterior two thirds of the deltoid from their insertion into the humerus and recess the deltoid muscle. Do not disturb the insertion of the scapular portion of the deltoid.
- Perform a Z-lengthening of the tendons of the teres minor and the infraspinatus.
- Immobilize the shoulder in a Velpeau bandage (reinforced with plaster) for 2 weeks. Begin active assisted and passive shoulder exercises while maintaining the limb in a protective Velpeau dressing between exercise periods.

## ELBOW

### *Flexion Deformity*

Elbow flexion deformity is common, but it is often mild and can be managed by passive stretching exercises. Occasionally, flexion tone and/or contracture become sufficiently severe to compromise hygiene, limit reach, interfere with crutch use, and present other functional limitations. Flexion deformity caused by spasticity or contracture is treated by biceps tendon lengthening, brachialis tenotomy, recession of the origins of the wrist flexors (excluding flexor digitorum profundus and superficialis), and, if necessary, anterior elbow joint capsulotomy. Preoperative musculocutaneous nerve block may be useful in distinguishing increased tone from contracture (9). Resist the temptation to release flexor muscle origins at the elbow to correct an ipsilateral flexed wrist, flexed fingers, or thumb-in-palm deformity, as this release tends to weaken the muscle excessively (5). Elbow flexion recovers postoperatively provided the biceps and brachialis were functioning before the procedure.

#### Elbow Flexor Release Technique

- Make an S-shaped incision in the antecubital fossa (Fig. 66.2*A*). Excise the lacertus fibrosus.

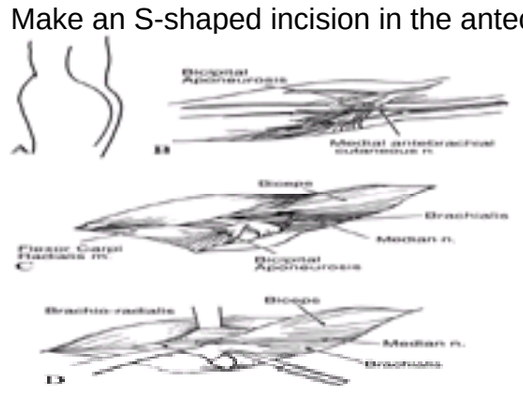


***Figure 66.2.*** **A:** Incision for elbow flexion release. **B:** The medial antebrachial cutaneous nerve must be protected. **C:** The bicipital aponeurosis is divided. The median nerve and brachial vessels are identified. **D:** Z-lengthening of the biceps tendon is performed at the musculotendinous junction. The brachialis insertion is raised from the ulna.

- Identify the medial antebrachial cutaneous nerve and mark it with a Penrose drain (Fig. 66.2*B*).
- Release the origin of the flexor carpi ulnaris from the medial epicondyle and from its attachment to the proximal ulna.
- Identify and protect the median nerve and brachial vessels (Fig. 66.2*C*).
- Release the pronator teres and flexor carpi radialis if there is wrist contracture.
- Isolate the biceps tendon lateral to the neurovascular structures and dissect soft tissue and paratenon from the tendon. Perform a Z-lengthening of the biceps tendon at the musculotendinous junction (Fig. 66.2*D*) (23). The extent of lengthening depends on the angle of contracture and the degree of spasticity; 3 or 4 cm of lengthening is usually appropriate (4).
- Identify and protect the radial nerve. Then identify the brachialis aponeurosis and divide its insertion into the ulna, and passively extend the elbow. If the deformity is resistant, incise the anterior elbow joint capsule. Capsulectomy is not required. It may be necessary to release the origin of the brachioradialis at the lateral condyle of the humerus.
- Some authors suggest transferring the ulnar nerve anteriorly to avoid nerve hypermobility postoperatively (4). If the nerve is under tension in the extended position, perform anterior subcutaneous transposition.
- Complete correction of flexion deformity should not be the goal; correction of the major component of the fixed deformity is usually sufficient.
- At the close of the procedure, release the tourniquet and obtain hemostasis. Introduce a Penrose or similar drain, which is removed at 24 hours.
- Immobilize the limb in a posterior splint in maximal unforced extension.
- Change to a plaster cast at the first dressing change.
- Active elbow flexion is started at 3 weeks postoperatively. Keep the limb in anterior and posterior plaster splints or an anterior-posterior plastic orthosis at all other times to preserve extension; continue this for the first 6 weeks. Use night splints for an additional 6 weeks.

## FOREARM

### *Pronation*

Severe pronation forces the child to abduct the shoulder and renders grasp nonfunctional (31). By itself, pronation deformity seldom requires surgical correction but may so limit use of the hand as to warrant such treatment. Two surgical measures have been suggested for correction of severe pronation deformity: pronator tenotomy, and rerouting of the pronator to function as a supinator (31).

Tenotomy is indicated when the forearm cannot be supinated to more than 45° to 30° from neutral (33). Rerouting offers the advantage of strengthening supinator power. While some authors have reported consistently good results following pronator teres rerouting, others have found the procedure somewhat unpredictable and capable of producing supination deformity (27,31). A fixed supination deformity is more disabling than a pronation contracture. Hence, approach this procedure with some caution.

Coexisting contractures of the forearm in pronation and of the wrist in flexion are common in cerebral palsy. The inability to extend the wrist and supinate the forearm compromises digital motion, power pinch, and grip. Prolonged pronation contracture may produce radial head dislocation (24). Release of the flexor pronator origin can provide considerable lengthening and improve appearance and function of an extremity with fixed deformities (14). In passively correctable deformities that assume a flexed position during grasp, transfer of flexor carpi ulnaris (FCU) to extensor carpi radialis brevis (ECRB) is recommended (8). A surgical technique is described in the following section on wrist flexion deformity. Supination may be improved after this transfer by suturing the FCU while the forearm is moderately supinated (2).

**Pronator Teres Tenotomy Technique**

- Make a 4 cm longitudinal incision on the anterolateral mid forearm over the pronator teres insertion.
- Develop the interval between the brachioradialis (BR) and the extensor carpi radialis longus (ECRL), exposing the pronator teres. Transect the insertion of pronator teres onto the radius.
- Close the wound and apply a long-arm cast with the forearm in 60° of supination. At 4 weeks, replace the cast with a posterior splint and begin active range of motion of the elbow. Discontinue the splint at 8 weeks (31).

**Pronator Teres Rerouting Technique**

- Make an incision on the anterolateral mid forearm over the pronator teres insertion.
- Identify and protect the lateral antebrachial cutaneous and the superficial radial nerves. Develop the interval between the BR and the ECRL.
- Dissect the insertion of the pronator teres off the radius along with a 2 cm periosteal strip. Incise the fascia covering the muscle and mobilize it well proximally.
- Make a large, long opening in the interosseous membrane. Pass the pronator teres through this opening and then posterior and lateral to the radius toward its anterolateral border.
- Drill a 1.6 mm transverse hole through the radius from the pronator teres insertion to the posterior medial cortex. Enlarge the anterolateral hole with a 2.8 mm drill. Weave a 2-0 nonabsorbable suture through the distal end of the pronator teres and pass this through the drill hole from anterolateral to posteromedial. Tighten the suture to secure the tendon. Supplement this with additional sutures through the tendon and periosteum.
- Apply a long-arm cast in 60° of supination. The postoperative regimen is as described for pronator teres tenotomy (27,31).

**WRIST**

***Flexion Deformity***

Flexion deformities of the wrist and fingers are common in cerebral palsy and interfere with grasp and release. Flexor–pronator release is recommended if both the wrist and the fingers are flexed; if the deformity is limited largely to the fingers, however, use a Z-lengthening tenotomy in the mid to distal forearm.

**Flexor–Pronator Slide Technique**

- Start the incision 5 cm proximal to the medial epicondyle and continue it distally across the antecubitum in a zigzag fashion to the midportion of the proximal forearm. Take care not to damage the medial antebrachial cutaneous nerve in the distal part of the incision and the medial brachial cutaneous nerve posterior to the medial part of the epicondyle.
- Identify the ulnar nerve and dissect it from its groove (Fig. 66.3*A*). Divide the medial intermuscular septum. Protect the ulnar nerve branches to the FCU and the two ulnar heads of the flexor digitorum profundus (FDP). Retract the ulnar nerve by vessel loops.

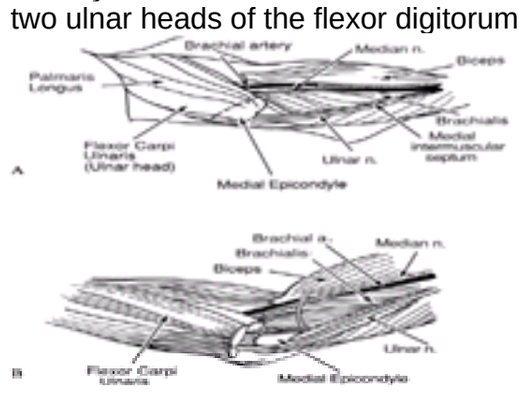


***Figure 66.3.*** **A:** The ulnar nerve is identified and the median intermuscular septum divided. **B:** The flexor–pronator origins are elevated from the ulna and advanced distally.

- Incise the lacertus fibrosus fascia. Identify and gently retract the median nerve and brachial artery. Take care to preserve the motor branches of the median nerve to the flexor–pronator muscles. This is an exacting dissection and must be performed with patience. Starting distally, elevate the FCU and FDP origins from the ulna and the interosseous membrane (Fig. 66.3*B*). Continue this dissection proximally along the ulna as far as the ulnar groove. The flexor digitorum superficialis (FDS) usually must be released from the radius and the interosseous membrane.
- Separate the flexor–pronator muscle mass from the underlying anterior capsule of the elbow, divide it at its origin on the medial part of the epicondyle, and advance it distally about 4 cm.
- The flexor–pronator muscle mass may be sutured to the underlying tissue at the desired reattachment point. If pronation deformity of the forearm is not a problem, bring the pronator teres origin over the periosteum of the ulna at the proper tension so that pronation of the forearm is not compromised.
- If a flexion contracture of the elbow persists, release the brachialis.
- Deflate the tourniquet and obtain hemostasis. Place drains in the forearm and the antecubitum; these should be removed at the first dressing change.
- By the close of the procedure, the wrist should dorsiflex 45° to 60° with the fingers in maximum extension. Use plaster splints to hold the forearm in supination, the wrist in 30° of extension, the metacarpophalangeal (MCP) joints in 25° of flexion, and the elbow flexed 45° to 90°.
- At the first dressing change, replace the splint with a cast, which is worn for 3 weeks. Active assisted motion is started after cast removal. Custom-molded anteroposterior splints that maintain the wrist in extension are worn between treatments for 6 weeks, and then only at night for an additional 6 months.

***Inadequate Extension***

Function in patients with wrist flexion contractures may be improved by Z-lengthening of the wrist flexors: FCU, flexor carpi radialis, and palmaris longus. This procedure works best if the patient has active wrist extensor power. Wrist flexor lengthening is not needed if the wrist can be voluntarily extended to at least 10° past neutral, and if it can be actively flexed and assists in finger extension (5).

Wrist arthrodesis is indicated only when there is no potential for active finger flexion and extension (24). Fusion lessens severe flexion deformities and is particularly helpful for athetoid patients (12). Perform arthrodesis only after testing hand function in a cast, with the wrist in the position chosen for the procedure. It is contraindicated if the patient depends on wrist flexion for release or wrist extension for grasp, or if other planned tendon transfers might be compromised by the arthrodesis. The fusion includes the radiocarpal, midcarpal, and carpometacarpal joints. The epiphyses and the distal radioulnar joint are preserved.

When grasp is compromised by inadequate wrist extension from weak extensors, but finger extension can be performed actively with the wrist passively extended, transfer of the FCU is recommended (8). The tendon of the FCU is passed subcutaneously around the ulnar border of the forearm and is transferred to the tendon of the ECRB. The transfer eliminates a deforming force pulling the hand into ulnar deviation and flexion.

Several prerequisites exist for this transfer. First, there must be satisfactory passive forearm supination and wrist and finger extension. Second, any fixed deformity should be corrected by successive stretching casts and exercises. Finally, there must be adequate digital motor control. The procedure has been widely used for many years with good results (5,18,24,25,29,33). However, some long-term studies report extension contractures and difficulty with grasp and release following this transfer

(10).

In an effort to define the indications for this transfer, the spastic hand has been classified into three groups based on the ability to grasp and release through wrist position (37):

- Type I: Fingers can actively extend with the wrist in less than 20° of flexion.
- Type II: Fingers can actively extend with the wrist in less than 50° of flexion.
- Type III: Fingers cannot extend with the wrist in any position.

Type I patients exhibit mild spasticity of the FCU and finger flexors. If indicated, tenotomy of the FCU may be of value in this group.

Children who can actively extend their fingers to near neutral with the wrist passively extended but cannot extend the wrist to neutral are most likely to benefit from an FCU-to-ECRB transfer (35,36). Children who cannot actively extend the fingers with the wrist passively extended but who can with the wrist flexed at 45° may also benefit.

Patients with type III deformity lack voluntary grasp and release patterns. The FCU-to-ECRB transfer is not indicated in this group (36). These patients may benefit from multiple tendon fractional lengthenings in the forearm, allowing the fingers to remain out of the palm for improved cosmesis and hygiene.

**FCU-to-ECRB Transfer Technique**

- Make a 3 cm longitudinal incision radial to the insertion of the FCU. Make a second 6 cm longitudinal incision along the palmar-ulnar aspect of the forearm. The two incisions extend over the muscle belly of the FCU from the wrist flexor crease to the junction of the middle and proximal thirds of the forearm.
- Expose the FCU, isolate the ulnar nerve, and tag it with a vessel loop posterior to the tendon (Fig. 66.4*A*). Split the muscle sheath of the FCU and transect the tendon just proximal to its insertion on the pisiform. Strip the muscle fibers of the FCU extraperiosteally from the ulna. Free the muscle proximally, without disturbing its nerve supply from the ulnar nerve. Continue the dissection throughout the length of the wound, allowing mobilization of the muscle sufficient to permit its passage in a straight line from its origin to the dorsum of the wrist.

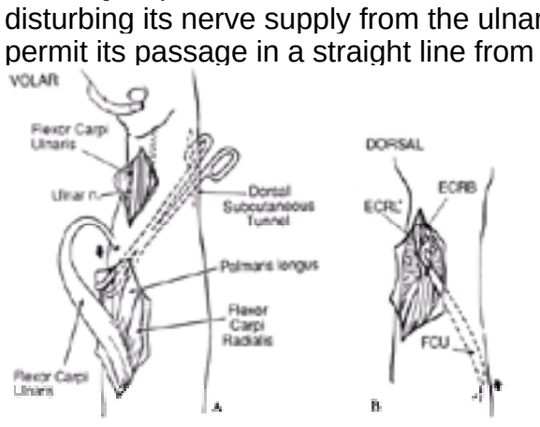


***Figure 66.4.*** **A:** The flexor carpi ulnaris is exposed, released distally, and freed proximally. **B:** The flexor carpi ulnaris (FCU) tendon is passed around the ulna through the subcutaneous tunnel and transferred to extensor carpi radialis brevis (ECRB). *extensor carpi radialis longos

- Make a third longitudinal incision over the wrist in line with the long metacarpal, beginning at the distal end of the radius and extending for 5 cm proximally. Incise the extensor retinaculum over the second compartment and identify the ECRB. By blunt dissection, prepare a tunnel extending from the proximal FCU incision to the dorsal radial incision. Construction of this tunnel is facilitated by use of a tendon passer.
- Pass the FCU tendon around the ulna through the subcutaneous tunnel (Fig. 66.4*B*). Make a slit in the tendon of ECRB with a #11 blade.
- Place the wrist in 40° of extension and the forearm in supination, then pass the tendon of the FCU through the slit in the ECRB. For the intratendinous suturing, use 3-0 nonresorbable suture. Secure the attachment of the FCU to the ECRB with additional interrupted sutures.
- Tension must be sufficient to maintain the wrist in neutral against gravity, but it should permit passive flexion to 15°.
- Close the wound and apply a long-arm cast with the forearm in supination and the wrist in 15° of extension.
- The cast is worn for 4 weeks; then active exercises for ulnar deviation and wrist extension are begun. A bivalved cast or a plastic splint is worn between exercise periods for 2 to 3 months. This program is discontinued when the wrist can be maintained actively in extension. A night brace is worn throughout this time and for an additional 4 months or until there is no tendency toward recurrence (8,24,29,33).

**HAND**

***Digital Flexion Deformity***

Proximal interphalangeal (PIP) flexion deformity may be caused by spasticity and myostatic contracture of the FDS and FDP muscles or by paresis of the extensor digitorum communis (EDC). Flexion deformity is increased on wrist extension and diminished on wrist flexion. Serial plaster casts with progressive wrist extension may lessen flexion deformity of the digits. If conservative treatment is ineffective, surgical lengthening of the spastic or contracted finger flexors is indicated (5). Do not perform lengthening if the wrist can be voluntarily brought to neutral without excessive digital flexion, or if the wrist flexors are weak. With this deformity, lengthening is preferable to flexor–pronator release.

To assess the amount of tendon lengthening required, hold the wrist in maximum extension, placing the MCP joints of the fingers in extension, and then observe the resulting posture of the fingers. Correction should change this finger position to one that is more functional for the activities of daily living.

**Fractional Flexor Lengthening Technique**

- Expose the flexor tendons through a midline incision on the palmar surface of the distal forearm (Fig. 66.5*A*). Divide the deep fascia.

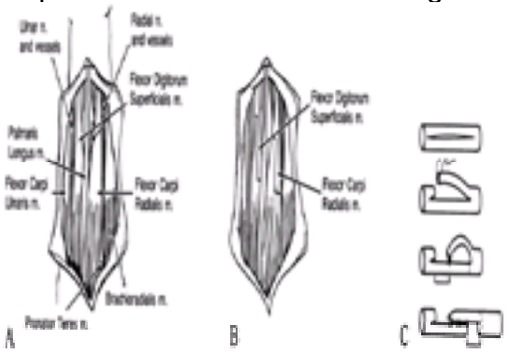


***Figure 66.5.*** **A:** Exposure of flexor tendons. **B:** Lengthening of flexor tendons by stepcut incisions. **C:** Goldner (4) suggests bisecting the tendon for a distance of twice that of the proposed lengthening. One slip of the tendon is divided and sutured halfway from the cut end to the intact tendon. The remaining portion is then cut distally.

- Identify and protect the ulnar nerve and artery on the radial side of the FCU tendon. Isolate the radial artery on the radial side of the flexor carpi radialis (FCR). Lengthen the FDS tendons by stepcut incisions at the musculotendinous junction (Fig. 66.5*B*). Goldner suggests bisecting the tendon for a distance twice that of the proposed lengthening (Fig. 66.5*C*) (5).
- Divide one slip of the tendon and suture it halfway from the cut end to the intact tendon, after passively extending the finger. Then cut the remaining portion of the tendon distally, without disturbing the underlying muscle tissue. This results in a controlled lengthening.
- With the wrist extended 50°, the PIP joints should be flexed 45°. Repair the incisions with 4-0 resorbable suture.
- Release of the FDP at the same operation may not be advisable because grasp is weakened if both extrinsic digital flexors are lengthened. See how the patient adjusts to lengthening of the superficialis tendons before considering surgery of the FDP.

- Expose the muscle tendon units of the FDP by retracting the FCR and the FDS and protecting and retracting the median nerve.
- Lengthen the FDP in a manner similar to that used for the FDS, but at a different level. Lengthen the flexor pollicis longus (FPL) if the thumb is held in a flexed position and interferes with pinch and grip.
- Patients with wrist flexion contractures may require FCR and FCU lengthening. Lengthening is not required if the fingers can be flexed easily while maintaining the wrist in active extension. If the procedure proves necessary, lengthen the FCR first. Lengthen the tendon of the FCU only if the FCR procedure provides insufficient correction.
- Release the tourniquet and achieve meticulous hemostasis at the end of the procedure. Do not close the deep fascia.
- Apply long-arm anteroposterior splints to the fingertips, including the thumb, with the elbow at 90°, the forearm supinated, the wrist in 40° of extension, and the fingers and thumb in neutral.
- Physical therapy for patients undergoing flexor tendon lengthening includes active exercises at 4 weeks after surgery. Bivalved plastic splints are worn between exercise periods. Night splinting continues for 6 months (5,33).

### *Inadequate MCP Extension*

If digital extension is unsatisfactory, a motor should be transferred to the EDC. The procedure is indicated when there is no significant contracture and a muscle is available for transfer that is synchronous with finger extension (8). The FCU, BR, and ECRB have been recommended for the transfer (5,22,29,33). We prefer transfer of the FCU into the EDC because the muscles are synchronous and the transfer produces a tenodesis effect (10,19).

#### FCU-to-EDC Transfer Technique

- The exposure is similar to that described for the FCU-to-wrist extensor transfer. Make a longitudinal incision that extends along the ulnar-palmar aspect of the forearm, from the palmar wrist crease to the junction of the proximal and middle thirds of the forearm.
- Expose the FCU and identify and protect the ulnar artery and nerve. Divide the FCU tendon at its insertion into the pisiform and free it proximally, while carefully preserving the proximal innervation of the tendon.
- Make a second longitudinal incision over the fourth dorsal compartment. Divide the extensor retinaculum and expose the EDC.
- Pass the tendon of the FCU through a subcutaneous tunnel to the dorsal incision. Hold the wrist and MCP joints in neutral. Split the FCU tendon into two segments and suture these into each of the tendons of EDC. Adjust the tension so that each finger's MCP joint hyperextends slightly when the wrist is flexed.
- Apply a long-arm cast with the wrist in 30° of extension and the MCP joints in neutral. This position is maintained for 4 weeks, at which point active exercises are started. Prescribe a splint that limits finger and wrist flexion, to be worn for 2 months, followed by a night splint for 6 months (29,33).

### *Swan-Neck Deformity*

Swan-neck deformity is characterized by hyperextension of the PIP joints with flexion at the distal interphalangeal (DIP) joints (Fig. 66.6*A*). In cerebral palsy, it usually results from muscle imbalance caused by the spastic intrinsics exerting excessive pull on the extensor mechanism. Contraction of the tight or spastic intrinsics results in PIP hyperextension. The tenodesis effect of the EDC while the wrist is flexed also contributes to the deformity. The palmar plate stretches and the lateral bands sublux dorsally, increasing the hyperextension of the PIP joint. The deformity impairs grasp and pinch. Treatment consists of superficialis tenodesis with or without capsulorrhaphy of the PIP joint, as described by Swanson (32).

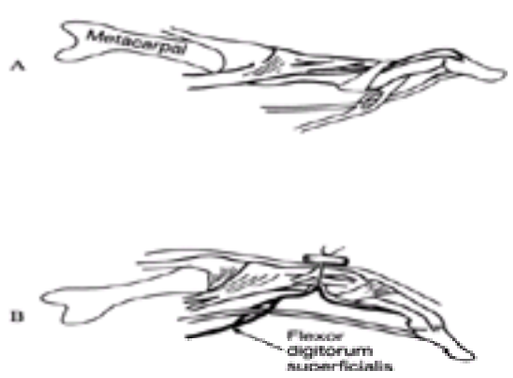


***Figure 66.6.*** **A:** Swan-neck deformity. **B:** The superficialis tendon is drawn into the cavity by passing the suture through the dorsal cortex and tying it over a button.

#### Superficialis Tenodesis Technique

- Make a mid-lateral incision from the midportion of the middle phalanx to the base of the proximal phalanx. For the index finger, the incision should be on the ulnar side; for the little finger, it should be on the radial side.
- Incise the retinacular ligament longitudinally. Gently retract the neurovascular bundle on the side of the incision to the other side.
- A modified Bruner incision from the center of the middle phalanx to the proximal palmar crease of the finger also provides good exposure for the procedure.
- Make an incision in the flexor sheath between the $A_2$ and $A_4$ pulleys; identify each flexor tendon by a vessel loop and retract it.
- Expose the palmar aspect of the proximal phalanx by subperiosteal dissection, and drill two small holes 1 cm apart in the palmar cortex of the proximal phalanx in a palmar-to-dorsal direction (Fig. 66.6*B*). Connect the two holes on the palmar aspect using a curet. Roughen the bone for attachment of the tendon.
- Draw the superficialis tendon into the medullary cavity by a nonresorbable 4-0 suture. Then pass the suture through the palmar cortex defect and out a hole in the dorsal cortex, to the dorsal aspect of the finger, and secure it over a button. Anchor the tendon to the bone with the PIP joint in 30° of flexion. Drill a 0.045 Kirschner wire (K-wire) across the joint from the proximal portion of the middle phalanx through the neck of the distal end of the proximal phalanx.
- Close the flexor sheath with fine resorbable suture. Repair the retinacular ligament and suture the skin.
- Capsulorrhaphy is required in some cases. Incise the capsule at right angles to the finger. With the joints in 30° of flexion, place 4-0 nonresorbable sutures in the distal end of the proximal flap and the proximal end of the distal flap (32,33).

### *Thumb-in-Palm Deformity*

Thumb-in-palm deformity is extremely disabling, as it prevents lateral pinch and grasp. The deformity consists of flexion, adduction, and external rotation of the first ray with flexion of the distal phalanx. The deformity may be due to adductor spasticity or to spasticity and contracture of the FPL. Stretching of the MCP joint capsule may produce instability of the joint. Secondary thenar space narrowing may develop. If severe, this can eventually lead to subluxation of the carpometacarpal joint (33).

Many procedures have been proposed for correction, including MCP and interphalangeal (IP) arthrodesis, webspace release, tendon transfer, tendon lengthening, and MCP capsulodesis (2,13,15,16 and 17,21,30). For planning correction, the classification scheme of Mital and Sakellarides is helpful (24).

- Type I deformity results from paresis of the extensor pollicis longus, with or without instability of the MCP joint. Procedures suggested to correct this include tendon transfer of the BR into the abductor pollicis longus (APL) and the extensor pollicis brevis (EPB), and rerouting of the extensor pollicis longus (EPL) (13,20,21). We recommend the BR transfer. If the joint is unstable, stabilize the MCP joint by capsulodesis or arthrodesis (1,7). Gelberman suggests arthrodesis if the MCP joint shows hyperextension deformity greater than 20° (2). If performed in a child, the procedure should not interfere with growth of the thumb (2). Reserve arthrodesis for cases in which soft-tissue procedures prove unsatisfactory. A different opinion is voiced by Goldner et al., who recommend simultaneous correction of the soft-tissue deformity and MCP joint arthrodesis (7).
- Type II deformity is caused by spasticity or contracture of the adductor pollicis. Treat adductor pollicis contracture by release of the transverse and oblique heads of the muscle. Myotomy is preferred to tenotomy, because it avoids hyperextension of the MCP joint while permitting release of the first metacarpal. If severe spasticity is present, simultaneously perform neurectomy of the motor branch to the adductor. Should the first dorsal interosseous contribute to the deformity, release it from the first or second metacarpal, or both.
- In type III deformity, there is paresis of the APL. We suggest tendon transfer of the BR to the APL. Full passive abduction of the first metacarpal and passive thumb extension are prerequisites for tendon transfer.
- Type IV deformity is caused by overactivity of the FPL. Perform Z-lengthening of the flexor palmaris longus in the distal forearm to overcome flexion deformity. Alternatively, some authors suggest the subcutaneous transfer of the flexor palmaris longus to the radial side of the proximal phalanx of the thumb, with tenodesis

or arthrodesis of the IP joint (30). This offers the advantage of augmenting thumb abduction.

Of course, many patients demonstrate more than one type of deformity, and treatment must be individualized accordingly (29). Deformities of long duration are more likely to demonstrate webspace contracture. Z-plasty of the skin of the thumb web and division of the fascia may be necessary. Children's skin, however, has sufficient elasticity to avoid the need for Z-plasty (5).

**Technique for Capsulodesis of the MCP Joint**

- Make a palmar zigzag incision over the MCP joint. Retract the neurovascular bundles.
- Incise the $A_1$ pulley and mobilize and retract the FPL.
- Incise the palmar plate, leaving its distal attachment intact. Release the insertions of intrinsics onto the plate.
- Introduce a 4-0 double-armed wire suture with pullout wire in Bunnell fashion into the palmar plate.
- Prepare a small groove on the neck of the metacarpal to accommodate the plate. Drill two holes to the dorsum of the metacarpal. Drill a 0.045 K-wire through the proximal phalanx, so that it may later be brought across the joint in retrograde fashion.
- Holding the joint in 30° of flexion, pass the suture through the apertures and tie it over a button on the dorsum of the thumb. Pass the K-wire across the MCP joint.
- Hold the thumb in abduction in a plaster cast. Remove the pullout wire at 6 weeks and the K-wire at 8 weeks.

**Technique for Arthrodesis of the MCP Joint**

- Make a radial mid-lateral incision. Incise the collateral ligament and capsule along the metacarpal head and dislocate the joint.
- Carefully remove the articular cartilage from the metacarpal head using a small rongeur. Remove the articular surface of the proximal phalanx without disrupting the physes. Drill two 0.045 K-wires through the subchondral bone of the proximal phalanx so that they may be passed retrograde across the MCP joint.
- Hold the joint in 10° of flexion and 10° of lateral rotation and pass the wires. Repair the capsule and collateral ligament with 4-0 resorbable suture. A thumb spica cast is worn for 4 weeks or until there is firm union. The pins, which have been cut subcutaneously, are left in place for about 1 year.

**Technique for Adductor Release**

- Make an incision in the thenar flexion crease, from the second metacarpal neck to just proximal to the wrist flexion crease (Fig. 66.7*A*). If deepening of the web is indicated, use a standard or four-quadrant Z-plasty incision. Make a transverse incision in the web, from the ulnar border of the proximal flexion crease of the thumb to the radial border of the proximal transverse palmar crease; then make two oblique cuts at a 60° angle.

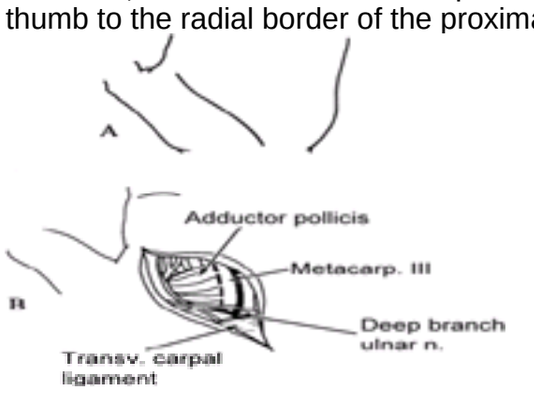


***Figure 66.7.*** **A:** Skin incision. **B:** The first dorsal interosseous is retracted radially and the adductor pollicis is identified.

- After the skin flaps are raised, incise the palmar fascia. Retract the flexor tendons to the index finger radially and those to the long finger ulnarly.
- Identify and retract the common digital nerve ulnarly.
- Incise the fascia over the adductor pollicis and first dorsal interosseous (Fig. 66.7*B*). Retract the first dorsal interosseous radially.
- Identify the tendon of the adductor pollicis. The transverse head of the adductor pollicis arises from the distal two thirds of the long finger metacarpal. The oblique head originates from the capitate and from the bases of the index and long metacarpals. Release the adductor from its origin.
- It is generally necessary to release the flexor pollicis brevis, the opponens pollicis, and the abductor pollicis brevis muscles as well. This may be accomplished by elevating their origins from the transverse carpal ligament.
- Preserve the deep branch of the ulnar nerve and perforating branches of the radial artery. It is rarely necessary to perform neurectomy of the innervation of the adductor pollicis. However, extreme spasticity may require careful dissection and neurectomy of the deep palmar branch of the ulnar nerve, which is the motor branch to the adductor.
- Release the tourniquet and obtain hemostasis.
- A cast holds the MCP joint in neutral and the IP joint in slight flexion. Apply a plastic splint at 4 weeks to maintain the position of abduction and opposition. Active and passive exercises are begun at 4 weeks to rehabilitate thumb function. The cast should be worn for 6 weeks if simultaneous tendon transfers have been performed. Night splints are worn for 6 months to prevent recurrence of the deformity (29,33).

**Technique for BR-to-APL Transfer**

- Make a radial longitudinal incision from the radial styloid process to a point 3 cm distal to the lateral epicondyle.
- Free the insertion of the BR from the radial styloid (Fig. 66.8*A*).

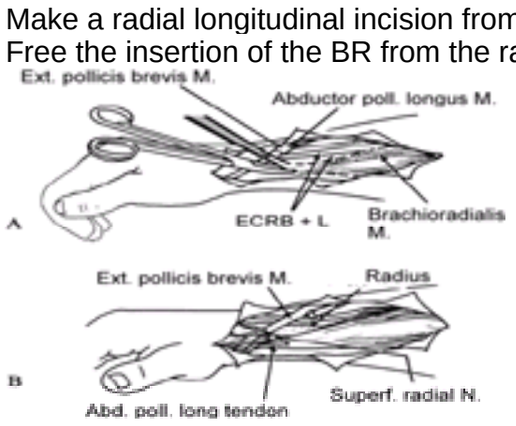


***Figure 66.8.*** **A:** The insertion of the brachioradialis is freed from the radial styloid. **B:** The distal cut end of adductor pollicis longus is woven through the brachioradialis.

- Protect the branches of the superficial radial nerve. The nerve travels along the forearm deep to the BR and can be found adjacent to the radial artery in the proximal forearm. In the distal forearm, the superficial radial nerve emerges from beneath the BR and penetrates the deep fascia.
- Dissect the tendon and muscle of the BR free from the antecubital fascia and adjacent muscles to which they are adherent. The muscle must be mobilized proximally as far as possible to gain maximal excursion.
- Transect the APL at its musculotendinous junction proximal to the dorsal retinaculum. Hold the first metacarpal in abduction, weave the distal cut end of the APL through the BR, and suture it with 3-0 nonresorbable suture (Fig. 66.8*B*).
- Tension should allow the first metacarpal to be adducted passively to within 2 cm of the palm, with the wrist in neutral. Tip pinch between the thumb and index must be preserved; check this after performing the transfer.
- Correct persistent extreme flexion of the MCP by transferring the proximal end of the APL to the EPB tendon.
- Release the tourniquet and obtain hemostasis.
- Apply an above-elbow cast with the wrist in neutral, the thumb in neutral, and the first metacarpal in maximal abduction. The cast is removed at 4 weeks, and a short-arm plastic thumb spica splint is worn to maintain the thumb in maximal abduction. Begin active exercises at 4 weeks to restore thumb function. Prescribe night splints for an additional 6 months (29,33).

**Technique for FPL Abductorplasty**

- Make a radial mid-axial incision from the middle of the distal phalanx to the neck of the first metacarpal. Develop the palmar skin flap, exposing the FPL.
- Transect the tendon opposite the proximal phalanx.
- Perform arthrodesis or tenodesis of the IP joint in 15° of flexion.
- Make a longitudinal incision in the forearm just radial to the FPL tendon. Curve the incision in an ulnar direction at its distal end just proximal to the wrist crease.
- Bring the distal end of the FPL to this wound. Prepare a subcutaneous tunnel from the lateral side of the MCP joint to the apex of the wrist incision. Pass the distal end of the FPL through this tunnel. With the thumb abducted 50° and the wrist in neutral, suture the transferred FPL to the dorsoradial proximal phalanx base without tension.
- Apply a plaster splint holding the thumb abducted and the wrist flexed 30° for 6 weeks. A plastic static thumb abduction splint is worn for an additional 6 weeks (30).

**Technique for EPL Rerouting** Extensor pollicis longus rerouting is a thumb abduction augmentation transfer performed only in conjunction with adductor–flexor intrinsic release (20). Despite acting as an IP extensor, the EPL also adducts the thumb. EPL rerouting eliminates a deforming force and converts this tendon to a more functional position.

- Identify the EPL through a dorsal distal forearm incision just proximal to Lister's tubercle.
- Make a second dorsal incision over the MCP joint and the proximal phalanx in the hand, again exposing the tendon.
- Dissect a narrow longitudinal strip of the EPL insertion in the midline of the dorsal thumb incision, leaving sufficient tissue for closure of the aponeurosis. Withdraw the tendon into the distal forearm.
- Release the forearm fascia allowing the EPL tendon to pass in a straight line to the thumb base.
- Place a tendon passer from the dorsal thumb incision along the path followed by the EPB and APL tendons through the first dorsal retinacular compartment. Direct the tip proximally into the dorsal forearm incision. Grasp and pull the EPL tendon distally through the first dorsal compartment into the dorsal thumb incision. Pass the tendon around the APL insertion, placing the direction of tendon pull radially. Suture the tendon into the MCP capsule. A tendon advancement of 1 to 2 cm should provide sufficient tension to maintain the thumb extended.
- If the MCP joint hyperextends passively, take care to insert the tendon into the metacarpal and not the proximal phalanx base. In this instance, a temporary K-wire should be placed across the MCP joint. Apply a short-arm thumb spica cast with the thumb in extension and maximal palmar abduction.
- Remove the case (and K-wire if needed) at 4 weeks. Apply a removable splint and begin range-of-motion exercises. Continue splinting for 6 weeks.

## CHAPTER REFERENCES

Each reference is categorized according to the following scheme: *, classic article; #, review article; !, basic research article; and +, clinical results/outcome study.


+ 1. Filler BC, Stark HH, Boyes JH. Capsulodesis of the Metacarpophalangeal Joint of the Thumb in Children with Cerebral Palsy. *J Bone Joint Surg Am* 1976;58:667.

# 2. Gelberman R. Cerebral Palsy. In: Bora FW, ed. *The Pediatric Upper Extremity: Diagnosis and Treatment.* Philadelphia: WB Saunders, 1986.

# 3. Goldner JL. Outline of Operative Procedures for Reconstruction of the Upper Extremity in Cerebral Palsy. In: Keats S, ed. *Operative Orthopaedics in Cerebral Palsy.* Springfield, IL: Charles C. Thomas, 1971.

# 4. Goldner JL. Upper Extremity Surgical Procedures for Patients with Cerebral Palsy. *Instr Course Lect* 1979;28:37.

# 5. Goldner JL. Surgical Treatment for Cerebral Palsy. In: Evarts CM, ed. *Surgery of the Musculoskeletal System*, 2nd ed. New York: Churchill-Livingstone, 1990.

+ 6. Goldner JL, Ferlic DC. Sensory Status of the Hand as Related to Reconstructive Surgery of the Upper Extremity in Cerebral Palsy. *Clin Orthop* 1966;46:87.

+ 7. Goldner JL, Koman LA, Gelberman R, et al. Arthrodesis of the Metacarpophalangeal Joint of the Thumb in Children and Adults. *Clin Orthop* 1990;253:75.

* 8. Green WT, Banks HH. Flexor Carpi Ulnaris Transplant and Its Use in Cerebral Palsy. *J Bone Joint Surg Am* 1962;44:1343.

# 9. Hoffer M. Cerebral Palsy. In: Green DP, ed. *Operative Hand Surgery*, 2nd ed. New York: Churchill-Livingstone, 1988.

+ 10. Hoffer MM, Lehman M, Mitani M. Long-term Follow-up on Tendon Transfers to the Extensors of the Wrist and Fingers in Patients with Cerebral Palsy. *J Hand Surg* 1986;11:836.

+ 11. Hoffer M, Perry J, Melkonian GJ. Dynamic Electromyography and Decision-making for Surgery in the Upper Extremity of Patients with Cerebral Palsy. *J Hand Surg* 1979;4:424.

+ 12. Hoffer MM, Zeitzew S. Wrist Fusion in Cerebral Palsy. *J Hand Surg [Am]* 1988;13:667.

+ 13. House JH, Gwathmey FW, Fuller MO. A Dynamic Approach to the Thumb-in-Palm Deformity in Cerebral Palsy. *J Bone Joint Surg Am* 1981;63:216.

+ 14. Inglis AE, Cooper W. Release of the Flexor Pronator Origin for Flexion Deformities of the Hand and Wrist in Spastic Paralysis: A Study of 18 Cases. *J Bone Joint Surg Am* 1966;48:847.

+ 15. Inglis AE, Cooper W, Bruton W. Surgical Correction of Thumb Deformities in Spastic Paralysis. *J Bone Joint Surg Am* 1970;52:253.

# 16. Keats S. *Cerebral Palsy.* Springfield, IL: Charles C. Thomas, 1965.

# 17. Keats S. Surgical Treatment of the Hand in Cerebral Palsy: Correction of Thumb-in-Palm and Other Deformities. *J Bone Joint Surg Am* 1965;47:274.

# 18. Keats S. *Operative Orthopaedics in Cerebral Palsy.* Springfield, IL: Charles C. Thomas, 1970.

# 19. Koman LA, Gelberman RH, Toby EB, Poehling GG. Cerebral Palsy: Management of the Upper Extremity. *Clin Orthop* 1990;253:62.

# 20. Manske PR, Strecker WB. Cerebral Palsy, Brain Injury, Stroke: Spastic Disorders of the Upper Extremity. In: Peimer C, ed. *Surgery of the Hand and Upper Extremity.* New York: McGraw-Hill, 1996.

* 21. Matev IB. Surgical Treatment of Flexion-Adduction Contracture of the Thumb in Cerebral Palsy. *Acta Orthop Scand* 1970;41:439.

+ 22. McCue FC, Honner R, Chapman WC. Transfer of the Brachioradialis for Hands Deformed by Cerebral Palsy. *J Bone Joint Surg Am* 1970;52:1171.

* 23. Mital MA. Lengthening of the Elbow Flexors in Cerebral Palsy. *J Bone Joint Surg Am* 1979;61:515.

+ 24. Mital MA, Sakellarides HT. Surgery of the Upper Extremity in the Retarded Individual with Spastic Cerebral Palsy. *Orthop Clin North Am* 1981;12:127.

+ 25. Omer GE, Capen DA. Proximal Row Carpectomy with Muscle Transfers for Spastic Paralysis. *J Hand Surg* 1976;1:197.

# 26. O'Reilly DE, Walentynowicz JE. Etiology Factors in Cerebral Palsy. *Dev Med Child Neurol* 1981;23:633.

+ 27. Sakellarides HT, Mital MA, Lenzi WD. Treatment of Pronation Contracture of the Forearm in Cerebral Palsy by Changing the Insertion of the Pronator Radii Teres. *J Bone Joint Surg Am* 1981;63:645.

* 28. Samilson RL, Morris JM. Surgical Improvement of the Cerebral Palsied Upper Limb: Electromyographic Studies and Results of 128 Operations. *J Bone Joint Surg Am* 1964;46:1203.

# 29. Smith RJ. Surgery of the Hands in Cerebral Palsy. In: Pulvertaft G, ed. *Operative Surgery: The Hand.* London: Butterworths, 1977.

+ 30. Smith RJ. Flexor Pollicis Longus Abductor Plasty for Spastic Thumb-in-Palm Deformity. *J Hand Surg* 1982;7:327.

+ 31. Strecker WB, Emanuel JP, Dailey L, Manske PR. Comparison of Pronator Tenotomy and Pronator Rerouting in Children with Spastic Cerebral Palsy. *J Hand Surg [Am]* 1988;13:540.

+ 32. Swanson AB. Surgery of the Hand in Cerebral Palsy and Swan-Neck Deformity. *J Bone Joint Surg Am* 1960;42:951.

# 33. Tachdjian MO. *Pediatric Orthopedics*, 2nd ed. Philadelphia: WB Saunders, 1990:1717.

+ 34. Tachdjian MO, Minear WL. Sensory Disturbances in the Hands of Children with Cerebral Palsy. *J Bone Joint Surg Am* 1958;40:85.

+ 35. Thometz JG, Tachdjian MO. Long-term Follow-up of the Flexor Carpi Ulnaris Transfer in Spastic Hemiplegic Children. *J Pediatr Orthop* 1988;8:407.

+ 36. Wenner SM, Johnson KA. Transfer of the Flexor Carpi Ulnaris to the Radial Wrist Extensors in Cerebral Palsy. *J Hand Surg [Am]* 1988;13:231.

# 37. Zancolli EA, Zancolli ER Jr. Surgical Management of the Hemiplegic Spastic Hand in Cerebral Palsy. *Surg Clin North Am* 1981;61:395.

# CHAPTER 67

# MANAGEMENT OF UPPER EXTREMITY DYSFUNCTION FOLLOWING STROKE OR BRAIN INJURY

*Mary Ann E. Keenan and Patrick J. McDaid*

**M. A. E. Keenan:** Director, Neuro-Orthopaedics Program, Department of Orthopaedic Surgery, Albert Einstein Medical Center, Philadelphia, PA, 19141; Professor of Orthopaedic Surgery, Professor of Rehabilitation Medicine, Temple University School of Medicine, Philadelphia, PA, 19132.
**P. J. McDaid:** Department of Orthopaedic Surgery, Albert Einstein Medical Center, Philadelphia, PA, 19141.

Introduction
- Stroke
- Traumatic Brain Injury
- Heterotopic Ossification
- Reflex Sympathetic Dystrophy

General Considerations for Decision Making
- Degree of Spasticity
- Timing of Neurologic Recovery
- Pattern of Neurologic Recovery
- Temporary Management of Spasticity During the Period of Physiologic Recovery

Evaluation of Residual Limb Deformities
- Assessment of Cognition and Communication
- Sensory Evaluation
- Evaluation of Limb Deformity and Functional Capability

Orthopaedic Management of Common Upper Extremity Deformities
- General Considerations
- Shoulder
- Elbow
- Forearm
- Wrist
- Hand

Chapter References

## INTRODUCTION

Cerebrovascular accident (CVA) and traumatic brain injury (TBI) are distinct syndromes. However, the stroke and brain-injured patient share many features (see, e.g.,3,42,46,52,55,56,84,85,89,92,109,128, 135,148,174,178,186,190,205,206,217,236,239). Both patient groups exhibit upper motoneuron (UMN) syndromes with impairment of motor control, spasticity, and stereotypical patterns of movement (synergy). Cognitive, memory, and sensory deficits are also commonly seen in these patients. Because of the similarities between stroke and TBI, there is a great deal of overlap in terms of specific surgical and nonsurgical techniques for treating the upper extremity problems caused by these conditions.

Lesions of the central nervous system (CNS), the peripheral nervous system, and the musculoskeletal system, and lesions causing pain may lead directly or indirectly to syndromes of restricted or excessive motion of the limbs. Syndromes of restricted limb motion are the most common type of movement impairment. Syndromes of excessive motion are less common. A distinction between restricted versus excessive motion is made. This is because the functional implications of each and the treatment of the problems they generate are very different. Syndromes of restricted limb motion are manifested by impaired access of the limb to targets in the environment during voluntary movement. Limbs are unable or are poorly able to move toward objects or places because motion across joints is restricted. An example is a patient with spastic finger flexors who attempts to open the hand to grasp an object. Another example seen after head injury is heterotopic bone formation about the elbow, which restricts joint motion and impairs use of the upper extremity even in the presence of voluntary muscle action. Limbs with restricted motion lose their operating range and are unable to be positioned adequately for function. The general treatment strategy for limbs with restricted motion is to identify and reduce sources of limb restriction.

Syndromes of excessive limb motion are manifested by impaired tolerances in the production of voluntary movement parameters such as movement amplitude, accuracy, timing, and force. Clinical conditions associated with excessive motion seen after head injury include such movement disorders such as hemiballismus, athetosis, tremors, and cerebellar ataxia. Biomechanical laxity in the musculoskeletal system may also be associated with excessive motion. For example, inferior subluxation of the shoulder may lead to excessive motion.

### *Orthopaedic Surgery as a Rehabilitation Tool*

The effects of injury to the brain extend beyond the confines of the skull and the subsequent cognitive function of the brain. The musculoskeletal system is profoundly effected by brain dysfunction. Hypertonicity, the unmasking of primitive reflexes, and impaired motor control contribute to the abnormal limb positions, contractures, and impaired mobility so frequently encountered in persons with brain injury.

The converse is also true. The brain is strongly affected by dysfunction of the musculoskeletal system. Just as the shoulder and elbow position the hand for grasping and manipulating objects, the musculoskeletal system gives mobility to the brain and positions it to interact with the world. Mobility of the individual is a key element of human life and of fundamental importance to our well-being.

Professionals working in the field of brain injury and stroke rehabilitation are knowledgeable about the cognitive and behavioral deficits that accompany brain injury. It has been our experience that less importance has been given to the musculoskeletal impairment that results from brain trauma or stroke. The penalties of musculoskeletal limitations for the individual can be devastating. Improving an individual's physical mobility is often therapeutic, leading to increases in their cognitive, behavioral, and emotional capacities.

Wellness promotion has become an objective of medical care. Which in the physically disabled population, means maximizing function and mobility in order to avoid the complications of chronic incapacity. Potential complications of physical immobility include decubiti, infection, pain, social isolation, and physical and emotional dependence. For society, this results in a costly loss of productivity for the patient and often family members as well.

### *Expectations and Timing of Orthopaedic Surgery*

When evaluating patients with CNS dysfunction, questions commonly arise regarding the indications for surgery, the cost, what outcome to expect, and the practicality of this approach. Consider these issues on an individual basis for each patient. General principles have been delineated that can serve as guidelines for decision making:

1. Operate early—before deformities are severe and fixed. Orthopaedic surgery is a powerful rehabilitation tool. It is often the only treatment that will correct a limb deformity or improve function. Surgery should not be considered a treatment of last resort when conservative measures have failed. Physical and occupational therapy cannot affect a permanent change in motor control. Drug therapy for increased muscle tone has generalized effects and cannot be targeted to specific offending muscles. Phenol blocks and botulinum toxin injections provide only temporary modulation of muscle tone. When a permanent treatment is needed to decrease muscle tone or redirect muscle force, consider surgery. The results of surgical intervention are improved when deformities are corrected early. Less muscle lengthening is needed when deformities are mild and there is little or no fixed contracture to overcome. Early surgery preserves maximum muscle

strength, joint capsule and ligament flexibility, and articular cartilage integrity. In general, the patient will also be in better physiologic condition to undergo surgery if there has not been a period of several years of immobility.

2. Better underlying motor control means better function for the extremity. Orthopaedic surgery cannot impart control to a muscle. Lengthening a spastic muscle can improve its function by diminishing the overactive stretch response and uncovering any control that was present. Successful surgery depends on a careful evaluation preoperatively to determine the amount of volitional control present in each individual muscle that is affecting limb posture and movement.

   Motor performance occurs on a continuous scale, with the disabled at the lower end and the elite athlete at the upper end. Infinitesimal improvements in the performance of elite athletes distinguish between the winner and loser. Incremental changes in limb function also result in performance improvements for the disabled individual. Surgery should not be reserved for patients with severe impairment and deformity. Individuals with milder degrees of impairment can benefit greatly from relatively simple procedures such as lengthening of the extrinsic finger flexors to regain sufficient fine motor control to perform more intricate hand functions. The amount of improvement correlates best with the degree of underlying motor control and not with the severity of the deformity
3. Distinguish between the function of the extremity and the function of the individual. We commonly speak of “functional” and “nonfunctional” surgical procedures. These terms refer to the expected outcomes for a limb but do not indicate the outcome for the person as a whole. Surgical releases of an arm contracted in a flexed and internally rotated position in a hemiplegic patient often allows the person to become independent in dressing, even though the arm itself remains nonfunctional.
4. Consider the cost of not correcting limb deformities. The cost of motor control evaluation using dynamic electromyography (EMG) is relatively modest for the benefits it provides. Dynamic EMG is a one time expense. The cost of performing an incorrect surgical procedure that fails to correct or worsens a limb deformity is much greater. The cost of performing a surgical procedure is likewise more cost effective when compared with a lifetime of attendant care, spasticity medications, repeated blocks, orthotics to control limb position, complications such as skin ulceration and infection, and lost productivity for the patient and caretakers.

## STROKE

Stroke is the leading cause of acquired hemiplegia and long-term disability in the United States (26,77,119,137,140,181,221,235,242). It is also the third leading cause of death. Roughly 600,000 people suffer a new or recurrent stroke each year. Management of the stroke patient has become a major priority for physicians treating the elderly. There are 4,000,000 stroke survivors alive today. The average patient who survives beyond the first few months has a life expectancy of greater than 6 years (10,79,80). Stroke victims survive long enough and achieve adequate function to justify aggressive rehabilitation.

### *Pathophysiology of Stroke*

Cerebral function depends on a continuous supply of oxygen. Any significant interruption of oxygenation by thrombosis, emboli, or hemorrhage results in neuron death and subsequent deficits in cognitive, sensory, and motor functions. Thrombosis is the most common cause of infarction and accounts for nearly three fourths of all CVAs (79,80). Arteriosclerosis is the most significant predisposing factor.

Cranial hemorrhage accounts for approximately one sixth of all CVAs, and includes spontaneous intracerebral hemorrhage and subarachnoid hemorrhage. Hypertension is commonly present in these patients. Isolated cerebral emboli account for less than 10% of CVAs.

Predisposing factors to CVAs include atherosclerosis, increasing age, genetic predisposition, hypertension, hyperlipidemia, hypercholesterolemia, obesity, cardiac anomalies (arrhythmias, myocardial infarction, hypotension, mural thrombosis), diabetes mellitus, collagen vascular disease (vasculitis, polyarteritis), hyperviscosity states (polycythemia, sickle cell anemia), oral contraceptive use, tobacco smoking, severe cerebrovascular spasm secondary to migraine headaches, and septic vasculitis (tuberculosis, syphilis, and mucormycosis).

### *Neurologic Impairment Following Stroke*

Distinct clinical syndromes arise from insults to specific areas of the cerebral cortex. CVAs involving the middle cerebral artery are the most common, and produce the typical hemiplegic picture of greater impairment in the upper extremity, face, and speech compared with lower extremity involvement. The middle cerebral artery supplies the largest area of cerebral cortex. This area controls sensory and motor function of the trunk, upper extremity, and face, as well as the functions of speech.

The anterior cerebral artery supplies the mid-cortex in the sagittal plane. This area of cerebral cortex controls sensory and motor function predominantly in the lower extremity. CVAs involving the anterior cerebral artery result in a hemiplegic picture of sensory and motor deficits chiefly involving the lower extremity.

The posterior cerebral artery supplies the visual cortex in the occipital region. Involvement of this artery typically results in visual impairment. Bilateral cortical involvement may lead to severe mental impairment, frontal release signs, loss of short-term memory, and inability to learn.

CVAs in the vertebral basilar system are rare. Deficits in balance and coordination arise from interruption of afferent and efferent pathways between the brain and spinal cord. Balance reactions are also dependent on limb control and proprioception (95,119,141,201).

**Cognitive Impairment** Cognitive deficits commonly follow CVAs. Impairment of mentation, decreased learning ability, and loss of short-term memory may occur (10,14,17,20,24,27,33,41,51,77,79,80,93,104,121,141,149,164,165,168,185,221,230,245). The patient's ability to cooperate with treatment affects rehabilitation potential. In patients with extensive frontal lobe deficits, these deficiencies may be severe. Patients with extensive frontal lobe pathology exhibit clinical features similar to senility, with lack of attention span and little motivation for recovery. Their prognosis for rehabilitation is poor.

Aphasia is a loss of ability to communicate. It may be receptive or expressive in nature. It usually involves both components. Aphasia occurs with lesions of the left hemisphere, usually without regard to hand dominance. A receptive aphasia hinders rehabilitation most strongly because the patient cannot understand instructions. Persistent receptive loss has a poor prognosis.

Expressive aphasia may be compatible with rehabilitation, allowing a patient to comprehend and follow instructions. Expressive aphasia may resolve significantly.

Apraxia, or impairment of execution (motor planning), is characterized by a loss of ability to perform a previously learned action, such as tying shoe laces or waving good-bye. Apraxia is not the result of motor or sensory loss. It occurs more commonly with right hemispheric involvement (left hemiparesis). The apraxia, however, occurs on both sides of the body. The prognosis with severe apraxia is generally poor. Some improvement with practice and repetition may occur. If impairment persists after 3 months, further improvement is unlikely (10).

**Sensory Impairment** A wide span of sensory loss can occur following stroke. Sensory perception occurs in the cerebral cortex and is most often affected by lesions of the middle cerebral artery. Sensory loss may be manifest by impairment of touch, pinprick, two-point discrimination, proprioception, discrimination of size, shape, texture, or point localization, or the presence of astereognosis. Impairment of sensory function in the upper extremity is a poor prognostic sign, even though motor function may be intact or only minimally impaired (14,20,25,26,27,33,34,41,53,77,93,97,104,121,126,137,138,141,154,164,165,167,168,173,191,198,221,223,230,234,241,244).

Lesions of the parietal lobe of the nondominant hemisphere may result in a lack of awareness of the involved side of the body (neglect). A failure to recognize and use the involved side may occur despite minimal motor involvement.

Disturbances of vision may occur. These include hemianopia (blindness in one eye), disturbance of perception, poor perceptual organization, loss of geometric sense, inability to copy figures, and failure of tasks involving spatial analysis. Hemianopia is likely to be permanent but it usually has little impact on rehabilitation potential. Disturbances in visual perception are more significant and may result in failures in activities of daily living (216).

**Motor Impairment** Motor impairment is commonly the most obvious sequela of stroke. Recovery follows a fairly typical pattern. A period of flaccid paralysis occurs, lasting from 24 hours to several weeks. This is followed by a period of increasing muscle tone. In general, the longer the period of flaccidity, the poorer the prognosis for functional recovery. In the arm, the shoulder adductor and internal rotator muscles become tight. The elbow, wrist, and finger flexors also develop marked tone. These changes are usually evident within 48 hours after the stroke. Any paralysis remaining after 3 months usually persists, although some slight improvement may occur over 6 months (10,14,17,20,24,25,26,27,29,31,33,34,41,51,53,67,77,79,80,86,91,93,97,104,110,119,121,124,125,126,137,138,140,141,149,154,164,165,166,167,168,173,181,185,191,198,200,201,205,221,222,223,225,230,231,232,233,234,241,243,244,249,250). Functional improvement may continue as a result of further

sensorimotor reeducation. Increasing muscle tone usually leads to muscle spasticity. Hyperactive deep tendon reflexes and clonus may appear.

Voluntary movement returns first in the most proximal muscle groups of the limbs and follows in a proximal-to-distal direction or pattern of recovery. Voluntary movement should be sought and examined during the early recovery phase, when flaccidity is present.

Motor control is graded in the extremity using a clinical scale (Table 62.1) (116,145,146). The extremity may be hypotonic or flaccid and without any volitional movement. A spastic extremity may be held rigidly without any volitional or reflexive movement. Patterned or synergistic motor control is defined as a mass flexion or extension response involving the entire extremity. Mass flexion in the upper extremity consists of shoulder abduction, forearm pronation, and flexion of the elbow, wrist, and fingers. Mass extension in the lower extremity consists of extension of the hip and knee with equinovarus of the foot and ankle. Synergistic movement may be reflexive, in response to a stimulus, but without volitional control. Some patients can also volitionally initiate the synergistic movement. Selective motor control with pattern overlay is defined as the ability to move a single joint or digit with minimal movement in the adjacent joints when performing an activity slowly. Rapid movements or physiologic stress make the mass pattern more pronounced. Selective motor control is the ability to volitionally move a single joint or digit independently of the adjacent joints. Spasticity can mask underlying motor control (Fig. 67.1).

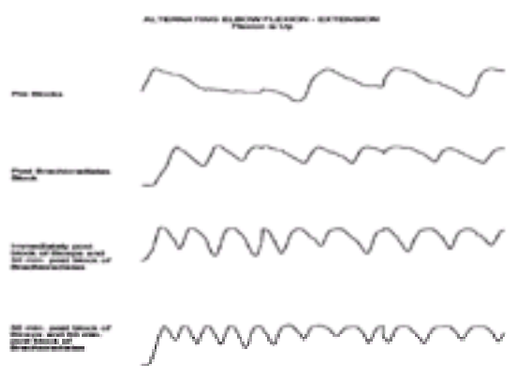

***Figure 67.1.*** This series of tracings records by electrogoniometer the maximum arc and frequency of elbow flexion—extension movement in a patient with traumatic brain injury. The first tracing is maximal effort before placement of a block. The second tracing shows improvement after a bupivacaine motor point block of the brachioradialis. Further improvement is noted immediately after bupivacaine block of the biceps and 30 minutes after block of the brachioradialis. After the biceps block has been allowed to set up, further improvement is noted. The blocks were used to demonstrate that there was volitional motor control in the elbow flexors that was previously masked by the spastic response of the muscles to movement. The blocks also preview the improvement to be gained by fractional lengthening of the elbow flexors. (With permission from Hisey MS, Keenan MAE. Orthopaedic Management of Upper Extremity Dysfunction Following Stroke or Brain Injury. In Green DP, Hotchkiss RN, Pederson WC, eds. *Operative Hand Surgery,* 4th ed. New York: Churchill Livingstone, 1998:287.)

Patterned movement, even when initiated volitionally, is a primitive form of motor control and of no functional use in the upper extremity. The hand requires some selective control for functional use. The lower extremity can more successfully use synergistic motions for functional activities, such as transfers or walking. For example, the patient can be taught to use the flexion movement to advance the limb and the extension pattern to provide limb stability during stance.

The final processes in sensory perception occur in the cerebral cortex, where basic sensory information is integrated to complex sensory phenomena such as proprioception, spatial relationships, shape, sight, and texture. Patients with severe parietal dysfunction and sensory loss may lack sufficient perception of space and awareness of the involved segment of their body to ambulate. Patients with severe perceptual loss may lack balance to sit, stand, or walk.

### *Orthopaedic Management of Stroke*

**The Period of Acute Injury** Efforts at this time are directed toward the medical stabilization of the patient. The orthopaedic surgeon is rarely involved in the acute care of the stroke patient. In some situations, the orthopaedic surgeon may be asked to assist with splinting extremities to prevent limb deformities.

**The Period of Physiologic Recovery** Spontaneous neurologic recovery occurs primarily during the first 6 months following a stroke. This is particularly true for recovery of muscle function. During the subacute phase, limb flaccidity changes to spasticity. The patient is commonly in a rehabilitation facility for a portion of this time. Muscle weakness can result in joint subluxation or ligamentous laxity if the limb is not protected using a sling to support the shoulder or splints to support the wrist. When spasticity becomes pronounced, temporary measures are used to prevent contracture formation until spontaneous neurologic recovery has ceased.

**The Period of Functional Adaptation to Residual Deficits** Generally the patient is neurologically stable after 6 months. Decisions can then be made regarding surgery to correct limb deformities and rebalance the muscle forces. This is the time of greatest contribution by the orthopaedic surgeon.

## TRAUMATIC BRAIN INJURY

Injury to the brain is a leading cause of disability and death in the United States (65,100,139,169,214,216,225,228,251). An epidemiologic study of physician-documented cases of TBIs occurring in San Diego County, California, in 1981 determined an annual incidence of 180 per 100,000 population (139).

Applying this rate to the United States population provides an estimate of 410,000 new cases of TBI cases each year. Eleven percent of these patients die shortly after the injury. Approximately 80% of the survivors have a good or moderate neurologic recovery. Most traumatic injuries to the brain are in individuals who are younger than 45 years old, and those who survive have a normal life span despite the injury.

### *Prognosis*

Prognosis following TBI has traditionally been predicted relative to the Glasgow Coma Scale (GCS) (Table 67.2) (99,100,225). The GCS evaluates a patient's responses to eye opening, motor responses, and verbal responses. The Glasgow Outcome Scale is frequently used to determine outcome following brain injury (Table 67.3). Using the GCS score obtained within 24 hours of the patient's admission to the hospital, a coma score of 11 or greater is associated with an 82% probability of moderate or good neurologic recovery. Lower scores have a significantly higher incidence of severe sequelae.

| | | |
|---|---|---|
| Eye opening: | Spontaneous | 4 |
| | Speech | 3 |
| | Pain | 2 |
| | None | 1 |
| Motor response: | Obeys | 6 |
| | Localizes | 5 |
| | Withdrawal | 4 |
| | Abnormal Flexion | 3 |
| | Extension | 2 |
| | None | 1 |
| Verbal response: | Oriented | 5 |
| | Confused | 4 |
| | Inappropriate | 3 |
| | Incomprehensible | 2 |
| | None | 1 |

* The Glasgow Coma Score is the total of the eye opening, motor response and verbal scores.
References: 99, 100, 223.

***Table 67.2. Glasgow Coma Scale****

| |
|---|
| Dead |
| Persistent vegetative state |
| Severely disabled |
| Moderately disabled |
| Good recovery |

* The Glasgow Outcome Scale is used to grade the long term recovery following Traumatic Brain Injury.
Reference: 99, 100, 223.

***Table 67.3. Glasgow Outcome Scale****

Age is an important factor determining neurologic outcome following brain injury regardless of the severity of injury. Patients younger than the age of 20 years at the time of brain injury experience as a group a 62% moderate or good neurologic recovery. Patients between the ages of 20 and 30 can expect a 46% chance of moderate or good neurologic recovery. In a series of pediatric patients with brain injury, overall 90% achieved a moderate or good neurologic recovery and only 8% expired or remained in a persistent vegetative state (94,95). Young children with a GCS score of 5 or better have a good prognosis for recovery. In addition to having a poorer prognosis for recovery, the cost and time required for rehabilitation of older patients is higher than that for younger patients (39).

Although it has been demonstrated to predict mortality accurately, recent studies have suggested the GCS as a single variable may have limited value as a predictor of functional outcome and many trauma centers are now using the Revised Trauma Score (RTS) to assist with triage of multitrauma patients. The RTS combines the GCS as well as the systolic blood pressure and respiratory rate, and is used to predict both mortality and disability (246,247).

The duration of coma is another prognostic indicator. If emersion from coma occurs within the first 2 weeks of brain injury, 70% of patients can be expected to achieve a good recovery. If the coma persists beyond 4 weeks, the chance of good recovery is much diminished. Brain stem involvement, as indicated by the presence of decerebrate or decorticate posturing, has a poor prognosis for outcome. If decerebrate posturing occurs and resolves within the first week after injury, 40% of patients will have a good neurologic recovery. If decerebrate posturing persist beyond the first week, only 9% of patients will achieve a good neurologic recovery. In a similar manner, the duration of posttraumatic confusion can also be an indicator of prognosis. If the period of posttraumatic confusion persists for more than 4 weeks, then one third of these patients will have a poor neurologic outcome. It should be remembered, however, that prognosis is a probability statement, and although various factors can be used as guidelines, none is an absolute indicator in the individual patient.

***Orthopaedic Management of Brain Injury***

**The Period of Acute Injury** The orthopaedic management of TBI can be divided into three distinct time periods (70,75,108). The initial phase of management occurs immediately following the injury in the acute care hospital. The majority of TBIs are the result of a motor vehicle accident. Multiple trauma is common. The orthopaedic surgeon is a consultant with a critical roll. Aggressive treatment of orthopaedic injuries at an early stage is important to functional outcome.

The first priority is to diagnosis all injuries accurately (6,38,40,45,57,59,61,65,68,70,73,76,78,81,98,105,108,133,142,170,214,215,216,228,237,245,246,251). It is common for injuries such as fractures or major peripheral nerve injuries to go undetected. Garland reported an 11% incidence of delayed diagnosis of fractures, with an average time to diagnosis of 57 days (65,214). In the comatose patient, obtain radiographs of all major joints and any other areas of suspect for injury. It is important not to assume that all neurologic deficits present are from the CNS injury. Stone and Keenan reported that 34% of brain-injured patients have missed peripheral nerve injuries (214). Especially in the presence of a limb fracture, look for a peripheral nerve injury (65,214).

After head injury, pain is often caused by reflex sympathetic dystrophy (RSD), deep vein thrombophlebitis, spasticity, occult fracture, and the formation of heterotopic ossification (HO) (36,61,62,81,82,170,209,214,215,228). If pain is treated promptly (and this depends on an accurate and early diagnosis), prolonged restriction of motion may be avoided. HO, fracture and fracture malunion restrict motion on the basis of lost structural integrity. Many brain-injured patients who recover cognitively have residual spasticity and impaired balance and consequently, are less able to compensate for such structural impediments (61,158). Peripheral nerve injury produces weakness and pain, both potential causes of restricted motion.

Brachial plexus injuries are problematic. Plexopathies have been reported in up to 10% of patients with TBI (45,65,214). They are particularly prevalent in blunt trauma, especially motorcycle accidents and ejections from a motor vehicle. They are often associated with fracture or dislocation, particularly clavicle fractures. If the plexopathy results in a flail arm in a patient with ipsilateral humerus fracture, there is a predisposition for delayed union.

The second rule of orthopaedic care is to assume that the patient will make a good neurologic recovery. All orthopaedic injuries should be treated promptly and appropriately. When possible, internal fixation is best. Spasticity develops, and casting a spastic joint in a flexed position may result in a joint contracture or an unsatisfactory reduction. Fracture healing is accelerated, presumably by the same humoral factors that contribute to heterotopic bone formation (8,111,194,226). Fracture malunion is a common and potentially avoidable complication (Fig. 67.2).

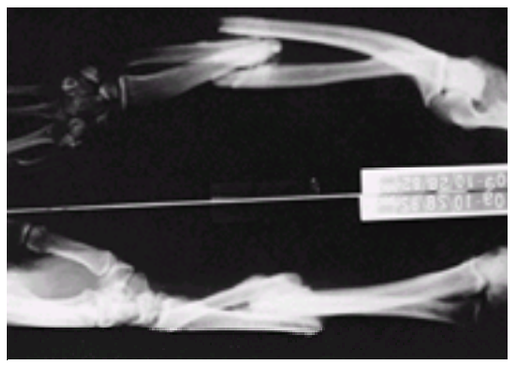

***Figure 67.2.*** Malunited fractures of the radius and ulna in a brain-injured patient. Because the patient was not expected to survive, the fractures were not treated initially.

The third principle is to expect lack of patient cooperation. As the patient emerges from coma, they may be anticipated to go through a period of agitation and confusion. Fracture care should be made as foolproof as possible because patient cooperation cannot be expected. Anticipating a possible period of agitation, traction and external fixators for treatment of extremity fractures should be avoided when possible (61,68,70,73,76,78,158,228,237,245).

**The Period of Physiologic Recovery** Following TBI, neurologic recovery can proceed for prolonged period of time. The majority of improvement in motor control occurs within the first 6 months following injury (42). Cognitive changes are made most rapidly in the early phases following brain injury but can continue for a very prolonged period of time, often years (Table 67.4) (88). Because the period of potential neurologic recovery following head injury is prolonged, definitive surgical procedures are avoided during the transitional stage. There is not an exact time that must elapse before considering surgery to improve musculoskeletal function (109). The orthopaedic surgeon must consider the rate of continued improvement in motor control when deciding at what point to intervene surgically. If the additional improvement in motor control will be overridden by the complications of contracture formation, osteopenia, peripheral nerve compression, and muscle atrophy, then early surgical intervention is appropriate.

| | |
|---|---|
| I | No response |
| II | Generalized response |
| III | Localized response |
| IV | Confused-agitated |
| V | Confused-inappropriate, nonagitated |
| VI | Confused-appropriate |
| VII | Automatic-appropriate |
| VIII | Purposeful-appropriate |

Reference: 88.

***Table 67.4. Rancho Levels of Cognitive Functioning***

During the period of physiologic recovery, the patient is commonly in a rehabilitation facility. Serious head injury is usually complicated by UMN syndrome (7,19,71,104,105,112,120,136,145). Spasticity is commonly severe and prevents adequate joint range of motion. Spasticity also interferes with the maintenance of limb position despite the most conscientious and aggressive treatment. Even in those situations in which joint motion can be maintained by a knowledgeable therapist, it commonly requires much force, which is painful for the patient, potentially harmful, and very time consuming. Lesser degrees of spasticity can also impede a patient's function or require the use of positioning devices that interfere with the use of an extremity.

Multiple complications can occur in the presence of spasticity (Table 67.5). Contractures are common. Limited positioning and myostatic contractures combined with the patient's diminished nutritional status can result in pressure sores or hygiene problems. When fractures are present, malunions can occur in the face of uncontrolled muscle tone and accelerated fracture healing. Joint subluxation can also occur from prolonged spasticity or the attempts to range a joint in the face of severe spasticity. If a ligamentous injury occurred at the time of injury, frank dislocation of a joint can be caused by hypertonicity. Spasticity also appears to be one of several etiologic factors in the formation of HO in a periarticular location (Fig. 67.3). (12,18,40,43,60,64,66,69,70,83,86,98,111,113,127,132,147,153,157,163,171,192,194,226,227,238). Another common complication of spasticity is acquired peripheral neuropathy (38,45,49,59,65,170,214). The most common peripheral neuropathies acquired with severe spasticity and contracture formation are ulnar neuropathy at the elbow, resulting from severe flexion and continuous pressure on the ulnar nerve, and carpal tunnel syndrome, secondary to severe wrist flexion and pressure of the median nerve against the leading edge of the transverse carpal ligament (Fig. 67.4) (170,214). During the period of physiologic recovery, the temporary control of spasticity is the major focus of treatment. Prevention of additional complications such as disuse muscle atrophy, joint contractures, HO, and peripheral neuropathies is critical to a good functional outcome (6,8,11,17,18,22,23,27,32,35,36,38,40,57,59,60,61,65,66,68,70,73,76, 78,81,82,83,86,98,103,104,107,108,111,113,126,132,133,147,153,155,157,158,164,171,172,176, 179,182,189,192,195,196,197,202,209,210,211,214,215,216,219,226,230,245). Early joint contractures are also best corrected during this phase of treatment. This is accomplished by first reducing spasticity and then correcting contractures by splinting, casting, and range-of-motion therapy.

| |
|---|
| Contractures |
| Decubitus ulcers |
| Hygiene difficulties |
| Fracture malunion |
| Joint subluxation or dislocation |
| Heterotopic ossification |
| Peripheral neuropathy |

Reference: 108, 125, 145, 146.

***Table 67.5. Complications of Spasticity***

***Figure 67.3.*** Lateral radiograph of the elbow in a patient with traumatic brain injury showing heterotopic ossification anteriorly causing ankylosis in 90° of flexion. There was no concomitant injury to the elbow and the radio-capitellar joint is not involved.

***Figure 67.4.*** Clinical photograph (**A**) and radiograph (**B**) of a patient with severe wrist flexion deformity and subsequent carpal tunnel syndrome from compression of the median nerve against the proximal edge of the transverse carpal ligament.

**The Period of Functional Adaptation to Residual Deficits** When physiologic neurologic recovery has ceased, the brain-injured patient is commonly left with residual limb deformities from spasticity, contractures, and muscle imbalance. It is at this time that definitive orthopaedic surgical procedures are performed to rebalance the muscle forces and correct the residual deformities (206).

**HETEROTOPIC OSSIFICATION**

HO presents clinically with an intense inflammatory reaction about the joint seen as redness, warmth, severe pain, and rapidly decreasing range of motion (4,12,18,35,36,38,40,43,47,54,59,60,61,62,63,64,66,69,70,74,83,86,98,111,113,127,132,147,163,175,193,194,195,196,202,209,210,211,218). Although the time of initial occurrence is variable, HO is usually detected 2 months following the onset of TBI. Generally, radiographs show evidence of the heterotopic bone in the form of spotty periarticular calcification.

The incidence of periarticular HO following TBI is 11%, with hips most commonly involved, followed by shoulders and elbows (66,111,132,226). Although the exact etiology of HO is not known, and likely multifactorial, it clearly has a predilection for joints surrounded by spastic or paretic muscle (66,226,238). A dramatic increase in incidence to 85% is seen in patients who have concomitant musculoskeletal injuries. Because of this increased incidence, consideration should be given to prophylaxis. Several modalities have been used with varying success. High-dose diphosphonates (Didronel) and nonsteroidal anti-inflammatory drugs, particularly indomethacin have been used in the early postinjury period (4,63,65,134,197,212,218,237). Radiation (800 cGy limited field) can be used within several days following the injury (4,47,62,63,147,153,202). Joint manipulation is also used, but the benefit of this procedure is unclear if the heterotopic bone has already begun to form (74,218). Formation of HO can be followed radiographically and by following serial alkaline phosphatase measurements. The HO is mature when the alkaline phosphatase has returned to a normal value, and the radiographs show a well-defined, bone mass with a cortex. Technetium bone scans show increased uptake for many years and are of little value in this situation. Serum osteocalcin levels to diagnose HO or determine its maturation are unreliable (163). Surgical excision is thought to carry a higher risk of recurrence if it is attempted before maturation. This comes from work with HO in spinal cord injury patients and has not been shown to be applicable to TBI patients (35,36,62,63,69,86,132,157,195,218). Early excision should be considered in cases in which the HO is causing progressive nerve or vascular compromise, or is threatening joint ankylosis.

### REFLEX SYMPATHETIC DYSTROPHY

RSD is characterized by constant, spontaneous, severe, burning pain and is usually associated with hypo- and hyperesthesia, hyperpathia, and allodynia, along with vasomotor and sudomotor disturbances that, if persistent, result in trophic changes (82). It commonly develops following CVA (posthemiplegic dystrophy), TBI, and surgery. It may be associated with trauma, which occurred concurrently with TBI, although the severity of the initial injury is unrelated to the severity of the ensuing symptoms.

Onset following trauma is usually within the first several weeks; however, with stroke and brain injury, the onset may be delayed and atypical. Because of this, RSD may remain undiagnosed in the stroke or brain-injured population until it becomes irreversible.

Radiographs that show patchy demineralization of involved epiphyses even during the first phase aid diagnosis. Subperiosteal resorption, tunneling of the cortex, and striation may be evident on good quality films. Unfortunately, none of these changes are specific for RSD. Triple phase bone scan may help with diagnosis. The pattern seen varies with the phase of the disease. In the acute phase, the flow (immediate), blood pool (early), and delayed (static) scan patterns all show increased uptake, usually in a periarticular distribution. False-negative results are frequent in the dystrophic phase, in which the flow and blood pool scans are normal, and the delayed scan shows a somewhat less prominent periarticular increase in uptake. In the atrophic phase, both the flow and early scans show decreased uptake, whereas the delayed phase is normal.

Treatment includes several modalities. Physical therapy, particularly active and active assisted range of motion, gentle muscle strengthening and conditioning, massage, and heat therapy have been effective. Tricyclic antidepressants (amitriptyline) may have their effect because of their inhibition of serotonin uptake at pain-suppressing neurons, prolonging the serotonin effect at the receptor. Narcotics have a role in low-dose epidural infusions in combination with local anesthetics. Systemic corticosteroids and adrenergic blocking agents have both been advocated. Nerve blocks, including stellate ganglion blocks, Bier blocks, surgical sympathectomy, and chemical sympathectomy have been reported with high percentages of patients improved. At present, we use a regimen of amitriptyline, physical therapy, and percutaneous sympathetic blockade.

## GENERAL CONSIDERATIONS FOR DECISION MAKING

### DEGREE OF SPASTICITY

The majority of stroke patients have a period of limb flaccidity before the gradual onset of increasing muscle tone or spasticity (resistance to quick stretch). Because of the mean older age of these patients compared with brain-injured patients, their muscles are also weaker. This, combined with the shorter period of spontaneous neurologic recovery (6 months), makes the temporary control of spasticity an easier task in stroke patients. The use of phenol nerve blocks or intramuscular botulinum toxin injection is therefore less common than in the TBI patient.

### TIMING OF NEUROLOGIC RECOVERY

The prolonged period of physiologic recovery, the intense level of spasticity (response to fast stretch), the presence of rigidity (resistance to slow stretch), and the strong muscles found in young TBI patients make the temporary control of spasticity much more difficult. Phenol nerve blocks, botulinum toxin injections, and casting are used more commonly and aggressively.

### PATTERN OF NEUROLOGIC RECOVERY

The majority of stroke patients (middle cerebral artery infarcts) have hemiplegic involvement with a nonfunctional upper extremity and a lower extremity with greater potential for function. The surgical procedures used to correct residual deformities in the upper extremity are more likely to be for the correction of contractual deformities than to improve function. Even when functional procedures are employed, the gains from these procedures are more moderate than in the brain-injured patient.

The young brain-injured patient, in contrast, is more likely to have quadriplegic involvement, concomitant peripheral nerve injuries, residual deformities from fractures, and joint limitation from HO but better return of motor control. Functional surgical procedures are more common in these patients.

### TEMPORARY MANAGEMENT OF SPASTICITY DURING THE PERIOD OF PHYSIOLOGIC RECOVERY

The treatment of spasticity depends on the time since injury and the prognosis for further recovery. In the period of physiologic recovery, temporizing interventions are used because permanent changes may result in chronic imbalance of forces across joints (11,13,16,28,44,50,70,71,72,102,104,107,122,123,129,130,131,156,159,200,205,229,240,242). Prevention of additional complications such as disuse muscle atrophy, joint contractures, HO, and peripheral neuropathies is critical to a good functional outcome. Several choices are available for treatment.

A combination of peripheral nerve blocks and casting and splinting techniques are commonly used to give temporary relief of spasticity. Casting maintains muscles fiber length and diminishes muscle tone by decreasing sensory input (11,70). Local anesthetic nerve blocks are very helpful when administered before cast application, because relieving the spasticity allows for easier limb positioning. Casts are used primarily for the correction of contractual deformities by applying a cast on a weekly basis. Serial casting is most successful when a contracture has been present for less than 6 months.

Oral antispastic agents may be used during this period. Antispastic agents that have sedating properties such as baclofen, diazepam, and clonidine may compromise patients with attention deficits or memory disorders, or both. Even a drug such as dantrolene sodium, which has a peripheral mechanism of action, may also cause drowsiness. Other serious side effects such as hepatotoxicity can occur. Continuous infusion of intrathecal baclofen has been reported to be useful in managing spasticity secondary to spinal cord injury. Such delivery avoids the cognitive side effects seen with oral delivery. Early studies have shown that intrathecal bolus infusions of baclofen via a catheter placed in the lumbar space may also be capable of reducing spastic hypertonia associated with brain injury (1,2,152).

Focal injection with neurolytic or chemodenervating agents is the most suitable approach for treating restricted motion secondary to spasticity. Neurolytic agents such as phenol and chemodenervation agents such as botulinum toxin A are used in this period because their effects are temporary, lasting only 3 to 5 months (13,16,28,44,70,71,72,101,102,104,107,122,123,129,130,131,156,159,229,242). These agents are used when restricted motion occurs as a result of focal spasticity. When these agents wear off, reevaluation is done to determine whether additional recovery has taken place and whether there is further indication for re-blocking. It is critical that the functional problems of the patient can be accurately ascribed to specific muscles. This is done by evaluation using multi-channel dynamic EMG (58,105,110,112,117,120,134,136,145,146,177,184). Even if many muscles in a limb are involved, a number of focal injections are possible and by doing so CNS side affects can be avoided. For patients with pathologies causing excessive motion, environmental modification weights, bracing, and oral medications may be considered

during the period of physiologic recovery.

### *Phenol Blocks*

Phenol, a derivative of benzene, denatures the protein membrane of peripheral nerves in aqueous concentrations of 5% or more. When phenol is injected in or near a nerve bundle, phenol's neurolytic action on the myelin sheath or the cell membrane of axons with which it makes contact serves to reduce neural traffic along the nerve. The onset of the destructive process with higher concentrations of phenol may begin to show effects several days after injection. The denaturing process induced by phenol extends biologically on the order of weeks, but eventually regeneration occurs. A phenol block is used as a temporizing measure rather than a permanent intervention. In our clinical experience and the experience of others, the effect of a phenol block typically lasts 3 to 5 months.

Histologically, it has been shown that phenol destroys axons of all sizes in a patchy distribution but more so on the outer aspect of the nerve bundle, onto which phenol is dripped. When phenol is percutaneously injected, it is likely that the nerve block will be incomplete. This is especially useful in situations in which a spastic muscle also has volitional capacity because under these circumstances, it is desirable to reduce spasticity while still preserving volitional capacity of a given muscle or muscle group.

The technique of phenol injection is based on electrical stimulation. Motor branches are injected close to the offending muscle or muscle group. These are referred to as motor points. A surface stimulator is briefly used to approximate the percutaneous stimulation site in advance. A 25 gauge Teflon-coated hypodermic needle is advanced toward the motor nerve. Electrical stimulation is adjusted by noting whether muscle contraction of the index muscle takes place. As the electrode gets closer to the motor nerve, less current intensity is required to produce a contractile response. The motor nerve is injected when minimal current produces a visible or palpable contraction of the muscle. Generally, 4 to 7 ml of 5% to 7% aqueous phenol is injected at each site. As with any injection, care needs to be taken not to inject into a blood vessel and this is done by aspirating before the injection (13,16,28,44,70,71,72,101,102,104,107,122,123,129,130,131,145,146,156,159,229).

### *Botulinum Toxin Blocks*

Botulinum toxin is a newer agent used in the localized treatment of spasticity. Ordinarily, an action potential propagating along a motor nerve to the neuromuscular junction triggers the release of acetylcholine (ACh) into the synaptic space. The released ACh causes depolarization of the muscle membrane, activating a biochemical sequence that leads to muscle contraction. Botulinum toxin type A is a protein produced by *Clostridium botulinum* that inhibits this calcium-mediated release of ACh at the neuromuscular junction. Botulinum toxin A attaches to the presynaptic nerve terminal and divides into a light and a heavy component. The light component invades the nerve cell and interferes with fusion proteins affiliated with vesicles of ACh, thereby preventing the release of ACh from their storage vesicles.

Botulinum toxin injection has been used to treat a variety of dystonias and is currently approved by the Food and Drug Administration (FDA) for the treatment of blepharospasm, facial spasm, and strabismus. A number of studies have reported its use in treating spasticity in individuals with cerebral palsy, stroke, head trauma, and multiple sclerosis (37,50,58,145,146,200,205,240). Clinical benefit lasts 3 to 5 months but may be more variable. Botulinum toxin is injected directly into an offending muscle, and depending on the size of the muscle being injected, dosing has ranged between 10 and 200 units (U). Current practice is to wait at least 12 weeks before re-injection and not to administer a total of more than 400 U in a single treatment session. Because this upper limit of 400 U may be reached rather quickly, a different strategy is needed for the limb requiring many proximal and distal injections. Botulinum toxin A and phenol may be combined, the former being injected into smaller distal muscles and the latter aimed at larger proximal ones. A 3- to 7-day delay between injection of botulinum toxin A and the onset of clinical effect is typical. Effects will not be seen by the patient immediately and usually a follow-up visit is arranged to check the result. The amount of toxin given for a particular muscle is variable.

The technique of botulinum toxin injection varies. Some physicians inject through a syringe attached to a hypodermic needle that doubles as a monopolar EMG recording electrode. Patients may be asked to make an effort to contract the targeted muscle or the muscle may be contracting involuntarily as in dystonia. After inserting the needle electrode, injection is made when EMG activity is recorded. For deep or small spastic muscles (e.g., finger flexors), electrical stimulation is preferred as a means of localizing the muscle before injection.

Botulinum toxin injections have gained much popularity in the past several years. The advantages of botulinum toxin are (a) ease of injection and (b) the lack of residual scaring after injection. The disadvantages of botulinum toxin are (a) high cost and (b) stimulation of antibody formation that requires higher doses for repeated injections. Phenol, in contrast, requires more technical expertise to localize the nerve or motor points for injection. Phenol is caustic and causes localized scarring of the nerve and muscle. Phenol, however, is inexpensive and readily available.

### *Common Techniques of Nerve and Motor Point Blocks*

**Shoulder Adduction Spasticity** Shoulder adduction and internal rotation spasticity are common in the upper extremity of both stroke and brain-injured patients. This deformity interferes with hygiene and upper body dressing. Phenol motor point blocks or botulinum toxin injections of the pectoralis major muscle are effective in reducing tone and improving shoulder adduction during the physiologic recovery phase (16,37,49,104,145,146,200,205,240).

- Inject botulinum toxin directly into the muscle.
- The effects of the botulinum toxin injection appear slowly over the ensuing 48 hours. Start physical therapy as the muscle relaxes.
- For phenol injections, localize the motor points using a surface stimulator over the pectoralis major muscle. Then use an insulated, Teflon-coated needle in conjunction with a nerve stimulator to localize more accurately the points where the motor nerves enter the muscle.
- Inject approximately 1 ml of a 5% aqueous solution of phenol at each point. A decrease in tone can be expected to last approximately 2 months, during which time an active therapy program can continue.
- There is an initial reduction in muscle tone immediately after the block. The muscle will continue to relax gradually over the next 24 hours.
- Begin physical therapy immediately using both active and passive techniques to increase shoulder range of motion. The duration of the block is approximately 2 months.
- Repeat blocks as needed during the period of time in which neurologic recovery can be expected to continue. In addition, blocks of the thoracodorsal nerve can also be performed.

**Elbow Flexor Spasticity** During the physiologic recovery phase, control of elbow flexor spasticity requires the elimination or decrease of excessive tone in each of the three flexor muscles. The brachioradialis muscle has been shown by dynamic EMG studies to be the most spastic of the elbow flexor muscles (112). Because the radial nerve innervates this muscle, it is necessary to perform a motor point block of the brachioradialis muscle (Fig. 67.5).

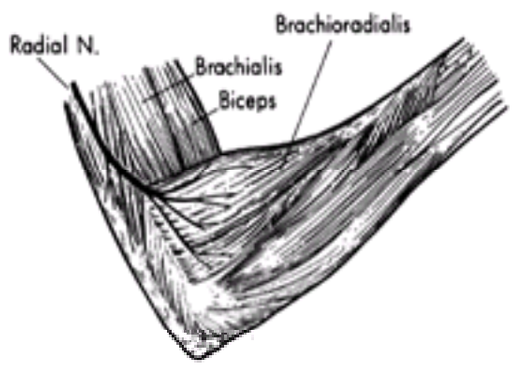


***Figure 67.5.*** A phenol injection of the motor branches of the radial nerve to the brachioradialis is used to reduce spasticity temporarily.

- Localize the motor points on the surface of the brachioradialis muscle using a surface stimulator. Then use an insulated Teflon-coated needle in conjunction with a nerve stimulator to localize more accurately to the motor points.
- Inject approximately 1 ml of a 5% solution of phenol in saline at each point. The ensuing block of the brachioradialis muscle takes effect over the following 24 hours.

Spasticity of the biceps and brachialis muscles also interfere with elbow extension. Botulinum toxin can be injected into the individual elbow flexor muscles. Alternately,

a phenol block of the musculocutaneous nerve will provide temporary relief (Fig. 67.6) (112). The block is commonly performed percutaneously. The musculocutaneous nerve has minimal corticosensory representation. Percutaneous phenol injection of the musculocutaneous nerve therefore does not interfere with sensation in the upper extremity. The advantages of performing the musculocutaneous nerve block percutaneously are (a) it does not require general anesthesia; (b) because no surgery is required, it is more readily done; and (c) it provides only a partial blockade of the action of the biceps and brachialis muscle. The partial block preserves the potential for upper extremity functional training.

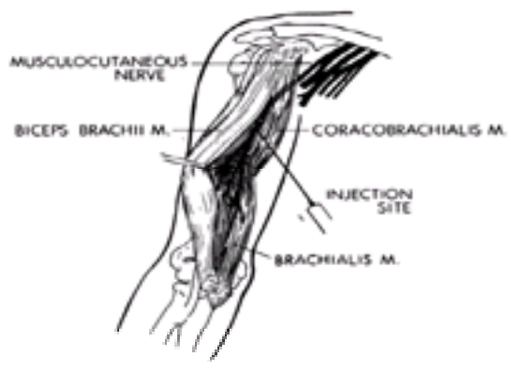


***Figure 67.6.*** A percutaneous injection of the musculocutaneous nerve can be used to diminish temporarily spasticity of the biceps and brachialis muscles.

- Perform phenol injection of the musculocutaneous nerve using a Teflon-coated needle and a nerve stimulator.
- Introduce the needle from the medial aspect of the arm and pass between the lower edge of the short head of the biceps and the brachialis. In a spastic patient, this interval is easily identified.
- Move the needle while applying stimulation until the point of maximal response is noted.
- Inject 3 ml of an aqueous solution of 5% phenol at this location. Use an aqueous solution for percutaneous injections to provide better diffusion of the phenol.

**Wrist and Finger Flexor Spasticity**

- Treat spastic forearm flexor muscles causing wrist and finger flexion deformities during the physiologic recovery phase with botulinum toxin injection of the muscles or with phenol motor point blocks (37,70,71,72,200,205,240). Because of the large sensory components of both the median and ulnar nerves, direct injection of the nerves with phenol is undesirable.
- To localize the point of entry of the motor branches into the muscles, use surface electrical stimulation. Mark the points of maximal response on the skin.
- For insulation, insert at these points a needle coated with Teflon. Use additional stimulation to define the motor points of the muscles further.
- When the motor point has been localized, inject an aqueous solution of phenol at each site. Do not inject more than 5 points in a forearm in 1 day to avoid excessive swelling and inflammation.
- Residual spasticity and mild contracture are commonly present despite motor point blocks or botulinum toxin. The blocks can be supplemented with functional electrical stimulation of the wrist and finger extensor muscles and by casting or splinting techniques.
- Perform gentle passive range of motion of the wrist and fingers. When motor control is present, include a program of active exercise and functional training.

**Intrinsic Spasticity in the Hand** Spasticity involving the intrinsic muscles of the hand is common but is usually masked by spasticity in the extrinsic finger flexors. An adducted thumb, limited extension of the metacarpophalangeal joints, or swan-neck positioning of the fingers should alert the physician to the possibility of underlying intrinsic spasticity. Botulinum toxin can be injected into the offending muscles. Alternately, a phenol block of the motor branches of the ulnar nerve in Guyon's canal can be administered after surgical exposure (Fig. 67.7) (103, 104,115,122,131). The close proximity of the sensory branch of the nerve makes percutaneous injection undesirable because loss of sensation in the hand or painful dysesthesia could develop with phenol injection of the sensory nerve.

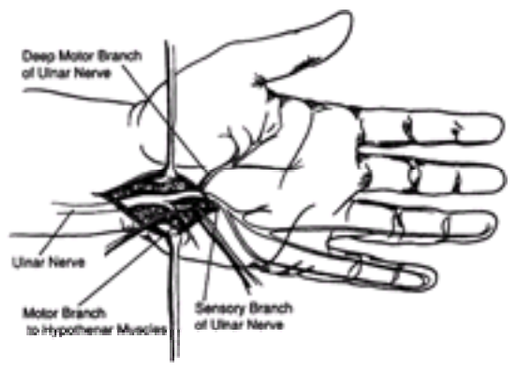


***Figure 67.7.*** Isolation of the motor branches of the ulnar nerve distal to Guyon's Canal. (Reprinted with permission from Keenan MA, Kozin SH, Berlet AC. *Manual of Orthopaedic Surgery for Spasticity.* New York: Raven Press, 1993.)

- Make an incision on the palmar surface of the hand radial to the pisiform bone and extend distally for 1 inch. Take care to prevent harm to the ulnar artery.
- Expose the ulnar nerve and identify the motor branches using a nerve stimulator. Generally, two motor branches are seen; the main branch lies beneath the sensory branch and a smaller motor branch can be seen entering the hypothenar muscles.
- Place a moistened gauze sponge under the nerves to be injected to protect the surrounding soft tissues.
- Inject the motor branch with 5% phenol in glycerin. Use phenol for surgical blocks when the nerve is being injected under direct vision. The glycerin allows the phenol to be released more slowly into the nerve, thereby prolonging its effect. The duration of the block lasts approximately 6 months.
- Unless combined with other surgery no splinting or casting is used postoperatively. Apply a soft dressing to the hand and begin active and passive exercises on the first postoperative day.

**Thumb-in-Palm Deformity** The thumb-in-palm deformity is heterogeneous in appearance and may be secondary to spasticity of multiple muscles (19,48,104,143,144,189,193,199,204,220). If flexion of the interphalangeal joint of the thumb is present, then perform a botulinum toxin injection or a motor point block of the flexor pollicis longus (71). When the thumb is in a severely adducted position, use phenol for a surgical block of the motor branches of the ulnar nerve (122).

- When the adduction deformity of the thumb is also secondary to spasticity of the median innervated muscles of the thenar eminence, a phenol block of the recurrent motor branch of the median nerve can be performed (107). Perform the block percutaneously using a Teflon-coated needle and nerve stimulator.
- The recurrent motor branch of the median nerve enters the thenar mass at the junction of a line drawn along the radial border of the long finger and Kaplan's cardinal line. Kaplan's cardinal line is drawn parallel to the proximal palmar crease beginning at the apex of the first web space (Fig. 67.8).

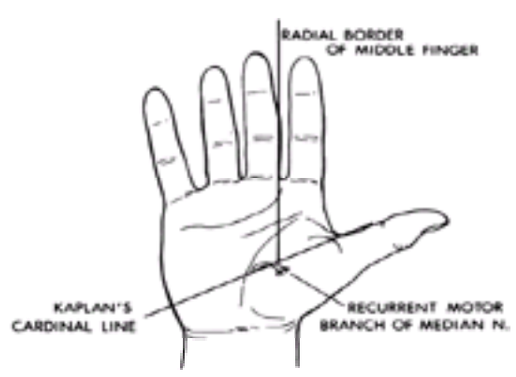

***Figure 67.8.*** The recurrent branch of the median nerve enters the thenar mass at the junction of a line drawn along the radial border of the long finger and Kaplan's cardinal line.

- Use a nerve stimulator and insulated needle to localize the nerve during the percutaneous injection. Then inject approximately 2 ml of aqueous phenol at the point of maximum response to stimulation.
- Casting or splinting may be needed after the block if a contracture is present. Employ active and passive range of motion exercises. Perform functional training when any motor control is present in the upper extremity.

## EVALUATION OF RESIDUAL LIMB DEFORMITIES

### ASSESSMENT OF COGNITION AND COMMUNICATION

Upper extremity function requires complex and highly sophisticated mechanisms working together in unison. Improving upper extremity function requires careful systematic evaluation before surgery. The goals of surgery must be practical and clearly understood by the patient and the family. Assessment includes an evaluation of cognition and communication skills (15,104,117,127,133,136,231). The patient must be capable of following simple commands and should also be able to cooperate with a postoperative therapy program.

### SENSORY EVALUATION

Intact sensation is essential to functional use of the hand (2,14,15,17,20,25,33,48,53,65,75,77,104,105,106,107,108,126,145,146,150,158,160,164,165,183,188,199,230,231,235). The basic modalities of pain, light touch, and temperature must be present. Two-point discrimination is a valuable predictive test. A patient rarely uses the hand for functional activities if the discrimination is greater than 10 mm. Proprioception and kinesthetic awareness of the limb in space are also important. Kinesthetic awareness is tested in a hemiplegic individual by placing the spastic limb in a position and asking the patient to duplicate this position with the sound limb while keeping the eyes closed. Stereognosis is not a practical test in spastic patients. They lack the fine motor control necessary to manipulate an object in the hand. It is helpful to observe the patient's spontaneous use of the hand. Visual perceptual deficits add increased problems involving motion of the limb and even awareness of the limb itself.

### EVALUATION OF LIMB DEFORMITY AND FUNCTIONAL CAPABILITY

Diffuse axonal injury, multifocal vascular pathology, and diffuse hypoxic encephalopathy lead to a large variety of posttraumatic motor phenomena, many of which are functionally significant (Table 67.6). Lesions affecting the corticospinal system, the cerebellum and its pathways, and the extrapyramidal system are common. Hemiparesis is the most common long-term residual problem of head injury. Many patients, however, have a brain stem syndrome consisting of ipsilateral ataxia and contralateral spastic hemiparesis. A small percentage have a pseudobulbar athetoid type of picture. The literature also identifies patients with residuals of bilateral hemiparesis, ataxia involving both sides of the body, and severe dystonic decerebrate posturing or rigidity. Many patients, especially during the early recovery stage from head injury reveal mixed signs such as spasticity combined with tremor and ataxia. Peripheral neuropathy is common after head injury, and focal dystonia, although unusual, is also seen. Because so many different aspects of the motor control system may be affected by a head injury, we present a way of organizing the unwieldy array of symptoms that emerge from a damaged nervous system. Our perspective is a practical one, namely taking into account the impact of movement disorders on the patient's ability to function in real life.

| *Limbs with restricted motion* | *Limbs with excessive motion* |
|---|---|
| 1. Spasticity, stiffness, and contracture | 1. Cerebellar ataxia |
| 2. Upper motoneuron patterns of dysfunction | 2. Brain stem syndrome |
| 3. Heterotopic ossification | 3. Clonus |
| 4. Bony malalignment and fracture malunion | 4. Ballismus |
| 5. Pain syndromes | 5. Chorea |
| 6. Pseudobulbar athetoid syndrome | 6. Tremors |
| 7. Brain stem syndrome | 7. Myoclonus |
| 8. Rigidity and bradykinesia | 8. Tics |
| 9. Dystonia, torticollis, bruxism, locked jaws | 9. Ligamentous and capsular instabilities |
| 10. Decorticate and decerticate rigidity | 10. Sensory disturbance |

Reference: 145, 146.

***Table 67.6. Clinical Phenomena Associated with Impaired Movement That Functionally Lead to Restricted or Excessive Motion After Traumatic Brain Injury or Cerebrovascular Accident***

Treatment of spasticity is most effective when functional problems are formulated and described in focal rather than diffuse terms. Treatment of focal problems lends itself well to surgical intervention, which can target particular muscles. Surgical lengthening, transfer, or release of targeted muscles can provide very effective solutions to problems of function that are clearly identified from the outset. The localizing approach is useful because it forces the clinician to indicate the desired outcome in advance. The outcome is based on an analysis that identifies the specific spastic muscles responsible for the problem. For example, if the clinical problem is an adducted shoulder that hinders access to the axilla, surgically releasing the pectoralis major will not solve the problem if the teres major and latissimus dorsi are really the culprits responsible for the problem. Identifying the specific offending muscles is critically important to localized strategies of intervention.

In a neurologically impaired patient, it is frequently difficult to distinguish between the many potential causes of limited joint motion. The possibilities include increase muscle tone, a myostatic contracture, the presence of periarticular HO, an undetected fracture or dislocation, joint subluxation, pain, or the lack of patient cooperation secondary to diminished cognition. Bony deformities may not exhibit an obvious clinical deformity but can be detected by radiography.

#### *Clinical Evaluation of Motor Control*

Evaluation of spasticity focuses on identification of three factors: (a) the clinical pattern of motor dysfunction, (b) the patient's ability to control muscles involved in the clinical pattern, and (c) the role of muscle stiffness and contracture in relation to the functional problem. For purposes of convenience, we identify six clinical patterns of upper extremity motor dysfunction that are most commonly seen (Table 67.7). Other variations of motor dysfunction occur but are less common. Various muscles may contribute to motor dysfunction across joints and limb segments in these clinical patterns. During evaluation, focus on the following characteristics of the involved part: (a) voluntary or selective control, (b) spastic reactivity, (c) rheologic stiffness, and (d) contracture. Ask five specific questions:

1. Adducted and internally rotated shoulder
2. Flexed elbow
3. Pronated forearm
4. Flexed wrist
5. Clenched fist
6. Thumb-in-palm

* The most typical patterns of upper extremity motor dysfunction following stroke or traumatic brain injury.
Reference: 145, 146.

***Table 67.7. Common Clinical Patterns of Motor Dysfunction in the Upper Extremity****

- Does the patient have voluntary control over a given muscle?
- Is the muscle spastic to passive stretch?
- Is the muscle, as an antagonist, activated during active movement generated by an agonist?
- Does the muscle have increased stiffness when stretched?
- Does the muscle have fixed shortening (contracture)?

When many muscles cross a joint, the characteristics of each muscle may vary. Because each muscle may contribute to motion and movement of the joint, information about each muscle's contribution is useful to the assessment as a whole. Treatment depends on such information (58,145,146).

Spasticity often masks underlying motor control. In the upper extremity, the most common pattern of spasticity is one of flexion. Passive range of motion of each joint should be established first. This is tested by slow extension of the joint to avoid the velocity sensitive response of the muscle spindle. When spasticity is significant and passive joint motion is incomplete, perform an anesthetic nerve block to assess whether a myostatic contracture is present (104,105,117,118,126). In order to evaluate passive joint motion in the entire upper extremity, perform a brachial plexus block using a local anesthetic.

Unmasking of primitive patterning reflexes further contributes to the motor impairment. Spasticity (hyperactive response to quick stretch), rigidity (resistance to slow movement), or movement dystonias may be present. The degree of spasticity within selected muscles can be graded clinically in response to a quick stretch as mild, moderate, or severe. There is surprising consistency between observers using this simple grading system. Another method of quantifying muscle tone, which is readily accessible and easily performed at the bedside, is to measure the amount of intramuscular pressure generated by a passive quick stretch or during functional use of the limb. Intramuscular pressure can be measured using a wick or slit catheter technique. The pressure generated within the muscle is proportional to the force of contraction (5,182).

Motor control can be graded in the extremity using a clinical scale (Table 67.1) (112). The patient should be observed clinically in a variety of functional tasks.

| | Motor control | Description |
|---|---|---|
| Grade 1 | Flaccid | Hypotonic, no volitional motion |
| Grade 2 | Rigid | Hypertonic, no volitional or reflexive motion |
| Grade 3 | Reflexive mass pattern (synergy) | Mass flexion or extension in response to stimulation. No volitional control |
| Grade 4 | Volitional mass pattern | Patient-initiated mass flexion or extension movement |
| Grade 5 | Selective with pattern overlay | Slow volitional movement of single joint with minimal movement in adjacent joints. Physiologic stress results in mass action. |
| Grade 6 | Selective | Volitional control of individual joints, independent of adjacent joints. |

References 105, 112, 117, 118, 120, 145, 146.

***Table 67.1. Clinical Scale of Motor Control***

Differentiating between the relative contributions of pain, increased muscle tone, and contracture to a limb deformity can be difficult. Anesthetic nerve blocks are extremely useful in assessing joint range of motion. The blocks can be easily performed without the use of special devices. By temporarily eliminating pain and muscle tone, patient cooperation is gained and the amount of myostatic contracture can be determined. By using local anesthetic blocks, the strength and motor control of the antagonistic muscle group can also be evaluated (Fig. 67.9).

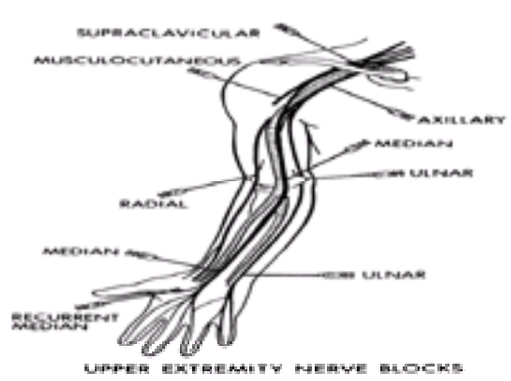


***Figure 67.9.*** Commonly performed diagnostic nerve blocks in the upper extremity using a local anesthetic.

***Laboratory-Assisted Assessment of Motor Control***

Clinical examination supported by laboratory studies is the mainstay of evaluation. The clinical questions of interest regarding a given problem include the following:

- Does the patient have selective voluntary control over the given muscle?
- Is the muscle activated dyssynergically (i.e., in antagonism to movement) when the patient attempts to move the relevant joint?
- Is the muscle resistive to passive stretch (i.e., spastic)?
- Does the given muscle have fixed shortening (i.e., contracture)?

Given the degree of clinical effort, patient morbidity and procedural costs involved in treating complicated movement dysfunction in patients with CVA and TBI, clinical examination alone may not be sufficient to answer these questions with a high degree of confidence. Technology-driven laboratory assessments that may include formal gait and motion analysis, dynamic EMG studies, and nerve blocks may be helpful (105,112,117,118,120). Dynamic multichannel EMG is acquired with simultaneous measurements of joint motion (kinematics) in the upper extremity. Kinetic, kinematic, and dynamic EMG data assist the clinician in interpreting whether voluntary function (effort-related initiation, modulation, and termination of activity) is present in a given muscle and whether that muscle's behavior is also dyssynergic (sometimes referred to as “out of phase” behavior). In addition, responses to different rates of passive stretch of muscle before and after local anesthetic nerve block can help the clinician distinguish between the dynamic, velocity-sensitive reflex resistance of spasticity versus passive muscle tissue stiffness and contracture. Somatosensory evoked potentials (SEPs) and motor evoked potentials (MEPs) provide information on the integrity of the sensory and motor pathways and may be helpful in predicting recovery of motor function after stroke (93). Combined with clinical information, laboratory measurements of muscle function often provide the degree of detail and confidence necessary for making conservative and surgical treatment decisions.

Combining the findings in several previous studies of spastic patients from our institution the following classification of EMG activity was devised to standardize terminology and may be used for either the upper or lower extremity (Table 67.8) (105,112,117,118,120).

| | |
|---|---|
| Class I | Normal Phasic Activity |
| Class II | Premature Prolonged Activity |
| Class III | Phasic Prolonged Activity |
| IIIA | Mild Prolongation Activity |
| IIIB | Moderate Prolongation Activity |
| IIIC | Severe Prolongation Activity |
| Class IV | Continuous Activity |
| Class V | Stretch Response Activity |
| Class VI | Absent Activity |

Reference: 105, 112, 118, 120, 145, 156.

***Table 67.8. Classification of Electromyographic Activity***

- Class I constitutes a normal phasic pattern with appropriate on and off EMG activity.
- Class II consists of EMG activity that, although phasic, begins prematurely and continues for a short period beyond the normal duration of activity for that muscle. This is more commonly seen in the lower extremity.
- Class III consists of phasic activity with prolongation beyond the normal timing of the muscle. Class III activity can be further subdivided into three patterns, depending on the degree of prolongation.
- Class IIIA consists of phasic activity with a short period of low-intensity EMG activity extending into the next phase of the flexion–extension cycle secondary to mild spasticity.
- Class IIIB consists of phasic activity with prolongation extending for at least half of the next phase of motion. This is indicative of a moderate amount of spasticity.
- Class IIIC represents a severely spastic muscle and consists of phasic activity with severe prolongation in which EMG activity is continued throughout the next phase of motion at a high intensity but the underlying phasic nature of the muscle activity is still distinguishable.
- Class IV consists of continuous EMG activity without phasic variations.
- Class V consists of EMG activity seen only in response to a quick stretch by the antagonist muscles. There is no volitional activation of the muscle. This pattern is common in the finger extensors.
- Class VI consists of absent EMG activity.

## ORTHOPAEDIC MANAGEMENT OF COMMON UPPER EXTREMITY DEFORMITIES

### GENERAL CONSIDERATIONS

The patterns of limb spasticity seen following stroke and TBI are very similar. The same orthopaedic procedures can be used in both patient populations. The orthopaedic treatment interventions will be described together. These procedures, however, are not applied equally to both patient groups. The degree of spasticity, the timing of neurologic recovery, and the pattern of spontaneous neurologic recovery are different between stroke and brain-injured patients. These differences account for the variation in the need for specific treatments between the two groups.

Patients who have had TBI or stroke present unique challenges to the surgical team. The patients may have behavioral deficits or cognitive limitations that would make them difficult to manage with regional anesthesia and sedation. Therefore, general anesthesia is preferred (67,215). The patients often have previously had a tracheostomy performed; therefore, an anesthesia team familiar with airway difficulties caused by this procedure is important. Great care must be taken when positioning these patients for long procedures because contractures of other portions of their bodies may increase the risk of pressure ulcer formation.

#### *Fracture Malunion*

Fracture malunions are common in the TBI patient. This is due to a combination of factors. Trauma concurrent with the brain injury may cause complex fractures, which are predisposed to malunion. Injuries may be missed in the initial resuscitation. Fracture healing may be acelerated by the same mechanisms that cause HO. The prognosis of the brain injury may be sufficiently poor that optimal internal fixation of fractures is not sought or obtained. Hemodynamic or pulmonary instability may cause optimal fracture fixation to be delayed. Poor patient compliance, agitation, and spasticity may alter the initial reduction. If this is not anticipated malunion may result.

**Shoulder and Elbow** Shoulder girdle injuries (scapula, clavicle, and acromioclavicular [AC] joint) are the most common upper extremity injuries in TBI (61,65). Most commonly, these injuries can be treated nonoperatively. Patient agitation and muscle spasticity may necessitate open reduction and internal fixation. Malunion of the proximal humerus may result from inadequate closed reduction or failed internal fixation. These problems are difficult to treat because of excessive scar formation, HO, and retraction of the tuberosities. Treatment of malunited tuberosity fractures is similar to acute injuries, with open reduction of the tuberosity to prevent subacromial impingement (9). In three-part and four-part fracture malunions, prosthetic replacement is generally indicated. If there is no evidence of avascular necrosis of the head and a congruent joint in a three-part fracture, osteotomy and internal fixation may be considered.

Because of the high risk of HO in TBI patients with elbow fractures (73), perform stable internal fixation so that early motion may be initiated. Prophylaxis for HO should also be considered in the acute injury phase when performing internal fixation in brain-injured patients. The drug therapy we employ is diphosphonate 20 mg/kg/day combined with indomethacin 50 mg tid. Low-dose radiation can also be employed (132).

**Forearm** Nonoperative treatment of both bones forearm fractures predictably gives unsatisfactory results, particularly loss of supination and pronation. Open reduction results in a 31% incidence of interosseus membrane ossification. For this reason, when performing open reduction and internal fixation of these fractures, use a two-incision technique. Minimize dissection, and use bone grafting cautiously (68). Consider prophylaxis for HO. Distal radius fractures are common. Treat malunions with osteotomy and internal fixation with bone grafting.

**Hand** Metacarpal malunions are of two types: apex dorsal angulation and malrotation. Patients with apex dorsal malunions are more symptomatic. This is especially true with fractures that are more proximal and with the radial metacarpal bones. This causes a pseudoclaw and painful grip. Treat with dorsal closing wedge osteotomy with percutaneous pin fixation or internal fixation. The rotationally malaligned fractures cause a gap between fingers and makes manipulation of small objects more difficult. This is particularly important to TBI patients, who may have motor control deficits that aggravate the situation. Correct these deformities with rotational osteotomy and fixation (87).

#### *Heterotopic Ossification*

Results of HO resection are better with higher cognitive function and when volitional movement of the involved joint is present (69). In addition, surgical excision of functionally significant periarticular HO often results in significant improvements in range of motion, independence, and quality of life (62,63,69,132). Radiographically immature lesions also have a higher rate of recurrence (18,47,60,62,63,69,111,127,132,147,157,195). It may not be feasible or desirable to allow the HO to reach maturity before resection, because although the risk of recurrence is higher, ankylosis of the joint and subsequent contracture worsen the over all functional result.

**Shoulder** Incidence of shoulder and elbow HO is similar in some reports (66), whereas elbow HO predominates in others (69,132,157). Shoulder HO radiographically appears to form inferomedial to the joint. This can be deceiving and computed tomography may be needed to localize the abnormal bone. When the bone is located anterior to the joint, use a deltopectoral incision. When it is necessary to resect a shoulder HO, it may also be necessary to release or lengthen internal rotators simultaneously without entering the joint capsule (63,127,132). Releasing the pectoralis major may produce a cosmetic defect, but its release is necessary when there is a severe internal rotation and adduction deformity. Close the wound in layers over a drain. When the HO is located posterior to the shoulder, it commonly follows the teres muscles from the scapula to the posterior humerus; therefore, use a posterior approach. Great care must be taken to identify the axillary nerve in normal tissue because it is commonly encased within the mass of heterotopic bone and is easily transected. Following HO resection begin range-of-motion exercises immediately.

**Elbow** HO occurs spontaneously after TBI in 4% of patients. In these cases, the HO does not involve the collateral ligaments or the radio-capitellar joint (Fig. 67.3). Even when joint ankylosis occurs, forearm rotation is maintained (63,127,132). HO forms in 90% of fractured or dislocated elbows in head injured adults (73). When HO follows trauma, it commonly forms in the collateral ligaments and may involve the radio-capitellar joint. Consider prophylactic treatment with either anti-inflammatory agents, diphosphonates, or radiation in patients with concurrent head injury and elbow trauma. When elbow HO does form, tardy ulnar nerve palsy should be suspected, particularly when the bone is located medial or posteromedial (113). Elbow HO occurs in 20% of patients with TBI and forearm fractures (68). Anterior HO

occurs roughly one third as often as posterior HO, with a posterolateral location the most frequent (61,63,69). Surgical approaches for elbow HO are posterolateral, medial, and anterolateral. Base the decision on which approach to use on plain radiographs, computed tomography with or without three-dimensional reconstructions, and the need to decompress any nerves. Unfortunately, delaying surgical excision for the suggested 12 to 18 months often results in severe elbow impairment. Even with this delay, however, recurrence is common (69,132).

Posterior HO is palpable subcutaneously. It extends between the lateral humeral condyle and the lateral olecranon. The elbow is commonly ankylosed in mild flexion. When excising the HO, it is helpful to resect the central bridge first, allowing some motion of the elbow and exposure of the posterior fat pad. Once motion is obtained, the landmarks can be identified more easily and the remainder of the HO can be resected from the humerus and olecranon. Preserve the fat pad to prevent recurrent contracture.

A medial approach is indicated when ulnar nerve transposition is necessary, when posterior HO extends medially, or when HO of the medial collateral ligament limits motion. In this approach, the ulnar nerve is identified proximally and protected. Occasionally, as the nerve is followed distally, it will dive through a gap between posterior and medial HO. If it is thus encircled, it must be freed and transposed anteriorly before HO resection (69,113,127,132).

Anterior HO generally forms in the midline and follows the brachialis to the coronoid. If the biceps is involved, proximal forearm synostosis may occur. With anterior HO the elbow is most often fixed in 90° of flexion. The anterolateral approach allows exposure of the HO, identification of the radial and median nerves, and the brachial artery. Should lengthening of the brachialis and biceps be necessary, this is also facilitated by this approach. First, resect the central bridge, establishing motion, then extend the elbow and resect the remaining HO. Anterior capsular release may be performed if necessary (63,127,132). Close wounds over drains in layers. Following resection of elbow HO, arc of motion averages 65°. Complications of resections include wound breakdown, posterior interosseous nerve palsy, and re-ankylosis (69,126,132,157).

**Forearm** Radioulnar synostosis can result in a profound decrease in upper extremity function. Often occurring following trauma, radioulnar HO can be particularly troublesome. When it is present, the posterolateral incision can be extended along the posterolateral border of the proximal ulna to gain access for removal. Remember that less extensive dissection minimizes the chances of a recurrence (68).

## SHOULDER

The paretic shoulder deserves special attention because it is a common source of pain. A variety of different factors contribute to the painful, immobile shoulder: RSD; brachial plexitis; inferior subluxation; spasticity with adduction, internal rotation contracture; adhesive capsulitis; spastic abduction; HO; and traumatic lesions, such as rotator cuff tears or fractures and dislocations.

### *Adhesive Capsulitis*

Adhesive capsulitis is commonly seen in patients following stroke and in those with RSD. They have a characteristically painful shoulder with limited glenohumeral motion. Three clinical and four arthroscopic stages have been identified (90,161,162,203) (Table 67.9). The treatment in this group of patients is similar to that for the general population. Nonsteroidal anti-inflammatory drugs, physical therapy, and intra-articular injections are all useful. Selected cases may benefit from manipulation under anesthesia.

| Stage | Characteristic |
|---|---|
| Clinical | |
| Painful | Gradual Onset of Diffuse Pain |
| Stiff | Decreased Range of motion; Affects activities of Daily Living |
| Thawing | Gradual Return of Motion |
| Arthroscopic | |
| 1 | Patchy fibrinous synovitis |
| 2 | Capsular contraction, fibrinous adhesions, synovitis |
| 3 | Increased contraction, resolving synovitis |
| 4 | Severe contraction |

Reference: 90, 161, 162.

***Table 67.9. Stages of Adhesive Capsulitis***

- Arthroscopic capsular release may be performed for adhesive capsulitis. Perform capsular release via a three-portal technique, with a standard anterior port and two posterior ports, one just above and one just below the posterior soft spot.
- Release the posterior superior capsule using the posterior superior port for a straight punch, with the arthroscope in the anterior port.
- Establish the posterior inferior port and with the arthroscope in the superior port, use a straight punch through the inferior port to release the inferior capsule. Take care to dissect the inferior capsule away bluntly from the underlying tissue to avoid injuring the axillary nerve.
- Begin range-of-motion exercises immediately. These exercises may be facilitated by a long-acting interscalene block. Botulinum toxin injections or phenol blocks of spastic shoulder muscles also fascilitate the postoperative rehabilitation.

### *Inferior Subluxation*

Inferior subluxation of the shoulder is a common occurrence in patients with flaccid paralysis of the shoulder girdle (Fig. 67.10). This is most commonly seen in stroke patients or in brain-injured patients with concomitant brachial plexus trauma. The subluxation is usually self-limiting, but occasionally, the shoulder will be chronically subluxated, causing pain. The patients typically have no functional use of the extremity. Patients complain of increased pain when upright. The pain may be due to chronic stretch on the shoulder capsule or from traction on the brachial plexus. Physical examination shows a positive sulcus sign, with little to no active motion of the involved shoulder. There is a prominence of the acromion and atrophy of the deltoid. There may be contracture of the shoulder in adduction and internal rotation. Subacromial or intra-articular injections of local anesthetics do not relieve the symptoms. Radiographs show inferior subluxation of the humerus on the glenoid (Fig. 67.10). Brachial plexopathy must be ruled out by using diagnostic EMG.

***Figure 67.10.*** AP radiographs of the shoulder in a patient with painful inferior subluxation before and after biceps suspension. Note inferior subluxation of the humerus preoperatively (**A**) with reduction after surgery (**B**) (With permission from Hisey MS, Keenan MAE. Orthopaedic Management of Upper Extremity Dysfunction Following Stroke or Brain Injury. In Green DP, Hotchkiss RN, Pederson WC, eds. *Operative Hand Surgery,* 4th ed. New York: Churchill Livingstone, 1998:287.)

Conservative treatment may include electrical stimulation to the deltoid and supraspinatus muscles use of a sling. This relieves the symptoms by elevating the humeral head in the glenoid. Although this technique is usually successful in the short run, this is frequently unacceptable to the patient as a permanent solution. A surgical

solution to this problem of excessive laxity is the biceps suspension procedure (Fig. 67.11).

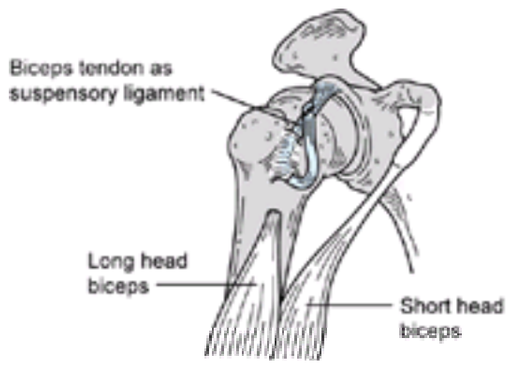


***Figure 67.11.*** The biceps suspension procedure.

Several procedures have been described to treat paralytic inferior subluxation of the shoulder, but none has gained widespread acceptance. Braun (31) has advocated using the coracoacromial ligament to suspend the humeral head. The lateral portion of the coracoid process together with the coracoacromial ligament is detached and transferred to the humeral head, where it is fixed using a cancellous lag screw. Garland has advocated detaching the proximal end of the long head biceps tendon, looping the tendon over the clavicle and securing it back on itself. With time, the paretic biceps muscle tends to stretch and the humerus once again subluxates inferiorly. Shoulder arthrodesis has also been performed but is not well accepted by the patient because it produces a rigid joint, which interferes with passive positioning, hygiene, and nursing care.

**The Biceps Suspension Procedure**

- The procedure we prefer is to convert the long head of the biceps tendon to a proximally based suspensory ligament. This preserves passive shoulder motion while correcting the subluxation. Because only the tendon is being used, there is no opportunity for paretic muscle to develop laxity and for the deformity to recur.
- Place the patient in the beach chair position with a small bolster under the scapula.
- Use a standard deltopectoral approach. If the pectoralis major is causing an adduction or internal rotation deformity, release it at its insertion.
- Identify the musculotendinous region, where the tendon of the long head of the biceps joins the muscle belly. Take care to preserve the musculocutaneous nerve, which enters the medial aspect of the muscle.
- Detach the long head of the biceps. To obtain the greatest length of tendon, attach the distal, muscular portion of the long head of the biceps to the conjoined tendon medially to preserve elbow flexion and supination strength. Then dissect the proximal portion of the long head of biceps tendon in the biceps groove and rotator interval. It is important to direct the biceps tendon in the groove in order to pull the humeral head proximally and medially during final tensioning of the graft and reduction of the glenohumeral joint (Fig. 67.11).
- Use a burr to drill a hole in the humeral neck in an anterior to posterior direction, just distal to the biceps groove. Burr a second hole in the proximal portion of the biceps groove, between the greater and lesser tuberosities. Use an angled curet to connect the two holes, forming a bony tunnel in the proximal humerus. Place a braided, nonabsorbable traction suture in the distal portion of the biceps tendon. Use a wire loop to pass the tendon from proximal to distal through the tunnel.
- Position the arm with the humeral head reduced in the glenoid and the arm in 30° of internal rotation. Using the suture, attach the distal tendon back to the proximal tendon, thus creating a suspensory loop of biceps tendon. Protect the repair in a sling for three months to allow bone-to-tendon healing.

***Spastic Abduction***

Overactivity of the supraspinatus muscle can cause spastic abduction posturing. The deformity is usually dynamic, becoming more prominent with ambulation, transfers, or other attempted activities (Fig. 67.12). The affected arm is held in an abducted posture, making balance while ambulating difficult. Patients complain that their balance is thrown off because of bumping into furniture, doorways, and people in crowds. Diagnosis requires examination of the patient at rest and during a variety of activities. It is also helpful to elicit from caretakers or family members any history of activities that trigger this posture. Use dynamic EMG to confirm that spasticity of the supraspinatus muscle is causing the deformity.

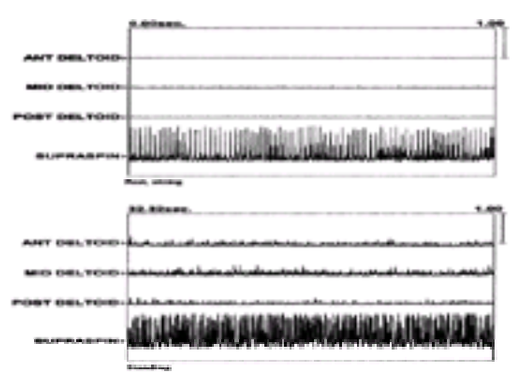

***Figure 67.12.*** Dynamic EMG of shoulder muscles in a patient with spastic abduction of the shoulder. Although standing causes a mild increase in activity of the deltoid muscle, the supraspinatus exhibits severe spasticity and is the cause of the dynamic abduction deformity.

***The Supraspinatus Slide***

It is possible to lengthen the supraspinatus effectively by means of a slide procedure. This procedure has been used successfully to correct spastic abduction deformity.

- Place the patient in the lateral decubitus position, with the affected extremity uppermost. To protect the brachial plexus, place an axillary roll in the unaffected axilla and ensure that all bony prominences are well padded.
- Make a 10 to 15 cm incision parallel to the scapular spine.
- Detach the trapezius insertion from the spine of the scapula, leaving a cuff of fascia for later reattachment (Fig. 67.13).

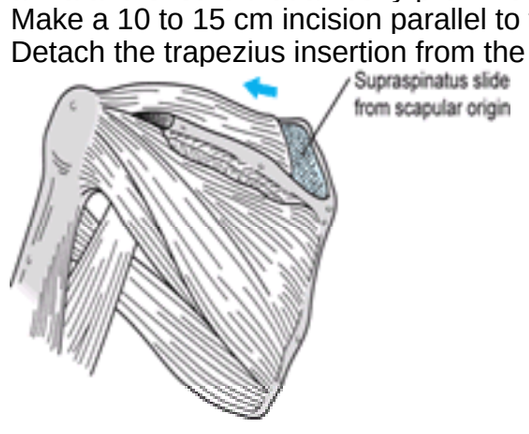


***Figure 67.13.*** The supraspinatus slide procedure for spastic abduction of the shoulder.

- Retract the deltoid laterally. Using a small periosteal elevator, elevate the origin of the supraspinatus subperiosteally from the medial border of the scapula. Continue the dissection laterally, taking care to avoid injury to the neurovascular pedicle at the suprascapular notch. Allow the muscle to slide laterally.
- Reattach the trapezius to the scapular spine. The remainder of the closure is performed in routine fashion. Allow the patient full, unrestricted postoperative motion.

### *The Adducted and Internally Rotated Shoulder*

The arm is adducted tightly against the lateral chest wall, and shoulder internal rotation causes the forearm to lie against the middle of the chest. The tendon of pectoralis major is often prominent when the examiner attempts to abduct and externally rotate the shoulder but other muscles contribute to the deformity. The glenohumeral joint normally functions as a universal joint, enabling the hand to reach an almost spherical volume of locations in three-dimensional space. When patients attempt to reach forward, spastic adductors and internal rotators can severely restrict acquisition of targets in the environment and on the body. The patient's ability to stabilize, push, or apply force to an object is also compromised. From the perspective of passive function goals such as skin care and axillary hygiene, spastic adductors and internal rotators hinder efforts of caregivers to gain access to the axilla to provide needed care. Restricted motion may impair dressing, washing, and bathing, and promote skin irritation and maceration. Passive manipulation of the shoulder during personal care may cause pain and trigger spastic resistance in reactive muscles.

Muscles that contribute to spastic adduction and internal rotation dysfunction of the shoulder include latissimus dorsi, teres major, the clavicular and sternal heads of pectoralis major, and subscapularis. Involvement of latissimus dorsi and teres major should be considered when hyperextension posturing of the shoulder is observed. Antagonistic activity in these muscles may be masking a patient's potential for active flexion. Diagnostic lidocaine block to the thoracodorsal nerve or the lower subscapular nerve may unmask that voluntary potential. When the pectoralis major is chronically spastic, the musculotendinous insertion of pectoralis major is prominent and tight. However, the two heads of this muscle may be differentially spastic, and EMG recordings from each or diagnostic lidocaine blocks to medial and lateral pectoral nerves may help to distinguish whether one or both heads are pathophysiologically active. Release of all four muscles may be required to relieve the deformity in a nonfunctional extremity (31,104,126). In patients who have evidence of underlying control of muscle function despite the presence of dyssynergy, the pectoralis major, latissimus dorsi, and teres major muscles can be fractionally lengthened at their muscle tendon junctions. Alternately, the teres major muscle can be partially released from its origin on the scapula and allowed to slide distally in the same manor as the supraspinatus slide.

### Anterior Shoulder Release

- Place the patient in a slight beach chair position with a small bolster under the scapula. Prep and drape the arm so that the entire arm and shoulder are accessible.
- Make an incision on the anterior shoulder beginning at the coracoid process and extending distally for approximately 7 cm.
- Identify the tendinous insertion of the pectoralis major tendon and use electrocautery to release it near its insertion (Fig. 67.14).

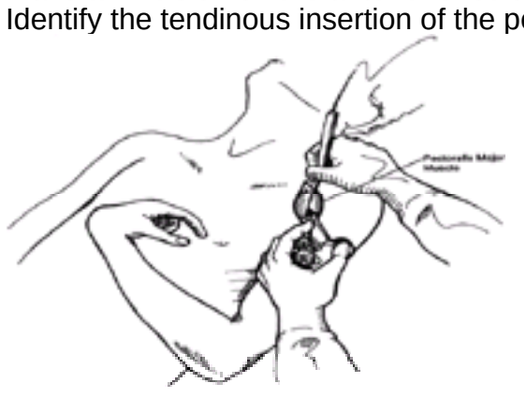

***Figure 67.14.*** Anterior shoulder release for internal rotation and adduction deformity. Release of pectoralis major muscle with electrocautery. (Reprinted with permission from Keenan MA, Kozin SH, Berlet AC. *Manual of Orthopaedic Surgery for Spasticity.* New York: Raven Press, 1993.)

- Expose the subscapularis and isolate it from the shoulder capsule near its insertion on the humerus. Release the subscapularis muscle without violating the glenohumeral joint capsule (Fig. 67.15).

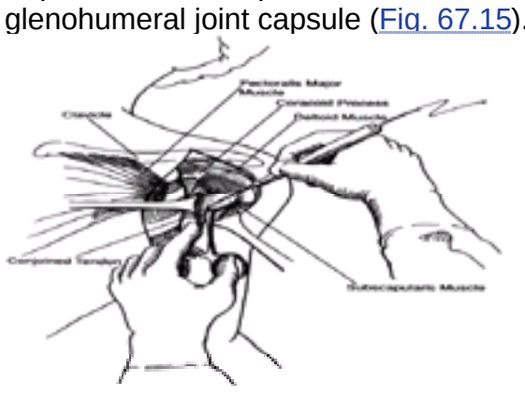

***Figure 67.15.*** Anterior shoulder release for internal rotation and adduction deformity. Isolation and release of subscapularis muscle. (Reprinted with permission from Keenan MA, Kozin SH, Berlet AC. *Manual of Orthopaedic Surgery for Spasticity.* New York: Raven Press, 1993.)

- Do not open the joint capsule or instability, or intra-articular adhesions may result.
- After identifying the latissimus dorsi and teres major muscles through the interval between the short head of the biceps and deltoid musculature, release these deforming muscles (Fig. 67.15).
- Place a drain deep into the wound prior to closure.
- Postoperatively, institute an aggressive mobilization program following skin healing and employ gentle range-of-motion exercises to correct any remaining contracture. Careful positioning of the limb in abduction and external rotation is necessary for several months to prevent recurrence.

### Fractional Lengthening of the Shoulder Muscles

- Place the patient in a 45° lateral position. Prep and drape the arm so that the entire arm and shoulder are accessible.
- Make an incision on the anterior shoulder directly over the palpable insertion of the pectoralis on the humerus. Retract the pectoralis major muscle upwards to visualize the muscle tendon junction on its undersurface near its insertion on the humerus. Sharply transect the tendinous fibers as they overlie the muscle belly. This allows the tendon to slide distally on the muscle belly while maintaining the integrity of the muscle tendon unit.
- Make a second incision over the posterior axillary fold and identify the lattissimus dorsi and teres major muscles at their insertion's on the humerus. Again, sharply transect the fibers of the tendons overlying the muscle bellies.
- Close the wounds in a routine fashion.
- Postoperatively, employ a sling for comfort for 2 to 3 weeks, and begin gentle active assisted range-of-motion exercises on the first postoperative day. Further lengthening of the muscles will occur with functional use of the arm during the next several weeks.

## ELBOW

### *Spastic Flexion*

Upright posture favors hypertonia in the “antigravity” elbow flexors of the upper limb. In the patient without motor control, severe flexion posturing can lead to skin maceration in the antecubital fossa, malodor, and skin breakdown. In reality, a continuum of volitional control is seen. Many patients complain that their elbows persistently “ride up” when they stand up and walk. They also complain that their flexed elbow hooks door frames and other people, and that putting on a shirt or jacket is a struggle. Kinesiologically, the elbow lengthens and shortens the upper extremity. Consequently, active dysfunction is characterized by impaired reaching for objects in the environment, placing them elsewhere or bringing them to the body.

**Functional Elbow Lengthening** Control of limb placement depends on both shoulder and elbow control. Smooth control of elbow flexion and extension is frequently impaired. The usual clinical picture is one of cogwheel motion on attempted extension of the elbow. Elbow extension range is often limited with a very prolonged period of extension. Elbow flexion is relatively normal. Laboratory examination using dynamic EMG helps to confirm the presence of volitional capacity as well as dyssynergy during movement for each of the elbow flexors. Obtain dynamic recordings from biceps, brachialis, brachioradialis, lateral, medial and long head of the triceps. Dynamic EMG combined with electrogoniometric measurement of elbow motion of stroke and TBI patients has revealed a consistent pattern of muscle activity responsible for this clinical picture (112,116). The pattern most commonly seen is that all three heads of the triceps muscle are operating in a normal phasic pattern. The brachioradialis muscle most frequently shows continuous spastic activity. One or both heads of the biceps muscle are also spastic. Less spasticity is observed in the brachialis muscle. This pattern of muscle activity is also common in patients with cerebral palsy. Armed with this information, a rational surgical plan can be devised to improve elbow control.

Fractional (myotendinous) lengthening is preferred whenever possible in spastic muscles. This allows the underlying tone and strength of the muscle to determine the amount of lengthening rather than having the surgeon estimate this elusive quantity. Lengthening over the muscle belly eliminates the need for suturing, and this diminishes the amount of scarring that occurs. A new tendon reforms and fills in the gap within several months. The fractional lengthening technique allows the patient to begin gentle active motion immediately after surgery because the muscle tendon unit remains intact. In contrast, a Z-lengthening technique requires immobilization for a minimum of 4 weeks to allow healing of the relatively avascular tendon and prevent inadvertent rupture.

Three methods are available to decrease tone in a spastic brachioradialis. Surgical lengthening of the brachioradialis can be used if volitional control is demonstrated on EMG. If little or no control is demonstrated, release of the severely spastic brachioradialis muscle at the level of the elbow may be performed. Lengthening of the spastic biceps and brachialis muscles as indicated by dynamic EMG is also performed to improve elbow motion and hand placement. Meals has advocated neurectomy of the radial nerve branches to the brachioradialis (151). This technique would not correct an established contracture of the brachioradialis.

*Technique of Functional Elbow Lengthening*

- Beginning with the biceps, make a longitudinal incision over the anterior arm starting just distal to the lower edge of the pectoralis major tendon and extending distally 5 cm.
- Expose the muscle tendon junction of both the long and short heads of the biceps. Then sharply transect the tendons directly overlying the muscle belly.
- Close the incision in a routine fashion.
- Apply a sterile tourniquet to the upper arm and inflate after exsanguination of the limb.
- Make a curved incision on the volar aspect of the elbow in the antecubital space. Begin the incision over the lateral border of the biceps muscle, pass medially across the antecubital crease and gently curve distally onto the anteromedial aspect of the forearm.
- Dissection develops the internervous interval between the brachioradialis and the biceps musculature. Identify and protect the radial nerve. If the brachioradialis has been demonstrated by dynamic EMG to be spastic and without any functional capacity, use electrocautery to transect it through its muscle belly proximally.
- Divide the lacertus fibrosis and expose the biceps tendon. Retract the biceps tendon to expose the underlying brachialis muscle. Sharply transect the broad band of tendinous fibers on the anterior surface of the brachialis muscle, leaving the underlying muscle tissue intact. Then extend the elbow, fractionally lengthening the brachialis by approximately 1 cm (Fig. 67.16).

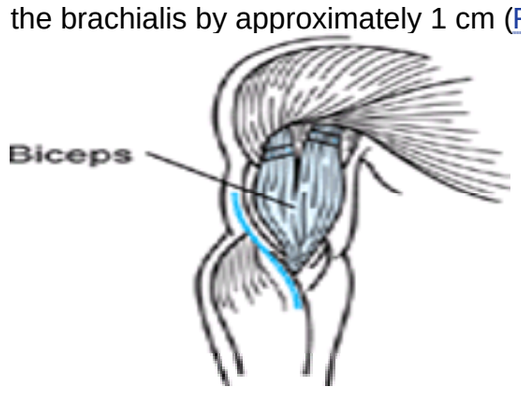


***Figure 67.16.*** Fractional lengthening of the long and short heads of the biceps at their proximal musculotendinous junction.

- In the presence of a severe rigid contracture, it may be necessary to perform a Z-lengthening of the biceps tendon. Make a Z-step cut for the entire length of the biceps tendon. Then suture the ends of the biceps tendon in a lengthened position using a nonabsorbable suture.
- Close the subcutaneous tissues and skin edges over a drain.
- In patients who have volitional function in the brachioradialis, fractionally lengthen the muscle at the myotendinous junction.
- Make a separate 3 cm longitudinal incision on the radial aspect of the forearm to identify the myotendinous junction of the brachioradialis. Roll the muscle, exposing its deep surface. Here the tendon extends more proximally. Sharply transect the tendinous fibers, allowing the brachioradialis to lengthen.
- If preoperative nerve conduction studies have shown an ulnar neuropathy at the level of the elbow, perform anterior transposition of the ulnar nerve.
- Close the skin incision over a drain in routine manner.
- When the biceps has been lengthened proximally, no immobilization is needed. Remove the drain within the first 24 hours following surgery and begin active range-of-motion exercises. Allow no resistive exercises for 3 weeks to prevent overlengthening of the muscles with resulting weakness. If a Z-lengthening of the biceps tendon was done distally, place the patient in a posterior splint with the elbow in 90° of flexion for 4 weeks to protect the biceps tendon repair. Functional elbow flexor lengthening has significantly enhanced the fluid control of elbow motion and improved hand placement in properly selected patients.

**Nonfunctional Elbow Release** Persistent spasticity of the elbow flexors causes a myostatic contracture and flexion deformity of the elbow. This results in skin maceration and breakdown of the antecubital space (115,116,126). This position of severe elbow flexion also predisposes the ulnar nerve to an acquired compression neuropathy by increasing the vulnerability to direct pressure and decreasing the cross sectional area of the cubital tunnel (113,214). Perform surgical release of the biceps tendon and brachioradialis muscle combined with lengthening or release of the brachialis, depending on the severity of the contracture. The joint capsule is generally not released. Gradual extension of the elbow with serial casting or physical therapy corrects the preoperative deformity and decreases the ulnar nerve compression. Anterior transposition of the ulnar nerve may be necessary to improve ulnar nerve function further.

- Make a curved incision on the volar aspect of the elbow in the antecubital space. Begin the incision over the lateral border of the biceps muscle, pass medially across the antecubital crease, and gently curve distally onto the anteromedial aspect of the forearm. When the contracture is severe and long standing, use a straight longitudinal incision to facilitate wound closure.
- Dissection develops the interval between the brachioradialis and the biceps musculature. Identify and protect the radial nerve.
- Using electrocautery, transect the brachioradialis through its muscle belly proximally (Fig. 67.17). Transect the biceps tendon and lacertus fibrosis at the level of the elbow.

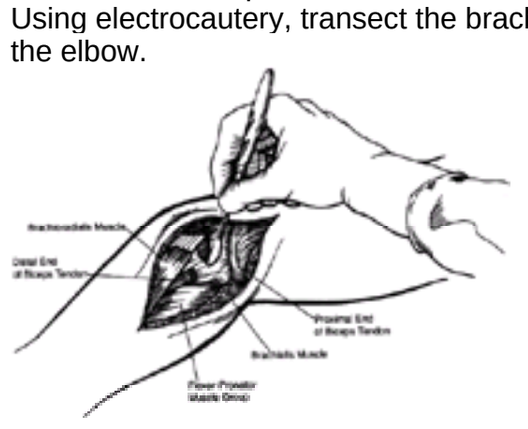

***Figure 67.17.*** Release of a nonfunctional elbow flexion contracture. The biceps tendon is transected. The brachioradialis muscle belly is divided proximally using electrocautery. The brachialis muscle is fractionally lengthened. (With persmission from from Keenan MA, Kozin SH, Berlet, AC. *Manual of Orthopaedic Surgery for Spasticity.* New York: Raven Press, 1993.)

- When the deformity is not severe, lengthen the brachialis muscle at its myotendinous junction by transecting the tendinous fibers on the anterior surface of the muscle, leaving the underlying muscle intact. Leave the remainder to counterbalance any pull by the triceps muscles.

- When the elbow flexion contracture is severe and has been present for many years, it may be necessary to completely transect the brachialis muscle.
- Avoid an anterior capsulectomy because of the associated increased stiffness and intra-articular adhesions postoperatively.
- If preoperative nerve conduction studies have shown an ulnar neuropathy at the level of the elbow, perform an anterior transposition of the ulnar nerve.
- Close the skin incision over a drain in routine manner. Approximately 50% correction of the deformity can be expected at surgery without causing excessive tension on the contracted neurovascular structures. Serial casting or drop out casts can be used to obtain further correction over the ensuing weeks (11,70,103,108,133).

### *Spastic Extension*

Spastic extension of the elbow is much less common than spastic flexion. These patients have frequently had a brain stem infarct or injury. They complain of difficulty reaching their face for activities of daily living.

**Triceps Lengthening** Experience with triceps lengthening for spasticity is limited because it is an uncommon problem. When needed, however, good results have been reported with surgical lengthening (187). A V-Y triceps plasty allows improved flexion range of motion, at the cost of decreased extension power and extensor lag. Use this procedure with caution in patients who rely on their arms to assist with ambulation or transfers because strength is lost with any lengthening procedure.

### *Ulnar Neuropathy*

Ulnar neuropathy occurs in stroke and brain-injured patients for a number of reasons. Prolonged elbow flexion with traction on the nerve can lead to decreased volume of the cubital tunnel, resulting in nerve compression. Support of the torso by leaning on a chronically flexed elbow may result in direct compression of the nerve. HO, particularly when it is in a posterior location, may involve the ulnar nerve causing a neuropathy. The patients are often limited in their ability to complain about ulnar nerve symptoms because of limited cognitive and communicative abilities. The diagnosis is usually suspected because of intrinsic atrophy, and it is confirmed using nerve conduction studies. A 2.5% incidence has been shown in patients with TBI at a large brain injury referral center (113,214).

Treatment is ulnar nerve transposition, often at the same time as elbow flexor lengthenings, flexor releases, or resection of HO. Subcutaneous transposition is preferred to avoid stimulation of HO formation.

## FOREARM

Supination and pronation deformities are commonly associated with elbow spasticity, wrist spasticity, or both. Pronation deformities are much more common. These deformities are most often treated together with the associated deformities. They seldom require treatment individually.

### *Spastic Pronation*

Pronation deformity of the forearm in an UMN lesion is more common than supination deformity. Pronation bias makes it difficult for a person to reach for a target underhand, whereas supination deformity impairs reaching for targets that require overhand reach. Many activities of daily living depend on active supination. The use of feeding and grooming utensils and clothes fasteners becomes problematic when spastic or contracted pronators restrict supination. Physical examination reveals a fully pronated resting position of the forearm. When passive supination range of motion exceeds active supination range, the possibility of pronator muscle dyssynergy during active supination should be suspected. Muscles that potentially contribute include pronator teres and pronator quadratus. Dynamic EMG studies of pronator teres, pronator quadratus, and biceps greatly augment clinical examination. Clinical examination does not easily predict which of the pronators might be retaining volitional capacity and which might be spastic. Both pronator muscles may show varying degrees of volition and spasticity. Interestingly, flexor spasticity of the powerful biceps often coexists with a pronated forearm deformity.

During the period of functional recovery, phenol or botulinum toxin may be injected into either or both pronators, depending on clinical and laboratory analyses. In the period of residual deficits, surgical lengthening of pronator teres and pronator quadratus may be performed depending on their individual voluntary capacities and the clinical goal is to improve active supination function by reducing pronator dyssynergy. The possibility of lengthening the pronator teres has long been recognized, but fractional lengthening of the pronator quadratus is of recent vintage. Release of the flexor-pronator origin was previously a common operation. We do not advocate this procedure because it does not target the individual muscles responsible for deformities. When an excessive amount of the pronator teres origin was released or when there was no function in the pronator quadratus muscle, an iatrogenic supination deformity occurred. The supination deformity was much less functional than a pronated forearm. When the pronators are contracted and not active volitionally, muscle releases may be considered, although passive functional advantages, other than cosmesis, may be difficult to come by.

#### Fractional Lengthening of the Forearm Pronators

- Approach the pronator teres in the interval between the mobile wad and the flexor carpi radialis in the midforearm. Take care to preserve the superficial radial nerve and radial artery that occupy this interval.
- Identify the pronator teres as it inserts on the radius. Perform myotendinous lengthening by cutting the tendinous fibers of the musculotendinous junction and allowing the tendon fibers to slide on the muscle belly, thereby lengthening the muscle tendon unit.
- When dynamic EMG has demonstrated that the pronator is spastic but does not have any volitional activity, release the pronator from its insertion on the radius. In either case, take care not to extend the dissection proximally into the supinator to avoid injury to the posterior interosseus nerve.
- Approach the pronator quadratus via an incision over the volar aspect of the forearm just proximal to the wrist crease.
- Retract the finger flexor tendons radially to expose the broad myotendinous junction of the pronator quadratus. Transect the tendon fibers, leaving the underlying muscle fibers intact. Then supinate the arm, separating the ends of the tendon fibers and lengthening the pronator quadratus (Fig. 67.18). When the pronator quadratus is contracted and does not have any functional capacity, transect to eliminate it as a deforming force.

***Figure 67.18.*** Intraoperative photograph showing pronator quadratus myotendinous lengthening. The arrow indicates the cut edge of the pronator quadratus tendon. (With permission from Hisey MS, Keenan MAE. Orthopaedic Management of Upper Extremity Dysfunction Following Stroke or Brain Injury. In Green DP, Hotchkiss RN, Pederson WC, eds. *Operative Hand Surgery,* 4th ed. New York: Churchill Livingstone, 1998:287.)

### *Spastic Supination*

Spastic supination is a far less common deformity but is also associated with elbow flexion deformities. Most often, this deformity is seen as a complication of the surgical flexor-pronator origin release. The biceps, supinator, or both may cause supination deformity. Physical examination supplemented by dynamic EMG may be used to determine the relative contribution of each.

Perform correction of the supination deformity in conjunction with correction of the elbow flexion deformity. As described previously, in the functional extremity, perform a biceps Z-lengthening. In a nonfunctional extremity, perform a distal biceps release. Often, at the conclusion of this procedure, the arm is able to achieve a functional range of pronation. If not, attention must be turned to the supinator.

- Lengthen the supinator by elevating the insertion from its radial insertion. Use a standard anterior approach to the elbow and proximal radius. An extension of the approach, as noted for the elbow release, is generally used.
- Approach the supinator in the plane between the brachialis and the brachioradialis.

- Ligate the radial recurrent artery to allow exposure of the supinator.
- The existing supination deformity facilitates exposure of the insertion of the supinator by pulling the posterior interosseus nerve laterally. Nevertheless, take extreme care must to visualize and preserve the nerve as it enters the arcade of Frohse.
- Incise the broad insertion of the supinator through the periosteum, exposing the shaft of the radius. Then elevate the supinator in a subperiosteal plane. Be careful to avoid excessive traction on the posterior interosseus nerve when elevating the supinator. Also, keep the dissection in the subperiosteal plane to avoid injury to the posterior interosseus nerve that comes in contact with the radius in 25% of patients. After elevating, the supinator, allow it slide. It will subsequently scar down in a lengthened position.
- Close the wound in routine fashion.

**WRIST**

A flexed wrist is common after TBI, but hyperextension deformity may also be seen. Patients complain of difficulty inserting their hand into shirts, jackets, and other narrow openings and they frequently have pain on passive motion. They may also have symptoms of carpal tunnel syndrome secondary to compression of the median nerve against the transverse carpal ligament by taut flexor tendons (170,214). In severe cases, wrist subluxation may be present. Radial or ulnar deviation and a clenched fist are often present as well.

***Spastic Flexion***

Muscles that potentially contribute to wrist flexion include the flexor carpi radialis (FCR), flexor carpi ulnaris (FCU), palmaris longus (PL), flexor digitorum sublimis (FDS), and flexor digitorum profundus (FDP). Singly or in combination, these muscles may have variable features of spasticity, contracture, and voluntary control. Because they have a larger cross-sectional area, wrist flexor muscles are generally stronger than their extensor counterparts. Despite a net balance of forces favoring flexion, the extent to which a patient may have voluntary control over wrist extensors should be investigated. Dynamic EMG studies and temporary diagnostic motor point blocks are helpful. When wrist hyperextension deformity is present, wrist extensors are typically volitional and spastic, wrist flexors are often poorly volitional and mildly spastic, and the fingers are tightly clenched into the palm.

Begin clinical examination by observing “resting” posture of the wrist. FCR, FCU, or both may bowstring across the wrist, and radial or ulnar deviation suggests their respective involvement. A clenched fist points to extrinsic finger flexors as having a role. If fingernails dig into the palm, FDP is likely to be involved. If the proximal interphalangeal (PIP) joint is markedly flexed but the distal interphalangeal (DIP) joint is not, involvement of FDS is likely.

Laboratory examination of the flexed wrist deformity includes recordings from FCR, FCU, ECR, ECU, FDS, and FDP. Kinesiologic study includes “isolated” muscle group testing along with whole limb movements such as reaching, grasping, and releasing objects. In addition, passive stretch of the wrist flexors and finger flexors provides an indication of spastic reactivity as seen electromyographically. Dynamic EMG findings are not easily predictable from clinical examination. Some patients show extensive activation of wrist extensors during extension and reaching efforts. Nevertheless, the wrist remains flexed because tension in the wrist flexors and finger flexors overbalances extensor forces. EMG activity in FCR is often present during attempts at wrist extension, and activity in FDS or FDP may be present. In patients with ulnar deviation, EMG activity is typically seen in FCU on reaching effort, but “isolated” testing also suggests that patients can often activate FCU voluntarily. Because EMG activity is not correlated with force production, diagnostic nerve blocks are often helpful in unmasking movement. Temporary chemical “weakening” of a dyssynergic wrist flexor may unmask strength in the wrist extensors sufficient to improve active wrist motion. A similar hypothesis can be used for the extrinsic finger flexors after dynamic EMG reveals whether the FDS or FDP is generating antagonistic activity acting to restrain wrist extension. Motor point block of the target muscle group or median or ulnar nerve blocks at the elbow may be performed to examine for active wrist extension during reach. Combined median and ulnar nerve blocks at or above the elbow also reveal the presence of muscle contracture.

When a patient has underlying voluntary control, surgical treatment for flexed and hyperextended wrists are myotendinous lengthenings. Selective muscle releases, wrist fusion, and proximal row carpectomy can be considered in the presence of severe deformities. Subtotal carpectomy combined with radio-carpal or radio-metacarpal fusion has been suggested for the treatment of severe flexion contracture either not amenable to, or refractory to, soft-tissue releases alone (185,189).

In patients with a severely contracted hand, a single-stage procedure consisting of superficialis-to-profundus transfer, wrist flexor release, FPL lengthening, wrist arthrodesis, carpal tunnel release, and ulnar motor branch neurectomy or intrinsic release can provide comprehensive correction. Such a definitive approach to severe deformities is associated with acceptable morbidity and eliminates the possibility of recurrence or undercorrection from untreated intrinsic pathology (189).

Spastic forearm flexor muscles causing wrist and finger flexion deformities are treated during the physiologic recovery phase by phenol motor point blocks (70,71 and 72). Because of the large sensory components of both the median ulnar nerves, perform motor point injections of the wrist and finger flexors using surface stimulation to localize the motor points. The blocks can be supplemented with functional electrical stimulation of the wrist and finger extensor muscles, and by casting or splinting techniques. Perform gentle passive range of motion of the wrist and fingers. When motor control is present, a program of active exercise and functional training is also employed. Electrical orthoses, which rely on functional electrical stimulation (FES), are available and have been shown to provide improvement in hand function in people with spinal cord injury or stroke. These devices are still in their early stages of development; however, technical advances in the field of FES provide hope for more widespread applicability in the future.

**Fractional Wrist Flexor Lengthening** In an extremity with documented volitional control, perform fractional lengthening of the appropriate wrist flexors. This is done in conjunction with lengthening of the extrinsic finger flexors, when indicated.

- Make a longitudinal incision on the volar surface of the forearm. Extend this incision distally if a carpal tunnel release is necessary. Divide the palmaris longus tendon if it is tight.
- Perform myotendinous lengthening by transecting the tendinous portion overlying the myotendinous junction (Fig. 67.19).

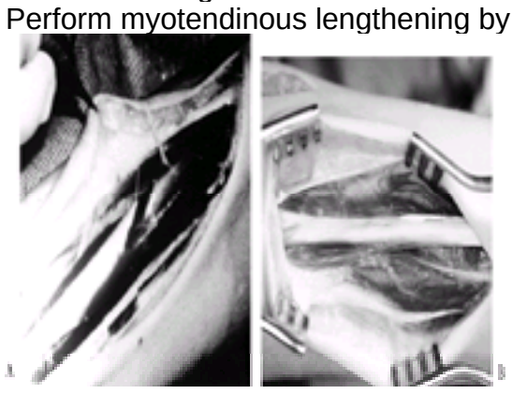

***Figure 67.19.*** Intraoperative photograph showing myotendinous lengthening of the flexor carpi radialis (**A**). At reoperation, intraoperative photograph of a different patient shows excellent healing of the myotendinous junction that had been lengthened 2 cm (**B**). (With permission from Hisey MS, Keenan MAE. Orthopaedic Management of Upper Extremity Dysfunction Following Stroke or Brain Injury. In Green DP, Hotchkiss RN, Pederson WC, eds. *Operative Hand Surgery,* 4th ed. New York: Churchill Livingstone, 1998:287.)

- Do not use immobilization after surgery. Begin a program of active exercise immediately. Don't allow passive stretching of the wrist for 3 weeks. Resistive exercises can be started 6 weeks after surgery.

**Wrist Flexor Release and Wrist Fusion** When wrist flexion deformities are severe and there is little or no function seen in the hand, perform a release of the wrist flexors. A proximal row carpectomy may be useful in patients with severe, long-standing contracture to correct the deformity. Then stabilize the wrist with a wrist fusion to eliminate the need for a wrist orthosis after surgery. Splints tend to be lost by these patients and their caretakers. Gravity alone can cause a recurrence of the flexion deformity. Unopposed wrist or finger extensor tone can result in a hyperextension deformity. Because the median nerve is compressed against the proximal transverse carpal ligament causing a painful neuropathy, perform a carpal tunnel release as well.

- Position the patient supine and apply an arm tourniquet.
- Make a volar forearm incision extending to the transverse carpal ligament.
- Identify and transect the tendons of the palmaris longus, flexor carpi radialis, and flexor carpi ulnaris. Take care to protect the radial and ulnar artery as well as the median, radial, and ulnar nerves.
- Perform carpal tunnel release.

- Close the volar incision in routine fashion.
- If wrist fusion is to be performed, supinate the forearm and make a longitudinal dorsal incision exposing the dorsal wrist joint. Remove Lister's tubercle.
- Perform capsulotomy of the radiocarpal, midcarpal, and third carpal-metacarpal joints.
- Using a high-speed burr, remove the articular cartilage and hard subchondral bone of the radiolunate, radioscaphoid, scaphocapitate, lunocapitate, and capitate-third metacarpal joints. Hyperflex the wrist to facilitate exposure.
- Position the wrist in 15° of extension, with the third metacarpal in line with the shaft of the radius. If this position is achieved only with excessive tension on the volar tissues, perform proximal row carpectomy.
- Graft the denuded surfaces with local autologous bone with or without allograft.
- Stabilize the wrist using a prebent titanium wrist fusion plate fixed distally to the third metacarpal with 2.7 mm screws and proximally to the radius with 3.5 mm screws (Fig. 67.20) (115,185,189).

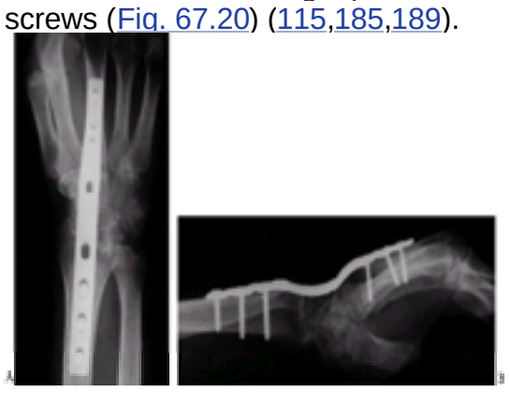

***Figure 67.20.*** Postoperative AP and lateral radiographs showing a dorsally placed wrist fusion plate. (With permission from Hisey MS, Keenan MAE. Orthopaedic Management of Upper Extremity Dysfunction Following Stroke or Brain Injury. In Green DP, Hotchkiss RN, Pederson WC, eds. *Operative Hand Surgery,* 4th ed. New York: Churchill Livingstone, 1998:287.)

- Close in a routine manner. Place the wrist in a well-padded splint or cast for 3 weeks. Remove the cast and sutures, and apply a splint for the following 3 weeks.

### *Spastic Extension*

Extension deformity of the wrist causes hygiene problems and may prevent release in patients with poor digital extension. Median nerve compression may also be caused by prolonged extension. If median nerve compression is diagnosed, perform carpal tunnel release.

#### Wrist Extensor Lengthening

- When volitional control has been demonstrated in the dyssynergic wrist extensors, perform myotendinous lengthening of the extensor carpi ulnaris through a short longitudinal incision on the ulnar border of the forearm. Identify the myotendinous junction and transect the tendinous portion, allowing the muscle to stretch.
- Identify the extensor carpi radialis longus and brevis in a separate longitudinal incision on the radial side of the forearm. Again, identify the myotendinous junction and cut the tendinous portion, allowing the muscle to lengthen.
- Close in routine fashion. Begin active motion immediately after surgery.

#### Wrist Extensor Release and Wrist Fusion

- When no volitional activity is seen in the wrist extensor muscle by clinical examination and dynamic EMG, perform tendon release with wrist fusion with or without proximal row carpectomy.
- Make a midline dorsal incision.
- Dissect medially, and laterally expose the distal extensor carpi radialis longus and brevis and the distal extensor carpi ulnaris. Transect these tendons proximal to their insertions.
- Perform wrist fusion with or without proximal row carpectomy, as described above.

## HAND

### *Functional Procedures versus Procedures for Hygiene*

Preoperative evaluation is performed to determine which extremities have sufficient volitional control of the muscles to allow surgical procedures aimed at restoring function to the hand. Often, severe deformities are present, but there is insufficient or no volitional activity in the muscles. In these cases, perform contracture releases to decrease pain, improve position and cosmesis of the hand, and to ease basic skin care and hygiene. The criterion for determining which procedures are most appropriate are summarized in Table 67.10.

| | *Functional* | *Nonfunctional* |
|---|---|---|
| Cognition | • Able to obey simple commands<br>• Able to cooperate with postoperative occupational therapy<br>• Able to retain what is taught from one session to another<br>• Able to assimilate newly taught activities into activities of daily living | • Does not obey commands<br>• Uncooperative with occupational therapy efforts<br>• No retention of information from one session to the next<br>• Unable to use what was taught in daily activities |
| Sensation | • Intact pain, light touch and temperature sensation<br>• Two-point discrimination less than 10 mm<br>• Kinesthetic awareness | • Absent pain, light touch or temperature sensation<br>• Two-point discrimination greater than 10 mm<br>• Unable to reproduce body positions |
| Spontaneous use of the Extremity | • Yes | • No |
| Motor Control | • Able to move affected extremity volitionally<br>• Palpable movement in involved extremity<br>• EMG shows volitional control during manual muscle testing (Class I, II, or III) (see Table 67.8) | • No volitional movement of extremity<br>• No movement palpable in involved extremity<br>• Continuous, stretch response or absent EMG activity during manual muscle testing (Class IV, V, or VI) |

[1] Criterion that may be used to determine whether an extremity is functional or non-functional. This may be used to select a treatment pathway.
Reference [185, 186].

***Table 67.10. Criterion For Functional vs. Nonfunctional Procedures****

### *Spastic Clenched Fist*

The spastic clenched fist deformity is common in brain injury or stroke involving the upper extremity. This pattern results from unmasking of the primitive grasp reflex. The fingers are typically clasped into the palm. Fingernails may dig into palmar skin, and access to the palm for washing may be compromised. When access is chronically restricted, skin maceration, breakdown, and malodor occurs. Patients may complain of pain when they or their caregivers attempt to pry the fingers open in order to gain palmar access. Some relaxation of finger tightness may occur if the wrist is positioned in extreme flexion. The deformity, however, is often accompanied by wrist flexion as well.

The degree of motor control may be masked by the severe amount of tone present in the finger flexors. First, establish passive range of motion. Following this, ask the patient to open and close the fingers and to flex and extend the wrist. If no active wrist or finger extension is seen, it is still important to assess whether there appears to be active control of finger flexion. In the continuum of neurologic impairment and recovery, control of wrist and finger flexion is seen before active control of extension. Place a finger in the patient's palm and ask the patient to grasp. Often, an increase in the pressure of grasp can be felt indicating underlying muscle control.

Next, perform an anesthetic block of the median nerve in the antecubital space to eliminate flexor tone temporarily. A block of the ulnar nerve in the cubital canal can supplement relaxation. With the flexor muscles relaxed, the activity of the extensor muscles can be more accurately evaluated. When extensor control returns, it is generally seen in the extensor indicis proprius muscle first (105,117,118,120).

Muscles that contribute to the clenched fist deformity include the FDS and FDP. If the PIP joints flex while the DIP joints remain extended, spasticity of FDS rather than FDP may be suspected. Dynamic EMG studies have shown that the flexor digitorum superficialis muscles exhibit a marked degree of spasticity, whereas the flexor digitorum profundus muscles are often normal or minimally spastic (105,117,118,120). Despite the marked increase in tone, it often has some underlying volitional control. The flexor profundus has less spasticity and better volitional control. Volitional control of the finger extensors is present in 50% of patients with spastic flexion deformities.

The intrinsics may be also be spastic along with the extrinsics, but an intrinsic plus posture (i.e. combined MCP flexion and PIP extension) is not seen because spastic extrinsic flexors dominate by flexing the PIP joints. Some degree of contracture of the extrinsics is typical of the chronically clenched fist. From the perspective of active functional potential, some degree of volitional control may also be present in either or both sets of extrinsic finger flexors. Spastic finger flexors may override and mask the patient's potential to extend the fingers. Sometimes, a patient presents with spasticity in just one or two muscle slips of either FDP or FDS. For example, we have seen a number of cases of index finger flexion traced to a spastic FDP muscle slip for that finger alone.

During the period of residual deficits and remediable function, a variety of orthopaedic options are available. When volitional control is demonstrated in the extrinsic flexor muscles by dynamic EMG, the fractional lengthening is indicated. In a hand with skin maceration and malodor from a clenched fist deformity in which no volitional movement is detected, more significant lengthening of the flexor tendons is required. In this situation, perform a superficialis-to-profundus (STP) tendon transfer.

**Fractional Lengthening of Extrinsic Finger Flexors in the Functional Hand**

- Make a longitudinal incision on the volar surface of the forearm, commonly at the same sitting with wrist flexor lengthenings (Fig. 67.19).
- Divide the palmaris longus tendon if it is tight. Perform the lengthening of the individual FDS and FDP tendons by sharply incising the tendon fibers as they overlie the muscle belly at the musculotendinous junction, allowing the tendon to slide distally.
- Lengthen the flexor pollicis longus tendon in an identical manner. This technique allows the tendons to lengthen with minimal scarring. By transecting the tendon over the muscle belly, no sutures are needed. This eliminates scarring from foreign body reaction to suture material. The underlying support and vascularity of the muscle provides an optimal environment for the tendons to heal and reconstitute themselves.
- Do not immobilize postoperatively. Begin the patient on a program of active and active assisted exercises on the first postoperative day. If the patient has significant pain or spasticity, a short volar splint can be used for comfort. Remove the splint for exercise. In patients with limited motor control, it is often useful to use the splint to position the wrist while the patient exercises the fingers. This immediate active motion allows the flexor tendons to continue to lengthen in the postoperative period as necessary.
- Ultimately, the amount of flexor lengthening is determined for each individual muscle by its underlying tone and control rather than by the surgeon's “educated guess” of tone while the patient is under anesthesia. By using this technique, we have had marked improvement in functional results when compared with our previous regimen of postoperative immobilization. In cases in which the motor control is very limited, extrinsic finger flexor lengthening can be combined with wrist fusion.

**Superficialis-to-profundus Tendon Transfer in the Nonfunctional Hand** In a hand with skin maceration and malodor from a clenched fist deformity in which no volitional movement is detected, more significant lengthening of the flexor tendons is required. In this situation, an STP tendon transfer is performed (21,30,114,115,189) (Fig. 21). This provides a more cosmetically pleasing hand position, aids in hygiene by getting the fingers out of the palms, and provides, at best, a mass action grasp pattern and at least a passive restraint to extension.

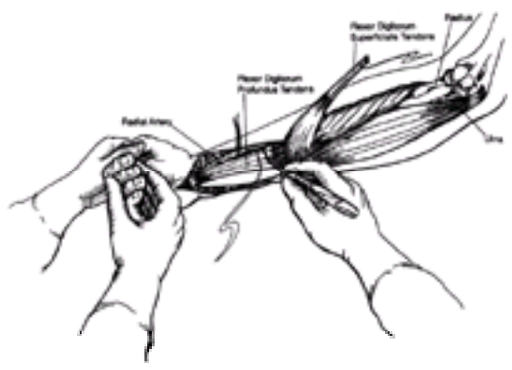

***Figure 67.21.*** Superficialis-to-profundus tendon transfer: The four superficialis tendons are sutured together distally and then transected for transfer. The profundus tendons are sutured together proximally and then cut. The fingers are extended, and the distal end of the superficialis tendons are then sutured en masse to the proximal end of the profundus tendons. (Reprinted with permission from Keenan MA, Kozin SH, Berlet, AC. *Manual of Orthopaedic Surgery for Spasticity.* New York: Raven Press, 1993.)

- Perform the STP tendon transfer through a longitudinal palmar incision that may be extended distally to allow release of the carpal tunnel and access to Guyon's canal.
- Identify and transect the palmaris longus tendon. Suture together the four superficialis tendons distally and then transect for the en masse transfer (21,114,115,189).
- Suture together the profundus tendons proximally and then cut. Extend the fingers and suture the distal end of the superficialis tendons en masse to the proximal end of the profundus tendons.

Several other surgical procedures are routinely performed in combination with the STP tendon transfer to treat the concurrent deformities. A neurectomy of the motor branch of the ulnar nerve is needed to prevent an intrinsic plus deformity from developing (21,114,115,122,189). If an intrinsic contracture is seen at the time of surgery following the STP lengthening, perform a release of the intrinsics.

- Use a carpal tunnel release to decompress the median nerve.
- To prevent a recurrent wrist flexion deformity from occurring secondary to passive wrist flexion, stabilize the wrist. Wrist extensor tenodesis has been attempted but often will stretch out with time.
- A cock-up wrist splint can be worn, but patient compliance is poor.
- A fusion of the wrist in 15° of extension provides the most reliable means of maintaining hand position and is now routinely performed. The surgical technique has been described earlier. A proximal release of the thenar muscles is often needed to correct a thumb-in-palm deformity (19,48,104,143,144,189,193,199,204,220).
- Because the STP transfer and wrist fusion are extensive surgery, we prefer to perform the thenar slide procedure at a later time, if it is indicated.
- Postoperatively, immobilize the wrist for three weeks in a short arm splint that includes the fingers and thumb. Hold the wrist in 15° of extension and immobilize the fingers with the metacarpophalangeal joints in 60° of flexion and the interphalangeal joints extended. Begin gentle range of motion of the metacarpophalangeal joints after cast removal. Use a volar wrist splint until the wrist fusion is healed.

***Spastic Thumb-in-palm Deformity***

The thumb-in-palm deformity is heterogeneous in appearance and may be secondary to spasticity of multiple muscles including the flexor pollicis longus muscle and the median and ulnar innervated thenar muscles (19,48,96,104,143,144,189,193,199,204,220). The thumb is held within the palm, the DIP joint of the thumb is commonly flexed, and the thumb is unable to function during key grasp or in three-jaw chuck grasp (i.e., in opposition to the pads of the index and third fingers). In addition, skin maceration and breakdown can occur if proper hygiene is prevented.

Clinically, spasticity of the flexor pollicis longus is indicated by flexion of the interphalangeal joint. Some patients may be able to extend the thumb if the wrist is flexed, suggesting that a spastic flexor pollicis longus (FPL) may be impeding active thumb extension when the wrist is more extended and FPL is tighter. The thumb-in-palm deformity may result from spastic activity in FPL, adductor pollicis (AP), or the thenar muscles, particularly flexor pollicis brevis. Adduction of the thumb metacarpal indicates spasticity of the AP muscle and possibly the first dorsal interosseous muscle. A quick stretch of the thumb into abduction often elicits a clonic response. An anesthetic block of the ulnar nerve in Guyon's canal at the wrist temporarily eliminates intrinsic tone. This will demonstrate the presence of any myostatic contractures and will also confirm that the AP was an offending muscle in the deformity. Contracture of the skin of the web space and interphalangeal joint contracture of the thumb may also develop over time. If some volitional potential in thumb extensors or thumb abductors is present, lengthening of the spastic FPL and AP will facilitate key

grasp. Dynamic EMG and lidocaine blocks are helpful to elucidate the specifics of motor control.

In the period of residual deficits and remediable function, orthopaedic treatment consists of fractional lengthening of the FPL at the myotendinous junction combined with a thenar muscle slide, in which the origins of the thenar muscles are detached from the transverse palmar ligament while preserving the neurovascular pedicle. Fractional lengthening of the FPL at the myotendinous junction will improve thumb extension. This is generally performed in conjunction with wrist or digital flexor lengthening. In order to provide a functional lateral pinch, it is desirable to stabilize the interphalangeal joint of the thumb. This may be done using a Moberg screw or a Herbert screw (Fig. 67.22).

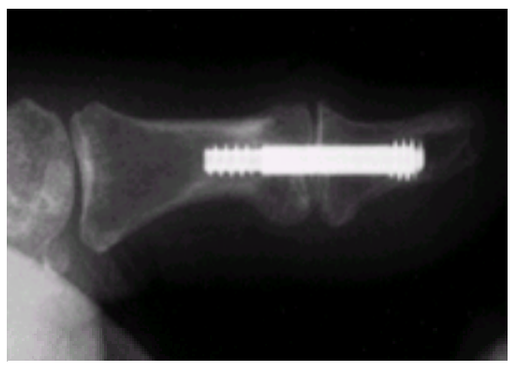

***Figure 67.22.*** Radiograph showing a Herbert screw that has been placed across the thumb interphalangeal (IP) joint in a thumb IP fusion. (With permission from Hisey MS, Keenan MAE. Orthopaedic Management of Upper Extremity Dysfunction Following Stroke or Brain Injury. In Green DP, Hotchkiss RN, Pederson WC, eds. *Operative Hand Surgery,* 4th ed. New York: Churchill Livingstone, 1998:287.)

- Make a stab incision on the tip of the thumb pulp, and under fluoroscopic guidance, pass the pilot hole for the through the tuft and shaft of the distal phalanx, across the joint, and into the proximal phalanx.
- Advance the screw through this hole, compressing the articular surfaces. In this patient group, we have not found it necessary to denude the interphalangeal joint surfaces.
- Protect the thumb in a thumb spica splint or cast for 3 weeks.

In those cases with a fixed adduction contracture, perform surgical lengthening of the thenar muscles (19,49,96,104,143,144,189,193,199,204,220). Generally, all of the thenar muscles are spastic or contracted, and a proximal myotomy is required to reposition the thumb and decrease the underlying tone in order to improve pinch function. Avoid distal releases because these often result in a hyperextension deformity of the metacarpophalangeal joint of the thumb (19).

A modified extensor pollicis longus (EPL) tendon rerouting procedure in combination with intrinsic muscle releases has been suggested for the treatment of severe deformities. In this method, the EPL tendon is transected proximal to Lister's tubercle. The distal stump is passed through the first compartment tunnel and is sutured to the proximal EPL stump. For mild deformities the EPL, rerouting may be performed alone (193).

**Thenar Muscle Slide**

- Under tourniquet control, make an incision along the thenar crease on the palm.
- Protect the neurovascular structures and flexor tendons ulnarly (Fig. 67.23).

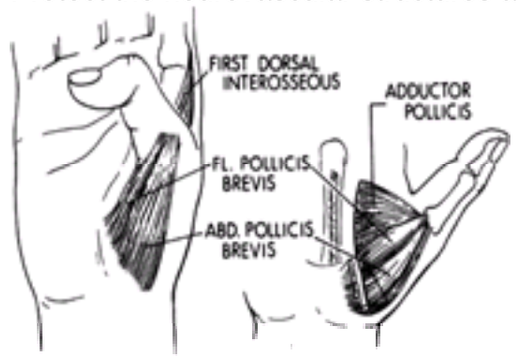


***Figure 67.23.*** Proximal myotomy of the thenar muscles used to correct a spastic thumb-in-palm deformity.

- Detach the origins of the flexor pollicis brevis, opponens pollicis, and AP muscles from their origins while protecting the recurrent branch of the median nerve.
- Preserve the transverse carpal ligament; do not enter the carpal canal.
- Extend the thumb, allowing the released muscles to slide radially and reattach in an improved position, thereby preserving function and preventing a hyperextension deformity.
- Release the origin of the AP muscle from the third metacarpal. Carefully dissect to retract the digital neurovascular bundles and flexor tendons to the index and long digits.
- Identify the deep palmar vascular arch and deep branch of the ulnar nerve as they penetrate the AP muscle between its oblique and transverse heads before adductor muscle release. Preserve the neurovascular supply of the adductor pollicis.
- If the first dorsal interosseous muscle is contracted, perform a release through a dorsal incision along the ulnar margin of the thumb metacarpal while protecting the radial sensory nerve. Release the origin of the first dorsal interosseus from its origin on the base of the first metacarpal.
- In persistent web space contractures despite appropriate muscle releases, perform a Z-plasty of the thumb web space.
- Postoperatively, immobilize the patient in a thumb spica splint for 3 weeks. Initiate active therapy a few days after surgery. The splint is removed for therapy but used at other times to position the thumb.

***Deformities from Intrinsic Spasticity***

When spasticity of the extrinsic flexors is present, intrinsic spasticity should be expected (15,21,25,28,29,103,104,105,106,107,108,114,115,117,121,122,125,126,133,136,145,146,189) However, intrinsic spasticity and contracture are frequently masked by the presence of extrinsic flexor spasticity or contracture. Extension of the fingers at the metacarpophalangeal joints may be blocked by spasticity of the interossei and lumbrical muscles of the hand. Another manifestation of intrinsic spasticity is the tendency to swan-neck or boutonnière positioning of the fingers. When a release or tendon lengthening of the spastic extrinsic flexor muscles has already been done, an intrinsic positive deformity of the hand is unmasked. These hand deformities can be painful and disfiguring. Such contractures often lead to maceration of the palmar skin and recurrent nail bed infections from poor hygiene.

The degree of tension caused by the intrinsic muscles can be demonstrated by comparing the amount of proximal interphalangeal joint flexion obtained with the metacarpophalangeal joints, both flexed and extended. If there is less proximal interphalangeal joint flexion with metacarpophalangeal joint extension, then the intrinsic tendons are tight. Perform this test both before and after a lidocaine block of the ulnar nerve at the wrist in order to distinguish between intrinsic tone and contracture.

Boutonnière deformities are commonly associated with intrinsic spasticity. They result from a combination of intrinsic spasticity combined with FDS tone. Swan-neck deformities may also result from increased intrinsic tone (Fig. 67.24). The central extensor band is relatively shortened relative to the lateral bands because of tension exerted by the intrinsics and long extensor. In both of these cases, take care to distinguish between deformities caused by the intrinsic spasticity that should improve with treatment and deformities resulting from the more usual mechanisms such as traumatic central slip injury with lateral band subluxation or traumatic mallet finger, because if not caused by spasticity the deformity will not improve with treatment for spasticity.

***Figure 67.24.*** Clinical photograph showing a patient with multiple swan-neck deformities following traumatic brain injury. (With permission from Hisey MS, Keenan MAE. Orthopaedic Management of Upper Extremity Dysfunction Following Stroke or Brain Injury. In Green DP, Hotchkiss RN, Pederson WC, eds. *Operative Hand Surgery,* 4th ed. New York: Churchill Livingstone, 1998:287.)

Because it is impossible to delineate fully the relative contributions and balance of spasticity and contracture of the intrinsic and extrinsic muscles by clinical assessment alone, we routinely obtain dynamic EMG studies of the intrinsic muscles before embarking on treatment of hand deformities. This is especially important before considering any surgical intervention.

In the period of residual deficits and remediable function, three treatment options are available. The procedure chosen is based on considerations of contracture and the presence or absence of volitional activity in the intrinsic muscles. When no significant intrinsic contracture is present and dynamic EMG indicates that there is no volitional control in the intrinsic muscles, perform a neurectomy of the motor branches of the ulnar nerve in the palm (Fig. 67.7). Leave the sensory branches intact to preserve protective sensation in the hand. When a contracture of the intrinsic muscles is present and the dynamic EMG study shows no volitional activity, perform a release of the lateral bands of the extensor hood mechanism at the level of the proximal phalanx (Fig. 67.25). In these cases, neurectomy of the motor branches of the ulnar nerve is performed simultaneously to prevent recurrence of the intrinsic plus deformity from spasticity of the interosseous muscles. When there is either a dynamic or static intrinsic plus deformity but the EMG demonstrates volitional control, release the interossei from their proximal origins on the metacarpals and allow to slide distally (207,208). A static deformity is one in which a myostatic contracture is present. A dynamic deformity is one in which the deformity results mostly from increased tone with little or no fixed contracture.

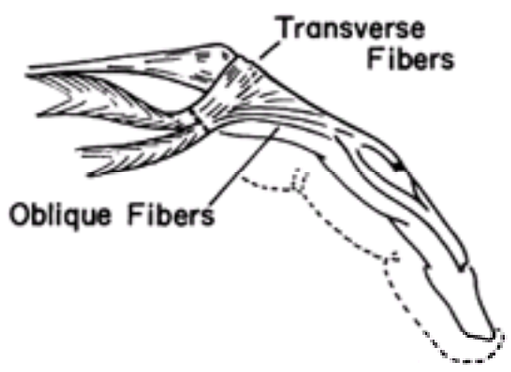


***Figure 67.25.*** Isolation and release of the intrinsic interossei and lumbricales muscles.

**Ulnar Motor Neurectomy** Make an incision on the palmar surface of the hand radial to the pisiform bone and extend distally for 1 inch.

- Be careful to prevent harm to the ulnar artery. Expose the ulnar nerve and identify the motor branches using a nerve stimulator. Generally, two motor branches are seen. The main motor branch lies beneath the sensory branch and a smaller motor branch can be seen entering the hypothenar muscles (Fig. 67.7) (115,122).
- After identifying these features, transect the nerves, taking care to preserve the ulnar artery and the sensory branch of the ulnar nerve (Fig. 67.7).
- Unless the procedure is combined with other surgery, no splinting or casting is necessary postoperatively. Apply a soft dressing to the hand and begin active and passive exercises on the first postoperative day.

**Lateral Band Intrinsic Release** In a hand in which a contracture of the intrinsic muscles is present and the dynamic EMG study shows no volitional activity, perform lateral band releases (Fig. 67.25).

- Make a midline longitudinal incision over the dorsum of the metacarpophalangeal joint and proximal phalanx of each finger. Dissect on both the ulnar and radial sides of the extensor mechanism.
- Identify the palmar edge of the lateral bands. Transect the lateral band and oblique fibers of the extensor hood on each side. Take care to preserve the transverse fibers of the sagittal extensor hood.
- Recurrent intrinsic plus deformities are common. This is thought to be secondary to residual attachment of the interossei muscles to the base of the proximal phalanges. To prevent recurrent deformities, perform a concomitant neurectomy of the motor branches of the ulnar nerve in Guyon's canal.

**Intrinsic Slide**

- In a hand with volitional control of the intrinsic musculature, perform intrinsic slides (207,208).
- Make two dorsal longitudinal incisions, one between the second and third and one between the fourth and fifth metacarpals.
- Preserve the extensor tendons while exposing the origins of the interossei on the shafts of the metacarpals. Elevate these origins from the metacarpals and extend the metacarpophalangeal joints while the interphalangeal joints are flexed, causing the intrinsics to be lengthened.
- Postoperatively, immobilize the hand in a bulky dressing for one week.
- The abductor digiti quinti muscle may contribute to a flexion deformity of the metacarpophalangeal joint of the fifth finger. The muscle can be fractionally lengthened by transecting the tendon within the muscle belly. This allows lengthening while preserving the function of the muscle.

***Intrinsic minus deformities***

A less common deformity pattern is the intrinsic minus hand. In these patients, the intrinsic muscles have normal or weakened tone, but there is spasticity of the extrinsic finger flexors. There may be increased tone in the extrinsic extensors as well. This pattern results in a claw hand posture, with hyperextension of the metacarpophalangeal joints and flexion of the proximal and distal interphalangeal joints. Ulnar neuropathy must be considered as a possible diagnosis. Hyperextension contracture of the metacarpophalangeal joint capsule is common. When it is present, the contractures require surgical release. Treatment of this deformity may also require lengthening of the extrinsic digital flexors or STP transfers, as described earlier.

Release of the dorsal capsule of the metacarpophalangeal joints from the metacarpal is often needed. Zancoli capsulodesis may also be required to restore metacarpophalangeal flexion and place the hand in a more functional and cosmetic position (220,248). Postoperatively, splint the hand with the metacarpalphalgeal joints flexed 70° for 3 weeks.

**CHAPTER REFERENCES**

Each reference is categorized according to the following scheme: *, classic article; #, review article; !, basic research article; and +, clinical results/outcome study.

# 1. Albright AL. Neurosurgical Treatment of Spasticity: Selective Posterior Rhizotomy and Intrathecal Baclofen. *Stereotact Funct Neurosurg* 1992;58:3.

+ 2. Albright AL, Barron WB, Fasick MP, et al. Continuous Intrathecal Baclofen Infusion for Spasticity of Cerebral Origin. *JAMA* 1993;270:2475.

# 3. Anmuth C, Esquenazi A, Keenan MAE. Lower Extremity Surgery for the Spastic Patient. In: Katz R, ed. *Spasticity,* Vol. 8. Philadelphia: Hanley & Belfus, 1994:547.

# 4. Ayers DC, Pellegrini VD, Evarts CM. Prevention of Heterotopic Ossification in High-risk Patients by Radiation Therapy. *Clin Orthop* 1991;263:87.

! 5. Bauman JU, Sutherland DH, Hanggi A. Intramuscular Pressure During Walking: An Experimental Study Using the Wick Catheter Technique. *Clin Orthop* 1979;145:292.

+ 6. Beck ER, Bell KR. Deep Venous Thrombosis in the Spastic Upper Limb. *Brain Inj* 1995;9:413.

# 7. Bell KR, Massagli TL. Subacute Brain Injury Rehabilitation: An Opportunity for Medical Education and Training. *Brain Inj* 1996;10:875.

! 8. Bidner SM, Rubins IM, Desjardins JV, et al. Evidence for a humoral mechanism for enhanced osteogenesis after head injury. *J Bone Joint Surg [Am]* 1990;72:1144.

# 9. Bigliani LU, Craig EV, Butters KP. Fractures of the Shoulder. In: Rockwood CA, Green DP, Bucholz RW, eds. *Fractures in Adults*, Vol. 1. New York: J.B. Lippincott, 1991:871.

+ 10. Bloch R, Bayer N. Prognosis in Stroke. *Clin Orthop* 1978;131:10.

+ 11. Booth BJ, Doyle M, Montgomery J. Serial Casting for the Management of Spasticity in the Head Injured Adult. *Phys Ther* 1983;63:1960

# 12. Bontke CF, Cobble ND. Rehabilitation in Brain Disorders. Clinical Manifestations and Medical Issues. *Arch Phys Med Rehabil* 1991;72:S320.

# 13. Botte MJ, Abrams RA, Bodine-Fowler SC. Treatment of Acquired Muscle Spasticity Using Phenol Peripheral Nerve Blocks. *Orthopaedics* 1995;18:151.

# 14. Botte MJ, Abrams RA, Keenan MAE, Mooney V. Limb Rehabilitation in Stroke Patients. *The Journal of Musculoskeletal Medicine* 1992;9:66.

# 15. Botte MJ, Keenan MA. Reconstructive Surgery of the Upper Extremity in the Patient with Head Trauma. *J Head Trauma Rehabil* 1987; 2:34-45.

+ 16. Botte MJ, Keenan MA. Percutaneous Phenol Blocks of the Pectoralis Major Muscle to Treat Spastic Deformities. *J Hand Surg [Am]* 1988;13:147.

# 17. Botte MJ, Keenan MAE. Brain Injury and Stroke. In: Gelberman RH, ed. *Operative Nerve Repair and Reconstruction.* Philadelphia: J.B. Lippincott Publishers, 1991:1413.

# 18. Botte MJ, Keenan MA, Abrams RA, et al. Heterotopic Ossification in Neuromuscular Disorders. *Orthopaedics* 1997;20:335; quiz 342.

+ 19. Botte MJ, Keenan MA, Gellman H, et al. Surgical Management of Spastic Thumb-in-palm Deformity in Adults with Brain Injury. *J Hand Surg [Am]* 1989;14:174.

# 20. Botte MJ, Keenan MAE, Jordan C. Stroke. In: Nickel VL, Botte MJ, eds. *Orthopaedic Rehabilitation.* New York: Churchill Livingstone, 1992:337.

+ 21. Botte MJ, Keenan MA, Korchek JI, Waters RL. Modified Technique for the Superficialis-to-profundus Transfer in the Treatment of Adults with Spastic Clenched Fist Deformity. *J Hand Surg [Am]* 1987;12:639.

# 22. Botte MJ, Moore TJ. The Orthopaedic Management of Extremity Injuries in Head Trauma. *J Head Trauma Rehabil* 1987;2:13.

+ 23. Botte MJ, Nickel VL, Akeson WH. Spasticity and Contracture. *Clin Orthop* 1988;233:7.

# 24. Botte MJ, Waters RL, Keenan MAE, et al. Orthopaedic Management of the Stroke Patient: Part I: Pathophysiology, Limb Deformity, and Patient Evaluation. *Orthop Rev* 1988;27:637.

# 25. Botte MJ, Waters RL, Keenan MAE, et al. Orthopaedic Mangement of the Stroke Patient: Part II: Treating Deformities of the Upper and Lower Extremities. *Orthop Rev* 1988;27:891.

! 26. Bowman BR, Baker LL, Waters RL. Positional Feedback and Electrical Stimulation: An Automated Treatment for the Hemiplegic Wrist. *Arch Phys Med Rehabil* 1979;60:497.

# 27. Braun RM, Gellman H. Stroke and Brain Injury. In: Green DP, ed. *Operative Hand Surgery*, Vol. 1. New York: Churchill Livingstone, 1993:225.

+ 28. Braun RM, Hoffer MM, Mooney V, et al. Phenol Nerve Block in the Treatment of Acquired Spastic Hemiplegia in the Upper Limb. *J Bone Joint Surg [Am]* 1973;55:580.

* 29. Braun RM, Mooney V, Nickel VL. Flexor-Origin Release for Pronation-Flexion Deformity of the Forearm and Hand in the Stroke Patient. *J Bone Joint Surg [Am]* 1970;52:907.

* 30. Braun RM, Vise GT. Sublimis-to-Profundus Tendon Transfers in the Hemiplegic Upper Extremity. *J Bone Joint Surg [Am]* 1973;55:873.

+ 31. Braun RM, West F, Mooney V, et al. Surgical Treatment of the Painful Shoulder Contracture in the Stroke Patient. *J Bone Joint Surg [Am]* 1971;53:1307.

# 32. Caldwell C, Braun RM. Spasticity in the Upper Extremity. *Clin Orthop* 1974;104:80.

# 33. Caldwell CB, Wilson DJ, Braun RM. Evaluation and Treatment of the Upper Extremity in the Hemiplegic Stroke Patient. *Clin Orthop* 1969;104:63.

! 34. Carey JR. Manual Stretch: Effect on Finger Movement Control and Force Control in Stroke Subjects with Spastic Extrinsic Finger Flexor Muscles. *Arch Phys Med Rehabil* 1990;71:888.

+ 35. Charnley G, Judet T, de Loubresse CG, Piriou P. Articulated Radial Head Replacement and Elbow Release for Post Head-injury Heterotopic Ossification. *J Orthop Trauma* 1996;10:68.

+ 36. Charnley G, Judet T, Garreau de Loubresse TC, Mollaret O. Excision of Heterotopic Ossification Around the Knee Following Brain Injury. *Injury* 1996;27:125.

+ 37. Childers MK, Stacy M, Cooke DL, Stonnington HH. Comaparison of Two Injection Techniques Using Botulinum Toxin in Spastic Hemiplegia. *Am J Phys Med Rehabil* 1996;75:462.

+ 38. Chua HC, Tan CB, Tjia H. A Case of Bilateral Ulnar Nerve Palsy in a Patient with Traumatic Brain Injury and Heterotopic Ossification. *Singapore Med J* 1997;38:447.

+ 39. Cifu DX, Kreutzer JS, Marwitz JH, et al. Functional Outcomes of Older Adults with Traumatic Brain Injury: A Prospective, Multicenter Analysis. *Arch Phys Med Rehabil* 1996;77:883.

+ 40. Citta-Pietrolungo TJ, Alexander MA, Steg NL. Early Detection of Heterotopic Ossification in Young Patients with Traumatic Brain Injury. *Arch Phys Med Rehabil* 1992;73:258.

# 41. Clifford B, Waters RL, Jordan C. Stroke: The Challenge. In: Sculco TP, ed. *Orthopaedic Care of the Geriatric Patient.* St Louis: C. V. Mosby, 1985.

# 42. Cope DN. The Effectiveness of Traumatic Brain Injury Rehabilitation: A Review. *Brain Inj* 1995;9:649.

* 43. Cohen RB, Hahn GV, Tabas JA, et al. The Natural History of Heterotopic Ossification in Patients Who Have Fibrodysplasia Ossificans Progressiva. A Study of Forty-four Patients. J Bone Joint Surg Am 1993;75:215.

# 44. Copp EP, Keenan J. Phenol Nerve and Motor point Block in Spasticity. *Rheumatol Phys Med* 1972;11:287.

+ 45. Cosgrove JL, Vargo M, Reidy ME. A Prospective Study of Peripheral Nerve Lesions Occurring in Traumatic Brain-injured Patients [see comments]. *Am J Phys Med Rehabil* 1989;68:15.

# 46. Craig CL, Zimbler S. Orthopedic Procedures. In: Glenn MB, Whyte J, eds. *The Practical Management of Spasticity in Children and Adults.* Philadelphia: Lea & Febiger, 1990:289.

+ 47. Cullen JP, Pellegrini VD Jr, Miller RJ, Jones JA. Treatment of Traumatic Radioulnar Synostosis by Excision and Postoperative Low-dose Irradiation. *J Hand Surg [Am]* 1994;19:394.

+ 48. Dahlin LB, Komoto-Tufvesson Y, Salgeback S. Surgery of the Spastic Hand in Cerebral Palsy. Improvement in Stereognosis and Hand Function after Surgery. *J Hand Surg [Br]* 1998;23:334.

+ 49. Decq P, Filipetti P, Feve A, et al. Peripheral Selective Neurotomy of the Brachial Plexus Collateral Branches for Treatment of the Spastic Shoulder: Anatomical Study and Clinical Results in Five Patients. *J Neurosurg* 1997;86:648.

+ 50. Dengler R, Neyer U, Wohlfarth K, et al. Local Botulinum Toxin in the Treatment of Spastic Drop Foot.*J Neurol* 1992;239:375.

! 51. De Quervain IA, Simon SR, Leurgans S, et al. Gait Pattern in the Early Recovery Period after Stroke. *J Bone and Joint Surg (Am)* 1996;64-A:1506.

! 52. Dickstein R, Heffes Y, Abulaffio N. Electromyographic and Positional Changes in the Elbows of Spastic Hemiparetic Patients During Walking. *Electroencephalogr Clin Neurophysiol* 1996;101:491.

! 53. Dimitrijevic MM, Stokic DS, Wawro AW, Wun CC. Modification of Motor Control of Wrist Extension by Mesh-glove Electrical Afferent Stimulation in Stroke Patients. *Arch Phys Med Rehabil* 1996;77:252.

+ 54. Djurickovic S, Meek RN, Snelling CF, et al. Range of Motion and Complications After Postburn Heterotopic Bone Excision about the Elbow. *J Trauma* 1996;41:825.

+ 55. Dombovy ML, Olek AC. Recovery and Rehabilitation Following Traumatic Brain Injury. *Brain Inj* 1997;11:305.

+ 56. Eames P, Cotterill G, Kneale TA, et al. Outcome of Intensive Rehabilitation after Severe Brain Injury: A Long-term Follow-up Study. *Brain Inj* 1996;10:631.

# 57. Enderson BL, Maull KI. Missed Injuries. The Trauma Surgeon's Nemesis. *Surg Clin North Am* 1991;71:399.

# 58. Esquenazi A, Keenan MA, Mayer N. Evaluacion y Manejo de Espasticidad, Contracturas y Disfuncion del Control Motor. *Kinesiologia* 1995;42:60.

+ 59. Fitzsimmons AS, O'Dell MW, Guiffra LJ, Sandel ME. Radial Nerve Injury Associated with Traumatic Myositis Ossificans in a Brain Injured Patient. *Arch Phys Med Rehabil* 1993;74:770.

+ 60. Frischhut B, Stockhammer G, Saltuari L, et al. Early Removal of Periarticular Ossifications in Patients with Head Injury. *Acta Neurol (Napoli)* 1993;15:114.

# 61. Garland DE. Clinical Observations on Fractures and Heterotopic Ossification in the Spinal Cord and Traumatic Brain Injured Populations. *Clin Orthop* 1988;233:86.

# 62. Garland DE. A Clinical Perspective on Common Forms of Acquired Heterotopic Ossification. *Clin Orthop* 1991;263:13.

# 63. Garland DE. Surgical Approaches for Resection of Heterotopic Ossification in Traumatic Brain-injured Adults. *Clin Orthop* 1991;263:59.

! 64. Garland DE, Alday B, Venos KG. Heterotopic Ossification and HLA Antigens. *Arch Phys Med Rehabil* 1984;65:531.

+ 65. Garland DE, Bailey S. Undetected Injuries in Head-injured Adults. *Clin Orthop* 1981;155:162.

* 66. Garland DE, Blum CE, Waters RL. Periarticular Heterotopic Ossification in Head-injured Adults. Incidence and Location. *J Bone Joint Surg [Am]* 1980;62:1143.

+ 67. Garland DE, Capen D, Waters RL. Surgical Morbidity in Patients with Neurologic Dysfunction. *Clin Orthop* 1979;145:189.

+ 68. Garland DE, Dowling V. Forearm Fractures in the Head-Injured Adult. *Clin Orthop* 1983;176:190.

* 69. Garland DE, Hanscom DA, Keenan MA, et al. Resection of Heterotopic Ossification in the Adult with Head Trauma. *J Bone Joint Surg [Am]* 1985;67:1261.

# 70. Garland DE, Keenan MA. Orthopedic Strategies in the Management of the Adult Head-injured Patient. *Phys Ther* 1983;63:2004.

+ 71. Garland DE, Lilling M, Keenan MA. Percutaneous Phenol Blocks to Motor Points of Spastic Forearm Muscles in Head-injured Adults. *Arch Phys Med Rehabil* 1984;65:243.

# 72. Garland DE, Lucie RS, Waters RL. Current Uses of Open Phenol Nerve Block for Adult Acquired Spasticity. *Clin Orthop* 1982;165:217.

+ 73. Garland DE, O'Hollaren RM. Fractures and Dislocations about the Elbow in the Head-Injured Adult. *Clin Orthop* 1982;168:38.

+ 74. Garland DE, Razza BE, Waters RL. Forceful Joint Manipulation in Head-injured Adults with Heterotopic Ossification. *Clin Orthop* 1982;169;133.

# 75. Garland DE, Rhoades ME. Orthopedic Management of Brain-Injured Adults. *Clin Orthop* 1978;131:111.

+ 76. Garland DE, Rothi B, Waters RL. Femoral Fractures in Head-injuries Adults. *Clin Orthop* 1982;166:219.

# 77. Garland DE, Waters RL. Orthopedic Evaluation in Hemiplegic Stroke. *Orthop Clin North Am* 1978;9:291.

# 78. Garland DE, Waters RL. Extremity Fractures in Head Injured Adults. In: MH M, ed. *The Multiply Injured Patient with Complex Fractures.* Philadelphia: Lea & Febiger, 1984:134.

+ 79. Garraway WM, Whisnant JP, Kurland LT, O'Fallon WM. Changing Patterns of Cerebral Infarction: 1945-1974. *Stroke* 1979;10:657.

+ 80. Garraway WM, Whisnant JP, Drury I. The Changing Pattern of Survival Following Stroke. *Stroke* 1983;14:699.

# 81. Gellman H, Keenan MA, Botte MJ. Recognition and Management of Upper Extremity Pain Syndromes in the Patient with Brain Injury. *J Head Trauma Rehabil* 1996;11:23.

# 82. Gellman H, Keenan MA, Stone L, et al. Reflex Sympathetic Dystrophy in Brain-injured Patients. *Pain* 1992;51:307.

# 83. Gennarelli TA. Heterotopic ossification. Brain Inj 1988; 2:175.

# 84. Gennarelli TA. Mechanisms of Brain Injury. *J Emerg Med* 1993;11 (Suppl 1):5.

# 85. Goldstein B, Hammond M. Physical Medicine and Rehabilitation. *JAMA* 1997;277:1891.

# 86. Goodman TA, Merkel PA, Perlmutter G, et al. Heterotopic Ossification in the Setting of Neuromuscular Blockade [See Comments]. *Arthritis Rheum* 1997;40:1619.

# 87. Green DP, Rowland SA. Fractures and Dislocations in the Hand. In: Rockwood CA, Green DP, Bucholz RW, eds. *Fractures in Adults*, Vol. 1. New York: J.B. Lippincott, 1991:441.

+ 88. Hagen C, Malkmus D, Durham P, Bowman. Levels of Cognitive Functioning. Rehabilitation of the Brain Injured Adult: Comprehensive Physical Management. Downey, CA: Professional Staff Association of Rancho Los Amigos Hospital, 1979:87.

# 89. Harrison CL, Dijkers M. Traumatic Brain Injury Registries in the United States: An Overview. *Brain Inj* 1992;6:203.

# 90. Harryman DT, II: Shoulders: Frozen and Stiff. *Instr Course Lect* 1993;42:247.

+ 91. Haselkorn JK, Mueller BA, Rivara FA. Characteristics of Drivers and Driving Record after Traumatic and Nontraumatic Brain Injury. *Arch Phys Med Rehabil* 1998;79:738.

+ 92. Hawkins ML, Lewis FD, Medeiros RS. Serious Traumatic Brain Injury: An Evaluation of Functional Outcomes. *J Trauma* 1996;41:257; discussion 263.

+ 93. Hendricks HT, Hageman G, van Limbeek J. Prediction of Recovery from Upper Extremity Paralysis after Stroke by Measuring Evoked Potentials. *Scand J Rehabil Med* 1997;29:155.

+ 94. Hillier SL, Metzer J. Awareness and Perceptions of Outcomes after Traumatic Brain Injury. *Brain Inj* 1997;11:525.

+ 95. Hillier SL, Sharpe MH, Metzer J. Outcomes 5 Years Post-traumatic Brain Injury (with Further Reference to Neurophysical Impairment and Disability). *Brain Inj* 1997;11:661.

+ 96. House JH, Gwathmey FW, Fidler MO-B. A Dynamic Approach to the Thumb-in-palm Deformity in Cerebral palsy. *J Bone Joint Surg [Am]* 1981;63:216.

+ 97. Hummelsheim H, Maier-Loth ML, Eickhof C. The Functional Value of Electrical Muscle Stimulation for the Rehabilitation of the Hand in Stroke Patients. *Scand J Rehabil Med* 1997;29:3.

# 98. Hurvitz EA, Mandac BR, Davidoff G, et al. Risk Factors for Heterotopic Ossification in Children and Adolescents with Severe Traumatic Brain Injury. *Arch Phys Med Rehabil* 1992;73:459.

* 99. Jennett B, Teasdale G, Galbraith S. Severe Head Injuries in Three Countries. *J Neurol Neurosurg Psychiatry* 1977;40:291.

* 100. Jennett B, Teasdale G, Braakman R, et al. Prognosis of Patients with Severe Head Injury. *Neurosurgery* 1979;4:283.

# 101. Jordan C. Current Status of Functional Lower Extremity Surgery in Adult Spastic Patients. *Clin Orthop* 1988;233:102.

+ 102. Katz J, Knott LW, Feldman DJ. Peripheral Nerve Injections with Phenol in Management of Spastic Patients. *Arch Phys Med Rehabil* 1967;48:97.

# 103. Keenan MA. The Orthopaedic Management of the Spasticity. *J Head Trauma Rehabil* 1987;2:62.

# 104. Keenan MA. Management of the Spastic Upper Extremity in the Neurologically Impaired Adult. *Clin Orthop* 1988;233:116.

# 105. Keenan MA. Surgical Decision Making for Residual Limb Deformities Following Traumatic Brain Injury. *Orthop Rev* 1988;17:1185.

* 106. Keenan MA, Abrams RA, Garland DE, Waters RL. Results of Fractional Lengthening of the Finger Flexors in Adults with Upper Extremity Spasticity. *J Hand Surg [Am]* 1987;12:575.

+ 107. Keenan MA, Botte MJ. Technique of Percutaneous Phenol Block of the Recurrent Motor Branch of the Median Nerve. *J Hand Surg [Am]* 1987;12:806.

# 108. Keenan MAE, Botte MJ. Traumatic Brain Injury. In: Nickel VL, Botte MJ, eds. *Orthopaedic Rehabilitation.* New York: Churchill Livingstone Publishers, 1992:361.

# 109. Keenan MA, Botte MJ, Hsu J, et al. Symposium: Orthopaedic Management of Patients with Traumatic Brain Injuries. *Contemp Orthop* 1993;27:357.

+ 110. Keenan MA, Creighton J, Garland DE, Moore T. Surgical Correction of Spastic Equinovarus Deformity in the Adult Head Trauma Patient. *Foot Ankle* 1984;5:35.

! 111. Keenan MA, Haider T. The Formation of Heterotopic Ossification after Traumatic Brain Injury: A Biopsy Study with Ultrastructural Analysis. *J Head Trauma Rehabil* 1996;11:8.

! 112. Keenan MA, Haider TT, Stone LR. Dynamic Electromyography to Assess Elbow Spasticity. *J Hand Surg [Am]* 1990;15:607.

* 113. Keenan MA, Kauffman DL, Garland DE, Smith C. Late Ulnar Neuropathy in the Brain-injured Adult. *J Hand Surg [Am]* 1988;13:120.

* 114. Keenan MA, Korchek JI, Botte MJ, et al. Results of Transfer of the Flexor Digitorum Superficialis Tendons to the Flexor Digitorum Profundus Tendons in Adults with Acquired Spasticity of the Hand. *J Bone Joint Surg [Am]* 1987;69:1127.

# 115. Keenan MAE, Kozin SH, Berlet AC. *Manual of Orthopaedic Surgery for Spasticity.* New York: Raven Press, 1993.

* 116. Keenan MA, Ahern R, Lazarus M., Perry J. Selective Release of Spastic Elbow Flexors in the Patient with Brain Injury. *J Head Trauma Rehabil* 1996;11:57.

# 117. Keenan MAE, Perry J. Evaluation of Upper Extremity Motor Control in Spastic Brain-injured Patients Using Dynamic Electromyography. *J Head Trauma Rehabil* 1990;5:13.

# 118. Keenan MAE, Perry J. Motion Analysis: Upper Extremity. In: Nickel VL, Botte MJ, eds. Orthopaedic Rehabilitation: Churchill Livingstone Publishers, 1992;243:2556.

* 119. Keenan MA, Perry J, Jordan C. Factors Affecting Balance and Ambulation Following Stroke. *Clin Orthop* 1984;165:71.

* 120. Keenan MA, Romanelli RR, Lunsford BR. The Use of Dynamic Electromyography to Evaluate Motor Control in the Hands of Adults Who Have Spasticity Caused by Brain Injury. J Bone Joint Surg [Am] 1989;71:120.

# 121. Keenan MA. Stroke. In: Kasser JR, ed. *Orthopaedic Knowledge Update 5.* Rosemont, IL: American Academy of Orthopaedic Surgeons, 1996;5:689.

+ 122. Keenan MA, Todderud EP, Henderson R, Botte M. Management of Intrinsic Spasticity in the Hand with Phenol Injection or Neurectomy of the Motor Branch of the Ulnar Nerve. *J Hand Surg [Am]* 1987;12:734.

+ 123. Keenan MA, Tomas ES, Stone L, Gersten LM. Percutaneous Phenol Block of the Musculocutaneous Nerve to Control Elbow Flexor Spasticity. *J Hand Surg [Am]* 1990;15:340.

+ 124. Keenan MA, Ure K, Smith CW, Jordan C. Hamstring Release for Knee Flexion Contracture in Spastic Adults. *Clin Orthop* 1988;236:221.

# 125. Keenan MAE, Waters RL. Surgical Treatment of the Lower Extremity After Stroke. In: Chapman M, ed. *Operative Orthopaedics.* Philadelphia:J.B. Lippincott Publishers, 1993:3449.

# 126. Keenan MA, Waters RL. Surgical Treatment of the Upper Extremity After Stroke or Brain Injury. In: Chapman M, ed. *Operative Orthopaedics.* Philadelphia: J.B, Lippincott Publishers, 1993:1529.

# 127. Keenan MA, Waters RL. Heterotopic Ossification. In: Skinner HB, ed. Diagnosis and Treatment in Orthopaedics. New Jersey: Prentice Hall, 1995:604.

+ 128. Kerrigan DC, Annaswamy TM. The Functional Significance of Spasticity as Assessed by Gait Analysis. *J Head Trauma Rehabil* 1997;12:29.

# 129. Khalili AA, Betts HB. Peripheral Nerve Block with Phenol in the Management of Spasticity. *JAMA* 1967;200:1155.

# 130. Khalili AA, Harmel MH, Forster S, Benton JG. Management of Spasticity by Selective Peripheral Nerve Block with Dilute Phenol Solutions in Clinical Rehabilitation. *Arch Phys Med Rehabil* 1964;45:513.

# 131. Kiwerski J. New Possibilities of Improving the Function of the Hand of Patients with Spastic Hemiplegia. *Int J Rehabil Res* 1984;7:293.

+ 132. Kolessar DJ, Katz SD, Keenan ME. Functional Outcome Following Surgical Resection of Heterotopic Ossification in Patients with Brain Injury. *J Head Trauma Rehabil* 1996;44:4.

# 133. Kolessar D, Keenan MAE. Surgical Management of Upper Extremity Deformities Following Traumatic Brain Injury. In: Stone LR, ed. *Neurologic and Orthopaedic Sequelae of TBI,* Vol. 7. Philadelphia: Hanley & Belfus, Inc., 1993:623.

# 134. Koman LA, Gelberman RH, Toby EB, Poehling GG. Cerebral Palsy. Management of the Upper Extremity. *Clin Orthop* 1990;253:62.

# 135. Kozin SH, Keenan MAE. Principles of Surgery for Adult Brain Injury. *Current Orthopaedics* 1991;5:75.

# 136. Kozin SH, Keenan MA. Using Dynamic Electromyography to Guide Surgical Treatment of the Spastic Upper Extremity in the Brain-injured Patient. *Clin Orthop* 1993;288:109.

# 137. Kraft GH, Fitts SS, Hammond MC. Techniques to Improve Function of the Arm and Hand in Chronic Hemiplegia. *Arch Phys Med Rehabil* 1992;73:220.

+ 138. Kralj A, Acimovic R, Stanic U. Enhancement of Hemiplegic Patient Rehabilitation by Means of Functional Electrical Stimulation. *Prosthet Orthot Int* 1993;17:107.

+ 139. Kraus JF, Black MA, Hessol M, et al. The Incidence of Acute Brain Injury in a Defined population. *Am J Epidemiol* 1984;119:186.

+ 140. Kumar R, Metter EJ, Mehta AJ, Chew T. Shoulder pain in hemiplegia. The role of exercise. *Am J Phys Med Rehabil* 1990;69:205.

+ 141. Loewen SC, Anderson BA. Predictors of Stroke Outcome Using Objective Measurement Scales. *Stroke* 1990;21:78.

+ 142. Malisano LP, Stevens D, Hunter GA. The Management of Long Bone Fractures in the Head-injured Polytrauma Patient. *J Orthop Trauma* 1994;8:1.

* 143. Matev I. Surgical Treatment of Spastic “Thumb-in-Palm” Deformity. *J Bone Joint Surg [Br]* 1963;45:703.

* 144. Matev I. Surgery of the Spastic Thumb-in-palm Deformity. *J Hand Surg [Br]* 1991;16:127.

# 145. Mayer NH, Esquenazi A, Keenan ME. Analysis and Management of Spasticity, Contracture, and Impaired Motor Control. In: Horn LJ, Zasler ND, eds. *Medical Rehabilitation of Traumatic Brain Injury.* Philadelphia: Hanley & Belfus, 1996:411.

# 146. Mayer N, Esquenazi A, Wannstedt G. Surgical Planning for Upper Motoneuron Dysfunction: The Role of Motor Control Evaluation. *The Journal of Head Trauma Rehabilitation* 1996;11:37.

+ 147. McAuliffe JA, Wolfson AH. Early Excision of Heterotopic Ossification about the Elbow Followed by Radiation Therapy. *J Bone Joint Surg Am* 1997;79:749.

# 148. McCollough NC III. Orthotic Management in Adult Hemiplegia. *Clin Orthop* 1978:38-46.

# 149. McCollough NC. The Role of the Orthopaedic Surgeon in the Treatment of Stroke. *Orthop Clin North Am* 1978;9:305.

# 150. McCulloch KL, Novack TA. Upper extremity functional assessment in traumatically brain-injured patients. *J Head Trauma Rehabil* 1990;4:1.

+ 151. Meals RA. Denervation for the Treatment of Acquired Spasticity of the Brachioradialis. *J Bone Joint Surg [Am]* 1988;70:1081.

+ 152. Meythaler JM, DeVivo MJ, Hadley M. Prospective Study on the Use of Bolus Intrathecal Baclofen for Spastic Hypertonia due to Acquired Brain Injury. *Arch Phys Med Rehabil* 1996;77:461.

+ 153. Meythaler JM, Tuel SM, Cross LL, Mathew MM. Heterotopic Ossification of the Extensor Tendons in the Hand Associated with Traumatic Spinal Cord Injury. *J Am Paraplegia Soc* 1992;15:229.

+ 154. Moberg E. Two-point Discrimination Test. A Valuable Part of Hand Surgical Rehabilitation, e.g. in Tetraplegia. *Scand J Rehabil Med* 1990;22:127.

+ 155. Money RA. Ectopic Paraarticular Ossification After Head Injury. *Med J Aust* 1972;1:125.

# 156. Mooney V, Frykman G, McLamb J. Current Status of Intraneural Phenol Injections. *Clin Orthop* 1969;63:122.

+ 157. Moore TJ. Functional Outcome following Surgical Excision of Heterotopic Ossification in Patients with Traumatic Brain Injury. *J Orthop Trauma* 1993;7:11.

# 158. Moore T. Traumatic Brain Injury. In: Kasser JR, ed. *Orthopaedic Knowledge Update 5.* Rosemont, IL: American Academy of Orthopaedic Surgeons, 1996:695.

# 159. Moritz U. Phenol Block of Peripheral Nerves. *Scand J Rehabil Med* 1973;5:160.

+ 160. Mowery CA, Gelberman RH, Rhoades CE. Upper Extremity Tendon Transfers in Cerebral Palsy: Electromyographic and Functional Analysis. *J Pediatr Orthop* 1985;5:69.

# 161. Murningham JP: Adhesive Capsulitis of the Shoulder: Current Concepts and Treatment. *Orthopaedics* 1988;2:153.

# 162. Murningham JP: Frozen Shoulder. In: Rockwood CA, Jr., Matsen FA, III, eds. *The Shoulder.* Philadelphia: W.B. Saunders, 1990.

! 163. Mysiw WJ, Tan J, Jackson RD. Heterotopic Ossification. The Utility of Osteocalcin in Diagnosis and management. *Am J Phys Med Rehabil* 1993;72:184.

+ 164. Nakayama H, Jorgensen HS, Raaschou HO, Olsen TS. Compensation in Recovery of Upper Extremity Function after Stroke: The Copenhagen Stroke Study. *Arch Phys Med Rehabil* 1994;75:852.

+ 165. Nakayama H, Jorgensen HS, Raaschou HO, Olsen TS. Recovery of Upper Extremity Function in Stroke Patients: The Copenhagen Stroke Study. *Arch Phys Med Rehabil* 1994;75:394.

+ 166. Nyberg L, Gustafson Y. Fall Prediction Index for Patients in Stroke Rehabilitation. *Stroke* 1997;28:716.

! 167. O'Dwyer NJ, Ada L, Neilson PD. Spasticity and Muscle Contracture Following Stroke. *Brain* 1996;119:1737.

+ 168. Olsen TS. Arm and Leg Paresis as Outcome Predictors in Stroke Rehabilitation. *Stroke* 1990;21:247.

+ 169. Olver JH, Ponsford JL, Curran CA. Outcome Following Traumatic Brain Injury: A Comparison Between 2 and 5 Years After Injury. *Brain Inj* 1996;10:841.

+ 170. Orcutt SA, Kramer WG, Howard MW, et al. Carpal Tunnel Syndrome Secondary to Wrist and Finger Flexor Spasticity. *J Hand Surg [Am]* 1990;15:940.

! 171. Otfinowski J. Heterotopic Induction of Osteogenesis in the Course of Neural Injury. *Patol Pol* 1993;44:133.

# 172. Ough JL, Garland DE, Jordan C, Waters RL. Treatment of Spastic Joint Contractures in Mentally Disabled Adults. *Orthop Clin North Am* 1981;12:143.

! 173. Panizza M, Balbi P, Russo G, Nilsson J. H-reflex Recovery Curve and Reciprocal Inhibition of H-reflex of the Upper Limbs in Patients with Spasticity Secondary to Stroke. *Am J Phys Med Rehabil* 1995;74:357.

! 174. Peacock WJ, Arens LJ, Berman B. Cerebral Palsy Spasticity. Selective Posterior Rhizotomy. *Pediatr Neurosci* 1987;13:61.

+ 175. Perlmutter MN, Synder M, Miller F, Bisbal R. Proximal Femoral Resection for Older Children with Spastic Hip Disease. *Dev Med Child Neurol* 1993;35:525.

# 176. Perry J. Contractures. A Historical Perspective. *Clin Orthop* 1987;219:8.

* 177. Perry J. Determinants of Muscle Function in the Spastic Lower Extremity. *Clin Orthop* 1993;131:10.

* 178. Perry J, Giovan P, Harris LJ, et al. The Determinants of Muscle Action in the Hemipareitc Lower Extremity. *Clin Orthop* 1978;131:71.

# 179. Perry J, Keenan MAE. Rehabilitation of the Neurologically Disabled Patient. In: Aminoff MJ, ed. *Neurology and General Medicine.* New York: Churchill Livingstone Publishers, 1989:747.

# 180. Perry J, Waters RL. *Orthopaedic Evaluation and Treatment of the Stroke Patient. Part III. Upper Extremity Management and Surgery. American Academy of Orthopaedic Surgeons Instructional Course Lectures, Vol. 24.* St. Louis: C. V. Mosby, 1975:51.

* 181. Perry J, Waters RL, Perrin T. Electromyographic Analysis of Equinovarus Following Stroke. *Clin Orthop* 1978;131:47.

! 182. Peter KS, Hsu JD, Keenan MA, Romansky SG. Histology and Intramuscular Pressure in Spastic Muscles. *The Journal of Head Trauma Rehabilitation* 1996;11:1.

+ 183. Pinzur MS. Flexor Origin Release and Functional Prehension in Adult Spastic Hand Deformity. *J Hand Surg [Br]* 1991;16:133.

+ 184. Pinzur MS. Dynamic Electromyography in Functional Surgery for Upper Limb Spasticity. *Clin Orthop* 1993;288:118.

+ 185. Pinzur MS. Carpectomy and Fusion in Adult-acquired Hand Spasticity. *Orthopedics* 1996;19:675.

+ 186. Pinzur MS. Surgical Correction of Lower Extremity Problems in Patients with Brain Injury. *The Journal of Head Trauma Rehabilitation* 1996;44:69.

# 187. Pinzur MS, Sherman RS, Dimonte-Levine P. Triceps Spasticity in Traumatic Hemiplegia: Diagnosis and Treatment. *Arch Phys Med Rehabil* 1977;68:446.

+ 188. Pinzur MS, Wehner J, Kett N, Trilla M. Brachioradialis to Finger Extensor Tendon Transfer to Achieve Hand Opening in Acquired Spasticity. *J Hand Surg [Am]* 1988;13:5492.

+ 189. Pomerance JF, Keenan MA. Correction of Severe Spastic Flexion Contractures in the Nonfunctional Hand. *J Hand Surg [Am]* 1996;21:828.

+ 190. Poulin de Courval L, Barsauskas A, Berenbaum B, et al. Painful Shoulder in the Hemiplegic and Unilateral Neglect. *Arch Phys Med Rehabil* 1990;71:673.

! 191. Prochazka A, Gauthier M, Wieler M, Kenwell Z. The Bionic Glove: An Electrical Stimulator Garment that Provides Controlled Grasp and Hand Opening in Quadriplegia. *Arch Phys Med Rehabil* 1997;78:608.

+ 192. Ragone DJ Jr, Kellerman WC, Bonner FJ Jr. Heterotopic Ossification Masquerading as Deep Venous Thrombosis in Head-injured Adult: Complications of Anticoagulation. *Arch Phys Med Rehabil* 1986;67:.

+ 193. Rayan GM, Saccone PG. Treatment of Spastic Thumb-in-palm Deformity: A Modified Extensor Pollicis Longus Tendon Rerouting. *J Hand Surg [Am]* 1996;21:834.

! 194. Renfree KJ, Banovac K, Hornicek FJ, et al. Evaluation of Serum Osteoblast Mitogenic Activity in Spinal Cord and Head Injury Patients with Acute Heterotopic Ossification. *Spine* 1994;19:740.

# 195. Ritter MA. Indomethacin: An Adjunct to Surgical Excision of Immature Heterotopic Bone Formation in a Patient with a Severe Head Injury. A Case Report. *Orthopedics* 1987;10:1379.

+ 196. Rocke DM, Zasloff M, Peeper J, et al. Age- and Joint-specific Risk of Initial Heterotopic Ossification in Patients Who Have Fibrodysplasia Ossificans Progressiva. *Clin Orthop* 1994;301:243.

# 197. Rogers RC. Heterotopic Calcification in Severe Head Injury: A Preventive Programme. *Brain Inj* 1988;2:169.

# 198. Roper BA. The Orthopedic Management of the Stroke Patient. *Clin Orthop* 1987;219;78.

# 199. Sakellarides HT, Mital MA, Matza RA, Dimakopoulos P. Classification and Surgical Treatment of the Thumb-in-palm Deformity in Cerebral Palsy and Spastic Paralysis. *J Hand Surg [Am]* 1995;20:428.

+ 200. Sampaio C, Ferreira JJ, Pinto AA, et al. Botulinum Toxin Type A for the Treatment of Arm and Hand Spasticity in Stroke Patients. *Clin Rehabil* 1997;11:3.

+ 201. Sandin KJ, Smith BS. The Measure of Balance in Sitting in Stroke Rehabilitaiton Prognosis. *Stroke* 1990;21:.

+ 202. Schaeffer MA, Sosner J. Heterotopic Ossification: Treatment of Established Bone with Radiation Therapy. *Arch Phys Med Rehabil* 1995;76:284.

+ 203. Shaffer B: Frozen Shoulder: A Long Term Follow-Up. *J Bone Joint Surg [Am]* 1992;74:738.

# 204. Silver CM, Litchman HM, Simon SD, Motamed M. Surgical Correction of Spastic Thumb-in-palm Deformity. *Dev Med Child Neurol* 1976;18:632.

+ 205. Simpson DM, Alexander DN, O'Brien CF, et al. Botulinum Toxin Type A in the Treatment of Upper Extremity Spasticity: A Randomized, Double-blind, Placebo-controlled Trial. *Neurology* 1996;46:1306.

+ 206. Smith CW, Levanthal L. Surgical Management of Lower Extremity Deformities in adult Head Injured Patients. *The Journal of Head Trauma Rehabilitation* 1987;2:53.

# 207. Smith RJ. Intrinsic Muscles of the Fingers: Function, Dysfunction, and Surgical Reconstruction. In: AAOS, ed. *Instructional Course Lectures, Vol. 24.* St Louis: C. V. Mosby, 1975:200.

# 208. Smith RJ. Surgical Treatment of the Claw Hand. In: AAOS, ed. *Symposium on Tendon Surgery in the Hand.* St. Louis: C.V. Mosby, 1975:181.

+ 209. Sobus KM, Alexander MA, Harcke HT. Undetected Musculoskeletal Trauma in Children with Traumatic Brain Injury or Spinal Cord Injury. *Arch Phys Med Rehabil* 1993;74:902.

+ 210. Sobus KM, Sherman N, Alexander MA. Coexistence of Deep Venous Thrombosis and Heterotopic Ossification in the Pediatric Patient. *Arch Phys Med Rehabil* 1993;74:547.

# 211. Spencer RF. Heterotopic Ossification in a Finger Following Head Injury. *J Hand Surg [Br]* 1991;16: 217.

# 212. Spielman G, Gennarelli TA, Rogers CR. Disodium Etidronate: Its Role in Preventing Heterotopic Ossification in Severe Head Injury. *Arch Phys Med Rehabil* 1983;64:539.

# 213. Stiles CM, Patel M, Keenan MAE. Anesthesia for Rehabilitation Surgery. In: Nickel VL, Botte MJ, eds. *Orthopaedic Rehabilitation.* New York: Churchill Livingstone Publishers, 1992:105.

+ 214. Stone LR, Keenan MA, Shin DY. Acquired limb loss in patients with traumatic brain injury. *Am J Phys Med Rehabil* 1990;69:135.

+ 215. Stone LR, Keenan MA. Deep-venous Thrombosis of the Upper Extremity after Traumatic Brain Injury. *Arch Phys Med Rehabil* 1992;73:486.

# 216. Stone L, Keenan MA. Peripheral Nerve Injuries in the Adult with Traumatic Brain Injury. *Clin Orthop* 1988;233;136.

+ 217. Strauss DJ, Shavelle RM, Anderson TW. Long-term survival of children and adolescents after traumatic brain injury. *Arch Phys Med Rehabil* 1998;79:1095.

+ 218. Subbarao JV. Pseudoarthrosis in Heterotopic Ossification in Spinal Cord-Injured Patients. *Am J Phys Med Rehabil* 1990;69:88.

# 219. Summerfield SL, DiGiovanni C, Weiss AP. Heterotopic Ossification of the Elbow. *J Shoulder Elbow Surg* 1997;6:321.

+ 220. Suso S, Vicente P, Angles F. Surgical Treatment of the Non-functional Spastic Hand. *J Hand Surg [Br]* 1985;10:54.

+ 221. Swaine BR, Sullivan SJ. Longitudinal Profile of Early Motor Recovery Following Severe Traumatic Brain Injury. *Brain Inj* 1996;10:347.

+ 222. Swaine BR, Sullivan SJ. Reliability of Early Motor Function Testing in Persons Following Severe Traumatic Brain Injury. *Brain Inj* 1996;10:263.

# 223. Swanson AB, de Groot Swanson G. Evaluation and Treatment of the Upper Extremity in the Stroke Patient. *Hand Clin* 1989;5:75.

+ 224. Taub E, Miller NE, Novack TA, et al. Technique to Improve Chronic Motor Deficit after Stroke. *Arch Phys Med Rehabil* 1993;74:347.

* 225. Teasdale G, Jennettt B. Assessment of Coma and Impaired Consciousness: A Practical Scale. *Lancet* 1974;2:81.

! 226. Tsur A, Sazbon L, Lotem M. Relationship Between Muscular Tone, Movement and Periarticular New Bone Formation in Postcoma-unaware (PC-U) Patients. *Brain Inj* 1996;10:259.

+ 227. van der Linden AJ. Spontaneous Regression of Neurogenic Heterotopic Ossification. *Int Orthop* 1984;8:25.

+ 228. Vara-Thorbeck R, Ruiz-Morales M. Severe Head Injury Combined with Orthopedic and Vascular Trauma of the Limbs. *Arch Surg* 1998;383:252.

+ 229. Wainapel SF, Haigney D, Labib K. Spastic Hemiplegia in a Quadriplegic Patient: Treatment with Phenol Nerve Blocks. *Arch Phys Med Rehabil* 1984;65:786.

# 230. Waters RL. Upper Extremity Surgery in Stroke Patients. *Clin Orthop* 1978;133:30.

# 231. Waters RL, Keenan MA. Surgical Treatment of the Upper Extremity after Stroke. In: Chapman M, ed. *Operative Orthopaedics*, Vol. 1. Philadelphia: J.B. Lippincott Publishers, 1988:1449.

+ 232. Waters RL, McNeal DR, Clifford B. Correction of Footdrop in Stroke Patients via Surgically Implanted Peroneal Nerve Stimulator. *Acta Orthop Belg* 1984;50:285.

* 233. Waters RL, Perry J, Garland D. Surgical Correction of Gait Abnormalities Following Stroke. *Clin Orthop* 1978;131:54.

+ 234. Waters R, Rhoades M, Montgomery J. Improvement of Physical Function after Stroke: Surgical and Orthotic Management. *J Am Geriatr Soc* 1975;23:248.

# 235. Waters RM, Van Heest A. Spastic Hemiplegia of the Upper Extremity in Children. *Hand Clin* 1998;14:119.

+ 236. Webb C, Rose FD, Johnson DA, Attree EA. Age and Recovery from Brain Injury: Clinical Opinions and Experimental Evidence. *Brain Inj* 1996;10:303.

+ 237. Webb LX, Bosse MJ, Mayo KA, et al. Results in Patients with Craniocerebral Trauma and an Operatively Managed Acetabular Fracture. *J Orthop Trauma* 1990;4:376-82.

! 238. Weiss S, Grosswasser Z, Ohri A, et al. Histocompatibility (HLA) Antigens in Heterotopic Ossification Associated with Neurological Injury. *J Rheumatol* 1979;6:88.

+ 239. Whitlock JA, Hamilton BB. Functional Outcome After Rehabilitation for Severe Traumatic Brain Injury. *Arch Phys Med Rehabil* 1995;76:1103.

! 240. Wilson DJ, Childers MK, Cooke DL, Smith BK. Kinematic Changes Following Botulinum Toxin Injection after Traumatic Brain Injury. *Brain Inj* 1997;11:157.

! 241. Wolf SL, Binder-MacLeod SA. Electromyographic Biofeedback Applications to the Hemiplegic Patient. Changes in Upper Extremity Neuromuscular and Functional Status. *Phys Ther* 1983;63:1393.

# 242. Wood KM. The Use of Phenol as a Neurolytic Agent. *Pain* 1978;5:205.

# 243. Yamamoto H, Olumara S, Morita S, Obata K, Furuya K. Surgical Correction of Foot Deformities After Stroke. *Clin Orthop* 1992;282:213.

+ 244. Yekutiel M, Guttman E. A Controlled Trial of the Retraining of the Sensory Function of the Hand in Stroke Patients. *J Neurol Neurosurg Psychiatry* 1993;56:241.

# 245. Young S, Keenan MAE. Extremity Fractures in the Brain-injured Patient. In: Nickel VL, Botte MJ, eds. *Orthopaedic Rehabilitation.* New York: Churchill Livingstone Publishers, 1992:401.

! 246. Zafonte RD, Hammond FM, Mann NR, et al. Revised Trauma Score: An Additive Predictor of Disability Following Traumatic Brain Injury? *Am J Phys Med Rehabil* 1996;75:456.

+ 247. Zafonte RD, Hammond FM, Mann NR, et al. Relationship Between Glasgow Coma Scale and Functional Outcome. *Am J Phys Med Rehabil* 1996;75:364.

* 248. Zancolli EA, Zancolli ER. The Infantile Spastic Hand. Surgical Indications and Management. *J Hand Surg (Am)* 1983;5:766.

+ 249. Zorowitz RD, Hughes MB, Idank D, et al. Shoulder Pain and Subluxation after Stroke: Correlation or Coincidence? *Am J Occup Ther* 1996;50:194.

+ 250. Zorowitz RD, Idank D, Ikai T, et al. Shoulder Subluxa-tion after Stroke: A Comparison of Four Supports. *Arch Phys Med Rehabil* 1995;76:763.

+ 251. Zuhosky JP, Dugan SA, Young JL, et al. A Retrospective Review of the Incidence and Rehabilitation Outcome of Concomitant Traumatic Brain Injury and Ligamentous Knee Injury. *Arch Phys Med Rehabil* 1998;79:805.

# CHAPTER 68

# RECONSTRUCTION OF THE UPPER EXTREMITY IN TETRAPLEGIA

*Michelle A. James*

**M. A. James:** Associate Clinical Professor, Department of Orthopaedic Surgery, University of California, Davis; Shriners Hospital for Children, Northern California, Sacramento, California, 95817.

Pathophysiology
Principles of Treatment
Indications, Assessment, and Relative Results
Elbow Extension
International Classification (IC)
Other Classifications
Surgical Techniques
Restoration of Elbow Extension: Deltoid to Triceps Transfer
Restoration of Elbow Extension: Biceps to Triceps Transfer
IC 0 OR 1: Restoration of Key Pinch And Grasp. Implantation of a Functional Electrical Stimulation System (Neuroprosthesis)
IC-1: Restoration of Key Pinch. Brachioradialis to Ecrb; Fpl and Epl Tenodesis; Split Fpl Transfer
IC-2: Restoration of Key Pinch. Brachioradialis to Fpl; Epl Tenodesis; Split Fpl Transfer
IC-3, IC-4, IC-5: Restoration of Key Pinch, Hook Grasp, Release, and Intrinsic Balance, and (IC-4 And IC-5 Only) Restoration of Thumb Abduction/Opposition
IC-6 AND IC-7: Restoration of Key Pinch, Hook Grasp, Thumb Extension, Intrinsic Balance, and Thumb Abduction/Opposition
IC-8 and IC-9: Restoration of Intrinsic Balance and Thumb Abduction/Opposition
Pitfalls and Complications
Author's Perspective
Chapter References

Tetraplegia resulting from spinal cord injury (SCI) is a devastating impairment. The abilities of the person with tetraplegia are drastically diminished. This loss of independence is especially catastrophic for young men with poor impulse control, the most common victims of SCI. People with complete tetraplegia have loss of normal use of their upper extremities and may require assistance with basic activities of daily living (ADLs), such as eating, dressing, and bladder and bowel care. They are unable to stand or walk, and because they lack sensation below the level of their SCI they must learn to protect their skin from pressure sores.

Before World War II, most people with tetraplegia survived for only a brief time, succumbing to pneumonia or renal failure. In the 1940s the prevention and care of the medical complications of tetraplegia began to improve, allowing people with this condition to survive longer. At this same time, the field of hand surgery was developing, and by the late 1940s hand surgeons began devising ways to improve upper extremity (UE) function in patients with tetraplegia. Pioneers in this field include Bunnell (2), Lipscomb et al. (37), Nickel et al. (47), and later Freehafer et al. (11,12), Lamb and Landry (34,35), Moberg (41,42), Zancolli (60,61), House et al. (21,22), McDowell et al. (39,40), Hentz et al. (17,18), Waters et al. (3,14,57), Allieu et al. (1), and others. Although current surgical techniques fall far short of returning normal function, the challenges of functional restoration in the tetraplegic hand have inspired some of the most innovative developments in hand surgery today.

## PATHOPHYSIOLOGY

In adults, traumatic tetraplegia is always accompanied by bony or ligamentous injury to the cervical spine. The cervical spine injury may be stable (for instance, gunshot wounds typically cause stable injuries) or unstable. The highest orthopaedic priority in the treatment of acute tetraplegia is to recognize spinal instability, and to prevent the unstable spine from further damaging the spinal cord (see Chapter 139 and Chapter 140). After internal fixation of the cervical spine provides stability, the patient can sit and upper extremity function can be fully assessed.

Upper extremity function and its recovery (or lack thereof) following SCI reflects the level and type of injury to the spinal cord. The level of cord damage often does not correlate with the level of bony injury. The cord is frequently damaged above or below the level of spine injury, and cord damage of varying severity may occur over several levels. The cord may be transected, or more commonly crushed or contused, and the body's response to the injury may cause further damage. Other neurologic injury—including injury to the brain, cervical nerve roots, and brachial plexus—may accompany SCI. The presence of lower motor neuron injury compounding upper motor neuron injury reduces treatment options, because muscles without an intact lower motor neuron cannot contract in response to functional electrical stimulation (see the section on Indications, Assessment, and Relative Results, below).

SCI is incomplete in about 50% of cases (16). From a functional standpoint, the designation “incomplete” can mean anything from total upper and lower extremity paralysis with retained perianal sensation, to minimal upper or lower extremity weakness, or both. In the first months after injury, an incompletely injured spinal cord may partially recover (55). A completely injured spinal cord will not recover, but muscles that are weak but not paralyzed immediately after injury (due to less severe SCI cephalad to the complete injury) will usually regain normal strength in the year after injury (7,30). Surgical reconstruction of the upper extremity should wait until further improvement is unlikely (33,39,40,56).

The paralyzed upper extremity may undergo changes that make surgical reconstruction less effective or even contraindicated. Some changes, such as severe spasticity and pain, are difficult to prevent or treat. Other changes, such as contractures, may be preventable with passive range of motion (ROM) exercises.

## PRINCIPLES OF TREATMENT

Repair of spinal cord injury is not yet possible. Steroids or other medications given within hours of injury may reduce further damage caused by the body's response to SCI. The major focus of treatment is rehabilitation, however, an on-going process in which people with SCI learn how to take care of themselves. As part of rehabilitation, upper extremity function may be improved or partially replaced by orthotic devices; modifications to cars, wheelchairs, and computers; environmental control units; service dogs; and upper extremity surgery. People with higher level tetraplegia require the help of another person with activities such as lower extremity dressing, food preparation, bathing, toileting, and transferring, and they must learn to instruct others in these activities (59).

The complex process of rehabilitation requires a focused team approach. The team is usually headed by a specialist in physical medicine and rehabilitation. Other physician team members include an orthopaedic spine surgeon, a urologist, a psychiatrist, and an upper extremity surgeon. Other professional team members include clinical nurse specialists in rehabilitation, physical and occupational therapists, therapeutic recreation specialists, and social workers. The patient and his family are important members of the team, because patient attitude and family support are the most important factors in successful rehabilitation. Although the team may have standardized goals determined by the level of SCI, they must also help the patient develop realistic goals and focus on these. Successful rehabilitation helps the patient reconnect with mainstream life, including returning to school or work. As a result of effective rehabilitation, many people with tetraplegia lead happy, fulfilling lives (Fig. 68.1).

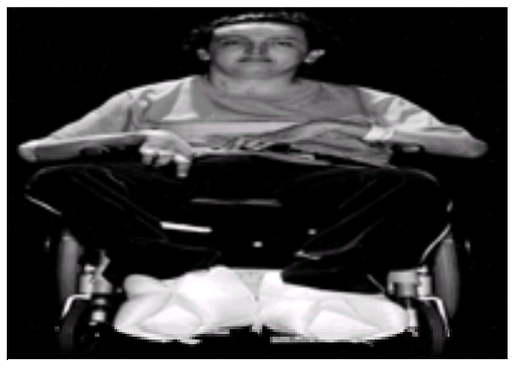

***Figure 68.1.*** This young man sustained a spinal cord injury in a diving accident at age 16. He joined his father's used car business as a salesman at age 18, following rehabilitation and bilateral deltoid to triceps transfers.

Upper extremity reconstruction is discussed with the patient early on, but it is not usually part of initial rehabilitation. Surgery cannot be planned until upper extremity function is stable, which usually occurs 1 year after injury. In addition, a person with tetraplegia who has spent time at home following her initial rehabilitation has more realistic goals and expectations of surgery. The upper extremity surgeon can help the patient develop these goals, and provide encouragement and contact with other people with tetraplegia who have undergone upper extremity reconstruction. Contraindications to upper extremity reconstruction are listed in Table 68.1.

| |
|---|
| Continued recovery of neurologic function |
| Severe UE spasticity |
| Neurogenic UE pain |
| Active heterotopic ossification in UE |
| Severe UE contractures |
| Unrealistic expectations |
| Poor adjustment and support |

***Table 68.1. Contraindications to Upper Extremity (UE) Reconstruction in Tetraplegia***

The general principles of tendon transfer are followed when planning upper extremity reconstruction in tetraplegia (49,51), although the tetraplegic patient may have so few donor muscles available that the surgeon must be creative or even bend the rules. Ideally, muscles selected for transfer have normal strength and appropriate excursion for their new function, and they can be spared without detriment to function. In tetraplegia, partially paralyzed muscles may be transferred if this will augment function (for instance, transfer of a portion of the deltoid muscle to the triceps improves elbow extension even if the deltoid is partially paralyzed [23]), and weakening one motion may be acceptable if the transfer supplies an entirely absent function (such as biceps-to-triceps or extensor carpi radialis longus [ECRL]–to–flexor digitorum profundus [FDP] transfers).

Elbow extension is the most useful function the surgeon can restore because it enables people with tetraplegia to extend their reach for eating, pushing elevator buttons, opening doors, transferring in and out of a wheelchair, and propelling a manual wheelchair (33,36,41). Following reconstruction of elbow extension, depending on which motors are available for transfer, the surgeon may reconstruct key (lateral) pinch, which is very useful for everyday activities such as eating with a fork and writing with a pen (Fig. 68.2). If additional motors are available for transfer, the surgeon may also reconstruct hook grasp and release, and thumb opposition.

***Figure 68.2.*** This patient is using surgically reconstructed key pinch to catheterize a stoma between the bladder and umbilicus. This enables her to catheterize herself in her wheelchair. **A:** Thumb extended. **B:** Key pinch.

People with tetraplegia are at increased risk of latex allergy, especially during surgery (54). All medical supplies that come into contact with people with tetraplegia should be latex free. They are also at risk of autonomic dysreflexia in response to noxious stimuli below their injury level, such as postoperative pain or bladder distention. In addition, they are at increased risk of postoperative pulmonary problems such as atelectasis or pneumonia because of paralysis of accessory muscles of respiration.

Because most patients with tetraplegia have impaired or absent sensation, the surgeon must liberally pad splints or casts applied postoperatively, to avoid causing pressure sores.

## INDICATIONS, ASSESSMENT, AND RELATIVE RESULTS

Soon after injury, the rehabilitation team focuses on retaining passive range of motion (PROM) in the upper extremities. PROM exercises should be performed regularly, especially before the patient is able to sit. If these exercises are neglected, shoulder stiffness and pain will develop and delay rehabilitation.

Once the patient can sit, upper extremity passive and active ROM and strength are carefully evaluated and reevaluated at frequent intervals for the first year after injury. Formal planning of upper extremity reconstruction begins when function plateaus. Elbow flexion contractures are frequently seen in patients with absent elbow extension. These contractures diminish the patient's ability to assist with transfers; unless these can be overcome with stretching or serial casting, reconstruction of elbow extension is contraindicated (15). Supination contractures are less common; these contractures may require osteotomy of the radius before pinch reconstruction. Other contractures are uncommon. See Table 68.1 for other factors that contraindicate upper extremity surgery.

### ELBOW EXTENSION

The algorithm in Figure 68.3 outlines the surgeon's planning strategy. Innervation of the triceps is variable (Fig. 68.4); if the triceps muscle is paralyzed, elbow extension should be reconstructed first. This is because pinch reconstruction uses the brachioradialis or pronator teres as a donor, and these muscles cross the elbow joint and are placed on optimal tension when the elbow is extended (3). Because the elbow must be immobilized in extension following tendon transfer to the triceps, this procedure is not readily combined with other upper extremity surgery.

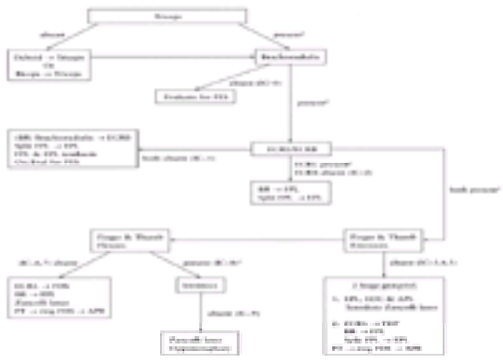

***Figure 68.3.*** Algorithm for upper extremity reconstruction in tetraplegia. Please see text for a description of the use of this algorithm.

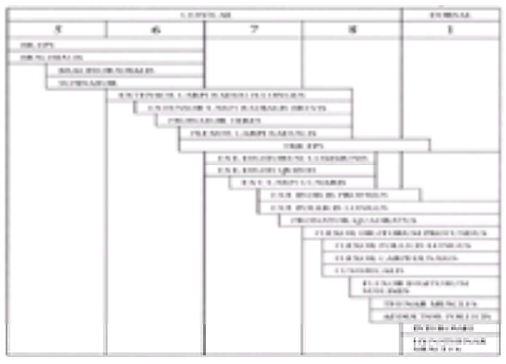

***Figure 68.4.*** Segmental innervation of muscles of the elbow, forearm, and hand (61). (From Zancolli EA. Functional Restoration of the Upper Limbs in Tetraplegia. In: Zancolli EA, ed. *Structural Dynamic Bases of Hand Function.* Philadelphia: JB Lippincott, 1978:231.)

The deltoid-to-triceps transfer is the type most commonly used to reconstruct elbow extension. In this operation, the posterior one third to one half of the deltoid muscle is detached at its origin and transferred to the triceps tendon, usually using an interposition graft. Fascia lata is easy to harvest and use as a graft (17). Good results have also been reported using toe extensor tendons and tibialis anterior (6,8,10,32,41,48), and using a turned-up portion of triceps to bridge the gap between the deltoid and the triceps (4,8). Graft interposition material tends to stretch out over time, diminishing active elbow extension; this deterioration may be reduced when the interposition graft is reinforced with nonabsorbable suture tape. Shoulder abduction strength is not diminished with this transfer, because the transferred deltoid is able to continue to function as a shoulder abductor (personal communication, Vincent R. Hentz, M.D). Transfer of a weak, partially paralyzed deltoid muscle provides useful elbow extension, also without diminishing shoulder abduction strength (23). People with tetraplegia are usually very pleased with the results of this procedure, which increases their reach and thereby their independence; it may allow them to assist with transferring in and out of their wheelchair, and propelling a manual wheelchair. In spite of the major drawbacks of this operation, such as postoperative immobilization with the elbow in extension, and prolonged rehabilitation to prevent the interposition graft from stretching out, patients consistently request the same procedure on the contralateral side (23,33).

Biceps-to-triceps transfer is indicated when the deltoid is paralyzed. Although this transfer weakens elbow flexion, the brachialis is usually strong enough to continue to flex the elbow against gravity (13,31,39,50). This operation may not be as consistently reliable as a deltoid-to-triceps transfer.

## INTERNATIONAL CLASSIFICATION (IC)

### *IC-0*

If all muscles below the elbow are paralyzed (IC-0; Table 68.2) the patient should be evaluated for a neuroprosthesis. Also called implanted functional electrical stimulation, and commercially known as the Freehand system, this complex system may provide grasp and key pinch when tendon transfers are not possible (5,25,26,28,46). A control unit implanted under the pectoralis muscle is programmed to stimulate muscles via implanted electrodes. The patient controls this unit by using a transducer attached to his chest wall and mechanically activated by contralateral shoulder motion (Fig. 68.5). In order to be stimulated by a neuroprosthesis, muscles must be paralyzed but not denervated (their lower motor neuron must be intact). The status of the peripheral nerves can be tested with transcutaneous stimulation to determine if the patient is a candidate for this operation. The surgeon and occupational therapist work together to determine which muscles are available for stimulation and transfer. If critically important muscles, such as wrist extensors, are denervated, their function may be replaced by transferring and stimulating a paralyzed but not denervated muscle. Planning, surgical implantation, and postoperative training are quite complex and require an experienced surgical and therapy team, and a highly motivated patient (53).

| Class | Muscle function | Description |
|---|---|---|
| 0 | No muscles functioning below the elbow | Flexion and supination of elbow |
| 1 | Brachioradialis | Same as above |
| 2 | Extensor carpi radialis longus (ECRL) | Extension of the wrist (weak or strong) |
| 3 | Extensor carpi radialis brevis (ECRB) | Extension of the wrist |
| 4 | Pronator teres (PT) | Extension and pronation of the wrist |
| 5 | Flexor carpi radialis (FCR) | Flexion of the wrist |
| 6 | Finger extensors (EDC) | Extrinsic extension of the fingers (partial or complete) |
| 7 | Thumb extensor (EPL) | Extrinsic extension of the thumb |
| 8 | Partial digital flexors (FDS, FDP) | Extrinsic flexion of the fingers (weak) |
| 9 | Lacks only intrinsics | Extrinsic flexion of the fingers |
| 0 | Exceptions | |

Sensibility evaluation: O = two-point discrimination > 10 mm ("Occasional"); Ca = two-point discrimination < 10 mm ("Catastrophic").
† This classification applies to muscles below the elbow. Muscles listed are left or better; a new muscle is added for each group.

***Table 68.2. International Classification for the Upper Extremity in Tetraplegia (39)***

***Figure 68.5.*** **A:** Diagram of the Freehand system. **B:** Young man with IC 1 SCI, who has undergone left upper extremity implantation of the Freehand neuroprosthesis. He is using lateral pinch generated by the neuroprosthesis to hold his fork. **C:** The same young man, using grasp generated by the neuroprosthesis to hold a water bottle.

### *IC-1*

If all muscles below the elbow are paralyzed except brachioradialis (IC-1; Table 68.2) the patient may be a candidate for a neuroprosthesis (see above), or for a combination of tendon transfers designed to restore key pinch (10,11,20,41,44). Key pinch is reconstructed by transferring the brachioradialis to provide wrist extension, and tenodesing the extrinsic thumb flexor and extensor tendons to the radius. After this surgery, wrist extension activates key pinch, and wrist flexion (by gravity) activates release. This provides approximately 1 kg of pinch strength; neuroprosthesis pinch strength is at least twice as strong, but the patient requires assistance donning the transducer to activate the neuroprosthesis (5,25). The thumb may require carpometacarpal arthrodesis (20) or interphalangeal joint stabilization with a transarticular Kirschner wire (41) or arthrodesis to stabilize pinch. Alternatively, pinch can be stabilized by transferring half of the flexor pollicis longus (FPL) tendon to the extensor pollicis longus (EPL) tendon, just proximal to the interphalangeal joint (split-FPL transfer) (45). Because people with tetraplegia usually do not like to have stiff hands, the split-FPL transfer, which provides stability without stiffness, is preferred to arthrodesis. Restoration of tenodesis pinch allows the patient to hold a fork, toothbrush, pen, catheter, or other small object.

### *IC-2*

If the brachioradialis and the ECRL are both functional (IC-2, Table 68.2), then the brachioradialis can be used to supply active key pinch by transferring it to the FPL (20,41). This procedure is supplemented by tenodesis of the EPL to the radius, and split-FPL transfer (45). Pinch strength is about 2 kg following this procedure (20).

### *IC-3*

When two wrist extensors are present in addition to brachioradialis (IC-3, Table 68.2),[1] the surgeon can restore key pinch in the same manner as for IC-2 (see above) and one of the wrist extensors (usually ECRL) can also be transferred to the finger flexors to restore hook grasp (22,44). No motor is available to provide active finger extension, so the extrinsic finger extensors should be tenodesed to the radius. Because the hand lacks intrinsic function, an intrinsic tenodesis, such as the Zancolli lasso procedure in which the paralyzed flexor digitorum superficialis (FDS) is tenodesed around the $A_1$ pulley] (17,60), improves grasp strength by preventing metacarpophalangeal joint hyperextension, or clawing, with grasp (38). These procedures are performed in two stages, an extensor phase and a flexor phase, with different positions of immobilization. In the extensor phase, EDC, EPL and abductor pollicis longus are tenodesed to the radius, and an intrinsic tenodesis is performed.[2] In the flexor phase, approximately 3 months later, the brachioradialis is transferred to the FPL, and the the ECRL is transferred to the FDP (21,22).

Restoration of grasp allows the patient to acquire and hold larger objects, such as a cup, and to pull up pants. However, if the extensor carpi radialis brevis (ECRB) is not full strength, the weakening of wrist extension caused by transfer of ECRL may be detrimental to key pinch, which is a more useful function. There is no consistently reliable way to determine the strength of ECRB. Some surgeons solve this dilemma by transferring ECRB instead of ECRL; this leaves wrist extension strong but causes radial deviation with extension. Another alternative is to omit grasp reconstruction and simply reconstruct key pinch as for IC-2.

### *IC-4 and IC-5*

Patients with pronator teres (PT) and flexor carpi radialis (FCR) strength (IC-4 and IC-5, Table 68.2) have an additional motor available for transfer. FCR is not usually transferred because no other motor is available to flex the wrist, and wrist flexion enhances release and improves the function of EDC tenodesis (see the section on IC-3 earlier). The PT can be transferred without detriment to function. In addition to the two-stage reconstruction described earlier for IC-3, as part of the flexor phase, the PT can be transferred to the ring FDS, which can then be transferred to the abductor pollicis brevis. The insertion and routing of this opponensplasty can be adjusted to restore adduction and opposition, in order to improve key pinch contact by counteracting the supination force of the FPL acting in the absence of thenar intrinsics (19,27). Many variations of these procedures have been described, including transferring the brachioradialis to the finger and thumb extensors instead of to the FPL, and using the PT or ECRL to provide grasp by transferring it to the FDP (14). Thumb carpometacarpal joint fusion may help improve grasp (22).

### *IC-6 and IC-7*

Patients with strong finger and thumb extensors (EDCs and EPLs) lack only active finger and thumb flexion and intrinsic function (IC-6 and IC-7, Table 68.2). If the EDC is present but the EPL is absent (IC-6), the extensor digiti quinti (EDQ) can be transferred to EPL. Otherwise, key pinch, hook grasp, intrinsic balance (Zancolli lasso), and adduction-opposition are restored as described earlier for IC-4 and IC-5; the Zancolli lasso can be performed at the same operation as pinch and grasp reconstruction and opponensplasty. Reconstructed grasp averages 5.5 kg, and key pinch averages 3.0 kg (22).

### *IC-8 and IC-9*

Patients who lack only intrinsic function (IC-8 and IC-9, Table 68.3) can benefit from opponensplasty using ring FDS and intrinsic tenodesis (Zancolli lasso); the Zancolli lasso works as an active, rather than passive, tether when the FDS is functional.

| *Level* | *Function* |
|---|---|
| C1, C2, C3, C4 | No forearm or hand function |
| C5 | Elbow flexion |
| C6 | C5 function plus radial wrist extension |
| C7 | C6 function plus centralized wrist extension, pronation, wrist flexion, weak elbow extension, and digit extension |
| C8 | C7 function plus strong elbow and digit extension, and weak digit flexion |
| T1 | C8 function plus strong digit flexion; lacks intrinsic function only |

***Table 68.3. Classification of Spinal Cord Injury (52)***

### *Sensibility*

Moberg has stressed the importance of intact sensibility in the outcome of upper extremity reconstruction in tetraplegia (41,43). At his suggestion, O (for “oculo,” or visual afferent) and Cu (for “cutaneous,” or sensory afferent) are added to the IC scheme to denote the sensibility of the individual extremity (Table 68.3). Although lack of sensibility may adversely affect the outcome of the procedure, even Moberg, who considers sensibility of prime importance, notes that in the absence of sensation, “restored grip was useful nonetheless” (41).

### OTHER CLASSIFICATIONS

The most common classification scheme used by orthopaedic surgeons and rehabilitation medicine specialists is based on level of nerve root injury (Table 68.3) (52). This system is not specific enough to help with planning upper extremity tendon transfers. Furthermore, individual muscles are innervated by multiple nerve roots (Fig. 68.4) and different individuals may have different innervation patterns. Triceps innervation is especially variable. For these reasons, the International Classification for the Upper Extremity in Tetraplegia (IC) was developed (Table 68.3). This is the classification system used to plan upper extremity reconstruction in tetraplegia.

## SURGICAL TECHNIQUES

### RESTORATION OF ELBOW EXTENSION: DELTOID TO TRICEPS TRANSFER (4,6,17,29,32,41)

- Perform the operation under general anesthesia. Place the patient on a large beanbag or other positioning device in the lateral decubitus position with the

operated side up. Pad the contralateral arm and both legs carefully. Inject the planned incision sites (Fig. 68.6), including the fascia lata graft donor site on the ipsilateral leg, with bupivacaine (Marcaine) with epinephrine (the patient probably has no sensation in the leg and the majority of the arm, but painful stimulus below the level of injury can cause autonomic dysreflexia).

***Figure 68.6.*** **A:** Incisions for deltoid to triceps transfer. **B:** Proximal surgical wound showing fascia lata graft attached to posterior deltoid.

- Through a curvilinear incision over the posterior deltoid, extending to the deltoid insertion, expose the deltoid muscle. The overlying fascia is not well developed. Visualize the anterior and posterior borders, and select one third to one half of the posterior deltoid to dissect free for transfer. Harvest periosteum and brachialis fascia distally to supplement the deltoid insertion as a sturdy attachment point for the transfer. A leash of vessels is consistently located just posterior to the deltoid insertion. Leave the anterior portion of the deltoid insertion attached to the humerus.
- Dissect the posterior deltoid proximally, separating the fibers. Stop at least 5 cm distal to the acromion, or no more than 7 cm proximal to the insertion, to avoid damaging the axillary nerve (44). Test the passive excursion of the posterior deltoid; it should be at least 2 cm, preferably 3 to 4 cm.
- Through a separate posterior longitudinal incision, expose the triceps aponeurosis. Make two 3 cm transverse incisions about 2 cm apart in the triceps tendon, reinforcing the corners with #0 nonabsorbable suture. Create a subfascial tunnel between the two triceps tendon incisions, and a subcutaneous tunnel between the two skin incisions. Measure the distance between the end of the deltoid and the triceps tendon with the elbow in 10° to 20° flexion and add 5 cm; this is the length of fascia lata interposition graft needed.
- Through a straight lateral incision extending from just below the greater trochanter to 5 to 7 cm proximal to the knee joint, expose the fascia lata. Harvest a piece of fascia lata about 5 cm wide and as long as needed. Detach the fascia lata at one end and weave #5 nonabsorbable suture tape through the fascia lata, then detach the other end.
- Pass the fascia lata graft through the subcutaneous tunnel. Wrap the proximal end around the posterior deltoid tendon, attaching it with several #0 non-absorbable sutures. While holding the elbow in 10° to 20° flexion, pass the graft into the proximal incision in the triceps and out the distal incision, firmly attaching it at both contact points with several #0 nonabsorbable sutures. Fold the excess back on itself and suture in place. Do not allow the elbow to flex more than 20°.
- Close all wounds with deep interrupted absorbable sutures, and skin with running subcuticular sutures.
- Apply a well-padded long arm cast with the elbow in 10° to 20° flexion.

### *General Rehabilitation and Post-operative Principles*

- Immobilize the arm, with the elbow in 10° to 20° flexion for 4 weeks. During immobilization, avoid active or passive adduction across the midline of the body, or forward flexion or abduction above 45°. When the cast is removed, fit the patient with a long arm splint with elbow hinges with hinge stops (Fig. 68.7). The purpose of this brace is to allow strengthening of the transfer without stretching out the interposition graft. Under the close supervision of a therapist, the patient actively strengthens the transfer by elbow extension exercises, starting with an arc of 20° to 0°, and increasing by 10° increments as soon as she can extend against gravity through the allowed arc. At night the brace is set at no more than 20° flexion. When the patient is able to extend against gravity from 90° to 0°, the brace is removed during the day. Nighttime bracing should be continued for at least 6 to 12 months.

***Figure 68.7.*** Elbow hinge brace used after deltoid to triceps transfer.

## RESTORATION OF ELBOW EXTENSION: BICEPS TO TRICEPS TRANSFER

- The indications for this operation are controversial and are still being developed. At present, it is indicated when the deltoid is paralyzed, which occurs rarely in patients eligible for tendon transfer. Please refer to Revol et al. (50) for details.

## IC 0 OR 1: RESTORATION OF KEY PINCH AND GRASP. IMPLANTATION OF A FUNCTIONAL ELECTRICAL STIMULATION SYSTEM (NEUROPROSTHESIS)

- The implantation of this system is complex and highly individualized, and the details are beyond the scope of this text. Please refer to work by Keith and others for details (25,28,53).

## IC-1: RESTORATION OF KEY PINCH. BRACHIORADIALIS TO ECRB; FPL AND EPL TENODESIS; SPLIT FPL TRANSFER (11,20,24,41,45,48)

- Perform the operation under general anesthesia and tourniquet. Inject subcutaneous bupivacaine preoperatively in the planned incision sites.
- Through a curvilinear incision on the dorsoradial border of the forearm, identify the brachioradialis muscle and detach its insertion (just proximal to the floor of the first dorsal compartment). Dissect it proximally, to approximately the distal three quarters and proximal one quarter junction of the muscle-tendon unit, or until it has 3 cm excursion. Do not damage the dorsal radial sensory nerve, which travels immediately deep to the brachioradialis.
- *Split FPL transfer*: Through a zig-zag palmar incision centered over the interphalangeal joint of the thumb, identify the FPL tendon just proximal to its insertion (Fig. 68.8). Transect the radial half of the tendon and dissect proximally, placing a nonabsorbable suture at the base of the split of the Y. Expose the EPL through a zigzag dorsal incision just proximal to the interphalangeal joint flexion crease. Reroute the radial split FPL around the radial side of the thumb and weave it through the EPL, adjusting the tension so that the thumb interphalangeal joint flexes less than 20° when the wrist is passively extended; attach it to the EPL with nonabsorbable sutures, and splint the transfer internally with a transarticular Kirschner wire.

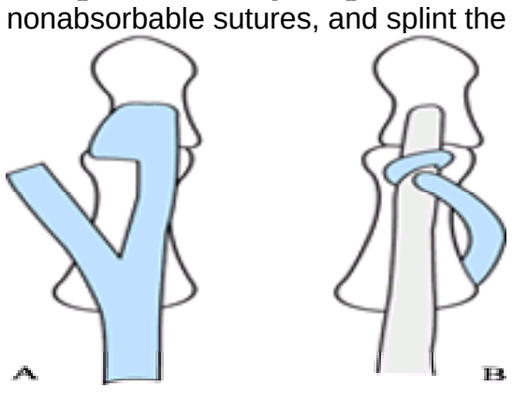

***Figure 68.8.*** Split FPL transfer (45). **A:** The radial half of the FPL tendon is detached. **B:** The detached portion of the FPL is inserted into the EPL. From Mohammed K, Walsh W, Peljovich AE, et al. *Anatomy and Neurological Relations to the Distal Deltoid.* May 1998; VI International Conference: Surgical Re-habilitation of the Upper Limb in Tetraplegia, Cleveland, OH: 874.

- *EPL tenodesis:* Identify the EPL tendon proximal to the dorsal retinaculum. Transect it and allow the proximal end to retract. Loop the distal end over the dorsal retinaculum, adjust the tension so that the thumb pad does not contact the index finger when the wrist is in flexion, and attach it to the retinaculum and to itself with nonabsorbable sutures. Alternatively, perform EPL tenodesis by passing it through two small holes in the distal radius (one on either side of Lister's tubercle) and suturing it back on itself. In addition, perform abductor pollicis longus (APL) tenodesis if this will help balance the thumb.
- *FPL tenodesis:* Through a longitudinal palmar incision over the distal forearm, identify the FPL tendon and transect it distal to its musculotendinous junction. Pass the tendon through two small elliptical windows in the cortex of the distal radius and adjust tension so the thumb pad firmly contacts the radial side of the index finger when the wrist is passively extended.
- Determine which radial wrist extensor tendon (ECRB, ECRL, or both) provides centralized wrist extension under passive tension, and weave the brachioradialis tendon through this wrist extensor (usually the ECRB alone). Set the tension with the elbow flexed at 90°, so that the transfer passively holds the wrist in slight extension, but still allows passive wrist flexion.
- Close all wounds with absorbable suture and apply a well-padded long arm cast with the elbow in 90° flexion, the forearm in neutral rotation, the wrist in 30° to 40° extension and the thumb in midrange radial and palmar abduction, with the interphalangeal joint in neutral.

***General Rehabilitation and Postoperative Principles***

- Immobilize the arm for 6 weeks, then begin active pinch training. No further protection is needed. Alternatively, remove the cast after 4 weeks and begin active ROM and pinch exercises supervised by an occupational therapist. Splint the wrist in 30° extension and the thumb in midrange abduction between exercises for 2 more weeks.

**IC-2: RESTORATION OF KEY PINCH. BRACHIORADIALIS TO FPL; EPL TENODESIS; SPLIT FPL TRANSFER (3,45,48,55,58)**

- Perform the operation under general anesthesia and tourniquet. Inject subcutaneous bupivcaine preoperatively in the planned incision sites.
- Perform the brachioradialis dissection and split FPL transfer and EPL tenodesis as outlined earlier (see the section on Restoration of Key Pinch for IC-1).
- Attach the brachioradialis tendon to the FPL tendon in the distal forearm with nonabsorbable suture. The FPL may be too small to accommodate weaving the brachioradialis; if this is the case, use an end-to-side attachment. Tension should be set with the elbow in 90° of flexion, so that the thumb contacts the long finger with the wrist in neutral.
- Close all wounds with absorbable suture and apply a bulky compressive dressing covered by a well-padded long arm cast, with the elbow in 90° flexion, the forearm in neutral rotation, the wrist in 30° to 40° extension, the thumb in midrange radial and palmar abduction, and the interphalangeal joint in neutral.

***General Rehabilitation and Postoperative Principles***

- Immobilize the arm for 6 weeks, then begin active pinch training. No further protection is needed. Alternatively, remove the cast after 4 weeks and begin active ROM and pinch exercises supervised by an occupational therapist. Splint the wrist in 30° extension and the thumb in midrange abduction between exercises for 2 more weeks.

**IC-3, IC-4, IC-5: RESTORATION OF KEY PINCH, HOOK GRASP, RELEASE, AND INTRINSIC BALANCE, AND (IC-4 AND IC-5 ONLY) RESTORATION OF THUMB ABDUCTION/OPPOSITION (8,9,10,12,14,21,22,27,38,44,60,61)**

- Perform the operations under general anesthesia and tourniquet. Inject subcutaneous bupivacaine preoperatively in the planned incision sites.
- *IC-3 Extensor phase: intrinsic tenodesis (Zancolli lasso)* (38,61). Through zigzag incisions centered over the distal palmar flexion crease of the finger, carefully pull on the FDS tendon distal to the $A_1$ pulley. Transect it at the chiasm. Avoid handling the FDP tendon. Attach the transected tendon to the palmar surface of the $A_1$ pulley with nonabsorbable suture, weaving it, if possible, after adjusting tension to create dynamic metacarpophalangeal joint flexion when the wrist is extended. Perform the same operation for the index, long, ring, and small fingers.
- *IC-4 and IC-5 extensor phase: intrinsic tenodesis (Zancolli lasso).* If the PT is present, it may be transferred during the flexor phase to abductor pollicis brevis (APB) to provide thumb abduction. Do not perform the Zancolli lasso procedure on the ring and small fingers if the PT is to be transferred to provide thumb abduction, because the ring FDS will be used to extend the PT.
- *IC-3, IC-4, and IC-5 extensor phase: extensor tenodesis.* Through a dorsal curvilinear forearm incision, identify the EDC, EPL, and APL tendons. Transect them distal to their musculotendinous junctions. Perform tenodeses by passing the EDC tendons through two small elliptical holes in the dorsal radius and by looping the EPL and APL around their dorsal retinacula. Adjust tension so that the fingers and thumb start to open (release) when the wrist is in neutral position, and fully release when the wrist is in flexion. Attach the EDC to itself, and the EPL and APL to the retinaculum, with nonabsorbable suture. Close all incisions with absorbable suture. Apply a bulky compressive dressing covered with a short arm cast, incorporating the thumb and metacarpophalangeal joints of the fingers. The wrist should be in extension, the metacarpophalangeal joints in 45° of flexion, and the thumb in radial and palmar abduction.
- *IC-3 flexor phase (at least 3 months after extensor phase; see* General Rehabilitation and Postoperative Principles *below):* Perform a split FPL transfer as described earlier (see the section on Restoration of Key Pinch for IC-1). Transfer the brachioradialis to the FPL as described above (see the section on Restoration of Key Pinch for IC-2). Transfer the ECRL to the index, long, ring, and small FDP as follows. First, through a palmar curvilinear forearm incision, suture the FDP tendons together with nonabsorbable suture, synchronizing them by adjusting their tension so that they flex in unison, with slightly more flexion in the ulnar digits; do not transect them (60). Make a generous window in the interosseous membrane proximal to the pronator quadratus. Transect the ECRL as far distal as possible, and pass it through the window to the palmar side of the forearm. Split it longitudinally and wrap it around the FDP tendons distal to their interattachment. Adjust the tension so that the fingertips touch the palm when the wrist is extended, and attach the ECRL to the FDP with nonabsorbable suture.
- *IC-4 and IC-5 flexor phase (at least 3 months after extensor phase; see*General Rehabilitation and Postoperative Principles *below):* Perform a split FPL transfer as described above (see the section on Restoration of Key Pinch for IC-1). Transfer the brachioradialis to the FPL as described earlier (see the section on Restoration of Key Pinch for IC-2). Transfer the ECRL to the index, long, ring, and small FDP as described earlier. Through the incision used to harvest the brachioradialis, identify and detach the PT. Transfer the PT to the ring FDS tendon in the distal forearm; because the PT tendon is broad, use an end-to-side or split and wrap around attachment, with nonabsorbable suture. Then detach the ring FDS at the chiasm, through a palmar incision at the level of the distal wrist flexion crease. Through a radial thumb incision at the level of the metacarpophalangeal flexion crease, expose the abductor pollicis brevis (APB) insertion. Split the ring FDS into two tails; attach one tail to the APB tendon and the other to the extensor hood, using nonabsorbable suture under enough tension to hold the thumb in radial abduction and to prevent it from supinating during pinch (9). Alternatively, the PT can be transferred to the FPL and the brachioradialis to the ring FDS (22).
- Close all incisions with absorbable suture. Apply a bulky compressive dressing covered with a long arm fiberglass cast with the elbow in 90° of flexion, the forearm in neutral rotation, the wrist in neutral, the fingers with metacarpophalangeal joints flexed and proximal interphalangeal joints extended, and the thumb in radial and palmar abduction.

***General Rehabilitation and Postoperative Principles***

- After the first stage, immobilize the arm for 6 weeks, then begin active transfer training and passive ROM exercises.
- Once the patient can activate the transfer well and ROM has returned to preoperative status (usually at least 3 months after the first operation), perform the second stage. After the second stage, immobilize the arm for 6 weeks, then resume active transfer training. No further protection is needed. Alternatively, remove the cast after 4 weeks and begin active ROM and pinch exercises supervised by an occupational therapist. Splint between exercises for 2 more weeks, with the wrist in neutral, the thumb in midrange abduction, and the fingers in flexion at the metacarpophalangeal joints and in extension at the proximal interphalangeal joints.

**IC-6 AND IC-7: RESTORATION OF KEY PINCH, HOOK GRASP, THUMB EXTENSION, INTRINSIC BALANCE, AND THUMB ABDUCTION/OPPOSITION (27,56)**

- Perform the operations under general anesthesia and tourniquet. Inject subcutaneous bupivacaine preoperatively in the planned incision sites.
- Perform the flexor phase as described earlier for IC-4 and IC-5. At the same anesthetic, add the Zancolli lasso as described earlier for IC-4 and IC-5.
- *IC-6*: Transfer EDQ to EPL, weaving the EDQ through the EPL and attaching it with nonabsorbable suture, after adjusting the tension as for EPL tenodesis.
- Close all incisions with absorbable suture. Apply a bulky compressive dressing covered with a long arm fiberglass cast with the elbow in 90° of flexion, the forearm in neutral rotation, the wrist in neutral, the fingers with metacarpophalangeal joints flexed and proximal interphalangeal joints extended, and the thumb in

radial and palmar abduction.

***General Rehabilitation and Postoperative Principles***

- Immobilize the arm for 6 weeks, then begin active pinch, grasp, and (IC-6 only) thumb extension training. No further protection is needed. Alternatively, remove the cast after 4 weeks and begin active ROM and pinch exercises supervised by an occupational therapist. Splint between exercises for 2 more weeks, with the wrist in neutral, the thumb in midrange abduction, and the fingers in flexion at the metacarpophalangeal joints and in extension at the proximal interphalangeal joints.

**IC-8 AND IC-9: RESTORATION OF INTRINSIC BALANCE AND THUMB ABDUCTION/OPPOSITION**

- Perform the operations under general anesthesia and tourniquet. Inject subcutaneous bupivacaine preoperatively in the planned incision sites.
- Perform the intrinsic tenodesis as described earlier. Transfer the ring FDS to the APB as described earlier, except the proximal attachment to PT is unnecessary if the ring FDS is sufficiently strong enough to provide thumb abduction/opposition.
- Close all incisions with absorbable suture. Apply a bulky compressive dressing covered with a short arm fiberglass cast with the wrist in neutral, the fingers with metacarpophalangeal joints flexed and proximal interphalangeal joints extended, and the thumb in radial and palmar abduction.

***General Rehabilitation and Postoperative Principles***

- Immobilize the arm for 6 weeks, then begin active pinch and grasp training. No further protection is needed. Alternatively, remove the cast after 4 weeks and begin active ROM and pinch exercises supervised by an occupational therapist. Splint between exercises for 2 more weeks, with the wrist in neutral, the thumb in midrange abduction, and the fingers in flexion at the metacarpophalangeal joints and in extension at the proximal interphalangeal joints.

## PITFALLS AND COMPLICATIONS

People with tetraplegia require expert and highly specialized preoperative, intraoperative, and postoperative care to prevent complications such as latex allergy, hypotension, pressure sores, pneumonia, wound infections, urinary tract infections, and autonomic dysreflexia.

## AUTHOR'S PERSPECTIVE

- Upper extremity reconstruction in tetraplegia is best performed by an experienced hand surgeon, because proper tensioning of tendon transfers remains a skill honed by practice. The surgeon's job is easier and the results of surgery are probably better if a rehabilitation team is available to help care for the patient in the perioperative period.
- Many patients benefit from intensive in-patient occupational and physical therapy after cast immobilization is discontinued. Intensive (twice-per-day) therapy sessions before and after large muscle transfer, such as deltoid-to-triceps transfer, allow the patient to strengthen the transferred muscle, and thereby improve the outcome of this operation. Travel to and from the therapist can be difficult for people with tetraplegia, so performing the therapy in an in-patient setting also enhances compliance.
- People with tetraplegia who are contemplating surgery can benefit enormously from meeting with others who have undergone the same operation or operations. If possible, these meetings should take place away from the hospital or physician's office, so the patients can talk freely. Tetraplegics who have worked hard to gain independence may be especially reluctant to undergo surgery because of fear of decreased independence during immobilization or after surgery.
- Although neuroprostheses are an exciting development, from a practical standpoint, they are not widely useful. Implantation and postoperative therapy are very complicated and require a highly motivated patient, surgeon, and therapist. The cost of the system (excluding the cost of the implantation surgery and preoperative and postoperative therapy) is more than $25,000. The biggest drawback, however, is that the patient with a neuroprosthesis in place requires assistance to don and doff the apparatus that makes the neuroprosthesis work.
- The split FPL transfer is a simple and very useful operation that allows the patient to gain thumb tip stability while maintaining thumb interphalangeal joint flexibility.
- A weak deltoid muscle is not a contraindication to deltoid-to-triceps transfer. If the muscle is weak, a larger portion—or even the entire deltoid—can be transferred to increase elbow extension power.

---

[1] Some experts believe that IC-2 cannot be distinguished from IC-3 on examination alone, and surgical exposure under local anesthesia is required to assess ECRB strength (39). In many cases, however, patients with IC-2 SCI will show radial deviation with active wrist extension. In patients with IC-3 SCI, a groove may be visible between ECRB and ECRL muscle bellies in the proximal forearm with resisted wrist extension (44).

[2] Some authors have recommended performing the intrinsic tenodesis during the flexor stage instead of the extensor stage (22). In theory, this may reduce the likelihood of FDP adhesions, because active FDP motion will begin sooner after the flexor stage than after the extensor stage. In addition, the optimal position of immobilization following intrinsic tenodesis is more compatible with the flexor stage. However, immobilization of the metacarpophalangeal joints in neutral or extension, however desirable to optimize finger extension following extensor tenodesis, is likely to lead to extension contractures of these joints, rendering the intrinsic tenodesis less effective.

## CHAPTER REFERENCES

Each reference is categorized according to the following scheme: *, classic article; #, review article; !, basic research article; and +, clinical results/outcome study.


+ 1. Allieu Y, Benichou M, Tessier P, et al. La Reanimation du Membre Superieur du Tetraplegique par Transferts Tendineux. *Chirurgie* 1986;112:736.

* 2. Boyes JH. *Bunnell's Surgery of the Hand*. Philadelphia: JB Lippincott Company, 1964:453.

+ 3. Brys D, Waters RL. Effect of Triceps Function on the Brachioradialis Transfer in Quadriplegia. *J Hand Surg* 1987;12A:237.

+ 4. Castro-Sierra A, Lopez-Pita A. A New Surgical Technique to Correct Triceps Paralysis. *Hand* 1983;15:42.

+ 5. Davis SE, Mulcahey MJ, Betz RR, et al. Outcomes of Upper Extremity Tendon Transfers and Functional Electrical Stimulation in an Adolescent with C5 Tetraplegia. *Am J Occup Ther* 1997;51:307.

+ 6. DeBenedetti M. Restoration of Elbow Extension Power in the Tetraplegic Patient Using the Moberg Technique. *J Hand Surg* 79;4:86.

+ 7. Ditunno JFJr, Stover SL, Freed MM, Ahn JH. Motor Recovery of the Upper Extremities in Traumatic Quadriplegia: A Multicenter Study. *Arch Phys Med Rehabil* 1992;73:436.

# 8. Ejeskar A, Dahilof A. Results of Reconstruction Surgery in the Upper Limb of Tetraplegic Patients. *Paraplegia* 1988;26:204.

+ 9. Freehafer AA. Tendon Transfers in Patients with Cervical Spinal Cord Injury. *J Hand Surg* 1991;16A:804.

+ 10. Freehafer AA, Kelly CM, Peckham PH. Tendon Transfer for the Restoration of Upper Limb Function after a Cervical Spinal Cord Injury. *J Hand Surg* 1984;9A:887.

+ 11. Freehafer AA, Mast WA. Transfer of the Brachioradialis to Improve Wrist Extension in High Spinal Cord Injury. *J Bone Joint Surg* 1967;49A:648.

+ 12. Freehafer AA, Vonhaam E, Allen V. Tendon Transfers to Improve Grasp after Injuries of the Cervical Spinal Cord. *J Bone Joint Surg* 1974;56A:951.

* 13. Friedenberg ZB. Transposition of the Biceps Brachii for Triceps Weakness. *J Bone Joint Surg* 1954;36A:656.

+ 14. Gansel J, Waters R, Gellman H. Transfer of the Pronator Teres Tendon to the Tendons of the Flexor Digitorum Profundus in Tetraplegia. *J Bone Joint Surg* 1990;72A:427.

+ 15. Grover J, Gellman H, Waters RL. The Effect of a Flexion Contracture of the Elbow on the Ability to Transfer in Patients Who Have Quadriplegia at the Sixth Cervical Level. *J Bone Joint Surg* 1996;78A:1397.

+ 16. Heinemann AW, Yarkony GM, Roth EJ, et al. Functional Outcome Following Spinal Cord Injury. A Comparison of Specialized Spinal Cord Injury Center vs. General Hospital Short-term Care. *Arch Neurol* 1989;46:1098.

# 17. Hentz VR, Brown M, Keoshian L. Upper Limb Reconstruction in Quadriplegia: Functional Assessment and Proposed Treatment Modifications. *J Hand Surg* 1983;8:119.

# 18. Hentz VR, Hamlin C, Keoshian LA. Surgical Reconstruction in Tetraplegia. *Hand Clin* 1988;4:601.

+ 19. House JH. Reconstruction of the Thumb in Tetraplegia Following Spinal Cord Injury. *Clin Orthop* 1985;195:117.

+ 20. House JH, Comadoll J, Dahl AL. One-stage Key Pinch and Release with Thumb Carpal-metacarpal Fusion in Tetraplegia. *J Hand Surg* 1992;17A:530.

+ 21. House JH, Gwathmey FW, Lundsgaard DK. Restoration of Strong Grasp and Lateral Pinch in Tetraplegia due to Cervical Spinal Cord Injury. *J Hand Surg* 1976;1:152.

+ 22. House JH, Shannon MA. Restoration of Strong Grasp and Lateral Pinch in Tetraplegia: A Comparison of Two Methods of Thumb Control in Each Patient. *J Hand Surg* 1985;10A:22.

+ 23. James MA, Nelson MA. *Deltoid to Triceps Transfer in Teenagers with Tetraplegia.* May 1998; VI International Conference: Surgical Rehabilitation of the Upper Limb in Tetraplegia, Cleveland OH.

+ 24. Johnson DL, Gellman H, Waters RL, Tognella M. Brachioradialis Transfer for Wrist Extension in Tetraplegic Patients Who Have Fifth-cervical-level Neurological Function. *J Bone Joint Surg* 1996;78A:1063.

+ 25. Keith MW, Kilgore KL, Peckham PH, et al. Tendon Transfers and Functional Electrical Stimulation for Restoration of Hand Function in Spinal Cord Injury. *J Hand Surg* 1996;21A:89.

# 26. Keith MW, Peckham PH, Thrope GB, et al. Functional Neuromuscular Stimulation Neuroprostheses for the Tetraplegic Hand. *Clin Orthop* 1988;233:25.

+ 27. Kelly CM, Freehafer AA, Peckham PH, Stroh K. Postoperative Results of Oppenensplasty and Flexor Tendon Transfer in Patients with Spinal Cord Injuries. *J Hand Surg* 1985;10A:890.

+ 28. Kilgore KL, Peckham PH, Keith MW, et al. An Implanted Upper Extremity Neuroprosthesis. Follow-up of Five Patients. *J Bone Joint Surg* 1997;79A:533.

+ 29. Kirsch RF, Acosta AM, Perreault EJ, Keith MW. Measurement of Isometric Elbow and Shoulder Moments: Postition-dependent Strength of Posterior Deltoid-to-triceps Muscle Tendon Transfer in Tetraplegia. *IEEE Trans Rehabil Eng* 1996;4:403.

+ 30. Kornsgold LM, Herbison GJ, Decena BF, Ditunno JFJ. Biceps vs. Extensor Carpi Radialis Recovery in Frankel Grades A and B in Spinal Cord Injury Patients. *Paraplegia* 1994;32:340.

+ 31. Kuz J, Van Heest A, House J. Biceps-to-triceps Transfer in Tetraplegic Patients: Report of the Medial Routing Techique and Follow-up of Three Cases. *J Hand Surg* 1999;24A:161.

+ 32. Lacey SH, Wilber G, Peckham PH, Freehafer AA. The Posterior Deltoid to Triceps Transfer: A Clinical and Biomechanical Assessment. *J Hand Surg* 1986;11A:542.

+ 33. Lamb DW, Chan KM. Surgical Reconstruction of the Upper Limb in Traumatic Tetraplegia. A Review of 41 Patients. *J Bone Joint Surg* 1985;65B:291.

* 34. Lamb DW, Landry R. The Hand in Quadriplegia. *Hand* 1971;3:31.

* 35. Lamb DW, Landry R. The Hand in Quadriplegia. *Paraplegia* 1972;9:204.

# 36. LeClercq C, McDowell CL. 4th International Conference on Surgical Rehabilitation of the Upper Limb in Tetraplegia. *Annals of Hand and Upper Limb Surgery (France)* 1991;259.

* 37. Lipscomb PR, Elkins EC, Henderson ED. Tendon Transfers to Restore Function of Hands in Tetraplegia, Especially Fracture-dislocation of the Sixth Cervical Vertebra on the Seventh. *J Bone Joint Surg* 1958;40A:1071.

+ 38. McCarthy CK, House JH, Van Heest A, et al. Intrinsic Balancing in Reconstruction of the Tetraplegic Hand. *J Hand Surg* 1997;22A:596.

# 39. McDowell CL, Moberg EA, House JH. The Second International Conference on Surgical Rehabilitation of the Upper Limb in Tetraplegia (Quadriplegia). *J Hand Surg* 1986;11A:604.

# 40. McDowell CL, Moberg EA, Smith AG. International Conference on Surgical Rehabilitation of the Upper Limb in Tetraplegia. *J Hand Surg* 1979;4:387.

* 41. Moberg E. Surgical Treatment for Absent Single-hand Grip and Elbow Extension in Quadriplegia. *J Bone Joint Surg* 1975;57A:196.

* 42. Moberg E. Reconstructive Hand Surgery in Tetraplegia, Stroke, and Cerebral Palsy: Some Basic Concepts in Physiology and Neurology. *J Hand Surg* 1976;1:29.

+ 43. Moberg E. The Unsolved Problem—How to Test the Functional Value of Hand Sensibility. *J Hand Ther* 1991;4:105.

+ 44. Mohammed KD, Rothwell AG, Sinclair SW, et al. Upper-limb Surgery for Tetraplegia. *J Bone Joint Surg* 1992;74B:873.

+ 45. Mohammed K, Walsh W, Peljovich AE, et al. *Anatomy and Neurological Relations to the Distal Deltoid.* May 1998; VI International Conference: Surgical Rehabilitation of the Upper Limb in Tetraplegia, Cleveland, OH.

+ 46. Mulcahey MJ, Betz RR, Smith BT, et al. Implanted Functional Electrical Stimulation Hand System in Adolescents with Spinal Injuries: An Evaluation. *Arch Phys Med Rehabil* 1997;78:597.

* 47. Nickel VL, Perry J, Garrett AL. Development of Useful Function in the Severely Paralyzed Hand. *J Bone Joint Surg* 1963;45A:933.

+ 48. Paul SD, Gellman H, Waters R, et al. Single Stage Reconstruction of Key Pinch and Extension of the Elbow in Tetraplegic Patients [See comments]. *J Bone Joint Surg* 1994;76A:1451.

# 49. Peckham PH, Freehafer AA, Keith MW. The Influence of Muscle Properties in Tendon Transfer. In: Brand PW and Hollister A, ed. *Clinical Mechanics of the Hand*. St. Louis: Mosby–Year Book, 1993:353-363.

+ 50. Revol M, Briand E, Servant JM. Biceps-to-triceps Transfer in Tetraplegia. *J Hand Surg* 1999;24B:235.

# 51. Smith RJ. Principles of Tendon Transfers. In: Smith RJ, ed. *Tendon Transfers of the Hand and Forearm*. Boston: Little, Brown and Company, 1987;13.

# 52. Smith RJ. Tendon Transfers for Quadriplegia. In: Smith RJ, ed. *Tendon Transfers of the Hand and Forearm*. Boston: Little, Brown, 1987:297.

+ 53. Triolo R, Nathan R, Handa Y, et al. Challenges to Clinical Deployment of Upper Limb Neuroprostheses. *J Rehabil Res Dev* 1996;33:111.

+ 54. Vogel LC, Schrader T, Lubicky JP. Latex Allergy in Children and Adolescents with Spinal Cord Injuries. *J Pediatr Orthop* 1995;15:517.

+ 55. Waters RL, Adkins RH, Yakura JS, Sie I. Motor and sensory recovery following incomplete tetraplegia. *Arch Phys Med Rehabil* 1994;75:306.

# 56. Waters RL, Gellman H, Tognella M. Functional Hand Surgery Following Tetraplegia. *Arch Phys Med Rehabil* 1996;77:86.

+ 57. Waters R, Moore KR, Graboff SR, Paris K. Brachioradialis to Flexor Pollicis Longus Tendon Transfer for Active Lateral Pinch in the Tetraplegic. *J Hand Surg* 1985;10A:385.

+ 58. Waters RL, Stark LZ, Gubernick I, et al. Electromyographic Analysis of Brachioradialis to Flexor Pollicis Longus Tendon Transfer in Quadriplegia. *J Hand Surg* 1990;15A:335.

+ 59. Yarkony GM, Roth E, Lovell L. Rehabilitation Outcomes in 120 Patients with C5 Quadriplegia. *Arch Phys Med Rehabil* 1987;68:672.

* 60. Zancolli EA. Surgery for the Quadriplegic Hand with Active, Strong Wrist Extension Preserved. A Study of 97 Cases. *Clin Orthop* 1975;112:101.

* 61. Zancolli EA. Functional Restoration of the Upper Limbs in Traumatic Quadriplegia. In: Zancolli EA, ed. *Structural and Dynamic Bases of Hand Function*. Philadelphia: J.B. Lippincott, 1978:229.

# CHAPTER 69

# CONGENITAL HAND MALFORMATIONS

*Michelle A. James*

**Michelle A. James:** Associate Clinical Professor, Department of Orthopaedic Surgery, University of California–Davis, Shriners Hospital for Children, Northern California, Sacramento, California, 95817.

Pathophysiology
Prenatal Development of the Hand
Genetics
Classification and Terminology
Principles of Treatment
Timing of Surgery
Skeletal Age
Congenital Hand Malformation Team
Peer Contact and Support Groups
Occupational Therapy and Therapeutic Recreation
Pain Control and Postoperative Care
The Thumb
Polydactyly
Pitfalls and Complications
Author's Perspective
Hypoplasia and Absence
Pitfalls and Complications
Author's Perspective
Trigger Thumb
Pitfalls and Complications
Author's Perspective
Clasped Thumb
Pitfalls and Complications
Author's Perspective
Triphalangeal Thumb
Pitfalls and Complications
Author's Perspective
The Fingers
Polydactyly
Pitfalls and Complications
Author's Perspective
Transverse Failure of Formation (Hypoplasia and Absence)
Pitfalls and Complications
Author's Perspective
Syndactyly
Pitfalls and Complications
Author's Perspective
Camptodactyly
Pitfalls and Complications
Author's Perspective
Clinodactyly and Longitudinal Epiphyseal Bracket (Delta Phalanx)
Pitfalls and Complications
Author's Perspective
Constriction Ring Syndrome
Pitfalls and Complications
Author's Perspective
The Hand, Wrist, and Forearm
Central Deficiency (Cleft Hand)
Pitfalls and Complications
Author's Perspective
Radius Deficiency
Pitfalls and Complications
Author's Perspective
Ulna Deficiency
Pitfalls and Complications
Author's Perspective
Madelung Deformity
Pitfalls and Complications
Author's Perspective
Acknowledgments
Chapter References

The hand connects the developing child to the world. The child's use of the hand enables the development of intelligence, and thereby language and culture (229). Remarkably, the child whose hands are malformed or even absent but whose brain is normal develops almost normally. As Southwood wrote in 1926 regarding congenital deficiency of the ulna, “From the functional viewpoint… the deformed limb is much more useful than its anatomical condition would have led one to expect” (190, p. 349). Few surgical operations have been conclusively proven to improve the function of the child's malformed hand, and surgeons tend to take credit for improvement that occurs because of growth and development.

Often, the biggest challenge to the family of a child with a malformed hand is the psychological adjustment to the hand's appearance (17). The hand surgeon is an educator and counselor, and when the family and surgeon share the goals of treatment, everyone is more satisfied with the outcome.

## PATHOPHYSIOLOGY

### PRENATAL DEVELOPMENT OF THE HAND

In the human embryo, upper limb buds appear 26 to 28 days after fertilization. During the next 25 days, the upper limb is completely differentiated (59,237).

The position of a cell on the limb bud during early development determines the fate of that cell. Growth occurs along three axes, and each growth axis is controlled by a key area of the upper limb: the apical ectodermal ridge (AER) promotes growth along the proximodistal axis; the zone of polarizing activity (ZPA) promotes growth along the anteroposterior axis, which is radioulnar in the embryo; and the dorsal ectoderm promotes growth along the dorsoventral axis (175,237).

Several different chemical signals induce or regulate activity of these key areas. These include fibroblast growth factors (FGF) expressed in the AER; FGF-8 may induce AER formation, and FGF-4 and FGF-8 together can replace AER function. Retinoic acid and sonic hedgehog protein together mediate the activity of the ZPA. Mice lacking Wnt-7a, a signaling molecule encoded by the Wnt gene family (and expressed in the dorsal ectoderm), show alterations in dorsoventral polarity (Table 69.1) (175,237). These chemical signals interact with each other infeedback loops: Sonic hedgehog induces the formation of an FGF, thereby influencing the AER, and sonic hedgehog expression depends on Wnt-7a (175,237). Chemical signals from the AER and ZPA also regulate the expression of homeobox (Hox) genes, which control the expression of other genes, confer positional information on different cell types, and determine limb patterns such as digit identity (118,175).

| Key areas | Growth promotion axis | Mediating factors |
|---|---|---|
| Apical ectodermal ridge (AER) | Proximodistal | Fibroblast growth factors FGF-4 and FGF-8 |
| Zone of polarizing activity (ZPA) | Anteroposterior | Retinoic acid and sonic hedgehog protein |
| Dorsal ectoderm | Dorso-ventral | Wnt-7a (mice) |

***Table 69.1. Key Areas Controlling Upper Growth in the Embryo (175,237)***

Congenital hand malformations may be caused by damage to the AER, ZPA or dorsal ectoderm, or faulty genetic control of these three essential control areas. In humans, researchers have localized the genes responsible for some congenital hand malformations, including preaxial polydactyly (237); in mice, this same malformation has been shown to be due to an additional ZPA on the limb bud, and the mutant genes responsible for ZPA duplication have been well mapped (134). Genetically programmed hand malformations may eventually become preventable, once their mechanisms are understood well enough to be manipulated.

### GENETICS

In large population studies, the reported incidence of congenital anomalies of the upper extremity varies between 3.4 and 16 cases per 10,000 live births (58,68,108,204). Most congenital malformations are more common in boys. Anomalies may be caused by genetic or environmental factors, or some combination of these. Genetic malformations are caused by chromosomal abnormalities, or single (mendelian) or multiple (polygenic) gene disorders. The genetic addresses of several hand malformations (two types of polydactyly, cleft hand and foot, and brachydactyly) are known (237). The next step after genetic localization is identification of the nucleotide sequence mutation; the genetic mutations causing several different orthopaedic conditions have already been identified (40).

The geneticist is an important member of the congenital hand malformation team. He or she keeps up with the rapid accumulation of new information in the field of molecular genetics, helps diagnose anomalies outside the musculoskeletal system (which are associated with more than 80% of heritable limb deficiencies [230]) and provides genetic counseling to families (32). Many hand anomalies are visible on prenatal ultrasound (18,39,77,170); genetic counseling is especially useful in this event.

### CLASSIFICATION AND TERMINOLOGY

The ideal classification system would be based on etiology, but little is known about the etiology of many congenital hand deformities. We know enough to understand that the same underlying cause can have many different effects, and the same effect can have a myriad of causes. Classification schemes also help the surgeon determine the prognosis and treatment, provide common nomenclature to describe observed conditions, and allow surgeons to communicate.

The most commonly used classification system for congenital upper limb malformations was originally proposed in 1968 by Swanson, Barsky, and Entin (196), and adopted in a modified form by the American Society for Surgery of the Hand and the International Federation of Societies for Surgery of the Hand (ASSH/IFSSH) in 1983 (Table 69.2) (195). Although this system has been used in at least two large studies of congenital hand anomalies (38,108), it is complex, many anomalies fit into more than one category, and some anomalies defy classification.

1. Failure of formation of parts (arrest of development)
   - Transverse arrest
   - Longitudinal arrest
2. Failure of differentiation (separation) of parts
3. Congenital tumorous conditions
4. Duplication
5. Overgrowth
6. Undergrowth
7. Congenital constriction ring syndrome
8. Generalized skeletal abnormalities

Modified from Swanson AB. A Classification for Congenital Limb Malformation. *J Hand Surg* 1976;1:8.

***Table 69.2. ASSH/IFSSH Classification of Congenital Upper Limb Malformations (195)***

Four different terms are used to refer to different mechanisms of dysmorphogenesis (173). Malformation is an interruption of normal morphogenesis, following which the affected structures fail to revert to normal form; most of the conditions described in this chapter are malformations. Deformation is the alteration in shape of structure that has differentiated normally. Disruptions or disruption sequences are structural defects resulting from destruction of a part that has differentiated normally, such as constriction ring syndrome. Dysplasia is the abnormal growth or differentiation of a structure.

## PRINCIPLES OF TREATMENT

### TIMING OF SURGERY

Whereas the surgeon focuses primarily on function, many parents and older children are extremely concerned about the appearance of the malformed hand. They may hope that surgery can make the hand appear normal, but normal appearance is possible only with certain types of malformations. Surgery to alter appearance is elective. If the outcome will be the same regardless of age, surgery should be postponed until the child is older than 2 years of age, when general anesthesia is safer (78). Surgery performed before the child starts school may reduce teasing by other children and prevent school absence. The parent and older child should share the surgeon's goals, and understand the risks and likely outcome of surgery.

Some operations improve both function and appearance, and have a better outcome if they are performed early. For example, thumb-index syndactyly release should be performed by the age of 6 months (65) and centralization for longitudinal deficiency of the radius by the age of 1 year (60). In these cases, the increased risk of anesthesia is outweighed by the benefits of surgery, if an experienced pediatric anesthesiologist is available (78) and if the infant does not have a bleeding disorder, heart anomalies, or other condition that further increases anesthetic risk.

The surgeon must be familiar with normal developmental milestones in order to assess the functional abilities of a child with a malformed hand. Palmar grasp with the thumb out of the palm begins at around 5 months of age, with the wrist held in flexion. By 9 months, most infants extend the wrist with grasp, and by 10 months they are able to oppose thumb tip to index tip precisely and to control voluntary release (59). When evaluating functional results of an operation performed on the hand of a small child, the surgeon should attribute to surgery only those functional improvements that are beyond what would be expected for a child of the same age with the same disability.

Most children younger than the age of 3 years do not notice a hand difference in themselves, and early motor development is unaffected by most upper extremity malformations. Infants with transverse or longitudinal deficiencies use both upper limbs or unilateral brachiothoracic grasp for prehension and may scoot instead of crawling, but these alternative developmental pathways are not deficiencies. Children in this age group adapt remarkably well to hand malformations, and parents of older infants and toddlers with hand malformations usually marvel at their child's abilities.

Children between the ages of 4 and 8 years with transverse and longitudinal deficiencies may have difficulty performing advanced dressing and hygiene activities (see

the section entitled Occupational Therapy and Therapeutic Recreation). They are in the process of developing a self-image. Surgery that significantly changes the appearance of a malformed hand will be easier psychologically for children younger than age 4 or older than age 8 years, because between these ages, they are old enough to understand what is happening but not old enough to understand why. Assuming normal intellectual development, after age 8 years children begin to gain the ability to reason, make stable choices, and give assent to elective surgery. Giving assent refers to the capacity of the child with developing decision-making skills to understand the proposed operation and agree to proceed. Obtain the assent of children older than age 8 years before proceeding with any elective operation.

In most cases, simultaneous surgery on bilateral hand malformations is contraindicated, because postoperative bilateral immobilization is frustrating for the younger child and disabling for the older child. If the operations are small and do not require cast immobilization, or if the child is very young for whom anesthesia poses a high risk, the inconvenience of bilateral immobilization may be outweighed by the benefit of simultaneous bilateral surgery. Long arm (above-elbow) casts are used for the postoperative immobilization of the hands of infants and younger children, who tend to wiggle out of short arm casts.

### SKELETAL AGE

Skeletal immaturity is not a contraindication to most operations used to reconstruct congenital hand malformations. The surgeon should take care to avoid injuring the physis of a growing bone unless the intent of the operation is to retard growth. Arthrodesis of digital joints can be performed in children without damaging the physis (105). Children with congenital hand malformations should be reexamined periodically until they reach skeletal maturity, to identify progressive deformities or recurrence of surgically corrected abnormalities (109).

### CONGENITAL HAND MALFORMATION TEAM

Congenital hand malformations are rarely encountered by most physicians. Complex malformations are most effectively treated by an experienced hand surgeon with the support of a congenital hand malformation team. The hand surgeon directs the child's care, with the assistance and support of the nursing and social services staff, who help educate the family and coordinate care. Other team members include the occupational therapist (see later), the orthotist and prosthetist, child life and therapeutic recreation specialists, a geneticist, a pediatric anesthesiologist, and a medical librarian.

### PEER CONTACT AND SUPPORT GROUPS

Parents of a newborn with a congenital hand malformation often feel bewildered and guilty, and underestimate their child's future abilities. The orthopaedic surgeon may be the first person parents encounter who is knowledgeable about their child's condition. The surgeon can be very helpful to the parents if he or she listens to them and answers their questions carefully and thoroughly. The first visit with parents of an infant with a hand deformity cannot be rushed.

Although some parents adjust rapidly, others have more difficulty accepting their child's malformation. Individual differences in parental adjustment do not relate to the severity or type of malformation, but rather to the amount of family support available (17) and other factors. Many parents benefit from meeting an older child with a similar malformation and his or her family. Parents and older children who are planning to proceed with an operation that changes the appearance of the hand, such as pollicization, may also benefit from meeting a child who has undergone the same procedure. The congenital hand malformation team can maintain a database of families willing to be peer contacts, to facilitate matching parents and children with an appropriate peer, and a list of family support groups for different syndromes, internet addresses for relevant websites, and handouts including *Children with Hand Differences: A Guide for Families,*[*] and *Superkids* newsletter.[†] The social worker can help refer families for psychological counseling when necessary.

### OCCUPATIONAL THERAPY AND THERAPEUTIC RECREATION

Children whose malformations limit more advanced functional abilities benefit from consultation with an occupational therapist at around age 3 years and again when they are ready to start school. On-going occupational therapy is indicated when the child is not meeting developmental milestones or is unable to perform age-appropriate activities of daily living. The child life therapist or therapeutic recreation specialist can suggest play activities intended to support the child's self-esteem and help the family and child adapt toys and recreational activities to the child's abilities.

### PAIN CONTROL AND POSTOPERATIVE CARE

Regional anesthesia is inadequate for pediatric hand surgery. Supplement general anesthesia with local anesthetic, and administer intravenous narcotic pain medication postoperatively until the child can take oral pain medication. Most children require pain medication for only 48 to 72 hours after surgery. Use a long arm fiberglass cast shell to cover the postoperative bulky compressive dressing (Fig. 69.1). If the cast does not turn a corner (the flexed elbow), the younger child will wriggle out of it. Release the tourniquet at least 10 minutes before dressing and cast application, to confirm the vascularity of the operated digit or digits and to allow for swelling. Apply the cast without stretching the fiberglass casting tape; the patient may be too young to complain of a too-tight dressing or cast.

***Figure 69.1.*** Long arm, flexed elbow fiberglass mitten cast shell, covering a bulky compressive hand dressing.

## THE THUMB

### POLYDACTYLY

#### *Assessment, Indications, and Relative Results*

In the United States, polydactyly is the second most common congenital hand malformation (after syndactyly), and the thumb is the most common duplicated or split digit (52). In China, thumb polydactyly is the most common congenital hand anomaly (86). Although the incidence of thumb polydactyly is most often sporadic, when it is associated with syndactyly, or when one or both of the bifid thumbs is triphalangeal, it is more likely to be caused by a genetic mutation; in these cases, it has been mapped to a specific gene (82,181). Polydactyly is caused experimentally by early disruption of the ZPA (237).

Thumb duplication may occur at the level of the carpometacarpal joint (CMCJ), metacarpal, metacarpophalangeal joint (MPJ), proximal phalanx, interphalangeal joint (IPJ), or distal phalanx. Split thumbs are thinner and shorter than normal, and have stiff joints, hypoplastic tendons with anomalous interconnections, and abnormal vascular anatomy; thus, neither has completely normal function (57). The ulnar thumb is usually larger and more functional than the radial thumb (57,158,179,222), but when the two “halves” are equal in size, or when both are triphalangeal, both are likely to be severely hypoplastic (85).

The Wassel type I thumb (Fig. 69.2) may have a wider than normal distal phalanx, with the remainder of the thumb entirely normal; this condition does not require surgical reconstruction. Wassel type I thumbs with duplication of the distal phalanx, and Wassel type II thumbs may be treated with a combination procedure, as described by Bilhaut (14).[*] In this procedure, the surgeon removes a central wedge of tissue (including bone, joint, physis, and nail bed and skin), and joins the two remaining parts together. No large series of Bilhaut procedures has been published. This procedure always causes a ridged nail, and if performed in a more proximal duplication, joint stiffness and growth arrest may occur (57,69,85,148,206). Most authors agree that this operation should be reserved for distally duplicated thumbs (Wassel type I or II) that are approximately equal in size.

***Figure 69.2.*** Wassel classification of thumb polydactyly.

For the remaining Wassel types, simple ablation of one split thumb is inadequate. Elements of the excised thumb, including collateral ligament, skin, and tendons, are used to augment the preserved thumb (29,57,85,122,158,206), to reduce the risk of angulation and joint instability (50,69,117,133,148,179,222). Reconstruction includes collateral ligament reconstruction, tendon realignment, and osteotomy, with the goals of stable and well-aligned joints, with the physes perpendicular to the long axis of the thumb. Even the carefully reconstructed thumb may angulate or develop joint instability with growth. Schedule follow-up visits for the child until he or she is skeletally mature, because more surgery, including osteotomy or an MPJ arthrodesis, may be necessary (96,98,105,122,148,158).

### *Classifications*

Geneticists divide thumb polydactyly into four types, based on associated malformations (201). Hand surgeons usually use the classification scheme described by Wassel, based on the level of duplication (Fig. 69.2 and Fig. 69.3) (222).

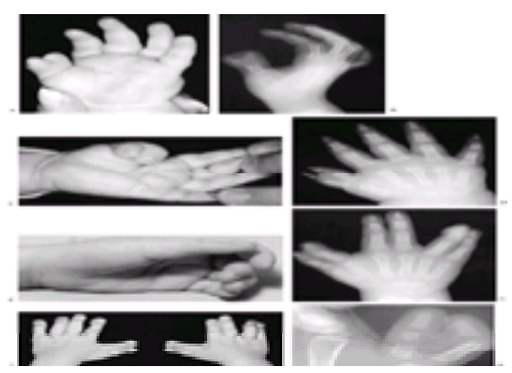

***Figure 69.3.*** Thumb polydactyly. **A:** Type I. **B:** Type II (although the two distal phalanges are joined by cartilage at the base). **C:** Type IV, preoperative. **D:** Type IV. **E:** Type IV, postoperative. **F:** Type VI. **G:** Type VI. **H:** Type VII.

Horii et al. has subdivided Wassel type IV into four subtypes (Fig. 69.4) (85). Light has also modified the classification described by Wassel, focusing on clinically apparent differences; he points out that Wassel's illustration of type IV thumbs is inconsistent with the remainder of the classification, because two proximal phalanges share a single epiphysis (Fig. 69.2) (110).

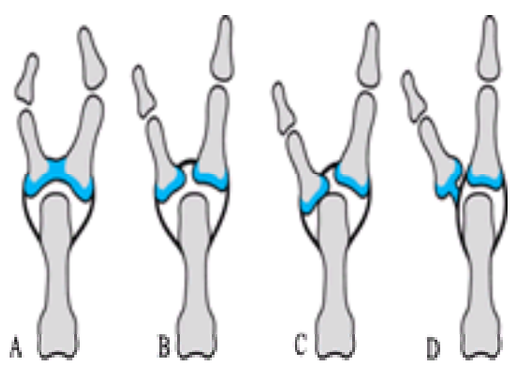


***Figure 69.4.*** Horii et al.'s subdivisions of Wassel type IV thumb polydactyly into four types.

### *Preoperative Management*

Inform parents that the retained reconstructed thumb will always be smaller than the contralateral normal thumb, and that further reconstructive surgery may be required. Describe the thumb as split rather than as duplicated, to help parents understand why the preserved thumb will not be normal (57).

### *Preoperative Planning*

Although many surgeons prefer to ablate the extra thumb and reconstruct the remaining thumb before the child's first birthday (57,86,158), there is only anecdotal evidence that the benefits of early surgery outweigh the increased risk of general anesthesia in infants younger than 1 year of age. If both thumbs are equal in size and the child uses them both, postpone surgery until the child is old enough to undergo functional testing to determine which thumb is the more functional. The extrinsic tendon anomalies found at surgery usually cannot be specifically diagnosed preoperatively, so be prepared to transfer tendons and correct angulation by osteotomy.

The vascular anatomy of both thumbs is likely to be abnormal. In most cases, each thumb has only one digital artery, located on its ulnar side (102).

### *Operative Technique*

1. Exploration, ablation of the smaller thumb, reconstruction of the retained thumb: types I and II when one thumb is smaller (Fig. 69.5B).

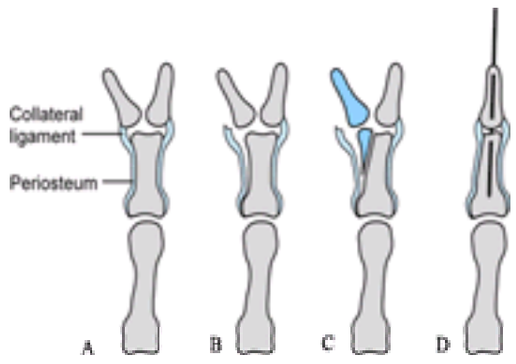


***Figure 69.5.*** Ligamentous periosteal flap for the treatment of Wassel type II or IV thumb polydactyly See text for details.

- Use loupe magnification, and perform the operation with the patient under general anesthesia and tourniquet. Have a surgical microscope available; it may be necessary to separate the digital nerves of the two thumbs.
- Plan incisions to avoid a longitudinal incision along the radial border of the reconstructed thumb.
- Through a dorsal zigzag incision, explore the thumbs for tendon abnormalities. Detach the extensor tendon from the smaller thumb.
- For type II thumbs, dissect the IPJ radial collateral ligament (RCL) off the distal phalanx of the thumb to be ablated (Fig. 69.5B). Preserve the IPJ-RCL attachment to the proximal phalanx; if necessary, extend it using a periosteal flap (Fig. 69.5C) (122).
- If the nails are connected, remove a portion of the nail bed, retaining an appropriate-sized nail for the underlying distal phalanx.
- Remove the bone from the smaller thumb after detaching the flexor tendon at its insertion.
- Separate the digital nerves to the two thumbs, and transect the nerve to the smaller thumb as far proximally as possible.
- For type II thumbs, shave the distal radial portion of the proximal phalanx. If the joint surface is angulated, perform a closing wedge osteotomy of the proximal phalanx, and fix it with a small longitudinal Kirschner wire crossing the IPJ (Fig. 69.5D).
- For type II thumbs, if the pull of the retained extensor or flexor tendon angulates the thumb at the IPJ, reinsert it or transfer the tendon from the ablated thumb to correct the angle of pull. Otherwise, transect the tendon that was previously attached to the ablated thumb
- For type II thumbs, reattach the IPJ-RCL using a nonabsorbable pullout suture.
- Close the skin with 5-0 chromic suture, augmenting the reconstructed thumb with eponychium and nail bed from the ablated thumb.
- Apply a bulky compressive dressing covered with a long-arm, flexed-elbow fiberglass cast shell.

2. Combination procedure: types I and II when the thumbs are the same size (Fig. 69.6 and Fig. 69.7).

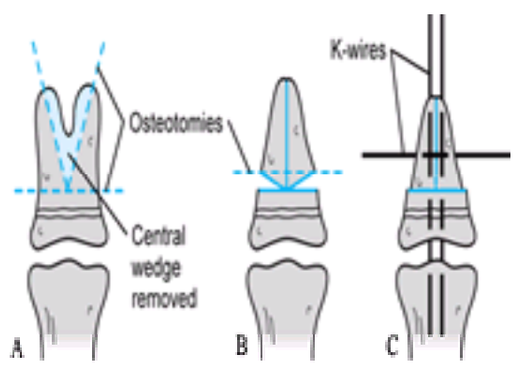


***Figure 69.6.*** Modification of combination (Bilhaut) procedure, which avoids damage to the physis and joint. See text for details. (Personal communication: H. Relton McCarroll Jr., M.D.)

***Figure 69.7.*** Modified combination (Bilhaut) procedure for type I thumb polydactyly. **A:** Preoperative dorsal view. **B:** Preoperative palmar view, with incision marked. **C:** Dorsal view, after central wedge resection. **D:** Postoperative dorsal view.

- Use loupe magnification, and perform the operation with the patient under general anesthesia and tourniquet.
- Remove the nail plates. Resect a central wedge of dorsal nail matrix, eponychium, and skin, and a similar-sized wedge of palmar skin. Leave enough skin and soft tissue on either side of the wedge so that when the two sides are approximated, the thumb is nearly normal size (Fig. 69.6A).
- Using a small oscillating saw, resect the central portions of the bone of the two thumbs, leaving enough bone so that when approximated, the distal phalanx is nearly normal size. Do not extend these osteotomies into the physis or joint. Instead, make a transverse osteotomy just distal to the physis, to avoid the risk of growth arrest and joint stiffness (Fig. 69.6B).
- Using 0.028 Kirschner wires, pin the two pieces of distal phalanx together, then pin them both longitudinally to the preserved base of the distal phalanx. Extend the longitudinal pins across the IPJ (Fig. 69.6C).
- Approximate the nail bed and eponychium using small absorbable suture. Replace the nail plate with antibiotic-impregnated gauze if the original nail plate does not fit.
- Close the skin with interrupted 5-0 chromic suture.
- Apply a bulky compressive dressing, and cover it with a long-arm, flexed-elbow fiberglass cast shell that covers the tip of the thumb and the Kirschner wires.

3. Exploration, ablation of the smaller thumb, reconstruction of the retained thumb: type III and IV thumbs.
   - Proceed as described earlier for type I and II thumbs when one is smaller, including tendon realignment and soft-tissue combination.
   - Do not resect the base of the proximal phalanx for type III thumbs; preserve the physis and joint surface and the MPJ-RCL of the radial thumb.
   - For type IV thumbs, detach the MPJ-RCL from the ablated thumb and reconstruct it, as described earlier for the IPJ-RCL of type II thumbs.
4. MPJ arthrodesis: type II and IV thumbs, if ligament reconstruction fails, resulting in painful thumb IPJ or MPJ instability before skeletal maturity (105).
   - Use loupe magnification and perform the operation with the patient under general anesthesia and tourniquet.
   - Approach the joint from the dorsal aspect, if possible, or use incisions from previous operations.
   - Use a sharp scalpel to remove articular cartilage sequentially from both joint surfaces. Expose the bony ossification center of the epiphysis of the proximal phalanx, but do not proceed beyond the ossific nucleus into the physeal plate. Expose the cancellous subchondral bone of the distal end of the metacarpal.
   - Oppose the two cancellous articular surfaces with the joint in neutral position, and hold them together with two crossed Kirschner wires.
   - Close the skin with interrupted 5-0 chromic suture.
   - Apply a bulky compressive dressing over the fingers and thumb, and cover it with a fiberglass cast shell.

### *General Rehabilitation and Postoperative Principles*

Remove the cast 4 to 6 weeks postoperatively, and check radiographs. Remove buttons and pullout sutures, and remove Kirschner wires after checking for bony union on radiograph (usually 6 to 8 weeks). Postoperative therapy is not necessary. Provide a custom-made splint when the IPJ or MPJ-RCL has been reconstructed for the

child to wear at night until 3 months after surgery.

## PITFALLS AND COMPLICATIONS

If the retained thumb is not reconstructed according to the principles described earlier, angulation and instability will occur with growth. These complications also occur when the retained thumb is especially hypoplastic, even if it is carefully reconstructed.

## AUTHOR'S PERSPECTIVE

Although some surgeons recommend thumb ablation and reconstruction at the age of 6 months (57,86,158), it is difficult to find room for two pullout sutures and a Kirschner wire in a tiny thumb. The operation is easier when the child is at least 1 year old, when the hand is considerably bigger.

Most children and their parents are pleased with the function of the reconstructed thumb if they can accept that it is not expected to be quite normal.

### HYPOPLASIA AND ABSENCE

#### *Assessment, Indications, and Relative Results*

Thumb hypoplasia and absence are part of longitudinal radial deficiency, which may involve the thumb alone, or the entire radial hand, wrist, and forearm. This condition is rare, (1:30,000 to 1:100,000 live births) (60), frequently bilateral, and often associated with congenital anomalies of the lower extremities, spine and other organ systems (including the cardiopulmonary, gastrointestinal, and genitourinary systems) (92). Several syndromes are characterized by hypoplastic or absent thumbs, usually combined with radius deficiency, including the VACTERL association (*V*ertebral, *A*nal, *C*ardiac, *T*racheo-*E*sophageal, *R*enal or *R*adial, *L*ung ), Holt-Oram syndrome and thrombocytopenia-absent radius (TAR) syndrome (see the section entitled Radius Deficiency) (92).

The hypoplastic thumb must be examined carefully for presence or absence of thenar intrinsic muscles, MPJ—ulnar collateral ligament (UCL) stability, extrinsic muscles (flexor and extensor pollicis longus), and CMCJ stability. There are six types of thumb deficiency (Table 69.3).

| Feature | Type 1 | Type 2 | Type 3a | Type 3b | Type 4 | Type 5 |
|---|---|---|---|---|---|---|
| Thumb size | Normal or small | Normal or small | Small | Small | Very small | Absent |
| Free web | Normal size and location | Distal and right | Distal and right | Distal and right | Floppy | Absent |
| Intrinsic muscles | APB and OP hypoplastic | APB and OP hypoplastic or absent | APB and OP absent or severely hypoplastic | APB and OP absent or severely hypoplastic | APB, OP, FPB and adductor absent | APB, OP, FPB and adductor absent |
| Extrinsic muscles | Normal | Normal or nearly normal | Abnormal: EPL and/or EPL absent or EPL-EPL connection or pulley abductor | Abnormal: EPL and/or EPL absent or EPL-EPL connection or pulley abductor | Absent | Absent |
| Ligaments | Normal | MP UCL lax | MP UCL and possibly RCL lax | MP UCL and possibly RCL lax | Absent | Absent |
| Bones and joints | All bones present, may be hypoplastic | All bones present and hypoplastic | All bones present and hypoplastic | Proximal metacarpal absent | Metacarpal, trapezium and scaphoid absent | Phalanges, metacarpal, trapezium and scaphoid absent |

Adapted from Blauth W, McCarroll HR Jr, Manske PR. Characteristics of Patients with Hypoplastic Thumbs. *J Hand Surg* 1994;19A:211-221.

***Table 69.3. Modified Blauth Classification (121)***

Type 1 hypoplastic thumbs do not require surgical reconstruction. The function of type 2 thumbs is enhanced by first web deepening, MPJ-UCL reconstruction, and opponensplasty (63,103). The abductor digiti minimi (ADM) muscle or the middle or ring flexor digitorum superficialis (FDS) can be transferred to provide opposition (63,128,194). Type 3a thumbs benefit from extrinsic thumb muscle realignment, transfer or reconstruction if passive IPJ motion is present, in addition to the procedures recommended for type 2 thumbs (75,130). After reconstruction, type 2 and 3 thumbs function well, although they are always smaller and weaker than a normal thumb. The child with a type 2 or 3a deficiency recognizes the thumb and is able to use it to a limited extent. Surgical reconstruction can be postponed until the child is able to use the enhanced ability to manipulate small objects, around 2 to 4 years of age; older children also benefit. The MPJ of type 3a thumb is globally unstable and may eventually require arthrodesis.

Reconstruction of types 3b and 4 thumbs is performed only in cultures in which the retention of a five-digit hand is of primary importance (130,151), because it requires multiple operations (including vascularized [151] or nonvascularized [207] bone graft from the patient's foot), and the final functional result is inferior to thumb ablation and index pollicization (23,103).

The child with a type 3b, 4, or 5 (absent) thumb uses an index-long side-to-side pinch (20,30,62,103,124,129,212). Index pollicization improves this pinch. The index finger is shortened by removal of the index metacarpal and rotated so that it can function as a thumb, and the hypoplastic thumb is removed (Table 69.4). This procedure requires the surgical rearrangement of the skin, skeleton, muscles, nerves, and blood vessels. Carefully plan and mobilize skin flaps to create a first web of appropriate depth, extending from the MPJ of the new thumb to the MPJ of the long finger. A pollicized index finger functions like a thumb (124), but the base is less mobile and stable; the appearance is usually quite satisfactory (Fig. 69.8 and Fig. 69.9). Increasing severity of thumb hypoplasia is associated with increased stiffness of the more radial fingers, especially the index finger; pollicization of the stiff index finger has a less satisfactory outcome than the same procedure performed on a more flexible finger.

| *Index finger* | *Pollicized digit* |
|---|---|
| Metacarpal head → | Trapezium |
| Metacarpophalangeal joint → | Carpometacarpal joint |
| Proximal phalanx → | Metacarpal |
| Middle phalanx → | Proximal phalanx |
| Distal interphalangeal joint → | Interphalangeal joint |
| Distal phalanx → | Distal phalanx |

From Manske PR, McCarroll HR Jr. Index Finger Pollicization for a Congenitally Absent or Nonfunctioning Thumb. *J Hand Surg* 1985;10A:606.

***Table 69.4. Pollicization—Index Finger (129)***

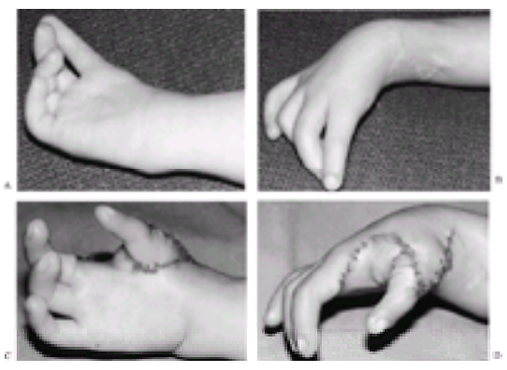

***Figure 69.8.*** Index pollicization (this patient has already undergone centralization of the carpus on the ulna; see Fig. 69.48). **A:** Preoperative palmar view. **B:** Preoperative dorsal view. **C:** Postoperative palmar view. **D:** Postoperative palmar view.

***Figure 69.9.*** Index pollicization (different patient from the one shown in Fig. 69.8). **A:** Tip pinch using new thumb. **B:** Tip pinch showing pronation of new thumb. **C and D:** Grasp using new thumb.

The timing of pollicization is somewhat controversial. Buck-Gramcko (20) and Flatt (63) argue for pollicization in the second 6 months of life, to allow the child to recognize the pollicized digit as a true thumb, and to give the former index finger the maximum amount of growth and development possible in its new position. Manske (124) has shown, however, that enhanced hand function following pollicization is not age dependent. Although pollicization is performed primarily to enhance function, it significantly changes the appearance of the hand; the most significant benefit of early surgery may be that this change occurs before the child has a fully developed self-image.

Occasionally, thumb deficiency is associated with severe mental retardation or developmental delay. This is a relative, but not absolute, contraindication to thumb reconstruction or pollicization. If the surgeon, occupational therapist, and parent agree that the thumb deficiency limits the child's function, the operation appropriate for the type of thumb hypoplasia (reconstruction or pollicization) is indicated.

### *Classification*

Thumb hypoplasia is classified according to a modification of the Blauth scheme, which helps determine prognosis and treatment. (Table 69.3 and Fig. 69.10) (16,63,92,103,130). The thumbs of children with TAR syndrome do not fit this classification scheme (91). This classification can be used in combination with a modification of the Bayne scheme for radius deficiency (Table 69.11) (91).

***Figure 69.10.*** Thumb deficiency: modified Blauth classification. **A:** Type 1, with mild flattening of thenar eminence. **B:** Type 2 (right hand). **C:** Type 3a, with lack of flexion at distal interphalangeal joint. **D:** Type 3a, with base of the thumb metacarpal present. **E:** Type 3b. **F:** Type 3b, with base of thumb metacarpal absent. **G:** Type 4. **H:** Type 4. **I:** Type 5. **J:** Type 5.

### *Preoperative Management*

Some of the anomalies associated with thumb deficiency may increase the risk of general anesthesia; postpone surgery until general anesthesia is safe.

If the radius is deficient and the hand requires centralization, perform centralization before index pollicization (see the section entitled Radius Deficiency). Hands with thumb hypoplasia amenable to reconstruction (types 2 and 3a) usually do not have radius deficiency requiring centralization (91).

Before surgical reconstruction, the child with a type 2 or 3a thumb may benefit from the application of a soft short opponens splint to preposition the thumb. If the child refuses to use the splint, it is probably not helpful and can be discarded.

Do not discourage the child with a deficient thumb from using side-to-side pinch between the index and long or ring and small fingers. The development of this type of pinch is associated with more severe thumb hypoplasia and is an indication that the thumb is probably not amenable to reconstruction; the child would benefit from thumb ablation and index pollicization (23).

### *Operative Technique*

1. Reconstruction of the type 2 hypoplastic thumb: fourfold Z-plasty, MPJ-UCL reconstruction and ADM opponensplasty (Fig. 69.11, Fig. 69.12 and Fig. 69.13)

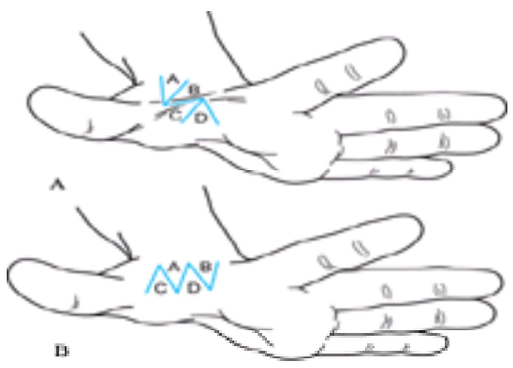

***Figure 69.11.*** Fourfold Z-plasty.

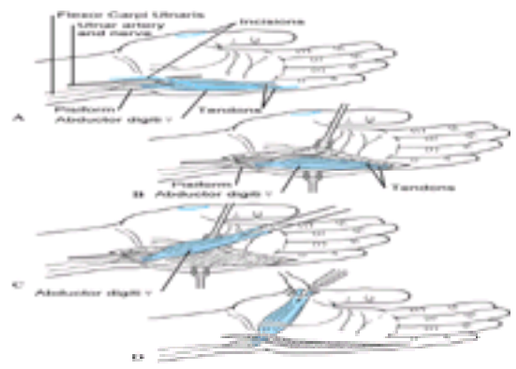

***Figure 69.12.*** ADM opponensplasty.

***Figure 69.13.*** ADM opponensplasty. **A:** ADM muscle (bottom of photo, with suture attached). Attachment site is at base of the thumb. **B:** ADM muscle showing path of transfer.

- Use loupe magnification and perform the operation with the patient under general anesthesia and tourniquet.
- Deepen the first web using a fourfold Z-plasty (Fig. 69.11). The angle of each flap tip should be 45° (63,233). Release the first dorsal interosseous and adductor pollicis fascia; release of the muscles is not usually necessary in the younger child, but if contractures of these muscles have developed, they can be partially released near their insertions (103).
- Sharply dissect free a proximally based flap of the MPJ-UCL, joint capsule and adductor pollicis insertion through the incision created by raising the skin flaps for the Z-plasty. Pull the flap tight, and secure it with nonabsorbable suture by passing the suture through a hole drilled distal to the proximal phalanx physis and tying it over a button on the radial side of the proximal phalanx (Fig. 69.11). Pin the thumb MPJ in 0° extension and neutral radioulnar deviation.
- Transfer the ADM to provide opposition (Fig. 69.12 and Fig. 69.13). Make a straight incision along the ulnar border of the palm, and curve it toward the palm, ending over the pisiform. Detach the ADM distally from the base of the small finger metacarpal, and elevate it proximally. Leave the muscle origin attached to the pisiform, to provide a firm proximal anchor and maintain the blood supply to the muscle (47,63). Create a generous subcutaneous tunnel across the palm, and pass ADM muscle through it, opening it like a book at its origin. Split the ADM tendon, and weave one slip of tendon into the radial capsule of the MPJ, and the other into the extensor pollicis longus (EPL) and tightened MPJ-UCL (63,128). Suture it in place with nonabsorbable 4-0 or 5-0 suture.
- Close the skin with 5-0 chromic suture.
- Apply a bulky compressive dressing over the thumb and fingers, and cover it with by an above-elbow fiberglass cast shell.

2. Reconstruction of the type 3a hypoplastic thumb.
   - Use loupe magnification and perform the operation with the patient under general anesthesia and tourniquet.
   - Deepen the first web, reconstruct the MPJ-UCL, and transfer the ADM as for the type 2 thumb, with one modification. Because the MPJ RCL is lax in type 3a thumbs, instead of inserting one slip into the radial capsule and the other into the EPL and ulnar capsule, attach one slip to the radial side of the base of the proximal phalanx and the other to the EPL (63,128).
   - Reconstruct the extrinsic tendons if passive IPJ motion is present. Tailor the reconstruction of the extrinsic tendons (EPL and flexor pollicis longus [FPL]) to the individual anomaly (75,130). The EPL may be hypoplastic or absent, the FPL aberrant or absent, or the two tendons may be interconnected. **If both EPL and FPL are to be reconstructed, perform these two procedures in 2 stages.**

     If EPL is absent, transfer the extensor indicis proprius (EIP) to the extensor surface of the base of the distal phalanx, using a pullout technique to attach the transfer.

     If the FPL is absent, transfer the ring FDS to the flexor surface of the base of the distal phalanx using a similar attachment technique; if pulley reconstruction is necessary, use local tissue or a toe extensor tendon (see Chapter 47 and Chapter 48 [flexor pulley reconstruction]).

     If the EPL and FPL are interconnected radially, release the connection and reroute the aberrant tendons, or if length is insufficient, transfer the EIP or FDS as described earlier.

   - Close the skin with 5-0 chromic suture.
   - Apply a bulky compressive dressing over the thumb and fingers, and cover it with an above-elbow fiberglass cast shell.
3. If collateral ligament reconstruction fails, resulting in painful thumb MP joint instability, perform MPJ arthrodesis (105) (see the section entitled Polydactyly for a description of this technique).
4. Pollicization of the index (type 3b, 4 or 5 hypoplastic thumb) (Fig. 69.14 and Fig. 69.15).

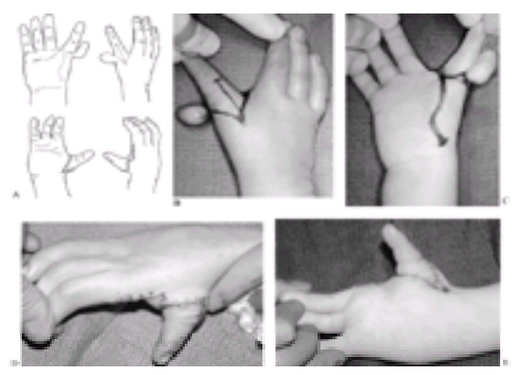

***Figure 69.14.*** Pollicization of index finger. **A:** Incisions when thumb is absent. **B:** Incisions for very hypoplastic thumb, dorsal view. **C:** Palmar view. **D:** Postoperative dorsal view. **E:** Postoperative palmar view. (**A** from Buck-Gramcko D. Pollicization of the Index Finger. *J Bone Joint Surg* 1971;53-A:1605.)

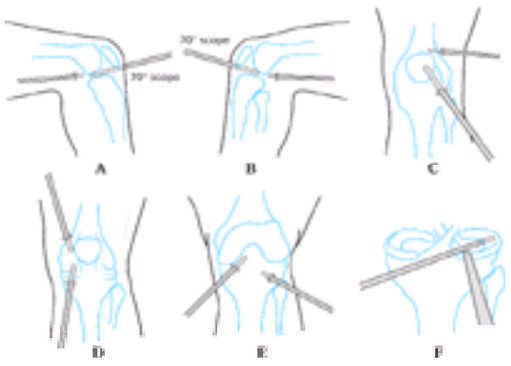

***Figure 69.15.*** Pollicization of index finger, type 3B thumb. **A:** Incisions (21) **B:** Incisions, dorsal view. **C:** Incisions, palmar view. **D:** Postoperative radial view. **E:** Postoperative palmar view.

- Buck-Gramcko's technique is recommended (20), with a few modifications (62,129). This technique is based on the work of Riordan (171), Zancolli (236), Littler (115), Malek (120), and others.
- Use loupe magnification; have an operating microscope available. Perform the operation with the patient under general anesthesia and tourniquet.
- Carefully plan and mark the skin incision before inflation of the tourniquet (Fig. 69.14 and Fig. 69.15). Curve around the index finger at the level of the proximal digital flexion crease on the palmar aspect. Extend the incision to the base of the long finger so that the index-long web skin is transposed with the index finger, preventing a dog ear at the radial base of the long finger. On the dorsum, angle the incision to a point at the MP joint. Extend the incision obliquely from halfway between the tip of the dorsal incision and the index-long web to the dorsum of the proximal IPJ (PIPJ). On the palm, extend the incision from the palmar radial circumferential incision to the base of the index metacarpal. Distally, curve this incision convex radially, and proximally, convex ulnarly. Avoid placing this incision too far ulnarly or the palmar wound will be difficult to close.
- If a hypoplastic thumb is present, incorporate it into the distal aspect of the palmar incision (Fig. 69.15).
- Inflate the tourniquet after exsanguination of the arm. Raise the dorsal and palmar flaps. Mobilize the dorsal flap superficial to the dorsal veins draining the index finger. Mobilize the radial and ulnar flaps on the dorsum of the index. If a hypoplastic thumb is present, remove it after mobilizing the flaps overlying the index metacarpal. Carefully preserve the dorsal veins to the index finger. They are of equal importance to the transposed finger's survival as are the digital arteries.
- Detach the insertion of the first dorsal interosseous muscle, and tag it with a nonabsorbable 4-0 suture. Mobilize the muscle proximally to expose the entire index metacarpal, but leave the muscle origin intact. Find the distal physis of the metacarpal with the tip of a #15 scalpel, and sharply transect the metacarpal through the physis. Remove the index metacarpal proximal to the physis.
- Detach the insertion of the palmar interosseous muscle from the dorsoulnar aspect of the base of the index finger and tag it with a nonabsorbable 4-0 suture. Transect the transverse intermetacarpal ligament between the index and long fingers.
- Isolate and tie off the radial digital artery to the long finger, if necessary. To place the index finger in its new position, sometimes you must split the common digital nerve to the index and long fingers.
- Release the index finger $A_1$ pulley. It is not necessary to shorten the extrinsic flexor and extensor tendons to the index finger (129).
- Place the new thumb in the bed created by removal of the index metacarpal, rotated 150° to 180°, and in 40° palmar abduction. Preposition the index MPJ (the new thumb CMCJ) in hyperextension, to place the available range of motion in a functionally useful arc. Suture the periosteum of the index metacarpal head to the capsule of the index CMCJ with at least three nonabsorbable 4-0 Dacron sutures.
- Gently and bluntly create tunnels for the first dorsal and palmar interosseous muscles under the radial and ulnar flaps on the dorsum of the new thumb, protecting the dorsal veins. Attach the insertions of these muscles to the extensor aponeurosis of the new thumb, using nonabsorbable 4-0 Dacron suture. Release the tourniquet. Observe that the digit is well vascularized and that there is no venous congestion.
- Close the skin incisions with 5-0 chromic, after rotating the palmar flap into the first web space, the tip of radial flap on the dorsum of the new thumb into the proximal end of the palmar incision, and the dorsal flap into the split between the radial and ulnar flaps on the dorsum of the new thumb. Trim excess skin as necessary but avoid tight closures. Close the palmar incision first.
- Apply a bulky compressive dressing over the thumb, fingers, and hand, and cover it with an above-elbow fiberglass cast shell.

***General Rehabilitation and Postoperative Principles***

Remove the cast (and pin, following MPJ-UCL reconstruction) after 6 weeks. For the reconstructed thumb, prescribe a custom-made soft neoprene short opponens splint for comfort and while sleeping for approximately 6 weeks. Therapy is not always necessary for thumb reconstruction or pollicization, but it may be helpful and reassuring for both the child and the parents.

If the child has not developed good opposition of the new thumb by 1 year after pollicization, ADM opponensplasty is indicated. Supplemental opponensplasty is most commonly needed when the first dorsal interosseous is hypoplastic (129). The surgeon can prepare the family for this possibility following the pollicization.

## PITFALLS AND COMPLICATIONS

If the subcutaneous tunnel for the ADM opposition transfer is too tight, or if the origin of the muscle is kinked, the transfer will not function well. If the reconstructed MPJ-UCL is too tight in the thumb with RCL laxity (type 3a) the thumb will deviate in an ulnar direction at the MPJ.

See Table 69-5 for the most common pitfalls of pollicization, and the best ways to avoid them. Necrosis of the new thumb is extremely rare (Buck-Gramcko reports one case of necrosis, in a patient with index finger arterial anomalies, in a series of 460 pollicizations [23]).

| *Pitfall* | *Examples* | *Result* | *How to avoid pitfall* |
|---|---|---|---|
| Incorrect indications | Very hypoplastic index | Poor function | Observe child's hand function carefully; do not pollicize index if child ignores it |
| Improper skin incisions | Palmar incision too far ulnar | Skin defect in web space; adducted pollicized index; poor function | Very careful planning of skin incisions |
| Damage to neurovascular structures | Unexpected anatomical variations | Necrosis of pollicized index, or failure to grow | Careful dissection and experience with operation |
| Inadequate skeletal adaptation | 1. Thumb too long<br>2. Hyperextension at the new MCPJ<br>3. First web too narrow | 1. Poor appearance<br>2. Poor appearance<br>3. Poor function | 1. Remove most of index metacarpal<br>2. Preposition index MCPJ in hyperextension<br>3. Fix pollicized index in adequate pronation and abduction |
| Skin problems | First web too deep | Poor appearance (thumb looks too long) | Remove palmar skin over index, so palmar flap is at former PIPJ level |

***Table 69.5. Pitfalls of Pollicization (23)***

## AUTHOR'S PERSPECTIVE

Most parents of children with hypoplastic or absent thumbs appreciate the opportunity to visit and talk with another child who has already undergone pollicization (preferably away from the surgeon, so the families can discuss advantages and disadvantages freely), and the opportunity to view preoperative and postoperative photos of a pollicized index finger.

This is a challenging operation that is best performed by an experienced hand surgeon. The wounds are easier to close and their appearance is better if the operation is completed in less than 2 hours without releasing the tourniquet. Careful wound closure, with meticulous trimming of excess skin, also improves the appearance of the

new thumb.

## TRIGGER THUMB

### *Assessment, Indications, Relative Results*

Trigger thumb is a relatively common condition; the incidence is estimated to be 3 in 1000 live births (174). Trigger thumb in children is probably acquired, not congenital; recent reports indicate that experienced examiners found no trigger thumbs in two large series of newborns (174,186). In theory, the normal infant thumb position (tightly clenched in the palm until about 2 months of age, with a strong grasp reflex [59]) may contribute to the development of trigger thumb by pulling the flexor tendon tight against the opening of the proximal pulley (174), causing tendon inflammation and edema at the theca.

The infant's thumb rarely “triggers,” or snaps (as does the adult's trigger digit), but instead usually presents as a fixed flexion contracture at the IPJ (average 35° [186]) (Fig. 69.16), or rarely as a fixed extension contracture (when the enlarged portion of the flexor pollicis longus [FPL] tendon gets trapped at the distal margin of the proximal pulley) (45,51,70,174,185,186,193). A palpable nodule in the FPL at the MPJ flexion crease of the thumb is almost always present; this nodule is probably caused by the bunching up and swelling of the FPL, which are attributable to chronic pressure from the proximal pulley (135,153,174). Differential diagnosis includes congenital clasped thumb and thumb hypoplasia.

***Figure 69.16.*** Trigger thumb.

The largest study of the natural history of this condition reported 12% spontaneous resolution for 131 trigger thumbs in 107 children observed for 6 months (average age at diagnosis was 2 years); for trigger thumbs noted at birth, the spontaneous resolution rate was 31% by 1 year of age. In this study, children who underwent surgery within 3 years of diagnosis did not have a residual flexion contracture of the IPJ, but children older than 4 years of age at surgery had a high rate of residual IPJ flexion contracture (41). Other authors have found a lower incidence of spontaneous correction (70,193) and no residual flexion contracture in children whose trigger thumbs were released after 3 years of age (185). Trigger fingers may also occur in children, but they are much rarer than trigger thumbs and more likely to resolve spontaneously (193).

Trigger digits in children have been reported to be associated with mucopolysaccharide storage disorders (215), juvenile arthritis (163), and diabetes mellitus (163,235). There is a slight familial predisposition, and bilateral involvement is not uncommon (41,193,214,232).

Although splint therapy was successful in 24 of 43 digits according to one report (150), surgical release of the $A_1$ pulley (45) (Fig. 69.17) is the treatment of choice. This is a simple and very successful operation; of 402 reported releases of trigger digits, 401 were successfully released (51,70,163,174,185,186,193,232), with only one recurrence (163) and no other significant complications. Do not use steroid injections for this condition in children (135).

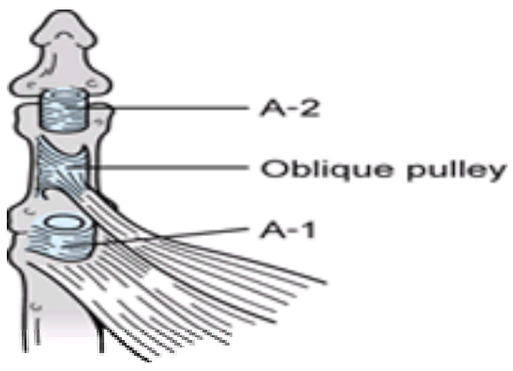


***Figure 69.17.*** Anatomy of thumb pulleys (45).

### *Preoperative Planning*

There is no compelling indication to release a trigger thumb in an infant before the age of 1 year. The trigger thumbs of children older than 3 years of age at the time of presentation are very unlikely to resolve spontaneously, and should be released to enhance the child's hand function and prevent a permanent flexion contracture of the IPJ.

### *Operative Technique*

Release of trigger thumb.

- Use loupe magnification and perform the operation with the patient under general anesthesia and tourniquet.
- The radial digital nerve to the thumb may be stretched over the nodular enlargement of the FPL tendon, in the region of the surgical incision. Make a transverse incision through dermis only, at the proximal digital flexion crease of the thumb, and do not hyperextend the thumb MPJ.
- Use blunt dissection to expose the flexor sheath. Locate and retract the ulnar and radial digital neurovascular bundles.
- Find the proximal margin of the $A_1$ pulley, and sharply incise it from proximal to distal. Excision of the pulley is not necessary; it will fall open as it is incised. Move the IPJ through its new passive range, and observe that the tendon nodule no longer impinges. If it continues to impinge when the joint is hyperextended, release a small amount of additional pulley. Do not debride the nodule (unless the patient has a mucopolysaccharide storage disease, in which case debridement may be necessary [215]).
- Pull on the FPL tendon with a Ragnell retractor to demonstrate that there are no other impediments to its excursion.
- Close the skin incision with interrupted 5-0 chromic suture.
- Apply a light compressive dressing, and cover it with Coban. A cast is not necessary.
- Remove the dressing after 7 to 10 days. No postoperative rehabilitation is necessary.

## PITFALLS AND COMPLICATIONS

Complications of this procedure are the result of errors in surgical technique. Do not release the oblique pulley, or the FPL tendon may bowstring; this result is cosmetically unappealing and reduces FPL efficiency. Take great care with the skin incision, because the radial digital nerve to the thumb is immediately

subcutaneous, especially when tented over the FPL nodule.

## AUTHOR'S PERSPECTIVE

A longitudinal skin incision may be slightly safer for the less experienced surgeon, but the radial digital nerve, which runs very close to the midline, can also be damaged with this incision, and the appearance of a healed transverse incision is much more satisfactory.

If the trigger thumb is diagnosed before the child is 1 year of age, observe the child until after the first birthday, when the risk of general anesthesia is lower and the trigger thumb is unlikely to resolve spontaneously. Trigger thumb in children should not be confused with trigger digit in adults, because the pathophysiology, natural history, and treatment differ (see Chapter 50: Trigger Digits).

## CLASPED THUMB

### *Assessment, Indications, and Relative Results*

Congenital clasped thumb is a rare condition seen in isolation or as a feature of syndromes such as Freeman-Sheldon syndrome or arthrogryposis (135,208). It is diagnosed after age 2 months, when the infant's normal palmar grasp pattern has diminished but the thumb remains in the palm. There is a genetic predisposition toward this condition, which is usually bilateral and occurs more often in males than in females (208).

If the thumb can be passively fully extended at the MPJ, casting or splinting in abduction and extension usually restores normal thumb position. This type of clasped thumb is due to hypoplastic extensor tendons overpowered by thumb flexor tendons, and positioning the thumb in extension for several months allows the extrinsic tendons to recover their balance (135).

When the thumb cannot be passively extended at the MPJ, associated thumb anomalies are commonly seen, including MPJ-UCL laxity, thenar muscle hypoplasia, and thumb CMCJ adduction contracture (135). Splinting may reduce the thumb MPJ flexion contracture but will not affect the other anomalies. Surgical correction should be tailored to the particular deformities and may include MPJ contracture release, FPL lengthening, ADM opponensplasty, tendon transfer to the EPL, and skin Z-plasty or thick split-thickness skin graft (135,139). Attempt splinting and stretching until the child is 2 to 3 years of age before resorting to surgery. Reconstruction may improve the position of the thumb, but does not restore normal function.

### *Classifications*

McCarroll has classified clasped thumbs as supple and complex. Supple thumbs have good passive range of motion. Complex clasped thumbs have passive contractures, and may be associated with arthrogryposis and Freeman-Sheldon syndrome (Fig. 69.18*A*) (135,136). Other, more elaborate schemes have been described (208,226,227), but they do not assist the surgeon with the prognosis and treatment more than McCarroll's simple scheme.

***Figure 69.18.*** Complex clasped thumb. **A:** Preoperative view. **B:** Postoperative view (following release; dorsal rotation flap was not necessary).

### *Preoperative Management and Planning*

The initial treatment of all clasped thumbs is splinting and stretching exercises. Supple thumbs will probably correct themselves, and complex clasped thumbs may improve, making surgery unnecessary or at least simpler.

Release may require a thick split-thickness skin graft for coverage. Graft harvested from just below the anterior iliac crest leaves a scar in an inconspicuous location and does not bear hair when the child enters puberty (see the section entitled Syndactyly.)

### *Operative Technique*

1. Tendon transfer (when supple thumbs that cannot be actively extended and splinting has failed).
   - Use loupe magnification and perform the operation with the patient under general anesthesia and tourniquet.
   - Explore the dorsum of the thumb through a zigzag incision. Determine the best attachment point for the transferred tendon: either the hypoplastic EPL or extensor pollicis brevis (if it pulls through) or extensor hood tissue on the dorsal base of the proximal phalanx.
   - Through a separate transverse incision at the level of the distal end of the dorsal extensor retinaculum of the wrist, explore the fourth dorsal compartment for the EIP tendon. This is the preferred tendon to transfer to the thumb extensor mechanism, but it is usually absent in patients with clasped thumbs (139). If it is present, transect it as far distal as possible, create a blunt subcutaneous tunnel between the wrist and thumb incisions, pass the EIP tendon through the tunnel, and weave it through the chosen recipient tissue, suturing it in place with nonabsorbable 4-0 suture. If the EIP is absent, transfer either the extensor carpi radialis longus (ECRL) (extended with a tendon graft from palmaris longus) or the ring FDS tendon (112,135,139,208). Adjust the tension of the transfer so that the thumb tip touches the index finger in a key pinch position when the wrist is passively extended and the thumb MPJ position is 0° when the wrist is in neutral position.
   - Close the thumb incision with interrupted 5-0 chromic suture, and close the wrist incision with a running absorbable subcuticular 4-0 suture and Steri-Strips.
   - Apply a bulky compressive dressing over the thumb, fingers, and hand, and cover it with an above-elbow fiberglass cast shell.
2. Thumb flexion-adduction contracture release and reconstruction (complex clasped thumbs).
   - Use loupe magnification and perform the operation with the patient under general anesthesia and tourniquet.
   - Explore the dorsal thumb through a longitudinal incision centered over the MPJ. Release the dorsal capsule of the MJP if it is adherent to the metacarpal head, because it can block MPJ extension (135).
   - Explore the first web and palmar MPJ structures through a fourfold Z-plasty (Fig. 69.10) or, if necessary, plan and raise a large, radially based dorsal rotation-advancement flap (Fig. 69.19) (67,136). Release the palmar plate of the MPJ and, if necessary, the RCL. Release the first dorsal interosseous fascia; the muscle does not usually require release.

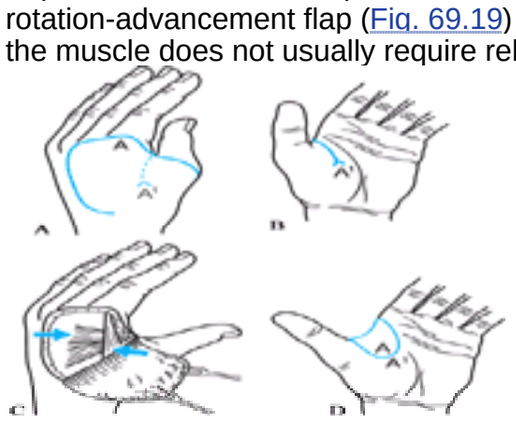

***Figure 69.19.*** Dorsal rotation flap. (From McCarroll HR Jr, Manske PR. The Windblown Hand: Correction of the Complex Clasped Thumb Deformity. *Hand Clin* 1992;17A:34.)

- If the adductor is tight, release the origin of the transverse head from the third metacarpal through a separate longitudinal midpalmar incision.
- If necessary, release the thumb CMCJ.
- Z-lengthen the FPL through a separate wrist incision.
- Reconstruct the MPJ-UCL with a pants-over-vest repair using available tissue. Pin the joint in neutral position place using a small Kirschner wire (Fig. 68.18*B*).
- If skin coverage is inadequate, harvest a thick split-thickness graft from the groin (see the section entitled Syndactyly). Shift local flaps from the fourfold Z-plasty so that the graft is situated over thenar muscle or palmar fascia, not in the web space. If a dorsal rotation flap is used, harvest a graft for the dorsum of the hand.
- Close hand wounds with interrupted 5-0 chromic suture and wrist wounds with running 4-0 absorbable subcuticular suture.
- Apply a bulky compressive dressing over the thumb, fingers, and hand, and cover it with an above-elbow fiberglass cast shell.

3. ADM Opponensplasty (may be performed at the same time as release and reconstruction, discussed earlier, or as a second stage for the complex clasped thumb that does not develop opposition after reconstruction).
   - See the section entitled Hypoplasia.
4. MPJ arthrodesis (for a painful or unstable MPJ in the older child).
   - See the section entitled Polydactyly.

### *General Rehabilitation and Postoperative Principles*

Remove the cast (and pin, if used) after 6 weeks. Prescribe a custom-made soft neoprene short opponens splint to be worn for comfort and while sleeping for approximately 6 weeks. Therapy is not usually necessary.

## PITFALLS AND COMPLICATIONS

Patients and parents are sometimes disappointed with the limited benefit and the extensive surgical scars following complex clasped thumb reconstruction.

## AUTHOR'S PERSPECTIVE

Reconstruction of a severely flexed and adducted thumb is a complex undertaking. Sometimes, this type of thumb is best left untreated until the child is older, when the MPJ can be fused.

Children with arthrogryposis often have adequate hand function in spite of very restricted joint motion and limited strength. Avoid operating on these patients unless the planned operation is likely to improve functional deficits perceived by the child or careful observers (parent, surgeon, and therapist).

## TRIPHALANGEAL THUMB

### *Assessment, Indications, and Relative Results*

The incidence of triphalangeal thumb is approximately 1 per 25,000 (57). This condition is considered a subtype of thumb polydactyly (201) and may be associated with many different syndromes (167). The gene for triphalangeal thumb has been mapped to chromosome 7q; this was the first human gene involved in pathologic morphogenesis of the hand to be localized (80).

Although adults with triphalangeal thumbs often believe that their function is normal (57), children with triphalangeal thumbs show developmental difficulties with fine motor skills (238), probably because the excessive length of the thumb makes opposition difficult. The distal phalanx is frequently partially duplicated, and many parents and older children do not like the appearance of this long, broad thumb (Fig. 69.20).

***Figure 69.20.*** Bilateral triphalangeal thumbs.

The extra (middle) phalanx is often hypoplastic, and may contain a longitudinal epiphyseal bracket (57). The infant with this anomaly may be treated with excision of the accessory phalanx; as long as this operation is performed early, the thumb IPJ usually retains stability and motion (57,157). For the older child, a reduction osteotomy may be performed, in which the proximal portion of the distal phalanx and the distal portion of the middle phalanx are removed; this operation also preserves motion and stability (94).

Alternatively, when the middle phalanx has a more normal appearance, the physes of the thumb ray can be ablated by epiphysiodesis when the child's thumb reaches the same length as the thumb of the same sex parent. This operation is the least invasive, but the extra segment is retained. If the triphalangeal thumb is nonopposable, it must be shortened and rotated by pollicization, followed by opponensplasty if necessary. None of these operations provide normal function, but shortening the thumb and providing opposition improve function.

### *Classifications*

Two types of triphalangeal thumb have been described. In the first type, the thumb is opposable and has an adequate first web space, a normal thumb CMCJ and a proximal metacarpal epiphysis. In the second type, the thumb is nonopposable; thenar muscles are absent. It has a narrow first web space and a distal metacarpal epiphysis; this type has also been called five-fingered hand (57).

### *Preoperative Planning*

Radiographic study is necessary to determine the size and shape of the extra phalanx, and to plan a reduction osteotomy (94).

### *Operative Technique*

1. Removal of accessory phalanx (hypoplastic middle phalanx; opposable triphalangeal thumb) (157).
   - Use loupe magnification and perform the operation with the patient under general anesthesia and tourniquet.

- Approach the accessory phalanx through a midlateral incision on the convex side of the thumb.
- Incise the collateral ligament and the adjacent periosteum longitudinally, and remove the accessory phalanx.
- Repair the collateral ligament and use a Kirschner wire to fix the IPJ in neutral position.
- Close the skin with 5-0 chromic suture.
- Apply a bulky compressive dressing over the thumb and hand, and cover it with an above-elbow fiberglass cast shell.

2. Reduction osteotomy (opposable triphalangeal thumb) (Fig. 69.21) (94).

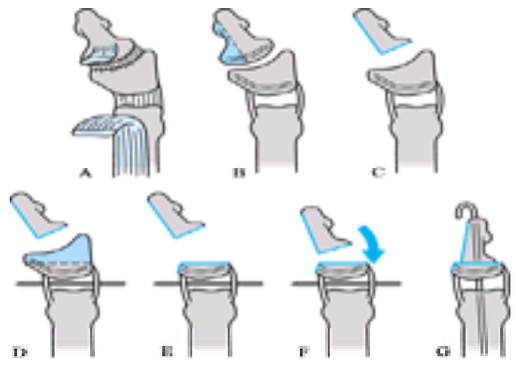


***Figure 69.21.*** Reduction osteotomy for triphalangeal thumb. See text for details. (From Jennings JF, Peimer CA, Sherwin FS. Reduction Osteotomy for Triphalangeal Thumb: An 11 Year Review. *J Hand Surg* 1992;17A:8.)

- Use loupe magnification and perform the operation with the patient under general anesthesia and tourniquet.
- Approach the middle phalanx and the distal IPJ (DIPJ) through a dorsal incision, detaching the extensor tendon (Fig. 69.21A).
- If necessary, narrow the nail and distal phalanx (Fig. 69.21B, Fig. 69.21C).
- Pass a fine Kirschner wire through the proximal IPJ (PIPJ), to orient transverse osteotomies (Fig. 69.21D).
- Excise the epiphysis of the distal phalanx, using a scalpel to transect the physis (Fig. 69.21E).
- Cut the middle phalanx perpendicular to the PIPJ, retaining the PIPJ collateral ligaments. This closing wedge shortens and realigns the thumb (Fig. 69.21F).
- Fix the osteotomies with longitudinal Kirschner wire or wires (Fig. 69.21G).
- Repair the extensor tendon with nonabsorbable nylon suture.
- Close the skin with 5-0 chromic suture.
- Apply a bulky compressive dressing over the thumb, fingers, and hand, and cover it with an above-elbow fiberglass cast shell.

3. Epiphysiodesis (opposable triphalangeal thumb).
   - Use loupe magnification and perform the operation with the patient under general anesthesia and tourniquet.
   - Through midlateral incisions on each side of the thumb, approach the physes of the three phalanges. The metacarpal physis is approached from a dorsal incision.
   - Using Fluoroscan guidance, use small curets (size 0000) to ablate the physeal cartilage.
   - Close the skin with 5-0 chromic suture.
   - Apply a soft bulky compressive dressing over the thumb and hand, and cover it with Coban.
4. Pollicization and opponensplasty (staged; nonopposable triphalangeal thumb) (see the section entitled Hypoplasia and Absence).

#### *General Rehabilitation and Postoperative Principles*

Remove the cast (and pin, if used) after 6 weeks with radiographic evidence of healing of osteotomies. Allow the child to use the hand as tolerated; therapy and splint immobilization are usually unnecessary.

## PITFALLS AND COMPLICATIONS

Because of the rarity of this malformation, only small series of patients have been reported. Postoperative instability and stiffness have not been reported, but undercorrection and overcorrection and recurrence of the deformity have occurred (94,157).

## AUTHOR'S PERSPECTIVE

If possible, excise the hypoplastic accessory phalanx early. Treatment of the well-developed triphalangeal thumb is more complex. If the thumb functions well, and the parents are not bothered by the appearance, defer treatment until the child is older, when epiphysiodesis is an option.

## THE FINGERS

### POLYDACTYLY

#### *Assessment, Indications, and Relative Results*

Finger polydactyly is a relatively common congenital malformation; in the United States, it is slightly less common and more often associated with a syndrome, than is thumb polydactyly. Finger polydactyly may be associated with chromosomal abnormalities, eye and orofacial abnormalities, bone dysplasias, and mental retardation (56). The small finger is the most commonly duplicated finger, especially in blacks (1 in 143 to 300 live births, compared with 1 in 1339 live births of whites [56,223]). Duplication of the index, long, or ring finger is quite rare and is usually associated with other hand anomalies, including cleft hand.

A duplicated small finger with a tiny pedicle may be ligated by a suture soon after birth. Remove duplicated digits with more substantial pedicles or those connected to other digits by webs (Fig. 69.22) when the child is older, because a large pedicle may bleed with suture ligation. The functional result of removal of a duplicated small finger is usually quite good, although suture ligation often leaves a bump. The outcome of removal of a duplicated index, long, or ring finger depends on the associated anomalies. Retained fingers are less likely to require reconstruction than are retained duplicated thumbs.

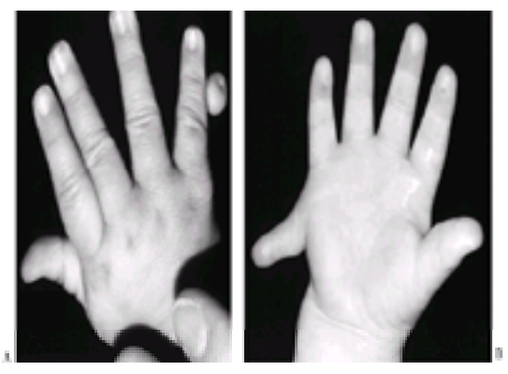

***Figure 69.22.*** Postaxial polydactyly. **A:** Small pedicle, but not small enough for suture ligation. **B:** Well-developed postaxial polydactyly, also not suitable for suture ligation.

### *Classifications*

Duplication of the index, long, or ring finger is described as central or axial, and duplication of the small finger is postaxial. The duplicated digit may articulate with a broad metacarpal head, or, less commonly, the metacarpal may also be duplicated (56). Temtamy and McKusick divided postaxial polydactyly into type A (fully developed extra digit) and type B (rudimentary or pedunculated extra digit) (201).

### *Preoperative Planning*

When the duplicated fingers are approximately equal in size, wait until the child is older than 1 year of age, and observe his or her use of the fingers to plan treatment. Determine which finger functions best and preserve it. Delay surgery until age 3 years of age in most cases. Ligate the type B finger in the newborn; inform the parents that the digit will turn black and fall off.

### *Operative Technique*

1. Suture ligation (type B postaxial duplication).
   - If the pedicle is broad, do not use suture ligation. Instead, perform a formal amputation under general anesthesia, through a zigzag incision.
   - If the pedicle is small, ligate the pedunculated digit at its base with undyed 2-0 Vicryl suture.
   - Apply a bulky compressive hand dressing and cover with Coban.
2. Ablation of a type A postaxial duplication (56).
   - Use loupe magnification and perform the operation with the patient under general anesthesia and tourniquet.
   - If the ulnarmost finger is to be removed, use an elliptical incision along the midaxial line. Detach and preserve the insertions of the ADM and the (MPJ-UCL). If the metacarpal is duplicated, extend the incision to remove it.
   - If the retained metacarpal head has an ulnar bulge, shave it.
   - Reattach the ADM and UCL to the retained finger.
   - Close the skin with interrupted 5-0 chromic suture.
   - Apply a bulky compressive dressing over the fingers and hand, and cover it with an above-elbow fiberglass cast shell.
3. Reconstruction of the duplicated index, long or ring finger.
   - In the case of duplicated index, long, and ring finger, each of these hands has a unique set of anomalies, which may include stiff joints, a longitudinal epiphyseal bracket, complex syndactyly, transverse phalanx, rotational or angulatory malalignment, and cleft hand. See the section entitled "Cleft Hand" and follow these basic principles; tailor the operation to the malformations:
     - Establish as normal a skeleton as possible. Combine parts from two fingers, if necessary.
     - Avoid damaging epiphyses and physes.
     - Correct bony alignment with phalangeal osteotomy.
     - Separate syndactyly, and plan flaps incorporating skin from the ablated digit so that no additional skin graft is needed.
     - Close the skin with interrupted 5-0 chromic suture.
     - Apply a bulky compressive dressing, and cover it with an above-elbow fiberglass cast shell.

### *General Rehabilitation and Postoperative Principles*

Keep the hand immobilized long enough for soft-tissue and bony healing, as appropriate. Splinting and therapy are not usually necessary.

## PITFALLS AND COMPLICATIONS

Suture ligation of the type B digit causes necrosis, which is distressing to some parents. Sometimes the necrotic digit does not fall off, and requires surgical removal. The residual bump left by suture ligation can be unsightly (223).

## AUTHOR'S PERSPECTIVE

Reconstruction of complex central duplications should be performed by an experienced hand surgeon. Residual deformity is common even when the hand is reconstructed by an expert. Sometimes, when both duplicated fingers are inadequate, removal of both (leaving a three-fingered hand) may be preferable.

## TRANSVERSE FAILURE OF FORMATION (HYPOPLASIA AND ABSENCE)

### *Assessment, Indications, and Relative Results*

This discussion pertains to fingers that have failed to form normally; differentiate them from fingers that are deformed prenatally by constriction ring syndrome (see the section entitled Constriction Ring Syndrome, and Table 69.6). Transverse failure of formation, or terminal deficiency, occurs in about 1.5 in 10,000 births (this estimate includes failure of formation at levels proximal to the fingers) (108), and 98% are unilateral (234). Short digits are often incompletely separated.

| *Feature* | *Transverse failure of formation* | *Constriction ring syndrome* |
|---|---|---|
| Inheritance | Not inherited | Not inherited |
| Sex | Equal | Equal |
| Laterality | Left more frequent than right, bilateral very rare | Right more frequent than left, bilateral common |
| Fingers affected | Central rays more frequent, thumb less frequent | Central rays more frequent, thumb less frequent |
| Level of amputation | More proximal (usually proximal to proximal phalanx) | More distal (usually distal to proximal phalanx) |
| Rudimentary finger and nail (nubbin) | Frequently present, may form soft tissue tube with bone shaft or more hypoplastic than soft tissue | Rarely present |
| Syndactyly | No sinus, no nonadjacent syndactyly | Sinus at base of syndactyly, occasional nonadjacent syndactyly |
| X-ray findings | Hypoplastic bones in adjacent digits and proximal to amputation in affected digit | No hypoplastic bones in adjacent digits or proximal to amputation in affected digit |
| Associated anomalies | Rare (occasionally associated with pectoralis muscle hypoplasia in Poland's syndrome) | Frequent toe amputations and acrosyndactyly, constriction rings, and amputations of the lower extremity, clubfoot, cleft lip/palate |

***Table 69.6. The Differential Diagnosis of Short and Absent Fingers: Transverse Failure of Formation vs. Congenital Constriction Ring Syndrome (90,142,162)***

Parents and children frequently request lengthening of short fingers, and surgeons have devised numerous ways to augment length. No single procedure, however, is vastly superior to any other, normal appearance is usually unattainable, and lengthening the digits of a child with a normal hand on the contralateral side does not improve function. Children with one normal hand perform most functional activities at about the same developmental age as children with two normal hands. Indications for reconstructing the unilateral aphalangic hand are based on the following principles:

1. Children will put almost any sensate reconstructed digit to good use.
2. More digits usually function better than fewer, as long as one does not get in the way of the others.
3. Increased length usually enhances function, although a stiff digit should be shorter than flexible ones (73).
4. When short digits are incompletely separated, web deepening enhances function and appearance.

Surgical reconstruction is not recommended for digits that have failed to develop metacarpals, with the exception of the thumb (see the section entitled Hypoplasia and Absence—Pollicization).

Operations designed to augment digital length include ablation of nubbins, “on-top-plasty,” in which one short digit is transplanted onto the top of another (42,49,61,166); web deepening (49,61); and single-stage osteotomy, distraction, and insertion of intercalary bone graft. Also included are distraction lengthening with or without second-stage bone grafting (81,101,164,166,188); nonvascularized toe phalanx transfers (22,61,73,90,169); and microvascular toe-to-hand transfer (71,99,100,113,114,220).

Nubbin ablation does not enhance function. “On-top-plasty” is technically difficult and diminishes the number of digits present. Web deepening is simple and useful, either by itself or when combined with another operation, but if webs are made deeper than normal, the metacarpals are “phalangized” and the appearance of the hand is usually aesthetically displeasing. Distraction lengthening of finger phalanges is not usually indicated, because stiff fingers should be short, or they will interfere with the function of more flexible fingers. Distraction lengthening of short metacarpals may enhance function and appearance.

Nonvascularized toe phalanx transfers are possible when a soft-tissue tube large enough to hold bone graft has developed distal to the metacarpal; toe phalanges are selected as a source of graft because terminally placed bone graft is resorbed unless it is cortically perimetered (61). The indications for free toe-to-hand transfer for transverse defects and symbrachydactyly are controversial, and the arterial supply, venous drainage, and nerves and muscles in a malformed hand are always abnormal and sometimes nonexistent. This operation is sometimes technically feasible, however, and it seems to preserve growth in many cases (99,220).

### *Classifications*

There are many different types of congenitally short digits and even more different names for them. Brachydactyly is the term most commonly, consistently, and accurately used to describe short fingers. Ectrodactyly is also used as a general descriptive term, but different authors define it differently; most commonly, it connotes digital absence. Some terms are used to describe specific types of short fingers, such as aphalangia (phalanges failed to develop, some soft-tissue structures may be present; Fig. 69.23), symbrachydactyly (short, webbed digits, more deficient centrally, previously called atypical cleft hand, Fig. 69.24), and symphalangia (absence of the proximal interphalangeal joints, Fig. 69.25), among many others.

***Figure 69.23.*** **A and B:** Aphalangia.

***Figure 69.24.*** Symbrachydactyly.

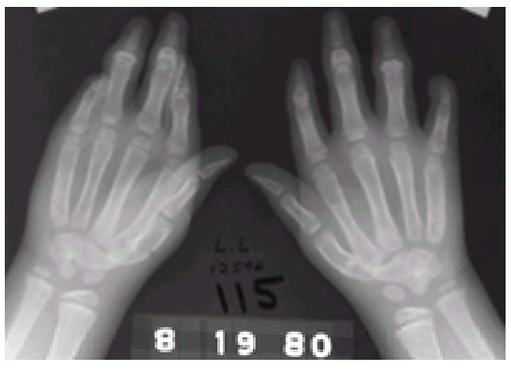


***Figure 69.25.*** Symphalangia.

Geneticists use extensive classification systems, such as Bell's classification of brachydactyly, to describe and categorize short fingers, because some types of short fingers have a dominant inheritance pattern. These systems do not help the surgeon predict function or plan treatment.

### *Preoperative Management*

Many parents are emotionally devastated by the birth of a child with aphalangia, especially when the deformity was not diagnosed prenatally. They may want to donate their own fingers or toes to their child, or obtain a cosmetic prosthesis immediately. Counsel parents early on that surgery cannot bring about normal appearance in most cases of aphalangia and that enhancing function will be the primary goal, at least until the child is old enough to participate in decision making, when enhancing appearance may take precedence. Peer contacts can be very valuable.

### *Preoperative Planning*

Several studies of toe proximal phalanx transfers have shown that the transferred toe phalanx physis is more likely to remain open and grow in younger patients (22,73,90,169). Growth of a transferred toe phalanx is negligible in many cases, however, and never normal, so surgery may be postponed until the child is older and the phalanx larger. Before performing toe proximal phalanx transfers, obtain radiographs with 10 cm markers of the affected hand or hands and feet; these radiographs provide an estimate of magnification, enabling accurate measurement of the toe phalanx. The transferred toe phalanx can be attached either to the end of the metacarpal (in which case it is effectively a one half joint transplant) or to a hypoplastic proximal phalanx.

### *Operative Technique*

1. Nubbin ablation.
   - Perform the operation with the patient under general anesthesia and tourniquet.
   - Remove all of the finger nubbins together, via an elliptical incision around the base of the nubbins.
   - Close with 5-0 chromic suture.
   - Apply a bulky compressive hand dressing, and cover with Coban.
2. Web deepening (see the section entitled Syndactyly).
3. “On-top plasty”: this operation is rarely indicated. See Dobyns (42) for details.
4. Metacarpal distraction lengthening (see Chapter 32 and Chapter 71) (101,161,164,188)
5. Nonvascularized toe proximal phalanx transfer (Fig. 69.26).

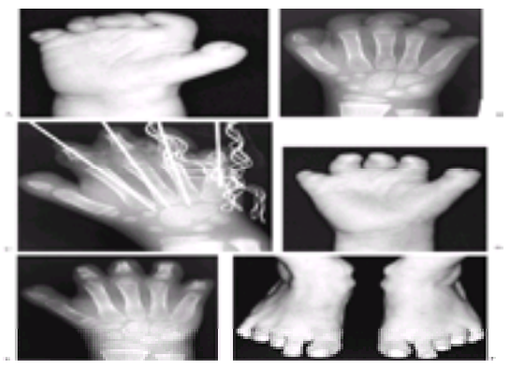

***Figure 69.26.*** Nonvascularized toe proximal phalanx transfers. **A:** Preoperative palmar view. **B:** Preoperative radiograph view, with soft-tissue tubes distal to metacarpals. **C:** Postoperative radiograph, following toe proximal phalanx transfers to index, long, ring, and small fingers. **D:** Palmar view, 2 years after phalanx transfer. **E:** Radiograph, 2 years after phalanx transfer. Note the open physis of the ring phalanx, and the resorption of the tips of the long and small phalanges. **F:** Feet, 4 years after phalanges were harvested from third and fourth toes of both feet.

- Use loupe magnification and perform the operation with the patient under general anesthesia and tourniquets.
- Drape free the affected hand and selected foot or feet. If four toe phalanges are needed, select the third and fourth toes of each foot.
- Explore the digits chosen to undergo toe phalanx transfer through dorsal chevron incisions. Split the extensor tendon, which inserts into subcutaneous tissue distally.
- Create a pocket in each digital tube, but take care not to remove too much subcutaneous tissue distally. Release the arm tourniquet while you harvest the toe proximal phalanges.
- Approach the selected toe or toes through a dorsal chevron incision. Split the extensor tendon.
- Dissect the toe proximal phalanx from distal to proximal. Stay subperiosteal distally, but leave the periosteum with the phalanx proximally. Remove the metatarsophalangeal collateral ligaments and part of the plantar plate with the phalanx; leave the flexor tendon intact.
- Suture the flexor and extensor tendons together.Close the wound with 5-0 chromic. After harvesting all of the toe phalanges needed, deflate the leg tourniquet or tourniquets.
- Reexsanguinate the hand and arm, and reinflate the arm tourniquet.
- Skewer the toe phalanx on a 0.035 or 0.045 in. Kirschner wire. Pass the wire antegrade by hand out of the tip of the previously prepared digital tube, then drive it retrograde into the finger hypoplastic proximal phalanx or metacarpal or both. If the fit seems tight, remove the phalanx, and trim the distal end before reinserting it.
- After all the phalanges have been inserted, deflate the tourniquet. If the tip of a digit is not vascularized, remove the phalanx, trim it, and reinsert it.
- If there is no proximal phalanx remnant present, attach the collateral ligaments to the metacarpal periosteum with absorbable suture.
- Check the Kirschner wire placement radiographically.
- Close the skin with interrupted 5-0 chromic suture.
- Apply a bulky compressive dressing over the fingers and hand, and cover it with an above-elbow fiberglass cast shell.
- Dress the foot or feet and apply a short-leg walking cast or casts.

6. Free toe-to-hand transfer (see Chapter 35 and Chapter 36).

#### *General Rehabilitation and Postoperative Principles*

Following nonvascularized toe proximal phalanx transfer, remove the leg cast or casts in 3 weeks. Change the hand cast under sedation in 6 weeks, and remove the second hand cast and Kirschner wires in the clinic 12 weeks after surgery. Obtain radiographs of the hand every 6 months, with markers placed 10 cm apart so magnification can be calculated, and the growth of the phalanx can be accurately measured. At a later date, deepen web spaces and lengthen transferred phalanges and metacarpals as indicated.

## PITFALLS AND COMPLICATIONS

The most common complications of toe proximal phalanx transfers are tip necrosis, physeal arrest, and resorption. Avoid early tip necrosis by taking care to trim the transferred phalanx to fit the digital tube. Late tip necrosis can occur if growth of the phalanx is especially vigorous, and may require a second operation to trim the tip of the phalanx. Toes from which proximal phalanges have been harvested are short, but toe complaints are rare following this operation. Do not fail to deflate the leg tourniquet after you have harvested all the toe phalanges needed.

## AUTHOR'S PERSPECTIVE

For nonvascularized toe proximal phalanx transfers, physeal arrest seems less likely to occur in younger children (especially those younger than 18 months of age at surgery) (22,73,169), but even the phalanges achieving the most growth do not grow as much or for as long as they would if they had been left in the toe (90). Waiting until the child is older and the phalanx is bigger seems sensible.

Counsel parents and older children about what they can expect from surgery. Often, they believe it can make short fingers normal. Peer contact with other children and families who have adjusted well to similar malformations is especially useful for children with short fingers. Sometimes, no matter how carefully they are counseled, parents and children are disappointed with the results of any operation.

Do not set the web more proximal than usual when separating short, webbed fingers. This procedure “phalangizes” the metacarpals, making the hand appear aesthetically displeasing. In addition, it requires release of the intermetacarpal ligament, which may make the digit unstable, and ligation of one of the digital arteries, which puts the digit at unnecessary risk of vascular insufficiency.

Free toe-to-hand transfer is not usually indicated for a unilateral malformation, because this operation does not restore normal appearance, and children with one normal hand are able to perform most developmental tasks.

### SYNDACTYLY

#### *Assessment, Indications, and Relative Results*

Syndactyly is the most common congenital hand malformation (1:2500 births); it may occur as an isolated anomaly (usually inherited in an autosomal dominant pattern) or as part of a syndrome (65). Syndromes commonly associated with syndactyly include Poland's syndrome (sporadic occurrence of symbrachydactyly associated with variable deficiency of the pectoralis major muscle), probably part of the subclavian artery supply disruption sequence (10,89,203) (Fig. 69.27); and acrosyndactyly, which occurs with congenital constriction band syndrome. Apert's syndrome is a complete and complicated form of syndactyly of multiple digits that is associated with craniosynostosis (Fig. 69.28) (2,203,210). Pfeiffer's syndrome is a mild syndactyly associated with acrocephaly (5,203). Other associated syndromes have been

described (203).

***Figure 69.27.*** Poland's syndrome.

***Figure 69.28.*** Apert's syndrome.

Syndactyly occurs most commonly between the long and ring fingers, followed by ring-small, index-long, and least commonly, thumb-index (65) (see the section entitled Cleft Hand in this chapter for a discussion of thumb-index syndactyly). The normal level of a finger web is halfway between the MPJ and PIPJ; for the thumb-index configuration, the normal web extends from the index MPJ to the thumb MPJ. If the distal web ends proximal to the PIPJ and extends no farther distal to normal level than the palm is deep, it can be adequately deepened with a butterfly flap without using skin graft. If the web extends distal to the PIPJ, release requires full-thickness skin graft. Harvest the graft from an inconspicuous location such as the groin (from an area that will not bear pubic hair at a later date, or the graft will bear hair in its new location).

***Classifications***

Hand surgeons classify syndactyly on the basis of clinical and radiographic findings, by both the degree of webbing and the presence of bony fusion or other bony anomalies (43,65,74). Syndactyly is described as incomplete when the web does not extend to the fingertips, and complete when the web extends to the tips; in complete syndactyly, the fingers may share a common nail (synonychia). The term simple is used to describe syndactyly that involves only soft tissues, complex when synostosis is present, and complicated when the webbed digits conceal polydactyly, dislocations, longitudinal epiphyseal brackets, and other bony malformations.

Geneticists have also classified syndactyly. Temtamy and McKusick propose five types based on localization of syndactyly in the hands and feet; these phenotypes seem to be correlated with genotype for isolated syndactyly (202).

***Preoperative Planning***

Obtain radiographs of both hands (and feet, if toe syndactyly is present) to help classify the syndactyly.

Neurovascular anomalies commonly accompany syndactyly, and the common digital arteries may branch distally, with one branch requiring ligation at the time of release. (A distally branching common digital nerve can be split into fascicles supplying each finger). Thus, when the syndactyly involves more than two digits, stage the releases to avoid operating on both sides of the same digit in the same procedure. At the second stage, refer to the report from the previous operation to ascertain whether a digital artery was ligated; if so, do not ligate the other artery to the same finger.

Time the surgery on the basis of the digits involved and the degree and complexity of the syndactyly. Release border digits early (usually around 6 to 12 months of age), because their length discrepancy may cause the longer digit to develop a flexion contracture and angulate toward the shorter one with growth. Although there is no such urgency to release long-ring or index-long syndactyly, parents may prefer early surgery. As long as anesthetic risk is not increased by airway, pulmonary, or cardiac anomalies, the experienced hand surgeon can honor this preference without compromising the long-term result.

If other hand or foot parts are to be ablated (e.g., a duplicated toe), schedule this operation for the same anesthetic as the syndactyly release, and harvest skin from the amputated part, because the color of foot skin better matches the hand than does groin skin.

***Operative Technique***

1. Butterfly flap (incomplete syndactyly release; Fig. 69.29).

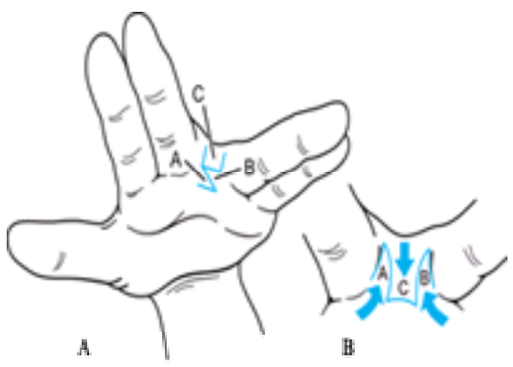


***Figure 69.29.*** Butterfly flap.

- Use loupe magnification and perform the operation with the patient under general anesthesia and tourniquet.
- Draw the flaps, aligning the proximal margin of the palmar Z with the normal level proximal digital flexion creases of the other digits. Each limb of the palmar Z and each limb of the dorsal rectangle should be the same length. The dorsal rectangle originates several millimeters proximal to the palmar proximal digital flexion creases, in order to create the normal dorsal-palmar slope of the web.
- Raise the dorsal rectangle at the subdermal level, taking a thin layer of subdermal fat with the flap.

- Raise palmar Z flaps of the same thickness.
- Transect distal fascial bands, protecting the digital neurovascular bundles.
- Interdigitate the dorsal and palmar flaps, attaching the corners of the dorsal rectangle to the palmar side at the normal level of the proximal digital flexion crease and wrapping a palmar flaps around the base of each digit.
- Close with interrupted 5-0 chromic suture.
- Apply a bulky compressive dressing, covered with either Coban (for the older child who can keep the dressing clean and dry) or an above-elbow fiberglass cast shell.

2. Complete syndactyly release (for syndactyly extending distal to the PIPJ; Fig. 69.30, Fig. 69.31 and Fig. 69.32).

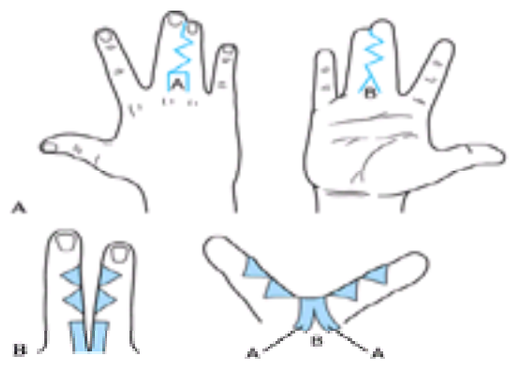


***Figure 69.30.*** Incisions for syndactyly release.

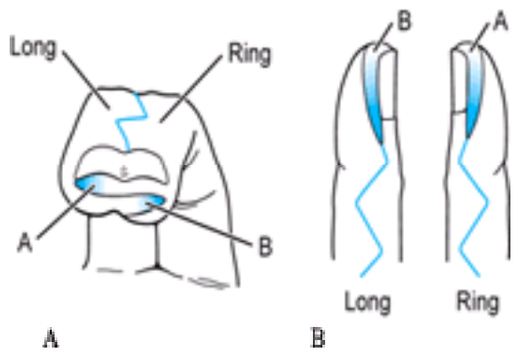


***Figure 69.31.*** Syndactyly tip release.

***Figure 69.32.*** Syndactyly release. **A:** Dorsal incisions. **B:** Palmar incisions. **C:** Tip incisions. **D:** Fingers spread open after release. **E:** Web reconstruction. **F:** After closing incisions and skin grafting. **G:** Immediately after cast removal.

- Use loupe magnification and perform the operation with the patient under general anesthesia and tourniquet.
- Prepare and drape the full-thickness graft donor site.
- Carefully plan and mark all flaps before inflating the tourniquet.
  - Place the base of the palmar V at the normal level of the proximal digital flexion crease. Place the base of the dorsal rectangle several millimeters proximal to the V, to create the normal dorsal-palmar slope of the web. The palmar V and the dorsal rectangle should be slightly longer than the depth of the palm. The sides of the dorsal rectangle should not extend beyond the midline of either digit (Fig. 69.30 and Fig. 69.31).
  - If the syndactyly is complicated, and there is no redundant soft tissue between the digits, consider using crossed triangles instead of the dorsal rectangle-palmar V technique described here.
  - Plan the palmar and dorsal triangular flaps on the fingers to interdigitate with each other after the fingers are separated.
- Elevate all flaps with a thin layer of subdermal fat.
- Separate the synonychia, if present (Fig. 69.31 and Fig. 69.32). Plan two long narrow flaps across the fingertips, one based on each fingertip. Each flap is the length of the nail. Raise these flaps carefully, and divide the nail, the nail bed, and any synostosis of the distal phalanges. Fold each flap down alongside the divided side of the nail to create the nail wall.
- Separate the digits carefully, searching for the neurovascular bundles.
- If the common digital artery and nerve bifurcate distal to the new web margin, separate the fascicles of the common digital nerve into the two proper digital nerves. Ligate the smaller of the two digital arteries, or the artery that does not supply a border digit (for example, preserve the radial digital artery to the small finger, since the ulnar digital artery to the small finger is often hypoplastic).
  - Secure the flaps in place with 5-0 chromic suture. Split the dorsal rectangular flap longitudinally, almost to its base. Wrap half around each finger, suturing the corner closest to the midline of the flap in the triangular defect adjacent to the palmar triangular flap.
  - Grafts are always needed on the proximal dorsal aspect of each finger. Usually one finger can be closed without any additional graft, and the remaining finger needs 3 to 5 grafts to fill in defects not covered by flaps.
  - Make patterns of all defects requiring grafts.
  - Deflate the tourniquet.
  - Transfer the patterns to the groin. Harvest thick split-thickness graft in the shape of the patterns. Stretch the skin while transferring the patterns and harvesting the grafts, or the grafts will be too big. Remove the remaining dermis from the groin wound and close in layers as a full-thickness defect.
  - Attach the grafts to the hand using interrupted 5-0 chromic suture.
  - Dress hand wounds with xeroform gauze and cotton balls soaked in normal saline. Apply a bulky compressive dressing, and cover it with an above-elbow fiberglass cast shell.

3. Separation of symbrachydactyly (see the sections entitled Transverse Failure of Formation [Hypoplasia and Absence] and Cleft Hand).
   - Follow the procedure described earlier. Avoid the temptation to make the webs deeper than normal in order to make the fingers appear longer.
4. Separation of thumb-index syndactyly (see the section entitled Cleft Hand).
5. Separation of syndactyly in Apert's syndrome: Syndactyly associated with Apert syndrome can be classified into several different types (210). All are complex, and involve at least one border digit. Because multiple operations will be necessary to separate the digits, operate as early as the pediatric anesthesiologist deems safe. If possible, coordinate syndactyly release to be performed at the same anesthetic as the craniofacial surgery these infants require. Reconstruct three fingers instead of four if bony and soft tissue are inadequate. The details of the treatment of this condition are too complex to cover in this chapter. See Upton (210) and Van Heest (216) for details.

### *General Rehabilitation and Postoperative Principles*

Instruct the parents to keep the cast dry. If it becomes wet, especially within the first week after surgery, the cast must be removed and the dressing changed, or the graft may fail. Remove the cast and dressing after 4 weeks; the child may then use the hand without restrictions. No splinting or therapy is necessary.

## PITFALLS AND COMPLICATIONS

Hypertrophic scarring in the web and “web creep” (a web margin that ends up more distal than the surgeon intended) are most commonly caused by too much tension in the web space closure. Plan pedicle flaps carefully so they cover the base of the web, because graft at the base will contract and narrow the web. Use graft generously, but avoid making each individual graft too large for its space, or the contour will not be smooth.

## AUTHOR'S PERSPECTIVE

This operation is not as simple as it seems. Like many hand operations, if it is not done well the first time, it is very difficult to redo well.

## CAMPTODACTYLY

### *Assessment, Indications, and Relative Results*

Camptodactyly is a Greek word meaning “bent finger,” which is used to describe a flexion contracture of the PIPJ, usually of the small finger. The incidence of camptodactyly is unknown.

The etiology of camptodactyly is multifactorial. Malformation of several different anatomic structures has been cited as the underlying cause of this deformity: anomalies of musculotendinous structures such as the lumbrical (87,141), the FDS (84,160,189), both of these (137), and the extensor mechanism (104,105).

Regardless of etiology, the initial treatments are splinting and stretching of the flexion contracture. The older child and adolescent should wear a static splint at night and a dynamic splint for 30- to 60-minute intervals during the day. The infant uses the static night splint only. Splinting usually improves the contracture (72,145,183), especially for isolated infantile camptodactyly (13), but many patients and parents find splinting and stretching too burdensome.

Surgical release is rarely indicated. Failure of the patient to use a splint is not an indication for surgery, inasmuch as postoperative management includes therapy and splinting. Surgery should be considered only when the contracture worsens in spite of splinting and interferes with function. The results of surgical release are often poor (less than 50% of fingers with postoperative increased range of motion) (48,183) and tend to deteriorate with follow-up (13).

### *Classifications*

Camptodactyly is classified by the age of the patient when initially seen, and whether the condition is associated with a syndrome (13). Type I, the most common type, is an isolated anomaly affecting the small finger. It is present in the infant and almost always improves with splinting and stretching. Type II is similar to type I, except that the patient with type II camptodactyly is first seen in adolescence (Fig. 69.33). This type also improves with splinting, and even if the deformity is severe, it rarely interferes with function (55). In type III camptodactyly, multiple digits are involved, the contractures are more severe than types I and II, and the child has an associated syndrome. Type III also improves with splinting, but is the most likely of the three types to require surgery.

***Figure 69.33.*** Adolescent camptodactyly.

### *Preoperative Management and Planning*

Use static splints custom fabricated by an experienced occupational therapist; for infants, the splint is forearm based, and for older children, the splint is hand or finger based. Finger-based dynamic splints are commercially available. Always first try splinting and stretching before surgical release.

Measure passive and active ranges of motion and any change in these ranges with wrist position, in order to help differentiate intrinsic from extrinsic causes. Obtain a lateral radiographic view of the involved digit; if the palmar aspect of the distal end of the proximal phalanx is flattened, the deformity is less likely to respond to surgical release than if it is not (55).

### *Operative Technique*

1. Corrective soft-tissue release and tendon transfer (small finger, less than 40° PIPJ flexion contracture) (55).
   - Use loupe magnification and perform the operation with the patient under general anesthesia and tourniquet.
   - Plan the incision to allow skin coverage for the straightened finger (midline palmar incision, which can be converted to Z-plasties; obtain consent for full-thickness skin graft) and to allow exploration of the palm.
   - Explore the full length of the fourth lumbrical; free any adhesions. Inspect the fourth palmar interosseous insertion.
   - Divide the small FDS just proximal to the vincula longa, through a window in the flexor sheath. Withdraw it into the palm. If possible, separate it from any adhesions to the ring FDS, pass it dorsal to the transverse metacarpal ligament, and transfer it to the radial lateral band of the extensor expansion. If the small FDS cannot be separated from the ring FDS, excise the small FDS and transfer the ring FDS instead.
   - If the PIPJ contracture is still greater than 30°, release as described in the next section.
2. Release of type III camptodactyly (7,104).
   - Use loupe magnification and perform the operation under general anesthesia and tourniquet.
   - Approach the PIPJ from the dorsum. Release the subluxated lateral band by transecting the transverse retinacular ligament; plicate the central slip.
   - Transfer the FDS to the radial lateral band of the extensor expansion, either through the dorsal incision, or through a separate palmar incision.
   - If the PIPJ flexion contracture is still greater than 30°, release as described in the next section.
3. PIPJ flexion contracture release.
   - Through a window in the flexor tendon sheath, release the proximal origin of the palmar plate and the check-rein ligaments. Stop here if the PIPJ can be straightened.
   - If not, release the proximal origins of the collateral ligaments. Stop here if the PIPJ can be straightened.
   - Release the FDS, if you have not already done so.
   - Hold the PIPJ as straight as possible with a Kirschner wire. Release the tourniquet; if the finger is not well vascularized, remove the Kirschner wire, allow the PIPJ to flex, and pin it in more flexion, ascertaining that the finger is well vascularized in the position of immobilization.

- Close the incision with Z-plasties of the longitudinal incision, or if necessary, full-thickness skin graft, using interrupted 5-0 chromic suture.
- Apply a bulky compressive dressing and cover with a fiberglass cast shell.

***General Rehabilitation and Postoperative Principles***

Remove the cast and pin after 4 to 6 weeks. Splint the finger in extension full time (except during bath or flexion exercises, which should be performed several times each day) for 4 to 6 more weeks. Splint at night indefinitely.

## PITFALLS AND COMPLICATIONS

The results of surgical treatment of camptodactyly are not very good, and any postoperative gains tend to diminish over time (48). The finger often loses as much flexion as it gains extension.

## AUTHOR'S PERSPECTIVE

Surgery is rarely indicated for this condition.

### CLINODACTYLY AND LONGITUDINAL EPIPHYSEAL BRACKET (DELTA PHALANX)

***Assessment, Indications, and Relative Results***

Clinodactyly is the deviation of a finger in the radioulnar plane (Fig. 69.34). It is usually caused by malformation of the distal end of the middle phalanx but may also be due to a longitudinal epiphyseal bracket (LEB, or delta phalanx) or to soft-tissue contracture (35). Although it can occur in any finger, it is most common in the small finger. This condition is quite common; in the United States, radial deviation of the small finger at the DIPJ may occur in up to 1% of normal children and 10% of children with other congenital anomalies (35); other series report up to 21% incidence in certain populations (200). Familial clinodactyly shows autosomal dominant inheritance with reduced penetrance and is not usually associated with other anomalies (200).

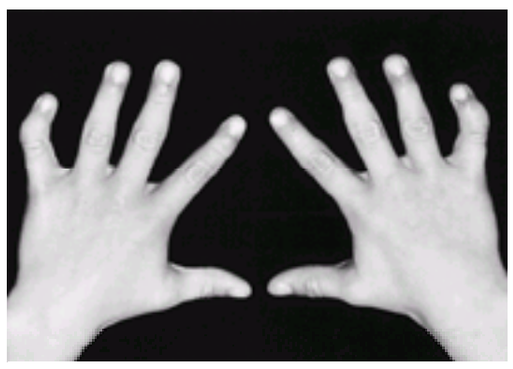

***Figure 69.34.*** Clinodactyly of bilateral small fingers.

Clinodactyly does not usually interfere with function. Splinting does not affect the deformity. Surgical treatment is indicated for worsening clinodactyly caused by an LEB, or when the patient is bothered by crossing of the flexed fingers.

Clinodactyly due to an LEB is likely to progress. This abnormal epiphysis occurs in bones with a proximal epiphysis (224), and extends longitudinally along the diaphysis and transversely across the opposite end of the affected bone, forming a C shape (Fig. 69.35) (154,218,231). For this type of clinodactyly, simple division of the abnormal LEB is not reliably successful (55). If the patient is skeletally immature, remove a portion of the midzone or isthmus of the continuous epiphysis and replace it with fat graft (physiolysis) (218). For clinodactyly of any etiology, regardless of skeletal maturity, an ulnar closing wedge osteotomy corrects the angulation (35,224). If modest lengthening is desired in addition to straightening, in the larger hand, a reversed-wedge osteotomy can be performed by removing a wedge of bone from the convex (usually ulnar) side, reversing it, and inserting it on the concave (usually radial) side (27,95).

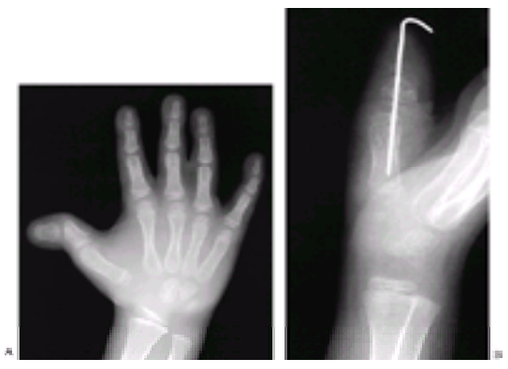

***Figure 69.35.*** Longitudinal epiphyseal bracket. **A:** Preoperative radiograph. **B:** Following closing wedge osteotomy.

***Classifications***

Geneticists have included clinodactyly in the classification for brachydactyly (200); others have hypothesized that it is a manifestation of polydactylism (224). Hand surgeons classify clinodactyly by the tissue involved and subclassify by severity of angulation and the presence of other malformations (Table 69.7) (35).

| *Type* | *Location of deformity* | *Angulation* | *Other* |
|---|---|---|---|
| Simple | Middle phalanx | 15° to 45° | |
| Simple complicated | Middle phalanx | 45° to 60° | |
| Complex | Middle phalanx and soft tissue | 45° | Syndactyly |
| Complex complicated | Middle phalanx and soft tissue | 45° to 60° | Polydactyly or gigantism |

Modified from Cooney WP III, Camptodactyly and Clinodactyly, In: Carter PR, ed *Reconstruction of the Child's Hand* Lea & Febiger: Philadelphia, 1991.

***Table 69.7. Classification of Clinodactyly (35)***

The LEB has been termed delta phalanx, longitudinally bracketed diaphysis, and C-shaped epiphysis. LEB has been classified into five types by the shape of the bone, and the presence and shape of the epiphysis (Table 69-8) (55).

| Type | | Description |
|---|---|---|
| A | Triangular bone | No radiographic evidence of physis |
| B | Trapezoidal bone | Normal-appearing proximal phalanx |
| C | Complete LEB | D shaped diaphyseal portion; epiphysis extends from proximal articular surface along entire concave border of phalanx |
| D | Incomplete LEB | Epiphysis in 2 parts, not an immature complete LEB |
| E | Complex LEB | Bizarre combination of >1 adjacent LEBs, associated with central polydactyly |

***Table 69.8. Classification of Longitudinal Epiphyseal Bracket (LEB) (55)***

### *Preoperative Planning*

Examine the involved finger or fingers radiographically to determine if the angulation is due to an LEB. Physiolysis requires further growth of the phalanx for straightening to occur; 7 years is the earliest age at which this operation has been reported, although the author estimates that the optimal age for this operation would be about 3 years (218). Osteotomy is difficult in very small phalanges; serial radiography helps the surgeon determine if the deformity is progressive and whether the phalanx is big enough for this operation.

### *Operative Technique*

1. Physiolysis (218).
   - Use loupe magnification and perform the operation with the patient under general anesthesia and tourniquet. Have radiography (Fluoroscan) available.
   - Through a midlateral incision on the radial (concave) side of the affected digit, reflect the periosteum to expose the diaphysis.
   - Use Kirschner wires or fine needles and radiography to locate the area to be removed.
   - Remove the isthmic region of the continuous epiphysis and physis with a fine rongeur.
   - Use a fine curet to remove bone from the metaphysis, leaving the cartilage of the longitudinal physis more prominent than the bone.
   - Wash out this cavity and fill it with fat graft harvested from the medial forearm (harvesting fat from the finger may cause scarring, which could tether growth).
   - Close the periosteum to hold the graft in place.
   - Close the wound with interrupted 5-0 chromic suture.
   - Immobilize by buddy-taping to the ring finger, or apply a bulky compressive dressing and cover it with a fiberglass cast shell.
2. Wedge osteotomy (closing or opening) (Fig. 69.36).

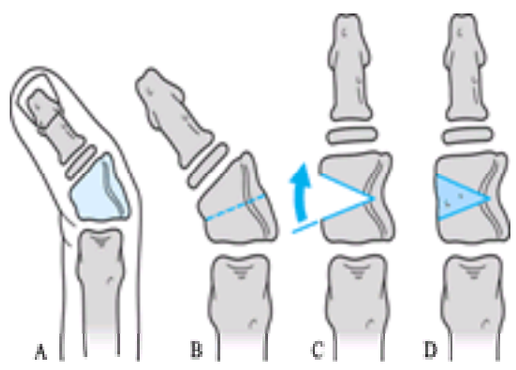


***Figure 69.36.*** Opening wedge osteotomy of longitudinal epiphyseal bracket. See text for details. (From Wood VE. Congenital Triangular Bones in the Hand. *J Hand Surg* 1977;2:179.)

   - Use loupe magnification and perform the operation with the patient under general anesthesia and tourniquet. Have radiography (Fluoroscan) available.
   - If possible, approach the affected phalanx from the dorsum. If this approach will damage the extensor mechanism, approach from the convex side of the deformity.
   - Insert a fine Kirschner wire or needle across the joint proximal to the affected phalanx. Plan the proximal cut of the wedge parallel to this wire.
   - Plan the distal cut of the wedge at an angle to the proximal limb sufficient to correct the angulation of the phalanx.
   - Plan either closing or opening wedge osteotomy (opening is preferable if additional length is needed, but requires bone graft).
   - Make the osteotomies using either a power saw with a 4 mm blade, or the tip of a fine bone cutter.
   - After adequate correction, pass a fine Kirschner wire antegrade through the osteotomy and out the tip of the digit, the back across the osteotomy. Cross as few joints as possible. If possible, pass another fine Kirschner wire to cross the osteotomy at an angle.
   - Close the wound with interrupted 5-0 chromic suture.
   - Apply a bulky compressive dressing over the fingers and hand, and cover it with a fiberglass cast shell.
3. Reverse wedge osteotomy.
   - Proceed as described earlier, except for the following:
   - Use a dorsal approach.
   - Plan the second, distal cut of the osteotomy to slightly undercorrect the deformity.
   - Use the tip of a fine bone cutter to make the osteotomies if at all possible, because the width of the saw blade or osteotome creates further shortening. Nibble away at the bone slowly, or it will splinter.
   - After the wedge is removed, place a small longitudinal Kirshner wire antegrade through the osteotomy, then replace the reversed wedge, and transfix it with the wire by driving it retrograde across the wedge and into the phalanx. Cross as few joints as possible. There will not be room for a second wire.

### *General Rehabilitation and Postoperative Principles*

After osteotomy, immobilize the hand and wrist (and elbow, if necessary, to keep the cast in place) for 4 to 6 weeks. Then remove the Kirschner wires if radiographic signs of healing are present. Splints and therapy are not usually necessary.

## PITFALLS AND COMPLICATIONS

Osteotomy of a small phalanx is a difficult operation. The reverse wedge technique is especially challenging in a small child's finger. Adjacent structures, including the interphalangeal joints, flexor and extensor tendons, and the neurovascular bundles are easily damaged.

## AUTHOR'S PERSPECTIVE

Although physiolysis is appealing as prophylactic operation, only one small series of this operation has been reported (218). I have used a similar operation for Madelung deformity with success (see the section entitled Madelung deformity in this chapter) (219).

In the growing child, osteotomy should be reserved for clinodactyly associated with an LEB. Clinodactyly associated with deformity of the distal end of the middle phalanx is unlikely to progress or cause functional limitations; wait until skeletal and emotional maturity before proceeding with surgical correction of this cosmetic deformity.

## CONSTRICTION RING SYNDROME

### *Assessment, Indications, and Relative Results*

The incidence of constriction ring syndrome (CRS) has been estimated at 1 in 15,000 live births (54); it is seen more commonly in spontaneously aborted fetuses than in term infants (6). The etiology of CRS is unclear; it is not genetic, but has been reported in identical twins (239). CRS frequently affects both arms or all four limbs (234), and is associated with clubfoot (66) and craniofacial clefts (31). Anomalies similar to those seen in CRS have been reported to be associated with maternal cocaine use and chorionic villus sampling (6,83). Leading theories about causation include disruption during blastogenesis; embryonic vascular disruption; and mechanical disruption (ensnaring of fetal fingers in the chorion) (6). CRS should be differentiated from transverse deficiency (142,162) (Table 69.6).

Multiple digits are usually involved, most commonly the index, middle, and ring fingers (Fig. 69.37) (111). Digits may be amputated, constricted by a partial or complete ring (a tight band of tissue), or webbed. Webbed fingers are typically short and fenestrated, with a sinus at the original web location (acrosyndactyly); syndactyly may be nonadjacent (146). Nail deformities are common (54). Surgical treatment includes Z-plasty of constriction rings and release of acrosyndactyly, usually when the child is older than 1 year of age. When the condition is severe with multiple-digit involvement, simple finger separation in the first 10 days of life can prevent serious later deformities. Deep circumferential rings may need to be released earlier if lymphedema is severe, if the vascular supply of the digit or extremity is compromised, or if the ring is causing a peripheral nerve palsy (209,228).

***Figure 69.37.*** Congenital constriction ring syndrome. **A:** Acrosyndactyly. **B:** Nonadjacent syndactyly. **C:** Constriction band.

Shallow constriction rings, or rings that occur in the normal location of a digital flexion crease, do not require release; the appearance will improve with growth and absorption of infant fat (54). With growth, angulatory or rotational malalignment may occur and require correction. Deformed nails may require ablation, if they become bothersome. Distraction osteogenesis and free toe transfers may be indicated; unlike finger hypoplasia, proximal neurovascular and musculotendinous structures are probably normal.

### *Classifications*

Many different names have been used to describe CRS, including constriction bands, annular rings or bands, amniotic band syndrome, and Streeter's syndrome. Acrosyndactyly is the term used to describe syndactyly associated with CRS: fusion of two or more digits with epithelial lined sinuses at or distal to the normal location of the web margin, indicating that the digits fused together after developing a web (24). Constriction rings, acrosyndactyly, and nonadjacent syndactyly are pathognomonic for CRS.

CRS has been classified into four types, all of which may occur in the same patient (165):

1. Simple constriction rings.
2. Constriction rings with distal deformity, with or without lymphedema.
3. Constriction rings with distal fusion (acrosyndactyly).
4. Intrauterine amputation.

Acrosyndactyly, or type 3, has been subclassified into mild (three phalanges, two interphalangeal joints in affected digits); moderate (two phalanges and only one interphalangeal joint); and severe (one phalanx and no interphalangeal joints) (65). Mild involvement is the least common.

### *Operative Technique*

1. Z-plasty of constriction ring (Fig. 69.38).

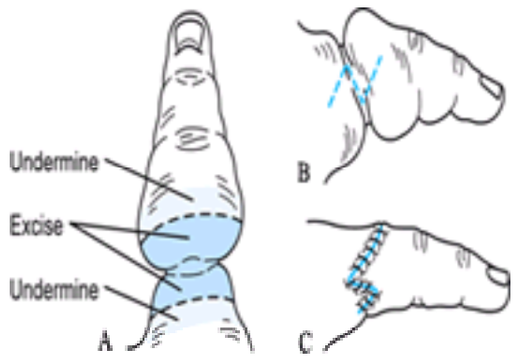


***Figure 69.38.*** Z-plasty of congenital constriction ring (211).

- Use loupe magnification and perform the operation with the patient under general anesthesia and tourniquet.
- Draw serial Z-plasties along the constriction ring. Release the entire circumference, if necessary (76). If the ring occurs at a normal digital flexion crease, that portion of the ring does not need to be released. The serial Z-plasty must start and end with a Z, or the flaps will not interdigitate properly.
- Raise the flaps as marked, including a thin layer of subdermal fat. Remove additional subcutaneous fat and lymphedematous tissue, or redistribute as necessary to improve the contour of the digit (Fig. 69-38) (211).
- Interdigitate the flaps, and suture in place with 5-0 chromic suture.
- Apply a bulky compressive dressing, and cover it with an above-elbow fiberglass cast shell.

2. Acrosyndactyly release.
   - Each of these conditions of the hands has a unique set of anomalies. Some resemble a bunch of grapes (54), and it may be difficult to match the fingertip with the finger. Follow these basic principles, and tailor the operation to the malformations:
     i. In especially severe cases, separate the digits to the level of the epithelial sinus early, and deepen the webs later when the child is older.
     ii. Use the epithelial sinus as the base of the web if it is found at the approximate normal web location. Excise the entire sinus if its location or size is inappropriate.
     iii. Plan local flaps to cover the web surface and, if necessary, the fingertips.
     iv. Defat to reduce the coverage needed and improve the contour; use a full-thickness skin graft as needed.
     v. Defat and use skin from any amputated parts as graft.
     vi. If necessary, revise webs when the child is a teenager.
3. Nail ablation (see Chapter 38).
4. Distraction osteogenesis (see Chapter 32 and Chapter 171).
5. Free vascularized toe transfer (see Chapter 35 and Chapter 36).

***General Rehabilitation and Postoperative Principles***

For constriction band release and acrosyndactyly release, remove the cast and dressing after soft-tissue healing has occurred (about 3 weeks). Splinting and therapy are not usually necessary.

## PITFALLS AND COMPLICATIONS

If a constriction ring is simply excised and the edges sutured (rather than treated with Z-plasty) the ring will recur.

If the epithelial sinus is not properly opened (to form the base of the web) or removed, an epidermal inclusion cyst will form, and eventually require surgical incision.

## AUTHOR'S PERSPECTIVE

Reconstruction of the severely involved hand should be performed by an experienced hand surgeon, because residual deformity is common even when the hand is reconstructed by an expert. Sometimes, when the skeleton is inadequate to support five digits, the surgeon may elect to reconstruct a four-digit hand.

## THE HAND, WRIST, AND FOREARM

See Chapter 165: Congenital Shoulder and Elbow Malformations for a discussion of transverse deficiency, and the section entitled Transverse Failure of Formation (Hypoplasia and Absence) in this chapter.

### CENTRAL DEFICIENCY (CLEFT HAND)

***Assessment, Indications, and Relative Results***

Flatt has described the cleft hand as “a functional triumph and a social disaster” (53) (Fig. 69.39). In the cleft hand, central bony elements are missing. The deficiency varies from absent long finger phalanges, to absent index, long, and ring finger rays (53), to monodactyly, or even absence of all digits (119). Wider clefts are associated with more adducted and deficient thumbs (53,127). Children and adults with this malformation are able to function almost normally, but they may hide their hands to avoid embarrassment.

***Figure 69.39.*** Cleft hands.

Cleft hand is a very rare anomaly, with an incidence between 1:90,000 and 1:150,000 live births (198). It is frequently inherited in an autosomal dominant pattern, with highly variable expression and penetrance (25,198). Chromosome defects associated with cleft hand have been mapped to two different loci: 7q21.2-q21.3 (25) and 10q25. Fibroblast growth factors 2 and 8, and 2 different HOX genes have also been mapped to 10q25 (168).

Cleft hand is usually associated with syndactyly (especially thumb-index) and cleft feet (Fig. 69.40), and is frequently associated with other musculoskeletal anomalies including central polydactyly, camptodactyly, longitudinal epiphyseal bracket, and absence of the tibia, and anomalies of other organ systems including cleft lip and palate (144,156,198,199). Cleft hand is also frequently associated with various syndromes (199). The true cleft hand should be differentiated from symbrachydactyly, formerly called atypical cleft hand (Table 69.9; see the section entitled Transverse Failure of Formation [Hypoplasia and Absence]) (125).

| *Feature* | *Cleft hand* | *Symbrachydactyly* |
|---|---|---|
| Absence/deficiency of finger ray(s) | Long ray absent; sometimes index, rarely ring absent | Several rays deficient |
| Laterality | Bilateral | Unilateral |
| Inheritance | Autosomal dominant | Not inherited |
| Shape of defect | V shaped | U shaped |
| Foot involvement | Yes | No |
| Associated syndactyly | Common | Uncommon |
| Other associated anomalies | Yes | No |

Modified from Flatt AE. The Care of Congenital Hand Anomalies, 2nd ed. St. Louis: Quality Medical Publishing, Inc, 1994.

***Table 69.9. Differential Diagnosis of Cleft Hand vs. Symbrachydactyly (53)***

***Figure 69.40.*** Cleft foot.

Because of the variable expressivity of this condition, different combinations of anomalies are seen in different cleft hands. Surgical treatment is not always indicated, and surgical planning is complex, because various operations may be indicated in varying combinations. Normal appearance is rarely attainable.

Surgery is usually indicated to improve thumb mobility by releasing the adducted thumb or thumb-index syndactyly, to separate other syndactylies, and to remove transverse bony blocks. Surgical closure of the cleft, correction of camptodactyly, and rotational osteotomies may be indicated, but these operations should be postponed until the child is older and the surgeon can be more certain that they will not interfere with function.

### *Classifications*

This condition was previously called lobster-claw hand; this term is no longer used. Ectrodactyly is sometimes used to describe cleft hand, but this term, which usually means missing digits, is used differently by different authors. Geneticists frequently call this condition split hand. Until recently, cleft hand was divided into two types—typical and atypical (8,121,176,198). Atypical cleft hand is now termed symbrachydactyly, and typical cleft hand is called cleft hand, or true cleft hand (Table 69.9) (53,125).

Nutt and Flatt described a classification of cleft hand based on which bones are missing; this complicated classification has 11 subtypes (152), but these subtypes do not help determine prognosis or treatment of this condition. Manske has classified cleft hand based on the characteristics of the thumb web (Table 69.10) (127). Types I and II are treated with thumb-web deepening and cleft closure; type III with web deepening, often combined with index-to-long metacarpal transposition or excision of bony remnants of the index; types IV and V did not usually require surgical correction.

| *Type* | *Description* |
|---|---|
| I | Normal web |
| IIa | Mildly narrowed thumb web |
| IIb | Severely narrowed thumb web |
| III | Syndactylized web (thumb-index syndactyly obliterates web) |
| IV | Merged web (index ray absent, thumb web merged with cleft) |
| V | Absent web (thumb and index rays absent, no thumb web) |

Modified from Manske PR, Halikis MN. Surgical Classification of Central Deficiency According to the Thumb Web. *J Hand Surg* 1995; 20A:687.

***Table 69.10. Classification of Cleft Hand Based on the Thumb Web***

In addition to mapping the gene for cleft hand, geneticists have described two types of nonsyndromal cleft hand based on two different inheritance patterns: in the first, cleft hand or foot is inherited in an autosomal dominant pattern with high penetrance; in the second, the gene is nonpenetrant, and expression may skip several generations (240). The second pattern implies the existence of another gene, which controls the expression of the cleft hand and foot gene.

### *Preoperative Planning*

Study both hands radiographically to determine which bones are absent or anomalous. If a transverse phalanx is present, remove it as soon as possible because it will cause the cleft to widen with growth. Thumb-web deepening can be combined with cleft closure, by transposing the index to the base of the long metacarpal and shifting the excess skin from cleft closure to the first web. If the thumb and index are syndactylized, however, cleft closure should be postponed, because the child may prefer prehension using the digits on either side of the cleft instead of the thumb, and cleft closure would interfere with this pattern.

If the child requires closure of foot clefts in order to wear shoes, schedule syndactyly release for the same anesthetic, because skin removed in order to close the foot cleft can be used as graft on the hand.

### *Operative Technique*

1. Deepening of thumb web.
   - Fourfold Z-plasty: see the section entitled Hypoplasia and Absence.
   - Dorsal rotation flap: see the section entitled Clasped Thumb in this chapter (this operation is inadequate for thumb-index syndactyly [67]).
2. Release of thumb-index syndactyly (Fig. 69.41)

***Figure 69.41.*** Thumb index syndactyly release. **A:** Palmar incisions. **B:** Dorsal incisions. **C:** Postoperative palmar view.

   - Syndactyly release: see the section entitled Syndactyly, with the following changes:
     i. Plan the base of the dorsal rectangular flap at the level of the thumb MPJ. Make this flap as wide as possible, but do not extend the sides of the rectangle past the midline of the thumb and index fingers.
     ii. Release the first dorsal interosseous and adductor pollicis fascia (217).
3. Removal of transverse phalanx (Fig. 69.42).

***Figure 69.42.*** Transverse phalanx.

- Removal of a transverse phalanx is combined with other operations including thumb web release and cleft closure, as indicated.
- Use loupe magnification and perform the operation with the patient under general anesthesia and tourniquet.
- Approach the transverse phalanx through a longitudinal zigzag dorsal incision.
- Remove the entire phalanx, including the periosteum. Removal is more difficult than it appears, because the phalanx is larger than radiography indicates (because of incomplete ossification) and is intimately connected to surrounding structures.
- If removal of the transverse phalanx destabilizes the MPJs, reconstruct collateral ligaments using available tissue.
- Reconstruct the transverse intermetacarpal ligament with nonabsorbable suture (see the section entitled Closure of Cleft).
- Close the skin incision with interrupted 5-0 chromic suture.
- Apply a bulky compressive dressing over the fingers and hand, and cover it with an above-elbow fiberglass cast shell.

4. Closure of cleft (Fig. 69.43 and Fig. 69.44).

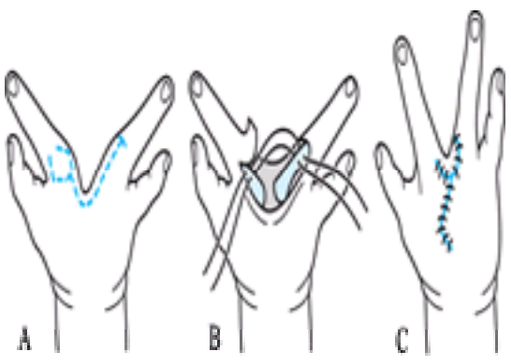


***Figure 69.43.*** Cleft closure. See text for details. (8)

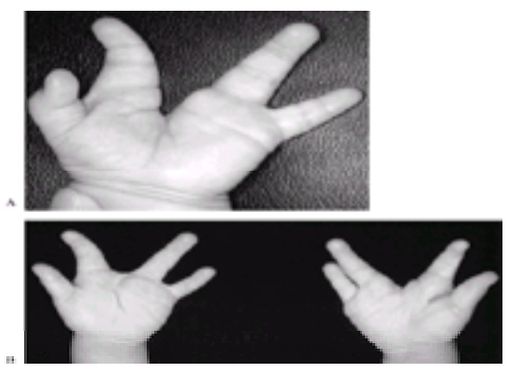

***Figure 69.44.*** Cleft hand. **A:** Preoperative palmar view. **B:** Postoperative palmar view (left hand).

- Use loupe magnification and perform the operation with the patient under general anesthesia and tourniquet.
- Plan skin incisions to produce zigzag interdigitations on both palmar and dorsal surfaces. Create a flap along the side of one digit to form the new web. A diamond shape works well for this (8) (Fig. 69.43A).
- Remove any bony or soft tissue holding the metacarpals apart.
- Construct an intermetacarpal ligament out of adjacent soft tissue. If no tissue is available, drill holes in the metacarpals as far distal as possible, but avoid damaging the epiphyses, and pass nonabsorbable suture through these holes to hold the metacarpals together.
- Close the skin with interrupted 5-0 chromic suture, excising excess skin as necessary and contouring the closure to create a normal web slope (Fig. 69.43B, Fig. 69.43C).
- Apply a bulky compressive dressing designed to support the cleft closure. Cover with an above-elbow fiberglass shell.

5. Transposition of the index finger (combined cleft closure and first web deepening) (Fig. 69.45)

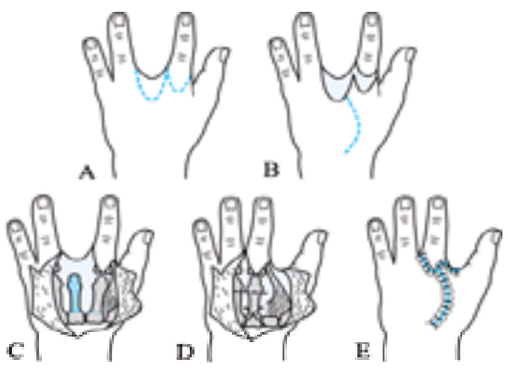


***Figure 69.45.*** Combined cleft closure and first web deepening. See text for details. (From Miura T, Komada T. Simple Method for Reconstruction of the Cleft Hand with an abducted thumb. *Plast Reconstr Surg* 1979;64;65.)

- If the thumb and index are not syndactylized (Manske type II), the index may be transposed, the cleft closed, and the excess skin from cleft closure used to deepen the web space, all at the same operation. This complex operation as originally described by Snow and Littler, is detailed elsewhere (53). A simpler modification, by Miura and Komada, is described in the following section (143).
- Use loupe magnification and perform the operation with the patient under general anesthesia and tourniquet.
- Approach the cleft and base of the index through a curved dorsal incision, combined with other incisions designed to transfer excess cleft skin to augment the first web. (Fig. 69.45A, Fig. 69.45B)
- Detach the index metacarpal at its base, releasing the adductor pollicis and first dorsal interosseous fascia, and possibly the thumb attachment of the first

dorsal interosseous.

- Move the index to the stump of the long metacarpal or its space. Check rotation, and pin it in place using Kirschner wires (Fig. 69.45C, Fig. 69.45D).
- Repair or create an intermetacarpal ligament (see the section entitled Closure of Cleft).
- Close the skin with interrupted 5-0 chromic suture (Fig. 69.45E).
- Apply a bulky compressive dressing over the fingers and hand, and cover it with an above-elbow fiberglass cast shell.

#### *General Rehabilitation and Postoperative Principles*

Keep the hand immobilized for 6 weeks after reconstruction of the transverse intermetacarpal ligament. Check bony healing radiographically and remove the pin or pins at 6 weeks postoperatively for index transposition. No splinting or therapy is necessary.

## PITFALLS AND COMPLICATIONS

The cleft is frequently used for prehension; do not close it until you are certain that thumb function can be restored. If the cleft is closed without construction of a transverse intermetacarpal ligament, it will widen (it may do so anyway). If the cleft is closed too tightly, or if the surgical scar contracts, the fingers may overlap, impairing function.

## AUTHOR'S PERSPECTIVE

This is a complex, highly variable condition that is best treated by an experienced hand surgeon. The treatment must be tailored to the individual cleft hand. Complete thumb-index syndactyly cannot usually be released to the normal thumb web level. If the only space available for prehension is the cleft (Fig. 69.39), surgery is not indicated, but peer contacts and counseling are often helpful.

### RADIUS DEFICIENCY

#### *Assessment, Indications, and Relative Results*

Radius deficiency is a rare condition (approximately 1:30,000 live births [198]) that is nearly always associated with thumb and carpal deficiencies and frequently associated with other upper extremity anomalies, anomalies of other organ systems, and syndromes (60,79,91,107,126,184,198). The newborn with radius deficiency should be carefully examined for signs of the VACTERL association (not inheritable; it may be accompanied by *V*ertebral, *A*nal, *C*ardiac, *T*racheo-*E*sophageal, *R*enal or *R*adial, and *L*ung anomalies), Holt-Oram syndrome (autosomal dominant inheritance of cardiac septal defects associated with upper limb anomalies), and TAR syndrome (autosomal dominant or recessive inheritance of completely absent radius with a near-normal thumb and thrombocytopenia) (3,4,9,12,177,180,199). Multiple other syndromes, many inheritable, are associated with radius deficiency. Radius deficiency is usually bilateral, although the two sides are frequently asymmetric; when the condition is unilateral, it is more common on the right (91,107).

All of the radial forearm structures are deficient to varying degrees. Flatt has described radial clubhand as “a profoundly abnormal hand joined to a poor limb by a bad wrist” (60), and he has meticulously documented multiple abnormalities of muscles, nerves, and blood vessels found in anatomical dissections of upper limbs with radius deficiency (184). The radial wrist extensors and extrinsic thumb motors are usually absent or aberrant. The radial nerve is usually absent below the elbow, and the median nerve is always present and often the most prominent structure on the radial side of the wrist. The radial artery is usually absent.

Children with type 0, 1, or mild type 2 radial deficiency (Fig. 69.46 and Table 69.11) usually require stretching and splinting, and no surgical treatment. Moderately severe type 2 is treated with radius lengthening; severe type 2 with centralization of the carpus on the end of the ulna. The wrist instability and radial deviation associated with types 3 and 4 (Fig. 69.46 and Table 69.11 and Table 69.12) is treated with centralization of the carpus on the end of the ulna, with the best results if aberrant radial wrist extensors are transferred to help maintain the new position, and if the operation is performed before the child is 1 year of age (60). Before centralization, serial casting or application of a distraction device (149,187) helps stretch the radial structures. Stabilization of the wrist enhances the appearance and function of the hand (60) but is difficult to maintain throughout growth; radial deviation tends to recur unless the wrist is quite stiff. Centralization is contraindicated for the following patients:

| Type | Thumb | Carpus | Distal radius | Proximal radius |
|---|---|---|---|---|
| N | Hypoplastic or absent | Normal | Normal | Normal |
| 0 | Hypoplastic or absent | Absence, hypoplasia or coalition | Normal | Normal, radioulnar synostosis, or congenital dislocation of the radial head |
| 1 | Hypoplastic or absent | Absence, hypoplasia or coalition | >2 mm shorter than ulna | Normal, radioulnar synostosis, or congenital dislocation of the radial head |
| 2 | Hypoplastic or absent | Absence, hypoplasia or coalition | Hypoplasia | Hypoplasia |
| 3 | Hypoplastic or absent | Absence, hypoplasia or coalition | Physis absent | Variable hypoplasia |
| 4 | Hypoplastic or absent | Absence, hypoplasia or coalition | Absent | Absent |

From James WO, McCarroll HRJ, Manske PR. The Spectrum of Radial Longitudinal Deficiency: A Modified Classification. *J Hand Surg* 1999;24:1140.

***Table 69.11. Modified Classification of Radial Longitudinal Deficiency (91)***

| Type | Definition | Description |
|---|---|---|
| 1 | Short distal radius | Distal radial epiphysis present but delayed; little radial deviation; thumb hypoplasia "almost always present" |
| 2 | Hypoplastic radius | Growth defective in proximal and distal radial epiphyses; "radius in miniature" |
| 3 | Partial absence of the radius | Defect can be proximal, middle or distal third, but most frequently proximal; "hand is radially displaced," "wrist is unsupported" |
| 4 | Total absence of the radius | Most common type; "hand is usually severely radially displaced" |

From Bayne LG, Klug MS. Long-term Review of the Surgical Treatment of Radial Deficiencies. *J Hand Surg* 1987;12A:169.

***Table 69.12. Classification of Radial Longitudinal Deficiency (Bayne) (11)***

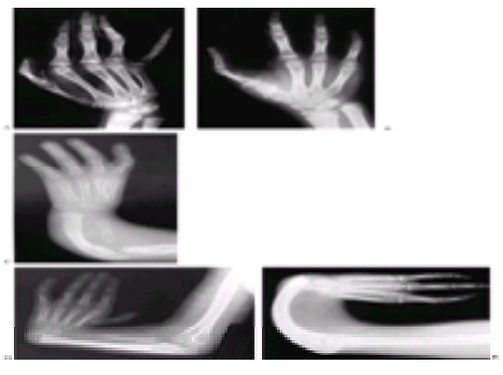

***Figure 69.46.*** Radius deficiency. **A:** Type 0 (carpal anomalies; distal radius is normal). **B:** Type 1 (short distal radius). **C:** Type 2 (radius is deficient proximally and distally). **D:** Type 3 (distal radius is absent). **E:** Type 4 (the entire radius is absent).

1. Infants younger than 6 months of age for whom major organ defects may not yet have been diagnosed.
2. Children with severe associated anomalies that significantly decrease life expectancy.
3. Adults with firmly established functional patterns (see Fig. 69.47) (60).

***Figure 69.47.*** Untreated radius deficiency in adults. **A:** Photo. **B:** Radiograph (different patient from that shown in *A*).

4. Children without adequate elbow flexion for the hand to reach the mouth after the wrist is straightened.

The entire arm is short; with unilateral involvement, the forearm may be only half as long as the unaffected side. Ulnar lengthening using the distraction osteogenesis (such as with the Ilizarov system) can successfully lengthen the forearm (1,28,97). This technique is primarily indicated to improve the appearance of unilateral radius deficiency, or to improve reach (for example, for personal hygiene) in bilateral radius deficiency. Patients should be carefully selected for this procedure, because the lengthening device requires meticulous care and may be in place for several months.

Vilkki (221) has recently described the combination of soft-tissue distraction and microvascular epiphysis transfer for the treatment of type 4 radius deficiency. Historically, attempts to treat longitudinal radius deficiency with surgical transfer of nonvascularized growing bone have failed, because the graft has not continued to grow (79,171,192). Vilkki's early results are promising, although the technique he describes is technically demanding.

### *Classifications*

The use of the term radial clubhand is diminishing in favor of longitudinal deficiency of the radius, or radius deficiency. The term radius is used to refer to the radius bone; the term radial is used to describe the radial structures of the forearm, wrist, and hand, including the radius, radial carpus, and thumb.

The best known classification scheme for radius deficiency, described by Bayne, includes four types based on increasing radiographic severity of the radius deficiency (Table 69.12) (11). In order to define Bayne type 1 better, and to include patients with deficiency of the thumb or carpus in the presence of a normal-length radius, James, McCarroll, and Manske have modified Bayne's classification scheme (Table 69.11 and Fig. 69.46) (91). This scheme is used in combination with the modified Blauth scheme for classifying thumb hypoplasia (Table 69.3).

### *Preoperative Management*

Start serial casting for the infant with radius deficiency as soon as possible after birth. Gently stretch the wrist as close to neutral as possible, and apply an above-elbow flexed elbow cast in the maximally corrected position with the elbow flexed. Change the cast weekly, stretching the wrist further at each cast change. When the wrist reachesneutral, apply a custom fabricated above-elbow orthoplast splint and instruct the parents to stretch the wrist several times each day. Continue with splinting and stretching until centralization is performed.

### *Operative Technique*

1. Centralization (ulnar approach) (131) (Fig. 69.48).

***Figure 69.48.*** Centralization for radius deficiency (same patient as shown in Figure 69.8). **A:** Pre-operative palmar view. **B:** Postoperative palmar view. **C:** Preoperative radiograph. **D:** Postoperative radiograph.

- Use loupe magnification and perform the operation with the patient under general anesthesia and tourniquet.
- Begin the incision at the level of the distal end of the ulna, near the dorsal wrist extension crease, just radial to the midline. Extend it ulnarward, initially transverse, then forming an ellipse in order to excise excess skin and subcutaneous tissue after the carpus is reduced onto the ulna.
- Identify and preserve the dorsal ulnar sensory nerve.
- Expose the extensor retinaculum.
- Identify the extensor carpi ulnaris; detach it from its insertion into the base of the fifth metacarpal, and retract it proximally.
- Raise the extensor retinaculum as a radially based flap.
- Identify and retract the finger extensor tendons radially. If radial wrist extensors are present, detach them and retract them proximally.
- Incise the wrist capsule transversely, exposing the distal ulna. The carpal bones will be palmar and radial to the distal ulna, and may be difficult to identify.
- Free the ulna of soft-tissue attachments distal to the physis. Detach the carpal bones from the palmar capsule.
- Serially carve away central carpus and shave distal ulna until the carpus fits on the end of the ulna without tension. Do not injure the distal ulna physis or attached soft tissue. Very tight wrists may require resection of the lunate and part of the capitate before the wrist can be reduced.
- If the ulna is quite bowed, perform a closing wedge osteotomy through a separate proximal incision.
- Pin the carpus on the distal ulna using a long Kirschner wire. The wire can exit either through the distal end of the long finger metacarpal or through the proximal ulna. If an ulnar osteotomy has been performed, use the same Kirschner wire to fix it.
- Imbricate the wrist capsule.
- Transfer radial wrist extensors into the distal fragment of the extensor carpi ulnaris. Reattach the extensor carpi ulnaris, advancing it to increase soft-tissue tension on the ulnar side.
- Pass the retinacular flap underneath the finger extensors.

- Excise excess skin and subcutaneous tissue.
- Close the skin with interrupted 5-0 chromic suture.
- Apply an above-elbow bulky compressive dressing, and cover with a fiberglass cast shell.

2. Ulnar lengthening (Fig. 69.49).

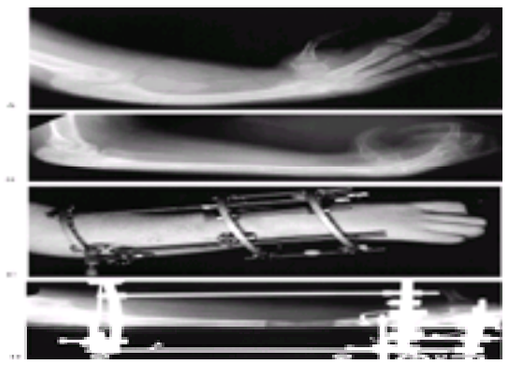

***Figure 69.49.*** Ulnar lengthening for radius deficiency. **A:** Preoperative radiograph. **B:** Postoperative radiograph. **C:** Ilizarov device in place during lengthening. **D:** Bone regenerating in gap created by lengthening.

- Follow the principles of Ilizarov lengthening of the forearm described in Chapter 32 and Chapter 171.
- Use two half-pins and one transfixion wire proximal to the osteotomy, and one half-pin and two transfixion wires (one in the ulna and one in the metacarpals) distal to the osteotomy.
- If the hand is radially deviated, correct the deviation at the same time as application of the fixator, using a closing wedge osteotomy through the carpus or distal ulna, and fixing it with Kirschner wires. Otherwise, radial deviation will worsen when the fixator is removed, because of increased tension placed on the radial soft tissue by the lengthening.

#### *General Rehabilitation and Postoperative Principles*

Keep the postcentralization cast and pin in place for 6 to 12 weeks. Apply a custom-made above-elbow orthoplast splint to maintain wrist position. Prescribe full-time wear for 3 to 6 months, then nighttime wear indefinitely.

For ulnar lengthening, wait 5 to 7 days before beginning to lengthen the ulna, then proceed at a rate of approximately 1 mm per day in three increments (the nuts in the pediatric Ilizarov set are six sided, so the child can advance 1/3 turn three times per day). Check progress on radiograph when lengthening begins and weekly thereafter, adjusting the lengthening rate depending on regenerate formation. Teach the child and family to perform the lengthening and pin care and to maintain elbow and digit motion. Stop lengthening when the regenerate appears thready or the elbow or digits start to develop flexion contractures. The ulna can usually be lengthened by 30% to 50%. Leave the fixator in place until four cortices are visible in the regenerated bone (this usually takes three times as long as bone lengthening), then remove the fixator under general anesthesia, and apply an above-elbow fiberglass cast.

## PITFALLS AND COMPLICATIONS

Preoperative serial casting, stretching, and splinting make reduction of the carpus on the distal ulna easier, but reduction is nonetheless difficult to accomplish. The postcentralization cast must be carefully molded and the elbow flexed to 90° or it will fall off—or worse, it will slip partway off with the child's wrist wedged in the flexed portion of the cast. With long-term follow-up, centralized wrists tend to be either stiff and straight, or flexible and deviated.

Nearly every patient who has undergone the Ilizarov procedure acquires at least one pin tract infection. Treat these infections with oral antibiotics unless the patient has a fever or cellulitis, in which case intravenous antibiotics are necessary. If the area is not carefully monitored, regenerated bone can heal too quickly (requiring a second osteotomy) or too slowly (requiring bone grafting). The proximal half-pins are the most troublesome; they tend to loosen if the fixator needs to remain in place for more than 6 to 8 months.

## AUTHOR'S PERSPECTIVE

Serial casting is difficult. The cast is best applied by two experienced people. Centralization is a technically demanding operation that is best performed by the experienced hand surgeon.

Ulnar lengthening is a tedious process, requiring realistic expectations and emotional stamina on the part of the patient. It should be reserved for the mature older child or teenager with good family support who can manage the care of the external fixator. Preoperative peer counseling (by another patient with a fixator in place) and preoperative psychological assessment by the social worker are helpful. The support of an Ilizarov procedure team (including a nurse, social worker, and occupational therapist) is very helpful to the surgeon.

### ULNA DEFICIENCY

#### *Assessment, Indications, and Relative Results*

Children with ulna deficiency, a very rare anomaly (approximately 1:100,000 live births [198]), have hypoplasia of the entire upper extremity. The elbow is malformed or absent (humeroradial synostosis) in the majority of cases (197). Deficiency of the ulna may be partial or complete, and a cartilaginous ulna “anlage” is often present (19,26,132,140,155). All children with ulna deficiency have hand and carpal anomalies; about 90% of hands are missing digits, 30% have syndactyly, and 70% have thumb abnormalities (33,64,123,197). Unilateral involvement is twice as common as bilateral involvement (197). This condition is often associated with other musculoskeletal anomalies, most commonly proximal femoral focal deficiency, fibula deficiency, phocomelia, and scoliosis (65,197,199), but it is rarely associated with anomalies of other organ systems (123,197,199). In spite of their upper extremity malformation, children with ulna deficiency usually function well (15,64,190).

In one small study, patients with ulna deficiency who underwent thorough functional testing had no deficits in bimanual function but performed one-handed tasks much more slowly with the affected side. Patients with humeroradial synostosis and absent or stiff fingers fared worst, and no correlation was found between functional abilities and classification systems based on the elbow or forearm (see the section entitled Classifications, later) (15).

Because ulna deficiency is so uncommon, most published series of patients with this condition are small, and authors disagree about its natural history. Two sequelae of ulna deficiency are especially controversial: progressive ulnar deviation at the wrist, and forearm instability. Some authors report that ulnar deviation at the wrist always worsens and is due to tethering by the ulna anlage; they advocate early excision of the ulna anlage to prevent progression (26,155). More recent reports disagree, and indicate that ulnar deviation usually does not progress; they advocate anlage resection only if progression is documented (64,132,140). In order to treat forearm instability, some authors advocate surgical construction of a one-bone forearm by cross-union between the radius and ulnar remnant (26); others believe that loss of forearm rotation is not a good trade-off for forearm stability (64).

Thumb reconstruction, release of syndactyly, and external rotation osteotomy of the humerus are well-accepted treatments for malformations associated with ulna deficiency. First web deepening, opponensplasty, thumb metacarpal rotational osteotomy, pollicization, and syndactyly release should be performed when the child is old enough to benefit from the operations, usually by age 1 to 4 years. The child in whom the hand rests on the buttock or flank and cannot reach the mouth or top of the head because of internal rotation of the arm and forearm, combined with humeroradial synostosis, benefits from external rotation osteotomy of the humerus (Fig. 69.50) (33,64,123,140). Lengthening may improve the appearance of a short forearm but is indicated only when the elbow is stable and has active elbow flexion.

***Figure 69.50.*** Ulnar deficiency.

### *Classifications*

The use of the term ulnar clubhand is diminishing; the preferred name for this condition is longitudinal deficiency of the ulna, or ulna deficiency.

Most classification systems for ulna deficiency are based on elbow and forearm anomalies (Kummel [106], Ogden [155], Riordan and Bayne [172], Swanson et al [197], Miller et al [140], and Dobyns et al [43]; (Table 69.13). Ogino and Kato (159) have used hand anomalies as the basis for classification. Cole and Manske have described the only classification system for ulna deficiency that correlates with treatment; their system is based on thumb and first web deformities, and can be combined with one of the elbow and forearm classifications (preferably that of Ogden, Bayne, or Swanson, because these classifications address both forearm and elbow anomalies) (Table 69.14).

| Characteristics | Kummel (106) | Ogden et al. (155) | Riordan and Bayne (172) | Dobyns et al. (43) | Swanson et al. (197) | Miller et al. (140) |
|---|---|---|---|---|---|---|
| Elbow | | | | | | |
| normal/near-normal humeroradial joint | I | | | | | |
| humeroradial synostosis | II | | III | IV | II | D |
| radial head dislocation | III | | | | | A,B* |
| Ulnar length | | | | | | |
| normal length ulna | | | | | | |
| Ulnar hypoplasia | | I | | I | I | |
| partial ulnar aplasia | | II | II | II | | |
| complete ulnar aplasia | | III | I | III | II | |
| Other upper extremity characteristics | | | | | | |
| congenital wrist amputation | | | | | IV | |
| internal rotation deformity below the shoulder | | | | | | C† |

* II, Radial head dislocation with complete ulnar absence and carpal webbing.
C, † Humeroradial synostosis with variable absence of the ulna and associated internal rotation deformity.
Modified from Cole, RJ, and Manske PR. Classification of Ulnar Deficiency According to the Thumb and First Web. J Hand Surg 1997;22A:479.

***Table 69.13. Classification of Ulna Deficiency Based on Elbow and Forearm Anomalies (33)***

| *Type* | *Characteristics* |
|---|---|
| A | Normal first web space and thumb |
| B | Mild first web and thumb deficiency |
| C | Moderate to severe first web and thumb deficiency; possible loss of opposition; malrotation of the thumb into the plane of the fingers; thumb-index syndactyly; absent extrinsic tendon function |
| D | Absent thumb |

Modified from Cole, RJ and Manske PR. Classification of Ulnar Deficiency According to the Thumb and First Web. *J Hand Surg* 1997;22A:479.

***Table 69.14. Classification of Ulna Deficiency According to the Thumb and First Web (33)***

### *Operative Technique*

1. Thumb reconstruction (first web deepening, opponensplasty, pollicization) (see the section entitled Hypoplasia and Absence).
2. Syndactyly release (see the section entitled Syndactyly).
3. Rotational osteotomy of the humerus (140).
   - Perform the operation with the patient under general anesthesia, and if possible, tourniquet (a sterile tourniquet may be necessary).
   - Use a lateral incision to approach the distal humerus subperiosteally. Score the bone longitudinally to mark the preosteotomy alignment, or place parallel Kirschner wires above and below the planned osteotomy site.
   - Make a transverse osteotomy, and rotate the distal fragment enough to place the hand in front of the trunk. If the soft tissue is tight, shorten the bone to prevent traction injury to neurovascular structures.
   - Fix the bone with crossed Kirschner wires or a small A-O plate.
   - Close the subcutaneous tissue with absorbable suture, and the skin with running subcuticular absorbable suture.
   - Apply a well-fitted above-elbow cast, and attach it to the body with a velpeau-type dressing.
4. Creation of one-bone forearm. This operation is rarely indicated. See Lloyd-Roberts (116) or Spinner et al. (191) for details.
5. Forearm lengthening (Ilizarov technique). (See Chapter 32 and Chapter 171, and the section entitled Radius Deficiency.)

### *General Rehabilitation and Postoperative Principles*

Remove crossed Kirschner wires when the humerus osteotomy site is healed. Therapy and splinting are not usually necessary.

## PITFALLS AND COMPLICATIONS

Because the child undergoing a humerus osteotomy usually has a humeroradial synostosis in extension, the postoperative cast cannot turn a corner and will tend to slip off, unless a Velpeau wrap is applied.

## AUTHOR'S PERSPECTIVE

There is scant evidence that surgery other than thumb reconstruction, syndactyly release, and rotational osteotomy improves function. Some authors have advocated combining a closing wedge osteotomy with the rotational osteotomy, in order to place the elbow in flexion. This procedure is probably not necessary, because children with humeroradial synostosis have a short upper limb and can usually reach the mouth once rotation is corrected. Similarly, although the forearm is usually supinated,

forearm rotational osteotomy is rarely necessary. Lengthening is not indicated unless the elbow is mobile and stable.

## MADELUNG DEFORMITY

### *Assessment, Indications, and Relative Results*

Madelung deformity is excessive radial and palmar angulation of the distal radius associated with an ulna-plus wrist, caused by a growth disturbance of the palmar and ulnar portion of the distal radial physis. This growth disturbance may be due to a combination of a bony lesion in the ulnar portion of the distal radius physis and an abnormal palmar ligament tethering the lunate to the radius proximal to the physis (219). The growth disturbance is the final common pathway for many different disorders, including dysplasia, trauma, chromosomal abnormalities, infection, and tumors. Girls are affected more often than boys, and the disorder is usually bilateral, appearing most commonly between the ages of 6 and 13 years (34,37,43,44,205).

Madelung deformity is most commonly due to dysplasia associated with Leéri-Weill syndrome (dyschondrosteosis), which is inherited in an autosomal dominant fashion with 50% penetrance (119,182). It may also be associated with other syndromes, including nail-patella syndrome (onycho-osteodysplasia) (88). Repetitive loading of the wrist in the growing child may cause Madelung deformity in gymnasts (gymnast wrist) (36) or in javelin throwers (37).

If the deformity is not painful, no treatment is necessary, although untreated Madelung deformity has been associated with spontaneous extensor tendon rupture, probably due to the ulna-plus deformity and disruption of the distal radioulnar joint (46,93). If the deformity is painful, and the patient is not skeletally mature, physiolysis may reduce pain and, with additional growth, improve the deformity (219). In the skeletally mature patient with wrist pain associated with Madelung deformity, correction of the deformity may be helpful. Correction may be attained by Ilizarov radial correction, radial closing wedge osteotomy, and ulnar shortening; radial opening wedge osteotomy (147); radial osteotomy and distal ulna resection (213,225); or radial osteotomy and SauveéKapandji procedure (178). Although osteotomy will also improve appearance, the magnitude of the operation renders it unjustifiable for this indication alone.

### *Classifications*

Rarely, growth may be disturbed on the dorsal and ulnar physis, causing a reverse Madelung deformity, in which the distal radius is angulated dorsally and radially (37,219). This type of Madelung deformity has the same underlying etiologies. One patient has been reported to have classic Madelung deformity on one side and reverse Madelung deformity on the other side (219).

### *Preoperative Planning*

If distal radius osteotomy is planned, use radiography to estimate the size and shape of the wedge to be removed or inserted. See wedge 4 determined by lines 1 and 2 in Fig. 69.51.

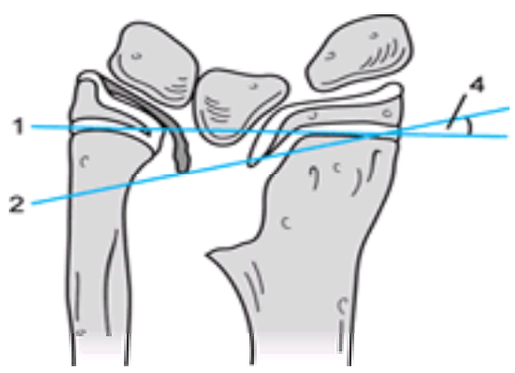


***Figure 69.51.*** Physiolysis for Madelung deformity. (From Vickers D, Nielsen G. Madelung deformity: surgical prophylaxis (physiolysis) during the late growth period by resection of the dyschondrosteosis lesion. J Hand Surg 1992;17B:401.)

### *Operative Technique*

1. Physiolysis (Fig. 69.51).
   - Use loupe magnification and perform the operation with the patient under general anesthesia and tourniquet.
   - Use a palmar transverse incision 1.5 cm proximal to the most proximal wrist flexion crease. Pass ulnar to the palmaris longus and flexor carpi radialis tendons, and protect the radial artery and median nerve. Locate and elevate the distal edge of the pronator quadratus muscle.
   - Raise a longitudinal flap of distal radius, based ulnarward, approximately 5 mm from the distal radioulnar joint. Take care not to injure the lunate. A sagittal section of the distal radius is now visible. Remove fibrous tissue and bone until the physis is identified; at first, it will be narrow and wavy. When physeal cartilage is clearly defined, use a burr to remove bone from the metaphyseal side so that the cartilage profile is proud from dorsal to palmar periosteum.
   - Release the tourniquet, and obtain hemostasis.
   - Reinflate the tourniquet, wash the cavity, obtain fat from a separate incision in the proximal medial forearm, and fill the cavity with fat.
   - Allow soft tissue to fall together to hold the fat in place.
   - Close the skin with a running absorbable subcuticular suture. Release the tourniquet.
   - Apply a bulky compressive dressing and a removable wrist splint.
   - The same procedure can be done dorsally for reverse Madelung deformity.
2. Dorsal closing wedge osteotomy of the distal radius and ulnar shortening (Fig. 69.52)

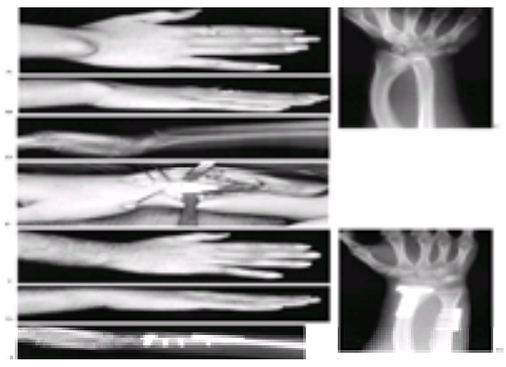

***Figure 69.52.*** Radial osteotomy and ulnar shortening for Madelung Deformity. **A:** Preoperative dorsal view. **B:** Preoperative ulnar view. **C:** Preoperative AP radiograph. **D:** Preoperative lateral radiograph. **E.** Intraoperative view, with Kirschner wires in place to help plan osteotomy. **F:** Postoperative dorsal view (immediately after cast removal). **G:** Postoperative ulnar view. **H:** Postoperative AP radiograph. **I:** Postoperative lateral radiograph.

   - Perform the operation with the patient under general anesthesia and tourniquet. Have Fluoroscan or C-arm fluoroscopy available.
   - Approach the ulna diaphysis (at approximately the distal 1/4, proximal 3/4 junction) through a longitudinal ulnar incision. Select a four-hole dynamic compression plate (244 series); prepare the distal two holes, then make a transverse osteotomy. Sharply dissect the interosseous membrane from the proximal fragment so that the cut ends can overlap.
   - Approach the distal radius through the third and second dorsal compartments. Remove Lister's tubercle. Score the radius longitudinally across the planned osteotomy location to help maintain correct rotation. Using fluoroscopy guidance, insert Kirschner wires distally close to the radiocarpal joint, one parallel to radial angulation and the other parallel to palmar angulation. Plan the distal cut to reduce radial angulation to 20° and palmar angulation to 10°. Make the proximal cut transverse. The radius osteotomy should be as close to the radiocarpal joint as possible, leaving room for a T or L plate for internal fixation.

Provisionally fix the osteotomy with Kirschner wires.
- Contour the selected plate. Apply to the dorsal distal radius. Remove the Kirschner wires.
- Under fluoroscopic guidance, pull the distal ulnar fragment proximally until the distal end of the ulna is neutral or slightly ulna-minus. Resect the appropriate amount of ulna; morsellize the resected portion and use for graft around the osteotomies if desired (avoid placing graft between the radius and ulna). Fix the two ends of the ulna with a four-hole plate, using the distal holes drilled earlier, and compressing at the osteotomy site.
- Close any available periosteum over the plates. Close subcutaneous tissue with absorbable suture and the skin with running subcuticular absorbable suture.
- Apply a bulky compressive dressing, and cover with an above-elbow plaster splint.

3. Sauveé-Kapandji procedure: see Chapter 43.

***General Rehabilitation and Postoperative Principles***

Immobilize the arm for 2 to 3 weeks following physiolysis. Therapy and splinting are not usually necessary. Following osteotomy, immobilize it in an above-elbow splint for 2 to 3 weeks, followed by a below-elbow cast for 3 more weeks. Remove hardware 1 year after surgery.

## PITFALLS AND COMPLICATIONS

If the physis is not adequately exposed or the fat graft not in intimate contact with the surgical defect, the physeal tether may recur following physiolysis.

## AUTHOR'S PERSPECTIVE

Like the physiolysis procedure Vickers has described for clinodactyly (see the section entitled Clinodactyly) (218), the author's results have not yet been widely reproduced. I have found this operation to provide pain relief.

Of the various osteotomies, radius closing wedge and ulnar shortening restores distal radius angulation and the relationship between the distal radius and ulna well, without requiring additional bone graft. The Suaveé-Kapandji procedure is preferable to distal ulna resection, but it should probably be used only as a salvage procedure if radius osteotomy and ulnar shortening fail to relieve pain.

## ACKNOWLEDGMENTS

Thank you to Deana Simonis, medical librarian, Shriners Hospital Northern California, for her assistance with references, and Julia Serat, photographer, Shriners Hospital Northern California, for her assistance with clinical photographs and radiographs. H. R. McCarroll, Jr., M.D. was the technical consultant for the section entitled Dorsal Closing Wedge.

* Area Child Amputee Center, Mary Free Bed Hospital and Rehabilition Center, 236 Wealthy S.E., Grand Rapids MI 49503.
† Superkids, 60 Clyde St., Newton, MA 02160-2250; www.superkids.org

* In most texts, this procedure is described as the Bilhaut-Cloquet procedure. No treatise by Cloquet on the treatment of thumb polydactyly has been found (50); thus Bilhaut should be given the credit.

## CHAPTER REFERENCES

Each reference is categorized according to the following scheme: *, classic article; #, review article; !, basic research article; and +, clinical results/outcome study.

+ 1. Abe M, Shirai H, Okamoto M, Onomura T. Lengthening of the Forearm by Callus Distraction. *J Hand Surg* 1996;21B:151.

+ 2. Al-Qattan MM, Al-Husain MA. Classification of Hand Anomalies in Apert's syndrome. *J Hand Surg* 1996;21B:266.

# 3. Alter BP. Arm Anomalies and Bone Marrow Failure May Go Hand in Hand. *J Hand Surg* 1992;17A:566.

# 4. Alter BP. Arms and the Man or Hands and the Child: Congenital Anomalies and Hematologic Syndromes. *J Pediatr Hematol Onco*l 1997;19:287.

+ 5. Anderson PJ, Hall CM, Smith PJ, et al. The Hands in Pfeiffer Syndrome. *J Hand Surg* 1997;22B:537.

# 6. Bamforth JS. Amniotic Band Sequence: Streeter Hypothesis Revisited. *Birth Defects* 1993;29:279.

# 7. Barmakian JT, Posner M, Silver L, et al. Proteus syndrome. *J Hand Surg* 1992;17A:32.

* 8. Barsky AJ. Cleft Hand: Classification, Incidence and Treatment. *J Bone Joint Surg* 1964;46A:1707.

# 9. Basson CT, Cowley GS, Solomon SD, et al. The Clinical and Genetic Spectrum of the Holt-Oram Syndrome (Heart-hand Syndrome). *N Engl J Med* 1994;330:885.

# 10. Bavinck JN, Weaver DD. Subclavian Artery Supply Disruption Sequence: Hypothesis of a Vascular Etiology for Poland, Klippel-Feil, and Mobius Anomalies. *Am J Med Genet* 1986;23:903.

* 11. Bayne LG, Klug MS. Long-term Review of the Surgical Treatment of Radial Deficiencies. *J Hand Surg* 1987;12A:169.

# 12. Beals RK, Robbins JR, Rolfe B. Anomalies Associated with Vertebral Malformations. *Spine* 1993;18:1329.

* 13. Benson LS, Waters PM, Kamil NI, et al. Camptodactyly: Classification and Results of Nonoperative Treatment. *J Pediatr Orthop* 1994;14:814.

* 14. Bilhaut M. Guerison d'un Pouce Bifide par un Nouveau Procede Operatoire. *Congres Francais de Chirurgie* 1889;4:576.

+ 15. Blair WF, Shurr DG, Buckwalter JA. Functional Status in Ulnar Deficiency. *J Pediatr Orthop* 1983;3:37.

* 16. Blauth W, Schneider-Sickert F. Numerical Variations. In: Blauth W, Schneider-Sickert F, eds. *Congenital Deformities of the Hand: An Atlas on their Surgical Treatment*. Berlin: Springer-Verlag, 1981:120.

+ 17. Bradbury ET, Hewison J. Early Parental Adjustment to Visible Congenital Disfigurement. *Child Care Health Dev* 1994;20:251.

+ 18. Bronshtein M, Stahl S, Zimmer EZ. Transvaginal Sonographic Diagnosis of Fetal Finger Abnormalities in Early Gestation. *J Ultrasound Med* 1995;14:591.

+ 19. Broudy AS, Smith RJ. Deformities of the Hand and Wrist with Ulnar Deficiency. *J Hand Surg* 1979;4:304.

* 20. Buck-Gramcko D. Pollicization of the Index Finger. *J Bone Joint Surg* 1971;53-A:1605.

+ 21. Buck-Gramcko D. Hypoplasia and Aplasia of the Thumb. In: Nigst H, Buck-Gramcko D, Millesi H, Lister G, eds. *Hand Surgery*. New York: Thieme Medical Publishers Inc., 1989:12.93.

+ 22. Buck-Gramcko D. The Role of Nonvascularized Toe Phalanx Transplantation. *Hand Clin* 1990;6:643.

+ 23. Buck-Gramcko D. Complications and Bad Results in Pollicization of the Index Finger (in Congenital Cases). *Ann Chir Main Membr Super* 1991;10:506.

+ 24. Burgess RC. Brachydactyly in Acrosyndactyly. *J Hand Surg* 1991;16A:125.

+ 25. Buss PW. Cleft Hand/foot: Clinical and Developmental Aspects. *J Med Genet* 1994;31:726.

* 26. Carroll RE, Bowers WH. Congenital Deficiency of the Ulna. *J Hand Surg* 1977;2:169.

+ 27. Carstam N, Theander G. Surgical Treatment of Clinodactyly Caused by Longitudinally Bracketed Diaphysis (“Delta Phalanx”). *Scand J Plast Reconstr Surg Hand Surg* 1975;9:199.

+ 28. Catagni MA, Szabo RM, Cattaneo R. Preliminary Experience with Ilizarov Method in Late Reconstruction of Radial Hemimelia. *J Hand Surg* 1993;18A:316.

+ 29. Cheng JCY, Chan KM, Ma GFY, Leung PC. Polydactyly of the Thumb: A Surgical Plan Based on Ninety-five Cases. *J Hand Surg* 1984;9A:155.

+ 30. Clark DI, Chell J, Davis TRC. Pollicisation of the Index Finger: A 27 Year Follow-up Study. *J Bone Joint Surg* 1998;80B:631.

+ 31. Coady MSE, Moore MH, Wallis K. Amniotic Band Syndrome: The Association Between Rare Facial Clefts and Limb Ring Constrictions. *Plast Reconstr Surg* 1998;101:640.

# 32. Cobben JM, Hiemstra S, Robinson PH. Genetic Counseling in Limb Reduction Defects. *Genet Couns* 1994;5:243.

* 33. Cole RJ, Manske PR. Classification of Ulnar Deficiency According to the Thumb and First Web. *J Hand Surg* 1997;22A:479.

+ 34. Cook PA, Yu JS, Wiand W, et al. Madelung Deformity in Skeletally Immature Patients: Morphologic Assessment Using Radiography, CT, and MRI. *J Comput Assist Tomogr* 1996;20:505.

# 35. Cooney WP III. Camptodactyly and Clinodactyly. In: Carter PR, ed. *Reconstruction of the Child's Hand*. Philadelphia: Lea & Febiger, 1991:209.

+ 36. De Smet L, Claessens A, Fabry G. Gymnast Wrist. *Acta Orthop Belg* 1993;59:377.

+ 37. De Smet L, Fabry G. Growth Arrest of the Distal Radial Epiphysis in a Javelin Thrower: Reversed Madelung? *J Pediatr Orthop (Part B)* 1995;4:116.

+ 38. De Smet L, Matton G, Monstrey S, et al. Application of the IFSSH(3)-classification for Congenital Anomalies of the Hand; Results and Problems. *Acta Orthop Belg* 1997;63:182.

# 39. Deschamps F, Teot L, Benningfield N, Humeau C. Ultrasonography of the Normal and Abnormal Antenatal Development of the Upper Limb. *Ann Chir Main Membr Super* 1992;11:389.

# 40. Dietz FR, Mathews KD. Update on the Genetic Bases of Disorders with Orthopaedic Manifestations. *J Bone Joint Surg* 1996;78A:1583.

* 41. Dinham JM, Meggitt BF. Trigger Thumbs in Children. A Review of the Natural History and Indications for Treatment in 105 Patients. *J Bone Joint Surg* 1974;56B:153.

+ 42. Dobyns JH. Segmental Digital Transposition in Congenital Hand Deformities. *Hand Clin* 1985;1:475.

# 43. Dobyns JH, Wood VE, Bayne LG. Congenital Hand Deformities. In: Green DP, Hotchkiss RN, eds. *Operative Hand Surgery*. New York: Churchill Livingstone, 1993:251.

+ 44. dos Reis FB, Katchburian MV, Faloppa F, Albertoni WM. Osteotomy of the Radius and Ulna for the Madelung Deformity. *J Bone Joint Surg* 1998;80B:817.

* 45. Doyle JR, Blythe WF. Anatomy of the Flexor Tendon Sheath and Pulleys of the Thumb. *J Hand Surg* 1977;2A:149.

+ 46. Ducloyer P, LeClercq C, Lisfranc R, Saffar P. Spontaneous ruptures of the extensor tendons of the fingers in Madelung's Deformity. *J Hand Surg* 1991;16B:329.

+ 47. Dunlap J, Manske PR, McCarthy JA. Perfusion of the Abductor Digiti Quinti After Transfer on a Neurovascular Pedicle. *J Hand Surg* 1989;14A:992.

* 48. Engber WD, Flatt AE. Camptodactyly: An Analysis of Sixty-six Patients and Twenty-four Operations. *J Hand Surg* 1977;2:216.

+ 49. Entin MA. Reconstruction of Congenital Aplasia of Phalanges in the Hand. *Surg Clin North Am* 1968;48:1155.

+ 50. Evans D. Polydactyly of the Thumb [Editorial; Comment]. *J Hand Surg* 1993;18B:3.

+ 51. Eyres KS, McLaren MI. Trigger Thumb in Children: Results of Surgical Correction. *J R Coll Surg Edinb* 1991;36:197.

# 52. Flatt AE. Classification and Incidence. In: Flatt AE, ed. *The Care of Congenital Hand Anomalies*. St. Louis, MO: Quality Medical Publishing, Inc., 1994a:47.

# 53. Flatt AE. Cleft Hand and Central Defects. In: Flatt AE, ed. *The Care of Congenital Hand Anomalies*. St. Louis, MO: Quality Medical Publishing, Inc., 1994l:337.

# 54. Flatt AE. Constriction Ring Syndrome. In: Flatt AE, ed. *The Care of Congenital Hand Anomalies*. St. Louis, MO: Quality Medical Publishing, Inc., 1994j:276.

# 55. Flatt AE. Crooked Fingers. In: Flatt AE, ed. *The Care of Congenital Hand Anomalies*. St. Louis, MO: Quality Medical Publishing, Inc., 1994h:196.

# 56. Flatt AE. Extra Fingers. In: Flatt AE, ed. *The Care of Congenital Hand Anomalies*. St. Louis, MO: Quality Medical Publishing, Inc., 1994k:292.

# 57. Flatt AE. Extra Thumbs. In: Flatt AE, ed. *The Care of Congenital Hand Anomalies*. St. Louis, MO: Quality Medical Publishing, Inc., 1994f:120.

# 58. Flatt AE. Genetics and Inheritance. In: Flatt AE, ed. *The Care of Congenital Hand Anomalies*. St. Louis, MO: Quality Medical Publishing, Inc., 1994c:15.

# 59. Flatt AE. Growth, Size and Function. In: Flatt AE, ed. *The Care of Congenital Hand Anomalies*. St. Louis, MO: Quality Medical Publishing, Inc., 1994b:25.

# 60. Flatt AE. Radial Clubhand. In: Flatt AE, ed. *The Care of Congenital Hand Anomalies*. St. Louis, MO: Quality Medical Publishing, Inc., 1994m:366.

# 61. Flatt AE. Small and Absent Fingers. In: Flatt AE, ed. *The Care of Congenital Hand Anomalies*. St. Louis, MO: Quality Medical Publishing, Inc., 1994g:149.

# 62. Flatt AE. The Absent Thumb. In: Flatt AE, ed. *The Care of Congenital Hand Anomalies*. St. Louis, MO: Quality Medical Publishing, Inc., 1994e:96.

# 63. Flatt AE. The Inadequate Thumb. In: Flatt AE, ed. *The Care of Congenital Hand Anomalies*. St. Louis, MO: Quality Medical Publishing, Inc., 1994d:67.

# 64. Flatt AE. Ulnar Deficiencies. In: Flatt AE, ed. *The Care of Congenital Hand Anomalies*. St. Louis, MO: Quality Medical Publishing, Inc., 1994n:411.

# 65. Flatt AE. Webbed Fingers. In: Flatt AE, ed. *The Care of Congenital Hand Anomalies*. St. Louis, MO: Quality Medical Publishing, Inc., 1994i:228.

+ 66. Foulkes GD, Reinker K. Congenital Constriction Band Syndrome: A Seventy-year Experience. *J Pediatr Orthop* 1994;14:242.

+ 67. Friedman R, Wood VE. The Dorsal Transposition Flap for Congenital Contractures of the First Web Space: A 20 Year Experience. *J Hand Surg* 1997;22A:664.

# 68. Froster UG, Baird PA. Upper Limb Deficiencies and Associated Malformations: A Population-based Study. *Am J Med Genet* 1992;44:767.

+ 69. Ganley TJ, Lubahn JD. Radial Polydactyly: An Outcome Study. *Ann Plast Surg* 1995;35:86.

+ 70. Ger E, Kupcha P, Ger D. The Management of Trigger Thumb in Children. *J Hand Surg* 1991;16A:944.

+ 71. Gilbert A. Toe Transfers for Congenital Hand Defects. *J Hand Surg* 1982;7:118.

+ 72. Goffin D, Lenoble E, Marin-Braun F, Foucher G. [Camptodactyly: Classification and Results of Treatment Based on a Series of 50 Cases]. *Ann Chir Main Membr Super* 1994;13:20.

+ 73. Goldberg NH, Watson HK. Composite Toe (Phalanx and Epiphysis) Transfers in the Reconstruction of the Aphalangic Hand. *J Hand Surg* 1982;7:454.

# 74. Gould JS. Syndactyly. In: Carter PR, ed. *Reconstruction of the Child's Hand*. Philadelphia: Lea & Febiger, 1991:127.

+ 75. Graham TJ, Louis DS. A Comprehensive Approach to Surgical Management of the Type IIIA Hypoplastic Thumb. *J Hand Surg* 1998;23A:3.

+ 76. Greene WB. One-stage Release of Congenital Circumferential Constriction Bands. *J Bone Joint Surg* 1993;75A:650.

+ 77. Haratz-Rubinstein N, Yeh MN, Timor-Tritsch IE, Monteagudo A. Prenatal Diagnosis of the Split Hand Anomaly: How Early Is Early? *Ultrasound in Obstetrics and Gynecology* 1996;8:57.

# 78. Harris MF. Milestones in Pediatric Anesthesia Risk. In: Carter PR, ed. *Reconstruction of the Child's Hand*. Philadelphia: Lea & Febiger, 1991:3.

* 79. Heikel HVA. Aplasia and Hypoplasia of the Radius. Studies on 64 Cases and on Epiphyseal Transplantation in Rabbits with the Imitated Defect. *Acta Orthop Scand* 1959;Supplementum no. 39:1.

! 80. Heutink P, Zguricas J, van Oosterhout L, et al. The Gene for Triphalangeal Thumb Maps to the Subtelomeric Region of Chromosome 7q. *Nat Genet* 1994;6:287.

+ 81. Hierner R, Wilhelm K, Brehl B. Distraction Lengthening of Metacarpal and Phalangeal Stumps in Congenital Hand Deformities—Personal Experience and Current Concept Review. *Handchir Mikrochir Plast Chir* 1998;30:196.

! 82. Hing AV, Helms C, Slaugh R, et al. Linkage of Preaxial Polydactyly Type 2 to 7q36. *Am J Med Genet* 1995;58:128.

+ 83. Holmes LB. Report of National Institute of Child Health and Human Development Workshop on Chorionic Villus Sampling and Limb and Other Defects. *Teratology* 1992;48:7.

+ 84. Hoogbergen MM, Schuurman AH, Kon M. Camptodactyly Caused by an Anomalous Origin of the Flexor Digitorum Superficialis Tendon. Case Report. *Scand J Plast Reconstr Surg and Hand Surg* 1996;30:71.

+ 85. Horii E, Nakamura R, Sakuma M, Miura T. Duplicated Thumb Bifurcation at the Metacarpophalangeal Joint Level: Factors Affecting Surgical Outcome. *J Hand Surg* 1997;22A:671.

+ 86. Hung L, Cheng JC, Bundoc R, Leung P. Thumb Duplication at the Metacarpophalangeal Joint: Management and a New Classification. *Clin Orthop* 1996;323:31.

+ 87. Inoue G, Tamura Y. Camptodactyly Resulting from Paradoxical Action of an Anomalous Lumbrical Muscle. *Scand J Plast Reconstr Hand Surg* 1994;28:309.

+ 88. Ioan DM, Maximilian C, Fryns JP. Madelung Deformity as a Pathognomonic Feature of the Onycho-osteodysplasia Syndrome. *Genet Couns* 1992;3:25.

# 89. Ireland DC, Takayama N, Flatt AE. Poland's Syndrome. *J Bone Joint Surg* 1976;58A:52.

# 90. James MA, Durkin RC. Nonvascularized Toe Proximal Phalanx Transfers in the Treatment of Aphalangia. *Hand Clin* 1998;14:1.

+ 91. James MA, McCarroll HR Jr, Manske PR. The Spectrum of Radial Longitudinal Deficiency: A Modified Classification. *J Hand Surg* 1999;24A:1145.

+ 92. James MA, McCarroll HRJ, Manske PR. Characteristics of Patients with Hypoplastic Thumbs. *J Hand Surg* 1996;21A:104.

+ 93. Jebson PJ, Blair WF. Bilateral Spontaneous Extensor Tendon Ruptures in Madelung's Deformity. *J Hand Surg* 1992;17A:277.

+ 94. Jennings JF, Peimer CA, Sherwin FS. Reduction Osteotomy for Triphalangeal Thumb: An 11 Year Review. *J Hand Surg* 1992;17A:8.

* 95. Jones GB. Delta Phalanx. *J Bone Joint Surg* 1964;46B:226.

+ 96. Kawabata H, Masatomi T, Shimada K, et al. Treatment of Residual Instability and Extensor Lag in Polydactyly of the Thumb [See Comments]. *J Hand Surg* 1993;18B:5.

+ 97. Kawabata H, Shibata T, Masatomi T, Yasui N. Residual Deformity in Congenital Radial Club Hands after Previous Centralisation of the Wrist. Ulnar Lengthening and Correction by the Ilizarov Method. *J Bone Joint Surg* 1998;80B:762.

+ 98. Kawabata H, Tada K, Masada K, et al. Revision of Residual Deformities after Operations for Duplication of the Thumb. *J Bone Joint Surg* 1990;72A:988.

+ 99. Kay SP, Wiberg M. Toe to Hand Transfer in Children. Part I: Technical Aspects. *J Hand Surg* 1996;21B:723.

+ 100. Kay SP, Wiberg M, Bellew M, Webb F. Toe to Hand Transfer in Children. Part 2: Functional and Psychological Aspects. *J Hand Surg* 1996;21B:735.

+ 101. Kessler I, Baruch A, Hecht O. Experience with Distraction Lengthening of Digital Rays in Congenital Anomalies. *J Hand Surg* 1977;2:394.

+ 102. Kitayama Y, Tsukada S. Patterns of Arterial Distribution in the Duplicated Thumb. *Plast Reconstr Surg* 1983;72:535.

# 103. Kleinman WB. Management of Thumb Hypoplasia. *Hand Clin* 1990;6:617.

+ 104. Koman LA, Toby EB, Poehling GG. Congenital Flexion Deformities of the Proximal Interphalangeal Joint in Children: A Subgroup of Camptodactyly. *J Hand Surg* 1990;15A:582.

+ 105. Kowalski MF, Manske PR. Arthrodesis of Digital Joints in Children. *J Hand Surg* 1988;13A:874.

* 106. Kummel W. Die Missbildungen der Extremitaeten durch Defekt, Verwachsung und Ueberzahl. *Bibliotheca Medica (Cassel)* 1895;3:1.

* 107. Lamb DW. Radial Clubhand. *J Bone Joint Surg* 1977;59A:1.

+ 108. Lamb DW, Wynne-Davies R, Soto L. An Estimate of the Population Frequency of Congenital Malformations of the Upper Limb. *J Hand Surg* 1982;7:557.

# 109. Light TR. Congenital Malformations and Deformities of the Hand. *Instr Course Lect* 1989;38:31.

# 110. Light TR. Treatment of Preaxial Polydactyly. *Hand Clin* 1992;8:161.

+ 111. Light TR, Ogden JA. Congenital Constriction Band Syndrome. Pathophysiology and Treatment. *Yale J Biol Med* 1993;66:143.

+ 112. Lipskeir E, Weisenbluth M. Surgical Treatment of the Clasped Thumb. *J Hand Surg* 1989;14B:72.

# 113. Lister GD. Toes to the Hand. In: Flatt AE, ed. *The Care of Congenital Hand Anomalies*. St. Louis, MO: Quality Medical Publishing, Inc., 1994:180.

# 114. Lister GD, Scheker LR. The Role of Microsurgery in the Reconstruction of Congenital Deformities of the Hand. *Hand Clin* 1985;1:431.

* 115. Littler JW. On Making a Thumb: One Hundred Years of Surgical Effort. *J Hand Surg* 1976;1:35.

+ 116. Lloyd-Roberts GC. Treatment of Defects of the Ulna in Children by Establishing Cross-union with the Radius. *J Bone Joint Surg* 1973;55B:327.

+ 117. Lourie GM, Costas BL, Bayne LG. The Zig-zag Deformity in Pre-axial Polydactyly. A New Cause and Its Treatment. *J Hand Surg [Br]* 1995;20:561.

# 118. Lovett M, Clines G, Wise CA. Genetic Control of Limb Development. In: Herring JA, Birch JG, eds. *The Child with a Limb Deficiency*. Rosemont, IL: American Academy of Orthopaedic Surgeons, 1998:13.

+ 119. Maisels DO. Theory of Pathogenesis of Lobster Claw Deformities. *Hand* 1970;2:79.

* 120. Malek R, de la Caffiniere JY. Pollicization de l'Index Chez l'Enfant. *Ann Chir Plast* 1971;16:198.

# 121. Manske PR. Central Deficiency. *Instr Course Lect* 1989b;XXXVIII:63.

+ 122. Manske PR. Treatment of Duplicated Thumb Using a Ligamentous/Periosteal Flap. *J Hand Surg* 1989;14A:728.

# 123. Manske PR. Ulnar Deficiency. *Instr Course Lect* 1989;XXXVIII:57.

+ 124. Manske PR. Long-term Functional Results after Pollicization for the Congenitally Deficient Thumb. *J Hand Surg* 1992;17A:1064.

+ 125. Manske PR. Symbrachydactyly Instead of Atypical Cleft Hand [Letter]. *Plast Reconstr Surg* 1993;91:196.

# 126. Manske PR. Longitudinal Failure of Upper-limb Formation. *Instr Course Lect* 1997;46:83.

+ 127. Manske PR, Halikis MN. Surgical Classification of Central Deficiency According to the Thumb Web. *J Hand Surg* 1995;20A:687.

+ 128. Manske PR, McCarroll HR Jr. Abductor Digiti Minimi Opponensplasty in Congenital Radial Dysplasia. *J Hand Surg* 1978;3A:552.

+ 129. Manske PR, McCarroll HR Jr. Index Finger Pollicization for a Congenitally Absent or Nonfunctioning Thumb. *J Hand Surg* 1985;10A:606.

+ 130. Manske PR, McCarroll HR Jr, James MA. Type III-A Hypoplastic Thumb. *J Hand Surg* 1995;20A:246.

+ 131. Manske PR, McCarroll HR Jr, Swanson K. Centralization of the Radial Clubhand: An Ulnar Surgical Approach. *J Hand Surg* 1981;6A:423.

+ 132. Marcus NA, Omer GE Jr. Carpal Deviation in Congenital Ulnar Deficiency. *J Bone Joint Surg* 1984;66A:1003.

+ 133. Marks TW, Bayne LG. Polydactyly of the Thumb: Abnormal Anatomy and Treatment. *J Hand Surg* 1978;3:107.

! 134. Masuya H, Sagai T, Wakana S, et al. A Duplicated Zone of Polarizing Activity in Polydactylous Mouse Mutants. *Genes Dev* 1995;9:1645.

# 135. McCarroll HR Jr. Congenital Flexion Deformities of the Thumb. *Hand Clin* 1985;1:567.

# 136. McCarroll HR Jr, Manske PR. The Windblown Hand: Correction of the Complex Clasped Thumb Deformity. *Hand Clin* 1992;8(1):147.

+ 137. McFarlane RM, Classen DA, Porte AM, Botz JS. The Anatomy and Treatment of Camptodactyly of the Small Finger. *J Hand Surg* 1992;17A:34.

# 138. Midwest Bioethics Center Task Force on Health Care Rights for Minors. Health Care Treatment Decision-making Guidelines for Minors. *Bioethics Forum* 1995;11:A1.

# 139. Mih AD. Congenital Clasped Thumb. *Hand Clin* 1998;14:77.

+ 140. Miller JK, Wenner SM, Kruger LM. Ulnar Deficiency. *J Hand Surg* 1986;11A:822.

+ 141. Minami A, Sakai T. Camptodactyly Caused by Abnormal Insertion and Origin of Lumbrical Muscle. *J Hand Surg* 1993;18B:310.

+ 142. Miura T. Congenital Constriction Band Syndrome. *J Hand Surg* 1984;9A:82.

+ 143. Miura T, Komada T. Simple Method for Reconstruction of the Cleft Hand with an Adducted Thumb. *Plast Reconstr Surg* 1979;64:65.

+ 144. Miura T, Nakamura R, Suzuki M, Watanabe K. Cleft Hand, Syndactyly and Hypoplastic Thumb. *J Hand Surg* 1992;17B:365.

+ 145. Miura T, Nakamura R, Tamura Y. Long-standing Extended Dynamic Splintage and Release of an Abnormal Restraining Structure in Camptodactyly. *J Hand Surg* 1992;17B:665.

+ 146. Moore MH. Nonadjacent Syndactyly in the Congenital Constriction Band Syndrome. *J Hand Surg* 1992;17A:21.

+ 147. Murphy MS, Linscheid RL, Dobyns JH, Peterson HA. Radial Opening Wedge Osteotomy in Madelung's Deformity. *J Hand Surg* 1996;21A:1035.

+ 148. Naasan A, Page RE. Duplication of the Thumb. A 20-year Retrospective Review. *J Hand Surg* 1994;19B:355.

+ 149. Nanchahal J, Tonkin MA. Preoperative Distraction Lengthening for Radial Longitudinal Deficiency. *J Hand Surg* 1996;21B:103.

+ 150. Nemoto K, Nemoto T, Terada N, et al. Splint Therapy for Trigger Thumb and Finger in Children. *J Hand Surg* 1996;21B:416.

+ 151. Nishijima N, Matsumoto T, Yamamuro T. Two-stage Reconstruction for the Hypoplastic Thumb. *J Hand Surg* 1995;20A:415.

+ 152. Nutt JN, Flatt AE. Congenital Central Hand Defects. *J Hand Surg* 1981;6:48.

+ 153. Oda Y, Uchida Y, Kojima T, Sugioka Y. Congenital, Multiple, Bilateral, Trigger Digits in a Child. *Int Orthop* 1993;17:20.

+ 154. Ogden JA, Ganey TM, Light TR, et al. Ossification and Pseudoepiphysis Formation in the “Nonepiphyseal” End of Bones of the Hands and Feet. *Skeletal Radiol* 1994;23:3.

+ 155. Ogden JA, Watson HK, Bohne W. Ulnar Dysmelia. *J Bone Joint Surg* 1976;58A:467.

+ 156. Ogino T. Teratogenic Relationship Between Polydactyly, Syndactyly and Cleft Hand. *J Hand Surg* 1990;15B:201.

+ 157. Ogino T, Ishii S, Kato H. Opposable Triphalangeal Thumb: Clinical Features and Results of Treatment. *J Hand Surg* 1994;19A:39.

+ 158. Ogino T, Ishii S, Takahata S, Kato H. Long-term Results of Surgical Treatment of Thumb Polydactyly. *J Hand Surg* 1996;21A:478.

! 159. Ogino T, Kato H. Clinical and Experimental Studies on Ulnar Ray Deficiency. *Handchir Mikrochir Plast Chir* 1988;20:330.

+ 160. Ogino T, Kato H. Operative Findings in Camptodactyly of the Little Finger. *J Hand Surg* 1992;17B:661.

+ 161. Ogino T, Kato H, Ishii S, Usui M. Digital Lengthening in Congenital Hand Deformities. *J Hand Surg* 1994;19B:120.

+ 162. Ogino T, Saitou Y. Congenital Constriction Band Syndrome and Transverse Deficiency. *J Hand Surg* 1987;12B:343.

+ 163. Paaske BP, Soe-Nielsen NH, Noer HH. Release of Trigger Finger in Children. Long Term Results. *Scand J Plast Reconstr Surg Hand Surg* 1995;29:65.

+ 164. Paneva-Holevich E, Yankov E. A Distraction Method for Lengthening of the Finger Metacarpals: A Preliminary Report. *J Hand Surg* 1980;5:160.

+ 165. Patterson TJS. Congenital Ring-constrictions. *Br J Plast Surg* 1961;14:1.

+ 166. Peimer CA, Alexander M. Digital Augmentation for Ectrodactyly: Management and Planning. *Hand Clin* 1990;6:607.

+ 167. Qazi Q, Kassner EG. Triphalangeal Thumb. *J Med Genet* 1988;25:505.

! 168. Raas-Rothschild A, Manouvrier S, Gonzales M, et al. Refined Mapping of a Gene for Split Hand–Split Foot Malformation (SHFM3) on Chromosome 10q25. *J Med Genet* 1996;33:996.

+ 169. Radocha RF, Netscher D, Kleinert HE. Toe Phalangeal Grafts in Congenital Hand Anomalies. *J Hand Surg* 1993;18A:833.

+ 170. Reiss RE, Foy PM, Mendiratta V, et al. Ease and Accuracy of Evaluation of Fetal Hands During Obstetrical Ultrasonography: A Prospective Study. *J Ultrasound Med* 1995;14:813.

* 171. Riordan D. Congenital Absence of the Radius. *J Bone Joint Surg* 1955;37A:1129.

# 172. Riordan DC, Bayne LG. The Upper Limb. In: Lovell WW and Winter RB, ed. *Pediatric Orthopaedics*. Philadelphia: J.B. Lippincott Company, 1986:649.

# 173. Robinson LK. Genetics and Dysmorphology: Approach to Diagnosis of the Child with a Limb Anomaly. In: Peimer CA, ed. *Surgery of the Hand and Upper Extremity*. New York: McGraw-Hill, 1996:1993.

+ 174. Rodgers WB, Waters PM. Incidence of Trigger Digits in Newborns. *J Hand Surg* 1994;19A:364.

# 175. Sadler TW. Embryology and Gene Regulation of Limb Development. In: Herring JA, Birch JG, eds. *The Child with a Limb Deficiency*. Rosemont, IL: American Academy of Orthopaedic Surgeons, 1998:3.

+ 176. Sandzen SC. Classification and Functional Management of Congenital Central Defect of the Hand. *Hand Clin* 1985;1:483.

+ 177. Schoenecker PL, Cohn AK, Sedgwick WG, et al. Dysplasia of the Knee Associated with the Syndrome of Thrombocytopenia and Absent Radius. *J Bone Joint Surg* 1984;66A:421.

+ 178. Schroven I, De Smet L, Zachee B, et al. Radial osteotomy and Sauveé-Kapandji procedure for deformities of the distal radius. *Acta Orthop Belg* 1995;61:1.

+ 179. Seidman GD, Wenner SM. Surgical Treatment of the Duplicated Thumb. *J Pediatr Orthop* 1993;13:660.

# 180. Setoguchi Y. Medical Conditions Associated with Congenital Limb Deficiencies. In: Herring JA, Birch JG, eds. *The Child with a Limb Deficiency*. Rosemont, IL: American Academy of Orthopaedic Surgeons, 1998:39.

+ 181. Seyhan A, Akarsu N, Keskin F. A Large Family with Type IV Radial Polydactyly. *J Hand Surg* 1998;23B:530.

+ 182. Sharif K, Saint-Martin C, Clapuyt P. Madelung Deformity as a Feature of the Leri-Layani-Weill Syndrome or Dyschondrosteosis. *J Belge Radiol* 1997;80:292.

+ 183. Siegert JJ, Cooney WP, Dobyns JH. Management of Simple Camptodactyly. *J Hand Surg* 1990;15B:181.

* 184. Skerik SK, Flatt AE. The Anatomy of Congenital Radial Dysplasia. *Clin Orthop* 1969;66:125.

+ 185. Skov O, Bach A, Hammer A. Trigger Thumbs in Children: A Follow-up Study of 37 Children below 15 Years of Age. *J Hand Surg [Br]* 1990;15:466.

+ 186. Slakey JB, Hennrikus WL. Acquired Thumb Flexion Contracture in Children. *J Bone Joint Surg* 1996;78B:481.

+ 187. Smith AA, Greene TL. Preliminary Soft Tissue Distraction in Congenital Forearm Deficiency. *J Hand Surg* 1995;20A:420.

+ 188. Smith RJ, Gumley GJ. Metacarpal Distraction Lengthening. *Hand Clin* 1985;1:417.

+ 189. Smith RJ, Kaplan EB. Camptodactyly and Similar Atraumatic Flexion Deformities of the Proximal Interphalangeal Joints of the Fingers. *J Bone Joint Surg* 1968;50A:1187.

* 190. Southwood AR. Partial Absence of Ulna and Associated Structures. *J Anat* 1926;61:346.

+ 191. Spinner M, Freundlich BD, Abeles ED. Management of Moderate Longitudinal Arrest of Development of the Ulna. *Clin Orthop* 1970;69:199.

* 192. Starr DE. Congenital Absence of the Radius. *J Bone Joint Surg* 1945;27:572.

+ 193. Steenwerckx A, De Smet L, Fabry G. Congenital Trigger Digit. *J Hand Surg* 1996;21A:909.

+ 194. Strauch B. Congenital Anomaly of the Thumb: Absent Intrinsics and Flexor Pollicis Longus. *J Bone Joint Surg* 1976;58:115.

* 195. Swanson AB. A Classification for Congenital Limb Malformation. *J Hand Surg* 1976;1:8.

+ 196. Swanson AB, Barsky AJ, Entin MA. Classification of Limb Malformations on the Basis of Embryological Failures. *Surg Clin North Am* 1968;48:1169.

+ 197. Swanson AB, Tada K, Yonenobu K. Ulnar Ray Deficiency: Its Various Manifestations. *J Hand Surg* 1984;9A:658.

# 198. Temtamy SA, McKusick VA. Absence Deformities as Isolated Malformations. In: Bergsma D, Mudge JR, Paul NW, Greene SC, eds. *The Genetics of Hand Malformations*. New York: Alan R. Liss, Inc., 1978f: 36.

# 199. Temtamy SA, McKusick VA. Absence Deformities as Part of Syndromes. In: Bergsma D, Mudge JR, Paul NW, Greene SC, eds. *The Genetics of Hand Malformations*. New York: Alan R. Liss, Inc., 1978:73.

# 200. Temtamy SA, McKusick VA. Brachydactyly. In: Bergsma D, Mudge JR, Paul NW, Greene SC, eds. *The Genetics of Hand Malformations*. New York: Alan R. Liss, Inc., 1978c:187.

# 201. Temtamy SA, McKusick VA. Polydactyly as an Isolated Malformation. In: Bergsma D, Mudge JR, Paul NW, Greene SC, eds. *The Genetics of Hand Malformations*. New York: Alan R. Liss, Inc., 1978:364.

# 202. Temtamy SA, McKusick VA. Syndactyly as an Isolated Malformation. In: Bergsma D, Mudge JR, Paul NW, Greene SC, eds. *The Genetics of Hand Malformations*. New York: Alan R. Liss, Inc., 1978:301.

# 203. Temtamy SA, McKusick VA. Syndactyly as Part of Syndromes. In: Bergsma D, Mudge JR, Paul NW, Greene SC, eds. *The Genetics of Hand Malformations*. New York: Alan R. Liss, Inc., 1978e:323.

# 204. Temtamy SA, McKusick VA. The Genetics of Hand Malformations. In: Bergsma D, Mudge JR, Paul NW, Greene SC, eds. *The Genetics of Hand Malformations*. New York: Alan R. Liss, Inc., 1978a.

+ 205. Thomas RD, Fairhurst JJ, Clarke NM. Madelung's Deformity Masquerading as a Bone Tumour. *Skeletal Radiol* 1993;22:329.

+ 206. Townsend DJ, Lipp EB, Chun K, et al. Thumb duplication, 66 years experience—a review of surgical complications. *J Hand Surg* 1994;19A:973.

+ 207. Tsujino A, Itoh Y, Hayashi K. Reconstruction of Floating Thumb by Transplanting the Fourth Metatarsal. *J Bone Joint Surg* 1994;76-B:551.

+ 208. Tsuyuguchi Y, Masada K, Kawabata H, et al. Congenital Clasped Thumb: A Review of Forty-three Cases. *J Hand Surg* 1985;10A:613.

+ 209. Uchida Y, Sugioka Y. Peripheral Nerve Palsy Associated with Congenital Constriction Band Syndrome. *J Hand Surg* 1991;16B:109.

* 210. Upton J. Apert Syndrome. Classification and Pathologic Anatomy of Limb Anomalies. *Clin Plast Surg* 1991;18:321.

+ 211. Upton J, Tan C. Correction of Constriction Rings. *J Hand Surg* 1991;16A:947.

+ 212. Vacher CH, Haddad R, Glicenstein J, Pavy B. L'hypoplasie Congenitale du Pouce: Etude Clinique a Propos de 30 Patients. *Annales de Chirurgie de la Main* 1997;16:316.

+ 213. Van Demark RE Sr, Van Demark RE Jr. Long-term Results after the Surgical Treatment of Madelung's Deformity: A Case Report. *J Hand Surg* 1993;18A:1008.

+ 214. Van Genechten F. Familial Trigger Thumb in Children. *Hand* 1982;14:56.

+ 215. Van Heest AE, House J, Krivit W, Walker K. Surgical Treatment of Carpal Tunnel Syndrome and Trigger Digits in Children with Mucopolysaccharide Storage Disorders. *J Hand Surg* 1998;23A:236.

+ 216. Van Heest AE, House JH, Reckling WC. Two-stage Reconstruction of Apert Acrosyndactyly. *J Hand Surg [Am]* 1997;22:315-322.

+ 217. Verdan C. The Thumb in Syndactyly. *Ann Chir Main Memb Super* 1982;1:29.

+ 218. Vickers D. Clinodactyly of the Little Finger: A Simple Operative Technique for Reversal of the Growth Abnormality. *J Hand Surg* 1987;12B:335.

+ 219. Vickers D, Nielsen G. Madelung Deformity: Surgical Prophylaxis (Physiolysis) During the Late Growth Period by Resection of the Dyschondrosteosis Lesion. *J Hand Surg* 1992;17B:401.

+ 220. Vilkki S. Advances in Microsurgical Reconstruction of the Congenitally Adactylous Hand. *Clin Orthop* 1995;314:45.

+ 221. Vilkki SK. Distraction and Microvascular Epiphysis Transfer for Radial Club Hand. *J Hand Surg* 1998;23B:445.

* 222. Wassel HD. The Results of Surgery for Polydactyly of the Thumb. A Review. *Clin Orthop* 1969;64:175.

+ 223. Watson BT, Hennrikus WL. Postaxial Type-B Polydactyly. Prevalence and Treatment. *J Bone Joint Surg [Am]* 1997;79:65.

* 224. Watson HK, Boyes JH. Congenital Angular Deformity of the Digits: Delta Phalanx. *J Bone Joint Surg* 1967;49A:339.

+ 225. Watson HK, Pitts EC, Herber S. Madelung's Deformity. A Surgical Technique. *J Hand Surg* 1993;18B:601.

* 226. Weckesser EC. Congenital Flexion-adduction Deformity of the Thumb (Congenital “Clasped Thumb”). *J Bone Joint Surg* 1955;37A:977.

+ 227. Weckesser EC. Congenital Clasped Thumb (Congenital Flexion-Adduction Deformity of the Thumb). *J Bone Joint Surg* 1968;50A:1417.

+ 228. Weinzweig N, Barr A. Radial, Ulnar, and Median Nerve Palsies Caused by a Congenital Constriction Band of the Arm: Single-stage Correction. *Plast Reconstr Surg* 1994;94:872.

# 229. Wilson FR. *The Hand*. New York: Pantheon Books, 1998.

# 230. Wilson GN. Heritable Limb Deficiencies. In: Herring JA, Birch JG, eds. *The Child with a Limb Deficiency*. Rosemont, IL: American Academy of Orthopaedic Surgeons, 1998:39.

+ 231. Wood VE. Congenital Triangular Bones in the Hand. *J Hand Surg* 1977;2:179.

+ 232. Wood VE, Sicilia M. Congenital Trigger Digit. *Clin Orthop* 1992;285:205.

* 233. Woolf RM, Broadbent TR. The Four-flap Z-plasty. *Plast Reconstr Surg* 1972;49:48.

* 234. Wynne-Davies R, Lamb DW. Congenital Upper Limb Anomalies: An Etiologic Grouping of Clinical, Genetic, and Epidemiologic Data from 387 Patients with “Absence” Defects, Constriction Bands, Polydactylies, and Syndactylies. *J Hand Surg* 1985;10A:958.

+ 235. Yosipovitch G, Yosipovitch Z, Karp M, Mukamel M. Trigger Finger in Young Patients with Insulin Dependent Diabetes. *J Rheumatol* 1990;17:951.

* 236. Zancolli E. Transplantation of the Index Finger in Congenital Absence of the Thumb. *J Bone Joint Surg* 1960;42A:658.

# 237. Zguricas J, Bakker WF, Heur H, et al. Genetics of Limb Development and Congenital Hand Malformations. *Plast Reconstr Surg* 1998;101:1126.

+ 238. Zguricas J, De Raeymaecker DMJ, Snijders PJLM, et al. Psychomotor Development in Children with Triphalangeal Thumbs: A Preliminary Study. *J Hand Surg* 1998;23B:526.

+ 239. Zionts LE, Osterkamp JA, Crawford TO, Harvey JP Jr. Congenital Annular Bands in Identical Twins: A Case Report. *J Bone Joint Surg* 1984;66A:450.

+ 240. Zlotogora J. On the Inheritance of the Split Hand/split Foot Malformation. *Am J Med Genet* 1994;53:29.

# CHAPTER 70

# MANAGEMENT OF THE ARTHRITIC HAND

*David R. Steinberg*

**D. R. Steinberg:** Department of Orthopaedic Surgery, University of Pennsylvania; and Penn Hand Specialists, Philadelphia, Pennsylvania, 19104.

Arthritides of the Hand
- Osteoarthritis
- Rheumatoid Arthritis
- Psoriatic Arthritis
- Gout

Nonsurgical Management
Surgical Indications for Hand Arthritis
- Osteoarthritis
- Rheumatoid Arthritis
- Psoriatic Arthritis
- Gout

Pitfalls and Complications
- Basal Joint Arthritis
- Druj Reconstruction
- Gout

Chapter References

Osteoarthritis (OA) and rheumatoid arthritis (RA) are the most common disease processes leading to deformity in the hand. It is important for the surgeon to be familiar with them and with some of the less typical arthritides, as well. Gout and psoriatic arthritis, for example, have certain unique characteristics with which the hand surgeon must deal (Table 70.1).

| Condition | Epidemiology | Common joint involvement | Associated features | Radiographic findings |
|---|---|---|---|---|
| Osteoarthritis | Perimenopausal female:male, 10:1<br>Posttraumatic | DIP<br>Thumb CMC | Mucous cyst<br>Activity-related | Joint-space narrowing<br>Peripheral osteophytes |
| Rheumatoid arthritis | Female: male, 2–4:1 | MP<br>DRUJ<br>Radiocarpal | Ulnar-volar subluxation<br>Swan-neck/boutonnière deformities | Osteopenia<br>Joint erosion<br>Ulnar translation of carpus |
| Psoriatic arthritis | 1%–7% of patients with psoriasis | DIP<br>PIP | Nail changes in 80%<br>Psoriasis<br>Fusiform digital swelling | IP ankylosis<br>"Pencil-in-cup" deformity<br>Arthritis mutilans |
| Gout | Males, 20–40 yr. | DIP<br>PIP | Tophi<br>Carpal tunnel syndrome<br>Joint contractures | Nodular soft-tissue masses<br>"Punched-out" periarticular lesions<br>Preservation of joint space until late |

DIP, distal interphalangeal joint; PIP, proximal interphalangeal joint; MP, metacarpophalangeal joint; DRUJ, distal radial ulnar joint; IP, interphalangeal.

***Table 70.1. Hand Arthritis—Differential Diagnosis***

## ARTHRITIDES OF THE HAND

### OSTEOARTHRITIS

Primary degenerative OA most frequently affects the interphalangeal (IP) and thumb carpometacarpal (CMC) joints. It is most common in perimenopausal and postmenopausal women. While OA of the thumb basal CMC joint can occur as an isolated entity, arthritis of the distal interphalangeal (DIP) joint often involves multiple digits, and arthritis of the proximal interphalangeal (PIP) joint usually occurs in conjunction with OA of the DIP joint. Interphalangeal OA in a single digit is often a sequela of trauma or sepsis. Symptoms of primary OA include gradual swelling and stiffness with minimal to mild pain. Marginal osteophytes appear in the DIP joint (Heberden's nodes) and PIP joint (Bouchard's nodes). With progression, the joint develops a mild flexion deformity and may deviate radially or ulnarly with collateral ligament involvement. A mucous cyst is a ganglion arising from the DIP joint via a pedicle, which often develops in conjunction with OA (33).

A more aggressive form of OA, erosive osteoarthritis, can affect the IP joints and is more likely to occur in middle-aged women (42,53). Erosive osteoarthritis causes pain, synovitis, and stiffness; radiography reveals progressive destruction of the IP joints. This condition may be differentiated from RA by the absence of systemic manifestations and certain radiographic characteristics (osteoporosis, more proximal joint involvement) (42).

The thumb CMC joint is the second most common site of OA in the hand (52). Postmenopausal women are affected ten times as frequently as men (2). It is usually an idiopathic condition in women; previous trauma is the usual etiology in men. Patients complain of pain at the base of the thumb and thenar eminence, with occasional radiation distally into the metacarpophalangeal (MP) joint and proximally into the wrist and forearm. Swelling, crepitus, weakness of pinch, and dorsoradial subluxation occur as arthritis and instability progress (Table 70.2). Tenderness over the palmar-radial aspect of the CMC joint and a positive axial grind test aid in diagnosis. Other causes of pain in this region that must be considered in the differential diagnosis include carpal tunnel syndrome, de Quervain's tenosynovitis, flexor carpi radialis (FCR) tendinitis, radiocarpal and triscaphe (scaphotrapeziotrapezoid) arthritis, and volar wrist ganglion. Radiographic evaluation should include Robert's hyperpronation view and the stress view as described by Eaton (Fig. 70.1) (22,56).

| | |
|---|---|
| Stage I | Pain, ligamentous laxity, positive CMC grind test |
| Stage II | Crepitus, subluxation, degenerative changes on radiography |
| Stage III | Pan-trapezial arthritis |
| Stage IV | Degenerative changes at metacarpophalangeal joint |

From Burton RI. Basal Joint Arthrosis of the Thumb. *Orthop Clin North Am* 1973;4:331.

***Table 70.2. Classification of Thumb Carpal Metacarpal (CMC) Osteoarthritis***

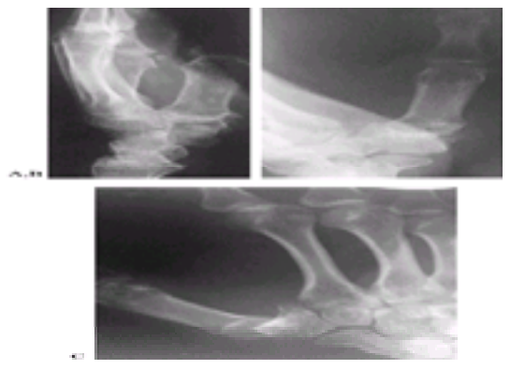

***Figure 70.1.*** Osteoarthritis of the thumb, carpometacarpal (CMC) joint. **A:** Posteroanterior (PA) view demonstrates loss of joint space, subchondral sclerosis, and periarticular osteophyte. **B:** Robert's hyperpronation view displays the entire trapezium and its borders. **C:** Application of ulnarly directed stress on the radial side of the distal phalanx demonstrates subluxation of the thumb CMC joint associated with ligamentous laxity and arthritis.

Degenerative arthritis of the MP and remaining CMC joints of the hand is much less common, and it is usually secondary to fracture, ligamentous instability, or sepsis. OA of the second or third carpometacarpal joints is called a *carpal boss.* This dorsal osteophyte develops gradually as a firm, tender mass on the dorsum of the hand. Symptoms may be aggravated by tendinitis of the overlying extensor carpi radialis brevis and longus. Some cases are associated with small dorsal ganglions. The carpal boss is best demonstrated on a lateral radiograph with the hand supinated 30°. Arthritis of the small-finger CMC joint is usually a result of trauma. This joint is best viewed on an anteroposterior (AP) radiograph with the forearm pronated 30°.

Osteoarthritis of the wrist usually occurs secondary to ligamentous injury, malunited or nonunited fractures, Kienbøck's disease, or crystal pyrophosphate deposition disease. Reviewing a large series of wrist radiographs, Watson and Ballet reported a 5% incidence of wrist OA (73). Of these cases, 57% involved a pattern that they termed scapholunate advanced collapse (SLAC). Arthritis first develops between the scaphoid and radius, followed sequentially by degenerative changes in the capitolunate and lunotriquetral joints (Fig. 70.2). It is most commonly a sequela of chronic scapholunate ligamentous instability or a scaphoid nonunion. Patients may complain of stiffness, pain, intermittent swelling, and clicking.

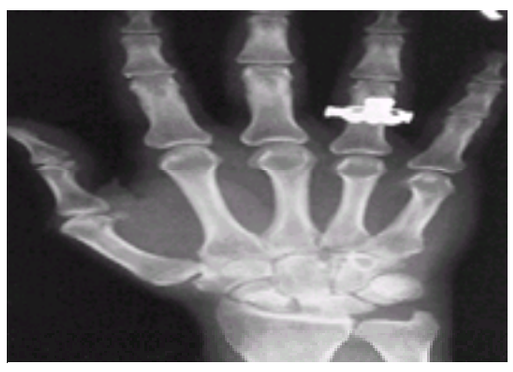

***Figure 70.2.*** Scapholunate advanced collapsed pattern of wrist arthritis secondary to chronic scaphoid nonunion. Degenerative changes are seen between the scaphoid and radial styloid, as well as in the scaphocapitate and capitolunate joints. There is no evidence of the proximal migration of the capitate associated with later stages of this disease.

Approximately another 40% of cases of wrist arthritis involve the triscaphe joint alone or a combination of triscaphe and SLAC patterns (74). Triscaphe arthritis is characterized by pain at the base of the thumb; it may coexist or be confused with arthritis of the CMC joint of the thumb.

**RHEUMATOID ARTHRITIS**

Rheumatoid arthritis is an inflammatory disease of the synovial tissues of joints, tendon sheaths, and bursae. The hallmark of this disease is proliferation of inflamed synovium that leads to progressive joint destruction and deformity. This disease is often symmetric and occurs two to four times more often in women than in men.

In evaluating a patient with RA, the physician must remember that it is a systemic disease; examination of the hand begins with the cervical spine and encompasses the entire upper extremity. Rheumatoid nodules, tenosynovitis, nerve compression, acute synovitis, and damage to periarticular soft tissues and articular cartilage secondary to chronic synovitis may lead to pain and dysfunction in the rheumatoid hand.

Rheumatoid arthritis of the wrist frequently leads to ulnar subluxation of the carpus with radial deviation of the hand. Dorsal subluxation of the distal ulna often occurs concomitantly. Because the finely balanced forces of intrinsic and extrinsic muscles are disrupted, these proximal deformities often result in palmar and ulnar subluxation of the MP joints, with secondary deformities of the IP joints.

Nodules may be cosmetically unacceptable or may interfere with function because of the direct pressure they apply or their location over a joint or tendon. They may erode through skin, and occasionally they can become infected. Rheumatoid nodules occur in 20% to 25% of RA patients, usually in association with an aggressive form of the disease.

Tenosynovitis can affect both the extensor and flexor tendons. Early in the course of the disease, symptoms of flexor tenosynovitis include pain and crepitus over the tendons. Digital range of motion becomes limited. Carpal tunnel syndrome is very common in RA patients, secondary to compression of the median nerve in the wrist by hypertrophic flexor tenosynovium. Involvement of digital flexor tendon sheaths results in fusiform swelling of the digits, limited finger flexion, and triggering. In later stages, tendons may rupture. Flexor pollicis longus (FPL) and index flexors are the most common tendons to rupture on the palmar side, often secondary to attrition over a palmar scaphoid osteophyte (23). Further ruptures may progress sequentially in a radial-to-ulnar direction.

Extensor tenosynovitis is painless and demonstrates very obvious swelling distal to the extensor retinaculum. Direct synovial invasion or attrition over the distal ulna (Vaughan-Jackson syndrome) may cause extensor tendon rupture (71). The extensor digiti quinti is usually the first tendon affected; remaining tendons rupture progressively from ulnar to radial. Because of the already limited motion in their hands, many patients will not be aware of ruptured extensor tendons; the physician must look closely for loss of active MP joint extension. This condition must also be differentiated from subluxating extensor tendons and from posterior interosseous nerve palsy. With ulnar subluxation of the extensor tendons over the MP joint, passive extension of the MP joint allows centralization of the tendons; the patient will then be able to maintain MP joint extension. In the presence of posterior interosseous nerve palsy, passive MP joint extension can be demonstrated by a tenodesis effect, in which passive wrist palmar flexion tightens intact digital extensors, resulting in subtle MP joint extension.

Symptoms of acute synovitis are pain, swelling, and transient stiffness; radiographs are normal. The presence of joint crepitus, permanent limitation of motion, and joint narrowing or erosion on radiographs indicates articular destruction secondary to long-standing synovitis (Fig. 70.3 and Fig. 70.4). The physician needs to look for subtle signs of fullness in the wrist and point tenderness over the radiocarpal or distal radioulnar joints (DRUJ). Arthritis of the DRUJ or more proximally at the elbow may limit forearm rotation.

***Figure 70.3.*** PA (**A**) and lateral (**B**) radiographs of the hand and wrist demonstrate generalized osteopenia, dorsal subluxation of the distal radioulnar joint, and ulnar translation of the carpus with loss of all contact between the radius and lunate.

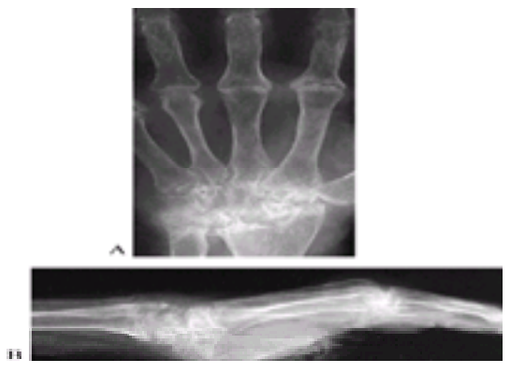

***Figure 70.4.*** PA (**A**) and lateral (**B**) radiographs of another patient with rheumatoid arthritis. There is mild involvement of the proximal interphalangeal joints, more significant involvement of the metacarpophalangeal joints with bony destruction, and severe involvement of the wrists with marked bony destruction and loss of carpal height.

Swollen MP joints may progress to flexion and ulnar-deviation deformities as continued synovitis causes extensor tendon subluxation, intrinsic tightness, and actual subluxation of the joint (Fig. 70.4). Chronic synovitis of IP joints can lead to digital deformities that can occur in many conditions but have come to be associated with RA. Primary mallet deformity occurs rarely when the terminal extensor tendon is stretched by dorsal synovitis of the DIP joint. Attenuation of the central slip caused by PIP joint dorsal synovitis may lead to a boutonnieère deformity. Swan-neck deformity can be caused by intrinsic tightness, palmar synovitis leading to attenuation of the palmar capsule, flexor digitorum sublimis (FDS) rupture, or overpull of the extensor secondary to a mallet deformity. The thumb may be similarly involved; these deformities are classified I through V on the basis of symptoms and primary joint of involvement (Table 70.3) (49).

| Stage | Joint pathology | Clinical appearance |
|---|---|---|
| I | MP[1] synovitis | Boutonnière MP[1] flexion, IP[2] hyperextension, extensor pollicis brevis attenuation |
| II | CMC synovitis | CMC subluxation, MP[1] flexion, IP[2] hyperextension (rare) |
| III | CMC synovitis → dorsoulnar subluxation | Swan-neck IP[2] flexion, MP[1] hyperextension |
| IV | MP[1] synovitis → UCL attenuation | Gamekeeper's thumb (ulnar laxity of MP[1] with adduction contracture) |
| V | Palmar MP[1] synovitis | MP[1] hyperextension, IP[2] flexion |

MP[1], metacarpophalangeal joint; CMC, carpometacarpal; UCL, ulnar collateral ligament; IP[2], interphalangeal joint.

***Table 70.3. Classification of Rheumatoid Thumb Deformities***

## PSORIATIC ARTHRITIS

Psoriatic arthritis (PA) is a seronegative inflammatory polyarthritis that occurs in 5% to 7% of patients with psoriasis. Skin lesions usually precede the arthritis by months to years (36). Eighty percent of patients demonstrate nail changes, especially in association with arthritis of the DIP joint (76). This form of arthropathy differs from RA in that inflammation occurs without significant synovitis (46). It often leads to stiffness and spontaneous fusion rather than to the instability seen in RA (6). The hand may be involved in as many as 84% of patients with PA (70).

Isolated involvement of the DIP joint and severe joint destruction ("arthritis mutilans") have been described as pathognomonic for PA. However, only 10% of patients with hand involvement have such symptoms (46). Most patients exhibit varying degrees of arthropathy affecting multiple joints. Clinically, PIP joint involvement is most severe; radiographically, however, DIP, PIP, and MP joints are affected with similar frequencies (6,70).

Distal IP joints are rarely symptomatic or deformed, although many may go on to spontaneous fusion. PIP joints often develop significant flexion contractures and spontaneous fusion, while the MP joint often stiffens in extension (Fig. 70.5). This finding does not occur in those 5% of patients with psoriatic arthritis mutilans, in which severe osteolysis of the phalanges and metacarpals leads to significant digital shortening and instability of IP and MP joints (36,46,72). This collapse and telescoping of the phalanges has been called *main en lorgnette* (opera glass deformity) (41). Fusiform swelling of the digits, acute dactylitis psoriatica, may be confused with flexor tenosynovitis. Fusiform swelling, however, involves the soft tissues of the entire digit and is often intermittent in nature. In wrists of moderately to severely affected patients, narrowing or obliteration of joint spaces and bony erosions often lead to stiffness or spontaneous fusion in functional positions (6).

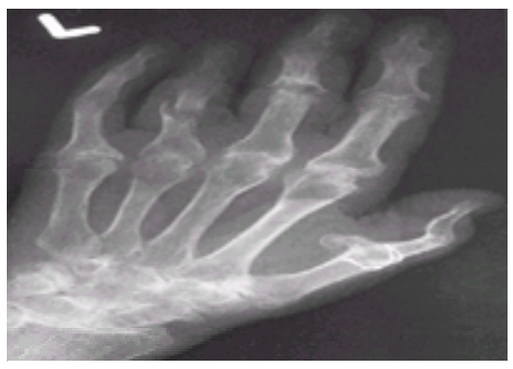

***Figure 70.5.*** Radiographic appearance of psoriatic arthritis in the hand. Distal interphalangeal joints as well as proximal interphalangeal joints of the small finger have undergone spontaneous fusion. There is bony destruction of the proximal interphalangeal joints of the long and ring finger with severe shortening of the ring finger (opera glass deformity). There is less significant involvement of the metacarpophalangeal joints. Clinically, this patient's wrists were asymptomatic.

Characteristic radiologic findings in early PA include joint-space narrowing, erosions, and subchondral osteopenia. More advanced stages reveal acro-osteolysis, “pencil-in-cup” deformities, IP joint ankylosis, and severe joint destruction.

**GOUT**

Gout is a disorder of uric acid metabolism most commonly seen in men in the second to fourth decades. Tophaceous gout occurs in 50% to 70% of untreated patients, often many years after the initial episode of acute arthritis (32). More recent experience indicates that approximately 10% of patients under stable medical management will develop clinically significant tophi (32,64). Urate crystals may be deposited in cartilage, periarticular soft tissues, and subcutaneous tissues. Progressive stiffness and aching of joints often develops into destruction and deformity by insidiously enlarging tophi. DIP and PIP joints are involved much more frequently than are MP joints. Symptoms of gout in the hand include median nerve compression; joint contractures; and chronic tenosynovitis, tendon ruptures, and digital flexion contractures secondary to flexor tendon involvement (Fig. 70.6) (14,17,29,47,51,64).

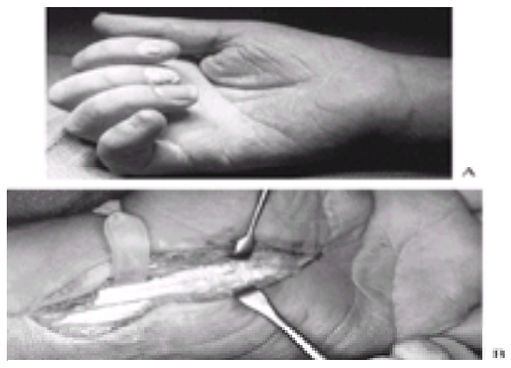

***Figure 70.6.*** **A:** Tophaceous gout has caused progressive flexion contractures of the digits as well as carpal tunnel syndrome in this patient. **B:** Carpal tunnel release and flexor tenosynovectomy were performed in this patient. Tophaceous deposits were also seen within the tendon substance.

Nodular soft-tissue masses, with or without calcification, are the earliest radiographic findings in tophaceous gout (67). Extra-articular tophi may erode into bony cortex, creating the “punched-out” lesions typically associated with gout. Intraarticular erosions begin in the periphery of the joint and proceed centrally; the joint space is usually preserved until late in the course of the disease (55).

## NONSURGICAL MANAGEMENT

Early stages of hand arthritides may be treated with a judicious combination of medical management, splinting, and hand therapy (Table 70.4). A multidisciplinary approach is needed, with participation of the surgeon, the hand therapist, and, in the inflammatory arthritides, the internist or rheumatologist. Knowledge of a patient's goals, expectations, vocation and avocations, social situation, and limitations of activities of daily living is necessary to formulate an individualized treatment plan.

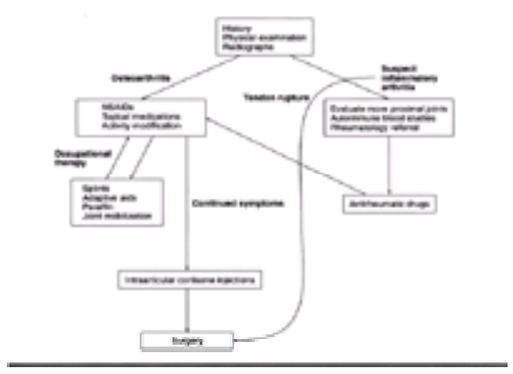

***Table 70.4. Management of Hand Arthritis***

Before instituting treatment, evaluate the entire patient, because many of these conditions involve more than just the hand. Arthritis of the more proximal joints of the upper extremity, cervical and lumbar spine, and lower extremities must be diagnosed. For successful restoration of hand function, the patient must have enough elbow and shoulder motion to properly position the hand in space. Lower-extremity disease may need to be controlled first to dispose of ambulatory aids that may be exacerbating upper-extremity symptoms. Alternatively, management of severely involved hands may take precedence in anticipation of rehabilitation following lower-extremity reconstruction. Extraarticular manifestations of inflammatory arthropathies (e.g., rheumatic cardiac or pulmonary disease) may affect the decision to treat a patient conservatively or with reconstructive surgery.

The goals of nonsurgical management include elimination of pain, reduction of inflammation, restoration of function, prevention of deformity, and a slowdown of the inevitable progression to joint destruction (Table 70.5). In the patient with inflammatory arthritis or gout, medical management by an internist (or rheumatologist) is crucial in alleviating acute episodes and bringing the entire disease process under control; therapy may take 3 to 4 months before it is effective (45).

Pain relief

Reduction of inflammation

Functional restoration

Prevention of deformity
- Soft-tissue
- Intraarticular

***Table 70.5. Treatment Goals for Hand Arthritis***

Nonsteroidal antiinflammatory drugs (NSAIDs) are the first line of treatment for early hand arthritis. I do not hesitate to combine this therapy with splinting and rest of the affected joints. Together, these are helpful in minimizing pain and inflammation. Resting splints may be used prophylactically for activities that exacerbate a patient's symptoms. In certain instances, such as a flare-up of OA of the DIP or the thumb basal joints, I often recommend continuous use of a splint for 2 to 3 weeks, followed by nighttime use for another 2 weeks.

The physician should work together with the therapist in prescribing the appropriate splint. A palmar splint with the wrist in neutral to 20° of extension is effective for treating arthritis of the wrist and carpal tunnel syndrome. The thumb with basal joint arthritis is best immobilized with a long opponens splint, leaving the IP joint free; a hand-based splint does not provide sufficient leverage to immobilize the CMC joint.

A combination of resting and functional splints can be effective in early stages of the inflammatory arthritides. Resting splints to immobilize the wrist can be used to treat flare-ups of acute synovitis or tendinitis of wrist flexors and extensors. A splint incorporating the MP joints may be helpful for acute synovitis or to treat early palmar and ulnar subluxation of these joints. IP joints may be included when treating exacerbations of flexor tenosynovitis. The physician or therapist should be aware of the increased susceptibility of rheumatoid skin to breakdown under these splints. Development of psoriatic skin lesions due to irritation beneath splints may also occur. Psoriatic dermatitis, known as the Koebner phenomenon, also has been observed at surgical incision sites and other wounds. Treat these lesions with daily application of topical steroid (58).

Functional splints, which correct mild deformities such as MP joint ulnar deviation and swan-neck and boutonnieère deformities, may improve overall function by realigning the hand and digits in patients who may not be ideal surgical candidates. Adaptive aids may be instrumental in improving specific activities of daily living (ADL). The therapist can provide individualized exercise programs and guidance in performing ADL, based on the patient's current stage of disease and her specific limitations. An appropriate exercise program will prevent joint stiffness and muscle atrophy.

Steroid injections are another nonsurgical method used by the physician. Inject joints (excluding the DIP joints), tendon sheaths, peritendinous insertions, and carpal tunnels that have not responded initially to an appropriate period of splinting and oral NSAIDs. A 1:1 ratio of 1% lidocaine and betamethasone sodium phosphate, using a 25- or 27-gauge needle, is preferred. Injections must be used judiciously because excessive intraarticular or peritendinous steroid administration can hasten cartilage degeneration (40) or lead to tendon ruptures (3). More effective responses can be expected when steroid injections are combined with 3 weeks of continuous splinting, as they maximize anti-inflammatory effects (28,75). In many cases, this combination of methods has been successful when previous steroid injection alone was not.

A variety of new antiarthritis medications currently are in limited clinical use: COX-2 inhibitors, glucosamine and chondroitin sulfate, intraarticular hyaluronic acid substitutes, and antirheumatic biological agents. The indications for these agents in hand and wrist arthritis have not yet been established.

## SURGICAL INDICATIONS FOR HAND ARTHRITIS

Consider palliative or reconstructive surgery when conservative therapy is no longer effective. The surgeon and patient must be aware of the goals and relative priorities of surgical treatment of arthritis of the hand, described by William Souter (63). Although Souter was writing about RA, these principles are applicable to any type of hand arthritis (Table 70.6).

| |
|---|
| Pain relief |
| Restoration of function |
| Prevention of function deterioration |
| Cosmesis |
| List is in order of increasing importance. |

***Table 70.6. Goals of Surgery for Hand Arthritis***

This prioritization is not final; surgical considerations must be individualized to each patient (Table 70.7). For instance, a patient whose RA leads to relatively painless destruction of the wrist and rupture of one or two extensor tendons needs immediate surgical intervention to prevent further tendon rupture. Deformity alone, however, is not an indication for surgery. Severe deformities in debilitated patients or in individuals with preservation of function may not require surgery. As stressed earlier, the physician must examine and talk with the patient several times to assess that person's impairment, expectations, and prognosis adequately. It is essential that patients be cooperative and motivated before complicated, staged reconstructive procedures are performed.

| |
|---|
| Osteoarthritis (OA) |
| Failed response to conservative treatment |
| Mucous cyst associated with painful joint or threatening skin integrity |
| Unstable interphalangeal joints interfering with hand function |
| Symptomatic stage III or IV thumb carpometacarpal osteoarthritis |
| Rheumatoid arthritis (RA) |
| Extrinsic flexor or extensor tendon rupture |
| Nerve compression |
| Painful rheumatoid nodules |
| Significant wrist synovitis or tenosynovitis unresponsive to 6 months of conservative treatment including intraarticular cortisone |

***Table 70.7. Surgical Indications***

Before performing surgery on the patient with inflammatory arthritis, the physician needs to take other factors into consideration. Be aware of possible involvement of the cervical spine; take appropriate radiographs and alert the anesthesiologist. Patients on maintenance doses of steroids may need perioperative parenteral corticosteroid supplementation. High doses of chronic steroids may interfere with wound healing. Discontinue use of aspirin and other NSAIDs 1 week before surgery to minimize platelet dysfunction. Other antirheumatic medications may adversely affect immunologic or hematopoeitic function; take appropriate precautions on the basis of preoperative laboratory studies.

### OSTEOARTHRITIS

Treat stable, painful DIP joints with mucous cyst excision and marginal osteophyte debridement. Excision of mucous cysts alone has a 25% to 50% recurrence rate (20,33). Cyst aspiration similarly has a high recurrence rate and may lead to an increased incidence of septic arthritis (59). Arthrodesis is the preferred treatment for an unstable, painful DIP joint.

Satisfactory treatment of the functionally impaired osteoarthritic PIP joint remains a problem. Arthrodesis of index and long fingers is superior to arthroplasty in restoring pinch strength. Arthrodesis provides more consistent results in the ulnar digits at the expense of grip strength and dexterity. Although silicone arthroplasty of these PIP joints may provide improved function, a recent report noted 20% to 35% bone resorption around these implants at 2 to 4 years after surgery (53).

Posttraumatic osteoarthritis of the small-finger CMC joint can be significantly disabling, in part because of the normal mobility of this joint. Excessive laxity secondary to chronic subluxation may be treated by arthrodesis; take care to maintain the metacarpal arch by fusing this joint in adequate flexion (30). Painful malunions of small-finger CMC fracture–dislocations also may be treated with arthrodesis, or with partial resection arthroplasty (7).

The CMC joint of the thumb is the joint in the hand most commonly treated surgically for osteoarthritis. The severity of arthritis has been classified into four stages based on clinical and radiographic involvement (Table 70.2) (10). Patients with stage I disease are most likely to respond to conservative treatment, including splinting,

NSAIDs, injection, activity modification, and thenar strengthening exercises. If symptoms continue after an adequate trial of conservative management, or in later stages of arthritis, surgical intervention may be indicated. A wide range of surgical techniques for the arthritic thumb CMC joint have been described (Table 70.8).

| Technique | Authors |
|---|---|
| Ligament reconstruction | Eaton, Littler, 1973<br>Eaton et al., 1984 |
| Partial trapezium excision | Burton, Eaton, 1975 |
| Flexor carpi radialis tendon double interposition | |
| Trapezium resection | Murley, 1949<br>Brown et al., 1954<br>Freeman, 1970<br>Thompson, 1980<br>Rheinstein, Schmerkotte, 1991 |
| With tendon interposition | Burton, Pellegrini, 1980 |
| With suspension plasty | Lim et al., 1996<br>Le Viet et al., 1996 |
| With ligament reconstruction and tendon interposition | |
| Implant hemiarthroplasty | |
| Silicone | Swanson, 1972<br>Amadio et al., 1982<br>Coughlin et al., 1991 |
| Silicone/Elastomer | Swanson et al., 1993 |
| Titanium | Swanson, Swanson, 1993 |
| Total carpometacarpal arthroplasty | |
| Cadaveric | Cadaveric, 1979<br>Swanson et al., 1991 |
| Beaton | Brown, 1983 |
| Steffee | Ferrari, Steffee, 1984 |
| Mayo | Cooney et al., 1987 |
| First metacarpal | |
| Osteotomy | Hobby et al., 1990 |
| Arthrodesis | Carroll, Hill, 1973<br>Bainbridge et al. 1993 |

***Table 70.8. Thumb CMC Joint Reconstruction***

Eaton et al. recommend ligament reconstruction with a split FCR tendon for CMC joints with no or minimal radiographic changes (21,22). More advanced CMC arthritis requires partial or total trapezium excision combined with a reconstructive procedure. Trapezial excision alone (48), silicone implant arthroplasty (52), and soft-tissue interposition arthroplasty (1,43,44) result in residual weak pinch and proximal metacarpal migration. Another problem with silicone implants is fragmentation and foreign-body giant-cell synovitis occurring in patients who use their thumbs a great deal (52,60). Various resurfacing arthroplasties have been advocated, but proceed cautiously because rates of 10% to 35% of subluxation and dislocation are reported (19,54,66).

Arthrodesis of the CMC joint is useful for young laborers who require a strong, pain-free thumb and are willing to sacrifice some mobility (including the ability to flatten the hand) (4). This procedure is contraindicated in patients with scaphotrapezial or pantrapezial arthritis.

***Carpal Boss Excision***

Surgery is indicated for the symptomatic carpal boss that has not responded to cortisone injections and splinting.

- Approach the osteophyte and associated ganglion through a transverse wrist incision over the bump.
- Retract the digital extensor tendons ulnarly and the wrist extensors radially.
- Excise the ganglion with its stalk and attached capsule.
- Approach the CMC joints through separate longitudinal incisions.
- With sharp osteotomes, excise any osteophytes down to normal cartilage.
- Reapproximate the capsule and periosteum.
- Immobilize the hand in a splint or cast for 4 to 6 weeks.

Patients can expect lasting symptomatic relief in more than 95% of cases (27).

***CMC Arthroplasty—Author's Preferred Technique***

The modification of Eaton and Littler's ligament reconstruction described by Burton and Pellegrini has resulted in a high percentage of satisfied patients (12,22). The ligament reconstruction, tendon interposition (LRTI) arthroplasty uses autogenous tissue, restores strength, and minimizes metacarpal migration. With complete trapezium excision, this procedure may be used for all stages of basal joint arthritis. The LRTI arthroplasty, as originally described, uses a split FCR tendon to reconstruct the palmar oblique ligament and function as a tendon spacer (Fig. 70.7). More recently, I have used the entire FCR tendon, as advocated by Burton (11): It is easier to harvest, and no adverse effects on recovery have been reported.

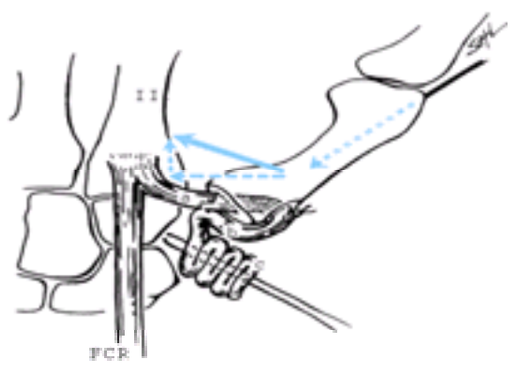


***Figure 70.7.*** Ligament reconstruction, tendon interposition arthroplasty. The forces producing proximal migration and radial subluxation of the metacarpal are neutralized by ligament reconstruction as indicated in the vector diagram. *a*, ligament reconstruction; *b*, metacarpal resurfacing; *c*, tendon arthroplasty spacer. (From Burton RI, Pellegrini VD Jr. Surgical Management of Basal Joint Arthritis of the Thumb. Part II. Ligament Reconstruction with Tendon Interposition Arthroplasty. *J Hand Surg [Am]* 1986;11:324.)

- Expose the CMC joint through a longitudinal incision along the radial border of the thumb metacarpal. Curve the proximal incision ulnarly into the distal wrist crease to expose the FCR tendon.
- Identify and protect the sensory branch of the radial nerve, the radial artery, and the palmar cutaneous branch of the median nerve.
- Reflect the thenar muscles distally and ulnarly from the metacarpal and trapezium.
- Longitudinally incise the fibro-osseous canal of the FCR to expose the tendon distal to the trapezium.
- Longitudinally incise the palmar-radial capsule to expose both the carpometacarpal and scaphotrapezial joints.
- Split the trapezium into two or four pieces with an osteotome or saw and remove them with a rongeur. Avoid injury to the joint capsule and FCR tendon.
- Excise the base of the thumb metacarpal perpendicular to its longitudinal axis. Place a hole in the metacarpal base between the extensor pollicis brevis (EPB) and the extensor pollicis longus (EPL) tendons with a gouge or drill positioned perpendicular to the plane of the thumbnail.
- Harvest 10–12 cm of the FCR tendon through two to three short transverse incisions in the forearm, transecting it proximally at its musculotendinous junction.
- Free the distally based tendon from its insertion and pass it into the metacarpal medullary canal and out of the dorsal cortical hole.
- Place a nonabsorbable figure-of-eight stitch in the deep capsule for later use. With the thumb in palmar abduction, stabilize the metacarpal by inserting two 0.045 in. Kirschner wires (K-wires) into the index metacarpal and trapezoid.
- While applying tension to the FCR tendon, suture it to the lateral metacarpal periosteum and then back to itself. Fold the remainder of the tendon on itself and suture it into the trapezial fossa with the previously placed deep capsular stitch (Fig. 70.7).
- Close the capsule with nonabsorbable suture. Close skin incisions and immobilize the arm in short-arm thumb spica for 4 weeks.

Begin rehabilitation with removal of the cast and K-wires at 4 weeks. Apply a removable thumb spica splint, which the patient should wear for another 2 to 4 weeks except when performing gentle assisted range-of-motion (AROM) exercises. Begin strengthening exercises at 6 to 8 weeks.

Functional improvement can occur as late as 1 year postoperatively. More than 80% of patients undergoing this or similar ligament reconstruction procedures demonstrate pain-free function and improved grip strength (12,21,69).

Reconstructive and salvage procedures for osteoarthritis of the wrist include various intercarpal arthodeses, proximal row carpectomy, and total wrist arthrodesis (see

Chapter 41, Chapter 42, and Chapter 72). Posttraumatic arthritis of the DRUJ may require surgical intervention if conservative therapy is ineffective. The historically popular Darrach procedure has fallen out of favor with many surgeons as increasing numbers of complications are recognized and as the biomechanics of the DRUJ are better understood. Alternative operations have been developed that attempt to maintain the integrity of the radioulnar and ulnocarpal ligaments while revising the painful DRUJ. These include hemiresection–interposition arthroplasty, matched distal ulna resection, and the Sauveé-Kapandji procedure. Each has its advocates and adversaries; there are no good studies documenting long-term results. Treatment decisions must be based on personal experience and theoretical advantages. See Lichtman, Ganocy, and Kim's comparative review of these procedures for a more in-depth discussion (38) (see also Chapter 43).

### RHEUMATOID ARTHRITIS

Low-profile functional splints may assist patients with mild swan-neck and boutonnieère deformities. A variety of reconstructive procedures are available for patients with more severe impairment. Similarly, significant involvement of MP and wrist joints may require surgical intervention. Although distal ulna resection has been more successful in the rheumatoid population, a Sauveé-Kapandji procedure is more appropriate in certain patients. This operation is preferable for younger, more active patients who require a stable radioulnar surface (for arthroplasty support), who demonstrate ulnar translocation of the carpus (less than 50% radiolunate contact), or who require augmentation of radiolunate fusion (68).

### PSORIATIC ARTHRITIS

The goals of surgery for patients with PA are different from those for patients with RA because of the fixed soft-tissue contractures and spontaneous joint fusions that accompany PA. MP arthroplasties for extension contractures may restore some function, but recurrent stiffness is not unexpected. Arthrodesis of PIP joints that have spontaneously fused in severe flexion allows more functional positioning of these digits (see Chapter 72). Arthritis mutilans may require more complex reconstruction, including a combination of arthrodesis and lengthening, to replace resorbed phalanges (26,57,72).

Surgery is rarely required for DIP joint and wrist deformity, because these become fixed in functional positions. The surgeon should also be aware of the increased infection rates reported in patients with PA (6). Preoperative betadine washing of the involved extremity has been suggested as a means to decrease perioperative infections.

### GOUT

Most patients with gout respond well to allopurinol, colchicine, and uricosuric agents (see Chapter 99). Five percent to 10% of patients require surgical intervention. Indications for surgery include nerve compression, tendon involvement (entrapment or rupture), diagnosis and control of infection, significant joint destruction, and cosmetically unacceptable tophi (35,47,64).

Treat nerve compression and tendon entrapment with judicious excision of tophi, tendon debulking, and synovectomy. Tendon rupture may be managed with side-to-side repair or tendon transfers. It is best to treat isolated ruptures of FDS tendons nonoperatively if there is no functional impairment. Unstable, painful joints may require arthroplasty or arthrodesis.

## PITFALLS AND COMPLICATIONS

### BASAL JOINT ARTHRITIS

Interview and examine the patient on a number of occasions before deciding to perform thumb CMC arthroplasty on an arthritic CMC joint. Some patients with stage III and IV radiographic changes have few symptoms and remain surprisingly functional.

Inspect both proximal and distal aspects of the trapezium during exposure. Radiography does not reveal degenerative changes of the scaphotrapezial joint in one third of cases (50). If there is no scaphotrapezial arthritis or thumb web-space contracture, the proximal one half of the trapezium may be left in place; most surgeons prefer a total trapeziectomy.

Carefully evaluate the MP joint preoperatively. For hyperextension instability greater than 30°, stabilize the joint with a volar plate advancement or MP arthrodesis.

### DRUJ RECONSTRUCTION

One potential disadvantage of resection techniques is instability of the end of the proximal ulna. Ulnar instability is most likely to occur in patients with significant preoperative DRUJ instability; neither this procedure nor other excisional arthroplasties of the distal ulna adequately addresses this problem. In these cases, continue above-elbow immobilization for 3 to 4 weeks before instituting gentle active range-of-motion exercise.

### GOUT

Traumatized tophi may undergo liquefaction with subsequent development of erythema, warmth, pain, and drainage of thick, opaque fluid. Differentiation of acute tophaceous gout from infection may require aspiration and crystal analysis or occasional incision and drainage.

### CHAPTER REFERENCES

Each reference is categorized according to the following scheme: *, classic article; #, review article; !, basic research article; and +, clinical results/outcome study.


+ 1. Amadio P, Millender L, Smith R. Silicone Spacer or Tendon Spacer for Trapezium Resection Arthroplasty—Comparison of Results. *J Hand Surg* 1982;7:237.

* 2. Aune S. Osteoarthritis in the First Carpometacarpal Joint. *Acta Chir Scand* 1955;109:449.

! 3. Balasubramanian P, Prathap K. The Effect of Injection of Hydrocortisone into Rabbit Calcaneal Tendons. *J Bone Joint Surg Br* 1972;54:729.

+ 4. Bamberger HB, Stern PJ, Kiefhaber TR, McDonough JJ, Cantor RM. Trapeziometacarpal Joint Arthrodesis: A Functional Evaluation. *J Hand Surg [Am]* 1992;17:605.

+ 5. Barron OA, Eaton RG. Save the Trapezium: Double Interposition Arthroplasty for Stage 4 Degenerative Arthritis. Presented at the annual meeting of the American Society for Surgery of the Hand, San Francisco, CA. September 15, 1995.

# 6. Belsky MR, Feldon P, Millender LH, et al. Hand Involvement in Psoriatic Arthritis. *J Hand Surg* 1982;7:203.

+ 7. Black DM, Watson HK, Vender MI. Arthroplasty of the Ulnar Carpometacarpal Joints. *J Hand Surg [Am]* 1987;12:1071.

+ 8. Braun R. Total Joint Arthroplasty at the Carpometacarpal Joint of the Thumb. *Clin Orthop* 1985;195:161.

+ 9. Breen T, Balcom W, Morgan WJ, et al. Functional Outcome of Resection Arthroplasty vs LRTI for Basal Joint Arthritis. Presented at the annual meeting of the American Society for Surgery of the Hand, Cincinnati, OH. October 27, 1994.

* 10. Burton RI. Basal Joint Arthrosis of the Thumb. *Orthop Clin North Am* 1973;4:331.

# 11. Burton RI. Ligament Reconstruction Tendon Interposition Arthroplasty. In: Lane LB, ed. *Atlas of the Hand Clinics: Carpometacarpal Joint*. Philadelphia: WB Saunders, 1997:77.

* 12. Burton RI, Pellegrini VD Jr. Surgical Management of Basal Joint Arthritis of the Thumb. Part II. Ligament Reconstruction with Tendon Interposition Arthroplasty. *J Hand Surg [Am]* 1986;11:324.

* 13. Carroll R, Hill N. Arthrodesis of the Carpometacarpal Joint of the Thumb. *J Bone Joint Surg Br* 1973;55:292.

# 14. Caudle RJ, Heim JM, Stern PJ. Digital Flexion Contractures Secondary to Tophaceous Gout. A Report of Three Cases. *Orthopedics* 1989;12:731.

+ 15. Cooney W, Linscheid RL, Askew LJ. Total Arthroplasty of the Thumb Trapeziometacarpal Joint. *Clin Orthop* 1987;220:35.

+ 16. Creighton J, Steichen J, Strickland J. Long-term Evaluation of Silastic Trapezial Arthroplasty in Patients with Osteoarthritis. *J Hand Surg Am* 1991;16:510.

+ 17. Cseuz KA, Thomas JE, Lambert EH, et al. Long-term Results of Operation for Carpal Tunnel Syndrome. *Mayo Clin Proc* 1966;41:232.

* 18. de la Caffiniere J. Trapeziometacarpal Arthroplasty by Total Prosthesis. *Hand* 1979;11:41.

* 19. Eaton RG. Replacement of the Trapezium for Arthritis of the Basal Articulations. *J Bone Joint Surg Am* 1979;61:76.

* 20. Eaton RG, Dobranski AI, Littler JW. Marginal Osteophyte Excision in Treatment of Mucous Cysts. *J Bone Joint Surg Am* 1973;55:570.

+ 21. Eaton RG, Lane LB, Littler JW, Keyser JJ. Ligament Reconstruction for the Painful Thumb Carpometacarpal Joint: A Long-term Assessment. *J Hand Surg [Am]* 1984;9:692.

* 22. Eaton RG, Littler JW. Ligament Reconstruction for the Painful Thumb Carpometacarpal Joint. *J Bone Joint Surg Am* 1973;55:1655.

# 23. Ertel AN, Millender LH, Nalebuff E, et al. Flexor Tendon Ruptures in Patients with Rheumatoid Arthritis. *J Hand Surg [Am]* 1988;13:860.

+ 24. Ferrari B, Steffee A. Trapeziometacarpal Total Joint Replacement Using the Steffee Prosthesis. *J Bone Joint Surg Am* 1986;68:1177.

* 25. Froimson A. Tendon Arthroplasty of the Trapeziometacarpal Joint. *Clin Orthop* 1970;70:191.

# 26. Froimson AI. Hand Reconstruction in Arthritis Mutilans. *J Bone Joint Surg Am* 1971;53:1377.

+ 27. Fusi S, Watson HK, Cuono CB. The Carpal Boss. A 20-year Review of Operative Management. *J Hand Surg Br* 1995;20:405.

+ 28. Gelberman RH, Aronson D, Weisman MH. Carpal-tunnel Syndrome: Results of a Prospective Trial of Steroid Injection and Splinting. *J Bone Joint Surg Am* 1980;62:1181.

# 29. Gelberman RH, Doty DH, Hamer ML. Tophaceous Gout Involving the Proximal Interphalangeal Joint. *Clin Orthop* 1980;147:225.

# 30. Gurland M. Carpometacarpal Joint Injuries of the Fingers. *Hand Clin North Am* 1992;8:733.

+ 31. Hobby J, Lyall HA, Meggitt BF. First Metacarpal Osteotomy for Trapeziometacarpal Osteoarthritis. *J Bone Joint Surg Br* 1998;80:508.

# 32. Kelley WN, Fox IR, Palella TD. Gout and Related Disorders of Purine Metabolism. In: Kelley WN, Harris ED Jr, Ruddy S, Sledge CB, ed. *Textbook of Rheumatology*, 3rd ed. Philadelphia: WB Saunders, 1989:1395.

* 33. Kleinert HE, Kutz JE, Fishman JH, McCraw LH. Etiology and Treatment of the So-called Mucous Cyst of the Finger. *J Bone Joint Surg Am* 1972;54:1455.

+ 34. Kleinman W, Eckenrode J. Tendon Suspension Sling Arthroplasty for Thumb Trapeziometacarpal Arthritis. *J Hand Surg [Am]* 1991;16:983.

# 35. Larmon WA. Surgical Management of Tophaceous Gout. *Clin Orthop* 1970;71:56.

# 36. Laurent MR. Psoriatic Arthritis. *Clin Rheum Dis* 1985;11:61.

+ 37. Le Viet D, Kerboull L, Lantieri LA, Collins DE. Stabilized Resection Arthroplasty by an Anterior Approach in Trapeziometacarpal Arthritis: Results and Surgical Technique. *J Hand Surg [Am]* 1996;21:194.

# 38. Lichtman DM, Ganocy TK, Kim DC. The Indications for and Techniques and Outcomes of Ablative Procedures of the Distal Ulna. *Hand Clin North Am* 1998;14:265.

+ 39. Lins R, Gelberman R, McKeown L, et al. Basal Joint Arthritis: Trapeziectomy with Ligament Reconstruction and Tendon Interposition Arthroplasty. *J Hand Surg [Am]* 1996;21A:202.

! 40. Mankin HJ, Conger KA. The Acute Effects of Intra-articular Hydrocortisone on Articular Cartilage in Rabbits. *J Bone Joint Surg Am* 1966;48:1383.

* 41. Marie P, Leéri A. Une varieéteé rare de rhumatisme chronique: La main en lorgnette (preésentation de pieéces et de coupes). *Bull Mem Soc Med Hop Paris* 1913;36:104.

# 42. Marmor L, Peter JB. Osteoarthritis of the Hand. *Clin Orthop* 1969;64:164.

+ 43. Menon J, Schoene H, Hohl J. Trapeziometacarpal Arthritis—Results of Tendon Interposition Arthroplasty. *J Hand Surg* 1981;6:442.

+ 44. Millender L, Nalebuff E, Amadio P. Interpositional Arthroplasty for Rheumatoid Carpometacarpal Joint Disease. *J Hand Surg* 1978;3:533.

* 45. Millender LH, Nalebuff EA. Evaluation and Treatment of Early Rheumatoid Hand Involvement. *Orthop Clin* 1975;6:697.

# 46. Moll JMH, Wright V. Psoriatic Arthritis. *Semin Arthritis Rheum* 1973;3:55.

# 47. Moore RJ, Weiland AJ. Gouty Tenosynovitis in the Hand. *J Hand Surg [Am]* 1985;10:291.

* 48. Murley AHG. Excision of the Trapezium in Osteoarthritis of the First Carpometacarpal Joint. *J Bone Joint Surg Br* 1960;42:502.

# 49. Nalebuff EA, Feldon PG, Millender LH. Rheumatoid Arthritis in the Hand and Wrist. In: Green DP, ed. *Operative Hand Surgery*, 2nd ed. New York: Churchill Livingstone, 1988:1655.

* 50. North ER, Eaton RG. Degenerative Arthritis of the Trapezium: A Comparative Roentgenologic and Anatomic Study. *J Hand Surg* 1983;8:160.

# 51. Ogilvie C, Kay NR. Fulminating Carpal Tunnel Syndrome due to Gout. *J Hand Surg Br* 1988;13:42.

+ 52. Pellegrini VD Jr, Burton RI. Surgical Management of Basal Joint Arthritis of the Thumb. Part I. Long-term Results of Silicone Implant Arthroplasty. *J Hand Surg [Am]* 1986;11:309.

+ 53. Pelligrini VD, Burton RI. Osteoarthritis of the Proximal Interphalangeal Joint of the Hand: Arthroplasty or Fusion? *J Hand Surg [Am]* 1990;15:194.

+ 54. Poppen NK, Niebauer JJ. “Tie-in” Trapezium Prosthesis: Long-term Results. *J Hand Surg* 1978;3:445.

# 55. Resnick D, Sartoris D, Cone RO III. Imaging. In: Kelley WN, Harris ED Jr, Ruddy S, Sledge CB, eds. *Textbook of Rheumatology*, 3rd ed. Philadelphia: WB Saunders, 1989:650.

* 56. Robert P. L'Articulation Trapezometacarpienne les Arthroses de Cette Jointure. *Bull Soc Radiol Med* 1936;24:687.

# 57. Rose JH, Belsky MR. Psoriatic Arthritis in the Hand. *Hand Clin North Am* 1989;5:137.

# 58. Ryan GM. Psoriatic Arthritis and Koebner Phenomenon [letter]. *J Hand Surg [Am]* 1991;16:180.

# 59. Siegel DB, Gelberman R, Smith R. Osteoarthritis of the Hand and Wrist. In: Moskowitz RW, Howell DS, Goldberg VM, Mankin HJ, ed. *Osteoarthritis: Diagnosis and Medical/Surgical Management*. Philadelphia: WB Saunders, 1992:547.

* 60. Smith RJ, Atkinson RE, Jupiter JB. Silicone Synovitis of the Wrist. *J Hand Surg [Am]* 1985;10:47.

+ 61. Sondergaard L, Konradsen L, Rechnagel K. Long-term Follow-up of the Cemented Caffiniere Prosthesis for Trapeziometacarpal Arthroplasty. *J Hand Surg [Br]* 1991;16:428.

+ 62. Sotereanos D, Taras J, Urbaniak J. Niebauer Trapeziometacarpal Arthroplasty: A Long-term Follow-up. *J Hand Surg [Am]* 1993;18:560.

* 63. Souter WA. Planning Treatment of the Rheumatoid Hand.*Hand* 1979;11:3.

# 64. Straub LR, Smith JW, Carpenter GK. The Surgery of Gout in the Upper Extremity. *J Bone Joint Surg* 1961;43:731.

+ 65. Swanson A, Swanson G. Implant Arthroplasty for the Thumb Basal Joints. *Semin Arthroplasty* 1991;2:91.

* 66. Swanson AB. Disabling Arthritis at the Base of the Thumb. *J Bone Joint Surg Am* 1972;54:456.

# 67. Talbot JH. *Gout*. New York: Grune & Stratton, 1967.

* 68. Taleisnik J. The Sauveé-Kapandji Procedure. *Clin Orthop* 1992;275:110.

+ 69. Thompson JS. Surgical Treatment of Trapeziometacarpal Arthrosis. *Adv Orthop Surg* 1986;10:105.

# 70. Trail IA, Stanley JK. The Hand in Psoriasis. *J Hand Surg [Br]* 1990;15:79.

* 71. Vaughan-Jackson OJ. Rupture of Extensor Tendons by Attrition at the Inferior Radio-ulnar Joint. *J Bone Joint Surg Br* 1948;30:528.

# 72. Walton RL, Brown RE, Giansiracusa DF. Psoriatic Arthritis Mutilans: Digital Distraction Lengthening: Pathophysiologic and Current Therapeutic Review. *J Hand Surg [Am]* 1988;13:510.

* 73. Watson HK, Ballet FL. The SLAC Wrist: Scapholunate Advanced Collapse Pattern of Degenerative Arthritis. *J Hand Surg [Am]* 1984;9:358.

* 74. Watson HK, Ryu J. Degenerative Disorders of the Carpus. *Orthop Clin North Am* 1984;15:337.

+ 75. Witt J, Pess G, Gelberman RH. Treatment of de Quervain Tenosynovitis. A Prospective Study of the Results of Injection of Steroids and Immobilization in a Splint. *J Bone Joint Surg Am* 1991;73:219.

# 76. Wright V. Psoriasis and Arthritis. *Ann Rheum Dis* 1956;15:348.

# CHAPTER 71

# ARTHROPLASTY OF THE HAND

*Jennifer Moriatis Wolf and Arnold-Peter C. Weiss*

**J. M. Wolf:** Department of Orthopaedics, Brown University School of Medicine, Rhode Island Hospital, Providence, Rhode Island, 02903.
**A.-P. C. Weiss:** Division of Hand, Upper Extremity, and Microvascular Surgery, Department of Orthopaedics, Brown University School of Medicine, Rhode Island Hospital, Providence, Rhode Island, 02903.

Arthroplasty of the Metacarpophalangeal Joints
Principles of Treatment
Operative Techniques
Postoperative Care
Pitfalls and Complications
Arthroplasty of the Proximal Interphalangeal Joints
Principles of Treatment
Operative Techniques
Postoperative Care
Pitfalls and Complications
Arthroplasty of the Carpometacarpal Joint of the Thumb
Principles of Treatment
Operative Techniques
Postoperative Care
Pitfalls and Complications
Chapter References

## ARTHROPLASTY OF THE METACARPOPHALANGEAL JOINTS

### PRINCIPLES OF TREATMENT

The primary indication for arthroplasty of the metacarpophalangeal (MCP) joints is advanced painful destruction of the joint by rheumatoid arthritis. The systemic effects of rheumatoid arthritis on the metacarpophalangeal joints are mediated by the formation of a pannus that is destructive to both the soft tissue and bone. In patients without advanced bone destruction at the MCP joints, intermediate procedures such as synovectomy and crossed intrinsic transfers can be utilized to improve function and decrease pain, although eventual progression and bony destruction will most commonly occur. Patients who suffer from isolated posttraumatic arthritis of the MCP joint, most commonly secondary to fracture, may also benefit from arthroplasty; the increased demands of these generally younger patients must be taken into account in assessing implant use, however. In osteoarthritis, implant use is most satisfactory in nonborder digits and in patients who will not accept joint fusion as a primary treatment modality.

The ideal candidate for arthroplasty is the rheumatoid patient who presents with significant pain or severe destruction of the MCP joints involving palmar subluxation of the proximal phalanx and early fixed hyperextension deformity of the proximal interphalangeal joint (Fig. 71.1) (20). The concept of MCP joint implant arthroplasty was first reported in 1959, with goals to both relieve pain and correct deformity (5). Since that time, a variety of implants have been developed and used for MCP replacement, with improved durability in materials coming with time. The primary prostheses used today are fashioned of silicone. The major implants in use today are the original Swanson implant (Wright Medical, Arlington, TN) (20), now used with metal grommets in an attempt to prevent implant failure; the neutral Avanta (Avanta, San Diego, CA) block design implant; and the newer anatomically neutral NeuFlex (DePuy, Warsaw, IN) implant, designed to decrease implant failure and improve functional arc of motion.

***Figure 71.1.*** Radiograph demonstrates severe palmar subluxation of the proximal phalanx on the metacarpal head resulting in pain and dorsal erosion of the proximal phalanx.

Carefully assess the rheumatoid patient prior to upper extremity surgery. Functional status, lower extremity problems, and level of pain are important issues prior to deciding whether or not implant surgery should go forward. Many patients with rheumatoid arthritis can function well with painless advanced deformities of the joints of the hand, although deformity, despite being relatively painless, should not be allowed to progress to a point where arthroplasty becomes technically very difficult. In addition, the status of the wrist also affects MCP arthroplasty outcome in that uncorrected fixed radial deviation of the wrist in the face of MCP joint replacement often leads to rapid recurrent ulnar drift and implant failure at the MCP joints postoperatively. Most authors advocate staged or simultaneous wrist fusion or arthroplasty to provide a stable fulcrum for MCP joint arthroplasty in these patients (17). In the majority of patients with rheumatoid arthritis, all four MCP joints are generally replaced at a single setting. The thumb MCP joint is generally not treated by implant arthroplasty due to the high forces that occur during function, and the relative lack of disability associated with fusion of the thumb MCP joint. In patients who have significant disease at the thumb MCP joint, fusion of this joint can frequently be undertaken simultaneously with implant arthroplasty of the index through small-finger MCP joints.

The majority of patients gain significant pain relief and increased level of function after MCP arthroplasty. The correction of ulnar deviation (Fig. 71.2), improved ability to perform activities of daily living, and improvement of extensor lag have been documented in several outcome studies. Change in range of motion has been variable, with some series reporting losses or gains of up to 10° from preoperatively (4,11,14,16). Until recently, the main objection to MCP joint arthroplasty has been the inability to obtain full flexion postoperatively. Anatomically neutral implants appear to allow improved functional flexion of the digits without a significant increase in extensor lag, thereby improving the overall arc of motion (Fig. 71.3). In addition, in anatomically neutral implants the compressive and tensile forces on the silicone is more evenly distributed through the functional arc of motion. Nevertheless, no long-term data are available on failure rates for anatomically neutral implants, and whether theoretical improvements lead to clinical improvements remains to be seen. All implants available in the United States and abroad have initially been found to be satisfactory, but with long-term follow-up they tend to fail.

***Figure 71.2.*** Ulnar deviation and an inability to extend the digits completely are fairly uniform in patients with longstanding rheumatoid arthritis.

***Figure 71.3.*** The NeuFlex implant is a departure from prior designs as it undertakes an anatomically neutral axis to decrease implant forces and improve functional arc of motion for the patient.

**OPERATIVE TECHNIQUES**

Two different surgical approaches are available. Use either a double longitudinal incision ($B_1$, $B_2$ Fig. 71-4), with one incision between the index and middle finger metacarpal heads and the second between the ring and small finger metacarpal heads, or a transverse incision at the level of the MCP joints (A, Fig. 71.4*A*). We favor the double longitudinal incision technique since postoperative range of motion exercises do not cause tension on the wound; if wound complications do occur, the implants are not directly exposed even in cases of wound dehiscence.

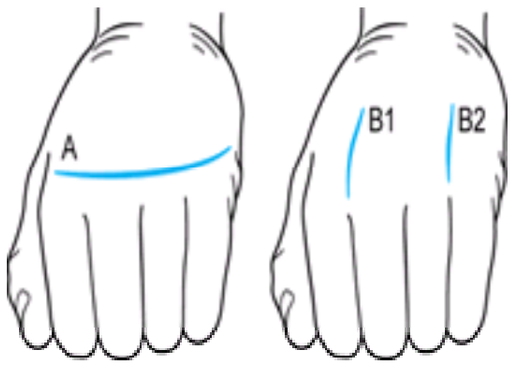


***Figure 71.4.*** The two types of incisions that can be utilized for metacarpophalangeal joint arthroplasty. See text for details.

- Use a #15 blade to make a 5–6 cm longitudinal incision from the finger web space proximally between the index and middle finger and ring and small finger metacarpal heads.
- Utilizing curved dissecting scissors, carefully dissect the subcutaneous tissues off the extensor tendon and extensor hood of both MCP joints immediately adjacent to the surgical incision.
- Utilizing a #15 blade, longitudinally incise the tight ulnar extensor hood.
- Use a Hohmann retractor and scissors to completely radially sublux the extensor tendon and hood of both MCP joints (Fig. 71.5).

***Figure 71.5.*** After longitudinally incising the ulnar extensor hood, the extensor tendon and surrounding structures are subluxed radially, exposing the metacarpophalangeal joint.

- The ring and small finger joints can also be exposed to allow sequential implantation of all implants in the same procedure.
- Now prepare the metacarpal head and proximal phalanx to allow placement of the proper-size implant.
- Protect tendinous structures using Hohmann retractors.
- Using a microsagittal saw, transect the MCP joint head at the distal metaphyseal flare (usually at the origin of the collateral ligaments) (Fig. 71.6).

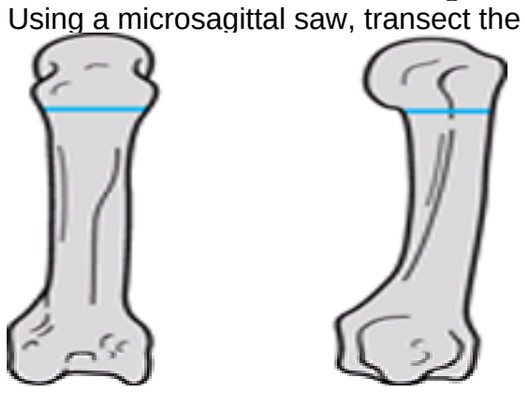

***Figure 71.6.*** Saw cuts at the distal flare of the metacarpal shaft just proximal to the metacarpal head exposing the joint space for preparation.

- Use a rongeur to remove any sharp pieces of bone and to debride any osteophytes present on the proximal phalanx base. Do not osteotomize the proximal phalanx except in cases of severe long-term subluxation, in which case remove some of the volar cortex to allow appropriate spacing between the phalanx and the metacarpal.

For appropriate implant sizing, utilize sequential broaching in both the metacarpal and phalangeal shafts. Use the presized broaches to rasp the intramedullary canals to as large a size as possible.

- Use a sharp awl to place a starting hole in both the metacarpal and phalangeal shafts (Fig. 71.7).

***Figure 71.7.*** A sharp awl is used to begin the starting hole in both the metacarpal and the phalangeal shafts.

- Perform a trial reduction using the trial implant size that corresponds to the last broach used (Fig. 71.8).

***Figure 71.8.*** Broaching should commence in progressively increasing sizes until the broach can no longer be seated, followed by trial implant placement with assessment of joint stability.

- Make sure that full flexion and extension can be obtained without implant pistoning, excessive tightness or laxity, or rotational deformity during motion.
- In the index finger, reconstruct the proximally and radially detached collateral ligament through drill holes in the metacarpal shaft to provide resistance for pinch.
- Then place the definitive implant and relocate the extensor tendon to the dorsal midline (Fig. 71.9 and Fig. 71.10). If excessive shortening and palmar subluxation is noted, release of the volar capsular structures may be required to get full flexion and extension and implant stability. It is imperative to reconstruct the radial extensor hood in an imbricated fashion to prevent recurrent ulnar subluxation of the extensor tendon.

***Figure 71.9.*** Definitive correctly sized implant is placed in the metacarpal shaft first, followed by placement in the phalangeal shaft. The implant should rest appropriately between the metacarpal and proximal phalanx, allowing full passive flexion and extension without restriction due to soft-tissue structures.

***Figure 71.10.*** Centralization of the extensor tendon may be accomplished by imbricating the radial hood with horizontal mattress sutures after the implant has been well seated.

- Use several horizontal 4-0 braided nonabsorbable mattress sutures to reef the radial extensor hood in a position to allow maintenance of the extensor tendon over the MCP joint dorsally.
- Check to make sure that a full range of motion occurs after reefing of the radial extensor hood without excessive joint tightness or resubluxation of the extensor tendon.
- Irrigate the wounds and close the skin using 5-0 interrupted horizontal mattress sutures (Fig. 71.11). Place a small drain in each of the wounds to prevent hematoma formation, if necessary. Apply a bulky dressing with a volar plaster splint that maintains all four fingers in full extension.

***Figure 71.11.*** The wounds are closed using interrupted 5-0 nylon sutures, taking care to protect the skin edges with small drains, placed for 1 day postoperatively to avoid hematoma formation. The patient is placed in a full-extension splint with all the fingers included except the thumb.

## POSTOPERATIVE CARE

Patients are generally admitted overnight for observation and 24 hours of intravenous antibiotics and pain medication. The splint and dressing remain in place for 5 to 10 days postoperatively (longer in patients who have had significant MCP joint palmar subluxation and shortening preoperatively). Remove the drains prior to hospital discharge. Remove sutures at the first postoperative visit. Have the patient evaluated by a hand therapist and have a molded full-extension pan splint placed as well as a dynamic extension splint to allow early range of motion of the digits while maintaining the extensor attitude of the MCP joints themselves (Fig. 71.12). We recommend splints for the first 4 to 6 weeks, with gradual reduction of their use by 2 to 3 months. In general, maximal functional range of motion is obtained at 3 to 4 months postoperatively (Fig. 71.13). These basic principles and techniques are germane to the use of all silicone arthroplasty implants available.

***Figure 71.12.*** A dynamic extension splint is helpful in maintaining metacarpophalangeal joint extension while allowing active flexion to occur in the postoperative rehabilitation period.

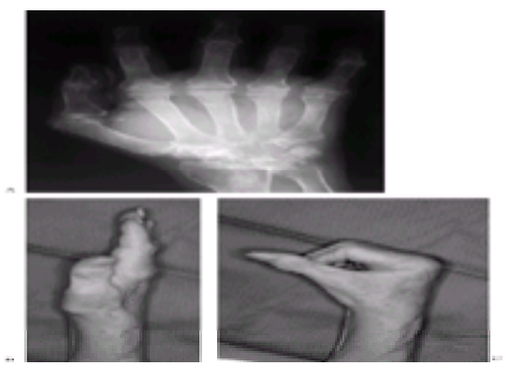

***Figure 71.13.*** Patient at 3 months after metacarpophalangeal arthroplasty. Anteroposterior radiograph (**A**) demonstrates excellent alignment of the MCP joints, with the ability to obtain full extension (**B**), and flexion at all metacarpophalangeal joints of 75° (**C**).

## PITFALLS AND COMPLICATIONS

Complications of MCP joint arthroplasty include wound infection, prosthetic failure, recurrence of deformity, tendon adhesions, and wound dehiscence. Implant fracture can be expected to occur over time, although recent design changes may prolong implant survival (Fig. 71.14). A recent report utilizing the Avanta MCP joint arthroplasty demonstrated surprisingly high fracture rates postoperatively at relatively early follow-up (2). Fracture of the implant is a radiographic diagnosis and on occasion is not clinically apparent, with patients maintaining some functional range of motion (although generally decreased) with only minimal increases in pain (11,16). Recurrence of deformity occurs after implant failure. Revision is not required unless symptoms warrant.



***Figure 71.14.*** A Swanson implant removed at revision metacarpophalangeal arthroplasty demonstrates implant failure at the stem–hinge interface (the most common site of implant failure with this design).

Recurrence of deformity, particularly ulnar deviation, is seen to some extent in almost every patient over time (11,14). Extensive soft-tissue release to balance the forces on the joint can prevent recurrent ulnar deviation. Functional splints also help prevent recurrent deformity during rehabilitation.

Infection is a relatively rare complication and generally will require implant removal. Avoid wound dehiscence and hematoma formations by using gentle and meticulous

soft-tissue technique.

## ARTHROPLASTY OF THE PROXIMAL INTERPHALANGEAL JOINTS

### PRINCIPLES OF TREATMENT

The proximal interphalangeal (PIP) joint is susceptible to destruction by synovial proliferation as seen in the MCP joints in rheumatoid arthritis. Painful PIP joints with loss of function are the primary indication for replacement (21). Advanced osteoarthritic destruction of the PIP joint can also produce similar symptoms. PIP joint arthrosisin osteoarthritis is far more commonly seen than at the MCP joint level (18). Frequently, the distal interphalangeal joint (DIP) is also involved in this process. Although arthroplasty for the DIP joint has been reported (2,3), results in general have been less than satisfactory. Most surgeons recommend fusion of the DIP joint by one of several methods as a definitive form of treatment for painful deformities (3). PIP joint arthroplasty for osteoarthritis, although not commonly performed, is a treatment option after failed conservative therapy. Arthroplasty of the PIP joints is best reserved for the nonborder digits, as is the case with the MCP joints due to the high forces generated by pinch and use of the hand (18). The same principles apply to the rheumatoid patient, although in general deformity is far more advanced and bone quality poor in the rheumatoid patient.

Options for implants at the PIP joints include silicone replacements similar to those used for the MCP joints as well as various metal/high-density-polymer designs (3). Recent reports have demonstrated excellent decrease in pain and relatively good long-term durability with silicone implant arthroplasty (1). Overall range of motion postoperatively, however, has demonstrated mixed results, generally equaling the preoperative abilities. Combining various metal/high-density-polymer designs with the use of bone cement simulates a more anatomic articulation; however, prosthetic loosening, fracture, and protrusion through the cortex have been noted (15). Nevertheless, the attractive anatomic contouring of these devices has led several investigators to continue their development and refinement.

### OPERATIVE TECHNIQUES

Dorsal, volar, and ulnar lateral approaches are used to approach the PIP joint. We favor a dorsal approach although we have used the volar approach quite successfully. Regardless of the approach used, several basic principles, if followed, allow appropriate implant placement and acceptable postoperative function.

- Incise the extensor mechanism between the central tendon and the lateral band so that no disruption of the central slip attachment occurs (Fig. 71.15).

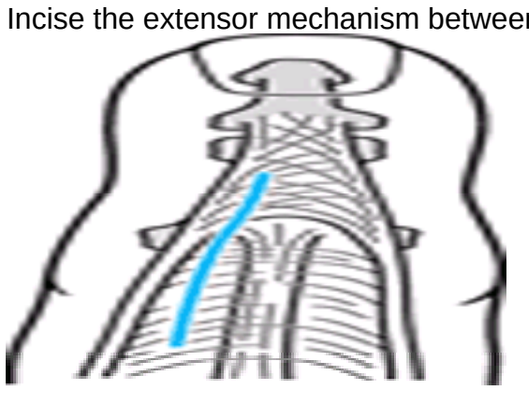

***Figure 71.15.*** For proximal interphalangeal joint arthroplasty using the dorsal approach, an incision between the central tendon and lateral band can be performed so as not to disrupt the central slip, decreasing the propensity for extensor lag postoperatively.

- Use a sagittal oscillating saw to resect the proximal phalanx distal condyles at the end of the flare, allowing exposure of the middle phalanx base. Use a rongeur to remove any osteophytes present on either side of the joint.
- Enlarge the endosteal cavities by using a small awl and then a dental burr followed by appropriate-size broaches to prepare the canals.

Broaching for PIP joint arthroplasty is challenging, as adequate bone stock must be maintained to prevent osseous fracture, and yet as large a size prosthesis as possible should be implanted. In addition, the gap between the proximal and middle phalanx shafts needs to be wide enough to allow placement of the implant. This may require some additional bone resection at the base of the middle phalanx or distal portion of the proximal phalanx. After appropriate broaching, several steps need to be taken to ensure appropriate arthroplasty.

- The trial prosthesis should have enough give-and-take that both stems can be advanced without buckling during flexion and extension of the finger.
- If any buckling or migration of the implant occurs, either a smaller implant should be used or the bone should be resected further to provide a larger gap.
- After the implant is placed, irrigate the joint and repair the extensor tendon using figure-of-eight 4-0 braided nonabsorbable sutures. Close the skin with horizontal mattress interrupted 5-0 nylon sutures. Apply a light bulky dressing as well as a volar splint holding the finger in full extension.

### HINTS AND TRICKS

Advantages to utilizing the volar approach are that the extensor mechanism is not compromised and postoperative extension does not need to be maintained for as long (Fig. 71.16).

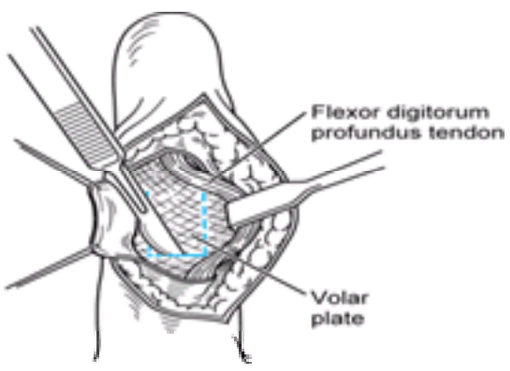


***Figure 71.16.*** The volar approach utilizes a standard Brunner skin-type incision, retraction of the flexor tendons, and proximal detachment of the volar plate, exposing the condyles of the distal proximal phalanx, which are then resected allowing implant placement and reconstruction of the volar plate through drill holes in the proximal phalanx.

### POSTOPERATIVE CARE

Keep the patient in a postoperative extension splint for 7 to 10 days, at which time the sutures are removed. Then fit a removable Orthoplast splint to maintain the PIP joint in full extension until 2 weeks after surgery, at which time gentle range-of-motion exercises can begin. Use the extension splint between exercises to prevent any extensor lag from occurring. If a volar approach is utilized, less attention needs to be directed toward extension splinting. With the volar approach, start early flexion as soon as possible to prevent adhesions to the flexor tendons. Recurrence of ulnar deviation (which is commonly seen preoperatively) can occur following PIP joint arthroplasty. Splint training of the digit may be required.

## PITFALLS AND COMPLICATIONS

As with MCP joint arthroplasty, a major complication is prosthetic failure. This complication may not be clinically significant unless recurrent pain and significant deformity occur. Other complications include prosthetic loosening, migration, and recurrence of deviation deformity. Erosion of the prosthesis through delicate skin can

lead to disastrous results in rheumatoid patients. Gentle skin retraction and care during the procedure is paramount. Infection is an uncommon complication; if present, it generally requires implant removal until well controlled.

## ARTHROPLASTY OF THE CARPOMETACARPAL JOINT OF THE THUMB

### PRINCIPLES OF TREATMENT

Painful degeneration of the thumb carpometacarpal (CMC) joint is most often secondary to osteoarthritis. This clinical entity is most commonly seen in postmenopausal women. Rheumatoid arthritis, repetitive stress injury, and hormonally induced changes have also been implicated as causes for basilar joint arthritis, but this occurs far less frequently than degenerative osteoarthritis (17). The extent of degenerative change in the CMC joint can be staged radiographically according to the classification of Eaton and Littler (Table 71.1) (9).

| *Stage* | *Radiographic appearance* |
|---|---|
| Stage I | Normal joint contours<br>Possible joint space widening secondary to effusion |
| Stage II | Narrowing of the trapeziometacarpal joint space<br>Osteophytes <2 mm in size |
| Stage III | Degenerative changes of the trapeziometacarpal joint space, with cystic and sclerotic change<br>Osteophytes >2 mm in size. The scaphotrapezial joint is normal |
| Stage IV | Degenerative destruction of both the trapeziometacarpal and scaphotrapezial joints |

Note: Table is based on a true lateral view of the thumb with the sesamoids superimposed.

***Table 71.1. The Eaton-Littler Classification of Basal Joint Arthritis***

Initial treatment of thumb CMC arthritis is conservative. A trial of nonsteroidal antiinflammatory medication and hand-based splinting of the thumb CMC joint is often successful in early and moderate cases. In addition, an injection of corticosteroid into the CMC joint can occasionally provide dramatic pain relief and increased function in patients, although long-term relief is not common. Some patients with extensive radiographic disease have minimal pain, and others with minimal radiographic disease have extensive pain; therefore, base treatment on the patient's symptoms rather than on the radiographs alone.

Historically, multiple surgical procedures have been performed for painful thumb CMC arthritis. Silicone implantation to replace the resected trapezium was developed by Swanson in 1968 (20). Smaller silicone wafers utilized in a hemitrapezial excision have provided excellent early symptomatic improvement, although silicone synovitis resulting in pain and bony destruction has occurred in long-term studies. As a result, silicone implantation of the thumb CMC joint has been all but abandoned. Metal implants have recently been advocated, although experience is limited and outcome uncertain (7). Arthrodesis of the thumb CMC joint is a viable option and is useful in younger, manual laborers who perform heavy work. It gives a predictable painless result despite sacrificing some range of motion (17,19).

Currently, some combination of excision of the trapezium and tendon interposition or ligament reconstruction is most commonly performed for arthroplasty of the thumb CMC joint (8). In 1970, Froimson introduced the concept of using a ball of tendon as an interpositional spacer between the carpus and thumb metacarpal after excision of the trapezium (10). Due to the potential for proximal migration of the thumb metacarpal, others have advocated ligamentous reconstruction utilizing the flexor carpi radialis tendon woven through the base of the thumb metacarpal (6). Outcome studies have not demonstrated that one technique provides substantially improved results over another (13). In fact, some authors have advocated excision of the trapezium alone without any interposition or reconstruction at all (12). Having utilized both techniques, we currently favor excision of the trapezium and tendon interposition without ligament reconstruction.

### OPERATIVE TECHNIQUES

- Make a 3.5 cm curvilinear incision dorsally over the thumb CMC joint.
- Protect the sensory branch of the radial nerve as it passes over the capsule.
- Incise the capsule longitudinally, exposing the trapezium.
- Excise as much capsule off the trapezium as possible and then use an osteotome and rongeur to morselize and remove the trapezium (Fig. 71.17).

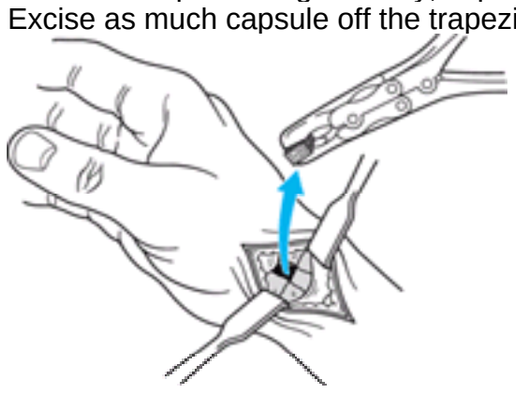

***Figure 71.17.*** The trapezium, after exposure through a longitudinal capsular incision, can be quartered with an osteotome and then removed piecemeal by a rongeur. The trapezium is large; ensure that all pieces are removed including any osteophytes or loose bodies present at the junction of the bases of the first and second metacarpals.

- Make sure that all osteophytes at the junction of the bases of the first and second metacarpals are removed.
- Place a small osteotome between the bases of the first and second metacarpal shafts and then transfix the thumb metacarpal in appropriate alignment by using a 0.045 Kirschner wire passed from the first metacarpal into the second metacarpal (Fig. 71.18).

***Figure 71.18.*** A postoperative radiograph demonstrates fixation of the thumb metacarpal “in space” to the index metacarpal via a single Kirschner wire with the distraction between the bases allowing soft-tissue interpositional ingrowth. Note the space where the trapezium has been excised and a soft-tissue tendon interposition performed. The Kirschner wire is generally left in for 4 weeks, after which it is removed and the cast discontinued to begin therapy.

- Now, make a transverse 1 cm incision over the palmaris longus at the wrist.
- After identifying the palmaris longus, use a Brand tendon stripper to harvest the palmaris longus and close the skin wound.
- Form a tendon ball or “anchovy” with the palmaris longus tendon using a braided 4-0 nonabsorbable suture (Fig. 71.19).

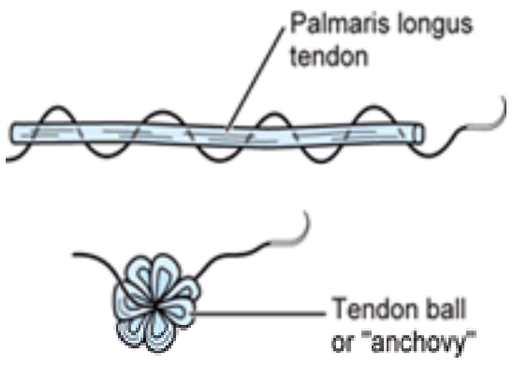


***Figure 71.19.*** Using a 4-0 nonabsorbable suture passed in a back-and-forth fashion through a free tendon graft (most commonly, the palmaris longus), sewing the suture onto itself, a tendon ball or “anchovy” can be fashioned and placed in the interposed position.

- Place the tendon anchovy beneath the distal-most portion of the flexor radialis tendon at the floor of the excised trapezium.
- Suture the anchovy so that it is fully interposed between the first and second metacarpal bases.
- Close the CMC capsule carefully, using interrupted absorbable sutures.
- Leave the Kirschner wires exposed outside the skin.
- Apply a large bulky dressing including a thumb spica splint that allows interphalangeal joint motion.

### POSTOPERATIVE CARE

Maintain the splint and dressing until 7 to 10 days postoperatively, then remove the sutures. Apply a below-elbow thumb spica cast allowing interphalangeal thumb motion and full MCP motion of the other digits. Maintain the cast for 4 weeks. Then remove the Kirschner wire in the office and place the patient in a removable Orthoplast splint. Begin hand therapy at 4 weeks with gradually increasing range-of-motion and strengthening exercises. Four weeks of therapy is usually required.

## PITFALLS AND COMPLICATIONS

Avoid injury to the sensory branch of the radial nerve. Avoid infection by administering intravenous antibiotics during the procedure. Patients undergoing thumb CMC arthroplasty can have significant swelling postoperatively. Avoid tight dressings.

### CHAPTER REFERENCES

Each reference is categorized according to the following scheme: *, classic article; #, review article; !, basic research article; and +, clinical results/outcome study.


+ 1 Ashworth CR, Hansraj KK, Todd AO, et al. Swanson Proximal Interphalangeal Joint Arthroplasty in Patients with Rheumatoid Arthritis. *Clin Orthop* 1997;342:34.

+ 2 Bass RL, Stern PJ, Nairus JG. High Implant Fracture Incidence with Sutter Silicone Metacarpophalangeal Joint Arthroplasty. *J Hand Surg [Am]* 1996;21:813.

# 3 Beckenbaugh RD. Implant Arthroplasty in the Rheumatoid Hand and Wrist: Current State of the Art in the United States. *J Hand Surg* 1983;8:675.

# 4 Beckenbaugh RD, Dobyns JH, Linscheid RLK, Bryan RS. Review and Analysis of Silicone-rubber Metacarpophalangeal Implants. *J Bone Joint Surg Am* 1976;58:483.

+ 5 Brannon E, Klein G. Experiences with a Finger-joint Prosthesis. *J Bone Joint Surg Am* 1959;41:87.

* 6 Burton RI, Pellegrini VD. Surgical Management of Basal Joint Arthritis of the Thumb. Part II. Ligament Reconstruction with Tendon Interposition Arthroplasty. *J Hand Surg [Am]* 1986;11:324.

+ 7 Cooney WP, Linscheid RL, Askew LJ. Total Arthroplasty of the Thumb Trapeziometacarpal Joint. *Clin Orthop* 1987;220:35.

+ 8 Dell PC, Muniz RB. Interposition Arthroplasty of the Trapeziometacarpal Joint for Osteoarthritis. *Clin Orthop* 1987;220:27.

* 9 Eaton RG, Glickel SZ, Littler JW. Tendon Interposition Arthroplasty for Degenerative Arthritis of the Trapeziometacarpal Joint of the Thumb. *J Hand Surg [AM]* 1985;10:645.

* 10 Froimson A. Tendon Arthroplasty of the Trapeziometacarpal Joint. *Clin Orthop* 1970;70:191.

+ 11 Gellman H, Stetson W, Brumfield RH, et al. Silastic Metacarpophalangeal Joint Arthroplasty in Patients with Rheumatoid Arthritis. *Clin Orthop* 1997;342:16.

+ 12 Gerris WH. Excision of the Trapezium for Osteoarthritis of the Trapeziometacarpal Joint. *J Bone Joint Surg Br* 1949;31:537.

+ 13 Gerwin M, Griffith A, Weiland AJ, et al. Ligament Reconstruction Basal Joint Arthroplasty without Tendon Interposition. *Clin Orthop* 1997;342:42.

+ 14 Hansraj KK, Ashworth CR, Ebramzadeh E, et al. Swanson Metacarpophalangeal Joint Arthroplasty in Patients with Rheumatoid Arthritis. *Clin Orthop* 1997;342:11.

* 15 Linscheid RL, Murray PM, Vidal M-A, Beckenbaugh RD. Development of a Surface Replacement Arthroplasty for Proximal Interphalangeal Joints. *J Hand Surg [AM]* 1997;22:286.

+ 16 Mannerfelt L, Andersson R. Silastic Arthroplasty of the Metacarpophalangeal Joints in Rheumatoid Arthritis. *J Bone Joint Surg Am* 1975;57:484.

# 17 Murray PM. Current Status of Metacarpophalangeal Arthroplasty and Basilar Joint Arthroplasty of the Thumb. *Clin Plast Surg* 1996;23:395.

+ 18 Pellegrini VD, Burton RI. Osteoarthritis of the Proximal Interphalangeal Joint of the Hand: Arthroplasty or Fusion? *J Hand Surg* 1990;15:194.

+ 19 Stark HM, Moore JF, Ashworth CR. Fusion of the First Metacarpotrapezial Joint for Degenerative Arthritis. *J Bone Joint Surg Am* 1977;59:22.

* 20 Swanson AB. Silicone Rubber Implants for Replacement of Arthritic or Destroyed Joints in the Hand. *Surg Clin North Am* 1968;48:1113.

* 21 Swanson AB, Maupin BK, Gajjar NV, de Groot Swanson G. Flexible Implant Arthroplasty in the Proximal Interphalangeal Joint of the Hand. *J Hand Surg [AM]* 1985;10:796.

! 22 Weiss APC, Moore DC, Akelman E, Crisco JJ. Metacarpophalangeal Mechanics after Silicone Joint Replacement. *Transactions of the 54th Meeting of the American Society for Surgery of the Hand*, Boston, MA, 1999.

+ 23 Wilgis EFS. Distal Interphalangeal Joint Silicone Interpositional Arthroplasty of the Hand. *Clin Orthop* 1997;342:38.

# CHAPTER 72

# ARTHRODESIS OF THE HAND AND WRIST

*Edward Akelman, Michael T. LeGeyt, and Dina Hulsizer Galvin*

**E. Akelman, M. T. LeGeyt, D. Hulsizer Galvin**: Department of Orthopaedics, Brown University–Rhode Island Hospital, Providence, Rhode Island, 02905.

Small-Joint Arthrodesis in the Hand and Wrist
- Indications for Surgery
- Finger Metacarpophalangeal, Proximal Interphalangeal, and Distal Interphalangeal Joints
- Thumb Interphalangeal, Metacarpophalangeal, and Carpometacarpal Joints
- Surgical Planning
- Surgical Techniques
- Incisions and Exposure of the Joints
- Proper Positioning
- Preparation of Bony Surfaces
- Cuts
- Methods of Fixation
- Wound Closure and Aftercare
- Pitfalls and Complications

Limited Wrist Fusion
- Functional Wrist Motions
- Indications for Surgery
- Degenerative Disorders
- Carpal Instability
- Surgical Techniques
- Principles of Intercarpal Arthrodeses
- Watson and Ashmead's Technique for STT Fusion
- Scaphocapitate Fusion
- Slac Reconstruction and Hamate-Capitate-Lunate-Triquetral Fusion
- Lunotriquetral Arthrodesis
- Pitfalls and Complications

Radiocarpal or Wrist Arthrodesis
- Indications for Surgery
- Biomechanics
- Surgical Considerations
- Surgical Techniques
- Steinmann Pin Technique
- Ao Wrist Fusion Plate
- Pitfalls and Complications

Chapter References

## SMALL-JOINT ARTHRODESIS IN THE HAND AND WRIST

Pain-free use of the hand is critical to independent functional and productive living. There are numerous medical conditions that limit the use of the small joints of the hand because of pain, deformity, dysfunction, and instability. Among these are trauma, infection, connective tissue disease, arthritides, osteoarthrosis, paralytic disorders, failed surgical procedures, and congenital deformities. Many medical and surgical advances have been made to improve the hand function of affected patients. One of the mainstays has been to perform arthrodeses of selected joints of the hand and wrist. Arthrodesis, or joint fusion, remains one of the most time-tested, reliable, and useful hand surgery procedures (39,62). Reasons to perform small-joint arthrodesis are to correct deformity, to relieve pain, to control instability, and to improve loss of function caused by neurovascular disease (9,48,55,74,89). A properly performed small-joint arthrodesis can markedly improve hand function and the overall quality of life for an afflicted patient.

### INDICATIONS FOR SURGERY

#### FINGER METACARPOPHALANGEAL, PROXIMAL INTERPHALANGEAL, AND DISTAL INTERPHALANGEAL JOINTS

Osteoarthritis commonly affects the distal interphalangeal (DIP) joints of the fingers and, to a lesser extent, the interphalangeal (IP) joint of the thumb. Other diseases that less commonly affect the DIP joints are psoriatic arthritis, rheumatoid arthritis, and infection. In all these diseases, hand function is limited by painful motion of the joints. Arthrodesis of the DIP joint is a successful way to eliminate the pain associated with these disorders.

The proximal interphalangeal (PIP) joints are more commonly involved in rheumatoid arthritis as well as osteoarthritis. Posttraumatic arthrosis of a single PIP joint is a common problem. The disability for the rheumatoid patient is the associated swan-neck or boutonnieére deformity, while for the posttraumatic arthritic patient it is usually pain. Arthrodesis of the PIP joints is a reliable method of returning function to these fingers, and it is especially appropriate for the index and small fingers because of their unique position as border digits.

Metacarpophalangeal (MCP) joints may be affected in multiple fingers in rheumatoid arthritis, or singly in posttraumatic arthritis. Arthroplasty is usually preferred for the MCP joints of the fingers to preserve good motion and function. Arthrodesis is useful for joints when arthroplasty is not indicated, or when a previous arthroplasty has failed.

Carpometacarpal arthrodesis, although less commonly performed, can also improve functional outcomes, particularly in the fourth and fifth carpometacarpal joints, which may have osteoarthrosis as a late sequela of fracture dislocations (15,17). Elimination of pain and increased stability improves hand function.

#### THUMB INTERPHALANGEAL, METACARPOPHALANGEAL, AND CARPOMETACARPAL JOINTS

The thumb interphalangeal (IP) joint is not unlike the IP joints of the digits. It is important for stable power pinch, which may be compromised in osteoarthritis because of pain or connective tissue disease caused by joint laxity.

The thumb MCP joint is different from the other MCP joints in that significantly more stress is placed on the ligamentous restraints than in the finger joints. This is because of the unique position of the thumb and its role in pinch and grasp. Instability of this joint is common because of chronic laxity after a missed acute tear of the ulnar collateral ligament (gamekeeper's thumb) and rheumatoid arthritis (19,48). While ligament reconstruction and soft-tissue procedures are usually preferred, in the arthritic thumb MCP joint, arthrodesis (Fig. 72.1, Fig. 72.2) provides a more lasting option and is generally preferred to arthroplastic techniques for a number of different disorders (36).

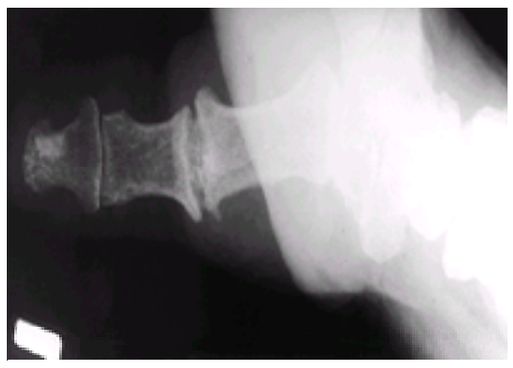

***Figure 72.1.*** Thumb metacarpophalangeal joint fusion, anteroposterior view.

***Figure 72.2.*** Metacarpophalangeal joint fusion, lateral view.

In the thumb, the joint most commonly affected with osteoarthritis is the carpometacarpal (CMC) joint (6). This is perhaps the most commonly involved joint in postmenopausal women with early osteoarthritis. It has been postulated to be secondary to laxity of the metacarpal volar beak ligament, allowing enough subluxation and incongruity of the joint to become pathologic. A second commonly affected group is young people with high demands on their hands (e.g., manual laborers) who have posttraumatic arthritis after an old intraarticular fracture of the base of the metacarpal (Bennett's or Rolando's fracture). Eaton et al. (28a) have classified this pattern of osteoarthrosis of the first CMC joint into four stages. Stage I has normal intraarticular cartilage with joint-space widening. In stage II, there is narrowing of the joint space but the articular contours are normal. Stage III disease has significant destruction of the thumb CMC joint, but the scaphotrapeziotrapezoidal (STT) joint is normal. In stage IV disease, there is destruction of the STT joint in addition to the first CMC joint. Arthrodesis of the thumb CMC joint is indicated for stage III disease but is contraindicated in the presence of any scaphotrapeziotrapezoidal disease (stage IV).

Patients who benefit most from an arthrodesis of the thumb CMC joint are usually young, active people who require a strong, stable, pain-free thumb to perform work activities (6,20). House et al. (43) found that arthrodesis of the first CMC improved hand function in patients with tetraplegia following spinal cord injury (see Chapter 68). Arthrodesis is the best salvage procedure for failed arthroplasty or previous infection of the first CMC joint. Older patients and patients whose demands for strength of pinch and grip are not high are better served with an arthroplasty (see Chapter 70). Moore et al. (72) reported successful use of arthrodesis for a rare problem, laxity of the thumb CMC joint in patients with Ehlers-Danlos syndrome. Thumb CMC arthrodesis significantly limits thumb motion, although some compensatory motion occurs at the STT and the MCP joints; therefore, in patients who require motion of the thumb, arthrodesis is contraindicated.

## SURGICAL PLANNING

Surgeons differ in the choice of skin incision; the approach to the soft-tissue envelope about a joint; the manner in which the joint surfaces are prepared; whether to use bone graft or bone substitutes, or no graft; fixation methods; and postoperative management, including rehabilitation (27). The goals of arthrodesis in the small joints of the hands are uncomplicated soft-tissue and skin healing, appropriate joint position, and bony union in the shortest possible time (15). The best techniques are simple, straightforward, and reliable, and they allow early motion of the remainder of the hand. Successful fusion requires a good soft-tissue envelope about the joint as well as well-vascularized bone at the fusion site. Address any deficiencies prior to undertaking a fusion.

## SURGICAL TECHNIQUES

### INCISIONS AND EXPOSURE OF THE JOINTS

- Straight longitudinal incisions are the best incisions for fusions in the small joints of the hand. Use gentle curved incisions, and H, Y, V, and other types of incisions, only in good-quality, well-vascularized skin and soft tissue. Expose the thumb carpometacarpal joint through a Wagner type of anterior incision or through a dorsal incision directly over the joint (see Chapter 37).
- Approach the DIP joints of the fingers and the IP joint of the thumb by transversely dividing the extensor mechanism and capsule. Debride the soft tissues as needed. We prefer excision of the radial and ulnar collateral ligament complexes prior to arthrodesis.
- Remove all marginal and dorsal osteophytes.
- Approach the digital PIP joints by dividing the extensor tendon mechanism longitudinally. Careful dissection preserves the interval between the extensor mechanism and the dorsal joint capsule. Preserve the joint capsule if possible.
- Approach the MCP joints of the fingers by dividing the ulnar sagittal fibers. Retract the entire extensor mechanism to one side and visualize the joint capsule. Then make a direct longitudinal approach through the capsule.
- Approach the MCP joint of the thumb by dividing the radial sagittal fibers, detaching the extensor pollicis brevis insertion, and pulling the extensor pollicis longus (EPL) ulnarly. Incise the joint capsule longitudinally and debride as indicated.
- For the carpometacarpal joint of the thumb, make a volar anterior approach.
- Elevate the origin of the thenar musculature from the thumb metacarpal and trapezial area.
- You may partially detach the thenar muscle and bone insertions of the abductor pollicis longus if necessary for exposure of the carpometacarpal joint. Pay careful attention to preserving the joint capsule for closure.

### PROPER POSITIONING

A patient who has disease throughout the small joints of the hand will generally be better served with an arthroplasty of the finger MCP joints and arthrodeses of the PIP and DIP joints. The position for arthrodesis in the fingers is critical to hand function. In general, there should be a gentle cascade from radial to ulnar with more flexion of the ulnar digits, as can be appreciated in the normal hand at rest.

- Fuse the MCP joint of the index finger in 25° to 30° of flexion, adding another 5° of flexion at each joint, moving ulnarly, to end at 40° to 45° of flexion in the small-finger MCP joint.
- There should be no radial or ulnar deviation at the MCP joints. Ensure that there is no rotational deformity, although some have suggested that gentle supination may help with thumb-pad pinch. There should be more flexion at the PIP joints than at the MCP joints in each digit.
- Fuse the index-finger PIP joint at 40° to 45° of flexion, with an additional 5° of flexion added at each PIP joint to end at 55° to 60° of flexion at the small-finger PIP joint.
- The DIP joints are very important to hand function. Fusion in too much flexion is disabling and cosmetically undesirable. Our experience is that too much extension of these joints is tolerated better than too much flexion. Fuse the DIP joint at 0° to 15° of flexion.
- The thumb position is most critical to hand function because of its unique role. Fuse the thumb MCP joint in approximately 10° flexion with no radial or ulnar deviation.
- Fuse the thumb IP joint in a position of 0° to 15° of flexion.

- Fuse the thumb carpometacarpal joint in 15° to 20° of extension, 45° of palmar abduction, and 5° to 10° of pronation.
- Check the positioning of all joint arthrodeses intraoperatively by temporarily fixing the joints with Kirschner wires (K-wires) prior to permanent fixation.

## PREPARATION OF BONY SURFACES

Successful arthrodesis of a small joint in the hand requires careful preparation of the bone surfaces of the joint (15,48). Excellent cancellous-to-cancellous bone contact gives the best chance for fusion.

### *Convex–Concave Technique*

The convex–concave surgical technique is generally accepted as the most straightforward method (15).

- Remove the articular cartilage and subchondral bone using a small curet or rongeur and expose the subchondral cancellous bone.

This allows maintenance of the normal contour of the joint; therefore, minimal shortening is required and positioning is easy in flexion/extension, radial/ulnar deviation, and rotation.

### *Cup and Cone Preparation*

The cup and cone technique can be used with all fixation systems. It is considered advantageous because it presents large, opposing cancellous surfaces for fusion (19,66), but it does increase digital shortening. Recently, cup and cone reamers have been made available commercially that provide matching surfaces in the joint. This method is generally used more commonly at the MCP joints. The CMC joint of the thumb can be fused using this method, with the cone being made from the first metacarpal base and the cup being fashioned in the trapezium. Carroll (16) has shown excellent results.

## CUTS

### *Transverse*

Transverse cuts preserve digital length and are commonly used (19). Although precise transverse or straight cuts are difficult to achieve, this is our preferred method, and it provides excellent arthrodesis rates (9).

### *Chevron*

The chevron arthrodesis popularized by Omer is believed to be more forgiving than transverse cuts (102,103). Cancellous bone area for fusion is improved, but the technique causes some digital shortening and is technically demanding. Cuts may be made with the apex of the chevron pointing either distally or proximally.

## METHODS OF FIXATION

Many techniques to stabilize small-joint arthrodeses have been used, and multiple studies have described consistent success using different techniques (5,9,12,15,16,17,19,20,27,31,36,45,48,49 and 50,54,55,58,66,67,74,82,83,85,86,88,89,93,96,102,103,107). They differ with regard to the degree of difficulty of using the instrumentation, whether bone grafts are harvested from other surgical sites, and technical difficulty.

In a biomechanical study, Kovach et al. (54) compared crossed K-wires, tension band wiring, and an interosseous loop supplemented by a K-wire in a PIP arthrodesis model. Tension band wiring was found to be the strongest. In a comparison study of four methods of fixation for CMC arthrodesis using crossed K-wires, cerclage wiring, and cup and cone with single K-wire and tension band wiring, Stokel et al. (86) found that tension band wire and cerclage techniques provided the most stable construct. Bamberger et al. (6) have used the cup and cone method originally described by Carroll and Hill (19) with staple or K-wire fixation. They found a 42% delayed union/nonunion rate for the staple method compared to an 11% rate of delayed union for the K-wire group.

### *Crossed K-Wires and Tension Band*

The crossed K-wire (15,19) (Fig. 72.3, Fig. 72.4) and tension band techniques (45,50,85,93) are the most frequently used of all fixation techniques in small-joint fusions (9,48). They provide stable fixation, are relatively uncomplicated technically, and may be used in conjunction with cup and cone, miter, or straight cut techniques. They allow easier adjustment of the arthrodesis site than many other techniques. Both techniques are excellent for the patient with rheumatoid arthritis, in whom inadequate bone stock may not allow screw techniques.

***Figure 72.3.*** Metacarpophalangeal joint fusion with Kirschner wire fixation, lateral view.

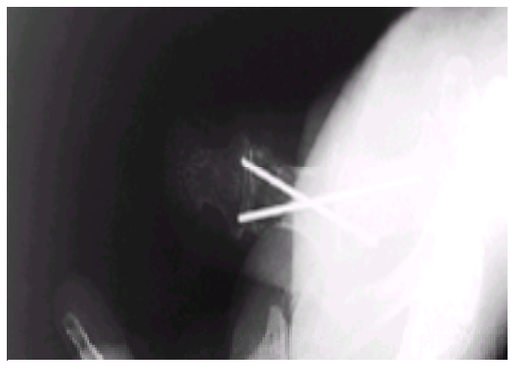

***Figure 72.4.*** Metacarpophalangeal joint fusion with Kirschner wire fixation, AP view.

- Prepare both bone ends at the joint for arthrodesis and ensure good bone-to-bone contact. Then stabilize the arthrodesis by driving two crossed K-wires from distal to proximal across the joint. Pins driven from proximal to distal may distract the arthrodesis.
- Drive one pin first, and then check the arthrodesis position by intraoperative radiographs or imaging on a fluoroscope. If the position is acceptable, drive the second pin and check the position once more. Position the pins to avoid prominence that might cause soft-tissue damage.
- We do not leave K-wires exposed but cut them off below the level of the skin. Remove the pins when fusion is healed, which is usually in 4–6 weeks.

- For the tension band technique, prepare the joint surfaces and position the joint.
- Drill two K-wires parallel to each other, leaving a dorsal wire protruding from the proximal portion of the distal bone, 6 mm distal to the cut surface.
- Drill a transverse hole through the proximal fragment and pass a malleable monofilament stainless steel wire of appropriate size through the hole.
- Tightly coapt the fusion site and pass the monofilament wire in a figure-eight fashion dorsally. Pass it beneath and tighten it around the ends of the K-wires. The arthrodesis site will be compressed as the figure-eight wire is tightened.
- Cut the pins as low as possible and contour them to fit closely to the bone dorsally. (See Chapter 11 for more details.)

When the fusion is healed, most pins and wires need to be removed as they are superficial and tender. Do not use tension band wire techniques at the DIP joint because of the possibility of injury to the germinal matrix of the nail.

***Internal Fixation—Screw Techniques***

Screw methods for fixing an arthrodesis provide stable rigid fixation, which is best used in young, active patients with high activity demands. Screw fixation usually permits early motion of the hand with a reduced risk of loss of fixation when compared to K-wire fixation. Many varieties of screws are currently available and all of them can be used to provide compression across the arthrodesis. Screw techniques require careful attention to technical detail.

***Herbert Screw*** The Herbert screw (Zimmer, Warsaw, IN) is a headless screw (see Chapter 11) originally used to fix fractures of the scaphoid (5,31,49,58).

- To perform an arthrodesis on a PIP joint utilizing the Herbert screw, prepare the joint surfaces as previously described.
- Drill a pilot hole with an 0.045 K-wire. Drill from the dorsal surface of the proximal phalanx into the medullary canal of the middle phalanx. We have found that starting the hole relatively proximal makes the dorsal cortical bridge larger, preventing fracture.
- Use a small-diameter Herbert screw drill bit to enlarge the drill hole through its entire length, from proximal to distal. Avoid breaking the dorsal cortical bridge between the entry hole and the fusion site.
- Enlarge the cortical opening with a small rongeur.
- Using a large-diameter Herbert screw drill, overdrill the hole in the proximal phalanx. Then insert a Herbert screw tap through the arthrodesis site.
- Use intraoperative radiography or fluoroscopy to help determine the size of the screw to be chosen. The screw should be at least 2 mm shorter than the measured length to allow the screw head to sink into the proximal phalanx and not cause soft-tissue irritation.
- Place the Herbert screw of appropriate size. It is important to hold the arthrodesis site compressed in appropriate position as the screw is tightened.

Arthrodesis can also be performed on the DIP joint using Herbert screw fixation (Fig. 72.5, Fig. 72.6).

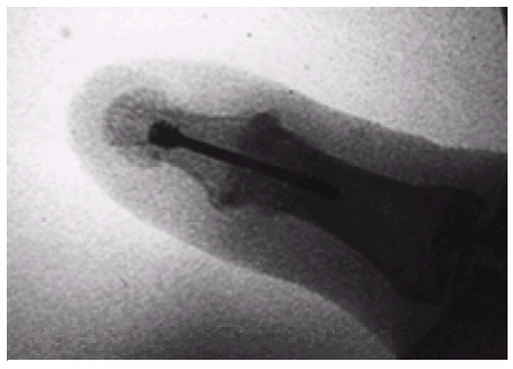

***Figure 72.5.*** Intraoperative confirmation of distal interphalangeal joint arthrodesis with Herbert screw fixation.

***Figure 72.6.*** Intraoperative confirmation of position, Herbert screw fixation, lateral view.

- After preparing the joint surfaces, make a K-wire pilot hole drilling from proximal to distal through the center of the distal phalanx. The wire exits just under the hard nail, through the distal skin.
- Make a transverse skin incision at this level and enlarge the pilot hole, using the small-diameter drill bit, from distal to proximal.
- Position the arthrodesis site, and pass the small-diameter drill across the joint from distal to proximal.
- Tap the drill hole from distal to proximal with the Herbert screw tap.
- Use intraoperative fluoroscopic imaging to determine the length of the screw.
- Place an appropriate-length Herbert screw from distal to proximal, countersinking the proximal threads of the Herbert screw deep enough to keep it from irritating the tip of the finger (84). Take care, as germinal matrix injuries can occur. Note that this technique at the DIP joint requires more extension than other techniques (Fig. 72.7, Fig. 72.8).

***Figure 72.7.*** Distal interphalangeal joint arthrodesis with Herbert screw fixation, AP view.

***Figure 72.8.*** Distal interphalangeal joint arthrodesis with Herbert screw fixation, lateral view.

**Acutrak Screw** The Acutrak variable pitch conical screw (Acutrak, Acumed, Beaverton, OR) has been designed specifically for small-joint fusions. Techniques are as previously described for the Herbert screw.

**AO Screw Fixation** Joint arthrodesis using the AO screw technique generally proceeds as described for the Herbert screw, with the following differences (88). The AO 2.7 mm screw is a standard screw with threads on one end and a head on the other; therefore, compression requires lag technique. Overdrill the proximal phalanx with a 2.7 mm drill bit to gain compression. Countersink the drill hole before you place the screw, which allows the screw to sit flush with the bone.

This screw can be inserted in a retrograde fashion for fusion of the DIP joint. In our experience, the AO screw head is too prominent, causing too much pain in the fingertip; therefore, we currently do not use it for DIP joint fusion.

#### *Internal Fixation—Plate Fixation*

Plate-and-screw fixation is the most stable construct available for performing an arthrodesis in the hand. Plating is an excellent technique when bone grafting is required. It requires significant soft-tissue stripping and is more complex, so it is used less commonly for a simple primary arthrodesis. Plate fixation is used more commonly for salvage of failed previous procedures.

- After the joint ends have been exposed and prepared for arthrodesis, expose the dorsal aspects of the proximal and distal bone surfaces as necessary for plate application.
- Once the bone ends are prepared and any bone graft has been selected, tailored, and placed, select a mini-semitubular plate that allows for at least two screws in the middle phalangeal shaft and two screws in the proximal phalangeal shaft. Generally, a four-hole plate will not bridge a significant defect, so a five- or six-hole plate may be required.
- Contour the plate to fit over any bone graft dorsally.
- Fix the plate with screws to the dorsal aspect of the distal bone first. Check the screw lengths using intraoperative fluoroscopy or radiographs.
- Use the dynamic compression principle (Chapter 11) to apply compression between the bone ends and across any graft that is needed.

Because of the extensive surgery as well as the prominence of the plate and screws, removal and/or extensor tenolysis may be required as a second-stage procedure.

#### *External Fixation*

Compression arthrodesis is possible with mini-external fixators (12,83). Fusion rates are excellent but we feel that most external fixation devices are too bulky and limit the motion of other digits. The transverse wires and compression devices may cause scarring of the extensor mechanism. External fixators are most appropriate for fusions after severe articular surface bone and soft-tissue injuries complicated by joint infection and osteomyelitis (102). We do not recommend external fixation for uncomplicated phalangeal and MCP joint arthrodeses.

### WOUND CLOSURE AND AFTERCARE

- We prefer absorbable sutures for closure of the joint capsule and extensor tendon mechanism because the lack of joint motion after fusion takes tension off the tendon repair. Nonabsorbable sutures may cause patient discomfort after surgery by irritating the skin edges.
- After closure of the deep soft tissues, injection of 0.5% bupivacaine may diminish postoperative discomfort.
- Close the skin with interrupted nonabsorbable sutures.
- Apply a well-padded bulky dressing, and splint the fused joints for comfort and to protect the arthrodesis. At 10–14 days, change the dressings and encourage motion at joints other than the fusion. Fashion an orthoplast splint to the fused joint and keep it in place until the fusion is radiographically solid. Protect thumb MCP and carpometacarpal fusions in thumb spica casts for 4–6 weeks.

## PITFALLS AND COMPLICATIONS

Although uncommon, complications in fusions of the small joints of the hand can be minimized by meticulous surgical technique (55,84,93). Management of complications begins with understanding the potential for them prior to surgery, and making the patient aware of them. Detect vascular compromise by carefully observing capillary refill in the operated digit after tourniquet deflation. Any impairment requires immediate intervention to prevent loss of the digit. Pin track infection can be minimized by keeping pins under the patient's skin. Diminish wound problems by using straight longitudinal dorsal incisions, especially in patients with immunocompromised status, such as those with diabetes mellitus or connective tissue diseases. Prevent nonunion by establishing broad bone contact at the arthrodesis site and stable fixation.

Progression of arthritis in adjacent joints is a concern in any arthrodesis because stress is added across these joints. Carroll (16) found no evidence of STT arthritis after CMC joint fusion in patients less than 50 years old who were followed for 3–25 years. More recently, Bamberger et al. (6) had radiographs of their series of patients reviewed independently for progression of STT arthrosis after CMC arthrodesis. They found progression of STT arthritis in 2 of 12 patients but attributed this to error in technique. Guiral et al. (38) reported a rare complication of arteriovenous fistula with venous aneurysm after thumb carpometacarpal joint arthrodesis. This was treated by ligation and resection of the aneurysm. A painful scar from injury to the branches of the radial sensory nerve is avoided by careful technique. Problems with painful implants can be resolved by removal.

# LIMITED WRIST FUSION

Limited wrist arthrodesis and intercarpal arthrodesis are useful for treating degenerative arthritis, carpal instability (57), fracture nonunion, ligament tears, Kienböck's disease (60,70), osteonecrosis of the carpus, and congenital synchondrosis or partial fusion of various carpal intercarpal joints (4,7,13,24,34,37,51,53,75,91,95,97,98,99,100 and 101,106). A less desirable alternative in some cases is proximal row carpetomy (8,25,46,52).

Successful treatment using these surgical procedures is based on the biomechanical principle of load transfer from one side of the carpus to another. The intercarpal mobility that is preserved compensates for the motion lost to arthrodesis.

Currently, the most commonly performed limited wrist fusion procedures include STT fusion; scaphocapitate (SC) fusion; lunotriquetral (LT) fusion; and fusion of the capitate, hamate, lunate, and triquetrum, which is known as a four-bone fusion.

### FUNCTIONAL WRIST MOTIONS

Recent studies have evaluated the range of motion needed for normal activities of daily living (ADL). Palmer et al. (73) showed that the range of motion of the wrist required for ADL is 5° of flexion, 30° of extension, 10° of radial deviation, and 15° of ulnar deviation. Brumfield and Champoux (14) showed that 10° of flexion and 35°

of extension are required. Ryu et al. (80) showed that 40° of extension, 40° of flexion, and 40° of combined radial and ulnar deviation are needed to perform ADL.

## INDICATIONS FOR SURGERY

### DEGENERATIVE DISORDERS

The scaphoid is unique in that it spans both the proximal and the distal carpal rows. Because of its unusual anatomy, deformity of the wrist follows well-delineated patterns when the scaphoid or its ligamentous restraints are injured (see Chapter 41 and Chapter 42). One of these patterns, the scapholunate advanced collapse (SLAC) pattern of wrist arthritis, accounted for 57% of degenerative wrist arthritis when Watson and Ballet (98) reviewed 4,000 radiographs. These authors also reported primary triscaphe joint arthritis in 27% of these patients and a combination of both in 15% of patients. The primary disorder in the SLAC wrist is that of scapholunate dissociation secondary to scapholunate interosseous ligament rupture (3). This allows for unopposed volar flexion of the scaphoid and the dorsal intercalated segmental instability (DISI) pattern (26). Lateral radiographs may show the scapholunate angle to be increased beyond 60°, which is felt to be the upper limit of normal. On an anteroposterior (AP) radiograph, the scaphoid appears foreshortened, has a “cortical ring” sign and there is a scapholunate gap of greater than 3 mm.

The SLAC pattern of arthritis begins in its earliest stage, stage 1 arthritis, with destruction of the distal aspect of the radioscaphoid joint (2). This is caused by the incongruity between the scaphoid and the scaphoid facet of the radius when the scaphoid is extremely volar flexed. In stage 2, the entire radioscaphoid joint is arthritic. Stage 3 is characterized by further separation between the scaphoid and the lunate, allowing the capitate to migrate proximally. When this occurs, the SC and capitolunate joints become arthritic. Stage 4, in which the radiolunate joint becomes arthritic, is rarely seen because the spherical shape of the proximal lunate and the lunate fossa of the radius make incongruity unlikely except in the most severe cases.

A nonunion of a fracture of the scaphoid also leads to a predictable pattern of wrist arthritis when not treated. Because of its similarity to the SLAC pattern in both progression and treatment, it has been called the scaphoid nonunion advanced collapse (SNAC) pattern. In it, volar flexion of the distal pole of the scaphoid leads to radioscaphoid arthritis (101). The proximal pole, restrained by the scapholunate interosseous ligament, remains in normal alignment with the lunate. Given the dissociation between the proximal and distal rows as a result of the nonunion, a DISI pattern of deformity results. If left untreated, the wrist will undergo the same degenerative pattern seen in a SLAC wrist.

Treatment of these two similar disorders has been mainly proximal row carpectomy (46) or scaphoid excision (52) and lunate-capitate-hamate-triquetral (four-corner) arthrodesis (Fig. 72.9 and Fig. 72.10). Although it is not yet clear whether proximal row carpectomy or four-corner fusion provides better results (106) for stage 2 or 3 SLAC/SNAC disease, it is clear is that scaphoid excision and four-corner fusion are preferred to proximal row carpectomy when the capitate head is arthritic.

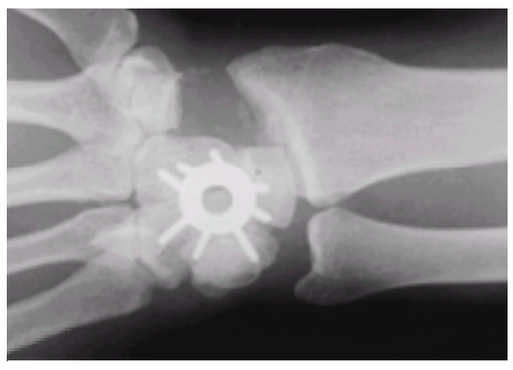

***Figure 72.9.*** Capitohamate triquetrolunate intracarpal arthrodesis with spider plate fixation.

***Figure 72.10.*** Capitohamate triquetrolunate intracarpal arthrodesis with spider plate fixation, lateral view.

With this procedure, pain relief and resolution of symptoms are predictable. In patients with stage 2 or 3 SLAC/SNAC disease, when strength is important and the patient's activities do not require a full range of wrist motion, we perform scaphoid excision and four-corner fusion, as described later.

Another common problem in the wrist is isolated STT arthritis. The pain associated with this disorder can be surprisingly debilitating. The disability associated with STT arthritis can be best appreciated in activities that axially load the thumb (e.g., strong pinch, key turning). Watson et al. (99) attributed rotatory subluxation of the scaphoid as a possible cause of isolated STT arthritis. They noted early degenerative changes in these joints when performing rotary subluxation of the scaphoid (RSS surgery). For isolated STT arthritis, STT arthrodesis has been found to give good function and excellent pain relief and is preferred by other authors (53,97).

A less common but equally disabling degenerative pattern of arthritis in the wrist occurs between the lunate and the triquetrum (24,42,51). This pattern of arthritis is most probably a result of a chronic lunotriquetal ligament tear that has not healed. Patients typically have the radiographic findings associated with volar intercalated segmental instability (VISI). The scapholunate angle on a lateral radiograph is less than 30°, the lower limit of normal. This indicates that the ligamentous complex between the lunate and the triquetrum is disrupted, allowing the lunate to volar-flex and align with the scaphoid. Another cause of isolated LT arthritis is incomplete carpal coalition of the lunate and triquetrum (1).

Degenerative wrist disease evolves when scaphoid nonunion is left untreated, and in the SLAC wrist deformity. Watson and Weinzweig (101) described the use of STT arthrodeses to manage scaphoid nonunion for three specific indications: scaphoid fractures with a very small proximal fragment, a distal scaphoid nonunion causing malalignment of the triscaphe joint, and scaphoid fracture in association with scapholunate dissociation. With small scaphoid proximal fragments, Watson prefers a dorsal approach with bone grafting of the nonunion, with a simultaneous triscaphe arthrodesis. STT arthrodesis is used in distal scaphoid nonunions to improve alignment in the STT joint. Scapholunate dissociation may be treated by intercarpal arthrodesis when it is associated with scaphoid fracture.

### CARPAL INSTABILITY

A detailed description of carpal instability can be found in Chapter 41. Instabilities result from a wide range of injuries that are either static or dynamic (24,65). Static instabilities have malalignments seen on standard radiographs. Dynamic instabilities may appear normally aligned on standard radiographs but are often exhibited on stress views or other special projections. Acute injuries (up to 1 week old) have the maximum potential to go on to primary healing of the ligaments. Subacute injuries (1–6 weeks old) still can heal and do not display fixed deformity or arthrosis. Chronic injuries older than 6 weeks have the least potential for healing, may have fixed deformities or arthrosis, and often require surgical repair and reconstruction. It is apparent that early detection is most important. The position of the lunate as seen on lateral radiographs is one of the key elements used to determine loss of normal carpal alignment. The terms *dorsal intercalated segmental instability* and *volar intercalated segmental instability* describe the malaligned dorsal or volar tilted lunate of unstable wrists (61). Although many instability classifications have been

proposed, none have gained universal acceptance, which underscores the complexities of these injuries and the lack of our present comprehension of this subject.

The effects of intercarpal arthrodesis on wrist kinematics is not well understood. When choosing the surgical procedure, consider the amount of wrist motion that will remain and to what extent compensatory increases in wrist motion will occur over time. Although the proximal and distal rows function separately, an intercarpal arthrodesis that links these rows will have long-term effects on wrist motion and on radiocarpal and ulnocarpal loading that could lead to degenerative arthritis in the long term. Gellman et al. (35) showed that fusion within a carpal row has minimal effect on wrist motion in all planes. Their study demonstrated that two thirds of flexion occurs at the radiocarpal joint and one third occurs at the mid-carpal joint. It also showed that capitolunate fusion caused the greatest loss of motion in a flexion/extension arc, with STT fusion causing the greatest loss of motion in the radioulnar plane.

Garcia-Elias et al. (34) studied the effects of intercarpal arthrodeses on wrist range of motion. They showed that STT fusions had a greater loss of flexion than SC fusion, which resulted in a greater loss of extension and radial deviation. Shear stress was noted to be increased at the radiolunate joint. Viegas et al. (95) reported that STT and SC fusions decrease axial load through the radioscaphoid fossa, while scapholunocapitate and capitolunate fusions distribute load through both the radioscaphoid and radiolunate fossae.

## SURGICAL TECHNIQUES

### PRINCIPLES OF INTERCARPAL ARTHRODESES

Watson and Weinzweig (101) have outlined three major principles that apply to limited wrist arthrodesis:

1. Unaffected joints must be left unfused.
2. Normal external dimensions of carpal bones included in the arthrodesis must be preserved.
3. Bone fixation must include only those bones that are involved in the arthrodesis.

Adherence to these principles is important. STT (triscaphe) fusion results in a single bony unit that preserves the external dimensions of these three carpal bones. Current indications for STT fusion are STT arthrosis, Kienböck's disease, and carpal instability, including static or dynamic rotary subluxation of the scaphoid.

### WATSON AND ASHMEAD'S TECHNIQUE FOR STT FUSION

- Make a dorsal transverse incision on the wrist just distal to the radial styloid (10).
- Expose the radial styloid through an incision in the capsule overlying the radial styloid and scaphoid junction.
- Remove the distal 5 mm of the styloid with a rongeur, sloping in a palmar direction from distal to proximal.
- Make a transverse dorsal capsular incision and evaluate the radioscaphoid interval.
- Watson and Ashmead (97) recommend performing a SLAC wrist reconstruction rather than a triscaphe arthrodesis if there is any articular cartilage damage. It is critical in an STT fusion to have normal articular cartilage between the distal radius and the proximal scaphoid.
- Remove the articular surfaces between the scaphoid, trapezium, and trapezoid with a small rongeur, taking only the proximal half of the trapezium and trapezoid articulations. Remove the hard subchondral bone down to softer cancellous surfaces.
- Remove the dorsal cortex of the trapezium and trapezoid to provide a broader surface area for bone graft.
- Use the distal radius as a source of cancellous bone for grafting (71). To harvest the graft, make a second, transverse incision 3 cm proximal to the radial styloid, extending from Lister's tubercle to just palmar to the first dorsal compartment. A flat surface on the radius can always be identified between the first and second extensor compartments, and a constant periosteal artery is seen in this area.
- Incise the periosteum and make a cortical window. Remove cancellous bone from the distal radius and replace the cortical window after harvesting the graft.
- The most important part of this procedure is the reduction of the scaphoid. Watson and Ashmead (97) do this by placing a 5 mm spacer, which is usually the handle of a small bone hook, into the scaphotrapezoid space to maintain the original external dimensions of the triscaphe joint and manipulate the scaphoid into proper position. Then drive one or two K-wires from the trapezium and trapezoid into the scaphoid, avoiding impingement of the radioscaphoid joint.
- Remove the spacer and pass a second K-wire on the ulnar side of fusion construct (Fig. 72.11).

***Figure 72.11.*** Capitohamate triquetrolunate arthrodesis with Kirschner wire fixation, AP view.

- Pin the scaphoid to lie at approximately 55° of palmar flexion relative to the long axis of the radius when seen on a lateral radiograph. When the wrist is placed in full radial deviation and 45° of dorsiflexion, the scaphoid tuberosity should be reduced.
- Densely pack cancellous bone into the spaces between the trapezium, the trapezoid, and the scaphoid.
- Cut the K-wires short and leave them under the skin.
- Close only the skin and subcutaneous tissues.

#### *Postoperative Care*

Apply a bulky noncompressive dressing, incorporating a long-arm plaster splint to place the hand in a functional position, with the wrist in slight extension and radial deviation, the forearm in neutral position, and the elbow at 90° of flexion. Three to 5 days later, change this and apply a long-arm thumb spica cast. At 4 weeks, exchange the cast for a short-arm thumb spica cast. At 6 weeks after surgery, if there is radiographic evidence of healing, remove the K-wires. Begin range-of-motion exercises once fusion is ensured.

### SCAPHOCAPITATE FUSION

Indications for scaphocapitate (SC) fusion include rotary subluxation of the scaphoid and scaphoid instability, resistant scaphoid nonunion, and Kienböck's disease.

- Make a longitudinal skin incision of sufficient length over the third dorsal compartment, and open the retinaculum.
- Free the EPL tendon proximally and distally, and transpose it radially. This allows retraction of the radial wrist extensors, the EPL, and the digital extensors.
- Make a longitudinal incision in the capsule and develop radial and ulnar flaps.
- Inspect the proximal scaphoid and distal radial articular cartilage as for the STT arthrodesis. If there is any indication of degenerative arthritis in the radiocarpal joint, do a SLAC wrist reconstruction instead.
- Remove the articular surface between the scaphoid and the capitate, using rongeurs and curets.
- Harvest a bone graft from the radius, as described previously for the STT fusion.
- After aligning the scaphoid, drive two 0.045 K-wires from the scaphoid into the capitate.
- Pack bone graft into the scaphoid–capitate gap. Cut off the K-wires under the skin, and close the capsule with absorbable suture. Close the third dorsal compartment with absorbable suture.
- Close the skin and subcutaneous fat with nonabsorbable suture and inject 0.5% bupivacaine for postoperative pain control.
- Postoperative immobilization is identical to that of the STT fusion, as is the postoperative management.

### SLAC RECONSTRUCTION AND HAMATE-CAPITATE-LUNATE-TRIQUETRAL FUSION

A SLAC wrist reconstruction along with excision of the scaphoid is an excellent method to treat radioscaphoid degenerative arthritis and chronic nonunion of the

scaphoid, as well as advanced destruction from scapholunate dissociation or idiopathic avascular necrosis of the scaphoid.

- Make a longitudinal incision dorsally, over the third and fourth dorsal compartments.
- Open the third dorsal compartment, and transpose the EPL tendon radially. Then retract the radial wrist extensors radially and the digital extensors ulnarly.
- Then open the capsule with a longitudinal incision and elevate the capsule to create radial and ulnar flaps.
- Excise the scaphoid.
- Prepare the articular surfaces between the capitate, lunate, triquetrum, and hamate by removing the articular cartilage and subchondral bone between them.
- Harvest cancellous bone proximally from the distal radius, as previously described.
- Anatomic alignment of the four carpal bones is important to provide an excellent outcome. The position of the lunate is critical.
- Flex the lunate from its extended position into a neutral position, generally by using a “joystick,” such as a 0.045 K-wire inserted into the lunate.
- Fix the remaining four carpal bones. Confirm proper position with a radiograph. K-wires (Fig. 72.11), Herbert and other types of screws, and, recently, new plate–screw systems have been used to provide fixation and allow early mobilization (Fig. 72.9, Fig. 72.10). After fixation, pack the intercarpal spaces with cancellous bone.
- Cut off any K-wires beneath the patient's skin and close the capsule with absorbable suture. Close the skin with nonabsorbable suture, and inject the operative site with 0.5% bupivacaine.

***Postoperative Care***

Apply a short-arm thumb spica splint, and exchange it 5–7 days later for a short-arm thumb spica cast. Generally, leave wires in for 6 weeks. At that time, remove the K-wires if early union is seen.

**LUNOTRIQUETRAL ARTHRODESIS**

Lunotriquetral (LT) arthrodesis is indicated in patients with LT instability, LT arthrosis, or LT ligament disruption.

- Make a longitudinal incision between the fifth and sixth dorsal compartments.
- Protect the dorsal sensory branch of the ulnar nerve throughout the procedure.
- Open the joint capsule between the lunate and the triquetrum.
- Remove the articular cartilage between these two bones down to subchondral bone.
- Place three 0.045 K-wires or compression screws across this joint.
- Pack the gap between the two bones with bone graft harvested from the radius as described previously.
- Close the capsule with absorbable sutures and the skin with nonabsorbable sutures.

***Postoperative Care***

Apply a padded long-arm splint and keep it in place for 5–7 days, then exchange it for a long-arm cast. Keep this in place for 6 weeks to allow for adequate healing, as evidenced clinically and radiographically. Then remove pins and use a short-arm splint for 4–6 weeks.

### PITFALLS AND COMPLICATIONS

Complications of limited wrist arthrodeses may be split into two categories: intraoperative complications and problems with long-term outcomes (13,53,106). Major complications from STT arthrodesis include radiocarpal arthrosis, trapeziometacarpal arthrosis, nonunion, osteomyelitis, and radial styloid scaphoid impingement (79). This last complication has been diminished by radial styloidectomy at the time of surgery. Inadequate reduction of the scaphoid in this procedure leads to a predictable progression of radiocarpal arthritis. The proximal pole of the scaphoid must be reduced anatomically into the scaphoid fossa of the radius, and the radioscaphoid angle must be approximately 45° to 55°.

Similar complications have been reported for SC arthrodesis. Long-term follow-up has shown a greater loss of wrist flexion with the latter procedure. Relatively few complications have been reported with the SLAC wrist reconstruction or four-bone arthrodesis. Nonunion has been rare, and the development of radiolunate arthritis and impingement between the fusion mass and the distal radius have been reported. The most common complication of LT joint arthrodesis is nonunion, with a reported incidence of 10% to 50% (13,52,53,91,100,106).

## RADIOCARPAL OR WRIST ARTHRODESIS

Radiocarpal or wrist arthrodesis involves fusion of the radiocarpal and mid-carpal joints, including the radiolunate, radioscaphoid, and radiocapitate joints. It is one of the oldest, most common, longest-used, and most successful reconstruction procedures for the wrist (39,40 and 41,44,59). It predictably relieves pain, but it does eliminate all radiocarpal motion.

### INDICATIONS FOR SURGERY

Currently, the most common indication for total wrist arthrodesis is posttraumatic degenerative arthritis of the radiocarpal and midcarpal joints (41). This includes chronic carpal dissociations as well as complex intracarpal and distal radius intraarticular fractures. Other indications for arthrodesis include the following:

- Chronic infection unresponsive to limited surgical debridement (29,30)
- Paralysis about the wrist and hand (arthrodesis provides the stability required for tendon transfers about the thumb and digits) (87)
- Rheumatoid arthritis and other inflammatory disorders involving the radiocarpal joint (18,28,63,64)
- Limited arthrodeses that have not provided stability or pain relief
- Loss of soft tissue and bone as a result of severe trauma or tumor resection

Spastic paralysis of the wrist from cerebral palsy, strokes, or polio can lead to severe disfigurement of the extremity and loss of hand function. Stabilization of the wrist makes the flexor and extensors of the wrist available as transfers to restore power and function to the fingers. Pomerance and Keenan (76) demonstrated that by performing total wrist fusion, tendon transfers, and muscle releases in a single staged procedure, they were able to correct the severe contractures of the hand and wrist with resolution of the preoperative hygiene problems. (See Chapter 66, Chapter 67 and Chapter 68 for more details.)

Most patients who are considered for arthrodesis have undergone failed attempts at both conservative and surgical treatments. Hastings et al. (41) reported that 71% of the 112 wrists that underwent arthrodeses for posttraumatic arthritis had undergone 137 prior surgical procedures, for an average of 2.3 procedures each. Field et al. (32) found a mean of three operations (mostly limited carpal fusions) performed on the wrist in their 20 patients undergoing arthrodesis for posttraumatic conditions. By the time many of these patients present for arthrodesis, they have so much pain in the wrist that they have little or no motion remaining. For these patients, a total wrist fusion improves stability and function, decreases deformity, and relieves pain.

### BIOMECHANICS

The usual recommendation is to fuse the wrist in dorsiflexion from 0° to 30° to preserve grip and pinch strength. Colonna (23) described power grip as maximal with the wrist in slight extension and slight ulnar deviation. Kraft and Detels (56) simulated wrist arthrodesis in varying degrees of flexion and extension in 20 normal volunteers by immobilizing them in leather gauntlets. This study showed that from 15° of flexion to 30° of extension, the grip strength was equal in all positions except for 15° flexion, where it was decreased. Their overall recommendation was to avoid fusing the wrist in flexion. They recommended placement of the wrist in palmar flexion only when there is bilateral involvement and one wrist is placed in extension, the other in flexion to improve independent feeding and perineal care.

Hastings et al. (41) found that function after radiocarpal fusion was comparable to that for limited wrist fusion. Whereas Jebsen et al. (47) and Purdue (90) found hand function to be poor based on testing, Field et al. (32) found that all patients were satisfied and would have had the procedure sooner. Weiss et al. (105) found that most patients functioned well after wrist arthrodesis for posttraumatic conditions and that the most difficult tasks were perineal care and manipulating the hand in tight spaces. Rayan et al. (78) reviewed the function of nine rheumatoid arthritis patients and found that even among those who underwent bilateral radiocarpal arthrodesis, seven of nine had improvement of subjective function, two of nine remained the same, and no patient was made worse.

Vicar and Burton (94) compared the results of arthroplasty versus radiocarpal arthrodesis in rheumatoid arthritis patients. They found that the arthrodesis group had overall 97% good results compared to 75% good results in the arthroplasty group. The arthrodesis group had an 18% complication rate, while the arthroplasty group had a 25% complication rate, 4 of 37 requiring revision, at an average follow-up of 51 months.

Radiocarpal arthrodesis seems to be the treatment of choice for the most severe wrist deformities, but efforts to perfect wrist arthroplasty and motion-preserving operations continue. While it is likely true that most patients would prefer a motion-sparing procedure to radiocarpal arthrodesis, function after complete wrist fusion is surprisingly good and therefore this remains the gold standard to which all other procedures should be compared. With the right indications, radiocarpal arthrodesis can salvage function for an otherwise debilitated patient.

Position for radiocarpal arthrodesis is directly related to the final function desired, and although a wrist fused in a poor position may be pain free, function suffers. The ideal position for radiocarpal arthrodesis is controversial. Several studies recommended fusion in 20° to 30° of extension (11,18,21,22,32,41,44,59,62,64,68,70,81,104) and Clayton and Ferlic (21) recommended neutral position. Although the ideal position for radiocarpal fusion likely will continue to be debated, functional outcome studies show that a position in 0° to 10° of extension and 0° to 10° of ulnar deviation seems to give the best results.

The methods advocated for radiocarpal arthrodesis are quite numerous. Techniques utilizing a distal radius sliding graft (22), an AO plate (101), and intramedullary pins or rods (64,68) have been described.

## SURGICAL CONSIDERATIONS

Evaluate patients medically and understand the medical diagnosis underlying the wrist deformity in patients with systemic disease before performing surgery. This is most important in evaluating patients with rheumatoid arthritis.

Rheumatoid arthritis is a systemic disease affecting many joints in the body. These patients often have a "**Z**-collapsed" deformity, where deformity in a proximal joint provokes a reciprocal deformity at a distal joint (70). Surgical procedures performed on any of these joints affect the more distal or proximal joints. In patients with rheumatoid arthritis, keep procedures minimal and simple. Wrist fusion using a Steinmann pin for intramedullary fixation is better than using a dorsal plate, as it is less likely to cause problems with the skin and extensor tendons. Stability is adequate, immobilization is shortened, an iliac crest graft is usually not required, and splinting and partial weight bearing early is possible. Millender and Nalebuff (68) reported that patients were able to walk with platform crutches 1 week after surgery using this technique. Another advantage of this procedure is that it can be performed rapidly enough to allow other surgical procedures to be performed concomitantly, as is necessary in many patients with severe rheumatoid arthritis (69). (See Chapter 70 for more details on treatment of the rheumatoid hand.)

Patients with posttraumatic arthritis place heavier loads and higher demands on their hands and wrists than do patients with rheumatoid arthritis. Rigid internal fixation is crucial. Recent studies have shown that plate fixation with the application of local bone graft provides reliable fusion and early rehabilitation (11,104).

## SURGICAL TECHNIQUES

### STEINMANN PIN TECHNIQUE

Perform surgery with preoperative intravenous antibiotics and axillary block or general anesthesia. All patients with connective tissue diseases or in whom there is concern of cervical spine instability are prescreened with cervical spine radiographs. Perform all surgery under tourniquet control, through a dorsal longitudinal skin approach to the extensor retinaculum.

We prefer a modification of techniques originally proposed by Clayton and Ferlic (21), Mannerfelt and Malmsten (64), and Millender and Nalebuff (68), as follows.

- Use a longitudinal skin incision just ulnar to Lister's tubercle.
- Make a longitudinal incision through the fascia of the third dorsal compartment, and transpose the EPL tendon.
- Incise the floor of the third compartment and extend it distally to the base of the third metacarpal, staying ulnar to the extensor carpi radialis brevis (ECRB) tendons.
- Using subperiosteal dissection, raise medial and lateral flaps to expose the entire distal radius, ulna, and carpus.
- We resect the posterior interosseous nerve in the floor of the fourth compartment to provide lasting pain relief. Because of the commonly associated disease of the distal radioulnar joint (DRUJ) in patients with rheumatoid arthritis, we prefer to perform a Darrach resection of the distal ulna by transecting the distal ulnar shaft just proximal to the ulnar head, using an oscillating saw (see Chapter 43).
- Use a subperiosteal approach to excise the entire distal ulna. Preserve the ulnar head for use as autogenous bone graft.
- Using a small rongeur, resect the remaining radiocarpal and intercarpal articular surfaces, including the third CMC and intercarpal joints, until you expose cancellous bone. Use the harvested distal ulna to fill the defects between the intercarpal joints. If more bone graft is needed, use a curet to harvest any needed bone from the distal radius through the base of Lister's tubercle.
- Insert a 3.2 or 3.6 mm Steinmann pin either down the medullary canal of the third metacarpal shaft or between the second and third metacarpal bases for more ulnar deviation, and bring it out distally through the skin.
- Reduce the wrist into final position, and slip a drill guide over the distal end of the pin. Slide a similar-size pin into the guide and tap the pin across the wrist into the radius in a retrograde fashion. Bury the pin distally under the skin.
- Confirm adequate pin position with intraoperative radiographs or insert the pin under fluoroscopic control.
- Transpose approximately one third to one half of the extensor retinaculum palmar to the extensor tendons, and suture it into place with absorbable sutures. Place a suction drain deep into the wound and bring it out distally for ease of removal the following day. Place subcutaneous sutures and then close the skin with nonabsorbable sutures in an interrupted fashion.

#### *Postoperative Care*

Apply a palmar plaster splint and dressing to control rotation. Remove the drain in 24 hours. After 1 week, remove the dressing and inspect the wound. Generally leave sutures in for 2 weeks and keep the patient in a splint or cast until their removal. At 2 weeks postoperatively, remove the sutures and place the patient into a short-arm cast for an additional 2–4 weeks, or until clinical and radiographic union is achieved. Encourage the patient to mobilize his or her fingers as much as possible until the cast is removed. At that time, evaluate the patient and treat any remaining stiffness with aggressive hand therapy.

### AO WRIST FUSION PLATE

When performing radiocarpal arthrodesis for indications other than rheumatoid arthritis, we prefer to use the AO method of plate fixation popularized by Hastings (39) and others (81) (Fig. 72.12 and Fig. 72.13). Most commonly, the indication for this type of arthrodesis is posttraumatic arthritis of the wrist or failed wrist arthroplasty.

***Figure 72.12.*** Radiocarpal arthrodesis using wrist fusion plate, AP view.

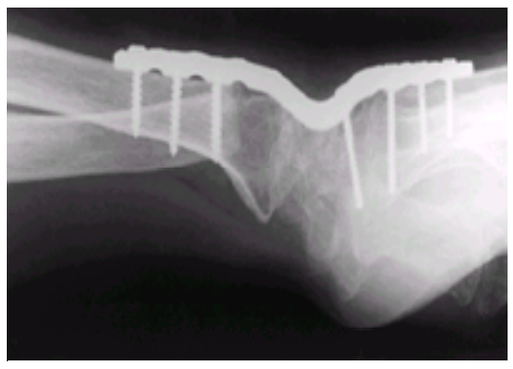

***Figure 72.13.*** Radiocarpal arthrodesis using wrist fusion plate, lateral view.

- Make a midline dorsal longitudinal skin incision.
- Open the third dorsal compartment and transpose the EPL tendon. Expose the entire carpus and distal radius, as well as the base of the third metacarpal subperiosteally. Do not enter the DRUJ unless there is concomitant disease that is being treated surgically. The best way to avoid the problem of DRUJ instability after arthrodesis is to keep the volar and dorsal radioulnar ligament complex intact.
- Decorticate the dorsal 50% of the joint surfaces of the radioscapholunate, the radioscaphocapitate, the scapholunate, the lunocapitate, and the capitate, and the third metacarpal base until you expose cancellous bone.
- Arthrodesis of the remaining joints of the carpus and the second carpometacarpal joint can be performed, but we add these joints only if concomitant arthrosis exists. Keeping the volar 50% of the articular surface intact maintains alignment of the carpus better than if the entire joint is taken.
- Harvest cancellous bone graft from the distal radius by removing Lister's tubercle and widening the cortical defect with a curet.
- Contour the dorsal surfaces of the distal radius, lunate, capitate, and third metacarpal base with an osteotome so that the plate fits against the bone without gaps or defects.
- Before fixing the plate to the wrist, pack cancellous bone graft between the joint surfaces to be fused. Apply the plate (we prefer the precontoured AO wrist fusion plate, which provides 10° to 15° of wrist extension) first to the third metacarpal with at least three 2.7 mm cortical screws. Stabilize the distal radius with at least three (usually four) 3.5 mm cortical screws. Then use a cancellous screw to affix the plate to the carpus (usually the capitate).
- Ensure that the position of the hardware is adequate with intraoperative radiographs or fluoroscopy, and make changes as necessary.
- Close the wound by transposing one third to one half of the extensor retinaculum volar to the extensor tendons over the plate.
- Place a suction drain deep into the wound and bring it out distally for removal the next day.
- Close the skin with interrupted horizontal mattress sutures of 4-0 nylon.

***Postoperative Care***

Apply a sterile bandage and a short-arm volar splint. After 1 week, remove the bandage and splint; inspect the wound and remove the sutures if it is adequately healed. Apply a custom-molded plastizote splint and begin a controlled-motion hand therapy protocol. Do not permit active exercises against resistance until clinical and radiographic union is achieved, usually in 6–10 weeks.

## PITFALLS AND COMPLICATIONS

Numerous authors using different surgical techniques have reported complications of radiocarpal arthrodesis. Clendenin and Green (22) divided these into major complications (requiring revision surgery or prolonged hospitalization) and minor (when morbidity is prolonged but resolves without further hospitalization). Major complications include nonunion, wound infection, painful neuromas, fracture of a previously healed fusion, iliac crest bone graft site complications, acute carpal tunnel syndrome, plate failure, DRUJ and ulnocarpal impingement (33,77,92), and chronic pain syndromes. Minor complications include postoperative pain caused by tight dressings, sensory neurapraxias, minor skin irritations, and necrosis. Hastings (39) noted that major complications are less common in internal fixation with a wrist fusion plate than in other surgical methods. Bone graft donor site morbidity can be diminished by using local bone graft for radiocarpal arthrodesis.

Overall rates of nonunion range from 5% to 20% (22,39), whereas rates of nonunion with the AO wrist fusion plate technique have been reported to be from 0% to 2% (32,41,104).

## CHAPTER REFERENCES

Each reference is categorized according to the following scheme: *, classic article; #, review article; !, basic research article; and +, clinical results/outcome study.


+ 1. Alberts KA, Engkvist O. Arthrodesis of the First Metacarpal Joint: 33 Cases of Arthrosis. *Acta Orthop Scand* 1989;60:258

# 2. Ashmead D, Watson HK. SLAC Wrist Reconstruction. In: Gelberman R, ed. *The Wrist*. New York: Raven Press, 1994.

+ 3. Ashmead D, Watson HK, Damon C, et al. Scapholunate Advanced Collapse Wrist Salvage. *J Hand Surg [Am]* 1994;19:741.

+ 4. Ashmead D, Watson HK, Weinzweigh J, Zeppieri J. One Thousand Intercarpal Arthrodeses. *J Hand Surg [Br]* 1996;21:10.

+ 5. Ayres JR, Goldstrohm GL, Miller GJ, Dell PC. Proximal Interphalangeal Joint Arthrodesis with the Herbert Screw. *J Hand Surg [Am]* 1988;13A:600.

+ 6. Bamberger HB, Stern PJ, Kiefhabert TR, et al. Trapeziometacarpal Joint Arthrodesis: A Functional Evaluation. *J Hand Surg [Am]* 1992;17:605.

+ 7. Bednar JM, Osterman AL. Carpal Instability: Evaluation and Treatment. *J Am Acad Orthop Surg* 1994;19A:1016.

+ 8. Begley BW, Engber WD. Proximal Row Carpectomy in Advanced Kienböck's Disease. *J Hand Surg [Am]* 1994;19:1016.

+ 9. Bishop AT. Small Joint Arthrodesis. *Hand Clin* 1993;9:683.

+ 10. Biyani A, Ebraheim NA, Lu J, Yeasting RA. A Modified Dorsal Approach to the Wrist for Arthrodesis of the Non-Rheumatoid Wrist. An Anatomical Study. *J Hand Surg [Br]* 1996;21:434.

+ 11. Bolano LE, Green DP. Wrist Arthrodesis in Post-Traumatic Arthritis: A Comparison of Two Methods. *J Hand Surg [Am]* 1993;18:786.

+ 12. Braun RM, Rhoades CE. Dynamic Compression for Small Joint Arthrodesis. *J Hand Surg [Am]* 1985;10:340.

+ 13. Brown RE, Erdmann D. Complications of 50 Consecutive Limited Wrist Fusions by a Single Surgeon. *Ann Plastic Surg* 1995;35:46.

! 14. Brumfield RH, Champoux JA. A Biomechanical Study of Normal Functional Wrist Motion. *Clin Orthop* 1984;187:23.

+ 15. Burton RI, Margles SW, Lunseth PA. Small Joint Arthrodesis in the Hand. *J Hand Surg [Am]* 1986;11:678.

+ 16. Carroll RE. Arthrodesis of the Carpometacarpal Joint of the Thumb. A Review of Patients with a Long Postoperative Period. *Clin Orthop* 1987;220:106.

+ 17. Carroll RE, Carlson E. Diagnosis and Treatment of Injury to the Second and Third Carpometacarpal Joints. *J Hand Surg [Am]* 1989;14:102.

+ 18. Carroll RE, Dick HM. Arthrodesis of the Wrist for Rheumatoid Arthritis. *J Bone Joint Surg Am* 1971;53:1365.

+ 19. Carroll RE, Hill NA. Small Joint Arthrodesis in Hand Reconstruction. *J Bone Joint Surg Am* 1969;51:1219.

+ 20. Chamay A, Piaget-Morerod F. Arthrodesis of the Trapeziometacarpal Joint. *J Hand Surg [Br]* 1994;19:489.

+ 21. Clayton ML, Ferlic DC. Arthrodesis of the Arthritic Wrist. *Clin Orthop* 1984;187:89.

+ 22. Clendenin MB, Green DP. Arthrodesis of the Wrist—Complications and Their Management. *J Hand Surg* 1981;6:253.

* 23. Colonna PC. A Method of Fusion of the Wrist. *South Med J* 1944;37:1.

# 24. Cooney WP III, Linscheid RL, Dobyns JH. Carpal Instability: Treatment of Ligament Injuries of the Wrist. *Instr Course Lect* 1992;41:33.

+ 25. Culp RW, McGuigan FX, Turner MA, et al. Proximal Row Carpectomy: A Multicenter Study. *J Hand Surg [Am]* 1993;18:19.

# 26. Dobyns JH, Linscheid RL, Chao EY, et al. Traumatic Instability of the Wrist. *Instr Course Lect* 1975;24:182.

+ 27. Doyle JR. Sliding Bone Graft Technique for Arthrodesis of the Trapeziometacarpal Joint of the Thumb. *J Hand Surg [Am]* 1991;16:363.

+ 28. Dray GJ, Millender LH, Nalebuff EA, Phillips C. The Surgical Treatment of Hand Deformities in Systemic Lupus Erythematosus. *J Hand Surg* 1981;6:339.

+ 28a. Eaton RG, Lane LB, Littler JW, Keyser JJ. Ligamentous Reconstruction for the Painful Thumb Carpometacarpal Joint: A Long-term Assessment. *J Hand Surg [Am]* 1984,9:692.

* 29. Ely LW. Study of Joint Tuberculosis. *Surg Gynecol Obstet* 1910;10:561.

* 30. Ely LW. An Operation for Tuberculosis of the Wrist. *JAMA* 1920;75:1707.

+ 31. Faithfull DK, Herbert TJ. Small Joint Fusions of the Hand Using the Herbert Bone Screw. *J Hand Surg [Br]* 1984;9:167.

+ 32. Field J, Herbert TJ, Prosser R. Total Wrist Fusion. A Functional Assessment. *J Hand Surg [Br]* 1996;21B:429.

+ 33. Friedman S, Palmar A. The Ulnar Impaction Syndrome. *Hand Clin* 1991;7:295.

! 34. Garcia-Elias M, Cooney WP, An KN, et al. Wrist Kinematics after Limited Intercarpal Arthrodesis. *J Hand Surg [Am]* 1989;14:791.

! 35. Gellman H, Kauffmann D, Lenihand M, et al. An In Vitro Analysis of Wrist Motion: The Effect of Limited Intercarpal Arthrodesis and the Contributions of the Radiocarpal and Midcarpal Joints. *J Hand Surg [Am]* 1988;13:378.

+ 36. Goldner JL, Koman LA, Gelberman R, et al. Arthrodesis of Metacarpophalangeal Joint of the Thumb in Children and Adults: Adjunctive Treatment of Thumb-in-Palm Deformity in Cerebral Palsy. *Clin Orthop* 1990;253:75.

+ 37. Gross SC, Watson HK, Strickland JW, et al. Triquetral-lunate Arthritis Secondary to Synostosis. *J Hand Surg [Am]* 1989;14:95.

+ 38. Guiral J, Ortega M, Manzanares J. Arteriovenous Fistula with Venous Aneurysm as a Complication of the Trapeziometacarpal Arthrodesis. *Acta Orthop Belg* 1993;59:404.

# 39. Hastings H. Arthrodesis of the Osteoarthritic Wrist. In: Gelberman R, ed. *The Wrist*. New York: Raven Press, 1994:107.

# 40. Hastings H. Wrist (Radiocarpal) Arthrodesis. In: Green DP, Hotchkiss RN, Pederson WC, eds. *Green's Operative Hand Surgery.* New York: Churchill-Livingstone, 1999:131.

+ 41. Hastings H II, Weiss APC , Quenzer D, et al. Arthrodesis of the Wrist for Post-Traumatic Disorders. *J Bone Joint Surg Am* 1996;78:897.

! 42. Horii E, Garcia-Elias M, An K, et al. A Kinematic Study of Luno-Triquetral Dissociations. *J Hand Surg [Am]* 1991;16:355.

+ 43. House JH, Comadoll J, Dahl AL. One-Stage Key Pinch and Release with Thumb Carpal-Metacarpal Fusion in Tetraplegia. *J Hand Surg [Am]* 1992;17:530.

# 44. Hulsizer DL, Weiss APC. Wrist Arthrodesis Seminars in Arthroplasty 1997;8:185.

+ 45. Ijsselstein CB, VanEgmond DB, Hovious SER, van der Meulen JC. Results of Small Joint Arthrodesis: Comparison of Kirschner Wire Fixation with Tension Band Wire Technique. *J Hand Surg [Am]* 1992;17:952.

+ 46. Inglis AE, Jones EC. Proximal Row Carpectomy for Diseases of the Proximal Row. *J Bone Joint Surg Am* 1977;59:460.

* 47. Jebsen RH, Taylor N, Trieschman RB, et al. An Objective and Standardized Test of Hand Function. *Arch Phys Med Rehabil* 1969;50:311.

# 48. Jones BF, Stern PJ. Interphalangeal Joint Arthrodesis. *Hand Clin* 1994;10:267.

+ 49. Katzman SS, Gibeault JD, Dickson K, Thompson JD. Use of a Herbert Screw for Interphalangeal Joint Arthrodesis. *Clin Orthop* 1993;296:127.

+ 50. Khuri SM. Tension Band Arthrodesis in the Hand *J Hand Surg [Am]* 1986;11:41.

+ 51. Kirschenbaum D, Coyle M, Leddy J. Chronic Lunotriquetral Instability: Diagnosis and Treatment. *J Hand Surg [Am]* 1993;18:1107.

+ 52. Kirschenbaum D, Schneider LH, Kirkpatrick WH, et al. Scaphoid Excision and Capitolunate Arthrodesis for Radioscaphoid Arthritis. *J Hand Surg [Am]* 1993;18:780.

+ 53. Kleinman WB, Carroll C IV. Scapho-trapezoid Arthrodesis for Treatment of Chronic Static and Dynamic Scapholunate Instability: A 10-year Prospective on Pitfalls and Complications. *J Hand Surg [Am]* 1990;15:408.

! 54. Kovach JC, Werner FW, Palmer AK, et al. Biomechanical Analysis of Internal Fixation Techniques for Proximal Interphalangeal Joint Arthrodesis. *J Hand Surg [Am]* 1986;11:562.

+ 55. Kowalski MF, Manske PR. Arthrodesis of Digital Joints in Children. *J Hand Surg [Am]* 1988;13:874.

+ 56. Kraft GH, Detels PE. Position of Function of the Wrist. *Arch Phys Med Rehabil* 1972;53:272.

+ 57. Krakauer JD, Bishop AT, Cooney WP. Surgical Treatment of Scapholunate Advanced Collapse. *J Hand Surg [Am]* 1994;19:751.

+ 58. Leibovic SJ, Strickland JW. Arthrodesis of the Proximal Interphalangeal Joint of the Finger: Comparison of the Use of the Herbert Screw with Other Fixation Methods. *J Hand Surg [Am]* 1994;19:181.

+ 59. Lenoble E, Ovadia H, Goutallier D. Wrist Arthrodesis Using an Embedded Iliac Crest Bone Graft. *J Hand Surg [Br]* 1993;18:595.

+ 60. Lin HH, Stern PJ. “Salvage” Procedures in the Treatment of Kienböck's Disease: Proximal Row Carpectomy and Total Wrist Arthrodesis. *Hand Clin* 1993;9:521.

* 61. Linscheid RI, Dobyns JH, Beabout JW, Bryan RS. Traumatic Instability of the Wrist: Diagnosis, Classifications and Pathomechanics. *J Bone Joint Surg Am* 1972;54:1612.

# 62. Louis DS, Hankin FM. Arthrodesis of the Wrist: Past and Present. *J Hand Surg [Am]* 1986;11:787.

# 63. Mannerfelt L. Total Arthrodesis of the Wrist. In: Simmen BR, Hagena FW, eds. *The Wrist In Rheumatoid Arthritis.* Basel, Switzerland: Karger, 1992.

+ 64. Mannerfelt L, Malmsten M. Arthrodesis of the Wrist in Rheumatoid Arthritis: A Technique without External Fixation. *Scand J Plast Reconstr Surg* 1971;5:124.

# 65. Mastey RD, Akelman E, Weiss A-PC. Fractures and Ligamentous Injuries of the Wrist. In: Beasley RW, ed. *Plastic Surgery.* Philadelphia: Lippincott-Raven, 1997:849.

+ 66. McGrath JC, Vigil DV, Cohen MJ. A Modified Approach to Cup and Cone Arthrodesis of the Small Joints in the Hand. *Contemp Orthop* 1996;32:335.

+ 67. Merle M, Voche PH. Absorbable Osteosynthesis:Experimental and Clinical Approach in Surgery of the Hand. *Bull Mem Acad R Med Belg* 1994;149:329.

+ 68. Millender LH, Nalebuff EA. Arthrodesis of the Rheumatoid Wrist: An Evaluation of Sixty Patients and a Description of a Different Surgical Technique. *J Bone Joint Surg Am* 1973;55:1026.

+ 69. Millender LH, Phillips C. Combined Wrist Arthrodesis and Metacarpophalangeal Joint Arthroplasty in Rheumatoid Arthritis. *Orthopedics* 1978;1:43.

# 70. Millender LH, Terrono AL, Feldon PG. Arthrodesis of the Rheumatoid Arthritic Wrist. In: Gelberman R, ed. *The Wrist*. New York: Raven Press, 1994:287.

+ 71. Mirly HL, Manske PR, Szerzinski JM. Distal Anterior Radius Bone Graft in Surgery of the Hand and Wrist. *J Hand Surg [Am]* 1995;20:623.

+ 72. Moore JR, Tolo VT, Weiland AJ. Painful Subluxation of the Carpometacarpal Joint of the Thumb in Ehlers-Danlos Syndrome. *J Hand Surg [Am]* 1985;10:661.

! 73. Palmer AK, Werner FW, Murphy D, Glisson R. Functional Wrist Motion: A Biomechanical Study. *J Hand Surg [Am]* 1985;10:39.

+ 74. Pellegrini VD Jr, Burton RI. Osteoarthritis of the Proximal Interphalangeal Joint of the Hand: Arthroplasty or Fusion? *J Hand Surg [Am]* 1990;15:194.

+ 75. Pin P, Young V, Gilula L, Weeks P. Management of Chronic Lunotriquetral Ligament Tears. *J Hand Surg [Am]* 1989;14:77.

+ 76. Pomerance JF, Keenan MA. Correction of Severe Spastic Flexion Contractures in the Nonfunctional Hand. *J Hand Surg [Am]* 1996;21:823.

+ 77. Quenzer DE, Linscheid RL. Ulnar Lengthening Procedures. *Hand Clin* 1993;9:467.

+ 78. Rayan GM, Brentlingers A, Purnell D, Garcia-Moral CA. Functional Assessment of Bilateral Wrist Arthrodeses. *J Hand Surg* 1987;12:1020.

+ 79. Rogers WD, Watson HK. Radial Styloid Impingement after Triscaphe Arthrodesis. *J Hand Surg [Am]* 1989;14:297.

! 80. Ryu JY, Cooney WP III, Askew LJ, et al. Functional Range of Motion of the Wrist Joint. *J Hand Surg [Am]* 1991;16:409.

+ 81. Sagerman SD, Palmer AK. Wrist Arthrodesis Using a Dynamic Compression Plate. *J Hand Surg [Br]* 1996;21:437.

+ 82. Sanderson PL, Morris MA, Fahmy NRM. A Long-term Review of the Harrison-Nicolle Peg in Digital Arthrodesis. *J Hand Surg [Br]* 1991;16;283.

+ 83. Seitz WH, Sellman DC, Scarcella JB, Froimson AL. Compression Arthrodesis of the Small Joints of the Hand. *Clin Orthop* 1994;304:116.

+ 84. Stern PJ, Fulton DB. Distal Interphalangeal Joint Arthrodesis: An Analysis of Complications. *J Hand Surg* 1992;6:1139.

+ 85. Stern PJ, Gates NT, Jones TB. Tension Band Arthrodesis of Small Joints in the Hand. *J Hand Surg [Am]* 1993;18:194.

! 86. Stokel EA, Tencer AF, Driscol HL, Trumble TE. A Biomechanical Comparison of Four Methods of Fixation of the Trapeziometcarpal Joint. *J Hand Surg [Am]* 1994;19:86.

+ 87. Szabo RM, Gelberman RH. Operative Treatment of Cerebral Palsy. *Hand Clin* 1985;1:525.

+ 88. Teoh LC, Yeo SJ, Singh I. Interphalangeal Joint Arthrodesis with Oblique Placement of an AO Lag Screw. *J Hand Surg [Br]* 1994;19:208.

# 89. Thompson JS. Small Joint Arthrodesis. In: Peimer CA, ed.*Surgery of the Hand and Upper Extremity.* New York: McGraw-Hill, 1996:973.

* 90. Tiffin J.*Purdue Pegboard Examiner Manual.* Chicago: Science Research Associates, 1968.

+ 91. Trumble T, Bour C, Smith R, Edwards G. Intercarpal Arthrodesis for Static and Dynamic Volar Intercalated Segment Instability. *J Hand Surg [Am]* 1988;13:396.

+ 92. Trumble TE, Esterling KJ, Smith RJ. Ulnocarpal Abutment after Wrist Arthrodesis. *J Hand Surg [Am]* 1988;13:11.

+ 93. Uhl RL, Schneider LH. Tension Band Arthrodesis of Finger Joints: A Retrospective Review of 76 Consecutive Cases. *J Hand Surg [Am]* 1992;17:518.

+ 94. Vicar AJ, Burton RI. Surgical Management of the Rheumatoid Wrist—Fusion or Arthroplasty? *J Hand Surg* 1986;11:790.

! 95. Viegas SF, Patterson RM, Peterson PD, et al. Evaluation of the Biomechanical Efficacy of Limited Intercarpal Fusion for the Treatment of Scapholunate Dissociation. *J Hand Surg [Am]* 1990;15:120.

+ 96. Voche P, Merle M, Membre H, Fockens W. Bioabsorbable Rods and Pins for Fixation of Metacarpophalangeal Arthrodesis of the Thumb. *J Hand Surg* 1995;6:1032.

# 97. Watson HK, Ashmead D. Triscaphe Fusion for Chronic Scapholunate Instability. In: Gelberman R, ed.*The Wrist.* New York: Raven Press, 1994:147.

+ 98. Watson HK, Ballet FL. The SLAC Wrist: Scapholunate Advanced Collapse Pattern of Degenerative Arthritis. *J Hand Surg [Am]* 1984;9:358.

+ 99. Watson HK, Ottoni L, Pitts EC, Handal AG. Rotary Subluxation of the Scaphoid: A Spectrum of Instability. *J Hand Surg [Br]* 1993;18:62.

+ 100. Watson HK, Ryu J, Akelman E. Limited Triscaphoid Intercarpal Arthrodesis for Rotary Subluxation of the Scaphoid. *J Bone Joint Surg Am* 1986;68:345.

# 101. Watson HK, Weinzweig J. Intercarpal Arthrodesis. In: Green DP, Hotchkiss RN, Pederson WC, eds. *Green's Operative Hand Surgery.* New York: Churchill-Livingstone, 1999:108.

# 102. Weiland AJ. Small Joint Arthrodesis and Bony Defect Reconstruction. In: McCarthy JG, ed. *Plastic Surgery*, vol 7: *The Hand.* Philadelphia: Saunders, 1990:4671.

# 103. Weiland AJ. Small Joint Arthrodesis. In: Green DP, Hotchkiss RN, Pederson WC, ed.*Green's Operative Hand Surgery.* New York: Churchill-Livingstone, 1999:95.

+ 104. Weiss APC, Hastings H. Wrist Arthrodesis for Traumatic Conditions: A Study of Plate and Local Bone Graft Application. *J Hand Surg [Am]* 1995;20:50.

+ 105. Weiss APC, Wiedeman G, Quenzer D, et al. Upper Extremity Function after Wrist Arthrodesis. *J Hand Surg* 1995;20:813.

+ 106. Wyrick JD, Stern PJ, Kiefhaber TR. Motion-Preserving Procedures in the Treatment of Scapholunate Advanced Collapse Wrist: Proximal Row Carpectomy versus Four-Corner Arthrodesis. *J Hand Surg [Am]* 1995;20:965.

+ 107. Zimmerman NB, Weiland AJ. Ninety-Ninety Intraosseous Wiring for Internal Fixation of the Digital Skeleton. *Orthopedics* 1989;12.99.

# CHAPTER 73

# INFECTIONS OF THE HAND

*Robert M. Szabo and Carl F. Palumbo*

**Robert M. Szabo:** Professor of Orthopaedics, Professor of Surgery, Division of Plastic Surgery; Chief, Hand and Upper Extremity Service, School of Medicine, University of California, Davis, Sacramento, California, 95817.
**Carl F. Palumbo:** Department of Orthopaedic Surgery, University of California, Davis, Medical Center, Sacramento, California, 95817.

Principles
Classification
Pyogenic Bacterial Infections
Nonpyogenic Infections
Specific Treatment and Techniques
Subcutaneous Abscess in the Hand and Forearm
Necrotizing Fasciitis
Closed-Space Infections
Suppurative Flexor Tenosynovitis
Radial and Ulnar Bursae Infections
Parona's Space Infections
Septic Arthritis
Human Bite and Clenched-Fist Infections
Animal Bites
Felon
Nail Bed Infections
Herpetic Infection and Herpetic Whitlow
Mycobacterial Infections
Fungal Infections
Hand Infections in Acquired Immunodeficiency Syndrome and Human Immunodeficiency Virus
Osteomyelitis
Postoperative Care
Pitfalls and Complications
Chapter References

Infection in the hand is common and can result in serious and permanent disability if appropriate management is delayed (6,7,13,15,16,30,33,34 and 35,41,52,54,55,63). Because loss of hand function follows an inadequately treated infection, make every effort to achieve complete and expedient resolution. In our experience treatment requires aggressive debridement when surgery is indicated, use of antimicrobials that cover the full spectrum of infecting agents known to be present in hand infections, and appropriate follow-up care.

Hand infection most often begins with penetration of the skin barrier and inoculation of the tissues. Tissue necrosis and impairment of circulation create an ideal environment for bacteria to flourish. Bacterial proliferation produces the initial signs of infection: erythema, calor, swelling, and tenderness. The local tissue reaction causes edema and further impairment of local circulation, with eventual abscess formation. The venous drainage of the hand (palmar to dorsal) and the fact that the skin is less tethered on the dorsum explain the preponderance of dorsal swelling in hand infections. Infection must be differentiated from noninfectious conditions such as gout, collagen vascular disease, inflammatory tenosynovitis, acute soft-tissue calcification, foreign-body reaction, and more rarely, neoplastic processes.

## PRINCIPLES

The goal of initial treatment is to arrest bacterial proliferation and remove purulent and necrotic tissue while leaving behind the well-vascularized and viable tissue (5,18,30). Whereas cellulitis is treated with antibiotics without surgery, once an abscess has become evident, surgical drainage is necessary (Fig. 73.1). Excise the abscess cavity, its walls, loculations, and all infected tissue as well. Thorough debridement improves blood supply, enabling natural humoral and cellular antibacterial factors and antibiotics to enter the infected area. Leave wounds open to allow drainage, except in larger joints (the wrist and proximally), in which closed-suction drainage may be used. After surgery, keep the hand initially immobilized and elevated. Once the wound is nontender, nonerythematous, and not indurated, encourage active motion to prevent stiffness that results when edema fluid is allowed to consolidate into fibrous tissue.

***Figure 73.1.*** Algorithm for diagnosis and treatment of hand infections. *BR*–, negative birefringence; *BR*+, positive birefringence; *CBC*, complete blood count; *CHEM-7*, blood chemistries; *CPPD,* calcium pyrophosphate disease; *DIP,* distal interphalangeal joint; *ER,* emergency room; *ESR,* sedimentation rate; *FB,* foreign body; *IV,* intravenous; *MCP,* metacarpal phalangeal joint; *PIP,* proximal interphalangeal joint; *ROM,* range of motion; *SQ,* subcutaneous.

The surgical objectives require a bloodless field, good lighting, skilled assistance, appropriate instruments, and anesthesia. Lancing in the emergency department is of limited use; the extent of infection in various compartments and tissue planes may not be recognized and thus go untreated (7,30,35,61). Lancing alone often delays resolution of the infection and leads to further tissue destruction (18,58).

Use a tourniquet to obtain a bloodless field so that neurovascular structures may be visualized, but exsanguinate by gravity only; an Esmarch bandage may spread the infection locally and proximally. Either a regional block or a general anesthetic is required; local anesthetics in inflamed tissues rarely give adequate anesthesia.

Antibiotics are essential in the treatment of hand infections (Table 73.1). Antibiotic use alone in initial stages often cures the infection and prevents serious sequelae. It is vitally important, however, that the antibiotic be chosen on the basis of the bacteria likely to be found in the wound. Gram-positive and gram-negative anaerobic organisms are often found in hand infections, in addition to the common and well-known gram-positive aerobic organisms *Streptococcus* and *Staphylococcus* (1,9,16,19,20,21,22 and 23,32,38,43,44,50).

***Table 73.1. Empiric Antibiotic Recommendations for Hand Infections****

In choosing an antibiotic, consider the following factors: Penicillinase-resistant penicillins (e.g., nafcillin) are ineffective against many anaerobic pathogens (19,20,22,59). Most hand infections are polymicrobial in nature (Table 73.2) (18,20,59,62). Incorrect initial selection of an antibiotic leads to a poor outcome in hand infections (18,43,58).

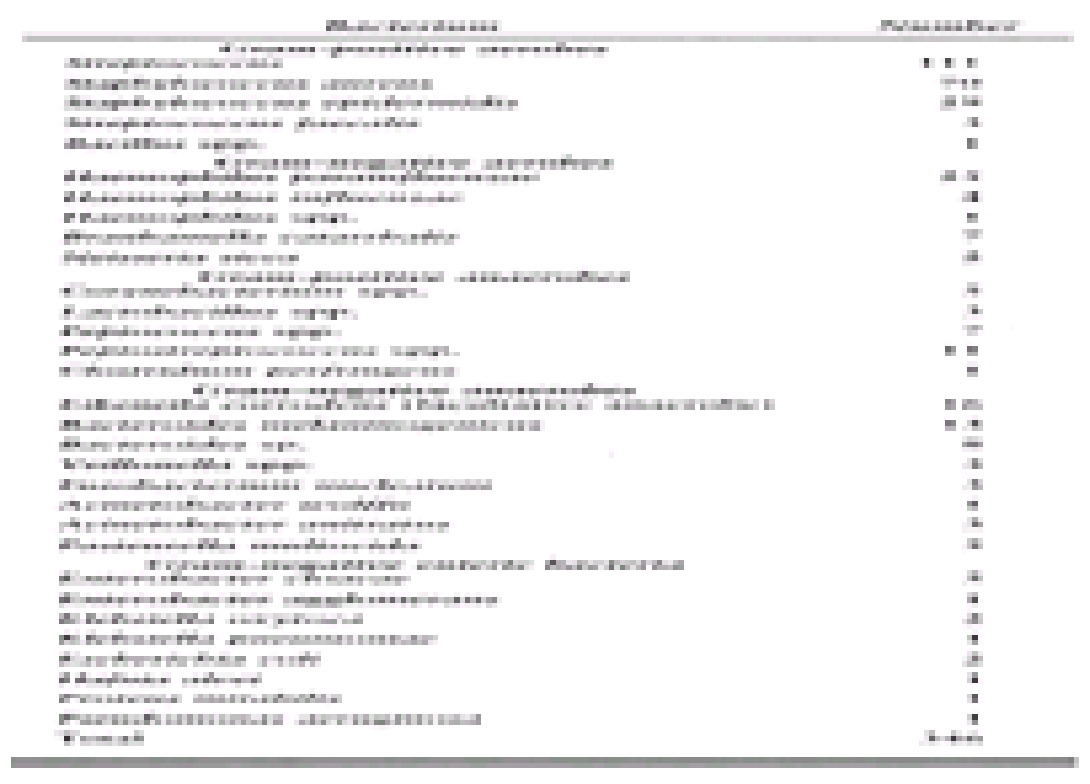

***Table 73.2. Organisms Cultured in 175 Hand Infections in Hospitalized Patients***

Lack of identification on initial Gram stain of subsequently cultured organisms is sufficiently common that Gram stains should not be used to exclude initial broad-spectrum coverage (43).

Initial treatment usually requires two antibiotics. Effective anaerobic coverage is provided by penicillin; effective aerobic gram-positive coverage is provided by either a penicillinase-resistant penicillin (e.g., nafcillin) or by a first-generation cephalosporin such as cefazolin (Ancef, Kefzol). Anaerobic coverage in penicillin-allergic patients is provided by cefoxitin (Mefoxin) (21). Clindamycin is bacteriostatic, and although it is effective against many anaerobes, it is ineffective against an important faculative anaerobic pathogen, *Eikenella corrodens* (9). Bactericidal agents are preferred.

Gram-negative enteric organisms are found in certain hand infections, including those in intravenous (IV) drug abusers and in mutilating injuries in dirty environments, such as that associated with farm machinery (16,44,52,62). Add an aminoglycoside antibiotic for initial treatment of these types of infections (51).

Tetanus immunization must be current. A booster is needed if the patient has not had one in the 5 years before the infection or injury. If the patient has had no previous immunization, administer 250 to 500 units of tetanus immune globulin in addition to tetanus toxoid. Follow up with a complete immunization schedule.

## CLASSIFICATION

### PYOGENIC BACTERIAL INFECTIONS

#### *Aerobic*

Infection appearing 24 to 48 hours after injury is typical of *Streptococcus*, whereas *Staphylococcus* usually takes 4 to 6 days to make itself known. Less common but often present are gram-negative bacteria of the *Enterobacteriaceae* such as *Escherichia coli*, *Enterobacter cloacae, Proteus*, and *Pseudomonas* (16,58,62). The latter are more common in infections related to IV drug abuse or contaminated environments such as farms, stagnant lakes, or sewers (16,39,44,52,62). In most hand infections, multiple pathogens are isolated on culture (58). Treat polymicrobial infection (Table 73.2) with broad-spectrum antibiotic coverage from the outset to avoid a poor outcome (18,43,58). Single antibiotic use rarely covers all offending organisms (18,34,59).

#### *Anaerobic*

Anaerobic bacteria are commonly overlooked as pathogens except in special circumstances such as clostridial infection in gas gangrene. Crush injuries that result in infection create an ideal environment for anaerobic organisms. Gram-positive anaerobic organisms, such as *Peptococcus* and *Peptostreptococcus*, are more frequently recognized, but gram-negative anaerobic bacteria are common isolates in hand infections (Table 73.2), either alone or with *Staphylococcus* and *Streptococcus*, especially in clenched-fist and human bite injuries (19,20,22,23,54,58).

These anaerobes are common human mouth flora and are important pathogens found in infections associated with IV drug abuse infections, because of the common practice of using saliva to lubricate the needle or moisten cotton used to strain impurities (23,44,58). The aerobic and anaerobic, gram-positive and gram-negative bacteria that infect hands are numerous, and we again emphasize the need to consider all pathogens when selecting an antibiotic (7).

### NONPYOGENIC INFECTIONS

Herpetic infections are common in the hands of health-care workers who deal with the mouth, such as dentists, dental hygienists, nurses, and anesthesiologists (31). They are self-limiting, and recognition of them is important to prevent overtreatment. Laboratory tests can confirm these infections, but the diagnosis is usually clinical.

The immune response to the mycobacteria, fungi, and related organisms is cell mediated rather than humoral antibody mediated, and therefore, often presents as a foreign-body—type reaction or nonspecific inflammation (3,10,12,25,65). Delay in diagnosis is common, and the diagnosis is often made only after failure of other treatment modalities. These organisms commonly infect the synovium. Once the diagnosis has been made, surgical intervention may be necessary; antibiotic treatment alone, however, is often indicated.

## SPECIFIC TREATMENT AND TECHNIQUES

### SUBCUTANEOUS ABSCESS IN THE HAND AND FOREARM

In surgical treatment, preserve as many of the veins as possible to reduce the deleterious effect of venous congestion. An abscess, which is usually the result of a puncture wound that inoculates the subcutaneous tissue, is recognized clinically as a raised area of erythema and induration with notable fluctuance. When seen in IV drug users, abscesses of the upper extremity vary in size and location but are mostly seen on the dorsum of the hand and forearm, in the antecubital fossa, and near

the deltoid insertion at the shoulder. An abscess must be drained. Hold antibiotics until intraoperative cultures are obtained.

- Base the incision over the apex of the abscess and in such a way that it can be extended proximally or distally in an extensile fashion because often the abscess proves to be larger than anticipated (Fig. 73.2). Incisions should be straight and extensile, curving only at skin creases so as to cross them at an angle of 60° or less.

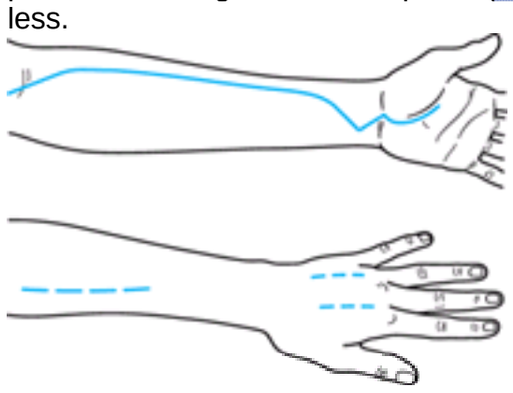

***Figure 73.2.*** Incisions for drainage of subcutaneous abscesses in the hand and forearm. Incisions are extensile. Only part of the incision may be necessary, but often the extent of infection is greater than expected. **A:** Palmar incision. **B:** Dorsal incision.

- Avoid sharp angles and skin flaps because they compromise skin already suffering from the decreased perfusion produced by the edema of the infection. Skin flaps created by surgical incisions in infection are at great risk for necrosis (55).
- Excise all infected tissue sharply; a large curet works well to remove the remains after most of the infected tissue has been sharply debrided. In infections related to IV drug abuse, identify and excise the thrombosed, infected vein along its course until uninfected tissue is found.
- Send fluid for Gram stain and aerobic or anaerobic cultures. Then begin IV antibiotics.
- Irrigate thoroughly with a pulsatile lavage system.
- Pack the wound and leave it open. Let the wound close secondarily; the vast majority will contract and epithelialize readily. For those wounds in which debridement has been extensive and secondary-intention healing would require a prolonged period, we recommend a meshed split-thickness skin graft placed over a completely granulated base at a later time. Delayed closure of a wound that is not completely resolved often results in recurrence of the infection because unseen residual infection can no longer drain. The conditions of abscess are, therefore, recreated.
- Initiate wet-to-dry dressing changes on the first postoperative day. These dressing changes are initially done by the nursing staff twice a day. Teach patients to change their own dressings in preparation for discharge from the hospital. As wound improvement is noted (decreased edema and erythema), change administration of antibiotics to the oral route and discharge patients with instructions to continue wet-to-dry dressing changes at home until the wound has completely healed.

## NECROTIZING FASCIITIS

Necrotizing fasciitis, historically called hospital gangrene or hemolytic streptococcal gangrene, manifests as an overwhelming infection within a short period of time. Necrotizing fasciitis is potentially a limb-threatening or life-threatening infection that more commonly affects patients with diabetes and IV drug abusers, who are especially at risk because of the decreased effectiveness of the immune response (2,24,44,52). The classic signs and symptoms are erythema, pain, advancing cellulitis, crepitance, skin necrosis, skin bullae, high fever, and other systemic signs of infection. When these patients are first seen, they may have a benign-appearing cellulitis. A tender, erythematous, swollen, and hot area quickly becomes tense, shiny, smooth, and more painful. Lymphadenitis and lymphangitis are rare (28). Within a few days, the skin color darkens and blisters, and bullae develop. These infections are usually associated with a significant leukocytosis (52). Radiographs may demonstrate soft-tissue gas. One organ system other than the integumentary or musculoskeletal system often is in failure (e.g., delirium, shock, respiratory failure, or renal failure).

Group A b-hemolytic *Streptococcus* is the most common organism cultured, although mixed aerobic-anaerobic and gram-positive and gram-negative infections also occur. Although the bacteriology of this infection may vary, the common mechanism of destruction is hypothesized to be the ability of the bacteria to produce various enzymes (i.e., hyaluronidase, lipase) (38). These bacterial enzymes facilitate necrosis of tissue, mainly fascia and fat, and thus allow the rapid spread of infection along tissue planes. Liquefactive necrosis of the fat and superficial fascia in the subcutaneous space leads to the characteristic appearance of a grayish, watery, and foul-smelling fluid often referred to as “dishwater pus.”

Although a rapidly progressive infection associated with a significant leukocytosis in a clinically deteriorating patient suggests the diagnosis of necrotizing fasciitis, a definitive diagnosis can be made at the time of surgery by the presence of necrotic fascia (64). Immediate radical surgical debridement is required until healthy muscle and fascia are seen proximally beyond the infected area. Absolutely all infected tissue must be debrided radically if the infection is to be controlled. Multiple debridements and even amputation may be necessary as a life-saving measure. The patient may deteriorate rapidly; clinical vigilance and frequent wound checks are mandatory.

## CLOSED-SPACE INFECTIONS

The hand is compartmented by the structures that pass through it (Table 73.3). Infection in one compartment generally is manifested by pain and swelling throughout the hand, with exquisite tenderness in the confines of the involved space. Knowledge of the anatomic boundaries of these spaces is important for diagnosis and treatment.

| *Space* | *Corresponding infection* |
|---|---|
| Flexor tendon fibro-osseous tunnel: | |
| Index, long, ring fingers | Flexor tenosynovitis |
| Thumb tendon/radial bursa | Radial bursa infection |
| Small finger flexors/ulnar bursa | Ulnar bursa infection |
| Radial and ulnar bursae | Horseshoe abscess (hypothenar space infection) |
| Webspace | Collar button abscess |
| Midpalmar space | Midpalmar space infection |
| Anterior adductor space | Thenar space infection |
| Posterior adductor space | Thumb webspace infection |
| Parona's space | Extension anterior to the pronator quadratus |

***Table 73.3. Spaces of the Hand and Their Infections***

### *Extension of Space Infections*

Infection in one compartment can extend to a contiguous compartment (Table 73.4). Adequate assessment, a necessary part of the preoperative examination, requires that the surgeon be aware of the possible patterns of extension (Fig. 73.3). Visual inspection offers clues, but as Kanavel notes, “The most conspicuous and valuable sign is the extension of the exquisite tenderness to the area involved” (29). If there is any doubt, exploration of the space where extension may have occurred is indicated at the time of surgical drainage of the known infected space.

| *Location of infection* | *Extension* |
|---|---|
| Flexor sheath infections: | |
| Ring, middle | Midpalmar space, webspaces |
| Index | Anterior adductor space |
| Thumb | Ulnar bursa (horseshoe abscess), wrist/ forearm (Parona's space) |
| Little | Radial bursa (horseshoe abscess), wrist/forearm (Parona's space) |
| Midpalm | Anterior adductor space, Parona's space/forearm, webspace |
| Anterior adductor | Midpalmar, index web, index flexor sheath, wrist/forearm |
| Webspace | Midpalmar, anterior adductor, flexor digital sheaths |

***Table 73.4. Extension of Space Infections***

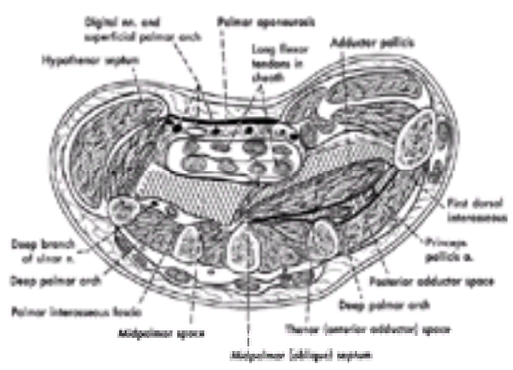


***Figure 73.3.*** Cross section through the proximal part of the hand demonstrating the palmar fascial spaces. (From Hollinshead WH, Rosse C. *Textbook of Anatomy,* 4th ed. Philadelphia: J.B. Lippincott, 1985.)

The deep spaces of the hand consist of the subfascial webspace, the dorsal subaponeurotic space, the midpalmar space, and the thenar space. These closed compartments are susceptible to infection, usually from direct traumatic inoculation, extension from an infected contiguous compartment, or less commonly, from hematogenous spread. The two most superficial deep spaces are the webspace and the dorsal subaponeurotic space; identifying infection in these spaces is easier; determining the involved space in the deep palm is more difficult.

**Webspace Infections** Symptoms of webspace infections are swelling and erythema over the palmar and dorsal surfaces of the involved webspace; characteristically swelling is greater dorsally than palmarly because of the greater suppleness of the dorsal skin. A webspace infection often occurs from deep spread of a superficially infected palmar callus. The fingers bordering the webspace involved are splayed because tissue pressure holds them apart. This type of infection is also called a collar button abscess after the old-fashioned dumbbell-shaped collar buttons. The infection begins palmarly, then spreads dorsally around or through the transverse metacarpal ligament to the dorsal webspace (11). Thus two abscess spaces are created, connected by a thin stalk. A neglected webspace infection can spread to the palm spaces through the lumbrical canals (27).

- Two incisions are needed (Fig. 73.4). Palmarly, make an oblique incision following the skin lines. Stay away from the web edge; an incision into or through the edge will cause contracture. The abscess is just below the skin, so deeper dissection is not indicated. Remember that in this area, the neurovascular structures lie just beneath the skin, so use great care.

***Figure 73.4.*** Dashed lines indicate incisions for drainage of webspace infections (**A**) and dorsal subaponeurotic space infections (**B**).

- Spread the margins of the incision gently to allow adequate drainage.
- Dorsally, make a longitudinal incision between the metacarpal heads that stays at least 5 mm proximal to the web edge. Excise the dorsal abscess cavity and break up all loculations.
- Place drains into the incisions after irrigation. Begin IV antibiotics after fluid or tissue for culture is obtained. Follow with the usual aftercare.

**Dorsal Subaponeurotic Space Infections** The dorsal subaponeurotic space is a potential space on the dorsum of the hand beneath the extensor tendons (29). Infection usually begins with direct inoculation beneath the extensor tendons. The patient has dorsal hand swelling and erythema, and often it is difficult to delineate a subcutaneous infection from one involving the subaponeurotic space. The deep space is involved unless proven otherwise and thus should be drained.

- Make two longitudinal incisions; one over the second metacarpal shaft and another over either the fourth or the fifth metacarpal shaft (Fig. 73.2*B*) to allow better coverage of the extensor tendons dorsally.
- Try to preserve the dorsal veins, which are important to control swelling.
- Explore deep to the extensor tendons, taking care not to injure them.
- Allow incisions to heal by secondary intention.
- Important: Prevent extensor lag by initiating early motion of the wrist and finger joints. Continue therapy during the entire healing stage.

***Palm Space Infections***

The palm spaces are potential spaces bounded by fascia in the central hand (Fig. 73.3). Anatomists do not agree on their exact anatomic boundaries. They lie dorsal to the flexor tendons and palmar to the intrinsic muscles of the hand, and proximally and distally, they merge to form potential extensions to other hand and forearm spaces. These extensions are a source of spread of infection.

**Thenar Space Infections** What is commonly called the thenar space is more appropriately identified as either the anterior or posterior adductor spaces (Fig. 73.3). Most thenar space infections involve the anterior adductor space. Its anterior boundary is the index finger flexor tendons and the midpalmar septum; its posterior boundary is the fascia over the adductor pollicis. Radially, the thenar intermuscular septum and ulnarly the midpalmar (oblique) septum complete this potential space (27).

Symptoms include pain, tenderness to palpation, and tense swelling in the space. Thumb adduction and opposition decrease the potential thenar space and cause an increase in pain. Therefore, the attitude of the hand with a thenar space infection is with the thumb in palmar abduction (11). Infection in the thenar space can spread from flexor tenosynovitis of the index finger. Distinguishing between an anterior adductor space infection and a posterior adductor space infection can be difficult. Usually, the anterior space is involved first and as the infection progresses, purulence tracts over the adductor pollicis to the posterior adductor space. If there is any

doubt, open both spaces.

***Anterior Adductor (Thenar) Space***

- Make a curvilinear incision in the palm parallel to the thenar crease on the ulnar side at the base of the thenar eminence (Fig. 73.5).
- Gently spread the palmar fascia in line with the incision. Identify and tag the digital nerves and flexors to the index finger.

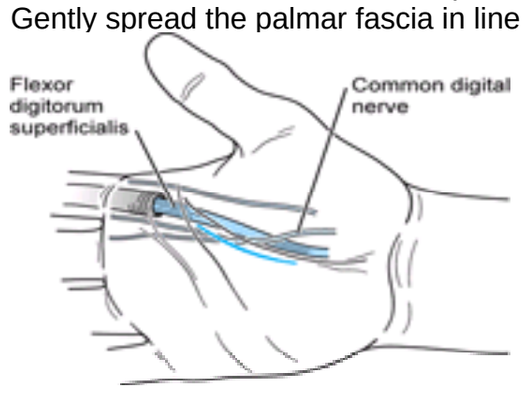


***Figure 73.5.*** Incision for drainage of thenar space infections.

- Gently retract the nerves.
- Enter the space beneath the flexors by blunt dissection, remembering that the superficial and deep palmar arches and recurrent branch of the median nerve are in this area.
- Open sufficiently to allow easy drainage.
- Send fluid for aerobic and anaerobic culture, then start IV antibiotics.
- Irrigate well. Place a penrose drain to keep the space open. Close the skin loosely.

***Posterior Adductor Space***

- Make a longitudinal incision dorsally between the thumb and index metacarpals (Fig. 73.5). Stay away from the edge of the thumb-index webspace to avoid webspace contractures.
- Incise the fascia, then retract the first dorsal interosseous muscle ulnarly and the extensor pollicis longus tendon radially. Take care to avoid the radial artery, which is in the proximal portion of the incision.
- Bluntly enter the space between the retracted muscles. Open sufficiently to allow easy drainage. Send fluid for aerobic and anaerobic cultures, then begin IV antibiotics.
- Irrigate well. Place a Penrose drain to keep the space open. Close the skin loosely.

**Midpalmar Space Infections** The midpalmar septum arises beneath the flexor tendons of the index finger, coursing obliquely posteriorly to its attachment on the third metacarpal. It divides the palm into the two main spaces of the anterior adductor (thenar) space and midpalmar space. Midpalmar space infections (Fig. 73.3) are less common than thenar space infections and occur from direct inoculation of this potential space (11) or spread from tenosynovitis of the long, ring, or small fingers. The midpalmar space is bordered anteriorly by the flexor tendons of the ring, long, and small fingers. Posteriorly, the second, third, and fourth palmar interossei, the third dorsal interosseus, and the ulnar third and the entire fourth metacarpal define this space. Its ulnar border is the hypothenar muscular septum, and the radial border is the midpalmar (oblique) septum (27).

- Make a transverse incision parallel and just proximal to the distal palmar crease, just through the skin at the ring finger. It will be over the area of the swelling. The digital neurovascular structures lie just below the skin, so take extreme care when making the skin incision (Fig. 73.6).

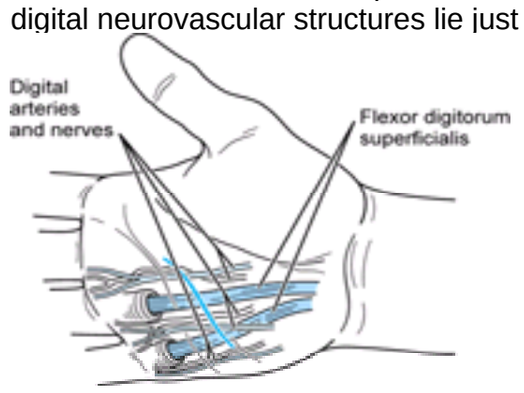


***Figure 73.6.*** Incision for drainage of midpalmar space infection.

- Once through the skin, gently dissect longitudinally and identify the digital nerves. Tag these features and retract them gently. Identify the deep and superficial flexor tendons to the ring finger. Because the space is dorsal to the flexors, blunt exploration radial and deep to these tendons will gain entrance into the space.
- Spread gently and open sufficiently to allow adequate drainage. Send fluid for aerobic and anaerobic cultures, then begin IV antibiotics.
- Irrigate, and place a Penrose drain to keep the space open. Close the skin loosely.

**SUPPURATIVE FLEXOR TENOSYNOVITIS**

Suppurative flexor tenosynovitis requires aggressive, appropriate, and prompt treatment to avoid severe disability of the digit or amputation. Acute flexor tenosynovitis is an infection of the tendon sheath that surrounds the flexor tendons. The synovial sheath consists of a visceral layer or epitenon that is adherent to the tendon and a parietal layer, which join at their most distal and proximal ends. The sheath extends from the midpalmar crease (metacarpal neck) to just proximal to the distal interphalangeal joint. The small finger flexor sheath is continuous with the ulnar bursa in the palm that surrounds the superficial and deep flexor tendons. The sheath around the flexor pollicis longus is continuous with the radial bursa (Fig. 73.7). Both of these palmar bursae extend just proximal to the transverse carpal ligament and, in 80% of individuals, they communicate (42).

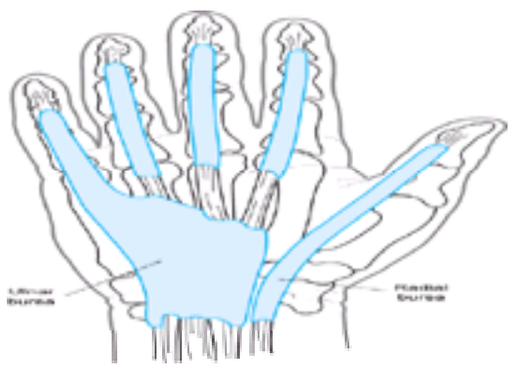

***Figure 73.7.*** Anatomy of the radial and ulnar bursae.

Flexor tenosynovitis can develop from the most innocuous-appearing small abrasions and tiny punctures; do not be fooled. These minor wounds are the indication that

the sheath has been inoculated with bacteria. The ring, long, and index fingers are most commonly involved; however, any digit may be affected. Kanavel (29) described four cardinal signs of infection of the flexor sheath:

1. Symmetric, fusiform swelling of the entire finger (sausage finger)
2. Semiflexed position of the digit
3. Exquisite tenderness over the course of the sheath
4. Exquisite pain on extending the finger

In advanced cases, all four signs will be seen, but in early cases, only one or two of these may been detected. The most reliable sign is tenderness over the flexor sheath (42).

When examining a patient with a flexor sheath infection, examine the other spaces of the hand as well, because extension of a sheath infection can occur into the palmar spaces, webspace, carpal canal, palm bursa, and Parona's space (see later). Although spread to any of the hand spaces can occur, typically flexor sheath infections of the middle, ring, and small fingers extend into the midpalmar space, and index finger infections extend into the anterior adductor space (thenar space).

The goal of treatment is to drain the infection and allow continued drainage without compromising the function and anatomy of the delicate structure that is the flexor tendon and its canal. Drainage can easily be accomplished, but the drainage procedure itself must not be detrimental to the sheath if the smooth gliding of the flexor tendon within the sheath is to occur after eradication of the infection. We believe that this technique is best accomplished through the intermittent irrigation of the sheath using a catheter (41,42).

Continuous irrigation through the catheter tube has the advantage of constant cleansing of the sheath. If fluid does not drain easily from the distal wound, it can be hydraulically forced into the sheath and surrounding tissues. Intermittent irrigation requires the observation of ready egress while infusing to avoid this potential problem. Antibiotic irrigation within the sheath is not recommended because it has not been proven to be superior to saline irrigation alone. Also, the effect of antibiotics on the flexor sheath with respect to inducing adhesions has not been studied.

### *Operative Technique*

- Use two incisions (Fig. 73.8). Make a transverse incision proximally in the area of the $A_1$ flexor pulley (metacarpophalangeal joint). This incision is made at the proximal palm crease in the index finger, at the distal palmar crease in the ring finger, and between the two for the long finger. Incise the skin only about 1 cm in length.

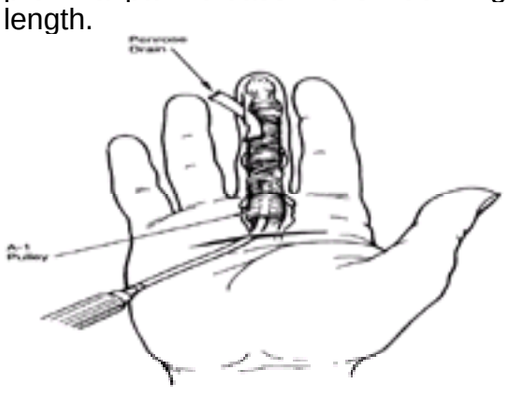

***Figure 73.8.*** Closed tendon sheath irrigation for flexor tenosynovitis.

- Gently dissect longitudinally in line with the palmar fascia (perpendicular to the incision), locating the digital nerves on either side of the tendon. Tag and gently retract them.
- Identify the tendon and the $A_1$ pulley in the base of the wound. Open the palmar synovial and fibrous covering that is the beginning of the flexor sheath; pus or, more commonly, slightly cloudy fluid will egress. Send a sample for culture; then start IV antibiotics.
- Make the second incision along the midlateral line of the digit on the ulnar side at the distal interphalangeal joint crease of the index and long fingers, or the radial side of the ring and little fingers. The midlateral line is that line created by connecting the dots that can be made at the end of the flexion creases when the finger is maximally flexed. Incise the skin. Bluntly dissect deeper to enter the flexor sheath.
- At the proximal wound, lift the $A_1$ pulley and thread a small catheter (#10 pediatric feeding tube fenestrated on its end) into the sheath for about 2 cm.
- Attach a syringe to the catheter end in the palm and irrigate saline through the catheter. Fluid should easily exit from the distal wound. If it does not, reposition the catheter or enlarge the opening distally. Several positioning attempts may be needed to achieve easy flow.
- Irrigate at least 500 ml of normal saline through the sheath to thoroughly cleanse it.
- Place a rubber wick made from a Penrose drain into the sheath through the distal wound to prevent closure. Suture the wick distally and the irrigating tube proximally to the skin to prevent their accidental removal. Approximate the proximal wound with one or two nylon sutures.
- Apply a bulky hand dressing that allows visualization of the distal wound but covers the palmar wound, and bring the catheter out through the dressing.

### *Postoperative Care*

Irrigate 20 to 30 ml of room-temperature saline slowly over 30 to 60 seconds through the catheter every 2 to 4 hours. Postoperative orders should include nursing precautions that when irrigating the catheter with saline, resistance to flow should be minimal, that egress should be seen, and that the patient will experience some discomfort. If resistance is excessive, flow is not seen distally, and the patient experiences excessive pain, the catheter may have become kinked or may have moved to an inappropriate area. Remove the catheter if easy flow cannot be regained. Continue the irrigation until the sheath is nontender (36 to 72 hours), then remove the catheter and wick, and apply a moist dressing for 2 to 3 more days, continuing IV antibiotics. Begin active range-of-motion exercises of the digit after catheter removal to prevent stiffness. Allow the wounds to close secondarily.

## RADIAL AND ULNAR BURSAE INFECTIONS

Infections may occur in the flexor sheaths of the little finger and thumb flexor tendons and their bursae (Fig. 73.6). The proximal extension of the thumb flexor sheath is the radial bursa. It extends proximal to the transverse carpal ligament. The proximal extension of the small finger flexor sheath is the ulnar bursa that also surrounds the superficial and deep flexor tendons and extends proximal to the transverse carpal ligament as well. As stated earlier, in approximately 80% of individuals, these bursae communicate. Infection that spreads between these two bursae can create a “horseshoe abscess.”

Kanavel's signs of suppurative flexor tenosynovitis are present in the digit; in addition, there is swelling, tenderness, and calor into the respective side of the palm and wrist. Treat these symptoms with catheter irrigation as described earlier; described below are the modifications appropriate to the anatomy of each digit and its bursa.

### *Radial Bursa*

- Make a distal thumb incision along the radial side at the interphalangeal joint crease. Stay dorsal to the neurovascular bundle. Identify and enter the flexor sheath.
- Pass a probe or other blunt instrument carefully down the canal until it presses up at the palmar wrist crease. Do not push the probe if you meet resistance. Gently redirect it. Make a longitudinal incision that does not cross the wrist crease.
- Enter the space and identify your probe.
- Pass a #10 pediatric feeding tube from proximal to distal for about 2 cm. Suture a wick distally and the irrigation tube proximally, as described for suppurative flexor tenosynovitis.
- The rest of the procedure is the same as for flexor tenosynovitis. Do not hesitate to make an additional incision in the palm if threading the catheter is difficult.

### *Ulnar Bursa*

The technique for treating an ulnar bursa is similar to that for a radial bursa, except the distal incision on the small finger is on the ulnar side of the digit at the distal interphalangeal joint (Fig. 73.9).

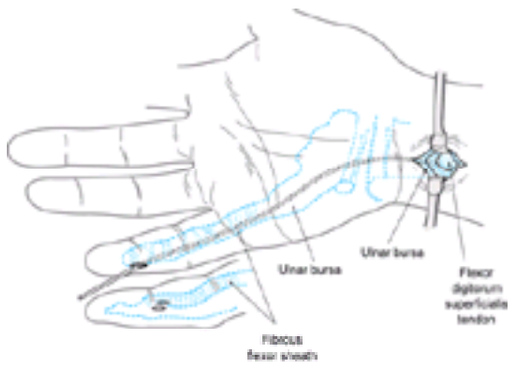


***Figure 73.9.*** Drainage of ulnar bursa infection and insertion of irrigation catheter.

## PARONA'S SPACE INFECTIONS

Parona's space is a potential space in the distal forearm between the deep flexor tendons and the pronator quadratus. It is usually infected only as a result of proximal extension of a hand space infection. With deep space palmar infections, always palpate Parona's space for fullness and tenderness. Clinically, infection is evident by tenderness in the distal forearm with pain on pronation and supination. Drainage is accomplished by an incision at the wrist and proximal forearm that often includes communication with the proximal portion of one of the bursa or palmar space infections. Bluntly dissect deep to the flexor tendons to enter the space. Enlarge sufficiently to allow adequate drainage.

## SEPTIC ARTHRITIS

Infection within a joint demands prompt treatment. If detected before fulminant proliferation of bacteria, aspiration for diagnosis and culture can be followed by antibiotic therapy alone. Medical literature documents the ability to eradicate the infection by antibiotics alone. The deleterious effect of pus on cartilage, however, necessitates surgical drainage if there is any doubt that the infection has been detected and treated early enough. Septic arthritis or infection of a joint space may affect any of the joints in the digits, thumb, or wrist. It is most likely secondary to direct penetration of the joint capsule, but hematogenous spread occurs as well. If there is no history of a bite, puncture near the joint, or a recent laceration, it is important to ask the patient about recent tooth abscesses, ear infections, other skin infections, gastrointestinal (GI) infections, and genitourinary (GU) infections. Gonococcal septic arthritis can be treated with antibiotics alone; it is important to question the patient about his or her sexual history.

A patient with a joint infection has a swollen, painful, erythematous, and warm digit, thumb, or wrist, localized to a specific joint. The pathognomonic sign of joint infection is exquisite pain on attempted motion of that joint. Cellulitis over a joint causes pain on motion, but the tenderness elicited by slow, gentle, passive motion in cellulitis is much different from the severe pain caused by any attempt at motion of an infected joint.

Diagnosis of a joint infection can be confirmed following joint aspiration. Send the aspirate for cell count with differentiation, Gram stain, anaerobic and aerobic culture, glucose, and crystal analysis. A white blood cell differential of greater than 50,000 (usually more than 75% segmented neutrophils), or the presence of bacteria on Gram stain or culture is diagnostic. A synovial fluid glucose of 40 mg less than the fasting blood glucose is consistent with an infectious process (53). Finally, a crystal analysis is necessary to rule out gout or pseudogout as a cause of the painful, red, swollen joint.

### *Aspiration of Phalangeal and Metacarpophalangeal Joints*

Aspirate with as large a needle as can be entered into the joint, ideally an 18 gauge needle or larger. A 20 or 22 gauge needle is usually the largest that will gain entrance into smaller joints. The joint space for the metacarpophalangeal joint is easily palpated just ulnar or radial to the extensor hood; take the edge of your fingernail and press. Aspirate after an antiseptic preparation. Giving a local anesthetic usually causes more discomfort than the single stick of the aspirating needle, but patients are not easily convinced of this fact.

The interphalangeal joint spaces can be located in a similar fashion. This location just next to the extensor tendon dorsally would correspond to a 10 o'clock or 2 o'clock position if the extensor tendon (top or dorsal) is considered as 12 o'clock.

- Use a large needle, ideally 18 or 20 gauge, or the largest needle that will enter the joint space.
- Palpate the joint space for the metacarpophalangeal joint, ulnar or radial to the extensor hood with the edge of your fingernail, feeling for the depression of the joint space.
- Aspirate after an antiseptic wash.
- Locate the interphalangeal joint in a similar fashion. Enter at the 10 or 2 o'clock position, with the extensor tendon as 12 o'clock.
- Aspirate after an antiseptic wash.

### Drainage of Metacarpophalangeal and Interphalangeal Joints

- Base the incision dorsally over the involved joint.
- Incise longitudinally through either the extensor tendon at the metacarpophalangeal joint or through the extensor mechanism at the proximal or distal interphalangeal joints.
- Enter the involved joint and thoroughly irrigate it.
- Leave a small wick (penrose drain) in the joint space to facilitate drainage. Reapproximate the extensor mechanism and loosely close the skin.
- Remove the penrose drain in 48 to 72 hours.

### *Aspiration of the Wrist*

The wrist joint includes the radiocarpal, radioulnar, ulnocarpal, and midcarpal joints. Septic arthritis may be found in any one or all of these joints; these spaces may or may not normally communicate. Direct the preoperative examination toward localizing the joint or joints involved. Pronation or supination pain indicates involvement of the radioulnar joint; flexion or extension pain indicates involvement of the radiocarpal, ulnocarpal, or midcarpal joints. Aspiration with an 18-gauge needle confirms clinical suspicions. The radial and ulnar styloids offer convenient landmarks; enter just distal to them.

### *Draining the Wrist*

- Enter the radiocarpal, radioulnar, midcarpal, and ulnocarpal joints through either a transverse or longitudinal dorsal skin incision. A transverse incision has the advantage that if you take care to isolate and preserve veins, you can make a completely circumferential incision so that all wrist joint spaces can be entered until the infected space can be found and drained.
- Make the skin incision, and then enter the joint space by blunt dissection between the appropriate extensor compartments. Enter between the third (extensor pollicis longus) and fourth (extensor indicis proprius, extensor digitorum communis) compartments to drain the radiocarpal, radioulnar, and midcarpal joints. Enter around the extensor carpi ulnaris or extensor digiti quinti tendons to drain the ulnocarpal joint.
- Send fluid for aerobic and anaerobic cultures. Begin IV antibiotics.
- Irrigate thoroughly with a pulsatile lavage system.
- Place a closed suction system drain. Close the joint capsule and skin incision over the drain. Leave the drain in for 3 to 5 days.
- Begin gentle active assisted and active range-of-motion exercises after drain removal.
- Continue IV antibiotics for a least 1 week. Follow with an oral agent for several weeks after hospital discharge. Antibiotic sensitivities and minimum inhibitory concentration (MIC) help guide the appropriate oral antibiotic regimen. Ideally, the oral dose will have been determined by greater than 1:8 serum bactericidal levels against the bacterium or bacteria isolated.

## HUMAN BITE AND CLENCHED-FIST INFECTIONS

Hand infections due to human bites are common and can have significant sequelae if they are not recognized and treated correctly (6,7,15,19,22,23,34). There are four classic mechanisms of infection, and these include self-inflicted (caused, for example, by nail biting), traumatic amputation (usually at the distal interphalangeal joint or pulp) from a bite, full-thickness bite wounds on any part of the hand, and finally a clenched-fist bite injury, usually following an altercation (14). The complications of incompletely treated human bite infections include arthritis, joint stiffness, osteomyelitis, toxic shock syndrome, and infrequently, death. Human mouth organisms inoculated into tissue are quite virulent (6,7,13,15,19,22,23,33,34 and 35,58,63).

In the preantibiotic era, amputation as a means to control a human-bite infection occurred in up to half of the affected patients. Death secondary to morsus humanis was reported as well. The introduction of antibiotics has not eliminated the complications associated with these infections. Even with antibiotics, 6% of human bites need amputation to control infection, 4% require late amputation, and 28% develop either osteomyelitis or other causes for stiff, disabled fingers (34).

The clenched-fist injury occurs with the fist closed, and the overlying dorsal skin and extensor tendon stretched distally. The tooth penetrates the skin, part or all of the tendon, the dorsal joint capsule, and potentially the metacarpal head. With the hand open, it may be difficult to recognize the extent of injury because the injury to the joint capsule and bone may be distal to the skin laceration and injury to the extensor tendon is proximal to the skin laceration (Fig. 73.10). Often, there is intra-articular violation with the potential for septic arthritis. Sometimes, osteochondral fractures of the metacarpal head or fracture of the metacarpal head or neck occur. The clenched-fist injury commonly involves the metacarpophalangeal joint of the long, ring, or little fingers, but any hand joint or digit can be involved.

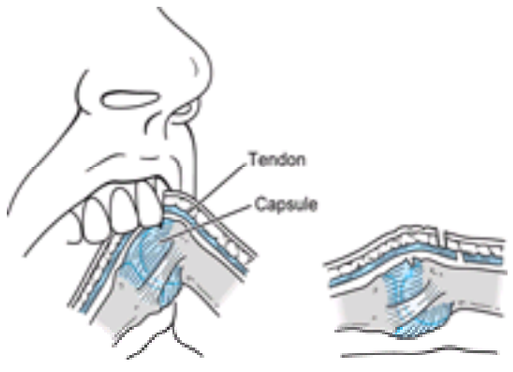


***Figure 73.10.*** A fight bite occurs during flexion (**A**) of the metacarpophalangeal joint. During extension (**B**) of the injured joint, the tendon or osteochondral injury may be obscured leading to a closed intra-articular injury.

For clenched-fist injuries, those that are treated early (i.e., in less than 24 hours) have a better prognosis than those seen later than 24 hours from the time of injury (29,34). Clenched-fist injuries may resemble a simple puncture wound over the metacarpohalangeal joint, but there usually is more extensive damage to the soft tissue and bony structures underneath.

The most common organisms responsible for human bite infections are *Staphylococcus aureus, Streptococcus* organisms, and *E. corrodens*. A plethora of microbes are isolated from the human mouth flora, however, and thus it is not uncommon to see mixed infections that could include*, Bacteroides* sp., *Neisseria* sp., *Clostridia* sp., spirochetes*, Micrococcus,* and rarely, *Actinomyces* (19,20,22,34,40).

Although *E. corrodens* is not the most common pathogen in human bite infections, it certainly seems to be the type most often associated with “fight bites.” *E. corrodens* has been isolated in 7% to 29% of human bite infections (4,20,47). Although it is a normal part of the human mouth flora, it is more readily cultured from dental scrapings than from saliva (47). It is a gram-negative rod and a facultative anaerobe and thus grows best in 10% $CO_2$.

Treatment begins in the emergency department with cultures (anaerobic, aerobic, 10% $CO_2$), radiographs to rule out a fracture or foreign body (i.e., tooth), and wound exploration. Dorsal puncture wounds around the metacarpohalangeal joint are considered to be clenched-fist injuries unless proven otherwise.

Fully flex and extend the involved metacarpohalangeal joint to determine extensor tendon involvement. A saline arthrogram may assist in determining joint involvement. A history of a human bite or lacerations (especially over a joint) obtained during a fight must be treated aggressively. Treatment requires surgical debridement of dead or questionably viable tissue and thorough irrigation of the subcutaneous space (especially a joint). Leave the wound open.

Antibiotics effective against gram-positive aerobic and gram-positive and gram-negative anaerobic bacteria are mandatory (19,20,21,22 and 23). First-generation cephalosporins such as cefazolin, cephalothin, and cephradine, or penicillinase-resistant penicillins are effective against the common gram-positive aerobic bacteria. Many anaerobes commonly isolated from clenched-fist and human bite infections, however, are resistant to penicillinase-resistant penicillins and clindamycin, which are common first choices in the treatment of skin infections (9,49,60).

The coverage of first-generation cephalosporins against human oral flora is variable, so a second antibiotic is necessary (21,49). The antibiotic of choice for these anaerobes is penicillin. Cefoxitin is effective against gram-positive aerobic bacteria and the anaerobes described, so it may be used as a single agent for penicillin-allergic patients (21).

***Operative Technique***

- Extend the traumatic wound proximally and distally.
- Remove the necrotic and infected tissue from the subcutaneous layer. The infraction often extends beyond the obvious site of injury. Explore nearby potential areas of invasion such as the dorsal subcutaneous space.
- Always open the joint if the injury is over or near a joint. The joint often appears uninvolved until arthrotomy is performed and the pus wells out. Enter the joint dorsally, making a 1 cm longitudinal incision in the capsule through the extensor tendon.
- Inspect the cartilaginous surfaces for lesions. An osteochondral defect or tooth indentation is common. Record such a finding and also the condition of the cartilage in the operative record. Divots and unhealthy-appearing cartilage are poor prognostic factors.
- Irrigate thoroughly by pulsatile lavage. Leave the wound *open*.

**ANIMAL BITES**

Ninety percent of all animal bites to humans are dog bites (57). Cats account for another 5% of animal bites. Although several bacteria including *S. aureus*, *Streptococcus viridans,* and *Bacteroides* species may produce infection, *Pasteurella multocida*, a gram-negative anaerobic bacterium, has been identified as an important pathogen in animal bite infections (1,21) (more commonly from cat than from dog bites). The presence of cellulitis, lymphangitis, serosangueinous, or purulent drainage within 12 to 24 hours after a cat or dog bite strongly suggests *P. multocida* as the offending organism (1).

Initial treatment consists of thorough irrigation and debridement of necrotic and damaged tissue. Be sure to culture the wound even if gross purulence is not found. Penicillin is the drug of choice for *P. multocida*, with tetracycline and cephalosporins as alternatives. Administer penicillin intravenously in combination with cefazolin; alternatively, amoxicillin-clavulanate potassium can be given orally for less severe infections (Table 73.1).

**FELON**

A felon is an infection in the pulp of a digit. Beneath the skin of the pulp lies fat. Numerous fibrous septae that tether the skin to the bone cause compartmentation of the fat to make shock-absorbing spaces. Infection in the digit pulp is therefore a series of small, closed-space infections, each needing incision and drainage. A felon is usually due to penetrating trauma to the tip of a digit. *S. aureus* is the most common organism found (45). The presenting symptom is an erythematous, swollen distal phalanx on the palmar side of the digit. It is important to distinguish a felon from herpetic whitlow, because the treatment of herpetic infection of the distal phalanx is nonsurgical. When the felon has organized into an abscess, drainage is indicated.

- Drain a felon that points palmar and midline by a midline approach (Fig. 73.11*A*). Drain a felon that does not point midline with a midlateral incision (Fig. 73.11*B*).

Avoid the “fish-mouth” incision, because it destabilizes the pulp and can cause flap necrosis.

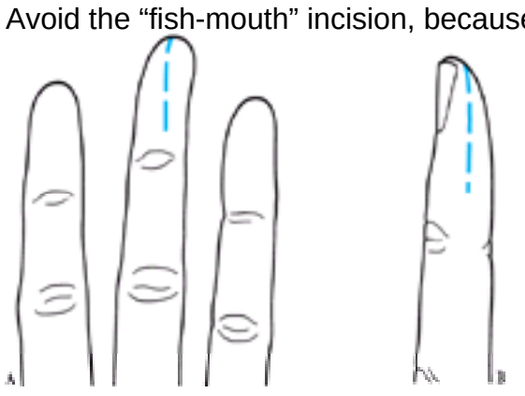

***Figure 73.11.*** Incision for drainage of a felon. All septae must be cut to allow appropriate drainage. **A:** Midline incision. **B:** Midlateral incision.

- Incise deeply all the way to the bone and all the way across the pulp to open all compartmentation spaces. Send fluid or tissue for culture. Begin antibiotics and irrigate thoroughly.
- Leave the wound open. Place a wick into the wound. Apply a bulky hand dressing to immobilize the hand for the first 24 to 48 hours.
- Remove the wick and begin whirlpool soaks four to five times a day. Apply a finger dressing incorporating damp gauze next to the wound. Encourage active finger and hand motion.

**NAIL BED INFECTIONS**

Where the skin of the dorsal digit meets the nail is an area sensitive to the disruptive influence of daily living and nail cosmetic practices, especially in those whose work or habits cause a continually damp or wet environment. Bacteria invade the fold of skin over the nail matrix, producing the characteristic lesion of inflammation, pain, and swelling. When it is confined to a side of the nail and involves the fold of skin and not the nail, the infection is called a paronychia. When it involves the base of the nail fold, it is an eponychia. Sometimes both sides of the nail and the eponychial fold are involved, and this infection is called a runaround abscess.

Infection that tracks deep to the nail plate and involves the nail bed is a subungual abscess and has more serious implications The localized superficial nail skinfold infection is not serious, but deep infection may invade bone and result in nail destruction, osteomyelitis, and amputation. A patient with a nail bed infection has swelling, pain, and erythema at the base of the fingernail or on the side of the nail. The bacterium that infects is almost exclusively *Staphylococcus*, except in children, in whom mouth flora can infect as well because of thumb-sucking (8).

Beware of the paronychia that is treated and then returns as a felon. Infection spreads from the nail bed to the pulp of the digit through bone; if such spread occurs, osteomyelitis of the distal phalanx is present.

Chronic paronychia involves a different pathologic process. Women who work with their hands in moist environments are more susceptible. The infection comes and goes throughout its course and leads to a painful thickened eponychial fold that sometimes accumulates whitish thick material. Most often, *Candida albicans* is the offending yeast. Conservative treatment of topical steroids and antifungals has met with limited success. Chronic paronychias often require marsupialization.

***Paronychia and Eponychia***

- After metacarpal block, use a Freer elevator or other blunt instrument and, beginning distally, elevate a few millimeters of the nail fold from the nail as far proximally as the infection extends. A blunt instrument helps prevent scoring that can later produce nail ridging. (Note: An incision usually is not needed for simple cases. A more extensive abscess may need a small incision adjacent to the eponychial fold and parallel to the nail plate.)
- Using an 18-gauge needle, prick the infected area to drain and break up loculations. Expect only a few drops of pus. Send these drops for culture, and begin an antibiotic effective against *Staphylococcus*.
- Cover the drained area with antibiotic-impregnated gauze and place it under the nail fold to allow continued drainage. Begin soaks in 24 hours and continue until healed.

***Chronic Paronychia***

- Use a digital block. Perform an eponychial marsupialization by excising a small crescent-shaped piece of the eponychial fold.
- Remove the skin and thickened tissue down to, but not including, the germinal matrix.
- If the nail plate is involved (damaged), remove the entire nail.
- Place xeroform gauze under the nail fold to promote drainage and keep the nail fold from closing.

***Subungual Abscess***

- If the nail has been elevated off the matrix by infection, a subungual abscess is present. Incise along the borders of the nail fold. Elevate the nail fold (Fig. 73.12).

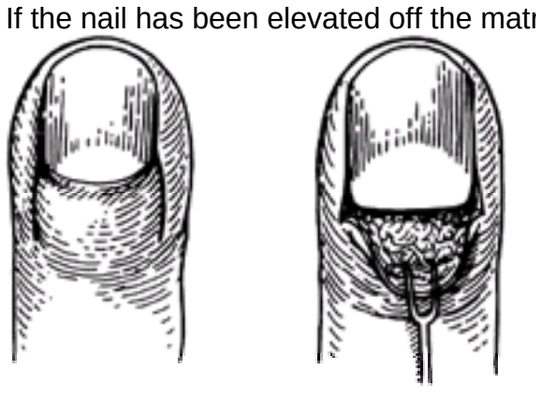

***Figure 73.12.*** Incision for drainage of a subungual abscess. After folding back the eponychium, the proximal nail plate is cut with scissors and removed.

- Remove the overlying nail plate to allow adequate drainage. If there is any question as to the extent of the subungual abscess, remove the entire nail. Remember, gently free the nail plate from the matrix with a blunt instrument to avoid injury to the matrix, which may result in ridging of the nail as it grows back.
- After removing nail plate, scoop the abscess contents out with a curet, gently scraping the surface of the nail matrix.
- If the nail is removed from the nail fold, place xeroform gauze under the nail fold.
- Request aerobic and anaerobic culture on the fluid. Begin IV antibiotics.

**HERPETIC INFECTION AND HERPETIC WHITLOW**

Herpetic infection in the hand most often occurs in the distal finger (31). It is most commonly seen in health care providers exposed to oral secretions such as dentists, nurses, and dental hygienists. Pain is the initial symptom. Vesicles 1 to 2 mm in diameter containing clear fluid occur on an erythematous base; as the infection progresses, the vesicles coalesce into bullae. The fluid may turn cloudy after being initially clear, but it is never purulent. Purpuric lesions can develop beneath the nails. Lymphangitis and lymphadenopathy may also occur and confuse the picture, simulating a bacterial infection. The pain continues for 2 to 4 weeks, with decreasing erythema. The hemorrhagic areas crust and then desquamate, leaving normal tissue.

Laboratory confirmation can be obtained by early culture of the vesicles, which grow characteristic plaques within 1 to 3 days. Serum titers of antibody to herpesvirus over 2 to 3 weeks may rise to greater than four times normal levels.

Note the self-limited nature of this illness. If incision and drainage are performed, no purulence will be expressed, and deeper tissues will be exposed to the

herpesvirus. An aggressive secondary bacterial infection then occurs all too often as the incision injures tissue that has already been compromised by the edema, pressure, and unhealthy conditions the viral “cellulitis” has created. Expectant observation is the key to treatment. Antiviral agents are not indicated.

**MYCOBACTERIAL INFECTIONS**

Mycobacterial infections may be caused by *Mycobacterium tuberculosis.* However, in the hand, infections are more commonly caused by atypical mycobateria such as *M. marinum, M. kansasii, M. avium, M. bovis,* and *M. intracellulare* (12,25). These infections typically occur in middle-aged people with a history of a puncture wound within 6 weeks of onset of symptoms. *M. marinum* is the most common atypical pathogen, and inoculation usually occurs in a seacoast environment or dock area (26). Although most atypical mycobacterial infections involve the skin, deeper structures are susceptible. Tenosynovial infections as well as bone and joint involvement have been documented.

Mycobacterial infections usually do not incite a systemic response, and thus, constitutional symptoms of infection are not present. Leukocytosis and an elevated sedimentation rate are rare. Pain, limitation of motion, and fullness of the involved area are noted, but signs and symptoms are intermittent. Skin infections are often associated with dermal or subdermal granulomas, which are the hallmark of diagnosis (26). Synovium is commonly involved. The synovitis is out of proportion to the disease initially suspected, such as collagen vascular disease, or nonspecific inflammatory synovitis. Fistulae may be present. Tenosynovial infections most commonly involve the flexor tendon sheaths of the fingers. Patients describe chronic swelling of the involved digit. Although pain is mild, the bulky synovium may interfere with finger function, and motion may be limited.

Although the history and physical exam are important, the key to diagnosis of atypical mycobacterial infections in the hand is biopsy and culture of the suspicious tissue. Diagnosis is based on finding Langhans'-type giant cells in tissue and the presence of acid-fast bacilli and positive culture; culture results take at least 6 weeks. Diagnosis is thus typically delayed and is made only after failure of response to initial treatment. Because cultures may take more than 6 weeks to grow, medical treatment is often initiated before definitive culture results if clinical suspicion is high.

Antibiotic treatment is the primary treatment after biopsy is obtained; complete surgical synovectomy is indicated if the synovium is heavily affected. Prolonged antituberculous therapy is recommended with two bactericidal antituberculous agents. Current antituberculous regimen consists of 2 months of isoniazid, ethambutol, and rifampin, followed by 7 months of isoniazid and rifampin. Sensitivities may vary, and medical treatment recommendations change and thus should be coordinated in consultation with an infectious disease specialist.

**FUNGAL INFECTIONS**

Fungal hand infections occur after trauma with implantation of the fungus or its spore into the skin, or as part of systemic spread, usually from a primary pulmonary infection that began with inhalation of spores (10,65). Fungal infections can be divided into cutaneous lesions, subcutaneous infections, and deep or systemic infections (48).

Primary cutaneous fungal infections of the hand are found most often in gardeners and others engaged in activities around soil, where fungi are ubiquitous. Cutaneous lesions are caused by dermatophytes that colonize nonliving cornified appendages such as skin, hair, and fingernails. Examples include dermatophytic infection of the glabrous skin (tinea corporis), the interdigital areas of the palms (tinea manuum), and the fingernails (onychomycosis or tinea unguium) (48). A scaling, pruritic skin lesion (usually not responsive to or exacerbated by topical steroids) is present on an obvious thickened and deformed fingernail. Potassium hydroxide microscopic slide preparations may provide a preliminary diagnosis, but fungal cultures need to be performed for a definitive diagnosis.

Most cutaneous lesions are readily treatable with a topical antifungal cream such as tolnaftate, miconazole, clotrimazole, or econazole. Have the patient apply it topically for 4 to 6 weeks. More severe or unresponsive lesions may require systemic griseofulvin or ketoconazole. Fingernail infections are resistant to treatment, but long-term systemic griseofulvin has met with the most success, with cure rates as high as 80%.

Cutaneous infection with one of the systemic mycoses—*Coccidioides immitis, Histoplasma capsulatum* or *Blastomyces dermatidis*—also occurs after trauma or can actually be a systemic manifestation of a primary lesion elsewhere. After traumatic implantation and an incubation period of several days to months, a subcutaneous nodule appears that may or may not be painful. A fistula or ulceration develops and enlarges with a raised, discolored, and verrucous border. Epithelial hyperplasia follows. Lymphatic invasion can occur; the lymph channels become cordlike. Nodules develop, ulcerate, and then spontaneously resolve, only to be replaced by new lesions.

The cutaneous mycoses, including sporotrichosis, chromomycosis, mycetoma, and phycomycosis, also produce hand infections The most common subcutaneous fungal infection is sporotrichosis (48). Sporotrichosis classically occurs after a prick from a rose thorn by subcutaneous inoculation of the spores of *Sporothrix schenckii*. After the *S. schenckii* organism incubates for a period of days to months, a small, nontender, movable, subcutaneous nodule develops. Epidermal infection ulcerates early, whereas a more subcutaneous nodule discolors, darkens, and then erupts through the skin. Spontaneous healing of the ulcer follows, but new lesions erupt. Lymphatic invasion occurs, raising cordlike tracks along the hand and arm. The other cutaneous mycoses present in a similar fashion.

The diagnosis of fungal infection is made by excisional biopsy of one of the lesions or by culture of drainage. A definitive diagnosis of sporotrichosis requires *S. schenckii* to be isolated on fungal culture. The treatment of choice is potassium iodide for 6 to 8 weeks. Itraconazole has recently been shown to be effective as well, and because its dosage is only once a day, it may prove to be more tolerable.

Deep fungal infections of the hand present on a delayed basis most commonly as tenosynovitis, septic arthritis, or osteomyelitis. Definitive diagnosis requires identification by a fungal culture, and treatment usually involves IV amphotericin B for more virulent fungal infections and oral ketoconazole or itraconazole treatment for more benign infections.

**HAND INFECTIONS IN ACQUIRED IMMUNODEFICIENCY SYNDROME AND HUMAN IMMUNODEFICIENCY VIRUS**

In the United States, an estimated 573,800 cases of acquired immunodeficiency syndrome (AIDS) were reported in persons older than 13 years old from 1981 through 1996, according to the Centers for Disease Control and Prevention HIV/AIDS Surveillance Report. The true incidence of human immunodefiency virus (HIV) infection currently exceeds 1 million people.

Although there is little written on hand infections in the HIV-positive person, there is a known high prevalence of infections in this population. At one institution, nearly 20% of patients hospitalized for upper extremity infections were HIV positive. An even more alarming discovery is that less than 10% of these individuals admitted to being HIV positive (56).

In a recent study, not only was IV drug abuse the most common risk factor for HIV infection, it also was the most common cause of upper extremity infections in the HIV-positive person (36). Although these infections may present atypically, the responsible organisms are usually similar to those that infect the immunocompetent host, with *S. aureus* being the most common pathogen (36). Furthermore, spontaneous infections may occur, herpetic infections may appear more virulent, and seemingly benign infections may need a more aggressive surgical approach. Any individual with an unusual hand infection should be tested for HIV infection.

**OSTEOMYELITIS**

Osteomyelitis can involve any of the bones in the hand. It is caused most often by open fractures or spread from neighboring infected soft tissues. The infection rate in open fractures ranges from 1% to 11%, with a higher risk coming from the more contaminated wounds with more severe soft-tissue injury (17,39). Although *S. aureus* and *Streptococcus* remain the most common pathogens, open injuries predispose to gram-negative, anaerobic, and polymicrobial organisms.

Pain, redness, warmth, and swelling are the usual clinical indications of osteomyelitis. Systemic manifestations are less common but include fever, an elevated white blood cell count with or without an increase in polymorphonucleocytes, and an elevated erythrocyte sedimentation rate. Radiographic evidence of osteomyelitis is usually seen in the subacute or chronic state and includes the presence of periosteal new bone formation, osteolysis, or a sequestrum. A bone scan is more sensitive and can suggest the presence of osteomyelitis much earlier than plain radiography (46). Diagnosis may be made by subperiosteal aspiration of pus, but negative findings on aspiration do not rule out the possibility of infection.

Treatment ranges from empirical antibiotic therapy to surgical drainage, followed by antibiotics. Acute osteomyelitis may initially be treated with antibiotics, immobilization, and elevation. Failure of an early and discernible response warrants surgical incision, but cultures taken following the administration of antibiotics are usually not helpful.

Treatment of chronic osteomyelitis requires surgical intervention. A sequestrectomy, diaphysectomy, and even digit or ray amputation are potential interventions to help control and eliminate infected bone. Staged procedures with antibiotic-impregnated polymethylmethacrylate spacers, followed by bone grafting and skin coverage, are sometimes necessary. Local rotational and free flaps allow subsequent elevation for reconstruction and are preferred to pedicled flaps. They must be placed in a clean and vascularized wound bed.

## POSTOPERATIVE CARE

Leave wounds open and cover them with wet saline gauze to promote drainage. Apply a plaster splint–reinforced long-arm bulky hand dressing, incorporating a cord to permit continuous elevation. Change the dressing at 36 to 48 hours to a maceration-type dressing of 25% strength Dakin's solution, which is changed daily. Begin active hand motion to prevent stiffness. Discharge the patient when the wound is without erythema, tenderness, induration, or swelling.

Change wet-to-dry dressings three times a day at home for the open wounds; antibiotics are prescribed on the basis of culture results and the disease process. Continue dressing changes until the wound is healed.

## PITFALLS AND COMPLICATIONS

An undrained area of infection is a common reason for failure to improve after initial debridement. Physical examination directed toward discovering possible places of spread before surgery will help uncover these extensions. When in doubt, open the space at the time of surgery.

Keep incisions out of skin creases. If an incision for drainage must cross the crease, angle it less than 60°; failure to do so results in contracture. Do not penetrate the webspaces for the same reason.

Flaps in the presence of infection are prone to necrosis. Use only longitudinal or gently curved incisions.

Do not miss a herpetic whitlow masquerading as a felon or paronychia. Incision of this already-compromised tissue may lead to secondary bacterial infection.

Antibiotic selection must be effective to eradicate all organisms present in a hand infection. Coverage against *Staphylococcus* and *Streptococcus*, as well as the anaerobic streptococci, is necessary. Gram-negative anaerobes are often present, especially in clenched-fist, human bite, and IV drug abuse infections. Initial antibiotic selection should be based on the type of injury known or suspected. Think of HIV infection in the IV drug abuser or the patient who is not improving in spite of customary treatment.

## CHAPTER REFERENCES

Each reference is categorized according to the following scheme: *, classic article; #, review article; !, basic research article; and +, clinical results/outcome study.


* 1. Arons MS, Fernando L, Polayes IM. *Pasteurella multocida*—The Major Cause of Hand Infections Following Domestic Animal Bites. *J Hand Surg [Am]* 1982;7:47.

+ 2. Atiyeh BC, Zaatari AM. Necrotizing Fasciitis of the Upper Extremity. J Emerg Med 1994;12:611.

+ 3. Benkeddache Y, Gottesman H. Skeletal Tuberculosis of the Wrist and Hand: A Study of 27 Cases. *J Hand Surg [Am]* 1982;7:593.

+ 4. Bilos ZJ, Kucharchuk A, Metzger W. *Eikenella corrodens* in Human Bites. *Clin Orthop* 1978;134:320.

# 5. Bingham D. Acute Infections of the Hand. *Surg Clin North Am* 1960;40:1285.

* 6. Boland F. Morsus Humanus. *JAMA* 1941;116:127.

+ 7. Boyce FF. Human Bites: Analysis of 90 (Chiefly Delayed and Late) Cases From Charity Hospital of Louisiana at New Orleans. *South Med J* 1942;35:1942.

+ 8. Brook I. Bacteriologic Study of Paronychia in Children. *Am J Surg* 1981;141:703.

+ 9. Brooks GF, O'Donoghue JM, Rissing JP, et al. *Eikenella corrodens,* A Recently Recognized Pathogen: Infections in Medical-surgical Patients and in Association with Methylphenidate Abuse. *Medicine* 1974;53:325.

# 10. Bullpitt P, Weedon D. Sporotrichosis: A Review of 39 Cases. *Pathology* 1978;10:249.

# 11. Burkhalter WE. Deep Space Infections. *Hand Clin* 1989;5:553.

+ 12. Bush DC, Schneider LH. Tuberculosis of the hand and wrist. *J Hand Surg [Am]* 1984;9:391.

+ 13. Butz RO. Human Bites: A Series Treated with Antibiotics. *Am J Surg* 1956;9:525.

# 14. Faciszewski T, Coleman DA. Human Bite Wounds. *Hand Clin* 1989;5:561.

+ 15. Farmer CB, Mann RJ. Human bite infections of the hand. *South Med J* 1966;59:515.

+ 16. Fitzgerald RH Jr, Cooney WPD, Washington JAD, et al. Bacterial colonization of mutilating hand injuries and its treatment. *J Hand Surg [Am]* 1977;2:85.

# 17. Freeland AE, Senter BS. Septic Arthtitis and Osteomyelitis. *Hand Clin* 1989;5:533.

+ 18. Glass KD. Factors Related to the Resolution of Treated Hand Infections. *J Hand Surg [Am]* 1982;7:388.

* 19. Goldstein EJ, Barones MF, Miller TA. *Eikenella corrodens* in Hand Infections. *J Hand Surg [Am]* 1983;8:563.

+ 20. Goldstein EJ, Citron DM, Wield B, et al. Bacteriology of Human and Animal Bite Wounds. *J Clin Microbiol* 1978;8:667.

! 21. Goldstein EJ, Gombert ME, Agyare EO. Susceptibility of Eikenella corrodens to Newer Beta-lactam Antibiotics. *Antimicrob Agents Chemother* 1980;18:832.

+ 22. Goldstein EJ, Miller TA, Citron DM, Finegold SM. Infections Following Clenched-fist Injury: A New Perspective. *J Hand Surg [Am]* 1978;3:455.

+ 23. Goldstein EJC. Infections Following Human Bites. *Infections in Surgery* 1985;4:849.

+ 24. Gonzalez MH, Kay T, Weinzweig N, et al. Necrotizing Fasciitis of the Upper Extremity. *J Hand Surg* 1996;21-A:689.

+ 25. Gunther SF, Elliott RC, Brand RL, Adams JP. Experience with Atypical Mycobacterial Infection in the Deep Structures of the Hand. *J Hand Surg [Am]* 1977;2:90.

# 26. Gunther SF, Levy CS. Mycobacterial Infections. *Hand Clin* 1989;5:592.

# 27. Hollinshead HW, ed. *Anatomy for Surgeons,* 2nd ed, Vol 3. New York: Harper & Row, 1969.

+ 28. Janevicius RV, Hann SE, Batt MD. Necrotizing Fasciitis. *Surg Gynecol Obstet* 1982;54:97.

* 29. Kanavel AB. *Infections of the Hand,* 7th ed. London: Bailliere, Tindall, and Cox, 1939.

# 30. Linscheid RL, Dobyns JH. Common and Uncommon Infections of the Hand. *Orthop Clin North Am* 1975;6:1063.

+ 31. Louis DS, Silva J Jr. Herpetic Whitlow: Herpetic Infections of the Digits. *J Hand Surg [Am]* 1979;4:90.

+ 32. Louria DB, Hensle T, Rose J. The Major Medical Complications of Heroin Addiction. *Ann Intern Med* 1967;67:1.

+ 33. Maier RL. Human Bite Infections of the Hand. *Ann Surg* 1977;106:423.

+ 34. Mann RJ, Hoffeld TA, Farmer CB. Human Bites of the Hand: Twenty Years of Experience. *J Hand Surg [Am]* 1977;2:97.

+ 35. Mason ML, Koch SL. Human Bite Infections of the Hand. *Surg Gynecol Obstet* 1930;51:591.

+ 36. McAuliffe JA, Selter DG, Hornicek FJ. Upper-Extremity Infections in Patients Seropositive for Human Immunodeficiency Virus. *J Hand Surg* 1997;22-A:1084.

! 37. McCord JM, Keele BB, Fridovich I. An Enzyme Based Theory of Obligate Anaerobiasis: The Physiological Function of Superoxide Dysmutase. *Proc Natl Acad Sci* 1971;68:1024.

+ 38. McKay D, Pascarelli EF, Eaton RG. Infections and Sloughs in the Hands in Drug Addicts. *J Bone Joint Surg [Am]* 1973;55:741.

+ 39. Mc Lain RF, Steyers C, Stoddard M. Infections in Open Fractures of the Hand. *J Hand Surg* 1991;16A:108.

+ 40. McWilliams CA. Actinomycosis of Phalanx of Finger. *Ann. Surg.* 1917;66:117.

* 41. Neviaser RJ. Closed Tendon Sheath Irrigation for Pyogenic Flexor Tenosynovitis. *J Hand Surg [Am]* 1978;3:462.

# 42. Neviaser RJ. Tenosynovitis. *Hand Clin* 1989;5:525.

+ 43. Nunley DL, Saski T, Atkins A, Vetto RM. Hand Infections in Hospitalized Patients. *Am J Surg* 1980;140:374.

+ 44. Orangio GR, Pitlick SD, Della Latta P, et al. Soft Tissue Infections in Parenteral Drug Abusers. *Ann Surg* 1984;199:97.

+ 45. Perry A, Gottlieb L, Zachary L. Fingerstick Felons. *Ann Plast Surg* 1988;20:249.

+ 46. Prchal CL, Kahen HL, Blend MJ. Detection of musculoskeletal infection with the idium-III leukocyte scan. *Orthopaedics* 1987;168:1253.

+ 47. Rayan GM, Putnam JL, Cahill SL. *Eikenella corrodens* in Human Mouth Flora. *J Hand Surg* 1988;13A:953.

# 48. Rippon JW, ed. *Medical Mycology,* 2nd ed. Philadelphia; W.B. Saunders Co, 1982.

! 49. Robinson JVA, James AL. In Vitro Susceptibility of *Bacteroides corrodens* and *Eikenella corrodens* to 10 Chemotherapeutic Agents. *Antimicrob Agents Chemother* 1974;6:542.

+ 50. Robson MC, Schmidt D, Heggers JP. Cefamandole Therapy in Hand Infections. *J Hand Surg* 1983;8A:560.

+ 51. Sarubbi FA Jr, Hull JH. Amikacin Serum Concentrations: Prediction of Levels and Dosage Guidelines. *Ann Intern Med* 1978;89:612.

+ 52. Schecter W, Meyer A, Schecter G, et al. Necrotizing Fasciitis of the Upper Extremity. *J Hand Surg* 1982;7A:15.

# 53. Schmid FR, ed. Arthritis and Allied Conditions: A Textbook of Rheumatology, 10 ed. Philadelphia: Lea and Febiger, 1985.

+ 54. Schmidt DR, Heckman JD. *Eikenella corrodens* in Human Bite Infections of the Hand. *J Trauma* 1983;23:478.

+ 55. Scott JC, Jones BV. Results of Treatment of Infection of the Hand. *J Bone Joint Surg* 1952;34-B:581.

# 56. Seltzer DG, McAuliffe JA, Campbell DR, Burkhalter WE. AIDS in the Hand Patient: The Team Approach. *Hand Clin* 1991;7(3):433.

# 57. Snyder CC. Animal Bite Wounds. *Hand Clin* 1989;5:571.

+ 58. Spiegel JD, Szabo RM. A Protocol for the Treatment of Severe Infections of the Hand. *J Hand Surg* 1988;13A:254.

+ 59. Stern PJ, Staneck JL, McDonough JJ, et al. Established hand infections: a controlled, prospective study. *J Hand Surg* 1983;8A:553.

+ 60. Sutter VL, Finegold SM. Susceptibility of anaerobic bacteria to 23 antimicrobial agents. *Antimicrob Agents Chemother* 1976;10:736.

+ 61. Van Niekerk JP. Hand Infections: Management and Results Based on a New Classification: A Study More Than 1,000 Cases. *S Afr Med J* 1966;40:316.

+ 62. Webb D, Thadepalli H. Skin and Soft Tissue Polymicrobial Infections from Intravenous Abuse of Drugs. *West J Med* 1979;130:200.

+ 63. Welch CE. Human Bite Infections of the Hand. *N Engl J Med* 1936;215:901.

# 64. Wilkerson R, Paull W, Coville FV. Necrotizing Fasciitis: Review of the Literature and Case Report. *Clin Orthop* 1985;216:190.

# 65. Zinsser H, ed. Microbiology. New York: Appleton, Century, Croft, 1980.

# CHAPTER 74

# TUMORS OF THE HAND

*Clayton A. Peimer and James S. Thompson*

**C. A. Peimer**: Departments of Orthopaedic Surgery and Anatomical Sciences, Hand Center of Western New York, Buffalo, New York, 14209.
**J. S. Thompson:** Asheville, North Carolina, 28801.

Overview
Benign Tumors
Malignant Tumors
Diagnosis of the Tumor
Biopsy Methods
Treatment Principles
Benign Tumors
Aggressive Tumors
Tumors of Soft Tissue
Cystic Lesions
Skin Tumors
Fibrous Tumors
Vascular Tumors
Nerve Tumors
Lipid Tumors
Synovial Tumors
Skeletal Tumors
Cartilage Tumors
Bone Tumors
Authors' Perspective
Chapter References

## OVERVIEW

Managing a patient with a neoplasm in the upper extremity will always be challenging; it is sometimes complex and may also be frustrating. Considerable skill and careful thought are needed to analyze diagnostic, treatment, and reconstructive problems, as well as to treat the patient to ensure survival and function while treating the tumor. The first issue is that an enlarging mass that represents an invasive or life-threatening tumor in the upper limb is unusual; circumspection and attention to detail should govern the approach to all tumors.

Hand tumors include soft-tissue and bone neoplasms (distal to the elbow, soft-tissue neoplasms predominate when serious diagnoses are considered); the majority are reactive nodules and cysts, connective tissue proliferations, foreign bodies, infections (that mimic neoplasms), and posttraumatic sequelae. Table 74.1 and Table 74.2 list tumors of the soft-tissues and hard tissues, respectively. Lesions that are small and appear innocent can be deadly, whereas large and seemingly worrisome masses may be easy to treat (Fig. 74.1). The surgeon who evaluates and treats tumors of the hand needs to be familiar with limb anatomy, tumor biology, and the range of treatment possibilities and their limitations. Ideally, the hand surgeon or orthopedist is part of a team consisting of medical and surgical oncologists, reconstructive surgeons, and therapists, who can offer state of the art experience in integrating care of the tumor, balancing patient survival against the desire to retain function. Lesions in the hand more often present earlier in their course than those at other sites, just because they are—by definition—more likely to be superficial and easily noticed. However, hand tumors that require a clean surgical margin will have a significant and often profound functional impact after treatment.



***Table 74.1. Tumors of Soft Tissue***

Tumors of cartilage
- Solitary enchondroma
- Multiple enchondromatosis
- Osteocartilaginous exostoses (solitary and multiple)

Bone tumors
- Giant cell tumor of bone
- Aneurysmal bone cyst
- Osteoid osteoma

Metastatic tumors

***Table 74.2. Tumors of Hard Tissue***



***Figure 74.1.*** **A:** A 43-year-old man with an enlarging phalangeal mass of considerable size. **B:** Radiographs reveal the soft-tissue tumor as having a fluid density suggestive of a lipoma. **C:** The diagnosis was confirmed at surgery and the large lipoma removed.

Musculoskeletal malignancies are considerably less common in the upper extremity than in the lower limbs (38,43,102). Surgeons not practicing in a musculoskeletal or cancer treatment center are not likely to see enough cases of aggressive and invasive but oncologically benign tumors or primary malignancies to be fully comfortable or entirely competent in their evaluation and management (58,102,131). Principles and definitions of tumor treatment are not different for the upper limb, although anatomic issues are.

**BENIGN TUMORS**

Benign tumors are most often classified according to the system of Campanacci (23).

1. Hyperplasia: An accumulation of cells resulting from accelerated proliferation.
2. Hamartoma: Congenital anomaly in which a tissue island is effectively excluded from regional maturation and cellular differentiation. This lesion has a structure similar to its tissue of origin; it is often multicentric and/or hemicorporal in locations. Hyperplasias and hamartomas stop growing when skeletal maturity is achieved.
3. Neoplasia: A new growth of cells that enlarges in an atypical, autonomous, progressive course.

In another sense, benign lesions can be categorized with respect to their temporal behavior.

- Latent (stage I) lesions are entirely quiescent. Latent tumors in bone and soft tissue may require only observation to ensure they have been correctly categorized.
- Actively growing lesions remaining in a limited anatomic zone are considered a separate category (stage II). Actively growing tumors may be controlled by local intralesional or marginal excision.
- Aggressive (stage III) lesions are characterized by regional invasion and spread (in a sense, they meet the generic minimum standards for Campanacci's neoplasia). Aggressive tumors require surgical margins wide enough to effect *en bloc* excision encompassing the entire lesion, and generally with a contiguous margin (“cuff”) of normal surrounding tissue to minimize recurrence.

Malignancies are another story altogether.

**MALIGNANT TUMORS**

The Musculoskeletal Tumor Society (MSTS) staging system, proposed by Enneking et al. (44,45) and others (59,102), constitutes the basis for treating and reporting malignant sarcomas, including those in the hand (Table 74.3). Nonetheless, there are as yet no standards of appropriate or safe surgery based on reproducible clinical data, because of the limited number and varying histologic types of cases historically reported using several methods and classifications (15,38,102,128,129,147). Therefore, what exactly constitutes a safe, clean surgical margin, and how much function need be sacrificed to ensure a patient's survival, are not irrefutably established (17,50,67). Use and reporting of larger numbers of cases with the same staging system will make treatment comparisons and definitions easier and more accurate. However, the anatomic implications of compartmentalization—based on the presence of a tissue barrier that inhibits easy extension of tumor cells—has a more limited application in the hand. That is to say, it is easy to understand a medial or lateral compartment in the thigh, and a volar or dorsal compartment in the forearm. However, the flexor sheath in the thumb extends from its interphalangeal joint to the wrist, and it communicates with the entire flexor compartment of the elbow. Yet, is the flexor surface of the thumb truly different from the flexor surface of the index where the synovial sheath is not continuous? The critical issue is that a surgical margin is not compromised when it endangers the primary goal of treatment—that is, permanently ridding the patient of the tumor. Musculoskeletal tumor surgery requires local control; but surgery now needs to be seen as part of a treatment paradigm that includes medical and radiation therapies, delivered to the patient or the tumor region before, during, and after the operation in appropriate cases (17,18,38,76,98,102,108,145,156).

| *Stage* | *Grade* | *Site* |
|---|---|---|
| IA | Low ($G_1$) | Intracompartmental ($T_1$) |
| IB | Low ($G_1$) | Extracompartmental ($T_2$) |
| IIA | High ($G_2$) | Intracompartmental ($T_1$) |
| IIB | High ($G_2$) | Extracompartmental ($T_2$) |
| III | Regional or distant metastasis (M) | |
| | Any G | Any (T) |

From Enneking WF, Spanier SS, Goodman MA. Current Concepts Review: The Surgical Staging of Musculoskeletal Sarcoma. *J Bone Joint Surg Am* 1980;52:1027, with permission.

***Table 74.3. Surgical Stages***

**DIAGNOSIS OF THE TUMOR**

The principles of evaluation and diagnosis include a careful and thorough history, physical examination, and addition of laboratory and imaging studies to determine the local and systemic status and stage of the tumor. These principles are discussed in more detail in Chapter 126. We emphasize that plain radiographs, technetium and/or gallium scintigraphy, computerized tomography (CT; extremity and chest), and magnetic resonance imaging (MRI) of the limb are required antecedents to surgical biopsy (34,41,62,79,103,140). CT scans and MRI can be particularly helpful in delineating whether a specific lesion is contained within a bone or a soft-tissue compartment, or if it has already extended across a natural barrier (Fig. 74.2). Imaging data are essential to planning the biopsy incision location and the extent of subsequent treatments.

***Figure 74.2.*** **A:** Radiograph showing a soft-tissue mass with calcifications, plus erosion of the third metacarpal and proximal phalanx in a 27-year-old man. The findings suggest an aggressive tumor, quite possibly a (malignant) synovial sarcoma. **B:** MRI demonstrates absence of marrow involvement by this well-defined circumferential soft-tissue tumor (*arrow*). These findings clearly support the diagnosis of benign, noninvasive neoplasm, but one that would require dorsal and palmar incisions for complete excision. Synovial chondromatosis was confirmed at surgery.

Imaging techniques and experience with their interpretation have improved notably in the past decade. High-resolution CT with reconstructed images of various views, and MRI sequences, sometimes enhanced with gadolinium, have improved identification of anatomic structures, have refined preoperative differential diagnosis, and have redefined and clarified tumor margins.

**BIOPSY METHODS**

It is not likely that a diagnosis can be made without a tissue sample. The biopsy of a potentially malignant lesion should be planned as carefully as that of the definitive surgical resection. The biopsy track will later have to be incorporated into the planned resection to allow for its removal with the tumor. Open incisional biopsy with intraoperative frozen section reviewed by an experienced musculoskeletal pathologist to confirm the acquisition of an adequate tissue sample remains the standard. Definitive diagnosis may require permanent sections and special techniques. Improvements in cytopathologic tissue processing have advanced the utilization of fine-needle aspiration and core needle biopsies in the diagnosis management of sarcoma. Cytopathology requires considerably greater attention to detail by both the surgeon and the pathologist to ensure that a complete and accurate diagnosis is made. Reliable immunohistochemical and cytogenic evaluations could potentially be obtained by needle aspirates, but presently fine-needle biopsy is confined to academic musculoskeletal and cancer centers where a large experience can be accumulated.

Biopsy is not a simple surgical procedure, and it is critical to the outcome of treatment. If a surgeon or the team available at the institution is unprepared, ill equipped, or inexperienced in completing all diagnostic studies and proceeding with definitive, comprehensive management, the patient should be referred before the biopsy is performed (86). The patient and surgeon must be prepared for the unexpected. “Benign growths” that otherwise appear “different” need to be biopsied; avoid an invasive attempt at excision of an unknown lesion (Fig. 74.3) that may contaminate surgical margins with tumor cells.

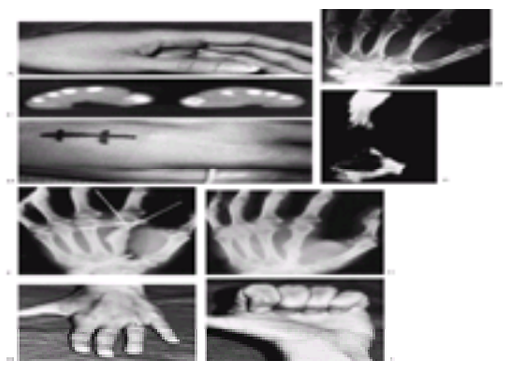

***Figure 74.3.*** **A:** Clinical appearance of the hand in a 24-year-old woman who reported a 10-week history of an enlarging, painful mass on the dorsum of the hand. **B:** Radiographs revealed endosteal invasion of the second metacarpal diaphysis and metaphysis without new bone formation, suggestive of a rapidly growing lesion. **C:** The CT scan revealed actual cortical destruction along the ulnar side of the metacarpal shaft. **D:** A small dorsal longitudinal incision (located so as to be entirely excisable) was used for the incisional biopsy under tourniquet control, without exsanguination. **E:** Radiograph of specimen. Permanent sections revealed an aneurysmal bone cyst, which was treated at a separate operation by *en bloc* second-metacarpal resection and iliac graft replacement. **F:** To maintain functional skeletal continuity, the second metacarpal head was transfixed to the third before bone resection. The Kirschner wires were left in place until union was solid. **G:** Therapy was started 2 weeks after surgery and motion recovered rapidly. **H,I:** Follow-up clinical photographs.

Hand and upper-limb surgeries are best performed in a bloodless field. Tourniquet control is safe for performing the biopsy and when treating tumors of the hand. Do not exsanguinate the extremity because this may cause dissemination of seed tumor cells—or bacteria—from the affected site. Elevate the arm for 2–4 minutes before inflating the pneumatic tourniquet. Do not use intravenous Bier block anesthesia (which requires exsanguination) when performing a biopsy or when removing an undiagnosed or known serious hand tumor. Very small tumors up to 1.0 cm in diameter can be effectively biopsied and excised simultaneously if limited to one tissue plane or compartment. Skin defects can be covered with synthetic semiocclusive materials until biopsy results are known. Hemostasis is required for deep biopsy wounds; therefore, release the tourniquet before wound closure to ensure a dry field. Do not use drains. Biopsy of bone tumors is best done by making a cortical window and harvesting a limited sample. Postoperative care and splinting follow routine principles.

## TREATMENT PRINCIPLES

**BENIGN TUMORS**

Benign tumors of soft tissue and bone can be removed utilizing intralesional or marginal surgical resection, often described as shelling out or bony curettage. Tumors with special characteristics and those that ought to have additional consideration because of their anatomic location and biologic potential will be discussed in later sections.

**AGGRESSIVE TUMORS**

When invasion occurs from a primary musculoskeletal malignancy or as a metastatic nidus, hand tumors may be serious (18,31). Hand anatomy and function make the treatment of these lesions special compared to other musculoskeletal sites. Treatment of the hand tumor may limit function and impair body image more severely than radical surgery performed elsewhere in the body. The application of historic “tumor margin minimums” to achieve a pure surgical cure may create a potentially unnecessary and debilitating functional deficit, particularly in larger tumors. Neoadjuvant therapy as discussed in Chapter 126 is important in treating aggressive tumors, as tumor shrinkage allows more limited operative excision with clean margins; this permits preservation of hand function while not risking survival of the patient.

Metastatic tumors in the hand may be the initial sign of primary malignancies in the lung or kidney, the breast, or the gastrointestinal and hematopoietic systems (Fig. 74.4). These malignancies may require only limited-intervention (e.g., palliative) surgery in conjunction with systemic therapies for an underlying but previously occult primary tumor.

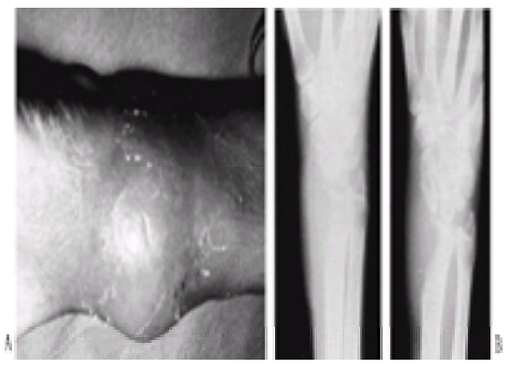

***Figure 74.4.*** Clinical (**A**) and radiographic (**B**) appearance of a painful, enlarging mass and osteolysis of the radius in a 70-year-old man. Incisional biopsy disclosed bronchogenic carcinoma; the arm was irradiated.

Aggressive neoplasms that are truly malignant must be distinguished from those that are only locally invasive and regionally destructive. Nonmalignant tumors can be safely and adequately handled by *en bloc* excision as long as the tumor is contained within the specimen. Aggressive but nonlethal tumors do not justify excision of important nerves and vessels, with rare exceptions. Improvements in imaging techniques and nonsurgical care allow the musculoskeletal oncologist to cut closer than the traditional 3–5 cm margin for bone and 1–2 cm margin for soft tissue without an increased risk of local recurrence. Close, but safe, negative margins decrease the loss of function in the extremity (Fig. 74.5). This approach requires intensive and extensive multidisciplinary preoperative planning from the musculoskeletal radiologist, radiation and medical oncologists, the oncologic surgeon, and the reconstructive upper-extremity surgeon. At the time of excision, carefully examine the margins of the specimen and sample histologically together with the pathologist. If the tumor has not been cleanly resected, the margins have to be expanded; additional regional adjuvants and systemic treatments may need to be added. If a safe and adequate tumor resection will destroy hand function, amputation is advised (Fig. 74.6).

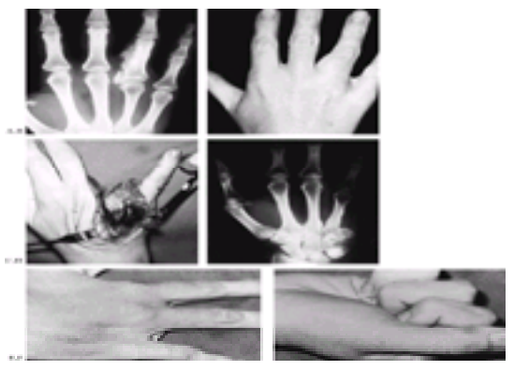

***Figure 74.5.*** Radiographic (**A**) and clinical (**B**) appearance of a slowly enlarging bony mass of the ring finger, which proved to be a parosteal osteogenic sarcoma. The patient was successfully treated by resection of the fourth ray and transposition of the fifth ray (**C**,**D**). She continues to be free of disease more than 7 years after surgery (**E**,**F**).

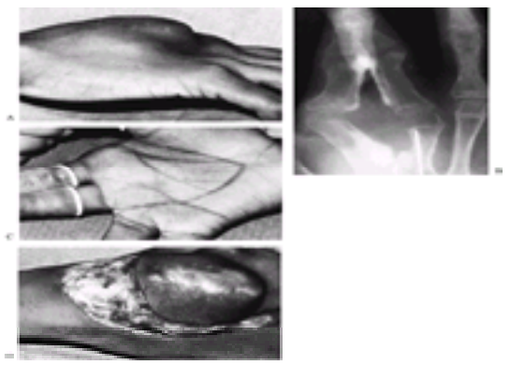

***Figure 74.6.*** **A,B:** After several local resections for a desmoplastic fibroma (extra-abdominal desmoid), a 14-year-old presented with an enlarging, painful, and radiographically destructive mass at the same site. The surgical plan was subtotal hand amputation with resection of the second and third rays. **C,D:** At surgery, the tumor was found to extend into the dorsal wrist; a below-elbow amputation was performed.

Wound closure is generally best done with local tissues, local flaps, and skin grafts. Do not use distant pedicle flaps for primary closure because of the risk of residual tumor cells in the resection area contaminating an otherwise clean donor area. Finger fillet flaps and local rotation flaps from portions of retained fingers, for example, are ideal for coverage in such circumstances. Complex reconstructive procedures that include vascularized soft tissue, bone, or composite flaps require integrated preoperative planning; they require a team of specialists in surgical tumor excision and hand reconstruction working simultaneously. Even seemingly traditional reconstructive procedures, such as pollicization, can be done primarily at the time of tumor resection if planning has been adequate and the local conditions are appropriate (Fig. 74.7).

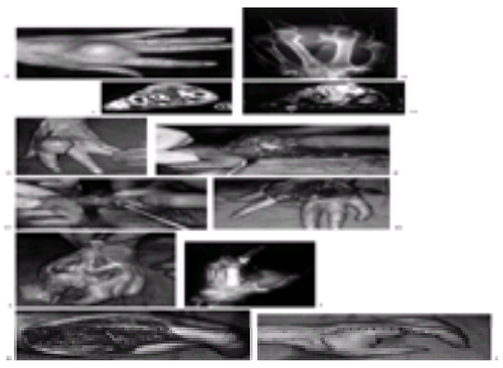

***Figure 74.7.*** This 68-year-old woman offers an example of these diagnostic and surgical principles. **A,B:** Radiographs and clinical appearance of a hard, painless lesion present for at least 10 years but which expanded rapidly in the previous 8 months. **C,D:** CT and T2-weighted MRI images delineate the location and extent of this chondral and calcific tumor; it is seen to involve the second metacarpal and extensor tendons, but *may not* invade the middle finger MCP joint. Chest x-rays were clear; longitudinal biopsy of the dorsal surface proved chondrosarcoma—a “low-grade” malignancy. **E.** *En bloc* resection of the second metacarpal also including skin and extensor tendons of the index and middle fingers in the “reactive zone.” At surgery, tumor was found in the middle finger MCP joint **(F),** just volar to the metacarpal head. Resection included excision of the MCP joint *en bloc* with the surrounding tissues **(G). H:** Following *en bloc* marginal to wide excision, but preserving flexor tendons and neurovascular bundles (protected by the adductor pollicis muscle, as noted on preoperative MRI). **I:** Radial neurovascular bundle of the index finger was retained in the filet flap of skin, and its ulnar neurovascular bundle preserved *to* the proximal and middle phalanges of the index finger. **J–K:** Reconstruction of the middle finger was achieved by transposing the index proximal phalanx, PIP joint, and base of middle phalanx to form a (vascularized) “third metacarpal/middle finger MCP joint.” The index flexors were used as a jump graft to reconstruct the middle finger extensors (including pulley construction to keep the mechanism dorsal to the new bone); closure was achieved by transposing the filleted digital flap. (Case courtesy of CA Peimer and BR McGrath.) [From Peimer CA, ed. *Surgery of the Hand*

*and Upper Extremity*. New York: McGraw-Hill, 1996:226 (Fig. 99-4).]

The focus of treatment for aggressive tumors of soft tissue and bone in the hand and forearm is surgery; however, the judicious use of pre- and postoperative radiation and chemotherapy will improve both local control and patient survival. Radiation therapy is probably the most widely used adjuvant. It can improve local control of malignant lesions when surgical margins are up to 1.0 cm in thickness. Careful planning after diagnosis and before treatment by experienced radiation and medical oncologists is required. Palliative external beam radiation can be used for patients with painful lesions in the hand and upper extremity. Preoperative radiation therapy and regional or systemic medications are useful if a lesion is close to a vital and potentially preservable structure. Brachytherapy can be similarly useful but may be difficult to utilize and more typically requires additional or special soft-tissue coverage methods. Chemotherapy management of osteogenic sarcoma, Ewing's sarcoma, and rhabdomyosarcoma is now well documented as discussed in Chapter 126, Chapter 128, and Chapter 129. However, present chemotherapy methods have not yet been proven to augment survival of patients with soft-tissue sarcomas in the hand other than rhabdomyosarcoma.

## TUMORS OF SOFT TISSUE

### CYSTIC LESIONS

#### *Ganglion Cyst*

The ganglion cyst, the most common tumor in the hand, is found more often in women. The most common sites are the dorsal carpus, generally arising from the scapholunate ligament, or at the palmar wrist, with origin from the scaphotrapezial and/or trapeziometacarpal joints. They often occur spontaneously as well as after trauma and in patients with osteoarthritis (7,88,96,162). The ganglion cyst may also arise on the palmar surface of the fibrosseous (flexor) sheath; these are termed retinacular cysts, sesamoid ganglia, or seed or pea ganglia. These occur as very small but firm, even hard, and often painful lesions over the palmar aspect of the metacarpophalangeal joint.

A ganglion cyst is mucus filled, with a fibrous wall, and it is not a true neoplasm. The lesion is typically connected to an underlying joint capsule or tendon sheath by a stalk that may be tortuous. The lesion may be tender as it expands or when it is impacted, and it hurts at the extremes of joint motion. Surgical excision is recommended for these lesions when they are unsightly or painful, interfere with function, and have not responded to conservative care such as needle aspiration and steroid injection. Our preferred technique for surgical excision is to aspirate and suction the cyst empty to improve the visualization and retraction of surrounding structures. This allows it to be excised through an extensile but small incision. Excision is usually curative in 95% of cases if the cyst and its stalk are removed with a very small cuff of contiguous joint capsule (Fig. 74.8).

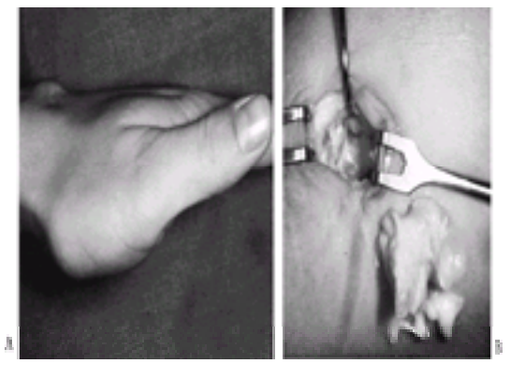

***Figure 74.8.*** **A:** A recurrent mass following two previous excisions of a dorsal radiocarpal ganglion cyst (performed elsewhere). **B:** At surgery, the cystic lesion, contiguous capsule, and satellite cysts were removed *en bloc* with the dorsal aspect of the scapholunate ligament. The lesion has not recurred.

#### *Mucus Cyst*

A mucus cyst is identical to a ganglion cyst. It usually arises dorsally from the distal interphalangeal joints of the fingers and thumb. These cysts may involve the distal germinal nail matrix, causing nail depression and grooving secondary to chronic local pressure. Spontaneous rupture or patients' attempts at aspiration can lead to serious complications such as septic arthritis and osteomyelitis.

As with removal of the ganglion cyst, excision of a mucus cyst must include its stalk, local small osteophytes, and joint capsule. Protect the terminal (extensor) tendon and germinal nail matrix. Closure of the skin may require a small rotation flap, skin advancement, or skin graft. If the underlying joint is arthritic and painful, arthrodesis may be indicated (see Chapter 72).

**HINTS AND TRICKS**

- Avoid overly vigorous retraction to protect nearby sensory nerves, tendons, and vessels. It is not uncommon for the volar wrist ganglion to “envelope” the radial artery; in such cases, the lesion need not be peeled off the artery. Leave a small piece of cyst wall on the artery. As long as the rest of the tumor and its stalk are removed, recurrence is avoidable while the risk of injury to the artery is lessened considerably.

#### *Epidermal Inclusion Cyst*

An epidermal inclusion cyst derives from buried epidermal cells, typically secondary to a traumatic or surgical wound (66). The original injury may be entirely unrecognized or unremembered, given the frequency with which small cuts occur in the hand. The mass is attached to skin and contiguous subcutaneous tissue; it contains keratin and may enlarge to a significant size. Carefully excise these cysts, taking care to avoid spilling the contents or damaging adjacent normal anatomy. Intraosseous components need to be curetted.

### SKIN TUMORS

#### *Squamous Cell Carcinoma*

Squamous cell carcinoma accounts for the vast majority of soft-tissue (skin and skin organ) malignancies of the hand. It is most commonly seen in older patients, and those with a history of chronic exposure to chemicals, ionizing radiation, and the sun (21,28,29,33,52,64,94,116). Logically, this tumor is found most often on exposed, often dorsal, skin surfaces, and it may be accompanied by ulceration (Fig. 74.9). The nail bed is a less common site for this lesion (Fig. 74.10). In contrast to keratoacanthoma (discussed next), these true malignancies are actually less rapidly growing. Because primary squamous cell carcinoma rarely metastasizes, it is amenable to cure by local excision, including clean margins of greater than 1 cm of normal skin. The depth of excision required depends on the size and extent of the lesion. Removal of superficial tumors leaves a defect that is coverable by direct local flap advancement or by skin graft. Treat tumors that extend into adjacent tendon or bone by *en bloc* resection or local amputation.

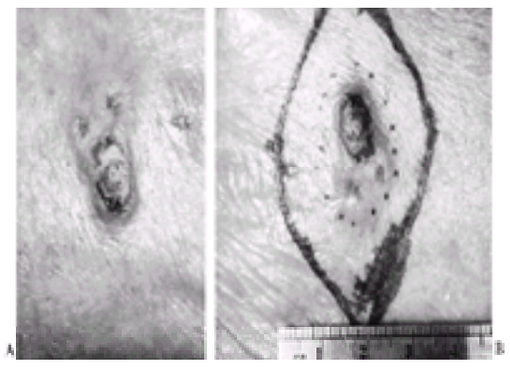

***Figure 74.9.*** **A:** This slowly growing skin ulcer on the hand of a 72-year-old retired construction worker was diagnosed by dermatologic punch biopsy as squamous cell carcinoma. **B:** Excision included a 1.5 cm cuff of normal skin. The tumor reactive zone is marked with a *dotted circle.*

***Figure 74.10.*** **A:** A chronic ulcer beneath the thumbnail of a retired dental hygienist was diagnosed as squamous cell carcinoma by dermatologic punch biopsy. **B:** Full-thickness excision of the radial half of the sterile and germinal nail matrix plus eponychium was performed. **C:** Suture tags were used for pathologic orientation. **D:** The frozen section confirmed tumor-free margins; a skin graft was applied to the resection zone.

Lymph node dissection is rarely indicated unless there is clearly nodal enlargement or the primary tumor is quite large. Sentinel node biopsy to evaluate the draining node basin is more common with melanoma (see later) (3,100,130,146).

***Keratoacanthoma***

Keratoacanthoma is a benign neoplasm that resembles squamous cell carcinoma. It is found in the same sites and locations and in the same older patient group as squamous cell carcinoma, but it is usually a much more rapidly growing tumor (69). It is usually diagnosed at excisional biopsy. Recurrences are uncommon, and the lesion is rarely locally aggressive.

***Malignant Melanoma***

Malignant melanoma is an aggressive and increasingly frequent skin cancer that too often is lethal. As the frequency of chronic sun exposure has increased, the incidence of the melanoma epidemic has increased as well (11,54,56,80,81,122,124,137,148,153,154). These tumors may be dark, multicolored, and multivariate, or they may have no pigment at all. Lesions are graded according to the level of skin invasion and the size or thickness of the tumor (Table 74.4). Most tumors can be treated surgically with a clean margin of 1 cm for level I or II lesions, to 5 cm for level III, IV, or V lesions and nodular lesions (Table 74.5).

| *Level* | *Description* |
|---|---|
| 1 | All tumor cells above basement membrane |
| 2 | Invasion into loose connective tissue of papillary dermis |
| 3 | Tumor cells at junction of papillary and reticular dermis |
| 4 | Invasion into reticular dermis |
| 5 | Invasion into subcutaneous fat |

Reproduced with permission from Peimer C, ed. *Surgery of the Hand and Upper Extremity.* New York: McGraw-Hill, 1996.

***Table 74.4. Criteria for Levels of Tumor Invasion as It Relates to Skin Histology***

| *Tumor Thickness (mm)* | *Excision Margin (cm)* |
|---|---|
| *In situ* | 0.5–1.0 |
| 0–1 | 1.0 |
| 1–2 | 1 or 2[a] |
| 2–4 | 2 |
| >4 | ≥4 |

[a] A 2 cm margin is preferable, but 1 cm is appropriate in anatomically restricted areas.
Reproduced with permission from Ross MI, Balch CM. Surgical Treatment of Primary Melanoma. In: Balch CM, Houghton AN, Sober AJ, Soong S, eds. *Cutaneous Melanoma.* St. Louis, MO: Quality Medical, 1998:141.

***Table 74.5. Margins for Melanoma Excision***

Lymph node evaluation by sentinel node biopsy and lymphatic mapping is being used in an increasing number of these cases, as well as in certain circumstances of squamous cell carcinoma (70,95,106,158).

The technique of sentinel node biopsy (lymphadenectomy) with lymphatic mapping requires participation of an experienced tumor surgeon familiar with the precise methods required (117). In overview, this is an inventive application of two vital-staining techniques used to precisely identify the primary (sentinel) lymph node in a node-basin draining an extremity. The idea behind the technique is that if this sentinel node can be accurately and reproducibly located, and it is found to be tumor free on biopsy, node dissection is not warranted. On the other hand, if this node is positive for tumor, at least additional node sampling, or a full node-basin dissection, will be required for staging and treatment. The method utilizes a combination of one visual and one nuclear stain. The affected extremity is injected with a microquantity of fat-based, colored dye and simultaneously with a microquantity of radioactive tracer. Both are absorbed into the lymphatic system. After approximately 1–2 hours, a

Geiger counter is applied to the axilla to locate the first (sentinel) node in the chain with significant uptake; this site is marked on the skin. Immediate surgical biopsy is aided by a sterile nuclear counter probe and the fact that the node has also been stained from the visible dye.

It has not yet been proven that this method is absolutely predictable for all tumors, but it has been highly dependable for common tumors of squamous cell origin.

Only the recognition of the malignant potential of an enlarging, multicolored, or irregularly bordered lesion leads to early treatment. Early treatment—before the tumor has invaded and metastasized—significantly increases chances for survival. The use of chemotherapy and other adjuncts has not been uniformly helpful, however.

## FIBROUS TUMORS

### *Nonneoplastic Lesions*

Nonneoplastic lesions include keloid, fasciitis, Dupuytren's disease, and fibromatoses, which have variable presentations and occur at different ages (2,49,68,82,109,115,117,135).

*Keloids* are posttraumatic phenomena. They generally occur in patients 10 to 25 years of age and are more common in blacks and others with darker skin color, most often with a family history. A keloid may continue to grow, albeit slowly, for months or years, or involute spontaneously. Surgical excision and radiation usually provide only temporary relief. Intradermal steroid injections and use of elastic garments can be helpful.

*Palmar fasciitis* (non-Dupuytren's) is also posttraumatic and is common in the same general age group.

*Fibromatoses* are often locally infiltrative, recurring lesions. This subset includes subdermal fibromatosis in infancy, infantile dermal fibromatosis/juvenile fibromatosis, calcifying aponeurotic fibroma, and palmar fibromatosis (i.e., Dupuytren's disease). These lesions sometimes need to be evaluated by an experienced histopathologist to distinguish them from aggressive processes and malignant fibrosarcomas or malignant fibrous histiocytomas. The benign fibromatoses tend to recur locally if incompletely excised.

### *Muscle Origin Tumor—Rhabdomyosarcoma*

Rhabdomyosarcoma makes up approximately 15% of primary sarcomas in the hand and forearm. However, it is the most common soft-tissue tumor from childhood to young adulthood. The tumor tends to differentiate “toward” typical striated muscle. Rhabdomyosarcomas have been subdivided into embryonal, alveolar, and pleomorphic subtypes. Often these tumors present as painful enlargements, but numbness or paresthesias secondary to nerve compression may be the original symptom.

The alveolar subtype seems to be the most common variant found in the hand; overall, it is reported as the second most common in frequency for this tumor. When presenting in the hand, the neoplasm may develop in an interosseous muscle with secondary bone changes, and with enlargement evident on the palmar or dorsal regions of the hand.

Treatment of rhabdomyosarcoma requires multidisciplinary surgical and medical oncology combined with radiation therapy. Control the disease locally by wide surgical resection, radiation, or the combination. Current survival rates are improving (17,18,36,62).

### *Fibrous Histiocytoma*

Fibrous histiocytomas, both benign and malignant, occur predominantly in men in their fourth decade of life (2,135,159). Benign fibrous histiocytoma has a recurrence rate of about 10% to 15%; marginal or wide *en bloc* excision is indicated, especially for larger masses. Malignant fibrous histiocytoma (MFH) seems to be the most common primary soft-tissue sarcoma distal to the elbow in adults. The majority of MFH cases are in patients 50 to 70 years of age. Although these sarcomas predominate in the lower extremity, particularly the proximal thigh, the upper limb is the next most common site. This tumor can manifest a wide range of histologic and clinical features; it may invade along subcutaneous or intermuscular planes. Most often, MFH arises in muscle and deep fascial structures and enlarges within its compartment of origin. The tumor is macroscopically solitary but often multilocular. Although it appears well circumscribed, this malignancy has satellite lesions nearby, within “reactive tissues” surrounding the mass. Micrometastases are common when dissection is performed through the tumor pseudocapsule. See Chapter 129 for a discussion of the treatment of MFH.

### *Fibroma*

Fibromas are benign, encapsulated lesions; they have a low rate of recurrence after local removal. Such tumors arise from the tendon sheath (tenosynovial fibromas) or adjacent to the fingernails (periungual).

### *Extra-abdominal Desmoid Tumors, or Desmoplastic Fibroma*

Extra-abdominal desmoid tumors are aggressive and nonmetastatic but are likely to recur. Recurrent lesions will progressively invade and may destroy (in conjunction with repeated attempts at surgical cure) function in the affected limb. Effective local treatment requires a wide *en bloc* excision, or even an amputation for recurrent and destructive cases (Fig. 74.6).

Regular, serial reexaminations of the patient are required because of the tendency of these tumors to recur. Treat recurrences promptly. These tumors are notable because they are more aggressive clinically than their histologic appearance would suggest. They behave like low grade sarcomas and may be quite difficult (89,110,121).

### *Fibrosarcoma*

Fibrosarcoma is sometimes a highly aggressive malignancy. It can be found in anatomic areas that have undergone chronic traumatization or burns. Treatment varies with tumor location, grade, and stage; *en bloc* excision or amputation is needed (2,32,48,60,65,71,72,122) (see Chapter 129).

## VASCULAR TUMORS

Vascular tumors may be congenital or acquired, malignant or benign. Most lesions are benign and congenital; many may be considered hamartomatous, and these are believed to be due to failure of differentiation of embryonic vascular channels. Acquired lesions include arteriovenous fistulae, false and true aneurysms, pyogenic granulomas, and glomus tumors (30,60,97,118,136).

### *Arteriovenous Malformation*

Congenital arterial venous malformation (AVM) is uncommon. Whether congenital or acquired, it is an arteriovenous shunt. These tumors can be difficult to excise if they are not localized to a limited anatomic region. They may involve adjacent bone, nerve, tendon, muscle, and subcutaneous tissue as well as skin. Lesions not effectively treatable by debulking may necessitate digital or ray amputation. Some limited lesions can be effectively treated by ligating the feeding vessels. In the upper extremity, when these malformations occur, most are low-flow and their treatment relates to the aesthetics and function of the extremity (118). The high-flow lesions risk a neonate's survival, necessitating emergency treatment by a skilled pediatric cardiovascular team to reverse the process.

### *Aneurysm*

False aneurysm is the most common posttraumatic vascular abnormality in the hand. Following trauma, patients develop a painful, pulsatile, locally tender mass (65,125). The diagnosis is made by arteriography. Treat with excision. If excision will compromise blood flow to the distal tissues, simultaneous arterial/microvascular reconstruction will be needed. True aneurysms are a rarity but not unknown.

### *Hemangioma*

Capillary hemangiomas are frequently congenital; most will fade significantly, or disappear entirely, by the time the child is about 2 years of age. Cavernous hemangiomas, which are more extensive and deeper, may compress or compromise adjacent structures. Treat surgically only those lesions that are enlarging and painful. Preoperative arteriography helps to determine the probability of distal-part survival following tumor resection, or the need for vascular reconstruction, if possible (Fig. 74.11). At surgery, release the tourniquet before wound closure to ensure hemostasis, as vigorous and persistent local bleeding may occur following extirpation (30,118,160).

***Figure 74.11.*** **A:** An enlarging, painful cavernous hemangioma in a 9-year-old. **B:** The venogram best demonstrated the lesion, but angiography revealed good flow to all digits. **C:** Dorsal and palmar incisions were required to remove the tumor. Note preservation of the motor branch of the ulnar nerve (*arrow*).

### *Glomus Tumor*

Glomus tumors are relatively uncommon; they may go undiagnosed for long periods. They tend to occur in adults 20 to 60 years of age and are commonly subungual. They are very painful. Patients may complain of relatively short-term or acute onset of pain, marked local tenderness, and extreme sensitivity to cold at the site of the lesion. Careful inspection of the tissues in the area of pain often reveals a small, round nodule, or a bluish discoloration under the skin or nail, which is also characterized by marked local tenderness. Patients may note severe pain if an ice cube is applied to the site of the suspected lesion. MRI is very useful in diagnosing glomus tumors, especially when patients have localized obscure pain and no other positive findings (141).

Treat with marginal excision. If the tumor is beneath the nail, excision requires removal of the nail and longitudinal incision of the nail matrix with removal of the lesion beneath (including curettage of bone, where appropriate). Reapproximate accurately the sterile and/or germinal matrix with fine, absorbable sutures. Replace the nail or insert nonadherent gauze in the eponychial fold. Neither need be sutured to the cuticle.

### *Kaposi's Sarcoma*

Kaposi's sarcoma (KS) historically was a rare vascular malignancy. Now, chronically immunocompromised patients such as those with acquired immunodeficiency syndrome (AIDS) or those who have had an organ transplant can suffer from these sarcomas (9,53,84,87). KS appears as a reddish purple or reddish brown skin tumor or nodule on the extremities or trunk and may be an early indication of human immunodeficiency virus (HIV) infection or progressing AIDS. These lesions should be treated palliatively, in conjunction with the patient's medical management. Where warranted, local treatment may be requested by the primary physician, but this is not common.

## NERVE TUMORS

### *Schwannoma/Neurilemoma*

The schwannoma (neurilemoma) is a common, solitary, and benign lesion arising from the Schwann cell. It is the most common tumor of the peripheral nerves, nerve trunks, and their branches. It is more frequent (or more frequently noticed) on a flexor surface. These tumors are generally less than 4.0 cm in diameter; masses 5.0 cm or more in diameter may be malignant (43,78,133,144). In general, symptoms are the result of nerve compression. Surgical treatment requires extirpation. Use magnification during the surgical dissection to minimize injury to adjacent and secondarily compressed, atrophic, but otherwise normal fascicles. Because the neurilemoma is well encapsulated, it can be dissected from the surrounding fasicles. Recurrences are unusual following excision.

Malignant schwannoma is not a degeneration of the benign variant; rather, it arises as a complication of neurofibromatosis. Malignant schwannoma requires wide excision and primary reconstruction; amputation may be needed for the aggressive, poorly differentiated tumors, which can have an extremely bad prognosis (see Chapter 129).

### *Neurofibroma*

The neurofibroma is a diffuse, mixed growth of Schwann cells, axons, and fibrous tissue, which occurs as a solitary lesion or may be part of multiple nerve and cutaneous tumors (von Recklinghausen's disease). Solitary neurofibroma is unlikely to recur following excision; however, multiple plexiform neurofibromas cannot be enucleated easily. Symptomatic plexiform neurofibromas that require removal usually require complete resection. Nerve grafting is necessary for reconstruction (107,138,144).

### *Lipofibromatous Hamartoma*

Lipofibromatous hamartoma is not a true tumor, as its name implies; its cause is unknown. The lesion is rare. It usually appears as a slow-growing painless mass in childhood. In the median nerve, its presence is associated with symptoms like those of carpal tunnel syndrome (4,85,119,123,138).

The treatment is controversial. Most agree that in symptomatic patients operative exploration is warranted and should include nerve decompression. At the carpal tunnel, release of the transverse carpal ligament and a small incisional biopsy of the nerve is done. Division of the antebrachial fascia may be necessary. Occasionally—perhaps rarely—epineurotomy is appropriate. Intraneural dissection often results in functional loss and is best avoided primarily.

Digital gigantism associated with the presence of this tumor in the median or ulnar nerves has been described (4). Children with this present with a grotesquely enlarged finger that may need amputation. More than one finger may be affected. Early treatment with physeal arrest is warranted. Some advocate removal of the branches of the digital nerve with preservation of the nerve trunk. Unfortunately, gradual, local neurologic deterioration can be anticipated in many of these cases, necessitating nerve excision or partial amputation.

## LIPID TUMORS

### *Lipoma*

The lipoma is a common, benign soft-tissue tumor in the upper limb. It is more often found in women, and a bit more commonly on the flexor surface of the hand. Patients complain of a slowly enlarging, painless, and often asymptomatic mass that at presentation may be of such impressive size that it interferes with function. Symptoms of compression neuropathy (when the lesion is in the carpal tunnel or a similar location) may be the presenting complaint. Excision of the tumor and pseudocapsule is usually a straightforward, curative procedure (83,101,113,135,157).

### *Liposarcoma*

Liposarcomas are extremely rare in the upper extremity. See Chapter 129 for details on diagnosis and management.

## SYNOVIAL TUMORS

### *Giant Cell Tumor of Tendon Sheath*

The giant cell tumor of the tendon sheath (fibrous xanthoma) is a soft-tissue lesion that is not related to, and should not be confused with, a giant cell tumor of bone. The two are of different origin, presentation, frequency, and behavior. These lesions are common on the flexor surface of the hand, where tenosynovial tissues predominate. Most of these tumors are found in the fingers, wrist, or palm. As they slowly enlarge, they have the potential to envelope tendons, invade bones and joints, and to surround neurovascular structures. Treatment is by thorough local excision while avoiding injury to adjacent anatomy (Fig. 74.12). The incidence of recurrence is reported to exceed 15%, but recurrence quite probably occurs from incomplete, inadequate excision (49,99,113,115). Should a recurrent tumor present, reexcision is indicated.

***Figure 74.12.*** Giant cell tumor of tendon sheath must be completely removed to prevent recurrence, while preserving the flexor pulleys and avoiding injury to the neurovascular bundles.

### *Epithelioid Sarcoma, Synovial Sarcoma, and Clear Cell Sarcoma*

The epithelioid, synovial, and clear cell sarcomas are among the more common primary soft-tissue malignancies in the distal portion of the upper extremity, distal to the elbow (1,6,8,19,22,35,46,47,61,74,77,93,105,111,114,126,139,149,152,155).

These lesions are grouped together because of their similar aggressive behavior and their tendency to present in a confusing and atypical fashion. Their spread is seemingly unpredictable, and they can include skin, vessels, and lymphatics at secondary regional and distant sites. Unfortunately, these neoplasms have a grave prognosis. For that reason, an otherwise benign-appearing, solid soft-tissue lesion in the hand or wrist must be approached with caution. Incisional biopsy with appropriate technique (Chapter 129) is important, as the tumor may turn out to be one of these potentially lethal sarcomas.

Once the diagnosis is established, appropriate multidisciplinary evaluation and staging, and surgical and medical treatment, including axillary node dissection (increasingly preceded by sentinel node biopsy) is advised. Radiation has been helpful in some cases; the value of radiation and chemotherapy is not yet well defined or entirely dependable, but it is increasingly part of the primary treatment.

# SKELETAL TUMORS

## CARTILAGE TUMORS

### *Enchondroma*

The solitary enchondroma is arguably the most common bone tumor in the hand. In the vast majority, the tumor presents as a pathologic fracture. It is most common in young adults. This speckled osteolytic lesion may be discovered incidentally on radiographs taken for another reason (Fig. 74.13), or because of enlargement of a finger or hand. However, pain is unusual without fracture.

***Figure 74.13.*** **A:** Expansile lytic lesion of the proximal phalanx of the middle finger was found incidentally on radiographs done for a little finger injury. Speckled radiographic appearance is typical for an enchondroma. The patient declined treatment of this relatively large, albeit asymptomatic, lesion. **B:** Two years later, a radiograph following a minor trauma showed a pathologic fracture through the slightly further enlarged tumor. **C:** Curettage and bone grafting were performed to treat the tumor and stabilize the phalanx. Graft incorporation and remodeling occurred without incident.

Very small enchondromas need only periodic observation. Plan to treat larger and enlarging tumors, as well as those associated with fractures. The presence of a fracture through the lesion does not ensure spontaneous tumor resolution during the course of bone healing. These tumors are amenable to adequate curettage. Most commonly, autogenous bone graft is added; but thorough curettage is the most important surgical step.

We prefer to treat both the lesion and the pathologic fracture simultaneously, to minimize morbidity and avoid double disability. In some patients, the addition of internal fixation, commonly with Kirschner wires, plus bone graft will be needed to stabilize the curetted infracted bone. Delay of surgical treatment until the bone has healed is a more traditional approach, but this can prolong a patient's disability because the hand has to recover first from the fracture and then from subsequent surgery. Furthermore, delay in treating the lesion delays the diagnosis, should the osteolytic tumor prove to be other than an enchondroma (12,73,112). Start postoperative hand therapy as soon as practical, considering the skeletal stability following trauma and treatment, in order to minimize tendon adhesions and joint stiffness.

### *Multiple Enchondromatosis*

Multiple enchondromatosis (Ollier's disease) is far less common than solitary lesions, but these multiple tumors have a tendency to be larger and unilateral, and they are associated with skeletal deformities (Fig. 74.14) (16,51). Ollier's disease is probably not hereditary. Maffucci's syndrome is Ollier's disease with associated angiomas of skin or soft tissue. The hand is most commonly involved, with tumors generally beginning in the metaphysis but gradually extending distally into the diaphysis, or proximally to the former epiphysis in adults. These lesions require curettage and *en bloc* excision; often the bone deformity will need osteotomy for finger realignment.

***Figure 74.14.*** Multiple enchondromatosis caused extensive deformity and dysfunction in this patient with a positive family history.

The risk of sarcomatous degeneration is considerably higher with multiple growing lesions and should be suspected if tumors become painful, begin to enlarge, or are associated with progressive deformity. Do an incisional biopsy to rule out malignancy.

### *Chondrosarcoma*

Chondrosarcomas in the hand are very rare but not unknown. Findings of histologic atypia in a cartilaginous lesion should not be regarded as a necessarily clinically worrisome issue. Consider the clinical presentation and histologic situation together—especially in the older or at-risk patient. Most malignancies are low grade. (See Chapter 128.)

### *Osteocartilaginous Exostoses or Osteochondroma*

Exostoses, both solitary and multiple, often originate as a hereditary problem that may cause significant and generalized skeletal deformities. Although the tubular bones of the hands are less commonly affected than the radius and ulna, they may be involved. Symptoms are generally caused by the presence of a bony mass, and complaints may include deformity (in the growing skeleton) and progressively diminished mobility because of bony block-to-joint motion. Treatment should include removal of the space-occupying lesion while preserving skeletal integrity and nearby soft tissues. The risk of malignant transformation of lesions in the hand is extremely low. The significant problem associated with these tumors is the need for reconstructive surgery to restore functional alignment of the (small and large) bones in the forearm, wrist, and hand (20,24,25,143).

Surgical treatment and reconstruction (as multiplanar osteotomy) require great care to avoid injury to the growing physis when the osteochondroma is found, because they typically are close to the physeal plate. Bowing of the radius or ulna, shortening of the forearm, and limitation of forearm rotation can be a reconstructive challenge necessitating tumor treatment and lengthening of any involved bones. Removal of the mass will not, per se, correct the deformity or necessarily restore lost joint motion, which may be accompanied by secondary fibrosis (see Chapter 127).

## BONE TUMORS

### *Giant Cell Tumor of Bone*

A giant cell tumor (GCT) of bone is relatively uncommon in the hand and wrist. It is usually a tumor of younger adults and may be associated with multicentric foci when found in the upper limb. The behavior of multicentric GCTs is different from that of solitary lesions. Those of the small tubular bones should always be considered more aggressive than those presenting in the larger bones (10,26,42,55,90,104,120,132,134,142,151,161). Small multicentric foci are not easily diagnosed on routine radiographs; do a bone scan when a GCT of bone is suspected to avoid missing the multicentric variant. Patients complain of pain and enlargement of the part, and localized tenderness. Pain may be due to an impending or pathologic fracture.

Curettage—with or without bone graft—and bone substitutes, bone cement, and other techniques have been used for GCT for various locations. When in the distal portion of the upper extremity, these tumors are likely to recur, however (Fig. 74.15). It is our opinion that GCTs of tubular bones in the hand and of the distal radius and ulna should be treated by *en bloc* excision or by ray resection with simultaneous replacement and reconstruction with bone graft, vascularized graft, or osteoarticular allograft, appropriate to the specific case. The precise surgical technique and approach depend on the particular lesion and patient. Tailor postoperative rehabilitation to the particular reconstructive procedure. See Chapter 127 for a more extensive discussion.

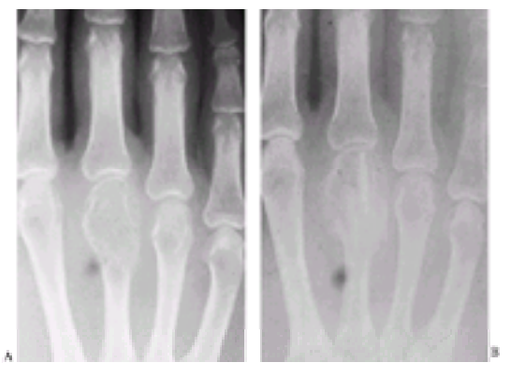

***Figure 74.15.*** **A:** Eccentric, lytic epiphyseal lesion of the third metacarpal proved to be a giant cell tumor of bone, which was treated by curettage and grafting. **B:** Tumor recurrence is seen as an enlarging zone of osteolysis, including graft destruction, nearly 4 months after curettage. Ray resection was required.

### *Aneurysmal Bone Cyst*

Aneurysmal bone cyst (ABC) is a benign hemorrhagic and cystic tumor of bone with a propensity for local recurrence (Fig. 74.3*E*, Fig. 74.3*F*, Fig. 74.3*G*, Fig. 74.3*H* and Fig. 74.3*I*). It is relatively uncommon in the hand. Most often it is a solitary, expansile lesion originating in the metaphysis of a long bone that has a “blown-out” appearance on the radiograph. ABC tends to be more common in the second and third decades, with a slight predominance for women. *En bloc* excision is the most dependable treatment. Radiographically, this tumor may be confused with GCT of bone, or with bone cyst, osteosarcoma, or Ewing's sarcoma. ABC, however, has a much lower recurrence rate than GCT of bone.

### *Osteoid Osteoma or Osteoblastoma*

Osteoid osteomas and osteoblastomas are benign, bone-forming tumors that often present as painful but otherwise radiographically obscure lesions in young patients. The propensity for a locus in the hand is not high, but it has to be considered in patients with localized pain and apparent enlargement of a small bone in the hand with periosteal a endosteal new bone formation (Fig. 74.16).

***Figure 74.16.*** **A:** Swelling and pain of 2 years' duration in a 17-year-old boy whose radiographs show retrocondylar bone formation surrounding a central, lucent nidus. **B:** At surgery, the diagnosis of osteoid osteoma was confirmed and the lesion was successfully treated by curettage.

The most difficult challenge in treatment is making the diagnosis. If plain films are nonspecific, a CT scan of the lesion using fine cuts is most likely to identify the nidus, which is diagnostic. Excision without recurrence is typical if the tumor nidus is excised (5,13,37,39,71,75,91,110).

### *Osteosarcoma*

High-grade intramedullary osteosarcoma is extremely uncommon in the hand and wrist (14,27,40,57,63,92,127,150). Of the various subtypes, the parosteal, periosteal, and low-grade central osteosarcomas have a lower incidence of metastasis and a higher overall survival than osteoblastic, chondroblastic, fibroblastic, and telangiectatic osteosarcomas.

Evolution and advancement in staging and multidisciplinary therapies have improved survival to nearly 70% in some series. Frequently, preoperative (neoadjuvant) chemotherapy is combined with other methods, including surgery. Pulmonary metastasis is the primary cause of death; however, limb salvage following regional or systemic neoadjuvants, combined with simultaneous (and most often complex microvascular) reconstruction, can salvage a useful hand without increased morbidity and mortality (see Chapter 126 and Chapter 128).

## AUTHORS' PERSPECTIVE

We emphasize here the principles of diagnosis and treatment for hand tumors rather than making an attempt to review every tumor or related condition that may present in the hand. Certain specific neoplasms have been described because they are common or could lead to death.

We strongly believe that surgeons treating tumors of the hand must be part of an oncology team. This team must be experienced and prepared to diagnose, biopsy, and excise these tumors, and simultaneously reconstruct the hand. Such a team includes musculoskeletal oncologists, medical oncologists, reconstructive surgeons, and radiation therapists, as well as experienced musculoskeletal pathologists. Treatment should achieve a cure, and function should be preserved whenever possible. Balancing these considerations may not be easy, but it is important to the patient's daily function, and ultimately to their survival.

### CHAPTER REFERENCES

Each reference is categorized according to the following scheme: *, classic article; #, review article; !, basic research article; and +, clinical results/outcome study.


+ 1. Adeyemi-Doro HO, Durosimi-Etti FA, Olude O. Primary Malignant Tumors of the Hand. *J Hand Surg [Am]* 1985;10:815.

+ 2. Adeyemi-Doro HO, Olude O. Juvenile Aponeurotic Fibroma. *J Hand Surg [Br]* 1985;10:127.

+ 3. Albertini JJ, Cruse CW, Rapaport D, et al. Intraoperative Radio-lympho-scintigraphy Improves Sentinel Lymph Node Identification for Patients with Melanoma. *Ann Surg* 1996;223:217.

+ 4. Amadio PC, Reinman HM, Dobyns JH. Lipofibromatous Hamartoma of Nerve. *J Hand Surg [Am]* 1988;13:67.

+ 5. Ambrosia JM, Wold LE, Amadio PC. Osteoid Osteoma of the Hand and Wrist. *J Hand Surg [Am]* 1987;12:794.

+ 6. Andrew TA. Clear Cell Sarcoma of the Hand. *Hand* 1982;14:200.

+ 7. Angelides AC, Wallace PF. The Dorsal Ganglion of the Wrist: Its Pathogenesis Gross and Microscopic Anatomy and Surgical Treatment. *J Hand Surg* 1976;1:228.

+ 8. Archer IA, Brown RB, Fitton JM. Epithelioid Sarcoma in the Hand. *J Hand Surg [Br]* 1984;9:207.

# 9. Ariyan S. Benign and Malignant Soft Tissue Tumors of the Hand. In: McCarthy JG, May JW Jr, Littler JW, eds. *Plastic Surgery: The Hand*, part 2, vol 8. Philadelphia: WB Saunders, 1990:5483.

+ 10. Averill RM, Smith RJ, Campbell CJ. Giant Cell Tumors of the Bones of the Hand. *J Hand Surg* 1980;5:39.

+ 11. Balch CM, Urist MM, Karakousis CP, et al. Efficacy of 2-cm Surgical Margins for Intermediate-thickness Melanomas (1-4 mm): Results of a Multi-institutional Randomized Surgical Trial. *Ann Surg* 1993;218:262.

+ 12. Bearman RM, Noe J, Kempson R. Clear Cell Sarcoma with Melanin Pigment. *Cancer* 1975;36:977.

+ 13. Bednar MS, McCormack RR Jr, Glasser D, Weiland AJ. Osteoid Osteoma of the Upper Extremity. *J Hand Surg [Am]* 1993;18:1019.

+ 14. Bertoni F, Bacchini P, Fabbri N, et al. Osteosarcoma, Low-grade Intraosseous Type, Histologically Resembling Parosteal Osteosarcoma, Fibrous Dysplasia, and Desmoplastic Fibroma. *Cancer* 1993;71:338.

+ 15. Binkovitz LA, Berquist TH, McLeod RA. Masses of the Hand and Wrist Detection and Characterization with MR Imaging. *Am J Roentgenol* 1990;155:423.

# 16. Bogumill G, Nelson MC, Lack EE. Lesions of Cartilage. In: Bogumill GP, Fleegler EJ, eds. *Tumors of the Hand and Upper Limb.* Edinburgh: Churchill Livingstone, 1993:327.

+ 17. Bray PW, Bell RS, Bowen CV, et al. Limb Salvage Surgery and Adjuvant Radiotherapy for Soft Tissue Sarcomas of the Forearm and Hand. *J Hand Surg [Am]* 1997;22:495.

+ 18. Brien EW, Terek RM, Geer RJ, et al. Treatment of Soft-tissue Sarcomas of the Hand. *J Bone Joint Surg Am* 1995;77:564.

+ 19. Bryan RF, Soule EH, Dobyns JH, et al. Primary Epithelioid Sarcoma of the Hand and Forearm: A Review of 13 Cases. *J Bone Joint Surg Am* 1974;56:455.

+ 20. Burgess RC, Cates H. Deformities of the Forearm in Patients Who Have Multiple Cartilaginous Exostosis. *J Bone Joint Surg Am* 1993;75:13.

+ 21. Butler ED, Hamill JP, Scipel RS, DeLorimier AA. Tumors of the Hand—A 10-Year Survey and Report of 437 Cases. *Am J Surg* 1960;100:293.

+ 22. Cadman NL, Soule EH, Kelly PJ. Synovial Sarcoma: An Analysis of 134 Tumors. *Cancer* 1965;18:613.

# 23. Campanacci M. *Bone and Soft Tissue Tumors.* New York: Springer-Verlag, 1990.

# 24. Campanacci M. Multiple Chondromas. In: Campanacci M, ed. *Bone and Soft Tissue Tumors.* New York: Springer-Verlag, 1990:229.

# 25. Campanacci M. Solitary Exostosis. In: Campanacci M, ed. *Bone and Soft Tissue Tumors.* New York: Springer-Verlag, 1990:183.

+ 26. Campanacci M, Baldini N, Boriani S, Sudanese A. Giant Cell Tumor of Bone. *J Bone Joint Surg Am* 1987;69:106.

+ 27. Campanacci M, Picci P, Gherlinzoni F, et al. Parosteal Osteosarcoma. *J Bone Joint Surg Br* 1984;66:313.

+ 28. Carroll RE. Epidermal (Epithelial) Cyst of the Hand Skeleton. *Am J Surg* 1953;85:327.

+ 29. Carroll RE. Squamous Cell Carcinoma of the Nail Bed. *J Hand Surg* 1976;1:92.

+ 30. Carroll RE, Berman AT. Glomus Tumors of the Hand. *J Bone Joint Surg Am* 1972;54:691.

+ 31. Castello JR, Garro L, Romero F, et al. Metastatic Tumors of the Hand. *J Hand Surg [Br]* 1996;21:547.

+ 32. Castro EB, Hajdu SI, Fortner JG. Surgical Therapy of Fibrosarcoma of Extremities: A Reappraisal. *Arch Surg* 1973;107:284.

+ 33. Chakrabarti I, Watson JD, Dorrance H. Skin Tumors of the Hand: A 10-year Review. *J Hand Surg [Br]* 1993;18:484.

+ 34. Cheng EY, Thompson RC Jr. New Developments in the Staging and Imaging of Soft Tissue Sarcomas. *J Bone Joint Surg Am* 1999;81:882.

+ 35. Chung EB, Enzinger FM. Clear Cell Sarcoma of Tendons and Aponeuroses: Further Observations Abstracted. *Lab Invest* 1978;38:338.

+ 36. Chung EB, Enzinger FM. Fibroma of Tendon Sheath. *Cancer* 1979;44:1945.

+ 37. Cohen MD, Harrington TM, Ginsburg WW. Osteoid Osteoma: 95 Cases and a Review of the Literature. *Semin Arthritis Rheum* 1993;12:265.

+ 38. Creighton JJ, Peimer CA, Mindell ER, et al. Primary Malignant Tumors of the Upper Extremity: Retrospective Analysis of 126 Cases. *J Hand Surg [Am]* 1985;10:805.

# 39. Dahlin DC. *Bone Tumors*, 3rd ed. Springfield, IL: Charles C Thomas, 1967.

+ 40. Dahlin DC, Unni KK. Osteosarcoma. In: *Bone Tumors*, 4th ed. Springfield, IL: Charles C Thomas, 1986:269.

# 41. Dell PC, Stern PJ. Benign and Malignant Neoplasms of the Upper Extremity. In: Peimer CA, ed. *Surgery of the Hand and Upper Extremity.* New York: McGraw-Hill, 1995:2231.

# 42. Enneking WF. Lesions of Uncertain Origin Originating in Bone. In: Enneking WF, ed. *Musculoskeletal Tumor Surgery.* New York: Churchill Livingstone, 1983:1425.

# 43. Enneking WF. *Musculoskeletal Tumor Surgery.* New York: Churchill Livingstone, 1983.

# 44. Enneking WF, Spanier SS, Goodman MA. Current Concepts Review: The Surgical Staging of Musculoskeletal Sarcoma. *J Bone Joint Surg Am* 1980;62:1027.

+ 45. Enneking WF, Spanier SS, Goodman MA. The Surgical Staging of Musculoskeletal Sarcoma. *Clin Orthop* 1982;153:106.

+ 46. Enzinger FM. Clear Cell Sarcoma of Tendons and Aponeuroses: An Analysis of 21 Cases. *Cancer* 1968;18:1163.

+ 47. Enzinger FM. Epithelioid Sarcoma: A Sarcoma Simulating a Granuloma or a Carcinoma. *Cancer* 1970;26:1029.

# 48. Enzinger FM, Weiss SW. *Soft Tissue Tumors*. St. Louis: CV Mosby, 1983.

# 49. Enzinger FM, Weiss SW. *Soft Tissue Tumors*, 2nd ed. St. Louis: CV Mosby, 1988.

# 50. Enzinger FM, Weiss SW, eds. *Soft Tissue Tumors*, 3rd ed. St. Louis, MO: Mosby, 1995.

+ 51. Feldman F. Primary Bone Tumors of the Hand and Carpus. *Hand Clin* 1987;3:269.

+ 52. Fink JA, Akelman E. Nonmelanotic Malignant Skin Tumors of the Hand. *Hand Clin* 1995;11:255.

# 53. Fitzpatrick TB, Johnson RA, Polano MK, et al., eds. *Color Atlas and Synopsis of Clinical Dermatology: Common and Serious Diseases*, 2nd ed. New York: McGraw-Hill, 1992.

# 54. Fleegler EJ. Skin Tumors. In: Green DP, ed. *Operative Hand Surgery*, vol. 2. New York: Churchill Livingston, 1982.

+ 55. Fogel GR, McElfresh EC, Peterson HA, Wicklund PT. Management of Deformities of the Forearm in Multiple Hereditary Osteochondromas. *J Bone Joint Surg Am* 1984;66:670.

# 56. Fraker DL. Hyperthermic Regional Perfusion for Melanoma of the Limbs. In: Balch CM, Houghton AN, Sober AJ, Soong S, eds. *Cutaneous Melanoma*, 3rd ed. St. Louis, MO: Quality Medical, 1998:281.

+ 57. Frassica FJ, Sim FH, Frassica DA, et al. Survival and Management Considerations in Post Irradiation Osteosarcoma and Paget's Osteosarcoma. *Clin Orthop* 1991;270:120.

# 58. Frassica FJ, Thompson RC Jr. Evaluation, Diagnosis, and Classification of Benign Soft-tissue Tumors. *Instr Course Lect* 1996;45:447.

+ 59. Geer RJ, Woodruff J, Casper ES, Brennan MF. Management of Small Soft-tissue Sarcoma of the Extremity in Adults. *Arch Surg* 1992;127:1285.

+ 60. Gelberman RI, Goldner JL. Congenital Arteriovenous Fistulas of the Hand. *J Hand Surg* 1978;3:451.

+ 61. Gerner RE, Moore G. Synovial Sarcoma. *Ann Surg* 1975;181:22.

+ 62. Giannakopoulos P, Sotereanos D, Tomaino M, et al. Benign and Malignant Muscle Tumors in the Hand and Forearm. *Hand Clin* 1995;11:191.

+ 63. Glasser DB, Lane JM. Stage IIB Osteogenic Sarcoma. *Clin Orthop* 1991;270:29.

+ 64. Graham GF, Clark LC. Statistical Update in Cryosurgery for Cancers of the Skin. In: Zacarian SA, ed. *Cryosurgery for Skin Cancer and Cutaneous Disorders.* St. Louis, MO: CV Mosby, 1985:298.

+ 65. Green DP. True and False Traumatic Aneurysms in the Hand. *J Bone Joint Surg Am* 1973;55:120.

+ 66. Greendyke SD, Wilson M, Shepler TR. Anterior Wrist Ganglia from the Scaphotrapezial Joint. *J Hand Surg [Am]* 1992;17:487.

+ 67. Gross E, Rao BN, Pappo AS, et al. Soft Tissue Sarcoma of the Hand in Children: Clinical Outcome and Management. *J Pediatr Surg* 1997;32:698.

# 68. Hajdu SI. *Pathology of Soft-Tissue Tumors.* Philadelphia: Lea & Febiger, 1964.

+ 69. Haws MJ, Neumeiser MW, Kenneaster DG, Russell RC. Management of Nonmelanoma Skin Tumors of the Hand. *Clin Plast Surg* 1997;24:779.

# 70. Ho VC, Sober AJ, Balch CM. Biopsy Techniques. In: Balch CM, Houghton AN, Sober AJ, Soong S, eds. *Cutaneous Melanoma*, 3rd ed. St. Louis, MO: Quality Medical, 1998:135.

# 71. Huvos A. *Bone Tumors: Diagnosis, Treatment and Prognosis.* Philadelphia: WB Saunders, 1979.

+ 72. Ivins JC, Dockerty MB, Ghormley RK. A Fibrosarcoma of the Soft Tissues of the Extremities: A Review of 78 Cases. *Surgery* 1950;28:495.

# 73. Jaffe HL. *Tumors and Tumorous Conditions of Bones and Joints.* Philadelphia: Lea & Febiger, 1958.

# 74. Jaffe HL. *Metabolic, Degenerative and Inflammatory Disease of Bones and Joints.* Philadelphia: Lea & Febiger, 1972.

# 75. Johnston JO. Differential Diagnosis and Treatment of Giant Cell Lesions. In: Bogumill GP, Fleegler EJ, eds. *Tumors of the Hand and Upper Limb*. Edinburgh: Churchill Livingstone, 1993:360.

+ 76. Johnstone PA, Wexler LH, Venzon DJ, et al. Sarcomas of the Hand and Foot: Analysis of Local Control and Functional Result with Combined Modality Therapy in Extreme Preservation. *Int J Radiat Oncol Biol Phys* 1994;29:735.

+ 77. Jones FE, Soule EH, Coventry MB. Fibrous Xanthoma of Synovium (Giant-Cell Tumor of Tendon Sheath, Pigmented Nodular Synovitis). A Study of 118 Cases. *J Bone Joint Surg Am* 1969;51:76.

+ 78. Keith JE Jr, Wilgis EF. Kaposi's Sarcoma in the Hand of an AIDS Patient. *J Hand Surg [Am]* 1986;11:410.

+ 79. Kobayashi H, Kotoura Y, Hosono M, et al. MRI and Scintigraphic Features of Extra-abdominal Desmoid Tumors. *Clin Imaging* 1997;21:35.

# 80. Kopf AW, Bart RS, Rodriguez-Sains RS, et al. *Malignant Melanoma.* New York: Masson, 1979.

# 81. Landis SH, Murray T, Bolden S, Wingo PA. Cancer Statistics, 1998. *CA Cancer J Clin* 1998;48:6.

# 82. Laskin WB, Weiss SW. Benign Fibrous Lesions. In: Bogumill GP, Fleegler EJ, eds. *Tumors of the Hand and Upper Limb.* Edinburgh: Churchill Livingstone, 1993:224.

+ 83. Leffert RD. Lipomas of the Upper Extremity. *J Bone Joint Surg Am* 1972;54:1262.

+ 84. Lister WA. Natural History of Strawberry Nevi. *Lancet* 1938;1:1429.

+ 85. Louis D, Hankin F, Greene T, et al. Long-term Follow-up of Lipofibroma of the Median Nerve. *J Hand Surg* 1985;10:403.

+ 86. Mankin HJ, Lange TA, Spanier SS. The Hazards of Biopsy in Patients with Malignant Primary Bone and Soft-Tissue Tumors. *J Bone Joint Surg Am* 1982;64:1121.

+ 87. Matloub HS, Muoneke VN, Prevel CD, et al. Glomus Tumor Imaging: Use of MRI for Localization of Occult Lesions. *J Hand Surg [Am]* 1992;17:472.

+ 88. Matthews P. Ganglia of the Flexor Tendon Sheaths in the Hand. *J Bone Joint Surg Br* 1973;55:612.

+ 89. McCullough WM, Parsons JT, Vander Griend R, et al. Radiation Therapy for Aggressive Fibromatosis. *J Bone Joint Surg Br* 1991;72:717.

+ 90. McDonald DJ, Sim FH, McLeod RA, Dahlin DC. Giant Cell Tumor of Bone. *J Bone Joint Surg Am* 1986;68:236.

+ 91. McLellan DI, Wilson FC Jr. Osteoid Osteoma of the Spine. *J Bone Joint Surg Am* 1967;49:111.

+ 92. Mervak TR, Unni KK, Pritchard DJ, et al. Telangiectatic Osteosarcoma. *Clin Orthop* 1991;270:135.

+ 93. Miettinen M, Vittanen I. Synovial Sarcoma: A Misnomer. *Am J Pathol* 1984;117:18.

+ 94. Moller R, Reymann F, Hou-Jensen K. Metastases in Dermatological Patients with Squamous Cell Carcinoma. *Arch Dermatol* 1979;115:703.

+ 95. Morton DL, Wen DR, Cochran AJ. Management of Early-stage Melanoma by Intraoperative Lymphatic Mapping and Selective Lymphadenectomy. *Surg Oncol Clin North Am* 1992;1:247.

+ 96. Nelson CL, Sawmiller S, Phalen GS. Ganglions of the Wrist and Hand. *J Bone Joint Surg Am* 1972;54:1459.

+ 97. Neviaser RI, Adams JP. Vascular Lesions in the Hand: Current Management. *Clin Orthop* 1974;100:111.

+ 98. Okunieff P, Suit HD, Proppe KH. Extremity Preservation by Combined Modality Treatment of Sarcomas of the Hand and Wrist. *Int J Radiat Oncol Biol Phys* 1986;12:1923.

+ 99. Oster LH, Blair WF, Steyers CM: Large Lipomas in the Deep Palmar Space. *J Hand Surg [Am]* 1989;14:700.

+ 100. Padilla PJ, Seigler HF, Urbaniak JR, Levin LS. Melanoma of the Upper Extremity. *Orthop Trans* 1994–1995;18:1090.

+ 101. Paletta FX, Senay LC Jr. Lipofibromatous Hamartoma of Median Nerve and Ulnar Nerve: Surgical Treatment. *Plast Reconstr Surg* 1981;17:915.

+ 102. Peabody TD, Gibbs CP, Simon MA. Evaluation and Staging of Musculoskeletal Neoplasms. *J Bone Joint Surg Am* 1998;80:1204.

+ 103. Peh WC, Truong NP, Totty WG, Gilula LA. Pictorial Review: Magnetic Resonance Imaging of Benign Soft Tissue Masses of the Hand and Wrist. *Clin Radiol* 1995;50:519.

+ 104. Peimer CA, Schiller AL, Mankin HJ, Smith RJ. Multicentric Giant Cell Tumor of Bone. *J Bone Joint Surg Am* 1980;62:652.

+ 105. Peimer CA, Smith RJ, Sirota RI, et al. Epithelioid Sarcoma of the Hand and Wrist: Patterns of Extension. *J Hand Surg* 1977;4:275.

+ 106. Pfeifer T, Weinberg H, Brady MS. Lymphatic Mapping for Merkel Cell Carcinoma. *J Am Acad Dermatol* 1997;37:650.

+ 107. Phalen GS. Neurilemomas of the Forearm and Hand. *Clin Orthop* 1976;114:219.

+ 108. Pisters PW, Harrison LB, Leung DH, et al. Long-term Results of a Prospective Randomized Trial of Adjuvant Brachytherapy in Soft Tissue Sarcoma. *J Clin Oncol* 1996;14:859.

+ 109. Poppen NK, Niebauer JJ. Recurring Digital Fibrous Tumor of Childhood. *J Hand Surg* 1977;2:253.

+ 110. Posner MC, Shiu MH, Newsome JL, et al. The Desmoid Tumor: Not a Benign Disease. *Arch Surg* 1989;124:191.

+ 111. Raben M, Calabarese A, Hinginbothan NL, et al. Malignant Synovioma. *Am J Roentgenol* 1965;93:145.

+ 112. Radstone DJ, Revell PA, Mantell BS. Clear Cell Sarcoma of Tendons and Aponeuroses Treated with Bleomycin and Vincristine. *Br J Radiol* 1979;52:238.

# 113. Ragsdale BD, Dupree WB. Neoplasms of the Fatty Tissues. In: Bogumill GP, Fleegler EJ, eds: *Tumors of the Hand and Upper Limb.* Edinburgh: Churchill Livingstone, 1993:254.

+ 114. Rajpal S, Moore RH, Karakousis GP. Synovial Sarcoma: A Review of Treatment and Survival in 52 Patients. *NY State J Med* 1984;84:17.

+ 115. Rankin G, Kuschner SH, Gellman H. Nodular Faciitis: A Rapidly Growing Tumor of the Hand. *J Hand Surg [Am]* 1991;16:791.

+ 116. Rayner CRW. The Result of Treatment of 273 Carcinomas of the Hand. *Hand* 1981;13:183.

# 117. Reintgen DS, Rapaport DP, Tanabe KK, Ross MI. Lymphatic Mapping and Sentinel Lymphadenectomy. In: Balch CM, Houghton AN, Sober AJ, Soong S, eds. *Cutaneous Melanoma*, 3rd ed. St. Louis, MO: Quality Medical, 1998;227.

+ 118. Rettig AC, Strickland JW. Glomus Tumors of the Digits. *J Hand Surg* 1977;2:261.

+ 119. Rinaldi E. Neurilemomas and Neurofibromas of the Upper Limb. *J Hand Surg* 1983;8:590.

# 120. Rock MG, Capanna R. The Treatment of Giant Cell Tumor of Bone. In: Stauffer RN, Ehrlich MG, Fu FH, et al., eds. *Advances in Operative Orthopaedics.* St. Louis, MO: CV Mosby, 1993:367.

+ 121. Rock MG, Pritchard DJ, Reiman HM, et al. Extra-abdominal Desmoid Tumors. *J Bone Joint Surg Am* 1984;66:1369.

+ 122. Rook A, Whimster I. Keratoacanthoma: A Thirty-year Retrospect. *Br J Dermatol* 1979;100:41.

# 123. Rosenberg AE, Dick HM, Botte M. Benign and Malignant Tumors of Peripheral Nerve. In: Gelberman RH, ed. *Operative Nerve Repair and Reconstruction.* Philadelphia: JB Lippincott, 1991:1587.

# 124. Roses DF, Harris MN, Ackerman AB. Diagnosis and Management of Cutaneous Malignant Melanoma. In: Roses DF, Harris MN, Ackerman AB, eds. *Major Problems in Clinical Surgery.* Philadelphia: WB Saunders, 1983:346.

+ 125. Sabin FRI. Origin and Development of the Primitive Vessels of the Chick and of the Pig. *Contrib Embryol* 1917;6:61.

# 126. Sim FH. Soft-Tissue Tumors: Diagnosis and Treatment. *Orthop Surg* 1980;1:1.

+ 127. Sim FH, Unni KK, Beabout JW, et al. Osteosarcoma with Small Cells Simulating Ewing's Tumor. *J Bone Joint Surg Am* 1979;61:207.

+ 128. Simon MA, Enneking WF. The Management of Soft-Tissue Sarcomas of the Extremities. *J Bone Joint Surg Am* 1976;58:317.

+ 129. Singer S, Corson JM, Demetri GD, et al. Prognostic Factors Predictive of Survival for Truncal and Retroperitoneal Soft-tissue Sarcoma. *Ann Surg* 1995;221:185.

+ 130. Slingluff CL Jr, Stidham KR, Ricci WM, et al. Surgical Management of Regional Lymph Nodes in Patients with Melanoma. Experience with 4682 Patients. *Ann Surg* 1994;219:120.

# 131. Smith RJ. Who Is Best Qualified to Treat Tumors of the Hand? *J Hand Surg* 1977;2:251.

+ 132. Smith RJ, Bushart TM. Allograft Bone for Metacarpal Reconstruction. *J Hand Surg [Am]* 1985;10:325.

# 133. Smith RJ, Lipke RW. Surgical Treatment of Peripheral Nerve Tumors of the Upper Limb. In: Omer GE, Spinner M, eds. *Management of Peripheral Nerve Problems.* Philadelphia: WB Saunders, 1980.

+ 134. Smith RJ, Mankin HJ. Allograft Replacement of Distal Radius for Giant Cell Tumor. *J Hand Surg* 1977;2:299.

+ 135. Specht EE, Staheli LT. Juvenile Aponeurotic Fibroma. *J Hand Surg* 1977;2:256.

# 136. Stack HG. Tumors of the Hand. *Br Med J* 1960;1:919.

# 137. Stadelmann WK, Rapaport DP, Soong SJ, et al. Prognostic Clinical and Pathologic Features. In: Balch CM, Houghton AN, Sober AJ, Soong S, eds. *Cutaneous Melanoma,* 3rd ed. St. Louis, MO: Quality Medical, 1998:11.

+ 138. Strickland JW, Steichen JB. Nerve Tumors of the Hand and Forearm. *J Hand Surg* 1977;2:285.

+ 139. Suit HD, Russell WO, Martin RG. Management of Patients with Sarcoma of Soft Tissue in an Extremity. *Cancer* 1973;31:1247.

+ 140. Sundaram M, McGuire MH, Herbold DR, et al. MRI in Planning Limb-Salvage Surgery for Primary Malignant Tumors of Bone. *J Bone Joint Surg Am* 1986;68:809.

+ 141. Suziki K, Takahashi S, Nakagawa T. False Aneurysm in a Digital artery. *J Hand Surg* 1980;5:402.

+ 142. Szabo RM, Thorson EP, Raskind JR. Allograft Replacement with Distal Radioulnar Joint Fusion and Ulnar Osteotomy for Treatment of Giant Cell Tumors of the Distal Radius. *J Hand Surg [Am]* 1990;15:929.

+ 143. Tagigawa K. Chondroma of the Bones of the Hand. A Review of 110 Cases. *J Bone Joint Surg Am* 1971;53:1591.

# 144. Templeton AC. Kaposi's Sarcoma. In: Andrade R, Gumpott SL, Popkin GI, et al., eds. *Cancer of the Skin*, vol 2. Philadelphia: WB Saunders, 1976.

+ 145. Terek RM, Brien EW. Soft-tissue Sarcomas of the Hand and Wrist. *Hand Clin* 1995;11:287.

+ 146. Thompson SC, Jolley D, Marks R. Reduction of Solar Keratoses by Regular Sunscreen Use. *N Engl J Med* 1993;329:1147.

+ 147. Trovik CS, Bauer HC. Local Recurrence of Soft Tissue Sarcoma a Risk Factor for Late Metastases. 379 Patients Followed for 0.5–20 Years. *Acta Orthop Scand* 1994;65:553.

+ 148. Tseng JF, Tanabae KK, Gadd MA, et al. Surgical Management of Primary Cutaneous Melanomas of the Hands and Feet. *Ann Surg* 1997;225:544.

+ 149. Tsuneyoshi M, Yokoyama K, Enjoji M. Synovial Sarcoma. A Clinicopathologic and Ultrastructural Study of 42 Cases. *Acta Pathol Jpn* 1982;33:101.

+ 150. Unni KK, Dahlin DC, Beabout JW. Periosteal Osteogenic Sarcoma. *Cancer* 1976;37:2476.

+ 151. Vander Griend RA, Funderburk CH. The Treatment of Giant Cell Tumors of the Distal Part of the Radius. *J Bone Joint Surg Am* 1993;75:899.

+ 152. Varela-Duran J, Enzinger FM. Calcifying Synovial Sarcoma. *Cancer* 1982;50:345.

+ 153. Veronesi U, Cascinelli N. Narrow Excision (1-cm margin): A Safe Procedure for Thin Cutaneous Melanoma. *Arch Surg* 1991;126:438.

+ 154. Veronesi U, Cascinelli N, Adamus J, et al. Thin Stage I Primary Cutaneous Malignant Melanomas: Comparison of Excision with Margins of 1 or 3 cm. *N Engl J Med* 1988;318:1159.

+ 155. Vincent RG. Malignant Synovioma. *Ann Surg* 1960;152:777.

+ 156. Vrouenraets BC, Keus RB, Nieweg OE, Kroon BB. Complications of Combined Radiotherapy and Isolated Limb Perfusion with Tumor Necrosis Factor Alpha + /– Interferon Gamma and Melphalan in Patients with Irresectable Soft Tissue Tumors. *J Surg Oncol* 1997;65:88.

+ 157. Warhold LG, Urban MA, Bora FW Jr, et al. Lipofibromatous Hamartomas of the Median Nerve. *J Hand Surg [Am]* 1993;18:1032.

+ 158. Warso M, Gray T, Gonzalez M. Melanoma of the Hand. *J Hand Surg [Am]* 1997;22:354.

+ 159. Weiss SW, Enzinger FM. Malignant Fibrous Histiocytoma. *Cancer* 1978;41:2250.

+ 160. Wollard HH. The Development of the Principal Arterial Stems in the Forelimb of the Pig. *Contrib Embryol* 1922;14:139.

+ 161. Wood VE, Sauser D, Mudge D. The Treatment of Hereditary Multiple Exostosis of the Upper Extremity. *J Hand Surg [Am]* 1985;10:505.

+ 162. Zubowicz VN, Ishii CH. Management of Ganglion Cysts of the Hand by Simple Aspiration. *J Hand Surg [Am]* 1987;12:618.

# CHAPTER 75

# ARTHROSCOPIC SURGERY OF THE WRIST

*Louis M. Adler and A. Lee Osterman*

**L. M. Adler:** New England Orthopaedics, Springfield, Massachusetts 01104.
**A. L. Osterman:** Philadelphia Hand Center, King of Prussia, Pennsylvania, 19406.

History
Indications
Equipment
Anatomy and Portals
Diagnostic Arthroscopy of the Wrist
Therapeutic Arthroscopy of the Wrist
Triangular Fibrocartilage Complex Lesions
Scapholunate Tears
Lunotriquetral Tears
Distal Radius Fractures
Scaphoid Fractures
Synovectomy
Dorsal Wrist Ganglia
Chondral Defects and Loose Bodies
Arthroscopic Radial Styloidectomy
Arthroscopic Proximal Row Carpectomy
Pitfalls and Complications
Chapter References

## HISTORY

Kenji Takagi described the first successful arthroscopy in 1920 (55). His primitive arthroscope had only limited utility, but over the next several decades he continued to improve the quality of arthroscopic equipment. In the late 1970s, an arthroscope suitable for use in small joints was developed, leading to Chen's description of wrist arthroscopy in 1979 (9). Over the last 20 years, wrist arthroscopy has advanced from a diagnostic to a therapeutic procedure as the principles of open surgical procedures have been adapted to the arthroscope (1,14,15,23,30,33,36,38,48,49,50,63,66). As in larger joints, this less invasive method may have decreased morbidity and shortened recovery time. Only time and careful evaluation of treatment outcomes will determine the ultimate benefit of each specific procedure.

## INDICATIONS

Wrist arthroscopy has both diagnostic and therapeutic indications. It can be used to confirm findings suggested by other diagnostic studies as well as for the diagnosis of wrist pain of unknown etiology. Indications for wrist arthroscopy are listed in Table 75.1.

| | |
|---|---|
| Diagnostic arthroscopy | Ligamentous injuries<br>TFCC disorders<br>Scaphotrapezoid ligament disruption<br>Lunotriquetral ligament disruption<br>Chondral defects<br>Wrist pain of unknown etiology |
| Therapeutic arthroscopy | Ligamentous injuries<br>Debridement or repair of TFCC injuries<br>Arthroscopic wafer procedure<br>Debridement or ARIF of scapholunate or triquetrohamate ligament tears<br>Arthroscopic treatment of fracture<br>Distal radius<br>Scaphoid<br>Synovectomy<br>Inflammatory arthritis<br>Septic arthritis<br>Dorsal ganglion resection<br>Chondral lesions<br>Chondroplasty<br>Loose body removal<br>Salvage procedures<br>Radial styloidectomy<br>Proximal row carpectomy |

TFCC, triangular fibrocartilage complex; ARIF, arthroscopic reduction and internal fixation.

***Table 75.1. Indications for Wrist Arthroscopy***

## EQUIPMENT

### *Setup*

- Position the patient supine on the operating table with the upper extremity supported on a hand table. Place a padded pneumatic tourniquet on the upper arm. In our experience, inflation of the tourniquet is required in approximately 50% of cases.
- Because of the small joint volume and the tightness of the wrist capsule, visualization requires distraction. Obtain distraction through suspension of the extremity from overhead. We prefer a distraction tower placed on the hand table (Fig. 75.1), as this allows conversion to open procedures without the need for redraping.

***Figure 75.1.*** Arthroscopic setup. Strap the extremity to the base of a traction tower placed on the hand table. Suspend all four fingers from the tower with finger traps. Ten to 15 pounds of traction is usually sufficient.

### *Instrumentation*

Arthroscopic instruments fall into four general categories: Scopes, probes, grasping instruments, and cutting instruments. Wrist arthroscopes are generally 2.5–3.0 mm

in diameter. An oblique viewing angle of 30° provides excellent visualization (Fig. 75.2).

***Figure 75.2.*** **Top to bottom:** A 2.5 mm arthroscope, cannula, and camera. A 30° viewing angle provides the best perspective

An angled probe is an extremely useful arthroscopic instrument (Fig. 75.3). Palpation with a blunt probe can help the arthroscopist define normal anatomy as well as identify pathology such as a triangular fibrocartilage complex (TFCC) injury.



***Figure 75.3.*** Arthroscopic instruments.

Cutting instruments are both manual or powered. An 18-gauge needle is a versatile arthroscopic instrument. The needle is commonly used to localize the joint prior to creation of a portal. It can also be used to spear or manipulate loose bodies, and to resect the edges of a central TFCC tear. More sophisticated manual instruments include basket forceps and suction punches (Fig. 75.3).

The most commonly used powered instruments include full-radius resectors and arthroscopic burrs. Full-radius resectors are used for soft-tissue excision such as synovectomy and debridement of ligament tears. They are not well designed for work with firmer tissues such as articular cartilage. These instruments function most efficiently at lower speeds in the range of 400 rev/min (64). At higher speeds, there is insufficient time for tissue to enter the aperture of the tip. Arthroscopic burrs are useful for treatment of osseous lesions as well as for salvage procedures. These instruments work most efficiently at speeds greater than 1,200 r/min (64).

## ANATOMY AND PORTALS

Wrist arthroscopy is performed via portals established on the dorsal aspect of the wrist. The radiocarpal portals are numbered according to their relation to the extensor compartments of the wrist. For example, the 3-4 portal is situated between the third and fourth extensor compartments (Fig. 75.4). There are also two mid-carpal portals, as well as portals for the distal radioulnar joint. Portals are established in the following manner.

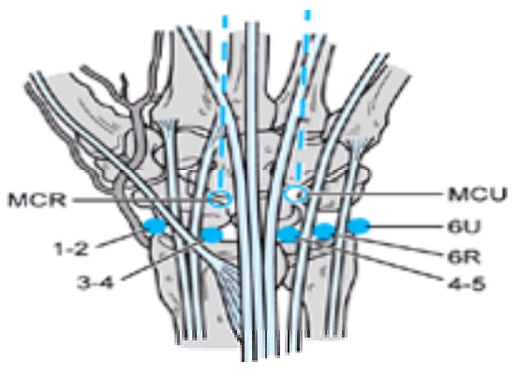


***Figure 75.4.*** The *mid-carpal ulnar (MCU) portal* is best located under arthroscopic view after the MCR portal is established. A gap between the proximal and distal carpal rows can be palpated along the midline of the fourth metacarpal.
The *1-2 portal* is located in the dorsal aspect of the anatomic snuffbox, just radial to the extensor pollicis longus tendon. Care must be taken to avoid injury to the radial artery. This portal provides visualization of the radial styloid, scaphoid, and distal radius.
The *3-4 portal* is most commonly used for radiocarpal arthroscopy. The portal is established directly distal to Lister's tubercle (approximately 1 cm) in the radiocarpal joint. It lies between the third and fourth extensor compartments.
The *4-5 portal* provides access to the ulnar wrist. It is located just ulnar to the fourth compartment and approximately 1 cm distal to Lister's tubercle. This portal should be established with arthroscopic visualization.
The *6R portal* also provides access to the ulnar aspect of the wrist. It is located distal to the ulnar head and radial to the extensor carpi radialis tendon. The portal is made just proximal to the triquetrum to avoid injury to the TFCC. Like the 4-5 portal, the 6R portal is established under arthroscopic visualization.
The *6U portal* can be used as an inflow or outflow portal. It is located ulnar to the extensor carpi ulnaris. Under arthroscopic visualization, the needle is inserted just distal to the ulnar styloid.
The *mid-carpal radial (MCR) portal* is established 1 cm distal to the 3-4 portal, along a line bordering the radial edge of the third metacarpal. A soft depression between the proximal and distal carpal rows can be palpated.

- Determine the correct site by palpation of the surface anatomy.
- Confirm the portal site by inserting an 18-gauge hypodermic needle into the joint.
- Use a scalpel to make a 3 mm longitudinal incision through the skin only.
- Use a hemostat to bluntly dissect to the level of the wrist capsule.
- Introduce the arthroscopic sheath into the joint with a blunt trocar.

Note: Once the arthroscope has been introduced, establish subsequent portals under arthroscopic visualization. The portals are described in Figure 75.4.

## DIAGNOSTIC ARTHROSCOPY OF THE WRIST

Historically, wrist arthrography was the gold standard for the diagnosis of soft-tissue wrist pathology. However, with the emergence of magnetic resonance imaging (MRI) and arthroscopy, the usefulness of this modality has been challenged (11,20,27,46,51). Although it can be performed as a single radiocarpal injection, the triple injection arthrogram as described by Zinberg et al. (70) is considered a better test. Inject the radiocarpal joint first. If no dye leakage is observed, inject the mid-carpal and distal radioulnar joints after the dye from the first injection has been cleared. Communication of dye between compartments indicates a tear.

Arthrography has a number of limitations. A high incidence of positive findings in the asymptomatic, contralateral wrist has led many investigators to question the significance of arthrographic findings (8). Obstruction of perforations by synovitis, or a flap acting as a one-way valve can lead to false-negative tests. Positive tests give no indication of the size of a tear or the degree of instability (62). A number of studies have revealed arthroscopy to have higher specificity and sensitivity than arthrography for the diagnosis of wrist soft-tissue injuries (Table 75.2) (11,12,27,47,62).

| *Authors* | *Patients (N)* | *Structure* | *Sensitivity* | *Specificity* |
|---|---|---|---|---|
| Roth and Haddad (47) | 37 | All | 0.76* | 1.0* |
| Levinsohn et al. (27) | 30 | TFC | 0.67* | 0.93* |
| | 16 | Scapholunate | 0.69* | 0.97* |
| | 21 | Lunotriquetral | 0.86* | 0.92* |
| Cooney (12) | | TFC | 1.0* | 0.92* |
| | 20 | Scapholunate | 1.0* | 0.92* |
| | | Lunotriquetral | 0.78* | 1.0* |
| Chang et al. (10) | 150 | All | 0.74 | 0.56 |
| Weiss et al. (62) | 50 | All | 0.56 | 0.83 |

* Sensitivities and specificities calculated using data provided in article.
TFC, triangular fibrocartilage.

***Table 75.2. Arthrography versus Diagnostic Arthroscopy***

For the diagnosis of soft-tissue wrist pathology, MRI has become the most widely used imaging modality. An early study suggested that MRI is inferior to arthrography for the diagnosis of tears of the triangular fibrocartilage, but the MRI technology utilized at that time has become obsolete (20). Many older studies relied on the “arthrogram effect,” which occurs when fluid (high signal intensity on a T2-weighted image) courses through the perforated structure. Two recent studies comparing higher-resolution MRI scans with arthroscopic evaluation demonstrated sensitivity of 100% and specificity of 90% for MRI in the diagnoses of TFC tears (46,58).

Potter et al. (46) reported the ability to localize the site of a TFCC tear with 100% sensitivity and 75% specificity. In the diagnosis of scapholunate injuries, MRI has been reported to have a specificity of 40% to 90% and a sensitivity of 100% (24,71). MRI is much less reliable for the diagnosis of lunotriquetral (LT) tears, demonstrating a sensitivity of 0% to 50% and specificity of 100% (24,71).

Magnetic resonance (MR) arthrography, a relatively modern technology, involves intracarpal injection of dye followed by MRI of the wrist. This procedure theoretically combines the best aspects of both arthrography and MRI. Using this technology, Scheck et al. (51) diagnosed scapholunate ligament injuries with a sensitivity and specificity of 90%. Further investigation of this technique will be required before an assessment of its utility can be made. Table 75.3 reviews the results of studies comparing these modalities to diagnostic arthroscopy.

| *Authors* | *Patients (N)* | *Structure* | *Sensitivity* | *Specificity* | *Comments* |
|---|---|---|---|---|---|
| Gilchrist et al. (19) | 20 | TFC | 0.93* | 1 | 3 mm or 5 mm sections |
| | 20 | TFC | 0.89 | 0.92 | |
| Zlatkin et al. (71) | 20 | Scapholunate | 0.86 | 1.0 | 3 mm sections |
| | 20 | Lunotriquetral | 0.50 | 1.0 | |
| Tomonaga et al. (58) | 31 | TFC | 1.0* | 0.94* | 1 mm sections |
| | | TFC | 0.80 | 0.70 | |
| Johnstone et al. (24) | 43 | Scapholunate | 0.37 | 1.0 | 1 mm sections |
| | | Lunotriquetral | 0 | 0.97 | |
| Potter et al. (46) | 77 | TFC | 1.0 | 0.9 | 1 mm sections |
| MR arthrogram versus diagnostic arthroscopy | | | | | |
| Scheck et al. (51) | 40 | Scapholunate | .90 | .87 | 0.4 mm to 1 mm sections |

* Sensitivities and specificities calculated using data provided in article.
TFC, triangular fibrocartilage.

***Table 75.3. MRI versus Diagnostic Arthroscopy***

Arthroscopy has become the gold standard for the diagnosis and classification of intercarpal wrist pathology. It enables the surgeon to assess the size and stability of a tear and identify the presence of associated synovitis or chondral defects.

## THERAPEUTIC ARTHROSCOPY OF THE WRIST

### TRIANGULAR FIBROCARTILAGE COMPLEX LESIONS

#### *Anatomy*

The TFCC is a ligamentous, cartilaginous structure composed of dorsal and volar radioulnar ligaments, the ulnar collateral ligament, the articular disc, the sheath of the extensor carpi ulnaris (ECU) tendon, and the ulnolunate and LT ligaments (Fig. 75.5) (43). The complex arises from the articular cartilage on the corner of the sigmoid notch of the radius and inserts into the base of the ulnar styloid as well as the ulnolunate and ulnotriquetral ligaments. The dorsal and volar radioulnar ligaments are fibrous thickenings within the dorsal and volar edges of the triangular fibrocartilage. The central disc is the thinnest portion of the complex (10). The vascularity of the TFC has been well studied (5,56). Like the knee's meniscus, only the peripheral 25% of the TFC is vascularized; therefore, only peripheral tears are considered reparable.

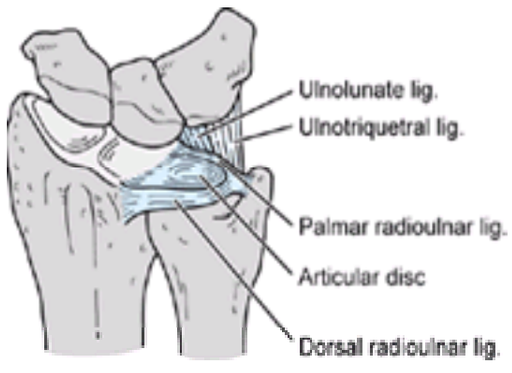


***Figure 75.5.*** The triangular fibrocartilage complex (*TFCC*) is a ligamentous, cartilaginous structure composed of the following components: dorsal and volar radioulnar ligaments, the ulnar collateral ligament, the articular disc, the sheath of the extensor carpi ulnaris tendon, and the ulnolunate and lunotriquetral ligaments.

### *Biomechanics*

The TFCC has two important biomechanical functions. In ulnar-neutral individuals, the complex transmits 20% of axially applied loads from the ulnar carpus to the distal ulna (43). The percentage of the load transmitted is directly proportional to the ulnar variance. The TFCC is also the major stabilizer of the distal radioulnar joint (42,43 and 44).

### *Classification*

Palmer's classification (41) of TFCC tears (Table 75.4) (Fig. 75.6) is the most commonly used. It divides injuries into two basic categories, traumatic (class I) and degenerative (class II).

| |
|---|
| Class I: Traumatic |
| A. Central perforation |
| B. Ulnar avulsion |
| C. Radial avulsion |
| Class II: Degenerative (ulnar impaction syndrome) |
| A. TFCC wear without cartilage abnormality |
| B. TFCC wear with lunate and/or ulnar chondromalacia |
| C. TFCC perforation with lunate or ulnar chondromalacia |
| D. Type II-C with lunotriquetral ligament disruption |
| E. Type II-D with ulnocarpal arthritis |

TFCC, triangular fibrocartilage complex.

***Table 75.4. Palmer's Classification of TFCC Lesions***

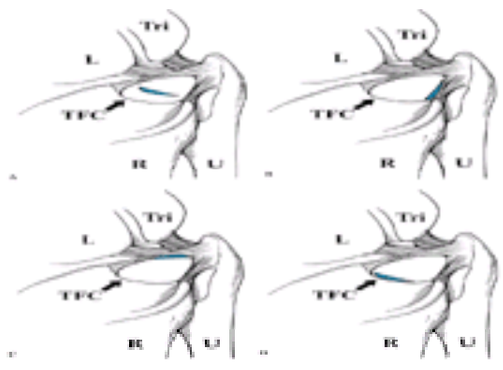


***Figure 75.6.*** Palmer classification of traumatic triangular fibrocartilage (*TFC*) tears. R, radius; U, ulna; L, lunate; TRI, triquetrum. **A:** Class I-A. **B:** Class I-B. Can be purely soft tissue or with ulnar styloid base fracture. **C:** Class I-C. **D:** Class I-D.

### *Class I: Traumatic Lesions*

Traumatic tears of the TFCC can occur through an extension–pronation force applied to an axially loaded wrist (a fall on an outstretched hand) or a dorsal rotation injury (29). These tears can also occur as the sequelae of a distal radius fracture.

To diagnose a TFCC tear, the surgeon must rule out ECU subluxation, LT injury, pisotriquetral arthritis, chondral lesions of the ulnar carpus, ulnar artery thrombosis, and ulnar neuropathy at the wrist. The patient may report having fallen on the pronated wrist, and twisting or distraction injury to the wrist. The patient may also report ulnar-sided, mechanical wrist pain, which is usually not disabling and is frequently accompanied by clicking.

On physical exam, the patient has ulnar-sided wrist tenderness, a positive response to a TFCC compression test (axial loading of the ulnarly deviated wrist), and varying degrees of instability of the distal radioulnar joint and supination of the ulnar carpus. Concomitant LT ligament injury may be present if there is tenderness over the LT interval, and if an LT ballottement test and a shuck test are positive (see Chapter 43).

**Radiologic Evaluation** Take plain radiographs with neutral rotation posteroanterior (PA) and lateral views. Carpal alignment, ulnar styloid morphology, and ulnar variance can be assessed through these views. Clenched-fist radiographs in full ulnar deviation may show evidence of dynamic variance changes. The role of more advanced imaging studies such as arthrography, triple-phase bone scan, and MRI remains controversial.

**Treatment** If not associated with significant instability of the distal radioulnar joint, the majority of TFCC injuries can be treated with 4 weeks of immobilization (Fig. 75.7) (37). A peripheral tear would be expected to heal because of its excellent vascular supply. In some patients, a local injection of corticosteroid to relieve inflammation, as well as a short course of wrist therapy, may be helpful. Many central tears may become asymptomatic despite their inability to heal (37).

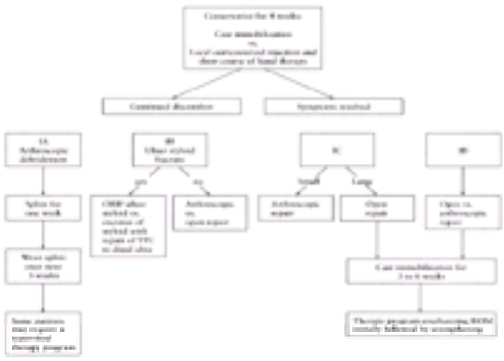

***Figure 75.7.*** Treatment of traumatic triangular fibrocartilage complex (TFCC) tears.

Surgical intervention is indicated in cases of significantly symptomatic TFCC injury after failure of an adequate conservative treatment program. Central perforations can be treated with either open or arthroscopic debridement. Peripheral tears should be repaired using either arthroscopic or open methods. The technique of arthroscopic repair varies with the location of the tear.

#### Debridement of Central Perforation of the TFCC

- Evaluate the radiocarpal joint through the 3-4 portal (Fig. 75.8*A*).

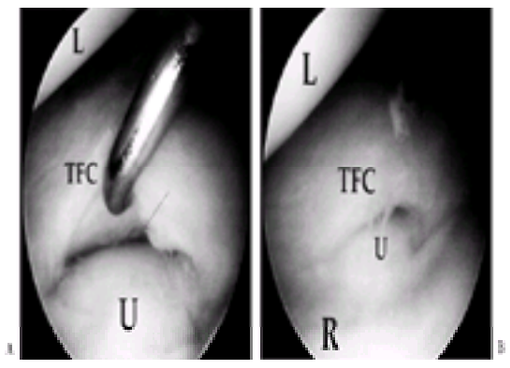


***Figure 75.8.*** **A:** Class I-A central traumatic tear of the TFCC. Note that the ulnar head is deep to the radius, indicating negative ulnar variance. **B:** Class I-A after debridement. Note the stable TFC rim and normal distal ulnar articular surface. L, lunate; TFC, triangular fibrocartilage; U, ulna; R, radius.

- Use the 4-5 or the 6R portal for instrumentation.
- Perform a synovectomy with a full-radius resector. This important step allows proper visualization of pathology.
- Debride the central two thirds of the TFCC with a suction punch or full-radius resector (Fig. 75.8*B*). A banana blade can also be used to resect the unstable portion of the TFCC. Do not use the distal ulna as a cutting board. Avoid injury to the dorsal and volar radioulnar ligaments and the peripheral TFCC; such injury will lead to destabilization of the distal radioulnar joint (DRUJ).
- Postoperatively, splint the wrist intermittently and initiate a therapy program stressing range-of-motion (ROM) exercises for 3–4 weeks. Then initiate a graduated strengthening program. Results from the literature are shown in Table 75.5.

| Authors | Technique | Cases (N) | Results | Follow-up (mo) | Comments |
|---|---|---|---|---|---|
| Menon et al. (32) | Open | 16 | 69% success<br>31% failure | ? | |
| Imbriglia and Boland (22) | Open | 16 | 88% good<br>12% failure | ? | |
| Minami et al. (33) | Arthroscopic | 16 | 69% excellent<br>31% poor | 35 | Excellent results in 100% of traumatic tears |
| Osterman (36) | Arthroscopic | 52 | 88% satisfied<br>12% failure | 23 | |

TFC, triangular fibrocartilage.

***Table 75.5. Debridement of Central TFC Tears***

### Arthroscopic Repair of Class I-B TFCC Tears

- Evaluate the radiocarpal joint through the 3-4 portal. A key to the diagnosis of a peripheral tear is the loss of normal tension in the TFCC. A probe will sink into the lax tissue (Fig. 75.9*A*).

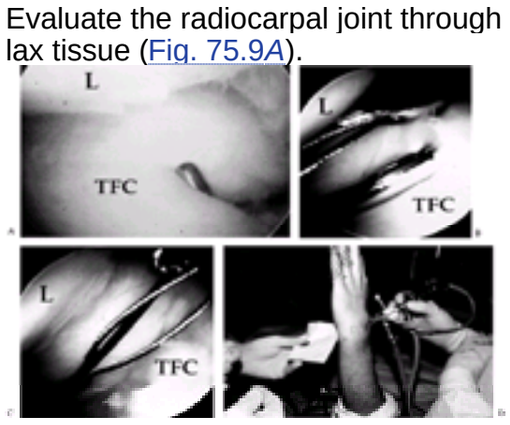


***Figure 75.9.*** **A:** Peripheral I-B tear. Note that the probe sinks into the lax TFC. L, lunate; TFC, triangular fibrocartilage. **B:** Out-to-in repair: Needles are passed through the capsule and the TFC; wire loop suture is passed through one needle. **C:** 2-0 PDS suture is passed through the other needle and lassoed by a wire loop. **D:** Suture tied at the capsule level through a 1 cm incision radial to the extensor carpi ulnaris. Generally, one to three sutures are used.

- Use the 4-5 or the 6R portal for instrumentation.
- Perform a synovectomy using a full-radius resector.
- Debride the edges of the tear with the full-radius resector.
- Make a 1 cm longitudinal skin incision radial to the ECU tendon. Then sharply open the radial aspect of the ECU tendon sheath.
- Retract the ECU and place two needles from the meniscal repair kit through the floor of the sheath and across the tear under arthroscopic visualization (Fig. 75.9*B*).
- Pass a 2-0 PDS (Meniscal MenderII, Instrument Maker, Inc., Okemos, Michigan) suture through one needle.
- Retrieve the suture with a wire loop passed through the other needle (Fig. 75.9*C*).
- Remove both needles, reapproximate the tear, and tie the suture over the dorsal wrist capsule. Multiple sutures may be necessary (Fig. 75.9*D*).
- Postoperatively, place the upper extremity in a long-arm splint with the forearm in neutral rotation and the wrist in neutral flexion and mild ulnar deviation. After suture removal, change to a long-arm cast for immobilization for a total of 6 weeks. Then splint intermittently and begin a therapy program stressing ROM initially, followed by a graduated strengthening program. Outcomes are detailed in Table 75.6.

| Authors | Technique | Cases | Results | Immobilization (wk) | Follow-up (mo) | Rating system |
|---|---|---|---|---|---|---|
| Bernardoni and Kleinman (21) | Open | 11 | 8 satisfactory<br>3 not | 12+ | 23 | ? |
| Conway et al. (13) | Open | 33 | 11 excellent<br>15 good<br>6 fair<br>1 poor | 8 | 7 | Modified Garland |
| Geissler et al. (14) | Arthroscopic | 43 | 29 excellent<br>12 good<br>1 fair<br>3 poor | 6–8 | 27 | Modified Mayo |
| Sagerman and Shaw (30) | Arthroscopic | 12 | 8 good or excellent | 8 | 17 | ? |
| Tomlin et al. (39) | Arthroscopic | 24 | 15 returned to work | 6 | 24 | None |

TFC, triangular fibrocartilage.

***Table 75.6. Repair of Peripheral TFC Tears***

**Arthroscopic Repairs of Class I-D TFCC Tears** Class I-D TFCC lesions involve radial detachment of the triangular fibrocartilage from the sigmoid notch of the distal radius. Normally, the articular cartilage of the distal radius continues around the medial corner and into the sigmoid notch. The triangular fibrocartilage originates from this articular location. Given this cartilage barrier, the healing potential for the TFCC at this site should be poor. If the cartilage is disrupted manually or by fracture, however, the triangular fibrocartilage can be reattached to vascularized bone. To perform this repair arthroscopically, we use an alignment guide similar to that described by Jantea et al. (23).

Class I-D lesions often accompany distal radius fractures. In this scenario, we use either 0.35 or 0.45 Kirschner wires (K-wires) to pin the triangular fibrocartilage back to the radius. The pins are left percutaneous and removed at 4 weeks.

- Evaluate the radiocarpal joint through the 3-4 portal.
- Use the 4-5 portal for instrumentation.
- Use a burr to debride the TFC attachment site to allow healing to fresh cancellous bone.
- Temporarily fix the TFC to the radial attachment site with a K-wire directed from the ulnar wrist.
- Place an alignment guide over the K-wire.
- Make a longitudinal incision between the first and second extensor compartments. Dissect bluntly to the wrist capsule.
- Drill an 18-gauge spinal needle through the jig into the radius, exiting at the radial reattachment site and the TFC.
- Place a second 18-gauge needle parallel to the first.
- Place a 2-0 PDS suture through one needle.
- Retrieve the suture with wire loop placed through the other needle.
- Reapproximate the tear and tie the suture over the wrist capsule.
- Postoperatively, place the upper extremity in a long-arm splint with the forearm in neutral rotation and the wrist in neutral flexion and mild ulnar deviation. After suture removal, change to a long-arm cast to immobilize the wrist for a total of 6 weeks. Then splint intermittently and begin a therapy program stressing ROM initially, followed by a graduated strengthening program.

The only available data regarding TFCC repair or debridement have been reported in case series (Table 75.5, Table 75.6) (13,14,21,22,32,36,50,59), and no randomized controlled studies have been published. Because of the lack of normalized data, it is difficult to compare the results of open versus arthroscopic treatment of TFCC injuries.

The theoretical advantages of arthroscopic treatment for TFCC tears include improved visualization of the tear as well as any associated intracarpal pathology and, in the case of TFCC debridement, earlier postoperative mobilization. Although the available data indicate that arthroscopic treatment offers comparable or superior results, further investigation with longer follow-up is warranted.

### *Class II: Degenerative Lesions*

Degenerative tears of the TFCC occur secondary to a chronic increase in the load borne by the ulnar side of the wrist. This problem tends to be progressive once it becomes symptomatic; therefore, surgical correction is often advised. The etiology of this “ulnar impaction syndrome” may be primary or secondary (Table 75.7).

| |
|---|
| Primary |
| Static positive ulnar variance |
| Dynamic positive ulnar variance |
| Secondary |
| Malunion of distal radial fractures |
| Distal radial growth arrest |
| Proximal migration of radius following radial head resection |

***Table 75.7. Causes of Ulnar Impaction***

Class II degenerative lesions are seen in older patients who have ulnar-sided wrist pain and no history of recent trauma. Such patients may have had a distal radius fracture in the past. On physical exam there is distal ulnar tenderness. A TFCC compression test is positive and there may be LT instability. Take PA and lateral plain film radiographs to assess ulnar variance and DRUJ congruity. Cystic lesions may be present in the ulnar lunate or distal ulna. A grip view shows the presence of dynamic ulnar impaction, and MRI reveals focal signal intensity changes in the ulnar part of the lunate and tears of the TFCC.

Arthroscopic examination should include evaluation of the chondral surfaces, the TFCC lesion, and the LT joint.

**Treatment** The primary goal of treatment is to decompress the ulnar aspect of the wrist. Treatment options include ulnar shortening osteotomy, partial ulnar-head resection, ulnar salvage procedures, including the modified Darrach procedure and hemiresection arthroplasty of the distal radial ulnar joint (Fig. 75.10).

***Figure 75.10.*** Treatment of degenerative tears of the TFCC.

Partial resection of the ulnar head, also known as the wafer procedure, can be performed via an open procedure or arthroscopically (17,30,69).

#### Arthroscopic Wafer Procedure

- Perform triangular fibrocartilage tear debridement as described previously. Note that the triangular fibrocartilage is usually fibrillated. The ulnar head has significant chondromalacia and is prominent (Fig. 75.11).

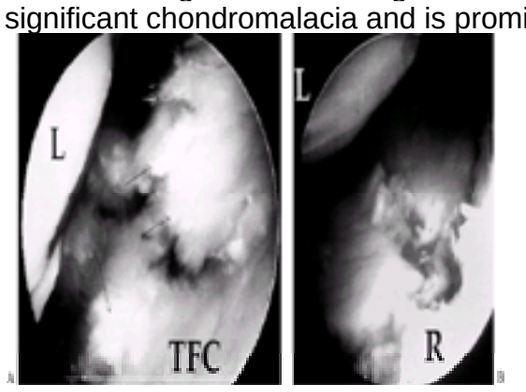

***Figure 75.11.*** **A:** Degenerative TFC tear. Note the fibrillated appearance of the TFC. **B:** Degenerative changes of the ulnar head, which is prominent. Arthroscopic wafer resection of the ulna was performed.

- Using a 4 mm burr introduced through the 6R portal, excise the distal ulna through the perforation in the TFCC. Rotate the forearm as you do so to allow even leveling of the joint. Knowing the size of the burr will help you to assess the depth of your resection.
- Negative ulnar variance of 2 mm is acceptable.

The only available data regarding the wafer procedure have been reported in case series (Table 75.8) (17,30,52,69). No studies directly comparing the results of the open versus the arthroscopic procedure have been published. Although the available data indicate that arthroscopic treatment offers comparable or superior results, further investigation with longer follow-up is warranted.

| Authors | Technique | Cases | Results | Followup (mo) | Classification |
|---|---|---|---|---|---|
| Schuurman and Bos (52) | Open | 7 | 3 excellent<br>2 good<br>1 fair<br>1 poor | 36 | Herzberg |
| Zelouf and Bowers (69) | Open | 31 | 14 excellent<br>10 good<br>6 fair<br>1 poor | 43 | Modified Mayo |
| Feldon et al. (17) | Open | 13 | 9 excellent<br>4 good | 32 | ? |
| Lohan et al. (30) | Arthroscopic | 20 | 15 good/excellent<br>5 fair/poor | 43 | Modified Mayo |

***Table 75.8. Results of the Wafer Procedure***

## SCAPHOLUNATE TEARS

### *Anatomy*

The interosseous scapholunate ligament is a C-shaped structure comprising dorsal, volar, and central components. The fibrous dorsal and volar components are the major stabilizers, while the membranous central component adds little to the ligament's strength (6).

Diagnosis of a scapholunate tear is made on the basis of history, physical examination, and radiography and arthroscopy. Some patients have experienced a fall on the outstretched hand with the wrist in dorsiflexion, but often there is no history of trauma.

Physical examination may reveal dorsal carpal soft-tissue swelling. There is tenderness over the dorsal scapholunate interval and over the anatomic snuff box and possibly the scaphoid tuberosity. There is decreased wrist motion and a scaphoid shift test is positive.

**Radiologic Evaluation** Radiologic evaluation should begin with plain film radiographs including neutral rotation PA, lateral, and clenched-fist views. The key radiographic features of scapholunate dissociation are an increased scapholunate gap (PA and clenched-fist PA views), palmar flexion of the scaphoid (lateral view), and cortical ring sign, which represents an axial projection of flexed scaphoid (PA view).

**Arthroscopy** Arthroscopy provides an excellent means of diagnosing and characterizing scapholunate injuries. The intrinsic scapholunate ligament can be easily seen from either the 3-4 or an ulnar radiocarpal portal. An ulnar portal is generally better as it allows easy access for a palpating probe through the 3-4 portal and provides excellent visualization of the volar, central, and dorsal portions of the ligament. Important information regarding ligament instability can also be obtained through mid-carpal arthroscopy. The alignment of the concave surface of the scapholunate joint is more easily assessed because the overlying interosseous ligaments are absent.

**Classification** Watson et al. (61) have developed a classification system for scapholunate injuries. This system is based on physical and plain radiographic findings (Table 75.9). Scapholunate ligament injuries can also be classified according to their arthroscopic appearance (Table 75.10).

| *Type* | *Description* |
|---|---|
| I: Dynamic | Clinically determined instability with no radiographic abnormality |
| II: Static | Clinically and radiographically determined instability |
| III: Degenerative | Either dynamic or static instability with intracarpal degenerative joint disease |
| IV: Secondary | Scapholunate instability secondary to indirect causes such as Kienböck's disease |

***Table 75.9. Watson's Classification of Scapholunate Instability***

| *Type* | *Radiocarpal findings* | *Mid-carpal findings* |
|---|---|---|
| I | Ligament stretched but intact | Minimal interface instability |
| II | Perforation of central portion of ligament | Minimal interface instability |
| III | Partial tear of dorsal ligament with synovitis | Interface instability that admits 2 mm probe |
| IV | Complete tear that allows arthroscope to pass from radiocarpal to mid-carpal joint | Interface instability that admits 2 mm probe; reactive chondral change in scaphotrapezial joint |

***Table 75.10. Arthroscopic Classification of Scapholunate Ligament Injuries***

**Treatment** No ideal, predictable treatment for scapholunate instability has been described. The open surgical treatment options for acute and chronic cases of scapholunate ligament lesions are described elsewhere (see Chapter 41). As mentioned previously, arthroscopy has a definite role in diagnosis but its therapeutic role

remains unproven. Arthroscopic options include ligament debridement with or without reduction and percutaneous pinning (Fig. 75.12).

***Figure 75.12.*** Treatment of scapholunate instability.

Arthroscopic debridement of frayed ligament edges may be sufficient in cases of perforation of the central portion of the ligament without evidence of scapholunate interface instability (class II). In separate studies with short-term follow-up, Ruch and Poehling (49) and Weiss et al. (63) both demonstrated improvement in 85% of their cases.

Arthroscopic reduction and percutaneous stabilization of unstable scapholunate intervals is based on the belief that a stable ankylosis can result from immobilization and adhesion formation along pin tracks across the joint. Whipple (66) reported a series of 40 patients with scapholunate instability treated in this manner with 2- to 7-year follow-up. He determined that 85% of patients treated within 3 months of symptom initiation who had less than a 3 mm difference in the scapholunate gap as compared with the normal contralateral side maintained stability and comfort. He noted only a 53% success rate if these selection criteria were not met.

**Arthroscopic Debridement, Reduction, and Percutaneous Stabilization of Scapholunate Ligament Injuries**

- Arthroscopically evaluate the radiocarpal and mid-carpal joints.
- Insert the scope via the 6R portal.
- Use the 3-4 portal as an instrument portal.
- Debride the interosseous scapholunate ligament with a suction punch or full-radius resector.
- Transfer the scope to the ulnar mid-carpal portal.
- Debride the STT articulation through the radial mid-carpal portal.
- Insert 0.045-inch K-wires from the dorsal wrist into the scaphoid and lunate. These will be used as “joysticks” to manually reduce the scapholunate joint.
- Insert 0.045-inch K-wires into the proximal scaphoid via the anatomic snuff box (avoid the radial artery, dorsal radial sensory nerve, and tendons). A 14-gauge angiocatheter can be used as a soft-tissue protector.
- Reduce the scapholunate interval using dorsally placed K-wires. Extend the scaphoid and flex the lunate. Confirm the reduction arthroscopically.
- Drive the radially based K-wires across the scapholunate interval. Add one more pin for a total of three. The goal is to create enough fibrosis to provide stability.

## LUNOTRIQUETRAL TEARS

### *Anatomy*

Like the scapholunate ligament, the LT ligament is a C-shaped structure with three components. There are fibrous dorsal and volar stabilizers and a membranous central portion.

Diagnosis is made on the basis of history, physical exam, and radiologic evaluation. The patient's history may include a fall on the dorsiflexed wrist. The patient has ulnar-sided, mechanical wrist pain, frequently with clicking. Physical exam reveals point tenderness over the LT joint. An LT shock test is positive: dorsal/volar translation of the triquetrum and pisiform while the lunate is stabilized causes crepitus and pain.

Plain radiographs often appear normal. Check ulnar variance on the PA view to help rule out ulnocarpal impaction. Bone scans will reveal increased uptake over the LT interval.

**Treatment Options** Traumatic LT tears must be differentiated from degenerative tears secondary to ulnocarpal impaction. Treat the latter with an ulnar carpal decompression procedure. Mild tears can be treated conservatively with nonsteroidal anti-inflammatory medications, local corticosteroid injections, and brief periods of immobilization. Treatment options for more severe injuries include ligament repair, ligament reconstruction, and intercarpal arthrodesis. Arthroscopic treatment, including ligament debridement and reduction with percutaneous pinning, is also possible. Debridement is indicated in cases of partial, stable ligament tears (49). Complete tears with LT instability can be treated with arthroscopic reduction and percutaneous stabilization if there is no associated volar intercalated segmental instability or positive ulnar variance (39). Such cases require open procedures.

**Arthroscopic Debridement, Reduction, and Percutaneous Stabilization of LT Ligament Injuries**

- The LT ligament is best viewed through the 6R or the 6U portal.
- Debride LT tears with a full-radius resector introduced via the 3-4 portal. Evaluate LT stability via the radial mid-carpal portal. A stepoff or gap at this articulation, and proximal hamate chondromalacia indicate significant instability.
- Reduce the LT articulation under arthroscopic visualization from the radial mid-carpal portal.
- Insert multiple 0.045-inch K-wires across the LT interval.

Osterman and Seidman (39) reported 80% good to excellent results in 20 patients treated in this manner at 32-month follow-up. They concurred with Pin et al. (45), noting the importance of differentiating isolated LT tears from cases of ulnar impaction, as the latter group requires an additional procedure—ulnar shortening osteotomy or arthroscopic wafer—to decompress the ulnocarpal joint.

## DISTAL RADIUS FRACTURES

Anatomic or near-anatomic reduction of the articular surface in cases of intraarticular distal radius fracture has become the standard of care since Knirk and Jupiter reported their findings in 1986 (25). They showed that 91% of patients with articular incongruency of 1–2 mm after reduction developed radiocarpal arthritis within 6 years. These findings were confirmed in additional studies (7,34). Wrist arthroscopy has become a valuable tool in the treatment of a small percentage of these fractures. Arthroscopy allows visual assessment of the congruency of the articular surface as well as for the diagnosis of concomitant ligamentous injury (18). It can be used in conjunction with various fixation techniques such as percutaneous pinning, external fixation, and open reduction with internal fixation. The indications for arthroscopic assistance in the treatment of distal radius fractures include the following:

- Intraarticular fractures with more than 2 mm of intraarticular stepoff
- Any distal radius fracture with a suspected associated carpal ligamentous injury

Arthroscopy is contraindicated in cases of compartment syndrome, severe soft-tissue injury, absent median nerve function, or open joint injury.

**Arthroscopic Reduction** Arthroscopic reduction should be performed between 3 and 7 days after injury (Fig. 75.13). If done more acutely, visualization might be obscured by bleeding, and after 7 days, fractures become more difficult to reduce. Palpation of extensor tendon intervals may be difficult on account of soft-tissue swelling. Other landmarks, such as the radial border of the long finger and the mid axis of the ring finger (longitudinal axes of the 3-4 and 4-5 portals, respectively) can usually be identified. Fluoroscopy may aid in placing needles and establishing portals. Traction is essential as ligamentotaxis helps with gross fracture reduction. Traction can be applied through the standard wrist tower, through finger traps and weight suspended off the end of a hand table, or, in cases where external fixation is

indicated, through the fixator itself.

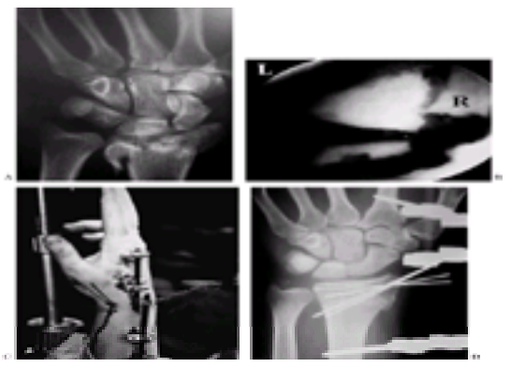

***Figure 75.13.*** **A:** Comminuted intraarticular distal radius fracture. **B:** Arthroscopic view showing disruption of the articular surface. L, lunate; R, radius. **C:** Arthroscopic reduction with use of both external and internal fixation. **D:** Postoperative reduction with anatomic alignment of the articular surface.

- Evaluate the radiocarpal joint via the 3-4 portal.
- Establish an outflow cannula at the 6U portal. Note: It is critical to maintain outflow to limit fluid extravasation and prevent compartment syndrome.
- Thoroughly debride the joint of fibrin clot and debris; use a full-radius resector introduced via the 6R portal.
- Reduce fractures with 0.062-inch K-wires placed percutaneously and used as joysticks.
- Stabilize the fragments with percutaneously placed 0.045- or 0.062-inch K-wires. Reduce the radial styloid fragment first and stabilize it with two 0.045-inch K-wires or a cannulated screw.
- If present, next reduce the lunate “die-punch” fragment to the radial styloid by elevating the impacted fragment with one or more K-wires. Stabilize the die-punch fragment with two transverse 0.045-inch K-wires running from the radial styloid. **Note: Melone four-part fractures usually require open reduction of the volar die-punch fragment. Perform this procedure through a limited, volar incision placed between the finger flexors and the ulnar neurovascular bundle. Elevate the fragment and stabilize it with a small buttress plate**.
- Bone-graft metaphyseal defects through limited incisions once the fragment fixation is completed.
- Evaluate the wrist for associated soft-tissue injuries.

In a series of 27 patients with intraarticular distal radius fractures treated by one of us (ALO), a significant number had associated soft-tissue injuries of the wrist, including scapholunate and LT ligament tears as well as injuries to the TFCC (15).

Two series (15,67) of patients with intraarticular distal radius fractures have described excellent results with the use of arthroscopically assisted reduction. At an average 27-month follow-up, Wolfe reported seven of seven patients returning to work with range of motion and maximal grip strengths averaging 92% and 98% of the uninjured side, respectively. Over the same average follow-up period, Culp and Osterman (15) reported 22 good or excellent results out of 27 cases.

## SCAPHOID FRACTURES

The scaphoid is the most commonly fractured carpal bone. These fractures tend to occur in young, male laborers. Thumb spica-cast immobilization is the standard treatment for the vast majority of scaphoid fractures. Because the scaphoid has a high rate of delayed union and nonunion, prolonged immobilization (a minimum of 3 months) is required. Open reduction and internal fixation are indicated for displaced fractures, as well as in cases of nondisplaced fractures in patients for whom cast immobilization presents an undue hardship. Arthroscopic reduction and internal fixation also has a role in the treatment of patients with scaphoid fractures.

### *Arthroscopic Reduction*

One of us (ALO) uses the equipment developed by Whipple (65) to facilitate scaphoid fixation. A standard arthroscopic setup is employed.

- Scaphoid displacement is best assessed via the mid-carpal radial (MCR) portal.
- Evacuate hematoma and debris with a full-radius resector via the mid-carpal ulnar (MCU) portal.
- If necessary, reduce the fracture through either direct manipulation of the scaphoid or the use of percutaneously placed joysticks.
- Stabilize the fracture with an 0.045-inch K-wire.
- Make a 2 cm incision radial to the flexor carpi radialis and centered over the scaphotrapezial joint. Continue dissection bluntly to the volar joint capsule. Elevate the capsule and excise the volar tubercle of trapezium.
- Place the arthroscope in the 4-5 portal and introduce the target hook of a Whipple compression jig through the 1-2 portal. Seat the hook on the dorsal aspect of the scaphoid 1–2 mm radial to the scapholunate ligament. Slide the guide barrel down to exposed articular surface of scaphoid and compress the jig. Use the guide pin to confirm correct placement.
- Place an accessory pin to control rotation.
- Place an appropriate-length Herbert–Whipple screw.
- Immobilize the extremity in a thumb spica splint for 10 days.
- Initiate protected wrist mobilization at 2 weeks.

Whipple (65) has reported his series of 20 cases of scaphoid fracture treated with arthroscopically assisted reduction and internal fixation. All fractures healed by the 12-month follow-up. The period of cast immobilization ranged from 3–4 weeks.

## SYNOVECTOMY

The possible etiologies of carpal synovitis include traumatic disorders, rheumatoid arthritis, pigmented villonodular synovitis, infections, and crystal deposition disorders such as gout and pseudogout. The differential diagnosis can often be narrowed by determining the location of hypertrophied synovium as well as the extent of its inflammation. The most common reason to perform arthroscopic synovectomy is debridement of tissue that is obscuring visualization. For example, symptomatic ligament tears are often associated with a localized synovitis; to diagnose and treat the injury, the synovial tissue must be removed. Removal of tissue is best accomplished with either a full-radius resector or a more aggressive side-cutting blade. Synovectomy is most efficiently performed with shaver speeds less than 600 rpm and oscillation of the cutting blade (64).

Complete carpal synovectomy may be indicated in cases of rheumatoid or septic arthritis. In patients with rheumatoid arthritis, whose symptomatic wrists are resistant to medical management but who have preserved joint spaces, open or arthroscopic synovectomy may provide symptomatic relief. The arthroscopic technique offers superior visualization and easier access to the synovium of all the wrist compartments than does open synovectomy. Usually, a complete synovectomy can be performed by alternating the arthroscope and full-radius resector between the 3-4 and 6R portals. Occasionally, the 1-2 or 6U portals may be required. Arthroscopy of the mid-carpal joint and the DRUJ is also performed. To examine the DRUJ, distract the wrist while it is in supination. Establish the viewing portal proximally and place the working portal just proximal to the TFCC.

Arthroscopic synovectomy is contraindicated in cases of associated dorsal tenosynovitis. This tenosynovium can be removed only through an open procedure. Additionally, extensor tendons weakened and displaced by the disease process are at increased risk for injury during establishment of arthroscopic portals.

Adolfsson and Nylander (1) described the treatment by arthroscopic carpal synovectomy of a series of 18 patients with rheumatoid arthritis. All patients noted a decrease in their pain and significant improvements in range of motion. Overall, morbidity and complications for arthroscopic synovectomy, particularly in terms of postoperative wrist stiffness and length of rehabilitation time, have been shown to be less severe than those incurred by open synovectomy (54).

Septic arthritis of the wrist requires prompt decompression. Arthroscopic management of sepsis has been shown to be effective in larger joints such as the knee and shoulder. Although no studies have addressed the role of arthroscopy in the treatment of wrist sepsis, its use is a logical consideration. In a series by one of us (ALO), six patients with septic arthritis were treated with arthroscopic drainage and appropriate antimicrobial therapy, and all had a successful outcome. Until the efficacy of

this approach is fully established, it should be employed with caution.

## DORSAL WRIST GANGLIA

Ganglia are mucin-filled cysts that are closely associated with either joints or tendon sheaths. They represent the majority of all soft-tissue tumors of the hand and wrist. The dorsal wrist ganglion is the most common of these cysts. Patients generally request treatment for their ganglia for cosmesis or because of discomfort or functional disturbances. Current treatment options include no treatment, aspiration with or without cortisone injection, and surgical excision. No treatment is not an unreasonable course of action in light of the spontaneous resolution rates of 28% to 58% that have been reported (38). Aspiration, with or without cortisone injection, has a reported success rate of 35% to 50%, whereas recurrence rates after surgical excision have been as high as 40%.

The key to successful surgical treatment is excision of the ganglion stalk and a small portion of the dorsal wrist capsule. Since the majority of dorsal wrist ganglia arise from the scapholunate interval, arthroscopic identification and excision of the stalk are possible in many cases. The advantages of arthroscopic excision over open excision are believed to be decreased wrist stiffness and an earlier return to function. Additionally, the arthroscope allows the identification of any additional carpal pathology that might be present.

### *Arthroscopic Ganglion Excision*

- Circle the ganglion with a marker (Fig. 75.14*A*).

***Figure 75.14.*** **A:** Dorsal ganglion usually arises from the area of the 3-4 portal. Viewing approach should be from the 6R portal. G, ganglion. **B:** Arthroscopic view of ganglion stalk prior to resection with full radius shaver. GS, ganglion stalk; L, lunate; C, radius.

- Approach the radiocarpal joint via the 6R portal to give best access to the stalk.
- Look for the stalk of ganglion arising from the dorsum of the scapholunate interval (Fig. 75.14*B*).
- If the stalk is not visualized (and it is not visualized one third of the time) resect 1 cm of dorsal capsule at the dorsal scapholunate angle with a suction punch or motorized shaver.
- If the stalk can be visualized, debride it with a suction punch or motorized shaver via a portal placed through the ganglion (usually the 3-4 portal).
- Resect 1 cm of the dorsal capsule with a suction punch or motorized shaver.
- Complete your arthroscopic evaluation of the wrist (include the mid-carpal joint).
- Ensure that the extraarticular sac has ruptured.
- Immobilize the wrist in a volar splint for 1 week.
- Use a Futuro splint as needed for comfort for up to 3 weeks with early active ROM exercises for the wrist.
- Avoid strenuous use of the hand until 6 weeks after surgery.

One of us (ALO) has reported a series of 18 dorsal wrist ganglia treated with arthroscopic excision (38). The ganglion stalk was visualized in 61% of cases. At an average follow-up of 16 months, there were no recurrences. Five patients developed increased grip strength and range of motion postoperatively, whereas two experienced losses in both categories. The remainder were unchanged. Additional intraarticular pathology was identified in half the cases. The average return to work time was 3.5 weeks.

## CHONDRAL DEFECTS AND LOOSE BODIES

Chondral defects are believed to be a common cause of wrist pain (3,26). There are a variety of causes of cartilage damage. Most often these lesions occur secondarily because of an existing wrist problem such as ligamentous instability, fracture, or inflammatory arthritis. Chondral defects can occur primarily as well. For example, the presence of a medial facet on the lunate is associated with an increased incidence of chondromalacia at the proximal pole of the hamate.

These defects are difficult to detect because the majority of them are not identifiable radiographically. In cases where the wrist pain is refractory to conservative treatment, arthroscopy can have a diagnostic and therapeutic role. Chondral lesions can be categorized with the system devised by Outerbridge (Table 75.11) (40).

| | |
|---|---|
| Type I | Softening of hyaline cartilage |
| Type II | Fibrillation and fissuring |
| Type III | A fibrillated lesion of varying depth |
| Type IV | Full-thickness defect |

***Table 75.11. Outerbridge Classification***

The usefulness of debriding of chondral lesions continues to be debated. The majority of the data published on this topic comes from studies performed on arthritic knees. While several authors have reported a significant decrease in pain after arthroscopic lavage and/or debridement, these studies have been limited by follow-up periods of a year or less (4,16,28). The work of Mosely et al. (35) suggests that the benefit of arthroscopic treatment in these patients is no more efficacious than a placebo.

With these concerns in mind, the accepted arthroscopic treatment of Outerbridge lesions grades I–III involves debridement of the accompanying synovitis and fibrillation. Chondral lesions are smoothed to reduce mechanical symptoms and to minimize the production of intraarticular debris. Thick chondral flaps can be debrided with a suction punch, whereas thin flaps are best debrided with a motorized shaver.

The treatment of grade IV injuries remains controversial. While no treatment has been shown to cause repair or regeneration of hyaline cartilage, chondral abrasion appears to stimulate fibrocartilage repair. This fibrocartilage patch probably cannot hold up under physiologic loads over time but it may bind to adjacent hyaline cartilage protecting against extension of the injury.

Loose bodies are commonly caused by chondral defects and degenerative arthritis. These bodies may produce mechanical symptoms such as pain, locking, and catching. Whereas large loose bodies can often be visualized on plain radiographs, small ones often cannot. Arthroscopy provides a minimally invasive means of removing loose bodies. When performing this surgery, it is best to obtain radiographs on the day of the procedure to help confirm the location of radiopaque bodies. Use the portal closest to the loose body for the arthroscope. A separate inflow portal helps to force the body toward the arthroscope. A percutaneously placed

hypodermic needle can act as a skewer if necessary. Small loose bodies can be retrieved with a basket forceps. Larger ones may require morcellization with a motorized shaver.

### ARTHROSCOPIC RADIAL STYLOIDECTOMY

Radial styloidectomy is an early salvage procedure that may provide symptomatic relief to patients with early radiocarpal arthritis. It is particularly useful in the treatment of patients in the first stage of scapholunate or scaphoid nonunion advanced collapse. It is often only a temporizing measure (31). The procedure can be performed either arthroscopically or in open fashion.

- Perform a standard arthroscopic evaluation, synovectomy, and debridement as necessary.
- Insert the arthroscope via the 3-4 portal and identify the radioscaphocapitate and long radiolunate ligaments. **Note: These ligaments must be preserved**. Introduce a 3 or 4 mm burr through the 1-2 portal and excise the styloid under arthroscopic visualization.
- Fluoroscopically confirm the amount of styloid removed.
- Arthroscopically confirm the decompression of radial impingement by radially deviating the wrist.
- Splint the wrist intermittently for 3 weeks.
- Initiate active ROM exercises at 1 week and begin a strengthening program at 4 weeks.

### ARTHROSCOPIC PROXIMAL ROW CARPECTOMY

Proximal row carpectomy is a salvage procedure for preserving motion in patients with later stages of scapholunate or scaphoid nonunion advanced collapse (57,68). Its success is based on the preservation of the articular surfaces of the proximal capitate and the lunate fossa of the radius. Arthroscopy can allow for evaluation of these surfaces as well as the performance of the procedure itself.

- Perform a standard arthroscopic evaluation, synovectomy, and debridement as necessary.
- Confirm that the proximal pole of the capitate and lunate fossa have acceptable articular surfaces.
- Establish a 4-5 viewing portal.
- Introduce a 4 mm burr via the 3-4 portal.
- Remove the proximal scaphoid.
- Initiate excision of the lunate from its radial side. **Note: Take care to avoid injuring the lunate fossa and proximal capitate**.
- Protect the proximal capitate with a Freer elevator introduced via a mid-carpal portal.
- Small osteotomes help to morcelize the bones.
- Remove large fragments with pituitary rongeurs.
- Confirm decompression of radial impingement arthroscopically by radially deviating the wrist. Perform radial styloidectomy as necessary.
- Immobilize the wrist for 4 weeks, then splint intermittently while initiating ROM exercises. Introduce strengthening exercises at 8 weeks.

Proximal row carpectomy is a widely accepted salvage option for the arthritic wrist (57,68). To date, no data regarding the arthroscopic procedure have been presented.

## PITFALLS AND COMPLICATIONS

The complication rate associated with arthroscopy of any joint is low. Small (53) observed a 0.59% rate of complications in his review of 395,000 cases. Assad et al. (2) identified 17 complications in 214 cases of diagnostic wrist arthroscopy. Reflex sympathetic dystrophy was most common (3.7%), followed by dorsal radial sensory nerve neuropraxia (2.3%) and tendon problems (0.9%). All complications resolved with nonoperative treatment.

One of us (ALO) reviewed 463 therapeutic arthroscopies he performed and noted a complication rate of less than 3%. The majority of these complications were related more to percutaneous pin fixation than to the arthroscopy. The morbidity was directly related to the technical difficulty of the procedure.

Warhold and Ruth (60) divided complications into four categories: (a) complications related to traction, (b) complications related to establishment of portals and insertion of instruments, (c) procedure-specific complications, and (d) miscellaneous complications. A list of these complications and the means of avoiding them appears in Table 75.12.



***Table 75.12. Complications of Wrist Arthroscopy***

When performed by an experienced surgeon, wrist arthroscopy is a relatively safe procedure that offers excellent visualization of the wrist with minimal soft-tissue dissection. Its diagnostic value is unquestionable. Its therapeutic usefulness continues to expand.

### CHAPTER REFERENCES

Each reference is categorized according to the following scheme: *, classic article; #, review article; !, basic research article; and +, clinical results/outcome study.


+ 1. Adolfson L, Nylander G. Arthroscopic Synovectomy of the Rheumatoid Wrist. *Br J Hand Surg* 1993;18B:92.

+ 2. Assad C, Richards RS, Roth JA, Patterson SD. Complications of Diagnostic Wrist Arthroscopy. Presented at 51st annual meeting of American Society for Surgery of the Hand, Nashville, TN, 1996.

# 3. Bain GI, Roth JM. The Role of Arthroscopy in Arthritis: “Ectomy Procedures.” *Hand Clin* 1995;11:51.

+ 4. Baumgaertner MR, Cannon WD, Vittori JM, et al. Arthroscopic Debridement of the Arthritic Knee. *Clin Orthop* 1990;253:197.

! 5. Bednar MS, Arnoczky SP, Weiland AJ. The Microvasculature of the Triangular Fibrocartilage Complex: Its Clinical Significance. *J Hand Surg [Am]* 1991;16:1101.

! 6. Berger RA. The Gross and Histologic Anatomy of the Scapholunate Interosseous Ligament. *J Hand Surg [Am]* 1996;21:170.

+ 7. Bradway JKL, Amadio PL, Cooney WP. Open Reduction and Internal Fixation of Displaced, Comminuted Intra-articular Fractures of the Distal End of the Radius. *J Bone Joint Surg Am* 1989:71:839.

+ 8. Cantor RM, Stern PJ, Wyrick JD, Michaels SE. The Relevance of Ligament Tears and Perforations in the Diagnosis of Wrist Pain: An Arthrographic Study. *J Hand Surg [Am]* 1994;19:945.

* 9. Chen YC. Arthroscopy of the Wrist and Finger Joints. *Orthop Clin North Am* 1979;10:723.

! 10. Chidgey LK, Dell PC, Bittar E, Spanier SS. Histologic Anatomy of the Triangular Fibrocartilage. *J Hand Surg [Am]* 1991;16:1084.

+ 11. Chung KC, Zimmerman NB, Travis NT. Wrist Arthrography versus Arthroscopy: A Comparative Study of 150 Cases. *J Hand Surg [Am]* 1996;21:591.

+ 12. Cooney WP. Evaluation of Chronic Wrist Pain by Arthrography, Arthroscopy and Arthrotomy. *J Hand Surg [Am]* 1993;18:815.

+ 13. Cooney WP, Linscheid RL, Dobyns JH. Triangular Fibrocartilage Tears. *J Hand Surg [Am]* 1994;19:143.

+ 14. Corso SJ, Savoie FH, Geissler WB, et al. Arthroscopic Repair of Peripheral Avulsions of the Triangular Fibrocartilage Complex of the Wrist: A Multi-center Trial. *Arthroscopy* 1997;13:78.

+ 15. Culp RW, Osterman AL. Arthroscopic Reduction and Internal Fixation of Distal Radius Fractures. *Orthop Clin North Am* 1995;26:739.

+ 16. Edelson R, Burks RT, Blocbaum RD. Short-term Effects of Knee Washout for Osteoarthritis. *Am J Sports Med* 1995;23:345.

+ 17. Feldon P, Terrono AL, Belsby MR. Wafer Distal Ulna Resection for Triangular Fibrocartilage Tears and/or Ulnar Impaction Syndrome. *J Hand Surg [Am]* 1992;17:731.

+ 18. Geissler WB, Freeland AE, Savoie FH, et al. Intraarticular Soft Tissue Lesions Associated with an Intraarticular Fracture of the Distal End of the Radius. *J Bone Joint Surg Am* 1996;78:357.

+ 19. Golimbu CN, Firooznia H, Melone CP, et al. Tears of the Triangular Fibrocartilage of the Wrist: MR Imaging. *Radiology* 1989;173:731.

! 20. Gundry CR, Kursunoglu-Brahme S, Schwaighofer B, et al. Is MR Imaging Better than Arthrography for Evaluating the Ligaments of the Wrist? In Vitro Study. *AJR Am J Roentgenol* 1990;154:337.

+ 21. Hermansdorfer JD, Kleinman WB. Management of Chronic Peripheral Tears of the Triangular Fibrocartilage Complex. *J Hand Surg [Am]* 1991;16:340.

+ 22. Imbriglia JE, Boland DS. Tears of the Articular Disc of the Triangular Fibrocartilage Complex: Results of Excision of the Articular Disc. *J Hand Surg* 1983;8:620.

# 23. Jantea CL, Baltzer A, Rutler W. Arthroscopic Repair of Radial-Sided Lesions of the Triangular Fibrocartilage Complex. *Hand Clin* 1995;11:31.

+ 24. Johnstone DJ, Thorogood S, Smith WH, Scott TD. A Comparison of Magnetic Resonance Imaging and Arthroscopy in the Investigation of Chronic Wrist Pain. *J Hand Surg [Br]* 1997;22:714.

* 25. Knirk JL, Jupiter JB. Intra-articular Fractures of the Distal End of the Radius in Young Adults. *J Bone Joint Surg Am* 1986;68:647.

+ 26. Koman LA, Poehling GG, Toby EB, Kammire G. Chronic Wrist Pain: Indications for Wrist Arthroscopy. *Arthroscopy* 1990;6:116.

+ 27. Levinsohn EM, Rosen ID, Palmer AK. Wrist Arthrography: Value of the Three Compartment Injection Method. *Radiology* 1991;179:231.

+ 28. Livesley PS, Doherty M, Needoff M, Moulton A. Arthroscopic Lavage of Osteoarthritic Knees. *J Bone Joint Surg Br* 1991;73:922.

# 29. Loftus JB, Palmer AK. Disorders of the Distal Radioulnar Joint and Triangular Fibrocartilage Complex: An Overview. In: Lichtman DM, Alexander AH, eds. *The Wrist and its Disorders.* Philadelphia: Saunders, 1997:393.

+ 30. Loftus JB, Palmer AK, Short WH. Arthroscopic Wafer for Ulnar Impaction Syndrome. Presented at 52nd annual meeting of the American Society for Surgery of the Hand, Denver, CO, 1997.

# 31. Mack GR, Kelly JP, Lichtman DM. Scaphoid Non-Union. In: Lichtman DM, Alexander AH, eds. *The Wrist and Its Disorders.* Philadelphia: Saunders, 1997:393.

+ 32. Menon J, Wood VE, Schoene HR, et al. Isolated Tears of the Triangular Fibrocartilage of the Wrist: Results of Partial Excision. *J Hand Surg [Am]* 1984;9:527.

+ 33. Minami A, Ishikawa J, Svenago N, Kasashima T. Clinical Results of Treatment of Triangular Fibrocartilage Complex Tears by Arthroscopic Debridement. *J Hand Surg [Am]* 1996;21:406.

+ 34. Missakian ML, Cooney WP, Amadio PL, Glidewell HL. Open Reduction and Internal Fixation for Distal Radius Fractures. *J Hand Surg [Am]* 1992;17:745.

+ 35. Moseley JB, Wray NP, Kuykendall D, et al. Arthroscopic Treatment of Osteoarthritis of the Knee: A Prospective, Randomized, Placebo-Controlled Trial. *Am J Sports Med* 1996;24:28.

+ 36. Osterman AL. Arthroscopic Debridement of Triangular Fibrocartilage Complex Tears. *Arthroscopy* 1990;6:120.

+ 37. Osterman AL, Bednar JM, Gambino K, Mahony K. The Natural History of Untreated Symptomatic Tears in the Triangular Fibrocartilage. Presented at the 51st annual meeting of the American Society for Surgery of the Hand, Nashville, TN, 1996.

# 38. Osterman AL, Raphael J. Arthroscopic Resection of the Dorsal Ganglion of the Wrist. *Hand Clin* 1995;11:7.

# 39. Osterman AL, Seidman G. The Role of Arthroscopy in the Treatment of Lunatotriquetral Instability. *Hand Clin* 1995;11:41.

* 40. Outerbridge RE. The Etiology of Chondromalacia Patellae. *J Bone Joint Surg Br* 1961;43:752.

* 41. Palmer AK. Triangular Fibrocartilage Complex Lesions. A Classification. *J Hand Surg [Am]* 1989;14:594.

! 42. Palmer AK, Glisson RR, Werrer FW. Relationship between Ulnar Variance and TFCC Thickness. *J Hand Surg [Am]* 1984;9:681.

* 43. Palmer AK, Werrer FW. The Triangular Fibrocartilage Complex of the Wrist: Anatomy and Function. *J Hand Surg [Am]* 1981;6:153.

+ 44. Palmer AK, Werrer FW, Glisson RR, Murphy DJ. Partial Excision of the Triangular Fibrocartilage Complex. *J Hand Surg [Am]* 1988;13:391.

+ 45. Pin PG, Young VL, Gilula LA, Weeks PM. Management of Chronic Lunotriquetral Tears. *J Hand Surg [Am]* 1989;14:77.

+ 46. Potter HG, Asnis-Ernberg L, Weiland AJ, et al. The Utility of High-Resolution Magnetic Resonance Imaging in the Evaluation of the Triangular Fibrocartilage Complex of the Wrist. *J Bone Joint Surg Am* 1997;79:1675.

+ 47. Roth JH, Haddad RG. Radiocarpal Arthroscopy and Arthrography in the Diagnosis of Ulnar Wrist Pain. *Arthroscopy* 1986;2:234.

# 48. Roth JH, Poehling GG, Whipple TL. Hand Instrumentation for Small Joint Arthroscopy. *Arthroscopy* 1988;4:126.

+ 49. Ruch DS, Poehling GG. Arthroscopic Management of Partial Scapholunate and Lunato-triquetral Injuries of the Wrist. *J Hand Surg [Am]* 1996;21:412.

+ 50. Sagerman SD, Short W. Arthroscopic Repair of Radial Sided Triangular Fibrocartilage Complex Tears. *Arthroscopy* 1996;12:339.

+ 51. Scheck RJ, Kubitzek C, Hierner R, et al. The Scapholunate Interosseous Ligament in MR Arthrography of the Wrist: Correlation with Non-enhanced MRI and Wrist Arthroscopy. *Skeletal Radiol* 1997;26:263.

+ 52. Schuurman AH, Bos KE. The Ulno-carpal Abutment Syndrome. *J Hand Surg [Br]* 1995;20:171.

+ 53. Small NC. Complications in Arthroscopy: The Knee and Other Joints. *Arthroscopy* 1986;2:253.

+ 54. Smiley P, Wasilewsik SA. Arthroscopic Synovectomy. *Arthroscopy* 1990;6:18.

+ 55. Takagi K. Arthroscope. *Clin Orthop* 1982;167:6.

! 56. Thiru-Pathi RG, Ferlic DC, Clayton ML, McClure DC. Arterial Anatomy of the Triangular Fibrocartilage of the Wrist and its Surgical Significance. *J Hand Surg [Am]* 1986;11:258.

+ 57. Tomaino MM, Delsignore J, Burton RI. Long-term Results Following Proximal Row Carpectomy. *J Hand Surg [Am]* 1994;19:694.

+ 58. Totterman SM, Miller RJ, McCance SE, Meyers SP. Lesions of the Triangular Fibrocartilage Complex: MR Findings with a Three Dimensional Gradient-Recalled-Echo Sequence. *Radiology* 1996;199:227.

+ 59. Trumble TE, Gilbert M, Vedder N. Arthroscopic Repair of the Triangular Fibrocartilage Complex. *Arthroscopy* 1996;12:588.

# 60. Warhold LG, Ruth RM. Complications of Arthroscopy and How to Prevent Them. *Hand Clin* 1995;11:81.

+ 61. Watson HK, Ryu J, Akelman E. Limited Triscaphoid Intercarpal Arthrodesis for Rotatory Subluxation of the Scaphoid. *J Bone Joint Surg Am* 1986;68:345.

+ 62. Weiss APC, Akelman E, Lambiase R. Comparison of the Findings of Triple Injection Cine-arthrography of the Wrist with Those of Arthroscopy. *J Bone Joint Surg Am* 1996;78:348.

+ 63. Weiss APC, Sachar K, Glowacki KA. Arthroscopic Debridement Alone for Intercarpal Ligament Tears. *J Hand Surg [Am]* 1997;22:344.

# 64. Whipple TL. Powered Instruments for Wrist Arthroscopy. *Arthroscopy* 1988;4:290.

# 65. Whipple TL. The Role of Arthroscopy in the Treatment of Intraarticular Wrist Fractures. *Hand Clin* 1995;11:13.

# 66. Whipple TL. The Role of Arthroscopy in the Treatment of Scapholunate Instability. *Hand Clin* 1995;11:37.

+ 67. Wolfe SW, Easterling KJ, Yoo HH. Arthroscopic Assisted Reduction of Distal Radius Fractures. *Arthroscopy* 1995;11:706.

+ 68. Wyrick JD, Stern PJ, Kiethaber TR. Motion-preserving Procedures in the Treatment of Scapholunate Advanced Collapse Wrist: Proximal Row Carpectomy Versus Four-Corner Arthrodesis. *J Hand Surg [Am]* 1995;20:965.

+ 69. Zelouf DS, Bowers WH. The Feldon Wafer Procedure—A Review of 35 Cases. Presented at the 52nd Annual Meeting of the American Society for Surgery of the Hand, Denver, CO, 1997.

+ 70. Zinberg EM, Palmer AK, Coren AB, Levinsohn EM. The Triple Injection Wrist Arthrogram. *J Hand Surg [Am]* 1988;13:803.

+ 71. Zlatkin MB, Chao PC, Osterman AL, et al. Chronic Wrist Pain: Evaluation with High-resolution MR Imaging. *Radiology* 1989;173:723.

# CHAPTER 76

# BIOMECHANICS AND FUNCTIONAL ANATOMY OF THE SHOULDER

*Jacquelin Perry*

**J. Perry:** Pathokinesiology Service, Rancho Los Amigos Medical Center, Downey, California, 90242.

Passive Elements of Function
Glenohumeral Joint
Bones
Ligamentous Structures
Scapulothoracic Articulation
Sternoclavicular Joint
Acromioclavicular Joint
Motions of the Shoulder Joints
Glenohumeral Joint Mobility
Scapulothoracic Mobility
Clavicular Joints
Muscular Control
Elevation
Biomechanics of Arm Elevation
Rotation
Depression
Arm Suspension
Horizontal Ranges
Conclusions
Chapter References

The shoulder is a complex of joints and controlling muscles that links the arm to the trunk. Large arcs of motion in all three planes allow the shoulder to perform a multitude of functions that include reaching, lifting, carrying, pushing, propelling, and placing the hand. Intricate synergy among the controlling muscles provides the necessary functional precision. Shoulder function, however, is determined not only by joint structure but also by the mode of dynamic control.

Fibrous tissue bands provide passive stability of the shoulder complex, rims and discs that Codman grouped under the gross classification of ligaments (9). These structures limit motion by the lack of tissue elasticity in the line of their collagen fibers (3% to 5% stretch). On the other hand, they allow motion in all other directions according to the characteristics of the ground substance. The bands, having a gellike proteoglycan ground substance binding the linearly aligned collagen fibers, are the most flexible. Stiffness of dense fibrous tissue or fibrocartilaginous stroma of the discs and labral rim limits their mobility to mild bending. Each joint has a unique system of ligaments.

Mobility at the shoulder is greater than at any other joint. Three skeletal segments are used: the humerus, the scapula, and the clavicle. The most prominent patterns of motion are arm elevation and rotation. Lesser actions are depression, horizontal motion, and support of the hanging arm. Each has specific biomechanical requirements of the passive structures and selected patterns of muscle action.

## PASSIVE ELEMENTS OF FUNCTION

The shoulder complex comprises four joints (Fig. 76.1). Of these, the glenohumeral joint is dominant both by its extensive range of motion and by clinical concerns. The second most important functional site is the scapulothoracic articulation. Mobility of the scapula on the thorax depends on the quality of the sternoclavicular and acromioclavicular joints. These provide the skeletal link between the scapula and the trunk.

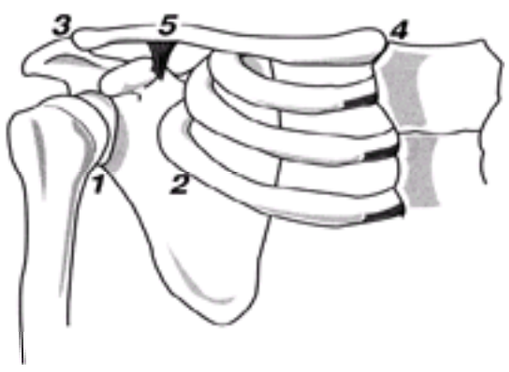


***Figure 76.1.*** The four critical areas of motion within the shoulder complex: (*1*) glenohumeral, (*2*) scapulothoracic, (*3*) acromioclavicular, and (*5*) sternoclavicular. Clavicular rotation (*4*) is the result of motion at *3* and *5*.

## GLENOHUMERAL JOINT

### BONES

Structurally, the ball-and-socket glenohumeral joint favors mobility over stability. The ball-shaped humeral head is approximately one third of a sphere (6), with an average radius of 26.9 mm in men (women's radii are 13% smaller) (64). Opposing it is a shallow bony socket formed by the glenoid fossa of the scapula. The bony surface of the glenoid fossa opposes only the central 35% of the humeral head, but a dense fibrous glenoid labrum enlarges the socket contact area to 75% (4,60). The flexibility of this dense fibrous rim lessens the shock of impact during aggressive motion.

The glenoid socket depth is approximately 9 mm in its vertical plane and 5 mm along its anteroposterior axis. In the superoinferior direction, the labrum increases the total socket depth 50%; horizontally it adds 60%.

Early measurements of the bony surfaces indicated incongruity between the humeral and glenoid curvatures (6). Recent measurements of the cartilaginous surfaces, however, have found that both surfaces accurately approximate a sphere, with the glenoid contour not differing significantly from the humeral shape (64). Further study has identified the peripheral cartilage of the glenoid to be thicker than the center. Humeral articular cartilage thickness is quite uniform.

Alignment of the glenohumeral joint is oblique to all three basic planes. Relative to the transverse axis of the elbow, the humeral head is retroverted 20° to 35° (61). It also makes a 45° vertical angle with the longitudinal axis of the humerus. These angulations align the central axis of the humeral head with the center of the glenoid fossa of the scapula as it rests on the posterior, lateral aspect of the chest wall (55). Scapular alignment defined in the quiet standing position is approximately 30° anterior to the body's transverse plane (30).

Anatomically, the glenoid fossa is tilted slightly upward relative to the scapular blade (2). In the quiet standing position, however, the glenoid has a 5° downward tilt (20). Horizontal alignment most commonly has 7° of retroversion (in 75% of specimens) but may reach 10° of anteversion (25%) (60).

## LIGAMENTOUS STRUCTURES

Passive stability of the glenohumeral joint is provided by the glenoid labrum, which deepens the socket, a capsule that encloses the joint, and several critically aligned linear bands (commonly called ligaments). The function of each structure is to prevent displacement of the humeral head beyond the margins of the glenoid socket.

### *Glenoid Labrum*

The glenoid labrum is a soft-tissue lip that extends peripherally from the rim of the fossa to deepen the glenoid socket (Fig. 76.2). Minor differences in labral depth have been found among the areas (varying from 3.0 to 3.8 mm), with the anterior and inferior being slightly greater than others (27). Average socket depth is doubled by the labrum. No correlation has been found between the size of the labrum and that of the glenoid (27). There is no consistency between right and left labra (44). The shape of the labrum also has been found to differ with the state of humeral head rotation (39). This latter fact supports the greater detail found by arthroscopy (11).

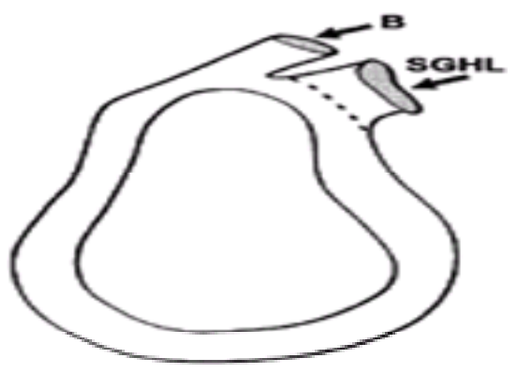


***Figure 76.2.*** The glenoid labrum. Its peripheral margin is attached to the rim of the glenoid fossa. While both the tendon of the long head of the biceps muscle (B) and the superior glenohumeral ligament (SGHL) appear to arise from the superior margin of the labrum, the biceps tendon also has a bony attachment. (Adapted from Harryman DT et al. The Role of the Rotator Interval in Passive Motion and Stability of the Shoulder. *J Bone Joint Surg Am* 1992;74:53, with permission.)

Investigators have described the structure of the labrum as either fibrocartilage (6,9,14) or dense fibrous tissue (11,39). Recent detailed histology has shown that the dominant composition is dense fibrous tissue without chondrocytes. Fibrocartilage is present only at the base of the more inferior portion of the labrum.

Structural differences are most marked between the superior and inferior portions of the labrum (11,44). Proximally, the labrum resembles a meniscus, with a roughly triangular cross section, which is loosely attached to the glenoid rim by thin connective tissue that stretches easily [mimicking a superior labral tear from anterior to posterior (a SLAP lesion)]. The superior area (12 o'clock) of the labrum inserts directly into the biceps tendon, and some of its collagen fibers extend over the rim to the tubercle. The interval between the biceps tendon insertion site (the supraglenoid tubercle) and the glenoid rim is a small (5 mm) recess.

In contrast, the lower portion of the labrum (4 to 6 or 8 o'clock) appears as a rounded, dense, fibrous tissue extension of the articular cartilage, which is firmly attached to the glenoid rim. In this area, there is a narrow fibrocartilagenous transitional zone joining the labrum to the hyaline cartilage margin (11,39).

Mechanically, glenohumeral stability is enhanced by the joint's concave contour and the labrum. In the presence of a compressive force, the joint resists passive translation (34). Passive stability in the superior and inferior directions is approximately twice that available against anterior and posterior forces. This difference correlates with the relative depth of the glenoid fossa. Excision of the labrum reduces the joint's resistance to translation by about 20% (36).

Translation has been found during active motion in the horizontal plane only at the extremes of external rotation and extension (the cocking position) (28). Then there is a 4 mm posterior displacement, corrected by either flexion or derotation. During all other arcs of motion, the humerus remains centered on the glenoid.

### *Capsule*

A continuous fibrous sac encloses the glenohumeral joint. Its attachment on the scapula most often is about 1 cm beyond the labrum, but approximately 20% of the capsule is contiguous with the base of the labrum. On the humerus, the capsule inserts primarily into the anatomic neck. Inferiorly, the capsular attachment drops down to the surgical neck of the humerus (7). Preservation of glenohumeral stability by an intraarticular vacuum appears to be an important function of the capsule (25,35).

With the capsule intact, researchers have found normal glenohumeral contact. Venting the capsule allows easy distraction and reduces the forces required for joint translation (8,23). A cadaver study of the dependent arm with an intact capsule found no subluxation even with sectioning of all the supporting muscles (35). Puncture of the capsule, however, allowed the humeral head to drop half the height of the glenoid, whether the muscles were intact or released.

### *Glenohumeral Ligaments*

Thickening within the anterior wall of the capsule provides structural reinforcement of the glenohumeral ligaments (GHL) to preserve passive joint stability (Fig. 76.3) (7). By their point of attachment on the humerus, these otherwise thin tissues have been designated as the superior, middle, and inferior glenohumeral ligaments (7). Initially, investigators considered these structures inconsistent (14), but recent investigations have found that they vary in size rather than presence or absence (7,18,39,45,66).

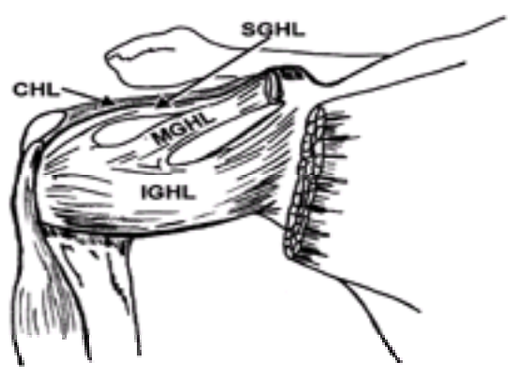


***Figure 76.3.*** Ligaments of the shoulder joint, anterior view. *CHL*, coracohumeral ligament; *SGHL,* superior glenohumeral ligament; *MGHL*, middle glenohumeral ligament; *IGHL*, inferior glenohumeral ligament. (Adapted from Ferrari DA. Capsular Ligaments of the Shoulder. *Am J Sports Med* 1990;18:20, with permission.

**Superior Glenohumeral Ligament** The most superior capsular thickening arises from the labrum just anterior to the tendon of the long head of the biceps brachii at the level of the coracoid base (Fig. 76.2, Fig. 76.3, and Fig. 76.4) (7,39,66). It passes under the supraspinatus muscle and inserts on the anatomic neck of the humerus, medial to the anterosuperior base of the lesser tuberosity.

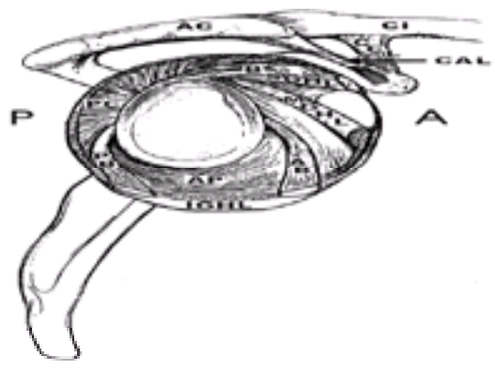


***Figure 76.4.*** Ligaments of the shoulder as they encircle the glenoid fossa. *B*, tendon of the long head of the biceps; *SGHL*, superior glenohumeral ligament; *MGHL*, middle glenohumeral ligament; *CAL*, coracoacromial ligament; *CCL*, coracoclavicular ligaments. Components of the inferior glenohumeral ligament: *AB*, anterior band; *AP*, axillary pouch; *PB*, posterior band; *PC*, posterior capsule. (Adapted from O'Brien et al. The Anatomy and Histology if the Inferior Glenohumeral Ligament Complex of the Shoulder. *Am J Sports Med* 1990;18:449, with permission.)

**Middle Glenohumeral Ligament** The most variable in size (12), the middle glenohumeral ligament (MGHL) arises just inferior to the superior GHL and inserts along the middle area of the anatomic neck of the humerus, opposite the lesser tuberosity (Fig. 76.3 and Fig. 76.4) (39,66).

**Inferior Glenohumeral Ligament** The thickest part of the capsule is the inferior glenohumeral ligament (IGHL). It is also very broad, arising from the lower half of the labrum (anterior, inferior, and posterior). The especially thick superior margin is designated the superior band, while the rest of the ligament is called an axillary pouch (Fig. 76.4). Both the superior band and the anterior pouch insert on the anatomic neck of the humerus (Fig. 76.3). The posterior pouch dips down to insert on the surgical neck (39,66).

Mechanical testing has shown that the glenohumeral ligaments restrain selective arcs of abduction and external rotation (66). With the arm dependent (abduction zero), all three ligaments are visibly slack. Strain measurements, however, register tension in the superior and middle GHLs (46). The addition of external rotation introduces tension (visible on radiographic examination of tissue markers) in the middle GHL and the superior band of the IGHL (66). Placing the arm in 45° of abduction further tightens the superior band of the IGHL. External rotation moves the superior band across the middle third of the joint and the inferior margin tightly under the humeral head. Abduction to 90° increases IGHL tautness and its coverage of the lower half of the joint (Fig. 76.5). The major strain is in the superior (anterior) band (46). There is little measurable tension in the MGHL and visibly it appears slack.

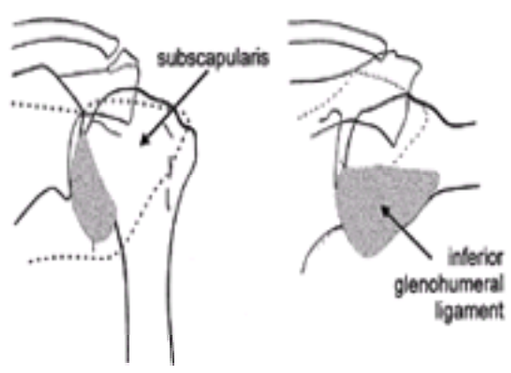


***Figure 76.5.*** Change in the “ligamentous” anterior wall of the shoulder joint with arm position. *Left:* No elevation, no rotation; subscapularis tendon covers the anterior glenohumeral surface. *Right:* 90° abduction and 90° external rotation; the inferior glenohumeral ligament covers lower half of the glenohumeral joint, replacing upwardly displaced subscapularis tendon. (Adapted from Turkel SJ. Stabilizing Mechanism Preventing Anterior Dislocation of the Glenohumeral Joint. *J Bone Joint Surg Am* 1981;63(8):1208, with permission.)

### *Coracohumeral Ligament*

The coracohumeral ligament has been identified as the most consistent of the capsular ligaments (17). It forms a “bridge-like anterior leading edge” over the rotator interval between the supraspinatus and subscapularis muscles (17). Arising from the lateral base of the coracoid process, it joins the capsule on its exterior surface and extends to both the greater and lesser tuberosities, forming part of the roof of the bicipital tendon sheath (Fig. 76.3) (8,17,18).

Passively, the coracohumeral ligament resists inferior and posterior translation (17). During quiet standing, however, the humeral head drops about 3 mm below the center of the glenoid (55). The coracohumeral ligament, in combination with the superior GHL, also limits maximal forward flexion (by obligatory translation) and external rotation (26).

### *Coracoacromial Ligament*

The trapezoidal coracoacromial ligament is a fibrous ribbon that forms the central portion of the coracoacromial arch (Fig. 76.4). Its greater base inserts on the underside of the acromion beyond the tip, creating a mass that varies considerably in thickness (2.0–5.6 mm). The coracoid insertion is on the apophysis (22). Studies of the skeletal arch have shown degenerative changes limited to the anterior third of the acromion. The frequency of degenerative findings is related to the slope and length of the acromion and the height of the arch (17). Acromial thickness and breadth are unrelated. The finding of an eburnated facet on the underside of the acromion is consistent with a recent mechanical study that showed the coracoacromial ligament passively restrains humeral subluxation in the shoulder with a deficient rotator cuff (17,19).

## SCAPULOTHORACIC ARTICULATION

The interval between the scapula and the underlying wall of ribs is not a true joint. Instead, a thin layer of loose areolar tissue separates the surfaces, allowing the scapula to glide freely in all directions. Incongruity between the angle of the ribs and the scapula is an occasional problem. The clavicle provides skeletal contact between the scapula and the trunk.

The clavicle, a mobile strut, adds some stability to the junction between the scapula and the thorax. It is expendable, however, if excised cautiously (29,58). People without a clavicle (congenitally or by surgical resection) have markedly increased scapular protraction and slightly reduced (10%) strength of arm elevation but no significant instability (29). Partial surgical excision must be designed to retain clavicular stability by retaining the coracoclavicular ligaments or sternoclavicular ligaments to a short medial segment. Otherwise, it is necessary to remove the entire shaft (1). Functional stability is retained by preserving the periosteal sheath and muscular attachments. Replacement of the bone with a fibrin strip also has been recommended (58).

Motion of the scapula depends on the mechanics of the joints at either end of the clavicle. Medially, the sternoclavicular joint is the articulation between the shoulder girdle and the trunk. At the lateral end, the acromioclavicular joint allows the scapula to rotate on the clavicle.

### STERNOCLAVICULAR JOINT

The junction between the clavicle and the sternum is the only skeletal attachment between the entire upper extremity and trunk (Fig. 76.1). This articulation consists of a large clavicular end; a small notch in the superior, lateral corner of the sternal manubrium; and the costocartilage of the first rib (3,69). While the joint is grossly saddle shaped, the vertical convexity is much greater than the anteroposterior concavity. Mobility is enhanced by a complete articular disc attached superiorly to the clavicle

and inferiorly to the cartilage of the first rib.

The upward alignment of the clavicle with its acromial end approximately 5 cm above the sternum is maintained by a dense thickening of the superior and posterior portion of the capsule (3). Simulation of arm weight (4.5 kg) suspended from the acromional end of the clavicle has been shown to depress the clavicle 50%, but twice that load caused little additional displacement. Depression of the clavicle was accompanied by a forward movement. Conversely, the sternal end of the clavicle moved upward and backward against the dense posterosuperior part of the capsule. Avulsion of the ligament from the sternum occurred with an 18 kg weight. *Gray's Anatomy* emphasizes the mass of the anterior sternoclavicular ligament without a reference to Bearn (3,69).

Elevation and rotation of the clavicle are limited by the costoclavicular ligaments, reinforced by a dense anterior sternoclavicular ligament and a thin posterior ligament. On the inferior surface, there is a dense, complex costoclavicular ligament spanning the first rib and clavicle. This arrangement provides good stability during the significant range of motion that occurs in all three planes (29).

### ACROMIOCLAVICULAR JOINT

The articulation between the scapula and the clavicle (Fig. 76.1) is unique because its major stabilizing ligaments are remote (coracoclavicular) despite there being a discrete local ligament lying on the superior surface of the joint (acromioclavicular ligament) (21). Restraint of posterior displacement of the clavicle and posterior axial rotation have been identified as the primary function of the acromioclavicular ligaments.

Both clinical experience and mechanical testing have demonstrated that joint stability is gained mainly from the bipartite coracoclavicular ligament, which is about 2 cm medial to the acromioclavicular joint. The conoid component of the coracoclavicular ligament complex is the primary restraint to anterior and superior rotation, and to anterior and superior displacement of the clavicle. The trapezoid ligament (vertical or horizontal) provides a much lower level of clavicular restraint. The relative contributions of these ligaments change with the direction and magnitude of loading and displacement.

## MOTIONS OF THE SHOULDER JOINTS

Arm elevation is classified by its planes of action (Fig. 76.6). *Flexion* occurs in the sagittal plane. *Abduction* is performed in the coronal (or frontal) plane. *Scaption* (a new term) refers to elevation of the arm in the plane of the scapula (30° to 40° anterior to the coronal plane).

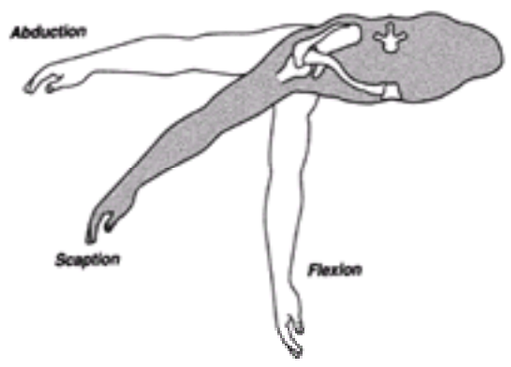


***Figure 76.6.*** The basic planes of arm elevation: flexion (sagittal plane), scaption (plane of the scapula on the thorax), and abduction (coronal plane).

No significant differences have been found in the maximal ranges of the types of arm elevation. Theoretically, the maximum is 180°, but few people have such mobility: Men average 168°, women 175° (16). Within the full range of arm elevation, humeral displacement contributes about 120° and the scapula 60°.

The two bones do not move in synchrony (Fig. 76.7) (1). Inman et al. identified a 30° delay in the onset of scapular rotation (scapular lag) (30). Doody et al. found a similar predominance of humeral motion at the end of arm elevation (16).

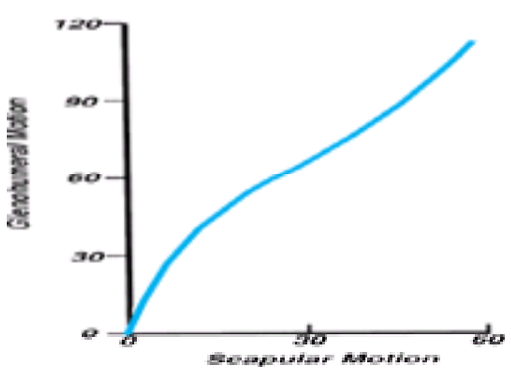


***Figure 76.7.*** Glenohumeral rhythm during scaption. The gross ratio of humeral to scapular motion is 2:1. During the first and last 30° of arm elevation, however, the humerus moves with minimal scapular participation.

### GLENOHUMERAL JOINT MOBILITY

Both flexion and abduction cause the inferior segment of the capsule to be slightly twisted (33); scaption does not. Also, inasmuch as there is more symmetry of muscle action with scaption (50,60), it represents the plane of neutral arm elevation.

The range of internal and external rotation varies with arm elevation (60). With the arm adjacent to the trunk, the range is greatest (180°), with external rotation being the larger arc (108° versus 71°) (5). Raising the arm to 90° reduces the total range to 120° and limits external rotation to 90° (forearm vertical). With full flexion or abduction, only a jog of rotation is possible. The relative contributions of humeral and scapular motion to arm rotation have not been determined.

### SCAPULOTHORACIC MOBILITY

Movement of the scapula on the thorax follows six major paths, with the direction being defined by the motion of the acromion. Upward rotation is the largest arc (60°). An undefined degree of downward rotation accompanies humeral extension behind the body line. Planar displacement of the scapula may be vertical or horizontal.

In the vertical plane, the motions are called elevation and depression. Horizontal scapular displacement is described by two terms. Moving away from the vertebral spine is either *scapular abduction* or *protraction*; conversely, movement toward the spine is *scapular adduction* or *retraction*. The second term for each motion is preferred to avoid confusion with the descriptions of total arm motion.

### CLAVICULAR JOINTS

Selected arcs of sternoclavicular and acromioclavicular motion combined with clavicular rotation provide the scapular mobility used in arm elevation (Fig. 76.8). The same motion patterns occur in flexion and abduction.

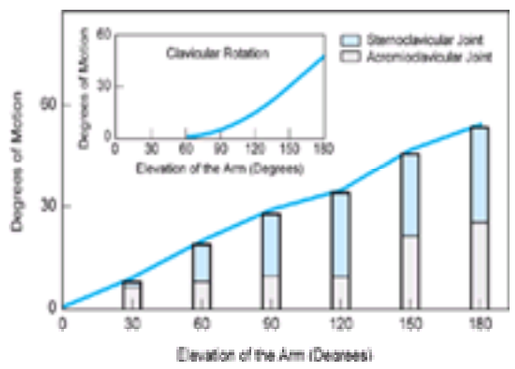


***Figure 76.8.*** The components of scapular elevation (*heavy line*). The contributions of the sternoclavicular joint (*darker shading*) and the acromioclavicular joint (*lighter shading*) motion differ during the range of arm elevation. Clavicular rotation (*inset*) is an essential component of terminal arm elevation.

At the sternoclavicular joint, there is a slow, steady rise of the clavicle, reaching 30° during the first 90° of arm elevation, with little gain thereafter. Clavicular protraction and rotation also take place at the sternoclavicular joint (29). By the end of full-arm elevation (180°), the clavicle has rotated 50°.

The acromioclavicular joint provides two small arcs of motion (15°) during the first and last 40° of arm elevation with no significant action in between (Fig. 76.8). Clavicular rotation is essential for the terminal arc of acromioclavicular mobility (29). The sigmoid contour of the clavicle relatively lengthens the coracoclavicular ligaments as the bone rotates; this lengthening permits the scapular rotation needed to complete the last 60° of arm elevation.

## MUSCULAR CONTROL

The muscles controlling the shoulder perform two functions: movement of the arm and dynamic stabilization of the glenohumeral joint (49). The 14 muscles contributing to these functions fall into four functional groups:

1. Three heads of the deltoid (anterior, middle, posterior)
2. Four rotator cuff muscles (supraspinatus, subscapularis, infraspinatus, teres minor) plus the biceps as an optional supplement
3. Two axiohumeral muscles (pectoralis major and latissimus dorsi) plus the teres major
4. Scapular muscle group (serratus anterior, trapezius, rhomboid, and levator scapulae)

The relative significance of these muscle groups depends on the mode of arm motion being used.

### ELEVATION

As the arm is elevated from a hanging position, the increasing moment resulting from the arm's weight must be overcome by increasing muscle force. Consequently, the torque that muscles must provide at 90° is twice that needed at 30° (Fig. 76.9). Arm elevation combined with preservation of glenohumeral stability involves three muscle groups: the deltoids, the rotator cuff, and the scapular rotators.

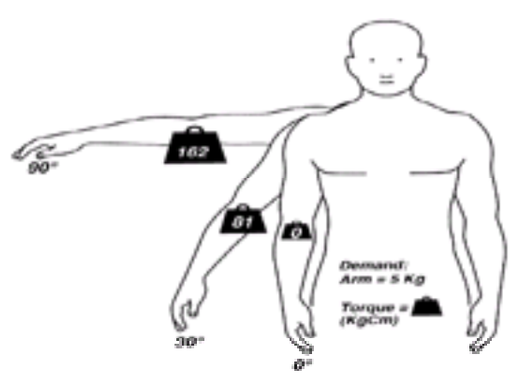


***Figure 76.9.*** The influence of arm position on the demands (torque) imposed on the shoulder muscles. Arm weight is 5 kg; arm's center of gravity is represented by the weight sign. At 0° (arm vertical), there is no torque. At 30° abduction, lateral displacement of the arm weight (functional lever) creates a torque of 81 kg-cm. Arm elevation of 90° further displaces the arm's center of gravity, presenting the greatest passive torque (162 kg-cm).

#### *Deltoids*

The anterior, middle, and posterior deltoid muscles are the primary source of arm elevation. Their relative participation varies with the plane of motion (50). Middle deltoid action is strong in all three planes of arm elevation. Anterior deltoid involvement is greatest in flexion and scaption. The posterior deltoid has a minor role except during abduction (Fig. 76.10).

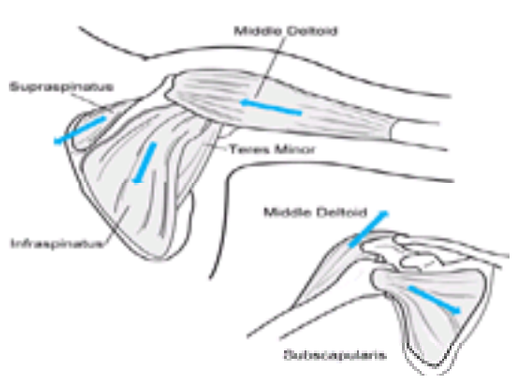


***Figure 76.10.*** The line of pull (*arrows*) of the deltoid and rotator cuff muscles. Note that the deltoid force direction has changed from being relatively vertical to being horizontal with increased arm elevation. The more downward alignment of the subscapularis muscle reflects the greater mass of vertical fibers.

#### *Rotator Cuff Muscles*

Four muscles extend from the scapula to the perimeter of the humerus. While each provides an arc of motion, they also function in synergy to stabilize the glenohumeral joint.

The supraspinatus muscle, by crossing the joint on its superior surfaces, is primarily an abductor. It also stabilizes the glenohumeral joint by compression (Fig. 76.10)

(30).

The subscapularis muscle, which crosses the glenohumeral joint anteriorly, has a distribution of its fibers that fans out from horizontal to vertical. The fibers' common function is internal rotation. The larger vertical mass provides a downward (humeral depression) force (Fig. 76.10) (30). The subscapularis is an essential component of the dynamic anterior wall that preserves joint stability during arm abduction and external rotation. With the arm dependent, the subscapularis tendon lies across the anterior surface of the glenohumeral joint. As the arm is elevated or externally rotated, the tendon moves upward, leaving the lower portion of the humeral head uncovered (66).

The infraspinatus muscle, on the posterior surface of the shoulder joint, also has a fan-shaped dispersion of its fibers. Its actions are external rotation and humeral depression. The smaller, adjacent teres minor is a second external rotator and is most active with the arm above horizontal (54).

The biceps brachii muscle, by inserting on the scapula, has a potential for influencing shoulder as well as elbow motion. The long head is more intimately involved than the short head, however, as the tendon closely contacts the humeral head. During normal function, the biceps brachii long head primarily serves the elbow independently of shoulder action (41).

The axiohumeral muscles—the pectoralis major and latissimus dorsi—extend from the chest wall to the proximal end of the humerus. They contribute to shoulder joint stability by two very different roles. With the arm dependent, these two large muscles provide a depressor force, which protects the glenohumeral joint from upward shear when the hand is being used to support the body weight. Conversely, during arm elevation and external rotation, these muscles oppose anterior shear. As it crosses the front of the joint, the pectoralis major contributes directly to the dynamic anterior wall in synergy with the subscapularis, while the latissimus acts indirectly by retracting the humerus toward the muscle's origin. The teres major supplements the latissimus.

***Scapular Muscles***

Upward rotation of the scapula during arm elevation is accomplished by synergistic action of the two largest scapular muscles (the serratus anterior and trapezius) (Fig. 76.11). In addition, these muscles also displace the scapula across the chest wall. Two other muscles, the rhomboids and levator scapulae, act as supplementary stabilizers.

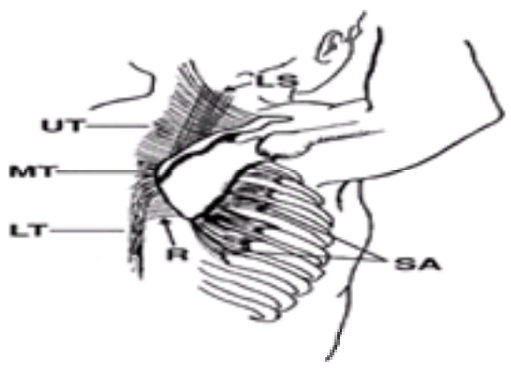


***Figure 76.11.*** Scapular muscles: lateral view with arm abducted and externally rotated (cocked). *SA*, serratus anterior; *UT,* upper trapezius, *MT,* middle trapezius, *LT,* lower trapezius; *R*, rhomboids; *LS*, levator scapulae. (Adapted from Pink MM, Perry J. Biomechanics. In*: Operative Techniques in Upper Extremity Sports Injuries*. St. Louis: Mosby, 1996:113, with permission.)

The serratus anterior, acting as a whole muscle, draws the vertebral border of the scapula toward the lateral rib cage, creating scapular protraction. The lower four segments, by their insertion on the inferior angle of the scapula, induce upward rotation.

The trapezius, as it covers the posterior chest wall from the vertebral spinous processes to the upper border of the scapular spine, provides scapular retraction. Upward rotation is accomplished by synergistic action of the upper and lower portions of the trapezius.

The rhomboids provide scapular stability as they retract the scapula toward the vertebral spines. The levator scapulae, lying between the neck and its insertion on the superior medial corner of the scapula, serves as a stabilizing pivot by resisting depression.

**BIOMECHANICS OF ARM ELEVATION**

Muscles, while creating motion, also produce forces within the joint. Their impact on stability relates to the angle that the muscle's line of pull makes with the plane of the glenohumeral joint. Also involved is the displacement of the action line from the center of rotation of the joint. A force perpendicular to the face of the glenoid creates compression and augments joint stability. In dynamic cadaver studies, muscle compression has proved to significantly increase the joint's resistance to translatory displacement (8). Conversely, forces parallel with the glenoid induce shear and lead to joint instability (Fig. 76.12) (56).

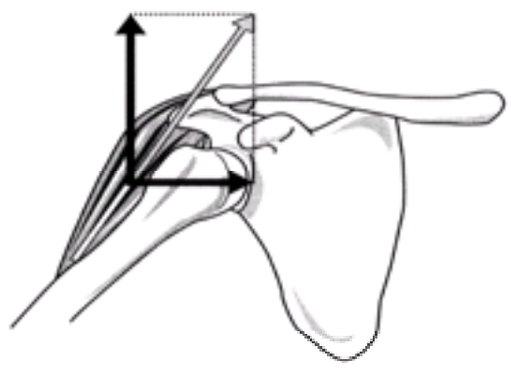

***Figure 76.12.*** Joint forces (*dark arrows*) resulting from the muscle's line of pull (*light arrow*). Perpendicular line to glenoid (*horizontal line*) represents compression. Parallel line (*vertical*) indicates shear. Note that at this arm position, the shear force of the deltoid is greater than its compression force.

The deltoids, which arise from the overhanging acromion, clavicle, and scapular spine and extend distally to the mid-humeral shaft, have a vertical alignment when the arm is down. As the arm is raised, the muscles become increasingly horizontal, which markedly changes their alignment with respect to the plane of the glenohumeral joint (48,49,56).

At 30° of arm elevation, the low angle of the deltoids results in a shear force 1.73 times greater than the compression force. Consequently, there is a tendency for upward displacement of the humerus on the glenoid that threatens joint stability and impingement of the rotator cuff against the acromion. Inspection of 200 scapulae showed a 22% incidence of an eburnated facet on the underside of the acromion (17).

Synergistic action of the supraspinatus reduces the intensity of the deltoid effort by providing part of the abduction force (70). In addition, the dominant joint force of the horizontally aligned supraspinatus is compression (2.73 times shear) (56). The subscapularis, infraspinatus, and teres minor muscles' activity provides downward force to counteract the deltoid's upward glenohumeral shear and reduce the necessary abduction force by 41% (63).

As the arm approaches 90° of elevation, the alignment of the deltoid becomes more horizontal and the muscle's shear-to-compression force ratio is reversed (S/C =

0.70) (56). Joint stability is correspondingly increased.

Electromyographic (EMG) studies during both free and fast arm elevation in all three planes confirm this synergy between the rotator cuff and the deltoid (30,50,51). In all positions of arm elevation (flexion, scaption, and abduction), the supraspinatus is a strong synergist of the deltoids (Fig. 76.13). During flexion, the stronger action of the anterior deltoid induces a posteriorly directed horizontal shear, which is opposed by greater infraspinatus muscle action (Fig. 76.13*A*). Similarly, in abduction the posterior head of the deltoid is more active. This creates a forward-directed shear that is resisted by the subscapularis (Fig. 76.13*C*). When these muscle synergies fail to occur, dynamic instability results (37).

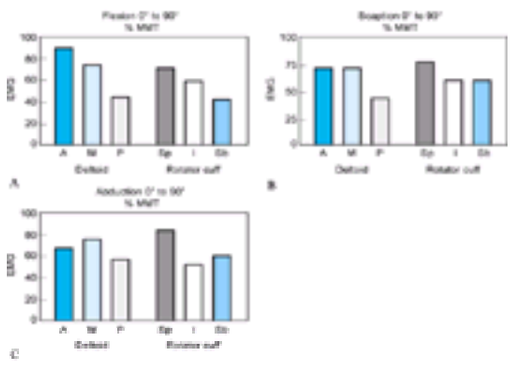

***Figure 76.13.*** Relative intensity of the glenohumeral muscles during free arm elevation indicated by EMG. **A:** Flexion. **B:** Scaption. **C:** Abduction. Deltoid: *A*, anterior; *M*, middle; *P*, posterior. Rotator cuff muscles: *Sp*, supraspinatus; *I*, infraspinatus; *Sb*, subscapularis. Height of bar indicates muscle effort compared to EMG of maximum manual muscle test (MMT).

The long head of the biceps brachii muscle may contribute to superior glenohumeral stability. During abduction, patients with isolated proximal biceps detachment were found to have increased superior displacement of the humeral head (68). Experimentally, the presence of a biceps force added torsional rigidity (57). Hence, the biceps brachii long head can be considered an accessory joint stabilizer, to be used when needed.

The concept of Inman et al. (30) of an obligatory deltoid/rotator cuff force couple is contradicted by the finding that the arm can be raised overhead with complete paralysis of either the deltoid or the supraspinatus (65). Selected anesthetic blocks of the axillary nerve innervating the deltoid, or of the suprascapular nerve innervating the supraspinatus and infraspinatus, have confirmed this clinical observation (10,67). Each nerve block reduced arm elevation strength approximately 50% but did not prevent a full range of motion.

Both muscle groups have accessory muscles that can provide partial substitution. For the deltoid, there is the long head of the biceps, the clavicular head of the pectoralis major, and the coracobrachialis. Supplements to the supraspinatus are the subscapularis and teres minor. Thus, inability to elevate the arm fully is not an essential sign of either a rotator cuff tear or deltoid paralysis.

Scapular muscle action increases the range of arm elevation by upwardly rotating the glenoid fossa. This action also preserves muscle length of the glenohumeral muscles. In addition, upward displacement of the acromion reduces the threat of humeral impingement. The relative intensity of contraction of the serratus anterior and the different divisions of the trapezius varies with arm position (13,38). The basic synergy was found by EMG to be between the lower serratus anterior and upper trapezius (Fig. 76.14) (13,38). During flexion, the need for scapular protraction as well as upward rotation made the serratus anterior the dominant muscle.

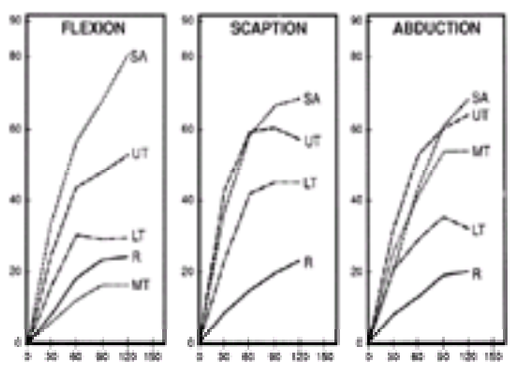


***Figure 76.14.*** Relative intensity of scapular muscle activity during arm elevation. Vertical axis: EMG as a percentage of maximum muscle test. Horizontal axis: degrees of arm elevation. *SA*, serratus anterior; *UT*, upper trapezius; *MT*, middle trapezius; *LT*, lower trapezius; *R*, rhomboid.

Upper trapezius action also was strong (38), but only minimal EMG activity was recorded in the middle head (30). Conversely, abducting the arm in the body's coronal plane includes scapular retraction. The serratus anterior was less intense, while both the upper and middle heads of the trapezius showed strong EMG (30,38). Scaption, as a neutral position between scapular abduction and adduction, displays a balanced synergy between the two rotator systems (serratus anterior and trapezius) (51). Lower trapezius activity was slightly increased in scaption but otherwise was of just moderate intensity.

Consequently, testing for paralysis of the serratus or trapezius is highly dependent on the plane of arm elevation used. Clinical experience with cases of isolated paralysis of either the serratus or the trapezius has shown that the patient may still raise the arm to approximately 90° but that full overhead reach cannot be accomplished (unpublished data).

A low level of activity by the rhomboid was found in all three planes of arm elevation (38). Inman et al. postulated participation of the levator scapulae as a component of the serratus force couple, but this finding was not supported by EMG (30). A recent study of the levator scapulae during arm elevation, however, showed a moderate level of activity, which increased as the arm moved higher (Pink M, unpublished data, 1998). The findings of incomplete scapular mobility in a recent case of levator scapulae tendon strain support the concept of this muscle's being a central stabilizer.

**ROTATION**

Sports that involve pitching and throwing and the tennis serve rely on humeral rotation as the terminal propulsive force (31,32,59). This rotation changes the coordination between the deltoid and rotator cuff from a synergy to a sequence. The mechanics of a baseball pitch provides one example: Cocking of the shoulder begins with elevation and horizontal extension, which are quickly augmented by aggressive external rotation to tense the propulsive muscles maximally. The rapid reversal of shoulder motion into accelerated internal rotation enables the propelling forces to throw the ball at high speed (Fig. 76.15).

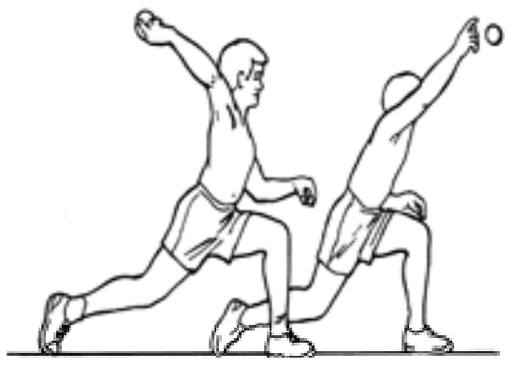

***Figure 76.15.*** The humeral rotation used in pitching. This is also representative of throwing and the tennis serve. Maximum external rotation of cocking and the internal rotation of acceleration are displayed. (Adapted from Glousman R et al. Dynamic Electromyographic Analysis of the Throwing Shoulder with Glenohumeral Instability. *J Bone Joint Surg Am* 1988;70:220, with permission.)

The EMG patterns during an average fastball pitch reflect this sequence of motions (Fig. 76.16). Early cocking relies on moderately intense deltoid (anterior, middle, and posterior) and supraspinatus activity to raise and retract the arm (15,31). Further cocking of the arm by maximal external rotation shifts the dominant muscle control to the rotator muscles (infraspinatus, teres minor, subscapularis), while the deltoids' role is reduced. Rapid reversal of dominant muscle control to the shoulder internal rotators (upper subscapularis, latissimus dorsi, teres major, and pectoralis major) first protects the anterior joint from strain at the end of cocking. Then, as the external rotators relax, these anterior muscles whip the arm forward with a strong propelling force, which throws the ball at high speed (Fig. 76.15) (15).

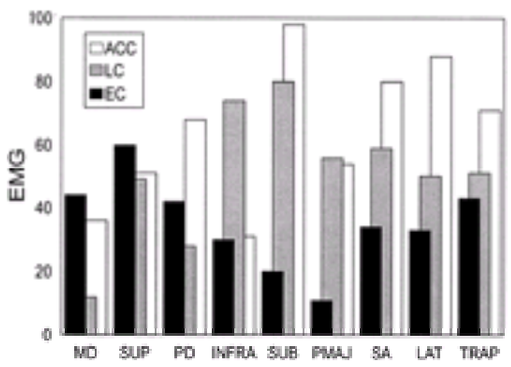


***Figure 76.16.*** EMG representation of relative intensity of muscular action during the dynamic rotational phases of pitching. Muscles: *MD*, middle deltoid; *SUP*, supraspinatus; *PD*, posterior deltoid; *INFRA*, infraspinatus; *SUB*, subscapularis; *PMAJ*, pectoralis major; *SA*, serratus anterior; *LAT*, latissimus dorsi; *TRAP*, trapezius. Phases: *EC*, early cocking; *LC*, late cocking; *ACC*, acceleration.

Vigorous action of the serratus anterior during late cocking adds upward rotation of the scapula to increase the range of arm motion (53). There also is vigorous levator scapulae activity (15). The fact that trapezius participation in early cocking and follow-through is much less than that of the serratus (24) suggests that the scapular retraction function of the trapezius is useful as a stabilizer but is not a dominant source of motion.

Thus, pitching and the other throwing sports emphasize rotation as a primary driving force, but they also rely on timely input of all the other shoulder muscles at their appropriate intensities. The threats to anterior and posterior joint stability are enhanced by the momentum imparted to the arm by the forward drive of the trunk and legs and the forearm inertia created by the flexed elbow, which creates a significant torque against the tissues of the glenohumeral joint.

**DEPRESSION**

Many circumstances call for the forceful downward push of the arm, such as hammering, swimming, and using the hand to raise the body from a sitting position or to propel a wheelchair.

During the freestyle swim stroke, the body is propelled forward by the hand pushing against the water (Fig. 76.17). The forces driving the arm are the pectoralis major, latissimus, and subscapularis (Fig. 76.18) (54,62). The simultaneous action of the teres minor counterbalances the internal rotation action of the propelling muscles. Serratus anterior synergy adds the scapula to the length of the pulling extremity. Peak effort occurs as the arm is perpendicular in the water (approximately 90° of shoulder flexion).

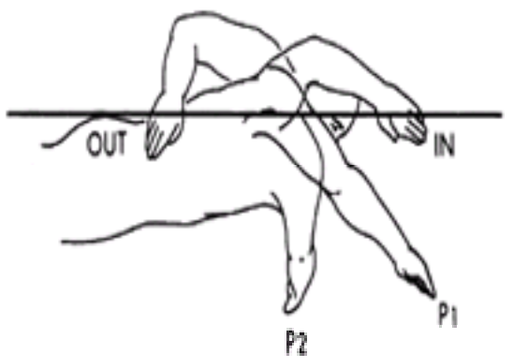


***Figure 76.17.*** The propulsion phase of a freestyle swim stroke. This begins shortly after hand entry into the water and continues until the vertical line has been passed. (Adapted from Scovazzo et al. The Painful Shoulder during Freestyle Swimming: An EMG Cinematographic Analysis of 12 Muscles. *Am J Sports Med* 1991;19:577, with permission.)

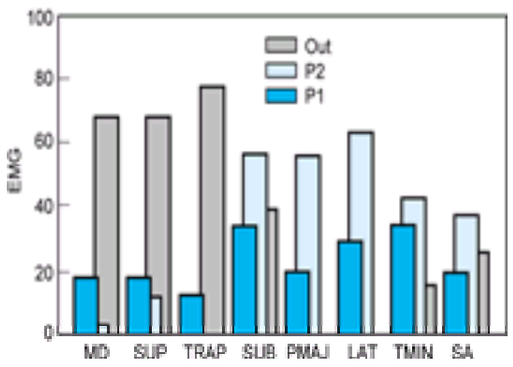


***Figure 76.18.*** EMG representation of the relative intensity of muscle action during a freestyle swim stroke. Muscles: *MD*, middle deltoid; *SUP*, supraspinatus; *TRAP*, trapezius; *SUB*, subscapularis; *PMAJ*, pectoralis major; *LAT*, latissimus dorsi; *TMIN*, teres minor; *SA*, serratus anterior. Phases: *P1*, pull, early; *P2,3*, pull, late; *OUT*,

hand exit.

After the hand enters the water, the shoulder continues to reach overhead (arm elevation mechanics) for a brief period. Arm depression then is initiated to propel the body. Soon after the arm has passed its peak propulsive alignment, the rhomboid, trapezius, and posterior deltoid muscles lift the arm from the water, and the mechanics of reach begin. Now the middle and anterior deltoids, supraspinatus, and subscapularis advance the arm in this recovery phase.

Pushing the body up from a seat with one's arms is a critical function for patients with spinal cord injury who rely on manual transfer (Fig. 76.19) (42,52). An EMG study of this maneuver found that the latissimus dorsi, lower trapezius, and sternal pectoralis major are the major lifting forces. The serratus anterior, while not significant in the vertical rise, shows strong activity when the body weight is shifted from one arm to the other in the depression transfer (52). A study of the prone push-up exercise shows the serratus anterior to be a major force when the trunk is elevated on the arms (40). Seldom does any head of the deltoid participate during the raise, but it is active in body positioning. Propelling a wheelchair relies on a downward forward force against the wheel rim. The muscles most active during the propulsion phase are the pectoralis major and the anterior deltoid (43).

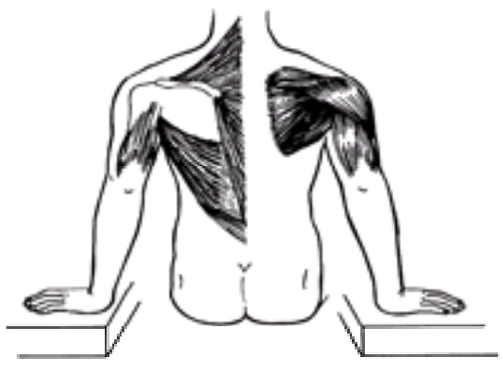

***Figure 76.19.*** Body raise; manual transfer of the body from a sitting position. *Left side:* raise muscles [latissimus dorsi, trapezius, pectoralis major (not shown), and triceps]. *Right side:* positioning muscles (deltoid, rotator cuff).

### ARM SUSPENSION

Supporting the hanging arm and carrying a heavy object use the same mechanics. The upper trapezius and levator scapulae muscles stabilize the scapula. Glenohumeral stabilization is more indirect. Experimentally, a strong downward tug on the arm fails to elicit any response by the longitudinal muscles (triceps, biceps, and anterior and middle deltoids) (2). Instead, the supraspinatus and to a lesser degree the posterior deltoid respond. The fact that both of these latter muscles have a horizontal alignment identifies compression, rather than lift, as the primary force needed to hold the humeral head into the glenoid fossa. This finding has been confirmed by studies of passive translation (36).

### HORIZONTAL RANGES

Movement of the elevated arm toward and away from the anterior midline may be called *horizontal flexion/extension* or *horizontal adduction/abduction*. The former term is preferred, as there is less chance for confusion with scapular motion. The pectoralis major, pectoralis minor, and serratus anterior bring about horizontal flexion. Often, the levator scapulae also participates (13).

Among the glenohumeral muscles, the most active during horizontal flexion are the clavicular head of the pectoralis major and the subscapularis (47). During the arm-retraction phases of pitching (late cocking) and swimming (early recovery), there is prominent action by the rhomboid, trapezius, posterior deltoid, and infraspinatus (24,47,62). A study of horizontal circumduction confirmed the posterior deltoid and added the infraspinatus as the dominant horizontal extensor muscles of the glenohumeral joint (47).

## CONCLUSIONS

Stability of the glenohumeral joint depends on central contact between the humeral head and the glenoid fossa. Mobility is enhanced by the flexibility of the glenoid labrum, limited glenohumeral ligamentous restraint, and the small contact areas of the clavicular articulations. The selective exchange among the various muscle groups must simultaneously provide dynamic stability as well as the wide versatility of motion that characterizes arm function. To meet these objectives, a continual balancing is necessary among the external glenohumeral muscles, the rotator cuff musculature, and the muscles controlling the scapula.

### CHAPTER REFERENCES

Each reference is categorized according to the following scheme: *, classic article; #, review article; !, basic research article; and +, clinical results/outcome study.


* 1. Abbott LC, Lucas DB. The Function of the Clavicle, Its Surgical Significance. *Ann Surg* 1954;140:583.

! 2. Basmajian JV, Bazant FJ. Factors Preventing Downward Dislocation of the Adducted Shoulder Joint: An Electromyographic and Morphological Study. *J Bone Joint Surg Am* 1959;41:1182.

! 3. Bearn JG. Direct Observations on the Function of the Capsule of the Sternoclavicular Joint in Clavicular Support. *J Anat* 1967;101:159.

* 4. Bechtol CO. Biomechanics of the Shoulder. *Clin Orthop* 1980;146:37.

! 5. Boone DC, Azen SP. Normal Range of Motion of Joints in Male Subjects. *J Bone Joint Surg Am* 1979;61:756.

* 6. Bost FC, Inman VT. The Pathological Changes in Recurrent Dislocation of the Shoulder. *J Bone Joint Surg Am* 1942;24:595.

! 7. Chandnani VP, Gagliardi JA, Murnane TG, et al. Glenohumeral Ligaments and Shoulder Capsular Mechanism: Evaluation with MR Arthrography. *Radiology* 1995;196:27.

! 8. Clark JM, Harryman DT II. Tendons, Ligaments and Capsule of the Rotator Cuff: Gross and Microscopic Anatomy. *J Bone Joint Surg Am* 1992;74:713.

* 9. Codman EA. *The Shoulder.* Brooklyn, NY: Medical Publishers, 1934;12.

! 10. Colachis SC, Strohm BR. Effect of Suprascapular and Axillary Nerve Blocks on Muscle Force in the Upper Extremity. *Arch Phys Med Rehabil* 1971;52:22.

! 11. Cooper DE, Arnoczky SP, O'Brien SJ, et al. Anatomy, Histology and Vascularity of the Glenoid Labrum. *J Bone Joint Surg Am* 1992;74:46.

! 12. Coumas JM, Waite RJ, Gross TP, et al. CT and MR Evaluation of the Labral Capsular Ligamentous Complex of the Shoulder. *Am J Roentgenol* 1992;158:591.

! 13. De Freitas V, Vitti M, Furlani J. Electromyographic Study of Levator Scapulae and Rhomboideus Major Muscles in Movements of the Shouder and Arm. *Electromyogr Clin Neurophysiol* 1980;20:205.

# 14. DePalma AF. *Surgery of the Shoulder*. Philadelphia: JB Lippincott, 1983.

! 15. DiGiovine NM, Jobe FW, Pink M, Perry J. An Electromyographic Analysis of the Upper Extremity in Pitching. *J Shoulder Elbow Surg* 1992;1:15.

! 16. Doody SG, Freedman L, Waterland JC. Shoulder Movements during Abduction in the Scapular Plane. *Arch Phys Med Rehabil* 1970;51:595.

! 17. Edelson JG, Taitz C, Grishkan A. The Coracohumeral Ligament: Anatomy of a Substantial but Neglected Structure. *J Bone Joint Surg Br* 1991;73:150.

! 18. Ferrari DA. Capsular Ligaments of the Shoulder: Anatomical and Functional Study of the Anterior Superior Capsule. *Am J Sports Med* 1990;18:20.

! 19. Flatow EL, Wang VM, Kelkar R, et al. The Coracoacromial Ligament Passively Restrains Anteriorsuperior Humeral Subluxation in the Rotator Cuff Deficient Shoulder. *Ortho Trans* 1996;20:633.

! 20. Freedman L, Munro R. Abduction of the Arm in the Scapular Plane: Scapular and Genohumeral Movements. *J Bone Joint Surg Am* 1966;48:1503.

! 21. Fukuda K, Craig EV, An K, et al. Biomechanical Study of the Ligamentous System of the Acromioclavicular Joint. *J Bone Joint Surg Am* 1986;68:434.

! 22. Gallino M, Battiston B, Annaratone G, Terragnoli F. Coracoacromial Ligament: A Comparative Arthroscopic and Anatomic Study. *Arthroscopy* 1995;11:564.

! 23. Gibb TD, Sidles JA, Harryman DT II, et al. The Effect of Capsular Venting on Glenohumeral Laxity. *Clin Orthop* 1991;268:120.

! 24. Glousman R, Jobe F, Tibone J, et al. Dynamic Electromyographic Analysis of the Throwing Shoulder with Glenohumeral Instability. *J Bone Joint Surg Am* 1988;70:220.

! 25. Habermeyer P, Schuller U, Wiedermann E. The Intra-articular Pressure of the Shoulder: An Experimental Study on the Role of the Glenoid Labrum in Stabilizing the Joint. *Arthroscopy* 1992;8:166.

! 26. Harryman DT II, Sidles JA, Harris SL, Matsen FA III. The Role of the Rotator Interval Capsule in Passive Motion and Stability of the Shoulder. *J Bone Joint Surg Am* 1992;74:53.

! 27. Hata Y, Nakatsuchi Y, Saitoh S. Anatomic Study of the Glenoid Labrum. *J Shoulder Elbow Surg* 1992;1:207.

! 28. Howell SM, Galinat BJ, Renzi AJ, Marone PJ. Normal and Abnormal Mechanics of the Glenohumeral Joint in the Horizontal Plane. *J Bone Joint Surg Am* 1988;70:227.

* 29. Inman VT, Saunders JBdM. Observations on the Function of the Clavicle. *Calif Med* 1946;65:158.

* 30. Inman VT, Saunders JBdM, Abbott LC. Observations on the Function of the Shoulder Joint. *J Bone Joint Surg Am* 1944;26:3.

! 31. Jobe FW, Moynes DR, Tibone JE, Perry J. An EMG Analysis of the Shoulder in Pitching. A Second Report. *Am J Sports Med* 1984;12:218.

! 32. Jobe FW, Tibone JE, Perry J, Moynes D. An EMG Analysis of the Shoulder in Throwing and Pitching. *Am J Sports Med* 1983;11:3.

! 33. Johnston TB. The Movements of the Shoulder Joint. A Plea of the Use of the 'Plane of the Scapula' as the Plane of Reference for the Movements Occurring at the Humero-scapular Joint. *Br J Surg* 1937;25:252.

! 34. Karduna AR, Williams GR, Williame JL, Lannotti JP. Kinematics of the Glenohumeral Joint: Influences of Muscle Forces, Ligamentous Constraints, and Articular Geometry. *J Orthop Res* 1996;14:986.

! 35. Kumar VP, Balasubramaniam P. The Role of Atmospheric Pressure in Stabilising the Shoulder: An Experimental Study. *J Bone Joint Surg Br* 1985;67:719.

! 36. Lippitt S, Matsen F. Mechanisms of Glenohumeral Joint Stability. *Clin Orthop* 1993;291:20.

! 37. McFarland EG, Jobe FW, Perry J, et al. Electromyographic Analysis of Recurrent Posterior Instability of the Shoulder. In: Post M, Morrey BF, Hawkins RJ, eds. *Surgery of the Shoulder*. St. Louis: Mosby Year Book, 1990:112.

! 38. McMahon PJ, Jobe FW, Pink MM, et al. Comparative Electromyographic Analysis of Shoulder Muscles during Planar Motions: Anterior Glenohumeral Instability versus Normal. *J Shoulder Elbow Surg* 1996;5:118.

! 39. Moseley HF, Overgaard B. The Anterior Capsular Mechanism in Recurrent Anterior Dislocation of the Shoulder. *J Bone Joint Surg Br* 1962;44:913.

! 40. Moseley JB, Jobe FW, Pink M, et al. EMG Analysis of the Scapular Rotator Muscles during a Shoulder Rehabilitation Program. *Am J Sports Med* 1992;20:128.

! 41. Moynes DR, Perry J, Nelson RW, Capen DA. Electromyography and Motion Analysis of the Upper Extremity in Sports. *Phys Ther* 1986;66:1905.

! 42. Mulroy S, Newsam C, Gronley JK, Perry J. Stroke Characteristics and Upper Extremity Motion of Spinal Cord Injured Patients during Wheelchair Propulsion. *Arch Phys Med Rehabil* 1992;73:954 (abst.)

! 43. Mulroy SJ, Gronley JK, Newsam CJ, Perry J. Electromyographic Activity of Shoulder Muscles during Wheelchair Propulsion by Paraplegic Persons. *Arch Phys Med Rehabil* 1996;77:187.

! 44. Neuman CH, Petersen SA, Jahnke AH. MR Imaging of the Labral-Capsular Complex: Normal Variations. *Radiology* 1991;157:1015.

! 45. O'Brien SJ, Neves MC, Arnoczky SP, et al. The Anatomy and Histology of the Inferior Glenohumeral Ligament Complex of the Shoulder. *Am J Sports Med* 1990;18:449.

! 46. O'Connell PW, Nuber GW, Mileski RA, Lautenschlager E. The Contribution of the Glenohumeral Ligaments to Anterior Stability of the Shoulder Joint. *Am J Sports Med* 1990;18:579.

! 47. Pearl ML, Perry J, Torburn L, Gordon LH. An Electromyographic Analysis of the Shoulder during Cones and Planes of Arm Motion. *Clin Orthop* 1992;284:116.

# 48. Perry J. Anatomy and Biomechanics of the Shoulder in Throwing, Swimming, Gymnastics, and Tennis. *Clin Sports Med* 1983;2:247.

# 49. Perry J. Muscle Control of the Shoulder. In: Rowe CR, ed. *The Shoulder*. New York: Churchill Livingstone, 1988;17.

! 50. Perry J, Barnes G, Merson J. Normal Electromyographic and Torque Values during Isokinetic Strength Testing of the Shoulder. *Orthop Trans* 1989;13:230.

! 51. Perry J, Barnes G, Merson J. Normal Electromyographic Values of Six Shoulder Muscles during Free Motion. *Orthop Trans* 1989;13(2):322.

! 52. Perry J, Gronley JK, Newsam CJ, et al. Electromyographic Analysis of the Shoulder Muscles during Depression Transfers in Subjects with Low-Level Paraplegia. *Arch Phys Med Rehabil* 1996;77:350.

+ 53. Perry J, Hoffer MM, Antonelli D, et al. Electromyography Before and After Surgery for Hip Deformity in Children with Cerebral Palsy. A Comparison of Clinical and Electromyographic Findings. *J Bone Joint Surg Am* 1976;58:201.

! 54. Pink M, Perry J, Browne A, et al. The Normal Shoulder during Freestyle Swimming: An Electromyographic and Cinematographic Analysis of Twelve Muscles. *Am J Sports Med* 1991;19:569.

! 55. Poppen N, Walker P. Normal and Abnormal Motion of the Shoulder. *J Bone Joint Surg Am* 1976;58:195.

! 56. Poppen NK, Walker PS. Forces at the Glenohumeral Joint in Abduction. *Clin Orthop* 1978;135:165.

! 57. Rodosky MW, Harner CD, Fu FH. The Role of the Long Head of the Biceps Muscle and Superior Glenoid Labrum in Anterior Stability of the Shoulder. *Am J Sports Med* 1994;22:121.

# 58. Rowe CR. Acromioclavicular and Sternoclavicular Joints. In: Rowe CR, ed. *The Shoulder.* New York: Churchill-Livingstone, 1988;293.

! 59. Ryu RKN, McCormick J, Jobe FW, et al. An Electromyographic Analysis of Shoulder Function in Tennis Players. *Am J Sports Med* 1988;16:481.

# 60. Saha AK. Mechanics of Elevation of Glenohumeral Joint. Its Application in Rehabilitation of Flail Shoulder in Upper Brachial Plexus Injuries and Poliomyelitis and in Replacemant of the Upper Humerus by Prosthesis. *Acta Orthop Scand* 1973;44:668.

# 61. Sarrafian SK. Gross and Functional Anatomy of the Shoulder. *Clin Orthop* 1983;173:11.

! 62. Scovazzo L, Browne A, Pink M, et al. The Painful Shoulder during Freestyle Swimming: An Electromyographic and Cinematographic Analysis of Twelve Muscles. *Am J Sports Med* 1991;19:577.

! 63. Sharkey NA, Marder RA. The Rotator Cuff Opposes Superior Translation of the Humeral Head. *Am J Sports Med* 1995;23:270.

! 64. Soslowsky LJ, Flatow EL, Bigliani LU, Mow VC. Articular Geometry of the Glenohumeral Joint. *Clin Orthop* 1992;285:181.

! 65. Staples OS, Watkins AL. Full Active Abduction in Traumatic Paralysis of the Deltoid. *J Bone Joint Surg* 1943;25:85.

! 66. Turkel SJ. Stabilizing Mechanisms Preventing Anterior Dislocation of the Glenohumeral Joint. *J Bone Joint Surg Am* 1981;63:1208.

! 67. VanLinge B, Mulder JD. Function of the Supraspinatus Muscle and Its Relationship to the Supraspinatus Syndrome. *J Bone Joint Surg Br* 1963;45:750.

! 68. Warner JJP, McMahon PJ. The Role of the Long Head of the Biceps Brachii in Superior Stability of the Glenohumeral Joint. *J Bone Joint Surg Am* 1995;77:366.

# 69. Williams PL, Warwick R, Dyson M, Bannister LH. *Gray's Anatomy*. New York: Churchill Livingstone, 1989.

! 70. Wuelker N, Plitz W, Roetman B, Wirth CJ. Function of the Supraspinatus Muscle: Abduction of the Humerus Studied in Cadavers. *Acta Orthop Scand* 1995;65:442.

# CHAPTER 77

# SHOULDER ARTHROSCOPY

*John P. Meehan*

**J. P. Meehan:** Department of Orthopaedic Surgery, University of California, Davis, Medical Center, Sacramento, California, 95817.

History
Equipment
Surgical Techniques
Position
Portals
Diagnostic Arthroscopy
Acromioclavicular Joint
Subacromial Decompression
Author's Perspective
Chapter References

## HISTORY

Shoulder arthroscopy as a diagnostic and therapeutic modality continues to evolve as our understanding of the anatomy and pathophysiology of the disease processes, as well as new technologies, allow us to treat a broader variety of shoulder ailments. Although there are reports in the literature regarding the use of the arthroscope in the 1930s and 1940s, it was Watanabe's work in the 1950s in developing more practical arthroscopic instrumentation that ultimately led to the development of routine knee arthroscopy in the 1970s (4). The routine use of the arthroscope in the shoulder lagged behind its use in the knee, but by the early 1980s its benefits as a less invasive surgery for the shoulder were clearly established. It was during the late 1970s and early 1980s that shoulder arthroscopy expanded its applications from that of diagnosis to that of treatment (2). Many procedures such as subacromial decompression, distal clavicle excision, and instability and rotator cuff repairs, which previously required open surgical incisions, could now be treated effectively with the use of shoulder arthroscopy.

## EQUIPMENT

The operating room should be equipped with a standard operating room table that allows adjustments for height; flexion/extension of the head, torso, and legs; and tilt in the long and short planes of the table. Typically, the video monitor, recorder, and printer are stored in a cabinet that allows easy viewing by all operating room personnel.

Shoulder arthroscopy is aided by continuous distention with a fluid medium. Normal saline is the fluid most commonly used, as it has demonstrated no harmful effects on articular cartilage or from systemic absorption. Both static (i.e., gravity-assisted) and arthroscopic pump systems are available and can be used according to the surgeon's preference (3).

The effectiveness of shoulder arthroscopy is augmented by the large variety of mechanical instrumentation available today. Mechanical shavers, burrs, and resectors can all assist the surgeon in treating the intraarticular as well as extraarticular conditions. The ability to use electrocoagulation and cautery in a fluid medium was an important advance for shoulder arthroscopy. While capillary oozing is readily controlled by the hemostatic pressure within the glenohumeral joint from either a pump or gravity system, the surgical electrode is extremely valuable for procedures within the subacromial space, where excessive bleeding from the coracoacromial artery is sometimes encountered.

A plethora of hand instruments, similar to the hand instruments in knee arthroscopy, have also been developed for the shoulder. Basket forceps, grasping forceps, curets, and probes are but a few of those available.

## SURGICAL TECHNIQUES

### POSITION

The two common positions for shoulder arthroscopy are the lateral decubitus position and the beach-chair position. Each position has advantages and disadvantages, and most surgeons choose the one they are most comfortable with, which is frequently the one they trained with. Proponents of the lateral position feel the continuous traction allows easier glenohumeral and subacromial arthroscopy. Proponents of the beach-chair position argue that it is more convenient for regional anesthesia and when converting to open procedures. I prefer the lateral decubitus position for most shoulder cases but occasionally utilize a beach-chair position if the possibility of an open capsular repair exists. The alternative is to reprep and redrape after the arthroscopy is performed in the lateral position.

- For the lateral decubitus position, place the patient on a standard operating table that is equipped with a bean bag. Kidney rests, adhesive tape, and thorax-positioning devices can be utilized to further stabilize patients after they are turned onto their side and after placing a padded roll to protect the neurovascular structures of the axilla.
- Flex the down-side leg at the hip and the knee, and tape over the pelvis, securing it to the operating room table to further stabilize the patient. Place a pillow between the legs. Protect the peroneal nerve and malleoli of the down-side leg. Flex the dependent arm forward.
- Flex the elbow, supporting it on a padded arm board. Support the cervical spine to prevent hyperextension that might cause a cervicobrachial radiculopathy. Tilt the torso 30° posteriorly to bring the glenohumeral joint horizontal with the floor.
- Place a plastic adhesive U-drape proximally, from a line just medial to the vertebral border of the scapula posteriorly, over the medial third of the clavicle superiorly and medial to the coracoid process anteriorly. Then place another smaller plastic adhesive drape across the ends of the U-drape at the mid-thorax level.
- Traction may be applied to the arm with various commercial devices. Secure the traction apparatus to the operating table in a position that allows abduction and forward flexion. Then various forms of skin traction can be applied to the forearm and hand. I prefer to wrap the hand and forearm with cotton cast padding (Webril), followed by reusable adhesive strips on the volar and dorsal forearm, with a loop around the hand to allow subsequent placement of a Z-hook and an S-hook, which can be attached to the traction apparatus.
- Secure the adhesive strips with elastic adhesive wrap (Coban) around the forearm. Place the remaining roll of Webril in the patient's palm to support the fingers. Do not exceed 10–15 lbs longitudinal traction, and adjust the traction weight downward depending on the individual patient. I most commonly use 7½ lbs.

The position of the arm varies slightly from surgeon to surgeon when the patient is in the lateral decubitus position, but it generally ranges from 20° to 70° of abduction and from 10° to 20° of forward flexion. In addition, a stack of towels or an assistant's hand can help provide a perpendicular translation force when placed between the chest wall and the proximal humerus.

While many surgeons feel the lateral position allows for easier diagnostic and arthroscopic procedures, many feel it is more difficult when converting to open procedures, especially open anterior capsular shifts and large rotator cuff tears. These surgeons employ a beach-chair position if conversion to an open procedure is anticipated. I have found that a capsular shift procedure can be performed without a reprep and redrape if the bean bag is deflated, the patient is allowed to fall back to a semisupine position, and the arm is rewrapped with a sterile cover. Only rarely is a complete reprep and redrape required. In addition, most open rotator cuff repairs can be performed simply by releasing traction, covering the hand and forearm with a sterile wrap, and either keeping the patient in the lateral position or deflating the bean bag and allowing her to fall back to a semisupine position.

## PORTALS

A variety of portals have been described for accessing the glenohumeral joint, the subacromial space, and the acromioclavicular (AC) joint.

### *Glenohumeral Joint*

For the glenohumeral joint, two portals are commonly used: a posterior portal and an anterior portal. Multiple variations of the anterior portal have been described.

- Before making skin incisions, be sure to outline the anatomic landmarks. Begin with the posterior angle of the acromion, which is subcutaneous and can be easily palpated in most patients. From this point, draw a line along the posterior acromion extending medially for a short distance, and anteriorly for a short distance along the lateral edge of the acromion. The angle formed is usually slightly obtuse rather than 90°.
- Identify the supraclavicular fossa by placing a thumb in the quadrangular space formed by the clavicle anteriorly, and the acromion laterally and posterolaterally.
- Outline the posterior edge of the clavicle and the medial margin of the acromion. Next, outline the anterior border of the clavicle, and the lateral border of the acromion, connecting with the previously drawn line.
- Place a circle over the coracoid process anteriorly, and draw in the coracoacromial ligament.
- Finally, estimate the position of the AC joint, which can be difficult in patients with arthritic changes (Fig. 77.1).



***Figure 77.1.*** Setup for glenohumeral portal.

- The entry portal is posterior, which provides adequate visualization of the glenohumeral joint and also allows placement of the other portals under direct arthroscopic visualization. Place the posterior portal in what has been described as the soft spot, or the posterior glenohumeral joint line, which typically is 2 cm inferior and 1 cm medial to the posterolateral corner of the acromion. Locate the soft spot by grabbing the humeral head with your hand, using the thumb to palpate the posterior glenohumeral joint line and the long finger to palpate the anterior glenohumeral joint line. Typically, one can translate the humeral head back and forth to confirm the position of the joint line.
- Make a 3–5 mm incision along Langer's lines through skin and subcutaneous tissues, being careful not to penetrate the deltoid muscle. With a blunt trocar in the arthroscopic cannula, advance in the direction of the coracoid through the deltoid muscle, through the infraspinatous and teres minor interval, to the posterior joint line. The blunt tip of the trocar can be used to palpate the curve of the humeral head and the stepoff of the posterior glenoid, and the interval of the joint line in between.
- The joint capsule will be soft with some elasticity, as opposed to the hard surfaces of the humeral head and the glenoid. With the nondominant hand around the cannula at skin level, use your dominant hand to advance the trocar through the capsule, which will be accompanied by a slight pop. Use the nondominant hand to prevent overpenetration, and also for more precise control of the trocar as it enters the joint. Some surgeons prefer to use a spinal needle first to access the joint. They can then confirm intraarticular placement of the needle by injecting 30–40 ml of saline through a syringe, and noting the resistance to injection and backflow from the needle after removal of the syringe. In the intact joint, the resistance slowly increases as fluid is injected, and the syringe can be removed after 15–20 ml have been inserted.
- After entering the joint, perform a diagnostic arthroscopy. Some surgeons create an anterior portal at this point to create an outflow and to allow the insertion of instrumentation to assist with the diagnostic portion of the procedure.

As the ability to perform more procedures with the arthroscope increased, so did the number of anterior portals described by various authors. The most frequently used anterior portal allows anterior instrumentation and visualization of the posterior portion of the joint. There are multiple techniques for creating this anterior portal. Most are performed under direct arthroscopic visualization with either an outside-in or an inside-out technique. While viewing with the arthroscope from the posterior portal, the interval in which the anterior portal will be established is a triangle formed by the long head of the biceps, the superior border of the subscapularis tendon, and the glenoid (3).

An outside-in technique frequently used is to make a skin incision directly in line with the arthroscope, which, if it is looking at the interval above, will be just lateral and slightly superior to the tip of the coracoid process. Some surgeons use a spinal needle to enter the joint prior to making the skin incision. An incision should never be made inferior or medial to the tip of the coracoid as this could potentially injure the neurovascular structures in the axillary sheath (4).

- Make a 3–5 mm skin incision. While looking at the shoulder from the outside, insert a 5.5 mm plastic cannula with a blunt trocar through the incision, through the anterior deltoid to the level of the joint. In most cases, the plastic cannula will be 180° opposite the arthroscopic cannula.
- At this point, shift your view to the video camera screen, which is still looking at the triangle formed by the superior border of the subscapularis tendon, the long head of the biceps tendon, and the glenoid.
- Advance the plastic cannula slightly to see an indentation of the anterior capsule in or near the superior aspect of the triangle above and make minute adjustments in the position or angle of the plastic cannula before advancing it under direct visualization into the joint. Alternatively, use an inside-out technique with the arthroscope and a Wissinger rod.
- Advance the arthroscope into the superior aspect of the previously mentioned triangle, and maintain the cannula in this position.
- Remove the scope from the cannula and place a Wissinger rod through the cannula, the joint, and the anterior deltoid; tent the skin. Now make the skin incision, and further advance the rod. Place the plastic cannula over the Wissinger rod and retrograde it into the joint. Remove the Wissinger rod and reintroduce the arthroscope to the posterior portal.

A third portal described for the glenohumeral joint is the superior portal. This portal is used must less frequently than the anterior and posterior portals. It is created in the supraclavicular fossa, bounded by the distal clavicle and the AC joint anteriorly, the acromion laterally, and the base of the spine of the scapula posteriorly (4). This portal can be used for inflow, as well as to view the posterior glenoid labrum, the posterior portion of the humeral head, and, with a limited view, the rotator cuff. It is a relatively safe portal; the only structure at risk is the suprascapular nerve, which is about 3 cm inferior to the intended course of the instrumentation.

- Palpate the skin approximately 1 cm medial to the acromion in the soft spot of the supraclavicular fossa. Then introduce a spinal needle at an angle of 40°, aiming slightly lateral and posterior, with the intention of entering the joint posterior to the attachment of the long head of the biceps and above the posterior superior glenoid rim.
- Make a small skin incision and pass a blunt trocar through the trapezius, the muscular portion of the supraspinatus, and the superior joint capsule into the glenohumeral joint.
- With the posterior portal, the nerves at risk for injury are the suprascapular nerve medially and the axillary nerve inferiorly. The suprascapular nerve lies approximately 2 cm medial to the posterolateral glenoid, travelling in the spinoglenoid notch. The axillary nerve travels through the quadrangular space at the inferior border of the teres minor, which is approximately 2–4 cm inferior to the portal placement as described.
- With the classic anterior portal, as long as you stay lateral to the coracoid process, the chances of a severe neurovascular injury are minimized. The cephalic vein is located anterior and lateral to the anterolateral acromion and is rarely injured with these techniques.

### *Subacromial Space*

The lateral and subacromial portals allow examination of the superior surface of the rotator cuff, the undersurface of the acromion (particularly the anterior inferior surface), and the coracoacromial ligament, and they allow access to the AC joint.

Multiple portals have been described for approaching the subacromial space from the lateral aspect of the shoulder. They can range anywhere from the anterior edge to the posterior edge, but they all must be at least 2 cm lateral to the lateral edge of the acromion to allow access to its entire undersurface. They should not be more than 3 cm from the lateral edge of the acromion, as the risk of injuring the axillary nerve increases. Anterolateral, mid-lateral, and posterolateral portals can be used,

depending on whether you need access to the AC joint (anterolateral) for distal clavicle excisions and subacromial decompressions, or the superior surface of the rotator cuff (mid-lateral) for rotator cuff repairs, or even accessory portals (posterolateral) if additional outflow is needed.

- To introduce a blunt trocar and scope cannula into the subacromial space, use the skin incision and the deltoid perforation from the primary posterior portal as described for the glenohumeral arthroscopy. Aim the scope cannula and blunt trocar slightly superior and toward the central aspect of the undersurface of the acromion.
- Use the blunt trocar to palpate the undersurface of the acromion, and distend the space with fluid through the cannula. Alternatively, using a syringe, inject 30 cc from a lateral approach prior to advancing the scope cannula. Fluid egress when the blunt trocar is removed provides confirmation.
- Under direct visualization, establish a lateral portal with a 5.5 mm plastic cannula through which instrumentation can be passed.
- Not uncommonly, the subacromial space is severely scarred and inflamed so that visualization is obscured. When this occurs, place a shaver or synovial resector through the lateral portal, with its teeth facing upward against bone, and begin shaving with an anterior to posterior sweeping motion until landmarks come into view. Similarly, the hypertrophied bursal tissue can be removed from the superior surface of the rotator cuff with gentle sweeping motions in an anterior to posterior direction.
- Considerable bleeding can be encountered, especially from the inflamed bursal tissues, so be prepared with electrocautery to assist with hemostasis. Once the bursal space is cleared, you should be able to visualize the superior surface of the rotator cuff from the AC joint to a point distal and lateral to the greater tuberosity.

The undersurface of the acromion is usually covered with a thick periosteal layer, and the anterior third is covered by the fibers of the coracoclavicular ligament, which attach under the anterior edge of the acromion, thereby forming the anterior roof of the acromial arch (6). The ligament is 2–3 cm wide at its acromial insertion.

## DIAGNOSTIC ARTHROSCOPY

### *Glenohumeral Joint*

- Begin the diagnostic arthroscopy with the patient in a lateral decubitus position, after entering the glenohumeral joint through the posterior portal and establishing an anterior portal for outflow and instrumentation. A nerve hook can be placed through the anterior cannula to assist with the procedure. Institute a systematic approach for reviewing the intraarticular anatomy of the shoulder, to avoid missing any abnormalities. Keep the orientation of the glenoid surface, as viewed on the video monitor, parallel to the floor, with the humeral head superior, the glenoid inferior, and the biceps tendon perpendicular and between the two (6). The initial view will allow inspection of the biceps tendon from the passage through the rotator cuff interval to its attachment to the superior labrum at the supraglenoid tubercle.
- Inspect the humeral head for articular surface defects, such as that seen with a Hill-Sachs lesion on the posterior superior humeral head. Do not confuse the Hill-Sachs lesion with the normal intracapsular portion of the humeral neck that is devoid of cartilage, the so-called anatomic bare patch. Also inspect the articular surface of the glenoid, remembering that a pitted area, less than 10 mm and with smooth chondral margins, is a normal finding in many older individuals (5). At this point, you may continue the arthroscopy in a posterior to anterior direction, or, as I prefer, in an anterior to posterior direction.
- Inspect the superior and anterior glenoid labrum. There is considerable anatomic variation in both the size and the attachments to the labrum. Inspect the insertion of the biceps tendon into the glenoid labrum for fraying or detachments, especially superior labral tears from anterior to posterior (SLAP lesions) (6) (Fig. 77.2; see also Color Fig. 77.2).

***Figure 77.2.*** (See Color Fig. 77.2.) Superior labral tear from anterior to posterior (SLAP lesion).

- Next, inspect the anterior glenoid labrum for fraying, and probe for possible detachments from the anterior glenoid neck, which, when associated with a history of dislocation, is called a Bankart lesion. When viewing the anterior superior labrum, make a mental note of a normal anatomic variant, in which the middle glenohumeral ligament forms a cordlike structure that is contiguous with the anterosuperior labrum, forming a foramen of variable size between the ligament and the labrum (6).
- Inspect the anterior glenohumeral ligaments, which are thickened portions of the anterior capsule and can be quite variable. The superior glenohumeral ligament is the most difficult to visualize arthroscopically. It appears as a confluence of the capsule at the inferior edge of the rotator interval, and it is frequently obscured by the biceps tendon.

The middle glenohumeral ligament can vary in width, but it typically passes the superior border of the subscapularis in an obliquely vertical manner (at approximately 45°) to insert on the superior glenoid. It can vary from being very discrete to absent, with a range of variations between (3). The inferior glenohumeral ligament is the most constant and clinically significant of the glenohumeral ligaments. It has been described as a suspensory sling that stabilizes the joint. It originates along the anterior and inferior labrum and attaches along the anteroinferior portion of the humeral neck. Its origin has been called a labrocapsular complex, which describes the confluence of the inferior glenohumeral ligament, the anterior inferior glenoid labrum, and the periosteum of the anteroinferior glenoid. The axillary recess, or inferior recess, is a loose outpouching of the capsule and synovium inferior to the humeral head. It is a lax portion of the inferior glenohumeral ligament between the antero- and posterosuperior bands.

- Visualize the posterior labrum by turning the lens of the camera and following the posterior glenoid from inferior to superior. If the shoulder is tight or if you have difficulty visualizing the posterior glenoid labrum in this manner, insert the arthroscope into the anterior portal.

The final structure to be inspected is the intraarticular or undersurface of the rotator cuff. The rotator cuff is made up of the tendons of the subscapularis, the supraspinatus, the infraspinatus, and the teres minor. The tendon of the subscapularis, located anteriorly, has already been inspected. The tendon of the supraspinatus is located adjacent and slightly posterior to the long head of the biceps.

- Inspect the insertion of the supraspinatus by following the long head of the biceps laterally. The insertions of the infraspinatus and teres minor are located posterior and inferior to the insertion of the supraspinatus. Abnormalities of the rotator cuff can range from fraying, or partial-thickness tears seen only on the undersurface (glenohumeral side), to full-thickness tears seen both on the undersurface and on the superior surface when viewed from the subacromial space.

### *Subacromial Space*

- Upon completion of the glenohumeral arthroscopy, withdraw the arthroscope after allowing the outflow to drain the shoulder joint. Insert a blunt trocar into the cannula and, using the same posterior portal skin incision, insert the arthroscope into the subacromial space as previously described, again aiming superior and for the midportion of the acromion. It is sometimes useful to use a sweeping motion of the cannula on the undersurface of the acromion to break up any adhesions that might be there.
- Remove the blunt trocar and insert the arthroscope with inflow attached. Orient the camera with the acromion at the top and the rotator cuff at the bottom of the screen. In some patients, there will be a distinct subacromial space and viewing will be easy. A normal subacromial space will have a thin, smooth bursal layer on the superior surface of the rotator cuff (1). The undersurface of the acromion will have a thin periosteal layer (Fig. 77.3)

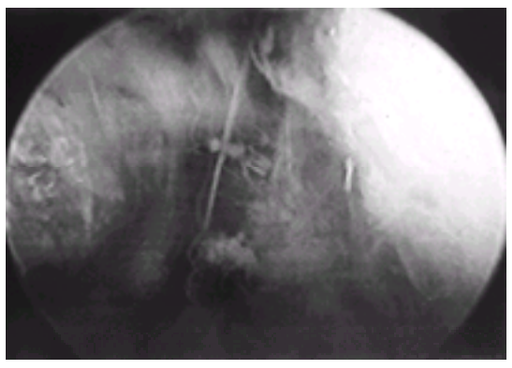

***Figure 77.3.*** Subacromial space with bursal layer.

- In patients with chronic impingement syndrome, the subacromial space can be difficult to visualize and may have a cobweb appearance from adhesions. In this situation, establish an anterolateral portal using the 5.5 mm plastic cannula with the orange-colored trocar, aiming perpendicular to the arthroscopic cannula and slightly in front of it. When the orange trocar comes into view, insert a shaver under direct visualization. With the blades positioned toward the undersurface of the acromion, remove the scarred tissues in a controlled and safe manner.
- Identify the anterior inferior surface of the acromion, the coracoacromial ligament, the AC joint medially, the superior surface of the rotator cuff as far lateral as possible, and especially the supraspinatus tendon near its musculotendinous junction. Frequently, a probe can be used from the anterolateral portal to help identify delaminations in the tendon or longitudinal tears that are not immediately obvious.
- Close the portals with simple nonabsorbable sutures or subcuticular sutures, depending on your preference.
- After diagnostic procedures, encourage the patient to begin range-of-motion exercises of the shoulder, elbow, wrist, and hand on the first postoperative day; the patient should also discard the sling when comfortable, typically within a week or by the first postoperative visit. Slowly reintroduce functional and recreational activities once motion and strength are regained.

## ACROMIOCLAVICULAR JOINT

- The AC joint is most commonly approached from the same portals as used for subacromial procedures, although separate transcutaneous portals specifically for the AC joint have been described. Place lumbar puncture needles either in the AC joint itself, or use to outline the anterior and posterior border of the joint (Fig. 77.4; see also Color Fig. 77.4). To aid in visualization of the distal clavicle, remove fibrosis or hypertrophied bursal tissue in the subacromial space.

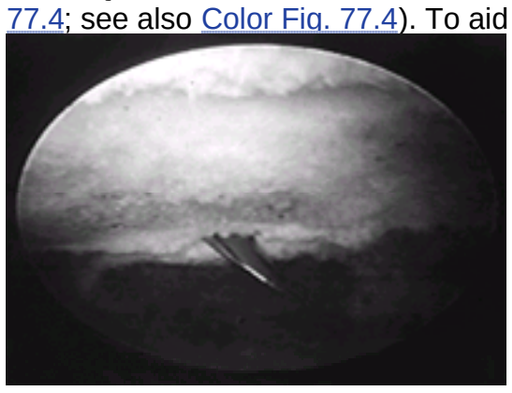

***Figure 77.4.*** (See Color Fig. 77.4.) Localizing the acromiocla-vicular joint.

- Because most arthroscopic AC joint procedures are performed in conjunction with a subacromial decompression, next remove the periosteal tissue on the undersurface of the acromion, the coracoclavicular ligament, and bone from the anteromedial border of the acromion to the posteromedial border. Once this bone is removed, the distal clavicle can be easily visualized.
- Approach the resection of the distal clavicle from the lateral approach or from the anterior approach. I perform the procedure from the lateral approach, with the arthroscope in the posterior portal and the instrumentation in the lateral portal. With an assistant pushing down on the superior surface of the distal clavicle, push the tip of the arthroscopic burr directly into the middle of the face of the distal clavicle to a depth of approximately 5–6 mm, depending on the patient. Using circular movements, enlarge the hole until the entire distal clavicle bone has been removed. The superior AC joint capsule and ligaments should remain intact. The goal is to create a space that is approximately 1 cm in width between the medial edge of the acromion and the cut surface of the distal clavicle (3). Alternatively, place the burr through the anterior portal and remove bone in an anterior to posterior direction.

## SUBACROMIAL DECOMPRESSION

As surgeons have become experienced with shoulder arthroscopy, they have realized the benefits of avoidance of deltoid detachment as well as early return of function associated with arthroscopic acromioplasty. Typically, this procedure is performed after a thorough glenohumeral joint and subacromial space arthroscopy, and after the diagnosis of impingement syndrome has been confirmed.

- Use the same portals as for the subacromial space arthroscopy, specifically the posterior and the anterolateral or mid lateral. I prefer to view the procedure with the arthroscope in the posterior portal and instrumentation inserted through the anterolateral or mid lateral portal.
- Insert a blunt instrument through the lateral portal and confirm the bone outlines of the anterior, anterolateral, and lateral acromion. Then insert an electrocautery device and incise the thickened periosteal tissues on the undersurface of the anterior acromion, as well as the hypertrophied coracoacromial ligament.
- When incising the coracoacromial ligament, a vessel is frequently encountered that can cause bleeding, which makes visualization difficult. At this point, advance the arthroscope with the inflow attached as close to the vessel as possible, providing a tamponade effect, and coagulate it with the electrocautery.
- Insert an arthroscopic shaver, typically a full-radius resector, through the lateral portal and remove the previously incised soft tissue. Expose the entire bone undersurface of the anterior acromion. Follow with a 5.0 mm arthroscopic oval burr. The goal is to remove enough bone to prevent further impingement, although surgeons differ as to what the actual amount is. I strive to remove at least a burr's width (5.0 mm) of bone from the projected undersurface, noting that frequently an anterior hook to the acromion requires additional bone removal. I begin by going from lateral to medial on the acromion, thereby allowing easier access to the medial structures. Sweep the burr from anterior to posterior, removing progressively less bone posteriorly. Typically, the distance of bone removal from anterior to posterior is around 2.0 cm. Medially, you should see the clavicular facet of the acromion.

## AUTHOR'S PERSPECTIVE

Detailed explanations and techniques for treating a variety of other common shoulder disorders are covered in chapter 78, chapter 79, and chapter 80. As the experience of surgeons and the development of instruments have improved, so has the ability to use the arthroscope to treat these conditions. Shoulder instability, glenoid labrum injuries, and many rotator cuff tears can now be approached with an arthroscope and/or limited incision techniques. Laser and radiofrequency devices are being applied with encouraging short to midterm results.

Additional applications include removal of loose bodies, synovectomy, biopsy, irrigation and debridement for infection, and treatment of refractory adhesive capsulitis.

## CHAPTER REFERENCES

Each reference is categorized according to the following scheme: *, classic article; #, review article; !, basic research article; and +, clinical results/outcome study.


# 1. Andrews JR, Schemmel SP. Arthroscopic Acromioplasty. *Surg Rounds Orthop* November 1989.

# 2. Craig EV. *The Shoulder: Master Techniques in Orthopaedic Surgery.* New York: Raven Press, 1995.

# 3. Ellman H, Gartsman GM. *Arthroscopic Shoulder Surgery and Related Procedures.* Philadelphia: Lea and Febiger, 1993.

# 4. Meister K. Diagnostic Arthroscopy of the Shoulder. In: Andrews J, Timmerman L, eds. *Diagnostic and Operative Arthroscopy*. Philadelphia: WB Saunders, 1997.

# 5. Morrison DS. Arthroscopic Surgery of the Shoulder. In: Chapman MW. *Operative Orthopaedics, 2nd ed.* Philadelphia: JB Lippincott, 1993:2361.

# 6. Snyder SJ. A Complete System for Arthroscopy and Bursoscopy of the Shoulder. *Surg Rounds Orthop* July 1989.

# CHAPTER 78

# CHRONIC AND ACUTE INJURIES OF THE ACROMIO-CLAVICULAR AND STERNO-CLAVICULAR JOINTS

*Michael A. Wirth and Charles A. Rockwood, Jr.*

**M. A. Wirth and C. A. Rockwood, Jr.:** Department of Orthopaedics, University of Texas Health Science Center, San Antonio, Texas 78284.

The Acromioclavicular Joint
- Mechanisms of Injury
- Classification of AC Injuries
- Clinical Assessment
- Radiographic Findings
- Treatment
- Prognosis

Pitfalls and Complications
- Complications of Acute Injuries
- Complications of Operative Treatment
- Chronic Conditions of the AC Joint
- Osteolysis of the Distal Clavicle

The Sternoclavicular Joint
- Anatomy
- Ligaments of the SC Joint
- Classification
- Other Conditions Affecting the SC Joint
- Mechanisms of Injury
- Clinical Assessment
- Radiographic Findings
- Treatment

Chapter References

## THE ACROMIOCLAVICULAR JOINT

The acromioclavicular (AC) joint is a diarthrodial joint located between the lateral end of the clavicle and the medial margin of the acromion process of the scapula (Fig. 78.1). DePalma (56) showed marked variability in the plane of the joint. Viewed from the front, the inclination of the joint may be almost vertical, or it may be inclined from downward medially, with the clavicle overriding the acromion by an angle as large as 50° (Fig. 78.2) (23,181).

***Figure 78.1.*** Anteroposterior view of the normal shoulder. Note the AC joint, the coracoid process, and the CC interspace.

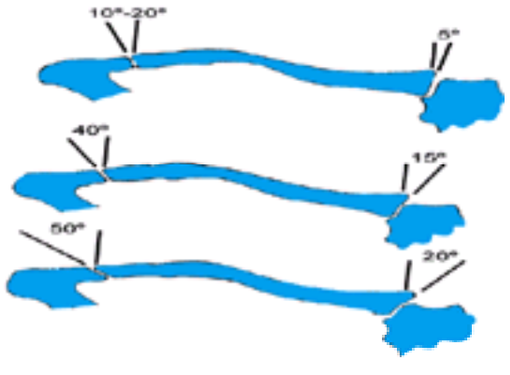


***Figure 78.2.*** Variations of the inclination of the AC and the SC joints. (Redrawn from DePalma AF. *Surgery of the Shoulder.* Philadelphia: JB Lippincott.)

The AC joint is stabilized by capsular (AC) and extracapsular [coracoclavicular (CC)] ligaments. The importance of the muscles that cross the joint (deltoid and trapezius) in providing the dynamic stability of the AC articulation cannot be overemphasized. A portion of the anterior deltoid provides dynamic suspensory support of the arm from the clavicle. The upper portion of the trapezius also contributes support. It is important to repair the deltoid or trapezius fascia in management of AC dislocation (110).

The AC joint is surrounded by a thin capsule reinforced by the superior, inferior, anterior, and posterior AC ligaments (Fig. 78.3). The fibers of the superior AC ligament (the strongest of the capsular ligaments) blend with those of the deltoid and trapezius muscles, which are attached to superior aspect of the clavicle and the acromion process, adding to the stability of the joint.

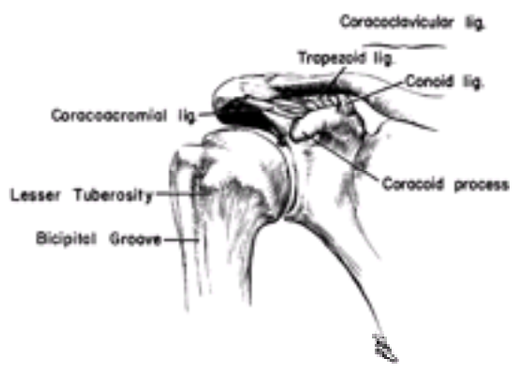


***Figure 78.3.*** Normal anatomy of the AC joint.

The CC ligament is very strong and heavy; its fibers run from the outer, inferior surface of the clavicular to the base of the coracoid process of the scapula (Fig. 78.3). It has two components: the conoid and the trapezoid ligaments.

The CC ligament is the prime suspensory ligament of the upper extremity and helps to couple glenohumeral abduction and flexion to scapular rotation on the thorax. Full overhead elevation cannot be accomplished without combined and synchronous glenohumeral and scapulothoracic motion (44,89,96) The clavicle rotates about its longitudinal axis through an arc of 40° to 50° during full abduction (89). Bearn (16) stressed the importance of the sternoclavicular (SC) ligaments in supporting the proximal end of the clavicle by preventing downward displacement of the distal end of the clavicle. Urist (181) showed that complete dislocation of the AC joint can occur horizontally without rupture of the CC ligament.

**MECHANISMS OF INJURY**

A direct force produced by the patient's falling onto the point of the shoulder with the arm at the side in an adducted position (Fig. 78.4) drives the acromion downward and medially and is the most common cause of AC injury (16). If no fracture occurs, the force first sprains the AC ligaments, then tears the AC ligaments and stresses the CC ligaments, and finally tears the deltoid and trapezius muscle attachments from the clavicle and ruptures the CC ligament, resulting in drooping of the shoulder (Fig. 78.5). The mechanism for inferior dislocation of the clavicle under the coracoid is thought to be a very severe direct force onto the superior surface of the distal clavicle, along with abduction of the arm and retraction of the scapula (122,142).

***Figure 78.4.*** The most common mechanism of injury is a direct force that occurs from a fall on the point of the shoulder.

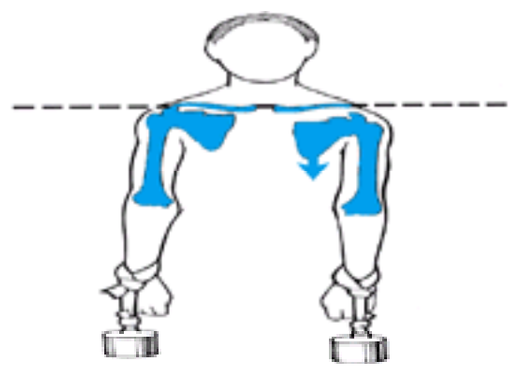

***Figure 78.5.*** Schematic drawing of a patient with a complete grade III AC dislocation. The major deformity seen in this injury is a downward displacement of the scapula and upper extremity—not an upward elevation of the clavicle.

Indirect injury results from a fall on the outstretched hand, which transmits a force up the arm, through the humeral head, and into the acromion process, producing mild, moderate, or severe AC joint injury. Forces can also be indirectly applied to the AC joint by a pull through the upper extremity, which can forcibly draw the shoulder downward and anteriorly (107).

**CLASSIFICATION OF AC INJURIES**

Originally, AC injuries were classified into only two or three grades (2,39,79). One of us (C.A.R.), however, has identified type IV, V, and VI dislocations, which are more likely to require surgery (186; Fig. 78.6; Table 78.1 and Table 78.2).

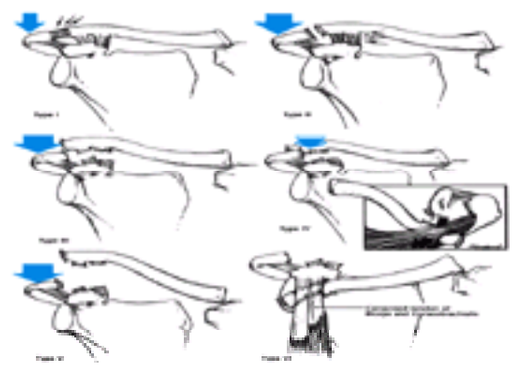

***Figure 78.6.*** Schematic drawings of the classification of ligamentous injuries to the AC joint. **Top left:** In the type I injury a mild force applied to the point of the shoulder does not disrupt either the AC of the CC ligaments. **Top right:** A moderate to heavy force applied to the point of the shoulder will disrupt the AC ligaments, but the CC ligaments remain intact. **Center left:** When a severe force is applied to the point of the shoulder both the AC and the CC ligaments are disrupted. **Center right:** In a type IV injury not only are the ligaments disrupted but the distal end of the clavicle is also displaced posteriorly into or through the trapezius muscle. **Bottom left:** A violent force applied to the point of the shoulder not only ruptures the AC and CC ligaments but also disrupts the muscle attachments and creates a major

separation between the clavicle and the acromion. **Bottom right:** This is an inferior dislocation of the distal clavicle in which the clavicle is inferior to the coracoid process and posterior to the biceps and corabrachialis tendons. The AC and CC ligaments are also disrupted.

| | Decade of life | | | | | | | | |
|---|---|---|---|---|---|---|---|---|---|
| | 1st | 2nd | 3rd | 4th | 5th | 6th | 7th | 8th | 9th |
| Number of injuries | 4 | 112 | 226 | 117 | 29 | 5 | 8 | 16 | 3 |

Based on a review of 520 acromioclavicular injuries treated at University Hospital, San Antonio, TX. Age range 9 to 87 years.

***Table 78.1. Frequency of AC Injuries by Patient Age***

| | Type of injury | | | | | |
|---|---|---|---|---|---|---|
| | I | II | III | IV | V | VI |
| Number of injuries | 185 | 119 | 204 | 4 | 7 | 1 |

Based on a review of 520 acromioclavicular injuries treated at University Hospital, San Antonio, TX. Age range 9 to 87 years.

***Table 78.2. Frequency of AC Injuries by Type***

*Type I.* A mild force to the point of the shoulder produces a minor strain of the fibers of the AC ligaments. The ligaments remain intact, and the AC joint remains stable.

*Type II.* A moderate force to the point of the shoulder is severe enough to rupture the ligaments of the AC joint. The distal end of the clavicle is unstable in the horizontal plane (i.e., anteroposterior), but vertical (i.e., superoinferior) stability is preserved by virtue of the intact CC ligament.

*Type III.* When a severe force is applied to the point of the shoulder, “complete” AC dislocation occurs, and the AC and CC ligaments are disrupted (see Fig. 78.6).

*Type III Variants.* Most often, complete separation of the articular surfaces of the distal clavicle and acromion is accompanied by complete disruption of the AC and CC ligaments. Children and adolescents occasionally sustain Salter-Harris type I or II injuries in which the epiphysis and intact AC joint remain in their anatomic locations while the distal clavicular metaphysis is displaced superiorly through a dorsal longitudinal rent in the periosteal sleeve (21,50,61,64,83,93). The importance of recognizing this injury is that the intact CC ligaments remain attached to the periosteal sleeve. Nonoperative management most often results in healing of the clavicular fracture and reestablishment of the integrity of the CC ligaments. A second uncommon variation of the type III injury involves complete separation of the AC joint combined with a fracture of the coracoid process (10,18,42,78,102,118,129,184,186).

*Type IV.* Posterior dislocation of the distal end of the clavicle, into or through the trapezius muscle, is relatively rare and can be so severe that the skin on the posterior aspect of the shoulder is tented (9,81,117,135,166).

*Type V.* A type V AC dislocation is a markedly severe version of the type III injury in which the distal clavicle is stripped of all its soft-tissue attachments and lies subcutaneously near the base of the neck.

*Type VI.* Inferior dislocation of the distal clavicle is an exceedingly rare injury (67,122,133,157,159) that is often the result of severe trauma and is frequently accompanied by multiple injuries.

**CLINICAL ASSESSMENT**

Examine patients, whenever possible, in the standing or sitting position, as the weight of the arm makes deformity more apparent.

In a type I injury, there is minimal to moderate tenderness and swelling over the AC joint without palpable displacement of the joint, only minimal pain with arm movements, and no tenderness in the CC interspace.

In a type II injury with subluxation of the AC joint, moderate to severe pain is present, the outer end of the clavicle may be noted to be slightly superior to the acromion, motion of the shoulder produces pain in the AC joint, and the outer end of the clavicle may appear to be unstable and free-floating.

In type III injuries with complete dislocation of the AC joint, the arm is held adducted close to the body and supported in an elevated position, the shoulder is depressed, the clavicle may be prominent enough to tent the skin (Fig. 78.7), and moderate pain is the rule. Any motion of the arm, particularly abduction, increases the pain. Look for an associated clavicular shaft fracture (103,190).

***Figure 78.7.*** This patient has a complete type III dislocation of the left AC joint. The left shoulder is drooping and there is prominence of the left distal clavicle. (From Rockwood CA, Young DC. Disorders of the AC Joint. In: Rockwood CA, Matsen F III, eds. *The Shoulder.* Philadelphia: WB Saunders.)

In a type IV injury, the clinical findings are those of a type III injury, but the end of the clavicle is displaced posteriorly.

The type V injury is a severe exaggeration of the type III in which the distal end of the clavicle appears to be grossly superiorly displaced toward the base of the neck. The patient has more pain than with type III injury, secondary to extensive muscle and soft-tissue disruption. The patient may have symptoms of traction on the brachial plexus.

In a type VI injury, the superior aspect of the shoulder has a flat appearance, as opposed to the rounded contour of the normal shoulder. With palpation, the acromion is prominent, and there is a definite inferior stepdown to the superior surface of the coracoid process. There may be associated fractures of the clavicle and upper ribs or injury to the upper roots of the brachial plexus (67,122,142).

**RADIOGRAPHIC FINDINGS**

Take routine anteroposterior views with the patient standing or sitting, with the back against the x-ray cassette and the arms hanging unsupported at the side, imaging both shoulders simultaneously on one large (14 × 17-in.) cassette.

A Zanca (192) view reflects the AC joint off the scapula by tilting the central beam 10° to 15° cephalad.

Take an axillary lateral view of the injured and normal shoulders, including the lateral third of the clavicle if possible. This view will reveal any posterior displacement of the clavicle as well as any small fractures that may have been missed on the anteroposterior view.

For stressed radiographic studies, take an anteroposterior radiograph with 10- to 15-lb weights suspended from each arm with wrist straps. The weights should be hanging from the wrists rather than held by the patient to encourage complete muscle relaxation (Fig. 78.5).

Occasionally a complete AC dislocation will not be apparent on routine radiographs because the patient has supported the injured shoulder with the opposite arm and reduced the AC joint. In addition, some type II injuries can be difficult to differentiate from type III injuries.

In a type I injury, the radiographs of the AC joint are normal, except for mild soft-tissue swelling, as compared with the uninjured shoulder. There is no widening, no separation, and no deformity. In a type II injury, the lateral end of the clavicle may be slightly elevated, and the AC joint may appear to be widened. Stress films reveal that the CC space is the same as that of the normal shoulder.

In type III injuries, the joint is totally displaced with the lateral end of the clavicle displaced completely above the superior border of the acromion. The CC interspace is significantly greater than that in the normal shoulder (Fig. 78.8).

***Figure 78.8.*** Radiograph appearance of a grade III injury to the right shoulder. Stress radiograph films were made to compare the right shoulder with the left. Not only is the right AC joint displaced compared with the left, but, more significantly, notice the great increase in CC interspace on the injured right shoulder compared with the normal left shoulder.

Rarely, complete AC dislocation will be accompanied by a fracture of the coracoid process rather than by disruption of the CC ligaments. Although the fracture of the coracoid process is difficult to visualize on routine radiographs, its presence should be suspected because of the presence of complete AC separation and a normal CC distance as compared with the uninjured shoulder.

In type IV injuries, the most striking feature is the posterior displacement of the distal clavicle, as seen on the axillary lateral radiograph (Fig. 78.9).

***Figure 78.9.*** Axillary view of type IV posterior dislocation with the distal clavicle and acromion outlined.

The characteristic radiograph feature of type V injuries is a marked increase (i.e., two to three times normal) in the CC interspace. The clavicle appears to be grossly displaced superiorly away from the acromion.

In type VI injuries, the dislocation of the distal clavicle can be subacromial or subcoracoid. In the subacromial type, radiographs reveal a decreased CC distance (i.e., less than the normal side), and the distal clavicle is in a subacromial location. The subcoracoid dislocation is characterized by a reversed CC distance, with the clavicle displaced inferior to the coracoid process.

**TREATMENT**

For type I injuries, apply ice bags to ease the discomfort and protect the shoulder from further injury until there is a painless full range of motion. Usually, the symptoms subside after 7 to 10 days of rest.

For a type II injury, apply a sling for 10 to 14 days or until the symptoms subside, followed by a gradual rehabilitation program. Advise the patient to avoid heavy lifting or contact sports for 8 to 12 weeks to allow complete ligament healing.

Surgery may be required for persistent pain after a type II AC injury (12). Pain can be caused by posttraumatic osteolysis of the clavicle, torn capsular ligaments trapped within the joint, loose pieces of articular cartilage, or a detached intra-articular meniscus that becomes displaced in and out of the joint like a torn meniscus in

the knee. An AC joint arthroplasty may be required. If the articular surface of the clavicle is degenerative, then perform an excision of the distal 2 cm of the clavicle in addition to joint debridement and meniscectomy.

Many authors recommend nonoperative management for type III AC dislocation (4,8,69,90,116,131,162,182,183,188). Banister and co-workers (8), in a randomized, prospective study, showed there was no difference between the operatively and nonoperatively treated patients except in those with severe separations (2 cm or greater), where operative fixation provided better results. No difference in strength and endurance has been found in those treated nonoperatively, comparing the injured with the noninjured side (69,116,162,188).

Convenience, shorter rehabilitation times, dissatisfaction with the results of surgical repairs, and reports of good functional outcomes have led many authors to favor "skillful neglect" over operative treatment (20,58,69,84,88,160,164). Ninety percent to 100% satisfactory results with 5- to 7-year follow-up in patients with type III AC dislocations can be expected. The types of nonoperative treatment available are described in Chapter 10.

### *Operative Techniques*

Four types of procedures have been described: AC joint fixation, CC ligament repair, distal clavicle excision, and dynamic muscle transfers.

#### Direct Fixation of the AC Joint

- Place the patient on a radiolucent table under general anesthesia. Prep and drape the shoulder with the upper extremity free.
- If closed technique is to be used, insert a $^{1}/_{8}$-in. or larger smooth Steinmann pin antegrade from the lateral edge of the acromion to the joint. Then reduce the joint closed and, under fluoroscopic guidance, insert the pin across the joint into the clavicle.
- Some authors prefer to open the joint for debridement and reduction. Use a "saber cut" incision 5 cm or so in length directly over the AC joint. Insert the pins retrograde from the joint into the acromion and then into the clavicle after reduction of the joint. Always bend the portion of the pin that protrudes through the lateral acromion process to lessen the possibility of medial migration (Fig. 78.10).

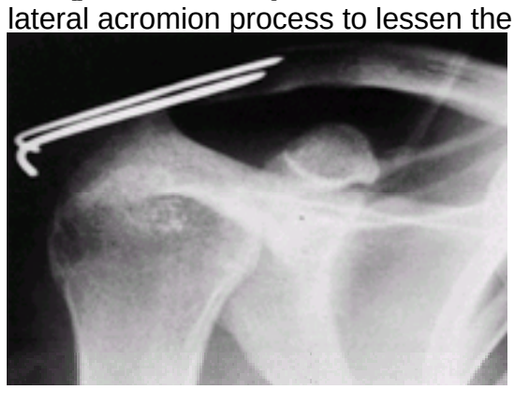

***Figure 78.10.*** Open reduction of the AC joint and stabilization of the joint with two pins effectively reduced the fractured coracoid. Note that the distal ends of the pins have been bent to prevent medial migration.

- Repair the ligaments as close to anatomic as possible and then do a layered closure of the wound with a subcuticular skin closure.

**Postoperative Care** Encourage patients to move the hand and elbow, avoiding excessive abduction of the shoulder to prevent breakage or migration of the pins. Rowe (155) recommends that abduction motion be limited to no more than 40°. Remove the pins after 6 to 8 weeks and begin range-of-motion and strengthening exercises.

### *Extra-articular CC Repairs*

The technique of placing a specialized screw between the clavicle and the base of the coracoid was described by Bosworth (24,25,26 and 27) in 1941. The screw was placed percutaneously without repair of the CC ligaments or exploration of the AC joint. Good results using various modifications of Bosworth's original technique have been reported (91,96,112; Fig. 78.11).

***Figure 78.11.*** Postoperative anteroposterior radiograph of the shoulder with Bosworth screw in place. Note that the AC joint has been reduced and the coarse lag threads of the screw are well seated into the coracoid process.

Coracoclavicular fixation can be obtained by looping various materials such as stainless steel wire (1,15), dacron arterial graft, velour dacron graft (92,134,141,175), or fascia lata (122,436) over the top of the clavicle and through or beneath the coracoid process.

These techniques have been associated with erosion of material through the distal clavicle and coracoid fracture (52,53,70,128).

The recommendations concerning removal of fixation devices after healing vary considerably. Neither Bosworth (24) nor Kennedy (97) recommended removal of the CC lag screw. Weitzman (185), however, recommended CC screw removal under local anesthesia at 8 weeks.

### *Excision of the Distal Clavicle*

Mumford (132) described simple excision of the distal clavicle, which is usually done for an old, symptomatic type II injury. In symptomatic type III injuries, in addition to the excision of the distal clavicle, there must be a reconstruction of the CC ligaments.

Although excision of the distal clavicle is usually indicated in a symptomatic, chronic, incomplete AC dislocation—and possibly in an acute injury with severe joint damage—we do not recommend excision of a normal clavicle for an acute AC dislocation.

### *Type IV and V Injuries*

Because of the severe posterior displacement of the distal clavicle in a type IV injury and the gross superior displacement in the type V, most authors recommend surgical repair (81,117,135,166). In a type IV injury, the patient is quite symptomatic when the distal end of the clavicle penetrates the trapezius muscle. In an inactive patient in whom the clavicle can be manipulated out of the trapezius muscle, a nonoperative approach is possible. If the clavicle cannot be manipulated out of the trapezius muscle, however, one of the previously described surgical procedures is indicated. In a type V injury, the deformity is so gross that surgical repair is usually indicated.

### *Type VI Injury*

All type VI injuries described in the literature (67,122,142,157) have been treated with surgery, as initial attempts at closed reduction failed. Gerber and Rockwood (67) reported using the extra-articular technique with the Rockwood CC lag screw, with repair of the ligaments and imbrication of the deltotrapezius fascia over the top of the clavicle.

### *Authors' Preferred Methods of Treatment*

Our treatment algorithm for traumatic AC injuries is shown in Fig. 78.12.

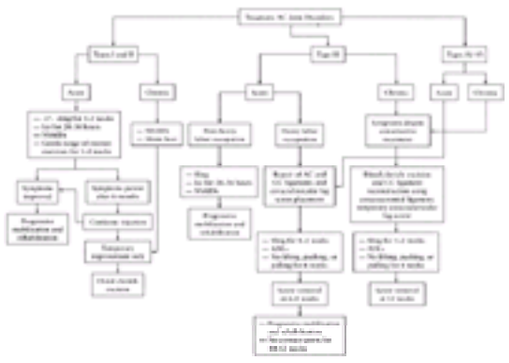

***Figure 78.12.*** University of Texas at San Antonio treatment algorithm for traumatic disorders of the AC joint.

**Type I Injury** For symptomatic treatment we apply an ice pack for the first 12 hours, followed by moist heat, and provide a sling to support the arm. We encourage the patient to rest the shoulder but to maintain a gentle, normal range of motion. The symptoms usually subside within 7 days. Advise patients to avoid heavy stresses, lifting, and contact sports until there is a full range of motion and no pain to joint palpation, which usually takes 2 to 3 weeks.

**Type II Injury** Treat as described above for a type I injury. The patient can use the arm for dressing, eating, and necessary everyday living activities when symptoms permit, usually about the seventh day. We advise patients to avoid heavy lifting, pushing, or contact sports for at least 6 weeks.

If the patient stresses the shoulder all day with heavy labor (i.e., pushes a wheelbarrow, swings a sledge hammer, does a lot of digging), then chronic pain can develop in the AC joint secondary to traumatic arthritis. If conservative measures fail, then an arthroplasty may be required.

**Type III Injury** We either restore the anatomy through an operative procedure or put the arm into a sling for a few days and gradually allow functional use of the shoulder. We do not use braces or strappings, which tend to irritate or ulcerate the tender skin on top of the shoulder.

For people who do heavy labor, and in those younger than 25 years of age who have not yet established their future occupation or sports, we proceed with surgical repair. An exception is a young athlete who regularly subjects the shoulder to violent, unprotected trauma (e.g., in soccer, rugby, and hockey). There is no sense in repairing an injury only to have it recur when the patient falls on the point of the shoulder. American football players with a grade III injury treated nonoperatively can perform well with special shoulder pads. Throwers can usually return to their sports with a grade III injury after 4 to 8 weeks. In patients doing heavy labor, however, operative repair yields a shoulder with more endurance that will stand up to repetitive stresses and heavy loads.

**Type IV, V, and VI Injuries** In type IV and VI injuries seen early, we recommend closed reduction to dislodge the clavicle from the trapezius muscle or from under the coracoid process. If it is successful, we then apply the same indications as above for a type III problem. If the reduction fails, then an operative reduction and repair are necessary. Type IV, V, and VI injuries require operative repair.

#### Operative Technique

- Place a 10 × 12-in. x-ray cassette under the patient's shoulder, and place the patient in the beach-chair position on the operating table. A special head rest is used so the top of the patient's shoulder is completely free at the top of the corner of the table. Deviate the head slightly toward the normal shoulder and secure it to the head rest so there is complete access to the superior aspect of the shoulder. Place the anesthesiologist and equipment at the opposite shoulder so the surgeon can stand at the top of the table. Preparation and draping must provide access from the top of the shoulder to the base of the neck.
- Make a strap-like incision in Langer's lines approximately 3 in. long (Fig. 78.13). Begin 1 in. posterior to the clavicle, then cross the clavicle 1 in. medial to the AC joint. Extend the incision downward to a point medial to the tip of the coracoid process. Undermine the incision so the AC joint, the distal 2 in. of the clavicle, and the anterior deltoid can be visualized.

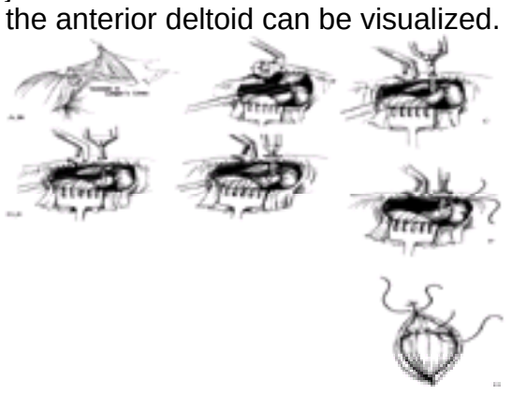

***Figure 78.13.*** The authors' repair for a complete AC dislocation. **A:** The skin incision is about 3 in. long and extends from the posterior edge of the clavicle, 1 in. medial to the AC joint, then down in Langer's lines to a point just medial to the tip of the coracoid process. **B:** The deltoid secondary to the injury is usually subperiosteally stripped away from the distal clavicle. It may have to be surgically detached to aid in identification and reapproximation to the CC ligaments and the base of the coracoid process. The distal end of the clavicle can be lifted up with a towel clip or a bone hook to aid in the placement of the sutures in the CC ligament. The AC joint is thoroughly debrided of the meniscus. If the AC ligaments are amenable to repair, they are preserved and later repaired. **C:** The distal end of the clavicle is held reduced adjacent to the acromion with a towel clip. A $^{3}/_{16}$-in. drill bit is used to make a hole in the clavicle directly above the base of the coracoid. **D:** Through the $^{3}/_{16}$-in. hole in the clavicle, a $^{9}/_{64}$-in. drill bit is used to create a hole through both cortices of the base of the coracoid. **E:** The specially designed lag screw of appropriate length is then placed through the clavicle until the smooth shank of the screw is in the clavicle. The nonthreaded nipple end of the screw is then passed into the hole of the coracoid, and the screw is tightened home to depress the clavicle down to the level of the acromion. **F:** The stay sutures in the CC ligaments are then tied, and the screw is tightened another half turn to take any tension off the reapproximated ligaments. **G:** The muscle attachments of the deltoid and trapezius are carefully repaired and, if possible, are imbricated over the top of the clavicle and the AC joint. Note: In measuring the length of the screw, it must be remembered to add 6 mm to the measurement of the depth gauge so that the heavy threads will purchase both cortices of the coracoid.

- In some instances, the deltoid and trapezius muscle fascia may have been torn from the distal 2 to 3 in. of the clavicle. If not, open this interval so the clavicle can be grasped with a clamp and lifted upward while the deltoid muscle is retracted distally to visualize the torn ends of the CC ligament and the base of the coracoid process. If the deltoid has been stripped off the clavicle with an intact periosteal tube, then split the deltoid distally 2 in. in line with its fibers, and detach the distal 2 in. from its insertion into the clavicle. This technique will allow exposure of the CC ligaments and the base of the coracoid process (Fig. 78.13).
- Grasp the distal end of the clavicle and lift it upward and debride the joint of the torn intraarticular disc and any loose tags of the AC ligament. Identify the torn ends of the CC ligament and tag them with two or three #1 cottony dacron sutures. Do not tie the sutures at this time.

- Reduce the AC joint anatomically. With the superior surface of the clavicle exposed and the base of the coracoid clearly visualized, place a screw vertically through the clavicle and both cortices of the base of the coracoid. Place a $^{3}/_{16}$-in. drill hole in the clavicle 1 to 1½ in. medial to the distal end of the clavicle, directly over the base of the coracoid. Next, drill a $^{9}/_{64}$-in. hole through the base of the coracoid (Fig. 78.13). Measure with a depth gauge for the screw length. Then insert Rockwood's modification of the Bosworth screw (DePuy Orthopaedics, Warsaw, IN) through the clavicle into the coracoid (Fig. 78.14). Be certain that the tip of the screw enters the hole in the center of the coracoid and doesn't skid off either side. As the screw is tightened, the clavicle is gradually reduced down to the level of the upper border of the acromion.



***Figure 78.14.*** Comparison of the modified CC lag screw (left) with the original Bosworth screw (right). The large head of the original screw made it possible to use the self-retaining screwdriver. Furthermore, the threads extended all the way down to the tip of the screw, making it difficult for the surgeon to place the screw into the hole in the base of the coracoid. The modified screw, which has a washer in place of the large head, can be used with a self-retaining screwdriver. The distal ¼ inch of the screw, which has no threads and is smooth tipped, is used to seek out the hole in the base of the coracoid. (Courtesy of DePuy Orthopaedics Co., Warsaw, IN.)

- Next, take a radiograph using the preoperatively positioned cassette under the shoulder to check the position of the screw (Fig. 78.15).

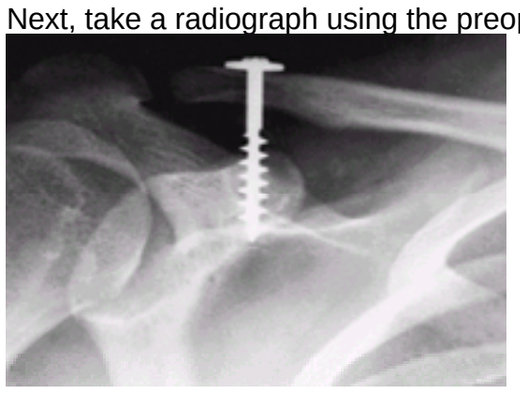

***Figure 78.15.*** Postoperative radiograph showing the acromioclavicular joint reduced and held temporarily in place with a special modified CC lag screw.

- At this point, tie the stay sutures in the CC ligament and then take another half-turn on the screw, which takes any tension off the sutures. The primary purpose of the screw is to hold the clavicle reduced vertically and horizontally to the scapula and to take tension off the CC ligament repair until the CC ligaments have healed.
- Repair the deltotrapezius muscle fascia back to the clavicle. Try double-breasting or imbricating the fascia over the top of the clavicle.

**Postoperative Care** Postoperatively, support the arm in a sling for 1 to 2 weeks but allow the patient to use the arm for gentle daily living activities. After 1 to 2 weeks, discontinue use of the sling and allow the patient to use the arm for most everyday living activities, avoiding any lifting, pushing, and pulling for 4 to 6 weeks. Ordinarily, by 3 weeks, most patients have a functional range of motion. Remove the screw by 6 to 8 weeks after surgery under local anesthesia. After screw removal, instruct the patient not to perform any heavy lifting, pushing, pulling, or contact sports for 10 to 12 weeks from the initial operative repair. Athletes are not permitted to return to contact sports until 12 weeks postoperatively, and only after they have recovered full strength of the shoulder with a full range of motion.

### PROGNOSIS

*Type I injury.* In general, the prognosis for a type I injury is excellent. Most patients recover full range of motion and have no pain within 2 weeks.

*Type II injury.* Most patients with a type II injury recover fully, leaving only a small percentage who require debridement or excision of the outer end of the clavicle because of arthritis in the joint (6,17,48,183).

*Type III, IV, V, and VI injuries.* Excellent results can be obtained in patients with type III, IV, V, and VI injuries with both operative and nonoperative treatment. Nonoperative treatment usually suffices in a sedentary office worker; people who do heavy labor do better with surgical repair. In general, given the proper treatment for a specific patient, the end results tend to be completely acceptable in more than 90% of patients.

## PITFALLS AND COMPLICATIONS

### COMPLICATIONS OF ACUTE INJURIES

Acromioclavicular separations may be associated with other injuries about the shoulder, neck, and chest, particularly in high-velocity injuries. Scapulothoracic dissociation is characterized by lateral displacement of the scapula, a severe neurovascular injury, and an injury to bone (either an AC separation, a displaced clavicle fracture, or an SC disruption). Scapulothoracic dissociations are, however, usually clinically obvious (see Chapter 15). Injuries associated with AC separations may, however, be less obvious and may include injuries to the chest wall and organs (9), fractures of the clavicle, the acromion process, and the coracoid process, and dislocation of the SC joint (190).

#### *Coracoclavicular Ligament Ossification*

Ossification of the CC ligament occurs whether the lesion is treated by conservative or operative means (5,126). In our experience, ossification does not seem to affect the late functional results.

### COMPLICATIONS OF OPERATIVE TREATMENT

Wound infection and osteomyelitis are rare. Complications unique to repair of the AC joint can occur (i.e., a fracture through a drill hole, loss of purchase of the internal fixation, metal failure, and migration of the fixation device to other parts of the body).

#### *Migration of Pins*

Pins and longitudinal wires across the AC joint tend to migrate or break because of motion in the joint. They have been reported to have migrated to the lung (119), spinal cord (137), neck (108), subclavian artery (163), aorta (73), and liver (150).

In most instances, pin migration can be prevented by bending a hook on the portion of the pin that protrudes from the acromion process. However, the pins can break, and then the proximal part of the pin is free to migrate. For that reason, most surgeons avoid the use of pins across the AC joint.

### *Failure of Soft-tissue Repairs*

Simple repair of the CC and AC ligaments without the additional support of internal fixation may lead to failure. This is particularly true in chronic complete injury to the AC joint when there is a major separation between the clavicle and the coracoid. Even the transfer of the acromial attachment of the CA ligament onto or into the medullary canal of the distal clavicle may fail.

### *Acromioclavicular Joint Arthritis*

Symptomatic arthritis of the AC joint may occur after both nonoperative treatment and surgical fixation of the AC joint. If there are significant findings of degenerative changes or traumatic injury to the AC joint at the time of initial repair, then excise the distal clavicle. Use of the CA ligament to reconstruct the CC ligaments is rarely indicated in the surgical management of acute AC trauma.

When AC arthritis occurs late after type I and II injuries, and the patient does not respond to nonoperative treatment, then excision of the distal clavicle is indicated. Distal clavicle excision may be performed as an open (76,132) or arthroscopic procedure (19,66,124,165,178).

## CHRONIC CONDITIONS OF THE AC JOINT

### *Degenerative Arthritis*

Deterioration of the fibrocartilaginous disc that separates the two articular surfaces of the AC joint begins in the second decade of life (55) and can progress as part of the natural aging process, associated with progressive AC joint space narrowing. Radiographic findings of AC degeneration are seen in nearly 60% of elderly patients, with tenderness of one or both AC joints in 42% to 70% of patients (87).

### *Rheumatoid Arthritis*

The AC joint is affected by rheumatoid arthritis in a fashion similar to that of other joints, with discomfort localized to this area in 63% of rheumatoid patients with painful shoulders (144).

Pathologic examination reveals proliferative synovial tissue, capsular swelling, and subchondral erosion, which is more marked inferiorly in the region of the coracoid process (148). Radiographic findings include joint space narrowing, osteopenia of the acromial process, inferior surface erosions of the distal clavicle, and osteolysis of the acromial end of the clavicle with tapering (2,3,129,144). These findings are progressive and are found in about 80% of rheumatoid patients with painful shoulders.

## OSTEOLYSIS OF THE DISTAL CLAVICLE

Posttraumatic osteolysis of the distal clavicle may follow an acute injury, or it may occur in patients who have repeated stress on the shoulder. Most cases involve weight lifters who complain of a dull ache, weakness, and pain with flexion and abduction. A 10° cephalic tilt radiograph of the AC joint may show osteoporosis, osteolysis, tapering, or osteophyte formation of the distal clavicle. Usually, bony changes are unilateral and do not occur in the acromion (Fig. 78.16). Technetium bone scans have also been found to be quite helpful (40).

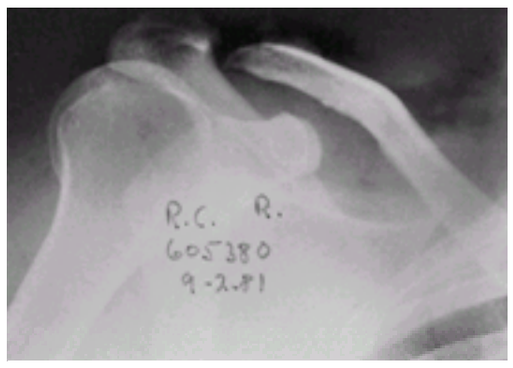


***Figure 78.16.*** Traumatic osteolysis of the right distal clavicle in a patient who had an injury to the right shoulder and gradually developed increasing pain. Radiograph made 3 months after the injury shows an absorption of the distal clavicle and new bone formation on the dorsal aspect of the clavicle. (From Rockwood CA, Green DP, eds. *Fractures, 3rd ed.* Philadelphia: JB Lippincott, 1991:1236.)

With activity modification and rest, the distal clavicle may reconstitute itself (105). Should symptoms not be relieved, then excision of the distal end of the clavicle may be necessary.

### *Authors' Treatment of Chronic Problems of the AC Joint*

Excision of the distal clavicle for a degenerative AC joint with an old type II injury is appropriate. We recommend excision of a minimum of 2 cm of the distal clavicle. If the excision of the distal clavicle is too small, it eventually may develop a spur that will impinge against the acromion, producing symptoms and pain just as before the operation.

If the clavicle has lost its attachment to the coracoid (i.e., a chronic type III, IV, V, or VI injury), the CC ligament must be reconstructed, and distal clavisectomy must be performed.

#### Authors' Method to Reconstruct a Chronic, Complete AC Dislocation

- Position, prep, and drape the patients, using the same surgical approach described for an acute repair of a type III injury. Excise the distal 2 cm of the clavicle. Remove enough clavicle so the stump of the clavicle is located just at the lateral edge of the base of the coracoid (Fig. 78.17). Then drill the medullary canal of the distal clavicle and widen it with a curet to be able to receive the transferred CA ligament.

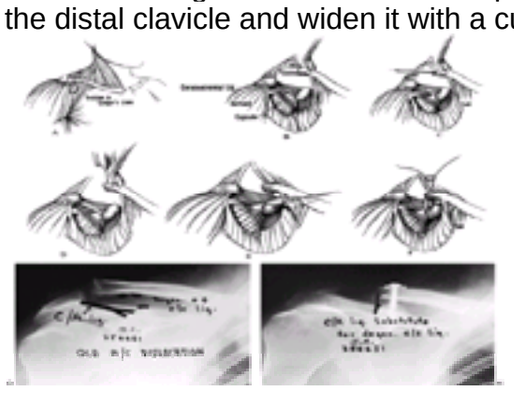

***Figure 78.17.*** The authors' method to reconstruct a chronic type III, IV, V, or VI AC dislocation. **A:** The incision is made in Langer's lines. **B:** The distal end of the clavicle is excised. **C:** The medullary canal is drilled out and curetted to receive the transferred CA ligament. **D:** Two small drill holes are made through the superior cortex of the distal clavicle. The CA ligament is carefully detached from the acromion process. **E–H:** With the CA ligament detached from the acromion, a heavy nonabsorbable suture is woven through the ligament. The ends of the suture are passed out through the two small drill holes in the distal end of the clavicle. The CC lag screw is inserted; and when the clavicle is reduced down to its normal position, the sutures used to pull the ligament snugly up into the canal

are tied.

- Use a knife blade to remove the acromial attachment of the CA ligament from the acromion (Fig. 78.17). With the clavicle held reduced to just above the base of the coracoid, determine if the CA ligament is long enough to reach into the intramedullary canal of the clavicle. This ligament can be further lengthened by detaching the anterior fasciculus of the CA ligament from the waist of the coracoid process. Then weave a heavy 1-0, nonabsorbable suture back and forth through the ligament so that both ends of the suture exit through the acromial end of the CA ligament.
- Drill two small holes in the superior cortex of the distal stump of the clavicle and into the medullary canal (Fig. 78.17). Now prepare the clavicle and coracoid process for insertion of a CC screw as described above for an acute repair.
- Before inserting the lag screw, pass the two ends of the suture in the CA ligament into the medullary canal and out the two small drill holes in the superior cortex of the clavicle. Then insert the lag screw through the clavicle and into the coracoid and tighten it to vertically reduce the clavicle down to just above the coracoid process. As previously described in treating an acute injury to the AC joint with the lag screw, be sure that the lag screw is long enough so that the threads have purchase in both cortices of the coracoid process.
- Then use the sutures to pull the CA ligament into the medullary canal. Tie the suture, securing the ligament into the distal clavicle (Fig. 78.17). Occasionally we will supplement the fixation with two pieces of nonabsorbable heavy suture that pass under the coracoid and through drill holes in the distal clavicle.
- Postoperatively, allow the patient to use the arm for everyday activities but avoid any heavy lifting, pushing, or pulling. After 12 weeks, remove the screw under local anesthesia.

## THE STERNOCLAVICULAR JOINT

### ANATOMY

The sternoclavicular (SC) joint is a diarthrodial joint and is the only true articulation between the clavicle and the axial skeleton (Fig. 78.18). The enlarged bulbous medial end of the clavicle is concave front to back and convex vertically; it therefore creates a saddle-type joint with the clavicular notch of the sternum (72,74).

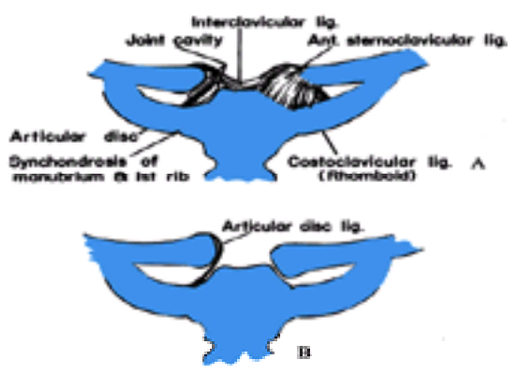


***Figure 78.18.*** **A:** Normal anatomy around the SC joint. Note that the articular disc ligament divides the SC joint cavity into two separate spaces and inserts onto the superior and posterior aspects of the medial clavicle. **B:** The articular disc ligament acts as a checkrein for medial displacement of the proximal clavicle. (Reprinted with permission form Rockwood CA, Matsen F III, eds. *The Shoulder.* Philadelphia: WB Saunders.)

### LIGAMENTS OF THE SC JOINT

The integrity of this joint comes from the intra-articular disc ligament, the extra-articular costoclavicular ligament (rhomboid ligament), the capsular ligament, and the interclavicular ligament. The intra-articular disc ligament is a very dense, fibrous structure that arises from the synchondral junction of the first rib to the sternum and passes through the SC joint, which divides the joint into two separate joint spaces (Fig. 78.18) (72,74). The upper attachment is on the superior and posterior aspects of the medial clavicle. The disc acts as a checkrein against medial displacement of the inner clavicle.

The costoclavicular ligament, also called the rhomboid ligament, is short and strong and consists of an anterior and a posterior fasciculus (16,43,74). The costoclavicular ligament attaches below to the upper surface of the first rib and at the adjacent part of the synchondral junction with the sternum and above the margins of the impression on the inferior surface of the medial end of the clavicle, sometimes known as the rhomboid fossa (72,74).

The interclavicular ligament connects the superomedial aspects of each clavicle with the capsular ligaments and the upper sternum (Fig. 78.18). According to Grant (72), this band may be comparable to the wishbone of birds. This ligament helps the capsular ligaments hold up the shoulder.

The capsular ligament covers the anterosuperior and posterior aspects of the joint and represents thickenings of the joint capsule (Fig. 78.18). The anterior portion of the capsular ligament is heavier and stronger than the posterior portion. It may be the strongest ligament of the SC joint, and it is the first line of defense against the upward displacement of the inner clavicle caused by a downward force on the distal end of the shoulder (16).

The SC joint is freely movable and functions almost as a ball-and-socket joint in that the joint has motion in all planes, including rotation (23,114). The clavicle, and therefore the SC joint, in normal shoulder motion is capable of 30° to 35° of upward elevation, 35° of combined forward and backward movement, and 45° to 50° of rotation around its long axis (Fig. 78.19). It is most likely the most frequently moved joint of the long bones in the body because almost any motion of the upper extremity is transferred proximally to the SC joint.

***Figure 78.19.*** Motions of the clavicle and the SC joint. **A:** With full overhead elevation, the clavicle elevates 35°. **B:** With adduction and extension, the clavicle displaces anteriorly and posteriorly 35°. **C:** The clavicle rotates 45° on its long axis as the arm is elevated to the full overhead position.

Although the clavicle is the first long bone of the body to ossify (fifth intrauterine week), the epiphysis at the medial end of the clavicle is the last of the long bones in the body to appear and the last epiphysis to close, ossifying between the 18th and 20th year and fusing around the 23rd to 25th year (72,74,146). This knowledge of the epiphysis is important, because many SC dislocations are actually fractures through the physeal plate.

There is a “curtain” of muscles consisting of the sternohyoid, sternothyroid, and scaleni posterior to the SC joint and the inner third of the clavicle. This curtain blocks the view of vital structures, including the innominate artery, innominate vein, vagus nerve, phrenic nerve, internal jugular vein, trachea, and esophagus (Fig. 78.20). Surgery on the SC joint takes place immediately adjacent to these vital structures.

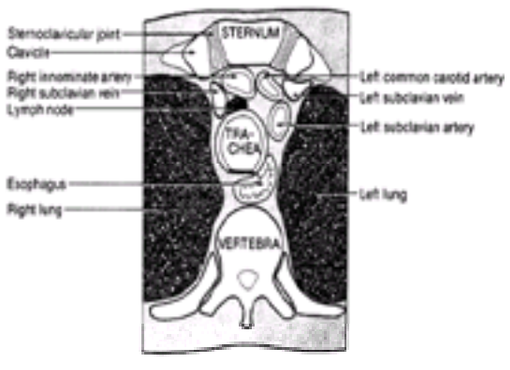


***Figure 78.20.*** Applied anatomy of the vital structures posterior to the SC joint. Sagittal views in a cross section demonstrate the structures posterior to the SC joint.

## CLASSIFICATION

The SC joint dislocations may be classified according to the anatomic position the dislocation assumes or according to etiology.

Anterior dislocations are the most common. The medial end of the clavicle is displaced anteriorly or anterosuperiorly to the anterior margin of the sternum. Posterior SC dislocation is uncommon. The medial end of the clavicle is displaced posteriorly or posterosuperiorly with respect to the posterior margin of the sternum.

Acute sprains to the SC joint can be classified as mild, moderate, or severe. In a mild sprain, all the ligaments are intact, and the joint is stable. In a moderate sprain, there is subluxation of the SC joint. The capsular, intra-articular disc, and costoclavicular ligaments may be partially disrupted. The subluxation may be anterior or posterior. In a severe sprain, there is complete disruption of the SC ligaments, and the dislocation may be anterior or posterior.

If the initial acute traumatic dislocation does not heal, mild to moderate forces may produce recurrent dislocations; this is a rare occurrence.

The original dislocation may go unrecognized, it may be irreducible, or the physician may decide not to reduce certain dislocations.

For a variety of nontraumatic reasons, the SC joint may subluxate or enlarge.

One or both of the SC joints may spontaneously subluxate or dislocate anteriorly during overhead motion. The problem usually is not painful (Fig. 78-21).

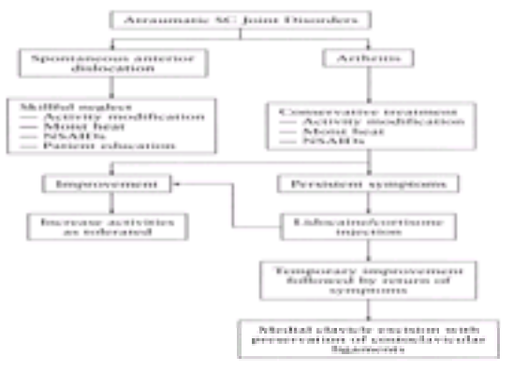


***Figure 78.21.*** University of Texas at San Antonio treatment algorithm for atraumatic SC joint disorders.

## OTHER CONDITIONS AFFECTING THE SC JOINT

### *Arthritis*

Degenerative and inflammatory arthritis (79,99,100) is encountered in the SC joint and can be secondary to trauma, condensing osteitis of the medial clavicle (31,161), SC hyperostosis, rheumatoid arthritis (33,63,191), rheumatoid spondylitis (149), scleroderma (99), psoriasis (170), polymyalgia rheumatica (140), secondary hyperparathyroidism (149,177), gout (49,177), leprosy (136), syringomyelia (51), tumor (51), and aseptic necrosis (106) and following radical neck resection, particularly with loss of the spinal accessory nerve (41,71,161,176). Routine degenerative arthritis in postmenopausal women has been singled out as “postmenopausal arthritis,” but it is not a unique disorder (22,29,156).

### *Condensing Osteitis of the Medial Clavicle*

Condensing osteitis of the medial clavicle usually occurs in women over the age of 40 and may be secondary to chronic stress on the joint. The joint is swollen and tender, and radionuclide studies reveal an increased uptake. Routine laboratory results are within normal limits. X-ray films show sclerosis and slight expansion of the medial third of the clavicle. The inferior portion of the sternum end of the clavicle shows sclerotic changes. Some osteophytes may be present, but the joint space is preserved. The changes of the medial clavicle are best detected with a CT scan. Most patients do well with conservative treatment (i.e., anti-inflammatory medications). Kruger and associates (101) recommend incisional or excisional biopsy in refractory cases.

### *Sternocostoclavicular Hyperostosis*

This condition, usually bilateral, affects adults of both sexes between 30 and 50 years of age. The process begins at the junction of the medial clavicle, the first rib, and the sternum as an ossification in the ligaments and later involves the bones. In some cases, the hyperostosis is extensive and forms a solid block of bone of the sternum, ribs, and clavicle. Patients may have peripheral arthritis. Subperiosteal bone changes have been noted in other bones (68). The condition has been graded into three stages by Sonozaki (177,178 and 179). Stage I is mild ossification in the costoclavicular ligaments; stage II is characterized by an ossific mass between the clavicle and the first rib; in stage III, a bone mass exists between the clavicle, sternum, and first rib. As might be expected with the fusion of the SC joint, shoulder motion is severely restricted.

Pustular cutaneous lesions of the palmar and plantar surfaces of skin may be seen. There is no specific laboratory test, except for an occasional elevation of the serum alkaline phosphatase (68).

### *Infection*

Spontaneous swelling with the appearance of joint subluxation may be associated with acute, subacute, or chronic bacterial arthritis. Predisposing conditions include intravenous drug addiction and the presence of the human immunodeficiency virus (HIV) (47,187). Common predisposing causes to infection in nonaddicts are bacteremia, infectious invasion from surrounding bone, rheumatoid arthritis, alcoholism, and chronic debilitating diseases. The CT scan is very helpful in making an early diagnosis of a septic SC joint (109,130,187).

Richter et al. (151) reported nine patients with infection of the SC joint secondary to tuberculosis. The average time from onset of the disease until diagnosis was 1.4 years.

## MECHANISMS OF INJURY

Because the SC joint is subject to practically every motion of the upper extremity, and because the joint is so small and poorly matched, one would think it would be the most commonly dislocated joint in the body. However, the ligamentous supporting structure is so strong and so designed that it is, in fact, one of the least commonly dislocated joints in the body. A traumatic dislocation of the SC joint usually requires tremendous forces, either direct or indirect.

When a force is applied directly to the anteromedial aspect of the clavicle, the clavicle is pushed posteriorly behind the sternum and into the mediastinum. A force applied indirectly to the SC joint from the anterolateral or posterolateral aspects of the shoulder is the most common mechanism of injury to the SC joint (85,123). If the shoulder is compressed and rolled forward, an ipsilateral posterior dislocation results; if the shoulder is compressed and rolled backward, an ipsilateral anterior dislocation results (Fig. 78.22).

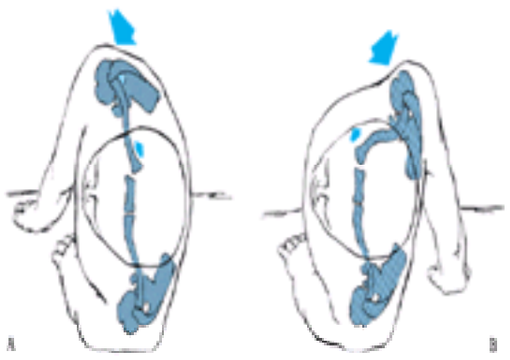

***Figure 78.22.*** Mechanisms that produce anterior or posterior dislocations of the SC joint. **A:** If the patient is lying on the ground, and a compression force is applied to the posterolateral aspect of the shoulder, the medial end of the clavicle will be displaced posteriorly. **B:** When the lateral compression force is directed from the anterior position, the medial ends of the clavicle are dislocated anteriorly.

## CLINICAL ASSESSMENT

In a mild sprain, the ligaments of the joint are intact. The patient complains of a mild to moderate amount of pain, particularly with movement of the upper extremity. The joint may be slightly swollen and tender to palpation, but instability is not noted.

A moderate sprain results in a subluxation of the SC joint. The ligaments are either partially disrupted or severely stretched. Swelling is noted, and pain is marked, particularly with any movement of the arm. Anterior or posterior subluxation may be obvious to the examiner when the injured joint is compared with the normal SC joint.

A severe sprain is analogous to a joint dislocation. The dislocation may be anterior or posterior. The capsular ligaments and the intra-articular disc ligament are ruptured. The patient with a SC dislocation has severe pain that is increased with any movement of the arm, particularly when the shoulders are pressed together. The patient usually supports the injured arm across the trunk with the normal arm. The affected shoulder appears to be shortened and thrust forward when compared with the normal shoulder. The head may be tilted toward the side of the dislocated joint. Discomfort increases when the patient is placed in the supine position, at which time it will be noted that the involved shoulder will not lie back flat on the table.

With an anterior dislocation, the medial end of the clavicle is prominent anterior to the sternum (Fig. 78.23) and can be palpated anterior to the sternum. It may be fixed anteriorly or be quite mobile.

***Figure 78.23.*** **A:** With the patient supine, view the clavicles from around the level of the patient's knees. It is apparent that the right clavicle is dislocated anteriorly. **B:** Clinically, an anterior dislocation of the right SC joint is evident (*arrow*).

The patient with a posterior dislocation has more pain than a patient with an anterior dislocation. The anterosuperior fullness of the chest produced by the clavicle is less prominent. The medial end of the clavicle is displaced posteriorly. The corner of the sternum is easily palpated, as compared with the normal SC joint. Venous congestion may be present in the neck or in the upper extremity (172). Breathing difficulties, shortness of breath, or a choking sensation may be noted. Circulation to the ipsilateral arm may be decreased. The patient may complain of difficulty in swallowing or a tight feeling in the throat or may be in a state of complete shock or possibly have pneumothorax.

Because of swelling, it can be difficult to distinguish between anterior and posterior dislocations.

## RADIOGRAPHIC FINDINGS

The routine anteroposterior or posteroanterior radiographs of the chest or SC joint may suggest that something is wrong with one of the clavicles, because it appears to be displaced as compared with the normal side (Fig. 78.24). It would be ideal to take a view at right angles to the anteroposterior plane, but because of human anatomy, it is impossible to take a true 90° cephalic-to-caudal lateral view.

***Figure 78.24.*** Anteroposterior radiograph of the SC joints with anterosuperior displacement of the left medial clavicle. The displacement is quite noticeable when the clavicles are outlined.

### *Heinig View*

With the patient supine, place the x-ray tube approximately 30 in. from the involved SC joint and direct the central ray tangential to the joint and parallel to the opposite clavicle (85). Place the cassette against the opposite shoulder and centered on the manubrium (Fig. 78.25).

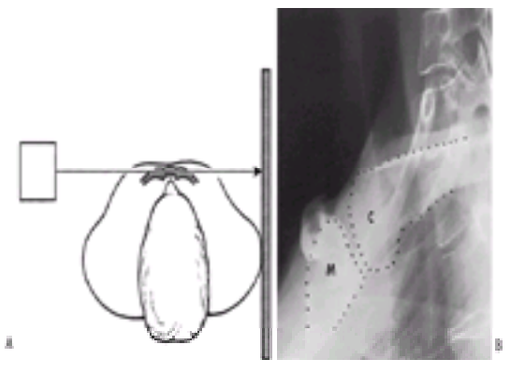

***Figure 78.25.*** **A:** Positioning of the patient for radiograph evaluation of the SC joint, as described by Heinig. **B:** Heinig view demonstrating a normal relationship between the medial end of the clavicle (*C*) and the manubrium (*M*).

### *Hobbs View*

For the Hobbs view (86), seat the patient at the x-ray table, high enough to lean forward over the table. Place the cassette on the table, and position the lower anterior rib cage against the cassette (Fig. 78.26). Have the patient lean forward so that the nape of the flexed neck is almost parallel to the table. The flexed elbows straddle the cassette and support the head and neck. Place the x-ray source above the nape of the neck, and direct the central beam through the cervical spine to project the SC joints onto the cassette.

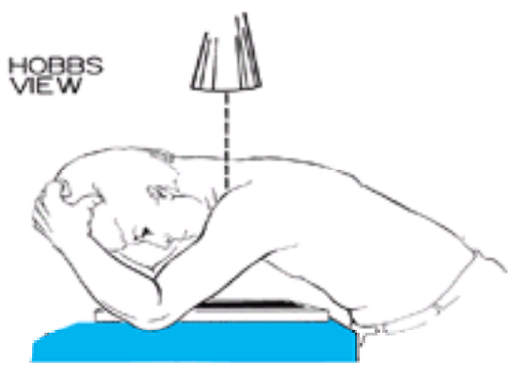


***Figure 78.26.*** Positioning of the patient for radiograph evaluation of the SC joint, as recommended by Hobbs. (Redrawn from Hobbs DW. The SC Joint: A New Axial Radiographic View. *Radiology* 1968;90:801.)

### *Serendipity View*

Rockwood described the “serendipity” view of the SC joint, which is a 40° cephalic tilt view (Fig. 78.27). On this view the medial end of the clavicle will be displaced more anteriorly for an anterior dislocation and posteriorly for a posterior dislocation compared with the normal side (Fig. 78.28).

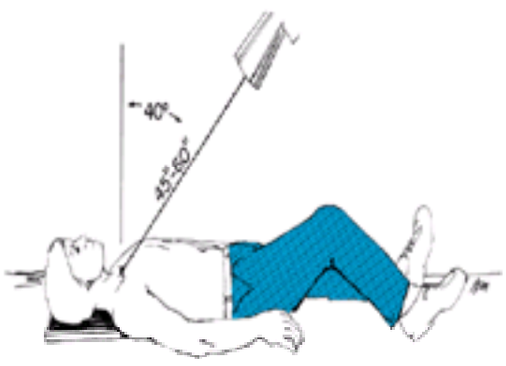

***Figure 78.27.*** Positioning of the patient to take the “serendipity” view of the SC joints. The x-ray tube is tilted 40° from the vertical position and aimed directly at the manubrium. The nongrid cassette should be large enough to receive the projected images of the medial halves of both clavicles. In children, the tube distance from the patient should be about 45 in.; in thicker-chested adults, the distance should be 60 in.

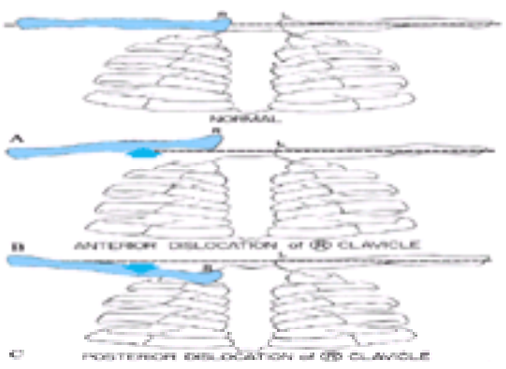

***Figure 78.28.*** Interpretation of the cephalic tilt x-ray films of the SC joints. **A:** In the normal person, both clavicles appear on the same imaginary line drawn horizontally across the film. **B:** In a patient with anterior dislocation of the right SC joint, the medial half of the right clavicle is projected above the imaginary line drawn through the

level of the normal left clavicle. **C:** If the patient has a posterior dislocation of the right SC joint, the medial half of the right clavicle is displaced below the imaginary line drawn through the normal left clavicle.

Without question, the CT scan is the best technique to study the SC joint (Fig. 78.29). It clearly distinguishes injuries of the joint from fractures of the medial clavicle and defines minor subluxations of the joint.

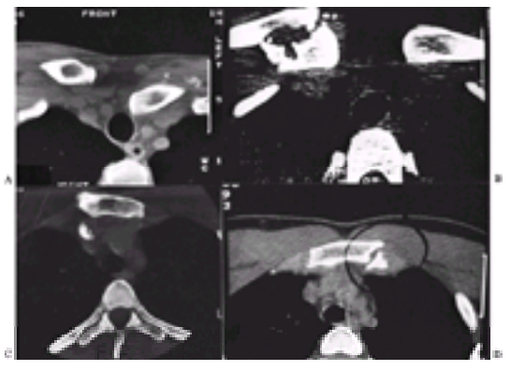

***Figure 78.29.*** Computed tomography scans of the SC joint demonstrating various types of injuries. **A:** Posterior dislocation of the left clavicle compressing the great vessels and producing swelling of the left arm. **B:** Fracture of the medial clavicle that does not involve the articular surface. **C:** Fragment of bone displaced posteriorly into the great vessel. **D:** Fracture of the medial clavicle into the SC joint. (Reprinted with permission from Rockwood CA, Matsen F III, eds. *The Shoulder.* Philadelphia: WB Saunders.)

## TREATMENT

### *Nonoperative Treatment*

For the mildly sprained SC joint, apply ice for the first 12 to 24 hours, followed by heat. Place the upper extremity in a sling for 3 to 4 days, then allow the patient gradually to use the arm in everyday activities.

For subluxation of the SC joint, treat symptomatically in the first 48 hours as above. Whether the joint is subluxated anteriorly or posteriorly, reduce it by drawing the shoulders backward as if reducing and holding a fracture of the clavicle. Use a figure-of-eight clavicle strap to hold the reduction. Also apply a sling and swath to hold up the shoulder and to prevent motion of the arm. Protect the shoulder for 4 to 6 weeks.

In anterior dislocations, closed reduction of the SC joint may be accomplished with local or general anesthesia or, in stoic patients, with conscious sedation or without anesthesia. Position the patient supine on a table, lying on a 3- to 4-in.-thick pad between the shoulders. In this position, the clavicle may reduce with direct gentle pressure over the anteriorly displaced clavicle. Sometimes, both shoulders must be pushed back to the table while an assistant applies pressure to the anteriorly displaced clavicle. When the pressure is released, the clavicle usually dislocates again, but occasionally the clavicle will remain reduced.

**Postreduction Care** If, with the shoulders held back, the SC joint remains reduced, stabilize the shoulders with a soft figure-of-eight dressing, a commercial clavicle strap harness, or a plaster figure-of-eight cast (see Chapter 10) combined with a sling. Continue immobilization for 6 weeks and then have the patient avoid strenuous activities for another 2 weeks. If the SC joint again dislocates when the reduction pressure is released, as it usually does, use a figure-of-eight dressing or a sling for symptomatic treatment. Although some authors have recommended operative repair of anterior dislocations of the SC joint, we believe that the operative complications are too great, and the end results are too unsatisfactory, to consider an open reduction.

Complications and associated injuries are common with posterior dislocation of the SC joint; prompt diagnosis and treatment are important.

Rule out damage to the pulmonary and vascular systems. A CT scan is indicated occasionally, combined with an aortogram, if vascular injury is suspected. Consultation with a thoracic or vascular surgeon may be indicated before reduction. Posterior dislocation of the clavicle into the right pulmonary artery has been reported (189).

General anesthesia is usually required for reduction of a posterior dislocation of the SC joint, although reduction with conscious sedation is possible. The treatment of choice for posterior SC dislocation is closed reduction (38,45,46,65,75,85,120,121,127,143,158,173).

**Methods of Closed Reduction** Many different techniques have been described for closed reduction of the posterior dislocation of the SC joint.

- For the abduction traction technique (57,65,127,152,158), position the patient supine with the dislocated shoulder near the edge of the table. Place a 3- to 4-in.-thick sandbag between the shoulders (Fig. 78.30).

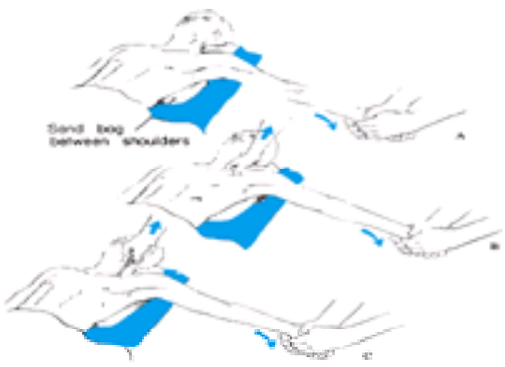


***Figure 78.30.*** Technique for closed reduction of the SC joint. **A:** The patient is positioned supine with a sandbag placed between the shoulders. Traction is then applied to the arm against countertraction in an abducted and slightly extended position. In anterior dislocations, direct pressure over the medial end of the clavicle may reduce the joint. **B:** In posterior dislocations, in addition to the traction, it may be necessary to manipulate the medial end of the clavicle with the fingers to dislodge the clavicle from behind the manubrium. **C:** In stubborn posterior dislocations, it may be necessary to sterilely prepare the medial end of the clavicle and use a towel clip to grasp around the medial clavicle to lift it back into position.

- Apply lateral traction to the abducted arm and gradually extend the shoulder. This procedure may be all that is necessary to accomplish the reduction. The clavicle usually reduces with an audible snap or pop, and it is almost always stable. Too much extension can bind the anterior surface of the dislocated medial clavicle on the back of the manubrium. Occasionally, it may be necessary to grasp the medial clavicle with your fingers to dislodge it from behind the sternum. If this maneuver fails, prep the skin, and use a sterile towel clip to grasp the medial clavicle to apply lateral and anterior traction to reduce it.
- In the adduction traction technique, position the patient supine with a 3- to 4-in. bolster between the shoulders. Apply traction to the arm in adduction while downward pressure is exerted on the shoulders. The pressure levers the clavicle over the first rib into its normal position. This technique may succeed when the abduction traction technique has failed (34).
- Alternative techniques include placing the patient supine on the table with three or four folded towels between the shoulders and applying forward pressure on both shoulders, or placing a knee between the shoulders of the seated patient and pulling back on both shoulders (62,85). Closed reduction usually becomes

more difficult after 48 hours, but it has been successful as late as 4 and 5 days after the injury (34,104).

**Postreduction Care** After reduction, immobilize the shoulders in extension for 4 to 6 weeks with a figure-of-eight dressing or similar dressing.

***Operative Treatment***

In an open reduction, try not to disturb the anterior ligaments, if possible. If anterior ligaments remain intact, then, with the shoulders held back in a figure-of-eight dressing, the reduction may be stable. If all the ligaments are disrupted, then stabilization of the SC joint or resection of the medial 1 to 1.5 in. of the medial clavicle and stabilization of the remaining clavicle to the first rib may be necessary.

Procedures to stabilize the unstable, recurrent, or unreduced SC dislocation include the following:

- Local ligament repair and pin or wire stabilization (30,32,54,56,62).
- Circlage wires across the joint (7,60,77,80,95,138,145,173,174).
- Figure-of-eight carbon fiber (36).
- Reconstruction of the SC ligaments with tendons or fascia of the sternocleidomastoid, subclavian, or pectoralis major muscles (11,37,72,74,82,115).
- Loops of fascia lata between the clavicle and sternum or first rib (7,98,113,125,171).
- *Arthodesis* (150) *is to be avoided.*

Most adults cannot tolerate posterior displacement of the clavicle into the mediastinum and late complications involving underlying vascular structures, so an operative procedure to correct the situation is nearly always required. These include open reduction and one of the reconstructions mentioned above or resection of the medial end of the clavicle (described under Authors' Preferred Method of Treatment; 13,14,28,121,125,147). Because children usually have an epiphyseal slip, remodeling will often correct the deformity, and surgery is rarely required (154).

***Authors' Preferred Method of Treatment***

**Anterior Dislocations** In most instances, knowing that the anterior dislocation will be unstable, we try to reduce the anterior displacement, using the technique previously described.

Most of the anterior injuries that we have treated in patients up to 25 years of age are not dislocations of the SC joint but type I or II physeal injuries, which heal and remodel without operative treatment. Patients older than 23 to 25 years with anterior dislocations of the SC joint do have persistent prominence of the anterior clavicle. It does not, however, seem to interfere with usual activities and, in some cases, has not even interfered with heavy manual labor.

We wish to reemphasize that we do not recommend open reduction of the joint and would never recommend transfixing pins across the SC joint.

We do not usually operate on acute posterior SC joint dislocations. Furthermore, once the joint has been reduced closed, it is usually stable. For closed reduction, we use the traction–abduction method previously described.

If the traction in abduction and extension is not successful, grasp or push down on the clavicle to dislodge it from behind the sternum. If unsuccessful, use the sterile towel clip method described previously. With the towel clip, grasp completely around the shaft of the clavicle, as the dense cortical bone prevents the purchase of the towel clip tines into the clavicle. Following the reduction, the SC joint is normally stable, but we always hold the shoulders back in a well-padded figure-of-eight clavicle strap for 3 to 4 weeks to allow for soft-tissue healing.

**Operative Technique** When operating on the SC joint, take care to evaluate the residual stability of the medial clavicle. If the costoclavicular ligaments are intact, the clavicle medial to the ligaments can be resected and beveled smooth (Fig. 78.31). If the ligaments are gone, the clavicle must be stabilized to the first rib. If too much clavicle is resected, or if the clavicle is not stabilized to the first rib, an increase in symptoms can occur.

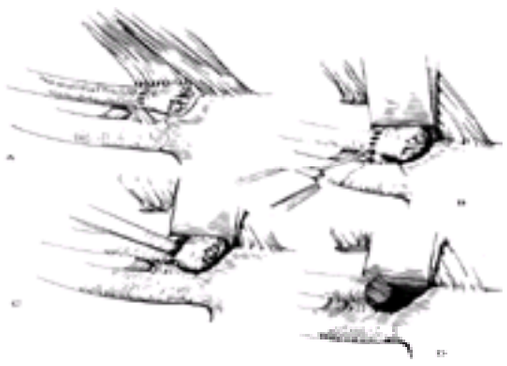

***Figure 78.31.*** Technique for resecting the medial clavicle for degenerative arthritis. **A:** Care must be taken to remove only that part of the clavicle medial to the costoclavicular (rhomboid) ligaments. There must be adequate protection for the vital structures that lie posterior to the medial end of the clavicle. **B,C:** An air drill with a side-cutting bur can be used to perform the osteotomy. **D:** When the fragment of bone has been removed, the dorsal and anterior borders of the clavicle should be smoothed to give a better cosmetic appearance.

- Place the patient supine, with three to four towels or sandbags between the scapulae. Drape the upper extremity free so that lateral traction can be applied during the surgery. In addition, place a folded sheet around the patient's thorax to be used for countertraction if traction on the involved extremity is required.
- Make an anterior incision that parallels the superior border of the medial 3 to 4 in. of the clavicle and then extends downward over the sternum just medial to the SC joint (Fig. 78.32). (Having a thoracic surgeon available may be advisable.) Remove sufficient soft tissues to expose the joint but leave the anterior capsular ligament intact.

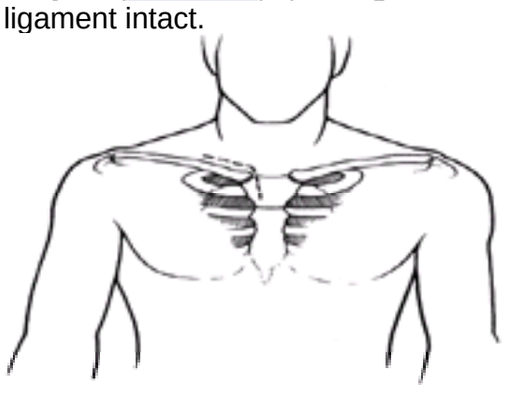

***Figure 78.32.*** Proposed skin incision for open reduction of a posterior SC dislocation.

- Reduce the clavicle with traction and countertraction while lifting up anteriorly with a clamp around the medial clavicle. Along with the traction and countertraction, it may be necessary to use an elevator to pry the clavicle back into its articulation with the sternum. When the reduction has been obtained, and with the shoulders held back, the reduction will be stable because the anterior capsule has been left intact.
- If the anterior capsule is damaged or is insufficient to prevent anterior displacement of the medial end of the clavicle, we recommend excision of the medial 1 to 1.5 in. of the clavicle and securing the residual clavicle to the first rib with 1-mm Dacron tape.
- Expose the medial clavicle by careful subperiosteal dissection. Identify and preserve any remnant of the capsular or intra-articular disc ligaments, as these structures can be used to stabilize the medial clavicle. Ordinarily, the intra-articular disc ligament is a very dense, fibrous structure that arises from the

synchondral junction of the first rib to the sternum and passes through the SC joint, dividing the joint into two separate spaces. The capsular ligament covers the anterosuperior and posterior aspects of the joint and represents thickenings of the joint capsule. This ligament is primarily attached to the epiphysis of the medial clavicle and is usually avulsed from this structure with posterior SC dislocations. Similarly, the intra-articular disc ligament is usually intact where it arises from the synchondral junction of the first rib and sternum and avulsed from its attachment site on the medial clavicle.

- If the sternal attachment site of these structures is intact, weave a nonabsorbable #1 cottony Dacron suture back and forth through the ligaments so that the ends of the suture exit through the avulsed free end of the tissue.
- Resect the medial end of the clavicle, being careful to protect the underlying structures. Do not damage the costoclavicular (rhomboid) ligament or the vascular structures that are located posterior to the medial clavicle and SC joint. Protect these vital structures by passing a curved crego or ribbon retractor around the posterior aspect of the medial clavicle. Drill holes through both cortices of the clavicle at the intended site of clavicular osteotomy, and then use an air drill with a side-cutting burr or an osteotome to complete the osteotomy. Bevel the anterior and superior corners of the clavicle with an air burr.
- Next, enlarge the medullary canal of the medial clavicle with drills and curets to receive the transferred intra-articular disc ligament (Fig. 78.33). Drill two small holes in the superior cortex of the medial clavicle, approximately 1 cm lateral to the site of resection (Fig. 78.34). Pass the free ends of the suture into the medullary canal of the medial clavicle and out two small drill holes in the superior cortex of the clavicle (Fig. 78.35). While the clavicle is held in a reduced position, pull the ligament tightly into the medullary canal of the clavicle and tie the sutures, thus securing the transferred ligament into the clavicle (Fig. 78.36). Complete the stabilization procedure by passing several 1-mm cottony Dacron sutures around the medial end of the remaining clavicle and securing the periosteal sleeve of the clavicle to the costoclavicular ligament.

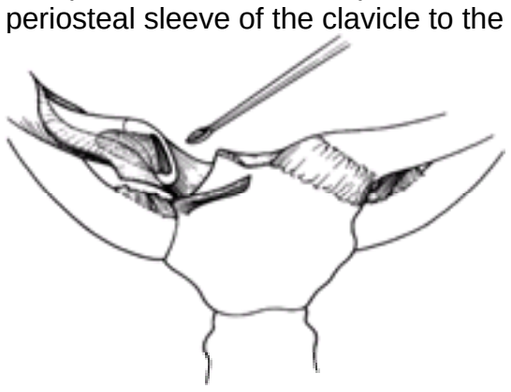

***Figure 78.33.*** The medullary canal of the medial clavicle is curretted in preparation for receiving the transferred intra-articular ligament.

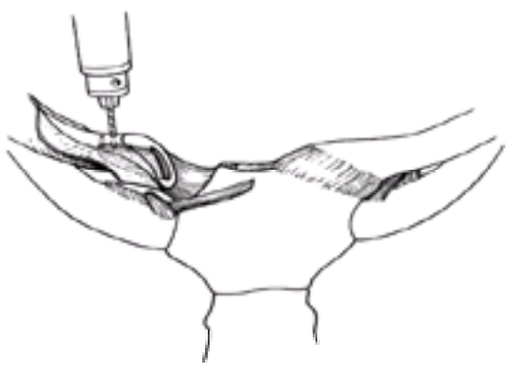

***Figure 78.34.*** Drill holes are placed in the superior cortex of the clavicle, approximately 1 cm lateral to the osteotomy site.

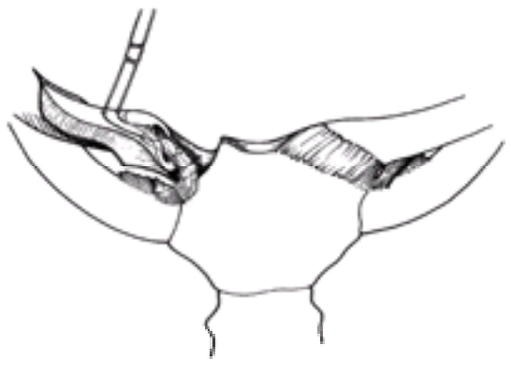

***Figure 78.35.*** The free ends of the suture are passed into the medullary canal and out the two holes in the superior cortex.

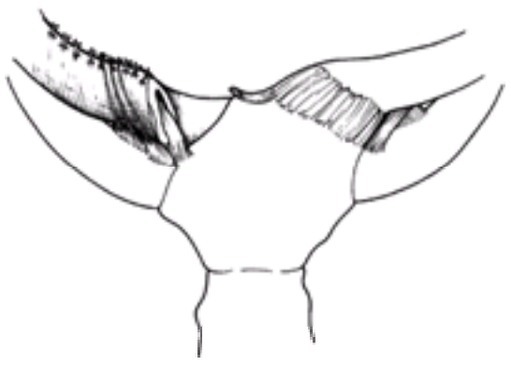

***Figure 78.36.*** Closure of the periosteal sleeve around the medial clavicle and secure fixation of these structures to the costoclavicular ligament.

- Postoperatively, keep the patient in a figure-of-eight dressing for 4 to 6 weeks to allow for healing.

### *Chronic Traumatic Dislocation of the SC Joint*

As previously described, most patients with an unreduced and permanent anterior dislocation of the SC joint are not very symptomatic, have almost a complete range of motion, and can work and even perform manual labor without many problems. In patients who have had a previous failed SC surgery, we perform a repeat arthroplasty with a resection of the medial clavicle, as described above.

If the patient has persistent symptoms of traumatic arthritis for 6 to 12 months following a dislocation, and if the symptoms can be completely relieved by injection of local anesthetic into the SC joint region, we perform an arthroplasty similar to that described earlier in this chapter.

### *Posterior Dislocation*

In the adult, because of the potential problems that can be associated with the clavicle remaining displaced posteriorly into the mediastinum, an open reduction is

usually indicated. This requires excision of the medial 1 in. of the clavicle and stabilization to the first rib as described above.

### *Spontaneous Subluxation or Dislocation*

We have seen 39 patients with spontaneous subluxation or dislocation of the SC joint. About the only symptoms they have is that the medial end of the clavicle subluxates or dislocates anteriorly when they raise their arms overhead (153). This occurs spontaneously and without any significant trauma. Many of these patients have generalized ligamentous laxity. This problem might be considered voluntary or involuntary because it occurs whenever the patient raises the arms to the overhead position. We explain to patients that surgery is of little benefit, that they should discontinue the voluntary aspect of the dislocation, and that in time either the symptoms will disappear or they will completely forget that the dislocation is a problem.

## CHAPTER REFERENCES

Each reference is categorized according to the following scheme: *, classic article; #, review article; !, basic research article; and +, clinical results/outcome study.


+ 1. Alldredge RH. Surgical Treatment of Acromioclavicular Dislocations (Abstract). *J Bone Joint Surg* 1965;46A:1278.

+ 2. Allman FL Jr. Fractures and Ligamentous Injuries of the Clavicle and Its Articulation. *J Bone Joint Surg* 1967;49A:774.

+ 3. Alpert M, Myers MM. Osteolysis of the Acromial End of the Clavicles in Rheumatoid Arthritis. *Am J Roentgenol* 1961;86:251.

+ 4. Anzel SH, Streitz WL. Acute Acromioclavicular Injuries: A Report of Nineteen Cases Treated Non-operatively Employing Dynamic Splint Immobilization. *Clin Orthop* 1974;103:143.

+ 5. Arner O, Sandahl U, Ohrling H. Dislocation of the Acromioclavicular Joint: Review of the Literature and a Report of 56 Cases. *Acta Chir Scand* 1957;113:140.

+ 6. Babe JG, Valle M, Couceiro J. Treatment of Acromioclavicular Disruptions: Trial of a Simple Surgical Approach. *Injury* 1988;19:159.

* 7. Bankart ASB. An Operation for Recurrent Dislocation (Subluxation) of the Sternoclavicular Joint. *Br J Surg* 1938;26:320.

+ 8. Bannister GC, Wallace WA, Stableforth PG, Hutson MA. The Management of Acute Acromioclavicular Dislocation: A Randomized Prospective Controlled Trial. *J Bone Joint Surg* 1989;71B:848.

+ 9. Barber FA. Complete Posterior Acromioclavicular Dislocation: A Case Report. *Orthopedics* 1987;10:493.

+ 10. Barentsz JH, Driessen AP. Fracture of the Coracoid Process of the Scapula with Acromioclavicular Separation: Case Report and Review of the Literature. *Acta Orthop Belg* 1989;55:499.

+ 11. Barth E, Hagen R. Surgical Treatment of Dislocations of the Sternoclavicular Joint. *Acta Orthop Scand* 1983;54:746.

# 12. Bateman JE. Athletic Injuries about the Shoulder in Throwing and Body-Contact Sports. *Clin Orthop* 1962;23:75.

# 13. Bateman JE. *The Shoulder and Neck.* Philadelphia: WB Saunders, 1972.

# 14. Bateman JE. *The Shoulder and Neck, 2nd ed.* Philadelphia: WB Saunders, 1978.

+ 15. Bearden JM, Hughston JC, Whatley GS. Acromioclavicular Dislocation: Method of Treatment. *J Sports Med* 1973;1(4):5.

! 16. Bearn JG. Direct Observations on the Function of the Capsule of the Sternoclavicular Joint in Clavicle Support. *J Anat* 1967;101:159.

+ 17. Bergfeld JA, Andrish JT, Clancy WG. Evaluation of the Acromioclavicular Joint Following First- and Second-Degree Sprains. *Am J Sports Med* 1978;6:153.

+ 18. Bernard TN Jr, Brunet ME, Haddad RJ. Fractured Coracoid Process in Acromioclavicular Dislocations: Report of 4 Cases and Review of the Literature. *Clin Orthop* 1983;175:226.

+ 19. Bigliani LU, Nicholson GP, Faltow EL. Arthroscopic Resection of the Distal Clavicle. *Orthop Clin North Am* 1993;24:133.

+ 20. Bjerneld H, Hovelius L, Thorling J. Acromio-Clavicular Separations Treated Conservatively: A 5-Year Follow-up Study. *Acta Orthop Scand* 1983;54:743.

+ 21. Björkenheim JM, Paavolainen P, Slatis P. Surgical Treatment of Acromioclavicular Dislocation (Abstract). *Acta Orthop Scand* 1983;54:533.

+ 22. Bonnin JG. Spontaneous Subluxation of the Sternoclavicular Joint. *Br Med J* 1960;2:274.

+ 23. Booth CM, Roper BA. Chronic Dislocation of the Sternoclavicular Joint: An Operative Repair. *Clin Orthop* 1979;140:17.

* 24. Bosworth BM. Acromioclavicular Separation: New Method of Repair. *Surg Gynecol Obstet* 1941;73:866.

* 25. Bosworth BM. Acromioclavicular Dislocation: End Results of Screw Suspension Treatment. *Ann Surg* 1948;127:98.

+ 26. Bosworth BM. Calcium Deposits in the Shoulder and Subacromial Bursitis. A Survey of 12,122 Shoulders. *JAMA* 1941;116:2477.

+ 27. Bosworth BM. Complete Acromioclavicular Dislocation. *N Engl J Med* 1949;241:221.

+ 28. Breitner S, Wirth CJ. [Resection of the Acromial and Sternal Ends of the Clavicular.] *Z Orthop* 1987;125:363.

+ 29. Bremner, RA. Nonarticular, Non-effective Subacute Arthritis of the Sterno-clavicular Joint. *J Bone Joint Surg* 1959;41B:749.

+ 30. Brooks AL, Henning GD. Injury to the Proximal Clavicular Epiphysis (Abstract). *J Bone Joint Surg* 1972;54A:1357.

+ 31. Brower AC, Sweet DE, Keats TE. Condensing Osteitis of the Clavicle: A New Entity. *Am J Roentgenol* 1974;131:17.

+ 32. Brown JE. Anterior Sternoclavicular Dislocation: A Method of Repair. *Am J Orthop* 1961;31:184.

+ 33. Buchmann M. Swelling of the Sternoclavicular Joint. *Acta Med Orient* 1958;17:65.

+ 34. Buckerfield CT, Castle ME. Acute Traumatic Retrosternal Dislocation of the Clavicle. *J Bone Joint Surg* 1984;66A:379.

* 35. Bunnell S. Fascial Graft for Dislocation of the Acromioclavicular Joint. *Surg Gynecol Obstet* 1928;46:563.

+ 36. Burri C, Neugebauer R. Carbon Fiber Replacement of the Ligaments of the Shoulder Girdle and the Treatment of Lateral Instability of the Ankle Joint. *Clin Orthop* 1985;196:112.

+ 37. Burrows HJ. Tenodesis of Subclavius in the Treatment of Recurrent Dislocation of the Sternoclavicular Joint. *J Bone Joint Surg* 1951;33B:240.

+ 38. Butterworth RD, Kirk AA. Fracture Dislocation of the Sternoclavicular Joint: Case Report. *Va Med* 1952;79:98.

+ 39. Cadenat FM. The Treatment of Dislocations and Fractures of the Outer End of the Clavicle. *Int Clin* 1917;1:145.

+ 40. Cahill BR. Osteolysis of the Distal Part of the Clavicle in Male Athletes. *J Bone Joint Surg* 1982;64A:1053.

+ 41. Cantlon GE, Gluckman JL. Sternoclavicular Joint Hypertrophy Following Radical Neck Dissection. *Head Neck Surg* 1983;5:218.

+ 42. Carr AJ, Broughton MS. Acromioclavicular Dislocation Associated with Fracture of the Coracoid Process. *J Trauma* 1989;29:125.

! 43. Cave AJE. The Nature and Morphology of the Costoclavicular Ligament. *J Anat* 1961;95:170.

# 44. Codman EA. Rupture of the Supraspinatus Tendon. In: *The Shoulder.* Brooklyn, NY: G. Miller, 1934;123.

+ 45. Collins JJ. Retrosternal Dislocation of the Clavicle (Abstract). *J Bone Joint Surg* 1972;54B:203.

+ 46. Cope R, Riddervold HO. Posterior Dislocation of the Sternoclavicular Joint: Report on Two Cases, with Emphasis on Radiological Management and Early Diagnosis. *Skel Radiol* 1988;17:247.

+ 47. Covelli M, Lapadula G, Pipitone N, et al. Isolated Sternoclavicular Joint Arthritis in Heroin Addicts and/or HIV Positive Patients: A Report of Three Cases. *Clin Rheumatol* 1993;12:422.

+ 48. Cox S. The Fate of the Acromioclavicular Joint in Athletic Injuries. *Am J Sports Med* 1981;9:50.

+ 49. Currey H. Primary Gout Affecting the Sternoclavicular Joint (Letter to the Editor). *Br Med J* 1976;1:583.

+ 50. Curtis RJ. Operative Management of Children's Fractures of the Shoulder Region. *Orthop Clin North Am* 1990;21:315.

+ 51. Daffner RH, Gehweileer JA Jr. Case Report 236: Diagnosis: Neuropathic Arthropathy of the Sternoclavicular Joint, Secondary to Syringomyelia. *Skel Radiol* 1983;10:113.

+ 52. Dahl E. Follow-up after Coracoclavicular Ligament Prosthesis for Acromioclavicular Joint Dislocation (Abstract). *Acta Chir Scand [Suppl]* 1981;506:96.

+ 53. Dahl E. [Velour Prosthesis in Fractures and Dislocations in the Clavicular Region.] *Chirurgie* 1982;53:120.

+ 54. Denham RH Jr, Dingley AF Jr. Epiphyseal Separation of the Medial End of the Clavicle. *J Bone Joint Surg* 1967;49A:1179.

# 55. DePalma AF, Callery G, Bennett GA. Variational Anatomy and Degenerative Lesions of the Shoulder Joint. *Instr Course Lect* 1949;VI:255.

# 56. DePalma AF. *Surgery of the Shoulder, 2nd ed.* Philadelphia: JB Lippincott, 1973.

+ 57. DePalma AF. Surgical Anatomy of the Acromioclavicular and Sternoclavicular Joints. *Surg Clin North Am* 1963;43:1540.

+ 58. Dias KK. Steingold RA, Richardson RA, et al. The Conservative Treatment of Acromioclavicular Dislocation: Review after Five Years. *J Bone Joint Surg* 1987;69B:719.

+ 59. Eaton R, Serletti J. Computerized Axial Tomography: A Method of Localizing Steinmann Pin Migration: A Case Report. *Orthopedics* 1981;4:1357.

+ 60. Ecke H. Sternoclavicular Dislocations. (Personal communication, 1984.)

+ 61. Eidman DK, Siff SJ, Tullos HS. Acromioclavicular Lesions in Children. *Am J Sports Med* 1981;9:150.

+ 62. Elting JJ. Retrosternal Dislocation of the Clavicle. *Arch Surg* 1972;104:35.

+ 63. Epstein BS. Sternoclavicular Arthritis in Patients with Scleroderma and Rheumatoid Arthritis. *Am J Roentgenol* 1963;89:1236.

+ 64. Falstie-Jensen S, Mikkelsen P. Pseudodislocation of the Acromioclavicular Joint. *J Bone Joint Surg* 1982;64B:368.

+ 65. Ferry AM, Rook FW, Masterson JH. Retrosternal Dislocation of the Clavicle. *J Bone Joint Surg* 1957;39A:905.

+ 66. Gartsman GM, Combs AH, David PF. Arthroscopic Acromioclavicular Resection: An Anatomical Study. *Am J Sports Med* 1991;19:2.

+ 67. Gerber C, Rockwood CA Jr. Subcoracoid Dislocation of the Lateral End of the Clavicle: A Report of Three Cases. *J Bone Joint Surg* 1987;69A:924.

# 68. Gerster JC, Lagier R, Nicod L. Case Report 31 Open-Quiz Solution. *Skel Radiol* 1985;14:53.

+ 69. Glick JM, Milburn LJ, Haggerty JF, Nishimoto D. Dislocated Acromioclavicular Joint: Follow-up Study of 35 Unreduced Acromioclavicular Dislocations. *Am J Sports Med* 1977;5:264.

+ 70. Goldberg D. Acromioclavicular Joint Injuries: A Modified Conservative Form of Treatment. *Am J Surg* 1946;71:529.

+ 71. Gorman JB, Stone RT, Keats TE. Changes in the Sternoclavicular Joint Following Radical Neck Dissection. *Am J Roentgenol* 1971;111:584.

# 72. Grant JCB. *Method of Anatomy, 7th ed.* Baltimore: Williams & Wilkins, 1965.

+ 73. Grauthoff VH, Klammer HL. [Complications Due to Migration of a Kirschner Wire from the Clavicle.] *Fortschr Rontgenstr* 1978;128:592.

# 74. Gray H. Osteology. In: Goss CM, ed. *Anatomy of the Human Body, 28th ed.* Philadelphia: Lea & Febiger, 1966;324.

+ 75. Gunther WA. Posterior Dislocation of the Sternoclavicular Joint: Report of a Case. *J Bone Joint Surg* 1949;31A:878.

+ 76. Gurd FB. The Treatment of Complete Dislocation of the Outer End of the Clavicle: A Hitherto Undescribed Operation. *Ann Surg* 1941;113:1094.

+ 77. Habernek H, Hertz H. [Origin, Diagnosis and Treatment of Traumatic Dislocation of Sternoclavicular Joint.] *Aktuel Traumatol* 1987;17:25.

+ 78. Hak DJ, Johnson EE. Avulsion Fracture of the Coracoid Associated with Acromioclavicular Dislocation: Case Report and Review of the Literature. *J Orthop Trauma* 1993;7:381.

+ 79. Hamilton-Wood C, Hollingworth P, Dieppe P, et al. The Painful Swollen Sterno-clavicular Joint. *Br J Radiol* 1985;58:941.

+ 80. Hartman TJ, Dunnagan WA. Cinearthrography of the Sternoclavicular Joint. (Personal communication, November, 1979.)

+ 81. Hastings DE, Horne JG. Anterior Dislocation of the Acromioclavicular Joint. *Injury* 1979;10:284.

+ 82. Haug W. Retention einer seltenen Sterno-clavicular-luxationsfraktur mittels modifizierter Y-Platte der AO. *Aktuel Traumatol* 1986;16:39.

+ 83. Havranek P. Injuries of Distal Clavicular Physis in Children. *J Pediatr Orthop* 1989;9:213.

# 84. Hawkins RJ. *The Acromioclavicular Joint.* Paper Presented at AAOS Summer Institute, Chicago, July 10–11, 1980.

+ 85. Heinig CF. Retrosternal Dislocation of the Clavicle: Early Recognition, X-ray, Diagnosis, and Management (Abstract). *J Bone Joint Surg* 1968;50A:830.

+ 86. Hobbs DW. Sternoclavicular Joint: A New Axial Radiographic View. *Radiology* 1968;90:801.

+ 87. Horvarth F, Kerry L. Degenerative Deformations of the Acromioclavicular Joint in the Elderly. *Arch Gerontol Geriatr* 1984;3:259.

+ 88. Imatani RJ, Hanlon JJ, Cady GW. Acute Complete Acromioclavicular Separation. *J Bone Joint Surg* 1975;57A:328.

* 89. Inman VT, Saunders JB, Abbott LC. Observations on the Function of the Shoulder Joint. *J Bone Joint Surg* 1944;26:1.

+ 90. Jakobsen BW. [Acromioclavicular Dislocation. Conservative or Surgical Treatment?] *Ugeskr Laeger* 1989;151:235.

+ 91. Jay GR, Monnet JC. *The Bosworth Screw in Acute Dislocations of the Acromioclavicular Joint.* Paper Presented at Clinical Conference, University of Oklahoma Medical Center, April, 1969.

+ 92. Kappakas GS, McMaster JH. Repair of Acromioclavicular Separation Using a Dacron Prosthesis Graft. *Clin Orthop* 1978;131:247.

+ 93. Katznelson A, Nerubay J, Oliver S. Dynamic Fixation of the Avulsed Clavicle. *J Trauma* 1976;16:842.

+ 94. Keats TE, Pope TL Jr. The Acromioclavicular Joint: Normal Variation and the Diagnosis of Dislocation. *Skel Radiol* 1988;16:159.

+ 95. Kennedy JC. Retrosternal Dislocation of the Clavicle. *J Bone Joint Surg* 1949;31B:74.

+ 96. Kennedy JC, Cameron H. Complete Dislocation of the Acromioclavicular Joint. *J Bone Joint Surg* 1954;36B:202.

+ 97. Kennedy JC. Complete Dislocation of the Acromioclavicular Joint: 14 Years Later. *J Trauma* 1968;8:311.

* 98. Key JA, Conwell HE, eds. *The Management of Fractures, Dislocations, and Sprains, 5th ed.* St. Louis: CV Mosby, 1951;458.

+ 99. Kier R, Wain S, Apple J, Martinez S. Osteoarthritis of the Sternoclavicular Joint: Radiographic Features and Pathologic Correlation. *Invest Radiol* 1986;21:226.

+ 100. Kofoed H, Thomsen P, Lindenbergs S. Serous Synovitis of the Sternoclavicular Joint: Differential Diagnostic Aspects. *Scand J Rheumatol* 1985;14:61.

+ 101. Kruger GD, Rock MG, Munro TG. Condensing Osteitis of the Clavicle: A Review of the Literature and Report of Three Cases. *J Bone Joint Surg* 1987;69A:550.

+ 102. Kumar A. Management of Coracoid Process Fracture with Acromioclavicular Joint Dislocation. *Orthopaedics* 1990;13:770.

+ 103. Lancourt JB. Acromioclavicular Dislocation with Adjacent Clavicular Fracture in a Horseback Rider: A Case Report. *Am J Sports Med* 1990;18:321.

+ 104. Leighton RK, Buhr AJ, Sinclairs AM. Posterior Sternoclavicular Dislocations. *Can J Surg* 1986;29:104.

+ 105. Levine AH, Pais MJ, Schwartz EE. Posttraumatic Osteolysis of the Distal Clavicle with Emphasis on Early Radiologic Changes. *Am J Roentgenol* 1976;127:781.

+ 106. Levy M, Goldberg I, Fischel RE, et al. Friedrich's Disease: Aseptic Necrosis of the Sternal End of the Clavicle. *J Bone Joint Surg* 1981;63B:539.

+ 107. Liberson F. The Role of the Coracoclavicular Ligaments in Affections of the Shoulder Girdle. *Am J Surg* 1939;44:145.

+ 108. Lindsey RW, Gutowski WT. The Migration of a Broken Pin Following Fixation of the Acromioclavicular Joint: A Case Report and Review of the Literature. *Orthopedics* 1986;9:413.

+ 109. Lindsey RW, Leach JA. Sternoclavicular Osteomyelitis and Pyoarthrosis as a Complication of Subclavian Vein Catheterization: A Case Report and Review of the Literature. *Orthopedics* 1984;7:1017.

+ 110. Lizaur A, Marco L, Cebrian R. Acute Dislocation of the Acromioclavicular Joint. Traumatic Anatomy and the Importance of Deltoid and Trapezius. *J Bone Joint Surg* 1994;76BN:602.

+ 111. Lom P. [Acromioclavicular Disjunction: I. Diagnosis and Classification, II. Surgical Treatment—the Author's Modification.] *Rozhl Chir* 1988;67:253.

+ 112. Lowe GP, Fogarty MJP. Acute Acromioclavicular Joint Dislocation: Results of Operative Treatment with the Bosworth Screw. *Aust NZ J Surg* 1977;47:664.

+ 113. Lowman CL. Operative Correction of Old Sternoclavicular Dislocation. *J Bone Joint Surg* 1928;10:740.

* 114. Lucas DB. Biomechanics of the Shoulder Joint. *Arch Surg* 1973;107:425.

+ 115. Lunseth PA, Chapman KW, Frankel VH. Surgical Treatment of Chronic Dislocation of the Sternoclavicular Joint. *J Bone Joint Surg* 1975;57B:193.

+ 116. MacDonald PB, Alexander MJ, Frejuk J, Johnson G. Comprehensive Functional Analysis of Shoulders Following Complete Acromioclavicular Separation. *Am J Sports Med* 1988;16:475.

+ 117. Malcapi C, Grassi G, Oretti D. Posterior Dislocation of the Acromioclavicular Joint: A Rare or an Easily Overlooked Lesion. *Ital J Orthop Traumatol* 1978;4:79.

+ 118. Martin-Herrero T, Rodriguez-Merchan C, Munuera-Martinez L. Fracture of the Coracoid Process: Presentation of Seven Cases and Review of the Literature. *J Trauma* 1993;30:1597.

+ 119. Mazet RJ. Migration of a Kirschner Wire from the Shoulder Region into the Lung: Report of Two Cases. *J Bone Joint Surg* 1943;25A:477.

+ 120. McKenzie JMM. Retrosternal Dislocation of the Clavicle: A Report of Two Cases. *J Bone Joint Surg* 1963;45B:138.

# 121. McLaughlin HL. *Trauma.* Philadelphia: WB Saunders, 1959.

+ 122. McPhee IB. Inferior Dislocation of the Outer End of the Clavicle. *J Trauma* 1980;20:709.

+ 123. Mehta JC, Sachdev A, Collins JJ. Retrosternal Dislocation of the Clavicle. *Injury* 1973;5:79.

+ 124. Meyers JF. Arthroscopic Debridement of the Acromioclavicular Joint and Distal Clavicle Resection. In: McGinty JB, Caspari RB, Jackson RW, et al, eds. *Operative Arthroscopy.* New York: Raven Press, 1991;557.

+ 125. Milch H. The Rhomboid Ligament in Surgery of the Sternoclavicular Joint. *J Int Coll Surg* 1952;17:41.

+ 126. Millbourn E. On Injuries to the Acromioclavicular Joint: Treatment and Results. *Acta Orthop Scand* 1950;19:349.

+ 127. Mitchell WJ, Cobey MC. Retrosternal Dislocation of the Clavicle. *Med Ann DC* 1960;29:546.

+ 128. Moneim MS, Balduini FC. Coracoid Fractures as a Complication of Surgical Treatment by Coracoclavicular Tape Fixation. *Clin Orthop* 1982;168:133.

+ 129. Montgomery SP, Loyd RD. Avulsion Fracture of the Coracoid Epiphysis with Acromioclavicular Separation. *J Bone Joint Surg* 1977;59A:963.

+ 130. Muir SK, Kinsella PL, Trevilcock RG, Blackstone IW. Infectious Arthritis of the Sternoclavicular Joint. *Can Med Assoc J* 1985;132:1289.

+ 131. Mulier T, Stuyek J, Fabry G. Conservative Treatment of Acromioclavicular Dislocation: Evaluation of Functional and Radiological Results after Six Years Follow-up. *Acta Orthop Belg* 1993;59:255.

* 132. Mumford EB. Acromioclavicular Dislocation. *J Bone Joint Surg* 1941;23:799.

+ 133. Naumann TH. [The Rare Case of Habitual Lateral Dislocation of the Clavicle in Dorsal Subacromial Direction: A Case Report.] *Z Orthop* 1986;124:34.

+ 134. Nelson CL. Repair of Acromio-clavicular Separations with Knitted Dacron Graft. *Clin Orthop* 1979;143:289.

+ 135. Nieminen S, Aho AJ. Anterior Dislocation of the Acromioclavicular Joint. *Ann Chir Gynaecol* 1984;73:21.

+ 136. Nittis S. Prominence of the Right Sternoclavicular Junction in Lepers. *Urol Cutan Rev* 1937;41:625.

+ 137. Norrell H. Llewellyn RC. Migration of a Threaded Steinmann Pin from an Acromioclavicular Joint into the Spinal Canal: A Case Report. *J Bone Joint Surg* 1965;46A:1024.

+ 138. Nutz V. [Fracture Dislocation of the Sternoclavicular Joint.] *Unfallchirurgie* 1986;89:145.

+ 139. Oppenheimer A. Arthritis of the Acromioclavicular Joint. *J Bone Joint Surg* 1943;25:867.

+ 140. Paice EW, Wright FW, Hill AGS. Sternoclavicular Erosions in Polymyalgia Rheumatica. *Ann Rheum Dis* 1983;42:379.

+ 141. Park JP, Arnold JA, Coker TP, et al. Treatment of Acromioclavicular Separations: A Retrospective Study. *Am J Sports Med* 1980;8:251.

+ 142. Patterson WR. Inferior Dislocation of the Distal End of the Clavicle. *J Bone Joint Surg* 1967;49A:1184.

+ 143. Peacock HK, Brandon JR, Jones OL. Retrosternal Dislocation of the Clavicle. *South Med J* 1970;63:1324.

+ 144. Petersson CJ. The Acromioclavicular Joint in Rheumatoid Arthritis. *Clin Orthop* 1987;223:86.

+ 145. Pfister U, Weller S. [Luxation of the Sternoclavicular Joint.] *Unfallchirurgie* 1982;8:81.

+ 146. Poland J. *Traumatic Separation of Epiphyses of the Upper Extremity.* London: Smith, Elder, 1898;135.

+ 147. Pridie K. Dislocation of the Acromio-clavicular and Sterno-clavicular Joints (Abstract). *J Bone Joint Surg* 1959;41B:429.

+ 148. Resnick D, Niwayama G. Resorption of the Undersurface of the Distal Clavicle in Rheumatoid Arthritis. *Radiology* 1976;120:75.

+ 149. Reuler JB, Girard DE, Nardone DA. Sternoclavicular Joint Involvement in Ankylosing Spondylitis. *South Med J* 1978;71:1480.

+ 150. Rice EE. Habitual Dislocation of the Sternoclavicular Articulation: A Case Report. *J Okla State Med Assoc* 1932;25:34.

+ 151. Richter R, Hahn H. Nubling W, Kohler G. [Tuberculosis of the Shoulder Girdle.] *Z Rheumatol* 1985;44:87.

# 152. Rockwood CA Jr. Dislocation of the Sternoclavicular Joint. In: Rockwood CA Jr, Green DP, eds. *Fractures, Vol. 1.* Philadelphia: JB Lippincott, 1975;756.

+ 153. Rockwood CA Jr, Odor JM. Spontaneous Atraumatic Anterior Subluxations of the Sternoclavicular Joint in Young Adults: Report of 37 Cases (Abstract). *Orthop Trans* 1988;12:557.

# 154. Rockwood CA Jr. The Shoulder: Facts, Confusions, and Myths. *Int Orthop* 1991;15:401.

# 155. Rowe CR. Symposium on Surgical Lesions of the Shoulder: Acute and Recurrent Dislocation of the Shoulder. *J Bone Joint Surg* 1962;44A:977.

+ 156. Sadr B, Swann M. Spontaneous Dislocation of the Sternoclavicular Joint. *Acta Orthop Scand* 1979;50:269.

+ 157. Sage J. Recurrent Inferior Dislocation of the Clavicle at the Acromioclavicular Joint. *Am J Sports Med* 1982;10:145.

+ 158. Salvatore JE. Sternoclavicular Joint Dislocation. *Clin Orthop* 1968;58:51.

+ 159. Schwarz N, Kuderna H. Inferior Acromioclavicular Separation: Report of an Unusual Case. *Clin Orthop* 1980;234:28.

+ 160. Schwarz N, Leixnering M. [Results of Nonreduced Acromioclavicular Tossy III Separations.] *Unfallchirurgie* 1986;89:248.

+ 161. Searle AE, Gluckman R, Sanders R, Breach NM. Sternoclavicular Joint Swellings: Diagnosis and Management. *Br J Plast Surg* 1991;44:403.

+ 162. Tibone J, Sellers R, Tonino P. Strength Testing after Third-degree Acromioclavicular Dislocations. *Am J Sports Med* 1992;20:328.

+ 163. Sethi GK, Scott SM. Subclavian Artery Laceration Due to Migration of a Hagie Pin. *Surgery* 1976;80:644.

+ 164. Sleeswijk-Visser SV, Haarsma SM, Speeckaert MTC. Conservative Treatment of Acromioclavicular Dislocation: Jones Strap vs. Mitella (Abstract). *Acta Orthop Scand* 1984;55:483.

+ 165. Snyder SJ. Arthroscopic Acromioclavicular Joint Debridement and Distal Clavicle Resection. *Tech Orthop* 1988;3:41.

+ 166. Søndergard-Petersen P, Mikkelsen P. Posterior Acromioclavicular Dislocation. *J Bone Joint Surg* 1982;64B:52.

+ 167. Sonozaki H, Azuma A, Okai K, et al. Inter-sterno-costo-clavicular Ossification with a Special Reference to Cases of Unilateral Type. *Kanto J Orthop Traumatol* 1978;9:196.

+ 168. Sonozaki H, Azuma A, Okai K, et al. Clinical Features of 22 Cases with Inter-sterno-costo-clavicular Ossification. *Arth Orthop Trauma Surg* 1979;95:13.

+ 169. Sonozaki H, Furusawa S, Seki H, et al. Four Cases with Symmetrical Ossifications between the Clavicles and the First Ribs of Both Sides. *Kanto J Orthop Traumatol* 1974;5:244.

+ 170. Spar I. Psoriatic Arthritis of the Sternoclavicular Joint. *Conn Med* 1978;42:225.

# 171. Speed K. *A Textbook of Fractures and Dislocations, 4th ed.* Philadelphia: Lea & Febiger, 1942.

+ 172. Stankler L. Posterior Dislocation of Clavicle: A Report of 2 Cases. *Br J Surg* 1962;50:164.

+ 173. Stein AH. Retrosternal Dislocation of the Clavicle. *J Bone Joint Surg* 1957;39A:656.

+ 174. Tagliabue D, Riva A. Le Lussazioni Sterno-claveari. *Minerva Orthop* 1985;36:876.

+ 175. Tagliabue D, Riva A. [Current Approaches to the Treatment of Acromioclavicular Joint Separation in Athletes.] *Ital J Sports Traumatol* 1981;3:15.

+ 176. Takimoto T, Ishikwaw S, Tanaka S, et al. Development of Significant Sternoclavicular Joint Hypertrophy Following Radical Neck Dissection. *Otorhinolaryngology* 1989;51:317.

+ 177. Teplick JG, Eftekhari F, Haskin ME. Erosion of the Sternal Ends of the Clavicles: A New Sign of Primary and Secondary Hyperparathyroidism. *Radiology* 1974;113:323.

+ 178. Tolin BS, Snyder SJ. Our Technique for the Arthroscopic Mumford Procedure. *Orthop Clin North Am* 1993;24:143.

+ 179. Tossy JD, Mead NC, Sigmond HM. Acromioclavicular Separations: Useful and Practical Classification for Treatment. *Clin Orthop* 1963;38:111.

+ 180. Urban J, Jaskiewicz A. [Idiopathic Displacement of Kirschner Wire to the Thoracic Cavity after the Osteosynthesis of Acromioclavicular Joint.] *Chir Narzadow Ruchu Ortop Pol* 1984;49:399.

* 181. Urist MR. Complete Dislocation of the Acromioclavicular Joint: The Nature of the Traumatic Lesion and Effective Methods of Treatment with an Analysis of 41 Cases. *J Bone Joint Surg* 1946;28:813.

+ 182. Van Fleet TA, Bach B. Injuries to the Acromioclavicular Joint. Diagnosis and Management. *Orthop Rev* 1994;23:123.

+ 183. Walsh WM, Peterson DA, Shelton G, Newmann RD. Shoulder Strength Following Acromioclavicular Dislocation and Coracoclavicular Ligament Rupture: A Case Report and Review of the Literature. *Clin Orthop* 1994;300:120.

+ 184. Wang K, Hsu K, Shih C. Coracoid Process Fracture Combined with Acromioclavicular Dislocation and Coracoclavicular Ligament Rupture: A Case Report and Review of the Literature. *Clin Orthop* 1994;300:120.

+ 185. Weitzman G. Treatment of Acute Acromioclavicular Joint Dislocation by a Modified Bosworth Method: Report on Twenty-four Cases. *J Bone Joint Surg* 1967;49A:1167.

+ 186. Wilson KM, Colwill JC. Combined Acromioclavicular Dislocation with Coracoclavicular Ligament Disruption and Coracoid Process Fracture. *Am J Sports Med* 1989;17:697.

+ 187. Wohlgethan JR, Newberg AH. Clinical Analysis of Infection of the Sternoclavicular Joint (Abstract). *Clin Res* 1984;32:666A.

+ 188. Wojtys EM, Nelson G. Conservative Treatment of Grade III Acromioclavicular Dislocations. *Clin Orthop* 1991;268:112.

+ 189. Worman LW, Leagus C. Intrathoracic Injury Following Retrosternal Dislocation of the Clavicle. *J Trauma* 1967;7:416.

+ 190. Wurtz LO, Lyons FA, Rockwood CA. Fracture of the Middle Third of the Clavicle and Dislocation of the Acromioclavicular Joint. *J Bone Joint Surg* 1992;74A:133.

+ 191. Yood RA, Goldenberg DL. Sternoclavicular Joint Arthritis. *Arthritis Rheum* 1980;23:232.

+ 192. Zanca P. Shoulder Pain: Involvement of the Acromioclavicular Joint: Analysis of 1,000 Cases. *Am J Roentgenol* 1971;112:493.

# CHAPTER 79

# DISORDERS OF THE ROTATOR CUFF

*Richard. A. Marder*

**R. A. Marder:** Department of Orthopaedic Surgery, University of California, Davis, School of Medicine, Sacramento, California, 95817.

Etiology and Pathophysiology
Classification
Clinical Evaluation
History
Physical Examination
Adjunctive Clinical Testing
Imaging
Diagnosis
Treatment
Natural History
Indications and Management
Nonoperative Management
Surgical Techniques
Subacromial Decompression
Open Acromioplasty
Arthroscopic Subacromial Decompression
Os Acromiale
Partial-Thickness Tears of the Rotator Cuff
Full-Thickness Tears of the Rotator Cuff
Mini–Open Repair of the Rotator Cuff
Irreparable Tears
Biceps Tendon Rupture
Results of Rotator Cuff Surgery
Complications of Rotator Cuff Surgery
Calcific Tendinitis
Arthroscopic Debridement of Calcific Tendinitis
Adhesive Capsulitis
Manipulation
Pectoralis Major Rupture
Repair of Pectoralis Major
Chapter References

Since the first report of a torn rotator cuff in 1834 (59), disorders of the rotator cuff have become universally recognized as the predominant cause of shoulder pain and impairment in athletes and the general population as well. Pathologic conditions include tendinitis, partial- and full-thickness tears of the supraspinatus and other rotator cuff muscles, calcific tendinitis, and degeneration of the long head of the biceps tendon. Recent advances in the management of these disorders include increased recognition of the role of dynamic causes of rotator cuff tendinopathy, an expanded role of arthroscopic evaluation and treatment, and improved fixation methods of tendon repair facilitating rehabilitation. Other conditions of the shoulder discussed in this chapter include rupture of the pectoralis major and adhesive capsulitis.

## ETIOLOGY AND PATHOPHYSIOLOGY

Myriad factors have been implicated in the development of rotator cuff tendinopathy. Patient age can be a clue to etiology. In the younger patient, especially the athlete, repetitive overuse, muscle imbalance and weakness, capsular contractures, and coexistent glenohumeral instability are potential causes (24,27,30). Abnormality of scapular rotation, because of the functional interdependency of the shoulder complex, can cause secondary rotator cuff dysfunction and pain (30,31). In middle-aged and older patients, primary tendon degeneration as well as morphologic alteration of the coracoacromial arch including degeneration of the acromioclavicular joint are the principal causes of symptomatic rotator cuff tendinopathy (8,12,38,39,40).

Compression or impingement of the superior surface of the rotator cuff tendons, especially the supraspinatus, against the undersurface of the anterior acromion and the coracoacromial ligament is a major mechanism for the production of rotator cuff pain (40). Progressive, unchecked mechanical impingement against the anterior-inferior acromion and coracoacromial (CA) ligament initiates a cycle of tendon degeneration, for which Neer (40) identified three stages, starting with edema and hemorrhage in the tendon, progressing to fibrosis and tendinitis, and culminating in spurs and eventual tendon rupture.

Neer (40) and others have postulated that primary alteration of the coracoacromial arch reduces the space for excursion of the rotator cuff tendons during humeral elevation, precipitating tendon degeneration. An increased incidence of tendinopathy has been noted in patients with a type II or III acromial configuration (Fig. 79.1), as well as in those with ununited acromial ossification centers (38,39). It appears, however, that in a number of cases, hypertrophic changes in the coracoacromial arch develop *after* primary degeneration of the rotator cuff has occurred (44,47). Further attrition can then occur as the degenerated rotator cuff tendons are compressed against a thickened acromion and CA ligament.

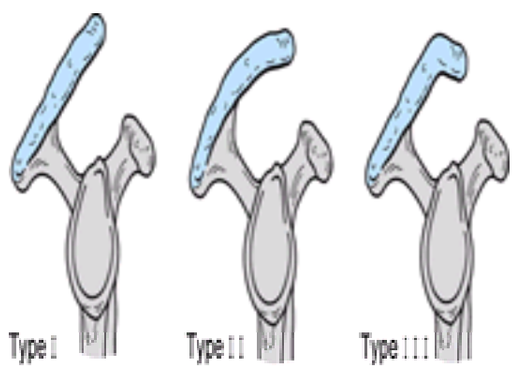


***Figure 79.1.*** Acromial morphology: *I,* flat; *II,* curved; and *III,* hooked.

Codman (12) was one of the first to recognize that tendon degeneration could occur on the undersurface (articular), superior surface (bursal), or within the substance of the supraspinatus tendon (mid-substance), creating partial-thickness lesions in these locations. Some lesions produce symptoms, and an unknown percentage progress to full-thickness tears. Most complete tears become manifest as the result of minor trauma superimposed on longstanding degeneration. Due to its intraarticular course, the long head of the biceps tendon is subjected to the same degenerative processes as the adjacent supraspinatus tendon.

In some instances, abnormal superior translation of the humeral head during overhead motion leads to compression of the supraspinatus against an unyielding but normal-shaped acromion and coracoacromial ligament. Weakness and imbalance of the rotator cuff muscles or the scapular muscles, glenohumeral subluxation, and tightness of the posterior shoulder capsule all produce rotator cuff pain as a result of dynamic compression (24,30,31).

Other mechanisms may account for the development of shoulder pain. Particularly in the throwing athlete, tensile failure from repetitive, eccentric overload occurs because the supraspinatus and posterior cuff muscles resist the forces of internal rotation, adduction, and distraction during the deceleration phase of throwing. Typically, undersurface partial tears occur in the posterior part of the supraspinatus as well as the infraspinatus (1). Acute overload of a healthy tendon contracting against excessive resistance occurs infrequently, resulting in massive rotator cuff avulsion, or in isolated rupture of the pectoralis major or long head of the biceps.

Recognition of the etiology and mechanism responsible for symptoms is important because treatment regimens differ. Whereas rotator cuff compression or impingement due to static abnormalities (abnormal subacromial outlet) may not resolve without surgical intervention, dynamic causes of rotator cuff compression most often respond to appropriate nonsurgical measures or to surgical correction of coexistent instability. Furthermore, rotator cuff tendinopathy that is not associated with an abnormal subacromial outlet may not respond to subacromial decompression (8).

## CLASSIFICATION

A classification scheme is helpful to formulate treatment, considering the various etiologies and the spectrum of rotator cuff injuries (Table 79.1). Using a scheme prevents the tendency to generalize all cases of rotator cuff pain as impingement syndrome. That sort of generalization leads to automatic subacromial decompression for refractory cases.

| |
|---|
| Tendinitis |
| Primary (intrinsic tendon degeneration) |
| Secondary ("impingement") |
| Structural |
| Acromial spurring (type II and III acromion) |
| On acromiale |
| Dynamic |
| Glenohumeral instability |
| Muscle imbalance |
| Posterior capsule contracture |
| Overuse |
| Partial-thickness tears |
| Superior surface (bursal) |
| Mid-substance |
| Undersurface (articular) |
| Full-thickness tears |
| Longitudinal (tendon split) |
| Transverse |
| Nonretracted |
| Retracted |
| Small (<1 cm) |
| Medium (1–3 cm) |
| Large (3–5 cm) |
| Massive (>5 cm) |
| Calcific tendinitis |
| Acute |
| Chronic |

***Table 79.1. Differential Diagnosis of Rotator Cuff Tendinopathy***

Although mechanical impingement does occur frequently in the shoulder, it is by no means the cause of all cases of rotator cuff tendinopathy. The tendency to refer to all instances of rotator cuff tendinopathy as impingement can lead to the inappropriate use of acromioplasty for every refractory case, which is analogous to the misuse of lateral release for patellofemoral pain in the lower extremity.

## CLINICAL EVALUATION

### HISTORY

Except in cases of an acute traumatic injury, patients with rotator cuff tendinitis usually describe an insidious onset of shoulder pain located over the anterior superior aspect of the shoulder. Pain occurs during or following overhead activity and is relieved by rest. Like patients with acromioclavicular (AC) joint pathology, some individuals with rotator cuff injury may experience pain with cross-arm adduction. With progression, pain may occur at rest, although usually it is less severe than that associated with activity, and it may awaken the patient at night. Rotator cuff pain can radiate laterally to the area of the deltoid attachment but not more distal. Pain radiating below the elbow suggests radicular pain from cervical or thoracic outlet disease.

In addition to shoulder pain, a complaint of weakness or stiffness of the shoulder may be elicited. A history of catching or popping can occur in partial rotator cuff tears but more likely indicates an internal derangement such as a labral tear, a superior labral tear from anterior to posterior (a SLAP lesion) (60), or loose body. Acute onset of pain in the absence of significant trauma, coupled with marked pain on attempted motion, raises the possibility of acute calcific tendinitis, infection, or acute brachial neuritis.

### PHYSICAL EXAMINATION

Carefully examine the cervical spine, especially in older patients, to rule out degenerative disc disease with radicular symptoms. In longstanding rotator cuff disease, inspection may reveal atrophy of the supraspinatus, infraspinatus, and deltoid muscles, as well as limited or asymmetric scapular rotation. Active and passive forward flexion and abduction, as well as internal and external rotation, may be reduced, compared with the unaffected side. Loss of internal rotation identifies posterior capsular tightness. Throwers often have increased external and decreased internal rotation of the shoulder. Look for pain or weakness with manual muscle testing of external rotation, abduction, and isolated supraspinatus. Elicit the impingement sign by passive elevation of the arm against the supraspinatus outlet, which is fixed by your hand to limit rotation. Perform the maneuver in overhead elevation (40) as well as in abduction with forced internal rotation of the humerus (26).

It can be difficult to diagnose anterior glenohumeral instability, especially when there is pain with maximum abduction and external rotation but no measurable laxity. Testing in the supine position can relax the patient sufficiently to allow detection of laxity. The relocation test may be of some benefit in distinguishing anterior laxity from rotator cuff disease (61): Apply a posterior force along the anterior aspect of the humeral head, which has been subluxated by abduction and external rotation of the arm. Accurate diagnosis may not be possible until examination is performed under anesthesia and arthroscopy shows a Hill Sachs lesion or a positive “drive-through” sign (66). Inferior laxity reproducing symptoms should alert you to the possibility of multidirectional instability.

Inability to initiate or maintain abduction suggests a large tear of the rotator cuff (Fig. 79.2). A smaller tear confined to the supraspinatus may cause weakness only with isolation of the supraspinatus (elevation of the arm, internally rotated in the scapular plane). Marked weakness in external rotation suggests a tear with posterior extension to include the infraspinatus. Perform isolated testing of the external rotators of the rotator cuff (infraspinatus and teres minor) in the lateral decubitus position with the elbow aligned with the thorax. To test subscapularis function, have the patient extend her arm and rotate it internally as much as possible, which positions the hand on the lumbar spine region. Inability to lift the hand posteriorly from the lumbar spine indicates weakness of the subscapularis and has been termed the *lift-off test* (21).

***Figure 79.2.*** Inability to maintain humeral abduction.

Palpate the AC joint to identify those patients with AC joint pathology. Although cross-arm adduction usually reproduces the pain of AC joint degeneration, it may be positive in patients with impingement syndrome as well. Selective injections and specific imaging as described below may be necessary to differentiate disorders of the

AC joint from those of the rotator cuff.

## ADJUNCTIVE CLINICAL TESTING

The most helpful diagnostic test is the injection of local anesthetic into the subacromial bursa as described by Neer (40). Use of a posterior or lateral subacromial approach is less painful than anterior injection; because the entry angle of the needle is directed upward toward the acromion, inadvertent laceration of the rotator cuff is less likely. After injection of approximately 10 ml of 1% lidocaine, repeat the examination. If rotator cuff tendinitis or a partial tear of the bursal surface is present, the injection will provide a minimum of 50% and often nearly 100% relief of symptoms. If no relief is obtained, the diagnosis is incorrect or the injection has not been delivered into the bursa. If there is a full-thickness rotator cuff tear, pain will be significantly relieved, but some weakness usually persists despite injection. Continued pain and tenderness at the AC joint may warrant an injection of 1–2 ml of lidocaine into this joint. If indicated in selected cases, a steroid may be combined with the local anesthetic.

## IMAGING

### *Radiographs*

Planar radiographs are frequently helpful in the diagnosis of rotator cuff pathology. Obtain at least two perpendicular views for every patient, consisting of an anteroposterior (AP) view of the glenohumeral joint and a supraspinatus outlet view. The supraspinatus outlet view is a lateral radiograph made in the plane of the scapula with the x-ray beam directed 10° inferiorly. On the AP view, nonspecific changes such as sclerosis and cysts in the area of the greater tuberosity and anatomic neck can be seen, as well as a decreased interval (normal, 7–15 mm) between the humeral head and the acromion, which suggests a full-thickness tear of the cuff.

Calcium deposits are usually apparent on a standard AP view (Fig. 79.3), but an AP view in external rotation may better define the lesion. Although advanced degeneration of the glenohumeral joint is usually characterized by joint narrowing, effacement of the humeral head, and spurring, especially inferiorly on the humeral head, early degenerative joint disease (DJD) may not be recognized even using a true AP radiograph of the glenohumeral joint. The outlet view defines any anterior acromial spurs, CA ligament ossification, or abnormal morphology of the acromion.

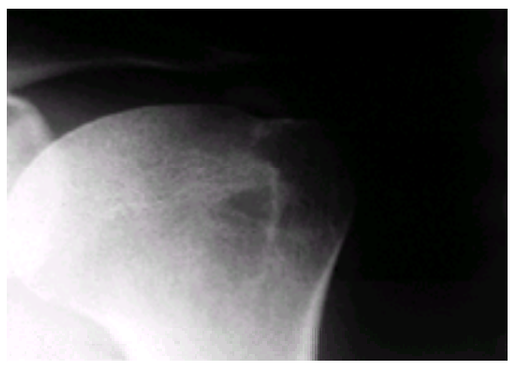

***Figure 79.3.*** Anteroposterior radiograph of calcium deposits in a supraspinatus tendon located well medial to its insertion.

Another view that may be helpful is an AP view with a 30° inferior tilt to identify any anterior prominence (spurring) of the acromion (52). If AC joint pathology is suspected, obtain a 10° inferiorly directed AP radiograph of that joint with reduced voltage. An axillary view is often useful to identify an os acromiale or a bony Bankart lesion. A computed tomography (CT) scan, however, may be necessary for optimal definition of an os acromiale.

### *Magnetic Resonance Imaging, Ultrasound, and Arthrography*

Use magnetic resonance imaging (MRI), ultrasound, and arthrography on a case-by-case basis. Ultrasound has been shown to be helpful in identifying full-thickness tears, but it is less accurate than arthrography or MRI and remains operator dependent (49). MRI has largely replaced arthrography for the diagnosis of rotator cuff disorders as it is noninvasive. It is very accurate in the diagnosis of full-thickness tears (Fig. 79.4) but less helpful for tendinitis and partial-thickness tears (28). In as many as 50% of *asymptomatic* individuals, MRI can demonstrate signal changes within the supraspinatus tendon consistent with partial-thickness and complete tears (58). Because incidental MRI-documented changes increase with patient age, clinical symptoms and signs are more important than MRI findings in determining treatment in older patients.

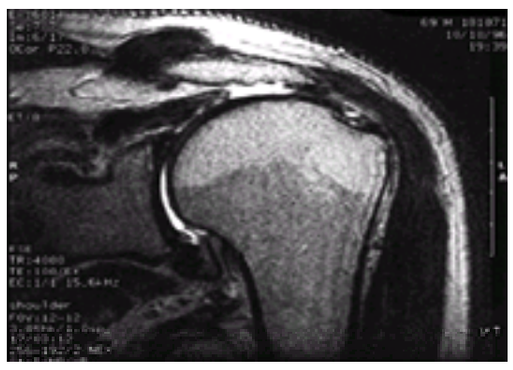

***Figure 79.4.*** MRI demonstrating full-thickness tear of the supraspinatus with wide retraction.

## DIAGNOSIS

A number of diagnoses must be excluded in the evaluation of the painful shoulder (Table 79.2). In older patients particularly, DJD of the glenohumeral joint and cervical radiculopathy must be considered. When mild, DJD may be not be evident radiographically but can cause tendinitis-like symptoms (17,55). Often, these patients have slight but detectable limitation of shoulder motion. In younger patients, glenohumeral instability and degenerative changes of the AC joint can be associated with symptoms and signs suggestive of rotator cuff tendinopathy. Although preoperative laxity testing may not reveal instability, it should be apparent with examination under anesthesia and confirmed by arthroscopic findings. AC joint tenderness, pain with cross-arm adduction, radiographic changes, and a positive technetium-99 bone scan will confirm AC joint degeneration. These conditions should be strongly suspected whenever nonsurgical or previous surgical treatment for rotator cuff tendinitis has been unsuccessful.

| |
|---|
| Rotator cuff tendinopathy |
| Glenohumeral instability |
| Glenohumeral DJD, labral tears, and loose bodies |
| Acromioclavicular joint DJD |
| Adhesive capsulitis |
| Suprascapular nerve entrapment |
| Scapulothoracic dysfunction |
| Brachial neuritis |
| Cervical DJD |
| Cervical radiculopathy |
| Apical lung tumor |

DJD, degenerative joint disease.

***Table 79.2. Pathologic Conditions of the Rotator Cuff***

## TREATMENT

### NATURAL HISTORY

Because the natural history of rotator cuff tendinopathy is unpredictable, establishing treatment guidelines remains challenging. Tendinitis, the most common manifestation of rotator cuff disease, usually responds to modification of activity or nonoperative treatment and typically does not progress to frank tendon rupture. Even in cases of a complete tear of the rotator cuff, some patients experience clinical resolution (7,29) while others remain symptomatic. A few may progress to cuff-tear arthropathy, characterized by superior migration of the humeral head, which initiates severe impingement leading to relentless joint degeneration with collapse of the head and erosion of the glenoid. In a retrospective review, Itoi and Tabata (29) noted satisfactory results in more than 80% of patients treated nonsurgically for a torn rotator cuff. Patients whose symptoms were present for more than a year and who had significant loss of motion and strength were unlikely to respond to nonoperative treatment.

Two related questions are thus raised: How can some patients compensate for the functional loss of the supraspinatus? And how do you identify the patient at risk for progressive, disabling tendinopathy?

Compensation can be explained on the basis of the synergistic effects of the other rotator cuff muscles (subscapularis, teres minor, and infraspinatus) together with the supraspinatus and deltoid in effecting humeral elevation (46,57). Because the other cuff muscles together can contribute to the power of elevation in magnitude similar to the supraspinatus, individuals who have adequate strength in these muscles may be able to function without significant problems following a tear of the supraspinatus.

The second question is more difficult to answer. Patients with a significant anterior acromial hook (type III acromion) are known to have a higher incidence of full-thickness tears (38). It is also apparent that repair of smaller tears produces better functional results than repair of larger tears. Assuming that an increase in tear size can occur over time due to further tearing as well as retraction, it would seem prudent to repair known tears earlier rather than later, especially in the active patient, regardless of age.

### INDICATIONS AND MANAGEMENT

Nonsurgical treatment remains the standard initial care for tendinitis. Surgery is indicated for those patients who fail to respond to nonoperative measures. Although some have attempted to define a specific period of time to try treatment without surgery, it seems more reasonable to rely on the patient's response to nonoperative management and the functional demands of the shoulder as the basis for determining future treatment. In this era of managed care, many patients have had several months of nonsurgical care before they are seen by an orthopaedist. In such cases, especially if there has been no improvement, an additional lengthy period of nonoperative treatment is unnecessary before surgery.

For tendinitis due to mechanical impingement, start a nonsurgical treatment program and reexamine the patient within 2 months. If there is minimal or no improvement, offer a subacromial steroid injection. If there continues to be minimal improvement over the next 2 months, then recommend subacromial decompression in cases associated with a type II or III acromion.

If a flat acromion (type I) exists, continue nonoperative treatment for a minimum of 3 months. Failure to improve with this regimen warrants arthroscopy. Many such patients will have readily apparent articular or bursal surface, partial-thickness tears. Others will have areas of thinning consistent with mid-substance tears discernible only by probing. In these cases, articular and bursal partial-thickness tears are debrided, or, if thickness is greater than 50%, repaired by open methods; mid-substance tears usually are excised and repaired. The question of whether to perform acromioplasty to treat tendinitis-like symptoms in the patient with a normal-shaped acromion is unsettled at present because of the unpredictable response.

For tendinitis secondary to overuse, glenohumeral instability, posterior capsular contacture, and muscle imbalance, direct nonoperative treatment toward correction of the primary diagnosis. With the exception of glenohumeral instability, nonoperative measures are nearly uniformly successful.

Throwers with articular (undersurface) partial-thickness tears of the supraspinatus or infraspinatus tendons may not respond to nonoperative measures directed at eliminating capsular contactures, muscle strengthening, and alteration of throwing mechanics. Except in the high-performance athlete, where nonoperative treatment is often abandoned earlier because of nonmedical considerations, nonoperative measures should be tried before arthroscopic debridement.

For active patients, once a torn rotator cuff is diagnosed, surgical repair is recommended. In less-active patients who do not rely on the shoulder for work or sports, employ a trial of nonoperative measures similar to the program used for impingement. If there is no significant improvement in pain and function within 2 to 3 months, I recommend surgical repair. If the patient shows initial improvement and maintains a satisfactory level of function, continue additional nonoperative therapy or self-exercise and follow the patient at regular intervals.

## NONOPERATIVE MANAGEMENT

A nonoperative regimen includes modalities directed at decreasing pain, stretching and range-of-motion (ROM) exercises, and a rotator-cuff-specific strengthening program consisting of isometric and isotonic exercises. Especially in cases of acute onset associated with overuse, rest may be the single most beneficial modality. Determine any specific ROM or strength deficits and then prescribe physical therapy using ice, heat, ultrasound, electrical stimulation, and transcutaneous nerve stimulation (based on patient response) to reduce pain in conjunction with posterior capsule stretching, scapulothoracic mobilization, and scapular strengthening exercises. Keeping within the pain-free ROM, start a light resistive exercise program emphasizing external rotator as well as supraspinatus strengthening.

Failure to improve from the initial use of an antiinflammatory and a supervised treatment program is reason to offer the patient a subacromial steroid injection. Give 40 mg of methylprednisolone and 7–8 cc of 1% lidocaine, followed by rest for a 1-week period before the resumption of resistance exercises. As symptoms subside and motion recovers, reintroduce the patient to functional activity. For a swimmer, gymnast, or tennis player, for instance, have a coach, therapist, or trainer monitor performance of activity to ensure that proper mechanics are being used and the patient remains pain free.

Surgical treatment is warranted for patients who do not demonstrate any improvement after nonoperative treatment, or if you suspect a rotator cuff tear. If the patient demonstrates improvement with the program but pain returns with activity, try activity modification. If unsuccessful, surgery is indicated. With a nonoperative program, as many as two thirds of patients can expect relief of symptoms, allowing continuation of activity.

## SURGICAL TECHNIQUES

### SUBACROMIAL DECOMPRESSION

Anterior-inferior acromioplasty with resection of the CA ligament is the standard treatment for patients with rotator cuff tendinitis due to mechanical impingement. Neer

initially described removal of a 1 cm anteriorly based wedge tapering approximately 2 cm posteriorly to the undersurface of the acromion (40). Others have since emphasized the importance of removing any acromial overhang anterior to the anterior edge of the distal clavicle (15,57) as well as along the medial border of the AC joint.

Surgery can be open or arthroscopic. The main advantages of arthroscopic decompression are the following:

- It enables the surgeon to evaluate the glenohumeral joint (for undersurface tears, for example, and SLAP lesions, DJD, and loose bodies).
- It can be done on an outpatient basis.
- It entails decreased perioperative morbidity and faster relief of pain.

The main disadvantage of arthroscopic decompression is that the procedure requires technical proficiency and can be difficult to learn.

**OPEN ACROMIOPLASTY**

- Place the patient in the beach-chair position. Use a folded sheet to stabilize the shoulder along the medial border of the scapula. Drape the arm free for manipulation, as manual traction and rotation can facilitate exposure of the rotator cuff.
- Inject the subcutaneous tissues with 10 ml of 1% lidocaine with 1:200,000 epinephrine to decrease bleeding. Make a 3 to 4 cm straplike incision parallel to and centered over the anterolateral edge of the acromion. This cut allows posterior as well as anterior extension, if necessary, to treat an associated rotator cuff tear. Incise the skin and subcutaneous layer to the level of the deltoid fascia. Obtain hemostasis with electrocautery. Insert a self-retaining retractor to increase exposure of the underlying deltoid.
- Identify the deltoid attachment to the acromion, the AC joint, and the lateral and anterior edge of the acromion. Split the deltoid at the level of the AC joint, limiting its distal incision to 3 cm to avoid injury to the axillary nerve innervating the anterior head of the deltoid. It is usually necessary to detach a short segment of the deltoid beginning at the AC joint and extending laterally for about 1 cm. Use electrocautery to incise the deltoid subperiosteally, and elevate its fibers from the anterior edge of the acromion. This technique preserves a satisfactory cuff of tissue for deltoid reattachment.
- Identify the coracoacromial ligament running obliquely from the medial border of the anterior acromion to the coracoid. Do not detach the ligament yet. Carefully open the bursa, which may be adherent to the undersurface of the acromion; introduce a fingertip to palpate the contour of the undersurface of the acromion. If necessary, apply gentle longitudinal traction to the humerus to increase exposure of the subacromial space. If placing a retractor under the anterior acromion, use care, as excessive force can cause fracture.
- Protect the rotator cuff with a malleable retractor while performing the acromioplasty. Excise any portion of the acromion extending anterior to the distal clavicle. Next, starting at the superior cortex of the anterior acromion direct a $^3/_4$-inch osteotome or small oscillating saw to remove the anteroinferior prominence of the acromion, tapering to exit about 1.5 cm posteriorly on the undersurface of the acromion. A flat acromion is the goal. The lateral deltoid will retain some connections to the osteotomized piece. Incise along the deltoid margin with electrocautery to mobilize the fragment anteriorly in one piece, pulling on it with a rongeur or Kocher clamp.
- Next, detach a 1 cm segment of coracoacromial ligament and remove the osteotomized fragment and ligament stump.
- Palpate the undersurface of the acromion. File rough areas with a rasp and remove any spurs along the inferior AC joint. Excise any residual bursal tissue to allow complete inspection of the rotator cuff while rotating the humerus. If necessary, repair any full- or partial-thickness tears of the rotator cuff.
- Repair the detached deltoid to its origin using horizontal mattress stitches with #1 nonabsorbable suture, or place small drill holes in the acromion for direct deltoid-to-bone reattachment if the soft-tissue repair is tenuous. Repair the longitudinal deltoid split with #0 absorbable sutures. Irrigate and check for bleeding. Close the subcutaneous tissue loosely with inverted 3-0 absorbable suture and the skin with a subcuticular suture. Apply a sterile dressing and place the arm in an immobilizer or commercial pillow splint, either of which provides better support than a simple sling.

**ARTHROSCOPIC SUBACROMIAL DECOMPRESSION**

- Place the patient in either the beach-chair or lateral decubitus position. Mark the outlines of the acromion, AC joint, posterior and lateral portals, and, if needed, anterior portal. Using gravity inflow or a mechanical pump, perform diagnostic arthroscopy of the glenohumeral joint. If gravity inflow is selected, it is helpful to add one ampule of 1:1,000 epinephrine per 3-liter container of irrigating solution to reduce bleeding. The supraspinatus outlet should be readily visible during the procedure in order to assess the amount of acromion to be removed.
- Replace the arthroscope, which is in the posterior portal, with a dull trocar, and then withdraw the arthroscope from the capsule and posterior deltoid. The trocar should move easily in the subcutaneous tissue. Palpate the lateral border of the acromion and advance the arthroscope sheath along this path toward the anterior limit of the acromion. Reinsert the arthroscope. If the bursal space is well visualized, proceed; if not, reinsert the trocar and advance the arthroscope sheath in a slightly more medial direction until the bursal space is entered. Taking the time to get adequate visualization at this point is the key to a well-performed, quick arthroscopic procedure.
- Insert an 18-gauge spinal needle through the lateral portal (2–3 cm distal to the lateral acromion and parallel with the posterior border of the clavicle). Palpate the CA ligament, the undersurface of the AC joint, and the acromion. If acceptable, make the portal incision, and if you see vessels on the soft tissue around the margins and undersurface of the acromion, electrocoagulate them prior to debridement. Place a nonconducting canula through the lateral portal (Fig. 79.5). Next, insert a 4.5 mm aggressive motorized shaver to begin stripping the periosteum and soft tissue covering the anterior acromion. Using the shaver or electrocautery, remove the periosteum and fibrous tissue from the lateral margin of the acromion as well, up to the point at which the deltoid fibers attach. Medially, the AC joint may not be apparent until externally balloted. The medial aspect of the acromion must be identified, as it can be a cause of recurrent symptoms if not adequately resected as well. Identify the coracoacromial ligament and divide it from the anterior and medial acromion, taking care not to injure the deltoid fibers immediately underneath (Fig. 79.6; see also Color Fig. 79.6).

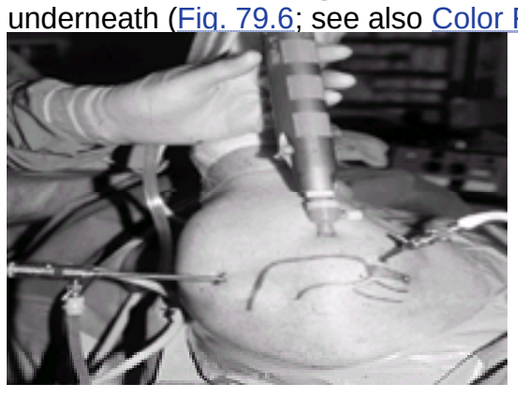

***Figure 79.5.*** Arthroscopic set-up for subacromial decompression. Shaver is inserted in the lateral portal created in line with the posterior axis of the distal clavicle 2–3 cm distal to the lateral edge of acromion.



***Figure 79.6.*** (See Color Figure 79.6) Coracoacromial ligament prior to division with electrocautery (undersurface of acromion is exposed for better visualization).

- Now that the anterior tip of the acromion, both medial and lateral borders, are well seen, introduce a round or elliptical burr from the lateral portal to begin the acromioplasty. Resect the leading edge of the acromion flush with the anterior edge of the distal clavicle (Fig. 79.7). Next, by referencing the posterior margin of the distal clavicle, mark the posterior extent of the acromioplasty by creating a shallow trough, no deeper than 5 mm, medial to lateral. Now, switch the arthroscope to the lateral portal and insert the burr posteriorly.

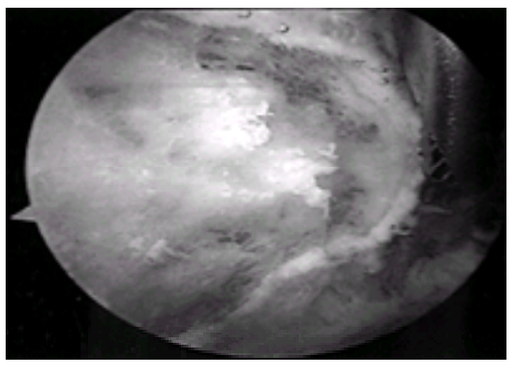

***Figure 79.7.*** Arthroscopic burr resecting the anterior edge of the acromion flush with the distal clavicle.

- Beginning at the level of the trough, continue the acromioplasty by sweeping the burr from medial to lateral and advancing it from posterior to anterior. Keeping the shaft of the burr in contact with the undersurface of the acromion posteriorly will result in an upward-sloping acromioplasty, protecting against either inadequate or excessive bone resection (54).
- Reinsert the arthroscope into the posterior portal to inspect the acromioplasty. The acromion should be flat when viewed from both posterior and lateral (Fig. 79.8; see also Color Fig. 79.8). Often, resecting from only one portal will result in a cup-shaped configuration of the acromion, with prominent spurs anterolaterally and anteromedially. Using these two portals both for viewing and for planing the acromion will eliminate this possibility (Fig. 79.9). At this point, if there are no spurs on the undersurface of distal clavicle, debride the remainder of the coracoacromial ligament, using the shaver. If possible, remove 1 cm to eliminate any possibility of reattachment. Using the shaver in this manner will protect from accidental deltoid detachment. Remove inferior spurs from the distal clavicle without disrupting the AC joint itself.

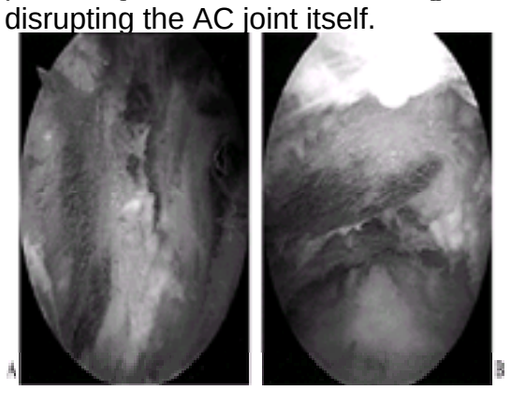

***Figure 79.8.*** (See Color Figure 79.8) Acromion planed flat when viewed from the posterior portal (**A**) and from the lateral portal (**B**).

***Figure 79.9.*** Radiographs showing an acromial spur before (**A**) and after (**B**) acromioplasty.

- Close the skin portals and apply a nonbulky dressing incorporating a cryotherapy pad, if desired. Use a sling or immobilizer for support.

Postoperatively, if arthroscopic decompression has been performed, start immediate active and passive ROM exercises. Pendulum exercises and motion performed *supine* are best tolerated in the immediate postoperative period. Advise the patient to avoid active abduction beyond 60° while standing or sitting for the first 3–4 weeks; such activity may result in painful impingement due to postsurgical dysfunction of the cuff. Initiate isometrics as early as 1–2 weeks.

Electrical stimulation is helpful in minimizing atrophy. Once ROM has been restored (in 4–6 weeks), start resistive exercises, but advise the patient to avoid heavy resistance and contact for a minimum of 3–4 months to prevent acromial fracture or reexacerbation of symptoms. Usually, high-demand activities (tennis, swimming, throwing) can be resumed within 4–6 months' time.

If open acromioplasty has been performed, especially if the deltoid has been elevated or detached, then rehabilitation will proceed more slowly. Do not allow the patient to perform significant active flexion or abduction for approximately 4 weeks. Rehabilitation then proceeds as above with return to activity requiring 1–2 additional months on average.

**OS ACROMIALE**

When os acromiale is associated with rotator cuff tendinitis, intraoperative assessment of motion of the fragment directs treatment. If the fibrous union between the fragments is secure, perform routine acromioplasty. If the nonunion is mobile, perform excision for small fragments (os acromiale), and open reduction and internal fixation for larger fragments (meta- or mesoacromion). Center a 4 cm incision over the anterior acromion and parallel to the acromial border to expose the nonunion, which is debrided of fibrous tissue, bone-grafted, and internally fixed with one or more small fragment screws. Rehabilitation is similar to that for open acromioplasty with active abduction delayed for 6 weeks.

**PARTIAL-THICKNESS TEARS OF THE ROTATOR CUFF**

Although recognized previously, arthroscopy has been key in the recognition and treatment of partial-thickness tears to the rotator cuff. The major issue in treating a partial-thickness tear is deciding whether to perform debridement alone, debridement with subacromial decompression, or excision and repair. This can prove to be a considerable dilemma, particularly in the young, active patient.

Even during arthroscopic examination of both the bursal and the articular side of the rotator cuff, it may prove difficult to determine the exact depth of the lesion. Moreover, midsubstance lesions may be extremely difficult to detect and measure because of the relatively normal appearance of surfaces in such lesions. Careful probing, use of a marking suture passing through both surfaces of the lesion, and injection of methylene blue dye to observe penetration, facilitate inspection and enable determination of the extent of a partial-thickness lesion.

Currently, lesions involving less than 50% thickness of the tendon are treated by debridement (Fig. 79.10), whereas those deeper than 50% are excised and repaired. Treat bursal-sided lesions with an accompanying type II or III acromion with decompression as well. If symptoms recur after debridement of a lesion, perform excision and repair. For postoperative management, follow the procedure outlined for subacromial decompression or repair, as relevant.

***Figure 79.10.*** Arthroscopic debridement of a partial-thickness undersurface tear.

**FULL-THICKNESS TEARS OF THE ROTATOR CUFF**

Techniques to repair the majority of full-thickness rotator cuff tears include direct repair of tendon to tendon, advancement of tendon to bone, local tissue releases and advancement to effect tendon-to-bone repair, and slight medialization of the repair site. Exposure through a deltoid-splitting (mini-open) incision rather than by detachment of the deltoid is ideal to minimize perioperative morbidity and reduce the risk of deltoid avulsion postoperatively, but the ultimate goal is a well-done repair. Deltoid detachment to expose and repair a tear of the rotator cuff is preferable to a deltoid-splitting incision with a compromised repair of the cuff. Depending on the surgeon's preference, open repair without arthroscopy remains an acceptable option (for incision and initial steps, see the section on Open Acromioplasty).

Advances in repair include the use of suture anchors to achieve direct tendon-to-bone healing. Suture anchors have been shown to have superior mechanical properties over transosseous suture fixation when loaded cyclically (10). Suture anchors perform best when inserted at 45° angles to the bony surface (in the manner of a tent stake). Transosseous fixation is improved by using 10-mm-long bony bridges, exiting the tunnels 10 mm distal to the tuberosity, and use of a plastic button to tie over in osteopenic bone (11). Using both suture anchor and transosseous fixation with suture provides optimum fixation, allowing early motion of the shoulder after rotator cuff repair.

**MINI–OPEN REPAIR OF THE ROTATOR CUFF**

- Place the patient in the lateral decubitus or beach-chair position and perform arthroscopy in the routine fashion. Arthroscopy is often helpful to identify the extent and reparability of a tear (Fig. 79.11 and Fig. 79.12). If the tear appears reparable with or without mobilization of the cuff, proceed with arthroscopic repair. (See below for the management of irreparable tears.) After decompression, perform arthroscopic mobilization of the cuff if desired, or proceed with open surgery.

***Figure 79.11.*** Arthroscopic view of a full-thickness tear with an obvious acromial spur overhead and an intact biceps tendon beneath a slightly retracted tear of supraspinatus.

***Figure 79.12.*** Incision parallel to the acromion to expose a rotator cuff tear. Arm is still suspended from overhead traction.

- With the patient in the same position, make a strap incision paralleling the lateral edge of the acromion (Fig. 79.12). Such an incision is preferable to a straight lateral incision, which can result in scarring to the underlying deltoid raphe with painful dimpling of the skin.
- Split the deltoid in line with its fibers at the anterolateral corner of the acromion (junction of the anterior and middle one third of the deltoid) (Fig. 79.13). Insert a smooth, self-retaining retractor to inspect the rotator cuff (Fig. 79.14). Gentle traction on the humerus often improves visualization.

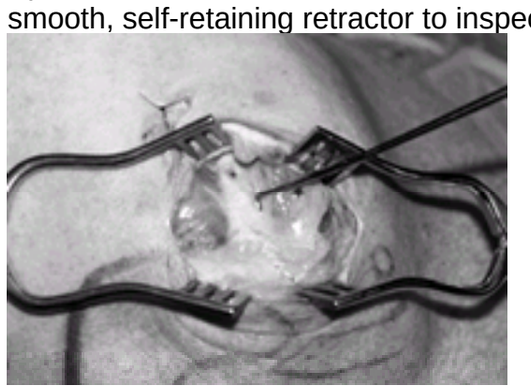

***Figure 79.13.*** Raphe between the anterior and middle heads of a deltoid. After splitting raphe, a self-retaining retractor allows more than adequate exposure of the torn supraspinatus.

***Figure 79.14.*** View of the torn rotator cuff using mini–open incision.

- Excise adherent bursal tissue to see the actual rotator cuff. Inspect the articular surface for any delamination in a horizontal plane.
- Retracted tears require mobilization. These tears are usually triangular or ovoid in shape, principally involving the supraspinatus tendon near its insertion. If mobilization is needed, apply stay sutures (#2 nonabsorbable) to the edges of the tear for traction. Start mobilizing with a blunt elevator or a finger along the superior surface, working medially. Gain additional excursion on the articular side by sharply incising the junction of the upper one half of the capsule and the cuff, staying peripheral to the labrum. Do not dissect more than 1 cm medial to the glenoid along the undersurface of the supraspinatus in order to avoid injury to the suprascapular nerve (65). Additional excursion can be gained by releasing the coracohumeral ligament, which can retract the anterior portion of the supraspinatus.
- Advance the mobilized cuff toward the tuberosity. Observe whether the leading edge can be directly advanced to bone (crescentic tear pattern) (Fig. 79.15). If the tear is V-shaped, partial side-to-side repair near the apex may be necessary, with the edge of the tear then advanced to the bony trough (Fig. 79.16). In some cases, the defect can be closed and secured to bone only by local transposition of tissue (Fig. 79.16). Alternatively, use a partial side-to-side closure and medial repair within 10 mm of the normal insertion (McLaughlin type V-Y repair).

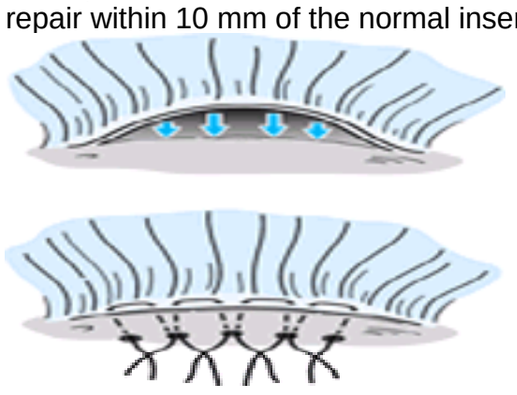

***Figure 79.15.*** Direct advancement to bone of a crescentic-type tear using repair by transosseous sutures.

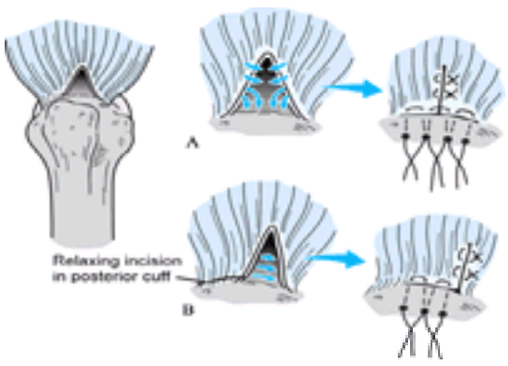


***Figure 79.16.*** Triangular tear. **A:** Repaired by side-to-side repair and advancement to trough by transosseous sutures. **B:** Repaired by local transposition using a relaxing incision in the posterior portion of the cuff.

- Prepare the area for bony attachment by lightly burring the cortical margin, leaving a shallow trough (5–7 mm) with intact lateral cortical bone to minimize the risk of suture pull-out. Insert interrupted horizontal mattress sutures with the sutures exiting the bursal surface to help force the tendon against the cancellous surface after repair. Using a small drill or awl of a diameter slightly larger than the suture, place multiple holes exiting lateral to the trough. For additional support, insert one or two suture anchors (#2 nonabsorbable) just medial to the trough, inclined at a 45° angle, as one would use to drive in a tent stake (Fig. 79.17). Suture anchors provide a “belt-and-suspenders” repair. Pass the sutures in the cuff edges using a suture passer or needle through the drill holes laterally. With the lateral sutures tensioned to achieve reduction, pass the sutures from the anchors at appropriate spots through the cuff.

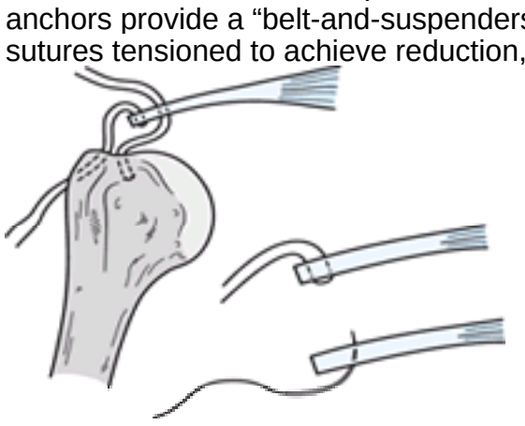

***Figure 79.17.*** Combined repair with suture anchor and transosseous suture. Note medial placement in the tendon for suture strands emanating from the anchor, and horizontal mattress suture exiting the superior surface of the tendon to facilitate compression against the cancellous surface of the trough when tensioned and tied over the transosseous bridge.

- Perform repair with the arm as close to neutral rotation as possible. Repair a longitudinal (side-to-side) tear with interrupted #0 absorbable sutures. For tendon tears from bone, apply traction through the sutures, passing laterally through the tuberosity, and tie the anchor sutures. Tie the lateral sutures individually, leaving only a small tag to minimize formation of bursal adhesions.
- Check the integrity of the repair with passive motion. Irrigate and remove any additional bursal tissue. Close the deltoid split with interrupted #0 absorbable sutures. Close the subcutaneous layer with deep sutures, and perform a subcuticular skin closure. Apply a nonbulky dressing incorporating a cryotherapy pad. Use an immobilizer for support or a commercial pillow splint for added comfort.

In designing the postoperative plan, it is important to consider the size of the tear, the type of repair (side-to-side versus tendon-to-bone), how easy it was to achieve repair (degree of retraction), intraoperative motion limits, and the age of the patient (quality of bone and tendon). Other factors include use of an abduction pillow versus a sling, the timing and extent of ROM exercises, and the rate of progression to resistive exercises and eventual return to activity. Patients typically do not progress in a straight-line fashion but rather can be expected to experience minor setbacks or temporary plateaus with regard to both postoperative pain and ROM. Patients do not experience maximal recovery for up to 1 year after surgery in many cases. Preoperative counseling is important to educate the patient about individual variability and length of recovery.

It is important to promote early motion of the shoulder without compromising the repair. If a longitudinal tendon split has been repaired without detachment of the deltoid, immediate passive ROM is acceptable, followed by active ROM excercise at 2–3 weeks. If the patient is elderly with osteopenic bone and a large, retracted tear, use of an abduction pillow for 4–6 weeks with only limited passive motion is appropriate. If the tear involves a significant portion of the infraspinatus, internal rotation may be tight and may pose a danger to the repair. Use of an abduction splint in such cases may avoid the extreme internal rotation imposed by a standard sling.

In general, have the patient perform passive motion using pendulum exercises and supine ROM for 4–6 weeks within an arc of motion of up to 75% of the limit that was observed at surgery. These restrictions are necessary before allowing active assisted motion in order not to threaten the repair. Overhead pulley exercises involve active muscle contraction and should be delayed until 4–6 weeks in most cases. Part-time use of the sling may be needed for up to 6–8 weeks. Once active control of the arm is achieved at 6–8 weeks, allow isometric exercises. At 10–12 weeks, initiate light resistive exercises. If pain develops, reduce exercises while maintaining motion. Modalities such as ice and interferential stimulation are useful.

If necessary, manipulation to gain motion can be performed at 12 weeks without risk of tearing the tendon from its repair site. In most cases, functional and progressive resistive exercises can be initiated by 4 months. Most activities can be resumed between 6 and 12 months.

**IRREPARABLE TEARS**

Some large and massive tears cannot be fully repaired despite extensive mobilization. The surgical options are then to medialize the repair as much as 10 mm along the lateral articular cartilage; perform a partial repair of the cuff; transpose the subscapularis tendon superiorly; fill the defect with allograft tissue, autograft tissue, or synthetic material; or transfer the latissimus dorsi.

Medialization of the supraspinatus insertion 10 mm or less maintains its mechanical advantage. Biomechanical and clinical evidence of the force-couple relationship of the intact subscapularis and infraspinatus to functionally substitute for the torn supraspinatus lends support to the concept of partial repair. It eliminates the unstable edges of a torn cuff, which may be the real cause of pain.

Among proponents of obtaining “coverage” of the humeral head, Cofield has reported success with transposition of the upper one half of the subscapularis tendon to fill the defect in the supraspinatus (13) (Fig. 79.18). This procedure disrupts the important force-couple between the subscapularis and infraspinatus–teres minor, which has been observed clinically and experimentally to effectively substitute for a torn supraspinatus. Because a transferred muscle loses approximately one grade of power, both subscapularis and latissimus dorsi transfers may be weakened.

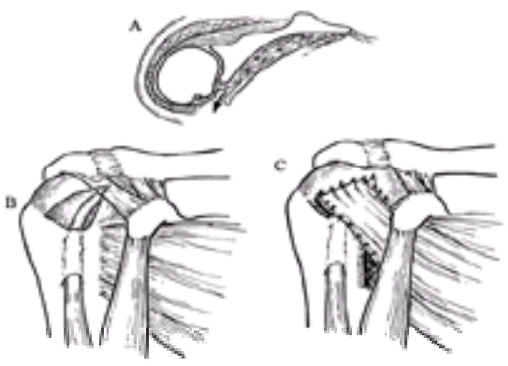


***Figure 79.18.*** Subscapularis transposition to cover a supraspinatus defect. **A.**Cross section of the shoulder showing release of the subscapularis tendon. **B.**Defect in the supraspinatus tendon. **C.**Transposition of the subscapularis tendon into the defect. (From Poppen NK. Soft-tissue Lesions of the Shoulder. In: MW Chapman, ed. *Operative Orthopaedics*, 2nd ed. Philadelphia: JB Lippincott, 1993:1651, with permission.)

Rockwood and others have advocated debridement alone for irreparable tears (9,52), which can be successful in relieving pain when followed by a program to strengthen the other cuff muscles, deltoid, and scapular rotators. If a tear is found to be irreparable, then traditional acromioplasty should be modified to prevent superior migration of the humeral head postoperatively. Removal of the CA ligament in the presence of a full-thickness tear can destabilize the glenohumeral joint leading to superior dislocation (68). In these instances, perform flattening, and even slight concave hollowing, of the acromion to achieve decompression, while preserving the CA ligament attachment to its anterior edge.

**BICEPS TENDON RUPTURE**

Impending or acute rupture of the long head of the biceps can be managed by extraarticular tenodesis. In the case of rupture, the deformity is obvious with distal migration of the muscle (Fig. 79.19). Weakness is usually confined to supination activities (e.g., use of a screwdriver), unlike distal biceps rupture, which causes elbow flexion weakness. Isolated rupture is seen in young athletes and laborers, but coexistent supraspinatus tendinopathy should be suspected in middle- and older-aged patients.

***Figure 79.19.*** Biceps rupture with distal migration of the muscle belly.

Impending and partial ruptures may be difficult to detect. Pain similar to rotator cuff tendinopathy is present, and tenderness anteriorly about the shoulder is common. Speed's test (resisted elevation of the supinated arm with the elbow extended) (22) and Yeargerson's test (resisted supination with elbow flexed) (70) may be positive. Tenodesis for bicipital tendinitis, however, is unsuccessful in as many as 50% of patients (4), and nonsurgical measures like those used in rotator cuff tendinitis are used to manage this condition.

If repair is elected for isolated rupture, use a combined arthroscopic and open approach. Do an arthroscopic inspection of the joint and rotator cuff, and resect the intraarticular portion of the torn long head of the biceps. Two short incisions may be needed for tenodesis: a 3 cm incision over the deltobicipital groove at the mid-arm to locate the often distally retracted and entrapped long head tendon, and a second 3–4 cm incision just anterior and distal to the acromion to expose the intertubercular groove. This proximal incision corresponds to the anterior portion of the saber-type incision used to expose the rotator cuff. A suture passer is helpful to deliver a retracted tendon into the proximal incision. Tenodesis is necessary because direct repair is usually not feasible, except in the rare instance of a tear at the musculotendinous junction (mid-arm level).

Although a keyhole recession can be used, a simpler method is to place two suture anchors in the middle of the groove, which has been lightly decorticated with a burr, and secure the tendon with horizontal #2 nonabsorbable mattress sutures. Have the patient wear a sling for 10–14 days, then allow active shoulder motion. Avoid

active use of the biceps for 4 weeks, and hold off on resistive exercises until 10 weeks.

## RESULTS OF ROTATOR CUFF SURGERY

The results of open or arthroscopic subacromial decompression are essentially equivalent, with approximately 75% to 90% of patients having a good or excellent result. Advocates of the arthroscopic approach note diminished perioperative pain, faster return of motion, and earlier return to activity. The arthroscopic procedure is technically demanding and, other than error in diagnosis, an inadequate or poorly performed acromioplasty is the major reason for failure of the procedure. Assuming a correct initial diagnosis, factors associated with a poor result include the following:

- Worker's compensation cases (25)
- Inadequate or excessive bone resection from the acromion
- Failure to remove inferior distal clavicle spurs compromising the supraspinatus outlet (50)
- Surgery performed in throwing athletes, some of whom possibly had coexistent glenohumeral instability (53,62,63)

Following direct tendon repair, satisfactory results can be expected in 75% to 90% of patients. Relief of pain rates highest, followed by lower scores for ROM and return of function. The following are useful guidelines to predict success when treating patients with rotator cuff tear:

- In general, small and moderate tears have better overall results (pain relief, motion, and function) than large and massive tears (16,27).
- Duration of symptoms and preoperative weakness correlate with the size of the cuff tear (2,16).
- Cuff integrity at follow-up correlates with improved strength, motion, and function but does not affect pain scores; large tears with involvement of the supraspinatus and infraspinatus have a retear rate greater than 50% (23).
- Return to previous activity level for the high-level competitive athlete is approximately 50% (62), whereas more than 80% of recreational athletes can return to activity (6).
- Rehabilitation time is prolonged by 25% when distal clavicle excision for AC joint DJD is performed concomitantly with rotator cuff repair (14).
- Persistent mechanical impingement and large or massive tears of the cuff are the two major reasons for surgical failure (5).
- Although a good outcome for pain relief, motion, and strength can be obtained in full-thickness tears treated by decompression only (9), improvement in pain *only* is most likely (15,19), and repair offers the best results (37).

## COMPLICATIONS OF ROTATOR CUFF SURGERY

Complications from arthroscopic and open surgery for rotator cuff disorders include retear or failure of cuff repair, infection, stiffness, acromial fracture, deltoid injury, and reflex sympathetic dystrophy. While technical factors may be involved to some degree, many of these complications are no different from those associated with other procedures. The patient's final outcome is frequently dependent on how early a complication is recognized and treated.

The rotator cuff may fail to heal or may retear. The most important factors associated with a failed repair are continued subacromial impingement and the presence of a large or massive rotator cuff tear at initial surgery (5). Additional treatment (revision of repair) is indicated if the patient experiences return of pain. Revision cuff repair can relieve pain in nearly 80% of such patients, although function is not likely to be improved significantly.

Infection is less likely in the shoulder due to its abundant vascularity, but recognition may be difficult. The traditional signs of heat, swelling, and redness are often not present initially. Diagnosis depends on suspicion of continuing or increasing pain at rest and with movement of the shoulder. Infection is more likely to develop following open surgery. If diagnosed early, infection can respond to arthroscopic debridement and irrigation, followed by appropriate antibiotic therapy. Established infection with necrotic tissue and copious granulation tissue usually requires open debridement. Preserve if possible any repair of the rotator cuff, even if repeat debridement may be needed.

Adhesions can develop quickly in the subacromial bursa even after arthroscopic debridement. Early motion is the key to prevention. If motion is slow to return during the first few weeks, increase formal therapy sessions to ensure compliance with motion exercises. Posterior capsular tightness can be a contributing factor in regaining motion by causing impingement pain with exercises. If the patient has achieved less than 60% of expected ROM by 6–8 weeks, then repeat arthroscopy with lysis of subacromial adhesions is indicated. After cuff repair, 12 weeks is required before the tendon is adequately healed for manipulation to be performed.

Fracture of the acromion has been described as a result of excessive acromioplasty (36). Rapid advancement of resistive exercises in the postoperative period may be a contributing factor. Fracture usually is not evident for several months after the index procedure. Radiograph patients with new onset of pain in the postoperative period. Treat large fragments by fixation; small fragments can be arthroscopically excised.

Denervation of the deltoid as well as detachment from the acromion can occur. Denervation results from distal extension of an incision transecting the axillary nerve as it courses posterior to anterior along the undersurface of the deltoid approximately 5 cm below the acromion. Weakness results in the denervated portion of the deltoid. Rarely, detachment of the deltoid occurs from inadvertent arthroscopic release during decompression of the subacromial bursa and by avulsion from its repair site following reflection during open surgery. Excessive retraction can produce a defect inferior to the acromion and a nonfunctioning segment of muscle. Early treatment by reattachment through drill holes in the acromion can be successful if performed within 6 weeks. After repair, maintain the shoulder in abduction for 3–4 weeks.

## CALCIFIC TENDINITIS

Calcific tendinitis is a common condition that affects middle-aged individuals predominantly. Calcification of a portion of the supraspinatus tendon is usually followed by resorption of the deposit and by reconstitution of the tendon. The clinical expression of this degenerative process is highly variable. Incidental asymptomatic calcification is common.

In its chronic form, patients can experience symptoms similar to tendinitis. Acute calcific tendinitis is quite dramatic, with sudden onset of severe pain, exquisite tenderness, and pain that increases with attempted shoulder motion. Differential diagnosis includes trauma, acute infection, and acute brachial neuropathy.

The etiology of calcific tendinitis remains unresolved. The condition is not caused by mechanical impingement, but tendon degeneration may be important (12). It appears that calcific tendinitis is preceded by fibrocartilaginous metaplasia of the involved portion of the tendon (64).

Radiographically, calcific deposits either appear as dense, well-defined opacities or are fluffy with irregular outlines. The calcific deposit usually appears within the substance of the supraspinatus tendon distinct from its bony insertion (Fig. 79.3). Initially dense and well bordered, the deposit becomes irregular and fluffy as the resorptive phase begins with rupture of calcium particles into the subacromial bursa, which is usually associated with acute pain.

Clinically, the patient who presents with acute dramatic pain is likely to respond to temporary immobilization, nonsteroidal anti-inflammatory drugs (NSAIDs), or subacromial injection of a steroid such as dexamethasone directly into the deposit. Lavage using two separate needles, one to inject lidocaine and sterile saline and the other for aspiration, may be helpful. Most patients typically improve regardless of treatment during the resorptive phase. In the asymptomatic patient, treatment is not necessary. Some patients with dense deposits develop symptoms of tendinitis, which are treated with a nonsurgical program similar to that for noncalcific tendinitis. Failure to improve with this regimen is an indication for surgery.

### ARTHROSCOPIC DEBRIDEMENT OF CALCIFIC TENDINITIS

- Use the same set-up as previously described for shoulder arthroscopy. After glenohumeral visualization, move the arthroscope into the bursa using the posterior portal initially.
- Visualize an area of increased vascularity on the bursal surface of the tendon (Fig. 79.20*A*; see also Color Fig. 79.20). Insert a probe or needle from the lateral portal to confirm the deposit by palpation. Uncover the deposit using a shaver (Fig. 79.20*B*). Note the chalklike flakes and nuggets (Fig. 79.20*C*). Continue debridement until the base is clean of calcium particles (Fig. 79.20*D*). A curet can be helpful in scraping out all remaining particles.

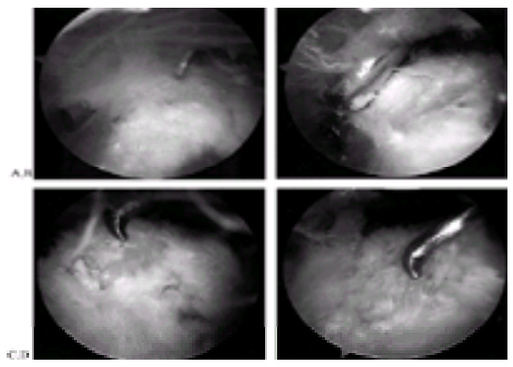

***Figure 79.20.*** (See Color Figure 79.20) Calcific tendinitis. **A:** Note inflamed area on bursal surface of the supraspinatus, which corresponds to an underlying calcific deposit. **B:** Unroofing of the calcific deposit by gentle shaving. **C:** Full extent of the deposit. **D:** After complete debridement, the tendon remains intact.

- If the defect is more than 50% the thickness of the tendon, do a repair; if it is less than 50% of that thickness, nothing further is necessary. Do not perform acromioplasty in either instance.
- Close the arthroscopic portals and place the arm in a supportive sling.

Postoperatively, follow the rehabilitation schedule for repair if appropriate. Otherwise, start early ROM allowing resistive exercises by 3 weeks and return to activity at 4–6 weeks.

## ADHESIVE CAPSULITIS

The clinical syndrome of shoulder pain and progressive loss of motion unassociated with trauma, followed by partial if not complete resolution over a prolonged time course, is commonly referred to as *adhesive capsulitis* or *frozen shoulder* (12,41). Adhesive capsulitis has been further classified as (a) primary or idiopathic and (b) secondary, on the basis of a precipitating condition or injury (35). Risk factors for the development of primary adhesive capsulitis include female sex, middle and older age, and diabetes. In fact, the first presentation of diabetes can be adhesive capsulitis. Secondary frozen shoulder can develop after trauma or surgery to the shoulder, cervical and intrathoracic disease including malignancy, and as a consequence of distant upper-extremity trauma (shoulder–hand syndrome).

Contradictory pathologic changes have been described in the literature, ranging from no synovial changes, to vascular synovitis and presence of intraarticular adhesions and capsular fibrosis, to no such changes (67). More recently, it has been suggested that contracture of the rotator cuff interval is the responsible mechanism (48). Regardless, reduction in volume of the capsule is the result of the pathologic process.

Clinically, the primary form can be categorized into three phases: freezing, frozen, and thawing, each representing approximately a 6-month period. The initial process can be painful, although in some patients loss of motion is the major complaint. Once established, pain usually tapers off and restricted motion remains the concern. Unfortunately, the condition can occur bilaterally, either simultaneously or sequentially.

Diagnosis of the idiopathic condition requires exclusion of secondary causes. Plain radiographs are unremarkable unless a secondary cause is identified. A saline-contrast MRI or traditional arthrogram will demonstrate decreased capsular volume with obliteration of the inferior capsular fold, and it will exclude abnormality of the rotator cuff. Perform these studies on a case-by-case basis.

Treatment is primarily nonsurgical. NSAIDs are useful for pain and may be indicated early in the disease because of the inflammatory changes described. Similarly, an intraarticular steroid injection (40 mg methylprednisolone) may be helpful. ROM exercises are the centerpiece of treatment. Passive exercises, especially external rotation and flexion stretching, use of a pulley, and distraction techniques employed by therapists, are especially beneficial. Ultrasound may be beneficial to increase capsular compliancy.

Surgical treatment is indicated when exercise and the passage of time do not improve ROM. Although arthroscopy has been used with limited success, the risk of incidental scuffing of the joint surfaces does not warrant it, in my opinion. The preferred treatment is manipulation.

### MANIPULATION

Exercise care to minimize the risk of humeral fracture or dislocation.

- Have the anesthetist administer propofol or a similar short-acting agent while monitoring the patient. Position the patient supine and have an assistant stand at the head of the table to apply downward force on the scapula while you perform manipulation.
- Grasp the arm near the shoulder joint, *not* at the elbow, to reduce the moment arm. Slowly but firmly begin flexing the humerus, overcoming adhesions. Usually, at least 90° or more will be easily obtained without excessive force.
- Grasp the arm at the elbow and begin to rotate externally with less force than used for flexion. As resistance increases, switch to flexion of the humerus until more motion is gained, then return to external rotation. Alternate this pattern until at least 80% of the normal ROM is gained.
- To reduce pain postoperatively and to encourage active ROM by the patient, inject 20 ml of 0.5% Marcaine into the glenohumeral joint. If possible, have the therapist begin working with the patient in the recovery area.

## PECTORALIS MAJOR RUPTURE

Rupture of the pectoralis major is an infrequent event, usually the result of weightlifting or other sporting activity. Complete and partial tears are recognized, with the shorter sternal fibers most often involved. Rupture is the result of eccentric loads applied to the muscle while the humerus is extended (18,69). Risk factors include male sex and steroid use.

Clinically, acute injury results in sudden, dramatic pain and weakness of the shoulder. Examination shows ecchymosis along the arm and upper chest wall, associated with pain and weakness with attempted resisted adduction of the arm (Fig. 79.21). Because of swelling, no defect is usually palpable in the anterior axillary fold.

***Figure 79.21.*** Ecchymosis associated with pectoralis major rupture.

Partial tears are less dramatic in presentation. In the acute setting, differential diagnosis includes fracture, dislocation, rotator cuff tear, and ruptures of the subscapularis and long head of the biceps tendon. Chronic tears are associated with pain and weakness with activity. On examination, there is a palpable defect in the

anterior axillary fold.

Plain radiographs are unremarkable. Ultrasound can be used to identify complete tears, but MRI is more accurate, differentiating complete from partial tears.

Repair is indicated for acute, complete tears in the active patient. Successful repair of chronic tears has been reported as well, however (32).

**REPAIR OF PECTORALIS MAJOR**

- Under general anesthesia or interscalene block, place the patient in the beach-chair position with the arm draped free.
- Make an incision along the deltopectoral groove extending distal to the anterior axillary fold. Retract the cephalic vein laterally with the deltoid, and in the lower incision identify the avulsed pectoralis tendon (Fig. 79.22).

***Figure 79.22.*** Avulsed pectoralis tendon retracted medially.

- Clear off the attachment area along the lateral lip of the bicipital groove, protecting the biceps tendon. Create a trough with a burr to maximize tendon-to-bone healing.
- Insert three #2 nonabsorbable suture anchors in this area and pass the ends through the tendon in a horizontal configuration. Alternatively, use drill holes exiting the trough laterally. With the arm in adduction and slight internal rotation, tie the sutures (Fig. 79.23).

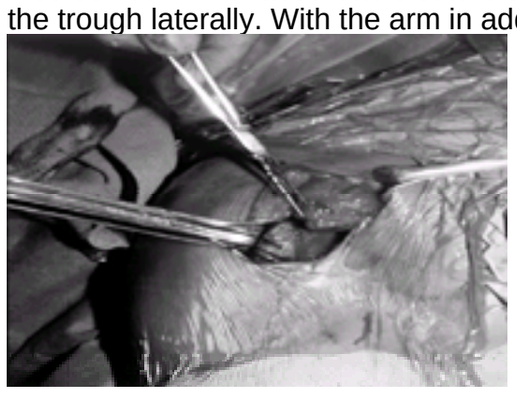

***Figure 79.23.*** Repair of the pectoralis tendon to its bony bed.

- Close the subcutaneous layer and skin in a routine manner. Apply an immobilizer for postoperative support.

Postoperatively, maintain the arm in the immobilizer for 4 weeks. Then allow forward flexion with the arm internally rotated. At 6 weeks, allow external rotation to neutral. Between 8 and 10 weeks, start additional external rotation. Do not start resistive exercises for internal rotation and adduction until 12 weeks. Return to activity usually takes 4–6 months.

**CHAPTER REFERENCES**

Each reference is categorized according to the following scheme: *, classic article; #, review article; !, basic research article; and +, clinical results/outcome study.


+ 1. Andrews JR, Broussard TS, Carson WG. Arthroscopy of the Shoulder in the Management of Partial Tears of the Rotator Cuff: A Preliminary Report. *Arthroscopy* 1985;1:117.

+ 2. Bartolozzi A, Ancheychik, Ahmad S. Determinants of Outcome in the Treatment of Rotator Cuff Disease. *Clin Orthop* 1994;308:90.

+ 3. Bassett RW, Cofield RH. Acute Tears of the Rotator Cuff: The Timing of Surgical Repair. *Clin Orthop* 1983;175:12.

+ 4. Becker DA, Cofield RH. Tenodesis of the Long Head of the Biceps Brachii for Chronic Bicipital Tendinitis. *J Bone Joint Surg [Am]* 1989;71:376.

+ 5. Bigliani LU, Cordasco FA, McIlveen SJ, et al. Operative Treatment of Failed Repair of the Rotator Cuff. *J Bone Joint Surg [Am]* 1992;74:1505.

+ 6. Bigliani LU, Kimmel J, McCann PD, et al. Repair of Rotator Cuff Tears in Tennis Players. *Am J Sports Med* 1992;20:112.

+ 7. Bokor DJ, Hawkins RJ, Huckell GH, et al. Results of Nonoperative Management of Full-thickness Tears of the Rotator Cuff. *Clin Orthop* 1993;294:103.

+ 8. Budoff JE, Nirschi RP, Guidi EJ. Current Concepts Review: Debridement of Partial-thickness Tears of the Rotator Cuff without Acromioplasty. *J Bone Joint Surg [Am]* 1998;80:733.

+ 9. Burkhart SS. Arthorscopic Treatment of Massive Rotator Cuff Tears. *Clin Orthop* 1991;267:45.

+ 10. Burkhart SS, Pagan JL, Wirth, MA, et al. Cyclic Loading of Anchor-based Rotator Cuff Repairs. Confirmation of the Tension Overload Phenomenon and Comparison of Suture Anchor Fixation with Transosseous Fixation. *Arthroscopy* 1997;13:720.

! 11. Caldwell GL Jr, Warner JJP, Miller MD, et al. Transosseous Rotator Cuff Fixation: The Weak Link? A Biomechanical Evaluation. *Orthop Trans* 1995;19:368.

* 12. Codman EA. *The Shoulder.* Boston: Thomas Todd, 1934.

+ 13. Cofield RH. Subscapular Muscle Transposition for Repair of Chronic Rotator Cuff Tears. *Surg Gynecol Obstet* 1982;154:667.

+ 14. Daluga DJ, Dobozi W. The Influence of Distal Clavicle Resection and Rotator Cuff Repair on the Effectiveness of Anterior Acromioplasty. *Clin Orthop* 1989;247:117.

+ 15. Ellman H. Arthroscopic Subacromial Decompression: Analysis of One- to Three-year Results. *Arthroscopy* 1987;3:173.

+ 16. Ellman H, Hanker G, Bayer M. Repair of the Rotator Cuff. *J Bone Joint Surg [Am]* 1986;68:1136.

+ 17. Ellman H, Harris E, Kay SP. Early Degenerative Joint Disease Simulating Impingement Syndrome. Arthroscopic Findings. *Arthroscopy* 1992;8:482.

! 18. Garrett WE Jr, Safran MR, Seaber AV, et al. Biomechanical Comparison of Stimulated and Nonstimulated Skeletal Muscle Pulled to Failure. *Am J Sports Med* 1987;15(5):448.

+ 19. Gartsman GM. Arthroscopic Acromioplasty for Lesions of the Rotator Cuff. *J Bone Joint Surg [Am]* 1990;72:169.

+ 20. Gerber C. Latissimus Dorsi Transfer for the Treatment of Irreparable Tears of the Rotator Cuff. *Clin Orthop* 1992;275:152.

+ 21. Gerber C, Krushell RJ. Isolated Rupture of the Tendon of the Subscapularis Muscle: Clinical Features in 16 Cases. *J Bone Joint Surg Br* 1991;73:389.

* 22. Gilchreest EL, Albi P. Unusual Lesions of Muscle and Tendons of the Shoulder Girdle and Upper Arm. *Surg Gynecol Obstet* 1939;68:903.

+ 23. Harryman DT II, Mack LA, Wang KY, et al. Repairs of the Rotator Cuff: Correlation of Functional Results with Integrity of the Cuff. *J Bone Joint Surg [Am]* 1991;73:982.

+ 24. Harryman DT II, Sidles JA, Clark JM, et al. Translation of the Humeral Head on the Glenoid with Passive Glenohumeral Motion. *J Bone Joint Surg [Am]* 1990;72:1334.

+ 25. Hawkins RJ, Chris T, Bokor D. Failed Anterior Acromioplasty: A Review of 51 Cases. *Clin Orthop* 1989;243:106.

+ 26. Hawkins RJ, Kennedy JC. Impingement Syndrome in Athletes. *Am J Sports Med* 1980;8:151.

+ 27. Hawkins RJ, Misamore GW, Hobeika PE. Surgery for Full-thickness Rotator Cuff Tears. *J Bone Joint Surg [Am]* 1985;67:1349.

+ 28. Iannotti JP, Zlatkin MB, Esterhai JL, et al. Magnetic Resonance Imaging of the Shoulder: Sensitivity, Specificity, and Predictive Value. *J Bone Joint Surg [Am]* 1991;73:17.

+ 29. Itoi E, Tabata S. Conservative Treatment of Rotator Cuff Tears. *Clin Orthop* 1992;275:165.

+ 30. Jobe FW, Kvitne RS, Giangarra CE. Shoulder Pain in the Throwing Athlete. The Relationship of Anterior Instability and Rotator Cuff Impingement. *Orthop Rev* 1989;18:963.

# 31. Jobe FW, Tibone JE, Jobe CM, et al. The Shoulder in Sports. In: Rockwood CA, Matsen FA III, eds. *The Shoulder.* Philadelphia: WB Saunders, 1990.

+ 32. Kretzler HH Jr, Richardson AB. Rupture of the Pectoralis Major Muscle. *Am J Sports Med* 1989;17:453.

+ 33. Lazarus MD, Chansky HA, Misra S, et al. Comparison of Open and Arthroscopic Subscromial Decompression. *J Shoulder Elbow Surg* 1994;3:1.

+ 34. Liu SH. Arthroscopically Assisted Rotator Cuff Repair. *J Bone Joint Surg Br* 1994;76:592.

+ 35. Lundberg BJ. The Frozen Shoulder. *Acta Orthop Scand* 1969;119:1.

+ 36. Matthews LS, Burkhead WZ, Gordon S, et al. Acromial Fracture: A Complication of Arthroscopic Subacromial Decompression. *J Shoulder Elbow Surg* 1994;3:256.

+ 37. Montgomery TJ, Yerger B, Savoie FH III. Management of Rotator Cuff Tears: A Comparison of Arthroscopic Debridement and Surgical Repair. *J Shoulder Elbow Surg* 1994;3:70.

+ 38. Morrison DS, Bigliani LU. The Clinical Significance of Variations in Acromial Morphology. *Orthop Trans* 1987;11:234.

+ 39. Mudge MK, Wood VE, Frykman GK. Rotator Cuff Tears Associated with Os Acromiale. *J Bone Joint Surg [Am]* 1966;66:427.

+ 40. Neer CS. Anterior Acromioplasty for the Chronic Impingement Syndrome in the Shoulder. A Preliminary Report. *J Bone Joint Surg [Am]* 1972;54:41.

+ 41. Nevaiser JS. Adhesive Capsulitis of the Shoulder. *J Bone Joint Surg* 1945;27:211.

+ 42. Norlin R. Arthroscopic Subacromial Decompression versus Open Acromioplasty. *Arthroscopy* 1989;5:321.

+ 43. Nutton RW, McBirnie JM, Phillips C. Treatment of Chronic Rotator-Cuff Impingement by Arthrscopic Subacromial Decompression. *J Bone Joint Surg Br* 1997;79:73.

+ 44. Ogata S, Uhthoff HK. Acromial Enthesopathy and Rotator Cuff Tear: A Radiologic and Histologic Post-mortem Investigation of the Coracoacromial Arch. *Clin Orthop* 1990;254:39.

+ 45. Oglivie-Harris DJ, Wiley AM, Sattarian J. Failed Acromioplasty for Impingement Syndrome. *J Bone Joint Surg Br* 1990;72:1070.

+ 46. Otis JC, Jiang CC, Wickewicz TL, et al. Changes in the Moment Arms of the Rotator Cuff and Deltoid Muscles with Abduction and Rotation. *J Bone Joint Surg [Am]* 1994;76:667.

! 47. Ozaki J, Fujimoto S, Nakagawa Y. Tears of the Rotator Cuff of the Shoulder Associated with Pathological Changes in the Acromion: A Study in Cadavera. *J Bone Joint Surg [Am]* 1988;70:1224.

+ 48. Ozaki J, Nakagawa Y, Sakurai G, et al. Recalcitrant Chronic Adhesive Capsulitis of the Shoulder. *J Bone Joint Surg [Am]* 1989;71:1511.

+ 49. Paavolainen P, Ahovuo J. Ultrasonography and Arthrography in the Diagnosis of Tears of the Rotator Cuff. *J Bone Joint Surg [Am]* 1994;76:335.

+ 50. Peterson CJ, Gentz CF. Ruptures of the Supraspinatus Tendon: The Significance of Distally Pointing Acromioclavicular Osteophytes. *Clin Orthop* 1983;174:143.

+ 51. Richardson AB, Jobe FW, Collins HR. The Shoulder in Competitive Swimming. *Am J Sports Med* 1980;8:159.

+ 52. Rockwood CA, Lyons FR. Shoulder Impingement Syndrome: Diagnosis, Radiographic Evaluation, and Treatment with a Modified Neer Acromioplasty. *J Bone Joint Surg [Am]* 1993;74:409.

+ 53. Roye RP, Grana WA, Yates CK. Arthroscopic Subacromial Decompression: Two to Seven Year Followup. *Arthroscopy* 1995;11:301.

+ 54. Sampson TD, Bisbet JK, Glick JM. Precision Acromioplasty in Arthroscopic Subacromial Decompression of the Shoulder. *Arthroscopy* 1991;7:301.

+ 55. Seltzer DG, Wirth MA, Rockwood CA. Complications and Failures of Open and Arthroscopic Acromioplasties. *Arthroscopy* 1992;8:173.

+ 56. Shaffer B, Tibone JE, Kerlan RK. Frozen Shoulder. *J Bone Joint Surg [Am]* 1992;74:738.

! 57. Sharkey NA, Marder RA, Hanson PB. The Entire Rotator Cuff Contributes to Elevation of the Arm. *J Orthop Res* 1994;12:699.

+ 58. Sher JS, Uribe JW, Posada A, et al. Abnormal Findings on Magnetic Resonance Images of Asymptomatic Shoulders. *J Bone Joint Surg [Am]* 1995;77:10.

+ 59. Smith JG. Pathological Appearances of Seven Cases of Injury of the Shoulder Joint, with Remarks. *Am J Med Sci* 1934;16:219.

+ 60. Snyder SJ, Karzel RP, Del Pizzo W, et al. SLAP Lesions of the Shoulder. *Arthroscopy* 1990;6:274.

+ 61. Speer KP, Harrington JA, Altchek DE, et al. An Evaluation of the Shoulder Relocation Test. *Am J Sports Med* 1994;22:177.

+ 62. Tibone JE, Elrod B, Jobe FW, et al. Surgical Treatment of Tears of the Rotator Cuff in Athletes. *J Bone Joint Surg [Am]* 1986;68:887.

+ 63. Tibone JE, Jobe FW, Kerlan RK, et al. Shoulder Impingement Syndrome in Athletes Treated by an Anterior Acromioplasty. *Clin Orthop* 1985;198:1334.

+ 64. Uhthoff HK, Loehr JW. Calcific Tendinopathy of the Rotator Cuff: Pathogenesis, Diagnosis, and Management. *J Am Acad Orthop Surg* 1997;5:183.

+ 65. Warner JP, Krushell RJ, Masquelet A, et al. Anatomy and Relationships of the Suprascapular Nerve: Anatomical Constraints to Mobilization of the Supraspinatus and Infraspinatus Muscles in the Management of Massive Rotator Cuff Tears. *J Bone Joint Surg [Am]* 1992;74:36.

+ 66. Warner JP, Warren RF. Arthroscopic Bankart Repair Using Cannulated Absorbable Fixation Device. *Oper Tech Orthop* 1991;1:192.

+ 67. Wiley AM. Arthroscopic Appearance of Frozen Shoulder. *Arthroscopy* 1991;7:138.

+ 68. Wiley AM. Superior Humeral Dislocation: A Complication Following Decompression and Debridement for Rotator Cuff Tears. *Clin Orthop* 1991;263:135.

+ 69. Wolfe SW, Wickiewicz TL, Cavanaugh JT. Ruptures of the Pectoralis Major Muscle. *Am J Sports Med* 1992;20(5):587.

* 70. Yeargason RM. Rupture of Biceps. *J Bone Joint Surg* 1931;13:160.

# CHAPTER 80

# SHOULDER INSTABILITY

*Deryk Jones and Jon J. P. Warner*

**D. Jones:** Department of Orthopaedic Surgery, Tulane University School of Medicine, New Orleans, Louisiana 70012.
**J. J. P. Warner:** Department of Orthopaedic Surgery, Harvard Medical School, Boston, Massachusetts 02114.

Anatomy and Pathophysiology
Classification
Clinical Evaluation
History
Physical Examination
Radiographic Evaluation
Examination Under Anesthesia
Arthroscopy: Basic Setup
Operative Technique
Portal Placement and Anatomy
Treatment Options
Surgical Techniques
Debridement of Labral Lesions
Repair of Superior Labral Lesions
Slap Lesion Repair
Arthroscopic Bankart Repair
Arthroscopic Capsular Shift
Laser or Thermal Capsular Shrinkage
Open Surgical Techniques
Chapter References

Historically, treatment of shoulder instability has focused on constraining the joint through soft-tissue reconstruction, which often has distorted anatomy instead of anatomically repairing the primary lesion of an injured capsule or labrum. Foremost examples of these reconstructive techniques include transfer of the subscapularis (Magnuson-Stack), imbrication of the subscapularis and capsule (Putti-Platt), and transfer of the coracoid process and conjoined tendon (Bristow-Latarjet). As surgeons have developed a better understanding of the functional anatomy of the shoulder, treatment of shoulder instability has relied on anatomic restoration.

## ANATOMY AND PATHOPHYSIOLOGY

Despite an articular mismatch resulting in only 25% to 30% glenohumeral contact at any one angle, stereophotogrammetric studies show close congruency between the articular surfaces of the glenoid cavity and the humeral head (148). Notwithstanding a flat radiographic appearance of the glenoid, the varying cartilage thickness on its surface allows a close concavity–convexity match to the humeral head, which provides stability through dynamic contraction of the rotator cuff. It has been termed the *concavity-compression mechanism of stability* and is described in further detail below (88,89).

Conditions affecting this precise relationship may clinically manifest as instability (Table 80.1). Examples include congenital dysplasia of the glenoid or humeral surfaces and glenoid fractures (Fig. 80.1). These conditions disrupt the concavity-compression effect by decreasing the surface area of contact and disrupting the close congruent fit of articular surfaces (18,55,182). Similarly, large Hill–Sachs or reverse Hill–Sachs lesions, posterolateral or anterolateral humeral head impaction fractures respectively, can affect this articular relationship (Fig. 80.2) (22,131,133,134). These fractures are created by direct contact between the humeral head and the glenoid rim during shoulder dislocations. While these lesions are present in more than 80% of anterior dislocations and 25% of anterior subluxations, they are rarely a contributing factor to instability. They become biomechanically relevant to joint stability when osteoarticular loss involves greater than 30% of the humeral head surface.

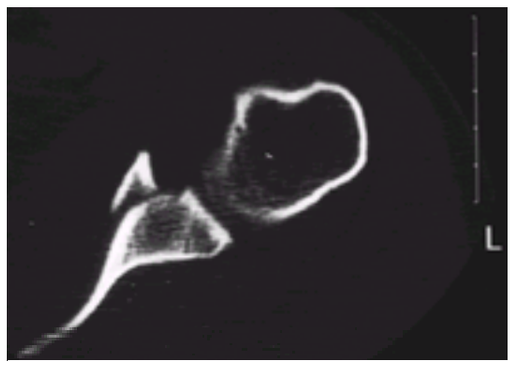


***Figure 80.1.*** Axial CT demonstrates a significant bony Bankart lesion with disruption of the concavity-compression mechanism.

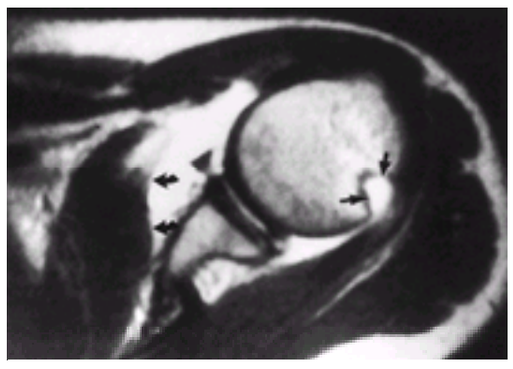

***Figure 80.2.*** Axial MRI with contrast demonstrates anterior capsular stripping (*large curved arrows*) with an associated Bankart lesion. In addition, a large Hill–Sachs lesion can be seen posteriorly (*smaller straight arrows*).

A fibrocartilaginous ring, the glenoid labrum, lines the glenoid cavity and contributes to glenohumeral stability by three mechanisms:

It acts as a “chock block” to humeral head translation (71).

It acts as a point of attachment for the glenohumeral ligaments and the long head of the biceps brachii (102,158).

It increases the surface area and the depth of the glenoid cavity, improving the conforming fit of the humeral head within the glenoid (47).

Avulsion of the glenoid labrum (Bankart lesion) has been implicated as the primary lesion associated with traumatic anterior shoulder dislocation (186,187). Because variability in the anatomy of the labrum is considerable, it is important to distinguish between true labral detachment and a variation of normal anatomy (31,181). As a rule, the labrum is often loosely attached to the glenoid rim above the equator of the glenoid cavity, and in fact there may be little or no labrum present along the anterosuperior glenoid rim. This anatomic variant has been termed a *sublabral foramen* (hole) (Fig. 80.3).

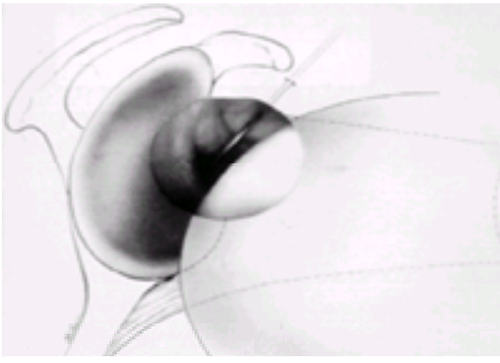

***Figure 80.3.*** Arthroscopic view through a posterior portal demonstrates an anatomic variant of the anterior glenoid labrum referred to as a sublabral hole. This should not be confused with a true Bankart lesion or a superior labrum anterior posterior (SLAP) lesion. (From Warner JJP, Warren RF. Arthroscopic Bankart Repair Using a Cannulated Absorbable Fixation Device. *Oper Tech Orthop* 1991;1:192, with permission.)

Below the equator of the glenoid, the labrum is securely attached to the glenoid rim and is actually a fibrocartilaginous transition zone to the glenohumeral ligaments. It functionally deepens the glenoid fossa, thus enhancing the concavity-compression mechanism of stability. Detachment of the glenoid labrum below the equator of the glenoid represents a functional disruption of the origin of the inferior glenohumeral ligament (IGHL), as well as a decrease in the concavity of the glenoid cavity.

The glenohumeral capsuloligamentous complex is characterized by collagenous thickenings of varying development in its anterior portion (Fig. 80.4) (11,13). These thick bands are called the glenohumeral ligaments due to their location along the glenoid rim. Table 80.1 shows the specific functional role of each ligament and the resulting pathology when each is injured. These ligaments and their interposed capsule are normally lax when the shoulder is positioned in the mid range of rotation. The rotator cuff muscles and long head of the biceps tendon (dynamic stabilizers) create the important concavity-compression effect (described below) that maintains stability (116,126,172).

***Figure 80.4.*** Arthroscopic view demonstrates normal anterior capsular ligamentous anatomy as viewed through a posterior arthroscopic portal (*H.H.*, humeral head; *G*, glenoid; *B*, biceps tendon; *S.G.H.L.*, superior glenohumeral ligament; *S.S.*, subscapularis; *M.G.H.L.*, middle glenohumeral ligament; *I.G.H.L.*, inferior glenohumeral ligament). (From Turkel SJ, Panio MW, Marshall JL, Girgis FG. Stabilizing Mechanisms Preventing Anterior Dislocation of the Glenohumeral Joint. *J Bone Joint Surg [Am]* 1981;63:1209, with permission.)

| Stability factor | Stability function | Pathology |
|---|---|---|
| Articular surface congruity | Concavity-compression effect | Dysplasia<br>Fracture<br>Hill-Sachs lesion<br>Reverse Hill-Sachs lesion |
| Glenoid labrum | Increased socket depth and surface area<br>Acts as anchor for ligaments | Bankart lesion |
| Negative pressure | Vacuum effect for stability | Capsular rupture<br>Rotator interval defect<br>Capsular laxity |
| CHL SGHL | Limits ER and inferior translation in adduction<br>Posterior translation in FF | Capsular injury or laxity<br>Rotator interval lesion |
| MGHL | Limits ER and inferior translation in adduction<br>Anterior translation in midabduction | Bankart lesion |
| IGHLC | Limits: Anterior, posterior, and inferior translation in abduction | Bankart lesion<br>Capsular injury |
| Rotator cuff | Dynamic joint compression and steering effect | Overuse injury (fatigue)<br>Rupture with or without dislocation |
| Biceps brachii (long head) | Dynamic restraint to superior and anterior translation | SLAP lesion<br>Rupture |
| Posterior capsule | Restraint to posterior translation in the flexed, adducted, internally rotated shoulder | Posterior capsular laxity |

CHL, coracohumeral ligament; ER, external rotation; FF, forward flexion; IGHLC, inferior glenohumeral ligament complex; MGHL, middle glenohumeral ligament; SGHL, superior glenohumeral ligament; SLAP, superior labral detachment anterior and posterior.
From Warner JJ, Micheli LW. Arthroscopic Repairs for Instability. In: Warner JJP, Iannotti JP, Gerber C, eds. Complex and Revision Problems in Shoulder Surgery. Philadelphia: Lippincott-Raven Publishers, 1997:195, with permission.

***Table 80.1. Glenohumeral Stability***

As the arm is rotated toward its end range, the glenohumeral ligaments function in a reciprocal fashion, acting as checkreins to prevent excessive humeral head translation at the extremes of motion (37,113,114 and 115,160). O' Brien et al. (113,114) compared the IGHL to a hammock; its anterior and posterior bands should tighten at terminal external rotation with the arm abducted 90° (Fig. 80.5). In addition to their action as static restraints to excessive translation and rotation, the capsuloligamentous structures may also have a proprioceptive role (85,173). It has been postulated that stretch and motion receptors within the glenohumeral capsule and ligaments relay proprioceptive feedback to the dynamic muscle stabilizers, thus acting as an afferent feedback loop to modulate muscle activity about this joint during active motion.



***Figure 80.5.*** The *IGHL* controls glenohumeral instability in a manner analogous to a hammock. **A:** With the arm in 90° of abduction, the IGHL supports the humeral head inferiorly. **B:** With external rotation, the anterior band of the ligament prevents anterior translation of the humeral head. **C:** The posterior band functions in a similar fashion with internal rotation to prevent posterior translation of the humeral head. (From Warner JJP, Caborn DN. Overview of Shoulder Instability. *Crit Rev Phys Rehabil Med* 1992;4:145, with permission.)

A clear understanding of normal glenohumeral capsular anatomy is essential for surgeons who seek to reestablish anatomy in an unstable shoulder (171). Procedures that repair the soft tissues while the joint is positioned in the mid range of motion shorten the capsuloligamentous complex. As a result, the joint may be captured, preventing full external rotation, an outcome associated with the development of early arthritis (59,61).

Another important characteristic of the glenohumeral joint is the presence of negative (less than atmospheric) intraarticular pressure. This condition results from high osmotic pressure in the interstitial tissue, which draws water from the joint (94). Any force that tends to displace the humeral head away from the glenoid increases this vacuum effect resisting further humeral head displacement. This effect is clinically relevant when the arm is hanging at the side and the muscles of the shoulder are relaxed (19,53,82,169). Conditions that disrupt this vacuum effect include capsular rupture, intraarticular fracture, developmental or acquired capsular defects (i.e., rotator interval lesion or capsular rupture), or a large, capacious capsule (45,169).

The rotator interval has increasingly been associated with clinical instability (72). This region of the capsule is a triangular space whose base is located near the coracoid process and its apex near the biceps sulcus (Fig. 80.6). The interval is bordered superiorly by the anterior margin of the supraspinatus tendon and inferiorly by the superior border of the subscapularis tendon. The area is completely bridged by capsule and supplemented by the coracohumeral and the superior glenohumeral ligaments. A deficiency of these ligaments and communication of the joint with the subdeltoid space lead to a significant sulcus sign (inferior laxity) (described later).

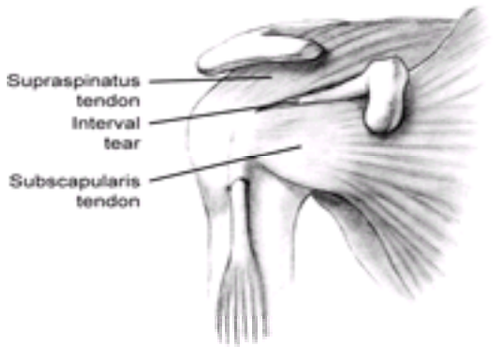


***Figure 80.6.*** Anatomy of the rotator interval. Injury to this region is associated with an increased sulcus sign with the arm at the side that does not decrease with full external rotation. (From Zarins B. Bankart Repair for Anterior Shoulder Instability. *Tech Orthop* 1989;3:23, with permission.)

The rotator cuff is a musculotendinous complex consisting of the teres minor, infraspinatus, supraspinatus, and subscapularis muscles. These muscles encircle the glenohumeral joint, and their insertion sites are broadly intermeshed with the underlying joint capsule (29,32,34). These intrinsic muscles have relatively short lever arms and pass close to the axis of rotation of the joint. As a result, they act more as primary stabilizers than as primary movers of the glenohumeral joint. The net effect of contraction of the rotator cuff muscles is to create a compressive load across the glenohumeral joint. This load steers the humeral head into the glenoid fossa, creating the concavity-compression mechanism (Fig. 80.7) (14,17,71,88,125,135,161).

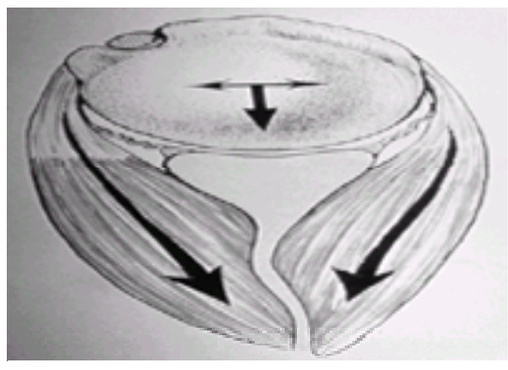

***Figure 80.7.*** The dynamic stability provided by the rotator cuff muscles produces a concavity-compression mechanism.

Injury to the rotator cuff can result from a single macrotrauma that exceeds the ultimate failure strength of the tendon(s). Alternatively, injury can be the result of repetitive submaximal loads that cumulatively disrupt the tendon fibers. Each scenario can be associated with actual shoulder instability. In individuals older than 40 years, the tensile properties of the rotator cuff tendons tend to deteriorate more rapidly than those of the glenohumeral capsule and ligaments. As a result, patients in this age group have a high incidence of rotator cuff tears associated with a traumatic shoulder dislocation (108,147).

Conversely, a young athlete who throws or swims may subject the shoulder to repetitive forces that cause gradual injury to the rotator cuff. For example, subtle degrees of shoulder subluxation may occur with repetitive motions such as in swimming. The capsuloligamentous tissues may stretch, and the joint may become more lax. An overload of the rotator cuff muscles can occur. The active (eccentric) contraction of the rotator cuff, which decelerates the humeral head during the swimming stroke or throwing motion, has been associated with rotator cuff injury (20).

The long head of the biceps brachii dynamically stabilizes the glenohumeral joint (73,74,75 and 76,126,174). Contraction markedly limits anterior and superior translation of the glenohumeral joint, increases torsional rigidity of the joint, and decreases strain in the IGHL. Clinical experience based on arthroscopic observations has demonstrated a correlation between shoulder instability and the presence of the superior labral anterior posterior (SLAP) lesion (145,172). This injury pattern represents a detachment of the origin of the long head of the biceps.

## CLASSIFICATION

We use a classification system originally proposed by the Hospital for Special Surgery. The system categorizes patients with shoulder instability on the basis of four criteria: frequency, cause, direction, and degree (Table 80.2) (33,142,187).

| | |
|---|---|
| Frequency | |
| | Acute |
| | Recurrent |
| | Fixed (chronic) |
| Cause | |
| | Traumatic event (macrotrauma) |
| | Atraumatic event (voluntary, involuntary) |
| | Microtrauma |
| | Congenital condition |
| | Neuromuscular condition (Erb's palsy, cerebral palsy, seizures) |
| Direction | |
| | Anterior |
| | Posterior |
| | Inferior |
| | Multidirectional |
| Degree | |
| | Dislocation |
| | Subluxation |
| | Microtrauma (transient) |

From Warner JJ, Altchek DW. Arthroscopic Repairs for Instability. In: Warner JJP, Iannotti JP, Gerber C, eds. Complex and Revision Problems in Shoulder Surgery. Philadelphia: Lippincott-Raven Publishers, 1997: 19, with permission.

***Table 80.2. Shoulder Instability Classification***

The *instability* itself may be acute or chronic, the differentiating feature being whether the event occurred within the previous 24 hours. The number of recurrences (*frequency of instability*) is also critical in this classification scheme, as it contributes to the level of damage to anatomic structures. This characteristic is extremely important when taken into consideration along with the degree and cause of the instability. This component of the history is critical in determining the appropriate treatment.

*Etiology* is subdivided into traumatic, microtraumatic, and atraumatic groups but also includes congenital and neuromuscular causes. The atraumatic group includes patients who exhibit a voluntary component. In this classification, these patients can be further subdivided into *group I:* voluntary instability, which is arm-position-dependent and usually posterior; and *group II:* voluntary instability exhibited by an ability to selectively contract muscles, causing a dislocation. While patients in group I can voluntarily demonstrate their instability, they choose to avoid dangerous arm positions. This condition subsequently affects activities of daily living (142). Conversely, patients in group II tend to have an underlying psychiatric problem, using their instability as a means to control their environment (132).

The *degree of instability* is also important in determining appropriate treatment options. Dislocation refers to complete dissociation of the articular surfaces of the humeral head and glenoid cavity. Subluxation describes increased humeral head translation within the glenoid cavity. Initial open procedures focused on the treatment of true glenohumeral dislocation. Arthroscopic evaluation has heightened the awareness of subtle labral, articular, and ligamentous damage that occurs because of unrecognized, recurrent episodes of subluxation (7,22,24,68,112).

The *direction of instability* has been a critical component of most classification systems. Traditionally, there was an assumption that 95% of shoulder instability was anterior (25). It has become increasingly apparent, however, that many athletes with ligamentous laxity have instability that is primarily posterior in nature (48,49,156,178). These patients suffer recurrent posterior subluxation and have a history of posterior shoulder pain rather than complaints of frank instability. This category of patients is more prevalent than previously recognized but should be distinguished from the rare true posterior dislocation that results from an acute traumatic event (16,110).

Hawkins et al. (64) reported on a series of 40 patients with 41 locked posterior shoulder dislocations. The initial physician missed the diagnosis in the majority of cases reviewed. In this series, the causes of posterior dislocation were motor vehicle accidents, seizures, alcohol-related injuries, or electroshock therapy. Recurrent anterior subluxation may also manifest as pain rather than instability. Repetitive, high-energy, overhead activities can cause progressive attenuation of the capsular, ligamentous, and labral structures (2,78,159). As these static stabilizers fail and the dynamic stabilizers weaken, anterior subluxation occurs, leading to impingement symptoms. Recognition of the underlying problem is critical in obtaining a successful surgical outcome.

## CLINICAL EVALUATION

### HISTORY

The history can raise suspicion of shoulder instability. A patient's age, occupation, employment status, activity level, hand dominance, and other medical problems are helpful in classifying the nature of the instability. Certain circumstances, such as work-related injuries or those with associated litigation, might affect patients' perceptions of their disabilities as well as their expectations for recovery and compliance with treatment (180).

Seek out specific complaints. For example, a patient may indicate that the arm “went dead” during a football tackle (158). This symptom is likely associated with a traumatic subluxation of the joint and the presence of a Bankart lesion. Another example is a patient who gives a history of having had a seizure and then awakening with the sensation of the joint “out of place.” This situation suggests a posterior dislocation as the result of unchecked internal rotation forces overcoming the weaker external rotators of the shoulder.

If pain is a major component of a patient's complaint, which activities cause the pain? Question athletes as to the type of sport, the position played, and the duration, frequency, and level of involvement. For example, throwers, swimmers, or tennis players may develop excessive capsular laxity as a result of subjecting their shoulders to repetitive microtrauma (83,125). The result is recurrent shoulder subluxation, which can create a sense of “looseness” or “slipping” with activity. In addition, as previously stated, secondary “nonoutlet” impingement can occur as anterior instability decreases the subacromial space, causing pain with overhead activities. Further, these same subluxations can create damage to the superior labral area, creating a SLAP lesion. Posterior subluxation has also been documented in athletes who require repetitive arm motion in front of the body, such as offensive-line football players and volleyball, softball, and baseball players (48,156,178). Throwing sports in particular lead to complaints of *posterior* shoulder pain during the follow-through phase, which has been associated with posterior subluxation and resultant microtrauma to the posterior capsulolabral complex.

### PHYSICAL EXAMINATION

A systematic evaluation includes observation for abnormal motion patterns and atrophy, palpation to localize painful areas, assessment of both active and passive range of motion, measurement of strength of the rotator cuff muscles, neurovascular evaluation, and finally provocative maneuvers for instability. Examine the opposite shoulder for comparison.

In evaluating shoulder motion, carefully document any scapulothoracic substitution for glenohumeral motion, scapular winging, and other abnormal motion patterns. Atrophy of the spinatus muscles may indicate a longstanding associated rotator cuff tear or injury to the suprascapular nerve. Similarly, atrophy of the deltoid may indicate an axillary nerve injury.

Assess patients for findings of generalized ligamentous laxity, including the ability to hyperextend the elbows more than 10°, apply the thumb to the forearm, hyperextend the metacarpophalangeal joints more than 90°, or touch the palm of each hand to the floor while keeping the knees extended (Fig. 80.8). While there is no direct relationship between generalized ligamentous laxity and shoulder instability, there is some association between hyperlaxity and glenohumeral capsular development.

***Figure 80.8.*** Systemic laxity. **A:** Wrist and metacarpophalangeal joint hyperextension. **B:** Elbow joint hyperextension. (A and B from Warner JJP. Shoulder. In: Miller

MD, Cooper DE, Warner JJP, eds. *Review of Sports Medicine and Arthroscopy.* Philadelphia: WB Saunders, 1995:125, with permission.) **C:** Knee hyperextension and thumb-to-forearm hyperflexibility. (From Gerber C. Observations on the Classification of Instability. In: Warner JJP, Iannotti JP, Gerber C, eds. *Complex and Revision Problems in Shoulder Surgery.* Philadelphia: Lippincott–Raven Publishers, 1997:16, with permission.)

A patient with an acute, unreduced anterior dislocation holds the painful arm in slight abduction and internal rotation (2,167). Before attempting any reduction maneuvers, perform a careful neurovascular examination to rule out brachial plexus and, more specifically, axillary nerve injuries (38,57,152). The latter condition may sometimes escape detection, as decreased sensation over the lateral deltoid is not always present with an injury to this nerve. In older (>60 years) individuals or younger ones who have sustained a severe trauma, be aware of the possibility of an associated fracture of the humerus (62). Proper radiographic imaging is particularly important before attempting closed reduction in such cases.

Many methods of closed reduction apply in the case of an acute shoulder dislocation. Perform all maneuvers as a gradual and gentle technique with appropriate analgesia to ensure muscle relaxation. Intravenous analgesia and intraarticular injection of a regional anesthetic are both successful, appropriate methods of anesthesia. A method of gentle traction in line with the arm using countertraction is usually successful.

Pay careful attention to a patient who has an unrecognized chronic (fixed) dislocation. The dislocation is most often posterior, although it may be anterior, and typically occurs in patients who are poor historians because of either alcohol use or dementia (64). In a patient with a fixed posterior subluxation, there is limitation of external rotation compared with the opposite shoulder. In addition, there is flattening of the anterior aspect of the shoulder with an associated prominence of the coracoid process and possibly some prominence and rounding of the posterior aspect of the shoulder. The application of excessive force in attempting a closed reduction in such a patient risks neurovascular injury or fracture.

Most patients who have instability are first seen by an orthopaedic surgeon in the office setting. They may have had a documented episode of instability or an injury with pain but no true sense of shoulder instability. After a careful neurovascular examination, it is important to assess active and passive range of motion. A discrepancy between active and passive motion may indicate either an associated rotator cuff tear or a nerve injury.

It is particularly important to identify a subscapularis tear in the setting of shoulder instability, a condition that is frequently missed (51,165). Patients with such tears have passively increased external rotation with the arm adducted at the side, as well as associated apprehension in this position. Strength assessment is also important. Significant external rotation weakness may indicate a rotator cuff tear.

Similarly, internal rotation weakness may be due to a subscapularis tear. In this situation, the patient has an associated lift-off sign (Fig. 80.9). If the patient lacks adequate internal rotation to perform this test, perform the belly-press maneuver instead to determine the patient's ability to pull the forearm in a posterior direction toward the mid abdomen while maintaining the flexed elbow anterior to this point. If the elbow remains posterior to the anterior aspect of the mid abdomen, there is likely a subscapularis tendon tear.

***Figure 80.9.*** Lift-off sign. **A:** With the arm internally rotated, assess the patient's ability to hold the arm off the lumbar region. **B:** An inability to perform this function is clinically consistent with a subscapularis rupture. If the patient lacks sufficient internal rotation to perform this test, perform the belly-press maneuver. (From Warner JJP. Shoulder. In: Miller MD, Cooper DE, Warner JJP, eds. *Review of Sports Medicine and Arthroscopy.* Philadelphia: WB Saunders, 1995:156, with permission.)

Various provocative maneuvers and drawer tests have been described to assess symptomatic humeral head translation and the direction of this movement. Neer and Foster (107) originally described the apprehension test for anterior instability. With the patient seated or standing, place the symptomatic shoulder into a position of 90° of abduction and maximum external rotation. Then move the arm so that it is posterior to the plane of the scapula, and apply an anterior force to the humeral head. The patient's withdrawing from the examiner or complaining about a sense of shoulder instability demonstrates apprehension (Fig. 80.10*A*).

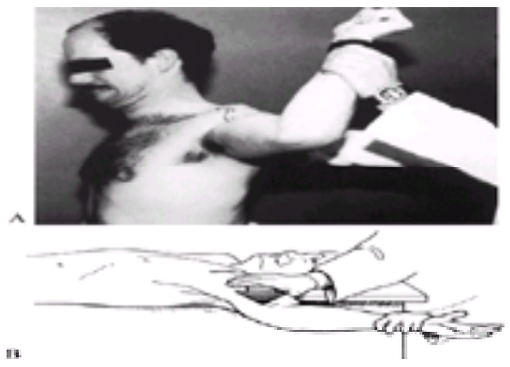


***Figure 80.10.*** Apprehension test. **A:** In a patient with suspected anterior instability, abduct the arm 90° and maximally externally rotate it with posterior pressure on the humeral head. The patient should express demonstrable anxiety over a possible dislocation.**B**: The relocation maneuver is performed with the patient supine and the arm in the same compromised position. (From Warner JJP. Shoulder. In: Miller MD, Cooper DE, Warner JJP, eds. *Review of Sports Medicine and Arthroscopy.* Philadelphia: WB Saunders, 1995:128, with permission.)

The complaint of pain is not specific for instability and may in fact be present with other conditions such as arthritis or rotator cuff disease. Kvitne and Jobe (83) proposed a modification of this maneuver to increase its specificity for anterior instability. Place the patient in a supine position, and perform the apprehension test as described above. Ask whether the patient has a sense of instability or simply pain. Place posterior pressure on the humerus, and ask whether this pressure relieves the sense of apprehension or pain (Fig. 80.10*B*). This “relocation maneuver” increases the specificity of the diagnosis of instability if the patient reports decreased apprehension. If this maneuver simply reduces pain, it is not diagnostic of instability and may be associated with a variety of other diagnoses, including a SLAP lesion or impingement syndrome (150).

One of us (JJPW) has found that an additional modification to this test increases both its sensitivity and specificity for the diagnosis of anterior shoulder subluxation. Perform the apprehension and relocation tests as described above. If the patient reports pain and not true apprehension, inject the subacromial space with 10 ml of lidocaine 1% (Xylocaine). After 10 minutes, repeat the examination. If the pain is due to rotator cuff disease, the injection will eliminate it. If, however, the pain is due to labral injury, it will persist after a subacromial injection (166).

Inconsistencies with the apprehension test led Gerber and Ganz (50) to develop the anterior and posterior drawer test to assess the shoulder for excessive translation compared with the contralateral side. Others have found merit in this method of examination and have developed grading scales for the degree of shoulder laxity (3,30,65). These tests may offer some insight into the degree and direction of instability. If one assesses laxity of the shoulder in an office setting, it is important to

determine whether translation of the humeral head is greater on the painful side and whether this translation causes symptoms (49). We have found laxity assessment by drawer testing to be of limited value in the office setting because patients tend to guard the painful shoulder. Instead, this method is used during examination under anesthesia to confirm the suspected degree and direction of shoulder instability.

Altchek et al. (3) and Hawkins et al. (65) proposed a grading scale for translation of the humeral head on the glenoid. Instability is graded on a scale of 0–3+ for all three directions. For anterior and posterior drawer testing, a grade of 0 represents no humeral head translation, while movement of the humeral head up to but not over the glenoid rim represents 1+ instability. Translation of the humeral head over the glenoid rim with an associated spontaneous reduction with relief of pressure represents 2+ instability. Frank dislocation and locking of the humeral head over the glenoid rim is graded as 3+ instability.

When these drawer tests are performed either in the office or in the operative setting, it is important to bear in mind that the position of the arm determines the degree of tension in the glenohumeral ligaments. With the arm at the side in adduction, the IGHL is relatively lax, and anterior and posterior drawer testing may be of limited value. In abduction, the IGHL comes underneath the humeral head and forms a hammock that passively limits anterior, posterior, and inferior translation (113,114). Perform anterior drawer testing with the shoulder positioned in abduction in the plane of the scapula. Maintain the arm in the neutral rotation while using one hand to place an axial load along the humerus and the other hand to apply an anterior or posterior force to the humerus (Fig. 80.11). Often you can feel the humeral head move back into the glenoid rather than out of the glenoid during this maneuver. The patient may note a painful click with such a maneuver. In our experience, this test is particularly helpful in identifying posterior instability.

***Figure 80.11.*** Anterior drawer test. With the arm in abduction and neutral rotation, apply an anterior force to the posterior aspect of the humerus to assess anterior humeral head stability. Perform the posterior drawer test with the arm in adduction, forward flexion, and internal rotation. Then apply a posterior force to the arm to assess posterior stability. (From Warner JJP. Shoulder. In: Miller MD, Cooper DE, Warner JJP, eds. *Review of Sports Medicine and Arthroscopy.* Philadelphia: WB Saunders, 1995:138, with permission.)

A modification of the posterior drawer test allows the examiner to elicit posterior apprehension. Perform this modification by placing the patient's arm in 90° of forward flexion and adduction while applying an axial load down the shaft of the humerus. Pain and a palpable shift and click suggest posterior labral injury and instability.

A modification of this test, termed the *jerk test,* has been described for posterior instability (12,86). With the patient seated, load the abducted shoulder axially into the glenoid with one hand, and with your other hand, palpate the posterior aspect of the shoulder. Then bring the arm into horizontal adduction anterior to the plane of the scapula; the humeral head may sublux posteriorly. Then bring the humerus posterior to the plane of the scapula; the humeral head may suddenly reduce into the glenoid. A palpable shift and pain accompany a positive test.

The sulcus sign is basically an inferior drawer test (Fig. 80.12). Neer and Foster (107) originally described it as the hallmark of inferior and multidirectional instability (MDI). Unfortunately, a common misconception has been that a large sulcus sign that is asymptomatic, thus indicating inherent joint laxity, is a positive finding. The key point is that this maneuver should be associated with pain and should reproduce the patient's symptoms to be clinically relevant as a finding of inferior instability.

***Figure 80.12.*** Sulcus sign. Assess inferior displacement of the greater tuberosity from the undersurface of the acromion. (From Gerber C. Observations on the Classification of Instability. In: Warner JJP, Iannotti JP, Gerber C, eds. *Complex and Revision Problems in Shoulder Surgery.* Philadelphia: Lippincott–Raven Publishers, 1997:22, with permission.)

Perform this test with the patient seated and the arm adducted at the side. Rotation of the shoulder is very important in assessing the degree of inferior instability. First, with the arm in the neutral rotation, pull the humerus inferiorly, and estimate the amount of separation between the acromion and the humeral head. Grade it on a 0–3+ scale (3): A separation of 1 cm is a 1+ sulcus sign, 2 cm is a 2+ sulcus sign, and 3 cm is a 3+ sulcus sign. Anatomically, a sulcus sign greater than 2+ indicates a capacious capsule and specific laxity of the anterosuperior capsular region (rotator interval).

As previously discussed, externally rotate the arm, and repeat the sulcus sign test. If the sulcus sign remains greater than 2+ with the arm in external rotation, there is a marked deficiency of the superior capsule, and a large rotator interval defect in the capsule is likely. This is the result of damage to the superior and middle glenohumeral ligaments, as well as the coracohumeral ligament. With this information before surgical repair, you then know that surgical reconstruction of this region with a capsular shift must be a component of the operation (60).

Four different types of MDI patterns have been described (119):

Type I: global instability

Type II: predominantly anterior and inferior instability

Type III: predominantly posterior and inferior instability

Type IV: anterior and posterior instability with no inferior component

The true existence of the last type has been questioned.

Since the description of superior labral pathology by Andrews et al. (5) in 1985 and of the SLAP lesion by Snyder et al. (145) in 1990, several examination techniques have evolved to diagnose this pathology. Andrews reported increased pain in patients during full shoulder flexion and abduction, with noticeable catching and popping. Snyder reported pain in patients during resisted shoulder flexion with elbow extension and forearm supination (biceps tension test).

Another useful diagnostic test is the compression–rotation test. With the patient supine, abduct the shoulder 90°, with the elbow flexed 90°. Apply a compression force to the humerus to trap the torn labrum (in the same manner as McMurray's test for the knee is performed). O' Brien et al. (114) suggested a maneuver that they believed is accurate for determining superior labral injuries. Place the patient's shoulder in 90° of forward flexion and then adduct it across the body. Ask the patient to flex the arm further against resistance when the shoulder is first internally rotated and then externally rotated. If pain occurs when the shoulder is rotated internally but not when it is rotated externally, the test is positive. Unfortunately, this test does not distinguish between acromioclavicular joint disease and a superior labral tear. We have found this test more useful than the other methods described above.

## RADIOGRAPHIC EVALUATION

The minimum radiography necessary for evaluation of an acute dislocation or suspected subluxation is a true anteroposterior (AP) view and an axillary view. These images will allow accurate determination of the position of the humeral head relative to the glenoid. A true AP radiograph is obtained by angling the x-ray beam 45° relative to the sagittal plane of the body (Fig. 80.13). A scapular Y or transcapular view can also give useful information about the position of the humeral head (Fig. 80.14), but it is not as accurate as an axillary view (Fig. 80.15). If a standard axillary view cannot be obtained, a Velpeau axillary view without removing the patient's arm from the sling will suffice (Fig. 80.16).

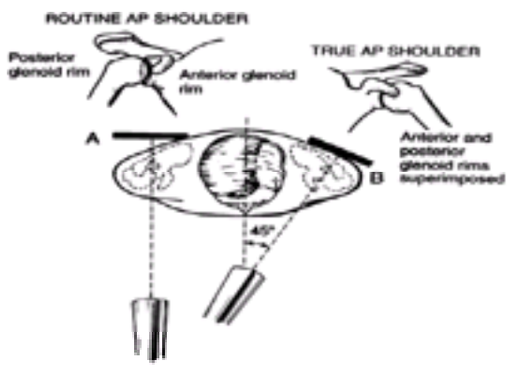


***Figure 80.13.*** A routine AP shoulder radiograph shows overlap of the anterior and the posterior glenoid rims. A true AP radiograph demonstrates superimposition of the anterior and the posterior glenoid rims, producing an excellent view of the glenohumeral joint. (From Warner JJP, Caborn DN. Overview of Shoulder Instability. *Crit Rev Phys Rehabil Med* 1992;4:145, with permission.)

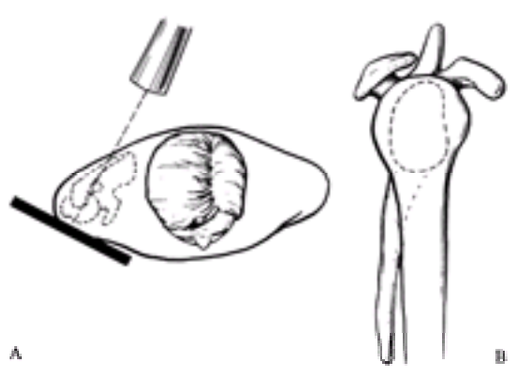


***Figure 80.14.*** Transcapular or Y view of the glenohumeral joint allows assessment of the humeral head location in relation to the glenoid cavity. (From Warner JJP, Caborn DN. Overview of Shoulder Instability. *Crit Rev Phys Rehabil Med* 1992;4:145, with permission.)

***Figure 80.15.*** Axillary view represents the “gold standard” in radiographic assessment of location of the humeral head relative to the glenoid cavity. (From Warner JJP, Caborn DN. Overview of Shoulder Instability. *Crit Rev Phys Rehabil Med* 1992;4:145, with permission.)

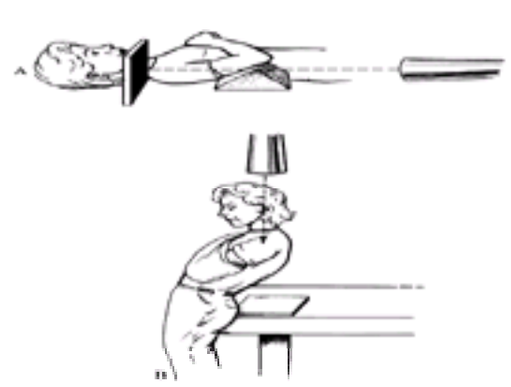

***Figure 80.16.*** Two common techniques used when a standard axillary view is difficult to obtain include the trauma axillary lateral (**A**) and the Velpeau axillary view (**B**). (From Warner JJP, Caborn DN. Overview of Shoulder Instability. *Crit Rev Phys Rehabil Med* 1992;4:145, with permission.)

In the office setting, a true AP view of the shoulder with the arm in internal rotation may demonstrate a Hill–Sachs lesion. A Stryker notch view is a special view that will also demonstrate a Hill–Sachs lesion (Fig. 80.17) (43,121).

***Figure 80.17.*** **A:** Arm position for obtaining the Stryker notch view. **B:** This view can demonstrate a Hill–Sachs fracture on the posterior humeral head surface. (From Warner JJP, Caborn DN. Overview of Shoulder Instability. *Crit Rev Phys Rehabil Med* 1992;4:145, with permission.)

The West Point axillary view may prove helpful in a patient suspected of having had an episode of instability. Take the image with the patient prone so that the anterior glenoid is shown in profile without an overlying acromial shadow (Fig. 80.18).

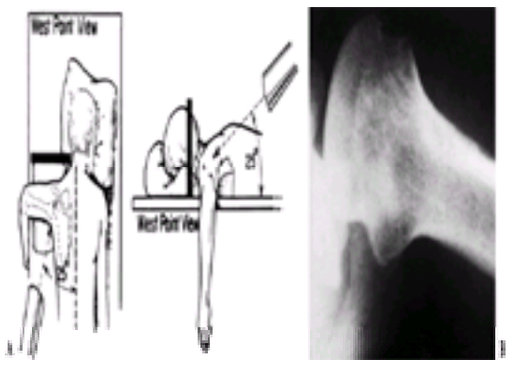

***Figure 80.18.*** **A:** Positioning for the Westpoint axillary view. **B:** This view allows visualization of the anteroinferior glenoid rim. (From Warner JJP, Caborn DN. Overview of Shoulder Instability. *Crit Rev Phys Rehabil Med* 1992;4:145, with permission.)

Adjuvant imaging techniques are helpful when additional information about the three-dimensional relationship and architecture of the joint or confirmation of the presence of a Bankart lesion is required. Computed tomography (CT) demonstrates bony injuries or abnormalities including glenoid hypoplasia, congenital version anomalies, acquired version abnormalities from erosion, and glenoid rim fractures (Fig. 80.1 and Fig. 80.19). In addition, it allows measurement of the size of a humeral head defect (Hill–Sachs lesion) in cases of chronic instability (55). When combined with intraarticular dye, CT arthrography also demonstrates a Bankart lesion and articular erosion.

***Figure 80.19.*** **A:** Three-dimensional CT reconstruction of a glenoid rim fracture. **B:** The same fracture after computerized removal of the humeral head.

Magnetic resonance imaging (MRI) with or without gadolinium has gained great favor, although unfortunately it is often used as a screening tool in the evaluation of patients. Its role should instead be to confirm the presence of lesions that may need surgical management. It is accurate in the detection of labral pathology (Fig. 80.20) (27,56). Recent advances in MRI technology such as high-resolution fast-spin and gradient-echo imaging make these methods particularly appealing for detecting anterior and superior labral injuries (26).

***Figure 80.20.*** **A,B:** MR arthrogram demonstrates anterior glenohumeral stripping with an associated Bankart lesion.

## EXAMINATION UNDER ANESTHESIA

Before arthroscopy or arthrotomy is undertaken, examination under anesthesia (EUA) can confirm or deny the preoperative impression (30,154). During EUA, muscle guarding is eliminated, and an accurate assessment of joint laxity is possible. As previously described, it is essential that laxity not be confused with instability; thus, it is important to compare the symptomatic shoulder with the asymptomatic side. Individuals who have had a previous dislocation will likely have a 2+ or 3+ anterior drawer test result (as described above) for the symptomatic shoulder compared with a 1+ – 2+ finding in the asymptomatic shoulder.

The finding of symmetric laxity, however, does not necessarily exclude instability because a Bankart lesion may be present without marked laxity on examination in a patient who has a history of subluxation (149,171). Furthermore, in very large individuals, the soft-tissue envelope of the shoulder may be so large that accurate

determination of a centimeter of translation of the humeral head on the glenoid may not be possible.

One area where we have found EUA to be helpful is in determining capsular laxity and rotator interval lesions (45), both of which are typically associated with MDI. If an individual is found to have a sulcus sign of more than 2+ and if this persists when an inferior drawer is applied with the arm in external rotation, there will be a large rotator interval defect, as well as marked anterior and inferior capsular laxity. In our hands, this is treated by a modified capsular shift, along with repair of a Bankart lesion if one is found to be present (60). Although other surgeons have used arthroscopic techniques in the treatment of this combination of problems, we generally treat only pure Bankart lesions with an arthroscopic repair technique (99,136,159).

Occasionally, EUA will identify a shoulder that can be dislocated posteriorly (3+) when anterior instability is suspected. It is usually in a patient with congenital laxity who has had a traumatic injury. We usually treat this condition with an open capsular shift method of repair.

## ARTHROSCOPY: BASIC SETUP

Arthroscopy of the shoulder can be performed in either the seated beach-chair or the lateral decubitus position (see Chapter 77).

The lateral decubitus position allows good visualization of the anterior and inferior glenohumeral structures by virtue of the applied traction, but it does not allow the surgeon to easily manipulate the shoulder through a full range of motion. Moreover, it can limit access to the anterior glenoid with crowding of the instrumentation and cannulas on the drapes and body. In addition, if there is a need to convert to an open procedure, it is usually necessary to reposition (and therefore reprepare and redrape) the patient. As stated previously, there is a risk of transient neuropraxia due to traction (81).

The beach-chair position, our preferred position, provides unrestricted access to the entire shoulder and allows free movement of the arm in all planes. In addition, visualization is possible in a more anatomic orientation. These criteria are essential if a diagnostic arthroscopy is to be performed that inherently requires an assessment of the anatomy of the glenohumeral ligaments. Further, it permits simple conversion from an arthroscopic to an open procedure. In addition, patients tolerate the use of an interscalene block without the need for supplemental general anesthesia, in contrast to patients in the lateral decubitus position. Table 80.3 compares the beach-chair position with the lateral decubitus position.

| *Lateral decubitus* | *Beach chair* |
|---|---|
| Requires weights for traction | Arm hangs free with gravity traction |
| Risk of traction neuropraxia | No risk of traction neuropraxia |
| Risk of plexus injury with anteroinferior portals | Less risk of plexus injury with anteroinferior portals |
| Limited ability to move shoulder during arthroscopy | Full freedom of shoulder motion during arthroscopy |
| Capsuloligamentous anatomy placed in a stretched and distorted position | Capsuloligamentous anatomy placed in its site, "neutral" orientation with different shoulder positions |
| Access to anterior glenoid cavity may be difficult | Easy access to anterior glenoid cavity |
| Requires patient repositioning and reprepparation for open procedure | Allows direct conversion to open procedure without position change or need to redrape |
| Interscalene block not as well tolerated | Interscalene block well tolerated |
| Minimal risk of camera fogging | Risk of camera fogging |
| Minimal risk of orthostatic hypotension | Risk of orthostatic hypotension |

From Warner JJP. Shoulder Arthroscopy in the Beach-chair Position: Basic Setup. Oper Tech Orthop 1991;1:147, with permission.

***Table 80.3. Advantages and Disadvantages of Lateral versus Beach-chair Arthroscopy***

### OPERATIVE TECHNIQUE

- If general anesthesia is used, it is important to secure the endotracheal tube to the side of the mouth opposite the injured shoulder. After anesthesia has been obtained, place the patient into the seated position, and perform an EUA. There are special beach-chair attachments that can be fitted to the table (Fig. 80.21) (163). If such a device is not available, place a long beanbag beneath the patient. In this setting, the table is fully flexed, apex down, at the patient's waist; the knees are then flexed downward approximately 45° with a footplate at the end of the table to prevent the patient from sliding down the table. Finally, the head of the table is elevated approximately 70° from the horizontal.



***Figure 80.21.*** Lateral (**A**) and anterior (**B**) views of the beach-chair attachment used for shoulder arthroscopy. (From Warner JJP. Shoulder Arthroscopy in the Beach-chair Position: Basic Setup. *Oper Tech Orthop* 1991;1:147, with permission.)

- Then harden the beanbag, leaving the entire medial border of the scapula free posteriorly for sterile preparation and draping. Obtain this same position with the use of a beach-chair attachment (Fig. 80.22). Place the uninjured arm on a well padded arm board or a stand that is positioned at the appropriate height to avoid undue pressure on the neck and shoulder. Shave the axilla, and prepare and drape the arm from the hand to the medial border of the scapula posteriorly.

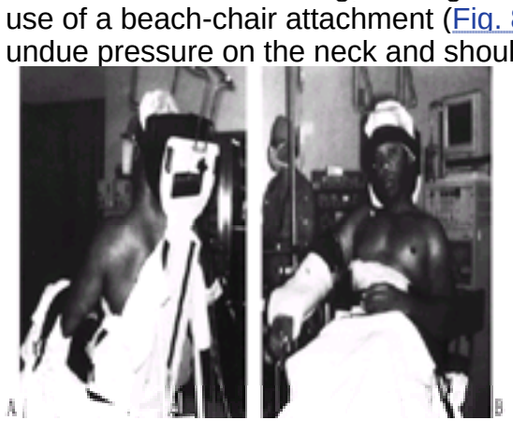

***Figure 80.22.*** Standard patient position for shoulder arthroscopy in the beach-chair position. **A:** The head is elevated 70° with the medial border of the scapula free and the entire shoulder free posteriorly. **B:** Anteriorly, the entire shoulder is free, with the uninjured forearm in a padded stand and the shoulder resting at a comfortable level. (From Warner JJP. Shoulder Arthroscopy in the Beach-chair Position: Basic Setup. *Oper Tech Orthop* 1991;1:147, with permission.)

- Angle the table so that the feet are away from the operative side to allow better visualization of the television monitor positioned on the opposite side of the table from the surgeon. Place a padded sterile stand for instrumentation at knee level on the opposite side of the table. Pass the tubing and arthroscopic equipment underneath the arm and across the patient's chest and then curve them forward over the shoulder. Use a clamp to secure the tubing in place; remove all instruments and tubing from beneath the arm and place them securely on the padded stand (Fig. 80.23).

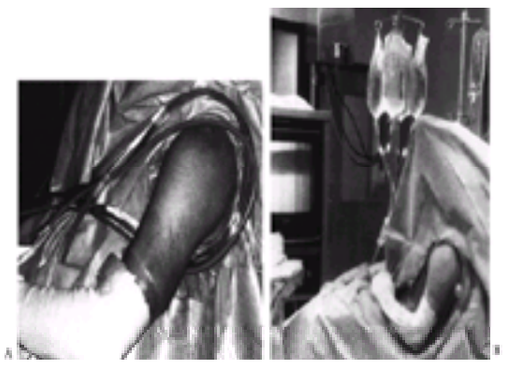

***Figure 80.23.*** **A:** Appropriate length of the arthroscopy tubing is established by bringing the tubing under the arm and over the shoulder. **B:** Position the table and patient at an oblique angle from the monitor for better visualization. Note the padded Mayo stand for instrumentation. (From Warner JJP. Shoulder Arthroscopy in the Beach-chair Position: Basic Setup. *Oper Tech Orthop* 1991;1:147, with permission.)

- Adding 1 ampule of epinephrine to each 3-l bag of irrigating solution limits bleeding. Commercially available fluid pressure pumps may be used, although we have had excellent visualization using simple gravity feed with elevation of two 3-l bags to a height of at least 7–8 ft (2 m).

## PORTAL PLACEMENT AND ANATOMY

Portal placement is extremely important when an arthroscopic Bankart repair is performed.

- Place the standard posterior portal for arthroscopy 1–2 cm inferior and medial to the posterolateral tip of the acromion (Fig. 80.24) (5,6,23,79,80,172). Its location can be confirmed by grasping the humeral head and applying an anterior drawer test. We usually place an 18-gauge spinal needle at this location to confirm orientation for insertion of the arthroscope.

***Figure 80.24.*** Posterior (**A**) and lateral (**B**) views of the lateral, posterior, and superior arthroscopic portals. A superior portal is rarely used. **C:** Insert a spinal needle into the glenohumeral joint posteriorly by aiming toward the coracoid process, and use it to insufflate the joint with normal saline. **D:** Insert an arthroscopic sheath and blunt trocar into the joint through a posterior incision in the same direction as the spinal needle. (From Warner JJP. Shoulder Arthroscopy in the Beach-chair Position: Basic Setup. *Oper Tech Orthop* 1991;1:147, with permission.)

- Then insufflate the joint with sterile saline. This step increases hydrostatic pressure in the joint and moves the humeral head away from the glenoid. It decreases the likelihood of articular cartilage damage during introduction of the arthroscope into the joint. Further, reflux of saline out of an open port confirms proper positioning in the joint.
- An anterosuperior portal is the primary working portal (Fig. 80.24*A*, Fig. 80.24*C*). Locate it by viewing with the arthroscope in the posterior portal and then placing an 18-gauge spinal needle into the joint just underneath the long head of the biceps tendon through the rotator interval. This portal is usually quite vertical in orientation. We make an effort to place it as superiorly as possible in the rotator interval to avoid crowding with the anteroinferior portal, which will be used for placement of the arthroscopic instruments (Fig. 80.25). We usually place a 6 mm cannula in this portal location.

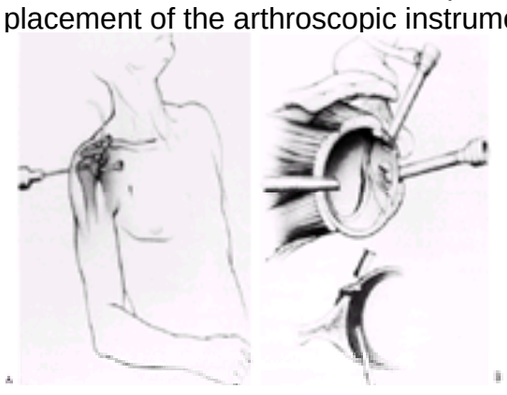

***Figure 80.25.*** **A:** Standard anterosuperior and anteroinferior arthroscopic portals. **B:** The anterosuperior portal enters the joint just below the biceps tendon, while the anteroinferior portal enters the joint just above the subscapularis tendon. Accurate placement of each portal is performed with the assistance of a spinal needle and an outside-in technique. (From Warner JJP, Warren RF. Arthroscopic Bankart Repair Using a Cannulated, Absorbable Fixation Device. *Oper Tech Orthop* 1991;1:192, with permission.)

- Once these two portals have been established, perform a review of the joint. A careful inspection begins with the biceps tendon and its origin and continues over the rotator cuff and posterior humeral head. Then inspect the glenoid rim (anterior and posterior) and glenohumeral ligaments (Fig. 80.26). In patients with a presumptive diagnosis of instability, look specifically for a Bankart lesion, capsular rupture, capsular laxity, a SLAP lesion, rotator cuff tear (partial or full), a Hill–Sachs lesion, or chondral injuries.

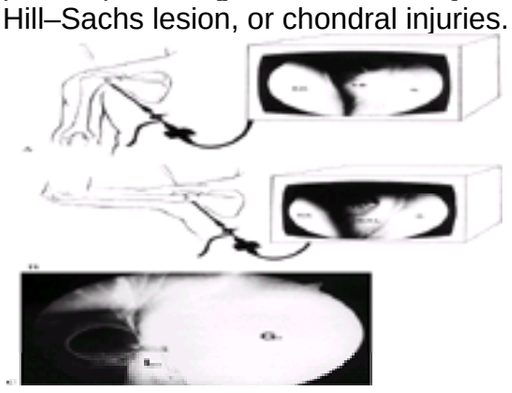

***Figure 80.26.*** **A:** The anterior band of the IGHL is visualized posteriorly and probed anteriorly with the arm in an adducted position. **B:** External rotation and abduction of the arm to 90° should increase tension in the ligament, producing a hammock-like effect. **C:** Probe analysis of the anterior labrum through the anterosuperior portal. (From Warner JJP. Shoulder Arthroscopy in the Beach-chair Position: Basic Setup. *Oper Tech Orthop* 1991;1:147, with permission.)

- SLAP lesions are typically type II in nature and are amenable to repair with current arthroscopic techniques (20,44,172,184). In patients younger than 45 years, rotator cuff tears are typically partial-thickness undersurface lesions of the supraspinatus tendon and are treatable through gentle debridement and correction of the underlying instability (156). Larger tears are associated with dislocations in patients older than 40 years (109). Pay careful attention to the presence of a

subscapularis tendon injury in patients older than 40. These injuries usually require formal open repair. Significant glenoid erosion, a large Hill–Sachs lesion, or frank posttraumatic arthritis signifies longstanding instability with associated capsular laxity or, in the worst scenario, dislocation arthropathy.

- The drive-through sign is a nonspecific, though somewhat helpful, finding for capsular laxity, described by Warren and associates (118,166,178). This finding is positive if you can sweep the arthroscope with little resistance from anterior to inferior into the axillary pouch.
- A modification of the drive-through sign that we have found more specific is termed the *arthroscopic drawer test* (166). View through the posterior portal with the patient's shoulder abducted. With the arm in abduction and external rotation, apply an anterior drawer. If the humeral head moves over the glenoid rim when the arm is in this position, there is significant capsular laxity (Fig. 80.27). The arthroscope may then be placed through the anterosuperior cannula, and both anterior and posterior drawer tests can be performed (Fig. 80.28).

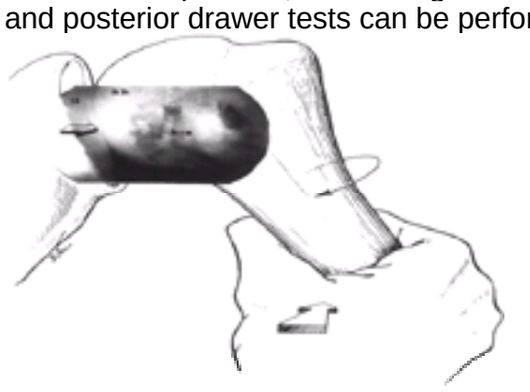

***Figure 80.27.*** Arthroscopic anterior drawer maneuver for assessing the grade of instability.

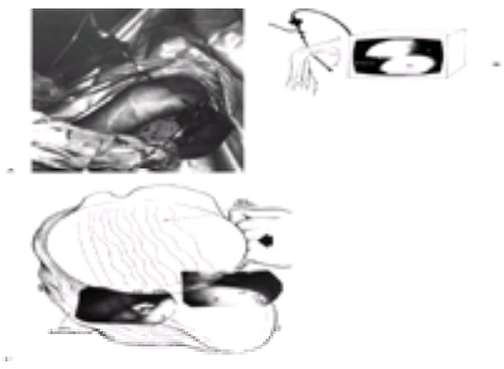

***Figure 80.28.*** **A:** Arthroscopic visualization can be performed anteriorly and is an excellent means of evaluating the anterior glenoid rim and labrum. **B:** View the humeral head from an anterosuperior perspective. **C:** Viewing through this same portal, apply an anterior drawer test (*broad arrow*), and assess the degree of humeral head (*HH*) instability. Notice the thin, lax anterior band (*thin arrows*) of the *IGHL* and the associated Hill–Sachs lesion (posterior humeral head). (From Swenson TM, Warner JJP. Arthroscopic Shoulder Stabilization: Overview of Indications, Technique, and Efficacy. *Clin Sports Med* 1995;14:841, with permission.)

- The examination should also focus on the quality and development of the glenohumeral ligaments (Fig. 80.29). There is typically great variation among the three glenohumeral ligaments. This development has been characterized on the basis of a 0–3+ scale (118). Zero represents absence of the ligament, while 1+ means that the ligament is thin and lax in nature or one-third the size of the biceps tendon. If the ligament is thick and robust in nature or one-half the size of the biceps tendon, it is graded as 2+, while 3+ means that the ligament is two-thirds the size of the biceps tendon or greater (168). We have found that individuals with marked laxity on drawer testing tend to have small or damaged glenohumeral ligaments compared with those who do not have marked laxity on drawer testing (Fig. 80.30) (170). We believe that thicker, more robust–appearing glenohumeral ligaments indicate a patient who is ideally suited for arthroscopic repair of a Bankart lesion. Optimal selection criteria for an arthroscopic versus an open stabilization procedure are provided in Table 80.4.

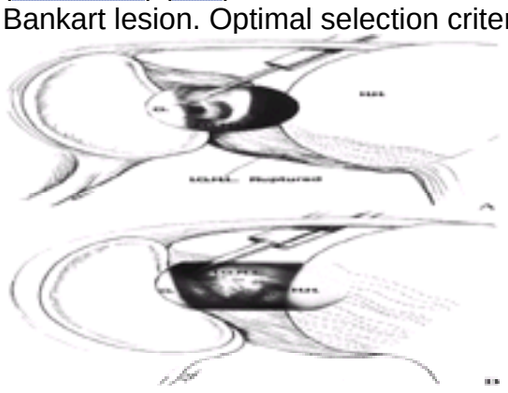

***Figure 80.30.*** Assess the degree of injury to the ligamentous structures, as well. **A:** A ruptured IGHL is visualized and probed. **B:** Debridement is performed for better visualization. (From Warner JJP. Arthroscopic Bankart Repair. In: Bigliani LU, ed. *Shoulder Instability.* Rosemont, IL: American Academy of Orthopaedic Surgeons, 1996:47, with permission.)

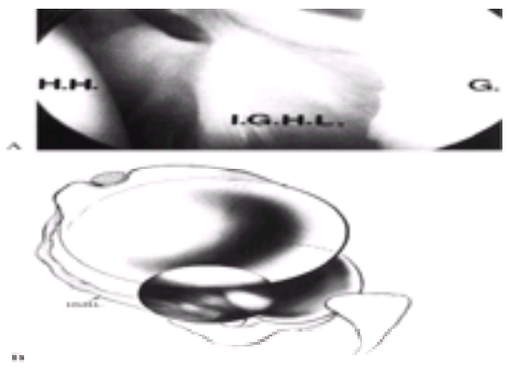


***Figure 80.29.*** It is important to assess the size and quality of the IGHL. Compare its size to the biceps tendon, which has a consistent diameter and presence. **A:** Thin, mobile *IGHL.* **B:** An anterior view further demonstrates the laxity associated with this ligament. (From Warner JJP, Altchek DW. Arthroscopic Repairs for Instability. In: Warner JJP, Iannotti JP, Gerber C, eds. *Complex and Revision Problems in Shoulder Surgery.* Philadelphia: Lippincott–Raven Publishers, 1997:26, with permission.)

| *Accept* | *Reject* |
|---|---|
| Discrete Bankart lesion | No Bankart lesion |
| Robust ligament and capsule | Capsular laxity on injury |
| No bony Bankart lesion | Bony Bankart lesion |
| No or small Hill–Sachs lesion | Large Hill–Sachs lesion |
| No arthritis | Arthritis |
| No rotator cuff tear | Rotator cuff tear |
| Sulcus sign ≤2 + | Sulcus sign >2 + |

From Warner JJ. Treatment Options for Anterior Instability: Open versus Arthroscopic. *Oper Tech Orthop* 1995;5:233, with permission.

***Table 80.4. Patient Selection Criteria for Arthroscopic versus Open Shoulder Stabilization Procedures***

- If the patient is deemed to be a suitable candidate for arthroscopic Bankart repair, an anteroinferior portal will be required for the placement of anchors and for knot-tying. Locate this portal with the patient's arm adducted at the side. Place it approximately 1 cm inferior and lateral to the coracoid process(Fig. 80.25). With the arm is in this position, thereis little risk of injury to the musculocutaneous nerve(5,6).
- Place a spinal needle from outside into the joint; its orientation should be just over the upper border of the subscapularis tendon. Because the arm is adducted, this tendon falls inferior to the equator of the glenoid, and access to the 4- to 5-o' clock position along the glenoid rim is possible. Remove the needle, and create the portal using a #11 blade. Place an 8 mm disposable cannula with a flow-restricting diaphragm in this portal to allow room for passage of the appropriate instrumentation (Fig. 80.31).



***Figure 80.31.*** This disposable cannula with a diaphragm maintains joint distention and contains an additional inflow–outflow portal. (From Warner JJP. Shoulder Arthroscopy in the Beach-chair Position: Basic Setup. *Oper Tech Orthop* 1991;1:147, with permission.)

### TREATMENT OPTIONS

As seen in the algorithm in Figure 80.32, there are many errant courses that result in ineffective treatment. A patient or a physician can make these errors. A successful outcome begins with an accurate diagnosis followed by the specific treatment required for that particular patient.

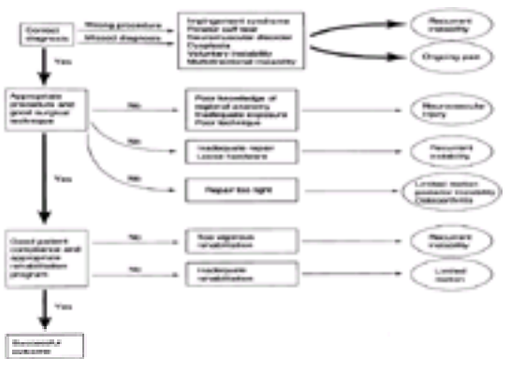

***Figure 80.32.*** Successful treatment requires a correct preoperative diagnosis and performance of an appropriate procedure with excellent technique followed by a good postoperative rehabilitation protocol. An error at any step will result in a poor clinical outcome. (From Warner JJP. Overview: Avoiding Pitfalls and Managing Complications and Failures of Instability Surgery. In: Warner JJP, Iannotti JP, Gerber C, eds. *Complex and Revision Problems in Shoulder Surgery.* Philadelphia: Lippincott–Raven Publishers, 1997:7, with permission.)

#### *Nonoperative Care*

Studies on the natural history of traumatic shoulder instability demonstrate a high rate of recurrence with nonoperative treatment (21). Rowe and Sakellarides (133) reported a recurrence rate of 58% in 398 patients with 53% follow-up. They noted a strong correlation between patient age and recurrence, with an incidence of recurrence of 94% in patients younger than 20 years, 79% in patients between 20 and 40 years, and 14% in patients older than 40 years. Subsequent studies verified this trend (62,69,103). A large Scandinavian study suggested that recurrence was less common in young males. Hovelius et al. (70) reported on 10-year follow-up of 245 patients with 247 primary dislocations. Recurrent dislocation requiring surgery occurred in 34% of 99 shoulders in the 12–22-year age range, 28% of 57 shoulders in the 23–29-year age range, and 9% of 91 shoulders in the 30–40-year age range. Recurrence rates are even higher in the pediatric age group. Marans et al. (93) reported one or more recurrent episodes of dislocation in all of the children in their study.

Despite an initial claim by Watson-Jones (179) in 1948 that immobilization in full internal rotation for 4 weeks produced complete stability, others have not reported such successful outcomes. In fact, the success of immobilization has been variable. Rowe and Sakellarides (133) reported that immobilization for 3 weeks decreased the recurrence rate. Henry and Genung (67) reported no significant improvement with immobilization. Aronen and Regan (6b) found a reduction in the recurrence rate to 25% if first-time dislocations were treated with isometric, isotonic, and isokinetic exercises (7). Burkhead and Rockwood (21) prescribed a shoulder exercise program for patients with a traumatic or atraumatic etiology. In the traumatic subluxation group, 16% responded favorably to a rehabilitation program, while 87% of the atraumatic subluxation group without psychological problems demonstrated a good-to-excellent outcome. Hovelius et al. (70) reported that the type and duration of initial treatment had no effect on the rate of recurrence.

Thus, it is clear that the most important factors in determining recurrence of instability after a traumatic injury are age and activity level. The following discussion considers surgical options in this category of patients.

## SURGICAL TECHNIQUES

### DEBRIDEMENT OF LABRAL LESIONS

Detrisac and Johnson (39) originally described five variations in labral anatomy; more recently, however, Detrisac (personal communication) changed the categories to two basic types. Type A labra were attached centrally and peripherally at the inferior, posterior, and anterior regions, but superiorly they were detached centrally and

peripherally. In contrast, type B labra were attached centrally and peripherally along the entire labrum.

Snyder et al. (146), who performed shoulder dissections, modified this description. They described an inferior labrum that consistently was triangular in shape and attached centrally and peripherally. A similar shape was demonstrated in the posterior labrum, although occasionally the undersurface of this area was not attached. The superior region once again showed consistent attachment peripherally, with a central portion that was free in varying degrees. The anterior labrum was attached at both the central and peripheral regions, appearing as a thickened band of capsule that was clearly distinguishable on histologic and gross assessment.

Several patterns of labral injury have been described. Flap tears are usually found in the anterosuperior, anteroinferior, or inferior labrum (146), associated with subluxation or frank dislocation. Other labral tears that have been described include bucket-handle and incomplete split tears, which have not necessarily been associated with instability, if located superiorly (120). Degenerative tears are labral lesions that coexist with degenerative joint disease.

Although initial reports on arthroscopic labral debridement were encouraging (4,54,122), later reports demonstrated a clear relationship between instability and labral pathology. In each study, despite early favorable results at 1- and 2-year follow-up, there was significant deterioration in clinical outcome. The authors in each article concluded that athletes whose sports involve overhead activity should be treated as if there is some underlying laxity or instability. Mere debridement of the labral pathology cannot be expected to be successful.

A study of 52 patients undergoing consecutive arthroscopic labral debridement at Columbia-Presbyterian Medical Center further strengthened these recommendations (35). The majority of these patients had SLAP lesions, while the remainder had either anteroinferior or posterior labral lesions. While no patient had a history of dislocation or clinically evident instability preoperatively, EUA revealed instability in 70% of patients with SLAP lesions and in all of the other patients.

At 1-year follow-up, 78% of the superior labral group versus 30% of the anteroinferior group had excellent results from debridement. These results deteriorated with time to 63% and 25% in each respective group at 2-year follow-up. The authors concluded that instability was frequently present in patients with labral pathology, and debridement would provide only short-term relief in this patient population. On the basis of these studies it is difficult to recommend labral debridement for most patients.

**REPAIR OF SUPERIOR LABRAL LESIONS**

In 1985, Andrews et al. (5) reported the association in athletes between throwing and injuries to the anterosuperior glenoid labrum and the insertion of the long head of the biceps brachii. These injuries were believed attributable to the large deceleration forces applied by the biceps muscle at the insertion point. Two studies further implicated the long head of the biceps in contributing to anterior and superior shoulder stability during abduction and external rotation (126,174). In 1990, Snyder et al. (145) retrospectively reviewed 700 patients who underwent shoulder arthroscopy and described four specific types of pathologic abnormalities in this area: the SLAP lesions (Fig. 80.33). A description of each type of SLAP lesion and the recommended treatment is provided in Table 80.5.

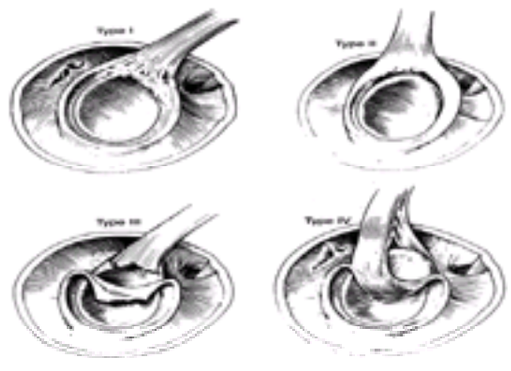

***Figure 80.33.*** The four types of SLAP lesions (Table 80.5). (From Snyder SJ, Wuh HCK. Arthroscopic Evaluation and Treatment of the Rotator Cuff Superior Labrum Anterior Posterior Lesion. *Oper Tech Orthop* 1991;1:212, with permission.)

| Type | Description | Treatment |
|---|---|---|
| I | Frayed, degenerate superior labrum<br>Intact attachment of biceps anchor to glenoid rim | Debridement<br>Observation |
| II | Detached superior labrum and biceps anchor from the glenoid rim<br>Presence or absence of fraying and degeneration of tissue | Repair unstable biceps insertion |
| III | Bucket-handle tear of superior labrum<br>Remaining biceps anchor and labrum intact | Arthroscopic debridement |
| IV | Bucket-handle tear of biceps anchor, continuing into the biceps tendon for variable distance | Repair or tenodesis of tendon<br>Based on symptoms and condition of remaining tissue |

***Table 80.5. SLAP Lesion Types and Appropriate Treatments***

Anatomic and histologic studies further characterized the superior labral area (21,31,129). These studies demonstrated a relative avascularity at the superior and anterosuperior regions compared with the posterior and inferior regions, and this may be one reason for the degeneration that occurs in this area. A retrospective review by Snyder et al. (144) involving 2,375 arthroscopic shoulder procedures over 8 years found SLAP lesions in 140 (6%) patients. Most lesions were classified as either type II (55%) or type I (21%) lesions. Only 28% had isolated superior labral pathology, 22% had associated Bankart lesions, and the remainder had associated rotator cuff pathology. Another review of 712 patients revealed that 17% had type I lesions, while 11.8% had other significant labral pathology (91). The authors had difficulty classifying the remaining pathology according to the criteria described by Snyder, but once again there was a high association between labral lesions and subtle instability or laxity on EUA.

**SLAP LESION REPAIR**

The correlation between glenohumeral instability and superior-labral and biceps-insertion pathology has led to the development of several arthroscopic repair techniques. In 1991, Yoneda et al. (184) described the use of an arthroscopic staple (Instrument Makar Inc., Okemos, MI) designed by Lanny Johnson. The patient population consisted of 10 young athletes (involved in overhead sports) with type II SLAP lesions. The standard lateral decubitus position was used, and the joint was visualized through the standard posterior portal. An anterosuperior portal was used for instrumentation.

The surgery involved arthroscopic debridement, abrasion, and stapling of the SLAP area. One staple (5.5 mm diameter) was used in each case. Patients were immobilized for 2–3 weeks; range of motion was then initiated, followed by strengthening exercises at 6 weeks. Because of concerns over staple migration and irritation, all staples were removed at an average of 3.9 months. On second-look arthroscopy, complete healing had occurred in four patients, with full continuity with the glenoid surface. The remaining repairs were deemed stable despite incomplete healing. More important, 80% of patients were found to have good-to-excellent results.

Reports of loosening and irritation with the arthroscopic staple have led to the development of alternative repair techniques (36,60,124). A transglenoid approach, originally developed for Bankart lesions and popularized by Caspari, has been applied to the SLAP lesion (24,44).

- With the patient in the lateral decubitus position, use standard posterior and superior portals for visualization and inflow. Establish a third anterior portal with a spinal needle; this portal will be used for instrumentation.
- Use a Caspari suture punch (Concept Inc., Largo, FL) through the anterior portal to place four to seven 2-0 polydioxanone (PDS) sutures from posterior to anterior along the labrum–biceps tendon complex. Place an additional one to two 0-PDS sutures into the biceps tendon, as well, to reinforce the repair.

- Make a transglenoid drill hole (1-o' clock position for right shoulders or 11-o' clock position for left shoulders), using a Beath needle placed through the anterior portal approximately 3–5 mm medial to the articular surface and exiting in the infraspinatus fossa posteriorly (Fig. 80.34*A*, Fig. 80.34*B*). Then pass all previously placed sutures through the glenoid neck, using the Beath needle (Fig. 80.34*C*). Tie the sutures through a small posterior incision over the infraspinatus fascia (Fig. 80.34*D*). Immobilize the patient for 1–2 weeks, and protect the shoulder in a sling for an additional 3–4 weeks. Field and Savoie (44) reported excellent results in 80% of the patients in whom they used this technique.

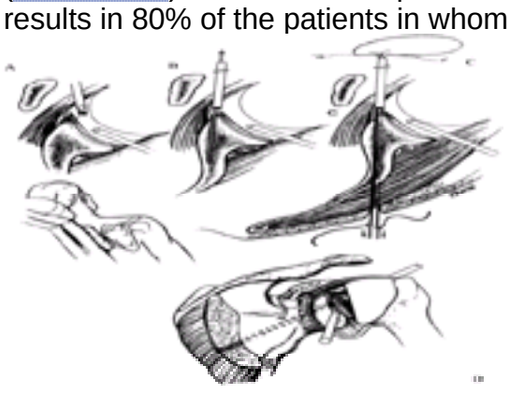

***Figure 80.34.*** Arthroscopic repair of a SLAP lesion using a transglenoid suture technique. **A:** Prepare the glenoid rim. **B:** Drill transglenoidally with a Beath needle. **C:** Pass the suture that is subsequently tied over the infraspinatus fascia. (From Altchek DW, Warren RF, Skyhar MJ. Shoulder Arthroscopy. In: Rockwood CA Jr, Matsen FA III, eds. *The Shoulder.* Philadelphia: WB Saunders, 1990:275, with permission.)

Some concerns have been raised about this technique, however (166), because it requires a separate posterior incision to tie the sutures. Tying over the infraspinatus muscle may lead to gaps at the repair site if muscle atrophy occurs. Further, the elastic nature of PDS suture makes it prone to gap 5–10 mm at the repair site (52). In addition, during transosseous pin placement, there is a risk of injury to the suprascapular nerve or one of its branches (140).

### *Alternative Technique*

A technique designed at the Southern California Orthopedic Institute (SCOI) avoids the inherent risk of transosseous sutures (28). The standard posterior, anterosuperior, and anteroinferior portals as previously described are used with this technique. Wichman and Snyder (180) described the more inferior portal as the anterior mid-glenoid portal.

- Place disposable cannulas with flow-restricting diaphragms into each anterior portal. For type II lesions, first use a shaver to debride the fibrous membrane over the glenoid neck. Then use a 4.0 mm ball-shaped burr to decorticate and create a notch beneath the SLAP region, avoiding the articular cartilage. SCOI recommends the use of the Revo screw system (Linvatec, Inc. Largo, FL), in which nonabsorbable suture is placed through the eyelet of the screw before implantation. Insert the Revo punch through the anterosuperior cannula at a 45° angle, impact it with a mallet, and remove it. Then place the screw with the attached braided, nonabsorbable suture (Fig. 80.35*A*, Fig. 80.35*B*).

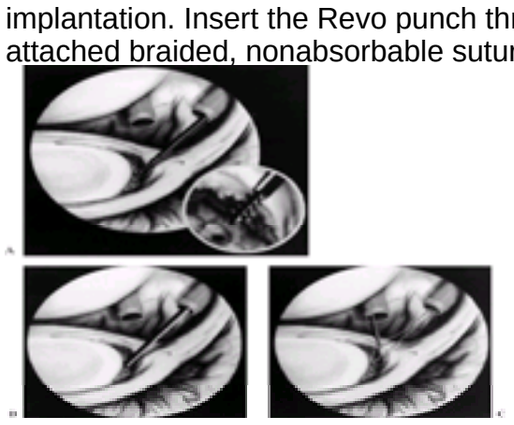

***Figure 80.35.*** SLAP lesion repair. **A:** Place a suture anchor into the prepared glenoid rim, using the anterosuperior arthroscopic portal. **B:** Firmly seat the anchor in the bone. **C:** Pass one limb of the suture through the anteroinferior portal. (From Cheng JC, Karzel RP. Superior Labrum Anterior Posterior Lesions of the Shoulder: Operative Techniques of Management. *Oper Tech Sports Med* 1997;5:249, with permission.)

- Apply tension to the suture through the cannula to assess the stability of the anchor. Then use a hook or grasper to retrieve one limb of the suture through the anteroinferior cannula (Fig. 80.35*C*). Place a crescent-shaped suture passer through the anterosuperior portal, and use it to pass a Shuttle Relay (Linvatec, Inc., Largo, FL) through the anterior superior labrum–biceps complex (Fig. 80.36*A*). The Shuttle Relay contains a central loop through which suture can be placed and then pulled back through the tissue.

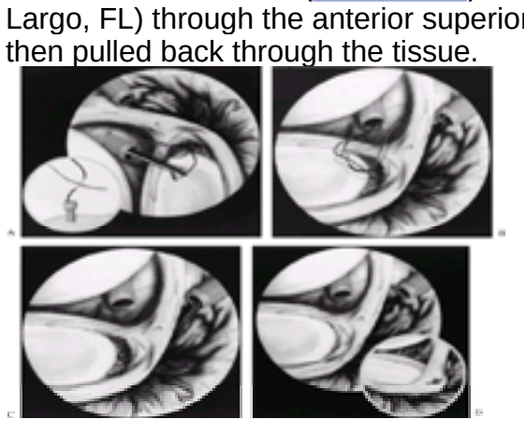

***Figure 80.36.*** SLAP lesion repair. **A:** Place a cannulated hook and Shuttle Relay through the SLAP lesion. Then expose the latter externally through the anteroinferior portal. Pass the suture through the eyelet portion of the Shuttle Relay. **B:** Pull the suture in a retrograde fashion through the SLAP lesion and the anterosuperior cannula. **C:** Repeat the process for the other limb. **D:** Tie the suture arthroscopically, creating a horizontal configuration. (From Cheng JC, Karzel RP. Superior Labrum Anterior Posterior Lesions of the Shoulder: Operative Techniques of Management. *Oper Tech Sports Med* 1997;5:249, with permission.)

- Pass the Shuttle Relay through the anteroinferior portal with a grasper, and expose the loop externally. Pass the limb of nonabsorbable suture in the anteroinferior portal through the loop of the relay. Then pass the suture through the tissue by applying tension on the other end of the Shuttle Relay still exposed through the anterosuperior portal (Fig. 80.36*B*). Thus, the relay and attached suture are pulled back through the tissue and out the anterosuperior cannula in a retrograde fashion.
- Repeat the process for the other limb of the suture, creating a horizontal mattress repair. Place a probe through the anteroinferior portal to reduce the entire complex, and use an arthroscopic knot pusher to tie the suture in place (Fig. 80.36*C*, Fig. 80.36*D*).
- An alternative to the Shuttle Relay is a suture-transport system (Smith and Nephew, Andover, MA) (Fig. 80.37). These instruments contain a sharp tip that is passed through the anterosuperior portal and directly through the tissue (Fig. 80.38*A*). The surgeon deploys two small metal arms and grasps one limb of the suture, pulling it back through the tissue and out the cannula (Fig. 80.38*B*). The process is repeated, and the sutures are tied in horizontal fashion.

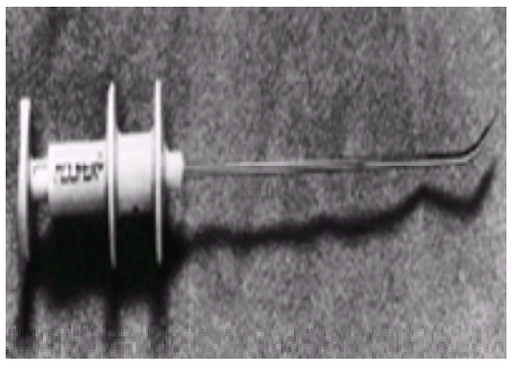

***Figure 80.37.*** Suture-transport system (Acufex). (From Cheng JC, Karzel RP. Superior Labrum Anterior Posterior Lesions of the Shoulder: Operative Techniques of Management. *Oper Tech Sports Med* 1997;5:249, with permission.)

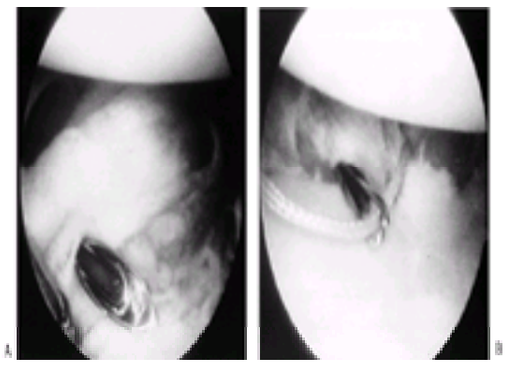

***Figure 80.38.*** SLAP lesion repair. **A:** Pass the transport system through the labral tissue. **B:** Deploy the central arms, and grasp the suture; then pass the suture back through the tissue, and tie it for an effective repair. (From Cheng JC, Karzel RP. Superior Labrum Anterior Posterior Lesions of the Shoulder: Operative Techniques of Management. *Oper Tech Sports Med* 1997;5:249, with permission.)

- In type IV lesions, for tears involving less than 30% of the torn biceps tendon, perform debridement and complete repair as for type II lesions. With greater involvement, perform a primary biceps tenodesis in elderly patients or a suture repair of the biceps tendon and labrum in younger patients. Good-to-excellent results with this technique have been reported in 74% of patients after long-term follow-up (153).

The numerous suture anchors on the market have different advantages and disadvantages (Fig. 80.39). Many surgeons prefer to use metal anchors for postoperative radiographic visualization in the event that an anchor dislodges from the bone, which is a potential risk with this technique. If an anchor loosens, the device must be removed because an intraarticular loose body could lead to cartilage damage. In addition, there are potentially grave complications from migration of a foreign object to the lung, subclavian artery, or spinal canal (90,96,98,111,138).

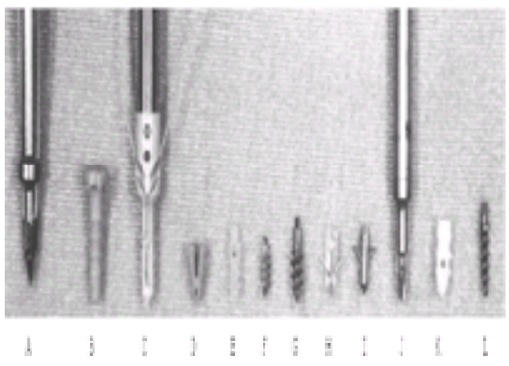

***Figure 80.39.*** Some suture anchors currently on the market. **A:** Arthrotek Harpoon Suture Anchor, Warsaw, IN. **B:** Acufex Suretac II, Andover, MA. **C:** Innovasive Devices Roc, Marlborough, MA. **D:** Acufex Tag Wedge, Andover, MA. **E:** Linvatec Bio-Anchor, Largo, FL. **F:** Linvatec Mini-Revo, Largo, FL. **G:** Linvatec Revo, Largo, FL. **H:** Mitek Stealth, Westwood, MA. **I:** Mitek G-II Anchor, Westwood, MA. **J:** Zimmer Statak. **K:** Acufex Tag Rd II, Andover, MA. **L:** Arthrex Fastak, Naples, FL. (From Elrod B. Arthroscopic Reconstruction of Traumatic Anterior Instability. *Oper Tech Sports Med* 1997;5:215, with permission.)

With this concern in mind, absorbable anchors have been developed. However, because they degrade, they raise concerns about the stability of the repair. Studies have focused on initial pullout strengths and degradation of the entire anchor (8,9,97). As most absorbable materi-als lose their strength in 4–6 weeks, there are also concerns over the degradation at the eyelet (20). This technique also requires secure intraarticular knot-tying with a certain level of experience before actual use in the operating room.

Warren and colleagues developed the Suretac device (Smith and Nephew, Andover, MA) to overcome some of the problems inherent in suture anchors (151,177). This implant is an absorbable, cannulated device composed of a synthetic copolymer (polyglyconate). The tack contains ribs for increased pullout strength (3.2 mm shaft diameter). It has a wide, flat head (6.5 mm diameter) to adequately hold tissues, and undergoes hydrolysis, thereby preventing a significant inflammatory response (Fig. 80.40). The rapid, 4-week bioabsorption profile prevents the possibility of loose fragments, as might occur with slower absorption profiles, but is considered long enough for adequate tissue healing. In most descriptions of procedures employing this implant, the beach-chair position has been used (117,172).

***Figure 80.40.*** Suretac implants.

***Authors' Preferred Method***

True complete superior labral detachments are a challenge to repair, but they are much more easily repaired through an arthroscopic than through an open approach because the overlying acromion makes exposure of the superior glenoid difficult through a deltopectoral approach. Furthermore, the diagnosis of a SLAP lesion is essentially an arthroscopic diagnosis.

For 6 years, one of us (JJPW) has used an arthroscopic technique that employs the Suretac device (172). In the past 2 years, a suture method has been developed. Both methods have proven efficacious. Theoretically, the suture method gives stronger immediate repair without any worry about deterioration of the strength of repair due to resorption of the polyglyconate anchor, as with the Suretac device.

- Perform both techniques with the patient in a beach-chair position. Use an anterosuperior portal with a 6 mm cannula with a flow-restricting diaphragm entering the joint just underneath the biceps tendon. Use an accessory anterolateral or transcuff portal, as well (Fig. 80.41).

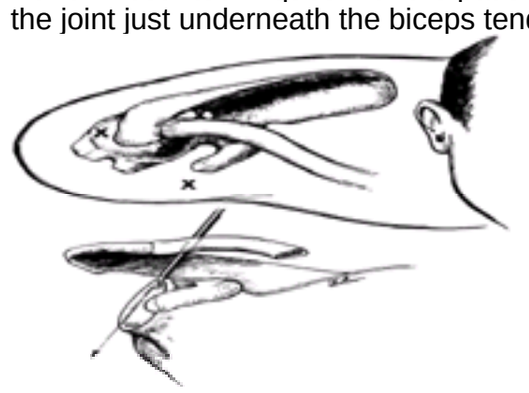

***Figure 80.41.*** SLAP lesion repair. The superior portal provides direct access to the superior labral area, but the surrounding soft tissues prevent adequate visualization and manipulation of lesion. There is also an increased possibility of drill slippage with resultant articular cartilage damage. Use of the lateral portal provides equal access and avoids these problems. (From Warner JJ, Kann S, Marks P. Arthroscopic Repair of Combined Bankart and Superior Labral Detachment Anterior and Posterior Lesions: Technique and Preliminary Results. *Arthroscopy* 1994;10:383, with permission.)

- Place an 18-gauge spinal needle through the rotator cuff from just lateral to the acromion to identify this latter portal. Position the needle so that the most direct angle to the superior labrum is possible. Then withdraw the spinal needle and use a #11 blade to make a portal through the rotator cuff while visualizing from within the joint. Insert another 6 mm cannula into the joint through the rotator cuff. The defect made in the cuff with this approach has not led to any significant clinical problems postoperatively.
- Using the anterosuperior portal, clear the superior glenoid rim of soft tissue, using a motorized shaver (Fig. 80.42), and decorticate the juxtaarticular margin with a burr (Fig. 80.43).

***Figure 80.42.*** SLAP lesion repair. Arthroscopic debridement of the superior and anterior labral areas can be performed through the anterosuperior portal. (From Warner JJ, Kann S, Marks P. Arthroscopic Repair of Combined Bankart and Superior Labral Detachment Anterior and Posterior Lesions: Technique and Preliminary Results. *Arthroscopy* 1994;10:383, with permission.)

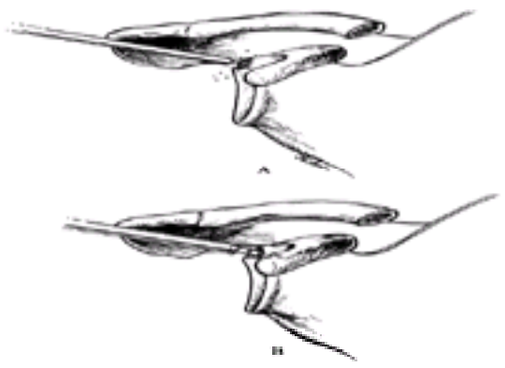

***Figure 80.43.*** SLAP lesion repair. The lateral portal provides direct access to the superior aspect of the glenoid for preparation (**A**) for and placement (**B**) of the Suretac device. (From Warner JJ, Kann S, Marks P. Arthroscopic Repair of Combined Bankart and Superior Labral Detachment Anterior and Posterior Lesions: Technique and Preliminary Results. *Arthroscopy* 1994;10:383, with permission.)

- Repair the SLAP lesion through the transcuff portal, using either one Suretac implant placed through the labrum–biceps tendon complex or two suture anchors placed just anterior and posterior to the biceps origin. When using the Suretac implant, place a cannulated drill with protruding guidewire (3 mm) through the transcuff portal (Fig. 80.44). The wire, which is locked in position, pierces the tissue and is used to bring the complex toward the prepared glenoid neck.

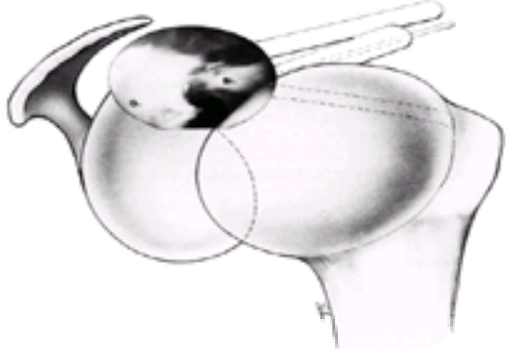

***Figure 80.44.*** Arthroscopic view of a type II SLAP lesion. An anterosuperior portal allows manipulation of the biceps (*Bi*) and preparation of the glenoid (*G*), while the lateral portal allows placement of the guidewire and drill. (From Warner JJ, Kann S, Marks P. Arthroscopic Repair of Combined Bankart and Superior Labral Detachment Anterior and Posterior Lesions: Technique and Preliminary Results. *Arthroscopy* 1994;10:383, with permission.)

- Advance the drill to a depth of one external mark (approximately 1–2 cm), and unlock the wire from the bit. Tap at its free end to release it from the drill, and remove the drill. The wire should remain in place, piercing the tissue. Place the tack over the wire, and tamp it into place with a cannulated pusher.

Usually, one Suretac implant is placed (Fig. 80.45). Technical errors encountered with the Suretac device will be discussed later in the chapter. Clinical and cadaveric

experience have demonstrated that the accessory anterolateral portal (localized with a spinal needle) can provide reliable access to the superior glenoid region (Fig. 80.46).

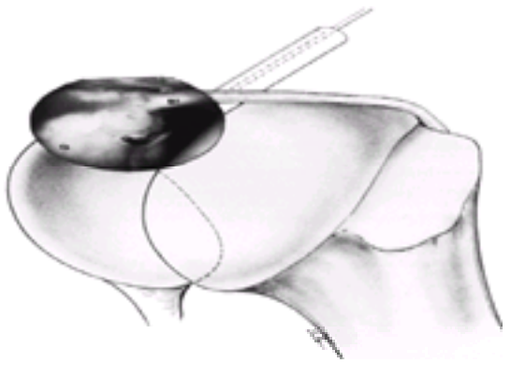

***Figure 80.45.*** Arthroscopic stabilization of a type II SLAP lesion with a Suretac implant. (From Warner JJ, Kann S, Marks P. Arthroscopic Repair of Combined Bankart and Superior Labral Detachment Anterior and Posterior Lesions: Technique and Preliminary Results. *Arthroscopy* 1994;10:383, with permission.)

***Figure 80.46.*** This cadaveric dissection demonstrates the direct localization of the superior glenoid and SLAP repair from a lateral direction. (From Warner JJ, Kann S, Marks P. Arthroscopic Repair of Combined Bankart and Superior Labral Detachment Anterior and Posterior Lesions: Technique and Preliminary Results. *Arthroscopy* 1994;10:383, with permission.)

Protect patients in a sling and swathe for 4 weeks. Initiate gentle passive range-of-motion exercises in a supervised setting 1 week postoperatively. Advise patients to avoid external rotation past neutral and forceful abduction greater than 60° for 4 weeks. With this technique, 86% satisfactory results were obtained at 2-year follow-up. Twelve of 13 athletes were able to return to full overhead function (117).

Alternatively, suture anchors can be used to repair these lesions.

- Use the anterosuperior portal for glenoid preparation and the transcuff portal for implant placement. Assess and prepare the area beneath the labrum–biceps tendon complex as described previously (Fig. 80.47*A*, Fig. 80.47*B*). Place suture anchors anterior and posterior to the complex. We have had experience with the Tag Rd II (Smith and Nephew, Andover, MA) and the ROC (Innovasive Devices, Inc., Marlborough, MA) suture anchor systems. As stated previously, there are many suture anchors on the market, each with its own advantages and disadvantages.



***Figure 80.47.*** Slap lesion repair. **A:** Prepare the superior labral region through the lateral portal, using a shaver. **B:** Use an arthroscopic burr to create a bleeding surface. **C:** Place the arthroscopic drill through the lateral portal. **D:** Implant a suture anchor after drilling has been performed.

- Regardless of the system used, drill the glenoid neck at a 45° angle from the articular surface through the transcuff portal (Fig. 80.47*C*). Remove the drill, and then tap the preloaded (braided, nonabsorbable material) suture anchor into place (Fig. 80.47*D*). Apply firm tension on the suture to assess fixation. Use either a Shuttle Relay or a suture-transport system to pass one limb of the suture through the biceps tendon, as previously described, using the anterosuperior portal (Fig. 80.48*A*).

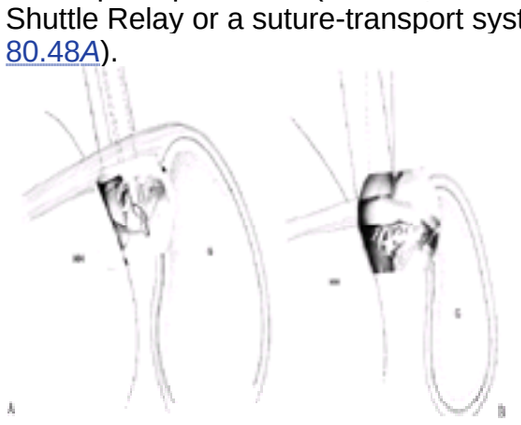

***Figure 80.48.*** Slap lesion repair. **A:** One arthroscopic knot has been tied anteriorly. Use a suture-transport system to pass an additional suture through the posterior portion of the SLAP lesion, using the lateral portal.

- Using arthroscopic knot-tying technique, fix the biceps anchor to the glenoid rim with a simple (not horizontal mattress) suture configuration (Fig. 80.48*B*). Assess the repair for stability at this point, and, if deemed necessary, place another suture anchor either anterior or posterior to the initial suture anchor for additional fixation.
- Use the same postoperative protocol as for the Suretac repair.

Preliminary results with this technique have been satisfying, although longer follow-up will be required to determine its true clinical efficacy.

## ARTHROSCOPIC BANKART REPAIR

Many of the arthroscopic techniques for SLAP lesion repairs were adapted from techniques for arthroscopic repair of Bankart lesions. Arthroscopic shoulder stabilization was initially attempted with an arthroscopic staple (79). Unfortunately, this technique was associated with a high recurrence rate and an unacceptably high rate of complications related to the implant (Table 80.6). Complications included breakage and migration of the staple, as well as articular and neurovascular injuries from the staple. This technique has largely been abandoned.

| Series | Patients (n) | Follow-up, mean (mo) | Recurrence (%) | Comments |
|---|---|---|---|---|
| Small, 1986[illegible] (141a) | 162 | — | — | 18 loose staples<br>6 staple impingement<br>2 bent staples<br>2 neuropraxia |
| Mazzocca, 1988 (96a) | 23 | 36 | 20 | 1 staple impingement<br>(removable stent) |
| Wiley, 1988 (180a) | 10 | 6–24 | 17 | |
| Hawkins, 1989 (63) | 50 | 59 | 16 | 4 loose staples<br>1 neuropraxia<br>1 broken staple |
| Wheeler, 1989 (179a) | 9 | >17 | 36 | |
| Caves, 1989 (16) | 12 | 86 | 33 | 1 staple impingement |
| Burger, 1990 (19a) | 52 | 25 | 33 | 3 loose staples<br>1 broken staple |
| Coughlin, 1992 (36) | 47 | 66 | 23 | 3 parietal staples |
| Lane, 1993 (83b) | 34 | 59 | 33 | 18% loose staples |
| Wilson, 1993 (181a) | 101 | 16.3 | 27 | |
| Johnson, 1993 (79) | 77 (series I)<br>124 (series II) | 24<br>36 | 21<br>34 | (<3 weeks in sling)<br>47% with pain<br>33% with shoulder loss |
| | 25 (series III) | 24 | 13 | 60% with pain |
| Rao, 1994 (123a) | 22 | 20 | 26 | |

[illegible]

From Warner JJ. Treatment Options for Anterior Instability: Open versus Arthroscopic. Oper Tech Orthop 1995;5:233, with permission.

***Table 80.6. Published Complications and Instability Recurrence Rates of the Arthroscopic Staple Technique***

Subsequently, Caspari and Morgan developed a transosseous suture repair technique that avoided the pitfalls of a juxtaarticular staple (24a,104,136). This method was based on the open technique developed by Reider and Ingles (166). In a manner similar to that previously described for SLAP lesion repairs, a Caspari suture punch is used to place PDS sutures through the IGHL. These sutures are then loaded onto a special pin with a hole at one end (Beath pin) and passed through a drill hole made at the anterior glenoid rim so that it exits out of the infraspinatus fossa (Fig. 80.34). These sutures are then separated into two limbs and tied over the infraspinatus fascia.

In the hands of the surgeons who developed this method of repair, results have been good to excellent over intermediate follow-up (157). Unfortunately, others have been unable to duplicate the success of these surgeons, and with longer follow-up, recurrence rates have beenreported in the 20% to 40% range (Table 80.7) (58,127,140,162,165).

| Series | No. of patients (n) | Follow-up, mean (mo) | Recurrence (%) | Comments |
|---|---|---|---|---|
| Morgan, 1987 (106) | 23 | 17 | — | |
| Wolin, 1993 (183a) | 45 | >24 | 27 | |
| Weber, 1990 (179a) | 23 | 27 | 17 | |
| Rose, 1990 (127) | 90 | >24 | 4 | |
| Caspari, 1991 (24a) | 49 | 24–72 | 4 | |
| Morgan, 1991 (103a) | 55 | 49 | 4 | |
| | 120 | 12–24 | 7.8 | |
| | 42 | — | 36.8 | All collision athletes |
| Lindholm, 1992 (83a) | 65 | 35 | 11 | |
| Boyd[illegible], 1992 (9a) | 16 | 24 | 0 | |
| Duncan, 1993[illegible] (41) | 60 | 12–36 | 0 | |
| Hecht[illegible], 1993 (109) | 26 | >24 | 0 | |
| Goldberg, 1993 (58a) | 38 | Preliminary | 10 | |
| Grana, 1993 (35a) | 27 | 36 | 15 | |
| Geiger, 1993 (48a) | 36 | 23 | 44 | |
| Foster, 1994 (47a) | 79 | 12–88 | 8 | |
| Anders, 1994 (5a) | 28 | 32 | 14 | |
| Wolfe, 1994 (162) | 99 | 24–72 | 40 | |
| Pagnani, 1994 (110) | 37 | 48–120 | 19 | |

[illegible]

***Table 80.7. Published Instability Recurrence Rates of the Arthroscopic Suture Technique***

As discussed previously, there are technical problems associated with this technique, such as placement of the drill hole too medially so that the Bankart lesion is not repaired, as well as suprascapular nerve injury from posterior exit of the pin. Finally, the need for an additional posterior incision has made this approach less desirable.

One of the first attempts to develop a reliable all intraarticular technique was made by Maki (92). He proposed drilling across the glenoid in a manner similar to the technique described above; however, a large suture (Mulberry knot) was tied in the PDS suture so that when it was pulled back it locked on the posterior cortex of the scapula. Internal knots were then tied over the anterior capsule and labrum with a special knot pusher and special knot-tying techniques. Current approaches to arthroscopic Bankart repair involve the use of suture anchors and internal knots or absorbable transfixing implants (42,127,183).

Regardless of which implant is used, arthroscopic methods of repair are continuing to evolve, along with an appreciation of more specific indications for their use. There are clear-cut advantages and disadvantages to arthroscopic stabilization procedures (Table 80.8). Appropriate patient selection is based on a detailed history and physical examination, imaging studies when indicated, and a careful EUA and arthroscopic inspection. In addition, other specific factors seem to be associated with a good result (Table 80.4).

| *Advantages* | *Disadvantages* |
|---|---|
| Less pain | Articular injury from implants |
| Less surgical morbidity | Technically more difficult |
| Selective anatomic repair | Long learning curve |
| Faster surgery | Need for posterior incision |
| Better range of motion | Higher recurrence rate |
| Faster recovery | May not be good for contact athlete |
| Better cosmesis | |

From Warner JJ. Treatment Options for Anterior Instability: Open versus Arthroscopic. Oper Tech Orthop 1995;5:233, with permission.

***Table 80.8. Arthroscopic Bankart Repair***

While some surgeons are exploring the role of arthroscopic capsulorrhaphy and thermal capsular shrinkage for patients with capsular laxity, we feel that the optimal patient for repair is one who has a discrete Bankart lesion with robust capsuloligamentous structures without significant capsular injury. In addition, it is preferable if there is no significant glenoid erosion or a bony Bankart lesion. While a small Hill–Sachs lesion is not a contraindication to arthroscopic repair, we believe that a large Hill–Sachs lesion is associated with recurrent episodes of dislocation and generally indicates significant capsular laxity. With these criteria, short-term follow-up studies have demonstrated a significant reduction to approximately 7% to 10% in postoperative failure rates (recurrences) after arthroscopic stabilization procedures (84,175,176).

### *Authors' Preferred Method*

- Perform arthroscopy with the patient in the beach-chair position.
- Use three portals for the arthroscopic Bankart repair: the standard posterior, anterosuperior, and anteroinferior portals (Fig. 80.49*A*). Accurate portal placement is

essential for proper technical execution of the procedure. The anterosuperior and anteroinferior portals must diverge so that intraarticular instrument crowding is not a problem.

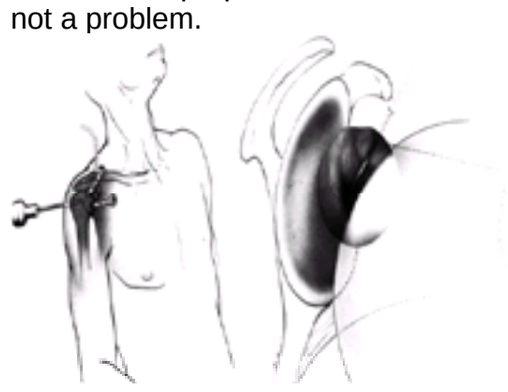

***Figure 80.49.*** Arthroscopic Bankart repair. **A:** Use anterosuperior and anteroinferior portals for a standard repair. **B:** Use a spinal needle to localize the correct position for portal placement. The location should allow access to the 4- and 5-o'clock positions along the glenoid rim. This method is referred to as the outside-in technique. (From Warner JJ, Warren RF. Arthroscopic Bankart Repair Using a Cannulated, Absorbable Fixation Device. *Oper Tech Orthop* 1991;1:192, with permission.)

- As previously discussed, place the anterosuperior portal just anterior and lateral to the acromioclavicular joint, so that a 6 mm cannula enters the joint vertically just beneath the biceps tendon. Locate the anteroinferior portal 1 cm inferior and lateral to the coracoid process, entering the joint just over the subscapularis tendon. Use a spinal needle before incising the skin to ensure access to the appropriate region along the anteroinferior glenoid neck (Fig. 80.49*B*). It should correspond to the 4- and 5-o' clock positions for the right shoulder and to the 7- and 8-o' clock positions for the left shoulder. If this inferior portal is not placed correctly, there will be a tendency for the drill to slip either medially or inferiorly when you attempt fixation. Insert a large, 8 mm cannula through this portal to allow placement of the appropriate instruments.
- As with SLAP lesions, adequately prepare the glenoid neck to ensure healing of soft tissue to bone, including the inferior glenoid rim, which usually requires enlargement of the Bankart lesion (Fig. 80.50*A*). Gain access to this region through the anteroinferior portal; use a motorized shaver and burr to create a bony trough along the anterior glenoid neck that prevents drill slippage during subsequent portions of the procedure (Fig. 80.50*B*, Fig. 80.50*C* and Fig. 80.50*D*).

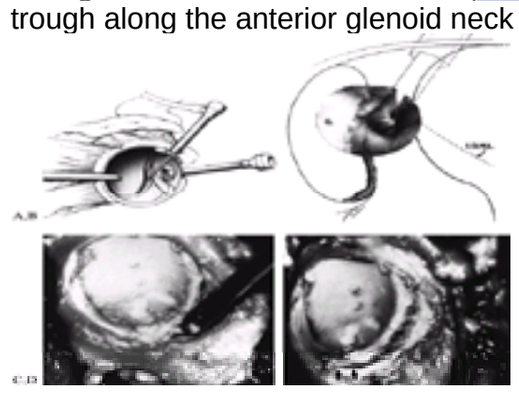

***Figure 80.50.*** Arthroscopic Bankart repair. **A:** The standard arthroscopic portals are depicted. Place an arthroscopic rasp through the anterosuperior portal to prepare the glenoid rim. (From Warner JJ, Warren RF. Arthroscopic Bankart Repair Using a Cannulated, Absorbable Fixation Device. *Oper Tech Orthop Surg* 1991;1:192, with permission.) **B:** An arthroscopic burr has been placed through the anterosuperior portal. **C:** This cadaveric dissection demonstrates glenoid preparation with the burr. **D:** Glenoid preparation has been performed up to the 5-o'clock position. (From Warner JJ, Miller MD, Marks P. Arthroscopic Bankart Repair with the Suretac Device. Part II. Experimental Observations. *Arthroscopy* 1995;11:14, with permission.)

- Use a 30° arthroscope placed through the posterior and anterosuperior portals to assess the preparation (Fig. 80.51). Alternatively, place a 70° arthroscope through the posterior portal to gain a bird's-eye view of the anterior glenoid region.

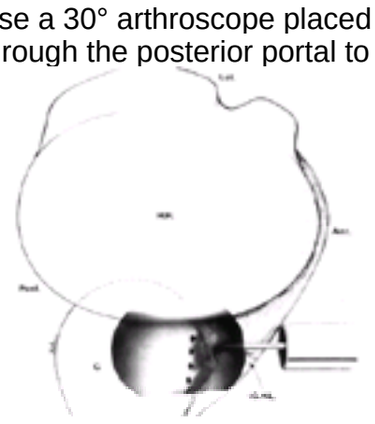

***Figure 80.51.*** Arthroscopic view through the anterosuperior portal demonstrates displacement of the anterior band of the *IGHL* with a probe. The anterior glenoid rim has been decorticated before arthroscopic repair (*arrows*). (From Warner JJP, Altchek DW. Arthroscopic Repairs for Instability. In: Warner JJP, Iannotti JP, Gerber C, eds. *Complex and Revision Problems in Shoulder Surgery.* Philadelphia: Lippincott–Raven Publishers, 1997:34, with permission.)

- In chronic instability, the detached capsulolabral complex may adhere by scar medially along the scapula. Neviaser (109) termed this an *anterior labral periosteal sleeve avulsion* (ALPSA) injury. It is essential to mobilize this tissue so that it can be reattached at its anatomic site adjacent to the articular margin of the glenoid. Use a hooked-tip electrocautery device and a knife–rasp to subperiosteally elevate the scarred capsulolabral tissue (Fig. 80.52*A*).

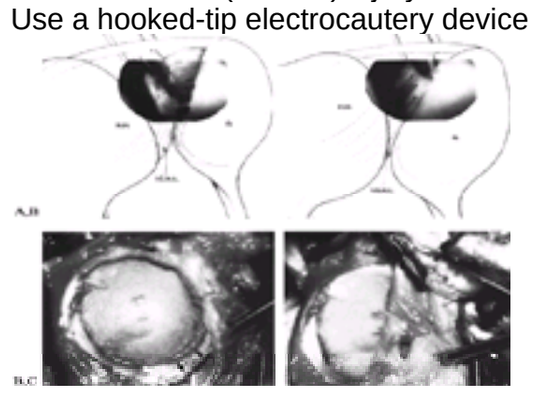

***Figure 80.52.*** Arthroscopic Bankart repair. **A:** Place an arthroscopic instrument through the anterosuperior portal and grasp the anterior band of the *IGHL* (*H.H.*, humeral head; *G.*, glenoid). **B:** Pull the IGHL in a posterosuperior direction, using an arthroscopic grasper. **C:** This cadaveric dissection demonstrates a persistent Bankart lesion after inadequate mobilization of the IGHL. (*arrows*). **D:** Appropriate superior shift of the anterior band of the IGHL avoids this problem by bringing the soft tissues firmly against the anteroinferior glenoid rim. (From Warner JJ, Miller MD, Marks P. Arthroscopic Bankart Repair with the Suretac Device. Part II. Experimental Observations. *Arthroscopy* 1995;11:14, with permission.)

- Place an arthroscopic grasper through the anterosuperior portal, and use it to pull the tissue into the appropriate position before repair with the Suretac implant (Fig. 80.52*B*, Fig. 80.52*C* and Fig. 80.52*D*). Place this device, using the same technique described previously for SLAP lesion repairs.
- Postoperatively, protect patients in a sling and swathe for 4 weeks. Allow them to shower, but they should avoid external rotation; advise them to maintain the arm internally rotated when it is out of the sling. Allow elbow motion, as well as activities of daily living, which generally involve limited forward flexion. After 4 weeks, allow active-assisted stretching and strengthening exercises. Allow swimming and throwing at 4 months and contact sports at 6 months.

Using many of the principals developed for the Suretac device, we recently increased our use of suture anchors along the anterior glenohumeral rim in patients with labral pathology and associated capsular laxity or stretch.

- With the patient in the beach-chair position, create posterior, anterosuperior, and anteroinferior portals as previously described. Once again, it is important to maintain adequate distance between the two anterior portals to avoid instrument crowding. A spinal needle is helpful in localizing the more inferior portal (Fig. 80.53*A*). The anteroinferior portal contains a large, 8.0 mm cannula to allow placement of the drill and suture hook during the procedure.

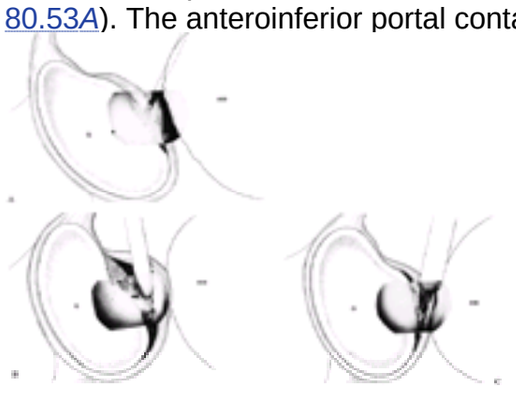

***Figure 80.53.*** Arthroscopic Bankart repair. **A:** Use a spinal needle to localize the appropriate portal location. **B:** Use arthroscopic electrocautery to mobilize the anterior band of the IGHL and prepare the anterior glenoid rim. **C:** Use an arthroscopic burr to create a bleeding surface to promote postoperative healing.

- Prepare the glenoid rim through the same anterior portals, making sure to effectively mobilize the anterior capsulolabral tissue (Fig. 80.53*B*). As previously described, create a trough with the burr to prevent the drill from slipping and possibly damaging the articular cartilage (Fig. 80.53*C*).
- This suture anchor system requires predrilling before anchor placement. Drilling is performed through the anteroinferior portal. The system contains a drill guide, which maintains appropriate orientation and drill hole location. Remove the drill and keep the guide in place. Tap the suture anchor loaded with braided suture into place (Fig. 80.54*A*). Apply tension to the suture ends to test the fixation.

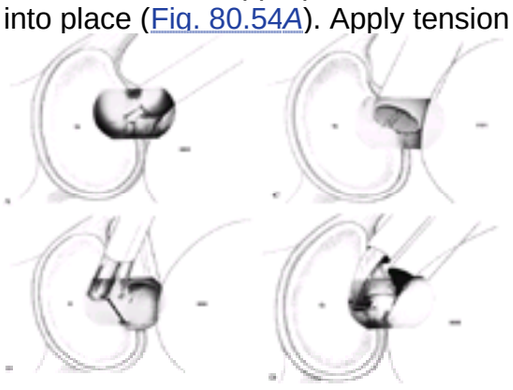

***Figure 80.54.*** Arthroscopic Bankart repair. **A:** Impact a suture anchor loaded with a nonabsorbable, braided suture into the anterior glenoid rim through the anteroinferior portal. **B:** Use a cannulated hook to pass the Shuttle Relay through the IGHL, and then pull it through the anterosuperior portal, using an arthroscopic grasper. **C:** Use the Shuttle Relay to pass the suture in the anterosuperior portal through the IGHL, which is then tied arthroscopically with half-hitch knots. **D:** Alternatively, use a suture-transport system to pass the suture through the soft tissue.

- Perform the remaining portion of the procedure, using a suture hook and Shuttle Relay system or a suture-transport system as previously mentioned. If the Shuttle Relay is to be used, pass one limb of the suture through the anterosuperior portal with a grasper. Pass a suture hook loaded with a Shuttle Relay through the anteroinferior capsule and IGHL. Take care to avoid tearing the tissue while grasping enough tissue to adequately reduce joint volume. If using the Shuttle Relay, advance it through the suture hook and pull it through the anterosuperior cannula with a grasper (Fig. 80.54*B*). Remove the suture hook while maintaining tension on the Shuttle Relay; then load the eyelet of the Shuttle Relay with the previously passed suture, and pull this suture in a retrograde fashion back through the tissue and the anteroinferior cannula.
- Leave the second limb of suture free, rather than passing it through the tissue. This technique pulls the tissue to the glenoid rim, and bunches it together to recreate the “chock block” effect of the labrum. Then tie the suture with an arthroscopic knot pusher (Fig. 80.54*C*). In the case illustrated, a half-hitch technique was used to secure the tissue, essentially tying the suture with alternating half-knots. There are other knot-tying techniques (i.e., Tennessee slider) that allow immediate locking of the stitch by pulling the post. These knots have the benefit of being lower profile.
- Alternatively, if using a suture-transport system, pass the device through the anteroinferior portal and tissue. Grasp one limb of the suture still in the anteroinferior portal, and pull the device and suture in retrograde fashion back through the tissue and cannula (Fig. 80.54*D*). Then use an arthroscopic knot pusher, and tie the nonabsorbable suture.

## HINTS AND TRICKS

As alluded to previously, there are several common technical errors to avoid with use of the Suretac device (176). Further, there are also problems that can arise with use of suture. These problems and the most appropriate methods of avoiding and solving them are presented in Table 80.9 and Table 80.10.

***Table 80.9.*** *Suretac Technical Errors*

| *Problem* | *Solution* |
|---|---|
| Bending of wire during drill placement and glenoid drilling | Allow only 2 to 3 mm of wire exposure, wire locked in place |
| Improper drill or wire placement: | |
| Above the equator of the glenoid (Fig. 80.55) | Appropriate portal localization with spinal needle |
| Slips medially and inferiorly | Preparation of deep bony trough along glenoid rim |
| Captures too little tissue +/- tissue of poor quality (Fig. 80.56) | Appropriate tissue mobilization and good patient selection (robust ligament) |
| Guidewire extraction during drill removal | Maintenance of wire placement:Unlock wire Tap in further before drill removal Remove drill with counterpressure |
| Head of Suretac buttonholes through tissue (Fig. 80.57) | Gentle impaction |
| Removal of Suretac causes bleeding | If occurs:Leave implant in place Debride head Place second, adjacent Suretac |
| Drill too deeply (exiting posterior cortex of scapula) | Drill depth of one external mark, which corresponds the length of the Suretac implant |
| Breakage or bending of Suretac during placement (Fig. 80.58*A*) | Adequate drilling (depth) before placement |
| Suretac may fall into axillary pouch (Fig. 80.58*B*) | Accessory posterior portal for retrieval (Fig. 80.58*E*) |
| Pull-out | Appropriate angle (45°) and depth<br>Test strength (i.e., pull on sutures) before use |
| Articular cartilage damage | Appropriate portal localization with spinal needle<br>Preparation of deep bony trough along glenoid rim<br>Angle away from the joint with drill<br>Avoid pull-out |
| Loose knot | Experience<br>Use nonabsorbable (i.e., not PDS) suture<br>Five or more throws per knot |
| Migration | Use metal device or marked device to help localize the implant |

***Table 80.10. Suture Anchor Technical Errors***

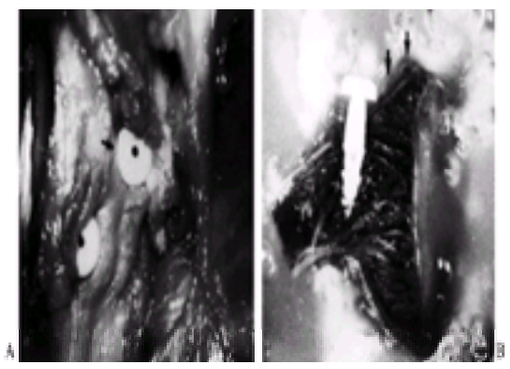

***Figure 80.55.*** Arthroscopic Bankart repair. **A:** The Suretac implant has been placed too far medially (*arrow*) in this cadaveric specimen. **B:** This coronal dissection demonstrates a medially placed implant. *Arrows* demonstrate the correct location for implant placement and a persistent capsulolabral separation that results from medial Suretac placement. (From Warner JJ, Miller MD, Marks P. Arthroscopic Bankart Repair with the Suretac Device. Part II. Experimental Observations. *Arthroscopic* 1995;11:14, with permission.)

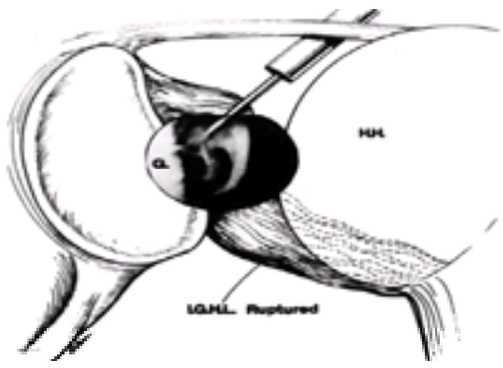


***Figure 80.56.*** Arthroscopic Bankart repair. **A:** Arthroscopic view demonstrates a rupture in the anterior band of the IGHL while the arm is in the neutral position. **B:** With the arm in abduction, the degree of damage is further demonstrated. Incompetent or damaged ligamentous tissues prohibit adequate arthroscopic shoulder stabilization. (From Warner JJP. Arthroscopic Bankart Repair. In: Bigliani LU, ed. *Shoulder Instability.* Rosemont, IL: American Academy of Orthopaedic Surgeons, 1996:47, with permission.)

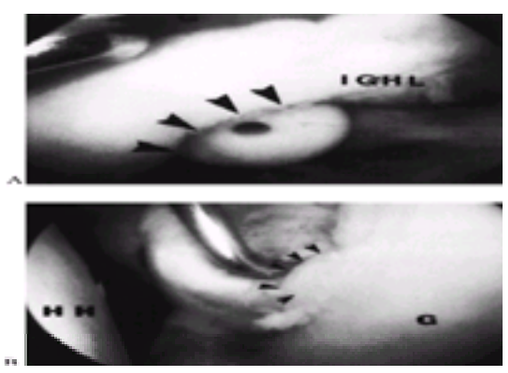


***Figure 80.57.*** Arthroscopic Bankart repair. **A:** Arthroscopic view through the anterosuperior portal demonstrates a Suretac implant that has buttonholed (*arrows*) through the anterior band of the *IGHL.* **B:** Viewing through the posterior portal demonstrates limited soft tissue under the head (*arrows*) of the device. (From Warner JJP, Altchek DW. Arthroscopic Repairs for Instability. In: Warner JJP, Iannotti JP, Gerber C, eds. *Complex and Revision Problems in Shoulder Surgery.* Philadelphia: Lippincott–Raven Publishers, 1997:39, with permission.)

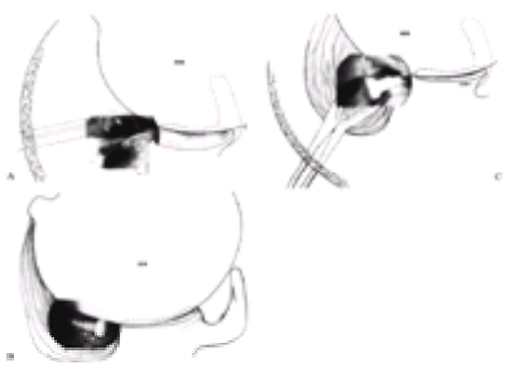

***Figure 80.58.*** Arthroscopic Bankart repair. **A:** Arthroscopic view through the anterosuperior portal demonstrates a bent guidewire and associated implant breakage during attempted repair of a posterior Bankart lesion. **B:** The Suretac has fallen into the axillary pouch. **C:** The implant is retrieved from the axillary pouch with the use of an accessory posterior portal (*HH*, humeral head). (From Warner JJP, Altchek DW. Arthroscopic Repairs for Instability. In: Warner JJP, Iannotti JP, Gerber C, eds. *Complex and Revision Problems in Shoulder Surgery.* Philadelphia: Lippincott–Raven Publishers, 1997:40, with permission.)

Maintain patients in a sling and swathe for 4 weeks. Allow bathing and elbow–wrist range of motion at 1 week, but external rotation past neutral should be avoided. Allow passive and active-assisted range-of-motion exercises and pulley exercises at 4 weeks. Initiate elastic band rotator cuff strengthening exercises at 2 months and weight training at 4 months. Allow noncontact sports at 4 months and contact sports at 6–9 months, depending on the level of contact.

**ARTHROSCOPIC CAPSULAR SHIFT**

Since Neer and Foster's (107) original description of MDI, many open techniques have been developed to stabilize patients with the condition (3,10,78,171). While results with these methods have been good, they have not been on par with the results after treatment of traumatic unidirectional anterior instability; return to overhead athletic activities has been less certain. Moreover, there is a perception that perioperative morbidity might be improved with a “less invasive” arthroscopic technique. For this reason, several surgeons have attempted to develop arthroscopic methods of capsulorrhaphy to treat patients with MDI. While some surgeons have reported

on their initial experience with these methods (Eugene Wolf and Steven Snyder, personal communications), little has been reported in the peer-reviewed literature.

Duncan and Savoie (41) described an arthroscopic inferior capsular shift in 1993. The technique involved dividing the anterior and inferior capsule with an end-cutting shaver. This division allowed the inferior capsule to be advanced superiorly. Sutures were tied with a transglenoid suture technique. This initial report was a preliminary study of 10 patients who were all found to have a “satisfactory” shoulder according to the Neer and Foster criteria. An average Rowe score of 90 was reported, as well. Modifications of this transglenoid suture capsulorrhaphy have been developed to address posterior instability (100).

Wichman and Snyder (180) described a technique of capsular plication in a select population with MDI and no associated labral pathology. All patients underwent a prolonged course of rehabilitation before surgical intervention, which allowed serial examinations. Over the weeks, the physicians' knowledge of the patient and the underlying disorder increased. Thus, patients with voluntary instability of a psychological nature could be identified.

- This technique is performed in the lateral decubitus position, using the standard posterior and anterosuperior portals as described previously. In addition, an anterior mid-glenoid portal is used corresponding to an area approximately 3 cm distal and 2 cm lateral to the anterosuperior portal. This portal is made through an outside-in technique and enters the joint just over the subscapularis tendon in a manner similar to the anteroinferior portal previously described.
- Place a large (8.4 mm) cannula into this portal to provide access for large suture hooks. For anterior plication, place the arthroscope posteriorly, and abrade the synovium along the anterior and inferior capsule with a rasp or 4.5 mm arthroscopic shaver (Fig. 80.59*A*). This abrasion creates bleeding, which will subsequently promote healing.

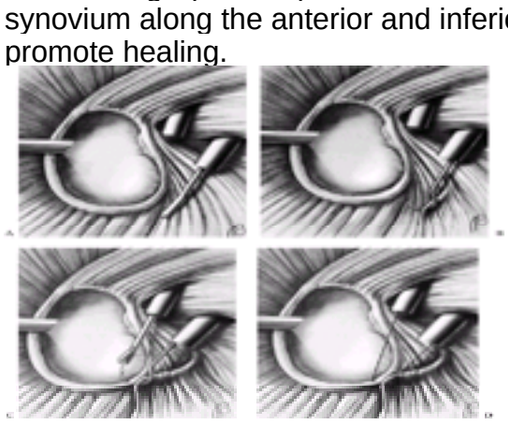

***Figure 80.59.*** Arthroscopic capsular shift. **A:** Use an arthroscopic rasp to prepare the anterior capsule through the anteroinferior portal. **B:** Pass a suture hook through the inferior capsule. **C:** The hook allows passage of the Shuttle Relay through the inferior capsule and labrum, and the relay is then passed through the anterosuperior portal using an arthroscopic grasper. **D:** Use the Shuttle Relay to pass the suture in a retrograde fashion through the tissue. (From Wichman MT, Snyder SJ. Arthroscopic Capsular Plication for Multidirectional Instability of the Shoulder. *Oper Tech Sports Med* 1997;5:238, with permission.)

- Pass a 90° suture hook with a loaded Shuttle Relay through the anteroinferior cannula and create a pinch stitch by taking anteroinferior capsule and advancing it superiorly and medially to the anteroinferior labrum (Fig. 80.59*B*). A 1-cm-thick fold is produced between the capsule and labrum.
- Deliver the Shuttle Relay through the end of the hook, and pull it through the anterosuperior portal with a grasper (Fig. 80.59*C*). Lead the eyelet of the Shuttle Relay with a braided, nonabsorbable suture, and pull it in a retrograde fashion through the labrum and capsule and out the anteroinferior portal (Fig. 80.59*D*). Repeat this process slightly more superiorly to create a horizontal mattress stitch (Fig. 80.60*A*).

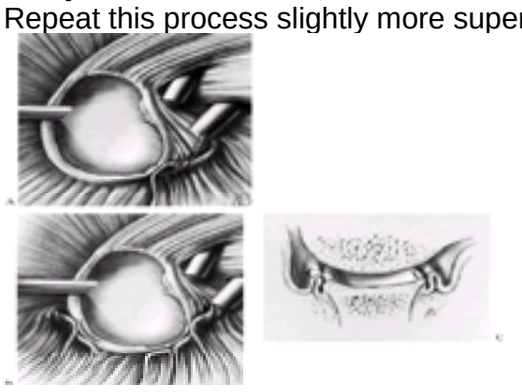

***Figure 80.60.*** Arthroscopic capsular shift. **A:** Repeat the process for the second limb of the suture to create an effective horizontal stitch. **B:** The process can be repeated anteriorly, inferiorly, and posteriorly for the patient with MDI. **C:** The goal is to decrease the capsular volume and recreate the “chock block” effect of the labrum. (From Wichman MT, Snyder SJ. Arthroscopic Capsular Plication for Multidirectional Instability of the Shoulder. *Oper Tech Sports Med* 1997;5:238, with permission.)

- Use an arthroscopic knot pusher to close the fold, with the knot away from the articular surface. Other sutures can be placed in this fashion in other regions of the joint, where necessary (Fig. 80.60*B*, Fig. 80.60*C*).
- If posterior plication is anticipated, it is recommended that the posterior portal be created slightly more superiorly. Of course, hook and suture placement would be performed with the arthroscope through the anterosuperior portal in this case.

With this technique, external rotation was preserved to within 10° of the preoperative level in 92% of patients at a minimum 2-year follow-up. An assessment of postoperative function using the American Shoulder and Elbow Society instrument revealed an improvement from a preoperative score of 63 to a postoperative score of 86.2 The average Rowe score postoperatively was 79.6. Five patients's conditions were rated unsatisfactory, with 19 patients having satisfactory ratings, according to Neer's criteria. The authors noted a disproportionately high number of workers' compensation cases in the unsatisfactory group. Interestingly, three patients underwent second-look arthroscopy (two for unrelated procedures) that revealed significant capsule formation at the site of previous plication and no adverse synovial reaction to the suture.

**LASER OR THERMAL CAPSULAR SHRINKAGE**

The use of heat to treat shoulder instability dates back to 460 BC when Hippocrates inserted a hot iron into the axilla, contracting the inferior aspect of the joint. This same concept has gained recent popularity, but laser and radiofrequency energy sources are used to produce the heat. The triple-helix structure of collagen unwinds at 65°C, undergoing a conformational change from a crystalline, extended state to a randomly coiled, contracted state (denatured) and producing shrinkage in capsular tissues (106). Current literature has focused on laser technology as a source of the thermal energy. Hayashi et al. (66) demonstrated a dose-dependent effect of nonablative laser energy on capsular tissue properties.

The Holmium:yttrium-aluminum-garnet (Ho:YAG) laser has received considerable attention (1,141). Laser energy at low power—less than 10 watts (1.0 joule per pulse at 10 hertz)—is recommended for laser-assisted capsular shrinkage. There are several disadvantages to the use of laser energy. First, lasers are very expensive and require a certain level of expertise and appropriate certification for use. Further, lasers produce significant power that can be difficult to control.

Radiofrequency thermal stimulation has been used as an alternative energy source that avoids some of the problems inherent in laser energy. Such devices are less expensive and are relatively easier to use. The ElectroThermal Arthroscopy system (ORATEC Interventions, Inc., Menlo Park, CA) integrates a thermocouple into the arthroscopic handpiece, creating a monopolar system. The current applied to the tissue at the dull probe tip is minimally invasive while still accomplishing collagen denaturation (S.P. Arnoczky, personal communication). This system contrasts with the vapor system from Mitek Surgical Products, Inc. (Westwood, MA), which represents a bipolar system without a thermocouple. Both products are radiofrequency systems.

These instruments have been applied over the past several years as an experimental treatment method. Their obvious appeal is that they can be used effectively in an outpatient setting. The procedure does not require a great deal of time or the use of sutures or implants. Unfortunately, while anecdotal reports concerning these procedures are appearing, there is currently no peer-reviewed literature available regarding the effectiveness of this technique. Nevertheless, thermal capsular shrinkage remains a possible alternative treatment. Its efficacy will need to be substantiated over the next 5–10 years with well controlled follow-up studies to assess whether there is a gradual restretching of the tissues with increased use.

## OPEN SURGICAL TECHNIQUES

The indications for open versus arthroscopic shoulder stabilization remain a controversial topic (164). As outlined in Table 80.4, the criteria for arthroscopic shoulder stabilization are becoming more clearly defined. As surgeons continue to improve their ability to arthroscopically shift the glenohumeral ligaments and repair labral lesions and as new technologies are developed, the number of patients who are candidates for open surgical procedures will decrease. Certainly, the presence of a large Hill–Sachs lesion or a bony Bankart lesion on radiographic examination is an indication for an open surgical approach. Likewise, patients without a significant Bankart lesion by MRI or CT may not be optimal candidates for an arthroscopic Bankart procedure. Similarly, findings consistent with significant capsular laxity or stretch, such as an atraumatic history or MDI findings on physical examination, should direct the surgeon toward open treatment options. Significant capsular damage, rotator interval lesions, or rotator cuff tears are also currently better repaired with open surgical techniques.

### *Open Anterior Shoulder Stabilization Procedures*

Many open procedures have been developed and popularized to treat anterior glenohumeral instability. TheMagnuson-Stack and Putti-Platt procedures attempted to realign and tighten the subscapularis tendon (158,179). The anterior capsule was also tightened by the latter technique. The du Toit staple capsulorrhaphy attempted to reattach the capsule and glenoid (15,143). The Bristow and other bone block procedures attempted to replace the injured anterior labrum and glenoid (10).

These procedures and their modifications achieved reasonable success rates in decreasing recurrent instability. Long-term follow-up studies continued to reveal low recurrence rates, but techniques that used metal staples or screws revealed high rates of hardware-related problems. Zuckerman and Matsen (188) retrospectively reviewed 37 patients who had previously been treated with a modified Bristow procedure, a staple capsulorrhaphy, or a modified Magnuson-Stack procedure. The hardware migrated or loosened in 24 shoulders and broke in three patients. Thirty-four patients required a second operation to remove the hardware. At reoperation, 41% demonstrated significant injury to the articular surface. Other studies have reported similar rates of hardware-related complications (59,185). Further, because of failure to correct the underlying anatomic problem, many patients had significant loss of external rotation or frank internal rotation contractures and subsequent glenohumeral arthritis (61).

In an attempt to avoid the use of hardware and correct the presumed anatomic abnormality, Rowe and colleagues popularized the Bankart procedure for anterior unidirectional instability (130,131,133,134).

- This technique uses a standard deltopectoral approach. Classically, the subscapularis tendon is incised vertically at its lateral insertion and sharply dissected medially from the anterior capsule (Fig. 80.61*A*). Several alternatives for subscapularis dissection have been developed that purportedly gave equal exposure of the anterior capsule (Fig. 80.61*B*, Fig. 80.61*C*) (77,96).




***Figure 80.61.*** Bankart procedure for anterior unidirectional instability. **A:** Perform a standard lateral subscapularis dissection 1 cm from its insertion onto the lesser tuberosity. **B:** An L-shaped dissection avoids the anterior circumflex humeral vessels but prevents complete access to the inferior capsule. **C:** Alternatively, the subscapularis muscle can be horizontally split, which avoids the need for later repair of the tendon. (From Zarins B. Bankart Repair for Anterior Shoulder Instability. *Tech Orthop* 1989;3:23, with permission.)

- Make a vertical capsulotomy approximately 0.5 cm lateral to the glenoid rim with the arm in complete external rotation (Fig. 80.62).

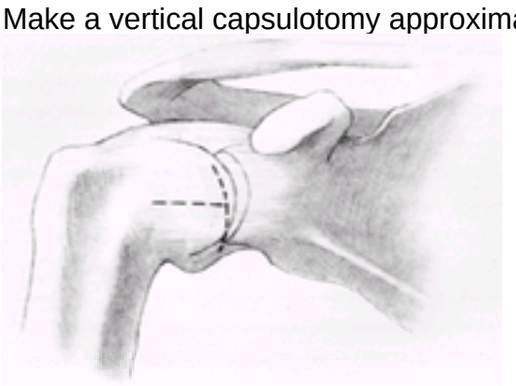

***Figure 80.62.*** Bankart procedure for anterior unidirectional instability. A medially based capsulotomy can be converted to a T-shaped capsulotomy that allows improved mobilization of the inferior axillary pouch in patients with increased anteroinferior instability. (From Zarins B. Bankart Repair for Anterior Shoulder Instability. *Tech Orthop* 1989;3:23, with permission.)

- With complete muscle relaxation, insert a humeral head retractor and inspect the glenoid for evidence of a Bankart lesion. If a Bankart lesion is present, repair the lateral capsular flap to the glenoid neck.
- Prepare this area with a curet to expose bleeding bone, and drill three holes; one at the 2-o' clock, one at the 4-o' clock, and one at the 6-o' clock positions for right shoulders (10-, 8-, and 6-o' clock positions for left shoulders) as demonstrated in Figure 80.63.

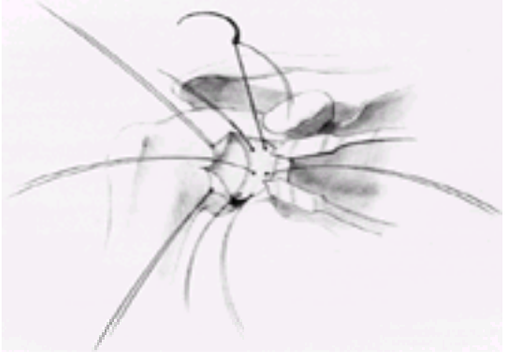

***Figure 80.63.*** Bankart procedure for anterior unidirectional instability. Make drill holes along the glenoid rim at the 1-, 3-, and 5-o'clock positions for right shoulders. (From Zarins B. Bankart Repair for Anterior Shoulder Instability. *Tech Orthop* 1989;3:23, with permission.)

- Pass sutures through the holes and the lateral capsular flap with a Mayo needle (Fig. 80.64*A*). Tie the flap down to the glenoid rim, and pass these same sutures through the small medial capsular flap, reinforcing the repair (Fig. 80.65).

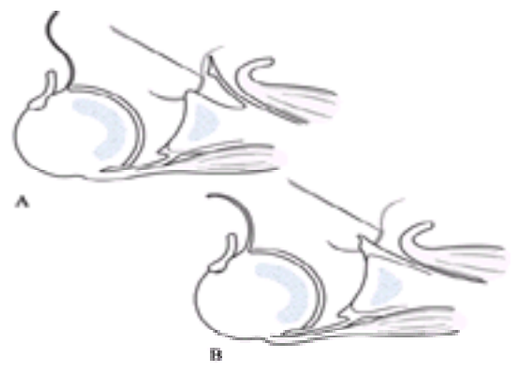


***Figure 80.64.*** Bankart procedure for anterior unidirectional instability. **A:** Pass the suture through drill holes in the glenoid rim. **B:** Alternatively, if there is no significant Bankart lesion, the suture can be placed directly through the anterior labrum. (From Zarins B. Bankart Repair for Anterior Shoulder Instability. *Tech Orthop* 1989;3:23, with permission.)

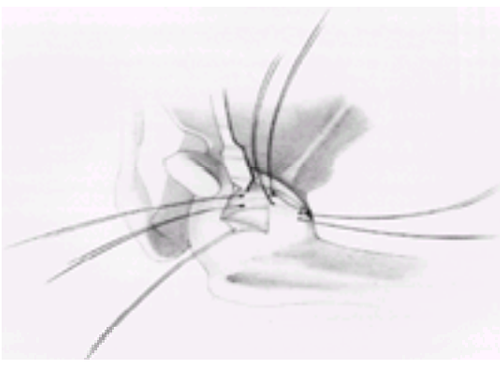

***Figure 80.65.*** Bankart procedure for anterior unidirectional instability. Pull the inferior capsular flap superiorly to the glenoid rim first. Arm position is critical during this portion of the procedure and determines final postoperative motion. Increasing abduction and external rotation will improve final postoperative motion. (From Zarins B. Bankart Repair for Anterior Shoulder Instability. *Tech Orthop* 1989;3:23, with permission.)

- If no Bankart lesion is found on inspection, merely place sutures through the labrum rather than drill holes (Fig. 80.64*B*).
- With the production of multiple suture anchors, many surgeons have modified the procedure, using these implants along the glenoid rim (87). Despite reports of good success with these devices, there remains a risk of technical failure and resultant instability or articular cartilage damage.

Rowe et al. (131,134) reported good-to-excellent results in 96.5% of patients, with a 3.5% recurrence rate, using this procedure. A loss of terminal external rotation, however, was noted in many patients. Further, only 33% of throwing athletes with involvement of the dominant arm were able to return to their original level of competition. Rosenberg et al. (128) demonstrated a statistical relationship between late degenerative changes and restriction of external rotation in 90° of arm abduction. These reports led others to modify the operative techniques to address these problems. In addition, the increased association between repeated subluxations or dislocations and subsequent capsuloligamentous injury has shifted attention toward correction of the associated capsular laxity.

The T-plasty modification of the Bankart procedure was developed to treat underlying anteroinferior capsular laxity with an associated Bankart lesion (3).

- Expose the anterior capsule as previously described. In addition to the vertical capsulotomy at the glenoid margin, create a transverse limb at the mid portion of the capsule (Fig. 80.62).
- If a Bankart lesion is visualized, prepare the glenoid neck as previously described. If there is no lesion, pass sutures through the labrum rather than through drill holes.
- Position the arm in 40° of external rotation and 45° of abduction. Then pull the inferior flap superiorly and medially to the upper rim to allow 40° external rotation (Fig. 80.66), reduce the inferior redundancy, and simultaneously correct for a Bankart lesion, if present. Pull the superior flap inferiorly and medially to reinforce the inferior flap (Fig. 80.67).

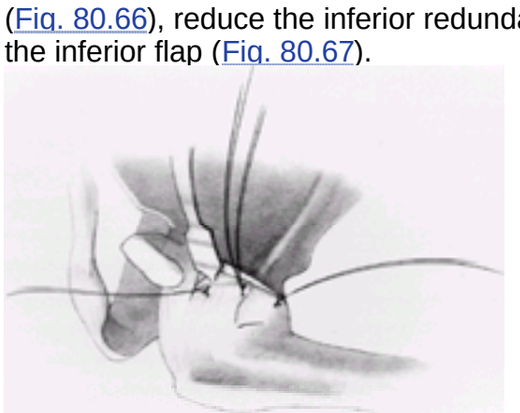

***Figure 80.66.*** T-plasty modification of the Bankart procedure. Pull the superior capsular flap inferiorly with the arm in slight abduction and external rotation. (From Zarins B. Bankart Repair for Anterior Shoulder Instability. *Tech Orthop* 1989;3:23, with permission.)

***Figure 80.67.*** T-plasty modification of the Bankart procedure. Pull the medial flap over the lateral flap to supplement the repair. (From Zarins B. Bankart Repair for Anterior Shoulder Instability. *Tech Orthop* 1989;3:23, with permission.)

Altchek et al. (3) reported on their experience with this procedure involving 42 shoulders in 40 athletes. Postoperatively, 20 shoulders had external rotation in adduction that was symmetric to the opposite side. The remaining22 shoulders, however, demonstrated a loss of 5° to 25° external rotation (average, 10°). Despite 95% excellent results with this procedure, throwing athletes in this study continued to report a decrease in maximum ball speed on throwing.

Jobe et al. (78) performed a similar operation but used a horizontal split in the subscapularis muscle to expose the anterior capsule. This method avoids the risk of postoperative subscapularis tendon disruption (59). Intraoperatively, they made sure no tension was present along the suture line until 90° of abduction and 45° of

external rotation was reached. Patients were then splinted in 90° of abduction, 45° of external rotation, and 30° of forward flexion. With this technique, they reported excellent results in 68% of a group of overhand athletes. Despite these efforts, six patients had a loss of 10° to 20° external rotation. An assessment of the 12 skilled pitchers in this study revealed that 50% returned to their former level of competition for at least one season.

As becomes apparent from these studies, it is difficult to obtain full terminal rotation postoperatively with this repair technique; further, full external rotation is necessary for high-level pitchers to obtain peak throwing velocity. In Neer and Foster's (107) classic article on MDI, the inferior capsular shift was introduced. Like the modified Bankart procedures described above, this technique involved a T-shaped capsulotomy, but the vertical cut was made laterally along the humeral neck and a horizontal cut was made between the middle glenohumeral ligament (MGHL) and the IGHL. If a rotator interval defect was noted, it was repaired and then the same horizontal cut created.

This operation was designed for patients with involuntary inferior and multidirectional instability. If a patient had an associated Bankart lesion, however, it was repaired with the use of an inside-out suture technique at the glenoid rim. A shallow trough was made laterally along the humeral neck. Neer and Foster recommended holding the arm in 10° external rotation while suturing the inferior flap to the stump of the subscapularis tendon and to the remaining cuff of capsule along the humeral neck. The superior flap containing the MGHL was then sutured over the inferior flap to reinforce the repair. The tension on the inferior flap was selected to reduce the inferior and posterior capsular laxity. The lateral capsulotomy, as opposed to the medial approach, has a greater ability to reduce capsular volume because the capsular circumference is largest laterally.

Bigliani et al. (10) reported on a series of inferior capsular shift procedures performed in 68 shoulders in 63 athletic individuals. On the basis of Neer and Foster's experience and the concept that anterior instability in the athlete represents a spectrum of pathology, they performed an inferior capsular shift in all cases. The inferior capsule was mobilized and shifted on the basis of the degree of inferior laxity demonstrated by EUA in each individual. Initially, the shoulders were repaired with the arm in 20° of abduction and 10° of external rotation. However, as it was noticed that only 50% of the overhead athletes involved in throwing had excellent results, abduction and external rotation were increased by 10° at the time of repair. Despite modifications in technique and postoperative mobilization, only 5 of 10 overhead athletes returned to their same level of competitiveness. Only two of six varsity or professional overhead athletes were able to return to the same level of sporting activity.

**Authors' Preferred Method** We prefer a selective capsular shift. This technique is based on the clinical observation that a spectrum of labral and capsuloligamentous pathology exists, as well as on experimental observations concerning the role of the glenohumeral ligaments (171).

As alluded to previously, patients with traumatic instability may have a Bankart lesion, while others may have capsular injury without labral pathology. It is generally believed that some capsuloligamentous damage is created with each episode of instability. As a result, it becomes difficult to categorize patients purely on the basis of history or physical examination. An operative repair should be able to address all intraarticular pathology adequately.

In addition, cadaver studies demonstrate that the superior glenohumeral ligament and the MGHL function as a static barrier to anteroinferior humeral head translation with the arm in adduction and external rotation (37,160). Similar studies demonstrate that the IGHL serves as a static restraint to translation with progressive increases in abduction and external rotation (113,114 and 115). As a result, in the technique that follows, each capsular flap is sutured with the arm in the position that maintains greatest tension on ligamentous structures being repaired, contributing, it is hoped, to overall postoperative motion.

Examination under anesthesia is performed as described previously, and the degree of capsular laxity is used to determine the amount the inferior capsule that should be mobilized.

- Place the patient in a semisitting position resting on a long bean bag. Contour the bag along the medial scapular border, allowing the injured shoulder and arm to hang over the edge of the table. First, mold and solidify the bag, and then pull the entire construct over the edge of the table. A McConnell Shoulder Holder (McConnell, Inc., Greenville, TX) allows proper positioning of the arm. Use a standard deltopectoral approach, with the incision maintained low in the axillary fold for better cosmesis. Place a self-retaining retractor into the interval. Make a small transverse incision, if needed, in the conjoined tendon just distal to the coracoid tip to increase medial exposure. Maintain manual retraction along the conjoined tendon to avoid a neuropraxic injury to the musculocutaneous nerve. Resect the coracoacromial ligament to better expose the superior capsule and evaluate the rotator interval.
- Isolate the anterior circumflex humeral vessels, and suture-ligate them at the inferior aspect of the subscapularis muscle. Use needle-tip electrocautery to dissect the subscapularis muscle from lateral to medial off the anterior capsule in the coronal plane. Palpate the axillary nerve; then visualize and isolate it with a vessel loop to avoid injuring it during surgery.
- If no significant rotator interval lesion is noted, create a T-shaped capsulotomy with the horizontal cut between the MGHL and the IGHL, ending at the equator of the glenoid. Make the vertical component of the capsulotomy just medial to the lateral insertion of the capsule into the humeral neck. At this point, consider the degree of capsular laxity demonstrated during the EUA. The position of the vertical capsulotomy may range from 6 o' clock to 8 o' clock along the humeral neck, depending on the degree of inferior laxity. If there is significant inferior laxity, choose the latter position. Carry the vertical component up to the supraspinatus tendon superiorly. With maximal muscle relaxation, place a humeral head retractor into the joint, and visualize the anterior labral region.

If a Bankart lesion exists, further mobilize it from the scapular neck, and place a three-prong retractor medially along the scapular neck for exposure. Then decorticate the glenoid surface, using a small osteotome. Place suture anchors (Acufex Microsurgical, Inc., Mansfield, MA) loaded with a #1 nonabsorbable suture into the 2-, 4-, and 6-o' clock positions for right shoulders or corresponding positions for left shoulders. Then place sutures through the capsule from the inside-out, and tie them over the capsule in a horizontal mattress fashion to repair the Bankart lesion (Fig. 80.68). Take care to repair the capsule without any shortening in a medial direction. No shifting of the capsule is performed at this point, as an anatomic repair of the Bankart lesion is the goal.

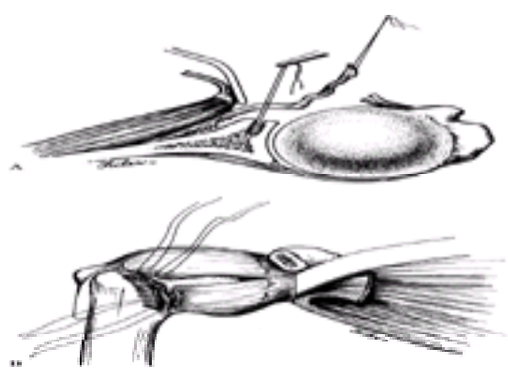

***Figure 80.68.*** Open selective capsular shift. **A:** After a lateral capsulotomy, mobilize the capsule laterally from its scarred position along the glenoid rim. Place a suture anchor along the rim, and pull each limb of the suture through the capsule. **B:** Typically, three suture anchors are placed and tied in horizontal fashion. An additional horizontal capsulotomy creates superior and inferior flaps. (From Warner JJP, Johnson D, Miller MD, Caborn DN. Technique for Selecting Capsular Tightness in Repair of Anteroinferior Shoulder Instability. *J Shoulder Elbow Surg* 1995;352, with permission.)

- Remove the humeral head retractor, and place the shoulder into 60° to 80° of abduction, 45° to 60° of external rotation, and 10° of forward flexion. Pull the inferior capsular flap superiorly and laterally, and suture it to the cuff of capsular tissue at the humeral neck (Fig. 80.69*A*). Adjust abduction and external rotation on the basis of the individual's needs. Thus, if the operation involves the dominant arm of a throwing athlete, position the arm in 80° of abduction and 60° of external rotation. Use lower degrees if treatment involves a nondominant arm or an athlete involved in a sport with limited overhead activity.

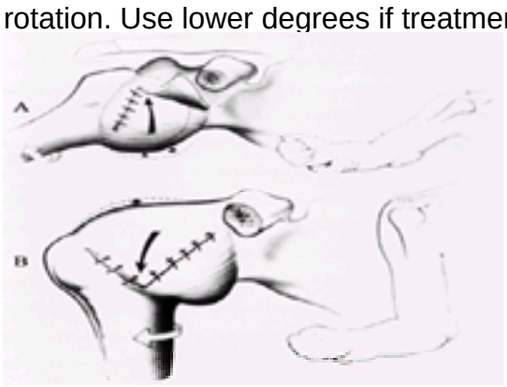

***Figure 80.69.*** Open selective capsular shift. **A:** Tie the inferior flap to the superolateral capsular tissue with the arm in 40° of abduction and between 45° and 80° of external rotation. The amount of rotation depends on the postoperative expectations of the patient. **B:** Tie the superior flap to the inferolateral tissue with the arm in neutral to 10° of abduction and 45° to 60° of external rotation. (From Warner JJP, Johnson D, Miller MD, Caborn DN. Technique for Selecting Capsular Tightness in Repair of Anteroinferior Shoulder Instability. *J Shoulder Elbow Surg* 1995;352, with permission.)

Following the repair of the inferior flap, reposition the arm in 0° of adduction and 45° of external rotation. The superior capsular flap is then sutured inferiorly and laterally over the other flap (Fig. 80.69*B*). Place sutures, which were previously placed through the inferior flap, through the superior flap to create a pants-over-vest closure.

Incorporate significant rotator interval defects, which are associated with increased inferior laxity in adduction, into the capsulotomy. This method is in contrast to repairing the defect as Neer and Foster recommend. The rotator interval becomes part of the horizontal cut to create an upside-down L-shaped capsulotomy (Fig. 80.70*A*, Fig. 80.70*B*). Suture the inferior capsular flap as previously described, but apply tension to the remaining superior capsule by repairing the horizontal portion of the inferior flap over the superior flap with the arm in 0° of adduction and 45° of external rotation (Fig. 80.70*C*, Fig. 80.70*D*).

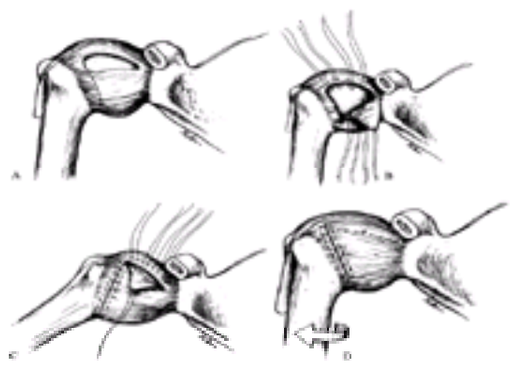

***Figure 80.70.*** Open selective capsular shift. **A:** A rotator interval lesion is demonstrated in associated with increased inferior laxity in neutral abduction that does not stabilize with increasing external rotation. **B:** Incorporate this capsular defect, if present, into the capsulotomy, creating an inverted L-shaped capsulotomy. **C:** Mobilize the tissue superiorly, and tie it to the lateral capsular tissue with the arm in abduction and external rotation. **D:** Subsequently, repair the rotator interval lesion with the arm in neutral abduction and external rotation. (From Warner JJP, Johnson D, Miller MD, Caborn DN. Technique for Selecting Capsular Tightness in Repair of Anteroinferior Shoulder Instability. *J Shoulder Elbow Surg* 1995;352, with permission.)

On completion of the repair, 90° of abduction should be possible in the scapular plane. Further, in this position, 60° of external rotation should be possible before tension is noted along the suture lines. With the arm in 0° of adduction, external rotation to 45° should be possible with minimal tension along the repair. Typically, an intraoperative drawer test is performed, and with the arm in 45° of abduction and neutral rotation, anterior and posterior drawer tests should not be greater than 1+ . The shoulder should further stabilize with increased abduction and external rotation, with the drawer tests decreasing to zero. The inferior drawer test should be 0–1+ with the arm at the side. If so, the subscapularis tendon is repaired anatomically.

Postoperatively, immobilize the arm in a sling and swathe for 3–4 weeks, allowing the patient to perform limited abduction for axillary care and dressing. During this period, allow the patient to flex and extend the elbow. Then remove the sling and institute unlimited active-assisted range-of-motion exercises, as well as isometric strengthening for external rotation, flexion, extension, and abduction of the arm. Caution the patient to avoid internal rotation for 6 weeks to prevent stress on the subscapularis repair.

At 6 weeks, allow isotonic strengthening exercises using elastic bands, and at 4 months allow the patient to swim, throw a ball, or hit gentle ground strokes in tennis. At 6 months, release the patient to more forceful throwing or swinging. Do not allow the patient to return to contact sports until 8 months after the operative procedure.

***Open Posterior Shoulder Stabilization Procedures***

The incidence of true posterior dislocations is rare. Yet there is increasing evidence that a higher prevalence of posterior subluxation exists, especially in overhead athletes, than previously recognized (50,123,156). Operative procedures that have treated posterior instability have been less successful than anterior procedures at preventing recurrent instability.

**Nonoperative Treatment** Because of the lower success rates with posterior procedures, it is important in primary and revision cases to attempt an adequate course of nonoperative management. Focus rehabilitation on strengthening the dynamic muscle stabilizers to correct for the deficient posterior static stabilizers. Specifically, exercises should focus on strengthening the rotator cuff and deltoid and scapular muscles. Further, the patient and the therapist should be educated to avoid forward flexion, adduction, and internal rotation, as these positions place increased stress on the posterior structures. If this process fails to alleviate symptoms or episodes of instability, it is important to focus on patient goals, as the outcome of surgical treatment may be unsatisfactory to the patient.

**Operative Techniques** Initial attempts at posterior stabilization procedures used either the Nicola procedure or the posterior Bankart procedure (40,95,101,102,137). These initial reports involved limited numbers of patients with mixed results. Boyd and Sisk (16) used a posterior capsulorrhaphy and posterior transfer of the long head of the biceps brachii in nine shoulders and reported no recurrences. Mowery et al. (105) reported on the use of a posterior bone block in five patients with recurrent posterior dislocations. Four of the five cases were rated as excellent at a minimum 2.5-year follow-up. However, closer evaluation revealed that one patient underwent screw removal, and one of the bone grafts was deemed osteoporotic at 3 years. Further, in the fifth case that was rated as good, the patient required a manipulation under anesthesia for limited motion and subsequently suffered from anterior instability.

These initial posterior procedures were performed on individuals with a history of dislocation. As noted by Hawkins et al. (63), the uncommon nature of posterior instability and confusion in the literature in differentiating subluxations from dislocations led to a poor understanding of this entity. In the same article, they retrospectively reviewed 50 shoulders in 35 patients treated for recurrent posterior instability. Only 11 patients had had a primary traumatic event before the onset of instability. Forty-one of the affected shoulders demonstrated voluntary, positional instability that affected activities of daily living. Thirteen of 26 shoulders that underwent surgical reconstruction (17 posterior glenoid osteotomies, six reverse Putti-Platt procedures, and three biceps tendon transfers) developed recurrent instability. The authors also noted that the posterior glenoid osteotomy was associated with osteoarthritis.

In 1989, Fronek et al. (48) presented a series of 24 patients with posterior subluxation who were divided into two groups. Members of the first group, who had less severe symptoms, were treated with physical therapy and had a 63% success rate. Group II consisted of individuals who either failed physical therapy or had more severe symptoms. They were treated with a posterior capsulorrhaphy with or without a posterior bone block. In this group, 91% suffered no additional episodes of instability. However, 70% of the athletes in both groups participated in sports at a diminished level.

Tibone and Ting (155) reported on their experience using a posterior staple capsulorrhaphy technique. Twenty athletes were treated for recurrent posterior subluxation, with eight of them also suffering from concomitant anterior instability. In this series, six patients suffered from recurrent posterior instability, while an additional three patients had moderate to severe pain. Significant complications that were a direct result of the procedure developed in five patients. They concluded that this technique was not an acceptable treatment option for posterior instability.

In 1993, Tibone and Bradley (156) reported on their experience using a posterior suture capsulorrhaphy technique that avoided the complications associated with staples or bone blocks.

- This technique, which was very similar to that described by Fronek et al. (48), used a posterior saber incision starting at the acromion and terminating in the posterior axillary fold. Split the deltoid muscle in line with its fibers approximately 2–3 cm medial to the posterolateral corner of the acromion for 5–6 cm, with care to avoid injury to the axillary nerve, which enters the muscle distal to the teres minor muscle.

- Develop the interval between the infraspinatus and teres minor muscles, and expose the underlying capsule. Make a T-shaped capsulotomy with the horizontal component at the glenoid rim.
- Transfer the inferior flap superiorly and medially. Secure it to the glenoid rim with #1 nonabsorbable suture placed through the labrum, if it is intact.
- If there is significant labral pathology, expose the glenoid rim, and prepare it as previously described for anterior repairs. Suture the capsular flap through bone holes, or secure it with suture anchors. Once again, the superior flap is sutured over the inferior flap to reinforce the repair. Position the arm in neutral rotation during the repair.

In these operations, there was no need to augment the repair with infraspinatus advancement or bone blocks. Researchers reported a 40% failure rate in 40 athletes who were followed adequately, attributing the failures to ligamentous laxity or unrecognized MDI. Importantly, they also noted worsening results as the athletes' competitive level increased and concluded that high-level athletes should be informed preoperatively of a possible poor outcome.

In 1994, Tibone and coworkers described a modification of this technique (139). A cadaveric and clinical investigation was undertaken to study an infraspinatus muscle-splitting approach to the posterior capsule. Dissection of 20 cadavers revealed that the suprascapular nerve entered the infraspinous fossa at the spinoglenoid notch as a single trunk, 22 mm medial to the glenoid rim. The infraspinatus muscle was bipennate in all specimens, with the tendinous interval an average of 14 mm inferior to the scapular spine. Limiting dissection in this interval to 1.5 cm medial to the posterior glenoid rim prevented damage to any suprascapular nerve branches. The researchers performed this approach in four patients and reported excellent exposure of the posterior capsule, labrum, and glenoid, thus avoiding tendon detachment. Electrodiagnostic testing revealed no significant denervation in these patients.

Neer and Foster (107) introduced a posterior capsular shift procedure in their classic article on the treatment of MDI. This technique has many features that are similar to their previously described anterior capsular shift.

- Make a 10 cm incision either horizontally at the level of the scapular spine or vertically just medial to the posterolateral corner of the acromion. The latter incision creates a more cosmetic postoperative scar.
- Detach the deltoid from the posterolateral aspect of the acromion and from the lateral 9.0 cm of the scapular spine.
- Split the deltoid muscle for approximately 3.0 cm inferiorly, exposing the infraspinatus muscle and tendon. This muscle–tendon unit is split obliquely, creating a superficial tendinous flap later used to reinforce the capsule. Mobilize the remaining infraspinatus muscle medially to expose the underlying capsule.
- Make a T-shaped capsulotomy with the horizontal component created laterally along the humeral neck. The authors noted that the arm should be progressively internally rotated during mobilization of the inferior capsular flap to protect the axillary nerve.
- Then place a humeral head retractor into the joint and visualize the labrum; if there is labral pathology extending beyond the inferior glenoid rim into the anterior aspect of the joint, a separate anterior incision is recommended to address the Bankart lesion. Posterior labral pathology is incorporated into the capsular shift as previously described for the anterior procedure. Once again, this is performed before advancement of the flaps.
- Position the arm in slight extension and external rotation during capsular reattachment. Then pull the superior flap inferiorly and laterally, and suture it to a shallow bony trough created at the humeral neck. Next, pull the inferior flap superiorly and laterally, and repair it over the superior flap. The superficial portion of the infraspinatus tendon is used to augment the posterior capsular repair. The deep portion of the infraspinatus muscle is then repaired to its origin to prevent postoperative weakness. Carefully reattach the deltoid muscle.

Postoperatively, keep patients in a plastic splint that extends from the wrist to the mid-arm level and around the waist. Keep the arm in neutral flexion and extension and 10° of external rotation for 6 weeks. Begin isometric deltoid and rotator cuff exercises at 8 weeks, and add progressive resistive exercises at 12 weeks. Using this technique in 25 shoulders, Bigliani et al. (11) reported good-to-excellent results in 88%. This assessment was based on stability, pain, range of motion, and activity level.

**Author's Preferred Method** After adequate general anesthesia has been obtained, place the patient into the lateral decubitus position with the injured side up. Place an axillary roll, and pad all potential pressure points on the downside. Inflate the bean bag, and contour it anteriorly and posteriorly. Prepare and drape the injured arm and hemithorax in sterile fashion. Apply a McConnell Shoulder Holder to the table opposite the surgeon, and use it to maintain appropriate arm position during the operation.

- Create a vertical incision in line with the posterior axillary fold, and carry it over the posterior acromial edge. Employ sharp dissection through the subcutaneous tissue down to the deltoid fascia. Raise subcutaneous flaps medially and laterally.
- Palpate the glenohumeral joint, and split the deltoid muscle in line with its fibers at this level (Fig. 80.71). If necessary, further elevate the deltoid subperiosteally off the acromion to the posterolateral corner of the acromion. This latter step is usually required for large, muscular patients.

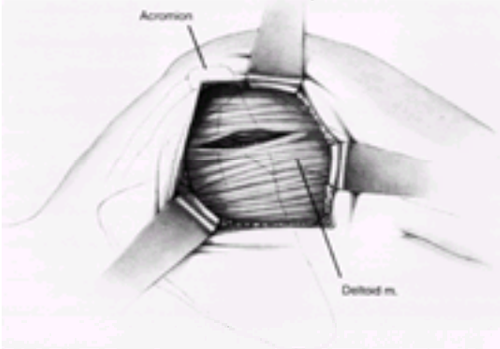


***Figure 80.71.*** Open posterior shoulder stabilization procedure. Make a standard split in the posterior deltoid muscle in line with the muscular fibers at the level of the glenohumeral joint. In muscular patients, decreased visualization may require periosteal elevation of the deltoid muscle from the scapular spine. (From Rowe CR, Yee LB. A Posterior Approach to the Shoulder. *J Bone Joint Surg [Am]* 1944;26:580, with permission.)

- Insert a self-retaining shoulder retractor, and adequately mobilize the subdeltoid plane to expose the underlying infraspinatus fascia (Fig. 80.72). Then externally rotate the arm, and split the infraspinatus at the equator of the glenoid in line with its fibers. Carefully, develop the plane between this muscle and the underlying capsule (Fig. 80.73). Take care with this step, as there are frequently adhesions, as well as a thin redundant capsule. If further visualization of the capsule along the humeral neck is required, a portion of the infraspinatus tendon insertion may have to be released. Maintain a cuff of tissue in this case to permit an anatomic repair later in the procedure.

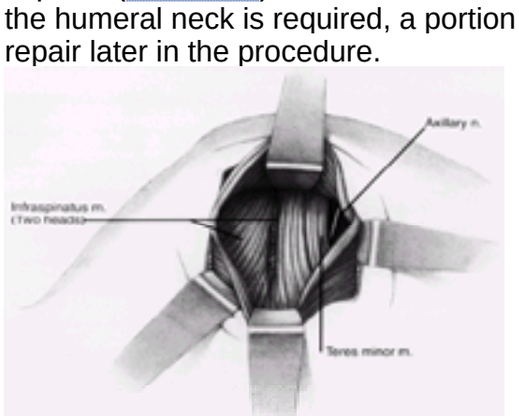


***Figure 80.72.*** Open posterior shoulder stabilization procedure. Develop the interval between the two heads of the infraspinatus muscle, which exposes the underlying capsule. Alternatively, the glenohumeral joint can be palpated, and the infraspinatus muscle can be split at this level. (From Rowe CR, Yee LB. A Posterior Approach to the Shoulder. *J Bone Joint Surg [Am]* 1944;26:580, with permission.)

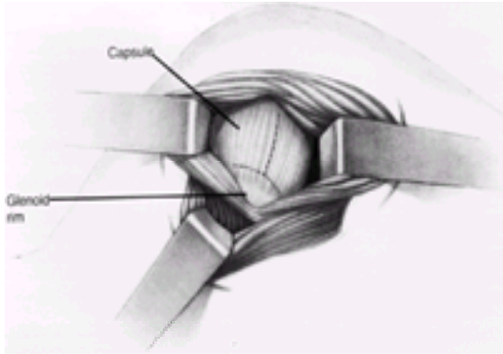


***Figure 80.73.*** Open posterior shoulder stabilization procedure. Make a medially based T-shaped capsulotomy. (From Rowe CR, Yee LB. A Posterior Approach to the Shoulder. *J Bone Joint Surg [Am]* 1944;26:580, with permission.)

- Place long, thin manual retractors along the infraspinatus muscle to aid in visualization at this point in the procedure. Carefully, create a vertical capsulotomy just off the glenoid margin to dissect inferiorly and allow adequate correction of the capsular laxity later in the procedure. Make a horizontal cut at the equator of the glenoid to create a T-type capsulotomy (Fig. 80.74). If there has been concomitant avulsion of the capsule from the humeral insertion site, incorporate it into the procedure to create an H-type capsulotomy.

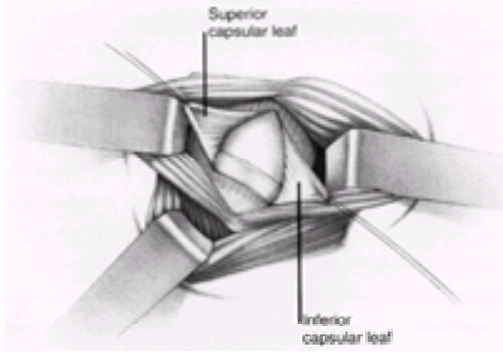


***Figure 80.74.*** Open posterior shoulder stabilization procedure. Raise capsular flaps to allow exploration of the posterior labrum. If a true posterior Bankart lesion is present, repair it, using either a suture anchor technique or transsosseus drill holes. (From Rowe CR, Yee LB. A Posterior Approach to the Shoulder. *J Bone Joint Surg [Am]* 1944;26:580, with permission.)

- Place a spiked retractor medially along the scapula to allow adequate visualization of the posterior labrum. If a posterior Bankart lesion exists, repair it at this point. Prepare the glenoid rim with a motorized burr and rasp to create a bleeding surface. Place double-loaded (#1 nonabsorbable) suture anchors at the 2- and 4-o' clock positions for left shoulders and at the 10- and 8-o' clock positions for right shoulders. Then repair the capsulolabral tissue with these sutures placed in standard horizontal mattress fashion. Retain the suture and attached needles for lateral closure of the capsulotomy. If no Bankart lesion exists, maintain this area intact, and place sutures directly through the labral tissue during later repair of the capsule.
- Then mobilize the inferior capsular flap in a superior and medial direction for a T-type capsulotomy (Fig. 80.75) to reestablish tension in the IGHL. Use the previously placed nonabsorbable sutures to secure the capsule to the glenoid surface. Pull the superior flap inferiorly and medially to supplement the thin capsular tissue. Suture this flap to the glenoid surface, using the previously placed nonabsorbable sutures, as well as to the underlying capsule (Fig. 80.76).

***Figure 80.75.*** Open posterior shoulder stabilization procedure. Tie the inferior capsular flap to the superomedial capsular tissue first to correct the posteroinferior laxity. (From Rowe CR, Yee LB. A Posterior Approach to the Shoulder. *J Bone Joint Surg [Am]* 1944;26:580, with permission.)

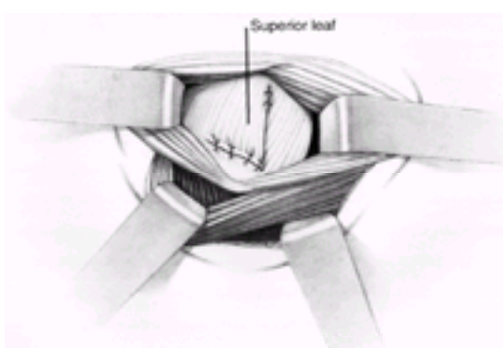


***Figure 80.76.*** Open posterior shoulder stabilization procedure. Repair the superior capsular flap to the inferomedial glenoid rim to supplement the repair. (From Rowe CR, Yee LB. A Posterior Approach to the Shoulder. *J Bone Joint Surg [Am]* 1944;26:580, with permission.)

- If a lateral capsular avulsion exists and an H-type capsulotomy has been created, also place suture anchors along the humeral neck. Repair the medial capsulolabral tissue as previously described, without significantly shifting the capsule. Once again, mobilize the inferior capsular flap superiorly and laterally to reestablish tension along the IGHL. Pull the superior flap inferiorly as above to supplement the repair.
- Repair the infraspinatus muscle anatomically to its insertion if it was released previously. Also repair the horizontal split in a side-to-side fashion. If the deltoid muscle was subperiosteally dissected from the acromion, reestablish the origin through transosseous drill holes. Complete the repair with nonabsorbable sutures.

Place the patient into a prefabricated gunslinger brace, with immobilization for 6 weeks. Then initiate active-assisted and active range-of-motion exercise. Allow light muscle-strengthening exercises (Theraband, Hygenic Corp., Malaysia) 3 months postoperatively but no heavy contact sports or significant labor until 6 months after the operative procedure.

## CHAPTER REFERENCES

Each reference is categorized according to the following scheme: *, classic article; #, review article; !, basic research article; and +, clinical results/outcome study.

+ 1. Abelow SP. Laser Capsulorrhaphy for Multidirectional Instability of the Shoulder. *Oper Tech Sports Med* 1997;5:244.

2. Allen AA, Warner JJ. Shoulder Instability in the Athlete. *Orthop Clin North Am* 1995;26:487.

+ 3. Altchek DW, Warren RF, Skyhar MJ, Ortiz G. T-plasty Modification of the Bankart Procedure for Multidirectional Instability of the Anterior and Inferior Types. *J Bone Joint Surg [Am]* 1991;73:105.

+ 4. Altchek DW, Warren RF, Wickiewicz TL, Ortiz G. Arthroscopic Labral Debridement: A Three-year Follow-up Study. *Am J Sports Med* 1992;20:702.

+ 5. Andrews JR, Carson WG Jr, McLeod WD. Glenoid Labrum Tears Related to the Long Head of the Biceps. *Am J Sports Med* 1985;13:337.

6. Andrews JR, Heckman MM, Guerra JJ. Diagnostic Arthroscopy of the Shoulder. In: Mcginty JB, Caspari RB, Jackson RW, Poehling GG, eds. *Diagnostic Arthroscopy of the Shoulder.* Philadelphia: Lippincott–Raven Publishers, 1996:647.

+ 6a. Arciero RA, Wheeler JH, Ryan JB, McBride JT. Arthroscopic Bankart Repair versus Nonoperative Treatment for Acute, Initial Anterior Shoulder Dislocations. *Am J Sports Med* 1994;22:589.

+ 6b. Aronen JG, Regan K. Decrasing the Incidence of Recurrence of First Time Anterior Shoulder Dislocations with Rehabilitation. *Am J Sports Med*1984;12:283.

+ 7. Baker CL, Uribe JW, Whitman C. Arthroscopic Evaluation of Acute Initial Anterior Shoulder Dislocations. *Am J Sports Med* 1990;18:25.

! 8. Barber FA, Feder SM, Burkhart SS, Ahrens J. The Relationship of Suture Anchor Failure and Bone Density to Proximal Humerus Location: A Cadaveric Study. *Arthroscopy* 1997;13:340.

! 9. Barber FA, Herbert MA, Click JN. Internal Fixation Strength of Suture Anchors—Update 1997. *Arthroscopy* 1997;13:355.

+ 9a. Benedetto KP, Glotzer W. Arthroscopic Bankart Procedure by Suture Technique: Indications, Technique, and Results. *Arthroscopy* 1992;8:111.

+ 10. Bigliani LU, Kurzweil PR, Schwartzbach CC, et al. Inferior Capsular Shift Procedure for Anterior-inferior Shoulder Instability in Athletes. *Am J Sports Med* 1994;22:578.

! 11. Bigliani LU, Pollock RG, Soslowsky LJ, et al. Tensile Properties of the Inferior Glenohumeral Ligament. *J Orthop Res* 1992;10:187.

! 12. Blasier RB, Soslowsky LJ, Malicky DM, Palmer ML. Posterior Glenohumeral Subluxation: Active and Passive Stabilization in a Biomechanical Model. *J Bone Joint Surg [Am]* 1997;79:433.

! 13. Boardman ND, Debski RE, Warner JJ, et al. Tensile Properties of the Superior Glenohumeral and Coracohumeral Ligaments. *J Shoulder Elbow Surg* 1996;5:249.

! 14. Bowen MK, Deng XH, Warner JJ, et al. The Effect of Joint Compression on Stability of the Glenohumeral Joint. *Trans Orthop Res Soc* 1992;17:289.

+ 15. Boyd HB, Hunt HL. Recurrent Dislocation of the Shoulder: The Staple Capsulorrhaphy. *J Bone Joint Surg [Am]* 1965;47:1514.

+ 16. Boyd HB, Sisk TD. Recurrent Posterior Dislocation of the Shoulder. *J Bone Joint Surg [Am]* 1972;54:779.

! 17. Bradley JP, Tibone JE. Electromyographic Analysis of Muscle Action about the Shoulder. *Clin Sports Med* 1991;10:789.

+ 18. Brewer BJ, Wubben RC, Carrera GF. Excessive Retroversion of the Glenoid Cavity: A Cause of Non-traumatic Posterior Instability of the Shoulder. *J Bone Joint Surg [Am]* 1986;68:724. [Erratum: *J Bone Joint Surg [Am]* 1986;68:1128.]

! 19. Browne AO, Hoffmeyer P, An KN, Morrey BF. The Influence of Atmospheric Pressure on Shoulder Instability. *Orthop Trans* 1990;14:259.

+ 19a. Burger RS, Shengel D, Bonatus T, Lewis J. Arthroscopic Staple Capsulorrhaphy for Recurrent Shoulder Instability. *Orthop Trans*1990;14:596.

+ 20. Burkhart SS, Fox DL. Case Report: Arthroscopic Repair of a Type IV SLAP Lesion—The Red-on-White Lesion as a Component of Anterior Instability. *Arthroscopy* 1993;9:488.

+ 21. Burkhead WZ Jr, Rockwood CA Jr. Treatment of Instability of the Shoulder with an Exercise Program. *J Bone Joint Surg [Am]* 1992;74:890.

+ 22. Calandra JJ, Baker CL, Uribe J. The Incidence of Hill-Sachs Lesions in Initial Anterior Shoulder Dislocations. *Arthroscopy* 1989;5:254.

23. Caspari RB. Anatomy and Portals for Arthroscopic Surgery of the Shoulder. In: Mcginty JB, ed. *Arthroscopic Surgery of the Shoulder Update: Techniques in Orthopaedics.* Rockville, MD: Aspen Systems, 1985;15.

+ 24. Caspari RB, Geissler WB. Arthroscopic Manifestations of Shoulder Subluxation and Dislocation. *Clin Orthop* 1993;291:54.

24a. Caspari RB, Savoie FH. Arthroscopic Reconstruction of the Shoulder; The Bankart Repair. In: Mcginty J, ed. *Operative Arthroscopy.* New York: Raven Press, 1991:50.

* 25. Cave EF, Rowe CR. Capsular Repair for Recurrent Dislocation of the Shoulder: Pathologic Findings and Operative Technique. *Surg Clin North Am* 1947;27:1289.

+ 26. Chandnani VP, Gagliardi JA, Murnane TG, et al. Glenohumeral Ligaments and Shoulder Capsular Mechanism: Evaluation with MR Arthrography. *Radiology* 1995;196:27.

+ 27. Chandnani VP, Yeager TD, DeBerardino T, et al. Glenoid Labral Tears: Prospective Evaluation with MRI Imaging, MR Arthrography, and CT Arthrography. *AJR* 1993;161:1229.

28. Cheng JC, Karzel RP. Superior Labrum Anterior Posterior Lesions of the Shoulder: Operative Techniques of Management. *Oper Tech Sports Med* 1997;5:249.

+ 29. Clark J, Sidles JA, Matsen FA. The Relationship of the Glenohumeral Joint Capsule to the Rotator Cuff. *Clin Orthop* 1990;254:29.

+ 30. Cofield RH, Nessler JP, Weinstabl R. Diagnosis of Shoulder Instability by Examination under Anesthesia. *Clin Orthop* 1993;291:45.

! 31. Cooper DE, Arnoczky SP, O' Brien SJ, et al. Anatomy, Histology, and Vascularity of the Glenoid Labrum: An Anatomical Study. *J Bone Joint Surg [Am]* 1992;74:46.

! 32. Cooper DE, O' Brien SJ, Warren RF. Supporting Layers of the Glenohumeral Joint: An Anatomic Study. *Clin Orthop* 1993;289:144.

33. Cooper DE, Warner JJ, Warren RF. Complications of Shoulder Instability in the Competitive Athlete. In: Bigliani LU, ed. *Complications of Shoulder Surgery.* Baltimore: Williams & Wilkins, 1993:247.

! 34. Cooper DE, Warner JJ, Warren RF. The Structure and Function of the Coracohumeral Ligament: An Anatomic and Microscopic Study. *J Shoulder Elbow Surg* 1993;2:70.

+ 35. Cordasco FA, Steinmann S, Flatow EL, Bigliani LU. Arthroscopic Treatment of Glenoid Labral Tears. *Am J Sports Med* 1993;21:425.

+ 36. Coughlin L, Rubinovich M, Johansson J, et al. Arthroscopic Staple Capsulorrhaphy for Anterior Shoulder Instability. *Am J Sports Med* 1992;20:253.

! 37. Curl LA, Warren RF. Glenohumeral Joint Stability: Selective Cutting Studies on the Static Capsular Restraints. *Clin Orthop* 1996;330:54.

+ 38. de Laat EA, Visser CP, Coene LN, et al. Nerve Lesions in Primary Shoulder Dislocations and Humeral Neck Fractures: A Prospective Clinical and EMG Study. *J Bone Joint Surg Br* 1994;76:381.

39. Detrisac DA, Johnson LL. *Arthroscopic Shoulder Anatomy: Pathologic and Surgical Implications.* Thorofare, NJ: Slack Publications, 1986:21.

+ 40. Dimon JH. Posterior Dislocation and Posterior Fracture Dislocation of the Shoulder: A Report of 25 Cases. *South Med J* 1967;60:661.

+ 41. Duncan R, Savoie FH. Arthroscopic Inferior Capsular Shift for Multidirectional Instability of the Shoulder: A Preliminary Report. *Arthroscopy* 1993;9:24.

42. Elrod BF. Arthroscopic Reconstruction of Traumatic Anterior Instability. *Oper Tech Sports Med* 1997;5:215.

+ 43. Engebretsen L, Craig EV. Radiologic Features of Shoulder Instability. *Clin Orthop* 1993;291:29.

+ 44. Field LD, Savoie FH. Arthroscopic Suture Repair of Superior Labral Detachment Lesions of the Shoulder. *Am J Sports Med* 1993;21:783.

+ 45. Field LD, Warren RF, O' Brien SJ, et al. Isolated Closure of Rotator Interval Defects for Shoulder Instability. *Am J Sports Med* 1995;23:557.

! 46. Flatow EL, Ateshian GA, Soslowsky LJ, et al. Computer Simulation of Glenohumeral and Patellofemoral Subluxation: Estimating Pathological Articular Contact. *Clin Orthop* 1994;306:28.

! 47. Flatow EL, Soslowsky LJ, Ateshian GA, et al. Shoulder Joint Anatomy and the Effect of Subluxations and Size Mismatch on Patterns of Glenohumeral Contact. *Orthop Trans* 1991;15:803.

+ 47a. Foster CR. Arthroscopic Shoulder Reconstruction for Instability. *Orthop Trans*1994;18:192.

+ 48. Fronek J, Warren RF, Bowen M. Posterior Subluxation of the Glenohumeral Joint. *J Bone Joint Surg [Am]* 1989;71:205.

+ 48a. Geiger DF, Hurley JA, Tovey JA, Rao JP. Results of Arthroscopic versus Open Bankart Suture Repair. *Orthop Trans* 1993;17:973.

49. Gerber C. Observations on the Classification of Instability. In: Warner JJP, Iannotti JP, Gerber C, eds. *Complex and Revision Problems in Shoulder Surgery.* Philadelphia: Lippincott–Raven Publishers, 1997:9.

+ 50. Gerber C, Ganz R. Clinical Assessment of Instability of the Shoulder: With Special Reference to Anterior and Posterior Drawer Tests. *J Bone Joint Surg Br* 1984;66:551.

+ 51. Gerber C, Kuechle DK. Isolated Rupture of the Tendon of the Subscapularis Muscle: Clinical Features of Sixteen Cases. *J Bone Joint Surg Br* 1991;73:389.

! 52. Gerber C, Schneeberger AG, Beck M, Schlegel U. Mechanical Strength of Repairs of the Rotator Cuff. *J Bone Joint Surg Br* 1994;76:371.

! 53. Gibb TD, Sidles JA, Harryman DT, et al. The Effect of Capsular Venting on Glenohumeral Laxity. *Clin Orthop* 1991;268:120.

+ 54. Glasgow SG, Bruce RA, Yacobucci GN, Torg JS. Arthroscopic Resection of Glenoid Labral Tears in the Athlete: A Report of 29 Cases. *Arthroscopy* 1992;8:48.

+ 54a. Goldberg BJ, Nirschl RP, McConnell JP, Pettrone FA. Arthroscopic Transglenoid Suture Capsulolabral Repairs: Preliminary Results. *Am J Sports Med* 1993;21:656.

+ 55. Goss TP. Fractures of the Glenoid Cavity. *J Bone Joint Surg [Am]* 1992;74:299.

+ 55a. Grana WA, Buckley PD, Yates CK. Arthroscopic Bankart Suture Repair. *Am J Sports Med* 1993;21:348.

+ 56. Green MR, Christensen KP. Magnetic Resonance Imaging of the Glenoid Labrum in Anterior Shoulder Instability. *Am J Sports Med* 1994;22:493.

+ 57. Groh GI, Rockwood CA Jr. The Terrible Triad: Anterior Dislocation of the Shoulder Associated with Rupture of the Rotator Cuff and Injury to the Brachial Plexus. *J Shoulder Elbow Surg* 1995;4:51.

+ 58. Gross MR. Arthroscopic Shoulder Capsulorrhaphy: Does it Work? *Am J Sports Med* 1989;17:495.

+ 59. Hawkins RH, Hawkins RJ. Failed Anterior Reconstruction for Shoulder Instability. *J Bone Joint Surg Br* 1985;67:709.

+ 60. Hawkins RJ. Arthroscopic Staple Repair for Shoulder Instability: A Retrospective Study of Fifty Patients. *Arthroscopy* 1989;5:122.

+ 61. Hawkins RJ, Angelo RL. Glenohumeral Osteoarthrosis: A Late Complication of the Putti-Platt Repair. *J Bone Joint Surg [Am]* 1990;72:1193.

+ 62. Hawkins RJ, Bell RH, Hawkins RH, Koppert GJ. Anterior Dislocation of the Shoulder in the Older Patient. *Clin Orthop* 1986;206:192.

+ 63. Hawkins RJ, Koppert G, Johnston G. Recurrent Posterior Instability (Subluxation) of the Shoulder. *J Bone Joint Surg [Am]* 1984;66:169.

+ 64. Hawkins RJ, Neer CS, Pianta RM, Mendoza FX. Locked Posterior Dislocation of the Shoulder. *J Bone Joint Surg [Am]* 1987;69:9.

+ 65. Hawkins RJ, Schutte JP, Janda DH, Huckell GH. Translation of the Glenohumeral Joint with the Patient under Anesthesia. *J Shoulder Elbow Surg* 1996;5:286.

! 66. Hayashi K, Thabit G, Vailas AC, et al. The Effect of Nonablative Laser Energy on Joint Capsular Properties: An *in Vitro* Histologic and Biochemical Study Using a Rabbit Model. *Am J Sports Med* 1996;24:640.

+ 67. Henry JH, Genung JA. Natural History of Glenohumeral Dislocation—Revisited. *Am J Sports Med* 1982;10:135.

+ 68. Hintermann B, Gachter A. Arthroscopic Findings after Shoulder Dislocation. *Am J Sports Med* 1995;23:545.

+ 69. Hovelius L. Anterior Dislocation of the Shoulder in Teen-agers and Young Adults: Five-year Prognosis. *J Bone Joint Surg [Am]* 1987;69:393.

+ 70. Hovelius L, Augustini BG, Fredin H, et al. Primary Anterior Dislocation of the Shoulder in Young Patients: A Ten-year Prospective Study. *J Bone Joint Surg [Am]* 1996;78:1677.

! 71. Howell SM, Galinat BJ. The Glenoid-labral Socket: A Constrained Articular Surface. *Clin Orthop* 1989;243:122.

+ 72. Itoi E, Berglund LJ, Grabowski JJ, et al. Superior-inferior Stability of the Shoulder: Role of the Coracohumeral Ligament and the Rotator Interval Capsule. *Mayo Clin Proc* 1998;73:508.

! 73. Itoi E, Hsu HC, An KN. Biomechanical Investigation of the Glenohumeral Joint. *J Shoulder Elbow Surg* 1996;5:407.

! 74. Itoi E, Kuechle DK, Newman SR, et al. Stabilising Function of the Biceps in Stable and Unstable Shoulders. *J Bone Joint Surg Br* 1993;75:546. [Erratum: *J Bone Joint Surg Br* 1994;76:170.]

! 75. Itoi E, Motzkin NE, Morrey BF. The Stabilizing Function of the Long Head of the Biceps with the Arm in a Hanging Position. *J Shoulder Elbow Surg* 1994;3(suppl.)32.

! 76. Itoi E, Newman SR, Kuechle DK, et al. Dynamic Anterior Stabilisers of the Shoulder with the Arm in Abduction. *J Bone Joint Surg Br* 1994;76:834.

77. Jobe FW. Unstable Shoulders in the Athlete. *Instr Course Lect* 1985;34:228.

+ 78. Jobe FW, Giangarra CE, Kvitne RS, Glousman RE. Anterior Capsulolabral Reconstruction of the Shoulder in Athletes in Overhand Sports. *Am J Sports Med* 1991;19:428.

79. Johnson LL. *Diagnostic and Surgical Arthroscopy of the Shoulder.* St. Louis, MO: Mosby, 1993:304.

+ 80. Johnson LL. The Shoulder Joint: An Arthroscopist's Perspective of Anatomy and Pathology. *Clin Orthop* 1987;223:113.

+ 81. Klein AH, France JC, Mutschler TA, Fu FH. Measurement of Brachial Plexus Strain in Arthroscopy of the Shoulder. *Arthroscopy* 1987;3:45.

! 82. Kumar VP, Balasubramaniam P. The Role of Atmospheric Pressure in Stabilising the Shoulder: An Experimental Study. *J Bone Joint Surg Br* 1985;67:719.

+ 83. Kvitne RS, Jobe FW. The Diagnosis and Treatment of Anterior Instability in the Throwing Athlete. *Clin Orthop* 1993;291:107.

+ 83a. Landsiedl F. Arthroscopic Therapy of Recurrent Anterior Luxation of the Shoulder by Capsular Repair. *Arthroscopy* 1992;8:296.

+ 83b. Lane JG, Sachs RA, Riehl B. Arthroscopic Staple Capsulorrhaphy: A Long-term Follow-up. *Arthroscopy* 1993;9:190.

+ 84. Laurencin CT, Stephens S, Warren RF, Altchek DW. Arthroscopic Bankart Repair Using a Degradable Tack: A Follow-up Study Using Optimized Indications. *Clin Orthop* 1996;332:132.

+ 85. Lephart S, Warner JJ, et al. Proprioception of the Shoulder Joint in Healthy, Unstable and Surgically Repaired Shoulders. *J Shoulder Elbow Surg* 1994;3:371.

+ 86. Lerat JL, Chotel F, Besse JL, et al. Dynamic Anterior Jerk of the Shoulder: A New Clinical Test for Shoulder Instability: Preliminary Study. *Rev Chir Orthop Reparatrice Appar Mot* 1994;80:461.

+ 87. Levine WN, Richmond JC, Donaldson WR. Use of the Suture Anchor in Open Bankart Reconstruction: A Follow-up Report. *Am J Sports Med* 1994;22:723.

+ 88. Lippitt S, Matsen F. Mechanisms of Glenohumeral Joint Stability. *Clin Orthop* 1993;291:20.

! 89. Lippitt S, Vanderhooft E. Glenohumeral Stability from Concavity-Compression: A Quantitative Analysis. *J Shoulder Elbow Surg* 1993;2:27.

+ 90. Lyons FA, Rockwood CA Jr. Migration of Pins Used in Operations on the Shoulder. *J Bone Joint Surg [Am]* 1990;72:1262.

+ 91. Maffet MW, Gartsman GM, Moseley B. Superior Labrum–Biceps Tendon Complex Lesions of the Shoulder. *Am J Sports Med* 1995;23:93.

+ 92. Maki NJ. Arthroscopic Stabilization: Suture Technique. *Oper Tech Orthop* 1991;1:180.

+ 93. Marans HJ, Angel KR, Schemitsch EH, Wedge JH. The Fate of Traumatic Anterior Dislocation of the Shoulder in Children. *J Bone Joint Surg [Am]* 1992;74:1242.

94. Matsen F, Thomas S, Rockwood C Jr., Wirth M. Glenohumeral Instability. In: Rockwood C Jr., Matsen F, eds. *The Shoulder.* Philadelphia: WB Saunders, 1990:637.

+ 94a. Matthews LS, Vetter WL, Oweida SJ, et al. Arthroscopic Staple Capsulorrhaphy for Recurrent Anterior Shoulder Instability. *Arthroscopy*1988;4:106.

+ 95. May H. Nicola Operation for Posterior Subacromial Dislocation of the Humerus. *J Bone Joint Surg [Am]* 1943;25:78.

+ 96. Mazat R. Migration of a Kirschner Wire from the Shoulder Region into the Lung: Report of Two Cases. *J Bone Joint Surg [Am]* 1943;25:477.

+ 97. McEleney ET, Donovan MJ, Shea KP, Nowak MD. Initial Failure Strength of Open and Arthroscopic Bankart Repairs. *Arthroscopy* 1995;11:426.

+ 98. McGaughan JS, Miller PR. Migration of Steinman Pin from Shoulder to Lung. *JAMA* 1969;207:1917.

99. McIntyre LF, Caspari RB, Savoie FH. The Arthroscopic Treatment of Anterior and Multidirectional Shoulder Instability. *Instr Course Lect* 1996;45:47.

+ 100. McIntyre LF, Caspari RB, Savoie FH. The Arthroscopic Treatment of Posterior Shoulder Instability: Two-year Results of a Multiple Suture Technique. *Arthroscopy* 1997;13:426.

101. McLaughlin HL. Posterior Dislocation of the Shoulder. *J Bone Joint Surg [Am]* 1962;44:1477.

+ 102. McLaughlin HL. Recurrent Anterior Dislocation of the Shoulder I. Morbid Anatomy. *Am J Surg* 1960;99:628.

# 103. Micheli LJ. Sports Injuries in Children and Adolescents: Questions and Controversies. *Clin Sports Med* 1995;14:727.

+ 103a. Morgan CD. Arthroscopic Transglenoid Bankart Suture Repair. *Oper Tech Orthop* 1991;1:171.

+ 104. Morgan CD, Bodenstab AB. Arthroscopic Bankart Suture Repair: Technique and Early Results. *Arthroscopy* 1987;3:111.

+ 105. Mowery CA, Garfin SR, Booth RE, Rothman RH. Recurrent Posterior Dislocation of the Shoulder: Treatment Using a Bone Block. *J Bone Joint Surg [Am]* 1985;67:777.

! 106. Naseef GS, Foster TE, Trauner K, et al. The Thermal Properties of Bovine Joint Capsule: The Basic Science of Laser- and Radiofrequency-induced Capsular Shrinkage. *Am J Sports Med* 1997;25:670.

* 107. Neer CS 2d, Foster CR. Inferior Capsular Shift for Involuntary Inferior and Multidirectional Instability of the Shoulder: A Preliminary Report. *J Bone Joint Surg [Am]* 1980;62:897.

* 108. Neviaser RJ, Neviaser TJ, Neviaser JS. Anterior Dislocation of the Shoulder and Rotator Cuff Rupture. *Clin Orthop* 1993;291:103.

* 109. Neviaser TJ. The Anterior Labroligamentous Periosteal Sleeve Avulsion Lesion: A Cause of Anterior Instability of the Shoulder. *Arthroscopy* 1993;9:17.

+ 110. Nobel W. Posterior Traumatic Dislocation of the Shoulder. *J Bone Joint Surg [Am]* 1962;44:523.

+ 111. Norell H, Loehr JF. Migration of a Threaded Steinmann Pin from an Acromioclavicular Joint into the Spinal Canal: A Case Report. *J Bone Joint Surg [Am]* 1965;47:1024.

+ 112. Norlin R. Intraarticular Pathology in Acute, First-time Anterior Shoulder Dislocation: An Arthroscopic Study. *Arthroscopy* 1993;9:546.

! 113. O' Brien SJ, Neves MC, Arnoczky SP, et al. The Anatomy and Histology of the Inferior Glenohumeral Ligament Complex of the Shoulder. *Am J Sports Med* 1990;18:449.

! 114. O' Brien SJ, Schwartz RS, Warren RF, Torzilli PA. Capsular Restraints to Anterior-posterior Motion of the Abducted Shoulder: A Biomechanical Study. *J Shoulder Elbow Surg* 1995;4:298.

! 115. O' Connell PW, Nuber GW, Mileski RA, Lautenschlager E. The Contribution of the Glenohumeral Ligaments to Anterior Stability of the Shoulder Joint. *Am J Sports Med* 1990;18:579.

! 116. Pagnani MJ, Deng XH, Warren RF, et al. Role of the Long Head of the Biceps Brachii in Glenohumeral Stability: A Biomechanical Study in Cadavera. *J Shoulder Elbow Surg* 1996;5:255.

+ 117. Pagnani MJ, Speer KP, Altchek DW, et al. Arthroscopic Fixation of Superior Labral Lesions Using a Biodegradable Implant: A Preliminary Report. *Arthroscopy* 1995;11:194.

+ 118. Pagnani MJ, Warren RF. Arthroscopic Shoulder Stabilization. *Oper Tech Sports Med* 1993;1:276.

+ 119. Pagnani MJ, Warren RF. MDI: Medial T-plasty and Selective Capsular Repair. *Sports Med Arthrosc Rev* 1993;1:249.

+ 120. Pappas AM, Goss TP, Kleinman PK. Symptomatic Shoulder Instability Due to Lesions of the Glenoid Labrum. *Am J Sports Med* 1983;11:279.

+ 121. Pavlov H, Warren RF, Weiss CB Jr, Dines DM. The Roentgenographic Evaluation of Anterior Shoulder Instability. *Clin Orthop* 1985;194:153.

+ 122. Payne LZ, Jokl P. The Results of Arthroscopic Debridement of Glenoid Labral Tears Based on Tear Location. *Arthroscopy* 1993;9:560.

+ 123. Pollock RG, Bigliani LU. Recurrent Posterior Shoulder Instability: Diagnosis and Treatment. *Clin Orthop* 1993;291:85.

+ 123a. Rao JP, Tovey JE, Zoppi A, et al. Comparison of Arthroscopic Capsulorrhaphy for Anterior Shoulder Instability: Stapling versus Suturing. *Orthop Trans*1994;17:972.

+ 124. Resch H, Gosler K, Thoeni H, Sperner G. Arthroscopic Repair of Superior Glenoid Labral Detachment (the SLAP Lesion). *J Shoulder Elbow Surg* 1993;2:147.

+ 125. Richardson AB, Jobe FW, Collins HR. The Shoulder in Competitive Swimming. *Am J Sports Med* 1980;8:159.

! 126. Rodosky MW, Harner CD, Fu FH. The Role of the Long Head of the Biceps Muscle and Superior Glenoid Labrum in Anterior Stability of the Shoulder. *Am J Sports Med* 1994;22:121.

+ 127. Rose DJ. Arthroscopic Suture Capsulorrhaphy for Anterior Shoulder Instability. *Orthop Trans* 1990;14:597.

+ 128. Rosenberg BN, Richmond JC, Levine WN. Long-term Follow-up of Bankart Reconstruction: Incidence of Late Degenerative Glenohumeral Arthrosis. *Am J Sports Med* 1995;23:538.

! 129. Rouse LM, Burkhead WZ, Neer CS. Vascularity of the Glenoid Labrum. *Orthop Trans* 1990;14:595.

+ 130. Rowe CR. The Bankart Procedure: Improvements and Options. *Surg Rounds Orthop* 1990;Feb:15.

* 131. Rowe CR, Patel D, Southmayd WW. The Bankart Procedure: A Long-term End-result Study. *J Bone Joint Surg [Am]* 1978;60:1.

* 132. Rowe CR, Pierce DS, Clark JG. Voluntary Dislocation of the Shoulder: A Preliminary Report on a Clinical, Electromyographic, and Psychiatric Study of Twenty-six Patients. *J Bone Joint Surg [Am]* 1973;55:445.

* 133. Rowe CR, Sakellarides HT. Factors Related to Recurrences of Anterior Dislocation of the Shoulder. *Clin Orthop* 1961;20:40.

+ 134. Rowe CR, Zarins B, Ciullo JV. Recurrent Anterior Dislocation of the Shoulder after Surgical Repair: Apparent Causes of Failure and Treatment. *J Bone Joint Surg [Am]* 1984;66:159.

+ 135. Saha AK. Dynamic Stability of the Glenohumeral Joint. *Acta Orthop Scand* 1971;42:491.

+ 136. Savoie FH, Miller CD, Field LD. Arthroscopic Reconstruction of Traumatic Anterior Instability of the Shoulder: The Caspari Technique. *Arthroscopy* 1997;13:201.

+ 137. Scott DJ Jr. Treatment of Recurrent Posterior Dislocations of the Shoulder by Glenoplasty: Report of Three Cases. *J Bone Joint Surg [Am]* 1967;49:471.

+ 138. Sethi GK, Scott SM. Subclavian Artery Laceration Due to Migration of a Hagie Pin. *Surgery* 1965;80:644.

! 139. Shaffer BS, Conway J, Jobe FW, et al. Infraspinatus Muscle-splitting Incision in Posterior Shoulder Surgery: An Anatomic and Electromyographic Study. *Am J Sports Med* 1994;22:113.

+ 140. Shea KP, Lovallo JL. Scapulothoracic Penetration of a Beath Pin: An Unusual Complication of Arthroscopic Bankart Suture Repair. *Arthroscopy* 1991;7:115.

! 141. Sheilds CL. Soft Tissue Shortening with the Ho:YAG Laser: Experimental Model, Structural Effects, and Histological and Ultrastructural Analysis. Presented at the Second Annual Meeting of the Orthopaedic Laser Society of North America and International Musculoskeletal Laser Society, South Lake, Tahoe, CA, December, 1995.

+ 142. Silliman JF, Hawkins RJ. Classification and Physical Diagnosis of Instability of the Shoulder. *Clin Orthop* 1993;291:7.

+ 143. Sisk TD, Boyd HB. Management of Recurrent Anterior Dislocation of the Shoulder: Du Toit-type or Staple Capsulorrhaphy. *Clin Orthop* 1974;103:150.

+ 143a. Small NC. Complications of Arthroscopy: The Knee and Other Joints. *Arthroscopy* 1986;2:253.

+ 144. Snyder SJ, Banas MP, Karzel RP. An Analysis of 140 Injuries to the Superior Glenoid Labrum. *J Shoulder Elbow Surg* 1995;4:243.

* 145. Snyder SJ, Karzel RP, Del Pizzo W, et al. SLAP Lesions of the Shoulder. *Arthroscopy* 1990;6:274.

146. Snyder SJ, Rames RD, Wolbert E. Labral Lesions. In: Mcginty JB, ed. *Operative Arthroscopy.* New York: Raven Press, 1991;491.

+ 147. Sonnabend DH. Treatment of Primary Anterior Shoulder Dislocation in Patients Older than 40 Years of Age: Conservative versus Operative. *Clin Orthop* 1994;304:74.

! 148. Soslowsky LJ, Flatow EL, Bigliani LU, Mow VC. Articular Geometry of the Glenohumeral Joint. *Clin Orthop* 1992;285:181.

! 149. Speer KP, Deng X, Torzilli PA, et al. Strategies for an Anterior Capsular Shift of the Shoulder: A Biomechanical Comparison. *Am J Sports Med* 1995;23:264.

+ 150. Speer KP, Hannafin JA, Altchek DW, Warren RF. An Evaluation of the Shoulder Relocation Test. *Am J Sports Med* 1994;22:177.

+ 151. Speer KP, Warren RF. Arthroscopic Shoulder Stabilization: A Role for Biodegradable Materials. *Clin Orthop* 1993;291:67.

+ 152. Spinner M. *Injuries to the Major Branches of Peripheral Nerves in the Forearm.* Philadephia: WB Saunders, 1978.

+ 153. Stetson WB, Snyder SJ, Karzel RP, et al. Long-term Clinical Follow-up of Isolated SLAP Lesions of the Shoulder. Presented at the Annual Meeting of the American Academy of Orthopaedic Surgeons, San Francisco, CA, February, 1997.

+ 154. Thomas SC, Matsen FA. An Approach to the Repair of Avulsion of the Glenohumeral Ligaments in the Management of Traumatic Anterior Glenohumeral Instability. *J Bone Joint Surg [Am]* 1989;71:506.

+ 155. Tibone J, Ting A. Capsulorrhaphy with a Staple for Recurrent Posterior Subluxation of the Shoulder. *J Bone Joint Surg [Am]* 1990;72:999.

+ 156. Tibone JE, Bradley JP. The Treatment of Posterior Subluxation in Athletes. *Clin Orthop* 1993;291:124.

+ 157. Torchia ME, Caspari RB, Asselmeier MA, et al. Arthroscopic Transglenoid Multiple Suture Repair: 2- to 8-Year Results in 150 Shoulders. *Arthroscopy* 1997;13:609.

+ 158. Townley CO. The Capsular Mechanism in Recurrent Dislocation of the Shoulder. *J Bone Joint Surg [Am]* 1950;32:370.

+ 159. Treacy SH, Field LD, Savoie FH. Rotator Interval Capsule Closure: An Arthroscopic Technique. *Arthroscopy* 1997;13:103.

! 160. Turkel SJ, Panio MW, Marshall JL, Girgis FG. Stabilizing Mechanisms Preventing Anterior Dislocation of the Glenohumeral Joint. *J Bone Joint Surg [Am]* 1981;63:1208.

! 161. Vanderhooft E, Lippitt S, Matsen FA. Glenohumeral Stability from Concavity Compression: A Quantitative Analysis. Presented at the Annual Meeting of the American Shoulder and Elbow Surgeons, Washington, DC, April, 1992.

+ 162. Walch G, Boileau P, Levigne C, et al. Arthroscopic Stabilization for Recurrent Anterior Shoulder Dislocation: Results of 59 Cases. *Arthroscopy* 1995;11:173.

+ 163. Warner JJ. Shoulder Arthroscopy in the Beach-chair Position: Basic Setup. *Oper Tech Orthop* 1991;1:147.

+ 164. Warner JJ. Treatment Options for Anterior Instability: Open versus Arthroscopic. *Oper Tech Orthop* 1995;5:233.

+ 165. Warner JJ, Allen AA, Gerber C. Diagnosis and Management of Subscapularis Tendon Tears. *Oper Tech Orthop* 1994;9:116.

166. Warner JJ, Altchek DW. Arthroscopic Repairs for Instability. In: Warner JJP, Iannotti JP, Gerber C, eds. *Complex and Revision Problems in Shoulder Surgery.* Philadelphia: Lippincott–Raven Publishers, 1997:19.

167. Warner JJ, Caborn DN. Overview of Shoulder Instability. *Crit Rev Phys Rehabil Med* 1992;4:145.

! 168. Warner JJ, Caborn DN, Berger R, et al. Dynamic Capsuloligamentous Anatomy of the Glenohumeral Joint. *J Shoulder Elbow Surg* 1993;2:115.

! 169. Warner JJ, Deng XH, Warren RF, et al. Superior-inferior Translation in the Intact and Vented Glenohumeral Joint. *J Shoulder Elbow Surg* 1993;2:99.

+ 170. Warner JJ, Janetta-Alpers C, Miller MD. Correlation of Glenohumeral Laxity with Arthroscopic Ligament Anatomy. *J Shoulder Elbow Surg* 1994;4[Suppl]:532.

+ 171. Warner JJ, Johnson D, Miller M, Caborn DN. Technique for Selecting Capsular Tightness in Repair of Anterior-inferior Shoulder Instability. *J Shoulder Elbow Surg* 1995;4:352.

+ 172. Warner JJ, Kann S, Marks P. Arthroscopic Repair of Combined Bankart and Superior Labral Detachment Anterior and Posterior Lesions: Technique and Preliminary Results. *Arthroscopy* 1994;10:383.

+ 173. Warner JJ, Lephart S, Fu FH. Role of Proprioception in Pathoetiology of Shoulder Instability. *Clin Orthop* 1996;330:35.

+ 174. Warner JJ, McMahon PJ. The Role of the Long Head of the Biceps Brachii in Superior Stability of the Glenohumeral Joint. *J Bone Joint Surg [Am]* 1995;77:366.

! 175. Warner JJ, Miller MD, Marks P. Arthroscopic Bankart Repair with the Suretac Device. Part II. Experimental Observations. *Arthroscopy* 1995;11:14.

+ 176. Warner JJ, Miller MD, Marks P, Fu FH. Arthroscopic Bankart Repair with the Suretac Device. Part I. Clinical Observations. *Arthroscopy* 1995;11:2.

+ 177. Warner JJ, Warren RF. Arthroscopic Bankart Repair Using a Cannulated, Absorbable Fixation Device. *Oper Tech Orthop* 1991;1:192.

178. Warren RF. Subluxation of the Shoulder in Athletes. *Clin Sports Med* 1983;2:339.

* 179. Watson-Jones R. Recurrent Dislocation of the Shoulder. *J Bone Joint Surg Br* 1948;50:6.

+ 179a. Weber SC. A Prospective Evaluation Comparing Arthroscopic and Open Treatment of Recurrent Anterior Glenohumeral Dislocation. *Orthop Trans* 1991;15:763.

+ 179b. Wheeler JH, Ryan JB, Arciero RA, Molinari RN. Arthroscopic versus Nonoperative Treatment of Acute Shoulder Dislocations in Young Athletes. *Arthroscopy* 1989;5:213.

+ 180. Wichman MT, Snyder SJ. Arthroscopic Capsular Plication for Multidirectional Instability of the Shoulder. *Oper Tech Sports Med* 1997;5:238.

+ 180a. Wiley MA. Arthroscopy for Shoulder Instability and a Technique for Arthroscopic Repair. *Arthroscopy* 1988;4:25.

+ 181. Williams MM, Snyder SJ, Buford D Jr. The Buford Complex—the “Cord-like” Middle Glenohumeral Ligament and Absent Anterosuperior Labrum Complex: A Normal Anatomic Capsulolabral Variant. *Arthroscopy* 1994;10:241.

+ 181a. Wilson FD, Adams G, Hile LE, et al. Arthroscopic Treatment of Recurrent Dislocating Shoulder. *Orthop Trans* 1993;14:979.

+ 182. Wirth MA, Lyons FR, Rockwood CA Jr. Hypoplasia of the Glenoid: A Review of Sixteen Patients. *J Bone Joint Surg [Am]* 1993;75:1175.

+ 183. Wolf EM, Wilk RM, Richmond JL. Arthroscopic Bankart Repair Using Suture Anchors. *Oper Tech Orthop* 1991;1:187.

+ 183a. Wolin PM. Arthroscopic Glenoid Labrum Suture Repair. *Orthop Trans*1990;14:597.

+ 184. Yoneda M, Hirooka A, Saito S, et al. Arthroscopic Stapling for Detached Superior Glenoid Labrum. *J Bone Joint Surg Br* 1991;73:746.

+ 185. Young DC, Rockwood CA Jr. Complications of a Failed Bristow Procedure and Their Management. *J Bone Joint Surg [Am]* 1991;73:969.

186. Zarins B. Bankart Repair for Anterior Shoulder Instability. *Tech Orthop* 1989;3:23.

+ 187. Zarins B, McMahon MS, Rowe CR. Diagnosis and Treatment of Traumatic Anterior Instability of the Shoulder. *Clin Orthop* 1993;291:75.

+ 188. Zuckerman JD, Matsen FA. Complications about the Glenohumeral Joint Related to the Use of Screws and Staples. *J Bone Joint Surg [Am]* 1984;66:175.

# CHAPTER 81

# INSTABILITY AND TENDON DISORDERS OF THE ELBOW

*Ronald E. Glousman*

**R. E. Glousman:** Los Angeles, California, 90045.

Anatomy
Biomechanics
Mechanisms Of Injury
Clinical Evaluation
Elbow Instability
Elbow Epicondylitis
Biceps and Triceps Rupture
Imaging
Indications and Treatment
Ulnar Collateral Ligament
Posterior Lateral Instability
Lateral and Medial Epicondylitis
Distal Biceps Rupture
Distal Triceps Rupture
Surgical Techniques
Ulnar Collateral Ligament Reconstruction Without Ulnar Nerve Transposition
Ulnar Collateral Reconstruction Combined with Submuscular Ulnar Nerve Transposition
Lateral Collateral Reconstruction
Lateral Epicondylitis
Medial Epicondylitis
Distal Biceps Rupture
Distal Triceps Tendon Rupture
Rehabilitation
Lateral Epicondylitis
Medial Epicondylitis
Distal Biceps Rupture
Distal Triceps Repair
Pitfalls and Complications
Ulnar Collateral Reconstruction
Lateral Collateral Ligament Reconstruction
Lateral Epicondylitis
Medial Epicondylitis
Distal Biceps Rupture
Repair of Distal Triceps Tendon Avulsion
Author's Perspective
Ulnar Collateral Ligament Reconstruction
Lateral Collateral Ligament Injury
Lateral Epicondylitis
Medial Epicondylitis
Distal Biceps Rupture
Distal Triceps Repair
Chapter References

While the elbow is a relatively stable hinge joint in flexion and extension, the ligament restraints and tendon insertions are subject to significant stress during the course of athletic activities. Whereas daily activities depend on the upper extremity for lifting and positioning, athletic activities require specific and precise motions for propulsive activity. Interaction between static restraints and the dynamic muscle unit allows for the versatile motion and power required in competitive performance. Most injuries to the elbow in the athletic population occur with overuse and repetitive activities, though acute traumatic injuries may occur (4,9,12,31,56). Typically, chronic repetitive stress injuries to the elbow occur during the valgus stresses imparted to the elbow in the course of athletic endeavors. The valgus forces seen during athletics produce tension overload to the medial soft-tissue restraints, compression injuries to the lateral radiocapitellar joint, and extension overload injuries within the posterior compartment (1,2,51,61). While less frequent in incidence, soft-tissue instability of the lateral capsule (lateral and posterior lateral instability) may occur (49).

Epicondylitis, whether lateral or medial, is a frequent source of elbow pain in both the athletic and the nonathletic populations (23,24,30,54,55). Although the term *tennis elbow* has become accepted as a descriptive and diagnostic term, it is something of a misnomer as it occurs more commonly in the nonathletic population.

Isolated disruption of the distal biceps tendon from the radial tuberosity, and avulsion of the triceps from the olecranon are relatively rare (3,6,7,11,16,40,45). Failure to diagnose and treat these two injuries may lead to significant disability, not only during athletic activity but with activities of daily living.

To best treat the various entities, a thorough understanding of the anatomy, pathophysiology, and clinical evaluation are necessary for an accurate diagnosis. While rehabilitation is usually successful in treating elbow tendon and ligament disorders, surgical alternatives now exist for those cases not responsive to an appropriate nonoperative treatment program.

## ANATOMY

The ulnar collateral ligament complex consists of an anterior, a posterior, and a transverse band (Fig. 81.1) (34,41,58,61). The anterior band, which is composed of two distinct bundles, is the most important restraint to valgus stress across the elbow. The ulnar collateral ligament is uniquely configured to provide stability throughout the full range of motion (ROM) of the elbow. The weaker posterior band, which is fan shaped, provides stability primarily beyond 90° of elbow flexion. The transverse ligament does not cross the ulnohumeral joint but exists as a thickening of the inferior joint capsule. The lateral collateral ligament complex is less consistent and not as well understood as the ulnar collateral ligament (Fig. 81.2). The annular part of the lateral collateral ligament originates from the lateral epicondyle and blends with the fibers of the annular ligament. The ulnar band of the lateral collateral ligament originates from the anteroinferior portion of the lateral epicondyle, crosses the radiocapitellar joint, and inserts on the tubercle of the supinator crest of the ulna.

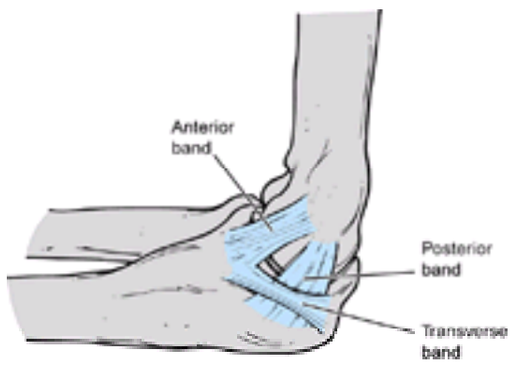

***Figure 81.1.*** Medial collateral ligament.

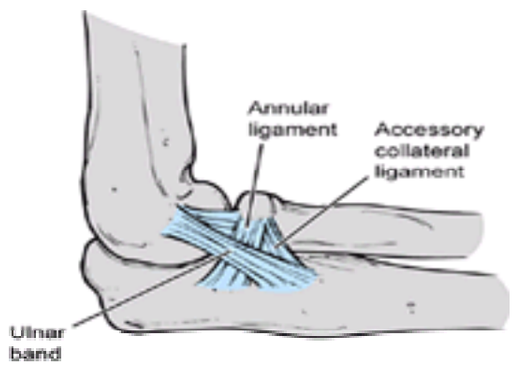


***Figure 81.2.*** Lateral collateral ligament.

## BIOMECHANICS

There are three primary elbow flexor muscles: brachialis, biceps, and brachioradialis (34,61). By inserting on the radius, the biceps acts as a supinator first and, second, flexes the elbow. With the arm pronated, the biceps is weaker because its functional leverage is less. The biceps also acts to decelerate elbow extension. The medial head of the triceps is most active during elbow extension, with the lateral and long head of the triceps supplementing the extension force. There is increased activity of the triceps with increasing elbow flexion resulting from its secondary action as a decelerator and from an increasing stretch reflex.

The remaining elbow-joint forces depend on arm position and the pattern of responding muscles. Maximal elbow flexion strength occurs at 90°, with decreasing force during extension (49,61). Because the flexor muscles have such a poor mechanical advantage with the elbow in relative extension, the isometric forces have to be greatest in this position. Flexor muscles introduce a posterosuperior compressive force across the distal humerus.

The baseball pitch has been divided into five stages, described as follows (Fig. 81.3) (22,32,39,60):

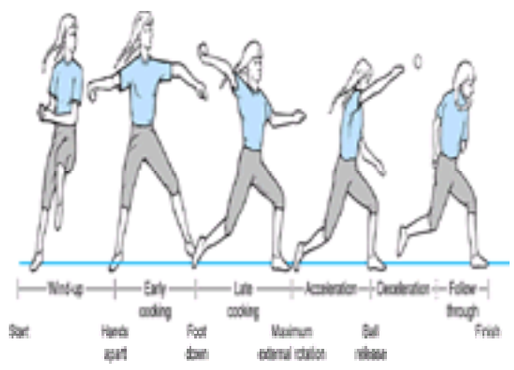


***Figure 81.3.*** Phases of the baseball pitch.

Stage 1. Windup or preparation stage, ending when the ball leaves the gloved hand.

Stage 2. Early cocking stage, a period of shoulder abduction and external rotation that begins as the ball is released from the nondominant hand and terminates with foot–ground contact.

Stage 3. Late cocking stage: Arm abduction continues until maximal external rotation at the shoulder is attained. Maximal valgus forces occur across the elbow during this stage.

Stage 4. Acceleration stage, starting with internal rotation of the humerus and ending with ball release.

Stage 5. Follow-through stage, starting with ball release and ending when all the motion is complete.

Analysis of the muscle groups about the elbow during a pitch has demonstrated low activity in all groups (61). In early and late cocking, muscle activity is of moderate intensity. Acceleration is an explosive, short stage with reduced muscle activity in follow-through. The low to moderate activity indicates that the muscle groups act primarily to position the arm to accept energy transfer from the upper arm and trunk.

Electromyographic analysis of the elbow in pitchers with ulnar collateral ligament insufficiency has been compared to that in pitchers without injury (32). Differences were seen during the late cocking and acceleration phases, which place the greatest stress on the ulnar collateral ligament. The extensor carpi radialis brevis and longus showed increased activity in the injured pitchers. The triceps, flexor carpi radialis, and pronator teres all showed less activity in the injured pitchers. One would expect enhanced muscle activity if the flexor carpi radialis and pronator teres were substituting for the deficient ulnar collateral ligament and functioning as dynamic stabilizers. However, the opposite was found. This pattern of asynchronous muscle activity may predispose the joint to further injury and attenuation of the ulnar collateral ligament.

Valgus stability of the elbow is derived equally from ulnar collateral ligament, the anterior joint capsule, and the bony articulation of the radiocapitellar joint when the elbow is in full extension (2,61,62,65). When the elbow is in 90° of flexion, the anterior bundle of the ulnar collateral ligament serves as a primary constraint of the elbow during valgus stress. Release or attenuation of the anterior portion of the ulnar collateral ligament leads to valgus laxity even when the radial head is present. The radial head is a secondary stabilizer that resists valgus and rotatory stresses when the anterior bundle of the ulnar collateral ligament is absent.

Stability of the elbow joint in resisting varus stress is provided by the bony architecture, the anterior joint capsule, and the lateral collateral ligament complex (2,49). The ulnar band of the lateral collateral ligament is the major stabilizer both in varus stress and in posterior lateral rotatory stress across the elbow joint.

## MECHANISMS OF INJURY

Most commonly, elbow injuries in the athletic population are caused by chronic repetitive overuse stress (37). Overhead athletic activities generate significant valgus forces that are transmitted to the stabilizing soft tissues about the medial aspect of the joint. These stresses are transmitted primarily to the ulnar collateral ligament complex, the flexor carpi ulnaris, and, to a lesser extent, the flexor–pronator muscle group. Poor throwing mechanics and/or muscle fatigue may lead to muscular dysfunction, allowing further stresses to be transmitted to the ulnar collateral ligament (4,37). When these forces are applied at a rate that exceeds tissue repair, progressive microscopic tearing and attenuation occurs within the ligament. Initially, this produces swelling and inflammation associated with pain and tenderness about the medial aspect of the joint. Further stresses from throwing may attenuate the ligament or cause further degeneration of the ligament fibers.

With repeated valgus stress over time, the ligament typically continues to attenuate, yielding clinically significant instability. With time, recurring and progressive medial

tension overload creates strong compressive forces over the lateral and posterior aspects of the joint. This may produce transient synovitis and osteochondral injuries, including osteochondritis dissecans and frank osteochondral fracture. Lateral compression stresses typically injure the capitellum, although radial head injuries may occur.

During the deceleration and follow-through phases of the throwing motion, extension injuries may occur within the posterior compartment (5,38). Repeated stresses may lead to a triceps muscle strain, avulsion of the tip of the olecranon process, hypertrophic olecranon spur formation, and posterior impingement.

Instability patterns of the lateral collateral ligament complex are uncommon and usually the result of an acute traumatic injury such as an elbow dislocation or a hyperextension injury (49,51,57,59). Lateral collateral ligament laxity rarely occurs after isolated varus stress to the elbow. A complete elbow dislocation is by far the most common cause for chronic lateral ligamentous insufficiency. It may also develop from elbow subluxations that may or may not be associated with fractures of the radial head. Iatrogenic lateral collateral ligament laxity may occur during release of the common extensor tendon for lateral epicondylitis or radial head excision with injury of the lateral collateral ligament complex.

Lateral epicondylitis begins as a microscopic tear within the origin of the extensor carpi radialis brevis (24,30,54). With repetitive trauma, this process results in mucoid degeneration and reactive granulation within the tendinous origin of the extensor carpi radialis brevis. It has been shown that this reactive granulation tissue contains a large number of free nerve endings and may lead to pain production with tension or compression. Nirschl and Pettrone (54) have described the histology as “angiofibroblastic hyperplasia.” The normal parallel orientation of the collagen fibers is disrupted by an invasion of fibroblastic and vascular granulation tissue. The overall intensity and duration of arm use will influence this tendinitis and degeneration. Lateral epicondylitis is directly related to activities that increase the tension and the stresses along the course of the wrist extensors and supinator muscles.

Athletic injuries that place a valgus force across the elbow may cause inflammation of the flexor–pronator muscle mass. The pronator teres and flexor carpi radialis are the most common sites of pathologic changes that include tissue overload with resultant microscopic tearing, tendinitis, and degeneration.

Distal biceps tendon ruptures typically occur in well-developed muscular men such as laborers and body builders (7,8,47). The majority of ruptures involve the dominant extremity and usually result from a single traumatic event with an intense biceps contraction overwhelmed by an unanticipated extension force. Most injuries occur when lifting, pulling, or straining with heavy objects. Chronic degeneration of the tendon of the radial tuberosity has been seen with both partial and complete rupture, and it has been postulated that chronic inflammation of the bursa at the radial tuberosity may contribute to degeneration of the biceps tendon, making the tendon more susceptible to rupture.

The mechanism of injury of triceps tendon avulsion is typically a fall on an outstretched arm (3,6,21,26,67). This occurs as a result of deceleration stresses superimposed on a contracting triceps muscle with or without a concomitant blow to the posterior aspect of the elbow. Most commonly, rupture occurs as the result of an abrupt, forceful, eccentric contraction of the triceps.

## CLINICAL EVALUATION

The typical differential diagnosis of medial elbow pain in the adult athlete is the following:

- Ulnar collateral ligament tendinitis and/or insufficiency
- Medial epicondylitis with a strain of the flexor–pronator muscle mass
- Ulnar neuritis

Typically, those activities that produce medial elbow pain with overhead activities and valgus stress will affect the ulnar collateral ligament. As the ulnar collateral ligament attenuates, there may be traction on the cubital tunnel producing secondary symptoms of ulnar neuritis. Primary ulnar neuritis in the overhead athlete is rare but can occur, especially if there is a bony spur in the cubital tunnel or a subluxating ulnar nerve that causes the nerve to become scarred and irritated over time (15). Patients with medial epicondylitis tend to exhibit pain primarily over the medial epicondylar origin rather than over the ulnar collateral ligament, which will tend to be extenuated with resisted palmar flexion of the wrist and fingers and typically not affected by valgus stress to the elbow. Patients with medial epicondylitis tend to have a history of pain associated with forearm and wrist activities such as pushing a heavy object, or with overuse of the flexor–pronator muscle mass in athletic activities such as golf. While symptomatic cervical radiculitis typically is not confused with lateral epicondylitis, the cervical spine must also be evaluated to rule out referred radicular pain that occurs isolated to the lateral epicondylar region.

### ELBOW INSTABILITY

The clinical diagnosis of elbow instability primarily depends on the patient's history and physical findings. Radiographic evaluation may provide correlative information but is not the basis by which a diagnosis is made. Patients with elbow instability typically give a history of repetitive stress to the elbow, though on occasion a single event may be causative.

The athlete who presents with medial-sided laxity of the ulnar collateral ligament will describe an insidious but progressive onset of medial elbow pain. The pain typically occurs during an athletic endeavor such as throwing a baseball, serving a tennis ball, or spiking a volleyball. Pain tends to be most noticeable during the late cocking and acceleration phases of the overhead motion but may progress over time to include pain during the entire activity, and it may even progress to include pain with activities of daily living. Athletes who have had ulnar collateral ligament insufficiency for a period of time often present with symptoms of associated ulnar neuritis secondary to traction stresses placed on the ulnar nerve during the overhead activity (31). Rest from activity will typically relieve the symptoms.

On occasion there is an acute event that occurs during an athletic activity, when the athlete senses a pop or sudden sharp pain along the medial aspect of the elbow joint. This may be the result of a valgus stress applied to a previously asymptomatic attenuated ligament. Acute injuries are typically associated with traumatic events such as falling on the outstretched elbow and may rarely present as a postreduction complication following an elbow dislocation.

Pain that originates from ulnar collateral ligament insufficiency typically occurs along the course of the ulnar collateral ligament. An athlete may complain of fatigue over time and lack of normal strength associated with athletic activities. As the inflammation along the ulnar collateral ligament progresses, athletes may notice pain and tenderness beyond the ulnar collateral ligament, extending into the cubital tunnel and flexor–pronator muscle mass. When the inflammation has progressed to include not only the ulnar collateral ligament but also the flexor–pronator muscle mass and ulnar nerve, a very careful assessment is required to help differentiate between the primary source of the pathology and the secondary problems.

Physical examination for those with ulnar collateral ligament insufficiency typically reveals tenderness along the course of the ulnar collateral ligament, especially at the mid and distal portions rather than the proximal origin at the medial epicondyle. Typically, the examiner will not note tenderness at the medial epicondyle itself unless there has been an associated inflammation of the flexor–pronator muscle mass.

The cubital tunnel is typically without tenderness unless there has been repeated ulnar neuritis secondary to traction stresses. When the ulnar nerve has been inflamed repeatedly, there may be a positive Tinel sign, and in addition there may be other focal ulnar nerve findings such as intrinsic muscular atrophy and loss of sensation in the ulnar distribution of the hand (27). Testing for valgus instability is best performed with the patient seated and his hand and wrist securely held between the examiner's elbow and trunk. The examiner firmly grasps the patient's elbow and proximal forearm while simultaneously palpating the ulnar collateral ligament at the medial joint line. Varus and valgus stress can then be applied to determine the presence of an end point and the degree of laxity (Fig. 81.4). It is important during stress testing that the elbow be flexed beyond 25° to eliminate the stabilizing effect of the olecranon within the olecranon fossa. It is also critical to compare the involved with the uninvolved elbow to differentiate between normal laxity and pathologic instability. Even asymptomatic overhead athletes tend to have increased medial laxity, and therefore the physical findings of laxity must be correlated with the areas of tenderness and the characterization of pain that occurs with activities. When ulnar collateral ligament insufficiency has been present over time, there may also be findings consistent with lateral compression injuries, including swelling, tenderness, or even crepitation around the radiocapitellar joint. Chronic ulnar collateral ligament insufficiency may cause or contribute to valgus extension overload that affects the posterior compartment, with findings of tenderness, crepitation, and even loose bodies within the posterior compartment. Decreased ROM and synovitis may result from the chronic secondary effects of ulnar collateral ligament insufficiency.

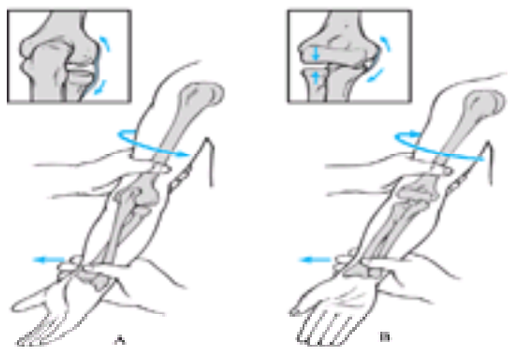

***Figure 81.4.*** Varus and valgus instability.

Patients with lateral collateral ligament insufficiency have symptoms that vary from frank recurrent dislocations to minor mechanical symptoms from occult subluxations. Patients may complain of pain, tenderness, catching, snapping, or frank symptoms of instability. Patients who have recurrent lateral subluxation can be mistakenly diagnosed as having a recurrent dislocation of the radial head, which may lead to unsuccessful and improper treatment. The typical patient has had an initial traumatic injury, such as a sprain, dislocation, or fracture of the elbow, or she has had surgery involving the lateral aspect of the elbow. Following this, she will have symptoms of recurring subluxation that can include clicking, catching, snapping, or even locking.

Patients with varus instability may be noted to have laxity on varus stress. O'Driscoll et al. (57) described patients with posterolateral instability and described the lateral pivot-shift test (Fig. 81.5) to identify these patients. This test involves flexion of the elbow from an extended position and supination of the forearm while the valgus stress and axial load is applied. This maneuver subluxates or dislocates the radial head posteriorly with rotatory subluxation of the ulnohumeral joint. When the lateral pivot-shift test is positive, there is a palpable and visible reduction of the radiohumeral joint together with the ulnohumeral joint when the elbow is flexed beyond 40°. The pivot-shift test may fail to cause apprehension in patients or may appear falsely negative in patients with severe instability when the elbow does not reduce with flexion. Be aware that the varus stress test may be normal in the presence of a positive pivot-shift maneuver and clinically significant lateral insufficiency.

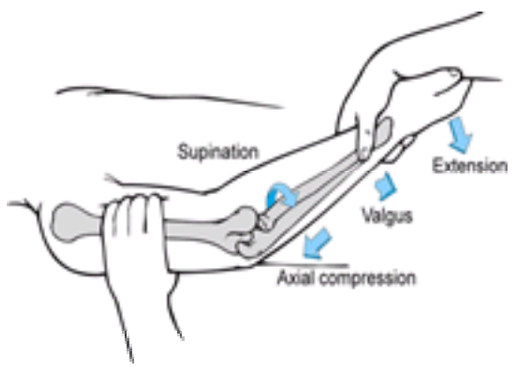


***Figure 81.5.*** Pivot-shift test.

**ELBOW EPICONDYLITIS**

The pain of lateral epicondylitis is insidious and progressive, and it occurs with grasping and lifting. While the term *tennis elbow* is typically used for this syndrome, most patients develop the symptoms from activities such as lifting at work, carrying luggage and briefcases, and typing (30,52,55). Pain originates over the lateral epicondyle but may radiate into the proximal forearm overlying the proximal extensor musculature. As the condition progresses, even light daily activities such as shaking hands, picking up a bottle, or grasping for a carton of milk may cause symptoms. During tennis, the lateral epicondylar pain typically occurs at the point of ball contact during the ground strokes and is more often noted with backhand than forehand strokes. Differential diagnosis of lateral epicondylitis includes the supinator syndrome with entrapment of the posterior interosseous nerve. Typically, these patients have pain overlying the proximal supinator musculature exacerbated with activities that include pronation and supination of the forearm. Usually there will be absence of tenderness along the lateral epicondyle unless there is combined lateral epicondylitis and radial nerve entrapment. Differential diagnosis may be difficult because posterior interosseous nerve entrapment may coexist with lateral epicondylitis in about 5% of patients. A selected injection of lidocaine in the lateral epicondyle or the proximal supinator may help differentiate these two diagnoses. Other causes of lateral elbow pain include arthrosis, osteochondral injuries to the capitellum, and lateral collateral ligament insufficiency.

Examination reveals tenderness overlying the extensor tendon origin at the lateral epicondyle. Resisted wrist and finger extension will reproduce the patient's pain along the lateral epicondyle, and resisted long-finger extension often produces the most pain. ROM of the elbow is usually normal unless there are other conditions such as arthrosis or bony elbow impingement. After repeated cortisone injections (19,20), there may be atrophy of the skin and subcutaneous tissue overlying the lateral epicondyle, causing a very prominent bony epicondyle.

Medial epicondylitis often presents as pain along the medial epicondyle, which is aggravated with resisted palmar flexion of the wrist and fingers, and pronation with the forearm. The onset of pain typically occurs in an insidious fashion, although there are cases that are traumatic in origin and present with acute onset of pain. The medial epicondyle pain is typically aggravated with activities that involve stress across the flexor–pronator muscle mass; it usually is not associated with valgus stress across the joint unless there is an associated inflammation of the ulnar collateral ligament. Pain along the cubital tunnel and ulnar nerve symptoms typically are absent unless there is an associated ulnar neuritis.

Examination will demonstrate tenderness overlying the origin of the flexor–pronator muscle mass at the medial epicondyle, and possibly radiation of tenderness into the substance of the flexor–pronator muscle mass. Resisted wrist flexion and forearm pronation will recreate the patient's pain. Elbow ROM is not affected by this condition unless there are unrelated entities such as osteoarthritis. While medial epicondylitis usually occurs as an isolated entity, associated ulnar neuritis may occur and, if it does, there will be tenderness along the cubital tunnel with a positive Tinel sign.

**BICEPS AND TRICEPS RUPTURE**

Distal biceps rupture most often occurs with the onset of a sudden sharp tearing sensation or pop within the anterior antecubital fossa. Subsequently, antecubital swelling and ecchymosis may occur, with pain aggravated by any flexion and supination of the forearm. The intense pain will change to a persistent dull ache, and the biceps musculature will retract proximally, yielding an asymmetrical appearance compared to the opposite extremity. The patient will complain of weakness and fatigue of the arm, especially with those activities that require elbow supination (such has using a screw driver) and repetitive elbow flexion and supination (such as hammering).

Physical examination of a distal biceps rupture can reveal deformity of the proximal biceps, but this deformity can be masked by antecubital swelling and ecchymosis. With palpation, there may be tenderness along the course of the distal biceps and a defect may be palpated. An intact lacertus fibrosus can be mistakenly interpreted as the biceps tendon, but comparison to the opposite extremity will reveal the differences between the injured arm and the normal intact biceps tendon. Elbow ROM will not be changed except as a result of pain at the extremes of motion. There will be decreased flexion strength and weakness in supination.

Patients with a triceps rupture will typically give a history of falling on an outstretched arm with acute pain and a tearing sensation. Examination reveals loss of the normal posterior contour of the arm and a palpable defect in a complete disruption. In a partial tear, tenderness typically is present at the muscle–tendon junction, but a defect is not palpable. Extension strength of the elbow is diminished or absent. Assess extension power with the patient seated and her arm draped over the back of a chair, or with the patient in a prone position with her forearm hanging over the table. In the normal extremity, squeezing the triceps muscle belly will produce some elbow extension, but no motion will occur if there is a complete rupture. If a traumatic event has not been eliminated as the cause of the triceps tendon injury, look for other sources such as referred cervical nerve root lesions.

## IMAGING

Plain radiographs are useful to diagnose radiocapitellar joint arthrosis, posterior elbow osteophytes, or loose bodies in particular. Radiographs may identify ossification within the ulnar collateral ligament, which typically is a sign of chronic inflammation rather than of an acute injury to the ligament (Fig. 81.6). Stress radiographs may reveal excessive laxity and medial joint line opening, especially compared to the opposite elbow. In patients with ulnar collateral ligament instability, radiographic valgus stress testing may be used to document the degree of instability when the diagnosis is in question. MRI may be used as an adjunctive diagnostic tool, as it will clearly delineate pathology within the ulnar collateral ligament (Fig. 81.8) (43). Unfortunately, the magnetic resonance imaging (MRI) scan is not always capable of delineating the difference between degenerative tendinitis that is otherwise asymptomatic, and symptomatic tendinitis or a tear with associated laxity. An MRI scan revealing a normal ulnar collateral ligament (Fig. 81.7) can provide impetus to search for a different diagnosis. Arthrography is not useful because of frequent false negative findings in cases of chronic ulnar collateral ligament insufficiency with an intact capsule.

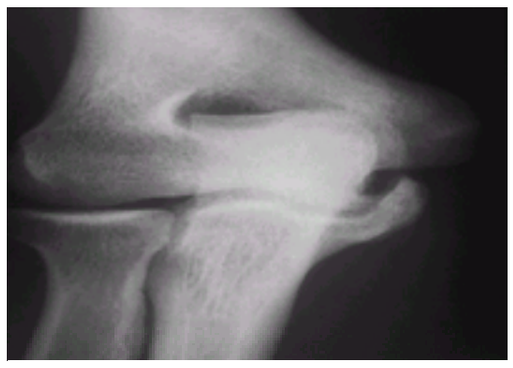

***Figure 81.6.*** Ulnar collateral ligament calcifications.

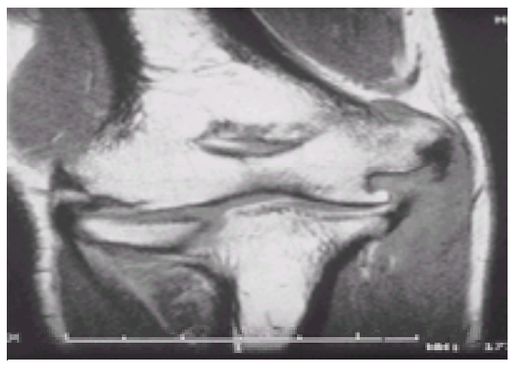

***Figure 81.7.*** MRI showing normal ulnar collateral ligament.

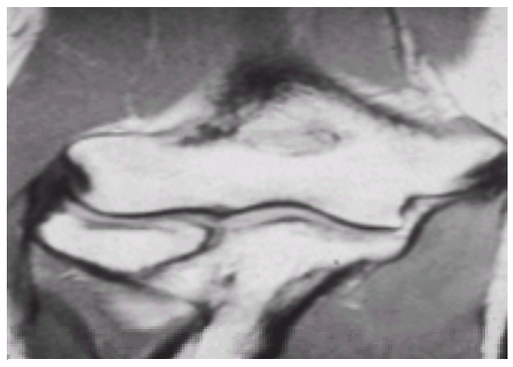

***Figure 81.8.*** MRI showing a tear in an ulnar collateral ligament.

Radiographic evaluation for lateral collateral ligament instability is typically unrevealing except for associated and unrelated bony pathology. Varus stress to the elbow typically does not reveal insufficiency, even when present. The presence of asymmetrical joint opening under radiographic varus stress, when present, may help to confirm the findings of examination.

Radiographs of those with lateral epicondylitis typically are normal, though approximately 20% to 25% may show calcification within the soft tissues about the lateral epicondyle (17,44). The occurrence of this calcification has no prognostic implication. These and other radiographic modalities such as MRI do not appear to add further diagnostic information (Fig. 81.9).

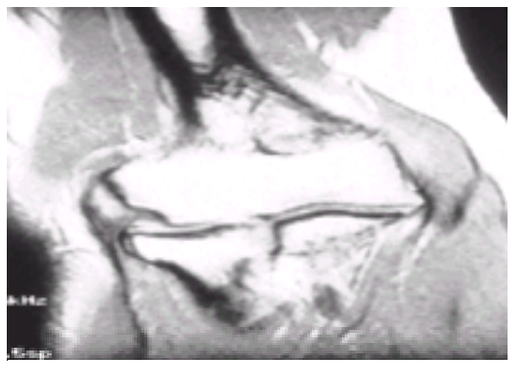

***Figure 81.9.*** MRI demonstrating lateral epicondylitis.

Plain elbow radiographs of those with medial epicondylitis typically are normal. Throwing athletes may have an associated ulnar traction spur and calcification within the ulnar collateral ligament.

Radiographs of a biceps tendon rupture may reveal irregularity of the biceps tuberosity, suggesting an underlying degenerative etiology. Elbow radiographs in those with a triceps avulsion may reveal a small avulsion fracture from the olecranon. It has been suggested that the “flake sign” will be present in two thirds of cases with a complete triceps rupture (48,64). When the physical examination is not revealing or is confusing due to significant swelling, an MRI scan may be valuable in differentiating between an incomplete and a complete tear of the triceps or biceps muscle tendon unit (Fig. 81.10). MRI is not necessary when complete rupture of

either the biceps or the triceps tendon is clinically obvious.

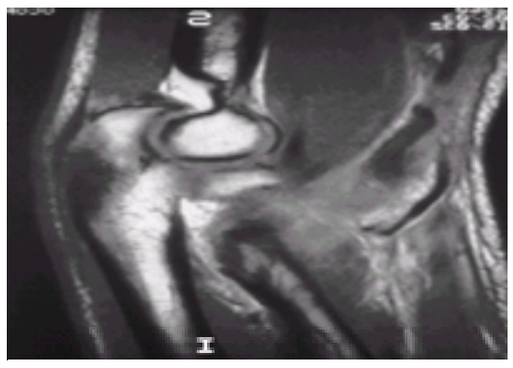

***Figure 81.10.*** MRI showing a torn distal biceps tendon.

## INDICATIONS AND TREATMENT

### ULNAR COLLATERAL LIGAMENT

Rest from the causative etiology (overhead throwing activities), nonsteroidal anti-inflammatory drugs (NSAIDs), and other modalities (e.g., ice) are the main focus of the initial treatment. Steroid injections of the ulnar collateral ligament can decrease the biomechanical strength of the ligament as well as mask clinical symptoms allowing too early a return to activity. After swelling and pain have subsided, a flexibility and strengthening program is completed before return to throwing. While most athletes with ulnar collateral ligament tendinitis and insufficiency will respond to conservative treatment, failure to do so after 3 to 6 months of treatment necessitates surgical intervention (13,22). Avoidance of valgus stresses avoids aggravation and possible attenuation of the ligament. Bracing, while theoretically feasible, has not proved efficacious. Athletes involved in valgus stress activities such as throwing, tennis, and volleyball are the most likely to fail nonoperative treatment.

### POSTERIOR LATERAL INSTABILITY

Although ulnar collateral insufficiency may be successfully treated nonoperatively, Morrey and O'Driscoll (53,57) have found that recurrent elbow instability due to lateral collateral ligament laxity does not improve with nonoperative treatment. As lateral collateral ligament insufficiency typically interferes with daily functional activities, early surgery is recommended in most cases. Less active patients who do not have significant instability may avoid surgery by modifying activities and using a hinge brace with an extension block.

### LATERAL AND MEDIAL EPICONDYLITIS

Treatment of epicondylitis is typically nonoperative, with surgery reserved for the minority who do not respond to conservative treatment (14). Advise modification or avoidance of all athletic and daily activities that aggravate symptoms. Useful measures include cryotherapy, NSAIDs, and counterforce bracing to reduce tensile stress along the epicondyle (55). A counterforce brace may inhibit full musculature expansion and therefore decrease the tension developed by the inflamed tendon proximal to the brace (29,35).

If the patient does not improve with conservative measures, corticosteroid injection can be administered (42). Mix the steroid with a local anesthetic. Avoid direct injection into the tendon, and inject over the inflamed tendon. If the injection has been efficacious but symptoms recur, administer a maximum of two to three injections over a 3-month period. If the etiology results from athletics, evaluate the biomechanics and equipment used during the sport. For example, a tennis racquet should be assessed for proper grip size. Lighter racquets made of low vibration materials and strung less tightly may dampen the impact forces on the extensor origin. Upon improvement in symptoms, institute a rehabilitation program to regain strength and flexibility. As strength, endurance, and flexibility improve, prescribe progressive eccentric and concentric resisted exercises. Indications for surgery include failure of a well-managed conservative program over a period of 3 to 6 months and impairment of athletic or daily living activities.

### DISTAL BICEPS RUPTURE

Surgical treatment remains the treatment of choice for an acute complete distal biceps rupture (8,16,46), although some recommend conservative treatment (18). Patients treated nonoperatively gain improvement in elbow flexion and supination over time, but they typically have significant loss of both elbow flexion and supination strength, as well as endurance (7,48). Isokinetic muscle testing has documented deficits in elbow flexion of 30% to 36% and supination deficits of 40% to 45% following conservative treatment (50).

In the case of delayed diagnosis, primary repair can be accomplished as late as 6 weeks following injury. Mobilization of the retracted tendon may be required. Late reconstruction has been used for those who have persistent symptoms, although it is not possible to reattach the distal biceps tendon to the radial tuberosity. Options for late reconstruction include direct repair of the biceps tendon to the brachialis muscle, which helps to restore elbow flexion strength but will not change the supination strength deficit. Late reconstruction can also involve an interposition graft such as a facial autograft (36).

Partial tears of the distal biceps tendon, while rare, do exist and are best diagnosed with an MRI scan. Provided that there is continuity of tendon to the radial tuberosity, partial tears may be treated conservatively. In the face of persistent symptoms, especially with resisted flexion and supination activities, the patient is at increased risk for eventual rupture of the tendon. Clinical judgment, with consideration of the severity of the patient's symptoms and functional status, dictates whether early surgical intervention or continued conservative treatment best suits the individual patient.

### DISTAL TRICEPS RUPTURE

Surgical repair is the treatment of choice for complete triceps tendon ruptures. When there is complete rupture of the triceps tendon mechanism, significant disability occurs without surgical repair (6,28,63). Triceps function is also important for the elderly who require the use of ambulatory aides and transfers because of lower extremity impairment. In the presence of a partial tear, conservative treatment may be employed. An MRI scan may be helpful in evaluating the degree of a partial tear. Persistent symptoms, such as pain and weakness with attempted elbow extension, despite conservative treatment, are indications for surgical treatment.

## SURGICAL TECHNIQUES

### ULNAR COLLATERAL LIGAMENT RECONSTRUCTION WITHOUT ULNAR NERVE TRANSPOSITION

Prior to a 1992 review of the operative technique for ulnar collateral ligament reconstruction (22), the ulnar nerve was always transferred anteriorly in association with an ulnar collateral ligament reconstruction. It has been shown, however, that there is an increased complication rate with transposition of the ulnar nerve, and therefore I now transfer the nerve only when clinically indicated. When the patient does not have chronic ulnar nerve symptoms, leave the ulnar nerve within the cubital tunnel. This requires a change in the technique for transfixing the ulnar collateral ligament graft proximally at the medial humerus. When the patient has clinically significant ulnar neuritis, transfer the ulnar nerve anteriorly in a submuscular fashion in conjunction with the ulnar collateral ligament reconstruction.

- Make an incision just above the medial epicondyle extending proximally 3 cm and distally 5 cm (Fig. 81.11*A*). Carry the dissection down to the fascia overlying the flexor–pronator muscle mass and overlying the cubital tunnel.

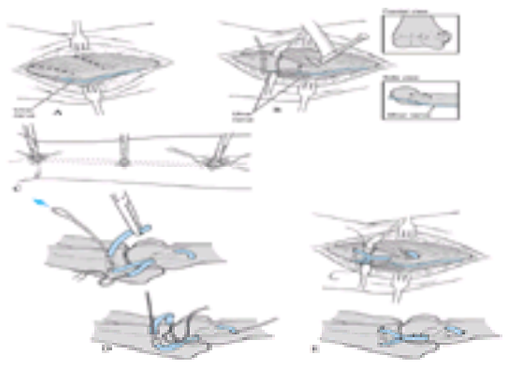

***Figure 81.11.*** Ulnar collateral reconstruction. **A:** Approach. **B:** Bone tunnel placement. **C:** Harvesting of palmaris longus tendon. **D:** Passage of graft. **E:** Fixation of graft.

- Protect and identify the underlying cutaneous branches of the medial antebrachial cutaneous nerve. Injury of this nerve will cause paresthesias or complete loss of sensation along the proximal medial forearm. In addition, there is the risk of developing an underlying neuroma, which could require further surgery. The cutaneous nerves tend to lie just above the flexor–pronator muscle fascia and to run in an oblique direction, from proximal lateral to distal medial, often parallel to the basilic vein.
- Identify the cubital tunnel and, using palpation, visualize the course of the ulnar nerve along the posterior aspect of the distal intermuscular septum and through the cubital tunnel, and its passage into the flexor carpi ulnaris.
- Identify the flexor–pronator muscle mass and its origin on the medial epicondyle. Split the muscle horizontally in line with its fibers overlying the ulnar collateral ligament. Bluntly dissect through the muscle down to the ulnar collateral ligament and surrounding capsule. Inspect the ulnar collateral ligament both by observation and palpation. There may be signs of obvious tissue degeneration, attenuation, or complete disruption of the ligament. Make a longitudinal incision in the ligament to inspect its substance. Changes may be revealed that were not apparent from the surface.
- Inspect the joint and determine the degree of valgus opening. If the ligament is lax, elevate the ligament and capsule in an anterior and posterior direction in subperiosteal fashion to gain exposure for subsequent placement of the ulnar collateral ligament graft into bony tunnels.
- Harvest the palmaris longus tendon graft (Fig. 81.11*B*). Previous studies (22) have not demonstrated any clinical difference with respect to the graft, including ipsilateral arm, contralateral arm, or tendon graft from the leg, such as plantaris or strip of Achilles tendon. When the palmaris longus tendon graft is present, it is the graft of choice; it is typically harvested from the ipsilateral extremity unless it is considered to be significantly smaller then the palmaris longus tendon graft from the opposite extremity. To harvest the palmaris longus graft, create a 2 cm transverse skin incision within the distal flexor crease of the wrist. Protect the median nerve and palmar cutaneous branches as the tendon is isolated at its insertion into the palmar fascia. Make two additional transverse incisions overlying the palmaris longus tendon, the most proximal incision over the muscle–tendon junction and an additional incision half-way between the muscle–tendon junction and the wrist crease. Free the tendon from its origin into the palmar fascia and place a #0 nonabsorbable braided suture through the end of the free tendon graft. Retrieve the tendon through the middle incision and then proximally at the muscle tendon junction. Finally, place a #0 nonabsorbable braided suture through the proximal end of the tendon.
- Create bone tunnels proximally and distally (Fig. 81.11*C*) with the tunnels having adequate size for the tendon graft. Typically, a 3.2 mm drill bit makes an adequate bony tunnel for passage of the graft. Place the converging drill holes at the proximal ulna orientated in a vertical direction and at the level of the coronoid tubercle just distal to the articular surface of the proximal ulna. Make the drill holes proximally at the medial epicondyle at the level of the anatomic origin of the anterior bundle of the ulnar collateral ligament. Begin the drill hole midway between the base and the tip of the medial epicondylar prominence. The holes are fashioned with a single entrance hole at the medial epicondyle, which then diverges into two separate anterior-superior and posterior-superior holes more proximally. Drill the posterior-superior hole to exit posterior to the first anterior-superior hole, but not in the cubital tunnel. Split the flexor–pronator muscle mass at a second location just proximal to the medial epicondyle in a longitudinal fashion to facilitate placement of the anterior-superior and posterior-superior drill holes.
- Pass tendon graft through the respective proximal and distal bone tunnels (Fig. 81.11*D*). Pull the graft taut and move the joint through a ROM to assess isometricity and valgus stability. Excess length of the tendon graft can be routed back through a bone tunnel upon itself to provide more tissue to overlie the joint. Avoiding valgus stress, pull the graft taut and suture it to itself with #0 nonabsorbable sutures (Fig. 81.11*E*) at 45° of elbow flexion.
- Close the remnant of the original medial collateral ligament and capsule in a side-to-side manner overlying the tendon graft, imbricating the overlying capsule with a #0 or #1 nonabsorbable suture.
- Release the tourniquet and achieve hemostasis. Repair the flexor–pronator muscle mass in a side-to-side manner. Close the wound with careful attention to avoid injury to the cutaneous nerve. Apply a long-arm posterior plaster splint to immobilize the elbow in 90° of flexion and neutral forearm rotation avoiding any valgus stress.

**ULNAR COLLATERAL RECONSTRUCTION COMBINED WITH SUBMUSCULAR ULNAR NERVE TRANSPOSITION**

In patients with chronic (as opposed to transient) ulnar neuritis associated with instability, a decompression of the ulnar nerve and submuscular ulnar transposition may be performed in conjunction with the ulnar collateral ligament reconstruction. The difference in technique requires removal and subsequent repair of flexor–pronator muscle mass origin at the medial epicondyle.

- Make a similar skin incision, except that 2–3 cm of proximal extension may be needed to expose the ulnar nerve and intermuscular septum. Again, protect the branches of the medial antebrachial cutaneous nerve.
- Unroof the cubital tunnel and free the ulnar nerve, tracing it proximally to the arcade of Struthers, which must be released. Mobilize the ulnar nerve using a Penrose drain for retraction. Dissect the ulnar nerve from the epicondylar groove. Divide the arcuate ligament and follow the nerve to the interval between the two heads of the flexor carpi ulnaris. The articular branches will be sacrificed but preserve the motor branches to the flexor carpi ulnaris during the distal dissection. Excise the medial intermuscular septum for 5–8 cm proximal to its attachment to the medial epicondyle to ensure that the transposed nerve will not rest against its edge and cause a new site of compression or impingement. Avoid the numerous vessels that underlie the intermuscular septum and are part of the extensive collateral circulation of the elbow.
- Detach the flexor–pronator muscle group 1–2 cm distal to the medial epicondyle, leaving the proximal tendon origin for later reattachment (Fig. 81.12*A*). Bluntly elevate the flexor–pronator muscle mass, avoiding injury to the median nerve and its branches. At this point, palpate and inspect the underlying ulnar collateral ligament.

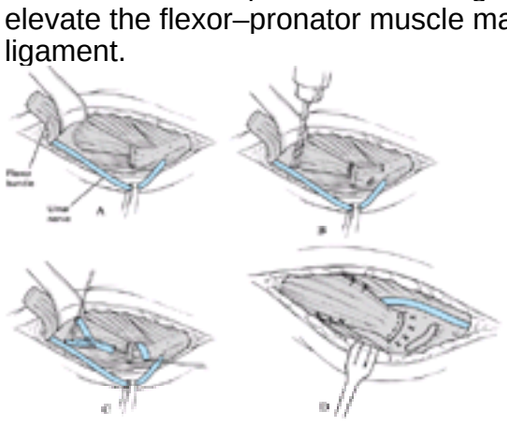

***Figure 81.12.*** Ulnar collateral reconstruction with ulnar nerve transfer. **A:** Exposure. **B:** Bone tunnels. **C:** Fixation of graft. **D:** Submuscular ulnar nerve transfer.

- Incise the ligament and capsule in a longitudinal fashion as previously described. Explore the joint and note the degree of valgus laxity and ligamentous pathology. Obtain a tendon graft in the manner previously described.
- Make converging drill holes in the proximal ulna (as previously described) at the level of the coronoid tubercle. The bone tunnels within the medial epicondyle may be made in the manner noted previously, or they may be made to exit within the cubital tunnel (Fig. 81.12*B*). If the proximal holes exit within the cubital tunnel, drill the hole again to create a single entrance hole anteriorly at the level of the anatomic origin of the anterior bundle of the ulnar collateral ligament between the base and tip of the medial epicondylar prominence. Make two divergent drill holes within the cubital tunnel, allowing a bone bridge within the cubital tunnel between the two posterior holes.
- Pass the graft in figure-eight fashion. Apply tension and observe the graft during ROM and valgus stress. If there is extra length of the graft, it may be passed back upon itself through one of the bony tunnels. Secure the graft by suturing it to itself with a nonabsorbable suture (Fig. 81.12*C*). Close the overlying capsule in a side-to-side imbricating manner with a #0 or #1 nonabsorbable suture.
- At this point, transpose the ulnar nerve anteriorly (Fig. 81.12*D*). Place the nerve anterior to the medial epicondyle and beneath the flexor–pronator muscle mass. It is important to take the elbow through a ROM to ensure that there are no areas of impingement along the new course of the ulnar nerve: Look for any

impingement on sutures or on a portion of the underlying ulnar collateral ligament repair.

- Place the sutures for reattachment of the flexor–pronator muscle mass under direct vision to avoid injury to the underlying ulnar nerve. Do not tie the sutures until all have been placed. This repair is by nonabsorbable suture to the tendinous cuff of tissue left at the medial epicondyle or through drill holes made within the medial epicondylar bone. Tie the sutures and observe that the ulnar nerve glides freely without any impingement or entrapment from the flexor–pronator muscle mass repair. Assess the integrity of the flexor–pronator repair during elbow ROM. Wound closure, postoperative immobilization, and rehabilitation are then performed as for patients without ulnar nerve transposition.

## LATERAL COLLATERAL RECONSTRUCTION

- Approach the elbow through a modified lateral Kocher's incision. Expose the joint capsule by reflecting the anconeus muscle posteriorly. Make a longitudinal incision through the extensor tendon origin to the lateral epicondyle and reflect the tendon anteriorly from the lateral epicondyle to expose the origin of the radial collateral ligament.
- Palpate the ulnar attachment of the lateral ulnar collateral ligament at the tubercle of the supinator crest deep to the fascia over the extensor carpi ulnaris and the supinator muscles. Reflect the triceps and anconeus from the posterior margin during reflection of the common extensor tendon origin. It is important to preserve the underlying capsule and the lateral ulnar collateral ligament.
- Findings may reveal a lax ulnar band of the lateral collateral ligament proximal to the annular ligament. The lateral pivot-shift maneuver can demonstrate subluxation of the radial head and ulnohumeral joints, as well as attenuation of the capsule. Make an arthrotomy at the level of the radiocapitellar and ulnohumeral joints. Treat any associated loose bodies, synovitis, and osteochondral injuries. Place plication sutures within the anterior and posterior aspect of the joint capsule, tying the sutures at the completion of the procedure.
- At this point, decide whether to do a ligamentous repair or a ligamentous reconstruction. When the lateral ligament is attenuated, reinforce the repair with an autogenous free tendon graft, typically using the palmaris longus, although other sources such as a plantarus or a medial strip of Achilles tendon may be used.
- If the lateral collateral ligament has become detached from the humerus, treat it with two #1 nonabsorbable sutures placed in Bunnell fashion in the lateral ligamentous complex including the radial collateral ligament and lateral ulnar collateral ligament. Bring these sutures through drill holes placed in the anatomic origin of the ligament at the midportion of the lateral epicondyle. Address further capsular redundancy by plicating the anterior and posterior capsule (Fig. 81.13).

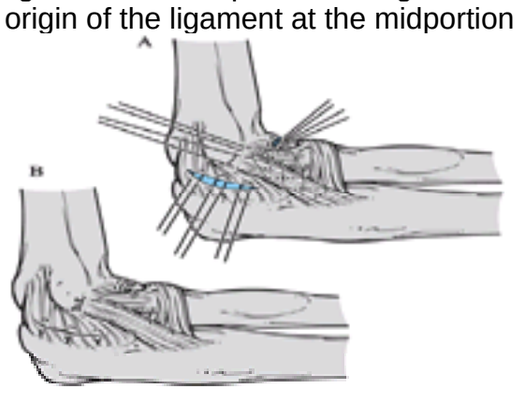


***Figure 81.13.*** Lateral collateral ligament repair. **A:**Placement of sutures for repair. **B:**Completion of the repair.

- Obtain a tendon graft as previously described for the ulnar collateral ligament. As with the ulnar collateral ligament reconstruction, an osseous tunnel must be created in the correct anatomic position (Fig. 81.14). Identify the insertion site of the lateral ulnar collateral ligament on the tubercle of the supinator crest of the ulna by palpation or by stressing the elbow in supination and varus. Make one hole in the ulna just posterior to this point, and another proximally near the annular ligament, so that a bridge of bone of 1–1.25 cm spans the holes.

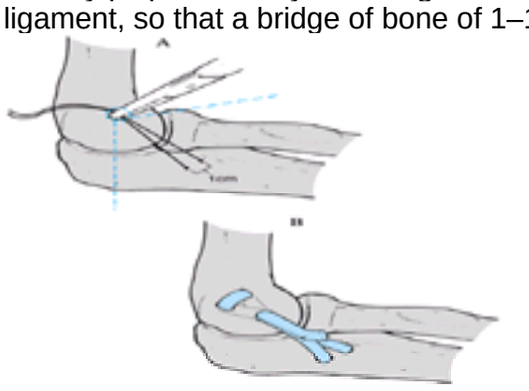


***Figure 81.14.*** Lateral collateral ligament (LCL) reconstruction. **A.**Determine the isometric point for the LCL. **B.**Drill holes and insert the polmaris longus tendon as described in the text.

- Determine the isometric point on the lateral epicondyle. Place a suture through the two holes in the ulna and extend it to the lateral epicondyle, holding it against the spot determined while flexing and extending the elbow to confirm isometricity.
- At the chosen site, drill the hole eccentrically in a posterior and proximal direction with reference to the isometric point. Exit posterior to the supracondylar ridge and 2 cm proximally. With a bone bridge of 1–1.5 cm, create a reentry tunnel from this site back to the original entry at the epicondyle.
- Pass the graft though these osseous tunnels using a suture passer, and flex the elbow to 30° with full pronation. Close the joint capsule so that the tendon graft becomes extraarticular and does not rub against the lateral margin of the capitellum.
- With tension placed on the tendon graft, use #0 nonabsorbable sutures to anchor the tendon to itself and to the surrounding soft tissues. Reapproximate the anconeus and extensor muscles along with the common extensor origin, and complete routine closure.

## LATERAL EPICONDYLITIS

Percutaneous release of the extensor tendon is described, but it is not recommended in the active population (10,33).

- Place the patient in a supine position with the upper extremity supported by an arm board. Drape the involved extremity free to allow for control of elbow and arm position during the procedure. Begin an incision just proximal and posterior to the lateral epicondyle, extending distally to the radiocapitellar joint (Fig. 81.15).

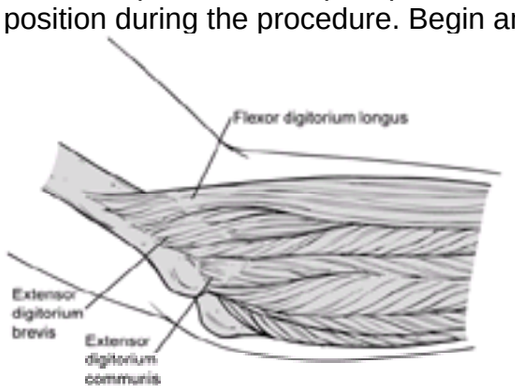


***Figure 81.15.*** Anatomy of extensor mechanism.

- While exposing the deep fascia through mobilization of subcutaneous flaps, take care to avoid any distal branches of lateral cutaneous nerves. After complete exposure of the extensor tendon and its aponeurosis (Fig. 81.16), palpate the extensor mechanism as it inserts into the lateral epicondyle.

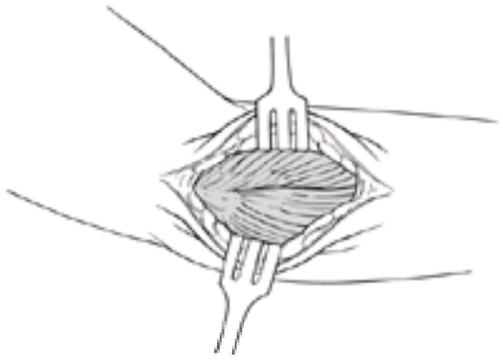

***Figure 81.16.*** Exposure of extensor mechanism laterally.

- Incise the deep antebrachial fascia directly over the epicondyle, and subsequently divide it distally toward the radiocapitellar joint, thus exposing the fibrinous origin of the common extensor tendon and the superior and inferior margins of the lateral epicondyle (Fig. 81.17). Elevate the superficial and distal fibers of the extensor carpi radialis longus anteriorly. Continue the incision subperiosteally and distally to the extensor carpi radialis brevis.

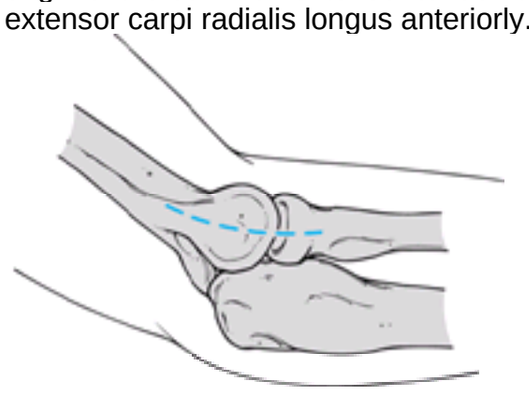

***Figure 81.17.*** Lateral approach over the lateral epicondyle and extending distally to the radial head.

- Incise the origin of the extensor brevis tendon longitudinally and elevate anteriorly. Carry the dissection distally through the synovial membrane into the lateral compartment of the elbow.
- Inspect the underlying extensor tendon mechanism that has been released subperiosteally (Fig. 81.18). Note any evidence of tears, granulation tissue, or fibrinous replacement of the tendon. Inspect the radiocapitellar joint and the overlying synovium.

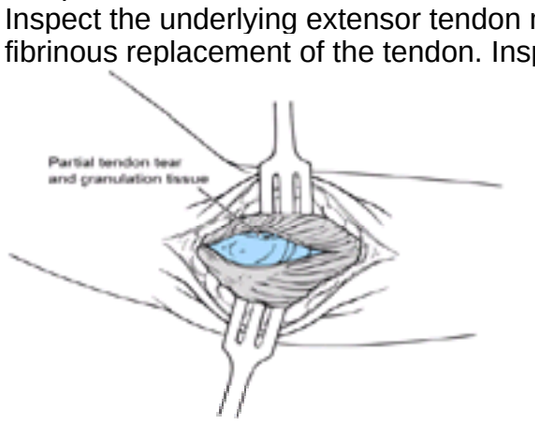


***Figure 81.18.*** Lateral exposure of the pathology in the ECRB and joint.

- Tears of various degrees and magnitudes are commonly found on the underside of the extensor carpi radialis brevis and frequently may penetrate distally to the level of the lateral compartment of the elbow joint. Therefore, follow the tendon to the level of the radiocapitellar joint to be sure that the entire pathology has been observed (Fig. 81.19). If a tear, granulation tissue, or fibrinous material is not identified in the extensor carpi radialis brevis, inspect the extensor carpi radialis longus proximally and the extensor digitorum distally.

***Figure 81.19.*** Excision of the degenerative portion of the ECRB tendon.

- Elevate the extensor origin in a subperiosteal fashion both anteriorly and posteriorly until the entire pathologic area of tendon tear and degeneration has been exposed. It is not necessary to elevate the entire extensor origin but merely that portion of the extensor tendon involved with disease. The normal muscle length should be preserved; this is accomplished by continuing the dissection in a longitudinal subperiosteal fashion, beginning with a longitudinal incision.
- The degenerative portion of the tendon typically occurs along its undersurface at its insertion into the lateral epicondyle. A nerve hook can be introduced for palpation of the partial-thickness tear within the tendon. Excise the degenerative portion of the tendon, as well as any abnormal granulation tissue and fibrillated torn edges. Typically this requires removal of a portion of the undersurface of the extensor carpi radialis brevis tendon.
- Using a rongeur, superficially decorticate the area of the lateral epicondyle that has been exposed (Fig. 81.20). This helps provide a cancellous bleeding surface for later reattachment of the extensor mechanism.

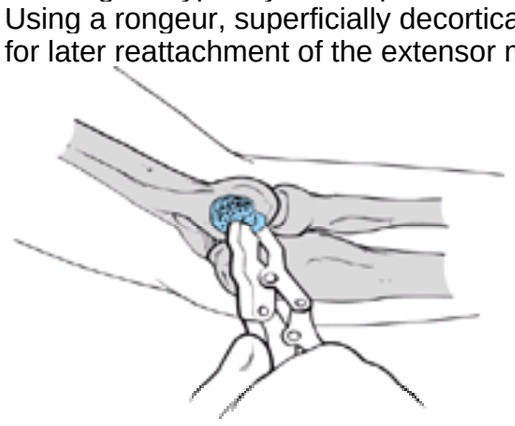

***Figure 81.20.*** Debridement of the lateral epicondyle.

- Use a $^{5}/_{64}$-inch drill bit (Fig. 81.21) to create a V-shaped tunnel in the lateral epicondyle, allowing passage of a slow-absorbing #0 suture through the bone (Fig. 81.22) for improved fixation, and eliminating any potential dead space between the tendon and the lateral epicondyle at the completion of the procedure.

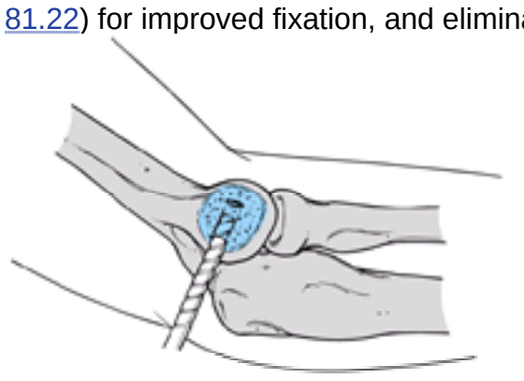

***Figure 81.21.*** Drilling of the lateral epicondyle.

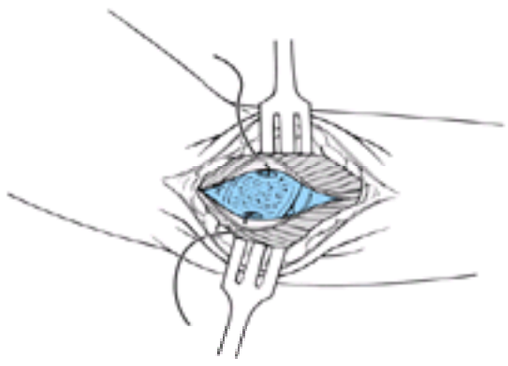

***Figure 81.22.*** Passage of suture through bone.

- Finally, perform a side-to-side repair using absorbable #0 suture, replacing the extensor tendon mechanism anatomically to the lateral epicondyle.
- Closure typically begins at the extensor carpi radialis longus (Fig. 81.23) and proceeds distally to include any remaining portion of the extensor carpi radialis brevis and synovial layer of the elbow joint. Release the tourniquet and obtain hemostasis. Close the subcutaneous tissue, and follow with a running subcuticular skin closure. Apply a soft dressing and place the elbow in a sling for comfort.

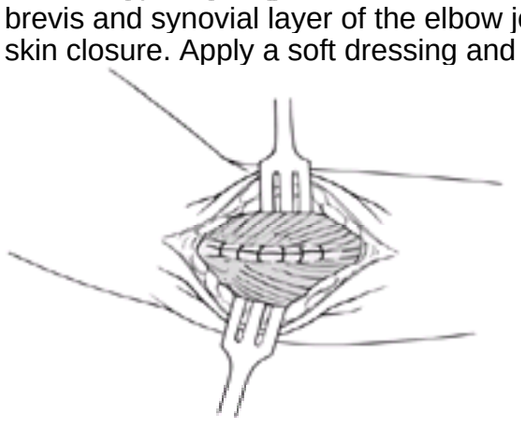

***Figure 81.23.*** Closure of extensor mechanism.

## MEDIAL EPICONDYLITIS

- Place the patient supine with the extremity resting on an arm board and the limb draped free. Incise anterior to the prominence of the medial epicondyle, extending distally approximately 4 cm. Identify and protect the underlying cutaneous nerves.
- Incise the common flexor at its origin on the medial epicondyle, extending the dissection through the central portion of the flexor–pronator muscle mass. Elevate the flexor–pronator muscle mass tendon origin in a longitudinal subperiosteal fashion off the medial epicondyle. Avoid inadvertent entry into the cubital tunnel.
- Inspect the underlying flexor–pronator tendon for any tear, granulation tissue, or fibrinous replacement. The degenerative portion of the tendon typically occurs along its undersurface at its insertion into the medial epicondyle. Use a nerve hook for palpation of partial thickness tears. Excise the degenerative portion of the tendon as well as any abnormal granulation tissue.
- Using a rongeur, decorticate the area of the medial epicondyle that has been exposed, creating a cancellous bleeding surface for later reattachment of the flexor tendon. Use a $^{5}/_{64}$-inch drill bit to create a V-shaped tunnel within the medial epicondyle to allow passage of a slow-absorbing suture through the bone for improved fixation and to eliminate dead space between the tendon and epicondyle postoperatively. Use caution while drilling, to avoid any entry into the cubital tunnel.
- Reapproximate the flexor tendon to itself, overlying the medial epicondyle in a side-to-side manner. Use simple interrupted #0 absorbable sutures to reapproximate the tendon. Release the tourniquet and obtain hemostasis. Close the subcutaneous tissue, and follow with a running subcuticular skin closure.

## DISTAL BICEPS RUPTURE

The biceps tendon is reinserted into the radial tuberosity through a modification of the two-incision technique described by Boyd and Anderson (16).

- Place the patient supine with the elbow extended and the forearm supinated on an arm board. Make an oblique incision beginning medially and proximally to the elbow crease, and extending distally and laterally (Fig. 81.24). The lacertus fibrosis may be intact and should be released to reveal the underlying hematoma and biceps tendon. Protect the underlying lateral antebrachial cutaneous nerve, which runs lateral to the biceps tendon. Identify the end of the tendon. Place two different-colored, nonabsorbable #2 sutures within the biceps tendon in a modified Kessler fashion (Fig. 81.25).

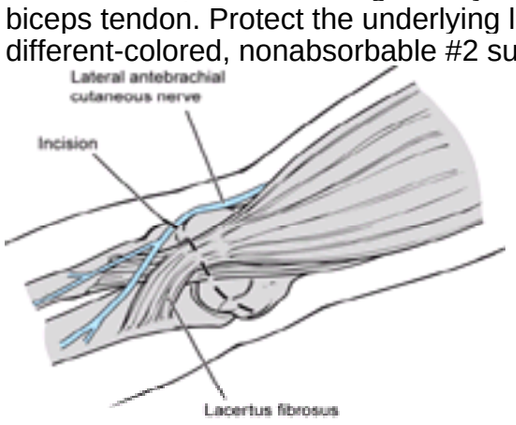


***Figure 81.24.*** Anterior incision for repair of a bicep tendon.

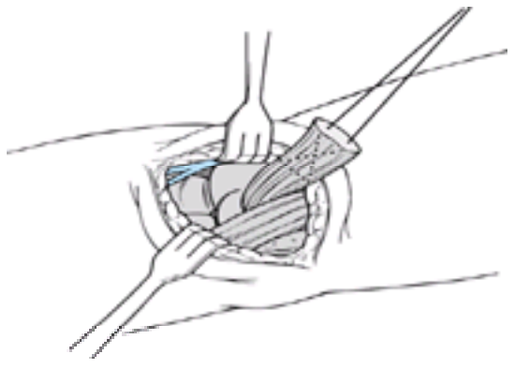

***Figure 81.25.*** Insertion of a suture into the end of the biceps tendon.

- Insert a curve clamp between the radius and the ulnar, down the tunnel vacated by the biceps tendon (Fig. 81.26). Flex the elbow and direct the curved clamp posterolaterally, tenting the skin on the forearm. Make a second 4–6 cm incision, paralleling the radial border of the ulnar. Split the extensor muscle mass carefully, avoiding exposure of the ulna. Avoidance of the ulna and its subperiosteum minimizes the postoperative risk of radioulnar synostosis.

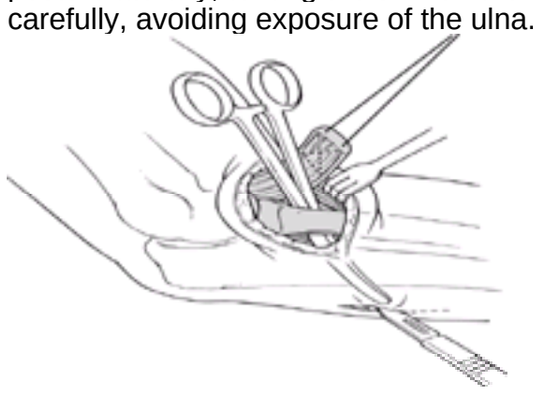

***Figure 81.26.*** Posterior incision.

- Identify the radial tuberosity and clear it of soft tissue. Make a $^{1}/_{8}$-inch drill hole within the radial tuberosity, enlarging it with a ¼-inch drill bit. Enlarge the cavity with a high-speed burr or curet. It is important to remove all bony debris after drilling, with copious irrigation. Drill two smaller holes through the edges of the cavity in the tuberosity using a $^{5}/_{64}$-inch drill bit.
- Pass the tendon from anterior to posterior through the soft-tissue tunnel between the radius and the ulna. Using a 24-gauge wire, a commercial suture passer, or a free needle, pass the nonabsorbable sutures through the cavity in the radial tuberosity, exiting through the smaller side-drilled holes. Using the different-colored sutures, bring one limb through each of the two side-drilled holes. Pull the sutures firmly with the arm in flexion and supination, and be sure by direct palpation that the tendon is seated within the bony defect created within the radial tuberosity. Before tying the suture, release the tourniquet and thoroughly irrigate and close the anterior incision. It is critical to close the anterior incision before tying the sutures of the biceps tendon through the posterior incision, as the elbow will remain in a flexed position following closure of the biceps tendon repair.
- Tie each of the sutures from the biceps tendon, and again inspect the distal tendon of the biceps to make certain that it is secured within the radial tuberosity. Tie the sutures securely with the elbow flexed 90° and the forearm supinated (Fig. 81.27). Irrigate the posterior wound thoroughly. Close the deep fascia with interrupted #0 absorbable suture, and close the subcutaneous tissue with a running subcuticular closure.

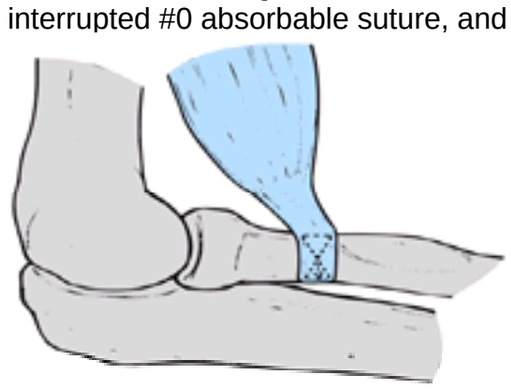

***Figure 81.27.*** Biceps repair.

**DISTAL TRICEPS TENDON RUPTURE**

- Use a posterior approach to the distal arm (Fig. 81.28) in either a supine lateral or prone position. Make the skin incision over the distal triceps mechanism and develop subcutaneous flaps, protecting any underlying cutaneous nerves. While the ulnar nerve does not need to be freed or transposed, it is critical to identify the course and to be aware of its position throughout the surgical repair. Isolate the avulsed triceps tendon and at this point inspect the posterior aspect of the joint. Excise any bone flecks accompanying the triceps tendon avulsion. If there has been a large fragment avulsed with the triceps tendon (often seen in the adolescent athlete), repair this fragment with either a tension band technique or screw fixation.

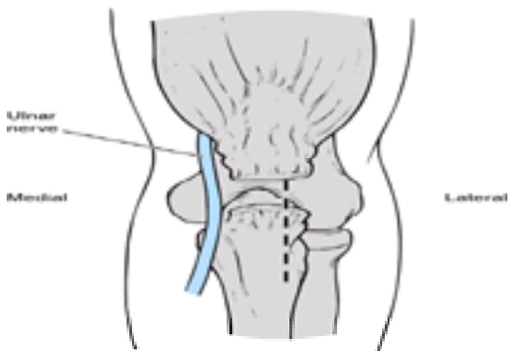


***Figure 81.28.*** Biceps repair.

- Place two different-colored #2 nonabsorbable sutures through the tendon in a modified Kessler fashion. Use crisscrossed bone tunnels in the olecranon as described by Morrey (48) to secure the sutures to bone (Fig. 81.29). Make sure that, as the sutures are placed through the bone and tension is placed on the tendon, the overlying fascia is not tethered, which would compromise the ulnar nerve.

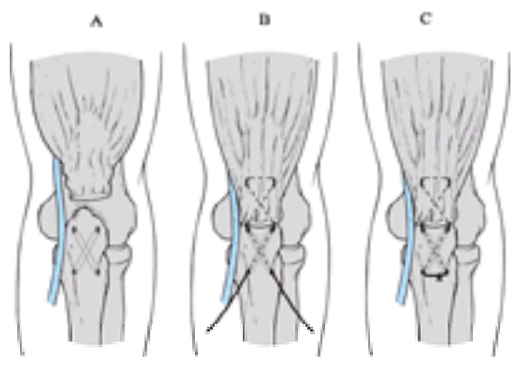


***Figure 81.29.*** Triceps repair.

- Deflate the tourniquet prior to closure and obtain hemostasis. Tie the sutures and check the integrity of the repair during ROM of the elbow. After routine closure, splint the elbow at 45° of flexion.

## REHABILITATION

### LATERAL EPICONDYLITIS

After repair for lateral epicondylitis, place the elbow in a soft dressing and allow gentle active-assisted ROM. In 7–10 days, remove the sutures. Encourage gentle passive and active flexion, extension, supination, and pronation. Initiate ROM exercises for the wrist and fingers, including squeezing a light rubber ball with the hand. Discourage activities that require lifting with the involved extremity, and avoid any resisted dorsiflexion of the wrist or fingers.

At 4 weeks, initiate light resisted isometric exercises. At 6 weeks, start a strengthening program, including isometric and isotonic exercises, that progresses on a graduated basis. Return to normal activities such as heavy lifting or athletics at 3 months.

### MEDIAL EPICONDYLITIS

Apply a soft dressing and splint for comfort to the elbow after surgical treatment of medial epicondylitis. Adopt a program similar to that described for lateral epicondylitis, with a similar time frame for return to sports and heavy activity.

### DISTAL BICEPS RUPTURE

After repair of a distal biceps rupture, maintain the forearm in supination with the elbow flexed 90°. Remove the sutures at 1 week while continuing to immobilize the elbow for 2 more weeks. At 3 weeks, initiate gentle active extension and passive flexion exercises, as well as gentle active pronation and passive supination exercises. At 6 weeks, continue ROM exercises and introduce isometric strengthening exercises in all planes. Initiate a progressive strengthening program that includes isotonic exercises at 12 weeks, and progressively continue until full ROM strength and endurance is restored. Do not recommend full activities until full ROM strength and endurance have been achieved, which typically takes 4 months following surgical repair.

### DISTAL TRICEPS REPAIR

After surgical repair of a distal triceps avulsion, immobilize the arm in a plaster splint at 45° of elbow flexion for 3 weeks. Remove sutures at 7–10 days postoperatively. Next, begin gentle passive extension and active flexion. At 6 weeks, initiate progressive resisted exercises beginning with isometric exercises, and progress to isotonic exercises with a progressive strengthening program. Unrestricted activity typically can be initiated 4 months after surgery, when full ROM, strength, and endurance have been achieved.

## PITFALLS AND COMPLICATIONS

### ULNAR COLLATERAL RECONSTRUCTION

In a review of ulnar collateral ligament reconstruction for medial elbow instability, all the complications except one postoperative hematoma were related to either cutaneous nerves or the ulnar nerve (22). Cutaneous nerve complications included a transient paresthesia, cutaneous neuroma, and residual pain. In the reconstruction group, 21% had ulnar nerve symptoms postoperatively. One third of this group had transient paresthesias that subsided after 4 months. The remaining two thirds required a revision procedure on the ulnar nerve, with the majority having residual paresthesias of the ulnar nerve during long-term follow-up. When performing an ulnar collateral ligament reconstruction, it is critical to be mindful of the potential iatrogenic neurogenic injuries that may occur. The cutaneous nerves off the medial antebrachial cutaneous nerve tend to be robust, and they are easily injured. Traction on the cutaneous nerves may result in transient postoperative paresthesias that typically resolve. It is the residual neuroma from an accidental transection of the nerve that results in the most difficulty in the postoperative course for these patients. Ulnar nerve problems are common, but their incidents may be reduced by separating those patients who require an ulnar nerve transfer from those who do not.

Previous reviews (22,39) of ulnar collateral ligament reconstruction from the Kerlan-Jobe Orthopaedic Clinic were limited to patients who uniformly had submuscular ulnar nerve transpositions performed as a part of their reconstructive procedure. The majority of patients with ulnar collateral ligament insufficiency do not require ulnar nerve transfer. It is critical in that group to be sure that, during the course of the surgical procedure, the cubital tunnel is not violated. For those patients who require an ulnar nerve transposition, strict attention to detail is required, as for any submuscular ulnar nerve transfer. It is imperative that any residual or new site of compression or impingement of the nerve be eliminated and that the nerve is noted to lie free underneath the flexor–pronator muscle mass following its repair at the conclusion of the procedure.

Pain during the follow-through phase of throwing may be due to impingement of the posterior medial olecranon in the olecranon fossa. Termed valgus extension overload, this may result in the development of osteophytes on the posteromedial margin of the olecranon and loose fragments of bone within the olecranon fossa. Although in many patients, impingement may be eliminated by restoration of the ulnar collateral ligament, I believe that it is important to remove any posterior osteophytes and loose bodies at the time of surgery.

After reconstruction of the ulnar collateral ligament, athletes must rehabilitate the shoulder along with the elbow and maintain good overall physical condition to minimize the risk of injury during the early postoperative period. Proper throwing mechanics, balance, and coordination must be restored before returning to competition.

Technical pitfalls at the time of surgery also include improper placement of the osseous tunnels in a nonisometric position. Other problems include penetration of the articular surface during drilling of the osseous tunnel, and loss of the bone bridge between the two surfaces of the osseous tunnel if forceful placement of the graft occurs without having previously ensured adequate communication between the two tunnels. Salvage of a disrupted bone tunnel may require the need for a bone anchor and fixation of the tendon graft into a trough. I have had no experience with this and cannot predict the difference in fixation strength between a tendon graft fixed within a bony tunnel and one fixed into a trough secured by bone anchor and sutures.

### LATERAL COLLATERAL LIGAMENT RECONSTRUCTION

The most common complication that occurs after lateral collateral ligament reconstruction is persistent instability (48,57). It is critical at the time of the procedure to determine the presence or absence of competency of the lateral ulnar collateral ligament, in addition to that of the remaining posterior and anterior lateral capsule. When a repair or reconstruction is being performed for the lateral ulnar collateral ligament, establish the isometric points proximally and distally to ensure stability in the postoperative period. In addition, at surgery, assess other pathologically lax sources for instability, such as the anterior and posterior capsule, which will require plication sutures as part of the repair. Injury to the cutaneous nerves, while less common than after a medial approach, may occur and can be a significant source of impairment for the patient. Careful attention to avoid any injury to the cutaneous nerves is imperative. In addition, be aware of the proximity of the radial nerve while

dissecting and immobilizing the anterior capsule.

### LATERAL EPICONDYLITIS

Failure of the procedure to provide clinical improvement may be caused by improper patient selection or improper diagnosis. The differential diagnosis of a patient with lateral epicondylitis includes degenerative arthrosis, forearm extensor tendinitis, lateral collateral ligament instability, and entrapment of the radial nerve. A preoperative assessment must be completed to distinguish between these various entities. An incomplete release or excision of the pathologic tissue may also cause persistent symptoms after the surgical procedure, so pay careful attention to technique.

In the course of surgical dissection, it is imperative that injury to the radial nerve be avoided when elevating the lateral epicondylar tendon anteriorly and exploring the radiocapitellar joint. During the initial dissection, when the longitudinal incision is made through the extensor tendon and carried distally to the radiocapitellar joint, iatrogenic injury to the radial collateral ligament may occur. The dissection must be carried out in a longitudinal fashion, and the lateral capsule must not be transected with a transverse incision. It is also critical that the lateral ulnar collateral ligament not be violated during the course of the dissection and repair.

### MEDIAL EPICONDYLITIS

Be sure during the initial dissection for the surgical treatment of medial epicondylitis to avoid any injury to the underlying cutaneous nerves, as noted previously. A common source of persistent postoperative pain is failure to adequately diagnose the underlying condition. Those patients with symptomatic collateral ligament insufficiency or ulnar neuritis will have persistent symptoms if their underlying disease is not recognized. During the surgical approach, avoid injury to the ulnar nerve at the cubital tunnel, and to the ulnar collateral ligament during the reflection and exploration of the tendinous origin of the flexor–pronator muscle mass. The origin of the ulnar collateral ligament lies just underneath the flexor–pronator muscle mass attachment to the medial epicondyle.

### DISTAL BICEPS RUPTURE

The incidence of radial nerve injury after distal biceps tendon reattachment is significantly reduced since the development of the two-incision technique. The radial nerve was vulnerable when we previously used an extended anterior approach. However, the two-incision technique has raised the incidence of radioulnar synostosis. When creating the posterior incision, a muscle-splitting approach must be performed rather than a subperiosteal dissection along the course of the ulna. It addition, the presence of the hematoma communicating with the radius and the ulna may also increase the risk of a postoperative synostosis.

It has been suggested that a bone anchor in the radial tuberosity may be used through a single anterior incision, avoiding the potential risks of radioulnar synostosis. We have no experience with this technique and do not know if this will again initiate an increased incidence of radial nerve injuries, nor do we know if the fixation strength of the biceps tendon to bone will be altered.

### REPAIR OF DISTAL TRICEPS TENDON AVULSION

Injury to the ulnar nerve during vigorous dissection and mobilization of the triceps may occur, but it is not commonly reported. Careful attention of the anatomic location to the ulnar nerve and avoidance of the cubital tunnel is imperative.

## AUTHOR'S PERSPECTIVE

### ULNAR COLLATERAL LIGAMENT RECONSTRUCTION

Reconstruction of the ulnar collateral ligament in overhead and throwing athletes unable to compete prior to surgery has been successful in returning the majority of them to their previous level of participation. Of 71 surgical procedures with valgus instability treated at the Kerlan-Jobe Orthopaedic Clinic, 14 had a direct repair and the remainder had a reconstruction using a free tendon graft (22). These patients were followed for 6.3 years postoperatively, and 68% of the reconstruction group returned to their previous level of participation. The mean time to return to competition was 12 months. The negative prognostic factors included previous operations on the elbow and being a baseball pitcher (as opposed to other throwing positions). Postoperative problems involving the cutaneous nerves or the ulnar nerve itself accounted for the major complications following this procedure. There were no differences in results when the source of graft material was evaluated, which included the ipsilateral palmaris longus tendon, the contralateral palmaris longus tendon, and the plantaris or partial Achilles tendon graft.

The incidence of ulnar collateral ligament insufficiency is not common in the general population, but it is quite frequent in the athletic population engaged in athletic activities that place valgus stress across the medial aspect of the joint. Most athletes with ulnar collateral ligament tendinitis or instability improve with conservative treatment and do not require surgical intervention. Those athletes not responding to conservative care, and those who wish to continue to pursue athletic endeavors, are excellent candidates for a surgical reconstruction. The results of surgical repair, especially in the chronic setting, are unpredictable. When addressing the problems of ulnar collateral ligament insufficiency surgically, it is recommended that a reconstruction be performed with the use of a free tendon graft. Postoperative complications may be minimized (a) by paying meticulous attention to avoid injury to the cutaneous nerves and (b) by limiting transposition of the ulnar nerve to those cases with preoperative clinical indications.

### LATERAL COLLATERAL LIGAMENT INJURY

Results of surgical treatment for lateral collateral ligament insufficiency have been reviewed at the Mayo Clinic (48,57) with 11 cases that were followed a minimum of 1 year. Six cases were rated as excellent, which indicated that the patients perceived the elbow to be normal. One case was considered to be good, which indicated no objective or subjective elements of instability, with residual mild pain or apprehension. Three patients were rated as fair, which indicated no objective instability but the patient did have subjective symptoms including an apprehension sign. Mild or moderate pain with the loss of more then 10° of motion was also present. There was one poor result with a recurrence of instability that was perceived and could be demonstrated by a positive pivot-shift maneuver.

The diagnoses of lateral collateral ligament and posterior lateral instability are not common. Keep these diagnoses in mind when evaluating any patient with lateral elbow pain. Many patients who failed treatment for lateral epicondylitis and other diagnoses for lateral elbow pain, in fact had lateral collateral ligament laxity that was not recognized. When the diagnosis is made and clinical symptoms are sufficient, the treatment is primarily surgical; there is little role for the nonoperative management.

### LATERAL EPICONDYLITIS

Nirschl and Sobel (55), Coonrad (23), and Leach and Miller (44) noted that 85% to 90% of patients returned to full activity without pain after surgical treatment of lateral epicondylitis. Approximately 10% to 12% were noted to have improvement, but with some residual pain, and 2% to 3% were felt to have no appreciable improvement as a result of the surgical procedure. At the Kerlan-Jobe Orthopaedic Clinic, 1,200 patients with a diagnosis of lateral epicondylitis were treated over a 10-year period (20). Of the 1,200 patients, 60 subsequently underwent surgical treatment for persistent symptoms. Of those 60, 39 were available for long-term follow-up. Although 94% had dramatic improvement in their symptoms, this did not correlate with the objective findings, which demonstrated that 36% had residual limitations from heavy lifting. Grip-strength deficits were found in 15%, and 100% had some degree of isokinetic strength deficit. It was concluded that while the procedure provides excellent subjective postoperative relief, the subjective results do not necessary correlate with objective findings of persistent weakness.

Tennis elbow or lateral epicondylitis is one of the more common diagnoses made by musculoskeletal specialists dealing with elbow problems. The results of conservative treatment are uniformly excellent. However, those patients who have associated entrapment of the radial nerve or other causes for lateral elbow pain must be identified. For those who fail conservative treatment, lateral epicondylitis surgery is predictable and excellent, but careful attention to detail is critical at surgery to avoid any injury to the lateral collateral ligament complex.

### MEDIAL EPICONDYLITIS

Vangsness and Jobe's review (66) of 35 patients with surgically treated medial epicondylitis revealed that subjective function improved from 38% to 98%. Excellent or good results were obtained in 97% and isokinetic grip-strength testing revealed no significance between the involved and uninvolved elbows.

Although the majority of patients presenting with medial epicondylitis may be treated conservatively with excellent results, the results of surgical treatment are uniformly excellent. The hallmark of an excellent outcome is an accurate diagnosis. In the athletic population, rule out underlying ulnar collateral ligament insufficiency and

symptoms associated with ulnar neuritis. Treatment of medial epicondylitis in the presence of these other diagnoses typically yields unpredictable results unless they are addressed appropriately.

## DISTAL BICEPS RUPTURE

A study by D'Alessandro et al. (25) consisted of weight lifters and body builders with high functional demands. All patients in this group were satisfied with their functional and cosmetic result and returned to full, unrestricted activities. Isokinetic testing demonstrated that supination strength and endurance was normal; in flexion, the patients had normal strength but averaged 20% less endurance. Morrey et al. (50) reported on seven patients with at least 15 months follow-up after a two-incision technique. Those treated early had at least 95% restoration of strength in all planes. Those who had a late reattachment or a late insertion into the brachialis had deficits in flexion and supination.

While distal biceps rupture typically occurs in the active population such as weight lifters and heavy laborers, it may occur in anyone, especially with a traumatic injury. Unlike a proximal biceps tendon rupture, a distal biceps tendon rupture left untreated will yield significant functional deficits. Except for those individuals who are otherwise inactive, an acute repair of the distal biceps tendon will yield predictable results with restoration of ROM and function. The two-incision technique is preferred because of the low incidence of radial nerve problems, but a muscle-splitting approach must be utilized to lower the incidence of postoperative radioulnar synostosis.

## DISTAL TRICEPS REPAIR

Morrey (48) has reported that the results of immediate or delayed repair have been uniformly good, with restoration of normal strength and full ROM. Approximately 20% of patients will develop a loss of 5° of terminal extension.

Although a complete avulsion of the triceps mechanism is rare, the physician treating an active athlete or heavy laborer population will undoubtedly encounter the injury. In cases of complete disruption, prompt diagnosis and surgical repair result in a predictable optimal outcome with excellent functional recovery.

## CHAPTER REFERENCES

Each reference is categorized according to the following scheme: *, classic article; #, review article; !, basic research article; and +, clinical results/outcome study.


+ 1. Albright JA, Jokl P, Shaw R, et al. Clinical Study of Baseball Pitchers: Correlation of Injury of the Throwing Arm with Method of Delivery. *Am J Sports Med* 1978;6:15.

! 2. An K-N, Kaufman KR, Chao EYS. Physiological Considerations of Muscle Force through the Elbow Joint. *J Biomech* 22(11):1249, 1989.

* 3. Anderson KJ, LeCrocq JF. Rupture of the Triceps Tendon. *J Bone Joint Surg Am* 1957;39:444.

# 4. Andrews JR. Bony Injuries about the Elbow in the Throwing Athlete. *Instr Course Lect* 1985;34:323.

# 5. Andrews JR, Craven WM. Lesions of the Posterior Compartment of the Elbow. *Clin Sports Med* 1991;10:637.

* 6. Bach BR, Warren RF, Wickiewica TL. Triceps Rupture: A Case Report and Literature Review. *Am J Sports Med* 1987;15:285.

* 7. Baker BD, Bierwagen D. Rupture of the Distal Tendon of the Biceps Brachii: Operative versus Non-operative Treatment. *J Bone Joint Surg Am* 1985;67:414.

* 8. Baker BE. Operative vs Non-operative Treatment of Disruption of the Distal Tendon of Biceps (abstract). *Orthop Rev* 1982;11:71.

# 9. Barnes DA, Tullos HS. An Analysis of 100 Symptomatic Baseball Players. *Am J Sports Med* 1978;6:62.

+ 10. Baumgard SH, Schwartz DR. Percutaneous Release of the Epicondylar Muscles for Humeral Epicondylitis. *Am J Sports Med* 1982;10:233.

* 11. Bennett BS. Triceps Tendon Ruptures. *J Bone Joint Surg Am* 1962;44:741.

# 12. Bennett GE. Elbow and Shoulder Lesions of Baseball Players. *Am J Surg* 1959;98:484.

+ 13. Bennett JB, Green MS, Tullos HS. Surgical Management of Chronic Medial Elbow Instability. *Clin Orthop* 1992;278:62.

# 14. Binder AI, Hazelman BL. Lateral Humeral Epicondylitis—A Study of Natural History and the Effect of Conservative Therapy. *Br J Rheumatol* 1983;22:73.

# 15. Boatright JR, D'Alessandro DF. Nerve Entrapment Syndromes at the Elbow. In: Jobe FW, ed. *Operative Techniques in Upper Extremity Sports Injuries.* St. Louis: Mosby, 1996:518.

* 16. Boyd JB, Anderson LD. A Method for Reinsertion of the Distal Biceps Brachii Tendon. *J Bone Joint Surg Am* 1961;43:1041.

+ 17. Carp L. Tennis Elbow Caused by Radiohumeral Bursitis. *Arch Surg* 1932;24:905.

+ 18. Carrol RE, Hamilton LR. Rupture of Biceps Brachii—A Conservative Method of Treatment. *J Bone Joint Surg Am* 1967;49:1016.

+ 19. Cassidy J, Bole G. Cutaneous Atrophy Secondary to Intra-articular Corticosteroid Administration. *Ann Intern Med* 1966;65:1008.

+ 20. Ciccotti MG, Lombardo SJ. Lateral and Medial Epicondylitis of the Elbow. In: Jobe FW, ed. *Operative Techniques in Upper Extremity Sports Injuries*. St. Louis: Mosby, 1996:431.

+ 21. Clayton ML, Thirupathi R. Rupture of the Triceps Tendon with Olecranon Bursitis. *Clin Orthop* 1984;184:183.

* 22. Conway JE, Jobe FW, Glouseman RE, et al. Medial Instability of the Elbow in the Throwing Athlete. *J Bone Joint Surg Am* 1992;74:67.

# 23. Coonrad RW. Tendonopathies at the Elbow. *Instr Course Lect* 1991;40:2532.

# 24. Coonrad RW, Hooper WR. Tennis Elbow: Its Course, Natural History, Conservative and Surgical Management. *J Bone Joint Surg Am* 1973;55:1177.

+ 25. D'Alessandro DF, Shields CL Jr, Tibon JE, et al. Repair of Distal Biceps Tendon Ruptures in Athletes. *Am J Sports Med* 1993;21:114.

+ 26. D'Alessandro DF, Shields CL. Biceps Rupture and Triceps Avulsion. In: Jobe FW, ed. *Operative Techniques in Upper Extremity Sports Injuries*. St. Louis: Mosby, 1996:506.

# 27. Del Pizzo W, Jobe FW, Norwood L. Ulnar Nerve Entrapment Syndrome in Baseball Players. *Am J Sports Med* 1977;5:182.

+ 28. Farrar EL, Lippert FG. Avulsion of the Triceps Tendon. *Clin Orthop* 1981;161:242.

+ 29. Froimson AI. Treatment of Tennis Elbow with Forearm Support Band. *J Bone Joint Surg Am* 1971;53:183.

+ 30. Glousman RE. Surgical Treatment of Lateral Epicondy litis (Tennis Elbow). *Tech Orthop* 1991;6:33.

# 31. Glousman RE. Ulnar Nerve Problems in the Athlete's Elbow. *Clin Sports Med* 1990;9:365.

! 32. Glousman RE, Barron J, Jobe FW, et al. An Electromyographic Analysis of the Elbow in Normal and Injured Pitchers with Medial Collateral Ligament Insufficiency. *Am J Sports Med* 1992;20:311.

+ 33. Goldberg EJ, Abraham E, Siegel I. The Surgical Treatment of Chronic Lateral Humeral Epicondylitis by Common Extensor Release. *Clin Orthop* 1983;233:208.

! 34. Gray H. *Anatomy of the Human Body*, 29th ed. Philadelphia: Lea & Febiger, 1973.

! 35. Groppel JL, Nirschl RP. A Mechanical and Electromyographical Analysis of the Effects of Various Joint Count Forcebraces on the Tennis Player. *Am J Sports Med* 1986;14:195.

+ 36. Hovelius L, Josefsson G. Rupture of the Distal Biceps Tendon: Report of Five Cases. *Acta Orthop Scand* 1977;48:280.

# 37. Jobe FW, Kvitne RS. Elbow Instability in the Athlete. *Instr Course Lect* 1991;40:17.

# 38. Jobe FW, Nuber G. Throwing Injuries of the Elbow. *Clin Sports Med* 1986;5:621.

* 39. Jobe FW, Stark H, Lombardo SJ. Reconstruction of the Ulnar Collateral Ligament in Athletes. *J Bone Joint Surg Am* 1986;68:1158.

+ 40. Johnson AB. Avulsion of Biceps Tendon from the Radius (abstract). *N Y Med J* 1897;66:261.

! 41. Jordon SE, Jobe FW. Anatomy and Histology of the Collateral Ligaments of the Elbow. Presented at the Seventh Open Meeting of the American Shoulder and Elbow Surgeons, San Francisco, 1993.

# 42. Kerlan RK, Glousman RE. Injections and Techniques in Athletic Medicine. *Clin Sports Med* 1989;8:541.

# 43. Kvitne RS, Jobe FW. Ligamentous and Posterior Compartment Injuries. In: Jobe, FW, ed. *Operative Techniques in Upper Extremity Sports Injuries*. St. Louis: Mosby, 1996:411.

# 44. Leach RE, Miller JK. Lateral and Medial Epicondylitis of the Elbow. *Clin Sports Med* 1987;6:259.

+ 45. Lee MHL. Rupture of the Triceps Tendon. *Br Med J* 1960;2:197.

+ 46. Louis DS, Hankin FM, Eckenrode JR, Jobe FW, Perry J, et al. Distal Biceps Brachii Tendon Avulsion: A Simplified Method of Operative Repair. *Am J Sports Med* 1986;14:234.

+ 47. Meherin JM, Kilgore ES. The Treatment of Ruptures of the Distal Biceps Brachii Tendon. *Am J Surg* 1960;99:636.

# 48. Morrey BF. Tendon Injuries about the Elbow. In: Morrey BF, ed. *The Elbow and Its Disorders*, 2nd ed. Philadelphia: WB Saunders, 1993:492.

! 49. Morrey BF, An KN. Articular and Ligamentous Contributions to the Stability of the Elbow Joint. *Am J Sports Med* 1983;11:315.

! 50. Morrey BF, Askew LJ, An KN, et al. Rupture of Distal Tendon of the Biceps Brachii: A Biomechanical Study. *J Bone Joint Surg Am* 1985;67:418.

+ 51. Morrey BF, Tanaka S, An KN. Valgus Stability of the Elbow: A Definition of Primary and Secondary Constraints. *Clin Orthop* 1989;265:187.

! 52. Morris M, Jobe FW, Perry J, et al. Electromyographic Analysis of Elbow Function in Tennis Players. *Am J Sports Med* 1989;17:241.

+ 53. Nestor BJ, O'Driscoll SW, Morrey BF. Ligamentous Reconstruction for Posterolateral Rotatory Instability of the Elbow. *J Bone Joint Surg Am* 1992;74:1235.

+ 54. Nirschl RP, Pettrone FA. Tennis Elbow. The Surgical Treatment of Lateral Epicondylitis. *J Bone Joint Surg Am* 1979;61:832.

+ 55. Nirschl RP, Sobel J. Conservative Treatment of Tennis Elbow. *Phys Sports Med* 1981;9:42.

+ 56. Norwood LA, Shook JA, Andrews JR. Acute Medial Elbow Ruptures. *Am J Sports Med* 1981;9:16.

* 57. O'Driscoll SW, Bell DF, Morrey BF. Posterolateral Rotatory Instability of the Elbow. *J Bone Joint Surg Am* 1991;73:440.

! 58. O'Driscoll SW, Horii E, Morrey BF, et al. Anatomy of the Ulnar Part of the Lateral Collateral Ligament of the Elbow. *Clin Anat* 1992;5:296.

! 59. O'Driscoll SW, Morrey BF, Korinek S, et al. Posterolateral Rotatory Instability of the Elbow: A Kinematic and Biomechanical analysis. *Orthop Trans Res Soc* 1990;15:6.

! 60. Pappas AM, Zawacki RM, Sullivan TJ. Biomechanics of Baseball Pitching: A Preliminary Report. *Am J Sports Med* 1985;13:216.

! 61. Perry J, Glousman RE. In: Nicholas JA, Hershman EB, eds.*Biomechanics of Throwing. The Upper Extremity in Sports Medicine.* St. Louis: Mosby, 1996:697.

! 62. Schwab GH, Bennet JB, Woods GW, et al. Biomechanics of Elbow Instability: The Role of the Medial Collateral Ligament. *Clin Orthop* 1980;146:42.

+ 63. Stannard JP, Burknell AL. Rupture of the Triceps Tendon Associated with Steroid Injections. *Am J Sports Med* 1993;21:482.

+ 64. Tarsney FF. Rupture and Avulsion of the Triceps. *Clin Orthop* 1972;83:177.

# 65. Tullos HS, King JW. Throwing Mechanism in Sport. *Orthop Clin North Am* 1973;4:709.

+ 66. Vangsness CT, Jobe FW. Surgical Treatment of Medial Epicondylitis. *J Bone Joint Surg Br* 1991;73:409.

+ 67. Viegas S. Avulsion of the Triceps Tendon. *Orthop Rev* 1990;19:533.

# 68. Wilson FD, Andrews JR, Blackburn TA, et al. Valgus Extension Overload in the Pitching Elbow. *Am J Sports Med* 1983;11:83.

# CHAPTER 82

# ARTHROSCOPIC TREATMENT OF THE ELBOW

*Laura A. Timmerman*

**L. A. Timmerman:** Team Physician, University of California, Berkeley, Berkeley, CA 94720.

Clinical Evaluation and Imaging of the Elbow
Indications
Preoperative Treatment
Surgical Techniques
Instrumentation
Location of Standard Portals
Arthroscopic Anatomy and Operative Technique
Surgical Treatment of Specific Lesions
General Rehabilitation and Postoperative Principles
Pitfalls and Complications
Author's Perspective
Chapter References

Arthroscopy of the elbow is a relatively recent advance in the treatment of elbow disorders (2,8). Its minimally invasive nature allows for rapid postoperative rehabilitation, which helps prevent the most common and dreaded complication of elbow surgery, arthrofibrosis. Arthroscopy permits better visualization of the elbow joint than does limited arthrotomy; arthroscopy of the elbow is difficult, however, because the joint is small and in close proximity to neurovascular structures. These reasons limit widespread use of the procedure.

## CLINICAL EVALUATION AND IMAGING OF THE ELBOW

History and physical examination are critical in evaluation of disorders of the elbow. The timing of the injury, whether it was acute or insidious in onset, is important. Acute trauma to the elbow may involve capsular injury, which is a contraindication to elbow arthroscopy.

Symptoms of locking are typical of a loose body. Loss of extension can be the first sign of elbow pathology in an adolescent, often before any complaints of pain. In older patients with degenerative changes, a loss of both flexion and extension is typical.

Additionally, the location of pain is informative. Lateral pain is seen in lateral epicondylitis and osteochondritis dissecans. Medial pain is associated with chronic valgus laxity, ulnar nerve symptoms, and medial epicondylitis. Posterior pain is typical of posterior impingement and triceps tendinitis. Anterior pain is less common and is associated with biceps tendinitis, anterior coronoid osteophytes, and arthritis.

If the symptoms are associated with throwing, it is useful to determine at which stage of the throwing motion pain occurs. Pain that occurs just before ball release when the arm is maximally cocked is associated with valgus laxity and ulnar collateral injuries. Pain after ball release is more often seen with posterior impingement injuries.

If the patient has a history of previous trauma, review the initial treatment along with the type and duration of physical therapy. Arthrofibrosis after elbow trauma is one of the most common abnormalities seen. An adequate course of physical therapy to try to restore motion and strength is necessary before surgery. Review previous surgeries with careful attention to whether the ulnar nerve has been transferred. A previous ulnar nerve transposition does not allow access to the medial portal and severely limits an arthroscopic operative procedure.

In physical examination of the elbow, include careful measurement of the preoperative range of motion using a long goniometer with the forearm in the same position for each measurement. Measurement by eye alone may not pick up flexion contracture. Compare measurements to those on the opposite side. Measure pronation and supination. Tenderness and crepitation over the radiocapitellar joint or posterior ulnahumeral articulation may indicate chondral injury in these areas. An effusion may be detected by palpation of the lateral soft spot.

Examine the elbow for signs of instability. With medial instability, valgus opening may be detected with the elbow flexed about 30° as a valgus force is applied to the forearm. This test may be easier to perform with the patient supine and the humerus maximally externally rotated, with the arm off the side of the table.

Test for posterolateral instability with a pivot-shift-type test (16). With the patient supine and the arm overhead and forearm in supination, apply a supination and valgus force to the elbow in an axial direction with it flexed 20° to 30°. Posterolateral subluxation will be visible and will decrease with further flexion of the elbow.

Valgus extension overload refers to the injuries associated with throwing (30) and includes medial tension, lateral compression, and posterior impingement injuries (22). Perform a valgus extension overload test by extending the elbow with a valgus force applied across the joint. This procedure forces the posteromedial olecranon to contact the humerus with impingement and pain. This test is also often positive with ulnar collateral ligament injuries.

Carefully inspect the ulnar nerve with attention to its position and whether it subluxes. (The nerve can be displaced over the medical epicondyle, or, with flexion of the elbow, the nerve will slide anteriorly.) This can be easily missed on physical examination. It is easier to visualize subluxation of the nerve medially with the patient supine.

Obtain routine radiographs, including an anteroposterior (AP), lateral, oblique, and an axial view. Radiographs alone are adequate to diagnose degenerative changes but may be completely normal in cases of osteochondritis dissecans and loose bodies. Magnetic resonance imaging (MRI) is useful to evaluate osteochondritis dissecans and ligamentous injuries (29). The ulnar collateral ligament is more easily visualized with either a contrast MRI or a computed tomography (CT) arthrogram. Computed tomography arthrography is also helpful to find loose bodies, but it is not foolproof. In one series of patients with known loose bodies, the preoperative radiographs were negative in 71% of the patients, and the CT-arthrogram was negative in 38% (3).

## INDICATIONS

Elbow arthroscopy is indicated for the diagnosis and removal of loose bodies, evaluation and treatment of osteochondritis dissecans of the capitellum, and excision of osteophytes from the coronoid and posterior olecranon. It is also indicated in release of posttraumatic contractures of the elbow, synovectomy in inflammatory disorders, and debridement of degenerative changes. It is useful in evaluation of the ulnar collateral ligament and detection of valgus instability as well as evaluation of the painful elbow with uncertain intraarticular pathology.

Contraindications to elbow arthroscopy include bony ankylosis and severe fibrous capsular contracture, which can make introduction of the arthroscope into the elbow joint difficult. An acute capsular tear in the elbow is also a contraindication, as fluid extravasation may occur that can collapse the joint; this makes visualization difficult and, additionally, presents the danger of compartment syndrome.

## PREOPERATIVE TREATMENT

Try to document the presence of an intraarticular derangement. If the specific disorder is not known, a preoperative intraarticular lidocaine injection can be useful to determine if pain is relieved. Undertake an adequate course of conservative treatment before surgery. Specific treatment guidelines are outlined with each diagnosis.

## SURGICAL TECHNIQUES

- Position the patient supine or prone, depending on your preference and the portals to be used. I prefer to use a general anesthetic because it offers complete muscle relaxation and avoids intraoperative patient discomfort. In addition, it allows an immediate postoperative neurologic examination in the recovery room, which is not possible if a block is used. Apply a tourniquet around the proximal arm before positioning and draping. For both the supine and prone position, place the arthroscopy equipment on the opposite side of the table from the surgeon.
- In the supine position, a standard operating table suffices. Place the hand in a gauntlet or suspension unit that is used for shoulder arthroscopy (Fig. 82.1). Then suspend the arm overhead to hold the shoulder in neutral rotation and 90° of abduction with the elbow flexed 90°. This position provides maximal protection of the neurovascular structures in the antecubital fossa. Use 5 lb of traction initially; when extension of the elbow is needed to work in the posterior compartment, add another 3 to 5 lb. Alternatively, prep the hand and suspend it with a sterile suspension device or finger traps if you plan a later open procedure. In general, for elbow arthroscopy, suspend the hand first and then sterilely prep the elbow and cover the forearm with a towel and clear sticky drape. A split drape works well for the supine position, and the arthroscopy drapes with bags attached are useful in collecting fluid. Sit on a rolling stool with the patient's elbow at a comfortable level. This arrangement allows access to both the medial and lateral sides of the elbow and rotation of the forearm.

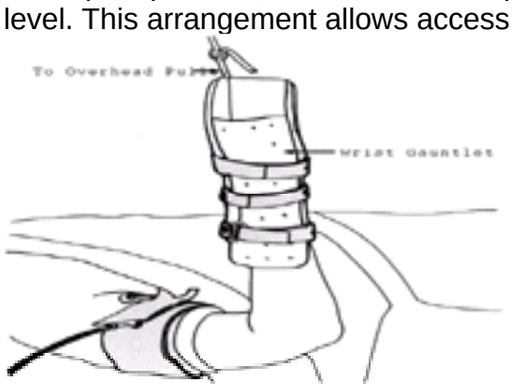


***Figure 82.1.*** Setup and patient positioning for elbow arthroscopy. The affected arm is statically suspended and positioned so that the elbow hangs freely off the side of the table.

- If the patient is prone, support the chest and abdomen to avoid compression (20) and place an arm board parallel to the operating table at the level of the patient's arm. Elevate the proximal arm and shoulder on a sandbag placed on the arm board. No traction is required; gravity alone distracts the elbow joint. The shoulder is in 90° abduction, and the elbow flexed 90°, with the forearm pointed to the floor. The surgeon then stands at the operating table with the elbow at chest level.
- There are many debates regarding the best position for elbow arthroscopy. In general, operative arthroscopy in the anterior compartment with release of the anterior capsule is easier in the supine position. Advocates of the prone position cite the greater ease of operating in the posterior compartment because the surgeon is not fighting gravity with the arm in this position. If a coupled videoarthroscope or “glass on glass” camera is not available, the prone position is preferred to avoid fogging of the camera (when the supine position is used, the fluid runs down the arthroscope and can cause fogging of the camera). I prefer the supine position and suggest that you select one position and develop proficiency with it. The elbow is a very difficult joint to examine and treat arthroscopically. It takes several cases before a reasonable level of ease with the procedure is achieved.

### INSTRUMENTATION

Standard arthroscopic instruments can be used in the elbow. The 4-mm, 30° arthroscope can be used throughout the procedure. Visualization with the larger arthroscope is much better than with the smaller 2.7-mm arthroscope. The 2.7-mm arthroscope is at times useful in the tight lateral compartment. I use a standard-sized shaver handpiece, with a 4.0-mm shaver tip; the smaller handpiece may be needed in the lateral compartment. Other instruments needed include a grasper for loose bodies and microfracture awls to abrade full-thickness chondral defects. An arthroscopic system that allows the camera and shaver to be placed through the same metal cannulas is very helpful in preventing loss of a portal. If they are not available, use switching sticks to change the position of the cannulas. Finally, an arthroscopic fluid system is very useful in maintaining pressure in the joint when the shaver is used. Two-portal arthroscopy can be used, as the debrider can be used as outflow. A pressure setting of approximately 30 to 35 mm Hg works well in the elbow joint. One ampule of epipherine added to each 3,000-cc bag is also helpful in controlling bleeding in the joint, in addition to the use of a tourniquet.

### LOCATION OF STANDARD PORTALS

- Outline the bony landmarks about the elbow with a marking pen, carefully marking the location of the ulnar nerve. With the hand covered and the elbow distended with fluid, it can be difficult to locate the standard anatomic landmarks. Identify the radial head as well as the medial and lateral epicondyles and the tip of the olecranon. The most commonly used portals are the direct lateral, anteromedial and anterolateral, posterolateral, straight posterior, and proximal medial (used in the prone position) portals.
- Locate the direct lateral portal among the lateral epicondyle, olecranon tip, and the radial head in the soft spot of the elbow (Fig. 82.2). This is a safe portal, as instrumentation introduced through this portal traverses only skin, a thin subcutaneous layer, the anconeus muscle, and joint capsule (Fig. 82.3).

***Figure 82.2.*** The direct lateral portal is located amid the lateral epicondyle, olecranon tip, and radial head. (From Andrews JR, Carson WG. Arthroscopy of the Elbow. *Arthroscopy* 1985;1:97.)



***Figure 82.3.*** Instruments placed in the direct lateral portal penetrate the anconeus muscle before entering the joint capsule.

- Locate the anterolateral portal approximately 2 to 3 cm distal and 1 cm anterior to the lateral epicondyle (Fig. 82.4). Make this portal over the radiocapitellar joint just anterior to the radial head, which is easily identified by pronating and supinating the forearm. This portal goes through the extensor carpi radialis brevis

muscle and comes within 7 mm of the radial nerve (Fig. 82.5) (12). In an anatomic study, Lynch and associates (12) found the radial nerve to be displaced 11 mm from the portal with 35 to 40 ml of fluid distention of the joint; without distention it is only 4 mm away.

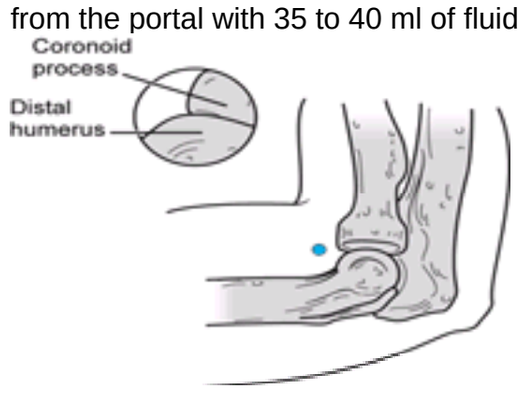


***Figure 82.4.*** Establish the anterolateral portal approximately 3 cm distal and 1 cm anterior to the lateral epicondyle. Arthroscopic anatomy as seen through this portal includes the distal humerus and the coronoid porcess of the ulna. (From Andrews JR, Carson WG. Arthroscopy of the Elbow. *Arthroscopy* 1985;1:97.)



***Figure 82.5.*** Instruments placed in the anterolateral portal penetrate the extensor carpi radialis brevis muscle and pass within 7 mm of the radial nerve. (From Chapman MW, ed. *Operative Orthopaedics, 2nd ed.* Philadelphia: JB Lippincott, 1993.)

- Locate the anteromedial portal approximately 2 cm distal and 2 cm anterior to the medial epicondyle (Fig. 82.6). Instruments in this portal pass through the tendinous portion of the pronator teres and the radial aspect of the flexor digitorum superficialis (Fig. 82.7). This portal comes within 1 cm of the median nerve and the brachial artery (12). Lynch showed that the median nerve was an average of 4 mm from this portal without distention and 14 mm with joint distention. The brachial artery averaged 9 mm of displacement without and 17 mm with joint distention.

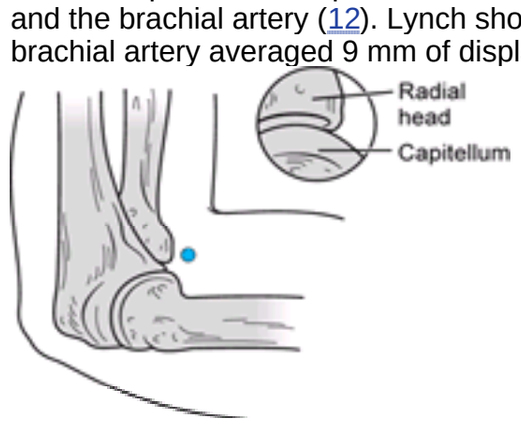


***Figure 82.6.*** The anteromedial portal. Instruments enter the skin approximately 2 cm distal and 2 cm anterior to the medial epicondyle. The arthroscopic view includes the capitellum and radial head. (From Andrews JR, Carson WG. Arthroscopy of the Elbow. *Arthroscopy* 1985;1:97.)



***Figure 82.7.*** Instruments passed in the anteromedial portal penetrate the tendinous portion of the pronator teres and the radial aspect of the flexor digitorum digitalis.

- Establish the posterior portals with the elbow in slightly more extension, which relaxes the triceps muscle and allows the posterior joint to be distended. The posterolateral portal is approximately 3 cm proximal to the olecranon tip, just off the lateral epicondylar ridge posterior and proximal to the lateral epicondyle (Fig. 82.8 and Fig. 82.9). The second posterior portal is the straight or working portal. It is used if there is need for a second operating portal posteriorly. Place it in the middle portion of the triceps tendon, splitting the triceps in line with its fibers. Take care to avoid too medial positioning of this portal, as the ulnar nerve is close. This portal comes within 18 mm of the ulnar nerve (12). I do not incise medial to the midpoint of the triceps tendon.

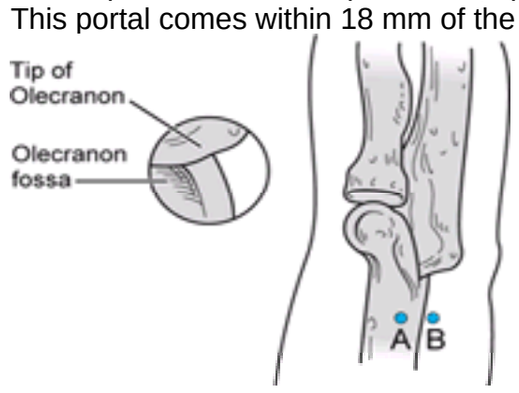


***Figure 82.8.*** With the elbow in 20° to 30° of flexion, (**A**) the posterolateral portal is established 3 cm proximal and 2 cm medial to the triceps tendon, and (**B**) the straight posterior portal is established 3 cm proximal to the olecranon tip and 2 cm medial to the posterolateral portal.

***Figure 82.9.*** Instruments placed in the posterolateral portal pass just lateral to the triceps tendon. Instruments in the straight posterior portal split the triceps tendon in line with its fibers.

- Place the proximal medial or the supracondylar anteromedial portal with the patient in the prone position (20). This portal is located 2 cm proximal to the medial epicondyle. Incise the skin and insert the cannula anterior to the intermuscular septum, avoiding injury to the ulnar nerve (Fig. 82.10). With the cannula directed toward the radial head, maintain contact with the anterior humerus, which protects the median nerve and the brachial artery (Fig. 82.11).

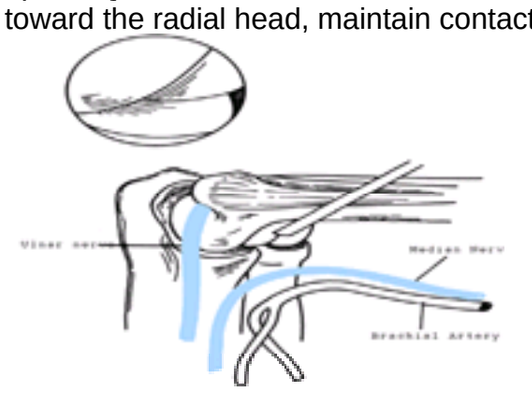


***Figure 82.10.*** Medial view of the left elbow. The proximal medial portal is used in the prone position.

***Figure 82.11.*** Arthroscopic view of the ulna (*u*) and humerus (*h*) in anterior compartment from the anterolateral portal.

**ARTHROSCOPIC ANATOMY AND OPERATIVE TECHNIQUE**

- After identifying the bony landmarks, inflate the tourniquet. I insert an 18-gauge needle into the soft spot, in the area of the direct lateral portal, aimed directly at the center of the joint. Then distend the elbow with approximately 30 to 40 ml of fluid, using intravenous tubing and a 50-ml syringe. The IV tubing allows for an easier injection. Confirm entry into the joint by the visible distention of the joint and the free backflow of fluid from the needle. Leave this needle in place with pressure applied to the syringe to distend the joint. Maximal distention of the joint displaces the antecubital neurovascular structures into a more anterior position, providing a safety margin.
- Place a second spinal needle for the anterolateral portal. The angle of this needle is then used as a guide for directing the cannula into the joint. Incise the skin only with a #11 blade; do not penetrate deeper to avoid damage to subcutaneous nerves. Use a staight hemostat to spread the tissues to the level of the joint capsule. Enter the joint with a blunt trocar. Because the capsule is trapped between the radial head and the capitellum, a change in angle is required toward the center of the joint once the trocar has passed over the radial head. Otherwise, the trocar has a tendency to track across the joint and enter in a more medial position, which makes visualization difficult. Direct the blunt trocar down toward the humerus. Palpate the medial epicondyle as the cannula is introduced; it stabilizes the arm and also serves as a point of reference. Once the cannula is in the joint, insert the arthroscope into the sheath without the fluid flowing in order to confirm an intraarticular location.
- With the arthroscope in the anterolateral portal, visualize the coronoid, humerus, and a portion of the radial head (Fig. 82.11). With extension of the elbow, the view of the trochlea of the humerus is improved. Take care not to pull the arthroscope out of the joint when attempting visualization of the radial head. Once a portal is established, leave a cannula in the portal to prevent extravasation of fluid.
- Then establish the anteromedial portal under direct arthroscopic visualization. This method is preferred to the use of an inside-out switching stick, as it allows for better control in placing the portal. Insert an 18-gauge spinal needle at a point 2 cm distal and 2 cm anterior to the medial epicondyle. When it is inside the joint, bring the needle over the humerus just above the articulation between the coronoid process and the humerus. Use the needle to test the optimal angle for the shaver. The portal needs to be made anterior enough to allow the shaver to be brought down onto the humerus if any debridement or anterior capsular release is anticipated. Make this portal in the same fashion as the anterolateral portal, with an incision in only the skin layer, and blunt dissection to the level of the joint capsule. Insert the cannula into the joint under direct visualization. With the arthroscope in the anteromedial portal, it is easy to visualize the radial head and capitellum (Fig. 82.12). Pronation and supination of the forearm provides additional visualization of the radial head. The coronoid process can also be seen if the scope is carefully withdrawn from the joint. The ulnar-radial articulation can be inspected through this portal. Small loose bodies are often found in this location. The anteromedial portal is critical for viewing the radial head, as visualization of the radial head from the anterolateral portal is very poor.

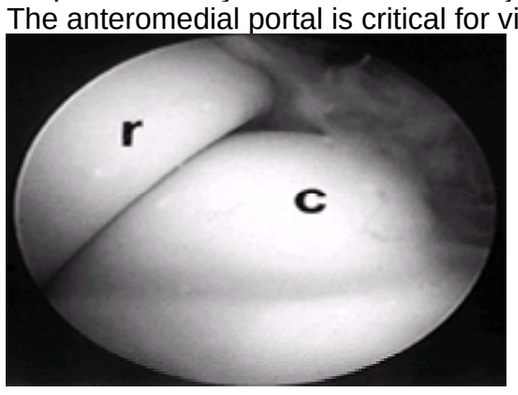


***Figure 82.12.*** Arthroscopic view of the radial head (*r*) and the capitellum (*c*) from the anteromedial portal.

- Next establish a direct lateral, or “soft spot” portal. Use a #11 blade to incise the capsule. Make the initial portal just off the center of the soft spot to help establish a second working portal in the lateral compartment. Use a straight hemostat in the portal to spread the capsule. Place a blunt trocar into the portal and direct it toward bone. Once bone is contacted, change the direction of the cannula to parallel the lateral capsule, which points the cannula toward the ceiling. This

technique allows the edge of the cannula to enter the joint, so that when the trochar is withdrawn, the cannula will remain inside the capsule. The lateral compartment is tight, and the small 2.7-mm arthroscope may be helpful. Through the straight lateral portal, the radial head, capitellum, articulations of both the trochlea and olecranon, and the ulna are visualized. The landmark of the lateral compartment is the articulation of the “three bones” (Fig. 82.13).

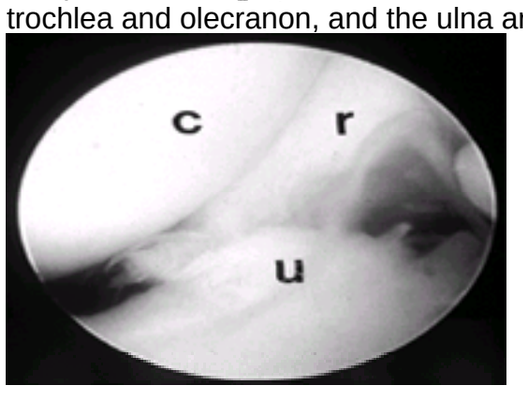


***Figure 82.13.*** Arthroscopic view of the lateral compartment including the capitellum (*c*), radial head (*r*), and ulna (*u*), as seen from the straight lateral, or soft spot, portal.

- Then establish a working portal in the lateral compartment. Introduce a spinal needle. Arthrofibrosis in a joint can be difficult to visualize. It is possible at times to place the shaver in the portal and then look for the movement in the synovium. Take care to avoid scuffing the cartilage. Once the shaver is visualized, place it slightly ahead of the arthroscope. The arthroscope can then follow the shaver down the olecranon curve to enter the posterior compartment. If the shaver is not used to clear the synovium in this area, it can be difficult to follow the curve of the ulna into the posterior compartment.
- Once the arthroscope is at the tip of the olecranon viewing in the posterior direction from the direct lateral portal, introduce an 18-gauge spinal needle through the posterolateral portal. With supine arthroscopy, the needle is directed almost toward the ceiling. After it is correctly positioned, use a #11 blade to make the portal, entering the capsule while visualizing the blade with the arthroscope. Use a hemostat to spread the capsule, and introduce the cannula into the portal site. The olecranon tip, the posterior olecranon fossa, and the posterior trochlea are visualized from this portal. Loose bodies are frequently encountered posteriorly in the olecranon fossa. The posteromedial olecranon osteophyte is seen, as well as chondral defects posteriorly.
- If a second operative portal is required posteriorly, make a straight posterior portal under direct visualization. Place an 18-gauge spinal needle at the level of the tip of the olecranon and pass it straight through the triceps, in the middle portion of the tendon. The needle can be used to confirm that the areas the shaver needs to reach will be accessible through this portal. Insert a #11 blade in line with the fibers of the triceps tendon. The posterior capsule can be difficult to enter, especially if there is a thickened olecranon bursa. Use a hemostat to expand the portal site. Once the portal is established, loose bodies can be removed, and debridement of posterior olecranon osteophytes can be performed as well as synovectomy of the posterior compartment. The ulnar nerve rests against the posteromedial capsule; exercise great care when shaving in the posteromedial area. Keep the back side of the shaver against this capsule, never allowing the mouth of the shaver to work against the capsule.

## SURGICAL TREATMENT OF SPECIFIC LESIONS

### *Loose Bodies*

Removal of loose bodies from the elbow is one of the most common arthroscopic procedures. Osteocartilaginous bodies are usually the result of osteochondritic lesions of the capitellum, osteochondral fractures of the radial head, and synovial diseases, such as synovial chondromatosis. The patient usually complains of catching and locking in the elbow, and a joint effusion may develop after a painful episode. Radiographs, CT-arthrograms, and MRI all may be negative preoperatively. The procedure is usually undertaken more on the basis of clinical findings than the results of imaging studies. It is important to obtain consent for a possible arthrotomy, as it may not be possible to remove the fragment arthroscopically.

A complete inspection of the elbow joint is necessary when searching for loose bodies, as defects from the anterior and lateral compartments can frequently lodge in the posterior compartment. The loose body may be drawn into view by using the shaver with full suction. If one loose body is encountered, make a careful search for others. In the anterior compartment, loose bodies are more easily removed through the lateral portal. If a large piece is too big to pull through the portal, it can be removed in piecemeal fashion. The Schlessinger grasper is useful for breaking a loose body into pieces, or a shaver can be used to break up the large fragment.

After removing loose bodies from the elbow, inform the patient that other loose bodies may have been left behind in the joint and, in addition, that new loose bodies may form (28). This is often the case in the throwing athlete, who continues to subject the joint to repetitive microtrauma. Once the portals are healed, start the patient on range-of-motion exercises and a strengthening program. Most athletes are ready to start throwing at 6 to 8 weeks after surgery. Several studies have shown the benefits of removal of loose bodies from the elbow, especially in the joint free of degenerative changes (5,8,17,18).

### *Osteochondritis Dissecans*

During the throwing motion, the valgus moment of the forearm about the elbow results in compression of the lateral joint. In the skeletally immature, osteochondritis dissecans can result, which is usually seen in throwing athletes or gymnasts (4,10,21). The patient usually has a flexion contracture, locking episodes caused by loose bodies, and pain, with decreased ability to participate in sports.

At arthroscopy, visualize the lateral joint from the anteromedial portal initially. The best visualization of the typical osteochondritis lesion, however, is from the soft spot, or straight lateral portal. Once the synovial tissue is debrided, locate the chondral defect. It is usually soft, and there may be a large flap of cartilage. A small (3.5 mm) shaver is useful both to probe and to debride the lesion. Use forceps or a small knife to debride the crater, and once the cartilage flaps are removed, use awls to microfracture the subchondral bone in an attempt to heal the area with fibrocartilage. Braungaraten et al. advise against attempting to reattach the fragment (4). After debridement, younger athletes are usually able to return to full activity, but older patients have less successful results (4,19,21).

### *Posterior Impingement*

In the throwing athlete, one of the most common causes of elbow pain is the formation of a posteromedial osteophyte on the olecranon, resulting in impingement and chondromalcia on the trochlea (1). The forces of throwing place a valgus force across the medial elbow, and with ball release a forced extension occurs. The combination of this valgus and extension force is referred to as “valgus extension overload syndrome” (22,30). In 72 professional baseball players requiring arthroscopy, 65% had posterior olecranon osteophytes requiring debridement, which was the most commonly performed procedure (3).

Patients usually complain of posteromedial joint pain during the throwing motion, especially after ball release. Physical examination typically reveals slight loss of full extension, and valgus and extension loading cause pain. Ulnar nerve symptoms may also be present. Assess the stability of the ulnar collateral ligament. Medial instability increases the valgus force across the elbow, and osteophytes may form in response to medial laxity. Routine radiographs are often normal. The osteophyte may be seen on an axial view (1) or on MRI. The diagnosis is usually based on the clinical history and the findings on physical examination.

Treatment is debridement of the osteophyte, which is best visualized on arthroscopy. Chondral defects on the posterior trochlea can be very difficult to see without the arthroscope.

- Position the patient supine and place the arthroscope in the posterolateral portal with the elbow in approximately 30° of flexion. Use a cannula in this portal because fluid extravasation can make it difficult to find the portal again. Make a second working portal and bring a shaver in through this portal.
- Initially debride the synovitis posteriorly in order to improve visualization. Then use a burr or shaver to debride the posterior olecranon osteophyte (Fig. 82.14). It is important to completely remove the posteromedial corner of the osteophyte, but the ulnar nerve is very close to this location; take care to keep the open side of the shaver away from the nerve.

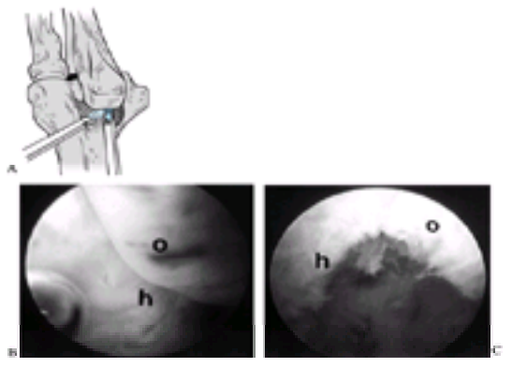


***Figure 82.14.*** **A:** A diagram of debridement of a posteromedial olecranon osteophyte. The camera is in the posterolateral portal, with the burr in the straight posterior portal. **B:** Arthroscopic view of the posterior compartment with olecranon osteophyte (*o*) and humerus (*h*). **C:** Arthroscopic view after debridement of the olecranon osteophyte.

- The question is how much of the osteophyte should be removed. When this operation was initially developed (1), a relatively generous excision of the osteophyte was recommended. In more recent years, however, less aggressive excision has been adopted because excessive debridement increases the stress on the ulnar collateral ligament. Typically 4 to 5 mm is removed, or enough to debride the loose fragments and prevent further impingement. If there is a chondral defect on the trochlea, use a burr to debride the lesion to stimulate bleeding and fibrocartilage formation.
- Once the portals are healed, start range-of-motion exercises, followed by a strengthening program. Athletes are usually able to return to an early throwing program by 6 to 8 weeks after surgery, but it may take 4 to 6 months for complete recovery.

In professional baseball players (3), there is a high rate of reoperation because of recurrence of the posteromedial osteophyte. In addition, 25% of the athletes who initially had debridement of the posterior osteophyte required an ulnar collateral ligament reconstruction. It is important to carefully assess the integrity of the ulnar collateral ligament in the presence of a posterior osteophyte. In athletes who continue to throw, this procedure is palliative and does not solve the underlying problem of overstress.

***Instability***

During the throwing motion, the medial soft tissues are subject to large forces. The anterior bundle of the ulnar collateral ligament is the primary stabilizer against valgus stress (9,13,23). Injuries to this ligament are usually the result of repetitive microtrauma (27); less commonly, sudden severe trauma can result in an acute tear. Maximum valgus instability occurs at 70° of elbow flexion (23) after sectioning of the anterior bundle of the ulnar collateral ligament (UCL). This instability can be difficult to detect clinically. It may be that the high forces of throwing are required to cause the painful symptoms.

The UCL is difficult to visualize arthroscopically (26). Only the anterior 20% to 30% of the anterior bundle and the posterior 30% to 50% of the posterior bundle are visualized, using both anterior and posterior portals (Fig. 82.15). A complete tear of the anterior bundle of the UCL can be missed during arthroscopy. With a ligament injury, however, laxity will result that can then be visualized arthrosocpically (27).

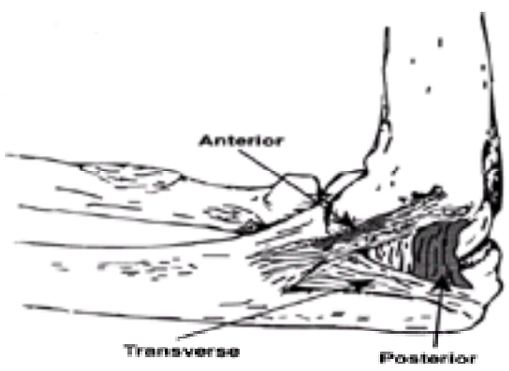


***Figure 82.15.*** The portion of the ulnar collateral ligament that is visible arthroscopically. (From Timmerman LA, Andrews JR. The histologic and arthroscopic anatomy of the ulnar collateral ligament of the elbow. *Am J Sports Med* 1994;22(5):667.)

From the anterolateral portal, the first structures visualized are the coronoid process and the trochlea. With the humerus stabilized, apply a valgus force to the forearm and assess the resulting opening between the humerus and olecranon (Fig. 82.16; see also Color Fig. 82.16). Normally there is no, or minimal (less than 1 mm), opening in the ulnohumeral joint. With injury to the UCL an increase in opening is seen, and with a complete large tear the arthroscope itself may be placed between the ulna and humerus. Reconstruction of the UCL may be indicated when the typical history and physical findings are present, a course of conservative treatment fails, and increased valgus opening of the joint is seen on arthroscopy.

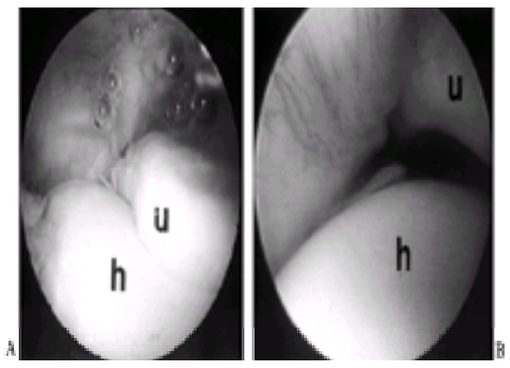


***Figure 82.16.*** (See Color Fig. 82.16) **A:** An arthroscopic view from the anterolateral portal in a right elbow of the humerus (*h*) and the ulna (*u*). **B:** With valgus stress applied, the increase in space between the ulna and the humerus is seen.

In posterolateral instability, as described previously (16), the forearm bones subluxate as a unit on the humerus in a pivot-shift fashion. A stress examination at the time of arthroscopy is useful to see this abnormal intraarticular movement (Fig. 82.17; see also Color Fig. 82.17).

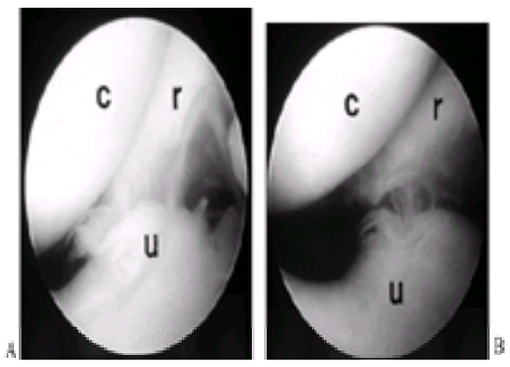


***Figure 82.17.*** (See Color Fig. 82.17) Arthroscopic view of the lateral compartment, demonstrating posterolateral subluxation of the forearm bones on the humerus. **A:** No stress. **B:** With stress. *c*, capitellum; *r*, radius; *u*, ulna.

### *Arthrofibrosis*

Posttraumatic arthrofibrosis is a common finding in the elbow joint that can be very difficult to treat. It is seen most commonly after an intraarticular fracture or dislocation. A nondisplaced radial-head fracture can result in significant elbow-joint contracture (6). Immobilization of the elbow, usually in 90° of flexion, is associated with the formation of fibrous bands in the anterior elbow. Although it is often stated that an arc of motion between 30° and 100° of flexion is required for functional activities of the elbow (14); for some activities, particularly in athletes, a flexion contracture of 10° to 20° may be symptomatic. Arthroscopic debridement of arthrofibrosis of the elbow can be successful (6,11,15,25).

#### Debridement of Arthrofibrosis

- The elbow must have at least 50° to 60° of motion for arthroscopic debridement to be considered. It may be difficult to inject fluid into the joint. Maintain pressure on the syringe as you make the anterolateral portal. Direct the trocar toward the humerus and take care not to pull the cannula back as the trochar is removed. Instead, advance the cannula slightly so that it stays inside the capsule. Then introduce the scope, looking for articular cartilage to confirm entry. If articular cartilage is not visualized, redirect the trochar. Once articular cartilage is seen, establish a second working portal medially. Use a switching stick to do so if the spinal needle is not visible.
- Bring in a shaver through the medial portal. Keep the open side of the debrider pointing toward the humerus. Release the anterior capsule and debride adhesions from the humerus. If the capsule is thickened, direct the shaver anteriorly with caution and debride this tissue (Fig. 82.18; see also Color Fig. 82.18).

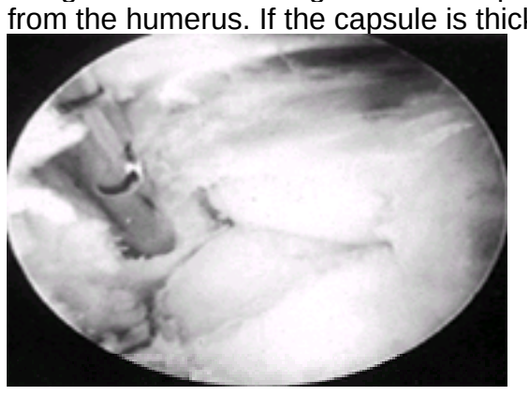

***Figure 82.18.*** (See Color Fig. 82.18) Arthroscopic view of arthrofibrosis in the anterior compartment.

- Once the humerus is visualized, use either the shaver or a small burr to re-form the anterior radial and olecranon fossae. The arthroscope and shaver can be interchanged, but take care not to withdraw the cannulas from the joint. It is easy to lose a portal and often difficult to reestablish it.
- Once the anterior tissues have been released, debride the lateral compartment. Then visualize through the posterolateral portal and debride the posterior compartment through the straight lateral portal. Even though most of the scarring may seem to be in the anterior compartments, significant scarring can be found posteriorly, with the olecranon fossa completely filled in. This condition prevents full extension. In a difficult case, soft-tissue swelling or lack of tourniquet time may preclude complete posterior debridement, which can be done at a second procedure. Once the arthroscopy is completed, manipulate the elbow to gain range of motion, which is documented with a sterile goniometer.
- Postoperatively, start gentle motion immediately; once the portals are healed (usually 4–5 days), pursue an active mobilization program. Usually a 50% improvement in motion can be expected. It may take 3 to 4 months before the patient is able to achieve the motion that is achieved on the operating table.

### *Degenerative Arthritis*

Degenerative arthritis of the elbow is not common, and it is usually the result of previous trauma or longstanding overuse. Typical complaints are of pain, loss of motion, and catching and locking. Radiographs usually demonstrate degenerative changes, including loss of joint spaces and formation of osteophytes. Large coronoid osteophytes can impinge anteriorly, preventing flexion, and posterior olecranon osteophytes can impinge and prevent extension. Loose bodies can cause locking or can block motion.

The procedure for debridement of degeneration of the elbow joint is similar to that described for arthrofibrosis. More bony work is usually required with degenerative arthritis, with emphasis on removing the osteophytes that impinge. A small ¼-in. osteotome is often useful; it can be introduced through the portal to remove large pieces of bone. A burr that fits through the cannula may be preferred to prevent loss of the portal site. The associated synovitis and capsular contractures can also be debrided. Caution the patient preoperatively that the procedure is palliative and that symptoms may recur.

### *Synovitis*

Synovitis is seen frequently with inflammatory disorders of the elbow (Fig. 82.19; see also Color Fig. 82.19). Treat rheumatoid arthritis involving the elbow arthroscopically; it may be easier to enter the joint in these cases, as the capsule tends to be lax and enlarged. Perform the synovectomy using the usual portals. Occasionally a synovial band will thicken in the elbow, creating symptoms of popping and catching (7), which are usually seen laterally and are referred to as a lateral band or plica. This thickening can result in impingement on the radial–capitellar joint, resulting in persistent lateral elbow pain. Its symptoms can be confused with those of lateral epicondylitis. The lesion can be visualized and debrided arthroscopically. Take care not to excessively debride the lateral capsule, including the annular and lateral collateral ligaments, to prevent destabilizing the joint.

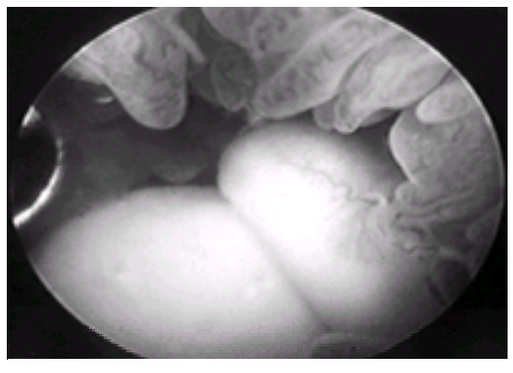

***Figure 82.19.*** (See Color Fig. 82.19) Arthroscopic examination of the anterior lateral compartment with extensive inflammatory synovitis.

## GENERAL REHABILITATION AND POSTOPERATIVE PRINCIPLES

After arthroscopy is completed, close the portals with suture, using a nylon in the skin or a subcutaneous absorbable suture. It can be difficult to apply Steri-Strips, as extensive soft-tissue swelling is often present. Injection of the joint with morphine helps postoperative pain. It is preferable not to inject a local anesthetic until after a neurologic examination can be completed in the recovery room; the agent can extravasate from the joint and produce a nerve palsy.

Place a bulky soft dressing with an ice pack. The compression ice dressings designed for the knee work well on the elbow, with the olecranon placed in the same area as the patella. If the patient is excessively uncomfortable in the recovery room, use an axillary block before discharge. A short course of antibiotics may be desirable if significant posterior debridement was performed, as the posterior triceps portal can sometimes drain excessively.

Instruct the patient to start with gentle grip exercises immediately and to work on gentle range of motion with the soft dressing in place. Increase motion as tolerated, with emphasis on maintaining extension and flexion. Once inflammation and swelling have subsided, initiate strengthening exercises. Initially use 1-lb weights, increasing gradually to a 5-lb weight; subsequently increase repetitions rather than increasing the weight.

## PITFALLS AND COMPLICATIONS

It is at times difficult to gain access to the joint, but familiarity with the procedure and careful patient selection improve the surgeon's ability.

Infection and neurovascular injury are complications common to all surgical procedures. They do not appear to occur at an increased rate in elbow arthroscopy. Occasionally persistent draining from a portal occurs, usually the posterior portal. Considerable soft-tissue swelling occurs posteriorly when both posterior portals are used, and the fluid can collect in the olecranon bursa. Treat this condition with immobilization and oral antibiotics.

Neurovascular damage has been reported (19,24), including injury to the posterior interosseus nerve with an anterolateral portal (24).

With excessive fluid extravasation, a forearm compartment syndrome can occur. Once the use of the portal is completed, insert a blunt trocar into the portal to prevent fluid from leaking out. Placement of the trocar also allows return to these portal sites later if needed.

With the supine position, severe fogging of the arthroscope will occur unless a coupled videoarthroscope is used.

## AUTHOR'S PERSPECTIVE

I prefer to position the patient supine because I am familiar with use of this position. I find it easier to work in the anterior compartment with the patient supine, and it is not different to do posterior debridement and inspection of the radiocapitellar articular in the supine position. If I plan an open procedure, I use the supine position to avoid having to reposition the patient.

Compared with the knee, ankle, shoulder, and wrist, the elbow is the most difficult joint to arthroscope, but skills improve considerably with experience. Among the most satisfied patients I have treated are those with arthrofibrosis of the elbow. They report improvement of both pain and function (25). A close second in patient satisfaction—although the procedure is less common—is the group of adolescents treated by debridement of osteochondritis dissecans. These patients typically regain range of motion quickly and are throwing at approximately 3 months. Removal of a loose body is the easiest operative procedure to perform, although an isolated loose body is not often present without another associated disorder, such as a posteromedial osteophyte or arthrofibrosis. The most difficult procedures to perform are debridement of extensive arthrofibrosis and debridement of a posteromedial olecranon osteophyte.

Elbow arthroscopy is becoming more common now and is probably the treatment of choice for several disorders discussed above. The major advantages of improved visualization and more rapid rehabilitation are tempered by the difficulty of the procedure and the remote risk of significant neurologic damage. Meticulous technique as outlined above gives the best assurance of a satisfactory outcome.

## CHAPTER REFERENCES

Each reference is categorized according to the following scheme: *, classic article; #, review article; !, basic research article; and +, clinical results/outcome study.


# 1. Andrews JR. Bony Injuries About the Elbow in the Throwing Athlete. In: *Instructional Course Lectures 34.* St. Louis: CV Mosby, 1985.

* 2. Andrews JR, Carson WG. Arthroscopy of the Elbow. *Arthroscopy* 1985;1:97.

+ 3. Andrews JR, Timmerman LA. Outcome of Elbow Surgery in Professional Baseball Players. *Am J Sports Med* 1995;23:404.

+ 4. Baungaraten TE, Andrews JR, Satterwhite YE. The arthroscopic classification and treatment of osteochondritis dissecans of the capitellum. *Am J Sports Med* 1998;26:520.

+ 5. Boe S. Arthroscopy of the Elbow. Diagnosis and Extraction of Loose Bodies. *Acta Orthop Scand* 1986;57:52.

+ 6. Byrd JWT. Elbow Arthroscopy for Arthrofibrosis after Type I Radial Head Fractures. *Arthroscopy* 1994;10:162.

+ 7. Clarke RP. Symptomatic Lateral Synovial Fringe (Plica) of the Elbow Joint. *Arthroscopy* 1988;4:112.

# 8. Guhl JF. Arthroscopy and Arthroscopic Surgery of the Elbow. *Orthopedics* 1985;8:1290.

! 9. Hotchkiss RN, Weiland AJ. Valgus Stability of the Elbow. *J Orthop Res* 1987;5:372.

+ 10. Jackson DW, Silvino N, Reiman P. Osteochondritis in the Female Gymnast's Elbow. *Arthroscopy* 1989;5:129.

+ 11. Jones GS, Savoie FH III. Arthroscopic Capsular Release of Flexion Contractures (Arthrofibrosis) of the Elbow. *Arthroscopy* 1993;9(3):277.

* 12. Lynch GJ, Meyers JF, Whipple TL, Caspari RB. Neurovascular Anatomy and Elbow Arthroscopy; Inherent Risks. *Arthroscopy* 1986;2:190.

* 13. Morrey BF, An KN. Articular and Ligamentous Contributions to the Stability of the Elbow Joint. *Am J Sports Med* 1983;11:315.

* 14. Morrey BF, Askew LJ, An KN. A Biomechanical Study of Normal Functional Elbow Motion. *J Bone Joint Surg* 1981;63A:872.

+ 15. Nowicki KD, Shall LM. Arthroscopic Release of a Posttraumatic Flexion Contracture in the Elbow: A Case Report and Review of the Literature. *Arthroscopy* 1992;8:544.

* 16. O'Driscoll SW, Bell DF, Morrey BF. Posterolateral Rotatory Instability of the Elbow. *J Bone Joint Surg* 1991;73A:440.

+ 17. O'Driscoll SW, Morrey BF. Arthroscopy of the Elbow. *J Bone Joint Surg* 1992;74A:84.

+ 18. Ogilvie-Harris LB, Schemitsch E. Arthroscopy of the Elbow for Removal of Loose Bodies. *J Arthrosc Rel Surg* 1993;9:5.

+ 19. Papillion JD, Neff RS, Shall LM. Compression Neuropathy of the Radial Nerve as a Complication of Elbow Arthroscopy: A Case Report and Review of the Literature. *Arthroscopy* 1988;4:284.

+ 20. Poehling GG, Whipple TO, Sicso L, et al. Elbow Arthroscopy: A New Technique. *Arthroscopy* 1989;5:222.

+ 21. Ruch DS, Poehling GG. Arthroscopic Treatment of Panner's Disease. *Clin Sports Med* 1991;10:629.

* 22. Slocum DB. Classification of Elbow Injuries from Baseball Pitching. *Tex Med* 1968;64:48.

! 23. Sojbjerg JO, Ovensen J, Neilsen S. Experimental Elbow Instability after Transection of the Medial Collateral Ligament. *Clin Orthop* 1987;218:186.

+ 24. Thomas AM, Fast A, Shapiro D. Radial Nerve Damage as a Complication of Elbow Arthroscopy. *Clin Ortoped* 1987;215:130.

+ 25. Timmerman LA, Andrews JR. Arthroscopic Treatment of Posttraumatic Elbow Pain and Stiffness. *Am J Sports Med* 1994;22:230.

! 26. Timmerman LA, Andrews JR. The Histologic and Arthroscopic Anatomy of the Ulnar Collateral Ligament of the Elbow. *Am J Sports Med* 1994;22:667.

+ 27. Timmerman LA, Andrews JR. Undersurface Tear of the Ulnar Collateral Ligament in Baseball Players. A Newly Recognized Lesion. *Am J Sports Med* 1994;22:33.

# 28. Timmerman LA, Andrews JR. Clinical Experience. In: Andrews JR, Soffer SR, eds. *Elbow Arthroscopy.* St. Louis: CV Mosby, 1994;131.

+ 29. Timmerman LA, Schwartz ML, Andrews JR. Preoperative Evaluation of the Ulnar Collateral Ligament by Magnetic Resonance Imaging and Computed Tomography Arthrography. Evaluation in 25 Baseball Players with Surgical Confirmation. *Am J Sports Med* 1994;22:26.

* 30. Wilson FD, Andrews JR, Blackburn TA, McCluskey G. Valgus Extension Overload in the Pitching Elbow. *Am J Sports Med* 1983;11(2):83.

# CHAPTER 83

# ANATOMY AND BIOMECHANICS OF THE KNEE

*Robert J. Johnson and Bruce Beynnon*

**R. J. Johnson and B. Beynnon:** Department of Orthopaedics, University of Vermont Medical School, Burlington, Vermont 05405.

Anatomy and Kinetics and Femoral–Tibial Articulations
Patellofemoral Articulation
The Menisci
Biomechanical Function
Meniscal Anatomy
Synovial Cavity of the Knee
Ligaments
Medial Side of the Knee
Anterior Aspect of the Knee
Lateral Aspect of the Knee
The Cruciate Ligaments
Authors' Perspective
Chapter References

The knee joint is the largest and probably the most complex joint within the human body. Its position between the two longest lever arms of the skeleton makes it vulnerable to injury by the tremendous moments that can be transmitted to it from loads applied at great distance to the ligaments and capsular structures that provide the structural integrity of the joint. Thus, it is not surprising that the knee joint is one of the most frequently injured joints. Because of its vital importance in support and locomotion of our bipedal existence, damage to its major components results in much discomfort and disability. An understanding of fundamental anatomy and biomechanics provides the basis for appropriate treatment of injury and disease processes involving the knee.

## ANATOMY AND KINETICS AND FEMORAL–TIBIAL ARTICULATIONS

The knee joint does not conform to any of the standard classifications of joints because it has some features of a ginglymus or hinge joint and some of an arthrodial joint, which by definition allows only gliding movement along opposing plane surfaces. The knee consists of three more or less independent articulations: one between each sphere-like condyle of the femur and a corresponding but more planar condylar surface of the tibia, with interposed menisci, and a third between the patella and the patellar or trochlear groove of the femur. None of the pairs of bearing surfaces is exactly congruent, which results in a combination of rolling and gliding motions determined by the restraints of a complex network of ligaments, capsular structures, and the contours of the bones themselves. This intricate arrangement of anatomic interrelationships allows the knee six degrees of freedom of motion: three rotations and three translations. The translations are anteroposterior (5 to 10 mm), compression–distraction (2 to 5 mm), and mediolateral (1 to 2 mm). These motions are limited by the ligaments, capsule, and to some degree the intracondylar eminences of the tibia and are of small magnitude in the normal knee. The rotations are flexion–extension, varus–valgus, and internal–external rotation, and in general they are much more extensive than the translations. Normal flexion and extension of the knee is variable, ranging from 0° to 15° of hyperextension to 130° to 150° of flexion. Internal and external rotation ranges from little or no motion in full extension to 20° to 30° with the knee flexed. Tightening of the capsular and ligamentous structures, which is greatest in full extension, accounts for this variation. The mean values for rotations during level walking, as determined by Kettelkamp et al. using an electrogoniometer, provide insight into the complexity of motion during function of the knee (Table 83.1) (46).

| | |
|---|---|
| Flexion–extension (swing phase) | 66.7° |
| Flexion–extension (stance phase) | 20.6° |
| Adduction | 8.4° |
| Abduction | 2.8° |
| Internal rotation | 7.2° |
| External rotation | 6.1° |

Data from Kettelkamp DB, Johnson RJ, Smidt GL, et al. An Electrogoniometric Study of Knee Motion in Normal Gait. *J Bone Joint Surg* 1970;52-A:775.

***Table 83.1. Mean Values for Rotations During Level Walking***

A reproducible pattern of all of these motions exists during gait for each person, with minor variations observed between individuals. They found that none of the knees tested extended fully during normal walking but extended slightly farther than in resting stance just before or at heel strike. The most common motion pattern observed revealed that maximum extension and external rotation occurred just before heel strike; maximum abduction occurred at heel strike, and maximum adduction during swing phase; and flexion and internal rotation, which began just before heel strike, continued to increase between heel strike and foot flat (Fig. 83.1). Similar patterns were observed by Marans et al., who used a more sophisticated electrogoniometric system (54). They measured not only the rotational degrees of freedom (flexion–extension, varus–valgus, and internal–external rotation) but also the translational degrees of freedom (anteroposterior, mediolateral, and superior–inferior). Only with evaluation of anteroposterior translation measurements during level walking were they able to distinguish between a group of normal knees and a group that were anterior-cruciate deficient. The knees with no anterior cruciate ligament (ACL) demonstrated greater anterior translation of the tibia relative to the femur during the swing phase of gait but not during the stance phase.

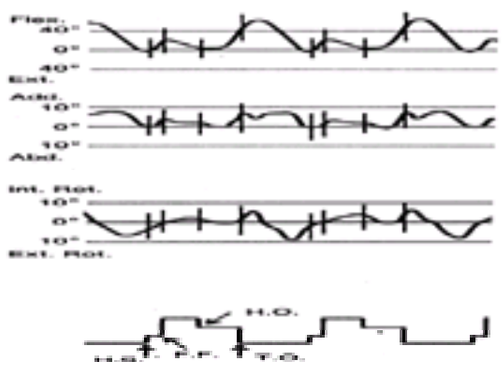


***Figure 83.1.*** Electrogoniometric patterns of knee motion of a normal knee. The 0° line represents the position in neutral stance (H.S., heel strike; F.F., foot flat; H.O., heel off; T.O., toe off). (From Kettelkamp DB, Johnson RJ, Smidt GL, et al. An Electrogoniometric Study of Knee Motion in Normal Gait. *J Bone Joint Surg* 1970;52-A:775.)

The axes of the rotations of the knee are not fixed in a single plane; thus, combinations of rotations and translations (coupled motions) are seen through the normal range of motion. The *flexion–extension* axis provides the most obvious example. This axis varies because the radii of the lateral and medial femoral condyles are dissimilar, and the tibial plateau topography varies from side to side as well. Viewed from the side, the medial femoral condyle has a more constant radius of curvature than does the lateral. Posteriorly, both condyles have similar radii, but anteriorly the lateral condyle rapidly attains a longer radius and appears to flatten out to a greater degree than the medial condyle. Often, near the midportion of the lateral condyle, a lateral groove passing diagonally, anteriorly, and laterally from the anterior aspect of the intracondylar notch produces a distinct indentation. This differentiates the lateral from the medial condyle as observed on a lateral roentgenogram. This lateral groove demarcates the extent of the articular surface of the femur, which articulates with the tibia (Fig. 83.2) (41). All articular surfaces anterior to this area contact only the patella. As viewed from its distal end, the medial femoral condyle extends anteriorly and inclines toward the lateral side, so it is somewhat longer than the lateral condyle. A small V-shaped indentation (medial groove) delineates the anterior extremity of the articular surface of the medial condyle that contacts the tibia (Fig. 83.2). This medial groove is well forward of its counterpart on the lateral femoral condyle and is probably often mistaken to be a pathologic process caused by a hypertrophic medial plica. It is, in fact, the area where the anterior horn of the medial meniscus abuts the femur when the knee is fully extended.

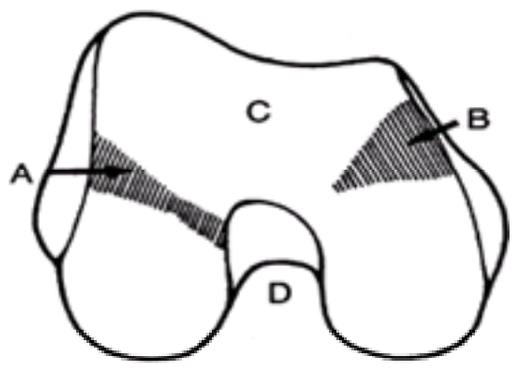


***Figure 83.2.*** Distal end of femur showing lateral (**A**) and medial (**B**) grooves in the articular surfaces of the medial and lateral femoral condyles and the patellar or trochlear surface (**C**) and intercondyloid fossa or notch (**D**). (From Jackson JP. Surgery of the Knee Joint. In: Jackson JP, Waugh W, eds. *Surgical Anatomy.* Philadelphia: JB Lippincott, 1984;5.)

The tibial plateau possesses two articular facets. The medial is a good deal longer in the sagittal plane than the lateral. Both facets appear to be slightly concave in the coronal plane, but the lateral facet demonstrates a convexity in the sagittal plane, producing a saddle shape (44,56,60). Thus, in the lateral compartment of the knee, the rounded femoral condyle rests on a convex surface of the tibia, which contributes to the complexity of stabilization of this joint. This stabilization is controlled by the interposed meniscus, the surrounding capsular and ligamentous structures, and the muscles crossing the knee joint.

In part because of the asymmetry of the contact areas of the tibia on the two femoral condyles, the tibia is obligated to externally rotate significantly during the last few degrees of full extension as the tibia rolls farther forward on the medial femoral condyle than on the lateral condyle. This screw home mechanism is also guided by the alignment and tension in the ligaments and capsular structures. In the fully extended position of the knee, the majority of the ligaments and capsular structures are under tension, thus allowing no further extension or external rotation. With active or passive flexion from full extension, the rotation process is reversed, with the tibia internally rotating relative to the femur during the first 10° to 20°. The motion of the femur relative to the tibial plateau during flexion is initially a pure rolling motion, but by 10° to 15° on the medial tibial and by 20° on the lateral side, sliding of the femur begins relative to the tibia and becomes progressively more important until flexion is complete (Fig. 83.3) (43). Thus, the contact area between the tibia and femur moves rapidly backward during the first 10° to 20° of flexion and then slowly progresses posteriorly to eventually ride entirely on the posterior horns of both menisci at the extreme of flexion. Because the lateral condyle rolls more than the medial over the corresponding tibial plateau, another manifestation of the screw home mechanism is explained. Kapandji observed that the 15° to 20° of initial rolling corresponds to normal range of movements required in flexion and extension during the stance phase of ordinary walking (43).

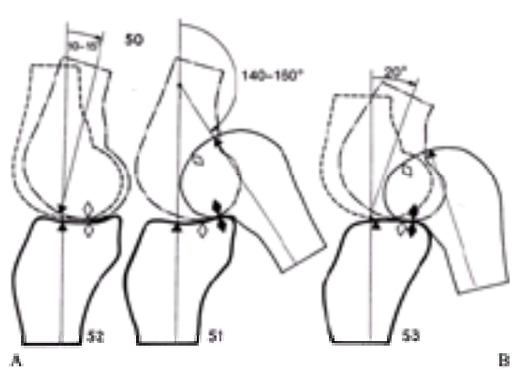


***Figure 83.3.*** Medial (**A**) and lateral (**B**) compartments of the knee demonstrating the amount of rolling and sliding of the femoral and tibial surfaces occurring during flexion. Starting from full extension, the femoral condyles roll without sliding. Sliding movement then becomes progressively more important, so that by the end of flexion, the condyles slide without rolling. For the medial condyle, pure rolling occurs only during the first 10° to 15° of flexion. For the lateral condyle, the rolling continues until 20° of flexion. (From Kapandji IA. *The Physiology of the Joints, Vol. 2. Lower Limb.* Edinburgh: Churchill Livingstone, 1970.)

## PATELLOFEMORAL ARTICULATION

The patellofemoral articulation provides an isolated articular surface for the control of the extensor mechanism of the knee as it glides over the anterior aspect of the joint. The extensor mechanism stabilizes the joint against gravity when the knee is flexed and assists in the forward propulsion of the mass of the body as the knee extends during gait. The patella contacts the patellar or trochlear surface of the femur during these activities (Fig. 83.2). Anteriorly, the condyles of the distal femur are separated from one another by this shallow articular depression, which averages 5 to 6 mm in depth. Inferiorly and posteriorly, the trochlear surface is continuous with the intercondyloid fossa or notch (Fig. 83.2). The lateral wall of the trochlear surface of the femur is more prominent than the medial and projects farther anteriorly. The patella has a multifaceted dorsal surface, which articulates with the trochlear groove. A median ridge divides the patella into two large facets. Most frequently, the lateral facet is greater in area than the medial, but a range of anatomic variations exist, sometimes making these facets nearly equal. A less distinct vertical ridge divides the medial facet into two separate surfaces in most knees. The more medial of these two facets has a more nearly sagittal orientation and contacts the femur along the medial side of the notch only when the knee is flexed past 90°.

Indistinct transverse ridges divide the medial and lateral facets into roughly equal-sized superior, middle, and inferior facets. In full extension the patella does not contact the articular surface of the femur but lies over an area of thin and smooth synovial tissue on the anterior shaft of the femur immediately proximal to the lateral aspect of the trochlear surface. This area is termed the supratrochlear tubercle. The transition from the articular cartilage to the supratrochlear tubercle is smooth above the lateral aspect of the trochlear groove, but it is often a sudden dropoff when viewed from the medial side (termed Outerbridge's ridge) (70). This arrangement conveniently allows the patella to ride smoothly above the articular surface in a superior and lateral direction as the knee is fully extended. The patella thus does not slide over the sharp dropoff observed proximal to the medial side of the trochlear groove during normal joint activity.

The articular cartilage on the posterior aspect of the patella near the median ridge is normally the thickest in the human body. This reflects the large patellofemoral joint reaction (PFJR) force that occurs between the patella and the trochlear surface during normal activities. Loads across the patellofemoral joint are indirectly related to the angle of knee flexion and directly related to the force generated within the quadriceps mechanism. Figure 83.4 presents a static representation of this in simplified terms. On the left diagram, the superincumbent mass (*W*) of the body is supported by the force (*M*) generated within the quadriceps. The line from the center of mass from the body falls well behind the flexion axis of the knee. The moment arm (*c*) in this situation is relatively small, and thus the quadriceps force (*M*) and the PFJR force (*R*) are relatively small. When the figure depicted flexes further (right diagram), decreasing the angle (b), the moment arm (*c*) increases. To allow this system to remain static, the new force (*M´*) generated within the quadriceps must significantly increase, which in turn increases the PFJR force (*R´*). The PFJR force estimated

for various activities is presented in Table 83.2.

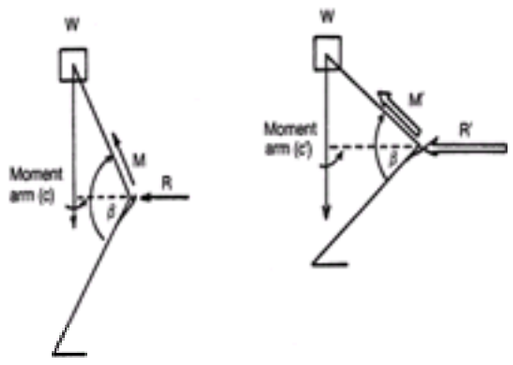


***Figure 83.4.*** Static representation of the patellofemoral joint reaction forces (*R* and *R´*) at two positions of flexion (see text).

| *Source* | *Activity* | *× Body weight (BW)* |
|---|---|---|
| Reilly and Martens[a] | Level walking | 0.5 × BW |
| Smidt[b] | Straight leg raise | 2.6 × BW |
| Reilly and Martens[a] | Stair climbing | 3.3 × BW |
| Dahlqvist, et al.[c] | Squatting | 7.0 × BW |
| Nisell[d] | Jogging | 7.0 × BW |

[a] Reilly DT, Martens M. Experimental Analysis of the Quadriceps Muscle Force and Patello-femoral Joint Reaction Forces for Various Activities. *Acta Orthop Scand* 1972;43:126.
[b] Smidt GL. Biomechanical Analysis of Knee Flexion and Extension. *J Biomech* 1973;6:79.
[c] Dahlqvist NJ, Mayo P, Seedhom BB. Forces During Squatting and Rising from a Deep Squat. *Eng Med* 1982;11:69.
[d] Nisell R. Mechanics of the Knee. *Acta Orthop Scand [Suppl]* 1985;214:50.

***Table 83.2. Patellofemoral Joint Reaction Force***

The patellofemoral contact area in the normal knee increases in response to the increased loads that develop as the knee flexion angle (b) decreases during most activities (Fig. 83.5) (40). For this reason, stress (force per area) increases less rapidly than the total force across the patellofemoral joint. However, if a weight is applied to the ankle, as in most weight-training programs, and the knee is extended against gravity plus the additional weight, the opposite effect is noted. In this situation, the area of contact decreases as the PFJR force increases. Thus, the PFJR stress becomes excessively high even for light weights applied at the ankle, as depicted in Figure 83.6 (76). For this reason, isotonic or isokinetic exercises through a full range of motion are not advised in the treatment of patellar pain syndromes. Quadriceps exercises that extend the knee through only the last 15° to 20° of extension are much more likely to be tolerated, as can be seen in Figure 83.6. Abnormal tracking of the patella, which allows lateral subluxation of only a few millimeters, confounds this principle. Under these circumstances, the larger load is borne on a relatively small contact area, greatly increasing the local stress (Fig. 83.7) (53). This undoubtedly contributes in many instances to the production of patellofemoral pain and, if severe, degeneration of patellar articular cartilage (chondromalacia). Many anatomic conditions can and do contribute to this common problem. These include hypoplasia of the trochlear groove, abnormal patellar articular configuration, underdevelopment of the vastus medialis, rotational malalignment of the proximal tibia relative to the distal femur, and an abnormally high valgus angle of the distal quadriceps mechanism (*Q* angle).

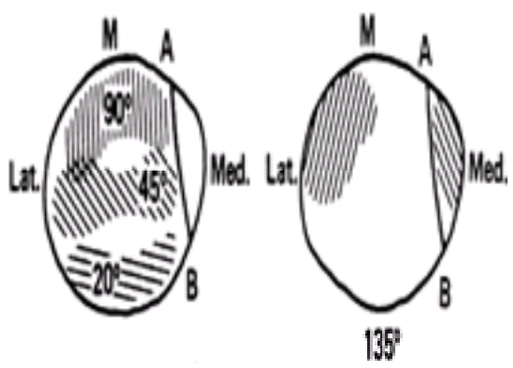


***Figure 83.5.*** Composite of patellofemoral contact area with the degree of flexion (M, location of the median ridge). (After Hungerford DS, Barry M. Biomechanics of the Patellofemoral Joint. *Clin Orthop* 1979;144:9.)

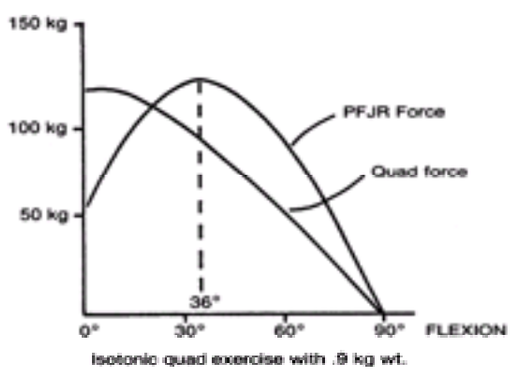


***Figure 83.6.*** Patellofemoral joint reaction force (PFJR) produced during extension of the knee from 90° of flexion to 0° while lifting a 0.9-kg weight. (After Reilly DT, Martens M. Experimental Analysis of the Quadriceps Muscle Force and Patellofemoral Joint Reaction Force for Various Activities. *Acta Orthop Scand* 1972;43:126.)

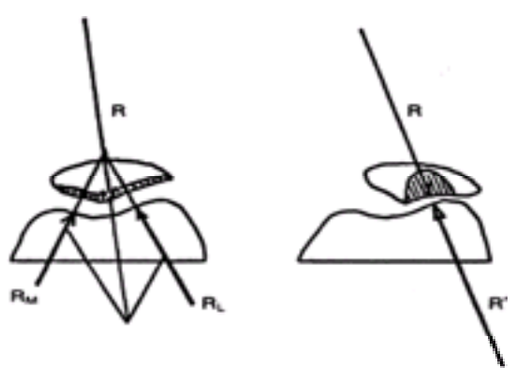

***Figure 83.7.*** Joint reaction forces (*R*, patella; $R_M$, medial trochlear groove of femur; and $R_L$ and *R´*, lateral trochlear groove of femur) before and after lateralization of the patella. (After Maquet P. Mechanics and Osteoarthritis of the Patellofemoral Joint. *Clin Orthop* 1979;144:70.)

The patella also increases the distance of the quadriceps mechanism from the axis of knee flexion. In so doing, it decreases the force (*M*) that is necessary to maintain static equilibrium, as depicted in Figure 83.4. Kaufer has shown that patellectomy decreases this effective moment arm by 31% at 0° flexion, 22% at 30°, 13% at 60°, 12% at 90°, and 10% at 120° (45). Maquet has shown that by increasing the quadriceps mechanism's moment arm, a 2-cm elevation of the tibial tubercle produces a 50% reduction in the PFJR force when the knee is flexed 45° (52,53). Thus, patellectomy is not advised, and tibial tubercle elevation procedures are effective in the treatment of patellar pain syndromes.

Huberti et al. simulated the squatting activity in human cadaveric specimens while measuring quadriceps force with a tensile load sensor and patella tendon force with a buckle transducer (37). They demonstrated that for knee flexion between 0° and 45°, the force developed in the patella tendon was greater than that in the quadriceps mechanism. With continued knee flexion to 120°, the patella tendon force was consistently less in comparison to the quadriceps force. The authors suggested that the patella not only functions as a pulley that changes the magnitude and direction of forces in the quadriceps and patella tendon but, in addition, has two distinct mechanical functions. In the first, more classically described function, the anteroposterior (AP) thickness of the patella can be attributed to increasing the effective movement arm of the quadriceps muscles and patella tendon, whereas in the second, the patella acts as a lever. Therefore, the parameters that define the proximal and distal lever arms of the patella have a direct effect on the balance of forces in the quadriceps and patella tendon. The authors reasoned that these parameters were the length of the patella, the location of the patella femoral contact area, and the angle between the quadriceps and patella tendon.

## THE MENISCI

### BIOMECHANICAL FUNCTION

The fibrocartilaginous C-shaped menisci that are interposed between the tibia and femur were long thought to be vestigial devices that had no significant function. Fairbank, in 1948, proposed that the menisci serve a load-transmission function and suggested that the joint space narrowing, osteophyte formation, and flattening of the femoral condyles frequently observed following meniscectomy most likely resulted from the loss of this function (24). Several investigators in the late 1960s (38,87) and early 1970s (42) reported less than satisfactory results in long-term follow-up investigations in a high proportion of patients undergoing meniscectomy, thus adding credence to Fairbank's observations (24). It was not until the mid-1970s that several reports confirmed the load transmission function of the menisci (48,81,83,92). Although some variation was reported, these investigations all estimated that 30% to 60% of the load transmitted across the joint passes through the menisci during weight-bearing activities. In 1979, Seedhom and Hargreaves reported that 70% to 99% of the total load acting on an intact joint is passed through normal menisci and that all of the load is transmitted through the posterior horns of the menisci if the joint is flexed beyond 75° (82). In several of these investigations, it was clearly shown that the ability of the joint to transmit a load was significantly reduced by removal of all or part of the menisci and that these structures assist in reducing stress across the joint (6,48,62,82,92). Seedhom and Hargreaves also showed that removal of part of the meniscus reduced the weight-transmitting function less than removing the entire structure as long as the circumferential continuity of the meniscus remains intact (82). Thus, the rationale for partial meniscectomy, made possible by arthroscopic techniques, was at least partially verified.

The ability of menisci to heal following operative repair has been well documented (23,29,77,79). However, it is probably too early to be certain that normal meniscal function is restored by these procedures in humans. Recent studies in animals suggested that the repair of peripheral longitudinal lesions produced compressive force displacement behavior indistinguishable from normal (6,61). However, repairs of radial tears are less successful in restoring normal biomechanics (61).

Meniscal allografts are being used to replace native menisci destroyed by trauma or removed surgically. Early follow-up studies with small numbers of cases suggest that meniscal function may be restored, but no evidence confirms that normal biomechanical behavior is established or that transplanted menisci are capable of protecting articular cartilage (15,49,91). In a human cadaver study, size-matched meniscal allografts resulted in improved load transition profiles compared to the meniscectomized state, but only by 55% to 65% (71). Further clinical animal and cadaveric studies are necessary to prove the efficacy of meniscal allografts.

The menisci also contribute to the stability of the knee. However, Markoff et al. (55) observed that although removal of menisci made the unloaded knee more lax, stability of the loaded knee was little affected. In unloaded human cadaver knees at 25° of flexion, Wang and Walker (93) evaluated the effect of rotatory laxity before and after removal of the menisci. They defined two types of rotatory laxity: primary and secondary. The former occurred at torques up to 0.5 nm and represented the looseness of the joint before significant resistance was encountered. The latter occurred at torques between 0.5 and 5 nm and represented significant resistance before plastic failure of soft-tissue structures. In their study this failure occurred at approximately 12.5 nm. Under such loads the ligaments were stretched but not totally disrupted, and, as might be expected, they found greater rotational instability after such ligamentous failure. They determined primary and secondary rotatory laxity of eight human knees before and after removal of both menisci. A 14% increase in primary rotatory laxity and a 2% increase in secondary laxity were observed. Although they thought that the increase in secondary laxity was not significant, they concluded that the menisci serve to restrict primary rotatory laxity, perhaps by acting as space-filling buffers.

Several investigators have found that meniscectomy had little effect on laxity in the anteroposterior plane in the otherwise intact knee (7,36,51). However, when the cruciate ligaments were severed, and these same anteroposterior loads were repeated before and after removal of the menisci, there were large differences in anteroposterior stability. The investigators concluded that the menisci apparently play an important role in preventing this instability when cruciate function has been lost. This may account for the frequent development of a torn meniscus after apparently isolated disruption of the ACL.

Many other functions have been attributed to the menisci, including shock absorption, increasing joint congruity, assisting with lubrication, preventing synovial impingement, and limiting extremes of flexion and extension. However, these functions are difficult to prove.

### MENISCAL ANATOMY

The medial meniscus is somewhat more C-shaped than the circular lateral meniscus (Fig. 83.8). This is because the posterior and anterior horns of the lateral meniscus attach to the nonarticular area of the tibial plateau, whereas those of the medial meniscus are well off the plateau. The anterior horn of the medial meniscus attaches well forward on the anterior surface of the proximal tibia, and the posterior horn is fixed within the groove on the posterior tibial surface just above the posterior cruciate attachment. The anterior horn of the lateral meniscus blends into the attachment of the anterior cruciate; the posterior horn attaches just behind the intercondyloid eminence, often blending into the posterior aspect of the ACL.

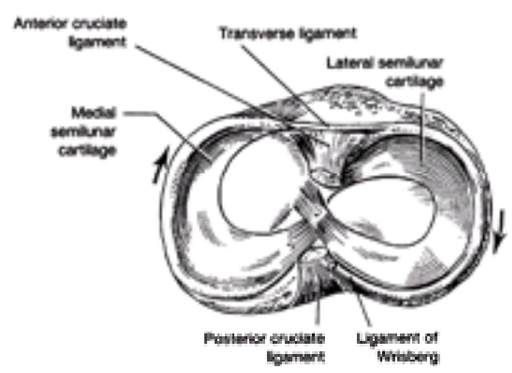


***Figure 83.8.*** Superior surface of tibia with superimposed medial and lateral menisci. (After Helfet AJ. *The Management of Internal Derangements of the Knee.* Philadelphia: JB Lippincott, 1963.)

A fibrous band that connects the posterior horn of the lateral cartilage to the anterior horn of the medial meniscus has occasionally been identified and is termed Barkow's ligament (35). The anterior horns of the menisci are connected by another fibrous band called the transverse ligament (Fig. 83.8). Variably present posterior and anterior meniscofemoral ligaments (Wrisberg's and Humphrey's ligaments) pass from the posterior horn of the lateral meniscus to the medial aspect of the notch.

Wrisberg's ligament passes posteriorly to the posterior cruciate, and Humphrey's ligament passes anteriorly. Usually only one of these structures is present, and they vary quite markedly in size.

The lateral meniscus is consistent in width throughout its course, whereas the medial meniscus is wide posteriorly and narrows significantly anteriorly. Both menisci are attached to the femur and tibia on their periphery by capsular sheets called meniscofemoral and meniscotibial ligaments. These attachments are continuous to the medial meniscus but are interrupted by the popliteus tendon as it passes between the lateral collateral ligament and the posterolateral aspect of the lateral meniscus (Fig. 83.9) (86). The posterior third of the lateral meniscus receives a strong insertion from the popliteus muscle into its posterior horn, which allows the meniscus to be pulled posteriorly as the knee flexes. The medial meniscus has no direct attachment from any of the muscles, but indirect capsular connections from the semimembranosus, at least in theory, may provide some ability to retract the posterior horn (69).

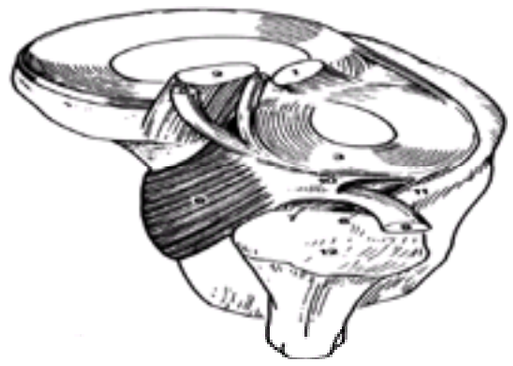

***Figure 83.9.*** Posterolateral structures, superior view, right knee. *1,* anterior cruciate ligament; *2,* posterior cruciate ligament; *3,* posterior horn lateral meniscus; *4,* anterior mensicofemoral ligament (Humphrey); *5,* posterior meniscofemoral ligament (Wrisberg); *6,* popliteofibular fascicle (anterior limb); *7,* popliteofibular fascicle (posterior limb); *8,* popliteus muscle; *9,* popliteus tendon (cut and reflected); *10,* superior popliteomeniscal fascicle; *11,* inferior popliteomeniscal fascicle; *12,* head of fibula. (From Stäbli H-U, Birrer S. The Popliteus Tendon and Its Fascicles at the Popliteal Hiatus. *Arthroscopy* 1990;6:209.)

Collagen fibers within the menisci are primarily oriented in a circumferential fashion, thus resisting the loads applied to them from the femur. In this manner they are suitably aligned to resist elongation, much as hoops prevent the expansion of a barrel.

## SYNOVIAL CAVITY OF THE KNEE

This largest joint cavity in the human body is lined by a smooth synovial surface that has a varying number of villous fronds and folds. Three of these folds are present consistently enough to have been given specific names (Fig. 83.10) (30). Most knees have a fold of synovium called the ligamentum mucosum or infrapatellar plica, extending from the midportion of the posterior surface of the infrapatellar fat pad to the apex of the intracondylar notch. If small, this structure is nothing more than a small fibrous band, but if well developed, it forms a septum from the anterior cruciate to the fat pad and divides the knee into distinct medial and lateral compartments. A small artery often courses through it from the apex of the intercondylar notch to the fad pad. Thus, if it is ruptured, it may contribute to hemarthrosis.

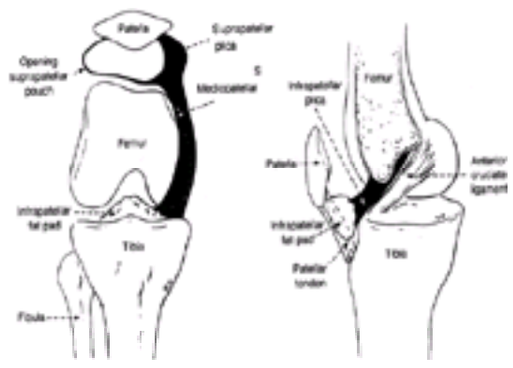

***Figure 83.10.*** Diagrammatic views of the plicas of the knee. (From Hardaker WT, Whipple TL, Bassett FH. Diagnosis and Treatment of the Plica Syndrome of the Knee. *J Bone Joint Surg* 1980;62-A:221.)

The suprapatellar pouch usually extends to 5 to 7 cm above the superior pole of the patella. In the embryo, the true suprapatellar pouch is separated from the rest of the knee joint by a fold of synovium perpendicular to the long axis of the femur just above the superior pole of the patella. This septum usually becomes perforated, but a portion of it often remains as a partial septum. Its medial side is most likely to persist as a crescentic fold. On occasion only a small perforation occurs through its central portion, or more rarely it remains intact into adult life. Inflammation and thickening of this structure may produce pain and crepitus.

The medial synovial plica (also termed the medial shelf, mediopatellar plica, plica alaris elongata, medial interarticular band, or Lino's band) extends perpendicularly to the medial aspect of the suprapatellar plica to the medial superior aspect of the infrapatellar fat pad. It is present in 19% to 60% of normal knees. This variation in incidence probably results from interpretation of how much of a synovial fold has to be present before the investigator judges it to be identifiable as a specific entity. Much emphasis has been given to pathology observed in this structure since knee arthroscopy has become common. Thickening and inflammation of this structure to the point of producing symptoms is rare, and its frequent excision must be observed with skepticism. The biomechanical function of all the plica structures is probably of minimal importance because function of the knee does not seem to be disturbed in their absence.

## LIGAMENTS

The ligaments of the knee function primarily to stabilize the joint by guiding and limiting motion; they are the most important static stabilizers. They consist of large, clearly identifiable structures, such as the collateral and cruciate ligaments, and less obvious capsular structures. Ligaments are a dense connective tissue primarily composed of collagen with lesser and varying amounts of elastin and reticulin fibers. Cellular elements, ground substance, vascular channels, and nerves also are present. Collagen fibers and their orientation within the tissue are responsible for the primary biomechanical behavior of each of these structures. The fibers of the large distinct ligaments are almost all arranged in parallel bundles, suiting them to withstand tensile loads, whereas capsular structures have a less consistent orientation, making them more flexible and not as strong in resisting uniaxial forces.

Although tendons and ligaments have many morphologic and histologic similarities, they also have many differences (1). Ligaments in general are more metabolically active than tendons, as demonstrated by increased plump cellular nuclei, higher DNA content, and more reducible cross-links and glycosaminoglycans. Collagen constitutes between 70% and 80% of the ligament's dry weight (25). The collagen within a normal ligament is more than 90% fibrillar type I with less than 10% type III (25). Minor variations in composition among the various ligaments of rabbit knees have been reported (1).

The insertion site of ligaments makes them able to distribute the stresses of loading at the bone–ligament interface in a gradual fashion, thus reducing the chance of failure. This is accomplished by collagen fibers passing from the ligament into the bone through four distinct zones: usual ligament morphology, a fibrocartilaginous matrix, mineralized fibrocartilage, and the bone itself (21). In spite of this transition, it has been shown in the anterior and posterior cruciates, the medial and lateral collateral ligaments, and the patellar tendon that some strain concentration occurs near the insertion sites (64).

The ability of a ligament to resist loading can best be understood by examining the load–elongation curve produced in the laboratory when bone–ligament–bone specimens are tested to failure (Fig. 83.11) (19). As load is applied, the ligament elongates. The stiffer the ligament, the steeper is the curve. In the resting position the ligament fibers are under minimal tension, and the collagen fibers within the ligament are wavy. As loading begins, little force is necessary to elongate the ligament, and thus, the curve is flat. During this phase the collagen fibers become aligned. The “toe” portion of the load deformation curve is variable in width, depending on the

relative normal laxity of the particular ligament.

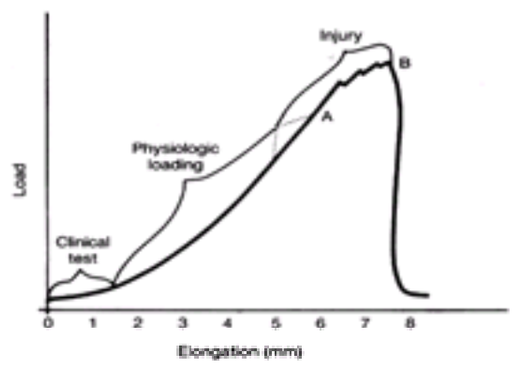


***Figure 83.11.*** Load-elongation curve of a bone–ligament–bone specimen tested to failure. **A:** Yield point. **B:** Maximum load. (After Cabaud HE. Biomechanics of the Anterior Cruciate Ligament. *Clin Orthop* 1983;172:26.)

As is well known from stress testing, ligamentous laxity varies widely from individual to individual. The transition from the toe to the linear portion of the curve represents the change in stiffness that an examiner perceives during a clinical stress test when the ligament's endpoint or “check rein” is reached. When all the collagen fibers are straightened, stiffness increases, and the curve becomes nearly linear. This portion of the curve is characterized by elastic deformation until near its upper end, at which point plastic failure begins. When the yield point is reached, the curve becomes irregular. After the maximum load is reached, the curve drops as the last few fibers are destroyed, and the curve returns almost straight down to baseline after all fibers fail.

Normal activities result in deformation along the linear portion of the curve approximately one fourth of the way to the yield point (64). The area under the load–deformation curve is equivalent to the amount of energy absorbed by the ligament during testing.

Variables such as age and strain rate dramatically affect the characteristics of the load–elongation curve. Young adults have a yield point as much as three times greater than older people, and people who have been immobilized for even short periods have greatly reduced ligament strength (63,66). The rate at which the ligament is loaded greatly affects its elongation behavior. Noyes et al. (65) demonstrated that human bone–ligament–bone ACL specimens that failed rapidly (0.6 seconds) show a 20% increase in load to failure over those that failed at a slower speed (60 seconds). In their experiments, the energy stored before failure was 30% greater in the group tested rapidly than in those that failed at the slower speed. At slow strain rates, avulsion of ligaments from bone is often seen, but at higher strain rates interstitial failures occur more frequently. Although both ligament and bone strength are favorably affected by increased strain rate, these observations suggest that this strain rate effect has a greater influence on bone than on ligament.

**MEDIAL SIDE OF THE KNEE**

The medial aspect of the knee can be divided into three layers of tissue (Fig. 83.12) (16,94). Within these layers are the muscles and tendons that pass by the joint as well as the medial collateral ligament, the deep medial ligament, and capsular structures. The superficial (first) layer is composed of the deep or crural fascia; the middle (second) layer is the medial collateral ligament, and the deep (third) layer is the capsule of the knee joint and the deep medial ligament. Only in an area roughly overlying the parallel fibers of the medial collateral ligament can all three layers be identified as separate entities.

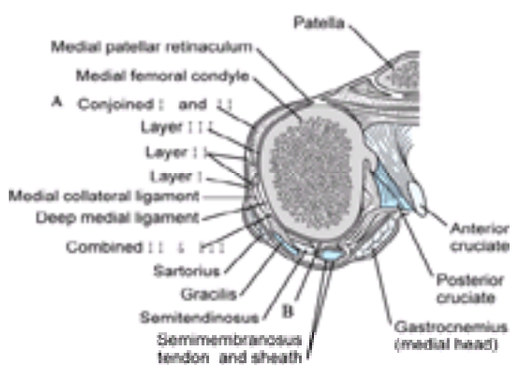


***Figure 83.12.*** Transverse section through the distal femur. **A:** The retinacular fibers, which are the conjoined layers I and II. **B:** The conjoined layer-II and -III fibers posterior to the medial collateral ligament. (Redrawn from Warren LF, Marshall JL. The Supporting Structures of the Medial Side of the Knee. *J Bone Joint Surg* 1979;61-A:56.)

The first layer is defined by the fascia that invests the sartorius muscle and tendon. It extends from the patella to the fascia of the popliteal space. Anteriorly, it blends with fibers of the second layer along a line 1 to 2 cm in front of the anterior margin of the medial collateral ligament (Fig. 83.12). From this point to the patella, the two layers are blended in an indistinguishable sheet of tissue, which in part becomes the patellar retinaculum. Posterior to the parallel fibers of the medial collateral ligament, the fibers of the first layer are distinct from the underlying structures, and between them and the second layer pass the gracilis, semitendinosus, and semimembranosus tendons (Fig. 83.12). Anteriorly and distally, the first layer blends into the periosteum at the tibial attachment of the sartorius. Anteriorly, it blends into the fascia overlying the quadriceps, and inferiorly, it blends into the deep fascia of the leg.

The most prominent structure in the second layer is the medial collateral ligament, in which parallel fibers extend from the medial epicondyle to blend with the periosteum along the medial border of the tibia beneath the pes anserinus tendons. Among the names assigned to this ligament are the tibial collateral, superficial medial collateral, and the internal lateral ligament. Probably the name most commonly used is the previously mentioned medial collateral ligament. The medial collateral ligament (parallel-fibered superficial portion) is the primary medial stabilizer of the knee, providing 57% to 78% of the restraining moment resisting valgus stress to the intact knee (28).

The parallel fibers of the medial collateral ligament in an average-sized knee are approximately 1.5 cm wide and 11 cm long. The femoral attachment of the parallel fibers is arranged around the varying flexion axis of the knee so that some portion of these fibers remains under tension throughout the range of knee motion. In full extension, the posteriormost fibers are taut, whereas in flexion, the more anterior fibers are under the greatest tension. Strain in the anterior fibers varies significantly during flexion (2). The fibers near the anterior border proximal to the joint were strained 4% above their normal resting length at full extension when the knee was passively flexed to 110°. At the joint line the anterior fibers strained 2%, and below the joint line only 1.5% during the same motion. Thus, a variable strain pattern is observed not only between the anterior and posterior portions of the superficial medial ligament but also along the course of the anterior or posterior fibers of this ligament.

Along the course of the parallel fibers of the medial collateral ligament, the three layers of the medial aspect of the knee can easily be distinguished (Fig. 83.12). Anterior to the medial collateral ligament, the fibers of the second layer often are divided vertically, but they eventually blend with the first layer to form the patellar retinaculum. Posterior to the medial collateral ligament, the fibers within the second layer above the joint line become obliquely oriented and appear to fan out from their attachment to the adductor tubercle, passing posteriorly and inferiorly (posterior oblique ligament) (16). These fibers form a sheet of tissue indistinguishable from the third layer beneath. Below the joint line, the fibers of the second layer also are obliquely oriented, flowing from the posterior margin of the parallel fibers of the superficial medial ligament toward the posteromedial aspect of the joint line. Warren and Marshall (94) suggest that all oblique fibers behind the parallel portion of the medial collateral ligament should be termed the oblique portion of the superficial medial ligament, but more commonly the portion above the joint line is called the posterior oblique ligament (16,39). An extension of the second layer passes from the anterior aspect of the medial femoral epicondyle anteriorly to the patella deep to the vastus medialis (Fig. 83.13). This structure is the patellofemoral ligament (94). Thus, the second layer extends from the level of the medial femoral epicondyle to the tibial attachment of the medial collateral ligament in its midportion. Posteriorly, this layer does not extend proximal to the capsular attachments superiorly, nor does it

extend inferior to the oblique portion of the medial collateral ligament.

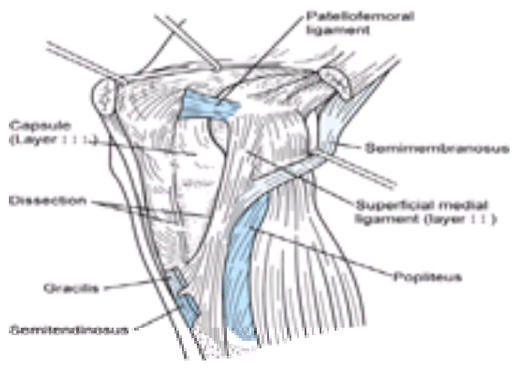


***Figure 83.13.*** Medial aspect of the knee with layer 1 removed to reveal the details of layers 2 and 3. The long (parallel) and oblique fibers of the medial collateral ligament can be seen posteriorly (layer 2), and the capsule anteriorly (layer 3). (Redrawn from Warren LF, Marshall JL. The Supporting Structures of the Medial Side of the Knee. *J Bone Joint Surg* 1979;61-A:56.)

The third layer is composed of the medial capsule and its thickened midportion, which forms the deep medial collateral ligament (also termed the deep layer of the medial ligament, short internal lateral ligament, or the middle capsular ligament). Its attachments to the tibia and femur delimit the margins of the articular cartilage. Anteriorly, it is distinct from the overlying retinaculum but quite thin and weak. Posteriorly, it blends with the second layer to envelop the posteromedial corner of the joint. The deep medial ligament is made up of short parallel fibers running from an attachment point on the femur approximately 0.5 cm distal to the medial epicondyle to the margin of the tibia just above the attachment of the anterior slip of the semimembranosus tendon (Fig. 83.14). It is approximately as wide as the overlying medial collateral ligament and is clearly separated from it by a bursa. Posteriorly, the margins of the deep and superficial ligaments blend as the second and third layers fuse together (Fig. 83.12).

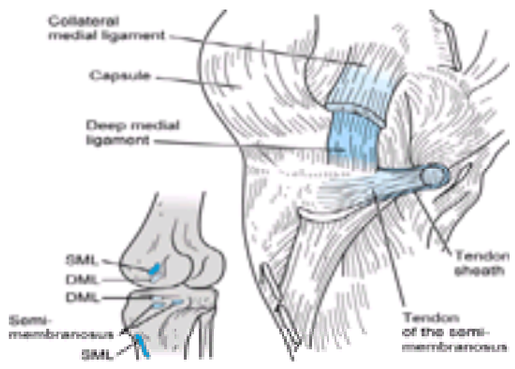


***Figure 83.14.*** Medial aspect of the knee, demonstrating the anatomic relationships of the deep structures and the insertion of the semimembranosus. SML, superficial medial ligament; DML, deep medial ligament. (From Warren LF, Marshall JL. The Supporting Structures of the Medial Side of the Knee. *J Bone Joint Surg* 1979;61-A:56.)

Warren and Marshall (94) observed that the semimembranosus tendon attaches directly to the posterior tubercle of the knee and to the tibia medially in a groove distal to the attachment of the third layer and beneath the medial collateral ligament. The semimembranosus tendon sheath contributes extensions blending with structures in the second layer (Fig. 83.14). The most distinct of these is a large contribution across the back of the joint to the lateral femoral condyle, the oblique popliteal ligament. Other frequently observed slips extend into the inferior and superior oblique portions of the medial collateral ligament and the fascia of the calf. No direct continuation of semimembranosus fibers passes directly into the posterior horn of the medial meniscus, as has sometimes been suggested (69). The complex insertion of the semimembranosus tendon indicates that besides being a strong knee flexor, it also serves to internally rotate the tibia on the femur and to tense the posteromedial capsular structures, which become lax as the knee is flexed. It also probably acts to protect the ACL from excessive stress by helping to prevent anterior subluxation of the tibia on the femur.

The semitendinosus, gracilis, and sartorius tendons pass the posteromedial aspect of the knee to form a conjoined tendon (pes anserinus) that passes superficially to the distal end of the medial collateral ligament and inserts into the anteromedial crest of the tibia several centimeters distal to the joint line. These muscles are primarily knee flexors, but they also act as internal rotators. They serve in conjunction with the quadriceps to reduce loads within the medial collateral ligament and assist in preventing anterior subluxation of the tibia on the femur at knee flexion angles from 0° to approximately 70° (22). Beyond 70° of flexion, the quadriceps acts synergistically with the ACL. Transplantation of the pes anserinus reduces the flexion power of this group of muscles by 30% in all positions of knee flexion between 0° and 90° while increasing internal rotation power by as much as 50% at positions between 30° and 60° of flexion (67).

**ANTERIOR ASPECT OF THE KNEE**

The fascia lata of the thigh invests the superficial surface of the quadriceps, the patella, and the patellar tendon. Its medial and lateral extensions contribute to the patellar retinaculum along with aponeurotic fibers from the vastus medialis and lateralis. Laterally, the facia lata thickens into the iliotibial tract and the iliopatellar band (Fig. 83.15) (88). The former inserts into the tubercle of Gerdy, and the latter inserts into the patella. Decussation of the superficial fibers of these two specialized portions of the fascia lata can be seen just above the level of the lateral epicondyle. Deeper portions of these complex structures are discussed in the section describing the lateral aspect of the knee. The patellofemoral ligaments are variably present; when present they range in width from 3 to 12 mm (75). They are thickenings of the joint capsule and pass from the epicondyles to their respective borders of the patella. Of 20 specimens dissected specifically to identify these structures, Reider et al. reported them to be present laterally in seven instances, medially once, and both medially and laterally in six specimens (75).

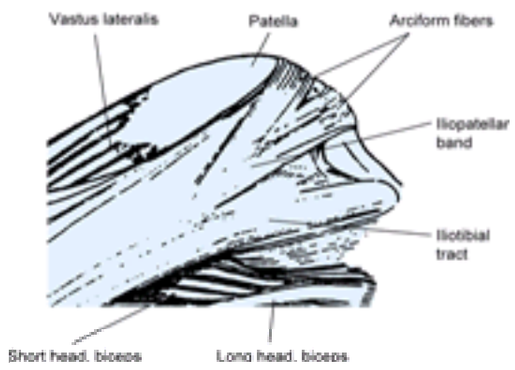


***Figure 83.15.*** Lateral aspect of the knee, demonstrating the iliopatellar band and iliotibial tract. (From Terry GC, Hughston JC, Norwood LA. The Anatomy of the Iliopatellar Band and Iliotibial Tract. *Am J Sports Med* 1986;14:39.)

The patellofemoral mechanism has already been described, but some details of the relationships of the quadriceps merit comment here. The four large quadriceps muscles form a tendon of insertion into the superior aspect of the patella, which has classically been described as consisting of three separate layers: a deep portion

arising from the vastus intermedius, a middle layer consisting of the two vasti, and a superficial layer from the rectus femoris. The actual insertion is variable, but most often a deep layer extending from the vastus intermedius can be separated from a more superficial portion from the other three muscles (75). The rectus femoris tendon is the longest (8 to 10 cm) and is roughly triangular; its base is 3 to 5 cm wide at the superior pole of the patella. It is the only tendon that consistently sends a significant number of its fibers anterior to the patella to be continuous with those of the patellar tendon. The inferior terminus of the vastus medialis obliquus is at the superior border of the patella in most knees, allowing a tendon of only a few millimeters in length to insert into the superior medial border of that bone. The muscle fibers of the inferior aspect of the vastus medialis are oriented at angles of 55° to 70° in relation to the sagittal plane near this insertion (75). The muscle fibers of the distal vastus lateralis also are oblique, ranging from 22° to 45°; they terminate well above the superior border of the patella, allowing a tendon averaging 2.8 cm in length to insert into the superior lateral aspect of the patella. Variable numbers of fibers from the distal vastus medialis and lateralis tendons insert into their respective retinacula (75).

The primary function of the quadriceps mechanism is to extend the knee, but just as important, it also controls flexion of the knee by antagonizing gravity and the hamstring muscles. Its insertion into the tibial tubercle and orientation anterior to the transverse axis of rotation of the distal femur allow it to assist in the prevention of posterior subluxation of the tibia on the femur if the knee is flexed less than approximately 70° (22). The quadriceps thus functions synergistically with the posterior cruciate ligament (PCL). In positions of knee flexion greater than 70°, it actually reverses this role and becomes a weak synergist of the ACL by tending to prevent anterior subluxation of the tibia on the femur. It also assists in stabilizing the patella within the patellofemoral groove by means of vertically and obliquely oriented fibers. Through the retinaculum, the quadriceps tenses the underlying anterior medial and anterior lateral joint capsule. Coupled with the muscles of the pes anserinus group, it reduces stresses within the medial collateral ligament when valgus moments are applied to the knee (73). It also has been proposed that via capsular attachments to the anterior horns of the menisci, the quadriceps functions to pull these structures anteriorly as the knee extends (44).

The patella tendon extends from the entire inferior aspect of the patella (closer to its superficial surface than to the articular surface) to the periosteum overlying the tibial tubercle. The majority of its fibers blend into the periosteum rather than inserting directly into bone. The length of the infrapatellar tendon is variable, but it is usually approximately equal to that of the patella.

**LATERAL ASPECT OF THE KNEE**

As with the medial side, the lateral aspect of the knee can be divided into three separate layers (80). The most superficial (layer 1) contains the iliotibial tract and its ramifications anteriorly and the biceps and its expansion posteriorly (Fig. 83.16). The second layer is formed by the retinaculum of the quadriceps anteriorly. Posteriorly, it is not complete and is composed of the two patellofemoral ligaments and their various attachments to other structures (Fig. 83.16 and Fig. 83.17). The patellofemoral ligaments extend from the retinaculum and split into a superior limb that inserts into the distal end of the intermuscular septum and an inferior expansion that fans out to insert into numerous lateral structures. These structures include the fabella when present, the lateral head of the gastrocnemius, and the iliotibial tract just below the termination of the lateral intermuscular septum. Terry et al. describe five different layers of the iliotibial tract and band, which differ somewhat in interpretation from what is presented here (88). Of note is the deepest layer of this structure, which Terry et al. term the capsuloosseous layer, and acts as an anterolateral ligament of the knee (88).

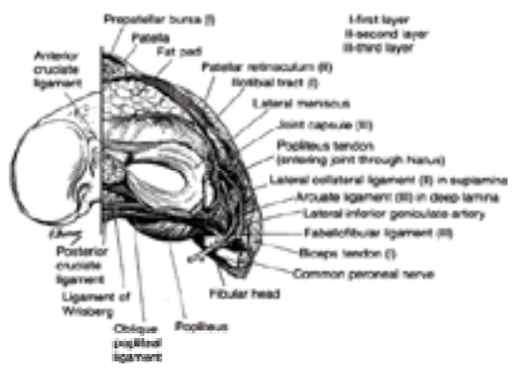


***Figure 83.16.*** View of the right knee joint from above after removal of the femur. (From Seebacher JF, Inglis AE, Marshall JL, et al. The Structure of the Posterolateral Aspect of the Knee. *J Bone Joint Surg* 1982;64-A:536.)

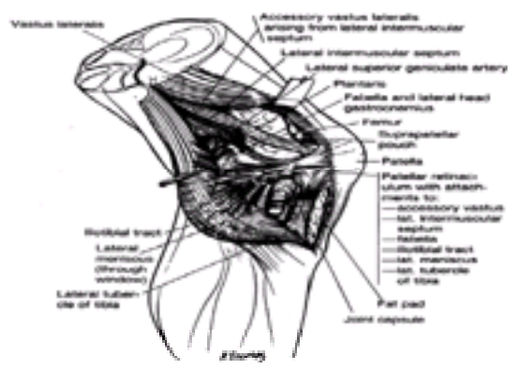


***Figure 83.17.*** Lateral aspect of the knee with layer 1 incised and peeled back from the lateral margin of the patella, showing layer 2. (From Seebacher JF, Inglis AE, Marshall JL, et al. The Structure of the Posterolateral Aspect of the Knee. *J Bone Joint Surg* 1982;64-A:536.)

The third layer is the lateral portion of the joint capsule, which is attached to the tibia and femur at the margins of the articular space (Fig. 83.16). This layer attaches to the margins of the lateral meniscus and is called the meniscofemoral capsule above and the meniscotibial capsule below that structure. It was formerly termed the coronary ligament. At the posterolateral aspect of the knee, the popliteus tendon passes through a hiatus in the capsule, thus rendering the capsule incomplete in its attachment to the meniscus (Fig. 83.9). As one moves posteriorly at approximately the midlateral position, the capsule (third layer) splits into two laminae (Fig. 83.16). The more superficial includes the lateral collateral ligament and ends posteriorly at the fabellofibular ligament (short external ligament). The deeper layer of the posterolateral capsule forms the meniscotibial and meniscofemoral portions of the posterior capsule and encompasses the arcuate ligament. The inferior lateral geniculate artery passes between the lateral collateral ligament and fabellofibular ligament and the underlying arcuate ligament at the level of the meniscus.

The lateral collateral ligament extends from the lateral epicondyle of the femur downward and slightly posterior to near the midportion of the superior surface of the fibula. It is a discrete cord-like structure that is under maximum tension in extension and becomes lax as the knee is flexed (4). Its lower end is nearly surrounded by the middle layer of the biceps insertion (58). In theory, this allows the biceps to maintain some tension within this structure, even when the knee is flexed. Such an effect has been demonstrated within the lateral collateral ligament during simulated contraction of the biceps in human cadaver knees (4). The lateral collateral ligament is the primary restraint preventing varus deformity of the knee (28).

The fabellofibular ligament and the arcuate ligaments insert on the tip (posterior aspect) of the styloid of the fibula just posterior to the lateral collateral ligament, with the former being the most superficial (Fig. 83.18). They extend superiorly and slightly posteriorly to blend with the origin of the lateral head of the gastrocnemius and the termination of the oblique popliteal Winslow's ligament. The arcuate ligament arches over the musculotendinous junction of the popliteus muscle as it passes upward toward its capsular hiatus. There is great variation in the size of the contribution of the arcuate and fabellofibular ligaments (80). In 13% of the dissections done by Seebacher and associates, the arcuate ligament alone was present; in 20% only the fabellofibular ligament was present; and in 67% both of these ligaments were present (80). In general, when a fabella is present, the fabellofibular ligament is large, and when even its cartilaginous remnant is not present, the ligament is very small or absent.

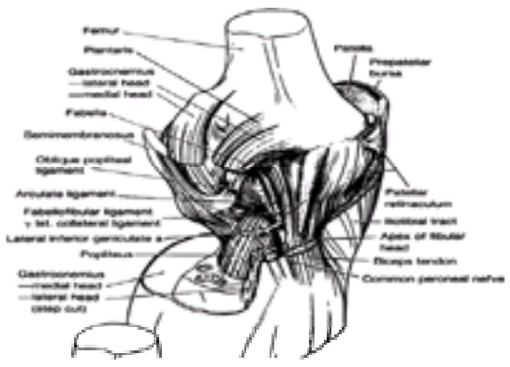


***Figure 83.18.*** Oblique view of the posterolateral aspect of the right knee after removing the two structural layers superficial to the joint capsule. (From Seebacher JF, Inglis AE, Marshall JL, et al. The Structure of the Posterolateral Aspect of the Knee. *J Bone Joint Surg* 1982;64-A:536.)

The popliteus muscle originates from the attachment of its tendon just anterior and inferior to the superior attachment of the lateral collateral ligament and the posterior aspect of the lateral meniscus. The contributions of these two sites are variable. Basmajian and Lovejoy proposed that a portion of it also arises from the arcuate ligament, thus giving it a fibular as well as femoral origin (8). It courses inferiorly and medially across the posterolateral aspect of the joint and inserts through its fleshy attachment to the posterior aspect of the tibia. The intricate relationship of the popliteus tendon to the superior and inferior popliteomeniscal fascicles as it passes by the lateral meniscus is demonstrated in Fig. 83.9 (86). The anteroinferior and posterosuperior meniscal fascicles are important stabilizers of the lateral meniscus. Sectioning of these structures increased anterior displacement of the lateral meniscus 18% when one fasciculus was sectioned and 78% when both fasciculi were sectioned (85). These displacements did not result in locking of the menisci but clearly could result in painful dysfunction clinically. The popliteus muscle functions synergistically with the PCL through Wrisberg's and Humphrey's ligaments when they are present. It internally rotates the tibia on the femur, especially during the first 10° to 20° of flexion. It acts as a weak flexor of the knee and draws the lateral meniscus posteriorly as the knee is flexed.

In a recent article, Maynard et al. point out that there has been much confusion about terminology and anatomic detail concerning those structures that attach to the fibular head (58). They propose the term popliteal fibular ligament for a consistent structure that passes from the popliteus tendon downward to the fibular head. They identified its presence in 20 of 20 cadaver dissections but state that most anatomy texts of the 20th century have not reported this structure. Biomechanical investigations performed by Maynard et al. revealed that this structure is nearly as large and about 56% as strong as the lateral collateral ligament. This anatomic observation has important ramifications for reconstruction of the complex lateral structures following damage to the lateral side of the knee. In contrast to the above findings, Kim et al. reported in a cadaver study correlating anatomic to magnetic resonance imaging (MRI) findings that a popliteofibular ligament was present in only 37.5% of 50 adult knees evaluated (47).

The biceps femoris tendon inserts into the posterolateral aspect of the knee in a multipart arrangement similar to that of the semimembranosus posteromedially (58,89). Its insertion can be divided into three distinct layers with attachments into the fibular head, proximal tibia, fascia around the leg, and posterior capsule of the knee joint, as well as an indirect attachment to the lateral collateral ligament. Thus, the biceps serves to flex the knee, antagonistically control extension of the joint, externally rotate the tibia on the femur, tense the lateral and posterior capsule, and dynamically control anterior displacement of the tibia on the femur. Its ability to tension the lateral collateral ligament was discussed previously.

## THE CRUCIATE LIGAMENTS

### *Anterior Cruciate Ligament*

The anterior cruciate ligament (ACL) resides completely within the notch of the femur and thus has no capsular attachments. It is surrounded by loose areolar tissue, from which it obtains its blood supply, primarily from the middle geniculate artery. Its areas of insertion on the tibia and femur are large, resulting in fibers of various length as they pass from the tibia posteriorly, laterally, and cephalad to the femur. In full extension all the fibers are under tension; as flexion occurs, all fibers relax, but those most posterior and lateral relax the most (5). Over 90° of flexion, the ligament rotates approximately 180° (Fig. 83.19) (24). During this maneuver, the fibers that originally were most anterior at their attachment site on the femur become most posterior, and vice versa.

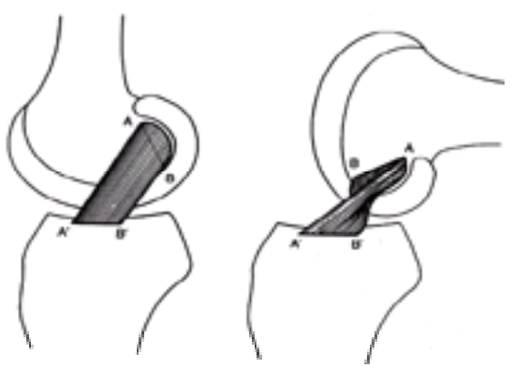

***Figure 83.19.*** Changes in shape and relative tension of the anterior (*A–A´*) and posterior (*B–B´*) portions of the anterior cruciate ligament in extension and 90° of flexion. (From Girgis FG, Marshall JL, Al Monajem, ARS. The Cruciate Ligaments of the Knee Joint. *Clin Orthop* 1975;106:216.)

The attachment on the tibia occurs on the nonarticular surface, extending from just behind the medial and lateral spines forward for approximately 3 cm (Fig. 83.20) (24). The ACL insertions on the tibia and femur are both nearly planar, with the femoral attachment being circular and the tibial attachment more oval (31). The attachment areas are nearly three times the ACL cross-sectional area at the midportion of the ligament. The femoral attachment of the ACL is far posterior on the lateral wall of the intracondylar notch (Fig. 83.21) (25). No fibers of the ACL are totally isometric, with the least variation in length (approximately 1.5 mm) occurring along fibers coursing through the anteromedial aspect of the structure (27,78,84).

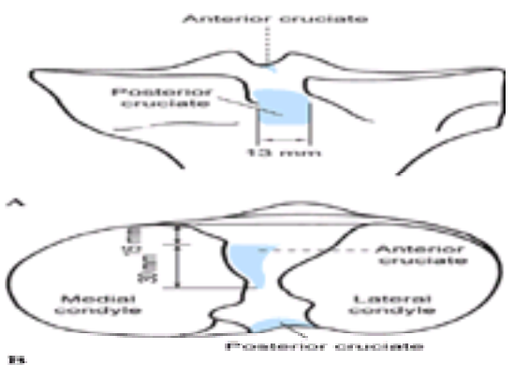


***Figure 83.20.*** Posterior upper portion of the tibia (**A**) and superior surface of the tibia (**B**), showing the average measurements and relationships of the tibial attachments of the anterior and posterior cruciate ligaments. (From Girgis FG, Marshall JL, Al Monajem ARS. The Cruciate Ligaments of the Knee Joint. *Clin Orthop* 1975;106:216.)

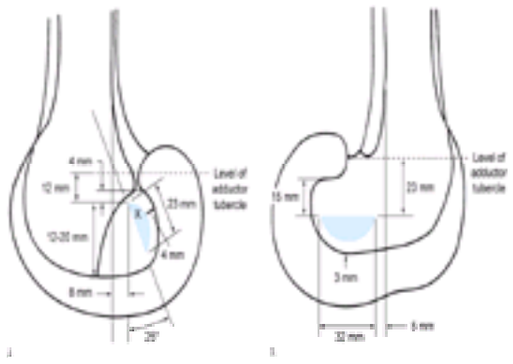

***Figure 83.21.*** Medial surface of the right lateral femoral condyle (**A**) and lateral surface of the right medial femoral condyle (**B**), demonstrating the average measurements and relationships of the femoral attachments of the (**A**) anterior and (**B**) posterior cruciate ligaments. **X** shows the approximate position of attachment of the "most isometric" fibers of the anterior cruciate ligament. (From Girgis FG, Marshall JL, Al Monajem ARS. The Cruciate Ligaments of the Knee Joint. *Clin Orthop* 1975;106:216.)

Girgis and associates found the average length of the ACL to be 38 mm and the average width to be 11 mm (26). Odensten and Gillquist observed similar dimensions and reported the average thickness to be 5 mm (68). Until recently, the maximum tensile strength measured in tests of young human cadaver ACLs was approximately 1,730 N, but recent tests by Woo, Rauch, and their colleagues measured maximum loads at failure as high as 2,500 N (66,74,95). The most important functions of the ACL are to act as the primary static restraint to anterior displacement of the tibia on the femur and to prevent hyperextension of the knee (17). Important secondary functions are to resist varus and valgus deforming moments affecting the knee and to resist internal rotation of the tibia (28).

Reattachment or replacement of a torn ACL demands exacting attention to placing the femoral attachment into the center of attachment of the anteromedial portion of the ligament (the X in Fig. 83.21). Variation from this site by more than a few millimeters most likely will result in an inappropriate strain pattern and possible failure of the procedure. Anterior placement of a graft or repair leads to excessive strain within the ligament, which results in failure of the procedure or prevention of flexion of the knee beyond 70° to 90° (5,34,42,50,72). Placement of the graft posteriorly in the over-the-top position results in the graft becoming excessively slack as the knee flexes (34). The site of reattachment of the graft on the femur appears to be much more critical for proper graft performance than the placement on the tibia (33,34).

There is no clear demarcation between the anteromedial and posterolateral portions of the ligament, as has sometimes been described. However, the variations in fiber lengths and attachment sites described previously do separate the anterior and posterior portions of the ligament functionally. The strain pattern within the fibers of the anterior aspect of the ligament are demonstrated in Fig. 83.22 (13). Damage to an isolated portion of the ACL produces abnormalities in ligament laxity during clinical testing. For instance, an intact posterior portion of the ACL with loss of the anterior portion results in a negative Lachman test, whereas the anterior drawer test demonstrates increased laxity. If, on the other hand, the anterior portion of the ACL is intact and the posterior portion is destroyed, the drawer test will be nearly normal, but the Lachman maneuver will reveal increased anterior translation.

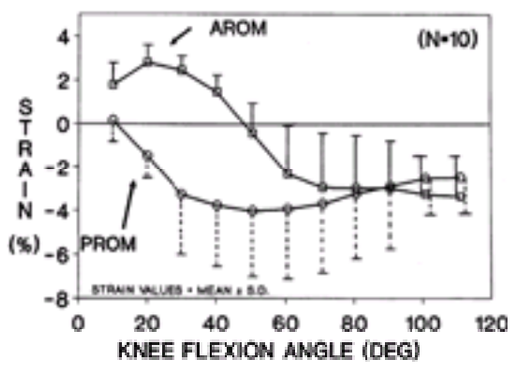


***Figure 83.22.*** Mean strain pattern in the anteromedial fibers of the human cadaver anterior cruciate ligaments during motion from full extension to 120° of flexion. AROM, active range of motion; PROM, passive range of motion.

Disruption of the anterior cruciate ligament may result not only in abnormal knee kinematics but also in changes to the neuromuscular system. Even low-demand activities such as walking may be performed in an abnormal manner. For example, subjects with an anterior-cruciate-deficient knee have been shown to reduce the flexion moment about their knee in an effort to reduce contraction of the antagonistic quadriceps muscles (9). This has been coined the quadriceps-avoidance gait.

The strain distribution of the cruciate ligaments varies along their length (i.e., the strains in the midsubstance portion of the ligament are different in comparison to those at the insertions (and about its cross section) (18). This has been investigated by Woo et al., who used a robot combined with a six-degree-of-freedom force transducer to apply load to the knee (96). They have shown that the restraint forces in the anteromedial and posterolateral aspects of the anterior cruciate ligament differ, and they change relative to knee flexion. A similar behavior occurs during passive flexion–extension of the knee (56).

Our approach was to measure the strain in the anteromedial aspect of the ACL in humans, the region of the ligament to which we have access with the arthroscope and our current differential variable-reluctance transducer (DVRT; MicroStrain, Burlington, VT). The study participants were patients who underwent a diagnostic arthroscopic surgery, typically for meniscectomy, and volunteered to participate under a protocol approved by our institutional human subjects review board. The surgical and experimental procedures were performed under local anesthesia, allowing study subjects full control of their musculature. The subjects had normal cruciate ligaments as documented by arthroscopic and clinical exam, normal range of joint motion, no history of previous ligament injury, and normal gait. After the surgical procedure was finished, the DVRT was implanted into the anteromedial aspect of the ACL to characterize its displacement pattern and calculate its strain behavior.

Movement of the knee from a flexed to an extended position, either passively or through contraction of the leg muscles, consistently produced an increase in ACL strain values (10). Rehabilitation exercises that produce low ACL strain values involve contraction of the dominant quadriceps muscle group with the knee flexed at 60° or greater (simultaneous quadriceps and hamstrings contraction, isometric contraction of the quadriceps) or were dominated by the hamstrings muscle group (isometric hamstrings muscle contraction; Fig. 83.23). Extension of the knee produced by contraction of the dominant quadriceps muscle group produced a substantial increase in ACL strain values, a finding that has been observed by Markoff et al. (56). The peak ACL strain values that were produced by squatting (a closed-kinetic-chain activity that induces a substantial compressive load across the tibiofemoral joint because of body weight as well as cocontraction of the leg musculature) were similar to those produced during open-kinetic-chain active extension of the knee (an activity that does not involve the compressive load produced by body weight) (12) (Fig. 83.24 and Fig. 83.25). The ACL strain values that were created by squatting were unaltered with the addition of an elastic resistance (the SportCord) that increased activity of the musculature spanning the knee. Thus, increasing resistance with the SportCord (producing a moderate increase in muscle activity) in an effort to strengthen the leg muscles during the squat exercise does not necessarily produce a significant increase in ACL strain magnitude. In contrast, increasing resistance during open-kinetic-chain active flexion/extension of the knee produces a significant increase in ACL strain magnitude (10). Currently, the limit of ACL graft strain during healing that is safe or unsafe is unknown. Therefore, we are unable to recommend what rehabilitation exercises should be performed based on whether they are safe or harmful. However, we feel it is important to point out the peak strain values that are produced during the quadriceps-dominated exercises (Table 83.3) may damage a healing ACL graft if they are used too early during rehabilitation, if they are performed at inappropriate knee flexion angles, or if they are advanced to include more challenging levels of muscle contraction.

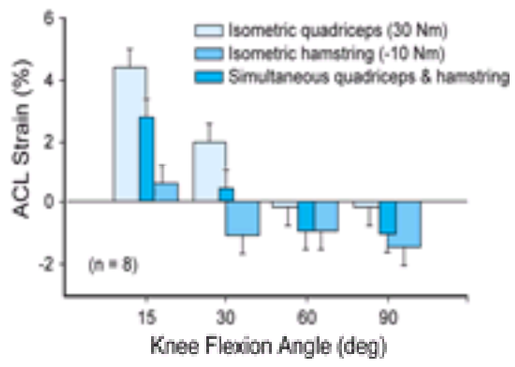


***Figure 83.23.*** Summary of effects of thigh muscle contraction on the strain in the anteromedial bundle of the anterior cruciate ligament *in vivo.* (From Beynnon BD, Johnson RJ, Fleming BC, et al. The Effect of Functional Knee Bracing in the Weightbearing and Non-weightbearing Knee. *Am J Sports Med* 1997;25:353.)

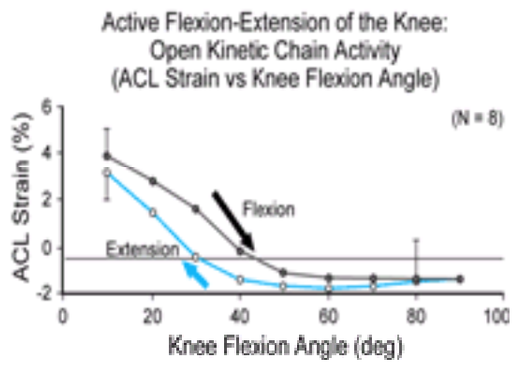


***Figure 83.24.*** Mean strain value produced by active flexion–extension motion of the knee within the anteriomedial bundle of the anterior cruciate ligament measured *in vivo* (*n* = 8). The ligament strain values are presented for extension and flexion motions of the knee. The *arrow* indicates data for flexion motion of the knee. (From Beynnon BD, Johnson RJ, Fleming BC, et al. The Strain Behavior of the Anterior Cruciate Ligament, A Comparison of Open and Closed Kinetic Chain Exercise. *Am J Sports Med* 1997;25:823.)

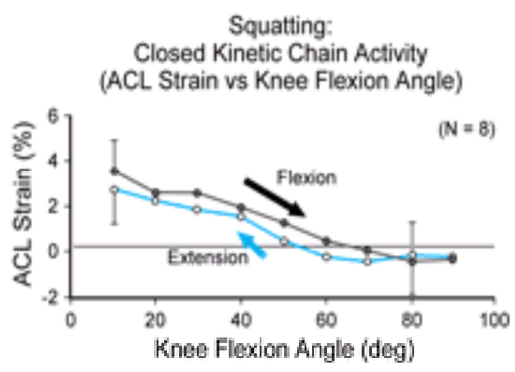


***Figure 83.25.*** Mean strain values for squatting as measured in the anteromedial bundle of the anterior cruciate ligament *in vivo* (*n* = 8). Strain values are presented for flexion and extension motions of the knee (flexion motion is indicated by the *arrow*). (From Beynnon BD, Johnson RJ, Fleming BC, et al. The Strain Behavior of the Anterior Cruciate Ligament, A Comparison of Open and Closed Kinetic Chain Exercise. *Am J Sports Med* 1997;25:823.)

| Rehabilitation activity | Peak strain | Number of subjects |
|---|---|---|
| Isometric quads contraction at 45° (30 Nm of extension torque) | 4.0 (3.6)% | 8 |
| Squatting with SportCord | 4.0 (1.7)% | 8 |
| Active flexion-extension of the knee with 45 N weight boot | 3.8 (3.5)% | 9 |
| Lachman test (150 N of anterior shear load) | 3.7 (3.8)% | 10 |
| Squatting | 3.6 (1.3)% | 8 |
| Active flexion–extension (no weight boot) of the knee | 2.8 (3.8)% | 10 |
| Simultaneous quads and hams contraction at 15° | 2.8 (3.9)% | 8 |
| Isometric quads contraction at 30° (30 Nm of extension torque) | 2.7 (3.5)% | 10 |
| Anterior drawer (150 N of anterior shear load) | 1.8 (3.9)% | 10 |
| Stationary bicycling | 1.7 (1.9)% | 8 |
| Isometric hams contraction at 15° (in −10 Nm of flexion torque) | 0.6 (3.9)% | 8 |
| Simultaneous quads and hams contraction at 30° | 0.4 (3.5)% | 8 |
| Passive flexion-extension of the knee | 0.1 (3.9)% | 10 |
| Isometric quads contraction at 60° (30 Nm of extension torque) | 0.0% | 8 |
| Isometric quads contraction at 90° (30 Nm of extension torque) | 0.0% | 10 |
| Simultaneous quads and hams contraction at 60° | 0.0% | 8 |
| Simultaneous quads and hams contraction at 90° | 0.0% | 8 |
| Isometric hams contraction at 30°, 60°, and 90° (in −10 Nm of flexion torque) | 0.0% | 8 |

***Table 83.3. Rank Comparison of Peak ACL Strain Values During Commonly Prescribed Rehabilitation Activities (Mean ± 1 Standard Deviation)***

Functional knee braces have been used to protect a healing ACL graft or to treat instability of the knee that results from an ACL disruption. Subjective studies have shown that braces help individuals with torn knee ligaments to improve athletic performance. Studies of knee kinematics have demonstrated that braces increase the stiffness of the tibiofemoral joint and produce reductions of anterior–posterior displacements, but this holds only for low shear load magnitudes. We have measured ACL strain in subjects during braced and unbraced conditions, demonstrating that bracing does not prestrain or harm the ACL, a finding that was in direct contrast to our earlier cadaveric studies. In our studies of subjects in a non-weight-bearing condition, we determined that the protective strain-shielding effect of a functional knee brace on the ACL was dependent on the magnitude of applied anterior load and internal–external torques (14). As the magnitude of applied anterior load and internal–external torque increased, the protection produced by the brace on the ACL decreased. We then progressed to systematically study the effect of the extrinsic forces produced by different brace strap tensions on the ACL in the presence of body weight (11). We determined that bracing significantly reduced ACL strain values for anteriorly directed loading of the tibia with the subject weight bearing. This response was very different from a non-weight-bearing response, which seemed to be dependent on the magnitude of externally applied load to the knee.

### *Posterior Cruciate Ligament*

The posterior cruciate ligament (PCL) attaches to the femur in a wide area on the medial wall of the intracondylar notch (Fig. 83.21) (26,90). From there the PCL descends posteriorly and somewhat laterally to pass the back of the tibial plateau and insert in a groove in the posterior surface of the tibia well below the joint line (Fig. 83.20) (26,90). The PCL femoral insertion is half-moon shaped and nearly planar, whereas its tibial attachment is more rectangular and covers a convex surface on the posterior tibial plateau (31). The PCL is surrounded by vascular loose areolar tissue with a synovial membrane sustaining the majority of its blood supply from the middle geniculate artery. The PCL's mean length is 38 mm, and its width is 13 mm (26). The ligament has a large anterior portion and a much smaller, more oblique posterior portion, but these structures are not clearly distinguishable. As in the ACL, there are no totally isometric fibers, but in general there is less variation in length in the posterior portion of the ligament than anteriorly. The strain within the posterior fibers was found to relax from 0° to 20° of flexion and then increase to a maximum of 6% in full flexion, whereas the strain observed in the anterior fibers is least at full extension and increases to nearly 20% at full flexion (Fig. 83.26) (3). Girgis et al. observed that the bulk of the PCL becomes most relaxed in extension, whereas the majority of the fibers within the ACL are loose in flexion (17,26). In 70% of knees, a structure reinforces the PCL, extending from the posterior horn of the lateral meniscus to the femur. If it passes behind the PCL, it is known as the posterior meniscofemoral ligament (Wrisberg's ligament), and if it passes anteriorly, it is named the anterior meniscofemoral ligament (Humphrey's ligament) (20). Rarely do both

of these structures coexist, but in some instances they are quite large. Clancy et al. (20) stated that when one of these structures is robust, it may mask the clinical laxity (posterior drawer sign in internal rotation) observed when the PCL has been destroyed.

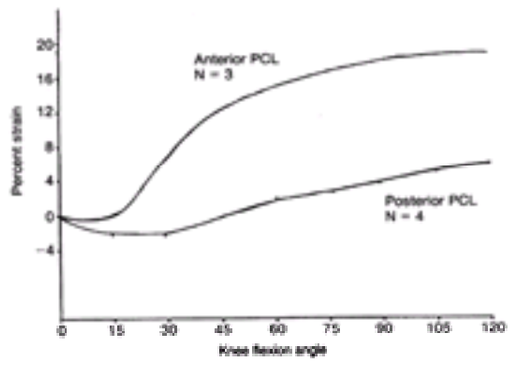


***Figure 83.26.*** Strain in the anterior and posterior portions of human cadaver posterior cruciate ligaments (PCL) during motion from full extension to 120° of flexion.

The PCL functions primarily to prevent posterior displacement of the tibia relative to the femur. With posterior displacements of more than 3 mm in the intact human knee, more than 90% of the restraining force (11) resides in this ligament (17). It secondarily assists in restraining varus and valgus moments to the knee and resists internal rotation of the tibia relative to the femur.

In a recent detailed anatomic comparison of the ACL and PCL, Harner et al. showed that the cross-sectional areas of both ligaments changed along their course from tibia to femur, with the ACL becoming larger as one passes distally and the PCL enlarging proximally (32). The PCL was found to be 1.5 times larger than the ACL proximally near its midportion, whereas it was only 1.2 times larger more distally. They also observed that the cross-sectional area of the meniscofemoral ligaments averaged approximately 22% of that of the entire PCL in the cadavers they studied. In further work from the University of Pittsburgh, Marks et al. found that mean cross-sectional area of collagen fibers within the ACL and PCL varies along their length (57). In the ACL the mean diameter of fibrils increases as one moves from proximal to distal, whereas the PCL shows exactly the opposite trend. This implies different exposure to strain along various portions of these ligaments. The complex nature of the cruciate ligaments needs to be considered when these structures are being replaced following injury.

## AUTHORS' PERSPECTIVE

The complexities of the anatomy and biomechanics of the human knee can be introduced only briefly in this short chapter. Many topics are only superficially discussed or totally ignored. Yet a thorough understanding of this information and the unexpressed details is mandatory if appropriate treatment is to be rendered to patients suffering disease and injury to their knees. We are experiencing an explosion of new research and literature concerning many subjects involving the biomechanics and anatomy of the knee. In many areas, our understanding of the intricate details of knee function is so superficial that at best our efforts to prescribe the appropriate surgical procedures and therapeutic regimens is marginal and, in some cases, inadequate. No area better exemplifies this point than the treatment of the ACL-deficient knee with the myriad therapeutic options present today. No single treatment method can be considered superior, simply because our knowledge is too limited. We are undoubtedly in a period when significant breakthroughs are likely at any time. It is the responsibility of us all to keep abreast of this information and apply it to our own practices.

### CHAPTER REFERENCES

Each reference is categorized according to the following scheme: *, classic article; #, review article; !, basic research article; and +, clinical results/outcome study.


! 1. Amiel D, Frank C, Harwood F, et al. Tendons and Ligaments: A Morphological and Biochemical Composition. *J Orthop Res* 1984;1:257.

! 2. Arms S, Boyle J, Johnson R, et al. Strain Measurement in the Medial Collateral Ligament of the Human Knee: An Autopsy Study. *J Biomech* 1983;7:491.

! 3. Arms SW, Johnson RJ, Pope MH. Strain Measurement in the Human Posterior Cruciate Ligament. *Orthop Trans* 1984;9:355.

! 4. Arms SW, Pope MH, Johnson RJ. Measurement of Strain in the Lateral Collateral Ligament of the Human Knee. *Orthop Trans* 1984;9:109.

! 5. Arms SW, Pope MH, Johnson RJ, et al. The Biomechanics of Anterior Cruciate Rehabilitation and Reconstruction. *Am J Sports Med* 1984;12:8.

! 6. Baratz ME, Fu FH, Mengato R. Meniscal Tears: The Effect of Meniscectomy and Repair on Intra-articular Contact Areas and Stress in the Human Knee. *Am J Sports Med* 1986;14:270.

! 7. Bargar WL, Moreland JR, Markoff KL, et al. *In Vivo* Stability Testing of Post-meniscectomy Knees. *Clin Orthop* 1980;150:247.

! 8. Basmajian MV, Lovejoy JF. Functions of the Popliteus Muscle in Man. *J Bone Joint Surg* 1971;53-A:557.

! 9. Berchuck M, Andriacchi TP, Bach BR, et al. Gait Adaptations by Patients Who Have a Deficient Anterior Cruciate Ligament. *J Bone Joint Surg* 1990;72-A:871.

! 10. Beynnon BB, Fleming BC, Johnson RJ, et al. Anterior Cruciate Ligament Strain Behavior During Rehabilitation Exercises *in Vivo. Am J Sports Med* 1995;23:24.

! 11. Beynnon BD, Johnson RJ, Fleming BC, et al. The Effect of Functional Knee Bracing in the Weightbearing and Non-weightbearing Knee. *Am J Sports Med* 1997;25:353.

! 12. Beynnon BD, Johnson RJ, Fleming BC, et al. The Strain Behavior of the Anterior Cruciate Ligament, a Comparison of an Open and Closed Kinetic Chain Exercise. *Am J Sports Med* 1997;25:823.

! 13. Beynnon BD, Pope MH, Fleming BC, et al. An *in-Vivo* Study of the ACL Strain Biomechanics in the Normal Knee. *Trans Orthop Res Soc* 1989;14:35.

! 14. Beynnon BD, Pope MH, Wertheimer CM, et al. The Effect of Functional Braces on Strain on the Anterior Cruciate Ligament *in Vivo. J Bone Joint Surg* 1992;74:1248.

! 15. Blyski-Austrow DI, Meade T, Malumed J, et al. Irradiated Meniscal Allografts: Mechanical and Histological Studies in the Goat. *Trans Orthop Res Soc* 1992;38:175.

! 16. Burger RS, Greenleaf J, James S. Medial and Posteromedial Structures of the Knee: An Anatomical and Functional Presentation. *Arch Am Acad Orthop Surg* 1997;1:21.

! 17. Butler DL, Noyes FR, Grood ES. Ligamentous Restraints to Anterior–Posterior Drawer in the Human Knee. *J Bone Joint Surg* 1980;62-A:259.

! 18. Butler DL, Sheh MY, Stouffer DC, et al. Surface Strain Variation in Human Patellar Tendon and Knee Cruciate Ligaments. *J Biomech Eng* 1990;112:38.

! 19. Cabaud HE. Biomechanics of the Anterior Cruciate Ligament. *Clin Orthop* 1983;172:26.

+ 20. Clancy WG, Shelbourne KD, Zoellner GB, et al. Treatment of Knee Joint Instability Secondary to Rupture of the Posterior Cruciate Ligament. *J Bone Joint Surg* 1983;65-A:310.

! 21. Cooper RR, Misol S. Tendon and Ligament Insertion. *J Bone Joint Surg* 1970;52-A:1.

! 22. Daniel DM, Stone M. Instrumented measurement of knee motion. In: Daniel D, Akeson W, O'Connor J, eds. *Knee Ligaments: Structure, Function, Injury and Repair.* New York: Raven Press, 1990.

+ 23. DeHaven KE, Black KP, Griffiths HJ. Open Meniscal Repair: Technique and Two to Nine Year Results. *Am J Sports Med* 1989;17:788.

* 24. Fairbank TJ. Knee Changes after Meniscectomy. *J Bone Joint Surg* 1948;30-B:664.

! 25. Frank C, Woo S, Andriacchi T, et al. Normal Ligament Structure, Function and Composition. In: Woo SL-Y, Buckwalter JA, eds. *Injury and Repair of the Musculoskeletal Soft Tissues.* Park Ridge, IL: American Academy of Orthopaedic Surgeons, 1988.

! 26. Girgis FG, Marshall JL, Al Monajem ARS. The Cruciate Ligaments of the Knee Joint. *Clin Orthop* 1975;106:216.

! 27. Graf B. Isometric Placement of Substitutes for the Anterior Cruciate Ligament. In: Jackson DW, Drez D Jr, eds. *The Anterior Cruciate Deficient Knee.* St. Louis: CV Mosby, 1987.

! 28. Grood ES, Noyes FR, Butler DL, et al. Ligamentous and Capsular Restraint Preventing Medial and Lateral Laxity in Intact Human Cadaver Knees. *J Bone Joint Surg* 1981;63-A:1257.

+ 29. Hamberg P, Gillquist J, Lysholm J. Suture of the New and Old Peripheral Meniscus Tears. *J Bone Joint Surg* 1983;65-A:193.

+ 30. Hardaker WT, Whipple TL, Bassett FH. Diagnosis and Treatment of the Plica Syndrome of the Knee. *J Bone Joint Surg* 1980;62-A:221.

! 31. Harner CD, Kashiwaquchi S, Livesay GA, et al. Insertion Site Anatomy of the Human Anterior and Posterior Cruciate Ligaments. *Trans 39 Ann Meet ORS* 1993;18:341.

! 32. Harner CD, Livesay GA, Kashiwaguchi S, et al. Comparative Study of the Size and Shape of Human Anterior and Posterior Cruciate Ligaments. *J Orthop Res* 1995;13:429.

! 33. Hefzy MS, Grood ES. Sensitivity of the Insertion Location on Length Patterns of Anterior Cruciate Ligament Fibers. *J Biomed Eng* 1986;108:73.

! 34. Hefzy MS, Grood ES, Noyes FR. Factors Affecting the Region of most Isometric Femoral Attachments Part II. The Anterior Cruciate Ligament. *Am J Sports Med* 1989;17:208.

+ 35. Helfet AJ. *The Management of Internal Derangements of the Knee.* Philadelphia: JB Lippincott, 1963.

! 36. Hsieh H, Walker PS. Stabilizing Mechanisms of the Loaded and Unloaded Knee Joint. *J Bone Joint Surg* 1976;58-A:87.

! 37. Huberti HH, Hayes WC, Stone JL, et al. Force Ratios in the Quadriceps Tendon Ligamentum Patella. *J Orthop Res* 1984;2:49.

+ 38. Huckle JR. Is Meniscectomy a Benign Procedure? A Long-Term Follow-up Study. *Can J Surg* 1965;8:254.

+ 39. Hughston JC, Eilers AF. The Role of the Posterior Oblique Ligament in Repairs of Acute Medial (Collateral) Ligament Tears of the Knee. *J Bone Joint Surg* 1973;55-A:923.

! 40. Hungerford DS, Barry M. Biomechanics of the Patellofemoral Joint. *Clin Orthop* 1979;144:9.

! 41. Jackson JP. Surgery of the Knee Joint. In: Jackson JP, Waugh W, eds. *Surgical Anatomy.* Philadelphia: JB Lippincott, 1984.

+ 42. Johnson RJ, Kettelkamp DB, Clark W, et al. Factors Affecting Late Meniscectomy Results. *J Bone Joint Surg* 1974;56-A:719.

! 43. Kapandji IA. *The Physiology of the Joints, Vol. 2, Lower Limb.* Edinburgh: Churchill Livingstone, 1970.

! 44. Kaplan EB. Factors Responsible for Stability of the Knee Joint. *Bull Hosp Joint Dis* 1957;18:51.

! 45. Kaufer H. Mechanical Function of the Patella. *J Bone Joint Surg* 1971;53-A:1551.

! 46. Kettelkamp DB, Johnson RJ, Smidt GL, et al. An electrogoniometric study of knee motion in normal gait. *J Bone Joint Surg* 1970;52-A:775.

! 47. Kim YC, Chung IH, Woo WK, et al. Anatomy and Magnetic Resonance Imaging of the Posterolateral Structures of the Knee. *Clin Anat* 1997;10:397.

! 48. Krause WR, Pope MH, Johnson RJ, et al. Mechanical Changes in the Knee after Meniscectomy. *J Bone Joint Surg* 1976;58-A:599.

# 49. Kuhn JE, Wojtys EM. Allograft Meniscus Transplantation. *Clin Sports Med* 1996;15:537.

! 50. Larson RV, Sidles JA, Matsen FA, Gaini L. Isometric Ligament Insertions in the Knee. *Am J Sports Med* 1987;15:394.

! 51. Levy IM, Torzilli PA, Warren RF. The Effect of Medial Meniscectomy on Anteroposterior Motion of the Knee. *J Bone Joint Surg* 1982;64-A:883.

! 52. Maquet P. Advancement of the Tibial Tuberosity. *Clin Orthop* 1976;115:225.

! 53. Maquet P. Mechanics and Osteoarthritis of the Patellofemoral Joint.*Clin Orthop* 1979;144:70.

! 54. Marans HJ, Jackson RW, Glossop ND, et al. Anterior Cruciate Ligament Insufficiency: A Dynamic Three-Dimensional Motion Analysis. *Am J Sports Med* 1989;17:325.

! 55. Markoff KL, Bargar WL, Shoemaker SC, et al. The role of joint load in knee stability. *J Bone Joint Surg* 1981;63-A:570.

! 56. Markoff KL, Gorek JF, Kabo JM, et al. Direct Measurement of Reluctant Forces in the Anterior Cruciate Ligament. *J Bone Joint Surg* 1990;72A:557.

! 57. Marks PH, Harner CD, Liversay GA, et al. Quantitative Electron Microscopy of the Human Cruciate and Meniscofemoral Ligaments. *Trans 40 Ann Meet ORS* 1994;19:60.

! 58. Marshall JL, Girgis FG, Zelko RR. The Biceps Femoris Tendon and Its Functional Significance. *J Bone Joint Surg* 1972;54-A:1444.

! 59. Maynard MJ, Deng X, Wichiewicz TL, et al. The Poplitealfibular Ligament: Rediscovery of a Key Element in Posterolateral Stability. *Am J Sports Med* 1996;24:311.

! 60. McLeod WD, Moschi A, Andrews JR, et al. Tibial Plateau Topography. *Am J Sports Med* 1977;5:13.

! 61. Newman AP, Anderson DR, Daniels AU, Dales MC. Mechanics of the Healed Meniscus in a Canine Model. *Am J Sports Med* 1989;17:164.

! 62. Newman AP, Anderson DR, Daniels AU, Lee KW. The Effect of Medial Meniscectomy and Coronal Plane Angulation on *in-Vitro* Load Transmission in the Canine Stiffle Joint. *J Orthop Res* 1989;7:281.

! 63. Noyes FR. Functional Properties of Knee Ligaments and Alterations Induced by Immobilization. *Clin Orthop* 1977;123:210.

! 64. Noyes FR, Butler DL, Grood ES, et al. Biomechanical Analysis of Human Ligament Grafts Used in Knee Ligament Repairs and Reconstructions. *J Bone Joint Surg* 1984;66-A:344.

! 65. Noyes FR, DeLucas JL, Torvik PJ. Biomechanics of Ligament Failure: An Analysis of Strain-Rate Sensitivity and Mechanisms of Failure in Primates. *J Bone Joint Surg* 1974;56-A:236.

! 66. Noyes FR, Grood ES. The Strength of the Anterior Cruciate Ligament in Humans and Rhesus Monkeys. *J Bone Joint Surg* 1976;58-A:1074.

! 67. Noyes FR, Sonstegard DA. Biomechanical Function of the Pes Anserinus at the Knee and the Effect of Its Transplantation. *J Bone Joint Surg* 1973;55-A:1225.

! 68. Odensten M, Gillquist J. Functional Anatomy of the Anterior Cruciate Ligament and a Rationale for Reconstruction. *J Bone Joint Surg* 1975;67-A:257.

! 69. Oretop N, Risberg B. *Studies on the Fine Structure of the Medial Meniscus and Ligaments and Their Anatomic Relationships in the Human Knee.* Medial Dissertation 63, Linkoping University, Sweden, 1978.

! 70. Outerbridge RE. Further Studies on the Etiology of Chondromalacia Patellae. *J Bone Joint Surg* 1964;46-B:179.

! 71. Paletta GA, Manning T, Snell E, et al. The Effect of Allograft Meniscal Replacement on Intraarticular Contact Area and Pressures in the Human Knee. *Am J Sports Med* 1997;25:692.

! 72. Penner DA, Daniel DM, Wood P, Mirshra D. An *in-Vitro* Study of Anterior Cruciate Ligament Graft Placement and Isometry. *Am J Sports Med* 1988;16:238.

! 73. Pope MH, Johnson RJ, Brown DW, et al. The Role of Musculature in Injuries to the Medial Collateral Ligament. *J Bone Joint Surg* 1979;61-A:398.

! 74. Rauch G, Allzeit B, Gotzen L. *Tensile Strength of the Anterior Cruciate Ligament in Dependence or Age.* Paper Presented at Biomechanics of Human Knee Ligaments: Proceedings of the European Society of Biomechanics, University of Ulm, Germany, 1987;24.

! 75. Reider B, Marshall JL, Koslin B, et al. The Anterior Aspect of the Knee. *J Bone Joint Surg* 1981;63-A:351.

! 76. Reilly DT, Martens M. Experimental Analysis of the Quadriceps Muscle Force and Patello-femoral Joint Reaction Force for Various Activities. *Acta Orthop Scand* 1972;43:126.

+ 77. Rosenberg TD, Scott SM, Coward DB, et al. Arthroscopic Meniscal Repair Evaluated with Repeat Arthroscopy. *Arthroscopy* 1986;2:14.

! 78. Sapega A, Mayer R, Schneck C, Komalakiranya N. Testing for Isometry During Reconstruction of the Anterior Cruciate Ligament. *J Bone Joint Surg* 1990;72-A:259.

+ 79. Scott GA, Jolly BL, Henning CE. Combined Posterior Incision and Arthroscopic Intra-articular Repair of the Meniscus. *J Bone Joint Surg* 1986;68-A:847.

! 80. Seebacher JF, Inglis AE, Marshall JL, et al. The Structure of the Posterolateral Aspect of the Knee. *J Bone Joint Surg* 1982;64-A:536.

! 81. Seedhorn BB, Dawson D, Wright U. Functions of the Menisci—a Preliminary Study. *J Bone Joint Surg* 1974;56-B:381.

! 82. Seedhom BB, Hargreaves DJ. Transmission of the Load in the Knee Joint with Special Reference to the Role of the Menisci. *Eng Med* 1979;8:220.

! 83. Shrive N. The Weight Bearing Role of the Menisci of the Knee. *J Bone Joint Surg* 1974;56-B:381.

! 84. Sidles J, Larson R, Garbini J, et al. Ligament Length Relationships in the Moving Knee. *J Orthop Res* 1988;6:593.

! 85. Simonian PT, Sussmann PS, van Trommel M, et al. Popliteomeniscal Fasciculi and Lateral Meniscal Stability. *Am J Sports Med* 1997;25:849.

! 86. Stäubli H-U, Birrer S. The Popliteus Tendon and Its Fascicles at the Popliteal Hiatus: Gross Anatomy and Functional Arthroscopic Evaluation with and without Anterior Cruciate Deficiency. *Arthroscopy* 1990;6:209.

+ 87. Tapper EM, Hoover NW. Late Results after Meniscectomy. *J Bone Joint Surg* 1969;51A:517.

! 88. Terry GC, Hughston JC, Norwood LA. The Anatomy of the Iliopatellar Band and Iliotibial Tract. *Am J Sports Med* 1986;14:39.

! 89. Terry GC, LaPrade RF. The Biceps Femoris Muscle Complex at the Knee. Its Anatomy and Injury Patterns Associated with Acute Anterolateral–Anteromedial Rotatory Instability. *Am J Sports Med* 1996;24:2.

! 90. VanDommellon BA, Fowler PJ. Anatomy of the Posterior Cruciate Ligament: A Review. *Am J Sports Med* 1989;17:24.

# 91. Veltri DM, Warren RF, Wickiewicz TL, et al. Current Status of Allograft Meniscal Transplantation. *Clin Orthop* 1994;303:44.

! 92. Walker PS, Erkman MJ. The Role of Menisci in the Force Transmission across the Knee. *Clin Orthop* 1975;109:184.

! 93. Wang CJ, Walker PS. Rotation Laxity of the Human Knee. *J Bone Joint Surg* 1974;61-A:56.

! 94. Warren LF, Marshall JL. The Supporting Structures of the Medial Side of the Knee. *J Bone Joint Surg* 1979;61-A:56.

! 95. Woo SL-Y, Adams DJ. The Tensile Properties of Human Anterior Cruciate Ligament (ACL) and ACL Graft Tissues. In: Daniel D, Akeson W, O'Connor J, eds. *Knee Ligaments: Structure, Function, Injury and Repair.* New York: Raven Press, 1990.

! 96. Woo SL-Y, Fox RJ, Sakane M, et al. Force and Force Distribution in the Anterior Cruciate Ligament and Its Clinical Implications. *Sportorthopad Sporttraumatal* 1997;13:37.

# CHAPTER 84

# PRINCIPLES OF ARTHROSCOPY OF THE KNEE

*David B. Coward*

**D. B. Coward:** Sacremento Knee & Sports Medicine, 2801 K Street, Suite 310, Sacremento, CA 95816.

Clinical Evaluation and Imaging
History
Physical Examination
Aspiration of the Knee
Imaging of the Knee
Indications for Knee Arthroscopy
Anesthesia
Surgical Techniques
Arthroscopic Portals
Anterolateral Portal
Anteromedial Portal
Posteromedial and Posterolateral Portals
Superolateral and Superomedial Portals
Accessory Portals
Diagnostic Arthroscopy
Diagnosis and Treatment of Synovial Disorders
Arthroscopic Synovectomy
Diagnosis and Treatment of Intra-Articular Loose Bodies
Osteochondritis Dissecans
Treatment of Loose Bodies
Diagnosis and Treatment of Synovial Plicas
Arthroscopic Medial Plica Removal
Rehabilitation
Pitfalls and Complications
Chapter References

Arthroscopy of the knee was first performed in 1918 when Kenji Takagi used a cystoscope to examine the intra-articular structures of the knee (65). Michael Burman, at the Hospital for Joint Diseases in New York, reported on his arthroscopic study of cadaveric joints, including the knee, in 1931 (4). He concluded that arthroscopy should be used for purposes of diagnosis rather than traditional open exploratory surgery. His report was met with little enthusiasm by his medical colleagues.

Arthroscopic surgery of the knee evolved slowly over the years. The first arthroscopic knee surgery was performed by Masaki Watanabe in 1955. The procedure involved a partial excision of pigmented villonodular synovitis. Watanabe performed the first arthroscopic meniscectomy in 1962 (69). In 1964, Robert Jackson visited Watanabe in Japan and brought the technique back to North America. Arthroscopic techniques were pioneered by Jackson (30), Robert Metcalf (41), Lanny Johnson (31), Ward Cassells (6), John McGinty (38,39), Richard O'Conner (50), and others. Over the past 25 years, the arthroscope has revolutionized the diagnosis and surgical treatment of disorders of the knee. The future holds nothing but promise for further advancements in treatment of the knee, as well as other joints.

## CLINICAL EVALUATION AND IMAGING

A thorough history and physical examination are imperative to the diagnosis and treatment of a knee disorder: magnetic resonance imaging (MRI) or arthroscopy cannot replace them. A systematic format allows an accurate examination to be undertaken. This chapter provides general guidelines for the key components of the knee examination. Other chapters deal with each specific area of the knee.

### HISTORY

Some knee problems and injuries are more commonly seen in specific age groups. Patellofemoral disorders, osteochondritis dissecans (OCD), Osgood-Schlatter disease, and rarely, tumors are seen in adolescents who complain of knee pain with no history of trauma. In patients between 20 and 50 years of age, trauma often leads to meniscus tears or ligament injuries. In patients over age 50 years, it is typical to see degenerative meniscus tears or degenerative arthritis in the absence of a specific history of trauma. Awareness of these age-related problems permits better focus in taking the history.

- Determine the mechanism of history. Was the injury due to a twisting or turning mechanism or a direct blow?
- Did the pain come on gradually or immediately following an injury?
- Was the patient able to continue the activity or forced to stop because of the injury?
- Tears of the anterior cruciate ligament are frequently due to a noncontact, twisting or turning injury, which is often associated with immediate severe pain lasting approximately 5 to 10 minutes. A pop is often heard as the injury occurs, and the patient cannot continue with the activity. Swelling occurs within 24 hours, accompanied by the loss of full knee extension (19).
- Cumulative minor trauma can lead to a degenerative meniscus tear and articular cartilage injury with no specific history of trauma.
- Is the pain diffuse or localized? Can the patient point with one finger to the locus of the pain? Such specificity may not be possible, because often the entire knee may injured. Patients with medial meniscus tears, in the absence of degenerative joint disease (DJD) often point to the medial joint line as the site of the problem.
- A history of activities that aggravate or alleviate the symptoms aids in diagnosis.
- Patellofemoral disorders are typically aggravated by bent-knee activities such as ascending or descending stairs, squatting, kneeling, riding in a car, or sitting in a theater.
- Meniscus tears are aggravated by twisting and turning maneuvers.
- Determine what activity limitations are present because of the knee problem.
- The presence of knee effusion reflects an intra-articular problem in the knee.
- Patients with a true knee effusion often feel that the knee is tight or stiff. When they are asked where the knee swelling occurs, these patients will sense their swelling to be in the lateral parapatellar or suprapatellar regions.
- With a communicating popliteal cyst, there is a sense of fullness in the posterior aspect of the knee as well as discomfort.
- Patients without a significant intra-articular knee effusion localize their sense of swelling in the inferior parapatellar region.
- Locking of the knee can occur when the normal movement of the knee is impaired; locking is associated with meniscus tears in the younger patient and loose bodies in the older patient.
- Beware of the acutely injured knee that feels “locked” and will not extend fully. Frequently, with acute ligament injuries, there is concomitant splinting or spasm of the hamstring musculature that impedes full extension of the knee and can be mistaken for mechanical locking. It is important to differentiate mechanical locking from pseudolocking.
- Complaints of buckling, giving way, and feelings of instability may be caused by quadriceps muscle weakness or inhibition, in which the knee can flex uncontrollably at times. This type of buckling is rarely disabling.
- A feeling that “the kneecap is going out” may be associated with patellofemoral instability.
- With anterior cruciate ligament instability, the individual may say, “The knee is going out of joint.”
- Some degree of disability is often associated with episodes of instability due to patellofemoral or anterior cruciate ligament disorders.
- Patients may describe snapping, grinding, popping, or clicking.
- In patellofemoral disorders, the patient frequently notes a grinding sensation, especially when walking up stairs.
- Establish whether the knee noise is associated with pain; many knees have nonpainful popping or clicking noises that are not pathologic. Painful pops or clicks are of more concern. Meniscus tears or plicas may be associated with painful popping or clicking.
- Has there been a previous problem with the knee? If so, has that problem been similar to or different from the present knee complaints?
- Has there been any previous attempt at treatment (nonsteroidal anti-inflammatory drugs, physical therapy, injections), and if so, what has been the response?

- Are there any other joints involved with a similar or different problem?
- Is there a family member with a history of orthopaedic problems?

A thorough, focused history often points to a diagnosis, which, in turn, allows for a more directed physical examination.

**PHYSICAL EXAMINATION**

- A reproducible, systematic approach to the physical examination of the knee is important for accurate diagnosis.
- Examine the ipsilateral hip and ankle, because some knee complaints are due to referred pain or reflect a disorder of the hip or ankle.
- Always compare the examination to the normal knee (if possible).
- Observe the patient standing and assess alignment, noting excess varus or valgus (Fig. 84.1).

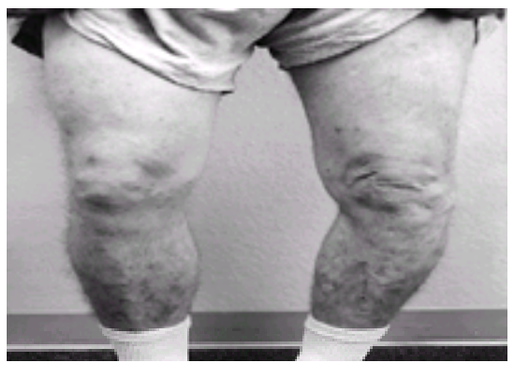

***Figure 84.1.*** While the patient is standing, evaluate varus or valgus alignment. Note the increased varus alignment in the left lower extremity.

- Have the patient walk, and note any abnormality such as a limp or a varus or valgus thrust (Fig. 84.2).

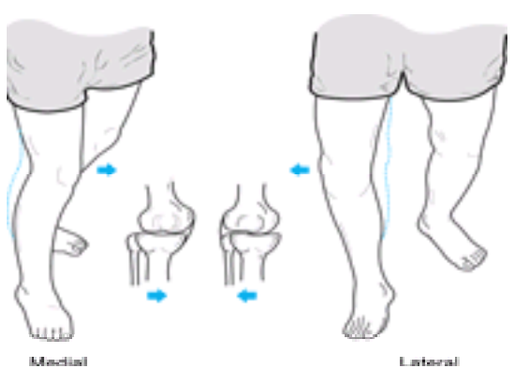


***Figure 84.2.*** A medial or lateral thrust is noted during the stance phase in gait. (Redrawn from Tria AJ, Klein KS. *An Illustrated Guide to the Knee.* New York: Churchill Livingstone, 1992, with permission.)

- Observe younger patients attempting to squat.
- Observe older patients getting into and out of a chair.
- Inspect the knee and lower extremity for previous incisions, scars, swelling, or ecchymosis.
- Place the patient in the supine position on an examination table (Fig. 84.3). Place a pillow beneath the knee to allow some flexion, because many knee disorders are painful in full extension. The extended position can cause the patient to splint and make the examination difficult.

***Figure 84.3.*** Examine the patient with a pillow under the injured knee to allow the knee to flex slightly. The fully extended position is often uncomfortable and may cause the patient to splint, making the examination difficult.

- Examine the uninvolved knee first for comparison (right-to-left knee variability is minimal). In the general population, there is a significant variability between different individuals.
- Assess the knee for quadriceps atrophy and tone by grasping the anterior aspects of both thighs and asking the patient to tighten up the muscles in both lower extremities simultaneously. Compare the two sides for tone and size differences.
- Measure the thigh circumference at a standard position above the patella (i.e., 10 cm) with the thigh muscles tensed. Measuring allows for comparison to past and future examinations.
- Ask the patient to perform a straight leg raise and watch for quadriceps lag. Inability to perform a straight-leg raise (SLR) can be associated with injury to the patellar tendon or quadriceps tendon.
- With the knee in near-full extension, estimate the quadriceps angle (Q angle) by drawing a line from the anterior superior iliac spine to the patella, and from the tibial tubercle to the patella (Fig. 84.4) (22). The acute angle formed by these two lines is the Q angle. In men, the Q angle is approximately 10°, and in women, it is 15°. Alternatively, the Q angle can be measured with the knee flexed to 90° (tubercle–sulcus angle). In this position, the normal Q angle is up to 8° (Fig. 84.5). An increase in the Q angle by either measurement is associated with patellofemoral disorders.

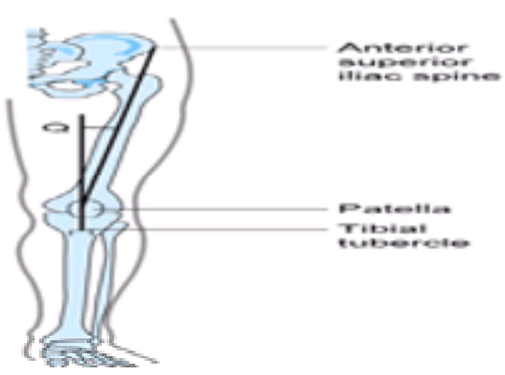

***Figure 84.4.*** Q angle measured in full extension. In men, Q angles greater than 10 degrees and, in women, Q angles greater than 15 degrees are associated with patellofemoral disorders.

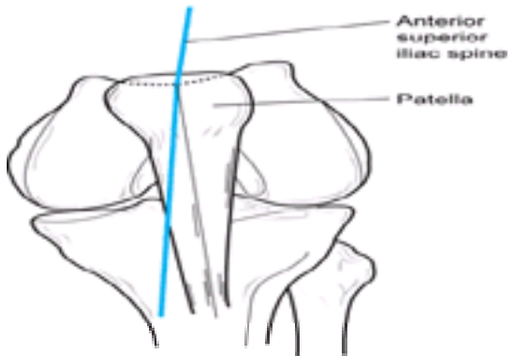


***Figure 84.5.*** Q angle measured at 90° of flexion. Values greater than 8° are associated with patellofemoral disorders.

- Document the range of motion in degrees, using a goniometer. There is significant variability among individuals.
- To demonstrate loss of extension reproducibly, examine the knee with the patient prone and estimate the heel height difference in cm (Fig. 84.6). Each 1 cm of heel height difference represents 1° loss of extension.

***Figure 84.6.*** With the patient prone, measure the heel height difference to demonstrate loss of knee extension objectively. Each 1 cm of heel height difference reflects a loss of extension of 1°.

- To document differences in flexion, measure the distance from the heel to the thigh in cm with the patient supine (Fig. 84.7).

***Figure 84.7.*** With the patient supine, measure the heel-to-thigh difference in centimeters to reflect loss of knee flexion accurately.

- Prone heel height difference and supine heel-to-thigh distance are measurements that are reproducible and more accurately reflect loss of extension or flexion.
- With the hip flexed to 90°, have the patient actively flex and extend the knee (Fig. 84.8). Note patellofemoral crepitus and other knee noise (90–90 testing). Attempt to palpate the anatomic location of the crepitus. Patellofemoral joint crepitus usually reflects articular cartilage damage on the patella or in the trochlear groove of the femur. Determine whether the patella is tracking centrally or laterally.

***Figure 84.8.*** With the patient supine and the hip flexed 90°, have the patient actively flex and extend the knee. Palpate the patella to demonstrate crepitus.

- With the knee in full extension, document patellar mobility and tilt.
- Palpate the knee to elicit areas of tenderness. It is beneficial to ask the patient whether palpation reproduces the pain. The diagnosis is enhanced if the pain can be reproduced; inability to reproduce the symptoms is an inconclusive finding.
- Palpate the entire knee including the medial and lateral patellar facets, inferior and superior poles of the patella, anterior patella, medial and lateral joint lines, the course of the medial and lateral collateral ligaments, the tibial tubercle, and all bursal locations.
- A systematic examination for ligament laxity of the knee permits diagnosis of most knee ligament injuries. Compare the examination with that of the normal knee. Test for varus or valgus laxity at 0° and 30° of knee flexion (Fig. 84.9).

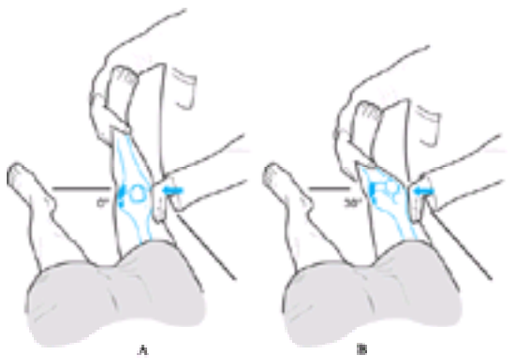

***Figure 84.9.*** Test for varus and valgus laxity at 0° and 30° of knee flexion. (Redrawn from Tria AJ, Klein KS. *An Illustrated Guide to the Knee.* New York: Churchill Livingstone, 1992, with permission.)

- In full extension, varus or valgus stress can be used to assess the collateral ligaments as well as the posteromedial and posterolateral capsular structures, posterior cruciate ligament, and anterior cruciate ligament. Examination at 30° of knee flexion isolates the collateral ligaments; increased laxity only at 30° suggests an isolated collateral ligament injury. Increased laxity at both 0° and 30° of flexion represents an injury to the collateral ligament as well as to the posterior ligament restraints and, less commonly, the anterior cruciate ligament.
- Estimate in millimeters (mm) the ligament laxity of the injured knee compared with that of the normal knee (27). Rate varus or valgus laxity as follows:

| *Grade* | *Amount of Opening* | *Associated Tear* |
|---|---|---|
| I | 0 to 5 mm | minimal or first degree |
| II | 5 to 10 mm | moderate or second degree |
| III | > than 10 mm | complete or third degree |

- Examine the anterior cruciate ligament (ACL) and posterior cruciate ligament (PCL) at 30° and 90° of flexion.
- Perform the Lachman test at approximately 30° of knee flexion. It is the most sensitive for detecting a tear of the ACL (Fig. 84.10). Check for the “end point”—a sensation analogous to a rope being pulled taut. In comparison to the normal knee, note the quality of the end point (same, soft, or absent). Document the change in the anterior excursion of the tibia. If the right and left difference is greater than 3 mm, it is likely (95% confidence level) that the ACL has been disrupted (10).

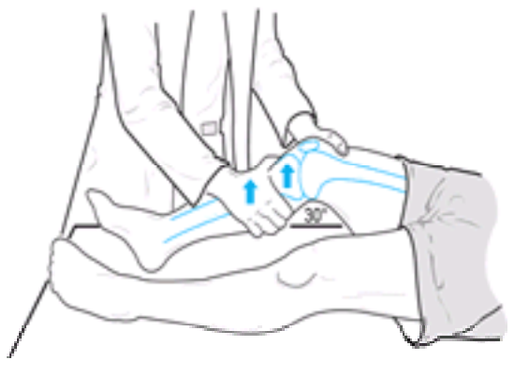

***Figure 84.10.*** The Lachman test, performed at 30° of knee flexion, is the most sensitive test for integrity of the ACL. (Redrawn from Tria AJ, Klein KS. *An Illustrated Guide to the Knee.* New York: Churchill Livingstone, 1992, with permission.)

- Several clinical tests have been developed to document ACL instability, including the pivot shift and flexion rotation drawer tests (Fig. 84.11) (10). These tests reduplicate clinical instability if it is due to the ACL.

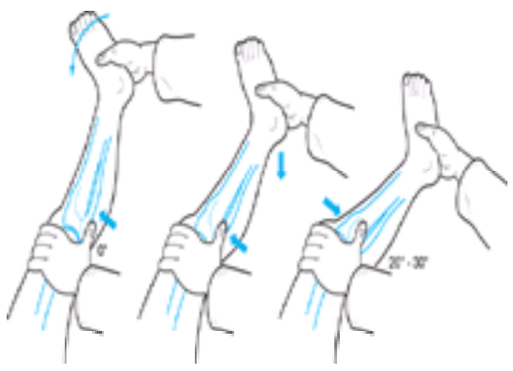

***Figure 84.11.*** The pivot shift test is useful in documenting the degree of instability in acute and chronic ACL injuries. The tibia is subluxed in extension and reduces as the knee is brought into extension. (Redrawn from Tria AJ, Klein KS. *An Illustrated Guide to the Knee.* New York: Churchill Livingstone, 1992, with permission.)

- The PCL can be tested at 30° of flexion but is easiest to test at 90° of flexion (18). With the hip flexed 45° and the knee at 90°, perform a posterior drawer test. Palpate the stepoff between the medial and lateral femoral condyles and tibial plateau (Fig. 84.12). Normally, the tibia sits 5 mm anterior to the femoral condyles, producing a stepoff. Loss of this normal stepoff is due to posterior displacement of the tibia on the femur, which is caused by laxity in the posterior ligamentous restraints. Estimate the tibial stepoff as follows:

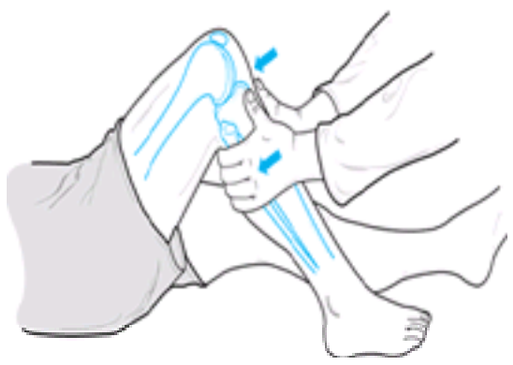

***Figure 84.12.*** Palpate the stepoff between the medial and lateral femoral condyles and the tibial plateaus to document PCL injury. Normally there is a 5 mm stepoff. (Redrawn from Tria AJ, Klein KS. *An Illustrated Guide to the Knee.* New York: Churchill Livingstone, 1992, with permission.)

| *Grade* | *Decrease in Tibial Stepoff* |
|---|---|

| | |
|---|---|
| I | 0–5 mm (tibial stepoff is still palpable) |
| II | 6–10 mm (tibia is equal to the femoral condyle) |
| III | >10 mm (tibia is posterior to the femoral condyle) |

- If the Lachman test is normal, an increase in the side-to-side anterior or posterior laxity at 90° of flexion represents an injury to the posterior ligamentous restraints.
- There are numerous specific tests that have been described to examine the knee ligaments. Try to isolate and assess the integrity of the four major ligaments of the knee. Recognize that most knee ligament injuries are not truly isolated but are more complex.

**ASPIRATION OF THE KNEE**

Aspiration of the knee is indicated to diagnose or remove a hemarthrosis, to look for fat droplets (lipohemarthrosis) that might suggest a fracture or osteochondral injury, or to perform synovial fluid analysis (Fig. 84.13). Aspiration aids in diagnosis and has therapeutic benefit as well.

***Figure 84.13.*** With the patient supine and pillow under the knee, aspirate knee effusions through a superolateral approach.

- Observe the fluid aspirated and determine if it is clear, cloudy, or bloody. Note the viscosity of the fluid.
- Clear fluid can be discarded. Send cloudy or bloody fluid for a cell count and differential, crystal analysis, and culture.
- Patients with crystal deposition disorders can have meniscus-like symptoms. Look for crystals on a polarized light microscope.
- Intra-articular disorders such as a meniscus tear or a loose body typically cause overproduction of normal clear synovial fluid.
- Gout or other crystal deposition disorders causes an inflammatory synovial fluid with a white blood cell count (WBC) of 5,000 to 20,000.
- Intra-articular infections typically have a WBC greater than 50,000.
- The presence of a hemarthrosis in a “stable” knee suggests an anterior cruciate injury or peripheral meniscus tear (11,47).
- Fat present in the hemarthrosis represents an osteochondral injury or fracture.
- A large effusion restricts knee range of motion. Aspiration improves motion and facilitates rehabilitation.
- Intra-articular injections with lidocaine help differentiate intra-articular from extra-articular knee disorders. An intra-articular injection with lidocaine temporarily relieves knee pain due to intra-articular knee disorders. Although this test is not 100% accurate, it appears in clinical practice to be at least 95% specific and sensitive.
- In patients with DJD, failure to relieve pain with an injection suggests that in addition to arthritis, there may be an extra-articular component of the knee pain that requires diagnosis.

**IMAGING OF THE KNEE**

Standard radiographs of the knee include anteroposterior (AP), lateral, notch, and patellofemoral views. The posteroanterior (PA) weight-bearing view of both knees at 45° of flexion is substituted for the notch view in individuals over age 40 years, those with previous knee surgery, or those with systemic arthritis. Evaluate the radiographs for abnormalities of the soft tissues, as well as for bone density. Extension weight-bearing views of both knees are useful in documenting degenerative changes (17); however, joint space narrowing is best noted on the PA 45° flexion weight-bearing view (Fig. 84.14) (56). A true lateral view taken at 30° of knee flexion allows for assessment of patellar height as well as osteophytes and loose bodies. The notch view and 45° flexion weight-bearing view are useful for demonstration of loose bodies, OCD, and narrowing of the intercondylar notch. The Merchant view (40) at 45° of flexion or Lauren view (36) at 20° of flexion demonstrates abnormalities of the patellofemoral joint, including joint space narrowing, patellar tilt, and patellar subluxation (Fig. 84.15).

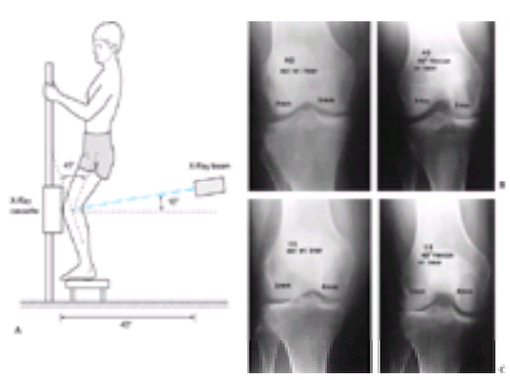

***Figure 84.14.*** **A:** Technique for the 45° PA flexion weight-bearing x-ray study of the knee. **B:** Demonstrating medial compartment joint space loss in flexion. **C:** Demonstrating lateral compartment joint space loss in flexion.

***Figure 84.15.*** **A:** Patient position for the Merchant view. **B:** Merchant view of both patellofemoral joints.

Oblique views can aid in detecting occult fractures, subtle tibial plateau fractures, or loose bodies. A cross-table lateral view can be used to demonstrate a lipohemarthrosis that suggests the presence of an intra-articular fracture (24). Use stress radiographs for patients with open growth plates to differentiate between a ligament and epiphyseal injury (42). In skeletally mature patients, use stress radiographs to document medial, lateral, anterior, or posterior instability objectively.

A 51-inch standing weight-bearing AP of the entire limb is useful for assessing the mechanical axis of the limb. The mechanical axis normally falls through the medial tibial spine (Fig. 84.16). Shift of the weight-bearing axis into either compartment leads to relative joint overload, as well as a change in the tension relationship of the collateral ligaments (Fig. 84.17). This view is essential for preoperative planning in patients undergoing total knee replacement, osteotomy, ligament reconstruction, meniscus reconstruction with an allograft, or chondrocyte autograft. Without proper attention to the mechanical axis before surgery, the outcome of these procedures may be compromised.

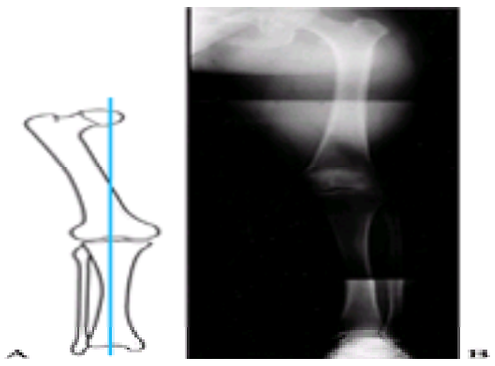

***Figure 84.16.*** The mechanical axis measured on a 51-inch weight-bearing AP is sensitive to demonstrating shift of the weight-bearing axis into the medial or lateral compartment.

***Figure 84.17.*** Fifty-one-inch standing AP weight-bearing view demonstrating shift of the weight-bearing axis into the medial compartment.

Arthrography is performed by injecting contrast material intra-articularly, and then obtaining radiographs in multiple projections, both with and without stress applied to the knee (Fig. 84.18). Although arthrography has been largely replaced by MRI, the former technique may be indicated in patients with contraindications to MRI. The primary reason for obtaining a knee arthrogram is for assessment of the menisci (2).

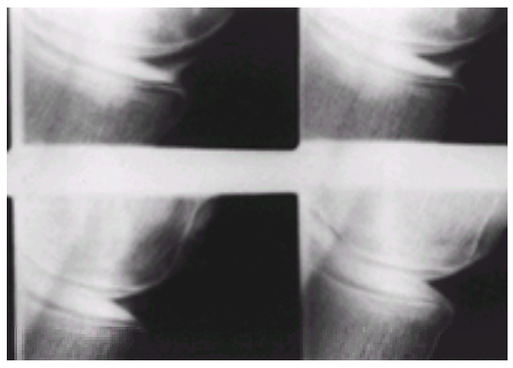

***Figure 84.18.*** Arthrogram demonstrating a tear of the posterior horn of the medial meniscus.

Arthrography may also be used to diagnose cruciate and collateral ligament injuries, OCD, chondral defects, plica, and popliteal cysts. The accuracy of arthrograms for the diagnosis of meniscal tears has been reported to be between 76% and 96% (13,28). In comparison to MRI, there are more false-negative results associated with the use of arthrography.

Radionuclide imaging is most frequently performed with technetium 99m/methylene diphosphonate, a compound that is readily absorbed by metabolically active bone (Fig. 84.19). The primary advantages of bone scanning are its high sensitivity in detecting early osseous disease and the ease of surveying the entire skeleton. Bone scans have been used in the diagnosis of primary and metastatic neoplasms, implant loosening, infection, reflex sympathetic dystrophy, osteonecrosis, occult fractures, stress fractures, and arthritis (16). When considering a valgus-producing osteotomy of the knee for genu varum, a bone scan is a more sensitive indicator of arthritis in the lateral compartment than plain radiographs (9). The disadvantages of bone scintigraphy are the radiation exposure, the length of time to perform the exam, and most important, the lack of diagnostic specificity. Despite the high sensitivity of bone scans, false-negative results may occur with certain neoplasms (multiple myeloma) and in elderly patients within 3 days after sustaining radiographically occult fractures.

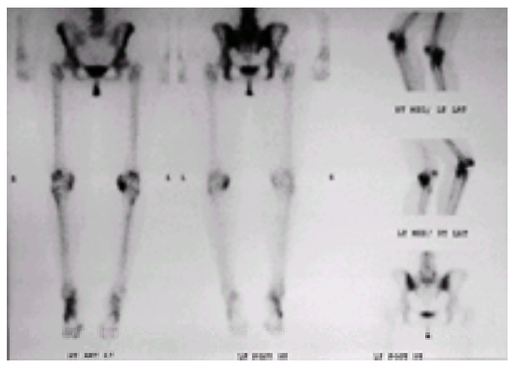

***Figure 84.19.*** Technetium 99m bone scan of the lower extremities demonstrating increased uptake in the medial compartment of the left knee.

The use of tomography and computerized tomography (CT) has declined with the advent of MRI, but it remains useful in the diagnosis of osteonecrosis, OCD, tibial

plateau fractures, and tumors, as well as for evaluation of patellar tracking, patellar tilt, and patellar subluxation (Fig. 84.20).

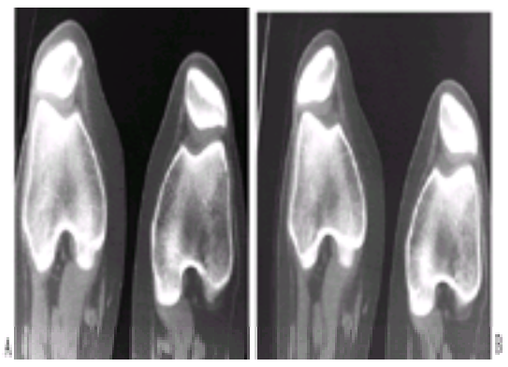

***Figure 84.20.*** CT image of the patellofemoral joint at 30° (**A**) with quad tightening and (**B**) without quad tightening.

Diagnostic imaging of the knee has been revolutionized by the development of MRI (23). After plain radiography, MRI is the imaging test of choice for evaluating internal derangements of the knee. The frequency with which this test should be used, however, is the subject of substantial controversy.

The scientific principles of MRI have been well described (55). MRI routinely generates high-resolution images in 3 mm to 5 mm sections of the knee in multiple anatomic planes. The advantages of MRI are that it is noninvasive and safe. However, the most significant advantage of MRI is the capability of generating high-contrast soft-tissue imaging that is not possible with other imaging techniques (Fig. 84.21).

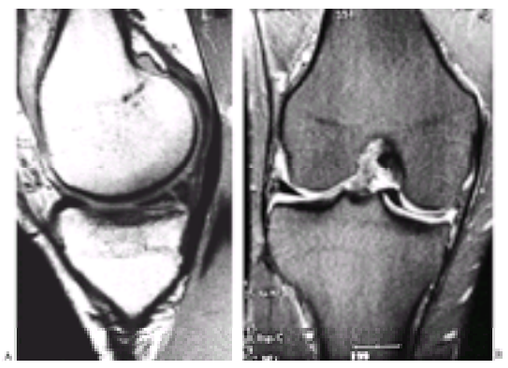

***Figure 84.21.*** MRI of the knee. **A:** A vertical tear of the posterior horn of the medial meniscus. **B:** A tear of the medial meniscus with displacement into the intercondylar notch.

The disadvantages of MRI include the relatively high cost and the fact that not all patients can fit into the scanner because of a weight and size limitation with standard closed MRI. There is also a subset of patients who cannot tolerate MRI because they are claustrophobic. MRI is contraindicated in patients with pacemakers, ferromagnetic intracranial aneurysm clips, cochlear implants, and intraocular metal fragments. Pregnancy is a relative contraindication. Open MRI can accommodate patients with claustrophobia or a size limitation. There is, however, an associated loss of image contrast owing to the need for a smaller magnet.

The interpretation of knee MRI is difficult when there has been previous injury or surgery. Retained ferromagnetic hardware creates artifacts, which may obscure adjacent abnormalities. After partial meniscectomy or meniscus repair, the accuracy of conventional MRI for detecting new meniscal abnormality decreases significantly. In order to optimize the imaging of patients suspected of having recurrent meniscal tears, MR arthrography is useful (2).

If the cost and utilization were not a concern, MRI would be useful in nearly all patients with knee problems. The cost and the time involved in performing the procedure prohibit its widescale use (23). MRI needs to be used selectively as a diagnostic tool for evaluating disorders of the knee. Before ordering MRI, it should be clear that the information obtained would impact or change the treatment program. Indications for MRI are determined individually. MRI of the knee may be used to diagnose the presence of meniscus tears, ligaments and tendon injuries, and osseous, osteochondral, and chondral lesions.

MRI is highly accurate for the evaluation of the ACL, PCL, and menisci (7,44). When comparing the accuracy rates of MRI versus knee arthroscopy, meniscus tears are identified with a 90% to 95% accuracy with MRI. ACL and PCL tears are identified with over 95% accuracy. Bone contusions, radiographically occult fractures, and spontaneous osteonecrosis of the knee are diagnosed with almost 100% accuracy on MRI. Equally important, negative findings on MRI of the knee is 95% accurate for the prediction of normal intra-articular structures. With an experienced evaluator, there are relatively few false-positive and false-negative results. MRI has rapidly evolved into a comprehensive and versatile tool for the evaluation of knee disorders.

## INDICATIONS FOR KNEE ARTHROSCOPY

Knee arthroscopy is indicated for the purposes of diagnosis or therapeutic treatment. Always take a complete history, do a physical examination, and obtain radiographs before proceeding with an arthroscopic evaluation of the knee. Other diagnostic studies are used as necessary for purposes of establishing a diagnosis. Arthroscopy is not meant to be used for every patient with knee pain. The Arthroscopy Association of North America has suggested the following guidelines for arthroscopy (64):

1. The arthroscopist should perform an adequate history and physical examination, as well as obtain radiographs or other pertinent laboratory evaluations of the patient if they have not already been performed.
2. The risks, benefits, alternatives of treatment, and potential complications should be carefully explained to each patient before an arthroscopic evaluation is performed.
3. The arthroscopist should exercise due consideration in selecting the correct arthroscopic procedure for a particular condition.
4. A detailed report of the procedure should be prepared, including the arthroscopic findings and description of the operation.

Institute initial conservative management for most disorders of the knee with few exceptions such as intra-articular fractures, intra-articular infections, and true mechanical locking. Conservative measures for the management of knee disorders include a range-of-motion and muscle-strengthening program.

Shelbourne's studies (59) on ACL injuries and timing of surgery have similar application to most other knee disorders. Under ideal circumstances, range of motion and muscle strengthening should be optimized before surgery. Postoperative rehabilitation is facilitated by a preoperative program of exercise. If surgery is undertaken before the patient regains range of motion, there is an increased risk of postoperative stiffness (29).

Activity modification plays a major role in the management of knee disorders. Minimizing or avoiding the activities that aggravate the knee will often reduce knee symptoms. Crutches or other ambulatory aids are recommended for individuals who have an antalgic gait following injury or onset of symptoms. Ice, elevation, and a compression dressing may aid in controlling intra-articular and extra-articular swelling. Immobilization may be useful to control pain and allow some injuries to heal, but its use should be carefully weighed against the joint stiffness that can occur with immobilization. Nonsteroidal anti-inflammatory drugs (NSAIDs) can be used to help reduce swelling and inflammation, but their use must be carefully balanced against the risk of gastrointestinal irritation and bleeding.

Intra-articular injections of lidocaine and a corticosteroid can be beneficial for both diagnosis and treatment. Suspected intra-articular disorders should have at least temporary improvement with an intra-articular lidocaine injection. Concomitant use of corticosteroids may provide a long-term therapeutic benefit for the individual. The use of intra-articular injections must be carefully individualized. A 70-year-old patient with DJD may be injected multiple times. An 18-year-old with an ACL injury and

meniscus tear will not benefit by intra-articular injections.

After conservative modalities have proven ineffective over a reasonable period of time and the individual remains disabled, consideration for an arthroscopic evaluation of the knee is warranted for purposes of diagnosis and treatment (52). A thorough preoperative medical evaluation is necessary to minimize operative complications.

Patient education plays a critical role in the outcome of arthroscopic surgery. Preoperatively, have a thorough discussion with the patient of the risks, benefits, alternatives of treatment, and postoperative rehabilitation. It is imperative to define clearly for the patient what to expect from surgery. The importance of postoperative rehabilitation for the success of the procedure should be emphasized. Written guidelines, illustrations, and videotapes facilitate the education process.

## ANESTHESIA

Perform arthroscopy under local, regional, or general anesthesia. The choice of anesthetic is determined by the patient's medical history and the procedure being performed, as well as the preference of the patient, surgeon, and anesthesiologist. Local anesthesia has gained popularity with the advent of office arthroscopy.

- Procedures that require less time and are not dependent on joint exposure (such as diagnostic arthroscopy, loose body removal, and lateral release) can be performed with local anesthesia and intravenous (IV) sedation.
- Local anesthesia is not adequate in procedures requiring use of a tourniquet for more than 20 minutes or in procedures requiring significant exposure of the joint such as meniscectomy or meniscus repair and procedures requiring bone drilling (58).
- Regional anesthesia is indicated in patients in whom general anesthesia is believed to be medically contraindicated. Additionally, there are patients who prefer regional anesthetics, including those with the desire to watch the procedure on the video monitor.
- General anesthesia is the preferred anesthesia for most arthroscopic procedures of the knee. It allows for complete muscle relaxation and facilitates adequate joint exposure.

## SURGICAL TECHNIQUES

- Position the patient supine. Place the operative knee in full extension or at 90° of flexion with the end of the table flexed. Position a tourniquet on the proximal thigh. It can be used at the discretion of the surgeon. Adequate exposure is facilitated by use of a leg-holding device or post. The nonoperative leg needs to be well padded and supported (Fig. 84.22).

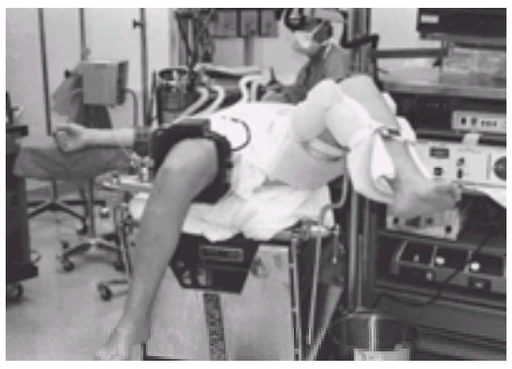

***Figure 84.22.*** Patient positioning for knee arthroscopy. A thigh holder is secured over or distal to the tourniquet. The nonoperative limb is placed in a well-padded leg support. This leg position insures easy access to the posteromedial compartment.

- Diagnostic arthroscopy is the initial phase of all procedures. Use a standardized and systematic approach to achieve a thorough and efficient evaluation of the entire knee joint before performing any type of surgical treatment. Avoid the temptation to focus on a specific problem and not complete the diagnostic arthroscopy. The only exceptions to this would be if a loose body were encountered or the knee was mechanically locked (due to a loose body or displaced meniscus fragment). Rather than lose the loose body within the joint, remove it first and then complete the diagnostic arthroscopy. A displaced meniscus tear should be reduced into its normal anatomic position before resuming the diagnostic arthroscopy.

### ARTHROSCOPIC PORTALS

Proper placement of arthroscopic portals is critical for the success of the procedure. The standard arthroscopic portals are anterolateral, anteromedial, superolateral, superomedial, posterolateral, and posteromedial (Fig. 84.23). The accessory portals include the midpatellar, transpatellar, accessory medial and lateral, and accessory posteromedial and posterolateral portals (Fig. 84.24). Knowledge of the surface and deep anatomy of the knee is a prerequisite for establishing portals safely and effectively. An accurately placed portal will allow instruments to be used effectively. An improperly placed portal can cause damage to the knee as well as hamper the surgical procedure.

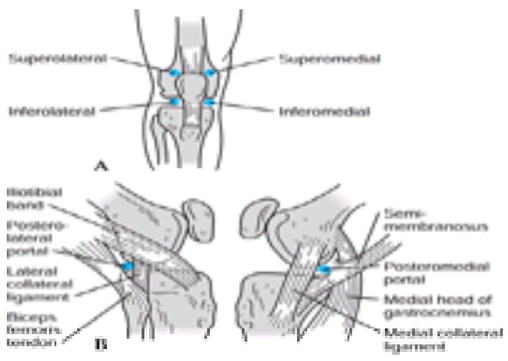


***Figure 84.23.*** Anatomic location of arthroscopic portals.

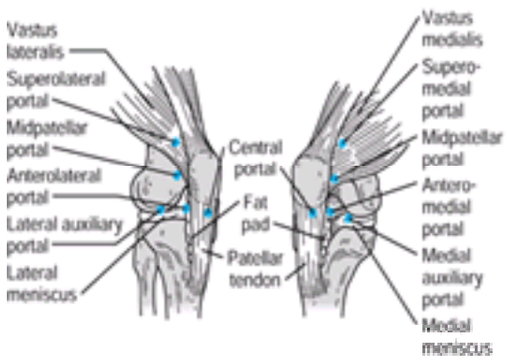


***Figure 84.24.*** Accessory arthroscopic portals. (Redrawn from Scott, WN, Insall JN, Kelly MA. Arthroscopy and Meniscectomy: Surgical Approaches, Anatomy and Techniques. In: Insall JN, ed. *Surgery of the Knee,* 2nd ed. New York, Churchill Livingstone, 1993, with permission.)

## ANTEROLATERAL PORTAL

The anterolateral portal is the primary viewing portal for knee arthroscopy. Establish it with the knee in 90° of flexion and distended with fluid. The landmarks for portal placement are the inferior pole of the patella and lateral joint line. There is a soft spot that can be palpated adjacent to the patellar tendon. Vertical incisions are extensile and facilitate portal adjustment if necessary.

- Direct a #11 blade toward the intercondylar notch, with the sharp edge of the blade facing superiorly to avoid any damage to the underlying meniscus or transverse meniscal ligament. Do not penetrate so deep that the articular cartilage or the ACL is injured.
- Pass a 5 mm blunt trocar through the portal to ensure ease of passage. Advance the blunt trocar to all desired areas of visualization to ensure that the arthroscope will be advanced easily into these areas.
- After the anterolateral arthroscopy portal has been established, all remaining portals can be made under arthroscopic control. Use the arthroscope to transilluminate the proposed portal site to document any vascular structures. Use an 18-gauge needle to predetermine the accuracy of the portal placement. Then use a #11 blade to establish the arthroscopic portal.

## ANTEROMEDIAL PORTAL

- Locate the anteromedial arthroscopy portal 1 cm above the joint line and approximately 5 mm from the medial border of the patellar tendon, to minimize the impingement of the fat pad.
- Use the arthroscope to transilluminate the area to avoid vascular structures and insert an 18-gauge needle at the portal site to ensure proper placement. Direct a #11 blade into the joint, aiming for the intercondylar notch. Place a blunt trocar through the portal to ensure ease of instrument passage into the joint.

## POSTEROMEDIAL AND POSTEROLATERAL PORTALS

- Visualize the posterior compartments of the knee using the anteromedial and anterolateral arthroscopy portals, and passing the instruments posteriorly through the intercondylar notch (45).
- Smaller diameter obturators facilitate passage into the posterior compartments.
- Pass the blunt obturator or sleeve along the intercondylar notch wall by touch. Flexing and extending the knee between 45° and 90° degrees often relaxes the soft tissues and allows the obturator or sleeve to pass into the posterior compartment.
- Establish the posteromedial portal with the knee flexed 90° and the joint distended with fluid. Pass the arthroscopic obturator or sleeve from the anterolateral arthroscopy portal along the medial intercondylar wall into the posteromedial compartment.
- Visualize the posteromedial compartment with a 30° or 70° arthroscope.
- Transilluminate the posteromedial skin area to identify the saphenous vein and other vascular structures.
- Palpate the posteromedial skin to determine the location of the arthroscopy portal.
- Pass an 18-gauge needle to ensure proper anatomic placement of the portal 1 cm posterior to the medial femoral condyle and 1 cm above the joint line.
- Make an incision in the skin with a #11 blade. Dissect bluntly down to capsule with a hemostat to avoid injury to the saphenous nerve. Pass the blunt obturator into the posteromedial compartment.
- Use the posteromedial portal for visualization of the medial meniscus, PCL, and posterior capsular structures.
- Pass instruments through this portal for loose body removal, meniscectomy, meniscus repair, PCL surgery, and synovectomy.
- Establish the posterolateral portal with the knee flexed 90° and the joint distended. Pass the arthroscopic obturator or sleeve along the lateral intercondylar wall from the anteromedial portal.
- Visualize the posterolateral compartment with a 30° or 70° arthroscope and transilluminate the posterolateral skin to identify any vascular structures.
- Palpate the posterolateral skin to identify the location of the portal site, 1 cm posterior to the lateral femoral condyle and 1 cm above the joint line. If the portal is placed too far posteriorly, the peroneal nerve can be injured. Pass an 18-gauge spinal needle into the joint to ensure proper placement.
- The lateral meniscus and posterior compartment can be visualized from this portal.
- Use this portal for loose body removal, meniscectomy, meniscus repair, and synovectomy.

## SUPEROLATERAL AND SUPEROMEDIAL PORTALS

- Place the knee into full extension and distend the joint.
- Pass the arthroscopic obturator or sleeve from the anterolateral portal into the suprapatellar pouch to allow direct visualization. Be careful to avoid injuring the articular cartilage of the trochlear groove and patella.
- Place the portals at the superior pole of the patella. If they are placed too distally, the portals will impinge on the patellofemoral joint.
- Transilluminate to identify the vascular structures. Pass an 18-gauge spinal needle to determine proper placement. Insert the spinal needle parallel to the patellofemoral joint axis.
- Use a #11 blade to incise the skin and establish the portal. Pass the blunt obturator into the joint. These portals are routinely used for inflow and outflow.
- Visualize the medial and lateral gutters, suprapatellar pouch, and plicas. Evaluate patellofemoral tracking by flexing the knee from 0° to 90° and observing the patella and its relationship to the trochlear groove.
- Assess for plica impingement while actively flexing and extending the knee and observing for plica impingement on the medial femoral condyle.

## ACCESSORY PORTALS

In addition to standard arthroscopic portals, accessory portals can be established in almost any anatomic region to facilitate surgery.

- Establish an accessory portal to minimize crowding of instrumentation.
- Use an accessory portal for better angulation for difficult meniscus tears or loose body removal.
- Use the accessory medial and lateral portals to facilitate anterior horn meniscectomy.
- Less commonly used portals are the accessory midpatellar lateral and medial portals, and the accessory posteromedial and posterolateral portals.
- Establish all accessory portals in the standard manner using transillumination and an 18-gauge spinal needle.

## DIAGNOSTIC ARTHROSCOPY

- The anesthesiologist administers a regional or spinal anesthetic. Examine the knee under anesthesia. Document the range of motion and stability of both knees.
- Secure the tourniquet to the proximal thigh. Place the injured leg in a leg-holding device distal to the tourniquet. For short thighs, a tourniquet can be placed within the thigh-holding device. There should be a minimum of 6 cm distance between the superior pole of the patella and the lower portion of the thigh-holding device. If the leg-holding device is applied too distally, there is not enough space to establish and use superior portals.
- Lower the foot of the table, allowing the knee to flex to 90°. Place the nonoperative limb in a well-leg support, allowing adequate access to the posteromedial compartment of the injured knee.
- Prep and drape the operative leg. If using a tourniquet, esmarch the leg and elevate the tourniquet. Distend the knee by placing a 2 mm Verres needle into the suprapatellar pouch through the superolateral or superomedial portal, with the knee in full extension. As the needle is inserted, the surgeon usually encounters synovial fluid as the needle enters the joint. Examine the fluid and send it for analysis if needed. Distend the knee with irrigation fluid.
- Flex the knee 90° and establish the anteromedial and anterolateral arthroscopy portals. Insert a blunt 5 mm obturator to ensure ease of passage through the portals into the compartments to be visualized.
- Place the arthroscopic sleeve or obturator through the anterolateral portal, pass posterior to the patella, into the suprapatellar pouch. Use a 4 or 5 mm 30° arthroscope with inflow through the arthroscopic sleeve and outflow through the Verres needle. Outflow through the arthroscope can allow debris to compromise visualization. Visualize the superior plica. Assess the synovium.
- Direct the arthroscope down the lateral gutter. A normal transverse fold of synovium covers the femoral attachments of the popliteus tendon and the lateral collateral ligament. Distal to this fold, note the popliteal hiatus and lateral meniscus.
- Bring the arthroscope back into the suprapatellar pouch and visualize the medial gutter. Assess the medial plica for impingement.
- Rotate the arthroscope to view superiorly and inspect the articular cartilage surface of the patella. Withdraw the arthroscope slowly, and inspect the articular cartilage surface of the trochlear groove as you bring the knee into 45° of flexion.
- Inspect the intercondylar notch, including the ACL and PCL. Palpate the ACL with a probe and determine its integrity. A prominent inferior plica (ligamentum mucosa) may obscure visualization. Resect the plica with a shaver if it compromises visualization, especially when you are attempting to establish the integrity of the ACL.
- Visualize the medial compartment, placing a valgus load on the knee with 10° to 15° of flexion to facilitate the process. Externally rotate the foot 15° to 20°. If the ACL is disrupted, it is important to maintain the external rotation or a subluxation may occur (pivot shift). If it does occur, bring the knee back into the neutral

position and re-examine the joint with the foot externally rotated. Use a probe to document the integrity of the meniscus and the articular cartilage surfaces (Fig. 84.25; see also Color Fig. 84.25). While applying a valgus load, slowly flex the knee maximally and inspect the remainder of the articular cartilage surface of the medial femoral condyle.

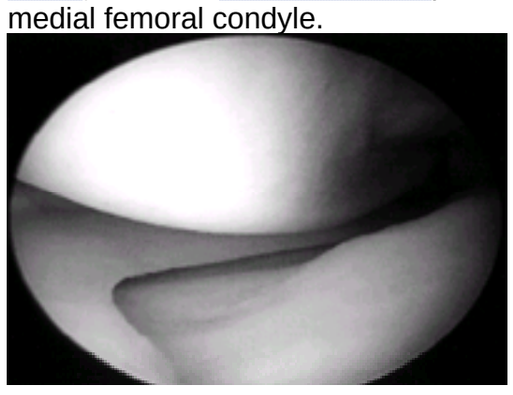

***Figure 84.25.*** (See Color Fig. 84.25.) Arthroscopic view of the medial compartment.

- Direct the arthroscope to the lateral compartment. If an inferior plica is present, pass the arthroscope over the plica with the knee in 45° of knee flexion, until you can see the lateral compartment. Apply a varus load to expose the lateral compartment. Probe the meniscus and articular cartilage surfaces (Fig. 84.26; see also Color Fig. 84.26). Visualize the popliteus tendon. Flex the knee maximally with varus stress to assess the remainder of the articular cartilage surface of the femoral condyle.

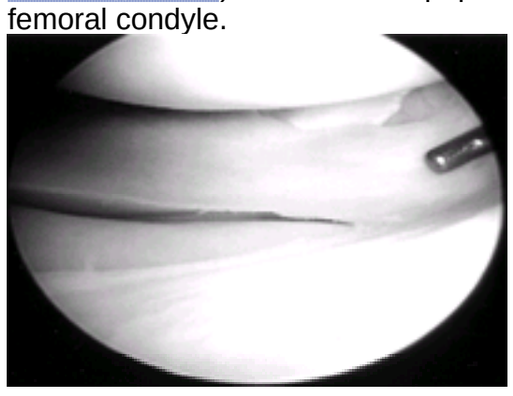

***Figure 84.26.*** (See Color Fig. 84.26.) Arthroscopic view of the lateral compartment.

- Visualize the posteromedial compartment by passing a blunt obturator or sleeve through the intercondylar notch from the anterolateral arthroscopy portal. Establish a posteromedial portal under direct visualization as necessary. A 30° arthroscope allows visualization of a majority of the posteromedial compartment. Occasionally, a 70° arthroscope is helpful. An anatomic communication to a popliteal cyst is present in 50% of knees. Withdraw the arthroscope slowly to visualize the PCL and the posterior attachment of the medial meniscus.
- Visualize the posterolateral compartment by passing the blunt obturator through the intercondylar notch from the anteromedial arthroscopy portal. Establish a direct posterolateral portal. A 30° arthroscope allows near complete visualization of the compartment, including the popliteal hiatus.
- With the knee in full extension, establish a superolateral portal. Insert the obturator or sleeve into the suprapatellar pouch to allow visualization of the patellofemoral joint. The medial and lateral gutters can be visualized from superiorly. Flex the knee from 0° to 90° and document patellar tracking (Fig. 84.27; see also Color Fig. 84.27). Probe the articular cartilage surface of the patella and trochlear groove.

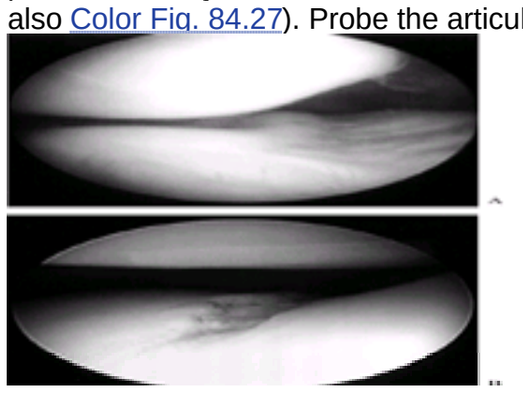

***Figure 84.27.*** Arthroscopic view of the patellofemoral joint from the (**A**) superolateral portal and (**B**) inferolateral portal, demonstrating an injury to the articular cartilage of the trochlear groove.

Always proceed in a systematic fashion through the diagnostic portion of the procedure. At best, clinical diagnosis is 80% accurate (32,49,67). At least 20% of the time, new findings are documented by the diagnostic portion of the procedure. It is important to visualize the entire knee joint before proceeding with the surgical portion of the procedure. The diagnostic portion of the procedure can be completed in less than 10 minutes.

## DIAGNOSIS AND TREATMENT OF SYNOVIAL DISORDERS

The synovium is the inner layer of the joint capsule and is affected in many knee conditions. Most synovitis is reactive and is noted in association with other intra-articular disorders of the knee, such as a meniscus tear or DJD. The synovium can become proliferative in disorders such as rheumatoid arthritis (51), pigmented villonodular synovitis (53), hemophilia, and synovial chondromatosis (43). In contrast to a reactive synovitis, the synovium in these entities can invade the menisci, ligamentous structures, and articular cartilage surfaces, causing an acceleration of the degenerative process, which has been best documented in patients with rheumatoid arthritis (70). A careful clinical evaluation, including knee aspiration, can usually eliminate other etiologies for the synovitis noted, limiting the diagnosis to a disorder of the synovium. If the diagnosis remains unclear and symptoms persist, an arthroscopic evaluation of the knee, to include synovial biopsy, is indicated.

Initial conservative management of synovitis is usually recommended. Place patients on a program of strengthening, flexibility, activity modification, NSAIDS, and intra-articular injections. Synovectomy is indicated when the synovial disorder remains symptomatic despite medical management for at least 6 months. Arthroscopic anterior and posterior synovectomy can accomplish a remission or at least a reduction of symptoms (26,51,53).

Open synovectomy gained little popularity because of the significant morbidity associated with the procedure, especially stiffness. With open synovectomy, the posterior compartments of the knee were usually left untreated. Technically, it was very difficult to remove the parameniscal synovium.

Arthroscopic anterior and posterior synovectomy has evolved into a procedure in which 95% of the diseased synovium can be removed (57). Relative contraindications to arthroscopic synovectomy include joint space narrowing greater than 3 mm, which is best demonstrated on the flexion weight-bearing view. In addition, local skin lesions such as rashes or infection should be resolved before surgery. The patient must be willing to undertake rehabilitation following surgery.

### ARTHROSCOPIC SYNOVECTOMY

Refer to Figure 84.28.

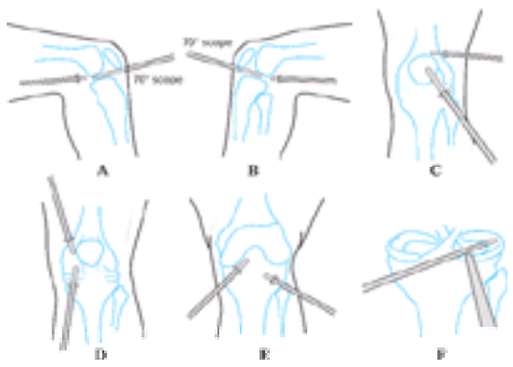

***Figure 84.28.*** Arthroscopic synovectomy is performed in a systematic fashion to allow for a complete anterior and posterior synovectomy.

- Using a standard arthroscopy setup, position the leg-holding device to allow easy access to the suprapatellar pouch.
- Position the nonoperative leg in a well-leg holder to facilitate access to the posteromedial compartment of the knee.
- Perform diagnostic arthroscopy to document all abnormalities before initiating the synovectomy.
- Begin the synovectomy in the posterior compartments. Remove the synovium from the intercondylar notch, especially the posterior aspect, to improve visualization significantly and allow for ease in development of the posterior arthroscopic portals.
- With the knee flexed 90°, pass a 30° or 70° arthroscope from the anterolateral portal into the posteromedial compartment. Rotation of the arthroscope allows visualization of the majority of the compartment. Inflow is accomplished through the arthroscope (Fig. 84.28A).
- Establish the posterior medial portal under direct visualization, with the compartment distended with fluid. Use a spinal needle to ensure proper placement of the posterior portals.
- Pass an obturator or sleeve into the posterior compartment through the posterior portal. Insert the 4.5 and 5.5 mm full-radius synovial resectors through the sleeve into the posterior portal and complete the synovectomy.
- Under direct visualization, insert an obturator or sleeve through the posteromedial portal. Remove the arthroscope from anterior and place it posteriorly through the sleeve to visualize the intercondylar notch from posteriorly.
- Pass the 4.5 mm synovial resector from the anterolateral portal into the posteromedial compartment, and remove the remaining synovium from the posterior intercondylar notch.
- With the knee flexed 90°, pass a 30° or 70° arthroscope from the anteromedial portal into the posterolateral compartment (Fig. 84.19B)
- Established the posterolateral portal under direct visualization, with the compartment distended with fluid. Use a spinal needle to ensure proper placement of the posterior portals. Avoid the peroneal nerve. Pass an obturator or sleeve into the posterior compartment through the posterior portal. Insert the 4.5 and 5.5 mm full-radius synovial resectors through the sleeve into the posterior portal and complete the synovectomy.
- Under direct visualization, insert an obturator or sleeve through the posterolateral portal. Remove the arthroscope from anterior and place it posteriorly through the sleeve to visualize the intercondylar notch from posteriorly.
- Pass the 4.5 mm synovial resector from the anteromedial portal into the posteromedial compartment, and remove the remaining synovium from the posterior intercondylar notch.
- Upon completion of the posterior synovectomy, look for bleeding vessels and cauterize them with an intra-articular cautery. This process can be enhanced by diminishing the inflow rate and allowing a small amount of bleeding to occur.
- Place the arthroscope into the suprapatellar pouch through the inferolateral portal with the knee in full extension. Use inflow through the arthroscope or through a separate inflow system.
- Insert the 4.5 and 5.5 mm synovial resectors through the superomedial or superolateral portals. In a systematic fashion, remove the entire synovial layer from the suprapatellar pouch (Fig. 84.28C).
- Visualize the proximal medial and lateral gutters from the inferior portals with the knee in full extension.
- Introduce the synovial resector through the superior portal to allow for triangulation. Reverse the arthroscope and synovial resector and complete the remainder of the synovectomy in each gutter (Fig. 84.28D).
- Meticulously debride the chondrosynovial junction, because synovial ingrowth from these areas leads to degeneration of the articular cartilage surfaces.
- Position the knee at 90° and visualize the intercondylar area. Use the inferior portals for visualization and insertion of the synovial resector.
- Remove diseased synovium invading the ACL and PCL with the 4.5 and 3.5 mm synovial resectors, trying to preserve as much ligament substance as possible (Fig. 84.28E).
- Expose the medial and lateral compartments in the routine manner (Fig. 84.28F). Excise the parameniscal synovium with the smaller synovial resectors (Fig. 84.29; see also Color Fig. 84.29).

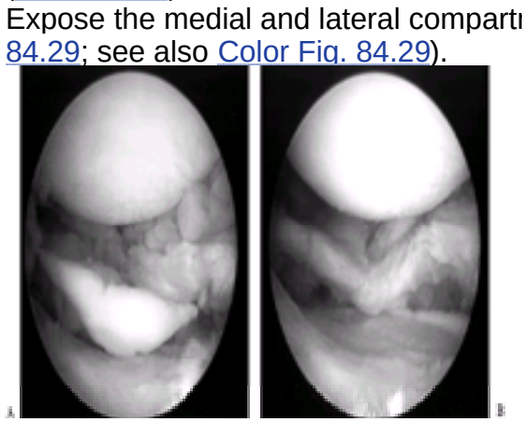

***Figure 84.29.*** Arthroscopic view of the lateral compartment (**A**) presynovectomy and (**B**) postsynovectomy.

- Curved synovial resectors facilitate excision of the synovium inferior to the anterior horns of the menisci.
- Perform a final diagnostic arthroscopy to identify any areas of residual synovitis.
- Use the intra-articular cautery for bleeding vessels. Release the tourniquet for a short period of time and then re-elevate it when bleeding occurs. This technique allows most significant bleeding vessels to be identified and cauterized. Use of the electrocautery minimizes postoperative swelling.
- Insert a $^{1}/_{8}$-inch hemovac drain for 1 to 4 hours. Keep a compression dressing in place for 2 days and then replace it with a thigh-high TED stocking.

After surgery, begin rehabilitation immediately, emphasizing range of motion and muscle strengthening exercises (see the section entitled Rehabilitation). Patients will need an ambulatory aid for 1 to 2 weeks. They can expect to return to activities in 2 to 3 months. Daily rehabilitation is critical for success. Initiate formal physical therapy as necessary.

## DIAGNOSIS AND TREATMENT OF INTRA-ARTICULAR LOOSE BODIES

Chondral and osteochondral loose bodies in the knee are occasionally noted in younger patients. In this age group, OCD and osteochondral fractures associated with ACL tears or patellar dislocations are the usual etiologies. Loose bodies occur more frequently in older patients, and are more often associated with the development of DJD. Osteonecrosis can also contribute to the formation of loose bodies. Synovial chondromatosis and synovial osteochondromatosis can develop in all age groups (8). Cartilaginous or osteocartilaginous loose bodies are formed by synovium and can become free within the knee joint. Thousands of small loose bodies can be formed in this manner.

### OSTEOCHONDRITIS DISSECANS

Osteochondritis dissecans (OCD) is most frequently encountered in individuals between the ages of 10 and 20 years (20). Cahill (5) has described a subgroup of young patients with OCD and open growth plates, a condition he called juvenile osteochondritis dissecans (JOCD). JOCD is typically seen in boys younger than 14 years of age and in girls younger than 12 years of age. JOCD has a much better healing potential and hence a better long-term prognosis. Cahill estimated that 50% of patients with JOCD heal with conservative care. In contrast, OCD in the older age group rarely heals without surgery.

The etiology of OCD remains controversial, but it appears to be traumatic, with interruption of the blood supply to consistent anatomic areas on the lateral femoral condyle, medial femoral condyle, and patella (1,20). In OCD, 80% of lesions are noted in the “classic” location: the posterolateral region of the medial femoral condyle;

15% of lesions are seen on the inferocentral region of the lateral femoral condyle. Less than 5% of OCD is located on the patella or trochlear groove. The overall incidence of OCD has been estimated to be 3:10,000 (37). Men predominate 3:1, with bilateral involvement in approximately 30% of JOCD and 5% of the older age group (46). The goal of treatment in OCD is to allow the lesion to heal either by conservative management or surgical intervention in an attempt to maintain integrity of the articular cartilage joint surface. OCD can progress to a completely detached loose body with a residual crater lesion in the articular cartilage surface. This crater lesion can accelerate the process of DJD.

Historically subjective complaints may be vague and not well localized (1). If the OCD fragment is hinged or detached, catching or locking may be observed. Physical examination findings vary depending on the stage of the disease. There may be joint line tenderness and a knee effusion. If the lesion is located in the classic position on the medial femoral condyle, Wilson's test may be positive (72). Wilson's test is performed by extending the knee from a flexed position, with the foot internally rotated. As the knee nears full extension, the tibial spine impinges on the intercondylar region of the medial femoral condyle. This maneuver can be painful in the presence of an OCD lesion located on the medial femoral condyle. There should be no pain associated with extension of a flexed knee with the foot externally rotated.

Radiographically, OCD appears as a well-circumscribed area of radiolucency surrounding an area of subchondral bone (Fig. 84.30). The standard AP view may not demonstrate the OCD lesion. The notch view or flexion weight-bearing view are best for demonstration of the OCD lesion on the femoral condyles (71). On the lateral radiographs, 90% of the lesions of the medial femoral condyle are located in a region defined by a line drawn through the posterior cortex of the femur and Blumenstadt's line. Of lesions on the lateral femoral condyle, 75% are noted posterior to the line drawn along the posterior cortex of the femur. In the patella, 80% of the OCD lesions are located in the midinferior region.

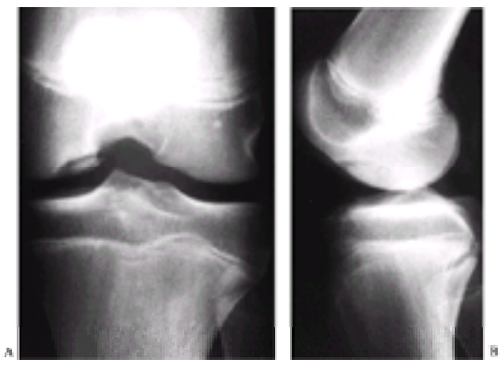

***Figure 84.30.*** Notch (**A**) and lateral (**B**)view of osteochondritis dissecans of the medial femoral condyle.

Arthrography, tomography, and CT can be used in further evaluation of the OCD lesion, but these methods have largely been replaced by MRI. Bone scans may be of value to stage the OCD lesion and evaluate the healing process. Cahill believed that bone scans were helpful for diagnosis and monitoring the clinical course of JOCD (5). A bone scan may be used to detect an early OCD lesion when radiographs are still normal.

MRI provides the most clinically relevant information regarding OCD (Fig. 84.31) (14). MRI can accurately predict the size of the lesion. The OCD lesion can be staged, because MRI will demonstrate whether or not a breach has occurred in the articular cartilage surface.

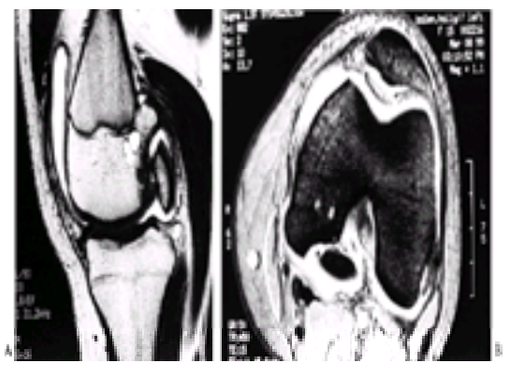

***Figure 84.31.*** CT (**A**) and MRI (**B**) of an osteochondritis dissecans lesion of the medial femoral condyle.

***MRI Classification of Osteochondritis Dissecans***

| ***Grade*** | ***Description*** |
|---|---|
| I | Thickening of articular cartilage surface |
| II | Breach of articular cartilage and decreased signal consistent with fibrous tissue surrounding the osteochondritis dissecans lesion |
| III | Separation of the articular cartilage and increased signal on T2-weighted images behind the osteochondritis dissecans fragment consistent with synovial fluid surrounding the lesion |
| IV | Loose body with crater lesion |

Arthroscopy is the final option for diagnosis of OCD. It allows for accurate diagnosis, staging, and treatment. The entire suspected OCD lesion must be carefully probed to identify the extent of the lesion. Grossly, the articular cartilage of the OCD lesion may appear to be almost normal in the early stage of OCD, but careful probing often identifies softening or a depression around the circumference of the OCD lesion.

Guhl developed an arthroscopic classification of OCD that reflects the potential natural history of OCD left untreated (25).

***Arthroscopic Classification of Osteochondritis Dissecans***

| ***Grade*** | ***Description*** |
|---|---|
| I | Intact articular cartilage with softening |
| II | Fissuring around the circumference of the lesion with early separation |
| III | Partially detached or hinged lesion |
| IV | Completely detached lesion with loose body |

Guhl's arthroscopic classification of OCD correlates accurately with the MRI classification. The MRI findings, in conjunction with the arthroscopic findings, are often necessary to determine the treatment that is indicated for each individual OCD lesion.

***Treatment of Osteochondritis Dissecans***

The goal of treatment of OCD is to restore an intact, congruent articular cartilage surface and prevent the development of degenerative arthritis (66).

- Take a complete history and perform a physical examination. Obtain plain radiographs and MRI to plan treatment of OCD lesions.
- JOCD with an intact articular cartilage surface can be treated without surgery (5). Activity modification with use of crutches until symptoms subside is recommended. Once the individual is symptom free, use of crutches can be discontinued. When radiographic evidence of healing is noted, activities can be

progressed. This process can take 4 to 12 months.

- In JOCD with an intact articular cartilage surface, 50% can be expected to heal with conservative management. Those that do not heal successfully will require surgery.
- Nonoperative management can be attempted in JOCD with stage II patients, but the results are less predictable.
- Arthroscopy is indicated for stage II, stage III, or stage IV lesions in all age groups (71). With arthroscopy, the location, size, stability, and status of the articular cartilage surface is accurately documented (Fig. 84.32; see also Color Fig. 84.32). Treatment is dependent on the age of the patient and stability of the lesion. Use arthroscopic drilling in stable OCD lesions in skeletally immature patients (3). Drilling allows a fibrin clot to form and stimulates a revascularization process of the fragment. Use a smooth 0.62 Kirschner (K) wire and make multiple drill holes at 3 mm increments (3).

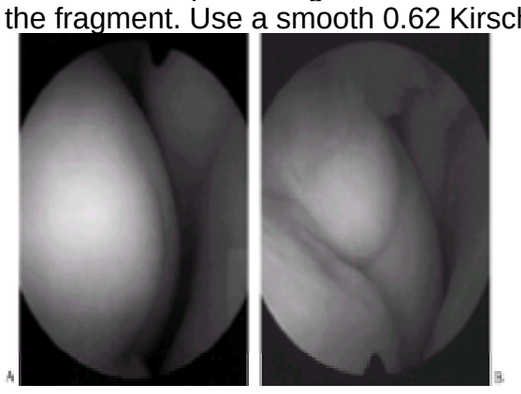

***Figure 84.32.*** (See Color Fig. 84.32.) Arthroscopic view of osteochondritis dissecans lesion of the medial femoral condyle.

- Arthroscopic screw fixation is indicated in skeletally immature patients with unstable lesions.
- Arthroscopic screw fixation is indicated for patients near skeletal maturity or older with stable or unstable regions.
- Two screws give best control of rotation and provide secure internal fixation of the OCD fragment (Fig. 84.33).

***Figure 84.33.*** Open reduction internal fixation (ORIF) of osteochondritis lesion of medial femoral condyle.

- Use cannulated screws, noncannulated 4.0 cancellous bone screws, or Herbert screws for fixation (33).
- In skeletally immature patients, it is important not to cross the epiphyseal line with the threaded screw.
- Use an image intensifier to determine screw placement accurately.
- Countersink the head of the screw just below the articular cartilage surface.
- For some unstable lesions, bone grafting with curettage of the base of the lesion will be necessary before screw fixation. Undertake this procedure in selected stage III and almost all stage IV lesions. An arthrotomy is usually required. Local cancellous bone graft can be obtained from the femur or tibia.
- In occasional grade IV lesions, the free fragment cannot fit easily back into its bed and may need to be contoured to fit anatomically.
- Following surgery, allow patients to work on a range-of-motion and muscle-strengthening program. Keep them non-weight bearing on crutches until the screws are removed.
- Remove the screw or screws at a second arthroscopic procedure 8 to 12 weeks after the initial operation. The OCD lesions can be visualized and the extent of healing documented.
- Radiographically it takes 6 to 12 months to achieve full bony union of the OCD fragment.
- Occasionally in some stage IV lesions, the free fragment is compromised and cannot be placed back into the site of origin. In these cases, remove the OCD fragment arthroscopically and treat the crater lesion. Treatment options include drilling, abrasion, microfracture, autogenous osteochondral grafting, chondrocyte autograft, and osteochondral allograft. Treatment is individualized based on the needs of the patient (see Chapter 86).

## TREATMENT OF LOOSE BODIES

Loose bodies can become entrapped in the knee joint and cause mechanical symptoms of catching or locking. At times, the patient can palpate or observe larger fragments moving around in the knee. A knee effusion is typically present. If the loose body is calcified, it will be seen on standard radiographs (Fig. 84.34). Noncalcified loose bodies, which are not visible on standard radiographs, can be identified by MRI if they are large enough. The most frequently encountered loose body is less than 5 mm in diameter and occurs as the articular cartilage surface of the knee joint gradually deteriorates in association with DJD (52,54). Larger loose bodies can be formed by substantial pieces of the articular cartilage surface breaking off or osteophytes fracturing. Some intra-articular loose bodies grow and enlarge within the environment of the knee joint.

***Figure 84.34.*** Loose body in the intercondylar notch noted on AP (**A**) and lateral (**B**) radiographs.

Initial conservative care is recommended for most patients with suspected intra-articular loose bodies unless they have a locked knee. Treat patients with a locked knee with urgent surgery and removal of the loose body, which is most often found in the intercondylar notch. All other individuals can undergo an initial program of conservative management. Conservative measures include a program of strengthening, flexibility, activity modification, and NSAIDs. Use intra-articular injections as needed. For those patients who have recurrent symptoms, arthroscopic loose body removal is recommended.

### *Loose Body Removal*

- Perform a thorough arthroscopic evaluation of the entire knee joint.
- Irrigate the knee or debride small loose bodies with a shaving tool. Frequently these small articular cartilage loose bodies become entrapped in the parameniscal recesses, popliteal hiatus, posterior compartments, and medial and lateral gutters.
- Introduce the shaver inferior to both menisci to remove any small parameniscal loose bodies. Use a grasping instrument for removal of larger loose bodies.
- Diminish the fluid inflow and outflow when the loose body is encountered. Turbulence can quickly cause the loose body to escape into another area of the knee.

- Establish a portal for insertion of a grasping instrument. Loose bodies smaller than 1 cm in diameter can be grasped and removed from the usual and customary arthroscopic portals. Large loose bodies may require enlargement of the arthroscopic portals for removal.
- Remove large loose bodies through the capsule and subcutaneous tissues slowly, while rotating the grasped loose body in a clockwise and counterclockwise fashion. Rotation minimizes the risk of dislodging the loose body in the subcutaneous tissues.
- A large loose body can become dislodged in the soft tissues between the knee joint and the skin incision during removal. If this event should occur, use a 2.75 or 4.0 mm arthroscope to visualize the soft tissues around the arthroscopic portal and localize the loose body. Once the loose body is identified in the soft tissues, insert a grasper through the same portal as the arthroscope and regrasp the loose body. If this technique fails, enlarge the arthroscopic portal and identify and remove the loose body.
- In the posterior compartments of the knee, break the large loose bodies into smaller pieces before removing them.
- For large loose bodies in the anterior compartments of the knee, transport the loose body to the suprapatellar pouch with a grasper. Establish a direct superolateral portal of appropriate size, insert a second grasper, and remove the loose body. There is less subcutaneous tissue present in the lateral parapatellar region, and the risk of losing the loose body in the soft tissues is diminished.
- Determine the site of origin of the loose body. By finding the source of the loose body, it is frequently possible to identify whether or not there are other associated loose bodies remaining in the joint. The fragments removed, like the pieces of a puzzle, should fit the chondral defect.
- Treat the remaining chondral defect (chondroplasty, microfracture, osteochondral transfer, chondrocyte autograft, osteochondral allograft) to diminish the risk of further propagation, loose body formation, and acceleration of the degenerative process.
- Acute osteochondral and chondral fractures are associated with lateral patellar subluxation or dislocation and ACL tears or instability.
- Osteochondral fractures with little attached subchondral bone should be removed as the predictability of healing is limited.
- Reattach osteochondral fractures with K-wires or screws if enough bone is present with the chondral fragment (Fig. 84.35). It appears that screw fixation alone provides the most predictable level of healing. The procedure can be performed arthroscopically but often requires a small arthrotomy.

***Figure 84.35.*** Osteochondral fracture of the medial patella treated with internal fixation. **A:** Osteochondral fragment in the intercondylar notch. **B:** Internal fixation with a single 4.0 cancellous screw.

## DIAGNOSIS AND TREATMENT OF SYNOVIAL PLICAS

In the embryologic development of the knee, mesenchymal tissue fills the space between the distal femoral and proximal tibial epiphyses. During development this tissue resorbs in some areas and becomes more dense in other areas forming the meniscus, ligaments, and articular cartilage surfaces. This resorptive process of mesenchymal tissue during embryologic development also leads to the development of four distinct synovial plicae (Fig. 84.36). The plicae's anatomic description is based on their relationship to the patella; superior, inferior, medial, and laterally based plicae can be identified. Until the advent of arthroscopy, synovial plicae were rarely diagnosed. As arthroscopy developed, the intra-articular synovial plicae were described and studied.

***Figure 84.36.*** Synovial plicae of the knee: medial, superior, lateral, and inferior.

The incidence of synovial plicae varies. It is estimated that approximately 67% of knees have an inferior plica, 55% have a superior plica, 25% have a medial plica, and less than 1% have a true lateral plica. A complete superior plica separating the superpatellar pouch into two compartments occurs in up to 5% of individuals. The incidence of pathologic plicae causing clinical symptoms remains very controversial (15). Clinically, the medial plica is most commonly implicated in knee disorders. Anatomically, the medial plica extends from the medial border of the suprapatellar pouch and attaches to the inferior fat pad, paralleling the medial border of the patella. The free inner margin of the medial plica can impinge on the medial trochlear groove of the patellofemoral joint. In theory, either inflammation or trauma can lead to fibrosis or thickening of the plica.

Historically, individuals with symptomatic medial plicas will report pain along the medial border of the patella that becomes worse with activities that involve repetitive flexion and extension of the knee. There may be an associated sense of popping, clicking, or snapping. On physical examination, a palpable cord or band is noted 1 cm medial to the medial border of the patella. Palpation of this cord causes pain, and this pain reproduces the symptoms the patient has been experiencing. Medial plica are normally not visualized on plain x-ray studies of the knee. Plicas can be noted on MRI scan, arthrograms, or CT scans. Unfortunately, it is difficult to determine from these studies whether a plica is clinically relevant.

Once the clinical diagnosis has been established, nonoperative management is recommended. Rest, with avoidance of aggravating activities, is most critical. Augment this regimen with a strengthening and flexibility program. Soft-tissue physical therapy modalities and anti-inflammatory medications may be useful. One or two local injections may be helpful in diagnosis and treatment. If all conservative measures fail, arthroscopy is indicated. (21,34,61).

### ARTHROSCOPIC MEDIAL PLICA REMOVAL

Perform a thorough diagnostic arthroscopy before removing the plica, to identify other possible intra-articular causes for knee symptoms.

- Visualize the medial plica from the superolateral arthroscopy portal (Fig. 84.37; see also Color Fig. 84.37). A symptomatic medial plica impinges on the medial trochlear groove between 0° and 60° of knee flexion. There may be an associated articular cartilage injury of the medial trochlear groove from this impingement.



***Figure 84.37.*** (See Color Fig. 84.37.) Medial plica viewed from superolateral arthroscopic portal.

- If the plica is not thickened and there is no obvious impingement, it is unlikely that resection of the plica will result in any clinical improvement. Leave normal plicae found incidentally at arthroscopy alone.
- Resect a clinically significant plica back to the capsular tissues using a combination of basket forceps and a shaver.
- Use an intra-articular cautery to prevent any postoperative hemarthrosis.
- Following surgery, use a standard postoperative arthroscopy rehabilitation program.

## REHABILITATION

The significance of a rehabilitation program in the treatment of disorders of the knee cannot be overstated. Shelbourne has documented the importance of early rehabilitation for ACL injuries before having surgery (59). His studies have demonstrated that patients with good range of motion and strength preoperatively were able to rehabilitate the knee more predictably following definitive surgery. Shelbourne also pioneered the concept of “accelerated rehabilitation” following surgery (60). Patients who have undergone ACL surgery are immediately allowed to initiate a range-of-motion and muscle-strengthening program and bear weight as tolerated. This accelerated program minimizes the risk of postoperative stiffness. These critical concepts of preoperative and postoperative rehabilitation apply for almost all disorders of the knee.

Rehabilitation following an injury or postoperatively may be initiated immediately in most disorders of the knee. Selected knee problems do require urgent or emergent surgery, such as a locked knee for a meniscus tear or loose body, some fractures about the knee, and certain knee ligament injuries. All other individuals will benefit by a preoperative program of rehabilitation. Most of this rehabilitation can be performed at home or in a gym facility and does not require formal physical therapy. Use formal physical therapy on a selected basis, in addition to the home program of exercise.

The key components of any rehabilitation program involve flexibility, strengthening, cardiovascular conditioning, and the eventual return to activities. Have patients perform passive extension in the supine position (Fig. 84.38) to regain flexibility. Place a roll or pillow under the ankle, with the knee left unsupported. Gravity helps stretch the knee into an extended position. If the patient can tolerate weights on the anterior aspect of the knee, the process can be accelerated. Passive extension can also be facilitated if the patient lies prone with the leg unsupported (Fig. 84.39). Weights can be added to the ankle as tolerated. Flexion can be obtained through an active and active-resistive program. The patient can use a towel or belt underneath the thigh to facilitate knee flexion (Fig. 84.40).

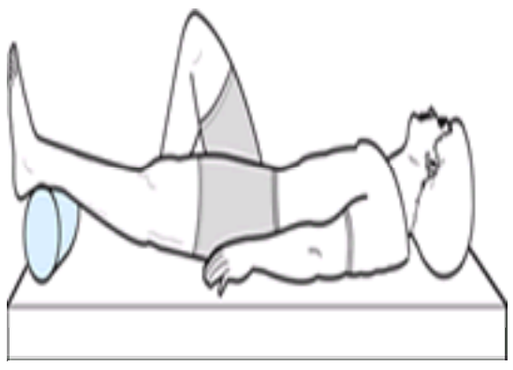

***Figure 84.38.*** Supine passive knee extension exercise.

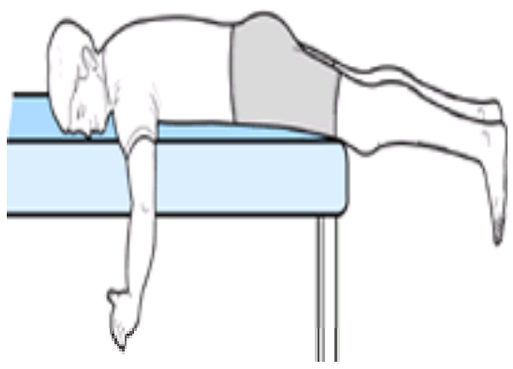

***Figure 84.39.*** Prone passive knee extension exercise.

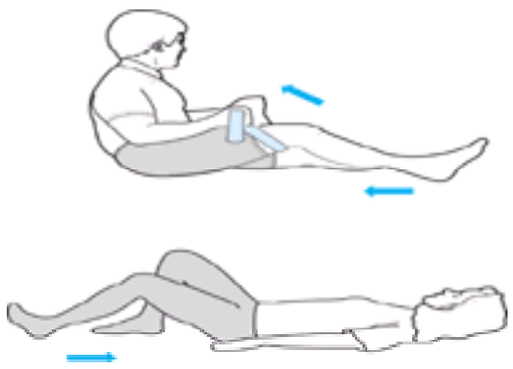

***Figure 84.40.*** Active and assisted knee flexion exercise.

Initiate a strengthening program with SLRs or short arc extension. Back and hip problems can be aggravated by SLRs; individuals with these disorders should avoid SLRs. Have patients perform short arc extensions in a supine or seated position. Once good muscle control has been obtained, have the patient initiate a program of mini-squats and calf raises. When range of motion and strength permit, begin cardiovascular conditioning with bicycling. Swimming, Nordic Trak, Stairmaster, and Ellipse machines are also useful for cardiovascular fitness in appropriately selected patients. Instruct patients to perform their exercises using light weights or resistance with high repetitions (25 to 50 reps) in order not to aggravate the injured knee.

After surgery, begin a rehabilitation program immediately. With few exceptions, most patients can be mobilized. Formal physical therapy may be required in selected patients. Following surgery, most patients should regain the range of motion by 2 months after surgery. If patients are having difficulty regaining extension, serial casting is frequently instituted, often within 1 or 2 weeks following surgery. Consider gentle knee manipulation under anesthesia for those patients who do not regain knee flexion by 6 to 8 weeks after surgery. Loss of range of motion is one of the most significant complications of knee surgery (29). A comprehensive preoperative and postoperative program of rehabilitation emphasizing flexibility, strength, and cardiovascular conditioning can minimize this risk.

## PITFALLS AND COMPLICATIONS

Arthroscopic surgery of the knee, like all surgical procedures, has a well-documented complication rate. Overall, arthroscopic procedures have a lower complication rate in comparison to traditional open knee surgery. In 1988, Small reported on complications occurring in over 10,000 arthroscopic procedures performed by experienced arthroscopic surgeons, including 8,700 procedures involving the knee (63). In his series, the overall complication rate was 1.68%. Knee complications included, in order of frequency, postoperative hemarthrosis, infection, deep vein thrombosis, anesthetic complications, instrument failure, reflex sympathetic dystrophy, iatrogenic ligament injury or fracture, and neurologic injury. Of note, Small did not report loss of range of motion as a complication, but other authors have (29).

Iatrogenic articular cartilage injury is the most frequent complication that occurs with knee arthroscopy. Make every attempt to avoid articular scuffing, the risk of which can be minimized by proper portal placement, adequate exposure, and careful technique. A knowledgeable assistant who holds the leg can aid significantly with exposure of the compartment being visualized.

The most common complication reported by Small was postoperative hemarthrosis (63). Procedures at risk include lateral retinacular release and synovectomy. This risk can be minimized by using drains and intra-articular cautery in such procedures. Postoperatively, most hemarthrosis can be managed by aspiration. Rarely, patients need to have repeat arthroscopy and intra-articular cautery of bleeding vessels.

Injuries to the medial collateral ligament can occur with overzealous stress in an attempt to gain exposure of the medial compartment (12). It is more common in patients older than 50 years of age. Most of these injuries represent second-degree tears that will heal uneventfully.

The most frequent anesthetic complications include nausea and vomiting with general anesthetics and spinal headaches with regional anesthetics. Adult respiratory distress syndrome requiring hospitalization has been reported. Careful preoperative evaluation of patients limits perioperative anesthetic complications.

Fluid extravasation has been reported, especially with pressurized inflow pumps (48). This complication can be minimized by periodically observing the leg to ensure that there is no excessive fluid in the soft tissues surrounding the knee. Compartment syndrome has been described in association with fluid extravasation (62).

Deep vein thrombosis is more frequent in older patients (35). It has been demonstrated that the incidence of deep vein thrombosis is increased by the use of a tourniquet for longer than 50 minutes (58). Pulmonary embolus was noted in 25% of these patients. It is important to recognize that in older patients with postoperative calf pain, tightness, or swelling, deep vein thrombosis is a potential complication. In at-risk patients, it is important to minimize venous stasis. Use elastic hose, sequential compression stockings, or Coumadin prophylaxis in high-risk patients.

Infections have been reported in less than 1% of all knee arthroscopies (62). *Staphylococcus epidermidis* is a pathogen that can be difficult to diagnose simply by culture. Clinical suspicion of *S. epidermidis* is warranted in the postoperative patient who has increasing pain and a swollen knee. On aspiration, the WBC is greater than 25,000. The C-reactive protein and sedimentation rate are usually elevated. Early arthroscopic debridement and intravenous antibiotics (frequently vancomycin) eradicates the infection. Institute rehabilitation to prevent permanent stiffness. Routine preoperative antibiotic prophylaxis is not recommended for most patients (70).

When establishing arthroscopic portals, it is not unusual to cause injury to sensory nerves or small vessels located in the subcutaneous tissue. Minimize the risk of such injury by bluntly dissecting through the soft tissues down to the capsular structure with a hemostat when making the portal. When establishing new portals, use transillumination to demonstrate vascular structures. Fortunately, major neurovascular injury is rare. The popliteal artery can be penetrated posteriorly (35). Prompt recognition is critical for successful revascularization of the leg.

Careful preparation and attention to detail can minimize complications of arthroscopic knee surgery. A thorough knowledge of knee anatomy is a prerequisite to performing arthroscopic knee procedures. The skill and experience of the surgeon will influence the complication rate.

### CHAPTER REFERENCES

Each reference is categorized according to the following scheme: *, classic article; #, review article; !, basic research article; and +, clinical results/outcome study.


# 1. Aichroth P. Osteochondritis Dissecans of the Knee. In: Insall JN, ed. *Surgery of the knee.* New York: Churchill Livingston, 1993:17.

+ 2. Applegate GR, Flannigan BD, Tolin BS, et al. MR Diagnosis of Recurrent Tears in the Knee. The Value of Intraarticular Contrast Material. *AJR Am J Roentgenol* 1993;161:821.

+ 3. Bradley J, Dandy DJ. Results of Drilling Osteochondritis Dissecans Before Skeletal Maturity. *J Bone Joint Surg [Br]* 1989;71:642.

+ 4. Burman MS. Arthroscopy or Direct Visualization of Joints: An Experimental Cadaver Study. *J Bone Joint Surg* 1931;13:669.

+ 5. Cahill BR. Osteochondritis Dissecans of the Knee: Treatment of Juvenile and Adult Forms. *J Am Acad Orthop Surg* 1995;3:237.

+ 6. Cassells SW. Arthroscopy of the Knee Joint. *J Bone Joint Surg Am* 1971;53:287.

+ 7. Cheung LP, King CP, Hollet MD, et al. Meniscal Tears in the Knee: Accuracy of Detection with Fast Spin-echo MR imaging and Arthroscopic Correlation in 293 Patients. *Radiology* 1997;2:508.

+ 8. Collican MR, Dandy DJ. Arthroscopic Management of Synovial Chondromatosis: Findings and Results in 18 Cases. *J Bone Joint Surg [Br]* 1989;71:498.

* 9. Coventry MB. Osteotomy about the Knee for Degenerative and Rheumatoid Arthritis: Indications, Operative Technique and Results. *J Bone Joint Surg [Am]* 1973;55:23.

+ 10. Daniel DM, Stone ML, Sachs R, et al. Instrumented Measurement of Anterior Knee Laxity in Patients with Acute Anterior Cruciate Disruption. *Am J Sports Med* 1985;13:401.

+ 11. DeHaven KE. Diagnosis of Acute Knee Injuries with Hemarthrosis. *Am J Sports Med* 1980;8:9.

+ 12. DeLee JC. Complications of Arthroscopy and Arthroscopic Surgery: Results of a National Survey. *Arthroscopy* 1985;1:204.

+ 13. De Smet AA. Meniscus Tears on Knee Arthrography: Patterns of Arthrographic Abnormalities. *Skeletal Radiol* 1985;14:280.

+ 14. Diapaola JD, Nelson DW, Colville MR. Characterizing Osteochondral Lesions by Magnetic Resonance Imaging. *Arthroscopy* 1991;7:101.

# 15. Dupont JY. Synovial Plica of the Knee: Controversies and Review. *Clin Sports Med* 1997;16:87.

# 16. Dye SF. Radionuclide Imaging of the Knee. In: Fu FH, Harner CD, Vince KD, eds. *Knee Surgery.* Baltimore: Williams & Wilkins, 1994:353.

* 17. Fairbanks TJ. Knee Joint Changes after Meniscectomy. *J Bone Joint Surg [Br]* 1948;30:664.

# 18. Fanelli GC, Gianotti BF, Edson CJ. Current Concepts Review. The Posterior Cruciate Ligament: Arthroscopic Evaluation and Treatment. *Arthroscopy* 1994;10:673.

+ 19. Feagin JA. The Syndrome of the Torn Anterior Cruciate Ligament. *Orthop Clin North Am* 1979;10:81.

# 20. Federico DJ, Lynch JK, Jokl P. Osteochondritis Dissecans of the Knee: A Historical Review of Etiology and Treatment. *Arthroscopy* 1990;6:190.

+ 21. Flanagan JP, Trakru S, Meyer M. Arthroscopic Excision of Symptomatic Medial Plica: A Study of 118 Knees with 1–4-year Followup. *Acta Orthop Scand* 1994;65:408.

# 22. Fulkerson JP, Kalenak A, Rosenberg TD, Cox JS. Patellofemoral Pain. *Instr Course Lect* 1992;41:57.

+ 23. Gelb HJ, Glasgow SG, Sapega AA, Torg JS. Magnetic Resonance Imaging of Knee Disorders: Clinical Value and Cost Effectiveness in a Sports Medicine Practice. *Am J Sports Med* 1996;24:99.

+ 24. Gregg JR, Nixon JE, DiStefano V. Neutral Fat Globules in Traumatized Knees. *Clin Orthop* 1978;132:219.

+ 25. Guhl JF. Arthroscopic Treatment of Osteochondritis Dissecans. *Clin Orthop* 1982;167:65.

+ 26. Higgenbothem CL. Arthroscopic Synovectomy. *Arthroscopy* 1985;1:198.

+ 27. Hughston JC, Andrews JR, Cross MJ, Moschi A. Classification of Knee Ligament Instabilities (I & II). *J Bone Joint Surg [Am]* 1976;58:159.

+ 28. Ireland J, Trickey EL, Stoker DJ. Arthroscopy and Arthrography of the Knee: A Critical Review. *J Bone Joint Surg [Br]* 1980;62:3.

+ 29. Irrang JJ, Harner CD. Loss of Motion Following Knee Ligament Reconstruction. *Sports Med* 1995;19:150.

+ 30. Jackson RW, Abe I. The Role of Arthroscopy in the Management of Disorders of the Knee. *J Bone Joint Surg [Br]* 1972;57:310.

+ 31. Johnson LL. Diagnostic and Surgical Arthroscopy: The Knee and Other Joints. St. Louis: CV Mosby, 1981.

+ 32. Johnson LL. Impact of Diagnostic Arthroscopy on the Clinical Judgement of an Experienced Arthroscopist. *Clin Orthop* 1982;167:75.

+ 33. Johnson LL, Uitvlugt G, Austin MD, et al. Osteochondritis Dissecans of the Knee: Arthroscopic Compression Screw Fixation. *Arthroscopy* 1990;5:179.

+ 34. Johnson DP, Eastwood DM, Witherow PJ. Symptomatic Synovial Plica of the Knee. *J Bone Joint Surg [Am]* 1993;75:1485.

+ 35. Kieser C. A Review of the Complications of Arthroscopic Knee Surgery. *Arthroscopy* 1992;8:79.

+ 36. Laurin CA, Dussalut R, Levesque HP. The Tangential X-ray Investigation of the Patellofemoral Joint: X-ray Technique, Diagnostic Criteria and Their Interpretation. *Clin Orthop* 1979;144:16.

+ 37. Linden B. The Incidence of Osteochondritis Dissecans in the Condyles of the Femur. *Acta Orthop Scand* 1976;46:664.

# 38. McGinty JB, ed. *Operative Arthroscopy.* New York: Raven Press, 1996.

+ 39. McGinty JB, Freedman PA. Arthroscopy of the Knee. *Clin Orthop* 1976;121:173.

* 40. Merchant AC, Mercer RL, Jacobsen RH, Cool CR. Roentgenographic Analysis of Patellofemoral Congruence. *J Bone Joint Surg* 1974;56A:1391.

+ 41. Metcalf RW. An Arthroscopic Procedure for Lateral Release of the Subluxating or Dislocating Patella. *Clin Orthop* 1982;167:9.

# 42. Micheli LJ, Foster TE. Acute Knee Injuries in the Immature Athlete. *Instr Course Lect* 1993;42:473.

+ 43. Milgram JW. Synovial Osteochondromatosis: A Histopathologic Study of 31 Cases. *J Bone Joint Surg [Am]* 1977;59:792.

+ 44. Miller MD, Osbourne JR, Warner JJP, Fu FH. MRI-arthroscopy Correlative Atlas. Philadelphia: W.B. Saunders, 1997.

+ 45. Morin WD, Steadman JR. Arthroscopic Assessment of the Posterior Compartments of the Knee via the Intercondylar Notch: The Arthroscopist's Field of View. *Arthroscopy* 1993;9:284.

+ 46. Mubarak SJ, Carroll NC. Juvenile Osteochondritis Dissecans of the Knee: Etiology. *Clin Orthop* 1981;157:200.

+ 47. Noyes FR, Bassett RW, Grood ES, et al. Arthroscopy in Acute Traumatic Hemarthrosis of the Knee: Incidence of Anterior Cruciate Tears and Other Injuries. *J Bone Joint Surg Am* 1980;62:687.

! 48. Noyes FR, Spievack ES. Extra-articular Fluid Dissection in Tissues during Arthroscopy: A Report of Clinical Cases and a Study of Intra-articular and Thigh Pressures in Cadavers. *Am J Sports Med* 1982;11:346.

+ 49. Oberlander MA, Shalvoy RM, Hughston JC. The Accuracy of the Clinical Examination Documented by Arthroscopy: A Prospective Study. *Am J Sports Med* 1993;21:773.

# 50. O'Connor RL. *Arthroscopy.* Philadelphia: J.B. Lippincott, 1977.

+ 51. Ogilvie-Harris DJ, Basinski A. Arthroscopic Synovectomy of the Knee for Rheumatoid Arthritis. *Arthroscopy* 1991;7:91.

+ 52. Ogilvie-Harris DJ, Fitsialos DP. Arthroscopic Management of the Degenerative Knee. *Arthroscopy* 1991;7:151.

+ 53. Ogilvie-Harris DJ, McLean J, Zarnett ME. PVS of the Knee: The Results of Total Arthroscopic Synovectomy, Partial Arthroscopic Synovectomy and Arthroscopic Local Excision. *J Bone Joint Surg [Am]* 1992;74:119.

+ 54. Rand JA. Role of Arthroscopy in Osteoarthritis of the Knee. *Arthroscopy* 1991;7:358.

+ 55. Resnick D, Kang HS. Internal Derangements of Joints, emphasis on MR imaging. Philadelphia: W.B. Saunders, 1997.

+ 56. Rosenberg TD, Paulos LE, Parker RD, et al. The 45 degree PA flexion weight bearing radiograph of the knee. *J Bone Joint Surg [Am]* 1988;70:1479.

# 57. Rosenberg TD, Paulos LE, Parker RD, Abbott PJ. Arthroscopic Surgery of the Knee. In: Chapman MW, ed. *Operative Orthopaedics.* Philadelphia: J.B. Lippincott, 1993.

! 58. Sapega AA, Heppenstall RD, Chance B, et al. Optimizing Tourniquet Application and Release Times in Extremity Surgery: A Biomechanical and Ultrastructural Study. *J Bone Joint Surg [Am]* 1985;67:303.

+ 59. Shelbourne KD, Foulk DA. The Timing of Surgery in Acute ACL Tears. *Am J Sports Med* 1995;23:686.

+ 60. Shelbourne KD, Nitz P. Accelerated Rehabilitation Following Anterior Cruciate Reconstruction. *Am J Sports Med* 1990;18:292.

+ 61. Sherman RMP, Jackson RW. The Pathological Medial Plica: Criteria for Diagnosis and Prognosis. *J Bone Joint Surg [Br]* 1989;71:351.

+ 62. Sherman OH, Fox JM, Snyder SJ, et al. “No Problem” Surgery: An Analysis of Complications in 2640 Cases. *J Bone Joint Surg [Am]* 1986;68:256.

+ 63. Small NC. Complications of Arthroscopic Surgery Performed by Experienced Arthroscopists. *Arthroscopy* 1988;4:215.

+ 64. Suggested Guidelines for the Practice of Arthroscopic Surgery. (Editorial.) *Arthroscopy* 1985;1:74.

* 65. Takagi N. Practical Experiences Using Takagi's Arthroscope. *J Jpn Orthop Assoc* 1933;8:132.

+ 66. Tayman RS, Desai K, Aichroth PM. Osteochondritis Dissecans of the Knee: A Long Term Study. *J Bone Joint Surg [Br]* 1991;39:46.

+ 67. Terry GC, Tagert BE, Young MJ. Reliability of the Clinical Assessment in Predicting the Cause of Internal Derangements of the Knee. *Arthroscopy* 1995;11:568.

# 68. Utsinger PD, Zvaidflev NJ, Ehrlich GE. *Arthritis: Etiology, Diagnosis, Management.* Philadelphia: J.B. Lippincott, 1985.

# 69. Wantanabe M, Takeda S, Ikeuchi H. *Atlas of Arthroscopy,* 2nd ed. Tokyo: Igaku Shoin Ltd, 1969.

+ 70. Wertheim SB, Gillespie S, Klaus R. Role of Prophylactic Antibiotics in Arthroscopic Knee Surgery. *Orthop Trans* 1993;4:1101.

+ 71. Williams JS, Bush-Joseph CA, Bach BR. Osteochondritis Dissecans of the Knee. *Am J Knee Surg* 1998;11:221.

+ 72. Wilson JN. A Diagnostic Sign in Osteochondritis Dissecans of the Knee. *J Bone Joint Surg* 1967;49A:477.

# CHAPTER 85

# MENISCUS TEARS

*Joseph C. Milne and Richard A. Marder*

**J. C. Milne:** The Bone and Joint Clinic, Fort Worth, Texas, 76104.
**R. A. Marder**: Department of Orthopaedics, University of California, Davis, Medical Center, Sacramento, California, 95817.

Anatomy and Function
Vascular Anatomy
Histology
Biomechanics
Stability
Mechanism of Injury
Clinical Assessment
Imaging
Nonoperative Treatment
Surgical Techniques
Partial Meniscectomy
Meniscal Repair
Pitfalls and Complications
Chapter References

The major tenet in current meniscal surgery is meniscal preservation. This has been driven by an enhanced appreciation of the contributions of the menisci to reducing articular contact stresses and to stabilizing the joint in concert with the principal ligaments (1,8,22,32,35,46,52). Of importance has been refinement of the criteria used to select appropriate treatment (repair, partial resection, or nonintervention) for the torn meniscus. Technical advances, including instrumentation for repair and resection, have facilitated both repair and resection. A promising potential development is the use of biological scaffolds and growth factors to enhance repair and stimulate meniscal regeneration (6,11,14,27).

## ANATOMY AND FUNCTION

### VASCULAR ANATOMY

Based on vascular supply, the meniscus can be divided into vascular and avascular zones (5,15). Only the peripheral meniscal rim (the red zone) is richly vascularized, representing approximately 25% of the entire meniscus. The central meniscus (the white zone) is completely avascular and without healing potential. A middle area (the gray zone) is in the transitional area between the periphery and the central meniscus and has limited potential for healing. Enhancement of healing beyond the red zone (peripheral 3–4 mm of the meniscus) has been attempted with a variety of techniques, including fibrin clot interposition, trephination of the peripheral rim to encourage vascular ingrowth into avascular regions, and various suture configurations; it has also been attempted experimentally by using biological scaffolds, cytokines, and other growth factors (6,11,12,14,26,29,38,42).

### HISTOLOGY

The meniscus is 75% water and 25% dry elements. Type I collagen accounts for most of the dry composition, providing tensile strength (21). Other components include hydrophilic proteoglycans and elastin. Proteoglycans regulate water content and, therefore, stiffness of the meniscus. Elastin aids in recovery from meniscal deformation associated with cyclic loading.

Most collagen fibers within the body of the meniscus are arranged circumferentially and are parallel to the tibia (13). Radial tie fibers extend from the periphery, perpendicular to the circumferential bands. This fiber orientation accounts for the increased pullout strength of vertical mattress sutures compared to horizontal mattress sutures (42). The surface layer of the meniscus is composed of randomly oriented fibers, which resist splitting and tearing.

### BIOMECHANICS

Of the compressive load in the knee joint, 85% is transmitted through the medial meniscus and 75% through the lateral meniscus (46). Meniscectomy has been shown to significantly decrease contact area and increase peak pressures. Under loading conditions, total meniscectomy can cause a fourfold increase in articular surface stresses, partial meniscectomy increases forces twofold, and repair can restore normal contact stresses (8,46). When compressive force is applied to the knee joint, the anterior and posterior attachments of the meniscus resist extrusion (49). This converts compressive force into hoop stress, which the circumferential orientation of the collagen fibers is ideally suited to withstand. The radial tie fibers and superficial layer resist shear stresses that attempt to separate the circumferential bundles, which would result in a vertical longitudinal tear.

### STABILITY

Levy et al. examined the role of the meniscus in limiting anteroposterior (AP) translation of the tibia relative to the femur. Although isolated sectioning of the meniscus had no effect on stability, sectioning it in a knee with a deficient anterior cruciate ligament (ACL) caused a significant increase in AP translation (32). The contributions of the medial meniscus to stabilizing the knee exceed those of the lateral meniscus. Other studies have shown a small but statistically significant increase in varus–valgus laxity after meniscectomy (35). These reports confirm the function of the meniscus as a secondary stabilizer.

## MECHANISM OF INJURY

Meniscal tears usually result from a single, acute rotational force applied to the weight-bearing knee that overloads the meniscus. Degenerative tears occur from repetitive submaximal forces applied to a meniscus having already undergone attritional wear from an irregular femoral articular surface; the majority involve the medial meniscus (39). Concomitant meniscal injury often accompanies tears of the ACL as well as multiple knee ligament injuries including dislocation of the knee. Whereas lateral meniscus injuries are most frequent in acute ACL tears, the medial meniscus is most often torn in chronic ACL insufficiency. In combined ACL and medial collateral ligament (MCL) injuries, meniscus tears occur less frequently with complete MCL tears (grade III) than with partial tears (grade II) and, in both instances, predominantly affect the lateral meniscus (48).

Tear patterns are typically described by configuration, acuity, and location. The most common tears are vertical longitudinal (bucket-handle), oblique (flap), radial, horizontal cleavage, and complex (Fig. 85.1). Most tears involve the posterior aspect of the meniscus. Tears are usually complete, traversing the entire surface of the meniscus, but they may be incomplete, affecting only the inferior or superior surface of the meniscus (Fig. 85.2; see also Color Fig. 85.2).

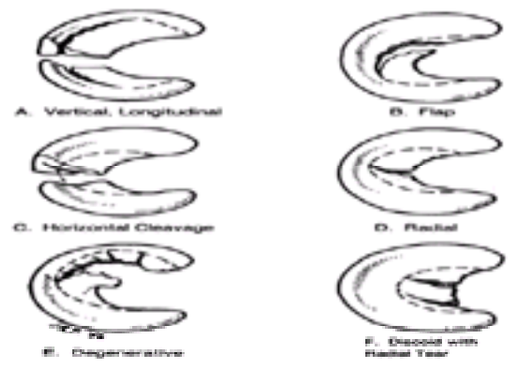


***Figure 85.1.*** Types of meniscal tears, shown with the typical lines of resection.

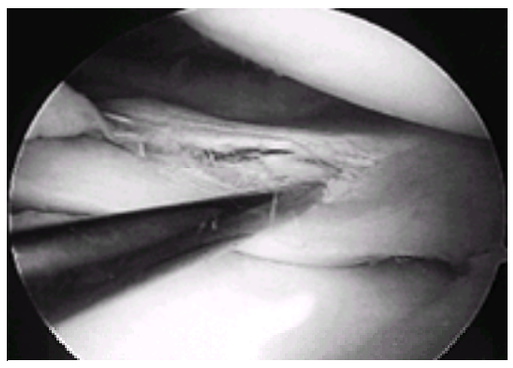

***Figure 85.2.*** (See Color Fig. 85.2) Incomplete tear of the superior surface of the lateral meniscus associated with an anterior cruciate ligament tear.

## CLINICAL ASSESSMENT

The torn meniscus typically causes pain during axial loading and rotation of the knee and may be accompanied by mechanical symptoms of catching, popping, giving-way, swelling, and locking. The patient may describe relief of symptoms with manual reduction of the displaced meniscal fragment. In the arthritic knee, it is useful to distinguish between patients with pain only and those with pain associated with one or more mechanical symptoms. In the absence of mechanical symptoms, it is unlikely that resection of a degenerative tear will give significant pain reduction.

Perform a complete knee examination, including assessment of limb alignment, gait pattern, and hip function, especially in the older patient who might have hip pain referred to the medial knee. Fowler and Lubliner delineated predictive criteria for meniscus tears (25). The most specific findings of a meniscus tear are a positive McMurray's test and block to extension. Unfortunately, the McMurray's test is the least sensitive test. Although joint line tenderness is very sensitive for a meniscus tear, it is the least specific test, especially in the presence of an acute ACL injury. Some patients will exhibit an effusion, and many will demonstrate pain with forced knee flexion as well as forced extension (spring or bounce test).

## IMAGING

Radiographs are mandatory; perform magnetic resonance imaging (MRI) on a case-by-case basis. For patients over the age of 40, perform AP weight-bearing radiographs in addition to a lateral view of the knee to exclude degenerative joint disease (DJD), loose bodies, osteonecrosis, and tumor. Take additional views such as a Merchant view to evaluate the patellofemoral joint, a notch view to look for loose bodies, and a weight-bearing PA in 45° of flexion to diagnose early DJD on an individual basis.

In the preoperative confirmation of a meniscal tear, MRI is a tremendous asset, with an overall accuracy approximating 90%. If cost were not a consideration, MRI would be routine in every patient as an adjunct to, but not as a substitute for, a thorough physical and adequate radiographic examination. In this day of managed care, many patients are referred who have classic symptoms, a confirmatory physical examination, and an MRI of the knee, but no radiographs. In our practices, we do not routinely order MRI for patients with a locked knee, a positive McMurray's, or symptoms and findings suggestive of a meniscus tear who have not responded to nonoperative treatment. In our experience, these patients have sufficient indication for proceeding directly to arthroscopy.

However, MRI can be misleading. Approximately 20% of patients with a type II signal (incomplete tear) have been found to have complete tears at arthroscopy (23). In addition, MRI is infrequently helpful in the previously operated meniscus to assess either healing after repair or reinjury in the patient with previous partial meniscectomy.

## NONOPERATIVE TREATMENT

Approximately 40% of patients with pain and swelling consistent with a meniscus tear, but with no history of locking, a block to extension, or ACL injury, can be treated nonoperatively with resolution of symptoms (33). Usual measures include nonsteroidal anti-inflammatories, a neoprene sleeve, muscle-strengthening exercises for the lower extremity, and sometimes a formal course of physical therapy. For patients with continuing symptoms, arthroscopic intervention is indicated.

While inherently unsettling to most surgeons, partial-thickness tears, incomplete radial tears, and stable vertical longitudinal tears less than 10 mm in length do not need resection. Shelbourne has shown that in patients undergoing ACL reconstruction, these tears remain asymptomatic and do not progress (24).

## SURGICAL TECHNIQUES

### PARTIAL MENISCECTOMY

Most meniscal tears are treated by arthroscopic partial meniscectomy. The goal of partial meniscectomy is to remove only the unstable or pathologic portion, leaving as much healthy meniscal tissue as possible while avoiding an abrupt transition to the remaining meniscus. Partial meniscectomy is indicated for radial tears not extending to the periphery, oblique tears, horizontal cleavage tears, degenerative tears, and irreparable vertical longitudinal tears that are more than 5 mm from the absolute periphery.

- See Chapter 84 for the general principles of arthroscopy.
- Portal placement is of primary importance in performing partial meniscectomy. With the arthroscope in the inferolateral portal, use a spinal needle to identify proper placement of the inferomedial portal and any accessory portals. The inferomedial portal for medial meniscectomy typically is just inferior to the level of the inferolateral portal and is made with the knee positioned in near extension with valgus and external rotation applied to visualize the posterior third of the meniscus, or in more flexion to visualize the anterior horn. If the spinal needle cannot be advanced to palpate the torn meniscus, the portal is not satisfactory. Choose either a more medial location immediately anterior to the MCL or an inframeniscal approach. If the posterior horn cannot be exposed without injury to the femoral condyle, use a posteromedial portal: With the arthroscope in the posteromedial compartment, pass through the intercondylar notch.
- If a lateral tear is encountered, make the inferomedial portal with the leg in the figure-four position. This needs to be at a higher level than the inferolateral portal to allow instruments to pass freely above the tibial spines. For posterior tears of the lateral meniscus, instrumentation is usually necessary through the inferolateral portal because of the tighter radius of curvature of the lateral meniscus, which limits access from the inferomedial portal.
- Once appropriate portals are established, resect using a combination of hand instruments and a motorized shaver (Fig. 85.3). Simple flaps and longitudinal tears can often be excised intact, using an arthroscopic knife or scissors to detach the segment. Debride most tears in a piecemeal fashion. A small up-biting punch, straight punch, right and left 90° punches, and a 4.5 mm full-radius resector will suffice for resection of most tears.

***Figure 85.3.*** **A,B:** Knife resection of flap tear. **C,D:** Motorized resection of flap tear.

- After resecting the meniscal tear, pass the arthroscope via the notch into the posterior compartments to ensure that all loose meniscal fragments have been removed.
- Use a three-portal technique to treat vertical longitudinal (bucket-handle) tears displaced into the notch (Fig. 85.4*A*; see also Color Fig. 85.4). For a medial meniscus tear, insert the arthroscope in the inferolateral portal as usual. Establish two inferomedial portals, using a spinal needle for localization. Place one portal either adjacent to the patellar tendon or through the patellar tendon. Make a second portal 2 cm medial to the first, taking care to enter just over the rim of the meniscus so that instruments can reach the posterior horn. Insert an angled arthroscopic scissors or a curved knife through the second portal, sectioning the anterior horn attachment in a tapered fashion (Fig. 85.4*B*). Switch the arthroscope to the inferomedial portal, and grasp the meniscus via the inferolateral portal. Now release the posterior extent of the tear with a small up-biter or meniscal knife through the anteriormost inferomedial portal or the transtendon portal (Fig. 85.4*C*). Smooth the margins using a 4.5 mm motorized shaver. Switch the arthroscope to the medial side and, with the shaver lateral, trim any remaining anterior irregularity, if needed.

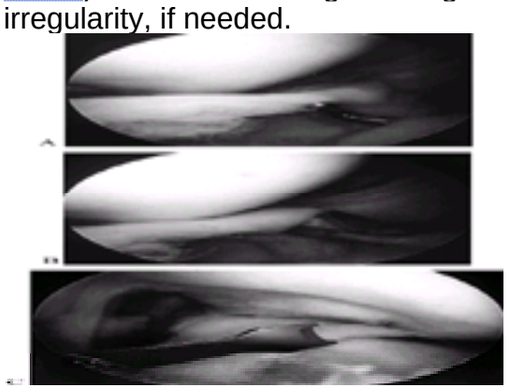

***Figure 85.4.*** (See Color Fig. 85.4) **A:** Displaced bucket-handle tear of the medial meniscus. **B:** Anterior horn of bucket-handle tear detached. **C:** Grasping the resected anterior horn through an inferolateral portal and arthroscopic meniscotome inserted through a transtendon portal to resect the posterior attachment (viewed from inferomedial).

- Deal with nondisplaced bucket handle tears the same way, or via a two-portal technique. If you use the latter, cut the posterior horn attachment via an ipsilateral portal, using a small up-biter, and leave a narrow bridge attached. Then divide the anterior horn attachment from whichever portal affords the best access. Remove the meniscus by avulsing the small remaining attachment of the posterior horn. Taper the margins to a smooth contour with punches and a motorized shaver.

### *Postoperative Management*

Use cryotherapy, compression, and limited weight bearing for 24–72 hours postoperatively to minimize swelling and attendant pain. Implement early isometric quadriceps exercises and range of motion without load when discomfort permits. Within a few days to 1 week after surgery, begin progression to unaided walking, cycling, and short-arc quadriceps exercises. Once the incisions are healed, swimming can be started. Normal activities can usually be resumed within 2–3 weeks but may take as long as 6 weeks. If the tear was complex or degenerative, defer running, squatting, and other stressful activities for a minimum of 3–4 weeks. Physical therapy can be beneficial to achieve an earlier return to activity, but it is not mandatory.

## MENISCAL REPAIR

Despite the first meniscal repair in 1885 by Annandale (4), complete or partial meniscectomy remained the treatment of choice of the vast majority of orthopaedists until the early 1980s. Interest in repair has been stimulated by DeHaven's work on open meniscal repair (16,17 and 18) and Henning's inside-out arthroscopic repair (28,29). Since that time, numerous basic and clinical science reports have validated the concept of meniscal repair (2,20,30,36,37,41,43,44). Accepted techniques include open repair, inside-out arthroscopic repair, outside-in arthroscopic repair, and all-inside repair.

Despite the many available options, the reported success rates of meniscal repair are similar, based on an average of published reports (2,9,18,20,30,34,36,37,41,43,47,51), with an overall healing rate of nearly 85% (Table 85.1). Interstudy comparisons are difficult due to varied techniques, as well as differences in types of tears, patient data, associated injuries, and postoperative assessment criteria. For instance, clinical success rates based on symptoms and function exceed anatomic healing rates (34,45).

| Author | Technique | Repairs (N) | Good/Excellent | Fair/Poor | Complications |
|---|---|---|---|---|---|
| Albrecht-Olsen et al. (1999) | Mixed | 68 | 57 | 11 | 3 |
| Shimozo et al. (1998) | Mixed | 29 | 29 | 0 | 1 |
| Rubman et al. (1998) | I-O | 198 | 159 | 12 | 2 |
| von Trommel et al. (1998) | O-I | 51 | 39 | 12 | * |
| Barber, Gewirtz (1997) | I-O | 65 | 58 | 7 | * |
| Hoelle et al. (1996) | I-O | 36 | 30 | 6 | 4 |
| Shiraiwa et al. (1996) | O-I | 22 | 19 | 3 | 0 |
| Perdue et al. (1996) | I-O | 45 | 41 | 4 | 1 |
| Reigel et al. (1996) | Inside | 87 | 87 | 0 | 0 |
| Rodeo, Warren (1996) | O-I | 90 | 77 | 13 | * |
| Shelbourne, Patel (1996) | I-O | 56 | 50 | 6 | * |
| DeHaven et al. (1995) | Open | 33 | 26 | 7 | 2 |
| Eggli et al. (1995) | I-O | 52 | 38 | 14 | * |
| Total | | 832 | 710 (85%) | 122 (15%) | |

I-O, inside-out; O-I, outside-in.
* Complications not reported.

***Table 85.1. Results of Meniscal Repair***

### *Indications for Repair*

Suitability for repair requires assessment of location, pattern, and age of the tear; quality of meniscal tissue; patient age; associated injuries; as well as surgical skill.

*Location.* We repair all tears in the red zone (0–3 mm from the periphery) and most in the gray zone (3–5 mm from the periphery). We repair only nonmacerated, nondeformed fragments in the gray zone. While recent work by Rubman et al. (44) has shown acceptable results from repair of tears in the white zone, this is not yet widely practiced.

*Tear pattern.* Repair is indicated for vertical longitudinal tears longer than 1 cm and for radial tears that extend into the red zone.

*Tissue quality.* We do not repair macerated and degenerative menisci. Similarly, we treat with partial meniscectomy those chronic tears that involve a meniscal deformity that precludes a functional repair.

We routinely perform meniscal repair in patients up to the age of 45 years. Over this age, we do repairs in some patients on a case-by-case basis, depending primarily on functional activity level, physiologic age, and willingness to follow a more lengthy and rigorous postoperative management protocol as contrasted to partial meniscectomy. Some older patients may elect partial meniscectomy to allow an earlier return to activity.

Once the reparable meniscus is identified, a surgical technique must be selected. Technical aspects of the two most popular arthroscopic methods are presented.

***Inside-out Technique***

This remains the most popular method. It allows accurate placement of sutures while protecting neurovascular structures by incorporating an accessory incision.

- Use either a rasp or small shaver to debride the tear margins to achieve smooth meniscal surfaces and excoriate the adjacent synovial tissue to produce slight bleeding.
- Make an accessory posteromedial or posterolateral incision to expose the capsule. For a medial tear, transilluminate the posteromedial knee through the notch to identify the saphenous vein, which travels with the nerve. Make a 3 cm longitudinal incision posterior to the MCL, centered just below the joint line (to accommodate the needles that will pass from superior to inferior). Retract the pes tendons posteriorly, along with the saphenous vein and nerve. Dissect the interval between the joint capsule and the medial head of the gastrocnemius, and insert a small vaginal speculum or commercially available specialized retractor into this interval to expose the posterior capsule while protecting the posterior neurovascular structures. The retractor will deflect needles exiting the joint, allowing easy retrieval.
- On the lateral side, make the incision along the posterior aspect of the lateral collateral ligament (Fig. 85.5) with the knee flexed approximately 90°. Develop the interval between the biceps femoris posteriorly and the iliotibial band anteriorly. Separate the lateral head of the gastrocnemius from the joint capsule. Insert the retractor in front of the lateral gastrocnemius to protect the adjacent peroneal nerve.

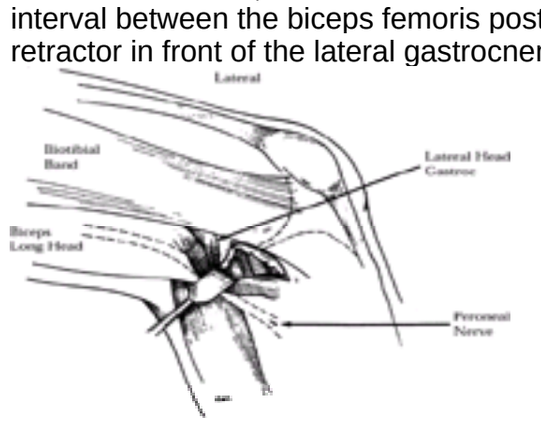


***Figure 85.5.*** Exposure of posterolateral capsule. Note that retractor must be placed in front of the lateral head of the gastrocnemius to protect the peroneal nerve.

- As with an all-inside repair (technique below), portal placement must allow the cannula to be placed perpendicular to the tear and horizontal to the joint line. This usually requires placement of sutures into the meniscus from the contralateral portal while viewing from the ipsilateral portal. Placement of the cannula in the contralateral portal also tends to angle the penetrating needle away from the popliteal region (Fig. 85.6). Because of the curvature of the meniscus, it is helpful to utilize cannulas of various angles (Fig. 85.7). A single cannula is preferable because it allows greater flexibility in placing the second arm of the stitch.

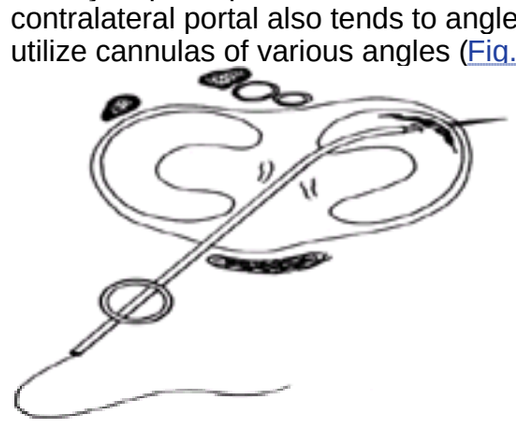

***Figure 85.6.*** A curved cannula inserted through the contralateral portal is used for suturing to avoid popliteal vessels and nerves.

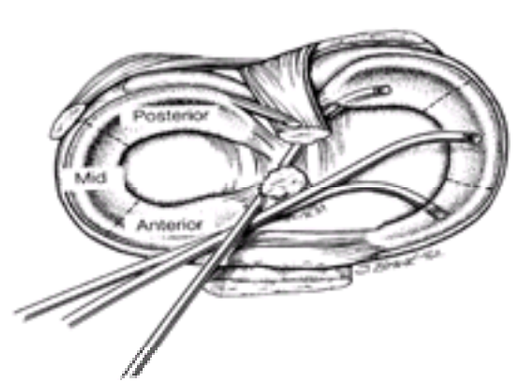


***Figure 85.7.*** Zone-specific cannulas for meniscus repair.

- For medial tears, position the knee near extension to facilitate passage of the needles into the posterior meniscus and to preserve the posterior capsular fold. For lateral tears, position the knee in flexion to avoid injury to the peroneal nerve, and insert a retractor in front of the lateral head of the gastrocnemius.
- Starting posteriorly, insert the appropriate curved cannula and advance a 10-inch needle with attached suture [2-0 nonabsorbable provides sufficient tensile strength (10)] to engage the torn fragment and reduce it to the margin. With the posterior retractor in place, push the needle through the meniscus margin posteriorly. Visualize the needle's exit before continuing to push it out of the posterior incision or using a needle driver to grasp and deliver it. Place the second needle vertically (42) with a 3 mm bridge between arms (Fig. 85.8). Place as many sutures as necessary, maintaining a 5 mm interval between sutures. Then tie the sutures directly over the exposed capsule. If concomitant ACL surgery is being performed, delay tying the sutures until after the surgery is completed. Release the tourniquet to allow blood to fill the meniscal repair site and then tie the sutures.

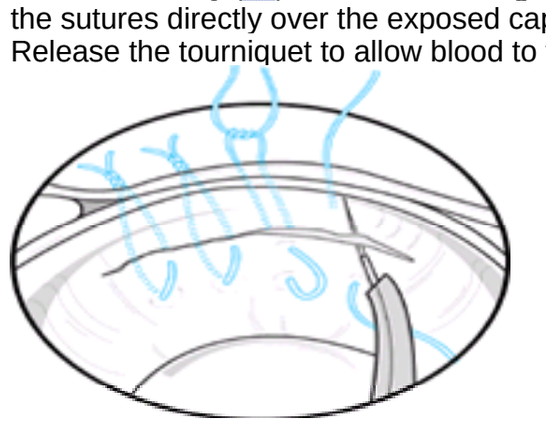

***Figure 85.8.*** Vertical mattress sutures placed through a cannula.

- For tears with an extreme anterior component, an outside-in suturing technique utilizing commercially available, modified spinal needles and suture passers can facilitate repair by allowing more precise needle placement.

***All-inside Technique***

This method does not require additional incisions; it decreases operative time and complications; and its healing rates are similar to those of inside-out repair (2,19). We use a meniscal arrow system (Bionx Implants, Blue Bell, PA). The arrow is made of a biodegradable polylactic acid that resorbs over a 3-year period. The implant has a barbed shaft with a 4 mm T-head, and it comes in 10 mm, 13 mm, and 16 mm lengths (Fig. 85.9). The barbs are perpendicular to the T-head to obtain maximum purchase in the circumferential fibers of the meniscal body. Pull-out strength of the arrow has been shown to be equivalent to horizontal mattress sutures (2,12). The instrumentation set contains five different cannulas with varying curvatures, allowing access to all regions of the meniscus (Fig. 85.10).



***Figure 85.9.*** Bionx meniscal arrows. Note that barbs are perpendicular to the T-head.

***Figure 85.10.*** Bionx instrumentation set, including curved cannulas.

- Prepare the tear margins as described above. Occasionally, it may be necessary to rasp the posterior horn of the medial meniscus from a posteromedial portal to avoid injuring the medial femoral condyle. Use a probe to estimate the necessary arrow length. Whenever possible, use 13 or 16 mm long arrows, because of their higher pullout strength (12).
- Insert the appropriately curved cannula parallel to the joint line and perpendicular to the tear to obtain optimum fixation. Posterior tears are best addressed with the cannula in the ipsilateral portal, while tears in the midportion require that the cannula be inserted through the contralateral portal.
- Use the cannula to hold the meniscus in a reduced position so that the arrow can enter the meniscus 3–4 mm from the tear. Insert the “spear” into the cannula, pushing it through the meniscus until its handle is seated, preparing a channel for the arrow (Fig. 85.11).

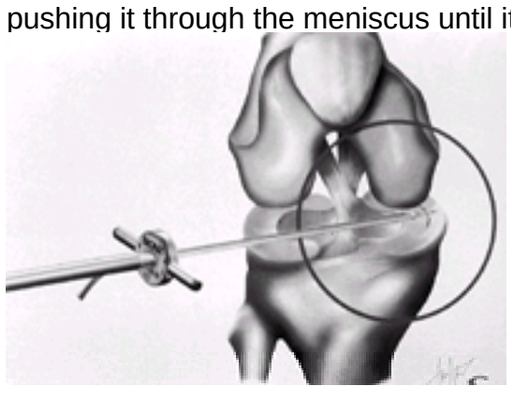

***Figure 85.11.*** Cannula holds the reduction, while a “spear” is used to create a channel for the arrow.

- Remove the spear and insert the appropriate-length arrow into the cannula. Now push the arrow down the cannula and across the tear. Be certain to push the inserter all the way down against the back of the cannula to ensure that the head of the arrow is countersunk into the meniscus. If removal of an arrow is necessary, rotate it 90° with a grasper (T-head perpendicular to tibia) prior to removal. This will reduce meniscal trauma by disengaging the barbs from the circumferential fiber bundles.
- For posterior tears, place the most posterior arrow first, followed by an arrow in the center of the tear. If the tear is in the midportion of the meniscus, place the first arrow centrally with subsequent arrows in the anterior and posterior extents of the tear. Place arrows every 5 mm (Fig. 85.12).

***Figure 85.12.*** Arrows stabilizing a vertical tear.

### *Postoperative Management*

Historically, most surgeons have prescribed limited motion and no weight bearing for several weeks after surgery, with a delay of 6 months or more to resume sports (16,29). Over the past several years, restrictions on patient activities after meniscal repair have eased considerably. Based on experimental and clinical studies, postoperative rehabilitation has progressed to early, full-weight-bearing, unlimited motion without bracing, and return to sports as soon as normal strength, motion, and flexibility are achieved (9,47).

When meniscal repair is performed in conjunction with ACL surgery, we follow the rehabilitation program for the cruciate ligament (see Chapter 89). When isolated meniscal repair has been performed in an acute tear where satisfactory apposition and fixation have been achieved, we use a modified accelerated protocol with a short, initial period of bracing (Table 85.2). Encourage early use of a stationary bicycle and isokinetic exercises, but avoid squatting and pivoting for 2–3 months. In our experience, return to full activity usually takes 3–4 months. If a patient develops pain or effusion, slow down or regress activity until symptoms subside. If symptoms do not resolve, investigate further (using arthrogram or arthroscopy) to evaluate the knee.

| Week | |
|---|---|
| 0–2 | Cryotherapy, compression, hinged brace permitting exercises from 0° to 100° ROM<br>Weight bearing as tolerated<br>Straight-leg raises, quadriceps isometrics, and toe raises |
| 2–4 | Discontinue bracing by 2 weeks<br>Unlimited ROM<br>Exercise bike, swimming<br>Closed-chain kinetic exercises |
| 4–8 | Stairmaster<br>Open-chain quadriceps exercises<br>Fast walking/running on treadmill |
| >8 | Functional, sport-specific exercises<br>Return to sports when ROM, flexibility, and strength are 90% or more compared to the contralateral knee |

ROM, range of motion.

***Table 85.2. Postoperative Management for Meniscal Repair***

## PITFALLS AND COMPLICATIONS

Delayed surgery in the knee with a history of locking, a block to extension, or associated ACL and meniscus tear can be associated with articular degeneration (50). Complications of open or arthroscopic meniscus surgery include failure to heal or retear after meniscal repair, neurovascular injury, hemarthrosis, deep vein thrombosis, reflex sympathetic dystrophy, infection, iatrogenic injury to intraarticular structures, especially the femoral condyles, osteonecrosis, and DJD (7,31,40).

The most important factor influencing meniscal healing is knee stability. In knees with concomitant ACL reconstruction, meniscal healing rates are approximately 90% to 100%. This contrasts sharply with success rates as low as 30% in the ACL-deficient knee (53). In isolated meniscal injury, healing rates are less than those observed in the knee undergoing simultaneous ACL reconstruction, but, as noted previously, they average 85%.

Saphenous neuropathy is the most frequent complication associated with meniscal repair (7). Injuries to the saphenous nerve or its infrapatellar branches are transitory in nearly 90%, resolving over a few months (7). While permanent injury is rare, a neuroma can occur, producing pain and numbness. With lateral meniscal repair, the peroneal nerve is at risk with any inside-out technique. Complications associated with meniscal arrows include pain secondary to prominent arrow tips, as well as breakage of arrows during insertion. A recent randomized study with 68 patients compared arrows to inside-out suture repair. Two infections occurred in the suture group and none in the arrow group; five patients had saphenous nerve pain in the suture group, compared to two in the arrow group (2).

## CHAPTER REFERENCES

Each reference is categorized according to the following scheme: *, classic article; #, review article; !, basic research article; and +, clinical results/outcome study.


! 1. Ahmed AM, Burke DL. In Vitro Measurement of Static Pressure Distribution in Synovial Joints—Part 1: Tibial Surface of the Knee. *J Biomech Eng* 1983;105:216.

+ 2. Albrecht-Olsen P, Kristensen G, Burgaard P, et al. The Arrow vs. Horizontal Suture in Arthroscopic Meniscus Repair. A Prospective Randomized Study with Arthroscopic Evaluation. *Knee Surg Sports Traumatol Arthrosc* 1999;7:268.

! 3. Albrecht-Olsen P, Lind T, Kristensen G, Falkenberg B. Failure Strength of a New Meniscus Arrow Repair Technique: Biomechanical Comparison with Horizontal Suture. *Arthroscopy* 1997;13:183.

* 4. Annandale T. An Operation for Displaced Semilunar Cartilage. *Br Med J* 1885;1:779.

! 5. Arnoczky SP, Warren RF. Microvasculature of the Human Meniscus. *Am J Sports Med* 1982;10:90.

+ 6. Arnoczky SP, Warren RF, Spivak JM. Meniscal Repair Using an Exogenous Fibrin Clot. *J Bone Joint Surg Am* 1988;70:1209.

+ 7. Austin KS, Sherman OH. Complications of Arthroscopic Meniscal Repair. *Am J Sports Med* 1993;21:864.

! 8. Baratz ME, Fu FH, Mengato R. Meniscal Tears: The Effects of Meniscectomy and of Repair on Intraarticular Contact Areas and Stress in the Human Knee: A Preliminary Report. *Am J Sports Med* 1986;14:270.

+ 9. Barber AF, Click SD. Meniscus Repair Rehabilitation with Concurrent Anterior Cruciate Reconstruction. *Arthroscopy* 1997;13:433.

+ 10. Barber FA, Gurwitz GS. The Effect of Synovial Fluid on Suture Strength. *Am J Knee Surg* 1988;1:189.

! 11. Bhargava MM, Attia ET, Murrell GAC, et al. The Effect of Cytokines on the Proliferation and Migration of Bovine Meniscal Cells. *Am J Sports Med* 1999;27:636.

! 12. Boenisch UW, Faber KJ, Ciarelli M, et al. Pull-out Strength and Stiffness of Meniscal Repair Using Absorbable Arrows or Ti-Cron Vertical and Horizontal Loop Sutures. *Am J Sports Med* 1999;27:626.

! 13. Bullough PG, Munuera L, Murphy J, et al. The Strength of the Menisci of the Knee as It Relates to Their Fine Structure. *J Bone Joint Surg Br* 1970;52:564.

! 14. Cook JL, Tomlinson JL, Kreeger JM, et al. Induction of Meniscal Regeneration in Dogs Using a Novel Biomaterial. *Am J Sports Med* 1999;27:658.

+ 15. Cooper DE, Arnoczky SP, Warren RF. Arthroscopic Meniscal repair. *Clin Sports Med* 1990;9:589.

+ 16. DeHaven KE. Meniscus Repair in the Athlete. *Clin Orthop* 1985;198:31.

+ 17. DeHaven KE, Black KP, Griffiths HJ. Open Meniscus Repair: Technique and Two to Nine Year Results. *Am J Sports Med* 1989;17:788.

+ 18. DeHaven KE, Lohrer WA, Lovelock JE. Long-term Results of open Meniscal Repair. *Am J Sports Med* 1995;23:524.

+ 19. Dossing K, Poulsen MB, Kristensen G. Meniscus Repair with Bionx Meniscus Arrow. *In press.*

+ 20. Eggli S, Wegmuller H, Kosina J, et al. Long-term Results of Arthroscopic Meniscal Repair. *Am J Sports Med* 1995;23:715.

! 21. Eyre DR, Wu JJ. Collagen of Fibrocartilage: A Distinctive Molecular Phenotype in Bovine Meniscus. *FEBS Lett* 1983;158:265.

* 22. Fairbank TJ. Knee Joint Changes after Meniscectomy. *J Bone Joint Surg Br* 1948;30:664.

+ 23. Fischer SP, Fox JM, Del Pizzo W, et al. Accuracy of Diagnoses from Magnetic Resonance Imaging of the Knee. *J Bone Joint Surg Am* 1991;73:2.

+ 24. Fitzgibbons RD, Shelbourne KD. “Aggressive” Non-treatment of Lateral Meniscal Tears Seen During Anterior Cruciate Ligament Reconstruction. *Am J Sports Med* 1995;23:156.

+ 25. Fowler PJ, Lubliner JA. The Predictive Value of Five Clinical Signs in the Evaluation of Meniscal Pathology. *Arthroscopy* 1989;5:184.

+ 26. Fox J, Rintz K, Ferkl R. Trephination of Incomplete Meniscal Tears. *Arthroscopy* 1993;9:451.

! 27. Hashimoto J, Kurosaka M, Yoshiya S, et al. Meniscal Repair Using Fibrin Sealant and Endothelial Cell Growth Factor: An Experimental Research Study in Dogs. *Am J Sports Med* 1992;20:537.

+ 28. Henning CE. Arthroscopic Repair of Meniscus Tears. *Orthopedics* 1983;6:1130.

+ 29. Henning CE, Lynch MA, Yearout KM, et al. Arthroscopic Meniscal Repair Using an Exogenous Fibrin Clot. *Clin Orthop* 1990;252:64.

+ 30. Horibe SH, Shino K, Maeda A, et al. Results of Isolated Meniscal Repair Evaluated by Second-look Arthroscopy. *Arthroscopy* 1996;12:150.

+ 31. Jaureguito JW, Elliot JS, Lietner T, et al. The Effects of Arthroscopic Partial Lateral Meniscectomy in an Otherwise Normal Knee: A Retrospective Review of Functional, Clinical, and Radiographic Results. *Arthroscopy* 1995;11:29.

+ 32. Levy IM, Torzilli PA, Warren RF. The Effect of Medial Meniscectomy on Anterior-posterior Motion of the Knee. *J Bone Joint Surg* 1982;64:883.

+ 33. Marder RA, Moehring HD. Nonoperative Treatment of MRI-Documented Meniscal Tears in Recreational Athletes. *Clin J Sport Med* 1994;4:182.

+ 34. Mariani PP, Santori N, Adriani E, Mastantuono M. Accelerated Rehabilitation after Arthroscopic Meniscal Repair: A Clinical and Magnetic Resonance Imaging Evaluation. *Arthroscopy* 1996;12:680.

! 35. Markolf KL, Bargar WL, Shoemaker SC. The Role of Joint Load in Knee Stability. *J Bone Joint Surg Am* 1981;63:570.

+ 36. Mintzer CM, Richmond JC, Taylor J. Meniscal Repair in the Young Athlete. *Am J Sports Med* 1998;26:630.

+ 37. Perdue PS, Hummer CD, Offosimo AJ, et al. Meniscal Repair: Outcomes and Clinical Follow-up. *Arthroscopy* 1996;12:694.

! 38. Post WR, Akers SR, Kish V. Load to Failure of Common Meniscal Repair Techniques: Effects of Suture Technique and Suture Material. *Arthroscopy* 1997;13:731.

+ 39. Rand JA. Role of Arthroscopy in Osteoarthritis of the Knee. *Arthroscopy* 1991;7:358.

+ 40. Rangger C, Klestil T, Gloetzer W, et al. Osteoarthritis after Arthroscopic Partial Meniscectomy. *Am J Sports Med* 1995;23:240.

+ 41. Reigel CA, Mulhollan JS, Morgan CD. Arthroscopic All-inside Meniscus Repair. *Clin Sports Med* 1996;15:483.

+ 42. Rimmer MG, Nawana NS, Keene GC, et al. Failure Strengths of Different Meniscal Suturing Techniques. *Arthroscopy* 1995;11:146.

+ 43. Rodeo SA, Warren RF. Meniscal Repair Using the Outside-to-Inside Technique. *Clin Sports Med* 1996;15:469.

+ 44. Rubman MH, Noyes FR, Barber-Westin SD. Arthroscopic Repair of Meniscal Tears That Extend into the Avascular Zone. *Am J Sports Med* 1998;26:87.

+ 45. Scott GA, Jolly BL, Henning CE. Combined Posterior Incision and Arthroscopic Intra-articular Repair of the Meniscus. *J Bone Joint Surg Am* 1986;68:847.

! 46. Seedhom BB, Hargreaves DJ. Transmission of the Load in the Knee Joint with Special Reference to the Role of the Menisci. Part II: Experimental Results, Discussion and Conclusions. *Eng Med* 1979;8:220.

+ 47. Shelbourne KD, Patel DV, Adsit WS, et al. Rehabilitation after Meniscal Repair. *Clin Sports Med* 1996;15:595.

+ 48. Shelbourne KD, Patel DV. Management of Combined Injuries of the Anterior Cruciate and Medial Collateral Ligaments. *J Bone Joint Surg Am* 1995;77:800.

+ 49. Shrive NG, O'Connor JJ, Goodfellow JW. Load-bearing in the Knee Joint. *Clin Orthop* 1978;131:279.

+ 50. Tasker I, Waugh W. Articular Changes Associated with Internal Derangement of the Knee. *J Bone Joint Surg Br* 1982;64:486.

+ 51. van Trommel MF, Simonian PT, Potter HG, et al. Different Regional Healing Rates with the Outside-in Technique for Meniscal Repair. *Am J Sports Med* 1998;26:446.

! 52. Walker PS, Erkman MJ. The Role of the Menisci in Force Transmission across the Knee. *Clin Orthop* 1975;109:184.

+ 53. Warren RF. Menisectomy and Repair in the Anterior Cruciate Ligament-deficient Patient. *Clin Orthop* 1990;252:55.

# CHAPTER 86

# CHONDRAL INJURIES

*John R. Raskind and Juan J. Rodrigo*

**J. R. Raskind and J. J. Rodrigo:** Department of Orthopaedic Surgery, University of California, Davis, Sacramento, California 95817.

Articular Cartilage: Composition and Structure
Cartilage Injury
Classification
Normal Tissue Response to Injury
Articular Cartilage Response to Injury
Osteochondritis Dissecans
Diagnosis and Treatment Options for Articular Injuries
Diagnosis
Partial-Thickness Injuries
Full-Thickness Injuries
Authors' Perspectives
Chapter References

The treatment of articular cartilage injuries remains a difficult challenge. Because joint surfaces have a limited intrinsic capacity for repair after they are damaged, they remain abnormal and may deteriorate over time. The natural history of chondral injuries has not been well defined, and there is a wide range of injuries from small partial-thickness lesions to large full-thickness articular defects. When considering treatment, you must include factors such as lesion location, size, and depth, associated instability, malalignment, age, and activity level (17). Although a broad range of treatment methods has been developed and short-term successes have been reported by many, no procedure has ever been shown to consistently restore a damaged articular surface to normal. Controlled studies comparing several current treatment methods for articular cartilage injuries are underway; however, long-term follow-up data will be needed before conclusions can be drawn.

## ARTICULAR CARTILAGE: COMPOSITION AND STRUCTURE

The mechanical and biological properties of articular cartilage are defined by its composition and structure. Normal articular cartilage has a highly organized structure composed of a small chondrocyte population surrounded by a large extracellular matrix (4,5). The matrix elements include collagen (primarily type II), proteoglycan aggrecan, glycoproteins, and water (4,18,20). Up to 80% of the weight of normal articular cartilage is water (4,22). Within this matrix, chondrocytes synthesize developing articular cartilage and play a role in both cartilage maintenance and degradation (5).

It is the biphasic nature of articular cartilage (solid and liquid) that provides its remarkable mechanical qualities. The solid phase consists of collagen and proteoglycans, and the liquid phase contains primarily water and electrolytes (4). When a compressive load is applied to a normal articular surface, the fluid phase takes the majority of the initial stress (5,22). Fluid flows out of the matrix to absorb the force. After a period of continuous loading, fluid has diffused out of the matrix, and the solid phase bears the load. When the load is removed, the fluid flows back into normal cartilage. In abnormal cartilage, the balance of fluid is poorly controlled, leading to abnormal force transmission and abnormal water concentration (19). A cycle of progressive damage is thus initiated (Fig. 86.1).

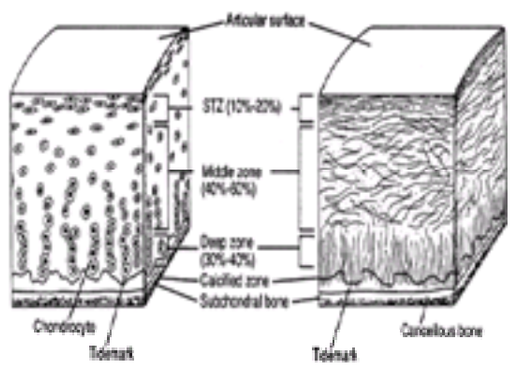


***Figure 86.1.*** Articular cartilage structure. (From Buckwalter JA, Mow VC, Ratcliffe A. Restoration of Injured or Degenerated Articular Cartilage. *J Am Acad Orthop Surg* 1994;2:193, with permission.)

## CARTILAGE INJURY

### CLASSIFICATION

A classification system is helpful for understanding the spectrum of articular cartilage injury. In 1961, Outerbridge (28) described a grading system for articular damage that was based on his findings with open operative procedures for patellar chondromalacia. This system was based on the size and gross appearance of surface lesions and did not include factors such as lesion depth or location or associated pathology on other joint surfaces. Although it was developed in the prearthroscopic era and is highly subjective, it remains the most widely used grading system for articular cartilage injury. Noyes and Stabler (23) refined the Outerbridge articular injury classification in 1989, basing their changes on arthroscopic findings. The articular lesion is defined on the basis of depth, diameter, and location. Lesions less than 10 mm are not considered clinically significant (Table 86.1).

| | |
|---|---|
| | *Outerbridge system* |
| Grade I | Softening and swelling of cartilage |
| Grade II | Fragmentation and fissuring, <0.5 in (1.25 cm) diameter |
| Grade III | Fragmentation and fissuring, >0.5 in (1.25 cm) diameter |
| Grade IV | Erosion of cartilage down to exposed subchondral bone |
| | *Noyes system* |
| Grade 1 | Cartilage surface intact (1A, some remaining resilience; 1B, deformation) |
| Grade 2A | Cartilage surface damaged (cracks, fibrillation, fissuring, or fragmentation); with less than one-half of cartilage thickness involved |
| Grade 2B | Depth of involvement greater than one-half of cartilage thickness but without exposed bone |
| Grade 3 | Bone exposed (3A, surface intact; 3B, surface cavitation) |

From AAOS Orthopaedic Knowledge Update 6, p. 344, with permission.

***Table 86.1. Classification of Articular Injuries***

### NORMAL TISSUE RESPONSE TO INJURY

When a normal, vascularized tissue is injured, a predictable cycle of repair is initiated (18,20). Necrosis of damaged cells begins immediately and depends on injury severity, blood supply, and oxygen content. Next, an inflammatory phase is mediated by the vascular system, with an influx of undifferentiated cells. A dense fibrin network forms the cellular “glue” to hold the tissue together (20). Finally, tissue repair occurs with neovascularization of the fibrin network into granulation tissue and scar.

### ARTICULAR CARTILAGE RESPONSE TO INJURY

Articular damage may result from a single severe impact or repetitive trauma (5). When a partial-thickness injury occurs, a chondral fissure or flap is often produced. The injured chondrocytes undergo necrosis with some matrix disruption, depending on degree of injury. But because the articular surface is avascular, the normal cycle of tissue repair cannot proceed. Without a blood supply, no hematoma is formed, fibrin is not produced, and the inflammatory phase cannot occur (5,18). In addition, without a fibrin network, the repair phase is very limited. The small amount of repair is generated solely by the remaining viable chondrocytes, as no supply of undifferentiated cells is available. These chondrocytes proliferate, but their response is incomplete and short-lived.

Small superficial lesions typically remain stable over time and do not progress to degenerative arthritis (18). Larger lesions with articular flaps and loose articular debris, however, cause joint effusion with mechanical symptoms and have the potential to progress to significant degenerative arthritis. Blunt trauma to articular cartilage is a particularly insidious injury. Initially, the gross appearance of the articular surface may be normal; however, microscopic examination will reveal disorganized collagen, increased water concentration, and decreased proteoglycan concentration (5). This type of blunt articular injury can later progress and degenerate.

### OSTEOCHONDRITIS DISSECANS

Osteochondritis dissecans (OCD) represents a special case of articular injury. Although the exact etiology is unknown, both the juvenile and adult forms likely develop from exercise-related repetitive subthreshold trauma that leads to subchondral stress fractures (6). The articular injury results when an osteochondral fragment becomes loose or separates. Ideally, one can initiate conservative or minimally invasive treatment before an OCD lesion separates. In the juvenile form, the open physes provide the potential for spontaneous healing, and the prognosis is good. The adult form, however, has little potential for healing and the prognosis is poor, with frequent early degenerative arthritis.

## DIAGNOSIS AND TREATMENT OPTIONS FOR ARTICULAR INJURIES

### DIAGNOSIS

Articular injuries are often difficult to identify by physical examination because their clinical presentation may be indistinguishable from or may coexist with a torn meniscus. Joint effusion and mechanical symptoms may be absent, and persistent pain after an injury may be the only complaint. Although a nonspecific finding, point tenderness over an area of articular damage can occasionally be elicited. The mechanism of articular injury is usually a twisting or shearing force, but articular damage may result also from direct trauma. The frequent association of chondral injury with chronic anterior cruciate instability has been well documented (7,13,36).

When a large knee hemarthrosis is aspirated, the presence of fat globules suggests a full-thickness chondral injury or osteochondral fracture. A high index of suspicion must be maintained to recognize a probable articular injury.

Some articular injuries can be detected preoperatively with conventional magnetic resonance imaging (MRI); however, the majority of articular lesions are found at the time of arthroscopic surgery. Specialized MRI using fast-spin echo sequences has been shown to have enhanced accuracy for partial- and full-thickness articular injuries and may allow preoperative diagnosis (29).

### PARTIAL-THICKNESS INJURIES

A wide range of articular injuries may be encountered at arthroscopy, and it is important to distinguish symptomatic lesions from those that are incidental findings. Correlate preoperative symptoms and physical findings, and look for associated pathology. Because partial-thickness injuries tend to remain stable over time, treat only those areas that have large articular flaps and impending loose bodies. To avoid making grooves or channels in the remaining cartilage surface, when debriding a lesion, rotate the cutting surface of the arthroscopic debrider blade 90°, and use only the blade edge in a tangential fashion to resect articular flaps (Fig. 86.2).

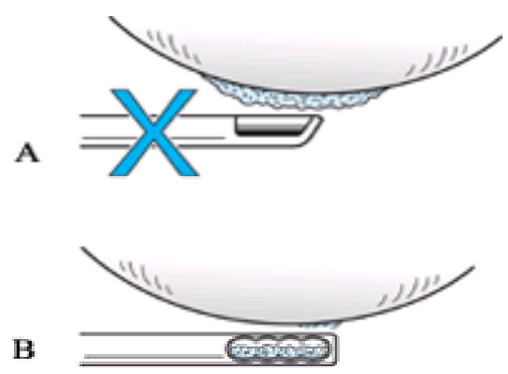


***Figure 86.2.*** Technique for arthroscopic debridement of loose chondral flaps. A: Do not debride with the mouth of the debrider directed toward the articular surface. B: Keep the mouth of the debrider at right angle (tangential) to the articular surface.

Avoid aggressive debridement, as this does not stimulate healing and may cause degeneration of the underlying cartilage. Despite the improved appearance of the articular surface after chondral shaving, Kim et al. (16) showed that further surface degeneration is common. Do not convert a partial-thickness injury to a full-thickness defect. Although there is enhanced healing potential when the subchondral bone is involved, there is little assurance that the fibrocartilage repair response will be any better than a carefully debrided partial-thickness injury, and it may lead to further deterioration of the damaged joint surface.

Laser chondroplasty may also improve the surface appearance of partial-thickness articular damage, but it has not been shown to stimulate healing. In addition, with a laser, there is the potential for thermal damage to the cartilage deep to the point of laser application that may later lead to development of a full-thickness defect or osteonecrosis. Recently, radiofrequency energy has been suggested as a means of stimulating articular healing (14), but further clinical studies are needed.

### FULL-THICKNESS INJURIES

#### *Osteochondritis Dissecans*

Although the overall prognoses for juvenile and adult OCD are very different, the treatment principles are similar. When a fragment separates from a weight-bearing surface, replace all potentially viable fragments, as removal of these fragments has a predictably poor outcome (6,33). Only those occasional fragments from non-weight-bearing surfaces may be removed with minimal adverse sequelae. Despite the frequent progression of adult OCD to degenerative arthritis, aggressive treatment with reattachment of the articular fragment may slow the progression or lessen the severity of the arthritis. After a full-thickness defect develops from an OCD lesion, one of the many treatments for focal defects can be used. Lesion size and location will help determine which treatment method is best. With osteochondritis dissecans, there may be an associated large bone defect that may require supplemental bone grafting.

#### *Focal Chondral Defects*

Over the last four decades, many treatment techniques have been developed for focal full-thickness chondral defects. These techniques began with open debridement,

spongialization, and osteotomy; evolved into arthroscopic debridement, abrasion arthroplasty, and microfracture; and now include autogenous osteoarticular mosaicplasty, autogenous chondrocyte implantation, and allograft replacement. As is often the case when many treatment options are used, no single method has been shown to be superior on a consistent basis. Because some good results have been reported with each technique, decision making for the treatment of full-thickness defects is challenging.

The various treatments can be categorized into four basic techniques: (a) stimulation of intrinsic healing potential, (b) alteration of loads, (c) transfer of autogenous tissue and cells, and (d) transfer of allograft tissue. Exact guidelines and indications for each technique are controversial. Many factors, including lesion location, size, and depth, patient age, activity level, alignment, and ligamentous instability, must be considered; and deciding which lesions to treat is difficult, as the natural history of chondral injuries is poorly understood (22). Equally important is the experience of the surgeon, as many of these techniques are technically demanding.

**Stimulation of Intrinsic Healing Potential** Since Pridie described spongialization of degenerative articular surfaces in 1959, many surgeons have developed techniques to stimulate healing of worn or damaged articular surfaces (11). Debridement with drilling, abrasion arthroplasty, and microfracture all share the basic principles of removing loose debris and degenerative cartilage, and penetrating the subchondral bone to produce bleeding. Using hand awls, instead of power drills, to create subchondral holes avoids thermal injury and creates microfractures of the trabecular bone (24,34). This in turn stimulates a tissue healing response (Fig. 86.3; see also Color Fig. 86.3).

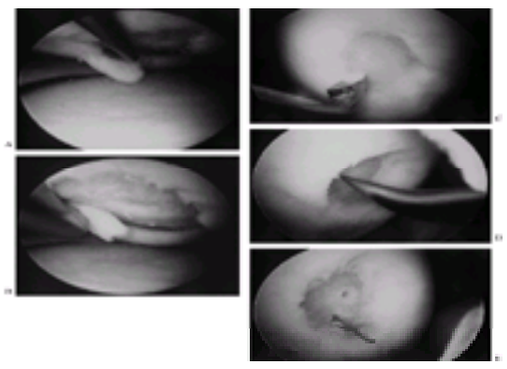

***Figure 86.3.*** (See Color Fig. 86.3.) Technique for debridement, abrasion arthroplasty, and microfracture. **A:** Arthroscopic view shows a chondral flap tear on the medial femoral condyle. **B:** The unstable flap and unstable edges of the cartilage are debrided. Note that this is a full-thickness defect exposing underlying subchondral bone. **C:** The debridement is completed by smoothing the edges with a curet. **D:** An awl is used to punch through (microfracture) the subchondral bone to bring cells into the defect. **E:** Two microfracture holes, with bleeding from one.

With subchondral bone penetration, a pluripotential stem cell line is released and, in the proper environment, can differentiate into a chondrogenic cell line (20,24). Although the perfect environment for chondrogenesis has not been defined, factors such as protected postoperative weight bearing and continuous passive motion (CPM) have been associated with enhanced healing (34,35). Other factors, such as transforming growth factor-b1, insulin-like growth factor (ILG-1), and bone morphogenic protein (BMP), appear to play an important role in the cartilage-healing environment and are being studied (4,5).

It is important to understand that subchondral penetration does not produce normal articular cartilage. Unlike hyaline cartilage, which contains primarily type II collagen, the regenerated cartilage from these techniques is fibrocartilage with a high concentration of type I collagen (18). It is not as smooth or durable as normal hyaline cartilage and tends to deteriorate over time (4,17).

An isolated chondral defect in an otherwise normal joint has a much better prognosis than a defect in an arthritic joint with diffuse chondral degeneration. Several studies have shown that drilling and abrasion of arthritic knees do not provide significant benefit over arthroscopic debridement alone and may actually accelerate the degenerative process (1,30). Smaller defects also have a better prognosis than larger ones, and unipolar defects have a better prognosis than bipolar “kissing lesions.” Overall, the short-term outcome from abrasion, drilling, and microfracture is fairly good, with variable degrees of symptomatic improvement for several years. The fibrocartilaginous repair tissue does deteriorate over time.

**Alteration of Loads** Historically, osteotomy has been used in an attempt to provide symptomatic relief for patients with damaged or degenerative joints. Its underlying principle is to shift a force concentration overload away from a damaged joint surface. Initially, symptomatic improvement can be achieved for patients with isolated unicompartmental disease, but results deteriorate with time. Insall et al. (12) reported good and excellent results from proximal tibial osteotomy in 85% of patients at 5 years but noted only 37% excellent results after 9 years. Some healing of articular lesions has been documented at second-look arthroscopic surgery after proximal tibial osteotomy (8), but preoperative arthroscopic evaluation has not been found to be a positive predictor of outcome (15).

For a focal chondral defect in an otherwise normal knee, consider osteotomy to correct significant associated limb malalignment. The role of osteotomy in a normally aligned limb is limited because the potential benefits are small, the potential complications are significant, and the potential compromise of future prosthetic reconstruction is well known (38).

**Autogenous Tissue Grafting** Autogenous grafting for articular defects is an attractive option, as it has the potential to transfer normal articular cartilage into a damaged area. There are no risk of disease transmission, no problem with tissue rejection, and a high rate of union. In addition, chondrocyte viability is maintained with fresh autogenous grafts (22). Unfortunately, the supply of expendable autogenous osteoarticular grafts is limited, and donor site morbidity is a major concern.

For smaller defects (up to 2.5 $cm^2$), an arthroscopic mosaicplasty as described by Hangody et al. (10) using small osteoarticular plugs can be performed with minimal donor morbidity (Fig. 86.4). In animal studies, the articular cartilage in the transplanted osteoarticular plugs has been shown to survive, with fibrocartilage filling the area between the plugs. The donor sites were also found to fill with fibrocartilage. Early clinical outcomes are promising, but the long-term outcome with this procedure is not known.

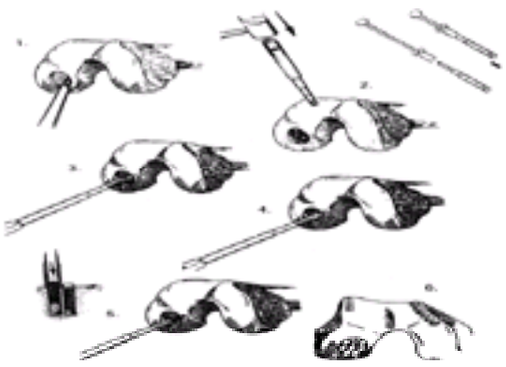

***Figure 86.4.*** Technique for osteoarticular mosaicplasty. 1: Preparation of recipient site. 2: Harvest of the grafts. 3,4: Preparation for the plug grafts. 5: Insertion of the plugs. 6: Completed mosaicplasty. (From Mandelbaum BR, Browne JE, Fu F, et al. Articular Cartilage Lesions of the Knee. *Am J Sports Med* 1998;26:855, with permission.)

For larger defects (>2.5 $cm^2$), there is usually not sufficient expendable articular cartilage to fill the defect by mosaicplasty. For femoral lesions, Outerbridge et al. (27) reported the use of a lateral patellar autograft. Graft incorporation was not a problem, and subsequent biopsy of transplanted articular cartilage demonstrated that the hyaline cartilage survived. However, donor site morbidity remains a major concern. Most of these cases necessitated removal of the lateral third of the patella, and at an average follow-up of 6.5 years, four patients had mild anterior knee pain, two had flexion contractures, and five had nonpainful patellar crepitation. Once again,

short-term results are encouraging, but the long-term outcome is unknown.

*Periosteal and Perichondrial Grafting* Success with periosteal and perichondrial grafting of articular defects has been reported both in animal models and in humans. The principle behind these procedures is to provide a new source of chondrogenic cells to repair the defect. Several series have been published, and some successful regeneration of hyaline cartilage has been achieved (21,25,26,31), but there are no long-term data or controlled studies. The limited supply of expendable perichondrium limits its use and makes periosteum a more attractive option. Meticulous technique is required in both graft harvest (to maintain cell viability) and graft fixation (to avoid unstable or redundant repair tissue). There is evidence that this technique works best in younger patients (5), and some problems with graft calcification have also been reported (2,24).

*Autologous Chondrocyte Implantation* In 1994, Brittberg et al. (3) published their initial clinical series of 23 patients with full-thickness chondral defects treated with autologous chondrocyte implantation (ACI). Their technique, which was developed initially in an animal model, involves a two-stage surgical procedure (9). At arthroscopy, cartilage slices are harvested from the non-weight-bearing trochlear margins or intercondylar notch, placed in sterile medium, and sent to the laboratory. The chondrocyte cells are isolated and cultured over 14–21 days to increase the number of cells 10- to 20-fold. A second open surgical procedure is performed in which a periosteal patch is sutured over the chondral defect and the cultured chondrocytes are injected under the patch. Fibrin glue is used to achieve a watertight seal (Fig. 86.5).

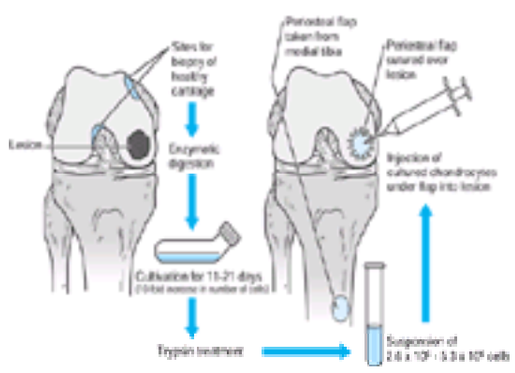


***Figure 86.5.*** Technique for autologous chondrocyte implantation. (Redrawn from Mandelbaum BR, Browne JE, Fu F, et al. Articular Cartilage Lesions of the Knee. *Am J Sports Med* 1998;26:856, with permission.)

With this technique, Brittberg et al. (3) reported 87% good and excellent results with femoral condyle lesions and noted repair of cartilage with a hyaline-like appearance at second-look arthroscopy in 73% of these lesions. Defects involving the patellofemoral joint did poorly, with only 28% good and excellent results. This was felt in part to be due to underlying patellar malalignment that was not corrected at the time of ACI.

Histologic studies of the hyaline-like repair tissue demonstrated an abundance of type II collagen. Animal studies have demonstrated that the repair is initiated by the injected chondrocytes, which repopulate the defect, and not by the periosteal patch (9). In addition, it is of particular interest that repeat arthroscopy on the successfully treated femoral condyle lesions demonstrated improvement of the hyaline-like repair tissue over time. Since the initial clinical report, tremendous interest in ACI has been generated, and the technique has been used in 1,896 cases recorded in the Genzyme Tissue Repair Registry (Genzyme, Inc., Cambridge, MA). The early data suggest moderate success with femoral defects, but few surgeons have duplicated the success rate of Peterson and the early Swedish experience (3). This underscores the importance of meticulous surgical technique, careful patient selection, and surgeon experience. Long-term controlled studies are in progress.

**Allograft Tissue Grafting** Osteoarticular allograft replacement of damaged articular surfaces has been the subject of studies for many years. The advantages of allografts include potential availability of young donor cartilage, graft material from identical anatomic location (orthotopic), and avoidance of donor-site morbidity. Disadvantages, however, include possible disease transmission and immunologic reactions (22). Freezing the allograft tissue decreases the immunogenicity of the subchondral bone but damages the viability of the transplanted chondrocytes (37).

Studies of osteoarticular allografts in humans have not been followed long enough to determine the long-term outcome, but several authors have reported promising early results (32). The best results appear to be in unipolar traumatic lesions treated with young orthotopic allografts (22). Osteoarticular allograft replacement should be reserved for patients with massive osteoarticular defects that cannot be treated with other methods. It can also be considered as a salvage procedure for patients who have large defects for which conventional treatments failed.

## AUTHORS' PERSPECTIVES

Although many issues in the treatment of chondral injuries are controversial, it is clear that any underlying ligamentous instability or malalignment must be corrected if the chondral injury treatment is to succeed. Although we recognize that abrasion arthroplasty and microfracture produce fibrocartilage repair tissue and not hyaline cartilage, our bias is to use this technique as the initial treatment for small and medium-sized focal chondral defects. It is an easy, inexpensive, low-morbidity procedure that can be performed at the time of initial arthroscopy. Should this fail, we use a secondary technique with ACI or osteoarticular plug autografts (mosaicplasty). Previous penetration of the subchondral bone does not appear to compromise outcome after ACI, as 7 of 23 patients in Brittberg et al.'s (3) original series had undergone drilling initially.

For larger chondral defects, particularly uncontained lesions on weight-bearing femoral condyles in young active athletes, we favor ACI or mosaicplasty as the initial procedure because abrasion arthroplasty with microfracture is less likely to succeed (Fig. 86.6) (17). In addition, for massive articular defects, particularly those associated with significant bone loss, osteoarticular allograft is the salvage option of choice. Until long-term data from controlled studies are available, use the above recommendations as general guidelines. Individualize the treatment of each patient, and perform only those procedures in which you have mastered technical proficiency.

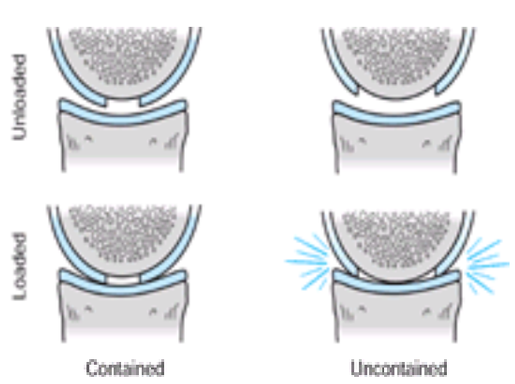


***Figure 86.6.*** Loading of contained and uncontained articular defects. (Redrawn from Mandelbaum BR, Browne JE, Fu F, et al. Articular Cartilage Lesions of the Knee. *Am J Sports Med* 1998;26:858, with permission.)

The frequent coexistence of chondral injury with ligament tears and meniscus injuries cannot be overemphasized. All too often, a patient is referred for orthopaedic consultation with an MRI scan showing a meniscus tear. The patient arrives, anticipating that a “work order” for arthroscopic meniscectomy is all that is required. After the simple procedure is completed, the patient assumes that he or she will be “normal” again. The possibility of a chondral injury or defect may never have been considered. If the findings at surgery are primarily chondral damage and the outcome is not “normal,” the patient becomes confused and upset. To avoid this, we recommend a brief preoperative discussion of possible chondral damage with all patients undergoing arthroscopic knee surgery. If MRI has been performed, we review the images with the patient, explain the limitations of the study, and discuss the possibility of additional findings at surgery that may require additional treatment.

## CHAPTER REFERENCES

Each reference is categorized according to the following scheme: *, classic article; #, review article; !, basic research article; and +, clinical results/outcome study.


* 1. Bert JM, Maschka K. The Arthroscopic Treatment of Unicompartmental Gonarthrosis: A Five-year Follow-up Study of Abrasion Arthroplasty plus Arthroscopic Debridement or Arthroscopic Debridement Alone. *Arthroscopy* 1989;5:25.

+ 2. Bouwmeester SJ, Beckers JM, Kuijer R, et al. Long-term Results of Rib Perichondrial Grafts for Repair of Cartilage Defects in the Human Knee. *Int Orthop* 1997;21:313.

* 3. Brittberg M, Lindahl A, Nilsson A, et al. Treatment of Deep Cartilage Defects in the Knee with Autologous Chondrocyte Transplantation. *N Engl J Med* 1994;331:889.

# 4. Buckwalter JA, Mankin HJ. Articular Cartilage. Part I and Part II. *J Bone Joint Surg Am* 1997;79:600.

# 5. Buckwalter JA, Mow VC, Ratcliffe A. Restoration of Injured or Degenerated Articular Cartilage. *J Am Acad Orthop Surg* 1994;2:192.

# 6. Cahill BR. Osteochondritis Dissecans of the Knee: Treatment of Juvenile and Adult Forms. *J Am Acad Orthop Surg* 1995;3:237.

+ 7. Cameron M, Buchgraber A, Passler H, et al. The Natural History of the Anterior Cruciate Ligament-deficient Knee. *Am J Sports Med* 1997;25:751.

* 8. Fujisawa Y, Masuhara K, Shiomi S. The Effect of High Tibial Osteotomy on Osteoarthritis of the Knee: An Arthroscopic Study of 54 Knee Joints. *Orthop Clin North Am* 1979;10:585.

+ 9. Grande DA, Pitman MI, Peterson L, et al. The Repair of Experimentally Produced Defects in Rabbit Articular Cartilage by Autologous Chondrocyte Transplantation. *J Orthop Res* 1989;7:208.

* 10. Hangody L, Karpati Z, Sukosd L, et al. Autologous Osteochondral Mosaicplasty for Replacing Knee Cartilage Defects in Dogs. *Int Orthop* 1997;5:175.

* 11. Insall JN. Intra-articular Surgery for Degenerative Arthritis of the Knee: A Report of the Work of the Late K. H. Pridie. *J Bone Joint Surg Br* 1967;49:211.

* 12. Insall JN, Joseph DM, Msika C. High Tibial Osteotomy for Varus Gonarthrosis. *J Bone Joint Surg Am* 1984;66:1040.

+ 13. Johnson DL, Urban WP, Caborn DNM, et al. Articular Cartilage Changes Seen with Magnetic Resonance Imaging-detected Bone Bruises Associated with Acute Anterior Cruciate Ligament Rupture. *Am J Sports Med* 1998;26:409.

+ 14. Kaplan L, Uribe JW, Saskin H, Markarian G. The Viability of Articular Cartilage following Radiofrequency-generated Energy Treatment. *Arthroscopy* 1999;15:569(abst).

* 15. Keene JS, Dyreby JR. High Tibial Osteotomy in the Treatment of Osteoarthritis of the Knee. *J Bone Joint Surg Am* 1983;65:36.

* 16. Kim HK, Moran ME, Salter RB. The Potential for Regeneration of Articular Cartilage in Defects Created by Chondral Shaving and Subchondral Abrasion. *J Bone Joint Surg Am* 1991;73:1301.

# 17. Mandelbaum BR, Browne JE, Fu F, et al. Articular Cartilage Lesions of the Knee. *Am J Sports Med* 1998;26:853.

* 18. Mankin HJ. The Reaction of Articular Cartilage to Injury and Osteoarthritis. Part I. *N Engl J Med* 1974;291:1285.

* 19. Mankin HJ. The Reaction of Articular Cartilage to Injury and Osteoarthritis. Part II. *N Engl J Med* 1974;291:1335.

# 20. Mankin HJ. Current Concepts Review: The Response of Articular Cartilage to Mechanical Injury. *J Bone Joint Surg Am* 1982;64:460.

+ 21. Moran ME, Kim HK, Salter RB. Biological Resurfacing of Full-thickness Defects in Patellar Articular Cartilage of the Rabbit: Investigation of Autogenous Periosteal Grafts Subjected to Continuous Passive Motion. *J Bone Joint Surg Br* 1992;74:659.

# 22. Newman AP. Articular Cartilage Repair. *Am J Sports Med* 1998;26:309.

* 23. Noyes FR, Stabler CL. A System for Grading Articular Cartilage Lesions at Arthroscopy. *Am J Sports Med* 1989;17:505.

# 24. O'Driscoll SW. Current Concepts Review: The Healing and Regeneration of Articular Cartilage. *J Bone Joint Surg Am* 1998;80:1795.

+ 25. O'Driscoll SW, Keeley FW, Salter RB. The Chondrogenic Potential of Free Autogenous Periosteal Grafts for Biological Resurfacing of Major Full-thickness Defects in Joint Surfaces under the Influence of Continuous Passive Motion: An Experimental Investigation in the Rabbit. *J Bone Joint Surg Am* 1986;68:1017.

+ 26. O'Driscoll SW, Salter RB. The Repair of Major Osteochondral Defects in Joint Surfaces by Neochondrogenesis with Autogenous Osteoperiosteal Grafts Stimulated by Continuous Passive Motion: An Experimental Investigation in the Rabbit. *Clin Orthop* 1986;208:131.

+ 27. Outerbridge HK, Outerbridge AR, Outerbridge RE. The Use of a Lateral Patellar Autologous Graft for the Repair of a Large Osteochondral Defect in the Knee. *J Bone Joint Surg Am* 1995;77:65.

* 28. Outerbridge RE. The Etiology of Chondromalacia Patellae. *J Bone Joint Surg Br* 1961;43:752.

+ 29. Potter HG, Linklater JM, Allen AA, et al. Magnetic Resonance Imaging of Articular Cartilage in the Knee: An Evaluation with Use of Fast-spin-echo Imaging. *J Bone Joint Surg Am* 1998;80:1276.

* 30. Rand JA. Role of Arthroscopy in Osteoarthritis of the Knee. *Arthroscopy* 1991;7:358

+ 31. Ritsila VA, Santavirta S, Alhopuro S, et al. Periosteal and Perichondral Grafting in Reconstructive Surgery. *Clin Orthop* 1994;302:259.

# 32. Rodrigo J. Revision Chondral Surgery. In: Zarins B, Marder RA, eds. *Revision of Failed Arthroscopic and Ligament Surgery.* Malden: Blackwell Science, 1998:83.

# 33. Rodrigo JJ, Steadman JR, Silliman JF. Osteoarticular Injuries of the Knee. In: Chapman MW, ed. *Operative Orthopaedics,* 2nd ed. Philadelphia: JB Lippincott Co, 1993:2077.

+ 34. Rodrigo JJ, Steadman JR, Silliman JF, Fulstone HA. Improvement of Full-thickness Chondral Defect Healing in the Human Knee after Debridement and Microfracture Using Continuous Passive Motion. *Am J Knee Surg* 1994;7:109.

* 35. Salter RB, Simmonds DF, Malcolm BW, et al. The Biological Effect of Continuous Passive Motion on the Healing of Full-thickness Defects in Articular Cartilage: An Experimental Investigation in the Rabbit. *J Bone Joint Surg Am* 1980;62:1232.

+ 36. Sherman MF, Warren RF, Marshall JL, Savatsky GJ. A Clinical and Radiographical Analysis of 127 Anterior Cruciate Insufficient Knees. *Clin Orthop* 1988;227:229.

+ 37. Stevenson S, Dannucci GA, Sharkey NA, Pool RR. The Fate of Articular Cartilage after Transplantation of Fresh and Cryopreserved Tissue-antigen-matched and Mismatched Osteochondral Allografts in Dogs. *J Bone Joint Surg Am* 1989;71:1297.

* 38. Windsor RE, Insall JN, Vince KG. Technical Considerations of Total Knee Arthroplasty after Proximal Tibial Osteotomy. *J Bone Joint Surg Am* 1988;70:547.

# CHAPTER 87

# PATELLOFEMORAL JOINT DISORDERS

*Alan C. Merchant*

**A. C. Merchant:** Department of Orthopedic Surgery, Stanford University School of Medicine and El Camino Hospital, Mountain View, California 94040.

Classification and Pathophysiology
- Patellofemoral Dysplasia

Clinical Evaluation
- History
- Physical Examination
- Radiography and other Imaging

Treatment and Surgical Indications
- Nonoperative Treatment
- Operative Treatment

Surgical Techniques
- Arthroscopic Patellar Debridement (“Shaving”)
- Arthroscopic Lateral Release
- Medial Tibial Tubercle Transfer
- Proximal Quadriceps Plasty
- Medial Patellofemoral Ligament Reconstruction
- Anteromedial Tibial Tubercle Plasty
- Patellectomy
- Total Patellofemoral Arthroplasty

Rehabilitation

Pitfalls and Complications
- Reflex Sympathetic Dystrophy
- Infrapatellar Contraction Syndrome
- Compartment Syndromes
- Iatrogenic Medial Subluxation of the Patella
- Loss of Correction

Chapter References

Historically, the patellofemoral joint received relatively little attention until well into the latter half of the 20th century. Yet today anterior knee pain and dysfunction are among the major reasons patients seek help. Why was this joint overlooked for so long? Perhaps the perspective of history will help to answer this question. During the embryonic stage of orthopaedic surgery, those general surgeons whom we would now call orthopaedists wrote infrequent yet classic articles about the patellofemoral joint. These surgeons were much more concerned, however, with life-threatening and crippling conditions such as compound fractures, osteomyelitis, pyogenic arthritis, tuberculosis, poliomyelitis, and birth defects. World Wars I and II kept the orthopaedic surgeons focused on trauma and infection. Furthermore, the general population in the United States had little time for sports involvement during two world wars and the Great Depression.

The advent of antibiotics in the 1940s and the polio vaccines in the 1950s changed the practice of orthopaedic surgery forever. At the same time, the prosperity of the 1950s and 1960s allowed increased participation in recreational, scholastic, and professional sports. Orthopaedists were ill prepared to treat the increasing numbers of patellofemoral complaints. It remains unknown how many *normal* menisci were removed for “giving way” and “internal derangement” symptoms that were actually caused by patellofemoral dysfunction. And patellectomy was all too frequently the final answer to a perplexing and unresolved clinical problem. Even during the development of “total” knee arthroplasties, the early designs completely ignored the patellofemoral compartment.

During the mid-1970s, the burgeoning interest in sports medicine, the development of accurate and reproducible axial radiographs, and the explosion of arthroscopy all combined to focus attention on this puzzling joint. Yet why are patellofemoral problems so frequent? I believe the answer is related to the fact that about 20% of an asymptomatic general population demonstrate objective radiographic abnormalities of the patellofemoral joint, presumably on a genetic basis (30).

Knowing that this joint mediates the forces generated by the largest muscles (quadriceps and hamstrings) through the largest lever arms (femur and tibia), one can now understand why these relatively minor variations, which become symptomatic as a result of the added physical demands of sports, are so frequent. This genetic theory also explains why patellofemoral dysplasia has such a strong familial predisposition.

Other factors that have retarded the understanding of this enigmatic and unique joint have been semantic and diagnostic confusion. Years ago a popular diagnosis in the literature was “traumatic dislocation.” But aren't all dislocations of the patella “traumatic”? Just ask the patient. What that term really implies is that trauma is the sole cause of the dislocation. After the advent of accurate axial knee radiographs in the 1970s, it was quickly recognized that the normal knee rarely suffers a patellar dislocation. Thus, it remains our duty to search for the abnormality or deficiency that causes the pain or instability, and we must remember that there are frequently multiple causes.

“Chondromalacia patellae” has been a misused and popular diagnosis over the years. Aleman (1) originated the term in 1928 to describe the gross appearance at surgery of previously traumatized articular cartilage. For accuracy and precision, this term should be used only within this meaning, never as a solitary diagnosis, and never equated with anterior knee pain. “Anterior knee pain syndrome” is a deception; it is a symptom masquerading as a diagnosis. Our medical colleagues treat a stomachache with a bland diet and antacids without resorting to the use of “stomachache syndrome.” Why then can't we treat anterior knee pain with rest, proper exercises, and antiinflammatories without calling it a syndrome? If one makes the diagnosis of anterior knee pain syndrome or chondromalacia patellae, there is the tendency to stop there and not continue searching for the primary anatomic cause (or causes, for they are frequently multiple). If a thorough search fails to discover a cause, there is nothing wrong with the diagnosis of “idiopathic chondromalacia” or “idiopathic anterior knee pain.”

Therefore, I would make a plea for a logical and scientific approach to the patellofemoral joint so that the formulation of treatment protocols is based on an accurate understanding of the complex pathophysiology of this fascinating joint.

## CLASSIFICATION AND PATHOPHYSIOLOGY

A clinical classification of patellofemoral disorders is presented in Table 87.1. This classification is designed for clinical use and based on etiology. Almost always the clinician can establish a diagnosis, or differential diagnosis, using only a detailed history, a thorough physical examination, and properly selected routine radiographs. Because many different patellofemoral disorders respond very well to the same nonoperative treatment protocols, the clinician can frequently provide definitive relief working only from a differential diagnostic list. Only about 10% of patellofemoral patients will fail to respond to these nonoperative measures (8). If surgery is the next option, and the diagnosis is still in doubt, then more sophisticated diagnostic studies such as bone scans, computed tomography (CT) scans, or diagnostic arthroscopy may be entertained. Furthermore, by focusing on etiologies rather than symptoms such as anterior knee pain or secondary changes such as chondromalacia (chondrosis), a rational treatment program naturally follows.

***Table 87.1. Classification of Patellofemoral Disorders***

The first group of the classification in Table 87.1 lists conditions caused by trauma, whether acute, repetitive, or delayed. These are self-explanatory for the most part and require little comment. Group II (patellofemoral dysplasia) deals with patients who have patellar pain and/or instability produced by the activities of daily living or the normal stress of sports. Patellofemoral dysplasia is discussed in more detail later in this chapter. Group III allows inclusion of that ever-shrinking group of patients with proven chondromalacia patellae for which no cause can be found. Groups IV and V contain the less common patellofemoral disorders, with no attempt to include rare entities such as tumors, infections, or metabolic disorders. Group VI has been added to the original classification (29) to include those patellofemoral disorders of iatrogenicorigin.

The same conceptual design of the Hauser procedure (19) that made it so successful in stopping recurrent dislocation of the patella contained the seeds of its own failure. Medial transfer of the tibial tubercle down onto the sloping side of the anteromedial face of the tibia decreased the lever arm through which the extensor mechanism worked, thereby increasing the patellofemoral joint reaction force. Too frequently, this produced secondary patellofemoral arthrosis. The short-term success rate of the Hauser procedure was improved by adding distal transfer as well. This may have been appropriate for those with a significant patella alta. However, the folly of treating all patients who had recurrent dislocations of the patella with one single operation, no matter what factors were causing their dislocations, became apparent in longer-term studies. The distal transfer in many patients produced a severe patella infera, which added to the secondary patellofemoral osteoarthrosis. Performing a lateral release on a patient who does not have a tight lateral retinaculum is always a mistake and easily leads to an iatrogenic medial patellar compression syndrome or iatrogenic chronic medial subluxation of the patella. Another cause for these iatrogenic complications is an excessive, or overzealous, release of the retinaculum and the vastus lateralis muscle as well (21,24).

### PATELLOFEMORAL DYSPLASIA

The majority of patients with complaints of patellar pain and instability will have objective abnormalities of the extensor mechanism and patellofemoral joint. These abnormalities are preexisting and developmental. Major examples include a shallow trochlea, an increased quadriceps angle (Q-angle), a vastus medialis obliquus (VMO) deficiency, and a patella alta or infera. These multiple abnormalities or factors all affect the proper function of the patellofemoral joint. Each abnormality is not just present or absent in any given patient but can vary from mild to severe anatomically, thus having a mild to severe effect on patellofemoral pathomechanics and symptoms.

A pattern of preexisting abnormalities, such as a shallow intercondylar sulcus, deficient vastus medialis obliquus, patella alta, chronic patellar subluxation, and so on, suggests an underlying genetic, developmental, or familial abnormality. The expression of these abnormalities can vary from mild to severe, but it is helpful to apply the overall and unifying term “patellofemoral dysplasia.” This term is a better diagnostic category than “maltracking syndrome” because it indicates a cause, developmental dysplasia, rather than a common physical characteristic, abnormal tracking. Patellofemoral dysplasia can be thought of as analogous to developmental dysplasia of the hip. Embryologically, the femoral trochlea develops early *in utero* (8 weeks), complete with its adult predominance of the lateral condyle (16). At this stage the knee is acutely flexed, and the patella is not even articulating with the trochlea. Therefore, pressure inhibition from a laterally subluxed patella cannot influence the trochlear depth. This is confirmed clinically by the many patients who have a shallow sulcus and no associated lateral patellar subluxation.

Perhaps the best explanation for the existence of patellofemoral dysplasia and why it is so common in the general population can be found in studies of comparative anatomy and phylogeny. Dye (11) has demonstrated that the bicondylar, cam-shaped design of the distal femur is of ancient origin, existing in early tetrapods about 360 million years ago. The patella did not appear until about 70 million years ago. The final human adaptations of the knee that allowed erect bipedal gait evolved from quadruped primates and did not occur until 3.5 million years ago. A valgus femorotibial angle allowed the supporting limb to approach the midline for efficient bipedal gait, but this change imparted a lateral thrust on the patella acting through an increased Q angle. The adaptation of a deeper patellofemoral trochlea with a prominent lateral femoral condyle and lateral patellar facet plus the development of the lower oblique fibers of vastus medialis, which is peculiar to humans (4), allowed the extensor mechanism to function without lateral dislocation of the patella. It could be possible that these relatively recent human adaptations of the extensor mechanism are less well “fixed” genetically and therefore show greater variability, thus explaining the frequency of patellofemoral dysplasia.

We should consider this group of patellofemoral disorders as a developmental dysplasia characterized by a continuum of anatomic deficiencies. This will tend to focus our attention on the search for sometimes subtle abnormalities to explain each patient's symptoms and help individualize our treatment to correct these deficiencies.

Having combined these conditions together under the large category of patellofemoral dysplasia, we must also subdivide this classification. This will allow those patients with symptoms, signs, and severity in common to be assessed as a group. Different treatment protocols can be developed and compared. To do this, we must evaluate each of the factors associated with patellofemoral disorders known to influence patellar instability and pain. The normal lateral vector imparted to the patella by the normal quadriceps angle is resisted by (a) the depth of the femoral trochlea with its larger lateral condyle and (b) the vastus medialis obliquus, whose fibers insert more distally and horizontally on the patella than those of the vastus lateralis. A deficiency of either the intercondylar sulcus or the VMO or both predisposes to patellar subluxation and dislocation. Any increase in the Q angle itself from any cause (e.g., internal femoral torsion, external tibial torsion, genu valgum) increases the lateral vector on the patella. There is also a dynamic increase in the Q angle when the foot is planted and the femur internally rotates during the common maneuver of cutting and pushing off; this predisposes to dislocation. The lateral tethering of a tight lateral retinaculum can also increase the lateral force on the patella, producing the tilt frequently seen radiographically. A high-riding patella (patella alta) will also increase patellar instability because it articulates in the more shallow superior portion of the sulcus for any given degree of knee flexion compared to the normal. That is, the knee must be flexed more to bring a high-riding patella safely within the deeper portion of the trochlea.

## CLINICAL EVALUATION

It is elementary—yet bears repeating—that the goal of clinical evaluation is to establish a differential diagnosis, a diagnosis, and a logical treatment plan. Because patellofemoral instabilities and pain almost never arise from a single cause, and in any given patient each of these multiple factors or abnormalities can present within a range from mild to severe, the clinician's job is to document each and its severity to discover the pathomechanics, the pathophysiology, and the correct diagnosis and to establish a logical treatment plan. It is foolhardy to search for one physical sign, such as the apprehension response, or one radiographic finding, such as patellar subluxation, to establish a diagnosis and a treatment protocol. Each element of this evaluation—the history, the physical examination, and the routine radiographs—plays an important and interlocking role. However, the physical examination is paramount in finding the physical abnormalities causing the patient's symptoms and suggesting corrective treatment, both nonoperative and surgical. Simple checklists can be very helpful in speeding up record keeping and keeping track of data. Both knees should be evaluated—as a control and because patellofemoral disorders are so frequently bilateral.

For the sake of brevity, this discussion focuses on the patellofemoral joint, with the understanding that it is only part of a complete knee evaluation that must also include examination of the ligaments, the menisci, and the femorotibial articulations. Common things do occur commonly, so be mindful that any given patient may have two or more conditions, and they may or may not be symptomatic at any given time or during certain activities.

### HISTORY

#### *Anterior Knee Pain*

Spontaneous onset of anterior knee pain or persistence after minor trauma indicates a preexisting condition. It is typically aggravated by flexed-knee activities such as going up and down stairs and hills (down often worse than up), squatting, kneeling, jumping, and prolonged sitting (“theater ache”). Constant and unremitting pain

suggests reflex sympathetic dystrophy of neuritic origin.

### *Giving Way*

Differentiate the sudden collapse, fall, and swelling (combined with a shallow trochlea and/or subluxation on x-ray) of true patellar instability from the sudden pain and inhibition release frequently aggravated by quadriceps weakness (with normal axial-view x-rays). Recurrent patellar dislocation and subluxation almost never occur with normal findings on axial-view radiographs.

## PHYSICAL EXAMINATION

### *Standing Limb Alignment*

*Internal femoral torsion* and *external tibial torsion* cause the patellae to “squint” and produce the “miserable malalignment” of James et al. (23). The final common pathway is an excess lateralizing force on the extensor mechanism, resulting in a lateral patellar compression syndrome. Check also for foot alignment, because *excess pronation* can be a cause for anterior knee pain.

### *Sitting Examination*

Assess the *tubercle–sulcus angle* (Fig. 87.1). Normal is 0°; compare later with the Q angle.

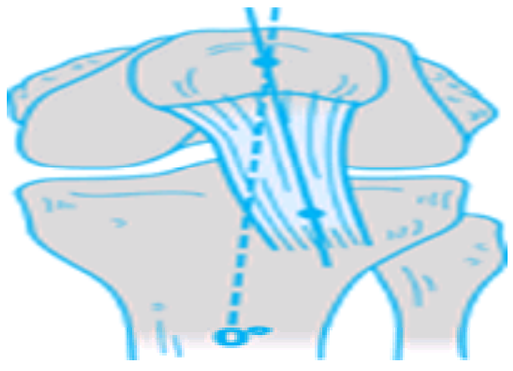

***Figure 87.1.*** Tubercle–sulcus angle. Normal ~0°.

Watch and feel the patella during its excursion through the trochlea in active extension and flexion. Does it translate, tilt, and rotate laterally at terminal extension? This is a **J** *sign* because its track follows the pattern of an inverted **J**. Look for x-ray confirmation later as patellar subluxation, tilt, or both on the axial view. A good assessment of the patellar position and attitude from 30° to 0° obviates the need for the more costly imaging of CT scans and magnetic resonance imaging (MRIs).

Look for a *deficient vastus medialis obliquus* by asking the patient to extend the knee against a fixed resistance at about 30°. The resultant quadriceps contraction will make the defect more apparent. Normally the VMO should reach and insert into the upper third of the patella.

Check for *crepitation* under load by palpation during extension and flexion with manual resistance at the ankle. Manual patellar compression at different degrees of knee flexion helps to localize segmental chondral lesions.

Carefully palpate the entire anterior knee to discover patellar or quadriceps tendinitis, lateral or medial patellofemoral joint line synovitis, and any neuromas in the lateral retinaculum or in prior scars.

The *patellar glide tests* are extremely important. They not only offer clues for the underlying pathomechanics leading to a correct diagnosis but also point to abnormalities to be corrected by exercise, bracing, or surgery. Moving the patella medially and laterally with the knee relaxed and flexed 30° demonstrates retinacular contracture or laxity. (Tip: Palpate the patellar tendon to determine if the patient has relaxed the quadriceps or not. If not, try performing this test with the patient supine and the knee relaxed over a pillow or bolster.) The patella should move about one fingerbreadth in each direction. Excessive lateral glide means medial laxity, even rupture of the medial patellofemoral ligament, and may evoke the “apprehension response” as the patient feels the familiar sensation of dislocation. Restricted medial glide means a tight lateral retinacular tether. (Tip: Performance of an isolated lateral retinacular release in spite of an already lax or normal lateral retinaculum represents unnecessary and possibly dangerous surgery.) Increased medial glide is found in hyperlax individuals (e.g., Ehlers-Danlos) and after a lateral release.

The *Fulkerson relocation test* (16) for iatrogenic medial subluxation (after either severance of the vastus lateralis tendon or excessive medial tibial tubercle transfer) is a variation of the glide tests. With the knee in extension, push the patella medially as far as possible and hold it there while flexing the knee passively. If the patella starts to impinge on the medial trochlear eminence and then suddenly reduces into the groove, and the patient confirms a reproduction of symptoms, the test is positive.

### *Recumbent Examination*

Because most studies have standardized the quadriceps angle assessment with the patient supine, the knee extended, and the patella anterior, measure it that way. If another method is chosen, be consistent. Measure from the anterior superior iliac spine to the patella (make sure the patella is centered at the trochlea) to the tibial tubercle. The complementary angle is the Q angle (Fig. 87.2). The average is about 15° ± 5°. Compare this measurement with the tubercle–sulcus angle performed earlier. The importance of assessing the lateralizing forces exerted on the patella by the position of the tibial tubercle cannot be overemphasized. Again, it provides one more piece of the pathomechanical puzzle for a correct diagnosis and leads to a logical treatment plan and a more accurate prognosis. For example, if a patient suffers recurrent patellar dislocations, and the only abnormalities are a shallow trochlea and a tight lateral retinaculum, the chances are excellent that an isolated lateral retinacular release will be successful. However, the finding of a 25° Q angle ruins that prognosis, and a medial tibial tubercle transfer will be needed in addition.

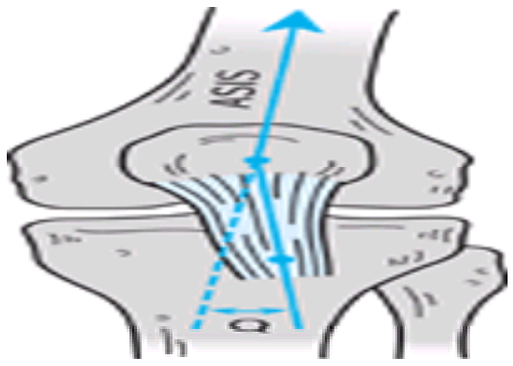


***Figure 87.2.*** Quadriceps (Q) angle. Normal ~10°–15°.

The *f*lexion *ab*duction *e*xternal *r*otation (FABER) or “Figure 4” test should always be included in every knee examination to rule out referred pain from hip pathology.

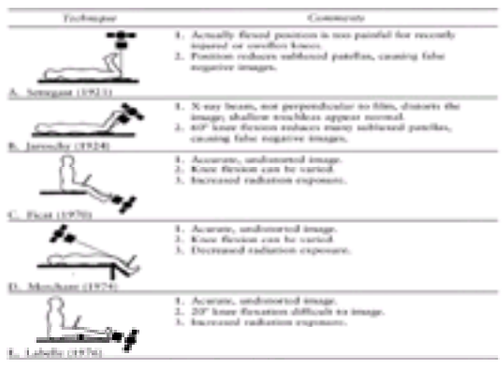

***Figure 87.4.*** Axial patellofemoral radiographic techniques.

Straight-leg raising demonstrates hamstring contracture as well as clues for pain of sciatic origin.

Ober's test for iliotibial band contracture correlates well with lateral knee pain.

A prone knee flexion examination will reveal quadriceps contracture if present.

With the patient still prone and the knee flexed 90°, the femur can be rotated into maximal internal and external rotation to assess internal and external femoral torsion. Then in the same position with the ankle at neutral, the thigh–foot angle is measured for external tibial torsion. These tests can quickly confirm a “miserable malalignment,” as discussed previously.

## RADIOGRAPHY AND OTHER IMAGING

Radiographs serve only as adjuncts to a careful history and physical examination of the knee. They are, after all, a physical image extending the physical examination. Radiographs must be used in context with all the rest of the clinical data to reach a differential diagnosis, the final diagnosis, and a reasonable treatment plan.

Rather than a preset battery of radiographic views, order each view based on clinical suspicions. For example, the tunnel view is most helpful when loose bodies or osteochondritis dissecans is suspected. Similarly, when spontaneous meniscal degeneration or osteoarthrosis is possible, the anteroposterior (AP) view should be taken during full (100%) weight bearing on one leg using a long (17-in.) film in order to maximize any joint space narrowing and to reveal angular deformity.

*Always order an accurate axial view for all knee disorders.* If the history and physical examination point to a patellofemoral problem, the axial view will provide the most radiographic information. Even if no such problem is suspected, it may be harmful to advise therapy without knowing the status of the patellofemoral joint. In 1988 we demonstrated that approximately 20% of the asymptomatic general population have objective radiographic subluxation of the patella (29). If such a patient is placed on “open chain” quadriceps exercises (an isokinetic machine, short-arc free weights, or isotonic free weights), the abnormally large joint reaction forces applied to the much smaller surface contact area can generate destructive forces very quickly, causing an iatrogenic chondrosis (chondromalacia) that is permanent.

### *Anteroposterior View*

Take the AP view as a full, 100% weight-bearing (standing on one leg) exposure on a long (17-in.) film if the patient is more than 35 years of age, has had a meniscectomy, has an angular deformity, or has signs of degenerative joint disease or a degenerative meniscal tear. This maximizes narrowing and reveals angulation. The posteroanterior 45° flexion weight-bearing view described by Rosenberg et al. (33) can be selected in addition. It is more sensitive and specific in assessing articular cartilage loss in the posterior compartments of the knee.

### *Lateral View*

The lateral view gives the best assessment of patellar height relative to the joint line: patella alta or infera. The Blackburne-Peel ratio is more accurate and consistent than the Insall-Salvati measurements (3) (Fig. 87.3). A long distal patellar tip, or “nose,” can distort the ratio, and on many films the tibial tubercle is difficult to locate.

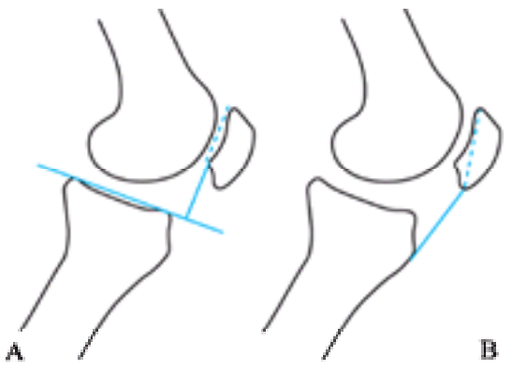


***Figure 87.3.*** Patellar height ratios: (**A**) Blackburne-Peel ratio 1:1 (±20%); (**B**) Insall and Salvati ratio 1:1 (±20%).

If the femoral condyles are superimposed as in a true lateral, and the image of the patella is oblique, the patella is tilted (rotated laterally).

### *Axial View*

Technique in obtaining the axial view is extremely important (28) (see Fig. 87.4 for various techniques). The clinician must know what technique was used for proper interpretation. Certain techniques cause image distortion (Fig. 87.4*B* and Fig. 87.5).

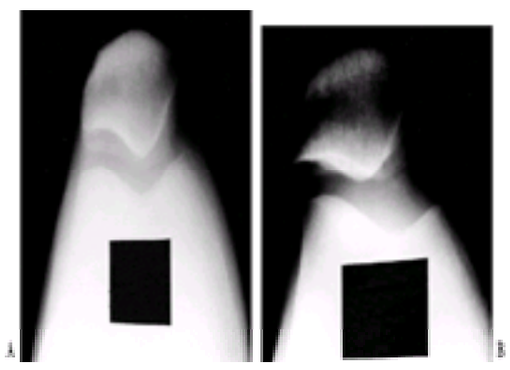

***Figure 87.5.*** Axial radiographs of the same left knee taken at the same time. **A:** By the Jaroschy (“Hughston”) technique, the patella is congruent, and the trochlea appears normal. **B:** By the “Merchant” technique, the patella is actually subluxed, and the trochlea is actually quite shallow.

The following criteria are necessary to obtain an accurate axial view:

- Central x-ray beam must be perpendicular to the film plane to avoid image distortion.
- Knees flexed 30° to 45°. Less than 30° is too technically demanding for clinical use, and more than 45° will reduce many subluxed patellae.
- X-ray tube about 2 m (6 ft) from the knee to minimize the distortion of magnification and parallax.
- Expose both knees on one film to allow comparisons. Dysplasias are usually bilateral.
- Strap legs and knees together. This prevents external rotation, which can simulate a low lateral condyle and allows the patient to relax (quadriceps contraction will reduce a subluxed patella).

The patellofemoral congruence angle (Fig. 87.6*B*) provides the least overlap between normal subjects and patients with known recurrent dislocation of the patella compared to other measurements. There is still some overlap, however, so it cannot be used as the only diagnostic criterion.




***Figure 87.6.*** Radiographic measurements of patellofemoral congruence.

Patellar tilt (17) (Fig. 87.7) is the angle between the transverse plane of the patella and a horizontal line parallel with the x-ray table. The normal value is 5° or less. Tilt can occur without lateral subluxation (translation) and usually is an indication of a tight lateral retinaculum, but physical examination remains the best determinant of lateral retinacular contracture.

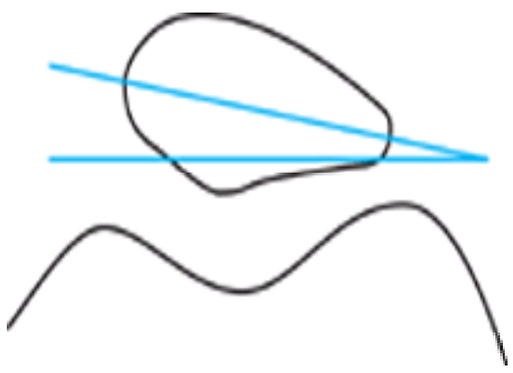

***Figure 87.7.*** Radiographic patellar tilt. Normal ~5° or less.

Radiographic clues in longstanding lateral patellar compression syndrome (Fig. 87.8) comprise the following:

***Figure 87.8.*** Radiographic clues of long-standing lateral patellar compression syndrome.

- Condensation (sclerosis) of the subchondral bone of the lateral patellar facet.
- Lateralization of trabeculae (perpendicular to the lateral facet rather than to the transverse plane of the patella).
- Lateral traction spurs.

***Summary***

These initial radiographs correlated with the history and physical examination will be sufficient to establish a working diagnosis for the great majority of patients with patellofemoral disorders. Other imaging modalities can be helpful with unusual or problem cases. A limited CT scan (15) can be helpful to evaluate patellar position and lateral tilt when the patient is too obese for physical assessment of a **J** sign at terminal extension. The three-phase technetium bone scan (scintigraphy) is the only clinical test that shows physiologic bone activity (10). It can be very useful for patients suspected of having reflex sympathetic dystrophy (RSD) and to document progress during treatment in difficult cases. Given the current accuracy of MRI in the community setting, it is best used for a suspected tumor, for preoperative localization of medial patellofemoral ligament tears (see below), or perhaps when no diagnosis can be established.

Table 87.2 is a diagnostic grid summarizing the various clinical findings needed to make the initial diagnosis or differential diagnosis and to formulate a rational treatment plan.

| History | Physical exam | X-rays | Diagnosis |
|---|---|---|---|
| Pain (and possibly crepitation) with flexed-knee activities. | Abnormalities that increase the lateral patellar vector (↑Q angle, tight lateral retinaculum, ↓ VMO). | Patella congruent in the trochlea; trochlea rarely shallow | LPCS (lateral patellar compression syndrome) |
| Pain (and possibly crepitation) with flexed-knee activities. | Abnormalities that increase the lateral patellar vector (↑Q angle, tight lateral retinaculum, ↓ VMO). | Patella subluxed (not congruent); trochlea frequently shallow | CSP (chronic subluxation of the patella) |
| Episodes of going way/ collapsing | Abnormalities that increase the lateral patellar vector (↑Q angle, tight lateral retinaculum, ↓ VMO). | Patella subluxed (not congruent); trochlea frequently shallow | RDP (recurrent dislocation of the patella) |
| Episodes of going way/ collapsingfalls as a child (acquired form after untreated patellar dislocation) | Patella dislocated onto the lateral side of the knee. | Patella dislocated onto the lateral side of the femur. | CDP (chronic dislocation of the patella) |

***Table 87.2. Diagnosis Grid for Patellofemoral Disorders (Dysplasia)***

## TREATMENT AND SURGICAL INDICATIONS

All treatment plans, when simplified to their essence, are the same: “fix what's wrong,” with the added caveat, “with the least risk.” Perhaps that is an oversimplification, but it might encourage the clinician to search for the various abnormalities affecting the extensor mechanism and then to select the safest treatment modality for each abnormality to start treatment. This job is even harder because each abnormality can vary from mild to severe and thus have a mild to severe effect on the extensor mechanism, thereby changing the prognosis for success. In patellofemoral disorders, there is never only one treatment protocol for one diagnosis. Instead, the clinician should try to understand the pathomechanics or pathophysiology leading to that diagnosis in that particular patient, then list each abnormality found in order to select an appropriate treatment modality for each factor.

For example, one frequently encounters patients with anterior knee pain after relatively minor trauma who fail to recover after a reasonable time. Evaluation finds a few mild deformities (mild VMO deficiency, mildly increased Q angle, and mild patellar subluxation on x-ray), leading to the diagnosis of chronic subluxation of the patella (CSP). Because these factors were all present before the injury, it is reasonable to assume that the quadriceps weakness that resulted from enforced rest and inactivity after the injury caused the decompensation. *Appropriate* quadriceps-strengthening exercises, perhaps along with a lateral buttress patellar brace during recovery, have an excellent chance of success. But should that same patient also have an extremely tight lateral retinaculum that does not respond to patellar taping, mobilization, and exercise techniques (the McConnell protocol) (18) in addition, then a lateral release will give the patient an excellent prognosis.

The treatment protocols must be adjusted not only to each patient's abnormal extensor mechanism factors but also to each patient's age, weight, height, sex, conditioning, activity level, general health, and expectations as well. For these reasons, it is not appropriate to list a treatment protocol or algorithm for each diagnosis but rather to list the various treatment modalities, both nonoperative and surgical, available for each abnormal factor affecting the extensor mechanism. The clinician can then individualize treatment for these multifactorial patellofemoral disorders.

### NONOPERATIVE TREATMENT

The nonoperative treatment for patellofemoral disorders will be successful about 90% of the time (8). Surgical indications will vary with the severity of the problem, the degree of disability for the patient, the age and health of the patient, and the specific surgery proposed. In general, the milder the objective findings, the longer one should persist with nonoperative management. In other words, when pain relief is the only measurement of surgical success, the surgeon should take a long time supervising the treatment, monitoring the exercise goals, learning the level of patient commitment to getting well, trying to assess the patient's pain threshold, learning the patient's expectations and desires, educating the patient on the benefits and risks of surgery, and just getting to know the patient and significant family members before embarking on a surgical treatment. Rather than set an arbitrary time limit such as 6 months for exercises before surgery is indicated, it is preferable to use the expected weight level to be reached, for example, 20 pounds. This must be monitored and verified.

#### *Antiinflammatory Treatment*

Antiinflammatory treatment has the goal of reducing pain and bringing the knee back into its “envelope of load acceptance” (12). These measures include the classic rest, ice, compression, and elevation (RICE), followed by nonsteroidal antiinflammatory drugs (NSAIDs), and finally judicious use of oral and intraarticular steroids, if necessary.

#### *Exercises*

Both hamstring and quadriceps contractures can cause anterior knee pain. Stretching these muscle groups will solve that problem.

*Appropriate* quadriceps-strengthening exercises are the mainstay of successful treatment and rehabilitation of patellofemoral disorders. I stress *appropriate* to highlight the unique biomechanical features of the patellofemoral joint. During physiologic loading (climbing for example), the patellar contact surface varies *directly* with knee flexion and load applied. As the load increases, so does the contact area of the patella, so the unit load on the patellar cartilage (the pounds per square inch) remains relatively stable. Conversely, during nonphysiologic resistive knee extensions, the load (patellofemoral joint reaction force) varies *inversely* with patellar contact area. Thus, the shrinking contact area of the patella must carry increasing loads; if the contact area is decreased even more by subluxation, the unit load can increase exponentially, and the articular cartilage can be damaged very quickly.

*Never* use knee extensions (e.g., isokinetic knee extensions, short-arc knee extensions, or isotonic free weights) against resistance. Start with supine straight-leg raises, assisted if necessary. Add straight-leg raises with weights to about 5 lb. Then switch to seated straight-leg weight lifting using the arms to protect the hip and lower back (Fig. 87.9). To be successful, a weight goal of 20 to 25 lb is average; for the athlete, even more. These exercise protocols have been shown to potentiate VMO strengthening: isometric quadriceps with simultaneous isometric hip adduction exercises, isometric quadriceps exercises done at 90° knee flexion (5), and foot forward (posterior pedal contact) with open, or *plie,* foot alignment during resistance cycling (36).

***Figure 87.9.*** Isometric progressive resistive quadriceps exercises (straight-leg weight lifting)

#### *Bracing*

- A patellar strap can be useful for patellar tendinitis.
- A patellar brace with full ring support can be comforting when the extensor mechanism is already balanced.
- A patellar brace with a lateral buttress pad helps resist lateral vectors.
- Longitudinal arch supports provide medial correction for the pronated foot.

### *Taping and Exercise*

The McConnell protocol (18) features patellar taping techniques designed to reduce the abnormal forces on the extensor mechanism to allow the patient to exercise and strengthen the musculature without pain. Once muscles are strengthened, the taping can be eliminated. However, this protocol requires a physical therapist who is dedicated to this complex subject of patellofemoral dysfunction and lower extremity muscular imbalance and is specifically trained in the McConnell technique. Such a therapist can be difficult to find.

## OPERATIVE TREATMENT

Solely diagnostic athroscopy for patellofemoral disorders is almost never indicated. All the forces acting on this joint are extraarticular and not visible through the arthroscope. If a pathologic plica is suspected, the arthroscopy is therapeutic. If done for “chondromalacia,” the surgeon had better understand the cause. Assuming it was posttraumatic (e.g., dashboard) and the extensor mechanism is well balanced, then the arthroscopic debridement is therapeutic. If the chondrosis is secondary to extensor mechanism malalignment (dysplasia), then the appropriate realignment surgery should follow the debridement, or the debridement will have been done in vain.

In general, the greater the physical abnormality, such as a severe patellar subluxation on radiographs, and the younger the patient, the sooner surgery should be performed. The results of realignment surgery are better when there is less chondrosis (“chondromalacia”). Conversely, salvage procedures, such as total patellofemoral arthroplasty, can be delayed until the level of disability and future activity expectations are appropriate.

After an initial patellar dislocation, the likelihood of subsequent dislocations will depend primarily on the severity of the underlying dysplasia. Sometimes an osteochondral fracture (loose body) with hemarthrosis is present, prompting arthroscopic surgery for its treatment. When this happens, the surgeon should evaluate the knees further. Axial radiography will show sulcus depth, and an MRI can determine if (and where) the medial patellofemoral ligament is torn. Then, under anesthesia, the lateral retinaculum can be assessed for tightness and the Q angle measured. With this information, at the same operation, the osteochondral fracture can be treated, a tight lateral retinaculum can be released, and a torn medial patellofemoral ligament can be repaired. This has a good chance of reducing the risk of future dislocations.

## SURGICAL TECHNIQUES

Just as in nonoperative treatment protocols for patellofemoral disorders, there is never just one surgical technique for each diagnosis. Again, the clinician must discover the various abnormal forces producing that diagnosis, try to understand the pathomechanics, and then select the safest technique, or combination of techniques, that has the best prognosis for success. For example, the lateral release is designed only to correct a tight lateral retinaculum. If it is already lax, don't release it. A medial tibial tubercle transfer is designed only to decrease the Q angle. It bears repeating that the only way to find these abnormalities is by physical examination.

### ARTHROSCOPIC PATELLAR DEBRIDEMENT (“SHAVING”)

- Be as conservative as possible. Remove only unstable cartilage. Even damaged cartilage will cushion the subchondral bone and reduce friction better than no cartilage.
- Use as many portals as needed to correctly position the instruments. Manipulating the patella can help position it for debridement.
- Try the proximal superomedial portal (see the discussion on arthroscopic lateral release below) for an excellent view.

### ARTHROSCOPIC LATERAL RELEASE

The indication for arthroscopic lateral release (Fig. 87.10) is a *tight* lateral retinaculum that is producing the patient's symptoms, which have not responded to *appropriate* nonoperative treatment. If it is not tight, don't release it. If the patient has a large Q angle as well, an isolated lateral release will not be sufficient; the tibial tubercle will usually have to be moved also.

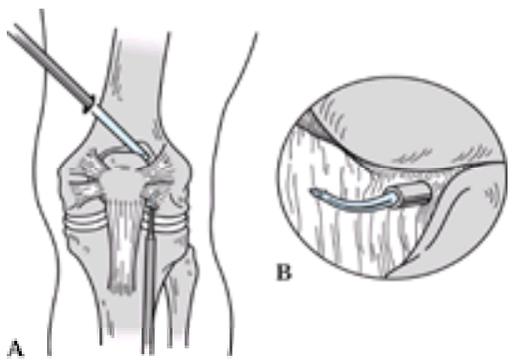


***Figure 87.10.*** **A:**Arthroscopic electrocautery lateral release. **B:** Inset shows the view utilizing the proximal superomedial portal. (Redrawn from Schreiber SN. Proximal Superomedial Portal in Arthroscopy of the Knee. *Arthroscopy* 1991;7:246.)

Because we originated the lateral release before the advent of arthroscopic surgery (27), it was an open procedure. As long as the main principles of hemostasis, adequacy of release, and avoidance of overrelease are addressed, the results will be the same. Currently, for cosmesis, we prefer the electrocautery, arthroscopic technique.

- Use the proximal superomedial portal for viewing (34).
- Percutaneously insert a guide needle 1 cm lateral to the lateral corner of the patella.
- Use the anterolateral joint line portal for the electrocautery. Apply but do not inflate the tourniquet. Advance slowly near the lateral superior geniculate artery in order to coagulate it before cutting it. This technique plus the compression dressing has almost eliminated significant postoperative hemarthroses.
- Avoid severing the vastus lateralis tendon by advancing superiorly in a straight line, *not* curving medially, until muscular fibers of the vastus lateralis are reached. Stop at this point, remove all instruments and cannulas, and test for adequacy. If the patella can be tilted up 70° to 90° with the knee in extension, the release is adequate. Frequently, tethering fibers distally located near the anterolateral joint line portal need to be cut.

### MEDIAL TIBIAL TUBERCLE TRANSFER

The indication for medial tibial tubercle transfer (Fig. 87.11) is a large Q angle that is causing the patient's symptoms, which have not responded to appropriate nonoperative treatment. When combined with an arthroscopic lateral release, this can be done through a short vertical incision at the tibial tubercle for better cosmesis.

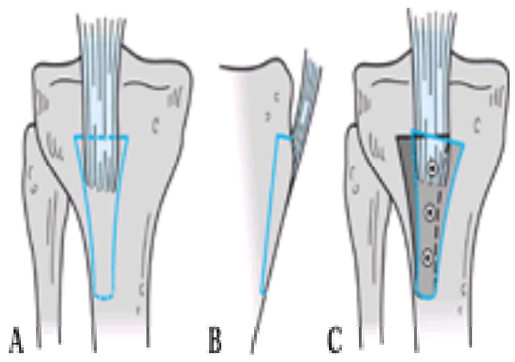


***Figure 87.11.*** Medial tibial tubercle transfer. **A,B:** Tubercle step-cut proximally and drilled distally, front and side views. **C:** Tubercle transferred medially and fixed.

- Step cut the osteotomy proximally to provide a buttress against the quadriceps force. Thin the cut, or drill the bone distally so it will crack and hinge there as the proximal end is moved medially.
- Correct the Q angle to about 5° to 10° measured intraoperatively with a large sterile metal goniometer. The goal is to normalize and avoid overcorrection. Check the tubercle–sulcus angle (Fig. 87.1) as well as patellar excursion with flexion and extension.
- Three-screw, bicortical, lag fixation provides excellent security. Trim the excess bone from the medial edge of the transferred tibial tubercle and pack it under the medial overhang as a bone graft. Complete the repair by sewing the previously elevated medial tibial periosteum to the medial edge of the patellar tendon.
- Release the tourniquet for hemostasis before closure. The anterior recurrent tibial artery lurks just lateral to the tibial tubercle. Uncontrolled hemorrhage from this artery can cause a disastrous compartment syndrome.

**PROXIMAL QUADRICEPS PLASTY**

The indication for proximal quadriceps plasty (Fig. 87.12) is a Q angle that is normal or has been corrected to normal and a patella that remains subluxed laterally, causing symptoms, or that recurrently dislocates. This occurs most frequently in the more severe forms of patellofemoral dysplasia, which have abnormally shallow trochleas.

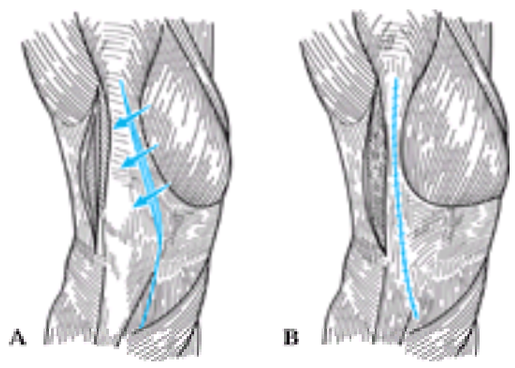


***Figure 87.12.*** Proximal quadriceps plasty. **A:**Lateral release. **B:**Tubulization of the extensor tendon. See text for details. (Redrawn from Insall J, Bullough PG, Burstein AH. Proximal "Tube" Realignment of the Patella for Chondromalacia. *Clin Orthop* 1979;144:63.)

The proximal realignment technique used by Insall et al. (22) offers excellent flexibility to increase the forces acting medially and reduce those acting laterally. It can be used for moderate alignment problems and can be modified laterally by releasing the lower third or half of the vastus lateralis from the lateral intermuscular septum and lateral femur to perform a derotation quadriceps plasty in those children with severe chronic dislocation of the patella.

Selective epidural analgesia for this surgery is shown in Table 87.3. When trying to realign the extensor mechanism when the trochlea is very shallow or flat, it is extremely difficult, if not impossible, to judge the proper correction yet avoid overcorrection. It has been compared to balancing a hockey puck on a cake of ice. If the patient is cooperative, and the anesthesiologist is facile with epidural and regional techniques, selective epidural analgesia will be extremely helpful. Because the motor nerves are spared, the patient can remain awake or under light short-term sedation. With adequate advance warning the anesthesiologist can awaken the patient after the first several repair sutures are in place. The patient then slowly extends the knee actively from 45° to 0° and back again to test the repair. The surgeon will see immediately if the result is correct, and adjustments can be made until it is.

Anesthesiologist
1. Insert an epidural catheter and locate the tip at the L1–2 level.
2. Inject 20 ml of 0.25% bupivacaine (without epinephrine) plus 25 μg of sufenta through the catheter initially.
3. 90 min later, add 20 ml of 0.125% bupivacaine (without epinephrine) through the catheter.

Orthopaedic surgeon
1. Use 30 ml of 0.25% bupivacaine with epinephrine.
2. For arthroscopic surgery, inject this intraarticularly.
3. For an open reconstruction, infiltrate the skin and subcutaneous tissue for the skin incision.

Patient
During surgery, after the initial realignment has been established and the initial sutures have been placed, the patient should be able to extend the knee *actively* in order to assess the correct alignment and balance.

From Howard J. Sweeney, M. D., *personal communication.*

***Table 87.3. Selective Epidural Analgesia***

**MEDIAL PATELLOFEMORAL LIGAMENT RECONSTRUCTION**

Reconstruction of the medial patellofemoral ligament (MPFL) (Fig. 87.13) is indicated in those patients with chronic dislocation of the patella and those with recurrent dislocation of the patella in whom the ligament is either absent or so incompetent as to be irreparable. This ligament has been shown to be the major static medial restraint on the patella (7,9,20). If the trochlea is shallow and does not provide restraint to lateral subluxation, simple imbrication of the medial retinaculum without MPFL repair or reconstruction will frequently fail by gradually stretching out again. Fithian and Meier (14) have described an excellent technique for *repair* of the MPFL if it can be identified and its femoral origin is found to be intact.

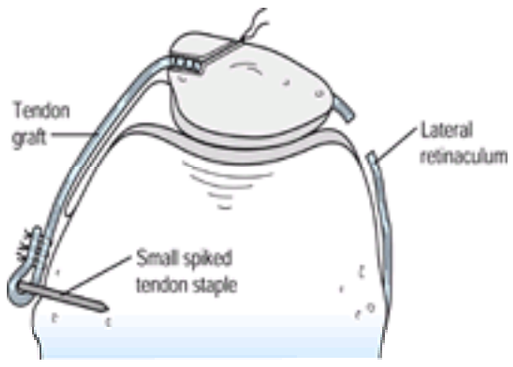


***Figure 87.13.*** Medial patellofemoral ligament reconstruction.

My recommendation for MPFL *reconstruction* is similar to that described by Muneta et al. (31). As with the anterior cruciate ligament, reconstruction of the MPFL requires re-creation of the original anatomy as closely as possible. Its origin is an isometric point just anterior to the medial epicondyle of the femur. It courses extraarticularly beneath the fascia of the VMO to insert on the medial edge of the patella in the upper third. It has a small cross-sectional area, so many donor sites for the autologous graft are available. I prefer the central area of the quadriceps tendon, which is immediately available.

- Harvest the tendon graft from the middle of the quadriceps tendon starting just above the patella, 5 to 7 mm wide and 3 to 4 mm thick; the entire thickness of the tendon is not required. Measure the length required and add about 2 cm.
- Whipstitch one end using #2 braided polyester suture leaving both ends long.
- Drill a 5 mm hole, 10 to 15 mm deep, into the medial edge of the patella at the insertion and enlarge it vertically with a small burr to accept the graft. From the depth of this socket hole, drill two smaller suture holes, diverging superiorly and inferiorly, through the anterior cortex, exiting a minimum of 1 cm apart. Secure the graft in the socket hole by tying the sutures over the bone bridge anteriorly.
- Using blunt dissection, pass the graft superficial to the synovium toward the medial epicondyle. Locate the isometric point of origin by temporarily fixing this end and moving the knee. P. J. Erasmus (13) has shown that, in the normal knee, the MPFL is tight in full extension and relaxes a few millimeters in flexion. This makes sense because it tethers the patella medially where the trochlea is shallow and relaxes in flexion as the increasing trochlear depth resists lateral dislocation.
- Once the isometric point has been located, prepare a bony bed and insert a small toothed ligament staple over the graft but do not set it. This will allow the use of a small clamp proximal to the staple in order to make a final check for isometricity and length. Then impact the staple securely. Finally, reverse the small remaining end of the graft, suturing it back onto itself and to the surrounding soft tissues with #1 braided polyester suture.

**ANTEROMEDIAL TIBIAL TUBERCLE PLASTY**

The anteromedial tibial tubercle plasty (Fig. 87.14) is a salvage procedure similar to the Maquet anterior tibial tubercle plasty. Anterior transfer increases the tibial lever arm of the extensor mechanism and reduces the patellofemoral joint reaction force. This is indicated when there is significant chondrosis (grade III or IV chondromalacia) that is causing severe disability. In fact, Maquet originally advocated anterior *and* medial transfer whenever medial correction was necessary (26). In practice, the anteromedial transfer will be utilized much more frequently than the anterior because most severe and symptomatic patellar chondrosis is secondary to the various forms of patellofemoral dysplasia with their attendant lateralization of the extensor mechanism. Anterior transfer is indicated only when the extensor mechanism is already well aligned, as in pure trauma. Any anterior transfer is contraindicated when the chondral defect involves the superior third of the patella because the change will extend or tip the patella back onto the proximal lesion (32) and can make the symptoms worse.

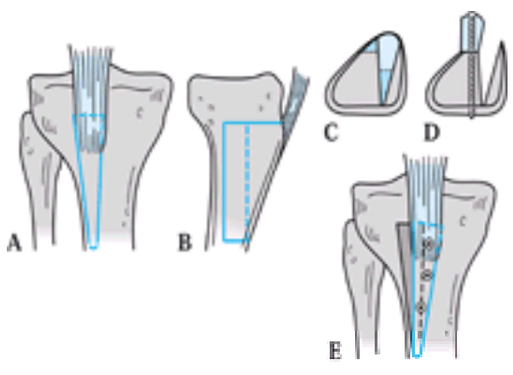


***Figure 87.14.*** Anteromedial tibial tubercle plasty. **A:** Front view of initial cuts. **B:** Side view of initial and secondary (*dotted line*) cuts. **C:** Cross section of initial and secondary (*dotted lines*) cuts. **D:** Cross section after anteromedial transfer and fixation. **E:** Front view after anteromedial transfer and fixation.

Technically, it is best to use local bone for grafting, and the distance of medial transfer and the distance of anterior transfer should be independent of one another.

By carefully cutting from anterior to posterior all around the tibial tubercle and the adjacent anterior tibial cortex all the way to the posterior cortex using thin saws and thin nontapered osteotomes, a rather large block of underlying cancellous bone can be lifted out carefully with the tibial tubercle (Fig. 87.14*A* and Fig. 87.14*B*).

- Cut a flat ledge on the medial side of the tibia (Fig. 87.14*C*). Flatten and taper the posterior surface of the cancellous bone under the tibial tubercle with a thin saw. Then rotate the tibial tubercle with its underlying bone block up onto that medial ledge with the distal end remaining almost in its original position. As much as 15 to 18 mm anterior elevation can be achieved with this method.
- Perform intraoperative goniometic measurement, temporary fixation, and patellar excursion testing as in the medial tibial tubercle transfer. Again, three-screw bicortical lag fixation provides excellent security. Remember to release the tourniquet before closure.

**PATELLECTOMY**

Patellectomy is a salvage procedure under any conditions; the results are best when it is done for a comminuted patellar fracture with a normal trochlea. If it is done for chondrosis from a patellofemoral disorder with a shallow and eroded trochlea, the results are generally worse. Furthermore, if pain relief is not achieved, there is no good alternative—no fall-back position.

Principles for performing a patellectomy in patellofemoral disorders include the following:

- Realign the extensor mechanism during the patellectomy carefully; the shallow trochlea promotes recurrent tendon dislocations. Either the West and Soto-Hall technique (Fig. 87.15) (35) or a modification of Insall's proximal realignment (discussed earlier) with a heavy purse-string suture bunching the soft tissues to create a “pseudopatella” work well.

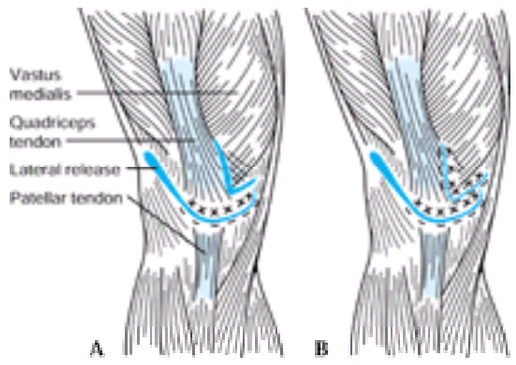


***Figure 87.15.*** Patellectomy with realignment of the extensor mechanism. **A:**Lateral release and transposition and repair. **B:** Vastus medialis advancement. See text for details. (Redrawn from West FE, Soto-Hall R. Recurrent Dislocation of the Patella in the Adult: End Results of Patellectomy with Quadricepsplasty. *J Bone Joint Surg* 1958:40-A:386.

- If reinforcement of the repair is necessary, a portion of the quadriceps tendon can be turned down.
- If medial tibial tubercle transfer is necessary distally, consider anteromedial transfer to improve the postpatellectomy biomechanics.
- If trochlear chondrosis is present, patellectomy results will be worse; therefore, consider total patellofemoral arthroplasty.

### TOTAL PATELLOFEMORAL ARTHROPLASTY

Total patellofemoral arthroplasty (TPFA) is a salvage procedure with indications similar to those for other total joint arthroplasties when isolated patellofemoral arthritis exists. After its introduction in the mid-1970s, TPFA fell into disfavor, largely, I believe, because of improper patient selection. More recent studies (2,6,25) have demonstrated 84% to 88% good and excellent long-term results. Because the etiology of most patellofemoral disorders and its secondary isolated patellofemoral arthritis is congenital, the average age of these candidates will be younger than the usual total joint arthroplasty patients. Therefore, it is extremely important for the clinician to impress on patients the need for future activity restrictions just as for total knee arthroplasty patients. If their expectations are higher, they are not ready for this operation.

As in patellectomy for patellofemoral disorders, the extensor mechanism must be aligned correctly at the time of TPFA if it has not been realigned before.

The best long-term results have been with techniques that utilize a chrome-cobalt-molybdenum trochlear implant with a deep or anatomically correct groove articulating with a high-density polyethylene patellar replacement that mates with it.

Ideally, the geometry of the trochlear implant should be identical with the geometry of the femoral component from a total knee arthroplasty system by the same manufacturer. This confers a big advantage should a revision to a total knee arthroplasty be required in the future. At that time, only the trochlear implant will need to be replaced by the femoral component. The patellar implant will not need to be exchanged because its geometry will also match the new femoral prosthesis perfectly.

Because these are often multiply operated knees, the use of antibiotic-impregnated cement is recommended.

## REHABILITATION

Postoperative rehabilitation for patellofemoral surgery focuses on two major goals: (a) regaining quadriceps strength and (b) restoring knee flexibility while protecting the knee during healing.

After arthroscopy, stiffness is rarely a problem, and no tissues require protection, so follow straight-leg raises quickly by isometric resistive (straight-leg weight-lifting) exercises. The weight goal is the same as the preoperative treatment goal.

Postoperative protection after extensor mechanism realignment requires only an *extension knee splint* (“knee immobilizer”) for a minimum of 6 weeks. Weight bearing in the extension knee splint does not stress the extensor mechanism, so it can start immediately after surgery and progress *as tolerated* to full weight bearing.

Gradual flexibility is obtained by having the patient perform *passive and active heel slides* as soon as pain allows. Teach the patient to sit on a bed (not dangle) and then remove the knee splint. By reaching under the knee with both hands and interlocking the fingers, the patient lifts the knee off the bed, allowing the heel to slide proximally. Because the patient is in control and can stretch the knee into as much flexion as pain allows, postoperative stiffness gradually decreases. A program of 10 repetitions four times a day usually produces 90° flexion in 3 to 4 weeks.

Quadriceps strengthening while protecting the extensor mechanism is more difficult to achieve. Start *quadriceps setting* immediately after surgery; it is frequently inhibited by pain. If there is no response by 1 week postoperatively, add biofeedback and electrical stimulation techniques. At 3 weeks, start *assisted straight-leg raising* with full *straight-leg raising* by 6 weeks. After 6 weeks, begin the patient on isometric resistive (*straight-leg weight-lifting*) exercises (Fig. 87.9). These are performed daily, two sets of 10 repetitions, with about 1 lb added every day or every other day. At 10 lb, the quadriceps is strong enough to prevent collapse, and the patient can discontinue the splint for walking. However, have the patient continue to lift to a 20- to 25-lb goal, depending on age and size.

## PITFALLS AND COMPLICATIONS

### REFLEX SYMPATHETIC DYSTROPHY

Patellofemoral surgery is prone to reflex sympathetic dystrophy (RSD), which is much easier to prevent than to treat. Prevention begins by being alert and sensitive to the individual with a low pain threshold and pain out of proportion to objective findings. A passive approach to getting well can be a clue. A prolonged active exercise and strengthening program monitored by the surgeon is invaluable for gaining insight about the patient's expectations, goals, effort, cooperation, and responses before surgery. Early recognition and treatment is more successful than treating a full-blown case. Keep a high index of suspicion in order to pick up the early warnings and start treatment promptly and aggressively.

### INFRAPATELLAR CONTRACTION SYNDROME

Again, prevention is much easier and more successful than treatment. The infrapatellar contraction syndrome begins with postoperative *quadriceps shutdown*; the patient is unable to activate this muscle. Place all patellofemoral patients on a straight-leg weight-lifting program preoperatively, even if it is not part of the nonoperative treatment. This trains the patient as well as the neuromuscular pathways so that they will be more easily recruited postoperatively. Again, early recognition and aggressive treatment with biofeedback and electrical stimulation are needed.

### COMPARTMENT SYNDROMES

Compartment syndromes can be prevented by releasing the tourniquet before closure to assure hemostasis. Also, prevent injury to the anterior recurrent tibial artery when working lateral to the tibial tubercle by staying on the bone; avoid straying into the soft tissues there.

### IATROGENIC MEDIAL SUBLUXATION OF THE PATELLA

Do not release the lateral retinaculum if it is already lax. This is especially bad with a hyperlax individual (e.g., Ehlers-Danlos syndrome).

Do not cut the vastus lateralis tendon. This can occur inadvertently by “getting lost” or by trying to achieve greater correction by overreleasing when what is usually needed is medial tibial tubercle transfer.

Avoid transferring the tibial tubercle too far medially. Measure the Q angle intraoperatively. Correct it to about 5° to 10°.

## LOSS OF CORRECTION

When repairing and realigning the extensor mechanism, use nonabsorbable or permanent sutures. This will allow early motion and exercise without risk of the soft-tissue repair stretching out.

## CHAPTER REFERENCES

Each reference is categorized according to the following scheme: *, classic article; #, review article; !, basic research article; and +, clinical results/outcome study.


* 1. Aleman O. Chrondromalacia Post-traumatica Patellae. *Acta Chir Scand* 1928;63:194.

+ 2. Argenson J-NA, Guillaume J-M, Aubaniac J-M. Is There a Place for Patellofemoral Arthroplasty? *Clin Orthop* 1995;321:162.

+ 3. Berg EE, Mason SL, Lucas MJ. Patellar Height Ratios: A Comparison of Four Measurement Methods. *Am J Sports Med* 1996;24:218.

! 4. Bose K, Kanagasuntheram R, Osman MBH. Vastus Medialis Oblique: An Anatomic and Physiologic Study. *Orthopedics* 1980;3:880.

+ 5. Boucher JP, King MA, Lefebvre R, Pepin A. Quadriceps Femoris Muscle Activity in Patellofemoral Pain Syndrome. *Am J Sports Med* 1992;20:527.

+ 6. Cartier P, Sonouiller JL, Grelsamer RP. Patellofemoral Arthroplasty. *J Arthroplasty* 1990;5:49.

! 7. Conlan T, Garth WP, Lemons JE. Evaluation of the Medial Soft-Tissue Restraints of the Extensor Mechanism of the Knee. *J Bone Joint Surg* 1993;75-A:682.

* 8. DeHaven KE, Dolan WA, Mayer PJ. Chondromalacia Patellae in Athletes. Clinical Presentation and Conservative Management. *Am J Sports Med* 1979;7:5.

! 9. Desio SM, Burks RT, Bachus KN. Soft Tissue Restraints to Lateral Patellar Translation in the Human Knee. *Am J Knee Surg* 1997;10:24.

+ 10. Dye SF, Boll DA. Radionuclide Imaging of the Patellofemoral Joint in Young Adults with Anterior Knee Pain. *Orthop Clin North Am* 1986;17:249.

* 11. Dye SF. An Evolutionary Perspective of the Knee. *J Bone Joint Surg* 1987;69-A:976.

* 12. Dye SF. The Knee as a Biologic Transmission with an Envelope of Function: Theory. *Clin Orthop* 1996;325:10.

+ 13. Erasmus PJ. *Reconstruction of the Medial Patellofemoral Ligament in Recurrent Traumatic Patellar Dislocation.* Paper Presented at International Society of Arthroscopy, Knee Surgery, and Orthopedic Sports Medicine, May 1997.

+ 14. Fithian SC, Meier SW. The Case for Advancement and Repair of the Medial Patellofemoral Ligament in Patients with Recurrent Patellar Instability. *Oper Tech Sports Med* 1999;7:81.

+ 15. Fulkerson JP, Schutzer SF, Ramsby G, Bernstein RA. Computerized Tomography of the Patellofemoral Joint Before and After Lateral Release or Realignment. *Arthroscopy* 1987;3:19.

* 16. Fulkerson JP. *Disorders of the Patellofemoral Joint, 3rd ed.* Baltimore: Williams & Wilkins, 1997.

+ 17. Grelsamer RP, Bazos AN, Proctor CS. Radiographic Analysis of Patellar Tilt. *J Bone Joint Surg* 1993;75-B:822.

# 18. Grelsamer RP, McConnell J. *The Patella: A Team Approach.* Gaithersberg, MD: Aspen Publishers, 1998.

* 19. Hauser EW. Total Tendon Transplant for Slipping Patella. *Surg Gynecol Obstet* 1938;66:199.

+ 20. Hautamaa PV, Fithian DC, Pohlmeyer AM, et al. The Medial Soft Tissue Restraints in Lateral Patellar Instability and Repair. *Clin Orthop* 1998;349:174.

+ 21. Hughston JC, Deese M. Medial Subluxation of the Patella as a Complication of Lateral Release. *Am J Sports Med* 1988;16:383.

* 22. Insall J, Bullough PG, Burstein AH. Proximal “Tube” Realignment of the Patella for Chondromalacia. *Clin Orthop* 1979;144:63.

# 23. James SL, Bates BT, Osternig LR. Injuries to Runners. *Am J Sports Med* 1978;6:40.

+ 24. Kolowich PA, Paulos LE, Rosenberg TD, Farnsworth S. Lateral Release of the Patella: Indications and Contraindications. *Am J Sports Med* 1990;18:359.

+ 25. Krajca-Radcliffe JB, Coker TP. Patellofemoral Arthroplasty; a Two to Eighteen Year Follow-up Study. *Clin Orthop* 1996;330:143.

* 26. Maquet PGJ. *Biomechanics of the Knee: With Application to the Pathogenesis and the Surgical Treatment of Osteoarthritis.* New York: Springer-Verlag, 1976.

* 27. Merchant AC, Mercer RL. Lateral Release of the Patella: A Preliminary Report. *Clin Orthop* 1974;103:40.

* 28. Merchant AC, Mercer RL, Jacobsen RH, Cool CR. Roentgenographic Analysis of Patellofemoral Congruence. *J Bone Joint Surg* 1974;56-A:1391.

* 29. Merchant AC. Classification of Patellofemoral Disorders. *Arthroscopy* 1988;4:235.

# 30. Merchant AC. Clinical Classification of Patellofemoral Disorders. *Sports Med and Arthroscopy Rev* 1994;2:211.

+ 31. Muneta T, Sekiya I, Tsuchiya M, Shinomiya K. A Technique for Reconstruction of the Medial Patellofemoral Ligament. *Clin Orthop* 1999;359:151.

+ 32. Pidoriano AJ, Weinstein RN, Buuck DA, Fulkerson JP. Correlation of Patellar Articular Lesions with the Results from Anteromedial Tibial Tubercle Transfer. *Am J Sports Med* 1997;25:533.

* 33. Rosenberg TD, Paulos LE, Parker RD, et al. The Forty-Five-Degree Posterioranterior Flexion Weight-Bearing Radiograph of the Knee. *J Bone Joint Surg* 1988;70-A:1479.

+ 34. Schreiber SN. Proximal Superomedial Portal in Arthroscopy of the Knee. *Arthroscopy* 1991;7:246.

* 35. West FE, Soto-Hall R. Recurrent Dislocation of the Patella in the Adult: End Results of Patellectomy with Quadricepsplasty. *J Bone Joint Surg* 1958;40-A:386.

! 36. Willis B, Burkhardt E, Walker J, Johnson M. Preferential VMO Activation Achieved, as a Treatment for Knee Disorders. Personal communication.

# CHAPTER 88

# TENDINOPATHIES ABOUT THE KNEE

*Eric A. Heiden*

**E. A. Heiden:** Department of Orthopaedic Surgery, University of California, Davis, Sacramento, California 95817.

Popliteal Tendinitis
Patellar Tendinitis
Quadriceps Tendinitis
Iliotibial Band Friction Syndrome
Pes Anserinus Bursitis
Semimembranosus Tendinitis
Patellar Tendon Rupture
Operative Techniques
Chronic Patellar Tendon Ruptures
Operative Techniques
Quadriceps Tendon Rupture
Operative Techniques
Chapter References

## POPLITEAL TENDINITIS

Be suspicious of popliteal tendinitis in long-distance runners and walkers who present with atypical posterolateral knee pain (23). Often these individuals are involved in activities such as cross-country running or backpacking where extensive downhill walking or running occurs. Pain will usually present insidiously along the lateral femoral condyle at the insertion of the popliteal tendon. This lateral-sided knee pain can be reproduced with weight bearing and 15° to 30° of knee flexion.

Physical examination will reveal point tenderness just anterior and posterior to the lateral collateral ligament. Palpation of the knee while in a “figure of four” position can help locate the area of maximal tenderness. Close examination will locate the area of tenderness just proximal to the lateral joint line. Often the symptoms can be reproduced by externally rotating the tibia, which places tension on the popliteus tendon.

Other possible etiologies, which can be ruled out by careful history and examination, should include a lateral meniscus tear, biceps femoris tendinitis, and iliotibial band friction syndrome. In those cases where the etiology remains in question, magnetic resonance imaging (MRI) or knee arthroscopy can be helpful in identifying any intraarticular pathology or tendon rupture (19,20,46).

Treatment should start with restricting participation in the inciting activity. Altering training habits such as running on the other side of the road or uphill may help alleviate the symptoms. Oral nonsteroidal antiinflammatory medicines are often helpful (23). In recalcitrant cases, the use of a local steroid injection around the tendon may be required. Other modalities such as ultrasound and deep transverse tissue friction massage may prove beneficial. To maintain aerobic conditioning, a program of cycling or deep-water aerobics should be initiated. After resolution of the symptoms, running can be gradually resumed.

## PATELLAR TENDINITIS

Patellar tendinitis is also known as jumper's knee, and for good reason. The extreme demands placed on the patellar tendon by the quadriceps muscle during explosive jumping, and especially eccentric loading, result in microtears and focal degeneration of the tendon at its bony insertion along the inferior pole of the patella. In younger individuals this is known as Sinding-Larsen-Johansson disease and is usually self-limiting. The poor blood supply within the tendon results in a slow rate of healing (5). Therefore, the clinical history of patellar tendinitis is often a long and protracted course, and one that may become a persistent and recurrent problem in the adult population.

Continuing to pursue activities that aggravate the injury will only worsen the degenerative changes within the tendon's origin. Histologic findings include pseudocyst formation at the interface of bone and mineralized fibrocartilage along the inferior pole of the patella (9). The fibrocartilage exhibits thickening with myxomatous and hyalin metaplasia. Areas of microtears within the tendon display mucoid degeneration and fibrinoid necrosis (39). These findings are consistent with insertional tendinopathy.

Symptoms usually arrive gradually with no history of a single inciting event. Typically, there is pain along the inferior pole of the patella or within the patella tendon itself. Patients may relate a history of participation in sports, such as basketball or volleyball, that involve jumping and running. Rarely is there a history of trauma. Palpation along the inferior pole will elicit tenderness. In some instances there may be palpable enlargement and thickening of the patellar tendon. In longstanding cases there may be crepitus with range of motion of the knee.

During the examination, take note of any musculotendinous imbalance. Heel cord, hamstring, and quadriceps tightness have been implicated as sources for patellar tendinitis. Also, vastus medialis oblique dysplasia and weakness of ankle dorsiflexors are thought to be possible causes of patellar tendinitis (2).

Radiographs are often unrevealing. Both AP and lateral views may show bony changes along the inferior pole of the patella such as sclerosis and cyst formation. A lateral view may reveal mild patella alta. Patella alta is thought to cause enhanced transmission of the force developed by the quadriceps to the patellar tendon. A bone scan will show increase uptake along the inferior pole. Magnetic resonance imaging is the most revealing study. It will localize the degenerative changes occurring both in the tendon and at the bone–tendon interface (14).

Treatment of patellar tendinitis involves activity modification with a controlled exercise program. It is important to remember that tendons are metabolically active and respond to stress with increased fiber size, number, and tensile strength (7). Initially, flexibility training and avoidance of activities that caused the symptoms are begun. Once the symptoms have subsided, a training program concentrating on eccentric exercises is started.

Treatment modalities such as ice, phonophoresis, and ionophoresis may prove beneficial as second-stage treatments in refractory cases. Ultrasound, deep tissue massage, and manual patellar mobilization may help.

Infrapatellar straps placed across the tendon can improve symptoms by altering the direction of mechanical force across the bone–tendon interface at the inferior pole of the patella. McConnell taping works in a similar manner but seems to have more consistent results than use of an infrapatellar strap (27).

The use of steroid injections for treatment needs to be undertaken with extreme caution. The patellar tendon is one of the highest load-bearing tendons, and there are numerous cases of patellar tendon rupture after steroid injection. If steroid injections are performed, then forced rest is advocated.

In chronic cases that are unresponsive to nonoperative management, an open procedure is warranted. Be cautious about surgical intervention, as the results are unpredictable (9,39). The MRI is useful in identifying the area of degenerative changes within the tendon. This area of focal degeneration needs to be debrided. After removal of the necrotic tissue, the tendon needs to be fixed to the patella through drill holes with use of large, #2 or #5, nonabsorbable suture. Multiple longitudinal incisions, in the direction of the fibers, at the area of degenerative change may stimulate a healing response and revascularity.

Return to activity is based on elimination of pain. After strength and flexibility have been addressed, a gradual return to sports can be started. Plyometrics can be helpful postoperatively. Plyometrics activity should be instituted cautiously and with supervision, however, as it may cause a relapse of symptoms.

## QUADRICEPS TENDINITIS

Pain along the superior pole of the patella, at the insertion of the quadriceps tendon, is quadriceps tendinitis. You would expect quadriceps tendinitis to be analogous to patellar tendinitis; however, it is seen much less frequently.

Pain often begins insidiously over the proximal pole of the patella. There may be a history of changes in training habits before the onset of symptoms. Palpation will reveal localized tenderness over the proximal pole. Pain can be reproduced with extension of the knee against resistance or with eccentric loading of the quadriceps. During the examination, other associated findings such as patellar malalignment or hamstring tightness may be present.

Radiographs usually reveal little (41), but calcifications within the tendon may be identified. The differential diagnosis should include a suprapatellar plica. A bone scan or MRI may be helpful in ruling out other sources of pain. The MRI is very helpful in localizing the affected area if operative intervention is warranted.

Treatment is similar to that for patellar tendinitis. This includes activity modification or active rest. Physical therapy exercises directed toward patellar tendinitis are helpful. Modalities such as ice, massage, ultrasound, iontophoresis, and phonophoresis can be instituted as second-stage treatments. The use of nonsteroidal antiinflammatories may prove beneficial. A corticosteroid injection into the quadriceps tendon is less risky than with patellar tendinitis, but it should be used with extreme caution.

Surgical treatment is rarely needed. When conservative therapy fails, the affected area needs to be localized with MRI. The area of degenerative tissue is excised, and any heterotopic calcifications are removed (9). Reattachment of the quadriceps tendon to the superior pole of the patella is performed with use of drill holes and large #2 or #5 nonabsorbable sutures of suture anchors.

The criteria for return to sports are similar to those for patellar tendinitis. Return to activity is based on the elimination of pain. Once range of motion, strength, and flexibility have been addressed, then a slow return to sports can be pursued.

## ILIOTIBIAL BAND FRICTION SYNDROME

Iliotibial band friction syndrome is a common tendinous overuse syndrome of the knee. Activities that involve repetitive knee flexion and extension will incite and aggravate the symptoms located over the lateral side of the knee. This is commonly seen in long-distance runners (29) and cyclists (24), where excessive friction between the iliotibial band and the lateral femoral condyle is the cause of the pain.

Point tenderness is located over the lateral femoral condyle. Inflammation and hyperplasia develop within the synovium below the iliotibial band, which is a lateral extension of the joint capsule (31). There may be a catching or grating noted as the iliotibial band passes over the lateral femoral epicondyle. Maximum discomfort is elicited by flexing the knee to about 30° (32). As this angle of knee flexion is encountered, the iliotibial band is passing posteriorly directly over the prominent lateral femoral condyle. During the physical examination, check for excessive tightness of the iliotibial band. The Ober's test has been described as a way to determine if any iliotibial band tightness exists. Athletes should be evaluated for other underlying factors that may predispose them to iliotibial band friction syndrome such as genu varum, tibial torsion, or excessive foot pronation.

Other entities that must be included in the differential diagnosis of lateral side knee pain include lateral meniscal pathology, biceps and popliteus tendinitis, and patellofemoral syndrome. The MRI can help confirm the diagnosis of iliotibial band friction syndrome in patients with an appropriate clinical history (30).

Cessation of the inciting activity is the first course of treatment. This, along with time and a stretching program, is often successful in eliminating the symptoms. Alteration of training activities and habits can be helpful. Cyclists may find relief by changing the height of their saddle or their foot position on the pedals. Runners can try altering stride length or changing the direction of running on the track.

Symptomatic treatment should include oral antiinflammatory medications (43). Use of other modalities such as ultrasound, phonophoresis, ionophoresis, and deep tissue friction massage may be beneficial. If the syndrome is recalcitrant to these measures, then complete activity restriction is required. Rarely do athletes not respond to nonoperative treatment.

If conservative measures are ineffective, then surgical intervention is indicated. The surgical technique involves removing inflamed tissue and doing an elliptical excision of the portion of the iliotibial band that contacts the lateral femoral epicondyle when the knee is flexed to 30°. Martens recommends removing a triangular section of the iliotibial band that contacts the lateral epicondyle with the knee in 60° of flexion (24). A gradual return to activities can be started at 3 weeks postoperatively.

## PES ANSERINUS BURSITIS

The tendinous aponeurosis of the sartorius, gracilis, and semitendinosus muscles makes up the pes anserinus. The per anserinus bursa is located directly beneath this aponeurosis and lies on top of the underlying superficial medial collateral ligament.

Repetitive flexion and extension of the knee can cause irritation of the bursa or the overlying pes tendons. Point tenderness along the anteromedial surface of the tibia, two fingerbreadths below the joint line, is present on examination. In longstanding cases there may be a palpable boggy fullness to the inflamed bursa. It can be difficult to distinguish bursitis from tendinitis clinically, but distinguishing them is unnecessary, as the two are treated in a similar fashion. It is not uncommon to find medial compartment osteoarthritis associated with pes anserinus bursitis (3). Other entities that must be considered in the differential diagnosis include medial meniscus tear or cyst, juxtaarticular bone cysts (26), and medial collateral ligament injury. The MRI can prove helpful in determining the etiology of pain along the medial side of the tibia (10).

Initial treatment involves active rest and avoidance of irritating activities. At the same time, a stretching and conditioning program is initiated, beginning with isometric exercises and electrical muscle stimulation and incorporating resistive exercises as symptoms allow. Ice and nonsteroidal antiinflammatory medication have proven beneficial.

Further treatment modalities can include ultrasound (3), phonophoresis, iontophoresis, and deep tissue transverse friction massage. Corticosteroid injections have also been successful in treating the symptoms (21,33). In refractory cases of chronic pes anserinus bursitis, a bursectomy may be necessary.

## SEMIMEMBRANOSUS TENDINITIS

Semimembranosus tendinitis occurs near the tendon's insertion along the posteromedial corner of the knee. This insertion is made up of a five-footed tendinous expansion that embraces the posteriomedial side of the tibia and knee (13,18). Strenuous, repetitive activities can elicit pain along the posteromedial knee joint.

Palpation of the knee joint often reveals point tenderness inferior to the posteromedial joint line and posterior to the superficial collateral ligament. The examination should include a comprehensive evaluation of the knee to rule out any intraarticular pathology that can mimic or be the source of the resulting tendinitis.

Begin treatment with cessation of any inciting activities. An exercise program with emphasis on hamstring and quadriceps static stretching should be started. As tolerated, an eccentric exercise program can be introduced.

Oral antiinflammatory medications have proven beneficial. Also, modalities such as ultrasound, phonophoresis, iontophoresis, and deep tissue massage can be helpful. A local injection with cortisone and an anesthetic can be beneficial both in differentiating the etiology and in treatment (37).

In chronic cases that fail conservative therapy, look for intraarticular etiology. An MRI can be valuable for evaluating any meniscal or articular cartilage pathology (13,18,40). In patients who remain symptomatic with no intraarticular pathology, surgery may be indicated. This involves a posteromedial approach to the tendinous insertion of the semimembranosus. Removing overlying inflamed soft tissue can initiate a “healing response.” Care should be taken to avoid violating the tendon itself (47).

## PATELLAR TENDON RUPTURE

Unlike patella fractures, ruptures of the patellar tendon are not uncommon and are frequently encountered in athletes. Rupture of the tendon is most often seen in middle-aged individuals who may deny any history of preexisting symptoms. There are case reports of patellar tendon rupture after procedures that violate the integrity of the patellar tendon, such as total knee arthroplasty, or after harvesting a patellar tendon graft for ACL reconstruction (25,35). Often individuals will describe the sensation of a sudden “pop” when force was applied to the extensor mechanism. With complete rupture of the patellar tendon, there is inability to support body weight on the affected side.

The amount of stress leading to rupture can vary greatly. Zernicke et al. describe an incident in which a force of approximately 17.5 times the body weight was produced by a power lifter before rupture of the patellar tendon (50). In other instances, only a trivial amount of force was applied before rupture. In these cases there is often an underlying autoimmune disorder that affects the integrity of the tendon (34,36,38,49).

The typical history of rupture involves application of a force across the extensor mechanism followed by a “pop” sensation (4,12,17,42). There may or may not be a history consistent with chronic inflammatory symptoms. Subsequently, injured individuals are unable to support themselves on the injured limb. They may even report severe proximal displacement of the patella.

On physical examination there will be a diffuse swelling throughout the knee because of the capsular disruption. Tenderness will be located at or below the inferior pole of the patella. The location of the patellas will be asymmetric. Patella alta will be present on the affected side. Patients may still have the ability to extend the knee against gravity if a portion of the extensor retinaculum remains intact. Typically there is a palpable defect in the patellar tendon at or just below the inferior pole of the patella.

Radiographs will demonstrate patella alta, particularly on the lateral view. If there is a question about tendon rupture, flexion of the knee will make any displacement more pronounced on the lateral view.

With patellar tendon rupture, surgical repair is required and should be performed acutely or within a few days for optimal results. There is no place for nonoperative treatment. Delaying the surgical repair will result in contracture of the extensor mechanism, which can seriously complicate the repair (22,45).

#### OPERATIVE TECHNIQUES

- Make a longitudinal incision near the midline. A transverse incision can also be made at the level of the inferior pole of the patella. Because future incisions can be compromised by a transverse incision, most surgeons prefer a longitudinal incision.
- After incising the skin down to the extensor mechanism, elevate flaps medially and laterally to allow exposure to the tendon and the torn extensor retinaculum.
- Evacuate the hematoma and identify and mobilize the torn ends of the tendon. By extending the knee, the two ends of the tendon can be reapproximated. If this is a bony avulsion injury, then the avulsion site on the patella should be rasped to expose bleeding bone.
- Then make three drill holes in the patella that begin at the site of the avulsion and exit the proximal anterior surface of the patella. Make these drill holes large enough to pass a #2 or #5 nonabsorbable suture. A wire can be used for the repair but must be removed at a later date; it could fragment. See Chapter 22 for an illustration showing placement of the drill holes.
- Place two large nonabsorbable sutures (#2 or #5) through the patellar tendon in a Bunnell-type weave technique. Pass these sutures through the drill holes and tie them over the proximal anterior surface of the patella. Additional interrupted sutures can be placed to reinforce the repair of the tendon. Multiple interrupted figure-of-eight stitches with a #2 nonabsorbable suture are then used to close the extensor retinaculum medially and laterally. Finally, evaluate the adequacy of repair by putting the knee through a gentle range of motion.

Postoperatively immobilize the knee in extension for 1 to 2 weeks before limited range of motion is allowed. Weight bearing is allowed early on. The amount of motion will depend on the strength of the repair. The extension brace can be discontinued after 6 to 8 weeks. During the rehabilitative course, a patient can actively control knee motion with the hamstrings while lying in the prone position.

### CHRONIC PATELLAR TENDON RUPTURES

With untreated patellar tendon ruptures, the extensor mechanism can contract so that it is difficult to position the patella distally for repair. The clinical and radiographic exam can help determine if the extensor mechanism can be positioned distally to allow a primary repair. When there is inadequate length, skeletal traction can be placed on the extensor mechanism to regain length as described by Justis (15), Kelikian et al. (16), and others (45). A transverse pin is placed in the patella to apply skeletal traction. This traction can be maintained up to 4 weeks, until the inferior pole of the patella is positioned about 2.5 cm superior to the tibial plateau with the knee in extension. Once the patella has been brought back to its appropriate position, the patellar tendon is primarily repaired.

Unfortunately, there is often a large defect in the tendon that needs to be reconstructed. Justis (15) recommends use of the fascia lata, as do Siwek and Rao (45). Weaving several strips of fascia lata through the two ends of the tendon can bridge the defect. Kelikian suggests use of the semitendinosus tendon (16).

#### OPERATIVE TECHNIQUES

- Harvest the semitendinosus tendon in a similar fashion to an anterior cruciate reconstruction (Chapter 89). However, maintain the insertion of the tendon on the tibia.
- Then pass the tendon through a transverse drill hole in the tibia at the level of the tibial tubercle and then through a transverse hole in the distal third of the patella.
- Then suture the free end of the tendon to itself after an appropriate tendon length has been obtained.

Postoperatively immobilize the knee in extension for 6 to 8 weeks. If the fixation is secure or augmented with wire or a large nonabsorbable suture, then motion and weight bearing can be instituted earlier.

Recently, Falconiero and others have described the use of an Achilles tendon–bone allograft to bridge the tendinous defect (8,28). Fixation of the Achilles tendon–bone allograft is augmented with a suprapatellar wire that is removed 8 weeks later. This treatment has allowed for much earlier mobilization and weight bearing. Use of a dacron graft has also been described as a method to reinforce and bridge the tendinous defect associated with a chronic rupture (22).

### QUADRICEPS TENDON RUPTURE

Rupture of the quadriceps tendon is most often seen in elderly patients and in patients with chronic disease (1,44,45,48). In a healthy population, quadriceps rupture is often seen in middle-aged individuals. This population is somewhat older than that seen for patellar tendon ruptures. David et al. described bilateral quadriceps tendon rupture (6). They implied that anabolic steroid use leads to tendon failure.

The clinical examination is similar to that of a patellar tendon rupture. Patients will be unable to extend the knee actively. Often there is a palpable defect 1 to 2 cm proximal to the superior pole of the patella. The patella will not retract distally; however, the patellar tendon will feel lax on examination.

As with patellar tendon ruptures, early repair of the quadriceps tendon is imperative if good functional restoration is to be obtained (45). When the repair is delayed, the extensor mechanism will retract proximally, which complicates the repair. There is no place for nonoperative treatment of a complete quadriceps tendon rupture except in nonambulatory patients.

To avoid contractures of the quadriceps tendon, perform the repair within a few days (11). Often the tendon ruptures within its substance 1 to 2 cm from the proximal pole of the patella. At the site of disruption degenerative changes are usually noted (44). The operative technique to repair an acute quadriceps tendon rupture is similar to that used to repair a patellar tendon rupture (11).

#### OPERATIVE TECHNIQUES

- Pass large, nonabsorbable #2 or #5 sutures through the quadriceps tendon in a Bunnell-type weave. Then pass these sutures through drill holes in the patella and tie them distally over the inferior anterior surface of the patella. Before reapproximation of the tendon, abrade the superior pole of the patella to obtain bleeding bone at the tendon's insertion site.
- Next, repair the extensor retinaculum with a #2 nonabsorbable suture. The knee is then flexed to evaluate the integrity of the repair. After repair, the knee can usually be flexed 45° to 90°.

- If the repair is tenuous, it must then be augmented by rotating a flap fashioned from the proximal quadriceps tendon, as described by Scuderi (44). This partial thickness quadriceps flap is rotated with the apex distally to cover the site of the repair and then sutured in place with large nonabsorbable sutures. The base of this flap is located about 5 cm proximal to the repair site and is horizontal to it. The apex of the flap is about 8 cm proximal to the flap's base.

Postoperatively, immobilize the knee into nearly full extension for 4 to 6 weeks. If the repair is secure, early motion can be started. Weight bearing is allowed, but only when the knee is in extension. Active quadriceps exercises should be avoided, but limited motion with use of the hamstrings while in the prone position is allowed. Until functional strength has returned, use an extension orthosis with ambulation.

A chronic rupture is much more difficult to repair. An attempt at lengthening the quadriceps is difficult or impossible because of changes in the quadriceps muscles. If the two ends can be reapproximated, then perform a repair with heavy nonabsorbable sutures as in an acute repair. If the tendon cannot be approximated, the Codivilla method can be employed (44,45). This entails a **V–Y** lengthening of the proximal quadriceps tendon. This repair can be reinforced with a fascia lata autograft.

Postoperative treatment is similar to that for acute repairs and depends on the integrity of the repair. It is important to warn patients that rehabilitation and outcome will be limited when repairs are delayed.

## CHAPTER REFERENCES

Each reference is categorized according to the following scheme: *, classic article; #, review article; !, basic research article; and +, clinical results/outcome study.


+ 1. Bhole R, Johnson JC. Bilateral Simultaneous Spontaneous Rupture of Quadriceps Tendons in a Diabetic Patient. *South Med J* 1985;78:486.

# 2. Black JE, Alten SR. How I Manage Infrapatellar Tendinitis. *Physician Sportsmed* 1984.

+ 3. Brookler MI, Morgan EF. Anserina Bursitis. A Treatable Cause of Knee Pain in Patients with Degenerative Arthritis. *Calif Med* 1973;119:8.

+ 4. Chmell SJ. Bilateral Spontaneous Patellar Tendon Rupture in the Absence of Concomitant Systemic Disease or Steroid Use. *Am J Orthop Apr* 1995;24:300.

# 5. Curwin S, Stanish WD. *Tendinitis, Its Etiology and Treatment.* Lexington, MA: DC Heath, 1984.

+ 6. David HG, Green JT, Grant AJ, Wilson CA. Simultaneous Bilateral Quadriceps Rupture: A Complication of Anabolic Steroid Abuse. *J Bone Joint Surg [Br]* 1995;77:159.

+ 7. El-Hawary R, Stanish WD, Curwin SL. Rehabilitation of Tendon Injuries in Sports. *Sports Med Nov* 1997;24:347.

+ 8. Falconiero RP, Pallis MP. Chronic Rupture of a Patellar Tendon: A Technique for Reconstruction with Achilles Allograft. *Arthroscopy* 1996;12:623.

+ 9. Ferretti A, Ippolito E, Mariani P, Puddu G. Jumper's Knee. *Am J Sports Med* 1983;11:58.

+ 10. Forbes JR, Helms CA, Janzen DL. Acute Pes Anserine Bursistis: MR Imaging. *Radiology* 1995;194:525.

# 11. Garret WE Jr. Traumatic Disorder of Muscle and Tendon. In: Chapman MW, ed. *Operative Orthopaedics, 2nd ed.* Philadelphia: JB Lippincott, 1993;3411.

+ 12. Greenbaum B, Perry J, Lee J. Bilateral Spontaneous Patellar Tendon Rupture in the Absence of Concomitant Systemic Disease or Steroid Use. *Orthop Rev* 1994;23:890.

+ 13. Hennigan SP, Schneck CD, Mesgarzadeh M, Clancy M. The Semimembranosus Tibial Collateral Ligament Bursa. Anatomical Study and Magnetic Resonance Imaging. *J Bone Joint Surg [Am]* 1991;20:1085.

+ 14. Johnson DP, Wokeley CJ, Watt I. Magnetic Resonance Imaging of Patellar Tendinitis. *J Bone Joint Surg [Br]* 1996;78:452.

# 15. Justis EJ. Affections of Muscles, Tendons, and Associated Structures. In: Edmonson E, Allen S, Crenshaw AH, eds. *Campbell's Operative Orthopaedics.* St. Louis: CV Mosby, 1980.

+ 16. Kelikian H, Riashi E, Gleason J. Restoration of Quadriceps Function in Neglected Tear of the Patellar Tendon. *Surg Gynecol Obstet* 1957;104:200.

+ 17. Kelly DW, Carter VS, Jobe FW, Kerlan RK. Patellar and Quadriceps Tendon Ruptures—Jumper's Knee. *Am J Sports Med* 1984;12:375.

+ 18. Kim YC, Yoo WK, Chung IH, et al. Tendinous Insertion of Semimembranosus Muscle into the Lateral Meniscus. *Surg Radiol Anat* 1997;19:365.

+ 19. Kimura M, Shirakura K, Hasegawa A, et al. Anatomy and Pathophysiology of the Popliteal Tendon Area in the Lateral Meniscus: 2. Clinical Investigation. *Arthroscopy* 1992;8:424.

+ 20. Kimura M, Shirakura K, Hasegawa A, et al. Anatomy and Pathophysiology of the Popliteal Tendon Area in the Lateral Meniscus: 1. Arthroscopic and Anatomical Investigation. *Arthroscopy* 1992;8:419.

+ 21. Larsson LG, Baum J. The Syndrome of Anserina Bursitis: An Overlooked Diagnosis. *Arthritis Rheum* 1985;28:1062.

+ 22. Levin PD. Reconstruction of the Patellar Tendon Using a Dacron Graft. *Clin Orthop* 1976;118:70.

+ 23. Mafield GW. Popliteus Tendon Tenosynovitis. *Am J Sports Med* 1977;5:31.

+ 24. Martens M, Libbrecht P, Burssens A. Surgical Treatment of the Iliotibial Band Friction Syndrome. *Am J Sports Med* 1989;17:651.

+ 25. Marumoto JM, Mitsunaga MM, Richardson AB, et al. Late Patellar Tendon Ruptures after Removal of the Central Third for Anterior Cruciate Ligament Reconstruction. A Report of Two Cases. *Am J Sports Med* 1996;24:698.

+ 26. Matsumoto K, Hukuda S, Ogata M. Juxta-articular Bone Cysts at the Insertion of the Pes Anserinus. Report of Two Cases. *J Bone Joint Surg [Am]* 1990;72:286.

+ 27. McConnell J. The Management of Chondromalacia Patellae: A Long Term Solution. *Aust J Physiother* 1966;2:215.

+ 28. McNally PD, Marcelli EA. Achilles Allograft Reconstruction of a Chronic Patellar Tendon Rupture. *Arthroscopy* 1998;14:340.

+ 29. Messier SP, Edwards DG, Martin DF, et al. Etiology of Iliotibial Band Friction Syndrome in Distance Runners. *Med Sci Sports Exerc* 1995;27:951.

+ 30. Murphy BJ, Hechtman KS, Uribe JW, et al. Iliotibial Band Friction Syndrome: MR Imaging Findings. *Radiology* 1992;185:569.

+ 31. Nemeth WC, Sanders BL. The Lateral Synovial Recess of the Knee: Anatomy and Role in Chronic Iliotibial Band Friction Syndrome. *Arthroscopy* 1996;12:574.

+ 32. Noble CA. The Treatment of Iliotibial Band Friction Syndrome. *Br J Sport Med* 1979;13:51.

# 33. O'Donoghue DH. Injuries of the Knee. In: O'Donoghue DH, ed. *Treatment of Injuries to Athletes, 4th ed.* Philadelphia: WB Saunders, 1987;470.

+ 34. Pritchard CH, Berney S. Patellar Tendon Rupture in Systemic Lupus Erythematosus. *J Rheumatol* 1989;16:787.

+ 35. Rand JA, Morrey BF, Bryan RS. Patellar Tendon Rupture after Total Knee Arthroplasty. *Clin Orthop* 1989;244:233.

+ 36. Rascher JL, Marcolin L, James P. Bilateral Sequential Rupture of the Patellar Tendon in Systemic Lupus Erythematosus. *J Bone Joint Surg* 1974;56A:821.

+ 37. Ray JM, Clancy WC Jr, Lemon RA. Semimembranosus Tendinitis: An Overlooked Cause of Medial Knee Pain. *Am J Sports Med* 1988;16:347.

+ 38. Razzano CD, Wilde AH, Phalen GS. Bilateral Rupture of the Infrapatellar Tendon in Rheumatoid Arthritis. *Clin Orthop* 1973;91:158.

+ 39. Roels J, Martens M, Mulier JC, Burssens A. Patellar Tendinitis (Jumper's Knee). *Am J Sports Med* 1978;6:362.

+ 40. Rothstein CP, Laorr A, Helms CA, Tirman PF. Semimbranosus–Tibial Collateral Ligament Bursitis: MR Imaging Findings. *Am J Roentgenol* 1996;166:875.

+ 41. Schmidt DR, Henry JH. Stress Injuries of the Adolescent Extensor Mechanism. *Clin Sports Med* 1989;8:343.

+ 42. Schwartzberg RS, Csencsitz TA. Bilateral Spontaneous Patellar Tendon Rupture. *Am J Orthop* 1996;25:369.

+ 43. Schwellnus MP, Theunissen L, Noakes TD, Reinach SG. Anti-inflammatory and Combined Anti-inflammatory/Analgesic Medication in the Early Management of Iliotibial Band Friction Syndrome. A Clinical Trial. *S Afr Med J* 1991;79:602.

+ 44. Scuderi C. Rupture of the Quadriceps Tendon. *Am J Surg* 1958;95:626.

+ 45. Siwek CW, Rao JP. Ruptures of the Extensor Mechanism of the Knee Joint. *J Bone Joint Surg* 1981;63A:932.

+ 46. Staubli H, Birrer S. The Popliteus Tendon and Its Fascicles at the Popliteal Hiatus: Gross Anatomy and Functional Arthroscopic Evaluation with and without Anterior Cruciate Ligament Deficiency. *Arthroscopy* 1990;6:209.

# 47. Steadman JR, Sledge SL. Nonoperative Treatment and Rehabilitation of Knee Injuries. In: Chapman MW, ed. *Operative Orthopaedics, 2nd ed.* Philadelphia: JB Lippincott, 1993;2055.

+ 48. Vainiopaa S, Bostman O, Patiala H, Ropkkanen P. Rupture of the Quadriceps Tendon. *Acta Orthop Scand* 1985;56:433.

+ 49. Wener JA, Schein AJ. Simultaneous Bilateral Rupture of the Patellar Tendon and Quadriceps Expansions in Systemic Lupus Erythematosus. *J Bone Joint Surg* 1974;56A:823.

! 50. Zernicke RF, Garhammer J, Jobe FW. Human Patellar Tendon Rupture. A Kinetic Analysis. *J Bone Joint Surg* 1977;59A:179.

# CHAPTER 89

# ISOLATED ANTERIOR CRUCIATE LIGAMENT INJURY

*James D. Ferrari and Bernard R. Bach, Jr.*

**J. D. Ferrari:** Department of Orthopaedics, University of Colorado Health Sciences Center, Denver Health Medical Center, Denver, Colorado 80204.
**B. R. Bach, Jr.:** Sports Medicine Section, Department of Orthopaedics, Rush–Presbyterian–St. Luke's Medical Center, Chicago, Illinois 60612.

Injury, Incidence, and Natural History
Clinical Evaluation and Imaging
History
Physical Examination
Instrumented Laxity Testing
Imaging
Indications and Treatment
Nonoperative Treatment
Timing of Surgery
Graft Selection
Biomechanical Factors
Bone–Patellar Tendon–Bone Autograft
Hamstring Tendons
Quadriceps Tendon
Bone–Patellar Tendon–Bone Allograft
Choosing the Graft
Surgical Techniques
Endoscopic Bone–Patellar Tendon–Bone Autograft Technique
Endoscopic Bone–Patellar Tendon–Bone Allograft Technique
Two-Incison Bone–Patellar Tendon–Bone Autograft Technique
Endoscopic Hamstring Tendon Technique
Endoscopic Quadriceps Tendon Technique
Rehabilitation
Pitfalls and Complications
Authors' Perspective
Summary
Chapter References

Anterior cruciate ligament (ACL) injury remains a common orthopaedic problem with an annual incidence of approximately 95,000 cases a year, and some 50,000 of these knees are reconstructed annually (42,74). During the 1990s, an explosion of both basic science and clinical research on the ACL has contributed greatly to our understanding of the ACL-deficient knee and its successful treatment. It is now widely agreed that reconstruction of the ACL is far superior to repair (36) and that extraarticular reconstruction is not necessary for isolated ACL insufficiency (85). Yet despite this plethora of research, controversy still surrounds many issues in ACL reconstruction, such as the appropriate timing of surgery, the method of reconstruction, and the means of fixation of the reconstruction.

The purpose of this chapter is to discuss the state of the art of isolated anterior cruciate ligament reconstruction in the skeletally mature individual. Anatomy and biomechanics of the ACL and ACL injury in the skeletally immature individual are discussed in Chapter 83 and Chapter 97, respectively.

## INJURY, INCIDENCE, AND NATURAL HISTORY

The classic history of a person sustaining an isolated ACL injury consists of a noncontact deceleration mechanism, usually occurring with a sudden stopping, cutting, or jumping maneuver. A “pop” is usually felt or heard, and the patient may describe a hyperextension injury. Infrequently, the patient is able to continue activity, and within a few hours the knee swells considerably, secondary to hemarthrosis. With the above history and the presence of a hemarthrosis, the likelihood is more than 70% that the patient has torn the ACL (79). Contact injuries are more likely to result in multiligament injuries, as is seen with O'Donoghue's classic triad in which a direct blow valgus load on the knee results in injury to the ACL, medial collateral ligament (MCL), and medial meniscus. The differential diagnosis for an acute traumatic hemarthrosis includes patellar subluxation or dislocation, osteochondral injury, peripheral meniscus tear, or intraarticular fracture.

The majority of ACL injuries are sustained in sports activities, with basketball, soccer, and skiing predominating in noncontact injuries. Contact injuries are frequently described in football players. The true incidence of ACL injuries is not known, as many patients sustaining injuries are unaware of the severity of the injury and may not seek medical attention initially. A reported 72 ACL injuries per 100,000 skier-days occur in skiing (37); in college football, 2.4 injuries occur per team per season (54). Recent NCAA statistics have also demonstrated an increased incidence of ACL injuries in female athletes compared to their male counterparts in equivalent sports, with women having a three to four times greater likelihood of injuring the ACL in soccer and basketball (4).

Although the natural history of the ACL-injured patient remains controversial, several studies have provided insight into the likely outcome of the ACL-injured patient. Noyes and co-authors specifically evaluated athletically active patients 5 to 10 years after they sustained their injuries (80). Approximately one third had symptoms of pain or giving way with all activities of daily living (ADL), one third had symptoms in sports but not in ADLs, and one third had no symptoms in sports or ADLs. Meniscectomy contributed significantly to pain and swelling, and radiographic changes of degeneration correlated with giving-way episodes and the level of athletic participation. Changes became manifest an average 109 months after injury and tended to worsen with increased length of follow-up. Patients who had symptoms with sporting activities and persisted in participation had the poorest prognosis. A subset of these patients underwent rehabilitation and activity modification, and they used a brace in sporting activities (81). One third of these patients were helped with this program, but another third worsened, and a final third remained the same. The patients who were helped still had symptoms with athletic activities, however. Patients who were unwilling to modify their activities had a worse prognosis and tended to require reconstructive surgery.

Barrack et al. (15) evaluated the results of bracing and rehabilitation in an active-duty military population and concluded that young adults involved in athletic and strenuous physical activity can expect unsatisfactory results. Only 11% of the patients were graded as excellent, and only 4 of 72 (5.5%) competed at the same level and performance of sport. Sixty percent either changed sports, discontinued sports, or limited sporting activity, and 88% were symptomatic with pain and giving way of the knee. Similar poor results were seen in a series of 40 patients followed nonoperatively (53). Only 14% were able to return to full athletic activity, and 88% were graded as fair to poor.

In a prospective outcome study, Daniel et al. further evaluated the ACL-injured patient and also evaluated who was most likely to require ACL reconstruction (35). Eighty-one percent of the 292 patients with a hemarthrosis had an ACL tear, and 49% of these patients had a meniscal tear diagnosed by arthroscopy, though not all of these meniscal tears required surgery. The best predictor of which patients required surgery was the number of preinjury hours per year spent in sporting activities that involved jumping, pivoting, hard cutting, and lateral motion (Table 89.1). More than 200 h per year (i.e., 4 h/week) was considered moderate to high risk for requiring surgery. Instrumented knee laxity measurements that demonstrated a manual maximum side-to-side difference greater than 5 mm were also predictive of the need for reconstructive surgery. Patients who required meniscal surgery had a greater incidence of joint arthrosis at final evaluation.

| Level | Sporting activity | Occupation |
|---|---|---|
| I | Jumping, pivoting, hard cutting: basketball, football, soccer, volleyball | Activity comparable to level I sports |
| II | Lateral motion, but less jumping or hard cutting than level I: baseball, racquet sports, skiing | Heavy manual work, climbing, working on uneven surfaces |
| III | Straight-ahead activity: jogging, running, swimming | Light manual work |
| IV | | Activities of daily living |

From Daniel DM, Stone ML, Dobson BE, et al. Fate of the ACL-Injured Patient. A Prospective Outcome Study. *Am J Sports Med* 1994;22:632.

***Table 89.1. Sports and Occupation Levels***

Clearly, active athletic participation by the ACL-deficient athlete with recurrent episodes of giving way places the knee at high risk for subsequent chondral and meniscal damage. Animal and human studies also support the concept that ACL deficiency predisposes for osteoarthritis (111), and animal studies demonstrate that ACL reconstruction is protective of articular cartilage (86). No human studies have yet to demonstrate that ACL reconstruction protects against articular surface degeneration, however. Andersson et al. reported on a randomized trial of three different treatment methods for ACL injury (3). Group I underwent primary repair with extraarticular augmentation, and group II had primary repair without augmentation, with both groups having all other injured structures concurrently repaired. Group III had all injured structures except the ACL repaired. One third of the patients in group III sustained meniscal tears after reconstruction. Patients in groups I and II had significantly fewer subsequent meniscal tears and had significantly more stable knees. It is well recognized that ACL reconstruction helps protect against further meniscal damage and that loss of the menisci predisposes the knee to articular degeneration. Success of meniscal repair is greatest when it is done in conjunction with ACL reconstruction (26). Hence, for the singular reason of protecting the menisci and its role in protection of articular cartilage, ACL reconstruction may be chondroprotective. Whether ACL reconstruction in and of itself prevents articular degeneration remains to be seen in more controlled, prospective studies with longer-term follow-up.

## CLINICAL EVALUATION AND IMAGING

Accurate and early diagnosis of ACL injuries has improved since the 1970s as much as has the treatment for the injury. Historically, many patients did not receive an accurate diagnosis until recurrent instability or mechanical symptoms from a meniscal tear occurred.

### HISTORY

Clinical evaluation should begin with a thorough history, and the mechanism of injury is obtained from the patient or any witnesses to the injury. Most ACL injuries are the result of noncontact and rotational forces. Valgus/external rotation, hyperextension, and deceleration mechanisms are commonly described. Varus injuries occur less frequently, are often contact injuries, and usually involve injury to the lateral ligaments. The classic “terrible triad” of ACL, MCL, and medial meniscal injuries caused by a direct blow to the lateral aspect of the knee is not as common as noncontact injuries and more often involves injury to the lateral meniscus than to the medial meniscus (104).

A history of hearing or feeling a “pop” or “snap” is highly suspicious for an ACL injury, with this finding accompanying the vast majority of ACL injuries. This is usually accompanied by the inability to continue athletic participation on the day of injury and the onset of a knee joint effusion within a few hours of injury. Any effusion within hours of injury is considered a hemarthrosis, and 70% to 80% of knee joint hemarthroses are secondary to ACL tears (79). Differential diagnosis of a hemarthrosis with an associated “pop” should include patellar dislocation or subluxation with retinacular tearing, an osteochondral lesion, MCL tear, a posterior cruciate ligament (PCL) tear, a fracture, or peripheral meniscus tear.

Patients who present with chronic ACL tears can generally recall the specific event that caused the injury, but often retrospectively report fewer symptoms after the initial event than are generally recalled by patients who present acutely. Nevertheless, complaints are geared toward a feeling of instability or “giving way.” Patients involved in pivoting sports will describe the need to “round out” corners and avoid hard cutting on the affected leg. Effusions may be associated with vigorous activity. Occasionally a second traumatic event or a “giving way” episode results in a meniscal tear that causes mechanical symptoms such as locking or catching in the knee (66).

### PHYSICAL EXAMINATION

- Ideally, examine the knee shortly after the injury, before swelling and pain prevent an accurate diagnosis. Examine the opposite leg to serve as a baseline for comparison. First inspect the injured leg for abrasions, contusions, ecchymoses, and the presence of an effusion. Next, palpate for point tenderness to evaluate associated injuries.
- Examine the patellofemoral joint for the presence of retinacular tearing or a dislocation or subluxation and perform patellar mobility and apprehension testing. Palpate the quadriceps and patellar tendons for defects at their respective insertions and ask the patient to perform a straight-leg raise.
- The lateral femoral condyle may be tender secondary to a bone bruise. Tenderness at the tibiofemoral joint lines may represent an associated meniscal tear, though the evaluation of meniscal pathology in the presence of an ACL tear is not as sensitive (106).

Aspiration of a tense effusion can be both therapeutic and diagnostic. It will relieve pressure and pain, allowing a more accurate physical examination to be performed, and the hemarthrosis can be examined for the presence of fat globules, which is indicative of an intraarticular fracture. It should be noted that with acute ACL tears, other pathologies commonly coexist, with an approximate 60% incidence of meniscal tears, 10% to 20% incidence of osteochondral fractures, and 20% incidence of associated ligamentous injuries (79).

Assess the range of motion and note any signs of mechanical blocking. This could be secondary to a displaced bucket-handle meniscal tear or a loose osteochondral fragment, but a block to full extension can be caused by hamstring spasm. Furthermore, the distal portion of the ACL may flip forward and produce a block in the anterolateral joint line with the knee in full extension, causing pain, which is usually retropatellar.

Stress the collateral ligaments in both full extension and 30° of knee flexion. Laxity is graded from I to III in 5-mm increments of joint opening. Grade III injuries connote complete disruption of the ligament. Rule out injury to the posterolateral structures by the “dial test,” in which external rotation of the tibia at 30° and 90° of knee flexion is compared to that on the opposite side. More than 10° of increased external rotation at 30° is indicative of a posterolateral corner injury and, if also present at 90°, indicates an injury to the posterior cruciate ligament as well (117).

The Lachman test is the most sensitive and reliable test for diagnosing ACL insufficiency (116). Flex the knee to 20° to 30°, stabilize the thigh with one hand (left hand for examining a right knee), and translate the tibia forward with the other hand. Note the amount of anterior translation and the presence or absence of a firm endpoint and compare it to the opposite side. Grade by comparing the amount of increased anterior translation on the injured side to the normal side, with 1 to 5 mm as grade I, 6 to 10 mm as grade II, 11 to 15 mm as grade III, and >15 mm as grade IV. Individual variations may exist; hence, the absence of a firm endpoint is a crucial factor in determining the presence of an ACL tear.

The anterior drawer test is much less sensitive in diagnosing ACL tears. It is performed with the knee flexed 90° and the foot stabilized. Perform it with the tibia in neutral rotation as well as in both internal and external rotation, as increased anterior translation in external rotation may signify injury to the posterolateral structures. Also do posterior drawer testing, as what may seem to be increased anterior translation from a reduced position may actually be reduction of the tibia from a posteriorly subluxated position. The quadriceps active test is a useful adjunct to the posterior drawer.

Pivot-shift testing is the most important physical exam maneuver performed, as this phenomenon is pathognomonic for ACL deficiency. There have been numerous descriptions of this test, with the knee placed in various positions, but all can produce the pivot-shift phenomenon. Our method is to place the hip in slight abduction and flexion and the knee in full extension with the tibia externally rotated, apply a valgus load, and flex the knee (6). This method is chosen because it results in fewer false-negative examinations. The pivot shift will occur in 15° to 30° of flexion. It represents a reduction of the anteriorly subluxated tibia on the femur as the knee is moved from extension to flexion. This reduction is the result of the iliotibial band moving from an anterior position relative to the center of the knee to a posterior position, contributing to the reduction. In examining a right knee, palpate the joint line with your left hand to ensure that what is being perceived is reduction of the anterior subluxated tibia rather than posterior subluxation of a reduced tibia, as can be seen with PCL injuries. Causes of false-negative results include a displaced

bucket-handle meniscal tear, a complete tear of the MCL, and a previous lateral extraarticular tenodesis of the iliotibial band. Grade the exam as a glide (1 + ), jump sensation (2 + ), or transient lock (3 + ).

### INSTRUMENTED LAXITY TESTING

Instrumented knee laxity testing has been extremely useful in the office diagnosis of the ACL-injured knee. Testing is especially helpful in the acute setting when patient guarding precludes an accurate physical examination. Instrumented laxity testing is generally minimally painful, and the support that rests under the patient's thigh facilitates hamstring relaxation. An objective and quantitative method of documenting ACL laxity also helps gain the patient's trust in the physician's diagnostic acumen, and it is imperative that laxity testing be performed for follow-up studies of ACL reconstruction.

Several studies have demonstrated the diagnostic accuracy of laxity testing (9,34). It is extremely unusual for normal knees to have an anterior maximum manual translation of more than 10 mm. Other criteria that are useful in diagnosing ACL injury are a maximum manual side-to-side difference exceeding 3 mm and a compliance index (the difference between the readings at 15 and 20 lb) of more than 2 mm. The maximum manual test is the strongest predictor of differentiating between normal and ACL-injured knees. Essentially, if the side-to-side difference between the injured and normal knees is 3 mm or greater at 15 lb, 20 lb, or maximum manual testing with the KT-1000 arthrometer (Medmetric, San Diego, CA), the likelihood of ACL injury is greater than 95%. Furthermore, if anterior translation of the injured knee is greater than 11 mm at any level tested, the likelihood of ACL injury is 95%.

### IMAGING

All patients being evaluated for an acute knee injury or under consideration for reconstructive surgery should undergo routine knee radiographs. Our current protocol is to take weight-bearing AP, lateral, and 45° PA views as well as a Merchant view of the patellofemoral joint. This allows us to evaluate the medial and lateral joint spaces for degeneration or osteochondral injuries, and the patellofemoral joint can also be examined for subluxation and/or tilt as well as degeneration or osteochondral injury. Though it is unlikely that plain film radiographs will have tremendous yield, occasionally bony avulsions of tibial eminences are noted; other findings, such as the lateral notch sign and the lateral capsular sign, or Segond fracture, may be pathognomonic of ACL injury (Fig. 89.1) (121).

***Figure 89.1.*** **A:** Anteroposterior radiograph of a skeletally mature right knee with chronic ACL insufficiency. A healed Segond fracture is noted by the bony spur on the lateral tibial plateau's lateral cortex, proximal to the fibula. **B:** Anteroposterior radiograph of a skeletally immature individual with a painful traumatic effusion. The x-ray reveals a lateral capsular avulsion, indicative of an injury to the ACL.

Imaging modalities such as knee arthrogram, CT scan, and bone scanning have little place in the evaluation of the ACL-injured patient. A thorough history, physical examination, and plain film evaluation, with the addition of instrumented laxity testing, is generally all that is needed for proper diagnosis. The addition of magnetic resonance imaging (MRI) (Fig. 89.2), though quite sensitive and specific for detection of ACL disruption and meniscal pathology as well as bone bruises, frequently does not change the treatment plan and adds cost to the care of the patient (41,45).

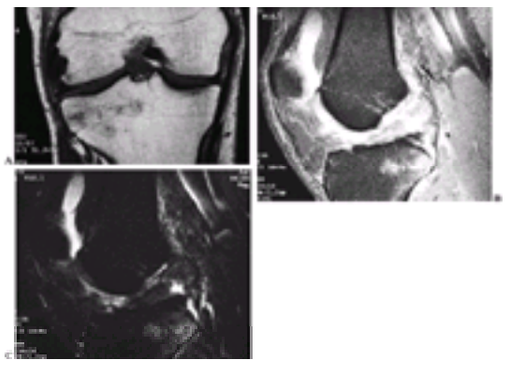

***Figure 89.2.*** Magnetic resonance image of an ACL-injured knee. **A:** Coronal $T_1$-weighted image depicting the intercondylar notch. The torn ACL displays higher signal intensity than the PCL. **B:** Intermediate and **C:** $T_2$-weighted sagittal images demonstrate the increased signal intensity of interstitial damage to the ACL. Also, note the increased signal intensity in the posterolateral tibial plateau indicative of a bone bruise.

Adalberth et al. prospectively evaluated 40 patients with acute hemarthroses of the knee with physical exam, plain radiography, scintigraphy, MR imaging, and arthroscopy. Eighty-five percent had ACL tears, and 83% of these had meniscal tears diagnosed by arthroscopy. The MRI was an excellent tool to detect meniscal tears that required surgery, but it was not sensitive or accurate in detecting partial-thickness meniscal lesions and stable full-thickness lesions (1). Eighty percent of ACL tears had bone bruises detected by both scintigraphy and MRI, usually in the lateral femoral condyle. The authors concluded that scintigraphy and MR imaging added little information to the physical examination, did not guide treatment, and was not as good as an arthroscopic evaluation. Other authors have also demonstrated that many of these meniscal tears associated with ACL injury are not symptomatic on exam and can be left alone at the time of surgery (106). Knowledge of their presence before surgery will not change the operative plan. Currently, we do not use routine MR imaging, and our primary utility of MRI is when a patient with an acute ACL tear still exhibits a painful knee flexion contracture 2 weeks postinjury. In this instance we use it to rule out a displaced bucket-handle meniscal tear. Should this be the case, we prefer to operate earlier than usual in order to reduce the meniscal tear, repair it if possible, and reconstruct the ACL.

## INDICATIONS AND TREATMENT

As outlined above, the true natural history of the ACL-deficient knee is not accurately known because of the differences in study design, the nonrandomized nature of many studies regarding treatment, the lack of truly long-term follow-up, and the inclusion of methods of treatment that have been shown to be inferior to current methods for surgical reconstruction and rehabilitation. Nevertheless, the studies outlined above clearly demonstrate that nonoperative treatment for the ACL-deficient patient who is involved in athletic activities that require cutting and jumping is uniformly unsuccessful and places the knee at risk for chondral injury and degeneration.

The decision to treat the ACL-injured patient operatively is based on many factors (Fig. 89.3). Activity level is perhaps the most important; the patient who is involved in many hours of level I and II sports, as defined by Daniel et al., is most at risk for recurrent instability and potential chondral injury (35). Patients employed in physical labor that places the knee at risk for giving way should be considered for reconstruction as well. Sedentary patients who do not participate in activities that place them at risk for recurrent injury may still have symptoms with activities of daily living, however. Essentially any patient with recurrent episodes of giving way is at high risk for further injury and is a candidate for surgery.

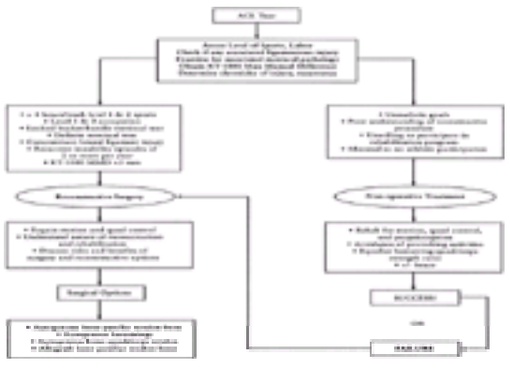

***Figure 89.3.*** Treatment algorithm for the ACL-deficient patient. This algorithm is meant only as a guide. No absolutes are intended. The decision to reconstruct the ACL should be made only after a discussion between the patient and the treating orthopaedic surgeon regarding ACL reconstruction has taken place.

As discussed above, patients with clear-cut signs and symptoms of meniscal injury should be considered for ACL reconstruction. Meniscal repair at the time of reconstruction is more successful than that done in isolation or in the face of a chronically unstable knee. The status of the menisci is perhaps the most important factor in preserving the articular cartilage over time.

Combined ACL and MCL injuries represent a more severe knee injury, but nonoperative treatment of the MCL with later reconstruction of the ACL results in fewer motion problems and more predictable healing of the MCL and stability of the reconstructed ACL than combined repair and reconstruction (104). On the other hand, associated lateral ligamentous injury should be addressed within a few weeks of injury with primary repair with or without augmentation, as results of acute repair of lateral ligamentous structures are superior to results of reconstruction of chronic laxity of the lateral ligaments (13,58). Acute repair should be done along with ACL reconstruction.

Currently, no arbitrary cutoff for age exists with regards to ACL reconstruction. Though it seems intuitive that the older patient likely spends less time in high-risk activities, in today's society more and more people are actively involved in athletic pursuits and wish to continue participation throughout their life. As ACL reconstruction has evolved into a less invasive and more successful procedure, age has become less of a determining factor in advocating operative treatment, and equivalent results can be expected in the older patient (14,92). In our practice, patients over 35 years of age comprise 8% of the ACL reconstructions, and those over 40 comprise 3%.

Once thought to be a contraindication to ACL reconstruction, preexisting chondral degeneration does not preclude successful ACL reconstruction (84,105). Shelbourne et al. in fact demonstrated that ACL-deficient patients with preexisting osteoarthritis had not only improvement in stability but also decreased pain, and the level of activity was able to be increased postoperatively as well (105). Noyes et al. were also able to demonstrate that patients with articular cartilage damage who underwent ACL reconstruction had improvements in pain, giving way, and function, and 79% were able to increase their athletic participation without aggravating their preexisting cartilage degeneration (84).

In general, guidelines we use in recommending ACL reconstruction to our patients include (a) participation in level I and II sports more than 4 h weekly, (b) KT-1000 maximum manual difference over 5 mm, and (c) more than two episodes of instability per year. Patients with definite displaced bucket-handle meniscal tears or knees with combined ACL and lateral ligament injury are also encouraged to have reconstruction. Perhaps the only contraindications to ACL reconstruction are active infection in the knee joint and loss of motion in the knee that is secondary to adhesions and/or arthrosis. A relative contraindication would be a patient with highly unrealistic expectations or a patient who is unwilling to participate in the postoperative rehabilitation.

**NONOPERATIVE TREATMENT**

When nonoperative treatment is chosen, it does not mean that no treatment is given. After an acute injury, control of pain and swelling via the established principles of rest, ice, compression, and elevation (RICE) is undertaken. Efforts are made early to reestablish full range of motion, especially full extension; although a knee immobilizer and crutches are generally used initially, a normal gait with full weight bearing is encouraged after 7 to 10 days. The acute inflammatory phase generally resolves within 1 to 3 weeks, and full range of motion is regained. Should full motion not be reestablished in this time frame, an MRI is recommended to evaluate the knee for a mechanical block, such as a displaced bucket-handle meniscal tear.

Once full range of motion is regained, a more aggressive rehabilitation is begun that emphasizes muscle strengthening and endurance. Avoid open-chain exercises such as leg extensions, which allow the quadriceps to anteriorly translate the tibia. Emphasize closed-chain exercises, which cause cocontraction of the quadriceps and hamstrings and thus minimize anterior tibial translation and patellofemoral contact stresses. These include minisquats, stairmaster, seated leg press, and cycling. Open-chain hamstring exercises can be performed without risk. One goal of these exercises is to equalize the quadriceps/hamstring strength ration from its normal 3:2 ratio to a 1:1 ratio.

When strength of the injured extremity is 70% of that on the normal side, begin proprioceptive exercises such as those done on a balance board. Progression to activities that may require cutting, pivoting, and twisting motion can be undertaken when the knee has 90% of the strength of the normal side. Though basic science studies have not been able to demonstrate that functional braces provide significant mechanical stability to prevent giving-way episodes, some patients feel that these braces improve confidence and enhance knee proprioception (20,27).

The final aspect of rehabilitation of the ACL-deficient knee is for the patient to determine which activities create instability, pain, and swelling, and then to modify the life style to avoid such activities. This will help avoid further injury and potential risk of degenerative joint disease.

In the chronic setting, patients often have marked quadriceps atrophy, which is a time-related phenomenon secondary to “quadriceps avoidance” and “hamstring overuse” (17). In these patients as well, begin a rehabilitation program that emphasizes muscle strengthening and endurance, proprioceptive control, and avoidance of activities that provoke instability.

**TIMING OF SURGERY**

One issue regarding ACL reconstruction that remains controversial is the timing of surgery. Many studies have shown that reconstruction done before 3 weeks carries a significantly higher incidence of postoperative arthrofibrosis and loss of motion (31,75,103). Studies that evaluated acute repairs and reconstructions had higher rates of postoperative knee stiffness that resulted in the need for reoperation (50). It must be realized, however, that many of these patients did not undergo an accelerated rehabilitation program emphasizing early restoration of full hyperextension, and in many cases the patients were immobilized for a period of time. Subsequently, some authors have demonstrated that acute reconstruction can be done without any increased risk of postoperative stiffness (59). Hunter et al. evaluated patients who were operated on within 48 h, between 3 and 7 days postinjury, between 1 and 3 weeks postinjury, and more than 3 weeks postinjury. Despite equivalent results for KT-1000 testing and passive flexion and extension at 1-year follow-up among all four groups, patients who were operated on more than 3 weeks postinjury achieved their full range of motion sooner than the other three groups. Furthermore, no patients operated on more than 3 weeks postinjury required repeat operation for motion problems or revision surgery, whereas 11 patients in the other three groups did require additional procedures.

The theoretical benefit to acute reconstruction is to prevent any additional trauma to the knee that could occur with a giving-way episode and to possibly decrease rehabilitation time. Despite the persistence of this controversy, no study has been able to demonstrate any benefit to acute reconstruction before the patient regains full range of motion, and the risk of motion problems and possible need for repeat operation to treat motion limitations remain higher. Furthermore, regaining motion preoperatively may allow postoperative rehabilitation time to be lessened by an easier restoration of motion.

Our current protocol is to operate when the patient has regained near full range of motion, has minimal effusion, and has regained quadriceps control. No time limit is placed on the patient. Some patients will regain motion within a few weeks, and others may take longer. It is extremely unusual, however, to operate before 2 weeks postinjury. Patients are generally enrolled in preoperative therapy to help with the restoration of motion and quadriceps function and to help prepare for the postoperative rehabilitation process. The patient is seen on a weekly basis to gauge progress and to ensure that a displaced bucket-handle meniscal tear is not present. It should be noted that often the distal stump of the ACL may flip anteriorly, and this may become impinged when the knee is passively extended, causing pain. This is not a concern and should not be interpreted as a displaced bucket-handle meniscal tear, which usually causes a more significant flexion contracture along with a loss of full flexion. This “prehab” process is invaluable in allowing us to get to know our patients and mentally preparing the patient for both surgery and

subsequent rehabilitation.

## GRAFT SELECTION

Once the decision is made to operatively reconstruct the ACL-deficient knee, the next decision to be made is how to reconstruct it. This is a complex issue, as there are not only a variety of autogenous and allograft tissues from which to choose but also a multitude of ways to secure the tissues in an anatomic position. In ACL reconstruction, the principal tissues used include both autograft and allograft bone–patellar tendon–bone grafts (BTB), autogenous semitendinosus and gracilis tendons (STG), and autogenous quadriceps tendon (QT). All of these grafts have advantages and disadvantages that must be weighed by both the surgeon and the patient in deciding on which graft source to use (Table 89.2).

| Graft | Pros | Cons | Relative indications and contraindications |
|---|---|---|---|
| Bone-patellar tendon-bone autograft | Strength<br>Bony fixation<br>Easily harvested<br>Excellent track record | Donor site morbidity<br>Patellar tendinitis<br>Kneeling pain<br>Patella fracture or tendon rupture (rare) | Ind<br>Patient desiring early return to sport<br>Con<br>Patellar instability or tendinitis<br>Occupation requiring prolonged kneeling<br>Narrow (<23 mm) tendon |
| Bone-patellar tendon-bone allograft | Readily available sources<br>Bony fixation<br>No graft harvest morbidity<br>Faster surgery<br>Smaller incisions<br>No graft sizing difficulties | Possible disease transmission<br>Longer graft incorporation time | Ind<br>Older patient desiring no graft site morbidity and minimal loss of work time<br>Con<br>Younger patient desiring early return to sport |
| Semitendinosus and gracilis | Small incision<br>Minimal donor site pain<br>Multibundled structure<br>Larger surface area for graft incorporation | Soft tissue fixation<br>Longer graft-to-bone incorporation time<br>Hamstring weakness<br>Can be difficult to harvest<br>Few studies using newer fixation techniques | Ind<br>Preexisting patellofemoral disease or occupation requiring kneeling<br>Con<br>Inferior results in females (32,95) |
| Quadriceps tendon | Small incision<br>Possibly less donor site morbidity<br>Strong and large graft | No track record<br>Bony fixation on one side only | Ind<br>Patient desiring autograft tissue with minimal donor site morbidity<br>Con<br>Quadriceps tendinitis or patellofemoral disease |

***Table 89.2. Pros and Cons of Various Graft Sources***

### BIOMECHANICAL FACTORS

Several biomechanical concepts must be understood when comparing grafts. The ultimate strength is the load at which a particular graft material fails. The material properties of a graft refer to the substance of the graft, whereas the structural properties refer to the entire graft complex. Material properties are determined by the orientation and collagen makeup of the tissue and are reflected by the stress–strain curve, whereas the structural properties are affected by the strength, stiffness, and three-dimensional orientation of the entire graft complex and are reflected by the load–deformation curve. Stiffness of tissues is determined by the steepness of the stress–strain or load–deformation curve. Stiffer grafts will take up load before less stiff grafts will, and less stiff grafts may stretch out, causing greater forces on the graft per amount of energy absorbed by the graft relative to a stiffer graft. It should be noted that most studies of strength and stiffness of graft materials and their fixation evaluate the structural properties by a single load to failure, which is probably not the primary mode of clinical graft failure. Cyclic loading more closely resembles the milieu in which grafts are subjected to stress and is in all likelihood the mode in which grafts most commonly fail clinically, especially in the first few months.

An appropriate graft will have similar strength and stiffness characteristics as the native ACL. The ultimate strength of the ACL is roughly 1,750 N, though this value is age-dependent (82,120). The eventual strength of the graft material will be decreased by roughly half when it is fully incorporated; hence, the graft material should initially be twice 1,750 N, or 3,500 N. Despite the high strengths of numerous graft materials, the limiting factor for biomechanical failure is the fixation of the graft until it has been incorporated into its femoral and tibial tunnels, as failures often occur within the first 3 to 6 months postoperatively. Bone-to-bone healing, as occurs with BTB grafts, is a process that takes approximately 6 weeks, whereas tendon-to-bone healing takes 8 to 12 weeks (94). During this time period the patient is undergoing a rehabilitation program that places the graft under stresses approximating 450 N (72,82). It is during this time frame that the fixation is the limiting factor for failure of the graft/fixation construct. Once graft incorporation has occurred, it is the strength of the graft that limits failure. Hence, the fixation should be able to withstand the stresses applied to the graft–fixation construct during the early rehabilitation program before graft incorporation.

### BONE–PATELLAR TENDON–BONE AUTOGRAFT

The most common and best-studied graft source for ACL reconstruction is the BTB autograft, harvested from the central third of the patella tendon. Numerous studies advocate its excellent short- and medium-term results (10,11 and 12,107). It is an easily accessible graft source; through the incision by which one harvests the graft, the inferolateral and inferomedial portals may be made as well as the entrance to the tibial tunnel. It is a strong graft, with an ultimate strength of 2,977 N (30), and its two bone blocks can be rigidly fixed with interference screws, leading to early graft incorporation. Because of the graft's strength and the rigidity of the fixation, aggressive rehabilitation can be undertaken with little risk of damage to the graft–fixation construct.

The use of interference screws for graft fixation is popular and well studied. Their appropriate use provides a construct that approaches the strength of the native ACL and nearly equals its stiffness (114). It is recommended that 9-mm screws be used on the tibial side, and 7-mm screws can be used on the femoral side in an endoscopic technique, but 9-mm screws should be used for a double incision technique (23,67). Screw length should equal the length of the bone plug. Pitfalls are many and include screw divergence or convergence, bone plug fracture, traction suture laceration, laceration of the graft's tendon, and graft advancement (7). These problems can be avoided with meticulous attention to detail and the use of appropriately sized cannulated screws. Alternatively, buttons on each end of the graft secured by sutures placed through the bone plugs can be used, but this results in a weaker, less stiff graft–fixation construct (23).

As with any graft source, however, drawbacks exist. Direct complications such as patella fracture or tendon rupture are exceedingly rare but do occur (19,22,28,47). Some studies indicate that its harvest may contribute to anterior knee pain, quadriceps weakness, and extensor mechanism dysfunction (95,97). Careful review reveals that many patients in these studies were acutely fixed, had failed repairs as revealed by positive pivot shifts, and were immobilized for up to 6 weeks, hence not undergoing an accelerated rehabilitation program. Later studies have not had nearly the rate of patellofemoral complications (11,12,107), and this is felt to be a result of accelerated rehabilitation programs and avoidance of acute reconstruction. Some reports evaluating the morbidity of harvesting the graft by comparing autograft BTB patients with allograft BTB patients show no difference in anterior knee pain (98). Methods of decreasing graft site morbidity include bone grafting of the patellar and tibial defects and loose closure of the tendon rent with the knee in flexion. Some kneeling pain, which may in fact be a result of the incision and not the graft harvest, is quite common in the first year postsurgery but diminishes with time.

### HAMSTRING TENDONS

Hamstring tendons, specifically the semitendinosus and gracilis tendons (STG), have been used for ACL reconstruction with clinical success equal to that of BTB autograft (2,71,88,89). The tendons can be harvested through a smaller incision than that used for harvesting BTB, which may help to minimize perioperative pain. Proponents of the use of STG point to its avoidance of causing donor site morbidity to the extensor mechanism. Nevertheless, this issue remains unresolved: Aglietti et al. noted a 16% incidence of anterior knee pain in BTB patients versus a 3% incidence in STG patients, whereas Marder et al. noted no difference (2,71). The tendons can be doubled, tripled, or even quadrupled, depending on the length of the tendon harvested, and a multibundled graft construct that is round rather than rectangular can be produced. This theoretically creates a larger surface area for graft incorporation as well as a geometric configuration that more closely resembles the native ACL. The strength of the tendons appears to be adequate, as extrapolating data from Noyes et al. reveals that doubling both semitendinosus and gracilis tendons could produce a graft construct with twice the strength of the native ACL (82).

The use of hamstring tendons has been criticized by some, as harvesting them removes a critical antagonist to anterior translation of the tibia. Hamstring strength recovery appears to be adequate at 2 years of follow-up, but weakness is noted for up to 9 months postsurgery (69,122). Local donor site pain is self-limiting and does resolve within 3 months, and the tendons themselves appear to regenerate (32).

Fixation of the STG tendons continues to evolve. Initial biomechanical studies comparing STG to BTB demonstrated that both graft constructs had strengths comparable to the intact ACL but that BTB was significantly stiffer than STG and more closely approximated the stiffness of the native ACL (114). This is likely because of the longer STG construct, which is fixed at the ends of the femoral and tibial tunnels rather than within the tunnels as the BTB with interference screws is (61). Later studies using younger specimens revealed that the differences in stiffness between quadrupled semitendinosus and BTB graft-fixation constructs were not significant but that semitendinosus grafts fixed with endobuttons and polyester tape proximally and #5 braided polyester suture around a post screw distally was stronger than BTB fixed with interference screws (96). Another method of STG fixation that appears to have biomechanical features that would support accelerated rehabilitation stresses includes placing the loop of tendons around a post placed through the femoral condyles into the femoral socket (29). Because of concerns with intratunnel graft motion and long distances between fixation points in constructs depending on sutures and buttons, some authors have advocated fixing STG grafts with

bioabsorbable interference screws, and strengths approaching those needed to withstand the stresses of rehabilitation were achieved in older cadaveric bone (25).

One critical feature of STG grafts is the time it takes for graft incorporation. Unlike bone-to-bone healing, as in the healing of BTB grafts, tendon-to-bone healing takes longer, with graft incorporation taking at least 8 to 12 weeks (94). Hence, the graft-fixation construct will be under stress for a longer period of time than the BTB graft-fixation construct.

### QUADRICEPS TENDON

The quadriceps tendon may be harvested with or without a bone block from the proximal pole of the patella, providing a graft that has a tendinous length of 7 cm and a thickness that is twice that of the patellar tendon (43,51). It can generally be harvested with an incision 4 to 5 cm in length, and notchplasty can often be performed concurrently with graft harvest. Minimal pain and morbidity to the extensor mechanism has been reported (44).

Biomechanical studies have found the graft to be of sufficient strength to undergo reconstruction and accelerated rehabilitation (51). As for graft fixation, the bony end may be fixed with an interference screw, and the tendinous end may be fixed with sutures tied over a post or with a bioabsorbable interference screw. Graft incorporation combines both bone-to-bone and tendon-to-bone healing. To date, no published reports of clinical results in peer-reviewed English journals exist, nor do any studies evaluating graft site morbidity.

### BONE–PATELLAR TENDON–BONE ALLOGRAFT

Obvious benefits exist in using allograft tissues for reconstructive surgery. The most common allograft tissue used in ACL reconstruction is BTB allograft. No donor site morbidity exists, and smaller incisions are used in performing the reconstruction, which enhances cosmesis and allows for shorter operative time. Allograft tissues are readily obtainable, and appropriately sized grafts may be fashioned without compromising remaining structures. Though final outcome regarding graft site morbidity at 2 years is similar in studies comparing allografts versus autografts, the early postoperative morbidity is less (50,112,115). The allograft tissue of choice for ACL reconstruction is BTB because of the ability to achieve rigid fixation with interference screws and bone-to-bone healing.

Several disadvantages to using allograft BTB exist, however, including the increased cost of the surgery because of the allograft. The most significant downside by far to using allografts is the possibility of disease transmission. Viral diseases such as human immunodeficiency virus and hepatitis are not eradicated by freezing tissue, and high-dose radiation cannot effectively kill viruses without damaging the graft tissue. Proper donor screening is the most effective means of decreasing risk of viral transmission, and the use of polymerase chain reaction techniques to screen for the presence of viruses decreases the risk even further to roughly 1 in 2 million. Since proper donor screening has been in place, no case of disease transmission has been reported (5).

A second major concern with allografts is the longer remodeling time. Though allografts readily heal in patterns similar to the healing and ligamentization of autografts, they do so at a slower rate (64). Mechanical properties of allografts are affected by the sterilization and processing methods as well. g-Irradiation weakens the graft (40,93) and, because it is not efficacious in eliminating viral disease, is probably not recommended. Ethylene oxide sterilization is effective in sterilization but produces synovial reaction after implantation and is not recommended (62). Sterility is assured through strict aseptic procurement and repeated bacterial and fungal culturing. Immunogenicity of grafts is a third concern, but appropriate processing can eliminate this problem. Deep freezing to –70°C decreases the antigenicity of the grafts without affecting the mechanical properties. This is a preferable method to freeze drying, as these grafts require long periods of time to rehydrate. Cryopreservation is also an excellent means of processing but is more costly and is best reserved for cartilaginous grafts.

### CHOOSING THE GRAFT

Several factors affect graft choice, and all must be tempered by the surgeon's familiarity with the technique and success with using a particular reconstructive method. Considerations are given in Table 89.2. The graft with the best track record is BTB autograft. Young, highly athletic individuals who will undergo an accelerated rehabilitation program and wish to return to competitive athletics in 4 to 6 months are excellent candidates for BTB autograft. Patients who desire less early postoperative graft site morbidity and do not wish to return to competitive athletics in such a short period of time may also consider hamstring reconstruction. Laborers who often kneel in their occupation and patients with preinjury abnormal patellofemoral biomechanics may also consider grafts other than autogenous BTB. The exact role for the use of quadriceps tendon is still evolving, though it may also have less early postoperative donor site morbidity. Allograft BTB is an excellent choice for older patients who desire no donor site morbidity and are not returning to competitive athletics in an accelerated time frame. Results in patients with chronic ACL deficiency, however, may not be as good as those with acute injury (60,83).

## SURGICAL TECHNIQUES

Though many graft choices and fixation techniques are available in ACL reconstruction, one common feature is the anatomic, impingement-free placement of the graft. If this is accomplished, knee stability can be restored, full range of motion can be achieved without undue stresses on the graft, and the patient can undergo an accelerated rehabilitation program and eventually return to athletic endeavors with full function. In this section we discuss methods for reconstructing the ACL with autogenous BTB using both endoscopic and two-incision techniques, allograft BTB reconstruction, endoscopic STG reconstruction using cross-pin femoral fixation, and endoscopic QT reconstruction. We go into detail on notch preparation and tunnel placement in the endoscopic BTB section and restrict our descriptions of the other techniques to aspects specific to that reconstructive method.

### ENDOSCOPIC BONE–PATELLAR TENDON–BONE AUTOGRAFT TECHNIQUE

#### *Positioning and Arthroscopic Setup*

The majority of our patients undergo general endotracheal anaesthesia using propofol (Diprivan, Stuart Pharmaceuticals, Wilmington, DE); narcotic anesthetics are avoided to reduce postoperative nausea.

- Place the patient in the supine position. Before placing the leg in a leg holder, perform a thorough examination under anesthesia including Lachman, anterior and posterior drawer, varus/valgus, and pivot-shift testing. Evaluate external rotation at 30° and 90° of flexion to assess for posterolateral instability and compare findings to the contralateral knee.
- If pivot-shift testing clearly demonstrates ACL insufficiency, harvest the BTB graft before diagnostic arthroscopy so that the inferolateral and inferomedial portals can be placed through the operative wound and the graft can be prepared by an assistant during the diagnostic arthroscopy.
- Though it is rarely used, place a tourniquet on the upper thigh before placing the leg in a leg holder. Secure the contralateral leg in a padded foot holder with the hip and knee slightly flexed, paying careful attention to padding the common peroneal nerve. The foot of the table must be fully flexed, and flexing the waist slightly minimizes lumbar extension. In the endoscopic technique, one must be able to flex the knee 100° to 110° of flexion to facilitate femoral screw placement in a parallel fashion. In the two-incision technique, it is not as crucial.
- Give 1 g of a first-generation cephalosporin such as cefazolin intravenously or 600 mg of clindamycin or 1 g of vancomycin if the patient is allergic to penicillin. After the leg is prepped and draped, infiltrate all portal sites and the anterior wound with 0.5% Marcaine (bupivacaine) with epinepherine in the subcutaneous tissue.

#### *Diagnostic Arthroscopy*

- For diagnostic arthroscopy, establish a superomedial or superolateral portal for outflow. The use of an arthroscopic pump has nearly eliminated the need for inflating the tourniquet for intraarticular hemostasis. Use an inferolateral portal for arthroscope placement and an inferomedial portal as a working portal. Attach the inflow to the arthroscopic cannula.
- Thorough diagnostic arthroscopy consists of evaluation of the suprapatellar pouch, patellofemoral joint, medial and lateral gutters, medial and lateral compartments, and the intercondylar notch.
- Pay particular attention to the menisci, which must be carefully evaluated for the presence of tears. Make all attempts to repair full-thickness longitudinal and bucket-handle tears, generally using an inside-out technique. Partial thickness tears and small tears less than 1 cm that are stable to probing we leave alone. Carefully note and grade all articular cartilage injuries.
- Visualize the intercondylar notch for evidence of the torn ACL: a long tibial ACL stump scarred to the PCL or roof (“vertical strut” sign) or failure of the ACL to extend to its normal femoral attachment (“empty lateral wall” sign) (8).

#### *Graft Harvest*

- Make the incision (Fig. 89.4) from the tip of the patella to 2 cm below the tibial tubercle, slightly medial to the midline, so the tibial tunnel can be placed through the incision. A smaller, more cosmetic incision can be used if adequate skin mobility is present. Carry the incision down sharply to the peritenon and then incise it with a #15 scalpel blade.

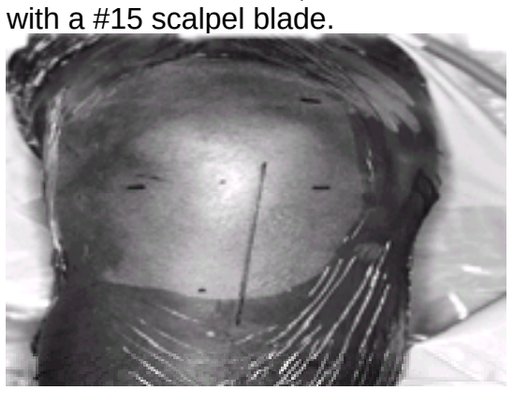

***Figure 89.4.*** View of a right knee. Make the incision slightly medial to the midline, from the distal tip of the patella to 2 cm below the tibial tubercle, approximately 8 cm in length. Placement of superomedial, inferomedial, and inferolateral portals is depicted as well. Should the graft harvesting occur before arthroscopy, place the inferomedial and inferolateral portals through the graft harvest incision.

- Extend the peritenon incision proximally and distally with Metzenbaum scissors and retract the edges medially and laterally to fully expose the patellar tendon.
- Measure the width of the tendon and document it in the operative dictation. Mark the midline both proximally and distally with a sterile marking pen and plan on a 10-mm-wide tendon with 10 mm by 25 mm bone plugs.
- Use a #10 scalpel blade to incise the tendon on one side of the graft. Extending the knee facilitates incising the patellar and tibial bone block edges, and flexing the knee places the tendon on tension, which helps guide the scalpel down the longitudinal axis of the tendon fibers. Placing a retractor distally helps prevent inadvertent extension of the distal aspect of the operative incision when outlining the tibial bone block with the scalpel. Incise the other side of the graft with the scalpel, being careful to remain parallel with the opposite side of the graft's fibers.
- Outline the distal cross-cut on the tibia and the proximal cross-cut on the patella. Use an oscillating saw with a #238 saw blade to create the tibial and femoral bone plugs. With the saw in your dominant hand, stabilize the saw with the nondominant thumb and place the nondominant index finger in the axilla between the inner and outer aspects of the graft to prevent inadvertent graft damage (Fig. 89.5).

***Figure 89.5.*** View of a right knee, harvesting the medial aspect of the tibial bone plug. Place the left index finger between the graft's tendon and the remaining medial third of the patellar tendon, and use left thumb to stabilize the oscillating saw.

- When making the other side of the bone plug, use an identical technique with hands switched. Score the tibial cortex and make an equilateral triangle on profile with the saw in order to maximize the remaining bone in the tubercle region beneath the medial and lateral thirds of the remaining patellar tendon (Fig. 89.6).

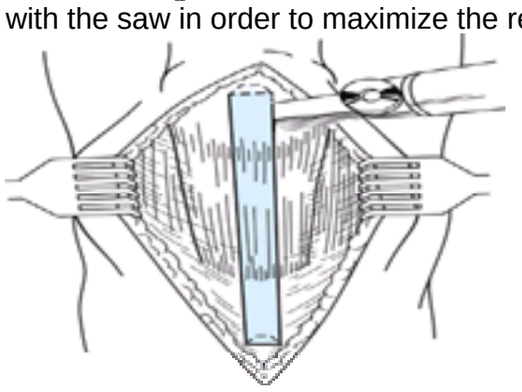

***Figure 89.6.*** This illustration depicts the geometric configuration of the trapezoidal patellar and triangular tibial bone plugs. (Redrawn from Hardin GT, Bach BR Jr, Bush-Joseph CA, Farr J. Endoscopic Single-Incision Anterior Cruciate Ligament Reconstruction Using Patellar Tendon Autograft. Surgical Technique. *Am J Knee Surg* 1992;5:144.)

- Make the distal cross-cut with the saw blade held 45° oblique to the cortex, with the corner of the blade used to cut the bone on each side of the tibial plug. Before lifting out the tibial bone plug, create the patellar bone plug with the saw. Make a trapezoidal graft on profile to avoid penetrating the articular cartilage; the depth of the cut should not exceed 6 to 7 mm.
- Make the proximal cross-cut holding the saw blade at a 45° angle and then place the blade parallel to the medial and lateral bone cuts to complete the cross-cut.
- Use ½-in. and ¼-in. curved osteotomes to gently lift the tibial plug out of its bed without levering. With soft tissue remaining on the patellar tendon, the patellar plug can be gently lifted out of its bed. Grasp the tibial plug with a laparotomy sponge, apply tension, and remove the fat pad from the tendon with Metzenbaum scissors. Release soft tissue attachments and take the graft to the back table for preparation.

***Graft Preparation***

- First measure the length of the graft's bone blocks, tendinous portion, and total length. Ideally one has harvested 10 mm × 25 mm bone plugs. If one bone plug is longer, use it on the femoral side to decrease length construct mismatch between the tibial tunnel and the graft.
- Use a small rongeur to contour the bone plugs. Save the excess bone removed for subsequent patellar defect bone grafting. A small spur of bone is often present proximal to the tendon insertion into the tibial bone plug and should be removed so that the bone edge is flush with the tendinous insertion. If one bone block is 11 mm wide, use it for the tibial tunnel side.
- Use a 0.062-in. Kirschner (K-) wire to make two drill holes in the tibial bone plug, placed parallel to the cortical surface through the cancellous portion of the graft. Place a #5 Ticron suture in each hole (Fig. 89.7).




***Figure 89.7.*** Photograph of the harvested tendon. Place two #5 Ticron sutures in the tibial bone plug and mark the distal cortical surface of the tibial plug with the

marking pen. Mark the tendo-osseous junction of the femoral bone plug as well. Bone plugs are approximately 25 mm long, with a tendon length of 42 mm.

- We have not had any incidences of suture cutout through the cancellous bone using this technique in more than 700 cases of ACL reconstruction. The suture holes are placed perpendicular to the cortex because of the risk of lacerating the sutures, as we place our interference screws on the cortical surface of the bone plugs. Alternatively, a 22-gauge wire can be placed rather than suture to preclude the potential for suture laceration. Because we use a “push-up” rather than “pull-through” technique in placing our graft intraarticularly, we do not need to place sutures in the femoral bone plug. If a “pull-through” technique using a passing pin is used, sutures may be placed in the femoral plug in an identical manner.
- After the graft is prepared, wrap it in a moist lap pad and place it in a kidney basin in the middle of the main instrument table. It is not immersed in water, as this will cause the graft to become edematous.

### *Notch Preparation and Notchplasty*

- Intercondylar notch preparation is performed while the graft is being prepared at the back table. While evaluating the notch configuration, note the presence of tibial eminence and notch wall osteophytes. Although significant notch width variability may be encountered, 20 to 22 mm is required to avoid graft impingement. Removal of the ligamentum mucosum from the notch apex facilitates visualization, and it is occasionally necessary to debride some fat pad.
- Remove the remaining ACL tissue with the combination of arthroscopic scissors, arthroscopic osteotome, and motorized 5.5 mm full-radius resector and remove all soft tissue from the lateral wall of the notch. Synovium overlying the PCL laterally may be removed to help visualize the posterior notch. This can often create bleeding that requires electrocauterization, however.
- The notchplasty is performed for two purposes. First, it promotes visualization of the “over-the-top” position and accurate placement of the femoral tunnel. Second, it helps prevent impingement of the graft with the knee in full extension.
- Initiate the notchplasty with a ¼-in. osteotome placed through the inferomedial portal. This allows for a more expeditious notchplasty, and the osteocartilaginous fragments can be removed with a grasper, the cartilaginous portion removed, and the remaining bone used to graft the patellar and tibial defects. Complete the notchplasty with a motorized 5.5 mm round burr, moving from anterior to posterior and from apex to inferior, with care taken to avoid misinterpreting a vertical ridge two thirds posteriorly as the true posterior outlet (Fig. 89.8).

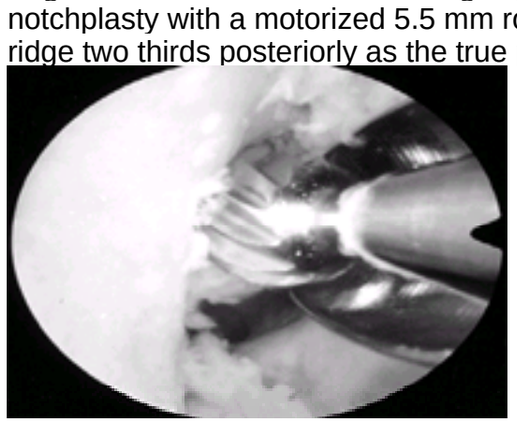

***Figure 89.8.*** Arthroscopic view of a right knee. The 5.5 mm round burr is just posterior to a vertical ridge that is two-thirds posterior to the entrance to the notch. Take this down to fully visualize the “over-the-top” position.

- When the ridge is identified, place the burr posterior to the ridge and move it from a posterior to anterior direction to smooth the ridge. Use a curet to remove soft tissue from the posterior outlet, and then hook a probe over the posterior edge to confirm proper “over-the-top” positioning (Fig. 89.9). Remove minimal bone from the femoral ACL insertion to avoid lateralizing the isometric point. Proper perpendicular camera orientation is crucial in avoiding excessive removal of lateral femoral condyle bone in the midportion of the notch and insufficient bone from the inferior portion of the notch.

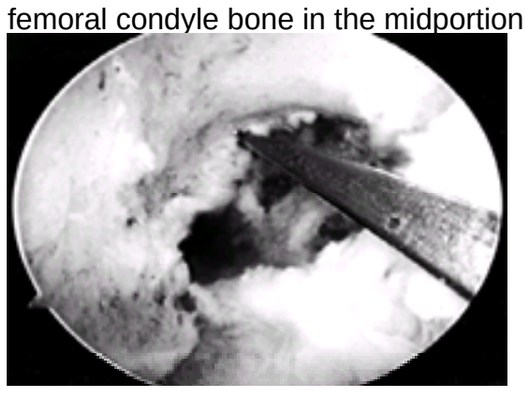

***Figure 89.9.*** Arthroscopic view of a right knee. All soft tissue has been cleared out to ensure visualization of the posterior edge of the notch. A probe is placed over the posterior edge of the femur in the “over-the-top” position.

### *Tibial Tunnel Placement*

- After completion of the notchplasty, prepare the tibial tunnel. Make a medially based rectangular periosteal flap just medial to the tibial tubercle graft harvest site. The tibial tunnel entrance is generally 1.5 cm medial to the tubercle, 1 cm proximal to the pes anserine tendons, and in line with the middle of the tibial graft site.
- Take care to avoid injuring the superficial medial collateral ligament, the pes anserine tendons, or the medial aspect of the patellar tendon as well. A more posteromedial starting point is desirable in the endoscopic technique to allow straighter access to the correct femoral tunnel position. The tibial tunnel's position will dictate to a certain extent the position of the femoral tunnel, as the femoral tunnel guide is placed through the tibial tunnel, unlike the two-incision technique (Fig. 89.10).

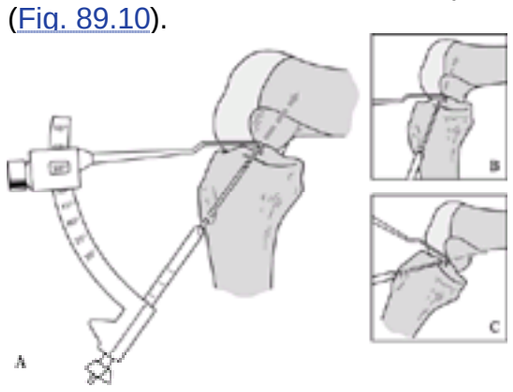


***Figure 89.10.*** Illustration of proper placement of the tibial tunnel. **A:**In general we tend to use steeper angles, such as 55° (as determined by the “*n* + 7” rule). A well-placed tunnel will allow for proper endoscopic placement of the femoral tunnel. A tunnel that is too steep (**inset B**) will preferentially place the femoral tunnel too far anteriorly, whereas a tibial tunnel that is flat (**inset C**) will tend to place the femoral tunnel too posterior, risking posterior cortical violation. Minor variances may be treated with appropriate flexion of the knee before placement of the “over-the-top” guide and femoral guide pin. (Redrawn from Hardin GT, Bach BR Jr, Bush-Joseph CA, Farr J. Endoscopic Single-Incision Anterior Cruciate Ligament Reconstruction Using Patellar Tendon Autograft. Surgical Technique. *Am J Knee Surg* 1992;5:144.)

- Several commercially available tibial tunnel guide systems are available for use in drilling the tibial tunnel. Attempt to optimize the match of the graft and tunnel length. The “*n* + 7” rule is helpful (but not absolute), whereby 7° is added to the length of the tendinous portion of the graft, producing the setting for the guide (73,87). For instance, if the tendon measures 48 mm in length, 7 is added to make 55, and the guide is set at 55°.
- We use several parameters to determine guide pin placement. By using the tibial ACL insertion footprint, ideally the guide pin should pierce the tibial cortex in the

middle of the footprint. This also should be keyed off the posterior edge of the anterior horn of the lateral meniscus by following the contour of the posterior edge to the midpoint of the notch. This is just lateral to the medial tibial spine. Last, the guide pin should enter the joint 7 mm anterior to the PCL (65,76). It should be kept in mind that because of soft tissue overlying the tibial plateau, where one sees the pin enter the joint is not necessarily where it exits the plateau surface. For this reason, erring more posteriorly prevents unwanted anterior tunnel placement. This, along with prevention of intercondylar notch “cyclops lesions,” is the purpose of debriding the ACL stump. In the coronal plane the tunnel should be midline in the notch. Erring slightly medially helps prevent impingement from the lateral femoral condyle.

- Each commercially available tibial tunnel guide system has inherent peculiarities. Place the tibial guide aimer through the inferomedial portal and use the anatomic guides discussed above to appropriately place the stylet of the guide (Fig. 89.11). The guide pin of the Acufex Protrac aimer (Smith & Nephew Endoscopy, Mansfield, MA) contacts the elbow of the aimer above the surface of the plateau, so we place the point of the aimer more posteriorly to prevent anterior tunnel placement. The arm of the aimer should be parallel to the articular surface. In cases of patella alta, when the anteroinferior portals are high relative to the articular surface, parallel placement of the point arm may be impeded by the soft tissues. It may be necessary to make an accessory inferomedial portal to ensure parallel placement.

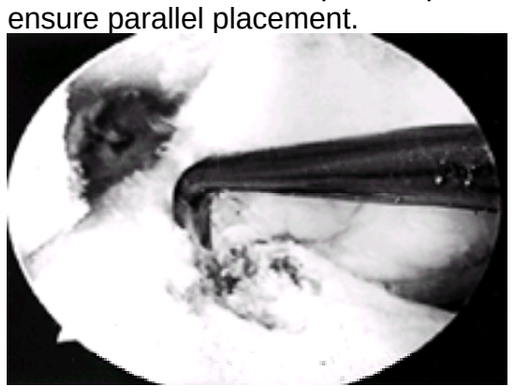

***Figure 89.11.*** Arthroscopic view of a right knee. Position the stylet tip of the arm of the aiming guide so that the guide pin enters the joint in the center of the ACL's tibial footprint, 7 mm anterior to the PCL. Use the posterior edge of the anterior horn of the lateral meniscus as a guide to judge anterior–posterior positioning.

- Retract the distal soft tissues and slide the cannulated guide arm of the aimer up to the tibial cortex, 1.5 cm medial to the tibial bone plug site, 1 cm above the pes anserine tendons (65). Drill a guide pin through the guide arm and into the joint (Fig. 89.12).

***Figure 89.12.*** Arthroscopic view of a right knee. The guide pin has entered the joint and engaged the elbow of the aiming guide's arm. At the level of the tibial plateau it is in the center of the tibial footprint of the ACL, 7 mm anterior to the PCL.

- After the pin penetrates the joint, remove the guide, check the pin placement, and extend the leg to ensure impingement-free extension (55,56). Slight alterations in pin placement may be done by free-hand drilling of another guide pin held tightly with Kocher clamps against the first pin, with appropriate adjustments made in the AP and medial–lateral planes.
- Depending on graft size, ream with a 10- or 11-mm cannulated headed reamer placed over the guide pin. Before entering the joint, turn off the arthroscopic pump.
- Collect all bone reamings with a cannulated bone chip harvester (Linvatec, Largo, FL) and use them for grafting the patellar and tibial bone plug defects (33,39) (Fig. 89.13). After the reamer and guide pin are removed, inspect the tip of the guide pin. Wash cancellous reamings out the tunnel and collect them onto an Owens gauze, which makes removal of the graft easier than from a standard laparotomy sponge. Plug the tunnel and turn the pump back on.



***Figure 89.13.*** Photograph of cannulated bone collector and reamer after reaming of the tibial tunnel. An abundance of bone can be collected and used to graft the patellar and tibial graft defects. (From Ferrari JD, Bach BR. Technical Note: Bone Graft Procurement for Patellar Defect Grafting in Anterior Cruciate Ligament Reconstruction. *Arthroscopy* 1998;14:543.)

- Remove loose bone and cartilage around the tunnel entrance with the shaver, and smooth posterior ridges of the tunnel with a motorized chamfer reamer and an arthroscopic hand rasp (Fig. 89.14).

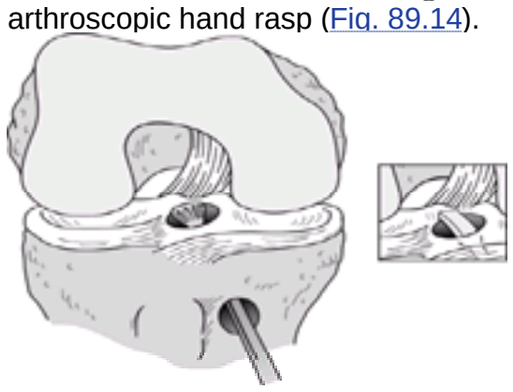

***Figure 89.14.*** Illustration of a right knee. After the tibial tunnel has been created, a posterior cortical lip is often present. This is smoothed down with the aid of a chamfer reamer and curved rasp (**inset**). Left alone and not smoothed, this edge could abnormally anteriorize the graft, cause chafing and possible rupture at the posterior aspect of the graft, and create difficulty in passing the graft into the femoral tunnel.

### *Femoral Socket Placement*

The goal of femoral socket placement is to prepare a tunnel that originates at the 1 o'clock position in the left knee and 11 o'clock position in the right knee and has a 1-

to 2-mm posterior cortical shell (Fig. 89.15). This provides for an anatomic and near-isometric position of the graft. Avoidance of posterior cortical “blow out” is minimized by meticulously clearing the soft tissue surrounding the “over-the-top” position and confirming the position with a probe. Use a retrograde femoral offset guide placed through the tibial tunnel that positions the guide pin 7 mm anterior to the posterior cortex. This leaves a 2-mm bone shell when a 10-mm reamer is used to make the tunnel (Fig. 89.16A). Alternatively, one could create an accessory inferomedial portal, place the femoral aimer through the portal, hyperflex the knee, and drill the femoral socket (Fig. 89.16B).

***Figure 89.15.*** Sagittal cross section of a femur showing a 7-mm “over-the-top” guide placed over the posterior edge of the notch and a guide pin placed through the guide and into the femur. Overreaming with a 10-mm reamer will leave a 2-mm posterior wall in the femoral socket. (From Hardin GT, Bach BR Jr, Bush-Joseph CA, Farr J. Endoscopic Single-Incision Anterior Cruciate Ligament Reconstruction Using Patellar Tendon Autograft. Surgical Technique. *Am J Knee Surg* 1992;5:144.)

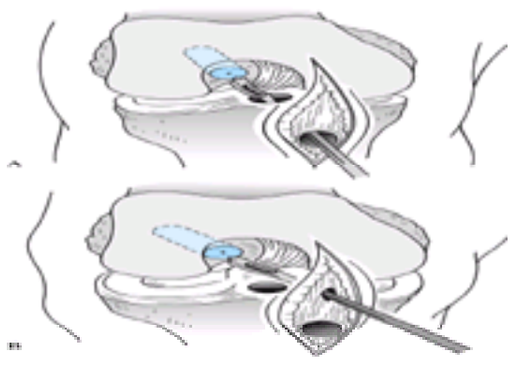

***Figure 89.16.*** **A:** Illustration of a right knee with the “over-the-top” guide placed through the tibial tunnel. **B:** Alternatively, place the guide through a low inferomedial portal and, with hyperflexion of the knee, position the guide and drill the pin. This method creates a femoral socket that is not dependent on the position of the tibial tunnel.

- With the pump turned off and the knee “dry,” place the offset guide through the tibial tunnel and in its “over-the-top” position. If necessary, place a probe in the inferomedial portal to retract the PCL.
- As mentioned above, we use a “push-in” rather than a “pull-through” technique, which doesn't require a passing pin. Drill the guide pin through the guide and to a depth of 2.5 to 3.5 cm, essentially the length that one plans on reaming, into the femur.
- Remove the guide and probe the pin for correct placement. Ream with a 10-mm reamer 1 cm into the femur, creating an “endoscopic footprint.” Back it out and probe for posterior cortical integrity and proper tunnel orientation. When this is confirmed, ream to a depth 5 to 7 mm greater than the length of the femoral bone plug (Fig. 89.17). This is done so that the femoral plug can be recessed to minimize graft–tunnel mismatch if needed. Furthermore, because the tunnel is drilled at an angle, the anterior aspect of the tunnel is not colinear with the posterior aspect. If one leaves the femoral plug flush with the anterior aspect of the tunnel, the graft will be anteriorized, which increases graft strain in flexion. Furthermore, if the bone plug protrudes below the posterior wall, it may be at risk for fracture. Hence, the graft must be recessed a few millimeters with respect to the anterior aspect of its tunnel regardless of graft–tunnel mismatch.

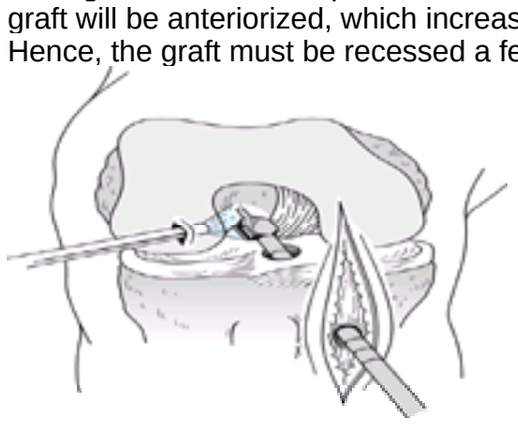

***Figure 89.17.*** Illustration of a right knee. Place the 10-mm reamer over the guide wire and drill to desired depth. (Redrawn from Hardin GT, Bach BR Jr, Bush-Joseph CA, Farr J. Endoscopic Single-Incision Anterior Cruciate Ligament Reconstruction Using Patellar Tendon Autograft. Surgical Technique. *Am J Knee Surg* 1992;5:144.)

- After the reamer is removed, flush loose bone from the knee with the aid of the pump and collect these reamings with the Owens gauze. Again, check tunnel integrity definitively by placing the arthroscope retrograde through the tibial tunnel into the femoral tunnel (Fig. 89.18).

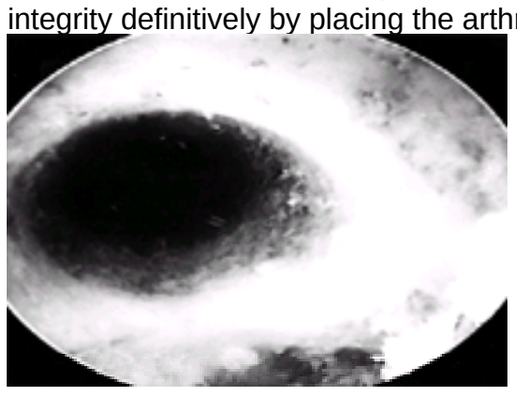

***Figure 89.18.*** Arthroscopic view of the right knee. The femoral socket's integrity is checked by placing the arthroscope up through the tibial tunnel.

- Perform a “phase II” notchplasty (Fig. 89.19). During the process of femoral tunnel reaming, if the reamer engages the lateral wall, use this observation to assist in fine-tuning the amount of lateral wall expansion. The femoral tunnel entrance should appear circular. If there is an oval appearance laterally, abrade the opening to produce a circular configuration. “Ellipticize” (i.e., eccentrically abrade) the anterolateral quadrant to aid in screw placement and chamfer the anterior ridge with a shaver to facilitate guide-pin placement.

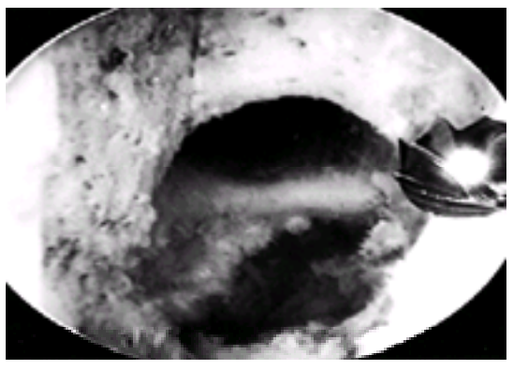

***Figure 89.19.*** Arthroscopic view of the right knee. “Phase II notchplasty” is performed with a 5.5-mm round burr. Smoothe the lateral wall of the notch at the entrance to the femoral socket with the burr.

### *Graft Placement and Fixation*

- After removing the graft from its gauze, place a two-pronged pusher at the base of the femoral bone plug (Fig. 89.20) and position a curved hemostat through the inferomedial portal with its tips pointed up. Then “push up” the graft through the tibial tunnel and grasp it with the hemostat at the junction of the proximal and middle third of the bone plug (Fig. 89.21*A*). Remove the pusher and guide the graft up into the femoral socket (Fig. 89.21*B*). Orient the cortical surface of the femoral plug posteriorly and in the coronal plane.

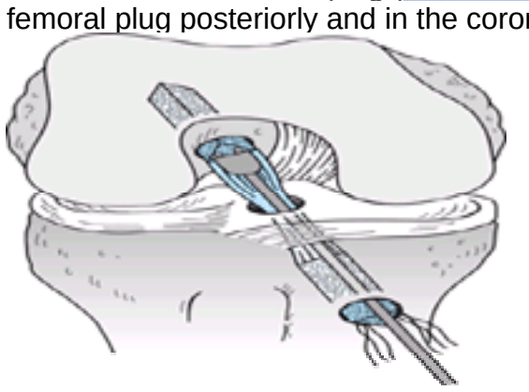

***Figure 89.20.*** Illustration of a right knee. Use a two-pronged pusher to guide the graft up the tibial tunnel. Remove the pusher from the tunnel before the tibial bone plug enters its tunnel, however, or the pusher will be difficult to remove. (Redrawn from Hardin GT, Bach BR Jr, Bush-Joseph CA, Farr J. Endoscopic Single-Incision Anterior Cruciate Ligament Reconstruction Using Patellar Tendon Autograft. Surgical Technique. *Am J Knee Surg* 1992;5:144.)

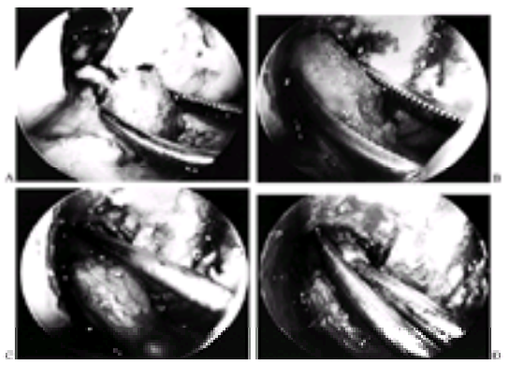

***Figure 89.21.*** Arthroscopic views of the right knee. **A:** Grasp the femoral bone plug with a curved hemostat placed through the inferomedial portal with tip pointed up. **B:** Then guide the graft up into the femoral socket. **C:** Once the plug is seated roughly 85% into its socket, place a Nitenol Hyperflex guide pin at the 11 o'clock position of the graft. Hyperflex the knee and gently push the pin to the back of the socket. **D:** Place the satellite pusher at the inferior edge of the femoral bone plug and tap the plug to seat it fully in its socket.

- Before fully seating the femoral plug into its socket, place the Nitenol hyperflex guide pin (Linvatec, Largo, FL) into the femoral socket at the 11 o'clock position of the graft. If difficulty is encountered in placing it in the tunnel, use the hemostat to create a small opening to guide it into the tunnel. Once the pin is initially positioned within the tunnel, flex the knee 100° to 120° and fully seat the guide pin within the tunnel (Fig. 89.21*C*). The pin should not be forced and should slide easily. It potentially could be placed through the bone plug or posterior cortex. If the guide pin appears too divergent from the graft, as often can be seen if patella alta is present, the accessory inferomedial portal is helpful in placing the guide pin more parallel with the graft and reducing screw divergence. As the knee is flexed, adjust the camera to visualize the “gap space interval” anteriorly between the femoral socket and the bone plug. Then use a satellite pusher to fully seat the bone plug in its socket (Fig. 89.21*D*).
- Check the tibial plug to make sure it is not protruding excessively from its tunnel. If there is marked graft–tunnel mismatch at this time, remove the graft and deepen the femoral socket.
- Use a 7 × 25 mm titanium fully threaded cannulated interference screw on the femoral side, as biomechanical studies indicate no significant difference between 7-mm and 9-mm interference screws for femoral fixation (67). We prefer interference screw fixation with nonheaded Kurosaka screws (Linvatec, Largo, FL), and we generally use a screw that matches the length of our graft. Apply maximum tension to the sutures as the screws are placed to avoid graft advancement. Place the femoral screw against the cancellous surface, thus reducing the potential for soft tissue injury or laceration; the tibial screw is placed against the cortical surface. Use cannulated screws to help prevent divergence.
- Place the screw over the guide wire and push it into the joint (Fig. 89.22). To maximize the potential for parallel placement of the femoral interference screw, hyperflex the knee 100° to 110°. This additional knee flexion will “compensate” for the difference created between the tibial tunnel angle and the angle created by the flexible Nitenol pin placed through the inferomedial portal. As the screw is being placed, apply light tension to the tibial plug's sutures, which helps prevent the graft from being lacerated by the screw. Pay careful attention to the tendinous portion of the graft just inferior to the femoral plug. If this tissue begins to rotate, the screw may be wrapping up or beginning to lacerate the tendon. When the screw is halfway positioned, remove the guide pin, or it may be difficult to remove the wire when the screw is fully seated. The screw is fully seated when its base is flush with or slightly above the base of the femoral plug; if it is not, fraying and graft disruption can occur with motion. Commercially available graft protection sleeves are available to reduce the potential for soft tissue laceration. If we decide to recess the femoral bone plug more than 5 mm, we will routinely use a protection sleeve.

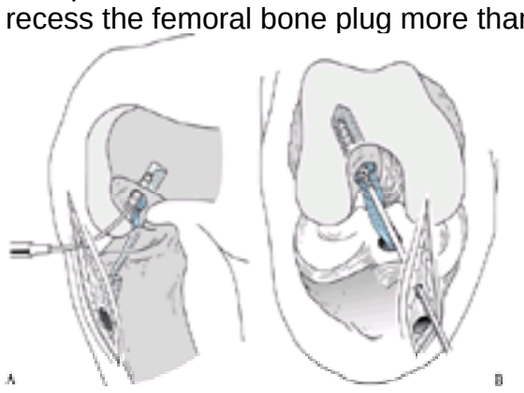

***Figure 89.22.*** Illustrations of a right knee. **A:** Lateral view depicting the interference screw being placed over the guide wire. The tibial plug has been externally rotated 180° so that the cortical surface is facing anteriorly. **B:** Anteroposterior view of the screw being placed. An accessory inferomedial portal facilitates parallel screw placement. (Redrawn from Hardin GT, Bach BR Jr, Bush-Joseph CA, Farr J. Endoscopic Single-Incision Anterior Cruciate Ligament Reconstruction Using

Patellar Tendon Autograft. Surgical Technique. *Am J Knee Surg* 1992;5:144.)

- Check the graft for "gross isometry." Hold the sutures in the tibial plug tightly and place an index finger at the extraosseous entrance of the tibial tunnel. Flex the knee from 100° to complete extension or hyperextension. As the knee moves from 30° to complete extension, 1 to 2 mm of motion is generally noted. Cycle the knee several times with tension placed on the graft. Last, view the graft arthroscopically to ensure that it is impingement-free in extension and does not abrade along the lateral wall with knee motion.
- An alternative means of graft passage is the use of a passing pin, which has an open slot at its base for placing suture. When using this technique, place two #5 Ticron sutures through both bone plugs. Place the pin through the "over-the-top" guide and drill through the femur. Tap the pin with a mallet through the anterolateral thigh and out the skin. Overdrill with the 10-mm reamer and pass the sutures through the bottom slot of the pin. Pull the pin out of the anterolateral thigh and securely grasp the sutures protruding out the pin hole. With a hand on each group of sutures, bring the graft into the knee joint. A probe in the inferomedial portal can facilitate placement of the femoral bone plug into its socket. After placing the femoral interference screw, remove the two #5 Ticron sutures from the anterolateral thigh.
- We prefer the "push-in" technique over the "pull-through" method because it avoids placing a pin through the thigh and possible complications such as a break in sterility, pin breakage, and creation of a stress riser in the femur (28). The "phase II" notchplasty and visualization of the femoral socket are also easier because the passing pin is not present, and no sutures need be placed through the femoral bone plug. Before tibial fixation, we externally rotate (i.e., toward the lateral side) the graft (100). This allows an anatomic rotation of the graft, can reduce graft–tunnel mismatch by shortening the graft construct, and allows the tibial screw to be placed against the cortical surface of the tibial plug, anterior to the graft. We do this for four reasons. First, with the screw placed anteriorly, when the knee flexes, there is no abrasion of the screw against the graft. If the screw is placed posteriorly and the screw tip extends beyond the tendo-osseous interval, knee flexion may result in abrasion of the graft. Second, the screw is more likely to diverge if placed posteriorly along the cancellous portion of the graft. Third, a screw placed posteriorly will anteriorize the graft, adversely affect isometricity, and possibly create impingement of the graft. Last, fixation is greater when placed along the cortical surface.
- One must ensure that the tibial plug is moving freely within the tibial tunnel before distal fixation is done. Occasionally the distal tip of the plug can get caught inside the tunnel on the inferior edge. If the plug is fixed in this position, graft tension will be lax. For fixation on the tibial side, position the knee in full extension and firmly tense the tibial plug sutures. Place a Nitenol hyperflex pin anterior to the tibial plug and secure the graft with a 9 × 20 mm screw. Recess the head of the screw just below the cortical surface of the tibia so that it is less likely to become symptomatic but is not difficult to remove should the situation arise. If the tibial plug has been recessed in its tunnel as a result of mismatch, choose a longer screw (Fig. 89.23).

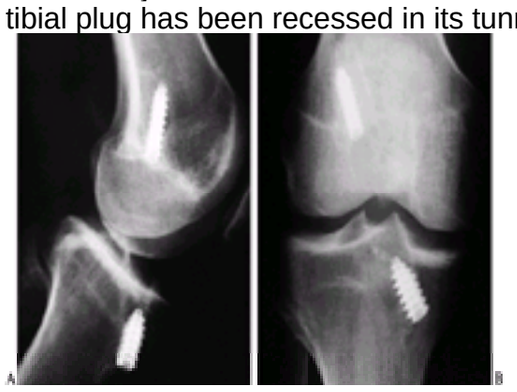

***Figure 89.23.*** Anteroposterior (**A**) and lateral (**B**) views of a right knee after ACL reconstruction with an endoscopic technique. The lateral view demonstrates proper posterior placement of the femoral tunnel with parallel screw placement. The tibial tunnel enters the joint in the midpoint of the tibial plateau, and the tibial screw is parallel to its bone plug. The AP view confirms parallel screw placement and placement of the femoral socket at the 11 o'clock position.

- Place the arthroscope back inside the knee for a final check of the graft's orientation and to ensure that proper graft tension is present at 20° to 30° of knee flexion. A Lachman and pivot-shift exam can be done at this time as well.

### *Methods of Addressing Graft Construct Mismatch*

As with most surgical problems, prevention is the best cure. By following the "*n* + 7" rule, most but not all graft construct mismatches can be avoided (73,87). Currently, our largest mismatches occur in using BTB allografts, when the allografts are derived from a cadaver of significantly larger size than the patient. Several methods are available to address mismatch problems. As mentioned above, small mismatches may be reduced by recessing the femoral bone plug deeper within its socket. If one is going to recess the femoral bone block, parallel placement of the interference screw is essential, as the potential for graft injury increases. Commercially available graft protectors can be used to further protect the soft tissue component of the graft. An accessory inferomedial portal should also be considered for screw placement.

To reduce graft–tunnel mismatch, externally rotate the graft 180° or, if more shortening is needed, one additional revolution (180° + 360°). If 15 mm of tibial bone is within the tibial tunnel, our choice is to use an interference screw. Alternatives to interference screw fixation include tying the sutures over a bicortical screw and washer or recessing the tibial tunnel's bed so that the tibial plug can be placed within it and be fixed with either two $^{7}/_{16}$-in. barbed staples or a bicortical 3.5-mm screw placed in a lag fashion. Last, should the entire bone plug be protruding, we remove the tibial bone block, place two #5 Ticron sutures in the tendon, perpendicular to one another in a Krackow fashion (see Fig. 89.44), for traction, and then place the free tibial bone block into the tunnel. We secure this entire construct with a 9 × 20 mm interference screw placed over a guide wire. This construct has been found to be significantly stronger and stiffer than fixation with the bone block sutures tied over a post (78).

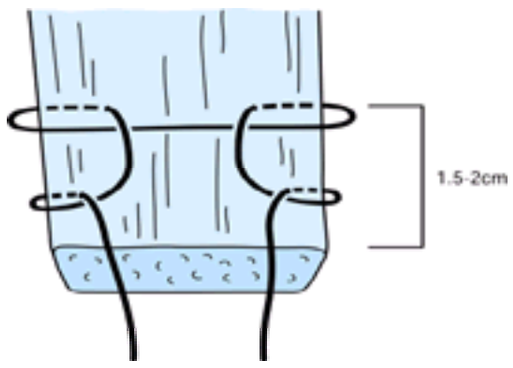


***Figure 89.44.*** The modified Krackow suture placed on the tendinous portion of the QT graft, begun 1.5 to 2 cm from the end of the tendon. See text for details. A second suture is placed in an identical fashion on the opposite side of the tendon.

### *Closure*

Loosely reapproximate the patellar tendon defect with three or four interrupted #1 Vicryl sutures while the knee is flexed, avoiding excessive shortening of the tendon. The osteoperiosteal flap overlying the tibial drill hole is also closed with #1 Vicryl. We graft the patellar bone defect with the collected bone reamings, and any remaining bone is used to graft the tibial donor site. We close the peritenon with a running 2-0 Vicryl suture, the subcutaneous layer with interrupted 2-0 Vicryl, and the skin with a running 3-0 Prolene. We inject 0.5% bupivacaine (Marcaine) with epinepherine into the periosteal region, deep surgical wound region, portals, skin, and intraarticularly. We do not use hemovac drains. Steri-Strip the wounds, then apply dry sterile gauze, Kerlex roll, an ice cryotherapy pad, and ace wrap. The cryotherapy pad must not contact the skin, or a superficial frostbite can occur. Last, place the leg in a hinged knee brace, which can be locked in extension.

## ENDOSCOPIC BONE–PATELLAR TENDON–BONE ALLOGRAFT TECHNIQUE

The technique of using BTB allograft differs little from that of BTB autograft. Other than arthroscopic portals, the only incision is a 1.5- to 2.0-cm incision made in line with the inferomedial portal, 1 cm above the pes anserine tendons and 1.5 cm medial to the tibial tubercle. A medially based periosteal flap is raised as previously

described for placement of the tibial tunnel. We prepare the graft in a fashion identical to that of autogenous BTB, with the only exception being using a 1- to 2-mm-wider tendinous portion.

Choice of allograft size and its preparation is critical. We use frozen, nonirradiated allograft prepared at a tissue bank certified by the American Association of Tissue Banks. The length of the patellar tendon should be known, as allografts with tendon lengths over 50 mm are too long for almost all women and smaller men, and this will create a graft–tunnel mismatch with an endoscopic technique. The tibial bone plug will thus protrude out of its tunnel, requiring alternative means of fixing the tibial side of the graft.

Because of the skin overlying the standard inferomedial portal, an accessory inferomedial portal is almost always required for placement of the femoral interference screw. This diminishes divergence between the femoral bone plug and the screw's guide pin.

**TWO-INCISON BONE–PATELLAR TENDON–BONE AUTOGRAFT TECHNIQUE**

The primary difference between endoscopic and two-incision ACL reconstruction using BTB autograft is the creation of the femoral tunnel. The orientation of the two-incision femoral tunnel differs from that of the endoscopic femoral tunnel, although the actual intraarticular placement should be identical. This is an important concept to recognize, particularly in revision situations. Graft harvest and tibial tunnel preparation are identical, but it is not critical that the tibial tunnel be placed as steep and in a distal anteromedial to proximal posterolateral direction, as the creation of the femoral tunnel is not dependent on the tibial tunnel's orientation. Graft preparation differs, as it includes placing sutures through both bone plugs for control of the graft during passage into the knee.

Benefits to the two-incision technique versus the endoscopic technique are that graft construct mismatches rarely occur, and complications of creation of the femoral socket such as posterior wall “blow out” are avoided. Disadvantages obviously include the extra lateral skin incision and morbidity of dissecting down to the “over-the-top” position. Femoral graft fixation necessitates a 9-mm screw for strength comparable to that of a 7-mm screw placed endoscopically, and because the femoral bone plug is not flush with the posterior wall of the femoral socket, stresses are placed on the tendinous portion of the graft.

Despite these theoretical disadvantages, no studies have demonstrated superior outcome of one technique over another (49,70,101). It is a technique that all ACL surgeons should have in their armamentarium, as it is especially useful in the revision of endoscopic reconstructions and in the unfortunate circumstance of posterior wall “blow out” (24,99). One of us (B. R. B.) performed two-incision ACL reconstructions from 1987 to 1991 before converting to an endoscopic technique.

***Femoral Tunnel Placement***

Historically, our normal sequence of events was to (a) place our tibial guide pin, (b) perform the lateral approach for femoral tunnel placement and place the femoral guide pin, (c) drill the femoral tunnel, and (d) drill the tibial tunnel. We preferred to prepare the femoral tunnel before the tibial tunnel in order to better maintain knee joint distention, allowing improved visualization of the femoral socket's integrity. If we were performing a two-incision technique today, however, we would most probably create our tibial tunnel initially and use the femoral endoscopic aimer to create a pilot hole on the femur. This would allow us to more easily and accurately create the femoral tunnel.

- To begin femoral tunnel placement, make a lateral skin incision over the midportion of the iliotibial band (ITB), from the lateral femoral epicondyle extending 4 cm proximally (Fig. 89.24).

***Figure 89.24.*** Photograph of a right knee depicting the lateral incision for placement of the femoral tunnel. The iliotibial band is exposed. (From Bach BR Jr. Arthroscopy-Assisted Patellar Tendon Substitution for Anterior Cruciate Ligament Insufficiency. *Am J Knee Surg* 1989;2:3.)

- Split the ITB in line with its fibers 2 cm anterior to its posterior edge. Elevate the vastus lateralis from posterior to anterior off the lateral intermuscular septum and femur and place a Chandler or Z retractor over the anterior femur to retract the extensor mechanism. Take care to avoid injury to the lateral collateral ligament origin at the flare of the metaphysis. The entry point should always be proximal to the origin of the ligament (Fig. 89.25).

***Figure 89.25.*** Bone model of a right knee. Place the bullet tip of the femoral drill guide at the flare of the metaphysis. This point is always proximal to the lateral collateral ligament.

- The superior lateral geniculate vessels require electrocauterization, as they may be a source of postoperative bleeding or hematoma. Bluntly dissect with a finger and use a 0.75-in. Cobb elevator subperiosteally to facilitate palpation of the posterior intercondylar notch (Fig. 89.26).



***Figure 89.26.*** Photo of a right knee. Use a Cobb elevator to reflect the vastus lateralis from posterior to anterior to expose the lateral condyle. (From Bach BR Jr. Arthroscopy-Assisted Patellar Tendon Substitution for Anterior Cruciate Ligament Insufficiency. *Am J Knee Surg* 1989;2:3.)

- Place a J-passer through the inferomedial portal or midpatellar rent to the “over-the-top” position and out the posterior capsule (Fig. 89.27*A*). A pistoning motion will dilate the capsule slightly, allowing for easier entrance intraarticularly.

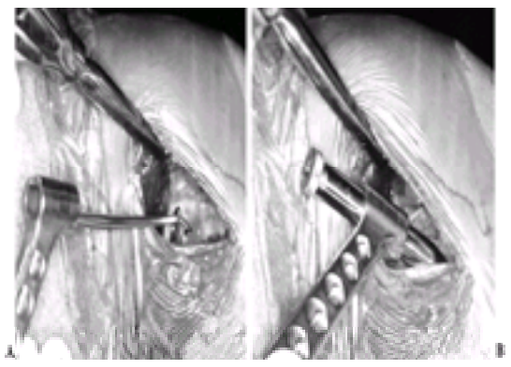

***Figure 89.27.*** **A,B:** Photographs of the right knee. Bring the J-shaped passer out of the incision from within the knee and grasp the stylet of the aiming guide. Pass the stylet into the joint with the passer and position the bullet tip of the aiming guide down on the femoral cortex (**B**). (From Bach BR Jr. Arthroscopy-Assisted Patellar Tendon Substitution for Anterior Cruciate Ligament Insufficiency. *Am J Knee Surg* 1989;2:3.)

- Attach the side-specific rear-entry guide to the J-passer and bring the guide into the joint via the “over-the-top” position. Once this is in place intraarticularly, push the bullet tip of the guide flush against the lateral femoral condyle (Fig. 89.27*B*). Reconfirm the position of the stylet arthroscopically with a probe. The goal is to achieve a tunnel with an intact posterior cortex 1 to 2 mm thick placed at the 11:00 to 11:15 position for a right knee or the 12:45 to 1:00 position for a left knee. Drill the guide pin from outside in, proximal to the lateral epicondyle and slightly posterior to the midline of the femoral metaphysis. Entry point of the femoral tunnel should be at or just proximal to the flare of the metaphysis. If it is placed any further distally, the angle into the intercondylar notch is too acute, placing bending stresses on the tendon as it enters the notch. If the entry is too proximal and the femoral cortex is violated, a stress riser could predispose to femoral fracture (Fig. 89.28).

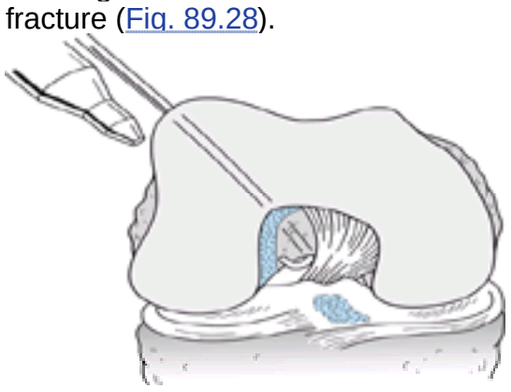

***Figure 89.28.*** Illustration of a right knee. With the aiming guide's stylet in the “over-the-top” position, drill a guide pin antegrade through the lateral femoral cortex into the knee joint. (Redrawn from Bach BR Jr. Arthroscopy-Assisted Patellar Tendon Substitution for Anterior Cruciate Ligament Insufficiency. *Am J Knee Surg* 1989;2:3.)

- Confirm pin position arthroscopically and remove the guide system (Fig. 89.29). Overream the pin with the appropriate-sized reamer (Fig. 89.30). A burr or shaver can then contour the superolateral aspect of the notch at the femoral tunnel entrance to prevent graft impingement.

***Figure 89.29.*** Arthroscopic view of a right knee. The guide pin has entered the joint and a probe is placed in the “over-the-top” position, confirming correct anterior-to-posterior placement.

***Figure 89.30.*** Illustration of a right knee depicting the cannulated reamer being placed over the guide pin to create the femoral tunnel. (Redrawn from Bach BR Jr. Arthroscopy-Assisted Patellar Tendon Substitution for Anterior Cruciate Ligament Insufficiency. *Am J Knee Surg* 1989;2:3.)

- Commercially available tunnel guides exist that allow the stylet to be placed through the inferomedial portal rather than through the “over-the-top” position (Arthrex, Inc., Naples, FL). Though this still requires a lateral incision to place the guide pin and drill the femoral tunnel, an “over-the-top” dissection is not needed, and the incision can be much smaller.

### *Graft Passage and Fixation*

- Prepare the tibial tunnel as described above for the endoscopic technique (Fig. 89.31). Flex the knee 60° for graft passage. Place a Yankauer suction tube retrograde through the tibial tunnel and into the femoral tunnel, and then place two 22-gauge wire loops retrograde through the suction tube and clamp them before removing the tube. Alternatively, commercially available silastic tube graft passers may be used.

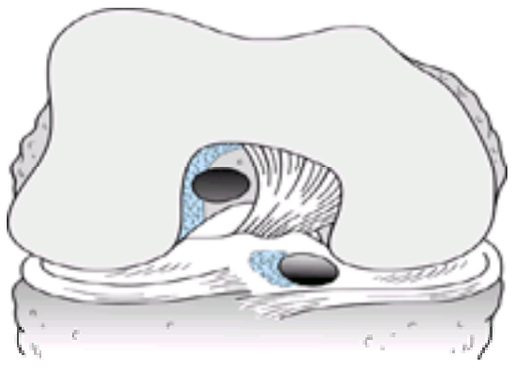

***Figure 89.31.*** Illustration of a right knee depicting placement of the femoral and tibial tunnels. (Redrawn from Hardin GT, Bach BR Jr, Bush-Joseph CA, Farr J. Endoscopic Single-Incision Anterior Cruciate Ligament Reconstruction Using Patellar Tendon Autograft. Surgical Technique. *Am J Knee Surg* 1992;5:144.)

- Loop the sutures from the tibial bone block separately through the wire loops and withdraw the wires out the tibial tunnel. Clamp the sutures outside the tibial tunnel and pull the graft into the femoral tunnel (Fig. 89.32).

***Figure 89.32.*** Illustration of a right knee. Pass the graft antegrade through the femoral tunnel into the joint and out the tibial tunnel. A probe is often needed to guide the tibial bone plug into its tunnel. (Redrawn from Nogalski MP, Bach BR Jr. Acute Anterior Cruciate Ligament Injuries. In: Fu FH, Harner CD, Vince KG, eds. *Knee Surgery.* Baltimore: Williams & Wilkins, 1994;679.)

- Under arthroscopic visualization, bring the tibial plug into the tibial tunnel, using a probe or hemostat to manipulate the plug into place. Potential obstructions include the PCL, lateral femoral wall, and intercondylar eminence.
- When the tibial plug is in place and the femoral plug is within its tunnel, place tension on both sets of sutures to assess for graft laxity. If laxity is present, either plug may be incarcerated within its tunnel, preventing the graft from being fully tensioned. If this is the case, tunnel expansion may be needed. Then assess the graft for impingement along the lateral femoral wall and anterior notch. If impingement is present, appropriate lateral or anterior notchplasty is required to prevent fraying of the graft.
- Secure the femoral side first. We prefer interference screw fixation with cannulated interference screws (Linvatec, Largo, FL). A screw that matches the length of our graft is generally used. One must apply maximum tension to the sutures as the screws are placed to avoid graft advancement. Direct the femoral plug's cortex laterally, and place a 9-mm screw against the cortex. If the graft is recessed within the tunnel, use a longer screw so that it can be more readily identified and removed in the future if need be.
- Rotate the tibial plug 90° externally to place the plug's cortex anterior, and place a 9-mm screw anterior while the knee is in full extension without a posterior Lachman, placing maximum tension on the tibial plug's sutures (Fig. 89.33). Fixation in extension avoids overconstraining the knee. One should avoid burying the interference screw intraosseously, as screw removal may be quite difficult in revision cases or if subsequent high tibial osteotomy is required (Fig. 89.34).

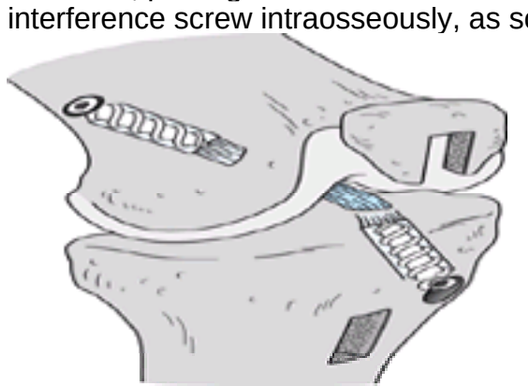

***Figure 89.33.*** Illustration of a right knee with the graft in place and secured with interference screws. Both screws lie against the cortex of their respective bone plugs. (Redrawn from Nogalski MP, Bach BR, Jr. Acute Anterior Cruciate Ligament Injuries. In: Fu FH, Harner CD, Vince KG, eds. *Knee Surgery.* Baltimore: Williams & Wilkins, 1994;679.)

***Figure 89.34.*** Anteroposterior (**A**) and lateral (**B**) views of a right knee after ACL reconstruction using a two-incision technique. Screws are parallel to their respective bone plugs. The lateral view demonstrates proper posterior placement of the femoral tunnel, and the tibial tunnel enters the joint in the midpoint of the tibial plateau. The AP view confirms placement of the femoral socket at the 11 o'clock position.

- Close the lateral wound with interrupted #1 Vicryl suture in the ITB, 2-0 Vicryl suture in the subcutaneous tissue, and a running 3-0 Prolene suture in the subcuticular skin. Cover the incision with Steri-Strips and a dry gauze dressing.

**ENDOSCOPIC HAMSTRING TENDON TECHNIQUE**

The semitendinosus and gracilis tendons have been used effectively in ACL reconstruction for many years. Numerous methods can be used to reconstruct the ACL, and the tendons can be folded to produce double-, triple-, or quadruple-stranded graft constructs. Various means of fixation are available, such as suture–post fixation, screws with spiked washers, barbed staple, soft tissue interference screws (both titanium and bioabsorbable), endoscopically placed buttons, and cross-pin fixation. Combinations of these techniques are generally used. Despite the numerous biomechanical studies that have evaluated these techniques, few studies clinically evaluating these newer methods exist in the literature. Our current method of hamstring reconstruction utilizes both semitendinosus and gracilis tendons looped over a femoral cross-pin (TransFix, Arthrex, Inc., Naples, FL). This results in four strands of tendon that can be fixed to the tibia with a combination of sutures tied over a post and a bioabsorbable interference screw. If sufficient tendon length is present, directly fix the tendons to the tibia with a screw and spiked washer, and a bioabsorbable

interference screw can be added to provide increased strength to the construct.

### *Graft Harvest*

- In most patients the pes anserine tendons are palpable over the proximal medial tibial crest. Center a longitudinal 3- to 4-cm incision three fingerbreadths below the medial joint line and two fingerbreadths medial to the tibial tubercle. After incising the skin and gently spreading through the subcutaneous tissues, bluntly dissect the subcutaneous tissue off the sartorial fascia as far back as the popliteal space. Identify the gracilis and semitendinosus tendons as they lie beneath the sartorial fascia. At their lateral tibial insertions, the two tendons coalesce. Three to four centimeters medial to the insertion, the tendons are distinct (Fig. 89.35).

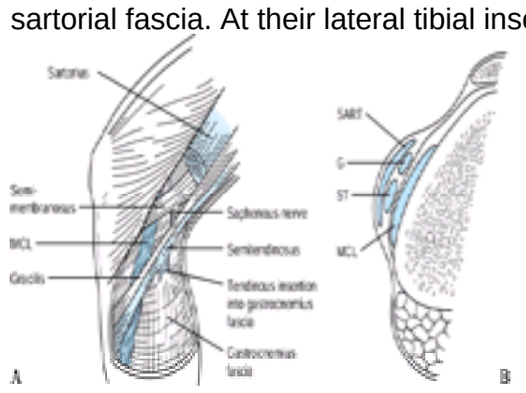


***Figure 89.35.*** **A:** The semitendinosus and gracilis tendons lie deep to the sartorial fascia. The tendons coalesce at their insertions distally and are more distinct as one palpates posteromedially. The gracilis is proximal to the semitendinosus, and the saphenous nerve crosses the gracilis at the posteromedial joint line. A consistent semitendinosus fascial band arises 7 to 9 cm proximal to the tendon's tibial insertion and inserts into the medial gastrocnemius fascia. **B:** Cross-sectional illustration revealing the relationships of the pes anserine tendons to the medial collateral ligament (MCL). *ST*, semitendinosus; *SART*, sartorius; *G*, gracilis.

- With a #15 scalpel blade, incise the sartorial fascia overlying the superior and inferior borders of the gracilis, parallel to the tendon, being careful not to incise too deeply, or the MCL fibers may be damaged. With a curved or right-angled clamp, free up the gracilis tendon from the underlying MCL and tibia. Do the same with the semitendinosus. Passing a Penrose drain around the tendons often helps with mobilization and retraction.
- Sharply detach the periosteal insertion of the gracilis from the tibia, taking care to gain the additional 2 cm the insertion provides. Grasp the end of the tendon with an Allis clamp. With a #2 Ethibond suture, run a baseball stitch from distal to proximal for 5 cm up one side of the tendon and then proximal to distal down the other side of the tendon. Clamp the two suture ends with a straight clamp. Perform the identical steps for the semitendinosus tendon, but clamp the sutures with a curved clamp.
- Harvest the gracilis tendon first because it is easier. With the leg in a figure-4 position, place traction on the gracilis sutures and palpate around the tendon for fascial slips to other structures. These need to be removed before tendon stripping. After this is done, place a closed-ended tendon stripper (Arthrex, Inc., Naples, FL) around the gracilis and gently advance the stripper up the leg, parallel to the path of the gracilis. The leg should be in the figure-4 position to reduce the risk of injury to the saphenous nerve, which crosses the gracilis at the posteromedial joint line. With gentle tension on the sutures, advance the stripper up the leg; when it is fully advanced, slowly increase the tension on the sutures until the graft releases. Note that the gracilis has muscle on both sides of the proximal tendon, whereas the semitendinosus has muscle on one side only.
- The semitendinosus has up to four fascial bands arising from its main tendon, and a consistent slip exists 7 mm proximal to the tibial insertion, inserting into the medial gastrocnemius fascia (38,90) (Fig. 89.35*A*). By gently tugging on the sutures, one can observe the skin overlying the popliteal fossa dimpling, indicating that tendinous slips are still present. The tendon should move freely out of the wound when tugged on and rebound when tension is released. All slips must be released before stripping. Place a finger around the tendon and palpate deeply for any remaining slips. Pass the tendon stripper over the tendon and advance it proximally and parallel to the tendon's course. The semimembranosus fascia envelops the semitendinosus 12 to 15 cm proximal to its insertion. Take care to advance the stripper into the sling rather than outside of it, or premature cutting of the tendon will occur (38) (Fig. 89.36). With the leg in the figure-4 position, gently advance the stripper with light tension on the sutures to maintain a parallel course. One should be able to harvest more than 20 cm of tendon, and the stripper should be advanced as far as possible. When this has been done, stabilize the stripper and place traction on the sutures, releasing the tendon.

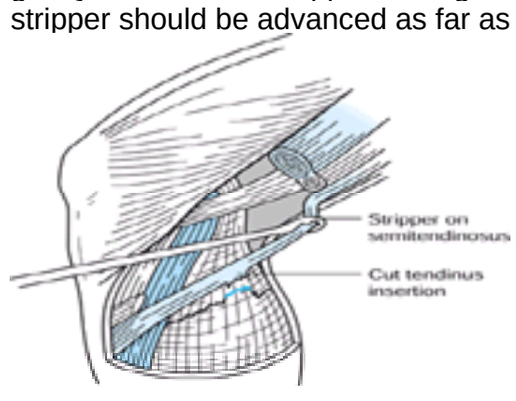


***Figure 89.36.*** Careful attention is essential when passing the tendon stripper over the semitendinosus tendon. The head of the stripper must pass beneath a fascial sling of the semimembranosus muscle or premature cutting of the semitendinosus will occur.

### *Graft Preparation*

- At a back table, remove all muscle tissue from both tendons and trim any fascial slips. Place identical baseball stitches on the proximal ends of the tendons. Because 20 cm is usually more than enough tendon length, the thin proximal ends of the tendons may be trimmed accordingly. Place different clamp types on each tendon's sutures to identify later when the tibial side is fixed. Use an umbilical tape to form a loop around both tendons and pass it through graft sizers.
- Choose a reamer diameter that is equivalent to the smallest sizing sleeve that passes over the four-stranded graft with minimal friction. Make circular marks on the proximal end of tendons 25 and 30 mm distal to the proximal end of the loop. A 40-mm-deep femoral socket will be drilled to accommodate the TransFix tunnel hook, and this line will be viewed arthroscopically.

### *Notchplasty and Tunnel Preparation*

- A minimal notchplasty should be used for visualization purposes only. Steps to prepare the tibial tunnel and femoral socket are identical to those of the BTB reconstructive technique described above.
- Ream the tibial tunnel with the appropriate-sized reamer, and place a diameter-specific over-the-top drill guide for the femoral socket guide pin placement. The femoral socket should be reamed to a depth of 40 mm.
- If desired on the tibial side, initial reaming may be done with a smaller reamer and cannulated dilators used to expand the size of the tunnels, compressing the cancellous bone to increase the density. If this is done, the outer cortex must be reamed with a reamer 1 mm larger than the final tunnel size to prevent dilator binding.

### *Graft Passage and Femoral Fixation*

- Fit the size-specific tunnel hook onto the drill guide C-ring at the 90° position and place the hook through the tibial tunnel into the femoral socket (Fig. 89.37).

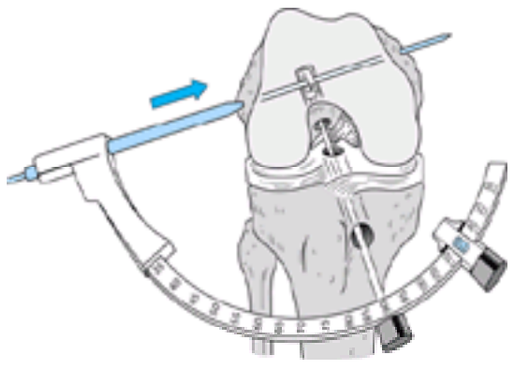

***Figure 89.37.*** With the drill guide C-ring set at 90° and the tunnel hook placed flush up the femoral socket, drill a 2.0-mm drill pin through the femoral condyles.

- Move the guide-pin sleeve down to mark the skin over the lateral femoral condyle and make an 8-mm incision in the skin and iliotibial band.
- While maintaining a constant knee flexion angle, place the guide-pin sleeve against the lateral femoral condyle, and drill a 2.0-mm guide pin through the femoral condyles and out the medial skin.
- Remove the C-ring but keep the tunnel hook up the femoral socket. Overdrill the pin with the 5-mm drill until the depth stop reaches the lateral femoral cortex, remove the drill, and place the TransFix dilator over the pin; tamp it down to the cortex and remove it (Fig. 89.38).

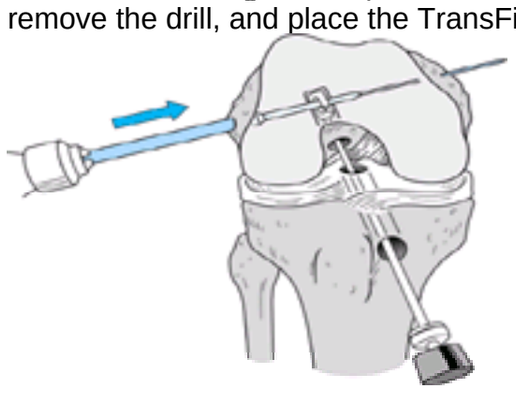

***Figure 89.38.*** After drilling the outer femoral cortex with the 5.0 mm drill, dilate the channel for the TransFix implant with the dilator.

- Place the wire loop of the Nitenol graft-passing wire into the slot on the lateral end of the guide pin and pull the graft-passing wire through the condyles from lateral to medial (Fig. 89.39). Equal lengths of wire should be protruding out both condyles, and both ends should be clamped with needle holders. The passing wire is now beneath the tunnel hook, which can be withdrawn out the tibial tunnel.

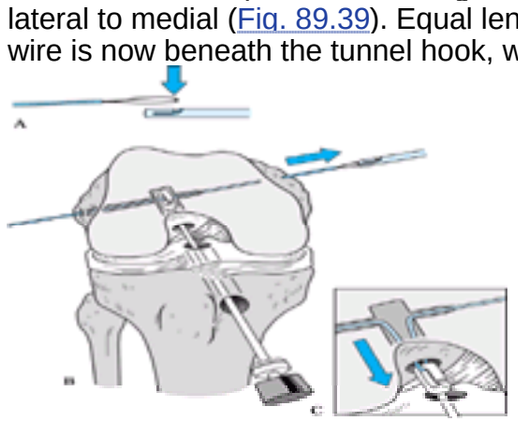

***Figure 89.39.*** Place the looped end of the Nitenol passing wire (**A**) into the lateral notched end of the drill pin and pull the passing wire through the femoral condyles. Withdraw the Nitenol passing wire into the femoral and tibial tunnels (**B**) with the tunnel hook to form a loop exiting the tibial tunnel (**inset C**).

- Disengage the tunnel hook from the Nitenol graft-passing wire, leaving a wire loop. Be careful not to form a twist in the wire, or difficulty can be encountered in passing the graft.
- Pass the tendons through the wire loop so that equal tendon lengths are present distally (Fig. 89.40). By pulling equal tension on both sides of the graft-passing pin with the needle holders, pass the graft through the tibial tunnel into the femoral socket. To ensure that the graft is fully seated in the femoral socket and that no bends in the wire are present, which could prevent wire removal after the TransFix implant is placed, slide the passing wire medially and laterally.



***Figure 89.40.*** Evenly loop the STG tendons around the loop of the passing wire and slide the tendons into their tunnels by pulling evenly on the medial and lateral ends of the passing wire.

- Place the implant over the wire until the lateral threaded head contacts the femoral cortex. Do not apply tension to the graft sutures. Tamp the implant's head flush to the cortex with the impactor (Fig. 89.41).

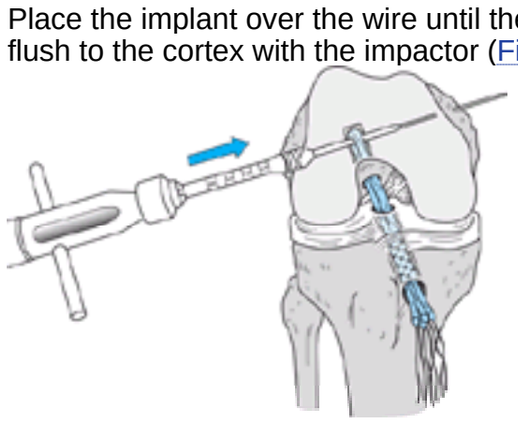

***Figure 89.41.*** Insert the TransFix implant into its channel over the guide wire and tamp the implant into place until the depth stop on the impactor contacts the lateral femoral cortex.

- Confirm proper location of the implant by firmly pulling on the graft's sutures, then remove the Nitenol passing wire. Check for “gross isometry” and cycle the knee

several times to remove creep from the graft construct.

### *Tibial Fixation*

- If adequate tendon length protrudes out of the tibial tunnel, we prefer to fix the tibial side with a screw and spiked washer (Linvatec, Inc., Largo, FL). Prepare a bone bed beneath the fixation point by roughening the tibial cortex. Drill bicortically and measure and tap. Add the width of the tendons and 2 mm for the washer to the measured depth.
- We find placing the screw bicortically and then backing it out is helpful to ensure both proper length and accurate screw passage. With the knee in full extension, grasp the gracilis sutures and semitendinosus sutures separately and place one end of each tendon around each side of the screw. With firm tension on all sutures, secure the screw bicortically.
- Should insufficient tendon length preclude using a screw and spiked washer, we choose to tie the graft's sutures over a bicortical post. Tension each tendon separately rather than as one large group. Because a one-handed knot-tying technique is used, make sure to change suture posts while tying to avoid creating a long slip knot. Secure the screw with a smooth washer bicortically. Another alternative is to secure the tendons with two barbed staples in a belt-buckle fashion (Fig. 89.42).

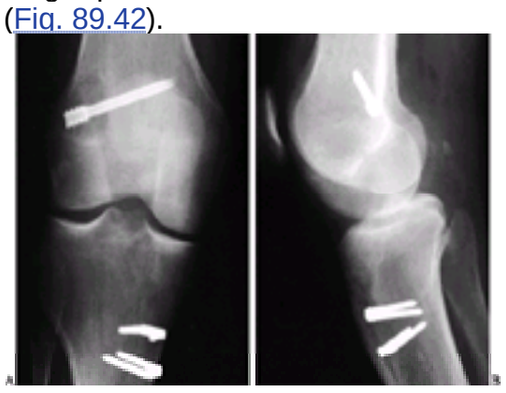

***Figure 89.42.*** Anteroposterior (**A**) and lateral (**B**) postoperative radiographs of a patient with the TransFix device in place. The tibial side was fixed with two barbed staples in a belt-buckle fashion. A bioabsorbable interference screw was also placed on the tibial side for increased stiffness and less potential creep of the graft construct.

- Concerns regarding the effect of the fixation point on isometry of grafts and pullout strengths (61,77) have caused us to supplement the tibial fixation with a bioabsorbable interference screw made of polylactic acid. Choose a screw diameter identical to the size of the tibial tunnel and a length that places the tip of the screw short of the tibial plateau. Fixation closer to the joint results in a graft construct that is stiffer with less potential for adverse creep.
- Close the portals and lateral stab wound with 3-0 Prolene suture. Secure the periosteal flap over the tibial tunnel with #1 Vicryl suture, and close the skin with 2-0 Vicryl in the subcutaneous tissue and a running 3-0 Prolene suture subcuticularly.

## ENDOSCOPIC QUADRICEPS TENDON TECHNIQUE

Though to date no peer-reviewed results of the use of the quadriceps tendon for ACL reconstruction appear in the English literature, the technique is gaining acceptance as an alternative graft source (43,113). Its primary benefit is its thickness and subsequent strength (43,51).

### *Graft Harvest*

Several anatomic features of the quadriceps tendon and its insertion on the patella are worth noting. Unlike the distal pole of the patella, the proximal pole has a curve in the sagittal plane, and a central ridge is readily palpable. The cortical bone is thicker proximally as well. From a point approximately 3 cm proximal to the patellar insertion, the quadriceps tendon's rectus femoris and vastus intermedius portions are inseparable, but farther proximally they can be parted. The tendon is also not perfectly centered with respect to the patella. Because the vastus medialis musculature curves laterally, it is best to harvest the graft slightly to the lateral aspect of the center of the patella, or deficient tendon may be left medially.

- Make the incision beginning 4 to 5 cm proximal to the tip of the patella and end at the proximal pole. Raise deep flaps to expose the proximal half of the patella and the quadriceps tendon and note the medial and lateral edges of the tendon.
- Plan for a bone plug that is 10 mm wide by 20 to 25 mm in length. This length is usually half the total length of the patella. With a #10 blade, outline the bone block and then make the medial cut in the quadriceps tendon. The desired depth is 7 mm, which is conveniently also the width of the #10 blade.
- Because of the central ridge in the patella, one must be cognizant of underestimating tendon depth where the tendon inserts. An assistant can spread a curved hemostat between the edges of the graft and remaining tendon for improved visualization of graft depth, as one also does not want to penetrate into the suprapatellar pouch. Should this occur, repair the pouch with 2-0 absorbable suture, or fluid distention will be lost in the knee. Seven to 9 centimeters of graft length can be harvested. Make a parallel cut in the lateral side of the tendon of the same length as the medial side for a tendon width of 9 to 10 mm (Fig. 89.43).

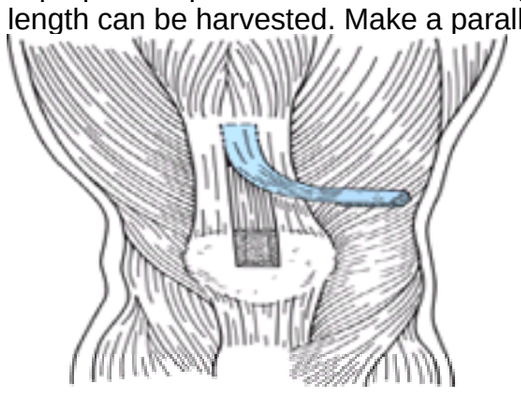

***Figure 89.43.*** Harvest the central quadriceps tendon graft slightly lateral to the midline, as the vastus medialis musculature curves laterally. Produce a bone block 20 to 25 mm in length, 10 mm in width, and 8 mm in depth and a tendon 7 mm thick, 10 mm wide, and at least 7 cm in length.

- With a #238 oscillating saw blade, harvest the bone plug, which should be trapezoidal in profile. Initially score the cortical bone by holding the saw perpendicular to the patella, then angle in slightly to form the trapezoid. The cross-cut can be made holding the saw at a 45° angle to the patella both medially and laterally, and both sides can be completed by placing the saw blade into both sides, proximal to distal, parallel to the cut edge.
- Place a ¼-in. osteotome at the proximal aspect of the bone block, deep to the tendon. Gently tap the osteotome from proximal to distal to make the floor of the bone plug. Use ½-in. and ¼-in. curved osteotomes to lift the bone block out gently. The bone block can then be grasped with a laparotomy sponge, and traction placed distally to bring the proximal aspect of the graft into the wound. At least 7 cm of tendon length is desired, and this should be measured from the proximal edge of the bone block.
- Place distal and anterior traction on the bone block to separate the graft from the posterior 1 to 2 mm of vastus intermedius tendon that remains behind. Place the curved hemostat from lateral to medial between the graft and the underlying vastus intermedius to facilitate separation of the graft. Use a scalpel or curved Mayo scissors to divide tendon fibers. Once adequate length is obtained, place firm traction on the bone block and cut the proximal end of the graft with curved Mayo scissors.

### *Graft Preparation*

- If a “pull-through” technique is being used, place two drill holes parallel to the cortical surface of the bone block using a 0.062-in. K-wire. Thread a #5 Ethibond suture into each hole and secure the ends with a hemostat.
- If a “push-up” technique is used, no sutures are needed. On the tendon side at a point 1.5 to 2 cm from the end of the graft, place a #5 Ethibond suture in parallel columns of Krackow locking whip stitches.
- This is most easily accomplished by doing the following (Fig. 89.44): Take the midpoint of the suture and place it over the graft, 1.5 to 2 cm from the end of the graft. Bring the needle end through the tendon from posterior to anterior, proximal (toward the bone block) to the suture overlying the tendon. Using a free Mayo needle, perform the identical step with the free end of the suture on the other side of the graft. Next, bring the needle through the tendon from posterior to anterior, distal to the first locking stitch, and lock this stitch as well. Do the same with the free end of suture. Clamp the suture ends together with a hemostat. Flip

the graft over and perform the same steps with another suture, which results in two #5 Ethibond sutures with two parallel rows of double Krackow locking sutures, 180° to one another. One must avoid piercing the first stitch with the second, and the sutures must be tensioned without any slack.

### *Tunnel Preparation and Graft Fixation*

- One benefit to the quadriceps tendon is that notchplasty can be performed while graft harvest takes place. Perform a notchplasty as outlined above and make a second incision over the proximal tibia for the tibial tunnel, as is done for the BTB allograft technique. Both tunnels may be 10 mm in diameter.
- Using either a “push-up” or “pull-through” technique, seat the bone plug in the femoral socket and fix the graft with a titanium interference screw 7 mm in diameter and with a length matching that of the bone plug.
- After cycling the graft several times, fix the tibial side with the sutures tied over a 4.5-mm bicortical screw post with a washer, with the knee in full extension. Tie the two ends of one suture to those of the other suture, ensuring equal tension on the graft. If desired, the graft construct can be theoretically strengthened and stiffened by placing a bioabsorbable interference screw up the tibial tunnel (61). We prefer a screw made of polylactic acid, 9 mm in diameter and with a 20 to 25 mm length. The tip of the screw can be placed just below the articular surface.
- Alternatively, place the tendinous portion of the graft in the femoral socket and secure it with a bioabsorbable interference screw. Secure the bony portion of the graft in the tibial tunnel with a 9 × 20 mm interference screw in a fashion identical to that described for a bone–patellar tendon–bone graft (see above).

### *Closure*

- Place bone graft collected during tunnel preparation in the patellar defect. The remaining tendon edges are not reapproximated. Palpation of this defect postoperatively reveals that it “fills in” within 6 weeks. Minimal tenderness is present at the donor site.
- Close the portals and tibial incision as described above and reapproximate the proximal wound with interrupted 2-0 Vicryl in the subcutaneous layer and a running subcuticular 3-0 Prolene. Cover with Steri-Strips.

## REHABILITATION

The stages of postoperative rehabilitation for ACL reconstruction coincide with the phases of graft healing and ligamentization. With a properly placed anatomic graft that employs modern fixation techniques, the graft–fixation construct is able to withstand the stresses placed on it by the tailored accelerated rehabilitation program. The program is not altered if meniscal repair has been performed, but a period of 3 to 4 weeks of protected weightbearing is instituted if microfracture arthroplasty or osteochondral autograft transfer has been done concurrently. We break down our ACL rehabilitation program into phases, each of which has its own set of goals, activities, and time course (Table 89.3) (118). Undoubtedly the most important goal to reach is obtaining full knee hyperextension, as this may diminish patellofemoral symptoms in the long term (102,108,109). Obtaining full flexion, normal patellar mobility, and a normal gait are other goals that are best achieved within the first few weeks. We utilize closed kinetic chain knee extension exercises and prone open kinetic chain knee flexion exercises. When the patient regains strength, endurance, agility, and confidence in the reconstructed knee, return to sport can occur. This is generally somewhere between 4 and 6 months.

| *Phase* | *Time period* | *Graft phase* | *Activities* | *Goals* |
|---|---|---|---|---|
| 1. Immediate postop | 0–2 weeks | Inflammatory | Three times daily: prone heel hangs, sitting hangs, passive ROM, quad sets, straight-leg raises, patellar mobilization | Full extension<br>Flexion >90°<br>Quad control<br>Full weightbearing |
| 2. Early phase | 2–6 weeks | Necrosis and synovial vascular invasion | Above exercises<br>Formal physical therapy 2–3 times/week<br>Closed-chain knee extension<br>Prone open-chain knee flexion<br>Stairstepper, stationary bike<br>Proprioceptive exercises | Normal gait<br>Normal full range of motion |
| 3. Middle phase | 6 weeks to 4 months | Cellular proliferation and ligamentization | Continue strengthening<br>Begin running<br>Progress to cutting<br>Agility exercises<br>Slide board<br>Functional testing | Maximize strength and endurance<br>Increase sport-specific activity<br>Improve confidence in knee |
| 4. Late phase | 4–8 months | Remodeling | Return to sports<br>Continue strengthening and increasing endurance to >80% strength, endurance, and agility of opposite knee | No pain, swelling, or instability<br>Return to sport |

***Table 89.3. Outpatient ACL Surgical Rehabilitation Activities and Goals***

As our patients undergo surgery on an outpatient basis, and third-party payers often do not reimburse for their use, we forgo the use of continuous passive motion (CPM) machines. Electrical stimulation is not used either. We do place patients in a postoperative rehabilitation brace. Patients wear this for 6 weeks and lock it in extension at night to minimize flexion contracture from intercondylar notch scar formation. It is taken off for range-of-motion exercises, and its use during ambulation is to protect the donor site from damage should a fall occur. When patients have rehabilitated their quadriceps to the point that it is within 1 cm of the opposite side's circumference, they are fitted for a functional brace, which is worn for a period of 1 year during athletic activities. This is not a requirement to return to sports, however.

It is important to recognize the patient who is at risk for motion problems postoperatively. If at 2 weeks a patient has a prone heel-height difference of 5 cm or greater, an aggressive program is instituted, which includes the use of an extension board (Instrument Makar, Inc., Okemos, MI). Problems with flexion may be aided by a slide board. If the flexion contracture has not been relieved in 6 weeks, some authors recommend arthroscopic debridement of intercondylar notch scar formation (63).

## PITFALLS AND COMPLICATIONS

Generalized complications such as infection, neurovascular injury, and thromboembolic disease are extremely rare. The rate of deep infection is reported at 0.3% (119). Suspected infections should be treated aggressively with repeated arthroscopic debridement and irrigation with intravenous antibiotics for 4 to 6 weeks. If infection cannot be brought under control, the graft must be removed. Patients can expect loss of motion, but the exact amount will vary and usually involves loss of flexion.

Motion problems can be avoided by ensuring that the patient has regained full range of motion before the reconstruction. Should motion difficulties arise postoperatively, they must be recognized early and treated aggressively, as described above. One other area where motion problems may arise is if the graft has not been placed anatomically. Proper placement of the graft's tunnels is crucial to obtaining a successful result and cannot be overemphasized. A tibial tunnel placed too far anteriorly will restrict extension as it becomes impinged on by the intercondylar notch. Either the extension loss persists, causing anterior knee symptoms, or the graft attenuates and fails (56). A femoral tunnel placed too far anteriorly will also be tight in extension and lead to failure.

Many specific pitfalls and complications are inherent in an exacting technical procedure such as ACL reconstruction, and most can be avoided by strict attention to detail and adequate visualization during the arthroscopic portion of the procedure. Specific pitfalls, their causes, and methods of correcting the problems are listed in Table 89.4.

***Table 89.4. Complications and Pitfalls of ACL Reconstruction and Their Solutions***

## AUTHORS' PERSPECTIVE

One of us (B. R. B.) recently reported minimum 2-year follow-up results using the endoscopic BTB technique (12). One hundred three patients were evaluated. Seventy-four percent had negative Lachman exams, 24% had grade 1 exams with firm endpoints, and two patients had grade 2 exams. Ninety percent had negative anterior drawer exams, with the remainder having grade 1 exams. Ninety-one percent had negative pivot-shift testing, and 9% had grade 1 pivot “slides.” The overall mean manual maximum side-to-side difference on KT-1000 testing was 1.1 mm. Eighty-six patients (83%) had side-to-side differences less than 3 mm, 14 (14%) had differences between 3 and 5 mm, and only three (3%) patients had differences greater than 5 mm. The mean Hospital for Special Surgery (HSS) knee score was 90, and the mean Lysholm score was 89. Preinjury and postoperative Tegner activity levels were not significantly different. Ninety-five percent indicated that they would undergo the same procedure if the contralateral knee were injured similarly. Ninety-three percent were completely or mostly satisfied with the procedure, 7% were somewhat satisfied, and only one patient was dissatisfied with the procedure. Five patients (5%) required reoperation for debridement of fibroproliferative “cyclops” lesions. A 14% incidence of patellofemoral complaints was present, with nearly all having minimal or mild complaints.

A recent 5- to 9-year follow-up study of patients operated on at our institution with the two-incision BTB technique has revealed excellent long-term results (11). Eighty-three percent of the 97 patients had a negative pivot-shift exam, with the remaining 17% having a grade 1 + “slip.” Seventy percent had less than 3 mm side-to-side difference on KT-1000 manual maximum side-to-side testing, and functional testing averaged less than 2% asymmetry for vertical jump, single-legged hop, and timed 6-m hop. Tegner activity levels were similar to preinjury levels, the mean Lysholm score was 87, and the Noyes sports functional score was 89. A low incidence of patellar pain (13%) on stair climbing was noted, and no patients exhibited any long-term patellar tendinitis symptoms. Ninety-seven percent of patients were satisfied with the results of the surgical procedure and would have the operation performed if they tore their contralateral ACL. Most importantly, when compared to an earlier 2- to 4-year follow-up study in the same cohort of patients, the results did not deteriorate with time (10).

Studies that have compared endoscopic to two-incision arthroscopically assisted ACL reconstruction have not demonstrated any significant differences between the two techniques (49,70,101). The endoscopic technique is technically more difficult but does result in less early perioperative morbidity. The two-incision technique, however, is one with which surgeons who perform ACL surgery should be familiar, as it is often employed in revision situations and is invaluable when posterior cortical “blow out” occurs during endoscopic reaming of the femoral socket.

Results of ACL reconstruction using BTB allograft and comparing these results to those of BTB autograft are summarized in Table 89.5. Differences between the two groups with regard to graft donor site morbidity become less apparent with longer follow-up, and significant differences with regard to subjective and objective stability are rarely found.

| Study | Allograft treatment | Physical exam | KT-1000 max manual | Rating scale | Comments |
|---|---|---|---|---|---|
| Shelton, 1997 (110) | Fresh-frozen Nonirradiated | No difference in Lachman Allo 20% + pivot Auto 7% + pivot | No difference Level of testing not noted | None used | No difference in ROM, thigh girth, or crepitus |
| Harner, 1996 (50) | Fresh-frozen Nonirradiated | Auto 92% I or grade 1 pivot Allo 89% | Auto 83% ≤5 mm Allo 80% ≤1 mm | No difference in IKDC or Cincinnati Score | Sig. higher loss of terminal extension in autografts |
| Stringham, 1996 (112) | Fresh-frozen Non irradiated | Pivots and Lachmans not noted | Auto 93% <5 mm Allo 92% ≤1 mm | No difference in Tegner and Lysholm | Four allograft rescues vs. no autograft rescues |
| Saddemi, 1995 (98) | Fresh-frozen Irradiated (2 Mixed) | No difference in stability exam. No difference in isokinetic testing or patellar exam. | No difference Tested at 40 lb; only arthrometric failures in allografts | None used | Two allograft patients with persistent effusions |

*Table 89.5. Studies with Direct Comparison of BTB Autograft and Allograft*

Evaluation of the results of STG reconstruction reveals similar results in comparison to the BTB technique. Howell et al. evaluated their results using double-looped STG grafts and found that 10% had positive pivot shifts and that 89% had KT-1000 manual maximum differences of less than 3 mm (57).

Few studies have directly compared the results of patellar tendon and hamstring techniques (Table 89.6). Marder et al. prospectively compared BTB and double-looped STG and found no significant differences with regard to KT-1000 testing, laxity examination, subjective complaints, quadriceps strength, or patellofemoral symptoms (71). The STG patients did have significantly weaker hamstring strength, however.

| Study | Lachman and pivot shift | Donor site morbidity | KT-1000 | Rating Scales | Comments |
|---|---|---|---|---|---|
| [illegible] | No differences | [illegible] | [illegible] | [illegible] | [illegible] |
| O'Neill, [illegible] | No differences [illegible] | No difference in PF crepitus, thigh girth, isokinetic testing | No difference in % pts. with ≤3 mm difference | IKDC: no pts. in ends BTB group had D rating (p < 0.002) | Overall no difference noted between STG, tendon, BTB, and ends BTB |
| Aglietti, [illegible] (2) | BTB: 79% neg. pivot STG: 70% neg. pivot | No difference in PF crepitus, 17% BTB w/ 1+/F extension loss vs. 3% in STG | No difference in % pts. with ≤3 mm difference | None | Trend toward better stability in BTB group. Recommended for younger pts. |
| Otero, [illegible] (89) | Sig. higher mean Lachman in STG group | PF crepitus in 29% BTB vs. 14% STG | No difference in mean KT at 5-year follow-up | Lysholm: no difference | 87% success for BTB 69% success for STG |
| Marder, [illegible] (71) | BTB: 79% neg pivot STG: 69% neg pivot (no difference) | Sig. weaker hamstring by Cybex testing in STG group | No difference in mean KT or % pts. with >2 mm difference | Zurich Score: no difference | Trend toward better stability in BTB group, but not significant |

[illegible]

*Table 89.6. Studies with Direct Comparison of BTB and Hamstring Reconstruction*

Aglietti et al. compared two-incision BTB to double-looped STG (2). No significant differences were noted in arthrometric measurements, pivot-shift testing, or patellofemoral crepitation. Significantly more patients returned to sport in the BTB group. More patients in the BTB group also had minor (<3°) extension loss. The authors concluded that routine use of BTB as a graft source was justified but that STG is preferable in older patients, patients with preexisting patellofemoral disease, and previous BTB harvest.

O'Neill prospectively evaluated endoscopic and two-incision BTB and quadruple-stranded STG and also found no differences in arthrometric measurements or IKDC evaluation (88). Quadriceps and hamstring strength testing results were similar as well. No advantages were noted for any of the three reconstructive techniques. Pivot-shift results were not reported.

## SUMMARY

Tremendous progression in basic science research and improvements in clinical follow-up studies have led to advances in the treatment of the ACL-deficient patient. Anterior cruciate ligament reconstruction is effective in restoring anterior stability of the knee and subsequently protecting the menisci. Studies with longer follow-up are needed to determine if ACL reconstruction will halt progression to osteoarthritis in the ACL-deficient patient. Numerous effective methods are now available for reconstruction. Though each method possesses inherent strengths and weaknesses, all follow the principles of anatomic placement of the graft with a fixation construct that can withstand the stresses of accelerated rehabilitation. This rehabilitation program is essential in restoring full range of motion and physiologic hyperextension and in diminishing postoperative patellofemoral complaints.

### CHAPTER REFERENCES

Each reference is categorized according to the following scheme: *, classic article; #, review article; !, basic research article; and +, clinical results/outcome study.


+ 1. Adalberth T, Roos H, Lauren M, et al. Magnetic Resonance Imaging, Scintigraphy, and Arthroscopic Evaluation of Traumatic Hemarthrosis of the Knee. *Am J Sports Med* 1997;25:231.

+ 2. Aglietti P, Buzzi R, Zaccherotti G, DeBiase P. Patellar Tendon versus Doubled Semitendinosus and Gracilis Tendons for Anterior Cruciate Ligament Reconstruction. *Am J Sports Med* 1994;22:211.

+ 3. Andersson C, Odensten M, Gillquist J. Knee Function after Surgical or Non-surgical Treatment of Acute ACL Tears. A Randomized Study with a Long-term Follow-up Period. *Clin Orthop* 1991;264:255.

# 4. Arendt E, Dick R. Knee Injury Patterns among Men and Women in Collegiate Basketball and Soccer. NCAA Data and Review of Literature. *Am J Sports Med* 1995;23:694.

# 5. Asselmeier MA, Caspari RB, Bottenfield S. A Review of Allograft Processing and Sterilization Techniques and Their Role in Transmission of the Human Immunodeficiency Virus. *Am J Sports Med* 1993;21:170.

+ 6. Bach BR, Warren RF, Wickiewicz TL. The Pivot-Shift Phenomenon: Results and Description of a Modified Clinical Test for Anterior Cruciate Ligament Insufficiency. *Am J Sports Med* 1988;16:571.

# 7. Bach BR. Technical Pitfalls of Kurosaka Interference Screw Fixation. *Am J Knee Surg* 1989;2:76.

* 8. Bach BR, Warren RF. “Empty Wall” and “Vertical Strut” Signs of ACL Insufficiency. *Arthroscopy* 1989;5:137.

* 9. Bach BR, Warren RF, Flynn WM, et al. Arthrometric Evaluation of Knees That Have a Torn ACL. *J Bone Joint Surg* 1990;72A:1299.

+ 10. Bach BR, Jones GT, Sweet FA, et al. Arthroscopy-Assisted Anterior Cruciate Ligament Reconstruction Using Patellar Tendon Substitution. Two- to Four-Year Follow-up Results. *Am J Sports Med* 1994;22:758.

+ 11. Bach BR, Tradonsky S, Bojchuk J, et al. Arthroscopically Assisted Anterior Cruciate Ligament Reconstruction Using Patellar Tendon Autograft. Five- to Nine-Year Follow-up Evaluation. *Am J Sports Med* 1998;26:20.

+ 12. Bach BR, Levy ME, Bojchuk J, et al. Single-Incision Endoscopic Anterior Cruciate Ligament Reconstruction Using Patellar Tendon Autograft. Minimum Two-Year Follow-up Evaluation. *Am J Sports Med* 1998;26:30.

* 13. Baker CL Jr, Norwood LA, Hughston JC. Acute Posterolateral Rotatory Instability of the Knee. *J Bone Joint Surg* 1983;65A:614.

+ 14. Barber FA, Elrod BF, McGuire DA, Paulos LE. Is an Anterior Cruciate Ligament Reconstruction Outcome Age Dependent? *Arthroscopy* 1996;12:720.

+ 15. Barrack RL, Bruckner JD, Kneisl J, et al. The Outcome of Nonoperatively Treated Complete Tears of the Anterior Cruciate Ligament in Active Young Adults. *Clin Orthop* 1990;259:192.

+ 16. Bear BJ, Cohen SC, Bowen M, et al. Patella Fracture after Anterior Cruciate Ligament Reconstruction Using Bone Patella Bone Autogenous Grafts. *Orthop Trans* 1996;20:9.

* 17. Berchuck M, Andriacchi TP, Bach BR, Reider B. Gait Adaptations by Patients Who Have a Deficient Anterior Cruciate Ligament. *J Bone Joint Surg* 1990;72A:871.

+ 18. Berg EE. Lateral Femoral Condyle Fracture after Endoscopic anterior Cruciate Ligament Reconstruction. *Arthroscopy* 1994;10:693.

+ 19. Berg EE. Technical Note—Management of Patella Fractures Associated with Central Third Bone–Patella Tendon–Bone Autograft ACL Reconstructions. *Arthroscopy* 1996;12:756.

! 20. Beynnon BD, Pope MH, Wertheimer CM, et al. The Effect of Function Knee-Braces on the Anterior Cruciate Ligament *in vivo. J Bone Joint Surg* 1992;74A:1298.

! 21. Beynnon BD, Fleming BC, Johnson RJ, et al. Anterior Cruciate Ligament Strain Behavior During Rehabilitation Exercises *in vivo. Am J Sports Med* 1995;23:24.

+ 22. Bonamo JJ, Krinick RM, Sporn AA. Rupture of the Patellar Ligament after Use of Its Central Third for Anterior Cruciate Ligament Reconstruction. *J Bone Joint Surg* 1984;66A:1294.

! 23. Brown CH, Hecker AT, Hipp JA, et al. The Biomechanics of Interference Screw Fixation of Patellar Tendon Anterior Cruciate Ligament Grafts. *Am J Sports Med* 1993;21:880.

+ 24. Bush-Joseph CA, Bach BR Jr, Bryan J. Posterior Cortical Violation of the Femoral Tunnel During Endoscopic Anterior Cruciate Ligament Reconstruction. *Am J Knee Surg* 1995;8:130.

! 25. Caborn DNM, Coen M, Neef R, et al. Quadrupled Semitendinosus–Gracilis Autograft Fixation in the Femoral Tunnel: A Comparison between a Metal and a Bioabsorbable Interference Screw. *Arthroscopy* 1998;14:241.

* 26. Cannon WD Jr, Vittori JM. The Incidence of Healing in Arthroscopic Meniscal Repairs in Anterior Cruciate Ligament-Reconstructed Knees versus Stable Knees. *Am J Sports Med* 1992;20:176.

# 27. Cawley PW, France EP, Paulos LE. The Current State of Functional Knee Bracing Research. A Review of the Literature. *Am J Sports Med* 1991;19:226.

+ 28. Christen B, Jakob R. Fractures Associated with Patellar Ligament Grafts in Cruciate Ligament Surgery. *J Bone Joint Surg* 1992;74B:617.

+ 29. Clark R, Olsen RE, Larson BJ, et al. Cross-Pin Femoral Fixation: A New Technique for Hamstring Anterior Cruciate Ligament Reconstruction of the Knee. *Arthroscopy* 1998;14:258.

! 30. Cooper DE, Deng XH, Burstein AL, Warren RF. The Strength of the Central Third Patellar Tendon Graft. *Am J Sports Med* 1993;21:818.

+ 31. Cosgarea AJ, Sebastianelli WJ, DeHaven KE. Prevention of Arthrofibrosis after Anterior Cruciate Ligament Reconstruction Using the Central Third Patellar Tendon Autograft. *Am J Sports Med* 1995;23:87.

+ 32. Cross MJ, Roger G, Kujawa P, Anderson I. Regeneration of the Tendons of the Semitendinosus and Gracilis Following Their Transection for Repair of the Anterior Cruciate Ligament. *Am J Sports Med* 1992;20:221.

+ 33. Daluga D, Johnson C, Bach BR. Primary Bone Grafting Following Graft Procurement for Anterior Cruciate Ligament Insufficiency. *Arthroscopy* 1990;6:205.

* 34. Daniel DM, Malcom LL, Losse G, et al. Instrumented Measurement of Anterior Laxity of the Knee. *J Bone Joint Surg* 1985;67A:720.

* 35. Daniel DM, Stone ML, Dobson BE, et al. Fate of the ACL-Injured Patient. A Prospective Outcome Study. *Am J Sports Med* 1994;22:632.

+ 36. Engebretsen L, Benum P, Fasting O, et al. A Prospective, Randomized Study of Three Surgical Techniques for Treatment of Acute Ruptures of the Anterior Cruciate Ligament. *Am J Sports Med* 1990;18:585.

+ 37. Feagin JA Jr, Lambert KL, Cunningham RR, et al. Consideration of the Anterior Cruciate Ligament Injury in Skiing. *Clin Orthop* 1987;216:13.

! 38. Ferrari JD, Ferrari DA. The Semitendinosus: Anatomic Considerations in Tendon Harvesting. *Orthop Rev* 1991;20:1085.

+ 39. Ferrari JD, Bach BR. Technical Note: Bone Graft Procurement for Patellar Defect Grafting in Anterior Cruciate Ligament Reconstruction. *Arthroscopy* 1998;14:543.

! 40. Fideler BM, Vangsness CT Jr, Lu B, et al. Gamma Irradiation: Effects on Biomechanical Properties of Human Bone–Patellar Tendon–Bone Allografts. *Am J Sports Med* 1995;23:643.

* 41. Fisher SP, Fox JM, Del Pizzo W, et al. Accuracy of Diagnoses from Magnetic Resonance Imaging of the Knee. *J Bone Joint Surg* 1991;73A:2.

# 42. Frank CB, Jackson DW. The Science of Reconstruction of the Anterior Cruciate Ligament. *J Bone Joint Surg* 1997;79A:1556.

! 43. Fulkerson JP, Langeland R. An Alternative Cruciate Reconstruction Graft: The Central Quadriceps Tendon. *Arthroscopy* 1995;11:252.

# 44. Fulkerson JP, Langeland R. The Central Quadriceps Tendon Graft for Cruciate Ligament Reconstruction. *Oper Tech Orthop* 1996;6:135.

+ 45. Glashow JL, Katz R, Schneider M, et al. Double-Blind Assessment of the Value of Magnetic Resonance Imaging in the Diagnosis of Anterior Cruciate and Meniscal Lesions. *J Bone Joint Surg* 1989;71A:113.

! 46. Goebel ME, Drez D Jr, Heck SB, Stoma MK. Contaminated Rabbit Patellar Tendon Grafts. *In vivo* Analysis of Disinfecting Methods. *Am J Sports Med* 1994;22:387.

+ 47. Hardin GT, Bach BR Jr. Distal Rupture of the Infrapatellar Tendon after Use of Its Central Third for Anterior Cruciate Ligament Reconstruction. Case Report. *Am J Knee Surg* 1992;5:140.

+ 48. Harner CD, Irrgang JJ, Paul J, et al. Loss of Motion after Anterior Cruciate Ligament Reconstruction. *Am J Sports Med* 1992;20:499.

+ 49. Harner CD, Marks PH, Fu FH, et al. Anterior Cruciate Ligament Reconstruction: Endoscopic versus Two-Incision Technique. *Arthroscopy* 1994;10:502.

+ 50. Harner CD, Olson E, Irrgang J, et al. Allograft versus Autograft Anterior Cruciate Ligament Reconstruction: 3- to 5-Year Outcome. *Clin Orthop* 1996;324:134.

! 51. Harris NL, Smith DAB, Lamoreaux L, Purnell M. Central Quadriceps Tendon for Anterior Cruciate Ligament Reconstruction. Part I: Morphometric and biomechanical evaluation. *Am J Sports Med* 1997;25:23.

+ 52. Hartzog CW, Ruff CG, Barnett GR, Nash CR. *Clinical Comparison of Intra-articular Anterior Cruciate Ligament Reconstruction Using Autogenous Semitendinosus Tendon in Males versus Females.* Paper Presented at the Annual Meeting of the American Orthopaedic Society for Sports Medicine, Sun Valley, ID, 1997.

* 53. Hawkins RJ, Misamore GW, Merritt TR. Followup of the Acute Nonoperated Isolated Anterior Cruciate Ligament Tear. *Am J Sports Med* 1986;14:205.

+ 54. Hewson GF, Mendini RA, Wang JB. Prophylactic Knee Bracing in College Football. *Am J Sports Med* 1986;14:262.

+ 55. Howell SM, Clark JA. Tibial Tunnel Placement in ACL Reconstruction and Graft Impingement. *Clin Orthop* 1992;283:187.

* 56. Howell SM, Taylor MA. Failure of Reconstruction of the Anterior Cruciate Ligament Due to Impingement by the Intercondylar Roof. *J Bone Joint Surg* 1993;75A:1044.

+ 57. Howell SM, Taylor MA. Brace-free Rehabilitation, with Early Return to Activities, in Knees Reconstructed with a Double-Looped, Semitendinosus and Gracilis Graft. *J Bone Joint Surg* 1996;78A:814.

* 58. Hughston JC, Jacobson KE. Chronic Posterolateral Rotatory Instability of the Knee. *J Bone Joint Surg* 1985;67A:351.

+ 59. Hunter RE, Mastrangelo J, Freeman JR, et al. The Impact of Surgical Timing on Postoperative Motion and Stability Following Anterior Cruciate Ligament Reconstruction. *Arthroscopy* 1996;12:667.

+ 60. Indelicato PA, Linton RC, Huegel M. The Results of Fresh-Frozen Patellar Tendon Allografts for Chronic Anterior Cruciate Ligament Deficiency of the Knee. *Am J Sports Med* 1992;20:118.

! 61. Ishibashi Y, Rudy TW, Livesay GA, et al. The Effect of Anterior Cruciate Ligament Graft Fixation Site at the Tibia on Knee Stability: Evaluation Using a Robotic Testing System. *Arthroscopy* 1997;13:177.

+ 62. Jackson DW, Windler GE, Simon TM. Intraarticular Reaction Associated with the Use of Freeze-Dried Ethylene Oxide-Sterilized Bone–Patellar Tendon–Bone Allografts in the Reconstruction of the Anterior Cruciate Ligament. *Am J Sports Med* 1990;18:1.

* 63. Jackson DW, Schaefer RK. Cyclops Syndrome. Loss of Extension Following Intra-articular Anterior Cruciate Ligament Reconstruction. *Arthroscopy* 1990;6:171.

! 64. Jackson DW, Grood ES, Goldstein JD, et al. A Comparison of Patellar Tendon Autograft and Allograft Used for Anterior Cruciate Ligament Reconstruction in the Goat Model. *Am J Sports Med* 1993;21:176.

# 65. Jackson DW, Gasser SI. Tibial Tunnel Placement in ACL Reconstruction. *Arthroscopy* 1994;10:124.

+ 66. Keene GCR, Bickerstaff D, Rae PJ, Paterson RS. The Natural History of Meniscal Tears in Anterior Cruciate Ligament Insufficiency. *Am J Sports Med* 1993;21:672.

! 67. Kohn D, Rose C. Primary Stability of Interference Screw Fixation. Influence of Screw Diameter and Insertion Torque. *Am J Sports Med* 1994;22:334.

! 68. Kurosaka M, Yoshiya S, Andrish JT. A Biomechanical Comparison of Different Surgical Techniques of Graft Fixation in Anterior Cruciate Ligament Reconstruction. *Am J Sports Med* 1987;15:225.

+ 69. Libscomb AB, Johnston RK, Snyder RB, et al. Evaluation of Hamstring Strength Following Use of Semitendinosus and Gracilis Tendons to Reconstruct the Anterior Cruciate Ligament. *Am J Sports Med* 1982;10:340.

+ 70. Lintner DM, Reat JF. One- versus Two-Incision ACL Reconstruction. A Prospective, Randomized Study. *Am J Knee Surg* 1997;10:198.

* 71. Marder RA, Raskind JR, Carrol M. Prospective Evaluation of Arthroscopically Assisted Anterior Cruciate Ligament Reconstruction. Patellar Tendon versus Semitendinosus and Gracilis Tendons. *Am J Sports Med* 1991;19:478.

! 72. Markolf KL, Gorek J, Kabo JM, et al. Direct Measurement of Resultant Forces in the Anterior Cruciate Ligament. *J Bone Joint Surg* 1990;72A:557.

! 73. Miller MD, Hinkin DT. The "*n* + 7 Rule" for Tibial Tunnel Placement in Endoscopic Anterior Cruciate Ligament Reconstruction. *Arthroscopy* 1996;12:124.

* 74. Miyasaka KC, Daniel DM, Stone ML. The Incidence of Knee Ligament Injuries in the General Population. *Am J Knee Surg* 1991;4:43.

+ 75. Mohtadi NG, Webster-Bogaert S, Fowler PJ. Limitation of Motion Following Anterior Cruciate Ligament Reconstruction: A Case-Control Study. *Am J Sports Med* 1991;19:620.

! 76. Morgan CD, Kalman VR, Grawl DM. Definitive Landmarks for Reproducible Tibial Tunnel Placement in Anterior Cruciate Ligament Reconstruction. *Arthroscopy* 1995;11:275.

! 77. Morgan CD, Kalman VR, Grawl DM. Isometry Testing for Anterior Cruciate Ligament Reconstruction Revisited. *Arthroscopy* 1995;11:647.

! 78. Novak PJ, Wexler GM, Williams JS Jr, et al. Comparison of Screw Post Fixation and Free Bone Block Interference Fixation for Anterior Cruciate Ligament Soft Tissue Grafts: Biomechanical Considerations. *Arthroscopy* 1996;12:470.

* 79. Noyes FR, Bassett RW, Grood, et al. Arthroscopy in Acute Traumatic Hemarthrosis of the Knee. Incidence of Anterior Cruciate Ligament Tears and Other Injuries. *J Bone Joint Surg* 1980;62A:687.

* 80. Noyes FR, Mooar PA, Matthews DS, Butler DL. The Symptomatic Anterior Cruciate-Deficient Knee. Part I: The Long-Term Functional Disability in Athletically Active Individuals. *J Bone Joint Surg* 1983;65A:154.

* 81. Noyes FR, Matthews DS, Mooar PA, Butler DL. The Symptomatic Anterior Cruciate-Deficient Knee. Part II: The Results of Rehabilitation, Activity Modification, and Counseling on Functional Disability. *J Bone Joint Surg* 1983;65A:163.

* 82. Noyes FR, Butler DL, Grood ES, et al. Biomechanical Analysis of Human Ligament Grafts Used in Knee-Ligament Repairs and Reconstructions. *J Bone Joint Surg* 1984;66A:344.

+ 83. Noyes FR, Barber SD. The Effect of an Extra-articular Procedure on Allograft Reconstructions for Chronic Ruptures of the Anterior Cruciate Ligament. *J Bone Joint Surg* 1991;73A:882.

+ 84. Noyes FR, Barber-Westin SD. Anterior Cruciate Ligament Reconstruction with Autogenous Patellar Tendon Graft in Patients with Articular Cartilage Damage. *Am J Sports Med* 1997;25:626.

* 85. O'Brien SJ, Warren RF, Pavlov H, et al. Reconstruction of the Chronically Insufficient Anterior Cruciate Ligament with the Central Third of the Patellar Ligament. *J Bone Joint Surg* 1991;73A:278.

* 86. O'Donoghue DH, Frank GR, Jeter GL, et al. Repair and Reconstruction of the Anterior Cruciate Ligament in Dogs. Factors Influencing Long-Term Results. *J Bone Joint Surg* 1970;53A:710.

! 87. Olszewski AD, Miller MD, Ritchie JR. Ideal Tibial Tunnel Length for Endoscopic Anterior Cruciate Ligament Reconstruction. *Arthroscopy* 1998;14:9.

+ 88. O'Neill DB. Arthroscopically Assisted Reconstruction of the Anterior Cruciate Ligament. A Prospective Randomized Analysis of Three Techniques. *J Bone Joint Surg* 1996;78A:808.

+ 89. Otero AL, Hutcheson L. A Comparison of the Doubled Semitendinosus/Gracilis and Central Third of the Patellar Tendon Autografts in Arthroscopic Anterior Cruciate Ligament Reconstruction. *Arthroscopy* 1993;9:143.

! 90. Pagnani MJ, Warner JJP, O'Brien SJ, Warren RF. Anatomic Considerations in Harvesting the Semitendinosus and Gracilis Tendons and a Technique of Harvest. *Am J Sports Med* 1993;21:565.

+ 91. Pinczewski LA, Clingeleffer AJ, Webb JM, Corry IS. *A Comparison of Endoscopic ACL Reconstruction Utilizing Patellar Tendon Autograft and Hamstring Tendon Autograft at Two Years.* Paper Presented at the Annual Meeting of the American Orthopaedic Society for Sports Medicine, Sun Valley, ID, 1997.

+ 92. Plancher KD, Steadman JR, Briggs KK, Hutton KS. Reconstruction of the Anterior Cruciate Ligament in Patients Who Are at Least Forty Years Old. A Long-Term Follow-up and Outcome Study. *J Bone Joint Surg* 1998;80A:184.

! 93. Rasmussen TJ, Feder SM, Butler DL, et al. The Effects of 4 Mrad of Gamma Irradiation on the Initial Mechanical Properties of Bone–Patellar Tendon–Bone Grafts. *Arthroscopy* 1994;10:188.

! 94. Rodeo SA, Arnoczky SP, Torzilli PA, et al. Tendon-Healing in a Bone Tunnel. A Biomechanical and Histological Study in the Dog. *J Bone Joint Surg* 1993;75A:1795.

+ 95. Rosenberg TD, Franklin JL, Baldwin GN, Nelson KA. Extensor Mechanism Function after Patellar Tendon Graft Harvest for ACL Reconstruction. *Am J Sports Med* 1992;20:519.

! 96. Rowden NJ, Sher D, Rogers GJ, Schindhelm K. Anterior Cruciate Ligament Graft Fixation. Initial Comparison of Patellar Tendon and Semitendinosus Autografts in Young Fresh Cadavers. *Am J Sports Med* 1997;25:472.

* 97. Sachs RA, Daniel DM, Stone ML, Garfein RF. Patellofemoral Problems after ACL Reconstruction. *Am J Sports Med* 1989;17:760.

+ 98. Saddemi SR, Frogameni AD, Fenton PJ, et al. Comparison of Perioperative Morbidity of Anterior Cruciate Ligament Autografts versus Allografts. *Arthroscopy* 1993;9:519.

# 99. Safran MR, Harner CD. Technical Considerations of Revision Anterior Cruciate Ligament Surgery. *Clin Orthop* 1996;325:50.

! 100. Samuelson TS, Drez D, Meletis GB. Anterior Cruciate Ligament Graft Rotation. Reproduction of Normal Graft Rotation. *Am J Sports Med* 1996;24:67.

+ 101. Sgaglione NA, Schwartz RE. Arthroscopically Assisted Reconstruction of the Anterior Cruciate Ligament: Initial Clinical Experience and Minimal 2-Year Follow-up Comparing Endoscopic Transtibial and Two-Incision Techniques. *Arthroscopy* 1997;13:156.

* 102. Shelbourne KD, Nitz P. Accelerated Rehabilitation after Anterior Cruciate Ligament Reconstruction. *Am J Sports Med* 1990;18:292.

* 103. Shelbourne KD, Wilckens JH, Mollabashy A, DeCarlo M. Arthrofibrosis in Acute Anterior Cruciate Ligament Reconstruction. The Effect of Timing of Reconstruction and Rehabilitation. *Am J Sports Med* 1991;19:332.

+ 104. Shelbourne KD, Nitz PA. The O'Donoghue Triad Revisited. Combined Knee Injuries Involving Anterior Cruciate and Medial Collateral Ligament Tears. *Am J Sports Med* 1991;19:474.

+ 105. Shelbourne KD, Wilckens JH. Intraarticular Anterior Cruciate Ligament Reconstruction in the Symptomatic Arthritic Knee. *Am J Sports Med* 1993;21:685.

+ 106. Shelbourne KD, Martini DJ, McCarroll JR, VanMeter CD. Correlation of Joint Line Tenderness and Meniscal Lesions in Patients with Acute Anterior Cruciate Ligament Tears. *Am J Sports Med* 1995;23:166.

+ 107. Shelbourne KD, Klootwyk TE, Wilckens JH, et al. Ligament Stability Two to Six Years after Anterior Cruciate Ligament Reconstruction with Autogenous Patellar Tendon Graft and Participation in Accelerated Rehabilitaion Program. *Am J Sports Med* 1995;23:575.

# 108. Shelbourne KD, Patel DV. Prevention of Complications after Autogenous Bone–Patellar Tendon–Bone ACL Reconstruction. In: Pritchard DJ, ed. *Instructional Course Lectures, Vol. 45.* Rosemont, IL: American Academy of Orthopaedic Surgeons, 1996;253.

# 109. Shelbourne KD, Patel DV. Rehabilitation after Autogenous Bone–Patellar Tendon–Bone ACL Reconstruction. In: Pritchard DJ, ed. *Instructional Course Lectures. Vol. 45.* Rosemont, IL: American Academy of Orthopaedic Surgeons, 1996;263.

+ 110. Shelton WR, Papendick L, Dukes AD. Autograft versus Allograft Anterior Cruciate Ligament Reconstruction. *Arthroscopy* 1997;13:446.

+ 111. Sherman MF, Warren RF, Marshall JL, Savatsky GJ. A Clinical and Radiographical Analysis of 127 ACL Insufficient Knees. *Clin Orthop* 1988;227:229.

+ 112. Shino K, Nakata K, Horibe S, et al. Quantitative Evaluation after Arthroscopic Anterior Cruciate Ligament Reconstruction. Allograft versus Autograft. *Am J Sports Med* 1993;21:609.

+ 113. Staubli HU. Arthroscopically Assisted ACL Reconstruction Using Autologous Quadriceps Tendon. In: Jakob RP, Staubli HU, eds. *The Knee and the Cruciate Ligaments: Anatomy, Biomechanics, Clinical Aspects, Reconstruction, Complications, Rehabilitation.* New York: Springer-Verlag, 1992;443.

! 114. Steiner ME, Hecker AT, Brown CH, Hayes WC. Anterior Cruciate Ligament Graft Fixation: Comparison of Hamstring and Patellar Tendon Grafts. *Am J Sports Med* 1994;22:240.

+ 115. Stringham DR, Pelmas CJ, Burks RT, et al. Comparison of Anterior Cruciate Ligament Reconstructions Using Patellar Tendon Autograft or Allograft. *Arthroscopy* 1996;12:414.

* 116. Torg JS, Conrad W, Kalen V. Clinical Diagnosis of ACL Instability in the Athlete. *Am J Sports Med* 1976;4:84.

# 117. Veltri DM, Warren RF. Posterolateral Instability of the Knee. In: Jackson DW, ed. *Instructional Course Lectures, Vol. 44.* Rosemont, IL: American Academy of Orthopaedic Surgeons, 1995;441.

# 118. Williams JS Jr, Bach BR Jr. Operative and Nonoperative Rehabilitation of the ACL-Injured Knee. *Sports Med Arthrosc Rev* 1996;4:69.

+ 119. Williams RJ III, Laurencin CT, Warren RF. Septic Arthritis after Arthroscopic Anterior Cruciate Ligament Reconstruction. *Am J Sports Med* 1997;25:261.

! 120. Woo SL-Y, Hollis JM, Adams DJ, et al. Tensile Properties of the Human Femur–Anterior Cruciate Ligament–Tibia Complex. The Effects of Specimen Age and Orientation. *Am J Sports Med* 1991;19:217.

+ 121. Woods GW, Stanley RF Jr, Tullos HS. Lateral Capsular Sign: X-ray Clue to a Significant Knee Instability. *Am J Sports Med* 1979;7:27.

+ 122. Yasuda K, Tsujino J, Ohkoshi Y, et al. Graft Site Morbidity with Autogenous Semitendinosus and Gracilis Tendons. *Am J Sports Med* 1995;23:706.

# CHAPTER 90

# ISOLATED POSTERIOR CRUCIATE LIGAMENT INJURY AND POSTEROLATERAL LAXITY

*Leslie J. Bisson and William G. Clancy, Jr.*

**L. J. Bisson:** Northtowns Orthopaedics, East Amherst, New York 14051.
**W. G. Clancy, Jr.:** Birmingham, Alabama 35255.

Epidemiology
Mechanism of Injury
Clinical Evaluation
Isolated PCL Injury
Combined PCL and Collateral Ligament Injury
Imaging
Routine Radiographs
Stress Radiographs
Magnetic Resonance Imaging
Bone Scan
Treatment
Nonsurgical Management of PCL Injuries
Surgical Management
Author's Perspective
Acute PCL Injury
Combined PCL and Plc Injury
Combined PCL and ACL Injury
Combined PCL and MCL Injury
Chronic PCL Insufficiency
Surgical Techniques
Fixation of PCL Avulsion Injuries
Two-Band and Two-Femoral-Tunnel Reconstruction of the Pcl
Biceps Femoris Tenodesis
Posterolateral Corner Reconstruction
Fibular Collateral Ligament Reconstruction
Postoperative Rehabilitation
Chapter References

The posterior cruciate ligament (PCL) is the stronger of the two cruciate ligaments and is the primary restraint to posterior tibial translation at 90° of knee flexion. The recent emphasis on reconstructive surgery in cases of anterior cruciate ligament (ACL) injury has stimulated an increased interest in the PCL, and investigators have begun to study the anatomy, biomechanics, and function of the PCL in greater detail. Additionally, there have been attempts to better document the natural history of the PCL-deficient knee as well as to define the optimum time and method of reconstruction in cases in which surgery is deemed necessary. Despite the large numbers of articles published recently on these topics, the management of injury to the PCL continues to be controversial. Support for both surgical and nonsurgical management can be found in the orthopaedic literature.

The posterolateral corner (PLC) is a complex that includes the lateral collateral ligament (LCL), popliteus tendon, fabellofibular ligament, arcuate ligament, popliteofibular ligament, and the short lateral ligament. The LCL resists straight varus rotation of the tibia, and the remaining structures restrain external tibial rotation. Isolated injury of the posterolateral corner is uncommon. When PLC injury occurs with injury to the PCL, both injuries must be appropriately diagnosed and treated to obtain a satisfactory outcome.

This chapter provides a summary of what is known about the epidemiology, mechanism of injury, clinical evaluation, imaging, treatment, and results of treatment of injuries to the PCL and PLC. A section at the end of the chapter outlines the preferences of the senior author (W.G.C.), who has treated more than 400 patients with PCL insufficiency.

## EPIDEMIOLOGY

Injuries to the PCL are much less frequent than those to the ACL (11,39,41). Indeed, it is thought that the PCL is injured about one-tenth to one-twentieth as often as the ACL (1). The incidence of both isolated and combined PCL injuries in series of surgically treated knee injuries ranges from 3.49% (54) to 20% (5,12). The symptoms and clinical signs of isolated PCL injury, however, may be subtle both to patient and to physician, and the injury may often be missed (17,28,77). When diagnosed, the isolated PCL injury is often treated nonsurgically.

These factors suggest that the true incidence of PCL injury is higher than that quoted in the literature. It is interesting to note that approximately 2% to 5% of the players participating in the National Football League's predraft physical examinations have evidence of isolated PCL laxity, and most of these players are unaware of having had a significant ligamentous injury (4). In a study that analyzed 500 knee ligament injuries with pathologic motion as measured by a KT-1000 arthrometer, 63% were found to be ACL injuries, and 7% were PCL injuries (19). Seventy-five percent of the ACL injuries were isolated, compared with 49% of the PCL injuries. It is not uncommon for PCL injuries to have associated injury to the ACL, medial collateral ligament (MCL), and the posterolateral corner (PLC) (33,34,47).

## MECHANISM OF INJURY

When discussing the mechanism of injury to the PCL, it is helpful for the examiner to differentiate between low-energy (i.e., athletic) and high-energy (i.e., motor vehicle accident) etiologies because of the higher incidence of combined ligamentous injuries and associated injuries in the latter (62). Injury to the PCL has been described as occurring in one of four ways (Fig. 90.1, Fig. 90.2 and Fig. 90.3): (a) a posterior force applied to the tibia with the knee in flexion (which often results in a midsubstance injury) (22), (b) a fall onto the flexed knee with the foot in plantarflexion (11,25), (c) hyperflexion (28), and (d) hyperextension (45). Two other less common means of injury have recently been described, including a noncontact, external rotation/posterior translation injury (67) as well as an external rotation/valgus injury (66).

***Figure 90.1.*** Mechanism of injury to the PCL: a posterior force applied to the proximal tibia with the knee in 90° of flexion. (From DeLee JC, Bergfeld JA, Drez D Jr, Parker AW. The Posterior Cruciate Ligament. In: DeLee JC, Drez D Jr, eds. *Orthopaedic Sports Medicine. Principles and Practice.* Philadelphia: WB Saunders, 1994,

with permission.)

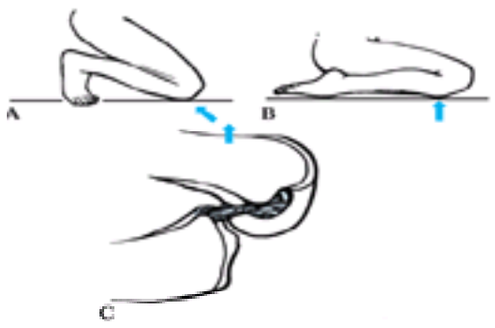


***Figure 90.2.*** Mechanisms of injury to the PCL. **A:** A fall onto the flexed knee with the foot in dorsiflexion results in force being transmitted through the patellofemoral joint. **B:** A fall onto the flexed knee with the foot in plantarflexion results in force being transmitted to the tibial tubercle and hence to the PCL. **C:** A hyperflexion injury can result in an avulsion of the origin of the PCL from the femur. (From DeLee JC, Bergfeld JA, Drez D Jr, Parker AW. The Posterior Cruciate Ligament. In: DeLee JC, Drez D Jr, eds. *Orthopaedic Sports Medicine. Principles and Practice.* Philadelphia: WB Saunders, 1994, with permission.)

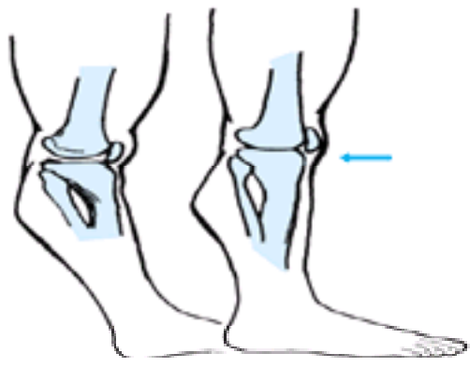

***Figure 90.3.*** Mechanism of injury to the PCL: hyperextension. (From DeLee JC, Bergfeld JA, Drez D Jr, Parker AW. The Posterior Cruciate Ligament. In: DeLee JC, Drez D Jr. *Orthopaedic Sports Medicine. Principles and Practice.* Philadelphia: WB Saunders, 1994, with permission.)

Injury to the PLC often results from a blow to the anteromedial proximal tibia, most commonly with the knee in extension (3,25,35,80). The result is a varus and rotational moment about the knee. Hyperextension alone or combined with external rotation and knee extension have also been implicated in noncontact injuries to the PLC (10,13,80).

## CLINICAL EVALUATION

### ISOLATED PCL INJURY

Many authors agree that diagnosis of injury to the PCL can often be confusing, particularly when it occurs acutely and is isolated. The presence of quadriceps muscle spasm may mask some of the findings on physical exam, and isolated injury to the PCL may be dismissed by the athlete as insignificant (4). A tense effusion such as occurs with an acute ACL injury is usually absent. For this reason, the history and physical exam are of paramount importance, not only to diagnose the injury itself but also to determine the site of the injury and therefore to help determine the appropriate treatment plan.

#### *History*

Knowledge of the mechanism of injury in cases of suspected PCL injury can help determine the likelihood of injury to the ligament as well as suggest the potential site of involvement along the length of the PCL. Injury to the midsubstance of the PCL often occurs following a direct blow to the anterior proximal tibia with the knee flexed (27,28). Midsubstance injuries may also occur after a fall onto the flexed knee with the foot in plantarflexion, which concentrates the bulk of the force on the tibial tubercle (25).

A blow to the anteromedial aspect of the proximal tibia with the knee in extension is a common mechanism in sports-related injuries and also results in midsubstance injury to the PCL as well as injury to the posterolateral corner structures. A pure hyperflexion injury without a force being applied directly to the proximal tibia often results in avulsion of the origin of the ligament from the medial femoral condyle, offering a chance for primary repair (25) (although the senior author has never seen a successful result of primary repair).

In cases of chronic PCL injury, a common complaint is discomfort in the knee while weight bearing in a semiflexed position, such as ascending or descending stairs or squatting down (18). Aching in the knee when walking long distances is also a common complaint (18). Approximately 50% of patients with symptomatic PCL insufficiency complain of instability or a sense of instability in the knee that is problematic when they are walking on uneven ground (18). Approximately half of the patients reported on by Cross and Powell (17) complained of retropatellar pain in the knee that was not present initially but developed at some point after the injury. Swelling and stiffness may vary and depend on the degree of associated chondral damage.

#### *Physical Examination*

Acute injury to the PCL may often be missed for several reasons. Often the athlete is unaware of having sustained a significant injury, because many patients have a full range of motion with very little hemarthrosis (4,11,16,18). Often it is only the posterior drawer test that causes any pain. The presence of a contusion over the proximal anterior tibia may be very helpful in suggesting injury to the PCL.

The importance of noting the relationship of the proximal tibia to the femur when the knee is flexed to 90° cannot be overemphasized. When the PCL is intact, flexion of the knee to 90° results in the anterior proximal tibia being positioned approximately 1 cm anterior to the distal femoral condyles (Fig. 90.4), referred to as a normal anterior stepoff. Loss of this normal anterior stepoff signifies injury to the PCL (11). The importance of detecting this posterior subluxation has been emphasized by Clancy et al. (11), who state that it is best viewed from the side with the knee flexed to 90°. This posterior subluxation of the proximal tibia with the knee flexed to 90° is also known as the posterior sag sign (of Godfrey).

***Figure 90.4.*** When the PCL is intact, flexion of the knee to 90° should result in the proximal tibial eminence being anterior to the distal femoral condyles by approximately 1 cm. (From DeLee JC, Bergfeld JA, Drez D Jr, Parker AW. The Posterior Cruciate Ligament. In: DeLee JC, Drez D Jr, eds. *Orthopaedic Sports Medicine. Principles and Practice.* Philadelphia: WB Saunders, 1994, with permission.)

The posterior drawer test performed at 70° to 90° of flexion has been regarded as the most reliable sign of PCL disruption (53,65) (Fig. 90.5). This test is graded with respect to the opposite knee. Loss of the normal anterior tibial stepoff compared with the opposite side, but with the proximal tibial eminence remaining anterior to the distal femur, is considered to be a 1 + posterior drawer. When the proximal tibial eminence can be translated posteriorly to the point where it is flush with the distal femoral condyles, the posterior drawer is graded 2 + . It is thought to signify complete disruption of the PCL. Translation of the proximal tibial eminence posterior to the distal femoral condyles is considered to be grade 3 + and is thought to signify complete PCL disruption and usually posterolateral ligamentous injury as well. This test, however, has been reported to be positive in as few as 10% to as many as 76% of patients with acute PCL disruptions (33,44,53,60).

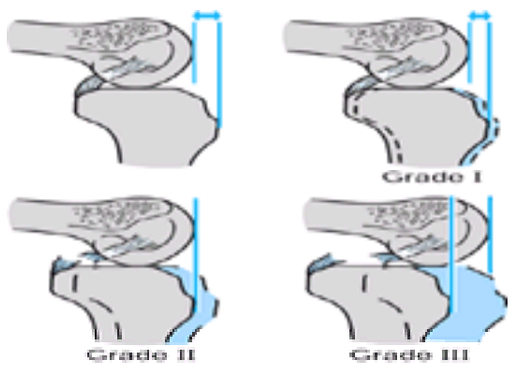


***Figure 90.5.*** Method of grading the posterior drawer test (see text for explanation).

Clancy et al. (11) stated that a 2 + posterior drawer, with the tibia held first in neutral and then in external rotation, is diagnostic of a complete disruption of the PCL. They also emphasized that 80% of patients with complete disruption of the PCL would have a normal posterior drawer sign with the tibia held in internal rotation. This loss of the posterior drawer with the tibia held in internal rotation is explained by the fact that internal tibial rotation tightens the meniscofemoral ligaments, which are usually intact following injury to the PCL. These ligaments are then able to resist attempted posterior tibial translation during the posterior drawer maneuver. We have also found meniscal injury to be uncommon both clinically and at arthroscopy when the PCL is injured. Keep in mind that muscle spasm and pain can significantly limit the utility of the posterior drawer test.

The accuracy of the posterior drawer test in the chronic setting has been documented by Rubinstein et al. (63). These examiners found that the posterior drawer test, including palpation of the tibial stepoff, was the most sensitive and specific clinical test for PCL insufficiency. Clinical examination for chronic PCL injury was 96% accurate, 90% sensitive, and 99% specific. The interobserver agreement for the grade of the injury was 81%.

Because the presence of muscle spasm has been shown to limit the effectiveness of the posterior drawer test in the acute setting, Daniel et al. (20) introduced the quadriceps active drawer test to detect PCL injury (Fig. 90.6). This test is based on the biomechanical relationship between the line of action of the patellar tendon and the resultant quadriceps muscle force. In an intact knee, the line of action of the patellar tendon tends to pull the proximal tibia anterior at low knee-flexion angles. At high knee-flexion angles, the PCL causes the femur to roll back on the proximal tibia, and the line of action of the patellar tendon therefore tends to pull the proximal tibia posterior.

***Figure 90.6.*** Performance of the quadriceps active drawer test. See text for explanation. (From Daniel DM, Stone ML, Barnett P, Sachs R. Use of the Quadriceps Active Test to Diagnose Posterior Cruciate Ligament Disruption and Measure Posterior Laxity of the Knee. *J Bone Joint Surg* 1988;70A:386, with permission.)

The angle of knee flexion at which the line of action of the patellar tendon is directly perpendicular to the surface of the tibial plateau is called the quadriceps-neutral angle and occurs at 60° to 90° of flexion in the intact knee. In a knee with the PCL injured or absent, rollback of the femur on the tibia does not occur with increasing knee flexion. Therefore, the line of action of the patellar tendon is always directed anteriorly.

The quadriceps-active drawer is performed with the subject relaxed in the supine position with the knee flexed 70° to 90°. The examiner stabilizes the patient's foot on the table and then asks the patient to slide the foot distally on the table. In the normal knee, the patellar tendon line of action will be directed posteriorly, and this quadriceps contraction will not cause any anterior translation of the proximal tibia. In the patient with deficiency of the PCL, however, the posterior sag of the proximal tibia results in the line of action of the patellar tendon being directed anteriorly, and this quadriceps contraction evokes a notable anterior translation of the proximal tibia. Daniel et al. (20) found the quadriceps active drawer test to be positive in the knees of 41 of 42 patients with documented disruption of the PCL. Anterior translation did not occur in the contralateral normal knee of these patients, nor did it occur in 25 knees with known disruption of the ACL. These authors found this test to be useful in both acute and chronic cases.

## COMBINED PCL AND COLLATERAL LIGAMENT INJURY

### *History*

Combined injuries to the PCL and posterolateral corner structures are often caused by a blow to the anteromedial tibia with the knee in extension. This mechanism of

injury is not uncommon in sports-related injuries to the PCL. A blow delivered to the lateral aspect of the knee causes a valgus force at the knee joint and first injures the MCL and the posteromedial capsule. Once these structures have been injured, the cruciate ligaments are the next restraints to valgus rotation. This mechanism of injury may cause combined ACL/MCL or PCL/MCL injuries. Finally, impact to the medial aspect of the knee first causes disruption of the lateral collateral ligament and the posterolateral corner structures. If the injury is severe enough, the central pivot ligaments are next to fail. This mechanism results in combined injury to the ACL and posterolateral structures or to the PCL and posterolateral structures.

The patient with combined PCL and collateral ligament injury often has a significant amount of pain compared with the patient with an isolated PCL injury. Disruption of the capsule that occurs in conjunction with collateral ligament injury may allow dissection of the hemarthrosis into the thigh and leg and therefore limit the amount of effusion present. The primary concern in the knee with multiple ligament injuries is the possibility of neurovascular injury. It has been reported that approximately 50% of knee dislocations become reduced spontaneously at the time of injury and are consequently not evident at the time of initial evaluation (24).

For this reason, suspect knee dislocation in any patient with disruption of multiple knee ligaments. Pay careful attention to the vascular and neurologic status of the extremity. Consult with a vascular surgeon to determine the need for arteriography or exploration in cases with any change in the vascular status of the injured extremity. Arteriography to rule out intimal injury is recommended in known instances of dislocation, even in the presence of normal pulses. Bear in mind that in combined PCL and lateral ligamentous injury there an incidence of peroneal nerve injury that approaches 30% (24).

An individual with chronic PCL and posterolateral laxity often complains of instability of the knee that is particularly bothersome when he is walking on uneven ground. The patient feels the knee give way at the posterolateral aspect, and he feels pain medially and posterolaterally. The medial pain is caused by increased medial joint loads, which are a result of the increased medial compartment loads secondary to PCL insufficiency (68) as well as of the varus thrust that is present during gait. The posterolateral pain is a result of stretching of those structures during the varus thrust component of gait.

***Physical Examination***

Use the tests described above to assess the integrity of the PCL. Varus laxity with the knee held in 30° of flexion indicates injury to the fibular collateral ligament as well as possible injury to the posterolateral structures. Place the leg in the figure-of-four position to allow palpation of the lateral collateral ligament and confirmation of its integrity. Use the external rotation recurvatum test to help determine the presence of injury to the posterolateral structures. Grasp the great toes of each leg with the knees in extension and lift each leg off of the examining table. Hyperextension as well as increased external rotation of the involved leg suggests significant injury to the posterolateral structures (Fig. 90.7). The posterolateral drawer test, which is positive when the lateral tibial plateau rotates externally and posteriorly at the end of the posterior drawer test, is another test helpful in determining the presence of injury to the posterolateral structures. It should be noted, however, that these tests have a relatively low sensitivity, being positive in only 25% and 33% of patients, respectively (23).

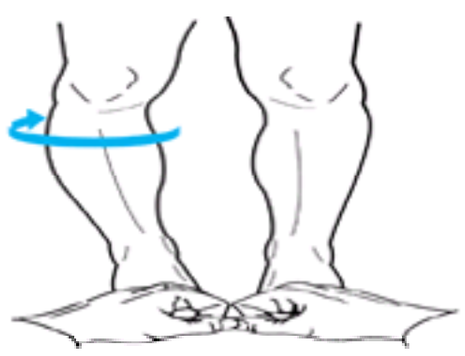

***Figure 90.7.*** The external rotation recurvatum test. (From Hughston JC, Norwood LA. The Posterolateral Drawer Test and External Rotational Recurvation Test for Posterolateral Rotary Instability of the Knee. *Clin Orthop* 1980;147:82, with permission.)

Gollehon et al. (30) have shown that a 15° increase in tibial external rotation at 30° of knee flexion is indicative of significant injury to the posterolateral structures. Increased external rotation of the tibia at 90° of flexion indicates injury to both the PCL and posterolateral ligament complex. The reverse pivot-shift test, introduced by Jakob et al. (38), is another test that is used to assess the posterolateral ligaments. In the reverse pivot-shift test, the knee is reduced in full extension. As the examiner applies a valgus and external rotation force while flexing the knee, the lateral tibial plateau can be felt to subluxate posteriorly. This maneuver creates a shifting sensation similar to that felt during the classic pivot shift in patients with ACL laxity. All of these tests are more profoundly positive in the presence of associated PCL insufficiency.

Detect injury to the MCL in combination with PCL injury by looking for increased valgus laxity at both full extension and 30° of flexion. The above-mentioned tests for PCL injury are also positive. There will also be a greater posterior translation of the medial tibial plateau during the posterior drawer test at 90° of knee flexion. It should be noted that PCL/MCL injury is less common than PCL/PLC injury. Finally, patients with injury to the PCL as well as both the medial and lateral sides of the knee exhibit symmetric posterior displacement of both tibial plateaus during the posterior drawer test.

## IMAGING

### ROUTINE RADIOGRAPHS

Standard anteroposterior (AP), lateral, tunnel, and axial patellofemoral views, usually taken in the case of acute PCL injury, often are not diagnostic. The lateral radiograph may show an avulsion of the PCL from its tibial insertion, but this is a relatively uncommon injury (Fig. 90.8) (75,76,77 and 78). In cases of chronic PCL insufficiency, radiographs may show evidence of arthrosis of the medial and patellofemoral articulations.

***Figure 90.8.*** Lateral radiograph of the knee demonstrating avulsion of the insertion of the PCL from the tibia. (From Cooper DE, Warren RF, Warner JJP. The Posterior Cruciate Ligament and Posterolateral Structures of the Knee: Anatomy, Function and Patterns of Injury. *Instr Course Lect* 1991;40:249, with permission.)

It is essential to take preoperative weight-bearing radiographs using a plumb line to determine the mechanical alignment of the limb (54). If the patient with posterolateral laxity and varus alignment has a ligamentous reconstruction without correction of the mechanical axis by osteotomy, the abnormal stresses imposed on the reconstruction by the varus alignment would be expected to result in failure of the reconstruction.

### STRESS RADIOGRAPHS

We have found stress lateral radiographs to be helpful in documenting the presence of injury to the PCL. Radiographs taken at 70° to 90° of flexion with first an anterior

and then a posterior stress are helpful for diagnosis of PCL insufficiency as well as for comparison with postoperative stress radiographs in order to allow an objective evaluation of results among investigators. Correction of the total AP translation to that present in the normal opposite knee is one objective way of suggesting that the restoration of normal biomechanics of the knee has been achieved.

Hewett et al. (32) recently studied the utility of stress radiographs in the documentation of complete PCL injury as well as in the differentiation between complete and partial tears of the PCL. These investigators found that 8 mm or more of increased posterior translation occurring with the application of an 89-N posterior load at 70° of flexion was indicative of a complete rupture of the PCL. They also found that stress radiographs were superior to both KT-1000 arthrometry and clinical exam in assessing the status of the PCL.

### MAGNETIC RESONANCE IMAGING

Magnetic resonance imaging (MRI) has greatly increased the accuracy with which acute ligamentous injuries of the knee may be detected and correctly diagnosed and has allowed the detection of other associated injuries to the menisci, cartilage, and subchondral bone (79). Not only can MRI confirm suspected injury to the PCL, it can also determine the site of injury to the ligament (Fig. 90.9). One of us (W.G.C.) has also noted that MRI may show a lesion in continuity of the PCL. This injury is characterized by increased signal in the midsubstance of the ligament without evidence of complete disruption and is characterized by laxity of the PCL on clinical exam. This injury may heal with a decrease in the initial laxity.

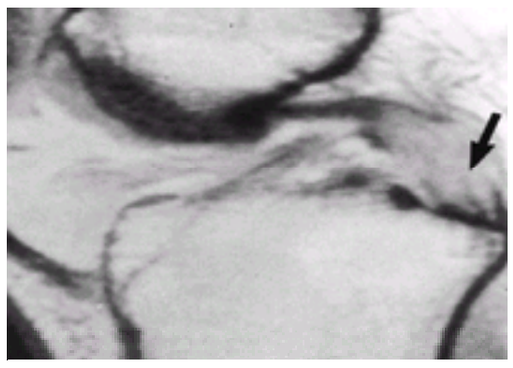

***Figure 90.9.*** Lateral MRI of the knee demonstrating midsubstance disruption of the PCL. (From DeLee JC, Bergfeld JA, Drez D Jr, Parker AW. The Posterior Cruciate Ligament. In: DeLee JC, Drez D Jr. *Orthopaedic Sports Medicine. Principles and Practice.* Philadelphia: WB Saunders, 1994, with permission.)

### BONE SCAN

A bone scan may be helpful in evaluating the progress of a patient with pain and isolated PCL insufficiency. Isolated chronic PCL insufficiency rarely leads to instability, and the disability from this injury is more often a result of pain secondary to articular cartilage changes. For this reason, it has been suggested that serial bone scanning may allow early diagnosis of changes of the articular cartilage in the patient who is being treated nonsurgically. Early recognition of increased joint contact pressures secondary to the abnormal knee biomechanics present in the knee with PCL insufficiency may allow a reconstruction to arrest these changes before irreversible progression takes place. This argument, however, assumes that reconstruction of the PCL restores the knee biomechanics to normal and prevents further deterioration of the articular cartilage. To date, no scientific study has confirmed this hypothesis.

## TREATMENT

The treatment of the knee with a PCL injury is controversial, and recommendations have been made for both surgical and nonsurgical management. A large part of the controversy arises from the fact that there are very few studies that document the long-term results of any form of treatment. Many studies do not differentiate between results obtained with isolated PCL injury versus combined injury patterns, or between results obtained in cases of chronic versus acute PCL insufficiency. The relative infrequency of PCL injury combined with the limited indications for operative treatment also make it difficult for one surgeon to gain a large experience in the treatment of the PCL-insufficient knee.

### NONSURGICAL MANAGEMENT OF PCL INJURIES

Several authorities have recommended nonsurgical management for *isolated* PCL injuries (14,18,28,44,57,64,74). Short-term follow-up studies of patients treated without surgery indicated that these individuals generally did well (28,57,64), but more recent long-term follow-up reports have documented worse clinical results as well as radiographic deterioration (21,42). When the PCL is torn, the patella and patellar tendon take on a more prominent role in the prevention of posterior tibial translation (8,17). Also, the increased posterior tibial sag that occurs in the PCL-deficient knee shortens the moment arm of the quadriceps, decreasing its mechanical advantage (71). Therefore, nonoperative management of PCL injuries should emphasize quadriceps strengthening as a key component of the rehabilitation program (57). Restoration of satisfactory quadriceps strength, however, does not necessarily ensure a good long-term clinical result (42).

The goal of physical therapy is to strengthen the muscles that act to prevent posterior tibial translation, particularly the quadriceps, while minimizing gravity-induced posterior tibial sag (50). Avoid open-kinetic-chain hamstring exercises (performed with the foot free, compared with closed-kinetic-chain exercises, which are performed with the foot fixed), which cause posterior tibial translation in the PCL-deficient knee (49). Closed-kinetic-chain exercises such as the squat cause less shear force at the tibiofemoral joint (49) and are the preferred method for strengthening the quadriceps.

Properly performed open-kinetic-chain exercises such as the leg extension may be used if certain precautions are followed. Green et al. (31) found that open-kinetic-chain extension exercises in the range from 70° to 0° of flexion minimized posterior tibial translation. Placement of the resistance pad distally on the leg during the exercise routine lessens articular contact pressures in the medial compartment and diminishes the posterior stresses on the secondary restraints (14,46).

The rehabilitation program employed for the patient with PCL injury involves three phases: (a) a maximum protection phase, which is used during the first 2 weeks following injury; (b) a moderate protection phase, used from week 4 to week 6 after injury; and (c) a minimal protection phase, used 6 to 8 weeks after injury.

Initiate the maximum protection phase following acute PCL injury and progress over the first 2 to 3 weeks. Encourage weight bearing as tolerated using two crutches. Use a brace permitting range of motion from 0° to 60°. When the individual is comfortable, begin straight-leg raises, knee extension from 60° to 0°, quadriceps isometrics at 60°, 40°, and 20°, and minisquats and leg presses from 0° to 45°. Over the next 2 to 3 weeks, progress to full weight bearing, begin cycling for range of motion, and increase leg-press range of motion up to 60° of flexion.

The moderate protection phase takes place from weeks 3 to 6 after the injury. Increase range of motion to normal as tolerated and discontinue bracing. Increase resistance exercises and begin activities such as the use of rowing and stairclimber machines. Running may be initiated in the pool during this phase. Introduce light resistance hamstring curls and step-ups.

The minimal protection phase begins at week 6 to 8. Continue all strengthening exercises and begin a running program, if appropriate. Patients may gradually return to sporting activities. Criteria to be met before returning to sports include absence of pain, tenderness, and swelling as well as isokinetic testing documenting at least 85% strength, comparing the injured to the normal side.

### SURGICAL MANAGEMENT

Manage patients diagnosed initially with either acute or chronic isolated injury to the PCL with the above rehabilitation program. Patients with injury to another major knee ligament in addition to the PCL, as well as those with isolated PCL injuries who continue to have pain or instability despite use of the above rehab program for at least 3 months, require evaluation for surgical reconstruction.

#### *Avulsion Fractures of the Tibial Insertion of the PCL*

Most authors have recommended operative repair of a displaced bony avulsion of the tibial insertion of the PCL (Fig. 90.10 and Fig. 90.11) (14,52,75,76 and 77). Treat undisplaced fractures with immobilization of the knee in extension, using the intact collateral ligaments to help prevent posterior sag (55,56).

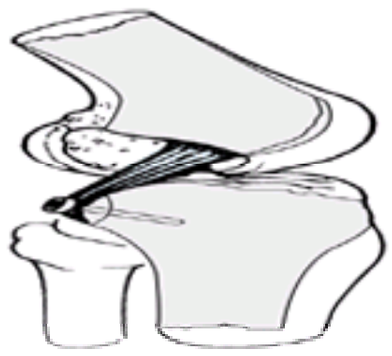

***Figure 90.10.*** Avulsion of the PCL from the tibia fixed with a screw. (From Bowen MK, Warren RF, Cooper DE. Posterior Cruciate Ligament and Related Injuries. In: Insall JN, Windsor RE, Scott WN, et al., eds. *Surgery of the Knee.* New York: Churchill Livingstone, 1993:536, with permission.)

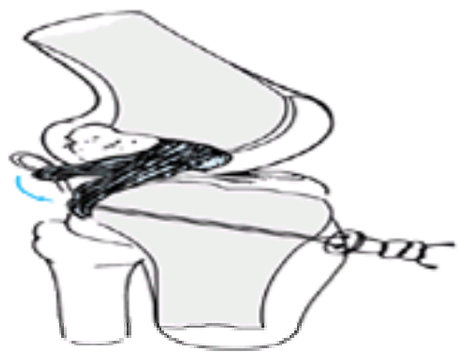

***Figure 90.11.*** Tibial avulsion of the PCL reattached with sutures placed through the bony fragment and secured over a button. (From Bowen MK, Warren RF, Cooper DE. Posterior Cruciate Ligament and Related Injuries. In: Insall JN, Windsor RE, Scott WN, et al., eds. *Surgery of the Knee.* New York: Churchill Livingstone, 1993:536, with permission.)

Surgical fixation of tibial avulsion fractures of the PCL has given almost uniformly excellent results, whereas nonsurgical treatment has a significant incidence of residual instability (46,77).

Torisu (75) treated 21 patients with avulsion fractures of the tibial insertion of the PCL using cast immobilization in small or nondisplaced fractures and staple fixation in large or displaced fragments. All patients had excellent or good result at an average of 4 years of follow-up. He reported satisfactory results in fractures less than 7 weeks old, whereas repairs delayed beyond 11 weeks resulted in less satisfactory outcomes.

### *Isolated PCL Injury*

Most authors have recommended a nonsurgical approach to the treatment of isolated PCL injuries (Table 90.1).

| Authors | Patients | Follow-up | Results |
|---|---|---|---|
| Dandy and Pusey (18) | 20 | 7.2 yrs | 92% return to sports; surgery not recommended<br>47% giving way<br>70% pain with ambulation |
| Torisu (72) | 30 | | 80% excellent/good<br>10% significant instability<br>10% meniscal injury |
| Cross and Powell (17) | 47 | 4.5 yrs | 81% excellent/good |
| Parolie and Bergfeld (37) | 23 | 4.2 yrs | 80% satisfactory<br>68% return to sport, Results correlated with quad strength |
| Tang et al. (74) | 43<br>14 isolated<br>29 combined | 4.3 yrs | 60% with degeneration on x-ray (in patients with isolated injury) |
| Fowler and Messieh (28) | 13 | 2.6 yrs | 3 good, 10 fair; all returned to sport |
| Dejour et al. (21) | 45 | 15 yrs | Degenerative changes at the follow-up |
| Keller et al. (42) | 34 | 4 yrs | 90% pain, 43% limited activities, 43% problems with ambulation, no correlation with quad strength |
| Geissler and Whipple (29) | | 2.2 yrs | 49% cartilage lesions, 36% meniscal injury (by arthroscopy) |
| Boynton and Torisu (6) | 38 | 13.6 yrs | 81% pain, 36% swelling |
| Kennedy and Grainger (44) | 37 | 11 mos | 44% with degenerative changes |

***Table 90.1. Results of Nonoperative Treatment for Isolated PCL Injuries***

Several conclusions can be made from these studies:

- The subjective results of nonsurgical treatment of the isolated PCL injury are not excellent (42). There is a 20% to 25% failure rate, and the majority of patients continue to complain of knee pain and activity limitations (42).
- There may be some correlation between quadriceps strength and outcome.
- There does not appear to be a strong association between subjective results and ligamentous stability.
- A substantial number of patients with isolated PCL injury will go on to develop degenerative changes of the knee, particularly in the medial compartment, with time.

To recommend reconstructive surgery for the isolated injury to the PCL, one must be convinced that the results of reconstruction are superior to those of nonoperative management. Unfortunately, there are no prospective randomized studies of operative versus nonoperative treatment. Very few reports divide the patients into isolated PCL versus combined PCL injuries. Bianchi (5) and Loos et al. (47) noted mixed results in surgically treated isolated PCL insufficiency, with the majority rated good or fair. Objective stability was often not restored, but patients rarely complained of functional instability. Richter et al. (61) reported an 8-year follow-up of 53 patients with isolated and combined PCL instabilities treated surgically with only 13% graded as nearly normal.

In contrast, Clancy et al. (11) reported excellent results in 15 patients treated operatively for acute PCL insufficiency, using ligament repair supplemented with a central third patellar tendon autograft passed through bony tunnels. Although this study offers good early results, it remains to be seen whether there is a decrease in the long-term incidence of degenerative arthritis.

### *Acute PCL Combined with Other Ligaments*

Disruption of the PCL as well as other major ligaments is usually a result of higher-energy injury but may also occur in sports. These injuries result in gross instability of the knee; therefore, most authors advocate operative treatment. For this reason, there are no large long-term studies of the results of nonoperative treatment; thus, it is impossible to determine whether surgical management improves on the natural history of these combined injuries. A wide variety of surgical approaches and tissues for

augmentation and reconstruction have been advocated.

Kennedy and Grainger (44) believe that repair of an injured PCL is superior to reconstruction. For reconstruction, they recommended passing hamstring tendons through drill holes in the tibia and medial femoral condyle, a procedure originally proposed by Hey-Groves. McCormick et al. (51) described reconstruction of a PCL and LCL injury using the tendon of the popliteus passed through drill holes in the medial femoral condyle. Soughmayd and Rubin (69) reported similar use of the semimembranosus tendon, preserving its distal attachment.

The results of several larger series are summarized in Table 90.2. Despite the fact that the materials used for repair or reconstruction were inferior to those used today, the results were a satisfactory functional outcome in the majority of patients. The stability of the knee after these procedures, however, is far from normal. Newer anatomic methods of PCL reconstruction using more than one graft and multiple femoral tunnels appear promising both biomechanically and clinically, but results using these methods are still preliminary.

| *Author* | *Patients* | *Follow-up* | *Technique* | *Results* |
|---|---|---|---|---|
| Moore and Larson (53) | 18 | 30.8 mos | Repair avulsion, reconstruct tears (using medial gastrocnemius) | 14/18 excellent/good |
| Hughston et al. (33) | 32 (22 ACL, 21 medial meniscus, 3 lateral meniscus) | 5–16 yrs (20 pts. evaluated) | Repair of PCL (medial meniscus used as graft in 9 cases) | 11 good, 4 fair, 1 poor, no "normal" knees |
| Lean et al. (40) | 46 | | Repair of PCL; mixed treatment of other ligament injuries | 32% poor results |
| Rauch (5) | 19 | | Repair avulsion; reconstruct tears (hamstring graft) | 48% good |
| DeLee et al. (24) | 10 (PCL/LCL) | 7.5 yrs (7 pts. evaluated) | All ligaments repaired | 5/7 good |
| Baker et al. (3) | 13 (PCL/PLC) | 56 mos (11 pts evaluated) | Repair of PCL, mixed treatment of other ligament repairs | All good functionally; 1/3 good, all with residual laxity; 1 poor objectively |
| Prentiss and Symmonds (59) | 20 | | | |

***Table 90.2. Surgical Treatment of PCL and Combined Ligament Injuries***

### *Chronic PCL Insufficiency*

Chronic PCL insufficiency usually results in symptoms from degenerative changes in the medial and patellofemoral compartments or from instability with subsequent stretching of the secondary restraints, particularly the posterolateral corner. There are few reports of successful nonsurgical management of chronic lesions. Hughston and Degenhardt (34), however, demonstrated that nearly half of their patients obtained functional stability with an aggressive rehabilitation program. These patients may have had lesser degrees of instability, however (22).

A number of procedures have been proposed to treat chronic instability. Tellberg (73), using lateral meniscus as a graft, had mixed results in seven patients. He advocated use of the meniscus because its length and size are appropriate, it is not dependent on revascularization, and it is a nearby intraarticular structure.

Table 90.3 summarizes the results of surgical treatment of chronic PCL insufficiency. Most of these studies used the medial head of the gastrocnemius muscle or meniscus as a substitute for the PCL; more recently, the central third of the patellar tendon and hamstring autografts, as well as patellar tendon and Achilles tendon allografts, have been used. Autografts provide strong, readily available tissue without the risk of disease transmission, whereas allografts have the advantage of no donor site morbidity. These reconstructions emphasize placement of bony tunnels at the sites of origin and insertion of the PCL, followed by insertion of strong graft tissue to substitute for the ligament. Paulos (58) has described an arthroscopically assisted technique using an Achilles tendon allograft.

| *Author* | *Patients* | *Follow-up* | *Technique* | *Results* |
|---|---|---|---|---|
| Hughston and Degenhardt (34) | 39 | 45 mos (26 pts. evaluated) | Medial gastrocnemius, 29; Medial meniscus, 4; Artificial ligament, 6; Medial meniscus + gastrocnemius | 28/26 good; 40% with 2+ drawer |
| Kennedy and Galpin (43) | 21 | min 8 mos (18 pts. evaluated) | Medial gastrocnemius | 80% excellent/good; Persistent posterior drawer |
| Insall and Hood (36) | 8 | | Medial gastrocnemius | 6/8 excellent/good; All improved |
| Tibone et al. (71) | 10 | | Medial gastrocnemius | 9/10 with persistent posterior drawer |
| Clancy et al. (11) | 33; 4 ACL, 1 PLC, 1 MCL | min 2 yrs (13 pts. evaluated) | Patellar tendon autograft | Isolated PCL, 6/7 excellent/good; Combined instabilities, 3/6 excellent/good |

***Table 90.3. Surgical Treatment of Chronic PCL Injuries***

Clancy et al. (11) summarized their experience in 33 patients with chronic PCL insufficiency in whom reconstruction was done using the central third of the patellar tendon as autograft. Twenty-three of 33 patients had evidence of degenerative changes on preoperative radiographs. Of 13 patients available for evaluation at a minimum of 2 years, four patients had associated ACL repairs, one had repair of the posterolateral corner, and one had repair of the MCL. All but two patients had good or excellent results.

Although the above studies included patients with associated laxity of the posterolateral structures, none specifically mentioned the preoperative alignment of the limb. Several authors have recently stressed the significance of varus alignment of the limb and, more important, of a varus thrust during gait (14,26,37). Soft-tissue procedures performed on the posterolateral corner in a limb that has a varus thrust during gait will tend to stretch out and fail over time. Despite the lack of studies demonstrating a long-term benefit, many authors (26,37) feel that the most reliable procedure in such a setting is a high tibial osteotomy.

It can be concluded from the above series that the majority of properly selected individuals who undergo PCL reconstruction for either isolated or combined injuries will obtain a satisfactory subjective result. It appears that the majority of individuals treated surgically for isolated PCL insufficiency will return to their preinjury activity level and have subjective, but not objective, stability. The results of surgery in combined PCL and other major knee ligament injuries are less predictable but offer satisfactory subjective results in the majority of patients. None of these operations, however, reliably restores objective stability, re-creates normal biomechanics, and prevents or delays the onset of degenerative disease. Although newer methods of reconstruction using multiple grafts to recreate both anatomic bundles of the PCL appear promising both biomechanically and clinically, long-term outcomes are currently unavailable.

## AUTHOR'S PERSPECTIVE

The senior author (W.G.C.) has surgically treated more than 400 patients for symptomatic isolated or combined PCL insufficiency. The following outlines his indications and preferred techniques.

### ACUTE PCL INJURY

We treat the majority of acute injury isolated PCL injuries without surgery. For displaced fractures of the origin or insertion of the PCL, we do an open reduction and internal fixation, followed by early motion. Incomplete injuries with a 1 + drawer test are a tear in continuity with interstitial lengthening, which can be seen on MRI. These injuries often tighten as healing progresses, and the posterior drawer test often diminishes to trace. Nonsurgical treatment is appropriate.

Laxity of 2+ on posterior drawer testing is consistent with a complete disruption of the PCL. In the absence of other major ligamentous injuries, we treat this injury without surgery. We advise surgery only if the patient exhibits continued instability or medial joint pain secondary to increased contact pressures in the medial compartment. In the patient with medial joint line pain and normal radiographs, we have found a technetium bone scan to be useful in defining the source of the pain.

Laxity of 3+ on posterior drawer testing indicates injury to the PCL and secondary restraints, most commonly the posterolateral corner structures. The treatment of these injuries is discussed in the section below.

### COMBINED PCL AND PLC INJURY

Try to repair PCL combined with PLC injury within 3 weeks of injury; early treatment permits primary repair rather than reconstruction. Splint the knee until the acute pain subsides and encourage active and active-assisted range of motion. Allowing 5 to 7 days to elapse from the time of injury until the time of surgery permits the joint capsule to seal and avoids extravasation of arthroscopy fluid into the leg from the injured posterolateral structures during the arthroscopic part of the procedure. We repair the PCL first, using the procedure outlined below, and then repair the PLC structures through a standard lateral approach. If a satisfactory primary repair is not possible, we do a biceps femoris tenodesis when the biceps femoris tendon is intact. We perform posterolateral corner reconstruction with an Achilles tendon allograft when the popliteus and biceps tendon complex are irreparable. These techniques are described below.

### COMBINED PCL AND ACL INJURY

As discussed earlier, these injuries are often unrecognized knee dislocations, requiring thorough neurovascular evaluation. Once the knee is reduced, splint it until the acute pain of the injury subsides, in a few days. Begin active range of motion within the limits of pain; once full extension and approximately 120° of flexion are achieved, perform elective reconstruction of the ACL and PCL. Reconstruct the ACL using an endoscopic technique with a patellar tendon graft. Reconstruct the PCL using the technique described below. Also see Chapter 91.

### COMBINED PCL AND MCL INJURY

Combined injury to the PCL and MCL is somewhat unusual. Grade I or II MCL injuries combined with PCL disruption can usually be treated without surgery, and the emphasis is on early range of motion and quadriceps strengthening. Grade III MCL injuries, characterized by laxity to valgus stress applied at full extension, have injury to the posterior oblique portion of the MCL as well as the anterior longitudinal portion. We treat these injuries with splinting and early range-of-motion exercises followed by early repair of the MCL and posterior oblique ligament as well as reconstruction of the PCL. It is important to ensure isometric repair of the MCL and posterior oblique ligament to avoid creating a flexion contracture. Reconstruct the PCL as described below.

### CHRONIC PCL INSUFFICIENCY

The patient with chronic insufficiency of the PCL may or may not have concomitant injury to the posterolateral structures. In isolated PCL injuries, we prescribe a rehab program to strengthen the quadriceps. Failure of this program to result in improvement of symptoms after 3 months results in our offering the patient the option of a PCL reconstruction. More commonly, the symptomatic patient also has some laxity of secondary restraints, particularly the posterolateral structures. In this setting we offer the patient a PCL reconstruction as well as reconstruction of the posterolateral structures using a tenodesis of a portion of the biceps tendon (9). When this procedure has been performed previously and failed, or when injury to the biceps tendon has occurred, we use an Achilles tendon allograft. Both of these techniques are described below.

## SURGICAL TECHNIQUES

### FIXATION OF PCL AVULSION INJURIES

- Two approaches for fixation of the displaced avulsion of the tibial insertion of the PCL have been advocated. Trickey (78) recommends the direct posterior approach, which gives the best view of the avulsion and allows easier internal fixation of the fragment with a screw. Perform the surgery in conjunction with an arthroscopic evaluation of the knee joint to allow treatment of any coexisting pathology.
- The second approach is that of a combined anterior medial arthrotomy and, when needed, a posterior medial arthrotomy performed through a medial parapatellar skin incision, as recommended by Hughston and associates (33,34).
- Tensile testing of knee ligament preparations in which bony avulsions occurred suggests that plastic deformation may occur within the ligament, resulting in a permanent increase in length. If this is the case, any bony avulsion should be countersunk at the time of fixation so that proper functional length and isometricity will result.
- Deliver the PCL and the attached bony avulsion through the intercondylar notch anteriorly. If there is a ligament of Humphrey or Wrisberg, and it is blocking delivery of the avulsion, transect it.
- Drill Steinmann pins from the anterior tibia and direct them posteriorly into the bed of the avulsion site, using the posteromedial capsulotomy to protect the deeper structures. Pass right-angle curets through the intercondylar notch to deepen the bed and allow countersinking of the avulsed fragment.
- Drill holes in the bone fragment and pass #2 or #5 nonabsorbable sutures through them. Then put the sutures in suture passers that have been placed through the holes previously drilled in the tibia. Pull these sutures through the tibial drill holes and tie them anteriorly while applying an anterior drawer with the knee flexed to 90°.
- Then place the knee in a splint in full extension, using the taut posterior capsule to prevent tibial dropback from gravity, which will occur if the knee is held in flexion. Use the splint for 6 to 8 weeks, but remove it daily to perform range-of-motion exercises as outlined in the postoperative rehabilitation protocol.

### TWO-BAND AND TWO-FEMORAL-TUNNEL RECONSTRUCTION OF THE PCL

We believe that there is excellent biomechanical evidence to support the theory that the PCL acts primarily as two separate functional bundles, with the anterolateral or anterocentral portion of the ligament acting predominantly in flexion and the posteromedial or posterior oblique portion of the ligament acting predominantly in extension (15). Because of the size of the sites of origin and insertion of the PCL, reconstruction of the ligament using a single graft requires that only one of these two bundles be reconstructed.

The majority of researchers to date have preferred to reconstruct the anterolateral or anterocentral portion of the ligament and have recommended tensioning the graft at 90° of flexion (7,70). This method reduces the posterior drawer as measured at the time of surgery, but laxity seems to develop with time. We feel that the laxity occurs as this portion of the PCL tightens with flexion and loosens with extension. Because the majority of functional activities are performed at less than 70° of flexion, the graft is subjected to posterior stresses at flexion angles that are significantly less than those at which it was tensioned. The result is cyclic fatigue and lengthening of the graft.

The posteromedial and posterior oblique portions of the PCL contain some fibers that exhibit isometric behavior under certain conditions, but placement of a 10- to 11-mm graft at the sites of origin and insertion of these fibers results in a large portion of the graft being outside the anatomic boundaries of the PCL.

We prefer to reconstruct both bundles of the PCL and pass two separate grafts through two separate femoral tunnels. These grafts are then passed through a single tibial tunnel, with the anterolateral/anterocentral graft being tensioned at 90° of flexion and the posteromedial/posterior oblique graft being tensioned at 30° of flexion, as described below.

The technique of PCL reconstruction involves 11 steps. Attention to detail and satisfactory performance of each of these steps in the proper order is necessary to ensure a satisfactory result.

- Step 1: Perform and document a complete examination of the knee under anesthesia.
- Step 2: Perform an arthroscopic inspection of the knee joint. Following the examination under anesthesia, prepare and drape the knee and insert a 30° arthroscope via a medial peripatellar portal. We do not use a tourniquet for any of our repairs. Make this portal with a vertical stab wound along the medial border of the patellar tendon at the level of the inferior pole of the patella, with the knee in approximately 30° of flexion. Inspect the knee in a systematic fashion, with particular attention to the medial and patellofemoral compartments. Substantial involvement of these compartments with degenerative changes is a relative contraindication to PCL reconstruction. Inspect the intracondylar notch, and identify the site of injury to the PCL. Chronic cases of PCL injury often show only laxity of the ligament, which may be most evident as diminished tension of the ligament at its insertion site into the tibia. There may also appear to be abnormal laxity of the anterior cruciate ligament, which is usually due to the abnormal posterior position of the tibia and which is eliminated with placement of the proximal tibia into its normal position with respect to the distal femur.
- Step 3: Harvest the graft from the central third of the patellar tendon. Harvest of the graft at this point in the procedure allows subsequent creation of a central portal through the fat pad at the site of the defect in the patellar tendon, and this portal will be used both to debride the remnant of the PCL from the femur as well as to position the tibial guide for the tibial tunnel. Extend the incision along the medial border of the patellar tendon both proximally and distally and define the medial and lateral borders of the patellar tendon. We prefer to harvest a 10-mm-wide graft from the central third of the patellar tendon and take 10-mm-wide, 20-mm-long grafts from both the patella and the tibial tubercle. Prepare the graft to allow easy passage through 10-mm tunnels and place three #5 ethibond

sutures through each end of the graft.

- Step 4: Debride the PCL remnant from the femur. Reinsert the arthroscope into the knee through the medial peripatellar portal and introduce the motorized shaver through the defect left by harvest of the patellar tendon. Debride the origin of the PCL from the medial femoral condyle. Preserve a portion of these fibers during the debridement; they are a valuable landmark for later tunnel placement. Preserve the curved ridge on the medial femoral condyle; it is also a helpful landmark because no PCL fibers occur posterior to this point.
- Step 5: Debride the tibial insertion site of the PCL through a posteromedial portal created at the level of the junction of the proximal medial tibia with the posterior portion of the medial femoral condyle. Advance the arthroscope into the intracondylar notch and insert the motorized shaver through the posteromedial portal. Debride with the shaver always facing toward the tibia to avoid inadvertent damage to the posterior capsule or neurovascular structures. Identify the tibial fovea. Define it using a curved shaver placed through the central fat pad portal, followed by use of an angled curet. Fully visualize the insertion site of the PCL to ensure proper placement of the tibial guide pin and to avoid popliteal artery or tibial nerve damage during subsequent drilling.
- Step 6: Create the tibial tunnel (Fig. 90.12). Once the site of insertion of the PCL has been fully identified, drill a guide pin from the anterior tibia, approximately 12 to 15 mm distal to the site of graft harvest from the tibial tubercle into the center of the insertion of the PCL. This entry point is quite important because it creates a rather vertical tunnel that eases graft passage into the tibia and also facilitates tensioning of the graft. It also avoids creating an oblique hole at the exit site of the tunnel in the fovea. Drilling a hole that enters medial or lateral to the tibial tubercle creates an oblique exit hole in the tibial fovea and may result in excessive medial or lateral placement of the graft. Run a 10-mm reamer over the guide wire, followed by a 12-mm reamer. Keep the arthroscope in the posteromedial portal during reaming to ensure that neither the guide pin nor the reamers penetrate the knee joint. Once the tibial tunnel has been reamed, debride the foveal site of any remaining tissue. Next pass a #5 ethibond suture through the tibial drill hole and out the central fat pad portal. This suture will be used during passage of the graft into the tibial tunnel.

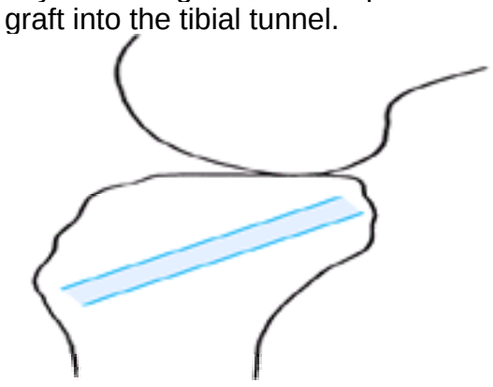

***Figure 90.12.*** Ideal site for the tibial tunnel, which enters the tibia distal to the site of graft harvest from the tibial tubercle and exits the proximal tibia in the center of the insertion site of the PCL.

- Step 7: Creation of the femoral tunnels (Fig. 90.13 and Fig. 90.14). Drill the femoral tunnels using the remaining fibers of the PCL on the medial femoral condyle as a guide. We drill a 10-mm anterior/proximal tunnel and an 8-mm posterior/distal tunnel, keeping the tunnels separated by a 3- to 4-mm bony bridge. Use a 00 curette to make marks in the medial femoral condyle at the desired tunnel sites. Insert the anterior/proximal tunnel guide pin in the intracondylar notch at the 10:30 position in a left knee (the 1:30 position in a right knee), approximately 6 mm posterior to the articular surface of the medial femoral condyle. Place the posterior/distal tunnel approximately 5 mm posterior and 5 mm distal to the anterior/proximal tunnel, taking care to keep the tunnel sites within the anatomic site of origin of the PCL. Both tunnels must be entirely anterior to the ridge in the medial femoral condyle (see Step 4, above). Make an incision over the vastus medialis muscle at the level of the adductor tubercle and elevate the fibers of the vastus medialis anteriorly. Use a vector guide to place a pin from the region of the adductor tubercle into the desired position of the anterior/proximal tunnel and drill with a 10-mm reamer over this guide. Drive a second guide pin from a separate site in the medial femoral condyle into the desired site of the posterior/distal tunnel and drill with an 8-mm reamer over this guide pin. Make sure that an adequate bony bridge separates these two tunnels. Pass two separate #5 ethibond sutures (which will be used later for graft passage) through these tunnels and out the central fat pad portal.

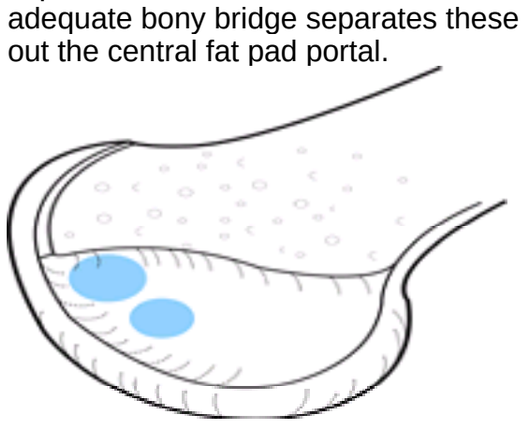

***Figure 90.13.*** Ideal sites for the positions of the femoral tunnels, as viewed from the side of a left knee with the lateral femoral condyle removed.

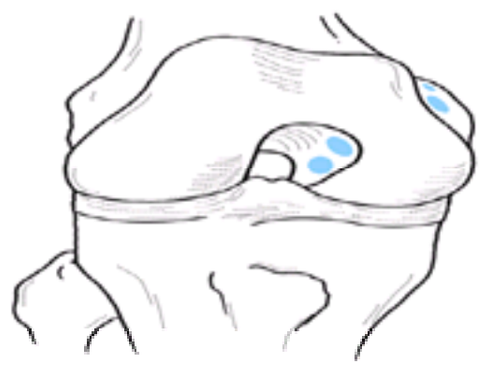

***Figure 90.14.*** Ideal sites for the positions of the femoral tunnels, as viewed in a right knee.

- Recently we placed the femoral tunnels using endoscopic technique. Using this method, we marked the femoral tunnel sites with the 00 currette as described above. We then use a specially designed custom guide and flexible guide pins and reamers to ream the two tunnels from the inside of the notch. Each tunnel is reamed to a depth of 25 to 30 mm with the appropriate-sized reamer, and a 4.5-mm drill is used to drill out the medial femoral cortex. The grafts are then fixed using an Endobutton device (Smith and Nephew, Andover, MA), allowing an entirely endoscopic reconstruction.
- Step 8: Harvest the hamstring or quadriceps tendon graft that you will use to reconstruct the posteromedial/posterior oblique portion of the PCL. Depending on your preference, use either the quadriceps tendon or the semitendinosus tendon. If you use the quadriceps tendon, make a separate vertical incision centered over the superior pole of the patella. Identify the quadriceps insertion into the patella and harvest an 8-mm-wide, 20-mm-long bone plug from the patella. Take an 8-mm-wide strip of quadriceps tendon that runs the length of the tendon. If the quadriceps tendon is excessively thick, harvest only the superficial lamina of the tendon. Place a #5 nonabsorbable braided suture through the tendon, which will be used to fix the tendon in the tibia.
- The semitendinosus tendon may be used instead of the quadriceps tendon. Harvest it in standard fashion, using the distal end of the original incision. Double the tendon over itself to form a double-stranded graft and fix it in the femur using either a standard button or an Endobutton (if an endoscopic technique is chosen).
- Step 9: Pass the grafts into the femur (Fig. 90.15). Pass the grafts into the femoral tunnels using the previously placed sutures through the central fat pad portal and the femoral tunnels. Place the quadriceps or semitendinosus graft first and then fix it at the medial femoral condyle using either a simple button (open technique) or an Endobutton (endoscopic technique). Following femoral fixation of this graft, pass the patellar tendon graft into the femur and fix it in a similar fashion.

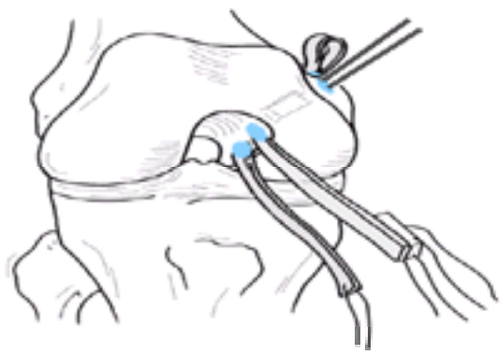

***Figure 90.15.*** Passage of the hamstring and patellar tendon grafts into the femur in a right knee (see text for explanation).

- Step 10: Pass the grafts into the tibia (Fig. 90.16 and Fig. 90.17). Once both grafts have been fixed at the medial femoral condyle, pass them through the central fat pad portal and into the tibia. Use the previously placed suture through the tibial tunnel. A graft passer (Depuy), which encloses the grafts and provides a smooth surface to slide through the tibial tunnel, facilitates the process. We have found that application of an anterior drawer at the time of graft passage into the tibia helps the graft to turn the corner at the proximal part of the tibial tunnel.

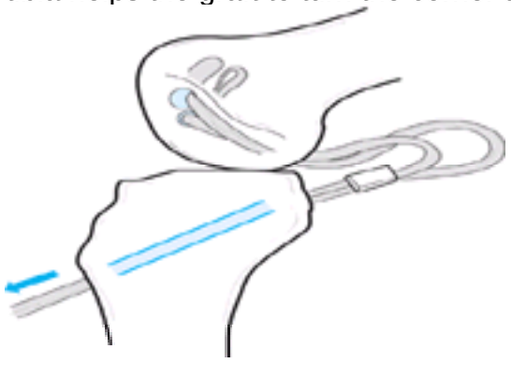

***Figure 90.16.*** Passage of the hamstring and patellar grafts into the tibia in a left knee (see text for explanation).

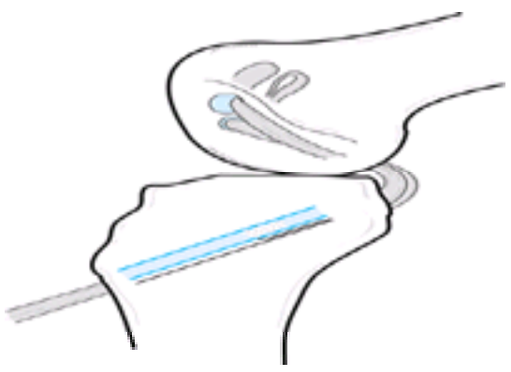

***Figure 90.17.*** Final view of a two-bundle PCL reconstruction as it would appear in a left knee, seen from the lateral side with the lateral femoral condyle removed.

- Step 11: Fix the grafts. The final step in the procedure is fixation of the grafts to the tibia. Fix the patellar tendon graft first. Tension it at 90° of flexion with an anterior drawer test. Tie the sutures from the patellar bone plug over a screw and washer and tighten them at the end of the procedure. Tighten the quadriceps or hamstring graft at 30° of flexion and tie these sutures over the same screw as those from the patellar tendon graft. Then irrigate the wounds and close in routine fashion. Begin a standardized rehab protocol on the first postoperative day. The patient is usually discharged from the hospital on the second postoperative day.

**BICEPS FEMORIS TENODESIS**

- Perform the procedure with a proximal thigh tourniquet and the patient in the supine position. Prep the leg and drape it free. Arthroscope the knee, and treat any injury to meniscal or ligamentous structures before doing the posterolateral surgery.
- Flex the knee to 90° and make a lateral curvilinear incision centered proximally over the lateral femoral epicondyle and progressing distally to the interval between Gerdy's tubercle and the fibular head (Fig. 90.18). Develop a posterior subcutaneous flap. Identify the common peroneal nerve posterior to the biceps tendon and protect it throughout the procedure.

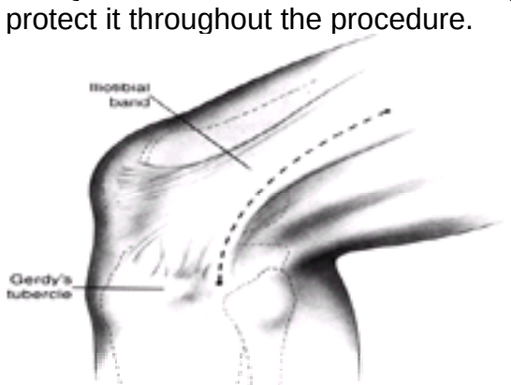


***Figure 90.18.*** The skin incision and its relationship to the iliotibial band and Gerdy's tubercle. (From Martin SD, Clancy WG. Posterolateral Instability of the Knee: Treatment Using the Clancy Biceps Femoris Tenodesis. *Op Tech Sports Med* 1996;4:182, with permission.)

- Split the iliotibial band parallel to its fibers from its midsubstance at the level of the lateral femoral epicondyle to its distal insertion (Fig. 90.19). Dissect the distal attachment of the iliotibial band free from the intermuscular septum to permit later passage of the biceps tendon. Strip any muscle fibers attached to the biceps femoris tendon distally so as not to interfere with the tenodesis (Fig. 90.20). Leave the lateral collateral ligament and its origin from the inferior half of the lateral epicondyle undisturbed. Use a ¼-in. osteotome to create a trough centered in the upper half of the lateral epicondyle, measuring 1 cm in width and 3 cm in length. Insert a 3.2-mm guide wire for a 7.0-mm cannulated cancellous screw into the trough, starting at the point anterior to the most proximal edge of origin of the lateral collateral ligament (Fig. 90.21). Drill the wire medially and slightly cephalad to avoid any tunnels used in cruciate ligament reconstruction.

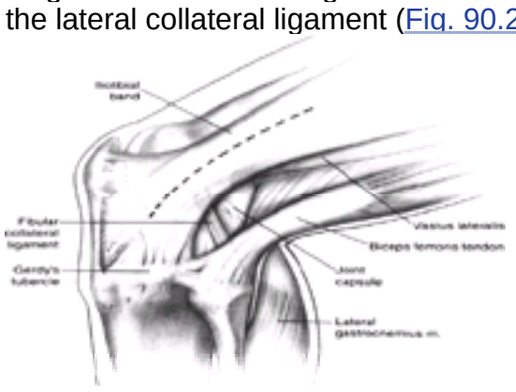

***Figure 90.19.*** Proper level of division of the iliotibial band for exposure of the lateral epicondyle. (From Martin SD, Clancy WG. Posterolateral Instability of the Knee: Treatment Using the Clancy Biceps Femoris Tenodesis. *Op Tech Sports Med* 1996;4:182, with permission.)

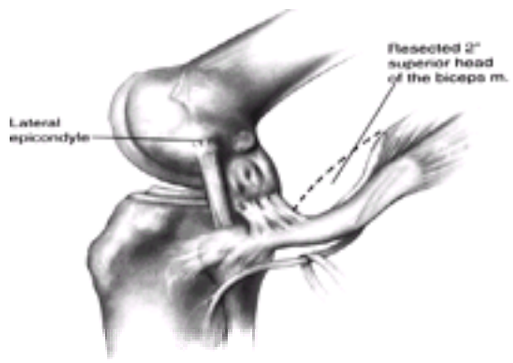


***Figure 90.20.*** Relationship of the peroneal nerve to the biceps tendon. *Dotted line* indicates the level of resection of the superior head of the biceps muscle. (From Martin SD, Clancy WG. Posterolateral Instability of the Knee: Treatment Using the Clancy Biceps Femoris Tenodesis. *Op Tech Sports Med* 1996;4:182, with permission.)

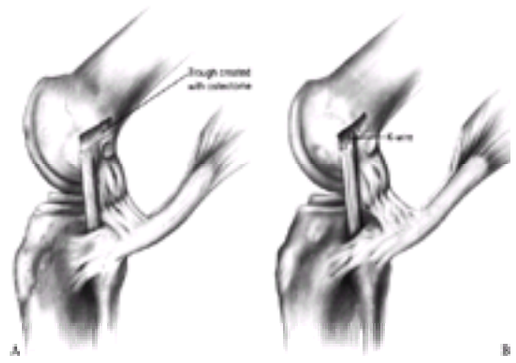

***Figure 90.21.*** **A:** Proper exposure of the lateral structures and location of the bony trough in the superior half of the lateral epicondyle. **B:** Proper placement of the K-wire in the bony trough. (From Martin SD, Clancy WG. Posterolateral Instability of the Knee: Treatment Using the Clancy Biceps Femoris Tenodesis. *Op Tech Sports Med* 1996;4:182, with permission.)

- Pass the biceps tendon beneath the inferior portion of the iliotibial tract and over the guide wire. Place a retractor around the transferred tendon to protect it from being cut by the threads of the screw (Fig. 90.22). Tighten the cancellous screw and a spiked ligament washer while tensioning the graft with the knee flexed to 30° and the tibia internally rotated (Fig. 90.23). The tip of the screw should engage the opposite cortex. Close the wound in routine fashion over a drain and place the leg in an extension splint. Allow weight bearing to tolerance and begin range-of-motion exercises at 6 weeks. Remove the screw and washer at 6 months.

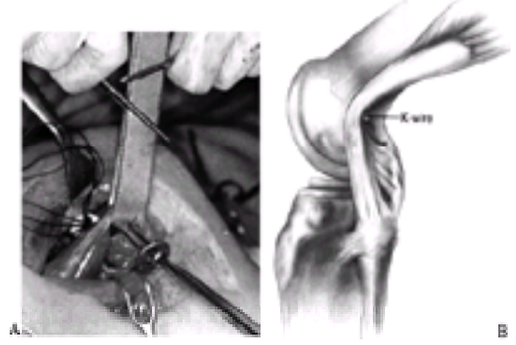

***Figure 90.22.*** **A:** Intraoperative photograph showing protection of the biceps tendon with a retractor during screw placement. **B:** Proper location of the biceps tendon transfer to the bony trough. (From Martin SD, Clancy WG. Posterolateral Instability of the Knee: Treatment Using the Clancy Biceps Femoris Tenodesis. *Op Tech Sports Med* 1996;4:182, with permission.)

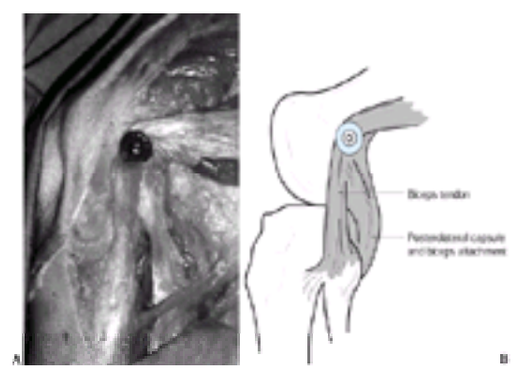

***Figure 90.23.*** **A:** Intraoperative photograph showing transferred tendon fixed with a screw and spiked washer. **B:** Transfer and fixation of biceps tendon leads to advancement of posterolateral capsule. (From Martin SD, Clancy WG. Posterolateral Instability of the Knee: Treatment Using the Clancy Biceps Femoris Tenodesis. *Op Tech Sports Med* 1996;4:182, with permission.)

## POSTEROLATERAL CORNER RECONSTRUCTION

- Use the same incision as for biceps tenodesis. Divide the midportion of the iliotibial tract longitudinally in similar fashion. Retract the biceps tendon and lateral head of the gastrocnemius from the posterior tibia and fibula.
- Drive a Kirschner (K-) wire through the tibia from anterior to posterior, entering just below Gerdy's tubercle and exiting just medial to the midsection of the fibular head at the posterolateral corner of the tibia. This maneuver will place the tunnel at the musculotendinous junction of the popliteus (Fig. 90.24). Drive a K-wire into the lateral epicondyle at the anterior superior aspect of the popliteal fossa. Use a suture through the tibial tunnel and then tie it to the K-wire to determine isometry as the knee is taken through a range of motion. The K-wire is ideally located when excursion of the suture is 3 mm or less through a full range of motion (Fig. 90.25). Once proper tunnel location is determined, drive a 10-mm reamer to a depth of 25 mm in the lateral epicondyle.

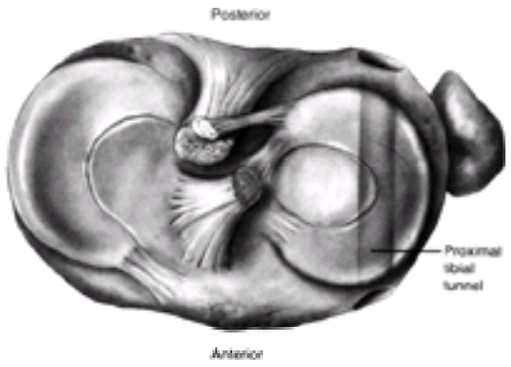


***Figure 90.24.*** Proper orientation of tibial tunnel for posterolateral corner reconstruction. (From Martin SD, Clancy WG. Posterolateral Instability of the Knee: Treatment Using the Clancy Biceps Femoris Tenodesis. *Op Tech Sports Med* 1996;4:182, with permission.)

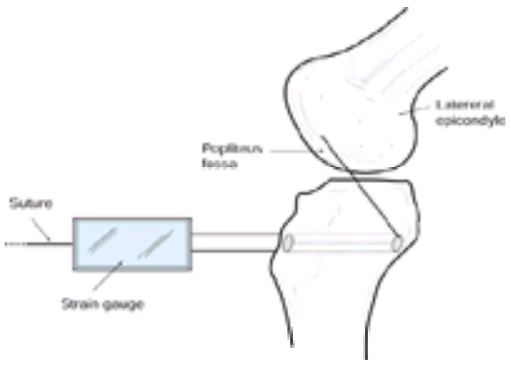


***Figure 90.25.*** Proper placement of K-wire at the superior aspect of the popliteal fossa and proper orientation of the tibial tunnel in the sagittal plane. (From Martin SD, Clancy WG. Posterolateral Instability of the Knee: Treatment Using the Clancy Biceps Femoris Tenodesis. *Op Tech Sports Med* 1996;4:182, with permission.)

- Fashion an Achilles tendon allograft with the calcaneus bone plug measuring 10 × 25 mm. Weave #5 nonabsorbable suture through the proximal end of the tendon to assist in graft passage. Fix the bone plug in the lateral epicondyle with a 7 × 25-mm interference screw. Pass the tendon medial to the iliotibial band and through the tibial tunnel from posterior to anterior. Put the knee through a range of motion to pretension the graft. Fix the graft to the proximal tibia with the knee flexed 30° and internally rotated. Provide fixation with two staples (Fig. 90.26) or with the #5 suture tied over a screw and washer if the graft is too short.

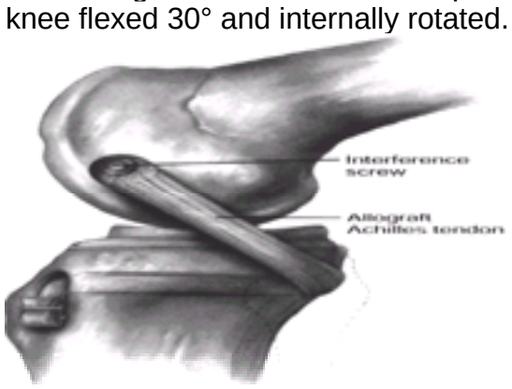


***Figure 90.26.*** Posterolateral allograft reconstruction with interference screw fixation on the femoral side and staple fixation on the tibial side. (From Martin SD, Clancy WG. Posterolateral Instability of the Knee: Treatment Using the Clancy Biceps Femoris Tenodesis. *Op Tech Sports Med* 1996;4:182, with permission.)

## FIBULAR COLLATERAL LIGAMENT RECONSTRUCTION

- If significant varus laxity exists after reconstruction of the posterolateral corner, reconstruct the fibular collateral ligament using patellar tendon allograft or autograft.
- Fashion a 10-mm graft with a 20- to 25-mm bone plug. Make a bony trough of similar dimensions in the lateral epicondyle. The inferior aspect of the trough should not extend beyond the inferior aspect of the lateral epicondyle (Fig. 90.27). Alternatively, a 10-mm tunnel can be created at the lateral epicondyle. Secure the bone block with a screw and washer for trough fixation or a 7-mm interference screw for tunnel fixation.

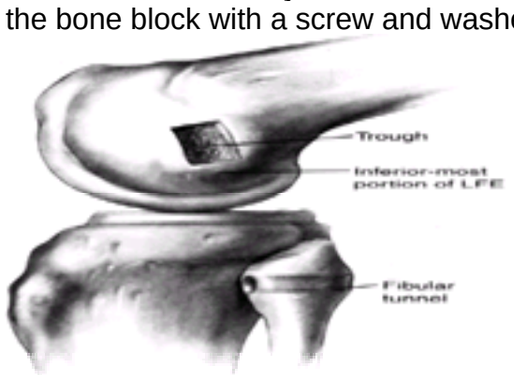


***Figure 90.27.*** Proper location of bony trough at the lateral femoral epicondyle for fibular collateral ligament reconstruction. Also note site of tunnel placement through the fibular head. (From Martin SD, Clancy WG. Posterolateral Instability of the Knee: Treatment Using the Clancy Biceps Femoris Tenodesis. *Op Tech Sports Med* 1996;4:182, with permission.)

- Make a transverse tunnel from anterior to posterior at the base of the fibular head (Fig. 90.27) with a ¼-in. drill bit. Protect the peroneal nerve during this procedure. Split the 10-mm graft longitudinally into two 5-mm strips and pass #0 suture through the tendon ends to allow graft passage. Pass the free tendon ends in opposite directions through the fibular tunnel and suture the ends to one another over the fibular head while applying a valgus force to the knee. Then close the longitudinal rent in the graft, which allows further tensioning (Fig. 90.28).

***Figure 90.28.*** Completed fibular collateral ligament reconstruction with screw fixation of bone plug on the lateral femoral condyle and suturing of tendon ends together after graft passage through the fibular head. (From Martin SD, Clancy WG. Posterolateral Instability of the Knee: Treatment Using the Clancy Biceps Femoris Tenodesis. *Op Tech Sports Med* 1996;4:182, with permission.)

## POSTOPERATIVE REHABILITATION

We divide the postoperative rehabilitation following PCL reconstruction into five phases: (a) immediate postoperative phase (first 2 weeks after surgery), (b) maximum protection phase (weeks 2 to 6), (c) controlled ambulation phase (weeks 6 to 12), (d) light activity phase (weeks 12 to 16), and (e) return-to-activity phase (weeks 16 to 24).

In the immediate postoperative phase, encourage the patient to bear 50% of weight as tolerated using two crutches and to perform ankle and hip exercises and knee extensions from 60° to 0°.

During the maximum protection phase, proceed with full weight bearing, multiangle quad isometrics at 60°, 40°, and 20°, leg press and squats from 0° to 60°, and well-leg bicycling. By week 4, range of motion should be to 90°, and bicycling can be encouraged for range of motion and endurance. Begin pool exercises at week 5.

The controlled-ambulation phase aims to increase quad strength by initiating swimming, closed-kinetic-chain rehabilitation, and a stretching program. By week 12, begin lateral step-ups, cycling for endurance (30 minutes), hamstring curls from 0° to 60° with low weight, and a walking program.

The light-activity phase continues with the above exercises and allows a light running program. By 5 to 6 months after the surgery, the patient should be performing plyometric exercises as well as agility and balance drills and may return to sport when KT-2000, isokinetic testing, and functional testing are satisfactory.

## CHAPTER REFERENCES

Each reference is categorized according to the following scheme: *, classic article; #, review article; !, basic research article; and +, clinical results/outcome study.


+ 1. Bach BR. Graft Selection for Posterior Cruciate Ligament Surgery. *Op Tech Sports Med* 1993;2:104.

+ 2. Baker CL, Norwood LA, Hughston JC. Acute Posterolateral Instability of the Knee. *J Bone Joint Surg* 1983;65A:614.

+ 3. Baker CL, Norwood LA, Hughston JC. Acute Combined Posterior Cruciate and Posterolateral Instability of the Knee. *Am J Sports Med* 1984;12:204.

+ 4. Bergfeld JA. Diagnosis and Nonoperative Treatment of Acute Posterior Cruciate Ligament Injury. *Instr Course Lect* 1990;208.

+ 5. Bianchi M. Acute Tears of the Posterior Cruciate Ligament: Clinical Study and Results of Operative Treatment in 27 Cases. *Am J Sports Med* 1983;11:308.

+ 6. Boynton MD, Tietjens MB. Long-Term Follow-up of the Untreated Isolated Posterior Cruciate Ligament-Deficient Knee. *Am J Sports Med* 1996;24:306.

! 7. Burns WC, Draganich LF, Pyevich M, Reider B. The Effect of Femoral Tunnel Position and Graft Tensioning Technique on Posterior Laxity of the Posterior Cruciate Ligament-Reconstructed Knee. *Am J Sports Med* 1995;23:424.

+ 8. Cain TE, Schwab GH. Performance of an Athlete with Straight Posterior Knee Instability. *Am J Sports Med* 1981;9:203.

# 9. Clancy WG. Repair and Reconstruction of the Posterior Cruciate Ligament. In: Chapman MW, ed. *Operative Orthopaedics.* Philadelphia: JB Lippincott, 1988;1651.

+ 10. Clancy WG, Meister K, Craythorne CB. Posterolateral Corner Collateral Ligament Reconstruction. In: Jackson DW, ed. *Master Techniques in Orthopaedic Surgery: Reconstructive Knee Surgery.* New York: Raven Press, 1995:143.

+ 11. Clancy WG, Shelbourne KD, Zoellner GB. Treatment of Knee Joint Instability Secondary to Rupture of the Posterior Cruciate Ligament. *J Bone Joint Surg* 1983;65A:310.

+ 12. Clendenin MB, DeLee JC, Heckman JD. Interstitial Tears of the Posterior Cruciate Ligament of the Knee. *Orthopaedics* 1980;3:764.

+ 13. Cooper DE. Tests for Posterolateral Instability of the Knee in Normal Subjects. Results of Examination under Anesthesia. *J Bone Joint Surg* 1991;73A:30.

# 14. Cooper DE, Warren RF, Warner JJP. The Posterior Cruciate Ligament and Posterolateral Structures of the Knee: Anatomy, Function and Patterns of Injury. *Instr Course Lect* 1991;40:249.

+ 15. Covey DC, Sapega AA, Sherman GM. Testing for Isometry During Reconstruction of the Posterior Cruciate Ligament. *Am J Sports Med* 1996;24:740.

+ 16. Cross MJ. Conservative Surgery in Posterior Cruciate Ligament Disruption. *J Bone Joint Surg* 1983;65B:99.

+ 17. Cross MJ, Powell JF. Long-term Follow-up of Posterior Cruciate Ligament Rupture: A Study of 116 Cases. *Am J Sports Med* 1984;12:292.

+ 18. Dandy DJ, Pusey RJ. The Long-term Results of Unrepaired Tears of the Posterior Cruciate Ligament. *J Bone Joint Surg* 1982;64B:92.

# 19. Daniel C. *Knee Ligament Injuries.* Presented in AAOS Postgraduate Course, *The Knee—Current Concepts.* St. Thomas, VI, June 1992.

+ 20. Daniel DM, Stone ML, Barnett P, Sachs R. Use of the Quadriceps Active Test to Diagnose Posterior Cruciate Ligament Disruption and Measure Posterior Laxity of the Knee. *J Bone Joint Surg* 1988;70A:386.

+ 21. Dejour H, Walch G, Peyrot J, Eberhard PH. The Natural History of Rupture of the Posterior Cruciate Ligament. *Rev Chir Orthop* 1988;74:35.

# 22. DeLee JC, Bergfeld JA, Drez D Jr, Parker AW. The Posterior Cruciate Ligament. In: DeLee JC, Drez D Jr, eds. *Orthopaedic Sports Medicine. Principles and Practice.* Philadelphia: WB Saunders, 1994.

+ 23. DeLee JC, Riley MB, Rockwood CA. Acute Posterolateral Rotatory Instability of the Knee. *Am J Sports Med* 1983;11:199.

+ 24. DeLee JC, Riley MB, Rockwood CA. Acute Straight Lateral Instability of the Knee. *Am J Sports Med* 1983;11:404.

+ 25. Donovan TL, Behling F, Nagel D. Posterior Cruciate Injury on Artificial Turf. *Orthop Trans* 1977;1:20.

# 26. Drez DJ Jr. *Nonoperative Treatment of PCL Injuries.* Presented at AAOS Course, *The Knee—Current Concepts.* St. Thomas, VI, May 1992.

+ 27. Fowler PJ. The Classification and Early Diagnosis of Knee Joint Instability. *Clin Orthop* 1980;147:15.

+ 28. Fowler PJ, Messieh SS. Isolated Posterior Cruciate Ligament Injuries in Athletes. *Am J Sports Med* 1987;15:553.

+ 29. Geissler WB, Whipple TL. Intraarticular Abnormalities in Association with Posterior Cruciate Ligament Injuries. *Am J Sports Med* 1993;21:846.

! 30. Gollehon DL, Torzilli PA, Warren RJ. The Role of the Posterolateral and Cruciate Ligaments in the Stability of the Human Knee: A Biomechanical Study. *J Bone Joint Surg* 1987;69A:233.

! 31. Green RB, Noble PC, Woods GW, Tullos HS. Rehabilitation of the Posterior Cruciate Deficient Knee: A Biomechanical Simulation. *Orthop Trans* 1989;13:319.

+ 32. Hewett TE, Noyes FR, Lee MD. Diagnosis of Complete and Partial Posterior Cruciate Ligament Ruptures. Stress Radiography Compared with KT-1000 Arthrometer and Posterior Drawer Testing. *Am J Sports Med* 1997;25:648.

+ 33. Hughston JC, Bowden JA, Andrews JR, Norwood LA. Acute Tears of the Posterior Cruciate Ligament. Results of Operative Treatment. *J Bone Joint Surg* 1980;62A:438.

+ 34. Hughston JC, Degenhardt TC. Reconstruction of the Posterior Cruciate Ligament. *Clin Orthop* 1982;154:59.

+ 35. Hughston JC, Jacobson KE. Chronic Posterolateral Rotary Instability of the Knee. *J Bone Joint Surg* 1985;67A:351.

+ 36. Insall JN, Hood RW. Bone-Block Transfer of the Medial Head of the Gastrocnemius for Posterior Cruciate Insufficiency. *J Bone Joint Surg* 1982;64A:691.

# 37. Jackson DF. *Posterior Cruciate and Associated Ligament Instabilities.* Presented at AAOS Annual Meeting, Washington, DC, 1992.

+ 38. Jakob RP, Hassler H, Staeubli HU. Observations on Rotatory Instability of the Lateral Compartment of the Knee. *Acta Orthop Scand [Suppl]* 1981:191.

# 39. Johnson JC, Bach BR. Current Concepts Review: Posterior Cruciate Ligament. *Am J Knee Surg* 1990;3:143.

+ 40. Jurist KA, Otis JC. Anteroposterior Tibiofemoral Displacements During Isometric Extension Efforts. The Roles of External Load and Knee Flexion Angle. *Am J Sports Med* 1985;13:254.

+ 41. Kannus P, Bergfeld J, Jarvinen M, et al. Injuries to the Posterior Cruciate Ligament of the Knee. *Sports Med* 1991;12:110.

+ 42. Keller PM, Shelborne KD, McCarroll JR, Rettig AC. Nonoperatively Treated Isolated Posterior Cruciate Ligament Injury. *Am J Sports Med* 1993;21:132.

+ 43. Kennedy JC, Galpin RD. The Use of the Medial Head of the Gastrocnemius Muscle in the Posterior Cruciate Deficient Knee. *Am J Sports Med* 1982;10:63.

* 44. Kennedy JC, Grainger RW. The Posterior Cruciate Ligament. *J Trauma* 1967;7:367.

! 45. Kennedy JC, Hawkins RJ, Willis RB, Danylchuk KD. Tension Studies of Human Knee Ligaments. Yield Point, Ultimate Failure, and Disruption of the Cruciate and Tibial Collateral Ligaments. *J Bone Joint Surg* 1976;58A:350.

+ 46. Lee HG. Avulsion Fracture of the Tibial Attachments of the Cruciate Ligaments. Treatment by Operative Reduction. *J Bone Joint Surg* 1937;29:460.

+ 47. Lipscomb AB, Johnston RK, Snyder RB. The Technique of Cruciate Ligament Reconstruction. *Am J Sports Med* 1981;9:77.

+ 48. Loos WC, Fox JM, Blazina ME, et al. Acute Posterior Cruciate Ligament Injuries. *Am J Sports Med* 1981;9:86.

+ 49. Lutz GE, Palmitier RA, An KN, Chao EYS. Comparison of Tibiofemoral Joint Forces During Open-Kinetic-chain and closed-kinetic-chain exercises. *J Bone Joint Surg* 1993;75A:732.

+ 50. Maday M, Fu FH, Harner CD, Irrgang JJ. *Posterior Cruciate Ligament Reconstruction Using Fresh Frozen Allograft Tissue: Indications, Techniques, Results and Controversies.* Presented as a Scientific Exhibit at the Annual Meeting of The American Academy of Orthopaedic Surgeons, San Francisco, February 1993.

+ 51. McCormick WC, Bagg RJ, Kennedy CW Jr, Leudins CA. Reconstruction of the Posterior Cruciate Ligament. Preliminary Report of a New Procedure. *Clin Orthop* 1976;118:30.

+ 52. McMaster WC. Isolated Posterior Cruciate Ligament Injury: Literature Review and Case Reports. *J Trauma* 1975;15:1025.

+ 53. Moore HA, Larson RL. Posterior Cruciate Liagment Injuries. Results of Early Surgical Repair. *Am J Sports Med* 1980;8:68.

* 54. O'Donoghue DH. Surgical Treatment of Injuries to Ligaments of the Knee. *JAMA* 1959;169:1423.

+ 55. Ogata K, McCarthy JA. Measurement of Length and Tension Patterns During Reconstruction of the Posterior Cruciate Ligament. *Am J Sports Med* 1992;20:351.

+ 56. Ogata K, McCarthy JA, Dunlap J, Manske PR. Pathomechanics of Posterior Sag of the Tibia in Posterior Cruciate Deficient Knees. *Am J Sports Med* 1988;16:630.

+ 57. Parolie JM, Bergfeld JA. Long-term Results of Nonoperative Treatment of Isolated Posterior Cruciate Ligament Injuries in the Athlete. *Am J Sports Med* 1986;14:35.

# 58. Paulos L. Posterior Cruciate and Associated Ligament Injuries. *Instr Course Lect.* Presented at the Annual Meeting of The American Academy of Orthopaedic Surgeons, Washington, DC, 1992.

+ 59. Pournaras J, Symeonides P. The Results of Surgical Repair of Acute Tears of the Posterior Cruciate Ligament. *Clin Orthop* 1991;267:103.

* 60. Radoievitch S. Les Ligaments des Menisques Interarticulaires du Genou. *Ann Anat Pathol* 1931;8:400.

+ 61. Richter M, Kiefer H, Hehl G, Kinzl L. Primary Repair for Posterior Cruciate Ligament Injuries. An Eight-Year Follow-up of Fifty-Three Patients. *Am J Sports Med* 1996;24:298.

+ 62. Rubinstein RA Jr, Shelbourne KD. Diagnosis of Posterior Cruciate Ligament Injuries and Indications for Nonoperative and Operative Treatment. *Op Tech Sports Med* 1993;2:99.

+ 63. Rubinstein RA Jr, Shelbourne KD, McCarroll JR, et al. The Accuracy of the Clinical Examination in the Setting of Posterior Cruciate Ligament Injuries. *Am J Sports Med* 1994;22:550.

+ 64. Satku K, Chew CN, Seow H. Posterior Cruciate Ligament Injuries. *Acta Orthop Scand* 1984;55:26.

+ 65. Savatsky GH, Marshall JL, Warren RF, Baugher WH. Posterior Cruciate Ligament Injury. *Orthop Trans* 1980;4:293.

+ 66. Shelbourne KD, Mesko JW, McCarroll JR, et al. Combined Medial Collateral Ligament–Posterior Cruciate Rupture. Mechanism of Injury. *Am J Knee Surg* 1990;3:41.

+ 67. Shelbourne KD, Rubinstein RA. Isolated Posterior Cruciate Ligament Rupture: An Unusual Mechanism of Injury. A Report of 3 Cases. *Am J Knee Surg* 1993;6:84.

! 68. Skyhar MJ, Warren RF, Ortiz GJ, et al. The Effects of Sectioning of the Posterior Cruciate Ligament and the Posterolateral Complex on the Articular Contact Pressures within the Knee. *J Bone Joint Surg* 1993;75A:694.

+ 69. Southmayd WW, Rubin BD. Reconstruction of the Posterior Cruciate Ligament Using the Semimembranosus Tendon. *Clin Orthop* 1980;150:196.

+ 70. Stone JD, Carlin GJ, Ishibashi Y, et al. Assessment of Posterior Cruciate Ligament Graft Performance Using Robotic Technology. *Am J Sports Med* 1996;24:824.

! 71. Tibone JE, Antich TJ, Perry J, Moynes D. Functional Analysis of Untreated and Reconstructed Posterior Cruciate Ligament Injuries. *Am J Sports Med* 1988;16:217.

+ 72. Tietjens BB. Posterior Cruciate Ligament Injuries. *J Bone Joint Surg* 1985;67B:674.

+ 73. Tillberg B. The Late Repair of Torn Cruciate Ligaments Using Menisci. *J Bone Joint Surg* 1977;59B:15.

+ 74. Torg JS, Barton TM, Pavlov H, Stine R. Natural History of the Posterior Cruciate Ligament-Deficient Knee. *Clin Orthop* 1989;246:208.

+ 75. Torisu T. Isolated Avulsion Fracture of the Tibial Attachment of the Posterior Cruciate Ligament. *J Bone Joint Surg* 1977;59A:68.

+ 76. Torisu T. Avulsion Fracture of the Tibial Attachment of the Posterior Cruciate Ligament. Indications and Results of Delayed Repair. *Clin Orthop* 1979;143:107.

+ 77. Trickey EL. Rupture of the Posterior Cruciate Ligament of the Knee. *J Bone Joint Surg* 1968;50B:334.

+ 78. Trickey EL. Injuries to the Posterior Cruciate Ligament. Diagnosis and Treatment of Early Injuries and Reconstruction of Late Instability. *Clin Orthop* 1980;147:76.

+ 79. Vellet AD, Marks PH, Fowler PJ, Munro TG. Occult Post-traumatic Osteochondral Lesions of the Knee: Prevalence, Classification, and Short Term Sequelae Evaluated with MR Imaging. *Radiology* 1991;178:271.

+ 80. Veltri DM, Deng X, Torzilli PA, et al. The Role of the Cruciate and Posterolateral Ligaments in Stability of the Knee. *Am J Sports Med* 1995;23:436.

# CHAPTER 91

# DISLOCATIONS AND MULTIPLE LIGAMENTOUS INJURIES OF THE KNEE

*Richard A. Marder and Jan P. Ertl*

**R. A. Marder:** Department of Orthopaedics, University of California, Davis, Sacramento, California 95817.
**J. P. Ertl:** Sacramento, California 95825.

Vascular and Neurologic Considerations
Definitions
Knee Dislocation
Combined Ligament Injury
Etiology
Classification
Anterior Dislocation
Posterior Dislocation
Medial, Lateral, and Rotatory Dislocations
Spontaneously Reduced Dislocation
Classification by Ligament Involvement
Clinical Assessment
Knee Dislocated with Intact Circulation
Knee Dislocated with Abnormal Circulation
Knee Dislocation, Spontaneously Reduced
Combined Knee Ligament Injury
Imaging Studies
Treatment
Immobilization Methods
Surgical Repair and Reconstruction
Surgical Techniques
Knee with ACL + PCL + MCL + Medial Capsule Torn; Posterolateral Complex Intact
Knee with ACL + PCL + FCL + Posterolateral Complex Torn; Medial Structures Intact
Knee with ACL + PCL + MCL + Medial Capsule + FCL + Posterolateral Torn (Global Laxity)
Knee with ACL + PCL Torn; Medial and Lateral Hinges Intact
Postoperative Care
Modifications of Postoperative Care
Results
Pitfalls and Complications
Summary
Chapter References

The rupture of multiple knee ligaments in conjunction with extensive capsular, meniscal, chondral, and extraarticular tendon injury comprises a potentially devastating condition. The spectrum of injury can range from multiplanar laxity to frank dislocation of the knee. Of foremost concern is the potential for neurovascular injury. Popliteal artery injury requires emergent multidisciplinary evaluation and treatment. Once perfusion of the limb has been assured, the orthopaedic surgeon faces a major task to stabilize the joint, restore a functional range of motion, and minimize, if not prevent, future degenerative changes of the joint.

## VASCULAR AND NEUROLOGIC CONSIDERATIONS

The popliteal artery, tethered proximally by the adductor hiatus and distally by the fibrous arch of the soleus, traverses the popliteal fossa adjacent to the posterior capsule of the knee (Fig. 91.1). These attachments create a bow string effect, rendering the artery susceptible to injury whenever the knee dislocates or even whenever multiple ligaments are torn (4,10,21,22,25,34). Approximately one third of knee dislocations have associated arterial injury, with anterior and posterior dislocations having the highest incidence, approaching 40% (7). Posterior knee dislocation, in which the tibia is driven posteriorly into the popliteal fossa, can directly contuse or lacerate the artery, whereas anterior dislocation, a result of excessive knee hyperextension, can result in complete arterial rupture or injury confined to the intimal lining, producing immediate or delayed thrombosis (10,21,22,25). Occlusion or rupture of the popliteal artery jeopardizes perfusion of the lower extremity in the vast majority of patients because of the inadequate collateral circulation about the knee (2,3).

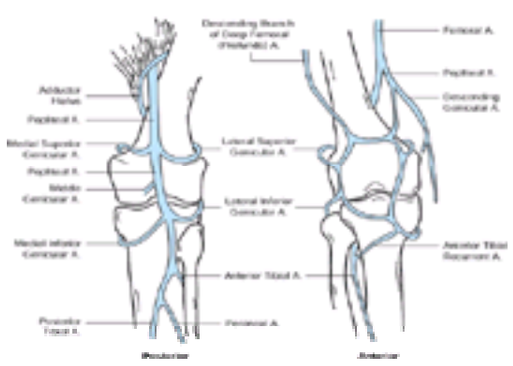

***Figure 91.1.*** Anterior and posterior views of the popliteal artery with its collateral circulation.

The posterior tibial and common peroneal nerves spanning the popliteal fossa are less rigidly fixed than the artery. This may account for a slightly lower incidence (approximately 25% overall) of nerve trauma in reported series (9,10,17,18,30,31,32 and 33). Injury is most likely to involve the peroneal nerve, although injury of the posterior tibial nerve can occur (36). Kennedy found that as little as 15° of hyperextension caused stretching of the peroneal nerve because of the cam-like effect of the lateral femoral condyle against the closely positioned nerve (10). Complete disruption or severe stretching with the nerve remaining macroscopically intact can occur. Good and Johnson (6) have reported the natural history of nerve injuries based on published series to be as follows: 60% no improvement, 32% complete recovery, and 8% incomplete recovery (9,10,17,18,30,31,32 and 33).

## DEFINITIONS

### KNEE DISLOCATION

A knee dislocation usually results in injury to both cruciate ligaments and one collateral ligament. Occasionally, knee dislocation can occur with one of the cruciates remaining intact (1,10,17,29,30). Typically, a dislocation causes extensive capsular injury as well as injury to the menisci, articular cartilage, extensor mechanism, and other structures including the iliotibial band as well as popliteus, biceps, and pes anserina tendons. After dislocation, the tibiofemoral joint may spontaneously reduce and be normally aligned or may remain subluxated or dislocated.

### COMBINED LIGAMENT INJURY

Combinations of one cruciate and one collateral ligament injuries occur, many of which also have extensive capsular injury. These patterns include:

- ACL[1] + MCL.
- ACL + MCL + medial capsule.
- ACL + posterolateral complex (LCL, popliteus, arcuate complex).
- PCL + posterolateral complex.
- PCL + MCL + medial capsule.

## ETIOLOGY

Most knee dislocations are caused by high-energy trauma such as motor-vehicle accidents, pedestrians being hit by cars, or contact sports (24,28,30,32); however, high-energy forces are not a prerequisite for knee dislocation, as lower-energy trauma from a fall or stationary hyperextension can cause dislocation (10).

## CLASSIFICATION

The dislocated knee has traditionally been classified according to the position of the tibia relative to the femur. Kennedy (10) identified five types of dislocation: anterior, posterior, medial, lateral, and rotatory (Fig. 91.2). Anterior and posterior dislocation account for the majority of cases.

***Figure 91.2.*** Classification of knee dislocations.

### ANTERIOR DISLOCATION

Anterior dislocation (Fig. 91.3) is produced by knee hyperextension with anterior displacement of the tibia relative to the femur. Kennedy observed tearing of the posterior capsule and PCL at an average of 30° of hyperextension. Continued hyperextension to 50° caused popliteal artery injury. Girgis observed that PCL injury occurred only following ACL rupture, which is consistent with clinical experience (5).

***Figure 91.3.*** Lateral radiograph of an anterior dislocation.

### POSTERIOR DISLOCATION

Posterior dislocation (Fig. 91.4) results from a posteriorly directed force applied to the anterior tibia of the flexed knee (dashboard injury). Experimentally, posterior dislocation has been produced by the application of 75 to 100 in.-lb of torque to the tibia with the knee in 20° of flexion (10). Kennedy found this injury difficult to reproduce in cadaveric experiments because of the tethering effect of the extensor mechanism that blocked displacement. He noted that patellar tendon rupture was associated with experimentally produced posterior knee dislocation. Clinically, a direct blow to the anterior tibia with the knee flexed nearly 90° is the mechanism responsible for most posterior dislocations.

***Figure 91.4.*** Lateral radiograph of a posterior dislocation.

### MEDIAL, LATERAL, AND ROTATORY DISLOCATIONS

Medial and lateral knee dislocations result from either direct valgus or varus forces applied to the proximal tibia. Kennedy noted that experimental reproduction was commonly associated with tibial plateau and supracondylar femur fractures. Clinically, medial and lateral dislocations have been observed in heavy laborers or victims of motor-vehicle accidents, mining accidents, and crush injuries (10).

Knee dislocations can have a mixed plane or rotatory component. This occurs when one element of the supporting structures remains intact, allowing the tibia to angulate and rotate relative to the femur. Of the rotatory types of injuries, posterolateral dislocation is important to recognize because it is often irreducible by closed

methods (8,23) (Fig. 91.5*A*, Fig. 91.5*B*). Reduction of this dislocation can be blocked by a buttonhole tear in the medial capsule, trapping the medial femoral condyle (Fig. 91.5*C*, Fig. 91.5*D*). This can result in a medial cutaneous skin furrow (35). This sign is an indication for immediate open reduction; delay may result in skin necrosis or further neurovascular compromise.

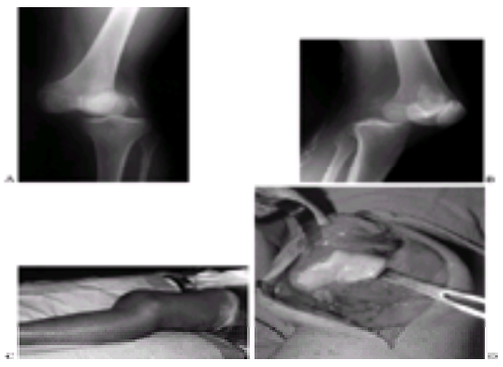

***Figure 91.5.*** **A:** Anteroposterior radiograph of a posterolateral dislocation with marginal patellar fracture. **B:** Lateral radiograph of a posterolateral dislocation. **C:** Appearance of knee before reduction. **D:** Medial femoral condyle buttonholed through medial capsule, blocking closed reduction.

### SPONTANEOUSLY REDUCED DISLOCATION

A knee can dislocate and then spontaneously reduce. The diagnosis may not be suspected because there is normal alignment and lack of excessive swelling. Diagnosis requires clinical demonstration of cruciate and collateral ligamentous injuries. A knee dislocation that has spontaneously reduced may demonstrate one or more of the following (34):

- Greater than 30°dg recurvatum (indicates PCL and posterior capsule disruption).
- Greater than 1 cm of anteroposterior (AP) excursion (indicates ACL and PCL tears), with soft endpoints.
- Lateral capsular sign (indicates ACL and lateral complex disruption).
- Large hemarthrosis or hematoma.

### CLASSIFICATION BY LIGAMENT INVOLVEMENT

Although Kennedy's scheme is helpful for understanding the mechanism of injury and applying reversing forces to effect closed reduction, a more useful classification identifies the structures that are torn and will need repair or reconstruction. Modified from Schenck to include associated capsular injury, the following are patterns of dislocation most often encountered (26):

1. ACL + PCL torn; MCL + LCL + capsule intact.
2. ACL + PCL + MCL + medial capsule torn; LCL + posterolateral intact.
3. ACL + PCL + LCL + posterolateral complex torn; MCL intact.
4. ACL + PCL + MCL + medial capsule + LCL + posterolateral complex torn.

Conceptually, this can be simplified to:

1. AP laxity; intact medial and lateral hinges.
2. AP laxity + medial laxity; intact lateral hinge.
3. AP laxity + lateral laxity; intact medial hinge.
4. AP laxity + lateral + medial laxity (global laxity).

## CLINICAL ASSESSMENT

An algorithm for management of the dislocated knee is shown in Fig. 91.6.

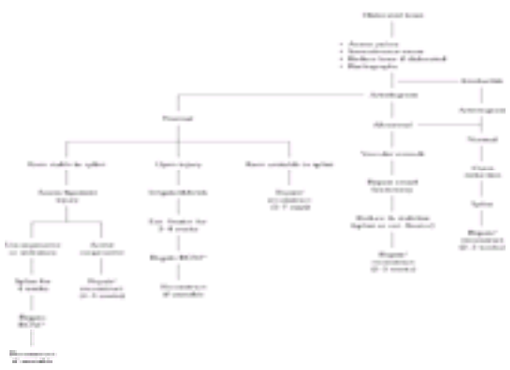

***Figure 91.6.*** Algorithm for management of the dislocated knee. *ROM*, range of motion.

### KNEE DISLOCATED WITH INTACT CIRCULATION

Evaluation of the grossly malaligned knee requires immediate vascular and neurologic assessment of the limb, followed by gentle closed reduction. Because fractures of the distal femur and proximal tibia as well as knee dislocation can cause gross deformity, gentle reduction is similarly beneficial in improving circulation in these conditions. Gentle longitudinal traction is usually sufficient to effect reduction or at a minimum improve alignment. Lifting the femur anteriorly in addition to longitudinal traction is helpful to avoid further trauma to the popliteal structures in the instance of an anterior dislocation. At this point, reassess the pedal pulses and repeat the neurologic exam. If pulses are present and bilaterally symmetric, splint the knee in 5° of flexion, avoiding hyperextension, and obtain radiographs. Once this is completed, methodically and gently assess the knee for ligamentous laxity (Fig. 91.7 , Fig. 91.8 and Fig. 91.9). Apply AP stress at 30° of flexion. Check varus–valgus laxity at 0° and 30° of flexion. If significant ligamentous injury has occurred, there will be abnormal tibial excursion and soft endpoints. If the collateral ligaments are intact but stretched (grade II sprain), return of intrinsic varus–valgus stability will be noted after reduction of the dislocation. Have the patient attempt to actively extend the knee even with some assistance while you palpate anteriorly for any defect in the extensor mechanism. An arteriogram (Fig. 91.10) in the radiology suite is necessary to exclude complete thrombosis, a small laceration, or an intimal injury. Obtain immediate consultation from a vascular surgeon if any abnormality is noted (see below). Admit the patient for observation of peripheral circulation and potential compartment syndrome and formulate the plan for surgical repair.

***Figure 91.7.*** Gentle valgus stress testing in extension reveals medial complex injury.

***Figure 91.8.*** Gentle varus stress testing in extension indicates lateral complex injury.

***Figure 91.9.*** Recurvatum of involved extremity, as compared to the contralateral extremity, indicates posterior laxity.

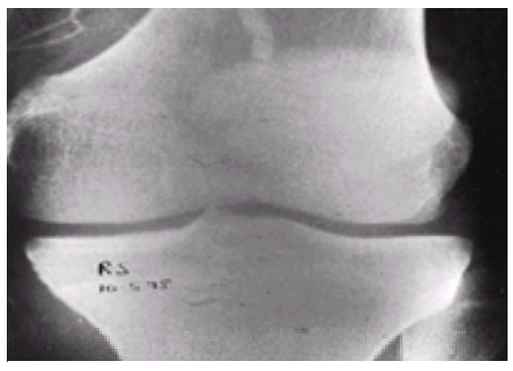

***Figure 91.10.*** Postreduction arteriogram reveals popliteal artery disruption.

**KNEE DISLOCATED WITH ABNORMAL CIRCULATION**

Immediate consultation with a vascular surgeon is needed for any of the following: abnormal distal pulses before or after attempted reduction, fullness in the popliteal area, open injury, or irreducible dislocation. Arteriography is usually performed in the operating room in expectation of popliteal exploration. This saves valuable time, as opposed to obtaining the arteriogram in the radiology suite. The return of distal pulses following reduction does not negate the urgency of further vascular evaluation. Return of distal pulses following closed reduction has been reported in the presence of complete popliteal artery disruption (9,16,22,25).

Revascularization is most successful when performed in the first 6 to 8 h after injury (2). It has been shown that after this time interval, irreversible muscle damage and gangrene occur, even if blood flow is reestablished (19). When revascularization is performed within 8 h, there is an 87% limb survival rate (7). Conversely, treatment of a popliteal vascular injury after 8 h has been reported to have an amputation rate as high as 85% (7).

Although these time limits have been well established, a successful and timely repair does not guarantee limb survival. Other factors such as age, the presence of an open wound, associated crush injuries, fractures, and extent of damage to the collateral circulation may affect the results. Delayed revascularization may be successful on occasion. Because ischemic tolerance is variable, delayed revascularization (from 36 h up to 4 days after injury) has led to limb survival (3,12). Therefore, the need for amputation should be evaluated on an individual basis and not performed prematurely if there is any potential for revascularization.

The usual vascular repair consists of a reversed interpositional saphenous vein graft, harvested from the contralateral limb. On completion of revascularization, a full four-compartment fasciotomy must be performed (4), followed by maintenance of the reduction of the knee. This requires cooperation between the orthopaedic and vascular surgeons to ensure protection of the vascular repair while facilitating treatment of the knee instability.

**KNEE DISLOCATION, SPONTANEOUSLY REDUCED**

Consider the patient with multiplanar knee laxity to have sustained a knee dislocation. These injuries have a similar incidence of neurovascular complications as do knees that present with gross deformity. Therefore, perform an examination as described above for the dislocated knee with intact circulation. We routinely obtain arteriograms for these patients, although satisfactory assessment using Doppler pressure measurements (ankle/arm pressure ratios) has been reported (34).

**COMBINED KNEE LIGAMENT INJURY**

The diagnosis of injuries to the cruciate ligament(s) and the collateral ligament(s) is usually obvious. It is crucial to establish whether there is accompanying injury to

either the posterolateral complex (PLS) or the medial complex [medial capsule and posterior oblique ligament (POL)]. Although ACL + MCL is a common injury pattern and does well with initial nonoperative treatment for the MCL followed by ACL reconstruction alone, untreated injury to the other medial structures (capsule and POL) can compromise an ACL reconstruction. Extensive injury to the medial capsular–ligament complex is indicated by:

- Greater than 5 mm valgus opening in full knee extension.
- Increased external tibial rotation at 30°dg of knee flexion.
- An increased anterior drawer test at 90°dg of flexion while in external rotation.

Similarly, extensive injury to the posterolateral corner (PLS) is characterized by:

- Increased (>10°dg side to side) external tibial rotation at 30°dg of flexion.
- Varus opening 5 mm in full extension.
- Anterior tibial translation in full extension greater than when in flexion (when ACL torn).

Because of the extensive soft tissue injury with these injuries, use a well-padded Robert-Jones (R-J) dressing incorporating medial and lateral splints with the knee in 5° of flexion. This is superior to a knee immobilizer. Subtle peroneal nerve injury (*in situ* injury) may accompany posterolateral disruptions. Although motor function can be difficult to grade accurately in the acute setting, decreased sensation in the first dorsal web space may be a clue to such injury. Monitor the patient in hospital for at least 24 h for possible vascular injury and remain alert to the potential for compartment syndrome. Early primary repair of a capsular injury typically has an outcome superior to reconstruction performed for chronic instability. Ideally, undertake surgical repair by 14 days, although surgery can still be successful as late as 3 weeks postinjury.

## IMAGING STUDIES

After reduction, obtain planar radiographs. At a minimum, an AP and a lateral in extension are necessary to determine if tibiofemoral alignment has been restored and can be maintained in a splint. Posterior subluxation can be difficult to detect, and, especially if nonoperative treatment is considered, a comparison view with the normal knee can be helpful. Oblique and tunnel views may demonstrate subtle avulsions and fractures. Stress radiographs are not routinely performed in acute cases but can be used to document instability in chronic cases.

Magnetic resonance imaging (MRI) is helpful to evaluate the articular cartilage and menisci as well as subtle posterolateral complex injury because the popliteus tendon and other lateral structures can be well visualized. Often MRI will show the type of cruciate injury (avulsion vs. midsubstance) that is helpful in preoperative planning of the type of repair or reconstruction (Fig. 91.11).

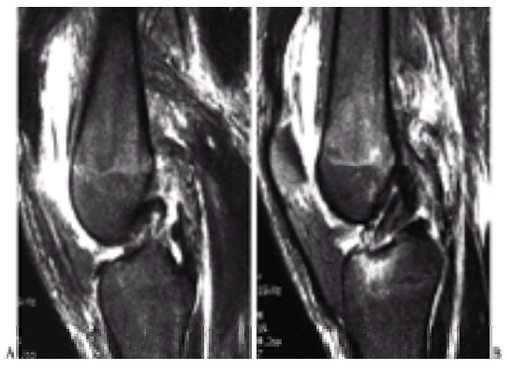

***Figure 91.11.*** Magnetic resonance image demonstrating midsubstance PCL rupture (**A**) and ACL tibial avulsion (**B**).

## TREATMENT

The goals of treatment are to:

- Ensure perfusion of the lower limb.
- Stabilize the knee joint while restoring functional range of motion (ROM).
- Minimize the development of posttraumatic joint degeneration.

Treatment of the dislocated knee can be divided into methods that rely on prolonged *immobilization* to achieve stability and those that allow early *mobilization* by primarily repairing or reconstructing torn structures. Immobilization choices include casting, casting supplemented with transarticular Steinmann pins transfixing the tibia to the femur, and external fixation bridging the knee joint. Another method is “olecranization” of the patella, which transfixes the patella to the tibia, preventing posterior tibial subluxation while allowing limited motion of the knee. All of these methods rely on indirect healing of ligaments, capsule, and muscles supplemented by scar formation during a period of immobilization. Methods that promote mobilization of the knee and limb involve surgical repair with limited or comprehensive reconstruction.

### IMMOBILIZATION METHODS

#### *Casting or Bracing*

After reduction and arteriogram, position the knee in 5° of flexion using a well-padded R-J dressing incorporating splints, extending from the proximal thigh to include the foot. Elevate the extremity, monitor the patient for 24 to 48 h in hospital, and then apply a groin-to-toes long leg cast in 5° of flexion or properly fit a long leg functional brace. Obtain radiographs to ensure that alignment is normal. Continue immobilization for 4 weeks and then begin range-of-motion exercises. This method is suitable for patients who are inactive or uncooperative either because of other injuries or personality or who decline surgical treatment.

#### *Casting and Supplemental Steinmann Pin*

If the reduction cannot be maintained by splints alone, reduce the knee under regional or general anesthesia and insert a single large-diameter Steinmann pin into the upper tibia starting medial to the tibial tuberosity and under fluoroscopic control advance it into the intercondylar notch to engage the lateral part of the distal femur in the metaphyseal region. The knee must be reduced before the pin is seated in the femur; perform a lateral radiograph if the fluoroscopic image is not clear. Use supplemental casting as described above. Disadvantages of this technique include the need for removal of the pin and the possibility of pin breakage with motion.

#### *“Olecranization” of the Patella*

This technique involves insertion of two parallel Steinmann pins from the superior pole of the patella to exit the inferior pole and engage the anteriormost portion of the intercondylar eminence on the tibia. This prevents posterior subluxation; however, with excessive motion of the knee, the pins can break or erode through the articular surface of the patella. Therefore, we rarely use this method of stabilization.

#### *External Fixation*

This is an effective method to maintain alignment of an unstable knee that does not rely on hardware traversing the interior of the joint. Its major indication is to treat the open dislocation where repeated wound procedures are necessary. The major disadvantage is that motion is sacrificed, and because of the passage of pins into the anterior or lateral femur, quadriceps adhesions are likely to develop. We prefer to remove the fixator at 3 to 4 weeks if wound healing is satisfactory, and, provided the knee is stable, start motion in a hinged brace. If the knee is unstable, then once motion is regained, perform arthroscopic assisted ACL and PCL reconstruction as described in Chapter 89 and Chapter 90.

## SURGICAL REPAIR AND RECONSTRUCTION

### *Indications*

Absolute indications for surgical treatment include open and irreducible dislocations. Relative indications include a redislocating or subluxating knee despite splinting and a knee dislocation or multiple ligament injuries in an active patient. Surgery is contraindicated in uncooperative patients and in patients likely to be unable to successfully rehabilitate the knee after surgery (e.g., patients with concomitant head trauma or severe polytrauma). Treat this group by immobilizing the knee initially, followed by reconstructive surgery if needed at the time their other injuries have resolved.

### *Key Considerations*

Developing a preoperative plan requires specific questions to be answered:

- When to perform surgery?
- What type of skin incision(s) to use?
- How to treat cruciate and collateral ligament, and capsular tears?
- What to do with the nerve injury?
- What is the role of arthroscopy?

### *Timing of Surgery*

Surgery can be performed immediately, early in the postinjury phase (up to 21 days), or months later. The advantages of performing surgery within a 21-day period is that structures can be discretely identified and repaired; once stability is achieved, motion of the knee at least on a limited basis can be initiated; and articular injuries can be precisely identified, which can be helpful in prognosticating outcome as well as guiding rehabilitation. Unless otherwise indicated (see below), there is no advantage in surgery performed immediately versus 7 to 21 days postinjury. This short delay allows ample preoperative monitoring of limb perfusion, promotes resolution of soft-tissue swelling, and allows the surgeon to put together a well-thought-out operative plan. Usually after a 48-h period of observation, the patient can be discharged home with the knee splinted. Forewarn the patient about the signs of delayed thrombosis and the possible need for urgent readmission, and schedule elective repair of the knee ligaments about 14 days after injury.

Exceptions to this regimen are open dislocations, irreducible dislocations, and dislocations redislocating or subluxating after splinting. Immediate surgery is performed in instances of dislocations associated with open injuries and irreducible dislocations. For open dislocations, irrigate and debride the wounds and joint as for an open fracture and then apply an external fixator to maintain reduction. For irreducible dislocations, perform open reduction, close the wound, and splint the knee. We prefer to wait 10 to 14 days before performing definitive surgical repair. If vascular repair is necessary, ligament surgery can be delayed up to 3 weeks if needed. This is because the extreme medial incision used by vascular surgeons does not allow adequate exposure of the joint without the mobilization of a large subcutaneous flap. In the face of compromised circulation, this can impair wound healing. Perform surgery within 5 to 7 days for dislocations that subluxate despite proper splinting.

### *Skin Incision*

If the posterolateral complex is torn and/or the peroneal nerve is injured, use a midlateral incision for exposing these structures together with a medial parapatellar skin incision for any medial knee and cruciate injuries, maintaining at least a 7 cm bridge of skin between the two incisions (Fig. 91.12 and Fig. 91.13). If the lateral structures are intact, then a longitudinal midline anterior incision can be used to expose the posteromedial corner, medial side, as well as the intercondylar region and remainder of the interior of the joint.

***Figure 91.12.*** Anteromedial incision.

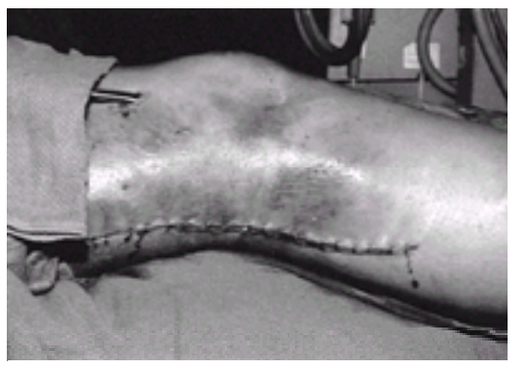

***Figure 91.13.*** Lateral incision.

### *Cruciate Surgery*

Repair avulsion-type injuries, especially where the PCL is avulsed from the femur, by advancing the ligament stump into its bony attachment. Treat midsubstance PCL tears by primary reconstruction with a patellar tendon bone (PTB) graft and midsubstance ACL tears with doubled semitendinosis and gracilis grafts. An alternate method advocated by Shelbourne et al. is to reconstruct only the PCL, leaving the ACL to be reconstructed on a delayed basis in the hope of minimizing postoperative stiffness (28). In our experience it is difficult to tension the PCL adequately while maintaining normal tibiofemoral alignment in the absence of the ACL. We utilize Clancy's method of simultaneously tensioning both ACL and PCL at 20° of knee flexion to achieve neutral positioning of the knee (see Chapter 90).

### *Collateral Ligaments and Capsule*

Repair avulsions with suture anchors and reapproximate midsubstance tears with nonabsorbable suture. Repair of the capsule is crucial for protecting the cruciate repairs. The capsule is often avulsed from one side of the joint. Drill holes placed in the AP plane are satisfactory for posterior capsule avulsions. Fix the capsular and collateral ligament repairs with the knee in 30° of flexion; secure the posterior capsule with the knee at no greater than 15° of flexion to avoid limitation of knee extension.

### *Peroneal Nerve*

If the nerve is grossly intact, do nothing other than decompress any external fascial bands, as there is approximately a 40% chance of spontaneous partial or complete recovery (9,10,17,30,31,32 and 33). Postoperatively, incorporate an ankle–foot orthosis (AFO) into the hinged knee brace (Fig. 91.14). If the nerve is disrupted (Fig. 91.15), tag the ends for later grafting. Unlike transection injuries, the extent of damage cannot be accurately assessed immediately because of proximal and distal hemorrhage. Satisfactory results have been reported when surgery was delayed for 3 months (37).

***Figure 91.14.*** Hinged knee brace incorporating AFO to maintain ankle in neutral position in patient with knee dislocation and complete peroneal nerve palsy.

***Figure 91.15.*** Stretch-and-tear injury to the common peroneal nerve results in “mop ends” that are difficult to reapproximate.

### *Arthroscopy*

Once capsular tears have partially healed (10–21 days), arthroscopy can be used to identify associated articular and meniscal injuries. Arthroscopic inspection of the knee usually requires less than 5 min, provided that gravity inflow is used, and therefore poses little risk of fluid extravasation into the calf. Although arthroscopic cruciate reconstruction can be performed in selected cases when the ACL and PCL ligaments are torn and the capsule and the collaterals are for the most part intact, most knee dislocations involve significant capsular and collateral tears that require open surgery. In these cases, we prefer to use arthroscopy for diagnosis only and perform repairs and reconstructions using open technique utilizing arthroscopic guides and instruments as described below.

## SURGICAL TECHNIQUES

### KNEE WITH ACL + PCL + MCL + MEDIAL CAPSULE TORN; POSTEROLATERAL COMPLEX INTACT

- Repeat the ligamentous examination of the knee to confirm the preoperative assessment. Administer a prophylactic antibiotic (cefazolin). Prep and drape both lower extremities free to determine correct AP postioning using lateral radiographs and observation of the normal knee's tibial plateau to femoral condyle relationship. Tourniquet use should be cleared by the vascular surgeon in cases with arterial injury and repair. Inflate the tourniquet no higher than 275 mm Hg.
- With the knee slightly flexed, start the incision 5 cm above the patella, extending it over the medial border of the patella, parallel to the medial aspect of the patellar tendon, and ending at the border of the pes anserinus, about 6 cm below the medial joint line. Open the medial retinaculum incorporating any tears, beginning at the superior border of the pes anserina tendons near the tibial tubercle. Identify the MCL and its site of rupture (usually from the medial femoral epicondyle or midsubstance) and continue to open the retinaculum along the sartorius toward the posterior corner of the knee to the vastus medialis muscle.
- At this point, swing the retinacular incision proximally toward the adductor tubercle in the interval between the medial gastrocnemius and the posterior oblique ligament. Open the joint anteriorly alongside the medial border of the patellar tendon. Retract the fat pad inferiorly, the MCL and medial capsule medially, and the patellar ligament and patella laterally to inspect the notch. It may be necessary to extend the capsular incision proximally to the midpoint of the patella.
- Remove any chondral debris and inspect the medial meniscus. To visualize the lateral meniscus, flex the hip to 90° and position the knee in the figure-of-four position.
- If the ACL is avulsed from the tibia or femur, place at least two sutures (#2 nonabsorbable) through the avulsed end of the ligament. For a tibial avulsion, pass the sutures through parallel drill holes placed in the curetted central bed of the tibial ACL attachment, using a tibial aiming device (Fig. 91.16). If the ACL is avulsed from the femur, maximally flex the knee and similarly place sutures in the torn end.

***Figure 91.16.*** Avulsion of ACL from tibia held with #2 nonabsorbable suture. Notice anteromedial capsular stripping, exposing proximal tibia.

- Expose the distal lateral femur by subcutaneous dissection through the prepatellar bursa and incise the iliotibial band at its midpoint, proximal to the flare of the lateral metaphysis, staying above the intermuscular septum. Elevate the vastus lateralis from the femur and retract it anteriorly.
- For femoral avulsions of the ACL, use a drill guide to insert, from outside in, parallel 3 mm Kirschner wires at the femoral insertion of the ACL (at the junction of the roof and wall of the notch, 2 to 3 mm anterior to the over-the-top position). Using a suture hook, deliver the sutures previously placed in the torn ligament to the lateral femur.
- If the ACL is a mop-end or midsubstance tear, reconstruct it with doubled hamstring tendons (Chapter 89). Do not fix the ACL repair or graft until the PCL is addressed.
- If the PCL is avulsed from the femur (Fig. 91.17*A*), place multiple sutures, similar to the ACL, in the torn end and pass them through parallel drill holes 8 mm posterior to the articular cartilage and at the 10:30 (L knee) or 1:30 (R knee) position on the medial femoral condyle (Fig. 91.17*B*).



***Figure 91.17.*** **A:** Avulsion of PCL from femur with long stump of ligament remaining intact. **B:** Avulsed PCL after repair through bony tunnel with sutures tied over 14 mm button.

- If tibial avulsion of the PCL has occurred, enter the joint through the usual tear or make an incision in the posteromedial capsule. Incise the inferior aspect of the posteromedial capsule along the upper tibia and identify the PCL bed. Place a tibial aiming device for the PCL through the notch into the tibial attachment site, staying on the lateral edge, and drill a 3 mm Kirschner wire to this point from the anteromedial tibia, starting immediately below the tibial tubercle. Make sure that there is sufficient spread between tibial tunnels for the PCL and an ACL graft to avoid convergence or fracture. Protect the contents of the popliteal fossa with a retractor or fingertip through the posteromedial incision. Overream the guide wire with a 6 mm cannulated drill and deliver the sutures placed in the torn end of the PCL through this tunnel with a suture-passer.
- Reconstruct a midsubstance rupture of the PCL with an autogenous patellar tendon bone graft as described in Chapter 90.
- Provisionally tension and fix the cruciate repairs/reconstructions simultaneously using an assistant. Position the knee in 20° of flexion to restore the normal tibiofemoral relationship. Lateral radiography of the injured and uninjured knees may be needed.
- Sutures around posts or tied over buttons allow repeated tensioning and graft retightening as needed to restore normal AP tibiofemoral position.
- After the cruciate ligaments have been provisionally addressed, repair the medial structures. Avulsion of the posteromedial capsule is usually from the tibia. Repair with sutures (#2 nonabsorbable) placed from anterior to posterior along the upper medial tibial plateau. If needed, reflect the retinacular layer from posterior to anterior to expose the MCL at the level of the medial femoral epicondyle and the joint. Gentle distal retraction of the pes tendons permits inspection of the MCL tibial attachment.
- Inspect the medial capsule and ascertain the status of the medial meniscus from inside the joint, using both the anteromedial and posteromedial capsular incisions. Repair the meniscus to the medial capsule (coronary ligaments) with vertical mattress sutures (#1 nonabsorbable).
- Fix MCL avulsions from the tibia or femur with a 6.5 mm cancellous screw and a soft-tissue spiked washer. Repair midsubstance injuries with whipstitch sutures (#2 nonabsorbable). Repair the posteromedial capsule incision or injury in vest-over-pants fashion using horizontal mattress sutures (#2 nonabsorbable) in 15° of flexion.
- Release the tourniquet before final closure. Close the iliotibial band, medial retinacular layer, and anteromedial capsular incision with absorbable sutures. Place drains in the subcutaneous layer. Reapproximate the subcutaneous layer with minimal sutures, and close the skin.

**KNEE WITH ACL + PCL + FCL + POSTEROLATERAL COMPLEX TORN; MEDIAL STRUCTURES INTACT**

- Use positioning, draping, and tourniquet as described above.
- Make two incisions—midlateral and anteromedial—separated by more than 7 cm. Make the lateral incision first, starting 7 cm proximal to the lateral femoral epicondyle in line with the posterior edge of the ilial–tibial band (ITB). With the knee flexed to 90°, curve the incision distally to pass over the anterior portion of the fibular head.
- With blunt dissection, elevate the posterior subcutaneous flap in the proximal part of the incision. Identify the peroneal nerve as it exits under the biceps; distally, the ITB and biceps insertion are frequently avulsed or torn (Fig. 91.18). Follow the peroneal nerve distally. If it is stretched, divide the fascial roof at its entrance into the anterolateral leg near the fibula. If it is torn, tag the ends for delayed reconstruction.

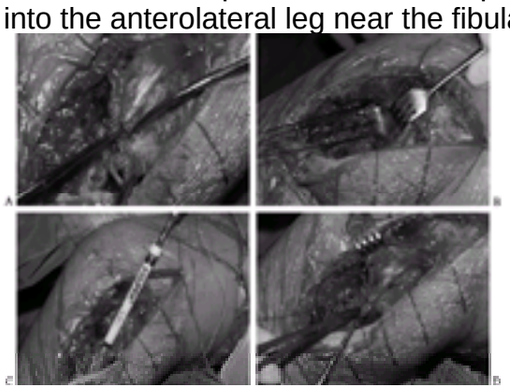

***Figure 91.18.*** Extensive disruption of lateral structures. **A:** Avulsion of biceps (*bottom clamp*) and avulsion of FCL from fibular head (*upper clamp*). **B:** Insertion of three suture anchors in upper lateral tibia to repair tibial coronary ligament and lateral capsule (retracted to show lateral meniscus rim and joint). **C:** Inserting suture anchor in fibular head. **D:** Lateral capsule repaired; inserting suture in avulsed end of FCL.

- Identify tears in the lateral capsule. This often is avulsed as a single sheet from one side of the joint. If not avulsed, open the capsule behind the FCL, which is avulsed or torn in its midsubstance. Repair the meniscus using vertical mattress sutures (#1 nonabsorbable).
- Find and repair the popliteus. It may be necessary to make an anterolateral capsular incision if the popliteus is torn from its femoral attachment. When opening the thin layer of capsule overlying the popliteus, avoid injury to it. Repair the popliteus and capsule with suture anchors (#2 nonabsorbable).
- Approach the medial knee as previously described using a curved skin incision centered over the medial femoral epicondyle and extending along the midmedial leg, maintaining at least 7 cm between the two incisions.

**KNEE WITH ACL + PCL + MCL + MEDIAL CAPSULE + FCL + POSTEROLATERAL TORN (GLOBAL LAXITY)**

- Perform surgery as described above using two incisions.
- In this injury expect to find the extensor mechanism torn. Inspect the patellar tendon using gentle subcutaneous dissection from the anteromedial incision. Repair midsubstance rupture of the patellar tendon with interrupted whipstitches (#2 nonabsorbable) reinforced by two or more interlocking, horizontal weaving (Krackow) sutures (#2 nonabsorbable) placed through drill holes in the patella or tibial tubercle, depending on where the tear is located (Fig. 91.19) (11). Repair avulsion injuries with similar interlocking sutures passed through drill holes in the respective bony attachment. Tighten all repairs to allow knee flexion to 60°. Do not use cerclage sutures.

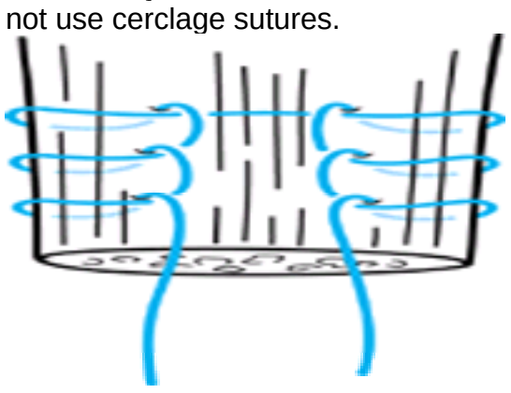

***Figure 91.19.*** Ligament fixation. Placement of the suture in a tendon. (Redrawn from Krackow KA, Thomas SC, Jones LC. A Stitch for Ligament–Tendon Fixation. *J Bone Joint Surg [Am]* 1986;68:764.)

### KNEE WITH ACL + PCL TORN; MEDIAL AND LATERAL HINGES INTACT

- This injury is not operated early. After motion has been regained (>120°), perform open or arthroscopic assisted reconstruction of both ligaments.
- These procedures are described in detail in Chapter 89 and Chapter 90. A few technical aspects deserve emphasis, however.
- For the PCL, use autogenous PTB, allograft PTB, or Achilles.
- For the ACL, use autogenous hamstrings, allograft PTB, or an achilles tendon graft. We prefer autogenous PTB for the PCL and doubled hamstrings for the ACL.
- Position the tibial tunnels carefully to avoid convergence. Place the PCL tibial tunnel inferior to the tibial tuberosity in the midline and the ACL tibial tunnel medial, midway between the posteromedial tibial brim and the tibial tuberosity.
- Pass the PCL graft first. Tension the grafts simultaneously with the knee at 20° of flexion. By using suture fixation around a post or over a 14-mm button, readjustment of graft tension is easy to accomplish. Simultaneous tensioning of the grafts aids in defining the neutral position of the tibia in relation to the femur.

## POSTOPERATIVE CARE

- At the completion of surgery, position the knee in near extension, avoiding hyperextension and using splints incorporated into a bulky R-J dressing from foot to groin. Elevate the extremity for 48 h, monitoring the neurovascular condition of the limb and remaining alert to the potential for compartment syndrome.
- Remove the drains by 48 h and replace the bulky dressing with a well-fitting, adjustable-hinged knee brace that is locked at 0° but allows motion from 0° to 45° during exercises. Do not allow the knee to hyperextend.
- At 2 to 3 days, start continuous passive motion (CPM) for 2-h sessions four times daily. Flexion in this range does not significantly increase strain in the PCL. If possible, continue CPM for at least 72 h in the hospital and preferably for an additional week at home.
- At 10 to 14 days, increase passive flexion to 60°. Use passive heel slides for flexion, but active extension can be performed from 60° to 0°.
- At 3 weeks start intermittent passive flexion to 90°, but restrict active flexion to 60°.
- Keep the brace locked in extension at all other times for the first 6 weeks, during which partial weight bearing is allowed. During this 6 weeks, use electrical stimulation, isometric quadriceps exercises, and straight-leg raises.
- At 6 weeks unlock the brace for unlimited motion and ambulation if the patient can control the knee with the quadriceps. At 6 weeks the brace is not necessary for sleeping or sitting in a safe environment.
- Continue bracing for another 2 to 3 weeks or longer, depending on patient preference. Thereafter, perform exercises in accordance with the protocol(s) for cruciate ligament injuries (Chapter 89 and Chapter 90).

### MODIFICATIONS OF POSTOPERATIVE CARE

#### *Extensor Mechanism Injury*

Do not allow straight-leg raises or any active extension of the knee until 6 weeks. Delay resistive quadriceps exercises until 3 months.

#### *Posterolateral Complex Repair*

Use non-weight-bearing activities for the first 6 to 8 weeks to minimize distraction of the lateral compartment with weight bearing. Use passive knee flexion only for the first 6 weeks, and no resistive hamstring exercises should be performed until 3 months after surgery.

## RESULTS

There are no long-term prospective studies to evaluate the results of the different methods of treating ligamentous injuries in the dislocated knee. The long-term incidence of degenerative arthritis remains unknown. Historically, a stable knee with 85° of flexion was considered a good result, and 105° was regarded as an excellent result. More recent studies have demonstrated improved results with early surgical repair/reconstruction and immediate motion (4,20,26,27,31).

Based on our experience with 35 knee dislocations or near dislocations, we have observed acceptable short- and midterm results (2 to 10 years) following early surgical repair/reconstruction of all torn ligaments combined with early motion of the knee in cooperative, active patients. With this regimen, 80% of operated patients can be expected to have 1 + or less total AP laxity and only trace to 1 + medial–lateral knee laxity with an arc of motion of 120°. This has allowed return to activity in nearly 75% of patients, although only 50% are able to resume preinjury activity levels without symptoms.

## PITFALLS AND COMPLICATIONS

Arterial occlusion has the potential to lead to amputation acutely and the development of chronic claudication if perfusion is incompletely restored. Nerve injury frequently results in sensory and motor abnormalities of the leg and foot. As previously noted, the majority of patients (60%) do not experience any improvement over time. Weakness or absent peroneal nerve function leaves the patient with a foot drop that usually requires an AFO, although tendon transfers or hindfoot arthrodesis may be used in certain cases.

Stiffness (arthrofibrosis), chronic knee instability, and degenerative joint disease are the major problems the orthopaedic surgeon must be prepared to deal with after initial injury and treatment. Although early motion minimizes the risk of stiffness, the intense fibroblastic response to injury may not be held in check. As many as 30% to 50% of patients may require treatment intervention to regain motion (20,27,31). If loss of extension is 10° or more at 4 weeks, and/or flexion is less than 90° and not improving at 6 weeks, then arthroscopic release of adhesions and gentle manipulation should be tried. Delay in treatment of limited motion in the postoperative period makes later treatment more difficult and often requires extensive soft-tissue releases.

Treat chronic instability with reconstruction of the cruciate ligaments and repair and reefing of the capsule and collateral ligaments. When repair is not possible, perform Clancy's biceps tenodesis for posterolateral instability (14) and reconstruct the MCL with a free hamstring or PTB graft in cases of chronic medial laxity (13). Progression of degenerative changes may require osteotomy or even joint replacement at a later time.

## SUMMARY

Knee dislocation is a complex injury that often requires a multidisciplinary approach. After satisfactory stabilization of the patient and treatment of any associated vascular injury, obtaining a stable knee with functional motion is the next goal. This requires accurate clinical assessment and good imaging to formulate an operative plan. It is important that the patient understand that a normal knee is not expected following such a severe injury. With technically well-performed surgical repair and/or reconstruction, early motion can be initiated, which is crucial in reducing postoperative stiffness. In our experience this provides the best short-term results. Nonetheless, the patient remains at risk for developing degenerative changes over time.

---

[1] ACL, anterior cruciate ligament; MCL, medial collateral ligament; LCL, lateral collateral ligament; PCL, posterior cruciate ligament.

## CHAPTER REFERENCES

Each reference is categorized according to the following scheme: *, classic article; #, review article; !, basic research article; and +, clinical results/outcome study.


+ 1. Cooper DE, Speer KP, Wickiewicz TL, et al. Complete Knee Dislocation without Posterior Cruciate Ligament Disruption. A Report of Four Cases and Review of the Literature. *Clin Orthop* 1992;284:228.

* 2. DeBakey ME, Simeone FA. Battle Injuries of the Arteries in World War II: An Analysis of 2,471 Cases. *Ann Surg* 1946;123:534.

+ 3. DePorto JM, Rafique M. Vascular Insufficiency Complicating Trauma to the Lower Limb. *J Bone Joint Surg [Br]* 1969;51:680.

+ 4. Frassica FJ, Sim FH, Staeheli JW, et al. Dislocation of the Knee. *Clin Orthop* 1991;263:200.

! 5. Girgis FG, Marshall JL, al Monajem ARS. The Cruciate Ligament of the Knee Joint: Anatomical, Functional and Experimental Analysis. *Clin Orthop* 1975;106:216.

# 6. Good L, Johnson RJ. The Dislocated Knee. *J Am Acad Orthop Surg* 1995;3:284.

* 7. Green NE, Allen BL. Vascular Injuries Associated with Dislocation of the Knee. *J Bone Joint Surg [Am]* 1977;59:236.

# 8. Hill JA, Rana NA. Complications of Posterolateral Dislocation of the Knee: Case Report and Literature Review. *Clin Orthop* 1981;154:212.

+ 9. Jones RE, Smith EC, Bone GE. Vascular and Orthopaedic Complications of Knee Dislocations. *Surg Gynecol Obstet* 1979;149:554.

* 10. Kennedy JC. Complete Dislocation of the Knee Joint. *J Bone Joint Surg [Am]* 1963;45-A:889.

+ 11. Krackow KA, Thomas SC, Jones LC. A Stitch for Ligament–Tendon Fixation. *J Bone Joint Surg* 1986;68:764.

+ 12. MacGowan W. Acute Ischaemia Complicating Limb Trauma. *J Bone Joint Surg [Br]* 1968;50:472.

+ 13. Marder RA. The Failed ACL Reconstruction. In: Zarins B, Marder RA, eds. *Revision of Failed Arthroscopic and Ligament Surgery, Vol 1.* London: Blackwell Science, 1998:1.

+ 14. Martin SD, Clancy WG Jr. Failed Reconstruction of Posterolateral Instability of the Knee. In: Zarins B, Marder RA, eds. *Revision of Failed Arthroscopic and Ligament Surgery, Vol 3.* London: Blackwell Science, 1998:27.

+ 15. McCoy GF, Hannon DG, Barr RJ, et al. Vascular Injury Associated with Low-Velocity Dislocations of the Knee. *J Bone Joint Surg [Br]* 1987;69:285.

+ 16. McCutchon JD, Gillham NR. Injury to the Popliteal Artery Associated with Dislocation of the Knee: Palpable Pulses Do Not Negate the Requirement for Arteriography. *Injury* 1989;20:307.

* 17. Meyers MH, Harvey JP Jr. Traumatic Dislocation of the Knee Joint. A Study of Eighteen Cases. *J Bone Joint Surg [Am]* 1971;53:16.

+ 18. Meyers MH, Moore TM, Harvey JP Jr. Follow-up Notes on Articles Previously Published in the Journal: Traumatic Dislocation of the Knee Joint. *J Bone Joint Surg [Am]* 1975;57:430.

+ 19. Miller HH, Welch CS. Quantitative Studies on the Time Factor in Arterial Injuries. *Ann Surg* 1949;103:428.

+ 20. Noyes FR, Barber-Westin SD. Reconstruction of the Anterior and Posterior Cruciate Ligaments after Knee Dislocation. *Am J Sports Med* 1997;25:769.

+ 21. O'Donnell TF Jr, Brewster DC, Darling RC, et al. Arterial Injuries Associated with Fractures and/or Dislocations of the Knee. *J Trauma* 1977;17:775.

+ 22. Ottolenghi CE. Vascular Complications in Injuries about the Knee Joint. *Clin Orthop* 1982;165:148.

* 23. Quinlan AG, Sharrard WJW. Posterolateral Dislocation of the Knee with Capsular Interposition. *J Bone Joint Surg [Br]* 1958;40:660.

+ 24. Roman PD, Hopson CN, Zenni EJ Jr. Traumatic Dislocation of the Knee: A Report of 30 Cases and Literature Review. *Orthop Rev* 1987;16:917.

+ 25. Savage R. Popliteal Artery Injury Associated with Knee Dislocation: Improved Outlook? *Am Surg* 1980;46:627.

# 26. Schenck RC Jr. The Dislocated Knee. *Instr Course Lect* 1994;43:127.

+ 27. Shapiro MS, Freedman EL. Allograft Reconstruction of the Anterior and Posterior Cruciate Ligaments after Traumatic Knee Dislocation. *Am J Sports Med* 1995;23:580.

+ 28. Shelbourne KD, Porter DA, Clingman JA, et al. Low-Velocity Knee Dislocation. *Orthop Rev* 1991;20:995.

+ 29. Shelbourne KD, Pritchard J, Rettig AC, et al. Knee Dislocations with Intact PCL. *Orthop Rev* 1992;21:607.

* 30. Shields L, Mital M, Cave EF. Complete Dislocation of the Knee: Experience at the Massachusetts General Hospital. *J Trauma* 1969;9:192.

+ 31. Sisto DJ, Warren R. Complete Knee Dislocation. *Clin Orthop* 1985;198:94.

+ 32. Taylor A, Arden P, Rainey HA. Traumatic Dislocation of the Knee. A Report of 40 Cases, 3 Cases with Special Reference to Conservative Treatment. *J Bone Joint Surg [Br]* 1972;54:96.

+ 33. Thomsen PB, Rud B, Jensen UH. Stability and Motion after Traumatic Dislocation of the Knee. *Acta Orthop Scand* 1984;55:278.

+ 34. Varnell RM, Coldwell DM, Sangeorzan BJ, et al. Arterial Injury Complicating Knee Disruption. *Am Surg* 1989;55:699.

* 35. Wand JS. A Physical Sign Denoting Irreducibility of a Dislocated Knee. *J Bone Joint Surg [Br]* 1989;71:862.

+ 36. Welling RE, Kakkasseril J, Cranley JJ. Complete Dislocations of the Knee with Popliteal Vascular Injury. *J Trauma* 1981;21:450.

+ 37. White J. The Results of Traction Injuries to the Common Peroneal Nerve. *J Bone Joint Surg [Br]* 1968;50:346.

# CHAPTER 92

# COMPLICATIONS OF KNEE SURGERY

*John R. Raskind*

**J. R. Raskind:** Department of Orthopaedic Surgery, University of California, Davis, Sacramento, California 95817.

Incidence and Causes
Conditions and Management
Hemarthrosis
Infection
Deep Venous Thrombosis and Pulmonary Embolism
Anesthetic Complications
Instrument Failure and Breakage
Reflex Sympathetic Dystrophy
Arthrofibrosis, Patella Infera, and Loss of Motion
Ligament Injuries
Fractures
Synovitis and Synovial Fistula
Neurovascular Injuries
Lost Meniscal Fragments
Author's Perspective
Chapter References

The rate of complications associated with knee surgery has decreased dramatically with the development and evolution of operative arthroscopy. Although all surgical procedures have some inherent risk, these less invasive techniques, when combined with meticulous surgical techniques, have a low incidence of problems. When complications do occur, early recognition and prompt intervention are essential.

## INCIDENCE AND CAUSES

The overall incidence of complications with knee arthroscopy is low, with published rates ranging from 0.8% to 8.2%. It is not surprising to note that both the frequency and severity of complications are lower with experienced arthroscopic surgeons.

In 1988, Small (25) reported a 19-month prospective Arthroscopy Association of North America study, which included 8,791 arthroscopic knee procedures performed by 21 surgeons with an average of 11 years of experience in operative knee arthroscopy. Based on rigid criteria, the overall rate of complication for knee arthroscopy was 1.85%. Hemarthrosis was the most common complication, followed by infection, thromboembolic disease, and anesthetic problems.

Among arthroscopic procedures in this study, lateral retinacular release had the highest rate of complications. Allograft and synthetic anterior cruciate ligament (ACL) reconstruction, synovectomy, and abrasion arthroplasty also had an increased incidence of problems. Meniscus repair (both inside-out and outside-in) had a lower rate of complication than meniscectomy.

## CONDITIONS AND MANAGEMENT

### HEMARTHROSIS

Postoperative hemarthrosis is the most common complication of knee arthroscopy, comprising 60% of all complications. It occurs in approximately 1% of all cases and is seen most often after lateral retinacular release (5,25). Other procedures that frequently result in hemarthrosis include arthroscopic synovectomy, meniscectomy, and ACL reconstruction. Use of a tourniquet can be associated with postoperative hemarthrosis because unrecognized intraoperative bleeding may occur (4,23). A coagulopathy (ASA-induced, liver dysfunction, or hemophilia) may first present as abnormal intraoperative or postoperative bleeding.

Treatment for hemarthrosis consists of brief immobilization, elevation, compressive dressing, and isometric quadriceps exercises. Oral nonsteroidal antiinflammatories may also be of benefit. Resume range-of-motion exercises once swelling is decreased. A tense effusion may require aspiration, but repeated aspiration may lead to septic arthritis and is not recommended. Rarely, a large hematoma may require repeat arthroscopic surgery. Consider checking a coagulation screen and a bleeding time in patients with unexplained bleeding.

### INFECTION

Infection following arthroscopic knee surgery is uncommon and occurs with an overall incidence of 0.24% (25). Risk of infection is increased with perioperative use of intraarticular steroids, with any break in sterile operative technique, in immunocompromised patients, and in patients with skin lesions in the operative field. Postpone elective arthroscopic procedures in any patient who has wounds, scrapes, or skin rashes that involve the operative field. Avoid intraoperative injection of corticosteroids because this has been associated with an increased rate of infection (1,11). In those patients who have had recent intraarticular corticosteroid injections, it is preferable to postpone elective procedures for 3 to 4 weeks to minimize the risk of infection.

The effectiveness of routine prophylactic antibiotics for knee arthroscopy remains unproven, but it should be considered for high-risk patients and with more extensive procedures (21). I recommend antibiotics for procedures that involve implants, internal fixation, osseous tunnels, or osteotomy.

Delay in diagnosis is common with postoperative knee infections, and a high index of suspicion is necessary to ensure early recognition (6,25). Immediate and aggressive treatment is required in any suspected septic knee to avoid severe articular damage. Make the diagnosis of infection by knee joint aspiration, sending the fluid for immediate Gram stain, cell count, and differential. Order routine aerobic and anaerobic cultures as well. Once an infection is confirmed, urgent surgical debridement, arthroscopically or open, and postoperative intravenous antibiotics are required. The type and duration of antibiotic therapy are dependent on the causative organisms and severity of infection. In some cases repeat surgical debridements may be necessary. With infection after ACL reconstruction, graft retention may be possible, but arthroscopic debridement alone may be inadequate because extraarticular spread of infection is frequent (9).

### DEEP VENOUS THROMBOSIS AND PULMONARY EMBOLISM

All surgical procedures of the lower extremity have some risk of thromboembolic complications. Knee arthroscopy, however, is associated with a lower risk than more extensive procedures such as total knee arthroplasty. Small (25) reported the overall incidence of deep venous thrombosis (DVT) with arthroscopic knee surgery to be 0.15%, and the incidence of pulmonary embolism (PE) was 0.05%. Of the 12 DVTs that occurred in Small's series, eight involved cases in which the tourniquet was used for an average of 50 min or more. Demers et al. (6) also reported a significantly higher incidence of DVT after knee arthroscopy with prolonged tourniquet times, suggesting a relationship between tourniquet use and thrombosis.

Although rare, fatal pulmonary embolism has been reported in young healthy patients after routine elective outpatient knee arthroscopy (20). A high index of suspicion is necessary to ensure early identification and treatment of thrombosis to reduce the risk of embolization. Noninvasive studies (or venography) are mandatory in any patient with suspected postoperative thrombosis. Initiate anticoagulation immediately for all patients with positive tests. The presence of a negative test in a patient with the clinical picture of DVT does not exclude the possibility of an evolving DVT, and careful follow-up with repeat studies is required. A ruptured popliteal cyst may mimic

thrombosis, but this diagnosis can also be established with noninvasive studies such as ultrasound or MRI.

Risk factors for postoperative thromboembolism include prolonged tourniquet use, hypercoagulable states (malignancy, oral contraceptives), morbid obesity, congestive heart failure, and history of prior thrombosis or pulmonary embolism (5,21).

Prevention of postoperative thromboembolic complications is best accomplished with early mobilization, range-of-motion exercises, and weightbearing as soon as possible. Aspirin may be of benefit for routine postoperative prophylaxis. Consider coumadin or low-molecular-weight heparin in patients at increased risk.

**ANESTHETIC COMPLICATIONS**

Anesthetic complications may occur with procedures using general, regional, or local anesthesia. Intubation may result in laryngeal, dental, or temporomandibular joint (TMJ) injury; neuromuscular blockade may reveal pseudocholinesterase deficiency or malignant hyperthermia; and intraoperative cardiac arrhythmia, infarction, or arrest may occur, although rarely. Spinal or epidural anesthetic can lead to spinal headache, transient spinal block, or epidural hematoma. Local anesthetics in high doses may produce systemic effects. A careful preoperative assessment by both surgeon and anesthesiologist can identify those patients at increased risk and minimize the likelihood of anesthetic-related complications.

**INSTRUMENT FAILURE AND BREAKAGE**

Most intraoperative instrument failure and breakage is preventable and results from improper instrument use or maintenance. With proper surgical technique and instrument care, the incidence of instrument breakage is minimal (5,25). Arthroscopic instruments, unlike osteotomes and elevators, are fragile and delicate and require special care and handling.

Never use an arthroscopic instrument that is dull, worn, or bent. If a broken metallic instrument fragment (or guide pin) does become an intraarticular loose body, a prepackaged sterile magnetic probe (for example, the “Golden Retriever,” Instrument Makar, Okemos, MI) is an indispensable tool. Intraoperative x-ray or fluoroscopy may occasionally be required to localize elusive fragments. Most broken instrument and pin fragments can be removed arthroscopically; although an accessory posterior portal may be helpful, an arthrotomy is seldom necessary.

**REFLEX SYMPATHETIC DYSTROPHY**

Reflex sympathetic dystrophy (RSD) of the knee is most common in patients who have sustained diffuse crush injuries or direct injuries to motor and sensory nerves. Patients who develop RSD often have some predisposing diathesis that is triggered by an injury. It may present initially as pain out of proportion to injury or physical findings.

Although many tests, including three-phase bone scan, can support the diagnosis of RSD, the diagnosis is made primarily on clinical grounds. The findings of delayed recovery with severe diffuse pain, skin sensitivity, and erythema should suggest early RSD (12,15,18). Treatment consists of sympathetic blockade, gentle restoration of joint motion to prevent fibrosis, and, if possible, elimination of the underlying painful stimulus.

Careful surgical technique and careful patient selection are the best means to avoid RSD. Inaccurate arthroscopic portal or meniscus repair incision placement can injure the infrapatellar branch of the saphenous nerve and incite RSD (15,18). Avoid prolonged immobilization, prolonged protected weightbearing, and diagnostic arthroscopy in patients with severe diffuse knee pain.

**ARTHROFIBROSIS, PATELLA INFERA, AND LOSS OF MOTION**

Arthrofibrosis of the knee can develop after trauma or elective surgery. It is seen most commonly with anterior cruciate injuries, particularly when ligament reconstruction is performed early following injury (3,22). The initial phase of arthrofibrosis begins with adhesions, which, if allowed to progress, lead to patellar entrapment, joint fibrosis, capsular contracture, and extracapsular scarring. Once patella infera has developed, permanent loss of motion is likely.

Treatment of arthrofibrosis is based on stage and severity (13). Early recognition and treatment are the best means to restore movement and function. In the *prodromal stage* (2 to 8 weeks), direct therapy at patellar mobilization and restoration of motion. Correct underlying causes of stiffness, such as graft impingement. Arthroscopic lysis of adhesions followed by gentle manipulation under anesthesia can relieve early patellar entrapment. A valuable technique involves using a blunt arthroscopic obturator in the superomedial portal to disrupt patellar adhesions. To maintain improvements in motion, postoperative epidural pain control combined with continuous passive motion (CPM) for 3 to 5 days is beneficial.

Once the *active stage* (8 to 20 weeks) of arthrofibrosis has developed, all patellar mobility has been lost, capsular contracture is established, and joint fibrosis has begun. At this stage, open surgical release is often required. When patella infera with severe limitation of motion is present, it is indicative of the *burned-out stage.* At this point, salvage procedures such as tibial tubercle osteotomy or patellar tendon lengthening may be necessary to improve knee flexion; however, do not expect restoration of normal motion (13).

Risk factors for developing arthrofibrosis include poor rehabilitation before surgery, early extensive ligament reconstruction, prolonged postoperative immobilization, older patients, associated fractures, and nonisometric graft placement (3,13,17,22). To prevent arthrofibrosis, postpone reconstructive procedures until knee motion has been restored following injury. At the time of reconstruction, it must be confirmed intraoperatively that full knee motion is possible, and postoperative immobilization should be with the knee in extension. Focus early rehabilitative exercises on regaining quadriceps control and full extension, followed by patellar mobilization and restoration of flexion (3). When recovery of motion is unusually slow, early intervention is essential to avoid the progression to active arthrofibrosis. Once established, arthrofibrosis invariably causes some degree of permanent stiffness.

**LIGAMENT INJURIES**

Iatrogenic ligament injuries occur most often when stress is applied to the knee during arthroscopy. The medial collateral ligament is most commonly injured, particularly when a rigid leg-holding device is used (5). In contrast, intraoperative cruciate ligament injuries are usually the result of instrumentation errors. Ligament damage may occur during notchplasty and tunnel preparation for cruciate reconstruction. Aggressive motorized debridement combined with poor arthroscopic visualization may lead to significant ligament injury. Many misadventures, including patellar ligament resection, have been reported (2).

Intraoperative ligament injury can best be avoided by careful surgical technique. Visualization is better accomplished by accurate portal placement than by forceful leg manipulation. Careful instrumentation under direct arthroscopic visualization will prevent inadvertent damage to ligaments and articular surfaces.

**FRACTURES**

Fractures of both the femur and tibia have been reported during knee arthroscopy (5,21,25). They are most often the result of excessive forceful manipulation of the leg but may also occur in pathologic bone. Before surgery, review a current set of knee radiographs (AP and lateral) in all patients scheduled for arthroscopic surgery to search for an occult neoplasm or other bone pathology (8).

Technical errors during ACL reconstruction may lead to perioperative fracture. Eccentric or aggressive patellar tendon harvest from the anterior patellar cortex may lead to fracture. Do not violate the proximal third of the patella and minimize the use of mallets and osteotomes. I recommend autogenous grafting of the bone defect with tunnel reamings. With endoscopic femoral tunnel preparation, multiple guide-pin perforations of the femoral cortex produce a stress riser and may lead to postoperative fracture (27).

Manipulation of the stiff postoperative knee requires caution because overly aggressive manipulation may yield disastrous results. Patellar fractures, long-bone fractures, extensor mechanism ruptures, and avulsions have all been reported to occur (5,21,24,25). Significant force during manipulation is seldom required or beneficial.

**SYNOVITIS AND SYNOVIAL FISTULA**

Persistent synovitis following knee arthroscopy may occur from chemical irritation induced by glutaraldehyde (Cidex) residue, from mechanical irritation caused by retained debris or degenerative arthritis, from crystalline arthritis (e.g., gout, pseudogout), and with septic arthritis (7). Once infection has been excluded, treat chronic

synovitis with compressive wraps, activity modifications, and oral antiinflammatories. Refractory cases may occasionally require repeat arthroscopy to treat sources of ongoing chemical or mechanical irritation.

Synovial fistulas may develop at arthroscopic portal sites. These are most common with procedures such as synovectomy and lateral release, which produce hemarthroses (5). The presence of significant degenerative arthritis and the use of posterior portals are also associated with an increased risk of fistula formation (16). Treat with 7 to 10 days of immobilization to allow wound healing. Prophylactic oral antibiotics (first-generation cephalosporin) are recommended but may lead to resistant pathogens should joint sepsis occur. Should the fistula fail to resolve with immobilization, excision and closure of the fistula tract are required.

### NEUROVASCULAR INJURIES

The majority of nerve injuries that occur with knee arthroscopy involve sensory nerves. Nerve damage may result from direct injury, tourniquet compression, or compartment syndrome. Although the actual deficit from a sensory nerve injury is usually minor, it may lead to neuroma formation or trigger reflex sympathetic dystrophy.

The infrapatellar branch of the saphenous nerve is most commonly injured (18). It may be damaged by inaccurate portal placement or with a posteromedial incision for meniscus repair. To minimize the risk of nerve injury with medial meniscus repair, use a posterior retractor, pass sutures with the knee extended using the anterolateral portal for suture placement, and tie suture under direct vision (26).

Motor nerve injuries are fortunately rare. Peroneal nerve injury may occur with lateral meniscus repair, but it has also been reported with both diagnostic arthroscopy and partial lateral meniscectomy (14,19). Perform operative procedures in the lateral compartment with the knee flexed in the figure-4 position, as the nerve is most easily injured by arthroscopic instruments with the knee extended (14). When repairing the lateral meniscus, minimize the risk of nerve injury by using a posterior retractor placed through a posterolateral incision, combined with suture passage from the anteromedial portal with the knee flexed (26).

Popliteal artery injury is rare and can be avoided with attention to the anatomy and proper surgical technique. Instrumentation of the posterior horn of the lateral meniscus must always be under direct arthroscopic visualization because of the close proximity of the popliteal artery. Prepare the tibial tunnel for PCL reconstruction only under direct arthroscopic observation to avoid guide-pin migration or overreaming. If a popliteal artery injury is suspected, an intraoperative vascular surgery consultation is mandatory.

### LOST MENISCAL FRAGMENTS

When meniscal fragments are lost and unretrievable, do a systematic inspection of all knee compartments. Lost fragments can often be found in the suprapatellar pouch, medial and lateral gutters, posterior knee, and under the menisci. If, after a careful search, the lost fragment cannot be located, conclude the procedure because the majority of even large lost fragments become attached to the synovium and do not produce symptoms (10). Similarly, bone fragments and debris generated during cruciate ligament reconstruction have been found to resorb spontaneously within 6 months (28).

## AUTHOR'S PERSPECTIVE

Knee arthroscopy is a valuable but technically demanding procedure. Complex arthroscopic reconstructive procedures require a higher level of proficiency than routine procedures and may lead to complications when attempted by an inexperienced arthroscopist. Regard newly developed procedures and instrumentation with caution until the necessary motor skills have been acquired and surgical indications have been established.

Motor skills laboratories provide an excellent opportunity for improving technical skills and learning new procedures. The Orthopaedic Learning Center at the American Academy of Orthopaedic Surgeons in Rosemont, Illinois, offers a broad range of hands-on arthroscopic surgical courses utilizing cadaver specimens. This type of training should be considered by most surgeons as a prerequisite for performing new and complex arthroscopic procedures.

Many arthroscopic complications result from careless preoperative evaluation, poor surgical technique, and inadequate postoperative rehabilitation. Base all surgical indications on thorough clinical evaluation because surgery without a preoperative diagnosis is seldom fruitful. Although operative speed is not always an indication of technical ability, abort procedures that cannot be completed in a reasonable amount of time to avoid problems from excessive tourniquet time, fluid extravasation, or prolonged patient positioning. After surgery, schedule regular follow-up visits to monitor postoperative progress and identify potential complications. These visits are a critical part of any successful surgical procedure; do not delegate them exclusively to paramedical personnel.

### CHAPTER REFERENCES

Each reference is categorized according to the following scheme: *, classic article; #, review article; !, basic research article; and +, clinical results/outcome study.


+ 1. Armstrong RW, Bolding F. Septic Arthritis after Arthroscopy. *Am J Infect Control* 1994;22:16.

+ 2. Bachner EJ, Parker RD, Zaas RD. Resection of the Patellar Ligament: A Complication of Arthroscopic Synovectomy. *Arthroscopy* 1989;5:76.

+ 3. Cosgarea AJ, Sebastianelli WJ, DeHaven KE. Prevention of Arthrofibrosis after Anterior Cruciate Reconstruction Using Central Third Patellar Tendon Autograft. *Am J Sports Med* 1995;23:87.

* 4. Coupens SD, Yates CK. The Effect of Tourniquet Use and Hemovac Drainage on Postoperative Hemarthrosis. *Arthroscopy* 1991;7:278.

* 5. DeLee JC. Complications of Arthroscopy and Arthroscopic Surgery: Results of a National Survey. *Arthroscopy* 1985;1:214.

+ 6. Demers C, Marcoux S, Ginsberg JS, et al. Incidence of Venographically Proved Deep Venous Thrombosis after Knee Arthroscopy. *Arch Intern Med* 1998;158:47.

+ 7. Harner CD, Mason GC, Fu FH. Cidex-Induced Synovitis. *Am J Sports Med* 1987:623.

* 8. Joyce MJ, Mankin HJ. Caveat Arthroscopos: Extra-articular Lesions of Bone Simulating Intra-articular Pathology of the Knee. *J Bone Joint Surg* 1983;65A:289.

+ 9. Kohn D. Unsuccessful Arthroscopic Treatment of Pyarthrosis Following Anterior Cruciate Reconstruction. *Arthroscopy* 1988;4:287.

+ 10. Mohr M, Henche HR. The Morbidity Associated with Lost or Irretrievable Resected Meniscal Fragments. *Arthroscopy* 1992;8:84.

+ 11. Montgomery SC, Campbell J. Septic Arthritis Following Arthroscopy and Intra-articular Steroids. *J Bone Joint Surg* 1989;71B:540.

+ 12. O'Brien SJ, Ngeow J, Gibney MA, et al. Reflex Sympathetic Dystrophy of the Knee. *Am J Sports Med* 1995;23:665.

* 13. Paulos LF, Wnorowski DC, Greenwald AE. Infrapatellar Contracture Syndrome. *Am J Sports Med* 1994;22:440.

+ 14. Piecha G, Pascher A, Schwarl F, et al. Transection of the Peroneal Nerve Complicating Knee Arthroscopy. *Arthroscopy* 1998;14:221.

+ 15. Poehling GG, Pollack FE, Koman LA. Reflex Sympathetic Dystrophy of the Knee after Sensory Nerve Injury. *Arthroscopy* 1988;4:31.

+ 16. Proffer DS, Drez DJ, Daus GP. Synovial Fistula of the Knee: A Complication of Arthroscopy. *Arthroscopy* 1991;7:98.

# 17. Roberts TS, Terry R. Complications of Knee Surgery. In: DeLee JC, Drez D, eds. *Orthopaedic Sports Medicine: Principles and Practice.* Philadelphia: WB Saunders, 1994;1528.

# 18. Rodeo SA, Forster BS, Weiland AJ. Current Concepts Review: Neurologic Complications Secondary to Arthroscopy. *J Bone Joint Surg* 1993;75A:917.

+ 19. Rodeo SA, Sobel M, Weiland AJ. Deep Peroneal Nerve Injury as a Result of Arthroscopic Meniscectomy. *J Bone Joint Surg* 1993;75A:1221.

+ 20. Rozencweig R, Schilt JS, Ochsner JL Jr. Fatal Pulmonary Embolus after Knee Arthroscopy. *Arthroscopy* 1996;12:240.

# 21. Samimi S. Complications of Knee Arthroscopic Surgery. In: Shahriaree H, ed. *O'Connor's Textbook of Arthroscopic Surgery.* Philadelphia: JB Lippincott, 1992;609.

* 22. Shelbourne KD, Wilckens JH, Mollabashy A, DeCarlo M. Arthrofibrosis in Acute Anterior Cruciate Ligament Reconstruction. *Am J Sports Med* 1991;19:332.

* 23. Sherman OH, Fox JM, Snyder SJ, et al. Arthroscopy—“No-Problem Surgery.” *J Bone Joint Surg* 1986;68A:256.

+ 24. Small NC. Complications in Arthroscopy of the Knee and Other Joints. *Arthroscopy* 1986;2:253.

+ 25. Small NC. Complications in Arthroscopic Surgery Performed by Experienced Arthroscopists. *Arthroscopy* 1988;4:215.

# 26. Small NC. Complications of Knee Arthroscopy. In: Andrews JR, Timmerman LA, eds. *Diagnostic and Operative Arthroscopy.* Philadelphia: WB Saunders, 1997; 412.

+ 27. Weiner DF, Siliski JM. Distal Femoral Shaft Fracture: A Complication of Endoscopic Anterior Cruciate Ligament Reconstruction. *Am J Sports Med* 1996;24:244.

+ 28. Wnorowski DC. The Fate of Intra-articular Debris Following Anterior Cruciate Ligament Reconstruction. *Arthroscopy* 1997;13:620.

# CHAPTER 93

# ARTHROSCOPY OF THE ANKLE

*Richard D. Ferkel and Steven J. McGrath*

**R. D. Ferkel:** Southern California Orthopedic Institute, Van Nuys, California, 91405.
**S. J. McGrath:** Southern California Orthopedic Institute, Van Nuys, California, 91405.

Clinical Evaluation and Imaging
History
Physical Examination
Imaging
Indications and Contraindications to Ankle Arthroscopy
Indications
Contraindications
Surgical Technique
Postoperative Care
Pitfalls and Complications
Conditions and Results
Soft-Tissue Lesions
Synovitis
Anterior Soft-Tissue Impingement
Syndesmotic Impingement
Posterior Soft-Tissue Impingement
Evaluation Algorithm
Osteochondral Lesions of the Talus
Other Methods
Loose Bodies
Osteophytes
Degenerative Arthritis
Acute Ankle Fractures
Ankle Instability
Authors' Perspective
Chapter References

Ankle arthroscopy is an evolving technique that became widely available to the orthopedist only during the past 15 to 20 years. With major advances in technique andequipment over the decade of the 1990s, ankle arthroscopy has proved to be an indispensable tool for the surgeon to both diagnose and treat pathology of the ankle (59).

Arthroscopy was first performed in Japan in 1918 by Takagi, who used a cystoscope to examine the intra-articular anatomy of a cadaveric knee (71). Kreuscher (45), in 1925, was the first American to report the use of an arthroscope in the knee. These early cystoscopes were cumbersome for articular use, with diameters of nearly 8 mm. Arthroscopy was considered not to be applicable to the ankle given the large diameter of these early instruments. However, a 3.5 mm arthroscope was invented in 1931. Soon after, in 1939, Takagi (71) published a standard arthroscopic examination of the ankle. Arthroscopy remained dormant, however, until the advent of fiberoptics, which aforded improved visualization potential. Watanabe (75) described the first ankle portal anatomy and portal placement in 1972 following 28 ankle arthroscopies. Chen (14,15) conducted the first large study with 67 clinical and 17 cadaveric ankle arthroscopies, including detailed descriptions of surgical anatomy.

Owing in part to the innovation of such surgeons as Drez, Guhl, Andrews, Parisien, Ferkel, and others, and owing in part to the rapid advances in fiberoptics and general arthroscopic technology, ankle arthroscopy and its applications have advanced exponentially during the past 15 years. Small-joint arthroscopy and instrumentation have made the clinical application of ankle arthroscopy safer, more reproducible, and more widely accepted as a standard of care for certain disorders of the ankle. The advantages of direct visualization of intra-articular anatomy and treatment of pathology via percutaneous incisions about the ankle are numerous and potentially include decreased pain and morbidity, faster rehabilitation, and an earlier return to activities of daily living and athletics.

## CLINICAL EVALUATION AND IMAGING

### HISTORY

Each patient has a unique history, which often leads to a narrowed differential diagnosis. Common descriptions include pain, catching, grinding, giving way, and swelling. It is essential to decide whether the problem is acute or chronic, because this feature directly affects evaluation and treatment. If possible, attempt to define the etiology; unfortunately, this can be vague for chronic injuries. Find out what exacerbates or improves the symptoms. The type of shoewear that was worn at the time of injury or during the onset of a more insidious problem is important. Prior history, including prior ankle injuries, as well as a general medical history, can lead to a particular diagnosis. A family history may raise suspicion for certain congenital anomalies.

Pain is the most common complaint. Localize it to very specific areas, and note its association with particular maneuvers. In the lateral ankle, for example, differentiate between the pain at the syndesmosis, anterior talofibular ligament, or sinus tarsi.

Locking is often confused with catching; however, these are two very separate entities. Locking generally indicates a mechanical block to motion secondary to a loose body, scarring, osteophyte, or some other abnormal intra-articular component. Catching generally indicates a tendon or cartilage abnormality affecting supple joint motion. Most important, give the patient the opportunity to tell you thoroughly in his or her own words what the chief problem is and to what extent this is incapacitating him or her.

### PHYSICAL EXAMINATION

Begin with observation of the patient's gait without shoes. Note any limp or asymmetry, and attempt to establish at what point in the gait cycle these abnormalities occur. Examine the general alignment of the lower extremities. Inspect the patient's shoes and the wear of the sole. Check carefully foot and ankle alignment while weight bearing and look for pes cavus or pes planus.

Next, seat the patient and inspect the ankle for swelling, contusion, or erythema. Palpate to elicit focal pain or tenderness. In chronic ankle sprains, look for tenderness at the syndesmosis, lateral ligaments, lateral gutter, or sinus tarsi. Posterior ankle pain is sometimes difficult to reproduce on examination; however, palpation can often differentiate between posteromedial osteochondral lesions of the talus and injuries to the Stieda process or the os trigonum. Assess both passive and active range of motion with comparison to the opposite side. Normal motion is approximately 20° of dorsiflexion and 50° of plantarflexion. The normal range of subtalar motion noted by Isman and Inman (43) in cadaver specimens varied from 20° to 60° of total motion. Clinically, subtalar motion is very difficult to isolate and determine (50). If limits in dorsiflexion are noted, remember to flex the knee to determine the source of the limitation. Examine the heel and heel cord. Achilles tendon problems are common and may be noted on palpation by nodular thickening, as in patients with chronic tendinosis. Assess muscle function.

Ligament testing is discussed in Chapter 95. Place the foot in plantarflexion, and invert the hindfoot while palpating the joint line to determine joint displacement and test the anterior talofibular ligament. Place the foot in dorsiflexion, and then invert the foot again while palpating the joint line for displacement to test the calcaneofibular ligament. Always compare with the contralateral side to determine if the laxity is pathologic or not.

Perform the anterior drawer test by holding the ankle in neutral and, with the tibia secured, pull the heel forward and internally rotate it while palpating the joint line.

Anterior displacement greater than 4 mm indicates a tear of the anterior talofibular ligament and may even indicate a double ligament tear, which includes the calcaneofibular ligament (27).

Injuries to the tibiofibular syndesmosis may be difficult to detect unless you have a high index of suspicion and specifically examine this structure. Perform the “squeeze test” by gripping the leg just above the midportion of the calf and squeezing on the fibular shaft. If distal pain is noted, then suspect an injury to the interosseous ligament and syndesmosis. Perform the “external rotation test” by applying an external rotation force to the ankle with the patient seated, with knees and ankles at approximately right angles. A syndesmosis injury results in pain over the anterior inferior tibiofibular ligaments or the inferior portion of the interosseous ligament.

### IMAGING

Routine radiographs of the ankle include anteroposterior (AP), lateral, and mortise (20° internal oblique) views. On the AP view, the fibula should overlap the tibia approximately 6 mm. On the mortise view, look for widening of the medial clear space of more than 3 mm.

Stress x-ray studies may be done manually or by using a mechanical device, or jig. Comparison x-ray studies are essential because there is a large variation in normal ligamentous laxity. We use the Telos device to generate a reproducible amount of stress. Sauser et al. (67) as well as Chrisman and Snook (17), using the Telos device, found that a talar tilt of 10° or more when compared with the opposite normal side was associated with a lateral ligament instability in 99 percent of cases. Normal values of talar tilt range from 5° to 23° (65).

Flick and Gould (33) believed that an increase of 4 mm in the anterior drawer test showed instability in the anterior talofibular ligament, whereas Laurin et al. (46) consider an increase of more than 9 mm to be abnormal. In general, an anterior drawer of 5 mm is normal; 5 to 10 mm may be within normal, whereas over 10 mm is definitely abnormal.

Tomograms are occasionally helpful for evaluating nonunions, or the presence of arthrodesis. However, with improved computerized tomography, plain tomograms are used far less. Arthrograms can be useful occasionally, but these images have been supplanted by magnetic resonance imaging (MRI) to evaluate ligament disruption. Ultrasound has limited applications to the ankle; however, it is an evolving technology that is useful for delineating cystic versus solid masses, and for locating foreign bodies and tendon tears (73).

Bone scans using technetium-99 have a high sensitivity and relatively low cost, which make them a useful screening tool for enthesopathies, stress fractures, occult trauma, delayed unions, and any other pathology causing increased bone turnover. Gallium-67 and indium-111 may be useful in the detection of infection (30).

Computed tomography (CT) is excellent for delineating cortical outlines and changes in bony densities, and to detect osteochondral lesions, loose bodies, coalitions, and fractures of the hindfoot. Both feet can be imaged simultaneously to help determine asymmetry, however anatomy is better defined when only one extremity is imaged at a time.

MRI is the preferred study to image soft tissues around the ankle and to evaluate bone and soft tissue tumors, ischemic necrosis, infection, and ligament and tendon injuries. Controversy exists over the best imaging technique for osteochondral lesions of the talus. CT is better for cortical anatomy; however, MRI provides an accurate assessment of the cartilage (30).

## INDICATIONS AND CONTRAINDICATIONS TO ANKLE ARTHROSCOPY

### INDICATIONS

Diagnostic indications for ankle arthroscopy include unexplained pain, swelling, stiffness, instability, hemarthrosis, locking, and popping. Therapeutic indications for ankle arthroscopy include articular injury, soft-tissue injury, bony impingement, arthrofibrosis, fracture, synovitis, loose bodies, osteophytes, osteochondral defects, arthrodesis, ankle instability, and ankle fractures.

### CONTRAINDICATIONS

Relative contraindications for ankle arthroscopy include moderate to severe degenerative joint disease with restricted range of motion, significantly reduced joint space, severe edema, and tenuous vascular status. The absolute contraindications for ankle arthroscopy include localized soft-tissue infection and severe degenerative joint disease.

## SURGICAL TECHNIQUE

The technique of ankle arthroscopy was originally adapted from knee arthroscopy, and shares similar equipment. However, the ankle joint is much smaller and tighter than the knee joint, which necessitates smaller instruments and a method of distracting the joint to maximize the working area. We prefer a 2.7 mm video arthroscope using both the 30° and 70° oblique lenses. With this setup, a lightweight chip camera is screwed directly onto the arthroscope. This method shortens the overall length of the videoscope and minimizes the levering effect on structures during surgery. The 30° obliquity has a superior field of vision; however, the 70° obliquity can be helpful for visualizing over the medial and lateral domes of the talus and into the gutters. An interchangeable cannula system is critical to allow changing the arthroscope and instruments to each portal while minimizing the risks of reentry. Standard instruments can be used; however, small-joint instruments are preferred. These instruments include 2.9 mm and 3.5 mm shavers and burrs, 3.5 mm and 4.5 mm ring and cup curets, 1.5 mm probes, 2.9 mm and 3.5 mm graspers and baskets, small osteotomes, rongeurs, and banana blades (Fig. 93.1 and Table 93.1).

***Figure 93.1.*** Ankle arthroscopy instruments are both shorter and smaller than large joint instruments. Various biters, graspers, curets, probes, suction punches, and small joint drill guides (as shown here) have been developed for the ankle and are essential to the ankle arthroscopist. See Table 93.1 for a complete listing of instruments needed for the majority of arthroscopic ankle procedures.

| |
|---|
| Three-chip camera (with two light cords) |
| Compatible light source |
| Regular and small-joint shaver systems |
| TV monitor |
| Power drill/reamer with Jacobs chuck |
| Soft-tissue ankle distractor |
| Disposable soft-tissue distractor padded strap |
| 2.9 mm full radius shaver, 2.9 mm and 3.5 mm abrader, 3.5 mm incisor blade |
| Skin marking pen and ruler |
| #11 scalpel and mosquito clamp |
| 22-gauge × 1.5-inch needle plus 18-gauge spinal needle |
| 19-gauge × 1.5-inch needle × 2 |
| 10-ml syringe with IV extension tubing |
| 3- to 10-ml syringes |
| Small-joint arthroplasty set |
| Wire driver (power) |
| 0.062-inch K-wire (smooth) |
| Minimal probes, biters |
| 2.7 mm short arthroscopes (30° and 70°) |
| 1.9 mm short arthroscope (30°) |
| Micro Vector drill guide system |
| Thigh holder |
| 2.7 mm suction punch |
| Small foot elevator |

***Table 93.1. Ankle Arthroscopy Instruments***

It is very important to have a high inflow and outflow system in ankle arthroscopy without the added risks of a pump. This can be obtained with a gravity flow system using a third portal in the posterolateral position. A pump system can be used with caution, if necessary, to help with hemostasis and distention for visualization. Fluid extravasation can occur rapidly in the ankle, causing rapidly increased compartment pressure, particularly in the anterolateral compartment of the leg.

An ankle distraction device is very important in ankle arthroscopy to maximize the working area and ability to visualize the entire joint. Methods may be either invasive or noninvasive. Invasive distractors use pins in the tibia and hindfoot for mechanical distraction. These pins have fallen out of favor owing to the development of improved noninvasive distraction devices. At present, sterile disposable straps attach to a distraction system hooked to the operating table and provide excellent access to the ankle (Fig. 93.2).

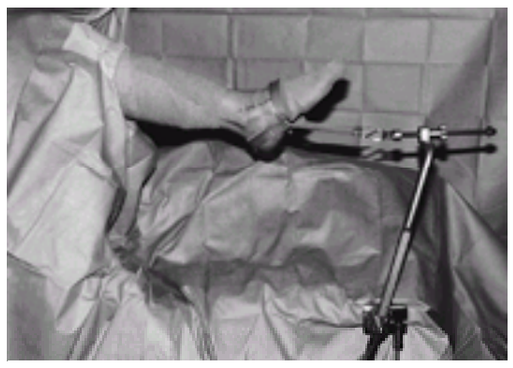

***Figure 93.2.*** The operative setup for ankle arthroscopy using soft-tissue distraction.

- Place the patient in the supine position with the hip flexed 45° to 50°, using a nonsterile thigh support and a tourniquet, which is used at the surgeon's discretion. Place a post against the greater trochanter to prevent external rotation of the hip (Fig. 93.3). With this setup, both anterior and posterior portals can easily be accessed without further manipulation of the patient's extremity.

***Figure 93.3.*** The patient is secured in a thigh holder that is well padded with additional foam pads anterior as well as posterior. A side bolster is used just proximal to the thigh support to minimize external rotation.

- Outline the dorsalis pedis artery, saphenous vein, and anterior tibial and peroneus tertius tendons on the surface of the ankle with a marking pen.
- Attempt to mark the superficial peroneal nerve and its branches as it crosses the joint while holding the foot and toes in plantar flexion and inversion (Fig. 93.4). The superficial peroneal nerve is the structure most at risk during ankle arthroscopy. It divides into the intermediate and medial dorsocutaneous branches approximately 6.5 cm proximal to the tip of the fibula. The intermediate dorsocutaneous branch passes the joint line just anterior to the common extensors of the fourth and fifth digits. The medial dorsocutaneous nerve crosses superficial to the common extensor tendons, parallel to the extensor hallucis longus tendons.

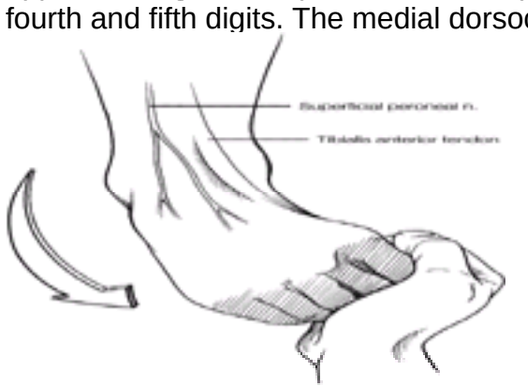

***Figure 93.4.*** By inverting and plantarflexing the foot, the superficial peroneal nerve can be palpated and the location noted. (Copyright 1996 by Lippincott-Raven Publishers. From Ferkel RD. *Arthroscopic Surgery: The Foot and Ankle.* Philadelphia: Lippincott-Raven Publishers:107, with permission. Illustration by Susan Brust.)

- Mark out the joint line and exsanguinate the extremity. Use a noninvasive ankle distractor, which is placed sterilely after prep and draping (Fig. 93.2).
- Do not overdistract the ankle, and remember to release the distraction partially after 1 hour to minimize the risk of nerve injury.
- See Figure 93.5*A* and Figure 93.5*B* for the standard portal placement.

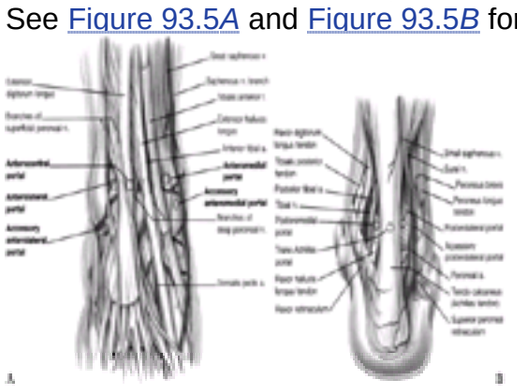

***Figure 93.5.*** Portals for ankle arthroscopy. **A:** Anterior anatomy and portals. The anterolateral and anteromedial are routinely used. **B:** Posterior anatomy and portals. The posterolateral portal is routinely used. (Copyright 1996 by Lippincott-Raven Publishers. From Ferkel RD. *Arthroscopic Surgery: The Foot and Ankle.* Philadelphia: Lippincott-Raven Publishers, 1996:104 and 106, with permission. Illustration by Susan Brust.)

- Distend the joint with sterile saline and insert an 18-gauge needle through the anteromedial portal. The greater saphenous vein is 9 mm medial and the greater

saphenous nerve is 7.4 mm medial to the anteromedial portal (20).

- Use a #11 scalpel to make a vertical stab wound while palpating the anterior tibial tendon. Dissect with a mosquito clamp through the subcutaneous tissues and capsule.
- Insert a blunt trochar with the arthroscopic cannula into the ankle joint, and insert the arthroscope into the cannula.
- Distend the ankle with normal saline in a 50 ml syringe attached by intravenous (IV) tubing to the arthroscopic cannula.
- Establish the anterolateral portal next under direct vision, using an 18-gauge spinal needle. Branches of the superficial nerve that are most at risk average 6.2 mm away from this portal (20). The incision is usually lateral to the tendon of the peroneus tertius, but placement can vary depending on the pathology to be addressed. Transillumination can help avoid injury to the underlying structures.
- Establish the posterolateral portal in the soft spot just lateral to the Achilles tendon, approximately 0.5-inch above the tip of the fibula. This portal is made under direct vision using an 18-gauge spinal needle placed through the posterolateral portal under the transverse ligament.
- Make a stab incision and insert a blunt trochar at approximately 45° toward the medial malleolus, entering inferior and slightly medial to the transverse tibiofibular ligament. The lesser saphenous vein and sural nerve are at risk when establishing this portal. The sural nerve is posterior to the lesser saphenous vein and generally 6 to 9 mm anterolateral to this portal (20).
- Attach the inflow to the posterolateral portal initially and outflow through the arthroscopic cannula and IV tubing.
- The anterocentral, posteromedial, and trans-Achilles portals are not used due to the increased morbidity associated with them (20).
- Transmalleolar and transtalar portals can be used for arthroscopic drilling or for screw insertion.
- Perform a 21-point examination.

The intra-articular anatomy of the ankle can be confusing and disorienting. The 21-point examination was developed by Richard D. Ferkel (22) to establish a reproducible and thorough intra-articular examination of the ankle. It consists of an 8-point anterior examination, a 6-point central examination, and a 7-point posterior examination (Table 93.2). View initially via the anteromedial portal. Use switching sticks to view the ankle from all three portals to provide a complete examination. This method also provides the arthroscopist with a reproducible means of documenting pathology found at time of arthroscopy (Fig. 93.6, Fig. 93.7 and Fig. 93.8; see color Fig. 93.6*B*, color Fig. 93.7*B* and color Fig. 93.8*B*).

| *8-Point anterior exam* | *6-Point central exam* | *7-Point posterior exam* |
|---|---|---|
| 1. Deltoid ligament | 1. Medial central tibiotalus | 1. Posteromedial gutter |
| 2. Medial gutter | 2. Middle tibiotalus | 2. Posteromedial talus |
| 3. Medial talus | 3. Lateral tibiotalus | 3. Posterocentral talus |
| 4. Central talus | 4. Capsular reflection/ FHL | 4. Posterolateral talus |
| 5. Lateral talus | 5. Transverse tibiofibular ligament | 5. Talofibular articulation |
| 6. Talofibular articulation | 6. Posterior inferior tibiofibular ligament | 6. Lateral gutter |
| 7. Lateral gutter | | 7. Posterior gutter |
| 8. Anterior gutter | | |

***Table 93.2. The 21-Point Arthroscopic Ankle Exam***

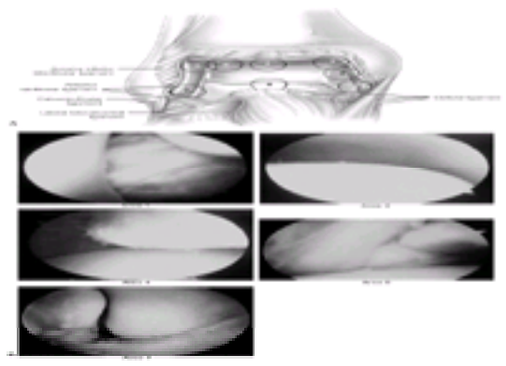

***Figure 93.6.*** An 8-point anterior examination as viewed from the anteromedial portal. **A:** The anterior ankle is examined starting at the tip of the medial malleolus. (See color Fig. 93.6*B*). **B:** Arthroscopic views are demonstrated at positions 1, 3, 4, 6, and 7. (Copyright 1996 by Lippincott-Raven Publishers. From Ferkel RD. *Arthroscopic Surgery: The Foot and Ankle.* Philadelphia: Lippincott-Raven Publishers, 1996:110, with permission. Illustration by Susan Brust.)

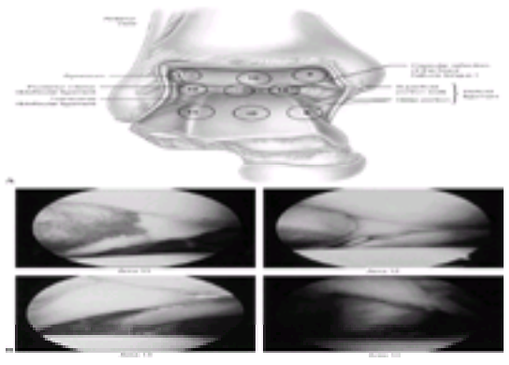

***Figure 93.7.*** A 6-point central examination as viewed from the anteromedial portal. **A:** The central examination is performed to examine the tibiotalar articulation. (See color Fig. 93.7*B*). **B:** Arthroscopic views of points 11, 12, 13, and 14. (Copyrighted 1996 by Lippincott-Raven Publishers. From Ferkel RD. Arthroscopic Surgery: The Foot and Ankle. Philadelphia: Lippincott-Raven Publishers, 1996:112, with permission. Illustration by Susan Brust.)

***Figure 93.8.*** A 7-point posterior examination as viewed from the posterolateral portal. **A:** The posterior examination begins along the posterior medial malleolus and is then rotated clockwise to complete the exam in the posterior recess. (See color Fig. 93.8*B*). **B:** Arthroscopic views of points 15, 16, 18, and 20. (Copyright 1996 by Lippincott-Raven Publishers. From Ferkel RD. Arthroscopic Surgery: The Foot and Ankle. Philadelphia: Lippincott-Raven Publishers, 1996:114, with permission. Illustration by Susan Brust.)

## POSTOPERATIVE CARE

The ankle is quite different from other joints in which we commonly use the arthroscope in regard to wound sealing and healing. Whereas not suturing portals at the knee can be advantageous, this is not the case at the ankle. Careful attention to wound closure is important. Close the portals with a 4-0 nylon, and then apply a compression dressing and short-leg posterior splint. Immobilization and elevation are important for the first 5 to 7 days postoperatively. If a compression stocking is used, it can be removed at 48 hours, dressings removed and bandages applied, followed by the stocking and splint. At 5 to 7 days, remove the splint and begin early motion with progressive weight bearing as tolerated, depending on the pathology treated.

## PITFALLS AND COMPLICATIONS

There are many potential complications of ankle arthroscopy (Table 93.3). In a series of 612 cases, Ferkel et al. (25) found an overall complication rate of 9%, with injury to superficial sensory nerves the most frequent problem. The superficial peroneal nerve was involved in 15 cases, the sural nerve in six cases, the greater saphenous nerve in five cases, and the deep peroneal nerve in one case. These complications were noted early in the development of the technique and are thought to be much lower using the technique described in the previous section. In this early study, Ferkel also reported complications with the invasive distractor, such as transient pain along the pin tracks, two stress fractures of the tibia, and one in the fibula secondary to the pin placement. Superficial wound infection was noted in six patients and deep wound infection in two patients. Compartment syndrome has not been reported.

Total complications 9.0% overall (55 of 612 cases):

Neurologic (27 of 55 complications)
- Superficial peroneal nerve injury, 15 of 27
- Sural nerve injury, 6 of 27
- Saphenous nerve injury, 5 of 27
- Deep peroneal nerve injury, 1 of 27

Superficial infections 8 of 55

Other:
- Adhesions
- Fractures
- Deep infection
- Instrument failure
- Ligament injury
- Incisional pain

***Table 93.3. Complications of Ankle Arthroscopy (Based on 612 Cases) (25)***

In general, complications can be minimized with careful preoperative planning and patient selection, noninvasive distraction, meticulous surgical technique, the use of switching sticks to change portals, careful use of shavers by always pointing away from the capsule, and appropriate postoperative care. We use perioperative antibiotics routinely.

## CONDITIONS AND RESULTS

### SOFT-TISSUE LESIONS

Soft-tissue lesions account for 30% to 50% of problems around the ankle. Most soft-tissue problems are related to the synovium; however, the capsule and ligamentous tissues can also be a source of pathology. Some of the common synovial etiologies include rheumatologic, infectious, degenerative, posttraumatic and neuropathic disorders (9,26,27,35,63). Capsular and ligamentous disorders tend to cause soft-tissue impingement located anterolateral, posterolateral, and in the region of the syndesmosis.

### SYNOVITIS

Synovitis can be generalized to the entire ankle or localized to a specific anatomic area. Patients with nonspecific gen- eralized synovitis of the ankle may present with swelling, aching, and soreness throughout. Trauma to the ankle is the most common cause; however, there may be no clear etiology. After a thorough workup and a sufficient course of conservative therapy, consider ankle arthroscopy. A high-flow volume system using a posterolateral portal for inflow is crucial in maximizing arthroscopic visualization. Depending on the findings, debride all synovitis, scar, or fibrosis. Treatment is essentially the same for both generalized and localized synovitis. Postoperatively, place the ankle in a short-leg splint for 1 week, followed by an elastic compression stocking and range-of-motion exercises with weight bearing as tolerated. Avoid active physical therapy for 2 to 3 weeks to allow soft-tissue healing and resolution of postoperative inflammation.

### ANTERIOR SOFT-TISSUE IMPINGEMENT

Chronic ankle pain following an inversion injury is quite common. The discomfort is usually located anterolaterally. This lateral gutter is bordered by the talus medially, the fibula laterally, the tibia and syndesmosis superiorly, and the anterior inferior tibiofibular ligament inferiorly. In 1950, Wolin et al. (77) first described a “meniscoid” band of thickened tissue between the fibula and talus as a source of anterolateral pinching and potential pain. This mass was thought to originate from a torn joint capsule. Waller (74) in 1982 described an anterolateral corner compression syndrome, which was similar to Wolin's description but was proposed to be the result of recurrent inversion injuries. In addition to soft-tissue impingement, other causes of chronic sprain pain include osteochondral lesions of the talus, loose bodies, occult fractures, peroneal tendon subluxation or tears, tarsal coalition, subtalar pathology, and degenerative joint disease (18).

Ferkel et al. (26) have performed arthroscopies in more than 290 patients with persistent anterolateral symptoms following inversion injury of the ankle. Their evaluation of 75 of these patients treated with arthroscopic debridement following failed conservative therapy demonstrated good to excellent results in 63 (84%) patients, with an average follow-up of 34 months. Others have noted similar results (18,47,52,62). The surgical findings generally include synovitis and fibrosis in the anterolateral gutter, with an occasional thickened band of tissue similar to the meniscoid lesion, as described by Wolin et al. (77) (Fig. 93.9).

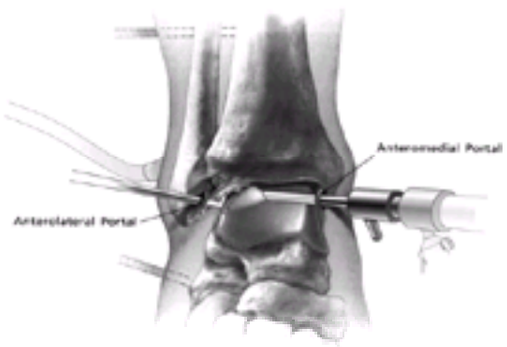


***Figure 93.9.*** Viewed from the anteromedial portal, anterolateral soft-tissue impingement with fibrosis and synovitis can be seen. (From Ferkel RD, Scranton PE Jr: Arthroscopy of the Foot and Ankle. *J Bone Joint Surg Am* 1993;75:1233. Copyright 1993 by *The Journal of Bone and Joint Surgery*, Inc., reprinted with permission.)

- Perform a careful ankle exam.
- Use 70° arthroscope from the anteromedial portal to look over the dome of the talus into the lateral gutter or view from the anterolateral portal and shave from

accessory anterolateral portal.

- Excise synovitis, scar bands, and chondromalacia (Fig. 93.10).

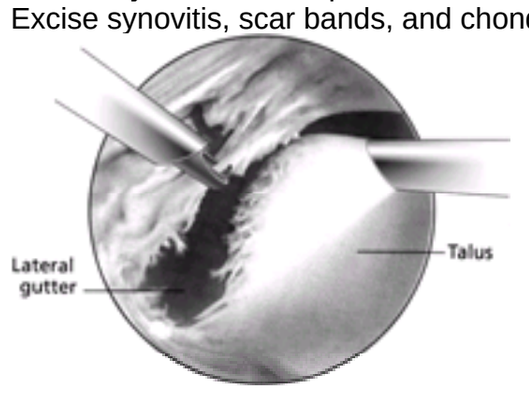


***Figure 93.10.*** Arthroscopic view from the anteromedial portal demonstrating excision of the anterolateral soft-tissue impingement using a full radius shaver entering from the anterolateral portal.

- Do not excise normal anterior talofibular ligament.
- Postoperative management: Apply a short-leg splint for 5 to 7 days, followed by a compression stocking and supportive brace. Start physical therapy 2 to 3 weeks after surgery. Participation in athletic endeavors can begin 4 to 6 weeks following surgery.

**SYNDESMOTIC IMPINGEMENT**

Following injury to the syndesmosis, synovitis and exuberant scarring can be a source of impingement. Clinical diagnosis is difficult unless there is a high incidence of suspicion. At arthroscopy, the synovium is inflamed in this area and encompassing the anterior inferior tibiofibular (AITF) ligament, often extending into the distal tibiofibular joint. A fascicle of the AITF has been noted by Bassett et al. (4) to be an additional factor in impingement, particularly if it is associated with laxity of the anterior talofibular ligament.

- Carefully examine the ankle.
- Debride synovitis and fibrosis of the anterior inferior tibiofibular ligament and tibiofibular joint.
- Excise separate fascicles of the AITF ligament that are causing abrasion of the talus.
- Rarely, it is necessary to remove the entire intra-articular portion of the AITF ligament.

**POSTERIOR SOFT-TISSUE IMPINGEMENT**

Posterior soft-tissue impingement can occur either independently or in conjunction with anterior soft-tissue impingement. Clinical evaluation and imaging are often not successful in identifying this entity. The diagnosis is usually made at the time of arthroscopy. The patients usually have a history of recurrent inversion injuries of the ankle. Symptoms may be more vague than in the patient with anterolateral impingement. Arthroscopic viewing from both anterior and posterior portals and distraction are essential in making the diagnosis (22).

Surgical findings in posterolateral impingement include hypertrophy or tearing of the posterior inferior tibiofibular ligament, transverse tibiofibular ligament, or the tibial slip (the tibial slip runs between the posterior inferior tibiofibular ligament and the transverse tibiofibular ligament) (23) or a pathologic “labrum” on the posterior lip of the tibia, causing impingement.

- Carefully examine the ankle.
- Remove posterior synovitis and pathologic posterolateral synovial nodules.
- Debride tears of the posterior ligaments.
- Be careful not to injure flexor hallucis longus and neurovascular structures.

**EVALUATION ALGORITHM**

Figure 93.11 outlines a treatment plan to assist in decision making for patients with chronic ankle pain.

***Figure 93.11.*** Algorithm for the management of chronic ankle pain. *H&P*, history and physical exam; *XR*, x-ray; *R.S.D.*, reflex sympathetic dystrophy. (Copyrighted 1996 American Academy of Orthopedic Surgeons. From Stetson WB, Ferkel RD. Ankle Arthroscopy; II. Indications and Results. *J Am Acad Orthop Surg* 1996;4:24. Reprinted with permission.)

**OSTEOCHONDRAL LESIONS OF THE TALUS**

Osteochondral lesions of the talus (OLT) have been described as a transchondral fracture, an osteochondral fracture, osteochondritis dissecans, a talar dome fracture, and a flake fracture (3). Controversy regarding uniform terminology is due mostly to the lack of a widely accepted mechanism of injury. Berndt and Harty's (5) original description in 1959 proposed the term “transchondral fracture” of the talus secondary to trauma (1,12). Other authors (11) have concluded that because not all cases have a clearly defined traumatic insult, the etiology must be due to bone pathology such as idiopathic osteonecrosis. We prefer the term “osteochondral lesions of the talus” to describe these lesions.

The true incidence of these lesions is unknown, but the incidence of diagnosis of OLT in a group of patients with chronic ankle pain has been reported as high as 81% (33). The incidence of bilateral lesions is approximately 10% (2,6). Medial lesions are more common and tend to be located more posterior than lateral lesions, which are more anterior (2,13,34). Medial lesions are deeper, cup shaped, and usually undisplaced, whereas lateral lesions are thin, wafer shaped, and often displaced. A history of chronic lateral ankle pain is common, and depending on the extent of the lesion, symptoms of swelling, stiffness, and giving way are common.

The diagnosis can be confirmed with plain radiographs; however, Zinman et al. (78) reported CT scans to be superior to plain films for diagnosis and follow-up. Berndt and Harty (5) described a classification based on plain radiographs in which four stages were proposed based on the compression and displacement of the fragment. Ferkel and Sgaglione (31) proposed a classification based on CT appearance (Table 93.4), which corresponds to the Berndt and Harty system but also considers the integrity of the articular surface and the presence of subchondral cysts (Fig. 93.12). Anderson et al. (2) have also developed an MRI classification. Based on our recent study (32), we recommend that MRI be performed in cases of chronic pain with unclear etiology, whereas CT can be performed when an OLT is seen on plain x-ray studies. Ferkel and Cheng (23) have also reported an arthroscopic staging system to help predict clinical outcome (Table 93.4; Fig. 93.13; see color Fig. 93.13).

| *Plain film based (5)* | *CT based (30)* | *Arthroscopy based (22)* |
|---|---|---|
| I Compressed fragment | I Cyst lesion/intact roof | A Smooth/intact cartilage |
| II Disrupted, not displaced | IIA Cyst lesion with break into talar dome | B Rough surface |
| III Partially displaced | IIB Open articular surface lesion with nondisplaced fragment | C Fibrillations/fissures |
| IV Displaced fragment | III Undisplaced lesion with lucency | D Flap present or bone exposed |
| | IV Displaced fragment | E Loose, undisplaced fragment |
| | | F Displaced fragment |

***Table 93.4. Classifications of Osteochondral Lesions of the Talus***

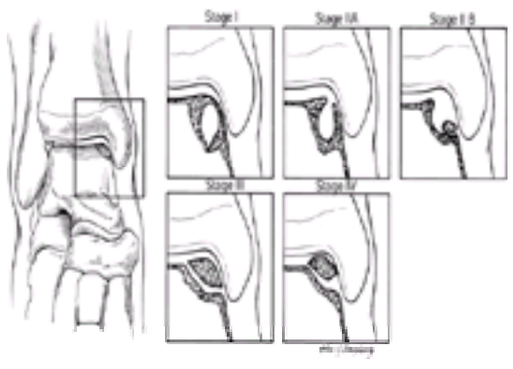


***Figure 93.12.*** CT scan classification of osteochondral lesions of the talus: Stage I is a cystic lesion within the dome of the talus, intact roof. Stage IIA is a cystic lesion with communication to the talar dome surface. Stage IIB is an open articular surface lesion with overlying nondisplaced fragment. Stage III is an undisplaced lesion with lucency. Stage IV is a displaced fragment. (Ferkel RD, Sgaglione NA. Arthroscopic Treatment of Osteochondral Lesions of the Talus: Long Term Results. *Orthop Trans* 1993;17:1011. Copyrighted 1996 by Lippincott-Raven Publishers. Illustration from Ferkel RD: *Arthroscopic Surgery: The Foot and Ankle*. Philadelphia: Lippincott-Raven Publishers, 1996. Illustration by Susan Brust.)

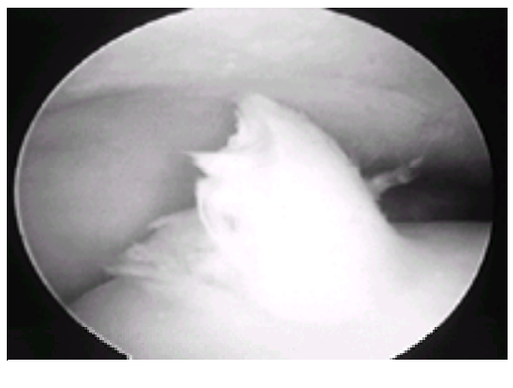

***Figure 93.13.*** (See color Fig. 93.13). Arthroscopic picture of a Stage D osteochondral lesion of the talus.

Treatment of OLT has generally been based on whether there is a displaced fragment that needs debridement (5,8,13,64). Conservative treatment consists of 6 to 12 weeks of casting, with progression to weight bearing as tolerated. For those who fail conservative treatment, open arthrotomy with malleolar osteotomy, distal tibia grooving, and percutaneous drilling under fluoroscopy have all been described for surgical treatment (1,31,36,72). These surgical approaches all can have significant morbidity, including soft-tissue trauma, malunion or nonunion of the malleoli, joint stiffness, and prolonged rehabilitation.

Ankle arthroscopy provides improved access and visualization for treatment of osteochondral lesions of the talus and is associated with reduced morbidity, results superior to open treatment, and faster rehabilitation (24,38).

### *OLT Treatment Principles*

**Acute**

- Conservative treatment for most stage I to III lesions
- Immediate surgery for all stage IV lesions
- Surgery for stages I to III that fail conservative treatment

**Chronic**

- Conservative treatment for stages I and II in adults, and stages I to III in children 18 or under
- Surgery for adults with stages III and IV, and children with stage IV
- If conservative treatment fails, surgery is performed regardless of the stage.

The most appropriate surgical treatment for full-thickness loss of articular cartilage is controversial. Penetration of the subchondral bone is required to create bleeding, fibrin clot formation, and eventual fibrocartilage formation (44,54,58). Different techniques have been developed to penetrate the subchondral bone, including drilling, abrasion, and microfracture (7,44). A recent comparison of the long-term effects of abrasion to drilling in rabbits demonstrated better results with drilling (34). Recently, microfracture has been advocated to avoid placing holes through the malleoli and to prevent heat necrosis; it also allows increased holes to be placed in the lesion with less morbidity (69). We recommend arthroscopic debridement and microfracture for small defects, and arthroscopic debridement and drilling with microfracture for larger defects. Bone grafting of defects larger than 1.5 cm in depth may also be considered. All patients are generally kept non-weight bearing for 4 to 8 weeks, but early range of motion should start at 1 week.

### *Operative Technique*

- Arthroscopically inspect, identify, and stage all lesions of articular surfaces.
- Excise any loose bodies or osteochondral fragments.
- Palpate and measure the talar articular surface to determine the size and extent of the lesion.
- Use a banana knife and ring curet to remove the primary osteochondral lesion if it is loose and avascular.
- Use 2.9 mm and 3.5 mm shavers, if desired, to debride the talar bed to smooth the edges.
- Insert a 90° microfracture awl for small lesions (Fig. 93.14*A*).

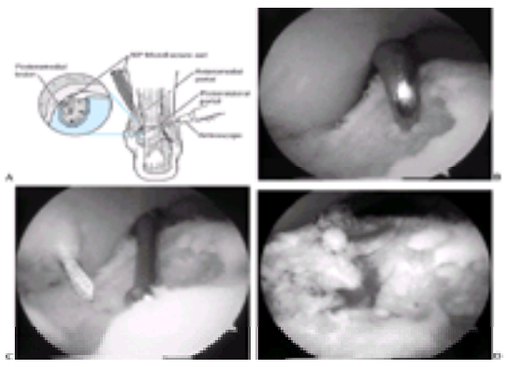

***Figure 93.14.*** (See color Fig. 93.14*B*, color Fig. 93.14*C* and color Fig. 93.14*D*). Arthroscopic treatment of osteochondral lesions of the talus. **A:** The left ankle is shown. Viewing from the posterolateral portal, a microfracture awl from the anteromedial portal penetrates the subchondral bone of a posteromedial lesion. **B:** Microfracture of the subchondral surface using an awl. **C:** Using a drill guide for transmalleolar drilling of the subchondral bone. **D:** The result of the above two treatments is a bleeding bone surface providing vascular access for cartilage formation.

- For larger lesions, use a 90° microfracture awl along the peripheral edge of the lesion and use a MicroVector (Smith and Nephew, Endoscopy, Andover, MA) to drill multiple holes in the center of the lesion (Fig. 93.14*B* and Fig. 93.14*C*; see color Fig. 93.14*B*, color Fig. 93.14*C* and color Fig. 93.14*D*).
- Drilling also can be performed transtalarly, through the sinus tarsi; this is usually done with an 0.062-inch K-wire.
- Use a bone graft for large deep cystic lesions (Fig. 93.15*A*, Fig. 93.15*B*, Fig. 93.15*C* and Fig. 93.15*D*; see color Fig. 93.15*B*, color Fig. 93.15*C* and color Fig. 93.15*D*).

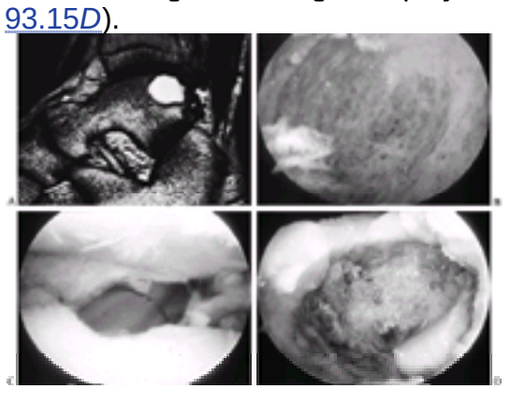

***Figure 93.15.*** Management of large osteochondral lesions of the talus. **A:** Preoperative MRI, T2-weighted image, demonstrates a large posterior osteochondral lesion. **B:** Arthroscopic view from a posterior portal shows the inside of the osteochondral lesion and depth. **C:** Arthroscopic bone grafting is performed via an osteochondral transplant cylinder. **D:** Arthroscopic view from a posterior portal of the bone graft filling the cyst near completion.

***Results***

Our results using this arthroscopic approach in 136 consecutive patients with OLT and in a subgroup of 64 patients, who fulfilled the study criteria, yielded 72% good to excellent results (American Orthopaedic Foot and Ankle Society Ankle/Hindfoot score of 84). At an average follow-up of 71 months, there was no correlation between imaging studies and clinical outcome; however, there was statistically significant correlation between arthroscopic staging and long-term results (31).

## OTHER METHODS

A variety of newer methods have been developed to treat articular cartilage defects. Chondrocyte transplantation has been studied extensively in Sweden and is currently undergoing clinical trials in the United States (10,55). Transplantation of autogenous osteochondral grafts taken from a donor site on the supracondylar ridge of the femur has also been tried in the ankle. Debate exists as to whether one large graft should be used or multiple small grafts (mosaicplasty) to fill the osteochondral lesion bed. A preliminary report (39) indicates excellent results in 11 patients with mosaicplasty. All techniques mentioned earlier so far require an arthrotomy, and future research is needed to determine their effectiveness.

### LOOSE BODIES

Loose bodies may either be chondral or osteochondral, and they usually are secondary to trauma. There are certain nontraumatic disorders, such as synovial chondromatosis, in which loose bodies may form as well (Fig. 93.16). Those fragments that contain bone may be detected on radiographs, but a cartilaginous fragment is not usually seen on plain radiographs. An arthrogram would likely show these intra-articular loose bodies, but MRI is the study of choice for cartilage lesions. Occasionally, a magnetic resonance arthrogram using gadolinium may be necessary to detect the more discrete lesions as well as show a possible cartilage area of origin. The surgeon needs to know preoperatively if the loose body is intra-articular, intracapsular, or extra-articular.

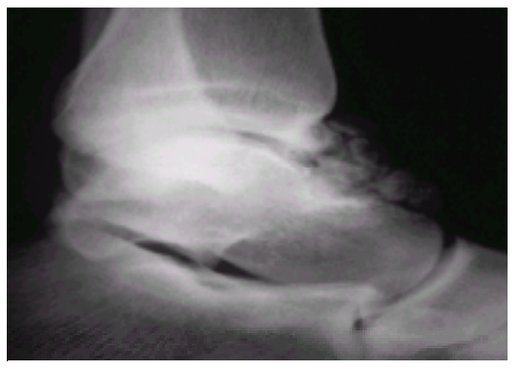

***Figure 93.16.*** Lateral radiograph of an ankle showing multiple loose bodies in the anterior and posterior recess of the ankle joint.

A 21-point arthroscopic examination must be thorough to avoid missing any fragments. Closely examine the articular cartilage following removal of fragments to address any residual articular defect.

- Look both anteriorly and posteriorly for loose bodies.
- Squeeze the posterior capsule to try to extrude loose bodies hidden in the posterior joint.

Postoperatively, place the ankle in a bulky compressive dressing with a short-leg splint for 5 to 7 days. Then change to a compressive stocking and begin early motion. Results depend on the underlying etiology of the loose bodies but are much less predictable in patients with degenerative changes (51).

### OSTEOPHYTES

Osteophytes most commonly occur at the distal anterior lip of the tibia and the adjacent talus. Normally, the angle between the distal end of the tibia and the talus is

greater than 60°. With osteophytic formation on the distal part of the tibia or talar neck, this angle can diminish to less than 60°, resulting in impingement.

Anterior impingement secondary to osteophyte formation is quite common following ankle injuries in athletes, with a reported incidence of 45% in football players and 59.3% in dancers (60). This spurring may cause decreased motion or pain, or both, at the ankle with dorsiflexion. Other areas in the ankle, such as the medial malleolus and the posterior lip of the tibia at the articular surface, may also have similar osteophyte formation. A classification system has been developed by Scranton and McDermott (68) to describe patterns of osteophyte formation around the ankle. A positive bone scan suggests that spurring may be the source of pain. CT scans can be helpful to determine the size and location of the osteophytes. Obtain weight-bearing and non-weight-bearing lateral radiographs in plantarflexion to identify the extent of the osteophyte and any loose bodies (Fig. 93.17*A* and Fig. 93.17*B*).

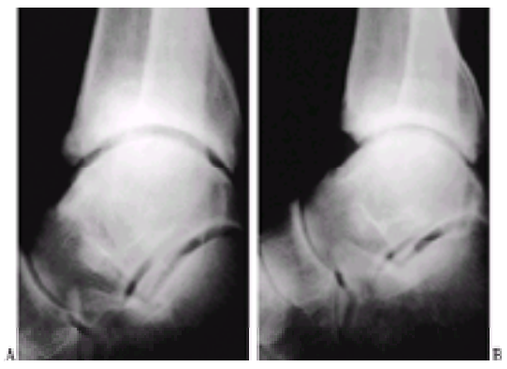

***Figure 93.17.*** **A:** Lateral radiographs of the tibiotalar joint showing preoperative osteophytes anteriorly. **B:** A postoperative radiograph following arthroscopic removal of the osteophyte.

- Remove all soft tissue around the osteophytes. Peel the soft tissue off anterior and inferior spurs with a Freer elevator and shaver.
- Identify the extent of the osteophyte before resection.
- Remove the osteophytes with a burr or osteotome, and rongeurs, as needed.
- Use intraoperative radiographs or fluoroscopy to verify complete excision.

Postoperatively, apply a bulky compressive dressing with a short-leg splint for 5 to 7 days, followed by early range-of-motion exercises and progressive weight bearing as tolerated. Commence physical therapy at 2 to 3 weeks postoperatively, and include stretching, strengthening, and proprioceptive training.

## HINTS AND TRICKS

If osteophytes are very large, look from the posterolateral portal to find the joint space and remove the medial corner of the osteophyte first, then switch back to the anterior portals for visualization and treatment of the remainder of the osteophyte.

### DEGENERATIVE ARTHRITIS

For surgery to be of any measurable benefit in an ankle with either posttraumatic or primary degenerative arthritis, a clearly defined reason for arthroscopy is required (16). Ankles with advanced degenerative disease do not benefit from ankle arthroscopy (19). Ankle arthrodesis may be indicated for the advanced degenerative ankle. Open arthrodesis requires an extensive surgical approach and has significant potential complications. With new advances in ankle distraction and ankle arthroscopic equipment, arthroscopic arthrodesis is an attractive alternative (56,61).

#### *Indications and Contraindications for Arthroscopic Ankle Arthrodesis*

Indications for arthroscopic ankle arthrodesis include intolerable ankle pain in the ankle with advanced degenerative arthritis that does not respond to conservative treatment. Contraindications include varus or valgus mal- alignment of more than 15 degrees, malrotation of the ankle, significant bone loss, active infection, previous failed fusion, reflex sympathetic dystrophy, neuropathic destructive process and AP translation of the tibiotalar joint requiring correction.

#### *Operative Technique for Arthrodesis*

- Position the patient supine on a radiolucent operating table. Position the leg such that the image intensifier can easily be positioned. The optimal position for arthrodesis of the ankle is neutral dorsiflexion. Avoid equinus, especially more than 10°, unless the patient has residual paralysis of the knee from poliomyelitis.
- Perform standard diagnostic arthroscopy with ankle distraction.
- Remove the entire articular surface of the tibial plafond, talar dome, and medial and lateral talomalleolar surfaces systematically using a motorized shaver, abrader, ring and cup curets, and pituitary rongeurs (Fig. 93.18; see color Fig. 93.18).

***Figure 93.18.*** (See color Fig. 93.18). When performing arthroscopic fusion take care to remove all articular cartilage with a combination of instruments. A curved curet is shown here.

- Make multiple small dimples in the subchondral bone of the tibia and talus with a burr to facilitate early bony union (Fig. 93.19; see color Fig. 93.19).

***Figure 93.19.*** (See color Fig. 93.19). A small joint drill guide can be used to drill the guide wires transmalleolar and thus arthroscopically assist in placement of the screws for fusion.

- Take care at all times to maintain the anatomic bony contour of the talar dome and tibial plafond.
- Remove all anterior and posterior osteophytes before insertion of screws.
- Insert the MicroVector arthroscopically to facilitate guide pin insertion.
- Then fix the ankle by placing a guide pin for a cannulated screw from the proximal part of the medial malleolus to just above the joint line. Drill a second pin laterally through the lateral malleolus into the posterior aspect of the joint line. Insert both medial and lateral guide pins from the posterior aspect of the malleoli, and angle them 45° inferiorly and 45° anteriorly (Fig. 93.20).

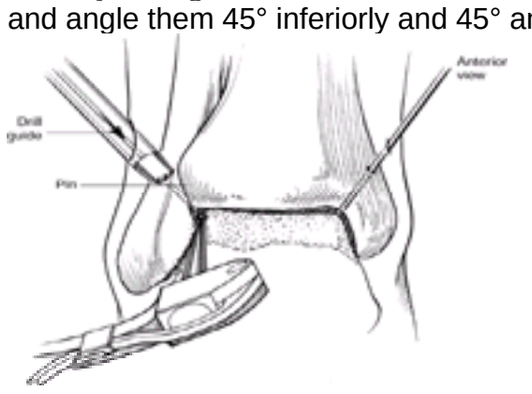


***Figure 93.20.*** Both pins are inserted from the posterior aspect of the malleoli and angled approximately 45 degrees anterior and inferior. Copyrighted 1996 by Lippincott-Raven Publishers, *Arthroscopic Surgery: The Foot and Ankle.* Richard D. Ferkel, Figure 11-13, pp. 26-27. Illustration by Susan Brust.

- Release distraction and put the ankle into a neutral position. Under fluoroscopy, also check the position of the guide pins.
- Advance the guide pins under fluoroscopic control, being careful not to penetrate the subtalar joint.
- Measure the length of the pins and insert 6.5 or 7.3 mm self-drilling, self-tapping screws under fluoroscopic control (Fig. 93.21).

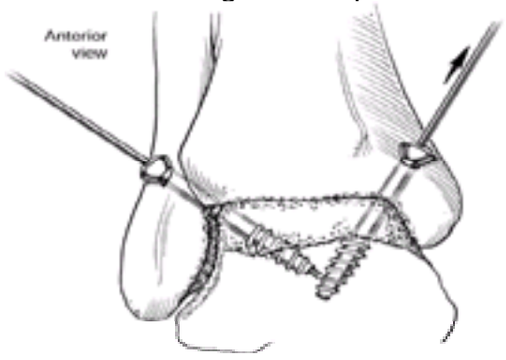


***Figure 93.21.*** Transmalleolar screw insertion with a 6.5 mm, self-drilling, self-tapping screw is performed such that all threads of the screw are within the talus; therefore, compression across the surfaces, and not distraction, will assist in fusion. (Copyrighted 1996 by Lippincott-Raven Publishers. Ferkel RD. *Arthroscopic Surgery: The Foot and Ankle.* Philadelphia: Lippincott-Raven Publishers, 1996:26, with permission. Illustration by Susan Brust.)

- Take radiographs to verify screw position and length, as well as ankle alignment.

Postoperatively, apply a well-padded short-leg cast that is split in the recovery room. At 1 week, remove the stitches and apply a new cast. Begin weight bearing at 2.5 to 3 weeks. Discontinue the cast or removable cast-boot device when bony union is seen on radiographs.

***Results***

Early clinical results with arthroscopic ankle arthrodesis are good to excellent in 85% to 92% of patients (37,55). When compared with open arthrodesis, arthroscopic fusion seems to have lower overall morbidity, quicker time to union, and shorter recovery and rehabilitation (57).

**ACUTE ANKLE FRACTURES**

Arthroscopy of acute ankle fractures allows the surgeon to assess directly the articular surfaces, remove fracture debris, assess for ligament damage, and in some instances, assist fracture reduction and percutaneous screw insertion (28,29). Arthroscopically assisted reduction and internal fixation can be accomplished in fractures with minimal to mild displacement that are easily reducible by manipulation, with minimal to mild ankle swelling and no neurovascular injury. Arthroscopy is also useful in treating syndesmosis disruptions, deltoid ligament tears, and posterior malleolar fractures, and in assisting in removal of debris in reduction of talar fractures. Triplane fractures have also been reportedly reduced with arthroscopic assistance with success (53,76).

- Place the patient supine on a radiolucent operating table.
- Use a standard arthroscopic setup.
- Apply gentle soft-tissue distraction.
- Remove all fracture debris, loose bodies, and hematoma.
- If the fracture cannot be reduced arthroscopically, then perform open reduction internal fixation.
- If arthroscopic fracture reduction is possible, reduce the fracture with large fracture clamps and maintain the reduction with guide pins from the AO cannulated screw set. After visual and fluoroscopic verification of reduction, measure the screw lengths and insert the appropriate size screws (Fig. 93.22*A*, Fig. 93.22*B* and Fig. 93.22*C*).

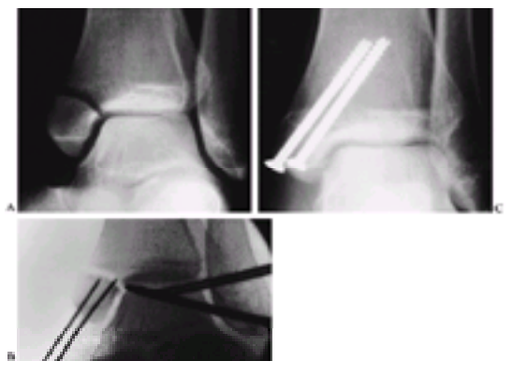

***Figure 93.22.*** Arthroscopically assisted treatment of a medial malleolar fracture. **A:** Preoperative x-ray study shows a displaced fracture with rotation. **B:** Intraoperative fluoroscopy shows initial fracture reduction and pin placement. These guide pins can be used to complete the reduction and then cross the fracture for screw placement. **C:** Screw placement and fracture healing 8 weeks postoperative.

Postoperatively, apply a cast that is split in the recovery room. Keep the patient non-weight-bearing, and remove sutures at the first postoperative visit. Subsequent immobilization is determined by the nature of the fracture and its fixation (see Chapter 25).

***Results***

Loren and Ferkel (48) reviewed 47 consecutive patients with acute fractures of the ankle treated with arthroscopy of the tibiotalar joint, followed by open reduction and internal fixation. Damage to the articular surfaces was noted in 29 of 47 (62%) ankles. Fracture debris and hemarthrosis were noted in all ankles. Several other

institutions have reported on the utility of arthroscopy for fractures (21,42,53,66). Further studies are needed to determine the long-term benefit of ankle arthroscopy in patients with acute ankle fractures.

### ANKLE INSTABILITY

Ankle instability is discussed in detail in Chapter 95. Arthroscopy can be a useful tool in the evaluation of chronic lateral ankle instability. Dynamic information that is not available with stress radiographs can be obtained at the time of arthroscopy (40,49). In a recent study, 92% of patients with ankle instability had intra-articular pathology (27). Failure to recognize these lesions may jeopardize the patient's clinical outcome following stabilization procedures (69). Before ligament reconstruction, we advocate arthroscopic ankle examination (70). Arthroscopic ligament stabilization is an evolving technique, and its use has been reported by Hawkins (40) for patients with mild instability with promising short-term results.

## AUTHORS' PERSPECTIVE

The future of ankle arthroscopy is exciting. With the development of new equipment and techniques over the past decade, we have seen the applications of ankle arthroscopy grow remarkably. Perhaps more important, the procedure has become more user friendly. Therefore, more patients can be treated with the lower morbidity and speedier recovery that is associated with arthroscopic surgery of the ankle compared with the standard open arthrotomy procedures for treatment of the same pathology. We can anticipate the evolution of this field to continue to parallel the rapid technologic advances seen in computers, optics, and audio and video equipment. These advances, along with improved surgical technique, experience, and long-term outcome studies, will pave the way for the next generation of ankle specialists.

### CHAPTER REFERENCES

Each reference is categorized according to the following scheme: *, classic article; #, review article; !, basic research article; and +, clinical results/outcome study.


+ 1. Alexander AH, Lichtman DM. Surgical Treatment of Transchondral Talar-dome Fractures (Osteochondritis Dissecans). *J Bone Joint Surg* 1980;62:646.

+ 2. Anderson IF, Crichton KJ, Grattan-Smith T, et al. Osteochondral Fractures of the Dome of the Talus. *J Bone Joint Surg* 1989;71:1143.

+ 3. Barth A. Die Enstehung and das Wachstum der freien Gelen Kkorper. *Arch Klin Chir* 1898;56:507.

+ 4. Bassett FH III, Gates HS III, Billys JB. Talar Impingement by Anteroinferior Tibiofibular Ligament. *J Bone Joint Surg* 1990;72A:55.

+ 5. Berndt AL, Harty M. Transchondral Fractures (Osteochondritis Dissecans) of the Talus. *J Bone Joint Surg* 1959;41:988.

+ 6. Bessen J, Wellinger C. L'Osteochondrite Dissequante de l'Astragale a Propos Def 12 Observations. *Rev Rhum* 1967;34:552.

+ 7. Blevins FT, Steadman JR, Rodrigo JJ, Silliman J. Treatment of Articular Cartilage Defects in Athletes: An Analysis of Functional Outcome and Lesion Appearance. *Orthopedics* 1998;21:761.

+ 8. Blom JM, Strijk SP. Lesions of the Trochlea Tali. *Radiol Clin North Am* 1975;44:387.

+ 9. Borton DC, Peereboom J, Saxby TS. Pigmented Villonodular Synovitis in the First Metatarsophalangeal Joint: Arthroscopic Treatment of an Unusual Condition. *Foot Ankle* 1997;18:504.

+ 10. Brittberg M, Lindahl A, Nilsson A, et al. Treatment of Deep Cartilage Defects in the Knee with Autologous Chondrocyte Transplantation. *N Engl J Med* 1994;331:889.

# 11. Buckwalter JA, Cruess RL. Healing of the Musculoskeletal Tissues. In: Rockwood CA Jr., Green DP, Bucholz RW, eds. *Fractures in Adults.* Philadelphia: Lippincott, 1991:181.

+ 12. Campbell CJ, Ranawat CS. Osteochondritis Dissecans: The Question of Etiology. *J Trauma* 1966;6:201.

+ 13. Canale ST, Belding RH. Osteochondral Lesions of the Talus. *J Bone Joing Surg* 1980;62A:97.

# 14. Chen Y. Arthroscopy of the Ankle Joint. In: Watanabe M, ed. *Arthroscopy of Small Joints.* New York: Igaku-Shoin, 1985.

+ 15. Chen YC. Clinical and Cadaver Studies on the Ankle Joint Arthroscopy. *J Jpn Orthop Assoc* 1976;50:631.

+ 16. Cheng JC, Ferkel RD. The Role of Arthroscopy in Ankle and Subtalar Degenerative Joint Disease. *Clin Orthop* 1998;349:65.

* 17. Chrisman OD, Snook CA. A Reconstruction of Lateral Ligament Tears of the Ankle: An Experimental Study and Clinical Evaluation of Seven Patients Treated by a New Modification of the Elmslie Procedure. *J Bone Joint Surg* 1969;51A:904.

+ 18. DeBerardino TM, Arciero RA, Taylor DC. Arthroscopic Treatment of Soft-tissue Impingement of the Ankle in Athletes. *Arthroscopy* 1997:13:492.

+ 19. Feiwell LA, Frey C. Anatomic Study of Arthroscopic Debridement of the Ankle. *Foot Ankle* 1994:15:615.

+ 20. Feiwell LA, Frey C. Anatomic Study of Arthroscopic Portal Sites of the Ankle. *Foot Ankle* 1993;14:142.

+ 21. Feldman MD, Nunley JA. *Evaluation of Intraarticular Damage in Displaced Extraarticular Ankle Fractures.* Presented at the Annual Meeting of the Eastern Orthopaedic Association, Scottsdale, Arizona, 1997.

# 22. Ferkel RD. *Arthroscopic Surgery: The Foot and Ankle.* New York: Lippincott-Raven, 1996.

# 23. Ferkel RD, Cheng JC. Ankle and Subtalar Arthroscopy. In: Kelikian A, ed. *Operative Treatment of the Foot and Ankle.* New York: Appleton-Croft, 1999:321.

+ 24. Ferkel RD, Fasulo GJ. Arthroscopic Treatment of Ankle Injuries. *Orthop Clin North Am* 1994;25:17.

+ 25. Ferkel RD, Guhl JF, Heath DD. Neurological Complications of Ankle Arthroscopy: A Review of Six Hundred Cases. *Arthroscopy* 1994;10:352.

+ 26. Ferkel RD, Karzel RP, Del Pizzo W, et al. Arthroscopic Treatment of Anterolateral Impingement of the Ankle. *Am J Sports Med* 1991;19:440.

+ 27. Ferkel RD, Komenda GA: *The Arthroscopic Findings Associated with the Unstable Ankle.* Presented at Specialty Day, American Orthopaedic Foot and Ankle Society, San Francisco, February 1997.

+ 28. Ferkel RD, Orwin JF. Ankle Arthroscopy: A New Tool for Treating Acute and Chronic Ankle Fractures. *Arthroscopy* 1993;9:352.

+ 29. Ferkel RD, Orwin JF. Arthroscopic Treatment of Acute Ankle Fractures and Postfracture Defects. In: Ferkel RD, ed. *Arthroscopic Surgery: The Foot and Ankle.* Philadelphia: Lippincott-Raven, 1996:185.

# 30. Ferkel RD, Schweitzer M, Brahme SK. Preoperative Evaluation and Imaging. In: Ferkel RD, ed. *Arthroscopic Surgery: The Foot and Ankle.* New York: Lippincott-Raven, 1996:13.

+ 31. Ferkel RD, Sgaglione NA. Arthroscopic Treatment of Osteochondral Lesions of the Talus: Long Term Results. *Orthop Trans* 1990;14:172.

+ 32. Ferkel RD, Zanotti RM, Komenda GA. Arthroscopic Treatment of Chronic Osteochondral Lesions of the Talus: Long Term Results. Submitted for publication.

+ 33. Flick AB, Gould N. Osteochondritis Dissecans of the Talus (Transchondral Fractures of the Talus): Review of the Literature and New Surgical Approach for Medial Dome Lesions. *Foot Ankle* 1985;5:165.

! 34. Frenkel SR, Menche DS, Blair B, et al. A Comparison of Abrasion Burr Arthroplasty and Subchondral Drilling in the Treatment of Full-thickness Cartilage Lesions in the Rabbit. *Trans Orthop Res Soc* 1994;19:483.

+ 35. Friscia DA. Pigmented Villonodular Synovitis of the Ankle: A Case Report and Review of the Literature. *Foot Ankle* 1994;15:674.

+ 36. Gebstein R, Conforty B, Weiss RE, et al. Closed Percutaneous Drilling for Osteochondritis Dissecans of the Talus. *Clin Orthop* 1986;213:197.

+ 37. Glick JM, Morgan CD, Myerson MS, et al. Ankle Arthrodesis Using an Arthroscopic Method: Long Term Follow-up of 34 Cases. *Arthroscopy* 1996;12:428.

# 38. Guhl JF. *Ankle Arthroscopy.* Presented at the Biennial meeting of the International Arthroscopy Association, Rome, 1989.

+ 39. Hangody L, Kish G, Karpati Z, et al. Treatment of Osteochondritis Dissecans of the Talus: Use of the Mosaicplasty Technique—A Preliminary Report. *Foot Ankle* 1997;18:628.

+ 40. Hawkins RB. Ankle Instability Surgery from an Arthroscopist's Perspective. In: McGinty JG, ed. *Operative Arthroscopy.* New York: Raven, 1991:747.

+ 41. Heller AJ, Vogler HW. Ankle Joint Arthroscopy. *J Foot Surg* 1982;21:23.

+ 42. Holt ES. Arthroscopic Visualization of the Tibial Plafond during Posterior Malleolar Fracture Fixation. *Foot Ankle* 1994;15:206.

! 43. Isman RE, Inman VT. Anthropometric Studies of the Human Foot and Ankle. *Bull Prosthet Res* 1969;10–11:97.

# 44. Johnson LL. Arthroscopic Abrasion Arthroplasty, Historical and Pathologic Perspective: Present Status. *Arthroscopy* 1986;2:54.

* 45. Kreuscher PH. Semilunar Cartilage Diseases. A Plea for Early Recognition by Means of the Arthroscope and Early Treatment of This Condition. *Ir Med J* 1925;47:290.

! 46. Laurin CA, Ouellet R, St. Jacques R. Talar and Subtalar Tilt: An Experimental Investigation. *Can J Surg* 1968;11:270.

+ 47. Liu SH, Raskin A, Osti L, et al. Arthroscopic Treatment of Anterolateral Ankle Impingement. *Arthroscopy* 1994;10:215

+ 48. Loren GJ, Ferkel RD. Arthroscopic Assessment of Occult Intraarticular Injury in Acute Ankle Fractures. Submitted for publication.

+ 49. Lundeen RO, Hawkins RB. Arthroscopic Lateral Ankle Stabilization. *J Am Podiatr Med Assoc* 1985;75:372.

# 50. Mann RA, Coughlin MJ. Surgery of the Foot and Ankle, 6th ed. St. Louis: Mosby–Year Book, Inc., 1993: 51.

+ 51. Martin DF, Baker CL, Curl WW, et al. Operative Ankle Arthroscopy, Long Term Followup. *Am J Sports Med* 1989;17:16.

+ 52. Meislin RJ, Rose DJ, Parisien JS, et al. Arthroscopic Treatment of Synovial Impingement of the Ankle. *Am J Sports Med* 1993;21:186.

+ 53. Miller MD. Arthroscopically Assisted Reduction and Fixation of an Adult Tillaux Fracture of the Ankle. *Arthroscopy* 1997;13:117.

! 54. Mitchell N, Shepard N. The Resurfacing of Adult Rabbit Articular Cartilage by Multiple Perforations Through the Subchondral Bone. *J Bone Joint Surg* 1976;58A:230.

+ 55. Minas T, Peterson L. Chondrocyte Transplantation. *Op Tech Orthop* 1997;7:323.

# 56. Morgan CP. Arthroscopic Tibiotalar Arthrodesis. In: McGinty JB, ed. *Operative Arthroscopy.* New York: Raven Press, 1991:695.

+ 57. Myerson MS, Quill G. Ankle Arthrodesis: A Comparison of an Arthroscopic and an Open Method of Treatment. *Clin Orthop* 1991;268:84.

+ 58. Naumetz VA, Schweigel JF. Osteocartilaginous Lesions of the Talar Dome. *J Trauma* 1980;20:924.

# 59. O'Connor RL. Arthroscopy. Kalamazoo, MI: Upjohn, 1977:12.

+ 60. O'Donoghue DH. Chondral and Osteochondral Fractures. *J Trauma* 1966;6:469.

+ 61. Ogilvie-Harris DJ, Lieberman I, Fitsialos D. Arthroscopically Assisted Arthrodesis for Osteoarthritic Ankles. *J Bone Joint Surg* 1993;75A:1167.

+ 62. Ogilvie-Harris DJ, Reed SC. Disruption of the Ankle Syndesmosis: Diagnosis and Treatment by Arthroscopic Surgery. *Arthroscopy* 1994;10:561.

+ 63. Patti JE, Mayo WEB: Arthroscopic Synovectomy for Recurrent Hemarthrosis of the Ankle in Hemophilia. *Arthroscopy* 1996;12:652.

+ 64. Roden S, Tillegard P, Unnander-Scharin L. Osteochondritis Dissecans and Similar Lesions of the Talus. *Acta Orthop Scand* 1953;23:51.

+ 65. Rubin G, Witten M. The Talar Tilt Ankle and the Fibular Collateral Ligaments: A Method for the Determination of Talar Tilt. *J Bone Joint Surg* 1960;42A:311.

+ 66. Saltzman Cl, Marsh JL, Tearse DS. Treatment of Displaced Talus Fractures: An Arthroscopically Assisted Approach. *Foot Ankle* 1994;15:630.

+ 67. Sauser DD, Nelson RC, Laurine MH, et al. Acute Injuries of the Lateral Ligaments of the Ankle: Comparison of Stress Radiography and Arthrography. *Radiology* 1983;148:653.

+ 68. Scranton PE Jr, McDermott JE. Anterior or Tibiotalar Spurs: A Comparison of Open Versus Arthroscopic Debridement. *Foot Ankle* 1992;13:125.

+ 69. Steadman JR, Blevins FT, Rodrigo JJ, Silliman J. Treatment of Articular Cartilage Defects in Athletes: An Analysis of Functional Outcome and Lesion Appearance. *Orthopedics* 1998;2:761.

+ 70. Taga I, Shino K, Inoue M, Nakata K, Maeda A. Articular Cartilage Lesions in Ankles with Lateral Ligament Injury: An Arthroscopic Study. *Am J Sports Med* 1993;21:120.

* 71. Takagi K. The Arthroscope. *J Jpn Orthop Assoc* 14:359, 1939.

+ 72. Thompson JP, Loomer RL. Osteochondral Lesions of the Talus in a Sports Medicine Clinic. *Am J Sports Med* 1984;12:460.

+ 73. Waitches GM, Rockett M, Brage M, Sudakoff G. Ultrasonographic-surgical Correlation of Ankle Tendon Tears. *J Ultrasound Med* 1998;17:249.

+ 74. Waller JF. Hindfoot and Midfoot Problems of the Runner in Symposium on the Foot and Leg. In: Mack RP, ed. *Running Sports.* St. Louis: Mosby–Year Book, 1982:64.

* 75. Watanabe M. *Selfoc-Arthroscope (Watanabe No. 24 Arthroscope) (Monograph).* Tokyo: Teishin Hospital, 1972.

+ 76. Whipple TL, Martin DR, McIntyre LF, Meyers JF. Arthroscopic Treatment of Triplane Fractures of the Ankle. *Arthroscopy* 1993;9:352.

+ 77. Wolin I, Glassman F, Sideman F, et al. Internal Derangement of the Talofibular Component of the Ankle. *Surg Gynecol Obstet* 1950;91:193.

+ 78. Zinman C, Wolfson N, Reis ND. Osteochondritis Dissecans of the Dome of the Talus. *J Bone Joint Surg* 1988;70:1017.

# CHAPTER 94

# TENDON LACERATIONS AND OTHER TENDON DISORDERS ABOUT THE ANKLE

*George Lian*

**G. Lian:** Department of Orthopaedic Surgery, University of California, Davis, School of Medicine, Sacramento, California 95816.

Tendon Lacerations
- Pathophysiology
- Principles of Treatment
- Assessment
- Classification
- Preoperative Management
- Operative Techniques
- Complications
- Conclusions

Flexor Hallucis Longus Tendon
- Clinical Presentation
- Radiographs
- Nonoperative Treatment
- Operative Treatment

Anterior Tibialis Tendon
- Anatomy
- Clinical Presentation
- Radiographs
- Treatment

Chapter References

## TENDON LACERATIONS

Lacerations to tendons about the foot and ankle can be caused by stepping on or dropping a sharp object such as glass onto the foot, which usually results in a clean sharp isolated tendon laceration. More violent crushing-type lacerations occur with motor vehicle accidents, power saw and lawnmower injuries, or dropping objects on the dorsum of the foot, all of which cause more extensive associated injuries (4,6).

Floyd et al. (4) showed that all tendon lacerations, with the possible exception of the flexor digitorum tendons, benefit from primary repair. They found in a number of cases that surgical exploration revealed additional significant injuries that were not appreciated in the clinical examination.

### PATHOPHYSIOLOGY

The tendon lacerations discussed here involve the following tendons: flexor hallucis longus (FHL), flexor digitorum longus (FDL), extensor digitorum longus (EDL), extensor hallucis longus (EHL), anterior tibial (AT), and posterior tibial (PT) tendons.

The FHL muscle originates from the deep posterior compartment of the leg. The FHL tendon passes beneath the sustenaculum tali and continues distally, crossing deep to the FDL tendon at the flexor knot of Henry. At this point the tendon produces a tendinous slip that inserts into the FDL tendon (16). The FHL tendon is covered by two synovial sheaths. The first provides coverage from the ankle joint to a point just distal to the flexor knot of Henry; the second provides coverage from the first metatarsal base to the tendon insertion.

The EDL, EHL, and AT tendons originate from the anterior compartment in the leg. Each muscle produces a tendon that is enclosed in a synovial sheath and is retained in position by a thickened section of crural fascia known as the extensor retinaculum. There are individual sheaths for the anterior tibial tendon and extensor hallucis longus tendon and a common sheath for the extensor digitorum longus tendons (17).

The anatomic features of the posterior tibial tendon are described in the posterior tibial tendon dysfunction section of Chapter 118.

The subcutaneous positions of the tendons about the foot and ankle predispose them to injury by direct trauma. Laceration of the plantar or dorsal aspect of the foot may produce disruption of tendinous, vascular, or neurologic structures.

### PRINCIPLES OF TREATMENT

Injuries associated with foot lacerations are commonly missed. Establish the full extent of the injury by careful physical examination, appropriate radiographic imaging, and, when necessary, surgical exploration. When primary repair is indicated, techniques used are similar to those for flexor tendon injuries in the hand.

### ASSESSMENT

Document the mechanism of injury. Determine the exact anatomic area of injury. Check the vascular and neurologic status and follow this by an analysis of tendon function. Remember that the FHL tendon provides a tendinous slip to the FDL tendon. If the FHL tendon is disrupted proximal to this slip, active flexion at the hallux interphalangeal joint may be produced by the FDL tendon. Therefore, the presence of active hallux interphalangeal joint plantarflexion does not rule out FHL tendon injury.

All lacerations require plain radiographic imaging to rule out concomitant bony injury and the presence of foreign material.

### CLASSIFICATION

Tendon lacerations can be classified on the basis of mechanism of injury, degree of injury (incomplete versus complete), location of injury (insertional versus noninsertional, relation to synovial sheath, relation to retaining structures), and by the presence of associated neurovascular or tendinous injury. With regard to laceration of the FHL tendon, the integrity of the flexor hallucis brevis is an important consideration.

### PREOPERATIVE MANAGEMENT

In the emergency department, provide routine wound care and give appropriate tetanus prophylaxis. Generally speaking, isolated tendon laceration about the foot may be treated by nonsurgical or surgical means. Repair primarily complete laceration of the Achilles, PT, AT, peroneal, EHL, and FHL tendons when local conditions are favorable. Functional (partial) lacerations as well as laceration of the brevis tendons are typically not repaired. Do a meticulous debridement and evaluation of associated structures and repair if needed.

### OPERATIVE TECHNIQUES

***Surgical Exploration and Repair of FHL Tendon Laceration***

- Use general or regional anesthesia and a proximal thigh tourniquet. Enlarge the plantar wound with proximal and distal extensions as required. If possible, avoid the weight-bearing surface of the foot.
- Inspect the FHL tendon, the FHB muscle and tendon, and surrounding neurovascular structures. If the FHL tendon laceration is distal to the tendinous connection with the FDL tendon, retraction of the FHL tendon is limited. Identify both ends of the tendon and meticulously debride the wound; then perform a primary tendon repair. Use a single-core 2-0 nonabsorbable suture. Repair the peripheral edges of the tendon with a smaller polydioxanone (PDS, Ethicon, Inc., Wayne, NJ) or nylon suture. After completion of the repair, verify excursion of the tendon.
- If primary repair cannot be accomplished, tenodese the adjacent FDL tendon to the proximal and distal ends of the FHL tendon. In the unusual event of a nonrepairable FHL tendon laceration accompanied by disruption of both heads of the FHB muscle, anastomose the proximal FHB muscle and the distal end of the FHL tendon.
- Because of the risk of formation of a painful neuroma, we do not repair digital nerve lacerations primarily but rather transplant them to a protected position, such as into a muscle belly. Repair the surgical extensions to the foot wound and immobilize the foot in slight plantarflexion.
- Postoperatively, do routine wound care to assure a viable wound with eventual successful closure. Over the course of 2 to 3 weeks, bring the foot gradually up to a neutral position. Begin passive range of motion at the hallux interphalangeal and the metatarsophalangeal joints. At 6 weeks postoperatively, start weight bearing in a removable cast boot. At 8 weeks postoperatively, begin a strengthening program followed by gradual resumption of activities without the cast boot.

***Surgical Exploration and Repair of the EDL, EHL, and AT Tendons***

- Use general or regional anesthesia and a proximal thigh tourniquet. Extend the dorsal wound as necessary in proximal and distal directions. If possible, keep the incision in line with, but not over, the injured tendon to minimize adhesions with overlying skin.
- Identify the proximal and distal ends of the lacerated tendons and systematically inspect surrounding structures. After meticulous debridement and irrigation of the wound, perform a primary tendon repair. Use a core suture of nonreactive, nonabsorbable material within the tendon substance to provide primary apposition, supplemented with a whipstitch of the tendon ends with a smaller running nylon or PDS suture (Ethicon, Inc. Wayne, NJ). If end-to-end or side-to-side repair cannot be performed, use a proximal or distal Z-lengthening to provide additional length.
- Close the surgical wound extensions primarily and immobilize the foot in a neutral to slightly dorsiflexed position. The addition of toe dorsiflexion may also be required.
- Postoperatively, provide routine wound care as discussed for FHL tendon lacerations. At 6 weeks postoperatively, begin range-of-motion exercises and weight bearing in a removable cast boot. At 8 weeks postoperatively, begin a strengthening program. Finally, discontinue the cast boot once local warmth and swelling have resolved. Maintain range of motion. Motion is often limited as a result of formation of local adhesions.

### COMPLICATIONS

Placing sutures in a traumatic wound increases the risk of infection. Therefore, perform primary tendon repair only if local wound conditions are favorable. Digital nerve injury may be complicated by neuroma formation or the onset of reflex sympathetic dystrophy. Minimize the risk of posttraumatic neuroma formation by transplanting the proximal end of the lacerated digital nerve into a local muscle belly. If a painful neuroma occurs, treatment with desensitization modalities is indicated. Occasionally, referral to a pain management specialist is required.

### CONCLUSIONS

When local conditions permit, we prefer primary tendon repair, especially in the pediatric and athletic population. Because of their propensity to form neuromas, we do not repair digital nerve lacerations but transplant the proximal nerve to a well-protected location.

## FLEXOR HALLUCIS LONGUS TENDON

Injury to the FHL tendon at the ankle has been recognized mostly in runners and dancers (2,3,7,8,50,12,15,19). The FHL tendon enters the foot through a fibro-osseous tunnel along the posteromedial ankle. This is defined superiorly by the posterolateral process of the talus, and it extends inferiorly to the sustentaculum tali on the medial side of the hindfoot. The tendon undergoes a change in direction within this tunnel from vertical proximally to horizontal distally (11). As a result, it can become irritated and develop intrasubstance tears that cause it to swell and become tethered.

### CLINICAL PRESENTATION

Pain is present in the posterior ankle deep to the Achilles tendon. Deep palpation in this area may cause tenderness. The pain may be aggravated by passive motion of the great toe. With significant swelling, the tendon may become entrapped and cause triggering, leading to clawing of the great toe (2,7,8,10,12,15,19). Entrapment can be verified by comparing great toe dorsiflexion with the ankle in the plantarflexed position and when dorsiflexed. With entrapment, dorsiflexion of the toe is limited with the ankle also dorsiflexed but possible when the ankle is plantarflexed (9).

### RADIOGRAPHS

Routine radiographs will be unremarkable. The presence of a large posterior process or os trigonum may cloud the diagnosis. Magnetic resonance imaging (MRI) is a useful test for evaluating questionable cases (11,19) where fluid can be identified about the tendon in the fibro-osseous tunnel and intrasubstance tears in the tendon may also be present.

### NONOPERATIVE TREATMENT

Nonoperative treatment consists of activity limitation and nonsteroidal antiinflammatory medications for 10 to 14 days. Immobilization in a short-leg walking cast with extended toe plate to prevent great toe motion may be helpful as well.

### OPERATIVE TREATMENT

Treat athletes who do not obtain relief with conservative methods or those who have persistent triggering of the great toe with release of the fibro-osseous tunnel of the FHL. The medial approach is favored because it allows access to the entire fibro-osseous canal. Full return of function can be expected with this procedure (2,8,10,12,14,19).

***Surgical Release of the FHL Sheath***

- Use a general or regional anesthetic and a thigh tourniquet. Place a bump under the opposite thigh to aid in exposure of the medial side of the posterior ankle.
- Make a curving longitudinal incision in line with the flexor tendons posterior to the medial malleolus. Begin 5 cm above the malleolus and extend distally to the level of the navicular bone.
- Divide the flexor retinaculum in line with the incision and identify the FDL by passively moving the toes. Enter the interval behind the FDL tendon and in front of the posterior tibial artery.
- Identify the FHL tendon and protect the neurovascular bundle, which is posterior. Retract the FDL tendon anteriorly. Passive motion of the great toe will aid in identifying the FHL tendon.
- Split the sheath from proximal to distal to the level of the sustentaculum tali. Identify the neurovascular bundle over the course of this dissection to avoid injuring it. Inspect the tendon for any tears and repair them as indicated.
- Close the wound by repairing the flexor retinaculum with #0 absorbable sutures. Close the subcutaneous layer and skin and apply a posterior splint.

Postoperatively, use crutches for 1 week and then remove skin sutures. Then start weight bearing as tolerated. Start strengthening therapy but avoid training activities for 6 weeks.

## ANTERIOR TIBIALIS TENDON

## ANATOMY

The anterior tibialis (AT) muscle originates from the proximal tibia and interosseous membrane. It becomes tendinous at the level of the distal tibial metaphysis. The anterior tibialis tendon passes over the front of the ankle and runs with a straight course under the superior extensor retinaculum to attach to the dorsum of the medial cuneiform and base of the first metatarsal. It is the primary dorsiflexor of the ankle and also helps invert the foot (3). Despite its subcutaneous course, the tendon is rarely injured, probably because it does not change direction against a bony fulcrum and because of its excellent blood supply (5,20).

## CLINICAL PRESENTATION

Tendinitis can occur from overuse, particularly from hiking downhill, and has been described from direct pressure against the tendon by ski boots (20). Rupture of the anterior tibialis tendon is an unusual injury that occurs in two distinct populations. The most common presentation is in the elderly, who usually have an atraumatic rupture and typically note the insidious onset of a foot drop (9,13). The second presentation is an acute traumatic rupture in older athletes, but it can also occur in young athletes (3,13,18).

Patients with tendinitis have tenderness over the course of the tendon and pain on resisted dorsiflexion of the ankle. A rupture can be diagnosed by a visual or palpable defect in the tendon, foot drop, and weakness of ankle dorsiflexion (Fig. 94.1).

***Figure 94.1.*** Rupture of anterior tibialis tendon. The ruptured anterior tibialis tendon has retracted, leaving a soft-tissue prominence on the dorsum of the foot.

## RADIOGRAPHS

Plain radiographs are unremarkeable. The rupture can be easily identified with an MRI scan (11,13). This is essentially a clinical diagnosis, however, and an MRI is usually not necessary.

## TREATMENT

Treat tendinitis with activity limitation and nonsteroidal medications. If pain is caused by direct pressure against the tendon, remove the irritant.

Chronic rupture in the older patient may be satisfactorily treated with a brace or may even be left untreated (1). The acute rupture is probably best treated with surgical reconstruction. In cases in which it is recognized early, a direct repair of the tendon is possible (9,13,18,20). If it has been unrecognized for several months, reconstruction with either an EHL tendon transfer or interposition of an EDL tendon graft may be used, allowing return to recreational activities (13).

## CHAPTER REFERENCES

Each reference is categorized according to the following scheme: *, classic article; #, review article; !, basic research article; and +, clinical results/outcome study.


+ 1. Bernstein RM. Spontaneous Rupture of the Tibialis Anterior Tendon. *Am J Orthop* 1995;24:354.

+ 2. Cowell HR, Elener V. Bilateral Tendonitis of the Flexor Hallucis Longus in a Ballet Dancer. *J Pediatr Orthop* 1982;2:582.

+ 3. Frey C, Shereff M. Tendon Injuries About the Ankle in Athletes. *Clin Sports Med* 1988;7:103.

+ 4. Floyd DW, Heckman JD, Rockwood CA. Tendon Lacerations in the Foot. *Foot Ankle* 1983;4:8.

! 5. Geppert MJ, Sobel M, Hannafin JA. Microvasculature of the Tibialis Anterior Tendon. *Foot Ankle* 1993;14:261.

+ 6. Griffiths JC. Tendon Injuries About the Ankle. *J Bone Joint Surg* 1965;47B:686.

# 7. Hamilton WG. Foot and Ankle Injuries in Dancers. In: Mann RA, Coughlin MJ, eds. *Surgery of the Foot and Ankle.* St. Louis: CV Mosby, 1993;1241.

+ 8. Hamilton WG. Stenosing Tenosynovitis of the Flexor Hallucis Longus Tendon and Posterior Impingement upon the Os Trigonum in Ballet Dancers. *Foot Ankle* 1982;3:74.

# 9. Jones DC. Tendon Disorders of the Foot and Ankle. *J Am Acad Orthop Surg* 1993;1:87.

+ 10. McCarroll JR, Ritter MA, Becker TE. Triggering of the Great Toe: A Case Report. *Clin Orthop* 1983;175:184.

+ 11. Mink JH, Deutsch AL, Kerr R. Tendon Injuries of the Lower Extremity: Magnetic Resonance Assessment. *Top Magn Reson Imag* 1991;3:23.

+ 12. Newman NM, Fowles JV. A Case of “Trigger Toe.” *Can J Surg* 1984;27:378.

+ 13. Ouzounian TJ, Anderson R. Anterior Tibial Tendon Rupture. *Foot Ankle* 1995;16:406.

+ 14. Sammarco GJ, DiRaimondo CV. Chronic Peroneus Brevis Tendon Lesions. *Foot Ankle* 1989;9:163.

+ 15. Sammarco GJ, Miller EH. Partial Rupture of the Flexor Hallucis Longus Tendon in Classical Ballet Dancers. *J Bone Joint Surg* 1979;61:149.

# 16. Sarrafian SK. Myology. In: Sarrafian SK, ed. *Anatomy of the Foot and Ankle, 2nd ed.* Philadelphia: JB Lippincott, 1993;240.

# 17. Sarrafian SK. Tendon sheaths and bursae. In: Sarrafian SK, ed. *Anatomy of the Foot and Ankle, 2nd ed.* Philadelphia: JB Lippincott, 1993;283.

+ 18. Stuart MJ. Traumatic Disruption of the Anterior Tibial Tendon while Cross-Country Skiing: A Case Report. *Clin Orthop* 1992;281:193.

+ 19. Trepman E, Mizel MS, Newberg AH. Partial Rupture of the Flexor Hallucis Longus Tendon in a Tennis Player: A Case Report. *Foot Ankle* 1995;16:227.

+ 20. Trevino S, Baumhauer JF. Tendon Injuries of the Foot and Ankle. *Clin Sports Med* 1992;11:727.

# CHAPTER 95

# ANKLE LIGAMENT INJURIES

*Richard A. Marder*

**R. A. Marder:** Department of Orthopaedic Surgery, University of California, Davis, School of Medicine, Sacramento, California 95817.

Pathomechanics
Clinical Assessment of Acute Lateral Sprains
Specialized Tests: Anterior Drawer and Talar Tilt Tests
Radiography
Ankle Arthrography and MRI
Diagnosis and Classification
Treatment of Acute Injuries
Nonoperative Treatment
Acute Surgical Repair
Postinjury Sequelae
Chronic Lateral Ankle Instability
Clinical Assessment
Treatment
Syndesmosis Sprain
Clinical Assessment
Radiographs
Nonoperative Treatment
Operative Treatment
Postinjury Sequelae
Sprains of the Deltoid Ligament
Chapter References

Sprains of the lateral ankle ligaments are among the most common musculoskeletal injuries (32). Most injuries are mild and heal uneventfully, but as many as 20% of patients develop chronic lateral instability (4,22,23,34,49). Injuries of the distal tibiofibular ligaments (syndesmosis sprains) are often associated with a protracted course of recovery and, in the case of extensive injury, can cause diastasis of the ankle mortise leading to subsequent arthritis (18).

## PATHOMECHANICS

Of the three lateral ankle ligaments reinforcing the tibiotalar capsule, the anterior talofibular (ATaF) and calcaneofibular (CF) ligaments are the most clinically significant (8), functioning in reciprocal fashion to resist inversion loads applied to the ankle (33). The ATaF progressively tightens as the ankle is moved from dorsiflexion through plantarflexion, with the CF developing maximal tautness in dorsiflexion (13,48).

Injury to the lateral ligaments typically occurs when excessive inversion force is applied to the plantarflexed ankle during loading or unloading of the foot. Sequentially, the ATaF is torn, followed by the CF and, ultimately, the posterior talofibular ligament (PTaF) (1,6,17,47). The spectrum of injury ranges from a mild sprain of one ligament to frank rupture of both. Rarely, the PTaF is the ultimate ligament to fail, an event that can cause frank dislocation of the ankle. Although isolated injury of the ATaF is common, isolated rupture of the CF is clinically unlikely (7,47).

The ankle mortise is stabilized by the anterior and posterior tibiofibular ligaments (ATF and PTF), the inferior transverse ligament, and the interosseous ligament. The ATF develops increasing strain with external rotation of the talus, and both tibiofibular ligaments undergo elongation with ankle dorsiflexion (13,14). The spectrum of injury to the syndesmosis can include latent or frank diastasis of the ankle mortise.

## CLINICAL ASSESSMENT OF ACUTE LATERAL SPRAINS

A comprehensive clinical assessment is required to properly evaluate the acutely sprained ankle (41) and is paramount to avoid missing adjacent injuries such as Achilles tendon rupture, peroneal tendon dislocation, or severe midfoot injury (Table 95.1). The mechanism may provide a clue to the type of injury: an inversion mechanism suggests a lateral ligament sprain, whereas a dorsiflexion or external rotation injury points to the possibility of a syndesmosis injury. A “pop” or tearing sensation combined with pain that precludes weight bearing as well as rapid swelling usually indicates a more severe injury.

| |
|---|
| Malleolar or physeal fracture |
| Fibular fracture |
| Anterior process of calcaneus fracture |
| Lateral process of talus fracture |
| Osteochondral fracture of talus |
| Fifth metatarsal fracture |
| Peroneal tendon subluxation/dislocation |
| Achilles tendon rupture |
| Subtalar injury |
| Midfoot sprain (tarsometatarsal disruption) |

***Table 95.1. Differential Diagnosis of Lateral Ankle Injuries***

Swelling and delayed ecchymosis are common. For the first few hours swelling remains localized and can aid in diagnosis. Swelling confined to the inframalleolar area that occurs with a lateral ligament sprain can be differentiated from the supramalleolar swelling seen in a syndesmosis injury as well as the more distal swelling seen over the sinus tarsi and midfoot that accompanies a subtalar or midfoot sprain. Localized tenderness is suggestive of but not specific to individual ligament injury. Palpate the malleoli, the entire fibula, joint margins, and tendons about the ankle, confirming structural integrity and eliciting any tenderness and crepitus. Tenderness proximal to the ankle joint is characteristic of a syndesmosis injury. Active and passive motion of the ankle is painful and decreased in both types of sprains. Measurement of motion does not aid in diagnosis or determination of severity. In addition to ascertaining the integrity of the Achilles by squeezing the calf muscles and looking for plantar flexion (31), assess the function of the peroneal tendons by active dorsiflexion and eversion. An important part of the exam is assessment of pedal pulses and the motor and sensory function of the ankle and foot. Peroneal compartment syndrome as well as traction injuries of the posterior tibial and peroneal nerves have been described in severe sprains (44,50).

## SPECIALIZED TESTS: ANTERIOR DRAWER AND TALAR TILT TESTS

Tests to evaluate stability of the lateral ankle ligaments include the anterior drawer test (ADT), which measures displacement of the talus in relation to the tibia (1,16). The primary restraint to the ADT is the anterior talofibular ligament. Injury of the calcaneofibular ligament does not affect the ADT (37). The preferred testing position is 10° of ankle plantarflexion, which allows maximum anterior talar translation (27). This test usually can be performed in the presence of swelling without inducing significant discomfort, as can Lachman's test for rupture of the anterior cruciate ligament of the knee. Stabilizing the distal leg with one hand, apply an anterior force to

the heel using the fingers while the thumb rests along the anterior aspect of the ankle over the talus. An increase of 3 to 5 mm side-to-side difference (STSD) on the ADT indicates rupture of the anterior talofibular ligament (1,25,26).

The talar tilt test (TTT) assesses both the anterior talofibular (primary restraint) and calcaneofibular (secondary restraint) ligaments. Performed in 10° of plantarflexion, the test also measures inversion of both the tibiotalar and subtalar joints. Palpating with the thumb along the tibiotalar joint allows an estimation of talar tilt to be made. A STSD of at least 5° on the TTT indicates rupture of both the anterior talofibular and calcaneofibular ligaments (9,10,15). Unlike the ADT, the TTT is often difficult to perform in the acute injury because of pain and swelling. In addition, in the chronic injury, it may prove difficult to differentiate subtalar motion. If abnormal laxity is suspected, the talar tilt test should be assessed using stress radiographs.

## RADIOGRAPHY

Take anteroposterior (AP), mortise, and lateral radiographs of the ankle after suspected injury of the lateral ankle ligaments. These radiographs may reveal associated osteochondral injuries, avulsion fractures of the collateral ligaments from the distal fibula, unsuspected widening of the mortise, as well as unsuspected fractures of the malleoli. Occasionally, additional radiographic views are necessary. If swelling and tenderness appear distal to the lateral malleolus along the lateral foot, include a medial oblique and an AP view of the foot to exclude fractures of the anterior process of the calcaneus or base of the fifth metatarsal.

Take stress radiographs on a case-by-case basis. If the anterior drawer and talar tilt tests are negative on physical examination, then stress radiographs are unnecessary. If clinical laxity is apparent, the specific degree of abnormal translation can be documented by obtaining both anterior drawer and talar tilt stress radiographs (Fig. 95.1 and Fig. 95.2). If desired, 15 ml of 1% lidocaine can be injected into the ankle for pain relief. The amount of anterior talar translation is measured as the distance from a constant point on the posterior aspect of the talus to the posterior lip of the tibia. Talar tilt is measured as the degree of angulation of the superior aspect of the talus as referenced against the neutral position of tibial plafond.

***Figure 95.1.*** Stress radiograph of a positive anterior drawer test (ADT).

***Figure 95.2.*** Abnormal stress radiographic talar tilt test (TTT) with more than 10° STSD: (**A**) injured ankle; (**B**) uninjured.

## ANKLE ARTHROGRAPHY AND MRI

Previously, ankle arthrography as well as peroneal tonography were utilized to diagnose lateral ankle ligament tears. Because so few acute lateral ligament injuries require early surgery, these studies are now rarely performed. Magnetic resonance imaging (MRI), although capable of demonstrating the anatomy of the injury, is best used for diagnosing suspected osteochondral lesions of the talus and peroneal tendon tears.

## DIAGNOSIS AND CLASSIFICATION

Individual ligament injuries are usually graded as mild, moderate, or severe depending on the degree of injury. Grading is more difficult in the ankle than in other structures because injuries can involve combinations of capsular rupture as well as partial or complete tearing of one or more ligaments. Black (3) introduced the concept of single-and double-ligament injuries, and Singer and Jones (50) popularized the concept of stable and unstable injuries. Table 95.2 is a compilation of various classification criteria to provide a useful system for characterizing these injuries (29,45,50). Stable injuries consist of a partial or complete tear of the anterior talofibular ligament alone or with at most a partial tear of the calcaneofibular ligament. Unstable injuries involve complete tears of both ligaments. In a stable injury the ADT alone may be slightly positive (3–5 mm STSD); in an unstable injury, however, the ADT will be markedly positive (>5 mm STSD), and the TTT will show more than 5° to 10° of STSD.

| Injury grade | Functional grade | Anatomic injury[a] | Laxity test[a] | Recovery |
|---|---|---|---|---|
| I | Stable | Partial tear ATaF, intact CF | − ADT<br>− TTT | 1–3 weeks |
| II | Stable | Complete tear ATaF, +/− partial tear CF | + ADT<br>− TTT | 2–6 weeks |
| III | Unstable | Complete tear ATaF, complete tear CF | + ADT<br>+ TTT | 4–10 weeks |

[a] Abbreviations: ATaF, anterior talofibular; ADT, anterior drawer test; CF, calcaneofibular; TTT, talar tilt test.

***Table 95.2. Classification of Lateral Ankle Sprains***

For the purposes of injury management, it is useful to differentiate stable from unstable sprains as well as to identify those patients with one of the following factors: (a) bony avulsion or osteochondral fragment or (b) acute injury superimposed on chronic, recurrent lateral instability.

## TREATMENT OF ACUTE INJURIES

The goals of treatment are to achieve a stable, painless ankle with normal motion and to minimize the time lost from activity. Although operative repair of significant ligament injuries has been the standard previously, control studies have shown no difference between the results of surgery and of nonoperative methods (20,22,34,43).

### NONOPERATIVE TREATMENT

#### *Stable Lateral Sprain*

Nonoperative treatment is indicated for stable lateral sprains. Initially use splinting and crutches until weight bearing is nonpainful and there is no limp. Prescribe range-of-motion (ROM) exercises and such modalities as ice, whirlpool, and electrical stimulation, as pain allows. Start dorsiflexion and peroneal strengthening exercises. Most patients can return to activity within 2 to 4 weeks.

#### *Unstable Lateral Sprain*

If supervised therapy is not available or the patient is unlikely to cooperate with the treatment schedule, then initial splinting and elevation followed by immobilization by a short-leg weight-bearing cast or a controlled ankle motion (CAM) walker is used to treat all unstable injuries for a period of 3 to 4 weeks. If access to therapy exists, prescribe an early functional rehabilitation program similar to that advocated by Garrick (24). Initial treatment utilizes intermittent cryotherapy and mechanical compression, splinting with a removable compression splint incorporating a felt horseshoe pad around the lateral malleolus or a U-shaped splint, and avoiding weight bearing until ambulation is nonpainful and there is no limp. Begin a program of ankle range of motion, peroneal and dorsiflexion muscle strengthening, followed by functional exercises (tilt board, jump rope, hopping). Depending on severity of injury, return to activity can take 4 to 10 weeks. Use of taping, an orthosis, and even high-top shoes may help decrease the likelihood of future sprains (28,39,46).

### ACUTE SURGICAL REPAIR

For bony avulsion injuries, use the approach to the distal fibula described in Chapter 3. Usually only one 4.0-mm cancellous screw can be inserted (Fig. 95.3). Protect the ankle in a splint for 1 week and have the patient use a CAM walker until clinical and radiographic evidence of union are seen (usually 6–8 weeks).

***Figure 95.3.*** ORIF of avulsion injury of the lateral malleolus.

Especially in the high-performance athlete, when a severe sprain occurs superimposed on a pattern of chronic recurrent instability, acute surgery may be necessary. For repair of these injuries, use the approach described for delayed repair (modified Brostrom) (6,7).

### POSTINJURY SEQUELAE

A number of patients continue to experience residual symptoms after a “routine” inversion sprain (Table 95.3). Common postsprain complications include ankle pain secondary to osteochondral lesions, ossicles, or the development of soft-tissue impingement syndrome at the anterolateral corner of the tibiotalar articulation (2,21,42). The most frequent problem, however, is recurrent instability.

| |
|---|
| Recurrent lateral instability |
| Osteochondral lesion of the talus |
| Soft-tissue impingement in the ankle (meniscoid lesion) |
| Tibiotalar synovitis |
| Ossicles, loose bodies |
| Subtalar instability, synovitis |
| Concomitant peroneal tendon subluxation or tear (peroneus brevis) |

***Table 95.3. Causes of Continuing Symptoms after Lateral Ankle Sprains***

## CHRONIC LATERAL ANKLE INSTABILITY

### CLINICAL ASSESSMENT

Following one or more inversion injuries, the patient may note continuing pain, swelling, giving way, or functional instability associated with pivoting and twisting on the affected ankle and foot. Physical examination demonstrates peroneal weakness and calf atrophy, tenderness to palpation over the lateral ligaments with chronic soft-tissue swelling, and, most significantly, abnormal laxity during the anterior drawer and the talar tilt tests. Routine radiographs may demonstrate ossicles about the tip of the lateral malleolus. The key to establishing the diagnosis is demonstration of abnormal laxity using stress radiographs, as previously described.

If radiography does not confirm laxity, consider another diagnosis. Peroneal subluxation can be diagnosed by observing retromalleolar tenderness and crepitus, with the ability to displace the tendons on examination or spontaneous subluxation of the tendons from the peroneal groove on active dorsiflexion and eversion of the foot and ankle. Suspect subtalar instability, which can mimic or coexist with lateral ankle instability, if total subtalar inversion exceeds that of the normal side. Subtalar instability, however, may go undetected unless stress radiographs are obtained or stress tomography of the subtalar joint is performed (38). In the absence of mechanical instability, loose bodies or ossicles of the tip of the lateral malleolus can produce symptoms of instability. Functional instability, as popularized by Freeman et al. (22), occurs from loss of proprioception after lateral ligament injury and is ameliorated by the same nonoperative exercise program utilized for mechanical instability.

### TREATMENT

#### *Nonoperative Treatment*

The majority of patients with symptomatic mechanical instability of the ankle respond to a program of peroneal strengthening, proprioceptive training, and use of an

ankle orthosis or brace or taping. A tilt board is especially helpful to recondition the ankle and lower leg and facilitates the transition back to sports.

### *Operative Treatment*

There are two main types of surgical procedures: delayed repair of the torn ligaments (7,13) and reconstruction (11,12,19,53). Success rates are approximately 85% for each procedure (11,12,19,26,29,53). In most instances, delayed primary repair of the anterior talofibular and calcaneofibular ligaments is possible and, as such, is the procedure of choice. Potential disadvantages of reconstructive procedures include limitation of ankle and subtalar motion by the nonanatomic location of the tendon graft and local morbidity from graft harvest (8,12). Indications for reconstruction as opposed to delayed primary repair include severe lateral ankle instability of long duration, evidence of subtalar hypermobility, or failure of a previous repair or reconstruction.

#### Delayed Primary Repair (Modified Brostrom)

- Arthroscopy as described in Chapter 93 is useful as the initial procedure because a number of patients may have chondral lesions of the medial talar dome. Before performing arthroscopy, mark the lateral branches of the superficial peroneal nerve as they cross the ankle to the foot. Plantarflexion of the ankle facilitates this procedure.
- Place a bump underneath the ipsilateral hip of the supine patient to allow internal rotation of the foot and ankle, exposing the lateral malleolus. Prepare the skin and drape the extremity free.
- Under tourniquet control, incise the skin (Fig. 95.4) using an oblique incision, starting along the anterior border of the lateral malleolus 2 to 3 cm proximal to the tip, passing inferiorly to end proximal to the visible and palpable peroneal tendons. Alternatively, with the ankle in maximum equinus, make the skin incision immediately posterior to the prominence of the lateral malleolus starting 3 cm proximal to the tip and following the peroneal tendons distally (Fig. 95.5). This incision completely avoids the lateral branches of the superficial peroneal nerve and the sural nerve, provides better access to the calcaneofibular ligament, and can be extended to perform an anatomic reconstruction with split peroneus brevis tendon, if necessary.

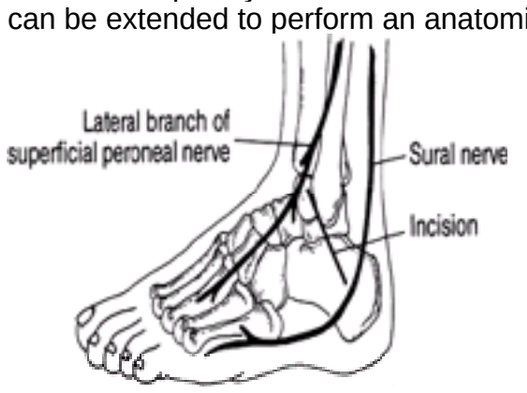


***Figure 95.4.*** Oblique skin incision for modified Brostrom repair. Note proximity of branches of superficial peroneal and sural nerves to ends of incision. (From Mann RA, Coughlin MC. *Video Textbook of Foot and Ankle Surgery.* St. Louis: Medical Video Productions, 1991.)

***Figure 95.5.*** With ankle plantarflexed, a longitudinal incision centered over the posterior aspect of the lateral malleolus allows access to lateral ankle ligaments. Proximal and distal extension (*dotted lines*) of the incision enables reconstruction using peroneus brevis tendon graft.

- Protect the lateral branches of the superficial peroneal nerve along the anterior extent of the incision and the sural nerve inferiorly and posteriorly as the subcutaneous tissue is incised. Palpate the talus and the tip of the fibula while passively moving the ankle to avoid inadvertently opening the subtalar joint.
- Starting anteriorly, incise the capsule and the normally attenuated anterior talofibular and calcaneofibular ligaments 5 mm from their insertion on the fibula (Fig. 95.6). Do not transect the ligaments more than midway from their fibular attachment points to avoid overtightening. For better exposure of the calcaneofibular ligament, open the sheath and posteriorly retract the peroneal tendons.

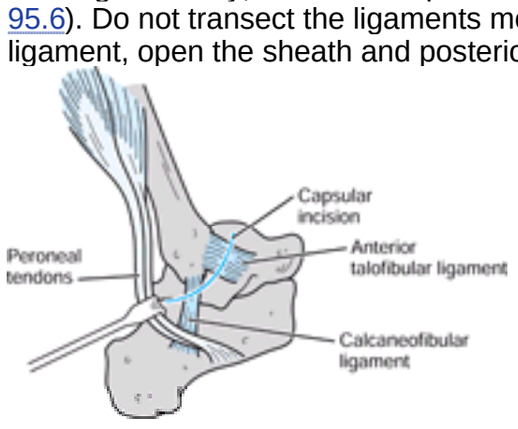


***Figure 95.6.*** Capsular incision for ATaF and CF ligament repair.

- Inspect the joint if it has not already been examined arthroscopically, debride chondral lesions, and remove loose bodies, as necessary.
- Preserving the proximal attachments of the anterior talofibular and calcaneofibular ligaments, perform gentle subperiosteal dissection of their fibular attachments in order to roughen the fibular surface for improved healing.
- Place two 1-0 nonabsorbable sutures in each distal ligament using a horizontal mattress-weaving configuration and advance the distal ligaments under the tips of their respective proximal attachments (Fig. 95.7). Tie the sutures on the anterior aspect while the ankle and foot are maintained in neutral flexion and slight eversion. Next, imbricate the proximal end of each ligament over its distal end in a vest-over-pants manner.

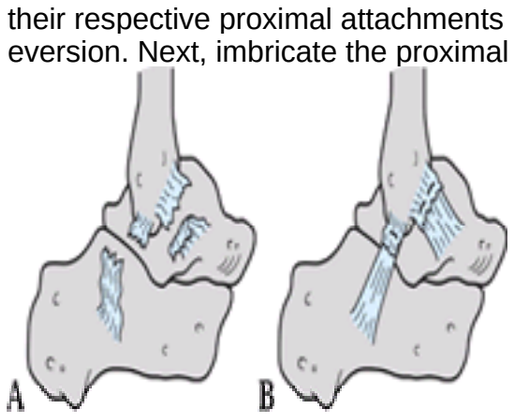


***Figure 95.7.*** A: Isolate and transect the ATaF and CF ligaments. B: Overlap and imbricate the ligaments.

- Repair the peroneal tendon sheath and the joint capsule with 2-0 absorbable suture. If additional support for the repair is desired, mobilize the inferior extensor retinaculum from the sinus tarsi and imbricate it to the fibular periosteum proximal to the ligament repair (26). This maneuver requires placing the foot in maximum eversion.
- Close the skin with interrupted 4-0 nylon sutures and apply a short-leg, well-padded U-shaped splint to maintain the ankle and foot in neutral position.

*Postoperative Management* Prescribe protected weight bearing until 10 days postoperatively, at which time remove the splint and sutures. Apply a short-leg walking cast or have the patient use a CAM walker for an additional 5 weeks. Start rehabilitation to regain active ankle and subtalar motion. As motion is regained, add resistive exercises for the peroneals and dorsiflexors of the ankle together with a tilt board for proprioceptive conditioning. Once motion is restored and strength is 90% that of the normal ankle, begin functional exercises including running and pivoting. The patient usually returns to activity by 3 to 4 months. Taping or use of an ankle orthosis is recommended during the first year after surgery.

### Reconstruction of the Lateral Ankle Ligaments

Reconstruction of the lateral ankle ligaments requires precise placement of the tendon graft to replicate normal anatomy, thereby avoiding the limitation of subtalar motion that occurs with the traditional Watson Jones and Chrisman Snook procedures (14). Anatomic reconstruction yields similar success in stabilizing the ankle (85%) without limiting subtalar motion (14) (refer to Fig. 95.8).

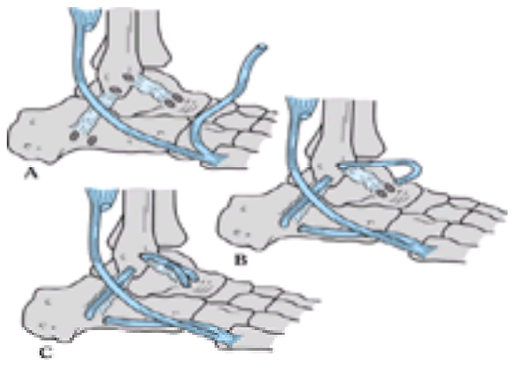


***Figure 95.8.*** Anatomic reconstruction for chronic lateral ligament laxity. **A:** Anterior half of peroneus brevis is harvested, leaving distal insertion intact. Drill holes are made in the calcaneus, fibula, and talar neck as described in the text. **B:** Split tendon is passed through the drill holes in the calcaneus and fibula. **C:** Tendon graft is passed through talar neck drill holes and sutured to itself.

- Position the patient supine with a bump beneath the ipsilateral hip. With the ankle in plantarflexion, make a 15-cm longitudinal incision centered over the prominence of the lateral malleolus and extending toward the base of the fifth metatarsal.
- Protect the sural nerve, which lies in the posterior portion of the incision. Open the peroneal tendon sheath and identify the peroneus brevis tendon running anterior to the peroneus longus at the ankle. Traction on the peroneus longus causes the hallux metatarsal to flex in a plantar direction. Dissect the muscle of the peroneus brevis from the anterior two thirds of the peroneus brevis tendon, splitting the tendon longitudinally to its attachment to the base of the fifth metatarsal (Fig. 95.8*A*). Place a whipstitch (#2 nonabsorbable suture) tapering the free end of the graft to ease passage through the bony tunnels.
- Make bony tunnels in the calcaneus, fibula, and talus with a 4.5-mm drill bit. Make a transverse tunnel at the calcaneal insertion of the CF ligament. Maintaining a 1-cm bony bridge, start both tunnels at 45° angles to converge beneath the cortical bridge. Connect and enlarge the drill holes with a curette. Now, at the fibular origin of the calcaneofibular ligament, drill a tunnel from posterior to anterior that exits at the origin of the anterior talofibular ligament. Next, drill a vertical tunnel on the neck of the talus at the insertion of the anterior talofibular ligament.
- Before passing the tendon graft, imbricate the anterior talofibular and calcaneofibular ligaments as described in the section on delayed primary repair. Pass the tendon graft sequentially through the calcaneal, fibular, and talar tunnels (Fig. 95.8*B*). Coating the tendon with mineral oil and using a commercially available curved suture passer are helpful in passing the graft.
- Position the ankle in neutral and the foot in near maximum eversion. Tighten the peroneal tendon graft. First, suture the graft (#0 absorbable suture) to the calcaneofibular ligament origin and insertion. Tighten the graft again and suture the free end of the graft to the anterior talofibular limb (Fig. 95.8*C*).
- Check that ankle and subtalar motion are preserved. Repair the peroneal tendon sheath at the level of the lateral malleolus (2-0 absorbable suture). Release the tourniquet, obtain hemostasis, and close the subcutaneous layer. Close the skin with interrupted 3-0 nylon mattress sutures. Apply a well-padded posterior splint.

*Postoperative Management* At 1 week remove the sutures and immobilize the ankle and foot in a short leg cast, allowing weight bearing as tolerated. At 6 weeks discontinue immobilization and start rehabilitation using the same schedule as for delayed primary repair. Patients can return to sports at 6 months. An ankle brace or orthosis is used for the first year of activity.

## SYNDESMOSIS SPRAIN

Often initially misdiagnosed as a lateral ankle sprain, injury to the syndesmosis can have significant ramifications including prolonged recovery from injury, ossification of the syndesmosis, and diastasis of the ankle mortise if complete ligament rupture occurs (5). Diastasis, latent or frank, can cause symptoms of instability, loss of power with push-off, and eventually arthrosis of the ankle joint (18).

### CLINICAL ASSESSMENT

Initially, swelling is supramalleolar but eventually spreads to involve the entire ankle. Tenderness is present over the anterior inferior tibiofibular ligament just above the ankle joint margin and may extend to the posterior aspect of the distal tibiofibular joint but does not extend to the inframalleolar region laterally. Tenderness along the deltoid ligament medially in the absence of tenderness of the lateral ankle ligaments should raise suspicion of a syndesmosis injury. Compression of the malleoli and squeezing of the midcalf (31), compressing hematoma within the injured syndesmosis, are quite painful. The usual ankle laxity tests are negative.

### RADIOGRAPHS

Obtain AP, lateral, and mortise views. If proximal tenderness is present, include the entire tibia and fibula to avoid missing an extensive syndesmosis rupture with associated proximal fibula fracture. On the AP view, the fibula should overlap the tibia by 42% of the width of the fibula, and on the mortise view the separation of the tibia and fibula should not exceed 5 mm (30). A comparison view is helpful (Fig. 95.9). Radiographic evidence of lateral talar shift in the absence of a fibula fracture confirms combined rupture of the deltoid ligament and syndesmosis (Fig. 95.10). If latent diastasis is suspected, obtain a stress AP or mortise view by applying external rotation to the foot and ankle.

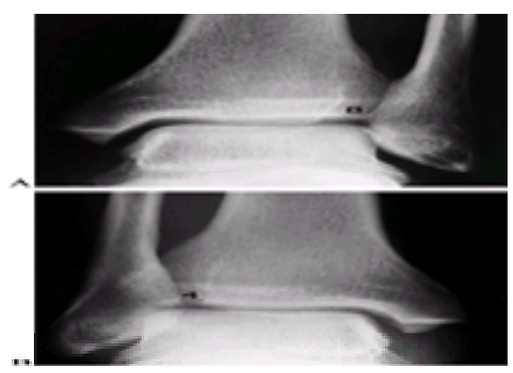

***Figure 95.9.*** Syndesmosis disruption (**A**) compared to normal mortise (**B**).

***Figure 95.10.*** Lateral talar shift confirming deltoid ligament tear associated with syndesmosis rupture.

### NONOPERATIVE TREATMENT

In the absence of diastasis and instability, the keys to successful early resolution are to keep the limb immobilized and have the patient keep weight off it. Between sessions for range-of-motion exercises and therapeutic modalities, immobilize the injury in either a bivalved short leg cast or a CAM walker. Do not allow weight bearing until the ankle is nonpainful and the patient is able to walk unprotected without a limp—usually 3 to 4 weeks but possibly up to 6 weeks. Thereafter, treatment is similar to that of a lateral ankle sprain.

### OPERATIVE TREATMENT

- If diastasis is present, either frank or latent, surgery is necessary.
- Anatomic reduction of the fibula into the sulcus on the tibia in both the medial–lateral and anteroposterior planes is essential. Fixation can be done using closed percutaneous technique, or the syndesmosis can be opened if reduction is uncertain or the injury is old and interposed scar tissue prevents reduction. Maintain closed reduction of the syndesmosis by a positional, nonlagged 3.5-mm cortical screw. In large men, a 4 to 5-mm cortical screw may be necessary to prevent breakage. Placed 2 to 3 cm above the tibiotalar joint, the screw should engage both fibular and tibial cortices.
- Postoperatively, use a well-padded U-splint for 1 week and then start ROM exercises and peroneal and dorsiflexor strengthening. Allow protected weight bearing for 3 to 4 weeks. If desired, remove the screw before return to sports at 2 to 3 months, although breakage is not likely (36).

### POSTINJURY SEQUELAE

Following a syndesmosis sprain, persistent pain and weakness with push-off during running and jumping are not uncommon. These symptoms may last for more than a year in the high-performance athlete. Stiffness of the ankle may develop as a result of ossification of the syndesmosis ligaments (Fig. 95.11). After ossification, patients experience a greater incidence of inversion sprains of the ankle (52). Excision of the ossification is usually not necessary, however.

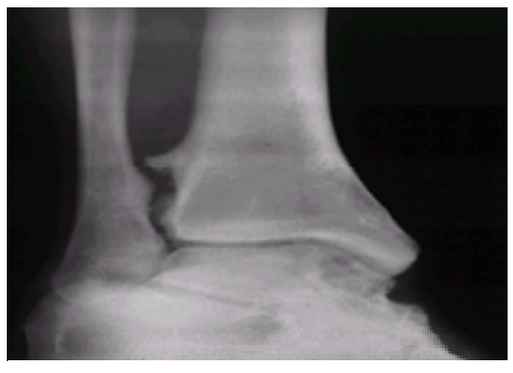

***Figure 95.11.*** Posttraumatic syndesmosis ossification.

## SPRAINS OF THE DELTOID LIGAMENT

Isolated sprains of the deltoid ligament on the medial side of the ankle are much less common than lateral injuries. Rupture of the deltoid ligament commonly accompanies fractures of the lateral malleolus because of external rotation-eversion or abduction injuries. These fractures are usually treated with internal fixation. Exploration and repair of the deltoid ligament is rarely required unless interposition prevents reduction or an osteochondral fracture is suspected.

Isolated sprains are characterized by an external rotation or ankle eversion injury with medial ankle pain. Physical examination usually provides the diagnosis, as there is localized tenderness and swelling directly over the ligament. Grade I tears are anterior and progress posteriorly as the tear increases in severity. There may be instability on eversion stress. Radiographs may be necessary to rule out a fracture. Other conditions that may mimic a deltoid ligament tear include injuries to the posterior tibial tendon or spring ligament.

Treat all grades of deltoid ligament tear nonoperatively. Stable injuries can be treated as described for lateral ligament sprains. More severe sprains that are very painful or are unstable may require use of a short leg walking cast or CAM walker for 3 to 4 weeks.

### CHAPTER REFERENCES

Each reference is categorized according to the following scheme: *, classic article; #, review article; !, basic article; and +, clinical results/outcome study.


+ 1. Anderson KJ, Lecocq JF, Lecocq EA. Recurrent Anterior Subluxation of the Ankle Joint: A Preliminary Report of Two Cases and an Experimental Study. *J Bone Joint Surg [Am]* 1952;34:853.

+ 2. Bassett FH III, Gates HS, Billys JB, et al. Talar Impingement by the Anterioinferior Tibiofibular Ligament. *J Bone Joint Surg [Am]* 1990;72:55.

+ 3. Black HM, Brand RL, Eichelberger MF. An Improved Technique for the Evaluation of Ligamentous Injury in Severe Ankle Sprains. *Am J Sports Med* 1978;6:276.

# 4. Boruta PM, Bishop JO, Braly WG, et al. Acute Lateral Ankle Ligament Injuries: A Literature Review. *Foot Ankle* 1990;11:107.

+ 5. Boytim MJ, Fischer DA, Neumann L. Syndesmotic Ankle Sprains. *Am J Sports Med* 1991;19:294.

+ 6. Brostrom L. Sprained Ankles. I. Anatomic Lesions in Recent Sprains. *Acta Chir Scand* 1964;128:483.

+ 7. Brostrom L. Sprained Ankles. VI. Surgical Treatment of “Chronic” Ligament Ruptures. *Acta Chir Scand* 1966;132:551.

! 8. Burks RT, Morgan J. Anatomy of the Lateral Ankle Ligaments. *Am J Sports Med* 1994;22:72.

# 9. Cass JR, Morrey BF. Ankle Instability: Current Concepts, Diagnosis, and Treatment. *Mayo Clin Proc* 1984;59:165.

! 10. Cass JR, Settles H. Ankle Instability: *In Vitro* Kinematics in Response to Axial Load. *Foot Ankle* 1994;15:134.

+ 11. Chrisman OD, Snook GA. Reconstruction of the Lateral Ligament Tears of the Ankle: An Experimental Study and Clinical Evaluation of Seven Patients Treated by a New Modification of the Elmslie procedure. *J Bone Joint Surg [Am]* 1969;51:904.

+ 12. Colville MR, Grondel RJ. Anatomic Reconstruction of the Lateral Ankle Ligaments Using a Split Peroneus Brevis Tendon Graft. *Am J Sports Med* 1995;23:210.

! 13. Colville MR, Marder RA, Boyle JJ, et al. Strain Measurement in Lateral Ankle Ligaments. *Am J Sports Med* 1990;18:196.

! 14. Colville MR, Marder RA, Zarins B. Reconstruction of the Lateral Ankle Ligaments: A Biomechanical Analysis. *Am J Sports Med* 1992;20:594.

+ 15. Cox JS. Surgical and Nonsurgical Treatment of Acute Ankle Sprains. *Clin Orthop* 1985;198:118.

* 16. Dehne E. Die Klinkik der Frischen und Habituellen Adduktionssupinationsdistorsion des Fusses. *Dtsch Z* 1934;242:40.

! 17. Dias LD. The Lateral Ankle Sprain: An Experimental Study. *J Trauma* 1979;19:266.

+ 18. Edwards GS Jr, DeLee JC. Ankle Diastasis without Fracture. *Foot Ankle* 1984;4:305.

* 19. Evans DL. Recurrent Instability of the Ankle: A Method of Surgical Treatment. *Proc R Soc Med* 1953;46:343.

+ 20. Evans GA, Hardcastle P, Frenyo AD. Acute Rupture of the Lateral Ligament of the Ankle: To Suture or Not to Suture? *J Bone Joint Surg [Br]* 1984;66:209.

+ 21. Ferkel RD, Karzel RP, Del Pizzo W, et al. Arthroscopic Treatment of Anterolateral Impingement of the Ankle. *Am J Sports Med* 1991;19:440.

+ 22. Freeman MAR. Treatment of Ruptures of the Lateral Ligaments of the Ankle. *J Bone Joint Surg [Br]* 1965;47:661.

+ 23. Freeman MAR, Dean MRE, Hanham IWF. The Etiology and Prevention of Functional Instability of the Foot. *J Bone Joint Surg [Br]* 1965;47:678.

+ 24. Garrick JG. When Can I... ? A Practical Approach to the Rehabilitation, Illustrated by Treatment of an Ankle Injury. *Am J Sports Med* 1981;9:67.

+ 25. Glasgow M, Jackson A, Jamieson AM. Instability of the Ankle after Injury to the Lateral Ligament. *J Bone Joint Surg* 1980;62B:196.

+ 26. Gould N, Seligson D, Gassman J. Early and Late Repair of Lateral Ligaments of the Ankle. *Foot Ankle* 1980;1:84.

+ 27. Grace DL. Lateral Ankle Ligament Injuries: Inversion and Anterior Stress Radiography. *Clin Orthop* 1984;183:153.

+ 28. Green TA, Hillman SK. Comparison of Support Provided by a Semirigid Orthosis and Adhesive Ankle Taping Before, During, and After Exercise. *Am J Sports Med* 1990;18:498.

+ 29. Hamilton WG, Thompson FM, Snow SW. The Modified Brostrom Procedure for Lateral Ankle Instability. *Foot Ankle* 1993;14:1.

+ 30. Harper MC, Keller TS. A Radiographic Evaluation of the Tibiofibular Syndesmosis. *Foot Ankle* 1989;10:156.

+ 31. Hopkinson WJ, St. Pierre P, Ryan JB, et al. Syndesmosis Sprains of the Ankle. *Foot Ankle* 1990;10:325.

+ 32. Jackson DW, Ashley RL, Powell JW. Ankle Sprains in Young Athletes: Relation of Severity and Disability. *Clin Orthop* 1974;101:201.

+ 33. Johnson EE, Markolf KL. The Contribution of the Anterior Talofibular Ligament to Ankle Laxity. *J Bone Joint Surg* 1983;65A:81.

# 34. Kannus P, Renstrom P. Current Concepts Review; Treatment for Acute Tears of the Lateral Ligaments of the Ankle: Operation, Cast, or Early Controlled Mobilization. *J Bone Joint Surg [Am]* 1991;73:305.

+ 35. Karlsson J, Bergsten T, Lansinger O, et al. Reconstruction of the Lateral Ligaments of the Ankle for Chronic Lateral Instability. *J Bone Joint Surg* 1988;70A:581.

+ 36. Kaye RA. Stabilization of Ankle Syndesmosis Injuries with a Syndesmosis Screw. *Foot Ankle* 1989;9:290.

+ 37. Larsen E. Experimental Instability of the Ankle: A Radiographic Investigation. *Clin Orthop* 1985;204:193.

! 38. Laurin CA, Ouellet R, St. Jacques R. Talar and Subtalar Tilt: An Experimental Investigation. *Can J Surg* 1968;11:270.

+ 39. Lofvenberg R, Karrholm J, Sundelin G, et al. Prolonged Reaction Time in Patients with Chronic Lateral Instability of the Ankle. *Am J Sports Med* 1995;23:414.

+ 40. Louwerens JWK, Ginai AZ, van Linge B, et al. Stress Radiography of the Talocrural and Subtalar Joints. *Foot Ankle Int* 1995;16:148.

+ 41. Marder RA. Current Methods for the Evaluation of Ankle Ligament Injuries. *J Bone Joint Surg* 1994;76A:1103.

+ 42. Meislin RJ, Rose DJ, Parisien JS, Springer S. Arthroscopic Treatment of Synovial Impingement of the Ankle. *Am J Sports Med* 1993;21:186.

+ 43. Moller-Larsen F, Wethelunc JO, Jurik AG, et al. Comparison of Three Different Treatments for Ruptured Lateral Ankle Ligaments. *Acta Orthop Scand* 1988;59:563.

+ 44. Nitz AJ, Dobner JJ, Kersey. Nerve Injury and Grades II and III Ankle Sprains. *Am J Sports Med* 1985;13:177.

# 45. O'Donoghue DH. *Treatment of Injuries to Athletes, 3rd ed.* Philadelphia: WB Saunders, 1976.

+ 46. Ottaviani RA, Ashton-Miller JA, Kothari SU, et al. Basketball Shoe Height and the Maximal Muscular Resistance to Applied Ankle Inversion and Eversion Moments. *Am J Sports Med* 1995;23:418.

+ 47. Rasmussen O. Stability of the Ankle Joint: Analysis of the Function and Traumatology of the Ankle Ligaments. *Acta Orthop Scand [Suppl]* 1985;211:1.

+ 48. Renstrom P, Wertz M, Incavo S, et al. Strain in the Lateral Ligaments of the Ankle. *Foot Ankle* 1988;9:59.

+ 49. Rijke AM, Jones B, Vierhout PA. Injury to the Lateral Ankle Ligaments of Athletes: A Posttraumatic Follow-up. *Am J Sports Med* 1988;16:256.

+ 50. Singer KM, Jones DC. Ligament Injuries of the Ankle and Foot. In: *The Lower Extremity and Spine in Sports Medicine, Vol. 1.* St. Louis: CV Mosby, 1986;475.

+ 51. Taga I, Shino K, Inoue M, et al. Articular Cartilage Lesions in Ankles with Lateral Ligament Injury: An Arthroscopic Study. *Am J Sports Med* 1993;21:120.

+ 52. Taylor DC, Englehardt DL, Bassett FH. Syndesmosis Sprains of the Ankle: The Influence of Heterotopic Ossification. *Am J Sports Med* 1992;20:146.

* 53. Watson-Jones R. *Fractures and Joint Injuries, 4th ed, Vol. 2.* Edinburgh: Livingstone, 1955;821.

# CHAPTER 96

# STRESS FRACTURES

*Richard A. Marder*

**R. A. Marder**: Department of Orthopaedics, University of California, Davis, Sacramento, California 95817.

Etiology
Pathophysiology
Diagnosis
Principles of Treatment
Treatment of Specific Injuries
Femoral Neck Stress Fractures
Anterior Tibial Stress Fractures
Stress Fractures of the Tarsal Navicular
Fractures of the Proximal Diaphysis of the Fifth Metatarsal
Chapter References

Stress fractures are most often encountered in athletes and military recruits. Runners, basketball and American football players, dancers, and aerobic fitness enthusiasts are those at significant risk for injury (6,13,16,17,25,27). The overwhelming majority of stress fractures occur in the lower extremity with 50% of cases involving the tibia and fibula (11,13,14,16,19). An increased incidence of stress fractures in women has been noted (3). Although most of these injuries heal uneventfully with only rest from the precipitating activity, certain stress fractures pose a challenge to achieve and maintain union. Among these, fractures of the fifth metatarsal proximal diaphysis, tarsal navicular, anterior tibial diaphysis, and femoral neck frequently require surgical treatment.

## ETIOLOGY

A stress fracture is the bony expression of an overuse injury. Of the numerous inciting factors that have been described, the most common are rapid increases in the frequency, duration, or intensity of an athletic activity. Anatomic and alignment factors such as tibia vara, pronation, cavus, limited joint motion, and decreased vascularity may be contributing factors in stress fractures of the lower leg and foot (16,25,27) (See Chapter 10).

## PATHOPHYSIOLOGY

Stress fractures develop as the result of repetitive loads that exceed the remodeling capability of the involved bone. Cyclic loading above the threshold level disrupts normal bone remodeling, and osteoblastic activity becomes outpaced by osteoclastic resorption. Li et al. have described the histologic changes in an experimental model (15). Initially, vascular congestion occurs, followed by osteoclast-mediated bone resorption in the haversian canals and interstitial lamellae. Small cracks appear at the cement lines of the haversian systems, which propagate into microfractures. Simultaneously, new bone formation occurs as a result of increased periosteal osteoblastic activity.

## DIAGNOSIS

Pain on exertion is the hallmark of a stress fracture. Typically, the onset of pain is vague and insidious. This may follow a recent increase in activity or a change in shoes or running surface. Usually, symptoms subside with rest; without interruption of activity, however, pain intensifies, performance is impaired, and overt fracture can occur.

The most consistent physical finding is tenderness on palpation. Pain often can be elicited by percussion over a distant site of the involved bone. Especially in the foot, soft-tissue swelling can be seen. A stress fracture of the tarsal bones or tibia should be suspected in the foot with pronation just as a stress fracture of a metatarsal should be considered in the cavus foot.

Diagnosis is usually suspected on the basis of the history and physical examination; confirmation requires radiographic studies. Routine radiographs may be unremarkable for as long as 3 weeks after the onset of symptoms and may never demonstrate an abnormality (20). The technetium diphosphonate bone scan, although not specific for diagnosis, is an extremely sensitive test for excluding a stress fracture (22,23 and 24,29). Rarely, pain may antedate a positive scan, and if symptoms continue, a repeat scan is recommended (18). If the bone scan demonstrates focal activity, tomography, computed tomography, or MRI can be used to anatomically define the stress fracture.

## PRINCIPLES OF TREATMENT

Depending on fracture location, treatment varies from rest to surgical stabilization. Most stress fractures of the lower extremity respond to avoidance of impact loading for a period of 4 to 8 weeks. During this time, aerobic conditioning can be maintained by bicycling, swimming, or water running. A graduated return to impact activity is started after resolution of pain. The most common fractures involving the proximal and distal tibia, fibula, calcaneus, and central metatarsals readily respond to this regimen.

Other measures, however, may be necessary. Refraining from weight bearing is mandatory if nonoperative treatment is selected for a stress fracture of the femoral neck. Immobilization and avoidance of weight bearing are usually required for successful treatment of a nondisplaced fracture of the tarsal navicular.

As discussed in the following sections, surgical treatment is needed for certain fractures:

- Femoral neck
- Anterior tibia
- Tarsal navicular
- Fifth metatarsal (Jones)

## TREATMENT OF SPECIFIC INJURIES

### FEMORAL NECK STRESS FRACTURES

The treatment of a femoral neck stress fracture is based on the prevention of displacement (1). If displacement occurs, nonunion, varus deformity, and osteonecrosis can result (5). A complaint of groin pain associated with activity requires investigation and treatment without delay to avoid these potential sequelae. Physical examination demonstrates pain with movement of the hip and often a reduction in range of motion.

If the initial radiographs, consisting of an anteroposterior (AP) pelvis and frog lateral view of the hip, are unremarkable, a bone scan is required. Evidence of a cortical infraction or uptake along the superior aspect of the femoral neck indicates a tensile-type fracture, which has a significant risk of displacement (8). Internal fixation to prevent this is recommended as soon as possible (5,8). The method of internal fixation of the femoral neck is described in Chapter 19.

Callus or scintigraphic uptake occurring on the inferior aspect of the femoral neck indicates a compression fracture that may be amenable to conservative treatment (8). If, however, a compression fracture is seen with a fracture line that extends toward the superior cortex, immediate internal fixation is advisable. Treatment of the stable compression-type femoral neck stress fracture consists of avoiding weight bearing and serial radiographs to ensure that displacement is not occurring and that healing

is progressing. Fracture healing may require up to 2 months from the time of diagnosis. Return to activity requires resolution of pain, a full range of motion of the hip, restoration of muscle strength and endurance, and radiographic evidence of a healed fracture.

## ANTERIOR TIBIAL STRESS FRACTURES

Stress fractures of the middle anterior diaphysis of the tibia are uncommon. First described in ballet dancers by Burrows, this injury typically presents with localized pain associated with jumping (6). On physical examination, there may be tenderness and palpable, irregular thickening of the anterior cortex. Radiographs demonstrate diffuse anterior cortical thickening containing one or more horizontal infractions (Fig. 96.1*A*, Fig. 96.1*B*).

***Figure 96.1.*** Stress fracture of the anterior middiaphysis of the tibia. Notice the extensive cortical hypertrophy in addition to the transverse infraction (**A**) and the multiple horizontal translucencies (**B**). **C:** Immediately after IM nailing. **D:** Healed fractures with extensive anterior cortical thickening.

A significant number of these injuries progress to nonunion or complete fracture despite rest and prolonged immobilization, which are the initial recommended treatment (12). Two factors may be responsible for this phenomenon: fracture distraction as a result of tensile forces that are concentrated along the anterior cortex and relative hypovascularity of the fracture area.

As reported by Rettig, use of noninvasive electrical stimulation can be successful in achieving union (21). Electrical stimulation is combined with immobilization in a patellar tendon-bearing (PTB) cast. The coils of the pulsed electromagnetic field's system are incorporated in the cast to overlie the fracture site. The stimulator is used approximately 12 hours each day for 4 to 6 months (4). A bivalved, removable cast facilitates nonimpact exercises of the lower extremity, including swimming.

If this regimen is unsuccessful, and the patient remains symptomatic, surgical treatment is indicated. If a single fracture exists, excision of the fracture site with cancellous bone grafting can be used, but for multiple fracture lines, intramedullary nailing is preferred (Fig. 96.1C, Fig. 96.1D) (2). In the athlete, avoid the patella-splitting approach to minimize the potential for patellar tendonitis. Intramedullary nailing is described in Chapter 24.

### *Excision and Grafting*

- Perform the procedure using a tourniquet and image intensifier.
- Make a longitudinal incision centered over the fracture, immediately lateral to the anterior tibial crest. Longitudinally incise the crural fascia adjacent to the tibial crest, and partially elevate the tibialis anterior to expose the fracture area. Elevate periosteum medial and lateral to the crest.
- Using sharp osteotomes, remove the fracture and adjacent callus *en bloc*.
- Use cancellous bone harvested from the iliac crest to fill the defect.
- Reapproximate the periosteum with interrupted stitches (0 absorbable). Position a 3-mm closed suction drain superficial to the reapproximated periosteum and bring it out through a separate proximal skin incision. Loosely reapproximate the fascia and close the subcutaneous tissue and skin in an atraumatic fashion using an Allgöwer stitch. Apply a well-padded splint to the lower extremity, and admit the patient overnight for observation.

**Postoperative Care** Apply a long leg cast 1 week postoperatively at the time of suture removal. Incorporate a noninvasive electrical stimulation unit to overlie the fracture area. Weight bearing is allowed as tolerated. A PTB cast can be applied at 8 weeks. Continue cast treatment until tenderness is absent and there is radiographic evidence of healing. A return to vigorous jumping activity or contact sports is not allowed until there is complete radiographic union. This may require 6 to 9 months.

## STRESS FRACTURES OF THE TARSAL NAVICULAR

Diagnosis of a stress fracture of the tarsal navicular is frequently delayed because of the insidious onset, vague complaints of pain on the dorsomedial aspect of the foot, and the frequency with which routine radiographs do not demonstrate the injury (27,28). Torg observed several factors associated with the injury, including limited ankle dorsiflexion, limited motion of the subtalar joint, shortening of the first metatarsal, metatarsus adductus, and hypovascularity of the central one third of the navicular (27). Diagnosis is made with scintigraphy and tomograms in the AP plane (Fig. 96.2).

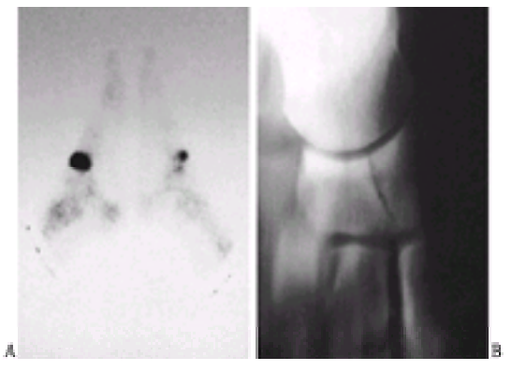

***Figure 96.2.*** **A:** Delayed bone scan indicating focal increased uptake in the region of the navicular bilaterally. **B:** Anteroposterior tomogram demonstrating navicular fracture.

The initial treatment of nondisplaced navicular stress fractures is avoidance of weight bearing and immobilization in a short leg cast for 8 weeks. Surgical treatment is indicated for fractures that are displaced at initial presentation or fail to heal with immobilization. The preferred method of surgical treatment is open reduction and internal fixation with lag screws.

### *Lag Screw Fixation*

- Under tourniquet control, make a dorsal incision centered over the navicular between the interval of the tibialis anterior and extensor hallucis longus tendons. Retract the deep peroneal nerve and dorsalis pedis artery laterally.
- With image intensification, approximate the fracture edges, and from a medial or lateral approach, insert two parallel 2-mm guide wires.
- Insert 4.0-mm cannulated lag screws of appropriate length, making sure that no threads cross the fracture site. If the fracture involves the extreme lateral third of the navicular, it may be necessary to cut off excessive screw threads. Occasionally, only one screw can be inserted.
- Cancellous grafting is not necessary unless the fracture edges are not compressed.
- Perform routine closure of the wound, and immobilize the ankle with a well-padded posterior or U-splint.

**Postoperative Care** At 10 days, remove the sutures and immobilize the ankle in a non-weight-bearing short leg cast for 4 weeks. A controlled ankle motion (CAM) walker allows protected weight bearing over the next 4 weeks. Eight weeks after surgery, remove the cast and begin rehabilitative exercises for the foot and ankle, allowing progressive weight bearing. Radiographic healing is required before resumption of running or jumping. Tomography may be necessary to document radiographic union. A return to full activity requires a minimum of 3 months (usually 4–6 months) following surgery.

## FRACTURES OF THE PROXIMAL DIAPHYSIS OF THE FIFTH METATARSAL

Proximal fifth metatarsal fractures have two patterns: avulsion injuries of the tuberosity (dancer's fracture) and fracture of the proximal diaphysis (Jones fracture) (Fig. 96.3). Whereas avulsion injuries usually heal without the need for surgical treatment, fracture of the proximal diaphysis often requires operative treatment, especially in the active patient. Although stress fractures of the fifth metatarsal may present as an acute injury, there is usually a history of discomfort antedating the traumatic event.

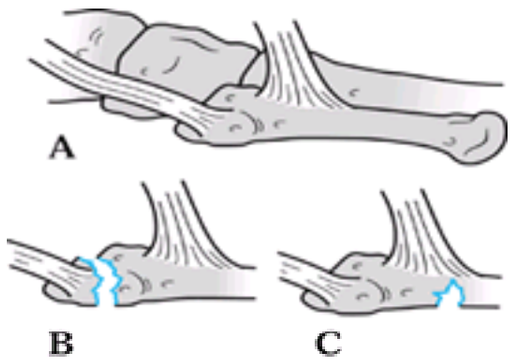


***Figure 96.3.*** Patterns of proximal fifth metatarsal fractures. Peroneal brevis and tertius insetions (**A**), dancer's avulsion fracture (**B**), and Jones fracture of the proximal diaphysis (**C**).

Diagnosis is suggested by the finding of localized pain and tenderness over the lateral and plantar aspects of the proximal diaphysis. This injury occurs frequently in basketball and American football players and is not associated with any specific foot configuration. At the time of presentation, routine radiographs can demonstrate the fracture. As Torg described, intramedullary sclerosis and widening of the fracture can be useful in diagnosing remote injuries that have progressed to delayed union or nonunion (Fig. 96.4) (26). Successful treatment must take into account the activity level of the patient and the chronicity of the fracture.

***Figure 96.4.*** Nonunion of the fifth metatarsal with intramedullary sclerosis and fracture widening.

In a recreational athlete with an acute injury, successful treatment can be achieved by cast immobilization combined with strict avoidance of weight bearing for 6 to 8 weeks. In the high-performance athlete, refracture after conservative treatment is not unusual, and therefore, intramedullary screw fixation can achieve early and persistent union with minimal morbidity and an early return to activity (7). If a fracture has progressed to delayed union or nonunion, intramedullary screw fixation or medullary curettage and inlay bone grafting can be successful (26).

### *Intramedullary Screw Fixation*

- Select regional, epidural, or general anesthesia, and position the patient on an operating table that allows intraoperative use of the image intensifier. The lower extremity should be internally rotated to provide access to the lateral border of the affected foot.
- Under tourniquet control, palpate the lateral base of the tuberosity of the fifth metatarsal, and make a longitudinal incision from this point extending proximally for 3 cm. Divide the subcutaneous tissue, protecting the branches of the sural nerve and the insertions of the peroneus tertius and peroneal brevis at the base of the tuberosity. Adduction of the forefoot increases exposure of the metatarsal base.
- Under image intensification, introduce a 3.2-mm drill in line with the axis of the metatarsal. If necessary to prevent penetrating the cortex of the shaft, reposition the drill. Insert a 4.5-mm malleolar screw into the hole, making sure that the screw remains intramedullary and that the threads completely pass distal to the fracture site (Fig. 96.5). The hole should not be countersunk to allow maximal compression. If the canal is large, and adequate purchase is not obtained with the 4.5-mm screw, redrill using a 4.5-mm drill bit and insert the appropriate length 6.5-mm cancellous screw. If desired, a cannulated screw system that allows insertion of an initial guide wire can be used.

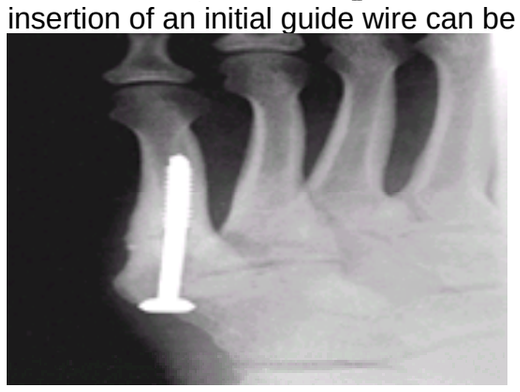

***Figure 96.5.*** Jones fracture after insertion of a malleolar screw

- Close the skin with interrupted sutures, and apply a well-padded splint to the foot and leg.

**Postoperative Care** As soon as swelling subsides, apply a short leg cast for 2 weeks, limiting weight bearing. After this period, remove the sutures and fit the patient with a CAM walker, allowing progressive weight bearing for an additional 3 to 4 weeks. Resistive exercises can be started during this period. Resolution of pain and radiographic healing usually occur by 8 weeks postoperatively. No further protection is necessary after return to activity.

### *Combined Intramedullary Screw Fixation and Inlay Bone Grafting*

This combined technique is reserved for established nonunions as evidenced by fracture widening and intramedullary sclerosis (Fig. 96.6).

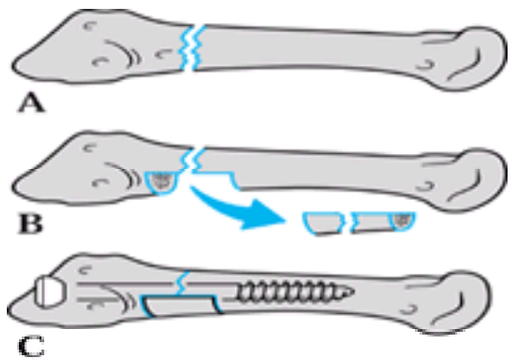


***Figure 96.6.*** Combined bone graft and internal fixation of a Jones fracture. Outlining the rectangular segment (**A**) and removing it (**B**). **C:** Insertion of a IM screw and placement of new corticocancellous graft from the iliac crest or distal tibia.

- With the patient positioned as above, make a straight 5-cm incision along the lateral border of the fifth metarsal, centered over the tuberosity.
- Identify and protect sensory branches of the sural nerve, and retract the peroneus brevis dorsally to expose the inferior aspect of the tuberosity. Expose the fracture by incising the periosteum.
- Use a curet and rongeur to trim the sclerotic ends of the fracture. Outline and remove a small rectangular cortical segment (2 × 1 cm) from the lateral and inferior area centered over the fracture (Fig. 96.6*A*, Fig. 96.6*B*).
- Using a template, obtain a corticocancellous block oversized by 2 mm in each direction from the iliac crest along with cancellous graft.
- Pack the fracture area and intramedullary canal with cancellous graft and press-fit the corticocancellous-block into the trough bridging the fracture.
- If additional stability is desired, insert an intramedullary screw as described above. This achieves a “belt and suspenders” method of fixation (Fig. 96.6*C*).
- Close the skin and apply a well-padded splint as previously described.

**Postoperative Care** Remove the sutures at 10 days and use a cast or CAM walker for protected weight bearing for 6 to 8 weeks. Return to activity usually takes 3 to 4 months.

## CHAPTER REFERENCES

Each reference is categorized according to the following scheme: 01, classic article; #, review article; !, basic research article; and +, clinical results/outcome study.


+ 1. Bargen JM, Tilson DM, Bridgeford DH. Prevention of Displaced Fatigue Fractures of the Femur. *J Bone Joint Surg* 1971;53:1115.

+ 2. Barrick EF, Jackson CB. Prophylactic Intramedullary Fixation of the Tibia for Stress Fracture in a Professional Athlete. *J Orthop Trauma* 1992;6:241.

+ 3. Barrow GW, Saha S. Menstrual Irregularity and Stress Fractures in Collegiate Female Distance Runners. *Am J Sports Med* 1988;16:209.

+ 4. Bassett CAL, Mitchell SN, Gaston SR. Treatment of Ununited Tibial Diaphyseal Fractures with Pulsing Electromagnetic Fields. *J Bone Joint Surg* 1981;63-A:511.

* 5. Blickenstaff MD, Morris JM. Fatigue Fracture of the Femoral Neck. *J Bone Joint Surg* 1966;48-A:2031.

+ 6. Burrows HJ. Fatigue Infraction of the Middle of the Tibia in Ballet Dancers. *J Bone Joint Surg* 1956;38-B:83.

+ 7. DeLee JC, Evans JP, Julian J. Stress Fracture of the Fifth Metatarsal. *Am J Sports Med* 1983;11:349.

+ 8. Devas M-B. Stress Fractures of the Femoral Neck. *J Bone Joint Surg* 1965;47-B:728.

# 9. Devas M-B. Stress Fractures in Athletes. *Proc R Soc Med* 1969;62:933.

# 10. Devas M-B. *Stress Fractures in Athletes.* Edinburgh: Churchill Livingstone, 1975.

+ 11. Greaney RB, Gerber FH, Laughlin RL. Distribution and Natural History of Stress Fractures in U.S. Marine Recruits. *Radiology* 1983;146:338.

+ 12. Green NE, Rogers RA, Lipscomb A-B. Nonunions of Stress Fractures of the Tibia. *Am J Sports Med* 1985;13:171.

# 13. James SL, Bates BT, Osternig LR. Injuries to Runners. *Am J Sports Med* 1978;6:40.

+ 14. Kimball PR, Savastano A-A. Fatigue Fractures of the Proximal Tibia. *Clin Orthop* 1970;70:170.

! 15. Li G, Zhang S, Chen G, et al. Radiographic and Histologic Analysis of Stress Fracture in Rabbit Tibias. *Am J Sports Med* 1985;13:285.

+ 16. Matheson GO, Clement DB, McKenzie DC, et al. Stress Fractures in Athletes: A Study of 320 Cases. *Am J Sports Med* 1987;15:46.

# 17. McBryde AM. Stress Fractures in Athletes. *J Sports Med* 1975;3:212.

+ 18. Milgrom C, Chisin R, Giladi M, et al. Negative Bone Scans in Impending Tibial Stress Fractures. *Am J Sports Med* 1984;12:488.

# 19. Orava S. Stress Fractures. *Br J Sports Med* 1980;14:40.

+ 20. Prather JL, Nusynowitz ML, Snowdy N-A. Scintigraphic Findings in Stress Fractures. *J Bone Joint Surg* 1977;59-A:869.

+ 21. Rettig AC, Shelbourne KD, McCarroll JR, et al. The Natural History and Treatment of Delayed Union Stress Fractures of the Anterior Cortex of the Tibia. *Am J Sports Med* 1988;16:250.

+ 22. Roub LW, Gumerman LW, Hanley EN. Bone Stress: A Radionuclide Imaging Perspective. *Radiology* 1979;132:431.

+ 23. Rupani MD, Molder LE, Espinola D-A. Three Phases of Radionuclide Bone Imagine in Sports Medicine. *Radiology* 1985;156:187.

+ 24. Siddiqui AR. Bone Scans for Early Detection of Stress Fractures. *N Engl J Med* 1978;298:1033.

+ 25. Sullivan D, Warren RF, Pavlov H, et al. Stress Fractures in 51 Runners. *Clin Orthop* 1984;187:188.

+ 26. Torg JS, Balduini FC, Zelko RR, et al. Fractures of the Base of the Fifth Metatarsal Distal to the Tuberosity: Classification and Guidelines for Non-surgical and Surgical Management. *J Bone Joint Surg* 1984;66-A:209.

+ 27. Torg JS, Pavlov H, Cooley LH. Stress Fractures of the Tarsal Navicular: A Retrospective Review of Twenty-One Cases. *J Bone Joint Surg* 1982;63-A:700.

+ 28. Towne LC, Blazina ME, Cozen LN. Fatigue Fracture of the Tarsal Navicular. *J Bone Joint Surg* 1970;52-A:376.

# 29. Wilcox JR. Bone Scanning in the Evaluation of Exercise Related Stress Injuries. *Radiology* 1977;123:699.

# CHAPTER 97

# ADOLESCENT SPORTS INJURIES

*Letha Y. Griffin and Xavier A. Duralde*

**L. Y. Griffin:** Staff, Peachtree Orthopaedic Clinic, Piedmont Hospital; Team Physician, Georgia State University and the Atlanta Glory Basketball Team, Atlanta, Georgia.
**X. Duralde:** Peachtree Orthopaedic Clinic, Atlanta, Georgia.

Overuse Injuries
Stress Fractures
Clinical Evaluation and Presentation
Imaging
Treatment
Difficult-to-Heal Fractures
Physeal Stress Fractures
Osteochondroses
Nonarticular Osteochondroses
Primary Articular Osteochondroses
Secondary Articular Osteochondroses
Osteochondritis of the Knee
Osteochondritis Dissecans of the Talus
Osteochondritis Dissecans of the Elbow
Acute Injuries of the Bone
Avulsion Fractures
Avulsion of the Anterior Superior Iliac Spine
Avulsion of the Anterior Inferior Iliac Spine
Avulsion of the Ischial Tuberosity
Avulsion of the Medial Epicondyle of the Elbow
Tibial Tubercle Avulsion
Anterior Cruciate Ligament Injuries
Tibial Spine Fractures
Meniscal Tears
Discoid Lateral Meniscus
Patellofemoral Joint Problems
General Conditioning and Rehabilitation Principles
Watch out for the Masqueraders
Chapter References

In the United States, it is estimated that 25 million scholastic athletes (202) participate in sports on a regular basis each year and 35 million nonscholastic athletes participate in community programs (196). All in all, sports account for 36% of the injuries of all kinds seen in children and adolescents in the United States yearly. Injuries are more frequent in boys than girls at a ratio of 1.8:1 and increase with age (26), a statistic that reflects lower levels of training intensity in the younger age group (76,193). Injuries tend to be sport specific and are more common in collision sports (26,182,223), with 40% to 80% of football players sustaining an injury yearly (196). Although catastrophic injuries do occur (156) the majority of injuries are minor (77,196). A full 25% of youth football players, however, require five days off during the season for sports-related injuries (77). Unorganized sports are associated with a higher rate of injury than organized athletics (49,223), a fact that underscores the importance of adult supervision in youth athletics.

## OVERUSE INJURIES

Overuse injuries are those caused by repetitive minor trauma that overwhelms the individual's healing capacity. Two scenarios have been blamed for the occurrence of overuse injuries in children: an inadequately trained athlete experiences high musculoskeletal demands (63) or an extremely fit athlete overtrains (197). Children rarely develop stress injuries during unstructured play, but under the pressures of coaches, parents, or occasionally, peers, they will press past pain into injury (192). With greater emphasis on excelling in a single sport, children have begun training for many hours a day at very young ages. The young runner runs 10 to 15 miles a day, an elite swimmer strokes up to 400,000 times in a 10-month season (161), a gymnast spends 4 to 6 hours a day in the gym, and a dancer dances a similar amount of time. Few studies have explored the ability of immature musculoskeletal tissue to adapt to increased physical stresses or the influence of factors such as psychological stress, hormonal fluctuations, and nutrition. Table 97.1 lists commonly reported risk factors for overuse injuries in children and adolescents.

Strenuous exercises
Bad mechanics
Fatigue
Overtraining
Muscular weakness
Inflexibility

* Adapted from Kibler WB, Chandler TJ. Musculoskeletal Adaptations and Injuries Associated with Intense Participation in Youth Sports. In Sullivan JA, Grana WA, eds. *The Pediatric Athlete*. Park Ridge: AAOS, 1990:203.

***Table 97.1. Risk Factors for Overuse Injuries in Children and Adolescents****

To minimize overuse injuries, children should be encouraged to limit practice hours; use good-quality, properly fitted equipment; cross train; and participate in conditioning programs to develop strength and flexibility. Overuse injuries in children most commonly affect the bone or its physis (stress fractures), cartilage at the attachment of tendons (nonarticular osteochondroses), or cartilage and bone at the joint surfaces (primary and secondary osteochondroses).

## STRESS FRACTURES

Stress fractures are less common in children than in adolescents and less common in adolescents than in adults (132,204,214). Before the advent of organized sports for children, stress fractures in this age group were rare; however, with emphasis on serious sports training at earlier ages, the incidence has increased (54). These fractures are most commonly reported in the tibia (50%), fibula (20%), pars interarticularis (15%), and femur (3%) (183). Sports most commonly associated with stress fractures are running (24%), basketball (13%), gymnastics (21%), football (9%), and ice skating (15%) (132). Upper extremity stress fractures are seen in baseball, tennis, swimming, and gymnastics.

### CLINICAL EVALUATION AND PRESENTATION

The clinical evaluation of a young athlete with a stress fracture is similar to that of an adult. Unlike the pain associated with soft-tissue overuse injuries, stress fracture pain is minimal or absent on arising in the morning, progressively gets worse with activity, and is relieved with rest. In certain sites where the bone is palpable directly

beneath the skin, such as the tibia, fibula, or distal radius, the athlete may be able to localize the pain to the specific site of involvement. At other sites—hip, femur, or humerus—pain localization may not be possible; the athlete vocalizes only that the limb “hurts” with increased activity. On physical examination, stressing the injured bone either by taping or applying digital pressure or angular or rotational stresses generally reproduces symptoms. There may be localized tenderness, warmth, or discoloration at the fracture site, but these findings are more typically seen after the athlete has been symptomatic for a while and may not be present in the early stages of injury. Young children may have a low-grade fever.

**IMAGING**

Plain radiographs in the early stages of bone injury may be normal. Radiographic findings may take several weeks or months to develop. In fact, if the athlete ceases activity when the symptoms first begin, the injury may never be seen radiographically (132). However, technetium-99M phosphate bone scans are positive within 6 to 72 hours of injury (85,132). The degree of uptake depends on the rate of bone repair and local blood flow. Uptake is typically localized, but diffuse uptake patterns may occasionally occur. Although they are highly sensitive, bone scans are not specific because other conditions, including infection and tumor, result in positive scans. Periostitis associated with inflammation at the origin of the posterior tibial muscle (shin splints) may be associated with a diffuse linear uptake pattern, which can be confused with a stress fracture. Imaging studies must be correlated with the clinical history and physical exam. Computed tomography (CT) scanning is less sensitive. Magnetic resonance imaging (MRI) is extremely sensitive to early stress reactions presenting as edema—that is, areas of low-intensity signal on T-1 weighted images that increase on T-2 weighted images. In advanced stress reactions, T-2 weighted images demonstrate low intensity bands continuous with the cortex, presumably representing fracture lines (10). Figure 97.1 presents Anderson and Greenspan's imaging algorithm (10) for suspected stress fractures.

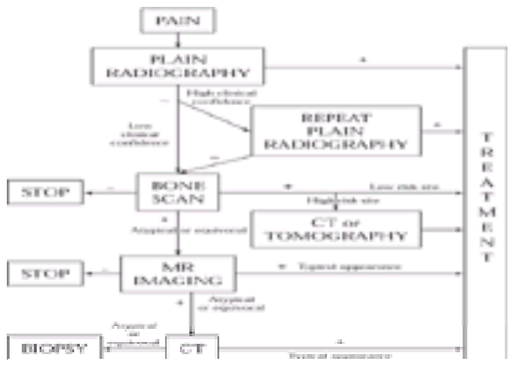


***Figure 97.1.*** Imaging algorithm for suspected stress fractures of bone. (From Anderson MW, Greenspan A. Stress Fracture. *Radiology* 199:1;1996.

**TREATMENT**

The philosophy of treating stress fractures in athletes is to decrease stress to the injured area while maintaining a conditioned state. The intact soft-tissue envelope (skin, muscle, tendon, and ligament) provide support for the injured bone. Therefore, crutches or a cane to decrease weight-bearing stress to the injured extremity rather than a cast may be all that is needed. The key phase in the treatment of stress fractures is to increase the stresses to the bone gradually within the limits of comfort, advancing from non-weight-bearing, nonimpact activities to weight-bearing, nonimpact activities, and finally, to weight-bearing impact activities (Fig. 97.2). Progression of each new activity should be done as in Figure 97.3. As part of the treatment for a stress fracture, try to identify and correct any causative factors.

***Figure 97.2.*** Recovering from a stress fracture: progression of activities.

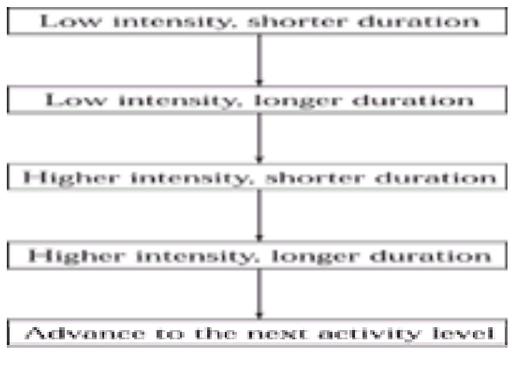


***Figure 97.3.*** Recovering from a stress fracture: progression within each activity

**DIFFICULT-TO-HEAL FRACTURES**

Although most stress fractures in children heal uneventfully, anterior midtibial cortical stress fractures and pars interarticularis fractures of the spine may take a prolonged time to heal (86). The former occur primarily in jumping sports (86,161). Some have recommended debridement and bone grafting for these fractures if union is delayed (10), whereas others have recommended electrical or ultrasound stimulation (172).

Fractures of the pars interarticularis should always be considered in the differential diagnosis of the young growing athlete with low back pain, especially if the athlete is involved in sports requiring repetitive hyperextension of the lumbar spine, such as football, dancing, skating, and gymnastics (183). On clinical examination, the athlete may not have pain on palpation of the area of injury despite complaining of unilateral low back pain with lumbar hyperextension. If radiographs are normal at the time of diagnosis, early prolonged protection in an antilordotic orthosis may result in healing in 4 to 6 months (54). This isthmic spondylolysis infrequently progresses to severe spondylolisthesis (183).

**PHYSEAL STRESS FRACTURES**

Physeal stress fractures are unique to children (33). Sites of involvement have included the distal radius in gymnasts (41,127), the proximal tibia (40) and distal femur (82) in runners, and the distal ulna in break dancers (78).

As in most overuse injuries, pain is insidious in onset. The diagnosis is made on the basis of history and physical examination. For distal radial fractures, the most common physeal stress fractures, the patient is typically a young male or female gymnast performing at a high intensity with no history of a single traumatic event but gradually increasing wrist pain. There is tenderness to palpation over the distal radius. Initially, range of motion may be full, but as the symptoms progress, range of motion decreases.

Wrist radiographs may at first appear normal, but widening of the growth plate with cystic changes and marginal irregularities, typically seen on the metaphyseal side of the plate, can be seen in those athletes who continue to participate despite pain (41,127).

If the gymnast avoids weight-bearing activities on the wrist when symptoms first begin and radiographs are normal, complete recovery follows. If symptoms persist and treatment is delayed until radiographic changes occur, time for healing is prolonged. Cast immobilization may be needed for rest compliance. In cases in which participation continues despite pain, a decrease in the growth of the distal radius with continued growth of the ulna can result in a positive ulna variance of between +0.35 and +0.68 mm (41,127).

Cahill et al. (37) described stress fractures of the proximal humerus in Little League pitchers who presented with vague pain during pitching. Radiographs, which were initially normal, soon demonstrated a widened proximal humeral physis and finally show callus with progressive healing. Complete healing took approximately 6 weeks.

## OSTEOCHONDROSES

The osteochondroses are a group of growth cartilage abnormalities that occur at the apophysis, at the joint surface, and at the physeal plate. They have been defined by Siffert (189) as “idiopathic conditions characterized by disorderliness of endochondral ossification, including both chondrogenesis and osteogenesis that comes upon a formerly normal growth mechanism” (Table 97.2). Some researchers believe that repetitive stress (microtrauma) is the primary precipitating factor (145) or at least a major contributing factor (64). However, the etiology of the osteochondroses is still debatable; vascular, hormonal, genetic, and metabolic factors as well as infections have all been proposed as precipitating or contributing causes. These conditions may merely represent abnormalities of maturation. Because diagnosis typically depends on radiographic confirmation (64,159,169), many of the osteochondroses carry the name of the individual who first described their radiographic appearance.

I. Articular Osteochondroses
   A. *Primary* involvement of articular and epiphyseal cartilage and subjacent endochondral ossification (e.g., humeral condylosis, Freiberg's disease)
   B. *Secondary* involvement of articular and epiphyseal cartilage as a consequence of avascular necrosis of subjacent bone (e.g., Perthes and Kohler's diseases, osteochondritis dissecans)
II. Nonarticular Osteochondroses
   A. At tendon attachments (e.g., Osgood-Schlatter disease)
   B. At ligament attachments (e.g., vertebral ring, epicondyles)
   C. At impact sites (e.g., Sever's disease)
III. Physeal Osteochondroses
   A. Long bones (e.g., tibia vara)
   B. Vertebrae (Scheuermann's disease)

From Siffert R. Classification of Osteochondroses. *Clin Orthop* 1981;158:10, with permission.

***Table 97.2. Siffert's Classification of the Osteochondroses[189]***

### NONARTICULAR OSTEOCHONDROSES

The nonarticular osteochondroses are summarized in Table 97.3. They typically occur during periods of rapid growth, are generally self-limited, and resolve without residual impairment (107). Symptomatic treatment is appropriate in young athletes to try to minimize morbidity and enhance recovery. Outcome studies justifying the expense of such treatment are lacking, and one could argue, as did Voltaire, that “the physician entertains the patient while nature cures the disease.”

***Table 97.3. The Nonarticular Osteochondroses (“The Apophysites”)***

1. Place patient in the supine position and adduct the arm across the body.
2. Make a small incision at the tip of the olecranon.
3. Under image intensification direct a guide pin for a cannulated, partially threaded 6.5 mm cancellous screw through the apophysis and into the shaft of the ulna.
4. With a small drill bit, make several holes through the apophysis, the physis, and the proximal ulna adjacent to the site.
5. Select the appropriate length screw to achieve good fixation by the distal through screws threads in the shaft of the ulna.
6. Insert the screw with a washer to keep screw from penetrating the tip of the apophysis.
7. If the nonunion site is wide, a small incision can be made over it and local bone graft from the proximal ulna can be used to enhance healing. Some prefer to use bone graft from the iliac crest rather than local bone graft.
   An alternative fixation method would be to use transolecranon Kirschner wires, around which a figure of 8 is achieved with wire suture, i.e., tension band wiring. Please see section on treatment of olecranon fractures for further details.
8. Postoperatively, the elbow is immobilized for approximately 3 weeks, after which passive range-of-motion exercises are begun. Active exercises can be started at approximately 6 weeks, when union has occurred radiographically.

***Table 97.3A. Treatment of a Nonunion of an Olecranon Apophyseal Stress Fracture***

### PRIMARY ARTICULAR OSTEOCHONDROSES

Primary articular osteochondroses have been defined as “diseases of the growth or ossification centers in children that begin as a degeneration or necrosis followed by regeneration or recalcification” (25).

#### *Pathophysiology*

Primary articular osteochondroses progress through three stages (46,159). Stage 1 is reactive edema of the articular tissues and active hyperemia of the metaphysis leading to decreased diffusion of nutrition to cells of the epiphysis. Thrombosis and trabecular microfracture further compromise the epiphysis, resulting in epiphyseal irregularities and thinning at the subcortical zone (stage 2). Peripheral ingrowth of the capillaries and mesenchymal cell differentiation are responsible for repair with

gradual replacement of necrotic tissue (stage 3).

### *Treatment*

Treatment focuses on activity modification and protective immobilization of the injured area until symptoms resolve and radiographic recovery is evident. In some cases, surgery is needed to correct residual anatomic abnormalities that prevent normal function. Two of the more common primary articular osteochondroses seen in young athletes are Freiberg's and Panner's diseases (Table 97.4).

***Table 97.4. The Primary Articular Osteochondroses***

## SECONDARY ARTICULAR OSTEOCHONDROSES

Secondary articular osteochondroses are characterized by involvement of the articular epiphyseal cartilage as a consequence of loss of support from destroyed subchondral bone (189). Included in this category are Legg-Calvé-Perthes syndrome, Köhler's disease, and osteochondritis dissecans, which in adolescent athletes occurs most commonly in the knee, ankle, and elbow (184) and can significantly impact athletic participation. Osteochondritis dissecans (OCD) has been characterized as an “isolated segment of epiphyseal and articular cartilage–covered necrotic bony centrum” (189) occurring in diarthroidal joints. The etiology remains obscure, but OCD is believed to be unlikely to be an inflammatory condition, even though its name implies that it is (164). Many authors favor a traumatic etiology, either a single traumatic event or repetitive stress, resulting in either vascular compromise to a bony segment or a subchondral fracture that fails to heal and therefore goes on to develop avascular necrosis (39,52,75). Some believe that a vascular insult in the absence of trauma may occur (65). Metabolic, hormonal, or genetic factors may enhance the vulnerability of certain individuals to OCD. Age may also be a predisposing factor, and a familial tendency has been found (74,155,208). Bilaterality has been reported as high as 33% in one series (87). Although the etiology of this entity remains obscure, there is agreement that the reparative process is more likely to occur before cessation of skeletal growth, and in fact, repair is the likely outcome in children; it may occur in adolescence, but it is rare in adults.

### *Pathophysiology*

The affected bony fragment is typically located at the superficial joint surface. Focal avascular necrosis is followed by reparative osteogenesis consisting of revascularization, granulation tissue invasion, osteoclasis of necrotic fragments, ingrowth of osteoid, and finally, remodeling of new bone. In the early stages of the lesion, the overlying articular cartilage is normal, but later it becomes softened, discolored, fibrillated, and fissured. Finally, from lack of support of the underlying subchondral bone, it eventually separates, leaving a bare area of bone that will ultimately fill with fibrous tissue. Even before the fragment separates completely, if the subchondral bone fails to heal but instead remains avascular, fibrous tissue may develop beneath the fragment. If a healing response occurs before cartilage collapse, the subchondral bone is characterized by active cellular processes with vascular ingrowth and active osteogenesis, providing once again a viable structural foundation for the overlying articular cartilage.

## OSTEOCHONDRITIS OF THE KNEE

Osteochondritis of the knee, named by Koenig in 1887 (36), was really first described in 1866 by Sir James Pagent, who termed it “quiet necrosis,” a name that perhaps more typifies its pathophysiology than does Koenig's term.

### *Clinical Evaluation*

The clinical presentation of the athlete with OCD of the knee is variable and nonspecific. The lesion may be noted in asymptomatic athletes on review of radiographs taken for an unrelated problem, may cause minor symptoms such as an ache in the knee aggravated by activity, may result in a slight effusion, or if the fragment separates, may cause frank locking or catching. The symptomatic individual may recall a precipitating traumatic event, often minor and not resulting in loss of time from sports or may recall no such event, but typically patients have been active in sports and exercise (36,175). In fact, participation in sports at a young age has been implicated as an etiologic factor in the development of OCD (4,36,119).

The age of onset is between 5 and 50 years (175,179), with the greatest incidence during the adolescent decade (175).

On physical examination, pain may be elicited by flexing the knee 90° and palpating for tenderness along the condyle. There may be slight swelling, but no instability is present. Typically there is a near full range of motion unless a fragment has become loose, resulting in mechanical locking of the knee. Thigh muscle atrophy and externally rotated gait may be noted. Pain may be elicited by flexing the knee to 90° and, with the tibia externally rotated on the femur, slowly extending the knee to approximately 30°. Internally rotating the tibia rapidly relieves this pain (Wilson's sign) (219).

### *Classification*

Various classification schemes exist for OCD, each with implications for treatment and prognosis. These include

1. Age or, more specifically, status of the physis at the time of diagnosis (164)
2. Scintigraphic appearance of the lesion, as correlated with radiographs (Fig. 97.4) (36)

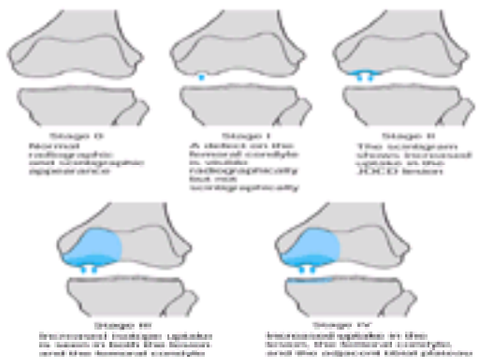

***Figure 97.4.*** Classification of osteochondritis of the knee: scintigraphic appearance, as correlated with radiographs. JOCD: Juvenile osteochondritis dissecans. (Redrawn from Cahill BR, Berg BC. 99M-Technetium Phosphate Compound Joint Scintigraphy in the Management of Juvenille Osteochondritis Dissecans of the Femoral Condyle. *Am J Sports Med* 11:329;1983.)

3. Location on the femoral condyle (Fig. 97.5) (39)

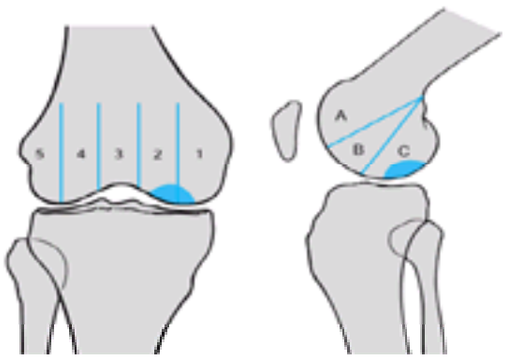


***Figure 97.5.*** Classification of osteochondritis dissecans by its location on the femoral condyle, as seen radiographically. (Redrawn from Cahill BR, Berg BC. 99M-Technetium Phosphate Compound Joint Scintigraphy in the Management of Juvenile Osteochondritis Dissecans of the Femoral Condyle. *Am J Sports Med* 11:329;1983.)

4. Appearance on imaging studies with contrast (MRI or CT) (112)
5. Intactness of the articular mantle and mobility of the fragment, as noted surgically (Fig. 97.6).

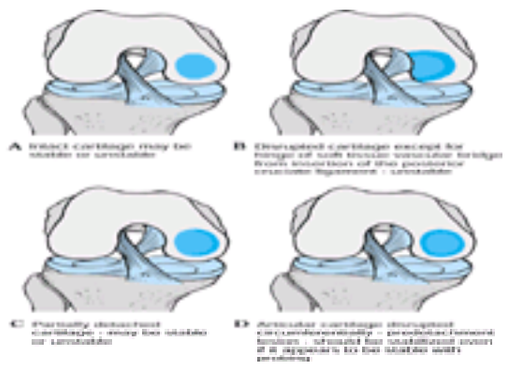

***Figure 97.6.*** Classification of osteochondritis dissecans of the knee by the appearance of the articular cartilage and the mobility of the fragment. (Redrawn from Cahill BR. Osteochondritis Dissecans of the Knee: Treatment of Juvenile and Adult Forms. *J Am Acad Ortho Surg* 3:237;1995, with permission.)

The status of the physis at the time of the diagnosis of OCD seems most critical in predicting outcome. Juvenile OCD, which occurs in children or young adolescents with open growth centers, has a higher probability of healing without the development of degenerative changes than does adult-onset OCD (36,120). The prognosis and course of OCD diagnosed in late adolescence is similar to that in adults.

***Imaging***

OCD classically occurs on the lateral aspect of the posterior portion of the medial femoral condyle and is frequently visible on routine radiographs of the knee. Tunnel views may be required to enhance visualization. The lesion's appearance is that of a well-circumscribed area of subchondral bone, which may be sclerotic or fragmented and is often separated from the femoral condyle by a crescent-shaped radiolucent line.

In 80% to 85% of patients, the lesions occur in the medial femoral condyle, with 15% to 20% in the lateral femoral condyle (Fig. 97.7). Bone scans that measure osteoblastic activity and regional blood flow can be used to evaluate the potential for fragment healing (39,124). However, Paletta et al. (162) demonstrated that although quantitative bone scanning with technetium-99M has a 100% predictive value for prognosis in patients with a open physis, it is less reliable in predicting healing in adolescents with a closed physis. Unfortunately, it is in the group of adolescents with a closed physis in whom outcome is unpredictable, and predictability by bone scans would be extremely helpful were it more reliable.

***Figure 97.7.*** Osteochondritis dissecans of the knee: common sites of occurrence. (From Linden B. The Incidence of Osteochondritis Dissecans in the Condyles of the Femur. *Acta Orthop Scand* 1976;47:664, with permission.)

CT with contrast or MRI with contrast can be used to outline the lesion and to determine the intactness of the overlying articular cartilage (112). Some authors argue that loose bodies within the joint are better visualized with arthrotomography rather than with MRI, although Mesgarzadeh et al. (140) reported adequate visualization of loose bodies with MRI.

***Treatment***

The algorithm for treatment for OCD, like its etiology, remains controversial. Most would agree, however, that the ultimate goal is to promote recovery of the subchondral bony defect while preserving the intactness of the overlying cartilage. Early literature is confusing because outcomes were not related to the age of the patient at the time of onset (a major determinant of prognosis).

The classification schemes previously discussed are extremely helpful in trying to formulate a treatment plan. Many agree that for symptomatic children with an open physis (juvenile osteochondritis dissecans [JOCD]) in whom contrast arthrography demonstrates an intact articular surface, nonoperative care is reasonable (87,119,176,198). For this group of patients, Cahill (36) recommends activity modification initially using crutches for non-weight bearing or partial weight bearing. He does not recommend braces or casts. When acute symptoms subside, discard crutches and institute recreational cycling, swimming, and lower extremity strengthening exercises. Perform serial bone scans every 4 months; the lesion is considered healed when bone scans revert to stage II lesions (Fig. 97.4). Cahill's reported average time to healing is 10 months. Schenck and Goodnight (184) support this scheme but would recommend splint, cast, or an immobilizer during the early stages of treatment to increase compliance. They suggest following healing with plain radiographs or occasionally serial MRI in lieu of bone scans (36). The success rate with JOCD treated conservatively has been reported to be 50% (36). However, Pappas (164) stated that if all JOCD patients are subclassified into Pappas category I and II (Table 97.5), successful treatment in category I (children and young adolescents) is usually ensured without surgery.

| | Category I | Category II | Category III |
|---|---|---|---|
| Skeletal age | Children through early adolescents | Girls 12–20, boys 14–20 | 20 years or older |
| Physes on radiographs | Open | Open or closed | Closed |
| Physiologic status | Immature | Maturing | Mature |
| Potential for healing of OCD lesion | Excellent without surgery | May require surgery | Generally requires surgery |

OCD, osteochondritis dissecans.
From Pappas AM. The Osteochondroses. *Pediatr Clin North Am* 1967;11:549, with permission.

***Table 97.5. Pappas's Classification of Osteochondritis Dissecans of the Knee***

Operative treatment in JOCD is indicated when conservative care fails to show progressive healing of the lesion on serial bone scans or when the cartilage mantle becomes disrupted, indicating instability of the fragment. How long conservative care should be pursued if symptoms persist without improvement or radiographs remain unchanged is debatable. Schenck and Goodnight (184) suggest 6 to 12 months of conservative care before considering surgical intervention.

Cahill (36) published a treatment algorithm for JOCD (Fig. 97.8), noting “with the exception of earlier surgical intervention, the principles of surgical treatment of OCD are identical of those for JOCD”:

***Figure 97.8.*** Algorithm for surgical treatment of osteochondritis dissecans (JOCD/OCD) of the knee. *ORIF*, open reduction and internal fixation; *ROM*, range of motion. (From Cahill BR. Osteochondritis Dissecans of the Knee: Treatment of Juvenile and Adult Forms. *J Am Acad Orthop Surg* 3:237;1995, with permission.)

- Visualize the lesion, and remove or flip-up the fragment on a tissue hinge.
- Clean and drill the base of lesion and fill the base with graft as needed.
- Replace the lesion.
- Bend the articular end of a smooth 0.062-inch pin to a right angle 1 mm from the end. Insert the pin through the lesion and the condyle so it exits from the epicondylar region. Insert the pin antegrade through the lesion and the condyle so it exits from the epicondyle. Place the drill on the pin as it exits from the epicondyle and drill until only a few millimeters of the pin are visible on the articular distal end.
- Place a clamp on the proximal end of the pin, and with a small slap hammer, seat the bent distal end into the articular cartilage.

Cahill found no difficulty removing these pins in a retrograde fashion thorough a small skin incision. Anderson et al. (7) also recommend antegrade drilling of pins into the articular cartilage. Guhl (90) described a technique similar to that of Cahill but used 0.062-inch K-wires threaded on one end. He inserted the pin antegrade with the smooth end and drove the smooth end through the defect into the condyle, exiting in the epicondylar region. The pin was then pulled retrograde until the threaded end was flush with the articular surface. Pins were removed in 4 to 6 weeks.

***Operative Technique***

Principles of operative treatment for osteochondritis dissecans of the knee are to (1) preserve the articular cartilage, especially on the weight-bearing areas; (2) enhance the blood supply; and (3) ensure stability of the bony fragment.

- If a lesion is stable at the time of surgery and has an intact cartilage mantle, perform antegrade (7) or retrograde drilling under image visualization (90,198) to enhance the vascularity of the fragment (Fig. 97.9). Cahill (36) believes that the intactness of the cartilage mantle is not critical, and even if there is a partial articular defect, if the fragment is stable with probing, no internal fixation is needed. Postoperatively, with stable lesions that are drilled, progress weight bearing as tolerated.

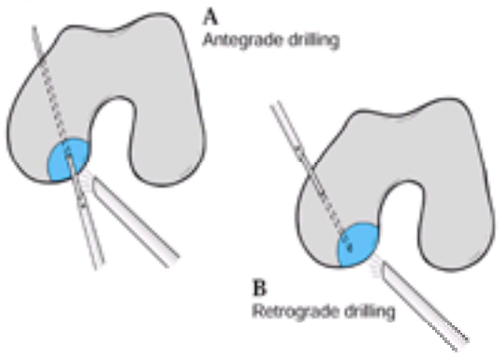


***Figure 97.9.*** Schematic diagram of (**A**) antegrade and (**B**) retrograde drilling of osteochondritis lesions of the medial femoral condyle.

- If the lesion is unstable or partially detached, remove the fragment from its base and curet the base of the fragment as well as the base of the lesion to debride all fibrous tissue.
- If there is a soft-tissue bridge at the insertion of the posterior cruciate ligament on the femoral condyle, preserve this potential vascular bridge by elevating the fragment on this as a hinge rather than removing the fragment.
- Drill the dense bone of the crater to enhance vascularity before replacing the fragment. In a partial or totally detached lesion, crater fragment mismatch may exist either because the fragment, nourished by joint fluid, grows larger than the crater or, because with the loss of subchondral bone, the fragment is too small.
- If the fragment is too large, sculpt it to fit the crater; if the crater is too large, graft the crater's base with local bone from the metaphyseal area of the tibia to provide support for the fragment (36,184,187). Take care to match the crater to the fragment as accurately as possible because inadequate reductions of the articular surface yield poor results (87).

Various devices exist to fix the fragment rigidly, including screws and pins (123) (biodegradable and nonbiodegradable) as well as bone pegs (Fig. 97.10 and Fig. 97.11) (79,103). Cahill (36) believes that metallic fixative devices may adversely affect the cartilage surface and prefers smooth pins over screws. Initially a sterile synovitius was observed with biodegradable self-reinforced polyglycolide rods and polylactic acid pins. This has not been seen with the newer biodegradable pins and screws made of the slower absorbing polylactide (133).

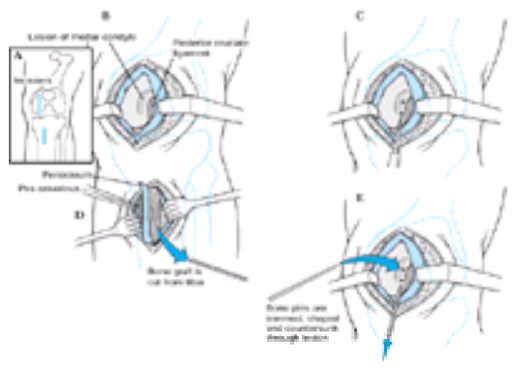

***Figure 97.10.*** Bone peg fixation of OCD lesion. **A:** Make two anteromedial skin incisions. **B:** Expose the lesion on the medial condyle. **C:** Place drill holes in the fragment across the lesion. **D:** Harvest bone graft from the tibia and fashion bone pins. **E:** Insert bone pins into the fragment to fix it. (Redrawn with permission from Gillespie HS, Day MD. Bone Peg Fixation in the Treatment of Osteochondritis Dissecans of the Knee Joint. *Clin Orthop* 143:126;1979, with permission.)

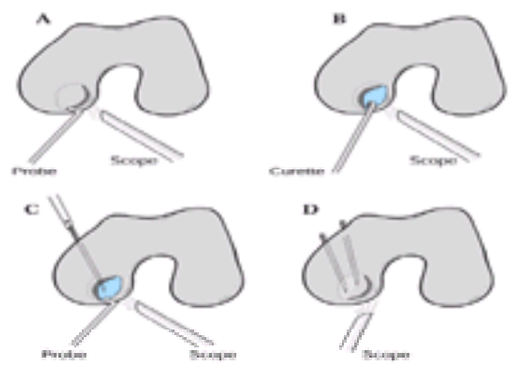


***Figure 97.11.*** Authors' preferred method for treating unstable partially detached lesions of the medial femoral condyle. **A:** Visualize and probe lesion. If unstable, hinge open lesion, preserving intact cartilage rim. **B:** Curet base of lesion and drill or pierce retrograde with arthroscopic awls or picks, taking care to perforate but not destroy subchondral plate. **C:** Replace lesion using bone if needed from femoral condylar region obtained percutaneously or with a hollow core drill from proximal tibial metaphysis. **D:** Stabilize the lesion with K-wire drilled antegrade until just piercing the articular cartilage surface, cutting pins beneath the skin *or* stabilized with PDS pegs by Johnson & Johnson placed retrograde under arthroscopic visualization.**Postoperative care:** Immobilize the knee for 3 to 5 days and then brace to allow full range of motion and begin strengthening exercises. No weight bearing is permitted for 8 to 10 weeks until radiographic healing is apparent.

Fixative devices are adaptable to either arthroscopic or open procedures. The decision of which technique to use depends on the ability of the surgeon to approach the fragment arthoscopically.

- If nonbiodegradable pins are used for fixation, they are generally removed at 3 to 8 weeks postoperatively (36,123). Postoperative care includes early range of motion, with strict adherence to non-weight bearing until the fragment is healed.
- Consider removal of only small fragments (184), fragments on the non-weight-bearing articular surface (36), or fragments that pose a significant fragment-crater mismatch. Treatment of the crater remains controversial. Doing nothing but fragment removal has yielded poor long-term results, even though short-term outcomes are generally good (8).
- The defect can be drilled or “picked” with arthroscopic awls (28) used to create microfractures in the subchondral bone to enhance vascularity of the bed and thus promote the development of type I fibrocartilage.
- Stabilize the edges of the defect by trephining (90) or spongialization (187) rather than saucerization (Fig. 97.12).

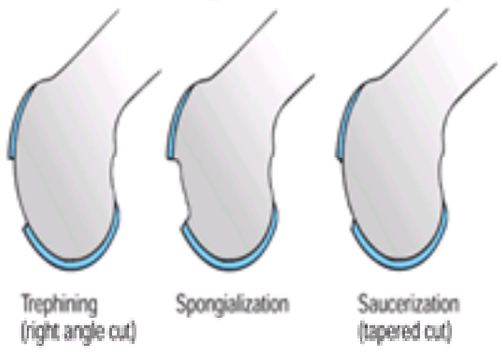


***Figure 97.12.*** Methods of dealing with articular cartilage defects. (Redrawn from Clanton TO, DeLee JC. Osteochondritis Dissecans—History, Pathophysiology, and Current Treatment Concepts. *Clin Orthop Rel Res* 167:50;1982, with permission.)

- Other options include filling the defect with a paste of mortilized autologus cartilage and bone taken from the joint (Construct Chondral Repair System by DePuy [207]), core autografts harvested with one of the several commercially available systems (MosiacPlasty by Smith and Nephew [92], OATS by Arthex [30], and COR System by Innovasive), or autologous cell culture grafting using the Genzyme technique (34).

Consider osteochondral allografts only for OCD lesions larger than 20 mm in diameter (47).

## OSTEOCHONDRITIS DISSECANS OF THE TALUS

Kappis (206) as described by Stone was the first to use the term OCD for lesions in the ankle. Whether the ankle lesion is the same pathologically as that in the knee is debatable.

### *Pathophysiology*

In 1959, Berndt and Harty (21) reviewed the literature on osteochondral lesions of the talus (191 lesions in 183 patients) and concluded that these lesions, whether they appeared on the medial (57%) or the lateral (43%) side of the talus, were trauma-induced transchondral fractures. Canale and Belding (42), in their survey of 31 lesions, found all lateral lesions were secondary to trauma, whereas only 9 of 14 medial lesions were associated with trauma.

Prognostically, lateral lesions have more persistent symptoms and a greater association with later degenerative changes. Roden et al.'s (179) data reinforced Canale and Belding's observation that medial talar lesions can heal spontaneously, have few symptoms, typically are not associated with degenerative changes, and may not all be trauma related, whereas lateral lesions are by and large all traumatic (69,131).

### *Classification*

Berndt and Harty's (21) radiographic classification (Table 97.6) remains popular. Pritsch et al. (170) correlated this system with a grading scale related to the arthroscopically observed intactness of the articular surface (Fig. 97.14) and concluded that the radiographic stage did not necessarily correlate with the severity of

hyalin cartilage injury (arthroscopic grading). They recommended using the arthroscopic rather than radiographic appearance for treatment decisions.

| Grade | Location | Description | Treatment |
|---|---|---|---|
| I | Medial or lateral | Compression fracture or nondisplaced fragment | Nonoperative care |
| II | Medial or lateral | Partial displaced or flap fragment | Nonoperative care |
| III | Medial | Complete avulsion of fragment without displacement | Trial of nonoperative care—i.e., brace, non-weight bearing for 4 to 6 months |
| | Lateral | Same as above | Fragment removed and base curetted |
| IV | Medial or lateral | Displaced fragment | Fragment removal and curettage of base |

* As suggested by Canale and Belding.[42]

***Table 97.6. Treatment of Osteochondritis Dissecans of the Talus Based on Berndt and Harty's Classification System[21] ****

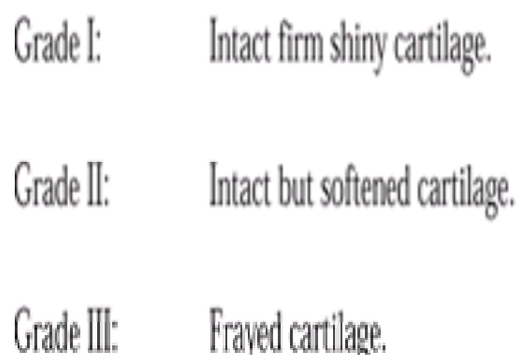


***Figure 97.14.*** Pritsch's classification of osteochondritis dissecans of the talus based on the intactness of the articular surface.

### *Imaging*

Osteochondritic lesions can generally be seen on a plain radiograph. A mortise view taken in plantar flexion highlights posteromedial lesions, whereas anterolateral lesions are best seen if the mortise view is done in dorsiflexion (206). Anderson et al. (9) recommends bone scans on patients in whom osteochondral lesions are suspected but routine films are negative.

CT and MRI, particularly if enhanced with contrast, provide accurate information on fragment size and location, and correlate fairly well with arthroscopic evaluation of cartilage congruity and fragment stability (9,66).

### *Treatment*

Canale and Belding (42) use the classification scheme of Berndt and Harty (21) as the basis for their treatment decisions (Table 97.6).

Procedures described to treat OCD include drilling intact lesions; open reduction internal fixation of detached lesions; and fragment excision and curettage, abrasion, or drilling of the base. Recently, autologous bone grafting techniques developed for osteochondritis of the knee have been tried for OCD lesions of the ankle. Lateral lesions are fairly easy to approach arthroscopically, whereas approaching medial lesions arthroscopically may pose some difficulty (66,170). Some authors prefer a medial malleolar osteotomy for visualization of medial lesions.

### *Operative Technique*

Ankle arthroscopy for OCD (Fig. 97.13) of the talus proceeds as follows:

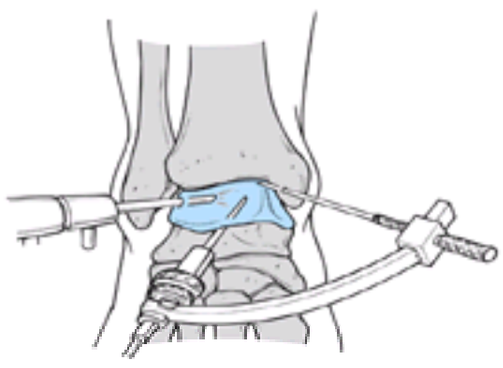

***Figure 97.13.*** Ankle arthroscopy for osteochondritis dissecans of the talus. (From Stone JW. Osteochondral Lesions of the Talar Dome. *J Am Acad Orthop Surg* 1996;4:63, with permission.)

- Prep and drape the extremity as for diagnostic ankle arthroscopy using the strap ankle distracter and 2.7 mm 30° and 70° arthroscopes.
- Inspect the joint, looking in all gutters as well as anteriorly and posteriorly for loose bodies.
- For anterolateral lesions, place the scope in the anteromedial portal, inserting instruments through the anterolateral portal. Probe the lesion to examine the intactness of its edges and base. Trephine the edges and debride the base of the crater with a ring curet. Use 0.062-inch smooth K-wires to drill the lesion.

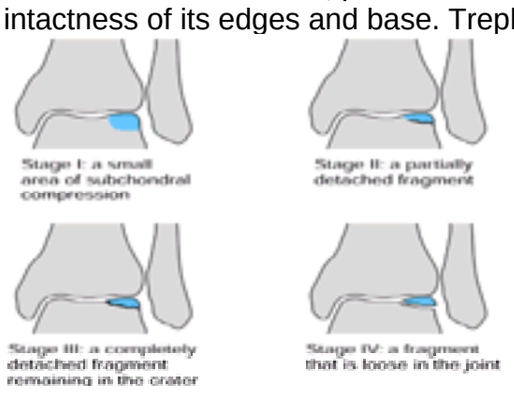


***Figure 97.15.*** Berndt and Harty Classification of OCD of the talus (see table 97.6).

- For anteromedial lesions, place the scope through the anterolateral portal and visualize the lesion through the anteromedial portal. The lesion may be difficult to reach for curetting and drilling if it is located far posteriorly. However, with plantar flexion of the foot, most lesions are accessible.
- If the lesion cannot be reached through the anteromedial portal for drilling, visualize the lesion arthroscopically, but insert the K-wires through the medial malleolus down into the lesion while plantarflexing and dorsiflexing the foot to aid in visualizing and drilling the lesion. This technique does violate the intactness of the ankle's articular surface.
- Alternatively, while watching arthroscopically, use a drill guide to drill transtalarly into the lesion, entering from the sinus tarsi into the talus in its nonarticular portion anterior to the anterior talofibular ligment insertion area.

Postoperatively, Stone (206) advises immobilizing the ankle for 6 weeks and then beginning active and passive motion exercises. Others immobilize the ankle for only 7 to 10 days and then start active range of motion and strengthening exercises, with weight bearing being delayed for 6 to 8 weeks. See section on ankle arthroscopy for additional procedures.

## OSTEOCHONDRITIS DISSECANS OF THE ELBOW

OCD of the elbow (found most frequently in the capitellum but occasionally also seen in the radial head) is part of the injury complex popularly termed “Little League elbow.” This term was originally used by Brodgon and Crowe (35) to describe clinical and radiographic changes on the medial side of the elbow in young baseball pitchers, but was expanded by Adams (3) to all the pathologic processes that occur about the elbow secondary to the stresses of pitching or throwing (Fig. 97.16), including not only medial tension injuries but also lateral compression and posterior fossa injuries. Repetitive medial tension forces on the growing youth's elbow include medial apophysitis, avulsions of the medial condyle, accelerated growth, or fragmentation of the medial epicondyle. Repetitive lateral compression forces are thought to be responsible for the development of OCD of the capitellum and radial head. The valgus position of the elbow as it is forcefully propelled forward by the shoulder with the wrist in a supinated position during the acceleration phase of pitching is the mechanism blamed for the development of these tension and compression loads (5) (Fig. 97.17). Children who pitch with a side-arm delivery are therefore more likely to develop symptoms (197).

***Figure 97.16.*** The five phases of pitching.

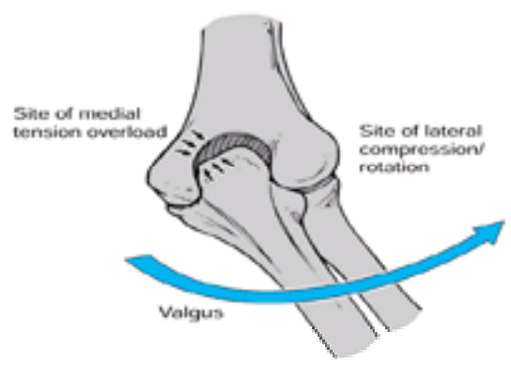


***Figure 97.17.*** Tension and compression loads on the elbow during acceleration phases of pitching. Right elbow, posterior aspect.

Injuries to the posterior fossa of the elbow occur from the posterior medial sheer force, which develops during late cocking and from the hyperextension that develops during follow-through. Such forces result in posterior medial spurs, olecranon spurs, stress or avulsion fractures of the olecranon apophysis (see the section on nonarticular osteochondroses), and traction spurs of the coronoid process.

The incidence of Little League elbow in the adolescent has been reported to be from 23% to 70% (190). Changes similar to those that occur in Little League elbow have been found in other throwing athletes (javelin throwers and tennis players) as well as gymnasts, the latter presumably from weight bearing on an extended valgus elbow.

### *Clinical Evaluation*

The child with Little League elbow is typically between 11 and 16 years of age and may complain only of decreased throwing performance but more typically complains of pain with activity that improves with rest. If the athlete continues to play with pain, the pain may last after playing hours. Night pain is rare. The pain may be diffuse but is generally limited to medial, lateral, or posterior aspects of the elbow. There may be a lack of full extension, and this may be the only complaint. Flexion is rarely limited.

On physical examination, in addition to a loss of extension, there may be a mild effusion or localized swelling over the medial epicondyle. Occasionally, muscle atrophy is apparent. Crepitation with motion can be present if there are loose bodies.

In some cases, more commonly seen in older athletes, traction on the ulnar nerve may result in altered sensation in the ring or little fingers. Rarely is there a lack of strength in the intrinsic muscle.

### *Classification*

Bianco's (25) classification system for osteochondritic lesions (Table 97.7) is based on the integrity of the cartilage mantle as noted by contrast imaging or arthroscopy.

| *Bianco's type* | *Description* | *Treatment options* | *Author's preferred treatment* |
|---|---|---|---|
| I | No evidence of subchondral displacement of the lesion or fracture of the articular cartilage, as noted on contrast imaging or arthroscopic evaluation | Nonoperative care (rest followed by rehabilitation exercises) | Rest from aggravating activities until x-ray evidence of revascularization of defect is noted |
| II | Subchondral detachment of the lesion or fracturing of articular cartilage | Remove fragment with or without drilling or curetting of crater OR replace and fix fragment with pins or screws | Remove fragment, debride edge of crater, and use arthroscopic “picks” to stimulate subchondral vascular response |
| III | Presence of loose bodies | Remove loose bodies, drill or curet crater | Remove loose bodies, treat crater as in type II |

Note: All treatment protocols include a rehabilitation program stressing active range of motion and upper extremity strengthening and flexibility.

***Table 97.7. Treatment Options for Osteochondritis Dissecans of the Capitellum Based on Bianco's Classification System[25,152]***

### *Imaging*

In most circumstances, the lesion of OCD appears as a rarefaction in the subchondral capitellum, often with a well-defined sclerotic border (Fig. 97.18). Loose bodies may or may not be identified. In the symptomatic athlete with normal radiographs or in the athlete whose lesion is seen on routine radiographs but in whom there is a question regarding the integrity of the cartilage mantle or the presence of loose bodies, arthrotomography or contrast MRI may be extremely helpful. In chronic cases of Little League elbow, routine films may also show an enlarged or beaked medial epicondyle, fragmentation or separation of the medial apophysis, an enlarged radial head, or fragmentation or widening of the olecranon epiphysis.

***Figure 97.18.*** Radiograph of 15-year-old pitcher. Note osteochondritis lesion of the capitellum.

### *Treatment*

For the symptomatic thrower whose x-ray study demonstrates an intact lesion, treat with cessation of the offending activity; range-of-motion exercises; and stretching and strengthening the muscles of the shoulder, arm, forearm, and wrist. Give particular attention to stretching the anterior elbow capsule. A cast or a splint may be needed for several weeks to enhance compliance with ceasing activity. Limit resistance weight training for 6 to 12 weeks. When radiographic revascularization and healing is evident on repeat serial x-ray studies, begin a gradual return to a throwing program, with emphasis on proper technique (Fig. 97.19).



***Figure 97.19.*** An example of gradual return to throwing program.

As in all children's and adolescents' throwing programs, place limits on the number of pitches thrown both in practices and games. A change of position for pitchers is advised, even if only on a temporary basis. The prognosis is favorable for adolescents who have lucent subchondral defects with intact overlying cartilage. Return to sports typically occurs within 6 months to 1 year but may be earlier based on resolution of symptoms and radiographic healing (60,190).

There is not unanimous agreement on how to treat Bianco's type II lesions (25). Some authors (121,164) recommend arthroscopic or open pinning of type II lesions *in situ* using unthreaded K-wires placed antegrade into the lesion and through the lateral condyle. The K-wires are left either under the skin or just above it to be removed in 6 to 8 weeks. Others (152,190) recommend surgery only for loose fragments that cause locking or catching. The three options available for treating loose fragments are (1) to replace the fragment using bone graft if needed, (2) to remove the fragment and either drill (or drill and curet) the base (most authors [136,164,190] recommend preservation of the subchondral plate when curetting), and (3) to simply remove the fragment (152,221).

Those favoring the second option argue that replacing the lesion yields poor results and 85% of those treated with a well-structured rehabilitation program following excision and drilling (or drilling and curetting) are able to throw successfully in 6 months to a year (136). Younger patients typically have a more favorable outcome no matter what stage of the lesion they have at the time of diagnosis.

### *Operative Technique*

McManama et al.'s (136) treatment of osteochondritis dissecans of the capitellum is as follows (Fig. 97.20):

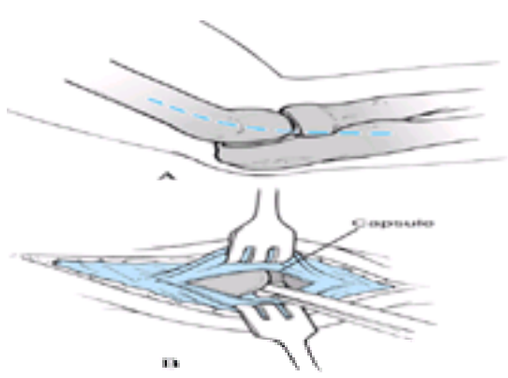


***Figure 97.20.*** McManama et al.'s treatment of osteochondritis dissecans of the capitellum. **A:** Superficial incision. **B:** Deep incision exposing joint. (From McManama GR, Micheli LJ, Beary VM. The Surgical Treatment of Osteochondritis of the Capitellum. *Am J Sports Med* 1985;12:11, with permission.)

- Make a lateral incision by beginning 1 to 2 cm proximal to the lateral epicondyle of the humerus. Extend the incision distally over the epicondyle and along the posterolateral surface of the forearm for 4 to 5 cm. Proximally, the deep incision should enter through the triceps posteriorly and the brachioradialis and extensor

carpi ulnaris anteriorly to expose the lateral condyle and the capsule covering the radial head. Distally, the deep incision should separate the extensor carpi ulnaris from the anconeus.
- Reflect the periosteum off the anterior and posterior surfaces of the humerus.
- Subperiosteally, reflect the common origin of the extensor muscle anteriorly off the lateral epicondyle.
- Open the joint capsule longitudinally. Explore the joint for loose bodies.
- Debride the capitellar chondral defects down to subchondral bone.
- Use a smooth K-wire to make multiple drill holes into the subchondral bone to obtain bleeding.

Postoperatively, if the fragment is removed and the lesion is drilled arthroscopically, use a sling for approximately 3 weeks. Begin range-of-motion and strengthening exercises at about 10 to 14 days. If an open procedure is performed, immobilization in a splint may be needed for several weeks before beginning the rehabilitation program. The decision to approach the lesion arthroscopically or open depends on the surgeon's ability to see and treat the lesion arthroscopically.

Although treatment for gymnasts with OCD of the capitellum is similar, the prognosis is less favorable (81,101,191).

## ACUTE INJURIES OF THE BONE

### AVULSION FRACTURES

Avulsion fractures in children and adolescents were previously thought to be rare but are now more common and occur almost exclusively during athletic activity (171). Secondary ossification centers remain open in different parts of the skeleton between 14 and 25 years of age, and the unification time for each particular apophysis correlates with the average age of occurrence of avulsion fractures at their respective locations (216). Longitudinal bone growth stimulates muscle tendon growth (38,114), but there is often a lag time for muscle tendon unit growth, resulting in a period of relative inflexibility of these soft tissues relative to the adjacent skeletal tissue. This occurs during or immediately after periods of rapid growth and also coincides with periods of relative weakness at the physis. This relative inflexibility is particularly a problem for muscle-tendon units that cross two joints, such as the rectus femoris, sartorius, hamstrings, gastrocnemius, iliotibial band, and iliopsoas. The great majority of avulsion fractures occur in children who are constitutionally tight and have just finished a growth spurt (146,149). Avulsion fractures are seen most commonly in ballistic sports such as soccer, track and field, and jumping sports in which a sudden violent contracture of a muscle tendon unit can lead to avulsion of the apophysis (118,146,149). Adolescent athletes who participate in running or jumping sports tend to be less flexible than age-matched controls, and flexibility is gained slowly (110). The mechanism of avulsion tends to result from either excessive stretching or a violent contraction (45) of the adjacent muscle tendon unit. Although conservative management is often successful, these fractures must be differentiated from neoplasm or normal sesamoid bones.

### AVULSION OF THE ANTERIOR SUPERIOR ILIAC SPINE

Avulsion fractures from the pelvis are usually related to sports (67) and occur secondary to eccentric muscle contraction associated with rapid deceleration or acceleration (Fig. 97.21) or excessive passive stretching such as by a cheerleader doing a split. Only rarely are these fractures due to a direct blow (196). The amount of displacement seen in these avulsion fractures is related to the degree of initial injury and to the associated soft-tissue attachments that may tether the avulsed fragment. The anterior superior iliac spine avulses secondary to extensive pulling of the sartorius, usually with the hip extended and the knee flexed (177). There is pain and swelling over the anterior superior iliac spine, and the average age of presentation is 15 years (178). Radiographs show displacement of the anterior superior iliac spine apophysis. Treat with bed rest, followed by progressive weight bearing on crutches for approximately 4 weeks. Surgery is rarely required, even if displacement is noted, and the athlete may return to sports after 2 to 3 months as pain allows (45).

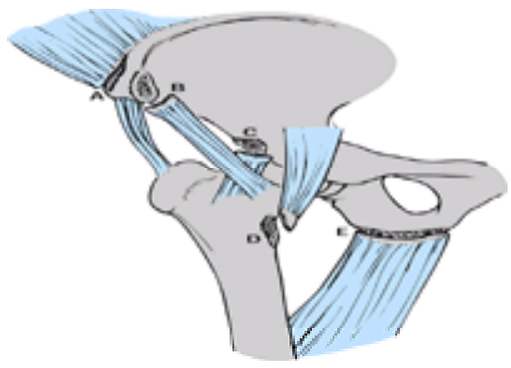


***Figure 97.21.*** Pelvic avulsion fractures in the growing athlete include the anterior superior iliac spine (A), anterior inferior iliac spine (B), ischial tuberosity (E) and more rarely the anteroinferior iliac spine (C) and lesser trochanter (D). These injuries occur around periods of rapid growth, but displacement of these fragments is often limited by adjacent soft tissues.

### AVULSION OF THE ANTERIOR INFERIOR ILIAC SPINE

The anterior inferior iliac spine may avulse secondary to excessive traction by the direct head of the rectus femoris, usually with the hip hyperextended and the knee flexed (Fig. 97.21). This injury typically occurs in kicking sports such as soccer, rugby, and football (215). This avulsion is much less common than that of the anterior superior iliac spine and occurs in a younger age group, averaging 13 years, reflecting the earlier age of fusion of this apophysis (171,216). Pain from this lesion is often difficult to localize (67), but patients will commonly be most comfortable in a position that relaxes the rectus femoris by keeping the hip flexed and knee extended. Radiographs may reveal minimal displacement of the anterior inferior iliac spine, and this fragment must be differentiated from an os acetabuli or acetabular epiphysis (215). Further displacement of this fragment is typically limited by the tethering effect of the reflected head of the rectus femoris. These respond well to bed rest, followed by progressive mobilization on crutches, with a fairly rapid return to sports as pain allows (44,45).

### AVULSION OF THE ISCHIAL TUBEROSITY

Avulsion of the ischial tuberosity occurs secondary to rapid traction on the hamstring muscles either with violent contraction or a sudden excessive passive stretch (1,22,55,108,149) (Fig. 97.21). This epiphysis is not ossified until 15 years of age and often is not united with the pelvis until 25 years of age (105). This fracture occurs in an older age group averaging 15 years of age and is usually sports related. Patients present complaining of acute-onset of pain in the ischium or chronic pain with a sudden exacerbation of symptoms (180). On physical examination, pain can be elicited by passive straight leg raising or abduction of the hip. Patients often notice the pain while sitting, and radiographs show a variable amount of displacement of the ischial apophysis. Wide displacement tends to be limited by the sacrotuberous ligament. Treatment of this lesion is controversial because wide displacement of the ischial tuberosity can lead to excessive callous formation, which causes pain when sitting (29). This problem rarely requires excision (180) but has led some authors (145,148,149) to recommend open reduction and internal fixation to avoid fibrous union, pain, and prominence. The vast majority of these cases can be treated successfully with conservative management with a period of bed rest, followed by progressive ambulation on crutches and slow advancement to sport as pain allows (108). In the absence of a characteristic history, periosteal reaction and callous formation in the area of the ischium must be differentiated from neoplasm or infection, and biopsy must be considered (94,98).

### AVULSION OF THE MEDIAL EPICONDYLE OF THE ELBOW

#### *Pathophysiology*

The elbow is the most frequent area of complaints by adolescent baseball players (89,212), and avulsion fractures of the medial epicondyle represent almost 12% of all fractures about the elbow in children. The peak age of occurrence is between 11 and 12 years, and boys outnumber girls 4 to 1 (6,18). This injury can follow a prodrome of medial elbow pain from apophysitis and overuse or may follow a single violent injury to the elbow. Ossification of the medial epicondyle occurs between 5 and 7 years of age, and the epicondyle continues to enlarge and finally fuses to the humerus at approximately 14 years of age in girls and 17 in boys (165). This is the last secondary ossification center to fuse in the distal humeral metaphysis. Two mechanisms for medial epicondylar avulsion have been proposed: Avulsion can occur by (1) violent contraction of the flexor pronator mass or (2) elbow dislocation associated with valgus stress in which the ulnar collateral ligament provides the avulsion force. Fracture by direct blow to the elbow is thought to be extremely rare. In younger children, a fall on the outstretched hand with the wrist extended tightens the flexor pronator mass and may result in this avulsion (Fig. 97.22). In the older adolescent athlete, the most common cause is throwing a baseball with sudden

contracture of the forearm muscles.

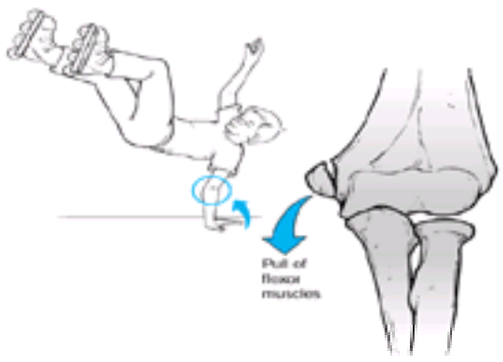


***Figure 97.22.*** The usual mechanism for avulsion of the medial epicondyle in the child is a fall on the outstretched hand with the elbow in extension and wrist held in hyperextension. The flexor pronator mass, which inserts on the medial epicondyle, avulses this fragment of bone. Adapted from ref. 178.

### *Classification*

There are two types of medial epicondyle fractures (220), and they are age dependent. Type I fractures with avulsion of a large fragment involving the entire epicondyle occur in younger children. This fragment may be displaced and malrotated. In the older adolescent patient, a small fracture fragment of medial epicondyle occurs and may be associated with avulsion of the anterior oblique portion of the medial collateral ligament. This fragment can be displaced distally and incarcerated in the joint. Medial epicondylar fractures can be either nondisplaced, minimally displaced (less than 5 mm displaced), significantly displaced (greater than 5 mm displaced), or entrapped, in which case the fracture fragment is typically seen at the joint line on x-ray study (178) (Fig. 97.23*A*).

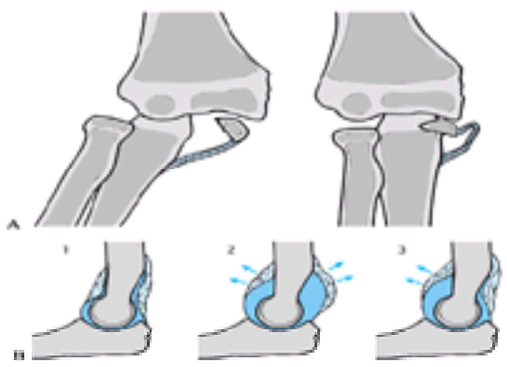

***Figure 97.23.*** **A:** Intraarticular displacement of the medial epicondyle and entrapment within the joint after reduction of dislocation of elbow. **B:** Intraarticular effusion at the elbow joint will lead to displacement of anterior and posterior fat pads, which is often easily visible on the lateral x-ray study of the elbow.1. Normal fat pads. 2. Displacement of anterior and posterior fat pads. 3. Isolated displacement of anterior fat pad.

### *Clinical Examination*

With a medial epicondyle fracture, the elbow is painful and swollen with ecchymosis over the medial epicondylar region and decreased motion due to pain and effusion. Point tenderness is noted at the flexor origin over the medial epicondyle, and significant valgus instability may be present. Check for function of the ulnar nerve (136,220).

### *Imaging*

Anteroposterior and lateral radiographs of the distal humerus may reveal only widening or irregularity of the apophyseal line. A displaced fragment is difficult to visualize on radiographs but may be missing from its usual location. The fat pad (Fig. 97.23*B*) sign is typically not seen because in older children this fragment is extra-articular, and in younger children this fracture is associated with rupture of the capsule and the dissemination of the joint effusion into the soft tissues. Fracture of the medial condyle, which is an intraarticular injury, is less common and can be ruled out on radiographs. Radiographs taken with the arm held in an abducted supinated position, which causes a valgus force at the elbow, will show any instability (186) (Fig. 97.24).

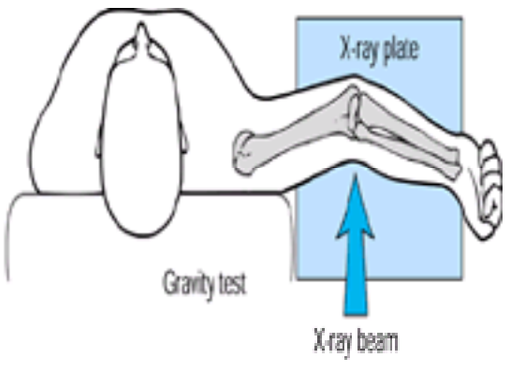


***Figure 97.24.*** The weight of the forearm exerts a gentle valgus stress on the injured elbow and reliably demonstrates valgus instability secondary to ulnar collateral ligament injury or medial epicondylar avulsion.

### *Treatment*

Treatment of minimally displaced and nondisplaced fractures of the medial epicondyle consists of a period of immobilization for several weeks, followed by gradual resumption in range of motion and return to throwing as pain allows (23,136). Incarcerated fragments require open reduction and internal fixation. This surgery usually results in closure of the growth plate, but because this epiphysis does not contribute to longitudinal growth of the humerus, growth disturbances are not significant. Treatment of displaced fractures of the medial epicondyle are controversial, and operative management is recommended primarily in throwing athletes (220). Nonoperative management in other children usually has good results despite the fact that fibrous union may occur (17,23,71). Ulnar nerve symptoms represent another indication for operative exploration. Even patients with minimally displaced fragments should be reevaluated for valgus instability 6 weeks following injury because fixation may be required in cases in which valgus stability is important.

### *Operative Technique*

The surgical technique for open reduction and internal fixation of medial epicondyle fractures is as follows (Fig. 97.25):

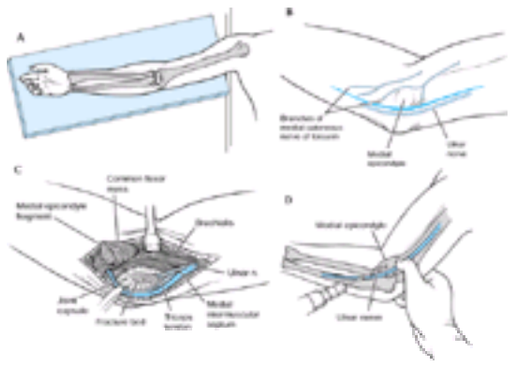

***Figure 97.25.*** Open reduction and internal fixation of medial epicondyle fractures. **A:** Position arm on a radiolucent table. **B:** Expose the medial epicondyle through a longitudinal incision. **C:** Identify the fracture and reduce it. **D:** Fix the fracture with one or more K-wires.

- Place the patient supine on the operating table, with the affected arm abducted onto a hand table (Fig. 97.25A).
- Incise the skin along the medial aspect of the elbow centered at the elbow joint (Fig. 97.25B).
- Identify the fracture fragment and remove fracture hematoma (Fig. 97.25C).
- Reduce the fragment and fix temporarily with K-wires. Fixation with one 3.5 mm screw is adequate if the bone fragment is large enough. Multiple K-wires can be used for smaller fragments. Lysis of adhesions around the ulnar nerve may be performed, but ulnar nerve transposition is typically not required (Fig. 97.25D).

## TIBIAL TUBERCLE AVULSION

### *Pathophysiology*

Tibial tubercle avulsion is fortunately a rare injury. It can follow a long history of apophysitis or occur as an acute injury (154). The average age of presentation of tibial tubercle avulsion is 14 years, with a strong male predominance. Because this injury may occur near the age of physiologic epiphysiodesis, growth problems following treatment are rare. Whereas Osgood-Schlatter disease is usually insidious, with mild symptoms creating partial disability, tibial tubercle avulsion typically occurs as an acute injury with marked pain and swelling and inability to stand or walk. Fractures are usually displaced, requiring surgical intervention. Avulsion of the tibial tubercle by the patellar ligament occurs with violent contraction of the quadriceps against the fixed tibia, as in jumping, or by acute passive flexion, as in landing, and accounts for the fact that this injury is most commonly seen with jumping or running sports (57,72,109). Children with tight hamstrings, pre-existing tibial apophysitis, and patella baja are at risk for this injury.

### *Clinical Examination*

Physical findings include the following:

- Acute swelling and tenderness is present, often associated with a kind effusion or tense hemarthrosis.
- A freely movable fragment at the tibial tubercle, and proximal patellar displacement is usually present.
- With a type I fracture, active knee extension may be possible, but in more displaced fragments, straight leg raising is not possible.
- A lateral radiograph of the knee is diagnostic and guides both classification and further treatment.

### *Treatment*

Treat minimally displaced fragments closed with casting in extension and molding over the proximal pole of the patella to decrease stress on the tibial tubercle. Minimal displacement, however, is rare, and displaced fractures of the type II or type III variety require open reduction and internal fixation, usually through a vertical incision. Larger fragments require the use of a screw, and small fragments can be treated with multiple pins with repair of the periosteal rupture (Fig. 97.26).

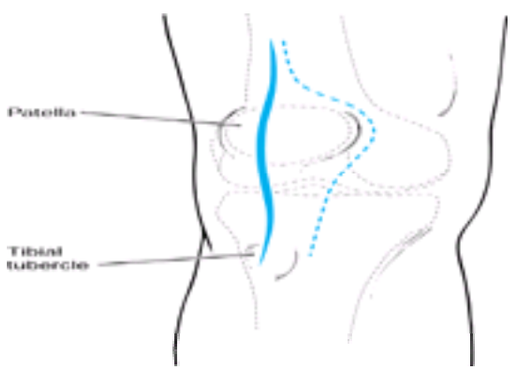


***Figure 97.26.*** Incision for open reduction and internal fixation of tibial tubercle avulsion fractures.

### *Operative Technique*

Open reduction and internal fixation of tibial tubercle avulsion fractures is as follows:

- Place the patient supine on the operating table and make a vertical incision centered over the tibial tubercle along the medial or lateral border.
- Remove any soft-tissue interposition at the fracture site and reduce the fracture fragment.
- If the fragment is large enough, fix this fragment with a cancellous screw extending through the tubercle and into the metaphysis.
- If comminution of the fragment is encountered, use multiple threaded Steinmann pins and reinforce these using periosteal sutures.

Postoperatively apply a well-fitting cylinder cast molded on either side of the tibial tubercle and proximal patella to reduce tension at the fracture site. Allow the patient to walk full weight bearing in a cylinder cast for the first month. Allow gentle range-of-motion exercises and quadriceps-strengthening exercises after a month with continued protected ambulation, and add resistive exercises when the tibial tubercle is no longer tender and healing is noted on x-ray study.

### *Complications*

The prognosis for treatment of this injury is excellent, with a return to sports possible in the vast majority of patients. No significant deformity usually results in acute cases (24,109,128). Although genu recurvatum can occur in skeletally immature athletes, tubercle avulsion usually occurs close to skeletal maturity, so this complication is rare. Loss of knee flexion and persistent quadriceps atrophy occurs rarely (178).

## ANTERIOR CRUCIATE LIGAMENT INJURIES

The true incidence of ligamentous injuries about the knee in children and adolescents is unknown (200) but considered rare. Reports of the incidence of anterior cruciate ligament (ACL) injuries in those younger than 14 to 15 years of age vary from 3.4% (122) to 10% (59), but the number or injuries appears to be increasing as children and young adolescents become more competitive in sports. The reported incidence of meniscal lesions associated with ACL injuries in children and adolescents is also variable. McCarroll et al. (134) reported a 60% rate of meniscal injury, and Staninski (203) reported a 47% incidence, but others (12,58,83) have

found the meniscus less frequently injured in ACL injuries in children than in adults.

### *Clinical Evaluation*

For a detailed discussion, see Chapter 89.

Because of the difficulty in obtaining an adequate evaluation in children, some authors have recommended early evaluation under anesthesia. However, others believe that if adequate time is taken to win the confidence of the injured adolescent or child, a reasonable evaluation can be accomplished.

In adolescent girls, a history of a twisting injury associated with a pop and severe pain followed by knee swelling and lack of extension can also be consistent with an episode of patella subluxation. Therefore, palpate the medial patella retinaculum for tenderness and manipulate the patella in the trochlear groove, noting its degree of movement and the patient's apprehension during the examination.

For preoperative planning, also assess prepubescent youngsters with an ACL injury for maturity by noting chronologic age, bone age as determined by left-hand anteroposterior (AP) radiographs in comparison to known standards, sexual development (e.g., Tanner classification; Table 97.8), growth remaining via assessment of parents' and siblings' heights, patient's projected height on basis of prior growth chart data (if available), and the extent of physeal closure on routine radiographs.

*Classification of sexual maturity stages in girls*

| Stage | Pubic Hair | Breasts |
|---|---|---|
| 1 | Preadolescent | Preadolescent |
| 2 | Sparse, lightly pigmented, straight, medial border of labia | Breast and papilla elevated as small mound, areolar diameter increased |
| 3 | Darker, beginning to curl, increased amount | Breast and areola enlarged, no contour separation |
| 4 | Coarse, curly, abundant, but amount less than adult | Areola and papilla form secondary mound |
| 5 | Adult feminine triangle, spread to medial surface | Mature, nipple projects, areola part of general breast contour |

*Classification of sexual maturity stages in boys*

| Stage | Pubic Hair | Penis/Testes |
|---|---|---|
| 1 | None | Preadolescent |
| 2 | Scanty, long, lightly pigmented | Slightly enlarged/enlarged scrotum, pink texture altered |
| 3 | Darker, starts to curl, small amount | Longer/larger |
| 4 | Resembles adult type, but less in quantity, coarse, curly | Larger; glans and breadth increase in size; scrotum dark |
| 5 | Adult distribution, spread to medial surface of thighs | Adult size |

* Adapted from Tanner JM. Growth at Adolescence. 2nd ed. Oxford: Blackwell Scientific Publications, 1962.

***Table 97.8. Tanner's Stages of Sexual Development****

### *Imaging Studies*

Take radiographs of the knee to assess the status of the physis and to exclude associated fractures or osseous congenital variations. Obtain stress radiographs as needed to rule out physeal injuries. MRI may be helpful in determining the extent of injury to the ligament and the status of other intraarticular structures (58,82). Take care in interpreting meniscal tears on MRI because a high incidence of false-positive results in children has been described (201).

### *Treatment*

Injury to the ACL in the preadolescent and adolescent is a difficult management problem. Most natural history studies of ACL injuries in children have deficiencies (12,32,83,104,168,195). Associated meniscal injuries are frequently not documented, and the maturity of the child is infrequently noted (14,83). Some authors have reported reasonable results following conservative measures (12,50), but most authors have reported a high incidence of reinjury (83,106,195).

Initially, protect the knee to allow secondary restraints and areas of cartilage contusion to heal. Identify associated meniscal injuries and treat as in adults with repair or resection. Implement a well-structured rehabilitation program to restore range of motion and strength as well as develop balance skills and proprioceptive feedback pathways. Teach youngsters proper jumping and landing techniques to prevent future reinjuring (19). Although it has not been well documented to eliminate instability, bracing can be clinically useful.

### *Operative Technique*

Criteria for electing to proceed with surgical reconstruction of the anterior cruciate ligament and the type of procedure chosen for the adolescent who is nearing growth completion (Tanner's stages 3, 4, or 5 with closing physes) follows guidelines established for adults. In the child or preadolescent (Tanner's stages 1 or 2 with widely open physes), the decision becomes more difficult because premature femoral or tibial physeal closure can result in a significant leg length discrepancy, especially in a young child.

The long-term outcome of the conservatively treated unstable ACL-deficient knee in the child is often poor. Recurrent episodes of pivoting result in meniscal and articular cartilage injury, often leading to early degenerative changes (83,135,134,150,151,167). However, placing hardware or even drilling tunnels across an open physis carries the risk of causing premature closure (52,122,134).

Primary reconstruction of the torn ACL has poor results in children, just as it does in adults (32,157). Extra-articular reconstructions also yield poor late results (125,135,157). Bergfeld, in an attempt to use an intraarticular reconstruction but avoid the physeal plate, developed what has been called the “tomato stake” procedure (167), which is performed as follows (Fig. 97.27):

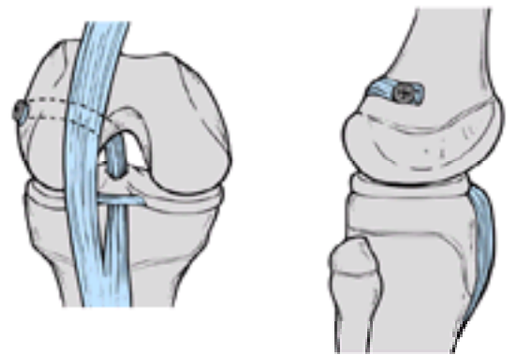

***Figure 97.27.*** Bergfeld's “tomato stake” procedure. (Adapted from ref. 58.)

- Make a midpatella tendon incision.
- Isolate the middle third of the patella tendon, leaving it attached at the proximal tibia.
- Pass the tendon over the front of the tibia, beneath the transverse ligament, through the knee, and around the top of the femur.
- Fasten the tendon to the femur *above the physis* with a staple; do not violate the physis with the staple.
- The stump of the ACL can be used to augment the reconstruction.

Parker et al. (167) modified this technique by creating a groove in the tibia and femur to make the tunnel more isometric and also added an extraarticular iliotibial band tenodesis. Brief (32) developed a procedure similar to that of Parker et al. but prepared the groove and passed the graft arthroscopically (Fig. 97.28). He reported using hamstring graft, but his technique can also be adapted for patella tendon graft. Brief's technique, incorporating the “groove” in the tibia suggested by Parker et al. (167)

to improve isometry, follows.

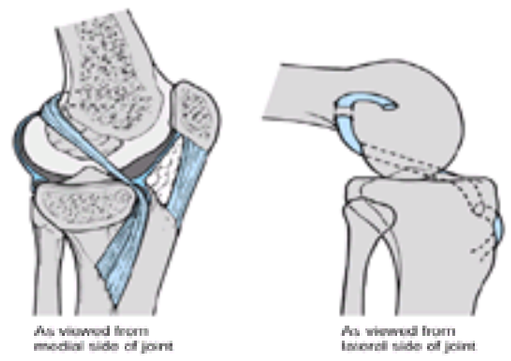


***Figure 97.28.*** Brief's arthroscopic modification (32) of the Parker and Drez's modified “tomato stake” procedure (167). Redrawn from ref. 32.

- Arthroscopically inspect the knee and correct intraarticular pathology.
- Create a groove in the anterior tibia through which a graft composed of gracilis and semitendinous tendons harvested through an oblique proximal tibial incision is brought up through the joint and around and over the top position of the femur.
- Fasten the graft to the distal lateral femur above the physis through a distal lateral thigh incision. (The middle third of the patella tendon can be substituted for the hamstring in this procedure.)

Lipscomb and Anderson (122) have reported no complications with drilling across the physis, as long as the fixation device does not cross the physis. In their series, only one patient had premature physeal closure, and this was attributed to placement of a fixation staple across the physis.

Smith and Tao (194), by using hamstring grafts put through standard tibial and femoral tunnels for adolescents within 1 to 2 years of skeletal maturity, reported no complications. For younger children who failed a well-structured conservative program, hamstring tendon grafts placed through standard tibial holes in the over-the-top femoral position was advised. McCarroll et al. (134) recommend activity modification, functional bracing, frequent follow-up, and delayed definitive hamstring reconstruction for the child with wide open physes who is several years from skeletal maturity. In contrast, Fowler (70) recommends a hamstring or patella-quadriceps tendon graft placed through small (6 mm) tibial tunnels and in the over-the-top position on the femur. In reviewing 29 young adolescents treated in this manner, he found no leg length discrepancies. All youngsters returned to their preoperative activity levels. The use of Achilles tendon or fascia lata allografts (7 mm) placed through a tibial tunnel and in the over-the-top position in the femur to replace the ACL in skeletally immature patients has been reported (11) on a limited series (eight patients) with good early results (58 months).

***Author's Preferred Treatment***

Initially, we treat nonoperatively a tear of the ACL in the child with widely open growth centers who is in Tanner's stage 1 or 2 and who has taller siblings and parents. We use MRI to help evaluate intraarticular structures, provide early protection until acute symptoms subside, and correct meniscal pathology if such exists. We then prescribe a well-structured rehabilitation program stressing range of motion, strength, proprioceptive skills, and guided return to functional activities.

We treat like adults adolescents in Tanner stages 3, 4, and 5 with radiographs demonstrating little growth remaining in their physes. We prefer quadruple hamstring tendon grafting with fixation above and below the physes.

In patients who fail conservative care but who have significant growth remaining, we use a modification of an extraarticular reconstruction (either DeLee's or a modified Andrew's), until the physes are closing and the athlete is in Tanner's stage 3, at which time an intraarticular reconstruction procedure can be done. DeLee's reconstruction (Fig. 97.29) is as follows:

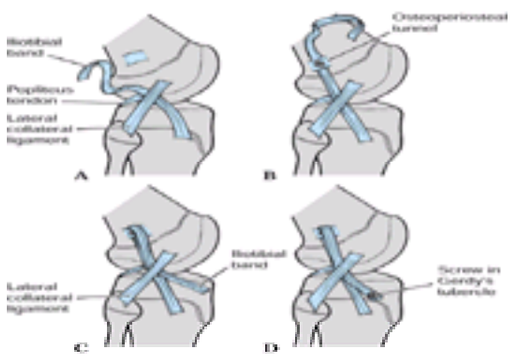


***Figure 97.29.*** DeLee's extraarticular reconstruction for the anterior cruciate ligament in children with mild to moderate laxity and significant growth remaining (more than 2 cm) in whom conservative care has failed. Adapted from ref. 58.

- Isolate a 2.5 cm wide strip of iliotibial band, 15 cm in length. Leave the iliotibial band attached to Gerdy's tubercle (Fig. 97.29A).
- Pass the strip beneath the fibular collateral ligament.
- Create an osteoperiosteal tunnel proximal to the physeal plates.
- Fix the graft in the tunnel with a ligament screw and washer (Fig. 97.29B).
- Next, pass the iliotibial band back distally beneath the fibular collateral ligament (Fig. 97.29C) and fix the ligament with a screw and washer to Gerdy's tubercle (Fig. 97.29D).

The Andrews procedure is as follows:

- Place a tourniquet high on the thigh and the knee in a leg holder immediately below the tourniquet, leaving most of the distal thigh exposed.
- Prep and drape the extremity in the typical fashion for arthroscopy.
- Inflate the tourniquet, tighten the knee holder, and perform a diagnostic arthroscopy, correcting any intraarticular pathology found.
- With the knee bent 90° in the knee holder and the foot hanging free, make a lateral incision in the distal thigh beginning approximately 8 cm above the knee joint and extending down to just above Gerdy's tubercle. Extend the incision through the subcutaneous tissue, exposing the iliotibial band.
- Longitudinally divide the iliotibial band to create a strip approximately one third the width of the band, situated 2 to 3 cm from its posterior border.
- Retract the remaining iliotibial band anteriorly and, using a periosteal elevator, denude the soft tissue and periosteum from the area of the femur at the lateral intermuscular septum just proximal to the beginning of the femoral condyle and above the physis. Use an osteotome to fish scale this area.
- Place a modified Kessler stitch with a 2-0 Polydec suture through the strip of iliotibial band, going distal to proximal.
- With tension on the iliotibial band through traction on the previously placed suture, staple the iliotibial band to the previously prepared bed on the femur.
- Close the wound in layers. Apply a sterile dressing and a limited motion brace from 30° to 90°.

Postoperatively, permit limited range of motion as described earlier, advancing from 30° to full flexion within 2 weeks. Begin close kinetic strengthening exercises in several days and advance over the next 6 to 8 weeks. Do not permit running for 3 to 4 months, and require brace protection for return to low-risk pivotal activities. This extraarticular repair is not intended to create a stable knee for high-risk activities but is merely used as a time-buying procedure for those who have failed conservative care in order to enhance stability for low-risk activities. The rehabilitation protocol is much like that used for nonoperative management.

Parker et al.'s (167) arthroscopic modification of Bergfeld's “tomato stake” procedure may be a reasonable alternative; however, this reconstruction is not ideal because

it uses a prime source of autologous graft material (patellar or hamstring tendon), which is placed in a nonisometric position, thereby subjecting it to failure over time. One needs to take care in grooving the over-the-top femoral tunnel not to groove the physis, which is only 2.5 cm proximal to the ACL's attachment (19).

## TIBIAL SPINE FRACTURES

In the past, it was believed that before closure of the physis, the intercondylar eminence offers less resistance to traction forces than the ACL, making it more commonly injured than the ACL in children (173,210). Recently, with the increased emphasis on competitive sports in children, increasing numbers of ACL midsubstance tears are being seen. In the athletic population, such injuries may be more frequent than eminence fractures (135,194).

### *Pathophysiology*

A fall or collision in sport, a fall from a bike, or a collision with a car are the most likely events resulting in a tibial eminence fracture (84). The mechanism of injury has not been well defined. Wiley and Baxter (218) suggest that injuries occur when, with the foot planted on the ground, the extended knee is axially loaded simultaneously with outward rotation of the femur on the tibia. Hyperflexion is another potential mechanism of injury.

Meyers and McKeever (142) reported that tibial eminence fractures in children were often the result of less violent injuries than those resulting in proximal tibial fractures in adults and were typically an isolated injury. In contrast, DeLee's (58) more recent review of this injury led him to conclude that this fracture was often associated with collateral or meniscal injury.

The tibial eminence is the area between the two tibial plateaus, consisting of the two tibial spines and the bony attachments for the anterior and posterior horns of the medial and lateral menisci (218). The ACL is partially attached to the medial spine (Fig. 97.30). Spine fractures in children occur through the cancellous bone beneath the subcortical plate. The fracture fragment typically includes the ACL and a variable-sized portion of the intermeniscal area (208). The ACL receives its blood supply from the middle genticular artery but can atrophy if it remains detached at one end due to a nondisplaced avulsion fracture (143).

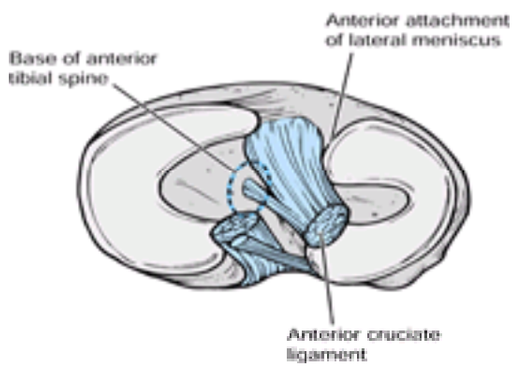


***Figure 97.30.*** Anatomy of the tibial eminence. (Redrawn from DeLee JC. Ligaments of the Knee. In: Stanitski CL, DeLee JC, Drez D Jr. eds. *Pediatric and Adolescent Sports Medicine.* Philadelphia: W.B. Saunders, 406;1994, with permission.)

### *Classification System*

The classification system of Meyers and McKeever (142,143) (Fig. 97.31) is still used to make treatment decisions. Zaricznyj (224) added a fifth category, type IV or III C, consisting of comminuted displaced eminence fractures.

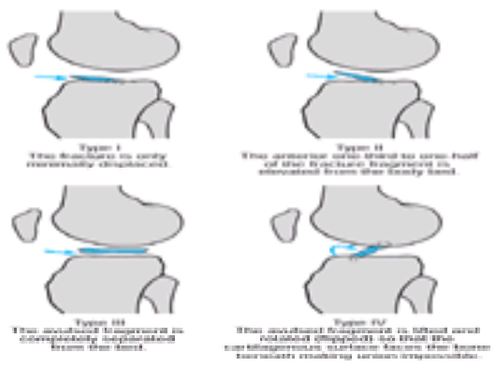

***Figure 97.31.*** Meyer and McKeever's classification of tibial eminence fractures.(From Meyers HH, McKeever FM. Fracture of the Intercondylar Eminence of the Tibia. *J Bone Joint Surg* 1959;41A:209, with permission.)

### *Clinical Evaluation*

The child with a tibial eminence fracture typically presents with a large hemarthosis. Because this injury is often associated with high-velocity trauma, look for associated neurovascular or collateral ligament injuries and assess the entire lower extremity.

### *Imaging*

The tibial spine fracture typically can be seen on standard radiographs of the knee, although tunnel and oblique views in nondisplaced fractures may be helpful. The avulsed bony fragment may be small compared with the cartilaginous fragment, making radiographic identification more difficult.

### *Treatment*

Nondisplaced type I fractures require only protection with a cast or a hinged knee brace locked in extension. Type II fractures can frequently be reduced by aspirating the joint, instilling local anesthesia, and then gently extending the knee. As the knee comes into full extension (the last 5° are critical [58,174]), the femoral condyle impinges on the fragment, resulting in its reduction. Following reduction, immobilize the knee in full extension by cast or brace until healing at 6 to 8 weeks. Note that Meyers and McKeever (143) and Medler and Jammason (138) recommend immobilization in 20° of flexion because in full extension, the ACL can exert tension on the fragment.

For types III and III + fractures as well as type IV fractures, we recommend arthroscopic or open reduction of the fragment with fixation using absorbable or nonabsorbable sutures, pins, or screws (Fig. 97.32 and Fig. 97.33). If left displaced, the eminence will likely block full extension and result in laxity of the ACL.

The open procedure for reduction of tibial eminence type III or irreducible type II fractures is as follows:

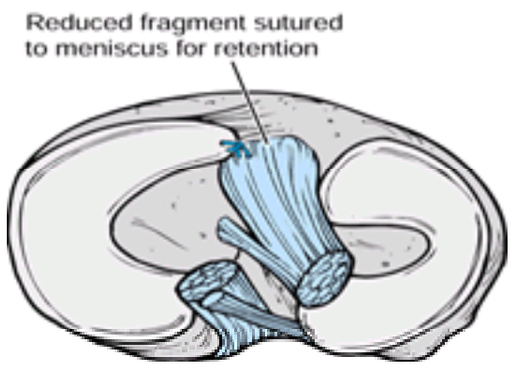


***Figure 97.32.*** Meyer and McKeever's method of fixation of tibial eminence fractures. Note the use of absorbable sutures placed through the fragment and sutured to the anterior horn of the medial meniscus, which are used in lieu of screws, pins, or transitional sutures (52,142,43).

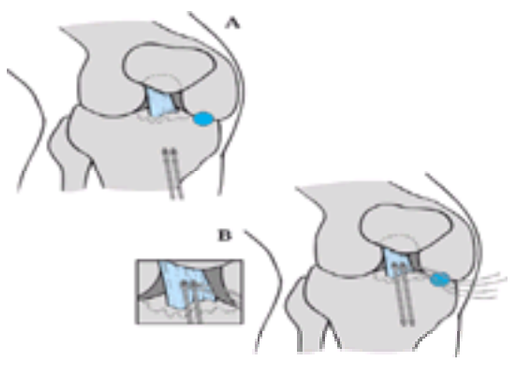


***Figure 97.33.*** Arthroscopic treatment of fractures of the tibial spine. (From Medlar RG, Jansson KA. Arthroscopic Treatment of Fracture of the Tibial Spine. *Arthroscopy* 1994;10:292, with permission.)

- Expose the knee joint through a distal portion of an anterior medial parapatella incision.
- Examine the joint for other associated pathology.
- Inspect the anterior horn of the menisci to make certain that they are not trapped beneath the fragment.
- Clear the fracture of any debris. Place the knee joint in extension to reduce the fragment.
- Drill two holes from distal to proximal through the tibial physis, entering the knee joint just medial and lateral to the fracture fragment or piercing the fragment itself. Take care to place these holes proximal to the physis.
- Place an 18- or 19-gauge wire or a 1-0 nonabsorbable suture through the distalmost portion of the ACL, just proximal to the fragment.
- Pass the suture through the previously drilled holes and tie them after the fragment is reduced.
- Flex and extend the knee to check for stability.

Arthroscopic treatment of tibial spine fractures proceeds as follows:

- After examination of the knee under anesthesia, elevate the leg and inflate tourniquet. Place the leg in leg holder and prep and drape the extremity in the usual sterile fashion.
- Examine the joint arthroscopically, correcting any associated injuries.
- Clean the fracture area of all loose and unstable tissue.
- Perform a trial fracture reduction using the probe to guide the fragment into position.
- Make an anteromedial proximal incision over the tibia and carry it down to bone.
- Place two drill-tipped guide wires through the tibia and through the fracture fragment (Fig. 97.33A).
- Insert spade-tipped guide pins through the drill holes and through the bony fragment using a probe or small rasp to hold the fragment reduced while passing the guide wires and pins.
- Use the Accufex suture passed from the shoulder set to pass a #1 PDS through a 7 mm cannula in the anteromedial portal (Fig. 97.33B).
- Thread the suture through the islet of the spade-tipped pins and bring it back through the same portal with a grasping instrument. Repeat this procedure for the other pins.
- Remove both pins from the knee, bringing the double strands of sutures with them.
- Tie the sutures protruding through the anteromedial portal and pull them back into the joint, creating a loop that snugly ties down the avulsed fragment.
- Tie the two loops together over the small bony bridge as they exit from the anterior tibia.
- Close wounds in a routine fashion.

Although most authors (52,73,142,151) report good to excellent results following open reduction and internal fixation with no laxity after healing of the fracture, others (218,224) report mild laxity without functional disability. The lack of significant functional disability despite evidence of mild to moderate clinical laxity has been attributed to either intact proprioceptive mechanisms or increased stability from enlargement of the reduced fragment secondary to the increase in its blood supply during healing (218). In contrast, Smith (195) and Gronkvist et al. (88) found residual symptoms and clinical instability in a significant number of patients, indicating that a reevaluation of treatment protocols was needed.

## MENISCAL TEARS

The incidence of meniscal tears is rising in the adolescent athlete primarily due to increased sports participation (24,185). This lesion represents one of the most common injuries seen in youth sports (57). Although rarely seen in children younger than 9 years of age (111,193), meniscal tears must be suspected in adolescents older than 12 years of age with signs of internal derangement of the knee following a twisting injury in sports (106). Menisci perform several very important functions in the knee (178). The emphasis of treatment is meniscal preservation (202). The menisci in children are more vascular, suggesting a greater ability to heal following injury (53). In adults, vascular channels are present in the peripheral third of the menisci, whereas in children, these vascular channels often extend up to or even beyond the halfway mark (78). The pattern of meniscal tearing in children also differs from that in adults in that the younger the patient, the more peripheral the meniscal tear tends to be (111).

Evaluation of children with internal derangement can be more difficult than in adults because they are poorer historians, but typically a more significant injury is required to tear the meniscus and it is often associated with tears of the ACL. Radiographs are typically normal. Consider MRI if tenderness and pain persist beyond 2 weeks. Beware of false-positive results (79).

Long-term results of total meniscectomy in adolescents is poor, with a large number of patients developing advanced degenerative changes in the knee (98,128,223). On the other hand, healing of meniscal repairs in adolescents is superior to that in adults (79,91,96,153).

The techniques used for meniscal repair in children do not differ from those in adults, and are described in Chapter 85.

### DISCOID LATERAL MENISCUS

#### *Pathophysiology*

Discoid meniscus is a congenital anomaly resulting in an enlargement of all or part of the meniscus (79). Lateral discoid meniscus is more common than the medial type and occurs in approximately 2% of the population (79).

### *Classification*

Discoid meniscus is a common cause of knee symptoms in children and adolescents (61,62). Discoid meniscus has been categorized into three major types by Watanabe et al. (214) (Fig. 97.34). Type I, the most common variety, is a complete disk-shaped semilunar type with a thinner center. Type II consists of an incomplete semilunar type with a concave or convex free edge. Type III is a hypermobile or Wrisberg-type, which lacks a posterior tibial attachment. Although the Wrisberg-type is the most rare, it is most likely to lead to symptoms because of its hypermobile nature. Types I and II discoid menisci are often asymptomatic, although athletes with these types are susceptible to a greater frequency of tears because of the relatively poor vascularity and thickness of the discoid meniscus (93). In the Wrisberg-type discoid meniscus, there is no posterior attachment to the tibial plateau, resulting in a hypermobile posterior horn that displaces into the intracondylar notch with extension because of traction on the lateral meniscal femoral (Wrisberg) ligament. This results in the often-symptomatic “snapping knee syndrome,” which is notable due to the audible clicking when the knee is moved (79).

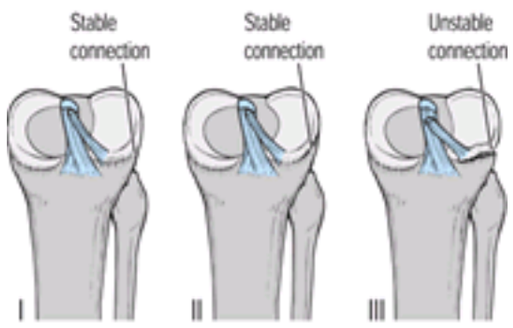


***Figure 97.34.*** Watanabe classification of discoid menisci. Type I, stable complete discoid meniscus. Type II, stable incomplete discoid meniscus. Type III, unstable discoid meniscus secondary to lack of a complete meniscotibial ligament.

### *Clinical Examination*

Adolescent athletes typically present with this disorder between 12 and 15 years of age and often complain of the classic meniscal symptoms of limited extension, snapping, locking, and pain. Physical examination may reveal loss of extension, quadriceps atrophy, and a variable effusion.

### *Imaging*

Radiographs may be normal but often show widening of the lateral joint space and squaring of the lateral femoral condyle. In addition, hypoplasia of the lateral tibial spine with tilting of the lateral tibial articular surface and apparent elevation of the fibular head may be noted. MRI reveals the presence of abnormally thickened meniscal tissue interposed into the central intercondylar zone, which may be limited to only one portion of the meniscus (79).

### *Treatment*

As with the treatment of tears of normal menisci in children and adolescents, the focus in treatment of symptomatic discoid lateral menisci is preservation of as much normal meniscal tissue as possible. A course of conservative management is indicated initially, but if symptoms persist, arthroscopy is indicated. Small loose fragments can be removed and peripheral tears may be considered for repair. Meniscoplasty has been recommended to reduce the thickness of the discoid meniscus and prevent recurrent tears. Hayashi et al. (93) advise leaving a rim of 6 mm in the complete type discoid meniscus and 8 mm in the incomplete type. This allows the remaining meniscus to participate in weight bearing (Fig. 97.35). The pattern of the meniscal tear will sometimes dictate the amount of meniscus to be resected. Several reports (20,62,93) have documented good results following total meniscectomy for discoid lateral meniscus. Total excision, however, should be the last resort to avoid the possibility of progressive degenerative arthritis.

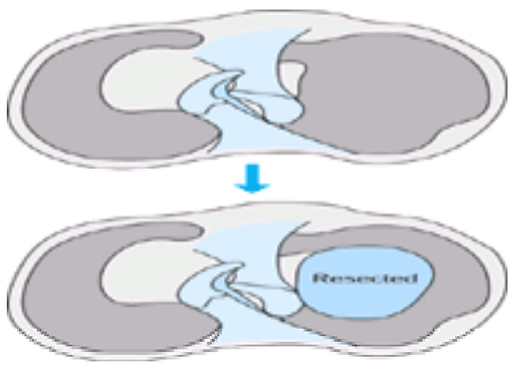


***Figure 97.35.*** Meniscoplasty by resection of the central portion of the discoid meniscus reduces the thickness of the meniscus to prevent recurrent tears.

## PATELLOFEMORAL JOINT PROBLEMS

Complaints relative to the patellofemoral joint in the child and adolescent athlete are extremely common and can be categorized as either patellofemoral stress syndrome, characterized by pain, or patellofemoral instability, with symptoms of subluxation and recurrent dislocation. Although laxity does play a part in both of these problems, it is one small part of an overall malalignment syndrome, which may include tissue imbalance, muscle weakness, angular and rotational deformities, and dysplastic bone (Fig. 97.36). Evaluation and treatment of these problems therefore must take into account the overall configuration of the patellofemoral joint so that treatment can be directed toward the specific pathology (217).

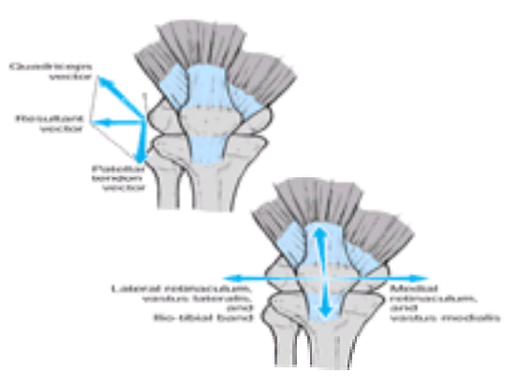

***Figure 97.36.*** Patellofemoral biomechanics. The patella depends on muscular, soft-tissue, and bony factors to maintain stable aligment in the patellofemoral joint.

Factors that increase the lateral pull on the patella or decrease the medial restraining mechanism will lead to lateral tracking of the patella with associated pain and instability (79,129,168,218) (Table 97.9). The cause of pain appears to be excessive tension and rotational forces on the peripatellar soft tissues (102) as well as excessive pressure on the lateral patellar facet (68). Patients typically present reporting diffuse generalized anterior knee pain that is exacerbated when weight bearing is performed on the bent knee with such activities as descending stairs and squatting. Patients may complain of associated instability, but true locking of the knee is uncommon, although a catching sensation is reported (79). Pain is often present after a period of prolonged sitting with the knee flexed. A history of sudden increase in training or in training errors is commonly obtained from these patients (102).

- Increase or femoral anteversion
- External tibial torsion
- Genu varum
- Excessive quadriceps angle
- Heel cord contracture
- Pronated feet
- Squinting patellae

***Table 97.9. Miserable Malalignment Syndrome***

Look for abnormalities around the knee, including in quadriceps angle; hamstring and iliotibial band tightness; patellar tilting; and rotational deformities of the tibia and femur; and carefully evaluate for pronation of the foot. Decreased thigh circumference indicates chronicity. Patients typically exhibit pain with patellar compression and tenderness to palpation of the patellar facets and retinaculum. Take AP, lateral, and tangential radiographic views of the patella to rule out other bony abnormalities, including bipartite patella, Sinding-Larsen-Johansson disease, and OCD. Evaluate for patella alta or baja on the lateral views. Tangential views such as the Merchant view (139) allow evaluation of patella maltracking or subluxation. Nonoperative management is successful in the vast majority of patients (59,222). Initially, reduce pain with physical therapeutic modalities, followed by a stretching program for the iliotibial band and hamstring muscles. Strengthen the vastus medialis obliquus (VMO) to increase the medial pull on the patella and improve patellar tracking. Foot orthotics may be helpful, and knee bracing with a Palumbo style brace may also reduce patellar stress. Slowly allow resumption of sports when flexibility and strength have been regained and pain is under control. Surgical treatment is rarely indicated, and although it is usually successful, failures of surgical management tend to lead to a significant disability (79).

The goal of surgical management is to improve patellar tracking. Lateral retinacular release may be indicated in patients with contracted lateral tissues but is contraindicated in the hypermobile patella. The articular surface of the patella is rarely a cause of symptoms in adolescent athletes, and therefore, arthroscopic chondral shaving is rarely indicated. Bony realignment is contraindicated with open physes, and any type of surgical intervention is contraindicated in patients who are not cooperative with rehabilitation, exhibit a psychosomatic component to their report, or have reflex sympathy dystrophy (79).

Like their counterparts with patellofemoral stress syndrome, adolescent athletes who present with patellar dislocation often exhibit anatomic features that render them susceptible to this problem (79) (Table 97.10).

- Shallow patellofemoral groove
- Patella alta
- Excessive quadriceps angle
- Ligamentous laxity
- Genu valgum
- Rotational malalignment of the femur and tibia
- Hypoplasia or atrophy of the vastus medialis obliquus
- Abnormal attachments to the patella from the iliotibial band

***Table 97.10. Risk Factors for Patellar Dislocation***

The force required to produce patellar dislocation is inversely related to the degree of malalignment and dysplasia encountered. Patients present usually between 16 and 20 years of age (31,48,97,116) following a single twisting maneuver involving the knee. Football, baseball, and basketball are commonly involved, but cases have been reported in gymnastics as well as cheerleading. Just as with patellofemoral stress syndrome, girls are more commonly affected than boys, and in almost one quarter of cases, a positive family history for patellofemoral instability is elicited (31). Dislocations frequently reduce spontaneously, and the adolescent athlete presents with diffuse knee pain and swelling. Physical examination may reveal an effusion, diffuse parapatellar tenderness, a positive apprehension test for patellar dislocation, and a palpable defect in the VMO insertion into the patella. Patients should be evaluated for signs of other ligamentous injury about the knee, which can occur with the same mechanism. Look for other sources of pain referred to the knee. Reduce persistent dislocations of the patella immediately with intravenous sedation and an intraarticular anesthetic if needed. As hamstring spasm resolves, the knee can be brought gently into extension, and spontaneous reduction usually occurs. Radiographic evaluation of the acutely injured knee includes AP and lateral x-ray studies, and this can be supplemented with a CT scan if these studies are nonconclusive. Osteochondral fragments may be noted in the joint, and bone fragments along the medial patellar margin, which are not free floating, may be evident.

Aspirate a tense hemarthrosis, if present. Immobilize the knee in extension up to 6 weeks (48). During this time, straight-leg raises for progressive strengthening are beneficial in reestablishing the pull of the VMO. Osteochondral fractures, which occur in approximately 10% of cases of patellar dislocation, require immediate surgery. Fragments larger than 5 mm may require repair, whereas smaller fragments can be excised (79). Approximately 75% of patients obtain acceptable results following closed treatment of patellar dislocation (48), but only 50% become asymptomatic. Risk factors for redislocation include osteochondral fragment, age younger than 14 years, participation in athletics, palpable medial defect, contralateral evidence of knee dysplasia, patellar hypermobility, prior dislocations, positive family history for dislocations, and patella alta (48). Recurrent dislocations can be treated conservatively as well with vigorous quadriceps strengthening, but patients with high-risk factors may benefit from early surgery. Surgery should be tailored to the pathology encountered, and the previously mentioned dysplastic features should guide the surgical approach (99). Options include lateral retinacular release and distal realignment procedures (15,48,95,127,141). Bony distal realignment procedures such as the Elmslie-Trillat procedure lead to an overall good result in more than 80% of cases (79) but are contraindicated in younger patients with open growth plates (95,126). Soft-tissue procedures such as medial plication, hemitransfer of the patella tendon, and semitendinosus transfer to the distal pole of the patella (2,15) have also enjoyed success. Results tend to be worse in children and adolescents with ligamentous laxity, and in younger children, surgery may be unpredictable and require a tibial tubercle transfer after skeletal maturity has been reached. Figure 97.37 shows the potential steps in patellar realignment in the growing child. Lateral release is nearly always necessary. Medial plication is usually required. Medial transfer to the lateral half of the patellar tendon is sometimes required. Tenodesis of the semitendinosis tendon to the patella is required for severe deformity in which the other three steps are inadequate.

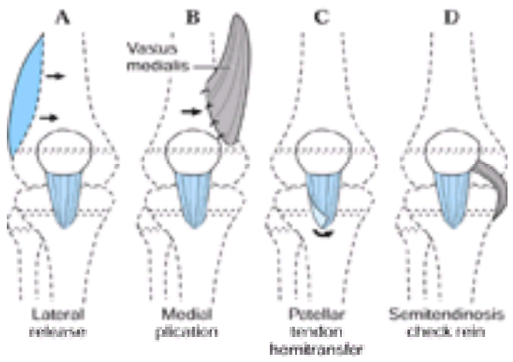


***Figure 97.37.*** The steps in patellar realignment in the growing child. Lateral release (**A**) is almost always required and medial plication (**B**) is usually required. Medial transfer of the lateral half of the patellar tendon (**C**) may also be required and tenodesis of the semitendinosis (**D**) is usually required only for severe deformity. (Adapted from Staheli LT. The Lower Limb. In: Morrissy RT, ed. *Lovell and Winter's Pediatric Orthopaedics, 3rd ed.* Philadelphia: JB Lippincott, 1990:741.

## GENERAL CONDITIONING AND REHABILITATION PRINCIPLES

The phases of a rehabilitation program for a child or adolescent are no different from those of an adult, although generally the child progresses through these phases more rapidly. A typical program may be divided into five phases:

- phase I—decreasing inflammation
- phase II—improving range of motion
- phase III—improve strength and proprioception
- phase IV—return to functional skills
- phase V—return to sport

One must master 75% to 80% of the goals of each phase before progressing to the next phase. Providing youngsters with short-term and intermediate goals will help maintain their interest and enthusiasm. One must also remember that children have short attention spans, and therefore, exercises need to be brief, simple, and fun. Incorporate range-of-motion, proprioception, and strengthening exercises into games using a variety of colorful equipment. During adolescence, exercising with peers often results in greater compliance.

Conditioning is as beneficial for children and adolescents, especially those involved in highly competitive sports, as it is for adults, and just as in adults, proper conditioning in children and adolescents is associated with a decrease in injury rates (118).

Strength training for children and prepubescent adolescents is appropriate provided the equipment is sized appropriately. (Hence free weights are frequently better than machines built for adults.) Although this age group lacks adequate androgen to develop muscle bulk, weight-training programs have been found to develop tone and strength and enhance performance (118).

A common misconception among coaches is the belief that all youngsters are flexible and do not need to stretch before and after practice and play. Particularly during periods of rapid growth, when young bones may be growing faster than the surrounding muscles, warming up and stretching is important in preventing overuse injuries such as the traction apophysites. (See section on nonarticular osteochondroses in this chapter.)

## WATCH OUT FOR THE MASQUERADERS

When evaluating children and adolescents who report pain with sports activity, one must always keep in mind that other systemic problems can masquerade as sport injuries. For example, a persistently swollen ankle in an 11-year-old may not be secondary to landing wrong while practicing a basketball drill but may be the first sign of juvenile rheumatoid arthritis; a swollen tender tibial tubercle or iliac crest may not be an acute traumatic apophysitis, but the inflammation may be secondary to infection (56); the first sign of leukemia may be fatigue with activity; and the early stages of osteogenic sarcoma may be confused radiographically with a healing stress fracture.

Beware also of the youngster who presents with symptoms far more severe than the objective findings or who frequents the physician's office with a variety of minor problems over a brief period of time. This adolescent, although strongly verbalizing his desire to “play through any pain,” may in reality be trying to use his “injury” as an “acceptable way out” of sports. Such a scenario is not infrequent during teenage years, when adolescents may no longer wish to continue to spend the long hours in training that has been required of them but instead may wish to spend more time socializing with friends. However, these adolescents fearing rejection and chastisement from disappointed parents, cannot admit to them that they just do not want to participate anymore. Often the physician must “read between the lines,” gain the athlete's confidence, and help the athlete deal with the situation in an acceptable manner.

## CHAPTER REFERENCES

Each reference is categorized according to the following scheme: 01, classic article; #, review article; !, basic research article; and +, clinical results/outcome study.


+ 1. Abbate CC. Avulsion Fracture of the Ischial Tuberosity. A Case Report. *J Bone Surg* 1945;27:716.

# 2. Adams JE. Injury to the Throwing Arm: A Study of Traumatic Changes in the Elbow Joints of Boy Baseball Players. *California Medicine* 1965;102:127.

# 3. Adams JE. Little League Survey: The Eugene Study (Editorial). *Am J Sports Med* 1976;4:207.

+ 4. Aichroth P. Osteochondritis Dissecans of the Knee: A Clinical Survey. *J Bone Joint Surg* 1971;53B:440.

! 5. Albright JA, Jokl P, Shaw R, et al. Clinical Study of Baseball Pitchers: Correlation of Injury to the Throwing Arm with Method of Delivery. *Am J Sports Med* 1978;6:15.

+ 6. Alonso-Llames M, Diaz-Peletier R, Moro MA. The Correction of Post Traumatic Cubitus Varus by Hemi-wedge Osteotomy. *Int Orthop* 1978;2:215.

+ 7. Anderson AF, Pagnani MJ. Osteochondritis Dissecans of the Femoral Condyles: Long Term Results of Excision of Fragment. *Am J Sports Med* 1997;24:830–834.

! 8. Anderson AF, Richards DB, Pagnani MJ, Hovis WD. Antegrade Drilling for Osteochondritis Dissecans of the Knee. *Arthroscopy* 1997;13:319.

+ 9. Anderson IF, Crichton KJ, Gattan-Smith T, et al. Osteochondral Fractures of the Dome of the Talus. *J Bone Joint Surg* 1989;71A:1143.

# 10. Anderson MW, Greenspan A. Stress Fractures. *Radiology* 1996;199:1.

+ 11. Andrews M, Noyes FR, Barber-Westin SD. Anterior Cruciate Ligament Allograft Reconstruction in the Skeletally Immature Athlete. *Am J Sports Med* 1994;22:48.

+ 12. Angel KR, Hall DJ. Anterior Cruciate Ligament Injuries in Children and Adolescents. *Arthroscopy* 1989;5:197.

+ 13. Bak K. Separation of the Proximal Tibial Epiphysis in a Gymnast. *Acta Orthop Scand* 1991;62:293.

+ 14. Baker RH, Carroll N, Dewar FP, et al. The Semitendinosus Tenodesis for Recurrent Dislocation of the Patella. *J Bone Joint Surg (Br)* 1972;54:103.

+ 15. Banas MP, Lewis RA. Nonunion of an Olecranon Epiphyseal Plate Stress Fracture in an Adolescent. *Orthopaedics* 1995;18:1111.

+ 16. Batten JM, Menelaus M. Fragmentation of the Proximal Pole of the Patella. *J Bone Joint Surg* 1985;67B:249.

+ 17. Bede WB, LeFebure AR, Rosmon MA. Fracture of the Medial Humerus Epicondyle in Children. *Can J Surg* 1975;18:137.

+ 18. Beekham F, Sullivan JE. Some Observations on Fractures of Long Bones in Children. *Am J Surg* 1941;51:722.

! 19. Behr CT, Paletta GA Jr, Potter HG, Wickiewicz TL. The Relationship of the Femoral Attachment of the ACL and the Distal Femoral Physeal Plate in the Skeletally Immature Knee: An Anatomic Study. Presented at the American Orthopaedic Society for Sports Medicine Annual Meeting, Vancouver, Canada, July 1998.

+ 20. Bellier G, Dupont JY, Larrian M, et al. Lateral Discoid Menisci in Children. *Arthroscopy* 1989;5:52.

* 21. Berndt AL, Harty M. Transchondral Fractures: Osteochondritis Dissecans of the Talus. *J Bone Joint Surg* 1959;41A:988.

# 22. Berry JM. Fractures of the Tuberosity of the Ischium Due to Muscular Action. *JAMA* 1912;59:1450.

# 23. Berstein SM, King JD, Sanderson RA. Fractures of the Medial Epicondyle of the Humerus. *Contemp Orthop* 1981;3:637.

+ 24. Betz RR, Longergan R, Patterson R, et al. The Percutaneous Lateral Retinacular Release. *Orthopaedics* 1982;5:57.

# 25. Bianco AJ. Osteochondritis Dissecans. In: Morrey BF, ed. *The Elbow and its Disorders.* Philadelphia: W.B. Saunders, 1985:254.

# 26. Bijur PE, Trumble A, Harel Y, et al. Sports and Recreation Injuries in US Children and Adolescents. *Arch Pediatr Adolesc Med* 1995;149:1009.

+ 27. Binek R, Levisohn EM, Bersani F, et al. Freiberg Disease Complicating Unrelated Trauma. *Orthopaedics* 1988;11:753.

+ 28. Blevins F, Steadman JR, Rodrigo JJ, Stillman J. Treatment of Articular Cartilage Defects in Athletes: An Analysis of Functional Outcome and Lesion Appearance. *Orthopaedics* 1997;21:761.

# 29. Blount WP. *Fractures in Children,* 2nd ed. Baltimore: Williams & Wilkins, 1965.

+ 30. Bobic V. An Update on Arthroscopic Osteochondral Autograph Transplantation. American Academy of Orthopaedic Surgery 65th Annual Meeting. New Orleans, March, 1998.

+ 31. Brattstrom H. Shape of the Intercondylar Groove Normally and in Recurrent Dislocation of Patella. *Acta Orthop Scand (Suppl)* 1964;68:1.

! 32. Brief LP. Anterior Cruciate Ligament Reconstruction without Drill Holes. *Arthroscopy* 1991;7:350.

! 33. Bright RW, Burstein AH, Elmore SM. Epiphyseal-plate Cartilage: A Biomechanical and Histological Analysis of Failure Modes. *J Bone Joint Surg* 1974;56:688.

+ 34. Brittberg N, Lindahl A, Nilsson A, et al. Treatment of Deep Cartilage Defects in the Knee with Autologous Chondrocyte Transplantation. *N Engl J Med* 1994;331:889.

# 35. Brogdon BE, Crow WF. Little League Elbow. *AJR Am J Radiol* 1960;83:671.

+ 36. Cahill BR. Stress Fractures of the Proximal Tibial Epiphysis: A Case Report. *Am J Sports Med* 1977;5:186.

+ 37. Cahill BR. Osteochondritis Dissecans of the Knee: Treatment of Juvenile and Adult Forms. *J Am Acad Orthop Surg* 1995;3:237.

! 38. Cahill BR, Berg BC. 99m-Technetium Phosphate Compound Joint Scintigraphy in the Management of Juvenile Osteochondritis Dissecans of the Femoral Condyle. *Am J Sports Med* 1983;11:329.

+ 39. Cahill BR, Tullos HS, Fain RH. Little League Shoulder. *Am J Sports Med* 1974;2:150.

# 40. Caine D, Roy S, Singer K, Broekhoff J. Stress Change of the Distal Radial Growth Plate: A Radiographic Survey and Review of the Literature. *Am J Sports Med* 1992;20:290.

# 41. Caldwell F. Lightboned and Lean Athletes: Does the Penalty Outweigh the Reward? *Phys Sports Med* 1984;12:139.

# 42. Canale ST, Belding RH. Osteochondral Lesions of the Talus. *J Bone Joint Surg* 1980;62A:97.

+ 43. Canale ST, Bourland WL. Fracture of the Neck and Interrochanteric Region of the Femur in Children. *J Bone Joint Surg* 1977;59A:431.

+ 44. Canale ST, Manugian AH. Irreducible Traumatic Dislocations of the Hip. *J Bone Joint Surg* 1979;61A:7.

* 45. Cann CE, Genant HK, Ettinger B, Gordon GS. Spinal Mineral Loss in Ophorectomized Women. *JAMA* 1980;244:2056.

# 46. Carson E. Sports Medicine Perspective: Unanswered Questions. *Orthopaedics* 1997;21:741.

+ 47. Carter C, Wilkinson J. Persistent Joint Laxity and Congential Dislocation of the Hip. *J Bone Joint Surg* 1964;46B:40.

+ 48. Cash JD, Hughston JC. Treatment of Acute Patellar Dislocation. *Am J Sports Med* 1988;16:244.

# 49. Chambers R. Orthopaedic Injuries in Athletes (Ages 6–17): Comparison of Injuries Occurring in Six Sports. *Am J Sports Med* 1979;7:195.

+ 50. Chick RR, Jackson DW. Tears of the Anterior Cruciate Ligaments in Young Athletes. *J Bone Joint Surg* 1978;60A:970.

# 51. Clain MR, Hershman EB. Overuse Injuries in Children and Adolescents. *Phys Sports Med* 1989;17:111.

+ 52. Clanton TO, DeLee JC, Sanders B, Neidre A. Knee Ligament Injuries in Children. *J Bone Joint Surg* 1979;61A:1195.

! 53. Clark CA, Ogden JA. Development of the Menisci of the Human Knee Joint. *J Bone Joint Surg* 1983;65B:538.

# 54. Coady CM, Micheli LJ. Stress Fractures in the Pediatric Athlete. *Clin Sports Med* 1997;16:225.

+ 55. Cohen HH. Avulsion Fracture of the Ischial Tuberosity. *J Bone Joint Surg* 1937;19:1138.

+ 56. D'Ambrosia RD, MacDonald GL. Pitfalls in the Diagnosis of Osgood-Schlatter's Disease. *Clin Orthop* 1975;110:206.

# 57. DeHaven KE, Linter DM. Athletic Injuries: Comparison by Age, Sport, and Gender. *Am J Sports Med* 1986;14:218.

# 58. DeLee JC. Ligamentous Injury of the Knee. In: Stanitski CL, DeLee JC, Drez D Jr, eds. *Pediatric and Adolescent Sports Medicine*, Vol. 3. Philadelphia: W.B. Saunders, 1994:406.

# 59. DeLee JC, Curtis R. Anterior Cruciate Ligament Insufficiencies in Children. *Clin Orthop* 1983;172:112.

# 60. DeSilva MF, Williams JS, Fadale PD, et al. Pediatric Throwing Injuries Above the Elbow. *Am J Orthop* 1998;27:90.

+ 61. Dickason JM, Del Pizzo W, Blazina ME, et al. A Series of Ten Discoid Medial Menisci. *Clin Orthop* 1982;168:75.

+ 62. Dickhaut SC, DeLee JC. The Discoid Lateral-Meniscus Syndrome. *J Bone Joint Surg* 1982;64A:1068.

# 63. Dietz WH, Strasburger VC. Children, Adolescents, and Television. *Curr Probl Pediatr* 1991;21:8.

# 64. Duthie RB, Houghton GR. Constitutional Aspects of the Osteochondroses. *Clin Orthop* 1981;158:19.

# 65. Enneking WE, ed. *Clinical Musculoskeletal Pathology,* 3rd ed. Gainsville, FL: University of Florida Press, 1990:166.

+ 66. Ewing JW. Arthroscopic Management of Transchondral Talar Dome Fractures (Osteochondritis Dissecans) and Anterior Impingement Lesion of the Ankle. *Clin Sports Med* 1991;10:677.

+ 67. Ferbach SK, Wilkinson RH. Avulsion Injuries of the Pelvis and Proximal Femur. *Am J Roentgen* 1981;137:581.

+ 68. Ficat RP, Philippe J, Hungerford DS. Chondromalacia of the Patella: A System of Classification. *Clin Orthop* 1979;144:55.

# 69. Flick AB, Gould N. Osteochondritis Dissecans of the Talus (Transchondral Fracture of the Talus): Review of the Literature and New Surgical Approval for Medial Dome Lesions. *Foot Ankle* 1985;5:165.

# 70. Fowler PJ. Management of the Acute Knee Injury in the Skeletally Immature Athlete. Instructional Course Presented at the 22nd AOSSM Mtg. Lake Buena Vista, FL, 1996.

+ 71. Fowles JV, Slimane N, Kassab MT. Elbow Dislocation with Avulsion of the Medial Humeral Epicondyle. *J Bone Joint Surg* 1990;72B:102.

+ 72. Frangakis EK. Intra-articular Dislocation of the Patella. A Case Report. *J Bone Joint Surg* 1974;56A:423.

+ 73. Garcia A, Neer CS. Isolated Fracture of the Intercondylar Eminence of the Tibia. *Am J Surg* 1958;95:593.

+ 74. Gardener TB. Osteochondritis Dissecans in Three Members of One Family. *J Bone Joint Surg* 1955;37B:139.

# 75. Garrett JC. Osteochondritis Dissecans. *Clin Sports Med* 1991;10:569.

! 76. Garrett WE. Clinical Pathological Perspectives. In: Cahill BR, Pearl AJ, eds. *Intensive Participation in Children's Sports.* Champagne, IL: Human Kinetics, 1993:195.

# 77. Garrick JG, Requa RK. Injuries in High School Sports. *Pediatrics* 1978;61:465.

+ 78. Gerber SD, Griffin PP, Simons BD. Break Dancer's Wrist: A Case Report. *J Pediatr Orthop* 1986;6:98.

+ 79. Gillespie HS, Day B. Bone Peg Fixation in the Treatment of Osteochondritis Dissecans of the Knee Joint. *Clin Orthop* 1979;142:125.

# 80. Goldberg B, Nicholas JA, Rosenthal PP, et al. Injuries in Youth Football. *Pediatrics* 1988;81:255.

# 81. Goldberg MJ. Gymnastic Injuries. *Orthop Clin North Am* 1980;11:717.

+ 82. Goodshall RW, Hansen CA, Raising DC. Stress Fractures Through the Distal Femoral Epiphysis in Athletes. *Am J Sports Med* 1981;9:2.

+ 83. Graf BK, Lange RH, Fujisaki CK, et al. Anterior Cruciate Ligament Tears in Skeletally Immature Patients: Meniscal Pathology at Presentation and After Attempted Conservative Treatment. *Arthroscopy* 1992;8:229.

# 84. Grana WA, Rashkin A. Pitcher's Elbow in Adolescents. *Am J Sports Med* 1980;8:333.

+ 85. Greaney RB, Gerber FH, Laughlin RL. Distribution and Natural History of Stress Fractures in U.S. Marine Recruits. *Radiology* 1983:146.

+ 86. Green NE, Rogers RA, Lipscomb AB. Nonunion of Stress Fractures of the Tibia. *Am J Sports Med* 1985;13:171.

+ 87. Green WT, Banks HH. Osteochondritis Dissecans in Children. *J Bone Joint Surg* 1985;35A:171.

+ 88. Gronkvist H, Hirsch G, Johansson L. Fracture of the Anterior Tibial Spine in Children. *J Pediatr Orthop* 1984;4:465.

# 89. Guggenheim JJ, Stanley RF, Woods GW, Tullos HS. Little League Survey: The Houston Study. *Am J Sports Med* 1976;4:189.

+ 90. Guhl JF. Arthroscopic Treatment of Osteochondritis Dissecans. *Clin Orthop* 1982;167:65.

+ 91. Hamberg P, Gillquist J, Lysholm J. Suture of New and Old Perpheral Meniscus Tears. *J Bone Joint Surg* 1983;65A:193.

+ 92. Hangody L, Kish G, Karpati Z, et al. MosaicPlasty for the Treatment of Articular Cartilage Defects: Application in Clinical Practice. *Orthopaedics* 1998;21:751.

+ 93. Hayashi LK, Uamaga H, Ida K, Miura T. Arthroscopic Meniscectomy for Discoid Lateral Meniscus in Children. *J Bone Joint Surg* 1988;70A:1495.

+ 94. Hedstrom SA, Lidgren L. Acute Hematogenous Pelvic Osteomyelitis in Athletes. *Am J Sports Med* 1982;10:44.

+ 95. Hejgaard N, Skive L, Perrild C. Recurrent Dislocation of the Patella. *Acta Orthop Scand* 673;980:51.

! 96. Henning CE, Lynch MA, Clark JR. Vascularity for Healing of Meniscus Repairs. *Arthroscopy* 1987;3:130.

+ 97. Henry JH, Craven PR. Surgical Treatment of Patellar Instability: Indications and Results. *Am J Sports Med* 1981;9:82.

+ 98. Highland TR, Lamont RL. Osteomyelitis of the Pelvis in Children. *J Bone Joint Surg* 1983;65:230.

* 99. Hughston JC. Subluxation of the Patella. *J Bone Joint Surg* 1968;50:1003.

+ 100. Hunter LY, O'Conner GA. Traction Apoplysitis of the Olecranon: A Case Report. *Am J Sports Med* 1980;8:51.

+ 101. Jackson DW, Runion PR, Morrison DS, et al. Osteochondritis Dissecans in the Female Gymnasts Elbow. AANA Annual Meeting Washington DC, 1988.

# 102. James SL. Chondromalacia of the Patella in the Adolescent. In: Kennedy JC, ed. *The Injured Adolescent Knee.* Baltimore: Williams & Wilkins, 1979:205.

! 103. Johnson EW, McLeod TL. Osteochondral Fragments of the Distal End of the Femur Fixed with Bone Pegs: Report of 2 Cases. *J Bone Joint Surg* 1977;59A:677.

* 104. Jones KG. Reconstruction of the Anterior Cruciate Ligament Using the Central One-third of the Patellar Ligament: A Follow-up Report. *J Bone Joint Surg* 1970;42A:1302.

# 105. Kane WJ. Fractures of the Pelvis. In: Rockwood CA Jr, Green DP, eds. *Fractures in Adults.* Philadelphia: JB Lippincott, 1975:1093.

# 106. Kannus P, Jarvinen M. Knee Ligament Injuries in Adolescents. Eight Year Follow-up of Conservative Management. *J Bone Joint Surg* 1988;70B:772.

# 107. Katz J. Nonarticular Osteochondroses. *Clin Orthop* 1981;158:70.

+ 108. Kelly J. Ischial Epiphysitis. *J Bone Joint Surg* 1963;45A:435.

+ 109. Kennedy JC. Complete Dislocation of the Knee Joint. *J Bone Joint Surg* 1963;45A:889.

# 110. Kibler WB, Chandler TJ. Musculoskeletal Adaptation and Injuries Associated with Intense Participation in Youth Sports. In: Cahill BR, Pearl AJ, eds. *Intensive Participation in Children Sports.* Champaign, IL: Human Kinetic, 1993:203.

# 111. King AG. Meniscal Lesions in Children and Adolescents: A Review of the Pathology and Clinical Presentation. *Injury* 1983;15:105.

! 112. Kramer J, Stiglbauer R, Engle A, Prayer K, Imhof H. MR Contrast Arthorgraphy (MRA) in Osteochondritis Dissecans. *J Comput Assoc Tomogr* 1992;16:254.

# 113. Krause BL, Williams JP, Catterall A. Natural History of Osgood-Schlatter's Disease. *J Pediatr Orthop* 1990;10:65.

+ 114. Krivickas LS. Anatomical Factors Associated With Overuse Sports Injuries. *Sports Med* 1997;13:132.

# 115. Kujala U, Kvist M, Heinonen O. Osgood-Schlatter's Disease in Adolescent Athletes. *Am J Sports Med* 1985;13:236.

+ 116. Larsen E, Lauridsen F. Conservative Treatment of Patellar Dislocations. *Clin Orthop* 1982;171:131.

# 117. Lehman RC, Gregg JR, Torg E. Iselin's Disease. *Am J Sports Med* 1986;14:494.

+ 118. Lepse PS, McCarthy RE, McCullough FL. Simultaneous Bilateral Avulsion Fracture of the Tibial Tuberosity. *Clin Orthop* 1988;229:232.

+ 119. Linden B. The Incidence of Osteochondritis Dissecans in the Condyles of the Femur. *Acta Orthop Scand* 1976;47:664.

+ 120. Linden B. Osteochondritis Dissecans of the Femoral Condyle: A Long-Term Follow-up Study. *J Bond Joint Surg* 1977;59A:769.

# 121. Lindholm TS, Osterman K, Vankka E. Osteochondritis Dissecans of the Elbow, Ankle and Hips: A Comparison Survey. *Clin Orthop* 1980;148:245.

+ 122. Lipscomb AB, Anderson AF. Tears of the Anterior Cruciate Ligament in Adolescents. *J Bone Joint Surg* 1986;68A:19.

+ 123. Lipscomb PR Jr, Lipscomb PR Sr, Bryan RS. Osteochondritis Dissecans of the Knee with Loose Fragments Treatment by Replacement and Fixation with Readily Removed Pins. *J Bone Joint Surg* 1978;60A:235.

! 124. Litchman HM, McCullough RW, Grandsman EJ, Schatz SL. Computerized Blood Flow Analysis for Decision Making in Treatment of Osteochondritis Dissecans. *J Pediatr Orthop* 1988;8:208.

+ 125. Losee RE, Johnson TR, Southwick WO. Anterior Subluxation of the Lateral Tibial Plateau A Diagnostic Test and Operative Repair. *J Bone Joint Surg* 1978;60A:1015.

+ 126. MacNab I. Recurrent Dislocation of the Patella. *J Bone Joint Surg* 1952;34:957.

+ 127. Mandelbaum BR, Bartolozzi AR, Davis CA, et al. Wrist Pain Syndrome in the Gymnast. Pathogentic, Diagnostic, and Therapeutic Considerations. *Am J Sports Med* 1989;17:305.

+ 128. Manzione M, Pizzutillo PD, Peoples AB, et al. Meniscectomy in Children: A Long-term Follow-up Study. *Am J Sports Med* 1983;11:111.

! 129. Maquet P. Mechanics and Osteoarthritis of the Fore Part of the Foot. *J Bone Joint Surg* 1967;49A:1665.

! 130. Margo MK. Surgical Treatment of Conditions of the Fore Part of the Foot. *J Bone Joint Surg* 1967;49A:1665.

! 131. Marks KL. Flake Fracture of the Talus Progressing to Osteochondritis Dissecans. *J Bone Joint Surg* 1952;34B:90.

+ 132. Matheson GO, Clement DB, McKenize DC, et al. Stress Fractures in Athletes: A Study of 320 Cases. *Am J Sports Med* 1987;15:46.

! 133. Matsusue Y, Nakamura T, Suzuki S, Iwasaki R. Biodegradable Pin Fixation of Osteochondral Fragments of the Knee. *Clin Orthop* 1996;322:166.

! 134. McCarroll JR, Rettig A, Shelbourne KD. Anterior Cruciate Ligament Injuries in the Young Athletes with Open Physes. *Am J Sports Med* 1985;16:11.

+ 135. McCarroll JR, Shelbourne KD, Porter DA, et al. Patellar Tendon Graft Reconstruction for Midsubstance Anterior Cruciate Ligament Rupture in Junior High School Athletes. *Am J Sports Med* 1994;22:478.

! 136. McManama GR, Micheli LJ, Beary VM. The Surgical Treatment of Osteochondritis of the Capitallum. *Am J Sports Med* 1985;12:11.

+ 137. Medlar RC, Lyne ED, Sohn RS. Sinding-Larsen-Johansson Disease Etiology and Natural History. *J Bone Joint Surg* 1978;60A:1113.

+ 138. Medler RG, Jansson KA. Arthroscopic Treatment of Fracture of the Tibial Spine. *Arthroscopy* 1994;10:292.

! 139. Merchant AC, Mercer RL, Jacobsen RH, Cool CR. Roentgenographic Analysis of Patellofemoral Congruence. *J Bone Joint Surg* 1974;56A:1391.

! 140. Mesgarzadeh M, Sapega A, Bonakdarpone A. Osteochondritis Dissecans Analyses of Mechanical Stability with Radiography, Scentigraphy and MR Imaging. *Radiology* 1987;165:775.

+ 141. Metcalf RW. An Arthroscopic Method of Lateral Release of the Subluxating or Dislocating Patella. *Clin Orthop* 1982;167:9.

* 142. Meyers HH, McKeever FM. Fracture of the Intercondylar Eminence of the Tibia. *J Bone Joint Surg* 1959;41A:209.

+ 143. Meyers HH, McKeever FM. Fracture of the Intercondylar Eminence of the Tibia. *J Bone Joint Surg* 1970;52A:1677.

# 144. Meyers J. Injuries to the Shoulder Girdle and Elbow. In: Sullivan JA, Grana WA, eds. *The Pediatric Athlete.* Park Ridge: AAOS, 1988:145.

# 145. Micheli LJ. The Traction Apophysitises. *Clin Sports Med* 1987;6:389.

# 146. Micheli LJ. Pediatric and Adolescent Sports Medicine. In: Griffin LY, ed. *Orthopaedic Knowledge Update: Sports Medicine.* Rosemont: American Academy of Orthopaedic Surgeons, 1994:349.

# 147. Micheli LJ. Sports Injuries in Children and Adolescents, Questions and Controversies. *Clin Sports Med* 1995;14:727.

# 148. Micheli LJ, Fehlandt AF Jr. Overuse Injuries to Tendons and Apophyses in Children. And Adolescents. *Clin Sport Med* 1992;11:713.

+ 149. Milch H. Avulsion Fracture of the Tuberosity of the Ischium. *J Bone Joint Surg* 1926;8:832.

+ 150. Mizuta H, Kubota K, Shiraishi M, et al. The Conservative Treatment of Complete Tears of the Anterior Cruciate Ligament in Skeletally Immature Patients. *J Bone Joint Surg* 1995;77B:890.

# 151. Molander ML, Wallin G, Wikstad I. Fracture of the Intercondylar Eminence of the Tibia: A Review of 35 Patients. *J Bone Joint Surg* 1981;63B:89.

# 152. Morrey BF. Osteochondritis Dissecans. In DeLee J, Drez D Jr, eds. *Orthopaedic Sports Medicine.* Philadelphia: W.B. Saunders, 1994:908.

# 153. Morrey BF, Regan WD. Fractures About the Elbow in Sports and Their Sequelae. In: DeLee JC, Drez D Jr, eds. *Orthopaedic Sports Medicine: Principles in Practice.* Philadelphia: W.B. Saunders, 1994:825.

+ 154. Morrissy RT, Eubanks RG, Park JP, Thompson SB. Arthroscopy of the Knee in Children. *Clin Orthop* 1982;162:103.

+ 155. Mubarak SJ, Carroll NC. Familial Osteochondritis Dissecans of the Knee. *Clin Orthop* 1979;140:131.

# 156. Mueller FO, Cantu RC. Catastrophic Injuries and Fatalities in High School and College Sports, Fall 1982—Spring 1988. *Med Sci Sports Exerc* 1990;22:737.

# 157. Nottage WM, Matsuura PA. Current Concepts and Review of the Literature. Management of Complete Traumatic Anterior Cruciate Ligament Tears in the Skeletally Immature Patient. *Arthroscopy* 1994;10:569.

! 158. Ogden JA, Southwick WO. Osgood-Schlatter's Disease and Tibial Tuberosity Development. *Clin Orthop* 1976;116:180.

# 159. Omer GE. Primary Articular Osteochondroses. *Clin Orthop* 1981;158:33.

* 160. Osgood RB. Lesion of the Tibial Tuberical Occurring During Adolescence. *Boston Med Surg J* 1903;148:114.

# 161. Outerbridge AR, Micheli LJ. Overuse Injuries in the Young Athlete. *Clin Sports Med* 1995;14:503.

! 162. Paletta GA Jr, Bednarz PA, Stanitski CL, et al. The Prognostic Value of Quantitative Bone Scan in Knee Osteochondritis Dissecans. *Am J Sports Med* 1998;26:7.

* 163. Panner HJ. A Peculiar Affliction of the Capitellum Humerus Resembling Calna-Pertho Disease of the Hip ACTA. *Radiology* 1928;10:234.

# 164. Pappas AM. Osteochondrosis Dissecans. *Clin Orthop* 1981;158:59.

# 165. Pappas AM. Elbow problems Associated with Baseball During Childhood and Adolescence. *Clin Orthop* 1982;163:30.

# 166. Pappas AM. The Osteochondroses. *Pediatr Clin North Am* 1967;14:549.

+ 167. Parker AW, Drez D Jr, Cooper JL. Anterior Cruciate Ligament Injuries in Patients with Open Physes. *Am J Sports Med* 1994;22:44.

+ 168. Paulos L, Rusche K, Johnson C, et al. Patellar Malalignment: A Treatment Rationale. *Phys Ther* 1980;60:1624.

# 169. Pizzutillo PD. Osteochondroses. In: Sullivan JA, Grana WA, eds. *The Pediatric Athlete.* Park Ridge: AAOS, 1988:211.

! 170. Pritsch M, Horoshovski H, Farine I. Arthroscopic Treatment of Osteochondral Lesions of the Talus. *J Bone Joint Surg* 1986;68A:862.

+ 171. Reed MH. Pelvic Fractures in Children. *J Can Assoc Radiol* 1976;27:255.

+ 172. Rettig AC, Shelbourne KD, McCarroll JR, et al. The Natural History and Treatment of Delayed Union of Stress Fractures of the Anterior Cortex of the Tibia. *Am J Sports Med* 1988;16:250.

+ 173. Rinaldi E, Mazzarella F. Isolated Fracture Avulsion of the Tibial Insertions of the Cruciate Ligament of the Knee. *Ital J Orthop Traumtol* 1980;6:77.

# 174. Roberts JM. Avulsion Fractures of the Proximal Tibial Epiphyses. In: Kennedy JC, ed. *The Injured Adolescent Knee.* Baltimore: Williams & Wilkins, 1979:141.

# 175. Roberts JM. Osteochondritis Dissecans In: Kennedy JC, ed. *The Injured Adolescent Knee.* Baltimore: Williams & Wilkins 1979:121.

+ 176. Roberts N. Osteochondritis Dissecans. *J Bone Joint Surg* 1957;39B:219.

+ 177. Robertson RC. Fracture of the Anterior-Superior Spine of the Ilium. *J Bone Joint Surg* 1935;17:1045.

# 178. Rockwood CA, Wilkins KE, King RE. *Fractures in Children,* 3rd ed. 1991.

+ 179. Roden S, Tillegard P, Unander-Scharin L. Osteochondritis Dissecans and Similar Lesions of the Talus. *Acta Orthop Scand* 1953;23:51.

+ 180. Rogge EA, Romano RL. Avulsion of the Ischial Apophysis. *J Bone Joint Surg* 1956;38A:442.

* 181. Rowe CR. Anterior Dislocations of the Shoulder: Prognosis and Treatment. *Surg Clin North Am* 1973;43:1609.

# 182. Rutherford GW, Miles RB, Brown VR, et al. *Overview of Sports Related Injuries of Persons 5 to 14 Years of Age.* Washington, DC: US Consumer Products Safety Commission, 1981.

# 183. Saperstein AL, Nicholas SJ. Pediatric and Adolescent Sports Medicine. *Pediatr Clin North Am* 1996;43:1013.

# 184. Schenck RC, Goodnight JM. Current Concepts Review Osteochondritis Dissecans. *J Bone Joint Surg* 1996;78A:439.

# 185. Schlonsky J, Eyring EJ. Lateral Meniscus Tears in Young Children. *Clin Orthop* 1973;97:117.

! 186. Schwab GH, Bennett JB, Woods GW. Biomechanics of Elbow Instability. *Clin Orthop* 1980;146:42.

# 187. Sebastianelli WJ, DeHaven KE. Chondral Fractures and Intra-articular Osteochondroses. In: DeLee JC, Drez D Jr. *Orthopaedic Sports Medicine.* Philadelphia: W.B. Saunders, 1994:1444.

* 188. Sever JW. *Apophysitis of the Oscalcus,* NY Med. 1912;95:1025–1029.

* 189. Siffert R. Classification of Osteochondroses. *Clin Orthop* 1981;158:10.

# 190. Singer KM, Butters KP. Osteochondroses of the Elbow. In: Stanitski CL, DeLee JC, Drex D Jr, eds. *Orthopaedic Sports Medicine: Principles and Practice.* Philadelphia: W.B. Saunders 1994:896.

+ 191. Singer KM, Roy SP. Osteochondroses of the Humeral Capitellum. *Am J Sports Med* 1984;12:351.

# 192. Smith AD. Sports Medicine Musculoskeletal Considerations for Children and Adolescents. In: Cahill BR, Pearl AJ, eds. *Intensive Participation in Children's Sports.* Champagne, IL: American Orthopaedic Society for Sports Medicine, 1993:1201.

+ 193. Smith AD, Stroud L, McQueen C. Flexibility Findings in Anterior Knee Pain Syndrome. *Am J Sports Med* 1987;15:410.

# 194. Smith AD, Tao SS. Knee Injuries in Young Athletes. *Clin Sports Med* 1995;14:629.

+ 195. Smith JB. Knee Instability After Fracture of the Intercondylar Eminence of the Tibia. *J Pediatr Orthop* 1984;4:462.

# 196. Staheli LT. The Lower Limb. In: Morrissy RT, ed. *Lovell and Winter's Pediatric Orthopaedics, 3rd ed.* Philadelphia: JB Lippincott, 1990:741.

# 197. Stanitski CL. Combating Overuse Injuries a Focus on Children and Adolescents. *Phys Sports Med* 1992;21:87.

# 198. Stanitski CL. Osteochondritis Dissecans of the Knee. In: Stanitski CL, DeLee JC, Drez D Jr, eds. *Pediatric and Adolescent Sports Medicine.* Philadelphia: W.B. Saunders, 1994:387.

# 199. Stanitski CL. Sinding-Larson-Johansson Disease. In: Stanitski CL, DeLee JC, Drez D Jr, eds. *Pediatric and Adolescent Sports Medicine.* Philadelphia: W.B. Saunders, 1994:325.

# 200. Stanitski CL. Anterior Cruciate Ligament Injury in the Skeletally Immature Patient: Diagnosis and Treatment. *J Am Acad Orthop Surg* 1995;3:146.

# 201. Stanitski CL. Arthroscopic and Clinical Correlation of Knee Magnetic Resonance Imaging Findings in Children and Adolescents. Oral Presentation, AAOS 65th Annual Meeting, New Orleans 1998.

# 202. Stanitski CL, DeLee JC, Drez D. Overuse Syndromes. In: *Pediatric and Adolescent Sports Medicine*. Philadelphia: W.B. Saunders, 1994;87.

+ 203. Stanitski CL, Harvell JC, Fu F. Observations on Acute Knee Hemarthrosis in Children and Adolescents. *J Pediatr Orthop* 1993;13:506.

# 204. Stanitski CL, McMaster JH, Scranton PE. On the Nature of Stress Fractures. *Am J Sports Med* 1978;6:391.

# 205. Steiner M, Grana WA. The Young Athlete's Knee: Recent Advances. In: Micheli LJ, ed. *Injuries in the Young Athlete.* Philadelphia: W.B. Saunders, 1988:527.

# 206. Stone JW. Osteochondral Lesions of the Talar Dome. *J Am Acad Orthop Surg* 1996;4:63.

+ 207. Stone K, Walgenback. A Surgical Technique for Articular Cartilage Transplantation to Full Thickness Cartilage Defects in the Knee Joint—Operative Techniques. *Orthopaedics* 1997;7:305.

+ 208. Stougaard J. Familial Occurrences of Osteochondritis Dissecans. *J Bone Joint Surg* 1964;46B:543.

# 209. Strizak AM. Knee Injuries. In: Nicholas JA, Hershman EB, *The Lower Extremity and Spine in Sports Medicine.* St. Louis: Mosby, 1995:1251.

# 210. Sullivan JA. Ligamentous Injuries of the Knee in Children. *Clin Orthop* 1990;255:44.

+ 211. Torg JS, Moyer RA. Nonunion of the Olecranon Stress Fractures Through the Olecranon Epiphyseal Plate Observed in an Adolescent Baseball Pitcher: 10 Case Reports. *J Bone Joint Surg* 1977;59:264

# 212. Torg JS, Pollack H, Sweterlitsch P. The Effect of Competitive Pitching on the Shoulder and Elbows of Pre-adolescent Baseball Players. *Pediatrics* 1072;49:267.

+ 213. Turtel AH, Andrews JR, Schob CK, et al. Fractures of Unfused Olecranon Physes: A Re-evaluation of this Injury in Three Athletes. *Orthopaedics* 1995;18:390.

# 214. Watanabe M, Takeda S, Kieuchi H. *Atlas of Arthroscopy,* 3rd ed. Tokyo: Igaushoin, 1979.

* 215. Watson-Jones R. Dislocations and Fracture-dislocations of the Pelvis. *Br J Surg* 1938;25:773.

# 216. Watts HG. Fractures of the Pelvis in Children. *Orthop Clin North Am* 1976;7:615.

! 217. Wiberg G. Roentgenographic and Anatomic Studies on the Femoropatellar Joint: With Special Reference to Chonfromalacia Patella. *Acta Orthop Scand* 1941;12:319.

+ 218. Wiley JJ, Baxter MP. Tibial Spine Fractures in Children. *Clin Orthop* 1990;255:54.

! 219. Wilson JN. A Diagnostic Sign in Osteochondritis Dissecans of the Knee. *J Bone Joint Surg* 1967;49:477.

+ 220. Woods GM, Tullos HG. Elbow Instability and Medial Epicondylar Fractures. *Am J Sports Med* 1977;5:23.

# 221. Woodward AH, Bianco AJ Jr. Osteochondritis Dissecans of the Elbow. *Clin Orthop* 1975;35:1110.

+ 222. Yates C, Grana WA. Patellofemoral Pain: A Prospective Study. *Orthopaedics* 1986;9:663.

+ 223. Zaman M, Leonard MA. Meniscectomy in Children: Results of 59 Knees. *Injury* 1981;12:425.

+ 224. Zaricznyj B. Avulsion Fracture of the Tibial Eminence: Treatment by Open Reduction and Pinning. *J Bone Joint Surg* 1977;59A:1111–1114.

# CHAPTER 98

# USE OF LASERS IN ORTHOPAEDIC SURGERY

*Kenneth B. Trauner*

**K. B. Trauner:** Department of Orthopaedic Surgery, University of California, Davis Medical Center, Sacramento, California, 95817.

Principles
- Laser Physics
- Laser–Tissue Interaction
- Mechanisms of Tissue Ablation
- Orthopaedic Laser Systems

Applications
- Meniscectomy
- Osteonecrosis
- Annealing
- Lateral Retinacular Release
- Laser-Induced Capsular Shift (Tightening)
- Laser Discectomy

Surgical Techniques
- Arthroscopic Meniscectomy
- Synovectomy
- Shoulder Arthroscopic Debridement
- Subacromial Decompression
- Shoulder Capsulorrhaphy—Laser-Assisted Capsular Shift

Experimental Techniques
- Removal of Polymethylmethacrylate
- Laser Osteotomy
- Tissue Welding
- Biostimulation
- Photodynamic Therapy

Chapter References

## PRINCIPLES

Over the past twenty years, laser technologies have been developed for endoscopic applications in many surgical disciplines. More recently, arthroscopic laser systems have been introduced in orthopaedic surgery as low-profile cutting tools. Initial orthopaedic studies used existing commercial and surgical laser systems, which were poorly suited for arthroscopic use. These lasers resected torn meniscal tissue but increased perioperative morbidity and required changes in surgical technique. Pulsed near-infrared systems later allowed delivery of high-power laser light to the joint tissues through small fiber optics and more convenient instrumentation. These near-infrared systems are now used in shoulder, knee, and spinal surgery. Several recent cases of osteonecrosis in laser-treated knees, however, have generated controversy regarding the safety of these devices (21,23,34,59).

### LASER PHYSICS

The term *laser* is an acronym for light amplification by stimulated emission of radiation. The laser is a device that produces high-intensity light energy with three unique properties. It is (a) monochromatic—the light has a single wavelength, (b) coherent—the light waves are in phase with one another, and (c) directional. These characteristics allow laser light, at high energies, to be transmitted through fiber optics, waveguides, or articulated arms to tissue. The light energy, for surgical applications, can then cut, coagulate, or ablate tissue.

Laser systems have four essential components (Fig. 98.1). The laser medium—a solid, liquid, or gas—determines the wavelength of the laser light. The resonator cavity sandwiches the medium between two mirrors—one partially reflective and the other fully reflective. The excitation source pumps high-energy electric or optical energy into the laser medium. A cooling system removes excess thermal energy from the resonator cavity to prevent damage to optical components.

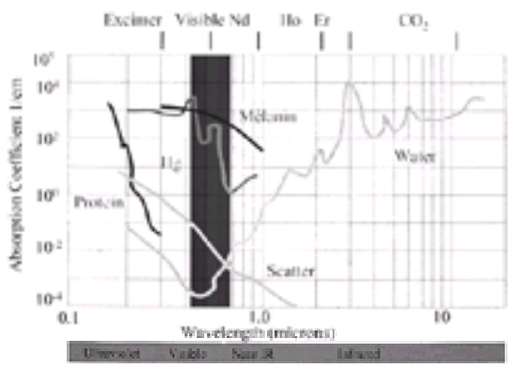


***Figure 98.1.*** The laser system is composed of a laser medium placed between two mirrors, one of which is partially reflective. Energy delivered to the medium produces light energy that is amplified between the two mirrors. Light escaping the output coupler has the unique properties of being monochromatic, directional, and in phase.

When light or electrical energy is released into the laser medium, the absorbed photons are stimulated into higher energy levels. The collapse of the electrons to their ground states releases photons of a specific wavelength. These photons are reflected between the two mirrors of the resonator cavity. High-intensity light eventually escapes through the partially reflective mirror.

The wavelength of the output light and the choice of laser medium characterize surgical laser systems. In the United States, most surgical systems produce visible, near-infrared or infrared laser energy. Ultraviolet systems have been approved for ophthalmic use but are not currently Food and Drug Administration (FDA)-approved for surgical applications. The standard media include $CO_2$ and argon gases, and yttrium alluminum garnet (YAG) crystals doped with heavy metals including holmium (Ho), erbium (Er), thulium, and neodynium (Nd).

The output light energy has two primary forms—continuous wave (CW) and pulsed. CW lasers produce a continuous beam of light energy similar to a flashlight. The conduction of heat that occurs during the use of a CW system may produce large peripheral zones of thermal damage. Pulsed laser systems produce high-intensity light over short time intervals. The high peak power of each laser pulse may produce explosive ablation of target tissues. The time between pulses allows for dissipation of thermal energy and prevents excessive damage due to thermal conduction.

For CW systems, the surgeon selects the average power to be delivered through the handpiece, in a manner similar to that seen in electrocautery. For a pulsed laser

system, the surgeon sets the energy per pulse and the repetition rate. The flow of light is controlled by a hand- or foot-switch. The focus (or defocus) of the light energy at the tissue level controls the light intensity and affects the zone and depth of laser-induced damage.

## LASER–TISSUE INTERACTION

The optical properties of tissue and the wavelength of the laser light are major determinants in controlling the effect of the laser light on the treated tissues. Light striking tissue reflects, refracts, scatters, or is absorbed by the tissue. All tissues have characteristic properties for each of these parameters, which vary as a function of wavelength. Most existing surgical laser systems target either the water within the tissue or selected chromophores—tissue pigments such as hemoglobin, hemosiderin, or melanin.

## MECHANISMS OF TISSUE ABLATION

Three mechanisms of action characterize laser ablation of tissue:

*Photothermal* Absorption of light energy creates molecular vibrations and heat. Heating water above 100°C causes vaporization. Pulsed infrared lasers deliver high peak powers of laser light in short time periods of less than a fraction of a second. Tissue ablation occurs by the explosive release of the vaporized tissue contents (Fig. 98.2). Heating tissues below the vaporization threshold produces thermal changes if collagen is heated above its phase transition temperature of 62°C.

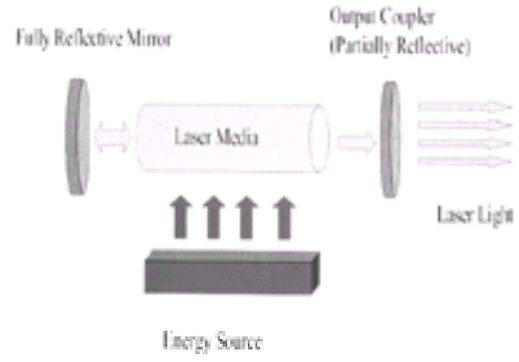


***Figure 98.2.*** Absorption spectra for tissue components. Near-infrared lasers are absorbed by the water within tissue, whereas visible lasers are absorbed by pigments such as hemoglobin or melanin.

*Photochemical* Ablation occurs when absorbed photons directly dissociate molecular bonds. If the energy of ultraviolet photons is greater than the energy of molecular bonds, photon absorption may directly disrupt the molecules for nonthermal cutting of tissue. The so-called cold excimer lasers operate by this mechanism.

*Photomechanical* When light energy is rapidly deposited in tissues, the thermal energy and rapid expansion of vaporization contents creates high shear stresses within the tissue. Photoacoustic shock waves may create damage at large distances from the site (73). The process may occur for any pulsed laser system operating throughout the ultraviolet, visible, or infrared spectrum (16,60).

## ORTHOPAEDIC LASER SYSTEMS

Initially, the choice of lasers for orthopaedics was determined by availability. Modification of existing surgical systems allowed passage of light energy into joint cavities. The earliest systems, using $CO_2$ laser media, varied considerably in their configurations. Both CW and pulsed systems were evaluated, with variable tissue effects. Ablation of cartilage produced excessive charring and thermal damage with all devices. As 10.6-micron light energy cannot pass through standard optical fibers, all $CO_2$ systems required large, cumbersome devices for light delivery to the joints. The requirement for joint distention with gas, the lack of proven benefit, and the limited availability of awkward instrumentation led to the early abandonment of the $CO_2$ laser arthroscopic devices.

Additional industrial and surgical systems also proved poorly suited for arthroscopic use. Solid state Nd:YAG surgical lasers are used in both CW and pulsed formats. The Nd:YAG lasers produce light (at 1.06 and 1.32 microns) that is readily transmitted through standard silica optical fibers. The Nd:YAG light is strongly absorbed only by pigmented or darkly stained tissue but not well absorbed by most intra-articular tissues. Because of its low tissue absorption, at high energies the light deeply coagulates tissue before producing changes at the tissue surface. Cutting effects vary significantly as desiccation or charring of the tissue surface substantially increases the light absorption characteristics.

Functionally, a Nd:YAG laser can coagulate and cause necrosis of tissue to a depth greater than 1 cm before any apparent cutting effect occurs at the tip of the instrument. A contact sapphire tip Nd:YAG laser system received limited use as an arthroscopic cutting tool for meniscectomy and occasional chondroplasty (44,49). Multiple cases of osteonecrosis have been reported with this laser system (23,34). However, it has been largely abandoned because of concerns about effectiveness and safety.

The excimer laser is an ultraviolet laser system that ablates and cuts tissues via nonthermal mechanisms. Tissue effects occur when ultraviolet light energy is absorbed by carbon–carbon double bonds of organic chromophores. Efficient light absorption limits the light penetration to within microns of the tissue surface. The high power density of the absorbed light generates precise and effective tissue-cutting effects with minimal thermal damage (3,8,17,22,53). Unfortunately, ultraviolet light energy cannot be transmitted down standard optical fibers, and development of convenient arthroscopic delivery systems has proven difficult. Only the 308-nanometer xenon chloride excimer laser can be delivered fiberoptically through expensive, nonflexible zirconia fluoride fibers.

The system itself uses toxic gases as a laser medium. Excimer arthroscopic systems have received limited use, and that has been largely in the European market (24,29). Nuss et al. (48) reported on the use of the 308 nm excimer laser in a prospective, randomized clinical trial of 70 patients with chondral degeneration. After a 6-month follow-up, the authors found a significant reduction in pain and in reactive synovitis in laser compared with control groups. No differences in level of disability or function were noted between groups.

### Ho:YAG LASER

The Ho:YAG laser is the most widely used arthroscopic laser system. It was specifically developed for arthroscopic use and has now been adapted for use in multiple surgical disciplines. The device produces pulsed 2.1-micron-wavelength laser light, which is readily transmitted down conventional optical fibers into low-profile handpieces. The Ho:YAG laser effectively cuts, coagulates, and ablates well-hydrated intra-articular tissues (72,75,76 and 77). The laser is used in contact or near contact mode.

Use of the device has been controversial. FDA approval for meniscectomy was granted in the late 1980s. Fanton et al. reported decreased postoperative symptoms and recuperation time following laser meniscectomy (19). No prospective, double-blind, randomized clinical studies have validated the original claims.

The Ho:YAG device cuts by ablative mechanisms. The pulsed 2.1-micron light energy is absorbed by the water within the well-hydrated intra-articular tissues. Rapid absorption, heating, and vaporization of tissue creates cavitation—an explosive expansion of the vaporized water. The amount of tissue ablated per pulse at low repetition rates correlates with the amount of energy delivered per pulse. Approximately 10 joules (J) of energy are required to remove 1 cubic millimeter of articular cartilage or meniscus (72). Each individual pulse creates a crater surrounded by a zone of thermal damage (40) (Fig. 98.3; see color Fig. 98.3).For low repetition rates, the damage extends approximately 350 microns laterally and 500 microns deep within the tissue (65,72,77). Clinically, the laser is used at repetition rates ranging from 10 to 30 hertz. At these rates, thermal diffusion may occur between pulses, and thermal damage may extend significantly greater distances within the tissue. *In vivo*, photoacoustic effects may produce damage in tissue remote from the laser site, especially if the laser is used in confined spaces (73).



***Figure 98.3.*** (See color Fig. 98.3). Thermal damage in meniscus after three shots at 1.5 J per pulse at a repetition rate of 1 Hz. Damage extends approximately 350 microns from the edges of the crater (trichrome stain, 40×).

Multiple studies have documented that the healing response of articular cartilage following laser irradiation is consistent with that following mechanical instrumentation (13,54,75). Partial-thickness defects do not heal, and full-thickness defects are characterized by fibrocartilaginous repair, which is less durable than the host tissue (75). Loss of cellularity and necrosis in subchondral bone is found consistently at the border of treated regions in an equine model (13).

## APPLICATIONS

### MENISCECTOMY

Meniscectomy is the primary arthroscopic application for which the laser was originally developed. The laser offers the theoretical advantage of less iatrogenic damage to articular surfaces when treating poorly accessible, posterior horn meniscal tears. Whereas mechanical instruments may abrade or inadvertently gouge chondral surfaces, the low-profile laser handpieces may be used in limited noncontact mode to ablate and cut the damaged posterior structures. Limited literature is available to substantiate these claims (19,66). Rather than minimizing damage, the laser, when used in an unsafe manner, may play a role in producing osteonecrosis in subchondral bone.

### OSTEONECROSIS

In the last five years, there have been multiple reports of osteonecrosis following laser arthroscopy with either the Nd:YAG or the Ho:YAG laser systems (21,23,34,59). Early laser tissue interaction studies suggested that thermal damage would be limited to the optical penetration of the tissue, which is approximately 300–500 microns. The studies, performed with low laser repetition rates on cartilage (13,54,63,72,75,77), did not address the tissue effects at the clinically relevant higher repetition rates. Studies suggest that osteonecrosis, in many cases, may be preexisting and may not relate to the use of the laser (33).

Additional animal studies suggest that the laser produces extensive subchondral damage if used to drill into articular surfaces (73). If the laser energy penetrates subchondral bone, the expansion of the vaporation bubble may produce a fluid wave within the confined space (Fig. 98.4).High shear stresses may tear blood vessels and produce hemorrhage several centimeters deep within the subchondral bone. Additional data suggest that less than 25 J of energy may induce this deleterious effect. These studies suggest that inadvertent direction of the laser energy into the articular cartilage with penetration of the calcified cartilage can cause damage, which may lead to osteonecrosis. Avoid drilling articular cartilage with any laser system.



***Figure 98.4.*** Expansion and collapse of a cavitation bubble in saline during a 0.5 J Ho:YAG laser pulse. These six images were obtained sequentially over 250 microseconds. The optical fiber has a diameter of 400 microns. Explosive cavitation may produce photoacoustic effects in confined spaces.

### ANNEALING

The Ho:YAG laser produces a zone of nonablated, thermally altered tissue when applied to either meniscus or articular cartilage. The laser can thermally alter tissue if the energy striking the tissue is less than the tissue ablation threshold. If held remotely from the tissue, the laser can deliver sufficiently low amounts of light energy to thermally alter the tissue without vaporization. At 62°C, collagen undergoes a phase transition from a triple helix to an amorphous gel. Due to gross structural changes, ordered collagenous tissues such as capsule or tendon “shrink” in length, whereas surfaces of meniscus or articular cartilage coagulate or “anneal.” In using the laser for meniscectomy, surgeons routinely produce smooth residual rims of meniscus (Fig. 98.5; see color Fig. 98.5).The durability and the long-term clinical value of the annealing treatment is unknown. Tissue tensile properties, long-term healing response, and short-term histopathologic effects of the annealing treatments have not been adequately characterized. Annealing should be considered experimental at this time.

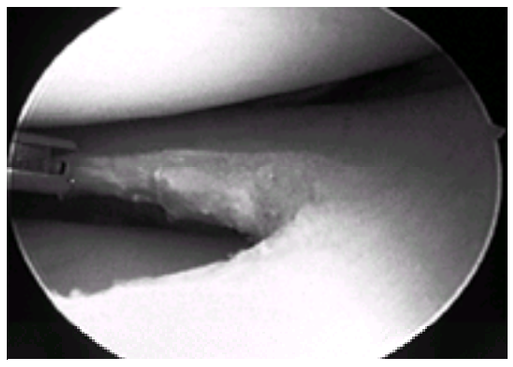

***Figure 98.5.*** (See color Fig. 98.5). Application of laser energy to the edge of a debrided meniscal tear. The long-term effects of this “annealing” treatment remain controversial.

### LATERAL RETINACULAR RELEASE

The Ho:YAG laser offers the theoretical advantage of limited hemostasis when performing cutting or ablative procedures. Two investigators have evaluated the

Ho:YAG laser for lateral retinacular release. In a retrospective review, Shapiro et al. suggested that laser-treated patients have lower morbidity than patients treated with electrocautery (61). A prospective study by Carter and Edinger demonstrated no clinical difference between laser and cautery groups (9).

### LASER-INDUCED CAPSULAR SHIFT (TIGHTENING)

Recognition of the thermal effects of the laser on shoulder joint capsule has led to the development of arthroscopic laser and radiofrequency techniques for treating excess capsular laxity (20,27,30,55,70). Symptomatic inferior and multidirectional instability is based on two factors in varying proportions: (a) the inherent laxity of the shoulder capsule, and (b) the activities of the patient (45). In cadaveric specimens, temperatures at or above 65°C cause significant shrinkage of glenohumeral joint capsular tissue (28). The shrinkage is achieved with use of nonablative laser energy without detrimental effects to the viscoelastic properties of the tissue (25).

Ultrastructural alteration of collagen fibril architecture caused by the thermal effect of laser energy is probably the dominant mechanism of laser-induced tissue shrinkage (27). Studies have demonstrated that remodeling of capsule is unimpeded following treatment (26). In cadaveric specimens, laser anterior capsuloplasty acutely reduces anterior and posterior translation (70). Studies have demonstrated variable consistency and durability of the thermal effects (55). The depth of the thermal effect and potential damage to surrounding structures has been questioned.

Recently, additional nonlaser thermal devices have been developed for thermal shrinkage procedures (15,43,50). Bipolar (Mitek, Arthrotec) and radiofrequency devices (Oratec) function by applying electrical or microwave energy to the collagenous tissues by direct contact. The radiofrequency device also incorporates temperature control in an attempt to limit the thermal damage. The bipolar devices pass electrical current from leads positioned at the tip to a grounding surface on the edge of the handpiece, whereas the radiofrequency device transmits energy directly into the tissue. The radiofrequency-induced thermal effects vary with the impedance of the tissues. Equivalent tissue effects have been reported for treating capsular tissues with laser and with nonlaser thermal devices (50).

### LASER DISCECTOMY

Many different laser systems have been evaluated for the development of laser discectomy techniques. The first discectomy study used the $CO_2$ laser on a canine model (17). This study and others using multiple animal models (4,12,80) demonstrated equivalent healing following cervical discectomy performed with either mechanical or $CO_2$ laser tools. Laser and mechanical tools both produced lower mean intradiscal pressures (11,12,52,80) due to a bulk modulus effect (78).

*In vitro* laboratory studies with many newer laser systems demonstrate the ability to remove intradiscal tissue (10,11,39,44,58). Ho:YAG, Nd:YAG, and potassiumitanyl-phosphate (KTP) all create defects greater than 1.5 cm in diameter with up to 1,200 J of energy. The greatest temperature elevations occur with the Nd:YAG laser (39). Temperatures remain within safe limits, however, in the region of the posterior longitudinal ligament adjacent to the nerve root.

Both the Ho:YAG (58) and the KTP lasers (69,79) are FDA-approved for discectomy procedures in the United States. No clinical results with the KTP system have been reported. The Ho:YAG system demonstrated no difference between treatment and nonoperative control groups in a nonrandomized study of lumbar discectomy (64).

Most clinical laser discectomy procedures have been performed in Europe. Choy et al. reported clinical results of outpatient laser discectomy performed with continuous-wave Nd:YAG laser systems (10). Laser energy was delivered by 400-micron optical fiber through a fluoroscopically placed 18-gauge spinal needle. Fair or good results were noted in only 78% of patients, with gross failure in 22% and one complication of discitis. The system is not currently available for use in spinal procedures in the United States.

The indications for laser discectomy remain controversial. Results have been comparable to other percutaneous techniques such as chymopapain injection (41). Use has been restricted to prolapsed or extruded discs but not sequestered discs. Laser ablation of subligamentous extruded nucleus pulposus has been noted to be ineffective. Indications for use remain restricted until further clinical and basic science studies can demonstrate spinal laser use to be both safe and effective.

Future developments in endoscopic and laser instrumentation may increase the indications for laser use. Lasers are currently being used experimentally in Europe for foraminal decompression and debridement of extruded discs. While lasers offer promise, future controlled clinical trials will be required before they attain an expanded role in spinal surgery.

## SURGICAL TECHNIQUES

### ARTHROSCOPIC MENISCECTOMY

The Ho:YAG laser is available from several manufacturers, with either rigid or flexible handpieces. Check the laser system for proper function before starting the procedure.

- Prepare and drape the knee in the usual fashion. After creation of standard arthroscopic portals and introduction of the arthroscope, carry out diagnostic arthroscopy in standard fashion.
- Identify intra-articular pathologies including meniscal tears. Choose a laser handpiece. I prefer to use a 30°-bend, recessed-tip device, which usually provides access to all regions of the joint. Plug the optical coupler attached to the handpiece into the laser system. Turn the system on and place it into standby mode. During laser use, wear protective laser goggles. Program laser parameters into the system. For meniscectomy, a power of 2 J per pulse and a repetition rate of 10 Hz are recommended.
- Place the laser handpiece into the joint with the tip in contact with the meniscal tear. Activate the laser with a foot pedal. Debride flap tears. If desired, also debride or anneal remnants of frayed meniscus. Conventional mechanical instruments may supplement laser treatments.
- The laser may also be used to coagulate bleeding vessels in a noncontact mode. After completion of debridement, place the laser in standby mode. Remove the instruments and close the wounds in the usual fashion.

### SYNOVECTOMY

Its hemostatic properties make the laser suitable for arthroscopic debridement of hypervascular rheumatoid synovitis. The procedure is indicated for patients with medically refractory monoarticular synovitis with no radiographic evidence of joint degeneration. Treatment of synovitis secondary to hemophilia has also been advocated (46).

- For synovectomy, set the laser at 2 J per pulse and a repetition rate of 10–20 Hz. Hold the laser 2–3 mm from the tissue to thermally necrose and coagulate synovium in a noncontact manner. With use of accessory posterior portals, extensive debridement of posterior compartment synovitis can be performed with minimal bleeding and improved visualization.

### SHOULDER ARTHROSCOPIC DEBRIDEMENT

Because of its ablative, thermal, and hemostatic properties, the laser has been used extensively for debridement of torn intra-articular tissues including superior labral anterior and posterior (SLAP) tears and other labral lesions. The use of the Ho:YAG laser for the debridement of rotator cuff lesions and biceps tendon tears is contraindicated because of the risk of damage to adjacent normal tissues.

- Place the patient in either a beach-chair or lateral decubitus position. Examination under anesthesia is performed preoperatively. Sterilely prep and drape the shoulder. Create standard anterior, mid-lateral and posterior portals and carry out diagnostic arthroscopy on the glenohumeral joint and subacromial bursa.
- If you identify a labral tear that requires debridement, turn the laser on and insert a 30° angled laser handpiece through the anterior or posterior operating portal that affords best access to the lesion. Laser parameters of 2 J per pulse at a repetition rate of 20 Hz (20 watts) are routinely used for debridement.
- Place the laser in active mode. Put the laser tip in contact or near contact with the tissue and activate the laser by foot pedal. Ablate the damaged tissues. As the energy is delivered, you can focus and defocus the beam by controlling the distance between the probe and the tissue.
- After completion of the debridement, place the laser in standby mode before removal of handpieces from the joint. Close wounds in routine fashion.

### SUBACROMIAL DECOMPRESSION

With use of mechanical tools for subacromial decompression, substantial bleeding is frequently a problem. It limits visualization, prolongs the procedure, increases fluid extravasation, and leads to increased perioperative morbidity. Use of the arthroscopic pump often is supplemented with epinephrine within the irrigation solution to limit

bleeding. The laser's hemostatic properties in a “defocused” mode make it useful in subacromial decompression procedures.

- After completion of glenohumeral arthroscopy as previously described, visualize the subacromial space with the arthroscope placed in the posterior portal. Place cannulas in the anterior and lateral mid-deltoid portals.
- Debride the subacromial bursa with a mechanical shaver according to standard technique. Use of the mechanical tools is faster for removal of larger tissue volumes and can be supplemented with use of the laser in defocused, noncontact mode to achieve hemostasis.
- Set the laser initially at 2 J per pulse and a repetition rate of 20 Hz (40 W), and use it after completion of the bursal resection to create a hemostatic field. Deliver the laser probe through the lateral portal. Expose the anterior and lateral margins of the acromion by laser debridement of the undersurface periosteum. Then reset the laser to a higher repetition rate of 30 Hz at a total average power of 60 W. Identify the coracoacromial ligament and resect it off the anterior edge of the acromion with the laser. Bleeding that is frequently encountered from the acromial branch of the thoracoacromial artery can be coagulated in noncontact mode with the laser. A mechanical shaver may complete the debridement and remove the remnant of the ligament. The subacromial periosteum is coagulated with the laser.
- Perform acromioplasty with standard burr to the desired level; additional bleeding may be coagulated with the laser as previously described. Maintain the laser in standby mode when the handpiece is removed from the joint. Close wounds in routine fashion. Postoperative rehabilitation is identical to that of nonlaser procedures.

### SHOULDER CAPSULORRHAPHY—LASER-ASSISTED CAPSULAR SHIFT

- Perform examination under anesthesia to confirm the magnitude and direction of the glenohumeral instability. Position, prep, and drape the patient, and perform diagnostic arthroscopy as previously described. After treating the intra-articular pathology according to standard arthroscopic technique, turn attention to the capsule.
- For the capsular treatments, use the 30° angled laser probe with laser settings of 1 J per pulse and a repetition rate of 10 Hz. For patients with anterior instability, introduce the laser through the anterior portal, with the arthroscope placed posteriorly. The laser is activated 5 mm from the tissue and advanced until shrinkage is observed without tissue ablation (Fig. 98.6).The laser probe energy is applied radially in brushstroke fashion from the edge of the glenoid laterally. The process is repeated sequentially.

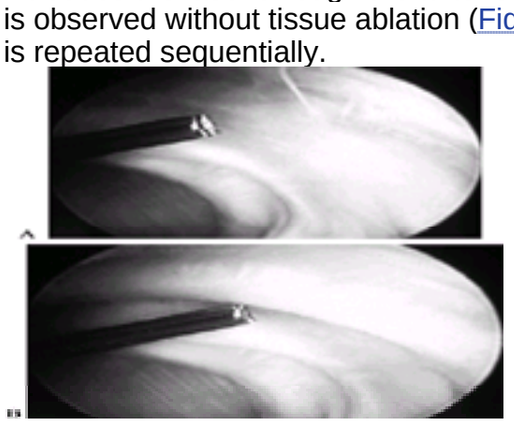

***Figure 98.6.*** Capsular shrinkage procedure. Ho:YAG laser energy is applied to anterior shoulder capsule in a noncontact mode. The two figures demonstrate the capsule pretreatment (**A**) and after application of laser energy (**B**). Note the contracted band of tissue at the tip of the device that appears after application of laser energy.

- Do not make repeat passes over treated areas; nearly all shrinkage occurs with the initial laser treatment. Additional laser energy may increase thermal damage beyond the capsule. Initiate the treatment posteroinferiorly, bring it into the axillary region, then to the region of the anterior inferior glenohumeral ligament. Advance the arthroscope for improved anterior visualization. Then treat the anterior capsule, and the anteroinferior, middle, and superior glenohumeral ligaments.
- Treat unidirectional posterior instability with similar technique, but place the arthroscope in the anterior portal with the laser probe in the posterior portal. The posterior structures are thermally treated starting in an anteroinferior location and advancing posteriorly.
- In the case of multidirectional instability, the capsule and ligaments are treated circumferentially. Visualization is improved if the posterior structures are treated first, in a manner similar to that described for posterior instability. The arthroscope and laser probe then exchange portals prior to treatment of anterior tissues. Close wounds in routine fashion.
- Tailor rehabilitation to the age of the patient and the direction of instability. For unidirectional anterior instability, keep older patients in a sling for 1 to 2 weeks, and younger patients, 2 to 3 weeks. Encourage patients to attain 90° of abduction and limit them to 45° of external rotation by 6 weeks. Rotation and abduction are then advanced as tolerated, limiting motion to the final 15° of abduction and external rotation until 12 weeks. Allow patients unrestricted return to sports and overhead throwing at 3–4 months, depending on strength, conditioning, and endurance.
- After posterior stabilization, stabilize the arm in 30° of external rotation for 4 weeks. Start glenohumeral and scapulothoracic exercises at that time, avoiding full internal rotation for 12 weeks.

## EXPERIMENTAL TECHNIQUES

### REMOVAL OF POLYMETHYLMETHACRYLATE

Removal of polymethylmethacrylate (PMMA) remains a difficult challenge for revision total joint surgeons. The laser offers the potential advantage of selective ablation of retained cement without damage to host bone (5,6,62,68). PMMA strongly absorbs infrared and near-infrared light energy. In the infrared region, the water within tissue absorbs light energy and the dry components of bone have minimal optical absorption. By using wavelengths of light that do not correlate with the absorption peaks for water, many researchers have documented efficient cement removal with infrared laser systems.

Clinically, laser cement removal techniques have not been widely adapted or developed because of concerns about safety, efficacy, and convenience. Vaporization of PMMA produces highly toxic byproducts that must be removed from the operating room with high-powered evacuation systems to prevent injury to personnel. Vaporization products are flammable and may ignite during the laser process. The infrared laser light cannot be transmitted through fiber optics, and cumbersome delivery systems are required.

Light produced by the $CO_2$ laser system, while effective at ablating cement, is nonselective and may also perforate and ablate host bone. Desiccation of the tissues in the surgical field may produce extensive charring. Visualization within the femoral canal is difficult and the interface between host bone and PMMA becomes difficult after use of the laser has been initiated. Access to the distal canal is often difficult with the free-beam $CO_2$ laser.

Intermediate success has been achieved with use of a laser waveguide, which pumps a nitrogen or $CO_2$ gas into the laser field. The gases reduce the oxygen content in the plume and dilute the vaporization contents, reducing the risk of ignition. The waveguide is also less cumbersome than the articulated arm handpieces for the $CO_2$ laser. Distal removal of cement from the femoral canal has proven difficult with these devices. Few surgeons are currently using the laser clinically or experimentally for cement removal in revision joint arthroplasty.

### LASER OSTEOTOMY

Lasers theoretically offer the advantage of cutting easily through calcified tissues with minimal trauma to the host tissues. Multiple laser systems, both CW and pulsed, at high peak powers efficiently ablate bone (32,35,42,47,48). Cutting through bone at rates comparable to mechanical tools requires larger, more expensive laser systems. In contrast to mechanical tools, the lasers can thermally damage the osteotomized bone. *In vivo* studies demonstrate delayed healing after ablation with near-infrared Er and Ho systems in rat tibial and calvarial bone (7,18). The lack of a readily adaptable high-powered lasers for osteotomy, the increased cost, the effectiveness of current mechanical tools, and concerns about impaired healing result in limited indications for laser osteotomy at this time.

### TISSUE WELDING

Tissue welding refers to techniques for joining severed collagenous connective tissues. The two primary welding mechanisms under investigation are based on thermal and photochemical mechanisms. The laser-based techniques use light energy to “melt” the end of the collagenous structures. The melting occurs as light disrupts collagen crosslinks and, in turn, the organized collagen triple helical structure. The collagen phase transition, and resulting “molten” mass, occurs within a narrow temperature range bridging 62°C (38). Tissue welding occurs when the molten uncrosslinked tissues are mechanically apposed, then recrosslinked. Limited success

has also been achieved with use of fibrin solders (67).

Photochemical techniques use light-activated chemicals to directly crosslink collagen of severed tissues. Experimental naphthalimide dyes have produced high-strength welds of menisci and articular cartilage. Preclinical studies with Barbados sheep have demonstrated healing and retention of articular cartilage welds for longer than 12 months (31,36,37). Photochemical techniques are early in development. Toxicity, safety, and efficacy studies will need to be done before the techniques are put to clinical use in humans.

## BIOSTIMULATION

Biostimulation is a controversial field of study in which low-level light energy is used to induce therapeutic effects. The theory is based on observations that low-level light energy increases cellular metabolism. Multiple endogenous chromophores within cells produce multiple complex *in vitro* cellular effects. The cellular effects are dependent on both wavelength and light dose (1,51).

Researchers postulate that patients can derive clinical benefit from low-level light treatments if the metabolic effects can be induced broadly throughout tissues. Studies have assessed the influence of low-level light on both fracture and wound healing in animals (2,14,81). Clinical trials in the United States currently evaluate biostimulation for the treatment of low back pain and carpal tunnel syndrome. No systems are currently approved for use in the United States.

## PHOTODYNAMIC THERAPY

Photodynamic therapy (PDT) is a new treatment modality in which light-activated chemicals are used to treat a variety of pathologic conditions. The FDA has currently approved the photosensitizer Photofrin for the treatment of lung cancer and multiple other applications. Additional dyes are in later-stage clinical trials. As both drug and light must reach the target tissue to induce therapeutic effects, PDT offers the potential for selective drug toxicity. The difficulty in delivering light energy to opaque solid musculoskeletal tumors has prevented the adoption of PDT techniques in orthopaedic oncology.

In orthopaedics, PDT has been most extensively evaluated for the treatment of inflammatory arthritis (Fig. 98.7; see color Fig. 98.7)(56,57,71,74). The hypervascular proliferative synovium of rheumatoid arthritis can be targeted and destroyed with PDT. Photosensitizers are delivered systemically or via intra-articular injection.

***Figure 98.7.*** (See also color Fig. 98.7) Photochemical treatment of a rabbit model of rheumatoid arthritis. Light delivered percutaneously to the anterior knee joint activates photochemicals that destroy the proliferative synovium.

Percutaneous optical fibers of transcutaneous techniques deliver light energy to the inflamed synovium. The light-activated dyes, or photosensitizers, are large multiconjugated structures that produce reactive oxygen species after absorbing the light energy of a specific wavelength. The singlet and triplet oxygen reacts locally to disrupt cellular and nuclear membranes inducing both necrosis and apoptosis. Direct occlusion of tissue neovasculature indirectly produces synovial necrosis. Activation of multiple photosensitizers with a variety of light-delivery systems produces synovial necrosis without apparent damage to the adjacent chondral or soft tissues. Development of these techniques remains at the preclinical research level.

## CHAPTER REFERENCES

Each reference is categorized according to the following scheme: *, classic article; #, review article; !, basic research article; and +, clinical results/outcome study.


! 1. Akai M, Usuba M, Maeshima T, et al. Laser's Effect on Bone and Cartilage Change Induced by Joint Immobilization: An Experiment with Animal Model. *Lasers Surg Med* 1997;21(5):480.

! 2. Allendorf JD, Bessler M, Huang J, et al. Helium-neon Laser Irradiation at Fluences of 1, 2, and 4 J/cm$^2$ Failed to Accelerate Wound Healing as Assessed by Both Wound Contracture Rate and Tensile Strength. *Lasers Surg Med* 1997;20(3):340.

+ 3. Bernard M, Grothues-Spork M, Hertel P, Moazami- Goudarzi Y. Reactions of Meniscal Tissue after Arthroscopic Laser Application: An in Vivo Study Using Five Different Laser Systems. *Arthroscopy* 1996;12(4):441.

! 4. Black J, Rhodes A, Lane GJ, et al. The Chronic Effects of Anterior Cervical and Percutaneous Lumbar Discectomy Using the Holmium:YAG Laser: An Animal Model. *State Art Rev (Spine)* 1993;7:31.

# 5. Booth RE Jr, Gordon SL, Carney MD. Use of the $CO_2$ Laser in Revision Hip Surgery. *Contemp Orthop* 1987;15:17.

! 6. Buchelt M, Kutschera HP, Katterschafka T, et al. Ablation of Polymethylmethacrylate by Ho:YAG, Nd:YAG, and Erb:YAG Lasers. *Lasers Surg Med* 1993;13(6):638.

! 7. Buchelt M, Kutschera HP, Katterschafka T, et al.Erb:YAG and Hol:YAG Laser Osteotomy: The Effect of Laser Ablation on Bone Healing. *Lasers Surg Med* 1994;15(4):373.

! 8. Buchelt M, Papaioannou T, Fishbein M, et al. Excimer Laser Ablation of Fibrocartilage: An in Vitro and in Vivo Study. *Lasers Surg Med* 1991;11(3):271.

+ 9. Carter T, Edinger S. Arthroscopic Lateral Release of the Knee. Presented at American Orthopaedic Society for Sports Medicine Specialty Day, Atlanta, GA, 1996.

# 10. Choy DS, Ascher PW, Saddekni S, et al. Percutaneous Laser Disc Decompression. A New Therapeutic Modality. *Spine* 1992;17:949.

# 11. Choy DSJ, Altman P. Fall of Intra-discal Pressure with Laser Ablation. *State Art Rev (Spine)* 1993;7:23.

+ 12. Choy DSJ, Altman PA, Case RB, Trokel SL. Laser Radiation at Various Wavelengths for Decompression of Intervertebral Disk. Experimental Observations on Human Autopsy Specimens. *Clin Orthop* 1991;267:245.

! 13. Collier MA, Haugland LM, Bellamy J, et al. Effects of Holmium:YAG Laser on Equine Articular Cartilage and Subchondral Bone Adjacent to Traumatic Lesions: A Histopathological Assessment. *Arthroscopy* 1993;9(5):536.

! 14. David R, Nissan M, Cohen I, Soudry M. Effect of Low-power He-Ne Laser on Fracture Healing in Rats. *Lasers Surg Med* 1996;19(4):458.

! 15. David TS, Drez DJ Jr. Electrothermally Assisted Capsular Shift. *IEEE Eng Med Biol Mag* 1998;17(3):102.

# 16. Dew DK. Laser Biophysics for the Orthopaedic Surgeon. [Review]. *Clin Orthop* 1995;310:6.

! 17. Dressel M, Jahn R, Neu W, Jungbluth KH. Studies in Fiber Guided Excimer Laser Surgery for Cutting and Drilling Bone and Meniscus. *Lasers Surg Med* 1991;11(6):569.

! 18. el Montaser MA, Devlin H, Sloan P, Dickinson MR. Pattern of Healing of Calvarial Bone in the Rat Following Application of the Erbium-YAG Laser. *Lasers Surg Med* 1997;21(3):255.

+ 19. Fanton G, Dillingham MF. The Use of the Holmium:YAG Laser in Arthroscopic Surgery. *Sem Orthop* 1992;7:102.

+ 20. Fanton GS. Shoulder Arthroscopy Using the Holmium-YAG Laser Method. State of the Art 1994 [in German]. *Orthopade* 1996;25(1):79.

+ 21. Fink B, Schneider T, Braunstein S, et al. Holmium: YAG Laser-induced Aseptic Bone Necroses of the Femoral Condyle. *Arthroscopy* 1996;12(2):217.

! 22. Fischer R, Hibst R, Schroder D, et al. Thermal Side Effects of Fiber-guided XeCl Excimer Laser Drilling of Cartilage. *Lasers Surg Med* 1994;14(3):278.

+ 23. Garino JP, Lotke PA, Sapega AA, et al. Osteonecrosis of the Knee Following Laser-assisted Arthroscopic Surgery: A Report of Six Cases. *Arthroscopy* 1995;11(4):467.

# 24. Glossop ND, Jackson RW, Koort HJ, et al. The Excimer Laser in Orthopaedics [Review]. *Clin Orthop* 1995;310:72.

! 25. Hayashi K, Markel MD, Thabit G 3rd, et al. The Effect of Nonablative Laser Energy on Joint Capsular Properties. An in Vitro Mechanical Study Using a Rabbit Model. *Am J Sports Med* 1995;23(4):482.

! 26. Hayashi K, Nieckarz JA, Thabit G 3rd, et al. Effect of Nonablative Laser Energy on the Joint Capsule: An in Vivo Rabbit Study Using a Holmium:YAG Laser. *Lasers Surg Med* 1997;20(2):164.

! 27. Hayashi K, Thabit G 3rd, Bogdanske JJ, et al. The Effect of Nonablative Laser Energy on the Ultrastructure of Joint Capsular Collagen. *Arthroscopy* 1996;12(4):474.

! 28. Hayashi K, Thabit G 3rd, Massa KL, et al. The Effect of Thermal Heating on the Length and Histologic Properties of the Glenohumeral Joint Capsule. *Am J Sports Med* 1997;25(1):107.

+ 29. Imhoff A, Leu H. Arthroscopic Operations with the Excimer Laser. Initial Experiences. In: Siebert W, Wirth C, eds.*Laser in der Orthopadie [Lasers in Orthopaedics].* Stuttgart, Germany: Thieme, 1991:48.

# 30. Imhoff AB, Roscher E, Konig U. Arthroscopic Shoulder Stabilization. Differentiated Treatment Strategy with Suretac, Fastak, Holmium: YAG-laser and Electrosurgery [Review] [in German]. *Orthopade* 1998;27(8):518.

! 31. Jackson R, Judy M, Matthews J, Nosir H. Photochemical Tissue Welding with 1,8-Naphthalimide Dyes: In Vivo Meniscal and Cartilage Welds. *Orthop Trans* 1999;22(3):992.

! 32. Jahn R, Dressel M, Neu W, Jungbluth KH. Ablation of hard biological tissue with the excimer laser [in German]. *Unfallchirurgie* 1992;18(5):261.

+ 33. Janecki CJ, Perry MW, Bonati AO, Bendel M. Safe Parameters for Laser Chondroplasty of the Knee. *Lasers Surg Med* 1998;23(3):141.

+ 34. Janzen DL, Kosarek FJ, Helms CA, et al. Osteonecrosis after Contact Neodymium:Yttrium Aluminum Garnet Arthroscopic Laser Meniscectomy. *Am J Roentgenol* 1997;169(3):855.

! 35. Jovanovic S, Schonfeld U, Prapavat V, et al. Effects of Pulsed Laser Systems on Stapes Footplate. *Lasers Surg Med* 1997;21(4):341.

! 36. Judy MM, Chen L, Fuh L, et al. Photochemical Cross-linking of Type I Collagen with Hydrophobic and Hydrophilic 1,8-naphthalimide Dyes. In: *SPIE Proceedings*, San Jose, CA, 1996.

! 37. Judy MM, Matthews JL, Boriak RL, et al. Heat-free Photochemical Tissue Welding with 1,8-naphthalimide Dyes Using Visible (420 nm) Light. In: *SPIE Proceedings*, San Jose, CA, 1993.

! 38. Kilkelly FX, Choma TJ, Popovic N, et al. Tendon Repair by Laser Welding: A Histologic and Biomechanical Comparison and Suture Repair with $CO_2$ and Argon Lasers. *Lasers Surg Med* 1996;19(4):487.

! 39. Lane GT, Prodoehl JA, Black SJL, et al. An Experimental Comparison of $CO_2$, Argon, Nd:YAG, and Ho:YAG Laser Ablation of Intervertebral Discs. *State Art Rev (Spine)* 1993;7:1.

! 40. Lane JG, Amiel ME, Monosov AZ, Amiel D. Matrix Assessment of the Articular Cartilage Surface after Chondroplasty with the Holmium:YAG Laser. *Am J Sports Med* 1997;25(4):560.

+ 41. Lavyne MH. Complications of Percutaneous Laser Nucleolysis (letter). *J Neurosurg* 1992;76:1041.

! 42. Lewandrowski KU, Lorente C, Schomacker KT, et al. Use of the Er:YAG Laser for Improved Plating in Maxillofacial Surgery: Comparison of Bone Healing in Laser and Drill Osteotomies. *Lasers Surg Med* 1996;19(1):40.

! 43. Lopez MJ, Hayashi K, Fanton GS, et al. The Effect of Radiofrequency Energy on the Ultrastructure of Joint Capsular Collagen. *Arthroscopy* 1998;14(5):495.

! 44. Miller DV, SJ O'Brien, Arnoczky SS, et al. The Use of the Contact Nd:YAG Laser in Arthroscopic Surgery: Effects on Articular Cartilage and Meniscal Tissue. *Arthroscopy* 1989;5(4):245.

+ 45. Neer CSD, Foster CR. Inferior Capsular Shift for Involuntary Inferior and Multidirectional Instability of the Shoulder. A Preliminary Report. *J Bone Joint Surg Am* 1980;62(6):897.

+ 46. Negrier C, Dechavanne M, Lalain JJ, Delacroix P. Successful Arthroscopic Synovectomy Using Holmium : Yag Laser and FEIBA in a High Responder Hemophiliac [letter]. *Am J Hematol* 1993;44(1):74.

! 47. Nelson JS, Yow L, Liaw LH, et al. Ablation of Bone and Methacrylate by a Prototype Mid-infrared Erbium:YAG Laser. *Lasers Surg Med* 1988;8(5):494.

! 48. Nuss RC, Fabian RL, Sarkar R, Puliafito CA. Infrared Laser Bone Ablation. *Lasers Surg Med* 1988;8:381.

+ 49. O'Brien S, Miller DV. The Contact Neodymium-yttrium Aluminum Garnet Laser. A New Approach to Arthroscopic Laser Surgery. *Clin Orthop* 1990;252:95.

! 50. Obrzut SL, Hecht P, Hayashi K, et al. The Effect of Radiofrequency Energy on the Length and Temperature Properties of the Glenohumeral Joint Capsule. *Arthroscopy* 1998;14(4):395.

! 51. Pogrel MA, Chen JW, Zhang K. Effects of Low-energy Gallium-aluminum-arsenide Laser Irradiation on Cultured Fibroblasts and Keratinocytes. *Lasers Surg Med* 1997;20(4):426.

! 52. Prodoehl JA, Lane GJ, Black J, et al. The Effect of Lasers on Intervertebral Disc Pressures. *State Art Rev (Spine)* 1993;7:17.

! 53. Prodoehl JA, Rhodes AL, Cummings RS, et al. 308 nm Excimer Laser Ablation of Cartilage. *Lasers Surg Med* 1994;15(3):263.

! 54. Pullin JG, Collier MA, Das P, et al. Effects of Holmium:YAG Laser Energy on Cartilage Metabolism, Healing, and Biochemical Properties of Lesional and Perilesional Tissue in a Weight-bearing Model. *Arthroscopy* 1996;12(1):15.

! 55. Pullin JG, Collier MA, Johnson LL, et al. Holmium:YAG Laser-assisted Capsular Shift in a Canine Model: Intraarticular Pressure and Histologic Observations. *J Shoulder Elbow Surg* 1997;6(3):272.

! 56. Ratkay LG, Chowdhary RK, Neyndorff HC, et al. Photodynamic Therapy: A Comparison with Other Immunomodulatory Treatments of Adjuvant-enhanced Arthritis in MRL-lpr Mice [see comments]. *Clin Exp Immunol* 1994;95(3):373.

! 57. Ratkay LG, Chowdhary RK, Neyndorff HC, et al. Treatment of Experimental Murine Arthritis with Transdermal Photodynamic Therapy. *SPIE Proceedings* 1995;2371:596.

# 58. Rhodes A, Black J, Lane GJ, et al. Clinical Use of the 2.1 Micron Holmium:YAG Laser and Percutaneous Discectomy. *State Art Rev (Spine)* 1993;7:49.

+ 59. Rozbruch SR, Wickiewicz TL, DiCarlo EF, Potter HG. Osteonecrosis of the Knee Following Arthroscopic Laser Meniscectomy. *Arthroscopy* 1996;12(2):245.

! 60. Schaffer J, Dark M, Itzkan I. Mechanisms of Meniscal Tissue Ablation by Short Pulse Laser Irradiation. *Clin Orthop* 1995;310:30.

+ 61. Shapiro GS, Fanton GS, Dillingham MF, Perkash R. Lateral Retinacular Release. The Holmium:YAG Laser versus Electrocautery. *Clin Orthop* 1995;310:42.

! 62. Shen JH, Joos KM, Manns F, et al. Ablation Rate of PMMA and Human Cornea with a Frequency-quintupled Nd:YAG Laser (213 nm). *Lasers Surg Med* 1997;21(2):179.

! 63. Sherk HH, Black JD, Prodoehl JA, Diven J. The Effects of Lasers and Electrosurgical Devices on Human Meniscal Tissue. *Clin Orthop* 1995;310:14.

+ 64. Sherk HH, Rhodes A, Black J, Prodoehl JA. Results of Percutaneous Lumbar Discectomy with Lasers. *State Art Rev (Spine)* 1993;7:141.

! 65. Shi W, Vari SG, van der Veen MJ, et al. Effect of Varying Laser Parameters on Pulsed Ho:YAG Ablation of Bovine Knee Joint Tissues. *Arthroscopy* 1993;9(1):96.

+ 66. Siebert W, Saunier J, Gerber B. Two-year Follow-up Results of Arthroscopic Laser Surgery of the Knee: European Multicenter Study. *Tech Orthop* 1995;10:309.

! 67. Small W, Heredia NJ, Celliers PM, et al. Laser Tissue Welding Mediated with a Protein Solder. In: *SPIE Proceedings*, San Jose, CA, 1996.

# 68. Smith CF, Johansen WE, Vangsness CT, et al. The Carbon Dioxide Laser. A Potential Tool for Orthopedic Surgery [Review]. *Clin Orthop* 1989;242:43.

# 69. Stith WJ, Judy MM, Hochschuler SH, Guyer RD. Choice of Lasers for Minimally Invasive Spinal Surgery. *Orthop Rev* 1991;20:137.

! 70. Tibone JE, McMahon PJ, Shrader TA, et al. Glenohumeral Joint Translation after Arthroscopic, Nonablative, Thermal Capsuloplasty with a Laser. *Am J Sports Med* 1998;26(4):495.

! 71. Trauner K, Gandour-Edwards R, Bamberg M, et al. Influence of Light Delivery on Photodynamic Synovectomy in an Antigen-induced Arthritis Model for Rheumatoid Arthritis. *Lasers Surg Med* 1998;22(3):147.

! 72. Trauner K, Nishioka N, Patel D. Pulsed Holmium:Yttrium-aluminum-garnet (Ho:YAG) Laser Ablation of Fibrocartilage and Articular Cartilage. *Am J Sports Med* 1990;18(3):316.

! 73. Trauner K, Parekh S, Naseef G, et al. Ho:YAG Laser Induced Osteonecrosis in a Porcine Knee Model. *Orthop Trans* 1998;22(1):94.

! 74. Trauner KB, Gandour-Edwards R, Bamberg M, et al. Photodynamic Synovectomy Using Benzoporphyrin Derivative in an Antigen Induced Arthritis Model for Rheumatoid Arthritis. *Photochem Photobiol* 1998;67(1):133.

! 75. Trauner KB, Nishioka NS, Flotte T, Patel D. Acute and Chronic Response of Articular Cartilage to Holmium:YAG Laser Irradiation. *Clin Orthop* 1995;310:52.

! 76. Vangsness CT Jr, Ghaderi B, Brustein M, et al. Ablation Rates of Human Meniscal Tissue with the Ho:YAG Laser: The Effects of Varying Fluences. *Arthroscopy* 1997;13(2):148.

! 77. Vangsness CT Jr, Watson T, Saadatmanesh V, Moran K. Pulsed Ho:YAG Laser Meniscectomy: Effect of Pulsewidth on Tissue Penetration Rate and Lateral Thermal Damage. *Lasers Surg Med* 1995;16(1):61.

* 78. White AA III, Panjabi MM. *Clinical Biomechanics of the Spine*, 2nd ed. Philadelphia: JB Lippincott, 1990:446.

# 79. Yeung AT. Considerations for Use of the KTP Laser for Disc Decompression and Ablation. *State Art Rev (Spine)* 1993;7:67.

! 80. Yonezawa T, Onomura T, Kosaka R, et al. The System and Procedures of Percutaneous Intradiscal Laser Nucleotomy. *Spine* 1990;15:1175.

! 81. Yu W, Naim JO, Lanzafame RJ. Effects of Photostimulation on Wound Healing in Diabetic Mice. *Lasers Surg Med* 1997;20(1):56.

# CHAPTER 99

# MANAGEMENT OF THE ARTHRITIC JOINT

*Juan J. Rodrigo and M. Eric Gershwin*

**J. J. Rodrigo and M. E. Gershwin:** Univesity of California, Davis, Sacramento, California 95817.

General Principles
- Arthritic Pain
- Histology
- Biochemistry
- Immunochemistry

Diagnosis
Principles of Nonsurgical Treatment
- Drug Treatment
- Physical Therapy

Principles of Surgical Treatment
Common Arthritic Diseases and their Treatment
- Osteoarthritis
- Rheumatoid Arthritis
- Juvenile Rheumatoid Arthritis
- Osteonecrosis (Avascular Necrosis)
- Gout
- Pseudogout
- Ankylosing Spondylitis
- Posttraumatic Arthritis

Chapter References

As much as 10% of the population of the United States is disabled by arthritis. Although arthritis has many causes, the common end result is deterioration of joint surfaces and progressive loss of joint function. The cause determines the clinical characteristics and the rate of deterioration for a given arthritic condition. Septic arthritis is often characterized by rapid deterioration, but primary osteoarthritis is characterized by a slow, insidious deterioration.

The national impact of osteoarthritis and rheumatoid arthritis is enormous. Musculoskeletal diseases account for more than 40% of all patients referred for vocational rehabilitation. Arthritis is the second most frequent cause of outpatient complaints among patients with chronic diseases. Musculoskeletal diseases account for 20% of all Medicare hospital costs. The number of days of work lost annually as a result of rheumatoid arthritis and osteoarthritis is staggering.

One of the most difficult problems that patients with arthritis and their families face is accepting that the disease is chronic, with little likelihood of spontaneous remission. People with arthritis must live with their disease, because they will not die of it. Therefore, accurate diagnosis and early appropriate comprehensive management are critical.

Approximately 50 years ago, only a handful of causes of arthritis were identified. We now recognize more than 100 causes. Although we may congratulate ourselves on the tremendous advances in diagnosis and treatment of patients, we have only begun to scratch the surface. Answers to the management of arthritis are likely to remain elusive in the near future.

It is important to identify as early as possible the patients who need more intensive treatment than others and the patients who are more likely to develop functional disability. Involvement with social services or peer support groups and consultation with other disciplines are crucial to the care of the patient. Do not allow a patient to become seriously functionally disabled before suggesting vocational rehabilitation. Several identifiable work factors are important in maintaining employment. The most important factor is having the autonomy to control the pace and content of work activities. Accessibility of the workplace is also an important consideration. We tend to lose sight of the young mother with arthritis and morning stiffness who is unable to dress her children for school, of the worker who loses his job because of recurrent absence, and of the marital breakdowns that are almost twice as frequent among arthritis patients as in the general population. The financial and social hardships are substantial.

After the clinical and functional evaluation, develop a management plan that addresses specific medical measures to control the arthritic process. Include the use of appropriate regimens of rest, exercise, and the various available physical and surgical modalities to relieve pain and maintain musculoskeletal function. If appropriate, encourage the use of assistive devices to further these goals and allow the patient to remain as independent as possible.

A critical feature of all management programs is the education of the patient about the disease process, the modalities of treatment, and the principles of joint protection and energy conservation. Many educational pamphlets and books are available from the Arthritis Foundation (4,29,67,22). If the patient understands the process and rationale for treatment, he or she is more likely to comply with the therapeutic regimen. Provide information about reasonable therapeutic goals and limitation of activity according to the patient's functional level. Suggest suitable modifications of the living and working environments and tasks. Relatively minor physical modifications may make major differences in the patient's independence.

## GENERAL PRINCIPLES

Arthritic conditions can be classified as low-inflammatory or high-inflammatory types. Patients with the low-inflammatory type have low leukocyte counts in the synovial fluid and laboratory findings consistent with low-level inflammatory activity; the affected joint often shows focal degeneration. Those with the high-inflammatory type have high leukocyte counts in the synovial fluid, laboratory findings consistent with high-level inflammatory activity, and usually show a more diffuse degeneration of the involved joints (Table 99.1).

***Table 99.1. Interpretation of Synovial Fluid Findings in the Setting of Undiagnosed Arthritis***

The classic types of low-inflammatory disease are primary osteoarthritis, produced by intrinsic degeneration of articular cartilage, and posttraumatic arthritis. The

classic type of high-inflammatory arthritis is rheumatoid arthritis. Other types include gout, arthritis of psoriasis, lupus erythematosus, ankylosing spondylitis, arthritis associated with bacterial infection (11), Reiter's syndrome, and arthritis of ulcerative colitis. There are some articular diseases that fit into neither category and that have unique characteristics, such as aseptic necrosis, “frozen” shoulder and other joint-stiffening conditions, as well as neuropathic joints.

### ARTHRITIC PAIN

The most common symptom of arthritis is pain in the joints. The pain may arise from soft tissues about the joint that are under tension or muscles that are in spasm, or from subchondral bone that is undergoing destruction as a result of the arthritic process. Other common and significant symptoms and signs of arthritis are loss of joint motion, instability of joints, and deformity. Many of the normal components of gait are significantly altered, including walking speed, step length, cadence, lateral motion of the pelvis, pelvic tilt, and transverse rotation of the pelvis.

### HISTOLOGY

The histologic characteristics of any given arthritic condition vary with the stage of the disease, and often these changes do not differentiate specific causes. Low-inflammatory and high-inflammatory arthritis may show chronic inflammation of the synovium, diffuse articular cartilage damage with fissures and subchondral cysts, and pannus extending across the articular surface. The pathology report often reads, “compatible with, but not diagnostic of, high-inflammatory arthritis.”

There is a mechanism of joint destruction in arthritis that is associated with the immune response. Antibodies produced by lymphocytes and plasma cells of the synovial membrane combine with antigens in the synovium (i.e., locally produced and altered IgG or an unknown antigen, “X”). In systemic lupus erythematosus, desoxyribonucleic acid (DNA) antigens are the most important finding. Some or all of these complexes may fix or activate complement, causing chemotactic substances to be produced. Ingestion of complexes by polymorphonuclear leukocytes leads to vacuole formation and release of lysosomal enzymes, which cause the destruction of articular cartilage and cell death.

### BIOCHEMISTRY

In arthritis, the major destructive process at the biochemical level is thought to be enzymatic degradation of the articular cartilage (36). In the various types of arthritic conditions, there is a decrease in the concentration of chondroitin sulfate, and the existing chondroitin sulfate has a decreased chain length. The enzymes thought to be responsible are hyaluronidase, which breaks down mucopolysaccharides, and collagenase, which breaks down proteins such as collagen.

These enzymes, called cathepsins, are responsible for cartilage degradation and may be found in the synovium, the synovial fluid polymorphonuclear cells, or the chondrocytes themselves. With the breakdown of matrix components, the production of new components by the cells increases in an attempt to repair the damage. With disease progression, however, the balance favors articular cartilage degradation. The mechanical and lubricating functions of cartilage are lost, and joint collapse progresses (7,50,75).

### IMMUNOCHEMISTRY

In high-inflammatory and low-inflammatory types of arthritis, IgG, IgM, and IgA levels are elevated in the synovial fluid. Rheumatoid factor, an IgM (19S) antibody that reacts with degraded IgG (7S) immunoglobulins, is found in 70% to 80% of adults with rheumatoid arthritis. For this reason, arthritis is considered one of the immune complex diseases (80). Rheumatoid factor is not specific to rheumatoid arthritis, because it is also found in approximately 25% of patients with systemic lupus erythematosus, scleroderma, and polymyositis. If this factor is found in high titer, however, it is characteristic of rheumatoid arthritis; usually the serum and synovial fluid levels of the factor are correspondingly elevated.

## DIAGNOSIS

The diagnosis of late-stage disease is usually obvious. A given arthritic condition, such as rheumatoid arthritis, usually creates a characteristic clinical picture that is not difficult to differentiate from other types of arthritis. The problem of diagnosis arises when the presenting symptom of a patient with arthritis is an acutely swollen joint or joints. A history of trauma at this point is often helpful for diagnosis of the condition, but if such a history is lacking, the diagnosis is best approached by turning to radiological and laboratory examinations.

The characteristic radiographic features of low-inflammatory osteoarthritis, arthritis secondary to trauma, or other conditions in which normal joint mechanics have been disrupted are the irregular narrowing of the joint surface and the appearance of osteophytes (Fig. 99.1). The radiograph is characterized by hypertrophic changes about the joint rather than the atrophic changes seen in high-inflammatory types of arthritis. It is common for cysts to form along the weight-bearing surfaces in the lower extremities. It is rare that a patient's presenting symptom is an acute attack of arthritis in a joint affected with osteoarthritis, unless he or she had a fall or other traumatic episode that aggravated a pre-existing abnormality. In these cases, a radiograph of the joint is helpful in determining the contribution of degenerative joint disease to the traumatic episode.

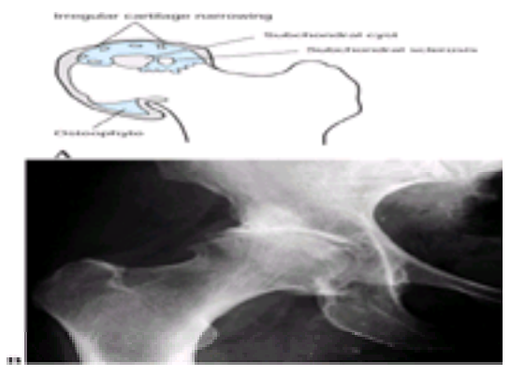

***Figure 99.1.*** **A:** The drawing depicts degenerative arthritis, which is characterized by focal narrowing of the surface cartilage with subchondral sclerosis on each site of the narrowing. Occasionally, there are subchondral cysts in this area. **B:** The radiograph shows a cyst in the acetabulum of a hip with degenerative arthritis in a 77-year-old female.

The characteristic radiographic features of high-inflammatory arthritis (i.e., rheumatoid arthritis, septic arthritis, and gout) include diffuse narrowing of the entire joint surface and the appearance of periarticular cysts (Fig. 99.2). The cysts are thought to be caused by erosion from the inflamed synovium at its reflection near the insertion of the joint capsule. The margins of the cysts are often “fuzzy” during the acute stage and sclerotic during the chronic stage. The uniform narrowing of the joint space is thought to be due to enzymatic digestion of the entire cartilage surface. Another radiographic feature common to high-inflammatory types of arthritis is osteoporosis of the bones near the joints.

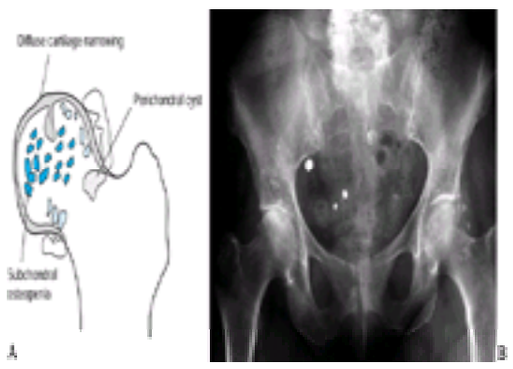

***Figure 99.2.*** The drawing depicts a high-inflammatory arthritis, which is characterized by diffuse narrowing of the entire joint surface. **A:** Occasionally, periarticular

cysts are seen near the reflection of the synovium. **B:** The radiograph shows these changes in a 65-year-old woman with rheumatoid arthritis affecting the right hip.

Perhaps the most important diagnostic procedure in the evaluation of the patient with the first episode of an acutely painful joint is arthrocentesis and synovial fluid analysis. The indications and contraindications for arthrocentesis are illustrated in Table 99.2. The technique of arthrocentesis involves infiltration of the skin with a local anesthetic by using a 25-gauge needle, followed by introduction of a 20-gauge needle into the joint. Joints that contain large amounts of fluid are the most successfully aspirated, but even these joints may have hypertrophic synovial folds that can block the needle tip, resulting in an unsuccessful aspiration. Approaches to various joints for arthrocentesis are illustrated in Figure 99.3.

| |
|---|
| ***Diagnostic indications*** |
| Evaluation of new monoarticular or polyarticular joint disease |
| Confirmation of activity of underlying disease versus new process |
| Inability to perform an adequate orthopaedic examination because of large synovial fusion |
| Suspicion of local sepsis |
| ***Therapeutic indications*** |
| Administration of a local anesthetic or long-acting corticosteroid preparation, or other drug for arthritis |
| Removal of toxic products from an infected joint |
| Relief of pain caused by pressure |
| ***Contraindications*** |
| Arthritis where entry into the joint is not feasible (spinal joints or fused joints) |
| Clotting abnormalities |
| Lack of experience for a given joint (hip, etc.) |

***Table 99.2. Indications and Contraindications for Arthrocentesis***

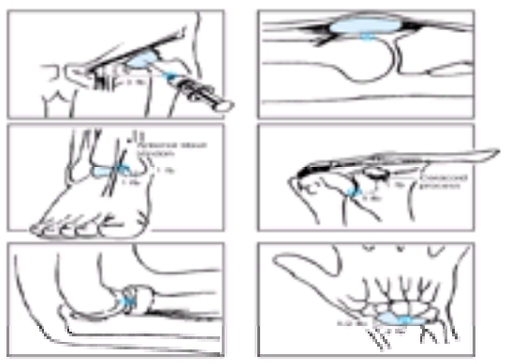

***Figure 99.3.*** Sites for introduction of a needle for arthrocentesis of various joints. Some joints are more difficult to aspirate (such as the hip, shoulder, elbow, and ankle) and should be examined with fluoroscopy. The needle is introduced into the subcutaneous tissue, and the fluoroscope is used to ensure that it is on target.

A synovial fluid analysis usually helps the diagnosis, but synovial biopsies and cartilage biopsies are often not diagnostic. A few exceptions to this principle are synovial biopsy in tuberculosis or sarcoidosis, which show the familiar Langhans' giant cells and central fibrinoid necrosis; a synovial biopsy in coccidioidomycosis that demonstrates the characteristic endospore; and a synovial biopsy from pigmented villonodular synovitis that differentiates this tumorous condition from arthritis.

Subject the extracted synovial fluid to several laboratory tests: gross appearance and the “string” test, mucin clot, leukocyte count and differential, microscopic examination of a wet preparation, polarized light examination, compensated polarized light examination, Gram stain examination, glucose content, and culture and sensitivity tests. Compare the glucose value of the synovial fluid with that of the serum glucose levels. These tests often confirm the diagnosis and can be carried out with only a few drops of synovial fluid (Table 99.3). Gout can often be diagnosed by the finding of negatively birefringent crystals in the fluid; pseudogout is characterized by positively birefringent crystals; and infection can be diagnosed by the identification of bacteria by Gram stain.

| *Characteristic* | *Normal* | *Noninflammatory* | *Inflammatory* | *Purulent* | *Hemorrhagic* |
|---|---|---|---|---|---|
| Color | Colorless | Xanthochromic | Xanthochromic to white | Depends on organism | Xanthochromic to frankly bloody |
| Clarity | Clear | Clear | Translucent to opaque | Opaque | Opaque (clear if centrifuged) |
| Viscosity | High | High | Low | Varies; may be high | High |
| Leukocytes per mm³ | 200 | 200–2000 | 2000–60,000 (average 20,000) | 20,000–200,000 (average 100,000) | Variable (usually) |
| Polymorphs (%) | <25% | <25% | >75% | >75% | Variable (usually <75%) |
| Glucose (mg%) (fasting) | Nearly equal to blood | Nearly equal to blood | Often lower than blood | Usually <50% of blood value | Nearly equal to blood |
| Culture | Negative | Negative | Negative* | Positive/negative | Negative |
| Spontaneous clot | No | Occasionally | Often | Often | Often |
| Mucin clot | Firm | Firm† | Friable | Friable | Friable† |

* Except for tuberculous or fungal arthritis.
† Recent effusions do not give firm clot because of serum additives.

***Table 99.3. Categories of Joint Fluid and Disease Associations***

The serum rheumatoid factor is positive in 70% to 80% of adult rheumatoid arthritis patients. It is rarely positive in juvenile rheumatoid arthritis. The lupus erythematosus test demonstrates a polymorphonuclear cell filled with antinuclear antibody (ANA) complexes. More frequently used tests are the fluorescent ANA tests, the results of which are classified as homogeneous, shaggy, or speckled. Homogeneous, the most common ANA pattern, is seen primarily in lupus erythematosus but occurs in other diseases as well; shaggy (peripheral or rim) is more specific to lupus erythematosus and is often associated with increased disease activity; speckled is characteristic of mixed connective tissue disease. In lupus erythematosus, the titers are higher than those in other rheumatic conditions.

Another helpful test is the HLA-B27. Of those patients with ankylosing spondylitis, 90% have the gene for the HLA-B27 antigen, a histocompatibility complex antigen controlled by a gene on chromosome 6. Other arthritic conditions, such as the arthritis of inflammatory bowel disease, appear to have an increased association with a positive HLA-B27 test if the arthritis is localized to the spine.

Synovial biopsy is usually unnecessary in diagnosing arthritis. However, if the history, physical findings, radiographic findings, and synovial analysis does not reveal the diagnosis, consider a synovial biopsy.

## PRINCIPLES OF NONSURGICAL TREATMENT

Treatment of arthritic conditions may be divided into nonsurgical and surgical approaches. Surgery should not be considered as a last alternative to nonsurgical treatment but rather as an adjunct that may be appropriate at any stage in the treatment of the disease. The treatment goals in arthritis are to prevent and correct deformity, preserve function, restore function, and relieve pain. The nonsurgical treatment primarily consists of drugs, physiotherapy, rest, and use of orthotic devices.

### DRUG TREATMENT

Of the drugs most commonly used, nonsteroidal anti-inflammatory drugs (NSAIDs) remain the first line of therapy in the treatment of arthritis, and they should be administered in a dose sufficient to control pain and relieve stiffness (14). Individualized dosage and emphasis on compliance are necessary. These drugs are best given after meals or after antacids to prevent gastrointestinal irritation. The most frequent side effects of NSAIDs are gastrointestinal irritation and bleeding. Gastrointestinal bleeding from NSAIDs is particularly a problem for people older than 60, those who smoke, and those with a history of gastrointestinal ulcer. All COX-1 NSAIDs can potentially induce gastrointestinal bleeding.

The use of NSAIDs has changed dramatically. The Food and Drug Administration has approved two new NSAIDs that are selectively inhibitory for cyclooxygenase-2 (COX-2). It was discovered approximately 10 years ago that there were two forms of cyclooxygenase. Both forms were inhibitory for the production of prostaglandins and, therefore, could potentially help inflammation. Inhibition of COX-1, however, also led to the loss of the protective effects of prostaglandins on the mucous membranes of the gastrointestinal tract, which predisposed the patient to upper gastrointestinal ulceration. Inhibition of COX-2 leads to protection from inflammation but does not produce the harmful side effect of gastric ulceration. Until recently, all NSAIDs have been COX-1 inhibitors. The first two of the new class of drugs, celecoxib and rofecoxib (44,70), became available in 1999. Celecoxib, in particular, is indicated in both osteoarthritis and rheumatoid arthritis and appears to spare the GI tract. It also does not inhibit platelet function. The use of Celecoxib has changed clinical practice and has made the use of COX-2 inhibitors a standard of care.

Glucosamine and chondroitin sulfate have been advocated as oral agents designed to stimulate aggrecan formation as well as hyaluronic acid formation. Aggrecan is the major proteoglycan (PG) in cartilage. It has a long protein core and chondroitin sulfate and keratin sulfate sidechains attached to it. Hyaluronic acid (hyaluronan) is made of alternating acetylglucosamine and glucuronic acid building blocks. It is the core molecule that aggrecan binds to through the link protein, forming the large PG molecule. It is thought that oral administration of the building blocks chondroitin sulfate and glucosamine will stimulate increased formation of the larger molecules. The glucosamine molecules reach the cellular machinery of the chondrocyte without being altered by intestinal absorption, while the chondroitin sulfate preparations undergo partial degeneration. *In vitro* studies (tissue culture) have shown that both chondroitin sulfate and glucosamine will stimulate glycosaminoglycan (GAG), PG, and collagen synthesis. *In vivo* studies have not demonstrated an anti-inflammatory effect on the cyclooxygenase system or the prostaglandin generation of metalloproteases, and there is little effect on bradykinin, serotonin, or histamine-mediated inflammation. However, there appears to be blockage of leukocyte esterase, hyaluronidase, and superoxide radical generation. Thus, these drugs might be considered “anti-reactive” as opposed to anti-inflammatory (21).

Several double-blind studies have addressed the safety and efficacy of glucosamine sulfate. In one study, 80 patients with focal or general osteoarthritis were randomized to glucosamine 500 mg three times daily versus placebo for 30 days (14). Symptoms were reduced in 72% of patients in the glucosamine group and 36% of patients in the placebo group. Improvement was noted in most by 20 days. Another study of 24 outpatients with osteoarthritis showed significant improvement in the scores for joint pain, tenderness, and swelling in 80% of patients in the glucosamine group versus 20% of patients in the placebo group (61).

Another important study compared glucosamine sulfate with ibuprofen in osteoarthritis of the knee (56). Two hundred inpatients were randomized to glucosamine 500 mg orally three times daily versus ibuprofen 400 mg orally three times daily for 4 weeks. No other analgesics, NSAIDs, or corticosteroids were allowed. Efficacy was measured by Lequesne's severity index and global assessment. Ibuprofen response was faster: 48% responded within 1 week, compared with 28% of the glucosamine treated groups. It should be noted that it takes 1 to 2 months for glucosamine sulfate to take effect. The overall response rate was equal: 52% versus 48%. Lequesne's severity index improved equally: ibuprofen (severity index = 16) to glucosamine (severity index = 10), respectively. Adverse effects were significantly higher in the ibuprofen group (35% ibuprofen versus 6% glucosamine), and the adverse event–related dropout rate was 7% for ibuprofen and 1% for glucosamine. Similar results were found in another study (47).

Chondroitin sulfate has also been studied, but not as extensively. In a trial comparing chondroitin sulfate (400 mg three times daily) with diclofenac (50 mg three times daily), adverse responses were few and equal in both groups (55). The response to diclofenac was prompt but was not sustained after withdrawal. The response to chondroitin sulfate response was slower, but ultimately greater and sustained 3 months after withdrawal.

Gold salts are second-line drugs for the treatment of rheumatoid arthritis. Chrysotherapy requires careful supervision because of the possible side effects of nephrotoxicity, blood dyscrasias, and gold allergy. Gold can be administered parenterally or orally. Methotrexate is becoming widely used for severe rheumatoid arthritis, and its use requires monitoring of blood counts and liver function tests.

Another class of drugs to be considered are steroids (e.g., prednisone). In rheumatoid arthritis, 5 to 10 mg of prednisone daily in divided doses can give good relief from pain, swelling, and inflammation. At these low levels, the side effects of cataracts, decreased resistance to infection, poor wound healing, psychological consequences, avascular necrosis, and osteoporosis are reduced. High dosages, such as 40 to 60 mg daily, are reserved for the acutely ill with life-threatening rheumatic flares. Lowering of high dosages should be attempted as soon as possible and may require concomitant use of other anti-inflammatory or antimetabolite drugs. Extremely close supervision of drug administration and side effects is required in seriously ill patients. Steroids should be administered only if other drugs have failed and then for as short a period of time as possible.

Another newer drug for the management of moderate to severe rheumatoid arthritis is Enbrel (Immunex, Seattle, Washington), which is a soluble, injectable tumor necrosis factor-a receptor that has been engineered to resemble human IgG1. Patients with moderate to severe rheumatoid arthritis self-administer 25 mg two times per week. The responses in some patients have been dramatic, particularly in those patients who have failed with other disease-remitting agents. It is expected in the next several years that similar products will likewise be approved. The overall goal is to selectively down-regulate the inflammatory response at the molecular level.

Hyaluronic acid as an injectable, large, linear GAG has now been studied in a double-blind fashion. There are two preparations now available, hylan G-F20 (Synvisc, Biomatrix, Richfield, New Jersey), and hyalectin (Hyalgan, New York, New York); both are processed from rooster combs. Synvisc has a molecular weight of 6 million and Hyalgan has a molecular weight of 730,000, as compared with naturally occurring hyaluronic acid with a molecular weight of 10 million. Because of the difference in molecular weight, it is recommended that Synvisc be given three times, 1 week apart; and Hyalgan be given five times, 1 week apart. Both Hyalgan and Synvisc have been shown to be significantly better than saline controls (1,13,45,46). The functional improvement was noted within 2 months after injections and was sustained for at least 1 year. No significant difference was noted in radiographic progression.

Another study compared Synvisc to NSAIDs and found no significant difference at 12 weeks, but there was significant improvement of Synvisc over the anti-inflammatory drugs by 26 weeks (2). It was noted that Synvisc plus NSAIDs were superior to Synvisc alone or NSAIDs alone. Finally, a study comparing Synvisc to intra-articular steroid injections showed no significant difference by 6 months (39).

Local steroids are of limited use, but they are of definite benefit and must be used selectively (20). They often are helpful in the early rehabilitation of an acute rheumatic flare. They also provide temporary relief of an acute flare of chronic synovitis. They should not be used more than two or three times per year, and at least 2 weeks should pass between repeat injections. If there is a question of infection, they should not be used, and the results (particularly the culture) of the synovial analysis should be examined before a steroid injection is given. The main limitation of repeated local steroid injection is the risk of infection and destruction of articular cartilage, tendon, or ligaments. They should never be injected directly into a tendon, for example, when treating patella tendonitis, achillis tendonitis, or rotator cuff tendonitis, but rather into the tendon sheath around the tendon.

**PHYSICAL THERAPY**

Physical modalities act as counterirritants to reduce pain, and are not capable of significantly increasing deep tissue temperatures or local circulation. Superficial heat or localized cold may relieve pain sufficiently to permit exercises. Therapeutic exercises are designed to increase muscle strength, reduce joint contractures, and maintain range of motion.

In using physical therapy, have patients avoid heavy loading exercises that compress the joint. For this reason, the majority of muscle-strengthening exercises are best done isometrically in a position of the joint that does not cause pain. On the basis of clinical experience, we have decided that if an activity or exercise produces pain that lasts for longer than 10 to 15 minutes after the activity, the activity is not advised. Passive range-of-motion exercise within pain tolerance is acceptable, but forceful, painful stressing must be avoided. Assisted and active range-of-motion and isometric muscle-strengthening exercises are highly recommended. Swimming, adaptive physical education, and activities of daily living are sometimes more appealing to the patient than a boring, structured exercise program.

Avoid prolonged bed rest, although periodic daily rest periods are essential. Resting with removable splints or braces that permit limited function of the limb may prevent deformity that would otherwise occur as a result of pain. Resting night splints may be applied to stretch out contracted joints, if the deformity is not too severe. All splints and other orthotic devices must be easy to apply and remove to permit continuation of the exercise program and, in conjunction with rest, to relieve pain and correct or prevent deformity. Complicated dynamic braces are of little value.

Avoid using cylindric, nonremovable plaster, or braces. Wedging of cylinder casts to overcome flexion deformity is usually ill advised. The use of orthotic shock absorbers in shoes can decrease joint impact in the lower extremity by as much as 40% (78). New developments in continuous passive motion devices appear

promising for improving joint motion and function after surgery and in the nonsurgical treatment of injuries (66).

## PRINCIPLES OF SURGICAL TREATMENT

Before considering surgery, perform adequate diagnostic procedures to determine whether the problem is due to tendon contractures, ligament or capsular contractures, bony deformities, or joint surface deterioration. Also important, consider the social disabilities suffered by the patient: What is it the patient cannot do that he or she would like to be able to do? After considering these factors, devise the treatment plan. Particularly in late-stage disease, surgery often can help improve the arthritic patient. Rarely can a cure be obtained.

The procedures available may be divided into two main categories: soft-tissue procedures and bone and joint procedures. The soft-tissue surgeries include synovectomy, capsulotomy and capsulectomies, tendon transfers, and other tendon procedures. The bone and joint procedures include arthroplasty, osteotomy, arthrodesis, excision of osteophytes and loose bodies that cause locking or mechanical joint damage, articular resection, chondroplasty to stimulate repair fibrocartilage, and biologic resurfacing using autograft or allograft cartilage. These techniques are discussed in Chapter 70 , Chapter 71 and Chapter 72 (Hand), Chapter 86 (Chondral Injuries) Chapter 101, Chapter 102, Chapter 103, Chapter 104, Chapter 105, Chapter 106, Chapter 107, Chapter 108 and Chapter 109 (Arthroplasty, Osteotomies, and Arthrodesis of the Major Joints), Chapter 117 (Foot), Chapter 125 (Osteonecrosis), and Chapter 153 and Chapter 154 (Spine). Conditions that almost always require surgery include unstable luxation of the cervical spine, ankylosis of the temporal mandibular joint with risk of starvation, severe ankylosis of both elbows in extension, severe deformities of the hips and knees, and deformities that cause severe compression of nerves or imminent or actual tendon ruptures. Table 99.4 summarizes the common surgical procedures and their indications.

***Table 99.4. Surgical Procedures Commonly Used in the Treatment of Arthritic Conditions***

## COMMON ARTHRITIC DISEASES AND THEIR TREATMENT

For a discussion of neuropathic joint disease, see Chapter 124. For information on septic arthritis, see Chapter 134 for adults or Chapter 176 for children.

### OSTEOARTHRITIS

Osteoarthritis is the most common joint disease and is, for the most part, a noninflammatory form of arthritis.

- It is characterized by progressive loss of articular cartilage, appositional new bone formation in the subchondral trabecular bone, and formation of new cartilage and new bone at the margins (osteophytes).
- Clinical features can include pain in the involved joint, which is frequently aggravated by activity and relieved by rest. Stiffness after periods of immobility is common.
- Advanced stages are characterized by enlargement of the joint, instability, limitation of motion, and functional loss.

#### *Epidemiology*

More than 80% of those older than 75 years of age suffer from some degree of osteoarthritis. The prevalence increases with age, and age is the most important predictive risk factor. Osteoarthritis is a major cause of disability, and the knee is involved more commonly than the hip. There are also racial differences, with whites having a higher incidence than Chinese, South African blacks, East Indians, and Native Americans.

Fewer than one half of those with radiographic evidence of osteoarthritis have significant symptoms; therefore, treatment is predicated on symptoms rather than on the degree of pathology. The damaged joint may be due to degenerative joint disease due to wear and tear, or it may be secondary to a previous traumatic episode. There is some evidence that there is a genetic predisposition (42). The presence of Heberden's nodes signifies a predisposition toward the development of osteoarthritis, and this may potentiate the effects of local etiologic factors, such as trauma or instability. For example, patients with Heberden's nodes who have meniscal tears are more likely to develop posttraumatic arthritis of the knee after meniscectomy (12). Other predictors of osteoarthritis are obesity, increased bone density, trauma, and repetitive stress (67).

#### *Pathogenesis*

In the early stages of osteoarthritis, there is actually an increase in thickness owing to increased water content (swelling) and an increase in the net rate of synthesis of PG. This is an attempt to repair articular cartilage, and may last for years in humans (62,63). With disease progression, the joint surface thins and the PG content decreases. Progressive fibrillation of the cartilage occurs, and eventually, the underlying bone is exposed. There is increased bone formation in the subchondral bone, and this leads to sclerosis that may be seen radiographically. Appositional growth of bone at the joint margins leads to osteophytes, or “spurs.” Spurs, along with thickening of the joint capsule, leads to limitation of motion.

Cartilage loss is the central process in osteoarthritis. After the initial attempts at repair with increased synthesis of collagen, PG, and hyaluronan, the catabolic activity at the biochemical level becomes high. Lysosomal proteases (cathepsins) and neutral metalloproteinase (such as stromelysin, collagenase, and gelatinase) account for much of the loss of cartilage. The concentration of collagenase increases with advancing disease, and matrix collagen decreases. Similarly, despite an increase in hyaluronan synthesis, there is a reduction in hyaluronan. A specific hyaluronidase has not been identified in cartilage, but several lysosomal enzymes can lyse hyaluronic acid and chondroitin sulfate. The cartilage loses aggrecan (49), which results in a loss of compressive stiffness and elasticity as well as an increase in fluid permeability. This may be due to a deficiency in link protein. The cells in osteoarthritic cartilage divide more actively than in normal cartilage, and the resultant cells are very metabolically active. However, the new cells do not produce a normal extracellular matrix due to biochemical deficiencies, which leads to further cartilage deterioration. Tissue inhibitors of metalloproteinase and plasminogen activator inhibitor can be secreted by chondrocytes to inhibit the degenerative process, but the balance appears in favor of the degradative enzymes.

#### *Clinical Findings and Diagnosis*

Osteoarthritis is usually not a systematic disease, and the symptoms remain localized to a joint. Clinical correlation of patient complaints with objective findings usually show a positive correlation, but the discrepancy between symptoms and pathological findings may be striking. The findings are usually local and may or may not be bilateral. There is progressive loss of motion and pain in the joint with physical activity, and the pain is usually relieved by rest. Acute inflammatory flares may be precipitated by trauma or exercise. The entire joint will be swollen, tender, and stiff. After the acute flare resolves, the tenderness will be localized to the area of maximum joint space narrowing. The joints most frequently involved are the hands, knees, hips, feet, and spine. The distal interphalangeal joints of the hands have characteristic spurs and lateral deviations called Heberden's nodes.

The laboratory tests are usually normal, and the tests are performed to rule out other arthritides. The erythrocyte sedimentation rate is normal in most patients, and the synovial fluid white cell count is less than 1000/$mm^3$.

Roentgenographic changes vary with progression of the disease. Early joint space narrowing may occur in the knee, with relatively minor changes seen at arthroscopy.

The end-stage changes are characterized by joint space narrowing, subchondral bony sclerosis, marginal osteophyte formation, and cyst formation (Fig. 99.4 demonstrates a shoulder with ostoarthritis). A variant form of osteoarthritis, erosive inflammatory arthritis, involves primarily the distal or proximal interphalangeal joints of the hands (16). Painful inflammatory episodes lead to deformity and ankylosis, but the end-stage disease frequently becomes asymptomatic.

***Figure 99.4.*** A radiograph showing osteoarthritis of the shoulder. Note the subchondral sclerosis and marginal osteophyte formation.

Although the diagnosis of osteoarthritis is usually straight forward, atypical presentations and osteoarthritis secondary to other conditions can lead to diagnostic difficulties. Such atypical presentations include the occurrence of osteoarthritis in joints infrequently involved, such as the elbow; the presence of osteoarthritis associated with a significant degree of inflammation, such as erosive inflammatory arthritis of the hands; or osteoarthritis associated with crystal deposition disease, such as the pyrophosphate of pseudogout.

### *Treatment*

Treatment consists of the physical therapy and drug therapy that have been outlined earlier. Many patients are overweight and require weight loss for successful treatment. Corticosteroids should not be given on a long-term basis. The likelihood of fixed deformity is much less in osteoarthritis than in the high-inflammatory types of arthritis. The surgeries outlined for arthritis in general apply to osteoarthritis (Table 99.4). The most common operations performed for the hip and knee are total joint replacements. Osteotomies to change the mechanical axis of weight bearing are useful for unicompartmental arthritis in the knee (76). Unicompartmental arthroplasty of the knee should be strongly considered in these cases as well. Another joint that most commonly requires surgery for osteoarthritis is the carpometacarpal joint of the thumb; the procedure usually recommended is fusion, although interposition arthroplasty is commonly performed (see Chapter 70).

## RHEUMATOID ARTHRITIS

Rheumatoid arthritis is a progressive systemic autoimmune disease of the synovial joints. The cause is unknown (26,67). It is characterized by chronic systemic erosive synovitis of peripheral joints and is associated with an elevated rheumatoid factor in the majority of patients. Associated nonarticular manifestations may include subcutaneous nodules, vasculitis, pericarditis, pulmonary nodules and interstitial fibrosis, mononeuritis multiplex, episcleritis, and Sjögren's and Felty's syndromes.

### *Epidemiology*

The estimates of prevalence, based on the criteria for the classification of the American Rheumatism Association, is 1% to 2% of the population in every part of the world (67). The incidence increases with age, with 0.3% of the population being affected younger than 35 years of age and 10% over the age of 65 (67). The incidence is higher in females than in males, with a ratio of 2.5 to 1. Genetic factors are clearly operative, but they also indicate that disease penetrance is low and that environmental risk factors play a significant role as well (54).

### *Pathogenesis*

The primary cause of rheumatoid arthritis is unknown. Investigations of the etiology have focused on interrelationships of infectious agents, genetics, and autoimmunity. It is known that rheumatoid arthritis has a higher incidence in those patients with an HLA-DR4 locus containing the amino acid sequence common to the DR1, Dw14, or Dw15 hypervariable region. It has been suggested that the third hyperavailable regions of the beta chains of HLA-DR4 may influence the susceptibility to disease by binding arthrogenic peptides; that they trigger disease by expanding or deleting particular T-cell populations; or both.

Rheumatoid factors are immunoglobulins (IgM) that react with the Fc portion of the IgG molecule. They are detected in about 3% of the normal population but are common in high titers in rheumatoid arthritis. Animal studies have shown that they are found when prolonged hypergammaglobulinemia is found, such as in chronic infections. They may help host defense mechanisms by cleaning small antigen-antibody complexes, but they may secondarily harm host structures by increasing deleterious inflammation. Certain polymorphysisms of the variable and constant regions of the rheumatoid factor kappa light chain are associated with an increased risk of rheumatoid arthritis, indicating that immunoglobulin genes, in addition to the major histocompatability locus DR4, may influence disease susceptibility.

Rheumatoid synovium is characterized by a massive tumor-like expansion of stromal connective tissue cells, primarily fibroblast-like cells and new blood vessels. The fibroblast-like cells are typically immature and highly invasive (forming a tissue called pannus). They appear more like transformed cells and express activation markers such as photo-oncogenes c-fos and c-jun and metalloproteinase such as collagenase and transin/stromelysin (67,80). These cells are not malignant but are stimulated by factors such as platelet derived growth factor (PDGF), fibroblast growth factor (FGF), Interleukin-I (IL-1), and tumor necrosis factor (TNF) to express the abnormal phenotype. It appears that the rheumatoid factor containing immune complexes precipitate out in the superficial layers of cartilage and stimulate further pannus invasion. The result of the multifaceted process is continuous pain, progressive deformity and disability.

### *Clinical and Laboratory Findings*

The characteristic early finding is an inflammatory synovitis. This must be documented by synovial analysis showing a leukocytosis of 2,000 cells/$mm^3$ to 50,000 plus cells/$mm^3$, biopsy proven synovitis, or characteristic periarticular erosions on x-ray study. Another diagnostic feature is the evolution of the disease process to bilaterally symmetric arthritis.

There is no one laboratory test, histologic test, or radiographic finding that is definitive for rheumatoid arthritis. Rheumatoid factor is present in 85% of patients with rheumatoid arthritis, and is frequently a predictor of the severe and unremitting form of the disease. The erythrocyte sedimentation rate is elevated with flares of the disease, as is the C-reactive protein level.

Structural damage to the joints usually begins between the first and second year of the disease. The synovitis tends to come and go following a sine wave pattern, but the structural damage tends to follow a straight line related to the amount of prior synovitis. Patients who undergo remission within the first year can become virtually symptom free. However, once structural damage occurs, there will be permanent disability.

As the disease progresses, the patient will manifest symptoms due to the structural deformity and recurrent synovitis. It is important to recognize the difference, because recurrent synovitis is usually treated pharmacologically, whereas structural deformity requires activity restriction, or reconstructive surgery. Morning stiffness (lasting 1 hour or more) is present with inflammatory flares, and usually disappears when a remission occurs. Structural damage is characterized by pain that occurs with activity but is relieved by rest, deformity, and joint space narrowing on radiographs in addition to periarticular cysts and diffuse subchondral osteopenia (Fig. 99.2).

Rheumatoid arthritis has a predilection for the large joints (knees, hips), the small joints of the hands (metacarpophalangeal joints and proximal interphalangeal joints, but not distal interphalangeal joints), and the carpal articulations. In the hands, deformities due to erosion of ligaments are common (swan-neck deformity, boutonniére deformity, hitchhiker's thumb). Shoulder involvement with rotation cuff tears and mechanical instability are common. In the feet, clawing of the toes and dorsal subluxations of the metaphalangeal joints are common. The subtalar joint is also frequently involved, and an everted foot is common. In the cervical spine, erosions of the transverse ligament of C-1 can result in subluxation of C-1 on C-2, and eventually superior migration of C2.

Rheumatoid arthritis is a systemic disease, and generalized malaise and fatigue are common. Significant involvement of other organ systems, however, is usually

limited to those patients with rheumatoid factor in the serum. Awareness of complicating conditions such as rheumatoid nodules and vasculitis, ocular manifestations, interstitial lung disease, pericarditis, neuropathies related to cervical spine instability, nerve entrapment, hyperchromic-microcytic anemia, and Felty's syndrome are important to be aware of, but discussion of these conditions is beyond the scope of this chapter. Further details can be found in larger rheumatoid texts (67).

The course of this disease varies considerably. About 10% of patients undergo spontaneous remission (69), and most long-term remissions occur within the first 2 years of the disease. Factors that are predictors for the more severe chronic form of the disease are the presence of rheumatoid factor, nodules, and the HLA-DR4 phenotype. Close to 90% of joints ultimately involved in a given patient are evident on clinical examination during the first year of the disease (65).

### *Treatment*

The general principles of nonoperative treatment previously outlined apply to rheumatoid arthritis. Soluble gold salts and methotrexate often give some relief in rheumatoid diseases but not in other arthritic processes (41). Corticosteroids have an important place in the treatment of rheumatoid arthritis. They are often helpful in low doses given over a long period, a regimen that avoids most of the systemic side effects seen with high doses. Biologics, such as tumor necrosis factor and receptor, will be more and more applicable for the treatment of rheumatoid arthritis. Prevent deformity by using splints on an alternating basis with range-of-motion exercises. Prescribe rest in the position of function during periods of acute inflammation and exacerbation of the disease. The position of function for the upper extremity is with the elbow at 90°, the forearm across the abdomen, with the wrist slightly dorsiflexed and the finger joints slightly palmarflexed. The position of function for the lower extremity is with the hip and knee fully extended, and the ankle at 90° to the tibia.

Synovectomy to reduce inflammation and slow cartilage erosion, and capsulotomy to increase motion, are used in rheumatoid arthritis much more frequently than in other arthritic conditions (60). To be effective, perform synovectomy before significant articular cartilage damage has occurred. Synovectomy is usually performed in the shoulder before rupture of the rotator cuff, in the wrist preferably before and after rupture of the finger or thumb extensor tendons, and in the knee before loss of articular cartilage and attenuation of the knee ligaments. Capsulotomy is often used as an isolated procedure, particularly about the knee to correct surgically joint deformities that are resistant to bracing and other forms of physical therapy. Capsulotomies are also used with arthroplasties.

Surgical treatment and reconstruction of the rheumatoid hand is complex, demanding, and often required (see Chapter 70). The shoulder, elbow, hip, and knee are the most common joints undergoing total joint arthroplasty, whereas fusion is most useful in the wrist and ankle. See Chapter 101 (shoulder), Chapter 102 (elbow), Chapter 70 , Chapter 71 and Chapter 72 (hand and wrist), Chapter 105 (hip), Chapter 107 and Chapter 108 (knee), and Chapter 117 (foot). Distal ankle arthroplasty is becoming more accepted due to new prostheses.

In rheumatoid arthritis, C1–C2 subluxations can result from attenuation and rupture of the transverse odontoid ligament (71). The condition varies in symptoms and severity. The patient may be asymptomatic and show only mild tenderness at the upper cervical spine on physical examination, or he or she may have headaches and neck pain. A cervical collar may give temporary symptomatic relief. Rarely, there are patients with long-tract neurologic signs in whom spine fusion may be indicated (see Chapter 154).

## JUVENILE RHEUMATOID ARTHRITIS

The three major subgroups of juvenile rheumatoid arthritis are defined by their extent at presentation: Still's disease (systemic onset), polyarticular onset, and pauciarticular onset (67). All are characterized by chronic synovial inflammation, but the disease must be present for more than 6 months before subclassification is possible.

### *Epidemiology and Clinical Presentation*

It is estimated that juvenile rheumatoid arthritis affects 65,000 tp 70,000 children in the United States. Juvenile rheumatoid arthritis exhibits many of the radiographic features of adult rheumatoid arthritis, including periarticular osteoporosis, articular erosions, and joint deformities. Additional features that are almost pathognomonic for this condition include a periosteal reaction and joint ankylosis, particularly affecting the apophyseal joints of the cervical spine. Growth retardation due to involvement of the epiphysis is a major problem in children with rheumatoid arthritis and is readily apparent on radiographs.

### *Systemic Onset*

About 10% of patients have a systemic onset. Boys and girls are equally involved, and the onset may be at any age. Spiking temperatures associated with an evanescent, salmon pink rash may occur at any time during the day but most often during the late afternoon. Diffuse lymphadenopathy, hepatosplenomegaly, pericardial effusions, and pleural effusions are common. Systemic attacks are usually self-limited and rarely life threatening, and may recur after months to years, unexpectedly. About 50% of patients develop severe, chronic arthritis, which continues after systemic manifestations have subsided (19).

### *Polyarticular Onset*

Arthritis in five or more joints occurs in approximately 40% of children with juvenile rheumatoid arthritis. Malaise and weight loss are common. Polyarticular involvement may occur at any time and has a 3:1 predilection for girls. Three fourths of the patients have systemic involvement.

### *Pauciarticular Onset*

This subtype occurs in about 50% of children with juvenile rheumatoid arthritis. This group has arthritis affecting four or fewer joints within the first 6 months of their disease, and about 50% only have one joint involved, usually the knee. Although synovitis may be chronic, the prognosis for joint function is often good. Iridocyliditis develops in 10% to 50% of children with pauciarticular juvenile rheumatoid arthritis. An ophthalmology consult is important.

### *Diagnosis*

Rheumatic fever may be difficult to differentiate from juvenile rheumatoid arthritis in younger patients. The presence of a streptococcal infection and positive serologic tests for Streptococcus help in making the differential diagnosis. Rheumatic fever usually is self-limited and has a relatively short course compared with juvenile rheumatoid arthritis. Differentiating rheumatoid arthritis from osteoarthritis is rarely a problem, because osteoarthritis occurs in the older age group and the presence of Heberden's node is often helpful in making the diagnosis. The sedimentation rate is rarely elevated in osteoarthritis. With septic arthritis, there is usually a single joint involved, and high fever, leukocytosis, and positive cultures are evident. Systemic lupus erythematosus may present a difficult diagnostic problem, but the positive ANA test and lupus erythematosus prep test are characteristic of systemic lupus erythematosus and are not noted in the juvenile form. In juvenile rheumatoid arthritis, the test for rheumatoid factor is usually negative.

### *Laboratory and X-ray Findings*

Rheumatoid factors are detected in only 15% to 20% of patients. ANAs are detected in 40% to 60%. Children who are consistently rheumatoid factor positive have more erosions, nodules, and vasculitis. Destructive arthritis occurs in about 50% of those with rheumatoid factor positive disease as compared with 10% in rheumatoid factor–negative disease. Radiographs show osteopenia about the affected joints. There is diffuse narrowing of the joint surfaces, and subluxation or dislocation may be evident.

### *Treatment*

The immediate goal for juvenile rheumatoid arthritis is relief of symptoms, maintenance of joint range of motion, and muscle strength. Although juvenile rheumatoid arthritis is often chronic, the prognosis for most children is good. At least 75% enter long remissions and have no residual deformity (22).

Aspirin is acceptable for treatment but causes Reye's syndrome (persistent vomiting and mental alterations), although this usually occurs more commonly when treating a child for fever accompanying viral infections. Ibuprofen, tolmetin, naproxen, and fenoprofen are frequently used as alternative treatments. Gold and hydroxychloroquine are occasionally used as slow-acting therapy in resistant cases, but steroids are discouraged. An ophthalmology consult for the treatment of iridocyclitis is important.

Synovectomy usually does not benefit juvenile rheumatoid arthritis. Total joint replacement may greatly improve joint function in longstanding diseases but must await

full bone growth.

## OSTEONECROSIS (AVASCULAR NECROSIS)

Osteonecrosis is death of bone cells (3,8,37,40,68,72), and a variety of treatments are necessary depending on the stage of the disease (3,5,8,37,40,68,72,82). It has been associated with a variety of clinical conditions, such as Gaucher's disease, steroid therapy, alcoholism, decompression sickness (Caisson's disease), hip dislocation, and fractured femoral neck, but the exact etiologic mechanism is unknown. There is also a certain group in which there is no predisposing factor; it is truly idiopathic. The femoral head is the most common site, but it may occur in the epiphysis of any long bone. Other terms are avascular necrosis and aseptic necrosis. The conditions and treatments are discussed in detail in Chapter 125.

## GOUT

Gout is a metabolic disorder in which deposition of crystals of monosodium urate results in one or more clinical presentations including:

- Gouty arthritis, which is characterized by recurrent attacks of acute severe or chronic articular and periarticular inflammation
- Accumulation of gouty tophi in the articular, osseous, and soft tissues
- Gouty nephropathy, which can lead to renal impairment
- Uric acid stones in the urinary tract

Hyperuricemia is the common denominator leading to these clinical syndromes, but hyperuricemia may occur in the absence of gout.

### *Epidemiology*

Gout occurs most frequently in adult men, with a peak incidence in the fifth decade. It is the most common inflammatory arthritis in men over the age of 30 years. It rarely occurs in men before adolescence or in women before menopause. Hyperuricemia occurs in approximately 13% of hospitalized adult men (67), but fewer than one in five will develop clinically evident urate crystal deposits.

### *Pathogenesis*

The catabolism of purines produces uric acid, and the lack of the enzyme uricase, which makes uric acid soluble in body fluids, can lead to the crystalline deposition of uric acid. There are many environmental and genetic influences on uric acid formation, transport and disposal, including: body weight, diet, lifestyle, social class, and hemoglobin level. The familial occurrence of gout is well known. Hyperuricemia occurs in 25% of first-degree relatives of patients with gout.

Urate crystalizes as a monosodium salt in oversaturated joint tissues. The decreased solubility of sodium urate at lower temperatures explains the predilection of the toes and ears for deposition. The histopathology of tophi shows a chronic foreign body granuloma surrounding monosodium urate crystals. The inflammatory reaction consists primarily of mononuclear cells and giant cells.

### *Clinical Findings*

The evolution of gout can result in presentation as asymptomatic hyperuricemia, acute gouty arthritis, and chronic tophaceous gout. Acute arthritis is the most common early clinical presentation. The metatarsal phalangeal joint of the great toe is involved most often and is affected at some time in three quarters of patients. Other common joints involved include the ankle, tarsal joints, and knee. Gout usually begins with abrupt onset in a single joint, often at night so that the patient awakens with severe unexplained joint pain and swelling. Attacks tend to dissipate spontaneously in 3 to 10 days without treatment, resulting in desquamation of the skin over the affected joint. Subsequent episodes may occur more frequently, involve other joints and persist longer.

Chronic tophaceous gout affects the helix of the ear and the periarticular tissues of the hands and feet. Secondary degenerative arthritis can develop as a result of erosion of the cartilage and subchondral bone. Tendons and the carpal tunnel may be involved.

### *Radiologic Findings*

During the initial attack, radiographs may only show soft-tissue swelling surrounding the affected joint. Later, irregular, asymmetric soft tissue swelling and calcification of tophi can occur. Bony erosions tend to be round or oval in shape with a sclerotic margin and interarticular or periarticular erosions showing a thin overhanging edge of displaced bone at the margins of the articular cartilage.

### *Laboratory Findings*

The diagnosis is best made on joint fluid analysis, in which rod- or needle-shaped crystals 3 to 20 µ in size are seen. Under a polarizing microscope, these show birefringence and bright yellow crystals parallel to the axis of slow vibration. Synovial fluid leukocyte counts can vary from 20,000 to 100,000. Serum uric acid levels may or may not be elevated.

### *Treatment*

Historically, colchicine has been the drug of choice but its use remains controversial due to its side effects. Up to 80% of patients can be expected to experience significant relief of pain within 48 hours when treated with oral colchicine. Gastrointestinal toxicity consisting of nausea, vomiting, diarrhea, and cramping abdominal pain can occur in up to 80% of patients and can be severe, leading to dehydration and electrolyte imbalance. Intravenous colchicine avoids the gastrointestinal symptoms and can result in response within 30 minutes, however, improper use of colchicine has led to serious toxicity and death.

For oral administration give 0.5 mg tablets hourly until one of three events occurs: (1) There is significant improvement of pain and inflammation, (2) Gastrointestinal toxicity occurs, or (3) a total dose of 8 mg has been received, assuming the patient has normal renal and liver function.

For intravenous therapy, a single intravenous dose should not exceed 3 mg and the total cumulative dose for a given attack should not exceed 4 mg in a total 24-hour period. Do not administer oral colchicine for at least 7 days after a full intravenous dose. Reduce the dose in older patients and those with renal or hepatic disease. Intravenous colchicine is contraindicated in combined renal and hepatic disease, when the glomerular filtration rate is less than 10 mm per minute or there is extra hepatic biliary obstruction.

NSAIDs started at their recommended maximal dose at the first sign of an attack may be successful and are less toxic than colchicine, but they are not without their gastrointestinal side effects as well. Many physicians prefer indomethacin for acute gout. Oral corticosteroids and adrenocorticotrophic hormone can be effective when colchicine and NSAIDs are contraindicated. Administer 20 to 40 mg doses of prednisone or its equivalent daily for 3 to 4 days and then gradually taper over 1 to 2 weeks.

Prophylactic treatment of interstitial gout is not indicated until an established pattern of frequency occurs. One 0.5 mg colchicine tablet twice daily effectively lowers the frequency of attacks. Efforts to reduce hyperuricemia are indicated in some patients. Limit foods with high purine content. Uricosuric drugs such as probenecid can be given at a dose from 0.5 g per day up to 1 g twice daily, until a targeted urate level is reached. Common side effects are rash and gastrointestinal upset. Xanthine oxidase inhibitors such as allopurinol are useful in patients in whom there is urate overproduction, nephrolithiasis, or other contraindications to uricosuric therapy.

Surgical treatment is usually not required except for the excision of tophi that are interfering with function, threaten to rupture tendons or erode through the skin, or which have eroded through skin and become infected. Because of infiltration of the tophaceous material throughout the connective tissues, excision can be difficult. Care must be taken to maintain the function of affected structures.

## PSEUDOGOUT

Specific identification of calcium pyrophosphate crystals in synovial fluid and on cartilage characterize the condition called pseudogout. Pathologic surveys indicate that 4% of the adult population have articular pseudogout at the time of death and that the incidence increases with age. The incidence of clinically symptomatic disease is

about one half that of classic gout. The male to female ration is about 1.4:1.

### *Etiology*

The arthritides of pseudogout can be hereditary, sporadic (idiopathic), or associated with trauma. The hereditary form is an autosomal dominant variety.

### *Clinical Features and Diagnosis*

Joint inflammation and joint degeneration may coexist. Frequently inflammation will occur early and later manifest as degeneration. The knee is the most frequent joint presenting with an acute attack. Trauma may preclude the attack as well as surgery, similar to gout. About 50% of patients will have progressive degeneration of multiple joints, with the knees most frequently involved, followed by the wrists, metacarpophalangeal joints, hips, shoulders, and elbows. However, most joints with radiologically evident CPPD calcification are not symptomatic.

The radiologic appearance of punctate and linear densities in articular hyaline or fibrocartilaginous surfaces is helpful and is called “chondrocalcinosis.” In the early phases, there is no joint space narrowing or degeneration. The inflammatory response appears to be related to a dose related response to crystals being shed from the joint surface. The joint aspirate will show rod-shaped crystals, frequently in leukocytes, and they will test out with positive birefringence.

### *Treatment*

Unlike gout, calcium phosphate crystals cannot be removed from joints. Acute attacks can be treated by aspiration of the joint and injection of steroids. Whether or not crystalline removal over time would prevent chronic degenerative joint disease is not known at this time.

## ANKYLOSING SPONDYLITIS

Ankylosing spondylitis (i.e., Marie-Strümpell disease) is an arthritic condition characterized by primary involvement of the sacroiliac joints and spine, leading to a full-blown bony ankylosis of the entire spine at the end stage of the disease. In approximately 25% of patients, there is involvement of the proximal joints of the limbs. It is predominantly a disease of young men, and the cause is unknown.

### *Etiology and Diagnosis*

Because there is a high incidence of the HLA-B27 antigen (about 95%) in patients with the disease, there may be a genetic predisposition. Making the correct diagnosis is often difficult in the early stages of the disease, but it is rarely difficult in the end stage. In the early stages, it may present as a lower lumbar disc degenerative condition, and there is usually sacroiliac joint involvement. Another diagnostic feature during early disease is a decreased chest expansion (<3.8 cm). In end-stage disease, the sacroiliac joints are fused, and the radiographic appearance of the spine is that of a complete fusion with a bamboo spine appearance. The patient often walks in a stooped position and has essentially no motion in the spine. Rheumatoid factor and serologic tests for other types of arthritis are usually negative.

Patients may exhibit extra-articular features, including iritis, cardiac conduction defects, aortic incompetence, spinal cord compression, and amyloidosis. The radiographic hallmarks of ankylosing spondylitis include squaring of the vertebral bodies and the development of delicate syndesmophytes.

### *Treatment*

Institute physical therapy, including hydrotherapy, and advise patient to sleep flat (without the use of pillows) to help prevent seriously flexed fusions of the neck. Pharmacologic treatment is essentially nonspecific, using anti-inflammatory drugs such as salicylates and NSAIDs. The orthopaedic surgical procedures involve spinal osteotomy in the cervical region and the lumbar region to correct severe flexion deformities of the spine (Fig. 99.5). These operations are major surgical procedures with considerable risk, and should not be undertaken lightly (see Chapter 153). Hip arthroplasty often is necessary if there is severe hip disease (see Chapter 105). The possibility of spinal fracture should be excluded in any patient with advanced ankylosing spondylitis who complains of neck or back pain after even mild trauma. Computed tomography is helpful in making the diagnosis.

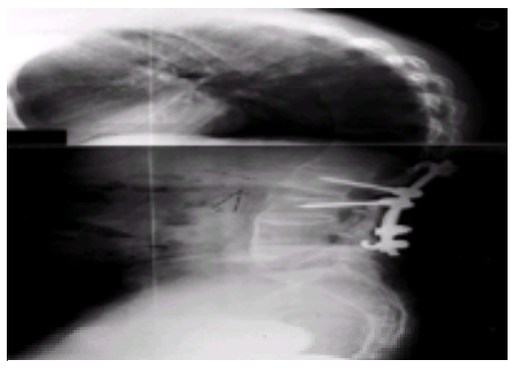

***Figure 99.5.*** A lateral roentgenogram of the spine after spinal osteotomy in a patient with ankylosing spondylitis. The vertebrae are squared off, and the spine is completely fused (Complements of Munish Gupta, M.D.).

## POSTTRAUMATIC ARTHRITIS

Many types of injury can lead to disabling arthritis because of involvement of the joint surfaces (48). Fractures involving the joint surfaces that do not heal in an anatomic position can produce arthritis. If ligamentous injuries do not heal in a satisfactory manner, a chronically unstable joint results, and the joint frequently develops degenerative arthritis as a result of chronic subluxation. In addition, many heritable disorders and developmental disorders can lead to mechanical malalignment and eventual arthritis (multiple epiphyseal dysplasia, slipped capital femoral epiphysis, congenital dislocation of the hips, neuropathic arthropathy, hemophiliac arthropathy, acromegalic arthropathy, and Paget's disease of bone) (68). The histologic changes are similar to those described for degenerative arthritis. These conditions can be relatively mild, and conservative measures, such as decreased activity and decreased mechanical stress, are satisfactory. The symptoms also frequently occur in the thirties and forties after an injury in the twenties, but the disability may not be severe at any age.

### *Treatment*

Isometric exercises are beneficial for posttraumatic arthritis, and considerable improvement can be gained. Anti-inflammatory medication is also important and should be used for short periods when the joint is relatively symptomatic.

Arthroscopic debridement alone is often beneficial in obtaining significant relief for a short period of time (6 months to 1 year). It is recommended as a temporizing procedure until more definitive procedures are required. Debridement may also be considered in the older patient who is medically unable to undergo a total joint replacement, but in whom short term improvement is desired.

The current mainstay of the arthroscopic procedures is debridement and drilling or microfracture through the subchondral bone of chondral defects. It is the procedure of choice after failed shaving or abrasion chondroplasty. Many patients gain long-term improvement and do not require osteotomy, open biologic resurfacing, or total joint replacement. The commitment is a major one, however, because the postoperative regimen requires 2 to 3 months of partial weight bearing and continuous passive motion (CPM) for 6 to 8 hours per day. After the initial rehabilitation, it is best if the patient gives up running, cutting, and jumping sports and concentrates on an isometric anaerobic exercise with bicycling or swimming for aerobic exercise. The surgery is relatively atraumatic compared with the demanding postoperative regimen, but only with such a rehabilitation program can a long-term durable repair be expected.

If a microfracture and drilling procedure fails, other considerations are a perichondral or periosteal autograft (15,30,31,32,35,38,43,59,73,74,81), mosaicplasty (shell

allografts) (23,24 and 25), or osteotomy (3,9,10,18,27,28,33,34,51,57,59,64,77,79.) A modification of the periosteal graft has been described, in which autologous cultured chondrocytes are injected under the periosteum (6). Normal joint cartilage is necessary on the other side of the joint if osteotomy is considered. If the lesion is small or involves a small joint in the hand, a perichondral autograft or periosteal autograft may be appropriate. Osteoarticular shell autograft plugs are also reasonable for small lesions, although their efficiency is not well proven. This is best in locations where there is little joint space narrowing or mechanical collapse. The subchondral bone must be intact; otherwise, an osteoarticular allograft should be considered.

If there is little joint space narrowing and no asymmetric mechanical collapse of the joint, an osteochondral allograft is a good consideration (17,52,53) This is particularly useful if multiple defects must be grafted in a joint, requiring a fairly large graft surface. In addition, when the subchondral bone is disrupted (for example, after a tibial plateau fracture), an allograft is quite useful. When multiple defects occur in a joint that is malaligned, then an osteotomy should be performed in combination with the allograft procedure (see Chapter 9).

Osteotomies are indicated primarily in the hip and the knee, and occasionally in the ankle to shift weight-bearing forces from arthritic areas of the joint to more normal areas. If there is significant subchondral bone loss in the joint then a shell allograft should be performed together with the osteotomy, or a prosthetic arthroplasty performed.

Some young patients do not desire multiple biologic resurfacing procedures for their chondral defects, but their symptoms are severe. It is not advisable to do a total joint replacement in young patients, however, a total joint replacement is a predictable means of providing a joint with minimal pain and adequate stability. Therefore, it is one reasonable alternative for a patient to choose, as long as he or she understands that the joint replacement will most likely wear out or become loose in 10 to 15 years. The patient should also understand that the scenario of multiple joint revisions involves increased risks of surgery and that the longevity of the subsequent joint revision will decrease. The patient should be advised that a joint replacement is not an end to the multiple biologic resurfacing procedures that he or she has been considering, but rather it is an opportunity to have a decent joint for 10 to 15 years before having a revision or salvage procedure. The patient is “buying” a good joint for his or her younger years but accepting the disability of a fusion or resection arthroplasty during the older years. A second alternative—and usually the one advised by the surgeon—is to use a cane and live with the disability during the young and middle years, and put off having a total joint replacement until the patient is retired. A third alternative is to have a fusion or resection arthroplasty after the failure of one or two biologic resurfacing procedures.

## CHAPTER REFERENCES

Each reference is categorized according to the following scheme: *, classic article; #, review article; !, basic research article; and +, clinical results/outcome study.


+ 1. Adams M. An Analysis of Clinical Studies of the Use of Cross-linked Hyaluronan, Hylan, in the Treatment of Osteoarthritis. *J Rheumatol* 1993;39(Suppl):16.

+ 2. Adams M, Atkinson M, Lussier A, et al. The Role of Viscosupplementation with Hylan G-F 20 (Synvisc) in the Treatment of Osteoarthritis of the Knee: A Canadian Multicenter Trial Comparing Hylan G-F 20 Alone, hylan G-F 20 with Non-steroidal Anti-inflammatory Drugs (NSAIDs) and NSAIDs Alone. *Osteoarthritis Cartilage* 1995;3:213.

+ 3. Aglietti P, Rinonapoli E, Sringa G, et al. Tibial Osteotomy for the Varus Osteoarthritis Knee. *Clin Orthop* 1983;176:239.

+ 4. Arthritis Foundation Committee on Evaluation of Synovectomy. Multicenter Evaluation of Synovectomy in the Treatment of Rheumatoid Arthritis. Report of Results at the End of Three Years. *Arthritis Rheum* 1977;20:765.

+ 5. Artlet J, Ficat P. Diagnostic Delisteonecrose Femorocapitale Primitive as Stade I (Stadepreradiologic). *Rev Chir Orthop* 1968;54:637.

+ 6. Brittberg M, Lindhal A, Nilsson A, et al. Treatment of Deep Cartilage Defects of the Knee with Autologus Chondrocyte Transplantation. *N Engl J Med* 1994;331:889.

! 7. Brocklehurst R, Bayliss MT, Maroudas A, et al. The Composition of Normal and Osteoarthritic Articular Cartilage from Human Knee Joints. *J Bone Joint Surg* 1984;66-A:95.

+ 8. Camp JF, Colwell CW. Core Decompression of the Femoral Head for Osteonecrosis. *J Bone Joint Surg* 1986;68A:1313.

+ 9. Coventry MB. Proximal Tibial Varus Osteotomy for Osteoarthritis of the Lateral Compartment of the Knee. *J Bone Joint Surg [Am]* 1987;69:32.

+ 10. Coventry MB, Bowman PW. Long-term Results of Upper Tibial Osteotomy for Degenerative Arthritis of the Knee. *Acta Orthop Belg* 1982;48:139.

! 11. Daniel D, Alceson W, Amiel D, et al. Lavage of Septic Joints in Rabbits: Effects of Chondrolysis. *J Bone Joint Surg* 1976;58-A:393.!

+ 12. Doherty M, Watt I, Dieppe P. Influence of Primary Generalized Osteoarthritis on the Development of Secondary Osteoarthritis. *Lancet* 1983;11:8.

+ 13. Dougados M, Nguyen M, Listrat V, Amor B. High Molecular Weight Sodium Hyaluronate (Hyalectin) in Osteoarthritis of the Knee: A 1 Year Placebo-controlled Trial. *Osteoarthritis Cartilage* 1993;1:97.

+ 14. Drovanti A, Bignamini AA, Rovati AL. Therapeutic Activity of Oral Glucosamine Sulfate in Osteoarthrosis: A Placebo Controlled, Double-blind Investigation. *Clin Ther* 1980;3:260.

+ 15. Engkvist O, Johansson SH. Perichondral Arthroplasty: A Clinical Study in 26 Patients. Scand *J Plast Reconstr Surg* 1980;14:71.

+ 16. Erlich GE. Inflammatory Osteoarthritis. 1. The Clinical Syndrome. *J Chron Dis* 1972;25:317.

+ 17. Flynn JM, Springfield DS, Mankin HJ. Osteoarticular Allografts to Treat Distal Femoral Osteonecrosis. *Clin Orthop* 1994;303:38.

+ 18. Fujisawa Y, Masuhara K, Shiomi S. The Effect of High Tibial Osteotomy on Osteoarthritis of the Knee: An Arthroscopic Study of 54 Knee Joints. *Orthop Clin North Am* 1979;10:585.

+ 19. Gedalia A, Person DA, Brewer EJ, et al. Hypermobility of the Joints in Juvenile Episodic Arthritis/arthoanalgia. *J Pediatr* 1985;107:873.

+ 20. Gray RC, Gottlieb NL. Intra-articular Corticosteroids: An Updated Assessment. *Clin Orthop* 1983;177:235.

+ 21. Griffing L. *Nonoperative Treatment of Osteoarthritis of the Knee: Glucosamine/chondroitin Sulfate, Hyaluronic Viscosupplementation, Cortisone Injections.* Proceedings of the Knee Society, Interim Meeting, Scottsdale, 1998.

+ 22. Hanson V, Kornreich H, Bernstein et al. Prognosis of Juvenile Rheumatoid Arthritis. *Arthritis Rheum* 1977;20(Suppl):279.

+ 23. Hangody L, Kirsh G, Karpati Z, et al. Arthroscopic Autogenous Osteochondral Mosaicplasty for the Treatment of Femoral Condylar Articular Defects: A Preliminary Report. *Knee Surg Sports Traumatol Arthrosc* 1997;5:262.

+ 24. Hangody L, Kirsh G, Karpati Z, et al. Mosaicplasty for the Treatment of Cartilage Defects: Application in Clinical Practice. *Orthopaedics* 1998;21:751.

+ 25. Hangody L, Szigeti I, Karpati Z, et al. New Method for the Treatment of Serious Localized Cartilage Damage in the Knee Joint. *Osteo Int* 1996;3:1.

# 26. Harris ED, Jr. Mechanisms of Disease: Rheumatoid Arthritis Pathophysiology and Implications for Therapy. N Engl J Med 1990;322:1277.

+ 27. Hirsch C, Goldie I, Ryba W. Intertrochanteric Osteotomy for Osteoarthritis of the Hip: A Radiological Evaluation. Clin Orthop 1972;86:63.

+ 28. Holden DL, James SL, Larson RL, et al. Proximal Tibial Osteotomy in Patients Who are 50 Years Old or Less: A Long Term Followup Study. *J Bone Joint Surg Am* 1988;70:977.

# 29. Hollander JL, ed. *Arthritis.* Philadelphia: Lea & Febiger, 1972.

+ 30. Homminga GN, Bulstra SK, Bouwmeester PS, et al. Perichondral Grafting for Cartilage Lesions of the Knee. *J Bone Joint Surg [Br]* 1990;72:1003.

+ 31. Homminga GN, Van der Lindent TJ, Terwindt-Rouwenforst EAW, et al. Repair of the Articular Defects by Perichondral Grafts: Experiments in the Rabbit. *Acta Orthop Scand* 1989;60:326.

# 32. Hvid I, Anderson LI. Perichondral Autograft in Chondromalacia Patellae: Report on a Case. *Acta Orthop Scand* 1981;52:91.

+ 33. Insall J, Falvo KA, Wise DW. Chondromalacia Patellae: A Prospective Study. *J Bone Joint Surg [Am]* 1976;58:1.

+ 34. Insall JN, Joseph DM, Msika C. High Tibial Osteotomy for Varus Gonarthrosis. *J Bone Joint Surg [Am]* 1984;66:1040.

+ 35. Jacoma HJ, Ritsila VA. Reconstruction of Patellar Cartilage Defects with Free Periosteal Grafts: An Experimental Study. *Scand J Plast Reconstr Surg* 1987;21:175.

# 36. Jaffe HL. *Metabolic, Degenerative and Inflammatory Disease of Bones and Joints.* Philadelphia: Lea & Febiger, 1972.

+ 37. Jergensen HE, Heller M, Genant HK. Magnetic Resonance Imaging in Osteonecrosis of the Femoral Head. *Orthop Clin North Am* 1985;16:705.

+ 38. Johansson SH, Engkvist O. Small Joint Reconstruction by Perichondral Arthroplasty. *Clin Plast Surg* 1981;8:107.

+ 39. Jones A, Pattrick M, Doherty S, Doherty M. Intra-articular Hyaluronic Acid Compared to Intra-articular Triamcinolone Hexacetonide in Inflammatory Knee Osteoarthritis. *Osteoarthritis Cartilage* 1995;3:269.

# 40. Jones JP, ed. Symposium. Osteonecrosis. *Clin Orthop* 1978;130:2.

+ 41. Kaye RL, Pemberton RE. Treatment of Rheumatoid Arthritis. A Review Including Newer and Experimental Anti-inflammatory Agents. *Arch Intern Med* 1976;136:1023.

+ 42. Kellegren JH, Lawrence JS, Bier F. Genetic Factors in Generalized Osteoarthrosis. *Ann Rheum Dis* 1963;22:237.

+ 43. Korkola DL. Periosteal Primary Resurfacing of Joint Surface Defects of the Patella due to Injury. *Injury* 1988;19:216.

+ 44. Langman MJ, Jensen DM, Watson DJ, et al. Adverse Upper Gastrointestinal Effects of Rofecoxib Compared with NSAIDs. *JAMA* 1999;282:1929.

+ 45. Listrat V, Ayral X, Patarnello F, et al. Arthroscopic Evaluation of Potential Structure Modifying Activity of Hyaluronan (Hyalgan) in Osteoarthritis of the Knee. *Osteoarthritis Cartilage* 1997;5:153.

+ 46. Lohmander LS, Dalen N, Englund G, et al. Intra-articular Hyaluronan Injections in the Treatment of Osteoarthritis on the Knee: A Randomized, Double-blind, Placebo Controlled Multicenter Trial. Hyluronan Multicentre Trial Group. *Ann Rheum Dis* 1996;55:424.

+ 47. Lopes Vaz AC. Double-blind Clinical Evaluation of the Relative Efficacy of Ibuprofen and Glucosamine Sulfate in the Management of Osteoarthrosis of the Knee in outpatients. *Curr Med Res Opin* 1982;8:145.

! 48. Mankin HJ. The Response of Articular Cartilage to Mechanical Injury. *J Bone Joint Surg* 1982;64A:460.

! 49. Mankin HJ, Dorfman H, Lipiello L. Biochemical and Metabolic Abnormalities in Articular Cartilage from Osteoarthritic Human Hips II: Correlation of Morphology with Biomechanical and Metabolic Data. *J Bone Joint Surg* 1971;53A:523.

! 50. Mankin HJ, Lipiello L. Biochemical and Metabolic Abnormalities in Articular Cartilage from Osteoarthritic Human Hips. *J Bone Joint Surg* 1970;52-A:424.

+ 51. Matthews LS, Goldstein SA, Malvitz TA, et al. Proximal Tibial Osteotomy: Factors that Influence the Duration of Satisfactory Function. *Clin Orthop* 1988;229:193.

+ 52. McDermott AG, Langer F, Pritzker KP, et al. Fresh, Small Fragment Osteochondral Allografts: Long-term Followup Study of First 100 Cases. *Clin Orthop* 1985;197:96.

+ 53. Meyers MH, Jones RE, Bucholz RW, et al. Resurfacing of the Knee with Fresh Osteochondral Allografts. *J Bone Joint Surg [Am]* 1989;71:704.

# 54. Mitchell DM. Epidemiology; Rheumatoid Arthritis Etiology, Diagnosis, and Treatment. In: Utsinger PD, Zvaifler NJ, Erlich GE. Philadelphia: JB Lippincott Co., 1985:133.

+ 55. Morreale P, Manopulo R, Galati M, et al. Comparison of the Antiinflammatory Efficacy of Chondroitin Sulfate and Diclofenac Sodium in Patients with Knee Osteoarthritis. *J Rheumatol* 1996;23:1385.

+ 56. Müller-Fabender H, Bach G, Haase W, et al. Glucosamine Sulfate Compared to Ibuprofen in Osteoarthritis of the Knee. *Osteoarthritis Cartilage* 1994;2:61.

+ 57. O'Donaghue DH. Treatment of Chondral Damage to the Patella. *Am J Sports Med* 1981;9:1.

+ 58. Osborne GV, Fahrini WH. Oblique Displacement Osteotomy for Osteoarthritis of the Hip Joint. *J Bone Joint Surg [Br]* 1950;32:148.

+ 59. Pastacaldi P, Engkvist O. Perichondral Wrist Arthroplasty in Rheumatoid Patients. *Hand* 1979;11:184.

# 60. Poss R, Sledge CB. Rheumatoid Disease. *Clin Orthop* 1984;182:2.

+ 61. Pujalte J, Llavore E, Ylescupidez F. Double-blind Clinical Evaluation of Oral Glucosamine Sulfate in the Basic Treatment of Osteoarthrosis. *Curr Med Res Opin* 1980;7:110.

! 62. Reddi AH. Role of Subchondral Bone Matrix Factors in the Repair of Articular Cartilage. In: Verbruggen G, Veys EM, eds. *Degenerative Joints.* Amsterdam: Excerpta Medica, 1985:271.

! 63. Reddi AH. Platelett-derived Growth Factor Enhances Demineralized Bone matrix—induced Cartilage and Bone Function. *Calcif Tissue Int* 1988;42:34.

+ 64. Robbins RHC, McMurray PJ. Osteotomy with a Note on the “Regeneration” of Articular Cartilage. *J Bone Joint Surg [Br]* 1960;42:480.

+ 65. Roberts WH, Daltroy LH, Anderson RJ. Stability of Normal Joint Findings in Persistent Clinical Rheumatoid Arthritis. *Arthritis Rheum* 1988;31:267.

! 66. Salter RB, Hamilton HW, Wedge JH, et al. Clinical Application of Basic Research on Continuous Passive Motion for Disorders and Injuries of Synovial Joints. A Preliminary Report of a Feasibility Study. *J Orthop Res* 1984;1:3.

# 67. Schumacher HR Jr, Klippel JH, Koopman WJ, eds. *Primer on the Rheumatic Diseases,* 10th ed. Atlanta: Arthritis Foundation, 1993.

+ 68. Scott RD, Urse JS, Schmidt R, Bierbaum BE. Use of TARA Hemiarthroplasty in Advanced Osteonecrosis. *J Arthroplasty* 1987;2:225.

# 69. Short CC, Bauer W, Reynolds WE. *Rheumatoid Arthritis.* Boston: Harvard University Press, 1957.

+ 70. Simon LS, Weaver AL, Graham DY, et al. Anti-inflammatory and Upper Gastrointestinal Effects of Celecoxib in Rheumatoid Arthritis: A Randomized Controlled Trial. *JAMA* 1999;282:1921.

+ 71. Smith PH. Natural History of Rheumatoid Cervical Luxations. *Ann Rheum Dis* 1972;31:341.

+ 72. Stulberg BH, Bauer TW, Belhobek GH. Making Core Decompression Work. *Clin Orthop* 1990;261:186.

+ 73. Sully L, Jackson IT, Sommerland BC. Perichondral Grafting in Rheumatoid Metacarpophalangeal Joints. *Hand* 1980;12:137.

+ 74. Tajima S, Aoyagi F, Maruyama Y. Free Perichondral Grafting in the Treatment of Temporomandibular Joint Ankylosis: Preliminary Report. *Plast Recontr Surg* 1978;61:876.

! 75. Thompson RC, Oegema TR. Metabolic Activity of Articular Cartilage in Osteoarthritis. An In Vitro Study. *J Bone Joint Surg* 1979;61-A:407.

+ 76. Tjornstrand BAE, Eqund N, Hagstedt BV. High Tibial Osteotomy: A Seven-year Clinical and Radiographic Follow-up. *Clin Orthop* 1981;160:124.

+ 77. Vainioppää S, Läike E, Erkki P, et al. Tibial Osteotomy for Arthritis of the Knee: A 5 to 10 Year Followup Study. *J Bone Joint Surg [Am]* 1981;63:938.

! 78. Voloshin A, Wosk J. Influence of Artificial Shock Absorbers on Human Gait. *Clin Orthop* 1981;160:52.

+ 79. Waugh W. Tibial Osteotomy in the Management of Osteoarthritis of the Knee. *Clin Orthop* 1986;210:55.

+ 80. Weissmann G. Lysosomes and Rheumatoid Joint Inflammation. *Arthritis Rheum* 1977;20:193.

+ 81. Wilbrand H, Engkvist O. Radiography in Joint Reconstruction with Perichondral Grafts. *Acta Radiol Diagn* 1979;20:967.

+ 82. Zizic TM, Marcoux L, Hungerford DS. The Early Diagnosis of Ischemic Necrosis of Bone. *Arthritis Rheum* 1986;29:1177.

# CHAPTER 100

# DESIGN AND PERFORMANCE OF JOINT REPLACEMENTS

*Peter S. Walker*

**P. S. Walker:** Director of Biomedical Engineering, Cooper Union Research Foundation, Albert Nerken School of Engineering, 51 Astor Place, New York, NY 10003.

Overview
Historical Development
Present Status
Future Directions
Applied Mechanics and Materials
Motion or Kinematics
Forces and Force Analysis
Pressures and Stresses
Material and Structural Properties
Hip Replacement
Hip Mechanics
Cemented Components
Uncemented Components
Special Hips—Custom and Conservative Designs
Evaluation Methods
Knee Replacement
Knee Mechanics
Condylar Replacements—Fixed Bearing
Stabilized or Guided-Motion Designs
Mobile Bearing Designs
Linked Designs
Patellofemoral Joint
Fixation
Wear and Deformation of Plastic
Testing and Simulators
Acknowledgments
Chapter References and Further Reading

## OVERVIEW

### HISTORICAL DEVELOPMENT

Among the earliest methods for treating arthritis (212) was interposition arthroplasty using soft and flexible materials, but the strength of these materials was inadequate. Rigid materials such as metal and glass in the form of condylar shapes attached to one of the joint surfaces provided some success, but there was still a problem with the apposing joint surface. In the knee, geometric inaccuracy leading to poor kinematics and abnormal soft-tissue tensions was also a problem. An interesting finding with condylar components, such as cup arthroplasty or MacIntosh tibial plateaus, was the formation of a fibrous membrane adjacent to the component, with a new bone plate beneath. This tissue modeling is now recognized to develop due to interface micromotion and to the stresses acting on the exposed trabecular ends. Even now, implants are designed with relatively smooth surfaces interfacing the bone; however, there is a higher incidence of pain, migration, and loosening with these implants compared with the more rigid methods of fixation. The success of more invasive components with uncemented intramedullary stems, such as hemiarthroplasties and knee hinges, depended largely on obtaining an acceptably low level of stem–bone micromotion and interface stresses on the bone (33).

Modern-day joint replacement began in the early 1960s, when Charnley introduced cemented metal-polyethylene components for the hip, and in the late 1960s, when this technology was transferred to the knee by Gunston (95). The principles proposed by Charnley were rigid fixation of the components to the bone, resurfacing of both joint surfaces, and the use of materials with low friction and wear. These principles, embodied in cemented metal-on-plastic components, have stood the test of time to this day (100,112).

### PRESENT STATUS

In the 1970s, there was a rapid expansion in the number of total joints used. A number of other hip designs were introduced that were fundamentally based on the Charnley design. An exception was the use of metal-on-metal in the McKee-Farrar design. There was a great deal of attention to surgical technique, especially obtaining good cement–bone apposition with high shear strength. Some total knees proved to be successful in the long term, but others fell by the wayside because of the lack of recognition of the kinematics, the role of the cruciates, the patellofemoral mechanics, and the requirements for adequate fixation. Most of the design forms used today, namely unicompartmentals, condylar replacements with or without cruciate retention, mobile bearing knees, stabilized condylars, and fixed and rotating hinges, were all introduced before the end of the decade. Ceramic-on-polyethylene and ceramic-on-ceramic replacements for the hip had been introduced before 1980.

The 1980s saw two substantial areas of development: more sophisticated instrumentation, especially for the knee, and uncemented components with porous coatings intended for indefinite fixation. In the knee, improved consistency of surgical technique was achieved as a result of more accurate alignment and soft-tissue balancing. Concerning porous coating, those designs in which rigid initial fixation was achieved obtained sufficient bone ingrowth for long-lasting results. Certain uncemented designs of hip stem, acetabular component, and femoral component of the knee have shown survivorship values (54) superior to those of cemented components. A hydroxyapatite (HA) coating (104,203) has similarly shown high durability from 5 to 10 years follow-up. The situation today is that a number of designs of hips, knees, and other joints have been shown to have a survivorship of greater than 90% at 10 years, such that the large majority of elderly patients can be treated confidently. Today's hip and knee systems offer a large variety of sizes and modular augments to deal with virtually every situation encountered in primary and revision surgery. The instrumentation systems are elaborate, usually well engineered, and often too complex, but they allow the surgeon to achieve accurate component placement and limb alignment.

### FUTURE DIRECTIONS

The main limitations of total hip and knee replacements are excessive wear of the ultra-high molecular weight polyethylene (UHMWPE) (126,236) and loosening. These two problems are related to some extent in that the accumulation of small particles causes a tissue response that, in turn, produces bone resorption. However, it is now evident that wear can be reduced in a number of ways. The main problem has been that gamma-irradiation of UHMWPE in air, followed by gradual oxidation either on the shelf or in the patient, has led to a degradation of mechanical properties and an increase in the wear rate (18,140,180).

Components that have been directly molded from UHMWPE have shown a reduced susceptibility to oxidation, which has resulted in reduced surface wear and a much lower incidence of the destructive delamination seen in total knee replacements (TKRs) (27). Gamma-irradiation and storage in an inert atmosphere, as well as enhanced cross-linking and stabilization to minimize subsequent oxidation, have resulted in reduced wear rates. For the hip joint, ceramic-on-UHMWPE can reduce wear by as much as 50%, whereas ceramic-on-ceramic and metal-on-metal produce minimal wear debris (65,82). If such improved bearings are combined with superior cement techniques or porous and bioactive coatings, much greater durability can be expected compared with that achieved in the past 2 decades.

In the knee, however, delamination due to high subsurface stresses is still a threat. Computer modeling of this process has now shown how appropriate surface geometry can substantially reduce the likelihood of delamination without compromising the freedom of motion (189). New advances will undoubtedly be made in the performance of TKR, especially for younger patients. The mobile bearing concept is one such approach for minimizing wear and improving function. However, further advances are likely in the form of guided motion knees providing optimal muscle lever arms and high flexion ranges. The superior functional performance of unicompartmental replacement performed on one or both sides of the joint opens up the possibilities of minimally invasive surgery (84), with the option of using

computer-assisted technologies. The boundary between biologic treatments and total joints will become an issue, and with both approaches improving and developing, the relative merits and applications will become an area for extensive research and evaluation (59,70,72,79,141,142,152,162,165,177).

## APPLIED MECHANICS AND MATERIALS

This section is not intended to be analytical but to provide a definition of engineering terminology and to convey the concepts of biomechanics and biomaterials relevant to joint replacement (159). The Standard International (SI) system of units (Table 100.1) is now in widespread use.

| Parameter | Units | Comments |
|---|---|---|
| Distance | Millimeter (mm); meter (m) | Centimeter (cm) can also be used |
| Mass | Kilogram (kg) | Average body weight (BW) is about 75 kg |
| Force | Newton (N) | 1 kilogram force (kgf) = 9.8 N |
| Pressure or Stress | Pascal (Pa) = $N/m^2$ megapascal (mPa) = $N/mm^2$ | The average contact pressure in a 22-mm diameter hip joint with 3 BW acting is about 6 mPa. Condylar total knees have pressures in the range 10 to 30 mPa. |
| Frequency | Hertz (Hz) = 1 cycle per second (cps) | |
| Velocity | Meter per second (m/s) | |
| Density | Kilogram per cubic meter ($kg/m^3$) | |
| Energy | Joule (J) (= N·m) | |

***Table 100.1. SI System of Units***

### MOTION OR KINEMATICS

The motion in a single plane is first considered. Figure 100.1 shows the knee schematically with an *origin* A fixed in the femur and a *contact point* B on the tibial surface. The knee is set in a *global axis system* ZY with origin O (the X axis is used for the lateral-medial direction for a right knee). The femur is first given a *rotation* F about A. The femur is next given a *displacement* or *translation* p in the negative Z direction. Finally, the femur is given an additional displacement d along the negative Y direction. The tibia has remained fixed with respect to the global axes, and the femoral motions could be described with respect to an axis system fixed in the tibia. The values F, p, and d are *vectors* in that they have magnitude and direction, often denoted with a line above or in bold type.

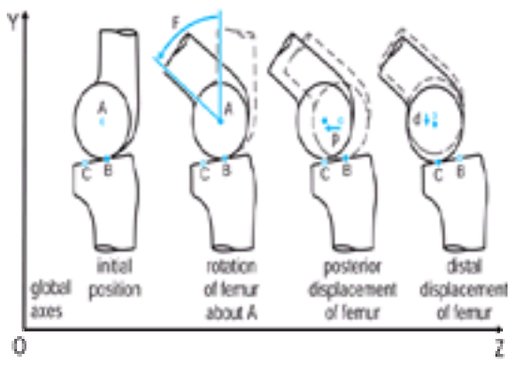


***Figure 100.1.*** Motion in a plane. Global axes, axes in the femur, and axes in the tibia are defined. In this case, three successive motions of the femoral axes relative to the global axes are shown: F, p, and d.

From a kinematics point of view, the final position of the femur can be obtained by a single rotation F about an axis D (Fig. 100.2). An *instant center of rotation* (207) is defined for small motions. The centers for a succession of small motions is the *instant center pathway,* not to be confused with the geometric centers of local radii of curvature. If the instant center is at the center of curvature, the motion at the contact point is called *pure sliding* (124). If the center is at the contact point, the motion is *pure rolling* (31). A center in between the two produces sliding and rolling combined.

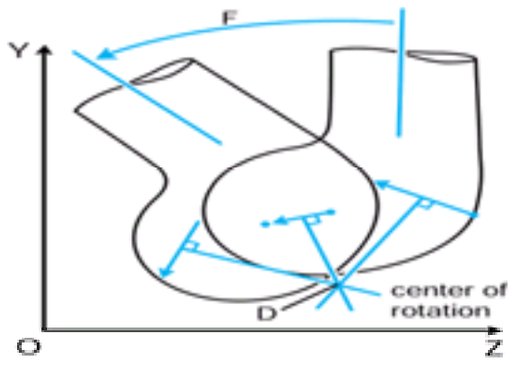


***Figure 100.2.*** Any two successive positions of a body in a plane can be obtained by a rotation about a single point.

In general, to visualize motion, it is usually easier to define rotations and displacements with respect to axes, rather than using centers of rotation (238) by the following principles:

- Define a global axis system.
- Define axes in each bone.
- Define each component of motion of one axis system relative to the other.
- Define the order in which the motions take place.

The importance of these principles is seen in visualizing *three-dimensional (3-D) motion.* In Figure 100.3, the femur is shown in its initial position on the tibia at zero flexion with contact points L and M. The femur is first rotated by 90° (flexed) about a transverse axis through A. Next the femur is rotated about a vertical axis through A fixed relative to the tibial axes. The lateral contact point moves posteriorly by *a* and the medial anteriorly by *a*. The femur is next translated posteriorly by *a*. The lateral contact point has now displaced posteriorly by a total of 2*a*, but the medial condyle is in its original position. In orthopaedic terms, as the knee has flexed, there has been an internal rotation of the tibia and a posterior translation of the femur.

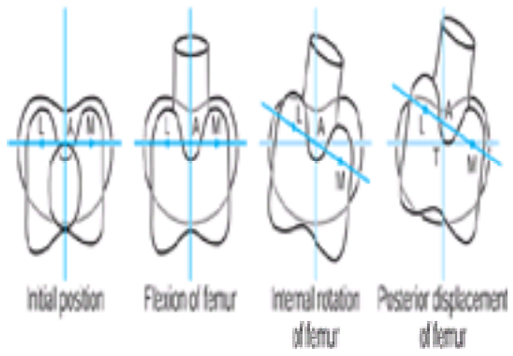


***Figure 100.3.*** Three-dimensional knee motion described by successive rotations and displacements. The figure depicts “average” knee motion from the extended to the flexed position.

Note that, depending on the order of the motions, the posterior displacement of the lateral contact point can occur on an unrotated or rotated tibia, producing a slightly different end result. The entire motion could have been achieved by a single rotation about and a displacement along a *screw axis* (235), but this is more difficult to visualize conceptually than the sequence of rotations and displacements described. In addition, the internal rotation and posterior displacement could have been achieved by a rotation about a vertical axis through the medial tibial condyle. Hence, it is important to define the method of describing the motion and which axes are used, to avoid misunderstanding and confusion.

For the hip joint, the origin of the femur is the center of the femoral head and the vertical axis is through the center of the knee (Fig. 100.4). The anteroposterior (AP) and mediolateral (ML) axes are self-evident, and all axes are mutually perpendicular. The axes in the acetabulum and femur are conveniently defined as being coincident with the hip in the neutral position. The motion of the femur is defined in relation to a fixed acetabulum as follows:

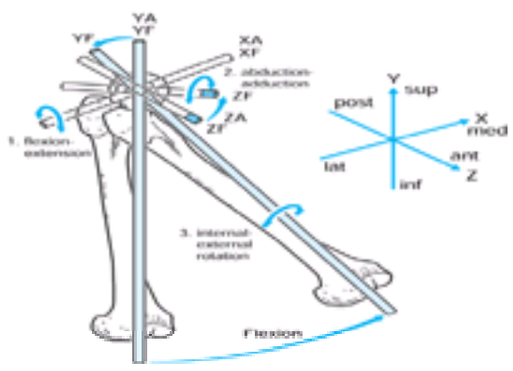


***Figure 100.4.*** Axes in the hip joint.

1. Flexion-extension about the XA axis.
2. Abduction-adduction about the ZA axis.
3. Internal-external rotation about the YF axis.

The importance of the orders of the rotation can be seen by reversing the order of the first two.

The motion of the knee is more complex in that it involves *six degrees of freedom*—three rotations, and three translations (56) (Fig. 100.5). The transverse axis in the femur can be chosen through the epicondyles. The other two axes are mutually perpendicular. For convenience, the axes of the tibia in the initial reference position at zero flexion can be taken to be the same as for the femur. Ordered motions are defined for the femoral axis system relative to the tibial axis system.

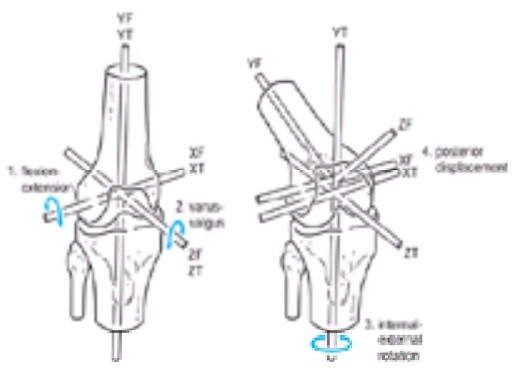


***Figure 100.5.*** Axes in the femur and tibia used to describe successive rotations and displacements. Flexion of the femur about XT, varus about ZT, external rotation about YT, and posterior displacement along negative ZT are shown.

1. Flexion-extension about XT.
2. Varus-valgus about ZT.
3. Internal-external rotation about YT (this can also be regarded as rotation of the tibia about YT).
4. AP displacement along ZT.

A modification in the way the axes are defined has been used to define a set of order-independent motions of the knee. This is the Grood-Suntay system (93), which has the advantage of ease of visualization.

For a joint with uniaxial motion, such as the elbow (67), it is useful to define the axes with respect to the axis of rotation, rather than using the long axes of the bones. The description of the motion can then be simplified to a single degree of freedom by the choice of the axis, which bisects the carrying angle (Fig. 100.6). This axis becomes a common axis in the humerus and ulna, the other two axes being mutually perpendicular as shown. In this case, the long axes of the bones are not coincident with the reference axes.

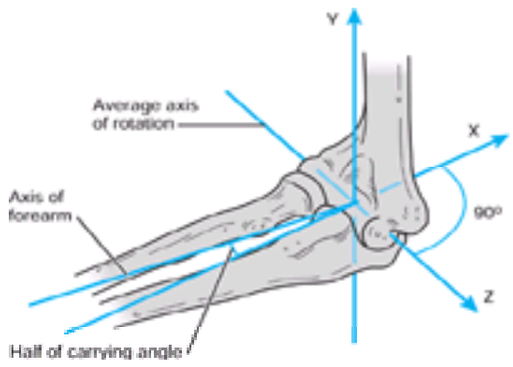


***Figure 100.6.*** For a uniaxial joint such as the elbow, one of the axes in each bone is taken along the axis of rotation, which bisects the “carrying angle.”.

The discussion in the previous section deals with different motions and the paths from the initial position to the final position. Successive rotations about three axes as shown in the preceding figures are called *eulerian or cardan angles* (6,235). *Transformation matrices* consisting of sines and cosines are used to convert the coordinates of points on the object from the initial to the final position with respect to one of the defined axis systems. A major interest in artificial joints is the continuum of motion during dynamic activities, an aspect that will be discussed later.

**FORCES AND FORCE ANALYSIS**

Forces, like motions, are vector quantities. In this case, they have magnitude, line of action, and point of application. Exactly the same axis systems used for the bones can be used to define the forces. For the hip in the neutral position, there are three *components* of force along each of the three axes, which can be combined into a single *resultant force* (Fig. 100.7). The forces on the femoral head are exactly *equal and opposite* to those on the acetabulum. If the femur is now moved to any arbitrary position, the resultant forces on the femoral head and in the acetabulum will still be equal and opposite. However, the three components of force along each of the femoral axes are now different from those along the acetabular axes. Hence, when defining the forces across a joint, it is important to specify the axis system to which the forces are referred. In reality, of course, the resultant force is representative of the pressure acting over a large surface area.

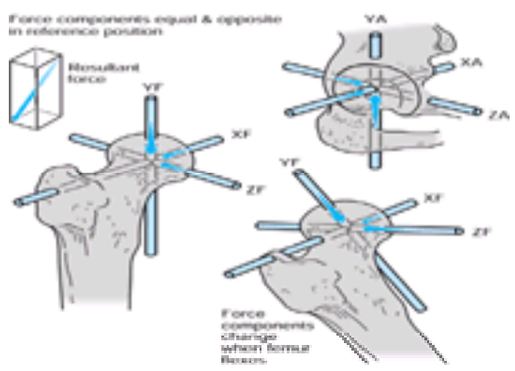


***Figure 100.7.*** When the axes in the femur and acetabulum are coincident, the three components and the resultant are equal. When the femur moves, the resultant is the same, but the components along the femoral axes are different.

In the knee, to represent the forces acting on the joint surfaces as well as along the axes, a *moment* in the frontal plane can be considered (Fig. 100.8). A moment has the units of force × distance, for example, N·m or N·mm. In the case shown, the main force is axial compression FY acting in the negative YT direction. An anterior *shear force* FZ is shown acting along positive ZT, and a varus moment MZ is shown acting about ZT. This set of forces and moments is shown *distributed* to the upper tibia. The compressive force and the varus moment produce a larger resultant force on the medial condyle than on the lateral condyle. The forces themselves are representative of the contact pressures and act at the *center of pressure* of each contact area. The shear force is transmitted to the tibia by the contact areas being on the upward anterior slopes of the tibial plateaus and by a force in the posterior cruciate ligament (PCL).

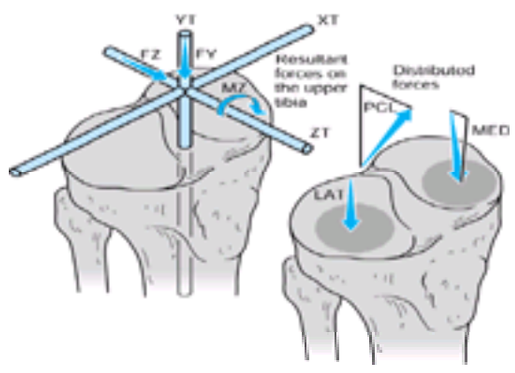


***Figure 100.8.*** Forces and moments acting on the upper tibia with respect to axes. The forces are shown distributed to the condylar surfaces and to the posterior cruciate ligament.

A method for the analysis of forces is shown in Figure 100.9, in which the problem is to calculate the forces on the face of the glenoid with the arm abducted and a weight in the hand (174). The steps are:

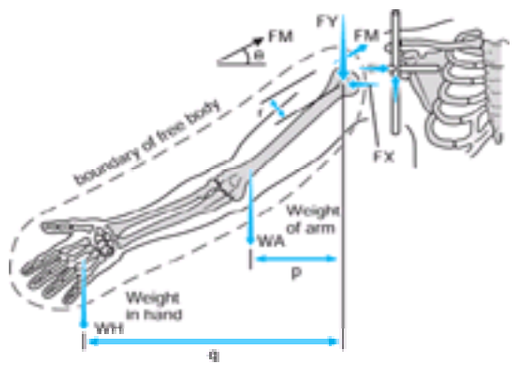


***Figure 100-9.*** To calculate the unknown forces at the joint, the forces are drawn and the arm is isolated as a “free body,” shown by the dotted line.

- Define axes in each bone. The humeral axes are not drawn here because only the forces with respect to the glenoid are considered.
- Define the forces on the glenoid. In this example, only the forces in the scapular plane FY and FX are considered.
- Draw these forces equal and opposite on the humeral head.
- Draw the other forces on the arm, namely the muscle forces FM, and the *external forces* WA (weight of the arm) and WH (weight in the hand).
- Define the arm as a *free body* by drawing a boundary around it and showing the forces that act across the boundary.

Assuming that the geometry is known (e.g., from radiographs), there are three unknowns, namely FX, FY, and FM. Three equations are thus required to obtain a solution.

*Resolve the forces* along the negative YG direction:

$$FY + WA + WH - FM \sin \theta = 0$$

Resolve the forces along the negative XG direction:

$$FX - FM \cos \theta = 0$$

*Take moments* in the clockwise direction about the center of the humeral head:

$$FM \cdot r - WA \cdot p - WH \cdot q = 0$$

(Note that FX and FY pass through the center of the humeral head, so their moments are zero.) The individual values are then solved from these three equations. This concept of isolating a defined entity as a *free body* and analyzing the forces across the boundary can be applied to numerous force analysis problems in the body. As with motion, the changing pattern of forces during activities is important.

**PRESSURES AND STRESSES**

Even though the resultant forces across joints are depicted with lines of action, in reality the forces are transmitted across areas on the joint surfaces. This results in a *contact pressure,* or *contact stress,* acting on the surface (124). The density of the subchondral bone plate will provide an indication of the pressure distribution (161).

$$\textit{Mean Contact Pressure} = \textit{Resultant Force} \div \textit{Contact Area}$$

The units of pressure are pascals, equal to newtons per square meter ($N/m^2$). Because this is such a small quantity, mega-pascals (mPa), equal to newtons per square millimeter ($N/mm^2$) are used. Whereas static analysis, as shown in the previous section, can be used to calculate resultant forces, to calculate pressures and stresses in an implant-bone system, more complex analyses are required. For simple geometries, elasticity (e.g., hertzian) equations can be used to calculate the contact areas and stresses in terms of the radii and the elastic properties of the materials. However, for realistic bone and implant shapes, *finite element analysis* (FEA) (15,16,44,175) is the most appropriate technique.

If a sphere is loaded onto a flat surface, a circular contact area is formed due to deformation of both surfaces (Fig. 100.10). The *pressure distribution* is hemispherical, with the maximum pressure at the center being 1.5 times the mean pressure. The same situation occurs if the lower surface is flat, a convex spherical surface, or a concave spherical surface.

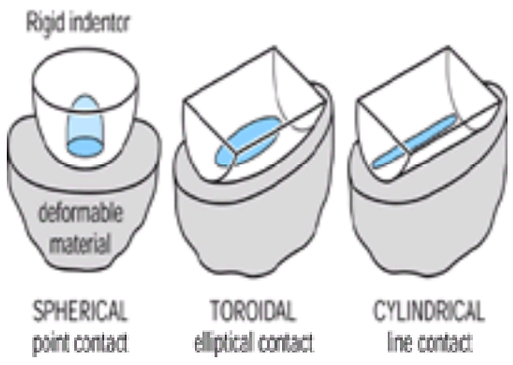


***Figure 100.10.*** Three types of contact in joints: spherical, cylindrical, and toroidal.

The contact area increases as any one or a combination of the following conditions occurs:

- Higher force.
- Lower elastic modulus (stiffness) of the materials.
- More conforming surfaces.
- Longer time the force is acting (due to “creep,” defined later).

The contact pressure increases as any one or a combination of the following conditions occurs:

- Higher force.
- Higher elastic modulus.
- Less conforming surfaces.
- For a stiff layer under a relatively soft layer.

The conformity has a major influence on the pressure, the relevant parameter being the *relative radius of curvature R* defined by:

$$\frac{1}{R} = \frac{1}{R_1} + \frac{1}{R_2}$$

where $R_1$ and $R_2$ are the radii of curvature for the two surfaces, and the radius of curvature is taken as positive for convex surfaces and negative for concave surfaces.

Thus, any two surfaces can be represented by a surface with radius *R* on a flat surface. The average contact pressures calculated for a given force (1000 N) and material properties (metal-on-plastic) are shown in Table 100.2. This table shows how the relative radius and the contact pressure change dramatically as the surfaces approach full conformity. The range covers a nonconforming knee to a hip joint with a small femoral–acetabular clearance (15). Note, however, that the standard hertzian equations lose accuracy when the contact radius ($R_2$) approaches the surface radius ($R_1$). Another factor is that the contact pressure does not necessarily predict the wear rate, which is so often assumed (148).

| Surface 1 (convex) $R_1$ | Surface 2 (concave) $R_2$ | Relative radius $R$ | Average contact pressure (mPa) $\sigma_{av}$ |
|---|---|---|---|
| 20 | −100 | 25 | 39.2 |
| 20 | −50 | 33 | 32.4 |
| 20 | −30 | 60 | 21.9 |
| 20 | −25 | 100 | 15.6 |
| 20 | −22 | 220 | 9.2 |
| 20 | −21 | 420 | 6.0 |
| 20 | −20.5 | 820 | 3.8 |
| 20 | −20 | ∞ | 0.8 |

***Table 100.2. The Relative Radii of Curvature and the Contact Pressure in a Spherical Metal-Plastic Contact, Covering the Range from Knees to Hips, for a Compressive Force of 1000 Newtons***

A cylinder on a flat surface (with an infinite radius of curvature) has a much larger contact area than does a sphere on the same flat surface (Fig. 100.10). Examples of arthroplasties with such contacts include some knees, elbows, ankles, and fingers. Today, most geometries in condylar knees are toroidal, between spherical and cylindrical, producing elliptical contact areas. This has the advantages of reducing contact stresses and avoiding “digging-in” at the sides if tilting occurs. The stresses beneath the surface in all types of contacts are extremely important in both natural and artificial joints, in terms of producing subsurface damage.

High pressures can act across implant–bone interfaces (39) (Fig. 100.11). (Note that the word “stress” can be substituted for the word “pressure” in this context.) In the case of metallic cemented or uncemented hips, the contact pressures are highest in the proximal-medial region but with high pressures distal-lateral also. The magnitudes of the pressures depend also on stem geometry and head offset. For uncemented stems, in which a “perfect” metal–bone fit is not achieved, local contact pressures can be very high due to the stiffnesses of the materials. An additional interface effect is due to friction between the metal and the bone, causing shear forces to act as shown in Figure 100.11 (101,198). If there is bonding across the interface from cement or from a porous or HA coating, the shear forces will be higher, decreasing the interface contact pressures. The interface *shear stress* is defined as:

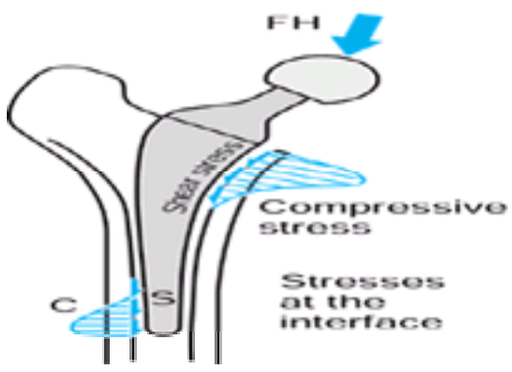


***Figure 100.11.*** Interface contact pressures and shear stresses for intramedullary fixation of a hip. The magnitudes of these stresses vary considerably depending on stem design, fixation method, bone geometry, head offset, and other factors.

$$strain = change\,in\,length \div original\,length = (L_1 - L_0)/L_0$$

In designing implant components for whatever location, the design goals for the interface stresses are:

1. Positive contact pressures at those interfaces that usually experience compression (e.g., acetabulum, upper tibia).
2. Minimum contact stresses on interfaces that usually do not experience compression (e.g., intramedullary canal).
3. Minimum shear stresses (e.g., acetabulum, upper tibia, intramedullary canal).

The implications of goals 2 and 3 are to minimize or avoid intramedullary fixation, or to design the component to minimize tension and shear.

On the outside surface of a structure on which no direct forces are acting, in general, there will be stresses acting in the plane of the surface (Fig. 100.12). If a small square is drawn on the surface, there will be one *direct stress* (*tensile* or *compressive*) acting on opposite faces and another direct stress acting on the other pair of faces. There will be a single value of *shear stress* acting to distort the square. If the square is now rotated, an orientation can be found at which the shear stress is zero. The direct stresses acting at this orientation are called the *principal stresses.* One of these is the maximum and the other the minimum. Tension is taken to be positive; compression negative. However, the principal stresses can be both negative, both positive, or one negative and one positive, depending on the loading conditions around the square of surface. The maximum shear stress is at 45° to the principal stresses.

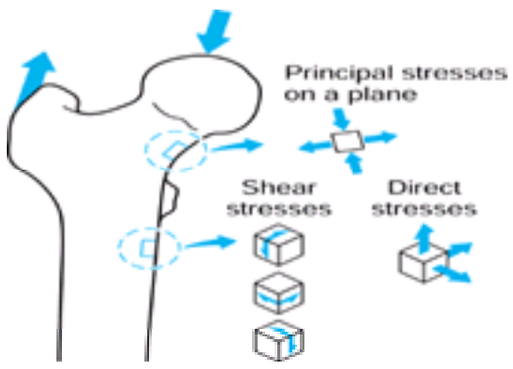


***Figure 100.12.*** At a location on a surface, there are two direct stresses and two shear stresses. An orientation can be found at which the shear stresses are zero. The direct stresses are now the principal stresses. A similar situation applies to a three-dimensional element of material.

In three dimensions, the general principles are the same. Here, a small cube of material is taken, which has three direct stresses and three shear stresses. At a certain orientation, the shear stresses are zero and the direct stresses are again called the principal stresses.

Stress calculations of bones and implant components often quote values of *Von Mises stress.* This term is convenient in that it describes the stress state at a point with a single number. In fact, it is calculated from the three principal stresses, and is a value that quantifies the likelihood of yielding, synonymous with the yield stress in direct tension.

Another often-used quantity is *strain energy density,* which is the amount of energy (force × distance) stored in the material due to the applied stresses deforming the material. This quantity is considered to be relevant to bone remodeling, whereby the response of osteoblasts within the bone material is proportionate to the amount of deformation and hence strain energy density. This is an “elastic” quantity recoverable on removal of the stresses, but yielding of the material is an additional consideration.

## MATERIAL AND STRUCTURAL PROPERTIES

Material properties relate only to the material itself and not to the shape of the object, whether it be a bone or an implant component. A fundamental property is *modulus of elasticity E,* which can be determined by a simple tensile or compressive test on a cylinder (Fig. 100.13):

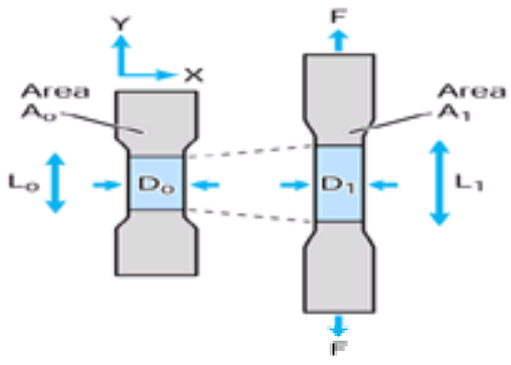


***Figure 100.13.*** A simple tensile test to calculate the modulus of elasticity *E*.

$$E = stress \div strain = \sigma/\epsilon$$

where *stress* = *force* ÷ *area* = $F/A_0$, and $A_0$ is the original cross-sectional area.

The change in a linear dimension is described by strain:

$$shear\ stress = shear\ force \div contact\ area$$

For stiffer materials, such as bone and metals, the strain is small, usually measured in microstrain. A typical strain value for the cortex of a long bone under peak load is on the order of 2000 to 3000 microstrain. For materials such as cartilage and ligament, however, the strain can be 10% or more, and hence the *true stress* after load application must be related to the deformed area $s_T = F/A_1$, where $A_1$ is the area with the force applied. Poissons ratio n defines the strain in directions perpendicular to the longitudinal strain:

$$\nu = \left(\frac{D_0 - D_1}{D_0}\right) \Big/ \left(\frac{L_1 - L_0}{L_0}\right) = \epsilon_x/\epsilon_y$$

For metals n equals 0.3, for plastics n equals 0.3 to 0.4, and for an incompressible material such as a fluid or rubber, n equals 0.5.

For metals, the stress-strain relation is linear (Fig. 100.14*A*). The elastic modulus, defined as the slope of the stress-strain curve, is constant. Ligament and tendon are *strain stiffening* due to the straightening of collagen fibrils (86). This means that the elastic modulus is not constant but increases steadily with strain. Rubbers usually exhibit strain stiffening also. Conversely, materials such as polyethylene exhibit strain-softening behavior, in which the elastic modulus appears to reduce with strain. For these nonlinear materials, modulus of elasticity has to be defined as a *tangent modulus* at a particular value of strain, as shown in Figure 100.14*A*.

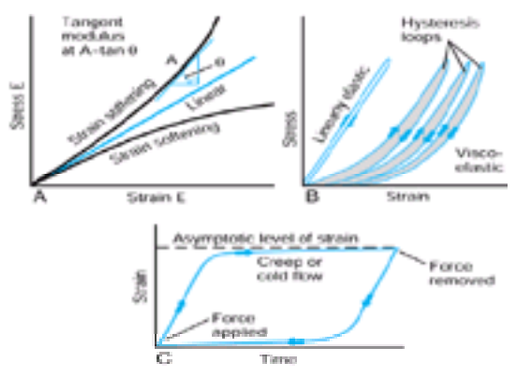


***Figure 100.14.*** **A:** Metals usually have a linear stress-strain curve. Biologic materials, rubbers, plastics, and composites are usually nonlinear. **B:** An elastic material recovers its initial shape immediately on load removal. For a viscoelastic material, there is a residual displacement and a hysteresis loop. **C:** Characteristics of creep or cold flow, when the load is maintained over a period of time, and then removed.

Materials for which the strain recovers immediately on removal of the force are called *elastic* (Fig. 100.14*B*). If there is a time delay in recovery and a hysteresis loop is formed, the material is defined as *viscoelastic,* and some energy is absorbed in the cycle. A *viscous* material, such as synovial fluid, does not recover the strain (or only a very small amount) after force removal.

In some materials, if a force is applied suddenly, there is an immediate strain, followed by a continued strain at a decreasing rate, reaching an asymptotic level (Fig. 100.14*C*). The behavior is called *creep* or *cold flow.* When the force is removed, the reverse process occurs. Polyethylene behaves in this way, as does articular cartilage, tendon, and ligament. Stretching exercises before a sporting activity put such tissues through viscoelastic and creep cycles. Acrylic cement, when subjected to sustained loading in a fluid environment at 37°C, shows some creep, and this may be relevant to the slight sinkage of polished hip stems over time.

Materials for which the properties are the same in all directions are called *isotropic.* Most artificial materials used in joints are of this type, although a number of experimental *composite materials* consisting of aligned fibers embedded in a polymeric matrix are nonisotropic. These materials are called *orthotropic* if a property such as modulus or strength is much greater in only one particular direction. Most biologic materials are orthotropic, which results from their structure, either aligned collagen fibers in the case of ligament and tendon, or aligned osteons in the case of bone (128). Articular cartilage is a special case with complex properties due to its triphasic composition of collagen fibers, mucopolysaccharide matrix, and fluid. The values of modulus of elasticity for the materials discussed cover a wide range (Table 100.3), and consequently, the transfer of forces between different structures is complex and can involve regions of stress concentration.

| Material | Modulus of elasticity (mPa) | Fatigue strength (mPa) |
|---|---|---|
| Alumina ceramic | 380000 | — |
| Zirconia ceramic | 210000 | — |
| Cobalt-chrome, cast | 220000 | 250 |
| Cobalt-chrome, forged | 220000 | 897 |
| Stainless steel, wrought | 200000 | 345 |
| Titanium | 100000 | 262 |
| Titanium-6Al-4Va | 110000 | 513 |
| Titanium-6Al-7Nb | 105000 | 500 |
| Acrylic cement | 2000 | 8 to 20 |
| UHMWPE | 600 | 11 |
| Cortical bone | 10000 | 20 to 30 |
| Cancellous bone (fem head) | 340 | — |
| Cancellous bone (prox tib) | 200 | — |
| Articular cartilage | 5 to 20 | — |

The enormous range is apparent. Note that the values are representative only, especially for the biological materials.

***Table 100.3. The Modulus of Elasticity and the Fatigue Strength of Biological and Artificial Materials***

Material failure in a single load episode can occur in either tension, compression, or shear. In general, tensile failure is the most common. If a material is stretched and fails suddenly, that is termed *brittle fracture.* Ceramics and acrylic cement behave in this way. Metals and polyethylene, on the other hand, are *ductile* in that there is a region of *plastic deformation* whereby the material elongates at essentially the same applied load. If the load is released, there is a *permanent deformation,* but the material can continue to be structurally useful in that condition. Permanent deformation in plastic tibial and patellar components is an example. Tendons and ligaments behave as if they were numerous fascicles in combination (41,241), with rupture of the tightest fascicles occurring first. If the load is released and sufficient fibers are intact, the structure can still function. Bone is close to being brittle, although there is some plastic deformation due to pull-out of osteons from the matrix (58,128,159).

Failure of a material can occur at stress levels below the level at which single cycle yield or fracture occurs due to repetitive cycling of forces, a process known as *fatigue.* This process has been observed on many orthopaedic devices including hip stems (93) (Fig. 100.15), tibial trays (1), and plastic liners (Fig. 100.16). The *fatigue strength* or *fatigue limit* is the stress below which no failure would occur no matter how many cycles of loading occurred (Table 100.3). This value is generally about two thirds of the failure stress for a single-load application. Fatigue failure initiates at the location of the highest stresses, and the crack gradually propagates through the section until the stress reaches the level at which complete failure occurs at a single load. The starting point of the crack can be a small defect in the material structure, such as an intergranular defect in metal or plastic (205). Even a reference number of a component etched onto a metal surface in a highly stressed region has been the initial location of a fatigue crack. Such defects are called *stress concentrations* or *stress raisers* in that they raise the stress level above the overall average level in that region (106). Sharp edges, corners, or grooves in implant components are common sites of stress concentration. Even defects just within the material, such as small bubbles in cement, can act as stress concentrations in the same way. Generally, biologic materials do not experience fatigue failure because the resting periods between loading episodes allow for restoration and remodeling. However, one theory for the development of osteoarthritis has been advanced: healed trabecular microfractures, failed in fatigue, produce an overly stiff supporting structure to the articular cartilage.

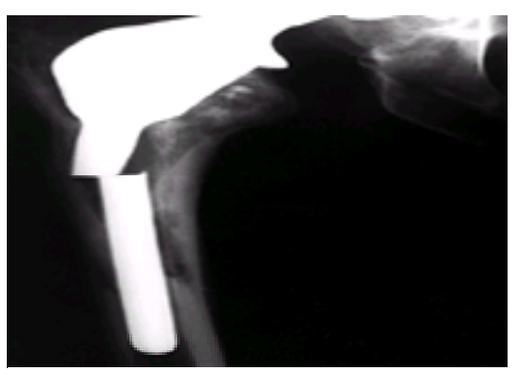

***Figure 100.15.*** A fractured revision hip stem, in which the lower part of the stem is rigidly supported but the proximal region was relatively unsupported, especially medially.



***Figure 100.16.*** Fatigue cracks in an UHMWPE tibial component. This is due to a degradation of mechanical properties from oxidation in a component that had been on the shelf for several years.

The stresses are complex in actual structures and can change rapidly from section to section, especially in the presence of implants. Combinations of bone and implant are called *composite structures.* An example of a component that acts in *series* with the bone is a metal-backed tibial plateau (Fig. 100.17). It is assumed that the resultant forces on the plastic surfaces are similar for the all-plastic and metal-backed components. However, at the resection level of the upper tibia, although the forces transmitted across this section are the same, the distribution is quite different. In the case of the plastic, there are high stresses directly under the contact areas. In contrast, the metal plate spreads the load over the entire upper tibia. The actual pressure distribution largely reflects the foundation stiffness of the underlying trabecular bone (154). At an individual trabecular level, the stresses are largely compressive in a vertical direction in the normal knee, but are varied and complex beneath an artificial knee, depending on the penetration and closeness of contact of the cement. At the level of the cortex, below the implant level, the stresses in the prosthetic case are similar to those of the normal knee.

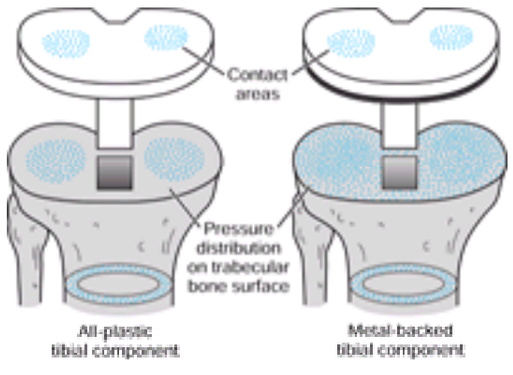


***Figure 100.17.*** The stress distribution on the upper tibial surface depends on whether the component is all-plastic or metal-backed. In the latter case, the distribution reflects the foundation stiffness of the trabecular bone. In the cortex, the stresses are equal and resemble normal.

In the normal intact hip, there are forces on the femoral head *H* and in the abductors *G,* such as to produce both compression and bending in the upper femur (34) (Fig. 100.18). This can be depicted at a level just below the lesser trochanter, where there is a resultant compressive force *C* acting down the center, together with a moment *M*. Force *C* produces a mean compressive stress of *C/A* at the section, where *A* is the area of bone. Moment *M* produces tensile stresses on the lateral half of the femur and compressive stresses on the medial half. These are called *bending stresses.* These two stress distributions are combined to produce the resultant stresses. The bending stresses usually dominate over direct stresses such that the lateral side is still in tension and the medial side is in increased compression.

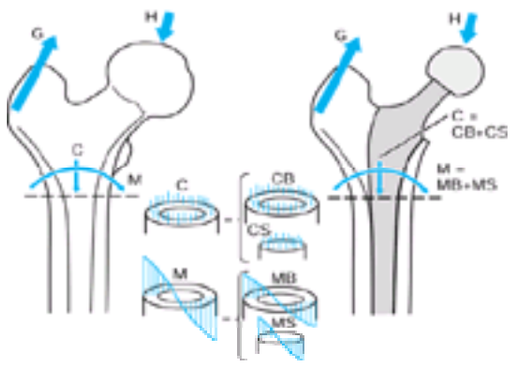


***Figure 100.18.*** The stresses in the bone at a section just below the lesser trochanter, for the intact femur, and after insertion of a hip stem. See text for details.

In a total hip replacement, a composite structure, the hip stem, and the bone act *in parallel.* It is assumed that the forces *H* and *G* are the same before and after hip replacement. At the section shown in Figure 100.18, compressive force *C* and bending moment *M* are now shared between the bone and the stem. For *C,* the proportions are $A_B.E_B:A_S.E_S$, where $A_B$ and $A_S$ are areas and $E_B$ and $E_S$ are the elastic moduli of the bone and stem, respectively. For *M,* the proportions are $E_B.I_B:E_S.I_S$ where $I_B$ and $I_S$ are the second moments of area or section moduli of the bone and stem, respectively. For a circular stem diameter *D*, $I_S = pD^4/64$. For a hollow femur with outer and inner diameters $D_o$ and $D_i$, respectively, $I_B = p(D_o^4 - D_i^4)/64$. The important effect of diameter can be seen. The product of *E.I* is called the bending stiffness. In practice, a hip stem has a much higher EI value than the bone for a narrow cortical thickness and large canal diameter. In this case, the proportion of the bending carried by the stem is high, and the bone can be seriously *stress protected.* At the other extreme, with a thick cortex and a narrow canal, the bone carries a high proportion of the bending.

***Friction, Lubrication, and Wear (Tribology)***

Tribology is concerned with the science of rubbing surfaces and is thus fundamental to the functioning of joints (82). Human joints are different from most bearings in engineering in that they operate under low sliding speeds and are expected to last a lifetime. Furthermore, they are constructed of a thin soft layer on a relatively hard layer, carry out motions in multiple directions, and are not necessarily fully conforming. The way in which they function so effectively is in maintaining a layer of viscous fluid between the cartilage surfaces such that direct rubbing of cartilage on cartilage occurs infrequently (227). A number of different lubrication mechanisms known in engineering have been found to apply to human joints, but their behavior is so complex that there is no direct analogy. The *coefficient of friction,* defined as the ratio of the frictional shear force to the compressive force, ranges from about 0.001 to 0.01. This means that, for a typical compressive force of 3 body weight (BW) (2000 N) on a hip or knee, the shear force is a mere 10 N. In contrast, a metal-polyethylene joint would have a shear force of at least 10 times that. Although friction is usually associated with sliding between two surfaces, a frictional shear force can also be transmitted during rolling, up to the level determined by the *dynamic friction coefficient.* The motion in that case is termed *tractive rolling.*

The lubrication mechanisms believed to occur during normal joint function are as follows (218,227). During a lightly loaded swing phase, synovial fluid is drawn in between the joint surfaces. On applying a force at the start of stance, a fluid film is maintained by a *squeeze film* mechanism, whereby the large surface area and the viscosity of the fluid mean that leakage of the film occurs at a very low rate. As movement begins, the film is further maintained or even enhanced by *elastohydrodynamic lubrication,* by which the area of contact is maintained due to the deformations of the bearing surfaces and fluid is pressurized as it is drawn into a thin converging wedge between the surfaces. In addition, as the cartilage surfaces are deformed, fluid is exuded between the surfaces (this has been termed *weeping lubrication*) and at the leading edge of the contact area. Fluid becomes trapped in small undulations in the cartilage surfaces, a mechanism called *trapped pool lubrication,* and a higher concentration of hyaluronic acid can result in a more viscous layer of synovial fluid, by so-called *boosted lubrication.* The hyaluronic acid protein complex chemically binds to the cartilage surface so that even if sliding occurs when there is minimal film thickness, *boundary lubrication* is provided.

In metal-plastic artificial joints, fluid film lubrication mechanisms are ineffective because of the hardness of the materials and the limited surface areas, so that surface-to-surface rubbing takes place during sliding. At each step, it is estimated that millions of submicron-sized plastic particles are released into the joint. The effect of wear on particles and osteolysis of the bone around the interface, as well as the mechanical effects of the change in geometry, are major limiting factors in the durability of artificial joints (82).

The first wear mechanism is termed *adhesive wear,* visualized as the sticking of a tiny region of the plastic surface on to the metal surface such that a fragment of plastic is pulled away (Fig. 100.19). It is now thought that such a mechanism may require multiple passes to build up sufficient *strain energy* in the *asperity* (a local high point) before it is released. A variation of this mechanism occurs when the adhesion results in a small fibril of plastic being stretched from an asperity and eventually released. The next mechanism is abrasive wear (83). In *two-body abrasive wear,* small sharp asperities on the metal surface, such as scratches, cut into the plastic surface. Crisscrossing of scratches on the plastic due to variations in motion paths accelerate this type of wear. *Three-body abrasive wear* occurs due to the entrapment of small particles between the sliding surfaces (51). In artificial joints, these particles can be plastic, acrylic cement, bone, HA, or metal debris from rough or sprayed surfaces. If such particles embed into the plastic surface, they can accelerate the wear locally. All of these mechanisms produce particles in the range of 0.1 µm to a few microns. The particle shapes are *granules, fibrils, or flakes* (47,48). For ceramic-on-ceramic or metal-on-metal joints, the wear mechanisms are similar but the rates of volumetric wear are much smaller than for metal-on-polyethylene joints, and the particle sizes are also smaller.

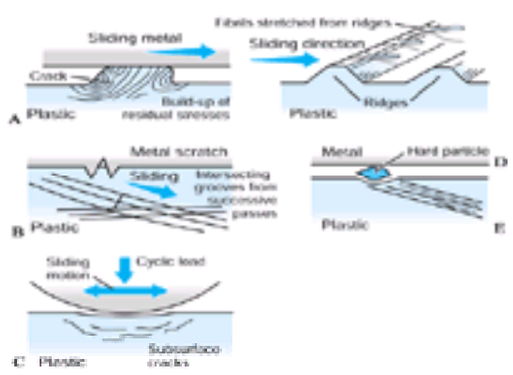


***Figure 100.19.*** A representation of different wear and damage mechanisms from a plastic surface: adhesive wear (**A**), two-body abrasive wear (**B**), three-body abrasive wear (**C**), delamination (**D**), and fretting (**E**).

A damage mechanism that has been particularly destructive in knee joints is *delamination* (62,205). This is a fatigue process whereby shear stresses at about 1 mm beneath the surface change in direction as sliding and rolling take place, initiating and propagating cracks in the material (176). When the cracks reach the surface, fragments of plastic are liberated. A surface once disrupted fragments at a rapid rate. It is noted that, because delamination is affected by subsurface stresses, it can occur due to rolling as well as sliding, although the stress magnitudes are slightly higher in sliding. *Pitting* is another fatigue damage phenomenon caused by tensile cracks initiating at the surface. The effect is usually local, seen as pits about 0.5 to 1.0 mm in diameter. The severity of both delamination and pitting depend on the

fatigue properties of the material, which, in turn, may depend on time-dependent phenomena such as oxidative degradation (62,77,135,180,182).

The basic equations for steady-state wear, excluding time-dependent damage such as delamination, are:

$$\textit{wear rate} = \textit{wear factor} \times \textit{load} \times \textit{sliding velocity}$$
$$\text{i.e. } u/t = k \times W \times v$$
$$\textit{wear volume} = \textit{wear factor} \times \textit{load} \times \textit{sliding distance}$$
$$\text{i.e. } u = k' \times W \times s$$

The wear factor may be a constant for a given pair of materials, but it can change over time if:

- The material properties change (e.g., due to yield, surface heating, in vivo oxidation, chemical effects).
- The surface of an initially polished hard material becomes scratched.
- Transfer films occur (e.g., due to surface heating, degraded joint fluid).

Another type of wear, not due to sliding in a bearing itself, is *fretting* (36). This occurs due to cyclic shear stresses across an interface between two parts intended to be statically fixed together. Examples are a modular femoral head on a taper and a plastic insert in a metal backing. The shear stresses can be generated due to elastic deformations from cyclic loading, including the Poissons effect. The latter occurs, for example, when the plastic of a tibial component becomes squeezed radially outward from a contact area. The motion due to the interface shear stresses can be submicron or even up to a millimeter in a loose snap-fit connection.

## HIP REPLACEMENT

### HIP MECHANICS

Typical angular rotations at the hip joint for a walking cycle are shown in Figure 100.20 (120). On heel-strike, there is about 30° of flexion, and at toe-off, about 10° of extension. The other two rotations are approximate because of the difficulty of separating femoral from pelvic motion. However, the range of abduction to adduction is about 11°, and for internal-external rotation, the range is about 8°. These rotations produce motions of individual points on the femoral head that traverse curved paths in the socket and cross over one another. This aspect is discussed further in the section dealing with hip-simulating machines.

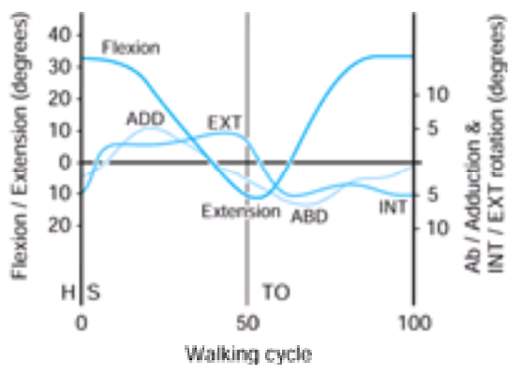


***Figure 100.20.*** Representative values for the rotations occurring in the hip joint during normal walking. (Data from Inman VT, Ralston HJ, Todd F, eds. *Human Walking.* Baltimore: Williams & Wilkins, 1981.).

The forces acting across the normal intact hip have been determined indirectly by using gait analysis and directly in total joints by using telemetry (20,21,187). The latter is more applicable to the subject of this chapter. These forces have been depicted as acting on the femoral head during different activities. Figure 100.21 shows that the line of action of the force during level walking changes much less than the angles of motion of the femur relative to the acetabulum. The projection on the acetabelum of these forces during walking results in a similar pattern but with larger angles of excursion. This means that the force vector moves somewhat more with the femur than it does with the acetabulum (74,75). The reason for this is that approximately two thirds of the hip force is produced by the abductors (10), which tend to apply their force parallel to the long axis of the femur (74,75).

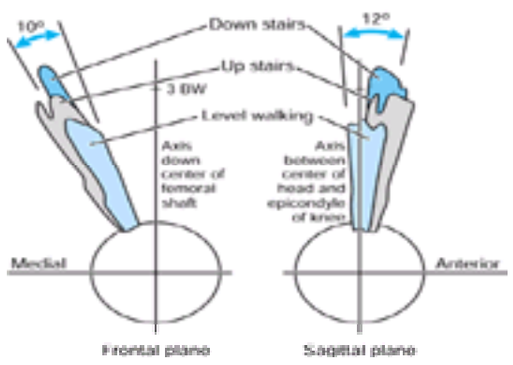


***Figure 100.21.*** The magnitudes and directions of the forces on the femoral head during the stance phases of different activities. (The data were determined by using telemetry [21].)

The directions of the resultant force on the joint are important to the function of total hips. For this purpose, it is useful to consider the forces relative to axes based on the long axis of the femur. In the frontal plane, the force makes an angle of 15° to 27° to the long axis of the femur during stance. This produces axial compression, a varus moment, and a medial-to-lateral force. In the sagittal plane, there is an important component peaking at approximately 0.75 BW acting from an anterior to posterior direction on the femoral head, which results in torsion (21,99). The latter is considered to be an important contributor to the compressive failure of trabecular bone in uncemented stems, and results in stem fractures initiating from an antero-lateral corner.

The peak forces during a range of different activities are shown in Figure 100.22. The exceedingly high force of 8 BW encountered accidentally in a stumble is important because a single force such as this, along with its torsional component (21), could lead to debonding at the implant–bone, cement–bone or cement–stem interfaces, or to cracking of the cement mantle (22,150,210). A factor that influences the mechanics of the hip is the offset of the femoral head from the femoral axis (167,184). This is frequently reduced from normal in a total hip replacement (THR). The effect is an increase in the force required in the abductors (10), leading to a higher resultant joint force, a more vertical resultant, and sometimes a gait abnormality. An increase in offset reduces forces but causes an increase in the bending moment on the stem. Failure to achieve the normal anteversion of the head and neck increases the axial torsion, which is undesirable (21).

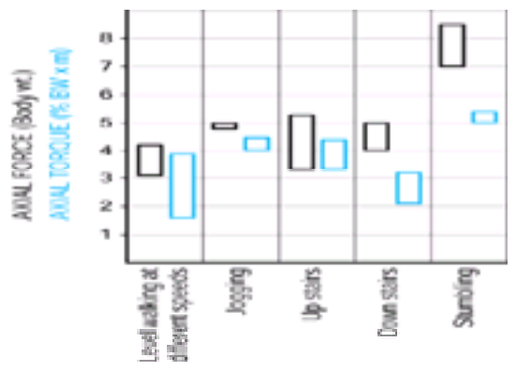


***Figure 100.22.*** The ranges of the peak forces in different activities measured by telemetry in two different subjects. (Data from Bergmann G, Graichen F, Rohlmann A. Hip joint loading during walking and running, measured in two patients. *J Biomech* 1993;26:969.)

**CEMENTED COMPONENTS**

Cemented femoral components have changed relatively little since the original Charnley design, although paradoxically, even a small change in design can result in a major change in performance. Fundamentally, the stem shape parallels the canal shape (167), leaving space for a cement mantle of 2 to 4 mm in thickness. In early designs such as the Charnley, Exeter, Stanmore, Muüller, and T28, the cement was not intended to bond to the stem. In contrast, at the cement–bone interface, these designs aimed for an intimate mechanical contact with rough bone or trabecular bone. Compressive, shear, and tensile stresses are transmitted to the bone surface (113), an unnatural situation, but one that is tolerated for long time periods.

It is well known that the stresses in the femur are changed from normal due to the presence of the stem, especially proximomedially, where the longitudinal compressive stresses are reduced to 20% to 30% of normal levels (110,223) (Fig. 100.23). Progressing distally, the stresses become closer to normal, reaching normal levels below the level of the stem tip. The reduction in a stress parameter, such as the Von Mises stress, particularly when it results in a reduction of bone density or volume, is called *stress protection* or *stress shielding* (30). Over a time period of approximately 5 to 10 years, this results in longitudinal removal of bone at the neck cut level, osteopenia, and resorption of bone away from the cement. If this process becomes extreme, the interface stresses around the remaining stem become excessive (150), leading to “clinical” loosening (94). In addition, wear particles can be more easily transported down the interface, producing lysis at locations all around the stem, especially distally (98). A further consequence of proximal bone loss is that the stem is only rigidly fixed in its distal half, increasing the bending stresses and increasing the possibility of fatigue fracture (94).

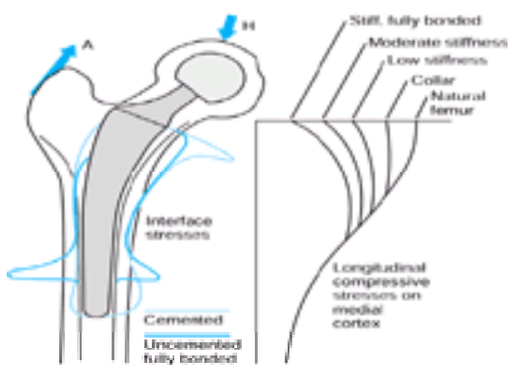


***Figure 100.23.*** Typical direct (compressive and tensile) stresses at the bone interface, and the longitudinal compressive stresses in the bone, after cemented or uncemented stems. The proximomedial stress-shielding is least with a functional collar and most with a fully bonded stiff stem. Some data are adapted from various papers by R. Huiskes and colleagues (see, e.g., references 113,114).

Dual energy x-ray absorptiometry (DEXA) scanning has now become the standard method for measuring and monitoring changes in bone density over time (201,202). In this technique, in the frontal plane, for example, an x-ray beam is scanned across the field, and measures of x-ray absorption are made, giving a measure of bone mass at a matrix of points in the field. Major changes in bone mass usually occur slowly, and it has been found that bone loss may be only 10% to 20% at 2 years, but that this loss can increase to as much as 50% in the proximal-medial region at 5 years.

The allowable level of stresses at the interface are known only approximately, but the goal is to minimize these stresses and to avoid local stress concentrations. Stresses within the bone should be as close to normal as possible. Cement and stem stresses, especially tensile, should be minimized and should not exceed the fatigue limit under normal loading conditions. All of these goals cannot be obtained simultaneously, but a number of guidelines for hip stem design exist:

- Stem bending stiffness should be much lower than that of the bone to minimize stress shielding.
- Avoid excessively flexible stems that elevate interface tensile and compressive stresses and produce excessive micromotion.
- Ensure that the cement mantle thickness is a minimum of 2 to 3 mm (122) (can be achieved using centralizers).
- avoid corners or any other feature on the stem that would cause stress concentrations in the cement or in the stem itself (22).
- Create smooth contours but with sectional shapes that will not twist within the cement mantle.
- Provide features such as proximolateral projections (e.g., “cobra” design) to provide a greater connection between stem and cement, a net increase in compressive stresses, and a reduction in tensile stresses
- Provide a means of centralization, especially proximomedial and distal, to avoid close metal–bone proximity, where lysis frequently occurs.
- Use third-generation cementing techniques, including cleaning the canal, distal plugging, pressurizing, and minimizing porosity (12,145)

Concerning the ideal surface finish for a stem, long-term clinical data suggest that a smooth surface or a near-smooth surface, in which there is no direct stem–cement bonding, produces successful results. The use of rough surfaces, or rough surfaces with a precoating of cement to obtain stem–cement bonding, has not been uniformly successful. It appears that shear and tensile stresses at the interface can cause progressive debonding and interface micromotion (150). The latter can then generate metal and cement debris, which enter the joint space, followed by accelerated wear of the UHMWPE liner. Evidence of stem–cement micromotion in all types of stem is frequently seen in retrievals and produces fretting wear of both stem and cement (Fig. 100.24).

***Figure 100.24.*** A retrieved hip stem showing that the original matte surface has been polished smooth due to micromotion between the stem and the cement. This is due to fretting wear.

The stem material for cemented components is important, and forged cobalt-chrome or stainless steel is usually preferred. Titanium alloys have been prone to surface wear or even crevice corrosion and are not in general suitable for cemented application. The ideal combination for a cemented stem with a modular head is to use cobalt-chrome alloy for both owing to the minimal corrosion on the taper connection (31) and reduced scratching of the femoral head over time. Other head materials are discussed later in this chapter. Because of its success in elderly patients, and even in younger patients (12,71,145) (although studies are variable on this issue), it is unlikely that the design of the standard cemented stem for primary cases will change substantially in the foreseeable future. Long-stem cemented components are used in revisions, but the cement penetration and shear strength are likely to be inadequate owing to the loss of most of the cancellous bone from the previous implant (146).

Standard cemented acetabular components consist of a solid UHMWPE hemisphere, or just greater than a hemisphere, with grooves on the outer surface for keying to the cement. A metal wire is usually embedded on the outside to measure the wear relative to the femoral head on radiographs. The range of motion (ROM) between the femoral neck and the socket before impingement occurs is important because it affects the potential for dislocation as well as loosening. It is notable that, as wear proceeds, the ROM steadily reduces, and this process can lead to problems for 22 mm heads in the long term. The factors affecting ROM are:

- ROM increases with head diameter. (However, there is an increase in volumetric wear with diameter.)
- ROM increases with decreasing neck diameter. (This is especially applicable to flexion-extension, in which the neck can be elliptical.)
- ROM decreases with a short neck if collar-socket impingement occurs.
- ROM decreases with “skirted” femoral heads, which increase head height and offset.
- ROM decreases in certain planes if the socket and stem are malpositioned.

Overall, the best compromise appears to be a head diameter in the range of 26 to 28 mm with an elliptical neck of minimum diameter for strength. In practice, the most widely used diameters are 28 mm and 22 mm. To obtain sufficient plastic thickness the minimum outer diameters of the acetabular component recommended for a 28 mm diameter head are 44 mm for plastic and 48 mm for metal-backed plastic. Below those diameters, a 22 mm head is recommended.

The principles of acetabular fixation (158) are the same as those for stems, notably intimate contact of the cement with a rough bone surface and penetration within the trabeculae. There is still uncertainty regarding removal of the subchondral plate (161) and the size and number of key holes (Fig. 100.25). Although retention of a subchondral plate is attractive for force transmission, areas of relatively smooth bone are prone to interface micromotion, bone resorption, and particle ingress. The loosening mechanism of cemented acetabular components is that the peripheral regions become infiltrated with UHMWPE debris, leading to bone resorption, followed by a creeping process that eventually involves the entire interface (192). This process has been conceptualized as a progressive increase in the “effective joint space.” Mechanical factors are also likely to play a role due to higher than normal stresses occurring in the trabecular bone (64). Steady migration of sockets into the acetabular bone is common, and acetabular component failure usually occurs at a higher rate than for stems in follow-up examinations after more than 10 years. The use of metal backing (115), which reduces the incidence of interface radiolucency in tibial components, has not been successful in cemented acetabular components. Simple finite element models indicated a more uniform stress distribution across the interface, but more complex 3-D models, which included the exact shapes, bone densities, and forces acting (64), have shown otherwise. This has highlighted the care needed in formulating and interpreting finite element models and the conclusions that may be drawn from them.

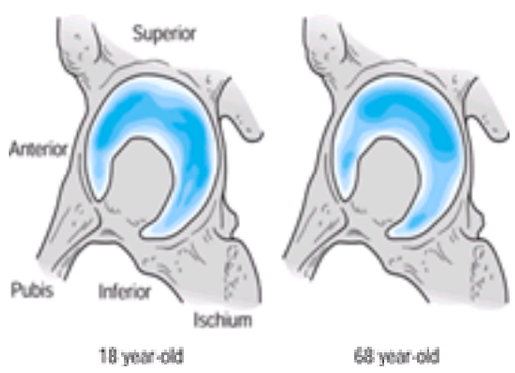


***Figure 100.25.*** Density of the subchondral bone in the acetabulum for two different ages. Assuming that the density reflects load transmission, in youth (*left*), there is more even distribution, which gradually converts to more localized superolateral load transmission over time (*right*). (Data from Muüller-Gerbl M. *The Subchondral Bone Plate,* Vol 141. *Advances in Anatomy, Embryology and Cell Biology.* Berlin: Springer-Verlag, 1998.)

## UNCEMENTED COMPONENTS

In the 1950s and 1960s, thin polished metal hemispherical shells were interposed between reamed surfaces of the femoral head and acetabulum in the expectation that new cartilaginous surfaces would form between the metal and the bone. The tissue formation, however, was unpredictable, consisting of localized islands of fibrocartilage and hyaline articular cartilage. There may still be possibilities for this type of approach if the type of tissue formation can be controlled to a greater degree. The Austin-Moore and similar hemiarthroplasties, generally with rectangular sectioned stems, were moderately successful with regard to fixation and pain relief, although most of the patients had limited functional requirements. Subsequently, many such uncemented stems with “satin” or smooth interface surfaces have been introduced in total hip stems, but have all been subject to bone resorption, interface micromotion, and migration, leading to unsatisfactory results.

Successful fixation of uncemented components depends on achieving tolerable stresses at the implant–bone interface and minimizing interface micromotion to approximately 50 µm or less over most of the interface. These conditions depend on the surface of the stem, the sectional shape, and the overall geometry. The major factors are

- *Stem Surface.* Smooth or satin stem surfaces are unsatisfactory and become surrounded by a thin layer of fibrous tissue and a bony shell, which is linked to the cortices with trabecular struts. Rough surfaces have been successfully used in designs such as the Zweymuller (PLUS, Endoprothetik AG, Switzerland) in cases in which rigid mechanical fixation with the diaphysis has been achieved at surgery. In suitable stem designs, porous surfaces have shown at least 25% of the surface area ingrown by bone, which has proved to be adequate for long-term fixation (42,80). The rate of bone ingrowth and the percentage of area ingrown are enhanced with HA or HA-tri-calcium phosphate (TCP) coating (203). Such coatings superimposed on rough or macrogrooved surfaces have demonstrated enhanced bone growth around the periphery of the stem, but bone has been sparse when gaps have been greater than approximately 1 mm (90,203). In all of the above-mentioned cases, the strongest bone attachment and areas of new bone formation have been where the implant was in contact with cortical bone or strong cancellous bone, in regions where high forces are transmitted (42,80,194).
- *Stem Sectional Shape* (Fig. 100.26). Circular or elliptical sections have the least potential for bone attachment, except where an initial interference fit is achieved and the stem is rough or coated. Corners that cut into the bone have been successful, but again only for certain surfaces and where the overall stem geometry has avoided excessive stresses at the stem corners. Grooves cut into the stem provide little benefit unless they are provided with a bioactive coating such as HA. On the other hand, multiple cutting flutes, especially when combined with a rough surface, provide stable fixation, particularly in torsion (232). A useful application of such flutes is in revision stem design (131)

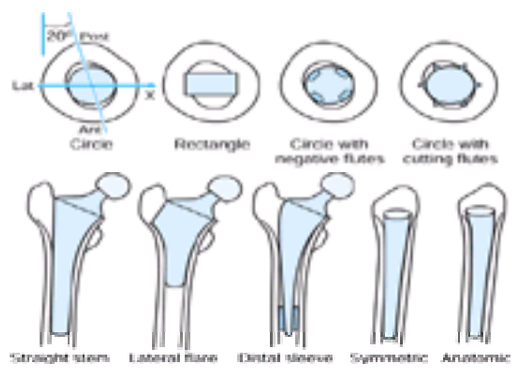


***Figure 100.26.*** The shape and orientation of the normal diaphyseal canal is shown. The most rigid fixation of stems occurs when the corners of a rectangular

stem or longitudinal cutting flutes cut into the cortical bone. Osseointegrated straight stems provide rigid fixation at the expense of proximomedial stress-shielding and difficulty of removal. The lateral flare provides rigid fixation and allows for a shorter stem, especially when designed anatomically in the ML view.

- *Overall Stem Geometry.* In the frontal view, most stems are either straight or have a lateral flare (Fig. 100.26). Generally, it has been found that reliable long-term fixation is obtained when rigid initial fixation has been achieved and most of the stem is rough or coated to promote subsequent bone apposition or ingrowth. Two examples are the Zweymuller and the AML (DePuy, Inc., Warsaw, IN). The main disadvantage of this approach, especially when the stem is both porous coated and long, occurs when removal of an ingrown stem becomes necessary. The lateral flare designs with a high neck cut attempt to maximize proximal fit-and-fill such that the stem can be of reduced length. This is possible because the proximal shape reduces the bending moment on the stem and also provides rigid axial load support. The stems are usually anatomic in shape, as seen in the ML view, to maximize the proximal fill. A question with uncemented stems is the number of sizes needed to provide adequate fit both proximally and distally in the large majority of cases. Some designs address this by using modular distal sleeves (50). Collars are an effective way of increasing the compressive stress component in the proximal femur, but this can be achieved reliably only if there is osseointegration into the underside of the collar (57,71).

It is often assumed that an uncemented stem will cause more proximal stress shielding than a cemented stem owing to its larger cross-sectional area (38,80). Laboratory tests have shown that this is not necessarily the case because the stem becomes tightly wedged in the femur, producing high circumferential tensile stresses as well as up to 50% of the axial compressive stress component (226). Where proximal bone ingrowth has been achieved, bone has been well preserved over time, based on DEXA-scanning data. However, serious proximal bone loss has occurred under the following conditions:

- Rigid distal fixation and inadequate proximal fixation.
- High bending stiffness of stem compared with bone (80) (i.e., thick stem, thin cortex)
- Excessive stem length.

Uncemented stems have an important application in revisions. The major goals in the design of a revision stem are to maximize axial and torsional stability, and to preserve or enhance the remaining bone. To achieve these goals, the following features are an advantage:

- A stem with distal longitudinal cutting flutes and a bone attachment surface (e.g., rough or HA-coated) to provide torsional, axial, and bending stability; if necessary, the long stem inserting into the diaphysis past the level of the previous stem.
- A proximally filling stem with cutting fins and grooves, and a bone attachment surface to attach to and load the proximal bone.
- A lateral flare to enhance axial stability, increase proximal bone loading, and reduce the bending moments on the distal stem
- A “platform collar” with a bone attachment surface to increase proximal bone stresses and increase axial stability.

Because of the extreme range of conditions of the bone, as well as patient factors, a graduated implant system is logical, basing the design decision on a hierarchy of factors (Fig. 100.27). Modular systems using separate proximal “plugs” and distal stems, or using a hollow proximal sleeve with a stem that locks within it (as in the S-ROM [DePuy-J&J, Warsaw, IN] system) (45) are useful approaches in dealing with these variations in an off-the-shelf system. A fragile or detached greater trochanter is problematic and can be held by hooks or wires. Circumferential bone wiring reduces hoop stresses on surgical insertion but may cause stress concentrations in future years. The most difficult revision situation occurs when the diaphysis below the level of the failed stem is thin. Here, the choice is between impaction allografting (91), with a risk of migration, or a very long uncemented or cemented stem affixing in the femoral condyles. The long stem can even be rigidly attached to a knee replacement in those cases in which both the hip and knee need revising or replacing.

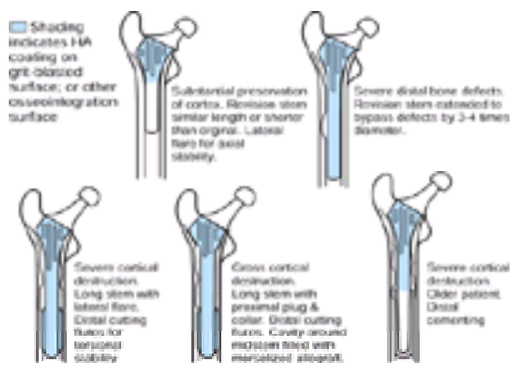


***Figure 100.27.*** A graduated approach for a revision hip system in which various design features are added according to the condition of the femur and status of the patient.

## SPECIAL HIPS—CUSTOM AND CONSERVATIVE DESIGNS

From a scientific point of view, a strong case can be made for providing a custom hip for every case, provided the surgery is suitably precise (14). For a cemented hip, there must theoretically be an ideal thickness and shape of cement mantle and an ideal stem length. For an uncemented hip, there must be an ideal fit and stem length to minimize interface micromotion (109) and produce the ideal combination of interface and bone stresses (110,232). In all cases, the ideal position of the femoral head can be obtained. However, the issue is complex, and separate considerations apply to cemented or uncemented, primary or revision (49,131). Some of the factors that are noted in the argument against the widespread adoption of custom stems are as follows:

- The stem design itself is only one part of the total operative procedure. Larger variations in clinical results may occur owing to technique variables rather than owing to the stem design. This point includes the fact that custom stems are not necessarily positioned in the intended location in the femur. However, a “Robodoc” type of approach (computer-controlled milling of the femoral canal based on preoperative computed tomographic [CT] imaging) might provide the eventual answer to this problem (14,171).
- Long-term deterioration of fixation, such as interface bone resorption and “clinical loosening,” may be dominated by biologic factors at the interface, including the effect of wear debris.
- There are no validated theoretical models for determining the ideal shape for a hip stem for any particular femoral geometry. Hence, the nearest fit from an off-the-shelf system may be as favorable as a custom design if the latter is designed by nonvalidated rules.
- Achieving an accurate fit-and-fill of a stem to the cortical bone (or an exactly uniform cement mantle) may not produce the ideal conditions for long-term success (181). This has been demonstrated for a closely fitting stem, but one without a surface that provided osseointegration, such as porous or HA coating.
- There are insufficient randomized and well-documented studies demonstrating that for routine use, a custom stem system produces better long-term results compared with an off-the-shelf system of comparable design features. Furthermore, the clinical measures—other than outright failure, which requires long follow-up and large numbers—are insufficiently sensitive to distinguish between two stem designs.
- The variations in femoral geometry are contained within a sufficiently narrow boundary that a multisized off-the-shelf system, in combination with reamers and rasps that can modify a given femur shape, can achieve an accurate fit in the large majority of cases.
- The logistics of producing custom hips involve additional technologic steps to determine the 3-D geometry of the femur, such as scaled radiographs (119), CT reconstruction, or even direct shape determination at surgery (160,181), such that there is a significant increase in the cost and administrative steps required, and there may be excessive delay in producing the custom hip
- It might be found at surgery that the custom hip was an unsatisfactory fit, so that an off-the-shelf system was needed as a back-up.

However, even accounting for the above-mentioned problems, there is still a justification for using custom hips in primary cases and even more so in revisions. It has been shown that very low rates of loosening, even superior to that obtained with cemented stems, can be achieved by using fully porous-coated or HA-coated stems that are fixed tightly into the diaphysis by appropriate reaming. However, proximal stress shielding is an undesirable consequence with this system. If the more preferable proximal stem fixation is required, the fit requirements are more stringent. In this situation, custom hips have an advantage. There is considerable empirical data that interface micromotion is the major cause of pain and bone resorption, and laboratory data have shown that micromotion can be minimized by implants with a close fit to cortical bone (46). Hence, in a large series of cases, custom stems should reduce the incidence of pain and interface radiolucency compared with an off-the-shelf design with the same design features (Fig. 100.28). Even if an off-the-shelf hip is used for the more “normal” anatomies, custom stems may still be used for abnormal situations. For revision hip replacements, the variations in the proximal shape after removal of the original stem, the diameter and curvature of the diaphysis below that region, and the required location of the femoral head are so great that a custom approach has a strong justification. Indications for custom hip

replacements are:

***Figure 100.28.*** Examples of custom hips used in primary cases, in which the anatomy ranged from normal to grossly abnormal. **Top left:** A custom hip used for normal anatomy. **Top right:** Subtrochanteric osteotomy in a 90° anteversion congenital dislocated hip using longitudinal cutting flutes across the osteotomy. **Bottom:** Grossly abnormal geometry for which CT scans were used to design a tongue-shaped stem and a stereolithographic plastic model was made for preoperative trials.

- Congenital dislocated hip (CDH), in which the femoral anteversion is in the range of approximately 30° to 60°. The custom stem is designed to fit the canal closely and to restore the normal 15° to 20° of anteversion.
- CDH in which the femoral anteversion is in excess of approximately 60°. Here, a subtrochanteric osteotomy is performed, the upper femur is rotated correctly at surgery, and the custom stem is designed with longitudinal cutting flutes to provide torsional stability across the osteotomy site (Fig. 100.28).
- CDH, juvenile rheumatoid arthritis (JRA), or other conditions in which the hip is exceptionally small or has severely abnormal anatomy (Fig. 100.28).
- In hips that are extremely large, or with large canals, for which the custom hip is made hollow or slotted to reduce the bending stiffness.
- After osteotomy, trauma, or other conditions, with abnormal geometry, sometimes requiring an osteotomy at surgery to restore normal geometrical relations
- Canals with extreme bowing in either the AP or ML views or with an overhanging greater trochanter, requiring a “banana-shaped” stem
- In revisions due to the wide range of bony conditions, proximal shape and bone loss, stem length required, anterior bow, distal diameter, and relation between the proximal and distal dimensions. A graduated approach is especially appropriate for revision hip replacements, as described earlier (Fig. 100.27).

In order to design and manufacture a custom hip stem (223), accurate determination of the 3-D canal shape is required (160). The most accurate method is by the use of CT scans (116,184). A number of commercially available software packages can be used to contour the inside and outside cortical bone boundaries, from which a 3-D model of the bone can be generated. The internal contouring requires definition of a suitable Hounsfield number (a value signifying bone density, where 100 equals water and 1000 equals cortical bone) distinguishing the boundary between cancellous and cortical bone. For purposes of reaming and rasping, a value of 500 to 600 has been shown to be suitable. Another method for determining the shape of the femoral canal that is more direct and less expensive but is restricted to femurs of relatively normal shape is to use scaled AP and ML radiographs (119). The canal outlines are digitized and then a 3-D computer model of the “average femur” is numerically distorted so that its canal outline fits that of the specific femur. This method has been shown to be accurate to better than 1 mm in the regions where a close stem fit is required.

Given the shape of the femoral canal, special software is needed to design the stem to a particular scheme. For example, it can be assumed that distal reaming and proximal rasping are performed to produce a more geometric shape for ease of manufacture and surgery. The general principle is such that the major load transmission occurs proximally (110), which results in the following ideal features:

- Medial, lateral, and anterior flares.
- A collar with a coating for osseointegration.
- A close-fitting proximal stem with an osseointegration coating.
- Proximal macrogrooves to minimize micromotion and provide additional bony stability should there be any deterioration of an HA coating
- A relatively short and smooth distal stem to restrict its function to controlling bending rather than transmitting axial forces.

For economy, convenience, and speed of manufacture of custom hip replacements, prewritten computer numerically controlled (CNC) software is required. This software provides instructions to a milling machine to produce the stem from a bar of preformed material. The end result is an integrated software package that covers both the design and manufacturing stages.

One approach for assessing the relative value of a custom hip system compared with an off-the-shelf system is to assume that accuracy of fit is the single criterion for comparison, and then to determine how many off-the-shelf sizes would be needed to fit the general population of femurs to a given accuracy. This requires that the most ideal set of sizes for the off-the-shelf system be synthesized. The problem can be solved in the following way:

- Produce a “training set” of approximately 100 successive osteoarthritic cases for which custom hip replacements have been produced, excluding shapes that clearly are outliers.
- Define the shape of the stem by *p* geometric variables, such as coordinates of numerous key points around the stem periphery.
- Use “principal component analysis” to reduce the variables, using linear combinations of the variables that best express the *p*-dimensional scatterplot of the original variables
- Synthesize an *n*-sized system such that if $n = 1$, that is the geometric mean, and if $n > 1$, the sizes synthesized provide the best fit for the largest number of the training set.

If such a process is carried out, data such as those shown in Figure 100.29 can be produced. If an accuracy of fit of 0.5 mm or better between the stem and the bone were required, then a 40-sized system would achieve this in just under 50% of all cases. However, if a 1 mm accuracy were satisfactory, a 20-sized system would deal with more than 80% of all cases. Virtually all cases could be dealt with using a 10-sized system if only 1.5 or 2 mm accuracy were required.

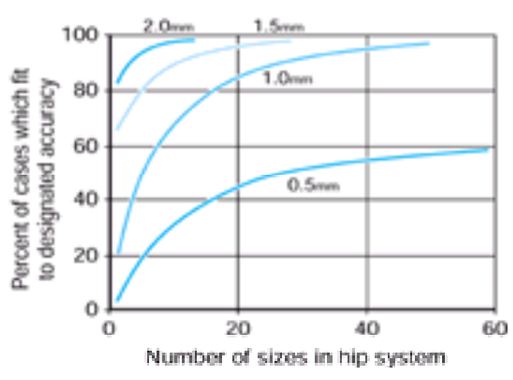


***Figure 100.29.*** Principal component analysis was used to synthesize best fit off-the-shelf hip systems with different numbers of sizes in the system. The percent of cases in the general population fitted to the specified accuracy is shown.

By taking an entirely different approach to hip replacement, namely surface replacement, the problem of fit is greatly simplified. Such an approach can be classified as a conservative hip, which can include several forms. A conservative hip is one that involves fixation to the femur and acetabulum such that its removal for any reason would allow the placement of standard primary hip components with little compromise. Early examples of conservative hips are the Aufranc cup arthroplasty and the various femoral head replacements with short pegs, such as the Judet (212). From the 1970s to the present, various surface replacements have been attempted using combinations of metal, ceramic and polyethylene for the components, and press-fit, cement, porous, and HA for fixation. There have been several problems with

surface replacement to date:

- The bone has remodeled inside the head to exaggerate the load transmission to the medial calcar, as predicted by FEA (Fig. 100.30).

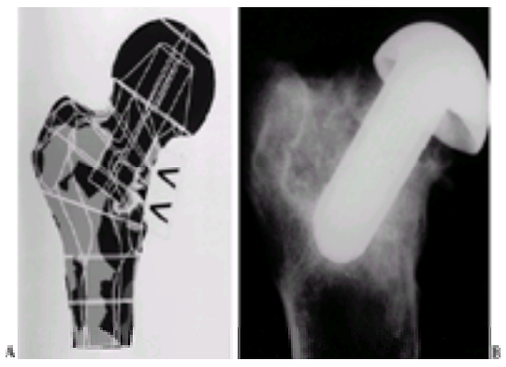

***Figure 100.30.*** **A:** The FEA analysis (Von Mises stress) shows decreased bone stress under the head and increased stress in the medial calcar region. **B:** The radiograph shows a conservative hip after 1 year in a goat, showing bone resorption under the head, and new trabeculae where the stem is close to the lateral cortex.

- Subsequent degradation of the implant–bone interface and overall loosening.
- Fracture of the neck level with the rim of the head component. The risk can be minimized by avoiding excess reaming, as well as by details of component design.
- Excessive reaming of the socket to accommodate sufficient thickness of UHMWPE. This has been solved by using thin shells of a cobalt-chrome (Co-Cr) alloy, a metal-on-metal bearing
- In cases of avascular necrosis of the femoral head.

Other possible conservative hip designs are shown in Figure 100.31. A modification to a standard surface replacement is Townley's TARA design. This design removes most of the head, greatly reducing the trabecular remodeling problem, whereas the short stem improves stability. Thrust-plate designs (e.g., Wiles, Huggler and Jacob) have met with some success in clinical follow-up, and further improvements to this type are possible by using surface textures and coatings for osseointegration. Advantages of this configuration are that good initial stability can be obtained to allow for osseointegration, and a normal modular head can be used. A key issue is that a proportion of the varus bending is transmitted by the neck collar and by the lateral plate because this has important remodeling consequences. Variants of the thrust-plate design use different fixation at the neck resection level, within the neck itself, and at the lateral cortex. FEA of hip stems with a lateral flare indicates that, for a high neck cut, the stem carries only a small bending moment, allowing its length to be shortened considerably. This provides the possibility of a “proximal plug” type of conservative hip. In this type, osseointegration can occur over a large surface area. Preserving part of the femoral neck for bone support is used in the Mayo conservative hip design (Zimmer, Inc., Warsaw, IN) and in the Pipino hip. Other conservative hip schemes include metal shrouds that cover regions of the outer proximal femur. Such designs could have application for abnormal femoral geometries and even for some revisions. From the acetabular perspective, those conservative designs that incorporate a femoral trunnion to use a standard modular head have an advantage for restoring the required head offset.

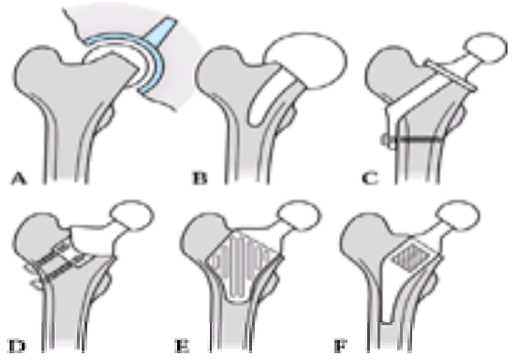


***Figure 100.31.*** Different designs of conservative hip: (**A**) metal-on-metal surface replacement (Amstutz, McMinn); (**B**) capping design with stem (Townley TARA); (**C**) thrust plate (Huggler-Jacob, Wiles); (**D**) stemless design (Munting & Verhelpen); (**E**) proximal CAD-CAM (Santori-Walker); (**F**) Mayo Conservative Hip (Morrey).

## EVALUATION METHODS

Methods used to characterize hip stems and to compare stems with each other can be divided into laboratory studies and clinical evaluations.

### *Laboratory Evaluation Methods*

**Fit-and-fill Geometric Evaluation** Fit-and-fill geometry involves evaluating the frontal view, sagittal view, and the sectional fits, from a given stem size range, in a representative selection of femurs. The goal with cemented stems is to achieve a uniform cement mantle thickness around each cross section, as well as minimum values of around 2 to 3 mm from distal to proximal. For uncemented stems, the goal is to achieve stem–cortical contact at those areas determined by the design philosophy, such as around the entire distal stem or on the lateral and medial flares. From a practical point of view, contact can be considered to be within a defined tolerance level such as 0.5 or 1.0 mm (119). In actual evaluations of this type on typical uncemented stems, it has been found that there is only a small percentage of contact with cortical bone.

**Migration and Micromotion Studies** Typically in migration and micromotion studies, the component is fitted into a plastic or cadaveric bone, cyclic forces are applied to the femoral head in a test machine, and the stem–bone motion is measured over time (193). It has been found that the stem subsides progressively, usually reaching an asymptotic limit after a few hundred cycles. The total subsidence is called “migration.” Thereafter, there is a cyclic elastic deformation between the stem and the bone, termed “micromotion.” The values of micromotion are usually in the range of 10-200 µm (109). It is estimated that a value of about 50 µm is acceptable before interface bone resorption would occur. Generally, better fit, a more anatomic stem, the presence of a lateral flare, and more cortical contact produce less migration and micromotion. To compare different stem designs, use of the same artificial femurs (although it provides reproducibility) might prejudice the results by being a better fit for one particular design; hence, a range of femoral shapes is preferable. The use of cadaveric bones is ideal for realistic geometry and bone properties, but large numbers are needed for statistical significance unless a small number of stems can be successively implanted into the same femur without prejudice.

**Finite Element Analysis** FEA has the major advantage that the stresses and strains in the entire system can be determined. The data can then be used to predict bone remodeling (201,230), interface failure, cement cracking, stem fracture, cement-stem debonding (210), and other factors (113). A relatively recent advance is iterative analysis, in which the material properties or a stem shape are changed as a result of the first stress analysis (114). For example, the elastic modulus values for the bone are changed to reflect the local stresses where a region of stem causing a stress concentration is smoothed away. The FEA is then rerun, and the process is repeated until a steady state is reached. Using this technique, the bone remodeling over time can be simulated, predicting the amount of bone loss in the steady-state situation. An initial proposal for a stem shape can be successively modified to minimize an objective function of the stresses at the interface and in the bone itself. The consequences of progressive cement debonding can be studied. However, there is still considerable skepticism concerning the ability of FEA to predict actual *in vivo* behavior. Indeed, many models are idealized, showing, for example complete stem–bone contact when, in reality, there is a variable mixture of gaps, as well as cortical and cancellous bone contact. Nevertheless, provided the model is appropriate to the intended question, the FEA method is invaluable for comparing different stems, using such criteria as the stresses, strains, or strain energy density in the system (185).

**Wear and Friction Measurement** Wear and friction measurement is discussed in the next section on clinical evaluation methods.

### *Clinical Evaluation Methods*

Apart from "standard" clinical and outcome studies, clinical evaluation methods (43,125) include migration studies, DEXA scanning, and measurement of wear from radiographs.

**Migration Studies** The most accurate migration study method is roentgen stereophotogrammetry (RSA), developed by Selvik in Sweden in the 1970s (196). The method involves placing small tantalum beads in the bone at the time of surgery, identifying landmarks in the component, and taking biplanar radiographs through a calibration cage (127,168). Digitization of the points to obtain coordinates allows the 3-D position of the component relative to the bone to be calculated to a high degree of accuracy, approximately 0.3 mm and 0.3°. As well as being used for migration over periods of several years, the "inducible" displacement at a particular time has been measured when the patient relaxes and then loads the leg. These data give an idea of the rigidity of the implant–bone interface.

The RSA method must be carried out prospectively. To use retrospective data, where radiographic and clinical data are available for a long follow-up time (e.g., 10 years), simpler methods have been developed using landmarks on the bone and component. In some methods, accuracy is enhanced using mathematical corrections for different x-ray orientations, as well as by using boundary detection methods. Accuracies of 0.5 mm and 0.5° can be achieved. A typical example of migration curves using such a method is shown in Figure 100.32. It is important to specify when the initial (time zero) measurement was taken because even the first few steps of weight bearing can cause as much migration as in the subsequent 6 months.

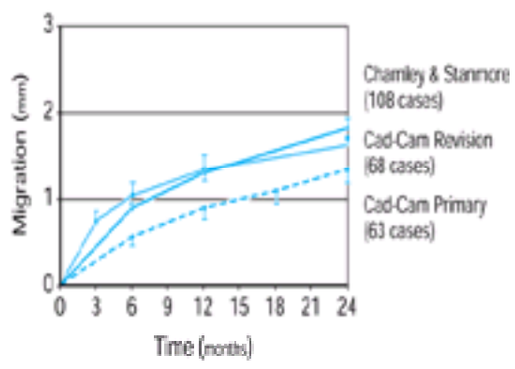


***Figure 100.32.*** Migration versus time curves for three groups of hip stems. The CAD-CAM hips, such as those shown in Figure 100.27 and Figure 100.28, are compared with standard cemented hips. The migration curves are useful early indicators of longer term loosening rates.

From studies of numerous designs of cemented and uncemented hips, it has been found that the migration behavior in the first 2 years correlates with loosening and radiolucency in the longer term (133,222). In particular, stems that are "continuous migrators," that is, those for which the migration rate at 2 years has not reduced to a very small level, usually go on to "clinical loosening" during the following few years. Hence, the method is invaluable for evaluating new hip designs in a short time period. However, it must be recognized that longer term effects such as socket wear, wear of the stem surface, fracture of the cement mantle and of the stem itself, and corrosion or fretting at interfaces are not addressed in such a short study.

**DEXA Scanning** DEXA scans are usually taken in the AP view to measure the total bone mineral surrounding the implant, the proximomedial region being of particular interest. The method is quantitative, unlike radiographic data from which only general impressions of bone density, or relative density, can be obtained (201). Great care is needed in the interpretation of DEXA data. Bone density can decrease in the postoperative months owing to the patient's a low activity level, and drugs can also have an effect. Large bone density changes are often apparent only after several years, although 2-year data would identify an implant with severe changes. Another factor is that whereas subsequent changes in bone density can depend on the initial stresses, calculated, for example, by FEA, if radiolucency subsequently develops due to interface problems, the stress distribution on and in the bone can change as a result.

**Measurement of Wear from Radiographs** At this time, the accumulation of wear debris and the subsequent osteolysis and loosening are the major limitations to durability of total hip replacements (69,98). Literally millions of particles are released on every step. The particles consist of granules released from the tops of asperities and ridges, or fibrils pulled away as small filaments. Particle size ranges from 0.1 to 1 µm (107). The wear rates, measured as the linear penetration into the socket, have averaged 0.05 to 0.1 mm per year for 22 mm joints, but the ranges in given series have varied considerably (96). Determining the effect of different variables on wear rate is difficult. In the laboratory, the test conditions are greatly simplified, but aging effects of the materials that occur in the body are not easily reproduced. In vivo, there are numerous variables, many of which cannot be accurately quantified. The main factors that affect the wear factor and the rate of wear in total hip replacements are the diameter (149), surface finish, and material of the femoral head, as well as polyethylene processing and patient factors.

- *The Diameter of the Femoral Head.* From the basic wear equations,

$$\text{wear rate} = \text{wear factor} \times \text{load} \times \text{sliding velocity}$$
$$\text{wear volume} = \text{wear factor} \times \text{load} \times \text{sliding distance}$$

  the volume of wear is proportional to the diameter, and the penetration is inversely proportional to the diameter of the femoral head. Penetration into the socket in itself is not a problem except when it begins to cause impingement, which can then loosen the socket or result in dislocation. For 22 mm heads, these problems may occur in longer follow-ups in heavy and active patients if the wear factor is unusually high. It is noted that the wear equations assume that the wear rate is independent of both surface area and contact pressure, which may be a reasonable assumption for the ranges encountered in hip joints (148,149).
- *Surface Finish of the Head.* Metallic femoral heads are manufactured with an exceedingly high polish of *Ra* value 0.01 to 0.02 µm. *Ra* is the mean value of the peaks and troughs with respect to a mean line (82). In a new head, asperities, projecting from the surface, are not present, except those made of materials such as cast cobalt-chrome. Hard carbides at grain boundaries can resist polishing and be slightly prominent. However, at surgery, the head can become scratched owing to the impingement of instruments or hard particles embedded in the impactor. In the patient, the head can become scratched by hard particles from a number of sources: The UHMWPE can have contaminants; the cement can release barium sulfate; the stem surface can shed metallic debris or HA from coatings (26); or bone particles can be present from surgery. The head itself can release hard particles due to rubbing. As well as becoming temporarily trapped between the bearing surfaces, particles can embed in the plastic, causing multiple scratches on the head. The end result is that the number of scratches on the head can accumulate over time. Typically, the *Ra* value of retrieved heads compared with new heads is two to three times higher for cobalt-chrome, higher still for stainless steel, and highest for titanium alloy. In contrast, the *Ra* value of ceramic heads changes little over time. Scratches with cutting edges above the mean are the most damaging, however. Over time, the wear factor *K* will increase due to the scratching. However, the penetration rate into sockets over time may still approximate to linear if the the patient gradually reduces his or her activity level.
- *Femoral Head Material.* In general, the harder and more wettable the material, and the better the initial surface finish, the less the wear. Alumina ceramics against UHMWPE have had a long history of clinical use and have shown wear rates approximately half those of metal on UHMWPE, which has been confirmed in hip simulator studies (237). Zirconia ceramics have a similar record, although with shorter follow-up at this time. However, zirconia is tougher than alumina and would probably be recommended over alumina. Alumina ceramic-on-ceramic bearings have shown exceedingly low wear rates, one to two orders of magnitude lower in volume than for metal or ceramic on UHMWPE. Zirconia-on-zirconia is not viable. The main drawbacks of ceramics are that stringent tolerances are required for the trunnions and for the bearing geometry itself, and a number of breakages of ceramic heads have been reported, although the incidence is well below 1%. Overall, the use of ceramic bearings from proven sources offer definite advantages, especially for younger and more active patients. Metal-on-metal bearings, using cobalt-chrome alloys, have likewise shown exceedingly low volumetric wear over long time periods. The reservations against more widespread use of these alloys are the unknown long-term systemic effects of metallic ions, although no adverse effects have yet been demonstrated in McKee-Farrar hip replacements, which have had more than 2 decades of follow-up. Metal-on-metal components can be designed with thin sections, which is an advantage for surface replacement hips.
- *Processing of Polyethylene.* In recent years, a great deal has been learned about the effects of gamma irradiation, most notably molecular chain scission and cross-linking (81). The latter can be due to oxidation over time when components are stored for several years before use or in service conditions. This factor, in turn, causes an increase in density, a degradation of mechanical properties, and a reduction in wear resistance. In such cases, retrieved sockets have shown a "white band" of degraded polyethylene at or just below the surface. In laboratory tests, the wear factor increases progressively with oxidation level. At this time, when gamma-irradiation is used for sterilization, the irradiation, together with the packaging, is carried out in an inert atmosphere to avoid the effect of oxygen. Other sterilization methods, such as ethylene oxide (ETO) and gas plasma, avoid chain scission and oxidation, and evidently reduce the wear factor. However, more recently, methods for minimizing the progress of oxidation have been developed. The free radicals produced by gamma-irradiation or by electron beam irradiation have been cross-linked by various postirradiation treatments such as controlled heating. The reductions in the wear factor have been dramatic, as measured in hip-simulating machines. However, with some processing methods, there is a reduction in mechanical properties so that suitable fatigue testing of

components is needed.

- *Patient Factors.* The wear rate will increase with the weight and activity level of the patient, and even the type of activity might have an effect. However, in radiographic studies of wear penetration, or studies of retrieved sockets, obtaining significance for a particular variable has proven difficult because of the effects of many other variables and the unknowns involved. Care must be taken to distinguish between wear factor *K,* which is a constant for that bearing (as long as the bearing does not change); wear rate, which depends on weight and activity level; and wear volume, which is the average wear rate times time.

***Hip-Simulating Machines***

Hip simulators have been used for more than 30 years to measure wear rates. Today, data from such machines are a requirement for the introduction of a new bearing combination. The proposed test method by the International Organization for Standardization (ISO) includes

- A physiologic single-axis force cycle in a direction fixed in the acetabulum.
- Three independent motion curves applied to the femur: flexion-extension, inward-outward rotation, and abduction-adduction (Fig. 100.4 and Fig. 100.20).
- Twenty-five percent calf serum at 37°C.
- Tests run at 1 Hz for 5 million cycles
- Dimensional and weight changes measured at intervals.

The major goals in specifying such a standard are to provide a method that produces results sufficiently representative of *in vivo* conditions and to allow for comparative data between different laboratories. No single test can, for practical reasons, reproduce physiologic conditions, which involve a range of activities and a host of other variables. The wide range of conditions in the patient population means that the results of a test must be viewed statistically and not in an absolute sense. A comparative test of a new bearing against a known standard is therefore necessary. Another factor is that, as with all wear tests, there can be a wide spread of results from nominally the same bearing, which has led to the requirement for multichannel machines (Fig. 100.33).

***Figure 100.33.*** A multistation AMTI-Boston hip simulating machine for long-term hip wear testing. The machine includes computer monitoring of the input forces and motions as well as other test parameters. (Photo courtesy Advanced Medical Technology, Inc., Watertown, MA.)

As hip simulators have evolved over the past two decades, several different mechanical configurations have been developed:

- The femur and acetabulum are either anatomically positioned (ideal for particle transport) or inverted (easier experimentally).
- The force is applied relative to the socket or to the femur (in reality, the force is more closely aligned with the femur)
- Independent motions about one, two, or three axes are applied. To assess this motion, the paths of multiple points on the femoral head traversing over the plastic socket can be mapped (211). Only for three independent motions do the patterns of the points resemble the physiologic patterns, namely loops that cross over each other. This is embodied in the present AMTI (Advanced Medical Technology, Inc., Watertown, MA) machine. However, two motions, as long as they are not in phase, will produce crossing loops but of different shape that can achieve similar wear rates. This type of motion applies to the McKellop and to the recent Leeds machines. Single-axis motion is inadequate in that straight or curved tracks are produced that do not cross over one another, and hence the wear rates are too low.

In recent years, it has been recognized that in addition to carrying out tests under ideal conditions, more adverse conditions need to be addressed. The effect on the wear rate of scratches on the femoral head or of hard particles introduced into the fluid are particularly important.

## KNEE REPLACEMENT

### KNEE MECHANICS

The general conception of normal knee motion is usually derived from the measurements of “passive motion” of knee specimens when the external forces are small (228). The tibia has either been passively flexed and held at successive flexion angles, or a small flexion moment has been applied, balanced by a force in the quadriceps (97,183). The motion itself has been described in several different ways, which has led to a number of misunderstandings. The “contact points” are defined as the common tangent of the femoral and tibial outlines, as seen on radiographs (although in reality only the bone outlines and not the cartilage outlines can be seen). These contact points displace posteriorly, with the lateral contact point moving much more than the medial (134,183) (Fig. 100.34). If the actual contact areas were plotted, however, although the areas would follow the same trend as the “points,” it would be difficult to define a point directly from the areas because the areas are of irregular shape and occur on both the cartilage and the menisci (2). Motion can also be described by defining axes in the femur, the transverse axis being through the centers of the lateral and medial posterior femoral condyles, or the epicondylar line. If the motion of the femoral origin at the center of the femur were plotted as a function of flexion, it, too, would move posteriorly with flexion, whereas the transverse x-axis would tilt slightly. This rigid body motion would not be the same as that determined from the contact points. For example, in a total knee replacement (TKR) seen in the sagittal view, it can readily be observed that if the tibial surface is dished, the contact point motion is much greater than the rigid body motion.

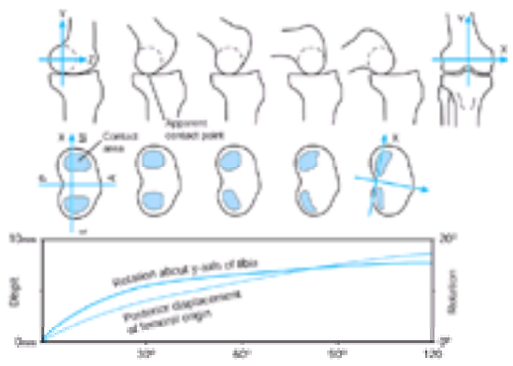

***Figure 100.34.*** Three methods for describing passive knee motion. **Top:** The contact points defined by the common tangent. **Center:** The contact areas. Lower: Rigid body motion of the femur relative to the tibia, based on axes defined in the femur and tibia. (Data from Rovick JS, Reuben JD, Schrager RJ, Walker PS. Relation Between Knee Motion and Ligament Length Patterns. *Clin Biomech* 1991;6:213.)

The passive motion of the knee can now be summarized in rigid body terms, with the axes as defined in Figure 100.34. As the knee is flexed from 0° to 120°, there is a posterior femoral displacement and internal tibial rotation about its y-axis. There is also a valgus rotation of the femur as the lateral femoral condyle moves down the slope of the tibial plateau. This motion is governed by the shape of the condylar surfaces, the different mobility of the menisci on the lateral and medial sides (219), and the locations and stiffnesses of the cruciate and collateral (especially the medial) ligaments (5,41,88,89,183,199,207,241). This “passive motion” of the knee is useful for

describing a middle path of knee motion for reference purposes.

Three effects will change this motion path considerably:

- An AP force or an internal-external torque is applied to the tibia about its y-axis at a given flexion angle (88,229) (Fig. 100.35). This produces displacements and rotations, which are termed *laxity* (108,123). The laxity is reasonably constant from about 30° to 120° of flexion but reduces as the knee is extended from 30°. An *envelope of passive motion,* defined as the boundaries within which the knee position can lie (24,25), is thus obtained.

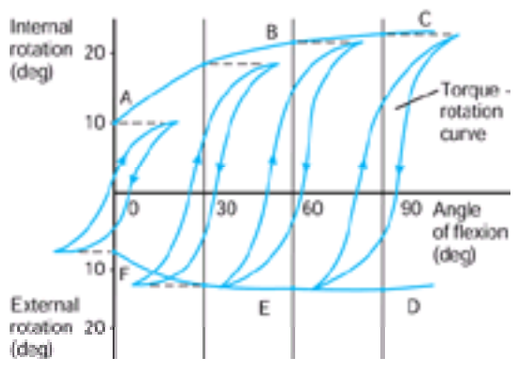


***Figure 100.35.*** The torque-rotation curves at different flexion angles describe the rotational laxity of the knee. A composite of the rotations describes the envelope of knee motion. Note that the x-axis represents the neutral rotation at that angle of flexion. The neutral positions relative to zero flexion change at subsequent flexion angles.

- An AP force is applied to the tibia along its z-axis, and *then* an internal-external torque about the y-axis is applied. The rotational laxity is reduced. Similarly, if the torque is applied first, the AP laxity is reduced. This is termed *coupled motion* (143,172). In the extreme positions, the laxities can be reduced to very small values
- A compressive force is applied along the tibial y-axis. The laxities are now reduced, AP laxity (108) more so than rotational laxity (147). The mechanism is that the dishing of the joint surfaces and the deformation of the surfaces require that the joint displace upward to move from its neutral position, thus requiring energy input. In the normal knee, frictional effects due to the compressive force are small.

In functional activities (7,73,132), the knee motion occurs within the envelopes of laxity. An infinite number of motion paths is possible; these paths are likely to vary even between successive steps (164). The major factors that determine the actual motion path are the external forces and the muscle forces (138). Whereas the principal force direction across the knee are along the long axis of the tibia, the combination of the applied forces results in shear forces and torques (Fig. 100.36). These force components have been calculated using measured values of the foot-to-ground force, the limb segment kinematics, and electromyography (EMG) data of muscle action, input to a knee model (136,155,156 and 157). In a recent study, telemetry data from an instrumented distal femoral replacement was used (206). During walking, there are three peak forces of 2 to 3 BW. The shear forces act in both anterior and posterior directions, with posterior being predominant, in a direction so as to tense the PCL. The torque is predominantly internal, the effect being to move the lateral tibial plateau forward. The forces do not increase dramatically for ascending and descending stairs, the largest increase of about 15% in the compressive force occurring in descending stairs (156). The patellofemoral forces are just less than half BW in walking but reach approximately 1 BW or more in rising from a chair or climbing stairs. The axial torques in level walking and on stairs are in the range of 6 to 8 N·m.

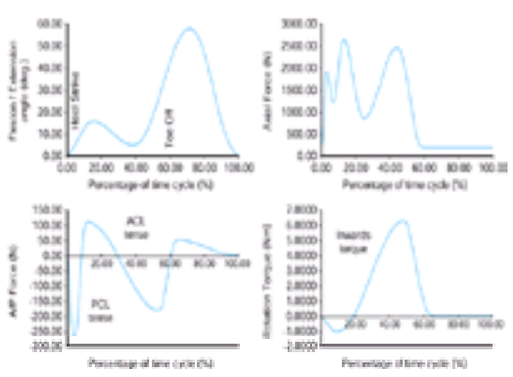

***Figure 100.36.*** The flexion angle, forces, and moments acting across the knee during normal walking, as specified in a current ISO-proposed standard for knee-simulating machines. These forces are distributed to the joint surfaces and to the ligaments.

## CONDYLAR REPLACEMENTS—FIXED BEARING

The most obvious form for a TKR is a replacement of the bearing surfaces using metal and plastic components, positioned so as to restore the neutral alignment of the knee and achieve the correct tensions in the ligaments (121). The simplest form is a compartmental type (a “uni”), which is applicable if the patellofemoral surfaces do not require replacement (55). Most often, only the medial side is required, but replacement of both sides as an alternative to a TKR has been used extensively in some centers. Some of the issues concerning compartmental knees are the following:

- When both the anterior cruciate ligament (ACL) and PCL are present and the components are correctly sized and positioned, the function is close to normal (231).
- When the ACL is absent (19), abnormal motion and even instability occur (92).
- Most designs have had a close-to-flat tibial surface, with a high sensitivity to the slope in the sagittal plane.
- The flat tibial surface, thin plastic, and metal backing have led to severe wear problems in some designs.
- Molded polyethylene flat components that are not metal backed have survived for long periods (up to 20 years) without serious wear (102).
- Loosening has been a problem, especially when the subchondral bone has been removed and there has been excessive AP sliding
- Surgical placement has been difficult in the absence of a precise instrumentation system.

On the basis that the AP movement of the contact point on the medial side is small, it appears logical to provide a dished tibial surface, which would alleviate a number of the above problems. Improved designs and instrumentation, coupled with small incisions, present an important opportunity for outpatient surgery in the appropriate indications.

One-piece tibial and femoral components covering both compartments are able to provide stable fixation, are self-aligning, and incorporate the patellofemoral surfaces; for these reasons, such designs are the most frequently used. A fundamental principle of condylar replacement is that the artificial surfaces are designed such that, in combination with the remaining joint structures, the laxity and stability characteristics are similar to those of the normal intact knee (144). In general terms, if all of the ligaments are preserved, the tibial surface requires only shallow dishing (Fig. 100.37). If the ACL is absent, posterior curvature is required (although in most designs there is insufficient curvature to compensate for the ACL). If both cruciate ligaments are absent, posterior and anterior curvatures are required (85).

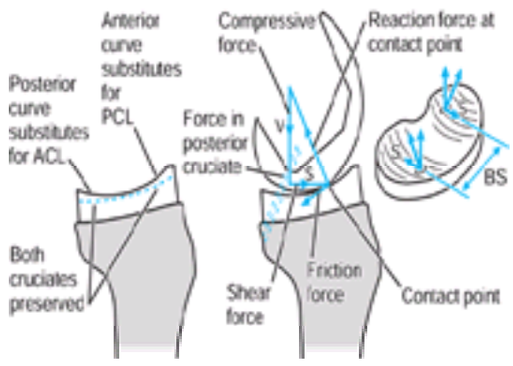


***Figure 100.37.*** The principles of the total condylar type of TKR. **Left:** Geometry of the tibial surface, depending on whether the cruciate ligaments are present or absent. **Center:** When there is a compressive force and a shear force on the femur, these forces are carried by the surfaces and the ligaments.**Right:** Torque *Q* is carried by the shear force components *S* acting at distance *BS, Q* = *S* × *BS*.

The AP shear force is shared between the cruciate ligaments and, to a lesser extent, other ligaments and soft tissues, and the reaction forces at the joint surfaces (19). The ACL is more tense in early flexion, and the PCL is more tense in high flexion (183). The fraction of the shear force carried by the cruciate ligaments depends on the tibial surface geometry, the location of the "bottom of the dish," and the placement of the components. Even modest dishing of the tibial surface (e.g., sagittal radius, 70 to 80 mm) provides considerable stability, especially when high compressive forces of 2 to 3 BW are exerted (144,214). In TKRs in which the PCL is preserved, the fraction of the shear force carried by the PCL depends on the curvature of the tibial surface, the curvature of the interfacing femoral surface (which depends on the angle of flexion), the location of the bottom of the tibial dish, the tightness of the PCL (which depends on the surgery), and the angle of flexion (89). In practice, the PCL, especially the anterior fibers, carry an increasing proportion of the anterior shear force with flexion (129). The different schemes for condylar TKR design have advantages and disadvantages:

- Combined ACL and PCL preservation (assuming the knee has both) requires condylar shapes and surgical placement within approximately 2 mm of ideal to be effective. The tibial component must leave space for both ligaments, and surgical exposure is more restricted.
- PCL preservation alone may result in an abnormally posterior contact point in early flexion (68), and there is no mechanism for producing anterior displacement of the femur as the knee extends.
- ACL and PCL sacrifice requires condylar shapes (or cams) with excessive rotational constraint under weight-bearing conditions. The AP displacement is limited, although an intercondylar cam may produce posterior femoral motion in high flexion
- A valid and reproducible method is needed for the bone cuts and for performing ligament releases to achieve ideal kinematic and stability characteristics. This condition applies more especially when one or both cruciate ligaments are preserved.

The basic principles of the stability and laxity of dished condylar surfaces, embodied in the original Total Condylar (Howmedica, Rutherford, NJ) (213,215,228) and in a number of other later designs, is shown in Figure 100.37. If there is a compressive force *V* acting down the long axis of the tibia, the femoral component locates at the bottom of the tibial dish. If a shear force *S* is superimposed, the femoral component displaces anteriorly such that the reaction force at the contact point exactly balances *V* and *S*. The contact point displacement is greater than the rigid body displacement. A torque applied to the tibia is equilibrated by an anterior displacement of one side of the knee and a posterior displacement of the other. The torque *Q* carried by the surfaces is *S* × *BS,* where *BS* is the bearing spacing. The total condylar type of design thus provides both stability and laxity, and has the advantages of moderate conformity for low wear, simplicity, and ease of surgery.

An interesting variation of a standard total condylar concept is an evolution of the Freeman and Freeman-Samuelson (Protek) designs (86). The medial side is almost fully conforming, whereas the lateral side has low conformity. This has the potential advantages of achieving physiologic motion and reducing wear on the more heavily loaded medial side.

In coupled motion, when AP displacement and internal-external rotation are combined, the laxity curves of a TKR are complex (Fig. 100.38). In neutral rotation, an AP laxity test, in which an anterior shear force is applied to the femur followed by a posterior shear force, produces anterior and posterior femoral displacements. As shown in Figure 100.38, when there is greater conformity anteriorly, the anterior femoral displacement is less. When rotation is superimposed, one femoral condyle moves up the posterior curve. Because of the greater anterior conformity, the movement up this curve is less than that at the posterior and, hence, there is a posterior shift in the neutral femoral position. When the AP laxity test is now carried out, the AP displacement is reduced. The more rotation that is superimposed, the less is the AP laxity and the more is the shift in the neutral position. If the femur is now flexed, the smaller posterior femoral radius is now in contact with the tibia, and the laxity is reduced. However, as shown in the geometric drawings of the sagittal femoral outline, the neutral position of the femur is now shifted *anteriorly.* These shifts in the neutral position, which are primarily dependent on femoral geometry, have an important effect on soft-tissue tensions and kinematics.

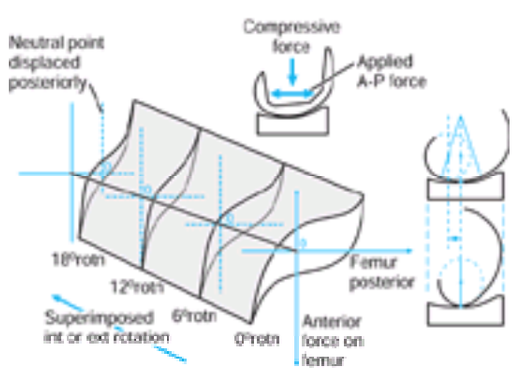


***Figure 100.38.*** Coupled motions, showing the effect of superimposed internal-external rotation on AP laxity. As rotation is increased, the AP laxity decreases and the neutral point of the femur moves posteriorly. The geometric profile drawings show that in flexion the rigid body motion of the femur moves anteriorly due to the sagittal curvature, and the AP laxity is increased.

Another important effect on kinematics is friction between the femoral and tibial surfaces (188) (Fig. 100.39). The coefficient of friction for metal on polyethylene surfaces is 0.05 to 0.1. For a condylar prosthesis implanted in a knee, without friction, the laxity curve would be strain stiffening (Fig. 100.14) with a hysteresis loop. However, owing to friction when a compressive force is acting and the shear force direction is reversed, as occurs during the gait cycle, there is a "stick" period without motion. In function, this will result in some erratic behavior of the motion, with combinations of rolling, sliding, and stick.

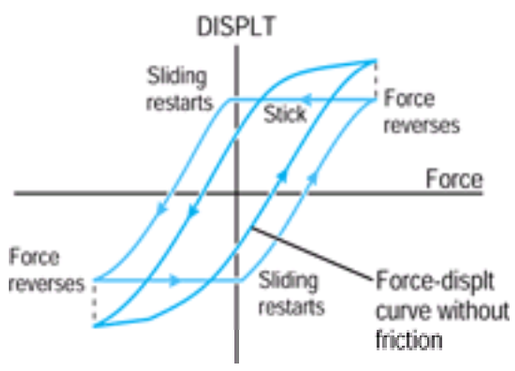


***Figure 100.39.*** Friction has an important effect on motion, by reducing the total laxity and by causing "stick" periods.

Based on the above-mentioned factors, it can be seen that the geometric parameters of a TKR play an important role in determining function and durability. The geometric considerations can be broadly categorized as being in the sagittal plane or the frontal plane.

***Sagittal Plane***

Geometric considerations in the sagittal plane consist of the following:

- The profile of the patellar flange replicates normal to produce correct quadriceps lever arms (7). Gait abnormalities (19) have been associated with profiles that are too prominent distal-anteriorly (8).
- The distal radius of the femoral component is larger than the posterior radius to provide greater stability and larger contact areas in early flexion.
- If the posterior-distal transition angle (PDTA) is about 20°, the large distal radius contacts the tibia during the stance phase of gait, maintaining relatively low contact pressures. However, this will result in a tendency for anterior sliding of the femur after 20° (Fig. 100.38).
- The posterior radius is similar to the anatomic radius (approximately 20 mm average) to maintain correct soft tissue lengths. This will result in increased laxity in flexion compared with extension, as in the normal knee.
- When the femur locates at the bottom of the tibial dish the radius in early flexion, the femur and tibia are in the correct anatomic relation to ensure normal patella and soft-tissue mechanics
- As the knee moves to zero flexion and into slight hyperextension, the contact point rolls anteriorly to provide an increased lever arm for the hamstrings and gastrocnemius.

***Frontal Plane***

Geometric considerations in the frontal plane consist of the following:

- The bearing spacing (Fig. 100.40) determines the varus-valgus moment before lift-off, and affects the feasibility of interchangeability between different sizes in TKR systems. A larger *BS* value is preferable.

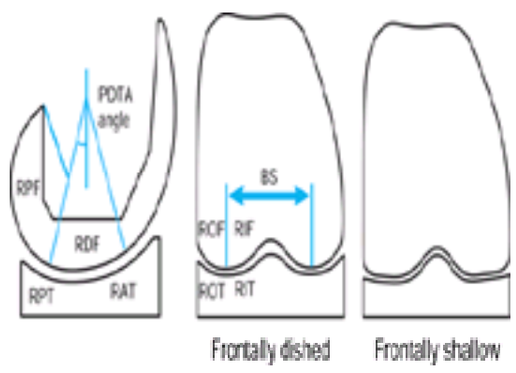


***Figure 100.40.*** Description of a condylar TKR using geometric parameters. These have an important effect on function and durability. BS, bearing spacing between the lowest points on the femoral condyles; PDTA, the angle of transition between the distal and posterior radii; RAT, anterior tibial radius; RDF, distal femoral radius; RIF, inner femoral radius; RIT, inner tibial radius; ROF, outer femoral radius; ROT, outer tibial radius; RPT, posterior tibial radius; RPF, posterior femoral radius.

- The inner femoral radius (RIF; Fig. 100.40) is determined by the requirement to provide an anatomical patellar groove.
- The outer femoral radius (ROF; Fig. 100.40) needs to be between approximately 25 mm and the sagittal tibial radius, which is 55 to 80 mm in contemporary designs. This is required to avoid the outside of the femoral condyles digging in during internal-external rotation.
- A femorotibial radial clearance of only 1 to 2 mm produces elliptically shaped contact areas with relatively low contact stresses.
- For a given clearance between the femoral and tibial radii, larger outer radii (ROF, ROT; Fig. 100.40) have the advantage of a larger area of contact and reduced contact stresses.
- When lateral lift-off occurs, the contact point for large radius surfaces will roll medially, counteracting further lift-off. In extreme cases, there may be some tendency to ML slipping. For a given clearance, there is a critical varus angle at which digging in occurs.
- When lateral lift-off occurs, the small radius surfaces rotates about the center of curvature and the contact point remains constant. ML stability is maintained
- For a given clearance between the femoral and tibial radii, surfaces of larger radius provide increased rotational laxity.

Experience with some condylar designs in the past 25 years (11) has shown satisfactory function and a survivorship of better than 95% at 10 years (78,130,178). However, other designs have shown serious problems, such as instability (including ML), tibial baseplate fracture, excessive wear and deformation, patella subluxation, limited flexion, and component loosening. In many cases, the problems have been related to unsatisfactory geometric features of design; in other cases, alignment has been the main problem (169,208).

**STABILIZED OR GUIDED-MOTION DESIGNS**

In the total condylar type of knee prosthesis, stability is provided by the articular surfaces and the retained ligaments. The motion of the femorotibial contact point is hence determined by these factors, in response to the external forces and the muscle forces. As indicated previously, designs with shallow tibial surfaces and preservation of both cruciate ligaments have the theoretical capability of reproducing normal kinematics. Fluoroscopic techniques have been used to record relative tibial and femoral knee motion during a range of activities. The method involves sequential high-resolution fluoroscopic images obtained in the sagittal plane. If the 3-D geometry of the femoral and tibial components is known and input to the computer, then the computer image can be moved into a 3-D orientation so as to match the radiographic image. In this way, the relative 3-D position of the femur on the tibia can be determined throughout the activity. The accuracy of such methods is now better than 1 mm and 1°. Interestingly, this method was originally developed for the military to identify high-flying aircraft.

Fluoroscopic studies of TKR patients (13,68,204) have shown the following:

- The smooth AP and rotation patterns measured in passive knee motion are not reproduced during weight-bearing activities, such as deep-knee bends and step climbing.
- The AP motion between the femur and the tibia is strongly influenced by the ground-to-foot and muscle forces.
- There are considerable differences in the AP motion between different individuals. Even the same individual produces variable AP motion for the same activity at different times.
- TKRs with high femorotibial conformity in the sagittal plane show more reproducible AP motion
- Condylar lift-off, mostly medial, occurs often, and it is more frequent and of greater magnitude with PCL-resecting devices and when the BS (Fig. 100.40) is low.

There is thus a rationale for designing condylar knees that control relative femorotibial motion in a more predictable way, at least during part of the flexion range. One scheme for controlling the kinematics is by the use of intercondylar cams.

Two cam types have been used since the 1970s. The first is embodied in the Kinematic (now the Kinemax) Stabiliser (Howmedica, Rutherford, NJ) (78) (Fig. 100.41), which consists of cam surfaces that are in contact throughout flexion and produce a progressively posterior movement of the femorotibial contact point with increasing knee flexion. The second type is used in the Posterior Stabilised Knee (Zimmer, Warsaw, IN), in which the cams interact only after about 70° flexion (233), thereafter producing a large posterior displacement of the contact point. The aims of these particular designs were to:

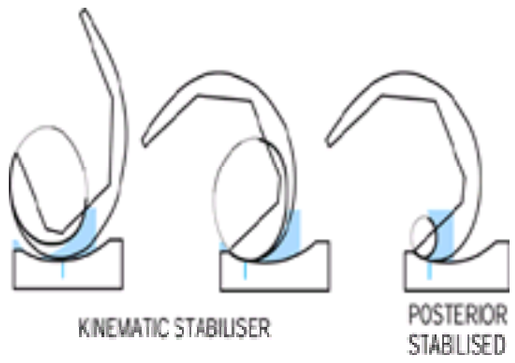


***Figure 100.41.*** Examples of early guided-motion knees, in which certain phases of the AP motion are controlled by intercondylar cams. **Top:** Kinematic (now Kinemax) Stabiliser (Howmedica, Rutherford, NJ). **Bottom:** Posterior Stabilised Knee (Zimmer, Warsaw, IN).

- Increase the quadriceps lever arm at high flexion angles.
- Increase the range of flexion by preventing posterior impingement of bone and soft tissues
- Prevent posterior tibial subluxation in flexion under the action of the hamstrings.

Important mechanical criteria concerning the cam design are as follows:

- The height of the contact points on the plastic cam should be minimized to minimize the rocking moments on the tibial component, and to reduce the possibility of fracture of the plastic post and component loosening.
- The cam should be shaped to allow internal-external rotation without digging in at the corners
- The amount of elevation of the femoral component before dislocation occurs (“hop height”) should be maximized.

However, if cams or guide surfaces, in combination with the condylar bearing surfaces themselves, are to provide ideal knee kinematics, the following criteria can be added:

- The device should control the location of the femorotibial contact points in the AP direction and internal-external rotation throughout the flexion range but allow some laxity about these contact points.
- The device should guide the contact points posteriorly with flexion (especially on the lateral side) and anteriorly with extension.
- The device should produce internal tibial rotation progressively with flexion and external rotation with extension.

The rationale is to provide optimal muscle lever arms and soft-tissue tensions to restore optimal function as closely as possible. By using special computer programs (225), the designs shown in Figure 100.41 and other types of intercondylar guide surfaces with different patterns of motion control can be synthesized (Fig. 100.42). Another example is the Superstabiliser-CCK type (137,191,213). (Superstabilizer is a product of Howmedica, Rutherford, NJ; CCK is a constrained condylar knee manufactured by Zimmer, Warsaw, IN.) This is designed primarily to carry varus-valgus moments, and hence, the computer program is used to maximize the area and strength of the plastic tibial post. In addition, it can be seen that the interaction between the femoral and tibial guide surfaces produces anterior femoral displacement toward extension and posterior displacement toward full flexion.

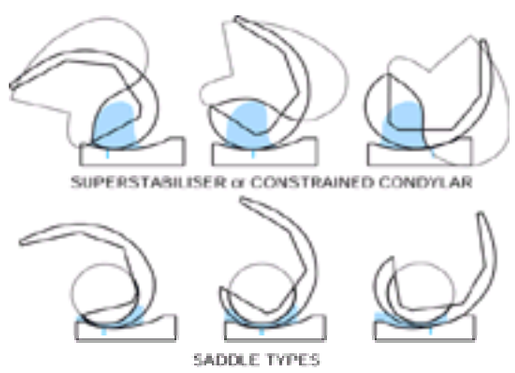


***Figure 100.42.*** Intercondylar guide surfaces with different patterns of AP motion control. **Top:** Superstabiliser (Howmedica, Rutherford, NJ)—Constrained Condylar Knee (Zimmer, Warsaw, IN). **Bottom:** Saddle type with AP control in the second half of flexion (*left*), the mid-range of flexion (*center*) or in the first half of flexion (*right*).

Another useful configuration occurs when the femoral guide surface is an eccentric circle and the tibial guide surface is a saddle (225). This can provide AP motion control in different parts of the flexion range (Fig. 100.42). By defining and varying geometric parameters of the above-mentioned types, different AP control patterns can be achieved. In another design using intercondylar guide surfaces (66), the saddle moved the contact from anterior to posterior during flexion, the second part of flexion using a ball-in-socket. In another design (76), the saddle shape was such as to induce pure rolling during flexion and extension.

Other designs have been introduced in which anterior femorotibial contact in early flexion and posterior contact in late flexion have been achieved using separate pairs of bearing surfaces. The TRAC (Biomet, Inc., Warsaw, IN) uses intercondylar guide surfaces, shown at the lower left of Figure 100.42, to transfer the contact from the first pair of bearing surfaces to the second. The Bi-Articular (Kyocera, Kyoto, Japan) uses conventional total condylar bearing surfaces until about 90° of flexion. On further flexion, intercondylar surfaces of spherical shape, which are posteriorly located, interact. The goals are maximum flexion and freedom of internal-external rotation.

**MOBILE BEARING DESIGNS**

The term “meniscal bearing” is used for a plastic bearing used on one side of the joint (92) (usually medial). A “mobile bearing” is a plastic bearing that includes both the medial and lateral compartments. A “mobile bearing knee” has come to mean any unicompartmental or total knee replacement incorporating a meniscal bearing or a mobile bearing (37). The purposes of a mobile bearing knee (Fig. 100.43) are to minimize the wear of the plastic and to allow relatively unrestrained motion to occur between the femur and the tibia.

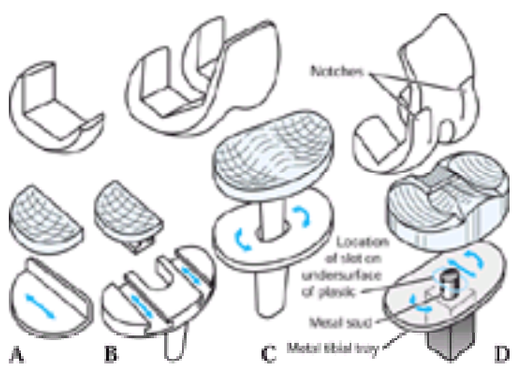


***Figure 100.43.*** Schemes for mobile bearing knees: **A:** unicompartmental (Oxford Knee, Biomet, Inc., Warsaw, IN); **B:** LCS (Depuy-J&J, Warsaw, IN), or Minns

(Zimmer, Warsaw, IN) with separate plastic components in tracks; **C:** LCS rotating platform; **D:** MBK (Zimmer, Warsaw, IN) with fully conforming femorotibial surfaces.

In concept, the components model the scheme of the natural knee such that nonconforming main bearing surfaces, which allow freedom of motion, have menisci interposed to increase the contact area (2,219). The deformability of the menisci allows for changing femorotibial geometry during flexion while still maintaining a large contact area. The constraint of a mobile bearing knee compared with a natural knee is less on the medial side and more on the lateral side.

There are two schemes for the femorotibial bearing surfaces:

1. Complete conformity throughout the full range of flexion. This is achieved in the Oxford (Biomet, Warsaw, IN) unicompartmental design, using spherical surfaces (53). However, this modular design does not provide for the patellofemoral joint. The Polyzoides Rotaglide (Corin Orthopaedic, Gloucestershire, United Kingdom) (173) has total condylar type components, but the femoral and tibial bearing surfaces are spherical, giving full contact throughout flexion from just anterior of the bottom of the tibial dish to the posterior tibial surface. There is a normal patellar flange. A recent design that achieves full contact from the anterior to the posterior of the tibial bearing surface is the MBK (Zimmer, Warsaw, IN) (225). This is achieved by notches in the medial and lateral sides of the femoral component (Fig. 100.43). The advantage of this scheme is the larger contact area and the resistance to anterior subluxation of the femur on the tibia.
2. Complete conformity in early flexion but partial conformity at higher flexion. One example is the LCS (Depuy-J&J, Warsaw, IN) (37). The reason for this compromise is to allow for a femoral component design of reasonably anatomic sagittal geometry with a radius that is larger distally than posteriorly. Full conformity is achieved during the major part of a level walking cycle, whereas partial conformity is restricted to the less frequent activities requiring higher flexion.

Until more data are available from knee simulator testing, it is not possible to assert which scheme will produce the least wear and plastic damage over the long term. However, surface wear, pitting, and delamination wear must all be considered in any comparison.

Concerning the design scheme of the meniscal or mobile bearings, there are four fundamentally different arrangements (Fig. 100.43 and Fig. 100.44):

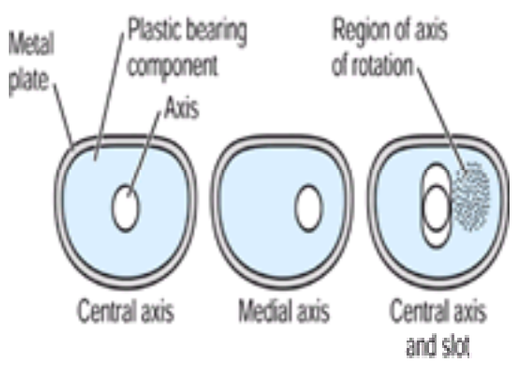


***Figure 100.44.*** For one-piece plastic components, there are several mechanical schemes for obtaining different femoral-tibial motions. For the axis plus slot, if the medial structures are tighter than the lateral, the axis of rotation can be variable and lie in the region found for the natural knee (shaded).

1. The plastic menisci are separate and are free to slide and rotate on their own metal plates (e.g., the Oxford). Even though this allows for the maximum freedom of motion, there is the possibility of bearing dislocation or excessive posterior overhang. In this simple type of design, components with a minimum thickness of 4 mm can be used.
2. The plastic menisci are separate and slide in curved (LCS) (DePuy-J&J, Warsaw, IN) or straight (Minns, Zimmer, Swindon, UK) tracks in a one-piece metal baseplate. Suitable clearances in the slots allow for combined sliding and rotation. The possibility of bearing dislocation is reduced, but overhang is still possible. Because of the slots, the overall component thickness has to be increased.
3. A one-piece mobile bearing is free to rotate about a central pivot. This factor eliminates the uncertainty of rotational placement at surgery and allows rotational freedom in function. However, when rotation occurs, the lateral side moves posteriorly and the medial side moves anteriorly, which does not resemble anatomic motion where the contact on the medial side remains reasonably constant. This problem can be solved by using a medial pivot at the expense of requiring left and right components.
4. A one-piece mobile bearing is free to rotate and free to translate AP. This bearing can accommodate anatomic motion, with an effective center of rotation on the medial side. The posterior displacement during flexion can be provided by a retained PCL or by muscle action. However, as with a fixed-bearing knee with a shallow tibial surface, in early flexion, the femoral component may not be sufficiently anterior.

Additional configurations of the above-mentioned schemes are possible to achieve roll-back with flexion and even roll-forward with extension. A posterior stabilized arrangement can be used, but this would require partially conforming femorotibial bearing surfaces. Guide surfaces, such as those described earlier, can interact between the femoral component and the metal tibial baseplate. This is applicable to either partially or fully conforming bearing geometry.

Comparisons can be made between the fixed and mobile bearing knee types:

- The kinematic analog of a meniscal bearing knee (such as the Oxford used on the medial and lateral sides) is a fixed bearing with shallow or flat tibial surfaces. In this case, the mobile bearing is preferable because the fixed-bearing plastic is liable to excessive deformation and wear in the long term owing to high contact stresses. At the same time, if UHMWPE can be made with enhanced resistance to wear and delamination, the two schemes become comparable
- The wear in a moderate-high conforming fixed bearing may be comparable with that in a mobile bearing. The fixed bearing, however, is too constrained in AP and rotation, whereas the mobile bearing has increased laxity and a variable neutral position, both of which are advantages.

A final point is that (at the time of writing) there are no reliable data on the wear rates, and the types of particles generated as a function of contact area and contact pressure. Hence, comparisons between different designs must be determined by simulator tests rather than automatically assuming that larger contact areas are an advantage, as has been commonly done in the last decade.

**LINKED DESIGNS**

Over the years, numerous different linked designs have been introduced, which reflects more the opportunity for inventive design rather than extensive need. The largest numbers continue to be used in Europe, whereas in the United States, the tendency is to use the most conservative design whenever possible, even if substantial soft-tissue balancing is required. The characteristics of a linked design are:

- Stability is provided in all degrees of freedom, varus-valgus and hyperextension being particularly important, although there can be some laxity (e.g., rotational) in one or more degrees of freedom.
- A linkage of some type, such as a hinge, provides the stability and prevents subluxation or dissociation
- Intramedullary stems are required for fixation.

The most conservative type of linked TKR is the intercondylar hinge (Fig. 100.45). The linkage is housed in the intercondylar region, preserving the condyles on each side (9). Versions of this type include the Attenborough (9), the St. Georg Endo (Waldemar-Link, Germany) model, the Sheehan (Howmedica, Rutherford, NJ), the Rotaflex (JJ Orthopaedics, Warsaw, IN), and the PFC S-ROM (J&J Orthopaedics, Warsaw, IN). The bearing surfaces can be extended to the full width of the knee, an advantage for reducing varus-valgus bending moments on the linkage. The patellofemoral resurfacing has been absent in some designs but ideally should be included. Advantages of the intercondylar design are:

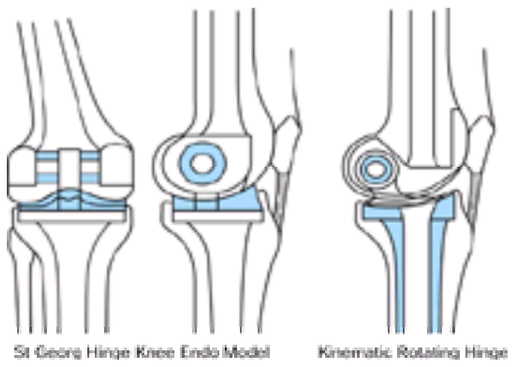


***Figure 100.45.*** Different configurations of hinged designs. **Left:** the St. Georg (Waldemar-Link, Germany) fixed or rotating intercondylar hinge. **Right:** the Kinematic Rotating Hinge (Howmedica, Inc, Rutherford, NJ). Shaded areas indicate plastic.

- Preservation of bone
- The anatomic location of the axis of rotation.

Disadvantages of the intercondylar design are:

- The relatively restricted size of the bearing components, with an increased potential for wear and deformation.
- The possibility of condylar fracture on each side
- The difficulty of linking the components at surgery, and the possibility of dislocation in extreme loading conditions (in some designs).

The least conservative type of linked TKR, in terms of bone resection, is the fixed hinge or rotating hinge. Placement is achieved by resection of about 25 mm from the distal femoral condyles and 10 mm from the upper tibia. An axle is then used to connect the femoral and tibial components, usually with plastic bushings to act as the bearing. The total thickness is determined by the required dimensions of the axle and bushings, and the ideal placement of the axle, which is close to the epicondylar line. A lower, or more posterior, axle location will reduce bone resection but result in abnormal tracking of the patella. It should be noted that the most important requirement in the placement of hinged replacements is that the patella locates at the correct level on the femoral flange with the knee in extension.

The fixed hinge is the simpler design and can be used for patients of low demand who would not overstress the fixation and for whom flexion-extension motion is sufficient. Examples are the Guépar (Benoist-Gerard), the St. Georg (Link), the Blauth (Allopro), and the original Stanmore. The rotating hinge, however, results in a more “natural” feel to the patient and can be more durable in the long term. Examples are the Kinematic and Kinemax Rotating Hinges (Osteonics-Howmedica, Rutherford, N.J.), the Finn (Biomet, Warsaw, IN), the Noiles (J&J Orthopaedics, Warsaw, IN), and the SMILES (Stanmore Implants Worldwide). More bone resection, however, is required to accommodate the extra bearing surface. The rotation can be achieved by a flat polished metal surface pivoted on a flat plastic surface, or by a convex metal surface in a dished plastic surface. The convex metal surface in a dished plastic surface is preferable because it provides a “soft” limit to rotation, reducing the possibility of instability or patellofemoral subluxation. Some medium- to long-term follow-up studies of linked designs have shown durability comparable to that associated with condylar replacements (32). That fact, coupled with the relative ease of surgery and the immediate stability, makes linked designs an attractive option for selected patients.

**PATELLOFEMORAL JOINT**

The function of the patellofemoral joint in the normal knee has been studied from many different aspects (3,4,7,103,111,117,163,200). The shape of the patella prosthesis surface can be either a dome, a rounded cone, or a gaussian curve (Fig. 100.46). The dome has been widely used in total condylar type designs but has several drawbacks:

- The plastic is thin at the sides, resulting in overall deformation of the component, especially in activities with high flexion.
- If the femoral flange has an anatomic profile (to accept a retained patella), the dome has two local areas of high stress, which are subject to wear and deformation
- If the profile of the patellar flange is a circular arc to match the dome, a retained anatomic patella is a poor fit.

The cone (Fig. 100.46) has increased plastic thickness at the sides and larger contact areas in the form of two “lines” rather than “points.” Finally, the gaussian shape further increases both the thickness and the contact area. In all of the designs, a medial offset to the peak is an advantage and eliminates the need to use a smaller size of symmetric design and medialize it. A rotating platform design produces the largest area of contact and potentially the least wear and deformation, at the expense of some extra thickness due to the metal backing and a second bearing surface. An additional factor in area of contact is the shape of the intercondylar cutout on the femoral component, as shown in Figure 100.46.

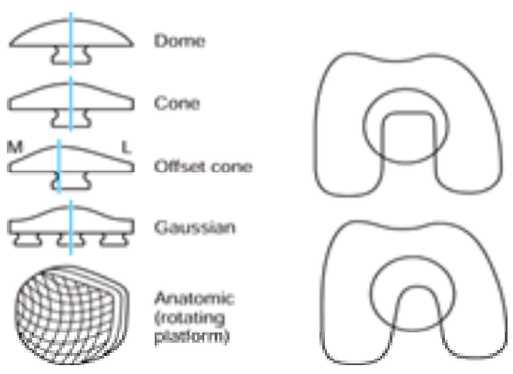


***Figure 100.46.*** Shapes of patellar component used in TKR (an “inset” patella is not shown). The narrower and more posterior the intercondylar cutout on the femoral component, the larger the contact area on the patella in high flexion.

Regarding stability, there is a perception that the dome is more forgiving in alignment and that the other types are susceptible to tilting and loading on the corners. In the front view, it can be seen that, owing to the angle between the lines of action of the patellar ligament and the quadriceps (the Q-angle), there will be resultant tensile and lateral shear forces on the patella itself (Fig. 100.47). The actual direction of the forces depends on the relative forces in the different parts of the quadriceps (3,4,103,117). In addition, there will be a compressive force between the patella (whether the natural patella or a plastic replacement) and the patellar flange, which increases with the flexion angle up to about 100° flexion (4). A 3-D force analysis can be carried out, based on the sectional view shown in Figure 100.47. If the resultant compressive force is central, equal resultants act on the lateral and medial facets (Fig. 100.48). However, in general, the lateral reaction force will be larger than the medial owing to the laterally directed component of the quadriceps and patellar tendon forces. As the Q-angle increases, the lateral force will increase and the medial force will decrease. However, as long as both forces are positive, the patella will be stable. At the point where the medial force reaches zero, the patella will become unstable and will be subject to tilting and subluxation. This is calculated to occur at a Q-angle of approximately 12° (117). Except in cases of extreme valgus, this is unlikely, and hence the cone and gaussian patellar components are likely to be stable.

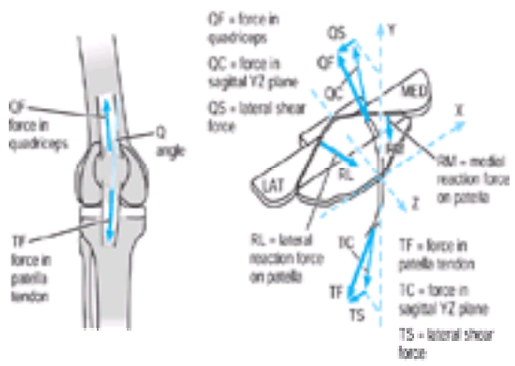


***Figure 100.47.*** The Q-angle between the quadriceps and patellar tendon forces results in a lateral shear force on the patella. The sectional view treats the patella as a free body (Fig. 100.9), from which the forces, including the lateral and medial facet forces, RL and RM, can be calculated.

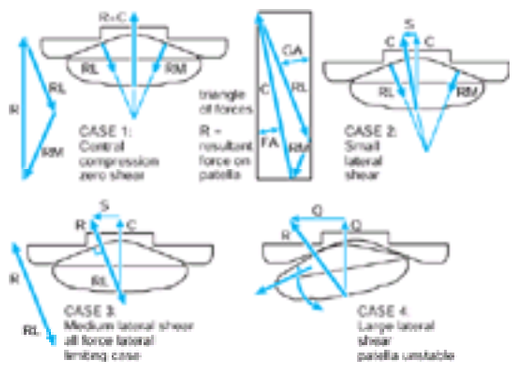


***Figure 100.48.*** The resultant forces between the patellar component and the femoral flange. As the lateral shear component is increased, a critical unstable situation is reached but at a high Q-angle.

**FIXATION**

The methods used to attach TKR components to the bone include cementation, press-fit fixation, porous-coating, and fixation with various macroscopic surface finishes or mesh. Any of the uncemented modes can include HA or other bioactive coating. The goals are to minimize interface micromotion (17,220), avoid interface bone resorption, and maintain intimate bone contact (170). An alternative goal, potentially achievable with press-fit fixation, is to obtain a stable interface with a thin fibrous tissue layer or velour-type material (154,224). In cementing at surgery, if the cement is applied in a viscous state with little pressure, the penetration will only be on the projecting trabecular tips, allowing distraction to occur when local tensile stresses are exerted (Fig. 100.49). In contrast, penetration of 2 to 4 mm, such that transverse trabeculae are engaged, results in small interface micromotion and an interface that can remain stable for long time periods. The most uniform penetration over the entire surface is achieved with cement applied by multiple applications of a gun nozzle.

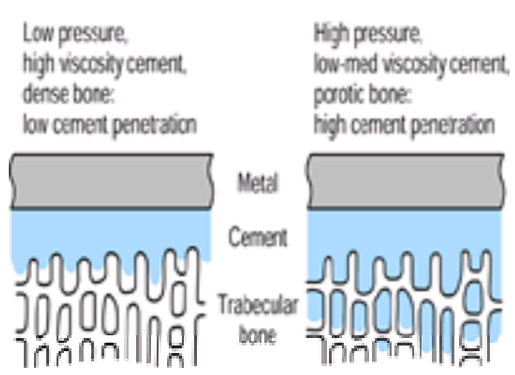


***Figure 100.49.*** The interface conditions between cement and trabecular bone for low and high penetration of cement.

Fracture of the cement mantle has not appeared as a problem in metal-backed components but has occurred with all-plastic components when there has been deformation due to poor or uneven bony support or bone overload from malalignment (178). Components with coatings, for which long-term fixation relies on ingrowth or apposition of new bone, require initial fixation that is sufficiently rigid for at least 2 to 3 months. Screws have been found to be an advantage for tibial components, whereas for femoral components (197), a tight AP fit has been adequate. However, the use of screws carries the risk of screw-tray fretting and of providing a track for wear debris particles, which produce osteolytic cavities. Press-fit fixation requires suitable macroscopic features and pegs to maintain a sufficiently low level of interface micromotion (221). In many cases, a stable fibrous tissue interface above a new subchondral layer has been formed, but so far, press-fit fixation has shown a higher incidence of loosening and pain than cementation.

Fixation also depends on the design of the component and the loading on the bearing surfaces (105,220). These factors, in turn, directly affect the stress distribution over the entire interface as well as the stresses in the bone itself (Fig. 100.50). In the sagittal plane, if the contact is less than approximately 25% from the edge, there will be excessive bone stresses beneath the load and tensile stresses opposite to the load. The actual pressure distribution at the interface reflects the foundation stiffness of the trabecular bone, whereas the magnitude of the stresses depends on the surface area of the component. The bone stiffness is modified in arthritic conditions, usually by increased and decreased stiffness on opposite compartments. CT studies show that, after realignment and insertion of a TKR, whereas the strong bone reduces in strength toward normal, the weak side gains in strength more slowly (118). Except in conditions of extreme edge loading, metal-backed components produce a more normal pressure distribution at the interface. In all-plastic components, there is a high pressure region at the interface beneath the contact area. Nevertheless, there is clinical evidence that plastic components with sufficient thickness (e.g., 10 mm) and a strong central peg are viable in patients with low activity levels and when there are no major bone defects or regions of osteoporosis (178). Regarding overall pressure distribution, central posts reduce the maximum interface stresses for offset loading, such as varus (179), as well as being effective against shear forces (Fig. 100.51). Design features located toward the periphery, such as pegs or keels, especially when they are embedded in hard cancellous bone, are effective against internal-external rotation (221).

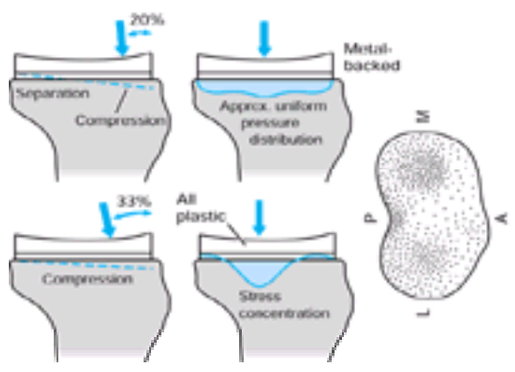


***Figure 100.50.*** Elastic deformations and interface stresses of tibial components on the upper tibia. The figure on the extreme right shows a typical foundation stiffness

on the resected upper surface, which is usually modified in arthritic conditions. See text for details.

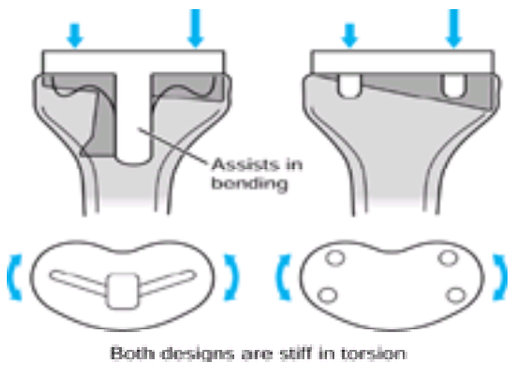


***Figure 100.51.*** Design features to transmit varus moments and axial torques more effectively to the bone.

An invaluable method for the measurement of component fixation in vivo has been RSA (52,105,166,186,196). One millimeter tantalum beads are implanted in the component and in the adjacent bone at surgery. Biplanar radiography at specific time intervals, with mathematical analysis, produce the component–bone movements or migrations over time. Continuous migrators after 1 to 2 years are predictive of future clinical loosening.

Cases with bone loss, including revisions, need special consideration (Fig. 100.52). Augments, such as spacers and wedges, are useful for replacing bone defects and for accurately reproducing the joint line (35). These augments can be screwed or cemented to the main components. For larger defects, space fillers made from metal or plastic are an alternative to bone grafting. Stems are useful for bypassing cavitary defects, for protecting against fractures, for traversing fracture sites or serious cortical defects, or for stabilizing allografts (179). When the TKR design carries varus-valgus moments, intramedullary stems are needed. In older patients, cemented stems are usually preferable, but uncemented fluted stems should be used if there is sufficient cortical thickness, in order to reduce the stress-shielding of the cancellous bone near the joint (209). Empirically, suitable stem lengths for Superstabiliser-CCK types of TKR are 100 to 120 mm, and 120 to 150 mm for rotating and fixed hinges. Revision of a failed cemented stem requires a new stem at least 50 mm longer. In all cases, attention is needed to prevent the stem tip from impacting the cortical wall, which frequently produces osteolysis, penetration, and even bone fracture.

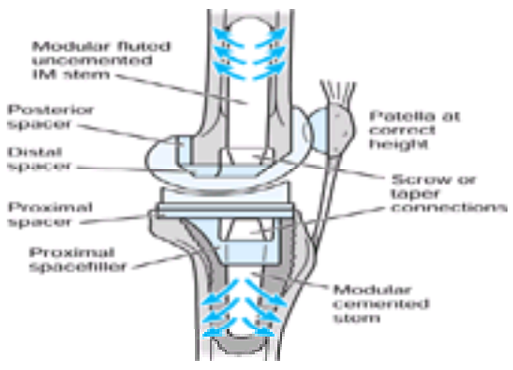


***Figure 100.52.*** Modular augments including spacers, space fillers, medial wedges (not shown), and stems; they are used in cases of bone loss including revisions. There is some stress protection of the distal femur and proximal tibia due to the stems.

## WEAR AND DEFORMATION OF PLASTIC

The basic terminology of lubrication and wear was described earlier in the discussion of tribology. In this section, wear mechanisms applied to TKR are discussed. These mechanisms have been deduced from retrieval studies, principally from components that have failed due to instability or loosening (18,27,28,29,60,61,63,139,234). Examples of wear in a range of retrieved TKR components are shown in Figure 100.53. Deformation frequently occurs in dome-shaped patellar components when they are used in anatomically shaped grooves (Fig. 100.54). For partially conforming condylar replacements, on the application of load, a contact patch is produced on each condyle, the shape depending on the geometry of the tibial and femoral surfaces (151,189,190). Contacts approximating circular are called *point contacts,* whereas when the surfaces are almost conforming in the frontal plane but only partially conforming in the sagittal plane, a cigar shape called a *line contact* is formed (Fig. 100.10). The contact area varies considerably, from about 150 $mm^2$ for moderate- to high-conformity knees in early flexion, down to 30 $mm^2$ for low conformity knees in flexion (Table 100.4). The corresponding maximum compressive pressures are 10 to 50 mPa at the centers of the contact areas, the mean pressure being the maximum divided by 1.5.

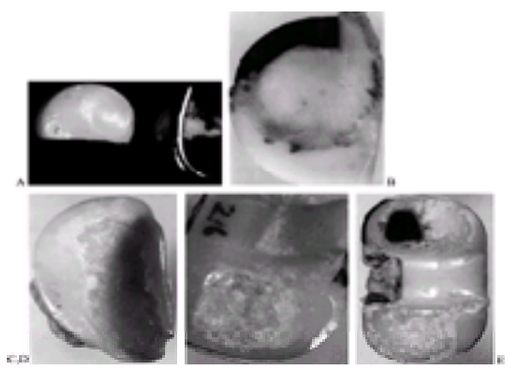

***Figure 100.53.*** Examples of wear on different TKR designs with different types of polyethylene: abrasive wear (**A**), adhesive wear (**B**), deformation (**C, D**), and delamination (**E**) can all be seen.

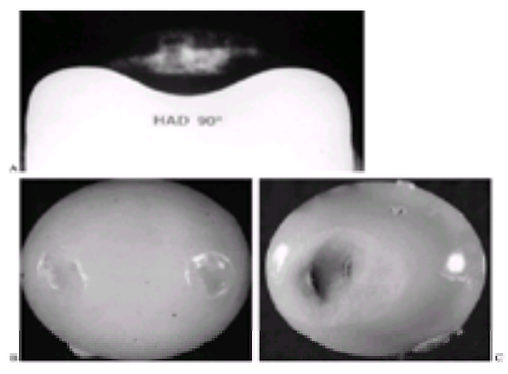

***Figure 100.54.*** An anatomically shaped patella is ideal for a retained patella. When a dome is used, however, deformation can readily occur, as in these examples.

| Contact area ($mm^2$) | Diameter of circle (mm) | Maximum contact pressure (mPa) | Mean contact pressure (mPa) |
|---|---|---|---|
| 150 | 13.8 | 10 | 6.7 |
| 75 | 9.8 | 20 | 13.3 |
| 30 | 6.2 | 50 | 33.3 |

***Table 100.4. Contact Areas (Diameters of Circular Areas Are Given) and Contact Pressures, Covering the Range for Condylar Replacement Knees in Extension and Flexion***

The yield stress of UHMWPE is about 15 mPa (135,151,176), above which permanent deformation will occur under the center of the contact area (182). In knees of low conformity, as the femur slides over the plastic surface, a deformed groove up to 0.3 mm deep occurs in the first few months of use, and thereafter the groove is steadily deepened by wear. In knees of moderate to high conformity, the deformed area is relatively small, with a depth of less than 0.1 mm. Within the contact area, there are a multitude of local contact points at a micron level, depending on the microroughness of both the metal and plastic surfaces. There are several mechanisms whereby small particles are released. Some of these mechanisms are fatigue processes requiring numerous cycles of sliding. Multidirectional sliding is also more damaging than sliding, which is predominantly limited to the same direction. The wear processes also depend on whether the kinematics involve rolling, tractive rolling, or sliding (23,28). These wear processes (27,60,61) are as follows:

- Adhesive wear occurs when the local frictional shear force on transverse ripples or asperities of polyethylene causes shear deformation or stretching of a fibril. The fibrils are typically 2 to 5 µm in length and 0.2 to 0.5 µm in diameter.
- Another form of adhesive wear occurs when a plastic asperity accumulates strain energy due to repeated deformations to the point where a crack develops and a surface particle is released. This typically produces granules of plastic 0.1 to 1.0 µm in size.
- A third form of adhesive wear occurs when a surface layer about 0.1 to 0.2 µm in thickness becomes sheared with respect to the underlying material, similar to the formation of a blister. Eventually, the layer fragments to form flakes approximately 2 to 10 µm across.
- A small scratch on the metal surface with ridges will produce direct cutting or ploughing into the plastic. Several passes across a groove in the plastic, especially at angles to previous passes, will release fibrils or granules of polyethylene. This is called two-body abrasive wear
- If hard particles become entrapped in the contact area, they will also cut grooves in the plastic, causing wear called three-body abrasive wear. Plastic particles themselves can produce this type of wear, but to a much lesser extent than hard particles such as metal, ceramic, or bone.

Scanning electron microscopy of the surfaces of retrieved plastic components illustrates the wear mechanisms (Fig. 100.55). Ripples perpendicular to the sliding direction are typical. Fibrils are seen to be stretched from the crests of the ripples, while there is also evidence of granule formation. Shearing of the surface layer results in fibrils or thin flakes. Fluid samples, after processing, can be filtered to show the resulting particles. They are categorized into granules, fibrils, and flakes (47,48). The types and sizes of particles are indicative of the wear mechanisms that were taking place. In general, smaller particles produce more expression of cytokines from cells.




***Figure 100.55.*** Scanning electron micrographs of retrieved plastic components. **Top left:** Ripples transverse to the sliding direction with fibrils and granules being formed on the crests of the ripples. **Top right:** Cracks shown in a section perpendicular to the surface, which coalesce to produce delamination. **Bottom left:** Shearing of a thin surface layer producing flakes. **Bottom right:** Processed and filtered fluid samples show wear particles of three types: GR, granules; FIB, fibrils; FL, flakes.

The above-mentioned phenomena are all related to the surface of the plastic. However, other wear mechanisms are more appropriately called “damage mechanisms.” These mechanisms involve more general breakdown of the surface region of the material, including failure that starts entirely subsurface (205). These damage mechanisms, and other phenomena that involve cracks at and under the surface, are dependent on the component geometry, the sliding conditions, and the type of UHMWPE (81,189,190). To illustrate this point, a typical contact situation is shown in Figure 100.56. Around the periphery of the contact area, radial tensile stresses occur of magnitude 0.13 times the maximum compressive stress (124). As sliding and rolling take place, at a particular location on the plastic surface, the stresses cycle between tensile and compressive. This is equivalent to the stresses in a bar of material subject to repeated bending in opposite directions. As a result, cracks will be produced on the surface, which will progress along the surface and into the material, but because the tensile stresses reduce with depth, the crack depth is limited. However, when the cracks are not perpendicular to the surface and adjacent cracks coalesce, pits are formed with typical dimensions of 0.5 to 2 mm in width and depth. Such pits are commonly seen on retrieved components (18,63,139), from low to high conformities (27), including mobile bearings.

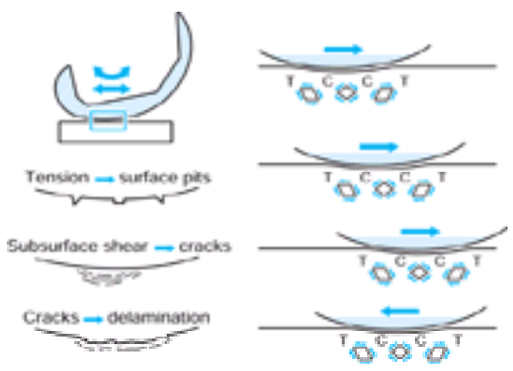


***Figure 100.56.*** As the femoral component slides and rolls across the surface, the surface stresses cycle between tension and compression, and the subsurface shear stresses change in direction. These cyclic stresses, representing a fatigue process, produce cracks, pits, and delamination.

A more severe form of damage occurs when cracks form and propagate beneath the surface. This is termed “delamination.” A typical crack depth is 1 mm, and the initial area affected can be several millimeters across, seen as a white patch (18,27,29). These cracks are associated with regions of maximum shear stress, which occur beneath the center of a contact area at a depth of approximately 0.25 times the contact width, usually 1 to 2 mm. The direction of the maximum shear stress is at 45° to the surface (Fig. 100.56). Beneath the periphery of the contact area in the cross-sectional plane, there are further peaks of shear stress of lesser magnitude oriented at 90° to the surface. The stress directions are opposite at the leading and trailing edges of the contact area. Hence, as the femoral component slides across the plastic, particular points beneath the plastic surface experience shear stresses that change in direction, producing a fatigue situation that leads to crack formation. Once the cracks reach the surface, the consequent disruption of the surface leads to rapid delamination of adjacent areas, eventually covering the entire contact region. Examples are shown in Figure 100.53 and in sectional view in Figure 100.55.

***Wear Models***

To predict the wear of TKR components as a function of the geometry, a number of simplified experimental or theoretical *wear models* have been used.

**Area of Contact** The most frequently used measure has been the area of contact, either measured in a loading machine or calculated using FEA (Fig. 100.57). This is based on the assumption that the amount of wear at the surface (adhesive and abrasive wear) and damage within the material (pitting and delamination) are inversely proportional to the contact area or proportional to the contact pressure. There are some data in the literature to support this, based on the testing of specimens in wear test machines, and there is the general impression from retrievals that the wear is more severe in designs with small contact areas, usually cruciate-retaining designs. There is, however, the question as to which angle or angles of flexion should be used to measure the contact area. If the majority of wear is assumed to occur during the stance phase of walking, then areas measured between about 0° and 15° of flexion are relevant. Depending on the posterior-distal transition angle (Fig. 100.40), these areas can differ considerably. There is also the possibility that severe wear occurs at the less frequent activities, which generate higher forces at higher flexion angles. Hence, the use of area of contact as a measure should include values for a range of flexion angles. A weakness of using contact area alone is that it does not account for sliding distance.

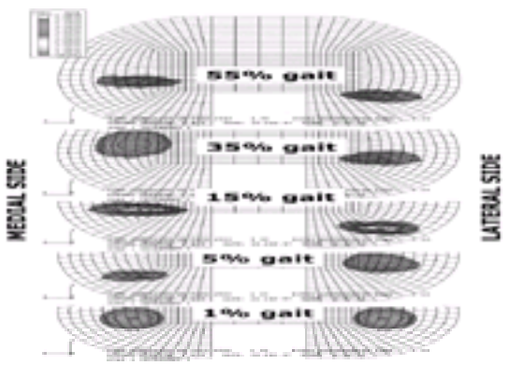


***Figure 100.57.*** The locations of the contact areas and the contact stresses calculated using finite element analysis, at different times in the gait cycle (191). The calculations took into consideration the forces and moments (including torque) between the femur and the tibia, the geometries of the femoral and tibial bearing surfaces in the contact region, and the frictional shear forces.

**Sliding Distance** Recalling the basic wear equation:

$$wear\ volume = wear\ factor \times load \times sliding\ distance$$

This equation refers to surface wear only and not to pitting and delamination. If it is assumed that the wear factor and load are the same for all TKRs, then the wear is proportional to the sliding distance, which is related to the femoral and tibial radii in the sagittal plane, in other words, the inherent constraint. Hence a simple indicator for wear is the AP sliding distance of the contact points (not the relative rigid body motion itself) for a typical activity cycle. For purposes of comparison between different TKRs, the sliding distance can be determined based on the data for walking and other activities, which shows that, in stance, along with an axial compressive force, there are both anterior and posterior shear forces. This can be simplified, as shown in Figure 100.58, by applying the compressive force first, followed by the anterior and posterior shear forces. As determined by the triangle of forces, the point of equilibrium is reached at a particular angle q on the plastic surface. This point is entirely dependent on the tibial radius and not the femoral radius, and can be calculated directly from the tibial dimensions. If the tibial articular geometry is shallow, so that the slope cannot be reached, the displacement limit would be from soft tissues, at an assumed distance of approximately 12 mm from neutral. The sliding distance is the distance between the anterior and posterior points. Although this test accounts for sliding distance, it does not account for the effect of contact pressure on the wear factor.

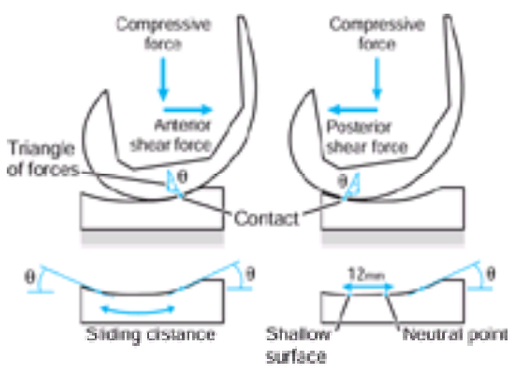


***Figure 100.58.*** A proposed measure for estimating the surface wear in a TKR where a cyclic shear force is applied and the sliding distance is used as a measure of the wear. The distance can be obtained directly from engineering drawings of the tibial component, using simple geometry: tan q = *shear force/compressive force.*.

Ideally what is needed for predictive purposes is a method involving all aspects of the TKR geometry, as well as the forces and motions in activity. The following damage function model describes such a method.

**Damage Function Model** The damage function model was produced to predict delamination rather than surface wear (189,190). However, the surface wear can easily be included, as will be explained later. As already described, delamination is due to the initiation and propagation of subsurface cracks in the polyethylene. The likelihood of a crack developing and the rate of crack propagation can be described by the strain energy input to an element of material during a complete activity cycle. Calculation of this parameter has been carried out as follows:

1. Specify the input forces, moments, and flexion angles on the knee during activity, and divide this into equal time increments.
2. Use specially written software (a kinematic solver) to determine successive contact point locations on the lateral and medial sides, at each increment, taking surface friction into account (188) (Fig. 100.57).
3. Use FEA to calculate the subsurface shear stresses at a multitude of quadrilateral elements below the surface of the plastic at each increment.
4. For each element, plot a shear-stress versus time curve.
5. By treating this in a manner similar to a force displacement curve, the shear strain energy can be calculated for each element as the areas under the curve.
6. Plot the shear strain energy, called the *damage function,* for the elements at different subsurface levels.

The result is a plot as shown in Figure 100.59. This plot shows a comparison between knees of different frontal and sagittal geometries, demonstating the regions of

plastic most likely to generate cracks, and predicts the relative susceptibilities of the different knees to delamination wear.

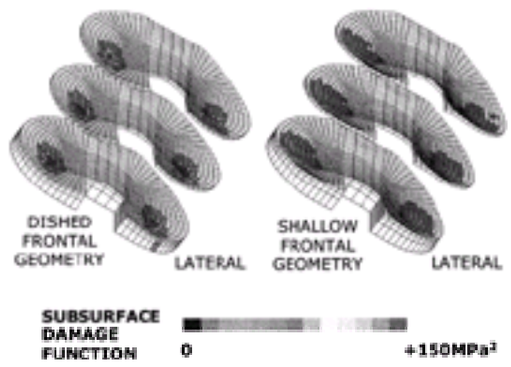


***Figure 100.59.*** Plots of the damage function for elements of plastic at different levels below the surface for condylar knees of different geometries (Fig. 100.40). High susceptibility to delamination (*left*) is predicted for small frontal femoral radius, high frontal femorotibial clearance, and small PDTA. At the other extreme of condylar geometry, delamination is predicted to be low (*right*). Also, the large frontal radius allows for adequate rotational laxity. (From Robinson R, Clark JE. Uncemented press-fit total hip arthroplasty using the identifit custom-molding technique. *J Arthroplasty* 1995;11:247.)

In the study described earlier, the surface wear could also be calculated. The method would be to use the basic wear equation for the incremental steps used in calculating the contact areas (Fig. 100.57). The wear in each increment would be the average load acting times the sliding distance. The wear factor could also be expressed as a function of the contact pressure. However, at this time, reliable data are not available.

The material properties of the UHMWPE have a major effect both on surface wear and on subsurface delamination. This has been discussed already in relation to hips, but there are a number of factors specifically related to knees. When retrieved tibial components are sectioned, the region of highest oxidation is typically 1 to 2 mm beneath the surface, although the zone can extend completely to the surface (18). It is noticeable that oxidation is highest beneath the contact areas, indicating a relation with fluid transport and local stress fluctuations. Such oxidation increases the density and the elastic modulus, and decreases the tensile strength, elongation to break, and toughness. All of these factors make the plastic more susceptible to delamination. Newer processing methods, which reduce oxidation are likely to extend the durability of UHMWPE before delamination occurs (18).

There is evidence from retrieval and laboratory studies that the use of directly molded polyethylene, even in designs of low conformity, avoids delamination almost completely, although surface wear from adhesion and abrasion is still observed (27,29). It is possible that such material is resistant to oxidation and degradation of mechanical properties.

Finally, wear debris can originate from locations other than from the bearing surfaces. “Back-side wear” between the plastic and the metal tray occurs due to micromotion at that interface. Snap-in capture mechanisms, combined with the manufacturing tolerances, can result in considerable motion under shear and torque, even up to 1 mm. If this is accompanied by a rough surface in the metal tray, severe wear can occur. The effects of such wear have been noted particularly in trays with holes for fixation screws, around which osteolytic lesions have developed.

## TESTING AND SIMULATORS

Physical tests, like computer models, are simplifications of reality that embody sufficient and appropriate characteristics of the actual situation to address the question being asked. In some cases, simple tests suffice; in other cases, a complex test is required.

### *Static Tests*

A commonly used method for determining the geometric relations and the forces within the knee is to mount the tibia on a base, apply a flexion moment to the femur, and balance the knee at a particular angle using a turnbuckle in the quadriceps. The original apparatus was termed the Oxford rig (97), but the design has since evolved (240) (Fig. 100.60). Aspects that have been studied using such a rig include:

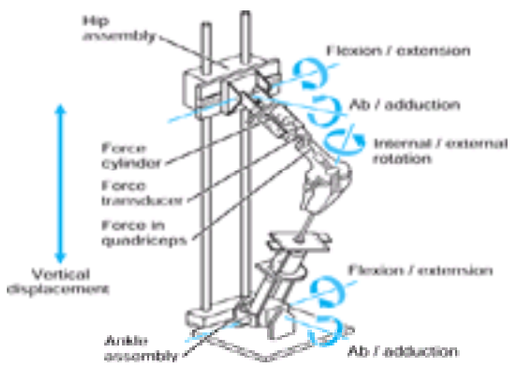


***Figure 100.60.*** An Oxford-type static loading test rig for studying the basic mechanics of the knee. The rig allows the full 6 degrees-of-freedom motion of the knee. A downward force at the hip is balanced by a force in a cable representing the quadriceps (240).

- The femorotibial contact point or area locations (111), determined radiographically or using pressure-sensitive film inside the knee.
- The orientation of and forces in the ligaments; the forces have been measured by small turnbuckles or by dissociation of bone blocks.
- The force in the quadriceps and in the patellar tendon using force transducers
- The patellofemoral contact areas and pressures, and the effect of different relative forces in the components of the quadriceps.

Limitations of the method are the low force magnitude, the fact that the force may not simulate the direction of the external force at the knee in the frontal and sagittal planes, and only one muscle being represented. Such factors can be addressed in more sophisticated versions of the rig. An extreme example is the use of a robot to position the femur on the tibia in a known 3-D orientation, which can then be used to study the contributions of different structures to resisting applied forces and moments.

### *Strength Testing*

Each new knee design needs to be tested for strength and wear before it is used in patients. In general, the tests should be carried out on the standard-sized components. The test should replicate as far as possible the physiologic conditions while maintaining mechanical simplicity. The rate of testing can be up to 5 Hz for metal components and up to 2 Hz where plastic is involved.

A number of tibial tray designs have failed in service, although the incidence has been low (1). The adverse design factors have been internal corners, notches, a thin plate, and grooves or coatings. The clinical factors have been patient weight and activity level, and loss of bony support under one condyle. The test proposed by the ISO involves clamping one half of the component and then applying a cyclic force to the unsupported condyle (Fig. 100.61). The test does not reproduce the changing contact point locations during function. Furthermore, it has been found that an appropriate force for testing is around 500 N, whereas forces at physiologic levels in walking of 2000 N or more (or even half this value for one-condyle loading) would cause most existing baseplates to fail in fatigue. In this sense, the test is an exaggeration of reality. A typical number of cycles for such tests is 10 million, although this would represent only 5 to 7 years of use in most patients.

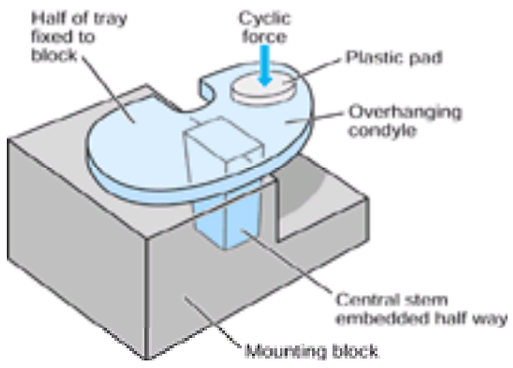


***Figure 100.61.*** The ISO test for mechanical strength of tibial trays. A finite element model can be used to predict the failure location (From Ahir SP, Blunn GW, Haider H Walker PS. Evaluation of a testing method for the fatigue performance of total knee tibial trays. *J Biomech* 1999;2:1049.)

The strength of plastic posts in stabilized designs, the security of fixation of the plastic in the metal tray, and the security of mobile bearing components can be tested using an applied cyclic shear force, possibly accompanied by a compressive force (Fig. 100.62). From a compilation of available force data in the knee, including that from a telemetrized distal femoral replacement, a suitable cyclic shear force is 750 N applied for 10 million cycles, interspersed with a force of 1250 N applied for a total of 0.5 million cycles. The former represents vigorous walking, and the latter represents the extreme forces that could be applied in rapid ascending or descending. In the opposite direction (such that the ACL would be tensed) suitable values are 500 and 750 N.

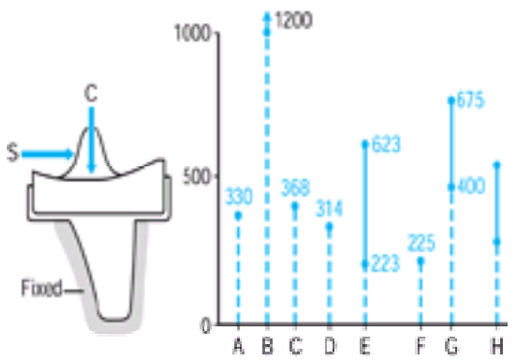


***Figure 100.62.*** Testing knee components in shear (*S*) with a compressive force (*C*) applied. Values of *S* in direction shown under different conditions: **A:** level walking (157); **B:** ascending (156); **C:** level walking (206); **D:** level walking (Andriacchi 1998, personal communication); **E:** TKR dislocation forces (Greenwald 1993, internal report, Cleveland Clinic, Cleveland, OH); **F:** TKR dislocation (144); **G, H:** TKR 5 mm from dislocation (188).

Designs such as superstabilizers and linked hinges require testing in varus loading (Fig. 100.63). This can be accomplished using a cyclic force that is offset from the centerline and medial to the medial femorotibial contact point. For comparative testing applicable to all designs, the offset distance from the center of the knee and the applied force should be the same. A normal value of the external moment acting at the knee during activity is 3% BW times height, whereas an extreme value is 6.5% BW times height (159). To determine a suitable test force, consider a value of the external varus moment of 5% × BW × height = 67,500 N·mm for a typical man. The moment carried by the reaction force of 3 BW on the medial condyle at 22 mm spacing = 44,550 N·mm. Hence, the moment carried by the central post is 22,950 N·mm. This can be applied by a force of C = 1000 N acting at 23 mm from the contact point or 45 mm from the center of the knee. In such a test, superstabilizers with plastic posts show considerable progressive angular deformation, which is reduced but not eliminated by metal reinforcement. Fixed or rotating hinges show only small deformations.

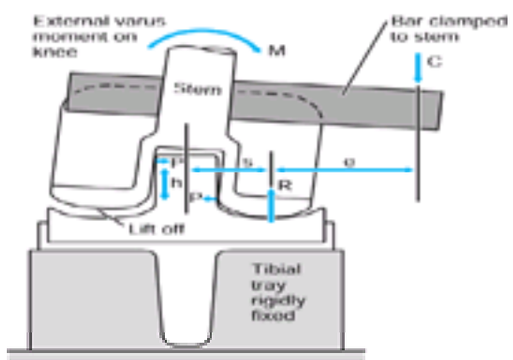


***Figure 100.63.*** Testing superstabilizers and similar designs in varus. The total moment *M* is equilibrated by *R* × *s* and by *P* × *h*. The moment *P* × *h* is produced by *C* × *e*, *C* being the cyclic test force.

To test the overall mechanical strength of a TKR, a complex knee simulator could be used. However, a uniaxial cyclic load machine can be used to apply multiaxial forces and moments. This is achieved by mounting the component at an angle and applying the force offset (Fig. 100.64). In this way, the following is applied by the single uniaxial force:

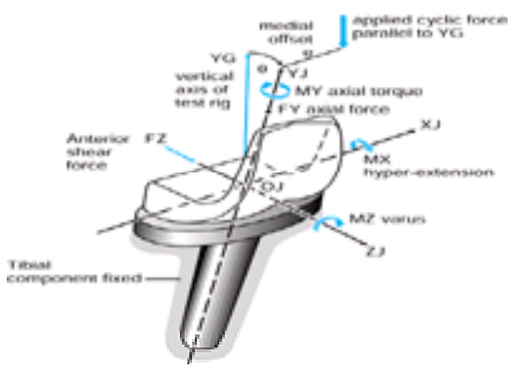


***Figure 100.64.*** If a total knee is extended by q and a single force offset by *e* is applied relative to the TKR axes, simultaneous force components and moments occur. This exerts a rigorous test condition on the device.

- Compressive force.

- AP shear force.
- Varus moment.
- Hyperextension moment
- Axial torque.

Such tests have the advantage of revealing weak points in a design not shown by simpler testing, as well as effectively applying several test modes simultaneously.

***Wear Testing***

The most difficult and time consuming testing is measuring wear and deformation in TKRs. If the primary concern is to compare a new plastic or a new metal surface, a pin-on-plate test is appropriate (Fig. 100.65). To produce a model that is simple but a close model to the actual TKR, a metal pin with a spherical surface at the end (femoral) is slid to-and-fro on a flat plastic plate (tibial) (216). To account for internal-external rotation, the pin is rotated cyclically about its own axis. The surrounding medium is 25% to 50% serum at 37°C. The fluid requires changing every 2 days to minimize degradation. The sliding distance is a total of 10 mm. The radius of the spherical end should produce a similar relative radius of curvature to the TKR design envisaged. A static load of 1000 N is applied, representing one condyle. Samples of fluid are collected every million cycles for particle analysis. A suitable characterization is to divide particles into granules, fibrils, and flakes, and measure the size ranges and the percentages of each (47,48). The rate of testing is limited to 1 Hz (2 Hz maximum) to avoid overheating at the contact. It is observed that in the first few hundred thousand cycles, deformation of the plastic predominates over wear, whereas as the contact pressure thereby reduces, deformation reduces and wear predominates. If the objective of a test is to determine the effect of load, contact area, or contact pressure on wear, the above-mentioned configuration can be reversed with a flat-ended plastic pin sliding on a flat metal plate.

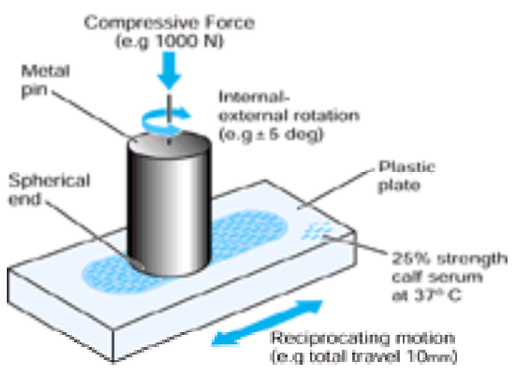


***Figure 100.65.*** A simple test for simulating the bearing conditions of a TKR to assess new materials or surfaces. The motion is a combination of sliding and rotation.

To test a knee for long-term durability when functional load and motion cycles are applied to an actual TKR, a knee simulator is required (40,217). If the goals of the design of a simulator are simplicity, low cost, reliability, and ease of use, then this would result in a machine that applies a constant compression force, only in flexion-extension. However, such a machine does not satisfy the criterion for a close simulation of reality, as previously described for hip Simulators. The input required is replication of a walking cycle, preferably with 5% to 10% of more rigorous inputs representing ascending and descending. This involves the following cyclic inputs:

- Compressive force.
- Varus moment.
- AP shear force.
- Internal-external torque
- Flexion-extension.

There is the inherent assumption that the forces and moments acting across the knee are independent of the type of TKR, no matter what the constraint. This leads to a concept for a knee simulator design called *force input* (217) (Fig. 100.66). In the test setup, the relative motions between the femur and tibia, except flexion-extension, are unconstrained. However, mechanical springs are mounted between the femoral and tibial holders, to simulate soft-tissue restraint. Although the input force data from the literature have been obtained by indirect means and are therefore uncertain, and accounting for the variations between individuals, estimates of the inputs can be specified to provide a reasonable representation of normal activity. Measurements of the output displacements and rotations show that the patterns are highly dependent on the constraints of the particular TKRs. In turn, the wear will depend on the displacements and rotations, and hence the force-input concept seems justified.

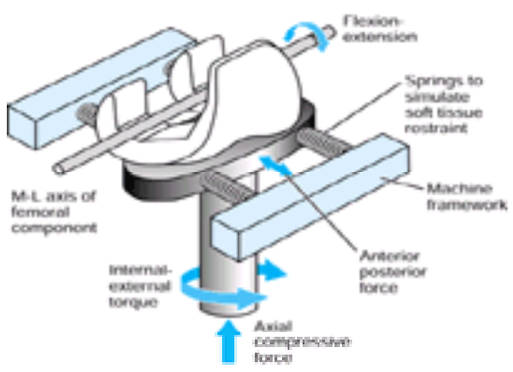


***Figure 100.66.*** Schematic of the force-input concept of a knee simulator design. The movement of each knee depends on its inherent constraint, with the springs representing soft-tissue restraint and preventing excessive movements.

An alternative scheme, which is less complex mechanically, is a displacement-input machine to which AP displacement and internal-external rotation are applied rather than force and torque (40). For the force-input approach, each knee moves according to its inherent constraint, and therefore, comparative testing would seem valid. For displacement-input, however, a means of specifying the input displacements for each individual knee is required. This could be achieved by using a simple test rig initially. However, fixed displacements and rotations would not allow for changes that might occur over time due to deformation and wear.

Another knee simulator design involves applying external forces, together with forces in the quadriceps and possibly other muscles. There would be some similarity with the scheme shown in Figure 100.60. To produce a dynamic version, however, there would be increased mechanical complexity and high demands on the control systems, but the overall scheme is more realistic and the patellofemoral joint can be tested simultaneously (personal communication: B.M. Hillberry, Perdue University).

It is to be emphasized that simulator tests of a particular knee design need to be compared with tests of an earlier design with known clinical history. Furthermore, the duration of the testing needs to be sufficient (153,195), at least 5 million cycles, to account for early bedding in, fatigue phenomena, and possible material degradation.

## ACKNOWLEDGMENTS

The author is indebted to the numerous colleagues who have contributed indirectly to this chapter. Thanks are especially due to the staff and associates of the Center for Biomedical Engineering (Faculty of Clinical Sciences, and Department of Mechanical Engineering, University College London), located at the Royal National Orthopaedic Hospital Trust, Stanmore, near London, UK.

### CHAPTER REFERENCES AND FURTHER READING

Each reference is categorized according to the following scheme: *, classic article; #, review article; !, basic research article; and +, clinical results/outcome study.


! 1. Ahir SP, Blunn GW, Haider H, Walker PS. Evaluation of a Testing Method for the Fatigue Performance of Total Knee Tibial Trays. *J Biomech* 1999;32:1049.

* 2. Ahmed AM, Burke DL. In-vitro Measurement of Static Pressure Distribution in Synovial Joints—Part 1: Tibial Surface of the Knee. *J Biomech Eng* 1983;105:216.

! 3. Ahmed AM, Burke DL, Hyder A. Force Analysis of the Patellar Mechanism. *J Orthop Res* 1987;5:69.

! 4. Ahmed AM, Burke DL, Yu, A. In-vitro Measurement of Static Pressure Distribution in Synovial Joints—Part II: Retropatellar Surface. *Transactions of the American Society of Mechanical Engineers 1983;*105:226.

! 5. Amis AA. Anterior Cruciate Ligament Replacement. Knee Stability and the Effects of Implants. *J Bone Joint Surg* 1989;71-B:819.

! 6. Andrews JG. On the Specification of Joint Configurations and Motions. (Letter to the Editor.) *J Biomech* 1984;17:155.

# 7. Andriacchi TP, Stanwyck TS, Galante JO. Knee Biomechanics and Total Knee Replacement. *J Arthroplasty* 1986;1:211.

! 8. Andriacchi TP, Yoder D, Conley A, et al. Patellofemoral Design Influences Function Following Total Knee Arthroplasty. *J Arthroplasty* 1997;12:243.

+ 9. Attenborough CG. Total Knee Replacement Using the Stabilized Gliding Prosthesis. *Ann R Coll Surg Engl* 1976;58:4.

# 10. Baker AS, Bitounis VC. Abductor Function after Total Hip Replacement: An Electromyographic and Clinical Review. *J Bone Joint Surg* 1989;71-B:47.

# 11. Balaraman V, Singh YP. Enumeration of Human Knee Prostheses—An Overview. *Biomed Sci Instrum* 1995;31:263.

+ 12. Ballard WT, Callaghan JJ, Sullivan PM, Johnston RC. The Results of Improved Cementing Techniques for Total Hip Arthroplasty in Patients Less Than Fifty Years Old. *J Bone Joint Surg* 1994;76-A:959.

! 13. Banks SA, Markovich GD, Hodge WA. In Vivo Kinematics of Cruciate-retaining and substituting Knee Arthroplasties. *J Arthroplasty* 1997;12:297.

# 14. Bargar, W. Shape the Implant to Fit the Patient. *Clin Orthop* 1989;249:73.

! 15. Bartel DL, Bicknell VL, Wright TM. The Effect of Conformity, Thickness and Material on Stresses in Ultra High Molecular Weight Components for Total Joint Replacement. *J Bone Joint Surg* 1986;68-A:1041.

* 16. Bathe K-J. *Finite Element Procedures.* Englewood Cliffs, NJ: Prentice-Hall Inc., 1996.

! 17. Beaupre GS, Vasu R, Carter DR, Schurman DJ. Epiphyseal Based Designs for Tibial Plateau Components—II. Stress Analysis in the Sagittal Plane. *J Biomech* 1986;19:663.

! 18. Bell C, Walker PS, Abeysundera M, et al. Effect of Oxidation on Delamination of Ultra-high-molecular-weight Polyethylene Tibial Components. *J Arthroplasty* 1998;13:280.

! 19. Berchuck M, Andriacchi TP, Bach BR, Reider B. Gait Adaptations by Patients Who Have a Deficient Anterior Cruciate Ligament. *J Bone Joint Surg* 1990;72-A:871.

* 20. Bergmann G, Graichen F, Rohlmann A. Hip Joint Loading During Walking and Running, Measured in Two Patients. *J Biomech* 1993;26:969.

* 21. Bergmann G, Graichen F, Rohlmann A. Is Staircase Walking a Risk for the Fixation of Hip Implants? *J Biomech* 1995;28:535.

! 22. Bhambri SK, Gilbertson LN. Micromechanisms of Fatigue Crack Initiation and Propagation in Bone Cements. *J Biomed Mater Res* 1995;29:233.

! 23. Bhargava V, Hahn GT, Rubin CA. An Elastic-plastic Finite Element Model of Rolling Contact. Part 2—Analysis of Repeated Contacts. *J Appl Mech* 1984;84-WA/APM-43:9.

! 24. Blankevoort L, Huiskes R. Validation of a Three-dimensional Model of the Knee. *J Biomech* 1996;29:955.

* 25. Blankevoort L, Huiskes R, De Lange A. The Envelope of Passive Knee Joint Motion. *J Biomech* 1988;21:705.

! 26. Bloebaum RD, Merrell M, Gustke K, Simmons M. Retrieval Analysis of a Hydroxyapatite-coated Hip Prosthesis. *Clin Orthop* 1991;267:97.

! 27. Blunn GW, Joshi AB, Lilley PA, et al. Polyethylene Wear in Unicondylar Knee Prostheses: 106 Retrieved Marmor, PCA and St. Georg Tibial Components Compared. *Acta Orthop Scand* 1992;63:247.

! 28. Blunn GW, Joshi AB, Minns RJ, et al. Wear in Retrieved Condylar Knee Arthroplasties. *J Arthroplasty* 1997;12:281.

! 29. Blunn GW, Walker PS, Joshi A, Hardinge K. The Dominance of Cyclic Sliding in Producing Wear in Total Knee Replacements. *Clin Orthop* 1991;273:253.

! 30. Bobyn JD, Mortimer ES, Glassman AH, et al. Producing and Avoiding Stress Shielding. *Clin Orthop* 1992;274:79.

! 31. Bobyn JD, Tanzer M, Krygier J, er al. Concerns with Modularity in Total Hip Arthroplasty. *Clin Orthop* 1994;298:27.

+ 32. Bohm P, Holy T. Is There a Future for Hinged Prostheses in Primary Total Knee Arthroplasty? *J Bone Joint Surg* 1998;80-B:302.

! 33. Boileau P, Walch G. The Three-dimensional Geometry of the Proximal Humerus. Implications for Surgical Technique and Prosthetic Design. *J Bone Joint Surg* 1997;79-B:857.

! 34. Brand RA, Pederson DR, Davy DT, et al. Comparison of Hip Force Calculations and Measurements in the Same Patient. *J Arthroplasty* 1994;9:45.

* 35. Brooks PJ, Walker PS, Scott RD. Tibial Component Fixation in Deficient Tibial Bone Stock. *Clin Orthop* 1984;184:302.

! 36. Brown SA, Flemming CAC, Kawalec JS, et al. Fretting Corrosion Accelerates Crevice Corrosion of Modular Hip Tapers. *J Appl Biomater* 1995;6:19.

+ 37. Buechel FF, Pappas MJ. Long-term Survivorship Analysis of Cruciate-sparing Versus Cruciate-sacrificing Knee Prostheses Using Meniscal Bearings. *Clin Orthop* 1990;260:162.

+ 38. Bugbee WD, Culpepper WJ, Engh CA Jr, Engh CA Sr. Long-term Clinical Consequences of Stress-shielding After Total Hip Arthroplasty without Cement. *J Bone Joint Surg* 1997;79-A:1007.

! 39. Buma P, van Loon PJM, Versleyen H, et al. Histological and Biomechanical Analysis of Bone and Interface Reactions Around Hydroxyapatite-coated Intramedullary Implants of Different Stiffness: A Pilot Study on the Goat. *Biomaterials* 1997;18:1251.

! 40. Burgess IC, Kolar M, Cunningham JL, Unsworth A. Development of a Six Station Knee Wear Simulator and Preliminary Wear Results. *Proc Inst Mech Eng [H]* 1997;211:37.

! 41. Butler DL, Kay MD, Stouffer DC. Comparison of Material Properties in Fascicle-bone Units from Human Patellar Tendon and Knee Ligaments. *J Biomech* 1986;19:425.

+ 42. Callaghan JJ. The Clinical Results and Basic Science of Total Hip Arthroplasty with Porous-coated Prostheses. *J Bone Joint Surg* 1993;75-A:299.

+ 43. Callaghan JJ, Dysart SH, Savory CF, Hopkinson WJ. Assessing the Results of Hip Replacements. *J Bone Joint Surg* 1990;72-B:1008.

! 44. Camacho DLA, Hopper RH, Lin GM, Myers BS. An Improved Method for Finite Element Mesh Generation of Geometrically Complex Structures with Application to the Skullbase. *J Biomech* 1997;30:1067.

+ 45. Cameron HU. The 3–6-year Results of a Modular Noncemented Low-bending Stiffness Hip Implant. *J Arthroplasty* 1993;8:239.

+ 46. Campbell ACL, Rorabeck CH, Bourne RB, et al. Thigh Pain after Cementless Hip Arthroplasty. *J Bone Joint Surg* 1992;74-B:63.

! 47. Campbell P, Ma S, Schmalzried T, Amstutz HC. Tissue Digestion for Wear Debris Particle Isolation. *J Biomed Mater Res* 1994;28:523.

! 48. Campbell P, Ma S, Yeom B, et al. Isolation of Predominantly Submicron-sized UHMWPE Wear Particles from Periprosthetic Tissues. *J Biomed Mater Res* 1995;29:127.

# 49. Cannon SR. Massive Prostheses for Malignant Bone Tumours of The Limbs. In: Kenwright J, Duparc J, Fulford P, eds. *European Instructional Course Lectures (EFORT)* 1997;3:90.

+ 50. Capello WN, Sallay PI, Feinberg JR. Omniflex Modular Femoral Component: Two-to-five Year Results. *Clin Orthop* 1994;298:54.

! 51. Caravia L, Dowson D, Fisher J, Jobbins B. The Influence of Bone and Bone Cement Debris on Counterface Roughness in Sliding Wear Tests of Ultra-high Molecular Weight Polyethylene on Stainless Steel. *Proc Inst Mech Eng [H]* 1990;204:65.

! 52. Carlsson LV, Albrektsson BEJ, Freeman MAR, et al. A New Radiographic Method for Detection of Tibial Component Migration in Total Knee Arthroplasty. *J Arthroplasty* 1993;8:117.

+ 53. Carr A, Keyes G, Miller R, et al. Medial Unicompartmental Arthroplasty. A Survival Study of the Oxford Meniscal Knee. *Clin Orthop* 1993;295:205.

+ 54. Carr AJ, Morris RW, Pynsent PB. Survival Analysis in Joint Replacement Surgery. *J Bone Joint Surg* 1993;75-B:178.

+ 55. Cartier P, Sanouiller J-L, Grelsamer RP. Unicompartmental Knee Arthroplasty Surgery. *J Arthroplasty* 1996;11:782.

* 56. Chao EY, Laughman RK, Schneider E, Stauffer RN. Normative Data of Knee Motion and Ground Reaction Forces in Adult Level Walking. *J Biomechanics* 1983;16:219.

+ 57. Cheng SL, Davey JR, Inman RD, et al. The Effect of the Medial Collar in Total Hip Arthroplasty with Porous-coated Components Inserted Without Cement. *J Bone Joint Surg* 1995;77-A:118.

! 58. Choi K, Kuhn JL, Ciarelli MJ, Goldstein SA. The Elastic Moduli of Human Subchondral Trabecular and Cortical Bone Tissue and the Size-dependency of Cortical Bone Modulus. *J Biomech* 1990;23:1103.

+ 59. Clark CR. The Prospective, Randomised, Double-blind Clinical Trial in Orthopaedic Surgery. *J Bone Joint Surg* 1997;79-A:1119.

! 60. Collier JP, Mayor MB, McNamara JL, et al. Analysis of the Failure of 122 Polyethylene Inserts from Uncemented Tibial Knee Components. *Clin Orthop* 1991;273:232.

! 61. Collier JP, Sperling DK, Currier JH, et al. Impact of Gamma Sterilization on Clinical Performance of Polyethylene in the Knee. *J Arthroplasty* 1996;11:377.

! 62. Connelly GM, Rimnac CM, Wright TM, et al. Fatigue Crack Propagation Behavior of Ultra High Molecular Weight Polyethylene. *J Orthop Res* 1984;2:119.

! 63. Currier BH, Currier JH, Collier JP, et al. Shelf Life and In Vivo Duration. Impacts on Performance of Tibial Bearings. *Clin Orthop* 1997;342:111.

! 64. Dalstra M, Huiskes R. Load Transfer Across the Pelvic Bone. *J Biomech* 1995;28:715.

! 65. Davidson JA. Characteristics of Metal and Ceramic Total Hip Bearing Surfaces and Their Effect on Long-term Ultra High Molecular Weight Polyethylene Wear. *Clin Orthop* 1993;294:361.

+ 66. Deane G. The Deane Knee: *A New Concept in Knee Joint Design. Proceedings of 'Total Knee Replacement' Conference.* Institution of Mechanical Engineers, London, 16 to 18 September, 1974, pp 140.

! 67. Deland JT, Garg A, Walker PS. Biomechanical Basis for Elbow-hinge Distractor Design. *Clin Orthop* 1987;215:303.

* 68. Dennis DA, Komistek RD, Hoff WA, Gabriel SM. In Vivo Knee Kinematics Derived Using an Inverse Perspective Technique. *Clin Orthop* 1996;331:107.

+ 69. Devane PA, Robinson EJ, Bourne RB, et al. Measurement of Polyethylene Wear in Acetabular Components Inserted with and without Cement. *J Bone Joint Surg* 1997;79-A:682.

* 70. Devore J, Peck R. *Statistics. The Exploration and Analysis of Data*, 3rd ed. Pacific Grove, Ca: Duxbury Press, 1997.

+ 71. Dorr LD, Kane TJ, Pierce-Conaty J. Long-term Results of Cemented Total Hip Arthroplasty in Patients 45 Years Old or Younger. *J Arthroplasty* 1994;9:453.

+ 72. Dowson J, Fitzpatrick R, Carr A, Murray D. Questionnaire on the Perceptions of Patients about Total Hip Replacement. *J Bone Joint Surg* 1996;78-B:185.

! 73. Draganich LF, Vahey JW. An In Vitro Study of Anterior Cruciate Ligament Strain Induced by Quadriceps and Hamstrings Forces. *J Orthop Res* 1990;8:57.

! 74. Duda GN, Schneider E, Brand D, Lierse W. Forces and Moments Along the Human Femur due to Muscular Activity. *Trans Orthop Res Soc* 1994;19:85.

! 75. Duda GN, Schneider E, Chao EYS. Internal Forces and Moments in the Femur during Walking. *J Biomech* 1997;30:933.

! 76. Elad D, Seliktar R, Mendes D. Synthesis of a Knee Joint Endoprosthesis is Based on Pure Rolling. *Engineering in Medicine* 1981;10:97.

! 77. Elbert KE, Wright TM, Rimnac CM, et al. Fatigue Crack Propagation Behaviour of Ultra High Molecular Weight Polyethylene Under Mixed Mode Conditions. *J Biomed Mater Res* 1994;28:181.

+ 78. Emmerson KP, Moran CG, Pinder IM. Survivorship Analysis of the Kinematic Stabilizer Total Knee Replacement. *J Bone Joint Surg* 1996;78-B:441.

+ 79. Engelberg R, Martin DP, Agel J, et al. Musculoskeletal Function Assessment Instrument: Criterion and Construct Validity. *J Orthop Res* 1996;14:182.

+ 80. Engh CA Jr, Culpepper WJ, Engh WJ. Long-term Results of Use of the AML in Total Hip Arthroplasty. *J Bone Joint Surg* 1997;79-A:177.

! 81. Farrar DF, Brain AA. The Miscrostructure of Ultra-high Molecular Weight Polyethylene Used in Total Joint Replacements. *Biomaterials* 1997;18:1677.

# 82. Fisher J, Dowson D. Tribology of Total Artificial Joints. *Proc Inst Mech Eng [H]* 1991;205:73.

! 83. Fisher J, Firkins P, Reeves EA, et al. The Influence of Scratches to Metallic Counterfaces on the Wear of Ultra-high Molecular Weight Polyethylene. *Proc Inst Mech Eng [H]* 1995;209:263.

# 84. Frank TG, Hanna GB, Cuschieri A. Technological Aspects of Minimal Access Surgery. *Proc Inst Mech Eng [H]* 1997;211:129.

+ 85. Freeman MAR, Swanson SAV, Todd RC. Total Replacement of the Knee Using the Freeman-Swanson Prosthesis. *Clin Orthop* 1973;94:153.

# 86. Freeman MAR, Railton GT. Should the Posterior Cruciate Ligament Be Restrained or Resected in Condylar Nonmeniscal Knee Arthroplasty? The Case for Resection. *J Arthroplasty* 1988;3:S3.

# 87. Fu FH, Harner CD, Johnson DL, et al. Biomechanics of Knee Ligaments. Basic Concepts and Clinical Application. *J Bone Joint Surg* 1993;75-A:1716.

! 88. Fukubayashi T, Torzilli PA, Sherman MF, Warren RF. An In Vitro Biomechanical Evaluation of Anterior-posterior Motion of the Knee. Tibial Displacement, Rotation, and Torque. *J Bone Joint Surg* 1982;64-A:258.

! 89. Garg A, Walker PS. Prediction of Total Knee Motion Using a 3-Dimensional Computer-graphics Model. *J Biomech* 1990;23:45.

+ 90. Geesink RGT, Hoefnagels NHM. Six Year Results of Hydroxyapatite-coated Total Hip Replacement. *J Bone Joint Surg* 1995;77-B:534.

+ 91. Gie GA, Linder L, Ling RSM, et al. Impacted Cancellous Allografts and Cement for Revision Total Hip Arthroplasty. *J Bone Joint Surg* 1993;75-B:14.

! 92. Goodfellow J, O'Connor J. The Anterior Cruciate Ligament in Knee Arthroplasty. *Clin Orthop* 1992;276:245.

* 93. Grood ES, Suntay WJ. A Joint Co-ordinate System for the Clinical Description of Three-dimensional Motions: Application to the Knee. *J Biomech Eng* 1983;105:136.

* 94. Gruen TA, McNeice GM, Amstutz HC. 'Modes of Failure' of Cemented Stem-type Femoral Components. *Clin Orthop* 1979;141:17.

* 95. Gunston FH. Polycentric Knee Arthroplasty. *J Bone Joint Surg* 1971;53-B:272.

! 96. Hall RM, Craig PS, Hardaker C, et al. Measurement of Wear in Retrieved Acetabular Sockets. *Proc Inst Mech Eng [H]* 1995;209:233.

* 97. Harding ML, Harding L, Goodfellow JW. A Preliminary Report of a Simple Rig to Aid Study of the Functional Anatomy of the Cadaver Human Knee Joint. *J Biomech* 1977;10:517.

+ 98. Harris WH. The Problem is Osteolysis. *Clin Orthop* 1995;311:46.

! 99. Harris WH, Mulroy RD, Maloney WJ, et al. Intraoperative Measurements of Rotational Stability of Femoral Components of Total Hip Arthroplasty. *Clin Orthop* 1991;266:119.

! 100. Harryman DT, Sidles JA, Harris SL, et al. The Effect of Articular Conformity and the Size of the Humeral Head Component on Laxity and Motion After Glenohumeral Arthroplasty. *J Bone Joint Surg* 1995;77-A:555.

! 101. Hashemi A, Shirazi-Adl A, Dammak M. Bidirectional Friction Study of Cancellous Bone-porous Coated Metal Interface. *J Biomed Mater Res* 1996;33:257.

+ 102. Heck DA, Marmor L, Gibson A, Rougraff BT. Unicompartmental Knee Arthroplasty. A Multicenter Investigation with Long-term Follow-up Evaluation. *Clin Orthop* 1993;286:154.

! 103. Hefzy MS, Yang H. A Three-dimensional Anatomical Model of the Human Patello-femoral Joint, for the Determination of Patello-femoral Motions and Contact Characteristics. *J Biomed Eng* 1993;15:289.

# 104. Hench LL, Wilson J, eds. *Introduction to Bioceramics.* London and Singapore: World Scientific Publishers, 1993.

! 105. Hilding MB, Lanshammar H, Ryd L. Knee Joint Loading and Tibial Component Loosening. *J Bone Joint Surg* 1996;78-B:66.

! 106. Hipp JA, Edgerton BC, An K-N, Hayes WC. Structural Consequences of Transcortical Holes in Long Bones Loaded in Torsion. *J Biomech* 1990;23:1261.

! 107. Hirakawa K, Bauer TW, Stulberg BN, et al. Characterization and Comparison of Wear Debris from Failed Total Hip Implants of Different Types. *J Bone Joint Surg* 1996;78-A:1235.

! 108. Hsieh HH, Walker PS. Stabilizing Mechanisms of the Loaded and Unloaded Knee Joint. *J Bone Joint Surg* 1976;58-A:87.

! 109. Hua J, Walker PS. Relative Motion of Hip Stems Under Load: An In Vitro Study of Symmetrical, Asymmetrical and Custom Asymmetrical Designs. *J Bone Joint Surg* 1994;76-A:95.

! 110. Hua J, Walker PS. Closeness of Fit of Uncemented Stems Improves the Strain Distribution in the Femur. *J Orthop Res* 1995;13:339.

! 111. Huberti HH, Hayes WC. Patellofemoral Contact Pressures. The Influence of Q-angle and Tendofemoral Contact. *J Bone Joint Surg* 1984;66-A:715.

* 112. Huiskes R. Failed Innovation in Total Hip Replacement. Diagnosis and Proposals for a Cure. *Acta Orthop Scand* 1993;64:699.

! 113. Huiskes R. The Various Stress Patterns of Press-fit, Ingrown and Cemented Femoral Stems. *Clin Orthop* 1990;261:27.

* 114. Huiskes R, Bocklagen R. Mathematical Shape Optimisation of Hip Prosthesis Designs. *J Biomech* 1989;22:793.

+ 115. Huk OL, Bansal M, Betts F, et al. Polyethylene and Metal Debris Generated by Non-articulating Surfaces of Modular Acetabular Components. *J Bone Joint Surg* 1994;76-B:568.

! 116. Husmann O, Rubin PJ, Leyvraz P-F, et al. Three-dimensional Morphology of the Proximal Femur. *J Arthroplasty* 1997;12:444.

! 117. Hvid I. The Stability of the Human Patello-femoral Joint. *Engineering in Medicine* 1983;12:55.

! 118. Hvid I, Bentzen SM, Jorgensen J. Remodeling of the Tibial Plateau After Knee Replacement. *Acta Orthop Scand* 1988;59:567.

! 119. Iguchi H, Hua J, Walker PS. Accuracy of Using Radiographs for Custom Hip Stem Design. *J Arthroplasty* 1996;11:312.

* 120. Inman VT, Ralston HJ, Todd F, eds. *Human Walking.* Baltimore: Williams & Wilkins, 1981.

# 121. Insall JN. Historical Development, Classification and Characteristics of Knee Prostheses. In: Insall JN, Windsor RE, Scott WN, et al., eds. *Surgery of the Knee,* 2nd ed. New York: Churchill Livingstone, 1993:677.

! 122. Jasty M, O'Connor DO, Henshaw RM, et al. Fit of the Uncemented Femoral Component and the Use of Cement Influence the Strain Transfer to the Femoral Cortex. *J Orthop Res* 1994;12:648.

! 123. Jilani A, Shirazi-Adl A, Bendjaballah MZ. Biomechanics of Human Tibio-femoral Joint in Axial Rotation. *The Knee* 1997;4:203.

* 124. Johnson KL. *Contact Mechanics.* Cambridge, England: Cambridge University Press, 1985.

+ 125. Johnston RC, Moines D, Fitzgerald RH, et al. Clinical and Radiographic Evaluation of Total Hip Replacement. A Standard System of Terminology for Reporting Results. *J Bone Joint Surg* 1990;72-A:161.

! 126. Joyce TJ, Unsworth A. A Comparison of the Wear of Cross-linked Polyethylene Against Itself with the Wear of Ultra-high Molecular Weight Polyethylene Against Itself. *Proc Inst Mech Eng [H]* 1996;210:297.

+ 127. Karrholm J, Malchau H, Snorrason F, Herberts P. Micromotion of Femoral Stems in Total Hip Arthroplasty. *J Bone Joint Surg* 1994;76-A:1692.

! 128. Keller TS, Mao Z, Spengler DM. Young's Modulus, Bending Strength, and Tissue Physical Properties of Human Compact Bone. *J Orthop Res* 1990;8:592.

+ 129. Kim H, Pelker RR, Gibson DH, et al. Rollback in Posterior Cruciate Ligament-retaining Total Knee Arthroplasty. *J Arthroplasty* 1997;12:561.

* 130. Knutson K, Lewold S, Robertsson O, Lidgren L. The Swedish Knee Arthroplasty Register. *Acta Orthop Scand* 1994;65:375.

+ 131. Kolstad K, Adalberth G, Mallmin H, et al. The Wagner Revision Stem for Severe Osteolysis. *Acta Orthop Scand* 1996;67:541.

! 132. Kowalk DL, Duncan JA, Vaughan CL. Abduction-adduction Moments at the Knee During Stair Ascent and Descent. *J Biomech* 1996;29:383.

+ 133. Krismer M, Stokl B, Fischer M, et al. Early Migration Predicts Late Aseptic Failure of Hip Sockets. *J Bone Joint Surg* 1996;78-B:422.

! 134. Kurosawa H, Walker PS, Abe S, et al. Geometry and Motion of the Knee for Implant and Orthotic Design. *J Biomech* 1985;18:487.

! 135. Kurtz SM, Rimnac CM, Santner TJ, Bartel DL. Exponential Model for the Tensile True Stress-strain Behavior of As-irradiated and Oxidatively Degraded Ultra High Molecular Weight Polyethylene. *J Orthop Res* 1996;14:755.

! 136. Kuster MS, Wood GA, Stachowiak GW, Gachter A. Joint Load Considerations in Total Knee Replacement. *J Bone Joint Surg* 1997;79-B:109.

+ 137. Lachiewicz PF, Falatyn SP. Clinical and Radiographic Results of the Total Condylar III and Constrained Condylar Total Knee Arthroplasty. *J Arthroplasty* 1996;11:916.

* 138. Lafortune MA, Cavanagh PR, Sommer HJ, Kalenak A. Three-dimensional Kinematics of the Human Knee During Walking. *J Biomech* 1992;25:347.

* 139. Landy MM, Walker PS. Wear of Ultra High Molecular Weight Polyethylene Components of 90 Retrieved Knee Prostheses. *J Arthroplasty* 1988;3(Suppl):S73.

! 140. Li S, Burstein AH. Current Concepts Review. Ultra-high Molecular Weight Polyethylene. *J Bone Joint Surg* 1994;76-A:1080.

* 141. Lieber RL. Statistical Significance and Statistical Power in Hypothesis Testing. *J Orthop Res* 1990;8:304.

+ 142. Lieberman JR, Dorey F, Shekelle P, et al. Differences Between Patients' and Physicians' Evaluations of Outcome After Total Hip Arthroplasty. *J Bone Joint Surg* 1996;78-A:835.

! 143. Loch DA, Zongping L, Lewis JL, Stewart NJ. A Theoretical Model of the Knee and ACL: Theory and Experimental Verification. *J Biomech* 1992;25:81.

! 144. Luger E, Sathasivam S, Walker PS. Inherent Differences in the Laxity and Stability Between the Intact Knee and Total Knee Replacements. *The Knee* 1997;4:7.

+ 145. Madey SM, Callaghan JJ, Olejniczak JP, et al. Charnley Total Hip Arthroplasty with Use of Improved Techniques of Cementing. *J Bone Joint Surg* 1997;79-A:53.

! 146. Mann KA, Ayers DC, Damron TA. Effects of Stem Length on Mechanics of the Femoral Hip Component After Cemented Revision. *J Orthop Res* 1997;15:62.

* 147. Markolf KL, Bargar WL, Shoemaker SC, Amstutz HC. The Role of the Joint Load in Knee Stability. *J Bone Joint Surg* 1981;63-A:570.

! 148. Marshek KM, Chen HH. Discretization Pressure-wear Theory for Bodies in Sliding Contact. *J Tribology* 1996;111:95.

! 149. Maxian TA, Brown TD, Pedersen DR, Callaghan JJ. A Sliding-distance-coupled Finite Element Formulation for Polyethylene Wear in Total Hip Arthroplasty. *J Biomech* 1996;29:687.

! 150. McCormack BAO, Prendergast PJ, Gallagher DG. An Experimental Study of Damage Accumulation in Cemented Hip Prostheses. *Clin Biomech* 1996;11:214.

! 151. McGloughlin TM, Monaghan JM. Contact Stress Analysis of the Tibial Component of Prosthetic Knee Implants. *Proc Inst Mech Eng [H]* 1997;211:391.

+ 152. McGrory BJ, Shinar AA, Freiberg AA, Harris WH. Enhancement of the Value of Hip Questionnaires by Telephone Follow-up Evaluation. *J Arthroplasty* 1997;12:340.

! 153. McLeod PC, Ketterkamp DB, Srinivasan V, Henderson OL. Measurements of Repetitive Activities of the Knee. *J Biomech* 1975;8:369.

! 154. Miegel RE, Walker PS, Nelson PC, et al. A Compliant Interface for Total Knee Arthroplasty. *J Orthop Res* 1986;4:486.

* 155. Morrison JB. Bioengineering Analysis of Force Actions Transmitted by the Knee Joint. *Biomed Eng* 1968;3:164.

* 156. Morrison JB. Function of the Knee Joint in Various Activities. *Biomed Eng* 1969;4:573.

* 157. Morrison JB. The Mechanics of the Knee Joint in Relation to Normal Walking. *J Biomech* 1970;3:51.

+ 158. Morscher EW. Current Status of Acetabular Fixation in Primary Total Hip Arthroplasty. *Clin Orthop* 1992;274:172.

* 159. Mow VC, Hayes WC, eds. *Basic Orthopaedic Biomechanics,* 2nd ed. New York: Lippincott-Raven, 1997.

* 160. Mulier JC, Mulier M, Brady LP, et al. A New System to Produce Intraoperatively Custom Femoral Prosthesis from Measurements Taken During the Surgical Procedure. *Clin Orthop* 1989;249:97.

! 161. Muüller-Gerbl M. *The Subchondral Bone Plate,* Vol. 141. *Advances in Anatomy, Embryology and Cell Biology.* Berlin: Springer-Verlag, 1998.

+ 162. Murray DW, Britton AR, Bulstrode CJK. Loss to Follow-up Matters. *J Bone Joint Surg* 1997;79-B:254.

! 163. Nagamine R, Otani T, White SE, et al. Patellar Tracking Measurement in the Normal Knee. *J Orthop Res* 1995;13:115.

! 164. Nahass BE, Madson MM, Walker PS. Motion of the Knee After Condylar Resurfacing—An In Vivo Study. *J Biomech* 1991;24:1107.

* 165. Niemcryk SJ, Kras TJ, Mallory TH. Empirical Considerations in Orthopaedic Research Design and Data Analysis. Part III: Multivariable Analysis. *J Arthroplasty* 1990;5:111.

+ 166. Nilsson KG, Karrholm J, Ekelund L, Magnusson P. Evaluation of Micromotion in Cemented vs Uncemented Knee Arthroplasty in Osteoarthrosis and Rheumatoid Arthritis. *J Arthroplasty* 1991;6:265.

* 167. Noble PC, Alexander JW, Lindahl LJ, et al. The Anatomic Basis of Femoral Component Design. *Clin Orthop* 1988;235:148.

+ 168. Onsten I, Carlsson AS, Sanzen L, Besjakov J. Migration and Wear of a Hydroxyapatite-coated Hip Prosthesis. *J Bone Joint Surg* 1996;78-B:85.

+ 169. Oswald MH, Jakob RP, Schneider E, Hoogewoud H-M. Radiological Analysis of Normal Axial Alignment of Femur and Tibia in View of Total Knee Arthroplasty. *J Arthroplasty* 1993;8:419.

! 170. Otani T, Whiteside LA, White SE. Cutting Errors in Preparation of Femoral Components in Total Knee Arthroplasty. *J Arthroplasty* 1993;8:503.

* 171. Paul HA, Bargar WL, Mittelstadt B, et al. Development of a Surgical Robot for Cementless Total Hip Arthroplasty. *Clin Orthop* 1992;285:57.

! 172. Piziali RL, Rastegar JC. Measurements of the Nonlinear, Coupled Stiffness Characteristics of the Human Knee. *J Biomech* 1977;10:45.

+ 173. Polyzoides AJ, Dendrinos GK, Tsakonas H. The Rotaglide Total Knee Arthroplasty. *J Arthroplasty* 1996;11:453.

! 174. Poppen NK, Walker PS. Forces at the Glenohumeral Joint in Adbuction. *Clin Orthop* 1978;135:165.

! 175. Prendergast PJ. Finite Element Models in Tissue Mechanics and Orthopaedic Implant Design. *Clin Biomech* 1997;12:343.

! 176. Pruitt L, Koo J, Rimnac CM, et al. Cyclic Compressive Loading Results in Fatigue Cracks in Ultra High Molecular Weight Polyethylene. *J Orthop Res* 1995;13:143.

# 177. Pugh S. *Total Design.* Wokingham, England: Addison-Wesley, 1994.

+ 178. Ranawat CS, Flynn WF Jr, Saddler S, et al. Long-term Results of the Total Condylar Knee Arthroplasty. *Clin Orthop* 1993;286:94.

+ 179. Reilly DT, Walker PS, Ben-Dov M, Ewald FC. Effects of Tibial Components on Load Transfer in the Upper Tibia. *Clin Orthop* 1982;165:273.

! 180. Rimnac CM, Klein RW, Betts F, Wright TM. Post-irradiation Aging of Ultra-high Molecular Weight Polyethylene. *J Bone Joint Surg* 1994;76-A:1052.

! 181. Robinson R, Clark JE. Uncemented Press-fit Total Hip Arthroplasty Using the Identifit Custom-molding Technique. *J Arthroplasty* 1996;11:247.

! 182. Rose RM, Radin EL. A Prognosis for Ultra-high Molecular Weight Polyethylene. *Biomaterials* 1990;11:63. !

! 183. Rovick JS, Reuben JD, Schrager RJ, Walker PS. Relation Between Knee Motion and Ligament Length Patterns. *Clin Biomech* 1991;6:213.

! 184. Rubin PJ, Leyvraz PF, Aubaniac JM, et al. The Morphology of the Proximal Femur. *J Bone Joint Surg* 1992;74-B:28.

! 185. Rubin PJ, Rakotamanana RL, Leyvraz PF, et al. Frictional Interface Micromotions and Anisotropic Stress Distribution in a Femoral Total Hip Component. *J Biomech* 1993;26:725.

* 186. Ryd L, Toksvig-Larsen S. Early Postoperative Fixation of Tibial Components: An In Vivo Roentgen Stereophotogrammetric Analysis. *J Orthop Res* 1993;11:142.

* 187. Rydell NW. Forces Acting on the Femoral Head-prosthesis: A Study on Strain Gauge Supplied Prostheses in Living Persons. *Acta Orthop Scand* 1966;37(Suppl 88).

! 188. Sathasivam S, Walker PS. A Computer Model with Surface Friction for the Prediction of Total Knee Kinematics. *J Biomech* 1997;30:177.

! 189. Sathasivam S, Walker PS. A Computer Model to Predict Sub-surface Damage in Tibial Inserts of Total Knees. *J Orthop Res* 1998;16:564.

! 190. Sathasivam S, Walker PS. The Conflicting Requirements of Laxity and Conformity in Total Knee Replacement. *J Biomech* 1999;32:239.

+ 191. Sathasivam S, Walker PS, Pinder IM, et al. Custom Constrained Condylar Total Knees Using CAD-CAM. *The Knee* 1999;6:49.

* 192. Schmalzried TP, Kwong LM, Jasty M, et al. The Mechanism of Loosening of Cemented Acetabular Components in Total Hip Arthroplasty. *Clin Orthop* 1992;274:60.

! 193. Schneider E, Eulenberger J, Wyder D, et al. A Comparative Study of the Initial Stability of Cementless Hip Prostheses. *Clin Orthop* 1989;249:200.

+ 194. Scott DF, Jaffe WL. Host-bone Response to Porous-coated Cobalt-chrome and Hydroxyapatite-coated Titanium Femoral Components in Hip Arthroplasty. *J Arthroplasty* 1996;11:429.

! 195. Seedhom B, Wallbridge NC. Walking Activities and Wear of Prostheses. *Ann Rheum Dis* 1985;44:838.

* 196. Selvik G. Roentgen Stereophotogrammetry. A Method for the Study of the Kinematics of the Skeletal System. *Acta Orthop Scand* 1989;60(Suppl 232):1.

! 197. Shimagaki H, Bechtold JE, Sherman RE, Gustilo RB. Stability of Initial Fixation of the Tibial Component in Cementless Total Knee Arthroplasty. *J Orthop Res* 1990;8:64.

! 198. Shirazi-Adi A, Danmak M, Forcione A, Paiement G. Friction Measurements at the Bone/Implant Interface—Application to Analysis of Cementless Prostheses. *Trans Orthop Res Soc* 1992;17:382.

! 199. Shoemaker SC, Markolf KL. Effects of Joint Load on the Stiffness and Laxity of Ligament-deficient Knees. *J Bone Joint Surg* 1985;67-A:136.

! 200. Singerman R, Pagan HD, Peyser AB, Goldberg VM. Effect of Femoral Component Rotation and Patellar Design on Patellar Forces. *Clin Orthop* 1997;334:345.

! 201. Skinner HB, Kilgus DJ, Keyak J, et al. Correlation of Computed Finite Element Stresses to Bone Density after Remodeling Around Cementless Femoral Implants. *Clin Orthop* 1994;305:178.

! 202. Smart RC, Barbagallo S, Slater GL, et al. Measurement of Periprosthetic Bone Density in Hip Arthroplasty Using Dual-energy X-ray Absorptiometry. *J Arthroplasty* 1996;11:445.

! 203. Soballe K, B-Rasmussen H, Hansen FS, Bunger C. Hydroxyapatite Coating Converts Fibrous Tissue to Bone Around Loaded Implants. *J Bone Joint Surg* 1993;75-B:270.

! 204. Stiehl JB, Komistek RD, Dennis DA, et al. Fluoroscopic Analysis of Kinematics after Posteriorcruciate Retaining Knee Arthroplasty. *J Bone Joint Surg* 1995;77-B:884.

# 205. Suh NP. *Tribophysics.* Englewood Cliffs, NJ: Prentice-Hall Inc., 1986.

* 206. Taylor S, Walker PS, Perry J, et al. The Forces in the Distal Femur and the Knee During Walking and Other Activities Measured by Telemetry. *J Arthroplasty* 1998;13:428.

! 207. Trent PS, Walker PS, Wolf B. Ligament Length Patterns, Strength, and Rotational Axes of the Knee Joint. *Clin Orthop* 1976;117:263.

+ 208. Uematsu O, Hsu HP, Kelly KM, et al. Radiographic Study of Kinematic Total Knee Arthroplasty. *J Arthroplasty* 1987;2:317.

+ 209. Van Lenthe H, De Waal Malefijt M, Huiskes R. Bone Resorption in the Distal Femur After Total Knee Arthroplasty Can Be Caused by Stress Shielding. *J Bone Joint Surg* 1997;79-B:117.

+ 210. Verdonschot N, Huiskes R. Cement Debonding Process of Total Hip Arthroplasty Stems. *Clin Orthop* 1997;336:297.

! 211. Viceconti M, Cavallotti G, Andrisano AO, Toni A. Discussion on the Design of a Hip Joint Simulator. *Med Eng Phys* 1996;18:234.

* 212. Walker PS. *Human Joints and Their Artificial Replacements.* Springfield, IL: Charles C Thomas, 1977.

+ 213. Walker PS. The Total-condylar Knee and Its Evolution. In: Ranawat CS, ed. *Total Condylar Knee Arthroplasty. Techniques, Results and Complications.* New York: Springer-Verlag, 1985:7.

! 214. Walker PS. Bearing Surface Design in Total Knee Replacement. *Engineering in Medicine* 1988;17:149.

! 215. Walker PS. Design of Kinemax Total Knee Replacement Bearing Surfaces. *Acta Orthop Belg* 1991;57(Suppl II):108.

! 216. Walker PS, Blunn GW, Lilley PA. Wear Testing of Materials and Surfaces for Total Knee Replacement. *J Biomed Mater Res* 1996;33:159.

! 217. Walker PS, Blunn GW, Broome DR, et al. A Knee Simulating Machine for Performance Evaluation of Total Knee Replacements. J *Biomech* 1997;30:83.

! 218. Walker PS, Dowson D, Longfield MD, Wright V. “Boosted Lubrication” in Synovial Joints by Fluid Entrapment and Enrichment. *Ann Rheum Dis* 1968;27:512.

! 219. Walker PS, Erkman MJ. The Role of the Menisci in Force Transmission Across the Knee. *Clin Orthop* 1975;109:184.

! 220. Walker PS, Greene D, Reilly D, et al. Fixation of Tibial Components of Knee Prostheses. *J Bone Joint Surg* 1981;63-A:258.

! 221. Walker PS, Hsu HP, Zimmerman RA. A Comparative Study of Uncemented Tibial Components. *J Arthroplasty* 1990;5:245.

! 222. Walker PS, Mai SF, Cobb AJ, et al. Prediction of Clinical Outcome of THR from Migration Measurements on Standard Radiographs. *J Bone Joint Surg* 1995;77-B:705.

* 223. Walker PS, Robertson DD. Design and Fabrication of Cementless Hip Stems. *Clin Orthop* 1988;235:25.

! 224. Walker PS, Rodger RF, Miegel RE, et al. An Investigation of a Compliant Interface for Press-fit Joint Replacement. *J Orthop Res* 1990;8:453.

! 225. Walker PS, Sathasivam S. The Design of Guide Surfaces for Fixed-bearing and Mobile-bearing Knee Replacements. *J Biomech* 1999;32:27.

! 226. Walker PS, Schneeweis D, Murphy S, Nelson P. Strains and Micromotions of Press-fit Femoral Stem Prosthesis. *J Biomech* 1987;20:693.

! 227. Walker PS, Unsworth A, Dowson D, et al. Mode of Aggregation of Hyaluronic Acid Protein Complex on the Surface of Articular Cartilage. *Ann Rheum Dis* 1970;29:591.

! 228. Walker PS, Wang C-J, Masse Y. Joint Laxity as a Criterion for the Design of Condylar Knee Prostheses. *Proc Inst Mech Eng* 1974;CP16:22.

+ 229. Wang C-J, Walker PS. Rotatory Laxity of the Human Knee Joint. *J Bone Joint Surg* 1974;56-A:161.

! 230. Weinans H, Huiskes R, van Rietbergen B, et al. Adaptive Bone Remodeling Around Bonded Noncemented THA: A Comparison Between Animal Experiments and Computer Simulations. *J Orthop Res* 1993;11:500.

+ 231. Weinstein JN, Andriacchi TP, Galante JO. Factors Influencing Walking and Stairclimbing Following Unicompartmental Knee Arthroplasty. *J Arthroplasty* 1986;1:109.

+ 232. Whiteside LA, Arima J, White SE, et al. Fixation of the Modular Total Hip Femoral Component in Cementless Total Hip Arthroplasty. *Clin Orthop* 1994;298:184.

+ 233. Wilson SA, McCann PD, Gotlin RS, et al. Comprehensive Gait Analysis in Posterior-stabilized Knee Arthroplasty. *J Arthroplasty* 1996;11:359.

! 234. Wimmer MA, Andriacchi TP. Tractive Forces During Rolling Motion of the Knee: Implications for Wear in Total Knee Replacement. *J Biomech* 1997;30:131.

! 235. Woltring HJ. 3-D Attitude Representation of Human Joints: A Standardization Proposal. *J Biomech* 1994;27:1399.

# 236. Wright TM, Goodman SB, eds. *Implant Wear: The Future of Total Joint Replacement.* Rosemont, ILL: American Academy of Orthopaedic Surgeons, 1996.

+ 237. Wroblewski BM, Siney PD, Dowson D, Collins SN. Prospective Clinical and Joint Simulator Studies of a New Total Hip Arthroplasty Using Alumina Ceramic Heads and Cross-linked Polyethylene Cups. *J Bone Joint Surg* 1996;78-B:280.

! 238. Wu G, Cavanagh PR. ISB Recommendations for Standardization in the Reporting of Kinematic Data. *J Biomech* 1995;28:1257.

* 239. Young WC. *Roark's Formulas for Stress and Strain,* 6th ed. New York: McGraw-Hill, 1989.

! 240. Zavatsky AB. A Kinematic-freedom Analysis of a Flexed-knee-stance Testing Rig. *J Biomech* 1997;30:277.

! 241. Zavatsky AB, O'Connor JJ. Three-dimensional Geometrical Models of Human Knee Ligaments. *Proc Inst Mech Engrs* 1994;208:229.

# CHAPTER 101

# PRIMARY ARTHROPLASTY OF THE SHOULDER

*Robert G. Marx and Edward V. Craig*

**R. G. Marx, E. V. Craig:** Craig: Hospital for Special Surgery, New York, New York, 10021.

Principles of Treatment
Indications and Contraindications
Results
Preoperative Evaluation
Surgical Techniques
Considerations for Specific Diagnoses
Primary Osteoarthritis
Rheumatoid Arthritis
Rotator-Cuff Tear Arthropathy
Arthritis of Recurrent Dislocations
Total Shoulder Replacement for Posttraumatic Arthritis
Prosthetic Replacement for Acute Fractures
Pitfalls and Complications
Outcome Measurement
Rehabilitation
Chapter References

The shoulder has a unique capacity for motion because of (a) the stable and painless articulation between the glenoid and the humeral head, (b) a subdeltoid space that is free of restricting structures, and (c) the integrated action of the acromioclavicular, sternoclavicular, and scapulothoracic articulations. The critical contribution of the soft tissues surrounding the glenohumeral joint cannot be overemphasized. The glenoid surface is only slightly curved, and its surface area is about 25% that of the humeral head. Thus, the humeral head rests against the glenoid surface, relying on the surrounding capsule and musculotendinous units for stability as well as mobility. Soft-tissue abnormalities such as scarring, contracture, laxity, muscle atrophy, neurologic disease, or rotator cuff tendinopathy severely compromise normal shoulder function.

The multiple variables of the soft-tissue and bony structures of the shoulder must be recognized in considering the role, indications, technique, and potential benefits and risks of shoulder arthroplasty.

The surgical technique of implant insertion in total shoulder arthroplasty is but a part of a process that also includes proper patient selection; evaluation of sternoclavicular, acromioclavicular, and scapulothoracic relations; evaluation of the integrity and function of the rotator cuff, laxity or contracture of the capsule and glenohumeral ligaments, and the power of the deltoid muscle; and the ability of the surgeon and patient to interact and cooperate in the rehabilitation essential for successful arthroplasty. If these variables can be handled successfully, pain relief following total shoulder replacement is predictable (10,38,51). However, although passive motion may be achieved through technically satisfactory attention to the many intraoperative variables, active motion will depend on the strength of the muscles powering the arthroplasty. Thus, adequate rehabilitation aimed at both motion and strength is essential.

The many arthropathies leading to degeneration of the glenohumeral joint have identifying features that can present unique problems of bone and soft-tissue reconstruction. It is important to recognize some of these features, as they may provide clues to intraoperative pitfalls. As an example, primary osteoarthritis presents the problem of asymmetric, posterior wear on the glenoid. Rheumatoid arthritis may display associated acromioclavicular disease, lower extremity disorders, elbow and wrist involvement, rotator cuff disease, osteopenia, and bone destruction, each of which will affect operative technique, postoperative rehabilitation, and the result. Posttraumatic arthritis often exhibits scarring and soft-tissue contracture, malunited tuberosities, or nerve injury. In rotator-cuff tear arthropathy, excessive wear into the acromioclavicular joint, acromion, and glenoid, combined with severe soft-tissue deficits, make reconstruction uniquely challenging (39). In addition, as the characteristics of each arthropathy influence the long-term results, patients may be better informed preoperatively by a surgeon who recognizes the differences between and stages of glenohumeral arthritic disease.

Thus, it is unrealistic to expect a single operative technique to apply to all patients who require total shoulder replacement. In this chapter, a general guide to the technique of primary replacement arthroplasty is followed by a discussion of some of the features of each arthropathy and its associated surgical reconstruction.

## PRINCIPLES OF TREATMENT

Prosthetic designs vary in their amount of inherent constraint. Most modern systems are modeled after the classic unconstrained arthroplasty, initially described by Neer (38). The popularity of this prosthesis stems in part from the fact that its insertion requires the removal of only that part of the humeral head and glenoid normally covered with articular cartilage. This minimizes bone removal, allowing duplication of normal anatomy by the implant and leaving some bone stock for salvage through arthrodesis if necessary. The Neer design relies on soft-tissue integrity to stabilize and move the implant because it replicates normal anatomy. Thus, the surgeon must be able to anticipate and treat capsular laxity or contracture and must be able to reconstruct a deficient rotator cuff.

The Neer II design features a proximal humeral component with two head thicknesses (15 and 22 mm), each with the same radius of curvature (Fig. 101.1). There are three different stem diameters (6.3, 9.5, and 12.7 mm) for each head thickness. The most commonly used stem lengths are 125 and 150 mm. An extra-long stem (252 mm) is used in tumor reconstruction or to treat an associated humeral shaft fracture. An extra-short stem (63 mm) is useful in some patients with juvenile rheumatoid arthritis or epiphyseal dysplasia (Fig. 101.2). The proximal humerus prosthesis may be used with or without bone cement for total shoulder arthroplasty. Hemiarthroplasty for traumatic reconstruction generally requires cement fixation to allow the implant to sit proud of the humeral shaft, thus restoring length and avoiding inferior subluxation of the head. Because its radius of curvature approximates the normal humeral head, the implant can be used without the glenoid component if the glenoid is free of disease, as in acute fractures and some cases of osteonecrosis (22).

***Figure 101.1.*** The Neer II proximal humerus. There are two head sizes, each with the same radius of curvature. The holes in the fin are for securing the tuberosities in fractures or after tuberosity osteotomy.

***Figure 101.2.*** The Neer II design has three different stem diameters for each head size. The variable stem lengths allow adjustments in unique situations such as tumor reconstruction or juvenile rheumatoid arthritis.

The standard glenoid component approximates the surface of the average adult glenoid and is made of high-density polyethylene. It has a keel that must be inserted into the neck of the scapula, and a radiographic marker wire (Fig. 101.3). Its radius of curvature matches that of the proximal humeral component (Fig. 101.4). More recently, a metal-backed glenoid was designed to minimize the stress on the polyethylene glenoid in hopes of avoiding implant breakage or prosthetic deformation in a high-demand patient (Fig. 101.5). The metal-backed implant is rarely used, as the all polyethylene components are used routinely.



***Figure 101.3.*** The standard polyethylene glenoid.

***Figure 101.4.*** The radius of curvature of the glenoid matches that of the proximal humeral component.



***Figure 101.5.*** The metal-backed glenoid component.

In recent years, several modular designs have become available. The modular designs are attractive in terms of ease of revision surgery, tensioning of soft tissues, inventory, and fracture treatment (26). The Biomet (Warsaw, IN) modular shoulder has four outer head sizes that each have three or four possible neck lengths. These heads can be used with stems ranging from 6 to 15 mm in diameter and 7 to 19 cm in length. The Kirschner Integrated Shoulder System (Biomet) adds modularity to the Neer design, and the Atlas further increases options by adding humeral modularity (Fig. 101.6).

***Figure 101.6.*** Components of the Atlas Modular Total Shoulder System.

Because unconstrained implants rely entirely on reconstruction of soft tissue for stability and motion, other prosthetic designs provide more inherent stability if the rotator cuff is deficient. Among the constrained designs are the Stanmore and the Michael Reese models (45). The trispherical prosthesis (Gristina), although constrained, is intended to allow more motion through a double ball-and-socket design. Constrained designs may not permit the forces across the joint to be shared with the surrounding soft tissue, and complications in some series have been high. In some constrained implant designs, the amount of bone resection has been greater than in a nonconstrained implant. As has been the experience with constrained implants in the lower extremity, loosening appears to be a greater problem. Although these designs may be considered in situations where there is no functioning rotator cuff, we felt that they are generally not indicated (46). Their use has been abandoned by most shoulder surgeons.

## INDICATIONS AND CONTRAINDICATIONS

The main indication for implant arthroplasty of the shoulder is pain from an arthritic glenohumeral joint that is unresponsive to nonoperative treatment such as rest, anti-inflammatory medications, or an occasional intra-articular injection. It is critical to identify the pain as coming from the glenohumeral joint and not from adjacent structures. Some patients may have mild radiographic arthritic changes, although their predominant pain comes from acromioclavicular joint disease, cervical spine disease, or impingement syndrome. A radiographic finding of mild arthritis in a patient with a recurrent dislocation may suggest that dislocation arthropathy is the source of pain (47), although the pain may originate from continued instability or hardware protrusion into the joint. A patient with rheumatoid arthritis may benefit from acromioclavicular joint resection or bursectomy if the radiographic changes are not severe. In addition, there is a precollapse phase before the development of cuff tear arthropathy when acromioplasty and cuff repair, rather than shoulder replacement, are better advised.

Poor motion is a less common indication for prosthetic replacement, because the gain in active motion with arthroplasty may be less predictable than improvement in pain. Active motion depends to a great degree on the surgeon's ability to reconstruct and rehabilitate the musculotendinous units moving the implant, which may or may not be limited by the disease. Rheumatoid patients may, in fact, have limited active motion because of associated rotator cuff weakness or rheumatoid myopathy, which implant insertion will not correct. A patient with cuff tear arthropathy may have pain relief following arthroplasty without improved active motion, because the cuff may be irreversibly weakened due to the length of time before treatment or the quality of residual tissue (39). Nevertheless, in some patients (notably those with ankylosing spondylitis or other rheumatic diseases), restricted motion may cause hardship with daily living activities or put undue stress on more distal joints. In this situation, it is reasonable to attempt to gain motion with prosthetic replacement.

Indications for prosthetic replacement are driven by the nature of the disease process. Humeral head replacement alone is indicated in the following situations:

- Four-part fractures, where it is anticipated that the articular segment is completely devoid of soft-tissue attachment and blood supply, making avascular necrosis likely (Fig. 101.7)

***Figure 101.7.*** A four-part fracture dislocation. The humeral head is devoid of soft-tissue attachment, late collapse is likely, and prosthetic replacement is the surgical treatment of choice.

- A head-splitting fracture with destruction of the articular surface
- Recurrent acute or chronic dislocations, where the articular impression fracture of the humeral head is 40% or more of the articular surface
- Osteonecrosis, if the disease has caused collapse or deformity of the humeral head but there is not yet disease of the glenoid
- Some forms of primary osteoarthritis, if the glenoid still has some cartilage remaining, and the glenoid surface is congruent
- Severe disease processes where the glenoid bone stock available for insertion of an implant is limited, such as in some forms of rheumatoid arthritis or revision surgery
- Elderly patients with nonunion of the surgical neck (Fig. 101.8)

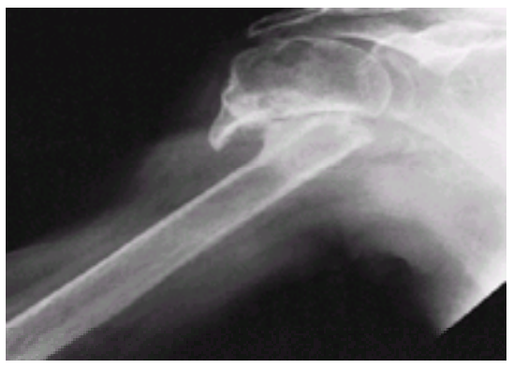

***Figure 101.8.*** Painful nonunion of surgical neck in a 78-year-old woman. Prosthetic replacement and tuberosity repair were selected because of the patient's age and osteopenia of the humeral head.

- Very young patients, if glenoid cartilage loss is not severe
- Some types of tumor reconstruction
- Some patients with rotator-cuff tear arthropathy

Hemiarthroplasty may also be combined with biologic resurfacing arthroplasty of the glenoid. A recent study reported on the short-term follow-up of hemiarthroplasty combined with biologic resurfacing of the glenoid with either capsule or autogenous fascia lata in patients with an average age of 48 years (9). Although the preliminary results are promising, longer follow-up with a greater number of patients is required before this procedure can be advocated for routine use.

Unconstrained total shoulder replacement is an excellent solution for glenohumeral arthritis if attention is paid to the details of surgery and rehabilitation. Following are the most common indications for total shoulder replacement:

- Primary osteoarthritis with destruction of both humeral head and glenoid (Fig. 101.9)

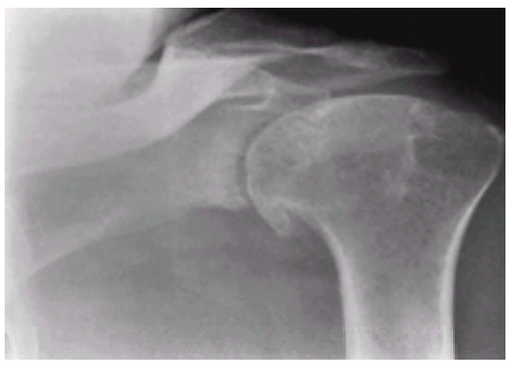

***Figure 101.9.*** AP radiograph of primary glenohumeral osteoarthritis, recognizable by the large, inferiorly protruding osteophyte and subchondral cyst formation.

- Osteonecrosis in which the incongruity of the humeral head has also destroyed the glenoid
- Rheumatoid arthritis, which usually affects the glenoid and humeral head (Fig. 101.10)

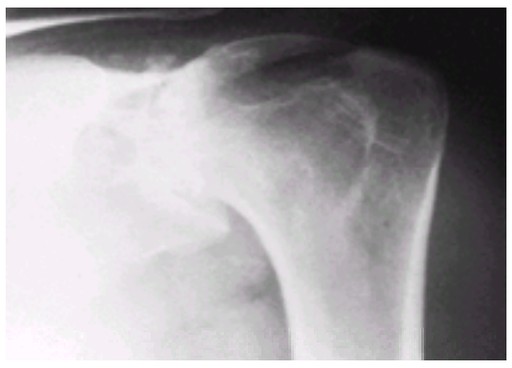

***Figure 101.10.*** Rheumatoid arthritis of the glenohumeral joint.

- Posttraumatic arthritis in which joint incongruity or malunion has destroyed the glenoid (Fig. 101.11)

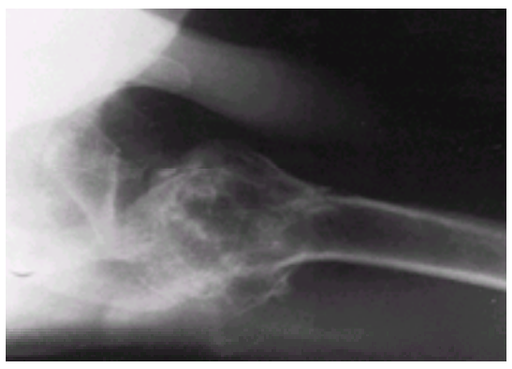

***Figure 101.11.*** Axillary radiograph in patient with posttraumatic arthritis. There is joint destruction, humeral head subluxation, and tuberosity malunion.

- Rotator-cuff tear arthropathy if the cuff is unreconstructible (Fig. 101.12)

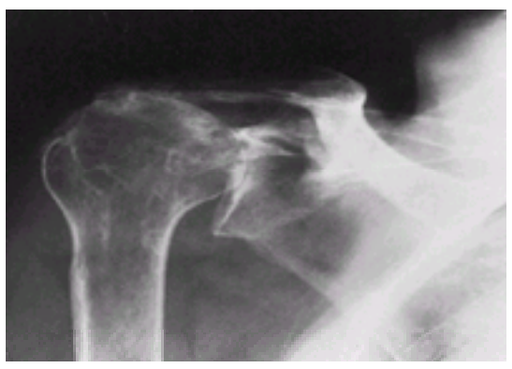

***Figure 101.12.*** Rotator-cuff tear arthropathy. There is severe superior migration of the humeral head, and wear into the acromion and the acromioclavicular joint. Severe glenohumeral arthritis is evident.

- Severe arthritis of dislocations, the result of repeated instability of the humeral head or capsulorrhaphy arthropathy (Fig. 101.13)

***Figure 101.13.*** Arthritis of recurrent dislocations. The patient had a previous Bristow procedure.

- Arthritis due to old infection that is quiescent or treated
- Failed prosthetic replacement, humeral head resection, or arthrodesis

Contraindications to total shoulder arthroplasty include the following:

- Active or recent infection
- Paralysis of both the deltoid muscle and rotator cuff muscles
- Neuropathic arthropathy

Because the nonconstrained implants rely entirely on the reconstructed rotator cuff tendons and deltoid for power, injury to the axillary and suprascapular nerves or other extensive paralytic processes will so weaken and destabilize the replacement that arthrodesis may be preferable. A Charcot joint is usually a contraindication, although in some neuropathic joints, stiffness and pain predominate and implantation is worth consideration.

Total shoulder arthroplasty is contraindicated in the presence of a rotator cuff tear if the tissue is inadequate for repair or if the muscle degeneration as documented on magnetic resonance imaging (MRI) is too severe to allow the cuff to centralize the head in the glenoid. Inadequate centralization of the humeral head in the presence of a glenoid component may lead to asymmetric loading of the glenoid, which can result in premature loosening (16). If the humeral head is fixed superiorly, it is also unlikely that cuff repair will be successful in the setting of total shoulder arthroplasty. In our experience, however, glenoid resurfacing allows more predictable pain relief. Therefore, we will consider reconstruction of massive rotator cuff tears using residual tendon, tendon transfers, or grafting if clinically indicated. Patient considerations also play a role in this decision, as does the technical difficulty of reconstructing a massive tear.

Glenoid bone loss that can be reconstructed by bone grafting is not considered a contraindication to arthroplasty (28), although some patients have such severe erosion and bone loss of the glenoid that insertion of a glenoid component may be impossible, and hemiarthroplasty of the humerus alone can be used.

A final relative contraindication to unconstrained arthroplasty is the patient's inability or unwillingness to cooperate with the extensive rehabilitation necessary for adequate functioning of the implant.

Although young age and vigorous activity level do not preclude shoulder replacement (50), consider alternative methods of treatment in the patient who cannot avoid impact-loading types of physical activity. In the patient with a prior infection, as with other arthroplasties, the joint must be free of infection before implantation.

## RESULTS

The implant with the longest track record is the Neer design (10,37). The Mayo Clinic experience with this total shoulder arthroplasty has recently shown the survivorship (defined as no further surgery) to be 93% at 10 years and 87% after 15 years (51). The diagnoses were mainly osteoarthritis and rheumatoid arthritis, with a lesser proportion of posttraumatic arthritis. Other series have also reported good pain relief in patients following total shoulder arthroplasty. In general, pain relief following shoulder replacement is independent of function. Function tends to be related to the diagnosis; soft-tissue adequacy is an important factor for success. Total shoulder arthroplasty in younger patients is not as successful as in the elderly (50). Also, revision surgery generally produces inferior results (44,49).

## PREOPERATIVE EVALUATION

Carefully evaluate the patient before surgery for cervical spine disease, acromioclavicular disease, and nerve and muscle deficits. Failure to recognize associated diseases before surgery can preclude a good result.

Carefully evaluate the patient's shoulder radiographically with anteroposterior (AP), lateral, and axillary views. An AP view may reveal the degree of osteophyte formation of the humeral head (Fig. 101.9), the amount of superior head migration, the status of the acromioclavicular joint, the presence of a subacromial spur, the thickness and size of the intramedullary canal of the humerus, and deformity or hardware in the humeral shaft. In the posttraumatic shoulder, it may indicate the position of the tuberosities and humeral head relative to the shaft. The lateral radiograph may indicate the amount of anterior or posterior subluxation of the humerus and the position of the tuberosities.

An axillary radiograph provides an excellent view of the amount and position of glenoid wear, the extent of medial migration, and the position of the humeral head (Fig. 101.11, Fig. 101.14). If there is asymmetric wear of the glenoid anteriorly or posteriorly, plans may include bone grafting at surgery. A computed tomography (CT) scan may be extremely helpful in assessing the position of the tuberosities and the amount of glenoid wear (Fig. 101.15). An axillary view may provide sufficient information regarding the glenoid orientation; however, a CT scan provides a clearer picture and may be useful for surgeons with less experience in shoulder arthroplasty. To avoid component malposition, it is crucial that posterior wear of the glenoid be identified prior to surgery, because glenoid version is difficult to assess intraoperatively.

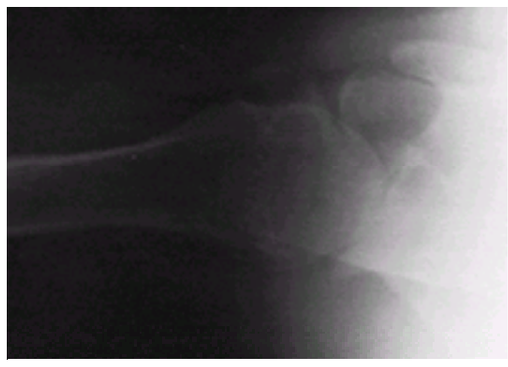

***Figure 101.14.*** Axillary radiograph showing the loss of joint space and degree of wear of the glenoid in a patient with primary osteoarthritis.

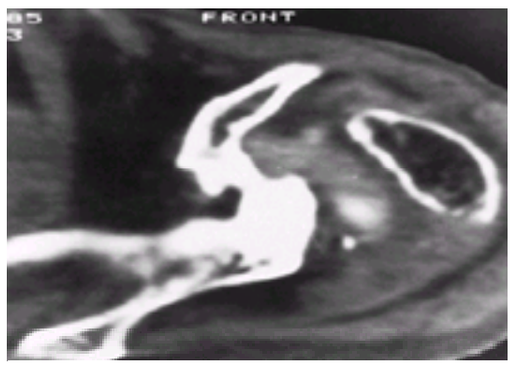


***Figure 101.15.*** CT scan in a patient with severe destructive rheumatoid arthritis. The humeral head has been completely destroyed, and there is marked bone loss of the glenoid.

If there is any suspicion of infection in the shoulder joint based on the history and physical examination, a complete blood count, erythrocyte sedimentation rate, and joint aspiration, as well as technetium and gallium scans, may be helpful in determining the current status of the infection.

Evaluate the patient's general health, and before surgery resolve any medical conditions that could lead to problems at the time of operation. In addition, a physical therapist should meet with the patient preoperatively to plan and explain the therapy program.

## SURGICAL TECHNIQUES

The choice of anesthesia depends on the surgeon, patient, and anesthesiologist. General anesthesia or interscalene block are the two most commonly used.

- Position the patient to avoid hyperextension of the neck. Fasten the head securely with tape to either a horseshoe head-rest or the operating table itself. This ensures that extremity movement during surgery will not dislodge the endotracheal tube. Place the patient in a semisitting or beach-chair position, with the hips flexed to 30°. Move the patient close to the table edge to permit hyperextension of his arm when the humeral component is inserted (Fig. 101.16). Because support of the arm will permit more effective posterior retraction of the humerus, secure to the operating table an arm board that can easily be moved into or out of the operating field. This aids exposure and insertion of the glenoid (Fig. 101.17) (17).

***Figure 101.16.*** Positioning the patient for total shoulder arthroplasty should enable the arm to be hyperextended for humeral component insertion or for rotator cuff mobilization.

***Figure 101.17.*** Glenoid exposure is aided by posterior humeral retraction, made easier by the support of an arm board.

- Place a towel under the medial border of the body of the scapula to stabilize it and ease exposure of the glenoid. Then secure the rest of the torso. Use adherent drapes to outline the area to be prepared and to keep the patient's hair from entering the operating field. Prepare the skin of the upper extremity from the base of the neck to the fingertips. If an assistant holds the wrist during scrubbing of the patient, the arm can be moved into abduction or adduction for ease of skin preparation. The skin preparation includes the lower third of the neck superiorly, the middle of the chest anteriorly, the midscapula posteriorly, and the chest wall at the level of the lower border of the scapula. Secure the drape with towel clips or skin staples, and place iodine-impregnated adhesive plastic draping on the entire operative field.
- Within 1 hour before the incision, give 1 g intravenous cephalosporin antibiotic.

Three surgical approaches have been used in shoulder replacement. The long deltopectoral approach with anterior deltoid detachment from the clavicle and acromion is no longer often used and has been supplanted by an approach that does not detach the deltoid from either the acromion or the clavicle. Sometimes detachment of the anterior deltoid may be necessary for exposure or mobilization of the tuberosities, anterior acromioplasty, or bone grafting of the glenoid. However, it is preferable to maintain the integrity of the deltoid origin to avoid the complication of deltoid detachment. We recommend a series of sequential releases to aid in exposure. Release the deltoid insertion over 1 to 2 cm in a subperiosteal fashion. A portion of the pectoralis major insertion may also be released, which should allow ample exposure. If greater exposure is needed, release the lateral portion of the conjoint tendon. In rare situations, it may be necessary to make a separate posterior approach, in addition to an anterior approach, for mobilization of tuberosities; for mobilization of scarred, retracted, rotator cuff; for glenoid bone grafting; or, in the case of a longstanding fixed posterior dislocation, to remove the humeral head from the posterior glenoid.

- If a long deltopectoral incision has been selected, infiltrate the skin and subcutaneous area with a 1:500,000 concentration of epinephrine. Avoid the axillary skin folds in the incision. Begin the incision at the clavicle, between the coracoid process and the acromioclavicular joint, and extend it distally to the lateral insertion of the deltoid muscle (about 17 cm) (Fig. 101.18). Place skin retractors and obtain hemostasis.

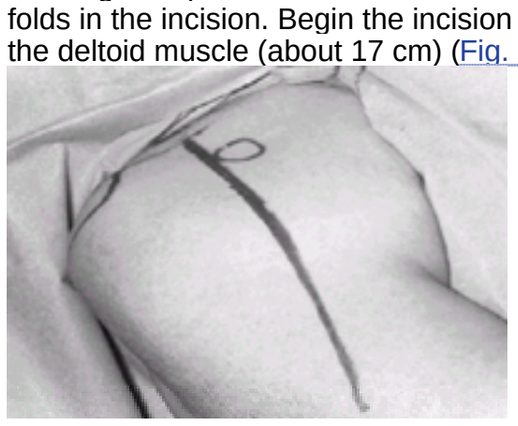

***Figure 101.18.*** Deltopectoral approach. Coracoid, acromion, and clavicle have been marked. The skin incision extends from the clavicle at a point between the coracoid process and acromioclavicular joint to the deltoid insertion.

- Incise the fascia over the deltoid and pectoralis. Develop the plane between the subcutaneous tissue and deltoid laterally and the pectoralis medially.
- Find the deltopectoral interval by identifying the “fat” over the cephalic vein in the infraclavicular triangle (Fig. 101.19). If the cephalic vein is not easily identified, the coracoid process may provide proximal identification of the deltopectoral interval, and the tendon of the pectoralis can be used as a guide to the deltopectoral interval distally. The cephalic vein is routinely ligated and removed.

***Figure 101.19.*** Identify the cephalic vein, the guide to the deltopectoral interval. It can be preserved, or ligated and excised.

- Bluntly dissect the deltoid free from adherent underlying bursa or rotator cuff. This is facilitated if the deltoid is relaxed by slightly abducting the arm to find the plane between the deltoid and the bursa. Bluntly dissect between the pectoralis and the clavipectoral fascia overlying the muscles attaching to the coracoid.
- Then retract the deltoid and pectoralis with blunt Richardson retractors. Gentle abduction of 20° to 25° relaxes the deltoid muscle for ease of retraction. In some pathologic conditions (rotator-cuff tear arthropathy, rheumatoid arthritis), the rotator cuff may at first glance appear indistinguishable from the bursa. Avoid excising what is thought to be inflamed, thickened bursa until it can be clearly distinguished from the tendinous portion of the rotator cuff.
- Incise the clavipectoral fascia superiorly until the coracoacromial ligament is identified. Then free the subscapularis bluntly from the conjoint tendon of the arm muscles, which should remain attached to the coracoid process to protect the brachial plexus and the musculocutaneous nerve from injury by retraction. Cauterize the acromial branch of the thoracoacromial artery, and under most circumstances divide the coracoacromial ligament (Fig. 101.20). Release of the coracoacromial ligament facilitates exposure and allows more room for the subscapularis repair at the end of the procedure. However, if the rotator cuff is deficient, do not release this ligament because it may diminish anterosuperior stability of the humeral head, increasing the risk of dislocation.

***Figure 101.20.*** Retraction may be rendered less traumatic by release of a small amount of the deltoid insertion. Retract the pectoralis major and muscles attached to the coracoid. Excise the coracoacromial ligament. See the text for important additional details.

- Free the subacromial bursa from any tissue to which it adheres, such as the undersurface of the acromion, before excision. This is more accessible if an assistant places slight traction on the operated arm. Place a blunt retractor, instrument, or finger between the rotator cuff and the bursa so the bursa can be well defined before its removal.
- Assess the integrity of the rotator cuff. Abduction and external rotation enables identification of the subscapularis and assessment of its thickness and integrity. Hyperextension and internal rotation of the shoulder bring the supraspinatus, infraspinatus, and teres minor tendons into the operative field. It is critical to identify the upper and lower margins of the subscapularis tendon. Identify the upper margin by tracing the subscapularis tendon from the coracoid process to the lesser tuberosity or by the rotator interval between the subscapularis and supraspinatus tendons. Identify the lower margin of the subscapularis by the anterior humeral circumflex vessels.
- Then externally rotate the humerus and cauterize the anterior humeral circumflex vessels. Maintaining the humerus in internal rotation during division of the subscapularis will jeopardize the axillary nerve, whereas external rotation and a little flexion help protect the axillary nerve.
- Now evaluate the anterior structures (which were evaluated in the office by examination prior to surgery) under anesthetic. Extensive subscapularis release will allow sufficient external rotation in most cases. However, if the patient is unable to externally rotate to neutral in the operating room under anesthetic, lengthen the capsule and subscapularis tendon. If the shoulder is tight anteriorly, divide the subscapularis tendon and capsule laterally, near the bicipital groove, and mobilize them as a single flap (Fig. 101.21). At the conclusion of the procedure, fix the subscapularis and capsule to bone at a more medial location using suture anchors. Repair the medial limb of the subscapularis tendon to the lateral limb of the capsule, effectively lengthening the anterior structures of the shoulder. Alternatively, perform a **Z**-lengthening of the capsule to the subscapularis.

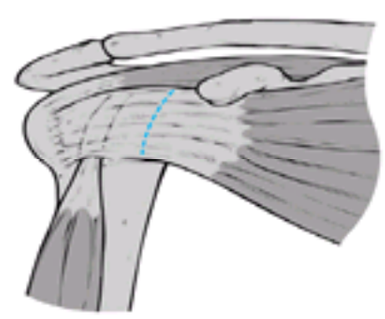

***Figure 101.21.*** Divide the subscapularis tendon and capsule.

- If there is no significant limitation to external rotation, divide the subscapularis tendon 1.5 cm medial to its insertion on the lesser tuberosity adjacent to the bicipital groove. Be certain to divide the subscapularis in its entirety by placing a curved clamp deep to the substance of the subscapularis to help with identification of the most superior and inferior margins during division (Fig. 101.22, Fig. 101.23). Detaching the subscapularis too close to its insertion on the lesser tuberosity leaves tissue that is inadequate for proper closure. When incising the subscapularis superiorly, divide only this tendon; do not inadvertently divide the biceps tendon in the interval between the subscapularis and supraspinatus. In many instances, the capsule and subscapularis can be divided together, unless preoperative evaluation has determined that tight anterior structures require subscapularis lengthening, as discussed previously.

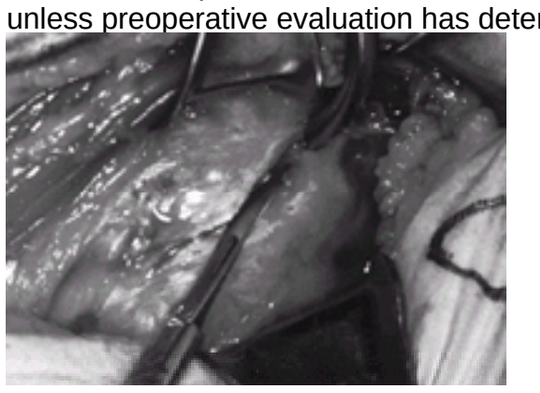

***Figure 101.22.*** Divide the subscapularis from superior to inferior in its entirety.

***Figure 101.23.*** Division of the subscapularis and capsule provides access to the joint. Avoid the biceps tendon at the superior margin. Cauterize the anterior humeral circumflex vessels at the inferior margin.

- Place several nonabsorbable sutures in the proximal subscapularis tendon for identification, retraction, and reattachment (Fig. 101.24). It is usually unnecessary to detach the muscles attached to the coracoid or to osteotomize the coracoid process. This adds exposure if needed, but take care to protect the musculocutaneous nerve. Mobilize the subscapularis superiorly by sectioning the soft tissue superficial to the biceps tendon in the direction of the base of the coracoid process. The subscapularis may be adherent to the coracoid process. Divide these adhesions for effective subscapularis mobilization and retraction. Although the anterior capsule is divided in its entirety, and even excised if abnormally thick, keep the most inferior capsule intact to protect the axillary nerve, which is at risk from traction and the heat generated during cement polymerization.

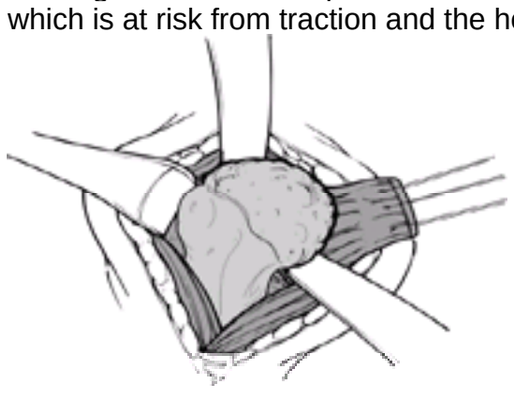

***Figure 101.24.*** Place stay sutures in the subscapularis for retraction. The subscapularis is the only muscle divided during the procedure, allowing dislocation of the humeral head before osteotomy.

- Dislocate the humeral head by gently extending and externally rotating the arm and placing a blunt elevator between the humeral head and the glenoid. Take care with osteopenic bone, as in rheumatoid arthritis, because the shaft can be fractured during dislocation of the head. The humeral head is now ready for osteotomy (Fig. 101.25).

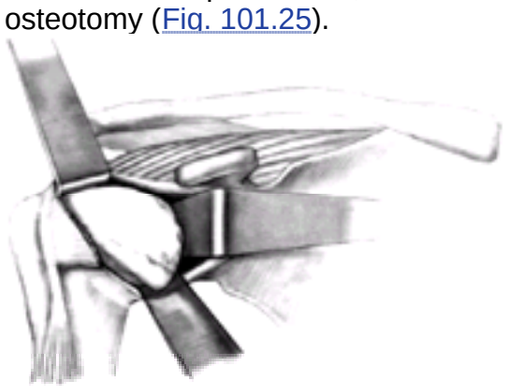

***Figure 101.25.*** Dislocate the humeral head, place the retractors superiorly and inferiorly, and identify the marginal osteophytes. (From Craig EV. Total Shoulder Replacement for Primary Osteoarthritis and Osteonecrosis. In: Craig EV, ed. *The Shoulder. Master Techniques in Orthopaedic Surgery.* Philadelphia: Lippincott Williams & Wilkins, 1997:18, with permission.)

- Before osteotomy of the humeral head, assess for osteophytes (Fig. 101.26), particularly inferiorly, which are common with osteoarthritis. These can mislead you to remove excess humeral neck and jeopardize the axillary nerve. Identification of the circumferential osteophytes enables more accurate identification of the amount of humeral head normally covered by articular cartilage. To remove osteophytes, position flat retractors between the humeral head and the inferior capsule and between the humeral head and superior rotator cuff. Remove the osteophytes with an osteotome or rongeur.

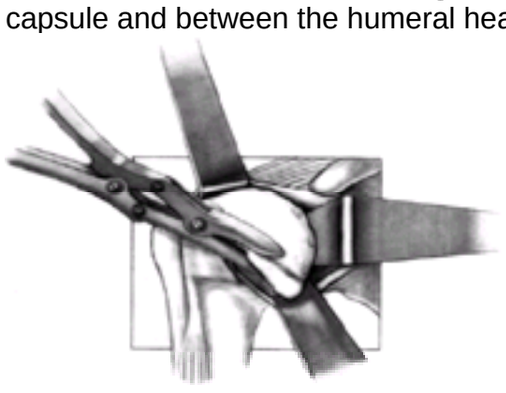

***Figure 101.26.*** Remove the most prominent marginal osteophytes. Any residual osteophytes can be excised after the trial stem is inserted. (From Craig EV. Total Shoulder Replacement for Primary Osteoarthritis and Osteonecrosis. In: Craig EV, ed. *The Shoulder. Master Techniques in Orthopaedic Surgery.* Philadelphia: Lippincott Williams & Wilkins, 1997:18, with permission.)

- The articular surface of the humerus is usually in 30° to 40° of retroversion relative to the transverse axis of the elbow. Gauge this by flexing the elbow to 90° and externally rotating the arm 30° to 40°, as required. Hold the trial implant against the humeral head to determine the osteotomy site and the appropriate retroversion of the osteotomy (Fig. 101.27). The usual amount of retroversion should be increased in patients with anterior instability, and decreased in patients with posterior instability. Numerous implants have guides to make the cut more accurate, including the intramedullary guide of the Atlas implant.



***Figure 101.27.*** Use the trial humeral component to mark the osteotomy site.

- If a resection jig is not used, mark the angle of the osteotomy site with cautery and osteotomize the humeral head with an oscillating or sharp osteotome saw. The three important components of the cut to judge are the neck–shaft angle, the degree of retroversion, and the superior–inferior depth.
- Begin the osteotomy just inside the supraspinatus insertion, at the sulcus between the articular cartilage and greater tuberosity (Fig. 101.28). A surprisingly small amount of bone is removed with the humeral head osteotomy (Fig. 101.29). Save the resected humeral head because it is an excellent source of bone graft.

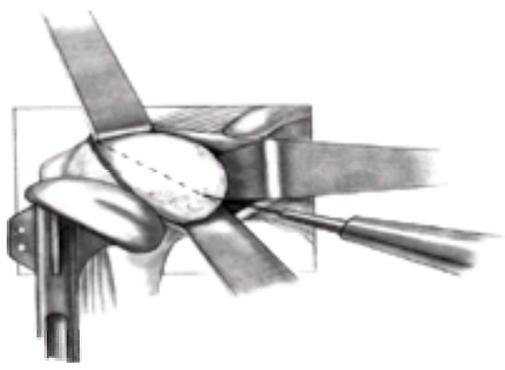

***Figure 101.28.*** Once the correct angle has been marked using the trial component as a guide, use an oscillating saw or sharp osteotome to make the cut, while protecting the soft tissues. If the osteotomy is to be made freehand, without a resection guide, a trial prosthesis may be utilized to identify the osteotomy site. (From Craig EV. Total Shoulder Replacement for Primary Osteoarthritis and Osteonecrosis. In: Craig EV, ed. *The Shoulder. Master Techniques in Orthopaedic Surgery.* Philadelphia: Lippincott Williams & Wilkins, 1997:20, with permission.)

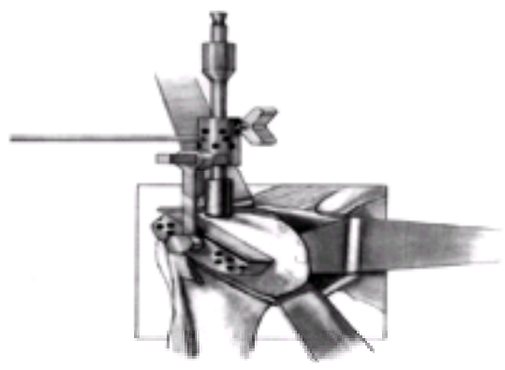

***Figure 101.29.*** Assemble the humeral head resection guide directly onto the **T**-handled reamer. The holes on the cutting jig are for pin placement, to secure the cutting jig to the humerus. Place a flexible rotator cuff probe beneath the supraspinatus and the biceps tendon to ensure the proper exit site for the osteotomy cut. (From Craig EV. Total Shoulder Replacement for Primary Osteoarthritis and Osteonecrosis. In: Craig EV, ed. *The Shoulder. Master Techniques in Orthopaedic Surgery.* Philadelphia: Lippincott Williams & Wilkins, 1997:22, with permission.)

- Locate the canal of the humerus with a curet or gouge, and then sequentially prepare it by using graduated **T**-handled reamers (Fig. 101.30). Protect the soft tissues during reaming.



***Figure 101.30.*** Use **T**-handled reamers to prepare the canal of the humerus (*top*). A glenoid guide (*bottom*) may be used for localization of the glenoid slot.

- Next, insert the trial humerus prosthesis into the intramedullary canal in about 25° to 35° of retroversion, which can be estimated by positioning the fin on the humeral component lateral and posterior to the bicipital groove. Sometimes it may be necessary to create a small vertical trough for the fin. During the insertion of the humeral prosthesis, keep the arm hyperextended off the side of the table and protect the biceps tendon and supraspinatus with retractors. If the humerus is correctly oriented in the appropriate amount of retroversion, the articular surface of the implant should face directly toward the glenoid with the arm in neutral rotation. Seat the trial implant with a mallet and impactor, then trim remaining osteophytes or protruding bone from around the implant. The depth of the insertion should permit the top of the humeral head to extend slightly above the most superior portion of the greater tuberosity. In addition, proper depth should permit closure of the rotator cuff over the implant. As described earlier, subscapularis lengthening may be required for complete closure of the anterior soft tissues.
- Selection of the appropriate humeral head implant is critical. Determine the correct head size from the size of the humeral head that has been removed, as well as from an assessment of whether the rotator cuff can be repaired around the implant. In general, a large head size provides a longer lever arm and the potential for more power, whereas a smaller head size makes it easier to close the rotator cuff around the prosthesis. Use the largest stem that fits in the intramedullary canal of the humerus. However, withhold final selection of the humeral component until the glenoid has been resurfaced and the ability to close the rotator cuff evaluated.
- Remove the trial prosthesis and use the arm board to position the shoulder for inspection of the joint and preparation of the glenoid. Explore the joint, remove loose bodies, and completely excise the synovium. Completely excise the anterior and posterior labrum. Inspect the glenoid to determine whether it will require resurfacing and whether the quality of bone is sufficient to accept a component. Posterior wear of the glenoid can be difficult to estimate in the operating room and should have been assessed preoperatively on an axillary view of the shoulder or a CT scan. Thoroughly inspect the rotator cuff and biceps tendon. Evaluate the acromioclavicular joint for arthritis and for inferiorly protruding osteophytes, which may cause mechanical impingement. Also, inspect the undersurface of the acromion for an overhanging subacromial spur, which may compromise the result. If necessary, perform an anterior acromioplasty and resect the distal clavicle. If there is a tear in the rotator cuff, mobilization for repair is less difficult once the humeral head has been removed. For even further exposure of a massively torn, retracted rotator cuff, excise the distal clavicle.
- Note that the humerus is prepared but the permanent implant is not inserted prior to glenoid preparation and insertion. We recommend the routine use of a cemented glenoid prosthesis. Prior to implanting a cementless glenoid component, the risks and benefits as well as the rationale for implant selection should clearly have been explained to the patient.
- Adequate muscle relaxation is essential to expose the glenoid. It is usually unnecessary to trim the glenoid osteophytes, although they may distort the normal glenoid anatomy and make orientation of the glenoid slot difficult to judge. For ease of insertion of the glenoid, adjust the arm board to bring the elbow level with the shoulder and support the elbow on operative draping or towels so that the humerus will not fall into hyperextension and obscure the glenoid. Carefully retract the proximal humerus posteriorly with the attached rotator cuff; this is facilitated by placing the ring retractor behind the posterior glenoid (Fig. 101.31). With a flat retractor, expose the inferior glenoid by retracting or excising some of the inferior capsular insertion. A second flat retractor may be needed anteriorly to retract some remnants of the anterior capsule (Fig. 101.31). Remove the remaining glenoid cartilage with a curet, taking care to preserve the subchondral bone. Because the base of the coracoid contains cancellous bone useful for anchoring the glenoid component, it is usually necessary to remove the soft tissue from the area between the superior glenoid and the base of the coracoid. During removal of the soft tissue to expose the base of the coracoid, do not divide the long head of the biceps.

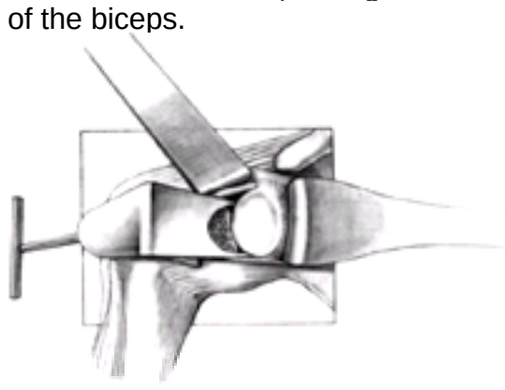

***Figure 101.31.*** Place a ring retractor behind the posterior rim of the glenoid, exposing the glenoid fossa and retracting the humeral shaft. (From Craig EV. Total Shoulder Replacement for Primary Osteoarthritis and Osteonecrosis. In: Craig EV, ed. *The Shoulder. Master Techniques in Orthopaedic Surgery.* Philadelphia: Lippincott Williams & Wilkins, 1997:27, with permission.)

- Prepare the glenoid for the keel or peg of the component. The slot for a keel extends along a line from a point immediately below the base of the coracoid to just above the infraglenoid tubercle, and it includes the cancellous bone at the base of the coracoid process (Fig. 101.32). Drill holes at the most superior and inferior aspects of the anticipated slot, and connect them with a burr or drill. Do not widen the glenoid slot excessively, or the component will toggle and secure seating will be difficult. The slot corresponds exactly to the size of the keel. Orient the slot so that it lies directly in the cancellous bone of the glenoid neck. This orientation is often difficult, particularly if excessive wear has occurred anteriorly or posteriorly. With the anterior capsule detached, palpate the anterior glenoid neck to aid proper orientation while the slot is deepened. If excessive asymmetric wear has occurred on the glenoid, orienting the slot and deepening it perpendicular to the flat surface of exposed glenoid can result in perforation of the cortex (Fig. 101.33).

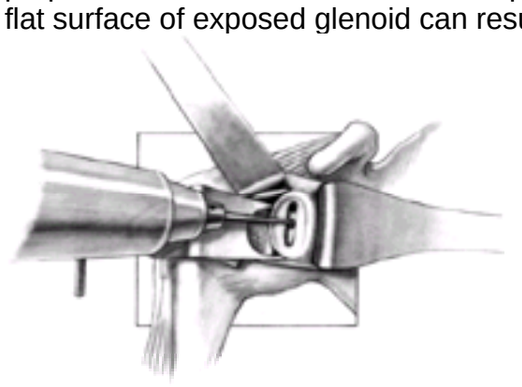

***Figure 101.32.*** In this arthroplasty system, create a slot from superior to inferior to house the glenoid keel. Widen this slot only to the normal glenoid component width, but it may be undermined superiorly and inferiorly for better and more secure cement penetration. (From Craig EV. Total Shoulder Replacement for Primary Osteoarthritis and Osteonecrosis. In: Craig EV, ed.*The Shoulder. Master Techniques in Orthopaedic Surgery.* Philadelphia: Lippincott Williams & Wilkins, 1997:29, with permission.)

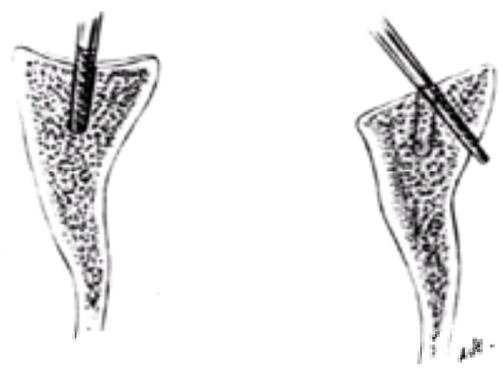

***Figure 101.33.*** The glenoid slot must be made along the exact axis of the glenoid in available cancellous bone. With excessive asymmetric glenoid wear, there is danger of cortical perforation if the drill bit is oriented perpendicular to the exposed glenoid rather than perpendicular to the glenoid neck.

- With the initial drill hole and superficial slot made, determine the orientation of the glenoid neck with a narrow curet. The arm must often be rotated internally or externally for optimal glenoid exposure. When this slot has been prepared, and the proper orientation of the glenoid neck has been found, undermine the slot superiorly into the cancellous portion of the base of the coracoid and inferiorly into the inferior glenoid neck (Fig. 101.34). A glenoid guide may be used for this part of the procedure (Fig. 101.35). Remove the remaining cartilage and subchondral bone with your preference of a burr or a reamer. The implant must be supported by subchondral bone.

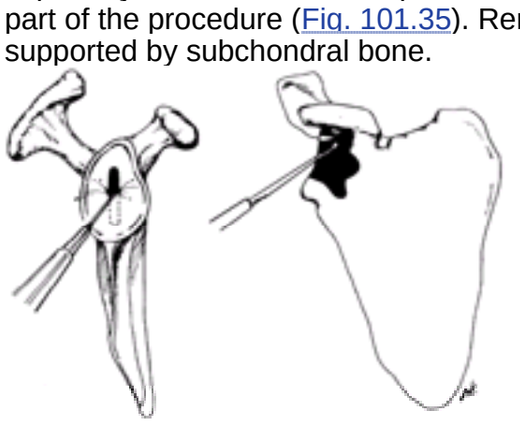

***Figure 101.34.*** In preparing the glenoid slot, undermine superiorly into the base of the coracoid and inferiorly into the cancellous portion of the glenoid neck.

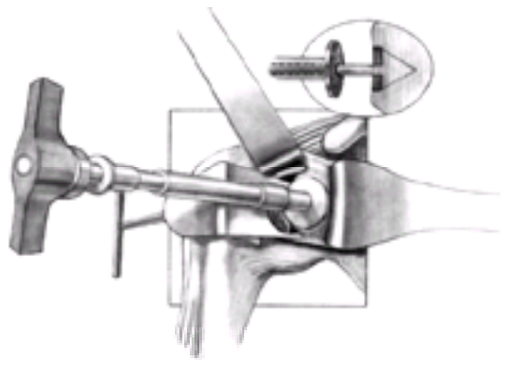

***Figure 101.35.*** Use the glenoid contouring device to prepare the exposed glenoid face to match precisely the posterior surface of the glenoid prosthesis. The keel attachment to the contouring device ensures contouring of only that amount of glenoid resurfaced by the prosthesis. The contouring device moves back and forth along the exposed extension of the stem-keel instrument. (From Craig EV. Total Shoulder Replacement for Primary Osteoarthritis and Osteonecrosis. In: Craig EV, ed.*The Shoulder. Master Techniques in Orthopaedic Surgery.* Philadelphia: Lippincott Williams & Wilkins, 1997:31, with permission.)

- If, during the preparation of the keel, the posterior or anterior cortex is perforated, pack the defect with cancellous bone before final glenoid insertion. Then use a burr to smooth ridges on the glenoid and ensure solid seating of the prosthesis on the glenoid. Inadequate removal of the peripheral synovium is a common error, particularly at the anterior inferior and posterior inferior aspects of the glenoid.
- Drill several holes in the remaining subchondral bone for bone cement penetration, and implant the trial glenoid (Fig. 101.36, Fig. 101.37 and Fig. 101.38). Eliminate any rocking. Several pitfalls exist in seating the trial glenoid that may result in prominence, rocking, or poor fit of the glenoid component (Table 101.1).

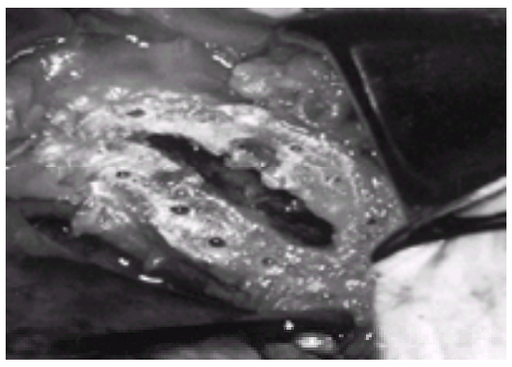

***Figure 101.36.*** Make multiple small drill holes in the subchondral bone to help anchor the cement.

***Figure 101.37.*** The trial glenoid is about to be inserted. The trial components for the standard and metal-backed glenoids are of different colors.



***Figure 101.38.*** The inserted trial glenoid. This must be seated securely on subchondral bone. There must not be any anterior and posterior rocking.

| |
|---|
| 1. If the cancellous bone in the center of the glenoid neck is not identified, deepening of the slot may result in abutment against or perforation of the anterior or posterior cortex, and the prosthetic glenoid may protrude and fail to rest on subchondral bone. |
| 2. A slot that extends too vertically can cause the component to rock in a superoinferior direction. |
| 3. A slot that is too wide can cause the glenoid component to toggle horizontally. |
| 4. In cases of severe bone loss, there may not be enough bone stock to seat the glenoid component; in these rare instances, a humeral prosthesis may be implanted without a glenoid. In addition, humeral head autograft or allograft in a revision may be used to augment the glenoid. |
| 5. Asymmetric glenoid wear may cause a glenoid component, even with the keel in the center of the glenoid neck, to fail to rest on adequate anterior or posterior subchondral bone. In such a situation, bone grafting the glenoid may be done. The humeral head can be used as a graft anchored with one or two small fragment screws so that the glenoid component will rest on adequate bone (Fig. 101.38). |

***Table 101.1. Pitfalls in Seating the Glenoid Component***

- As with other arthroplasties that use bone cement to anchor components, cement technique is critical. Irrigate the wound, using the water pick with antibiotic solution to rid the glenoid of clot and fibrinous debris. Before cementing the glenoid component, remove all blood and bone fragments from the depths of the glenoid slot. To ensure dry bone surfaces, dry the slot with surgical sponges, and use hydrogen peroxide irrigation, staggered cement insertion if necessary, or even hypotensive anesthesia if a dry field cannot be obtained.
- Use a syringe to ensure penetration of cement into the depths of the prepared glenoid. Insert the glenoid component by hand and hold it until the cement hardens. Remove excess cement, particularly from the posterior recess. Anterior cement may bind the subscapularis and impede tendon closure. Be aware that the cement often adheres to the ring retractor and may make removal difficult.
- Once the glenoid prosthesis has been inserted and cement polymerization has occurred, check the prosthesis for security of fixation (Fig. 101.39). Once the glenoid is cemented and the ring retractor is removed, be careful when delivering the proximal humerus into the wound that the greater tuberosity does not lever against the newly cemented glenoid. It is helpful to place a bone hook in the neck of the humerus, pulling laterally while the arm is gently rotated externally (Fig. 101.40). Ensure adequate clearance of the greater tuberosity by palpation. Check the joint for loose fragments of methacrylate as well as any fragments that may protrude beyond the edge of the glenoid component. Remove them carefully with an osteotome or rongeur.

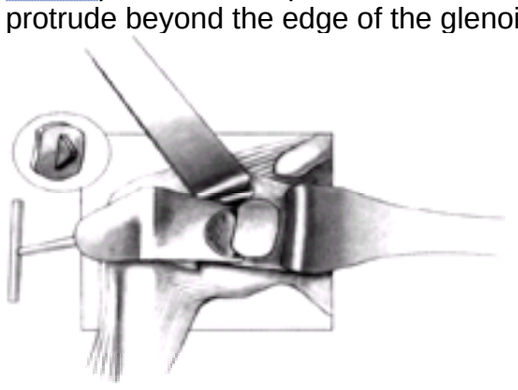

***Figure 101.39.*** Cement a standard polyethylene glenoid component into place. (From Craig EV. Total Shoulder Replacement for Primary Osteoarthritis and Osteonecrosis. In: Craig EV, ed.*The Shoulder. Master Techniques in Orthopaedic Surgery.* Philadelphia: Lippincott Williams & Wilkins, 1997:45, with permission.)

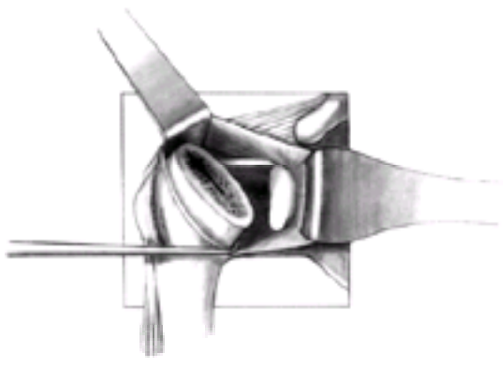

***Figure 101.40.*** With the glenoid implantation completed, expose the humeral osteotomy site. Lateral traction with a bone hook during the external rotation diminishes the likelihood that the greater tuber- osity will impinge and lever on the posterior glenoid component. (From Craig EV. Total Shoulder Replacement for Primary Osteoarthritis and Osteonecrosis. In: Craig EV, ed.*The Shoulder. Master Techniques in Orthopaedic Surgery.* Philadelphia: Lippincott Williams & Wilkins, 1997:34, with permission.)

- Soft-tissue balancing is critical for motion, stability, and prosthetic longevity. Before inserting the humeral head, make a final check to ensure that the soft tissue is completely mobilized, especially if the rotator cuff has been torn and retracted. The biceps tendon has a tendency to get caught beneath the humeral head as the component is being inserted, so gently retract it. Check the trial humeral head once again to make sure that the orientation is correct. The humeral component should face directly toward the glenoid with the arm in neutral rotation (Fig. 101.41). The top of the humeral head should be superior to the top of the greater tuberosity, to prevent impingement of the greater tuberosity. The fin of the prosthesis should be just lateral to the bicipital groove (Fig. 101.42).

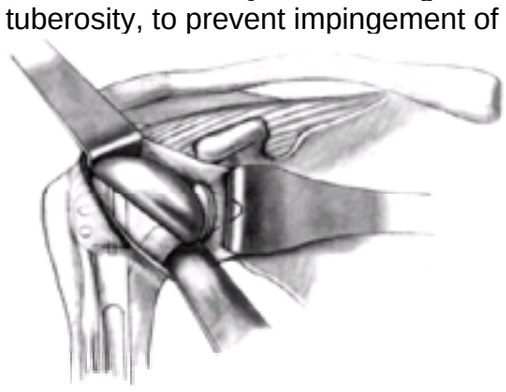

***Figure 101.41.*** Reduce the humeral head, and test motion and stability. (From Craig EV. Total Shoulder Replacement for Primary Osteoarthritis and Osteonecrosis. In: Craig EV, ed.*The Shoulder. Master Techniques in Orthopaedic Surgery.* Philadelphia: Lippincott Williams & Wilkins, 1997:38, with permission.)

***Figure 101.42.*** Insert the prosthesis in 40° of retroversion from the transverse axis of the elbow. With proper retroversion, the fin of the prosthesis is usually lateral to the bicipital groove, and with the arm in neutral rotation, the center of the humeral component articulates directly with the glenoid.

- Check the height of the humeral component so that soft tissues can be closed. There are potential problems associated with leaving the humeral prosthesis too proud. It may not articulate properly with the glenoid, it may abut the undersurface of the acromion, or closure of the subscapularis tendon may not be possible. The dangers of seating the prosthesis too low are that the prominent greater tuberosity may impinge, the prosthesis may be unstable, or the myofascial sleeve may have inadequate deltoid tension to allow maximum power postoperatively. Check this with the humerus reduced, putting traction on the arm in a longitudinal direction. The prosthesis should not be seated so deeply that the humerus subluxates inferiorly with traction.
- Whether to cement the humeral component is a matter of surgical judgment (17). If the humeral component has a secure press fit, and the intact tuberosities prevent rotation, then the component may be used without cement. This is particularly appealing in young patients, in whom the avoidance of methylmethacrylate may be preferred. In addition, if glenoid revision becomes necessary, the uncemented humeral component can be an advantage when removing the prosthesis. The humeral component should be cemented in older patients, in patients with rheumatoid arthritis, in osteoporotic bone, or if doubt exists about rotational stability. If cementing, irrigate the canal and dry with a sponge. Place a sponge temporarily in the glenoid to prevent excess methacrylate from extruding into the glenoid as the humeral component is inserted. A bone plug may be used to contain the cement in the humeral canal.
- Component orientation may be difficult to maintain during insertion of the humeral head. Inadvertent malrotation may be prevented by temporarily placing a small, thin curet or Steinmann pin in a hole of the fin of the prosthesis to ensure the exact amount of retroversion until seating of the humeral component is near completion (when using systems in which an inserter that maintains precise version is not available) (Fig. 101.43).

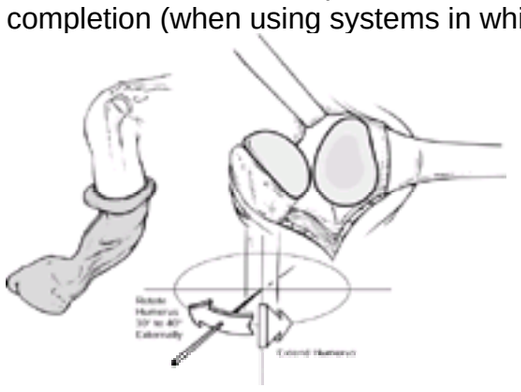

***Figure 101.43.*** When inserting the humeral component, maintain proper orientation, with the arm extended and externally rotated the desired amount (usually 40°).

- Reduce the humeral head and bring the subscapularis to its point of division for closure. Test the shoulder for stability in forward elevation, external rotation, and internal rotation. It is particularly important after rotator cuff closure, and before wound closure, to bring the arm into external rotation and forward elevation. Thus, the exact ranges of motion sought in therapy can be observed directly, and any tension on the suture lines can be identified. Soft-tissue contracture must be corrected at surgery. If motion is not obtained intraoperatively, postoperative rehabilitation is not likely to restore it.
- Close the subscapularis with a nonabsorbable suture (Fig. 101.44). In some instances, if there is severe contraction, once the joint has been resurfaced it may be difficult to reapproximate the subscapularis. Subscapularis release will often allow direct repair; however, in certain cases, subscapularis tendon lengthening may be performed, as described earlier in this chapter.



***Figure 101.44.*** Suture the only detached muscle, the subscapularis, to the site of its detachment on the humerus.

- Place a Hemovac drain between the deltoid and the rotator cuff, and bring it out through a site separate from the skin incision.
- Close the deltopectoral interval with an absorbable suture, and close the wound in layers. Apply a sterile dressing and support the shoulder with a postoperative sling and wrap, with the arm in neutral rotation (Fig. 101.45). Take final radiographs to document the position of the prosthesis (Fig. 101.46).

***Figure 101.45.*** Place the arm in a sling and elastic bandage, with the arm in neutral rotation.

***Figure 101.46.*** Radiographic appearance of the total shoulder arthroplasty.

Postoperative immobilization may require modification depending on the conditions encountered intraoperatively. For example, in some patients with rheumatoid arthritis or severe cuff tear arthropathy, an abduction brace may be necessary if the quality of the soft tissue is poor. Patients who have had fixed posterior dislocation and have excessive posterior capsular laxity may need to be kept in an external rotation brace to allow the soft tissues to tighten.

Although this outline is a general guide to performing total shoulder replacement arthroplasty, each case must be individualized, both for intraoperative technique and postoperative rehabilitation. The subsequent sections deal with features unique to each diagnostic category of the disease process.

## CONSIDERATIONS FOR SPECIFIC DIAGNOSES

### PRIMARY OSTEOARTHRITIS

Primary osteoarthritis of the shoulder can be recognized radiographically by the large circumferential osteophyte (seen on the AP radiograph as an inferior protrusion), the sclerosis on both sides of the joint, and subchondral cyst formation in the humeral head. The axillary view often reveals asymmetrical glenoid wear (erosion posteriorly) with apparent posterior subluxation. It is thus critical to evaluate the shoulder before surgery with at least AP and axillary views (Fig. 101.47, Fig. 101.48 and Fig. 101.49). A CT scan may be useful in assessing the amount of asymmetric glenoid wear.

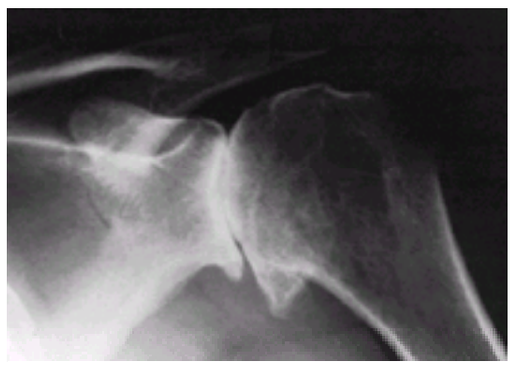

***Figure 101.47.*** Primary osteoarthritis of the shoulder. A large inferior osteophyte, subchondral cyst formation, and sclerosis on both sides of the joint.

***Figure 101.48.*** Primary osteoarthritis. An axillary view reveals the extent of joint space narrowing.

***Figure 101.49.*** Primary osteoarthritis. An axillary view reveals asymmetric glenoid wear, as the posterior glenoid is worn more deeply than the anterior glenoid, and showing apparent posterior subluxation of the humeral head typical of this disease.

The patient with primary osteoarthritis is the ideal candidate for total shoulder replacement because the rotator cuff is almost always normal (12,37). However, several features of primary osteoarthritis may make replacement of the shoulder technically difficult. Loose bodies occur frequently and must be carefully sought intraoperatively. The inferior osteophyte may be quite large and overhang the proximal metaphysis (15). As previously cautioned, during division of the subscapularis tendon, take extreme care to protect the axillary nerve, which courses close to the subscapularis and capsule and is in jeopardy when trimming the osteophyte. The “macro head” with the large circumferential osteophyte can give the impression that a large amount of articular surface must be resected. The unwary surgeon may remove excessive bone while osteotomizing the head. To guard against this, it is usually helpful to trim the obvious osteophytic excrescences first. The remaining humeral head will more accurately reflect exactly how much bone must be removed. Remove only the area of humeral head normally occupied by articular cartilage. This makes it appealing to use a trial implant to mark the area of osteotomy before beginning head resection.

Exposure is the key to glenoid preparation. This is facilitated by global capsulotomy or capsulectomy. Preparing the glenoid in osteoarthritis may be technically difficult because of uneven glenoid wear. Perforation of the cortex may occur while preparing the glenoid slot if this factor is not considered. Determine the correct orientation of the slot by palpation of the neck of the glenoid or by use of a straight blunt instrument along the anterior glenoid neck. If uneven wear exists, the implant may not rest properly on the subchondral bone, and further reconstruction of the glenoid should be considered. This is usually accomplished by reaming or trimming the glenoid with a burr or rongeur to allow secure prosthetic seating. Although the excessively worn side can be built up with cement, this is unwise, because the excess cement mantle may crack and loosen. If the wear is more severe, bone grafting of the excessively worn side can be accomplished using the humeral head (Fig. 101.50), although this is rarely required (40).

***Figure 101.50.*** Total shoulder replacement with glenoid bone grafting for asymmetric glenoid wear. The graft is fixed with a navicular screw.

A few patients with osteoarthritis may have associated disease of the acromioclavicular joint or an associated overhanging anterior acromion. If so, an acromioclavicular joint resection or anterior acromioplasty may be required. It is uncommon to have a rotator cuff tear with osteoarthritis, but if this does exist, repair it at the time of the arthroplasty.

**RHEUMATOID ARTHRITIS**

Technical problems with the rheumatoid shoulder result from the severe, unpredictable destruction of both bone and soft tissue, which is the hallmark of the disease (Fig. 101.51, Fig. 101.52, Fig. 101.53 and Fig. 101.54). Severe medial and superior wear of the glenoid, cuff defects of varying sizes, poor soft-tissue quality, associated acromioclavicular joint disease, osteoporosis, and severe bone loss are among the factors that present technical difficulties (29,36,52).

***Figure 101.51.*** Rheumatoid arthritis of the shoulder. Superior migration of the humeral head, cyst formation, marginal erosion, and severe joint destruction.

***Figure 101.52.*** Rheumatoid arthritis with severe superior and medial destruction of the glenoid.

***Figure 101.53.*** In this patient with rheumatoid arthritis, there is a fracture of the acromion from superior migration, wear into the acromioclavicular joint, and severe medial migration of the humerus with glenoid bone loss.

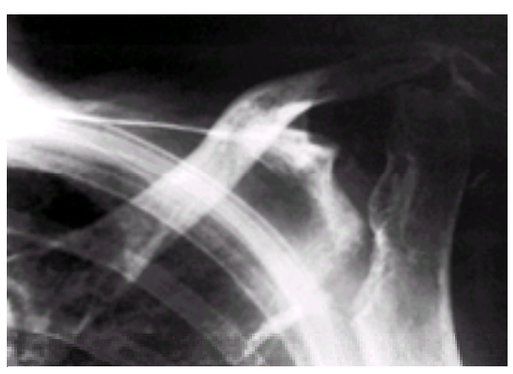

***Figure 101.54.*** Rheumatoid arthritis with severe bone loss in the proximal humerus. The amount of glenoid bone loss precluded insertion of a glenoid component, and a proximal humeral component alone was used.

Considerations in the rheumatoid shoulder include the following:

- Evaluate the acromioclavicular joint preoperatively. If radiographic acromioclavicular arthritis exists, if there is tenderness of the acromioclavicular joint, or if there is bone loss from the distal clavicle, excise the distal clavicle.
- Because there is usually dramatic subacromial bursal disease, carefully excise the bursa. The bursa in rheumatoid arthritis may be confused with the rotator cuff tendons, so the limits must be defined during excision. Extensive synovectomy is almost always needed for exposure.
- In addition to joint involvement, rheumatoid arthritis myopathy may weaken the normal humeral head–depressor effect of the rotator cuff, causing the humeral head to ride upward, even in the absence of a cuff tear. This can sometimes cause secondary impingement and may require an acromioplasty. Myopathy may also limit postoperative strength, despite satisfactory passive range of motion.
- Superior head migration may occur from rotator cuff weakness, a feature often accentuated by the use of crutches or a cane. In this situation, leave the coracoacromial ligament intact to prevent anterosuperior head migration.
- The rotator cuff is torn in about 30% of rheumatoid arthritis patients. Such tears are usually not massive and should be repaired at the time of surgery, with direct suture into bone by the usual methods of cuff closure. More often, the rotator cuff is thin and of poor quality.
- Severe osteopenia can weaken bone and result in humerus fracture during initial head dislocation, and tuberosity fracture at the time of humeral head osteotomy or during retraction of the humerus for glenoid insertion. The glenoid can also be fractured if the retractor is used too forcibly.
- In rheumatoid arthritis, always cement the humeral component because the severe osteopenia will often not permit a secure press fit.
- The glenoid may be severely eroded deep into the neck of the scapula. To assess this, a preoperative CT scan is helpful.
- If the glenoid bone loss is extensive, and bone stock does not allow glenoid component insertion, the humeral head may be used alone as a hemiarthroplasty. Postoperative rehabilitation often requires modification in the rheumatoid patient because of contralateral arm, ipsilateral elbow, or wrist and hand disease.

In recent years, there has been concern that a deficient rotator cuff may provide inefficient humeral head depression (16). With a nonconstrained arthroplasty, the head may ride up, impact the superior rim of the glenoid, and asymmetrically load the glenoid. There is concern that this may lead to stresses on the component and potential implant failure (16). For this reason, some authors have argued that if the rotator cuff cannot be reconstructed with functioning tissue, consideration should be given to a humeral head prosthesis alone without a glenoid component (16). The ideal treatment for this most difficult group of patients remains uncertain.

**ROTATOR-CUFF TEAR ARTHROPATHY**

Cuff tear arthropathy is recognized radiographically by severe destructive glenohumeral arthritis; superior migration of the humeral head because of a nonfunctioning cuff; severe superior and medial wear into the glenoid, the coracoid, the acromioclavicular joint, and the acromion; rounding of the greater tuberosity from mechanical impingement; and variable collapse of the humeral head (Fig. 101.55) (39). There may be an unfused acromial epiphysis. Cuff tear arthropathy combines the difficulty of excessive and longstanding major soft-tissue defect with severe glenohumeral destruction. MRI is useful to evaluate muscle wasting and fatty infiltration of the cuff musculature. For most massive defects, if there is fatty infiltration of the cuff muscles, the restoration of cuff continuity may not be associated with increased muscle power. However, the static superior tenodesis effect may contribute to increased active range of motion or function. Also take patient age and function into account in the decision-making process. The following are technical modifications for cuff tear arthropathy:

***Figure 101.55.*** Cuff tear arthropathy of the glenohumeral joint. There is loss of the acromiohumeral interval; deep wear into the acromion, acromioclavicular joint, and glenoid; and rounding of the greater tuberosity from mechanical impingement wear. This is an extremely difficult reconstruction because of the extensive bone and soft-tissue loss.

- Preserve the coracoacromial ligament to prevent anterosuperior head migration (14).
- Do not perform glenoid replacement for end-stage cuff tear arthropathy, because if the cuff is unable to center the head, a “rocking horse” effect may occur, leading to loosening (16).
- Good results have been reported with hemiarthroplasty for arthrosis associated with massive cuff tears (1,53).

By definition, this syndrome is associated with a massive tear of the rotator cuff. With attention to meticulous surgical planning and details, with patience, and with knowledge of alternative means for coverage, the rotator cuff may be reconstructed around the unconstrained implant (14). This reconstruction is technically demanding. The following technical steps can help provide soft-tissue coverage:

- Before surgery, prepare the thigh for possible use of a fascia lata graft.
- Position the arm near the side of the table so that hyperextension and internal rotation will expose the infraspinatus and teres minor, which have retracted posteriorly. External rotation and slight abduction will expose the subscapularis anteriorly.
- Before excising the subacromial bursa on entering the deltopectoral interval, use a blunt elevator to clear the soft tissue from the undersurface of the acromion to free the adherent rotator cuff.
- Placing sutures in the rotator cuff (rather than clamps) will enable traction to be placed on the cuff for mobilization, while preserving tissue integrity, and will permit tension on the sutures to assess tendon mobility.
- Before cementing the humeral component into place, place drill holes in the greater and lesser tuberosities and pass sutures through them if cuff reconstruction is planned.
- If a larger head is used for stability, rotator cuff closure may be difficult. Thus, a smaller head may be a better choice in patients with cuff tears because available soft tissue will be more easily approximated to the greater tuberosity.

Massive cuff tears usually begin in the supraspinatus tendon, which retracts and is scarred to the base of the coracoid and undersurface of the acromion. The tear then extends to the infraspinatus and teres minor. The tendon of the infraspinatus is pulled inferiorly by the teres minor and is adherent to the posterior inferior humeral head. The following sequential steps in soft-tissue mobilization for later implant coverage are necessary:

- Release the multiple adhesions between the rotator cuff, bursa, and deltoid bluntly by finding the plane between the bursa and the cuff posteriorly, and by rotating the humerus as adhesions are bluntly or sharply divided.
- Perform the humeral head osteotomy first, after which cuff mobilization is easier (Fig. 101.56).

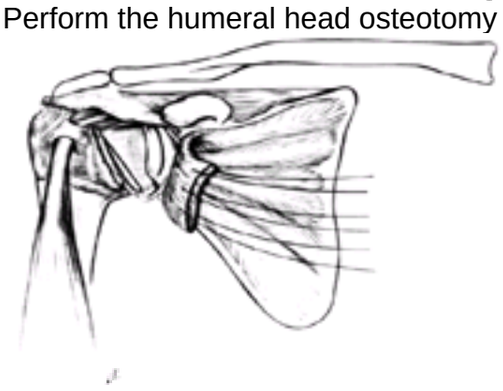

***Figure 101.56.*** In cuff tear arthropathy, mobilize the rotator cuff after humeral head osteotomy and before glenoid component insertion.

- Retrieve the infraspinatus tendon (which has been pulled inferiorly by a portion of intact teres minor) by pulling cephalad as adhesions are freed.
- The supraspinatus tendon usually retracts posteriorly, but a portion, pulled by intact subscapularis, may adhere to the base of the coracoid process. Retrieve this by bluntly freeing it from the base of the coracoid process. Although you can safely incise along the lateral edge of the coracoid process to free or retrieve scarred tendon, dissection medial to the coracoid process jeopardizes both the musculocutaneous and suprascapular nerves (Fig. 101.57).

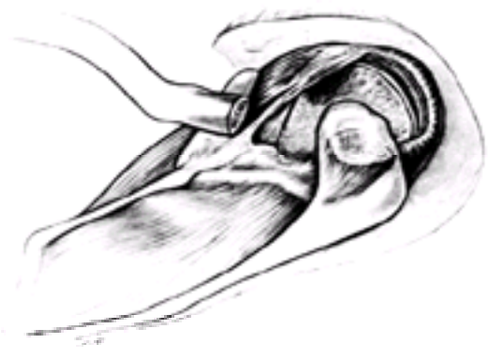

***Figure 101.57.*** Cuff tear arthropathy. Early distal clavicle excision aids in exposure of the retracted supraspinatus, which is often adherent to both the base of the coracoid and the undersurface of the acromion. The torn infraspinatus is pulled inferiorly by tension from some intact teres minor fibers.

- The subscapularis is often bound by dense adhesions to the inferior base of the coracoid. Release these adhesions to increase subscapularis mobility.
- Although the biceps tendon is often ruptured, if it is intact, suture other tendons to it. Occasionally, with deficient posterior tendons, the biceps tendon can be moved posteriorly by creating a new bicipital groove. Suture the infraspinatus into the intact biceps tendon.
- The subscapularis can be transferred to make up for an extensive superior defect. Identify the interval between the subscapularis and the capsule. Separate the subscapularis from this underlying capsule. Leave the inferior portion of the subscapularis intact to help act as a humeral head depressor and rotate the superior four fifths of the subscapularis superiorly for coverage or suture it into the biceps tendon (Fig. 101.58).

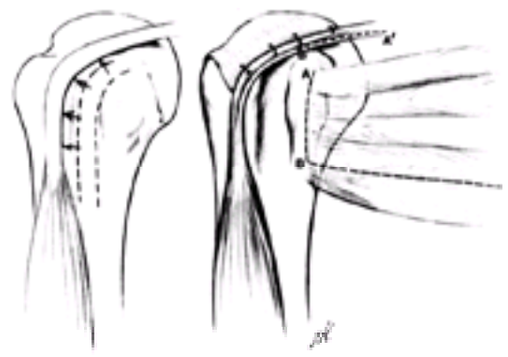

***Figure 101.58.*** With severe cuff deficiency, an intact biceps may be moved posteriorly to help provide superior or posterior soft-tissue coverage, and it can be used as a stent into which the mobilized spinatus tendons can be sutured. The upper four fifths of the subscapularis can be moved superiorly for added superior coverage.

- Mobilize the teres minor and infraspinatus tendons from within the joint by making a posterior capsular incision close to the glenoid. This may enable these two tendons, retracted and scarred to the posterior capsule, to be retrieved.
- Dissect the conjoined tendon of the short head of biceps and coracobrachialis from the coracoid process. Flexing the elbow may provide some coverage of the gap in the supraspinatus tendon, although this will not reach to the supraglenoid tubercle. During this mobilization, avoid traction on the musculocutaneous nerve. Usually, little additional coverage is obtained by this maneuver.
- With severe posterior and inferior retraction of the cuff, it may adhere to the posterior glenoid neck, making retrieval extremely difficult. Occasionally, a separate posterior incision may be needed to help mobilize the cuff from this retracted position.
- If there is insufficient tendon to provide coverage after complete mobilization, consider fascia lata grafting, freeze-dried cadaver grafting (such as Achilles tendon allograft), or other methods of additional coverage for large tendon deficits.

**ARTHRITIS OF RECURRENT DISLOCATIONS**

The arthritis of recurrent dislocation can be classified into four groups:

1. *Acute:* In the acute setting, a posterior shoulder dislocation may lead to the loss of a significant portion of the articular surface. If the involvement is greater than 40%, consider hemiarthroplasty, depending on whether the patient is a suitable candidate. Gerber and Lambert (18) described the use of osteoarticular allografts for this condition with a satisfactory outcome.

2. *Chronic:* Dislocation arthropathy associated with recurrent shoulder dislocations is usually the result of anterior dislocation (47). This can be recognized radiographically by osteophyte formation on the humeral head and the presence of a Hill-Sachs lesion on axillary view. There may also be anteroinferior wear of the glenoid from recurrent anterior translation.

3. *Hardware penetration:* Penetration of hardware about the shoulder has been documented to cause premature osteoarthritis of the glenohumeral joint (Fig. 101.59) (7,56). The use of screws and staples about the shoulder has decreased, which has lessened the incidence of this severe complication (42).

***Figure 101.59.*** Tomogram of the glenohumeral joint in a patient who had a surgical procedure for recurrent dislocation. A staple has penetrated the glenohumeral joint and destroyed the humeral head.

4. *Capsulorrhaphy sequella:* Internal rotation contracture following anterior shoulder reconstruction for instability has been associated with arthrosis (24). Anterior release has been documented to be effective for patients who have suffered from this problem (33,35). These patients occasionally require total shoulder arthroplasty. If a shoulder replacement is planned for a patient with this condition, prepare for a subscapularis release and lengthening (Fig. 101.60, Fig. 101.61), as described earlier in this chapter.

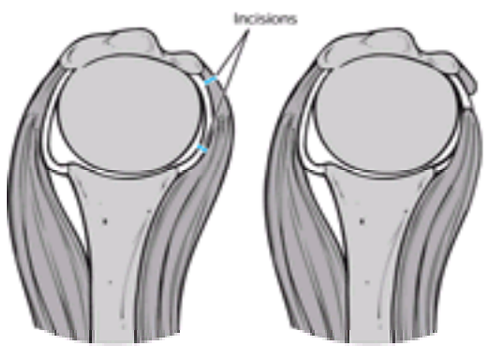


***Figure 101.60.*** Subscapularis capsular lengthening. Incise the subscapularis 1.5 cm from its insertion, identify the interval between subscapularis and capsule, and incise the capsule near the glenoid. Then suture the subscapularis to the lateral capsular flap, effectively adding length to the subscapularis.

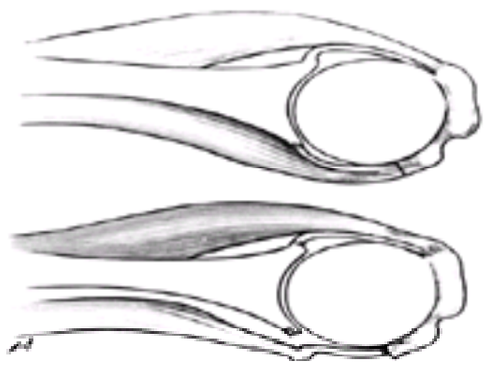

***Figure 101.61.*** The reverse undercutting method. If the subscapularis and capsule have been incised together at the beginning of the procedure, divide the capsule near the glenoid attachment at the conclusion of the arthroplasty, and cut the capsular–subscapularis interval in a reverse manner toward the lesser tuberosity insertion. Then bring the free end of the capsule outward and suture it to the original site of the subscapularis division, effectively lengthening the subscapularis and permitting more external rotation.

### TOTAL SHOULDER REPLACEMENT FOR POSTTRAUMATIC ARTHRITIS

Posttraumatic arthritis presents unique problems in arthroplasty. Malunion or nonunion of tuberosities, nerve injuries, and shortening of the subscapularis muscle commonly occur. The humeral head has often collapsed and healed in excessive retroversion, anteversion, varus, or valgus relative to the shaft and tuberosities. Prior internal fixation may have to be moved. Identification of the position of the tuberosities relative to the head may be extremely difficult and should be determined preoperatively, either by plain radiograph or CT scan with or without three-dimensional reconstruction. If the relative position of the tuberosities to the shaft is not severely distorted, maintaining the greater tuberosity and attached rotator cuff in continuity with the shaft makes rehabilitation less complicated. If there is severe displacement or malunion, however, the tuberosities must be osteotomized and repositioned. This adds the problems of fixation and union to the other technical challenges.

Additional exposure can be obtained by releasing the deltoid insertion subperiosteally, the pectoralis major tendon, and the conjoint tendon, in that order, as required. Consider direct visualization of the axillary and musculocutaneous nerves if previous trauma or prior surgery has distorted the anatomy sufficiently to make identification of these nerves uncertain.

### PROSTHETIC REPLACEMENT FOR ACUTE FRACTURES

In some fractures of the proximal humerus (head-splitting or large impression fractures), the extent of cartilage destruction may make preservation of the humeral head impractical (21). In four-part displaced fractures, the degree of displacement has almost certainly disrupted blood supply to the remaining shell of the humeral head because of tenuous soft-tissue attachments. Considering that later total shoulder replacement for posttraumatic arthrosis is difficult and unpredictable, because of distorted anatomy, malunited tuberosities, nerve injury, and bone loss, primary arthroplasty is recommended to treat the acute fracture (21). This single operation is usually more successful than a failed open reduction and internal fixation followed by arthroplasty. The technique for proximal humeral replacement alone in acute fractures follows.

- While the patient is being prepared in the operating room, avoid excessive abduction because neurovascular injury can occur from the sharp, bony fragments.
- Make a long deltopectoral incision from the clavicle to the lateral deltoid insertion and develop the deltopectoral interval. The clavipectoral fascia is often disrupted, but if it is not, incise it to the level of the coracoacromial ligament. Retract the coracoid muscles and pectoralis medially, and the deltoid laterally.
- Locate the biceps tendon; it is a reliable guide to location and identification of the tuberosities. It also provides a guide for the amount of soft-tissue tension after insertion of the prosthesis.
- Develop the interval between the supraspinatus tendon and the subscapularis by dissecting the biceps tendon toward its origin. Then remove the fragment or fragments of humeral head and evacuate the hematoma. With anterior fracture–dislocations, the humeral head may be in close proximity to the axillary artery or brachial plexus. Consider an angiogram in elderly patients if there are signs of vascular compromise. Carefully use a tap from the large fragment set as a “cork-screw” to assist in removal of the head if it is difficult to access. Prepare the medullary canal as in standard total shoulder replacement.
- Because rotational stability is usually lost once the tuberosities have fractured, cement the humeral component, reattaching the tuberosities to the prosthetic fin. Before cementing the prosthesis in place, drill holes in the humeral shaft and the tuberosities, and pass #5 nonabsorbable sutures for later reattachment of the tuberosities. Do not excise the tuberosities; bone healing is essential to ensure continuity of the attached tendons.
- Cement the prosthesis in 30° to 40° of retroversion. The prosthesis must be placed proud enough that tuberosities can be sutured around the fin of the implant, and tension on the soft-tissue myofascial sleeve is preserved. This usually amounts to approximately 1–2 cm, although the distance from the humeral shaft should be assessed in each individual case. Seating the prosthesis too low on the humeral shaft will make the soft tissues slack, resulting in a weakened deltoid and an unstable prosthesis. In addition, tuberosity prominence can result in mechanical impingement. A slack biceps at the time of the humeral trial is often an indication that the prosthesis has been seated too deeply into the humerus. Reattach the tuberosities with #5 nonabsorbable suture. Secure the tuberosities to one another, to the fin of the implant, and to the humeral shaft segment itself. While the tuberosities are being sutured together, hold them securely to the fin with a towel clip.
- If there is severe comminution or bone loss, consider adding bone graft at this time. Close the interval between the supraspinatus tendon and the subscapularis with nonabsorbable suture, copiously irrigate the wound, and place suction drains deep to the deltoid muscle. Then reapproximate the deltopectoral interval.

Rehabilitation following fracture differs from the rehabilitation after inserting a prosthesis with intact rotator cuff and bone. The tuberosities must heal before active muscle contraction is begun to avoid displacement. Nevertheless, begin passive or assistive exercises in 5 or 6 days. Delay assistive external rotation for 2 weeks to allow some healing of the tuberosities.

## PITFALLS AND COMPLICATIONS

Complications can occur during or after total shoulder arthroplasty. Injuries to the brachial plexus and the vascular structures are of particular concern. The reported incidence of neurologic complications following total shoulder replacement in the largest reported series was 4% (34). However, of these, only 1% had deficits that interfered with rehabilitation, and most neurologic deficits resolved.

Fortunately, infection is uncommon following total shoulder replacement (54). As is the case with hip and knee arthroplasty, increased infection rates are seen in patients with host-related risk factors such as diabetes mellitus, rheumatoid arthritis revision surgery, and previous infection (36,54).

Intraoperative humerus fracture has been reported to occur during manipulation of the limb, reaming of the intramedullary canal, broaching of the canal, and insertion of the prosthesis (54). Treat intraoperative humeral fractures with cerclage wire and a long-stem prosthesis (19) or dynamic compression plating. Intraoperative fracture of the glenoid is less common. Treatment of this complication involves the use of bone graft or a revision implant with a wedge to accommodate the defect (54).

Postoperative fracture of the humeral shaft may be treated nonoperatively, but it generally requires surgery (6). The pathologic anatomy of the injury should dictate the choice of treatment (19). One study of nine periprosthetic fractures suggested that long oblique and spiral fractures be treated nonoperatively, whereas transverse and short oblique fractures be treated with surgery (55).

Shoulder instability is the most common perioperative complication of shoulder arthroplasty (13,41). The instability may be secondary to soft-tissue imbalance, component malposition, bony deformity, or a combination of these (41). Instability can be anterior, posterior, inferior, or superior. Anterior instability is most commonly due to subscapularis rupture. Less commonly, this pattern of instability can be due to increased anteversion of the humeral or glenoid components (41). Subscapularis tendon rupture, if diagnosed early, can be repaired directly. Late diagnosis often leads to an irreparable situation, requiring pectoralis major tendon transfer or Achilles tendon allograft to reconstruct the anterior soft tissues.

Increased humeral retroversion can lead to posterior instability. However, posterior glenoid wear, which is common in degenerative arthrosis, may lead to a retroverted glenoid component if this osseous deformity is not noted in the preoperative planning and accounted for at the time of surgery. Soft-tissue imbalance can be dealt with by lengthening the tight anterior structures, tightening the loose posterior structures, revising a malpositioned glenoid or humeral component, or using a larger humeral head implant (27,41).

Inferior instability occurs when the humeral component is inserted too low, usually following reconstruction for a complex proximal humeral fracture (41). The humeral component should always be cemented proud on the humeral shaft in hemiarthroplasty for four-part fracture. In addition, intraoperative attention to soft-tissue tension, particularly of the biceps tendon, can help avoid this problem.

Superior instability is the most difficult form of shoulder instability to treat following an arthroplasty. It is usually caused by a rotator cuff tear. Deficiency of the coracoacromial ligament will worsen the problem and lead to anterosuperior migration of the implant. Therefore, the coracoacromial ligament should be left intact if an arthroplasty is performed in a patient whose cuff tear is so large that the depressant activity of the rotator cuff is lost. Also, the rotator cuff should be carefully

reconstructed at the time of arthroplasty if any deficiency exists (41).

Radiographic evidence of resorption around the glenoid component, which suggests loosening, has been shown to occur in 30% to 100% of cases (2,40,46,51). However, the majority of these implants are not clinically symptomatic (48). Lucent lines around humeral components are less common than in the glenoid; however, symptomatic loosening of humeral components is rare in most series (2,40,51,54).

## OUTCOME MEASUREMENT

Health-related quality of life is an important part of patient assessment. There has been an increase in the emphasis on outcomes research as expenditures for health care have increased and the justification for resource allocation has become paramount (30). Although detailed review of this topic is beyond the scope of this chapter, some important concepts with respect to outcome evaluation should be mentioned.

Traditionally, orthopaedic surgeons have evaluated the results of surgery with assessments such as radiographs and physical examination. These measures do not take into account the patients' perspectives. There are many questionnaires available to measure patient outcomes for individuals with disorders of the shoulder. These instruments have been tested for reliability, validity, and responsiveness to clinically significant change (3,4). Scales that are specific to the shoulder and upper limb and that can therefore be used for the assessment of patients before and after total shoulder arthroplasty include the simple shoulder test (32), the shoulder rating questionnaire (31), and the DASH (an acronym for disabilities of the arm, shoulder, and hand) (25). The latter tool is specific to the entire upper limb, allowing comparisons of patients with various disorders, whereas the former instruments are specific exclusively to the shoulder joint.

Generic health-status measures, such as the SF-36, are used to measure overall health. These instruments have a broader perspective, including emotional, social, mental, and physical health, and do not restrict attribution to a particular disorder. Generic health status measures are valuable because they allow comparisons across conditions and treatments. The disadvantage of these questionnaires, however, is that they may not measure clinically important change because an isolated problem may not be reflected in this global measure (5,23). The specific measures are more responsive to change in the phenomenon of interest and may be more relevant (20,43).

Both generic and joint- or region-specific questionnaires should be used to evaluate patients undergoing total shoulder arthroplasty. Investigators should avoid nonstandardized outcome assessment tools in the evaluation of patients who have undergone total shoulder replacement, because this complicates comparison across different groups (3,4). Measures of impairment, such as diagnostic imaging and physical examination, complement health-related quality-of-life instruments and remain an important part of patient outcome assessment.

## REHABILITATION

Success of total shoulder replacement is intimately related to postoperative rehabilitation (8). The unique character of the shoulder, where stability and function depend on the surrounding soft tissues, makes it essential that the postoperative focus be on the care of the soft tissues and in particular on the rotator cuff.

Rehabilitation depends on the pathology encountered, the goals of the surgeon and the patient, and the resolution of the intraoperative variables. It can be broadly divided into early and late phases. In the early period, the immediate aim is to maintain the motion achieved in the operating room following bone and soft-tissue reconstruction by preventing adhesions in both the subacromial and the glenohumeral joint spaces. This requires protection of repaired or reconstructed soft tissues.

The operating surgeon must provide direction in rehabilitation. After intraoperatively assessing implant stability and tension in repaired tissue, the surgeon makes the decisions concerning the desired pace toward the short-term goal of improved range of motion. Although passive range of motion can be established through effective bone and soft-tissue surgery, the degree of active range of motion depends critically on the muscle power of the rotator cuff and deltoid muscles. While the early phase of rehabilitation concentrates on establishing range of motion, it is important to add strengthening exercises later for muscle rehabilitation. The timing and progress of rehabilitation must be individualized.

Neer (37) suggested a broad rehabilitation program that is safe, effective, and, most important, easy to understand, so the patient can reliably continue it after discharge. In the first phase after surgery, range of motion is established by a series of exercises aimed at restoring forward elevation in the plane of the scapula, external rotation, and internal rotation. The exercises are all patient-assisted, although more recently Neer emphasized that passive motion can be an effective means of establishing range of motion. A typical rehabilitation program is performed five times daily for 15–20 minutes each session. Rehabilitation after total shoulder arthroplasty is more intensive than after hip or knee replacement, and it is the key to success.

The patient begins with a brief warm-up of Codman's gravity-assisted pendulum exercise by bending at the waist and making circles with the operated arm. This is followed by assistive forward elevation, standing and using an overhead pulley, with the unoperated arm acting to raise and lower the operated arm. External rotation is performed with the patient supine, the arm at the side, and the elbow flexed to 90°, with the arm pushed into external rotation by a stick or cane. Internal rotation is initiated by stretching both arms into extension and cephalad toward the scapula.

Continuous passive motion has been shown to maintain motion comfortably in the early postoperative period, provided there is adequate bone and soft-tissue reconstruction (11). Patients who exercise with continuous passive motion achieve adequate motion more rapidly and can be safely discharged earlier from the hospital without compromising soft-tissue and bony repair. Whether continuous passive motion itself is important or whether it acts merely to deliver passive motion remains to be seen.

Early motion must be instituted after total shoulder replacement to minimize postoperative adhesions. A mechanical (continuous passive motion) device can be used, a physical therapist can be involved, or assistive exercises can be performed by the patient. It is important that progress be monitored closely, as many patients lack the confidence or understanding to carry on with the program by themselves. Where stability of the implant or the quality of the soft-tissue repair is such that early motion is unsafe, modify the basic program just described.

As motion improves and tendons heal, add strengthening exercises. It appears most important to concentrate on the anterior and middle deltoid and the rotator cuff, especially the infraspinatus and teres minor. Therapy for this area is often initiated as isometric exercises, with the later addition of active resistive exercises. One effective means of adding progressive resistive exercises is with an elastic exercise band, a dental dam, or surgical tubing, a portable and inexpensive method that may effectively be used at home.

Rehabilitation following total shoulder replacement continues for at least 1 year, with more resistive exercises added as strength improves.

Table 101.2 shows a typical rehabilitation program for patients with osteoarthritis, in whom the deltoid and rotator cuff are normal and the only muscle detached and repaired is the subscapularis. In patients with a severe soft-tissue deficit, such as cuff tear arthropathy, and in some patients with rheumatoid arthritis, the program might be modified as shown in Table 101.3.

| | |
|---|---|
| Day of surgery | Initiate passive flexion and extension of the elbow and begin passive motion aided by a physical therapist or use a continuous passive motion machine, concentrating on forward elevation and external rotation. |
| Postoperative day 1 | Begin passive forward elevation, and continue external rotation. |
| Postoperative day 2 | Commence patient-assisted range-of-motion (Codman's) exercises, forward elevation using an overhead pulley, and supine external rotation with cane. |
| Postoperative day 3 | Begin hyperextension and internal rotation. |
| Postoperative days 10–14 | Begin isometric external rotator and deltoid muscle exercise. |
| Postoperative week 4 | Initiate resistive exercises for the anterior and middle deltoid, supraspinatus, infraspinatus, and teres minor muscles. |
| Postoperative week 6 | Begin resistive internal rotation exercises. |
| Postoperative month 3 | Use late stretching for forward elevation, external rotation, internal rotation, and further resistive exercises. |

***Table 101.2. Total Shoulder Rehabilitation Program after Arthroplasty for the Osteoarthritic Patient***

| | |
|---|---|
| Day of surgery | Begin elbow passive range of motion. |
| Postoperative day 1 | Continue elbow, wrist, and hand range of motion. |
| Postoperative day 5 | Initiate gentle therapist-initiated passive forward elevation, and external rotation. A family member may be instructed in passive range-of-motion techniques before hospital discharge, so this protected rehabilitation can be continued at home. Occasionally, the soft tissues may need to be rehabilitated from a protective postoperative brace. |
| Postoperative week 4 | Transition to patient-initiated assistive forward elevation with an overhead pulley, and supine external rotation with a cane, and internal rotation. |
| Postoperative week 6 | Begin isometric deltoid, and external and internal rotator strengthening. |
| Postoperative week 12 | Add resistive external rotation exercises. |

***Table 101.3. Modified Rehabilitation Program for Soft-Tissue Reconstruction***

## CHAPTER REFERENCES

Each reference is categorized according to the following scheme: *, classic article; #, review article; !, basic research article; and +, clinical results/outcome study.


+ 1. Arntz CT, Jackins S, Matsen FA II. Prosthetic Replacement of the Shoulder for the Treatment of Defects in the Rotator Cuff and the Surface of the Glenohumeral Joint [Published Erratum Appears in *J Bone Joint Surg Am* 1993;75:1112]. *J Bone Joint Surg Am* 1993;75:485.

+ 2. Barrett WP, Franklin JL, Jackins SE, et al. Total Shoulder Arthroplasty. *J Bone Joint Surg Am* 1987;69:865.

+ 3. Beaton DE, Hogg-Johnson S, Bombardier C. Evaluating Changes in Health Status: Reliability and Responsiveness of Five Generic Health Status Measures in Workers with Musculoskeletal Disorders. *J Clin Epidemiol* 1997;50:79.

+ 4. Beaton DE, Richards RR. Measuring Function of the Shoulder. A Cross-sectional Comparison of Five Questionnaires. *J Bone Joint Surg Am* 1996;78:882.

+ 5. Bombardier C, Melfi CA, Paul J, et al. Comparison of a Generic and a Disease-specific Measure of Pain and Physical Function after Knee Replacement Surgery. *Med Care* 1995;33:AS131.

+ 6. Boyd AD Jr, Thornhill TS, Barnes CL. Fractures Adjacent to Humeral Prostheses. *J Bone Joint Surg Am* 1992;74:1498.

# 7. Brems JJ. Arthritis of Dislocation. *Orthop Clin North Am* 1998;29:453.

+ 8. Brown DD, Friedman RJ. Postoperative Rehabilitation following Total Shoulder Arthroplasty. *Orthop Clin North Am* 1998;29:535.

+ 9. Burkhead WZ Jr, Hutton KS. Biologic Resurfacing of the Glenoid with Hemiarthroplasty of the Shoulder. *J Shoulder Elbow Surg* 1995;4:263.

+ 10. Cofield RH. Total Shoulder Arthroplasty with the Neer Prosthesis. *J Bone Joint Surg Am* 1984;66:899.

# 11. Craig EV. Shoulder Arthroplasty. In: Scott WN, Stillwell WT, eds. *An Atlas of Surgical Technique*. Rockville, MD: Aspen, 1987.

# 12. Craig EV. Total Shoulder Replacement for Primary Osteoarthritis and Osteonecrosis. In: Craig EV, ed.*The Shoulder. Master Techniques in Orthopaedic Surgery*. New York: Raven Press, 1995:311.

# 13. Cuomo F, Checroun A. Avoiding Pitfalls and Complications in Total Shoulder Arthroplasty. *Orthop Clin North Am* 1998;29:507.

+ 14. DiGiovanni J, Marra G, Park JY, Bigliani LU. Hemiarthroplasty for Glenohumeral Arthritis with Massive Rotator Cuff tears. *Orthop Clin North Am* 1998;29:477.

# 15. Fenlin JM Jr, Frieman BG. Indications, Technique, and Results of Total Shoulder Arthroplasty in Osteoarthritis. *Orthop Clin North Am* 1998;29:423.

+ 16. Franklin JL, Barrett WP, Jackins SE, Matsen FA II. Glenoid Loosening in Total Shoulder Arthroplasty. Association with Rotator Cuff Deficiency. *J Arthroplasty* 1988;3:39.

+ 17. Friedman RJ. Humeral Technique in Total Shoulder Arthroplasty. *Orthop Clin North Am* 1998;29:393.

+ 18. Gerber C, Lambert SM. Allograft Reconstruction of Segmental Defects of the Humeral Head for the Treatment of Chronic Locked Posterior Dislocation of the Shoulder. *J Bone Joint Surg Am* 1996;78:376.

+ 19. Groh GI, Heckman MM, Curtis RJ, Rockwood CA. Treatment of Fractures Adjacent to Humeral Prosthesis. *Orthop Trans* 1994–1995;18:1072.

+ 20. Guyatt GH, Feeny DH, Patrick DL. Measuring Health-related Quality of Life. *Ann Intern Med* 1993;118:622.

+ 21. Hartsock LA, Estes WJ, Murray CA, Friedman RJ. Shoulder Hemiarthroplasty for Proximal Humeral Fractures. *Orthop Clin North Am* 1998;29:467.

+ 22. Hattrup SJ. Indications, Technique, and Results of Shoulder Arthroplasty in Osteonecrosis. *Orthop Clin North Am* 1998;29:445.

+ 23. Hawker G, Melfi C, Paul J, et al. Comparison of a Generic (SF-36) and a Disease Specific (WOMAC) (Western Ontario and McMaster Universities Osteoarthritis Index) Instrument in the Measurement of Outcomes after Knee Replacement Surgery. *J Rheumatol* 1995;22:1193.

+ 24. Hawkins RJ, Angelo RL. Glenohumeral Osteoarthrosis. A Late Complication of the Putti-Platt Repair. *J Bone Joint Surg Am* 1990;72:1193.

+ 25. Hudak PL, Amadio PC, Bombardier C. Development of an Upper Extremity Outcome Measure: The DASH (Disabilities of the Arm, Shoulder and Hand) [Corrected]. The Upper Extremity Collaborative Group (UECG) [Published Erratum Appears in *Am J Ind Med* 1996;30:372]. *Am J Ind Med* 1996;29:602.

+ 26. Iannotti JP, Williams GR. Total Shoulder Arthroplasty: Factors Influencing Prosthetic Design. *Orthop Clin North Am* 1998;29:377.

+ 27. Ibarra C, Craig EV. Soft-tissue Balancing in Total Shoulder Arthroplasty. *Orthop Clin North Am* 1998;29:415.

+ 28. Ibarra C, Dines DM, McLaughlin JA. Glenoid Replacement in Total Shoulder Arthroplasty. *Orthop Clin North Am* 1998;29:403.

+ 29. Kelly IG, Foster RS, Fisher WD. Neer Total Shoulder Replacement in Rheumatoid Arthritis. *J Bone Joint Surg Br* 1987;69:723.

# 30. Kuhn JE, Blasier RB. Assessment of Outcome in Shoulder Arthroplasty. *Orthop Clin North Am* 1998;29:549.

+ 31. L'Insalata JC, Warren RF, Cohen SB, et al. A Self-Administered Questionnaire for Assessment of Symptoms and Function of the Shoulder [Comments]. *J Bone Joint Surg Am* 1997;79:738.

+ 32. Lippitt SM, Harryman DTI, Matsen FA I. A Practical Tool for Evaluation of Function: The Simple Shoulder Test. In: Matsen FA I, Fu FH, eds.*The Shoulder: A Balance of Mobility and Stability.* Rosemont, IL: American Academy of Orthopaedic Surgery, 1993.

+ 33. Lusardi DA, Wirth MA, Wurtz D, Rockwood CA Jr. Loss of External Rotation following Anterior Capsulorrhaphy of the Shoulder. *J Bone Joint Surg Am* 1993;75:1185.

+ 34. Lynch NM, Cofield RH, Silbert PL, Hermann RC. Neurologic Complications after Total Shoulder Arthroplasty. *J Shoulder Elbow Surg* 1996;5:53.

+ 35. MacDonald PB, Hawkins RJ, Fowler PJ, Miniaci A. Release of the Subscapularis for Internal Rotation Contracture and Pain after Anterior Repair for Recurrent Anterior Dislocation of the Shoulder. *J Bone Joint Surg Am* 1992;74:734.

+ 36. McCoy SR, Warren RF, Bade HA II, et al. Total Shoulder Arthroplasty in Rheumatoid Arthritis. *J Arthroplasty* 1989;4:105.

+ 37. Neer CS II. Replacement Arthroplasty for Glenohumeral Osteoarthritis. *J Bone Joint Surg Am* 1974;56:1.

+ 38. Neer CS II. Unconstrained Shoulder Arthroplasty. *Instr Course Lect* 1985;34:278.

+ 39. Neer CS II, Craig EV, Fukuda H. Cuff-tear Arthropathy. *J Bone Joint Surg Am* 1983;65:1232.

+ 40. Neer CS II, Watson KC, Stanton FJ. Recent Experience in Total Shoulder Replacement. *J Bone Joint Surg Am* 1982;64:319.

+ 41. Norris TR, Lipson SR. Management of the Unstable Prosthetic Shoulder Arthroplasty. *Instr Course Lect* 1998;47:141.

+ 42. O'Driscoll SW, Evans DC. Long-term Results of Staple Capsulorrhaphy for Anterior Instability of the Shoulder [Erratum Appears in *J Bone Joint Surg Am* 1993;75:791]. *J Bone Joint Surg Am* 1993;75:249.

+ 43. Patrick DL, Deyo RA. Generic and Disease-specific Measures in Assessing Health Status and Quality of Life. *Med Care* 1989;27:S217.

+ 44. Petersen SA, Hawkins RJ. Revision of Failed Total Shoulder Arthroplasty. *Orthop Clin North Am* 1998;29:519.

+ 45. Post M. Constrained Total Shoulder Replacement. *Instr Course Lect* 1985;34:287.

+ 46. Rodosky MW, Bigliani LU. Indications for Glenoid Resurfacing in Shoulder Arthroplasty. *J Shoulder Elbow Surg* 1996;5:231.

+ 47. Samilson RL, Prieto V. Dislocation Arthropathy of the Shoulder. *J Bone Joint Surg Am* 1983;65:456.

# 48. Smith KL, Matsen FA, 3rd. Total Shoulder Arthroplasty versus Hemiarthroplasty. Current Trends. *Orthop Clin North Am* 1998;29:491.

+ 49. Sperling JW, Cofield RH. Revision Total Shoulder Arthroplasty for the Treatment of Glenoid Arthrosis. *J Bone Joint Surg Am* 1998;80:860.

+ 50. Sperling JW, Cofield RH, Rowland CM. Neer Hemiarthroplasty and Neer Total Shoulder Arthroplasty in Patients Fifty Years Old or Less. Long-term Results. *J Bone Joint Surg Am* 1998;80:464.

+ 51. Torchia ME, Cofield RH, Settergren CR. Total Shoulder Arthroplasty with the Neer Prosthesis: Long-term Results. *J Shoulder Elbow Surg* 1997;6:495.

# 52. Waldman BJ, Figgie MP. Indications, Technique, and Results of Total Shoulder Arthroplasty in Rheumatoid Arthritis. *Orthop Clin North Am* 1998;29:435.

+ 53. Williams GR Jr, Rockwood CA Jr. Hemiarthroplasty in Rotator Cuff-deficient Shoulders. *J Shoulder Elbow Surg* 1996;5:362.

+ 54. Wirth MA, Rockwood CA Jr. Complications of Total Shoulder-Replacement Arthroplasty. *J Bone Joint Surg Am* 1996;78:603.

+ 55. Wright TW, Cofield RH. Humeral Fractures after Shoulder Arthroplasty. *J Bone Joint Surg Am* 1995;77:1340.

+ 56. Zuckerman JD, Matsen FA II. Complications about the Glenohumeral Joint Related to the Use of Screws and Staples. *J Bone Joint Surg Am* 1984;66:175.

# CHAPTER 102

# ARTHROPLASTY AND ARTHRODESIS OF THE ELBOW

*Graham J. W. King*

**G. J. W. King:** Associate Professor, Orthopaedic Surgery, Hand and Upper Limb Centre, University of Western Ontario, St. Joseph's Health Centre, London, Ontario, N6A 4L6, Canada.

Elbow Arthroplasty
- Interposition Arthroplasty
- Debridement Arthroplasty
- Unlinked Total Elbow Arthroplasty
- Linked Total Elbow Arthroplasty
- Revision Total Elbow Arthroplasty

Elbow Arthrodesis
- Indications
- Contraindications
- Operative Technique
- Rehabilitation
- Results
- Complications

Chapter References

## ELBOW ARTHROPLASTY

### INTERPOSITION ARTHROPLASTY

Resection and interposition arthroplasty are now infrequently performed with the advent of successful replacement arthroplasty. Resection arthroplasty should be avoided due to the gross instability that results from removal of the distal humerus and proximal ulna. The most common indication for resection arthroplasty is a failed infected total elbow arthroplasty (88). Interposition arthroplasty continues to be used in selected patients with elbow arthritis. The procedure consists of interposing fascia or dermis between the humerus and ulna while maintaining the overall shape of these bones to preserve stability.

#### *Indications*

The most common indication for interposition arthroplasty of the elbow is incapacitating pain and stiffness due to old sepsis, prior trauma, hemophilia, or inflammatory arthropathy. With improved prosthetic arthroplasties of the elbow, interposition arthroplasty is now most commonly used for young patients with posttraumatic arthritis for which the results of total elbow arthroplasty are less reliable. Patients with more than 50% loss of articular cartilage and joint incongruity should be considered for an interposition arthroplasty rather than a surgical debridement. Interposition arthroplasty can be considered in young patients whose elbows are ankylosed but whose functional demands require motion. Patients must be able to cooperate in the postoperative rehabilitation program, which is an essential part of the success of interposition arthroplasty.

#### *Contraindications*

Patients with recent sepsis should undergo staged debridement before interposition arthroplasty. Delay arthroplasty until all epiphyses are closed. Patients with a poor soft-tissue envelope should have flap coverage before any type of elbow arthroplasty. Consider elbow arthrodesis or tendon transfers before interposition arthroplasty for patients with inadequate muscle power for flexion and extension. Avoid interposition arthroplasty in heavy laborers because pain relief is often incomplete. Patients who require ambulatory aids for walking may develop increased elbow instability after surgery, which may impair their ability to ambulate. Accept an ankylosed elbow in a functional position because the results of interposition arthroplasty in such circumstances are less reliable than for other indications.

#### *Operative Technique*

A variety of different materials have been employed for interposition arthroplasty. Of these, the most popular have been the use of fascia lata or skin (5,6,33,41,50,55,78). Some surgeons have advocated the use of an articulated external fixator to distract the elbow in the postoperative period to improve the outcome (55). There are no comparative series evaluating the efficacy of adding a distraction device to an interposition arthroplasty. In spite of this, distraction interposition arthroplasty has become increasingly popular because it allows immediate postoperative elbow motion while maintaining stability. Distraction of the joint in the postoperative period may have an additional advantage by allowing the interposition material to become biologically attached to the underlying bone before being subjected to compression and shear loading.

- With the patient supine, prep and drape the arm and inflate a sterile tourniquet.
- Make a midline posterior elbow incision, staying just lateral to the tip of the olecranon (15). Elevate a full-thickness lateral flap and identify the Kocher interval between the anconeus and extensor carpi ulnaris (Fig. 102.1).

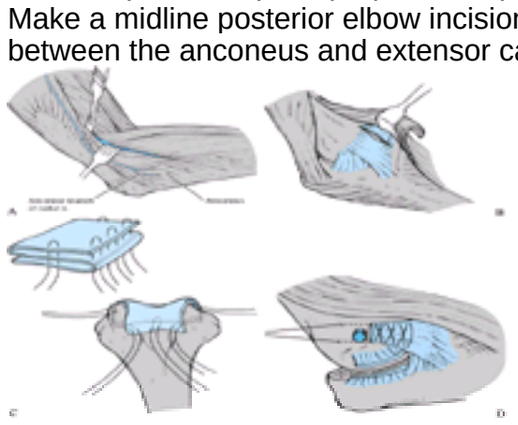

***Figure 102.1.*** Interposition arthroplasty technique: **A:** The Kocher interval is identified between the anconeus and the extensor carpi ulnaris. **B:** The lateral collateral ligament complex is detached from its humeral origin, and the elbow is subluxated to achieve wide access to the joint. **C:** The fascia lata is folded onto itself and wrapped over the articular condyles of the distal humerus and secured with nonabsorbable sutures. **D:** The elbow is reduced, and the lateral ligaments are repaired through drill holes in the lateral epicondyle using nonabsorbable sutures.

- Elevate the common extensor origin off the lateral epicondyle and supracondylar ridge anteriorly. Reflect the anconeus posteriorly.
- Detach the lateral collateral ligament complex from its humeral origin to achieve wide access to the elbow. The triceps may need to be elevated off the olecranon in continuity with the anconeus, and the medial collateral ligament may have to be partially released in some patients to achieve adequate exposure, particularly in those with very stiff elbows.
- Excise the anterior and posterior capsule and remove any osteophytes to improve motion.
- Using a burr, smooth and contour the greater sigmoid notch of the olecranon and the trochlea of the distal humerus. Take care to minimize removal of subchondral bone because this often results in excessive bone resorption in the postoperative period.
- If possible, preserve the radial head to maximize the stability of the elbow. It can be debrided if it is mildly arthritic; however, it should be excised if it is involved

with advanced disease.

- Make a 25 cm incision over the proximal lateral thigh. Remove a 10 cm wide by 25 cm long portion of fascia lata. Do not close the fascial defect.
- Fold the fascia lata onto itself to create a three-ply graft. Wrap the fascia over the articular condyles of the distal humerus, and secure it with #1 braided nonabsorbable sutures.
- Reduce the elbow and repair the lateral ligaments through drill holes in the lateral epicondyle. Close the fascia between the anconeus and extensor carpi ulnaris to augment lateral elbow stability.

Consider an articulated external fixator to maintain motion while protecting the interposed graft tissue during healing. Options include the Dynamic Joint Distractor (Howmedica, Rutherford, NJ) developed by Morrey (Fig. 102.2) or the Compass Universal Hinge (Smith & Nephew Richards, Memphis, TN) developed by Hotchkiss (Fig. 102.3).



***Figure 102.2.*** Dynamic Joint Distractor.



***Figure 102.3.*** Compass Universal Elbow Hinge.

The Dynamic Joint Distractor uses a large threaded pin, which is placed through the axis of rotation of the distal humerus as well as two pins for fixation in the ulna. Adjustable distraction of the joint is permitted. This device maintains stability of the elbow while allowing early active and passive mobilization. It is easy to apply; however, because the intraarticular axis pin is left in the distal humerus, it may have a higher incidence of postoperative joint sepsis.

The Compass Universal Elbow Hinge places two to three pins in the humerus and two pins in the ulna. All pins are placed remote from the axis of the joint, which reduces the possibility of postoperative infection. Distraction of the joint is permitted, and a worm gear mechanism allows the patient controlled passive postoperative mobilization of the elbow. This hinge is bulkier and somewhat more difficult than the Dynamic Joint Distractor to apply.

The technique for using an articulated external fixator is as follows:

- Identify the axis of motion of the elbow, passing from the center of the radius of curvature of the capitellum laterally to just anterior and distal to the medial epicondyle, and place a guide pin. Take care to identify and protect the ulnar nerve (Fig. 102.4).

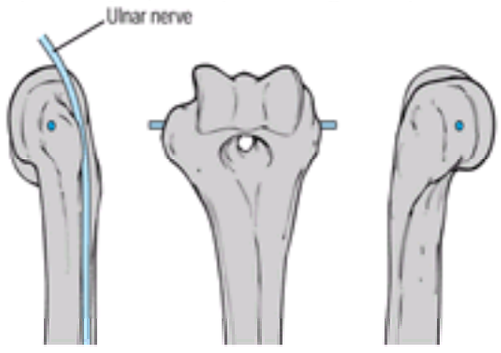


***Figure 102.4.*** Elbow flexion axis.

- Reduce the elbow joint and repair the soft tissues as previously described.
- Mount the fixator on the central axis pin and apply the remainder of the pins for the articulated external fixator. Distract the joint 2 to 3 mm to prevent dislodgement of the graft during early active and passive mobilization.

### *Rehabilitation*

Administer a continuous axillary block either preoperatively or in the recovery room to facilitate postoperative pain control. With an axillary catheter in place, the patient and therapist can initiate immediate postoperative passive range of motion. Alternatively, employ a continuous passive motion machine. Use ice packs to control edema. Commence active assisted motion after removal of the axillary block. Throughout the postoperative period, maintain elbow and forearm motion, along with meticulous pin site care. Remove the elbow distraction device 6 weeks after surgery. Begin passive stretching at 6 weeks and strengthening at 12 weeks. Provide resting extension and static progressive flexion splints after fixator removal to help regain motion under the supervision of a physical therapist.

### *Results*

Morrey et al. (55) have reported good results with distraction interposition arthroplasty. Pain was reduced, although at least half the patients had some residual discomfort. Motion increased from an average arc of 27° preoperatively to 107° postoperatively (Fig. 102.5). Unlike earlier reports of interposition arthroplasty without distraction, the stability achieved with this approach has been good. Others (5,6,33,41,50,78) have reported good results from interposition arthroplasty without distraction (Table 102.1).

***Figure 102.5.*** Interposition arthroplasty: A 22-year-old woman with posttraumatic ankylosis of the elbow following a fracture of her distal humerus and forearm. **A:** Preoperative anteroposterior (AP) radiograph demonstrating a loss of joint space and heterotopic ossification. **B:** Preoperative lateral radiograph. **C:** Intraoperative appearance of the articular surface of the distal humerus with extensive loss of the articular cartilage of trochlea and absence of capitellum. **D:** Interposition graft secured in place on the distal humerus. **E:** Postoperative AP radiograph in Compass Elbow Hinge demonstrating joint distraction. **F:** Postoperative lateral radiograph in Compass Elbow Hinge showing correct articular alignment. **G:** One-year postoperative anterior posterior radiograph showing maintenance of joint space. **H:** One-year postoperative lateral radiograph demonstrating some postoperative resorption of the distal humerus. The patient achieved adequate functional outcome with motion from 30° to 130°, minimal pain, and no instability.

| Author | Year | Indication | Interposition material | Number | Motion arc (degrees) | Pain | Stability |
|---|---|---|---|---|---|---|---|
| MacAusland WR[10] | 1921 | MHSC | Fascia Lata | 17 | 90 | – | Stable |
| Campbell WC[7] | 1922 | MHSC | Triceps Tongue | 2 | 85 | – | – |
| Campbell WC[8] | 1924 | MHSC | Triceps Tongue | 9 | 95 | – | – |
| Knight RA and Van Zandt IL[42] | 1952 | MHSC | Triceps | 45 | – | 84% Good | – |
| Harris L et al.[13] | 1964 | RA | Dermis | 22 | 78 | Mild-Moderate | – |
| Shahriaree H et al.[79] | 1979 | MHSC | Gelfoam | 31 | 80 | None-Mild | Moderate Laxity |
| Murray BF[57] | 1990 | OA | Fascia Lata | 6 | 107 | None to Mild | Mild Laxity |

***Table 102.1. Interposition Arthroplasty Results***

### *Complications*

Elbow instability, stiffness, heterotopic bone formation, infection, bone resorption, and incomplete pain relief have been reported following interposition arthroplasty. Minimize the incidence of these complications by careful patient selection and meticulous operative technique. Avoid bone resorption by preservation of the subchondral cortex when performing the intraoperative joint debridement. Minimize infection by careful pin site care and early removal of any distraction device. Patients who are left with residual pain and instability following interposition arthroplasty may be aided by an elbow arthrodesis or a prosthetic arthroplasty.

## DEBRIDEMENT ARTHROPLASTY

Debridement arthroplasty has long been performed for patients with osteoarthritis. Even though there is increasing experience with arthroscopic debridement, there are limited clinical reports available documenting the medium- and long-term results of this procedure (see Chapter 82). As a consequence, open debridement is preferred for selected patients with primary or secondary osteoarthritis.

### *Indications*

The most common indication for debridement arthroplasty is primary osteoarthritis of the elbow. In one series (83), the prevalence of osteoarthritis was reported at 2% of 1,000 patients attending a fracture clinic. This disorder is most commonly found in men, particularly those involved in heavy manual labor. Osteoarthritis occurs secondary to trauma and other disorders such as Panner's disease, osteochondritis dessicans, and synovial osteochondromatosis. Cubital tunnel syndrome is commonly associated with elbow osteoarthritis, up to 40% in one series (66). At present, the primary indication for debridement arthroplasty is the younger patient with evidence of loose bodies or impinging osteophytes and a preserved joint space. Older patients with advanced arthritis may be better candidates for a total elbow arthroplasty. Patients who have impingement pain—that is, pain at the extremes of motion with minimal pain in the central arc—are considered ideal. Patients with pain throughout motion generally have more articular destruction and may require an alternative procedure such as an interposition or prosthetic arthroplasty. Patients with a well-preserved ulnohumeral joint but advanced involvement of the radial capitellar joint can be considered for a radial head excision in combination with a debridement arthroplasty. Patients must be able to understand and cooperate in the postoperative rehabilitation program if a successful result is to be obtained from a debridement arthroplasty.

### *Contraindications*

Consider patients with advanced joint space loss for alternate procedures such as interposition arthroplasty as described above or total elbow replacement. Consider patients with a poor soft-tissue envelope for flap coverage, either concomitant with debridement or before it.

### *Operative Technique*

Various procedures have been described for debridement arthroplasty of the elbow. All involve resection of impinging osteophytes and removal of loose bodies. Excise the radial head only if it is involved by advanced disease.

Several surgical approaches have been described, including posterior, medial, and lateral approaches. The use of a posterior midline incision provides the most flexibility while performing the surgical procedure. Regardless of the surgical approach, remove all osteophytes, particularly on the olecranon and coronoid process, which typically impinge as the elbow is extended and flexed, respectively.

**Medial Approach** If the patient has ulnar nerve symptoms preoperatively, routinely perform an anterior ulnar nerve transposition as part of the operative procedure. Particularly in patients who lack elbow flexion preoperatively, increased motion of the elbow after surgery may stretch the ulnar nerve and exacerbate these symptoms.

- Make a midline posterior elbow incision centered just medial to the tip of the olecranon. Develop a full-thickness medial skin flap and perform an anterior ulnar nerve transposition.
- Expose the anterior aspect of the elbow by developing the interval between the pronator teres and flexor carpiradialis, as described by Hotchkiss (Fig. 102.6) (32). Excise the tip of the coronoid process if it is redundant and remove any loose bodies. Excise the anterior capsule. Clear the coronoid and radial fossi of any impinging osteophytes so that near-full elbow range of motion is achieved at the completion of the debridement.

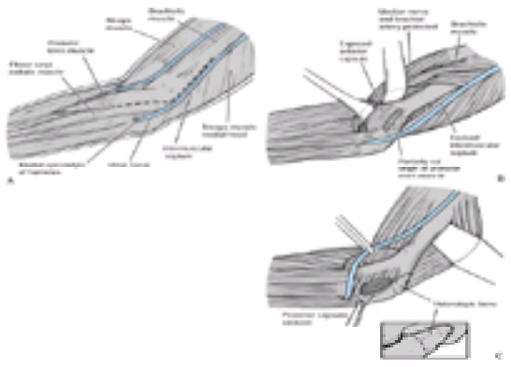

***Figure 102.6.*** Debridement arthroplasty—medial approach: **A:** After isolation and transposition of the ulnar nerve, the interval between the pronator teres and flexor carpi radialis is developed to expose the anterior aspect of the elbow. **B:** The anterior capsule is excised, as well as any loose bodies or impinging osteophytes. **C:** The triceps is elevated posteriorly to expose the posterior capsule, which is excised.

- Elevate the triceps off the posterior aspect of the humerus. Excise the tip of the olecranon and remove any osteophytes or loose bodies from the olecranon fossa. Resect the posterior capsule to optimize the postoperative range of motion.

**Lateral Approach** Patients who do not have ulnar nerve symptoms can be approached using lateral muscular intervals. Preserve the lateral ulnar collateral ligament. Visualization of the coranoid process is more difficult than with a medial approach.

- Make a midline posterior elbow incision centered just lateral to the tip of the olecranon. Develop a full-thickness lateral skin flap and identify the interval between the extensor carpi radialis longus and extensor digitorum comminus (Fig. 102.7) (8). An approach through this interval provides adequate access to the anterior aspect of the elbow while avoiding damage to the lateral ulnar collateral ligament.

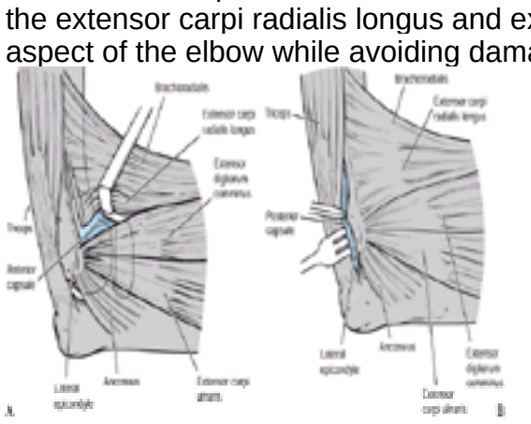

***Figure 102.7.*** Debridement arthroplasty—lateral approach: **A:** The anterior capsule can be approached from the lateral side of the elbow through the interval between the extensor carpi radialis longus and extensor digitorum communis. **B:** The olecranon and olecranon fossa are exposed by elevating the triceps off the posterior aspect of the humerus.

- Excise the anterior capsule and any osteophytes, as described for the medial approach.
- Expose the olecranon and olecranon fossa by elevating the triceps off the posterior aspect of the humerus and excise the posterior capsule and any osteophytes.

**Transhumeral Approach** Outerbridge and Kashiwagi (37) have described a procedure whereby the distal humerus is fenestrated through the olecranon and coronoid fossae (Fig. 102.8). Humeral fenestration is particularly useful when the olecranon and coronoid fossae are obliterated by hypertrophic osteophytes.

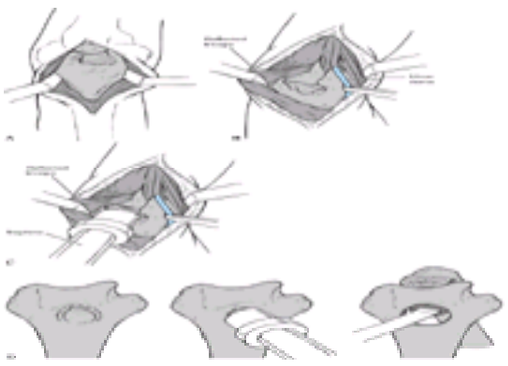

***Figure 102.8.*** Outerbridge-Kashiwagi arthroplasty: **A:** The triceps tendon is split in the midline, and the olecranon fossa is exposed. The tip of the olecranon is excised. **B:** Alternatively, expose the ulnar nerve and partially elevate the triceps off the tip of the olecranon to expose the olecranon fossa. **C:** The distal humerus is fenestrated using a Cloward drill. **D:** By working through the fenestration of the distal humerus, osteophytes can be removed from the coronoid and a partial excision of the anterior capsule achieved.

- Make a midline posterior elbow incision centered just medial to the tip of the olecranon. Perform a midline split in the triceps tendon to visualize the posterior aspect of the distal humerus. If there is a pre-existent ulnar neuropathy, transpose the ulnar nerve anteriorly during the same procedure. Alternative exposure can be obtained by elevating the triceps from medial to lateral off the tip of the olecranon.
- Fenestrate the distal humerus using a Cloward drill. Ensure central placement of the drill on the olecranon fossa such that the medial and lateral columns of the distal humerus are not violated. Direct the drill 40° cephalad to correlate with the shaft-capitellar angle of the distal humerus. The drill should exit the anterior aspect of the elbow in the region of the coronoid fossa.
- Working through the fenestration in the distal humerus, remove any coronoid osteophytes with an osteotome and excise the anterior capsule (Fig. 102.9).

***Figure 102.9.*** Debridement arthroplasty: **A:** Anteroposterior radiograph of a 52-year-old laborer with persistent stiffness and pain at the extremes of motion. Note preservation of the ulnohumeral and radiocapitellar joint spaces with obliteration of the normal radiolucency seen in the region of the olecranon fossa. **B:** Lateral radiograph showing osteophytes on the coronoid as well as the olecranon. **C:** Postoperative anteroposterior radiograph showing fenestration of the central portion of the distal humerus. **D:** Lateral radiograph showing adequate excision of the olecranon and coronoid osteophytes.

### *Rehabilitation*

Administer a continuous axillary block either preoperatively or in the recovery room to facilitate postoperative pain control. Begin elbow motion immediately after surgery with a continuous passive motion machine for 48 hours. Following the discontinuation of the axillary block, commence active motion. Use extension splinting at night to minimize postoperative flexion contractures. A static progressive flexion splint may be used intermittently during the day to optimize postoperative elbow flexion.

### *Results*

Debridement arthroplasty improves pain in more than 80% of patients in most reported series (Table 102.2) (31,53,56,66,86). Although preoperative pain is generally markedly reduced, many patients have mild residual pain, particularly with heavier activities. Gains in motion have been modest, on the order of 20° to 25°. The procedure provides durable pain relief in spite of the tendency to redevelop osteophytes at long-term follow-up (66).

| Author | Year | Number | Mean follow-up (yrs) | Motion improved (degrees) | Pain improved (%) |
|---|---|---|---|---|---|
| Morrey[31] | 1985 | 111 | 4.5 | – | 88 |
| Morrey BF[56] | 1992 | 15 | 2.3 | 21 | 93 |
| Tsuge K et al.[86] | 1994 | 29 | 5.3 | 34 | 100 |
| Herold K et al.[53] | 1997 | 27 | 2.5 | 34 | – |
| Oka Y[66] | 1998 | 38 | 5.9 | 24 | 95 |

***Table 102.2. Debridement Arthroplasty Results***

### *Complications*

Elbow instability, stiffness, heterotopic bone formation, infection, ulnar neuropathy, and incomplete pain relief have been reported following debridement arthroplasty. The most common cause of persistent pain is incomplete osteophyte excision and advanced articular degenerative changes. With careful patient selection and meticulous operative technique, patient satisfaction has been high with this procedure.

## UNLINKED TOTAL ELBOW ARTHROPLASTY

Constrained, semiconstrained, unconstrained, and resurfacing are all terms that have been used to describe categories of elbow arthroplasties. These terms are somewhat misleading because even “unconstrained” implants have some intrinsic constraint by virtue of the interlocking shape of their articular surfaces (39). A more simplified classification designates implants as linked or unlinked.

Unlinked replacements rely on the capsuloligamentous tissues as well as the intrinsic constraint of the implant to maintain joint stability (40). The decision to use an unlinked or a linked arthroplasty depends on the amount of bone destruction, the status of the capsuloligamentous tissues of the elbow joint, and the surgeon's experience with these devices. Numerous unlinked implants have been developed. The most popular designs in current use are the Capitellocondylar (Johnson & Johnson) (10,16,17,74,76,87), Kudo (44,45 and 46), Pritchard ERS (Depuy), Sorbie (Wright Medical) (79), and Souter (Howmedica) (48,54,69,75,80).

Many of the early unlinked elbow replacements were designed without stems on either the humeral or ulnar components. A high incidence of mechanical loosening was reported with these early designs (44,46,47,75); however, improved results have been reported with newer stemmed devices. At present, there is no consensus as to whether a radial head replacement should be used in conjunction with the humeral and ulnar components. Although there is a theoretical basis for a radial head component from the perspective of load transfer, this has not been confirmed by clinical experience (85).

All unlinked designs replicate the axis of motion of the elbow to optimize ligamentous balance and maintain joint stability. Differences between implants include the type and length of intramedullary fixation and the shape of the articular surfaces. For example, the depth of the trochlear groove is much greater in the Souter implant than the capitellocondylar design (Fig. 102.10). The intrinsic constraint of these two devices is clearly different, which may have implications with regard to the incidence of dislocation and loosening. The more constrained the implant, the greater the transfer of loads to the bone–cement interface and, hence, the greater potential for loosening. Conversely, less constrained devices may have a higher tendency to postoperative instability or dislocation.



***Figure 102.10.*** **A:** The humeral component of the Souter total elbow arthroplasty has a deep trochlear groove. **B:** The capitellocondylar design has a shallower trochlear groove with much less intrinsic constraint.

### *Indications*

Pain, stiffness, and loss of elbow function due to rheumatoid arthritis comprise the most common indication for total elbow replacement. Joint space loss, with relatively well-preserved bone stock and adequate capsuloligamentous tissues, is the main indication for an unlinked design. Patients with advanced bone destruction and joint instability are best treated with a linked device, as is discussed later in this chapter. Patients with rheumatoid arthritis who have less joint destruction may be candidates for synovectomy (either open or arthroscopically), with or without radial head excision as a means to defer arthroplasty. Other forms of inflammatory arthritis, such as hemophilia, are also indications for total elbow arthroplasty. Posttraumatic arthritis is an increasingly common indication for replacement arthroplasty; however, careful consideration should be given to patient age and functional demands because failure rates have been higher in these patients. Patients with periarticular nonunions and acute fractures generally require a linked implant due to bone loss.

### *Contraindications*

Inadequate bone stock and incompetent collateral ligaments are the most frequent contraindications to unlinked arthroplasty. Previous infection has been considered an absolute contraindication to elbow arthroplasty. However, in selected patients, replacement arthroplasty can be considered despite remote sepsis. A staged debridement of the elbow that yields negative cultures should be performed before proceeding with an elbow arthroplasty in the face of previous infection. Elbow arthrodesis is considered a relative contraindication for replacement arthroplasty. The conversion of an elbow fusion to an arthroplasty is challenging, and the outcome

is unpredictable. A linked arthroplasty will usually be required due to bone loss and ligamentous insufficiency. Paralysis of muscles about the joint or inadequate soft tissues would be considered relative contraindications if they can not be improved preoperatively.

### *Operative Technique*

The preferred surgical technique will be specific to the implant used. The Sorbie device (79) is the author's preferred unlinked total elbow arthroplasty (Fig. 102.11). One of the principles of treatment for most unlinked implants is to preserve the medial collateral ligament. Accordingly, most surgical approaches are through an extended Kocher approach (Fig. 102.12). Sublux the elbow on the intact medial collateral ligament to achieve adequate exposure for placement of the components. Management of the ulnar nerve is controversial, but most surgeons recommend identification and protection of the nerve with or without formal transposition.

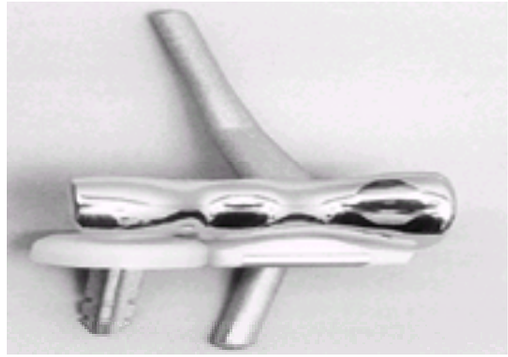

***Figure 102.11.*** Humeral, ulnar, and radial components of the Sorbie-Questor total elbow arthroplasty.

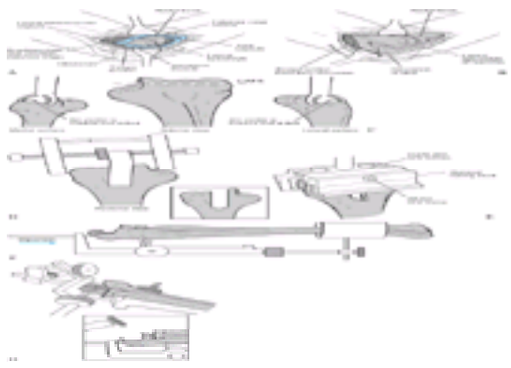

***Figure 102.12.*** Sorbie total elbow arthroplasty: **A:** Through an extended Kocher approach, the lateral collateral ligament complex is identified and detached from the lateral epicondyle. **B:** The triceps is elevated off the olecranon from lateral to medial and the elbow is subluxated on the intact medial collateral ligament to achieve adequate exposure for placement of the components. **C, D, E:** After identification of the axis of rotation of the distal humerus appropriate bone cuts are made and the distal humerus is prepared. *CAFE*, central axis of rotation. **F, G:** By using a specialized ulnar cutting jig, the greater sigmoid notch of the ulna is prepared. (Redrawn from “The Sorbie-Questor Total Elbow System” brochure, with permission from Wright Medical Technology.)

- Make a midline posterior elbow incision just medial to the tip of the olecranon to avoid damage to cutaneous nerves (15). Identify and transpose the ulnar nerve into a subcutaneous pocket through a medial flap.
- Expose the elbow with a lateral flap and an extended Kocher approach. Elevate the triceps off the olecranon from lateral to medial and hinge the elbow open on the intact medial collateral ligament.
- Make bone cuts and open medullary canals by using instruments specific for the implant to be done.
- Before cementing the definitive components, perform a trial reduction and ensure congruent tracking of the arthroplasty. Flex and extend the elbow with the forearm held in pronation to tension the medial collateral ligament and close the lateral side of the elbow that has been destabilized by the surgical exposure. If there is maltracking, reposition one or both of the components.
- Perform a linked arthroplasty if there is instability due to an incompetent medial collateral ligament or persistent incongruity in spite of component repositioning. An unlinked elbow arthroplasty that is unstable or maltracks intraoperatively usually continues to function poorly postoperatively.
- Prepare the medullary canals with pulse lavage, dry thoroughly, and insert antibiotic-laden cement retrograde by using a cement gun. Pressurize the cement if the medullary canal is adequately occluded with cement restrictors (18).
- Insert the components and reduce the elbow. Hold the elbow at 90° flexion and full forearm pronation while the cement sets. Elbow reduction allows the components to align with one another and enhances implant tracking.
- Place drill holes through the lateral epicondyle to accommodate sutures that reattach the lateral collateral ligament complex. Close the fascia of the Kocher interval to augment lateral elbow stability, as has been described by Cohen et al. (8). Reattach the triceps tendon to the olecranon using nonabsorbable sutures. Close the skin over suction drains.
- Evaluate elbow stability throughout motion. Splint the elbow in a position of stability, generally 60° of flexion, taking care to avoid any pressure over the posterior incision (Fig. 102.13).

***Figure 102.13.*** **A:** AP radiograph of a 44-year-old man with polyarticular rheumatoid arthritis of 20 years' duration. Note complete loss of joint space with relative preservation of bone architecture. **B:** Lateral radiograph. **C:** Postoperative anteroposterior radiograph following Sorbie total elbow arthroplasty. The patient had complete relief of pain and restoration of a functional arc of elbow motion. **D:** Lateral postoperative radiograph.

### *Rehabilitation*

Begin motion within 48 hours alternating with a resting splint at 90°. Have the patient perform elbow flexion and extension with the forearm fully pronated for 6 weeks to protect the lateral ligament repair. Active assisted flexion and passive gravity-assisted extension protect the triceps tendon repair. Have the patient avoid extension past 30° for the first 3 to 4 weeks to guard against posterior subluxation or, worse, dislocation of the elbow. Permit forearm pronation and supination only with the elbow at 90° of flexion. Apply a resting extension splint 4 to 6 weeks after surgery if the patient is having difficulty achieving extension. Continue this treatment for 12 weeks. Counsel patients not to lift more than 5 kg and not to participate in any upper extremity impact sports (e.g., golf, tennis) after total elbow arthroplasty.

### *Results*

There are numerous published results of unlinked elbow arthroplasty (Table 102.3) (17,44,45,46,47 and 48,69,72,73,74 and 75,80,87). The greatest reported experience in North America is with the capitellocondylar total elbow prosthesis (18). The inventor of this implant has had excellent results, with only a 1.5% incidence of postoperative dislocation. However, other surgeons have reported instability in up to 20% of patients (87). The mechanical loosening rate of this implant has been low in patients with rheumatoid arthritis.

***Table 102.3. Unlinked Arthroplasty Results***

Similar results with other unlinked arthroplasties have been reported from Europe, Great Britain, and Japan. Souter et al. (80) reported good functional results with the Souter total elbow arthroplasty as well as a low incidence of loosening and instability.

### *Complications*

The most devastating complications of unlinked total elbow arthroplasty are infection and instability. Infection is difficult to eliminate. Immediate surgical debridement is essential if the implant is to be retained. Intravenous antibiotics followed by suppressive antibiotics may allow retention of the implant. If the infection is acute, either in the postoperative period or from a hematogenous source, then consider debridement. Manage late, indolent infections, or persistent sepsis in spite of debridement, by removal of the implant and all cement. Reimplantation of an infected elbow arthroplasty remains controversial; however, a staged revision arthroplasty may be successful.

Postoperative subluxation or dislocation of an unlinked arthroplasty often requires revision to a linked design. Carefully evaluate the radiographic position of the components before revision. If one or both components are malpositioned, then consider repositioning. If the component position is adequate, perform closed reduction and casting to allow capsule and ligament healing. If the elbow remains unstable after a period of immobilization and the component position is acceptable, repair or reconstruction of one or both of the collateral ligaments may stabilize the arthroplasty. If stability cannot be achieved by component repositioning or ligament reconstruction, consider revision to a linked arthroplasty.

Damage to the ulnar nerve can occur at any time during surgery. If the ulnar nerve is not protected and transposed, it may be compressed while the elbow is subluxed to place the components. The ulnar nerve may be damaged by power instruments or cement leakage due to its proximity to the olecranon.

Intraoperative fractures of one or both humeral columns may preclude the successful placement of an unlinked design. Consider intraoperative conversion to a linked arthroplasty. Open reduction and internal fixation of the columns can be performed in patients with good bone quality and reconstructible fractures. Cortical perforation or fracture of the humerus or ulna can occur due to the small diameter of the medullary canals. Extravasation of cement with damage to neural structures may occur. Careful repair of the triceps tendon to the olecranon is required to prevent triceps disruption and postoperative extension weakness.

The elbow may become stiff due to inadequate capsular release during surgery or a delay in postoperative rehabilitation. Heterotopic ossification can occur, particularly in patients with hypertrophic osteoarthritis. Wound healing problems are uncommon with postoperative extension splinting and suction drains. Delayed wound healing is occasionally seen in patients with rheumatoid arthritis, particularly those on steroids. Treat minor areas of superficial dermal necrosis by delayed mobilization and extension splinting. Consider surgical debridement, with or without flap coverage, in patients with full-thickness skin loss to avoid secondary infection.

## LINKED TOTAL ELBOW ARTHROPLASTY

The initial experience with fully constrained hinged arthroplasty of the elbow had a high mechanical loosening rate (13,26,59,64). The advent of improved loose-hinge linked designs has improved survivorship equaling that of unlinked elbow arthroplasties at medium-term follow-up. Biomechanical data suggest that muscle activation about the elbow may allow semiconstrained linked arthroplasties to function within the laxity of their loose hinge (65). This limits loading of the bone–cement interface and may explain the lower mechanical loosening rates relative to a fixed hinge. Linked devices have a significant advantage over unlinked designs because instability is uncommon. Commonly used linked devices include the Morrey-Coonrad (Zimmer) (7,9,27,58,79), GSB (Gschwend-Scheier-Bahler) (Allopro) (28,29,30), and the Osteonics (43) prostheses.

### *Indications*

Linked devices allow broader indications for total elbow arthroplasty from rheumatoid arthritis to posttraumatic arthritis, bone loss due to tumors, nonunions, and fractures. Be careful when considering total elbow arthroplasty in patients who do not have rheumatoid arthritis. Those with high functional demands and single joint disease will have a higher mechanical failure rate due to the excessive loading they place on their implants. In addition, consider age, vocation, and avocations of the patient. Some linked designs can be employed with loss of the distal humerus up to the level of the proximal aspect of the olecranon fossa and loss of the proximal ulna to the level of the coronoid (58). Most linked designs do not incorporate a radial head component, and therefore, the presence of the proximal radius is not required.

### *Contraindications*

Patients with a recent or remote history of an infection have a higher risk of postoperative infection for any total elbow arthroplasty, including linked designs. Do not consider total elbow arthroplasty for patients who cannot be expected to comply with the postoperative restrictions. Such surgery requires a satisfactory soft-tissue envelope, adequate muscle power, and a functional hand.

### *Operative Technique*

The chosen surgical technique is specific for each implant design. The author's current preferred linked implant is the Morrey-Coonrad design (Coonrad III) (Zimmer, Warsaw IN) (Fig. 102.14).

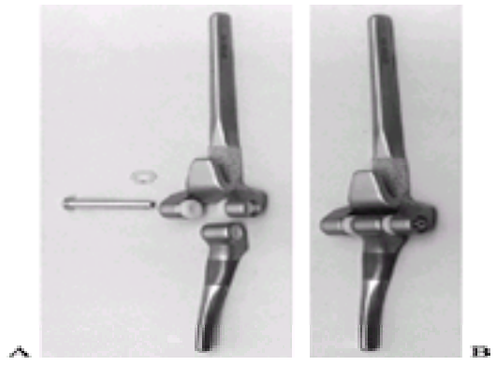


***Figure 102.14.*** Morrey-Coonrad linked total elbow arthroplasty: **A:** Humeral component with beaded flange, ulnar component with polymethylmethacrylate (PMMA)

precoat, axis pin, and locking clip. **B:** Appearance after assembly of the arthroplasty.

- Position the patient supine with a sterile tourniquet in place. Make a midline posterior elbow incision centered just medial to the tip of the olecranon. Elevate a full-thickness fasciocutaneous flap and transpose the ulnar nerve into an anterior subcutaneous pocket.
- Use a Bryan-Morrey approach (57) for patients without significant distal humeral bone loss (Fig. 102.15). Elevate the triceps off the olecranon from medial to lateral in continuity with the anconeus to expose the distal humerus. This creates a continuous sling of the extensor mechanism.

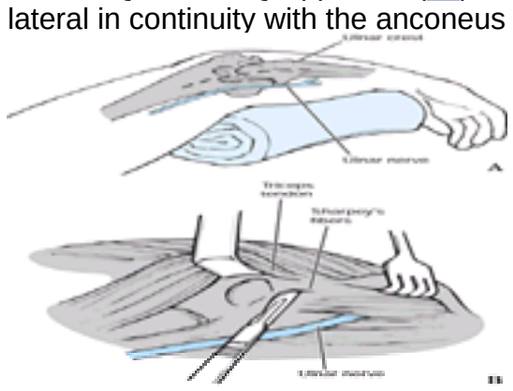

***Figure 102.15.*** Triceps-reflecting Bryan-Morrey approach: **A:** A midline posterior elbow incision is used. **B:** After identification and anterior transposition of the ulnar nerve, the triceps is elevated off the olecranon from medial to lateral in continuity with the anconeus to expose the distal humerus.

- Use a triceps-sparing approach (58,68) in elbows with deficient distal humeral columns (Fig. 102.16). Work through either side of the triceps while preserving its attachment to the olecranon. Take care to identify and protect the ulnar nerve.

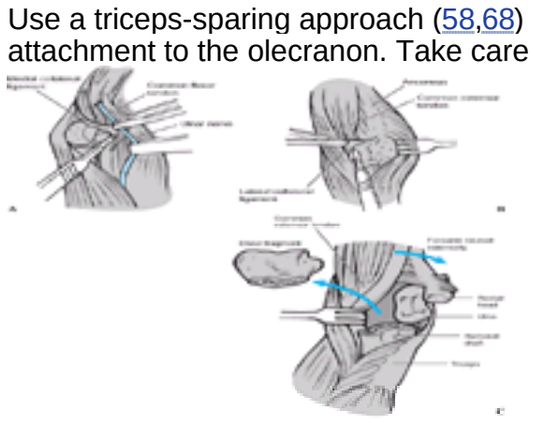

***Figure 102.16.*** Triceps-sparing approach: **A:** The medial collateral ligament is divided. **B:** The lateral collateral ligament and lateral common extensor origins are released from the lateral epicondyle. **C:** The distal humerus and ulna are delivered through the lateral muscular interval.

- Divide the humeral origins of the collateral ligaments to dislocate the elbow and facilitate exposure of the proximal ulna and distal humerus (Fig. 102.17). Excise the tip of the olecranon and coronoid to avoid restricting postoperative elbow motion by abutting the humeral component.

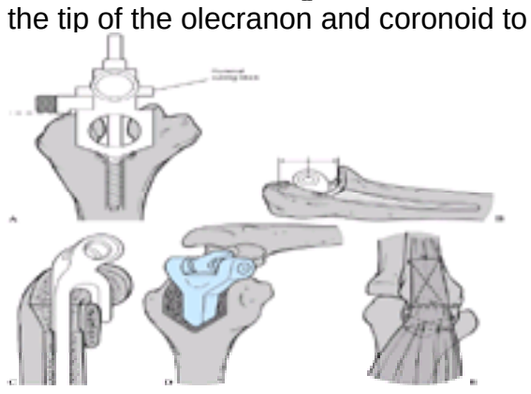

***Figure 102.17.*** Morrey-Coonrad total elbow arthroplasty surgical technique: **A:** After obtaining exposure of the distal humerus, the intercondylar area is opened and an alignment stem is placed into the humeral canal. A humeral cutting block sits on the capitellum, and appropriate saw cuts are made. **B:** The ulnar canal is opened with a burr, and the tip of the olecranon is excised. Ulnar rasps are used, and a trial placement of the components and reduction of the joint is performed. **C:** Cement is injected, and the components are inserted. A bone graft is placed behind the humeral flange. **D:** The components are connected with an axis pin and locking clip. **E:** The triceps is reattached to the olecranon with nonabsorbable sutures through drill holes. (Modified from “Coonrad/Morrey Total Elbow: Surgical Technique” brochure, with permission from Zimmer Corp.)

- Open the humeral canal in the midline at the level of the olecranon fossa and place the humeral cutting block over the intramedullary guide. Excise the intercondylar portion of the distal humerus using a microsagittal saw. Prepare the humeral canal with appropriate-sized rasps and place a trial humeral component. Use a humeral component with a 100 cm stem for most patients; however, a 150 cm component can be used for those with deficient distal humeral bone stock or severe osteopenia. Use a 100 cm stem if there is shoulder disease that may necessitate the need for a shoulder arthroplasty in the future.
- Excise the radial head if it is diseased. Open the medullary canal of the ulna with a power burr and widen with ulnar rasps. Insert trial components and articulate the implant. Ensure that an adequate range of motion is achieved without impingement of the olecranon, coronoid, or radial head on the implant.
- Plug the humeral and ulnar canals with cement restrictors. Lavage and dry the canals and inject antibiotic-laden cement retrograde using a cement gun. Cement the ulnar component first and allow the cement to cure. Inject the humeral canal and insert the component. Place an autogenous local cancellous bone graft beneath the anterior flange of the humeral component. Articulate the components using an axis pin before fully seating the humeral component.
- Hold the elbow in extension until the cement sets. Reattach the triceps to the olecranon with sutures through drill holes. Ensure that the ulnar nerve is secured anteriorly in a subcutaneous pocket. Close the wound over suction drains and splint the elbow in extension with anterior plaster slabs (Fig. 102.18).

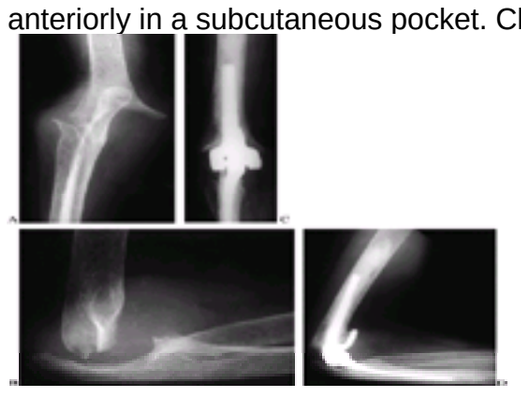

***Figure 102.18.*** **A:** AP radiograph of a 68-year-old woman with a 30-year history of polyarticular rheumatoid arthritis. Note the advanced bone loss and articular destruction. The patient presented with a painful unstable elbow. **B:** Lateral radiograph. **C:** Postoperative AP radiograph following a Morrey-Coonrad arthroplasty through a triceps-sparing approach. **D:** Lateral radiograph.

### *Rehabilitation*

Begin active assisted flexion and forearm rotation 24 to 48 hours postoperatively. Have the patient perform gravity-assisted extension exercises to protect the triceps repair for a 6-week period. If a triceps-sparing approach was used, active assisted extension exercises can be initiated immediately. Have the patient use a night extension splint for 12 weeks to optimize elbow extension and a 90° daytime resting splint for 6 weeks. Long-term restrictions are identical to those recommended for an unlinked arthroplasty.

### *Results*

Numerous reports document the improvements in function following linked total elbow arthroplasty (Table 102.4) (7,9,12,21,22,23,24,25,26,27,28,29 and 30,34,36,43,51,56,57,58,59 and 60,64,77,84). The loosening rate of the Morrey-Coonrad device has been low at medium-term follow-up in patients with rheumatoid arthritis (27). Unfortunately, in patients with posttraumatic arthritis, the mechanical loosening rate has been considerably higher (77). The clinical experience with the Pritchard Mark II hinge device has been less successful (51).

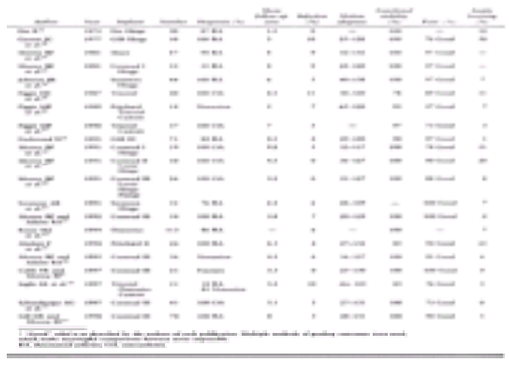

***Table 102.4. Linked Arthroplasty Results***

The GSB implant was originally designed as a fully constrained hinge and had a high loosening rate (28,30). A semiconstrained metallic polyethylene bushing was added, and excellent clinical results have been reported with this modified implant (30). Although the loosening rate of this implant has been low, disassembly of the linkage mechanism has occasionally occurred.

### *Complications*

The complications of linked total elbow arthroplasty are similar to those previously discussed for unlinked designs (61). The major difference has been that elbow instability is uncommon, given appropriate intraoperative coupling of the implant. Failure of the linkage mechanism requiring revision has been reported with a number of available linked devices. This has been a particular problem for the Triaxial device (52), but failure of the linkage bearings has also been reported in patients with Morrey-Coonrad prostheses (77). The mechanical loosening rate of these devices in younger patients with posttraumatic arthritis is of concern at short- to medium-term follow-up (77). Osteolysis has been seen in some patients. Fracture of the ulnar component has occurred with the Morrey-Coonrad device in patients after falls or heavy lifting (27).

## REVISION TOTAL ELBOW ARTHROPLASTY

In spite of the advances in total elbow arthroplasty design and implantation, the increasing numbers of implants being performed, as well as the tendency to extend the indications to younger, more active patients have resulted in failures requiring revision.

### *Indications*

The most common indication for revision elbow arthroplasty is mechanical loosening. This may be asymptomatic or present with an insidious onset of pain. Occasionally, loosening presents as an acute fracture due to cortical thinning from osteolysis (Fig. 102.19). Patients with progressive osteolysis, even in the absence of significant symptoms, should be considered for revision before the development of extensive bone loss (Fig. 102.20).

***Figure 102.19.*** **A:** AP radiograph of a well-functioning Morrey-Coonrad total elbow arthroplasty 4 years following the index procedure for posttraumatic arthritis. **B:** Note the osteolysis evident at the tip of the ulnar component. **C:** AP radiograph following a pathologic fracture of the ulna at the site of the aforementioned osteolysis 1 year later. **D:** Lateral radiograph. **E:** AP radiograph following a revision of the ulnar component. Note the cement leakage evident at the tip of the ulnar component through a cortical perforation. **F:** Lateral radiograph.

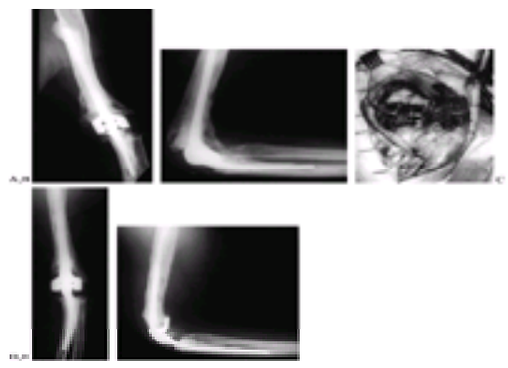

***Figure 102.20.*** **A:** AP radiograph of a 67-year-old woman 10 years after revision total elbow arthroplasty for posttraumatic arthritis. The patient has mild aching pain in the elbow that is worse following activities. Cement leakage is evident at the tip of the humeral component. **B:** Lateral radiograph. Note the radiolucency around the ulnar component and the osteolysis evident at the tip. **C:** Intraoperative photograph of titanium synovitis from a loose total elbow arthroplasty. **D:** AP radiograph following revision to a long-stem cemented Morrey-Coonrad total elbow arthroplasty. This gave the patient complete pain relief and return of function. **E:** Lateral radiograph demonstrating autogenous bone graft behind the flange of the humeral component.

Patients with instability of an unlinked total elbow arthroplasty are particularly challenging to treat (Fig. 102.21). Removal of well fixed, cemented implants often results in bone loss, which complicates the revision. Component failures from polyethylene wear of the coupling mechanisms may occur, particularly in younger, more active patients. Component fracture is occasionally seen and requires revision of the fractured component (Fig. 102.22). An infected total elbow arthroplasty that has not responded to debridement requires removal and conversion to an excisional arthroplasty (59,62). Delayed reimplantation has been reported and may be an option for selected patients (89).

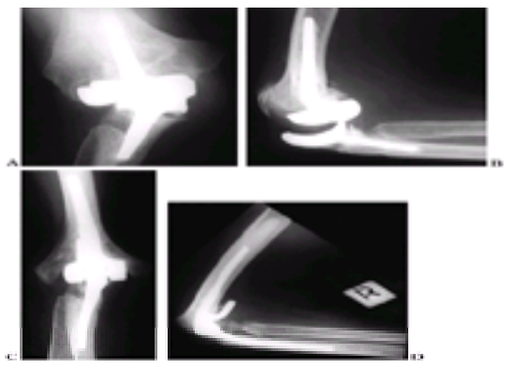

***Figure 102.21.*** **A:** AP radiograph of a 51-year-old woman with longstanding rheumatoid arthritis 18 months after capitellocondylar arthroplasty. **B:** Lateral radiograph showing persistent joint subluxation. **C:** Postoperative AP radiograph following revision to a linked arthroplasty. **D:** Lateral radiograph with pain-free elbow at 4-year follow-up.

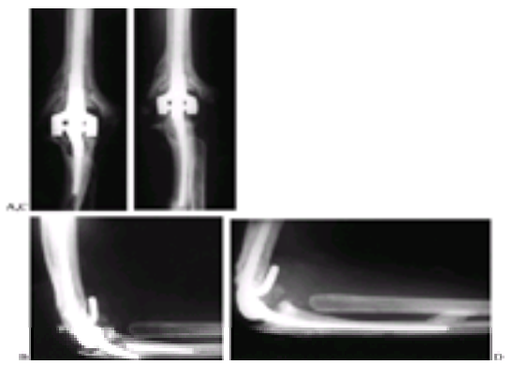

***Figure 102.22.*** **A:** AP radiograph of a 32-year-old man 3 years after total elbow arthroplasty for posttraumatic arthritis. The patient developed pain and a sense of instability of the elbow following lifting a heavy object. **B:** Note the fracture that has occurred through the beaded portion of the ulnar component. In newer versions of this implant, these beads have been removed to avoid the stress riser effect of their application. **C:** AP radiograph following revision of the ulnar component with impaction grafting of the proximal ulna using autogenous iliac crest bone graft. **D:** Lateral radiograph demonstrating some cement leakage from a cortical perforation in the ulna.

### *Contraindications*

Undertake with caution revision arthroplasty in patients with recent or remote history of infection, as outlined earlier. Consider coverage procedures before proceeding with revision arthroplasty for patients with a poor soft-tissue envelope. Consider excisional arthroplasty (13) or allograft or total elbow arthroplasty (TEA) composite reconstruction (11,25) for patients with inadequate bone stock.

### *Operative Technique*

A linked prosthesis is indicated for most revision procedures due to bone loss, which occurs frequently with implant loosening and extraction (38). Exceptions to this would be a stable, unlinked design with aseptic loosening of one or both components, which can be successfully revised while preserving the soft tissues and bone (27).

Before proceeding with revision surgery, be sure that there is an adequate inventory of both standard and long stemmed implants. Standard linked designs can typically be used with or without composite allograft reconstruction, even in the most difficult revision cases (38). Other surgeons have reported using custom designed revision implants with good results at short-term follow-up (20,21,24). Ultrasonic cement removal devices have simplified the removal of cement from the small medullary canals. Use a sterile tourniquet to facilitate extended surgical exposure as needed.

- Use previous skin incisions, if possible, to avoid flap necrosis. Identify and protect the ulnar nerve, even if it has previously been transposed.
- Use a triceps-sparing approach, if possible, to avoid detachment of the triceps from the olecranon, which is often atrophic from previous surgery. Use a Bryan-Morrey or extended Kocher approach with elevation of the triceps from the olecranon if the patient has preserved distal humeral bone.
- Extract loose implants and remove all loose cement from the canals by using standard instruments or an ultrasound device, as indicated. Consider using a cortical window for retrograde removal of well-fixed implants. Leave well-fixed cement that does not interfere with component placement rather than risk cortical perforations and fractures. Remove all cement in cases of infection by using a cortical window in the humerus or ulna, or both.
- Expose the radial nerve in patients undergoing cement removal from the humerus because damage has been reported from power instruments and cement leakage through a cortical perforation at the time of component reinsertion (38).
- Consider the ulnar bow toward the radius, which predisposes the ulna to cortical perforation at the time of cement removal with straight-stemmed revision instruments. Expose the subcutaneous border of the ulna to guide cement removal.
- Place the trial implants and assess the need for cancellous or structural autograft or allograft bone. Use antibiotic-impregnated cement, taking care to avoid cement leakage from cortical perforations and consequent damage to nerve structures. Perform a meticulous soft-tissue closure over suction drains and splint the elbow in full extension.

### *Rehabilitation*

Depending on the soft-tissue status, early or delayed motion may be indicated. Immobilize patients with tenuous soft coverage in an anterior splint with the arm in the extended position for as long a period as necessary to ensure adequate soft-tissue healing. Immobilization of up to 3 weeks allows restoration of a functional arc of motion while avoiding problems from wound slough. The therapy program generally follows that of a primary elbow arthroplasty but may need to be adjusted in patients with significant bone loss who have had structural allografts. If the triceps tendon is left in continuity, both active assisted flexion and extension can begin in the early postoperative period.

### *Results*

Recent reports of revision elbow arthroplasty demonstrate functional results and survivorship rates approaching those of primary elbow replacement at short- to medium-term follow-up (Table 102.5) (14,19,21,24,38,63). Patients with posttraumatic arthritis have had a higher failure rate than those with rheumatoid arthritis, similar to those undergoing primary elbow replacement (38). The complication rate has been higher with revision total elbow arthroplasty, even in experienced hands, indicating that revision total elbow arthroplasty should be performed only by those with extensive experience with primary elbow arthroplasty.

| Author | Year | Implant | Number | Diagnosis (%) | Mean follow-up (yrs) | Infection (%) | Motion (degrees) | Functional stability (%) | Pain* (%) | Aseptic loosening (%) | Revision (%) |
|---|---|---|---|---|---|---|---|---|---|---|---|
| Figgie HE et al.[illegible] | 1986 | Custom | 1 | 100 RA | 1.4 | 0 | 57–125 | 100 | 100 Good | 0 | 0 |
| Figgie HE et al.[illegible] | 1987 | Custom | 4 | – | – | 25 | 25–115 | 75 | – | 25 | 25 |
| Shoney RF and Bryan RS[illegible] | 1987 | Mix | 21 | 67 RA | 5.1 | 9 | 26–128 | 97 | – | 24 | 24 |
| Ferlic DC and Clayton ML[illegible] | 1990 | Mix Linked | 9 | 78 RA | 1.5 | 0 | 28–125 | 89 | 86 Good | 22 | 22 |
| Dunn CM et al.[illegible] | 1990 | Mix Custom Linked | 26 | 100 RA | 3 | 0 | – | 100 | – | 8 | – |
| Eng GJW et al.[illegible] | 1997 | Constrained III | 41 | 48 RA | 6 | 0 | 27–128 | 100 | 93 Good | 5 | 7 |

* "Good" relief is as described by the authors of each publication. Multiple methods of grading outcomes were used, which make meaningful comparisons between series impossible.
RA, rheumatoid arthritis.

***Table 102.5. Revision Arthroplasty Results***

### *Complications*

Infection may be more common with revision arthroplasty due to the prolonged operative times and the extent of surgical exposures. Intraoperative fractures frequently occur with component or cement removal. Cortical perforation of the humerus has resulted in injury to the radial nerve from cement removal devices and from cement leakage at the time of arthroplasty replacement. Nonunion of allografts has been a problem, particularly when they are placed in a subcutaneous location. Further experience with these grafts is required. Aseptic loosening and failure of the articulating bearings have been reported at longer term follow-up.

## ELBOW ARTHRODESIS

Arthrodesis of the elbow is a salvage procedure indicated to relieve pain and restore stability in situations for which other reconstructive techniques are contraindicated. A successful fusion generally provides good pain relief; however, the loss of motion significantly impairs the patient's functional abilities (60,67) and therefore even a successful arthrodesis renders only a fair outcome.

In the past, surgeons have recommended that the elbow be fused at 90° of flexion; however, because there is no truly good position for a stiff elbow, a trial of immobilization in different positions is recommended to allow the patient to participate in the decision. Generally, an arthrodesis at approximately 45° of flexion provides the best appearance and function for activities such as writing and bimanual tasks. This however, compromises the patient's potential for self-care. A 90° or 110° position allows the use of the arm for eating, but prevents many extrapersonal activities and care of the perineum.

### INDICATIONS

The best indication for elbow arthrodesis is posttraumatic unilateral arthritis of the elbow in a young, healthy, active patient. These are patients who are not candidates for or who will not tolerate the limitations imposed by an interposition or replacement arthroplasty. Patients with postinfectious arthritis, tuberculous arthritis, or chronic osteomyelitis may also be candidates for elbow arthrodesis. Arthrodesis is occasionally used as an option for patients with juvenile rheumatoid arthritis; however, interposition arthroplasty or total joint replacements are preferred because of the already impaired function of their adjacent joints. Elbow arthrodeses have been attempted following failed total elbow arthroplasty, but fusions in these circumstances are very difficult to achieve and fraught with complications.

### CONTRAINDICATIONS

Patients with limited motion in adjacent joints, such as the spine, shoulder, wrist, or hand, are poor candidates for elbow arthrodesis because they cannot compensate for the loss of elbow motion. Bilateral elbow disease is a relative contraindication.

### OPERATIVE TECHNIQUE

Numerous techniques have been described for elbow fusions including no internal fixation (1,4), limited internal fixation (2,35,42,70,71), plate fixation (49,81,82), external fixation (3), and combined internal and external fixation. Plate fixation is preferred in patients undergoing arthrodesis without active sepsis.

- Use a triceps-sparing posterior approach. Transfer of the ulnar nerve is usually required
- Apply a 10- to 12-hole dynamic compression plate with eight cortices of fixation above and below the elbow that is contoured to the posterior aspect of the distal humerus and proximal ulna. A tensioning device facilitates compression of the arthrodesis.
- Fashion the bone ends to maximize bone apposition and to fit the needs of the position selected for fusion. Use an autogenous iliac crest bone graft to promote fusion (Fig. 102.23).




***Figure 102.23.*** Elbow arthrodesis–plate fixation: **A:** Dynamic compression plate and tensioning device. **B:** Radiographic appearance of a successful arthrodesis. (From McAuliffe JA, Burkhalter WE, Ouellette EA, Carneiro RS. Compression Plate Arthrodesis of the Elbow. *J Bone Joint Surg* 1992;74:300, with permission.)

- When there is evidence of ongoing or recent infection, perform a staged radical debridement with the removal of all internal fixation from the elbow. Treat patients with active sepsis initially with an external fixator using a triangulated lateral half-frame to achieve stabilization of the elbow while allowing adequate debridement and soft-tissue coverage (Fig. 102.24). Following debridement, perform delayed cancellous bone grafting to assist in achieving union. External fixation can be used as a definitive technique to achieve arthrodesis or subsequently changed to internal fixation by means of a plate.

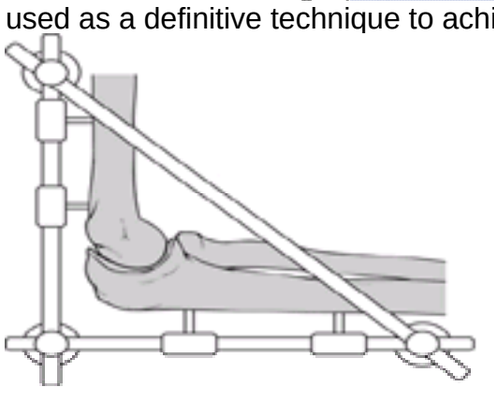

***Figure 102.24.*** Elbow arthrodesis–external fixation.

## REHABILITATION

Immobilize the elbow postoperatively until fusion occurs. Take care to ensure hand, wrist, and shoulder motion are preserved. It is important to maintain rotation of the forearm because the radius is not usually involved in the fusion except under exceptional circumstances.

## RESULTS

Good results have been reported by a number of surgeons, with the goal being successful fusion of the elbow (Table 102.6) (2,3,8,35,42,49,70,71,81,82). Functional outcome studies have yet to be reported on patients with elbow arthrodesis due to the current infrequency of this procedure. In the series by McAuliff et al. (49), successful fusion was achieved in all but one patient despite a lack of postoperative immobilization.

| Author | Year | Fixation | Number | Diagnosis | Mean follow-up (years) | Fusion Rate (%) | Pain* (%) | Infection (%) |
|---|---|---|---|---|---|---|---|---|
| Staples OS[2] | 1952 | Screws | 1 | OA | 2.8 | Second attempt 100 | 100 Good | 0 |
| Koch M and Lipscomb PR[3] | 1967 | Screws | 17 | 11 TB 4 OA | — | 47 | — | — |
| Spier W[8] | 1973 | Plate | — | — | — | — | — | — |
| Bonnel F[7] | 1974 | Ex-Fix | 1 | OA | 4.7 | 100 | 100 Good | — |
| Arafiles R[2] | 1981 | Screws | 11 | TB | — | 100 | — | — |
| Rashkoff E and Burkhalter WE[35] | 1986 | Plate | 4 | OA | 4 | 100 | 83 Good | 0 |
| Irvine GB and Gregg PJ[42] | 1989 | Screws | 3 | OA | — | 100 | — | — |
| McAuliffe JA | 1992 | Plate | 13 | OA | — | 93 | 93 Good | 7 |
| Pascal BP and Chilling RJ[71] | 1995 | Plate | 1 | Failed TEA | 1.4 | 100 | — | 0 |

* "Good" relief is as described by the authors of each publication. Multiple methods of grading outcomes were used which make meaningful comparisons between series impossible.
OA, osteoarthritis; TB, tuberculosis; TEA, total elbow arthroplasty.

***Table 102.6. Arthrodesis Results***

## COMPLICATIONS

Symptomatic nonunion has been reported in up to 50% of patients undergoing elbow arthrodesis. The current use of more reliable methods of internal fixation and autogenous cancellous bone has improved the frequency of fusion. Nonunions still occur. Careful debridement of dead and devitalized tissue, as well as control of infection, are critical to achieve union of an elbow fusion. Soft-tissue coverage is a concern with placement of posterior bulky hardware. Late fractures have been reported through a solid arthrodesis as well as adjacent to internal fixation from a stress riser effect. Avoid removal of internal fixation from an elbow fusion. However, if symptoms from hardware persist, waiting at least 18 months postoperatively will allow cortical remodeling and may decrease the likelihood of a fracture. Give appropriate protection to support the arm following hardware removal in these patients.

## CHAPTER REFERENCES

Each reference is categorized according to the following scheme: *, classic article; #, review article; !, basic research article; and +, clinical results/outcome study. (Note: For the references below, page number precedes volume number.).


* 1. Albee FH. Arthrodesis of the Elbow. *J Bone Joint Surg* 1933;15:979.

* 2. Arafiles RP. A New Technique of Fusion for Tuberculous Arthritis of the Elbow. *J Bone Joint Surg* 1981;1396:63A.

* 3. Bonnel F. Technique D'arthrodese du Coude par Fixateur Externe. *J Chir (Paris)* 1974;79:107.

* 4. Brittain HA. Arthrodesis of the Elbow. In: *Architectural Principles in Arthrodesis.* Edinburgh: E & S Livingstone, 1942:99.

* 5. Campbell WC. Arthroplasty of the Elbow. *Ann Surg* 1922;615:76.

* 6. Campbell WC. Mobilization of Joints with Bony Ankylosis: An Analysis of One Hundred and Ten Cases. *JAMA* 1934;976:83.

+ 7. Cobb TK, Morrey BF. Total Elbow Arthroplasty as Primary Treatment for Distal Humeral Fractures in Elderly Patients. *J Bone Joint Surg* 1997;826:79A.

! 8. Cohen MS, Hastings H. Post-traumatic Contracture of the Elbow. *J Bone Joint Surg* 1998;805:80B.

+ 9. Connor PM, Morrey BF. Total Elbow Arthroplasty in Patients Who Have Juvenile Rheumatoid Arthritis. *J Bone Joint Surg* 1998;678:89A.

+ 10. Davis RF, Weiland AJ, Hungerford DS, et al. Nonconstrained Total Elbow Arthroplasty. *Clin Orthop* 1982;156:171.

* 11. Dean GS, Holliger EH, Urbaniak JR. Elbow Allograft for Reconstruction of the Elbow with Massive Bone Loss. *Clin Orthop* 1997;12:341.

* 12. Dee R. Total Replacement of the Elbow Joint. *Orthop Clin North Am* 1973;415:4.

+ 13. Dee R. Reconstructive Surgery Following Total Elbow Endoprosthesis. *Clin Orthop* 1982;196:170.

+ 14. Dent CM, Hoy G, Stanley JK. Revision of Failed Total Elbow Arthroplasty. *J Bone Joint Surg* 1995;691:77-B.

! 15. Dowdy PA, Bain GI, King GJW, Patterson SD. The Midline Posterior Elbow Incision. *J Bone Joint Surg* 1995;696:77B.

+ 16. Ewald FC, Scheinberg RD, Poss R, et al. Capitellocondylar Total Elbow Arthroplasty. *J Bone Joint Surg* 1980;1259:62A.

* 17. Ewald FC, Simmons ED, Sullivan JA, et al. Capitellocondylar Total Elbow Replacement in Rheumatoid Arthritis. *J Bone Joint Surg* 1993;498:75A.

! 18. Faber KJ, Cordy ME, Milne AD, et al. Advanced Cement Technique Improves Fixation in Elbow Arthroplasty. *Clin Orthop* 1997;150:334.

+ 19. Ferlic DC, Clayton ML. Salvage of Failed Total Elbow Arthroplasty. *J Shoulder Elbow Surg* 1995;290:4.

+ 20. Figgie HE, Inglis AE, Mow C. Total Elbow Arthroplasty in the Face of Significant Bone Stock or Soft Tissue Losses. *J Arthroplasty* 1986;71:1.

+ 21. Figgie HE, Inglis AE, Ranawat CS, Rosenberg GM. Results of Total Elbow Arthroplasty as a Salvage Procedure for Failed Elbow Reconstructive Operations. *Clin Orthop* 1987;185:219.

+ 22. Figgie MP, Inglis AE, Mow CS, Figgie III HE. Salvage of Non-Union of Supracondylar Fracture of the Humerus by Total Elbow Arthroplasty. *J Bone Joint Surg* 1989;1058:74A.

+ 23. Figgie MP, Inglis AE, Mow CS, Figgie III HE. Total Elbow Arthroplasty for Complete Ankylosis of the Elbow. *J Bone Joint Surg* 1989;513:74A.

+ 24. Figgie MP, Inglis AE, Mow CS, et al. Results of Reconstruction for Failed Total Elbow Arthroplasty. *Clin Orthop* 1990;123:253.

+ 25. Foulkes GD, Mitsunaga MM. Allograft Salvage of Failed Total Elbow Arthroplasty. *Clin Orthop* 1983;113:296.

* 26. Garrett JC, Ewald FC, Thomas WH, Sledge CB. Loosening Associated with G.S.B. Hinge Total Elbow Replacement in Patients with Rheumatoid Arthritis. *Clin Orthop* 1977;170:127.

+ 27. Gill DRJ, Morrey BF. The Coonrad-Morrey Total Elbow Arthroplasty in Patients Who Have Rheumatoid Arthritis. A Ten to Fifteen-Year Follow-Up Study. *J Bone Joint Surg* 1998;1327:80-A.

+ 28. Gschwend N. The Case for a Linked Elbow Prosthesis. *Rheumatology* 1991;98:15.

+ 29. Gschwend N, Loehr J, Ivosevic-Radovanovic D, et al. Semiconstrained Elbow Prostheses with Special Reference to the GSB II Prosthesis. *Clin Orthop* 1988;104:232.

+ 30. Gschwend N, Simmen BR, Matejasky Z. Late Complications in Elbow Arthroplasty. *J Shoulder Elbow Surg* 1996;86:5.

+ 31. Hertel R, Pisan M, Lambert S, Ballmer F. Operative Management of the Stiff Elbow: Sequential Arthrolysis Based on a Transhumeral Approach. *J Shoulder Elbow Surg* 1997;82:6.

32. Hotchkiss R. *Compass Universal Hinge.* Smith & Nephew Richards, Memphis, TN, 1998.

+ 33. Hurri L, Pulkki T, Vainio K. Arthroplasty of the Elbow in Rheumatoid Arthritis. *Acta Chir Scand* 1964;127:459.

+ 34. Inglis AE, Inglis AE Jr, Figgie MM, Asnis L. Total Elbow Arthroplasty for Flail and Unstable Elbows. *J Shoulder Elbow Surg* 1997;29:6.

+ 35. Irvine GB, Gregg PJ. A Method of Elbow Arthrodesis: Brief Report. *J Bone Joint Surg* 1989;145:71B.

* 36. Johnson JR, Getty GJM, Lettin AWF, Glasgow MMS. The Stanmore Total Elbow Replacement for Rheumatoid Arthritis. *J Bone Joint Surg* 1984;732:66B.

* 37. Kashiwagi D. Intra-articular Changes of the Osteoarthritic Elbow. *J Jap Orthop Assoc* 1978;1367:52.

+ 38. King GJW, Adams RA, Morrey BF. Total Elbow Arthroplasty: Revision with Use of a Non-Custom Semiconstrained Prosthesis. *J Bone Joint Surg* 1997;394:79A.

! 39. King GJW, Glauser SJ, Westreich A, et al. In Vitro Stability of an Unconstrained Total Elbow Prosthesis. *J Arthroplasty* 1993;291:8.

! 40. King GJW, Itoi I, Niebur GL, et al. Motion and Laxity of the CapitellocondylarTotal Elbow Prosthesis. *J Bone Joint Surg* 1994;1000:76A.

* 41. Knight RA, Van Zandt IL. Arthroplasty of the Elbow. *J Bone Joint Surg* 1952;610:34-A.

+ 42. Koch M, Lipscomb PR. Arthrodesis of the Elbow. *Clin Orthop* 1967;151:50.

+ 43. Kraay MJ, Figgie MP, Inglish AE, et al. Primary Semiconstrained Total Elbow Arthroplasty. *J Bone Joint Surg* 1994;636:76B.

+ 44. Kudo H. Non-Constrained Elbow Arthroplasy for Mutilans Deformity in Rheumatoid Arthritis. *J Bone Joint Surg* 1988;234:80B.

+ 45. Kudo H, Iwano K. Total Elbow Arthroplasty with a Non-Constrained Surface-replacement Prosthesis in Patients Who Have Rheumatoid Arthritis: A Long-Term Follow-Up Study. *J Bone Joint Surg* 1990;355:72A.

* 46. Kudo H, Iwano K, Watanabe S. Total Replacement of the Rheumatoid Elbow with a Hingless Prosthesis. *J Bone Joint Surg* 1980;277:62A.

+ 47. Lowe IW, Miller AJ, Allum RI, Higginson DW. The Development of an Unconstrained Elbow Arthroplasty. *J Bone Joint Surg* 1984;343:66B.

+ 48. Lyall HA, Cohen B, Clatworthy M, Constant CR. Results of the Souter-Strathclyde Total Elbow Arthroplasty in Patients with Rheumatoid Arthritis. *J Arthroplasty* 1994;279:9.

+ 49. McAuliffe JA, Burkhalter WE, Ouellette EA, Carneiro RS. Compression Plate Arthrodesis of the Elbow. *J Bone Joint Surg* 1992;74:300.

* 50. MacAusland WR. Mobilization of the Elbow by Free Fascia Transplantation with Report of Thirty-One Cases. *Surg Gynecol Obstet* 1921;223:33.

+ 51. Madsen F, Seijbjerg JO, Sneppen O. Late Complications with the Pritchard Mark II Elbow Prosthesis. *J Shoulder Elbow Surg* 1994;17:3.

+ 52. Matarese W, Stuchin SA, Kummer FJ, Zuckerman JD. Polyethylene Bearing Component Failure and Dislocation in the Triaxial Elbow. *J Arthroplasty* 1990;365:5.

+ 53. Minami M, Ishii S. *Outerbridge-Kashiwagi Arthroplasty for Osteoarthritis of the Elbow Joint.* Amsterdam: Elsevier Science Publishers, 1985;189.

+ 54. Montgomery R, Stevenson T, Morrison G. Souter Strathclyde Total Elbow Replacement: A Long Term Follow-Up. *J Shoulder Elbow Surg* 1997;188:6.

+ 55. Morrey BF. Post-Traumatic Contracture of the Elbow. *J Bone Joint Surg* 1990;601:72A.

+ 56. Morrey BF. Primary Degenerative Arthritis of the Elbow: Treatment by Ulnohumeral Arthroplasty. *J Bone Joint Surg* 1992;409:74B.

+ 57. Morrey BF, Adams RA. Semiconstrained Arthroplasty for the Treatment of Rheumatoid Arthritis of the Elbow. *J Bone Joint Surg* 1992;479:74A.

+ 58. Morrey BF, Adams RA. Semiconstrained Elbow Replacement for Distal Humerus Nonunion. *J Bone Joint Surg* 1995;67:77B.

+ 59. Morrey BF, Adams, RA, Bryan RS. Total Replacement of Post-Traumatic Arthritis of the Elbow. *J Bone Joint Surg* 1991;607:73B.

* 60. Morrey BF, Askew LJ, An KN, Chao EY. A Biomechanical Study of Normal Functional Elbow Motion. *J Bone Joint Surg* 1981;872:63A.

+ 61. Morrey BF, Bryan RS. Complications of Total Elbow Arthroplasty. *Clin Orthop* 1982;204:170.

* 62. Morrey BF, Bryan RS. Infection after Total Elbow Arthroplasty. *J Bone Joint Surg* 1983;330:65A.

+ 63. Moorey BF, Bryan RS. Revision Total Elbow Arthroplasty. *J Bone Joint Surg* 1987;523;69-A.

* 64. Morrey BF, Bryan RS, Dobyns JH, Linscheid RL. Total Elbow Arthroplasty: A Five-year Experience at the Mayo Clinic. *J Bone Joint Surg* 1981;1050:63A.

! 65. O'Driscoll SW, An KN, Korinek S, Morrey BF. Kinematics of Semi-constrained Total Elbow Arthroplasty. *J Bone Joint Surg* 1992;297:74B.

+ 66. Oka Y, Ohta K, Saitoh I. Debridement Arthroplasty for Osteoarthritis for the Elbow. *Clin Orthop* 1998;127:351.

! 67. O'Neill OR, Morrey BF, Tanaka S, An KN. Compensatory Motion in the Upper Extremity After Elbow Arthrodesis. *Clin Orthop* 1992;89:281.

+ 68. Pierce TD, Herndon JH. The Triceps Preserving Approach to Total Elbow Arthroplasty. *Clin Orthop* 1998;144:354.

+ 69. Poll RG, Rozing PM. Use of the Souter-Strathclyde Total Elbow Prosthesis in Patients Who Have Rheumatoid Arthritis. *J Bone Joint Surg* 1991;1227:73A.

+ 70. Presnal BP, Chillag KJ. Radiohumeral Arthrodesis for Salvage of Failed Total Elbow Arthroplasty. *J Arthroplasty* 1995;699:10.

+ 71. Rashkoff E, Burhalter WE. Arthrodesis of the Salvage Elbow. *Orthopedics* 1986;733:9.

+ 72. Risung F. The Norway Elbow Replacement: Design, Technique and results after Nine Years. *J Bone Joint Surg* 1997;394:79B.

* 73. Roper BA, Tuke M, O'Riordan, Bulstrode CJ. A New Unconstrained Elbow. *J Bone Joint Surg* 1986;566:68B.

+ 74. Ruth JT, Wilde AH. Capitellocondylar Total Elbow Replacement. *J Bone Joint Surg* 1992;95:74A.

+ 75. Rydholm U, Tjornstrand B, Pettersson H, Lidgren L. Surface Replacement of the Elbow in Rheumatoid Arthritis. *J Bone Joint Surg* 1984;737:66B.

+ 76. Schemitsch EH, Ewald FC, Thornhill TS. Results of Total Elbow Arthroplasty after Excision of the Radial Head and Synovectomy in Patients Who Had Rheumatoid Arthritis. *J Bone Joint Surg* 1996;1541:78A.

+ 77. Schneeberger AG, Adams R, Morrey BF. Semicon- strained Total Elbow Replacement for the Treatment of Post-Traumatic Osteoarthritis. *J Bone Joint Surg* 1997;1211:79A.

+ 78. Shahriaree H, Sajadi K, Silver CM, Sheikholeslamzadeh S. Excisional Arthroplasty of the Elbow. *J Bone Joint Surg* 1979;923:61-A.

! 79. Sorbie C, Shiba R, Siu D, et al. The Development of a Surface Arthroplasty for the Elbow. *Clin Orthop* 1986;100:208.

+ 80. Souter WA. *Anatomical Trochlear Stirrup Arthroplasty of the Rheumatoid Elbow*. Amsterdam: Elsevier Science Publishers, 1985:305.

+ 81. Spier W. Beitrag zur Technik der Druckarthrodese des Ellenbogengelenks. *Mschr Unfallheilk* 1973;274:76.

* 82. Staples, OS. Arthrodesis of the Elbow Joint. *J Bone Joint Surg* 1952;207:34A.

+ 83. Stanley D. Prevalence and Etiology of Symptomatic Elbow Osteoarthritis. *J Shoulder Elbow Surg* 1994;386:3.

+ 84. Swanson AB, de Groot Swanson G, Masada K, et al. Constrained Total Elbow Arthroplasty. *J Arthroplasty* 1991;204:6.

+ 85. Trepman E, Vella M, Ewald FC. Radial Head Replacement in Capitellocondylar Total Elbow Arthroplasty: 2 to 6 year Follow-up Evaluation in Rheumatoid Arthritis. *J Arthroplasty* 1991;67:6.

+ 86. Tsuge K, Mizuseki T. Debridement Arthroplasty for Advanced Primary Osteoarthritis of the Elbow. *J Bone Joint Surg* 1994;641:76B.

+ 87. Weiland AJ, Weiss APC, Wills RP, Moore RJ. Capitellocondylar Total Elbow Replacement. *J Bone Joint Surg* 1989;217:71-A.

+ 88. Wolfe SW, Figgie MP, Inglis AE, et al. Management of Infection about Total Elbow Prostheses. *J Bone Joint Surg* 1990;198:72A.

+ 89. Yamaguchi K, Adams RA, Morrey BF. Infection after Total Elbow Arthroplasty. *J Bone Joint Surg* 1998;481:89A.

# CHAPTER 103

# FAILED SHOULDER ARTHROPLASTY: REVISION AND ARTHRODESIS

*Guido Marra, Ken Yamaguchi, Evan Flatow*

**G. Marra:** Loyola University Medical Center, Dept. of Orthopaedic Surgery, Maywood, IL, 60153.
**K. Yamaguchi:** Washington University, Dept. of Orthopaedic Surgery, St. Louis, MO, 63110.
**E. Flatow:** Mt. Sinai Hospital, Dept. of Orthopaedic Surgery, New York, New York, 10029.

A. Revision Shoulder Arthroplasty
Goals of Treatment
Evaluation
Indications and Treatment
Instability
Rotator Cuff Tear
Infection
Loosening
Results
Pitfalls and Complications
Neurologic Injury
Fracture
B. Shoulder Arthrodesis
Goals of Treatment
Indications
Paralysis
Infection
Failed Shoulder Arthroplasty
Glenohumeral Instability
Rotator Cuff Tear, Osteoarthritis, and Rheumatoid Arthritis
Reconstruction After Tumor Resection
Contraindications
Treatment Alternatives
Surgical Technique
Postoperative Care
Glenohumeral Arthrodesis in the Presence of Bone Loss
Results
Pitfalls and Complications
Humerus Fracture
Infection
Nonunion
Malposition
Authors' Perspective
Chapter References

## A. REVISION SHOULDER ARTHROPLASTY

The incidence of failure after shoulder arthroplasty is lower than other major joint reconstructions (48). However, when complications occur after shoulder arthroplasty, the resulting functional deficits can be profound, significantly limiting activities of daily living. Proper indications, surgical technique, and good postoperative rehabilitation of primary shoulder arthroplasty can avoid most complications; however, some are unavoidable. It is important to be aware of potential complications and to be prepared to address them as they arise.

## GOALS OF TREATMENT

When a patient presents with continuing symptoms after a shoulder replacement, carefully evaluate the potential factors that may be contributing to the failure, keeping in mind that the rotator cuff, capsule, and ligaments, although invisible on radiographs, are often more important than the position of the components. When contemplating revision surgery, you must have a reasonable idea of what you expect to accomplish at reoperation; exploratory procedures are less likely to succeed than is the correction of an identifiable problem.

## EVALUATION

When a patient presents with a prosthetic failure, a careful and methodical evaluation is essential to planning appropriate treatment (Table 103.1). Review all previous records, including the original preoperative radiographs, prior operative reports (including information about the make and size of the previous implants), and follow-up treatment and therapy records. Ask the patient specifically about recent dental work as well as about any episodes of fever, chills, redness, or drainage that might indicate infection. The therapy history is important both to assess whether the exercise regimen was appropriate and to gain a sense of the patient's reliability and compliance with aftercare: a revision to release scar will be of little help if the patient will not perform the postoperative range-of-motion exercises. Review all available postoperative radiographs, not just the most recent ones. Although different beam angles and technique can make comparison difficult, it is often possible to see increasing periprosthetic lucent lines or frank component migration, indicative of loosening.

| *Modality* | *Information sought* |
|---|---|
| All patients | |
| History | |
| Original preoperative x-rays | Initial bone loss/deformities |
| Operative notes | Technical problems |
| Postoperative course | Signs of infection (e.g., drainage) |
| Rehabilitation history | Assessment of patient compliance with therapy |
| Physical examination | Stiffness, active loss (e.g., rotator cuff, subscapularis, or deltoid) |
| Serial radiographs | Evaluation of component position, loosening, migration |
| ESR, CBC with differential | Signs of infection |
| Selected patients | |
| Aspiration | Bacteriologic diagnosis of infection |
| Bone scan/indium WBC scan | Loosening vs. infection |
| Arthrogram | Rotator cuff tears, loosening (dye tracks down interface) |
| EMG | Nerve lesions |
| MRI (special sequences) | Cuff and subscapularis loss |

ESR, erythrocyte sedimentation rate; CBC, complete blood count; WBC, white blood cell; EMG, electromyography; MRI, magnetic resonance imaging.

***Table 103.1. Evaluation of Failed Shoulder Arthroplasty***

On physical examination, assess the active and passive range of motion. Loss of passive motion may be an indication either that contractures were not adequately released at the first operation or that the postoperative exercise regimen failed to maintain motion. Increased external rotation combined with an active internal rotation lag (loss of terminal active internal rotation) suggests a loss of the subscapularis insertion. Loss of terminal active internal rotation is revealed by the lift-off test or the

stomach press sign. In the lift-off test (Fig. 103.1), the patient puts the hand of her affected arm on her lower lumbar spine and is asked to lift the dorsum of her hand off her spine. The test is positive if she is unable to lift her hand off her back, indicating compromise of the subscapularis tendon. Weakness of elevation and external rotation may suggest loss of the rotator cuff, but always consider a nerve or brachial plexus injury. Assessing elbow and hand motor function can be helpful in this differential. Investigate other sources of pain that may be referred to the shoulder, such as a cervical radiculopathy.

***Figure 103.1.*** The lift-off test can be used to evaluate the integrity of the subscapularis. From Gerber C, Farron A, Hersche O. Isolated Ruptures of the Subscapularis. *J Bone Joint Surg Am* 1997;78:1015, with permission.

Obtain carefully positioned radiographs, including an anteroposterior (AP) view in the plane of the scapula (ideally, both the glenoid and the humeral components should be shown in profile), an outlet lateral view, and an axillary view. Fluoroscopically positioned films can be used to achieve precise orientation (39). The humerus is seen in profile when the arm is externally rotated by an amount equal to the retroversion in which the humeral component was originally placed. The glenoid is generally best seen when a true AP of the scapula is taken: This gives the best imaging of the cement mantle and of lucent lines.

We generally obtain an erythrocyte sedimentation rate and a complete blood count with differential on all cases of failed arthroplasties. If these are normal, and there is no other indication of infection, then we do no further evaluation. If there is some suspicion, then joint aspiration followed by a bone and indium-labeled white blood count scans are performed. In some situations, a biopsy for culture and pathologic examination may be performed.

While early magnetic resonance imaging (MRI) and computed tomographic (CT) scans were unable to provide adequate images in the presence of a large metal implant, current techniques allow some information to be obtained. MRI scans with special sequences can show subscapularis avulsions and can demonstrate massive cuff deficiency and cuff muscle atrophy. Small tears at the supraspinatus insertion, however, are often obscured by implant artifact. CT arthrography with the use of digital subtraction software can provide useful information in cases of suspected glenoid loosening, and it allows an accurate evaluation of glenoid bone stock, especially in patients who have had a hemiarthroplasty.

Triple-phase bone scan, while not specific, is highly sensitive for loosening or infection and may be a useful adjunct test (13). An electromyogram may be helpful in ruling out nerve and plexus injuries and cervical radiculopathy.

## INDICATIONS AND TREATMENT

The source of problems may have been in the planning of the original replacement (improper indications for surgery or poor patient education), or they may have occurred during the surgery (technical errors), immediately after (e.g., improper aftercare), or years after (e.g., trauma or late loosening). Nevertheless, it is most useful to classify prosthetic failure by the mode of failure at the time the patient presents for treatment. The most common types of failure after shoulder arthroplasty are listed in Table 103.2

| |
|---|
| Instability |
| Stiffness |
| Rotator cuff tears |
| Infection |
| Component loosening |
| Nerve injury |
| Fracture |

***Table 103.2. Causes of Failure in Total Shoulder Arthroplasty***

### INSTABILITY

Successful prosthetic reconstruction of the shoulder joint requires accurate alignment of the prosthetic joint surfaces and careful balancing of the surrounding soft tissues. Instability following arthroplasty can result from failure to achieve one or both of these objectives and is best considered according to the direction of instability (Table 103.3).

| *Direction* | *Related factors* |
|---|---|
| Anterior | Subscapularis rupture<br>Increased humeral head anteversion<br>Increased glenoid anteversion |
| Posterior | Redundant posterior capsule<br>Increased glenoid retroversion<br>Increased humeral retroversion |
| Inferior | Improper humeral length |
| Superior | Rotator cuff tear<br>Coracoacromial arch incompetence<br>Improper humeral length |

***Table 103.3. Instability Patterns and Related Factors***

Rates of postoperative subluxation or dislocation following total shoulder replacement have been reported to be as high as 18.2% (18). There are some conflicting reports about the most common instability pattern seen after arthroplasty (5,18,72,73). A collective review of clinical series published before 1988 found that anterior instability occurred most frequently, followed by posterior and inferior instability (18). In contrast, Boyd et al. (5) reported a series of 127 shoulders and found that 23% of shoulders demonstrated superior migration. When approaching prosthetic instability, categorization according to the direction of subluxation is useful for developing

a rational approach to treatment.

***Anterior Instability***

The most frequent instability pattern following shoulder arthroplasty is anterior (Fig. 103.2). Determine whether the instability is acute, recurrent, or chronic. A dislocation in the early postoperative period may be caused by unprotected movement or trauma, not by a structural problem; closed reduction and motion within a protected range, avoiding extension and external rotation, may lead to a stable arthroplasty. Once chronic or recurrent instability is present, look for etiologies such as subscapularis rupture and component malposition.

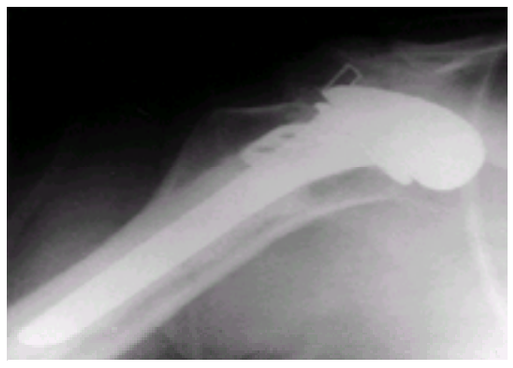

***Figure 103.2.*** Postoperative radiograph of a total shoulder replacement performed for osteoarthritis, demonstrating anterior dislocation. Closed reduction with protected range of motion provided a satisfactory outcome with no recurrence of instability.

Subscapularis deficiency after total shoulder replacement is more common than was previously recognized. Etiologies include inadequate surgical repair, use of a sharp-edged or an oversized humeral head, and an overly aggressive physical therapy program. Frank dislocations do not always result, but there is usually some element of static anterior subluxation, best appreciated on the axillary view.

Integrity of the subscapularis can be evaluated clinically using the lift-off test or the modified lift-off test (26,27). Careful evaluation of passive range of motion can reveal increased external rotation compared to that of the contralateral extremity. Take scapular AP and axillary radiographic views to assess prosthetic stability and version. In the case of chronic subscapularis rupture, static anterior subluxation may be observed on the axillary view. An MRI with digital subtraction software, or an arthrogram, is useful for assessing the integrity of the subscapularis. A CT arthrogram with digital subtraction can determine component version and stability.

Moeckel et al. (49) reported seven cases of subscapularis rupture following arthroplasty. All patients underwent repair, with rerupture occurring in three cases. These patients underwent reoperation using an Achilles tendon allograft as a static anterior restraint. Wirth and Rockwood (73) described pectoralis major transfer for subscapularis deficiency. This technique transfers the pectoralis major tendon over the conjoint tendon to the greater tuberosity. Recently, transfer of the pectoralis under the conjoint tendon has been described as a salvage procedure for chronic loss of the subscapularis (H. Resch, personal communication, 1998).

Glenoid anteversion or inadequate humeral retroversion may lead to increased anterior humeral head translation but rarely causes frank dislocation unless the mal-alignment is severe. However, if inadequate retroversion in combination with soft-tissue deficiencies is found, revision of the humeral component, and reconstruction of the anterior soft-tissue deficiencies must be considered (18,72,73). Wirth and Rockwood reported on 18 anterior instabilities in 1994 (72). Four shoulders were treated with closed reduction and immobilization and 14 underwent operative treatment. Clinical results were guarded regardless of treatment (72).

***Superior Instability***

Superior humeral migration following total shoulder arthroplasty is often seen in association with an attenuated or dysfunctional rotator cuff. When the dynamic stabilizing effect of the rotator cuff is lost, the humeral head migrates superiorly because of the unopposed pull of the deltoid. Component malposition, including humeral lengthening and an inferiorly placed glenoid component, is a less common cause of superior instability. Subtle superior subluxation of the humeral component is not always painful (5,73). However, eccentric superior loading of the glenoid component has been linked to glenoid loosening (25).

Symptomatic anterosuperior humeral migration is of greater concern. This can be especially severe if both cuff deficiency and loss of the passive stabilizing effect of the coracoacromial arch (resulting from surgical decompression) are present. Options for this difficult problem include attempts to reconstruct the cuff with direct repair or tendon transfers; revision of the humeral component to place it in increased retroversion, and/or to replace it with a wider head that is less able to escape between the remaining acromion and the coracoid; and coracoacro- mial arch reconstruction with fascia or bone grafts. However, little information exists to support the efficacy of any of these approaches, and early results have been disappointing (21).

***Inferior Instability***

Inferior instability following total shoulder arthroplasty is an infrequent complication and is most commonly seen in patients undergoing arthroplasty for acute fracture of the proximal humerus. In fracture cases, normal bony landmarks have been obliterated, making intraoperative determination of appropriate humeral length extremely difficult. Neer (53) emphasized the importance of maintaining proper tension on the myofascial sleeve of the shoulder. Preoperative templating using the contralateral extremity can be a useful method to determine prosthetic height. Intraoperatively, prosthetic height should allow for 50% inferior translation. If greater translation occurs, more humeral length is required. This may require the addition of bone graft to augment humeral shaft length. Inferior subluxation may also result from nerve injury with deltoid paralysis.

When recognized early, treat inferior subluxation by sling support to prevent permanent capsular stretching. When an axillary nerve injury is present, electrical stimulation may help to prevent atrophy of the deltoid. Inferior subluxation resulting from insufficient component height is difficult to correct with revision surgery, but it may be improved if the myofascial sleeve can be properly retensioned.

***Posterior Instability***

Posterior instability following total shoulder replacement usually presents as intermittent subluxation rather than as recurrent or chronic dislocation, and it is often related to technical problems at the initial procedure. Component malposition most commonly occurs on the glenoid side because erosion of the posterior glenoid is a common occurrence in osteoarthritis of the shoulder. When not recognized and corrected at the time of surgery, increased glenoid retroversion can result. Furthermore, this can be compounded by posterior capsular redundancy secondary to longstanding posterior humeral subluxation and inadequate release of anterior contractures, which then force the head posteriorly.

Early recognition of posterior subluxation before soft-tissue healing is complete may allow nonoperative treatment to be effective, especially when component malposition is not severe. Exercises can be modified to avoid flexion and internal rotation, and in severe cases a brace may be worn temporarily to keep the arm in slight extension and slight external rotation between exercise sessions. The patient may be told to perform activities with the palm up.

When malposition is severe, or if the posterior subluxation is longstanding, you may need to consider revision surgery. A malpositioned glenoid may require revision into a more appropriate angle. Revision of a modular humeral stem is not usually required unless it is also malpositioned. When there is no apparent glenoid retroversion, or if the soft tissues are also imbalanced, posterior capsulorrhaphy can be performed to eliminate redundancy. This may be performed from an anterior approach if component revision is also being performed. Place imbricating sutures in the posterior capsule. The imbrication may be side to side, or, if glenoid revision is being performed, suture anchors may be placed in the posterior glenoid and the sutures placed through the posterior capsule before implanting the new component. If no component malposition is present, a posterior approach may be used for the capsulorraphy.

**ROTATOR CUFF TEAR**

Rotator cuff rupture occurs in 2% of patients who have undergone total shoulder arthroplasty (18). Neer et al. (56) reported five rotator cuff tears in their 1982 review of 261 total shoulders. Two patients underwent surgical repair, two had no pain but were unable to raise their arms, and one patient had intermittent pain but refused

further surgical intervention. Cofield (14) reported five rotator cuff ruptures in his review of 77 unconstrained Neer prostheses. One patient suffered severe pain, had limited range of motion, and was considering further surgery. The remaining four patients had no pain but had functional weakness.

Rotator cuff tears that occur after total shoulder replacement for osteoarthritis with an initially intact cuff may present with pain and increasing weakness. Base the decision to repair the cuff on the degree of symptoms and functional compromise. If the humeral component was placed too proud, revise the humerus at the time of cuff repair, lest the compression against the acromion and the increased stress in the cuff tendon as it winds around the overly superior head lead to a retear. In such a situation, the cuff is most easily repaired while the prosthetic head is out.

### *Repair of Rotator Cuff Tear*

- In the absence of humeral malposition, you may approach tears involving the supraspinatus and/or infraspinatus tendons from a standard superior deltoid-splitting approach.
- Preserve the coracoacromial arch for stability, but shell out and remove any large acromial spurs.
- If the coracoacromial ligament must be detached to remove a spur, then reattach it with transosseous sutures to the acromion.
- Identify and mobilize the torn rotator cuff. Fixation to the tuberosity presents a unique challenge. Bone tunnels can sometimes be created for fixation despite the presence of a cemented humeral component. When severe osteopenia is present, you may achieve bone augmentation with commercially available plastic reinforcement devices (Cuff Link, Innovasive, Marlborough, MA) or with the use of small plates. Suture anchors can also facilitate repair.
- Repair the rotator cuff tissue with modified Mason-Allen stitches (28).
- Meticulous repair of the deltoid incision is essential.

Have the patient perform passive range-of-motion exercises postoperatively for 6 weeks, staying within the limits determined at surgery. Follow with a graduated stretching program. Delay resistive exercises until 3 months postoperatively (53).

## INFECTION

Infection complicates shoulder arthroplasty in less than 0.5% of cases (18). This rate is lower than those seen in replacement of the hip and knee, which range from 0% to 3%. This may be in part a result of the excellent soft-tissue coverage and abundant vascularity present in the shoulder. The hip and knee literature have identified rheumatoid arthritis, male sex, skin ulcers, diabetes, postoperative urinary tract infections, trauma, and revision arthroplasty as potential risk factors for the development of sepsis (23,69). Prosthetic replacement for shoulder trauma has higher rates of infection than that for arthritis, with rates ranging from 3.1% to 4.8% (13,18,72). This increase is likely because of the additional soft-tissue trauma, bone damage, and hematoma.

The presentations of aseptic loosening and late infection after total shoulder arthroplasty can be similar. Codd et al. (13) found no preoperative investigation to be a reliable indicator for active sepsis in an arthroplasty. They found a 20% false-negative rate for joint aspiration, a 40% false-negative rate for triple-phase bone scans, and a 13% false-negative rate for intraoperative cultures. Analysis of preoperative blood work showed that white blood cell counts were usually within normal limits, and in 13% the sedimentation rate was normal. (These problems occur in the hip and knee as well.) When infection is suspected in a patient with shoulder arthroplasty, a thorough evaluation is required. When in doubt, an open biopsy sent for pathologic evaluation and culture is the most reliable assessment tool.

Early reports recommended resection arthroplasty for infected shoulder replacements (15,53). In contrast, treatment options for infected total hips and knees in- clude irrigation and debridement, immediate exchange arthroplasty or staged reimplantation, and resection arthroplasty. The application of these principles to infected shoulder arthroplasties has been reported recently (13).

Because shoulder arthroplasty infection is uncommon, a treatment algorithm has yet to be defined. Given the poor functional results for activities performed at or above shoulder level with resection arthroplasty (15,52), reimplantation is the preferred treatment (Fig. 103.3).

***Figure 103.3.*** Treatment algorithm for infection following shoulder arthroplasty. ESR, erythrocyte sedimentation rate; CBC, complete blood count; NSAIDs, nonsteroidal anti-inflammatory drugs; WBC, white blood cell count; ROM, range of motion.

Codd et al. (13), in a series of 16 patients with septic shoulder arthroplasties, showed that reimplantation of another prosthesis after treatment of the deep infection is a reasonable option. These patients had no recurrence of infection at an average follow-up of 47 months. Base decisions about timing and whether to do another arthroplasty on the relative virulence of the organism, the chronicity of the infection, and the overall health of the patient. In rare cases of early infection (less than 6 weeks after surgery) by antibiotic-susceptible organisms, irrigation and debridement without component removal may be considered by inference from the hip literature; however, data for the shoulder are limited.

### *Technique for Infected Total Shoulder Replacement*

In preoperative planning, determine the make and size of the implant that is in place. Have the appropriate instrumentation for prosthetic extraction available, as well as flexible osteotomes, ultrasonic cement removal systems, and specialized cement removal instrumentation.

- Use an extended deltopectoral incision. Excise sinus tracts as part of the skin incision.
- Tissue planes are often obliterated by the infection. Employ caution throughout the procedure to protect the neurovascular structures.
- Release the upper 1 cm of the pectoralis major tendon if necessary to facilitate exposure.
- Identify the subscapularis, and localize the axillary nerve along the inferior margin of the muscle.
- Gently free the anterior surface of the subscapularis tendon from the posterior surface of the conjoined tendon. Take care to protect the musculocutaneous nerve. It lies an average of 66 mm from the tip of the coracoid, with a range of 31 to 82 mm (24).
- Release the subscapularis tendon from the proximal humerus. Identify and remove sutures used previously for subscapularis closure, because they may act as a nidus of infection.

### *Removal of Infected Shoulder Arthroplasty*

When a cemented arthroplasty is infected, both the prosthesis and cement mantle need to be removed entirely. Take great care in these cases, as the risk for humeral fracture is high. The loose, infected humeral stem and cement mantle can often be removed as one piece.

- If the cement mantle is well fixed, break it with thin, flexible osteotomes and extract the prosthesis.
- An ultrasonic cement removal system may be helpful to free the humeral stem and assist in clearing the canal of remaining cement. The use of intraoperative fluoroscopy and x-rays is of great assistance.
- Take multiple cultures from the prosthesis and canal, and send the interface tissue for pathologic analysis.
- Remove glenoid components: Cut the face of the glenoid components from the underlying pegs or keel with an osteotome. Then remove the peg or keel from the glenoid with curets and osteotomes. In the presence of an osteolytic glenoid, removal of the implant is best performed with the use of a high-speed burr to minimize the risk of fracture.
- Place an antibiotic-impregnated polymethylmethacrylate cement hemiarthroplasty spacer in the humeral canal (Fig. 103.4). Palacos (Smith & Nephew Richards,

Memphis, TN) is used because of its superior elution characteristics (20,34). The spacer provides local antibiotic delivery, eliminates dead space, and prevents contracture of the soft-tissue envelope about the shoulder.

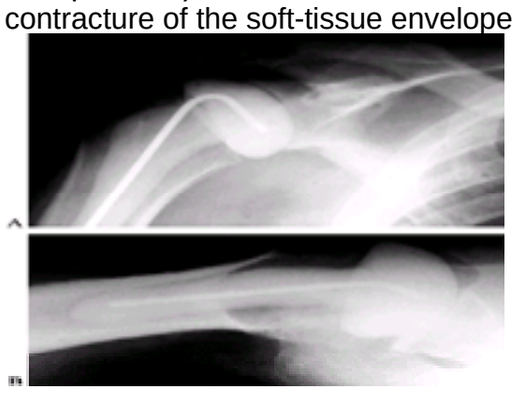

***Figure 103.4.*** Anteroposterior (**A**) and lateral (**B**) radiographs of an antibiotic spacer placed after removal of an infected prosthesis.

- Repair the subscapularis with nonabsorbable monofilament sutures, and close the deltopectoral interval over the suction drains. Leave drains in place for 48 hours.

**HINTS AND TRICKS**

When extracting a humeral stem, it is useful to attach the humeral stem inserter to the fixed prosthesis. The use of a slap-hammer attachment allows the extraction force to be transmitted along the long axis of the humeral stem. This substantially decreases the force required to remove the prosthesis.

- Place the patient on appropriate intravenous antibiotics.

Undertake revision arthroplasty after an appropriate course of antibiotics, usually at least 6 weeks. When the patient's functional demands are modest, when the organism is virulent or resistant to antibiotics, or when immunologic compromise is present, consider simple removal of the cement spacer and a resection arthroplasty.

**LOOSENING**

The increased frequency of arthroplasty in the treatment of arthritic shoulder conditions, and the increased functional demands of patients with shoulder implants have led to concern over implant loosening. Aseptic loosening in hip and knee prostheses is well documented and is thought to be induced by wear particles that stimulate giant cell–mediated bone resorption (31,35,36,38,57,67). A recent study characterized the particulate debris generated in the total shoulder arthroplasty when radiographic evidence of osteolysis was present. The particles were larger and more varied in shape than those in total hip arthroplasties that required revision (70). No information is currently available regarding the immune response generated by particles of this size.

Clinical series of shoulder implants have demonstrated few revisions for symptomatic component loosening, particularly on the humeral side. Indeed, aseptic loosening of cemented humeral components is extremely rare. In their 1982 series, Neer et al. (56) reported only two patients with such loosening among 94 total shoulders with radiographic evidence of humeral loosening. Although both were symptomatic, neither underwent revision arthroplasty. Information regarding press-fit humeral stems is more varied, but the rate of loosening would appear to be, if anything, higher than that of cemented stems. Cofield (16) reported that less than 1% of cemented humeral stems demonstrated radiographic evidence of loosening, compared to 12% of uncemented stems. Several stems with textured surfaces have been introduced to facilitate bone adherence to the prosthesis, but long-term follow-up is lacking (16,22,47). A new problem introduced by these designs is the difficulty of removing a malaligned or infected ingrowth stem that is not loose.

Most concerns for long-term loosening have centered on the glenoid component. Lucent lines about the glenoid component have been reported in 30% to 83% of cases (18,53), with progression occurring in 12% to 16% of cases. The clinical significance of these radiolucent zones is unclear. Several authors have attributed glenoid lucencies to technical errors occurring at the time of glenoid placement (7,12,63,64). Neer (53) believed that radiolucencies about a glenoid component could be caused by a number of factors, including inconsistent radiographic technique, variable density and strength of glenoid bone stock, stress shielding caused by the glenoid component, and disuse osteoporosis. Both Neer (53) and Brems (7) reported higher incidences of radiolucent lines in cases performed earlier in their series, and that it might be related to inexperience with the technique in earlier cases. Clear radiographic evidence of humeral loosening is pres- ent when a completely circumferential radiolucent line of greater than 1 mm width is seen to progress at the bone–cement/prosthesis interface, or when the prosthesis changes position on serial plain radiographs.

Revision for symptomatic glenoid loosening (Fig. 103.5) remains uncommon (2.8%) (7). In a series of 70 total shoulder replacements followed for 5–11 years, complete lucent lines of 1.5 mm or more were found in one third of the glenoid components, but only three components required revision (32). However, unlike the situation with a lower extremity, the use of one arm may be decreased by compensating with the other arm; thus, the rate of revision may underestimate the true rate of component loosening.

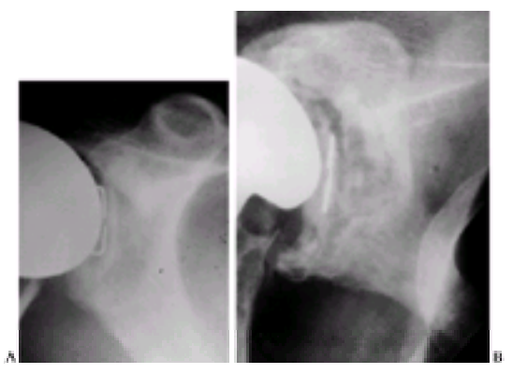

***Figure 103.5.*** **A:** One-year follow-up radiograph of a total shoulder replacement performed for osteoarthritis. **B:** At the 15-year follow-up, progressive lucency is seen around the glenoid.

***Surgical Revision for Loose Implants***

Surgical revision for loose implants requires careful preoperative planning. Special instrumentation is often required, including high-speed motorized burrs, thin flexible osteotomes, and ultrasonic cement removal systems. Have a full complement of prostheses available, including long and short stems. Use prior operative notes to identify the size and make of the failed implant. Have full instrumentation for both insertion and removal available for the system, as well as multiple humeral head sizes. Even if you prefer a different system (which may be employed if all prior components are removed), situations may arise in which the prior system is useful (e.g., if the stem is well fixed but the modular head needs to be resized). Careful preparation will give you greater flexibility during the operation. Hold preoperative antibiotics until intraoperative cultures have been obtained.

- In making a long deltopectoral approach, incorporate the prior incision when possible. The coracoid serves as an important landmark.
- Open the deltopectoral interval, and release the upper 1 cm of the pectoralis tendon to facilitate exposure.
- Identify the underlying subscapularis tendon, and localize the axillary nerve along its inferior margin.
- Release the subscapularis from the proximal humerus, preserving as much tendon length as possible.
- Examine the humeral component for malposition.
- When the stem is loose, it can be removed from the shaft with little damage to the humerus. Removal of a porous-coated stem can be extremely difficult, especially if the textured coating extends to the distal stem. Begin removal with bone and/or cement removal at the stem. This can be done with small curved

curets and thin osteotomes.

- Place an extraction device, and pull it in line with the stem. Use instruments specifically designed for this, to minimize the force required for extraction.
- If attempts at removal fail, it may be necessary to cut a longitudinal slot anteriorly in the humeral shaft, one third of its circumference in width and three quarters of the stem's length long, giving it a laterally based soft-tissue hinge, to extract the stem (Fig. 103.6). In a standard-length prosthesis, this lies well above the spiral groove, minimizing risk to the radial nerve.

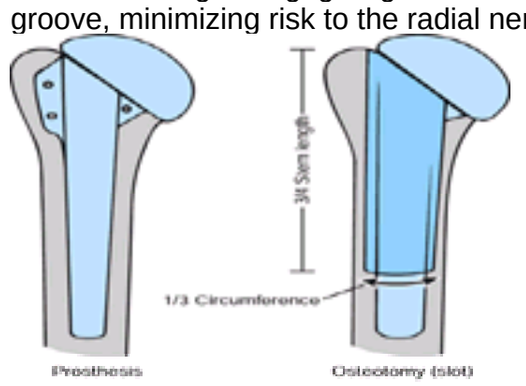


***Figure 103.6.*** Osteotomy used to extract a well-fixed prosthesis.

- With the stem removed, take cultures and frozen sections from the bone–implant interface. If more than 10 polymorphonuclear cells are seen per high-power field, place an antibiotic spacer until final cultures and pathology are obtained. If there is no evidence of infection, remove the antibiotic spacer and implant final components in a second operation. If a modular humeral component does not need to be revised but glenoid work is indicated, remove the head and leave the stem in place. Protect it from damage.
- Retract the humerus posteriorly to visualize the glenoid.
- If a humeral head component is being converted to a total shoulder replacement because of glenoid wear and pain, perform a glenoid resurfacing at this time.
- If revision of a glenoid component is required, clear the soft tissue from the rim of the component. If the component is loose, it can be removed easily. If the face of the glenoid component is well fixed but worn or malpositioned, it can be cut from the underlying pegs or keel with a sharp, curved osteotome. The keel or pegs can be extracted from the glenoid with a high-speed burr or curved osteotomes.
- Remove the cement, and obtain cultures and frozen section.

Consider glenoid reimplantation when the remaining glenoid bone stock is sufficient for implant support and the cuff muscles are intact or repairable (53,54 and 55). Otherwise, removal of the glenoid component with conversion to a hemiarthroplasty is preferred. Both approaches may yield good results. Although glenoid bone deficiency can be bone grafted (55), this is rarely performed. Central defects can be treated with impacted particulate graft with cement fixation of the glenoid component, or as a staged grafting procedure. In staged grafting, the defect is packed with cancellous allograft and a hemiarthroplasty is performed. When graft consolidation occurs, a glenoid is implanted at a later date, usually 6 weeks to 3 months. Rim defects can be treated with corticocancellous bone graft fixed with screws. When screw fixation is not feasible, secure the graft with heavy absorbable sutures.

- Place a humeral trial component to determine implant stability and motion. Take care to properly size the components; this is critical for implant stability and postoperative motion.
- Place heavy nonabsorbable sutures around the lesser tuberosity and humeral neck for repair of the subscapularis, then implant the humeral stem with antibiotic-impregnated cement.
- In cases where humeral slotting was necessary to remove the implant, close the osteotomy and secure it with cerclage wires or cables. Maintain complete visualization of the osteotomy during cementation, as extravasation of cement can occur, which may lead to thermal injury of the radial nerve.

## RESULTS

The results of revision shoulder arthroplasty depend on the preoperative condition of the surrounding soft tissues. Neer and Kirby (54) found that, although pain relief is often possible when specific causes are found, functional recovery is limited. Results of published series are listed in Table 103.4.

| *Name* | *Type of Failure* | *Number of Patients* | *Motion (Elev/ER)* | *Pain Relief (%)* |
|---|---|---|---|---|
| Mondel et al. (49) | Instability | 7 | 83/5 | NS |
| Neer and Kirby (54) | Mixed | 34 | NS | 85 |
| Boyd et al. (5) | Instability | 29 | 104/32 | 86 |
| Boyd et al. (6) | Fracture | 7 | 78/33 | 57 |
| Caldwell et al. (8) | Mixed | 13 | NS | 62 |
| Wirth and Rockwood (71) | Mixed | 25 | NS | 76 |
| Wright and Cofield (74) | Fracture | 9 | 80/31 | 78 |
| Codd et al. (13) | Infection | 16 | NS | 100 |
| Lynch et al. (42) | Neurologic | 16 | NS | 93 |

NS, not stated. *Elev*, Elevation; *ER*, External Rotation.

***Table 103.4. Results of Revision of Failed Shoulder Arthroplasty***

## PITFALLS AND COMPLICATIONS

### NEUROLOGIC INJURY

Neurologic injury after total shoulder replacement is, fortunately, a rare occurrence. The rates of injury are much lower than the 0% to 3% reported for total hips and knees. The cause of nerve injury is most often traction or compression, but accidental transection is possible. Injuries to the axillary, musculocutaneous, ulnar, and radial nerves have been reported (18,42,72,73). Most injuries are neuropraxias that resolved with time. Lynch et al. (42) reviewed 417 patients undergoing total shoulder ar- throplasty and found that 18% of shoulders had a neu- rologic deficit after surgery. Most of those deficits involved the upper and middle trunks of the brachial plexus. Of the 18 shoulders affected, four had lesions that interfered with their rehabilitation. This series identified the long deltopectoral approach, use of methylmethacrylate, and shorter operative times as risk factors for injury.

Patients undergoing total shoulder arthroplasty should have a careful neurologic evaluation postoperatively. If a deficit is identified, institute physical and occupational therapy to maintain joint mobility. When indicated, provide support with splints. If there is no clinical evidence of neurologic recovery in 4–6 weeks, obtain electromyography and nerve conduction studies to document the extent and type of injury and to provide a baseline for monitoring improvement in nerve function. If no improvement is seen in 3 months, consider exploration of the nerve for neurolysis or nerve grafting.

### FRACTURE

Fracture following prosthetic shoulder replacement is rare, occurring in 1.6% to 1.8% of patients (6,74). Boyd et al. reported seven patients with humeral shaft fracture following shoulder arthroplasty. Two were treated nonoperatively: One developed a painful nonunion but refused surgical intervention, and the other attained union but required revision for a loose glenoid component. Five patients underwent operative intervention when conservative treatment failed after an average of 8 weeks of treatment. Two of those patients developed radial nerve palsies following the fracture, which prompted early surgical exploration. All fractures united.

Wright and Cofield (74) classified periprosthetic fractures according to their morphology:

- Type A: The fracture is centered at the tip of the prosthesis and extends proximally for one third the length of the stem.

- Type B: The fracture is centered at the tip of the prosthesis with slight proximal extension.
- Type C: The fracture is distal to the tip of the stem.

Fractures that fell into category C behaved like closed humerus fractures, and those in categories A and B had a greater risk of nonunion. The authors recommended surgical treatment for type A fractures, operative treatment for type B fractures when satisfactory alignment could not be achieved with closed means or if no evidence of union was present by 3 months, and nonoperative management for type C fractures. Groh et al. (30) reported on four postoperative fractures that occurred an average of 14 months after arthroplasty. They were treated with a fracture brace and early range-of-motion exercises. At an average of 9 weeks, all fractures had united.

Given the paucity of data, it is difficult to establish reliable rules for the treatment of these fractures. We prefer conservative treatment with immobilization in a functional brace if the fracture is well aligned and has a long oblique pattern with a stable stem. However, if the fracture is unstable or the humeral stem loose, we recommend open reduction and internal fixation.

***Fixation of a Periprosthetic Fracture***

- Use Henry's extensile anterolateral exposure (see Chapter 1). Make a longitudinal incision along the lateral aspect of the arm to expose the biceps tendon.
- Retract the biceps medially to reveal the brachialis muscle. Avoid injury to the musculocutaneous nerve. Identify and protect the radial nerve if it is in the region of the fracture.
- Split the brachialis fibers longitudinally to expose the humeral shaft. Visualize the entire fracture.
- You must evaluate the humeral stem intraoperatively, either with imaging or by direct examination. If the stem is stable and well fixed, reduce the fracture and stabilize it with a large plate, using screws and cables to fix it to the bone depending on its location and configuration.
- Autologous bone graft is recommended to increase the chances for union (4).
- When the humeral stem is loose, perform revision shoulder arthroplasty with a long-stem humeral component.
- Reduce the fracture, and fix it with cerclage cables or wires before the final implantation of the prosthesis stem.

**B. SHOULDER ARTHRODESIS**

In an age of progressive improvements in shoulder ar- throplasty and other reconstructive procedures, the indications for shoulder arthrodesis have become limited. However, glenohumeral arthrodesis remains an important and valuable treatment option for restoring useful function in situations where arthroplasty either has failed or is not indicated. Whereas the optimal results seen with glenohumeral arthrodesis do not compare with those seen with conventional arthroplasty, it should be noted that when arthrodesis is indicated, significant and meaningful improvement in quality of life can be obtained. Although arthrodesis is performed uncommonly, numerous reports show that a functional fusion can be obtained reliably with an acceptable complication rate (2,17,33,40,51,59,60,61 and 62,65).

## GOALS OF TREATMENT

The specific goal of glenohumeral arthrodesis is to obtain a solid bony fusion between the proximal humerus and the scapula that alleviates pain and allows function through scapulothoracic motion (Fig. 103.7).

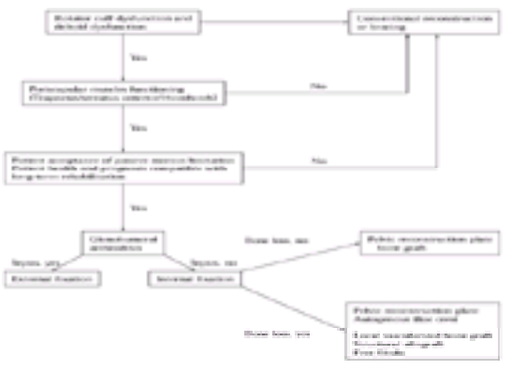

***Figure 103.7.*** Algorithm for indications and type of shoulder arthrodesis for failed shoulder arthroplasty.

## INDICATIONS

The indications for glenohumeral arthrodesis are listed in Table 103.5. Glenohumeral arthrodesis is a reliable means of obtaining shoulder stability and function sufficient for most activities of daily living in patients in whom this would not otherwise be attainable (33,59). Shoulder stability may come with significant loss of motion because all glenohumeral rotation is lost. In some patients who do not have much glenohumeral motion, the additional loss of motion is negligible. Shoulder arthroplasty is preferred when the final outcome provides stability and good pain control.

| |
|---|
| General (minimal requirements) |
| Pain and/or dysfunction of shoulder |
| Loss of both rotator cuff and deltoid function |
| No alternative reconstructive option |
| Strong periscapular musculature |
| Trapezius, serratus anterior, rhomboids functioning |
| Specific |
| Paralytic shoulders |
| Brachial plexus injury |
| Anterior poliomyelitis |
| Combined supraclavicular and axillary nerve injuries |
| Septic arthritis |
| Failed arthroplasty |
| Tumor reconstruction |
| Rare |
| Glenohumeral instability |
| Osteoarthritis |
| Rheumatoid arthritis |
| Complete rotator cuff tear |

***Table 103.5. Indications for Shoulder Arthrodesis***

Surprising function can be obtained after a glenohumeral arthrodesis because of scapulothoracic motion. The procedure reliably controls pain originating in the glenohumeral joint. Counsel patients carefully about the advantages and disadvantages of glenohumeral arthrodesis. Either arthrodesis or arthroplasty is generally hard to reverse. Glenohumeral fusion after a failed arthroplasty, and arthroplasty after takedown of an established glenohumeral fusion are both technically challenging surgical procedures with compromised results.

A general minimum requirement for the performance of a glenohumeral arthrodesis is sufficient strength of the axial and scapular musculature to maintain stability of the scapula. This includes adequate trapezial function. The patient should be in sufficiently good health to withstand major surgery. Additionally, because postoperative recovery (including strengthening of periscapular musculature) can be prolonged, glenohumeral arthrodesis requires a mature patient with long-term goals. This is particularly relevant in patients needing reconstruction after tumor resection.

**PARALYSIS**

Arthrodesis is generally the treatment of choice for a flail shoulder. Paralytic shoulder secondary to anterior poliomyelitis, upper-trunk brachial plexus lesions, and axillary nerve palsy in the presence of a nonfunctional rotator cuff are indications for arthrodesis. The flail shoulder is a particularly strong indication for an arthrodesis when good elbow and hand function and strong periscapular musculature are present (44,45,59,61,65). In addition to limited function, patients with flail shoulders may

have significant pain associated with inferior luxation of the humeral head.

A flail elbow or hand ipsilateral to a flail shoulder is not necessarily a contraindication to glenohumeral arthrodesis. A concurrent procedure to restore elbow flexion can be performed, either staged or simultaneously. Indeed, an arthrodesis can significantly improve the results of an elbow flexorplasty by stabilizing the arm in reference to the axial skeleton and by placing the arm in a more flexed position. For the completely flail upper extremity, a shoulder arthrodesis can be performed with an elbow flexorplasty, to improve quality of life, even with a dysfunctional hand (59,61,75) (see Chapter 59, Chapter 60 and Chapter 178).

Axillary nerve palsy as an indication for shoulder arthrodesis is controversial. Most agree that deltoid dysfunction alone is not a sufficient indication—rotator cuff dysfunction is generally required in addition. The restoration of rotator cuff and/or deltoid function with muscle transfers is difficult and generally requires multiple surgeries.

Before considering an arthrodesis, consult a hand and upper extremity surgeon; for example, in the case of an axillary nerve laceration, cable grafting can give surprisingly reliable functional return. Other nerve grafting and muscle transfer procedures are available that may make shoulder fusion unnecessary (see Chapter 59, Chapter 60 and Chapter 178).

### INFECTION

Septic arthritis was historically the primary indication for glenohumeral arthrodesis (58,68). While it remains an important indication, arthroplasty has become more accepted. The surrounding musculature is often preserved and functional despite prior sepsis, making it amenable to prosthetic reconstruction (13). Thus, if the septic arthritis can be eradicated, an arthroplasty is preferred.

### FAILED SHOULDER ARTHROPLASTY

Failed prosthetic arthroplasty is a rare but accepted indication for arthrodesis when seen in conjunction with loss of both deltoid and rotator cuff functions. When function of the deltoid and/or rotator cuff muscles is preserved, a revision arthroplasty is preferred. Anterior superior instability, however, may best be treated with arthrodesis. In these people, the rotator cuff as well as the anterior deltoid is usually dysfunctional. Incompetence of the coracoacromial arch can result in migration of the prosthesis anteriorly and superiorly into a subdeltoid, almost subcutaneous, location. In addition to significant dysfunction, these patients often have severe pain. Because periscapular musculature is still intact, a successful arthrodesis could alleviate the problem and provide significant functional gains. However, arthrodesis after failed shoulder arthroplasty is difficult because of the loss of proximal humeral bone, in particular the head of the humerus.

### GLENOHUMERAL INSTABILITY

Failed reconstructive procedures for instability have been an indication for glenohumeral fusion. More recently, arthrodesis does not appear to be a good alternative for failed shoulder instability reconstructions. Outcome data suggest that many people who obtain arthrodesis in this situation continue to be unhappy, persistently perceiving instability in the glenohumeral joint despite a radiographic fusion (59). Additionally, pain from the glenohumeral joint is often persistent despite any obvious objective reasons. Before exploring arthrodesis as a surgical alternative, exhaust every other treatment option. Assess the patient's psychological makeup carefully.

### ROTATOR CUFF TEAR, OSTEOARTHRITIS, AND RHEUMATOID ARTHRITIS

For shoulder dysfunction and pain secondary to rotator cuff tear, osteoarthritis, or rheumatoid arthritis, advances in conventional reconstructive procedures have made glenohumeral arthrodesis relatively contraindicated. The deciding factor in each of these three clinical scenarios is the function of the rotator cuff and deltoid. Loss of these two important muscle groups makes arthrodesis the best choice in most patients.

### RECONSTRUCTION AFTER TUMOR RESECTION

Glenohumeral arthrodesis is often the procedure of choice following removal of periarticular shoulder tumors when the proximal humerus can be preserved. Because the rotator cuff and the deltoid are often removed as part of the resection, stability is difficult to achieve without arthrodesis. After aggressive bone resection, vascularized bone graft or allograft reconstruction may be necessary to achieve an arthrodesis (11,41,43).

**HINTS AND TRICKS**

In patients in whom a glenohumeral arthrodesis is likely to be performed, do not use the trapezius for a muscle transfer, because this is an extremely important muscle for function and pain relief following arthrodesis.

## CONTRAINDICATIONS

Do not do a glenohumeral arthrodesis if a reasonable method of shoulder reconstruction is available. In general, if the rotator cuff or deltoid still functions, then a total shoulder or hemiarthroplasty can be performed. Additionally, do not do a glenohumeral arthrodesis in the presence of a flail scapula. In patients who have partial periscapular function, lost trapezius function is a contraindication to arthrodesis.

Because glenohumeral arthrodesis requires a prolonged recovery to achieve bone healing as well as periscapular strengthening, it is relatively contraindicated in people who cannot tolerate prolonged rehabilitation, those who have limited life spans, and those in whom bone healing would be a problem. For this reason, shoulder arthrodesis is generally contraindicated in patients who are physiologically over the age of 70 years.

## TREATMENT ALTERNATIVES

Glenohumeral arthrodesis can be performed either extra-articularly or intra-articularly, or with both methods, using external or internal fixation. Extra-articular arthrodesis is not used often now and was primarily indicated in patients with tuberculous arthritis in whom there were concerns about disseminating an intra-articular infection (29,58,68).

Intra-articular arthrodesis can be achieved with external and/or internal fixation. External fixation is now rarely indicated because of the superiority of internal fixation. It is indicated in patients with an active infection of the shoulder. Fixation can be achieved by using half-pins in the clavicle, acromion, scapular spine, and glenoid neck (37,40,51).

Internal fixation is the preferred method for achieving glenohumeral arthrodesis. Its advantages are rigid fixation, better maintenance of arthrodesis position, and decreased length of time in plaster or orthotic immobilization. The postoperative care is easier.

## SURGICAL TECHNIQUE

The operative technique we prefer for glenohumeral arthrodesis with internal fixation is that of Richards et al. (59,60 and 61).

- Place the patient in an upright beach-chair position with the entire arm, including the scapula, draped free. Place a bump along the medial border of the scapula to position the scapula laterally.
- Make an extensile deltopectoral incision that extends vertically from the spine of the scapula 2–3 cm medial to the acromioclavicular joint and then down a line from the coracoid process toward the deltoid insertion (Fig. 103.8*A*) (see Chapter 1). This avoids placing the incision directly over the plate. In patients with paralytic shoulders and complete atrophy of the deltoid, soft-tissue coverage of the plate is a concern.

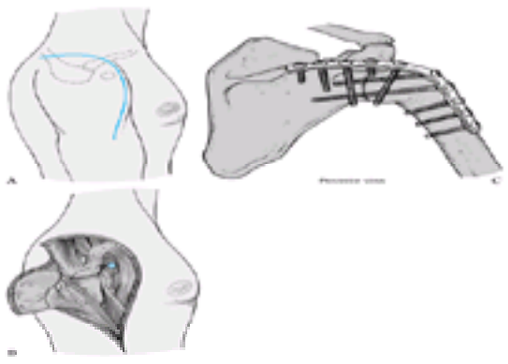

***Figure 103.8.*** **A:** Incision for an extended deltopectoral approach for the shoulder arthrodesis. **B:** Reflect the deltoid off the lateral clavicle and acromion as needed for exposure. Release of a portion of the insertion into the humerus is helpful. **C:** Ten-hole 4.5 mm AO reconstruction plate contoured along the spine of the scapula over the acromion and onto the humerus, and fixed with multiple lag screws.

- Develop a subcutaneous lateral flap at the level of the deep fascia.
- Identify the deltopectoral interval, and remove the deltoid from the anterolateral clavicle as well as the anterior and lateral acromion. If distal extension is necessary, also release the anterior two thirds of the deltoid insertion. In comparison to a muscle-splitting approach, releasing the deltoid from the anterior and posterior maintains it for coverage of the plate and spares the axillary nerve, avoiding a possible neuroma (Fig. 103.8*B*).
- Release the anterior and superior rotator cuff directly off its humeral attachment, and retract it medially. Do not excise it. Maintaining the rotator cuff musculature for later repair can help contain bone graft.
- Dislocate the humeral head anterolaterally to expose the glenoid.
- Place a posterior glenoid retractor, and decorticate the glenoid. A standard glenoid reamer from a total shoulder set is helpful for concentric decortication of the glenoid.
- Decorticate the humeral head using large curets and a rasp. Maintain the semicircular contour of the proximal humerus to provide a congruent surface area for fixation against the glenoid.
- For fixation, we do not generally recommend superior translation of the humeral head against the undersurface of the acromion. Rather, center the humeral head on the glenoid. This provides a large concentric area of contact, and the glenoid vault is an important area for obtaining screw purchase for fixation and compression of the humeral head against the scapula.
- Apply iliac crest bone graft to bridge the gap between the humeral head and the acromion.
- Alternatively, Richards et al. (61) reported a technique in which the humeral head is translated superiorly for bony abutment against both the undersurface of the acromion and the glenoid. Using this method, bone grafting was not necessary to achieve fusion in most cases. This technique is preferred by many.
- Position the arm for fusion, using an arm holder. Our preferred position is at 20° of abduction, 20° to 30° of forward flexion, and 40° of internal rotation (Fig. 103.9).

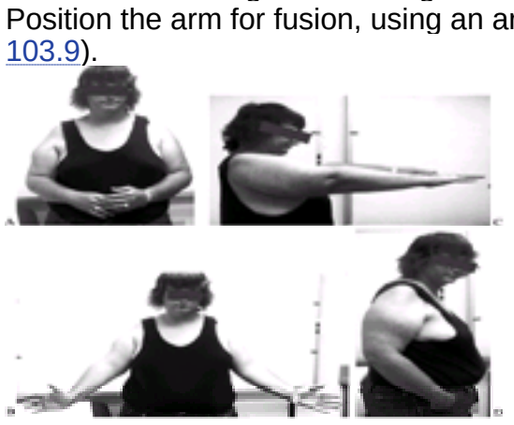

***Figure 103.9.*** **A–D:** Clinical photographs of a patient's arm fused in 20° of abduction, 30° of forward elevation, and 40° of internal rotation. The patient is able to achieve sufficient motion for activities of daily living.

The position for arthrodesis has been controversial. Early recommendations from the American Orthopaedic Association established criteria of 45° to 50° of abduction, 15° to 25° of forward flexion, and 25° to 30° of internal rotation (1). Additionally, the method for measuring the position of fixation has varied. Early recommendations used the medial border of the scapula in reference to the long axis of the humerus. Now most surgeons use the side of the body as the reference point and place the arm at 20° to 30° abduction from the side of the patient.

Early recommendations for arthrodesis positioning have been modified. Rowe (66) observed that the previous recommendation of 45° to 50° for abduction was excessive. This position could result in uncomfortable scapular winging when the arm was resting at the side. He noted that shoulder flexion and internal rotation were important for activities of daily living, and some abduction was required to provide clearance for axillary hygiene. Richards et al. (59) noted that the optimum position of glenohumeral arthrodesis is one that allows the hand to be raised in the midline with elbow flexion so that the mouth can be reached. Abduction should not exceed that which allows the arm to rest comfortably at the side. To make it easy, Richards recommends placing the hand on the face and setting the shoulder at 30° of abduction, 30° of forward flexion, and 30° of internal rotation.

## HINTS AND TRICKS

- It is important to note that regardless of the position of fusion, the arm will rest at the side a significant amount of the time. Thus, a significant amount of scapular winging would occur if the arm were fused in too much abduction, causing chronic pain due to excessive tension on the trapezius (Fig. 103.10).

***Figure 103.10.*** The ideal position for arthrodesis is in less than 30° of abduction. **A:** The shoulder is fused in excessive abduction. **B:** When the arm rests at the side, excessive tension occurs in the upper trapezius which can cause chronic pain.

- Once the position of fusion is established, fix the proximal humerus to the glenoid with two 6.5 mm, partially threaded cancellous screws with washers, either independently or through a precontoured plate.
- Next, contour a 10- to 14-hole, 4.5 mm pelvic reconstruction plate to fit over the spine of the scapula across the acromion and down the lateral side of the proximal humeral shaft. The length of the plate is dictated by what is necessary to obtain three bicortical screws distal to the surgical neck of the humerus as well as three cortical screws into the spine of the scapula. Often, a screw can be placed through the acromion into the proximal humerus in a superior-to-inferior direction (Fig. 103.8*C*). Use either 4.5 mm cortical or 6.5 mm cancellous screws depending on the quality of the bone. Securely compress the head of the humerus to the glenoid using lag technique.
- Test the entire construct for stability. If there are concerns about the strength of fixation, a spica cast or a rigid orthosis may be necessary.

- In many circumstances in which an arthrodesis is necessary, significant scapular and proximal humeral osteopenia has occurred (Fig. 103.11*A*). Screw purchase in the scapular spine can be poor. The strength of the fixation can be improved by placing cerclage wires around the pelvic reconstruction plate and the base of the acromion (Fig. 103.11*B*).

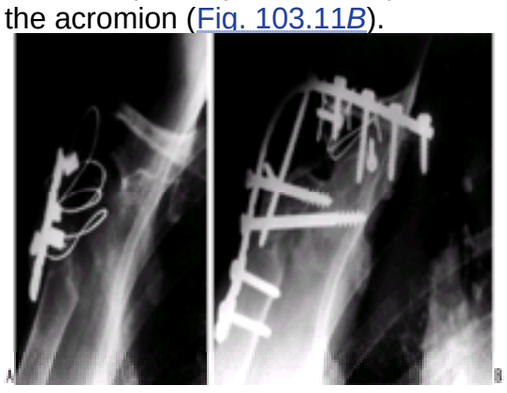

***Figure 103.11.*** **A:** Radiographs of a patient who had a previously failed hemiarthroplasty and hypoplastic glenoid. Because there was bone loss on the humerus and a hypoplastic glenoid, she went on to nonunion after an unsuccessful attempt at arthrodesis. **B:** Revision glenohumeral arthrodesis was performed using plate fixation and local vascularized bone graft. Note that plate fixation to the spine of the scapula was augmented with three cerclage wires.

**POSTOPERATIVE CARE**

Unless a rigid external orthosis is necessary because of inadequate internal fixation, use a soft, removable abduction pillow. It will unload the weight of the arm and is easily removed for hygiene; thus it is better tolerated than the orthosis for the 8- to 12-week period that is often necessary to obtain a solid fusion. Once clinical or radiographic fusion has been obtained, place the patient on a rehabilitation program for periscapular strengthening. Give particular attention to strengthening the trapezius, rhomboids, and serratus anterior. Throughout the postoperative period, employ elbow range-of-motion and hand exercises in conjunction with shoulder rehabilitation.

## GLENOHUMERAL ARTHRODESIS IN THE PRESENCE OF BONE LOSS

Achieving glenohumeral fusion in the presence of proximal humeral or glenoid bone loss such as after failed total shoulder arthroplasty is challenging. Autogenous bone grafting is always indicated in these situations. Additionally, vascularized local bone graft transfers can be effective. The axillary border of the scapula provides a convenient and excellent source for local vascularized bone graft (Fig. 103.12). The axillary border of the scapula is well vascularized by the circumflex scapular artery and muscular attachments of both the teres minor and teres major. To utilize this transfer, extend the vertical saber incision posteriorly approximately 7 cm.

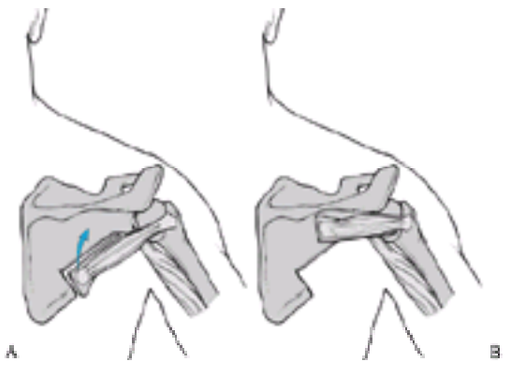

***Figure 103.12.*** Schematic of the technique for local vascularized bone grafting. **A:** Muscle pedicle bone graft developed from the lateral border of the scapula. **B:** Graft transferred to bridge the glenohumeral joint posteriorly.

- Take the subcutaneous dissection to the superficial deltoid fascia, and release the deltoid off the posterior spine, exposing the infraspinatus and teres minor.
- Split the infraspinatus–teres minor interval up to the glenoid neck, and place multiple drill holes in the scapula along the line between the infraspinatus and teres minor.
- Sharply free the axillary border away from the scapular body by using an osteotome to connect the drill holes. Leave the glenoid intact. Superiorly, the transverse cut is inferior to the glenoid neck and inferiorly the cut is proximal to the inferior angle of the scapula, which leaves the important attachment site of the serratus anterior. Protect the origin of the teres minor from the scapula, as it maintains the vascularity.
- Rotate the axillary border bone graft horizontally, and fix it to the scapular body just inferior to the scapular spine, as well as the proximal humerus laterally (Fig. 103.12).
- Intercalary allograft or a free microvascularized fibular graft might be helpful in very difficult fusions with loss of bone

## RESULTS

Union following shoulder arthrodesis that employs internal fixation and supplemental external support is generally over 90%. Earlier series, which relied primarily on external support, achieved union but required immobilization for at least 6 months. Pain relief after shoulder arthrodesis is less predictable, with many patients reporting some postoperative discomfort (33,59). Overall patient satisfaction after arthrodesis has not been universally established. A recently published functional outcome analysis of 33 patients found that the single best predictor of the ability to perform activities of daily living was preoperative diagnosis. Satisfaction rates were highest in osteoarthritis, brachial plexus injuries, and failed total shoulders (59). Published results of shoulder arthrodesis are listed in Table 103.6.

| Series | Date | Patients (N) | Fixation | Spica / orthosis | Union (%) | Time to union (wk) | Pain relief (%) | Satisfaction (%) |
|---|---|---|---|---|---|---|---|---|
| Gill (29) | 1931 | 17 | Osteotomy | Yes | 100 | N/S | N/S | N/S |
| Watson-Jones (60) | 1933 | 3 | Osteotomy | Yes | 100 | 18.7 | 100 | 100 |
| Cassell (9) | 1937 | 11 | Wire | Yes | 100 | 12–14 | N/S | N/S |
| Moseley (38) | 1961 | 3 | Nails | Yes | N/S | N/S | N/S | N/S |
| Davis and Cassell (19) | 1962 | 10 | Screw | Yes | 100 | 11 | N/S | 70 |
| Mar (40) | 1962 | 14 | Screw | Yes | 93 | N/S | N/S | N/S |
| Chaseley and Houston (10) | 1964 | 19 | External fixator | Yes | 95 | N/S | 100 | 100 |
| Bebrus et al. (3) | 1973 | 11 | Screw and cortical graft | Yes | 100 | N/S | 91 | 82 |
| Riggins (42) | 1976 | 4 | Plate | No | 100 | N/S | 100 | 100 |
| Malin (41) | 1977 | 7 | Pins | Yes | 100 | 12 | N/S | N/S |
| Cofield and Briggs (17) | 1979 | 71 | Mixed internal fixation | Yes (90%) | 95 | 16 | 75 | 82 |
| Richards et al. (61) | 1983 | 14 | Plate | Yes | 100 | 16 | 79 | N/S |
| Johnson et al. (37) | 1986 | 4 | Screws, external fixator | No | 100 | 4–10 | N/S | N/S |
| Nagano et al. (51) | 1989 | 11 | External fixator | No | 100 | 12 | N/S | N/S |
| Kozielkowski and Wallace (40) | 1991 | 4 | Screws, external fixator | No | 100 | N/S | N/S | N/S |
| Richards et al. (59) | 1995 | 11 | Plate | Yes | 95 | N/S | 67* | 82 |

* 1/12, 6%
N/S, not stated

***Table 103.6. Results of Shoulder Arthrodesis***

## PITFALLS AND COMPLICATIONS

### HUMERUS FRACTURE

Glenohumeral fusions are often performed in osteopenic bone, where a stress riser distal to the plate is dangerous. It is not surprising that a high fracture rate can occur in this area. Cofield and Briggs (17) reported a fracture rate of 15%. Because this complication often occurs with only minor trauma, closed treatment is often successful. If a glenohumeral arthrodesis is established and internal fixation of a distal humerus fracture becomes necessary, then removal of the proximal plate is recommended for the future to prevent a stress riser.

### INFECTION

Infection has been a relatively rare complication. Treat it as you would infected fractures or implants elsewhere (see Chapter 132 and Chapter 135). In general, avoid removal of in- ternal fixation devices until you achieve an arthrodesis. Following this, remove all internal fixation and perform repeat irrigation and debridements and treat with intravenous antibiotics as necessary to eradicate the infection. If the internal fixation has loosened in the presence of infection, remove it and convert to external fixation augmented by an external orthosis.

### NONUNION

Clinical union of the arthrodesis site has been a reliable measure of outcome for glenohumeral arthrodesis. Nonunion is rare. In Cofield's (17) series of 71 shoulders, only 4% went to nonunion. Richards et al. (59) reported similarly high fusion rates.

### MALPOSITION

In general, patients with arthrodesis can tolerate a large range of flexion and rotation positions. Glenohumeral abduction, in contrast, is poorly tolerated in adults at angles greater than 40°. This is because of the significant scapular winging and trapezial tension that occur when the arm is resting at the side. When malposition causes significant pain or dysfunction, an osteotomy may be required. It is generally performed in the humerus distal to the glenohumeral fusion.

## AUTHORS' PERSPECTIVE

Revision shoulder arthroplasty and shoulder arthrodesis can improve functional activities and relieve pain. Careful preoperative evaluation is critical to the planning and success of these procedures. Preoperative counseling is important to provide the patient with realistic postoperative expectations. With realistic expectations and a clear preoperative plan, good clinical results can be expected in these challenging clinical situations.

### CHAPTER REFERENCES

Each reference is categorized according to the following scheme: *, classic article; #, review article; !, basic research article; and +, clinical results/outcome study.


+ 1. Barr J, Freiberg JA, Colonna PC, Pemberton PA. A Survey of End Results on Stabilization of the Paralytic Shoulder. Report of the Research Committee of the American Orthopaedic Association. *J Bone Joint Surg [Am]* 1942;24:699.

+ 2. Barton NJ. Arthrodesis of the Shoulder for Degenerative Conditions. *J Bone Joint Surg Am* 1972;54:1759.

+ 3. Beltran JE, Trilla JC, Barjan R. A Simplified Compression Arthrodesis of the Shoulder. *J Bone Joint Surg Am* 1975;57:538.

+ 4. Bonutti PM, Hawkins RJ. Fracture of the Humeral Shaft Associated with Total Replacement Arthroplasty of the Shoulder. A Case Report. *J Bone Joint Surg Am* 1992;74:617.

+ 5. Boyd AD, Thornhill TS, Barnes CL. Postoperative Proximal Migration in Total Shoulder Arthroplasty. *J Arthroplasty* 1991;6:31.

+ 6. Boyd AD, Thornhill TS, Barnes CL. Fractures Adjacent to Humeral Prosthesis. *J Bone Joint Surg Am* 1992;74:1504.

+ 7. Brems JJ. The Glenoid Component in Total Shoulder Arthroplasty. *J Shoulder Elbow Surg* 1993;2:47.

+ 8. Caldwell GL, Dines DM, Warren RF. Revision Shoulder Arthroplasty. Presented at the Annual Meeting of the American Shoulder and Elbow Surgeons, San Francisco, CA, Feb., 1993.

+ 9. Carroll RE. Wire Loop Arthrodesis of the Shoulder. *Clin Orthop* 1957;9:185.

+ 10. Charnley J, Houston JK. Compression Arthrodesis of the Shoulder. *J Bone Joint Surg Br* 1964;46:614.

+ 11. Cheng EY, Gebhardt MC. Allograft Reconstructions of the Shoulder after Bone Tumor Resection. *Orthop Clin* 1991;22:37.

+ 12. Codd TP, Arroyo JS, Flatow EL. Glenoid Revision Surgery in Total Shoulder Arthroplasty. *Semin Arthroplasty* 1997;8:328.

+ 13. Codd TP, Yamaguchi K, Pollock RP, et al. Infected Shoulder Arthroplasties: Treatment with Staged Reimplantation versus Resection Arthroplasty. *Orthop Trans* 1996;20:59.

+ 14. Cofield RH. Total Shoulder Arthroplasty with the Neer Prosthesis. *J Bone Joint Surg Am* 1984;66:899.

+ 15. Cofield RH. Shoulder Arthrodesis and Resection Arthroplasty. *Instr Course Lect AAOS* 1985;34:268.

+ 16. Cofield RH. Uncemented Total Shoulder Arthroplasty. 1994 *Clin Orthop*, 1994,304;86.

+ 17. Cofield RH, Briggs BT. Glenohumeral Arthrodesis. *J Bone Joint Surg Am* 1979;61:668.

+ 18. Cofield RH, Edgerton BC. Total Shoulder Arthroplasty. Complications and Revision Surgery. *Instr Course Lect* 1990;39:449.

+ 19. Davis JB, Cottrell GW. A Technique for Shoulder Arthrodesis. *J Bone Joint Surg Am* 1962;44:657.

+ 20. Duncan CP, Marsi BA. The Role of Antibiotic-loaded Cement in the Treatment of an Infection after a Hip Replacement. *J Bone Joint Surg Am* 1994;76:1742.

+ 21. Duralde XA, Connor PM, D'Alessandro DF. Anterosuperior Instability of the Shoulder. Presented at the 15th Open Meeting of the American Shoulder and Elbow Surgeons, Anaheim, CA, February 7, 1999.

+ 22. Faludi II, Weiland AJ. Cementless Total Shoulder Arthroplasty: Preliminary Experience with Thirteen Cases. *Orthopedics* 1982;5:321.

# 23. Fitzgerald RH. Infected Total Hip Arthroplasty: Diagnosis and Treatment. *J Am Acad Orthop Surg* 1995;3:249.

! 24. Flatow EL, Bigliani LU, April EW. An Anatomic Study of the Musculocutaneus Nerve and Its Relationship to the Coracoid Process. *Clin Orthop* 1989;244:166.

+ 25. Franklin JL, Barrett WP, Jackins SE, Matsen FA. Glenoid Loosening in Total Shoulder Arthroplasty. *J Arthroplasty* 1988;3:39.

+ 26. Gerber C, Farron A, Hersche O. Isolated Ruptures of the Subscapularis. *J Bone Joint Surg Am* 1997;78:1015.

+ 27. Gerber C, Krushell RJ. Isolated Rupture of the Tendon of the Subscapularis Muscle. Clinical Features in 16 Cases. *J Bone Joint Surg Br* 1991;73:389.

+ 28. Gerber C, Schneeberger AG, Beck M, Schlegel U. Mechanical Strength of Repairs of the Rotator Cuff. *J Bone Joint Surg Br* 1994;76:371.

+ 29. Gill AB. A New Operation for Arthrodesis of the Shoulder. *J Bone Joint Surg* 1931;13:287.

+ 30. Groh GI, Heckman MM, Curtis RJ, Rockwood CA. Treatment of Fractures Adjacent to Humeral Prosthesis. *Orthop Trans* 1994;18:1072.

+ 31. Harris WH, Schiller AL, Scholler JM, et al. Extensive Localized Bone Resorption in the Femur following Total Hip Replacement. *J Bone Joint Surg Am* 1976;58:612.

+ 32. Hawkins RJ, Bell RH, Jallay B. Total Shoulder Arthroplasty. *Clin Orthop* 1989;242:188.

+ 33. Hawkins RJ, Neer CS. A Functional Analysis of Shoulder Fusion. *Clin Orthop* 1987;223:65.

+ 34. Hoff SF, Fitzgerald RH, Kelty PJ. The Depo Administration of Penicillin G and Gentamycin in Acrylic Bone Cement. *J Bone Joint Surg Am* 1981;63:798.

! 35. Isaac GH, Wroblewski BM, Atkinson JR, Dowson D: A Tribiological Study of Retrieved Hip Prosthesis. *Clin Orthop* 1992;276:115.

+ 36. Jasty MJ, Floyd WE, Schiller AL, et al. Localized Osteolysis in Stable, Non-septic Total Hip Replacement. *J Bone Joint Surg Am* 1986;68:912.

+ 37. Johnson CA, Healy WL, Brooker AF, Krackow KA. External Fixation Shoulder Arthrodesis. *Clin Orthop* 1986;211:219.

+ 38. Jones SM, Pinder IM, Moran CG, Malcom AJ. Polyethylene Wear in Uncemented Total Knee Replacements. *J Bone Joint Surg Br* 1992;74:18.

+ 39. Kelleher IM, Cofield RH. Fluoroscopically Positioned Radiographs of Total Shoulder Arthroplasty. *J Shoulder Elbow Surg* 1992;1:306.

+ 40. Kocialkowski A, Wallace WA. Shoulder Arthrodesis Using an External Fixation. *J Bone Joint Surg Br* 1991;73:180.

+ 41. Kumar VP, Satku SK, Mitra AK, Pho RW. Function following Limb Salvage for Primary Tumors of the Shoulder. Ten Patients Followed 4 (1–11) Years. *Acta Orthop Scand* 1994;65:55.

+ 42. Lynch NM, Cofield RH, Silbert PL. Neurologic Complications after Total Shoulder Arthroplasty. *J Shoulder Elbow Surg* 1996;5:53.

+ 43. MacDonald W, Thrum CB, Hamilton SGL. Designing an Implant by CT Scanning and Solid Modelling: Arthrodesis after Excision of the Upper Humerus. *J Bone Joint Surg Br* 1986;68:208.

+ 44. Mah JY, Hall JE. Arthrodesis of the Shoulder in Children. *J Bone Joint Surg Am* 1990;72:582.

+ 45. Makin M. Early Arthrodesis for a Flail Shoulder in Young Children. *J Bone Joint Surg Am* 1977;59:317.

+ 46. May VR. Shoulder Fusion: A Review of Fourteen Cases. *J Bone Joint Surg Am* 1962;44:65.

+ 47. McElwain JP, English E. The Early Results of Porous-coated Total Shoulder Arthroplasty. *Clin Orthop* 1987;218:224.

# 48. Miller SR, Bigliani LU. Complications of Total Shoulder Replacement. In: Bigliani LU, ed. *Complications in Shoulder Surgery*. Baltimore: Williams & Wilkins, 1993:59.

+ 49. Moeckel B, Altcheck DW, Warren RF, et al. Instability of the Shoulder after Arthroplasty. *J Bone Joint Surg Am* 1993;75:492.

+ 50. Mosely HF. Arthrodesis of the Shoulder in the Adult. *Clin Orthop* 1961;20:156.

+ 51. Nagano A, Okinaga S, Ochiai N, Kurokawa T. Shoulder Arthrodesis by External Fixation. *Clin Orthop* 1989;247:97.

+ 52. Neer CS. Degenerative Lesions of the Proximal Humeral Articular Surface. *Clin Orthop* 1961;20:116.

# 53. Neer CS. *Shoulder Reconstruction.* Philadelphia: W. B. Saunders, 1990.

+ 54. Neer CS, Kirby RM. Revision of Humeral Head and Total Shoulder Arthroplasties. *Clin Orthop* 1982;170:195.

+ 55. Neer CS, Morrison DS. Glenoid Bone-grafting in Total Shoulder Arthroplasty. *J Bone Joint Surg Am* 1988;70:1154.

+ 56. Neer CS, Watson KC, Stanton FJ. Recent Experience in Total Shoulder Replacement. *J Bone Joint Surg Am* 1982;64:319.

+ 57. Nolan JF, Bucknill TM. Aggressive Granulomatosis from Polyethylene Failure in an Uncemented Knee Replacement. *J Bone Joint Surg Br* 1992;74:23.

+ 58. Putti V. Arthrodesis for Tuberculosis of the Knee and Shoulder. *Chir Organi Mov* 1933;13:217.

+ 59. Richards RR, Beaton DE, Hudson AR. Shoulder Arthrodesis with Plate Fixation: A Functional Outcome Analysis. *J Shoulder Elbow Surg* 1993;2:225.

+ 60. Richards RR, Sherman RMP, Hudson AR, Waddell JP. Shoulder Arthrodesis Using a Modified Pelvic Reconstruction Plate: A Review of Eleven Cases. *J Bone Joint Surg Am* 1988;70:416.

+ 61. Richards RR, Waddell JP, Hudson AR. Shoulder Arthrodesis for the Treatment of Brachial Plexus Palsy. *Clin Orthop* 1985;198:250.

+ 62. Riggins RS. Shoulder Fusion without External Fixation. *J Bone Joint Surg Am* 1976;58:1007.

+ 63. Rodosky MW, Bigliani LU. Surgical Treatment of Nonconstrained Glenoid Component Failure. *Oper Tech Orthop* 1994;4:226.

+ 64. Rodosky MW, Weinstein DM, Pollock RP, et al. On the Rarity of Glenoid Component of Glenoid failure. *J Shoulder Elbow Surg* 1995;4:S13.

+ 65. Rouholamin E, Wootton JR, Jamieson AM. Arthrodesis of the Shoulder following Brachial Plexus Injury. *Injury* 1991;22:271.

+ 66. Rowe CR. Re-evaluation of the Position of the Arm in Arthrodesis of the Shoulder in the Adult. *J Bone Joint Surg Am* 1974;56:913.

+ 67. Schmalzried TP, Jasty MJ, Harris WH. Periprosthetic Loosening in Total Hip Arthroplasty. Polyethylene Wear Debris and the Concept of the Effective Joint Space. *J Bone Joint Surg Am* 1992;74:849.

+ 68. Watson-Jones R. Extra-articular Arthrodesis of the Shoulder. *J Bone Joint Surg* 1933;15:862.

# 69. Windsor RE, Bono JV. Infected Total Knee Replacements. *J Am Acad Orthop Surg* 1994;2:44.

! 70. Wirth MA, Agrawal CM, Mabrey JD, et al. Isolation and Characterization of Polyethylene Wear Debris Associated with Osteolysis following Total Shoulder Arthroplasty. *J Bone Joint Surg Am* 1999;81:29.

+ 71. Wirth MA, Rockwood CA. Analysis of Failed Humeral Head and Total Shoulder Arthroplasty. *Orthop Trans* 1994;18:977.

+ 72. Wirth MA, Rockwood CA. Complications of Shoulder Arthroplasty. *Clin Orthop* 1994;307:47.

# 73. Wirth MA, Rockwood CA. Current Concepts Review: Complications of Total Shoulder-replacement Arthroplasty. *J Bone Joint Surg Am* 1996;78:603.

+ 74. Wright TW, Cofield RH. Humeral Fracture after Shoulder Arthroplasty. *J Bone Joint Surg Am* 1995;77:1340.

+ 75. Zancolli E, Mitre H. Latissimus Dorsi Transfer to Restore Elbow Flexion. An Appraisal of Eight Cases. *J Bone Joint Surg Am* 1973;55:1265.

# CHAPTER 104

# OSTEOTOMIES ABOUT THE HIP—ADULTS

*Roland J. Barr and Richard F. Santore*

**R. J. Barr:** Southern Orthopaedics Associates, Southern Illinois Healthcare, Carbondale, Illinois, 62901.
**R. F. Santore:** Dept. of Orthopaedic Surgery, University of California at San Diego, and Sharp Memorial Hospital, San Diego, California, 92123.

Patient Evaluation
History
Examination
Radiographic Assessment
Patient Selection and Timing
Preoperative Planning
Pelvic Osteotomies and the Acetabulum
Chiari Pelvic Osteotomy
Shelf Procedures and Slotted Acetabular Augmentation
Periacetabular Osteotomies
Unique Features of the Periacetabular Osteotomy
Operative Technique
Postoperative Care
Complications
Conversion of Failed Periacetabular Osteotomy to Total Hip Replacement
Combined Periacetabular and Intertrochanteric Osteotomies
Periacetabular Osteotomy for Legg-Calvé-Perthes Disease
Results
Slipped Capital Femoral Epiphysis
Indications
Planning and Operative Technique for the Imhauser Osteotomy
Results
Intertrochanteric Osteotomy for Osteoarthritis
Patient Evaluation and Planning
Valgus–Extension Intertrochanteric Osteotomy
Varus–Extension Intertrochanteric Osteotomy
Results
Removal of Fixation Implants After Osteotomies
Pitfalls and Complications
Authors' Perspective
Chapter References

With the advent of total hip arthroplasty three decades ago, the number of osteotomies about the hip for the treatment of adult hip disease has understandably decreased. However, despite the advancements in joint replacement technology, the challenges remain much as they were in the early 1970s. Even an optimal hip replacement is not expected to survive for a lifetime in a healthy patient younger than 50 years, especially given today's longer life expectancy. Survivorship of joint replacements in younger adults is possibly less than 10 years (21,25,27,30,40,41,56,102,126,143,152).

Polyethylene wear, aseptic loosening, bone loss, and a host of other potential problems are encountered in young adult patients [defined as being 20–50 years old (7)] who undergo total joint replacement. Complications such as these call for alternative treatments for the patient with a life expectancy exceeding 20 to 25 years. What is to be done for these patients? Many are told that they must modify their activities and palliate their pain until they reach an appropriate age, while their hip continues to deteriorate. A significant portion of these patients, particularly if identified before they develop advanced arthritis, can be successfully treated with an osteotomy of the pelvis or proximal femur (or both).

There is mounting evidence that anatomically abnormal hips do not last a lifetime. In addition, studies have suggested that many hips—actually a majority—that develop osteoarthritis have preexisting pathology (7,150,151,169,170 and 171). Such secondary arthritis is generally the result of a biomechanical abnormality affecting the joint. The major predisposing diseases include developmental dysplasia of the hip (DDH), Legg-Calvé-Perthes (or Perthes) disease, slipped capital femoral epiphysis (SCFE), osteonecrosis, and trauma, of which the most common is DDH. Reports vary, but taken together the prevalence of significant osteoarthritis with these diseases by 50 years of age is between 20% and 50%. For dysplasia, the risk is probably 25% to 50%, depending on the severity of involvement, in spite of current treatment methods (33,109,176). For Perthes disease, the chance for painful arthritis by 50 years of age is around 50% (7,91,147,149,173). In the case of SCFE, it is only about 20%, but it certainly varies with the severity of the slip (22,53,118). Often in these patients the childhood hip disease was subclinical and went undiagnosed until the onset of adult hip pain. Nevertheless, many of these patients required hip replacement surgery before 50 years of age.

The morphologic anomalies following these diseases can result in excessive shear and compressive stresses on the hyaline cartilage and subchondral bone. When the biomechanical tolerance and potential for repair of the joint are exceeded, progressive secondary degeneration occurs. Additionally, as the life expectancy of our population increases, so does the opportunity for an underlying hip condition to express itself as symptomatic secondary degenerative arthritis.

The treatment of dysplasia has been greatly improved by the development and success of the Bernese periace-tabular osteotomy (49,51,75,83,93). Prior to the development of this operation, diagnosing dysplasia in painful adult hips did not seem as important. Most of the surgical procedures were of a salvage nature for relatively more advanced arthritis such as valgus–extension intertrochanteric or Chiari osteotomies, and these did not correct the primary abnormality. Partly because of this “salvage” mindset, physicians have not been taught a sense of urgency about making the diagnosis or referring patients for early surgical consultation. Indeed, the presence of moderately severe acetabular dysplasia is frequently overlooked by nonpediatric radiologists, primary care physicians, and even orthopaedists. Increased education and discussion about dysplasia and the other causes of secondary hip arthritis can facilitate earlier treatment in younger adults with painful hips.

As our knowledge in this area has increased, so has the importance of early diagnosis for these at-risk hips. When an anatomic abnormality exists that exposes the joint cartilage to high stresses, and this situation is correctable by osteotomy, the potential long-term benefits of reorienting or realigning the joint must be considered. Salvage of a young patient's joint cartilage holds more promise for a good life-long result than does an early implant arthroplasty. In other cases, an osteotomy may serve as a bridge to carry the patient safely into the age range appropriate for total joint replacement. In this chapter, we do not support the indiscriminate selection of osteotomy for any adult hip disease, as the majority of patients with established hip arthritis are best managed by total hip replacement (THR) surgery. In this chapter, we define the indications for, and appropriate selection of, osteotomies of the pelvis and femur for specific problems in the adult hip.

## PATIENT EVALUATION

### HISTORY

Many patients who present with a hip problem amenable to treatment with an osteotomy do not give a history of a childhood hip disorder. They may have vague anterior groin or greater trochanteric pain, which has been treated for years as a “groin pull” or “trochanteric bursitis.” They complain of difficulties with athletics and endurance. Some may come with radiographs that have been interpreted as normal despite the presence of significant dysplasia.

### EXAMINATION

Assess the patient's general health, noting the degree of fitness or presence of obesity. Observe gait and check for Trendelenberg's sign. Check the range of motion in all planes. Carefully document the actual and apparent leg lengths as well as strength and neurologic status of the lower extremities. Examine other joints as they may

relate to the affected hip, especially the back, contralateral hip, and ipsilateral knee. Provocative tests are useful in patients with suspected pathology in the labrum of the hip, including any with dysplasia (30,42,73,88). These include the apprehension test of hip extension and external rotation, as well as the impingement test of flexion–adduction–internal rotation (2,3,26,34,39,42,81,92). When an angular proximal femoral osteotomy is being considered, examine the hip for the position of comfort. Arthroscopy and magnetic resonance imaging (MRI) are useful in assessing labral pathology and avascular necrosis (AVN) (27,67,81,92). With the exception of MRI for AVN, these studies should not be considered mandatory prior to osteotomy.

**RADIOGRAPHIC ASSESSMENT**

Take an anteroposterior (AP) radiograph of the pelvis, as well as AP and frog-lateral views (Fig. 104.1*A*, Fig. 104.1*B*) of the involved hip. One of the most useful additional views is the false-profile radiograph (Fig. 104.20*C*). This nearly lateral view is taken in the standing position with the greater trochanter of the affected hip against the cassette and the ipsilateral foot placed parallel to the cassette. Rotate the contralateral leg, and with it the pelvis, backward about 20°, or just enough so that the hip joints are not superimposed on one another. This special oblique view provides the best radiographic documentation of the anterior coverage of the femoral head, and it is a true lateral view of the proximal femur.

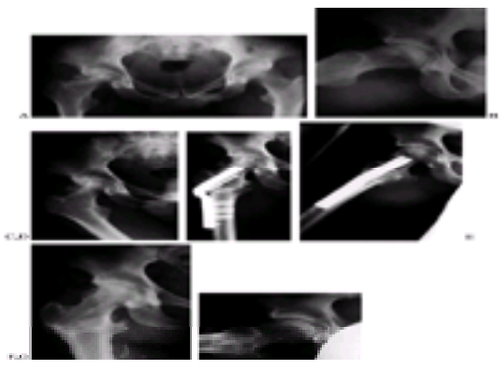

***Figure 104.1.*** Preoperative radiographic evaluation of the hip. This patient has avascular necrosis of the hip and is being evaluated for an intertrochanteric osteotomy. **A:** AP view. **B:** Frog-lateral view. **C:** AP view in adduction. **D:** Postoperative AP radiograph after valgus osteotomy. **E:** Postoperative lateral view. **F:** AP view after hardware removal showing good preservation of the joint space. **G:** Lateral view after hardware removal.

***Figure 104.20.*** PAO for Perthes disease. **A:** AP view of the left hip in a 52-year-old man with a history of bilateral Perthes disease. The contralateral hip had already been treated with a primary and revision total hip arthroplasties. **B:** AP view of the hip 3 months after PAO and trochanteric advancement. **C:** Preoperative false-profile view. **D:** False-profile view 6 months postoperatively. At 1 year he used a cane only rarely and was working without restrictions. His preoperative back and hip pain was relieved.

An AP view of the hip with the femur in abduction–internal rotation provides a preview of the potential enhancements of coverage afforded by a rotational acetabular osteotomy (Fig. 104.23*A*, Fig. 104.23*B*). Functional views of the hip with the femur in abduction and adduction permit characterization of the joint space and demonstration of the adequacy of motion in the required plane prior to any angular intertrochanteric osteotomy (ITO) (Fig. 104.1*A*, Fig. 104.1*C*). Performing these views under fluoroscopy is another alternative; this can provide simultaneous information about the positions of relative comfort. An AP radiograph with the hip in adduction and flexion approximates the position of the joint after a valgus–extension ITO (Fig. 104.1*C*). If the overall alignment of the lower extremity will be changed by an osteotomy, take a full-length standing radiograph for measuring the biomechanical axis. This allows prediction of the effect of the surgery on the weight-bearing axis, especially as it may affect the knee.

***Figure 104.23.*** Failure after an initially successful PAO. **A:** AP radiograph of the left hip in a 47-year-old woman with hip pain for less than a year. **B:** Abduction–internal rotation functional AP view of the left hip. **C:** AP view of the left hip early after PAO. **D:** By 1½ years postoperatively, arthritis had progressed and pain increased. **E:** A total hip arthroplasty was required 3½ years after the PAO when the patient was 50 years old.

For osteonecrosis (or AVN), special plain radiographs can help with spatial localization of the necrotic segment of the femoral head (137,138). Anterior lesions can be visualized on an AP of the hip taken with the hip in about 30° of flexion. The posterior femoral head can be better seen with the hip in extension with the central beam of the x-ray angled caudally about 40°. An MRI is usually performed in patients with AVN. It helps to localize and quantify the head involvement as well as assess the contralateral hip for a disease that is often bilateral.

A three-dimensional computed tomography (CT) scan is used routinely as a preoperative planning tool in some centers (75,98). The images and sometimes additional three-dimensional plastic models can provide a more detailed understanding of coverage deficiencies that may be present. These CT scans are not necessary, however, to determine which patients are appropriate for surgery. In fact, most decisions regarding reconstructive surgery of the hip can be made on the basis of high-quality plain radiographs.

**PATIENT SELECTION AND TIMING**

Age is one of the key issues when a patient is considered for an osteotomy around the hip joint. In patients older than 60 years, there must be a compelling reason to choose a hip osteotomy over implant arthroplasty. Being over 60, however, is not by itself an absolute contraindication to a hip osteotomy. A patient's physiologic age and life expectancy are more relevant than chronologic age. The actual status of the joint cartilage and lifestyle of the patient are more important than any assumptions

about arthritis or activity based solely on a patient's age.

In general, all the osteotomies described in this chapter have the best results when performed for clearly correctable biomechanical abnormalities in joints with at most mild arthrosis. Good range of motion also correlates with a better long-term outcome for hip osteotomies. Deviation from these principles may still yield good results, but at an increased risk of failure. One of the most difficult decisions frequently encountered is determining just how much arthrosis is too much. The risks of increased stiffness, pain, or other modes of clinical failure increase with the degree of preoperative degenerative changes. The amount of risk that the surgeon and patient are willing to assume may be tempered by other factors such as the patient's age and surgical options. Figure 104.2 shows a patient with a dysplastic hip whose arthritis progressed rapidly, leading to cancellation of a planned periacetabular osteotomy. Figure 104.3 by comparison shows a patient with moderate preoperative arthrosis who has done well after a periacetabular osteotomy.

***Figure 104.2.*** **A:** AP radiograph of the left hip in a healthy and active 52-year-old woman with a 4-year history of hip pain. Periacetabular osteotomy was discussed as the probable treatment of choice. **B:** This AP radiograph taken 7 months later showed rapid progression of the arthritis, requiring cancellation of the osteotomy that was planned.

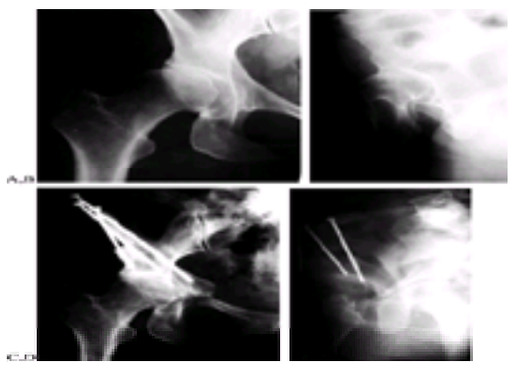

***Figure 104.3.*** AP radiograph of the right hip (**A**) and a false profile view (**B**) of a 43-year-old woman with right hip pain and moderately advanced arthrosis. A periacetabular osteotomy is seen on the AP (**C**) and false-profile views (**D**). The patient had a delayed union of the pubis, but by 8 months after surgery she was asymptomatic and back to full activity with no limp.

The ideal candidate for an osteotomy is highly motivated and has a realistic understanding of the potential risks and benefits of the procedure, including the possible need for an extended period of rehabilitation. Moderate obesity should be considered a relative contraindication and morbid obesity a nearly absolute contraindication. Absolute contraindications to osteotomy include neuropathic arthropathy, severe osteopenia, inflammatory arthritis, and active infection. Relative contraindications include a stiff joint, advanced age or arthrosis, and smoking.

## PREOPERATIVE PLANNING

Detailed preoperative planning helps reduce complications and provide for reproducible results. An AP radiograph with a magnification marker in the plane of the bone allows scaled digitization of the image for computer planning (78,108,130) (see Chapter 26). The computer facilitates the exploration of many possible surgical plans with accuracy and speed. Sound planning, and successful surgery, does not require computer-based planning. In fact, the majority of the world's leading osteotomy surgeons have never used, or relied on, computer planning. The principle is that careful planning of the goals of the surgery and the specific surgical techniques must be considered prior to surgery. Issues that can be planned preoperatively include osteotomy level, angulation, wedge resection, leg length, displacement, effect on mechanical axis alignment, fixation choice(s), bone grafting, and compatibility with future THR. Bring all the relevant preoperative planning drawings or computer printouts to the operating room and post these for easy reference during the procedure. Attention to detail and technique during the surgery follows from attention to the procedural details before the surgery.

## PELVIC OSTEOTOMIES AND THE ACETABULUM

### CHIARI PELVIC OSTEOTOMY

#### *Rationale*

The Chiari pelvic osteotomy in adults is a salvage procedure for patients with arthritis caused by acetabular dysplasia. In general, young patients with fixed subluxations and/or femoral head deformities are well suited for this procedure. It is a capsular interposition arthroplasty and an extra-articular acetabular augmentation utilizing a slightly inclined (distal–lateral to proximal–medial) supra-acetabular iliac osteotomy. Chiari initially described this procedure in 1955, and he later reported the results of more than 600 cases in 1974 (31). His original methods included a relatively minimal exposure through an anterolateral approach. He made a slightly upsloping, inferiorly concave osteotomy just above the joint capsule. He rarely used internal fixation and patients were immobilized in a hip spica cast. Most of Chiari's patients were children, although adults were included in his study, and 104 had coexisting arthritis. Subsequent reports by Chiari and others on the results in adults have better defined the indications and outcomes (28,76,128,136,177). Many of Chiari's large group of patients would now be treated with a rotational pelvic osteotomy.

The Chiari procedure accomplishes two goals. First, the displaced superior fragment forms a lateral shelf over the pathologically lateralized and uncovered femoral head. The proximal fragment can be manipulated anteriorly as well as laterally. Through metaplastic transformation, this new buttress and the interposed capsule produce a fibrocartilaginous articular surface. This broadens the surface area available for weight bearing. The coverage also prevents progression of the subluxation and is not dependent on joint congruity.

The second goal is the medialization of the hip joint, usually around 1.5 cm, which reduces the resulting joint reaction forces. The inferior fragment is hinged on the symphysis pubis, and displacement actually slightly increases the already abnormal inclination of the acetabulum. This is more than compensated for by the medialization and improved coverage (162,179). Additionally, the osteotomy increases hip abduction, an essential goal for many patients. Although the Chiari procedure is conceptually one of the easier pelvic osteotomies to visualize, its results are very dependent on precise surgical technique (46).

Most patients who are candidates for a Chiari osteotomy have a limp and a Trendelenberg gait preoperatively. Usually only the antalgic portion of a limp will be improved by the procedure. Some authors (see later) have reported an improvement in the Trendelenberg lurch in a majority of patients, attributing the improvement to the medialized hip center and to advancement of the greater trochanter in some patients. In general, advise patients that their Trendelenberg lurch may not improve and can worsen postoperatively. This is, in part, because the traditional surgical approach involves stripping of the tensor and much of the abductor musculature from the lateral iliac wall.

### *Indications and Contraindications*

Table 104.1 outlines the indications and contraindications for Chiari osteotomy. We use Chiari pelvic osteotomy in young adults and middle-aged patients with DDH, refractory hip pain, and an uncovered femoral head, in whom acetabular redirection is not indicated, usually because of incongruity or fixed subluxation of the femoral head. This is most often secondary to hip dysplasia, although Chiari also included patients with coxa magna after Perthes disease (or childhood AVN). The procedure is contraindicated when the proximal femur or acetabulum can be repositioned to provide coverage for a congruous joint using an acetabular redirection with or without femoral osteotomy. Another contraindication is lack of hip mobility. At least 70° (to 90°) of flexion and 10° (to 20°) of adduction are required. A relative contraindication is physiologic age over 45 years, especially with significant arthritic changes. This is because of the poorer results in this age group as well as the competitive benefits of THR. Other relative contraindications include a totally uncovered hip or severe proximal migration prohibiting access to the appropriate iliac slope for the osteotomy and resulting in insufficient breadth of the iliac wing and dangerous proximity to the sciatic notch. This last problem may be overcome with intraoperative traction in some patients.

| |
|---|
| *Indications* |
| Developmental dysplasia of the hip (DDH) with hip pain resistant to conservative management |
| Joint incongruity and/or loss of femoral head sphericity |
| Hip subluxation with poor head coverage with or without a steeply sloped socket (high acetabular index) |
| Failure of previous containment procedures |
| *Contraindications* |
| Suitability for rotational pelvic osteotomy |
| Marked joint stiffness |
| Significant hip joint arthrosis (not absolute) |
| *Relative contraindications* |
| Older than 45 years of age (physiologic) |
| Totally uncovered hip |
| Severe proximal migration prohibiting access to the appropriate slope of the ileum for the osteotomy (This may be overcome in some by intraoperative traction or a purely transverse iliac cut.) |

***Table 104.1. Indications and Contraindications for Chiari Osteotomy***

As Scher and Jakim (136) and others (125,159) have demonstrated, where there is significant coxa vara or incongruity (femoral head flattening), a valgus–extension ITO can be combined with the Chiari procedure. This moves the broader surface of the head into the weight-bearing zone, where superior–lateral eccentric loading of the head would otherwise occur. As with most intertrochanteric osteotomies, the decision is guided by preoperative adduction and abduction radiographs (31,89,136,). Figure 104.4 shows a 17-year-old patient with bilateral dysplasia and arthritis who underwent a combined Chiari and valgus–extension ITO on the left. At over 3 years this hip has no pain or limp.

***Figure 104.4.*** Chiari osteotomy combined with a valgus ITO. Preoperative AP view of the left hip (**A**) and false-profile view (**B**) in a 17-year-old girl with bilateral hip dysplasia, arthritis, and leg-length inequality. Postoperative AP view of the pelvis (**C**) and false-profile view of the left hip (**D**) after Chiari osteotomy with simultaneous extension ITO and femoral shortening of 3 cm. AP view of the pelvis (**E**) and false-profile view (**F**) 3 years after surgery. The patient had no left hip pain and no Trendelenberg sign, but she elected for total hip replacement on the contralateral hip within the next year.

### *Operative Technique for Chiari Osteotomy in Adults*

- Position the patient supine on a radiolucent table, with the pelvis and leg draped free, or on a fracture/traction table with the leg slightly abducted and externally rotated. Utilize routine antibiotic and thromboembolic prophylaxis throughout the procedure.
- Make a 10-cm-long anterolateral ilioinguinal incision beginning at the iliac crest and extending medially. The less cosmetic iliofemoral (Smith-Peterson) approach may be preferred for more exposure or in larger patients, or for combined pelvic and femoral osteotomies through one incision.
- Develop the interval between the sartorius and tensor facia lata muscles. Retract the tensor laterally and preserve the lateral femoral cutaneous nerve medially.
- Expose the iliac wing by subperiosteal dissection medially and laterally. Minimize lateral stripping to minimize injury of the hip abductor muscles.
- Release the tensor, sartorius, and direct head of the rectus femoris from their origins off the ilium.
- Expose the anterior and lateral hip joint capsule. Do not incise or damage the capsule, especially superiorly.
- Separate the tendon of the rectus femoris from the capsule and divide the reflected head. The curved insertion of the rectus serves as a marker for the level of the osteotomy.
- Dissect subperiostially from the capsule to the sciatic notch posteriorly and place a blunt retractor, such as a relatively radiolucent flexible metal ribbon. Similarly, place a retractor medially after careful dissection to the greater sciatic notch.
- Radiographically confirm the starting point and direction of the osteotomy with a pin drilled into the pelvis just superior to the capsule.
- Use curved osteotomes to complete the semicylindrical osteotomy, inclining 15° superiorly from inferolateral to superomedial. A less steep inclination may be necessary in the case of proximal head migration. In such a case, the osteotomy could exit into the sacroiliac joint, which would block the desired displacement.
- A Gigli saw can be used to cut the most posterior portion from the sciatic notch anteriorly about 1 cm. This reduces the danger of injuring the neurovascular structures in the sciatic notch from an osteotome or bone splinters or spikes. Alternatively, a Gigli saw or power saw can be used for the entire cut. The senior author (RS) prefers the Gigli technique for safety and simplicity.
- After carefully completing the osteotomy of the medial cortex, displace the osteotomy. Release any traction on the leg and abduct the hip. Displace the inferior fragment medially 1–1.5 cm but at times up to 2.5 cm (76) as needed to provide 80% to 100% lateral coverage of the femoral head. Because the sacroiliac joint allows some lateral motion of the proximal fragment, not all of the osteotomy displacement results in hip center medialization. Confirm that the displacement has occurred both posteriorly and anteriorly, because a posterior hinge may remain (13).
- Evaluate any remaining deficiency in coverage, which is common anteriorly. Harvest a supplemental corticocancellous shelf graft from the iliac wing as needed. Wedge this into the osteotomy, or otherwise secure the graft.
- Place internal fixation from the iliac wing across the osteotomy to eliminate the need for a spica cast in adults. We use long 4.5 mm AO (Synthes, Paoli, PA) solid cortical screws. Figure 104.5 shows a patient with a Chiari osteotomy in which a supplemental graft was used. After more than 4 years, she remains asymptomatic using no walking aids.

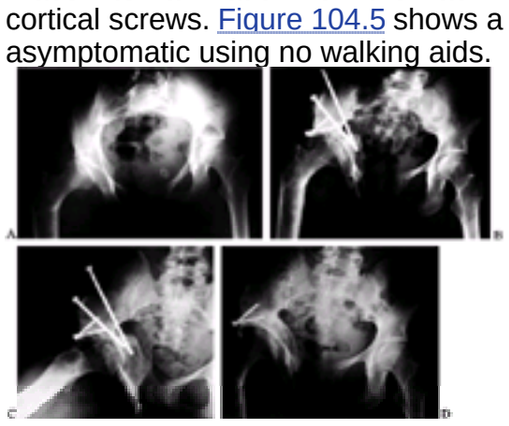

***Figure 104.5.*** Chiari osteotomy with a bone graft. **A:** AP view of the pelvis in a 29-year-old woman with a history of a prior Sutherland pelvic osteotomy and increasing hip pain. **B:** AP view of the pelvis 1 month after Chiari osteotomy. **C:** Lateral view 2½ months after the Chiari osteotomy. **D:** AP view of the pelvis 4 years after surgery. The patient is asymptomatic, working full time, using no walking aids, and has a moderate limp because of a short right leg.

- Where more than 75% displacement of the osteotomy is required, consider placement of a bone graft medially to assist with healing.
- Confirm the radiographic appearance of the osteotomy and check hip range of motion, to be certain that there is no block to flexion anteriorly.
- Irrigate the wound and close it in layers over a suction drain.
- Take care to repair all muscles, suturing the tendons back to bone through drill holes where initial release was from bone. Avoid injury to the lateral femoral cutaneous nerve.

### *Postoperative Care*

Postoperatively, begin protected ambulation as soon as tolerated. Do not allow active flexion or abduction exercises initially, to allow repaired muscles to heal. Weight bearing is partial for 6 weeks. Most patients can bear full weight by 3 months if healed, with longer healing times expected for osteotomies with greater displacements.

### *Results*

Pain relief is significant in 80% to 90% of patients in the first few years and remains reduced in 50% to 60% at 15–20 years follow-up. Because pain relief is a primary goal of this surgery in adults, the reported rates of good and excellent results in the literature are similar. Lack et al. (76) reported 75% good results at 15 years in 100 hips in patients older than 30 years at the time of operation. During these 15 years, 20% of patients required THR at an average time of 11.5 years after osteotomy. Windhager et al. (177) also summarized the results of many patients who had undergone Chiari osteotomy at a mean follow-up of 25 years, showing 51% continued good results out of 236 patients. In patients who had developed pain, the period of significant pain relief was an average of 17 years. Zlatic et al. (179) reported 87% complete or nearly complete pain relief in adults at the 9-year follow-up. De Waal Malefijt et al. (36) described 61% good results in their adult patients at 5 years, with the poor results mostly attributable to technical errors. Betz et al. (14) reported 88% good or excellent results in 24 patients with follow-up ranging from 3 to 20 years. When performed as a time-buying salvage operation for the hip, it seems reasonable to expect 10–15 years of good service from the Chiari osteotomy.

Gait improvement is less dramatic than pain relief because a positive Trendelenberg limp may persist in some and normalize in others. Graham et al. (55) found no change in the Trendelenberg test after 58 osteotomies were followed for 3.5 years. Other authors have reported that the Trendelenberg gait was the same or slightly worse at short- and long-term follow-up (28,36,179). By contrast, another group of authors reported improved Trendelen- berg gait without osteotomy of the greater trochanter (63,85,128). Osteotomy of the greater trochanter with advancement shows more significant improvement in the Trendelenberg test. For example, Matsuno et al. (89) described a lateral approach with greater trochanteric advancement. They reported only 2 of 66 patients with a Trendelenberg gait at a minimum 6-year follow-up, and 80% good results in 100 adult cases at 9 years.

Although abduction may improve, overall range of motion does not. Severe limitation of motion has been reported, but its incidence may be reduced by the use of internal fixation and early physical therapy. In general, there is not a strong relationship between preoperative radiographic findings and clinical results following Chiari osteotomy (28,63).

Nishina et al. (117) reported on the importance of an intact labrum, as determined by preoperative hip arthrography, for good results following Chiari osteotomy in adults. In their series, all 23 hips with normal labra had good or excellent results at 4 years, whereas 1 of 21 with torn labra and 10 of 20 with detached labra had fair or poor results. The authors felt that a detached labrum was a contraindication to the procedure. Gadolinium-enhanced MRI is now our preferred method for evaluating the labrum. If the capsule is opened at the time of surgery, either for inspection or resection of a labral tear, secure repair is essential, as an intact capsule is a prerequisite for a successful Chiari result.

Several authors have investigated the effects of age and arthritis on the outcome after Chiari osteotomy. As may be expected, in adults the results are best and most durable in patients who are younger and have no signs of arthritis at the time of surgery. Reynolds (128) found that without severe dysplasia or arthritis, patients achieved significant and lasting improvement in 29 of 32 cases (90%) at a 5-year follow-up. However, those with more severe dysplasia and/or arthritis failed in 9 of 12 cases. Calvert et al. (28) found significant correlation between either younger age at operation or absence of arthritic changes on preoperative radiographs and Harris hip scores of 49 hips at a 14-year follow-up. Windhager's (177) review of patients most of whom had undergone Chiari osteotomy, found that the oldest third of the patients developed the worst arthritis at a 25-year follow-up and that subjectively poor results were seen in patients with preoperative signs of arthritis. In a report of subsequent Chiari patients, Lack et al. (76) more clearly defined the effects of age in an adult-only population. They showed 80% good results for patients younger than 45 years of age at operation (age range, 30–44 years) and only 50% good results for patients older than 44 years of age.

Conversion of a Chiari to a THR is difficult. (The intuitive concept that a prior Chiari facilitates cup insertion techniques is not valid.) Such an arthroplasty should be viewed as a revision acetabulum with the presence of scar, bone defects, and anatomic distortions anticipated. Especially important is the recognition that the anteroposterior host bone diameter is much less than the perceived superoinferior or mediolateral dimension. It is necessary to avoid excessive reaming of the anterior and posterior walls. Furthermore, the projecting shelf of bone anteriorly and laterally may be a source of impingement that predisposes to dislocation of the hip replacement if not dealt with at the time of arthroplasty by resection of bone.

### *Complications*

Complications specific to the Chiari osteotomy are summarized in Table 104.2. Complications and how to avoid them are discussed in detail by Benson and Evans (13), Fixsen (48), and Hoffman et al. (62).

| | |
|---|---|
| *Limb-length discrepancy.* | Patients often start with the operative leg 1 to 4 cm shorter, which tends to further shorten about 1 cm with the pelvic osteotomy, depending on the slope of the cut (179). |
| *Meralgia paraesthetica* | (trauma to lateral femoral cutaneous nerve). Common (up to 50%) but usually temporary (28,84) |
| *Failure to improve pain.* | Especially in older patients with arthritis (28,76,128,177) |
| *Worsened Trendelenberg gait.* | Adequate medialization of the hip joint, minimization of trauma to the abductors, and advancement of the greater trochanter, when indicated, all diminish this consequence/complication. |
| *Interference with childbirth.* | Unilateral Chiari osteotomy does not preclude normal vaginal delivery. The majority of women with bilateral osteotomies, however, deliver by cesarean section. |
| *Sciatic (including peroneal) nerve injury.* | Avoid this by careful operative technique. |
| *Major hemorrhage.* | Early experiences with gluteal vessel injury by Chiari were not repeated after he began using overlapping Hunt retractors in the sciatic notch. |

***Table 104.2. Complications of the Chiari Osteotomy***

### *Summary*

In adult patients with painful hip dysplasia who are not candidates for redirectional acetabular osteotomy, the Chiari procedure offers a good choice when surgery is required (139). The more ideal patients do not have advanced arthritic deterioration and are much too young to be reasonable candidates for THR. In these properly selected patients, 10–20 years of significant pain relief may be expected, making the Chiari osteotomy a durable salvage option.

## SHELF PROCEDURES AND SLOTTED ACETABULAR AUGMENTATION

A variety of extra-articular acetabular augmentation osteotomies can be classified as shelf procedures. These bone-grafting surgeries are cousins of the Chiari type of osteotomy in that they are capsular interposition arthroplasties. They rely on capsular metaplasia into fibrocartilage as well as bony remodeling to provide coverage over an otherwise deficiently contained femoral head. In these procedures, an iliac bone graft is created or inserted immediately superior to the hip capsule. A variety of techniques, shapes, and fixation methods have been described. A common feature among these methods is the importance of graft placement in direct apposition to

the superior capsule and the prevention of graft displacement. Because of these considerations, most authors have recommended postoperative spica casting (129,145,146,153,167). The use of casts and the dependence on bony remodeling are part of the reason that this type of procedure, when done alone, is probably best reserved for pediatric patients. In addition, the need for certain pediatric procedures, such as open reduction of hip dislocations, provides access to the hip joint and an opportunity for supplemental shelf grafting. The use of simple shelf augmentations in adults has diminished markedly since the development of redirectional acetabular osteotomies.

Today, the most common use for a shelf procedure in adults is as an adjunct to another coverage osteotomy, particularly that of Chiari. As discussed in the preceding section on the Chiari osteotomy, a shelf graft is a useful supplement to extend the capsular arthroplasty surface, usually anteriorly but also laterally (74). Conceptually, the combination of these procedures is logical because they both are designed to rely on metaplasia of the joint capsule to fibrocartilage and can be applied to the same patients. The shelf procedures have the benefit of being able to be tailored to adjust coverage in an anterior or posterior direction more than is possible with a Chiari osteotomy.

The buttress provided by a shelf graft is less stable than with other pelvic osteotomies, even when using a slotted technique. Hardware breakage, recurrent subluxation, or graft failure due to displacement can occur. Many authors recommend spica casting; however, complications from the cast itself can be significant (175), especially in large adolescents or adults. When combined with another primary procedure, almost any of the described shelf augmentations can be performed with little increase in surgical risk or technical difficulty. Our experience supports the use of a shelf procedure in combination with a Chiari osteotomy, but we do not any longer perform shelf grafting alone or in combination with periacetabular osteotomy.

## PERIACETABULAR OSTEOTOMIES

Developmental dysplasia of the hip is associated with a high incidence of premature arthritis of the hip (7,107,150,169,171). In the award-winning, retrospective review of 130 hips with so-called idiopathic or primary osteoarthritis, Stulberg and Harris (151) discovered a 48% incidence of dysplasia of the hip as the etiologic factor. Additionally, Cooperman et al., in a minimum 22-year follow-up study of 32 hips in 20 patients with acetabular dysplasia (center–edge angle < 20°), found a 100% incidence of roentgenographic evidence of degenerative joint disease (33).

Symptoms and radiographic changes present early in adult life. Once established, degenerative changes progress rapidly (169).

Ganz et al. (51) have described three variations of clinical presentation. In an early one, there may be muscle-related trochanteric or anterolateral discomfort only. In another subgroup, there is sudden onset of pain, giving way, and clicking. These patients have the so-called acetabular rim syndrome, often associated with a tear of the acetabular labrum. Finally, there are those who present with already-established arthritis, secondary to the underlying dysplasia.

Rotational pelvic osteotomies have emerged over the past 15 years as the most effective procedures for adults with prearthritic or early arthritic symptoms due to the adult sequelae of childhood dysplasia of the hip (5,10,44,49,51,59,61,64,66,79,96,97,99,101,109,113,114,115 and 116,140,147,148,155,156,158,165,168,178) (Fig. 104.6). Congruency of the hip is a near absolute requirement. Dislocation and fixed subluxation are contraindications, as is the presence of significant arthritis. The periacetabular (Bernese or Ganz) osteotomy offers the most theoretical and practical advantages, and it has largely supplanted the role formerly played by varus–extension ITO of the femur for adult dysplasia.

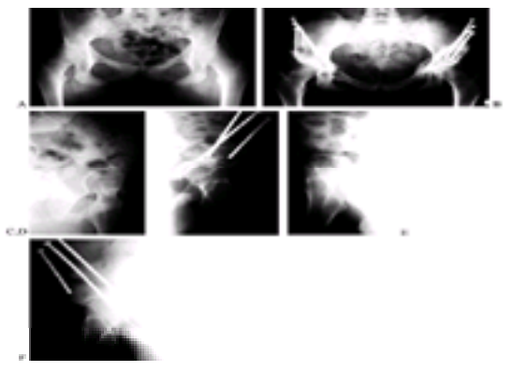

***Figure 104.6.*** Classic periacetabular osteotomy (PAO). **A:** AP radiographic view of the pelvis in a 20-year-old woman with bilateral hip pain for over a year. **B:** AP view of the pelvis 1 week after a right PAO and 7 months after a left PAO. By 3 months after the second PAO, the patient had no pain or limp bilaterally. **C:** False-profile view of the left hip preoperatively. **D:** False-profile view postoperatively. **E:** False-profile view of the right hip preoperatively. **F:** False-profile view postoperatively.

Just prior to his retirement, Heinz Wagner of Germany stated that rotational osteotomies of the pelvis were the most worthwhile operations he had performed in his illustrious career as both a children's and an adult reconstructive hip and knee surgeon. It was not uncommon in his experience to have an enduring good result 30 years after the osteotomy (personal communication, 1989).

There have been many successful types of rotational pelvic osteotomies introduced and used over the last 40 years, including the spherical dome or dial (Wagner, Ninomiya and Tagawa, Eppright), single innominate (Salter), double innominate (Sutherland), triple innominate (LeCoeur, Hopf, and Steele), and the juxta-articular triple (Tonnis), among others. All share the same main principle of redirecting the position of the acetabulum to reduce sheer forces and decrease compressive forces on the articular cartilage. Rotational osteotomies do not result in an increase of the amount, size, or volume of articular cartilage or supporting bone. The quantity of cartilage that already exists is rotated into a more favorable position to achieve one or more objectives. These objectives include achievement of a more horizontal position of the acetabular sourcil in the frontal plane as visualized on AP radiograph, enhanced appearance of femoral head coverage on the frontal radiograph, and enhanced anterior coverage.

A number of myths exist regarding the capabilities of these procedures. One is the erroneous concept that rotational pelvic osteotomies increase articular cartilage volume or amount. The apparent increase seen on AP radiographs after successful redirections is accomplished at the expense of loss of coverage or contact elsewhere (usually medial and posterior). The losses elsewhere may have implications for future THR as well as for instability of the hip in cases of extreme correction. Another myth is the concept that the hip will be totally normal after the osteotomy. Many hips manifest radiographic evidence of joint space narrowing, early osteophytes, and subchondral sclerosis that reflect some element of permanent and irreversible damage to articular cartilage and the joint environment. Although regression of some of these elements (sclerosis and cysts) may occur after favorable architectural changes, the joint is never as normal as a joint unaffected by dysplasia.

The role of Chiari osteotomy in adult hip surgery has changed, commensurate with the improvement in the reliability of pelvic rotational osteotomies. Whenever a rotational osteotomy can be performed, it is preferable to a Chiari. However, in cases of fixed subluxation in young patients, impressive results lasting many years are possible, frequently aided by concomitant valgus ITO, as previously described.

### UNIQUE FEATURES OF THE PERIACETABULAR OSTEOTOMY

A fundamental difference between the periacetabular osteotomy (PAO) as developed by Ganz et al. (51) in the mid 1980s, and the other rotational osteotomies, is the ability of this technique to achieve three-dimensional freedom of the acetabulum without transection of the posterior column of the ilium. In Figure 104.7, note the superior appearance of the acetabulum on the right side in this 33-year-old woman who had a triple innominate osteotomy of the left hip followed by a PAO several years later on the right. The right side has no residual dysplasia and is 100% free of all symptoms. Three or four 4.5 mm screws achieve secure fixation of the acetabular segment to the ilium above. Full-weight-bearing gait without limp is sometimes possible within 8 weeks of surgery. Further, the segment can be rotated anteriorly as well as laterally to customize the coverage enhancement based on variations of pathology. Importantly, these changes are accomplished without lateralization of the center of rotation of the femoral head. In rare cases, deliberate medial or posterior rotation can be done to correct less common types of dysplasias.

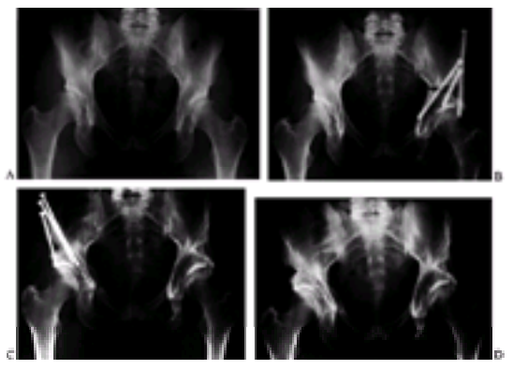

***Figure 104.7.*** Triple (Steele) osteotomy on the left hip and PAO on the right hip in the same patient and by the same surgeon. **A:** AP view of the pelvis in a 33-year-old woman with bilateral hip dysplasia and pain in the left hip. **B:** AP view of the pelvis following left triple (Steele) pelvic osteotomy. **C:** AP view of the pelvis 4 years later following the onset of right-sided hip pain and performance of a right PAO. Patient was working full time without restrictions before 6 months after PAO. Recovery from the triple osteotomy was more prolonged. **D:** AP view of the pelvis 1½ years after the PAO. The patient had occasional symptoms on the left secondary to some restriction of motion, but no pain.

**OPERATIVE TECHNIQUE**

The PAO was conceived by Reinhold Ganz et al. (51) at the Kantonspital in Bern, Switzerland, and was based on their experience in surgery for pelvic fractures. Understandably, the surgical approach was borrowed from that used successfully for complex double-column fractures with mobilization of the femoral neurovascular bundle and the development of distinct surgical “windows” requiring complete reflection of the tensor fascia and gluteal muscles off the lateral wall of the ilium. Although this exposure afforded good access, problems were encountered, including femoral vein thrombosis, a high incidence of heterotopic ossification and long-lasting or permanent limp due to abductor muscle insufficiency, among others.

Murphy and Millis of Boston (110) modified their approach to expose the medial side of the ilium only, avoid- ing stripping the lateral wall of the tensor fascia and gluteal muscles. Matta (personal communication, 1992) devised a double oblique fluoroscopic intraoperative view to permit radiographic visualization of the difficult osteotomy of the ischium without direct surgical exposure through a medial window. Santore and Stevens (personal communication, 1993) perfected the use of grooved subperiosteal retractors to cut the pubic bone with a Gigli saw from the direct anterior approach without access through a medial window. An expanded discussion of the technique for this osteotomy is warranted because of its emergence as the procedure of choice for symptomatic DDH.

- Position the patient supine on a fully radiolucent operating table. Be certain that fluoroscopic visualization of the operated hip is excellent on all views. Do a wide preparation and drape the involved hip to well above the iliac crest. Drape the extremity free (Fig. 104.8).



***Figure 104.8.*** Drape the iliac crest free (right shown here). The planned incision along the anterior iliac crest is outlined.

- Make a longitudinal Smith-Peterson type of incision over the iliac crest and extending several inches distal and lateral to the anterior superior iliac spine (ASIS).
- Incise the deep fascia lateral to the tensor muscle medial border to protect the lateral femoral cutaneous nerve.
- Make an oblique osteotomy of the medial half of the ASIS and reflect the sartorius and iliacus muscles medially in continuity with this bone and each other (Fig. 104.9).



***Figure 104.9.*** Do a splitting osteotomy of the anterior superior iliac spine (ASIS) with the attached origin of the sartorius muscle. The rake to the right is retracting the sartorius medially.

- Incise and detach the indirect and the direct heads of the origin of the rectus femoris and reflect them medially.
- Do not strip any of the muscles from the lateral aspect of the ilium, including the tensor.
- Address the superior pubic ramus first. Expose it with careful subperiosteal dissection, first superiorly, then inferiorly. Protect the obturator nerve and vessels, which lie directly beneath the pubic arch using subperiosteal retractors. Transect the superior pubic ramus with a Gigli saw (Fig. 104.10).



***Figure 104.10.*** Perform an osteotomy of the superior pubic ramus by exposing it through the incision (Fig. 104.8, Fig. 104.9) and placing dual retractors around the pubic bone. A Gigli saw has been passed around the pubic bone and will be used to cut it safely from posterior to anterior.

- Next, address the ischium near its attachment to the body of the ilium 1 cm below the joint. Approach the ischium underneath the iliopsoas tendon and place the cutting edge of a specially designed 40° angled osteotome (Synthes, Paoli, PA) in the proper position under fluoroscopic control using the previously described double oblique view to ensure that the ischial cut does not violate the joint space and is oriented in the correct trajectory. This trajectory is from inferolateral to

superomedial. The ischium is not transected.

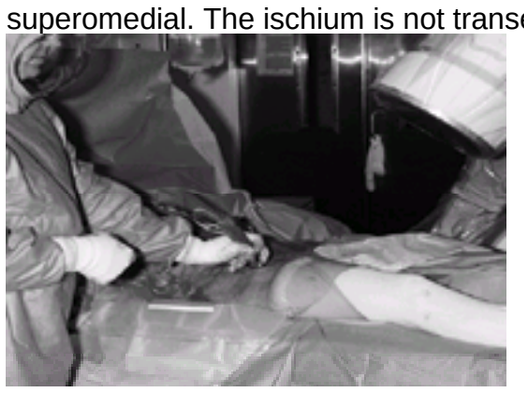

***Figure 104.11.*** For the osteotomy of the ischium, an angled AO (Synthes) osteotome is positioned under fluoroscopic control to cut it partially through from inferolateral to superomedial.

- Cut the ilium using an oscillating saw from the ASIS toward the sciatic notch, stopping 10–15 mm short of the pelvic brim (iliopectinate line) (Fig. 104.12). Then use a curved standard ½-inch osteotome to cut across the pelvic brim as originally described by Ganz et al. (51). Next, use the angled Synthes osteotome to cut parallel to the posterior column intersecting with the previous cut made in the ischium.

***Figure 104.12.*** Cut the ilium with a power saw from just inferior to the ASIS toward the sciatic notch, stopping approximately 15 mm above the pelvic brim, which is marked by the iliopectinate line (refer to Fig. 104.17).

- The final cut frees the acetabulum from its continuity with the ilium. Insert the angled osteotome into the medial osteotomy of the quadrilateral surface and transect the ilium from medial to lateral, carefully avoiding the hip joint.
- Mobilize the free acetabular segment with an osteotome inserted as a lever into the osteotomy and/or with the aid of a Schanz screw inserted into the fragment (Fig. 104.13, Fig. 104.14). Ensure that the fragment is completely mobile and then reduce it back to its original position.

***Figure 104.13.*** After cutting the lamina quadrilatera with an angled Synthes osteotome (not shown), mobilize the acetabular fragment with the same osteotome. The osteotome is shown in the iliac osteotomy with the ASIS just above the osteotome.

***Figure 104.14.*** More extensive anterior mobilization is shown here.

- Arthrotomy of the hip joint may now be performed with optimum timing since recovery of clear fluid suggests that the hip joint has not been penetrated. Inspect the labrum of the hip and resect any tears or detachments (Fig. 104.15). The capsule may be left open to allow assessment of possible impingement of the femoral neck caused by anterior reorientation of the acetabulum.

***Figure 104.15.*** Now re-reduce the acetabulum and perform an anterior arthrotomy to inspect the labrum, which was normal in this hip.

- Reorient the acetabulum fragment to improve both lateral and anterior coverage of the femoral head. This can be continuously monitored under fluoroscopic control using the AP and double oblique views. In the frontal plane, achieve a horizontal sourcil without under- or overcorrection. Anterior coverage enhancement is just as important as the lateral coverage. Multiple attempts are often necessary until optimal radiographic appearance is achieved. Confirm the final position with an AP radiograph before placing definitive fixation.

- Now fix the osteotomy by inserting three or four AO 4.5 or 3.5 mm pelvic screws from the superior iliac crest in an inferomedial direction into the acetabular segment (Fig. 104.16, Fig. 104.17). Whenever possible, direct a screw approximately 145 mm in length into the tear-drop area of the acetabulum at the far medial aspect of the acetabular segment. Be certain that the osteotomy is stable.



***Figure 104.16.*** Internally fix the osteotomy in the corrected position with four 4.5 mm cortical AO (Synthes) screws. This provides very rigid fixation.

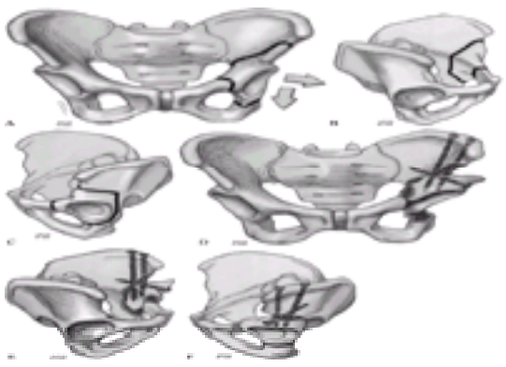

***Figure 104.17.*** Periacetabular osteotomy. Cuts drawn on an AP view of the pelvis for the left hip (**A**). Cuts seen on the inner wall of the pelvis (**B**). Cuts seen on the outer wall of the pelvis (**C**). Osteotomy with screw fixation seen from the front (**D**), inside (**E**), and outside (**F**). The method of screw fixation varies. The senior author (RS) prefers three or four screws from the top of the iliac crest into the acetabular fragment. (From Trousdale RT, Ganz RG. Periacetabular Osteotomy. In: Callaghan JJ, Rosenberg AG, Rubash HE, eds. *The Adult Hip*, Vol. 1. New York: Lippincott-Raven, 1998:792, with permission.)

- Ensure hemostasis, place two drains deep in the wound, and perform a layered closure. Reattach the ASIS osteotomy, which contains the origins of the sartorius and rectus femoris tendons with strong (#5) nonabsorbable suture (Fig. 104.18). Take care to avoid injury to the lateral femoral cutaneous nerve during the fascial layer closure (Fig. 104.19).



***Figure 104.18.*** Appearance of the ilium after repair of the ASIS osteotomy.



***Figure 104.19.*** Final appearance of the repair of the abdominal wall and fascia before skin closure.

Figure 104.20 shows a patient with a history of bilateral Perthes who had already had a contralateral joint replacement. He underwent a combined PAO and trochanteric advancement and by 1 year was working without restrictions and had rare need of a cane.

Figure 104.7 shows a comparison between a triple pelvic (Steele) osteotomy on the left and a PAO on the right by the same surgeon. Note the better correction obtained after the PAO. Recovery after the “triple” was more prolonged than after the later PAO.

**POSTOPERATIVE CARE**

Use continuous catheter epidural analgesia for 3 days. Mobilize patients from bed to chair the day following surgery if they can tolerate it. Start the patient walking with physical therapy as soon as tolerable, utilizing a walker or two crutches to bear the weight of the limb. Physical therapy is not prescribed after discharge from the hospital. Weight bearing as tolerated with crutches is permitted after 6 weeks. Full weight bearing without support is usually achieved at 10–12 weeks after surgery.

We recommend removal of all screws once the osteotomy is fully healed, as they can be a source of discomfort. Very long screws deep within the ilium can eventually fail due to micromotion within the pelvis. Removing these prior to breakage avoids complications that might lead to a later total hip arthroplasty.

Many patients have bilateral dysplasia and require bilateral osteotomies. We suggest spacing these 6–12 months apart so that the initially operated hip is rehabilitated before operating on the second hip.

Figure 104.6 shows a patient with bilateral DDH and classic indications for PAO. She underwent osteotomies 7 months apart and had no pain or limp by 3 months after the procedure.

The Bernese osteotomy can be used to salvage a hip after prior surgeries in specific cases: Figure 104.21 shows a patient who was referred for a revision PAO after failure of an attempted periacetabular procedure 1 year earlier. Figure 104.22(*B*), Figure 104.22(*C*), Figure 104.22(*D*) and Figure 104.22(*E*) shows the use of a PAO to salvage a hip after a prior Chiari on the right (and as a primary procedure on the left).

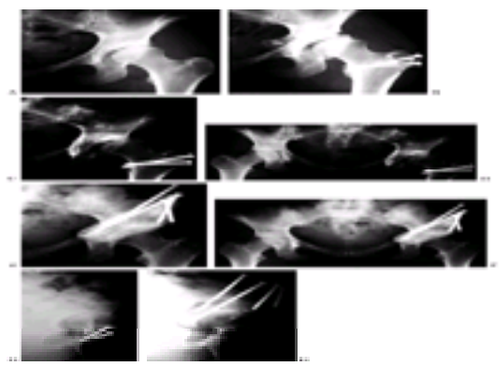

***Figure 104.21.*** Revision of a previous, inadequate PAO. AP view of the left hip in a 31-year-old woman with dysplasia and pain (**A**). This AP view of the left hip shows an attempted periacetabular procedure done elsewhere (**B**). AP views of the hip (**C**) and pelvis (**D**) over a year later show subluxation of the hip with poor coverage and the patient had increasing pain. A revision PAO was done. At 3 months after surgery, the patient was already walking without aids and limping only late in the day. At 8 months after surgery, it is healed (**E**,**F**). False profile view of the left hip preoperative before revision (**G**) and postoperative when healed (**H**).

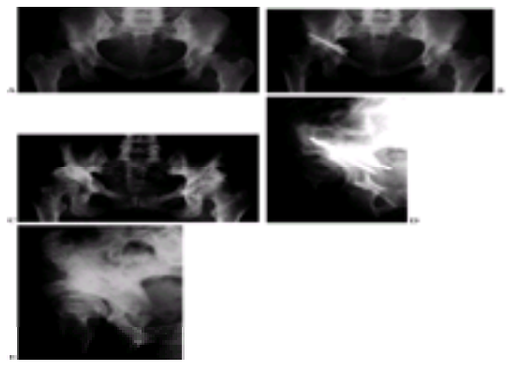

***Figure 104.22.*** PAO salvage of a failed Chiari osteotomy. **A:** AP radiograph of the pelvis in a 37-year-old woman prior to Chiari osteotomy for the right hip done elsewhere. **B:** Postoperative radiograph after the Chiari procedure. **C:** This radiograph of the pelvis is 4 years after a salvage PAO on the right. Patient had no pain and no limp on left but did have a Trendelenberg limp on right. **D:** This false-profile view of the right hip is just prior to salvage PAO. **E:** A postoperative radiograph.

## COMPLICATIONS

Complications are significant in both frequency and severity. The learning curve is steep. Davey and Santore (35) have shown that the incidence of significant complications decreases impressively with increasing experience. A 2.9% incidence of serious complications persists after gaining considerable experience. Life-threatening hemorrhage; intra-articular penetration or fracture; posterior-column fracture; malunion; nonunion; malposition of the socket; hardware breakage; paralysis in the distribution of the sciatic, obturator, or femoral nerves; thrombosis; phlebitis; pulmonary embolization; heterotopic ossification; hardware-related bursitis; numbness in the distribution of the lateral femoral cutaneous nerve; herniation of bowel into the operative field; and vascular injury can occur. Blood loss can be substantial and intraoperative use of the cell saver and postoperative use of reinfusion drains are recommended.

The breadth and seriousness of the potential complications deserve added emphasis, since the operation is ideally suited to young adults with early, often minimal, symptoms. Figure 104.21 shows a 31-year-old woman who was seen after a failed attempt at a dome-type osteotomy. A PAO was done proximal to the previous cuts with an excellent radiographic and clinical result.

The upper age limit for the operation has not been established. The senior author (RS) has performed the operation on patients up to the age of 60. Patients above the age of 50 must be screened very carefully. They should be excellent candidates in terms of all physiologic and radiographic criteria.

## CONVERSION OF FAILED PERIACETABULAR OSTEOTOMY TO TOTAL HIP REPLACEMENT

Unlike the situation with post-Chiari hips, the conversion of a failed PAO to a THR because of progression of arthritis is virtually indistinguishable from a routine primary THR, especially for surgeons who use the posterior approach for THR. One area for particular attention is the anterior impingement in the case of excessive anterior displacement of the osteotomy segment at the time of the index osteotomy. Additionally, after complications such as gross medial or proximal displacement or malposition, major intra-articular fracture or heterotopic ossification, the conversion can be quite difficult (Fig. 104.23).

## COMBINED PERIACETABULAR AND INTERTROCHANTERIC OSTEOTOMIES

A small minority, 10% or less, of cases of adult PAO are significantly aided by adjunctive ITO. However, even in cases of moderate concomitant valgus of the upper femur, PAO alone is usually sufficient and is associated with a much-enhanced speed of recovery. In cases of high valgus neck–shaft angle (greater than 145°), varus with extension helps to restore more physiologic biomechanical parameters, including offset, greater trochanter-tip-to-center-of-femoral-head parallelism and to correct anterior extrusion of the femoral head by virtue of the extension component in the sagittal plane (60). The senior author (RS) prefers to perform a precisely planned ITO first, through a separate straight lateral incision in the supine position, followed by the PAO under the same anesthetic. Figure 104.28(*A*), Figure 104.28(*B*) illustrates a 29-year-old woman from Japan who underwent varus–extension ITO to normalize abductor mechanics, followed by PAO under the same anesthetic. She is asymptomatic, now 6 years after surgery.

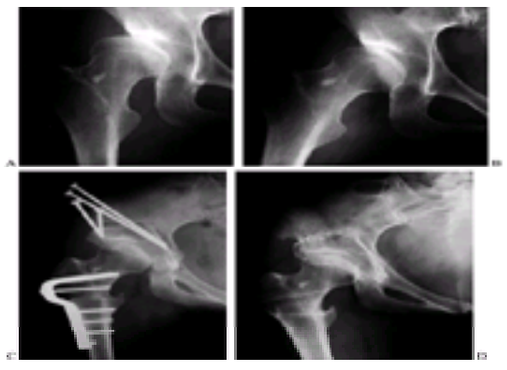

***Figure 104.28.*** Combined varus ITO and PAO. **A:** AP view of the right hip of a 29-year-old woman with several years of right hip pain. **B:** Abduction–internal rotation AP view of the right hip prior to surgery. **C:** AP view of the right hip following PAO and simultaneous varus–extension ITO. The patient required 4 months of rehabilitation to achieve a normal unassisted gait. **D:** AP view of her right hip 2 years later, when she had no limp and was playing tennis.

Currently, we would do the PAO alone and have a very low incidence of combined ITO/PAO. Up to 6 months or more is required before normal walking resumes, and limp may persist for up to a year after the surgery. Circumstances that add to the appeal of the ITO include a significant, ipsilateral leg-length inequality and/or limb malrotation. The varus osteotomy can be planned to equalize the leg lengths. A transverse, non-wedge-resecting technique allows full correction of any malrotation. When the leg lengths are equal preoperatively, an open hinge technique for the varus should be utilized, which minimizes the shortening inherent in varus osteotomies. An intraoperative adjunctive ITO is rarely, if ever, indicated. A better strategy would be to readjust the position of the PAO to maximize coverage.

**PERIACETABULAR OSTEOTOMY FOR LEGG-CALVÉ-PERTHES DISEASE**

The combination of moderate acetabular dysplasia and high-riding greater trochanter is seen in adults as a sequela to childhood Perthes disease (11). Options for treatment include lateral–distal advancement of the greater trochanter alone, ITO of the upper femur alone, PAO alone, or a combination of PAO of the acetabulum and distal–lateral advancement of the greater trochanter. The preference of the senior author (RS) has been the latter option, which addresses the two principal features responsible for disability: the acetabular dysplasia and the dysfunction of the abductors related to the high-riding trochanter. A unique technical consideration in this subset of patients is the close anatomic relationship of the lesser trochanter to the ischium. This requires that the ischial osteotomy be done on the medial surface of the iliopsoas tendon. Great care must be taken to avoid injury to the neurovascular structures in this region. The trochanteric osteotomy must be done prior to the repositioning of the acetabular segment into its new position. Otherwise, the position of the trochanter limits your ability to laterally rotate the acetabular segment fully. Once the periacetabular segment has been rotated and fixed, the trochanter is advanced and fixed.

Acceptance criteria include minimal central head fragmentation, good mobility of the hip, and good joint congruence. Blood loss is greater and postoperative rehabilitation more difficult after this combined procedure than after isolated PAO alone. Although trochanteric advancement alone would address the abductor insufficiency and augment endurance for walking and standing, the opportunity to combine definitive correction of the dysplasia with the biomechanical enhancement of the abductors in one surgery and one rehabilitation period is a significant advantage of this strategy.

Figure 104.20 shows a 52-year-old man with disabling pain and abductor weakness. PAO and trochanteric lateralization were combined under one anesthetic. He returned to full-time work 8 months after surgery.

**RESULTS**

The results of PAO for arthritis secondary to dysplasia at 4 years after surgery (range, 2–8 years) are excellent if minimal (Tonnis grade I) arthritis was present at the time of surgery (159). In this subgroup, Harris hip score improved from 58 to 94. No patient required conversion to a total hip arthroplasty. Conversely, in the nine hips with Tonnis grade III changes preoperatively, the average Harris score improved only modestly, from 59 to 67. Five (56%) were converted to THR and 8 of 9 (89%) had a Harris score below 70 by the time of final follow-up. Therefore, patients with evidence of grade III (severe) arthritis are not suitable candidates, based on an 88% failure rate within 5 years of the osteotomy.

In the moderate arthritis subgroup (grade II Tonnis), the average Harris score went from 67 to 89 and one of the 18 was converted to a THR. Overall, there were 31 secondary operations in this series of 42 patients (42 hips), for a total of 73 operations in the 4-year (average) period including the index osteotomy, indicative of the nontrivial nature of the decision to perform major pelvic osteotomy in adults.

A more recent 11-year (average) follow-up of the first cohort of 75 periacetabular osteotomies by the group in Bern, Switzerland, revealed a 73% incidence of good or excellent results (141). The average age of the patients was 29 (range, 13–56) and 18% had been converted to THR, with 49 subsequent operations in the 71 hips available for follow-up. Unfavorable outcomes were associated with older chronologic age at time of surgery, presence of significant arthritis, and insufficient anterior coverage at the time of surgery.

Matta et al. (90) reported on a U.S. series of 78 hips in 70 patients, with a minimum follow-up of 2 years on 66 (85%) of the 78 hips (90). The average age was 33.6 (range, 19–51) with 17% excellent, 59% good, 12% fair, and 12% poor at the follow-up (averaging 4 years after surgery). There were 17 subsequent procedures (26% incidence) including 10 adjunctive intertrochanteric osteotomies, five THRs, and two resections of heterotopic ossification. At the time of submission for publication, there were three more pending conversions to THR, for a total conversion rate of 8 of 66 (12%).

A Boston series of 130 patients (135 hips) with minimum follow-up of 2 years (range, 2–7) demonstrated a rate of conversion to THR of 4%. The average age of patients in the series was 29 (range, 10–55) (111).

Jeffrey Mast, one of the codevelopers of the procedure, reported on the minimum 2-year follow-up of 123 procedures in 115 patients (161). Overall, 83% of the hips were rated as good or excellent at final follow-up. The average preoperative Harris score of 65 increased to 89 at final follow-up. As in other series, there were a high number of subsequent surgeries, that is, 70 in 44 patients, including seven THRs at an average of 41 months after the PAO (5.6%). The frontal plane center–edge angle of Wiberg increased from 6° (range, –20° to +20°) to 29° (range, –10° to +60°). The anterior center–edge angle of Lequesne (80) increased from an average of 3° to an average of 23°. In this series, PAO alone or in combination with ITO or trochanteric advancement was utilized successfully in multiple underlying conditions, including Legg-Calvé-Perthes disease (10 hips), Charcot Marie Tooth disease (four hips), epiphyseal dysplasia (three hips), SCFE (one hip), posttraumatic dysplasias (one hip), and postinfectious dysplasia (one hip).

Tonnis reported intermediate-term follow-up data on 216 of 1,400 juxta-articular pelvic osteotomies, 138 in adults, at an average 7.3 years after surgery (157). Although pain relief was seen in 82%, Trendelenburg gait was common and 81% of adults had no change or worsening of limp compared with preoperative status. Best results were seen in patients with concentric, nonarthritic hips preoperatively.

Although effective at short and medium follow-up, PAO is technically demanding, associated with a relatively high incidence of perioperative complications and reoperations, and should be utilized with caution in patients with advanced arthrosis on screening radiographs.

## SLIPPED CAPITAL FEMORAL EPIPHYSIS

The treatment of SCFE is discussed in Chapter 172. Several authors have reported on the acute treatment of SCFE with immediate corrective ITO accompanying the pinning of the slipped epiphysis (8,134). This approach has been abandoned because of excessive occurrence of AVN and chondrolysis (47,50,163). Most patients with SCFE are now treated with pinning *in situ* (29), and any resulting deformity is addressed later, depending on its severity and the symptoms (144). Because of the high risk of early-onset degenerative arthritis, treatment of a symptomatic moderate to severe SCFE is better performed early, once the child has matured and results of initial treatment are evident. This allows for maximal remodeling and preempts years of abnormal biomechanics that can cause significant cartilage damage (134). Occasionally, the deformity of relative greater trochanteric overgrowth can occur because of proximal femoral physeal arrest following an SCFE (71). This may be amenable to a simpler trochanteric osteotomy, as in the patient in Figure 104.24, with advancement of the greater trochanter.

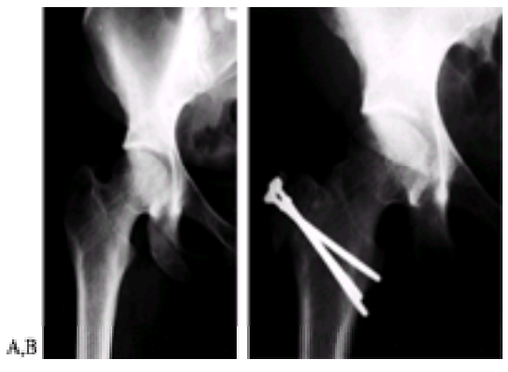


***Figure 104.24.*** Isolated advancement of the trochanter for SCFE. **A:** AP view of the right hip in a 36-year-old woman with a history of a SCFE treated in adolescence. Patient had lateral hip pain and a Trendelenberg limp that was worse when she was fatigued. **B:** AP view of the right hip 1 month after isolated trochanteric advancement. By 9 months after surgery, the Trendelenberg limp was gone, although the patient had some end-of-day fatigue.

### INDICATIONS

The typical deformity seen following an SCFE is a posterior and varus (medial) displacement of the epiphysis relative to the rest of the femur, with the posterior displacement usually the most significant. Additionally, the femoral shaft is relatively externally rotated as part of the deformity. The external rotation is directly related to the posterior slip of the epiphysis. When the slip angle is 30° to 60°, correction of all three components of the deformity is preferred, utilizing an ITO. The angulation of the ITO is flexion and valgus with internal rotation of the distal fragment as needed. The so-called triplane ITO was proposed by Imhauser (68) and introduced to the English literature by Southwick (144). It is, in fact, a biplane ITO with additional rotational correction included when necessary.

### PLANNING AND OPERATIVE TECHNIQUE FOR THE IMHAUSER OSTEOTOMY

Planning for the operation includes careful documentation of the slip angle on biplane radiographs. On physical examination, document the range-of-motion deficits, leg lengths, and positions of comfort. On radiographs, confirm the mobility and congruency of the hip in adduction and extension (the relative direction that the femoral head will need to move after a valgus-flexion ITO). These measurements determine the degree of correction that will need to be made in each plane.

The procedure is similar to a valgus ITO for arthritis, which is described in detail in the next section of this chapter. The following details require attention:

- The flexion component of the osteotomy corrects for the posterior slip of the epiphysis. This requires insertion of the blade plate so that the chisel is angled with the distal aspect rotated anteriorly as it is inserted into the proximal fragment. Correction of the posterior displacement with an anterior repositioning of the proximal segment will result in the plate sitting flush on the lateral surface of the femoral shaft.
- In this same osteotomy, orient the cuts to produce a closing wedge laterally to correct the varus deformity. A full lateral wedge resection, equal to the magnitude of the planned valgus, is necessary to avoid lengthening of the limb.
- To measure the rotational correction, insert parallel Kirschner wires (K-wires) above and below the osteotomy for referencing. Even more important, though, is to monitor the patella for anterior position prior to fixation.
- Check the range of motion of the hip after fixation is in place to identify any bony blocks to motion, especially in flexion or adduction. If present, this may require excision of impinging bone or repositioning of the fragments. With detailed preoperative planning and technique, surgical complications such as limb-length inequality, rotational or angular malposition, and nonunion can be minimized.

### RESULTS

Imhauser (68) reported in 1977 the results of 68 hips in 55 patients with 11- to 22-year follow-up. Of these, only 27% showed early degenerative changes and one had severe coxarthrosis and complained of pain. Five hips had significant limitation of motion, with one patient dissatisfied by this. Imhauser felt that these results represented a large improvement over historical controls.

In 1967, Southwick (144) reported on a series of 55 patients, with 28 hips having greater than a 5-year follow-up. He did not perform any *in situ* pinning of the epiphysis in the osteotomy group but used spica casting postoperatively for all acute slips. There were no cases of AVN in the 55 patients. Three hips required a second operation, all for bony impingement blocking either adduction or flexion; all of these had subsequent excellent results. All hips experienced ½–1 inch of shortening. Southwick stated that slips greater than 60° could not be fully corrected because of excessive shortening of the femur. In those patients with more than a 5-year follow-up, he reported 21 excellent, five good, and two fair results.

In 1996, Schai et al. (134) reported on 51 patients with unilateral chronic slips with angles of 30° to 60° who were treated by early corrective ITO. The average patient age was 12.6 (girls) to 14.6 years (boys), and mean follow-up was 24 years, with the surgery done an average of 6 months after the first symptoms. At the latest exam, 55% of the patients had no symptoms or radiographic deterioration, 28% had moderate osteoarthritis, and 17% had severe osteoarthritis. The authors stated that this 17% represents a significant improvement over what they believe to be a 28% to 40% chance of developing early onset degenerative arthritis if these severe slips are left uncorrected.

Several studies have helped to define the natural history of SCFE and serve as the control for most of the series in the literature. Goodman et al. (53) in 1997 studied more than 2,600 skeletons and found that the morphology of the hip after the slip was a major risk factor for the development of high-grade osteoarthrosis. In a Swedish study (118) of 30 untreated grade 3 slips (see Chapter 172) with at least a 20-year follow-up, 57% had pain and 43% had limitations in walking activity, despite an average age of less than 40 years. In a distillation of these studies, Aronson et al. (8) concluded that by the fourth decade, severe SCFE increases the risk of hip osteoarthritis by a factor of 20 over the normal population. Aronson et al. (8) reported on a series of Bombelli's patients, which included 24 grade 2 slips corrected by primary triplane ITO. The group with more than a 2-year follow-up had a 39% gain in total arc of motion after having had a preoperative mean slip angle of 58°. Less aggressive bony wedge removal than that described by Southwick (144) resulted in fewer problems with limb shortening. All were pain free at 2–10 years follow-up, with no cases of AVN, chondrolysis, infection, or nonunion.

## INTERTROCHANTERIC OSTEOTOMY FOR OSTEOARTHRITIS

Total hip replacement is the standard surgical treatment for osteoarthritis of the hip against which other surgical options must be weighed. Even with modern advances, however, hip replacement cannot yet be offered to younger adults routinely. Early failures, primarily due to rapid wear and loosening, have been well documented in patients younger than 50 years (30,40,41,155). Proximal femoral osteotomy therefore remains an important and effective treatment option for the painful osteoarthritic hip in adults.

The techniques for ITO have descended from Pauwels in Germany (119) and have been followed or modified by Müller (105), Bombelli (16,17,18 and 19,132), Wagner and Holder (166), and others in Europe and many countries around the world (1,6,7,9,15,23,32,38,52,54,57,58,65,69,70,72,77,82,84,94,95,103,104,106,121,123,124,127,133,135,137,138,163,172,174). ITO has a record of success in the treatment of osteoarthritis of the hip, whether primary or secondary. Most authors have reported better results from ITO in patients with secondary hip arthritis, such as from dysplasia, SCFE, or Perthes disease (77,86,87,99,103,104,122,127). These patients have a definable biomechanical predisposition to develop degenerative arthritis. Because the predisposing deformity can often be improved or even completely normalized by ITO, it is understandable that results have been superior in this group. Surgical intervention may both relieve pain and decelerate further deterioration of the hip.

Historically, groups of patients who underwent varus ITO have had better long-term results than those who had valgus ITO. The selection criteria for those receiving a varus osteotomy, however, often resulted in these patients being younger, with less radiographic arthrosis and better joint congruity. Therefore, patient selection has been biased, making comparisons between these procedures in the literature difficult. In fact, with the advent of modern periacetabular rotational osteotomies, the indications for isolated ITO in the adult have narrowed considerably, particularly for varus ITO. Currently, the most common osteotomy of the proximal femur indicated for significant adult arthritis is a valgus–extension ITO. *Valgus* and *extension* refer to the position of the distal fragment at the osteotomy site. Therefore, a valgus–extension ITO moves the proximal fragment and the hip joint itself toward adduction and flexion. For this reason, therefore, passive positioning of leg in adduction–flexion preoperatively anticipates to some degree the status of the hip after a valgus–extension osteotomy.

### PATIENT EVALUATION AND PLANNING

Several aspects of the patient workup merit special attention when considering a varus or valgus ITO. In addition to performing a routine evaluation, determine the position of comfort by history and exam. Relief of pain in adduction suggests improvement from a valgus osteotomy. Perform functional radiographs in abduction and adduction, and/or examine the patient under fluoroscopy. With the hip positioned to replicate the planned effect of an ITO, joint congruency and the remaining joint space should be improved, or at least similar. A false-profile view will reveal any deficiency in anterior coverage, which may favor the addition of an extension component to the osteotomy.

Carefully document the actual and apparent limb-length inequality because there is a profound potential effect of ITO. Given equal leg lengths preoperatively, routinely remove wedges from the osteotomy site with valgus osteotomies, or preserve maximal length in varus ITO, using no wedges at all. Preserving or improving limb length almost always takes precedence over the goal of obtaining total apposition of the raw cut surfaces at the osteotomy site.

A full-length standing radiograph can be helpful to document overall limb alignment preoperatively by displaying the mechanical axis (see Chapter 26 and Chapter 32). All things being equal, lateral shaft displacement will accompany a valgus ITO, and relative medial displacement of the distal fragment occurs with a varus ITO. This is necessary to accommodate future total hip stem insertions and minimize any frontal plane mechanical axis derangement, which may predispose to later knee (or ankle) problems. Nevertheless, planning for the placement of a future total hip stem generally takes priority over shaft displacement when considering final position of the fragments after osteotomy. The patient in Figure 104.25(*A*), Figure 104.25(*C*), Figure 104.25(*E*) demonstrates the importance of limb-length planning. Her leg was 1½

inches short before, but equal in length and pain free after a valgus ITO with no wedge and lateral shaft displacement.

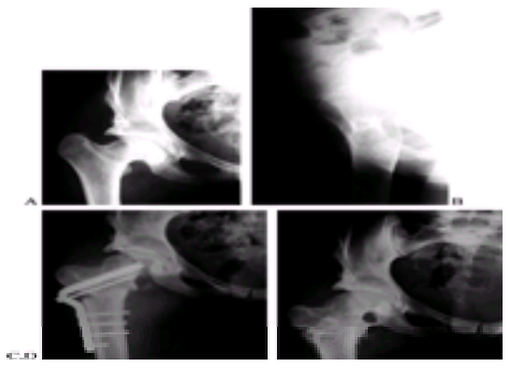

***Figure 104.25.*** Leg-length discrepancy and arthritis treated with valgus ITO. This 32-year-old woman with a history of hip dysplasia, childhood hip surgeries, and treatment-related osteonecrosis. **A:** AP view of the right hip. **B:** False-profile view. The right lower extremity was 1½ inches (3.75 cm) short. **C:** AP view of the right 6 months after a valgus ITO. **D:** AP view of the right hip 15 months postoperative. After hardware removal, the patient had no pain, a 95° flexion arc, and equal leg lengths.

## VALGUS–EXTENSION INTERTROCHANTERIC OSTEOTOMY

The most common indication for ITO is for the adult sequelae of DDH. Bombelli (16,17,18 and 19) has studied and categorized the morphologic features of osteoarthritis of the dysplastic hip, including a nomenclature for the osteophytes that develop. The vast majority of patients (95% of Bombelli's valgus–extension series) have superolateral rather than medial degenerative changes. The superolateral group also had the best results in Bombelli's series as well as those of others (54,77).

The rationale of the valgus–extension osteotomy is to utilize the noninnervated medial “capital drop” osteophytes as a new fulcrum along with the “floor” osteophytes of the acetabulum. This more medial fulcrum acts as a new center of rotation for the hip joint. Lateral impingement is reduced, and weight-bearing forces are moved away from the painful superolateral femoral head and toward the medial osteophytes, and the lever arm of the body weight is reduced. “Roof” osteophytes also play a role. The additional extension component to the osteotomy allows improved anterior coverage of the femoral head and elimination of any fixed flexion contracture. Extension, which refers to the relative position of the distal fragment at the osteotomy site, is therefore “apex-anterior.” Ideally, these features improve joint congruity and the radiographic joint space, as well as increasing the weight-bearing surface area. In patients with some flexion (with or without adduction) contracture, a valgus–extension ITO moves the restricted anatomic range of motion closer to the functional range of motion needed for daily activities. This reduces a major source of pain and impingement. The extension component also relaxes stresses of hyperlordosis on the lumbar spine and often permits patients to rest without pain in the supine position for the first time in years.

### *Indications and Contraindications*

Indications and contraindications for valgus–extension ITO are listed in Table 104.3. Figure 104.26 shows a patient who had a valgus ITO on the left with later recurrence of some pain at 7 years. He had a mild valgus ITO on the right for protrusio-pattern arthritis.

| |
|---|
| *Indications* |
| Pain due to stress overload or secondary degenerative arthritis of the hip |
| Physiologic age less than 50 years, or total hip arthroplasty otherwise inappropriate |
| Flexion arc of at least 60° (45° to 80°, depending on author) |
| Must have at least 15° or more of passive adduction for a valgus or 15° of passive abduction for a varus osteotomy |
| Equivalent or improved hip joint congruency on functional radiographs or fluoroscopic exam in adduction (valgus) or abduction (varus) with or without flexion |
| Pain improved in adduction (valgus) or abduction (varus) with or without flexion |
| Motivated patient, able to understand the benefits and limitations of ITO |
| *Contraindications* |
| Excessively stiff hip |
| Obesity (body-mass index > 35) (criterion of senior author, RS) |
| Inflammatory arthritis |
| Incongruency, made worse with adduction if valgus ITO (planned abduction for varus ITO) |
| Other surgery is more appropriate, for example, where the primary deformity is acetabular and is amenable to pelvic osteotomy |
| Cigarette smoking |
| *Relative contraindications* |
| Mild obesity (body-mass index > 30, < 35) (criterion of senior author, RS) |
| Older than 70 years of age |
| Heavy laborer |

***Table 104.3. Indications and Contraindications for Valgus (and Varus) Extension Intertrochanteric Osteotomies***

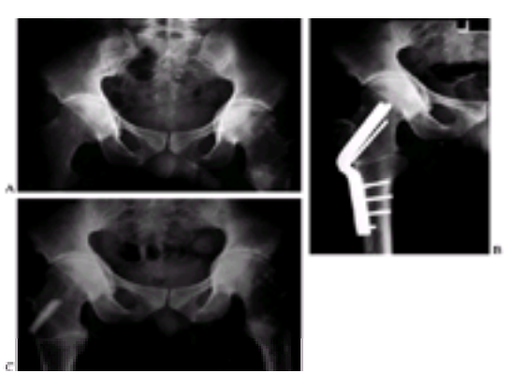

***Figure 104.26.*** Arthritis with bilateral protrusio acetabulae treated with a valgus ITO. **A:** AP view of the pelvis in a 28-year-old with a history of a left ITO done elsewhere 4 years earlier with initial pain relief. **B:** AP view of the right hip early following a mild valgus–derotation right ITO. **C:** AP view of the pelvis 1 year after surgery. By 2½ years, the patient rated the right hip as “excellent,” while symptoms had recurred on the left.

### *Operative Technique*

- Position the patient supine with the operative hip at the edge of a radiolucent operating table. Place a bump under the sacrum and prepare and drape the hip and leg free.
- Perform a lateral approach to the proximal femur through a straight lateral incision, or one that curves anteriorly in the proximal limb if access to the hip joint is needed.
- Reflect the vastus lateralis muscle anteriorly from the posterolateral aspect of the femoral shaft, and release the origin from the vastus tubercle. The femoral neck need not be routinely exposed if good fluoroscopic images are obtained.
- Slide a K-wire along the anterior surface of the femoral neck to mark the anteversion of the femoral neck.
- Mark the site of the chisel insertion by drilling a transverse 7/64-inch K-wire at the level of the vastus tubercle, (usually) parallel to the first K-wire and at an angle in the frontal plane that corresponds to the preoperative plan. Confirm by fluoroscopy.
- Generally, we use a 120° or 130° plate for a valgus ITO. For a 30° valgus correction with a 130° plate, insert the wire at 80° from the lateral cortex of the shaft and parallel to the femoral neck pin on the lateral view (Fig. 104.27). Make fine adjustments to the start point and lateral position based on AP and lateral imaging. The wire should be in the center or slightly inferior portion of the neck on the AP view, and in the center of the neck on the lateral view. The greater trochanter is posterior, so the blade should enter anterior to the midtrochanteric line to avoid exiting the posterior femoral neck.

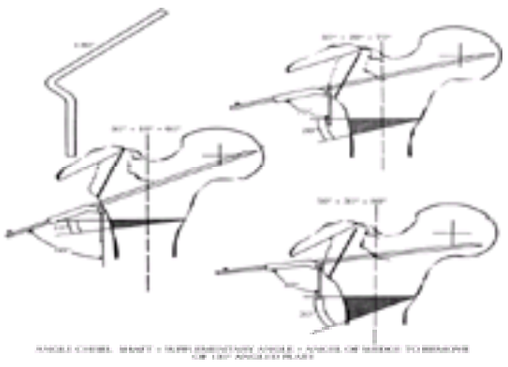

***Figure 104.27.*** Classic Bombelli geometric preoperative planning strategy for 10°, 20°, and 30° valgus osteotomies, using the 130° angled plate. (From Bombelli R, Aronson J. Biomechanical Classification of Osteoarthritis of the Hip. In: Schatzker J, ed.*The Intertrochanteric Osteotomy.* New York: Springer-Verlag, 1984:115, with permission.)

- Drill in a final reference K-wire perfectly parallel to the wire marking the course of the blade, but 1–2 cm superior to it in the greater trochanter. This will help guide placement of the seating chisel if the initial wire loosens or needs to be bent or removed. Remove the initial extraosseous femoral neck wire.
- Clean the blade insertion site of any remaining soft tissue.
- Prepare the lateral cortex for the seating chisel using the AO (Synthes) 4.5 mm triple drill guide in the site of the second K-wire and rotated posterior to the femoral shaft for the desired amount of extension. Confirm that the passage for the chisel through the neck will be safe by checking a lateral radiographic view with drill bits in the outer holes of the triple guide. Use the router as needed to further develop this opening in the outer cortex to prevent bone splintering or incarceration of the seating chisel.
- Now slowly impact the seating chisel, parallel in both planes to the reference K-wire and rotated posteriorly for the desired extension component. Preset the attached adjustable angle guide on the chisel to be parallel to the femoral shaft to monitor the frontal plane insertion angle, that is, 80° to the shaft. Check multiple AP and lateral images during insertion.
- Back the chisel out several times as it gets deeper, to prevent incarceration.
- Prior to doing the femoral osteotomy, score the anterior cortex longitudinally as a reference for rotation, or insert reference K-wires above and below the osteotomy.
- Leaving the chisel in place, perform the osteotomy 1.5 cm below the chisel, 90° to the shaft. The preoperative plan should place the osteotomy at the upper border of the lesser trochanter. Cut slowly with an oscillating saw using retractors to protect the posterior soft tissues. Use copious irrigation to prevent overheating. Adduct and externally rotate the leg vigorously after the osteotomy. This permits access to the iliopsoas tendon insertion into the lesser trochanter. This is released from the lesser trochanter with the electrocautery device.
- Next, correct the rotation prior to removing any bone wedges.
- Then use the oscillating saw to remove a biplanar wedge of appropriate size from the proximal end of the distal fragment. For example, if 30° of additional valgus and 10° of extension of the proximal fragment were desired, a wedge that combined these two amounts would be removed. The cuts can be made sequentially rather than as a single cut; it is technically easier to do two separate cuts but more bone is usually sacrificed. The location of the apex of the wedge removed relative to the medial-lateral width of the femur determines the degree of apposition of the surfaces of the osteotomy and the gain in length. Placing the apex at the medial cortex maximizes the contact area in the osteotomy and minimizes the gain in length.
- Remove the seating chisel and carefully insert the blade plate by hand along the same path. Impact to final depth while checking images in two planes. Lateralization of the shaft is built into the selected blade plate according to preoperative planning, but it can be fine-tuned at this stage by the final depth of blade insertion. For instance, if the plan calls for 15 mm of lateral shaft displacement, and the seating chisel depth of insertion was 70 mm, use an 85 mm 130° plate to achieve full insertion and 15 mm of lateral shaft displacement.
- Insert a 4.5 mm cortical screw into the head fragment through the most proximal hole in the plate before use of the compression device.
- Without using excessive force on the implant, manipulate the fragments and dissect soft tissues as needed to allow easy apposition of the bone ends. Before osteosynthesis, resect any planned wedges from the proximal surface of the distal fragment.
- Apply a Verbrugge clamp (Synthes, Paoli, PA) and approximate the plate to the lateral cortex of the shaft. With the osteotomy reduced, tighten the clamp. Pay attention to the displacement in the sagittal plane to avoid creating difficulties with future femoral stem placement.
- The calibrated compression device is now used. Avoid aggressive compression, which may place the lateral bone bridge at risk. Make sure that the patella is in an anterior position to control leg rotation.
- Gently flex the hip and knee to confirm normal rotational alignment.
- Insert one or two screws in the side plate. Check images in two planes for implant position and fragment alignment. If satisfactory, then complete screw insertion.
- Use any removed bone as graft around the osteotomy after thorough irrigation.
- Insert a drain and close the wound in layers.

### *Postoperative Care*

Postoperatively, initiate physical therapy with toe-touch weight-bearing the day after surgery. Do not allow straight leg raises or active abduction exercises during the initial 6 weeks. Begin weight bearing with two crutches at 6 weeks after surgery and keep the patient bearing only partial weight until bony healing and strength allows transition to one crutch or cane, usually between 12 and 14 weeks. We remove the implants at 12–24 months postoperatively.

## VARUS–EXTENSION INTERTROCHANTERIC OSTEOTOMY

Isolated varus ITO is rarely performed now because most patients previously selected for varus osteotomy are usually candidates for a PAO. Some patients with acetabular and femoral deformities may require both procedures. Indications for an isolated varus ITO include minimal femoral head deformity and little or no acetabular dysplasia, a valgus neck–shaft angle, signs of early lateral joint arthritis, and improved joint congruency on abduction radiographs (99). Medial displacement of the femoral shaft has been suggested in the past as the most important part of an ITO (37,95,127). Experience over the past 20 years, however, has shown that good results do not depend on medial displacement, and that problems with healing as well as with future femoral stem placement increase with the degree of displacement. In fact, deliberate medial displacement of the distal fragment is strongly contraindicated for this reason.

Varus ITO has several drawbacks. Significant shortening of the leg is guaranteed if wedges are resected. An opening wedge technique can preserve some length but is associated with a longer time to complete bony union. A Trendelenberg gait is common and may persist permanently. Simultaneous or staged osteotomy and distal transfer of the greater trochanter may be required to combat abductor dysfunction. A bulge from the prominence of the greater trochanter due to varus positioning can be undesirable and can predispose to bursitis over the plate and trochanter. A longer period of rehabilitation should be anticipated following a varus ITO. Figure 104.28 shows a case of combined varus ITO with PAO. The patient had a 4-month rehabilitation to a normal unassisted gait and was playing tennis with no limp at 1 year.

### *Indications and Contraindications*

The indications and contraindications for varus–extension ITO are listed in Table 104.3.

### *Operative Technique*

The surgical technique for varus–extension ITO is similar to that for valgus–extension ITO, but there are some significant differences.

- Position the patient, expose the hip, and insert guide wires in a fashion similar to that described previously for the extension–valgus ITO.
- Generally, a 90° blade plate is utilized for a varus ITO. For a 15° varus correction with this plate, insert the guide wire at 75° from the lateral cortex of the shaft and parallel to the femoral neck pin on the lateral view (Fig. 104.29). Make fine adjustments based on AP and lateral imaging. The wire should be in the center or slightly inferior portion of the neck on the AP, and down the center of the neck on the lateral view. The greater trochanter is a posterior structure, so the blade should enter anterior to the midtrochanteric line to avoid exiting the posterior femoral neck.

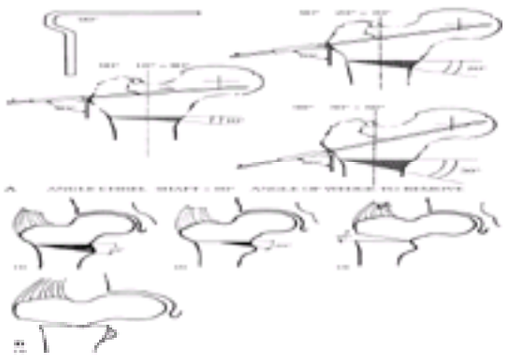

***Figure 104.29.*** **A:** Use of AO (Synthes) chisel device and geometry for 10°, 20°, and 30° varus osteotomy. Rarely are varus osteotomies of greater than 15° indicated. **B:** Varus ITO: (*1*) full wedge, (*2*) partial wedge, (*3*) no wedge. No wedge with medial displacement and impaction (*4*) is the authors' preferred method. (From Bombelli R, Aronson J. Biomechanical Classification of Osteoarthritis of the Hip. In: Schatzker J, ed. *The Intertrochanteric Osteotomy.* New York: Springer-Verlag, 1984:129,130, with permission.)

- Insert a final reference K-wire perfectly parallel to the wire marking the course of the blade, but 1–2 cm superior to it in the greater trochanter. This will help guide placement of the seating chisel if the above wire loosens or needs to be bent or removed. Remove the initial extraosseous femoral neck wire.
- Prepare the insertion site for the blade plate as described for the extension–valgus ITO and insert the chisel.
- Leaving the chisel in place, perform the transverse osteotomy 1.5 cm distal to the chisel using an oscillating saw as described previously.
- Without wedge resection, impaction and compression of the medial cortex of the proximal fragment into the canal of the distal fragment can provide adequate bone contact without further reduction in length from wedge resection.
- Carefully control rotation of the distal segment.
- Any additional medial displacement of the shaft, beyond what occurs as a consequence of pure *in situ* varus, is avoided, to facilitate future THR stem insertion.
- Insert the blade plate and secure it to the shaft of the femur as described previously. Then use the compression jig.
- Gently flex the hip and knee to confirm that normal rotational alignment has been maintained.
- Insert one or two screws. Check images in two planes for implant position and fragment alignment. If satisfactory, then complete screw insertion.
- Irrigate the wound, insert a drain, and close the wound in layers.
- Postoperative procedure is similar to that of the extension–valgus osteotomy already described.

### RESULTS

The experience with ITO gained in the past four decades has helped to define the modern indications and technique for the procedure. Good long-term results are particularly sensitive to proper patient selection, preoperative planning, and intraoperative technical details. Despite the success and ongoing advances in total hip arthroplasty, there is growing evidence supporting the continued viability of ITO as an important treatment option for arthritis of the hip. In 1980, Morscher (103) reviewed the results of 263 patients at his own institution and compared them with the results of the Swiss multicentric study of more than 2,200 ITOs from 1970. Sixty percent of his patients were more than 50 years old. Sixty-eight percent of patients with arthritis secondary to dysplasia had a varus ITO, with good to excellent results in 88%. They performed varus osteotomies in patients with lateral joint space narrowing and sclerosis, minor head deformities, and congruency in abduction. Valgus ITOs were done for pronounced head deformities and congruency in adduction. Summarizing their overall results, they had excellent long-term outcomes in one-third of all patients and satisfactory results in another third; one-third eventually needed total hip arthroplasty. Additionally, they noted that the group of long-term failures were considered failures early, although many went more than 5 years before conversion to an artificial joint.

Langlais et al. (77) reported the results of 150 valgus–extension ITOs in patients with severe arthritis. Mean follow-up was 6 years, and 45% were older than 65 years. In patients under 50 years at the time of surgery, with secondary arthritis, 83% were pain free at the 10-year follow-up, with 77% good or excellent results. Overall results were good in 68% at the 3-year follow-up and 62% at the latest follow-up. Results for patients with concentric hips and primary osteoarthritis were only half to two-thirds as good as for posttraumatic or other secondary arthritis. Radiographic improvement of the joint space was seen in 60% of all patients.

Maistrelli et al. (87) published the results of 277 valgus–extension osteotomies in patients with a mean age of 52 years. At 11–15 years of follow-up, they reported 67% good or excellent results. Results were better in those under 40 years old (76% good or excellent). Patients with unilateral disease had better results (77% good or excellent) than those with bilateral disease (40% good or excellent). Good results were obtained in 68% if preoperative flexion was 60° or more compared to only 31% if flexion was less than 60°. As with the preceding study, a mechanical etiology for arthritis predicted results almost twice as good (71% good or excellent) as for patients with primary arthritis (42% good or excellent). Maistrelli et al. (87), Bombelli et al. (18,19), and others (9,23) have recommended a minimum biplane correction of 20° to obtain their expected results. Santore and Bombelli (132) reported the results of 45 patients with a mean age of 50 years. At the 11-year (average) follow-up they had 75% good to excellent results, which included 35 valgus and 10 varus ITOs. The average Harris hip score increased from 44 to 84. Unlike in previous reports, older patients or those with preoperative hip stiffness did not have worse outcomes.

There have not been any recent large series reporting on varus ITO, in part because of the success of rotational pelvic osteotomies. Most reports include a combination of pelvic and femoral varus and valgus osteotomies, although when done for arthritis, an extension component has usually been combined with both types. Morscher's (103) summary of the large Swiss series reported the varus ITO results separately, with nearly 90% good to excellent long-term outcomes. Detenbeck et al. (38) reported a series of 59 ITOs according to the method of Pauwels in patients with a mean age of 57 years. Results at 2½ years were satisfactory in 80% (32 excellent, 15 good). The majority of patients had a varus procedure, and these results (89% satisfactory) were superior to the results in valgus osteotomy (65% satisfactory). These results cannot be directly compared because of the different selection criteria for each group. In a more recent report, Iwase et al. (70) followed 110 hips with dysplasia more than 20 years after ITO, with nearly equal numbers of varus and valgus osteotomies. Again, varus osteotomy was selected for early coxarthrosis (mean age, 25 years) and valgus for end-stage disease (mean, age 37 years). Using the endpoint of a Harris hip score of less than 70 or a salvage surgery, the 10- and 15-year survival rates for varus osteotomy were 89% and 87% and for valgus ITO were 66% and 38%, respectively. The younger age range in this series was almost certainly a factor in the excellent long-term outcomes, which also included 82% good to excellent 20-year results for their varus osteotomies.

Recent publications have documented a favorable experience with ITO. Gotoh et al. (54) reported on 31 valgus–extension ITOs in patients with a mean age of 43 years, including four that had a concomitant Chiari osteotomy. The good results in these osteotomies had a survivorship of 85% at 5 years, 67% at 10 years, and 51% at 15 years. Good radiographic results correlated with the size of the preoperative osteophytes, particularly the width of the capital drop and length of the roof osteophytes. D'Souza et al. (43) published a series of 25 hips (6 varus–extension and 19 valgus–extension osteotomies) with a mean age of 38 years and average follow-up of 7 years. Four hips (16%) were converted to total hip arthroplasty at an average of 8 years after ITO, with a survival rate at 12 years of 67%. Schneider (137), in a report with 12–15 years of follow-up, also found that the median time to conversion to total hip arthroplasty was 8 years. Despite the fact that many of the studies in the literature have included inhomogeneous groups and less than ideally selected patients, similar selection criteria and results in properly selected patients have emerged over the years. There is a growing consensus that at 10 years or more after surgery, 70% to 80% of patients continue to have satisfactory results following an appropriate angulation ITO (77,87,103,120,123,132,135,137).

### REMOVAL OF FIXATION IMPLANTS AFTER OSTEOTOMIES

We routinely remove implants after osteotomies of the pelvis and proximal femur for several reasons. Some patients have pain related to the implants. Even patients who do not have tenderness to palpation over the hardware can experience pain relief after removal. With pelvic osteotomies, long cortical fixation screws are used, often more than 130 mm in length. These are at some risk for fatigue failure due to repetitive strain in the pelvis. Removal of these screws from the iliac crest is a simple outpatient procedure if performed before screw breakage, but is otherwise much more complicated. Patients who have an osteotomy of the pelvis or proximal femur are at increased risk for requiring a subsequent THR; therefore, we feel that it is prudent to remove implants that might interfere with subsequent surgery.

## PITFALLS AND COMPLICATIONS

Many of the complications of osteotomy of the pelvis or proximal femur are not specific for osteotomy surgery and will not be discussed in detail here. These include anesthetic complications, blood loss and transfusion requirements, infection, deep venous thrombosis, and perioperative medical problems such as urinary tract infection or myocardial infarction. These complications are best avoided by treating most major osteotomy patients like total hip arthroplasty patients. Common total joint replacement protocols are generally applicable and may include autologous blood donation, cell-saver for certain cases, perioperative antibiotic and thromboembolic prophylaxis, and use of an arthroplasty-style operating theater. As osteotomy patients are, by selection, physiologically younger than total joint

patients, surgery is better tolerated, and nonspecific complications such as those listed previously are unusual.

Other complications are more specific for osteotomy surgery and deserve special consideration:

- Trochanteric bursitis or painful bursae over implants (24,112)
- Malunion, that is, undercorrection, overcorrection, malrotation, retroversion (PAO only)
- Delayed union and nonunion
- Implant breakage
- Penetration of the hip joint
- Loss of fixation
- Changes in leg length
- Abductor weakness and limp
- Difficulty with subsequent THR (154)
- Nerve injury, especially of the lateral femoral cutaneous nerve (PAO)
- Intraoperative fracture of the femoral neck, acetabulum, or the lateral bone bridge below the blade of the blade plate
- Clinical failure in spite of a well-performed procedure, including increased hip joint stiffness, and persistent or increased pain. Figure 104.23 shows a 47-year-old woman who, after a technically successful PAO, maintained a pain-free status for 6 months, followed by failure requiring THR. The degree of difficulty of the THR was no different from that of a standard primary THR.

The first six complications are familiar to surgeons who routinely care for fractures around the hip joint. The most common complication seen with osteotomy of the pelvis or proximal femur is bursitis. The nearly subcutaneous position of the greater trochanter and iliac crest makes prominent hardware nearly unavoidable. This is commonly seen over large-fragment screw heads at the iliac crest following pelvic osteotomy, and laterally over a blade plate in the proximal femur. Routine removal of the implants usually eliminates this problem. When varus of the proximal femur is present or when the greater trochanter has been lateralized, trochanteric bursitis can persist despite hardware removal, because of the prominence of the greater trochanter (2).

Probably the most common serious complication from an ITO around the hip is overcorrection when performing a varus proximal femoral osteotomy. This may lead to abductor weakness, an unresolvable Trendelenberg limp, marked leg-length inequality, and patient dissatisfaction. Overcorrection, undercorrection, and rotational malalignment can all lead to a problematic malunion. Malunion after osteotomy can result from several potential sources, including malpositioning following a poor or inadequate preoperative plan; error in technical execution of a good plan; or postoperative loss of a good position obtained in the operating room secondary to other problems such as delayed union, poor internal fixation, or patient noncompliance.

A reliable technical plan can be made only with an adequate radiographic workup and skillful preoperative tracing or computer templating. For many osteotomies, a complete plan includes having multiple options or variations clearly spelled out. Other than inappropriate patient selection, error in technical execution of a good osteotomy plan is perhaps the most common complication described in the literature, and it is also the complication most within the surgeon's control. Sufficient experience with these osteotomies is required to avoid these errors.

In the operating room, critical factors include adequate surgical exposure, good radiographic control with both the image intensifier and confirmatory plain films, and the skill and patience for precision. With rigid internal fixation and good immediate alignment and position, a loss of position is unlikely. However, premature weight bearing or delayed union can predispose to such a shift. Helping to prevent delayed union and fostering bony healing is somewhat within the surgeon's immediate control, as discussed next.

Delayed union and nonunion are not preventable but can be minimized by following a few principles. Rigid internal fixation is critically important. If there is any question of stability at the time of surgery, ensure stability by reengineering the osteosynthesis. As long as fixation and other factors are appropriate, however, even point-contact apposition (as in a varus ITO) can be expected to heal, although restricted weight bearing may be required for a longer period of time.

In general, bone grafts are not needed, even with large gaps in the pelvis or upper femur. Exceptions include significantly displaced Chiari osteotomies, markedly displaced periacetabular pubic, ischial, or iliac cuts, and nonunions of the proximal femur or pelvis.

Breakage of implants, loss of fixation, hardware penetration, and cutout are all directly related to the problem of achieving stability and union of the osteotomy and/or fracture site. Documented recent breakage of fixation implants generally indicates that the osteotomy has not healed. Whether implant breakage is a significant clinical problem depends on the stability remaining in the construct and the stage of healing. If the osteotomy or proximal femoral fracture is unstable, then broken implants make revision surgery more difficult and more urgent. Hardware penetration into the hip joint following cutout of an implant from the femoral head also calls for an expedited revision to prevent additional damage to the articular cartilage of the hip.

One of the characteristics of osteotomy around the hip joint that can be either an asset or a liability is the potential for affecting leg length. This is most prominent with proximal femoral osteotomy but can be seen with pelvic osteotomies as well. The Chiari procedure tends to cause shortening, which can be significant depending on the slope of the osteotomy and the degree of displacement. A PAO can result in a slight lengthening, although this is typically minimal (less than 1 cm). A valgus ITO has the potential for lengthening of several centimeters. If the operative leg is short, this can be a principal benefit and can contribute to the indications for the surgery. This is commonly seen with malunions, femoral neck nonunions with collapse, congenital varus deformity, and SCFE. However, if leg lengths are equal or the operative leg is long, then full-wedge resection combined with removal of an additional segment of bone from the distal fragment may be necessary because of the inherent lengthening effect of a valgus ITO.

The greatest difficulty with leg length after osteotomy around the hip accompanies varus ITO. For major angular corrections (> 15° of varus), resection of any bone wedges essentially guarantees a noticeable amount of limb shortening. The patient needs to understand this aspect of the surgery before the fact. With minimal or no wedge resection and rigid fixation, maximum length can be preserved during a varus ITO. Accuracy in preoperative planning combined with careful intraoperative verification can help to ensure that the expected leg lengths are obtained following any hip osteotomy.

A postoperative limp is a complication that can be long lasting and the source of patient dissatisfaction following surgery. A chronic limp not caused by pain is usually secondary to abductor dysfunction. Procedures that damage or shorten the abductors or place them at a mechanical disadvantage are most likely to cause a limp or a Trendelenberg lurch. These include pelvic osteotomies that involve release of the abductor origin laterally for exposure, Chiari osteotomies, and varus osteotomies of the proximal femur. This type of limp can take a year or more to improve or can be permanent. The patient should, of course, be educated about this before surgery. In some cases, a preoperative Trendelenberg limp can be improved after osteotomy. This is usually seen when greater trochanter advancement is performed or when a valgus ITO improves suboptimal abductor mechanics.

Changes in alignment of the proximal femur influence the biomechanical axis through the knee. This can lead to secondary knee pain and arthritis after a hip procedure. In frontal plane angular osteotomies, a valgus ITO places a valgus stress on the knee, whereas a varus ITO generates varus forces and increases medial joint loading. Lateral displacement of the shaft (distal) fragment at the time of a valgus ITO can correct the mechanical axis and eliminate abnormal forces at the knee secondary to the hip surgery. The converse is true for varus ITO. In the rare patient receiving a valgus ITO who also has medial knee arthritis, some lateral mechanical axis shift may be desirable, and therefore less lateral displacement of the osteotomy is indicated. In addition to frontal plane displacement, anterior shaft displacement generally accompanies a flexion ITO, and posterior displacement accompanies an extension ITO. The significance of this displacement that is not seen on the AP radiograph should not be underestimated when planning for a subsequent THR. Despite the importance of displacement, as discussed, if a choice must be made between obtaining the full displacement desired and obtaining a proximal femur compatible with future total hip stem placement, the displacement that is compatible with the future THR is preferred.

Osteotomy can make subsequent THR surgery more difficult on both the pelvic and femoral sides (20,45). Of the pelvic osteotomies discussed, the Chiari procedure creates the most difficulty for acetabular component placement, which is more fully discussed in the Chiari osteotomy section of this chapter. The periacetabular rotational osteotomies generally do not alter the difficulty of cup placement. While better superior and lateral coverage is obtained in an otherwise dysplastic hip, this is at the expense of posterior and inferior coverage, leaving a partially deficient bed of host bone for acetabular fixation. The most significant postosteotomy arthroplasty challenges come on the femoral side when a previous ITO with excessive displacement or subtrochanteric osteotomy has been done. Intraoperative perforation of the femoral shaft or fracture, component malalignment, and compromised fixation, whether cemented or uncemented, may potentially lead to early failure of the femoral component (12,1,42).

In some cases, a revision osteotomy of the femur is necessary prior to proceeding with a THR, although this is usually done at the time of the hip replacement. The presence of an implant such as a blade plate from a previous osteotomy can be a source of problems for a subsequent THR. Simultaneous implant removal and THR surgery results in slightly increased operative time and possibly an increased infection rate for the THR. The presence of open screw holes can diminish the effectiveness of cement pressurization when a cemented femoral component is used. For these reasons, we prefer early hardware removal of fixation devices years

prior to any implant arthroplasty, as advocated by Ferguson et al. (45) at the Mayo Clinic.

Nerve injury after proximal femoral osteotomy is rare. The femoral, obturator, and sciatic nerves are generally well protected, and no major cutaneous nerves are at risk with the straight lateral incision. Nerve injury is more common after pelvic osteotomy. The lateral femoral cutaneous nerve is at risk with any anterior exposure of the pelvis. Despite every attempt to preserve this nerve, anterolateral thigh numbness and paresthesias are quite common. The typical injury to the nerve is a traction neuropraxia. The majority of these palsies completely resolve with time, but some patients do have a permanent sensory deficit. The major nerves that pass the hip joint are all at risk with a pelvic osteotomy, particularly in a rotational periacetabular procedure. The femoral nerve is close to the anterior and medial retractors. The obturator nerve is at risk during the pubic osteotomy. Use of a Gigli saw for the pubic cut may reduce the chance for damage to the obturator neurovascular bundle. The sciatic nerve is in jeopardy at the sciatic notch, whether from laceration from an osteotome or bone spike, or from traction. With complete pelvic osteotomies into the sciatic notch area, such as a Chiari, use of a Gigli saw for this cut, as well as specialized or malleable retractors, may minimize the risk of sciatic injury. Avoid paralytic anesthetic agents, as they preclude recognition of any inadvertent stimulation of a motor nerve.

One of the more dreaded complications is AVN. This may apply to the femoral head or to the acetabulum, depending on the location of the osteotomy. Osteotomies closer to the joint surface are more likely to disrupt the critical blood supply to the mobilized joint fragment. Therefore, as a general rule, the smaller and more isolated the fragment, the greater the risk of AVN. This is one of several reasons that we (and others) prefer the Bernese PAO over the spherical rotational or dial acetabular osteotomies. It also supports our preference for intertrochanteric over femoral neck or cuneiform proximal femoral osteotomies. Minimize the soft-tissue stripping during surgery to reduce the chances of AVN. The remaining blood supply of either a rotated acetabular fragment or femoral head is via the ligamentum teres capitis and the capsule, especially its posterior anastomoses. When an incision into the capsule is necessary, use a minimum of dissection to respect the importance of this circulation. In some cases, such as in a SCFE (with or without reduction) or a femoral neck fracture nonunion, the risk of AVN is significant. In patients who have surgery within a year of injury, it may be difficult to determine the potential role that an osteotomy plays in increasing this risk.

In addition to AVN, other complications potentially related to creation of a thin or short fragment are fracture and intra-articular hardware. The dial osteotomy is performed closer to the articular surface than a triple pelvic or Bernese periacetabular procedure. Difficulties in stabilizing the fragment or in avoiding intra-articular penetration are more challenging with the dial osteotomy or similar procedures. On the femoral side, cuneiform and femoral neck osteotomies and cases of femoral neck nonunion provide less proximal bone for safe placement of fixation hardware. Quality fluoroscopic images in multiple planes with some use of live fluoroscopic visualization may be necessary to document safe screw placement. Trauma surgeons have described the use of a sterile esophageal stethoscope along the quadrilateral plate (or, in fact, against any nearby bone) as a method of audibly detecting the unmistakable scraping sound of an intra-articular screw in radiographically uncertain cases (4). We have not found this to be necessary. Radiographically uncertain screws generally do not have to be tolerated in osteotomy surgery, for which screw placement options are usually more varied than they are in complex pelvic fracture osteosynthesis.

Another site for potential intraoperative or postoperative fracture is the lateral bone bridge of the proximal fragment of an ITO. A 15–20 mm bridge of intact bone is needed between the seating chisel entry site and the osteotomy for safety. The integrity of this bone must be assessed during surgery, especially in revision or femoral nonunion cases. Change from a higher-angle blade plate to a lower-angle blade plate may be required to ensure stable osteosynthesis. This should be ascertained in preoperative planning, rarely during surgery itself.

A discouraging problem is persistent or increased pain or increased stiffness following osteotomy. Heterotopic ossification can appear after an otherwise uncomplicated osteotomy, more commonly on the pelvic side. It is usually an incidental finding but can cause symptomatic stiffness. Increased stiffness independent of pain in the hip is more common after surgery in patients with more advanced arthritis. Persistent or increased pain is also more common in patients with worse preoperative degenerative changes. Strict adherence to described surgical indications will minimize the number of such clinical failures. The guidelines to patient selection previously discussed are not rigid but serve as guides by which the patient and surgeon can come to understand the potential risks and benefits of a given procedure. Once the surgeon understands the patient and the patient is educated about the treatment options, together they can decide whether an osteotomy will best serve the patient's needs.

## AUTHORS' PERSPECTIVE

The most significant development in the last decade in this field has been the adoption of the Bernese PAO as the procedure of choice for the painful hip with prearthritic or early arthritic changes secondary to underlying dysplasia in adults.

The philosophy of true adult reconstructive surgery of the hip as an interest area within the field of orthopaedic surgery should include osteotomies of the pelvis and upper femur as well as arthrodesis when indicated, in addition to primary and revision arthroplasty.

On the femoral side, ITO has an enduring role in posttraumatic conditions (femoral neck nonunions, malunion), osteonecrosis (131), SCFE and superolateral arthritis secondary to dysplasia, among others.

I (RS) cannot emphasize too strongly the importance of careful preparation and detailed, virtually step-by-step planning prior to any osteotomy surgery. Particularly with regard to the PAO, when the best results are achieved prior to irreversible radiographic deterioration, complications could leave a patient much worse off than before the surgery, and at a young age. Careful study, multiple cadaveric dissections, and visits to centers with extensive experience are valuable building blocks. This surgery should not be undertaken casually or infrequently.

The bones of the pelvis and upper femur are remarkable organs, capable of extensive remodeling, filling-in of gaps and defects, and healing of arthritis. The art of patient selection is as important as the ability to perform the surgery. Obesity, lack of motivation, and unrealistic expectations are as important contraindications to surgery as an adverse radiographic variable. On the other hand, the pleasure of observing periarticular joint space remodeling, relief of pain, and restoration of function after a successful osteotomy is one of the most rewarding aspects of reconstructive surgery in adults.

### CHAPTER REFERENCES

Each reference is categorized according to the following scheme: *, classic article; #, review article; !, basic research article; and +, clinical results/outcome study.


+ 1. Adam A, Spence AJ. Intertrochanteric Osteotomy for Osteoarthritis of the Hip. *J Bone Joint Surg Br* 1958;40:219.

+ 2. Allen WC, Cope R. Coxa Saltans: The Snapping Hip Revisited. *J Am Acad Orthop Surg* 1995;3:303.

+ 3. Altenberg AR. Acetabular Labrum Tears: A Cause of Hip Pain and Degenerative Arthritis. *South Med J* 1977;70:174.

+ 4. Anglen JO, DiPasquale T. The Reliability of Detecting Screw Penetration of the Acetabulum by Intraoperative Auscultation. *J Orthop Trauma* 1994;8:404.

+ 5. Anwar MM, Sugano N, Matsui M, et al. Dome Osteotomy of the Pelvis for Osteoarthritis Secondary to Hip Dysplasia. An over Five-Year Follow-up Study. *J Bone Joint Surg Br* 1993;75:222.

+ 6. Appel H, Friberg S. Effect of Osteotomy on Pain in Idiopathic Osteoarthritis of the Hip. *Acta Orthop Scand* 1973;44:710.

# 7. Aronson J. Osteoarthritis of the Young Adult Hip: Etiology and Treatment. *Instr Course Lect* 1986;35:119.

+ 8. Aronson J, Bombelli R, Benedini A, Santore RF. Slipped Capital Femoral Epiphysis: A Functional Comparison of in Situ Pinning and Primary Osteotomy. *Techniques in Orthopedics* 1989;4:64.

# 9. Aronson J, Schatzker J, eds. *The Intertrochanteric Osteotomy.* Berlin: Springer-Verlag, 1984.

+ 10. Azuma H, Taneda H. Rotational Acetabular Osteotomy in Congenital Dysplasia of the Hip. *Int Orthop* 1989;13:21.

+ 11. Beck M, Mast JW. The Periacetabular Osteotomy in Legg-Perthes-like Deformities. *Semin Arthroplasty* 1997;8:102.

+ 12. Benke GJ, Baker AS, Dounis E. Total Hip Replacement after Upper Femoral Osteotomy: A Clinical Review. *J Bone Joint Surg Br* 1982;64:570.

+ 13. Benson MK, Evans DC. The Pelvic Osteotomy of Chiari: An Anatomical Study of the Hazards and Misleading Radiographic Appearances. *J Bone Joint Surg Br* 1976;58:164.

+ 14. Betz R, Kumar SJ, Palmer CT, MacEwen D. Chiari Pelvic Osteotomy. *J Bone Joint Surg Am* 1988;70:182.

# 15. Bohler N, Lack W. The Role of Osteotomies in the 90s. *Orthopedics* 1995;18:819.

# 16. Bombelli R. *Osteoarthritis of the Hip*, 3rd ed. Berlin: Springer-Verlag, 1993.

# 17. Bombelli R.*Structure and Function in Normal and Abnormal Hips: How to Rescue Mechanically Jeopardized Hips.* Berlin: Springer-Verlag, 1993.

# 18. Bombelli R, Gerundini M, Aronson J. The Biomechanical Basis for Osteotomy in the Treatment of Osteoarthritis of the Hip: Results in Younger Patients. *Hip* 1984:18.

# 19. Bombelli R, Santore RF, Poss R. Mechanics of the Normal and Osteoarthritic Hip: A New Perspective. *Clin Orthop* 1984;182:69.

+ 20. Boos N, Krushell R, Ganz R, Mueller M. Total Hip Arthroplasty after Previous Proximal Femoral Osteotomy. *J Bone Joint Surg Br* 1997;79:247.

# 21. Booth RE Jr. The Closing Circle: Limitations of Total joint Arthroplasty. *Orthopedics* 1994;17:757.

+ 22. Boyer DW, Mickelson MR, Ponseti IV. Slipped Capital Femoral Epiphysis. Long-term Follow-up of One Hundred and Twenty-one Patients. *J Bone Joint Surg Am* 1981;63:85.

! 23. Brand R. Hip Osteotomies: A Biomechanical Consideration. *J Am Acad Orthop Surg* 1997;5:282.

+ 24. Braunstein EM, Weissman BN, Sosman JL, Drew M. Complications of Intertrochanteric Rotational Osteotomy. *Skeletal Radiol* 1983;10:258.

# 25. Buckwalter JA, Lohmander S. Current Concepts Review. Operative Treatment of Osteoarthrosis. Current Practice and Future Development. *J Bone Joint Surg Am* 1994;76:1405.

+ 26. Byrd JWT. Labral Lesion. An Elusive Source of Hip Pain. Case Reports and Literature Review. *Arthroscopy* 1996;12:603.

# 27. Callaghan JJ. Results of Primary Total Hip Arthroplasty in Young Patients. *Instr Course Lect* 1994;43:315.

+ 28. Calvert PT, August AC, Kemp HB, Catterall A. The Chiari Pelvic Osteotomy. A Review of the Long-term Results. *J Bone Joint Surg* 1987;73:626.

+ 29. Carney BT, Weinstein SL, Noble J. Long-term Follow-up of Slipped Capital Femoral Epiphysis. *J Bone Joint Surg Am* 1991;73:667.

+ 30. Chandler HP, Reineck FT, Wixson RL, et al. Total Hip Relacement in Patients Younger Than Thirty Years Old: A Five-year Follow-up Study. *J Bone Joint Surg Am* 1981;63:1426.

* 31. Chiari K. Medial Displacement Osteotomy of the Pelvis. *Clin Orthop* 1974;98:51.

+ 32. Collert S, Gillstrom P. Osteotomy in Osteoarthritis of the Hip. A Prospective Study. *Acta Orthop Scand* 1979;50:555.

+ 33. Cooperman DR, Wallensten R, Stulberg SD. Acetabular Dysplasia in the Adult. *Clin Orthop* 1983;175:79.

+ 34. Czerny C, Hofmann S, Neuhold A, et al. Lesions of the Acetabular Labrum: Accuracy of MR Imaging and MR Arthrography in Detection and Staging. *Radiology* 1996;200:225.

+ 35. Davey JP, Santore RF. Complications of Periacetabular Osteotomy. *Clin Orthop* 1999;363:33.

+ 36. De Waal Malefijt MC, Hoogland T, Nielsen HKL. Chiari Osteotomy in the Treatment of Congenital Dislocation and Subluxation of the Hip. *J Bone Joint Surg Am* 1982;64:996.

+ 37. DePalma A, Rothman R, Klemek J. Osteotomy of the Proximal Femur in Degenerative Arthritis. *Clin Orthop* 1970;73:109.

+ 38. Detenbeck L, Coventry M, Kelly P. Intertrochanteric Osteotomy for Degenerative Arthritis of the Hip. *Clin Orthop* 1972;86:73.

+ 39. Donnell JH, Catterall A. The Torn Acetabular Labrum. *J Bone Joint Surg Br* 1986;68:400.

+ 40. Dorr LD, Luckett M, Conaty JP. Total Hip Arthroplasty in Patients Younger Than 45 Years. A Nine to Ten Year Follow-up Study. *Clin Orthop* 1990;260:215.

+ 41. Dorr LD, Takei GK, Conaty JP. Total Hip Arthroplasties in Patients Less Than 45 Years Old. *J Bone Joint Surg Am* 1983;65:474.

+ 42. Dorrell JH, Catterall A. The Torn Acetabular Labrum. *J Bone Joint Surg Br* 1986;68:400.

+ 43. D'Souza SR, Sadiq S, New AMR, et al. Proximal Femoral Osteotomy as the Primary Operation for Young Adults Who Have Osteoarthrosis of the Hip. *J Bone Joint Surg Am* 1998;80:1428.

+ 44. Eppright RH. Dial Osteotomy of the Acetabulum in the Treatment of Dysplasia of the Hip. *J Bone Joint Surg Am* 1975;57:1172.

+ 45. Ferguson GM, Cabanela ME, Ilstrup DM. Total Hip Arthroplasty after Failed Intertrochanteric Osteotomy. *J Bone Joint Surg Am* 1994;76:252.

+ 46. Fernandez DL, Isler B, Muller ME. Chiari's Osteotomy. A Note on Technique. *Clin Orthop* 1984;185:53.

+ 47. Fish JB. Cuneiform Osteotomy of the Femoral Neck in the Treatment of Slipped Capital Femoral Epiphysis. A Follow-up Note. *J Bone Joint Surg Am* 1994;76:46.

+ 48. Fixsen JA. Anterior and Posterior Displacement of the Hip after Innominate Osteotomy. *J Bone Joint Surg Br* 1987;69:361.

+ 49. Ganz R, ed. Alternatives to THA: Pelvic and Femoral Osteotomies in the Treatment of Early Osteoarthrosis of the Hip in the Young Adult. *Semin Arthroplasty* 1998;8:1.

+ 50. Ganz R, Buchler U. Osteotomy and Revascularization in Aseptic Necrosis of the Femoral Head. In: *The Hip. Proceedings of 11th Meeting of the Hip Society.* St. Louis: Mosby, 1983:296.

+ 51. Ganz R, Klaue K, Vinh TS, et al. A New Periacetabular Osteotomy for the Treatment of Hip Dysplasias, Technique and Preliminary Results. *Clin Orthop* 1988;232:26.

+ 52. Goldie IF, Anderson GBJ, Olsson SS. Long-term Follow-up of Intertrochanteric Osteotomy in Osteoarthritis in the Hip joint. *Clin Orthop* 1973;93:265.

+ 53. Goodman DA, Feighan JE, Smith AD, et al. Subclinical Slipped Capital Femoral Epiphysis. Relationship to Osteoarthrosis of the Hip. *J Bone Joint Surg Am* 1997;79:1489.

+ 54. Gotoh E, Inao S, Okamoto T, Ando M. Valgus-extension Osteotomy for advanced Osteoarthritis in Dysplastic Hips. Results at 12 to 18 Years. *J Bone Joint Surg Br* 1997;79:609.

+ 55. Graham S, Westin GW, Dawson E, Oppenheim WL. The Chiari Osteotomy. A Review of 58 Cases. *Clin Orthop* 1986;208:249.

+ 56. Hally DK, Wroblewski BM. Long-term Results of Low-friction Arthroplasty for Degenerative Joint Disease in Patients 30 Years of Age or Younger *Clin Orthop* 1986;211:43.

! 57. Harris WH, Enneking WF. Characteristics of the Articular Cartilage Formed after Intertrochanteric Osteotomy: A Case Report. *J Bone Joint Surg Am* 1995;77:602.

+ 58. Harris NH, Kirwan E. The Results of Osteotomy for Early Primary Osteoarthritis of the Hip. *J Bone Joint Surg Br* 1964;46:477.

+ 59. Hartofilakidis G, Stamos K, Ioannidis TT. Rotational Acetabular Osteotomy for Severe Dysplasia of the Hip. *J Bone Joint Surg Br* 1997;79:510.

+ 60. Hersche O, Casillas M, Ganz R. Indications for Intertrochanteric Osteotomy after Periacetabular Osteotomy for Adult Hip Dysplasia. *Clin Orthop* 1998;347:19.

+ 61. Hijikata H, Tagawa H, Toyoshima H. Rotational Acetabular Osteotomy with Resection of Capital Drop. *Hip Joint* 1985;11:277.

+ 62. Hoffman DV, Simmons EH, Barrington TW. The Results of the Chiari Osteotomy. *Clin Orthop* 1974;98:162.

+ 63. Hogh J, Macnicol MF. The Chiari Osteotomy: A Long-term Review of Clinical and Radiographic Results. *J Bone Joint Surg Br* 1987;69:365.

+ 64. Hopf A. Huftpfannenverlagerung jurch Doppelte Beckenotsteotomie zur Behandlung der Huftgelenksdysplasie und Subluxation bei Jugendlichen und Erwachsenen. *Z Orthop* 1966;101:559.

+ 65. Huang CH. Treatment of Neglected Femoral Neck Fractures in Young Adults. *Clin Orthop* 1986;206:117.

+ 66. Huang SC, Hwang YF, Liu HC, et al. Triple Innominate Osteotomy and Rotational Acetabular Osteotomy in the Treatment of Congenital Hip Dysplasia. *J Formos Med Assoc* 1997;96:91.

+ 67. Ikeda T, Awaya G, Suzuzki S, et al. Torn Acetabular Labrum in Young Patients: Arthroscopic Diagnosis and Management. *J Bone Joint Surg Br* 1988;70:13.

+ 68. Imhauser G. Late Results of Imhauser's Osteotomy for Slipped Capital Femoral Epiphysis. *Z Orthop* 1977;115:716.

+ 69. Iwase T, Hasegawa Y, Kataoka Y, et al. Long-term Results of Intertrochanteric Varus Osteotomy for Arthrosis of the Dysplastic Hip (Over 10 Years' Follow-up). *Arch Orthop Trauma Surg* 1995;114:243.

+ 70. Iwase T, Hasegawa Y, Kawamoto K, et al. Twenty Years' Follow-up of Intertrochanteric Osteotomy for Treatment of the Dysplastic Hip. *Clin Orthop* 1996;331:245.

+ 71. Iwersen LJ, Kalen V, Eberle C. Relative Trochanteric Overgrowth after Ischaemic Necrosis in Congenital Dislocation of the Hip. *J Pediatr Orthop* 1989;9:381.

+ 72. Jacobs MA, Hungerford DS, Krackow KA. Intertrochanteric Osteotomy for avascular Necrosis of the Femoral Head. *J Bone Joint Surg* 1989;71:200.

+ 73. Klaue K, Durnin CW, Ganz R. The Acetabular Rim Syndrome. A Clinical Presentation of Dysplasia of the Hip. *J Bone Joint Surg Am* 1991;73:423.

+ 74. Klaue K, Sherman M, Porren S, et al. Extra-articular Augmentation for Residual Hip Dysplasia. *J Bone Joint Surg Br* 1993;75:750.

+ 75. Klaue K, Wallin A, Ganz R. CT Evaluation of Coverage and Congruency of the Hip Prior to Osteotomy. *Clin Orthop* 1988;232:15.

+ 76. Lack W, Windhager R, Kutschera HP, Engel A. Chiari Pelvic Osteotomy for Osteoarthritis Secondary to Hip Dysplasia. Indications and Long-term Results. *J Bone Joint Surg Br* 1991;73:229.

+ 77. Langlais F, Roure JL, Maquet P. Valgus Osteotomy in Severe Osteoarthritis of the Hip. *J Bone Joint Surg Br* 1979;61:424.

+ 78. Langlotz R, Bachler R, Berlemann U, et al. Computer Assistance for Pelvic Osteotomies. *Clin Orthop* 1998;354:92.

+ 79. LeCoeur P. Corrections des DeFauts D'orientation de l'Articulation Coxofemorale par Osteotomei de l'Isthme Iliaque. *Rev Chir Orthop* 1965;51:211.

+ 80. Lequesne M, DeSeze S. Le Faux Profil du Bassin. Nouvell Incidence Radiographique pour l'Etude de la Hanche. Son Utilite dans les Dysplasies et les Differentes Coxopathies. *Rev Rhum Mal Osteoartic* 1961;28:643.

+ 81. Leunig M, Werlen S, Ungersbock A, et al. Evaluation of the Acetabular Labrum by MR Arthrography. *J Bone Joint Surg Br* 1997;79:230.

+ 82. Lowell JD. Results and Complications of Femoral Neck Fractures. *Clin Orthop* 1980;152:162.

+ 83. MacDonald SJ, Hersche O, Rodriguez J, Ganz R. The Bernese Periacetabular Osteotomy for the Treatment of Adult Hip Dysplasia. *Chir Organi Mov* 1997;82:143.

# 84. Macnicol M, ed.*Color Atlas and Text of Osteotomy of the Hip.* London: Mosby-Wolfe, 1996.

+ 85. Macnicol MF, Makris D. Distal Transfer of the greater Trochanter. *J Bone Joint Surg Br* 1991;73:838.

+ 86. Maistrelli G, Fusco U, Avai A, Bombelli R. Osteonecrosis of the Hip Treated by Intertrochanteric Osteotomy. A Four- to 15-year Follow-up. *J Bone Joint Surg Br* 1988;70:761.

+ 87. Maistrelli GL, Gerundini M, Fusco U, et al. Valgus-Extension Osteotomy for Osteoarthrosis of the Hip: Indications and Long-term Results. *J Bone Joint Surg Br* 1990;72:653.

+ 88. Mast JW, Mayo KA, Chosa E, et al. The Acetabular Rim Fracture: A Variant of Acetabular Rim Syndrome. *Semin Arthroplasty* 1997;8:97.

+ 89. Matsuno T, Ichioka Y, Kaneda K. Modified Chiari Pelvic Osteotomy: A Long-term Follow-up Study. *J Bone Joint Surg Am* 1992;74:470.

+ 90. Matta JM, Stover MD, Siebenrock K. Periacetabular Osteotomy through the Smith-Petersen Approach. *Clin Orthop* 1999;363:21.

+ 91. McAndrew M, Weinstein S. A Long Term Followup of Legg-Calvé-Perthes Disease. *J Bone Joint Surg Am* 1984;66:860.

+ 92. McCarthy JC, Day B, Busconi B. Hip Arthroscopy: Application and Technique. *J Am Acad Orthop Surg* 1995;3:115.

+ 93. McClellan JW 3rd, Garvin KL. Adolescent and Young Adult Hip Dysplasia. The Role of Bernese Periacetabular Osteotomy. *Nebr Med J* 1995;80:271.

+ 94. McGory BJ, Estok DM 2nd, Harris WH. Follow-up of Intertrochanteric Osteotomy of the Hip during a 25-year Period. *Orthopedics* 1998;21:651.

+ 95. Miegel RE, Harris WH. Medial Displacement Intertrochanteric Osteotomy in the Treatment of Osteoarthritis of the Hip. A Long-term Follow-up Study. *J Bone Joint Surg Am* 1984;66:878.

+ 96. Millis MB. Reconstructive Osteotomies of the Pelvis for the Correction of Acetabular Dysplasia. In: Sledge CB, ed. *Master Techniques in Orthopaedic Surgery: The Hip.* New York: Lippincott-Raven, 1998:157.

+ 97. Millis MB, Kaelin AJ, Schluntz K, et al. Spherical Acetabular Osteotomy for Treatment of Acetabular Dysplasia in Adolescents and Young Adults. *J Pediat Orthop B* 1994;3:47.

+ 98. Millis MB, Murphy SB. Use of Computed Tomographic Reconstruction in Planning Osteotomies of the Hip. *Clin Orthop* 1992;274:154.

# 99. Millis MB, Murphy SB, Poss R. Osteotomies about the Hip for the Prevention and Treatment of Osteo-arthrosis *J Bone Joint Surg Am* 1995;77:626.

# 100. Millis MB, Murphy SB, Poss R. Osteotomies about the Hip for the Prevention and Treatment of Osteoarthrosis. *Instr Course Lect* 1996;45:209.

# 101. Millis MB, Poss R, Murphy SB. Osteotomies of the Hip in the Prevention and Treatment of Osteoarthritis. *Instr Course Lect* 1992;41:145.

+ 102. Mont MA, Maar DC, Krackow KA, et al. Total Hip Replacement without Cement for Non-inflammatory Osteoarthritis in Patients Who Are Less Than Forty-five Years Old. *J Bone Joint Surg Am* 1993;75:740.

+ 103. Morscher EW. Intertrochanteric Osteotomy in Osteoarthritis of the Hip. In: *The Hip. Proceedings of the Eighth Open Scientific Meeting of the Hip Society.* St. Louis, MO: Mosby, 1980:24.

# 104. Morscher E, Feinstein R. Results of Intertrochanteric Osteotomy in the Treatment of Osteoarthritis of the Hip. In: Schatzker J, ed. *The Intertrochanteric Osteotomy.* New York: Springer-Verlag, 1984.

# 105. Müller ME. Intertrochanteric Osteotomy: Indication, Preoperative Planning, Technique. In: Schatzker J, ed. *The Intertrochanteric Osteotomy.* New York: Springer-Verlag, 1984.

# 106. Müller ME, Allgöwer M, Schneider R, Willenegger H. *Manual of Internal Fixation; Techniques Recommended by the AO Group*, 2nd ed. Berlin: Springer-Verlag, 1979.

+ 107. Murphy SB, Ganz R, Müller M. The Prognosis of Untreated Acetabular Dysplasia of the Hip. A Study of Radiographic Factors That Predict the Outcome. *J Bone Joint Surg Am* 1995;77:985.

+ 108. Murphy SB, Kijewski PK, Millis MB, et al. The Planning of Orthopaedic Reconstructive Surgery Using Computer-aided Simulation and Design. *Comput Radiol* 1988;12:33.

+ 109. Murphy SB, Kijewski PK, Millis MB, et al. Acetabular Dysplasia in the Adolescent and Young Adult. *Clin Orthop* 1990;261:214.

+ 110. Murphy SB, Millis MB. Periacetabular Osteotomy without Abductor Dissection Using Direct Anterior Exposure. *Clin Orthop* 1999;364:92.

+ 111. Murphy SB, Millis MB, Hall JE. Surgical Correction of Acetabular Dysplasia in the Adult: A Boston Experience. *Clin Orthop* 1999;363:38.

+ 112. Nakagawa M, Iwata H, Sugiura S, et al. The Evaluation of Intertrochanteric Osteotomy in Relation to Osteotomized Angle and Leg-Length Discrepancy for Osteoarthritis of the Hip. *Clin Orthop* 1980;152:277.

+ 113. Nakamura S, Ninomiya S, Takatori Y, et al. Long-term Outcome of Rotational Acetabular Osteotomy: 145 Hips Followed for 10–23 Years. *Acta Orthop Scand* 1998;69:259.

+ 114. Nakamura T, Yamamura M, Nakamitu S, Suzuki K. The Displacement of the Femoral Head by Rotational Acetabular Osteotomy: A Radiographic Study of 97 Subluxated Hips. *Acta Orthop Scand* 1992;63:33.

+ 115. Ninomiya S. Rotational Acetabular Osteotomy for the Severely Dysplastic Hip in the Adolescent and Adult. *Clin Orthop* 1989;247:127.

+ 116. Ninomiya S, Tagawa H. Rotational Acetabular Osteotomy for the Dysplastic Hip. *J Bone Joint Surg Am* 1984;66:430.

+ 117. Nishina T, Saito S, Ohzono K, et al. Chiari Pelvic Osteotomy for Osteoarthritis: The Influence of the Torn and Detached Acetabular Labrum. *J Bone Joint Surg Br* 1990;72:765.

+ 118. Ordeberg G, Hansson LI, Sandstrom S. Slipped Capital Femoral Epiphysis in Southern Sweden. Long-term Result with No Treatment or Symptomatic Primary Treatment. *Clin Orthop* 1984;191:95.

* 119. Pauwels F. The Place of Osteotomy in the Operative Treatment of Osteoarthritis of the Hip. *Triangle* 1968;8:196.

* 120. Pauwels F. *Biomechanics of the Normal and Diseased Hip.* Berlin: Springer-Verlag, 1976.

+ 121. Pellicci PM, Hu S, Garvin KL, et al. Varus Rotational Femoral Osteotomies in Adults with Hip Dysplasia. *Clin Orthop* 1991;272:162.

+ 122. Perlau R, Wilson MG, Poss R. Isolated Proximal Femoral Osteotomy for Treatment of Residua of Congenital Dysplasia or idiopathic Osteoarthritis of the Hip. Five to Ten-year Results. *J Bone Joint Surg Am* 1996;78:1462.

# 123. Poss R. Current Concepts Review: The Role of Osteotomy in the Treatment of Osteoarthritis of the Hip. *J Bone Joint Surg Am* 1984;66:144.

# 124. Poss R. Intertrochanteric Osteotomy in Osteoarthritis of the Hip. *Instr Course Lect* 1986;35:129.

+ 125. Racalbuto S, Macchiavello V, Greco G. Chiari Osteotomy in Assocition with Intertrochanteric Osteotomy in Adults. *Ital J Orthop Traumatol* 1993;19:151.

+ 126. Ranawat CS, Atkinson RE, Salvati EA, et al. Conventional Hip Arthroplasty for Degenerative Joint Disease in Patients between the Ages of Forty and Sixty Years. *J Bone Joint Surg Am* 1984;66:745.

+ 127. Registad A, Gronmark T. Osteoarthritis of the Hip Treated by Intertrochanteric Osteotomy. A Long-term Follow-up. *J Bone Joint Surg Am* 1984;66:1.

+ 128. Reynolds DA. Chiari innominate Osteotomy in Adults: Technique, Indications and Contra-indications. *J Bone Joint Surg Br* 1986;68:45.

+ 129. Saito S, Takaoka K, Ono K. Tectoplasty for Painful Dislocation or Subluxation at the Hip. *J Bone Joint Surg Br* 1986;68:55.

+ 130. Santore RF. Computers for Surgical Planning of Orthopaedic Procedures. *Instr Course Lect* 1995;44:527.

# 131. Santore RF. Intertrochanteric Osteotomies for Femoral Head Necrosis. *Semin Arthroplasty* 1998;9:3242.

+ 132. Santore RF, Bombelli R. Long-term Follow-up of the Bombelli Experience with Osteotomy for Osteoarthritis: Results at 11 Years. In: *The Hip. Proceedings of 11th Meeting of the Hip Society.* St. Louis, MO: Mosby, 1983:106.

+ 133. Santore RF, Dabezies EJ Jr. Femoral Osteotomy for Secondary Arthritis of the Hip in Young Adults. *Can J Surg* 1995;38(suppl. I):33.

+ 134. Schai P, Exner GU, Hansch O. Prevention of Secondary Osteoarthrosis in SCFE: Long-term Follow-up Study after Corrective ITO. *J Pediatr Orthop* 1996;5:135.

# 135. Schatzker J. *The Intertrochanteric Osteotomy.* Berlin: Springer-Verlag, 1984.

+ 136. Scher MA, Jakim I. Combined Intertrochanteric and Chiari Pelvic Osteotomies for Hip Dysplasia. *J Bone Joint Surg Br* 1991;73:626.

+ 137. Schneider R. Results of intertrochanteric Osteotomies in Patients with Coxarthrosis 12–15 Years after Surgery. In: Weil HH, ed. *Joint Preserving Procedures of the Lower Extremities. Progress in Orthopaedic Surgery*, Vol. 4. Berlin: Springer-Verlag, 1980:39.

# 138. Schneider R. Intertrochanteric Osteotomy in Osteoarthritis of the Hip joint. In: Schatzker J, ed. *The Intertrochanteric Osteotomy.* New York: Springer-Verlag, 1984.

+ 139. Schreiber A. Long-term Results of Chiari Pelvic Osteotomies, In: Weil HH, ed. *Joint Preserving Procedures of the Lower Extremity.* Berlin: Springer-Verlag, 1980:31.

+ 140. Shindo H, Igarashi H, Taneda H, Azuma H. Rotational Acetabular Osteotomy for Severe Dysplasia of the Hip with a False Acetabulum. *J Bone Joint Surg Am* 1996;78:871.

+ 141. Siebenrock KA, Scholl E, Lottenbach M, Ganz R. Bernese Periacetabular Osteotomy. *Clin Orthop* 1999;363:9.

+ 142. Soballe K, Boll KL, Kofod S, et al. Total Hip Replacement after Medial-displacement Osteotomy of the Proximal Part of the Femur. *J Bone Joint Surg Am* 1989;71:692.

+ 143. Sochart DH, Porter ML. The Long-term Results of Charnley Low-friction Arthroplasty in Young Patients Who Have Congenital Dislocation, Degenerative Osteoarthrosis or Rheumatoid Arthritis. *J Bone Joint Surg Am* 1997;79:1599.

* 144. Southwick WO. Osteotomy through the Lesser Trochanter for Slipped Capital Femoral Epiphysis. *J Bone Joint Surg Am* 1967;49:807.

+ 145. Staheli LT. Slotted Acetabular Augmentation. *J Pediatr Orthop* 1981;1:321.

+ 146. Staheli LT, Chew DE. Slotted Acetabular Augmentation in Childhood and Adolescence. *J Pediatr Orthop* 1992;12:569.

+ 147. Steel HH. Triple Osteotomy of the Innominate Bone. *J Bone Joint Surg Am* 1973;55:343.

+ 148. Steel HH. Triple Osteotomy of the Innominate Bone. A Procedure to Accomplish Coverage of the Dislocated or Subluxated Femoral Head in the Older Patient. *Clin Orthop* 1977;122:116.

+ 149. Stulberg S, Cooperman D, Wallensten R. The Natural History of Legg-Calvé-Perthes Disease. *J Bone Joint Surg Am* 1981;63:1095.

+ 150. Stulberg SD, Cordell LD, Harris WH, et al. Unrecognized Childhood Disease: A Major Cause of Idiopathic Osteoarthritis of the Hip. *Hip* 1975;212.

+ 151. Stulberg SD, Harris WH. Acetabular Dysplasia and Development of Osteoarthritis of the Hip. In: *The Hip. Proceedings of the 2nd Open Scientific Meeting of the Hip Society.* St. Louis, MO: Mosby, 1974;82.

+ 152. Sullivan PM, MacKenzie JR, Callaghan JJ, Johnston RC. Total Hip Arthroplasty with Cement in Patients Who Are Less Than Fifty Years Old: A Sixteen- to Twenty-two-year Follow-up Study. *J Bone Joint Surg Am* 1994;76:863.

+ 153. Summers DN, Turner A, Wynn-Jones CH. The Shelf Operation in the Management of Late Presentation of Congenital Hip Dysplasia. *J Bone Joint Surg Br* 1988;70:63.

+ 154. Suominen S, Antti-Poika I, Santavirta S, et al. Total Hip Replacement after Intertrochanteric Osteotomy. *Orthopedics* 1991;14:253.

+ 155. Sutherland DH, Greenfield R. Double Innominate Osteotomy. *J Bone Joint Surg Am* 1977;59:1082.

+ 156. Takatori Y, Ninomiya S, Nakamura S, et al. Long-term Follow-up Results of Rotational Acetabular Osteotomy in Painful Dysplastic Hips: Efficacy in Delaying the Onset of Osteoarthritis. *Am J Orthop* 1996;25:222.

+ 157. Tonnis D. Treatment of Residual Dysplasia after Developmental Dysplasia of the Hip and Prevention of Early Coxarthrosis. *J Pediatr Orthop* 1993;2B:133.

+ 158. Tonnis D, Arning A, Bloch M, et al. Triple Pelvic Osteotomy. *J Pediatr Orthop* 1994;3B:54.

+ 159. Trousdale RT, Ekkernkamp A, Ganz R, et al. Periacetabular and Intertrochanteric Osteotomy for the Treatment of Osteoarthrosis in Dysplastic Hips. *J Bone Joint Surg Am* 1995;77:73.

# 160. Trousdale RT, Ganz RG. Periacetabular Osteotomy. In: Callaghan JJ, Rosenberg AG, Rubash HE, eds. *The Adult Hip*, Vol. 1. New York: Lippincott-Raven, 1998:789 (graphic from p. 792).

+ 161. Trumble SJ, Mayo KA, Mast JW. The Periacetabular Osteotomy. Minimum 2-Year Followup in More than 100 Hips. *Clin Orthop* 1999;363:54.

+ 162. Utterback JD, MacEwen GD. Comparison of Pelvic Osteotomies for the Surgical Correction of the Congenital Hip. *Clin Orthop* 1974;98:104.

+ 163. Velasco R, Schai PA, Exner GU. SCFE: A Long-term Follow-up Study after Open Reduction of the Femoral Head Combined with Subcapital Wedge Resection. *J Pediatr Orthop* 1998;7B:43.

# 164. Wagner H. Osteotomies for Congenital Hip Dislocation. In: *The Hip. Proceedings of the 4th Open Scientific Meeting of the Hip Society.* St. Louis, MO: Mosby, 1976:45.

+ 165. Wagner H. Experiences with Spherical Acetabular Osteotomy for Correction of the Dysplastic Acetabulum. *Progress in Orthopaedic Surgery*, Vol. 2. New York: Springer-Verlag, 1978.

# 166. Wagner H, Holder J. Treatment of Osteoarthritis of the Hip by Corrective Osteotomy of the Greater Trochanter. In: Schatzker J, ed. *The Intertrochanteric Osteotomy.* New York: Springer-Verlag, 1984.

+ 167. Wainwright D. The Shelf Operation for Hip Dysplasia in Adolescence. *J Bone Joint Surg Br* 1976;58:159.

+ 168. Wedge JH. Osteotomy of the Pelvis for the Management of Hip Disease in Young Adults. *Can J Surg* 1995;38(Suppl. I):S25.

+ 169. Wedge JH, Wasylenko MJ. The Natural History of Congenital Disease of the Hip. *J Bone Joint Surg Br* 1979;61:334.

+ 170. Weinstein SL. Natural History of Congenital Hip Dislocation (CDH) and Hip Dysplasia. *Clin Orthop* 1987;225:62.

+ 171. Weinstein SL. Natural History and Treatment Outcomes of Childhood Hip Disorders. *Clin Orthop* 1997;344:227.

+ 172. Weisl H. Intertrochanteric Osteotomy for Osteoarthritis: A Long-term Follow-up. *J Bone Joint Surg Br* 1980;62:37.

+ 173. Wenger DR. Trapdoor Procedure for Osteonecrosis with Segmental Collapse of the Femoral Head in Teenagers. *J Pediatr Orthop* 1995;15:7.

+ 174. Werners R, Vincent B, Bulstrode C. Osteotomy for Osteoarthritis of the Hip. A Survivorship Analysis. *J Bone Joint Surg Br* 1990;72:1010.

+ 175. White RE Jr, Sherman FC. The Hip-shelf Procedure: A Long-term Evaluation. *J Bone Joint Surg Am* 1980;62:928.

* 176. Wiberg G. Studies on Dysplastic Acetabula and Congenital Subluxation of the Hip Joint: With Special Reference to the Complication of Osteoarthritis. *Acta Chir Scand Suppl* 1939;83:1.

+ 177. Windhager R, Pongracz N, Schonecker W, Kotz R. Chiari Osteotomy for Congenital Dislocation and Subluxation of the Hip: Results after 20 to 34 Years Follow-up. *J Bone Joint Surg Br* 1991;73:890.

+ 178. Yano H, Sano S, Nagata Y, et al. Modified Rotational Acetabular Osteotomy (RAO) for Advanced Osteoarthritis of the Hip Joint in the Middle-aged Person. First Report. *Arch Orthop Trauma Surg* 1990;109:121.

+ 179. Zlatic M, Radojevic B, Lazovic C, Lupulovic I. Late Results of Chiari's Pelvic Osteotomy. A Follow-up of 171 Adult Hips. *Int Orthop* 1988;12:2149.

# CHAPTER 105

# PRIMARY TOTAL HIP ARTHROPLASTY

*Daniel J. Berry*

**D. W. Berry:** Mayo Clinic, Rochester, MN, 55905

Principles of Treatment
Preoperative Evaluation
Indications
Implant Choice
Cemented Acetabular Components
Uncemented Acetabular Components
Cemented Femoral Components
Uncemented Femoral Implants
Hybrid HIP Replacement
Preoperative Planning
Surgical Technique
Postoperative Care
Treatment Results
Pitfalls and Complications
Infection
Dislocation
Nerve Injury
Vascular Injury
Heterotopic Ossification
Intraoperative Fracture
Late Complications of Total HIP Arthroplasty
Chapter References

Total hip arthroplasty (THA) is a remarkably successful and predictable procedure that provides pain relief, functional improvement, and improved quality of life for several hundred thousand patients each year worldwide (58,71,83,96). The success of hip arthroplasty is predicated on proper patient selection, use of well-designed implants, and skilled technical execution of the procedure. Long-term results demonstrate that THA is durable in many patient populations (1,10,17,62,78,93,94,120,134), although they also demonstrate durability problems in specific patient groups (19,21,35,37,67). Durability also depends on implant type, method of fixation, and technique of insertion. The excellent results of hip replacement have driven patients and surgeons to expand the indications for the procedure to patients with higher functional demands and more difficult anatomic problems, with a consequent increase in the mechanical demands on implant fixation and prosthesis-bearing surfaces (4,6,23,68,89,122).

THA has been used for more than three decades. During this time, operative techniques and implant technology have matured. Many principles that have contributed to the success of the procedure are now widely accepted. At the same time, implants and surgical techniques continue to evolve. Today, surgeons are confronted with many choices of implant design, fixation type, and bearing surface. This chapter reviews the indications, results, and techniques of primary THA. Where possible, the focus is on broadly applicable principles. Unresolved issues and unsolved problems are also addressed.

## PRINCIPLES OF TREATMENT

Treatment of the damaged hip joint is determined by the diagnosis, symptom severity, the degree of hip joint damage, and the patient's functional demands.

Nonoperative management is appropriate for patients with milder hip symptoms and less damage to the hip joint, and for those who by virtue of age, activity level, or medical problems are not candidates for operative treatment. The mainstays of nonoperative treatment include nonsteroidal anti-inflammatory medications, activity modification, use of a cane, and, when appropriate, weight loss.

Some patients with hip problems are candidates for operations that preserve the hip joint (see Chapter 104). Arthroscopy has a limited role: it is particularly useful to manage symptomatic labral tears and intra-articular loose bodies. Pelvic and femoral osteotomies have a limited but important role, particularly in the treatment of younger patients with mild to moderate joint damage and anatomy that is amenable to correction with joint surface redirection. Many young patients with developmental hip dysplasia and minimal arthritis are candidates for redirectional pelvic osteotomies. Some younger adults with proximal femoral abnormalities due to childhood hip problems such as Perthe's disease or slipped capital femoral epiphysis are candidates for intertrochanteric femoral osteotomy. Selected patients with osteonecrosis of the femoral head may benefit from femoral osteotomy or other procedures designed to preserve the femoral head. Finally, arthrodesis is an option for some young patients with a single destroyed hip joint and high activity demands, but the operation is less well accepted by patients than it once was (see Chapter 106).

Many alternatives to hip arthroplasty are technically more difficult to perform or less predictable with respect to outcome than THA. With the exception of arthrodesis, alternatives to THA are most successful when advanced hip arthritis is not present. For most patients of middle age or older with severely damaged hip joints and marked hip pain, THA offers the most reliable pain relief and restoration of function.

## PREOPERATIVE EVALUATION

A systematic approach to the preoperative evaluation of patients considered for THA is essential. It ensures proper patient selection and exclusion for the procedure, collection of critical physical findings, and proper radiographic evaluation. Because most candidates are older, many have significant comorbidities involving cardiac, pulmonary, renal, hepatic, neurologic, or hematologic systems. The patients should be evaluated, when appropriate, by an internist.

Take the patient's history with three major goals in mind:

- Determine the source of symptoms.
- Determine whether the symptoms are severe enough to warrant consideration of THA.
- Determine whether the patient has contraindications to THA.

Establish the pain location and chronology. Most pain caused by intra-articular hip pathology is felt in the groin, buttock, lateral hip, “deep hip area,” thigh, knee, or a combination of several of these anatomic areas. Pain is typically increased with weight bearing and often is worse after the patient has been on his or her feet for a period of time. Exclude spinal, neurologic, vascular, and tumor problems as sources of the pain. Establish the symptom severity by learning the pain intensity and frequency, the degree to which pain limits ambulation, and the amount the pain limits use of stairs and other activities, such as putting on shoes and socks, getting in and out of vehicles, and sexual function. Ask what limitations the hip problem places on the patient's life, and consider whether the limitations that bother the patient can realistically be improved with arthroplasty. Search for contraindications for which THA should be considered only cautiously (Table 105.1). Perform a preoperative medical evaluation.

- Advanced age with serious medical illnesses
- Concomitant musculoskeletal problems that make substantial functional improvement from hip surgery unlikely
- Cognitive or behavioral problems that make compliance with postoperative regimen unlikely
- Unrealistic expectations by the patient
- Minimal or insufficient radiographic findings
- Younger patients who anticipate activity level above that recommended following joint arthroplasty

***Table 105.1. Contraindications to Surgery***

Direct the physical examination to four major issues:

- Establish the source of pain felt in the hip area and confirm the functional impact on the patient.
- Make objective measurements of range of motion and leg lengths that bear on the feasibility of performing a hip arthroplasty and that impact on how the hip arthroplasty is performed.
- Establish whether the patient has adequate neurovascular function and muscle strength.
- Identify any distant sites of infection that might elevate the risk of implant infection.

Many patients with hip pain have a Duchenne's sign, in which the patient leans toward the affected hip in the stance phase of gait, thereby transferring the center of gravity of the body closer to the affected hip, and reducing the resulting joint reactive force. Pain is often present at the extremes of hip motion, especially flexion combined with internal rotation. The Stinchfield test, in which the patient performs a resisted straight-leg raise in a supine position (Fig. 105.1), selectively loads the hip and can distinguish hip joint pain from other nearby musculoskeletal sources. Soft-tissue tenderness around the hip can result from trochanteric bursitis or local soft-tissue problems such as tendinitis. Record hip motion. Measure apparent and true leg lengths. Check and record neurovascular status. Evaluate the muscle strength, especially the hip abductors and quadriceps. Look for evidence of local or distant infection including dental disease or lower extremity ulcers.

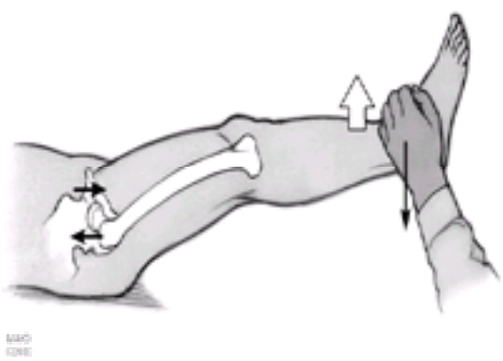

***Figure 105.1.*** The Stinchfield test: With the patient in a supine position, a resisted straight leg raise loads the hip joint selectively. Pain in the hip area (particularly the groin or proximal or anterior thigh) with this test suggests hip joint pathology.

Make radiographs to establish the source of the hip pain and the diagnosis leading to the hip pain, establish the severity of hip disease, and provide information needed for preoperative planning and templating. The standard radiographs needed for these purposes include an anteroposterior (AP) film of the pelvis, an AP film of the affected hip and upper part of the femur, and a lateral view of the hip. Frog lateral or Lowenstein lateral films provide the best lateral view of the proximal femur, but true lateral films of the hip are necessary to provide a lateral view of the acetabulum. Use magnification markers to aid templating.

Special tests are helpful in selected circumstances. A magnetic resonance imaging (MRI) scan can demonstrate early osteonecrosis of the femoral head. Radionucleotide bone scans identify stress fractures and tumors. Some patients with radiographic evidence of hip arthritis have atypical or complex symptoms that leave the source of discomfort in doubt. Intra-articular injection of the hip with a local anesthetic under fluoroscopic guidance is valuable to confirm or exclude the hip as the source of pain.

## INDICATIONS

Necessary prerequisites for consideration of elective hip replacement include significant hip pain or dysfunction, or both, caused by intra-articular hip problems. This finding must be confirmed by radiographic evidence that the hip joint is damaged sufficiently to explain the symptoms. The symptom severity necessary to justify hip arthroplasty requires judgment about the potential operative risks and benefits in a given patient. The more severe a patient's pain and the more profound the disability, the stronger the indication for hip arthroplasty. In distinction, the milder the symptoms and the fewer the limitations, the more cautiously surgery should be recommended. Most patients with pain that markedly limits ambulation, interferes with sleep, or requires narcotic pain medication are strong candidates for surgery. Patients with moderate to severe pain that occurs with moderate activity such as walking several blocks also deserve strong consideration for surgery. Although severe hip pain is the strongest indication for surgery, marked functional loss associated with less pain is a relative indication in some patients. Severe loss of function due to hip stiffness, particularly if it is associated with a marked flexion contracture, is a relative indication in a few patients. For less debilitating symptoms, the surgeon and patient must assess the degree to which the patient's symptoms restrict activities that the patient expects to resume after THA, and then they must balance the risks with the potential benefits of the surgery.

By far the most common diagnosis leading to hip arthroplasty is osteoarthritis. Other diagnoses include inflammatory arthritis, osteonecrosis of the femoral head, developmental dysplasia of the hip, other developmental or congenital hip abnormalities, traumatic conditions leading to secondary degenerative arthritis of the hip, some proximal femoral fracture nonunions, occasional acute displaced proximal femur fractures that are not ideal for internal fixation or hemiarthroplasty, and some tumors around the hip.

Active infection is a contraindication to total hip replacement. In most circumstances anatomically distant bacterial infection should be treated before THA. Hip area pain in the absence of demonstrable hip pathology is a contraindication to surgery. Age, medical illness, or orthopaedic comorbidities that make it unlikely that the patient would obtain substantial functional benefit from THA are relative contraindications to surgery. Cognitive, behavioral, and substance abuse problems that may preclude compliance with critical portions of the postoperative regimen, such as hip dislocation precautions, are also relative contraindications.

Patient populations who have increased short-term and long-term risk for complications should be considered more cautiously. The threshold for surgery should be higher in patients with medical comorbidities that put them at markedly elevated operative risk (34). Young and very active patients who are at higher risk for mechanical arthroplasty failure and subsequent multiple revision procedures should consider arthroplasty cautiously. Finally, unrealistic expectations should prompt a review of the goals of the procedure with the patient and re-evaluation of the indications for elective surgery.

## IMPLANT CHOICE

Many implant designs and types of fixation are available. A surgeon must choose between cemented and uncemented acetabular and femoral implants. If uncemented acetabular implants are chosen, the surgeon must decide whether to augment the press-fit of the socket with further fixation such as screws. If cemented femoral implants are chosen, the surgeon must decide whether to use an implant with a collar as well as whether to use an implant with a polished or a rougher surface finish. If an uncemented femoral implant is chosen, wedge-shaped metaphyseal filling proximally porous-coated implants, tapered implants, and extensively porous-coated implants are all available. Implant materials vary, the most common being cobalt-chromium and titanium. Different surface finishes, including porous-coated surfaces,

plasma-sprayed surfaces, roughened titanium surfaces, and hydroxyapatite-coated surfaces, are also all available. The wide array of choices can make the best implant choice for a specific patient difficult. See Chapter 100 for details on these various prostheses and their biomechanics.

Surgeons performing joint arthroplasty should understand the features associated with success or failure of cemented implants and uncemented implants.

Polymethylmethacrylate (PMMA) bone cement can provide strong and durable fixation of THA implants to bone. Cement is stronger in compression than tension. Voids in cement weaken it; technologies such as centrifugation and vacuum mixing have been introduced to reduce cement voids. Whether these technologies will reduce cemented implant loosening rates is unproven. Cement must provide stability at two interfaces: the interface between the cement and bone, and the interface between the implant and cement. The bone-cement interface gains strength from interdigitation of the cement with the microstructure of cancellous bone and from the internal macrogeometry of the bone into which the cement is implanted. Cement interdigitation into bone is achieved by pressurizing the cement into the cancellous bone microstructure. The best means of providing stability between the implant and the cement is controversial. Some implants have roughened, textured, or treated surfaces designed to enhance the strength of the implant-cement bond (7,24,31,97). Others have polished surfaces that may remain mechanically stable by virtue of macrogeometry even if the stem is not bonded to the cement (13,27). Stability in these cases may be maintained by slight subsidence of the stem and engagement of the tapered stem in the tapered cement mantle. Most cemented femoral implants appear to function best when the component is surrounded by a continuous cement mantle (5). Defects in the full-thickness cement mantle are associated with premature loosening of some implant types and localized osteolysis (2,5,40).

Uncemented prosthetic fixation relies on bone ingrowth into a porous implant surface (41) or bone ongrowth to a biologically active implant surface (20), such as grit-blasted titanium or a ceramic such as hydroxyapatite (32,61). Smooth press-fit implants that lack coatings or texturing to provide for bone ongrowth or ingrowth have not enjoyed reliable long-term fixation in patients with THA (39,76). For porous ingrowth to occur reliably, the optimal pore size appears to be 100 to 400 µm (20). The most popular materials for biologic fixation have been cobalt-chromium and titanium. Biologically active osteoconductive ceramics have gained popularity, although it is unproven whether they have advantages over porous metal surfaces. Regardless of the surface material, a key prerequisite for bony fixation of uncemented implants is stable initial fixation of the implant against bone. Micromotion of less than 50 µm favors bone ingrowth, whereas larger amounts of micromotion tend to allow only fibrous fixation (20). For stable long-term biologic fixation to occur, the implantation must be securely fit against bone of sufficient strength to resist forces that could lead to micromotion before bone ingrowth occurs.

For the acetabulum, I prefer uncemented porous-coated hemispherical sockets fixed with screws for most primary THAs (Fig. 105.2, Fig. 105.3 and Fig. 105.4). The indications for an uncemented socket are especially strong in young patients, for whom cemented sockets have a higher loosening rate. I reserve cemented sockets for patients with previous therapeutic pelvic radiation and for elderly patients with very poor bone quality. Good cases can be made for both cemented and uncemented femoral stems. Regardless of the fixation method, femoral results depend on technique, so choose a method or methods that you can perform well. I tend to use uncemented femoral fixation for young active patients with good bone quality and cemented fixation for older patients or those with poor bone quality. Femoral canal morphology influences decisions about femoral fixation (Fig. 105.5). Patients with a very small canal diameter and thick cortices (Dorr type A bone) (36) are good candidates for uncemented implants. Patients with a typical canal geometry (Dorr type B bone) are good candidates for either a cemented or uncemented implant. Patients with a very large canal diameter and thin cortices (Dorr type C bone) are often good candidates for cemented fixation. Patients with large diameter femoral canals appear to be at greater risk for thigh pain and stress shielding if uncemented implants are used. I tend to use uncemented, fully porous-coated femoral implants for patients with Dorr type A bone (Fig. 105.2), uncemented proximally coated metaphyseal filling implants for young patients with Dorr type B bone (Fig. 105-3), and cemented femoral implants for older patients with Dorr type B bone and for patients with Dorr type C bone (Fig. 105.4).

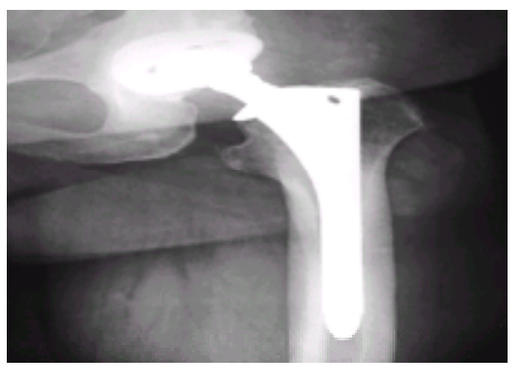

***Figure 105.2.*** AP radiograph of an uncemented total hip arthroplasty using an extensively porous-coated femoral component.

***Figure 105.3.*** AP radiograph of an uncemented total hip arthroplasty using a proximally hydroxyapatite-coated uncemented stem.

***Figure 105.4.*** AP radiograph of a hybrid total hip arthroplasty using an uncemented socket and a cemented stem.

***Figure 105.5.*** The Dorr classification of femoral bone morphology (36). The proximal femoral morphology is helpful in determining the favored femoral implant geometry and type of fixation. From left to right: Type A, Type B and Type C bone.

## CEMENTED ACETABULAR COMPONENTS

Cemented acetabular components provide excellent early results, but loosening increases with time and is much more common after the first decade compared with other components. Loosening (90,116,119) is more common in younger patients (4,21). Acetabular loosening often causes fewer symptoms in the elderly. Loosening of cemented sockets correlates with the quality of the bone–cement interface achieved at surgery: better interfacescorrespond to better implant survivorship. Cemented acetabular loosening is due in part to linear osteolysis along the bone–cement interface caused by particulate debris from the joint implant surface (114). Factors such as younger age, and higher activity and large femoral head size, which increase polyethylene wear, correlate with higher acetabular component loosening rates.

## UNCEMENTED ACETABULAR COMPONENTS

Uncemented porous-coated sockets were developed to increase durability over cemented sockets. Midterm results demonstrate that porous-coated uncemented sockets can become osteointegrated and perform well clinically (25,50,52,70,84,102,112,132) (Table 105.2). Uncemented porous-coated sockets now have been implanted for more than a decade, so relevant comparison to cemented sockets is becoming possible. Results demonstrate that some uncemented sockets can perform at least as well as cemented sockets 10 years after surgery, even in demanding patient populations (6). However, some first-generation uncemented sockets experienced a high failure rate related to a 32-mm head size, thin polyethylene, poor polyethylene-socket congruity, and poor liner–shell locking mechanisms (3,136). Many of these problems have been eliminated or reduced with newer designs.

| Author | Study year | N | Socket type | Mean age | Follow-up years (range) | Revised for aseptic loosening | Socket revised for PE wear or osteolysis or liner failure | Clinically–radiographically bone failure pending revision for loosening/wear | Femoral head |
|---|---|---|---|---|---|---|---|---|---|
| Latimer and Lachiewicz (70) | 1996a | 136 | Harris-Galante* with screws | 50 | Mean 7 (5–10) | 0% | 1.5% | 0% | 28 mm CoCr or 1.50 |
| Anton et al. (3) | 1996a | 159 | Porous Coated Anatomic† | 58 | Mean 5 (2–8) | 2.5% | 4% (all liner) | 1% | CoCr 32 mm or unspecified |
| Bourne et al. (10) | 1999 | 168 | Harris-Galante* | 67 | Mean 9.1 | 2.5% | 1.8% (all liner failure) | 0.6% | Alumina ceramic |
| Gokan and Harris (21) | 1999 | 196 | Harris-Galante* | 59 | Mean 10 | 0% | 2.6% (2 for osteolysis, 3 for liner dislocation) | 0.6% (all osteolysis) | CoCr (22, 26, 28, 32 mm head size) |
| Engh (44) | 1997 | 225 | Anatomic Modullary Locking (AML)‡ | 53 | Min 10 yr. | 1.8% | 4.3% (all PE wear/lysis) | 1.3% | CoCr (32 mm) |

*Harris-Galante (Zimmer, Warsaw, IN).
†Porous Coated Anatomic (Howmedica/Osteonics, Rutherford, NJ).
‡Anatomic Modullary Locking (DePuy, Warsaw, IN).
PE=polyethylene

***Table 105.2. Uncemented Sockets***

Most porous-coated uncemented sockets have demonstrated a low loosening rate, and implant fixation to bone appears to be more favorable for uncemented sockets than for cemented sockets at a similar time interval. Exceptions to these good results have been threaded, nonporous-coated sockets and sockets with hydroxyapatite over a smooth substrate surface, both of which have had higher loosening rates.

For uncemented designs with a good fixation record, the two main modes of failure have been osteolysis, and catastrophic failure of the polyethylene liner. Catastrophic failures are typically due to wearing through of very thin polyethylene, polyethylene fracture, or failure of the liner—shell locking mechanism (12). Catastrophic failures have diminished markedly with improved locking mechanisms and recognition that very thin polyethylene shells are undesirable. Osteolysis remains the single biggest problem associated with uncemented cups (Table 105.2). The three main strategies used to reduce osteolysis are

- Reduce wear debris from the bearing surface.
- Reduce wear debris from nonbearing surfaces.
- Reduce access of the wear debris to bone.

Polyethylene wear debris from the bearing surface can be minimized by

- Using smaller femoral head sizes
- Avoiding titanium femoral heads
- Avoiding oxidized polyethylene sterilized in air by gamma irradiation (see Chapter 100)

Polyethylene debris from nonbearing surface sources can be reduced by

- Improved liner–shell locking mechanisms
- Avoiding impingement between the prosthetic neck and polyethylene liner

To date, it is uncertain whether wear debris can be restricted absolutely from reaching the pelvic bone. Cups without holes are used with the rationale that eliminating holes from the cup may reduce debris access to bone. However, some cups without screw holes have demonstrated high rates of pelvic osteolysis (the particulate debris gains access to bone peripherally around the cup), so it is unclear that this strategy reduces lysis rates (111). The majority of uncemented sockets with midterm results demonstrating good fixation had screws, pegs, or spikes to augment initial socket fixation, and it is yet to be proven that uncemented cups placed without fixation augmentation will perform as well.

## CEMENTED FEMORAL COMPONENTS

Several cemented femoral component designs have demonstrated excellent survivorship at 20 and more years after THA (Table 105.3). However, some early and some more modern designs have demonstrated high failure rates. Modern cementing techniques demonstrate good long-term results when coupled with successful prosthesis design (16,56,77,91,119) (Table 105.4). These techniques include use of a medullary canal plug and retrograde filling of the canal with cement. Other innovations, such as pulsatile lavage of the femoral canal, cement pressurization, cement porosity reduction, and centralization of the implant in the cement mantle, may further enhance durability of cemented implant fixation, but this remains unproven.

| Author | Study year | N | Mean age | Follow-up | Acetabular survivorship free of revision for aseptic loosening | Femoral survivorship free of revision for aseptic loosening |
|---|---|---|---|---|---|---|
| Schulte et al. (116) | 1995 | 338 | 63 | 20 yrs | 20 yrs = 86% | 20 yrs = 95% |
| Berry (10) | 1998 | 2000 | 64 | 25 yrs | 25 yrs = 89.9% | 25 yrs = 98.8% |

*Table 105.3. Cemented Stems—First Generation, Charnley Total Hip Arthroplasty*

| Author | Study year | N | Mean age (years) | Follow-up (years) | Implant type | Revised for femoral aseptic loosening | Unrevised radiographically loose | Mechanical failure rate |
|---|---|---|---|---|---|---|---|---|
| Mulay et al. (77) | 1997 | 336 | 69 | Minimum 15 yrs | Charnley[a] | 1% | 2% | 3% |
| Smith et al. (119) | 1998 | 360 | 61 | Mean 18 yrs (12–20) | CAD or HD-2[b] | 5% | 12% | 6% |
| Bourne et al. (16) | 1998 | 191 | 67 | Mean 12 (10–15) | HD-2[b] | 3% | 1% | 17% |

[a] Charnley (Zimmer, Warsaw, IN).
[b] CAD and HD-2 (Howmedica Osteonics, Rutherford, NJ).

*Table 105.4. Cemented Stems—Second Generation*

Durability of cemented femoral components depends critically on implant design. Implants with a broad medial border that reduces medial cement stresses perform better than implants with a sharp medial border (123). The implant needs to remain mechanically stable in the cement mantle. There appear to be several strategies that can successfully achieve this goal. The first is use of smooth tapered stems that remain stable within the cement even if the stem is not bonded to the cement (i.e., a taper within taper arrangement). The second is use of rougher stems that remain bonded to the cement by virtue of geometry and surface finish. The surface finish of cemented implants has recently attracted much attention, based on the finding that if rough surface implants debond from the cement, osteolysis ensues (121). The process is caused by the debonded rough stem abrading the surrounding cement and creating a large amount of particulate debris. This problem increases with adverse combinations of surface finish and stem geometry. At present, there is no consensus that a single ideal surface finish exists for all stems. Rather, it appears that there are certain combinations of stem geometries and surface finish that function well together and others that do not.

## UNCEMENTED FEMORAL IMPLANTS

Many early uncemented femoral component designs had problems with loosening and thigh pain (15,53,55,88). The problem of thigh pain often resulted from loose implants but also occurred in some patients with well-fixed stems, probably secondary to micromotion betweenthe distal tip and femoral endosteum or stress concen-tration at the stem tip (22,127). Uncemented femoral de-signs have improved, and now the best clinical resultsreported with uncemented implants match those of ce-mented implants (18,33,43,85,100,103,106,107) (Table 105.5).

| Author | Year | N | Mean follow-up (years) | Mean age | Implant | Description | Revised for aseptic loosening | Additional radiographically loose | Marked femur | Significant thigh pain |
|---|---|---|---|---|---|---|---|---|---|---|
| Gruen and Harrington (46) | 1992 | 110 | 6.2 | 53 | Omnifit-PSG[a] | Proximal HA coated titanium | 0% | 0% | 0% | 2.7% were scored if thigh |
| Mulliken et al. (96) | 1996 | 856 | 2.7 | 63 | Mallory-Head[b] | Circumferentially proximally plasma sprayed titanium sprayed | 0% | 0.2% | 0% | 6% thigh pain |
| Engh et al. (40) | 1997 | 174 | 11 | 55 | Anatomic Modullary Locking (AML)[c] | Cobalt-chrome circumferentially porous coated | 1.7% | 1.1% | 1.1% | 1.6% thigh pain |
| McLaughlin and Lee (86) | 1997 | 141 | 10 | 57 | Taperloc®[d] | Proximal 1/2 coated tapered titanium | 0.6% | 3% | 0.6% | 2.7% were scored if thigh |
| Soma et al. (118) | 1999 | 100 | 11.6 | 58 | Porous Coated Anatomic (PCA)[e] | Circumferentially proximally porous coated cobalt chromium | 2% | 3% | 1% | 4% (2% with mild thigh pain) |

[a] Omnifit-PSG (Howmedica Osteonics, Rutherford, NJ).
[b] Mallory-Head (Biomet, Warsaw, IN).
[c] Anatomic Modullary Locking (AML), Warsaw, IN.
[d] Taperloc® (Biomet, Warsaw, IN).
[e] Porous Coated Anatomic (Howmedica Osteonics, Rutherford, NJ).

*Table 105.5. Uncemented Stems*

To be successful, the uncemented implant must initially achieve axial and rotational stability in the femur. Implants fixed in the metaphysis, at the metaphyseal–diaphyseal junction, or in the diaphysis appear to work in some design iterations. A surface coating that provides for long-term biologic fixation is necessary. Porous coating with cobalt-chromium (43,55,100) or titanium beads, titanium fiber metal (84) or plasma spray (86,90), roughened titanium surfaces (106), and hydroxyapatite coatings (48,108) have been be successful. The main goal of uncemented implants is to improve long-term durability over cemented implants. Studies of selected uncemented implants at 10 and more years are encouraging, but longer follow-up is needed before definitive comparison to cement fixation can be made.

## HYBRID HIP REPLACEMENT

The combination of an uncemented socket and a cemented stem is commonly called hybrid hip replacement. The goal of this combination of implants is to take advantage of the clinical reliability, durability, and ease of use of uncemented sockets and cemented femurs. The method has produced excellent midterm results and is presently popular in North America (Table 105.6).

| Author | Study year | N | Mean age | Follow-up (years) | Implant/socket | Acetabular component—aseptic failure | Femoral component—aseptic failure | Acetabular component—unrevised, dislocated | Femoral component—unrevised, dislocated | Mean postop hip score |
|---|---|---|---|---|---|---|---|---|---|---|
| Mulder et al. (87) | 1995 | 120 | 67 | 5.2 (0–12) | Harris-Galante[a] cup/Porcom stem[b] | 0% | 0% | 1.6% | 1.6% | HHS[c] = 86 |
| Woodson and Huber (135) | 1996 | 123 | 67 | 6.6 | Harris-Galante[a] cup/Porcom stem[b] | 0.8% (loose dissociation) | 5.2% (stem fracture or loose) | 0% | 1.6% | HHS[c] = 91 |
| Lewallen and Cabanela (71) | 1996 | 130 | 67 | 5.8 | Harris-Galante and Osteonics Cup[a] Porcom HDI-2[b], Precoat[d], Precoat[e], Osteonics[f] | 0.7% (loose) | 2.1% (loose) | 0.7% (loose) | 2.1% | Moderate or severe pain in only 3.7% of uncemented hips |
| Chakey and Harris (26) | 1999 | 100 | 65 | 10 | Harris-Galante[a] cup/Porcom[b] | 1% (1 hip loose dissociation, 1 hip loose, stem loose) | 1% (loose) | 0% | 1% | HHS[c] = 92 |

[a] HHS = Harris Hip Score (%).
Excellent = 90–100 points.
Good = 80–89 points.
Fair = 70–79 points.
Poor = <70 points.
[b] Harris-Galante Cup (Zimmer, Warsaw, IN).
[c] Porcom Stem (Zimmer, Warsaw, IN).
[d] Osteonics (Howmedica Osteonics, Rutherford, NJ).
[e] HDI (Howmedica Osteonics, Rutherford, NJ).
[f] Precoat Stem (Howmedica Osteonics, Rutherford, NJ).

*Table 105.6. Hybrid Total Hip Arthroplasty*

## PREOPERATIVE PLANNING

Planning implant size, position, and availability before surgery reduces operative time and complications. In planning, also address leg length and hip stability. Preoperative planning requires information obtained from the patient's history, physical examination, and radiographs.

Plan surgery with templates on radiographs with a known magnification. Simulate optimum socket size, location, and position (Fig. 105.6*A*). Both the AP and true lateral films of the hip and pelvis help determine implant size. The goal is to optimize socket orientation and contact with native bone and to restore the normal hip center of rotation when possible. The optimal socket position is 40° to 45° of abduction on the AP radiograph and 10° to 25° of anteversion on the true lateral radiograph. Most surgeons prefer to target the lower range of anteversion when an anterolateral approach to the hip is used, and the higher range when a posterolateral approach is used. Anticipate areas where bone removal or graft reconstruction will be required. In most cases of degenerative disease, plan to remove a small amount of medial bone to place the acetabular prosthesis in an appropriate position, that is, touching the lateral aspect of the foveal bone (radiographically, the teardrop). On the AP radiograph, note the amount of socket left uncovered laterally. On the true lateral radiograph, note the position of the socket relative to the ischium and anterior wall of the acetabulum (Fig. 105.6*B*). Knowing the expected relationship of the socket to the pelvic landmarks improves socket positioning during surgery. Finally, mark the socket center of rotation on preoperative radiographs (Fig. 105.6*A*).

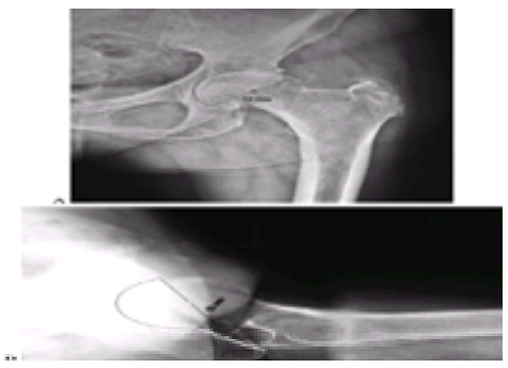

***Figure 105.6.*** **A:** AP hip radiograph with acetabular component template in place. The cup is oriented in approximately 40° of abduction. The cup is positioned properly, with the medial socket against the lateral aspect of the radiographic teardrop. From the templating, the surgeon can anticipate the need to deepen the socket slightly by reaming away osteophytes medially so as to position the socket properly. The planned center of hip rotation is marked with a dot. **B:** True lateral hip radiograph with acetabular component template in place. The cup is oriented in about 20° of anteversion. From templating, the surgeon should expect that the rim of the acetabular component will be inset slightly with respect to the anatomic acetabular rim.

Use femoral component templates to determine femoral implant geometry, size, position, and neck length. Patient factors and surgeon preference guide the choice of implant design and fixation. Preoperative templating also plays a role in choosing the implant design: certain femoral canal geometries are more favorable for cemented implants, whereas others are better for uncemented implants. Very poor bone quality, very large canal diameters, and marked canal deformities are indications to consider cement fixation. In contrast, excellent bone quality with thick cortices and a small canal diameter are indications to consider uncemented implants more strongly. The Dorr classification of canal morphologies (36) is helpful in organizing this decision-making process (Fig. 105.5).

Overlay templates of the chosen femoral design on the radiograph. Properly sized cemented implants leave room for a cement mantle of appropriate size and also leave adequate cancellous bone after broaching for cement interdigitation (Fig. 105.7). Most templates show the outline of the broach corresponding to each implant size, making it possible to visualize the amount of intramedullary cancellous bone left after broaching. Choose uncemented implants to fit and fill the part of the femur in which that particular implant obtains fixation (Fig. 105.8*A* and Fig. 105.8*B*). Different implants variously obtain fixation in the metaphysis, at the metaphyseal–diaphyseal junction, and in the diaphysis. Identify the femoral neck osteotomy level necessary to provide restoration of leg length. When possible, choose a neck resection level that avoids long modular femoral necks with a “skirt” because such devices allow less motion before impingement between the prosthetic femoral neck and the acetabular polyethylene (126). Choose a prosthesis that restores femoral offset (Fig. 105.9). If an implant of proper size cannot restore offset, then consider a stem design with a higher femoral offset. Many implant companies now provide implants with high and standard offset options. High offset stems commonly provide better restoration of femoral offset without excessive leg lengthening in patients with varus femoral necks. Restoring femoral offset allows the abductors to function more efficiently (thereby reducing limp) and also helps restore soft-tissue tension (thus improving hip stability).

***Figure 105.7.*** AP radiograph of the hip with template for a cemented femoral component. The template shows the broach envelope (a *dotted outline,* which simulates the minimum cement mantle), as well as the femoral component (*solid line)*. Note that the implant size chosen should leave some cancellous bone behind after broaching to provide for cement interdigitation.

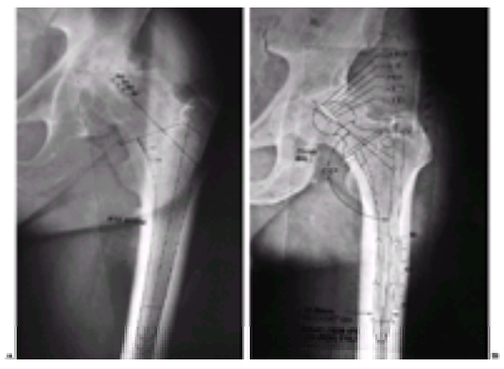

***Figure 105.8.*** **A:** AP hip radiograph template for a proximally coated uncemented stem. Note that with this type of implant, priority is given to obtaining a good fit in the metaphyseal and metaphyseal-diaphyseal junction areas. **B:** AP hip radiograph with a template for an extensively porous-coated uncemented stem. Note that with this type of implant, priority is given to getting a good fit in the diaphysis.

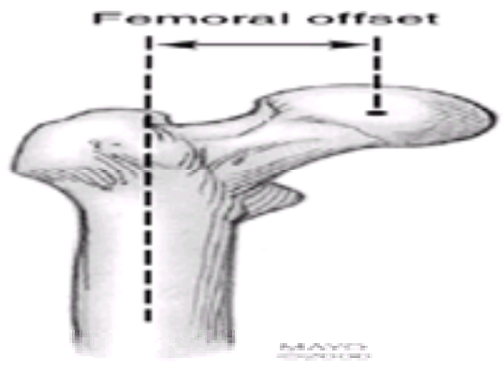


***Figure 105.9.*** The femoral offset is the horizontal distance from a line drawn through the center of the femoral canal along its long axis to the center of the femoral head. AP hip radiographs taken with the hip externally rotated tend to underestimate the true femoral offset.

Templating predicts the effects of implant location, design, and size on leg length and femoral offset. Once the center of hip rotation is determined by acetabular templating, the difference between the femoral head center and the acetabular center on templating predicts change in leg length: if the templated center of the femoral head is superior to the templated acetabular center, the leg will be lengthened by that amount, and if the templated center of the femoral head is inferior to the templated acetabular center, the leg will be shortened by that amount (Fig. 105.10). The position of the templated femoral head center to the templated acetabular center from medial to lateral corresponds roughly to femoral offset restoration (Fig. 105.10).

***Figure 105.10.*** AP hip radiograph with acetabular and femoral templates demonstrating the position of possible modular femoral neck lengths relative to the planned center of hip rotation (The inferior dot marks the center of the acetabular component.) Femoral head centers inferior to the planned center of the acetabulum shorten the leg relative to the preoperative condition, whereas femoral head centers superior to the planned center of the acetabulum lengthen the leg relative to the preoperative condition. Likewise, femoral head centers lateral to the planned center of the acetabulum reduce femoral offset relative to the preoperative status, whereas femoral head centers medial to the planned center of the acetabulum increase femoral offset relative to the preoperative status. The term femoral offset in this context is used as an approximation because true femoral offset refers only to the femur and is not dependent on the center of the acetabulum. The patient's symptomatic leg was 4 mm shorter than the opposite side preoperatively so the femoral component position is chosen to provide proper leg length reconstitution with a +5 mm modular neck length. To obtain proper femoral offset, and thus to help restore soft tissue tension and abductor lever arm, a high-offset femoral component is chosen.

Mark the chosen femoral neck osteotomy, the femoral head center of rotation for each available neck length, and (for collared implants) the relationship of the collar to the medial femoral neck.

## SURGICAL TECHNIQUE

- Position the patient in either the lateral or supine position. Advantages of the lateral position are that soft tissues fall away from the wound, the assistant has better visualization of the procedure, and both anterior or posterior approaches to the hip joint are possible. The main disadvantage is the possibility the pelvis may tilt during surgery, making acetabular orientation difficult (Fig. 105.11). This problem can be reduced by making sure the pelvis is held securely with a positioning device. Advantages of the supine position include more certain pelvis position and easier direct comparison of leg lengths intraoperatively. The supine position restricts the surgical approach, however: Only anterior hip dislocation is possible. Pad the opposite leg and arms for all positions to prevent skin and nerve problems.

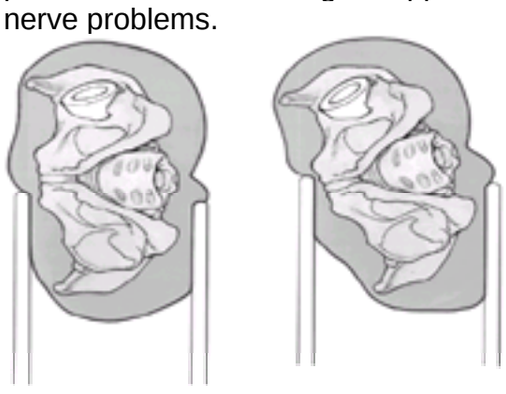

***Figure 105.11.*** The pelvis can roll when the patient is in the lateral decubitus position. This is particularly common with the posterior approach, in which femoral retraction tends to cause the pelvis to roll forward. When the pelvis is rolled forward, the acetabular component anteversion falsely appears to be greater than it is in reality. Failure to recognize this problem can lead to insufficient acetabular component anteversion and posterior hip instability.

- Give the first dose of antibiotics within an hour before the skin incision is made. Perioperative antibiotics are one of the most effective means of preventing infection. For most patients, use a broad-spectrum, first-generation cephalosporin. For patients with an allergy that precludes using cephalosporin, use another intravenous antibiotic with a gram-positive bacterial spectrum. Continue the prophylactic antibiotic for 24 to 48 hours after surgery.
- A variety of exposures are available for THA. Most can be categorized as variations of anterolateral, posterolateral, or transtrochanteric approaches (see Chapter 3). The main advantage of anterolateral approaches is the low dislocation rate; the main disadvantage is the potential for abductor muscle dysfunction to cause a limp after surgery (owing to poor abductor healing or abductor denervation). The posterior approach spares the abductors, and postoperative limp is uncommon; the main disadvantage of the posterior approach is a higher reported rate of hip dislocation. Both anterior and posterior approaches have strong followings, and the choice of approach is best left to the surgeon. Consider patients at very high risk for posterior dislocation good candidates for an anterolateral approach. I use both approaches selectively; I use the anterior approach for patients at higher dislocation risk and the posterior approach for patients judged at lower dislocation risk. The transtrochanteric approach provides excellent hip exposure but is associated with more blood loss and a risk of trochanteric nonunion or migration. Reserve the transtrochanteric approach for unusual cases with special anatomic considerations, such as marked proximal femoral deformities or revision surgery.
- In the *anterolateral exposure,* make an incision directly over the proximal lateral femur centered on the greater trochanter. Curve the incision slightly posteriorly at the proximal third of the incision. Divide the iliotibial band in the direction of its fibers, and split the interval between the tensor fascia lata and gluteus maximus. Reflect the anterior third of the gluteus medius and the gluteus minimus in continuity with the anterior third of the vastus lateralis from the proximal femur. To avoid injury to the superior gluteal nerve, take care not to extend the incision in the gluteus medius more than 5 cm from the trochanter (60,104). Note that the gluteus minimus fibers run at 90° to those of the gluteus medius. The anterior, superior, and inferior hip capsule can be excised to gain exposure or can be preserved if exposure is satisfactory. Place a retractor in the ilium to hold the soft tissues out of the field. See Chapter 3 for more details.
- In the *posterior exposure,* make a Kocher-style incision centered over the greater trochanter. The distal limb is parallel to the femur and the proximal limb is

parallel to the gluteus maximus muscle fibers. Split the iliotibial band in the direction of its fibers and then divide the fascia of the gluteus maximus in the direction of its fibers in line with the skin incision. Split the gluteus maximus using a muscle-splitting technique. Identify the sciatic nerve by visualization or palpation. Protect it throughout the procedure. Identify the piriformis tendon and divide the fascia along its superior border. Pass a periosteal elevator through the interval between the gluteus minimus and the hip capsule. Detach the short external rotators from the posterior femur to expose the posterior hip capsule. Keep the short external rotator tendons as long as possible and tag them with a suture. Control branches of the circumflex femoral vessels on the deep border of the quadratus femoris muscle. Perform a capsular incision inferiorly and superiorly that extends from inferior to superior, then take the capsule down from the femur, leaving it attached to the posterior wall of the acetabulum. This creates a large posteriorly based capsular flap that can be repaired later (101). Make the capsular flap the maximum size possible. See Chapter 3 for more details.

- Place a pin in the pelvis if you intend to make direct leg length measurements intraoperatively, and mark a point on the femur against which to compare measurements.
- Dislocate the hip and identify the lesser trochanter. Use cutting guides or implant trials to mark the level and orientation of the femoral neck osteotomy. Base the level on preoperative planning relative to the greater trochanter, center of the femoral head, and lesser trochanter. Cut the femoral neck with an oscillating saw. If anterolateral exposure is used, retract the femur posteriorly with a bone hook. If posterior exposure is used, retract the femur anteriorly with a cobra retractor placed against the anterior wall of the acetabulum. Make sure no soft tissues are interposed between the retractor and the pelvis. In the posterior approach, release the gluteus maximus tendon to facilitate anterior retraction of the femur if needed. Anterior capsulotomy also helps translate the femur anteriorly. Remove the labrum and visualize the entire rim of the acetabulum. Proper acetabular preparation is not possible without satisfactory acetabular exposure. Poor exposure increases the likelihood of acetabular implant malposition and hip instability. Place retractors carefully around the acetabulum to avoid injury to neurovascular structures. If a posterior retractor is placed, make sure it is against bone and that the sciatic nerve is protected.
- For a *cemented acetabulum,* remove remaining soft tissues from the fovea. Good visualization of the floor of the fovea provides a guide to determine the depth of reaming. Remove large osteophytes around the inferior, posterior, and anterior rim of the acetabulum with an osteotome or rongeur. Superior osteophytes can usually be left in place. Preserve the transverse ligament because this will help restrict inferior cement extrusion. Remove remaining acetabular cartilage with a large curet. Use small reamers to remove bone to, but not beyond, the base of the lateral aspect of the fovea. The fovea corresponds to the teardrop radiographically, and reaming usually should not be deeper than the lateral fovea, except when a shallow socket is present. Use sequentially larger reamers to create a hemisphere of bleeding subchondral bone, keeping the reamer centered in the acetabulum. Strike a compromise between excessive reaming, which removes all the subchondral bone and leaves behind only very weak bone, and insufficient reaming, which leaves a bed of only sclerotic bone. If only weak bone is left, loosening can result from implant migration through soft bone; conversely, if only sclerotic bone is exposed, a poor bone–cement interface may result, leading to early loosening.
- Make holes for cement fixation into the ilium, the pubis, and the ischium with a curet, large burr, or drill. Some surgeons prefer a few large holes into each area, whereas others prefer multiple smaller holes $^{1}/_{8}$ to ¼ inch in diameter. Larger holes remove more bone but expose more cancellous bone for cement interdigitization. I prefer multiple moderate-sized drill holes. Place a trial implant into the socket and position it appropriately. Note its position relative to pelvic landmarks. Mix the cement and wait until it reaches a doughy stage. Introduce the cement into the socket and pressurize it into the bone. The cement can be finger pressurized, or pressurized with a cement gun or special acetabular pressurizers. A sponge inside a rubber glove works well for this purpose but tends to extrude cement around the rim of the acetabulum. I prefer to pressurize the cement into each part of the acetabular surface with my thumb.
- Insert the socket into the acetabulum with a positioning device and hold it securely in proper position until all cement is hardened. The ideal socket position is 40° to 45° of abduction and 10° to 25° degrees of anteversion. Many surgeons err on the lower side of anteversion for the anterior approach and the higher side for a posterior approach. Remove any cement around the periphery of the socket before it hardens. Ensure that no large pieces of cement remain after all the cement is hard.
- For an *uncemented socket,* remove soft tissue from the fovea and large inferior, anterior and posterior osteophytes. Excise the transverse ligament. Use a small reamer to reach the lateral aspect of the fovea and then ream with sequentially larger reamers to expose a bleeding hemisphere of subchondral bone. Keep the reamers centered in the acetabulum by judging the reamer position relative to the peripheral rim of the socket. There is a tendency for power reamers to migrate superiorly and posteriorly. Maintain pressure on the reamer to keep it centered. Use a curet to remove cysts. Feel for a residual prominent rim of bone around the periphery of the socket. This rim of bone may be left behind inadvertently during the reaming process but should be removed with a burr or reamer before inserting an implant. Place particulate cancellous bone graft obtained from the reaming into any cysts and into any defects left in the area of the fovea. Test the size of the acetabular hemisphere with trial implants. Impact an uncemented implant into the acetabulum. In most cases, choose an implant 1 or 2 mm larger than the size of the last reamer to obtain a good press-fit. Position the socket as recommended for cemented implants. Make sure the socket is “bottomed out” (i.e., that it contacts bone not only peripherally but also in the dome). I always use screws, fins, or pegs to augment fixation, but some surgeons do so only selectively. If none are used, it is imperative to make certain that the press-fit of the socket is very rigid. Avoid placing screws anterior to a line drawn from the anterosuperior iliac spine to the ischium to avoid injury to intrapelvic vascular structures (63,129) (Fig. 105.12). The best area is the superior dome of the acetabulum into the ilium. Place a trial liner in the socket.

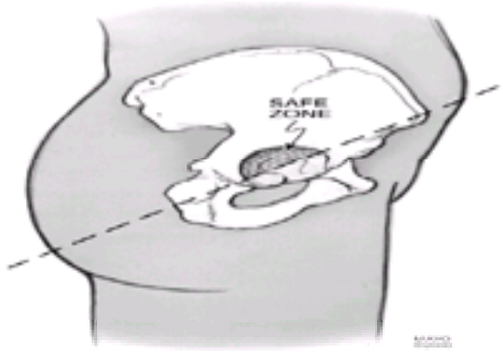


***Figure 105.12.*** The “safe zone” for acetabular screw placement (Redrawn from Wasliewski RC, Cooperstein LA, Kruger MP, Rubash HE. Acetabular anatomy and the transacetabular fixation of screws in total hip arthroplasty. *J Bone Joint Surg* 1990;72A:501, with permission.) In the anterior two quadrants, the risk of neurovascular injury if a drill or screw extends beyond the far cortex is high. In the posterior two quadrants, there is less risk but the sciatic nerve still needs to be respected.

- Before preparing the femur, remove soft tissues just medial to the greater trochanter to allow access to the piriformis fossa. If these soft tissues are not removed, instruments and the implant tend to be pushed into a varus position. Open the femoral canal with a T-handled broach or awl. The proper starting point is usually the piriformis fossa, which is located directly over the medullary canal. Avoid an excessively medial starting point, which can lead to varus alignment. There is a tendency with a high neck cut to introduce instruments into the canal in flexion due to femoral neck anteversion; avoid this problem by starting more posteriorly in the femoral neck.
- For a *cemented femur,* prepare the femur with broaches alone or reamers and broaches. Use reamers only to start the canal preparation, and avoid excessive reaming. Good remaining cancellous bone is required for cement interdigitation. As the canal is prepared, avoid varus or valgus orientation of the instruments. Broach the canal in proper anteversion, usually about 15°. After the final broach is in place, use a calcar planer to smooth the femoral neck. Perform a trial reduction and check anterior and posterior hip stability, leg length, and soft-tissue tension. Remove any loose, unsupportive, cancellous bone from the canal with a uterine curet or canal brush. Place a cement restrictor at an appropriate depth in the femoral canal to provide about 2 cm of cement distal to the tip of the stem. Resorbable or permanent plugs (polyethylene) are convenient. Plugs can also be created by the surgeon from bone or methacrylate. Clean the intramedullary canal with pulsatile lavage and dry with sponges or a vaginal packing gauze. Some surgeons use sponges with thrombin or dilute epinephrine to reduce canal bleeding. Keep the canal packed until you are ready to inject the cement. The best means of preparing cement is controversial: Some favor mixing under a vacuum, some favor centrifugation, and others use neither. Both vacuum mixing and centrifugation were developed to reduce cement porosity, which may improve cement strength. Introduce the cement into the canal retrograde using a cement gun. Pressurize the cement column to allow the cement to interdigitate into the cancellous bone. Introduce the femoral component into the canal and hold it securely in proper position until all cement has hardened.
- The methods of implanting an *uncemented femoral component* are specific to the implant design. Techniques associated with each implant differ because of different instrumentation and because different parts of the femur are used to gain fixation. Nevertheless, several important points are common to insertion of most uncemented femoral components. Obtain rigid fixation of the implant against strong, hard bone. Recent understanding of uncemented implant fixation has emphasized the importance of gaining rigid rotational stability of uncemented implants. Proper and precise sizing of the uncemented implant is essential to obtain initial rigid fixation and subsequent biologic fixation. Prepare the femur with reamers or broaches until contact is made in the appropriate area of the canal with hard endosteal or cortical bone. A press-fit of the real implant is predicated on having a cavity slightly smaller than the implant. Too large a cavity from imprecise preparation or poor instruments provides unsatisfactory initial implant stability. Too small a cavity can lead to femoral fracture when the implant is inserted. Be sure to prepare the femoral canal in the proper orientation. Avoid varus malalignment, which gives the tactile impression that canal preparation is complete prematurely and leads to implant undersizing.
- Perform a trial reduction before the real femoral component is inserted and again after the real implant is securely in place. Many surgeons perform this step after the real socket has been placed, but some perform a trial reduction with both trial acetabular and femoral implants. The goals of trial reduction are to test hip stability and leg length, and to exclude prosthesis impingement. Reduce the hip and test posterior hip stability with the hip flexed, adducted, and internally rotated. Test the hip in the mid zone of flexion with maximum adduction (the so-called “position of sleep”). Test anterior stability of the hip in extension and external rotation. Some surgeons take an AP radiograph of the pelvis with the trial implants in place to check position and radiographically verify restoration of leg length and center of rotation of the hip.
- If posterior stability is unsatisfactory, determine the cause. Is there insufficient acetabular or femoral anteversion? Is there soft-tissue or bony impingement

between the femur and pelvis? Is soft-tissue tension insufficient? If implants are not ideally positioned, reposition the appropriate component. Small adjustments in acetabular component position can be made using elevated lip liners if modular uncemented sockets are used. Elevated lip liners increase hip stability in one direction at the expense of hip stability or range of motion in the opposite direction (69). If impingement is present, try to remove the source. Commonly, some remaining an-terosuperior hip capsule, part of the head of the rectus femoris tendon, or the anterior aspect of the greater trochanter are sources of impingement with the hip flexed and internally rotated. Redundant posterior inferior capsule can cause impingement between the femur and ischium with the hip in extension and external rotation.

- Test the soft-tissue tension. If it is lax, a longer neck length may be needed. Soft-tissue tension is often less in small women or in patients with profound muscle relaxation. Relying solely on soft-tissue tension to choose neck length can lead to inadvertent overlengthening of the limb. Sometimes soft-tissue tension can be improved without increasing leg length by increasing the femoral offset. Increase offset by using a high-offset femoral implant or by placing the same implant deeper in the femur and using a longer neck length. Make sure the prosthetic femoral neck does not impinge on the acetabular polyethylene. If it does, consider repositioning the acetabular component. Prosthetic impingement can lead to hip instability or polyethylene wear.
- Judge whether leg length has been restored according to the preoperative plan (133). If a pin was placed in the pelvis intraoperatively, compare the distance from the pin to the fixed point marked on the femur (compared with the same measurement performed before femoral neck osteotomy). Use bony landmarks, including the position of the femoral head relative to the greater trochanter and position of the femoral collar relative to the lesser trochanter, to help estimate the leg length based on preoperative templating. Compare the position of the patient's knees and heels to one another compared with their relative position before femoral neck osteotomy. The legs must be in the same relative positions for this to be a valuable test. An intraoperative radiograph of the pelvis and both hips can provide information on leg lengths. None of these tests of leg length are perfect, but all provide some information concerning relative leg length in surgery.
- Irrigate the wound and make sure fragments of cement or bone are removed. Obtain good hemostasis.
- To close the anterolateral approach, reattach the gluteus minimus, medius, and vastus lateralis muscles to their beds using strong absorbable or nonabsorbable sutures passed through bone. Meticulous repair is necessary because failure of the abductors to heal can cause limp and hip instability.
- To close the posterolateral approach, reapproximate the capsule and short external rotators to the posterior aspect of the abductors and the greater trochanter. If possible, reattach the soft tissues with sutures passed through bone. This may not be possible if the leg has been lengthened or if the femoral offset is markedly increased. Avoid overtensioning the piriformis tendon, which passes over the sciatic nerve. A good repair of the capsule and short external rotators may reduce the risk of early hip dislocation after a posterior approach (Fig. 105.13) (101). Close the remaining tissues in layers. I prefer, as do others, to use closed suction drains; some surgeons do not. Treat the patient with intravenous antibiotics for 24 or 48 hours after surgery. There is no evidence that longer treatment has any advantage.

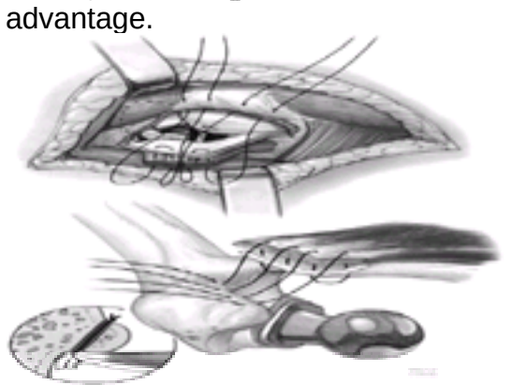

***Figure 105.13.*** Diagram showing formal soft tissue repair of the posterior capsule and short external rotators after posterior approach to the hip.

## POSTOPERATIVE CARE

Patients treated with THA are at risk for venous thromboembolic disease. Most North American surgeons use some prophylaxis for this potentially life-threatening complication (75,92). Available measures include warfarin (28,74), low-molecular-weight heparin (29,98,105), unfractionated heparin, aspirin, dextran, and mechanical foot or leg compression devices (128,131). Warfarin or low-molecular weight heparin is widely used in North America (18,29,46). If warfarin is used, the target international normalized ratio (INR) is usually 1.5 to 2.2. The ideal treatment duration is not defined and varies from 1 to 6 weeks. I prefer 2 to 3 weeks of treatment under routine conditions, and 6 weeks for patients with a history of venous thromboembolic disease or strong risk factors for thromboembolic disease. Low-molecular-weight heparin should be used according to the manufacturer's recommendations concerning timing of administering the first dose. If the drug is given too early, bleeding complications are more common. See Chapter 5 for additional details.

Mobilize the patient, if possible, the day after surgery. Individualize the weight-bearing regimen according to the type of implant fixation. Most surgeons allow cemented and hybrid hip replacements to begin partial weight bearing immediately. The duration of arm support varies, but by 6 weeks most patients can begin to make the transition to a cane. The postoperative regimen after uncemented THA is more controversial. Some allow immediate weight bearing, whereas others restrict weight bearing for 8 to 12 weeks. Those who advocate immediate weight bearing believe that it stimulates bone healing; those who advocate protected weight bearing believe it provides time for tissue ingrowth before maximally loading the femoral implant.

Discuss hip dislocation precautions with the patient. Show the patient hip positions that can lead to dislocation and demonstrate how to avoid them. Show the patient how to rise from a chair and get in and out of bed safely.

## TREATMENT RESULTS

Total hip arthroplasties of many different designs can provide excellent pain relief and a very good level of function for moderate activities. Studies have demonstrated a high level of patient satisfaction after THA (58,71,83). For patients with well-fixed implants, most decrements in function in large series are due to increasing disability with age (62). When implants fail for mechanical reasons, many patients develop pain and poorer function (95) and require revision surgery. Thus function free of mechanical failure is considered a key parameter of arthroplasty success. Mechanical failure rates depend on fixation method, implant design, and demographic factors (Table 105.2, Table 105.3, Table 105.4, Table 105.5 and Table 105.6).

## PITFALLS AND COMPLICATIONS

### INFECTION

Infection after THA is uncommon; it presently occurs in about 0.5% of primary hip arthroplasties (47). The single most important factor in preventing early infection is use of perioperative antibiotics (45). Careful surgical technique, low traffic in the operating theater, body exhaust suits, and laminar flow may also reduce the risk of early infection (47). Late prosthetic infection can occur from bacteremia. Recent guidelines developed by the American Academy of Orthopaedic Surgeons suggest that for 2 years after hip arthroplasty, prophylactic antibiotics be given to all patients for dental and other procedures that might cause bacteremia. The recommendations for prophylaxis for dental or oral procedures for patients with no penicillin allergy are for amoxicillin 2.0 g orally 1 hour before a dental procedure and for amoxicillin 2.0 g orally before a gastrointestinal or genitourinary procedure. Alternative antibiotics for dental or oral procedures are cephalexin 2.0 g orally or clindamycin 600 mg orally 1 hour before the procedure, and for genitourinary or gastrointestinal procedures, ciprofloxacin 750 mg orally 1 hour before the procedure. For immunocompromised patients, other patients at high risk for infection, and for certain high-risk procedures, lifetime prophylaxis for dental or other invasive procedures is recommended.

Infection of a hip prosthesis is a serious complication that requires prompt treatment. If the problem is identified early, infection may be treated successfully with prompt surgical treatment and proper antibiotics. More typically, however, treatment of the infection requires implant removal. In North America, most surgeons prefer a two-stage approach to treat most patients with infected implants, but under specific circumstances, one-stage reimplantation may also be considered (47) (see Chapter 135).

### DISLOCATION

The frequency of hip dislocation varies dramatically in different series, from 0.3% to greater than 10%. In most large series, the range is around 2% to 3%. The period of highest risk for dislocation is the first 3 months after surgery, but there is always some risk of dislocation, and first-time dislocations can occur even years after a THA. Certain patient populations are at risk for dislocation: females have a higher risk than males (130), and patients treated with a posterolateral approach are at higher risk than those treated with an anterolateral approach (130). The risk of dislocation can be minimized by preoperative, intraoperative, and postoperative measures. Preoperative measures include appropriate patient selection, careful templating, and consideration of an anterolateral approach for patients at high risk for

posterior dislocation. Intraoperative attention to component position (especially the acetabulum), as well as soft-tissue tension, care to seek and remedy impingement sources, and meticulous repair of the tissues during closure help reduce the risk of dislocation. Postoperative patient education and prophylactic abduction bracing for selected patients are also helpful.

Most dislocations are treated by closed reduction. Before reduction, make a true lateral radiograph of the hip (in addition to a standard AP radiograph) to confirm the direction of dislocation. Most first and second dislocations are treated nonoperatively with patient education and with an abduction bracing program; however, re-current dislocations usually require reoperation. Whenreoperation is considered, determine the etiology ofdislocation. Component malposition, impingement, or inadequate soft-tissue tension are the most frequent categories. Once the specific problem has been identified, institute specific measures to address that problem. Conversion to constrained sockets (49) or bipolar implants are also effective means of managing dislocation, but these measures are usually reserved for problem patients who have failed previous operative attempts to gain hip stability or who have markedly deficient abductor mechanisms. See Chapter 106 for additional details.

**NERVE INJURY**

Injury to the sciatic, femoral, obturator, or superior gluteal nerves can occur during THA (104). Injury to the sciatic nerve, particularly the peroneal division of that nerve, is probably the most common injury. Women, patients with peripheral neuropathy, and patients with lumbar disc disease are at increased risk (115). Marked lengthening of the leg is associated with a higher risk of palsy, but a specific cut-off for the maximum amount of lengthening that can be performed safely has not been identified. The etiology of nerve injury is unknown in many cases (109,115). Reoperation is indicated if hematoma is thought to contribute to the palsy. Many patients recover significant function over time; some early recovery of function and initial incomplete dysfunction correlate with better likelihood of eventual complete recovery. Treatment during the recovery period involves bracing with an ankle-foot orthosis, skin care, and pain management for dysesthetic pain.

**VASCULAR INJURY**

Injury of major vascular structures during THA is rare. The main vessels at risk are the femoral artery anteriorly, the obturator artery inferiorly, and the iliac vessels medial to the pelvis. Avoid socket screw placement anterior to a line between the anterior superior iliac spine and ischium to minimize the risk of iliac vessel injury (63,129).

**HETEROTOPIC OSSIFICATION**

Minimal heterotopic bone formation after THA is frequent, but severe heterotopic bone that markedly limits hip range of motion is uncommon (Fig. 105.14). Patients at risk include those who have previously formed heterotopic bone after another hip operation, patients with diffuse idiopathic skeletal hyperostosis (DISH), patients with pelvic Paget's disease, and probably patients with active ankylosing spondylitis. Men are at higher risk than women. Heterotopic bone formation can cause pain while the process is active early after THA. The process may not be visible on radiographs for 6 to 8 weeks after the operation. Mature ectopic bone typically does not cause pain.

***Figure 105.14.*** AP hip radiograph demonstrating heterotopic bone formation. The patient had marked limitation of motion.

Effective measures to prevent heterotopic ossification formation are available but must be instituted early (preferably within 3 days postoperatively) to be effective (30,66). Nonsteroidal anti-inflammatory medicines given for a duration of 2 to 6 weeks after surgery reduce the risk of heterotopic ossification (65). Low-dose radiation therapy (600 to 800 cGy) given in a single or divided dose to the field at risk either immediately before or within the first 3 days after surgery has also proven effective (54,99). Radiation shielding is useful to avoid irradiation of bone around uncemented implants and to avoid irradiation of trochanteric osteotomies or abductor muscles. Patients that develop heterotopic bone with marked limitation of range of motion can be treated effectively with surgical excision of heterotopic bone. Most surgeons prefer to wait 1 year after THA to excise the bone. If heterotopic bone is excised, treat the patient with an effective method to prevent recurrence. See Chapter 124 for additional information.

**INTRAOPERATIVE FRACTURE**

Intraoperative fractures of both the acetabulum and the femur can occur during hip arthroplasty and are much more common during insertion of press-fit uncemented implants (8). Acetabular fractures are less common than femur fractures. Minimize acetabular fractures by avoiding an excessive discrepancy between the diameter of the final reamer and the outside diameter of the socket and by testing with trial components before impaction of the final implant (64). Most intraoperative acetabular fractures are minor cracks of the posterior wall of the acetabulum that do not compromise acetabular implant stability or pelvic integrity. More extensive fractures occur rarely and may require stabilization of the pelvis with plates. When an acetabular fracture is recognized intraoperatively, consider augmenting fixation of the socket with screws (118). Intraoperative femur fractures can be minimized by careful attention to preoperative planning, proper implant sizing, and surgical technique. Fractures occur most often during broaching and during implant insertion. Patients with unusual femoral geometries and poorer bone quality are at higher risk. A prophylacticcerclage wire around the proximal femur may preventfracture during canal preparation or implant seatingin patients at high risk for fracture. The pattern of intraoperative fractures varies according to implant design. Metaphyseal fractures of the femoral neck are most common with proximally coated metaphyseal filling implants, whereas extensively coated diaphyseal filling implants more often cause diaphyseal cracks (117). Most small cracks that do not compromise implant fixation or femoral integrity can be treated with cerclage fixation without changing femoral component design. If the fracture compromises implant fixation, a different implant is required; the type chosen depends on fracture location and severity.

**LATE COMPLICATIONS OF TOTAL HIP ARTHROPLASTY**

***Implant Loosening***

Improvements in cemented and uncemented implants and techniques have reduced the problem of implant loosening, but it still is a major long-term problem. Choosing well-designed implants and using meticulous surgical techniques are the most effective means to reduce loosening. For cemented components, make sure implant alignment is optimum, obtain good cement interdigitation with bone, and obtain an adequately thick, circumferential cement mantle. For uncemented implants, size the implant optimally and obtain secure fixation to good-quality bone. Most patients with implant loosening develop pain: acetabular loosening is most commonly felt in the buttock or groin, femoral loosening most commonly in the thigh. Weight-bearing pain associated with loose implants is often triphasic: patients experience pain with initiation of weight bearing, feel better after a short distance of ambulation, then develop more pain as they walk farther. The treatment of most symptomatic loose implants for medically fit patients is revision surgery (see Chapter 106).

***Polyethylene Wear and Osteolysis***

As the durability of implant fixation has improved, wear of the polyethylene bearing surface and associated osteolysis have become limiting factors in the durability of many arthroplasties, particularly in young active patients (Fig. 105.15). Some wear of the polyethylene bearing surface of THA occurs in all patients. Marked polyethylene wear leads to billions of submicron-sized polyethylene debris particles in the periprosthetic space (57,110). This debris causes osteolysis (81) by a pathway, the details of which are still being worked out, that involves mediators of inflammation and a cellular response. Factors known to correlate with increased volumetric polyethylene wear (and hence more polyethylene debris) include large femoral head size (32 mm or greater), thin polyethylene (less than 6 mm), titanium femoral heads, and polyethylene oxidized by gamma irradiation in air (11,124). There is some evidence that ceramic femoral heads against polyethylene-bearing surfaces may produce less polyethylene wear. However, to produce a dramatic reduction in the problem of polyethylene wear and associated osteolysis, major efforts

are being directed toward the development of new bearing surfaces. These include ceramic-on-ceramic surfaces, metal-on-metal bearing surfaces, and a new class of highly cross-linked polyethylenes. Further clinical experience is needed to determine whether these new bearing surfaces will dramatically reduce the problem of bearing surface wear and osteolysis without causing new unanticipated problems (135).

***Figure 105.15.*** Marked polyethylene wear (note femoral head eccentricity in the socket) and associated extensive periprosthetic acetabular and femoral osteolysis.

Osteolysis associated with particular debris occurs in patterns based on access of the debris to the periprosthetic pelvic and femoral bone (9,14,80,113,125). When marked particulate debris–induced periprosthetic osteolysis occurs, intervention should be considered. The specific type of treatment is contingent on the status of implant fixation, the pattern of osteolysis, and specific features of the acetabular and femoral implants (see Chapter 106) (9,79).

### *Stress Shielding*

Implantation of an intramedullary femoral component changes the stress distribution in the proximal femur and leads to bone remodeling (26,59). Bone loss around femoral implants by this mechanism is called stress shielding. The amount of bone loss that occurs, regardless of implant design fixation type, correlates with the quality of bone prior to hip implantation (82). Bone that is more osteopenic preoperatively leads to a higher percent of postoperative bone loss. Larger, stiffer, uncemented implants, and particularly extensively coated implants in which distal bone ingrowth is possible, appear to be at higher risk for marked stress shielding (43,44). If stress shielding occurs, in most cases, only observation is recommended. To date, the primary problem caused by stress shielding has been poor bone quality if a further operation is required. As long as the stem continues to function well, stress shielding appears to remain a clinically silent problem.

### *Postoperative Periprosthetic Femur Fracture*

Postoperative periprosthetic femur fractures are treated according to their location and the fixation status of the femoral component. An excellent classification system that helps guide treatment is available (38). Treat fractures involving the trochanters operatively if the displacement is unacceptable or if the etiology is progressive osteolysis. Fractures around the femoral stem or stem tip almost always need to be treated surgically. Nonoperative treatment is associated with a high rate of nonunions and malunions, and requires prolonged immobilization. Most fractures around well-fixed stems can be treated with open reduction and internal fixation using strut allografts and plates that allow fixation with combinations of cerclage, wires or cables, and screws. See Chapter 20 for more details. Fractures around loose implants are treated with revision, usually to longer stemmed implants in association with fracture stabilization with cerclage fixation, strut allografts, or plates (72).

## CHAPTER REFERENCES

Each reference is categorized according to the following scheme: *, classic article; #, review article; !, basic research article; and +, clinical results/outcome study.


+ 1. Alsema R, Deutman R, Mulder TJ. Stanmore Total Hip Replacement. A 15- to 16-year Clinical and Radiographic Follow-up. *J Bone Joint Surg* 1994;76B:240.

+ 2. Anthony PP, Gie GA, Howie CR, Ling RSM. Localized Endosteal Bone Lysis in Relation to the Femoral Components of Cemented Total Hip Arthroplasties. *J Bone Joint Surg* 1990;72B:971.

+ 3. Astion DJ, Saluan P, Stulberg BN, et al. The Porous-coated Anatomic Total Hip Prosthesis: Failure of the Metal-backed Acetabular Component. *J Bone Joint Surg* 1996;78A:755.

+ 4. Ballard WT, Callaghan JJ, Sullivan PM, Johnston RC. The Results of Improved Cementing Techniques for Total Hip Arthroplasty in Patients Less than Fifty Years Old. A Ten-year Follow-up Study. *J Bone Joint Surg* 1994;76A:959.

+ 5. Barrack RL, Mulroy RD, Harris WH. Improved Cementing Techniques and Femoral Component Loosening in Young Patients with Hip Arthroplasty. A 12 Year Radiographic Review. *J Bone Joint Surg* 1992;74B:385.

+ 6. Berger RA, Jacobs JJ, Quigley LR, et al. Primary Cementless Acetabular Reconstruction in Patients Younger than 50 Years Old. 7- to 11-year Results. *Clin Orthop* 1997;344:216.

+ 7. Berger RA, Kull LR, Rosenberg AG, Galante JO: Hybrid Total Hip Arthroplasty. 7- to 10-year Results. *Clin Orthop* 1996;333:134.

# 8. Berry DJ. Epidemiology: Hip and Knee. Periprosthetic Fractures After Major Joint Replacement. *Orthop Clin North Am* 1999;30:183.

# 9. Berry DJ. UHMWPE: The Good, Bad and Ugly: Management of Osteolysis Around Total Hip Arthroplasty. *Orthopedics* 1999;22:805.

+ 10. Berry DJ. *Twenty-five Year Survivorship of 2000 Consecutive Primary Charnley Total Hip Arthroplasties.* Presented at the AAOS Annual Meeting, New Orleans, LA, March 19–23, 1998.

# 11. Berry DJ. Polyethylene Wear: Factors Influencing. *Orthopedics* 1996;19:729.

+ 12. Berry DJ, Barnes CL, Scott RD, et al. Catastrophic Failure of the Polyethylene Liner of Uncemented Acetabular Components. *J Bone Joint Surg* 1994;76B:575.

+ 13. Berry DJ, Harmsen WS, Ilstrup JM: The Natural History of Debonding of the Femoral Component from the Cement and Its Effect on Long-term Survival of Charnley Total Hip Replacements. *J Bone Joint Surg* 1998;80A:715.

+ 14. Bobyn JD, Jacobs JJ, Tanzer M, et al. The Susceptibility of Smooth Implant Surfaces to Peri-implant Fibrosis and Migration of Polyethylene Wear Debris. *Clin Orthop* 1995;311:21.

+ 15. Bourne RB, Rorabeck CH, Ghazal ME, Lee MH. Pain in the Thigh Following Total Hip Replacement with a Porous-coated Anatomic Prosthesis for Osteoarthrosis. A Five-year Follow-up Study. *J Bone Joint Surg* 1994;76A:1464.

+ 16. Bourne RB, Rorabeck CH, Skutek M, et al. The Harris Design-2 Total Hip Replacement Fixed with so-called Second-generation Cementing Techniques. A Ten to Fifteen-year Follow-up. *J Bone Joint Surg* 1998;80A:1775.

+ 17. Britton AR, Murray DW, Bulstrode CJ, et al. Long-term Comparison of Charnley and Stanmore Design Total Hip Replacements. *J Bone Joint Surg* 1996;78B:802.

+ 18. Burt CF, Garvin KL, Otterberg ET, Jardon OM. A Femoral Component Inserted without Cement in Total Hip Arthroplasty. A Study of the Tri-lock Component with an Average Ten-year Duration of Follow-up. *J Bone Joint Surg* 1998;80A:952.

+ 19. Callaghan JJ. Results of Primary Total Hip Arthroplasty in Young Patients. *J Bone Joint Surg* 1993;75A:1728.

+ 20. Callaghan JJ. The Clinical Results and Basic Science of Total Hip Arthroplasty with Porous-coated Prostheses. *J Bone Joint Surg* 1993;75A:299.

+ 21. Callaghan JJ, Forest EE, Olejniczak JP, et al. Charnley Total Hip Arthroplasty in Patients Less than Fifty Years Old. A Twenty to Twenty-five Year Follow-up Note. *J Bone Joint Surg* 1998;80A:705.

+ 22. Campbell ACL, Rorabeck CH, Bourne RB, et al. Thigh Pain after Cementless Hip Arthroplasty: Annoyance or Ill Omen? *J Bone Joint Surg* 1992;74B:63.

+ 23. Capello WN, D'Antonio JA, Feinberg JR, Manley MT. Hydroxyapatite-coated Total Hip Femoral Components in Patients Less than Fifty Years Old. Clinical and Radiographic Results after Five to Eight Years of Follow-up. *J Bone Joint Surg* 1997;79A:1023.

+ 24. Clohisy JC, Harris WH. Primary Hybrid Total Hip Replacement, Performed with Insertion of the Acetabular Component without Cement and a Precoat Femoral Component with Cement. An Average Ten-year Follow-up Study. *J Bone Joint Surg* 1999;81A:247.

+ 25. Clohisy JC, Harris WH. The Harris-Galante Porous-coated Acetabular Component with Screw Fixation. An Average Ten-year Follow-up Study. *J Bone Joint Surg* 1999;81A:66.

+ 26. Cohen B, Rushton N: Bone Remodeling in the Proximal Femur after Charnley Total Hip Arthroplasty. *J Bone Joint Surg* 1995;77B:815.

+ 27. Collis DK, Mohler CG. Loosening Rates and Bone Lysis with Rough Finished and Polished Stems. *Clin Orthop* 1998;355:113.

+ 28. Colwell CW, Collis DK, Paulson R, et al. Comparison of Enoxaparin and Warfarin for the Prevention of Venous Thromboembolic Disease after Total Hip Arthroplasty. Evaluation During Hospitalization and Three Months after Discharge. *J Bone Joint Surg* 1999;81A:932.

+ 29. Colwell CW, Spiro TE, Trowbridge AA, et al. Use of Enoxaparin, a Low-molecular-weight Heparin, and Unfractionated Heparin for the Prevention of Deep Venous Thrombosis after Elective Hip Replacement. A Clinical Trial Comparing Efficacy and Safety. *J Bone Joint Surg* 1994;76A:3.

+ 30. Coventry MB, Scanlon PW. The Use of Irradiation to Discourage Ectopic Bone: A Nine-year Study in Surgery about the Hip. *J Bone Joint Surg* 1981;63A:201.

! 31. Crowninshield RD, Jennings JD, Laurent ML, Maloney WJ. Cemented Femoral Component Surface Finish Mechanics. *Clin Orthop* 1998;355:90.

+ 32. Dalton JE, Cook SD, Thomas KA, Kay JF. The Effect of Operative Fit and Hydroxyapatite Coating on the Mechanical and Biological Response to Porous Implants. *J Bone Joint Surg* 1995;77A:97.

+ 33. D'Antonio JA, Capello WN, Jaffe WL. Hydroxyapatite-coated Hip Implants: Multicenter Three-year Clinical and Roentgenographic Results. *Clin Orthop* 1992;85:102.

+ 34. Dearborn JT, Harris WH. Postoperative Mortality after Total Hip Arthroplasty. An Analysis of Deaths after Two Thousand Seven Hundred and Thirty-six Procedures. *J Bone Joint Surg* 1998;80A:1291.

+ 35. Devitt A, O'Sullivan T, Quinlan W. 16- to 25-year Follow-up Study of Cemented Arthroplasty of the Hip in Patients Aged 50 Years or Younger. *J Arthroplasty* 1997;12:479.

! 36. Dorr LD, Faugere MC, Mackel AM, et al. Structural and Cellular Assessment of Bone Quality of Proximal Femur. *Bone* 1993;14:231.

+ 37. Dowdy PA, Rorabeck CH, Bourne RB. Uncemented Total Hip Arthroplasty in Patients 50 Years of Age or Younger. *J Arthroplasty* 1997;12:853.

# 38. Duncan C, Masri BA. Fractures of the Femur after Hip Replacement. *Instr Course Lect* 1995;44:293.

+ 39. Duparc J, Massin P. Results of 203 Total Hip Replacements Using a Smooth, Cementless Femoral Component. *J Bone Joint Surg* 1992;74B:251.

+ 40. Ebramzadeh E, Sarmiento A, McKellop HA, et al. The Cement Mantle in Total Hip Arthroplasty. Analysis of Long-term Radiographic Results. *J Bone Joint Surg* 1994;76A:77.

+ 41. Engh CA, Hooten JP, Zettl-Schaffer KF, et al. Evaluation of Bone Ingrowth in Proximally and Extensively Porous-coated Anatomic Medullary Locking Prostheses Retrieved at Autopsy. *J Bone Joint Surg* 1995;77A:903.

+ 42. Engh CA, Hooten JP, Zettl-Schaffer KF, et al. Porous-coated Total Hip Replacement. *Clin Orthop* 1994;298:89.

+ 43. Engh CA, Bobyn DJ, Glassman AH. Porous-coated Hip Replacement: The Factors Governing Bone Ingrowth, Stress Shielding and Clinical Results. *J Bone Joint Surg* 1987;69B:45.

+ 44. Engh CA Jr, Culpepper WJ III, Engh CA. Long-term Results of Use of the Anatomic Medullary Locking Prosthesis in Total Hip Arthroplasty. *J Bone Joint Surg* 1997;79A:177.

+ 45. Espehaug B, Engesaeter LB, Vollset SE, et al. Antibiotic Prophylaxis in Total Hip Arthroplasty. Review of 10,905 Primary Cemented Total Hip Replacements Reported to the Norwegian Arthroplasty Register, 1987 to 1995. *J Bone Joint Surg* 1997;79B:590.

+ 46. Francis CW, Pellegrini VD, Totterman S, et al. Prevention of Deep-vein Thrombosis after Total Hip Arthroplasty. Comparison of Warfarin and Dalteparin. *J Bone Joint Surg* 1997;79A:1365.

+ 47. Garvin KL, Hanssen AD. Infection after Total Hip Arthroplasty. *J Bone Joint Surg* 1995;77A:1576.

+ 48. Geesink RGT, Hoefnagels NHM. Six-year Results of Hydroxyapatite-coated Total Hip Replacement. *J Bone Joint Surg* 1995;77B:534.

+ 49. Goetz DD, Capello WN, Callaghan JJ, et al. Salvage of a Recurrently Dislocating Total Hip Prosthesis with Use of a Constrained Acetabular Component: A Retrospective Analysis of Fifty-six Cases. *J Bone Joint Surg* 1998;80:502.

+ 50. Goldberg VM, Ninomiya J, Kelly G, Kraay M. Hybrid Total Hip Arthroplasty. A 7- to 11-year Followup. *Clin Orthop* 1996;333:147.

+ 51. Harris WH. Traumatic Arthritis of the Hip after Dislocation and Acetabular Fracture: Treatment by Mold Arthroplasty. An End-result Study Using a New Method of Result Evaluation. *J Bone Joint Surg* 1969;51A:737.

+ 52. Harris WH. Hybrid Total Hip Replacement. Rationale and Intermediate Clinical Results. *Clin Orthop* 1996;333:155.

+ 53. Havelin LI, Espehaug B, Vollset SE, Engesaeter LB. Early Aseptic Loosening of Uncemented Femoral Components in Primary Total Hip Replacement. A Review Based on the Norwegian Arthroplasty Register. *J Bone Joint Surg* 1995;77B:11.

+ 54. Healy WL, Lo TCM, DeSimone AA, et al. Single-dose Irradiation for the Prevention of Heterotopic Ossification after Total Hip Arthroplasty. A Comparison of Doses of Five Hundred and Fifty and Seven Hundred Centigray. *J Bone Joint Surg* 1995;77A:590.

+ 55. Heekin RD, Callaghan JJ, Hopkinson WJ, et al. The Porous-coated Anatomic Total Hip Prosthesis, Inserted without Cement. Results after Five to Seven Years in a Prospective Study. *J Bone Joint Surg* 1993;75A:77.

+ 56. Herberts P, Malchau H: How Outcomes Studies Have Changed Total Hip Arthroplasty Practices in Sweden. *Clin Orthop* 1997;344:44.

! 57. Hirakawa K, Bauer TW, Stulberg BN, et al. Characterization and Comparison of Wear Debris from Failed Total Hip Implants of Different Types. *J Bone Joint Surg* 1996;78A:1235.

+ 58. Hozack WJ, Rothman RH, Albert TJ, et al. Relationship of Total Hip Arthroplasty Outcomes to Other Orthopaedic Procedures. *Clin Orthop* 1997;344:88.

+ 59. Hughes SS, Furia JP, Smith P, Pellegrini VD. Atrophy of the Proximal Part of the Femur after Total Hip Arthroplasty without Cement. A Quantitative Comparison of Cobalt-chromium and Titanium Femoral Stems with Use of Dual X-ray Absorpiometry. *J Bone Joint Surg* 1995;77A:231.

! 60. Jacobs LGH, Buxton RA. The Anatomy of the Superior Gluteal Nerve: Its Relevance to the Direct Lateral Approach for Hip Arthroplasty. *J Bone Joint Surg* 1989;71A:1239.

+ 61. Jaffe WL, Scott DF. Total Hip Arthroplasty with Hydroxyapatite-coated Prostheses. *J Bone Joint Surg* 1996;78A;1918.

+ 62. Kavanagh BF, Wallrichs S, Dewitz M, et al. Charnley Low-friction Arthroplasty of the Hip: Twenty-year Results with Cement. *J Arthroplasty* 1994;9:229.

+ 63. Keating EM, Ritter MA, Faris PM. Structures at Risk from Medially Placed Acetabular Screws. *J Bone Joint Surg* 1990;72A:509.

+ 64. Kim YS, Callaghan JJ, Ahn PB, Brown TD. Fracture of the Acetabulum during Insertion of an Oversized Hemispherical Component. *J Bone Joint Surg* 1995;77A:111.

+ 65. Kjaersgaard-Andrsen P, Schmidt SA. Total Hip Arthroplasty: The Role of Anti-inflammatory Medications in the Prevention of Heterotopic Ossification. *Clin Orthop* 1991;263:78.

+ 66. Knelles D, Barthel T, Karrer A, et al. Prevention of Heterotopic Ossification after Total Hip Replacement. *J Bone Joint Surg* 1997;79B:596.

+ 67. Kobayashi S, Takaoka K, Saito N, Hisa K. Factors Affecting Aseptic Failure of Fixation after Primary Charnley Total Hip Arthroplasty. Multivariate Survival Analysis. *J Bone Joint Surg* 1997;79A:1618.

+ 68. Kronick JL, Barba ML, Paprosky WG. Extensively Coated Femoral Components in Young Patients. *Clin Orthop* 1997;344:263.

+ 69. Krushell RJ, Burke DW, Harris WH. Elevated-rim Acetabular Components: Effect on Range of Motion and Stability in Total Hip Arthroplasty. *J Arthroplasty* 1991;6:S53.

+ 70. Laupacis A, Bourne R, Rorabeck C, et al. The Effect of Elective Total Hip Replacement on Health-related Quality of Life. *J Bone Joint Surg* 1993;75A:1619.

+ 71. Latimer HA, Lachiewicz PF. Porous-coated Acetabular Components with Screw Fixation. Five to Ten Year Results. *J Bone Joint Surg* 1996;78A:975.

+ 72. Lewallen DG, Berry DJ. Periprosthetic Fracture of the Femur after Total Hip Arthroplasty. Treatment and Results to Date. *J Bone Joint Surg* 1997;79A:1881.

+ 73. Lewallen DG, Cabanela ME. Hybrid Primary Total Hip Arthroplasty. A 5- to 9-year Follow-up Study. *Clin Orthop* 1996;333:126.

+ 74. Lieberman JR, Wollaeger J, Dorey F, et al. The Efficacy of Prophylaxis with Low-dose Warfarin for Prevention of Pulmonary Embolism following Total Hip Arthroplasty. *J Bone Joint Surg* 1997;79A:319.

+ 75. Lieberman JR, Geerts WH. Prevention of Venous Thromboembolism after Total Hip and Knee Arthroplasty. *J Bone Joint Surg* 1994;76A:1239.

+ 76. Lombardi AV, Mallory TH, Eberle RW, et al. Failure of Intraoperatively Customized Non-porous Femoral Components Inserted without Cement in Total Hip Arthroplasty. *J Bone Joint Surg* 1995;77A:1836.

+ 77. Madey SM, Callaghan JJ, Olejniczak JP, et al. Charnley Total Hip Arthroplasty with Use of Improved Techniques of Cementing. The Results after a Minimum of Fifteen Years of Follow-up. *J Bone Joint Surg* 1997;79A:53.

+ 78. Malchau H, Herberts P, Wang YX, et al. Long-term Clinical and Radiological Results of the Lord Total Hip Prosthesis. A Prospective Study. *J Bone Joint Surg* 1996;78B:884.

+ 79. Maloney WJ, Herzwurm P, Paprosky W, et al. Treatment of Pelvis Osteolysis Associated with a Stable Acetabular Component Inserted without Cement as Part of a Total Hip Replacement. *J Bone Joint Surg* 1997;79A:1628.

+ 80. Maloney WJ, Jasty M, Harris WH, et al. Endosteal Erosion in Association with Stable Cementless Femoral Components. *J Bone Joint Surg* 1990;72A:1025.

+ 81. Maloney WJ, Smith RL. Periprosthetic Osteolysis in Total Hip Arthroplasty: The Role of Particulate Wear Debris. *J Bone Joint Surg* 1995;77A:1448.

+ 82. Maloney WJ, Sychterz C, Bragdon C, et al. Skeletal Response to Well Fixed Femoral Components Inserted with and without Cement. *Clin Orthop* 1996;333:15.

+ 83. Mancuso CA, Salvati EA, Johanson NA, et al. Patients' Expectations and Satisfaction with Total Hip Arthroplasty. *J Arthroplasty* 1997;12:387.

+ 84. Martell JM, Pierson RH, Jacobs JJ, et al. Primary Total Hip Reconstruction with a Titanium Fiber-coated Prosthesis Inserted without Cement. *J Bone Joint Surg* 1993;75A:554.

+ 85. McAuley JP, Moore KD, Culpepper WJ, Engh CA: Total Hip Arthroplasty with Porous-coated Prostheses Fixed without Cement in Patients who are Sixty-five Years of Age or Older. *J Bone Joint Surg* 1998;80A:1648.

+ 86. McLaughlin JR, Lee KR. Total Hip Arthroplasty with an Uncemented Femoral Component. Excellent Results at Ten-year Follow-up. *J Bone Joint Surg* 1997;79B:900.

+ 87. Mohler CG, Kull LR, Martell JM, et al. Total Hip Replacement with Insertion of an Acetabular Component without Cement and a Femoral Component with Cement. Four to Seven-year Results. *J Bone Joint Surg* 1995;77A:86.

# 88. Mont MA, Hungerford DS. Proximally Coated Ingrowth Prostheses. A Review. *Clin Orthop* 1997;344:139.

+ 89. Mont MA, Maar DC, Krackow KA, et al. Total Hip Replacement without Cement for Non-inflammatory Osteoarthrosis in Patients Who Are Less than Forty-five Years Old. *J Bone Joint Surg* 1993;75A:740.

+ 90. Mulliken BD, Bourne RB, Rorabeck CH, Nayak N. A Tapered Titanium Femoral Stem Inserted without Cement in a Total Hip Arthroplasty. Radiographic Evaluation and Stability. *J Bone Joint Surg* 1996;78A:1214.

+ 91. Mulroy WF, Estok DM, Harris WH. Total Hip Arthroplasty with Use of So-called Second-generation Cementing Techniques. A Fifteen-year-average Follow-up Study. *J Bone Joint Surg* 1995;77A:1845.

+ 92. Murray DW, Carr AJ, Bulstrode CJK. Pharmacological Thromboprophylaxis and Total Hip Replacement (Editorial). *J Bone Joint Surg* 77B:3-5, 1995.

+ 93. Neumann L, Freund KG, Sørenson KH. Total Hip Arthroplasty with the Charnley Prosthesis in Patients Fifty-five Years Old and Less. Fifteen to Twenty-one Year Results. *J Bone Joint Surg* 1996;78A:73.

+ 94. Neumann L, Freund KG, Sørenson KH. Long-term Results of Charnley Total Hip Replacement. Review of 92 Patients at 15 to 20 Years. *J Bone Joint Surg* 1994;76B:245.

+ 95. Nilsson LT, Franzén H, Carlsson ÅS, Önnerfält R. Early Radiographic Loosening Impairs the Function of a Total Hip Replacement. The Nottingham Health Profile of 49 Patients at Five Years. *J Bone Joint Surg* 1994;76B:235.

+ 96. Norman-Taylor FH, Palmer CR, Villar RN. Quality-of-life Improvement Compared after Hip and Knee Replacement. *J Bone Joint Surg* 1996;78B:74.

+ 97. Oishi CS, Walker RH, Colwell CW. The Femoral Component in Total Hip Arthroplasty. Six to Eight-year Follow-up of One Hundred Consecutive Patients after Use of a Third-generation Cementing Technique. *J Bone Joint Surg* 1994;76A:1130.

+ 98. Paiement GD, Wessinger SJ, Hughes R, Harris WH. Routine Use of Adjusted Low-dose Warfarin to Prevent Venous Thromboembolism after Total Hip Replacement. *J Bone Joint Surg* 1993;75A:893.

+ 99. Pellegrini VD, Gregoritch SJ. Postoperative Irradiation for Prevention of Heterotopic Ossification following Total Hip Arthroplasty. *J Bone Joint Surg* 1996;78A:870.

+ 100. Pellegrini VD, Hughes SS, Evarts CM. A Collarless Cobalt-chrome Femoral Component in Uncemented Total Hip Arthroplasty. *J Bone Joint Surg* 1992;74B:814.

+ 101. Pellicci PM, Bostrom M, Poss R. Posterior Approach to Total Hip Replacement Using Enhanced Posterior Soft Tissue Repair. *Clin Orthop* 1998;355:224.

+ 102. Petersen MB, Poulsen IH, Thomsen J, Solgaard S. The Hemispherical Harris-Galante Acetabular Cup, Inserted without Cement. The Results of an Eight to Eleven-year Follow-up of One Hundred and Sixty-eight Hips. *J Bone Joint Surg* 1999;81A:219.

+ 103. Ragab AA, Kraay MJ, Goldberg VM. Clinical and Radiographic Outcomes of Total Hip Arthroplasty with Insertion of an Anatomically Designed Femoral Component without Cement for the Treatment of Primary Osteoarthritis. *J Bone Joint Surg* 1999;81A:210.

+ 104. Ramesh M, O'Byrne JM, McCarthy N, et al. Damage to the Superior Gluteal Nerve after the Hardinge Approach to the Hip. *J Bone Joint Surg* 1996;78B:903.

+ 105. RD Heparin Arthroplasty Group (The). RD Heparin Compared with Warfarin for Prevention of Venous Thromboembolic Disease following Total Hip or Knee Arthroplasty. *J Bone Joint Surg* 1994;76A:1174.

+ 106. Robinson RP, Deysine GR, Green TM. Uncemented Total Hip Arthroplasty Using the CLS Stem: A Titanium Alloy Implant with a Corundum Blast Finish. Results at a Mean 6 Years in a Prospective Study. *J Arthroplasty* 1996;11:286.

+ 107. Rorabeck CH, Bourne RB, Laupacis A, et al. A Double-blind Study of 250 Cases Comparing Cemented with Cementless Total Hip Arthroplasty. Cost-effectiveness and Its Impact on Health-related Quality of Life. *Clin Orthop* 1994;298:156.

+ 108. Rothman RH, Hozack WJ, Ranawat A, Moriarty L. Hydroxyapatite-coated Femoral Stems. *J Bone Joint Surg* 1996;78A:319.

+ 109. Schmalzried TP, Amstutz HC, Dorey FJ. Nerve Palsy Associated with Total Hip Replacement: Risk Factors and Prognosis. *J Bone Joint Surg* 1991;73A:1074.

+ 110. Schmalzried TP, Callaghan JJ. Wear in Total Hip and Knee Replacements. *J Bone Joint Surg* 1999;81A:115.

+ 111. Schmalzried TP, Guttmann D, Grecula M, Amstutz HC. The Relationship Between the Design, Position, and Articular Wear of Acetabular Components Inserted without Cement and the Development of Pelvic Osteolysis. *J Bone Joint Surg* 1994;76A:677.

+ 112. Schmalzried TP, Harris WH. The Harris-Galante Porous-coated Acetabular Component with Screw Fixation: Radiographic Analysis of 83 Primary Hip Replacements at a Minimum of Five Years. *J Bone Joint Surg* 1992;74A:1130.

+ 113. Schmalzried TP, Jasty M, Harris WH. Periprosthetic Bone Loss in Total Hip Arthroplasty: Polyethylene Wear Debris and the Concept of the Effective Joint Space. *J Bone Joint Surg* 1992;74A:849.

+ 114. Schmalzried TP, Kwong LM, Jasty M, et al. The Mechanism of Loosening of Cemented Acetabular Components: Analysis of Specimens Retrieved at Autopsy. *Clin Orthop* 1992;274:60.

+ 115. Schmalzried TP, Noordin S, Amstutz HC. Update on Nerve Palsy Associated with Total Hip Replacement. *Clin Orthop* 1997;344:188.

+ 116. Schulte KR, Callaghan JJ, Kelley SS, Johnston RC. The Outcome of Charnley Total Hip Arthroplasty with Cement after a Minimum Twenty-year Follow-up. *J Bone Joint Surg* 1993;75A:961.

+ 117. Schwartz JT, Mayer JG, Engh CA. Femoral Fracture during Noncemented Total Hip Arthroplasty. *J Bone Joint Surg* 1989;71A:1135.

+ 118. Sharkey PF, Hozack WJ, Callaghan JJ, et al. Acetabular Fracture Associated with Cementless Acetabular Component Insertion: A Report of Thirteen Cases. *J Arthroplasty* 1999;14:426.

+ 119. Smith SW, Estok DM, Harris WH. Total Hip Arthroplasty with Use of Second-generation Cementing Techniques. An Eighteen-year-average Follow-up Study. *J Bone Joint Surg* 1998;80A:1632.

+ 120. Sochart DH, Porter ML. The Long-term Results of Charnley Low-friction Arthroplasty in Young Patients Who Have Congenital Dislocation, Degenerative Osteoarthritis, or Rheumatoid Arthritis. *J Bone Joint Surg* 1997;79A:1599.

+ 121. Sporer SM, Callaghan JJ, Olejniczak JP, et al. The Effects of Surface Roughness and Polymethylmethacrylate Precoating on the Radiographic and Clinical Results of the Iowa Hip Prosthesis. *J Bone Joint Surg* 1999;81A:481.

+ 122. Sullivan PM, MacKenzie JR, Callaghan JJ, Johnston RC: Total Hip Arthroplasty with Cement in Patients Who Are Less than Fifty Years Old. *J Bone Joint Surg* 1994;76A:863.

+ 123. Sutherland CJ, Wilde Ah, Borden LS, Marks KE: A Ten-year Follow-up of 100 Consecutive Muller Curved-stem Total Hip Replacement Arthroplasties. *J Bone Joint Surg* 1982;64A:970.

+ 124. Sutula LC, Collier JP, Saum KA, et al. Impact of Gamma Sterilization on Clinical Performance of Polyethylene in the Hip. The Otto Aufranc Award. *Clin Orthop* 1995;319:28.

+ 125. Urban RM, Jacobs JJ, Sumner DR, et al. The Bone-implant Interface of Femoral Stems with Non-circumferential Porous Coating. A Study of Specimens Retrieved at Autopsy. *J Bone Joint Surg* 1996;78A:1068.

+ 126. Urquhart AG, D'Lima D, Venn-Watson E, et al. Polyethylene Wear after Total Hip Arthroplasty: The Effect of a Modular Femoral Head with an Extended Flange-reinforced Neck. *J Bone Joint Surg* 1998;80A:1641.

+ 127. Vresilovic EJ, Hozack WJ, Rothman RH. Incidence of Thigh Pain after Uncemented Total Hip Arthroplasty as a Function of Femoral Stem Size. *J Arthroplasty* 1996;11:304.

+ 128. Warwick D, Harrison J, Glew D, et al. Comparison of the Use of a Foot Pump with the Use of Low-molecular-weight Heparin for the Prevention of Deep-vein Thrombosis after Total Hip Replacement. A Prospective, Randomized Trial. *J Bone Joint Surg* 1998;80A:1158.

+ 129. Wasielewski RC, Cooperstein LA, Kruger MP, Rubash HE. Acetabular Anatomy and the Transacetabular Fixation of Screws in Total Hip Arthroplasty. *J Bone Joint Surg* 1990;72A:501.

+ 130. Woo RYG, Morrey BF. Dislocations after Total Hip Arthroplasty. *J Bone Joint Surg* 1982;64A:1295.

+ 131. Woolson ST. Intermittent Pneumatic Compression Prophylaxis for Proximal Deep Venous Thrombosis after Total Hip Replacement. *J Bone Joint Surg* 1996;78A:1735.

+ 132. Woolson ST, Haber DF. Primary Total Hip Replacement with Insertion of an Acetabular Component without Cement and a Femoral Component with Cement. Follow-up Study at an Average of Six Years. *J Bone Joint Surg* 1996;78A:698.

+ 133. Woolson ST, Harris WH. A Method of Intraoperative Limb Measurement in Total Hip Arthroplasty. *Clin Orthop* 1985;194:207.

+ 134. Wroblewski BM. 15–21 Year Results of the Charnley Low-friction Arthroplasty. *Clin Orthop* 1986;211:30.

+ 135. Yoon TR, Rowe SM, Jung ST, et al. Osteolysis in Association with a Total Hip Arthroplasty with Ceramic Bearing Surfaces. *J Bone Joint Surg* 1998;80A:1459.

+ 136. Xenos JS, Callaghan JJ, Heekin RD, et al. The Porous-coated Anatomic Total Hip Prosthesis, Inserted without Cement. A Prospective Study with a Minimum of Ten Years of Follow-up. *J Bone Joint Surg* 1999;81A:74.

# CHAPTER 106

# FAILED HIP ARTHROPLASTY: REVISION AND ARTHRODESIS

*Paramjeet S. Gill and Wayne G. Paprosky*

**P. S. Gill:** Division of Orthopaedic Surgery, University of California, San Francisco School of Medicine, San Francisco, California and University Medical Center, Fresno, California.
**W. G. Paprosky:** Department of Orthopaedic Surgery, Rush Medical College, Chicago, Illinois and Central DuPage Hospital, Winfield, Illinois.

Revision Hip Arthroplasty
Etiology and Mechanisms of Failure
Aseptic Loosening
Component Design
Infection
Clinical Results
Indications
Evaluation of the Patient: History and Physical Examination
Physical Examination
Investigation
Radiographic Evaluation
Cemented Components
Uncemented Components
Comparison of Results
Femoral Revision
Acetabular Revision
Classification of Defects and Treatment Plan
Femoral Defects
Paprosky Femoral Defect Classification
Acetabular Defects
Preoperative Planning
Templating
Extended Trochanteric Osteotomy
Exposure
Posterior Approach
Acetabular Exposure
Femoral Revision
Acetabular Revision
Structural Grafting
Pelvic Discontinuity
Revision with a Metal-Backed Component
Postoperative Management
Intraoperative Complications
Blood Loss
Vascular Injury
Neurologic Injury
Postoperative Complications
Limb Lengthening
Thromboembolic Disease
Dislocation
Heterotopic Ossification
Arthrodesis of the Hip
Indications and Contraindications
Preoperative Planning
Surgical Technique
Cabanela and Pagnano Hip Arthrodesis
Benaroch Intra-Articular Arthrodesis
Arthrodesis with a Muscle Pedicle Bone Graft
Hip Arthrodesis with Cobra-Plate Fixation
Arthrodesis with an Anterior Plate
Arthrodesis of the Hip In the Absence of the Femoral Head
Pitfalls and Complications
Results
Conversion of Hip Arthodesis to Total Hip Arthroplasty
Author's Perspective
Chapter References
Arthrodesis of the Hip

## REVISION HIP ARTHROPLASTY

Hip arthroplasty is one of the most successful surgical procedures yet developed. It provides millions of people with freedom of mobility and preserves their independence. Originally intended for the elderly, low-demand user with significant arthritis, hip arthroplasty has been so successful that it is now used in increasingly younger, more active patients. In the appropriate patient, total hip arthroplasty can now be considered at any time after skeletal maturity and has largely supplanted other options, such as hip fusion, as a form of treatment acceptable to the majority of patients. With older patients living longer and arthroplasty being performed in younger patients, the need for revision arthroplasty has dramatically increased.

Revision surgery is more complicated than primary arthroplasty and has become a focus for arthroplasty surgeons (Fig. 106.1) (44). Revision arthroplasty ranges from simply exchanging the polyethylene liner of a cup to major pelvic reconstruction. It demands more of the surgeon and of the hospital. The key to successful revision surgery is preparation for multiple possibilities and clear plans as to what to do for each possible eventuality.

***Figure 106.1.*** **A:** Periprosthetic fracture treated with plates and strut grafts. **B:** Refractures with weight bearing. **C:** Revised with a fully coated component acting as intramedullary fixation reinforced with strut grafts.

## ETIOLOGY AND MECHANISMS OF FAILURE

Hip prostheses have a finite life span. In older patients, this factor may not present a problem, because they will not outlive their prosthesis. It is, however, a problem in younger patients. Of the many causes of failure, including aseptic loosening, component failure, infection, and femoral fracture, the most common is aseptic loosening, which accounts for more than 80% of all failures (73).

### ASEPTIC LOOSENING

The principal cause of aseptic loosening is the generation of particle debris, to which the body responds with an inflammatory reaction resulting in focal or linear osteolysis (Fig. 106.2). Particles may originate from several sites, principally at the articulation of the head with the liner, with backside wear of the liner on the shell, at any modular junction or at the prosthesis cement interface (Fig. 106.3).

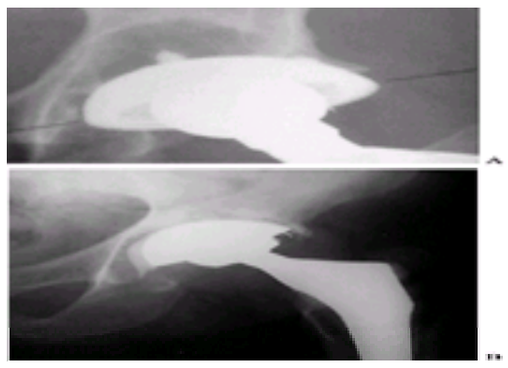

***Figure 106.2.*** **A:** Focal osteolysis in the supracetabular region. Cup remains stable. **B:** Linear osteolysis leading to an unstable cup.

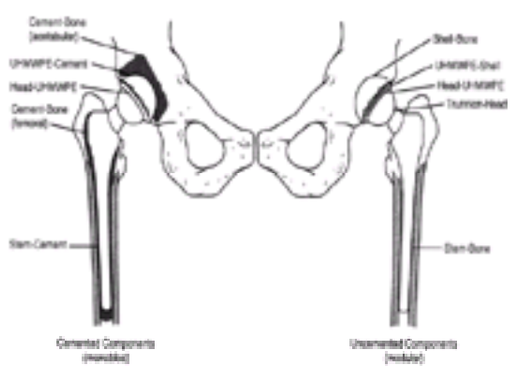

***Figure 106.3.*** Multiple interfaces acting as potential particle generators in total hip replacement. UHMWPE, ultra high molecular weight polyethelene.

The main source of particles is the polyethylene liner, which is the limiting factor in implant longevity. The presence of microscopic polyethylene particles in the joint fluid initiates a macrophage response that leads to the release of lytic enzymes that can cause bone destruction and loosening of the prosthesis (64,89). The joint fluid may conduct particles to bone where they incite lysis. All periprosthetic areas accessible to joint fluid are vulnerable, and this area is defined as the “effective joint space” (89).

The effective joint space can be decreased, thus protecting portions of the arthroplasty, by prosthetic design and surgical technique. An example of this is the use of porous coating. Some of the early uncemented, proximally porous-coated components had noncircumferential coating. This allowed joint fluid access to the distal portion of the stem, causing osteolysis (7). Modern components have circumferential porous coatings proximally to promote bone ingrowth that acts as a relative seal against the passage of joint fluid distally and thus decreases the effective joint space. Acetabular components are similarly designed with fewer screw holes to diminish access to the supra-acetabular region. This design may decrease the size and number of osteolytic lesions. Decreasing the effective joint space is more difficult with cemented designs.

### COMPONENT DESIGN

It is clear that small changes in component design can have major effects on the longevity of the implant. In one prosthesis, laser etching was used to write on the stem, and this led to stem fractures in the area of the etching (109). Review of previous failures has built consensus in the design of modern prostheses as compared with those available 20 years ago. Catastrophic failures are rare.

Most femoral components are made of either cobalt chrome alloys or titanium, and acetabular components are made principally of titanium. Titanium heads, which were widely used until they were shown to be a poor bearing material, have been supplanted by cobalt chrome or ceramic. A major goal in hip prosthesis design is better durability of polyethylene. Previous attempts at improving the durability of polyethylene have included carbon fiber reinforcement and higher crystallinity forms of polyethylene such as Hylamer (DePuy, Dupont), both of which have met with little success (34). Alternative bearing surfaces of ceramic and metal on metal are under investigation.

### INFECTION

Infection following joint replacement has decreased with the use of preoperative antibiotic prophylaxis. The use of laminar air flow and body exhaust suits may reduce the risk of infection but has not been proven (29,57,93). The current rate of infection is 0.5% to 2% in primaries and 2% to 4% in revisions (2,29,32,87).

### CLINICAL RESULTS

Femoral components cemented with hand mixing and finger packing (first-generation techniques) have demonstrated failure rates as high as 40% at 10 years and as low as 7% at 20 years (91,101). Second-generation techniques, with a medullary plug, lavage of the intramedullary canal, and retrograde cement delivery, have demonstrated failure rates as low as 7% at 15 years (72). Third-generation techniques with porosity reduction of the cement and pressurization may provide further improvement. Cemented acetabular fixation has not been improved comparably. First-generation techniques for cemented cups have had failure rates up to 30% at 10 years, and second-generation techniques have had failure rates of 44% at 14 years (43,72).

Uncemented components have shown good results on femoral and acetabular sides, although the length of follow-up is generally less than that of cemented components. The Anatomic Medullary Locking (AML, DePuy, Warsaw, Indiana) stem has the longest follow-up, with a 1.5% loosening at 11 years (66). Uncemented acetabuli have shown some excellent intermediate results, with revision rates as low as 1.4% at 10 years; however, long-term results remain to be seen (51).

### INDICATIONS

#### *Aseptic Loosening*

Aseptic loosening is a radiographic diagnosis that does not constitute an indication for surgery by itself. Loose, symptomatic components should be revised if the

patient can tolerate the surgery medically. Asymptomatic patients may require surgery if osteolysis is progressive. Because osteolysis is usually asymptomatic until component stability is compromised, routine follow-up evaluation is appropriate. Osteolytic lesions can be bone grafted with an exchange of the acetabular liner and femoral head at an early stage (65) (Fig. 106.4). Limited surgery becomes less feasible as the lesion enlarges.

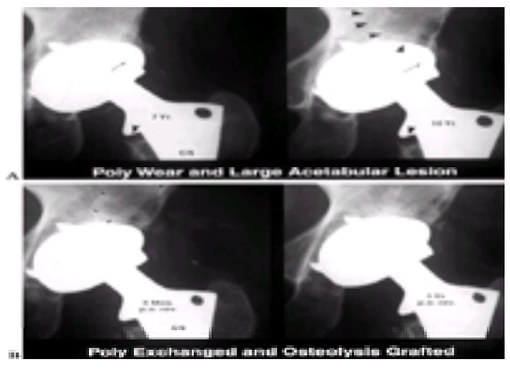


***Figure 106.4.*** **A:** Polyethylene wear leading to large supra-acetabular lesion. Note asymmetric position of the head in the cup. **B:** Cup is stable; therefore, retained and osteolytic lesion grafted with good results.

### *Septic Loosening*

Established sepsis, with or without loosening, requires surgical treatment, usually to remove components. In North America, most infected arthroplasties are treated by a staged exchange (29,58). The first stage involves removal of the components with or without placement of an antibiotic spacer, accompanied by intravenous and oral antibiotic therapy. Depending on the microorganism and the patient's response to the treatment, reimplantation can be performed 6 to 12 weeks later (58). Some infections, such as those caused by virulent gram-negative bacteria, cannot be treated by this protocol, and the patient may require a Girdlestone excisional arthroplasty (29). Some patients may not be fit enough to tolerate two operative procedures, and single-stage revision with antiobiotic impregnated cement should be considered.

### *Recurrent Dislocation*

Revision of recurrent hip dislocation is perhaps the most difficult type of revision surgery. The many causes of dislocation include component malposition, neuromuscular problems, and lack of patient compliance. Malposition of the acetabular or femoral components is the most common cause (47,69). The offending malposition may be apparent only at surgical revision. A malpositioned component may require revision despite being well fixed. If the acetabulum is the culprit, then alternatives to removal include liners with peripheral buildups. These buildups, or lips, come in varying thicknesses and can be rotated in the area of instability. If the femoral component is malpositioned, there are fewer options. One solution is a constrained acetabular liner. A constrained liner has polyethylene that extends past the midpoint, or maximal circumference of the femoral head (Fig. 106.5). The femoral head must be forced into the polyethylene to reduce the hip and then a locking ring locks the head in place. This design decreases hip motion and increases the stress necessary to dislocate the hip. However, the strain that occurs when this device prevents dislocation is transferred to the component bone interface and may lead to early loosening. Another concern is a higher rate of wear. The use of these devices should be limited to situations without other good alternatives (35).

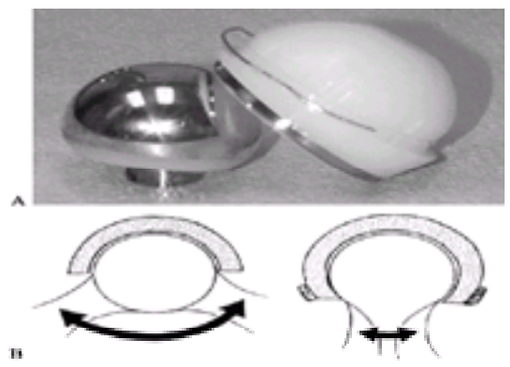

***Figure 106.5.*** **A:** Bipolar constrained liner, which is inserted into a metal-backed shell. **B:** Motion is decreased with a constrained design, and stress at interfaces is increased. (Reprinted from Cameron HH. Modified Cups. *The Orthopedic Clinics of North America* 1998;28:277, with permission.)

In some patients, recurrent dislocation may be solved by changing femoral heads to increase the neck length. There is a limit to the leg lengthening that the patient will accept, especially when the problem is an inadequate offset of the stem.

Less commonly, the problem is neurologic or related to the abductors. A trochanteric nonunion can be treated with reattachment and fixation. If the problem is a short abductor lever arm, a trochanteric advancement can increase the muscle tension. If the problem is purely neurologic, there are few solutions and a constrained cup may be needed.

### *Femoral Fracture*

The treatment of periprosthetic fractures is dictated by the location of the fracture and the bone quality, and how these factors affect component stability. Fractures distal to the prosthesis may not affect fixation and can be treated with conventional open reduction and internal fixation (ORIF). Fractures that affect component fixation can sometimes be treated with ORIF or may require revision of the component. This procedure is covered in Chapter 20 and elsewhere (111).

## EVALUATION OF THE PATIENT: HISTORY AND PHYSICAL EXAMINATION

Surgical planning begins with the patient's history and physical examination (25). Details of the history can vary, and not all patients have pain. Osteolysis of periprosthetic bone before mechanical loosening of a component can be completely asymptomatic.

Pain, when present, should be localized anatomically, and the temporal quality should be determined. Thigh or knee pain is most commonly associated with the femoral component, and pain in the groin or the buttock with the acetabular component. Pain that shoots down into the calf is rarely associated with the hip, and spinal or other pathology may be the cause. Simple muscle strains or bursitis can cause thigh pain. Groin pain may be secondary to muscle strain or possibly to hernias.

The temporal nature of the pain is important. When did the pain start? Is the pain present all the time? If not, when does it occur? Patients in whom the pain never improved following primary arthroplasty should be suspected of being infected. This is also true for patients who have pain at rest and at night. Mechanical loosening commonly presents with start-up pain or pain on activity. For example, pain in the thigh when rising from a chair is often due to a loose femoral component.

Infection must always be considered before revision surgery. Question patients about their postoperative course following the primary arthroplasty. Was there drainage? Did it require debridement? Did they receive antibiotics for extended periods of time postoperatively? Question patients for possible recent infections that may have seeded the prosthesis, such as recent hospital admissions, surgical procedures, dental procedures, or infection requiring antibiotics.

Evaluate the patient's functional status to assess the impact that the hip problem is having on daily and social activities. There are several functional scales such as the Harris Hip Score or the Hospital for Special Surgery Hip rating system that help to determine the level of the patient's disability (40,107). These can be useful in

measuring improvements in the patient's status postoperatively.

A medical history and review of systems should note conditions that increase the risk of surgery, such as a history of previous thromboembolic disease. Factors that increase the risk of infection include obesity, smoking, diabetes, steroid use, suppressed immune status, and malnutrition, which is quite common in the elderly (29,95).

It is important to review the operative record from the primary surgery. This provides insight into technical difficulties that were encountered and also describes the type of components implanted and their sizes. This is especially important to ensure compatibility when only one component will be revised.

## PHYSICAL EXAMINATION

Two priorities in the physical exam are to establish limb-length discrepancy (LLD), if present, and to evaluate abductor strength. Note the use of walking aids and presence of a limp. Is the limp antalgic or Trendelenburg (104), or is it the result of a short limb or another problem? LLDs should be quantified because they are a frequent cause of patient complaints. True limb length measured from the anterior superior iliac spine to the medial malleolus can be compared with the apparent limb length measured from the umbilicus to the medial malleolus. Any discrepancy between the two measurements may indicate an oblique pelvis or a fixed flexion contracture of the hip. Another test for LLD that incorporates the patient's perception of his or her limb-length discrepancy is to use foot blocks of variable sizes. Place the blocks incrementally under the shorter limb until the patient “feels balanced.” Posteriorly, the S-2 dimples can be examined to verify that the pelvis is level. This can be confirmed radiographically with a standing anteroposterior (AP) view of the pelvis. This test may give the most accurate idea of what the patient would like in terms of leg lengths. However, it is important to explain to the patient that hip stability is the priority during surgery and that leg lengths may not be equalized.

Evaluate abductor strength by using the Trendelenburg test and having the patient abduct the leg against gravity while in the lateral supine position. Examine the existing incision for signs of infection and evaluate its usefulness in a revision. Perform a thorough neurovascular examination, paying careful attention to the peroneal nerve distribution because it is the most commonly injured in primary arthroplasty.

## INVESTIGATION

The principal laboratory studies are those necessary to rule out infection. Infection can present a diagnostic challenge, and the workup for infection involves both preoperative and intraoperative studies.

### *Preoperative Investigations*

Preoperative studies include a peripheral white blood cell count (WBC), erythrocyte sedimentation rate (ESR), and a C-reactive protein (CRP). The WBC is rarely useful, and in one study, only 8 of 52 patients with an infected arthroplasty had an elevated WBC (12). Neither the ESR nor the CRP is specific to infection, and either can be elevated by inflammatory and neoplastic conditions (15). However, if patients with inflammatory conditions such as rheumatoid arthritis or recent operations are excluded, the ESR and CRP become useful tools, as has been shown in a recent prospective study. This study demonstrated a sensitivity and specificity of .82 and .85 for the ESR and .92 and .96 for the CRP (100). However, if both tests were negative, the probability of infection was found to be zero, and if both tests were positive, then the probability of infection was .83. An ESR greater than 30 mm/hr and a CRP greater than 10 mg/L are considered positive (99).

Aspiration of the hip was previously recommended for all failed arthroplasties (76). However, more recently, many authors have favored a more limited role for aspiration owing to varying reports of the sensitivity of this test (4,37). Aspiration is not indicated when there is no clinical evidence of infection and when the ESR and CRP are negative. Aspiration should be used when an infection is suspected because it can provide confirmation of clinical suspicions and can identify the infecting organism. Aspiration is also indicated when the inflammatory markers ESR and CRP give mixed results, with one being positive and the other being negative, or when an inflammatory condition such as rheumatoid arthritis is present (100).

### *Intraoperative*

Hold preoperative antibiotics on patients undergoing revision surgery. Once the pseudocapsule is exposed, aspirate the joint for fluid. This fluid can be sent for cell count, Gram's stain, and both aerobic and anaerobic cultures. Give antibiotics once the joint has been aspirated.

Synovial fluid with a white blood cell count of more than 50,000 and a neutrophil count of greater than 80% is suggestive of a bacterial infection (49,52). However, this test has a poor sensitivity, with a recent study demonstrating 18 negative results in 28 periprosthetic infections (100). Similarly, the Gram stain has been shown to be unreliable, with one study demonstrating a sensitivity of 0 out of 32 infected hips (14). Intraoperative cultures of tissue and fluid are very accurate, and some would consider them to be the gold standard for the diagnosis of infection (77). Postoperative antibiotic treatment is also dependent on the culture results; therefore, several samples should be sent to ensure adequate results. The last of the intraoperative tests is the histologic sample sent for frozen section (27). This has been shown to be a reliable test to differentiate septic from aseptic failure of the hip (28,60,67). Studies with large numbers of infections have shown sensitivity from .80 to .91 and specificity from .94 to .99 (28,60). The histologic sample that is sent should be from an area of the hip that shows inflammation. The sample is then examined for the number of polymorphonuclear neutrophils (PMNs) per high-power field (HPF). More than 5 PMNs/HPF suggest infection, and more than 10 PMNs/HPF indicate a probable active infection (28,60,67). The frozen section and cultures are the best of the intraoperative tests to rule out infection.

## RADIOGRAPHIC EVALUATION

Take three views initially: AP pelvis, AP hip, and a lateral view of the hip. After the initial evaluation, it may be necessary to obtain full-length femur x-ray studies or 45° oblique (Judet) views of the pelvis, which are useful for evaluating the integrity of the bony columns above the acetabulum. The iliac oblique view shows the posterior column and the anterior wall, and the obturator oblique shows the anterior column and posterior wall. These views are not routinely required but are necessary when there is evidence of column destruction on the plain films. Radiographic evaluation of loosening is improved by having previous films for comparison. Radiographic evidence that differentiates aseptic from septic loosening is rare; however, some believe that periosteal new bone formation is pathognomonic of deep infection (29). Endosteal scalloping and rapid progression of lysis can also be suggestive of infection (62).

## CEMENTED COMPONENTS

The radiographic interpretation of loosening can be categorized according to O'Neill and Harris (76) (Fig. 106.6):

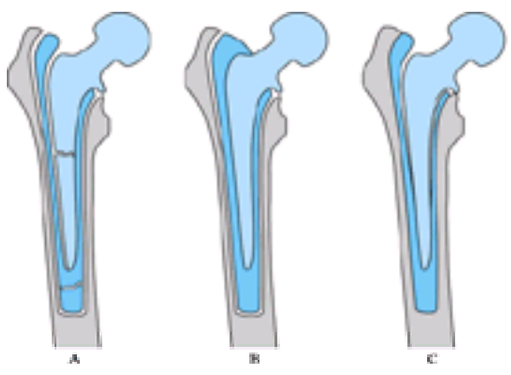


***Figure 106.6.*** Radiographic evaluation of the cemented femoral component. (**A**) Definitely loosening; (**B**) probable loosening; (**C**) possible loosening. See text for details.

- *Definite Loosening:* Migration of the component or cement column, fracture or fragmentation of the cement, fracture or deformation of the component, radiolucency at the cement-bone interface (Fig. 106.7).

***Figure 106.7.*** Radiograph showing cement fracture, circumferential radiolucency of the cement–bone interface and proximal femoral lysis.

- *Probable Loosening:* Presence of a radiolucent zone at the cement–bone interface around the periphery of the entire component on at least one radiograph, extending for more than 50% of the stem circumference.
- *Possible Loosening:* Presence of a radiolucent zone at the cement–bone interface extending for more than 50% but less than 100% of the periphery of the component, and less than 50% of the stem circumference.

These guidelines need to be correlated with clinical findings. Several studies have concluded that subsidence of the femoral component of less than 2 mm does not affect the long-term result and is not a sign of loosening.

Radiographic evaluation of the cemented acetabulum differs slightly because loosening occurs more often at the cement–bone interface rather than component–cement interface, as with femoral components. Signs of a loose cemented acetabular component include

- Radiolucent zone more than 2 mm wide surrounding the entire component.
- Migration of the cup, which is seen as changes in the horizontal inclination and the version.

**UNCEMENTED COMPONENTS**

Engh et al. (24) outlined several radiographic signs that indicate bone ingrowth (Fig. 106.8):

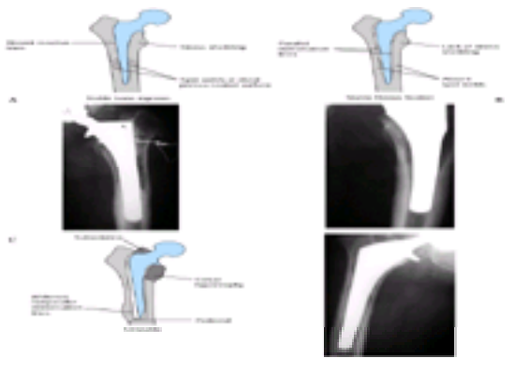

***Figure 106.8.*** Radiographic features of cementless component fixation. Absence of signs of bone ingrowth indicate possible instability: (**A**) bone ingrown; (**B**) fibrous stable. (**C**) fibrous unstable.

- Spot welds that occur at the distal limit of the porous coating
- Stress shielding of the proximal femur
- Lack of a distal pedestal
- Lack of reactive lines around the porous-coated portion of the stem

All of the above-mentioned signs indicate bone ingrowth, and their absence suggests that the stem has either stable or unstable fibrous fixation (Table 106.1).

| |
|---|
| *Stable Fibrous Fixation* |
| • Absence of signs of bone ingrowth |
| • Small distal pedestal |
| • Radiolucent line around the circumference of the prosthesis that is less than 1 mm thick with reactive bone formation that is parallel to the prosthesis |
| • Lack of proximal stress shielding or slight calcar hypertrophy |
| *Unstable Fibrous Fixation* |
| • Solid distal pedestal |
| • Calcar hypertrophy |
| • Reactive lines around the prosthesis that are divergent |
| • Gross migration of the component |

***Table 106.1. Signs of Stable and Unstable Fibrous Fixation***

## COMPARISON OF RESULTS

### FEMORAL REVISION

The major problem in revision hip arthroplasty surgery is loss of bone due to osteolysis and mechanical destruction by loose components. The remaining bone is sclerotic and fragile in comparison to when a primary arthroplasty is performed.

Sclerotic bone compromises the bond that can be formed between cement and bone due to the lack of interdigitation that is normally available with a fresh cancellous bed. Bench testing has shown that the shear strength of the bone cement interface is reduced by 79% in the revision setting (19). The revision femur frequently has metaphyseal and diaphyseal bone defects that preclude producing a solid cement mantle.

As with primary arthroplasty, there are two principal methods of fixation of components: cemented and uncemented. The majority of early revisions were performed with cement, using first-generation techniques, but these revisions have demonstrated failure rates of 12% to 44% (9,44,81,82) (Table 106.2). More recent studies using second and third-generation cementing techniques have shown better results, but failure rates still remain high at 10% to 23% (42,72,86,106) (Table 106.3; Fig. 106.9).

| Author (ref) | Hips (n) | Average age | Follow-up (average) | Re-revision rate (%) | Radiographic loosening (%) |
|---|---|---|---|---|---|
| Pellicci et al. (81,82) | 99 | 64 | 8.1 yrs | 19 | 29 |
| Kavanagh et al. (44) | 166 | 63.8 | 4.5 yrs | 6 | 44 |
| Callaghan et al. (9) | 139 | 62.1 | 3.6 yrs | 4.3 | 12 |

***Table 106.2. Cemented Femoral Revision with First-Generation Techniques***

| Author (ref) | Hips (n) | Average age | Follow-up (average) | Re-revision rate (%) | Radiographic loosening (%) |
|---|---|---|---|---|---|
| Kaiser et al. (42) | 79 | 63.7 | 11.9 yrs | 5.4 | 16.6 |
| Mulroy and Harris (72) | 49 | 52.8 | 15.1 yrs | 16 | 25 |
| Raaymakers et al. (85) | 331 | 64 | 6.0 yrs | 5.7 | 9.4 |

***Table 106.3. Cemented Femoral Revision with Modern Cementing Techniques***

***Figure 106.9.*** Failure of a cemented revision with a long stem after 4 years.

The use of uncemented stems in revision arthroplasty has become more common because of the poor results with cemented fixation. Uncemented components can be proximally or fully porous coated. Uncemented components require adequate living bone stock to be in intimate contact with the prosthesis in a mechanically stable setting so that bone ingrowth can occur. The implant must be rotationally and axially stable at the time of implantation to maximize the opportunity for biologic ingrowth.

Proximally porous-coated components aim for fixation in the metaphysis of the femur; this is the area of the femur that is most commonly damaged by the primary arthroplasty. The metaphysis of the femur also shows the greatest amount of anatomic variability among patients, making it more difficult to achieve stable fixation with intimate bone contact. Proximally coated revision devices have demonstrated failure rates from 20% to 50% (5,63,108) (Table 106.4; Fig. 106.10). Failure rates of proximally fixed modular devices that can more clearly fit the metaphysis, such as the S-Rom (J & J, Stanford CT), have been slightly better but remain high at 10% (10).

| Author (ref) | Hips (n) | Average age | Follow-up (average) | Re-revision rate (%) | Radiographic loosening (%) |
|---|---|---|---|---|---|
| Berry et al. (3) | 375 | 68 | 4.7 yrs | 16.8 | 38 |
| Malkani et al. (63) | 49 | 62 | 2.8 yrs | 8.7 | 20 |
| Worrinow and Delaney (10) | 28 | 55 | 5.5 yrs | na | 48 |

***Table 106.4. Uncemented Femoral Revision with Proximally Porous-Coated Components***

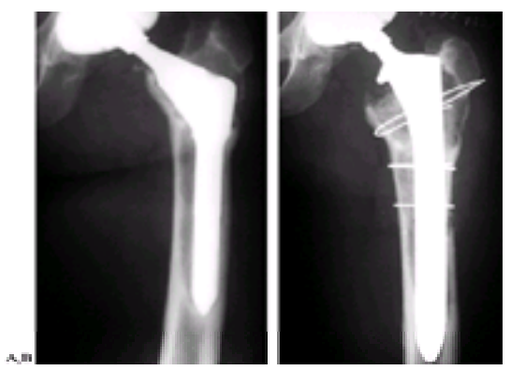

***Figure 106.10.*** **A:** Failure of a revision using a proximally porous-coated device after 2 years. **B:** Re-revised with a long-stemmed, fully porous-coated device.

The term “bypass fixation” is sometimes used to describe fully porous-coated femoral components because they obtain their fixation in the diaphysis of the femur. The femoral diaphysis is able to support a prosthesis in the majority of cases because it is usually less affected by bone defects than the metaphysis. The cylindrical

diaphysis is easier to fill with a component, and revisions with this technique have results that approach those of primary hip arthroplasty, with failure rates from 3% to 7% (50,55,68) (Table 106.5).

| Author (ref) | Hips (n) | Average age | Follow-up (average) | Re-revision rate (%) | Radiographic loosening (%) |
|---|---|---|---|---|---|
| Krishnamurthy et al. (50) | 297 | 59.6 | 8.3 yrs | 1.7 | 2.4 |
| Lawrence et al. (55) | 93 | 56.0 | 7.4 yrs | 5.3 | 6.9 |
| Mumford and Harmsen (68) | 173 | 62.4 | 5.0 yrs | 2.3 | na |

na, not applicable or not reported.

***Table 106.5. Uncemented Femoral Revision with Fully Porous-Coated Components***

Failures with bypass fixation occur (1) when the canal fill is less than 90% and (2) when less than 4 to 6 cm of diaphysis supports the prosthesis (50). If these two conditions are satisfactory, the success rate compares with that of primary arthroplasty (Fig. 106.11). There are two principal disadvantages with this technique: stress shielding and the difficulty of removing an ingrown, fully coated stem. Stress shielding is more pronounced in stems greater than 13.5 mm in diameter and in cobalt chrome stems as compared with titanium (24). Revision stems are larger than primary stems due to loss of bone and are frequently greater than 13.5 mm in diameter. Therefore, patients who have undergone this type of revision surgery are at increased risk of stress shielding. Although stress shielding associated with the use of large cobalt chrome stems is present on radiographs, it has not presented clinical problems to date. Patients with significant stress shielding secondary to a large revision components may require repeat revision in the future, and management of proximal bone atrophy may become an issue. Removal of an ingrown fully coated femoral stem is difficult; however, it is rarely necessary.

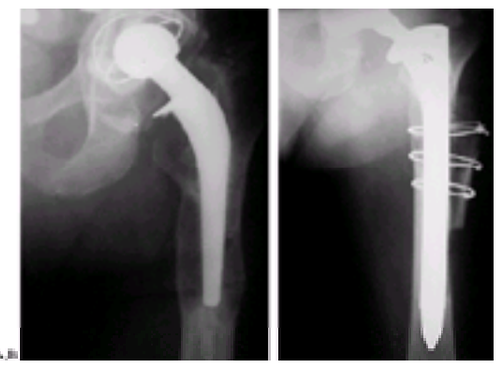

***Figure 106.11.*** **A:** Failed primary cemented component with extensive proximal femoral destruction. **B:** Bypass fixation using a long-stemmed fully porous-coated device obtaining fixation in healthy supportive diaphyseal bone.

More recently, cemented revisions have been performed with “impaction grafting.” This technique claims to restore femoral bone stock and can be used despite large femoral defects (Fig. 106.12). The major potential advantage of this technique is the restoration of femoral bone, which is particularly important in the young patient who may require future re-revision. Bypass fixation can induce proximal femoral remodeling and restoration of bone stock, with the advantage of avoiding bone grafting, which is expensive and includes the risk of infection. Early results with impaction grafting have been promising, with good functional and radiographic results. There is some histologic evidence of bone reconstitution. The current indication for impaction grafting is a femoral isthmus incapable of providing rotational stability to a fully porous-coated stem (22,97).

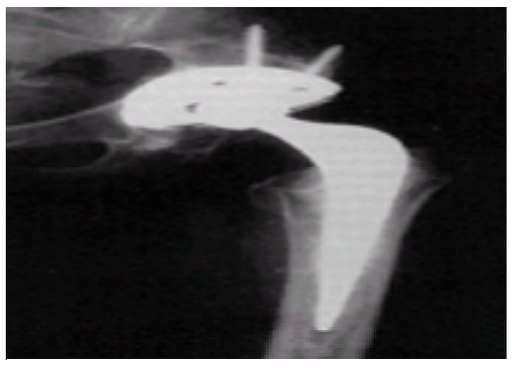

***Figure 106.12.*** Successful reconstruction using impaction grafting. (Reprinted from Duncan CP, Masterson EL. Impaction Allografting with Cement for the Management of Femoral Bone Loss. *The Orthopedic Clinics of North America* 1998;28:297, with permission.)

## ACETABULAR REVISION

Acetabular reconstruction is less controversial. Cemented acetabular revision has been more disappointing than cemented femoral revision. Several studies have shown a 10% to 20% repeat revision rate from as early as 3.6 to 7.4 years (44,46,85) (Table 106.6). As with cemented femoral revisions, this high failure rate is secondary to sclerotic and compromised bone that prevent the formation of a good cement mantle (19). Modern cementing techniques in acetabular revision have not improved the results. Based on these results, there is no place for cemented cups in revision surgery except in conjunction with a cage or allograft.

| Author (ref) | Hips (n) | Average age | Follow-up (average) | Re-revision rate (%) | Radiographic loosening (%) |
|---|---|---|---|---|---|
| Kavanagh et al. (44) | 166 | 61.8 | 4.5 yrs | 1.8 | 20 |
| Raaz et al. (86) | 307 | 64 | 5.5 yrs | 1.8 | 20.6 |
| Kershaw et al. (46) | 60 | 61 | 6.3 yrs | 3.3 | 11.6 |

***Table 106.6. Cemented Acetabular Revision***

By contrast, uncemented acetabular revision has been very successful (Table 106.7). Silverton et al. (96) showed a repeat revision rate of 0% at 8.3 years, and other studies show comparable results (23,96,102). The advent of “jumbo” cups available in sizes up to 80 mm in diameter has enabled the reconstruction of large defects and reduced the need for structural grafts (Fig. 106.13). Success with uncemented cups depends on achieving more than 50% host bone contact with stable initial fixation. When these criteria cannot be met, alternatives such as a high hip center, oblong cup, or cages and allograft must be considered.

| Author (ref) | Hips (n) | Average age | Follow-up (average) | Re-revision rate (%) | Radiographic loosening (%) |
|---|---|---|---|---|---|
| Silverton et al. (96) | 138 | 70 | 8.3 yrs | 0 | 8 |
| Tanzer et al. (102) | 140 | 3.5 yrs | 1.4% | 3.6 | na |
| Emerson et al. (23) | 45 | 55 | 2.0 yrs | 0 | 2.2 |

na, not applicable or not reported.

***Table 106.7. Uncemented Acetabular Revision***

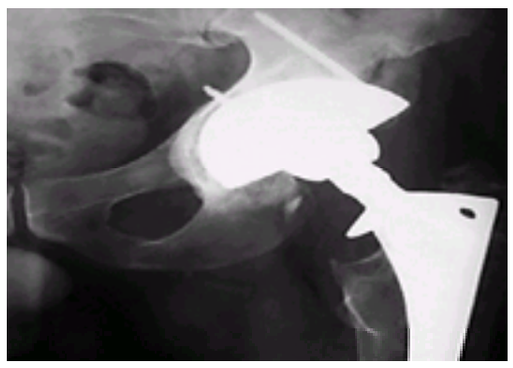

***Figure 106.13.*** Revision of a large acetabular defect with a “jumbo” cup. Peripheral screws are used to enhance initial fixation.

Uncemented cups implanted in the ilium with a high hip center have been controversial. They can be used in the presence of bone loss in the superior acetabulum, where a cup cannot be placed in the normal position owing to anatomic constraints such as a mismatch between the acetabular AP and the superoinferior diameters. Host bone is still available superiorly where the ilium becomes thinner. However, nonanatomic placement of the cup changes the biomechanics of the hip significantly and subjects the cup to higher mechanical loads. Several studies (18,53,84) of this technique have demonstrated failure rates that range from 42% to 72% (Fig. 106.14). Accordingly, the hip center should be as close to anatomic as possible.

***Figure 106.14.*** High hip center was used in the primary arthroplasty for developmental dysplasia of the hip. This failed, was revised, and more normal biomechanics were restored. Offset is not optimal, and the greater trochanter has fractured.

The oblong cup is a device that fills the superior defect and does not depend on bone graft reconstruction yet preserves the anatomic center of rotation. Implants are available “off the shelf,” or they can be custom ordered. These prostheses have shown good initial results in small groups of patients with short-term follow-up. One multicenter trial reported 64 cases, with an average follow-up of 44 months with 97% cup retention (11,75). The chances of long-term fixation should theoretically be good because there is a large surface available for biologic fixation (Fig. 106.15). This is in contrast to cages and rings that have no or limited potential for biologic fixation.

***Figure 106.15.*** **A:** Oblong cup showing large surface area for potential ingrowth. **B:** Cup filling large segmental superior defect. Reprinted from Cameron HH. Modified Cups. *The Orthopedic Clinics of North America* 1998;28:277, with permission.)

Cages and rings have been used to handle the most difficult acetabular reconstructions. These devices have been studied at short to intermediate duration follow-up, and the patients are few. The initial results have been encouraging, with failure rates between 0.5% and 12% at 5 years (6,8,70,83). These devices are used principally to bridge bone defects, as in the case of acetabular discontinuities, and they must be secured to both the ilium and the ischium. Cages require solid contact with host bone or they will fail due to cyclic loading. The long-term results are unknown, and at present, their use should be restricted to situations in which an uncemented cup

cannot be used (Fig. 106.16).

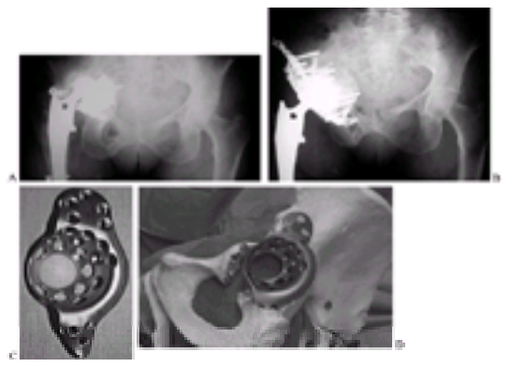

***Figure 106.16.*** **A:** Paprosky Type 3B defect with extensive loss of host bone and high hip center. **B:** Reconstruction using a cage and allograft with restoration of anatomic center of rotation. **C:** Burch–Schneider cage. **D:** Cage bridging the defect with secure fixation in the ischium and to the ilium.

Good initial results of impaction grafting of the acetabulum have been described. However, the number of patients and duration of follow-up are small. The technique is not yet widely used.

## CLASSIFICATION OF DEFECTS AND TREATMENT PLAN

A classification system should provide a standardized description and a guide to treatment. Numerous systems assess bone loss, but none has found widespread acceptance or been validated independently.

### FEMORAL DEFECTS

The American Academy of Orthopaedic Surgeons (AAOS) has adopted a classification system that divides femoral bone loss into segmental and cavitary defects (16).

Segmental femoral defects involve loss of bone in the cortical shell of the femur and are divided into partial and complete. Cavitary defects may be cancellous or cortical, with cancellous defects being less severe. Erosion of the cortex is by definition a cortical cavitary defect. Combined defects have both segmental and cavitary bone loss.

This system also describes femoral alignment, stenosis, and the level of bone loss. Level 1 is proximal to the bottom of the lesser trochanter. Level 2 is 10 cm distal to level 1, and level 3 is everything distal to this. This system provides a fairly accurate description of the femoral defect but does not incorporate a treatment plan.

### PAPROSKY FEMORAL DEFECT CLASSIFICATION

The Paprosky classification system evaluates the ability of the femoral diaphysis to support an uncemented, fully porous-coated prosthesis (3) (Fig. 106.17). This system is less detailed in its description of the bony defect present than the AAOS system, yet it is more useful in decision making for an uncemented femoral revision. By using this classification system, the appropriate method of treatment can be chosen preoperatively (Table 106.8).

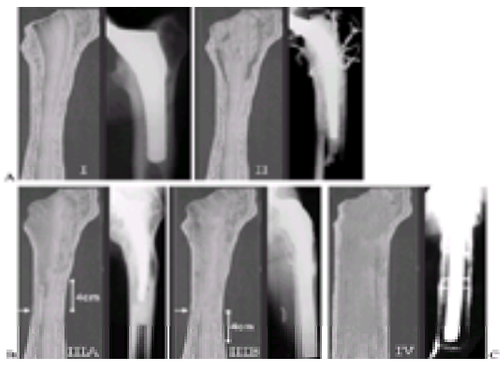

***Figure 106.17.*** Paprosky Femoral Defect Classification. **A:** Type 1 defect minimal damage able to support any type of prosthesis. Type 2 defect metaphyseal damage unable to support a proximal porous-coated device. Treat with bypass fixation or possible cemented revision in the elderly. **B:** Type 3A defect extensive proximal femoral damage diaphyseal fixation is available proximal to the isthmus. Type 3B defect has damage that extends even further and diaphyseal fixation is available only past the isthmus. What appears to be a radiographic type 3B may not be able to support a prosthesis intraoperatively and must then be treated as a type 4. **C:** Type 4 defect has extensive diaphyseal involvement. It is unable to provide rotational and axial stability to a fully porous-coated device and is treated with impaction grafting or an allograft prosthetic composite.

| | |
|---|---|
| *Type 1*<br>• Minimal defects usually secondary to an Austin Moore prosthesis or resurfacing procedures.<br>• Treatment: Manage as a primary arthroplasty. In the younger patient, use proximal or fully porous-coated components; in the elderly, cemented revisions can be successful. | *Type 3A*<br>• Defects involve the metaphysis and the junction with the diaphysis. Fixation with a fully porous-coated stem can be achieved proximal to or at the isthmus of the femur.<br>• Treatment: Fully coated, bowed stem or, more rarely, a straight stem. |
| *Type 2*<br>• Defects isolated to the metaphysis with a normal diaphysis.<br>• Treatment: Although revision with cement or a proximally porous coated stem may be possible, revision can definitely be accomplished with a fully coated stem. | *Type 3B*<br>• Defects extend slightly beyond type 3A defects, but reliable fixation can be achieved just past the isthmus of the femur.<br>• Treatment: Fully coated, bowed stem or impaction grafting.<br>*Type 4*<br>• Extensive defects with metaphyseal and diaphyseal bone loss and a widened canal that cannot provide adequate fixation to a long stem.<br>• Treatment: Impaction grafting or allograft prosthetic composite (APC). |

***Table 106.8. Paprosky Femoral Defect Classification System and Treatment Plan***

A fully coated long stem will work in all types 1 through 3A; in types 1 or 2, other options can be used. Type 3B is the most difficult to evaluate and will require intraoperative evaluation of the ability of the isthmus to support a fully coated long stem. Without 4 to 6 cm of intimate bone contact, impaction grafting or an allograft prosthetic composite (APC) will be required, as in the type 4 femur. If, during preoperative templating, it appears questionable that the femoral isthmus can support a long fully porous-coated stem, then you must treat it as a type 3B or type 4 femur and be prepared for impaction grafting or the use of an APC.

### ACETABULAR DEFECTS

The AAOS acetabular defect classification system has some radiographic validity, but it is based principally on the intraoperative assessment of bone loss (17). This system divides bone loss into two major types: segmental (type 1) or cavitary (type 2). A segmental deficiency is loss of bone in the supporting hemisphere of the acetabulum. These defects involve the rim of the acetabulum or the medial wall and may compromise the ability of the acetabulum to provide rigid fixation to an

acetabular component. Cavitary defects involve volumetric loss of bone but are contained within a shell of bone. These defects rarely affect the ability of the acetabulum to support a cup. Type 3 defects refer to combined segmental and cavitary bone loss and are the most common type found in revision hip surgery. Type 4 defects refer to a pelvic discontinuity and Type 5 to a hip arthrodesis (Fig. 106.18).

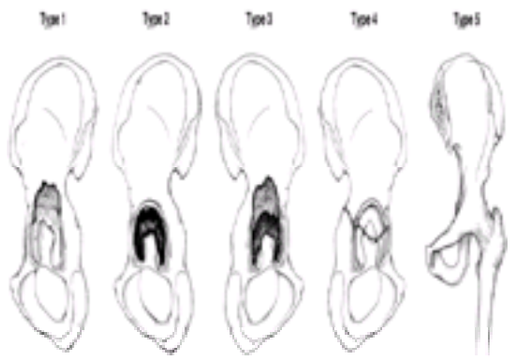

***Figure 106.18.*** Classification of acetabular defects according to the American Academy of Orthopaedic Surgeons Committee on the Hip: type 1, segmental; type 2, cavitary; type 3, combined segmental and cavitary; type 4, pelvic discontinuity; and type 5, hip fusion. (Reprinted from the *Journal of the American Academy of Orthopaedic Surgeons* 7:1, with permission.)

The Paprosky classification system for acetabular defects is based on preoperative AP radiographs and uses four landmarks to evaluate bone destruction (Table 106.9). These landmarks allow for preoperative quantification of the defect and treatment planning (79). Two of the four are measurements from a horizontal line tangent to the tops of the obturator foramina (Hilgenreiner's line) (Fig. 106.19). The other two radiographic landmarks are Kohler's line and the teardrop. Remember to allow for magnification when making measurements.

| |
|---|
| **Center of Head**<br>Superior displacement is measured as the distance from Hilgenreiner's line to the center of the head of the existing component. Note whether the superior displacement is greater than 3 cm and its direction medial or lateral. Superior displacement represents loss of bone superiorly where the two columns meet in an inverted Y. Displacement greater than 3 cm represents a more severe deformity and is a Paprosky type 3 defect. |
| ***Ischial Lysis***<br>Measure the distance from Hilgenreiner's line to the inferior edge of the osteolytic lesion involving the ischium. This represents damage to the posterior column. Greater than 1.5 cm of bone loss represents destruction of 20% to 25% of the acetabular bone stock. |
| ***Tear Drop***<br>The tear drop corresponds to the cotyloid fossa. The medial wall defines the depth of the acetabulum and its disappearance indicates damage to the medial wall as well as to the inferior portion of the anterior and posterior columns. Loss of the tear drop signifies loss of 10% to 15% of host bone. |
| ***Kohler's Line***<br>The destruction of this landmark represents medial migration of the component and signifies destruction of the medial wall, the midportion of the anterior column, and, to a lesser extent, the posterior column. |

***Table 106.9. Paprosky Radiographic Landmarks to Evaluate Bone Destruction***

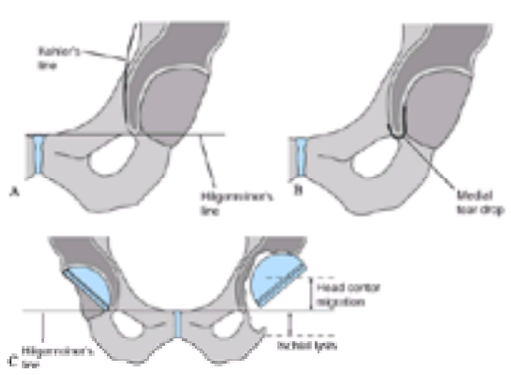


***Figure 106.19.*** (**A**) Kohler's line, (**B**) teardrop, (**C**) superior obturator line (Hilgenreiner's line), used as a reference to measure superior displacement of the femoral head center and to measure inferiorly the amount of ischial lysis.

Acetabular defects can be classified into one of three major types with five subtypes by evaluation of these four radiographic landmarks (Table 106.10; Fig. 106.20).

| | |
|---|---|
| **Type 1**<br>• Minimal superior migration, no ischial lysis, no tear drop destruction, no violation of Kohler's line.<br>• Treatment: Uncemented cup and possibly cancellous grafting. | • Treatment: There are several options available for the type 3A defect, depending on the degree of bone destruction, the patient's age, and the patient's activity level. If greater than 50% of host bone is available, an uncemented cup may be used if stability can be achieved. In the younger patient, bone stock may be restored with structural grafting even if the cup is stable. If the cup is unstable despite greater than 50% host bone present, then two options exist: structural graft (preferred) to support an uncemented cup (best option in the young or active patient) or a cage to bridge the defect (best option for the use of structural bone graft for the elderly or less active patient). |
| **Type 2A**<br>• Minimal increase in bone destruction compared to type 1. Superior migration less than 1 cm, minimal ischial lysis, minimal tear drop lysis.<br>• Treatment: Uncemented cup and possibly cancellous grafting. | **Type 3B**<br>• Massive acetabular defect with superior migration of greater than 3 cm and medial migration with loss of the tear drop and violation of Kohler's line. Ischial lysis is severe with compromise of the posterior column. This defect is likely to have a pelvic discontinuity. Destruction of both columns renders them unsupportive, and a sufficient medial wall defect is present.<br>• Treatment: Because there is less than 50% of host bone available, an uncemented cup alone will fail. As with the type 3A defect, treatment depends on the age and activity level of the patient. In the elderly patient with a large cavitary defect but some rim, a cage with autologous graft can be used. If there is insufficient rim support or the cavitary defect is so large that the cage would be unsupported, a structural graft can support the cage. In the younger patient, use structural graft for both support and for bone restoration in conjunction with a cage. An acetabular allograft will be required when there is severe posterior column damage in any patient regardless of age. Some surgeons advocate using the cage as a plate in the case of a pelvic discontinuity. We treat discontinuities with a posterior plate and then reconstruct the acetabulum. |
| **Type 2B**<br>• Greater distortion of the superior rim but less than 3 cm superior migration. The superior dome is still supportive. Minimal ischial and tear drop lysis. Cup has migrated to but not through Kohler's line.<br>• Treatment: Uncemented cup and possibly cancellous grafting. | **Type 4**<br>• Significant superior dome destruction with greater than 3 cm superior migration. Mild to moderate ischial lysis exists and the lateral portion of the tear drop is often destroyed. Kohler's line may be partially violated, however, the displacement here is primarily superior rather than medial. The dome is unable to support a prosthesis, however, depending on the degree of superior migration, the columns are still partially intact and may support a porous coated prosthesis. |
| **Type 2C**<br>• Greater medial destruction of bone with minimal superior migration similar to that seen in type 2A. Medial migration causes moderate to severe tear drop lysis and violation of Kohler's line. Ischial lysis is minimal.<br>• Treatment: Uncemented cup and possibly cancellous grafting or medial wall structural grafting. | |

***Table 106.10. Paprosky Acetabular Defect Classification System and Treatment***

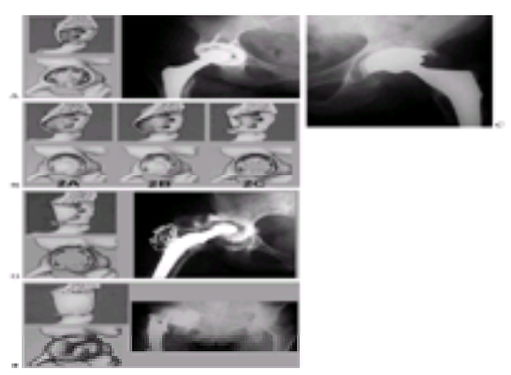

***Figure 106.20.*** Paprosky classification of acetabular defects: (**A**) type 1, minimal damage; (**B**) type 2A–C, increased destruction but greater than 50% host bone

available for uncemented cup fixation. Head center has migrated superiorly less than 3 cm; (**C**) radiograph demonstrating a type 2A defect; (**D**) type 3A defect, more extensive destruction, with greater than 3 cm superior migration of the head center. (**E**) type 3B defect, major pelvic destruction with superior and medial migration and greater than 3 cm head center migration, less than 50% host bone available for reconstruction.

The Paprosky classification guides treatment. Types 1 and 2 may have large cavitary defects but can be treated with an uncemented cup because the defects are contained and the supporting rim of the acetabulum is largely intact. The type 3 defects include large cavitary and segmental defects, effectively becoming partially uncontained cavitary defects. In this situation, an uncemented cup depends on sufficient host bone for stability. This is not always available, necessitating the use of cages and allografts. In the type 3B acetabulum, the host bone cannot be relied on and must be supplemented with either cancellous or structural grafts.

## PREOPERATIVE PLANNING

The goal of revision surgery is to re-establish the normal biomechanics of the hip as well as possible and to maximize the patient's function. The need for preoperative planning must be emphasized because revision hip surgery is demanding of the surgeon, the equipment, and the institution. Preparation begins with a clear understanding of why the hip is being revised and how it will be done. Often only one component will be revised; therefore, multiple implant systems are required. The surgeon must be familiar with them. Previous operative reports are essential to establish the type of component in place and their sizes. Many older systems were nonmodular, or replacements are now unavailable. Therefore, the surgeon must be prepared to remove a well-fixed component or perhaps cement a polyethylene liner into a metal-backed cup. These decisions should be considered preoperatively to avoid unfortunate surprises in the operating room.

### TEMPLATING

Begin the templating by determining the LLD (Fig. 106.21*A*).

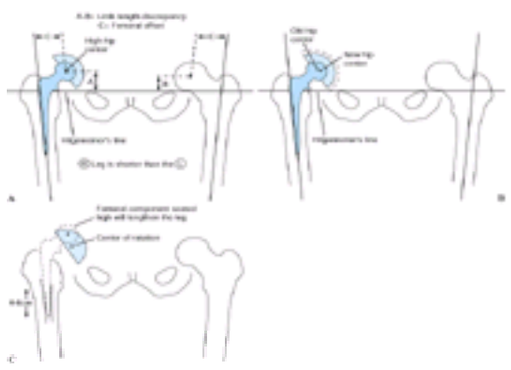

***Figure 106.21.*** **A:** Determine the limb-length discrepancy (LLD) and offset. **B:** Template the acetabulum and establish the new center of rotation. **C:** Template the femur and position the femoral component so that it restores limb lengths and offset and has durable fixation to host bone.

#### *Acetabulum*

- Use the lesser trochanters, the ischial tuberosities, and greater trochanter as landmarks.
- Correlate the measured limb length discrepancy (LLD) with the clinically noted LLD.
- Mark the preoperative center of rotation (COR). Measure the displacement of this COR from Hilgenreiner's line. Using known radiologic landmarks, determine the degree of acetabular destruction.
- Evaluate the integrity of the columns.

Use the Paprosky classification system to determine the degree of destruction and plan the reconstruction. Any system can be used, as long as the acetabulum can be visualized in three dimensions.

- Decide whether an uncemented acetabular component can be placed using component templates and mark the new COR on the AP hip radiograph. Look for superior rim support of the acetabular prosthesis and the integrity of Kohler's line (Fig. 106.21*B*).
- Template for alternatives if fixation with a standard cup is questionable. Decide whether bone graft or cages may be required. Prepare for pelvic plating in the presence of pelvic discontinuity.
- Note the COR of the new cup in comparison to the old COR. This will be the change in leg length contributed by the acetabular component. If the new COR is higher, the limb will be shortened and vice versa. Mark the position of the new COR on the AP hip x-ray film.

#### *Femur*

As previously discussed, the location and severity of femoral bone defects will determine the type of component. Fixation must be stable to both rotational and axial forces. Fully porous-coated devices must meet two criteria: (1) templates should show greater than 90% canal fill and (2) 4 cm of undisrupted diaphysis at or before the femoral isthmus (50) (Fig. 106.21*C*).

- On the AP radiograph, select a component to satisfy the two requisites noted earlier.
- Assess and plan to restore offset because this is an important contributor to hip stability.
- Position the selected femoral component to make up any LLD that remains after templating the new acetabular component. If the leg needs to be lengthened further, template the femur so that the center of the femoral head sits above the planned acetabular center by the amount of the LLD remaining so when the hip is reduced, the LLD is eliminated. Likewise, position the femoral component lower if you want to avoid lengthening the leg.
- Look for potential conflicts of the prosthesis with the proximal femur and on the lateral radiograph. If a stem longer than 175 mm (7 inches) is to be used, a conflict with the anterior cortex may exist in the lateral plane and a curved stem will be needed.

### EXTENDED TROCHANTERIC OSTEOTOMY

An extended trochanteric osteotomy should be templated because its location affects the choice of implant. The location of the osteotomy is a compromise between enhancing exposure and maintaining component fixation.

- Plan the distal extent of the osteotomy at the most advantageous location to accomplish the necessary task. To remove cement, this would be at the most distal extent of the cement mantle. To remove a porous-coated component, this would ideally be at the junction of the metaphyseal and diaphyseal portion of the stem. An osteotomy is also indicated when there has been varus remodeling of the femur caused by a loose femoral component. Varus remodeling prevents appropriate reaming and placement of the new component. With varus remodeling present, the osteotomy should ideally end at the apex of the varus deformity (Fig. 106.22*A*).

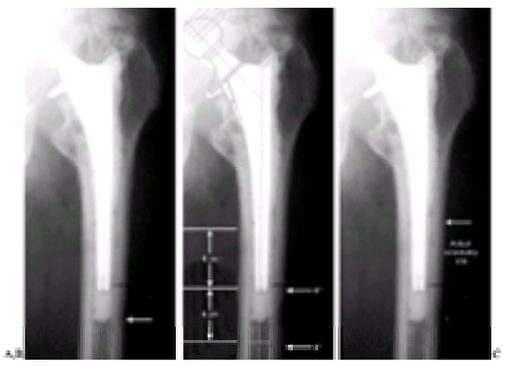

***Figure 106.22.*** **A:** The arrow indicates the osteotomy site that would maximize access for cement removal. **B:** The template shows fixation surfaces for a 150 and 200 mm (6 and 8 inch) component and the 4 cm minimal fixation required for each. Placement of the osteotomy at the site in **A** compromises the fixation available. **C:** A compromise is made, and the osteotomy is moved more proximally because the distal cement is not well bonded and should not be difficult to remove.

- Template the planned revision component and check to determine whether its fixation will be compromised by the distal extent of the osteotomy. Fully coated stems require at least 4 to 6 cm of isthmus fit (Fig. 106-22*B*).
- It is often necessary to shorten the distal extent of the osteotomy so that component fixation is not compromised. A compromise between maximizing exposure and maintaining fixation must be reached (Fig. 106-22*C*).

## EXPOSURE

Revision hip arthroplasty requires a more extensive exposure than primary surgery. Posterior, lateral, or anterior approaches can be used. Base selection on previous incisions, the component to be revised, anticipated degree of difficulty, and the surgeon's familiarity with the approach. Surgical approaches are covered in Chapter 2 and Chapter 3. It is occasionally necessary to combine two approaches, as with a major acetabular protrusio when an intrapelvic approach may be needed to avoid vascular injury.

The posterior approach is used commonly and provides good access to both the femur and acetabulum. It is extensile and allows for plating of the posterior column and structural grafting of the acetabulum.

### POSTERIOR APPROACH

- Position the patient in the lateral decubitus position so that the acetabular component can be oriented intraoperatively. Secure the pelvis so that there is no motion during the case. Pad the patient appropriately and insert an indwelling urinary catheter.
- Take care that the positioning device used to secure the patient does not interfere with extensions of the incision either proximally or distally.
- Prep and apply sterile drape so that the proximal incision can extend almost to the midline of the body and the distal incision to the knee.
- Use and extend previous incisions when possible. Do not create parallel incisions that are less than 6 cm apart or incisions that converge at less than 60°. At times, these guidelines will have to be ignored. Fortunately, because of superior vascularity (as compared with the knee), wound problems are rare.
- Incise the fascia latae in the same plane as the skin incision. Develop a plane between the fascia latae anteriorly and the underlying vastus lateralis and gluteal muscles. This is best achieved by attaching two clamps to the fascia and retracting it anteriorly. Use blunt and sharp dissection to develop this plane quickly. Repeat the procedure posteriorly.
- Release the gluteus maximus tendon completely, about 1 cm from its insertion on the posterior aspect of the femur. This approach decreases the tension placed on the sciatic nerve and allows for translation of the femur anteriorly.
- Palpate the sciatic nerve but do not routinely expose it.
- Split the gluteus maximus muscle body proximally for the full length of the incision.
- Incise the posterior pseudocapsule in line with neck of the prosthesis until you reach the junction of the posterior and lateral femur. At this junction, extend the incision distally. Now the external rotators can be reflected posteriorly as a full-thickness flap, exposing the joint and the posterior aspect of the femur.
- Debride the scar.
- Dislocate the hip and remove a modular head, if present. Dislocation, if impossible owing to protrusion, can be achieved with a standard trochanteric osteotomy, a vastus slide, or an extended trochanteric osteotomy.

### ACETABULAR EXPOSURE

Exposure is the key to acetabular reconstruction. This often seems daunting in the face of extensive scar and difficult visualization. However, with patient removal of scar and gradual retraction of the femur anteriorly, a femoral osteotomy is usually unnecessary with a posterior approach.

- Incise the capsule superiorly at the 12 o'clock position. Then dissect subperiosteally along the superior and anterior edges of the acetabulum.
- Place a Hohmann retractor at the 2 o'clock position at the junction of the superior and the anterior acetabular rims. Do not place the retractor on the thin portion of the anterior wall or you risk creating a segmental defect. Alternately, a Taylor retractor may be placed on the anterior ilium, which is useful when the anterior wall and column appear fragile.
- Gently lever the retractor anteriorly and release the capsular tissue bluntly or sharply until the superior and anterior portions of the acetabulum are exposed.
- Release a tight inferior capsule with electrocautery because there are vessels in this area. This will facilitate anterior translation of the femur.
- Place a second retractor into the obturator fossa after the inferior capsule is released. This retractor can be used to translate the femur distally and anteriorly.
- Dissection at the posterior aspect of the acetabulum must be carried out very carefully owing to the proximity of the sciatic nerve passing over the ischium. It is best to use blunt dissection as much as possible in this area. Place an Overhill, self-retaining retractor to hold back the posterior capsule. Hohmann and Taylor retractors can also be used but may be more risky.

It is important to clear the acetabular edges of all soft tissue so that the bony defects can be completely evaluated. The medial wall must be cleared of fibrous tissue to assess cavitary and segmental defects.

#### *Extended Trochanteric Osteotomy*

Some revisions require greater exposure than that achievable by soft-tissue dissection alone. There are bony procedures that expose the acetabulum and femur. The most useful is the extended trochanteric osteotomy.

Indications for an extended trochanteric osteotomy include

1. Acetabular exposure
2. Removal of femoral components or cement
3. Neutral reaming of varus and valgus femoral remodeling
4. Adjustment of abductor tension
5. Promotion of femoral remodeling

The extended trochanteric osteotomy is versatile and reduces operative time, blood loss, and complications. The extended trochanteric osteotomy may be regarded as a conservative approach to revision hip surgery. It allows direct visualization during cement removal and reduces the incidence of cortical perforation. It allows controlled access to the femoral canal and facilitates removal of well-fixed cemented and uncemented stems. It allows reaming of the femur parallel to the canal, which is important when using long-stemmed components or when there has been varus remodeling of the femur secondary to aseptic loosening. The osteotomy is useful in the presence of malunions of the greater trochanter or femur that prevent reaming parallel to the axis of the medullary canal.

The extended trochanteric osteotomy is easier to perform once the femoral component has been removed. This is not always possible, and the technique is modified slightly with the femoral stem in place.

- Position the hip in 0° of flexion with internal rotation of approximately 20°.
- Create a long bony segment comprising the lateral third of the femur with minimal stripping of the musculotendinous sleeve composed of the gluteus medius and minimus proximally and the vastus lateralis distally (Fig. 106.23*A*).

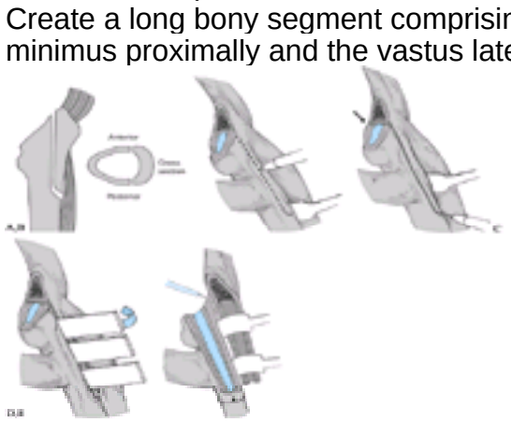

***Figure 106.23.*** **A:** Outline of extended trochanteric osteotomy in two planes. **B:** Expose the posterolateral femur, raise the vastus lateralis in a limited area, and mark the cut. **C:** Complete the cut with a saw and distally use the pencil burr. If the femoral component is in place, cut the anterior aspect of the proximal femur in the area of the arrow, thus creating a fracture plane on the anterior cortex, which is not exposed. **D:** Slowly open the osteotomy. **E:** Release contracted tissue anteriorly before displacing the osteotomized fragment.

- The longitudinal limbs of the osteotomy are on the anterolateral and posterolateral cortex of the femur, parallel to the long axis of the femur. The transverse limb of the osteotomy joins the two longitiudinal limbs and is transverse to the length of the femur. The goal is to create a coffin lid composed of the lateral third of the femur. The length of the osteotomy is based on preoperative templating and is covered in that section of this chapter.
- Expose the femur from the proximal neck cut to the templated distal extension of the osteotomy, along the junction of the posterior and lateral femur. Do not elevate the vastus lateralis for the length of the incision because this approach will devascularize the planned osteotomy segment. Do not expose the anterior cortex.
- Reflect the vastus lateralis anteriorly for 2 cm of its length at the distal extent of the osteotomy and retract it.
- Mark out the planned osteotomy using a narrow diameter pencil burr. Mark out the longitudinal portion along the posterolateral femur, then curve it gently onto the lateral cortex to mark the distal extent of the osteotomy. Curving the transition from a longitudinal to a distal cut reduces stress risers that could lead to fracture. Avoid 90° transitions (Fig. 106.23*B*).
- The anterior cortex does not need to be exposed except for a small 1 to 2 cm area that can be accessed where the retractor is retracting the vastus lateralis. In this area, extend the distal osteotomy from the lateral cortex to the anterolateral cortex from distal to proximal, marking the anterolateral cortex for 1 to 2 cm. The distal portion of the osteotomy can be completed with the burr (Fig. 106.23*C*)
- Complete the posterior longitudinal portion with an oscillating saw along the lines marked with the burr. Once the posterior cortical cut is complete, cut the anterior cortex from inside the femur using the posterior cortical cut as guide going from back to front. The anterior cortex should be cut at the same depth as the posterior cortex so that the osteotomy segment has a uniform depth.
- When the femoral component is still in place, the anterior femoral cortex cannot be cut directly. Cutting the anterior cortex for short distances both proximally and distally creates a controlled fracture and prevents stripping of the vastus lateralis that would otherwise be necessary to expose this area. Distally, the cut is marked as previously described, going from lateral cortex to the anterolateral, using the narrow diameter burr and cutting the anterior cortex for 1 to 2 cm from distal to proximal. The proximal femur should be cleared of anterior capsule for 1 to 2 cm distal to the neck cut. This should be proximal and anterior to the vastus lateralis origin. Using the pencil burr, the anterior cortex is cut for 1 to 2 cm. Exposure of the proximal anterior femur can be improved by flexing the femur 30°, and this area can usually be reached with the stem in place.
- Open the osteotomy slowly with two wide osteotomes. Pay careful attention to the distal aspect for fracture extension (Fig. 106.23*D*).
- With the osteotomized segment gently retracted anteriorly, release the scar along the anterior osteotomy plane from inside the femur. This scar tissue is most pronounced proximally. If this scar tissue is not released, the segment may fracture during retraction. This is a critical step in performing the osteotomy (Fig. 106.23*E*).
- A trial reduction of the hip allows for adjustments of abductor tension or repositioning of the femoral component. The osteotomy is not closed until the final reduction has been performed.
- It is often necessary to contour the inside of the greater trochanter with a barrel-shaped burr before closure so that it fits over the shoulder of the component.
- Close the osteotomy with two or more cables, depending on the length of the segment.
- Pass the cables around the femur, deep to the vastus lateralis, and tighten them partially with the hip reduced (Fig. 106.24).



***Figure 106.24.*** Osteotomy closed with cerclage cables passed deep to the vastus lateralis.

- Maintain tension on the cables as the hip is taken through a range of motion to check stability.
- If the reduction is stable then crimp and cut the cable sleeves in final position.
- Do not be alarmed if the osteotomy does not reduce with bone-to-bone contact. With greater deformities of the proximal femur or previous varus stems, anatomic reduction may be neither possible nor necessary.

The extended trochanteric osteotomy is stable because the vastus lateralis prevents proximal migration and the gluteus tendons remain attached, preserving abductor strength. An intact muscular sleeve, consisting of the gluteii and vastus lateralis, are the keys to successful healing. We experienced no nonunions in 122 cases (3). The most common complication (10%) has been fracture of the segment, but this was not clinically significant, and the incidence of this complication decreases with increased experience. Proximal migration has been limited to less than 2 mm (3).

One drawback of the extended trochanteric osteotomy is that it cannot be used to provide exposure or adjust abductor tension in the presence of a well-fixed cemented component that is being removed temporarily, the so-called “tap-in, tap-out” procedure. Its use in cemented revisions is also limited, although it can function with impaction grafting.

### *Trochanteric Osteotomy*

The traditional transtrochanteric approach popularized by Charnley is another method of exposure (13). This approach provides excellent exposure because the trochanter is detached from the femur and reflected superiorly with the gluteal muscles attached (Fig. 106.25*A*). In revision surgery the proximal femur is often damaged and the greater trochanter is compromised by osteolysis. This factor has significant drawbacks in the reattachment of the trochanter. Healing is usually fibrous, and fixation of the small proximal segment is difficult, even with the use of claws and grips.

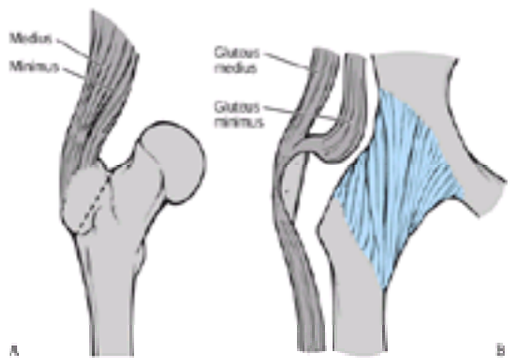


***Figure 106.25.*** **A:** Sagittal view of the trochanteric osteotomy. **B:** Sagittal view of the trochanteric slide.

### *Trochanteric Slide*

As a modification of the lateral approach, the trochanteric slide involves an osteotomy of the anterior trochanteric bone, which is reflected anteriorly in continuity with the gluteus medius and vastus lateralis. Make the osteotomy just lateral to the gluteus minimus insertion, or alternatively, it can be made thicker to include the gluteus minimus with the fragment. Reattach the slice of trochanter with cerclage wire around the lesser trochanter and through the bony fragment. Stability is usually excellent following reattachment owing to the opposing pulls of the gluteus medius and vastus lateralis (Fig. 106-25*B*). The trochanteric slide can improve visualization in the difficult primary arthroplasty as well as the revision. In addition, the dissection can be extended proximally for exposure of the ilium with less risk to superior gluteal neurovascular structures as can be encountered with the modified Hardinge approach (39). The mobility of the trochanteric fragment has the advantages of re-establishing abductor tension and facilitating fixation to a proximal femoral allograft.

## FEMORAL REVISION

### *Component Removal*

Femoral components may be easily removed if loose, or their removal may require much equipment and time. Cemented components are easier to remove than cement, and the most difficult to remove is the fully porous-coated ingrown stem.

Numerous tools are used for the removal of specific components. Other instruments are used more generally for cement and component removal. The Moreland (DePuy, Warsaw, IN) hand tools are useful for the removal of cemented and uncemented components. Other similar systems (Osteonics, Allendale, New Jersey) provide extraction devices and multiple hand tools with specific functions such as splitting cement or drilling into a cement plug (Fig. 106.26).

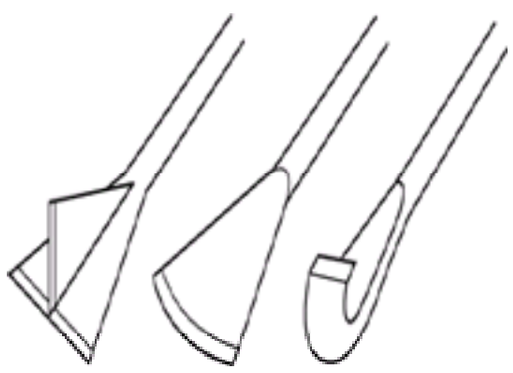

***Figure 106.26.*** Cement splitting tools.

Low-torque, high-speed burrs such as the Anspach (Lake Park, FL), Midas Rex (Fort Worth, TX), or the Ultra-Power (Warsaw, IN) should be available. They are versatile in revision surgery, and cutting heads with the ability to cut metal should be available in various shapes and sizes.

Once the hip has been exposed and dislocated, the modular femoral head must be disengaged from the Morse taper of the neck. This can usually be accomplished by placing a bone tamp at the undersurface of the femoral head and striking it sharply with a hammer. Dedicated instruments are also available from most manufacturers. Removal of the head facilitates acetabular exposure and should be done early in the exposure, even if the femoral component is to be retained. Protect the Morse taper on the femoral neck from scratches with a sponge from scratches during the surgery.

If the femoral component is to be revised, it can be removed immediately to improve acetabular exposure. An extended trochanteric osteotomy, if necessary for femoral component removal, improves acetabular exposure. If acetabular exposure does not seem to be a problem, there are advantages to leaving the femoral component in place until later. The femoral neck can be used as a fulcrum to transpose the femur anteriorly, although this should be done gently. Also, removal of the femoral component and cement leaves the femur as a fragile tube that is susceptible to fracture. Finally, removal of the component and or cement leads to increased bleeding from the canal. If the femoral component does not interfere with exposure, we leave it in place during the acetabular revision.

There are fewer options if the femoral component is to be retained. When exposure is a problem, the cemented femoral component may be tapped out of the cement mantle, with good results on replacement. With the femoral component removed, if there is a solid bond between the cement and bone, then either the same or a new femoral component can be recemented into place. If a new component is to be used, the cement mantle will require reshaping proximally and distally with high-speed burrs. This procedure can be useful with an intact and well-bonded cement mantle in cases in which cement removal will compromise the femur, as in a patient with severe osteopenia.

Femoral component removal begins with exposure of the proximal femur:

- Clear the “shoulder” of the prosthesis of soft tissue or bone that may limit access to the lateral component, or that may impede removal of the implant.
- Clear the entire proximal femur of fibrous tissue to view the component–bone or cement–bone interface around the entire prosthesis.
- Removal is safer once the proximal component can be visualized.

### *Cemented Stem Removal*

Cemented stem removal can be divided into three steps: (1) disruption of the cement prosthesis interface, (2) removal of the component, and (3) removal of the cement.

- Disrupt the interface proximally where any cement overhanging the shoulder is removed. The greater trochanter may fracture if this area is not cleared before removal of the component.
- After the proximal cement is fractured with a thin osteotome, disimpact the prosthesis with an extraction device.
- A component with a methylmethacrylate precoating to enhance the cement bond will not be extracted as easily. In this case, either continue to disrupt the cement mantle using flexible osteotomes or, more safely, with an extended trochanteric osteotomy.

### *Cement Removal*

Specialized hand tools are most useful for cement removal. Cement removal can be hazardous and commonly leads to cortical perforation. If the cement is grossly loose, it can often be removed as a unit by drilling a hole into the center of the distal cement, tapping threads into the cement, and screwing in an extraction device to remove the cement. Cement that is well bonded to the diaphysis is difficult to remove and will require high-speed burrs, a light to illuminate the canal, and possibly an image intensifier.

The extended trochanteric osteotomy is a safe and fast method to remove cement. Based on preoperative templating, the osteotomy should be extended as far distally as possible without compromising fixation of the revision stem.

- Split cement that is intact circumferentially into three or four segments with T- or V-shaped cement removal chisels. Do this before disrupting the bone–cement interface (Fig. 106.27). If the cement mantle is not disrupted, the chisels tend to lever against the bone and can lead to femur fracture.

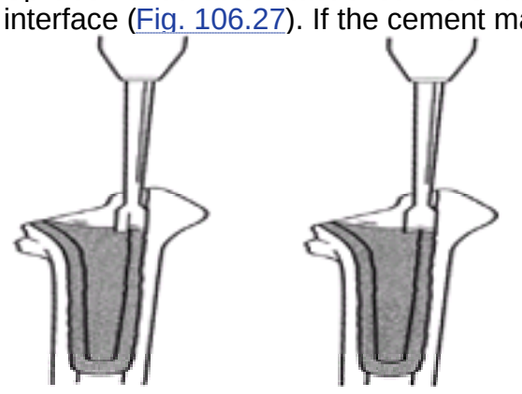

***Figure 106.27.*** Proximal metaphyseal cement can be split with special T- or V-shaped cement removal chisels.

- Patiently remove cement from proximal to distal in 1 to 2 cm segments. The well-bonded distal cement plug will be difficult to remove.
- If there is space between the plug and bone, a small hook can be passed beyond the plug to then remove it.
- If there is no space, drill into the distal plug with drill guides that fit tightly into the femoral canal and centralize the drill bit (Fig. 106.28). Tap the threads in the hole and screw in a threaded extractor. Try to remove the cement as a unit only if it does not extend past the isthmus or is not well bonded. If the unit is solidly bonded, split the cement through the drill hole and use hooks to remove it piece by piece.

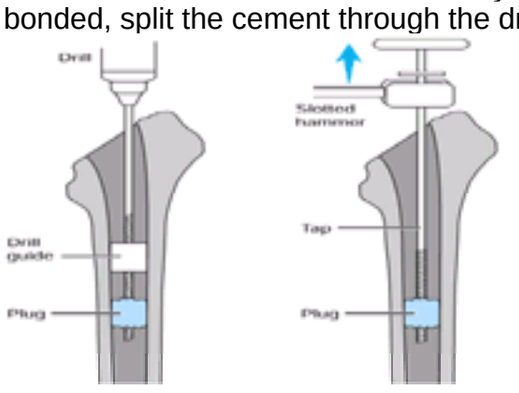


***Figure 106.28.*** Drill guides allow a tap to be placed centrally in the distal cement. If the cement is not well bonded, it can then be disimpacted.

We do not attempt to remove well-bonded cement or distal plugs without an extended trochanteric osteotomy. The osteotomy has decreased the frequency of perforations and expedited complete cement removal. Failure to remove small pieces of well-bonded cement can misdirect reamers and lead to component malposition and femoral fracture.

***Cementless Stem Removal***

The principles of interface disruption are the same as with cemented components but are more difficult. The techniques depend on the extent of the fixation surface; a proximally porous-coated component can be removed with or without an osteotomy using flexible osteotomes, whereas a fully porous-coated component will require an osteotomy or distal cortical windows.

The type of fixation—bone ingrown, fibrous stable, or fibrous unstable—will influence the ease of removal. A fibrous unstable component can be removed fairly easily, as shown here:

- Remove soft tissue and bone from around the shoulder of the prosthesis.
- Use an axial force to remove the component (Fig. 106.29).

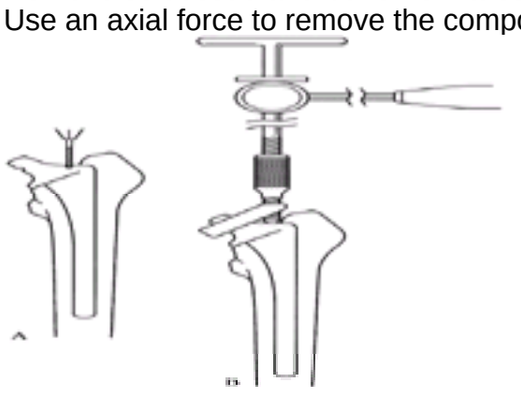

***Figure 106.29.*** A universal extraction device can be used for modular femoral components. **A:** If they are not already present, special notches must be made on these femoral components by using a carbide bit, and **B:** attachment of the device to the femoral component can allow for extraction.

- If the component shows no signs of moving after 5 to 10 heavy blows, reassess the situation. Is there a proximal obstruction? Is the component partially bone ingrown or fibrous stable?
- Do not force the component out because this can fracture the femur. For components that are proximally coated and “bone ingrown” or fully coated and “fibrous stable,” start by disrupting the bone prosthesis bond proximally.
- Establish access to the interface with a narrow-diameter burr or osteotomes. Establish “straight shot” access to the lateral aspect of the component by removing any overhanging greater trochanteric bone.
- Use flexible osteotomes to disrupt the bond around the prosthesis.
- Use an axial force to extract the component.

If removal is unsuccessful or the component is fully porous coated and bone ingrown, proceed with the extended trochanteric osteotomy or a cortical window. The extended trochanteric osteotomy provides better access to the proximal portion of the stem and more direct, straight access to the distal portion with the trephines.

The osteotomy would proceed as follows:

- Extend the trochanteric osteotomy distally to the junction of the metaphyseal and diaphyseal stem (Fig. 106.30).

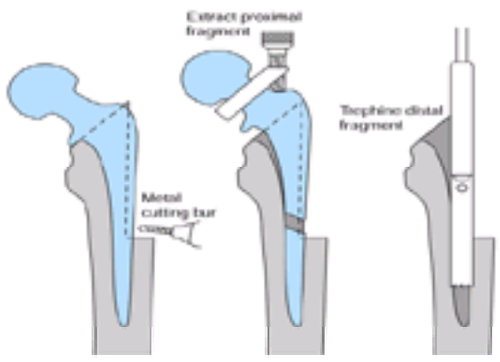


***Figure 106.30.*** Removal of a well-fixed fully porous-coated component through an extended trochanteric osteotomy, cutting the stem and using trephines.

- Disrupt the proximal bone prosthesis interface extensively with flexible osteotomes before opening the osteotomy. This will decrease the chance that the segment will fracture. Medial access is difficult and can be achieved by cutting the collar of the prosthesis.
- Open the osteotomy by hinging it anteriorly.
- Cut the stem at the metaphyseal–diaphyseal junction using a metal-cutting, carbide-tip, high-speed, low-torque burr.
- Disrupt the well-bonded proximal interface with use of a Gigli saw (Fig. 106.31).

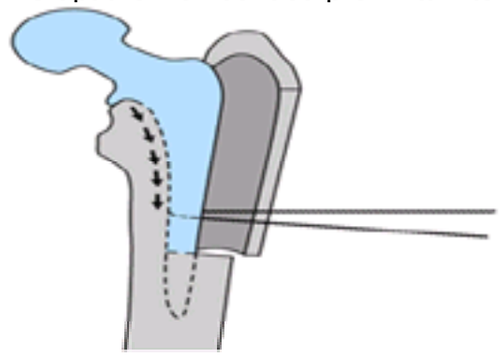

***Figure 106.31.*** Use of a Gigli saw to disrupt the medial interface, which is the most difficult to access.

- Drill over the distal cylindrical portion of the stem with trephines.

The cortical window achieves results similar to the extended trochanter osteotomy.

- Use a high-speed burr to create a window in the lateral femoral cortex at the junction of the metaphyseal and diaphyseal portions of the stem (Fig. 106.32).

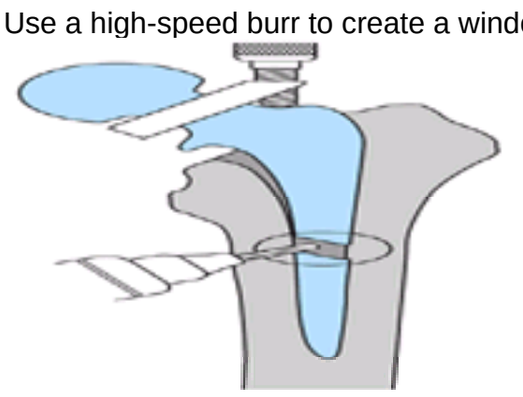

***Figure 106.32.*** Cortical window at the stem metaphyseal–diaphyseal junction used to cut the stem, which is then removed as in Figure 106.31.

- Cut the femoral stem with a metal-cutting burr through this window.
- Remove the proximal portion of the stem after disrupting the proximal bone prosthesis interface with flexible osteotomes.
- Drill over the distal portion of the stem with trephines.

Evaluate the femur for defects after removing the pseudomembrane, exposing healthy bone. Classify the defect based on the intraoperative evaluation and the preoperative templating. This information is used to decide treatment.

***Bypass Fixation***

The goal with bypass fixation is to achieve axial and rotational stability in the diaphysis of the femur, bypassing the metaphyseal bone. This can be achieved if at least 4 cm of undisrupted diaphysis is available to support the prosthesis and if more than 90% of the canal can be filled.

- Remove all cement and neocortex from the canal.
- Remove any overhanging trochanter or proximal sources of impingement because reaming must be performed in neutral alignment. In femurs with varus remodeling, this may not be possible. Failure to ream neutrally will lead to component malposition or femoral fracture.
- Perform an extended trochanteric osteotomy if neutral reaming cannot be achieved.
- The length of reaming depends on the stem chosen for revision; therefore, at least 4 to 6 cm of undisrupted bone must be available distal to the osteotomy site.
- Ream no farther than the area required for fixation.
- Use straight reamers for straight stems and flexible reamers for curved stems.

The femur has an anterior bow with the apex anterior and approximately 175 mm (7 inches) distal to the lesser trochanter. Therefore, any straight stems longer than 175 mm (7 inches) may impinge or perforate the anterior cortex of the femur. Long curved stems have a far lower incidence of anterior cortical perforation than long straight stems (Fig. 106.33).

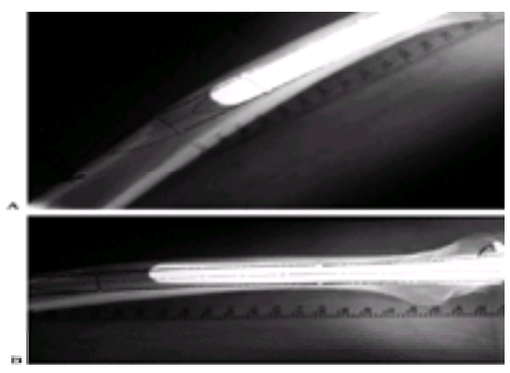

***Figure 106.33.*** **A:** A 200 mm (8-inch) straight-stem template shows conflict with the anterior cortex. A shorter stem was inserted, but the anterior cortex was still

thinned by reaming. **B:** A 200 mm (8-inch) bowed-stem template shows a much better fit if a long-stemmed component had been needed.

- Sequentially wider reamers are applied until the cortex is contacted. Keep in mind that the size templated is usually within one size of the actual component.
- Plan on reaming to 0.5 mm less than the implant diameter with the Solution (DePuy, Warsaw, IN). This applies to most fully coated nontapered stems, but this amount should be checked for each prosthesis.
- A good test of whether the right size has been chosen is to take a reamer on a T-handle and try to rotate it manually in the canal. The appropriate size provides rotational stability. For example, if you have reamed to 16.0 mm, with plans to implant a 16.5 mm component, use the 16.5 mm reamer on a T-handle to test for rotational stability.
- If rotational stability is not achieved, continue reaming to the next size.
- Perform trial implantation before reaming to the final size. In most systems, the trial broaches are smaller distally than the planned stem.
- If an osteotomy has been performed, tighten a cable around the femur, distal to the osteotomy, before impacting the stem, to decrease the chance of a fracture.
- Measure the prosthesis and femoral canal with calipers. Do the same for the final reamer so that the true size differential between reamer and component is known. Owing to manufacturing and sharpening of the reamers, they may differ from their stated size by as much as 0.5 mm each, leading to a potential 1 mm mismatch.
- Insert the component initially by hand, rotating it back and forth to advance. If more than 5 to 6 cm remains proud, it will be necessary to ream line to line (Fig. 106-34).

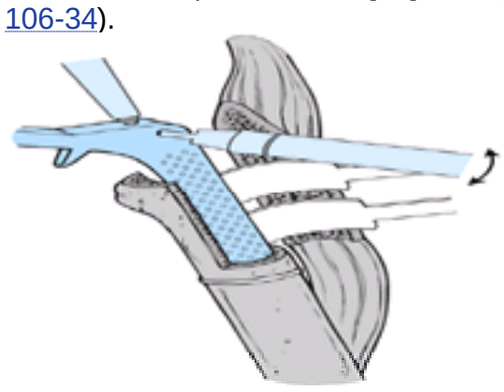

***Figure 106.34.*** Stem is inserted by hand using an impaction device as a pusher and a reamer through the shoulder of the prosthesis to toggle the component back and forth to advance it.

- After the component has been advanced maximally by hand, begin hitting it with the mallet. At this point, it is crucial to maintain the anteversion as determined by the trial reduction because once the prosthesis engages in the underreamed distal zone, it will be very difficult to rotate.
- The prosthesis should advance with each hammer blow, and the distal femur should be watched for fracture.

### *Proximal Porous Coating*

Devices that rely on proximal fixation require good fit and fill in the metaphysis. In revision surgeries, this bone is often sclerotic, fragile, and expanded. A proximally porous-coated device can be used if the metaphysis has sufficient structural integrity to provide rotational and axial stability. With proximal bone destruction, the metaphyseal portion of the implant will need to be larger than in a primary. The diaphysis, by contrast, may be undamaged (Fig. 106.35). The stem of the larger implant may be too large for the femoral diaphysis. Extensive medullary canal reaming may be necessary to accommodate the larger stem.

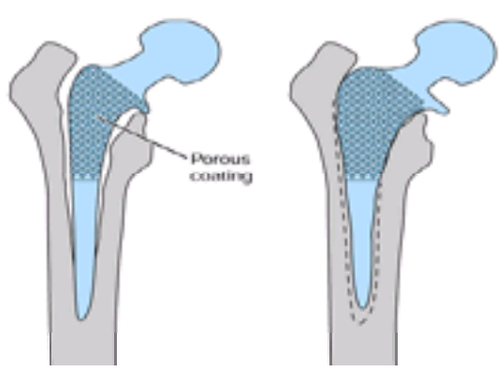


***Figure 106.35.*** Proximally coated devices that require good fit and fill in the metaphysis for stability must be larger in the revision setting, and this may compromise diaphyseal bone stock.

- Assess the proximal femur for its ability to support a proximally porous-coated device.
- Maintain the integrity of the proximal femur and the greater trochanter. Avoid an extended trochanteric osteotomy.
- Remove sclerotic bone that may misdirect reamers or broaches.
- The greater trochanter may interfere with broaches. Therefore, remove impeding bone before broaching.
- Use reamers to assess the diaphyseal canal diameter. Then insert a broach that matches the diaphyseal size and assess this for proximal stability. If it is unstable proximally, change the version or go to the next size, keeping in mind that you will have to enlarge the diaphysis to achieve proximal fixation. If it appears that going up one or two sizes will achieve proximal fixation, then it may be worthwhile. However, if excess diaphysis is being removed, it may be better to switch to a fully porous-coated device.

### *Cemented Revision*

The major difference between performing a cemented revision and a cemented primary arthroplasty is in the preparation of the femoral canal. In a primary arthroplasty, there will be healthy cancellous bed proximally and good diaphyseal bone distally. This will not be the case in the revision and the femur will have to be prepared far more thoroughly than in a primary.

- Remove all previous cement and pseudomembrane.
- Burr sclerotic bone down to bleeding bone, being careful to avoid perforation.
- Revisions require more cement than a primary, and two vacuum mixers may be required.

### *Impaction Grafting*

Impaction grafting uses small pieces of cancellous bone graft to create a new medullary canal into which a component can be cemented. In creating a new canal, bone graft will be compacted into the femur forcefully. The integrity of the femur must be restored to sustain this (22,97).

- Expose the proximal femur completely and clear it of pseudomembrane.
- Examine the femur for cavitary and segmental defects.
- Repair segmental defects to convert them to contained defects using mesh or strut grafts, or both, that are held with cerclage wires.
- Cerclage the fragile femur prophylactically with multiple cables before impacting bone graft because graft impaction can generate significant hoop stresses.
- Pass a guidewire through the center of a thick distal intramedullary plug.
- Seat this plug 2 cm distal to any lytic lesion. It is imperative that the plug is solidly in place and that the guidewire be neutrally aligned. If necessary, obtain a radiograph at this point to ensure that the alignment is correct. Perform the bone packing and trial insertion with a cannulated system to guide the position of the

stem.

- Passing a K-wire transversely through the femur just distal to the plug can prevent distal plug migration.
- Prepare cancellous chips of 3 to 5 mm in diameter. Chips that are too small can compromise the fixation by providing insufficient structural support, allowing stem subsidence (33).
- Place the graft into the canal and begin impacting it with the cannulated tamps (Fig. 106.36*A*).

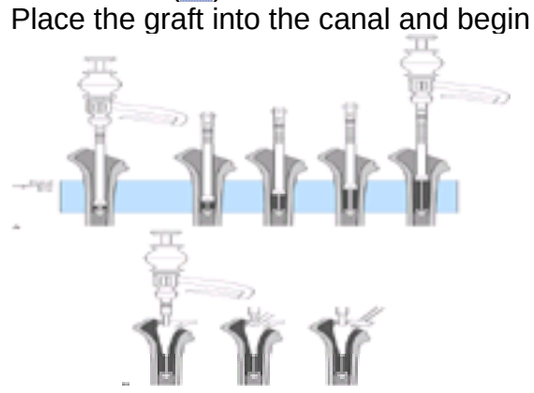

***Figure 106.36.*** **A:** Stages of distal impaction of the graft. See text for description. **B:** Proximal impaction with cannulated tamps and then trials with vigorous impaction of graft proximally. See text for description.

- Continue to pack more bone distally to proximally.
- When most of the canal has been filled, use the cannulated tamps (one to two sizes smaller than the prosthesis to be used) to compact bone.
- Pack the bone graft tightly—this is considered important to a success. When there is a uniform layer of 5 to 6 mm of bone around the new canal, remove the guidewire.
- The trials are oversized relative to the implants to allow for a cement mantle (Fig. 106.36*B*). They should be impacted to the appropriate depth as determined by trial reduction. The bone packing should be tight enough to prevent removal of the trial by hand.
- Introduce cement in a more liquid state than in primary arthroplasty so that it can penetrate into the bone graft. Then pressurize it with a cement gun equipped with a proximal seal.
- The stem used by the developers of this technique is of a highly polished, collarless, double-tapered design. It is intended to subside in the cement mantle with time, thus “engaging” the cement somewhat like a Morse taper (33).
- Keep the patient on protected weight bearing for 8 to 12 weeks postoperatively.

### *Allograft Prosthetic Composite and Strut Grafts*

The use of an allograft prosthetic composite (APC) is complex and required infrequently, even at institutions that perform many revisions. Structural allograft is necessary when the host femur is incapable of stable fixation of a revision component (Fig. 106.37). Strut grafts can be used when there are small, noncircumferential segmental defects. A structural allograft will be necessary for circumferential defects greater than 5 cm in length. Proximal circumferential segmental defects less than 5 cm long can be treated with calcar replacing or long-necked components.

***Figure 106.37.*** **A:** Allograft prosthetic composite. APC performed using modular components with cement distally and uncemented proximally. Junction is reinforced with strut grafts. **B:** Four and a half years later, the construct is stable. Experience has shown that cementing the proximal portion and uncemented distal fixation gives the best long-term results.

Strut grafts are easily applied and held with cerclage wires and have shown very reliable rates of healing (38). They can be used in many situations to span defects or as you would use plates to support deficient areas.

Proximal femoral allografts are best used with long-stemmed components that are cemented into the proximal segment and press fit distally into the host. This may require custom components because the allograft is often quite narrow, yet the diaphyseal host femur has a large circumference with thin cortices. The junction between allograft and host is important (38) and may be constructed as a butte, step-cut, or side-sleeve junction, or with the allograft telescoped into the host distally (Fig. 106.38). There is no consensus as to which type of junction is the best, but the greater the stability, the greater the chance of graft survival. The type of junction selected depends principally on the rotational stability of the prosthesis in the distal femur. A butte joint may suffice if distal stability is adequate. A step-cut joint can improve rotational stability but is technically more difficult. The junction can also be supplemented with strut grafts and plates for additional stability. Avoid cement intrusion into all junctions.

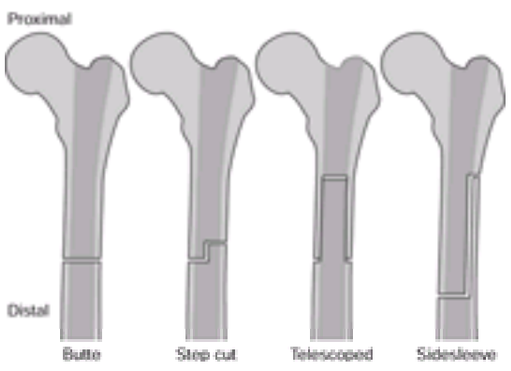


***Figure 106.38.*** Variety of joints used at the junction of host bone and proximal femoral allograft.

- Split the remaining proximal femur in two in the mediolateral plane, extending this distally to good bone.
- Preserve the soft tissue attached to the proximal femur. This bone can be wrapped around the allograft to preserve muscular attachments.
- Prepare the allograft to accept the prosthesis that best fits the distal femur without overreaming the allograft. There may be a mismatch between the allograft and host. A normal distal press fit may not be possible if the allograft is to be preserved.
- Avoid screws in the allograft because they lead to fracture.

The prosthesis must achieve stable fixation in the host distally. If the junction between graft and host is above the isthmus, reliable fixation can be achieved in the isthmus. If the junction is distal to the isthmus or the femur is a Paprosky type 4, isthmus fit will not be possible. In this case, the prosthesis will need to be cemented

into the host or fixed with interlocking screws into a custom implant.

## ACETABULAR REVISION

### *Removal of Acetabular Components*

The goal of acetabular component removal is to minimize loss of acetabular bone. Well-fixed or even partially fixed components that are forced out can result in extensive bone loss and may convert a straightforward reconstruction into a very complex affair. For this reason, consider retaining a stable metal-backed acetabular component. Porous-coated acetabular components are associated with areas of focal osteolysis. This focal osteolysis occurs in noningrown areas where the joint fluid has access to the supra-acetabular region. If this area is limited and the osteolysis does not affect the stability of the cup, it is advisable to retain the cup, apply bone graft to the lesion, and exchange the polyethylene (65) (Fig. 106.39). Six criteria should be satisfied to retain the cup:

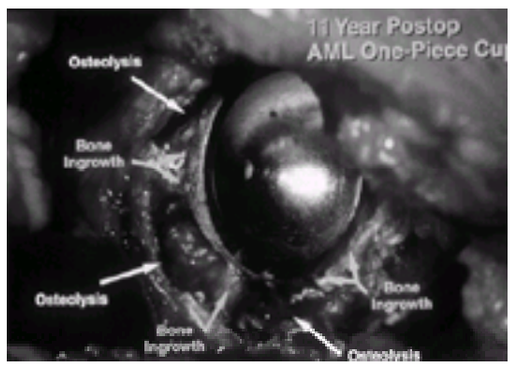


***Figure 106.39.*** Uncemented cup demonstrating the persistence of areas of bone ingrowth despite extensive osteolysis.

1. Cup position must be satisfactory.
2. Socket must be modular.
3. Locking mechanism of the shell must be intact.
4. Metal shell must not be damaged by femoral head penetration.
5. New polyethylene must be at least 8 mm thick.
6. Socket design must have an acceptable track record.

Failure to meet these criteria does not necessitate cup removal. The patient's age, activity level, and the reason for revision also should be considered. However, if two or more criteria are not met, cup removal may be preferable.

Removal of a well-fixed cup can be time-consuming and destructive. The average revision cup is 10 mm larger than a primary cup, reflecting loss of bone secondary to loosening and loss of bone during removal (65). The possibility of cutting a cup into sections should be considered. Cobalt-chrome cups are more difficult to cut than titanium cups. Any cup that is sitting directly on or medial to the teardrop should be sectioned rather than removed with curved osteotomes (Fig. 106.40). Curved osteotomes in this situation can damage the anterior column and injure the intrapelvic structures. We have a low threshold for cutting the cup, which facilitates removal and minimizes bone loss. When cups are more lateral, curved osteotomes can safely be used.

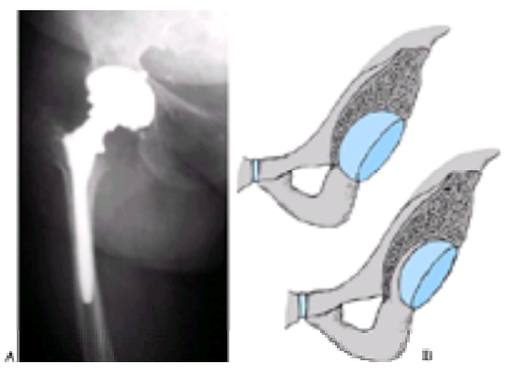

***Figure 106.40.*** **A:** Radiograph showing a cup sitting just medial to the teardrop in an osteoporotic patient. **B:** The use of an osteotome to remove stable cups that sit on or medial to the teardrop results in potentially disastrous anterior column bone loss and risk to intrapelvic structures.

Removal of cemented and porous ingrowth components differs somewhat, but the basic principle is the same: disruption of the interface between the component and the bone. Cemented cups usually have linear rather than focal osteolysis and therefore cannot be bone grafted. They also have a high loosening rate after 10 years, and therefore, they should be retained only if the cup is solid and the patient has a modest life expectancy (43,72).

### *Removal of Uncemented Components*

Remove uncemented acetabular components as follows:

- Expose all edges of the component. Remove modular polyethylene liners and be prepared for locking mechanisms that may require specialized extraction tools. Removal of the polyethylene improves visualization and gives access to the medial aspect of the cup, where there may be screw or insertion handle holes. Check all screw holes for screws, because some shorter screws may not be visible on radiographs.
- Establish a plane at the bone–component interface with a high-speed pencil burr (Fig. 106.41). Develop this plane around the entire perimeter of the cup to a depth of approximately 1 cm. This is easiest superiorly and posteriorly, and becomes more difficult anteriorly and inferiorly. With this plane developed, there is now access to the posterior aspect of the cup.

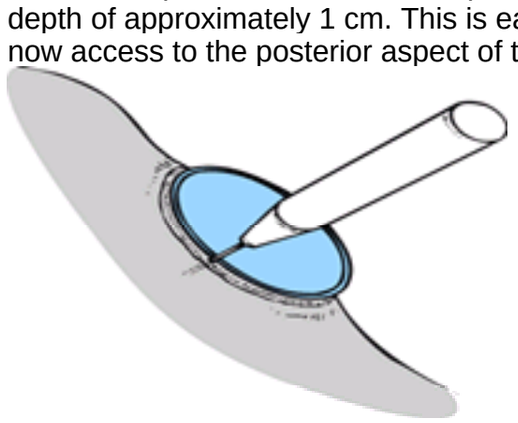

***Figure 106.41.*** Use a pencil burr to develop the interface between prosthesis and bone, allowing access to curved osteotomes.

At this point, a decision must be made based on preoperative planning. If the cup is medial to or directly on the teardrop, it is advisable to cut the cup and remove it in pieces. Use of osteotomes in the presence of medial bone deficiency can lead to major anteromedial bone loss or injury to intrapelvic structures. Use osteotomes only if there is medial bone present.

- The interface can be disrupted further with curved Moreland instruments. Begin by using the short-curved, and progress to the long-curved, going around the entire perimeter of the cup (Fig. 106.42*A*).

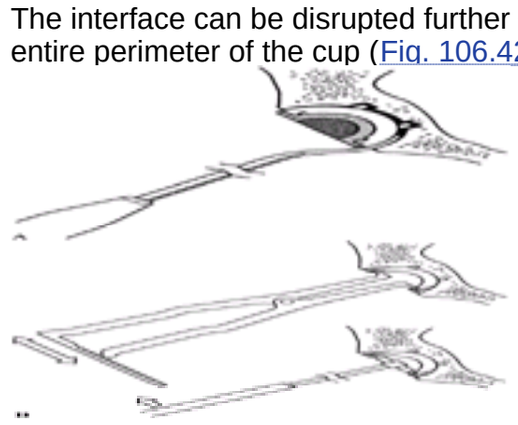

***Figure 106.42.*** **A:** The acetabular gouge can be inserted between polyethylene and cement or between cement and bone. Gentle placement around the edges of the component and cement can loosen them from the uderlying bone, allowing removal of the component, cement, or both. **B:** The cementless cup extractors and levers can lock into the metal portion of the cementless acetabular component. A gentle rocking motion allows extraction of the component. Before levering with these tools, it is important to loosen the bone–prosthesis interface with curved acetabular osteotomes.

- Using an acetabular grabber device, toggle the cup gently to establish areas that are still bonded and concentrate on disrupting them (Fig. 106.42*B*). Neither rock the cup forcefully nor pound it out because this method will lead to bone loss.

Despite complete disruption of the interface, some cups will still need to be cut for safe removal. This is usually because of fibrous or bony ingrowth on the inferomedial aspect of the cup, which is least accessible to the pencil burr and the curved osteotomes.

Sectioning a stable metal-backed cup is the safest approach to removing it. Section it into two or three pieces under constant irrigation and protect the soft tissues from metal debris. Section a metal-backed component as follows:

- Having gone through the previous steps, place sponges around the perimeter of the cup to keep metal debris from contaminating surrounding tissues.
- Use a metal cutting burr under constant irrigation to divide the cup in two halves from anterior to posterior.
- Try to remove the superior half with careful use of the short, curved osteotomes and an acetabular grabber.

The superior half is generally easier to remove than the inferior half, which frequently needs to be divided again. We now proceed directly to a three-limbed Mercedes-type cut, with the top of the star at the 12 o'clock position (Fig. 106.43).

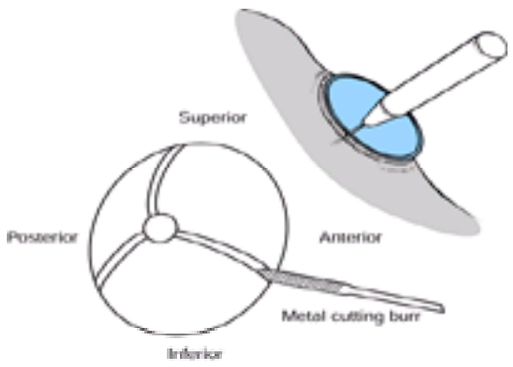


***Figure 106.43.*** Acetabular component cut in three to facilitate removal.

### *Removal of Cemented Components*

Follow the steps initially outlined for uncemented cup removal, including the development of an interface with the pencil burr.

- Drill into the center of the polyethylene with a large drill (i.e., 6 to 8 mm) and then screw a tap into the hole. Once securely attached to the cup, apply a slotted hammer to the tap. If the cup appears solid, disrupt the cement bond and remove the polyethylene. Cement removal is then fairly easy. Pay attention to cement plugs. It is occasionally necessary to section the cup, which is best done with a saw.

### *Assessment of Bone Stock*

Once the component and scar tissue have been removed, carefully assess bony defects. Complete removal of fibrous tissue is necessary. This is especially important inferiorly where the teardrop, or cotyloid fossa, should be identified to establish the appropriate center of rotation. Failure to identify this feature may lead to an inadvertent high hip center.

- Examine the peripheral rim for defects, which may affect cup fixation. The location and size of these defects affects the ability of the acetabulum to support the cup.
- Assess cavitary defects for size to determine bone graft requirements and to determine if they compromise stability.
- Pelvic discontinuity can easily be missed if medial fibrous tissue has not been removed. Most discontinuities have a deceptive fibrous union and should be tested by attempting to move the superior acetabulum and assessing whether the pelvis moves as a unit. The discontinuity usually extends transversely across the acetabulum from the 3 to 9 o'clock positions.

Treatment can proceed based on the preoperative plan and the intraoperative assessment of bone loss. The need for structural grafting can usually be predicted with preoperative templating. Have bone graft in the form of femoral heads, distal femurs, and a hemipelvis available, especially if there is no bone bank. Femoral heads are not very useful as structural grafts.

Structural grafts are required whenever the bone stock of the acetabulum is compromised and cannot provide rigid cup fixation. Allograft can be used to restore bone stock in young patients, who may not require graft for stability. Structural grafts are most commonly needed for segmental defects located superiorly and posteriorly.

- Assess the need for a graft by placing a trial acetabular component after the initial reaming. If the cup is covered by bone superiorly and posteriorly to its widest diameter, the cup will likely be stable. Structural grafts will then be needed for bone stock restoration and not for stability (Fig. 106.44). The planned cup must have greater than 50% host bone contact.

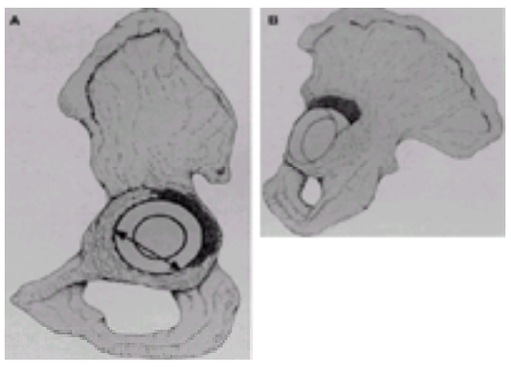

***Figure 106.44.*** A trial component wedged into position can help assess the extent of defects and how these defects affect stability.

- If there is inadequate posterior or superior coverage, structural grafting will be needed.
- At least 50% of the cup must be in contact with host bone.

With these deformities, treat the segmental defect first with a structural graft and provisional fixation. A discontinuity should be plated, and the plate should buttress the structural graft. One can then implant a prosthetic cup if there is more than 50% contact with host bone. A cage or cemented cup and allograft will be required for less than 50% contact with host bone.

**STRUCTURAL GRAFTING**

Small segmental defects can be filled with allograft femoral heads, whereas larger defects will require distal femurs. Very large defects or those of the posterosuperior column will require hemipelvis allografts. As previously discussed, structural grafting can produce successful results if certain principles are followed (30,31,38,78):

- Rigid fixation
- Buttressing of the graft against host bone
- Alignment of the graft trabeculae along the lines of stress transfer
- Placement of screws along the lines of stress transfer.

***"Number 7" Graft***

The "number 7" designation of this graft comes from a distal femoral allograft, where part of the supracondylar area of the allograft is preserved, forming the vertical stem of the seven. The flange that is created is critical to the successful healing of the allograft and is far more stable than femoral heads (Fig. 106.45).

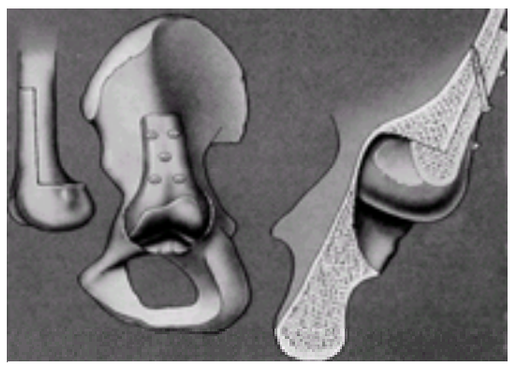

***Figure 106.45.*** Number 7, or hockey stick, graft is cut from the distal femur.

- Prepare the acetabulum to accept the graft by using a reamer to create a more hemispherical defect. This should not be done aggressively, in order to preserve residual bone.
- Use a concave reamer 2 mm larger than that used to shape the defect on the femoral head or distal femur to create a matching shape to the defect.
- Position the graft in the acetabular defect. The supracondylar extension of the "seven" should have intimate contact with the ilium.
- Secure the graft with screws. Plate a discontinuous posterior column, with the plate spanning the allograft.

***Acetabular Allograft***

Fortunately, full acetabular allografts are required only for Paprosky type 3B defects in which there is less than 50% host bone contact. Host coverage of the prosthesis can be assessed with trial components or reamers. Hemipelvic allografts are superior to acetabular allografts because they provide a larger superior flange to allow for fixation to the host pelvis. Male donors are also preferred because their acetabuli have larger inner diameters, which allow for the placement of a larger cage, more cement, and thicker polyethylene. Unlike the femoral heads and distal femurs, the hemipelvic graft must be matched to the side of the patient. The goal is to shape the graft so that it locks into the acetabular defect.

The technique for a full acetabular allograft is as follows:

- Cut the graft from the hemipelvis as shown in Figure 106.46. Leave sufficient bone superiorly to create a large flange that will secure the graft and lock it into place.

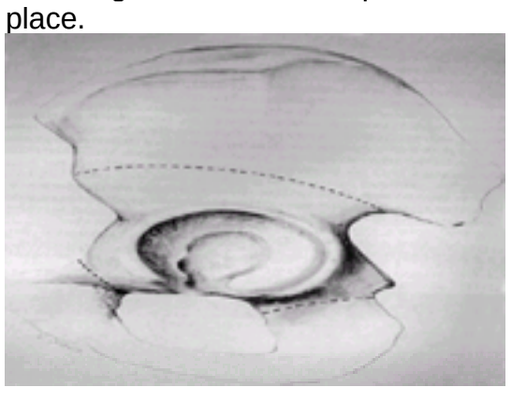

***Figure 106.46.*** Allograft pelvic graft: Cut the graft from the pelvis as shown.

- Cut a trough on the medial aspect of the allograft corresponding to the superior and posterior rim of the defect. This locks the allograft into the defect.
- Do not thin the graft excessively while creating a trough or the allograft could be fractured. The trough should be 1 cm wide and approximately 1 cm deep, depending on the size of the allograft.
- The medial surface of the allograft must be shaped to fit the defect. Use the concave reamers on the medial aspect of the allograft. This reamer should be 2 mm larger than the reamer used to size and shape the defect. A barrel-shaped burr is useful to shape the allograft.
- Place the graft in the defect and rotate it until the best fit is achieved. Detailed shaping of the medial surface is usually necessary to achieve an ideal fit.
- Secure the graft to the host with screws through the allograft and into the ilium. A plate along the posterior column crosses the allograft and extends onto the ilium

(Fig. 106.47 and Fig. 106.48).

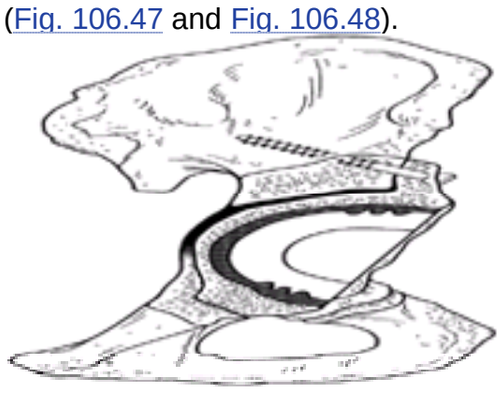

***Figure 106.47.*** Graft is secured with screws directed along the lines of force transmission through the flange.

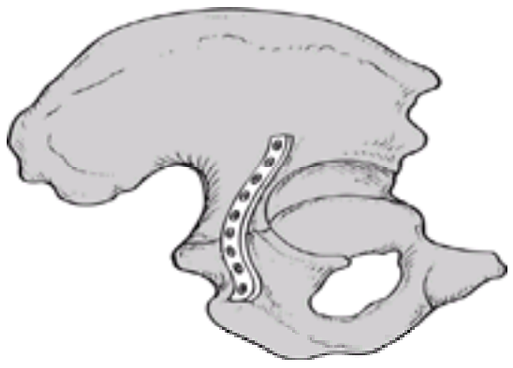

***Figure 106.48.*** A discontinuity must be fixed internally. The most secure method is with use of a posterior plate.

**PELVIC DISCONTINUITY**

Pelvic discontinuity is rare but requires plate fixation. Discontinuity results from a transverse fracture that extends from the anterior column through the medial wall and out the posterior column (Fig. 106.49). It is often associated with segmental and cavitary bone loss, which may require structural or cancellous grafting. When required, a graft should be performed before the plating. This technique is covered elsewhere.

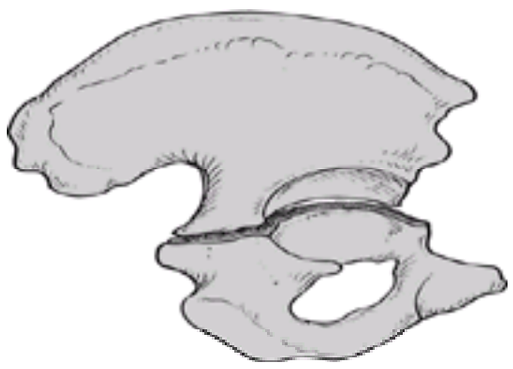

***Figure 106.49.*** Pelvic discontinuity usually extends from 3 to 9 o'clock.

Despite the disruption of both columns, most cases require only posterior column fixation. Although isolated anterior column deficiencies do not require fixation, isolated posterior column disruption should be plated owing to the tremendous stress placed on the posterior column during weight bearing.

- Expose the ilium superior to the superior rim, and extend this exposure along the posterior rim onto the ischium. The exposure must be performed carefully because this is the most common site of sciatic nerve injury.
- Use the plate templates to obtain a mold of the area to be plated. Curved pelvic reconstruction plates work best and are generally eight holes or greater.
- Mold the plate with benders using the plate template as a guide. Once the plate matches the pelvic anatomy, secure it with screws (Fig. 106.48). Large fragment screws are more secure but can be placed with only limited angulation. Small fragment screws may be oriented with greater freedom, and in cases of severe deficiency, this will increase the chance of secure purchase.
- The fracture site must be compressed, as with all fracture fixation.

Once plated, the acetabulum can be reconstructed using a metal-backed cup or a cage.

With the advent of “jumbo” cups, the majority of acetabular revisions can be performed using a metal-backed cup supplemented with screw fixation. These cups can sometimes be used in the presence of a discontinuity, often with structural allograft in conjunction with posterior plating.

**REVISION WITH A METAL-BACKED COMPONENT**

Acetabular defects are usually greater in the superoinferior dimension than in the anteroposterior dimension. Placement of a hemispherical cup into an oblong defect dictates that the AP diameter will need to be increased without compromising the rim integrity. The superior portion of the cup may remain partially uncovered as a compromise. This is acceptable as long as the cup has at least 50% contact with host bone. It is important to remember that bone is sclerotic and more fragile in revision surgery.

The goal of reaming is to create a hemisphere. There are usually irregularities in the rim, with areas of protruding bone that may give a false idea of the cup size. This bone can misdirect the reaming if you attempt to remove it with progressively larger reamers. The reamer displaces and destroys good bone.

- Obtain a rough estimate of the acetabular size using either a reamer or a trial component.
- Use smaller reamers to ream irregularities selectively in the rim and in the depth of the cup so that it more closely matches a hemisphere (Fig. 106.50).

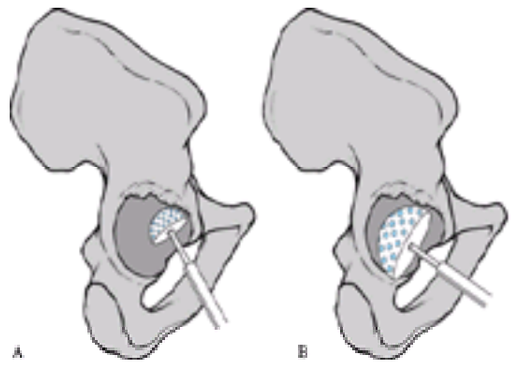

***Figure 106.50.*** **A:** Initial reaming should be done with a reamer much smaller than the defect. This should be used to ream areas selectively that may misdirect a larger reamer. **B:** Using a reamer that more closely matches the final size will lead to good bone being lost as you ream away the minor irregularities.

- Once the periphery and depth of the cup are fairly regular, begin reaming with sequentially larger reamers to create a true hemisphere. Do not compromise the anterior and posterior columns in an effort to obtain superior coverage.
- Place a trial component one to two sizes greater than the last reamer in 40° of horizontal inclination and 20° of anteversion. This position is optimal but may be unobtainable due to compromised bone stock.
- Perform a trial reduction, and if satisfied with the stability, implant the actual component. Mark the anteversion of the trial acetabular component before removing it.
- Perform necessary cancellous bone grafting. Use the last reamer in reverse to compact the cancellous graft.
- Check the component size with calipers and underream by 1 mm. A 2 mm press fit in revisions is sometimes difficult to obtain owing to the sclerotic nature of the bone.
- Drill screw holes into areas most likely to provide fixation. The safe zones for screw placement are posterosuperior and posteroinferior (Fig. 106.51). The most dangerous quadrant is anterosuperior.

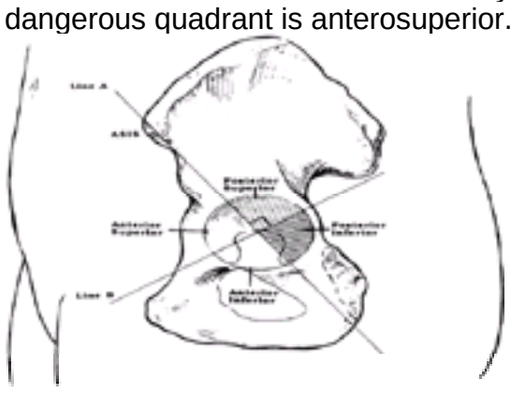

***Figure 106.51.*** The quadrant system divides the acetabulum, with the safest zones for screw placement being posterosuperior and posteroinferior.

- Check the position of the cup and if satisfied proceed with screw fixation.
- Do not tighten any screw fully until all are in place or the cup position can be altered.

## POSTOPERATIVE MANAGEMENT

Postoperative management should be individualized and include guidelines regarding restricted weight bearing and dislocation.

When a porous-coated component has been implanted, restrict weight bearing to less than 50% of body weight for a minimum of 6 weeks. Extend this period if there are concerns about the stability of the construct. If structural graft has been used on the acetabulum, then extend restricted weight bearing to 12 weeks. Depending on the type of graft, the type of fixation and the component used, weight bearing may be restricted up to 1 year although this is rarely required. Weight bearing is usually restricted for 6 weeks after cancellous grafting. The extended trochanteric osteotomy does not change postoperative management.

The second major concern in the postoperative period is dislocation. Patients are educated about hip precautions, and these warnings are reinforced at each follow-up period. Patients are also placed in a Newport (hip spica-type) brace whenever they are out of bed (Fig. 106.52). In patients who have demonstrated instability, the brace is kept on 24 hours a day for a minimum of 6 weeks. The restricted motion allows for soft-tissue healing and muscle strengthening, thus reducing the chance of dislocation. Postoperative management is otherwise comparable to primary arthroplasty.

***Figure 106.52.*** Patient with Newport (hip spica-type) brace to limit range of motion and decrease chance of dislocation.

## INTRAOPERATIVE COMPLICATIONS

### BLOOD LOSS

Blood loss is far greater in revision surgery, with patients routinely losing 1 to 2 L. The use of nonautologous transfusion can be limited by several methods. Predeposit autologous blood involves the collection of 1 to 4 units of blood from the patient before surgery over a period of several weeks. This blood is then available for tranfusion postoperatively. This technique has reduced the need for nonautologous blood significantly. One study demonstrated a need for nonautologous donation in 71% of patients who did not predeposit and only 8% in those that did (110). Another preoperative method of reducing nonautologous transfusion is the use of erythropoeitin. At present, this method is being used on a restricted basis for orthopedic procedures with several ongoing studies (26). Goldberg et al. found that in those patients that did not predonate the use of erythropoetin reduced the need for nonautologous transfusion from 54% to 17% (36).

Anesthetic techniques also affect blood loss. Epidural and spinal anesthesia have demonstrated lower rates of intraoperative blood loss than general anesthesia (45,92). These regional anesthetic techniques should be used whenever possible. Intraoperatively, blood can be salvaged by washing and anticoagulating aspirated blood, which can be given back to the patient, decreasing transfusion requirements. This procedure should be performed routinely on revision surgeries (105). Postoperative reinfusion of blood collected in drains also salvages lost blood; however, this blood is not washed. This blood can be given back to the patient, although some surgeons have reservations about this technique due to possible contaminants such as fat.

### VASCULAR INJURY

Vascular injury occurs in 0.2% to 0.3% of primary arthroplasty (48,74). In revision surgery, the incidence is somewhat higher, although the exact prevalence is difficult to establish (56,94). The most commonly injured vessels are the femoral and external iliac arteries (56). Injuries occur most commonly from placement of retractors over the anterior brim of the acetabulum, where the femoral artery is vulnerable. Injury can also occur during screw placement, with the greatest danger being anterosuperior, where the external iliac vessels are at risk, and anteroinferior, where the obturator vessels are at risk (Fig. 106.51) (48,74). Screws should ideally be placed in the posterior half of the acetabulum where there is less risk of vascular injury and the screw fixation is superior.

### NEUROLOGIC INJURY

Neurologic injury occurs in 0.6% to 1.3% of primary total hip arthroplasties (20,41). In revisions, nerve injury is more common and several large series have reported injury rates from 1.4% to 7.5% (1,20,88). This higher rate of injury associated with revision procedures may be due to several reasons. Direct injury to the nerve is possible from the use of screws, cerclage cables, or the prolonged use of retractors. Also, there is more scar tissue, which may tether nerves, predisposing the nerve to traction injury. Acute limb lengthening of greater than 4 cm has been associated with increased risk of neural injury, with the peroneal division of the sciatic nerve most at risk (41). It is important to plan the revision so that the limb lengthening is limited to 4 cm or less. Hematoma formation can also cause nerve compression and delayed palsy, and if hematoma is suspected, it should be decompressed (98).

## POSTOPERATIVE COMPLICATIONS

### LIMB LENGTHENING

Limb lengthening is a frequent complication of revision hip surgery and is a common cause of litigation. Lengthening more than 25 mm (1 inch) beyond normal can lead to back or knee pain and increase the risk of neurologic injury. At times, lengthening is required to ensure hip stability. This should be discussed with the patient preoperatively to avoid dissatisfaction postoperatively. Careful preoperative planning and patient education can avoid this problem or diminish its effects.

### THROMBOEMBOLIC DISEASE

Prevention of thromboembolic complications is controversial (61). There is little conformity in the prophylaxis of deep vein thrombosis (DVT), with some patients receiving chemical or mechanical prophylaxis and others receiving nothing. In North America, a compression device is usually combined with heparin, low-molecular-weight heparin, warfarin, or aspirin. Each seems to provide protection to the patient, but it is difficult to determine which is the most effective with the fewest side effects. The incidence of fatal pulmonary embolism after primary total hip arthroplasty is 0.35% (54,59). For large DVTs that form above the knee, treatment should consist of heparinization, followed by 3 to 6 months of warfarin anticoagulation. Thrombi that form distal to the knee can be left untreated with clinical and Doppler follow-up after 1 week to assess for progression (see Chapter 5 and Chapter 7).

### DISLOCATION

Dislocation complicates 5% to 7% of revision surgery as compared with primary rates of dislocation as low as 2% to 3% (21,69). The higher rate of dislocation can be attributed to several factors: integrity of the soft-tissue envelope in the revision setting, altered abductor attachments, the extensile exposures that are required, and the occasional need for nonanatomic component positioning. Dislocation rates have been linked to gender, with women having almost twice as many dislocations as men. Age, gender, and surgical approach are significant risk factors that are not unique to the revision setting. The most common cause of dislocation in both the primary and revision setting is component malposition, most frequently the acetabular component. Kahn et al. (47) examined recurrent dislocation and found that in 50% of patients, it was due to inadequate anteversion of the acetabulum. The surgeon should also be aware of impingement of the femoral neck on scar tissue anteriorly or on the cup posteriorly. This should be evaluated carefully during surgery. The possibility of impingement is increased when a small diameter femoral head is used with a larger diameter prosthetic neck. Longer neck length femoral heads with a collar that fits over the Morse taper are often required in revisions to obtain stability. The collar may impinge on the femoral neck. Most dislocations occur in the immediate postoperative period. If early dislocation can be avoided, the hip muscles become stronger and a pseudocapsule forms, making dislocation more difficult. All of our patients who have undergone revision surgery are braced in a hip spica-type Newport brace that is worn whenever the patient is out of bed for the first 6 to 8 weeks. The most important factor in preventing hip dislocation is patient compliance. Patients must be educated as to safe and unsafe positions and be provided with any aids such as grabbers that may prevent an unsafe position.

### HETEROTOPIC OSSIFICATION

The incidence of heterotopic ossification in revision surgery is somewhat higher than in primary arthroplasty owing to the increased exposure required, especially when the abductors are stripped from the ilium. Routine prophylaxis with radiotherapy is not required. Patients who have demonstrated previous heterotopic ossification are irradiated within 72 hours of surgery with 1 dose of 800 centigrays (80). Indomethacin has been shown to be effective in a once-daily dose for 2 weeks (90). However, nonsteroidal medications interfere with bone ingrowth, and therefore, many surgeons hesitate to use them in the presence of porous-coated components, bone grafts, or osteotomies, although a specific adverse effect on arthroplasties has not been documented (103).

## ARTHRODESIS OF THE HIP

***Technical Contributor Michael W. Chapman***

At present, arthrodesis of the hip is rarely performed. Most orthopaedic surgeons specializing in either adult reconstructive surgery or pediatric orthopaedics, even after many years of practice, may have performed only one or two in their career. The vast majority of residents completing training have not performed a hip arthrodesis, let alone having seen one.

During the first half of the twentieth century, arthrodesis of the hip was fairly common because there were few other alternatives available for severe incapacitating arthritis of the hip. With the development of total hip arthroplasty in the 1960s, the indications for arthrodesis of the hip decreased dramatically. Equally as important, the prevention of severe long-term disabling disease of the hip has improved substantially because of increased awareness on the part of primary care physicians and orthopaedic surgeons of developmental dysplasia of the hip, slipped capital femoral epiphysis, and infections in the hip. In developed countries, the severe sequela of these disorders is now being prevented. Equally as important, treatment for these disorders has improved substantially, thus avoiding the worst long-term consequences. Other operations developed in the last 30 years of the twentieth century, such as intertrochanteric and periacetabular osteotomies, provide an excellent alternative for young persons with symptomatic arthritis of the hip (see Chapter 104). The development of microvascular surgery and free bone transplant during this same period of time now provides an alternative for the treatment of avascular necrosis of the femoral head, as discussed in Chapter 125. In underdeveloped countries, arthrodesis of the hip is performed more commonly because the sophisticated procedures discussed in the previous paragraph are not readily available and the causes of severe disabling disorders of the hip differ, in that infection and paralytic diseases such as poliomyelitis are much more common.

Arthrodesis of the hip remains an important tool in the armamentarium of the adult and pediatric reconstructive orthopaedic surgeon. This is because a total hip arthroplasty has not yet proven to have a sufficient life span in young active people that the procedure is justified unless the patient is willing to face the uncertainties of early revision arthroplasty and eventually either a resection arthroplasty or arthrodesis (14). In spite of their uncertain future, many patients still elect to undergo total hip arthroplasty rather than arthrodesis because of their unwillingness to accept the functional limitations of a fused hip.

The first successful arthrodesis of the hip reported in the literature was that by Huesner of Germany in 1894 (26). Since then, over 20 different techniques to arthrodese a hip have been described. (45) Hip arthrodeses can be classified into three main categories: intra-articular, extra-articular, or combined intra-articular and extra-articular. Other distinguishing characteristics of hip fusion are whether or not postoperative immobilization in a spica cast is required or whether rigid internal fixation that eliminates the need for cast immobilization is used, whether subtrochanteric osteotomy is performed, and whether muscle pedicle bone grafts are used. Extra-articular arthrodeses were developed in the early part of the twentieth century to treat joint infections such as tuberculosis. This is because the extra-articular arthrodesis avoided invading the infected area and arthrodesis of the joint combined with other medical treatment often resulted in resolution of the infection. Albee (4,5) and Maragliano (33) described the earliest extra-articular arthrodeses in the 1920s, and Brittain (12,13) introduced his ischiofemoral arthrodesis in the 1940s. Because these early arthrodeses were performed without internal fixation and used spica cast immobilization, prolonged periods of immobilization were required and nonunion was common. Farkas (23) in 1939 introduced the concept of a subtrochanteric osteotomy below the hip fusion, which prevented direct transmission of forces to the hip fusion by movement of the extremity through the long lever arm of the femur and lower extremity. Abbott and associates (1,2,3) further refined this technique, introducing the concept of arthrodesis in wide abduction, followed by secondary subtrochanteric osteotomy to reposition the limb for difficult cases. Watson-Jones (49,50) introduced the use of internal fixation for arthrodesis of the hip as early as 1938. Charnley (17) attempted to improve the success rate by centrally displacing the femoral head into the medial pelvis, combining this procedure with compression screw fixation in an attempt to increase stability. To increase the success rate further, Davis (19,20) used a muscle pedicle bone graft harvested from the anterior ilium to bridge across the hip joint to facilitate early consolidation. This has been modified by

Ranawat et al. (39) with a particular goal of avoiding injury to the hip abductor musculature in order to provide optimal circumstances for eventual conversion of the arthrodesis to total hip arthroplasty in later life. Truly rigid fixation was used by Müller (35,36). This procedure was refined by Schneider (42), who introduced the cobra-head plate and pelvic osteotomy. These items resulted in one of the most stable arthrodesis constructs available today, which generally does not require any external immobilization. Murrell and Fitch (37) have modified this fusion to preserve the abductors for later conversion to total hip arthroplasty. The original description by Schneider (42) essentially sacrificed the abductors, precluding successful conversion to a total hip prosthesis. Kostuik and Alexander (29,30) modified Schneider's arthrodesis for failed hip arthroplasty in cases in which there is substantial loss of bone stock by using the cobra-plate in combination with an anterior plate producing a double-plate reconstruction. Matta (34) has advocated an anterior approach using an anterior compression plate to optimize conditions for conversion to a total hip arthroplasty but mixed results (11) have not led to its wide adoption as a technique at this time. Other types of fixation have been advocated to improve the union rate or avoid injury to the abductors, including insertion of a compression hip screw across the hip joint into the pelvis (38), intramedullary nail fixation from the ilium into the femoral shaft (6), and augmentation of internal fixation with iliofemoral external fixation (48).

## INDICATIONS AND CONTRAINDICATIONS

Hip arthrodesis is a major surgery, even more so than primary total hip arthroplasty, and it has a more difficult postoperative course of treatment because of the time required for consolidation of the arthrodesis. For that reason, arthrodesis is the procedure of last choice for disabling disease of the hip other than resection arthroplasty. Be certain that the patient has had a full and an adequate regimen of nonoperative treatment and that other procedures that would preserve better function such as osteotomies above or below the hip joint have been considered and rejected as feasible, or have failed.

The ideal candidate for hip arthrodesis is an active person younger than 40 years of age, usually a laborer or individual who places high demands on her hip, with severe disabling involvement of one hip, normal health, and no impairment of function in the thoracolumbosacral spine or ipsilateral knee. The most common indication is posttraumatic degenerative arthritis, and the second is the sequelae of septic arthritis. Other indications are avascular necrosis or cartilage necrosis in the young adult and tuberculosis of the hip, which is rare in developed countries today. Women are less likely to accept arthrodesis, but arthrodesis is compatible with sexual function and vaginal childbirth. The gait pattern of patients with unilateral hip fusion is characterized by increased compensatory motion in the lumbar spine and in the ipsilateral knee, decreased gait velocity, decreased stride length, decreased cadence, and asymmetry of gait (8,24). Barnhardt and Stiehl (7) followed six patients who had an arthrodesis at an average age of 30.8 years for an average follow-up of 11.7 years. All patients who were working at the time of arthrodesis returned to work, but all complained of low back pain; all had impaired ambulation due to ipsilateral knee pain; and five of the six believed that their sexual function was impaired. This points out the importance of a thorough workup of the spine and both lower extremities to be certain that the joints above and below the hip fusion are as close to normal as possible. Patients must be warned as they become older that some low back pain and ipsilateral knee pain is expected. Incapacitating back pain is the most common reason for subsequent conversion of an arthrodesis to a total hip arthroplasty.

Contraindications include significant disability or impaired function in the lumbosacral spine and ipsilateral knee, systemic disease such as rheumatoid arthritis or lupus erythematosus, and active pyogenic infection in the hip. Relative contraindications are an occupation that requires prolonged sitting and extreme obesity. Contralateral hip disease is a relative contraindication; however, total joint arthroplasty on one side and arthrodesis on the other is an acceptable combination for some patients. Poor bone quality because of osteoporosis or metabolic bone disease and major bone loss due to tumors, infection, or revision arthroplasty are associated with a much higher incidence of nonunion, failure, and disability due to shortening of the limb.

Patient selection is critical to success and patient satisfaction. Most young patients today who are candidates for unilateral hip arthrodesis are reluctant to accept the procedure because of the superb short-term results of total hip arthroplasty. It is important to have patients who have undergone a hip fusion available who are willing to talk to candidates for fusion because this is the best way to demonstrate the capability of a hip fusion in activities of daily living and gain an understanding of its positive and negative aspects. Sometimes, placing the patient in a removable orthosis with a locked hip hinge or a pantaloon-type hip spica cast will give him or her a better feeling for its limitations and whether or not they receive relief by immobilization.

### PREOPERATIVE PLANNING

Perform a thorough physical examination and history to be certain that the patient meets the indications for the procedure and has no contraindications as described earlier. Radiographs of the ipsilateral knee are unnecessary if the patient is asymptomatic and the examination is normal. Obtaining an AP and lateral radiograph of the lumbosacral spine is wise, even in asymptomatic patients with a normal examination to rule out occult spinal conditions that might be aggravated by a hip fusion. The focus of preoperative planning otherwise is on the exact technique of fusion to be used. This depends on the patient's bone quality, history of previous surgeries (which may affect the choice of surgical approach), and the condition of the hip as far as whether its configuration is fairly normal or there is pre-existing bone loss, shortening, or other considerations that may require specialized techniques to ensure fusion or regain some leg length.

## SURGICAL TECHNIQUE

The most important goal is to achieve appropriate position of the arthrodesis, which is important to optimize function and minimize and delay both the incidence and the severity of subsequent low back and ipsilateral knee pain. Recommendations for positioning of the arthrodesis have varied from 20° to 45° of flexion, 10° of adduction to 10° of abduction, and neutral to 20° of external rotation (9). Benaroch et al. (8) found in 13 adolescents, who were operated on at an average age of 15.6 years at an average of 6.6 years follow-up, some adduction drift in the fusion. The lowest incidence of low back pain occurred when their fusion was between 20° to 25° of flexion, less than 2 cm short, and in 0° of abduction. Based on my personal experience and a consensus of the literature, I suggest placing the hip in 20° of flexion and neutral abduction, and placing the foot in the plane of the progression of gait to match the opposite normal side, which is usually 0° to 10° of external rotation.

The next most important goal is to achieve fusion. A high union rate is achieved by resecting any necrotic bone and ensuring that well-vascularized bone of the femoral head and acetabulum are in apposition, maximizing the cancellous bone surfaces in contact, using rigid internal fixation, and when necessary, augmenting fusion with an iliac crest bone graft or a vascularized muscle pedicle graft, or both.

Because hip fusion today is most commonly performed in young adults and the incidence of subsequent low back pain seems to be significant, the need for conversion to total hip arthroplasty once the patient is older than 60 years of age is quite high. For that reason, use a technique that preserves the function of the hip abductor muscles as well as other important motors about the hip.

Last, by using rigid internal fixation in the presence of good quality bone, it should be possible to avoid any external immobilization. It is wise to have patients use crutches until the fusion is solid but the lack of an orthosis or spica cast enables them to rehabilitate quickly and keep unaffected joints and muscles in good condition.

The following techniques and modifications meet these criteria.

### CABANELA AND PAGNANO HIP ARTHRODESIS

In the second edition of this book, Cabanela described a simple intra-articular fusion technique combined with internal fixation and postoperative external support with a single spica or mini-spica cast (14,38).

- Position the patient on a fracture table, placing the foot in the foot holder on the traction device for the table.
- Expose the hip joint through a standard Watson-Jones approach (see Chapter 3). Detach the anterior third of the gluteus medius insertion into the greater trochanter to facilitate exposure of the hip.
- Next, externally rotate the hip and flex it to place the capsule on stretch and to relax the femoral nerve and vessels to keep them away from the operative field. Detach the reflected head of the rectus femoris from the joint capsule and separate the psoas from the capsule, if necessary. Place Hohmann retractors superiorly and inferiorly around the capsule to facilitate exposure.
- Incise the anterior capsule in line with the femoral neck, and then perform a sufficiently large anterior capsulectomy that dislocation of the hip anteriorly is possible.
- Have a nonsterile assistant remove the foot from the foot holder and place the leg into a figure-of-four position, which facilitates dislocation of the hip. Complete capsulectomy is sometimes required to mobilize the femoral head and to obtain access to the acetabulum.
- Holding the femoral head out of the way, totally debride the acetabulum down to bleeding cancellous bone. Begin with sharp long curets to remove the cartilage and soft tissue and then ream the acetabulum with a debris retaining reamer (Fig. 106.53).

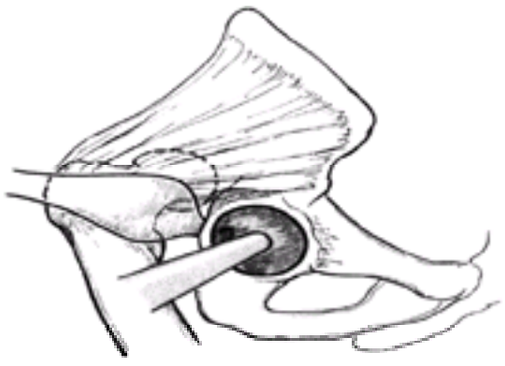

***Figure 106.53.*** Dislocate the hip and ream the acetabulum with debris-retaining reamers.

- Next clean the femoral head of soft tissue and cartilage with curets and ream it into a spherical shape down to bleeding cancellous bone using spherical female reamers, such as those used in surface replacement (Fig. 106.54). Using reamers with similar diameters on the acetabulum and femoral head ensures a more congruous fit.

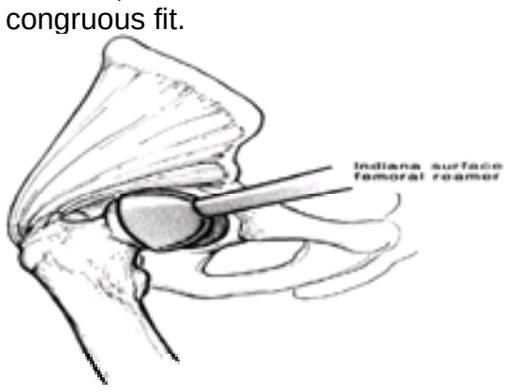


***Figure 106.54.*** Debride the femoral head down to bleeding cancellous bone using a surface replacement femoral reamer of a size similar to that of the acetabulum.

- Now reduce the femoral head into the acetabulum, place the foot back into the foot holder on the fracture table, and place the hip in 20° of flexion, neutral abduction, and slight external rotation (0° to 10°).
- Verify the correct position with AP and lateral radiographs. The width of field available on the typical fluoroscope is usually inadequate to judge alignment, so use large radiographic plates. Proper flexion can be maintained by using appropriate table attachments or by placing a crutch beneath the distal thigh to prop the hip into flexion.
- The fit of the femoral head into the acetabulum is usually somewhat loose; therefore, pack any available space with cancellous bone chips acquired from the reamings.
- Ensure that the hip is in proper position and internally fix the proximal femur to the acetabulum with a compression hip screw, using a side plate of 135° to 140° with three to four screws in the side plate.
- The technique for inserting the hip screw is identical to that for standard hip fracture fixation except that the guide pin is inserted across the hip joint into the superior medial bone of the acetabulum and the compression screw is placed into the solid bone in the acetabulum. Fix the side plate to the femur and then use the compression screw of the device to apply compression across the joint.
- Insertion of two 6.5 mm cancellous bone screws around the hip screw supplements and improves the fixation.
- Ensure hemostasis, place a drain at the level of bone, and close the wound in layers in the usual accepted fashion.
- Apply a sterile dressing and then place the hip into a single hip spica while on the fracture table.

***Postoperative Care***

- When the patient is comfortable, which is usually by the second or third postoperative day, have physical therapy stand the patient at bedside and begin walking with assistive devices supporting the weight of the limb on the floor but allowing no weight bearing.
- Before hospital discharge, it is usually wise to change the spica cast because this gives surgeon the opportunity to check the wound, remove staples or sutures, apply adhesive wound closures if appropriate, and apply a much more snug, better fitting cast.
- The home environment requires an overhead frame with a trapeze attached to either a regular or a hospital bed for 3 months.
- At 8 to 12 weeks after surgery, remove the spica cast and obtain radiographs to verify maintenance of position and to check healing. If healing is progressing satisfactorily, at that time, apply a pantaloon type of mini-spica cast, leaving the extremity free from the knee distally.
- Then progress weight bearing with crutches and remove the cast at 12 to 14 weeks if the fusion is consolidated on radiographs. If there is any question, continue a pantaloon spica cast or hip orthosis until union is solid.
- Most patients require 5 to 6 months before unlimited weight bearing is possible. Manual laborers will require 10 to 12 months before they are able to return to work.

**BENAROCH INTRA-ARTICULAR ARTHRODESIS**

Benaroch and associates (8) described a simple method of hip arthrodesis for use in adolescent patients.

- Approach the hip through an anterolateral approach, extending it proximally to expose the inner surface of the ilium immediately superior to the acetabulum.
- Perform an anterior capsulotomy or capsulectomy, dislocate the hip, and denude the femoral head and acetabulum as described earlier for the Cabanela fusion.
- Reduce the hip and place the extremity in appropriate position for the fusion. Internally fix the femoral head to the acetabulum by inserting two 6.5 mm cancellous screws with washers from the inner surface of the ilium across the hip joint into the femoral head.
- Before tightening the screws to compress the femoral head into the acetabulum, perform a subtrochanteric osteotomy.
- Postoperative management is similar to that described earlier.

Using this technique, Benaroch and associates obtained solid fusion in 11 of 13 patients. The two patients with nonunions had good stability and only mild symptoms.

**ARTHRODESIS WITH A MUSCLE PEDICLE BONE GRAFT**

Davis (19,20) first described in 1954 the use of a muscle pedicle bone graft in fusion of the hip. The difficulty with his technique is that it transfers the origins of the tensor fascia lata and the anterior fibers of the gluteus medius and minimus, which can significantly interfere with the function of the hip if later conversion to a total hip arthroplasty were required. To preserve the function of the abductors, Ranawat et al. in 1971 (39) described the use of the anterior ilium containing the origins of the sartorius and rectus femoris as a muscle pedicle bone graft. If a muscle pedicle bone graft is needed to ensure healing of a hip fusion, this is now my preferred technique.

***Modified Ranawat Technique***

- Position the patient in the lateral decubitus position on a fracture table supporting the trunk, pelvis, and lower extremity in the appropriate position.
- Expose the hip, anterior pelvis, and proximal femoral shaft through a modified Smith-Petersen approach. Expose the inner table of the ilium, iliac crest, the anterosuperior and anteroinferior iliac spines, and the pubic portion of the acetabular rim. Leave the sartorius and rectus femoris origins intact.
- Next harvest the muscle pedicle bone graft from the anterior ilium, including the origins of the sartorius and rectus femoris muscles, as illustrated in Figure 106.55. Although Ranawat et al. described harvesting the pedicle bone graft with osteotomes, I prefer an oscillating saw because it minimizes the risk of fracture of either the graft or the ilium. With the oscillating saw, transect the ilium 4 cm medial to the anterosuperior iliac spine (ASIS) and cut inferiorly parallel to the anterior border of the ilium to enter the acetabulum and then exit anteriorly, including the anteroinferior iliac spine (AIIS). Reflect the graft inferiorly and away from the hip joint to avoid injury to the origins of the hip abductor muscles.

***Figure 106.55.*** Muscle pedicle bone graft for hip arthrodesis. Remove a 3 to 4 cm wide portion of the anterior ilium as illustrated, with the origins of the rectus femoris and sartorius attached. Spare the origins of the gluteus medius, minimus, and tensor fascia lata. Make a 1.5 cm wide × 1.5 cm deep trough in the anterosuperior aspects of the acetabulum, femoral head, and femoral neck, which will receive the graft.

- Place the pedicle bone graft in a moist sponge and retract it laterally to expose the hip joint.
- Dislocate the hip and prepare it for fusion, as described for the Cabanela technique. Ranawat et al. do not recommend dislocation when the patient's hip is extremely stiff preoperatively. In that situation, they rely entirely on the internal fixation and muscle pedicle bone graft to secure union.
- The authors describe fixation of the femoral head to the acetabulum with Knowles pins or a Smith-Peterson nail, followed by a subtrochanteric osteotomy of the femur, when indicated. Most surgeons today would probably use a compression hip screw for fixation, as described in the Cabanela technique and would probably not perform a subtrochanteric osteotomy.
- With osteotomes or an oscillating saw, make a slot from the anterior acetabulum across the hip joint through the femoral head and into the femoral neck, which is 1.5 cm deep and wide (Fig. 106-55).
- Insert the muscle pedicle bone graft into this slot, with the rectus femoris origin distally near the intertrochanteric line. This avoids stretching or twisting the vascular pedicle.
- Secure the bone graft to the ilium and to the head of the femur with appropriately sized screws using lag technique to compress the graft into place (Fig. 106.56).

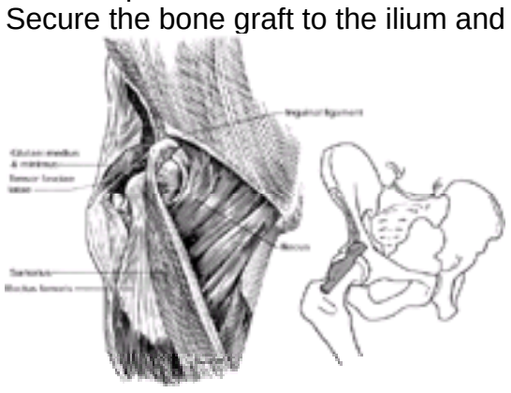

***Figure 106.56.*** Impact the muscle pedicle graft in the trough across the hip joint, with the most inferior portion of the graft at the intertrochanteric line. Fix it into position with an interfragmentary compression screw using lag technique in both the ilium and femur (not illustrated).

- Close the wound over a suction drain, being certain to securely repair the abdominal muscles and the lateral end of the inguinal ligament to the soft-tissue attachments along the iliac wing. Ranawat et al. then applied a one and one-half spica cast.

**Postoperative Care** Ranawat et al. immobilized patients in a one and one-half hip spica cast for 6 weeks, and they modified the cast to allow knee motion at about 6 weeks depending on the stability of the fusion. In their 10 patients, they performed a subtrochanteric osteotomy in five. All but one hip fused in a patient who did not have a subtrochanteric osteotomy, and one subtrochanteric osteotomy went on to nonunion. For a typical case see Figure 106.57.

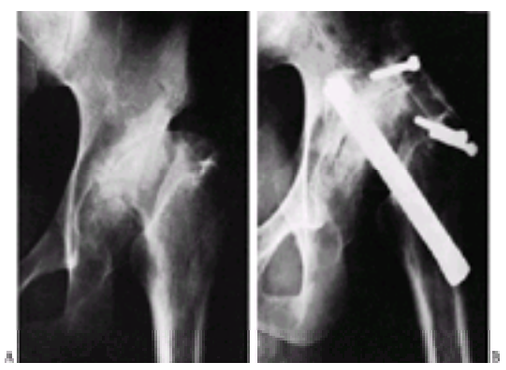

***Figure 106.57.*** Arthrodesis of a hip using the Ranawat muscle pedicle graft. **A:** AP radiograph of the left hip with severe degenerative arthritis due to dysphasia of the hip. **B:** AP radiograph 3 months after arthrodesis. The pedicle bone graft is fixed with one screw in the ilium and two screws in the neck of the femur. Rather than using the Smith-Peterson nail for the arthrodesis as shown in this case, most surgeons today would use a compression hip screw or multiple compression screws. (From Ranawat CS, Jordon LR, Wilson PD Jr. A Technique of Muscle-pedicle Bone Graft in Hip Arthrodesis: A Report of Its Use in Ten Cases. *J Bone Joint Surg* 1971;53A:928, with permission.)

## HIP ARTHRODESIS WITH COBRA-PLATE FIXATION

Although this arthrodesis provides excellent fixation, Schneider's (42) original technique required sacrifice of the abductor mechanism. Murrell and Fitch (37) have modified Schneider's technique to preserve the function of the hip abductors in the event later conversion to total hip arthroplasty becomes necessary. The primary disadvantage of this technique and any technique that uses a plate for fixation is that the end of the plate becomes a stress riser below the stiff hip and the potential site for fracture in the event of significant trauma.

### *Murrell and Fitch Technique*

- Position the patient supine on a radiolucent operating table with a bump under the ipsilateral buttock. The authors prepare and drape both lower extremities, including the pelvis, because this method permits better assessment of leg lengths and allows a Thomas test to be performed to verify the amount of flexion in the arthrodesis after temporary fixation. Make a mid-lateral longitudinal incision beginning 3 to 4 cm distal to the iliac crest extending directly over the prominence of the greater trochanter to a point 8 cm distal to the tip of the greater trochanter.
- Incise the fascia lata in line with a skin incision and place a Charnley retractor. Identify the sciatic nerve and protect it throughout the procedure.
- Reflect the vastus lateralis off the lateral intermuscular septum and release its origin and elevate it medially to expose enough shaft of the femur for application of the cobra plate. Delineate the anterior and posterior margins of the gluteus medius and minimus insertions.
- With an oscillating saw, osteotomize the greater trochanter, as illustrated in Figure 106.58*A*. Reflect the trochanter and attached hip abductors superiorly off the joint capsule and hold them with two large Steinmann pins inserted into the iliac wing (Fig. 106.58*B*).

***Figure 106.58.*** Murrell and Fitch modification of the AO cobra-plate arthrodesis of the hip. **A:** After exposure of the hip and proximal femur, osteotomize the greater trochanter, preserving the attachments of the hip abductors to the trochanter. **B:** Reflect the greater trochanter and attached gluteus medius and minimus superiorly, exposing the supra-acetabular area by subperiosteal dissection. Maintain the retraction of the greater trochanter with two Steinmann pins inserted into the ilium. Expose the lateral acetabulum from the sciatic notch posteriorly to the iliopectineal imminence anteriorly and place two blunt Hohmann retractors to protect the soft tissues anteriorly and the sciatic nerve and gluteus vessels posteriorly. The line of the osteotomy through the ilium is illustrated. **C:** Displace the distal acetabular fragment and femoral head medially, approximately the width of the ilium at the site of the osteotomy, and temporarily fix a nine-hole cobra plate to the lateral aspect of the ilium, just above the osteotomy, and to the shaft of the femur, using the AO tensioner. Apply compression after the desired position of the hip has been obtained. **D:** Complete the fixation by securing the cobra plate to the ilium with six screws and to the neck and the shaft of the femur distally with six screws. Reattach the greater trochanter in an anatomic position with a screw and washer. (Washer is not shown). **E:** Lateral view of the fixation. (From Murrell GA, Fitch RD. Hip Fusion in Young Adults, Using a Medial Displacement Osteotomy and Cobra Plate. *Clin Orthop* 1994;300;147, with permission.)

- Complete the exposure with a capsulotomy of the hip. The hip capsule can be excised as necessary to gain exposure. Elevate the periosteum off the outer table of the iliac wing to the sciatic notch posteriorly and to the ASIS and AIIS anteriorly. Place blunt Hohmann retractors in the sciatic notch to protect the sciatic nerve and superior gluteal vessels and a second retractor anteriorly over the iliopectineal eminence.
- With an oscillating saw, make a transverse osteotomy of the ilium from lateral to medial, extending from the iliopectineal eminence to the sciatic notch at the superior edge of the acetabulum, taking an 0.5 cm wafer of bone from the superior pole of the femoral head. Do not cut completely through the ilium with the oscillating saw, but complete the osteotomy with an osteotome to avoid cutting intrapelvic neurovascular structures.
- Remove cartilage and sclerotic cortical bone down to bleeding cancellous bone from the acetabulum and the superior half of the femoral head using curets and osteotomes.
- Reduce the femoral head into the acetabulum, and displace the femur and the distal portion of the acetabulum medially for a distance equal to the full thickness of the ilium at the osteotomy. Facilitate this procedure by placing a curved blunt instrument such as Hohmann retractor into the osteotomy to level the distal pelvis distally.
- Temporarily secure the cobra-plate with one screw in the proximal fragment and the compression screw in the femur, as illustrated in Figure 106-58*C*.
- To confirm proper position of the hip fusion, remove the bump under the hip and insert Steinmann pins into the right and left ASIS. Or simply palpate the ASISs to be certain that the limb is positioned into neutral abduction or adduction. Determine the position of rotation, which should be 0° to 10° by noting the position of the patella and malleoli relative to the ASIS. With the patient lying flat on the table, the hip will normally be in approximately 20° flexion. This can be confirmed with a radiograph. Before completing the fixation, take AP and lateral radiographs, including the entire pelvis on the AP view, to confirm position. Use a Thomas test to be certain that the position of the hip in flexion on the operated side is correct.
- Once you are certain that the position is good, compress the hip with the AO tensioner and secure the plate to the ilium above and femur below by filling the remaining screw holes with bicortical 4.5 mm cortical screws. Secure the greater trochanter in anatomic position, as seen in Figure 106.58*D* and Figure 106.58*E* by drilling a hole through the middle of the trochanteric fragment and securing it back into position using a screw and washer inserted through the appropriate hole in the cobra plate. Pack cortical cancellous bone obtained from the debridement of the hip around the hip joint and take final radiographs to verify the position of the fusion and fixation.
- Thoroughly irrigate the wound, place drains, and perform a layered closure.

***Postoperative Care***

- Encourage patients to be out of bed and bear partial weight as soon as they are comfortable and no later than the second or third day after surgery.
- Continue partial weight bearing to the weight of the limb with two crutches for 6 weeks. Early motion and gentle muscle rehabilitation can begin for unaffected joints.
- Radiograph the hip at 6 weeks and then at 6-week intervals until solid union is evident, which is usually around 12 to 14 weeks postoperatively. At that time, progress the patient to full weight bearing as tolerated.

Murrell and Fitch reported on the results in eight patients operated on at an average of age 17 years with a follow-up interval from 1 to 4.5 years. All eight hips went on to union, with no significant complications. The mean preoperative Harris hip score was 45 points, and the average at follow-up was 84 points. The average shortening of the operated limb was 2.6 cm, with a range of 0 to 4.7 cm. A typical patient is seen in Figure 106.59.

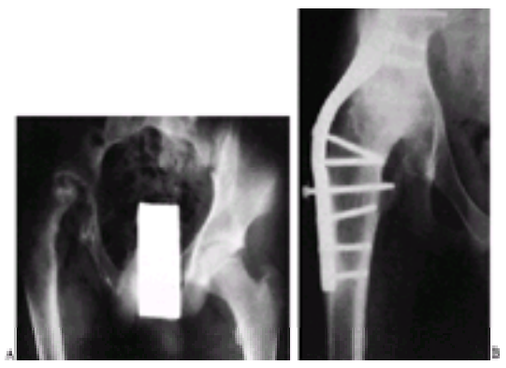

***Figure 106.59.*** **A:** Preoperative radiograph of a 13-year-old boy with a severely painful, stiff, adducted hip and leg length discrepancy of 4 cm, secondary to slipped capital femoral epiphysis (SCFE) with avascular necrosis of the femoral head. **B:** AP radiograph showing solid fusion of the hip. The patient had a 7 cm leg-length discrepancy, which was equalized with Ilizarov femoral lengthening. (From Murrell GA, Fitch RD. Hip Fusion in Young Adults, Using a Medial Displacement Osteotomy and Cobra Plate. *Clin Orthop* 1994;300:151, with permission.)

**ARTHRODESIS WITH AN ANTERIOR PLATE**

In spite of the modification of Murrell and Fitch of the cobra-plate arthrodesis of the hip, the pelvic osteotomy and extensive surgery in the abductor mechanism will no doubt compromise eventual function of the abductor mechanism if a total hip arthroplasty is performed. Matta described a technique using anterior plate fixation to avoid any interference with the hip abductors.

***Modified Matta Technique (34)***

- Position the patient supine on a radiolucent operating table.
- Through a Smith-Peterson approach (see Chapter 3) expose the hip joint, proximal femoral shaft, and the inner pelvic brim by taking down the sartorius origin and reflecting it medially with the iliopsoas. Avoid dissection on the outer wall of the ilium in the region of the hip abductors.
- Dislocate the hip anteriorly and prepare it for intra-articular arthrodesis as described for the Cabanela fusion. Relocate the hip, and fix it in appropriate position using multiple 6.5 cancellous screws inserted from the prominence of the greater trochanter up the femoral neck across the hip joint into the acetabulum.
- With an osteotome or oscillating saw, make a slot on the iliopectineal eminence on the anterior border of the acetabulum and partially into the femoral head to accommodate an AO 4.5 mm broad plate. Use a template to delineate the configuration of the anterior aspect of the femur through the slot and up the inner wall

of the ilium along the iliopectinate line. Select a broad plate long enough to obtain at least four bicortical screws of fixation in the ilium above the hip and in the femur below the hip. This will provide three or four holes in the plate for fixation across the hip joint. Bend the plate to fit. It is important to have the slot on the anterior aspect of the pelvis deep enough that extreme bends in the plate are avoided.
- With bicortical 4.5 mm cortical screws, secure the plate to the femur, hip joint, and ilium. In the region of the hip, avoid hitting the screws already in place and run the screws from anterior to posterior in a bicortical fashion, taking care to avoid injury to the sciatic nerve. Superiorly, it is important to have the plate along the iliopectinate line because the pelvis is fairly thick in this area, offering excellent screw purchase. If the plate is positioned more laterally on the wall of the ilium, the bone is sufficiently thin that fixation will not be secure.
- Close the wound over drains and treat the patient postoperatively as described earlier for the cobra-plate arthrodesis.

Brien et al. (11) performed anterior compression plate arthrodesis in 16 patients followed for an average of 4.5 years after surgery. Of 11 patients undergoing primary fusion, five (45%) did not heal. More important, five patients undergoing repeat fusion for a previously failed surgical arthrodesis did not heal. They concluded that anterior plate fixation alone was inadequate in patients with limited bone stock, and I would agree. The anterior plate must be combined with intra-articular arthrodesis and intra-articular compression fixation at right angles to the plate to obtain sufficient stability. It can be combined with cobra-plate fusion for arthrodeses in the absence of the femoral head, as described below.

### ARTHRODESIS OF THE HIP IN THE ABSENCE OF THE FEMORAL HEAD

In the early part of the twentieth century, the most common cause of loss of the femoral head and bone stock around the hip was destruction due to infection. Neglected nonunion of the femoral neck in conjunction with osteonecrosis of the femoral head can also result in substantial bone loss. Today, the most common cause of loss of the femoral head and bone stock is failure of total hip arthroplasty.

Abbott et al. (1,2,3) described arthrodesis of the hip in wide abduction, placing the proximal femur into the acetabulum to achieve arthrodesis. Patients were treated in a spica cast in wide abduction, and when the arthrodesis was solid, they performed a subtrochanteric osteotomy with bilateral spica cast immobilization to place the limb in functional position. Because of the staged surgery and prolonged immobilization in a spica cast, I am not aware that this procedure is being performed today.

Bosworth (10) described a method for arthrodesis of the proximal femur to the ischium when the femoral head was absent. Achieving fusion between the femoral shaft and the ischium was challenging owing to limited bone stock and the inability to fix this fusion internally.

Kostuik and Alexander (29,30) described a modification of the cobra-plate technique for arthrodesis after removal of a failed total hip arthroplasty.

#### *Kostuik and Alexander Technique*

- The technique is performed as described earlier for the Murrell and Fitch modification of the cobra-plate arthrodesis with the following modifications:
- After removal of the total hip prosthesis components from the acetabulum and femur insert the remaining proximal femoral shaft into the acetabulum and internally fix it with the cobra-plate. Kostuik and Alexander advocate placing the hip into 5° to 10° of abduction to compensate for the shortening, which in their group averaged 4.6 cm. The only disadvantage of this method is that it forces the patient to walk with a constant pelvic tilt. I believe that fusing the patient in a neutral position and then either using shoe lifts or equalizing the leg length with an Ilizarov lengthening or closed intramedullary shortening of the opposite femur, if the patient desires to have leg lengths equalized, is a better choice.
- Next, harvest an iliac crest bone graft and pack it around the arthrodesis site.
- Reattach the greater trochanter. If needed, the trochanter can be fixed across the arthrodesis site to function as a muscle pedicle bone graft.
- Finally, add an AO broad plate anteriorly, as described above for the Matta fusion.

**Postoperative Care** Because the bone stock in these patients is deficient and the bone is often osteoporotic the authors recommend routine use of a hip spica postoperatively. They continued this for an average of 3.3 months, at which time it was discontinued and the patient was then gradually progressed to full weight-bearing using assistive devices. They reported their results in 14 patients. Of these 14 patients, the arthrodesis healed in 13. One nonunion occurred in a patient in whom only the cobra plate was used. With repeat grafting, this nonunion healed. All patients were ambulatory; three used a cane, and nine returned to sedentary work.

## PITFALLS AND COMPLICATIONS

Proper patient selection, careful surgical technique using compression fixation across broad surfaces of bleeding cancellous bone, combined with adjunctive fixation and muscle pedicle bone graft in difficult cases, and protecting the fusion as necessary postoperatively will minimize the occurrence of complications (18). Use prophylactic antibiotics routinely. In most cases, previous surgery will have been performed, which increases the incidence of infection somewhat. In these cases, do not administer antibiotics until deep cultures of the bone and soft tissues in the hip are taken and then institute intraoperative antibiotics. If cultures are positive, treat the patient with the appropriate antibiotics for 6 weeks postoperatively. Prophylaxis against thromboembolic problems is indicated. Nonunion rates of 10% to 35% occurred with older techniques (9,16,44,46). However, modern techniques of arthrodesis, even after failed arthroplasty, have reduced the nonunion rate to 0 to 7% (15,21,28,29,30,37,38,41,47). Malunion is rare today if internal fixation is used (22). The challenge is determining the position of the hip intraoperatively. I find that using a fully radiolucent operating table and positioning the patients supine enhances the changes of obtaining optimal position for the arthrodesis. The double bean bag technique of Blasier and Holmes (9) can be adopted for the supine position.

## RESULTS

Long-term follow-up of patients with hip arthrodesis shows a high incidence of patient satisfaction of 70% after 30 years' follow-up (15,43). There is little question that the average patient with severe disabling pain and instability of a hip has improved function after a hip arthrodesis. Murrell and Fitch (37) showed an improvement in the Harris hip score from 45 points to 84 points in their eight patients. Roberts and Fetto (41), with 8.5 years of average follow-up in 10 young patients, showed 70% with good or very good pain relief and 90% with good or excellent functional results. However, longer term follow-up shows that most patients develop symptomatic low back pain and ipsilateral knee pain, which can impair function. This problem can be minimized by achieving ideal position of the hip fusion. However, in our aging population, these problems will lead to an increasing incidence of conversion of hip arthrodesis to total hip arthroplasty. Therefore, techniques that preserve the anatomic relationships of the hip and protect the abductor mechanism are important (7,8).

## CONVERSION OF HIP ARTHODESIS TO TOTAL HIP ARTHROPLASTY

As mentioned earlier, conversion of a hip arthrodesis to total hip arthroplasty is usually indicated for disabling low back or ipsilateral knee pain that is not responsive to nonoperative treatment. Malposition of an arthrodesis that aggravates these problems is also an indication for THP if an osteotomy to correct the position is not appropriate. Kreder et al. (31) reported on 40 patients who had an arthrodesis converted to a hip replacement. These patients had a 10% rate of infection and 10% incidence of revision. Five percent had the prosthesis removed and went on to resection arthroplasty owing to infection within 4 years of the conversion. These results point out that there is a high rate of complications associated with conversion of a hip arthrodesis to arthroplasty. Patients must be aware of these potential problems before undergoing conversion. Kilgus et al. (27) described conversion of 41 fused hips in 38 patients to a total hip replacement, with an average follow-up of 7 years. The postoperative arc of flexion averaged 87° and LLD averaged 2.5 cm. They noted that hip abductor muscle strength improved for at least 2 years after arthroplasty. The majority of patients experienced complete or significant relief of pain, improved mobility of the hip, and decreased dependence on walking aids. In the 41 hips, there were nine failures—four because of sepsis, four because of loosening, and one because of malposition of the acetabular component. Survivorship analysis of the prosthesis predicted a probability of survival of the implant of 96% at 13 years postoperatively. Rittmester et al. (40) addressed the issue of total knee replacement for arthritis below a total hip arthroplasty. Their data suggested that a knee replacement alone in a patient with a fused hip is not likely to provide a satisfactory outcome. They recommended conversion of the hip fusion to a total hip arthroplasty, followed by total knee replacement. The details of conversion of hip arthrodesis to a total arthroplasty are discussed in the first section of this chapter.

## AUTHOR'S PERSPECTIVE

Orthopaedic surgeons today perform hip arthrodesis infrequently. Only in the practices of adult reconstructive hip surgeons doing large numbers of revision arthroplasties is hip fusion reasonably common. These procedures are large operations that require attention to technical details to ensure a high rate union with good functional position of the hip. I advise all surgeons who perform hip arthrodesis infrequently to not only read a chapter such as this but also return to the original articles quoted earlier to refamiliarize themselves with the important technical details of this challenging operation. Because my practice is predominantly reconstruction after the complications of major trauma, most of the arthrodeses I have performed have been in the presence of pre-existing deformity; loss of bone stock, particularly in the

femoral head and neck; and often after infection. In undertaking fusion under these circumstances, it is important to avoid the complication of infection by resolving any infection preoperatively and avoiding arthrodesis until there has been an infection-free interval of at least 1 year. Second, take deep cultures of bone and soft tissues, and treat the patient prophylactically with antibiotics until cultures return negative. If cultures are positive, treat the patient with 6 weeks of appropriate intravenous antibiotics.

To obtain optimal position of the hip, I prefer to place the patient supine, modifying the double bean bag technique (9) to ensure perfect position of the hip arthrodesis in neutral abduction, 20° of flexion, and slight external rotation before prepping the hip. I confirm this with radiographs before the skin incision. I find this much easier to do before prepping and draping the patient, and the double bean bag ensures that the position is maintained at the time of internal fixation.

For the arthrodesis itself, I frequently combine techniques. When there is loss of bone substance, I perform an intra-articular fusion with compression screw fixation across the hip joint combined with an anterior plate, or I will use the modified double plate–cobra plate method described by Kostuik and Alexander (30). To this I will add the anterior iliac crest muscle pedicle bone graft (39). I have not used a postoperative spica cast in adults for 20 years because I can usually obtain sufficiently stable fixation that external immobilization is not necessary.

## CHAPTER REFERENCES

Each reference is categorized according to the following scheme: *, classic article; #, review article; !, basic research article; and +, clinical results/outcome study.


+ 1. Amstutz HC, Ma SM, Jinnah RH, Mai L. Revision of Aseptic Loose Total Hip Arthroplasties. *Clin Orthop* 1982;170:21.

+ 2. Anonymous Vital and Health Statistics: National Hospital Discharge Survey—Annual Summary, 1990. 112:1992 (Abstract).

# 3. Arabindi R, Barba M, Solomon MI. Bypass Fixation. *Orthop Clin North Am* 1998;29:2.

+ 4. Barrack RL. Harris WH. The Value of Aspiration of the Hip Joint Before Revision Total Hip Arthroplasty. *J Bone Joint Surg Am* 1993;75:66.

+ 5. Berry DJ, Harmsen S, Ilstrup D, et al. Survivorship of Uncemented Proximally Porous-coated Femoral Components. *Clin Orthop* 1995;319:168.

+ 6. Berry DJ, Muller ME. Revision Arthroplasty Using an Anti-protrusio Cage for Massive Acetabular Bone Deficiency. *J Bone Joint Surg* 1992;74B:711.

+ 7. Bobyn JD, Jacobs JJ, Tanzer M, et al. The Susceptibility of Smooth Implant Surfaces to Periimplant Fibrosis and Migration of Polyetheylene Wear Debris. *Clin Orthop* 1995;311:21.

# 8. Brady OH, Masri BA, Garbuz DS, Duncan CP. Use of Reconstruction Rings for the Management of Acetabular Bone Loss during Revision Hip Surgery. *Journal of the American Academy of Orthopaedic Surgeons* 1999;7:1.

+ 9. Callaghan JJ, Salvati EA, Pellici PM, et al. Results of Revision for Mechanical Failure after Cemented Total Hip Replacement, 1979 to 1982. A 2 to 5 Year Follow-up. *J Bone Joint Surg* 1985:67A:1074.

# 10. Cameron HU. Revision of the Femoral Component: Modularity. In: Callaghan JJ, Rosenberg AG, Rubash HE, ed. *The Adult Hip.* Philadephia: Lippincott-Raven Publishers, 1998:1479.

# 11. Cameron H. Modified Cups. *Orthop Clin North Am* 1998;28:2.

+ 12. Canner GC, Stienberg ME, Heppenstall RB, Balderston R. The Infected Hip after Total Hip Arthroplasty. *J Bone Joint Surg* 1984;66A:1393.

* 13. Charnley J. Arthroplasty of the Hip: A New Operation. *Lancet* 1961;2:129.

+ 14. Chimento GF, Finger S, Barrack RL. Gram Stain Detection of Infection During Revision Arthroplasty. *J Bone Joint Surg* 1996;78B:838.

# 15. Covey DC, Albright JA. Current Concepts Review. Clinical Significance of the Erythrocyte Sedimentation Rate in Orthopaedic Surgery. *J Bone Joint Surg* 1987;69A:148.

+ 16. D'Antonio JA, McCarthy JC, Bargar WL, et al. Classification of Femoral Abnormalities in Total Hip Arthroplasty. *Clin Orthop* 1993;296:133.

# 17. D'Antonio JA, Capello WN, Borden LS, et al. Classifcation and Management of Acetabular Abnormalities in Total Hip Arthroplasty. *Clin Orthop* 1989;243:126.

! 18. Doehring TC, Rubash HE, Shelley FJ, et al. Effect of Superior and Superolateral Relocations of the Hip Center on Hip Joint Forces: An Experimental and Analytical Analysis. *J Arthroplasty* 1996;11:693.

+ 19. Dohmae Y, Bechtold JE, Sherman RE. Reduction in Cement Bone Interface Shear Strength Between Primary and Revision Artrhoplasty. *Clin Orthop* 1988;236:214.

+ 20. Edwards BN, Tullos HS, Nobel PC. Contributory Factors and Etiology of Sciatic Nerve Palsy in Total Hip Arthroplasty. *Clin Orthop* 1987;136:218.

+ 21. Eftekhar NS. Dislocation and Instability Complicating Low Friction Arthroplasty of the Hip Joint. *Clin Orthop* 1976;121:120.

+ 22. Elting JJ, Mikhail WE, Zicat BA, et al. Preliminary Report of Impaction Grfating for Exchange Femoral Artroplasty. *Clin Orthop* 1995;319:159.

+ 23. Emerson RH, Head WC, Berklacich FM, Malinin T. Noncemented Acetabular Revision Arthroplasty Using Allograft Bone. *Clin Orthop* 1989:249:30.

+ 24. Engh CA, Bobyn JD, Glassman AH. Porous Coated Hip Replacement: The Factors Governing Bone Ingrowth, Stress Shielding, and Clinical Results. *J Bone Joint Surg* 1987;69B:45.

+ 25. Evans BG, Cuckler JM. Evaluation of the Painful Total Hip Arthroplasty. *Orthop Clin North Am* 1992;23:303.

+ 26. Faris PM, Ritter MA, Abels RI. The Effects of Recombinant Human Erythropoetin on Perioperative Transfusion Requirements in Patients Having a Major Orthopaedic Operation. *J Bone Joint Surg* 1996;78A:62.

+ 27. Fehring TK, McAlister JA Jr. Frozen Histologic Section as a Guide to Sepsis in Revison Joint Arthroplasty. *Clin Orthop* 1994;304:229.

+ 28. Feldman DS, Lonner JH, Desai P, Zuckerman JD. The Role of Intraoperative Frozen Sections in Revision Total Joint Arthroplasty. *J Bone Joint Surg* 1995;77A:1807.

# 29. Fitzgerald RH. Infected Total Hip Arthroplasty: Diagnosis and Treatment. *Journal of the American Academy Orthopaedic Surgeons* 1995;3:249.

# 30. Garbuz DS, Masri BA, Czitrom AA. Biology of Allografting. *Orthop Clin North Am* 1998;28:2.

# 31. Garbuz DS, Penner MJ. Role and Results of Segmental Allografts for Acetabular Segmental Bone Deficiency. *Orthop Clin North Am* 1998;28:2.

+ 32. Garvin K, Hanssen A. Infection after Total Hip Arthroplasty. *J Bone Joint Surg Am* 1995;77:1576.

+ 33. Gie GA, Linder L, Ling RSM, et al. Impacted Cancellous Allografts and Cement for Revision Total Hip Arthroplasty. *J Bone Joint Surg* 1993;75B:14.

+ 34. Gill PS, Nourbash PS, Paprosky WG. *A Comparison of Hylamer and Enduron Polyethyene Liners.* Poster Presentation at the Meeting of the American Academy of Orthopaedic surgeons, Anaheim, CA, 1999.

+ 35. Goetz DD, Capello WN, Callaghan JJ, et al. Salvage of a Recurrently Dislocating Total Hip Prosthesis with Use of a Constrained Acetabular Component: A Retrospective Analysis of Fifty-six Cases. *J Bone Joint Surg Am* 1998;80:502.

+ 36. Goldberg MA, McCutchen JW, Jove MD, et al. A Safety and Efficacy Comparison Study of Two Dosing Regimens of Epoetin Alfa in Patients Undergoing Major Orthopaedic Surgery. *Am J Orthop* 1996;25:544.

+ 37. Gould ES, Pollev HG, Boben SE. Role of Routine Percutaneous Hip Aspirations Prior to Prosthesis Revision. *Skeletal Radiol* 1990;19:427.

# 38. Gross AE, Hutchison CR. Proximal Femoral Allografts for Reconstruction of Bone Stock in Revision Arthroplasty of the hip. *Orthop Clin North Am* 1998;28:2.

* 39. Hardinge K. The Direct Lateral Approach to the Hip. *J Bone Joint Surg* 1982;64B:17.

* 40. Harris WH. Traumatic Arthritis of the Hip after Dislocation and Acetabular Fractures: Treatment by Mold Arthroplasty. *J Bone Joint Surg* 1969;51A:737.

+ 41. Johanson NA, Pellicci PM, Tsairis P, Salvati EA. Nerve Injury in Total Hip Arthroplasty. *Clin Orthop* 1983;179:214.

+ 42. Katz RP, Callaghan JJ, Sullivan PM, Johnston R. Results of Cemented Femoral Revision Total Hip Arthroplasty Using Improved Cementing Techniques. *Clin Orthop* 1995;319:178.

+ 43. Kavanagh BF, Dewitz MA, Ilstrup DM, et al. Charnley Total Hip Arthroplasty with Cement. *J Bone Joint Surg* 1989;71A:1496.

+ 44. Kavanaugh BF, Ilstrup DM, Fitzgerald RH Jr. Revision Total Hip Arthroplasty. *J Bone Joint Surg* 1985:67A:517.

+ 45. Keith I. Anaesthesia and Blood Loss in Total Hip Replacement. *Anaesthesia* 1977;32:444.

+ 46. Kershaw CJ, Atkins RM, Dodd CAF, Bulstorde CJK. Revision Total Hip Arthroplasty. *J Bone Joint Surg* 1985;67A:517.

+ 47. Khan MA, Brakenbury PH, Reynold IS. Dislocation Following Total Hip Replacement. *J Bone Joint Surg Br* 1981;63:214.

+ 48. Kirkpatrick JA, Callaghan JJ, Vandemark RM, Goldner RD. The Relationship of the Intrapelvic Vasculature to the Acetabulum: Implications in Screw Fixation of the Acetabular Components. *Clin Orthop* 1990;258:183.

+ 49. Krey PR, Bailen DA. Syniovial Fluid Leukocytosis. A Study of Extremes. *Am J Med* 1979;67:436.

+ 50. Krishnamurthy AB, MacDonald SJ, Paprosky WG. 5 to 13 Year Follow-up Study on Cementless Femoral Components in Revision Surgery. *J Arthroplasty* 1997;12:839.

+ 51. Kull LR, Jacobs JJ, Tompkins GS, et al. Primary Cementless Acetabular Reconstruction: Osteolysis and Interface Changes at Seven to Ten Year Follow Up. *Orthop Trans* 1995;19:401.

+ 52. Kunnamo I, Pelkonen P. Routine Analysis of Synovial Fluid Cell Is of Value in the Differential Diagnosis of Arthrititis in Children. *J Rheumatol* 1986;13:1076.

+ 53. Lachiewicz PF, McCaskill B, Ingliss A, et al. Total Hip Arthroplasty in Juvenile Rheumatoid Arthritis. *J Bone Joint Surg Am* 1986;68:502.

+ 54. Laupacis A, Bourne R, Rorabeck C, et al. The Effect of Elective Total Hip Replacement on Health Related Quality of Life. *J Bone Joint Surg Am* 1993;75:1619.

+ 55. Lawrence JM, Engh CA, Macalino GE. Outcome of Revision Hip Arthroplasty Done without cement. *J Bone Joint Surg* 1994;76A:965.

+ 56. Lewallen DG: Neurovascular Injury Associated with Hip Arthroplasty. *J Bone Joint Surg* 1997;79A:70.

+ 57. Lidwell OM, Lowbury EJJ, White W, et al. Effect of Ultraclean Air in Operating Rooms on Deep Sepsis in the Joint after Total Hip or Knee Replacement: A Randomized Study. *Br Med J* 1982;285:10.

+ 58. Lieberman JR, Callaway GH, Salvati EA, et al. Treatment of the Infected Total Hip Arthroplasty with a 2 Stage Reimplantation Protocol. *Clin Orthop* 1994;301:205.

+ 59. Lieberman JR, Geerts WH. Current Concepts Review. Prevention of Venous Thromboembolism after Total Hip and Knee Arthroplasty. *J Bone Joint Surg Am* 1994;76:1239.

+ 60. Lonner JH, Desai P, DiCesare PE, et al. The Reliabilty of Analysis of Intraoperative Frozen Sections for Identifying Active Infection during Revision Hip or Knee Arthroplasty. *J Bone Joint Surg* 1996;78A:1553.

# 61. Lotke P. Controversies Associated with Thromboembolic Disease. In: Steinberg ME, Garino JP, ed. *Revision Total Hip Arthroplasty.* Philadelphia: Lippincott Williams & Wilkins, 1999:457–462.

+ 62. Lyons CW, Berquist TH, Lyons JC, et al. Evaluation of Radiographic Findings in Painful Hip Arthroplasties. *Clin Orthop* 1985;195:239.

+ 63. Malkani AL, Lewallen DG, Cabanela ME, et al. Femoral Component Revision Using an Uncemented, Proximally Coated, Long-stem Prosthesis. *J Arthroplasty* 1996;11:411.

! 64. Maloney WJ, Smith RL, Castro F, Schurman DJ. Fibroblast Response to Metallic Debris In Vitro Enzyme Induction Cell Proliferation and Toxicity. *J Bone Joint Surg Am* 1993;75:835.

+ 65. Maloney WJ, Herzwurm P, Paprosky W, et al. Treatment of Pelvic Osteolysis Associated with a Stable Acetabular Component Inserted without Cement as Part of a Total Hip Replacement. *J Bone Joint Surg Am* 1997;79:1628.

+ 66. McAuley JP, Moore KD, Culpepper WJ 2nd, Engh CA. Total Hip Arthroplasty with Porous Coated Prostheses Fixed without Cement in Patients Who Are Sixty-five Years of Age or Older. J Bone Joint Surg Am 1998;80:1648.

+ 67. Mirra JM, Amstutz HC, Matos M, Gold R. The Pathology of the Joint Tissues and Its Clinical Relevance in Prosthesis Failure. *Clin Orthop* 1976;117:221.

+ 68. Moreland JR, Bernstein ML. Femoral Revision Hip Arthroplasty with Uncemented, Porous Coated Stems. *Clin Orthop* 1995;319:141.

+ 69. Morrey BF. Instability After Total Hip Arthroplasty. *Orthop Clin North Am* 1992;23:237.

+ 70. Morscher EW. Management of the Bone-deficient Hip: Mangement of Acetabular Deficiency. *Orthopedics* 1995;18:859.

+ 71. Mulroy RD Jr, Harris WH. The Effect of Improved Cementing Techniques on Component Loosening in Total Hip Replacement: An 11 Year Radiographic Review. *J Bone Joint Surg* 1990:72B:757.

+ 72. Mulroy WF, Harris WH. Revision Total Hip Arthroplasty with the Use of So-called Second Generation Cementing Techniques for Aseptic Loosening of the Femoral Component. A Fifteen-year Average Follow-up Study. *J Bone Joint Surg* 1996:78A:325.

+ 73. Mulroy WF, Estok DM, Harris WH. Total Hip Arthroplasty with Use of So Called Second Generation Cementing Techniques. *J Bone Joint Surg* 1995;77A:1845.

+ 74. Nachbur B, Meyer RP, Verkkala K, Zurcher R. The Mechanisms of Severe Arterial Injury in Surgery for the Hip Joint. *Clin Orthop* 1979;141:122.

+ 75. Newman MA, Barger WL, Christie MJ, et al. Mulitcenter Study of Acetabular Reconstruction Using an Oblong Cup: 2–7 Year Results. San Francisco: AAOS, 1997.

+ 76. O'Neill DA, Harris WH. Failed Total Hip Replacement: Assessment by Plain Radiographs, Arthrograms, and Aspiration of the Hip Joint. *J Bone Joint Surg* 1984;66A:540.

+ 77. Padgett DE, Silverman A, Schajowicz F, et al. Efficacy of Intraoperative Cultures Obtained during Revision Total Hip Arthroplasty. *J Arthroplasty* 1995;10:420.

+ 78. Paprosky WG, Magnus RE. Principles of Bone Grafting in Revision Total Hip Arthroplasty: Acetabular Technique. *Clin Orthop* 1994;298:147.

+ 79. Paprosky WG, Perona PG, Lawrence JM. Acetabular Defect Classification and Surgical Reconstruction in Revision Arthroplasty. A Six Year Follow-up Evaluation. *J Artrhoplasty* 1994;9:33.

+ 80. Pellegrini VD, Konski AA, Gastel JA, et al. Prevention of Hetertopic Ossification with Irradiation after Total Hip Arthroplasty. *J Bone Joint Surg Am* 1992;74:186.

+ 81. Pellici PM, Wilson PDJ, Sledge CB, et al. Long Term Results of Revision Total Hip Replacement. A Follow-up Report. *J Bone Joint Surg* 1985;67A:513.

+ 82. Pellici PM, Salvati EA, Robinson HJ. Mechanical Failures in Total Hip Replacement Requiring Reoperation. *J Bone Joint Surg* 1979:61A:28.

+ 83. Peters CL, Curtain M, Samuelson KM. Acetabular Revison with the Burch-Schneider Antiprotrusio Cage and Cancellous Allograft Bone. *J Arthroplasty* 1995;10:307.

+ 84. Ranawat CS, Dorr LD, Inglis AE. Total Hip Arthroplasty in Protrusio Acetabuli and Rheumatoid Arthriitis. *J Bone Joint Surg* 1980;62A:1059.

+ 85. Raut VV, Sinery PD, Wroblewski BM. Cemented Revison for Aseptic Acetabular Loosening. *J Bone Joint Surg* 1995;77B:357.

+ 86. Raut VV, Sinery PD, Wroblewski BM. Revision for Aseptic Stem Loosening Using the Cemented Charnley Prosthesis. *J Bone Joint Surg* 1195;77B:23.

+ 87. Salvati EA, Robinson RP, Zeno SM, et al. Infection Rates after 3175 Total Hip and Total Knee Replacements Performed with and without Horizontal Unidirectional Filtered Air-flow Systems. *J Bone Joint Surg Am* 1982;64:525.

+ 88. Schmalzreid TP, Amstutz HC, Dorey FJ. Nerve Palsy Associated with Total Hip Replacment. *J Bone Joint Surg Am* 1991;73:1074.

+ 89. Schmalzried TP, Jasty M, Harris WH. Periprosthetic Bone Loss in Total Hip Arthroplasty: Polyethylene Wear Debris and the Concept of the Effective Joint Space. *J Bone Joint Surg Am* 1992;74:849.

+ 90. Schmidt P, Kjaersgaard-Andersen P, Pedersen NW, et al. The Use of Indomethacin to Prevent the Formation of Heterotopic Bone after Total Hip Arthroplasty: A Randomized Double-blinded Clinical Trial. *J Bone Joint Surg Am* 1988;70:834.

+ 91. Schulte KR, Callaghan JJ, Kelley SS, Johnston RC. The Outcome of Charnley Total Hip Arthroplasty with Cement after a Minimum Twenty Year Follow up. *J Bone Joint Surg Am* 1993;8:961.

+ 92. Sculco TP, Ranawat C. The Use of Spinal Anesthesia for Total Hip Replacement. *J Bone Joint Surg Am* 1975;57:173.

! 93. Shaw JA, Bordner MA, Hamory BH. Efficacy of the Sterishield Filtered Exhaust Helmet in Limiting Bacterial Counts in the Operating Room during Total Joint Arthroplasty. *J Arthroplasty* 1996;11:469.

+ 94. Shoenfield NA, Stuchin SA, Pearl R, Haveson S. The Management of Vascular Injuries Associated with Total Hip Arthroplasty. *J Vasc Surg* 1990;11:549.

+ 95. Tannenbaum DA, Matthews LS, Grady-Barson JC. Infection Around Joint Replacements in Patients Who Have a Renal or Liver Transplantation. *J Bone Joint Surg Am* 1997;79:36.

# 96. Silverton CD, Rosenberg AG, Sheinkopf MB, et al. Revision Total Hip Arthroplasty Using a Cementless Acetabular component: Technique and Results. *Seminars in Arthroplasty* 1995;6:109.

+ 97. Sloof TJ, Buma P, Schreurs BW. Acetabular and Femoral Reconstruction with Impacted Graft and Cement. *Clin Orthop* 1996;324:108.

+ 98. Solheim LF, Hagen R. Remoral and Sciatic Neuropathies after Total Hip Arthroplasty. *Acta Orthop Scand* 1980;51:531.

+ 99. Spangehl MJ, Duncan CP, O'Connoll JX, Masri BA. *Prospective Analysis of Preoperative and Intraoperative Studies for the Diagnosis of Infection in Revision Total Hip Arthroplasties.* Presented at the Meeting of the American Academy of Surgeons, San Francisco, CA, 1997.

+ 100. Spangehl MS, Masri BA, O'Connell JX, Duncan CP. Prospective Analysis of Preoperative and Intraoperative Investigations for the Diagnosis of Infection at the Sites of Two Hundred and Two Revision Total Hip Arthroplasties. *J Bone Joint Surg Am* 1999;81A:672

+ 101. Sutherland CJ, Wilde AH, Borden LS, Marks KE. A Ten Year Follow-up of One Hundered Consecutive Muller Curved Stem Total Hip Replacement Arthroplasties. *J Bone Joint Surg* 1982;64A:970.

+ 102. Tanzer M, Drucker D, Jasty M, et al. Revision of Acetabular Components with an Uncemented Harris Galante Porous Coated Prosthesis. *J Bone Joint Surg* 1992;74A:987.

! 103. Trancik T. The Effect of Piroxicam, Meclofenamate, and Prostaglandin F-2 Alpha on Bone Ingrowth into Porous Coated Implants. *Seminars in Arthroplasty* 1992;3:178.

* 104. Trendelenberg F. *Dtsch Med Wschr* (RSM Translation) 1895;21:21.

+ 105. Turner RH, Capozzi JD, Kim A, et al. Blood Conservation in Major Orthorpedic Surgery. *Clin Orthop* 1990;256:299.

+ 106. Weber K, Callaghan J, Goetz D. Revision of a Failed Cemented Total Hip Prosthesis with Insertion of an Acetabular Component without Cement and a Femoral Component with Cement—A Five to Eight Year Follow-up Study. *J Bone Joint Surg* 1996:78A:982.

* 107. Wislon PD Jr, Amstutz HC, Czerniecki A, et al. Total Hip Replacement with Fixation by Acrylic Cement: A Preliminarty Study of 100 Consecutive McKee-Farar Prosthetic Replacements. *J Bone Joint Surg* 1972;54A:207.

+ 108. Woolson ST, Delaney TJ. Failure of Proximally Porous Coated Femoral Prosthesis in Revision Total Hip Arthroplasty. *J Arthroplasty* 1994;10(Suppl):s22.

+ 109. Woolson ST, Milbauer JP, Bobyn JD, et al. Fatigue Fracture of a Forged Cobalt-chromium Femoral Component Inserted with Cement: A Report of 10 Cases. *J Bone Joint Surg Am* 1997;79:1842.

+ 110. Woolson St, Watt JM. Use of Autologous Blood in Total Hip Replacement. *J Bone Joint Surg* 1991;73A:76.

# 111. Younger AS, Dunwoody I, Duncan CP. Periprosthetic Hip and Knee Fractures: The Scope of the Problem. *Instr Course Lect* 1998;47:251.

## ARTHRODESIS OF THE HIP

* 1. Abbott LC, Fischer FJ. Arthrodesis of the Hip, with Special Reference to the Method of Securing Ankylosis in Massive Destruction of Joint. *Surg Gynecol Obstet* 1931;52:863.

* 2. Abbott LC, Lucas DB. Arthrodesis of the Hip in Wide Abduction. *J Bone Joint Surg Am* 1954;36:1129.

+ 3. Abbott LC, Lucas DB. Arthrodesis of the Hip: A Two-stage Method for Difficult Cases. *Surg Clin North Am* 1956;36:1035.

* 4. Albee FH. Arthritis Deformans of the Hip: A Preliminary Report of a New Operation. *JAMA* 1908;50:1977.

* 5. Albee FH. Extra-articular Arthrodesis of the Hip for Tuberculosis. *Ann Surg* 1929;89:404.

+ 6. Altchek M. Hip Fusion. (Letter.) *Clin Orthop* 1992;282:311.

+ 7. Barnhardt T, Stiehl JB. Hip Fusion in Young Adults. *Orthopaedics* 1996;19:303.

+ 8. Benaroch TE, Richards BS, Haideri N, Smith C. Intermediate Follow-up of a Simple Method of Hip Arthrodesis in Adolescent Patients. *J Pediatr Orthop* 1996;16:30.

+ 9. Blasier RB, Holmes JR. Intraoperative Positioning for Arthrodesis of the Hip with the Double Beanbag Technique. *J Bone Joint Surg Am* 1990;72:766.

* 10. Bosworth DM. Femoro-ischial Transplantation. *J Bone Joint Surg Am* 1942;24:38.

+ 11. Brien WW, Golz RJ, Kuschner SH, et al. Hip Joint Arthrodesis Utilizing Anterior Compression Plate Fixation. *Arthoplasty* 1994;9:171.

* 12. Brittain HA. Ischiofemoral Arthrodesis. *J Bone Joint Surg Br* 1941;29:93.

* 13. Brittain HA. Ischiofemoral Arthrodesis. *J Bone Joint Surg Br* 1948;30:642.

+ 14. Cabanela ME. The Painful Young Adult Hip: Surgical Alternatives. *Perspectives on Orthopaedic Surgery* 1990;1:1.

+ 15. Callaghan JJ, Brand RA, Pedersen DR. Hip Arthrodesis: A Long-term follow-up. *J Bone Joint Surg Am* 1985;67:1328.

+ 16. Carter PJ, Wickstrom J. Arthrodesis of the Hip: An Assessment of Results in 100 Patients. *South Med J* 1971;64:451.

* 17. Charnley J. Stabilization of the Hip by Central Dislocation. In Proceedings of the British Orthopaedic Association. (Abstract.) *J Bone Joint Surg Br* 1955;37:514.

+ 18. Coleman SS. Primary Hip Fusions in Adolescents and Young Adults. *Surgical Rounds for Orthopaedics* 1990:4:67.

* 19. Davis JB. The Muscle Pedicle Bone Graft in Hip Fusion. *J Bone Joint Surg Am* 1954;36:790.

* 20. Davis JB, Fagan TE, Beals RK. Follow-up Notes on Articles Previously Published in the Journal: Muscle-pedicle Bone Graft in Hip Fusion. J Bone Joint Surg Am 1971;53:1645.

+ 21. Endo N, Takahashi HE, Toyama H, et al. Arthrodesis of the Hip Joint Using an External Fixator. *Orthopaedic Science* 1999;4:342.

+ 22. Evrarel J, Jourtoulle P, Roure JL, et al. Les Arthrodèses de Hanche Pour Arthrite Septique: Étude Critique. *Rev Chir Orthop* 1985;71:87.

* 23. Farkas A. A New Operative Treatment of Tuberculosis Coxitis in Children. *J Bone Joint Surg* 1939;21:323.

+ 24. Gore DR, Murray P, Sepic SB, Gardner GM. Walking Patterns of Men with Unilateral Hip Fusion. *J Bone Joint Surg Am* 1975;57:759.

+ 25. Greiss ME, Thomas RJ, Freeman MAR. Sequelae of Arthrodesis of the Hip. *J R Soc Med* 1980;73:497.

* 26. Huesner. Resektion in Einem Fall von Angeborener Hüftluxation. *Zentrabl F Chir* 1884;45.

+ 27. Kilgus DJ, Amstutz HC. Wolgin MA, Dorey FJ. Joint Replacement for Ankylosed Hips. *J Bone Joint Surg Am* 1990;72:45.

+ 28. Klemme WR, James P, Skinner SR. Results of Hip Arthrodesis in Adolescents Using the Cobra-head Plate for Internal Fixation. *Pediatr Orthop* 1998;18:648.

+ 29. Kostuik J, Alexander D. Arthrodesis for Failed Hip Arthroplasty. *Clin Orthop* 1984;188:173.

+ 30. Kostuik J, Alexander D. Arthrodesis of the Hip: Review of 371 Cases. *J Bone Joint Surg Am* 1961;43:923.

+ 31. Kreder HJ, Williams JI, Jaglal S, et al. A Population Study in the Province of Ontario of the Complications after Conversion of Hip or Knee Arthrodesis to Total Joint Replacement. *Can J Surg* 1999;43:433.

* 32. Lipscomb PR, McCaslin FE. Arthrodesis of the Hip: Review of 371 Cases. *J Bone Joint Surg Am* 1961;43:923.

* 33. Maragliano D. Nuovi Punti di Appoggio Chirurgico nelle Lussazione Vere da Coxite. *Chir Organi Mov* 1921;5:225.

+ 34. Matta JM. Hip Joint Arthrodesis Utilizing Anterior Compression Plate Fixation. (Letter/comment.) *J Arthroplasty* 1994;9:665.

+ 35. Müller ME. Arthrodesis of the Hip Using the Cross-plate. in Hip Surgery: Twelve Hip Procedures. *AO Bulletin* Sept. 1967;48.

# 36. Müller ME, Allgöwer M, Schneider R, Willeneggar H. *Manual Internal Fixation,* 3rd ed. New York: Springer-Verlag, 1990.

+ 37. Murrell GA, Fitch RD. Hip Fusion in Young Adults, Using a Medial Displacement Osteotomy and Cobra Plate. *Clin Orthop* 1994;300:147.

# 38. Pagnano MW, Cabanela ME. The Hip: Arthrodesis. In: Morrey BF, ed. *Reconstructive Surgery of the Joints,* ed 2, New York: Churchill Livingstone, 1996.

+ 39. Ranawat CS, Jordan LR, Wilson PD Jr. A Technique of Muscle-pedicle Bone Graft in Hip Arthrodesis: A Report of Its Use in Ten Cases. *J Bone Joint Surg Am* 1971;53:925.

+ 40. Rittmeister M, Starker M, Zichner L. Hip and Knee Replacement after Longstanding Hip Arthrodesis. *Clin Orthop* 2000;371:136.

+ 41. Roberts CS, Fetto JF. Functional Outcome of Hip Fusion in the Young Patient. Follow-up Study of 10 Patients. *Arthroplasty* 1990;5:89.

* 42. Schneider R. Hip Arthrodesis with the Cobra Head Plate and Pelvic Osteotomy. *Reconstr Surg Traumatol* 1974; 14:1.

+ 43. Sponseller RD, McBeath AA, Perpich M. Hip Arthrodesis in Young Patients. A Long-term Follow-up. *J Bone Joint Surg Am* 1984;66:853.

+ 44. Stewart MJ, Coker TP. Arthrodesis of the Hip: A Review of 109 Patients. *Clin Orthop* 1969;1:136.

# 45. Stewart M. Arthrodesis. In: *Campbell's Operative Orthopaedics,* 6th ed. St. Louis: CV Mosby, 1980.

+ 46. Stinchfield FE, Cavallaro WV. Arthrodesis of the Hip Joint: A Follow-up Study. *J Bone Joint Surg Am* 1950;32:48.

+ 47. Strathy GM, Fitzgerald RH. Total Hip Arthroplasty in the Ankylosed Hip. *J Bone Joint Surg Am* 1988;70:963.

+ 48. Tavares JO, Frankovitch KF. Hip Arthrodesis Using the AO Modular External Fixator. *Pediatr Orthop* 1998;18:651.

* 49. Watson-Jones R. Arthrodesis of the Osteoarthritic Hip. *JAMA* 1938;110:278.

* 50. Watson-Jones R, Robinson WC. Arthrodesis of the Osteoarthritic Hip Joint. *J Bone Joint Surg Br* 1956;38:353.

# CHAPTER 107

# OSTEOTOMIES OF THE KNEE FOR OSTEOARTHRITIS

*James C. Karegeannes and Russell E. Windsor*

**J. C. Karegeannes:** Adult Reconstruction Surgery Fellow, Hospital for Special Surgery, New York, NY, 10021.
**R. E. Windsor:** Associate Professor of Surgery, Cornell University Medical College, Chief: Knee Service, Associate Attending Surgeon, Hospital for Special Surgery, New York, NY, 10021.

Introduction
History
Pathophysiology
High Tibial Osteotomy
Indications
Preoperative Planning
Combined Procedures
Operative Procedure
Postoperative Management
Complications
Total Knee Arthroplasty After Proximal Tibial Osteotomy
Alternative Methods of Proximal Tibial Osteotomy
Proximal Tibial Osteotomy for Lateral Compartment Arthritis
Distal Femoral Varus Osteotomy
Pitfalls and Complications
Chapter References

## INTRODUCTION

Osteotomy of the tibia or femur was originally used to address osteoarthritis of the knee. Surgery was performed to shift load bearing from one arthritic tibiofemoral compartment to the other, less affected compartment. Success rates of 65% at 10 years (9) and 63% at 9 years (24) are reported after high tibial osteotomy (HTO) for medial compartment arthritis. Current prosthetic knee arthroplasty techniques have provided successful results in over 93% of patients at 10 years (12). The role of osteotomy has decreased in the face of these outstanding results from joint replacement (50). Prosthetic arthroplasty requires activity modification to protect the implant. The implant also has a finite life span and may require repeated surgery to replace failed devices. Realignment osteotomy is viewed as a way to allow unrestricted patient activity and to delay the time to joint replacement surgery (23,40,42).

## HISTORY

Sir Robert Jones first reported on the use of tibial realignment osteotomy to correct severe genu varum from rickets (47). Jackson (25) was the first to report his experience with femoral and tibial osteotomies to treat osteoarthritis with associated valgus and varus knee alignment. Jackson and Waugh (26) published a more detailed follow-up report. Their greatest success was with tibial osteotomy to correct varus knees. Subsequent reports by Wardle (47), Garièpy (15), and Coventry (5) more clearly defined the indications and techniques of the operation, specifically an osteotomy performed between the tibial tuburcle and the joint line.

## PATHOPHYSIOLOGY

Realignment osteotomies are based on the presumption that excessive force carried across the joint from the abnormal alignment of the limb leads to degeneration within the affected joint compartment (5,26). A cadaveric model has demonstrated that increased contact pressures in the knee accompany increasing varus or valgus alignment of the tibia (33). With time, the excessive pressure leads to breakdown of the cartilage matrix, with loss of the cartilage structural integrity (3). The altered stress may also cause architectural changes in the subchondral bone, further altering the joint geometry (4). In the medial compartment of the knee, for example, once arthritis is established, serial examination reveals clinical and radiographic progression in nearly all cases (39). The goal of realignment osteotomy has been traditionally to alter the vector of forces across the knee, to unload the affected compartment, and thereby to gain relief of pain.

## HIGH TIBIAL OSTEOTOMY

The most commonly performed procedure for medial osteoarthritis is a lateral closing wedge, valgus-producing proximal osteotomy. Valgus malalignment is usually due to lateral femoral condyle undergrowth and is best addressed through distal femoral osteotomy (16).

### INDICATIONS

The main indication for valgus (HTO) is knee pain with isolated medial compartment arthritis on radiographs (1,16,22,24). Also, patients with anterior cruciate ligament insufficiency with medial joint space narrowing will benefit from osteotomy. Osteotomy alone or in conjunction with anterior cruciate ligament reconstruction will help remove the varus forces that are present. The patient will generally report morning stiffness and medial knee pain with weight bearing that is relieved with rest and anti-inflammatory medication. The patient's arthritis should be from a structural cause due to osteoarthritis or posttraumatic arthritis. Knee range of motion should approach 90° of flexion with full extension. Any laxity should be addressed before osteotomy, although a lateral closing wedge osteotomy performed above the tibial tubercle can tighten the medial collateral ligament (16) by creating a valgus force sufficient to cause an opening of the medial joint. Also, performing an open-wedge osteotomy on the medial side will tighten the medial collateral ligament.

The patient's age is a significant factor to consider. Osteotomy is traditionally reserved for patients younger than 65 years of age; however, older patients with high activity levels may be candidates for HTO, whereas younger patients with lower activity levels may be candidates for knee replacement. The decision to operate must be individualized to each patient's circumstance.

The most significant contraindication to valgus-producing osteotomy is symptomatic or radiographic arthritis in one or both of the other joint compartments. Other generally accepted contraindications are varus deformity greater than 15°, flexion contracture greater than 15°, or underlying inflammatory arthritis (1,6,37,42). The procedure, by design, results in valgus alignment of the lower extremity, which may be unacceptable to some patients.

### PREOPERATIVE PLANNING

The patient's history of symptoms should be typical for arthritis. Inspect the affected leg for alignment, fixed knee deformities, range of motion, stability, and the integrity of the skin on the knee. Radiographs of the knees during weight bearing demonstrate the extent of arthritis and loss of joint space. Single standing, full-length radiographs offer the best method to determine limb alignment and to plan the osteotomy (19).

We prefer the method developed at Nara University (14,34) for determining the degree of resection performed with a lateral closing wedge (Fig. 107.1).

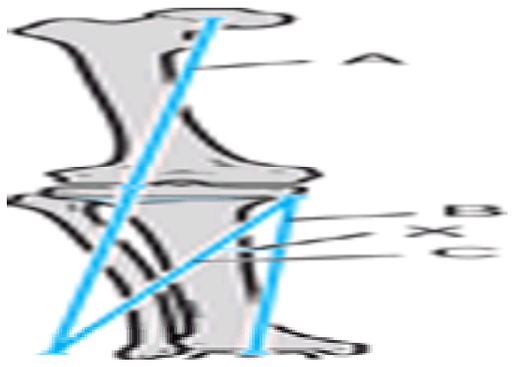


***Figure 107.1.*** Determine the desired angle of correction from standing long-leg films by the method of Miniaci et al. (34). See text for details.

- First, draw the predicted mechanical axis of the affected limb on the full-length radiograph by connecting a point from the center of the hip to a point on the lateral tibial plateau that is one third of the way from the center of the knee to the lateral margin of the lateral plateau (line A). Extend this line to the level of the ankle.
- Make a second line (line B) from the point on the proximal medial tibia that will be the pivot point of the osteotomy to a point in the center of the ankle.
- Draw a third line (line C) from the medial pivot point to a point on the predicted mechanical axis (line A) that is at the level of the ankle. The angle (X) between the second and third lines (lines A and B) is the angle of the wedge to be resected.

The method outlined earlier only addresses deformity in the medial or lateral plane. Paley et al. (40,41) have pointed out that the center of rotation of the deformity, while close to the knee joint, can vary in position from patient to patient. The apex of the osteotomy should fall very close to the point of maximal deformity to avoid the creation of a secondary deformity. The patient may also have an associated rotational or sagittal plane deformity. Procurvatum deformity was the most commonly encountered deformity associated with tibia vara. All of these variations must be recognized during preoperative planning so that they may be corrected at surgery.

### COMBINED PROCEDURES

Coventry (8) suggested that diagnostic arthroscopy be performed in order to examine the lateral and patellofemoral joint spaces before osteotomy. However, Keene and Dyreby (27) demonstrated that lateral compartment involvement noted on arthroscopy does not predict failure of valgus osteotomy. Korn (28) made the same observation in a more recent study. The combination of a valgus-producing osteotomy and the Maquet tibial tubercle elevation procedure for patellofemoral and medial compartment arthritis gives only 50% good or excellent results in short-term follow-up (2,21,44,). The role of prophylactic osteotomy in patients with excessive varus alignment has not been established.

## OPERATIVE PROCEDURE

The technique for the osteotomy depends on the proposed method of fixation. We prefer internal fixation of the osteotomy with an **L** plate and screws, as described by Hofmann et al. (20). When combined with preservation of the medial tibial cortex, this construct provides rigid fixation of the osteotomy, which allows early range of motion of the knee and shorter rehabilitation time (18). There are two osteotomy systems available in North America that use this type of plate. Both also use angular cutting jigs to allow more precise bone cuts.

- Perform surgery under a spinal or epidural block. Position the patient supine and use a tourniquet. Give prophylactic antibiotics before inflation of the tourniquet. A straight anterior midline incision may be used but will need to be extended proximally and distally for adequate exposure of the lateral tibia.
- We prefer an **L**-shaped incision. Begin it laterally at the joint line and extend it parallel to the joint to the midline and then extend it distally along the anterior tibia as necessary. The vertical midline of this incision can be incorporated into an anterior midline approach for total knee arthroplasty.
- Dissect the cephalad anterior compartment muscles at a subperiosteally level off the tibial cortex. Carry the dissection distally only as far as needed to accommodate the plate.
- Once the lateral tibia is exposed, carry the dissection posteriorly to the proximal tibiofibular joint. The tibiofibular joint can be handled in three different ways. The fibular head may be resected and the lateral collateral ligament sutured to the iliotibial band (8). Alternatively, a segment of proximal fibula may be resected (34). Finally, the joint may be disrupted, allowing the fibular head to slide proximally when the osteotomy is closed (20). We prefer the fibular slide because we believe proximal resection compromises lateral stability of the knee and resection of a shaft segment puts the superficial peroneal nerve at risk of injury. To complete the exposure, incise the anterior joint capsule, and place a periosteal elevator into the joint. Use the elevator to disrupt the remaining joint capsule.
- After exposing the tibia, line up the transverse osteotomy jig provided with each system with the articular surface of tibial plateau under fluoroscopic guidance. Once this jig is satisfactorily positioned, place two Steinmann pins across the tibial metaphysis by using the holes in the proximal guide. The Steinmann pins parallel the articular surface and serve as a reference from which all cuts are made. Place a variable-angle drill guide over the proximal pins. The guide directs two distal pins in at the desired angle of the resection (Fig. 107.2). Exchange the variable-angle guide for proximal and distal cutting blocks (Fig. 107.3*A*), and perform cuts with an oscillating saw (Fig. 107.3*B*). The two arms of the osteotomy meet at a point just lateral to the medial cortex.

***Figure 107.2.*** Tibial osteotomy angle cutting jig in place. **B:** Fluoroscopic view of angle cutting jig in place.

***Figure 107.3.*** **A:** Osteotomy cutting blocks in place. **B:** Fluoroscopic view of completed wedge resection.

- Remove the wedge of bone from the tibia (Fig. 107.4*A*). Removing the resection wedge can be difficult if the posterior bone cuts are incomplete. Poor visualization and concern over the safety of posterior soft-tissue structures can result in undercutting this portion of the osteotomy. A hand osteotome can be used to complete the cut, but the osteotome must not plunge beyond the cortex. A curved curet is also useful in removing the bone.

***Figure 107.4.*** **A:** Pins have been removed, and the **L** plate and the proximal cancellous screws have been placed. A ratcheted clamp is in place to close the osteotomy. **B:** Fluoroscopic view of completed osteotomy with fixation plate.

- Once the wedge is removed, close the osteotomy. Apply the **L** plate and hold it with two cancellous screws through the proximal, transverse arm of the plate. Each osteotomy system provides a special ratcheted clamp that attaches to the distal arm of the plate through an empty screw hole, and to the tibial cortex by an additional drill hole or separate pin (Fig. 107.4*A*). Slowly compress the clamp and close the osteotomy. The medial cortex should deform rather than fracture. Integrity of the medial cortex is imperative to maintain stability of the osteotomy. Once the osteotomy is closed, lock the clamp to hold the osteotomy closed and place two or three bicortical screws through the distal arm of the plate (Fig. 107.4*B*).
- Before closing the wound, perform a subcutaneous fascial release of the anterior compartment muscles off the tibial crest. Then reapproximate the muscles to the tibial periosteum by interrupted, absorbable tacking sutures. This covers the plate and osteotomy site. Close the wound in layers over a drain. Apply a soft knee wrap in the operating room.

### POSTOPERATIVE MANAGEMENT

Start continuous passive motion in the recovery room at 0° to 60°, and advance as tolerated to 90°. Administer antibiotics over 24 hours, and remove the drain on the first or second postoperative day. Place the patient in a hinged knee brace and encourage knee range of motion. The brace is worn for 8 to 12 weeks. Allow partial weight bearing and crutch ambulation. Full activity can be resumed once there is radiographic evidence of healing. Early motion helps avoid patella infera (48). We recommend removal of the implant 1 year after surgery.

### COMPLICATIONS

Complications after HTO are relatively uncommon. Early complications include tibial plateau fractures, superficial wound infections, deep venous thrombosis and pulmonary emboli, peroneal nerve palsy, and anterior compartment syndrome (6,19,20,22). Hernigou et al. (19) reported 10 inadvertent plateau fractures followed for 10 years or more. All fractures were treated conservatively, healed uneventfully, and did not seem to affect the results of the surgery. If peroneal nerve palsy develops, rule out compartment syndrome. Catastrophic complications reported in the literature are very rare. Coventry (6) reported one arterial thrombosis leading to limb amputation. The one study that compared results of staple fixation of the osteotomy with those of plate fixation noted a much higher rate of wound infection with the plate fixation (18). Late complications include nonunion, loss of correction, and disease progression in the remaining knee compartments (6,19,22). The method of fixation does not seem to affect the rate of late complications (18).

### TOTAL KNEE ARTHROPLASTY AFTER PROXIMAL TIBIAL OSTEOTOMY

Several groups have reported reliably good results from HTO up to 10 years after surgery (9,19,24,38,45). Failures increase with time owing to progression of arthritis into the remaining joint compartments or recurrence of varus deformity. We advise patients to anticipate 8 to 10 years of pain relief following tibial osteotomy. Failed HTO is best addressed with total knee arthroplasty. Unfortunately, proximal tibia osteotomy can compromise the result of total knee arthroplasty (35,38,49). Nizard et al. (38) compared patients who underwent knee replacement after HTO with a matched group of patients undergoing primary knee replacement. More pain was reported in those who had a previous HTO. Functional scores were similar. Patella baja, lateral soft-tissue scarring, and abnormal proximal tibia anatomy have all been problems in arthroplasty patients who have had an HTO (35,38,49). These results must be considered when advising patients who are considering tibial osteotomy.

## ALTERNATIVE METHODS OF PROXIMAL TIBIAL OSTEOTOMY

Several alternative methods of performing and stabilizing the osteotomy have been proposed. The dome osteotomy, attempts to allow correction with minimal bone loss, and maintenance of tibial length (29,31,). Forming the hemispherical osteotomy can be technically difficult. More extensive exposure of the tibia is needed, and the resulting bone segments can be less stable because all cortices are involved in the osteotomy.

The proximal osteotomy may be angled upward, placing the apex of the wedge proximal and medial, and the lateral segment more distal (23,34). This technique leaves more bone in the proximal segment. The proximal tibiofibular joint is not exposed, and a fibular osteotomy is required to allow compression of the tibial osteotomy.

Puddu et al. (43) has introduced the opening wedge medial osteotomy with the addition of a specialized fixation plate. The defect created is filled with illiac crest bone graft. The osteotomy is then held with a specially designed bone plate. Early results are encouraging. This technique is bone conserving but may place greater loads on the proximal fragment because the bone graft acts like a wedge under the proximal plateau segment.

Another new method uses the Orthofix dynamic external fixator (11,13).

- Apply the fixator pins medially with two cancellous threaded pins in a transverse array proximally and two bicortical pins distally.
- Then perform a medial corticotomy 4 to 5 cm below the tibial plateau without violating the lateral cortex. Apply the fixator and hold the corticotomy closed for 10 days until early callus has formed.
- At 10 days, start distraction at 1 mm a day until the desired correction is obtained. Then lock the frame for 3 to 4 weeks until consolidation occurs. When the lengthening site is stable, unlock the frame to allow compression across the osteotomy site and advance weight bearing. Remove the frame 12 to 14 weeks after application.

This method allows early knee motion and may avoid the extensor mechanism seen with traditional methods of osteotomy fixation. Also, all implants are removed at the completion of treatment. This method may compromise future arthroplasty by introducing bacteria to the bone adjacent to the pins (37). Initial reports of knee replacement after use of the Orthofix fixator have not included any joint infections (10,30). This technique requires close attention to detail and a cooperative patient. Complications include pin track infection, loss of position, delayed consolidation, and nonunions. These can be difficult to treat.

## PROXIMAL TIBIAL OSTEOTOMY FOR LATERAL COMPARTMENT ARTHRITIS

Jackson and Waugh (26) reported poor results with a medial closing wedge tibial osteotomy for lateral compartment arthritis. Coventry (7) also had limited success with this method. Patients did well clinically; however, technical considerations made the surgery less than satisfactory. An excessively large wedge of bone was required for correction beyond 12°. Also, the joint line remained in valgus, potentially complicating future procedures. Supracondylar femoral osteotomy was recommended for correction of larger deformities.

## DISTAL FEMORAL VARUS OSTEOTOMY

Valgus deformity of the knee may lead to arthritis affecting the lateral compartment predominately. The defect is not in the tibial plateau but is caused by hypoplasia of the lateral femoral condyle. Preoperative planning for the supracondylar osteotomy is similar to the tibial osteotomy. Use standing long-leg films of the lower extremities to calculate the degree of valgus deformity. Plan correction to obtain neutral anatomic alignment, although the ideal degree of correction is not well established (32). Both Coventry (8)and Morrey and Edgerton (36) recommend fabrication of a triangular metal plate, with the two long sides reproducing the desired angle of correction as calculated from preoperative films (Fig. 107.5*A*). Sterilize the triangular plate and use it as a template at the time of surgery. Use a 95° blade plate to hold the osteotomy. Staples are not adequate (8,36). The angle of the template must be increased by 5° if a 95° blade plate is to be used.

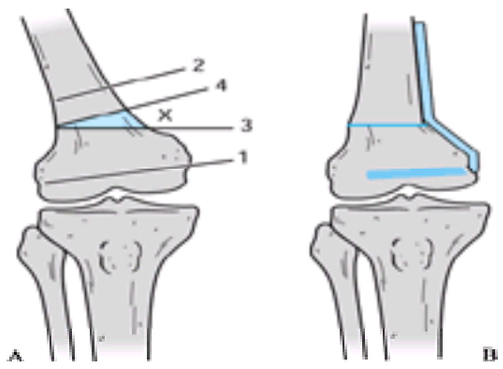


***Figure 107.5.*** **A:** Distal femoral osteotomy by the medial approach. The degree of valgus alignment (X) is calculated from standing long-leg films. Place Steinmann pins in the sequence outlined in the text. The wedge osteotomy is represented by the shaded segment. Undercutting the angle allows impaction of the proximal segment into the distal segment. **B:** Apply the blade plate medially.

Approach the distal femur either medially or laterally. The femoral vessels must be protected if the medial approach is selected. An anterior skin incision can be used; however, most authors prefer to approach the operated side directly. The medial approach with slight variation, has been described by Morrey and Edgerton (36) and by Healy et al. (17) (see also Chapter 3).

- Make a medial longitudinal skin incision 10 cm in length or longer, if needed. Reflect the vastus medialis muscle anteriorly. Expose the femoral cortex from the insertion of the joint capsule to a point sufficiently proximal to accommodate the side plate.
- Under fluoroscopic guidance, drill a guide pin for the blade plate chisel across the femur 2.5 cm proximal to the condyles (107.5A,1). Direct the pin at a gentle angle from anterior to posterior to keep it centered within the condyles. Place a second, proximal Steinmann pin perpendicular to the femoral shaft proximal to the osteotomy site (107.5A,2). Use a third pin to reproduce the desired angle of correction in relation to the perpendicular, proximal pin (Fig. 107.5A,4). Place this pin between the first two pins. The prefabricated angle template can help with proper placement of this pin. It is important to prepare for easy blade plate placement by seating the chisel fully into the condyles before the actual osteotomies are performed.
- Perform the osteotomy with an oscillating saw. Keep the distal side of the osteotomy proximal to the adductor tubercle. Guide the transverse, proximal cut by visually referencing the pin placed perpendicular to the femoral shaft. A fourth pin may be placed coincident with the proximal osteotomy line to act as a guide for the saw (107.5A,3). The angle of the wedge should be kept slightly less than the desired angle of correction. The proximal segment can be impacted into the distal segment to obtain the desired correction. Converge the two osteotomies to a point several millimeters medial to the lateral cortex.
- Before completing the osteotomy, seat the blade plate in the distal fragment. Take care to align the blade plate along the posterior femoral cortex. Use a varus force to close the osteotomy site. The side plate can be used as a lever to assist in closing the osteotomy. An osteotome may be used to perforate the lateral cortex, if needed. Undercutting the angle of the osteotomy allows impaction of the proximal segment into the metaphyseal bone until the desired angle is achieved. After the osteotomy is closed, the blade plate can be further impacted into the distal femoral condyles (107.5B).
- Use three to four bicortical screws to fix the plate to the proximal segment; place one cancellous screw through the plate into the distal segment.
- The lateral approach follows a similar sequence. Make an anterior or direct lateral incision. Use the prefabricated angle template to direct the tip of the blade into the distal femur (Fig. 107.6*A*). Make the osteotomy perpendicular to the shaft, above the adductor tubercle. Seat the blade. As the plate contacts the cortex of the lateral shaft, the proximal segment is impacted onto the distal segment and the correction is obtained (Fig. 107.6*B*).

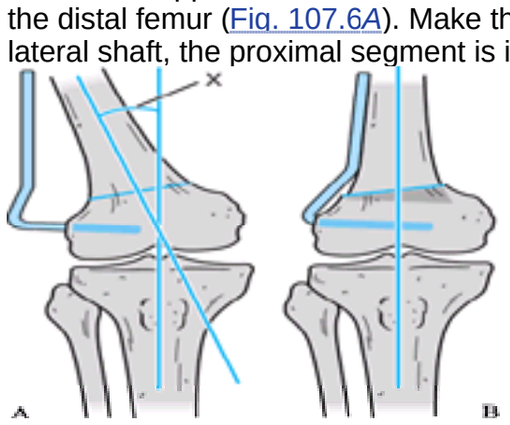


***Figure 107.6.*** **A:** Distal femoral osteotomy by the lateral approach. Insert the tip of the blade into the distal segment, with the plate parallel to the desired final alignment line. Place the prefabricated angle template between the plate and femoral shaft to ensure that the blade is directed at the proper angle. Perform the osteotomy above the adductor tubercle. **B:** Impact the proximal segment into the distal segment because the blade is seated. The plate comes to rest against the cortex shaft.

Start the patient on early motion with protected weight bearing until there is radiographic evidence of healing (Fig. 107.7).

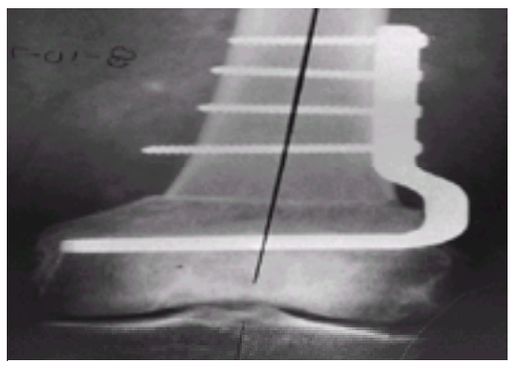

***Figure 107.7.*** Radiograph of healed supracondylar osteotomy.

## PITFALLS AND COMPLICATIONS

The most common complication is nonunion of the osteotomy (17,32,42). Avoid nonunion by ensuring that the osteotomy is rigidly fixed with good impaction of the bone fragments. If residual motion is evident after fixation, consider additional fixation such as an anteroposterior interfragmentary screw or a smaller supplementary plate. Avoid stiffness of the knee by early motion, supervised, if necessary, by a therapist to be certain that the patient regains motion.

### CHAPTER REFERENCES

Each reference is categorized according to the following scheme: *, classic article; #, review article; !, basic research article; and +, clinical results/outcome study.

+ 1. Berman AT, Bosacco SJ, Kirshner S, Avolio A Jr. Factors Influencing Long-term Results of High Tibial Osteotomy. *Clin Orthop* 1991;272:194.

+ 2. Bourguignon RL. Combined Coventry-Marquet Tibial Osteotomy: Preliminary Report of to Cases. *Clin Orthop* 1981;160:144.

! 3. Buckwalter JA, Mankin HJ. Articular Cartilage: Degeneration and Osteoarthritis, Repair, Regeneration, and Transplantation. *Instr Course Lect* 1998;47:487.

# 4. Burr DB. The Importance of Subchondral Bone in Osteoarthrosis. *Curr Opin Rheumatol* 1998;10:256.

* 5. Coventry MB. Osteotomy of the Upper Portion of the Tibia for Degenerative Arthritis of the Knee: A Preliminary Report. *J Bone Joint Surg [Am]* 1965;47:984.

+ 6. Coventry MB. Osteotomy About the Knee for Degenerative and Rheumatoid Arthritis: Indications, Operative Technique, and Results. *J Bone Joint Surg [Am]* 1973;55:23.

+ 7. Coventry MB. Proximal Tibial Varus Osteotomy for Osteoarthritis of the Lateral Compartment of the Knee. *J Bone Joint Surg [Am]* 1987;69:32.

# 8. Coventry MB. Osteotomies About the Knee: Principles of Treatment. In: Chapman MW, ed. *Operative Orthopaedics,* 2nd ed. Philadelphia: J. B. Lippincott Co, 1993.

+ 9. Coventry MB, Ilstrup DM, Wallrichs SL. Proximal Tibial Osteotomy: A Critical Long-term Study of Eighty-seven Cases. *J Bone Joint Surg [Am]* 1993;75:196.

+ 10. Elting JJ. *Total Knee Arthroplasty following Medial Frame Distraction High Tibial Osteotomy.* Paper presented at the annual meeting of the American Academy of Orthopaedic Surgery, Anaheim, February 1999.

+ 11. Elting JJ, Cicoria A, Boman TE. Proximal Tibial Osteotomy and Unilateral Frame Distraction for Osteoarthritis of the Knee. *Suppl Int J Orthop Trauma* 1993;3:89.

+ 12. Font-Rodriguez DE, Scuderi GR, Insall JN. Survivorship of Cemented Total Knee Arthroplasty. *Clin Orthop* 1997;345:70.

+ 13. Fowler JL, Gie GA, MacEachhern AG. Upper Tibial Valgus Osteotomy Using a Dynamic External Fixator. *J Bone Joint Surg [Br]* 1991;73:690.

+ 14. Fujisawa Y, Masuhara K, Shiomi S. The Effect of High Tibial Osteotomy on Osteoarthritis of the Knee. An Arthroscopic Study of 54 Knee Joints. *Orthop Clin North Am* 1979;210:585.

* 15. Garièpy, R. Genu Varum Treated by High Tibial Osteotomy. [Abstract.] *J Bone Joint Surg [Br]* 1964;46:783.

# 16. Grelsamer RP. Unicompartemtnal Osteoarthritis of the Knee. *J Bone Joint Surg [Am]* 1995;77:278.

+ 17. Healy WL, Wilk RM. Osteotomy in Treatment of the Arthritic Knee. In: Scott WN, ed. *The Knee.* St. Louis: Mosby, 1994.

+ 18. Hee HT, Low CK, Seow KH, Tan SK. Comparing Staple Fixation to Buttress Plate Fixation in High Tibial Osteotomy. *Ann Acad Med Singapore* 1996;25:233.

+ 19. Hernigou P, Medevielle D, Debeyre J, Goutallier D. Proximal Tibial Osteotomy for Osteoarthritis with Varus Deformity. *J Bone Joint Surg [Am]* 1987;69:332.

+ 20. Hofmann AA, Wyatt RWB, Beck SW. High Tibial Osteotomy: Use of an Osteotomy Jig, Rigid Fixation, and Early Motion Versus Conventional Surgical Technique and Cast Immobilization. *Clin Orthop* 1989;271:212.

+ 21. Hofmann AA, Wyatt RWB, Jones RE. Combined Coventry-Marquet Procedure for Two-compartment Degenerative Arthritis. *Clin Orthop* 1984;190:186.

+ 22. Holden DL, James SL, James RL, Slocum DB. Proximal Tibial Osteotomy in Patients Who are Fifty Years Old or Less: A Long-term Follow-up Study. *J Bone Joint Surg [Am]* 1988;70:977.

# 23. Hutchinson CR, Cho B, Wong N, et al. Proximal Valgus Tibial Osteotomy for Osteoarthritis of the Knee. *Instr Course Lect* 1999;48:131.

+ 24. Insall JN, Joseph DM, Misika C. High Tibial Osteotomy of Varus Gonarthrosis: A Long-term Follow-up Study. *J Bone Joint Surg [Am]* 1984;66:1040.

# 25. Jackson JP. Osteotomy for Osteoarthritis of the Knee. [Abstract.] *J Bone Joint Surg [Br]* 1958;40:826.

* 26. Jackson JP, Waugh W. Tibial Osteotomy for Osteoarthritis of the Knee. *J Bone Joint Surg [Br]* 1961;43:746.

+ 27. Keene JS, Dyreby JR. High Tibial Osteotomy in the Treatment of Osteoarthritis of the Knee. *J Bone Joint Surg [Am]* 1983;65:36.

+ 28. Korn MW. A New Approach to Dome High Tibial Osteotomy. *Am J Knee Surg* 1996;9:12.

+ 29. Krempen JF, Silver RA. Experience with the Maquet Barrel-vault Osteotomy. *Clin Orthop* 1982;168:86.

+ 30. Liebelt RA. Personal Communication. December 1998.

+ 31. Maquet P. Valgus Osteotomy for Osteoarthritis of the Knee. *Clin Orthop* 1976;120:143.

+ 32. McDermott AG, Finklestein JA, Farine I, et al. Distal Femoral Varus Osteotomy for Valgus Deformity of the Knee. *J Bone Joint Surg [Am]* 1988;70:110.

! 33. McKellop HA, Sigholm G, Redfern FC, et al. The Effect of Simulated Fracture-angulation of the Tibia on Cartilage Pressures in the Knee Joint. *J Bone Joint Surg [Am]* 1991;73:1382.

+ 34. Miniaci A, Ballmer FT, Ballmer PM, Jakob RP. Proximal Tibial Osteotomy: A New Fixation Device. *Clin Orthop* 1989;246:253.

+ 35. Mont MA, Alexander N, Krackow KA, Hungerford DS. Total Knee Arthroplasty After Failed Proximal Tibial Osteotomy for Osteoarthritis. *Orthop Clin North Am* 1994;25:515.

# 36. Morrey BF, Edgerton BC. Distal Femoral Osteotomy for Lateral Gonarthrosis. *Instr Course Lect* 1992;42:77.

# 37. Murphy SB. Tibial Osteotomy for Genu Valgum: Indications, Preoperative Planning, and Technique. *Orthop Clin North Am* 1994;25:477.

+ 38. Nizard RS, Cardinne L, Bizot P, Witovet J. Total Knee Replacement after Failed Tibial Osteotomy: Results of a Matched-pair Study. *J Arthroplasty* 1998;13:857.

+ 39. Odenbring S, Eglund N, Knutson K, et al. Revision after Osteotomy for Gonarthrosis: A 10–19-year follow-up of 314 cases. *Acta Orthop Scand* 1990;61:128.

# 40. Paley D, Maar DC, Herzenberg JE. New Concepts in High Tibial Osteotomy for Medial Compartment Osteoarthritis. *Orthop Clin North Am* 1994;25:483.

! 41. Paley D, Tetsworth K. Mechanical Axis Deviation of the Lower Limbs. Preoperative Planning of Uniapical Angular Deformities of the Tibia or Femur. *Clin Orthop* 1992;280:48.

# 42. Phillips MJ, Krackow KA. Distal Femoral Varus Osteotomy: Indications and Surgical Technique. *Instr Course Lect* 1999;48:125.

+ 43. Puddu G, Cipolla M, Franco V, Gianni E. *A Plate for Open Wedge Tibial and Femoral Osteotomies.* Paper presented at the annual meeting of the American Academy of Orthopaedic Surgery, Specialty Day—The American Orthopaedic Society for Sports Medicine, Anaheim, February 1999.

+ 44. Putnam MD, Mears DC, Fu FH. Combined Marquet and Proximal Tibial Valgus Osteotomy. *Clin Orthop* 1985;197:217.

+ 45. Ritter MA, Fechtman RA. Proximal Tibial Osteotomy: A Survivorship Analysis. *J Arthroplasty* 1988;3:309.

+ 46. Sundaram NA, Hallett JP, Sullivan MF. Dome Osteotomy of the Tibia for Osteoarthritis of the Knee. *J Bone Joint Surg [Br]* 1986;68:782.

* 47. Wardle EN. Osteotomy in the Management of Osteoarthrtis of the Knee. *Surg Gynecol Obstet* 1962;115:61.

+ 48. Westrich GH, Peters LE, Haas SB, et al. Patella Height after High Tibial Osteotomy with Internal Fixation and Early Motion. *Clin Orthop* 1998;354:169.

+ 49. Windsor RE, Insall JN, Vince KG. Technical Considerations of Total Knee Arthroplasty after Proximal Tibial Osteotomy. *J Bone Joint Surg [Am]* 1988;70:547.

! 50. Wright J, Heck D, Hawker G, et al. Rates of Tibial Osteotomies in Canada and the United States. *Clin Orthop* 1995;319:266.

# CHAPTER 108

# PRIMARY TOTAL KNEE ARTHROPLASTY

*Dennis W. Burke and Hugh O'Flynn*

**D. W. Burke:** Department of Orthopaedic Surgery, Massachusetts General Hospital and Harvard Medical School, Boston, Massachusetts, 02114.
**H. O'Flynn:** Ipswich, MA 01938.

Indications
Classification
Cruciate-Retaining Knee Arthroplasty
Cruciate-Substituting Knee Arthroplasty
Mobile-Bearing Knee Arthroplasty
Technical Considerations
Surgical Procedure
Preoperative Evaluation
Surgical Preparation
Operative Technique
Postoperative Care
Pitfalls and Complications
Nonmechanical Complications
Mechanical Complications
Authors' Perspective
Chapter References

Total knee arthroplasty (TKA) is one of the most successful and commonly performed orthopedic surgeries. In 1997, a total of 277,000 knee arthroplasties were performed, reflecting annual increases in the 1990s of more than 10%. In comparison, only 139,000 total hip arthroplasties (THA) were performed, and the yearly growth is lower (13) (Fig. 108.1). Improvements in design, standardization of operative technique, infection prophylaxis, and fixation techniques have led to extremely low rates of revision. The best results for TKA at 10 and 15 years compare to or surpass the best results of THA.

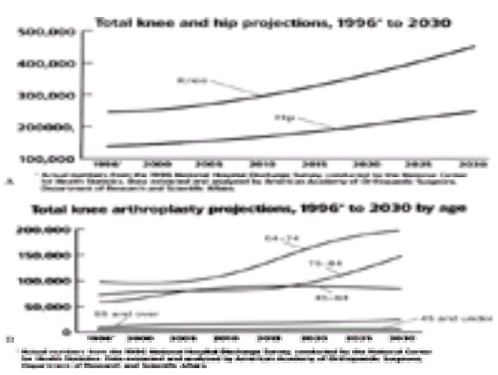


***Figure 108.1.*** Total hip and knee arthroplasty projections (**A**), 1996 to 2030, and total knee arthroplasty projections (**B**), 1996 to 2030, by age. (From Future Demand for Orthopedic Skills to Soar. *AAOS Bull* 1999;47:14, with permission.)

The goals of the TKA are threefold: pain relief, restoration of normal limb alignment, and restoration of a functional range of motion. A successful result demands precise surgical technique, sound implant design and kinematics, appropriate materials, and patient compliance with rehabilitation. This approach can be applied to implantation of any well-designed prosthesis.

Specifically a TKA must provide flexion and extension and resist nonphysiologic motions such as varus or valgus or supraphysiologic translation. Failure to resist nonphysiologic forces within design tolerances results in fracture of bone, progressive loss of fixation, or loss of bone or soft tissue around the prosthesis. Accurate bone cuts and soft-tissue preparation facilitate the success of the TKA.

## INDICATIONS

The most common indication for primary TKA is primary and secondary osteoarthritis of the knee. The next most frequent indication is rheumatoid arthritis and other arthritic disorders, such as secondary arthritis from hemophilia and other types of arthropathy. End-stage arthritis may occur in the knee joints and lower extremities with normal alignment or may occur in lower extremities with flexion contractures, hyperextension of the knee, varus or valgus angulation either through the knee joint or adjacent to it, or rotary malalignment. These malalignments may be secondary to an underlying disease process or previous injury and, in part, are due to the arthritis itself, which can produce angulation through asymmetric wearing of the knee joint. All of these malalignments must be taken into consideration when planning for TKA. Indications for TKA include any arthritic disorder of the knee that is nonresponsive to the usual nonoperative treatment, including appropriate nonsteroidal anti-inflammatory or other arthritis medications, occasional bracing, limitation of activities, and use of assistive devices such as a cane or crutches. When the patient's pain is such that he or she can no longer accomplish his or her required activities of daily living or the quality of life is such that they are willing to undertake the risks of major surgery, then TKA may be indicated. It is preferable that patients undergoing TKA have a remaining normal life expectancy of between 20 and 30 years so that the need for repeat arthroplasty for a failed TKA will be minimal. Arthroplasty may be indicated in a younger age group, but the patient must understand the limitations of the procedure, be willing to modify his or her lifestyle to prolong the life of the prosthesis, and be willing to risk the lower success rate in a revision TKA. Patients undergoing TKA in the vast majority of cases have significant arthritis involving all three compartments of the knee. TKA may be indicated with only unicompartmental or bicompartmental involvement when less surgically aggressive alternatives do not provide an adequate solution for the patient's problems.

Contradictions to TKA include active infection in the knee, ipsilateral extremity, or elsewhere in the body that would make the risk of infection in the TKA high; inadequate bone stock due to osteoporosis or other metabolic bone disease or bone loss that cannot be replaced with an allograft or a specialized prosthesis; neurologic disease that would preclude motor control of the knee or lead to a Charcot knee; and generally poor health or systemic disease that would made the risk of major surgery and general or regional anesthetic too risky. Other than performing no surgery, the primary alternative to TKA, especially when the risk of infection is high, is knee arthrodesis, which is discussed in Chapter 109.

## CLASSIFICATION

Three broad types of arthroplasty are used in uncomplicated primary TKR today: cruciate-retaining, cruciate-substituting, and mobile-bearing knees. For more complex reconstructions in which instability due to ligament failure is present, nonlinked constrained arthroplasties have been used. (Linked constrained devices such as “hinges” are rarely used or even indicated.) All of these arthroplasties are descendants of the successful Total Condylar knee (Hospital for Special Surgery, New York, NY), the gold standard for resurfacing types of total knee replacement. In the best designed of each category, long-term results are excellent in terms of fixation, function, pain scores, and motion (Table 108.1). Philosophical differences in kinematics, constraint, and methods of bony preparation, and subtle differences in postoperative results underlie the continued development of parallel designs.

| Author(s) | Type | Implant | Success (%) | Follow-up (years) |
|---|---|---|---|---|
| Rand (31) | PCLR | PCLR | 91 | 10 |
| Dennis (9) | PCLR | PCLR | 93 | 10 |
| Mulkani (19) | PCLR | Kinematic Condylar[a] | 96 | 10 |
| Ranawat (27) | PS | Total Condylar PS[b] | 94 | 15 |
| Font-Rodriguez (12) | PS | Total Condylar PS | 98 | 14 |
| Stern (42) | PS | Total Condylar PS | 94 | 13 |
| Burchel (7) | Rotating Platform | DePuy LCS[c] | 95 | 7.6 |
| Stuhl (43) | Rotating Platform | DePuy LCS | 100 | 7 |

[a]Hoboken, Rutherford, NJ
[b]Hospital for Special Surgery, New York, NY
[c]Depuy, Warsaw, IN
PCLR, posterior cruciate ligament retaining; PS, posterior stabilized.

***Table 108.1. Results of Cemented Primary Total Knee Replacement***

## CRUCIATE-RETAINING KNEE ARTHROPLASTY

The theoretical basis for retention of the posterior cruciate ligament (PCL) in TKA suggests that with a posterior tether between the femur and the tibia, stresses bypass the arthroplasty components, proprioception is maintained (49), and more normal motion (femorotibial rollback) is preserved. Preservation of quadriceps power and physiologic rollback may theoretically result in a more normal gait in walking stairs (2,3). Whether cruciate retention or sacrifice results in an arthroplasty with greater motion has not been established. The demands of balancing the anatomic function of the PCL dictate that the normal joint line be closely restored (24,34), possibly further improving patellofemoral kinematics. In order to facilitate the femoral rollback, tibial polyethylene components were historically kept relatively flat (Fig. 108.2) in the anteroposterior (AP) direction, with a physiologic posterior slope. This avoided the “kinematic conflict” of a dished polyethylene, preventing normal rollback (Fig. 108.3). Although some laxity is necessary to preserve range of motion (46), more anametric posterior cruciate–sparing prostheses depend entirely on the soft tissues to resist posterior translation (20,40,46). Later iterations of cruciate-retaining implants have added more congruence to the articular polyethylene to improve stability and contact stresses.

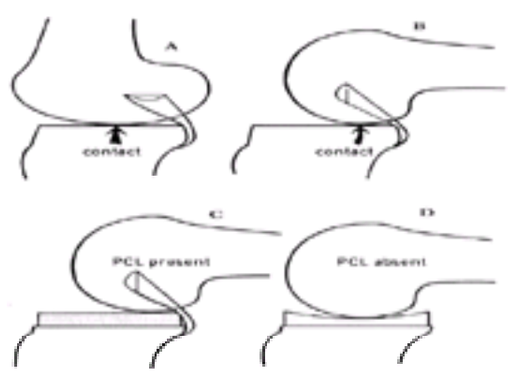


***Figure 108.2.*** The effect of posterior cruciate ligament (PCL) retention on prosthetic design. Because of the rollback enforced by the PCL (**A, B**), the prosthetic tibial surface has historically been flat to allow this movement. **C, D:** When the PCL was absent, a dished tibial plateau has been used. (From Insall JM, ed. *Surgery of the Knee,* 2nd ed. New York: Springer Verlag, 1991:600, with permission.)

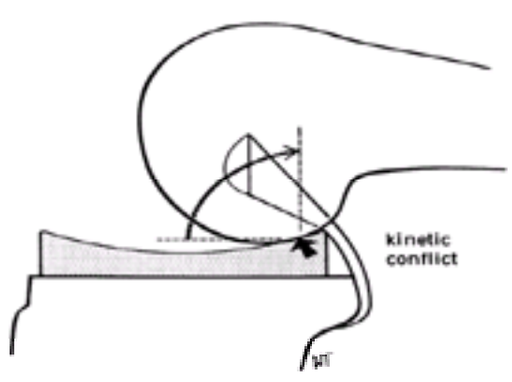


***Figure 108.3.*** Kinematic conflict occurs if concepts are mismatched. In this case, the posterior cruciate ligament is preserved using a dished tibial component. Impingement occurs posteriorly with flexion. (From Insall JM, ed. *Surgery of the Knee,* 2nd ed. New York: Springer Verlag, 1991:600, with permission.)

With retention of the PCL, the level of the joint line must be kept at or near anatomic height after resurfacing with the arthroplasty. Failure to do this will result in a tight PCL, which will produce restricted flexion, excess femur on tibia rollback (so-called “booking”) (Fig. 108.4), and a high posterior polyethylene-bearing load, potentially leading to articular failure. The technical challenge with a PCL-retaining knee design is to realign the limb and restore full motion while keeping the PCL under proper tension.

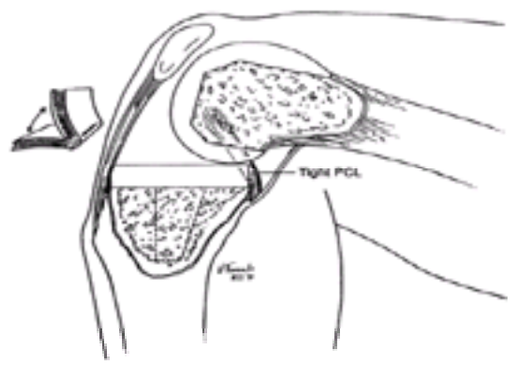


***Figure 108.4.*** An overtight PCL causes “booking.” There is excessive rollback of the femur, and the knee hinges open. (From Insall JM, ed. *Surgery of the Knee,* 2nd ed. New York: Springer Verlag, 1991:602, with permission.)

Although these theoretical advantages are compelling, Lotke (18) was able to demonstrate normal physiologic tension in only 1 of 10 knees undergoing a posterior cruciate-retaining TKA. Stiehl (44) fluoroscopically visualized clinically well-functioning PCL-retaining TKAs and found nonphysiologic AP movement. Some cases demonstrated “roll forward” rather than “roll back” (Fig. 108.5). Laskin (16), Pagnano (26), and Waslewski (50) showed clinical evidence of late failure of the PCL with sagittal laxity. Other authors with large series show no evidence of this phenomenon (9,19). The risks of excessive laxity include gait abnormality with eccentric loading, secondary soft-tissue attenuation, and edge loading with resultant high contact stresses on polyethylene components. Progressive weakening or elongation of the PCL

and subsequently the capsule and collaterals could lead to osseous deformity and frank joint subluxation.

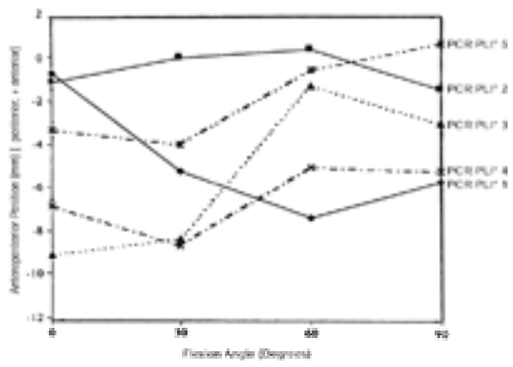

***Figure 108.5.*** Medial condyle contact positions for five randomly selected subjects having a posterior cruciate–retaining design with a posterior lipped insert. Note that some knees roll forward and others roll back, and that magnitude and starting points vary. This is a stochastic process. (From Dennis DA, Clayton ML, O'Donnell S, et al. Posterior Cruciate Condylar Total Knee Arthroplasty. Average 11-year Follow-up Evaluation. *Clin Orthop* 1992;168:52, with permission.)

**CRUCIATE-SUBSTITUTING KNEE ARTHROPLASTY**

Sacrifice and substitution for the PCL gives predictable femorotibial kinematics and may facilitate balancing knees with greater angular deformity, especially when secondary changes in the PCL contribute to the deformity. The function of the PCL is partially replaced by using a more congruent articular surface and commonly a tibial spine and femoral cam mechanism (Fig. 108.6). Historically, the most popular designs had a higher rate of patellofemoral complications. Impingement of fibrous tissue proximal to the patellar component or in the notch can cause “patellar clunk” (48). Patellar pathology may be partially due to the relative elevation of joint line (Fig. 108.7) that can occur using the gap technique of bone preparation, and the relative patella baja that this produces. The femoral profile of early models was boxy in the AP plane without recession of the trochlear groove, increasing tension on the patellar retinaculum (Fig. 108.8). Recently improved designs more physiologically duplicate patellofemoral anatomy and mechanics.

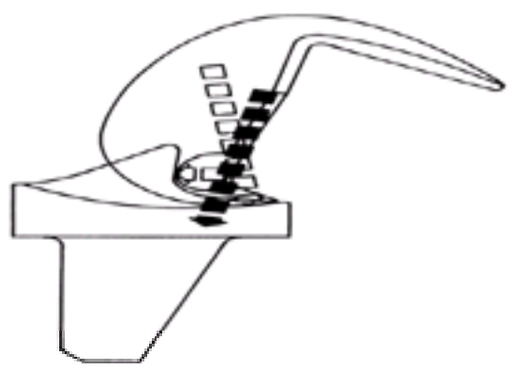

***Figure 108.6.*** The cam mechanism of the posterior stabilized knee simulates the function of the PCL and causes a rollback of the femur on the tibia with flexion. The resulting vector of forces passes distally through the fixation peg. (From Insall JN, Lachiewicz PF, Burstein AH. The Posterior Stabilized Condylar Prosthesis. A Modification of the Total Condylar Design. Two to Four Year Clinical Experience. *J Bone Surg [Am]* 1982;64:1317, with permission.)

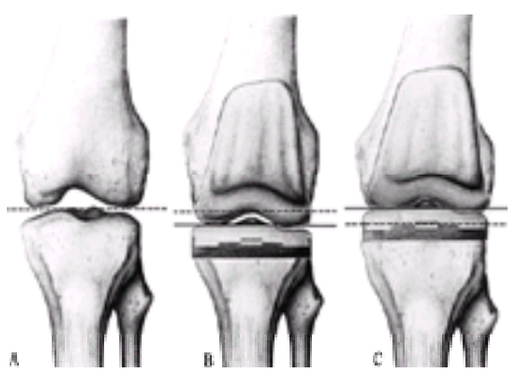


***Figure 108.7.*** Spatial position of the joint line. **A:** The normal joint line is indicated by the dotted line. **B:** The joint line has been abnormally lowered *(solid line)* owing to overresection of the proximal tibia and underresection of the distal femur. **C:** The joint line has been abnormally elevated *(solid line)* owing to underresection of the proximal tibia and overresection of the distal femur. (From Laskin RS, ed. *Total Knee Replacement.* New York: Springer Verlag, 1991:58, with permission.)

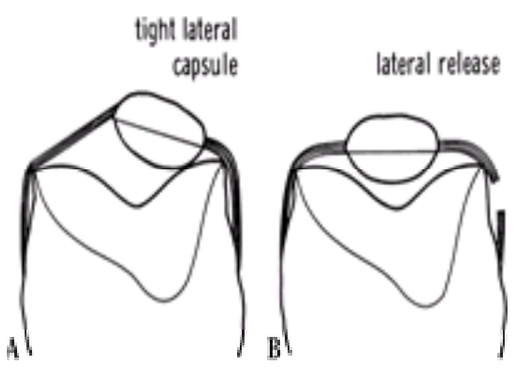


***Figure 108.8.*** Effect of a tight patellar retinaculum: **A:** A tight lateral capsule causes patellar subluxation and loss of flexion. **B:** A good lateral release corrects this problem. (From Insall JM, ed. *Surgery of the Knee,* 2nd ed. New York: Springer Verlag, 1991:646, with permission.)

**MOBILE-BEARING KNEE ARTHROPLASTY**

The mobile-bearing total knee, although implanted in a minority of knees in the United States at present, is attracting interest because of its distinct potential design advantages. These designs rely on highly congruent femoral and tibial articular surfaces to produce very low contact stresses, theoretically reducing polyethylene wear. Allowing the tibial articular surface to “float” by a combination of gliding, rotating, or sliding mechanisms mitigates the kinematic conflict created by highly congruent surfaces. Fluoroscopic information suggests that *in vivo* kinematics may imperfectly replicate design goals (43). To date, only one mobile-bearing design (Depuy LCS, Warsaw, IN) has been approved by the U.S. Food and Drug Administration (FDA) (Fig. 108.9), although there has been considerable early experience overseas with

other novel implants.

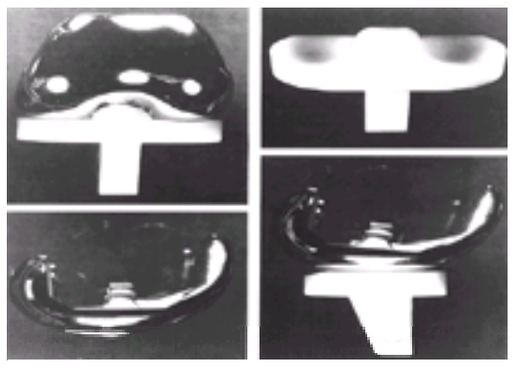

***Figure 108.9.*** The Depuy LCS knee.

Contemporary use in the United States is approximately 45% each for cruciate-retaining and cruciate-substituting designs, and 10% for mobile-bearing designs, with the cruciate-substituting and mobile-bearing designs increasing in popularity. All three implant types are viable and have proven long-term results. All have theoretical and practical pluses and minuses (Table 108.2).

***Table 108.2. Advantages and Disadvantages of Types of Tibial Knee Implants***

## TECHNICAL CONSIDERATIONS

The design goal of the knee arthroplasty is to relieve pain and restore normal function to the arthritic knee. The shapes of the reconstructed femur and tibia, particularly in the sagittal plane, dictate the kinematics of the reconstructed knee. The soft tissues are physiologic restraints with limited elasticity. Within the range of patient sizes and limitations of ligaments, a variety of sizes is needed. The contours of the articulating surfaces create constraint, and in some cases, a more constrained articulation can substitute for ligamentous deficiency.

Accurate limb alignment minimizes stresses on bearing and fixation interfaces. The main goal of instrumentation is to provide consistent accurate alignment by referencing from osseous landmarks. Alignment may be assessed as “anatomic” or “mechanical.” The mechanical axis of the limb is defined by a line that passes through the hip center and through the center of the ankle. It typically falls on the medial side of the center of the knee joint. Although the consistent reproduction of a mechanical axis that passes through the central area of the knee is a goal, the landmarks are difficult to measure accurately in the operating room. Anatomic axis landmarks, by contrast, are readily available, easy to instrument, and can reasonably approximate the mechanical axis. Most contemporary arthroplasty instrumentation references from the anatomic axes. The relationship of the longitudinal axes of the femur and tibia define the femorotibial angle or anatomic axis (Fig. 108.10).

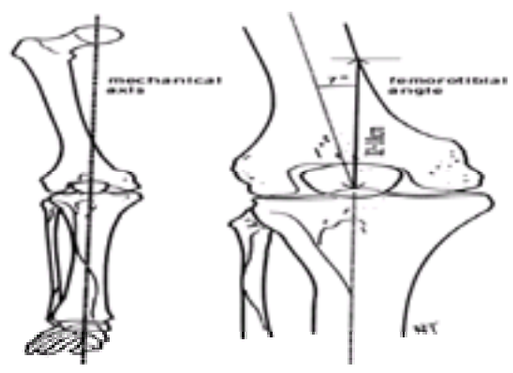


***Figure 108.10.*** Comparison of the anatomic and mechanical axes. The mechanical axis usually corresponds to a femorotibial angle of about 7° and intersects the medial femoral cortex 12 to 18 cm proximal to the knee.

Precision is paramount because an asymmetry of only 5% can lead to liftoff of the femoral component on the tibia, with compressive forces all on one side and tensile forces on the other. Subtle malalignment can magnify with time as soft tissues attenuate under excessive forces (Fig. 108.11). Specifically, varus alignment of the tibial component has been associated with a higher rate of radiolucency about the prosthesis and a higher rate of loosening (Fig. 108.12).

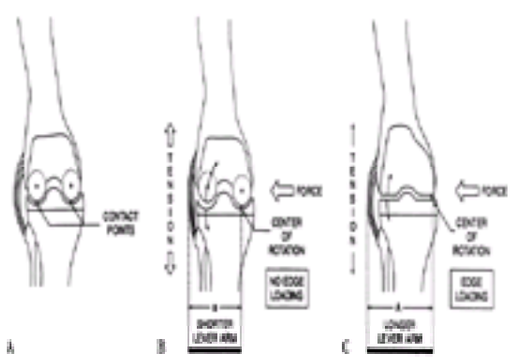

***Figure 108.11.*** Edge loading between the femoral and tibial components can occur owing to AP instability or varus valgus forces in a TKA design with a flat tibial bearing surface as shown in **C. A:** Dished tibial component with central contact points. **B:** Dished tibial component with varus stress maintains central contact and loading. **C:** Flat tibial component with varus stress can result in edge loading medially. (From Laskin RS, ed. *Total Knee Replacement.* New York: Springer Verlag,

1991:92, with permission.)

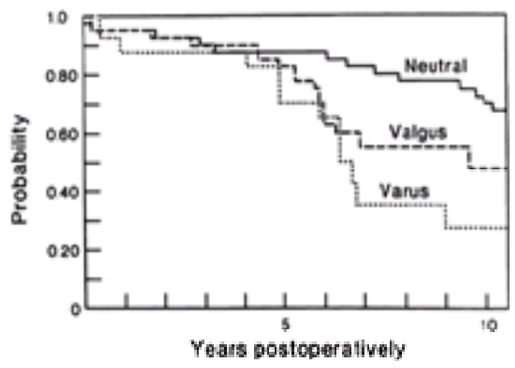


***Figure 108.12.*** Malalignment in a TKA significantly reduces survivorship of the implant. (From Lewallen DG, Bryan RS, Peterson LF. Polycentric Total Knee Arthroplasty. A Ten-year Follow-up Study. *J Bone Joint Surg [Am]* 1984;66:1211, with permission.)

Fixation of TKA components has been reliably achieved with both cemented and cementless techniques, but the use of methacrylate cement remains the standard and generally the most widely used technique.

## SURGICAL PROCEDURE

### PREOPERATIVE EVALUATION

Take good-quality radiographs on large cassettes in both the AP and lateral planes. AP weight-bearing films demonstrate better any potentially dynamic instability. They also accentuate joint space narrowing. A Merchant view (or other similar radiograph) is useful to evaluate patellofemoral mechanics (23). A tunnel view may be useful to evaluate for osteonecrosis.

Fixed angular deformities and contractures need to be released at the time of surgery either through soft tissue or bony maneuvers. The stiff knee can present a challenge for exposure alone. Any knee with gross ligamentous instability, particularly in the medial-lateral plane, may need to have specially stabilized components or ligamentous augmentation for a successful procedure.

Rule out and evaluate for potential serious vascular disease in the lower extremity. A consultation with a vascular surgeon may be necessary. Prior vascular surgery, particularly with the use of a prosthetic graft, may be a contraindication for use of a tourniquet.

Assessment of the skin is also important in arthroplasty. There is nothing more discouraging after undertaking a technically successful arthroplasty than to have a skin slough that leads to infection and dismal failure. Try to avoid flaps and undermining of the skin, particularly laterally over the patella to avoid potentially devastating problems. In general, old incisions performed for prior medial or lateral menisectomy, which are either oblique or behind the midline, can be ignored. Cross transverse incisions for patellectomy or high tibial osteotomy at 90°. More recent parapatellar incisions are problematic. In general, include recent parapatellar incisions in the line of the main incision if practical. Use the most lateral longitudinal incision if it will allow adequate access to the knee for arthroplasty. Give special consideration to patients with local skin problems such as psoriasis. Preoperative dermatology consultation can significantly improve local skin lesions and reduce the risk of infection.

In the absence of long bone and hip deformities, standard 36-inch radiographic films with the patient standing are adequate for preoperative planning. Three-foot films may be used to assess mechanical axis versus anatomic axis, but they usually are needed only to assess angular deformity away from the knee joint or unusual hip offsets.

Template for the size of prosthetic components on the radiographs with acetate overlays that are compensated for radiographic magnification. Preoperative templating is only an approximation of the required prosthetic sizing—never use templating to determine the precise size used at surgery. Often, the exact size determined in surgery will vary from templating by plus or minus one size. Templating provides the opportunity to consider the surgical plan, including correct techniques to address deformities and need for soft-tissue releases. Occasionally, templating reveals the need for a very small or very large component, which requires—if not a custom device—at the least a special request before surgery. Prior surgical procedures may significantly alter the normal anatomic landmarks. Prior proximal tibial osteotomies may make conventional tibial components difficult to use owing to an offset of the tibial axis relative to the plateau. Prior hardware, such as staples or screws, may have to be removed. Severe bone deficiencies, such as those that result from marked valgus deformity or a long-standing varus deformity, may require modular prosthetic augmentations (28) or grafting (38).

### SURGICAL PREPARATION

After templating of radiographs, it is imperative that the appropriate surgical instruments be available for the procedure. These instruments may include special jigs, measuring devices, or cutting tools. Administer a dose of prophylactic antibiotics before inflation of the tourniquet. A first-generation cephalosporin is an appropriate choice. If there is an allergy to a first-generation cephalosporin, the alternatives include vancomycin or clindamycin (4).

- Position the patient carefully in the supine position on the operating table. Take great care to prevent peripheral nerve palsies, which can occur during the prolonged positioning in the recumbent position in the anesthetized patient. Protect the elbows with foam pads and gently flex them approximately 30°. Elevate the patient's buttock on the operative side with a soft roll to produce a stable upright positioning of the knee. Occasional sciatic nerve palsy has been seen from prolonged positioning on a hard buttock roll. When the patient is rolled to the opposite side using the buttock roll, the contralateral leg often lies in external rotation. To avoid pressure on the peroneal nerve on the nonoperated side place the heel on a soft elevation pad and pad the lateral side of the knee.
- Secure two separate bumps to the table on the operated side as leg positioners. Position them such that the knee is in full extension when the leg lies on top of the bumps, in approximately 30° of flexion when the foot is placed on the first bump, and in 100° of flexion when the second bump is used. These are the three main positions of the knee used when the surgical procedure is performed (Fig. 108.13). These bumps stabilize the knee and free the surgeon's and assistant's hands. Once the patient is positioned and the bumps are set, the extremity should be stable with the patella pointing directly at the ceiling. There may be a tendency for the limb to roll into external rotation. If this occurs, gently rotate the table toward the opposite limb until the knee is in a stable position straight up and down. Secure the patient with a strap.

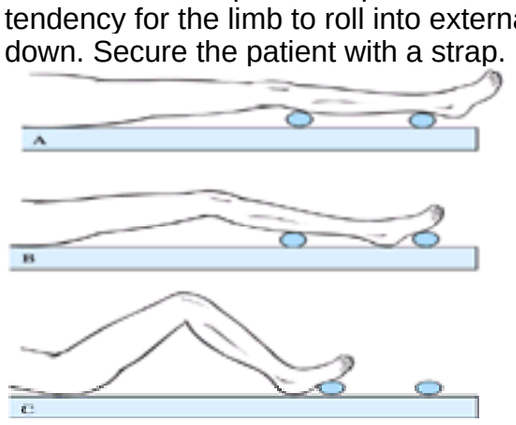

***Figure 108.13.*** The use of bumps can facilitate intraoperative positioning. **A:** Full extension to check alignment. **B:** 30° position for the surgical exposure and wound closure. **C:** Position used for bone cuts.

- Finally, take a “walk around” the patient just before scrubbing. Check all peripheral nerve sites for appropriate padding. The tourniquet should have been placed

on the thigh as high as possible and the skin protected with soft webril padding. If the patient is obese or short limbed, a sterile tourniquet may be used to ensure adequate access to the surgical field. Place protective vinyl draping distal to the tourniquet to prevent dripping of potentially caustic scrub solutions under the pressure tourniquets. Confirm with the anesthesiologist that preoperative antibiotics have been given.

- Reaffirm that the correct limb is being prepared. Although it is rare, wrong limb side surgery does occur and is disastrous for patient and surgeon. The American Academy of Orthopedic Surgeons has made recommendations to minimize this complication (47). Whatever system is used, it is the attending surgeon's ultimate responsibility to confirm that the operation is performed on the correct knee.
- Shave the skin around the knee immediately before the procedure to limit compromise of the skin surface. Extended time between shaving and surgery promotes colonization of small nicks with bacteria.

The regimens for prepping and draping the patient vary among hospitals and among surgeons. However, particularly in TKA, the margins of the surgical field are subject to compromise unless very careful preoperative draping is done. Now surgically scrub the limb and do a final skin prep with an antibacterial solution. Take meticulous care during draping. Drape the skin sterilely as high as possible, to avoid drape creep, and to at least 4 inches below the tibial tubercle. Apply an adherent sterile vinyl dressing, preferably iodine-impregnated (3M Ioban, Minnesota Mining Co, Minneapolis, MN). Leave at least 1 inch of plastic adhesive drape above and below the planned or extended incision to ensure that the drapes do not lift up during the procedure, thus preventing irrigation fluid and other fluids from the surgical site from entering areas of contamination and vice versa. Always use a wide prep and drape to provide for an extensile exposure. It will be frustrating to find oneself “prepped out of the field” or to have the field contaminated by an inadequate level of prepping.

- Avoid excessively bulky drapes on the lower extremity. Precise alignment in total knee replacement depends on the ability to palpate the tibial spine, the malleoli, or bones of the foot. A bulky drape on the foot obscures landmarks and makes surgery more difficult. Use a plastic-impregnated stockinet that covers the lower extremity, and place over it an elastic Coban wrap (3M, Minneapolis, MN), which effectively walls off the foot from the sterile upper leg, holds the stockinet on precisely, and provides a graded compression for prophylaxis against venous stasis. Most important, it does not mask the palpable subcutaneous landmarks of the lower extremity, thereby allowing more accurate bone cuts.

**OPERATIVE TECHNIQUE**

- With the patient prepped and draped, flex the knee to a 30° position and mark the surgical incision. Flexion produces tension on the anterior tissues, which allows a more precise surgical exposure. A midline longitudinal incision is preferred unless otherwise dictated by prior skin incisions. The exposure should be extensile, extending approximately five fingerbreadths above the superior patella and five fingerbreadths below the inferior patella.
- The technique of arthrotomy, soft-tissue handling, and initial exposure is key to preventing problems. Put a thumb on one epicondyle and a finger on the other epicondyle, and visualize the knee in 30° of flexion to mark a center point. This is not necessarily the center of the patella; often, the center of the patella can be misleading. Mark the center of the femur proximally at the appropriate length and distally place your finger over the tibial tubercle and make a mark on the medial aspect of the finger. The incision must be perpendicular to the skin at all skin contours. This means that proximally the belly of the blade should be as parallel to the limb as possible.
- Carry the incision through the midpoint of the knee and distally just medial to the tibial tubercle, with the blade angled perpendicular to the tibia so that it internally rotates as the incision is carried distally. This will minimize skin flap compromise and potential necrosis.
- Then carry the incision through the deep fat and the prepatellar bursa, being careful to preserve the epitenon above the patellar tendon and to roll back the layer of soft tissue just above the epitenon. Preserve this for later closure; if a careful incision is made, it makes a very nice layer for later closure.
- Perform a medial arthrotomy with a new knife blade. The location of the quadriceps tendon can be very deceiving proximally. The most superior portion of the tendon can be biased laterally if only the visual landmarks are used, and this may lead the surgeon to transect the bulk of the quadriceps. Often, just deep to some of the quadriceps muscle fibers, there is additional tendon medial to the visible quadriceps tendon (Fig. 108.14).

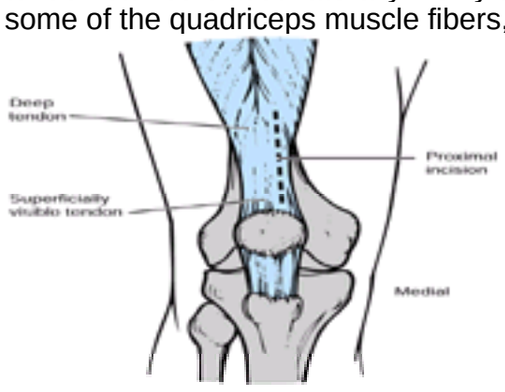


***Figure 108.14.*** The exposure of the proximal superficial quadriceps tendon may deceive the surgeon as to its true location. Palpate the tendon to be certain that the incision is along its medial border.

- Use a #10 blade perpendicular to the tendon, through its full thickness, and carry the arthrotomy longitudinally in a gentle curve, which will start at the midpoint of the quadriceps tendon proximally, curve around the patella so that it intersects a point just medial to the patella, and then curve back to a point on the tibial tubercle medially. It is important that the arthrotomy be gently curving and transect a minimum of quadriceps muscle fibers. Incorporate a millimeter or two of the most medial portion of the patellar tendon distally. When a medial soft-tissue sleeve is raised around the tibia, the closure toward the tibial tubercle is often precarious. Incorporating an inconsequential amount of the patellar tendon distally helps secure this layer and again lower the risk of infection.
- In the inferior region of the arthrotomy, split the fat pad with the medial bulk of fat maintained. This facilitates the lateral exposure, which is especially important in more difficult tight knees or heavy patients. This leaves a fair amount of fat pad for closure even when the lateral fat pad is removed to expose the difficult knee. Do not compromise the patellar tendon.
- After the intersection of the incision with the tibial tubercle, bring the incision parallel to the shaft of the tibia and carry it distally for a few more millimeters.
- Place a right angle retractor medially and transect the anterior horn of the medial meniscus. Elevate a medial soft-tissue sleeve with electrocautery or a sharp #10 scalpel. Release the soft-tissue sleeve from proximal to distal, staying strictly at the subperiosteal level to maintain the vascularity of the medial flap of tissue. The viability of this flap is critical for covering the implant.
- The extent of the medial dissection depends at this point on pre-existing angular deformities. For a severe varus knee, the medial exposure can be extended into a medial release. The medial collateral ligament is a tight band on the medial aspect of the knee and can be easily transected by slight malposition of the scalpel during dissection along the anteromedial and posteromedial tibia. It is best to proceed with a subperiosteal stripping of the medial aspect of the joint with a Cobb-type elevator to ensure that the collateral ligament is protected. Once the deep portion of the medial collateral ligament (MCL) has been elevated, place the Z-type retractor between the MCL and bone to gain medial exposure. Remove large medial osteophytes at this point as part of the medial release.
- Elevate the patella, with the knee in extension and pulled toward the surgeon. Release tight bands in the patellar retinaculum or plica with electrocautery and avoid the patella.
- Place a retractor along the medial joint line and flex the knee to 90° or 100°. The potential for patella tendon avulsion exists in the tight knee. As the knee is flexed, carefully watch the insertion of the patella tendon to avoid any excessive flexion that may avulse the patella tendon. If the patella cannot be easily everted without the risk of patella tendon avulsion, obtain more extensile exposure either by extending the arthrotomy proximally, doing more distal soft-tissue releases, or considering quadriceps release or tibial tubercle osteotomy. This situation most often occurs in the very obese patient or the patient with prior knee surgery, such as proximal tibial osteotomy, in which the patella tendon is scarred and tight. Once patella tendon avulsion occurs, it is very difficult to treat, so this complication is best avoided. We favor a tibial tubercle osteotomy over proximal soft-tissue releases.
- At this point, flex the knee greater than 90°. The patella should be everted, both femoral condyles should be evident, and the tibial plateau should be at least partially visualized. Next, inspect the entire knee and identify and make a note of the intraoperative pathology.
- The anterior cruciate ligament is generally resected for all arthroplasties, and this enhances exposure. Place a hemostat behind the anterior cruciate ligament from the lateral to the medial direction and transect the ligament by electrocautery. It is best to remove the stump of the anterior cruciate ligament off its femoral insertion on the lateral side.
- In knees with advanced arthritis, the PCL may be partially or totally obliterated by notch osteophytes. Using a 1-inch osteotome, remove medial and lateral osteophytes to expose the PCL attachment to the femur. Most knees will have an intact PCL. In some cases, it may be anatomic in structure but have abnormal function.
- If the PCL is being intentionally sacrificed for surgical technique, it is best done at this point. The PCL lies immediately in front of the posterior capsule, which lies in front of the neurovascular structures. The PCL should not be sacrificed in a cavalier fashion, but it should be done precisely. Place a curved clamp behind the PCL to define its substance and direction, then take electrocautery and remove the PCL subperiosteally off the femoral attachment. Once it is completely detached from the femur, retract the detached end forward and transect it at its insertion on the tibia.
- Now release the anterior horn of the lateral meniscus. Separate the remaining fat pad beneath the patellar tendon from the patellar tendon using a hemostat down to the level of the lateral joint line, and transect it with electrocautery. This frees the lateral meniscus. Then place a Kocher clamp on the lateral meniscus and use electrocautery along the margin of the lateral meniscus anteriorly. Then place the meniscus under tension with the clamp, and release the lateral periphery of the meniscus with a #15 blade in a precise curvilinear fashion along to its insertion next to the PCL. Branches of the lateral geniculate artery are just outside the insertion of the lateral meniscus and can be easily transected during the removal. These branches commonly bleed if they not cauterized at this time.

Once the lateral meniscus is removed, place a Z-type retractor in the corner overlying the lateral tibial condyle to gain extensile exposure of the flexed knee.

### *Principles of Balancing: Measured Resection versus Flexion Gap*

Most modern knee instruments are quite precise. They generally rely on intramedullary alignment for the femur. The tibia may use either intramedullary or extramedullary alignment guides (11). It is important to follow the manufacturer's instructions and at the same time to understand the underlying mechanical principles of TKA so adjustments can be made to suit the pathology encountered at surgery.

Contemporary instrumentation uses either measured resection or flexion or extension gap balancing methods to determine the location, depth, and angulation of bone cuts. The techniques are more similar than different and ultimately result in the same or nearly the same anatomical outcome. Measured resection uses trials as spacer blocks, whereas blocks are typically used in the gap measurement method.

The gap technique of bone preparation typically begins with tibial resection perpendicular to the tibial axis.

- Make the cut 5 to 9 mm below the articular surface of the more normal side. Check ligament balance.
- The femoral flexion gap is created by sizing the anterior posterior diameter of the femur from the anterior cortical surface, selecting the appropriate size, and adjusting the rotation for ligament tension before the cuts are made to create the femoral flexion gap. After the flexion gap is created, measure it with spacers and use this information to create the extension gap (Fig. 108.15).

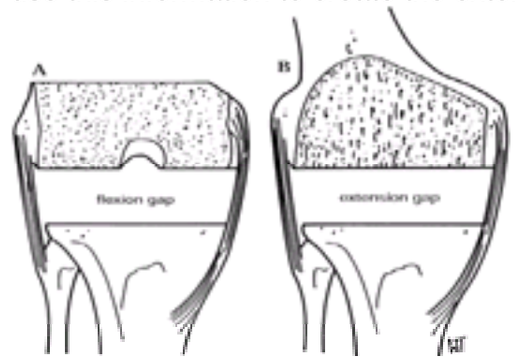


***Figure 108.15.*** After resection of the distal femur and proximal tibia, the extension gap **(B)** must equal the flexion gap exactly **(A).** (From Insall JM, ed. *Surgery of the Knee,* 2nd ed. New York: Springer Verlag, 1991:626, with permission.)

The gap technique is simple and widely applicable, but has the possible disadvantages of midrange laxity (only 0° and 90° are checked) and possible elevation of the joint line. Elevation most commonly occurs in a knee with a preoperative flexion contracture, and an aggressive flexion gap cut on the femur results in a femoral component that is relatively undersized (34).

The femur is usually resected first when proceeding with the so-called measured resection technique of TKA. Proponents suggest that the femur is more readily accessible upon first exposure. The measured resection technique works by resecting a measured amount of bone from both the femoral and tibial condyles. This resected bone is to correspond as closely as possible to the amount of implant being replaced (Fig. 108.16). This is also known as a joint line technique because the joint lines are fairly well maintained and the normal anatomy is essentially resurfaced. This is particularly important when the implant is designed to retain the PCL. Slight elevation of the joint line in PCL-retaining designs can have adverse effects on knee kinematics (24).

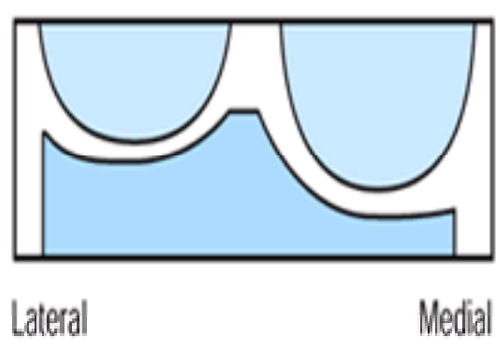


***Figure 108.16.*** Flexion cuts forming equal resection when combined.

Close matching of the AP dimensions on the femoral side and consistent femoral rollback without the “booking” phenomenon avoids increased posterior stresses and the limited flexion associated with a tight PCL or excessive translation with a loose PCL. In the case of a tight PCL, recession (37,57) from the tibial side after the tibial cut and balancing can allow interpolation between sizes. Flexion contracture can be addressed with posterior capsular release (Fig. 108.17).

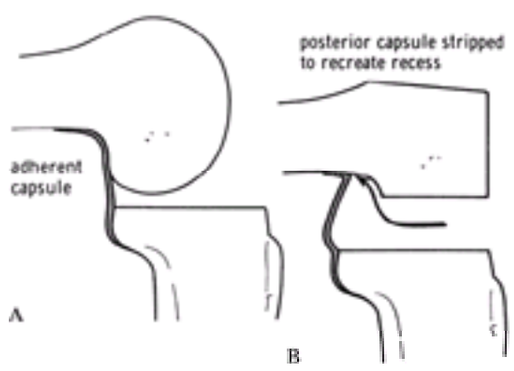


***Figure 108.17.*** Posterior capsular release from the femur to reduce a flexion contracture. **A:** The posterior capsule is adherent. **B:** The original recess is re-established. (From Insall JM, ed. *Surgery of the Knee,* 2nd ed. New York: Springer Verlag, 1991:643, with permission.)

### *Preparation of the Distal Femur for Cuts*

The goal of the femoral preparation is to resurface the abnormal femur with a femoral implant articulating surface. The distal level of the femoral implantation is critical to preserve the proper level of the joint line. The flexion and extension gap must be correct. The varus and valgus alignment and proper external rotation are critical. At least four directions for spatial relations must be carefully maintained or reproduced to result in a good arthroplasty: joint level, rotation, coronal plane angulation, and sagittal plane angulation. Initial preparation of the distal femur to ensure correct rotation includes marking a line in the sulcus of the trochlear groove, the so-called Whiteside's line, or the AP axis (53). The AP axis of the distal femur is defined by a line through the deepest part of the patellar groove anteriorly and the center of the intercondylar notch posteriorly. This line defines the center of the femoral condyles and the plane to which the knee component must be perpendicular.

- Make the center drill hole into the medullary canal, approximately $^{3}/_{8}$ inch (9 mm), just medial to the center of the notch to provide the best line of axillary alignment. Put your opposite hand on the femoral shaft proximally to provide appropriate directional control, through tactile feedback, to locate the intramedullary canal. Place the hole just above the insertion of the PCL if this exists, but not so anterior that there is any risk of perforating the anterior cortex. Drill the hole straight and make it slightly larger than the intramedullary guide rod.
- Once the hole is drilled, aspirate marrow products to prevent embolization. The intramedullary guide rod should be fluted for self-venting and approximately 30 cm in length to the femoral axis. Take care not to place the drill hole in the midline of the femoral condyles because an abnormal valgus angulation will occur because this is not aligned with the medullary canal (Fig. 108.18).

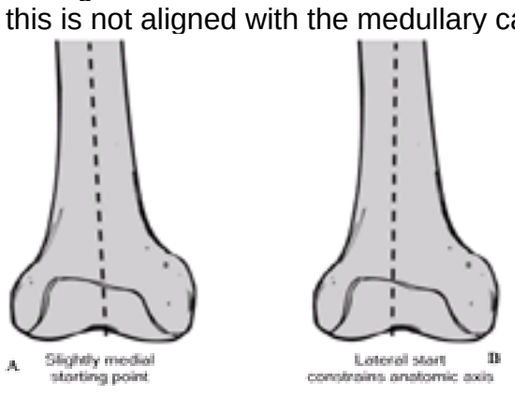


***Figure 108.18.*** Malposition of the center drill hole may lead to a varus femoral component. On this right femur, drawing **A** shows the preferred slightly medial starting point. In **B**, a lateral entry will constrain the anatomic axis, producing valgus alignment.

### *Rotation of the Femoral Component*

Rotation of the femoral component is key for a number of reasons. The patellofemoral mechanics are altered dramatically by femoral component rotation. An excessively internally rotated femoral component will have much higher rates of patellar subluxation and altered patellofemoral mechanics. In general, some external rotation of the femoral component is desirable. Also, because tibial resections are performed perpendicular to the long axis—not the normal 3° medial inclination of the tibial plateau—an externally rotated femoral component is necessary to make the flexion gap equal (Fig. 108.19).

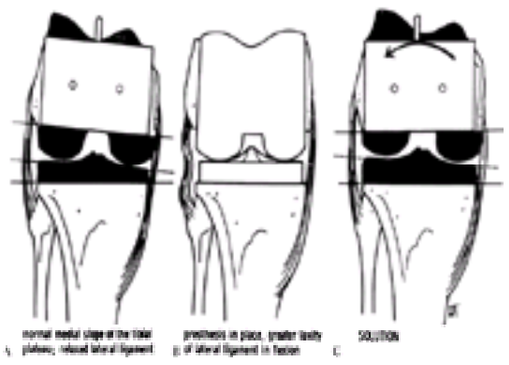

***Figure 108.19.*** External rotation of the femoral component ensures a square extension gap. **A:** When the femoral cuts are made in relative internal rotation, the normal medial slope of the tibial plateau results in a relaxed lateral ligament complex. **B:** This results in greater laxity of the lateral ligament in flexion. **C:** The lateral ligament is tightened by externally rotating the prosthesis. (From Insall JM, ed. *Surgery of the Knee,* 2nd ed. New York: Springer Verlag, 1991:624, with permission.)

The order of cuts depends on the instrumentation. The distal cut is typically made in a preset angle of varus or valgus from the mechanical axis, marked by the intramedullary guide. Most surgeons select 5° or 6° of valgus, altering this for special circumstances when the anatomic axis departs from the mechanical axis.

### *Determining External Rotation*

Three distinct anatomic landmarks are used to determine the external rotation of the femoral component. No one landmark by itself is always reliable. Use all three in combination to reach a consensus as to what is the proper external rotation alignment.

- The transverse axis of the femoral component should be perpendicular to the anteroposterior axis, or so-called Whiteside's line.
- The transepicondylar axis reliably produces 3° to 5° degrees of external rotation to the posterior femoral condyles.
- The posterior femoral condylar axis references 3° of external rotation with respect to the condyles.

In general, the epicondylar axis is the most reliable from the anatomic point of view, but the epicondyles may be difficult to palpate. The posterior condylar axis is generally reliable but suspect in valgus knees or in rheumatoid arthritis. A deficient lateral condyle may produce false external rotation. In cases of severe arthritis with marked anterior osteophytes, the intratrochlear groove may be abnormal. We prefer checking three landmarks and making a final determination on their confluence, erring on the side of external rotation. In the case in which a tibial cut is made first, an additional reference for a balanced flexion gap is available. Some instrumentation sets are able to reference the tibial cut and use soft-tissue tension to determine the rotation of the femoral cuts. This can be dangerous, depending on the extent of soft-tissue contractures and which structures have been released before using the instruments.

### *Anterior and Posterior Sizing*

After the distal femoral cut is made and the external rotation has been determined, make the anterior and posterior femoral cuts. In general, there are two references or approaches that may be used at this point. One is the anterior referencing technique, whereby the anterior cut is made first by referencing from the anterior cortex. This approach ensures that no notching of the femur for anterior femoral flange occurs. The difficulty with this technique is that the exact location of the posterior femoral condyles is somewhat indeterminate because of the finite number of component sizes that are available. In general, take care in measuring the size of the femoral component. The other method of measurement, used by most systems, is some type of caliper or jig system to measure the distance between the posterior condyles and the anterior cortex. If the size registers between two sizes, which it often does, in general the smaller size is preferable to avoid “overstuffing” the knee. Overstuffing the knee is a phenomenon that occurs when too large a femoral component is placed. If the component is placed too far posteriorly, a tight flexion gap and decreased flexion will occur. If an oversized component is placed too far anterior, the extensor mechanism may impinge on the femoral flange, creating a tight knee.

In the so-called “greyhound knee,” named for its resemblance to canine anatomy, there is a mismatch between the AP diameter of the knee and the narrower medial-lateral dimension of the femoral condyle. After selecting the proper AP dimension of the component, an overhang on the medial and lateral sides becomes apparent. Proper implant system selection can minimize this phenomenon.

An important intermediate step is to check the bone cuts for evidence of the appropriate rotations. The anterior cut on the femoral condyles should leave a higher and longer prominence laterally, and the removed bone fragment typically looks like a mountain, called the Matterhorn sign (Fig. 108.20). The posterior cuts should show similar asymmetry, with more medial than lateral bone resected in most cases.

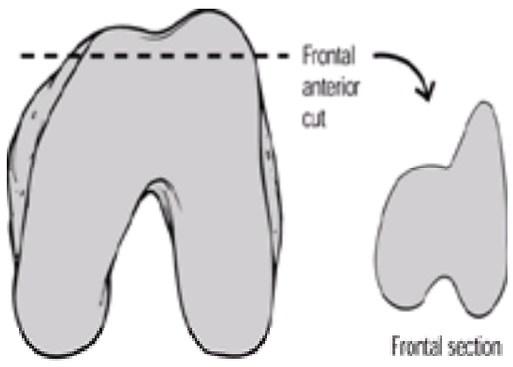


***Figure 108.20.*** The Matterhorn sign seen on this frontal view of the excised fragment of the femoral condyles.

Many systems require some additional bony preparation, such as a box for a PCL cam or a recessed trochlear groove for improved patellar articulation.

***Removing the Posterior Osteophytes***

Remove posterior osteophytes after the chamfer and other finishing cuts. The posterior osteophytes not only act as a mechanical block to limit flexion but also tent the posterior capsule and limit full extension.

- With the knee held in extreme flexion, retract the femur superiorly with a blunt bone hook placed in the intercondylar notch. Use a 1-inch sharp, curved osteotome to resect posterior osteophytes from the medial, lateral epicondyles. Take care to avoid injury to the neurovascular structures.
- Once these osteophytes are resected, remove adherent capsular attachments by either curettage or rongeur. A soft sulcus should result behind the posterior condyles and in front of the posterior capsule. This approach will maximize the potential extension and flexion of the knee (Table 108.3).

| |
|---|
| Oversized femoral component |
| Improper external rotation |
| Notching of the femur |
| Improper axial alignment |

***Table 108.3. Pitfalls of Femoral Preparation***

After the appropriate anterior, posterior, and distal femoral cuts, turn your attention to the tibia. It may be appropriate at this point to check the extension and flexion gaps again. The flexion gap is determined by the space between the femur and the tibia at 90° flexion, and the extension gap is determined by the space between the femur and the tibia at full extension. This can be a guide to the amount of resection needed on the tibial side and, equally important, to the need for future ligamentous release.

***Tibial Resection***

The tibia is generally resected perpendicular to its long axis. The anatomic axis of the tibia is in 3° of varus. Implant systems initially attempted to replicate this slight varus profile. Because of the inability to reproduce angular cuts about the knee precisely, often an attempt to produce a slight, 2° to 3° varus will produce a 5° to 6° varus cut, which has been shown to lead to early component loosening. Therefore, attempt a perpendicular cut with the knowledge that a slight varus cut plus 2° to 3° should not significantly alter clinical results. We prefer to use an extramedullary technique.

- Select a tibial cutting guide that allows for multidirectional orientation, including rotation resection height, varus-valgus alignment, and posterior-tibial tilt. In general, place the rotational alignment of the tibial cutting edge such that the profile of the cutting guide is centered on the medial edge of the tibial tubercle. This is best determined by sighting down on top of the tibia in the so-called “bird's-eye view” (Fig. 108.21). Once the rotation used for the cutting guide is determined, provisionally pin it in place.

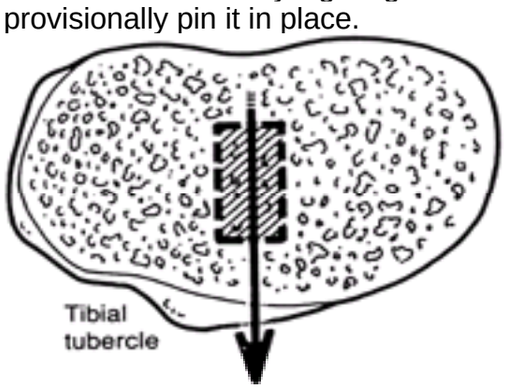


***Figure 108.21.*** Overhead view of the right tibia. To establish correct rotation, the tibial component should align just medial to the tibial tubercle. (From Insall JM, ed. *Surgery of the Knee,* 2nd ed. New York: Springer Verlag, 1991, with permission.)

- Next, secure the yoke of the distal end of the tibia cutting guide above the ankle. Take care not to put the yoke of the distal portion of the tibial guide at the ankle joint. Because of the fibula and widening of the ankle joint, this will produce an offset that can produce a varus deformity. Place the yoke approximately two thirds of the way down the tibia to ensure as neutral a cut as possible. It is imperative that this yoke be secured to the tibia.
- Place the tibial alignment cutting guide such that it is in the proximal region right over the center of the tibial tubercle. The bulk of the patellar tendon may tend to bias the cutting jig medially, producing a more varus angulation, so a smaller footprint for the cutting block is recommended. Distally, place the tip of the cutting guide over the anterior tibialis muscle compartment, in general parallel to the anterior border of the tibia. All of these landmarks can generally be palpated. Take care in patients with severe foot deformities, such as rheumatoid arthritis, that have abnormal landmarks. Avoid the general tendency to produce a varus cut. If the tibial cutting guide allows for medial-lateral translation of the distal portion of its guide, almost always place it medially so that the tip of the cutting guide is over the anterior tibialis tendon (Fig. 108.22).

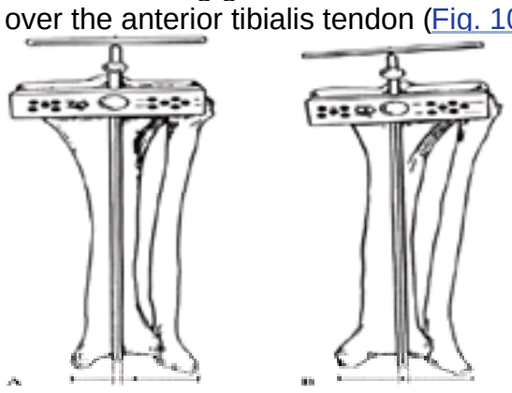

***Figure 108.22.*** Position of tibial cutting jig: In **A,** the guide is aligned with the anterior tibial tendon and first web space of the toes, producing an appropriate cut. In **B,** the alignment jig is centralized on the ankle joint, which is too lateral, resulting in excessive varus in the cut of the tibial plateaus.

- After the varus-valgus position has been determined, set the tibial height. A variety of guides are available that can confirm the position of the cutting jig relative to the tibia, including thin flat curved wing-shaped devices, or jigs that can measure from the cutting surface to fixed points above the tibial surface. In general, in most knees, there is one so-called “normal” tibial plateau; the other is worn. We prefer to take 10 mm off the “normal” side. This usually results in only slight subchondral resection on the “abnormal” side. Place the anatomic tilt or anterior-to-posterior caudal downslope of the tibia at approximately 5°. If the implant system has built-in posterior tibial tilt in the tibial tray, then a neutral cut can be made. Avoid putting the tibial plate into extension, which can produce a tight flexion gap and decreased motion (Table 108.4).

| |
|---|
| Varus alignment |
| Avoid by using a small footprint cutting guide that avoids the patella tendon |
| Avoid medial offset at the ankle by aligning with the anterior tibial tendon insertion or second ray |
| Malrotation–congruence in extension, contribution to varus |
| Elevation of joint line due to an oversized femoral component |
| Reverse tilt. This produces a tight flexion space. |

***Table 108.4. Pitfalls of Tibial Preparation***

- Size the tibial component to provide the largest possible area to reduce force per unit of area while avoiding overhang of the tibial plateau, particularly posterolaterally. The rotation should match the femur in extension, which typically is at the medial third of the tibial tuberosity.

### *Saving the Posterior Cruciate Ligament*

Several steps can be taken to preserve the PCL.

- Make a slot just in front of the PCL using a reciprocating saw. Place an osteotome with parallel sides in front of the PCL. With the osteotome in place, use a reciprocating saw to cut on the medial and lateral aspects of the insertion of the PCL, thus preserving a bone block to which it is attached.
- Then resect the proximal tibia, protecting the medial collateral ligament on the inside of the knee, the patellar tendon on the outside of the knee, and the posterior vascular structures.
- Then lift off the tibial plateau in one piece after releasing it from the soft-tissue attachments along its periphery.

### *Balance of the Knee*

At this point, perform rigorous medial and lateral ligament balancing, and flexion and extension gap balancing using appropriately sized blocks. Alternatively, if the femoral preparation has been completed, trial components may be inserted and ligament balance checked. In general, balance the knee with soft-tissue releases rather than by bony cuts.

### *Ligament Balancing*

Depending on the complexity of the knee replacement, ligament balancing can be straightforward or complex. Plan to have more constrained implants available if the preoperative deformity is excessive. Specifically, in patients with greater than 15° of varus or valgus deformity, it may be necessary to move to a more constrained implant. These implants can make up for deficient medial or lateral collateral ligaments. However, remember that constrained knee implants have had poor longevity.

There are seven main points of ligament balancing that must be achieved for an arthroplasty to be successful. These are listed in Table 108.5. Surgical techniques of reconstruction can differ widely. In the patient with minimal to moderate deformity, with acceptable surgical instrumentation from a modern TKA kit, balancing can be as simple as placing the trial components and checking the seven points of balancing (Table 108.5) to ensure that the jigs did their work. More complex knee deformities may require release of the posterior capsule, the posterolateral corner, lateral collateral, iliotibial band, or the MCL from its tibial insertion. At this point, balancing may require conversion from a posterior cruciate–retaining prosthesis to a posterior cruciate–sacrificing and replacing prosthesis, because the PCL can at times contribute to deformity, particularly in the patient with severe pre-existing deformity.

| |
|---|
| 1. Achieve full extension of the knee. |
| 2. Achieve good medial-lateral balance at full extension. |
| 3. Achieve good medial-lateral balance at 90° of flexion. |
| 4. The patella must track well during full motion without touching it. |
| 5. See that maximal flexion occurs with the patella reduced and without excessive rollback of the femur on the tibia. |
| 6. Demonstrate good rotational balance in extension when relative rotation of the femoral and tibial components is compared. |
| 7. Overall varus-valgus alignment must be correct. |

***Table 108.5. Seven Points of Ligament Balancing***

### *Varus Deformity*

Varus is the most common and often the simplest deformity to correct. However, in extreme cases, it can be as challenging as any knee deformity.

- Varus deformity can be resolved by making the tibial cut perpendicular to the axis of the tibia and taking a minimal cut medially. However, commonly there is still medial tightness, particularly in extension, after appropriate bone cuts.
- Further steps include removing medial osteophytes on the femur and tibia, and releasing the joint capsule at the medial side of the tibia with careful attention to preserve the continuity of the MCL. If this does not achieve balance, the MCL can be released from its distal insertion on the tibia. Use a subperiosteal dissection of the medial collateral ligament from the tibia. It can be either partially or completely released from its insertion on the tibia with a very low amount of force to break up any remaining Sharpey's fibers connecting the ligament to bone (Fig. 108.23).

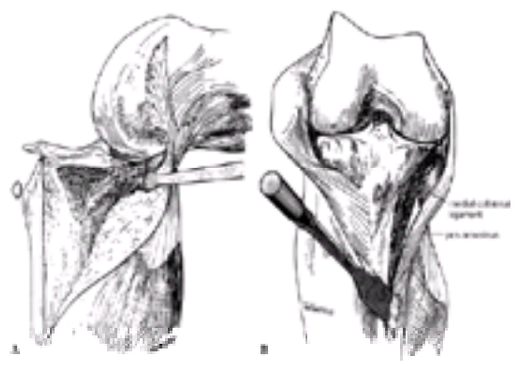

***Figure 108.23.*** **A:** Completed varus release. **B:** The superficial medial collateral ligament can be detached if necessary.

- Additional releases can include the pes anserina as a secondary constraint medially. Release the posterior capsule and PCL if further correction is needed, and finally, the origin of the medial gastrocnemius can be released (Table 108.6).

1. Excise all offending osteophytes.
2. Release subperiosteally the deep medial collateral ligament.
3. Release subperiosteally the superficial medial collateral ligament.
4. Consider release of the pes anserina.
5. Release the posterior capsule.
6. Release the origin of the medial gastrocnemius muscle.

***Table 108.6. Techniques of Sequential Varus Release (Do These in Sequence from 1 to 6)***

### *The Valgus Knee*

The valgus knee is technically more difficult to realign and balance. After appropriate resection of the femur and tibia, a persistent valgus deformity due to ligamentous imbalance requires a release of the lateral structures.

- The tightest structure is usually the iliotibial band with the knee in full extension. Release this from the inside out using a #15 blade perpendicular to the long axis of the iliotibial band at the joint line. In the more severely valgus knees (greater than 15° degrees), more extensive lateral releases may be necessary.
- Starting from the anterior direction, subperiosteally take the supporting lateral structures off the femoral condyle. The popliteus tendon inserts just anterior to the lateral epicondyle.
- Then remove the lateral collateral ligament from its epicondylar insertion in a subperiosteal fashion. This dissection can be carried down to the posterior lateral aspect of the capsule. The biceps femoris is rarely released.
- The iliotibial band can be released at Gerdy's tubercle. It is important to perform these releases sequentially, releasing structures only as necessary (Fig. 108.24).

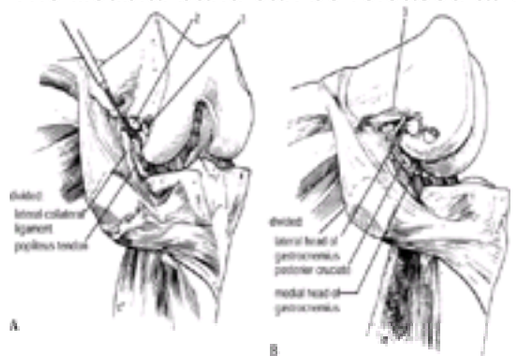

***Figure 108.24.*** Valgus release to balance the knee. **(A)** First, release the iliotibial band with the knee in extension from the inside out, perpendicular to the long axis of the band and at the joint line with a #15 blade. It may also be released at Gerdy's tubercle. **(B)** If the knee is still tight, release more by detaching the structures (1,2 and 3) attaching to the lateral epicondyle using subperiosteal dissection. The biceps femoris rarely requires release.

With severe valgus deformity, a more stabilized arthroplasty should be available in case posterolateral instability results from excessive lateral release or medial instability results from MCL incompetence. In general, more severe lateral and medial corrections are more easily dealt with using cruciate-substituting devices because of the potential for a contracted PCL, which in itself may be the limiting factor in deformity correction (Table 108.7).

1. Release the iliotibial band at the joint line.
2. Release the popliteus tendon at its femoral insertion.
3. Subperiosteally release the lateral collateral ligament at the femoral epicondyle.
4. Release the posterolateral capsule and posterior cruciate ligament.
5. Rarely is biceps tendon release necessary.
6. Finally, assess the need for supplemental stability with a different implant.

***Table 108.7. Soft Tissue Release for Valgus Deformity (Do These in Sequence from 1 to 6)***

Combined deformities, specifically valgus flexion contractures, are often the most challenging and require careful evaluation of the anatomy of the knee. A more aggressive distal femoral resection combined with lateral and posterior releases and perhaps a more constrained knee prosthesis may be the best solution.

### *Flexion and Extension Gap*

At this point, it is imperative to recheck the flexion and extension gaps of the knee. With the knee in full extension and with gentle traction on the heel, place a spacer block to judge the relative tightness of the extension gap that was produced. At final fit, the limb should be near an anatomic 7° of valgus at the knee. Both the medial and lateral ligaments should be under equal tension and the leg should be in full extension. In the ideal situation, both the medial and lateral ligaments will be equally

tense. Then place the spacer block at 90° of flexion.

Unequal gap size is a frequent technical error (Fig. 108.25). Three situations exist in which imbalance of the flexion and extension gaps may occur. Test the patient for these imbalances intraoperatively, and correct whatever problem is detected.

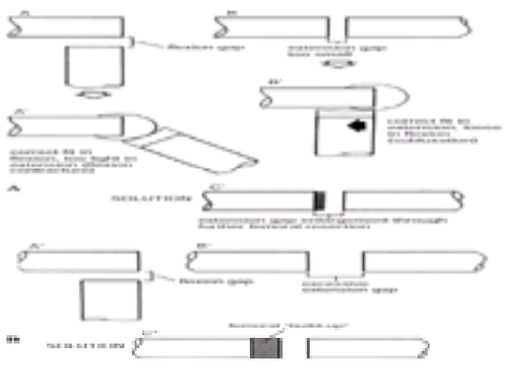

***Figure 108.25.*** **A:** The flexion gap in A is larger than the extension gap seen in B. As seen in A', this results in a knee that is too tight in flexion, producing a flexion contracture. As seen in B', if this problem is approached by using a thinner tibial component, the prosthesis will be too loose in flexion. As seen in C', the solution is to excise more bone from the distal femur. **B:** In A" and B", the extension gap is excessive. As seen in C", this is solved by a “build-up” on the femoral side. (From Insall JM, ed. *Surgery of the Knee,* 2nd ed. New York: Springer Verlag, 1991:632, with permission.)

1. *Too tight in flexion and too tight in extension.* This situation usually can be best corrected by either decreasing the thickness of the tibial insert or, if necessary, recutting the proximal tibia.
2. *Too tight in flexion and satisfactory in extension.* This situation may occur for several reasons. Too large a femoral component, especially on anterior reference knee systems, overstuffs the flexion gap. In this case, the femoral component can be downsized by one. A tight PCL will show five signs (Table 108.8). The PCL itself will have “bowstring” tension, excess rollback of the femur on the tibia produces “booking,” the tibial component tends to sublux anteriorly in its tray, and the femoral component subluxes off the femur. To correct this condition, recess the PCL off the femur or tibia, increase the slope of the tibial component, or increase the flexion gap by downsizing the prosthesis.

| |
|---|
| 1. “Bowstring” tension of the PCL. |
| 2. Incomplete flexion or forced flexion. |
| 3. Excess rollback occurs at greater than 90° of flexion. |
| 4. A tibial tilt develops whereby the tibial plate will tend to sublux anteriorly due to a too-tight flexion gap. |
| 5. The femoral component will tend to sublux anteriorly because of the tight posterior joint. |

***Table 108.8. Indications for Recession of the Posterior Cruciate Ligament***

3. *Tight in extension and satisfactory in flexion.* This situation is produced either by a posterior capsular contracture, which can be released, or by posterior osteophytes. If this maneuver does not work, more distal femur can be resected to produce equal extension and flexion gaps.

***Patella***

Patella preparation usually follows the application of femoral and tibial trial components after ligament balancing has been achieved. This should not be interpreted, however, as reducing the importance of the patellofemoral articulation, which has been the source of the majority of complications in TKA. This is particularly true with earlier, boxier femoral components or when the importance of patellar tracking was not as highly appreciated as it is now. The complication known as the patella clunk (48) (Fig. 108.26) results from fibrosis on the quadriceps tendon that catches on the anterior aspect of the femoral component.

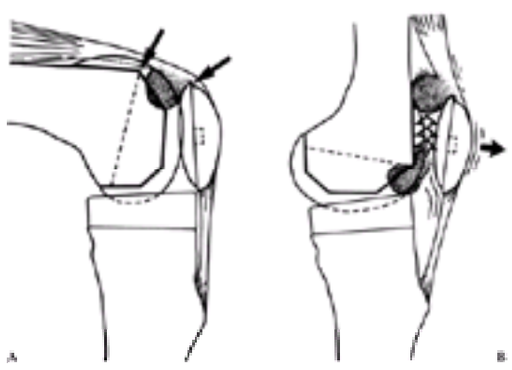

***Figure 108.26.*** Patellar clunk. **A:** Patellar clunk syndrome results from impingement of fibrous tissue between the patellar dome and the anterior femoral condyle. **B:** This problem usually causes pain during extension as the tissue is dragged over the condyle. Although this syndrome has been identified in some cases of posterior stabilized arthroplasty, it has also occurred with other prostheses. The offending fibrous tissue may be resected arthroscopically. (From Vernace JV, Rothman RH, Booth REJ, Balderston RA. Arthroscopic Management of the Patellar Clunk Syndrome Following Posterior Stabilized Total Knee Arthroplasty. *J Arthroplasty* 1989;4:179, with permission.)

Because the typical surgical exposure is medial parapatellar, the surface of the patella is easily accessible for cutting. Replace the resected articular surface so that the thickness of the patella stays roughly the same and the patellofemoral joint is not overstuffed. Avoid resection of too much bone, which can result in fracture of the patella. Position the patella medially on the flat resection surface to enhance tracking. Appropriate external rotation of the femoral and tibial components, along with lateral translation of the femoral and tibial components, can diminish the tension on the lateral retinacular structures and improve tracking.

- Begin preparation of the patella with reflection of the fat pad and synovium from around the periphery. Remove all osteophytes. Visualize the margin of the patella without compromising the patellar and quadriceps tendons.
- Cut the patella freehand or with one of many cutting jigs, the goal of which is to make a flat cut of the patella (Fig. 108.27). Asymmetric cuts can produce patellar tilt. Most components have pegs that are inserted into drill holes in the patella.

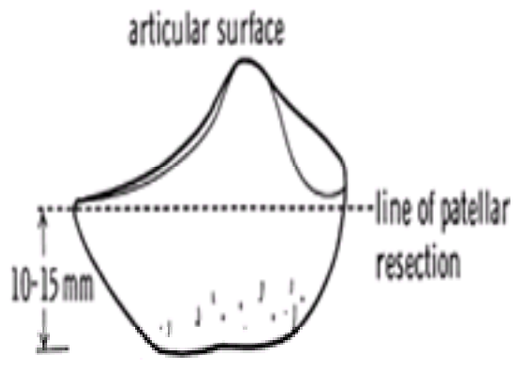


***Figure 108.27.*** Level of patella resection. (From Insall JM, ed. *Surgery of the Knee,* 2nd ed. New York: Springer Verlag, 1991:645, with permission.)

- Perform a trial of patellofemoral tracking using the rule of “no thumb,” or touch-free central patellofemoral tracking. There should be no subluxation. Removal of lateral patellar bone beyond the prosthesis may decrease tension laterally. Verify final tracking with the actual components, with the tourniquet down and before a lateral release is performed. With modern implants, the need for lateral release should be less than 5% of cases. A tibial tuberosity transfer or medial capsulorraphy, or both, may be necessary in extreme cases.

Resurfacing of the patella is controversial. There are several situations for which there is general consensus on the need to resurface. Most surgeons would agree that all knees with inflammatory arthritis should be treated with patellar resurfacing. People with severely arthritic, deformed patellae may benefit from patellar resurfacing. Some surgeons resurface the patella routinely.

### *Preparation for Cementing*

- In preparation for cementing, remove the trial components and lavage the bone surfaces to be cemented with normal saline. The attention paid to draping at the beginning of the case pays off now. A tight seal of the adhesive plastic drapes proximally and distally can ensure that fluid does not flow between nonsterile and sterile areas of the field.
- Clear the bone surfaces of debris. In addition, prepare sclerotic bone with a pick or drill point to produce multiple small shallow holes to encourage interdigitation of cement. Holes made in a line may predispose the bone to fracture, so make them random.
- After all bone surfaces are lavaged and debris has been removed, mix the cement. Then bring the final components into the field. Cement the tibia first. Vigorously pressurize the cement, in a doughy state, into the tibial plateau. After the cement is pressured, add a 1-mm-thick flat layer of cement on the tibial plateau. This uniform surface will ensure an adequate cement mantle in spite of tibial bone irregularities, which may not be apparent.
- Apply the tibial component and impact it into position. Vigorous impaction may improve cement pressurization, but take care not to fracture the tibia. Remove excess cement, particularly posterior to the tibial tray.
- For the femur, apply a donut-shaped piece of cement to the dry distal femur starting on both distal condyles and then onto the anterior femur. Pressurize the cement by finger and smooth it onto a uniform thickness. Do not allow cement to extrude posteriorly.
- Place a small amount of cement on the posterior rails of the femoral component and pressurize manually with the thumb. Remove excess cement before applying the femoral component.
- The femoral component must be applied neither in flexion nor in extension. Often, a pair of guiding posts or a notch, or both, aid the placement of the femoral component. Then impact the component into position and remove excess cement.
- Place a trial articular surface on the tibial component and extend the knee fully. It may find its own balance while the cement remains doughy. Flex the knee, remove excess cement, and bring the knee back to extension and keep it there until the cement has cured completely.
- The patellar component can be cemented with the knee extended. Apply the cement to the patella with tuberculin syringes that are cut off and have liquid cement aspirated into them. Use these syringes to pressurize the cement peg holes.
- Apply an even layer of cement to the undersurface of the patellar component with the inferior portions of the three pegs visualized. Place the patellar component onto the three holes in the patella and apply a patella clamp (5). Pressurize evenly and remove excess cement.
- After the cement has hardened, flex and extend the knee, and check the balance. Verify the seven points of ligament balancing (Table 108.5) and patellar-femoral tracking. If the patella lifts laterally while tracking, patellar bone beyond the polyethylene component can be removed on the lateral side. The effect is similar to that of a lateral release without the deleterious side effects of a soft-tissue release. If the patella still tracks poorly, then a full lateral patellar retinacular release can be performed.

### *Wound Closure*

- Irrigate all of the soft tissue, and prosthetic and bony surfaces of the knee joint vigorously. Deflate the pneumatic tourniquet and electrocoagulate bleeding points. In the posterior knee and the posterior lateral corner, the lateral geniculate vessels may bleed vigorously. It is important to perform pulsatile irrigation hemostasis to eliminate cement and other particles that cause rapid wear.
- After the knee has been irrigated, exchange the trial tibial articular insert for the final polyethylene liner. This is a good time to reassess knee balance, particularly in extension, and to determine whether moving up or down one size in tibial thickness may improve stability in flexion and extension. It is vital to check behind the posterior condyles of both the medial and lateral sides of the femur to ensure that extraneous cement has been removed. This cement can limit motion, or break off and cause third-body wear.
- Now close the knee. We prefer to close the extensor mechanism with a running monofilament resorbable suture. Closure of the extensor mechanism should be full thickness, with adequate purchase of soft tissue on both sides producing a watertight seal of the joint. This is easily achieved on the quadriceps side but can be very challenging distally. That is one reason why the initial incision is so important. A small amount of patellar tendon incorporated into the most distal portion of the incision of the arthrotomy gives a good purchase of the medial soft tissue and can ensure a watertight seal distally. A proficient closure helps prevent infection.
- After closure of the extensor mechanism, use another running monofilament to close the deep fat layer, which also includes the peritenon but not the deep dermis. Close the skin with staples. Dress the wound.

### *Tibial Tubercle Osteotomy*

Difficulty with exposure can be encountered in patients with severe angular deformity, with bone deficiency, or with prior surgery, or in obese patients. In these patients, we prefer to perform a tibial tubercle osteotomy rather than a quadricepsplasty. Our technique allows early mobilization, has excellent healing, and has a low complication rate.

The tibial tubercle osteotomy helps when the patella cannot be everted or when exposure is particularly poor. The tibial tubercle osteotomy is useful for treating other disorders around the knee as well.

- Perform the standard arthrotomy and then use an oscillating saw to make the osteotomy. We recommend an osteotomy that produces a 1-cm-thick bone block at the insertion of the patellar tendon into the tibial tubercle. It extends 8 cm distally on the tibia, tapering to a sharp edge.
- Initiate the tibial tubercle osteotomy by extending the medial periosteal incision along the anterior border of the tibia, marking the tubercle. Place the oscillating saw parallel to the tibia and make a 1-cm-thick cut beneath the tubercle from medial to lateral across the tibia with the saw but not through the lateral periosteum. Keep the lateral periosteal hinge intact laterally.
- Use an osteotome or a reciprocating saw to make a cut parallel to the joint line and approximately 2 cm distal to it at a 45° angle to meet the initial osteotomy site. Evert the patella and the tubercle, and the osteotomy should hinge open. Minimal release of the periosteal hinge may allow better mobilization. Releasing the lateral meniscus and lateral soft-tissue attachments at the capsule along with the fat pad may also improve access to the joint.
- At completion of the arthroplasty, closure of the osteotomy is simple. Reduce the patella into the femoral trochlear groove and then close the osteotomy. The lateral soft-tissue attachments have been maintained throughout the procedure.
- Insert four guidewires transversely approximately 1 cm deep and spread out along the cut surface of the tibia. Pass these guidewires through the periosteal hinge laterally. Then bend them over the top of the tubercle fragment, and tighten them securely into place. Anatomic reduction of the tubercle at the angled proximal cut restores the preoperative tension in the extensor mechanism. Closure of the soft tissues over the tibial tubercle osteotomy is assisted by a careful initial incision and arthroplasty.

## POSTOPERATIVE CARE

Begin motion according to your preferences and the clinical situation. Early motion can improve recovery and shorten the hospital stay. The continuous passive motion (CPM) machine is useful for obtaining early motion. The intent is to achieve extension early and then to advance the CPM by 10° or more each day to achieve 90° by the time of discharge from the hospital. Allow the patient to bear weight on the first postoperative day. Use a knee immobilizer only until sufficient quadriceps control has returned.

## PITFALLS AND COMPLICATIONS

Long-lasting complications of TKA are rare, and long-term success is generally the rule. Complications can be divided into mechanical and nonmechanical etiology.

### NONMECHANICAL COMPLICATIONS

The most common nonmechanical complications of TKA are thromboembolism and postoperative anemia.

Thromboembolism occurs in approximately 50% of patients mainly at or below the level of the knee; 10% are proximal to the knee. Pneumatic compression devices (52) and low-molecular-weight heparins (8) may lower this incidence somewhat. Prophylaxis against propagation and migration to pulmonary embolus is the mainstay of current treatment regimens (51), and pharmacologic and mechanical intervention should be routine postoperatively. Deep venous thrombosis is largely asymptomatic, and patients may be treated empirically after hospital discharge or undergo screening studies, the most popular of which is Doppler ultrasound.

Although TKA can be performed entirely under tourniquet to minimize intraoperative blood loss, calculated estimates of perioperative blood loss using hematocrits suggest a blood loss of 1500 ml for a cemented procedure, and 2000 cc for an uncemented procedure (17). Dropping the tourniquet for hemostasis before closure or use of a postoperative drain may actually increase overall blood loss (6,33). Although omission of these steps is considered by some surgeons to be contrary to general surgical principles, elimination of these steps rarely results in a surgically significant hematoma. Appropriate strategies for blood conservation include preoperative autologous blood donation (56), preoperative use of erythropoetin, and postoperative blood salvage (14,21).

Vascular injury during knee replacement is extremely rare and potentially disasterous (22,29,36).

Neurologic injury after knee arthroplasty is most common in the presence of valgus deformity, especially the flexion valgus deformity of severe rheumatoid arthritis (35). This is almost entirely restricted to peroneal nerve injuries and occurs less than 1% of the time.

Wound problems are often found in the multiply operated or medically compromised patient. Careful surgical approaches and aggressive treatment of postoperative wound problems can prevent infection. Local or free muscular flap coverage may be necessary for loss of soft tissues (15).

The infected TKA is a costly complication that occurs in approximately 1% of all knees (54). Preoperative antibiotics, carefully controlled operative environments, and meticulous surgical technique are required to minimize incidence. Host factors such as diabetes or corticosteroid treated inflammatory arthritis, surgical factors such as complexity of the procedure or postoperative drainage, and late exposure to hematogenous seeding by dental or urologic manipultion or infection elsewhere in the body may predispose the patient to infection (54). In the early postoperative infection, perform an open or arthroscopic lavage of the knee and administer systemic intravenous antibiotics. This approach may salvage the prosthesis. The standard of care for treating late or established infection is resection of the prosthesis, followed by a period of intravenous antibiotics and then reimplantation of a new prosthesis (see Chapter 109) (55).

### MECHANICAL COMPLICATIONS

The majority of the mechanical complications of total knee replacement can be minimized with careful attention to proper soft-tissue balance in all planes. Patients with more challenging preoperative deformity or motion restriction should be counseled about possible postoperative shortcomings. This is especially true with preoperative motion deficits. If a knee passes the seven points of ligament balancing intraoperatively, late instability should be uncommon. Minimizing the risk of instability as a complication is discussed in the technique segment of this chapter.

Aseptic loosening of the TKA is typically different from aseptic loosening of the total hip arthroplasty. Polyethylene debris–induced, macrophage-initiated osteolysis is considerably more rare. This problem is thought to be due to the different wear environment of the TKA. Threefold larger wear particles are produced in a shearing, less-conforming environment. These larger particles are less likely to induce a macrophage response and lead to a lower rate of aseptic loosening (39). Malalignment, especially of the tibial component in varus (48), can lead to mechanical subsidence of the tibial component and loosening.

Supracondylar femur fracture above TKA may occur owing to the inherently elevated loads at the proximal end of the anterior flange of the femoral component, owing to intraoperative notching of the anterior femur (1), or owing to the osteopenia of stress shielded bone under the femoral component. Rarely, osteolysis may contribute. Special cases include diaphyseal fracture above a stemmed femoral component or fracture through the stress riser between total hip and TKAs. Stable internal fixation with either a fixed angle device or a retrograde nail through an open notch is generally preferred (10,41) (see Chapter 20).

Tibial fracture is associated with malalignment or component loosening (30). The fracture may be bypassed with a stemmed prosthesis.

Prosthetic failure in contemporary arthroplasties is limited to delamination (39) or fracture of tibial polyethylene components or failure of metal-backed patellae (45). In the compromised environment with either mechanical imbalance or secondary to polyethylene failure, a tibial metal backing may rarely crack. This type of mechanical failure may often lead to particulate-induced synovitis and mechanical symptoms.

Extensor mechanism complications are the most common reason for revision knee arthroplasty. These complications were addressed in the technique section.

## AUTHORS' PERSPECTIVE

The modern TKA has instrumentation that facilitates reproducible alignment and proper ligament balance, and materials and design that permit functional and durable recovery of motion. When implanted in closely monitored and maintained surgical and rehabilitation environments, it has a remarkable and predictable record of success. Most of the mechanical and some of the nonmechanical complications of knee replacement are preventable by meticulous surgical technique with careful cross checking of anatomic landmarks and soft-tissue tensions with appropriate jigs.

## CHAPTER REFERENCES

Each reference is categorized according to the following scheme: *, classic article; #, review article; !, basic research article; and +, clinical results/outcome study.


+ 1. Aaron RK, Scott R. Supracondylar Fracture of the Femur after Total Knee Arthroplasty. *Clin Orthop* 1987;219:136.

+ 2. Andriacchi TP, Galante JO. Retention of the Posterior Cruciate in Total Knee Arthroplasty. *J Arthroplasty* 1988;3(Suppl):S13.

+ 3. Andriacchi TP, Galante JO, Fermier RW. The Influence of Total Knee-replacement Design on Walking and Stair-climbing. *J Bone Joint Surg [Am]* 1982;64:1328.

# 4. Antimicrobial Prophylaxis in Surgery. *Med Lett Drugs Ther* 1997;39:97.

+ 5. Bal BS, Sampath SA, Burke DW. A Technique for Cementing of the Patellar Component in Total Knee Arthroplasty. *Am J Orthop* 1995;24:358.

+ 6. Beer KJ, Lombardi AV Jr, Mallory TH, et al. The Efficacy of Suction Drains after Routine Total Joint Arthroplasty. *J Bone Joint Surg* 1991;73A:584.

# 7. Buechel FF, Pappas MJ. New Jersey Low Contact Stress Knee Replacement System. Ten-year Evaluation of Meniscal Bearings [published erratum appears in *Orthop Clin North Am* 1989;20:preceding 519]. *Orthop Clin North Am* 1989;20:147.

+ 8. Colwell CW Jr, Spiro TE, Trowbridge AA, et al. Efficacy and Safety of Enoxaparin Versus Unfractionated Heparin for Prevention of Deep Venous Thrombosis after Elective Knee Arthroplasty. Enoxaparin Clinical Trial Group. *Clin Orthop* 1995;321:19.

+ 9. Dennis DA, Clayton ML, O'Donnellal. Posterior Cruciate Condylar Total Knee Arthroplasty. Average 11-year Follow-up Evaluation. *Clin Orthop* 1992;281:168.

# 10. DiGioia AM III, Rubash HE. Periprosthetic Fractures of the Femur after Total Knee Arthroplasty: A Literature Review and Treatment Algorithm. *Clin Orthop* 1991;271:135.

+ 11. Engh GA, Petersen TL. Comparative Experience with Intramedullary and Extramedullary Alignment in Total Knee Arthroplasty. *J Arthroplasty* 1990;5:1.

+ 12. Font-Rodriguez, DE, Scuderi GR, Insall JN. Survivorship of Cemented Total Knee Arthroplasty. *Clin Orthop* 1997;345:79.

# 13. Future Demand for Orthopedic Skills to Soar. *AAOS Bull* 1999;47:14.

+ 14. Gannon DM, Lombardi AV, Mallory TH, et al. An Evaluation of the Efficacy of Postoperative Blood Salvage after Total Joint Arthroplasty: A Prospective Randomized Trial. *J Arthroplasty* 1991;1:109.

# 15. Klein NE, Cox CV. Wound Problems in Total Knee Arthroplasty. In: Fu FH, Harner CD, Vince KG, eds. *Knee Surgery,* Vol 2. Philadelphia: Williams & Wilkins, 1994:1539.

+ 16. Laskin RS, O'Flynn HM. The Insall Award. Total Knee Replacement with Posterior Cruciate Ligament Retention in Rheumatoid Arthritis. Problems and Complications. *Clin Orthop* 1997;345:24.

+ 17. Lotke PA, Faralli VJ, Orenstein EM, et al. Blood Loss after Total Knee Replacement: Effects of Tourniquet Release and Continuous Passive Motion. *J Bone Joint Surg* 1991;73A:1037.

! 18. Lotke PA, Williams JL, Corces A. Strain Characteristics of the Posterior Cruciate Ligament after Total Knee Arthroplasty. *J Knee Surg* 1993;6:104.

+ 19. Malkani AL, Rand JA, Bryan RS, Wallrichs SL. Total Knee Arthroplasty with the Kinematic Condylar Prosthesis. A Ten-year Follow-up Study. *J Bone Joint Surg [Am]* 1995;77:423.

! 20. Markolf KL, Finerman GM, Amstutz HC. In Vitro Measurements of Knee Stability after Bicondylar Replacement. *J Bone Joint Surg [Am]* 1979;61:547.

+ 21. Martin JW, Whiteside LA, Milliano MT, et al. Postoperative Blood Retrieval and Transfusion in Cementless Total Knee Arthroplasty. *J Arthroplasty* 1992;7:205.

+ 22. McPherson EJ, Friedman RJ. Arterial Thromboembolism Associated with Total Knee Arthroplasty: A Report of Two Cases. *Am J Knee Surg* 1992;5(Suppl):94.

+ 23. Merchant AC, Mercer RL, Jacobsen RH, Coal CR. Roentgenographic Analysis of Patellafemoral Mechanics. *J Bone Joint Surg* 1974;56A:1391.

+ 24. Mihalko WM, Krackow KA. Posterior Cruciate Ligament Effects on the Flexion Space in Total Knee Arthroplasty. *Clin Orthop* 1999;360:243.

# 25. National Center for Health Statistics. *1997 National Hospital Discharge Survey.* 1997.

+ 26. Pagnano MW, Hanssen AD, Lewallen DG, Stuart MJ. Flexion Instability after Primary Posterior Cruciate Retaining Total Knee Arthroplasty. *Clin Orthop* 1998;356:39.

+ 27. Ranawat CS, Flynn WFJ, Saddler S, et al. Long-term Results of the Total Condylar Knee Arthroplasty. A 15-year Survivorship Study. *Clin Orthop* 1993:286:94.

+ 28. Rand JA. Modular Augments in Revision Total Knee Arthroplasty. *Orthop Clin North Am* 1998;29:347.

+ 29. Rand JA. Vascular Complications of Total Knee Arthroplasty: Report of Three Cases. *J Arthroplasty* 1987;2:89.

+ 30. Rand JA, Coventry MB. Stress Fractures after Total Knee Arthroplasty. *J Bone Joint Surg* 1980;62A:226.

+ 31. Rand JA, Ilstrup DM. Survivorship Analysis of Total Knee Arthroplasty. Cumulative Rates of Survival of 9200 Total Knee Arthroplasties [see Comments]. *J Bone Joint Surg [Am]* 1991;73:397.

+ 32. Ritter MA, Faris PM, Keating EM, Meding JB. Postoperative Alignment of Total Knee Replacement. Its Effect on Survival. *Clin Orthop* 1994;299:153.

+ 33. Ritter MA, Keating EM, Faris PM. Closed Wound Drainage in Total Hip or Total Knee Replacement: A Prospective Randomized Study. *J Bone Joint Surg* 1994;76A:35.

+ 34. Ritter MA, Montgomery TJ, Zhou H, et al. The Clinical Significance of Proximal Tibial Resection Level in Total Knee Arthroplasty. *Clin Orthop* 1999;360:174.

+ 35. Rose HA, Hood RW, Otis JC, et al. Peroneal-nerve Palsy Following Total Knee Arthroplasty. *J Bone Joint Surg* 1982;64A:347.

+ 36. Rush JH, Vidovich JD, Johnson MA. Arterial Complications of Total Knee Replacement: The Australian Experience. *J Bone Joint Surg* 1987;69B:400.

+ 37. Scott RD, Thornhill TS. Posterior Cruciate Supplementing Total Knee Replacement Using Conforming Inserts and Cruciate Recession. Effect on Range of Motion and Radiolucent Lines. *Clin Orthop* 1994;309:146.

+ 38. Sculco TP, Choi JC. The Role and Results of Bone Grafting in Revision Total Knee Replacement. *Orthop Clin North Am* 1998;29:339.

! 39. Shanbhag AS, Bailey HO, Hwang DS, et al. Quantitative Analysis of Ultrahigh Molecular Weight Polyethylene (UHMWPE) Wear Debris Associated with Total Knee Replacements. *J Biomed Mater Res* 2000;53:100.

! 40. Shoemaker SC, Markolf KL, Finerman GA. In Vitro Stability of the Implanted Total Condylar Prosthesis. Effects of Joint Load and of Sectioning the Posterior Cruciate Ligament. *J Bone Joint Surg [Am]* 1982;64:1201.

+ 41. Sisto DJ, Lachiewiecz PF, Insall JN. Treatment of Supracondylar Fractures Following Prosthetic Arthroplasty of the Knee. *Clin Orthop* 1985;196:265.

+ 42. Stern SH, Insall JN. Posterior Stabilized Prosthesis. Results after Follow-up of Nine to Twelve Years [see Comments]. *J Bone Joint Surg [Am]* 1992;74:980.

+ 43. Stiehl JB, et al. In Vivo Determination of Condylar Lift-off and Screw-home in a Mobile-bearing Total Knee Arthroplasty. *J Anthroplasty* 1999;14:293.

+ 44. Stiehl JB, Komistek RD, Dennis DA, et al. Fluoroscopic Analysis of Kinematics after Posterior-cruciate-retaining Knee Arthroplasty. *J Bone Joint Surg [Br]* 1995;77:884.

+ 45. Stulberg SD, Stulberg BN, Hamati Y, et al. Failure Mechanisms of Metal-backed Patellar Components. *Clin Orthop* 1988;236:88.

+ 46. Thatcher JC, Zhou XM, Walker PS. Inherent Laxity in Total Knee Prostheses. *J Arthroplasty* 1987;2:199.

+ 47. Two Ways to Avoid Wrong Site Surgery. *AAOS Bull* 1998;46.

+ 48. Vernace JV, Rothman RH, Booth REJ, Balderston RA. Arthroscopic Management of the Patellar Clunk Syndrome Following Posterior Stabilized Total Knee Arthroplasty. *J Arthroplasty* 1989;4:179.

+ 49. Warren PJ, Olanlokun TK, Cobb AG, Bentley G. Proprioception after Knee Arthroplasty. The Influence of Prosthetic Design. *Clin Orthop* 1993;297:182.

+ 50. Waslewski GL, Marson BM, Benjamin JB. Early, Incapacitating Instability of Posterior Cruciate Ligament-retaining Total Knee Arthroplasty. *J Arthroplasty* 1998;13:763.

# 51. Weinmann EE, Salzman EW. Deep-vein Thrombosis. *N Engl J Med* 1994;331:1630.

+ 52. Westrich GH, Menezes A, Sharrock N, Sculco TP. Thromboembolic Disease Prophylaxis in Total Knee Arthroplasty Using Intraoperative Heparin and Postoperative Pneumatic Foot Compression. *J Arthroplasty* 1999;14:651.

+ 53. Whiteside LA, et al. The Anteroposterior Axis for Femoral Rotational Alignment in Valgus Total Knee Arthroplasty. *Clin Orthop* 1995;321:168.

+ 54. Wilson MG, Kelley K, Thornhill TS. Infection as a Complication of Total Knee-Replacement Arthroplasty: Risk Factors and Treatment in Sixty-seven Cases. *J Bone Joint Surg* 1990;72A:878.

+ 55. Windsor RE, Insall JN, Urs WK, et al. Two-stage Reimplantation for the Salvage of Total Knee Arthroplasty Complicated by Infection: Further Follow-up and Refinement of Indications. *J Bone Joint Surg* 1990;72A:272.

+ 56. Woolson ST, Pottorff G. Use of Preoperatively Deposited Autologous Blood for Total Knee Replacement Surgery. *Orthopedics* 1993;16:137.

+ 57. Worland RL, Jessup DE, Johnson J. Posterior Cruciate Recession in Total Knee Arthroplasty. *J Arthroplasty* 1997;12:70.

# CHAPTER 109

# REVISION KNEE ARTHROPLASTY AND ARTHRODESIS OF THE KNEE

*Kelly G. Vince*

**K. G. Vince:** Associate Professor, University of Southern California, Los Angeles, California, 90033.

Revision Knee Arthroplasty
History of Revision Knee Arthroplasty Surgery
Principles of Treatment
Clinical Assessment of Pain in the Failed TKR
No Pain Relief After Arthroplasty
Initial Pain Relief
Mechanical Symptoms Plus Discomfort
Physical Examination
Investigation of the Failed TKR
Aspiration of Joint Fluid
Radiographs
Bone Scan
Computed Tomography Scan
Indications for Revision TKR
Studies of Contemporary Revision Knee Arthroplasty
General Results
Results of Different Fixation Options
Reoperation After Revision TKR
Treatment of Infection
Revision of Unicompartmental Replacement
Preoperative Planning
The Role for Arthroscopy
Problems Requiring Surgery But not Total Revision
Wear
Global Stiffness or Instability
Osteolysis
Recurrent Effusion
Nine Mechanical Plans for Revision TKR
Loosening and Progression of Arthritis
Instability
Malrotation and Patellar Instability
Undiagnosed Pain
Breakage and Wear
Sepsis
Extensor Mechanism Rupture
Stiffness
Fracture
Planning: Skin and Soft Tissues
Surgical Exposure
Component Removal
Three-Step Revision Technique
Step 1: Reconstruct the Tibial Platform
Step 2: Stabilize the Knee in Flexion
Step 3: Stabilize the Knee in Extension
The Patella—A Fourth Step
Postoperative Care and Rehabilitation
Pitfalls and Complications
Alternatives to Revision TKR
Arthrodesis
Resection Arthroplasty
Amputation
Arthrodesis of the Knee
Indications
Infection
Arthritis
Neuropathic Joints
Surgical Techniques
Position of the Arthrodesis
External Fixation, Compression Arthrodesis
Arthrodesis with Intramedullary Nails
Arthrodesis with Plate Fixation
Pitfalls and Complications
Author's Perspective
Chapter References

## REVISION KNEE ARTHROPLASTY

Revision knee arthroplasty surgery is distinctly different from primary reconstructions of the arthritic joint. Although it is essential to master the principles and techniques of primary surgery before tackling revisions, primary surgery will not, by itself, prepare the surgeon to cope with the failed prosthetic knee joint.

Primary total knee replacement (TKR) usually follows a well-choreographed routine with a coherent sequence of steps that are easily performed with well-designed instruments. The bone is usually solid, ligaments are usually intact, and skin is adequate to cover and protect the reconstructed joint. Revision surgery does not offer this. Whereas in a primary arthroplasty, the surgeon can depend on instruments that refer to particular osseous landmarks, neither the landmarks nor good instruments are available for revisions.

The failed knee is in disarray. The failure must be explained at several levels: Why is there pain? Why has a component broken? Why is the joint unstable? If these questions are unanswered prior to revision, a suitable mechanical plan for the revision will not be apparent and the patient will not benefit from the revision.

Once the reasons for failure are clear, it is essential to plan the procedure carefully. Anticipation of problems mandates familiarity with the failed and revision implants. Wariness and improvisation are important in revision surgery. Alternative plans must be available. We seek perfection in the primary, and the “perfect compromise” in the revision.

The successful approach to revision knee arthroplasty includes adherence to general principles, an operative plan that addresses the cause of failure, and an orderly sequential plan for performing the surgery. I use a three-phase approach, as described later.

Long operations, extended hospital stays, and costly implants make revision surgery expensive (30). An increased incidence of complications increases costs as well. The latitude for errors—of both judgment and technique—is less than with primary TKR. In the final analysis, revision surgery is best avoided by a well-conceived and precisely executed primary knee replacement. Table 109.1 lists the steps to be taken in evaluating and planning for revision of a failed knee arthroplasty.

| |
|---|
| Assess the situation |
| What are the symptoms? |
| How do objective findings explain the symptoms? |
| What type of failure is this? |
| Why has this type of failure occurred? |
| How can I prevent this failure from occurring in the revision? |
| Explain how the revision surgery will address the problems |
| Visualize the three-step reconstruction with specific description of how the problems will be solved. |
| Plan for the required equipment and materials and implants. |

***Table 109.1. Confronting the Failed Knee Arthroplasty***

## HISTORY OF REVISION KNEE ARTHROPLASTY SURGERY

The techniques and results of revision knee arthroplasty have improved over the last two decades. No surgeon can perform revisions as they were done 20 years ago and expect to produce acceptable results. The contemporary standard of care has been elevated by progress in technique and implants.

Successful revision was at first inconceivable—even primary knee arthroplasties were approached with trepidation. In the 1970s, H. H. Young noted that the modified Walldius hinge prostheses had not survived more than 10 years (175). The high failure rates were compounded by damage to bone and ligaments (15). The results of second operations were abysmal, and arthrodesis was difficult to achieve. Many patients with failed hinge arthroplasties were forced to manage with resection arthroplasty (96), and some required amputation (125,174). This led to the belief that knee arthroplasty was a flawed surgery and that revision was not feasible.

As uni- and bicondylar resurfacing arthroplasties supplanted hinges, revision arthroplasty *became* feasible. In general, however, revision meant little more than a repeat of the original operation (73,131,149). Polycentric and interposition prostheses such as the McIntosh were poorly suited for revision arthroplasty (129,166). Later, tricompartmental resurfacing designs, without customization or specific adaptation, still led to disappointing results when used for revisions (32,58,85,124), except in selected cases (45,55,126). The incomplete understanding of the unique problems of revision surgery is obvious in articles that combined primary and revision knee arthroplasties in the same series.

Revision knee surgery was soon recognized as a distinct challenge. Rand and Bryan (124), in reviewing 427 revision knee arthroplasties performed between 1970 and 1980 with a wide range of implants, established three criteria to qualify the result as successful: (a) mild or no pain, (b) knee flexion to 90°, and (c) mild or no instability. Two years after revision surgery, only 59.6% of patients had “successful” results.

Linked constrained devices were sometimes regarded as necessary for revision surgery despite problems with the designs (82). They soon proved inadequate, often failing rapidly and dramatically (6,15). It became clear that the chance of a satisfactory result diminished with each operation (6,124).

The kinematic rotating hinge (KRH) was conceived as a device that had less than full constraint (it had full rotational freedom) but could still stabilize a knee in the absence of collateral ligaments. Rand et al. (128) described 23 revision arthroplasties with the KRH at 29–79 months (mean, 50 months) after surgery. The complication rates were high and the surgeons advised that the implant be limited to patients without functional collateral ligaments, whose knees could not be managed by soft-tissue reconstruction. Essentially, this was a prosthesis of last resort. It eventually became apparent that even very bad cases could be revised with specially adapted resurfacing or nonlinked constrained implants (136).

A single 1982 issue of the journal *Clinical Orthopedics* (19,75,146) made the point that revision surgery demands special principles, techniques, and implants. “Repeat primary replacement” is inadequate. Early revision was advised once evidence of component loosening appeared to avoid further bone loss. The patellar “turn-down” surgical approach, skeletonization of the bone ends, and a special axial slap-hammer extractor were developed for exposure and implant removal. Custom resurfacing designs with augmented metal trays and a central stem could substitute for bone defects and provide good fixation to compromised bone (2). Constrained condylar implants, which were stable to varus and valgus stresses but were unlinked, were recommended for knees without competent collateral ligaments. In this 1982 volume, Insall and Dethmers (75) stated that there was no longer an indication for hinge prostheses.

True understanding of revision surgery means diagnosing the cause of failure and reporting results accordingly. “Failed total knee arthroplasty” is not a diagnosis. Jacobs, working with Hungerford and Krackow (76), reported in an important paper that 83% of their patients who had definable mechanical problems achieved good or excellent results from revision arthroplasty. By contrast, the patients in whom no definable problem could be ascertained before their operations were not improved, emphasizing this important principle of revision knee arthroplasty. Their paper was significant because they analyzed the results of revision arthroplasty according to the cause of failure. Failed linked devices, comprising a minimum of cases (3/28), were all revised for loosening and presented considerable technical challenges. Instability and malrotation accounted for fewer cases but were easier to revise. Flexion was generally good, with mean values of 97° after revision from a preoperative mean of 86°.

Progress in understanding the failed knee arthroplasty has led to improved surgical techniques for revision, and superior results. Specificity in diagnosis and treatment have become the principles of revision knee arthroplasty.

## PRINCIPLES OF TREATMENT

*Establish a specific diagnosis.* The diagnosis or cause of failure must be established specifically prior to revision. Revision knee arthroplasty performed without a diagnosis is unlikely to help the patient.

Jacobs et al. (77) described four types of failure; Vince and Long (158) added four more causes of knee arthroplasty failure, and a ninth, fracture, can be included (Table 109.2). Thus, eight of nine causes of knee arthroplasty are amenable to revision surgery. A knee may exhibit facets of more than one type of failure. For example, a prosthesis with catastrophic failure of polyethylene with consequent osteolysis may also be loose. An infected knee may have developed loosening, and a loose arthroplasty may have become unstable. Try to distinguish the primary reason for failure.

| *Type* | *Diagnosis* | *Results after revision good/excellent (%)* |
|---|---|---|
| 1 | Loosening and progression of arthritis in a unicompartmental replacement | 76 |
| 2 | Instability | 100 |
| 3 | Malrotation and patellar instability | 100 |
| 4 | Undiagnosed pain | 0 |
| 5 | Breakage | — |
| 6 | Sepsis | — |
| 7 | Extensor rupture | — |
| 8 | Stiffness | — |
| 9 | Fracture | — |

TKR, total knee replacement.
Types 1–4: Jacobs MA, et al. Revision Total Knee Arthroplasty for Aseptic Failure. Clin Orthop 1988;226:78.
Types 5–8: Vince KG and Long W. Revision Knee Arthroplasty: The Limits of Press Fit Medullary Fixation. Clin Orthop 1988;317:172.

***Table 109.2. Nine Types of Failure That Are Indications for Revision TKR***

Figure 109.1*A* shows a patient with a dislocating patella misdiagnosed as collateral ligament instability. The use of a constrained implant of any type in the knee that remains malaligned will fail rapidly.

***Figure 109.1.*** **A:** Patellofemoral radiograph of patient who presented with symptoms of “giving way.” Reconstruction of medial collateral ligament was performed by her surgeon, but in fact the buckling was caused by patellar dislocation. **B:** Intraoperative photograph showing that the patella tracks directly over the lateral femoral condyle. The patellar tracking problem resulted from malrotation of the femoral and tibial components.

Instability may result from a host of causes including collateral ligament incompetence, component subsidence, pain that causes muscle inhibition, and extensor mechanism problems. Problems are often related, such as component malrotation and patellar instability. In fact, it would be fair to hypothesize that all patellar complications result from maltracking, which in turn is caused by malrotation of either the tibial or femoral components (Fig. 109.1*B*).

Inexplicable pain is a distinct cause for concern and caution but not an indication for surgery. A patient with pain in the presence of otherwise unremarkable findings may have had inappropriate expectations of the primary surgery and is unlikely to benefit from revision. Evaluate such patients thoroughly for infection, reflex sympathetic dystrophy (RSD), and component malrotation (Fig. 109.2).

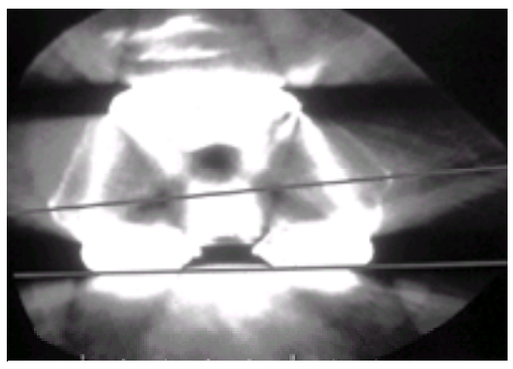

***Figure 109.2.*** Computerized tomography (CT) scan of distal femur showing internal rotation of the femoral component. In most cases, this leads to patellar complications. In some cases, the knee is painful and stiff without enough flexion for dislocation to occur. Internal rotation of the femoral component, difficult to diagnose on plain radiographs, presents as painful “mystery knees,” which are caused by internal rotation of the femoral and/or tibial components.

Breakage of prosthetic components was a major cause for revision in the early 1990s when earlier, flawed designs began to fail. After identifying which type of failure has occurred, determine the cause to ensure that the scenario is not replicated in the revision. The temptation in dealing with worn modular articular polyethylene is to replace it. This would however, simply reestablish the original environment of failure.

Stiffness is perhaps the best example of revision requiring a complete evaluation of the failed arthroplasty. There is rarely a quick or easy fix for this problem. The analysis must be very specific as to whether the knee lacks flexion, has a flexion contracture, or is globally tight. Each scenario requires a different approach.

*Do not perform a “repeat primary arthroplasty.”* The original cause of failure must be rectified and the damage caused by the failure must be reconstructed. Bone loss is common to most revisions. Fixation, which may have been straightforward in the primary procedure, can be achieved in the revision only with the use of bone graft and special implants if there are defects and the bone is too sclerotic for conventional cement techniques (Fig. 109.3).

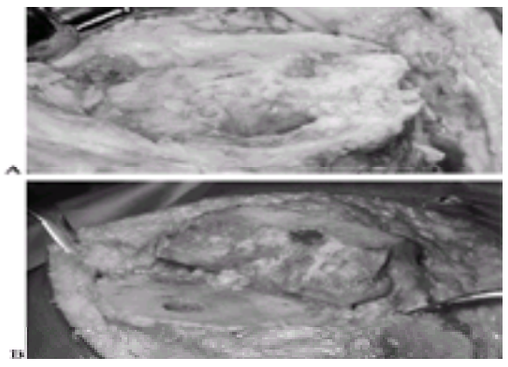

***Figure 109.3.*** **A:** Intraoperative photograph of the proximal tibia after removal of components. The bone is sclerotic, is covered with a fibrous membrane, and lacks the normal cancellous surface of bone seen in primary knee arthroplasties. **B:** Intraoperative view of healthy cancellous bone at the time of primary knee arthroplasty. Bone cuts have been made and the knee is ready for implantation.

*Pay attention to all aspects of reconstruction.* Once you have opened the failed knee arthroplasty and face the complete disarray and destruction, the course of action may be unclear. Although bone defects, for example, present an immediate challenge, they cannot be reconstructed without attending to joint stability and prosthesis fixation, and ultimately restoring functional kinematics to the joint. Skin and soft-tissue coverage problems are prevalent and require attention. Preoperative planning must take all of these issues into consideration.

*Use appropriate implant technology.* There is an unfortunate although understandable response by the surgeon faced with a badly failed knee arthroplasty: “This is such a bad-looking failure that I will certainly need a large, constrained implant if not a hinge!” This response is misguided. There are specific reasons to use built-in constraint in a prosthesis, to supplement fixation, and to add modular augmentations (components); these become apparent during the course of the revision. It is

inappropriate to simply use a “revision implant”—there are systems available that offer many options.

*Plan the surgery.* Planning ensures preparedness. It requires anticipation of all possible eventualities to avoid costly surprises in surgery. A thorough plan for revision TKR (Table 109.3) provides a way to ensure that the necessary equipment, instruments, graft material, and implants will be available at surgery, as well as a sequential intraoperative guide to what should be accomplished in the revision.

| |
|---|
| Evaluation, investigation, and diagnosis |
| Mechanical plan specific to the diagnosis |
| Intraoperative sequence |

***Table 109.3. Critical Components of a Plan for Revision Knee Arthroplasty***

A specific mechanical plan that identifies each shortcoming of the failed knee and describes a solution must be part of the plan. The tight knee with a flexion contracture, for example, will require an aggressive release of the posterior capsule and probably resection of additional distal femoral bone. This would not be appropriate for the unstable knee that needs to have the deforming forces (malalignment) eliminated, and stabilizing forces (ligament reconstruction or constraint) reconstituted. The sequential plan indicates when each part of the procedure should be carried out, and the mechanical plan describes what has to be accomplished.

## CLINICAL ASSESSMENT OF PAIN IN THE FAILED TKR

Most problem knee arthroplasties present with pain; clues for the cause of the pain are the time of onset and the nature of the pain (Table 109.4).

| *Pain relief after primary TKR* | *Consider these causes* |
|---|---|
| None—same pain as before TKR | Referred from spine or hip<br>Reflex sympathetic dystrophy<br>Low pain threshold<br>Poor indication for surgery |
| None—different pain after TKR | Sepsis<br>Reflex sympathetic dystrophy<br>Tight knee<br>Failed ingrowth |
| Pain relief for months to years, then new onset of pain | Sepsis<br>Mechanical failure<br>Wear/breakage<br>Loosening |

***Table 109.4. Evaluating Pain in the Problem Total Knee Replacement (TKR)***

### NO PAIN RELIEF AFTER ARTHROPLASTY

#### *Same Pain Persists*

If there was never any pain relief after surgery and essentially the same pain persists, consider referred pain from the hip or spine, preexisting sepsis, a tight arthroplasty, or failed bone ingrowth. Carefully evaluate the ipsilateral hip and the spine. Internal rotation of the ipsilateral hip that is limited on physical exam and reproduces the knee symptoms is very important. Treat an arthritic hip prior to knee arthroplasty, as much of the knee pain may be referred from the hip. A technetium (Tc) bone scan and injection of local anesthetic into the hip joint are helpful in the differential diagnosis.

Sometimes the preoperative pain is caused by a joint effusion. Pain accompanied by a general feeling of tightness or fullness, or pain that is perceived in the popliteal region, may be associated with a tense effusion. A postoperative effusion can reproduce this same pain.

Perhaps the most trying situation of all is the patient who, in retrospect, was suffering from sympathetically mediated pain (RSD). The characteristic history of inordinate pain relative to physical findings may be present, but cardinal symptoms such as skin hypersensitivity and intolerance to light touch, for example of bed sheets, may be absent. Awareness of the possibility is important to avoid unnecessary surgery. Consultation with a pain-management expert will help the patient cope with understandable frustration and anger. Lumbar sympathetic blocks are helpful to diagnose and treat this very difficult clinical situation.

#### *New and Different Pain*

Postoperative pain that differs from the preoperative pain requires a workup for infection. Culturing an aspirate of the knee, with the patient off antibiotics, is essential to establishing the diagnosis. The infected knee replacement may present with only slight warmth and swelling, or with frank drainage and soft-tissue loss. Some factors in the history create particular risk. Prior osteomyelitis adjacent to the knee, although dormant for many years, has been associated with a 15% infection rate in knee arthroplasty. Prior surgery (especially with implants), antimetabolite medications (including corticosteroids), and some medical conditions (notably rheumatoid arthritis) are suspected of increasing the risk of infection. The data, all from small series, are inconclusive.

A different pain that has been present ever since the surgery implies that the arthroplasty or the technique of insertion may be at the root of the problem. Knees that have been implanted with a greater degree of stability and tightness than the patient can tolerate may be painful. Malrotation of the components can also create a painful situation, with tightness and binding of the components.

Uncemented arthroplasties in which bone ingrowth has not occurred will usually be painful from the outset. During the recovery phase, as postoperative pain recedes, the patient is left with discomfort that is worse on weight bearing and that never really abates. Careful fluoroscopic examination of all the interfaces allows accurately directed plain radiographs that will illustrate this situation (44).

Reflex sympathetic dystrophy may also occur for the first time after knee arthroplasty surgery. The prospects for prompt resolution of the RSD are improved by early referral to a pain management specialist.

#### *Different Pain with Stiffness*

The knee that moved well prior to surgery but became stiff and painful afterward may be difficult. A knee prosthesis that is tight, for whatever mechanical or surgical reason, is likely to be painful. Conversely, a knee that is painful may hurt too much for the patient to participate in physical therapy. RSD is a frequent companion to the tight painful knee.

### INITIAL PAIN RELIEF

### *New Pain Months to Years Postoperatively*

The appearance of a new or different type of pain after a period of pain relief may indicate late infection. It is, however, the typical presentation for any number of mechanical failings in the knee, most commonly loosening and breakage. Breakage, or extensive wear of components, is probably encountered more commonly than loosening in the current era. Mechanical failure may also be accompanied by symptoms of lost motion, buckling, instability, or catching and grinding.

### *New Onset of Pain at Rest*

Pain of mechanical origin is usually present with activities. The loose prosthesis hurts more with weight bearing and the tight knee hurts more when flexion is attempted. Pain from a patellar fracture is worse with activities, such as stair climbing, that increase the force on the extensor mechanism.

Unremitting pain of new onset, present at rest and worse with activities, is characteristic of sepsis. RSD, which also produces rest pain, is unlikely to have a late onset. The presence of an effusion, from whatever cause, may result in pain at rest.

## MECHANICAL SYMPTOMS PLUS DISCOMFORT

Some patients describe mechanical symptoms that are accompanied by but are more serious than their pain. Instability may take different forms: The patient may experience buckling, caused by giving way of the extensor mechanism, in turn caused by either pain or subluxation of the patella. True varus–valgus instability is generally apparent and accompanied by malalignment when severe. The patient easily demonstrates catching or grinding that usually accompanies catastropic polyethylene wear.

## PHYSICAL EXAMINATION

Use the physical examination to evaluate the patient fully, with attention to the spine and hips as well as the knees. Evidence of infection or catastrophic polyethylene wear may lead to lymphadenopathy, particularly at the groin. Check the dentition and sinuses, as they may be sources of sepsis. Examine gait for evidence of instability and limp. The characteristic walk of a patient with hip pathology, dipping of the shoulder ipsilateral to the painful hip, may indicate referred hip pain.

**Observation** Swelling may affect the entire limb or just the knee joint. Local swelling may result from chronic scarring in a tight joint, extensive thickening of synovium, or an effusion. The entire leg may be affected by edema or lymphedema. Inability to fully extend the knee may result from an effusion or a fixed flexion contracture. There can be sympathetically mediated pain without the characteristic waxy pallor that is sometimes mimicked by tight swelling in the early postoperative period. Many normally healing knees will have a characteristic neurodermatitis rash that accompanies an area of paresthesia lateral to the skin incision (138).

**Palpation** Begin palpation of the knee with gentle stroking of the skin, which may reveal the hypersensitivity that is often associated with RSD. Increased warmth is common during the first 3 months after surgery and may be exacerbated by overly aggressive physical therapy. Increased warmth out of context of the patient's recovery from surgery, however, is suggestive of sepsis. Palpate for specific areas of tenderness that may indicate a mechanical problem between the prosthesis and bone or the prosthesis and soft tissues. Palpate the posterior aspect of the knee to detect a popliteal or Baker's cyst, which reflects a large effusion, which may come from a failed arthroplasty. Palpate the pulses and evaluate for circulation to eliminate peripheral vascular disease as a possible cause of the patient's pain and to be certain that there is adequate circulation for reconstructive surgery.

**Motion** Motion must be quantified, with clear distinctions established between passive and active motion. The average flexion of most arthroplasties by 3 months following surgery will be about 115°. This is influenced heavily by the preoperative motion, so it is important for you to know what that was. It is unrealistic to expect that a revision arthroplasty will improve a patient with less than 90° of knee flexion if the patient had only 60° of flexion prior to the primary replacement. By contrast, the patient who flexes to only 60° but had near normal motion prior to the primary surgery may benefit from timely revision before the soft tissues contract.

**Strength** Pain or neurologic disorders may compromise apparent strength. The patient with spinal stenosis who has quadriceps weakness may behave like the polio patient who must “back knee” to walk. This may create loosening, wear, and instability in the arthroplasty.

Look for an “extensor lag,” which is due to extensor strength that is inadequate to extend the knee through its full passive extension. This can be caused by muscle weakness, inhibition due to pain, and anatomic and mechanical problems in the extensor mechanisms. Carefully palpate the extensor mechanism to look for sites of discrete tenderness or gaps, which may suggest patellar fracture or tendon rupture. Although some of these problems are treatable, chronic extensor lags can be difficult to eliminate completely with revision surgery.

**Instability** Most patients can demonstrate, if not describe, their knee instability. Determine precisely what type of instability is present and what the mechanical remedy will be. Many patients whose knees are buckling or giving way will use the term *instability* when the problem is in the quadriceps mechanism. See Table 109.5 for interpretations of instability symptoms and Table 109.6 for causes of buckling.

| Symptom | Interpretation |
|---|---|
| Pain | Any painful condition may cause pain inhibition and giving way of the knee (buckling). |
| Poor motion | Failure to achieve full extension increases the likelihood that the quadriceps will not be strong enough to maintain full extension. |
| Buckling (giving way) | Involuntary giving way is usually associated with failure of the extensor mechanism or true failure of the collateral ligaments. Pain from any source may be responsible. |
| Instability | Perceived instability with every step and even at rest is due to ligamentous incompetence, malpositioning of components, loosening with subsidence, or catastrophic wear. |
| Catching | Usually the knee catches when the patient tries to extend from a fully flexed position under load due to wear superior to the patella on the quadriceps tendon (i.e., patellar slunk syndrome). |
| Grinding | Catastrophic wearing through of polyethylene |

***Table 109.5. Patient Symptoms Associated with Instability***

| |
|---|
| Extensor mechanism pain |
| Quadriceps weakness |
| Patellar fracture |
| Patellar tendon rupture |
| Quadriceps tendon rupture |
| Patellar subluxation/dislocation |
| Effusion |
| Flexion contracture |

***Table 109.6. Anatomic Causes of Giving Way (Buckling) of the Knee***

Knees may dislocate in the anteroposterior (AP) plane, which occurs most commonly in flexion. The patient will be able to demonstrate this phenomenon, and you can confirm it with a conventional drawer test and posterior sag sign. Other methods of assessing instability, so useful in the normal knee, are not applicable to the arthroplasty. An arthroplasty with posterior or anterior instability in extension is likely to manifest global instability. The patient will probably walk in marked

hyperextension, if indeed he is able to bear weight at all.

Varus–valgus instability is disabling. The patient falters with each step and usually depends heavily on assistive devices. This type of instability is usually accompanied by significant malalignment, which has either been the cause or the result of the instability. Comparing the physical examination with the radiographs will reveal whether instability is from collateral ligament failure, loosening and subsidence of components, or destructive wear of polyethylene (Fig. 109.4).

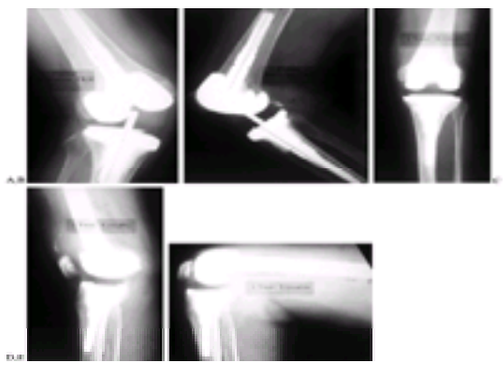

***Figure 109.4.*** AP (**A**) and lateral (**B**) radiographs of an 83-year-old woman with valgus instability in a revision arthroplasty despite the use of a constrained condylar implant. The problem results from loss of ligamentous integrity, combined with malalignment that increases the deforming force on the polyethylene of the tibial component. Weight-bearing AP radiograph (**C**) of a 71-year-old woman with a nonconstrained posterior stabilized implant showing good stability in the varus and valgus planes. Lateral weight-bearing radiograph (**D**) showing hyperextension. This patient had failure of the posterior structures as a result of spinal stenosis and weakening of the extensor mechanism, which caused her to walk with recurvatum to prevent buckling. Lateral radiograph in flexion (**E**) showing that the flexion gap remains stable.

The unstable knee arthroplasty may be deceptively stable to varus and valgus stress testing when locked in full extension, because of tension on the posterior structures. This knee, when flexed to about 30°, reveals significant instability. The medial collateral ligament (MCL), so crucial to good arthroplasty function, should be assessed for strength prior to revision. A knee may be unstable with a structurally intact but unbalanced ligament. It can be made to be functional with the appropriate releases or advancement. The knee in which the MCL has suffered complete failure becomes a far larger challenge.

**Extensor Mechanism** Palpation may reveal quadriceps or patellar tendonitis, or a fatigue fracture of the patella. Catches, clicks, or “jumping out of place” may result from subluxation or patellar dislocation. The patellar “clunk” occurs when scar under the quadriceps tendon catches under the anterior edge of the femoral component when the knee flexes deeply. This may initially be a small piece of synovium, which hypertrophies with each subsequent episode of catching. Eventually, the patient notes a dramatic “catch” when trying to rise from a seated position. The scar catches and with further effort escapes from the notch with an audible and sometime painful “clunk” (10,72). The offending scar may be excised arthroscopically or with a limited arthrotomy (Fig. 109.5).

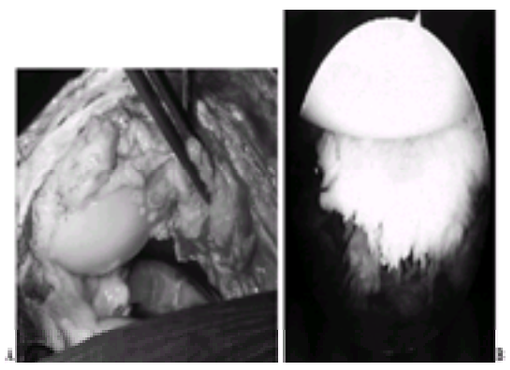

***Figure 109.5.*** **A:** Intraoperative view of scar on the quadriceps tendon that has been catching on the anterior femoral flange of a total knee arthroplasty, creating the patellar clunk. **B:** Arthroscopic visualization of scar on the quadriceps tendon, above the patella. Removal of this scar eliminates the patellar clunk.

Patellar subluxation is usually a dynamic phenomenon that requires careful observation of the functioning knee to diagnose. Patellae that dislocate are more easily diagnosed. Dislocation generally occurs with flexion, and the extensor mechanism often reduces with extension. Because component malrotation is usually at the root of the problem, there may be apparent differences in the amount of internal rotation of the flexed hip joints, only because the femoral component itself is internally rotated (Fig. 109.6). Internal rotation of the tibial component can be appreciated by looking at the externally rotated position of the foot with the patient sitting with his legs hanging over the edge of the examining table. Confirm any suspicion of malrotation with a computed tomography (CT) scan of the arthroplasty, which will allow comparison of the position of the prosthesis relative to the transepicondylar axis.

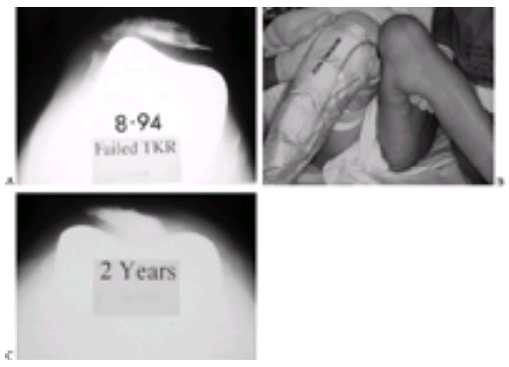


***Figure 109.6.*** **A:** Patellofemoral radiograph demonstrating the relationship between patellar maltracking and other complications, such as patellar component loosening and patellar fracture, all three of which are observed here. The underlying problem is internal rotation of the femoral component. **B:** Physical examination showing apparently greater internal rotation of the left hip than of the right, resulting from internal rotation of the femoral component. **C:** Two years after revision knee arthroplasty, the residual patellar bone, too small to resurface, does nonetheless track centrally after correction of the internal rotation of the femoral component.

## INVESTIGATION OF THE FAILED TKR

### ASPIRATION OF JOINT FLUID

Aspirate the joint and send fluid for a leukocyte count and for culture and sensitivity of aerobic, anaerobic, and fungal organisms (49,97). More than 25,000 leukocytes per cubic millimeter indicates sepsis, especially if a majority of the cells are polymorphonuclear cells. Repeat cultures if there is a negative culture from the aspirate of an arthroplasty suspected to be infected. Barrack et al. (7) found preoperative aspiration to be reasonably sensitive (75%) and highly specific (96%) for the detection of infection. Early work with biochemical evaluation of polymerase chain reactions of aspirated fluid promise a high degree of sensitivity and specificity (98). This assay,

however, is not yet widely available for the diagnosis of infection in knee arthroplasties.

## RADIOGRAPHS

### *Plain Films*

For evaluation of the problematic knee arthroplasty, take plain radiographs using 18-inch (45 cm)-long cassettes with the patient bearing full weight on the limb of concern. This usually reveals the extent of subsidence and of ligamentous laxity. Take the lateral projection with the patient standing and then with the knee flexed maximally. This technique reveals subluxation in extension as well as recurvatum and flexion contractures. The lateral flexed view helps the technician obtain a true lateral projection and reveals tibial femoral instability that may not occur in extension. The tibial slope is displayed best in this view, and flexion can be measured. Posterior osteophytes that may impede flexion are apparent, and the size of the femoral component is easy to measure.

The greatest technical challenge in obtaining accurate radiographs is control of rotation. Failure to do so creates studies with limited value. When it seems impossible to obtain a true AP projection of both components—on one radiograph the tibia is viewed correctly but on another it is rotated while the femur is viewed accurately—the diagnosis of malrotated component is established (Fig. 109.7).

***Figure 109.7.*** **A:** AP radiograph of an uncemented knee arthroplasty that has failed because of pain, stiffness, and patellar subluxation. While this shows a symmetric view of the tibial component, the femoral component is clearly viewed obliquely. **B:** The lateral radiograph shows that the femoral component has been translated posteriorly, further contributing to a tight flexion gap and poor motion. **C:** Patellofemoral view showing subluxation of the patella that has resulted from malrotation. This subluxation, creating the sense of impending dislocation with further flexion, causes the patient to stop knee flexion during physical therapy and contributes to poor motion.

Evaluate the patellofemoral joint with either “sunrise” or Merchant views (108) (Fig. 109.8). These projections assess patellar bone cuts and tracking. Component wear and breakage, bone fracture, and patellar dislocation are apparent.

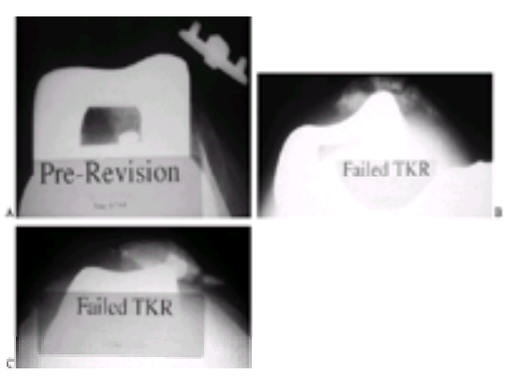


***Figure 109.8.*** Patellofemoral (Merchant) radiographs showing a range of patellar pathology: dislocation (**A**), fracture with component loosening (**B**), and lateral tracking and (**C**) catastrophic wear of a metal-backed button.

Plain radiographs of the contralateral knee, if no arthroplasty is present, may be of use to estimate revision component size. Do not commit to a component size at this point, because derangements in the soft tissues of a failed knee arthroplasty, whether abnormally tight or loose, may necessitate the choice of larger or smaller devices. Evaluation of serial radiographs of the failed knee arthroplasty are helpful to understand precisely what has led to the current situation. Finally, radiographs of the arthritic knee immediately prior to the primary arthroplasty are helpful. If these do not show very extensive arthritic changes, then search for other sources of referred pain. In the absence of these, the arthroplasty may have been performed prematurely, before serious arthritis had developed.

### *Fluoroscopic Views*

When tibial components were manufactured exclusively of polyethylene, radiolucent lines between the cement interface and the bone or component were much easier to visualize (Fig. 109.9*A*, Fig. 109.9*B*). Metal-backed tibial baseplates frequently obscure the interface so that fluoroscopic views are necessary to ensure that the x-ray beam is parallel to the interface (34).

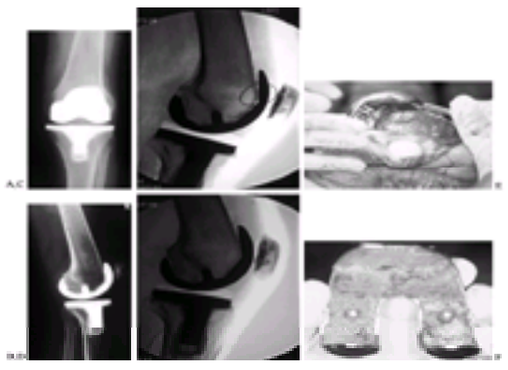

***Figure 109.9.*** **A:** AP radiograph of a painful, stiff total knee arthroplasty with ostensibly good alignment and well-fixed tibial component. **B:** Lateral radiograph of a painful, stiff, uncemented total knee arthroplasty with some radiolucency anteriorly. The component is slightly oversized. When templating for revision, use a slightly smaller femoral component to improve flexion. **C:** Fehring's (44) lateral fluoroscopic view of the anterior interface, showing extensive radiolucency and a limited ingrowth. **D:** Lateral fluoroscopic radiographs demonstrate complete radiolucencies in the posterior flange. This femoral component is loose. Attempts at flexion are painful because the tibia rocks the femoral component anteriorly. **E:** Intraoperative photographs demonstrating the ease of removal of the loose femoral component. **F:** Intraoperative picture of the uncemented femoral component, where there has been very little if any bone ingrowth.

When cemented femoral components loosen, progression to subsidence is usually rapid. Failure of bone ingrowth into the uncemented component can be a source of

pain that is difficult to visualize without fluoroscopic views (109). These may have to be oriented to each of the three major interfaces of the femoral component(anterior, distal, and posterior) (Fig. 109.9*C*, Fig. 109.9*D*, Fig. 109.9*E* and Fig. 109.9*F*). Fehring and McAvoy (44) evaluated 20 painful knee arthroplasties with this technique and identified 14 that appeared loose. At revision, all 14 were loose and improved by revision surgery.

#### *Stress Views*

Stress radiographs are not usually necessary for the assessment of problem knee arthroplasties, especially if standing films have been obtained. They can be useful, however, to quantify varus or valgus instability or when there is doubt as to whether fractures adjacent to the arthroplasty have healed.

### BONE SCAN

Technetium bone scans are highly sensitive but lack specificity in the evaluation of a painful knee arthroplasty (33,133). Hofmann et al. (70) found that these scans frequently demonstrate mild to moderate activity during the first year after surgery, whether cemented or uncemented fixation has been used. High variability has been noted. Loosening cannot easily be distinguished from bone remodeling in this period. Henderson et al. (64) studied three groups in whom they performed Tc bone scans: asymptomatic knees undergoing scans for other reasons, septically or aseptically loose arthroplasties, and painful knees without radiographic evidence of loosening. They concluded that sequential $^{99m}$Tc-MDP and 67-gallium (67-Ga) citrate scintigrams are useful for demonstrating the presence of aseptic and septic loosening in knee prostheses, and that pain with a normal scan appearance is probably not caused by loosening or infection. Gallium scans alone are not generally reliable, but indium-labeled (In-111) white cell scans—more specifically, In-111-labeled immunoglobulin G (In-111-IgG) scintigraphy—has been regarded as highly sensitive and fairly specific for detecting late infection (79,106). Scans, however, are never substitutes for aspiration of the joint.

### COMPUTED TOMOGRAPHY SCAN

Rotational malalignment of femoral and/or tibial components has been revealed as a cause of patellofemoral complications (16). There is agreement that the femoral component should be aligned parallel to the transepicondylar axis of the distal femur, defined as a line passing between the two attachment points for the collateral ligaments. CT scanning would be ideal to evaluate the rotational position of the femoral component relative to the epicondylar axis, were it not for its expense and the artifact created by the chrome cobalt in most femoral components. Nonetheless, many arthroplasties can be imaged sufficiently well with modern scanners to identify the epicondyles on the femur and the prosthesis, despite scatter of the beam. A plain radiographic method has also been described by Eckoff et al. (35,36).

## INDICATIONS FOR REVISION TKR

Revision knee arthroplasty may be recommended to a patient dissatisfied with his present knee arthroplasty when a specific mechanical diagnosis is made and a coherent plan for surgery to correct the problem can be established. Do not consider revision for trivial problems. Do not do a revision unless the benefits clearly outweigh the risk of complications.

Some indications are compelling. Treat the infected knee, except in highly unusual circumstances or when the infection is of very recent onset, promptly and aggressively with a two-stage reimplantation protocol. Revise a loose prosthesis because it will continue to damage bone. Patients with poor flexion or a flexion contracture deserve an adequate time period following surgery in which to work aggressively on rehabilitation. However, stiffness combined with obvious mechanical impediments to motion requires revision as early as 3 months after the primary arthroplasty. Patellar tracking problems, especially if symptomatic, inexorably lead to greater complications. They should be treated by a surgeon who is willing to revise the entire arthroplasty if necessary to correct underlying rotational problems (Fig. 109.10).

***Figure 109.10.*** AP radiograph of a painful, stiff uncemented total knee arthroplasty. The components appear large and there are circumferential radiolucencies around the tibial component. **B:** Lateral radiograph showing oversized femoral component, loose tibial component that has subsided anteriorly, and extensive osteophyte formation posteriorly. Calcification is also present in the patellar tendon. This knee had minimal flexion.

## STUDIES OF CONTEMPORARY REVISION KNEE ARTHROPLASTY

### GENERAL RESULTS

Despite improvements in knee revision knee arthroplasty, the results are inferior to primary knee replacement. It is difficult to compare the published series of revisions (38), because techniques and causes of failure differ widely. There is no large series with a minimum 10-year follow-up. The general dependence on constrained devices emphasizes the importance of a long-term study, given the high risk of late loosening with these implants.

There are three series that may be compared, using similar although not identical implants and techniques. Vince and Long (158) reported early loosening in a group of 44 revisions when nonlinked constrained implants had been implanted with press-fit modular stem extensions in patients with poor-quality bone. They reported good functional results without failures due to loosening when (nonconstrained) posterior stabilized implants were used, but a failure rate approaching 20% when constrained implants were necessary. In a follow-up to this study (159) that described 98 revisions, the use of constrained implants decreased. The overall failure rate was 7%, with instability a greater problem than loosening.

Haas et al. (60) described the results of 76 (nonseptic) revision knee arthroplasties with an average follow-up of 3.5 years (range, 2–9 years) with this modular system. Their overall failure rate was 8%.

Peters et al. (118) from Rush-Presbyterian Hospital in Chicago reported their experience with 57 revisions evaluated at an average follow-up of 62 months (range, 36–120 months). Four (7%) clinical failures were reported, three of which were due to instability after the implantation of a posterior stabilized implant. In this series, the surgeons resorted to nonlinked constrained implants in an unusually high percentage of cases, when compared to the experiences of Vince and Long (158) and Haas et al. (60).

### RESULTS OF DIFFERENT FIXATION OPTIONS

#### *Stems*

Use medullary stem extensions in revision surgery when bone quality is poor, defects have been reconstructed, or a constrained implant has been used. Many surgeons limit the use of methacrylate cement by using modular stems that can be applied to the femoral and tibial components and that achieve a tight fit in the medullary canal.

Fully cemented stems have been advocated by Rand et al. (114) at the Mayo Clinic, who reviewed 40 revision knees in 35 patients with the Kinematic Stabilizer (Howmedica, Rutherford, NJ) prostheses implanted with fully cemented stem extensions in one or both long bones. Radiolucencies did not progress, and no failures of fixation were reported. Although the superiority of fixation with full cementation is not generally disputed, there is still concern as to how destructive removal may prove

if one of these reconstructions becomes infected. Various intramedullary stem extensions are shown in Figure 109.11.

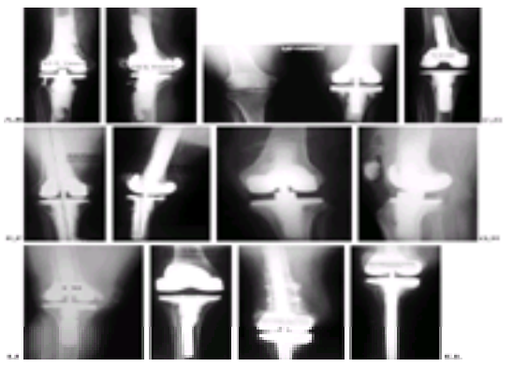

***Figure 109.11.*** Intramedullary stem extensions. **A,B:** Fully cemented nonmodular stem with the original Total Condylar III (Howmedica, Rutherford, NJ) femoral component, used here because of poor bone quality with a posterior stabilized nonmodular tibial component. **C:** Fully cemented fixed stem extension with a constrained articulation. **D:** Press-fit modular stem extension with methacrylate cement applied only to the component. Note the nonconstrained posterior stabilized prosthesis. The femoral stem extension is undersized relative to the medial lateral dimension of the endosteal canal—it does not, however, compromise the alignment of the prosthesis. The tibia, by contrast, fills the canal but as a result lies in valgus. **E,F:** AP and lateral radiographs of fully cemented, 145 mm stem extensions. Note the constrained articulation. These are indicated in the presence of poor quality bone when constrained prostheses are used. **G,H:** AP and lateral radiographs of a constrained articulation, necessitated by medial collateral ligament incompetence with fully cemented, short or “stubby” stem extensions. **I:** Loose noncemented femoral stem extension. Note the constrained articulation, which most likely contributed to the loosening and the increased valgus alignment resulting from the tight press-fit of a straight stem in an asymmetric bone. **J:** Offset stems, used without cement. Note the tight fit in the canal without compromising the alignment of the arthroplasty. This revision was performed for instability, and accordingly, a larger femoral component was selected. **K,L:** Extremely long uncemented stem used in a second reimplant for sepsis in a patient who had already failed one two-stage reimplantation. These very long stems have been used to stabilize large structural allografts and should never be fully cemented.

### *Uncemented Revision TKR*

Several investigators continue to evaluate uncemented revisions. Mow and Weidel (113) described 15 revisions in selected cases, of which eight had both components implanted without cement. Two required revision for tibial component loosening. In a later study with uncemented porus-coated anatomic (PCA) revision components, 6 (16.6%) of 36 revisions failed. Three of these were for tibial component loosening.

Cementless primary and revision knee arthroplasties have been developed by Whiteside over the last two decades. In 1993, Whiteside (167) reported the results of 56 cementless knee arthroplasties followed for a minimum of 2 years after surgery. The technique is based on rigid fixation of the implants into the remaining shell of distal femur and proximal tibia. Morcelized cancellous bone was employed to fill all defects. There were two failures of fixation. Uncemented revision knee arthroplasty is appealing but technically demanding.

### *General Bone Defects*

Numerous techniques have been developed to reconstruct deficient bone in revision surgery. There may be fundamental differences between bone defects—what works for one patient may not work for another, and proven techniques for primary arthroplasty are not always useful in the revision. Elia and Lotke (37) described their experience with 40 revision arthroplasties in the presence of significant bone loss. They reported good results but wisely commented in their conclusions on the importance of (a) restoring the mechanical alignment of the knee with accurate component positioning; (b) filling all bone defects with bone, cement, or modular spacers; (c) using stems to assist in component support; and (d) adherence to soft-tissue balancing.

### *Modular Augmentations*

Modular prosthetic systems have become widely available for revision knee arthroplasty, enabling surgeons to deal with the numerous different problems that present at revision. Typical systems include augmentation for tibial and femoral components. Although these are usually regarded as a means of reconstructing defective bone, each has a specific kinematic implication that can be exploited. For example, the distal femoral components can tighten the extension gap of the knee selectively and if used on one condyle alone will alter alignment. A medial distal femoral augmentation increases valgus alignment. This effect is most dramatic on the posterior condyle, where symmetric medial and lateral augmentation will tighten the knee in flexion and an augmentation on one side will change the rotation of the component. Internal malrotation of the femoral component, observed commonly in knee arthroplasty, can be corrected with a posterior lateral augmentation. The proximal tibia can be reconstructed reliably with augmentation blocks and wedge-shaped augmentations. Rand (122,123), reporting 41 consecutive revision arthroplasties with cruciate retaining or posterior stabilized prostheses, supported the reliability of modular augmentation in revision knee arthroplasty.

### *Allograft*

The failed knee arthroplasty is often so destructive of bone that innovative approaches are required. Large custom prostheses, highly regarded in tumor reconstructions, have not been as successful in revision total knee arthroplasty. Massive structural allografts have, however, been used extensively, with surprisingly good results (Fig. 109.12). Mow and Wiedel (112) described 15 revision knee arthroplasties with large segmental, cavitary, or combination defects that were reconstructed with structural allografts. These were followed for 30–101 months, with one failure directly related to the graft.

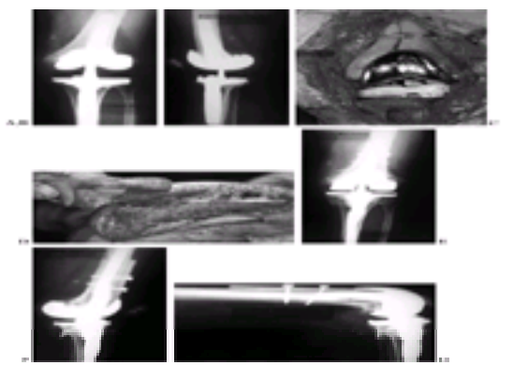

***Figure 109.12.*** Structural allografts. **A:** AP radiograph of a failed revision total knee arthroplasty. The amount of missing bone would have been better managed with structural allografts. Failure occurred due to loosening and instability. Note the excess valgus alignment despite the femoral stem extension. **B:** Lateral radiograph of failed revision total knee arthroplasty. **C:** Intraoperative photograph of a distal femoral structural allograft applied to the second revision. **D:** Intraoperative photograph of a proximal tibial allograft shaped and ready to be applied to the proximal tibia. Fixation is achieved by the interlocking sculpted shape that maximizes contact area, and by the intramedullary stem on the tibial implant. **E:** AP radiograph of a second revision knee arthroplasty with distal femoral and proximal tibial allografts. **F,G:** Lateral radiograph of second revision in extension and flexion.

One of the most extensive experiences with allograft reconstruction of the knee has been at the University of Toronto. Ghazavi et al. (53), reporting the surgical experience of Gross et al. (57), found that of 30 knees with either distal femoral or proximal tibial allograft reconstruction, seven (33%) ended as failures at an average of 50 months (range, 24–132 months) of follow-up. The failures were due to infection in three, tibial component loosening in two, fracture of the graft in one, and nonunion of the graft to host in one. They concluded that “properly applied allograft can be used to reconstruct massive bone defects, provide stability and support for

implants, and restore bone stock in the event that additional operative treatment is necessary."

Whiteside (167) has avoided the use of large structural allografts by packing defects with cancellous bone. Even large structural defects have been reconstructed this way, applying 6-inch medullary stems to bypass the defects. Whereas the stems were smooth and uncemented, the components themselves were porous coated. Generally good results were described in a series of 20 knees, with persistent pain requiring revision in only one patient.

Tsahakis et al. (148) described structural allografting for large uncontained defects in 19 cases. The results were good at an average of 2.1 years, representing a preliminary experience with the technique.

An innovative approach, borrowed from hip arthroplasty surgery, is that of impaction grafting (Fig. 109.13). Some surgeons have used this term to describe compaction of cancellous bone in small contained defects, but Ullmark and Hovelius (150) have employed the technique in the medullary canal in three patients. Their results are promising at 28 months of followup.

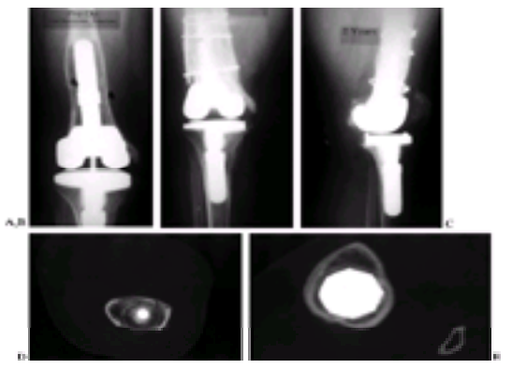

***Figure 109.13.*** Impaction grafting. **A:** AP radiograph of a loose revision arthroplasty that was performed 4 years earlier as a reimplantation after infection. The constrained component has contributed to loosening, which has been further complicated by a fracture of the femur. **B,C:** AP and lateral radiographs of second revision total knee arthroplasty with impaction grafting of the femur, further secured with medial and lateral strut allografts because of a fracture. **D:** CT scan of the femur, proximal to the femoral component, showing consolidated impaction grafting and strut allografts in place. **E:** CT scan of proximal tibia showing a press-fit stem extension without impaction grafting.

### *Constrained Prosthesis*

There have long been attempts to stabilize difficult knee arthroplasties using constrained and even hinged prostheses. There is a general, although not universal, preference for unconstrained implants where feasible. This places greater demands on the surgeon, who must reestablish stability and motion with the patient's own soft tissues. There are times in the operating room when soft tissues are lacking and it is difficult to stabilize the arthroplasty without resorting to mechanical constraint. When mechanical substitution for soft tissues is needed, what devices are available and to what extent are they reliable and effective?

Although constrained prostheses promise stability, they do so at the risk of an increased incidence of loosening. Linked, constrained devices (hinges) have enjoyed popularity in some centers (13) but generally have been abandoned because of poor results (6,62,74). Rotating hinges, although still linked devices, have been employed as an alternate (128,142).

The nonlinked constrained devices have held more promise. They are constrained to rotation and provide stability to varus and valgus forces and also resist posterior dislocation in flexion. However, they lack the hyperextension stop that is integral to the hinge. The Kinematic Total Condylar III prosthesis (Howmedica, Rutherford, NJ) was the original nonlinked constrained device. Mechanical substitution for collateral ligament function was provided by a prominent tibial eminence that rested between the femoral condyles. Both tibial and femoral components featured nonmodular, narrow-diameter intramedullary stems that were fully cemented into the medullary canal. The results with these implants proved surprisingly good (24,71,92,121,132).

To avoid the introduction of methacrylate cement deeply into the medullary canal, modular stem extensions were added to achieve a press-fit inside the canal, and cement fixation could be reserved for the cut bone surface of the tibia and femur. Haas et al. (60) with 76 cases concluded that there was no significant difference in the failure rates when uncemented stems were used with 57 (75%) posterior stabilized or 19 (25%) constrained implants. They did not study revisions for sepsis. They reported a total of six failures, two of which were the result of aseptic loosening. One failure was in the posterior stabilized articulation group (1.75%), and the other was in the constrained condylar group (5.3%). The experience of Vince and Long (158) revealed that of 44 revisions (which included revisions for sepsis), all three (23%) failures occurred in the group of 13 with constrained articulations.

See Table 109.7 for a comparison of three series by Haas et al. at the Hospital for Special Surgery in New York) (60), Peters et al. at Rush-Presbyterian Hospital in Chicago (118), and Vince et al. at Los Angeles (159).



***Table 109.7. Comparison of Revision TKR Results***

## REOPERATION AFTER REVISION TKR

The results of revision knee arthroplasty may be summarized in the Mayo Clinic experience with reoperations after revision knee arthroplasty surgery (145) (Table 109.8). Loosening is not the major cause of failure. The more frequent problems require reoperations without revision. The Mayo Clinic group reviewed 655 revision knee arthroplasties and discovered that 46 (7%) of them required a total of 60 (9%) additional surgeries. The extensor mechanism was the most common site of problems leading to reoperation in 19 knees (41%).

| | Stuart et al. (145) number (%) | Vince et al. (159) number (%) |
|---|---|---|
| Total revisions | 655 (100.0) | 98 (100.0) |
| Total reoperations | 60 (9.2) | 17 (17.4) |
| Extensor mechanism | 19 (2.9) | 5 (5.1) |
| Loosening | 10 (1.5) | 4 (4.1) |
| Deep infection | 9 (1.4) | 2 (2.0) |
| Wound problems | 9 (1.4) | 0 (0.0) |
| Tibial/femoral instability | 8 (1.2) | 5 (5.1) |
| Stiffness | 4 (0.6) | 1 (1.0) |
| Wear debris synovitis | 1 (0.2) | 0 (0.0) |

***Table 109.8. Cause and Incidence of Reoperations after Revision***

The series by Vince et al. (159) (Table 109.8) included revisions for sepsis, which the Mayo series did not. Again, the extensor mechanism was the most common site of problems requiring additional surgery, not all of which were complete revisions. Whereas tracking problems and fractures of the patella may have roots in the surgical technique, extensor lag, which is one of the most perplexing complications of revision arthroplasty, is difficult to predict. It may be improved in some cases by a shortening of the extensor mechanism, accomplished with a distal advancement of the vastus medialis. Figure 109.14 shows distal advancement of the rectus femoris. Extensor mechanism allografts are new treatments that show promise.

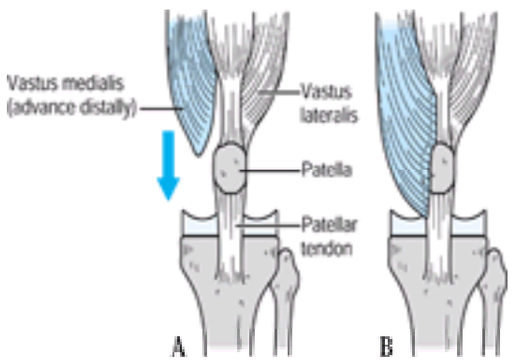


***Figure 109.14.*** Distal advancement of the rectus femoris.

**TREATMENT OF INFECTION**

Two-stage reimplantation protocols, although taxing for patient, surgeon, and health care system, have been recognized in North America as the most reliable means of eradicating infection (50,170). The original protocol, from the Hospital for Special Surgery in New York, has been followed for many years (171). Other series have described results with antibiotic-impregnated polymethylmethacrylate (PMMA) spacers that were implanted when the prosthesis was removed (14,59,65) (Fig. 109.15). Spacer blocks that allow some knee motion have been studied (69). Although most surgeons prefer spacer blocks because they provide local delivery of antibiotics, the maintenance of tissue planes, and improved stability during the period of explantation of the prosthesis, other surgeons have reported bone loss associated with the spacers (18). One-stage reimplantations, popular in some centers with extensive experience, do not yield the same high success rate (161). To reduce the number of surgeries, it may be argued that using a one-stage revision, and reserving a two-stage revision for the failures, makes sense (140).



***Figure 109.15.*** **A:** Cement spacer block seen on an AP radiograph of a primarily infected knee arthroplasty that has been removed. Originally, the patient had posttraumatic arthritis from a motorcycle accident. A spacer block, impregnated with antibiotic, was inserted between the deformed tibia and the femur. **B:** Templates for the fabrication of a custom tibial baseplate that will accept modular stem extensions. **C:** AP radiograph after reimplantation with custom-fabricated tibial baseplate and standard, fully cemented, short-stem extensions.

In the original reports, patients were selected for entry into the two-stage protocol. Other institutions have published experiences with unselected infected knee arthroplasties that have not been as good. In one of the most recent large studies, Hirakawa et al. (68) noted a 92% success rate when the infection complicated a primary knee arthroplasty in a patient who had no previous surgery (Table 109.9). This dropped to 41% when there had been multiple previous surgeries. *Staphylococcus epidermidis* is the most common organism in most series(50).

| | Cure rate (%) |
|---|---|
| Infecting organism | |
| Low virulence | 80.0 |
| Polymicrobial | 71.4 |
| High virulence | 66.7 |
| Diagnosis | |
| Osteoarthritis | 82.0 |
| Rheumatoid arthritis | 54.0 |
| Primary TKR only | 92.0 |
| Multiple previous surgeries | 41.0 |

From Hirakawa K, et al. Results of 2-stage Reimplantation for Infected Total Knee Arthroplasty. *J Arthroplasty* 1998;13:22.

***Table 109.9. Cure Rates for Infected TKRs***

When infection recurs after a two-stage reimplantation, the patient may be treated according to the protocol a second time. In their experience with 12 such patients, Backe et al. (5) at the Hospital for Special Surgery elected to arthrodese and not reimplant three of them. Infection did not return in the nine repeat reimplantations and

three fusions.

### REVISION OF UNICOMPARTMENTAL REPLACEMENT

The failed unicompartmental replacement poses a specific, controversial situation. Whether this represents a relatively easy revision is debated, although there is agreement that the failed unicompartmental replacement cannot reliably be reconstructed with another unicompartmental prosthesis. Figure 109.16 shows revision of a unicompartmental replacement.

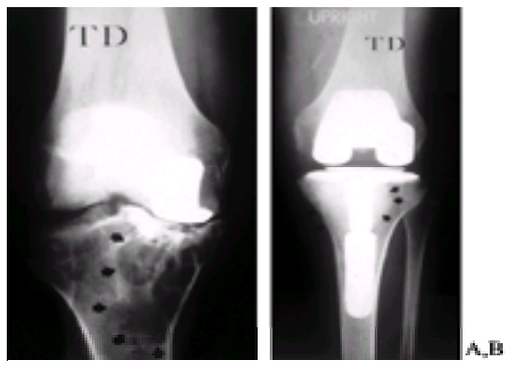


***Figure 109.16.*** Revision of a unicompartmental arthroplasty. **A:** Failed medial unicompartmental knee replacement in a 48-year-old male laborer. There is extensive osteolysis. **B:** Revision was performed with impaction grafting of a contained defect of the entire proximal medial tibial. *Arrows* indicate the extent of graft material. Closer to the keel, a thin layer of methacrylate cement can be seen.

Surgeons working at the Brigham Hospital in Boston (8) have presented data supporting the idea that the unicompartmental replacement may be used as a temporizing measure because it is an easier revision. As such, it might be an option for the younger patient who realizes that additional surgery is inevitable given a normal lifespan. The original study has been updated with similar conclusions (99).

Padgett et al. (117), collaborating with colleagues from the Hospital for Special Surgery in New York, have reported a different experience, and they feel that revision of a failed unicompartmental replacement presents much the same challenge as a failed tricompartmental replacement. They found significant osseous defects in 76% of failed unicompartmental replacements, with 62% of revisions exhibiting radiolucent lines. They reject the concept that the unicompartmental replacement is a more conservative surgery.

## PREOPERATIVE PLANNING

Preoperative autologous blood donation has been recommended for arthroplastic surgery in general, and this includes revision procedures. Thorough medical evaluation is, of course, essential, especially because the average age of revision patients is even older than that of primary patients in most series (88). The essential elements of planning, however, are the diagnosis of the failure and a detailed mechanical plan to rectify the causes of the failure (153).

## THE ROLE FOR ARTHROSCOPY

Arthroscopy has been used with limited success to rectify the problems of knee arthroplasty (78,110,163). It has virtually no role in the treatment of the infected knee arthroplasty, despite occasional reports of short-term success (47). Acute infections, at times amenable to open debridement with exchange of the polyethylene, often ultimately require a two-stage reimplantation protocol.

Some surgeons have used arthroscopy to release adhesions prior to manipulation of a stiff arthroplasty. This is not necessary when the manipulation is done within 6–8 weeks after surgery. The chronically stiff knee will generally require a well-planned complete revision. Some benefit has been described from arthroscopic resection of the posterior cruciate ligament (PCL) in the stiff cruciateretaining arthroplasty. In one series, 10 knees gained an average of 40° of flexion with this approach (169).

Patellar tracking problems are invariably the cause of patellar fracture, catastrophic wear, and component loosening. In turn, the tracking problems are generally the result of malrotation of the femoral or tibial components that require full revision surgery (16). Accordingly, arthroscopic intervention, limited to lateral patellar retinacular release, is inadequate. Even proximal realignment, failing as it does to correct the root cause of the tracking problem, will be ineffectual.

The disorder described previously as a “patellar clunk” has been identified most commonly in early designs of posterior stabilized implants. The offending scar can easily be resected from the quadriceps tendon arthroscopically, with complete resolution of symptoms (152). Other surgeons, applying arthroscopy to the resection of a variety of bands and fibroses, have had mixed results (100,104). The literature on arthroscopic evaluation and treatment of the problematic knee arthroplasty is summarized in Table 109.10.

| | Author | Year | Reference |
|---|---|---|---|
| Diagnosis | | | |
| Fracture of tibial polyethylene | Wasielewski and Frankel | 1989 | 164 |
| Wear | Mintz et al. | 1991 | 110 |
| Dissociation of tibial components | Davis et al. | 1991 | 28 |
| General diagnosis | Boyd et al. | 1991 | 13a |
| Fracture of tibial polyethylene | Havel and Giddings | 1994 | 63a |
| General diagnosis | Knight et al. | 1997 | 87 |
| General series | | | |
| General diagnosis and treatment | Wasielewski and Frankel | 1989 | 163 |
| General diagnosis and treatment | Johnson et al. | 1990 | 78 |
| Scar resection | | | |
| Patellar clunk | Vertrace et al. | 1989 | 152 |
| Lysis of adhesions | Lawrence and Kan | 1992 | 95 |
| Intra-articular fibrous bands | Lintner et al. | 1994 | 100 |
| Periprosthetic fibroses | Markel et al. | 1996 | 104 |
| Miscellaneous | | | |
| Hemarthrosis clearing | Zarnow et al. | 1996 | 176 |
| Release posterior cruciate ligament | Williams et al. | 1996 | 169 |
| Pseudomeniscus | Schur et al. | 1997 | 139 |
| Popliteus tendon dysfunction | Allardyce et al. | 1997 | 5 |

***Table 109.10. Role of Arthroscopy in the Failed Total Knee Arthroplasty***

## PROBLEMS REQUIRING SURGERY BUT NOT TOTAL REVISION

Problems may arise in knee arthroplasties that require surgery but not revision of the components. Most problems, however, are due to malposition of all components, and require complete revision. Complete revision offers the best chance to set everything right, and to ensure that compatible components are implanted. Techniques for component removal and for fixation of new devices have markedly improved. Complete removal is rarely as destructive as it previously was, even in the worst situation in which a porous-coated component has been well fixed with methacrylate cement (172).

### WEAR

Modularity was introduced as a means of limiting inventory and providing surgeons with options during surgery. There was also a hope that worn polyethylene components could simply be removed from the baseplates without disrupting the fixation interface. Although this is sometimes possible, bone may have been destroyed by osteolysis, the components may have loosened, and defects may need reconstruction, effectively eliminating simple polyethylene exchange as an option. In addition, the environment that has led to catastrophic wear should not be replicated. For example, thin polyethylene components or malalignment must be corrected by revision, not modular exchange.

Sometimes, however, alignment or instability can be corrected by exchanging the polyethylene for a custom-manufactured, angled bearing insert (Fig. 109.17). If the prosthesis permits, exchange to a more constrained insert may restore stability. The knee that is malaligned in valgus, for example, with a correctable deformity, can benefit from a polyethylene tibial insert that is manufactured on an angle so that it is thicker on the lateral side (141).

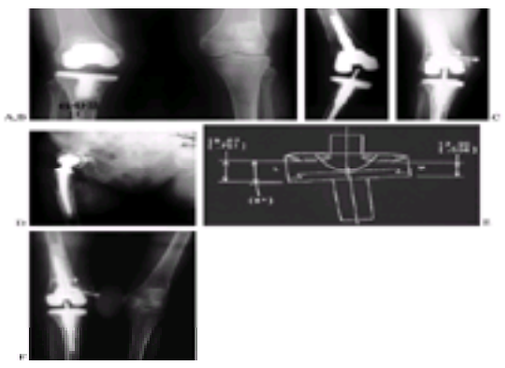

***Figure 109.17.*** An 83-year-old patient with recurrent valgus instability in a primary revision and second revision. **A:** AP radiograph of a primary knee arthroplasty in this patient, performed for osteoarthritis with valgus deformity where soft-tissue releases were not performed. The tibial component was placed in varus, and the femoral component in slightly excess valgus.**B:** AP radiograph of the failed first revision, where a constrained prosthesis was implanted. The femoral component was implanted with excess valgus (note the stem against the medial cortex). The tibial component had been extensively cemented and is also in valgus. The medial soft tissues failed despite the constrained component, largely because of malalignment. **C:** The patient underwent a second revision arthroplasty, which also failed. This AP radiograph shows that the femoral component was revised with full cement fixation of the stem extension and repositioning (note the femoral stem tip now against the lateral cortex) to reduce valgus alignment. A proximal advancement of the medial collateral ligament was performed. The tibial component was not revised because of the extensive cement fixation. Even the combination of decreased valgus alignment, lateral ligament release, medial ligament reconstruction, and constraint have not stabilized the knee. **D:** This situation was complicated because the patient had an older-model total hip arthroplasty on the same side as the unstable revision knee. The acetabular component is not medialized and the stem has a valgus neck–shaft angle. Accordingly, to restore a neutral mechanical axis to the arthroplasty below it, only 2° to 3° of valgus alignment will be required in the knee. Anything more imparts a large deforming force on the revision knee. **E:** Schematic diagram of a custom fabricated tibial insert with a 6° varus orientation. This allows the tibial angle to be corrected without removing the well-fixed tibial component. **F:** AP radiograph of a third revision knee arthroplasty. The femoral and tibial components have been left in place, but the angled tibial insert has been exchanged and the medial ligament has been reconstructed with vascular dacron. This arthroplasty has remained stable at a 5-year follow-up largely because of the reduction in the valgus deforming forces.

### GLOBAL STIFFNESS OR INSTABILITY

Global instability or tightness (equal instability or tightness in flexion and extension) can often be improved by limited revision surgery. Because the tibia has an equal effect on both flexion and extension gaps, revision of just the tibial component or even exchange of the tibial polyethylene alone may remedy the situation. However, an unacceptably thin polyethylene insert should not be inserted to increase motion. Revision of the tibial baseplate with resection of additional tibial bone and soft-tissue releases is preferred (156).

### OSTEOLYSIS

Osteolysis may present with large cystic destruction of bone but without loosening of components. It is sometimes feasible to graft these lesions with compacted particulate bone. This should be accompanied by an attempt to eradicate the mechanical environment that led to the failure in the first place; for example, at a minimum, exchange the tibial polyethylene (41). When there is any doubt as to the viability of the fixation, a full revision is preferred. At that time, there will be superior access to bone defects with better reconstruction possible. Figure 109.18 presents an illustrative case of reconstruction for osteolysis.

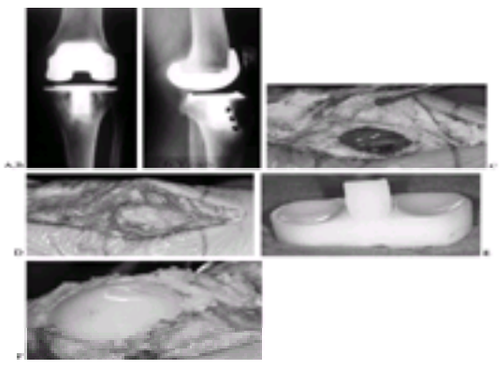

***Figure 109.18.*** Osteolysis treated with bone grafting. **A:** An unusual case of osteolysis in a well-aligned posterior stabilized knee arthroplasty 6 years after implantation. Osteolytic lesions are apparent on either side of the central tibial keel. **B:** Lateral radiograph of posterior stabilized knee arthroplasty at 6 years, showing a large osteolytic lesion (*arrows*) directly under the tibial tubercle. **C:** Intraoperative photograph of large osteolytic cavity viewed from the medial side of the tibial tubercle. A flap of periosteum has been elevated from the tubercle. **D:** The osteolytic cavity was curetted and packed with particulate iliac crest bone autograft combined with allograft. This eventually failed when the tibial component became loose and then required revision knee arthroplasty. **E:** The removed modular posterior stabilized tibial insert showing very little wear. **F:** The patellar component showing more extensive wear on the lateral facet.

### RECURRENT EFFUSION

On occasion, a patient may experience recurrent swelling in a knee arthroplasty. This is generally related to higher levels of activity and can be expected to subside. At times, this may be persistent and bothersome. Some result from wear debris. Debridement and synovectomy may prove beneficial, especially if the tibial polyethylene insert is exchanged and the cause of the wear is addressed.

Recurrent swelling may result from hemorrhage into the knee. A series of 30 such patients has been evaluated by Kindsfater and Scott at the Brigham Hospital in Boston (86). They found that nine knees responded to conservative care alone, and that open synovectomy was curative in 14 of 15 patients whose hemarthroses recurred regularly. They attributed the bleeds to entrapment of proliferative synovium or the fat pad between prosthetic components.

## NINE MECHANICAL PLANS FOR REVISION TKR

### LOOSENING AND PROGRESSION OF ARTHRITIS

Prosthetic loosening results from the victory of forces that favor loosening over those that resist it. The most important force resulting in loosening is generated by malalignment, most commonly varus alignment of the tibial femoral axis. The medial side of the tibia is overloaded, bone subsides, and the component is no longer solidly attached to bone. The solution is to reestablish the desired alignment of the limb. This is generally around 7° of valgus tibial femoral angle, but more specifically it is a neutral mechanical axis, as depicted by the line running from the center of the hip through the knee and ankle.

Most prostheses that fail because of subsidence and loosening will also have bone defects that must be reconstructed. Cement, particulate bone graft, modular prosthetic augmentations, and large structural allografts all play a role. The surgeon will need to anticipate these problems and plan to have the appropriate material

available.

Most knees that fail from malalignment have never had the appropriate ligament balance performed. A knee that is in varus prior to the primary procedure and then is implanted in varus is unlikely to have had an adequate medial release. Conventional ligament releases are appropriate for the majority of these cases. Increased joint constraint and the more arcane ligament advancements and reconstructions are usually not required.

When loosening has been the cause of failure, there will generally be a need for enhanced fixation at the time of revision. This will usually take the form of intramedullary stem extensions, which are usually modular additions to the prosthesis. These may be long and achieve three-point fixation inside the medullary canal, or they may be of wider diameter with more of a press fit. In selected cases, such as poor-quality bone where a constrained implant is planned, it may be appropriate to fully cement the stem with techniques commonly used in hip arthroplasty.

The loose prosthesis that was originally implanted with a porous ingrowth surface may no longer be amenable to uncemented fixation. The same requirements in terms of correction of malalignment and augmenting fixation are appropriate.

**INSTABILITY**

Instability, like loosening, can be viewed as the competition between two sets of forces, those that stabilize the knee versus those that induce the instability. Instability occurs in an anterior–posterior direction, or varus–valgus, or both.

The arthroplasty with anterior–posterior instability is usually dislocating posteriorly. This is usually because of failure to achieve a balance between the flexion and extension gaps. A flexion gap that is too large requires a polyethylene insert that is thicker than can be accommodated in extension. Anterior tibial dislocation can also occur in this situation, but it is observed less often because the hamstring muscles pull the tibia posteriorly. Excessive posterior tibial slope may drive the tibia forward, and anterior slope will contribute to posterior instability. Assess the slope prior to surgery and correct it during the revision.

Late posterior instability may result from erosion or rupture of the PCL, as has been described by Laskin and O'Flynn (94). It presents with instability, recurvatum, and synovitis around the PCL. Late posterior instability has also been noted as a consequence of progressive wear, which usually erodes the posterior articular surface of the tibia and results in the femur “rolling off” the back of the knee.

The strategy of revision requires that the knee be made tighter in flexion. This is solved by inserting a larger revision femoral component to decrease the size of the flexion gap. It is misguided to simply insert a thicker tibial polyethylene insert, because, although this may stabilize the knee in flexion, it will create a flexion contracture. When the flexion gap is too large to be stabilized by increasing the size of the femoral component, even in conjunction with a posterior stabilized design, it may be necessary to resort to a nonlinked constrained implant, with a higher tibial spine. Ligament advancements, anteriorly on the distal femur, can selectively tighten the knee in flexion (157). In addition, tightening of the extensor mechanism with a distal advancement of the vastus medialis will enhance the effect of the patella as a buttress against the distal femur to prevent posterior tibial dislocation. When a patellectomy is present, it may be necessary to perform this advancement. In the patient with a patellectomy, posterior tibial instability, and an extensor lag, implantation of an allograft extensor mechanism may prove very useful.

Varus–valgus instability can be exceedingly difficult to overcome. Valgus instability is most common and results from an incompetent or stretched-out MCL and valgus malalignment. The malalignment generates huge forces that stress the soft tissues on the medial side. Correction of alignment is an essential first step in trying to stabilize these knees. All attempts at stabilization, whether through the use of constraint in the prosthesis or soft-tissue reconstruction, are doomed without the appropriate alignment.

The preferred alignment of most arthroplasties may have to be reduced to less valgus when competence of the MCL is in question. Even though this may risk overload of the medial tibial bone, and loosening, it may be essential to decrease the valgus moment arm to stabilize the knee.

The desired alignment in these knees must be calculated carefully from full-length films that show the hip, knee, and ankle. Special attention is required when the patient has a hip arthroplasty in which the neck–shaft angle of the prosthesis is quite valgus, and especially if the acetabular component has been implanted in a somewhat lateral position. This patient may require as little as 2° of valgus tibial femoral angle at the knee to achieve a neutral mechanical axis.

Constrained arthroplasties intended to stabilize the knee may paradoxically be responsible for instability if they compromise alignment. These devices are commonly manufactured with a fixed bearing angle between the femoral component and the intramedullary stem extension that is required with most constrained devices. The asymmetry of the tibia combined with the goal of inserting larger-diameter intramedullary stems often results in up to 5° of valgus at the tibial component. In addition, if the femoral stem extension sits against the medial intramedullary wall, often the result of deficient lateral femoral condylar bone, there may be up to 12° of valgus in a knee that needs only 2°. The forces favoring valgus instability are huge and can shred a collateral ligament or dislocate a constrained implant. Correct alignment is paramount. No hinge can be expected to stabilize a malaligned prosthesis.

Just as the deforming forces must be eliminated, stabilizing forces must be restored through intact collateral ligaments or a constrained implant. When conventional releases are inadequate to stabilize the implant, mechanical constraint, ligament advancement, or ligamentous allograft reconstruction is required.

It will never be adequate to simply insert thicker polyethylene to restore stability to a knee where the collateral ligaments are either unbalanced or incompetent. Consider the MCL that has undergone plastic failure with elongation. If the knee is lengthened in an effort to equalize the lateral side with the pathologically long medial side, as progressively thicker polyethylene is inserted, the posterior structures remain intact and begin to limit flexion. This ultimately creates a knee with persistent valgus instability (due to failure of the MCL) in conjunction with a flexion contracture.

Instability can occur in conjunction with strong and healthy collateral ligaments. This usually is the result of loosening and subsidence of the components. When they are restored to a normal position, by reconstruction of bone defects and reestablishment of fixation, the knee is stable. Apparent varus instability is often from subsidence of the tibial component that protects the MCL. Instability associated with patellar dislocation is associated with malrotation of components. This must be corrected.

Global instability is often associated with gross loosening of the components and rupture of the extensor mechanism, all of which require treatment. Consider inherent soft-tissue deficiencies, such as Ehler-Danlos syndrome, or neurologic diagnoses, such as polio or spinal stenosis, which leave the patient with a weak quadriceps. This causes a “back-kneed” gait in recurvatum, which accelerates loosening. Hinges are sometimes considered in the treatment of the unstable knee, but they are only very rarely required. Greater attention to alignment, component size, and reconstruction of available soft tissues is usually more successful.

**MALROTATION AND PATELLAR INSTABILITY**

Malrotation of the components and patellar instability are usually linked (16). The internally rotated femoral component has a lateral femoral trochlea that is higher but more medial. The patella is likely to snap up and over it during flexion. In addition, the articular groove will be displaced medially, distant from the track the patellar needs to follow.

All patellar complications may be related to maltracking, which can lead to fracture of the bone or loosening of the polyethylene button. Wear of metal-backed buttons is accelerated by lateral tracking because the joint reaction force is focused on the lateral side where the patellar polyethylene is likely to be thin. Surgery for any patellar complication must consider the possibility of maltracking as a cause. Complete revision arthroplasty may be necessary.

The most common solution for internal rotation of the femoral component is the use of the posterolateral femoral component augmentation, which drives the component out of internal rotation. The epicondylar axis is the most reliable guide to proper femoral component orientation.

**UNDIAGNOSED PAIN**

The patient with undiagnosed pain should not be subjected to revision arthroplasty (77). Not knowing the cause of failure, the surgeon is unlikely to be able to achieve a cure. Some pain is the result of problems unrelated to the knee arthroplasty, such as referred pain from the spine or hip or sympathetically mediated pain. Infection must be considered: Aspirate the knee for cultures, cell count, and differential analysis. Internal rotation of the femoral component, difficult to diagnose on plain radiographs, can easily be quantified with CT. Discussion of such cases with an experienced colleague will benefit surgeon and patient alike. A precise diagnosis and mechanical plan will be necessary for all these patients.

## BREAKAGE AND WEAR

Catastrophic wear of knee arthroplasty components must be revised in such a way that the destructive environment is not replicated. Complete revision is usually required to correct the malalignment that may have been at the root of the problem, and to ensure that adequate polyethylene thickness can be accommodated. In this respect, the mechanical plan will resemble that for failure due to loosening. Revision to an updated prosthetic design in which adequate contact areas are provided to reduce wear is appropriate. The inevitable areas of osteolysis require graft reconstruction. Synovectomy is often important to eliminate wear particles and decrease persistent swelling.

## SEPSIS

Infections are multifactorial problems that are not easily treated (12). Open debridement of acute infections within 2 weeks of surgery or within a short period after the presentation of an acute infection in an established arthroplasty can be justified. Arthroscopic intervention is less likely to be successful in curing the infection. One-stage reimplantation is possible for the infected knee arthroplasty, but clearly the risk of recurrent infection is higher with this approach.

Two-stage reimplantation protocols are the most reliable method for the eradication of infection in knee arthroplasties. The best results of two-stage protocols are obtained after appropriate patient selection. Some infected knees, either because of the type of organism, the condition of the soft tissues, or the condition of the patient, inevitably lead to resection arthroplasty. Windsor et al. (171), with Insall, reported 1 of 38 infected knees with a recurrence of the same infecting organism at 4 to 10 years. Three other patients suffered recurrence with different organisms attributed to a compromised immune system. More recently, work from Cleveland identified specific risk factors that are associated with relatively poor results from the two-stage protocol (68).

The two-stage protocol is not simply a removal of the prosthesis. Rather, it is a detailed and disciplined medical and surgical approach to the problem that requires an aggressive debridement of the infected knee joint. The original protocol of leaving the knee devoid of foreign material has been supplanted by the insertion of a PMMA spacer block, loaded with antibiotics. This delivers high-dose local antibiotics, and it preserves tissue planes for later total joint reimplantation. In an effort to maintain motion, articulated spacers have been employed.

## EXTENSOR MECHANISM RUPTURE

Extensor mechanism rupture may be the worst problem in knee arthroplasty surgery, regarded by many as more difficult to treat than sepsis. Repairs of the torn tissue are notoriously ineffectual, but there has been a report of good results after transferring the semitendinosus, attached to its origin, as a means of reestablishing the integrity of the mechanism (17). Emerson et al. (39,40) have employed extensor mechanism allografts and reported excellent results. These grafts must be implanted with surprising tension, often at the cost of some flexion, for the patient to regain useful extensor strength. At the time of grafting, the tension of the extensor reconstruction can be checked by lifting the thigh. Passive flexion should be about 60°. Most patients will eventually gain motion of 90° or more.

As with so many other problems that require repeat surgery in knee arthroplasty, it is essential to consider what factors and forces may have led to the rupture initially. These must be corrected. The most common constellation of problems are those that increase the tensile forces in the extensor mechanism, such as an oversized femoral component, malrotation, excessively thick patellar construct, and so on. Figure 109.19 shows radiographs and intraoperative photographs of an extensor allograft.

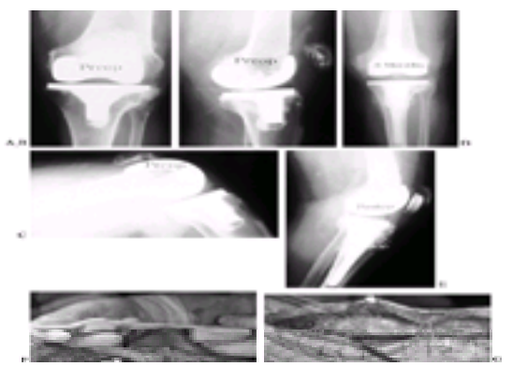

***Figure 109.19.*** Extensor allograft. **A:** AP radiograph of a failed total knee arthroplasty due to extensor mechanism rupture, poor motion, and malrotation in a 74-year-old woman with a contralateral above-knee amputation for congenital deformity. **B:** Lateral radiograph in extension showing an effusion and mild patella alta. **C:** Lateral radiograph in flexion confirming patellar tendon rupture. **D:** AP radiograph 3 months after revision surgery, with extensor mechanism allograft. **E:** Lateral radiograph showing extensor mechanism allograft with patellar component resurfacing, the host patella left in place, and wire cerclage fixation of the tubercle. **F:** Intraoperative photograph of an extensor mechanism allograft immediately prior to implantation, showing (*from left*) quadriceps tendon, patella, patellar tendon, and tibial tubercle. **G:** Intraoperative photograph showing alternative tibial tubercle fixation with two small fragment screws. The allograft is placed deep in the knee, directly against the components. The extensor mechanism is closed tightly, leaving only 45° to 60° of passive flexion intraoperatively.

## STIFFNESS

The stiff total knee arthroplasty has long been considered inappropriate for revision, as these knees often become stiff because of the patient's aggressive healing response. More frequently, however, the scar that is observed in these knees is the result of the stiffness and not the cause of the problem.

If the patient cannot easily bend at the knee fairly quickly after surgery, he is at risk for loss of motion and resultant scarring. This includes patients who are unwilling or unable to comply with physical therapy. Those whose pain is simply too severe after surgery to allow movement of the knee will undoubtedly suffer stiffness. Adequate analgesia and even readmission to the hospital for epidural analgesia under which motion can be initiated may be appropriate. Medical complications that make physical therapy difficult, as well as wound problems or a hemarthrosis, predispose the patient to stiffness.

Look for referred pain from either the spine or the hip that may preclude comfortable knee flexion, and treat the underlying problem. After this is resolved, revision to increase motion may be indicated.

Occult infection may lead to stiffness because of the associated pain and swelling. Aspiration is key to establishing the diagnosis. RSD may be difficult to diagnose. Lumbar sympathetic blocks are useful for diagnosis and treatment. These patients may respond to revision to increase motion, performed under continuous epidural anesthesia that is used for several days after surgery. Failure of bone ingrowth may cause pain throughout the rehabilitation period that precludes successful therapy. These patients benefit most often from revision to a cemented implant.

Mechanical factors may be responsible for the stiffness; these can be resolved during the revision to ensure that maximum motion is achieved. Like instability, poor motion may be caused by poor flexion, a flexion contracture, or global stiffness. The former two require different approaches, and the last a combined approach.

The mechanical factors that contribute to poor flexion are largely those that determine the dimensions of the flexion gap and the tension in the extensor mechanism. Oversized femoral components or those that are implanted too posteriorly make the knee tight and lead to stiffness. The PCL that was tight and should have been released or recessed at the time of primary surgery may need to be revised to a cruciate substituting design. Tibias that have inadequate posterior slope or, worse, anterior slope, require attention. Malrotation, causing the components to bind and jam painfully with flexion, may be responsible for poor motion. In addition, internal rotation of the femoral component may predispose to dislocation of the patella. The patient, sensing that a dislocation is about to occur as the knee flexes, will resist flexing, much like a patellar apprehension sign. This leads to scarring and the inability to flex.

The patella that has been cut obliquely or that has become too thick as the result of resurfacing makes it difficult to bend the knee. At the time of revision, this problem is easy to solve because there is adequate bone for removal of the prosthesis, resection of additional bone, and repeat resurfacing. Ultimately, the limiting factor to the improvement of flexion will be the extensibility of the quadriceps muscle. When poor flexion is chronic, it may be impossible to gain motion, because the muscle itself is

scarred and tight. In selected cases, a Thompson quadricepsplasty may improve motion but at the risk of sacrificing quadriceps strength (Fig. 109.20).

***Figure 109.20.*** Thompson quadricepsplasty. Isolate the rectus femoris tendon from the vastus medialis and vastus lateralis and release the medial and lateral quadriceps retinaculum as necessary. Lyse adhesions in the knee and excise the intermedius muscle, which is scarred down to the femur.

Flexion contractures are more easily improved by revision surgery. Exchanging the polyethylene for a thinner insert can be dangerous, risking instability in flexion. Revision surgery is preferred, with removal of the distal femur and aggressive posterior soft-tissue releases (156).

**FRACTURE**

Revision knee arthroplasty is rarely performed for the treatment of fractures, but this can be a very successful approach. Most common is a supracondylar femoral fracture. Most of these require treatment with conventional plates or locked intramedullary rods introduced either retrograde or antegrade (see Chapter 20). At times, however, the distal femoral fragment may be highly comminuted or osteoporotic. Revision with a distal femoral allograft will be appropriate.

Proximal tibial fracture or osteotomies (performed in an effort to correct arthroplasty alignment) that have not healed respond well to revision of the tibial component with an intramedullary stem extension across the fracture site.

## PLANNING: SKIN AND SOFT TISSUES

Many catastrophic wound problems may be prevented with prophylactic reconstruction of soft tissues. Tissue expanders have been used successfully in knees with multiple previous scars and adherent skin (54,102,115,137). Surgical transfer of muscle has the added appeal of enhancing blood supply to the compromised area; it can be performed prior to the revision or after removal of an infected component but prior to reimplantation. The gastrocnemius is the most easily transferred (52), but free flaps, although technically more difficult to transfer, have some added advantages (105).

## SURGICAL EXPOSURE

A standard anterior midline approach is effective in the majority of revision knee arthroplasties (Fig. 109.21) (see Chapter 3). Careful attention to detail in the release of scar and reconstruction of the “gutters” along the intermuscular septae adjacent to the femur are the secrets to a gentle patellar eversion without rupture of the extensor mechanism. A lateral patellar retinacular release facilitates exposure. More difficult cases may require an extension of the exposure either proximally or distally. Tibial tubercle osteotomy frequently is associated with complications (168,173). Proximal soft-tissue releases are easily performed. A patellofemoral “turn-down” is the most radical and is rarely required in even the most difficult revisions (147). Currently, a limited, very proximal transection of the quadriceps tendon, referred to as a snip, is favored (51). More aggressive exposure of the distal femur, to the point of skeletonizing, may be necessary for the stiff knee arthroplasty (1).

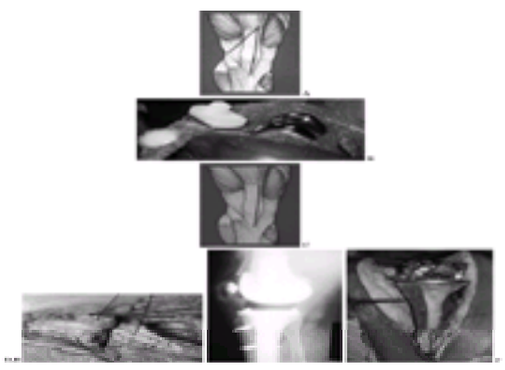

***Figure 109.21.*** Surgical approaches. **A:** The classic patellar turn-down arthrotomy derived from the Coonse Adams surgical approach to the knee. Some surgeons have advocated its use as a means of lengthening the extensor mechanism to increase flexion. This may produce a disabling extensor lag. **B:** Intraoperative photograph showing the unparalleled exposure with a full patellar turn-down. This technique is rarely if ever required. **C:** The modified quadriceps snip approach. Many surgeons angle the proximal transverse cut from more distal on the medial side to more proximal on the lateral side. This maneuver may not be necessary if the approach is made slowly, with careful attention to detail and the release of scar. **D:** Intraoperative photograph of the closure of the quadriceps snip, showing the sutures transversely across the quadriceps tendon. Clearly, these alone will not be adequate to resist the tensile forces in the extensor mechanism. The strength of the closure comes from the standard side-to-side closure of the arthrotomy. **E:** Lateral radiograph of a revision knee arthroplasty, in which a tibial tubercle osteotomy has been performed and secured with cerclage wires. Placing these wires poses a danger to the neurovascular structures behind the knee. **F:** Intraoperative photograph of the tibial tubercle osteotomy demonstrating excellent exposure but with compromise to the cylinder of the tibia with potential compromise of tibial component fixation.

## COMPONENT REMOVAL

Well-fixed components must be removed without damage to the underlying bone (Fig. 109.22). Several techniques have been developed, all requiring patience. The Gigli saw fits easily into the interface and was originally recommended for the removal of well-fixed, uncemented implants. The saw, however, may drift, in which case bone will be damaged (46). High-speed metal-cutting burrs have been employed to facilitate removal (4). Slow advancement of narrow osteotomes, which may be stacked on top of each other, is the classic technique. A reciprocating saw also works well. Long intramedullary stems and porous-coated devices pose serious challenges in the event removal is required and should not be implanted with full cement fixation.

***Figure 109.22.*** Component removal. The fixation interface must be disrupted completely to permit safe removal of components without bone loss. The reciprocating saw works well in this capacity, with better control than the Gigli saw.

## THREE-STEP REVISION TECHNIQUE

The planning and execution of a revision knee arthroplasty must follow a coherent program. The three-step technique is a path that the surgeon can follow during revision knee arthroplasty (Fig. 109.23). The cause of failure will dictate what is to be accomplished at each of the three stages (155).

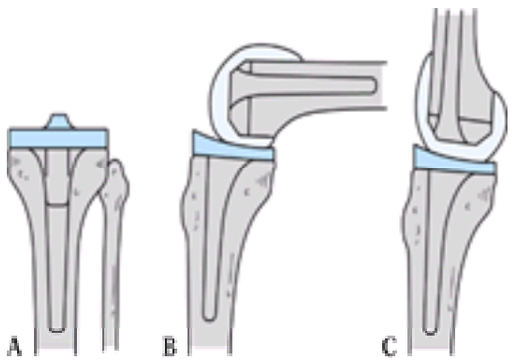


***Figure 109.23.*** Three-step revision knee arthroplasty. **A:** Step 1: Reconstruct the tibial platform. This establishes a foundation to use as a reference for all other work. The tibia is selected first, because its surface is always in contact with the femur regardless of the position of flexion. **B:** Step 2: Stabilize the knee in flexion by confirming the correct rotational position of the femur (step 2a), selecting the femoral component size that will stabilize the soft tissues in flexion (step 2b), and then selecting a combination of femur and tibial polyethylene that provides a reasonable joint line height (step 2c). **C:** Step 3: Stabilize the knee in extension by seating the femoral component either more proximally (only in rare cases of extreme flexion contracture) or more distally with the use of distal femoral augmentations or structural allografts.

Instruments, except for very general devices that help ascertain alignment and component position, are not generally useful. Trial components, especially those attached to intramedullary stems, are very useful. Even spacer blocks, used so widely in primary knee arthroplasty, may be misleading in revision surgery where asymmetric bone loss precludes meaningful insertion of blocks into the flexion and extension gaps.

### STEP 1: RECONSTRUCT THE TIBIAL PLATFORM

The tibial articular surface is always in contact with the femur, whether the knee is flexed or extended. By contrast, only the posterior articular surface of the femur articulates in flexion, and the distal surface is in contact with the tibia in extension. The tibia serves as the foundation for the reconstruction of the knee joint (Fig. 109.23*A*).

Accordingly, in the first step, reestablish the tibial baseplate (but not the articulating surface) surface by inserting a trial component. Bone-graft reconstruction of defects may be necessary. Frequently, some sort of intramedullary stem extension to enhance fixation is needed. Several good classification systems exist for bone defects, which may be contained or noncontained, or they may be be a massive structural defect (Table 109.11). Contained defects can be managed with particular graft or even cement; noncontained defects are best reconstructed with modular prosthetic augments; and massive defects require allograft.

| *Defect* | *Solution* |
|---|---|
| Contained | Particulate graft/cement |
| Noncontained | Modular prosthetic augmentations |
| Massive | Structural allograft |

***Table 109.11. Classification and Treatment of Bone Defects***

### STEP 2: STABILIZE THE KNEE IN FLEXION

Phase 2 of the reconstruction, rebuilding the knee in flexion, is when the most important work is done. Three important goals must be satisfied in this step:

- Step 2a: Determine the correct rotational position of the femoral component relative to osseous landmarks.
- Step 2b: Choose the femoral component size and position it to stabilize the knee in flexion.
- Step 2c: Pair the most appropriate femoral component and tibial polyethylene component to place the joint line at the desired level.

#### *Step 2a: Rotation*

Establishing the rotational position of the femoral component on the femur is perhaps one of the most important steps in knee arthroplasty surgery, although its importance has only recently been appreciated. Most instrument systems for primary surgery easily take their reference from the posterior articular condyles, but these condyles do not exist at revision. Furthermore, although the articular surface is easily appreciated in the primary and it usually resides in a predictable relationship to the transepicondylar axis (103), this is not always the case. There is agreement that the transverse axis of the femoral component should correspond to the transepicondylar axis (11,119).

#### *Step 2b: Femoral Component Size*

Align the rotational position of the femoral component with the distal femur anatomically to ensure comfort, central patellar tracking, good motion, and stability. This is the key to restoring the mechanics of the knee. The AP dimension of the component is the most important dimension to consider, and it must be chosen according to the tightness of the soft tissues about the knee. The femoral component must be chosen to stabilize the knee in flexion and never to simply fit the existing bone, which will be unpredictably smaller than normal. The largest size that can be employed will reach the medial and lateral sides of the distal femur—if something larger is required to stabilize the flexed knee, then either the collateral ligaments have failed from plastic deformation or there is significant bone loss from the upper tibia that necessitates bone graft reconstruction.

#### *Step 2c: Joint Line Position*

The knee may be stabilized in flexion with more than one size of femoral component—a larger component may do well with a thinner tibial polyethylene insert, a smaller one with a thicker polyethylene insert. The difference between these two will be the level of the joint line. The location of the anatomic joint line proximal to the fibular head can be predicted to be a portion of the width of the transepicondylar axis (119). Assuming that the patellar tendon has not been stretched or detached, this is a readily available indicator of the desired joint line. If the joint line is below the inferior pole of the patella, you can assume that the reconstruction is near anatomic and that joint line height will not compromise extensor mechanism function.

### STEP 3: STABILIZE THE KNEE IN EXTENSION

With the knee reconstructed in flexion, it is relatively easy to extend the joint and seat the femoral component against the tibial polyethylene insert to stabilize the knee in extension (Fig. 109.23*C*). The relative position of the femoral component in the femur should be maintained and modular augmentation blocks or distal femoral allograft added to finalize the revision.

In more difficult revision surgery, you may find that the flexion gap gapes open and cannot be stabilized with even the largest femoral component and a very thick tibial insert, or the knee may have varus or valgus instability in extension. In these circumstances, decide whether to use constrained articulation that will compensate for soft-tissue deficiency or to reconstruct the deficient ligaments (90,157).

### THE PATELLA—A FOURTH STEP

Leave in place a well-fixed all-polyethylene component that tracks well and is compatible with the revision component, but remove a loose polyethylene component or a well-fixed metal-backed component. If adequate bone remains, do revision resurfacing with an all-polyethylene device. If the bone is inadequate to accept a patellar prosthesis, trim it to fit the femoral component and leave it unresurfaced. Patellectomy is a poor choice because it leads to rupture of the extensor mechanism. The scaphoid-shaped patella that results from extensive osteolysis is a source of problems. It tends to hug the lateral femoral condyle, risking dislocation, yet it is too thin to either support a patellar implant or to be trimmed into a functional piece of bone.

A vertical osteotomy may be performed from the inferior pole to the superior, from the inside of the patella. This leaves the anterior soft tissues intact. The medial and lateral parts of the patella can then be cracked “up” away from the knee into the shape of a gull's wing. This “gull-wing osteotomy” (Fig. 109.24) is used rarely, it does not disrupt the extensor mechanism, and it allows even a very small fragment of bone to articulate well against the femur (154). Small pieces of bone graft can be added through the osteotomy to the ventral surface. These consolidate well with time. The technique for the gull-wing osteotomy is shown in Figure 109.25.

***Figure 109.24.*** Gull-wing patellar osteotomy. **A:** Lateral radiograph of failed TKR. **B:** AP radiograph of revision knee arthroplasty with stem extensions, compacted bone graft in contained tibial defects, and a (nonconstrained) posterior stabilized articulation. **C:** Sagittal gull-wing patellar osteotomy 1 month after revision for extensive patellar bone loss and a residual scaphoid shell of patella that would not track centrally and could not be resurfaced. Patellectomy risks extensor mechanism rupture. **D:** Gull-wing osteotomy with bone graft 3 years after revision arthroplasty, showing consolidation of medial and lateral fragments.

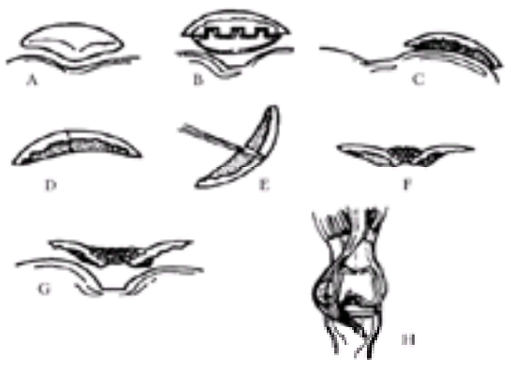

***Figure 109.25.*** Gull-wing osteotomy technique. **A:** The normal patella should track centrally between the femoral condyles as viewed on a Merchant-type patellofemoral radiograph. **B:** The resurfaced patella is also expected to track centrally. **C:** When very little bone is left because of osteolysis, the shell of bone often tracks laterally, hugging the lateral femoral condyle and risking dislocation. **D:** Plan a sagittal osteotomy, from the superior aspect of the patella to the inferior pole. **E:** With the patella everted, complete the osteotomy with a saw. **F:** Crack the medial and lateral halves of the patella ventrally and place a bone graft ventrally. **G:** This new gull-wing shape will track centrally between the two condyles. **H:** The everted patella, demonstrating where the osteotomy is planned.

## POSTOPERATIVE CARE AND REHABILITATION

I no longer use the bulky, cotton-padded Jones compression dressing. I now prefer a simple sterile absorbent dressing held in place by a tubular elastic fishnet gauze. This has the advantage of being lightweight, allowing easy examination of the knee after surgery without the uncomfortable lifting to wrap and unwrap circular dressings. The small dressing seems to convey to the patient that the knee is ready to use, a psychological factor that accelerates rehabilitation. Immobilization is rarely advantageous except to allow excessive swelling to subside. The goals of revision knee arthroplasty should be to create a stable, mobile, well-fixed arthroplasty ready for physical therapy (Fig. 109.26).

***Figure 109.26.*** **A:** Postoperative dressing as described in text. **B:** Completed dressing with comfortable elevation on a pillow.

Protected motion is required in the early phases after extensor mechanism allograft. Although motion is important, it should probably be passive, without proceeding past a point that risks rupture of the mechanism. Use a dial-lock hinge brace, set to limit flexion to about 60° initially, with additional droplocks to keep the knee extended during ambulation. Let the patient bear weight to a comfortable level. Implant structural allograft with sufficient stability to allow early weight bearing. These grafts rarely become stronger with time.

## PITFALLS AND COMPLICATIONS

Failure to establish a clear mechanical diagnosis is the most common pitfall in revision knee arthroplasty. Failure to recognize that malrotation may be at the root of many knee problems—all patellar complications, the stiff knee, instability, and the painful “mystery knee”—is relatively frequent. Regarding the revision as simply a repeat primary, without acknowledging that special concepts, skills, implants, and instrumentation are required, produces poor results. Depending on instruments that rely on osseous landmarks that no longer exist does not work well. Venturing to achieve a solid press fit inside the asymmetric tibia or femur with stem extensions often leads to malalignment.

The most common reasons for poor results and reoperations after revision lie in the extensor mechanism. Femoral and tibial component malrotation may be at the root of the problem, but often bothersome extensor lags limit the function of the knee. This problem has not been solved satisfactorily. Constrained components are often overused in situations when nonconstrained implants would suffice, and at times there may be too much reliance on constraint even when it is needed. The constrained component will fail if the revision is malaligned or if soft-tissue releases and reconstructions have been ignored.

## ALTERNATIVES TO REVISION TKR

The alternatives to revision knee arthroplasty are not good. In the face of true mechanical failure, revision is indicated. It should not be deferred if bone stock is being damaged by loosening, infection, or osteolysis. In very destructive failures, with extensive bone loss, keep in mind that revision knee arthroplasty is easier to accomplish than a solid fusion.

### ARTHRODESIS

Sound arthrodesis can be difficult to achieve after failed arthroplasty, especially if there has been extensive bone loss. The best technique is difficult to discern, given the relatively few cases that require this treatment. The subject has been reviewed extensively (27,89). The preferred method, in terms of the mechanics, is undoubtedly the intramedullary nail (29,38,63,80,93,120) (Fig. 109.27). Unfortunately, the knee that is likely to be considered for arthrodesis is the failed, infected arthroplasty for which there is concern over dissemination of the infection inside the bone with an intramedullary device. External fixators have been used (61,127). Plating would seem to have little to recommend it because it lacks the mechanical advantages of the intramedullary rod and yet still introduces metal into an area of previous sepsis (116).

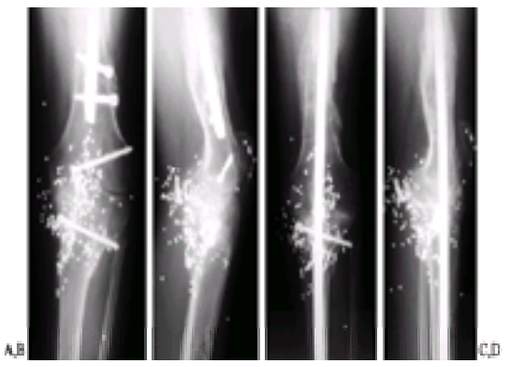


***Figure 109.27.*** Arthrodesis. AP (**A**) and lateral (**B**) radiographs of posttraumatic arthritis of the knee after a gunshot wound and femur fracture. The knee was stiff, painful, and deformed. AP (**C**) and lateral (**D**) radiographs of knee arthrodesis with a long intramedullary rod. The anterior bow has been rotated to create a few degrees of valgus alignment.

### RESECTION ARTHROPLASTY

An arthroplasty that has failed, either because of incurable infection or perceived impossibility of bone reconstitution, may simply be left as it is, producing a resection arthroplasty. The functioning capability of these patients is usually poor (43,81,146).

### AMPUTATION

Above-knee amputation is rarely necessary at any time after knee arthroplasty (62,76). Chronic infection that is active and a threat to the patient's general health, and that has not responded to multiple surgeries, is the most common indication for amputation. Bone loss alone, unless colossal, can usually be reconstituted in the healthy patient with allograft, as can the extensor mechanism. Indeed, combined proximal tibial allografts with the extensor mechanism included may be a solution.

# ARTHRODESIS OF THE KNEE

***Technical Contributor: Michael W. Chapman***

Christian and Donley (25) state that the first reported arthrodesis of the knee was performed by Professor Albert of Vienna in 1878 for instability of the knee due to residual of poliomyelitis. Fusion of the knee was the only surgical solution for a painful or unstable knee until the introduction of arthroplasty of the knee joint in the last quarter of the 20th century. Hibbs treated tuberculosis of the knee with arthrodesis in 1911 (66,67). Key (83) first used external fixation with compression for arthrodesis of the knee in 1932, and in 1937 (84) he used a large central autogenous bone peg to achieve fusion of the knee. Charnley (21) refined the technique of arthrodesis with compression using external fixation in 1948, and the general principles he established continue to be used for arthrodesis utilizing external fixation (21,22 and 23).

Küntscher (91) in 1948 described arthrodesis of the knee by inserting his intramedullary nail from the tip of the greater trochanter across the knee into the tibia. Chapchal (20) modified Küntscher's technique by inserting the nail through an anterior window in the femur, obtaining fusion in 85% of his patients. Because of the risk of fracture at the cortical window, the latter technique has never become popular and intramedullary nailing for arthrodesis of the knee today is modeled after the original technique described Küntscher. Fusion of the neuropathic knee is difficult. Lucas and Murray (101) described arthrodesis of the knee by double-plate fixation in 1961, demonstrating that fusion of a Charcot knee was feasible.

Arthrodesis of the knee is a salvage procedure to be used only when other alternatives, such as total knee arthroplasty, cannot resolve problems of instability and/or pain in the knee caused by disabling arthritis, infection, or other disorders. A knee fusion is quite disabling, as it eliminates the most important joint for lower extremity function. Arthrodesis of the ankle or hip produces almost imperceptible changes in gait, whereas fusion of the knee produces an obvious stiff-legged gait with significant increases in energy expenditure in walking. Climbing or descending stairs and walking on hills or rough terrain are always a problem. Patients with arthrodesis of the knee have difficulty using public transportation because of the need to bend the knee to sit. They must usually sit on the aisle in theaters and may have difficulty getting up after falling. Dressing is more difficult. Patients must be warned about these problems prior to arthrodesis of their knees. Patients benefit preoperatively by immobilization of the knee in a cast or brace so they will have a realistic picture of what their function will be like after arthrodesis. Satisfaction rates of 80% to 90% are reported in most series as discussed later, primarily because the arthrodesis usually eliminates the pain and instability that necessitated the procedure (135).

## INDICATIONS

Indications for arthrodesis of the knee include the following:

- Postinfectious destruction of the knee
- Posttraumatic destruction of the knee in a young, active individual who desires to continue vigorous activity
- Paralytic conditions with severe deformity
- Neuropathic arthropathy
- Occasionally in malignant conditions about the knee
- After failed arthroplasty, when an attempt at revision arthroplasty is unwise for the patient or not possible

The knee may be fused in children as early as age 6 or 7 years, but the risk of growth arrest by surgical procedures around the physes is significant. If possible, fusion should be delayed (by the use of braces and crutches) until full growth has been obtained.

The most important principle in fusion of the knee is the use of compression, either by external fixation, or by internal fixation with the addition of load bearing when possible. This increases the stability and area of bone contact.

Green and Kolsnick (56) achieved a 78% rate of fusion when noncompression arthrodesis (resection of the joint plus internal fixation with or without bone graft) was used and a failure of fusion when crossed Steinmann pins were used.

Occasionally, in untreated tuberculosis or hemophilia, spontaneous fusion occurs in a poor position. Deformity is often severe after the disease has subsided, and the extremity is usually fixed in flexion, abduction, and external rotation. Also, the tibia is frequently subluxated or dislocated on the femur. If the deformity is mild, enough bone can be removed from the condyles of the tibia and femur to allow approximation of the osseous surfaces in the most anatomic and functional position. If the deformity is severe, however, capsulotomy, as well as other soft-tissue releases, may be necessary before the bones can be approximated and fused in the most functional position.

With arthrodesis of the knee, some length is lost because of the resection of the joint surfaces as well as the positioning of the fusion in 10° to 15° of flexion. Shortening of up to 2 cm is of some benefit, in that it allows better clearance of the foot during walking, assists in dressing, and relieves tension in the hamstring tendons and sciatic nerve. Shortening of more than 2.5 cm may require the use of a small shoe lift, but the entire leg-length discrepancy should not be compensated for.

### INFECTION

Arthrodesis can be obtained in the presence of active infection (26). Principles for obtaining arthrodesis in the presence of infections include thorough debridement of all infected and necrotic tissues, stable external fixation, and good postoperative drainage of the wound. Staged surgery is usually advisable, with initial eradication of the infection followed by fusion. If the wound is left open at the time of arthrodesis, drainage usually ceases when the fusion becomes solid (26).

Arthrodesis of the knee for tuberculosis is frequently performed in children. There may be partial destruction of one condyle without destruction of the other. It is important to excise all the tuberculous material and necrotic bone and to administer combined antimicrobial therapy (see Chapter 176). Soft-tissue releases also may be indicated.

In cases of failed arthroplasty caused by infection, remove all implant materials and necrotic bone before fusing the knee. Knee fusions after failed unicompartmental arthroplasties have a relatively high fusion rate (about 90%), whereas fusions after TKRs are difficult, with a first-time rate of fusion of only 50% (89). Staged surgery is advisable when gross pus is present around the prosthesis. First remove the prosthesis, bone cement, and necrotic tissue. Treat the infection with intravenous antibiotics. Consider using an antibiotic-impregnated spacer or beads. After the acute infection has resolved, perform an arthrodesis, usually with bone graft and external fixation.

### ARTHRITIS

In most patients with arthritis, total knee arthroplasty is the procedure of choice. There is an occasional young adult, particularly a young man who desires to continue working at heavy labor, for whom an arthrodesis, despite its functional limitations, may be the best choice in view of the fact that a total knee arthroplasty would not be expected to last for very many years under these circumstances. The alternative would be to perform a total knee joint arthroplasty, recognizing that if the knee joint and subsequent revisions were to fail, arthrodesis would be necessary. As discussed later in this chapter, arthrodesis following failed total joint arthroplasty has a lower success rate than primary knee fusion, and it usually does not give as good a functional result, as substantial shortening may be necessary. Treatment of hemophilic arthropathy, which may require fusion, is discussed in Chapter 136.

### NEUROPATHIC JOINTS

Arthrodesis of the knee for neuropathic joint disease is difficult and unusual. See Chapter 124 for a full discussion of Charcot neuroarthropathy.

Successful fusion of the neuropathic knee joint requires complete debridement of joint surfaces down to viable bleeding bone, and thorough debridement of the joint detritus including complete synovectomy (31). Supplemental autologous bone graft may be indicated. Solid fixation of the arthrodesis with biplanar external fixation, intramedullary nailing and compression, or double-plate fixation is necessary until solid radiographic union is evident. Intramedullary nailing, when feasible, is probably the fixation of choice, as a nail is not as susceptible to fatigue failure in bending as plates are, and the problem of loosening of external fixation pins in osteoporotic bone is avoided. Union rates of 100% have been described using intramedullary fixation (31,151). Double-plate fixation (101) works well, but weight bearing must be avoided and external support utilized until solid fusion is obtained.

## SURGICAL TECHNIQUES

### POSITION OF THE ARTHRODESIS

- In the AP plane, place the knee in anatomic position relative to the opposite normal extremity (5° to 7° of valgus), and in about 10° of external rotation. The position of flexion and extension depends on relative leg lengths and other coexisting problems, such as muscle paralysis. With only knee disease, arthrodesis in 10° to 15° of flexion allows clearance of the foot when walking and is the most efficient position for walking. However, with bone loss of more than 2.0 cm, fusion in full extension may be indicated to gain more length.

### EXTERNAL FIXATION, COMPRESSION ARTHRODESIS

Compression arthrodesis of the knee with external fixation was first described by Key and is now commonly used (48,56,111,174). The technique was popularized by Charnley (21,22), who developed the Charnley clamp, which is used as an initial compression device followed by a plaster cast. Charnley and Lowe (23) reported a 98.8% fusion rate in 171 patients treated with an average of 9 weeks of external fixation and a plaster cast. Stewart and Bland (143) obtained solid fusion in 100% of 30 knees that were externally fixed for an average of 15.5 weeks.

External fixation has been used to obtain fusion after failed TKRs, particularly when infection has occurred (9,134,162). External fixation is the best technique for previously infected knees, because it avoids implants in the infected bone. Pin track infections and fixation pin failure are disadvantages of external fixation. Green and Kolsnik (56) reported successful fusions in 13 of 16 patients using external fixators, but pin track infections occurred in six.

- Position the patient supine on a radiolucent operating table and prepare and drape the entire affected extremity. A sterile tourniquet is useful to control hemorrhage.
- Through a long anterior median parapatellar incision, reflect the patella laterally, and expose the knee joint.
- If necessary, perform a thorough debridement of the knee, excising all nonviable bone and detritus, and perform a synovectomy, particularly if fusing a neuropathic knee or a knee that was previously infected. Send the debrided deep tissues for culture and sensitivities. Debride the articular surfaces of the tibia, femur, and patella down to bleeding subchondral bone.
- Using the alignment jig system from any standard total knee arthroplasty system (Fig. 109.28), make the distal femoral and proximal tibial cuts to obtain 0° to 15° of flexion, 5° to 7° of valgus, and 10° of external rotation. Shape the underside of the patella to match the patella to the denuded patellofemoral groove. The patella can also be excised.

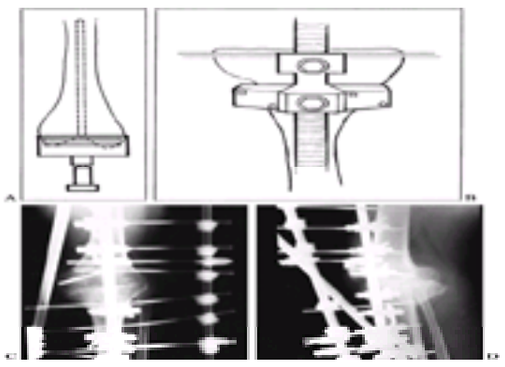

***Figure 109.28.*** Knee arthrodesis with external fixation. **A:** Cut the distal femur using a guide from a total knee replacement guide system. **B:** Make a proximal tibial cut using a total knee replacement guide system. **C:** Apply a biplanar external fixator to compress the two surfaces. **D:** Denude the patellofemoral surfaces, and fix the patella to the anterior femoral surface using two screws.

- If difficulty in obtaining fusion is anticipated, obtain bone graft from the iliac crest, and cover all contact surfaces with morcelized iliac crest autograft. Bring the joint surfaces together in proper alignment, and apply the external fixator. One or two large Steinmann pins inserted across the knee are often useful to maintain position while the fixator is applied.
- The technique of application of the external fixator depends on the type of fixator. Follow the manufacturer's instructions. Various external fixation devices can be used (Fig. 109.29). Follow the basic principles for application of external fixators as discussed in Chapter 11. Circular fixators using Ilizarov principles can also be used, as discussed in Chapter 32. If a single-plane external fixator is used, such as the Hoffmann, Charnley, and Wagner devices, it is critical that a minimum of two of the thickest transfixation pins possible be placed proximally and two distally, and that compression be applied. Under fluoroscopic control, insert the most proximal transverse fixation pin in the femur and the most distal pin in the tibia first, utilizing a template or the external fixator itself as a guide. Be certain that these pins are oriented so that when compression is applied, the arthrodesis site will be evenly compressed without a tendency toward displacement. Once you are happy with the position of the fixator, and with its mechanics, insert the additional transverse pins in the tibia and femur. Using a minimum of four pins will limit any tendency for the arthrodesis site to shift due to a parallelogram effect. Most surgeons use at least six fixation pins in total.

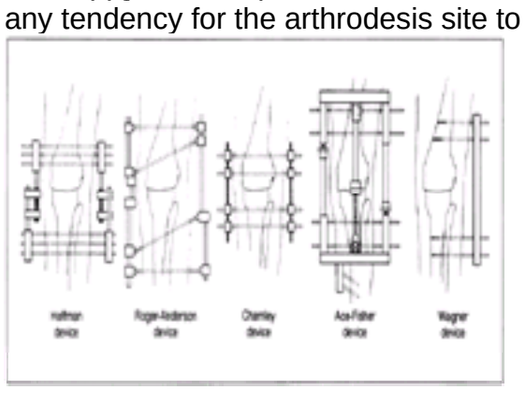

***Figure 109.29.*** Various types of external fixation systems used to arthrodese the knee.

- If the patient's bone is osteoporotic, prolonged external fixation is anticipated, or the arthrodesis is difficult (as in a neuropathic knee or after failed total knee arthroplasty, where interposition bone grafts may be utilized), then biplanar or multiplanar fixation may be indicated. This can be achieved with the Ace-Fisher device (Fig. 109.29), or with a circular Ilizarov frame utilizing full and half-pins. If the uniplanar devices are used in the frontal plane, adding an independent fixator with half-pins placed in the anterior to posterior direction, which then can be cross-connected to form a Delta frame, works equally well. This type of fixation utilizing an AO fixator (Synthes, Paoli, PA) is shown in Figure 109.28*C*, Figure 109.28*D*.
- Next, fix the patella, if it has been saved, into the anterior femoral groove with two oblique lag screws.
- Secure hemostasis, place a deep drain, and close the quadriceps mechanism and skin. Apply a soft compression dressing.

***Postoperative Care***

Most patients can be allowed to walk immediately after surgery with assistive devices bearing the weight of the leg (approximately 30–40 pounds), assuming there is good bone contact and compression across the arthrodesis site and the patient's bone quality is good. Initiate routine care of the external fixator pin sites as described in Chapter 11. Have the patient check the components of the external fixator daily to be certain that loosening does not occur. Apply a modified elastic stocking and have the patient elevate the extremity when not walking to minimize edema. Once the wound has healed, the patient can usually be seen at 6-week intervals until fusion occurs.

In many patients, the knee appears to be radiographically fused on the immediate postoperative radiographs because of the excellent apposition and compression across the broad bone surfaces between the femur and tibia. Although solid union of an arthrodesis in our hands has occurred as early as 6–8 weeks, I recommend leaving the external fixator in place until at least 12 weeks unless pin problems require earlier removal of a portion or all of the external fixator frame and pins. When radiographic and clinical union is evident, remove the external fixator and apply a removable long leg orthosis (some prefer a cylinder cast) and allow the patient to bear full weight for an additional 4 weeks. Then it is usually possible to allow the patient to resume normal activities without external protection. In the arthrodesis of neuropathic joints, or in situations where intercalary bone graft has been utilized to maintain leg length (such as after failure of knee arthroplasty), prolonged external protection may be necessary to ensure that the arthrodesis does not fail.

**ARTHRODESIS WITH INTRAMEDULLARY NAILS**

Intramedullary nailing for fixation of a knee arthrodesis has the advantages of more limited soft-tissue dissection, the potential for immediate weight bearing, an absence of pin track complications, easier rehabilitation, and a high rate of fusion. Intramedullary nailing is particularly useful when bone loss at the knee does not permit compression fixation, and where large allografts or autographs have been used to bridge an area of bone deficiency (such as following tumor resection or failed total knee arthroplasty). The major disadvantages are that nailing can be technically challenging, additional blood loss from the medullary canals can be a problem, and it is more difficult to obtain optimal alignment.

Using intramedullary nails, Mazet and Urist (107) successfully fused 11 of 12 patients, and Harris and Froehlich (63) reported success in 7 of 8 cases of failed total knee arthroplasty. Knutson et al. (89) reported success in 5 of 5 knees treated with intramedullary rods after failed total knee arthroplasty, Drennan et al. (31) reported a successful fusion in 9 Charcot knees treated with intramedullary fixation, and Vander Griend (151) reported 100% success in his series. In difficult cases, a combination of intramedullary rods and an external fixator has been used (42).

Vlasak et al. (160) compared intramedullary nail fixation for knee arthrodesis to external fixation; with 13 knees in each group, they had a 100% union rate with intramedullary nails and only a 38% union rate with external fixation following failed TKR. Because of the bone loss associated with failed TKR, intramedullary nailing appears to have a distinct advantage. Ellingsen and Rand (38) arthrodesed 18 knees after failed total knee arthroplasty (nine had had failed attempts at arthrodesis using external fixation). They were successful in 16 of 18 (89%) knees. They pointed out, however, that even though intramedullary nail arthrodesis has a high success rate for salvage of failed total knee arthroplasty, the surgical technique is technically demanding and lengthy, and complications are frequent (occurring in 10 of the 18 knees).

Malignant or aggressive benign bone tumors about the knee requiring radical resection are generally treated with a total knee arthroplasty. However, arthrodesis using intramedullary nails with intercalary allografts (151,165), or nailing combined with a vascularized fibular bone graft (130), has been successful when arthroplasty is contraindicated or not feasible.

Long Küntscher nails have been used most frequently for arthrodesis of the knee, but the weakness of this nail and the inability to lock it has limited its usefulness. Current locked intramedullary nailing systems, especially those specifically designed for arthrodesis of the knee such as the Knee Fusion Nail (Smith and Nephew, Memphis, TN) and special modular nails make intramedullary arthrodesis technically easier and permit maintenance of length or compression across the arthrodesis site utilizing the interlocking screws. These special nails offer different diameters for the femur and tibia to match the intramedullary anatomy. In nonmodular designs, the nail must be inserted from the usual entry site in the pyriform fossa proximally on the femur. Most authors described inserting the nail through the isthmus of the

tibia to within 2–6 cm of the ankle joint. Recent experience, however, with newer interlocking intramedullary nails has shown that the nail in the tibia need be inserted only down to the isthmus where good stability can be obtained by cross locking the nail (personal communication, MW Chapman, 2000). This makes the nailing technically easier to do.

Since knee arthrodesis today is most frequently done for failed total knee arthroplasty, the following technique is described for locked intramedullary nail arthrodesis following failed knee arthroplasty.

***Operative Technique***

- Preoperatively, take full-length AP and lateral radiographs of the involved extremity to include the hip joint and ankle. On these radiographs, carefully inspect the medullary cavity of both bones to be certain that they will accommodate the nail to be used. Use appropriate templates to determine the length and diameter of the nail required. In most cases, the nail should extend from the tip of the greater trochanter of the femur to the isthmus of the tibia. If there are problems in the tibia or osteoporosis, plan to have the nail extend down to within 2–3 cm of the ankle joint. Average-sized individuals will require an intramedullary nail 50 cm or more in length, which usually must be ordered from the manufacturer ahead of time (hospitals rarely stock nails this long). The diameter of nail used depends on the size of the bones and the condition being treated. Try to use a nail that is 11 mm or more in diameter in order to have sufficient strength.
- These procedures tend to be rather long and require significant manipulation and moving of the patient, so a general anesthetic is usually recommended. Positioning of the patient is challenging: A direct anterior approach to the knee and a posterior or lateral approach to the buttock are both necessary to accomplish the procedure. The patient can be placed in the supine position on a fracture table, which facilitates imaging, but I prefer the supine position on a fully radiolucent operating table. Place a bump under the buttock and position the patient so that the incision required to insert the nail through the buttock can be safely made. To improve exposure of the buttock, it is sometimes useful to place the patient in the lateral decubitus position, prepare and drape the entire lower extremity and buttock, and then roll her into the supine position for the majority of the procedure. She then can be rolled partially toward the lateral decubitus position as necessary for the insertion of the nail in the buttock. A sterile tourniquet can be used on the proximal thigh during the debridement of the knee to limit hemorrhage, but this is not desirable during the nailing.
- Expose the entire knee joint through an anterior longitudinal median parapatellar incision, utilizing the old surgical scar in most cases.
- Once the distal femur, proximal tibia, and total knee joint are exposed, mark the femur with an osteotome or electrocautery to provide reference lines for determining rotation and length after the prosthesis is removed.
- Utilizing the instrumentation appropriate for the total knee, remove all total knee components, and cement. Remove all debris from the soft tissues and bone, preserving as much viable bone stock as possible. If the patella has decent bone stock, preserve it for use as a bone graft; otherwise, excise it.
- Submit debrided bone for culture and sensitivities, and initiate intravenous antibiotics. If the culture proves to be positive, prolonged treatment with intravenous antibiotics may be indicated.
- In most cases, it is now possible to place the rough ends of the tibia and femur into apposition. Their irregular surfaces often provide a good interlock. The driving of the intramedullary nail automatically determines alignment in both the anteroposterior and lateral planes. Be certain that the foot is at the proper progression angle, which is usually about 10° of external rotation.
- Asymmetrical loss of bone may limit bone contact and require recutting of the joint surfaces with total knee instrumentation to obtain good bone apposition. Although this may be necessary, it is not generally recommended, as it results in excessive shortening.
- Insert a ball-tipped reaming guide pin into the medullary canal of the femur. In most cases, this is best done through a short buttock incision using the standard technique for intramedullary nailing of the femur (see Chapter 11 and Chapter 20). An alternative technique that allows percutaneous insertion of the nail into the proximal femur is to run a sharp-tipped, flagged Küntscher guide pin retrograde up the medullary canal to exit the proximal femur and come to lie beneath the skin in the buttock. To avoid injury to the sciatic nerve, and to have an appropriate skin incision, it is essential to flex and adduct the hip so that the guide pin exits the skin as close to the tip of the greater trochanter as possible. It is important to visualize this carefully on the fluoroscope, so that the guide pin exits at the pyriform fossa on the femur. An incision 2–3 cm long can then be made on the buttock in line with the fibers of the gluteus maximus to expose the tip of the guide pin. Then use a guide-pin exchange tube to exchange the Küntscher guide pin for a ball-tipped reaming guide pin.
- Ream the medullary canal of the femur to obtain a diameter 2 mm wider than that of the nail to be used. This can be done antegrade or retrograde.
- Ream the medullary canal of the tibia over a ball-tipped guide pin antegrade from the knee joint. Ream through the isthmus so that passage of the nail will not be impeded if the length has been mismeasured.
- Save contents of the medullary canal and bone reamings for bone graft around the arthrodesis.
- With the knee in the appropriate position for arthrodesis, insert the femoral guide pin into the tibia and measure to be certain that the appropriate-length nail has been selected.
- Drive the medullary nail antegrade down the femur, taking care to avoid fracture of the femur or incarceration of the nail. The nail should move down the femur easily with each blow of the mallet. If significant resistant is encountered, inspect the nail and femur carefully under fluoroscopy to be certain the orientation of the nail is correct. Ream the medullary canal larger if necessary. Drive the nail until it protrudes from the distal end of the femur about 2 cm.
- Now position the tibia over the end of the nail in apposition with the femur and using the previously drawn reference lines be certain that the position of the arthrodesis is correct. The overall curvature of the nail will generally produce about 10° to 15° of flexion in the knee fusion. Position the tibia for proper valgus and rotation.
- Complete the driving of the medullary nail into the tibia. As in the femur, the nails should drive easily with minimal resistance.
- Ensure good compression across the arthrodesis site by placing a small drill hole in the femur and another one in the tibia and inserting into these the tines of a pointed fracture-reduction forceps, which then can be used to compress the arthrodesis site. Often, two are needed, one anteriorly and one laterally.
- Place two transverse locking screws through the distal end of the nail in the tibia, and lock the nail in the proximal femur using the jigs provided by the manufacturer.
- Fill any gaps in the arthrodesis site with the reaming materials and, if necessary, autologous bone graft harvested from the iliac crest.
- Close the wounds in layers over a suction drain and apply a sterile dressing incorporating the extremity with a soft compression dressing from the toes to the groin.

**Postoperative Care** Mobilize the patient as soon as possible postoperatively. When the bone quality is good, and if the arthrodesis site has excellent contact and is in compression, immediate weight bearing with assistive devices is usually possible. Where there is osteoporosis or poor bone contact at the arthrodesis site, limit weight bearing to the weight of the leg until fusion occurs. Solid fusion is usually evident at 12–16 weeks, at which time the use of ambulatory aids can be discontinued. External immobilization of any type is usually unnecessary. See Figure 109.27 for a typical case.

**ARTHRODESIS WITH PLATE FIXATION**

Lucas and Murray (101) described knee arthrodesis using anterior and medial plates resulting in successful fusion in 17 of 18 knees. This fusion is useful in difficult situations, such as Charcot's joints and where significant bone loss between the femur and tibia requires large bone grafts. These may be autografts from the iliac crest, sliding grafts from the anterior femur or tibia, or large allografts. The strong dual plates are necessary to protect the graft during healing and remodeling (Fig. 109.30, Fig. 109.31).

***Figure 109.30.*** Plate fixation of a large allograft placed between the femur and tibia. Protection of the bone graft by the plate is needed in this type of fusion for many years until the allograft has been incorporated.

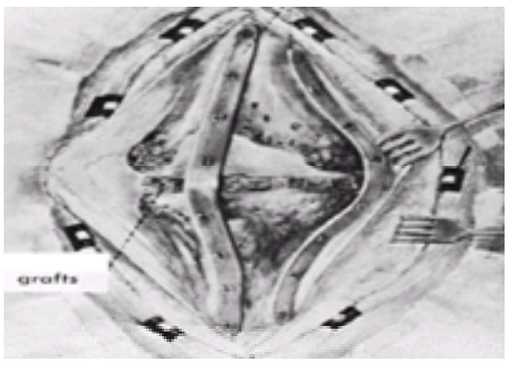


***Figure 109.31.*** Double-plate fixation for the fusion of a neuropathic joint. (From Lucas DB, Murray WR. Arthrodesis of the Knee by Double Plating. *J Bone Joint Surg Am* 1961;43:795, with permission.)

Nichols et al. (116) used dual medial and lateral dynamic compression plates to successfully fuse 11 knees. Although medial and lateral plates are not biomechanically as strong as two plates at 90° to each other, these authors felt that eliminating the anterior plate reduced the incidence of wound problems. In addition, they suggested using plates of two different lengths to avoid the stress riser that might occur at the end of two plates of equal length.

The primary advantage of plate fixation is that it avoids the pin complications of external fixation. Also it is easier for the patient during the postoperative period. When compared to intramedullary nailing, it requires less surgical exposure and less surgery time, and it is technically easier for most surgeons. It is particularly useful when large intercalary bone grafts are used, as better fixation and better bone apposition is usually possible. The major problem with plate fixation is the increased incidence of soft-tissue problems that result from the bulk of the implants at the knee and their position immediately beneath the skin flaps. There is a risk of fracture of the tibia or femur at the end of the plates, which is more likely with a fused knee.

Stiehl and Hanel (144) described the combination of intramedullary nail and medial compression plate fixation in eight difficult knees, all of which united. They recommend their technique for difficult salvage situations, when segmental allografts may be required.

***Operative Technique***

- Place the patient in a supine position on a radiolucent operating table, and prepare and drape the extremity from the toes to the groin. Prepare the iliac crest if bone graft is required.
- Make a long longitudinal median parapatellar incision to expose the knee joint. Incise the periosteum in a similar line on both the femur and the tibia, and expose the distal femur and proximal tibia subperiosteally.
- Cut a V in the anterior femur to accept the patella, and cut a similar V underneath the patella to create a good fit with the depression in the anterior femur. The patella can also be excised.
- Debride the knee joint, and leave the PCL in place. Prepare the surfaces of the distal femur and proximal tibia using a TKR jig.
- Place the knee arthrodesis in appropriate position and temporarily fix the two bones with crossed Steinmann pins. Use templates to establish the contours for anterior and medial, large, broad plates and use plate benders to fit them to the anterior and medial surfaces.
- Use 12- to 16-hole plates and secure the plates to the femur and tibia with at least five bicortical screws through each plate in each fragment using compression techniques.
- If the patella is retained, fix it to the femur with two screws.
- Pack any defects of the joint margins with cancellous bone from the iliac crest.
- Close the wounds in layers over a drain and apply a soft supportive dressing.

**Postoperative Care** After surgery, place the patient in a cylinder cast and allow touch-down weight-bearing with crutches until 12 weeks, when partial weight-bearing is begun if the radiographs demonstrate evidence of early union. Full healing on radiographs is usually evident by 16–24 weeks, at which time full weight-bearing is possible.

## PITFALLS AND COMPLICATIONS

The complications of arthrodesis of the knee are the same as those of any major orthopaedic surgery for complicated conditions. As noted previously, the incidence of complications is significant, as knee fusion is usually a salvage procedure for multiple failed surgeries of the knee, for severe infection, or for bone loss resulting from tumor resection. A problem with knee arthrodesis using external fixation is loosening or infection of the fixation pins followed by nonunion of the arthrodesis. The pin problems can be minimized using the meticulous technique described in Chapter 11, and by avoiding full weight-bearing until solid arthrodesis is present.

A risk of nonunion can be minimized by the use of biplanar or multiplanar fixation utilizing compression applied across broad viable bone surfaces at the site of arthrodesis. Excessive shortening may be unavoidable, but it can be minimized by avoiding unnecessary resection when the arthrodesis follows failed total knee arthroplasty, and by using intercalary bone grafts when necessary. Another approach is to perform limb lengthening with Ilizarov techniques after successful knee fusion.

The risk of infection can be minimized by performing staged arthrodesis when fusion is being performed for infection or when the suspicion of infection is high. If infection occurs in the presence of stable fixation, then irrigation and debridement, with maintenance of the fixation, combined with appropriate intravenous antibiotics, will often control the infection until fusion occurs. Once fusion is present, the infection may spontaneously resolve, or removal of the implants will then result in the resolution of the infection. Infection in the presence of an unstable arthrodesis and implants usually requires the removal of the implants, irrigation and debridement, and treatment with antibiotics, followed by repeat fusion when the infection has completely resolved, usually utilizing multiplanar external fixation.

## AUTHOR'S PERSPECTIVE

The most common indication for knee arthrodesis in my practice, and in that of most surgeons, is failed total knee arthroplasty. My preferred technique for this is fusion with intramedullary fixation. I reserve external fixation arthrodesis for primary arthrodesis when there is infection, and where infection has been a significant problem in a failed total knee arthroplasty. Double-plate arthrodesis of the knee is most common in the practices of surgeons treating malignant tumors of the knee that are not amenable to total joint arthroplasty and require intercalary allograft for reconstruction. This is not a common procedure in my practice, nor in the practice of most community surgeons, so careful attention to the details outlined in this chapter are necessary for a high rate of success.

## CHAPTER REFERENCES

Each reference is categorized according to the following scheme: *, classic article; #, review article; !, basic research article; and +, clinical results/outcome study.


+ 1. Aglietti P, et al. Arthroplasty for the Stiff or Ankylosed Knee. *J Arthroplasty* 1989;4:1.

! 2. Albrektsson BE, et al. The Effect of a Stem on the Tibial Component of Knee Arthroplasty. A Roentgen Stereophotogrammetic Study of Uncemented Tibial Components in the Freeman-Samuelson Knee Arthroplasty. *J Bone Joint Surg Br* 1990;72:252.

+ 3. Allardyce TJ, Scuderi GR, Insall JN. Arthroscopic Treatment of Popliteus Tendon Dysfunction following Total Knee Arthroplasty. *J Arthroplasty* 1997;12:353.

+ 4. Alpert SW, Stuchin SA, Lubliner JA. Technique for Removal of Femoral Components with Intercondylar Articulation in Total Knee Arthroplasty. *Bull Hosp Joint Dis* 1993;53:48.

* 5. Backe HA Jr, Wolff DA, Windsor RE. Total Knee Replacement Infection after 2-stage Reimplantation: Results of Subsequent 2-stage Reimplantation. *Clin Orthop* 1996;331:125.

+ 6. Bargar WL, Cracchiolo AD, Amstutz HC. Results with the Constrained Total Knee Prosthesis in Treating Severely Disabled Patients and Patients with Failed Total Knee Replacements. *J Bone Joint Surg Am* 1980;62:504.

+ 7. Barrack RL, et al. The Coventry Award. The Value of Preoperative Aspiration before Total Knee Revision. *Clin Orthop* 1997;345:8.

+ 8. Barrett WP, Scott RD. Revision of Failed Unicondylar Unicompartmental Knee Arthroplasty. *J Bone Joint Surg Am* 1987;69:1328.

+ 9. Behr JT, Chmell SJ, Schwartz CM. Knee Arthrodesis for Failed Total Knee Arthroplasty. *Arch Surg* 1985;120:350.

+ 10. Beight JL, et al. The Patellar “Clunk” Syndrome after Posterior Stabilized Total Knee Arthroplasty. *Clin Orthop* 1994;299:139.

+ 11. Berger RA, et al. Determining the Rotational Alignment of the Femoral Component in Total Knee Arthroplasty Using the Epicondylar Axis. *Clin Orthop* 1993;286:40.

# 12. Bindelglass DVK. The Infected Total Knee Arthroplasty. *Am J Knee Surg* 1991;4:94.

+ 13. Blauth W, Hassenpflug J. Are Unconstrained Components Essential in Total Knee Arthroplasty? Long-term Results of the Blauth Knee Prosthesis. *Clin Orthop* 1990;258:86.

+ 13a. Bocell JR, Thorpe CD, Tullos HS. Arthroscopic Treatment of Symptomatic Total Knee Arthroplasty. *Clin Orthop* 1991;271:125.

+ 14. Booth RE Jr, Lotke PA. The Results of Spacer Block Technique in Revision of Infected Total Knee Arthroplasty. *Clin Orthop* 1989;248:57.

+ 15. Brady TA, Ranawat C, Kettelkamp DB. Salvage of the Failed Total Knee Arthroplasty. *Orthop Trans* 1977;1:1101.

* 16. Briard JL, Hungerford DS. Patellofemoral Instability in Total Knee Arthroplasty. *J Arthroplasty* 1989;4(suppl):S87.

+ 17. Cadambi A, Engh GA. Use of a Semitendinosus Tendon Autogenous Graft for Rupture of the Patellar Ligament after Total Knee Arthroplasty. A Report of Seven Cases. *J Bone Joint Surg Am* 1992;74:974.

+ 18. Calton TF, Fehring TK, Griffin WL. Bone Loss Associated with the Use of Spacer Blocks in Infected Total Knee Arthroplasty. *Clin Orthop* 1997;345:148.

+ 19. Cameron HU, Hunter GA. Failure in Total Knee Arthroplasty: Mechanisms, Revisions, and Results. *Clin Orthop* 1982;170:141.

+ 20. Chapchal G. Intramedullary Pinning for Arthrodesis of the Knee Joint. *J Bone Joint Surg Am* 1948;30:728.

* 21. Charnley J. Positive Pressure in Arthrodesis of the Knee Joint. *J Bone Joint Surg Br* 1948;30:478.

+ 22. Charnley J. Arthrodesis of the Knee. *Clin Orthop* 1960;18:37.

* 23. Charnley J, Lowe HG. A Study of the End-Results of Compression Arthrodesis of the Knee. *J Bone Joint Surg Br* 1958;40:633.

+ 24. Chotivichit AL, et al. Total Knee Arthroplasty Using the Total Condylar III Knee Prosthesis. *J Arthroplasty* 1991;6:341.

# 25. Christian CA, Donley BG. Arthrodesis of the Ankle, Knee, and Hip. In: Canale ST, ed.*Campbell's Operative Orthopaedics.* Philadelphia: Mosby, 1998:145.

+ 26. Clawson RS, McKay DW. Arthrodesis in the Presence of Infection. *Clin Orthop* 1976;114:209.

+ 27. Damron TA, McBeath AA. Arthrodesis following Failed Total Knee Arthroplasty: Comprehensive Review and Meta-analysis of Recent Literature. *Orthopedics* 1995;18:361.

+ 28. Davis PF, Bocell JR Jr, Tullos HS. Dissociation of the Tibial Component in Total Knee Replacements. *Clin Orthop* 1991;272:199.

+ 29. Donley BG, Matthews LS, Kaufer H. Arthrodesis of the Knee with an Intramedullary Nail [Comments]. *J Bone Joint Surg Am* 1991;73:907.

+ 30. Dreghorn CR, Hamblen DL. Revision Arthroplasty: A High Price to Pay. *Br Med J* 1989;298:648.

+ 31. Drennan DB, Fahey JJ, Moylan DJ. Important Factors in Achieving Arthrodesis of the Charcot Knee. *J Bone Joint Surg Am* 1971;53:1180.

+ 32. Dupont JA, Campbell ED, Lumsden RM. Total Knee Arthroplasty Revisions. *Orthop Trans* 1980;4:321.

+ 33. Duus BR, Boeckstyns M, Stadeager C. The Natural Course of Radionuclide Bone Scanning in the Evaluation of Total Knee Replacement—A 2 Year Prospective Study. *Clin Radiol* 1990;41:341.

+ 34. Ecker ML, et al. Long-term Results after Total Condylar Knee Arthroplasty. Significance of Radiolucent Lines. *Clin Orthop* 1987;216:151.

+ 35. Eckhoff DG, Metzger RG, Vandewalle MV. Malrotation Associated with Implant Alignment Technique in Total Knee Arthroplasty. *Clin Orthop* 1995;321:28.

+ 36. Eckhoff DG, et al. Assessing Rotational Alignment in Total Knee Arthroplasty. *Clin Orthop* 1995;318:176.

+ 37. Elia EA, Lotke PA. Results of Revision Total Knee Arthroplasty Associated with Significant Bone Loss. *Clin Orthop* 1991;71:114.

+ 38. Ellingsen DE, Rand JA. Intramedullary Arthrodesis of the Knee after Failed Total Knee Arthroplasty. *J Bone Joint Surg Am* 1994;76:870.

* 39. Emerson RH Jr, Head WC, Malinin TI. Reconstruction of Patellar Tendon Rupture after Total Knee Arthroplasty with an Extensor Mechanism Allograft. *Clin Orthop* 1990;260:154.

* 40. Emerson RH Jr, Head WC, Malinin TI. Extensor Mechanism Reconstruction with an Allograft after Total Knee Arthroplasty. *Clin Orthop* 1994;303:79.

+ 41. Engh GA, Parks NL, Ammeen DJ. Tibial Osteolysis in Cementless Total Knee Arthroplasty. A Review of 25 Cases Treated With and Without Tibial Component Revision. *Clin Orthop* 1994;309:33.

+ 42. Fahmy NRM, Barnes KL, Noble J. A Technique for Difficult Arthrodesis of the Knee. *J Bone Joint Surg Br* 1984;66:367.

* 43. Falahee MH, Matthews LS, Kaufer H. Resection Arthroplasty as a Salvage Procedure for a Knee with Infection after a Total Arthroplasty. *J Bone Joint Surg Am* 1987;69:1013.

+ 44. Fehring TK, McAvoy G. Fluoroscopic Evaluation of the Painful Total Knee Arthroplasty. *Clin Orthop* 1996;331:226.

! 45. Figgie HED, Goldberg VM. Some Success Rates of Revision Total Knee Arthroplasty. *Orthop Rev* 1988;17:464.

+ 46. Firestone TP, Krackow KA. Removal of Femoral Components during Revision Knee Arthroplasty. *J Bone Joint Surg Br* 1991;73:514.

+ 47. Flood JN, Kolarik DB. Arthroscopic Irrigation and Debridement of Infected Total Knee Arthroplasty: Report of Two Cases. *Arthroscopy* 1988;4:182.

+ 48. Frymoyer JW, Hoaglund FT. The Role of Arthrodesis in Reconstruction of the Knee. *Clin Orthop* 1974;101:82.

+ 49. Fukasawa N, Shirakura K. Candida Arthritis after Total Knee Arthroplasty—A Case of Successful Treatment without Prosthesis Removal. *Acta Orthop Scand* 1997;68:306.

+ 50. Gacon G, et al. [Two Stage Reimplantation for Infection after Knee Arthroplasty. Apropos of a Series of 29 Cases.] *Rev Chir Orthop Reparatrice Appar Mot* 1997;83:313.

+ 51. Garvin KL, Scuderi G, Insall JN. Evolution of the Quadriceps Snip. *Clin Orthop* 1995;321:131.

+ 52. Gerwin M, et al. Gastrocnemius Muscle Flap Coverage of Exposed or Infected Knee Prostheses. *Clin Orthop* 1993;286:64.

+ 53. Ghazavi MT, et al. Reconstruction of Massive Bone Defects with Allograft in Revision Total Knee Arthroplasty. *J Bone Joint Surg Am* 1997;79:17.

+ 54. Gold DA, Scott SC, Scott WN. Soft Tissue Expansion Prior to Arthroplasty in the Multiply-operated Knee. A New Method of Preventing Catastrophic Skin Problems. *J Arthroplasty* 1996;11:512.

# 55. Goldberg VM, et al. The Results of Revision Total Knee Arthroplasty. *Clin Orthop* 1988;226:86.

# 56. Green SA, Kolsnick R. Arthrodesis of the Knee. *Orthopedics* 1985;8:1514.

# 57. Gross AE, Allen G, Lavoie G. Revision Arthroplasty Using Allograft Bone. *Instr Course Lect* 1993;42:363.

+ 58. Gschwend N. Replacement Arthroplasty of the Knee joint Trends and Treatment after Failure. *Can J Surgery* 1983;26:407.

+ 59. Gusso MI, et al. The Spacer Block Technique in Revision of Total Knee Arthroplasty with Septic Loosening. *Chir Organi Mov* 1995;80:21.

+ 60. Haas SB, Insall JN, et al. Revision Total Knee Arthroplasty with Use of Modular Components with Stems Inserted without Cement. *J Bone Joint Surg Am* 1995;77:1700.

+ 61. Hak DJ, Lieberman JR, Finerman GA. Single Plane and Biplane External Fixators for Knee Arthrodesis. *Clin Orthop* 1995;316:134.

+ 62. Hanssen AD, Trousdale RT, Osmon DR. Patient Outcome with Reinfection following Reimplantation for the Infected Total Knee Arthroplasty. *Clin Orthop* 1995;321:55.

+ 63. Harris CM, Froehlich J. Knee Fusion with Intramedullary Rods for Failed Total Knee Arthroplasty. *Clin Orthop* 1985;197:209.

* 63a. Havel PE, Giddings JC. Fracture of Polyethylene Tibial Component in Total Knee Arthroplasty Diagnosed by Arthroscopy. *Orthopedics* 1994;17:357 (Discussion p. 358).

+ 64. Henderson JJ, et al. The Value of Skeletal Scintigraphy in Predicting the Need for Revision Surgery in Total Knee Replacement. *Orthopedics* 1996;19:295.

# 65. Henderson MH Jr, Booth RE Jr. The Use of an Antibiotic Impregnated Spacer Block for Revision of the Septic Total Knee Arthroplasty. *Semin Arthroplasty* 1991;2:34.

* 66. Hibbs RA. An Operation for Stiffening the Knee Joint, with Report of Four Cases from the Service of the New York Orthopedic Hospital. *Ann Surg* 1911;53:404.

* 67. Hibbs RA, von Lackum HL. End-results in Treatment of Knee Joint Tuberculosis. *JAMA* 1925;85:1289.

+ 68. Hirakawa K, Stulberg, et al. Results of 2-stage Reimplantation for Infected Total Knee Arthroplasty. *J Arthroplasty* 1998. 13:22.

+ 69. Hofmann AA, et al. Treatment of Infected Total Knee Arthroplasty Using an Articulating Spacer. *Clin Orthop* 1995;321:45.

+ 70. Hofmann AA, et al. Bone Scans after Total Knee Arthroplasty in Symptomatic Patients: Cemented versus Cementless. *Clin Orthop* 1990;251:183.

71. Hohl WM, et al. The Total Condylar III Prosthesis in Complex Knee Reconstruction. *Clin Orthop* 1991;273:91.

* 72. Hozack WJ, et al. The Patellar Clunk Syndrome: A Complication of Posterior Stabilized Total Knee Arthroplasty. *Clin Orthop* 1989;241:203.

+ 73. Hunter GA, Cameron HV, Welsh RP, et al. The Natural History of the Failed Knee Replacement. *Orthop Trans* 1980;3:389.

+ 74. Inglis AAWP. Revision of Failed Knee Replacements Using Fixed-axis Hinges. *J Bone Joint Surg Br* 1991;73:757.

* 75. Insall JN, Dethmers DA. Revision of Total Knee Arthroplasty. *Clin Orthop* 1982;170:123.

+ 76. Isiklar ZU, Landon GC, Tullos HS. Amputation after Failed Total Knee Arthroplasty. *Clin Orthop* 1994;299:173.

* 77. Jacobs MA, et al. Revision Total Knee Arthroplasty for aseptic Failure. *Clin Orthop* 1988;226:78.

+ 78. Johnson DR, et al. The Role of Arthroscopy in the Problem Total Knee Replacement. *Arthroscopy* 1990;6:30.

+ 79. Johnson JA, et al. Detection of Occult Infection following Total Joint Arthroplasty Using Sequential Technetium-99m HDP Bone Scintigraphy and Indium 111 WBC Imaging. *J Nucl Med* 1988;29:1347.

+ 80. Jorgensen PS, Torholm C. Arthrodesis after Infected Knee Arthroplasty Using Long Arthrodesis Nails. A Report of Five Cases. *Am J Knee Surg* 1995;8:110.

* 81. Kaufer H, Matthews LS. Resection Arthroplasty: An Alternative to Arthrodesis for Salvage of the Infected Total Knee Arthroplasty. *Instr Course Lect* 1986;35:283.

# 82. Kaufer H, Matthews LS. Revision Total Knee Arthroplasty: indications and Contraindications. *Instr Course Lect* 1986;35:297.

* 83. Key J. Positive Pressure in Arthrodesis for Tuberculosis of the Knee Joint. *South Med J* 1932;25:909.

* 84. Key JA. Arthrodesis of the Knee with a Large Central Autogenous Bone Peg. *South Med J* 1937;30:574.

+ 85. Kim LF, Finerman GAM. Results of Revisions for Aseptic Failed Knee Arthroplasties. *Orthop Trans* 1983;7:535.

+ 86. Kindsfater K, Scott R. Recurrent Hemarthrosis after Total Knee Arthroplasty. *J Arthroplasty* 1995;10 (Suppl):S52.

+ 87. Knight JL, Atwater RD, Guo J. Early Failure of the Porous Coated Anatomic Cemented Unicompartmental Knee Arthroplasty. Aids to Diagnosis and Revision. *J Arthroplasty* 1997;12:11.

+ 88. Knight JL, Sherer D, Guo J. Blood Transfusion Strategies for Total Knee Arthroplasty: Minimizing Autologous Blood Wastage, Risk of Homologous Blood Transfusion, and Transfusion Cost. *J Arthroplasty* 1998;13:70.

+ 89. Knutson K, et al. Arthrodesis after Failed Knee Arthroplasty. A Nationwide Multicenter Investigation of 91 Cases. *Clin Orthop* 1984;191:202.

* 90. Krackow KA, Holtgrewe JL. Experience with a New Technique for Managing Severely Overcorrected Valgus High Tibial Osteotomy at Total Knee Arthroplasty. *Clin Orthop* 1990;258:213.

* 91. Küntscher G. Praxis der Marknagelung. Stuttgart: Schattauer Verlag, 1962.

+ 92. Lachiewicz PF, Falatyn SP. Clinical and Radiographic Results of the Total Condylar III and Constrained Condylar Total Knee Arthroplasty. *J Arthroplasty* 1996;11:916.

+ 93. Lai KA, Shen WJ, Yang CY. Arthrodesis with a Short Huckstep Nail as a Salvage Procedure for Failed Total Knee Arthroplasty. *J Bone Joint Surg Am* 1998;80:380.

+ 94. Laskin RS, O'Flynn HM. The Insall Award. Total Knee Replacement with Posterior Cruciate Ligament Retention in Rheumatoid Arthritis. Problems and Complications. *Clin Orthop* 1997;345:24.

+ 95. Lawrence SJ, Kan RO. Arthroscopic Lysis of Adhesions after New Jersey LCS Total Knee Arthroplasty. *Orthopedics* 1992;15:943.

+ 96. Lettin AW, Neil MJ, Citron ND, et al. Excision Arthroplasty for Infected Constrained Total Knee Replacements. *J Bone Joint Surg Br* 1990;72:220.

+ 97. Levine M, Rehm SJ, Wilde AH. Infection with *Candida albicans* of a Total Knee Arthroplasty. Case Report and Review of the Literature. *Clin Orthop* 1988;226:235.

* 98. Levine MJ, et al. Molecular Genetic Diagnosis of Infected Total Joint Arthroplasty. *J Arthroplasty* 1995;10:93.

+ 99. Levine WN, et al. Conversion of Failed Modern Unicompartmental Arthroplasty to Total Knee Arthroplasty. *J Arthroplasty* 1996;11:797.

+ 100. Lintner DM, Bocell JR, Tullos HS. Arthroscopic Treatment of Intraarticular Fibrous Bands after Total Knee Arthroplasty. A Follow-up Note. *Clin Orthop* 1994;309:230.

+ 101. Lucas DB, Murray WR. Arthrodesis of the Knee by Double Plating. *J Bone Joint Surg Am* 1961;43:795.

+ 102. Mahomed N, et al. Soft-tissue Expansion before Total Knee Arthroplasty in Arthrodesed Joints. A Report of Two Cases. *J Bone Joint Surg Br* 1994;76:88.

+ 103. Mantas JP, et al. Implications of Reference Axes Used for Rotational Alignment of the Femoral Component in Primary and Revision Knee Arthroplasty [Comments]. *J Arthroplasty* 1992;7:531.

+ 104. Markel DC, et al. Arthroscopic Treatment of Peripatellar Fibrosis after Total Knee Arthroplasty. *J Arthroplasty* 1996;11:293.

+ 105. Markovich GD, Dorr LD, Klein NE, et al. Muscle Flaps in Total Knee Arthroplasty. *Clin Orthop* 1995;321:122.

+ 106. Maxon HR, et al. A Comparative Study of Indium-111 DTPA Radionuclide and Iothalamate Meglumine Roentgenographic Arthrography in the Evaluation of Painful Total Hip Arthroplasty. *Clin Orthop* 1989;245:156.

+ 107. Mazet R, Urist MR. Arthrodesis of the Knee with Intramedullary Nail Fixation. *Clin Orthop* 1960;18:43.

* 108. Merchant AC, et al. Roentgenographic Analysis of Patellofemoral Congruence. *J Bone Joint Surg Am* 1974;56:1391.

+ 109. Mintz AD, Pilkington CA, Howie DW. A Comparison of Plain and Fluoroscopically Guided Radiographs in the Assessment of Arthroplasty of the Knee. *J Bone Joint Surg Am* 1989;71:1343.

+ 110. Mintz L, et al. The Arthroscopic Evaluation and Characteristics of Severe Polyethylene Wear in Total Knee Arthroplasty. *Clin Orthop* 1991;273:215.

111. Morris HD, Mosiman RS. Arthrodesis of the Knee. A Comparison of the Compression Method with the Non-Compression Method. *J Bone Joint Surg Am* 1951;33:982.

+ 112. Mow CS, Wiedel JD. Structural Allografting in Revision Total Knee Arthroplasty. *J Arthroplasty* 1996;11:235.

+ 113. Mow CS, Wiedel JD. Revision Total Knee Arthroplasty Using the Porous-coated Anatomic Revision Prosthesis: Six- to Twelve-year Results. *J Arthroplasty* 1998;13:681.

+ 114. Murray PB, Rand JA, Hanssen AD. Cemented Long-stem Revision Total Knee Arthroplasty. *Clin Orthop* 1994;309:116.

+ 115. Namba RS, Diao E. Tissue Expansion for Staged Reimplantation of Infected Total Knee Arthroplasty. *J Arthroplasty* 1997;12:471.

+ 116. Nichols SJ, Landon GC, Tullos HS. Arthrodesis with Dual Plates after Failed Total Knee Arthroplasty. *J Bone Joint Surg Am* 1991;73:1020.

+ 117. Padgett DE, Stern SH, Insall JN. Revision Total Knee Arthroplasty for Failed Unicompartmental Replacement. *J Bone Joint Surg Am* 1991;73:186.

+ 118. Peters CL, et al. Revision Total Knee Arthroplasty with a Cemented Posterior-Stabilized or Constrained Condylar Prosthesis: A Minimum 3-year and Average 5-year Follow-up Study. *J Arthroplasty* 1997;12:896.

+ 119. Poilvache PL, et al. Rotational Landmarks and Sizing of the Distal Femur in Total Knee Arthroplasty. *Clin Orthop* 1996;331:35.

+ 120. Puranen J, Kortelainen P, Jalovaara P. Arthrodesis of the Knee with Intramedullary Nail Fixation. *J Bone Joint Surg Am* 1990;72:433.

+ 121. Rand JA. Revision Total Knee Arthroplasty Using the Total Condylar III Prosthesis. *J Arthroplasty* 1991;6:279.

+ 122. Rand JA. Modularity in Total Knee Arthroplasty. *Acta Orthop Belg* 1996;62(Suppl 1):180.

+ 123. Rand JA. Modular Augments in Revision Total Knee Arthroplasty. *Orthop Clin North Am* 1998;29:347.

+ 124. Rand JA, Bryan RS. Revision after Total Knee Arthroplasty. *Orthop Clin North Am* 1982;13:201.

+ 125. Rand JA, Bryan RS. The Outcome of Failed Knee Arthrodesis following Total Knee Arthroplasty. *Clin Orthop* 1986;205:86.

+ 126. Rand JA, Bryan RS. Results of Revision Total Knee Arthroplasties Using Condylar Prostheses. A Review of Fifty Knees. *J Bone Joint Surg Am* 1988;70:738.

+ 127. Rand JA, Bryan RS, Chao EY. Failed Total Knee Arthroplasty Treated by Arthrodesis of the Knee Using the Ace-Fischer apparatus. *J Bone Joint Surg Am* 1987;69:39.

+ 128. Rand JA, Chao EY, Stauffer RN. Kinematic Rotating-hinge Total Knee Arthroplasty. *J Bone Joint Surg Am* 1987;69:489.

# 129. Rand JA, et al. Revision Total Knee Arthroplasty. *Instr Course Lect* 1986;35:305.

+ 130. Rasmussen MR, Bishop AT, Wood MB. Arthrodesis of the Knee with a Vascularized Fibular Rotatory Graft. *J Bone Joint Surg Am* 1995;77:751.

+ 131. Rooser B, et al. Revision Knee Arthroplasty in Rheumatoid Arthritis. *Clin Orthop* 1987;219:169.

+ 132. Rosenberg AG, Verner JJ, Galante JO. Clinical Results of Total Knee Revision Using the Total Condylar III Prosthesis. *Clin Orthop* 1991;273:83.

+ 133. Rosenthall L, Lepanto L, Raymond F. Radiophosphate Uptake in Asymptomatic Knee Arthroplasty. *J Nucl Med* 1987;28:1546.

+ 134. Rothacker GW, Cabanela ME. External Fixation for Arthrodesis of the Knee and Ankle. *Clin Orthop* 1983;180:101.

+ 135. Rud B, Jensen UH. Function after Arthrodesis of the Knee. *Acta Orthop Scand* 1985;56:337.

+ 136. Samuelson KMF, MA.R, Day WH. Bone Grafting and Non-cemented Revision Arthroplasty of the Knee. *Clin Orthop* 1980;4:1980.

+ 137. Santore RF, et al. Tissue Expansion Prior to Revision Total Knee Arthroplasty. *J Arthroplasty* 1997;12:475.

+ 138. Satku K, Fong PH, Kumar VP, Lee YS. Dermatitis Complicating Operatively Induced Anaesthetic Regions around the Knee. A Report of Four Cases. *J Bone Joint Surg Am* 1993;75:116.

+ 139. Scher DM, Paumier JC, DiCesare PE. Pseudomeniscus following Total Knee Arthroplasty as a Cause of Persistent Knee Pain. *J Arthroplasty* 1997;12:114.

+ 140. Scott IR, Stockley I, Getty CJ. Exchange Arthroplasty for Infected Knee Replacements. A New Two-stage Method. *J Bone Joint Surg Br* 1993;75:28.

+ 141. Shaw JA. Angled Bearing Inserts in Total Knee Arthroplasty. A Brief Technical Note. *J Arthroplasty* 1992;7:211.

+ 142. Shaw JA, Balcom W, Greer RBD. Total Knee Arthroplasty Using the Kinematic Rotating Hinge Prosthesis. *Orthopedics* 1989;12:647.

+ 143. Stewart MJ, Bland WG. Compression in Arthrodesis. A Comparative Study of Methods of Fusion of the Knee in Ninety-Three Cases. *J Bone Joint Surg Am* 1958;40:585.

+ 144. Stiehl JB, Hanel DP. Knee Arthrodesis Using Combined Intramedullary Rod and Plate Fixation. *Clin Orthop* 1993;294:238.

+ 145. Stuart MJ, Larson JE, Morrey BF. Reoperation after Condylar Revision Total Knee Arthroplasty. *Clin Orthop* 1993;286:168.

+ 146. Thornhill TS, Dalziel RW, Sledge CB. Alternatives to Arthrodesis for the Failed Total Knee Arthroplasty. *Clin Orthop* 1982;170:131.

+ 147. Trousdale RT, et al. V-Y Quadricepsplasty in Total Knee Arthroplasty. *Clin Orthop* 1993;286:48.

+ 148. Tsahakis PJ, Beaver WB, Brick GW. Technique and Results of Allograft Reconstruction in Revision Total Knee Arthroplasty. *Clin Orthop* 1994;303:86.

+ 149. Turner RH. Revision of Total Knee Replacement Implants. *Orthop Trans* 1980;4:89.

+ 150. Ullmark G, Hovelius L. Impacted Morselized Allograft and Cement for Revision Total Knee Arthroplasty: A Preliminary Report of 3 Cases. *Acta Orthop Scand* 1996;67:10.

+ 151. Vander Griend R. Arthrodesis of the Knee with Intramedullary Fixation. *Clin Orthop* 1983;181:146.

+ 152. Vernace JV, et al. Arthroscopic Management of the Patellar Clunk Syndrome following Posterior Stabilized Total Knee Arthroplasty. *J Arthroplasty* 1989;4:179.

# 153. Vince K. Planning Revision Total Knee Arthroplasty. *Semin Arthroplasty* 1997.

+ 154. Vince K, Blackburn D. Gull Wing Patellar Osteotomy in Total Knee Arthroplasty. (Submitted.)

# 155. Vince KG. Revision Knee Arthroplasty Technique. *Instr Course Lect* 1993;42:325.

# 156. Vince KG. Stiff Total Knee Arthroplasty. In: Fu CFH, Vince KG, eds. *Knee Surgery.* Baltimore: Williams & Wilkins, 1993.

+ 157. Vince KG. Collateral Ligament Reconstructions in Difficult Primary and Revision Total Knee Arthroplasty. In: American Academy of Orthopedic Surgeons. San Francisco, 1997.

+ 158. Vince KG, Long W. Revision Knee Arthroplasty. The Limits of Press Fit Medullary Fixation. *Clin Orthop* 1995;317:172.

+ 159. Vince KM, Murphy M, Kharrazi D, et al. Revision Total Knee Arthroplasty with a Modular Prosthesis and a Three Step Reconstruction Technique: 2 to 10 Year Follow Up. Presented at the 10th Combined Orthopedic Associations of the English-Speaking World Meeting. Auckland, New Zealand, 1998.

+ 160. Vlasak R, Gearen PF, Petty W. Knee Arthrodesis in the Treatment of Failed Total Knee Replacement. *Clin Orthop* 1995;321:138.

* 161. von Foerster G, Kluber D, Kabler U. [Mid- to Long-term Results after Treatment of 118 Cases of Periprosthetic Infections after Knee Joint Replacement Using One-stage Exchange Surgery.] *Orthopade* 1991;20:244.

+ 162. Wade PJF, Denham RA. Arthrodesis of the Knee after Failed Knee Replacement. *J Bone Joint Surg Br* 1984;66:362.

+ 163. Wasilewski SA, Frankl U. Arthroscopy of the Painful Dysfunctional Total Knee Replacement. *Arthroscopy* 1989;5:294.

+ 164. Wasilewski SA, Frankl U. Fracture of Polyethylene of Patellar Component in Total Knee Arthroplasty, Diagnosed by Arthroscopy. *J Arthroplasty* 1989;4(Suppl):S19.

+ 165. Weiner SD, Scarborough M, Vander Griend RA. Resection Arthrodesis of the Knee with an Intercalary Allograft. *J Bone Joint Surg Am* 1996;78:185.

+ 166. Wertzberger KL, Bryan RS. Analysis of Failed Total Knee Arthroplasty, Excluding Infection, Undergoing Reoperation. *Orthop Trans* 1979;3:265.

* 167. Whiteside LA. Cementless Revision Total Knee Arthroplasty. *Clin Orthop* 1993;286:160.

+ 168. Whiteside LA. Exposure in Difficult Total Knee Arthroplasty Using Tibial Tubercle Osteotomy. *Clin Orthop* 1995;321:32.

+ 169. Williams RJ 3rd, et al. Arthroscopic Release of the Posterior Cruciate Ligament for Stiff Total Knee Arthroplasty. *Clin Orthop* 1996;331:185.

+ 170. Wilson MG, Kelley K, Thornhill TS. Infection as a Complication of Total Knee-replacement Arthroplasty. Risk Factors and Treatment in Sixty-seven Cases. *J Bone Joint Surg Am* 1990;72:878.

* 171. Windsor RE, et al. Two-stage Reimplantation for the Salvage of Total Knee Arthroplasty Complicated by Infection. Further Follow-up and Refinement of Indications. *J Bone Joint Surg Am* 1990;72:272.

+ 172. Windsor RE, Scuderi GR, Insall JN. Revision of Well-fixed Cemented, Porous Total Knee Arthroplasty. Report of Six Cases. *J Arthroplasty* 1988;3(Suppl):S87.

+ 173. Wolff AM, et al. Osteotomy of the Tibial tubercle During Total Knee Replacement. A Report of twenty-six Cases [Comments]. *J Bone Joint Surg Am* 1989;71:848.

+ 174. Woods GW, Lionberger DR, Tullos HS. Failed Total Knee Arthroplasty. Revision and Arthrodesis for Infection and Noninfectious Complications. *Clin Orthop* 1983;173:184.

+ 175. Young HH. Use of a Hinged Vitallium Prosthesis (Young Type) for Arthroplasty of the Knee. *J Bone Joint Surgery Am* 1971;53:1658.

+ 176. Zaman TM, Grigoris PG, O'Hara J. Arthroscopic Shaving of a Hematoma after Total Knee Arthroplasty. *Arthroscopy* 1996;12:500.

# CHAPTER 110

# FRACTURES OF THE HINDFOOT

*Timothy J. Bray*

**T. J. Bray:** Reno Orthopaedic Clinic, Reno, Nevada, 89503.

Talus Fractures
- Pathophysiology
- Radiographic Evaluation
- Fractures of the Neck of the Talus
- Surgical Techniques
- Postoperative Management and Complications
- Fractures of the Body of the Talus
- Fractures of the Head of the Talus
- Transchondral Dome Fractures
- Fractures of the Lateral Process
- Fractures of the Posterior Process
- Peritalar Dislocations
- Author's Perspective

Calcaneus Fractures
- Pathologic Anatomy
- Principles of Treatment
- Surgical Techniques
- Pitfalls and Complications
- Authors' Perspective

Chapter References

## TALUS FRACTURES

### PATHOPHYSIOLOGY

Although fractures and dislocations of the talus account for less than 1% of all fractures, they are fraught with serious complications, including skin necrosis, infection, avascular necrosis, malunion, nonunion, ankle and subtalar arthrofibrosis, and posttraumatic arthritis (18,23,51,55,72,81). Injuries range from osteochondral fractures of the dome to fractures of the talar neck and body, with or without subluxation or dislocation of the ankle and subtalar joints. With advances in methods of treatment, morbidity is decreasing and complications are being managed more effectively.

#### *Anatomy and Blood Supply*

The talus is made up of the body posteriorly, which articulates with the tibia, posterior subtalar facet, and lateral malleolus; the head anteriorly, which articulates with the navicular, anterior and middle subtalar facets, and calcaneonavicular ligament; and the neck, which has no articulations.

The talus is unique because its external surface is 60% articular cartilage and it has no muscular attachments (46). Because of its large articular surface and lack of muscular attachments, the talus has a limited surface area for vascular supply. Although it has a rich blood supply, with contributions from all three main arteries of the lower limb, the limited access makes its blood supply particularly vulnerable to injury. The three main extraosseous vascular sources are arterial branches to the dorsal neck arising from the anterior tibial and peroneal arteries, the artery of the sinus tarsi arising from the anterior tibial and peroneal arteries, and the artery of the tarsal canal arising from the posterior tibial artery (Fig. 110.1). Additionally, the deltoid branch of the artery to the tarsal canal supplies blood to the medial talar body (46,62). Numerous smaller channels enter through capsular and ligamentous attachments.

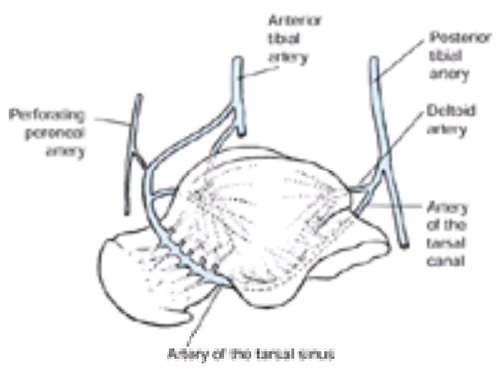


***Figure 110.1.*** Blood supply of the talus. The three main arterial contributions are shown, in addition to the deltoid branch to the medial talar body. (From Mayo KA. Fractures of the Talus: Principles of Management and Techniques of Treatment. *Tech Orthop* 1988;3:42, with permission.)

In addition to the extraosseous blood supply, a rich network of intraosseous anastomoses has been described (54). Peterson et al. (71) demonstrated injury to the intraosseous arterial network in nondisplaced, experimentally produced talar neck fractures, with progressive damage to the main extraosseous arterial channels as fracture displacement progressed.

#### *Mechanisms of Injury*

Talar neck fractures are high-energy injuries caused by major traumatic events. They make up 50% of all major injuries to the talus (23). Once termed aviator's astragalus, talar neck fractures are no longer caused primarily by flying accidents; motor vehicle accidents and falls from heights are now more common mechanisms of injury. These fractures initially were thought to be caused by forced dorsiflexion of the talus against the anterior margin of the tibia, but laboratory studies have shown that they are more likely caused by a dorsally directed shear force exerted against the sole of the foot with the body of the talus fixed between the tibia and calcaneus. Fractures occur in a vertical or slightly oblique plane between the middle and posterior subtalar facets, and the distal fragment is characteristically displaced dorsally and medially (18). The force required to fracture the talus is roughly twice that required to fracture either the calcaneus or the navicular (74). With additional force, the body of the talus is dislocated posteriorly out of the ankle mortise, usually medial to the Achilles tendon.

#### *Classification*

Talus fractures were classified by Coltart (23) into chip and avulsion fractures, compression fractures of the head, fractures of the neck, and fractures of the body.

Dislocations and fracture–dislocations were further subdivided into those associated with dislocations of the ankle, subtalar, and midtarsal joints.

Hawkins (41) further subdivided talar neck fractures into three types (Fig. 110.2). Type I fractures are nondisplaced and disrupt only those blood vessels entering the body via the dorsal talar neck in addition to intraosseous vessels crossing the neck. Type II fractures are displaced with subluxation or dislocation of the subtalar joint. These fractures disrupt the dorsal neck arterial branches and the branches entering inferiorly from the sinus tarsi and tarsal canal, leaving undisturbed only the vessels entering through the deep deltoid ligament and medial talar body. Type III fractures are displaced with dislocation of the talar body from both the ankle and the subtalar joints. The body of the talus is usually displaced posteriorly and medially, stretching and compressing the neurovascular bundle. All three main sources of blood supply to the body of the talus are disrupted in these injuries. Canale and Kelly (20) added type IV, which are fractures associated with complete dislocation of the talar body and subluxation or dislocation of the talar head from the talonavicular joint.

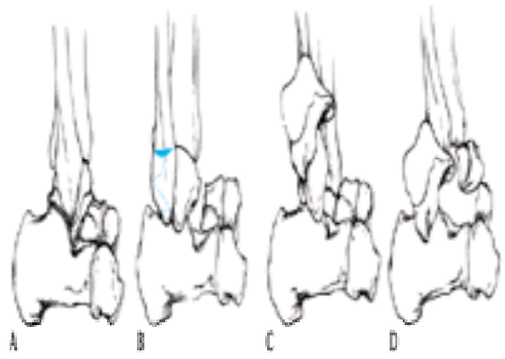


***Figure 110.2.*** Modified Hawkins (41) classification of talar neck fractures. **A:** Type I, nondisplaced. **B:** Type II, displaced with subluxation or dislocation of the subtalar joint. **C:** Type III, displaced with dislocation of the talar body from both ankle and subtalar joints. **D:** Type IV, subluxation or dislocation of talar head in addition to dislocation of talar body. (From Delee JC. Fractures and Dislocations of the Foot. In: Mann RA, ed. *Surgery of the Foot*, 5th ed. St. Louis: Mosby, 1986:656, with permission.)

## RADIOGRAPHIC EVALUATION

Take high-quality anteroposterior (AP), lateral, and oblique radiographs of the ankle and foot. Canale and Kelly (20) described a pronated oblique view of the midfoot to better visualize the talar neck and head (Fig. 110.3). Look for associated injuries. Tomograms or computed tomography (CT) scans are occasionally required to assess the fracture configuration and displacement.

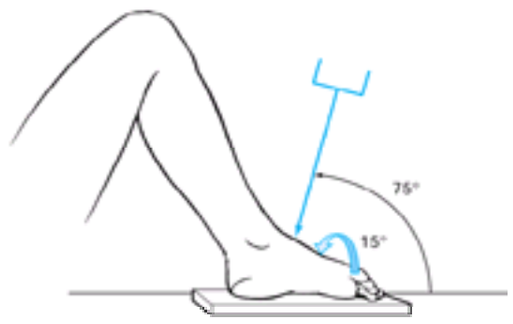


***Figure 110.3.*** Pronated oblique view of midfoot to better visualize the talar neck. Ankle is in maximal equinus, with foot pronated 15°. Direct the roentgen tube 75° from the horizontal. (From Delee JC. Fractures and Dislocations of the Foot. In: Mann RA, ed. *Surgery of the Foot*, 5th ed. St. Louis: Mosby, 1986:656, with permission.)

## FRACTURES OF THE NECK OF THE TALUS

### *Principles of Treatment*

Nonoperative treatment is usually appropriate for nondisplaced (type I) talar neck fractures. Treat in a short-leg, non-weight-bearing cast for 6–8 weeks. Once union occurs, begin progressive weight bearing and mobilization of the ankle and subtalar joints.

Operative treatment is generally reserved for displaced talar neck fractures (types II, III, and IV). Reduction is difficult to maintain using closed methods because of tearing of the talocalcaneal interosseous ligament (33). Type II fractures require anatomic reduction to correct subtalar incongruity. Fractures of type III or IV require prompt reduction of the talar body to reduce the risk of pressure necrosis of the overlying skin. Early reduction and rigid internal fixation reestablishes soft-tissue circulation, enhances bony revascularization, and allows early motion, which reduces the risk of persistent edema, soft-tissue atrophy, stiffness, and osteoporosis (i.e., “fracture disease”) (24,63,86). Open injuries require immediate and thorough irrigation and debridement of the wound, anatomic reduction, internal fixation, and appropriate antibiotics.

Whereas most type II fractures can be reduced by closed methods using fluoroscopic guidance, most type III and IV fractures require open reduction. Reduction of the talar body into the mortise is often facilitated by equinus positioning of the foot and axial traction through a calcaneal pin. Reduce the body as gently as possible to prevent further damage to the blood supply and articular cartilage. Osteotomy of the medial malleolus may facilitate reduction of the dislocated talar body; it also protects the deep deltoid blood supply to the talus (32).

Use smooth wires or guide pins for preliminary fixation and rigid screw fixation for definitive fixation. Screws prevent fracture displacement and malunion, and they enhance body union and early mobilization of the ankle and subtalar joints. Screws placed anterior to posterior allow visualization of the fracture, but often they must be placed through the weaker talar neck or talar head articular surface (38,86). Screws placed posterior to anterior avoid disruption of the talonavicular joint and further damage to the dorsal blood supply to the talar neck, but they do not allow direct visualization of fracture reduction (30,48,93) unless a combined anterior and posterior exposure is performed. A mechanical study by Swanson et al. (85) demonstrated that posterior screw fixation gives more rigid fixation than anterior screws, and both are superior to Kirschner wire (K-wire) fixation. The choice of surgical approach ultimately depends on the presence and location of traumatic wounds, the condition of skin, fracture classification and configuration, and the presence of adjacent fractures (53). Cannulated screws are now available for percutaneous fixation of fractures accurately reduced using closed methods (20).

## SURGICAL TECHNIQUES

### *Posterior Fixation*

Posterior screw fixation can be completed through either a posterolateral or a posteromedial approach. The posterolateral approach avoids the neurovascular bundle and is generally recommended for type II fractures.

- Place the patient in the prone or lateral decubitus position with the affected extremity uppermost. Make a 4 cm longitudinal incision just lateral to the Achilles tendon, taking care to protect the sural nerve, which is anterior (Fig. 110.4).

***Figure 110.4.*** Make the skin incision for the posterolateral approach to the talus just lateral to the Achilles tendon.

- Locate the posterior process of the talus through the peroneus brevis and flexor hallucis longus tendons (Fig. 110.5).

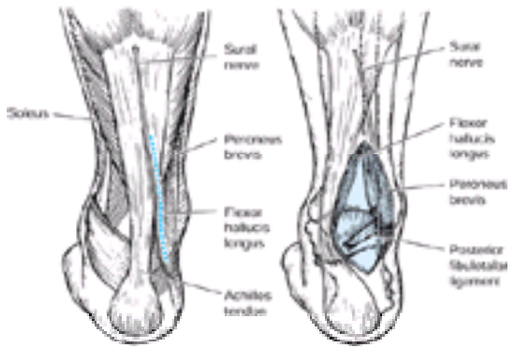


***Figure 110.5.*** Posterolateral approach to the talus. Retract the sural nerve anteriorly. Expose the posterior talus through the interval between the peroneus brevis and flexor hallucis longus tendons. (From Mayo KA. Fractures of the Talus: Principles of Management and Techniques of Treatment. *Tech Orthop* 1988;3:42, with permission.)

- Next, perform a closed reduction by plantar-flexing and abducting the forefoot under fluoroscopic guidance. Use a 2.0 mm K-wire as a “joystick” to manipulate the fracture if needed. If you cannot obtain an adequate closed reduction, make a small anterior incision to facilitate the reduction.
- Drive two K-wires from the nonarticular aspect of the talar body into the talar head to hold the reduction, and reassess the reduction with standard radiographs if needed (53).
- Achieve rigid fixation with dual 4.0 mm cancellous screws, entering just lateral to the posterior process (Fig. 110.6). Be certain that threads extend past the fracture site but not into the talonavicular joint. Try to place screws perpendicular to the fracture plane for maximal compression. With the advent of cannulated screws, talar neck fractures can be rigidly fixed percutaneously using a single 6.5 mm cancellous screw entering through the posterior, nonarticular part of the talus (20).

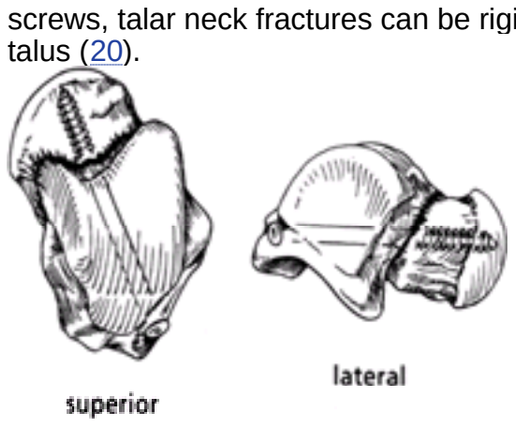


***Figure 110.6.*** Posterior cancellous screw fixation of a talar neck fracture. Notice that the screw enters the nonarticular aspect of the posterior talus. It passes directly through the center of the talar neck, as perpendicular to the fracture plane as possible. (From Adelaar RS. Fractures of the Talus. *Instr Course Lect* 1990;34:147, with permission.)

The posteromedial approach is useful for talar body dislocations because it allows osteotomy of the medial malleolus, facilitating reduction of the dislocated body (or fixation of concomitant medial malleolar fractures).

- Place the patient in the supine position with a sandbag under the contralateral buttock and with the affected extremity in a figure-four position. Make a 6 cm longitudinal incision between the medial malleolus and the Achilles tendon (Fig. 110.7), taking care to carefully isolate the neurovascular bundle (Fig. 110.8). Carry dissection posterior to posteromedial neurovascular structures.

***Figure 110.7.*** Make the skin incision for the posteromedial approach to the talus between the medial malleolus and Achilles tendon.

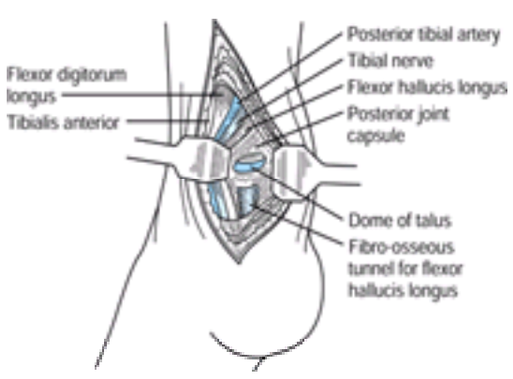


***Figure 110.8.*** Posteromedial approach to the talus. (From Hoppenfeld S, deBoer P.*Surgical Exposures in Orthopaedics: The Anatomic Approach.* Philadelphia:

Lippincott, 1984:487, with permission.)

- To reduce the dislocated talar body, place a Steinmann pin in the calcaneus for axial traction if needed.
- If you still cannot reduce the dislocated body, dissect subcutaneously and perform a medial malleolar osteotomy. To osteotomize the medial malleolus, predrill screw holes for reattachment. Perform the osteotomy at 30° to 45° from the plane of the articular surface, toward the medial corner of the tibial plafond. Take care not to disrupt the tenuous deltoid ligament blood supply.
- After reducing the talar body, develop the interval between the flexor hallucis longus and the peroneus tendons. The flexor hallucis longus occasionally needs to be dislocated medially out of its groove.
- Proceed with reduction and fixation of the fracture as described for the posterolateral approach.
- Reattach the medial malleolus with dual 4.0 mm cancellous screws (30).

### *Anterior Fixation*

Anterior fixation can be done through either an anteromedial or an anterolateral incision. The anteromedial approach is most widely used and can be combined with medial malleolar osteotomy to improve exposure, or it can be used to fix concomitant medial malleolar fractures.

- Make a curvilinear incision just medial to the tibialis anterior tendon (Fig. 110.9). Take care to avoid the saphenous vein and nerve. Carry the dissection down to the ankle joint capsule and neck of the talus.

***Figure 110.9.*** For the anteromedial approach to the talus, make a curvilinear incision just medial to the tibialis anterior tendon.

- Dissect subcutaneously to perform a medial malleolar osteotomy, if necessary (Fig. 110.10).

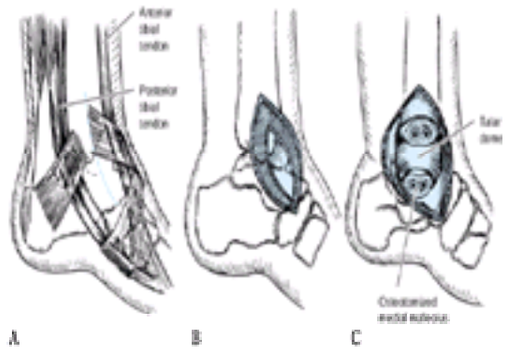


***Figure 110.10.*** Anteromedial approach to the talus. **A:** Skin incision in relationship to the deep structures. **B:** Incise the deep fascia and open the ankle joint capsule. **C:** Osteotomize the medial malleolus with a sharp osteotome just distal to the plafond of the tibia if further exposure is required. (From Mayo KA. Fractures of the Talus: Principles of Management and Techniques of Treatment. *Tech Orthop* 1988;3:42, with permission.)

- Next, identify the talar neck fracture, and reduce it using small K-wires placed in the individual fragments for manipulation, if needed. Take care to correct any dorsomedial displacement or angulation of the distal fragment.
- Achieve rigid fixation using 4.0 mm cancellous screws placed through the nonarticular talar neck, or directly through the talar head after countersinking (Fig. 110.11).

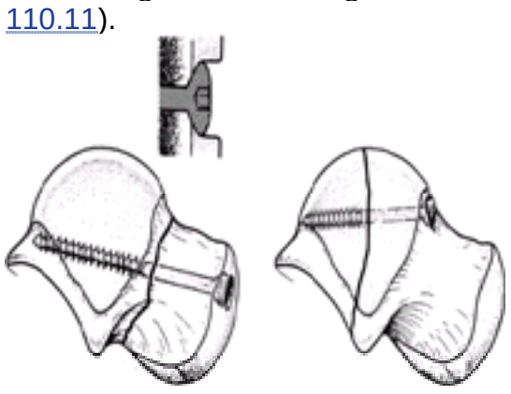

***Figure 110.11.*** Anterior screw fixation of a talar neck fracture. **A:** Screws placed through the articular cartilage must be countersunk below the articular surface. **B:** The preferred fixation, if possible, is through the neck of the talus. (From Grob D, Simpson LA, Weber BG, Bray T. Operative Treatment of Displaced Talus Fractures. *Clin Orthop* 1965;199:88, with permission.)

The anterolateral approach provides better visualization of the lateral talar neck and sinus tarsi.

- Make a slightly curved incision from 2 cm anterior to the distal aspect of the fibula toward the fourth metatarsal base (Fig. 110.12).

***Figure 110.12.*** For the anterolateral approach to the talus, make a curvilinear incision just anterior to the lateral malleolus, toward the fourth metatarsal base.

- Incise the fascia and extensor retinaculum, taking care to preserve any branches of the superficial peroneal nerve.

- Dissect lateral to the extensor digitorum longus and peroneus tertius tendons. The sinus tarsi and talar neck can be exposed by retracting these tendons medially (Fig. 110.13).

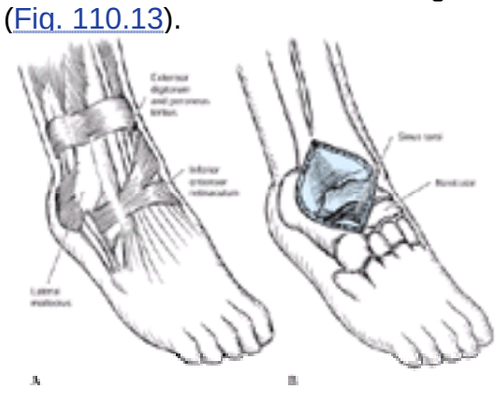

***Figure 110.13.*** Anterolateral approach to the talus. **A:** Skin incision in relationship to the deep structures. **B:** Incise the extensor retinaculum and capsule lateral to the extensor tendons and expose the tarsal sinus and talar neck. (From Mayo KA. Fractures of the Talus: Principles of Management and Techniques of Treatment. *Tech Orthop* 1988;3:42, with permission.)

- Reduce the fracture as described for the anteromedial approach, and stabilize it using 4.0 mm cancellous screws placed through the talar neck into the body.

### *Combined Approaches*

Recent mechanical studies have suggested that fracture gaping occurs on the contralateral side of single-sided anterior fixation constructs. The mechanics of screw fixation placed either laterally or medially may cause the fracture to gape open on the other side, resulting in malreduction or instability. Therefore, combined anterolateral and anteromedial approaches provide the advantages of both approaches and rigid, anatomic reduction and debridement of the subtalar joint. The surgical technique is exactly the same as described for the approaches performed individually. To date, there is little scientific evidence that suggests the two-incision approach provides better functional outcomes than any of the other techniques. There may be a biomechanical advantage to fixation if small miniplates are used bilaterally, rather than screws as commonly described.

## POSTOPERATIVE MANAGEMENT AND COMPLICATIONS

### *Postoperative Care and Rehabilitation*

Support the extremity in a well-padded splint until wounds are healed. If rigid fixation has been achieved, institute early ankle and subtalar motion using a removable fracture brace or splint once soft tissues are healed, generally by 10–14 days. Begin progressive weight bearing in a removable brace when fracture union is evident, usually by 6–8 weeks.

### *Complications*

Acute complications of talar neck fractures include skin necrosis and infection. Skin necrosis is generally seen only with type III and IV fractures, and it can be minimized by prompt reduction of the talar body. Infection may occur after open injuries but can often be avoided by early irrigation and debridement, rigid fracture fixation, delayed wound closure, and prophylactic antibiotics. However, if the talar body is completely avascular, an established osteomyelitis may be resistant to treatment (55).

Late complications include avascular necrosis, nonunion, malunion, and posttraumatic arthritis. Absence of avascular necrosis can often be recognized at 6–8 weeks by the presence of subchrondral atrophy in the dome of the talus (Hawkins' sign) (41). Its absence, however, is not a definite indicator of avascular necrosis (18), nor does its presence rule out small areas of necrosis. Magnetic resonance imaging (MRI) is the most useful modality for diagnosing avascular necrosis. However, MRI requires the use of nonferromagnetic screws (1) because it cannot be used after internal fixation with stainless steel screws (53).

The incidence of avascular necrosis depends on the amount of vascular disruption. Type I fractures have minimal arterial disruption, with rates of avascular necrosis of 0% to 13%. Some authors have postulated that avascular necrosis in this group is caused by an occult, displaced injury that spontaneously reduces (81). Type II fractures have moderate disruption of vascular channels and avascular necrosis rates of 20% to 50%. Type III and IV fractures have disruption of most arterial sources, with avascular necrosis rates of up to 100%.

The wide variation in reported incidences of avascular necrosis is probably the result of differences in methods of detection and methods of acute fracture management. Several series (17,24,32,38,86) report lower rates of avascular necrosis with open reduction and internal fixation (ORIF).

Controversy regarding treatment of avascular necrosis stems from the finding that not all avascular tali go on to collapse, and that those destined to collapse often do so only after a number of years (17,18,41). Although no study has unequivocally proved that protected weight bearing reduces the likelihood of collapse, many authors (30,53,86) recommend use of a patellar tendon-bearing brace until the revascularization process is complete. Davis et al. (29) showed a decrease in weight transmitted across the ankle joint with this brace. If the avascular process involves only a portion of the talar body, allow full weight bearing in a cast or brace that neutralizes varus–valgus ankle stresses (24).

For severe collapse of the avascular talar body, alternatives include tibiocalcaneal fusion with or without interposition iliac crest bone grafting, and the Blair tibiotalar fusion (8,31,50,53,59,77). The Blair fusion is generally preferred because it preserves heel height, maintains the medial longitudinal arch, and allows for some hindfoot motion (1,30,53,81). However, if the talar head cannot be salvaged, tibiocalcaneal fusion with interposition iliac crest bone grafting provides a stable hindfoot in most cases.

Delayed union has been reported in up to 15% of talar neck fractures, but nonunions are rare, generally occurring in less than 1% of fractures (71). The incidence is even lower when rigid internal fixation is used (24,53,81). Malunions are more common, reported in up to 27% in some series (18,20). Most are either dorsal or varus malunions, and anatomic reduction with rigid internal fixation reduces the incidence (18,20,55). Dorsal “beak” resections have been successful for symptomatic dorsal malunions, and triple arthrodesis has been used to treat varus malunions (20).

The incidence of ankle and subtalar posttraumatic arthritis varies from 40% to 90% (18,20,48,51,70). Causes are initial traumatic damage to the articular cartilage, avascular necrosis, and fracture malunion. Arthrofibrosis and loss of motion can be minimized by promoting venous drainage with elevation of the extremity in the early postoperative period, and by early mobilization of the ankle and subtalar joints (55). Subtalar or triple arthrodesis is indicated for symptomatic subtalar arthritis, and tibiotalar arthritis is best managed by ankle arthrodesis. Take care to accurately localize the symptomatic joint before proceeding with arthrodesis (18).

## FRACTURES OF THE BODY OF THE TALUS

Fractures of the talar body make up 10% to 25% of all injuries to the talus, depending on which fracture subtypes are included (23,83). Large forces are required to fracture the body. Because of its crucial role in the ankle and subtalar joints, any residual incongruity may cause symptoms. Although the mechanism of injury and general morphology of these fractures are similar to those of talar neck fractures, the prognosis is generally worse, and therefore we consider these fractures separately (23,57,83).

### *Classification*

Fractures of the talar body were initially classified by Sneppen et al. (83). This classification was modified by Delee (30) into five groups: I, transchondral dome fractures; II, shear fractures; III, posterior tubercle fractures; IV, lateral process fractures; and V, crush fractures (Fig. 110.14). Shear fractures can be further subdivided into coronal, sagittal, and horizontal fractures. Only shear (II) and crush (V) fractures are discussed in this section; groups I, III, and IV will be considered separately.

***Figure 110.14.*** Classification of talar body fractures. (From Delee JC. Fractures and Dislocations of the Foot. In: Mann RA, ed. *Surgery of the Foot*, 5th ed. St. Louis: Mosby, 1986:656, with permission.)

### *Nonoperative Treatment*

Manage shear and crush fractures of the talar body with closed treatment when displacement is minimal (less than 2 mm). Apply a short-leg, non-weight-bearing cast for 6–8 weeks or until union is apparent. If the fracture fragments appear stable, begin cautious early motion using a removable fracture brace or splint before this time, if desired. Thereafter, begin progressive weight bearing in a removable fracture brace. Manage displaced horizontal shear fractures with closed treatment if a satisfactory closed reduction can be obtained using a combination of calcaneal pin traction and manipulation (9). Immobilize in a short-leg, non-weight-bearing cast until union occurs.

### *Operative Technique and Postoperative Care*

Perform operative fixation of displaced talar body fractures when comminution is limited. For shear fractures in the coronal plane, operative approaches, fixation techniques, and postoperative management are essentially identical to those described for talar neck fractures (1). Because of the larger anterior fragment, these fractures often are more amenable to posterior screw fixation than are neck fractures. Shear fractures in the sagittal plane can be fixed with screws through an anteromedial or anterolateral approach. Medial malleolar osteotomy may be necessary for adequate visualization and internal fixation (32). Irreducible horizontal shear fractures can be managed by open reduction with or without pin or screw fixation. Be certain that pins or screw heads are countersunk below the articular surface. Herbert screws through the articular surface provide satisfactory fixation of these fractures.

Displaced, comminuted fractures of the talar body are occasionally not amenable to ORIF. Various authors (8,11,31,33,50,59,69) have recommended primary talectomy, tibiocalcaneal fusion, pantalar arthrodesis, and Blair fusion for irreparable fractures. Primary talectomy should rarely be performed acutely because it may compromise subsequent reconstruction, and no harm results when definitive treatment is delayed. Tibiocalcaneal fusion results in loss of heel height and medial longitudinal arch, whereas pantalar arthrodesis precludes hindfoot motion. With severe collapse of the talar body, the Blair tibiotalar fusion maintains heel height, preserves the medial longitudinal arch, and allows for some tibiopedal motion (1,8,30,31,50,59,81).

### *Complications*

Complications of talar body fractures are similar to those seen with talar neck fractures: avascular necrosis, nonunion, malunion, arthrofibrosis, and posttraumatic arthritis of the ankle and subtalar joints. However, the incidence of these complications is higher with talar body fractures, leading to a larger proportion of poor results.

The incidence of avascular necrosis with coronal shear fractures is about 25% for nondisplaced fractures, 40% to 50% for displaced fractures, and 90% for displaced fractures with complete dislocation of the body (30,57,83). Because these fractures occur more posteriorly than talar neck fractures, and because the fracture line may exit medially through the deltoid ligament attachment, even minimal displacement may result in complete avascularity of the talar body. In horizontal shear fractures, the incidence of avascular necrosis of the dome is even higher due to complete isolation from all vascular sources (9).

Delayed union is most common in displaced fractures and in those developing avascular necrosis; nonunion is rare after talar body fractures (57). Malunion can develop in up to one third of displaced fractures when inadequately reduced (83).

Posttraumatic arthritis is extremely common after talar body fractures because the fracture line passes through both the talar dome articular surface and the posterior facet of the subtalar joint. Other causes of arthritis include acute cartilaginous injury, malunion, and avascular necrosis (11,23,83). Sneppen et al. (83) found a 75% incidence of degenerative arthritis in fractures that healed without displacement.

## FRACTURES OF THE HEAD OF THE TALUS

Fractures of the head of the talus account for only 5% to 10% of all talus injuries. These fractures result from longitudinal compression of a plantar-flexed foot, with or without a simultaneous abduction or adduction force (23,69). Fractures are either a compression type or a split in the longitudinal or oblique plane. Because the head of the talus is well vascularized, avascular necrosis is uncommon (1).

Manage nondisplaced fractures in a short-leg, non-weight-bearing cast with a well-molded arch for 6–8 weeks until union occurs. Displaced fractures often require surgical intervention. If the fracture fragment involves more than half of the articular surface, ORIF through an anteromedial approach is usually preferred, whereas if the fracture involves less than half of the articular surface, excision is often the best treatment. Late problems include talonavicular joint arthrosis and midtarsal instability (1).

## TRANSCHONDRAL DOME FRACTURES

Transchondral fractures of the talar dome are extremely uncommon injuries, making up only 0.09% of all fractures (7). Known by several terms (transchondral fracture, osteochondral fracture, flake fracture, osteochondritis dissecans), these lesions are most likely traumatic in origin (7,64,65,75,76). Many affected patients are treated originally for sprains or more serious ankle injuries (2,4). Characteristic locations are the anterolateral and posteromedial talar dome, with roughly equal proportions in each location (7,19,76). Lateral lesions are typically wafer like or flakelike, whereas medial lesions are often cup-shaped (19) (Fig. 110.15).

***Figure 110.15.*** Classic locations and configurations of transchondral dome fractures. (From Delee JC. Fractures and Dislocations of the Foot. In: Mann RA, ed. *Surgery of the Foot*, 5th ed. St. Louis: Mosby, 1986:656, and redrawn from Canale ST, Belding RH. *J Bone Joint Surg Am* 1980;62:97, with permission.)

### *Classification*

Berndt and Harty (7) originally classified transchondral dome fractures. Stage I lesions involve a small area of subchondral compression of the talar dome. Stage II lesions are partially detached osteochondral fragments. Stage III lesions are completely detached, with the fragment remaining within the crater formed by its detachment. Stage IV lesions are completely detached, with the fragment displaced from its original location (Fig. 110.16*A*). Recently, with the advent of better imaging techniques, including CT and MRI, Fisher et al. (35) have added stage V, the radiolucent defect (subchondral cyst) (Fig. 110.16*B*). They found, using these imaging techniques, that 80% of osteochondral lesions were purely cavitary, with no associated bony or cartilaginous fragments in the joint.

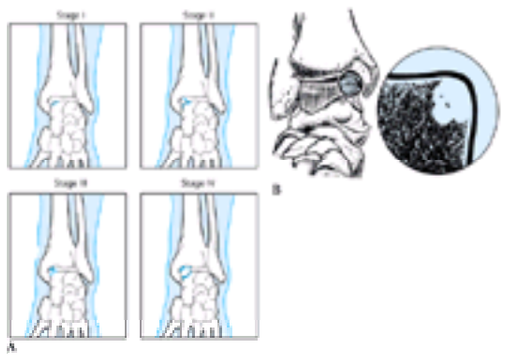

***Figure 110.16.*** Classification of transchondral dome fractures. (From Canale ST, Belding RH. Osteochondral Lesions of the Talus. *J Bone Joint Surg Am* 1980;62:97, with permission.)

### *Radiographic Evaluation*

Before the advent of CT and MRI, transchondral dome fractures were largely evaluated using plain radiographs and tomograms. Plain radiographs, although mandatory in the evaluation of these lesions, are often negative (4,35). Bone scanning is an excellent screening tool because it has a sensitivity for these lesions approaching 100% (35). Further evaluation requires MRI when radiographs are negative, or CT scans when bony involvement is seen on radiographs (4,35). MRI can detect cartilaginous lesions or areas of subchondral compression (stage I lesions), and CT scanning can delineate cavitary lesions (stage V) or assess displacement of osteochondral fragments (stage II, III, and IV lesions).

### *Nonoperative Treatment*

Controversy exists regarding the best form of treatment for various stages of transchondral dome fractures. Most authors (7,19,30,75,81) recommend at least 6 weeks of cast immobilization for acute, nondisplaced lesions. Some (30,75) recommend a trial of immobilization even for chronic, nondisplaced lesions. Operative treatment is indicated for persistent symptoms after an adequate trial of conservative treatment or when the osteochondral fragment is displaced.

### *Operative Technique*

Operative intervention usually involves removal of the fragment when present and drilling of the defect to promote revascularization and fibrocartilaginous metaplasia (28,64,76,81). Only acute lesions involving at least one third of the medial or lateral dome are treated by ORIF. Fibrin adhesives and absorbable pins have recently been developed for this use.

Medial lesions can be approached either through an anteromedial approach with osteotomy of the medial malleolus or through a posteromedial approach without osteotomy of the medial malleolus (35). Lateral lesions can be reached through a standard anterolateral approach.

Recently, arthroscopy has been used to treat transchondral dome fractures. Arthroscopic removal of loose fragments, curettage, debridement, and drilling of the defect greatly reduce postoperative morbidity as compared to open treatment (2,94) (see Chapter 93).

### *Postoperative Care and Rehabilitation*

A period of 6–12 weeks of non-weight-bearing and early ROM exercises is recommended after arthroscopic or open treatment of transchondral dome fractures (2,30,94). After internal fixation of larger transchondral dome fragments, delay weight bearing until fracture union is present (81).

### *Complications*

The most commonly reported complications after treatment of transchondral dome fractures are limitation of ankle motion and posttraumatic arthritis. Results are influenced by the stage, location, and size of the lesion; weight and activity level of the patient; type of treatment; and extent of delay in treatment (75,76,81). In general, nondisplaced lesions have a more favorable prognosis than displaced lesions, with results of medial lesions being superior to lateral lesions in some series (75). A delay in treatment longer than 12 months may worsen the prognosis (65). Several authors (2,7,19,65,76) suggest that surgically treated lesions have a better prognosis than those that are not surgically treated.

Although Canale and Belding (19) reported a 50% incidence of degenerative ankle arthritis at 11 years regardless of the type of treatment, Bauer et al. (6) reported only 2 of 30 patients with degenerative changes at a mean of 21-years follow-up.

## FRACTURES OF THE LATERAL PROCESS

The lateral talar process is the most lateral aspect of the talus (Fig. 110.17). It articulates with both the distal fibula and the posterior facet of the calcaneus and serves as the attachment point for several ligaments, including the anterior taliofibular and lateral talocalcaneal ligaments. Fractures of the lateral talar process account for 24% of talar body fractures (81).

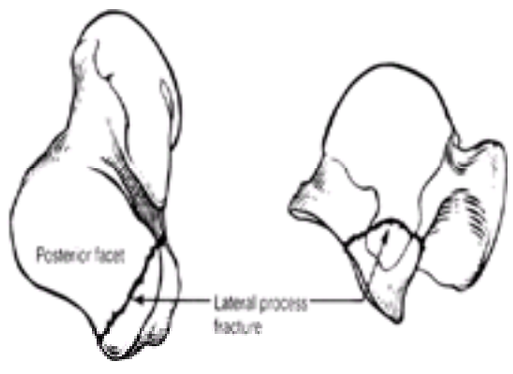


***Figure 110.17.*** Lateral talar process fracture. Note the involvement of the articular surfaces for both the talofibular and subtalar joints. (From Delee JC. Fractures and Dislocations of the Foot. In: Mann RA, ed. *Surgery of the Foot*, 5th ed. St. Louis: Mosby, 1986:656, with permission.)

Lateral process fractures are most likely caused by a combination of forced dorsiflexion and inversion, a mechanism similar to that causing lateral ankle sprains (40,60). Indeed, the signs and symptoms of lateral process fractures and lateral ankle sprains are almost identical. Therefore, this injury should be considered when any patient complains of posttraumatic lateral ankle pain.

#### *Radiographic Evaluation*

Standard radiographs include AP, lateral, and mortise views of the ankle. A 20° internal oblique view of the ankle best demonstrates this fracture (60). Tomograms and CT scans are also useful in delineating fracture fragment size and displacement (30).

#### *Nonoperative Treatment*

Most authors recommend conservative treatment for nondisplaced fractures. Because the lateral process involves a weight-bearing surface, 4–6 weeks in a short-leg, non-weight-bearing cast is generally recommended (40,81,83). Some recommend attempted closed reduction of displaced fragments, and others recommend open reduction because of the difficulty in obtaining a satisfactory closed reduction (30,40,81).

#### *Operative Technique and Postoperative Care*

Open reduction and internal fixation are indicated for large, displaced fragments; small or comminuted fragments are best treated by excision (40,60). Lateral process fractures can be successfully reached through a modified anterolateral approach. Begin the incision 5 cm proximal to the ankle joint, curving just distal to the tip of the fibula (30). Rigid internal fixation with a cancellous screw is generally preferred.

After either ORIF or fragment excision, immobilize the ankle for 2–3 weeks. Thereafter, allow ROM exercises using a removable splint. After ORIF, allow weight bearing when union is demonstrated radiographically, usually by 6 weeks. After excision, allow progressive weight bearing at 3 weeks (30).

#### *Complications*

Even nondisplaced fractures can result in restricted subtalar motion, pain, and arthritis (47,83). Bony overgrowth in the region of the sinus tarsi can cause impingement with the fibula or calcaneus (40). Delay in diagnosis and treatment worsens the prognosis (40,81). Nonunion, malunion, or impingement are indications for exploration and fragment excision or subtalar arthrodesis if significant arthritis is present (40,81).

### FRACTURES OF THE POSTERIOR PROCESS

The posterior process of the talus consists of medial and lateral tubercles separated by a groove for the flexor hallucis longus tendon (Fig. 110.18). The lateral tubercle serves as the attachment for the posterior talofibular ligament. Lateral tubercle fractures are much more common than medial tubercle fractures and must often be distinguished from a commonly found accessory bone, the os trigonum (54). The mechanism of injury for fractures of the lateral tubercle of the posterior process is either forced plantar flexion with impingement against the tibial plafond or forced dorsiflexion with avulsion of the tubercle by the posterior talofibular ligament (30).

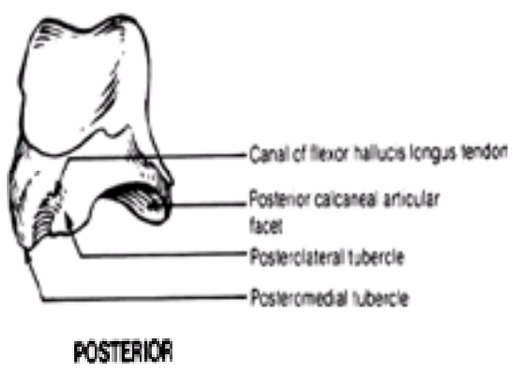


***Figure 110.18.*** Medial and lateral tubercles of the posterior talar process. (From Delee JC. Fractures and Dislocations of the Foot. In: Mann RA, ed. *Surgery of the Foot*, 5th ed. St. Louis: Mosby, 1986:656, with permission.)

#### *Radiographic Evaluation*

Lateral and 30° oblique radiographs best demonstrate the lateral tubercle. An acute fracture can be distinguished from a normal os trigonum by technetium bone scanning (68).

#### *Nonoperative Treatment*

Most acute posterior process fractures are successfully treated by 6 weeks of cast immobilization. Most authors recommend non-weight-bearing because the inferior surface normally articulates with the calcaneus. Symptomatic chronic injuries can often be successfully treated with a course of cast immobilization (30,68).

#### *Operative Technique*

If symptoms persist longer than 4–6 months, surgical excision of the posterior process fragment is indicated. This can be done through either a posterolateral or a posteromedial approach. ORIF can be considered for acute fractures of large fragments (30,68).

### PERITALAR DISLOCATIONS

Peritalar (subtalar) dislocation involves simultaneous dislocation of both the talonavicular and the talocalcaneal joints, resulting in disruption of joint capsules, the interosseous talocalcaneal ligament, and additional supporting structures both medially and laterally. These injuries are rare and result from high-energy mechanisms (12).

#### *Classification*

Peritalar dislocations are classified as medial, lateral, anterior, or posterior, depending on the direction of displacement of the foot with respect to the talus. Medial dislocations are by far the most common, making up 80% of all subtalar dislocations (12). The talus may also rarely undergo total dislocation from the subtalar and ankle joints.

#### *Radiographic Evaluation*

Subtalar dislocations can easily be missed if AP, lateral, and oblique radiographs are not obtained and carefully studied. An AP view of the foot often discloses a medial or lateral subtalar dislocation by the absence of the talar head in the concavity of the navicular (5).

#### *Nonoperative Treatment*

Most subtalar dislocations can be treated by closed reduction and cast immobilization. Reduce the dislocation by flexing the knee, applying gentle traction to the forefoot, accentuating the deformity to unlock the dislocation, and reversing the deformity. Digital pressure over the talar head may aid in reduction of medial or lateral

dislocations (11). After reduction, immobilize the foot in a short-leg, non-weight-bearing cast for 4–6 weeks, followed by progressive weight bearing and range of motion (ROM) (81).

***Operative Technique***

Irreducible dislocations are usually secondary to buttonholing of the talar head through the joint capsule or tendons. Medial dislocations are most commonly entrapped by extensor tendons, whereas lateral dislocations may be entrapped by the posterior tibial tendon (47) (Fig. 110.19). When you cannot reduce these injuries closed, perform open reduction through a longitudinal incision over the talar head, followed by gentle unlocking of the involved structures and reduction of the dislocation. Postoperative management is similar to that for closed reduction.

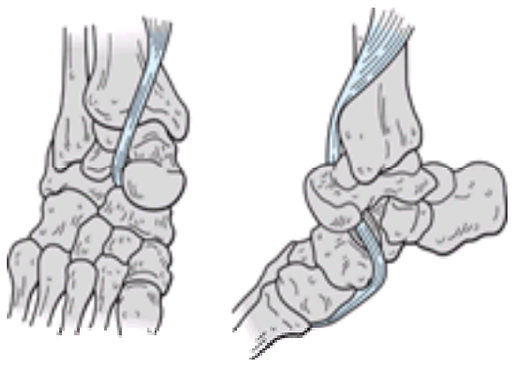

***Figure 110.19.*** This lateral subtalar dislocation is irreducible because of entrapment by the tibialis posterior tendon, which has slipped out of its normal position in the groove of the posterior tibia. (From Leitner B. Obstacles to Reduction in Subtalar Dislocations. *J Bone Joint Surg Am* 1954;36:304, with permission.)

***Complications***

Although most subtalar dislocations result in variable degrees of subtalar arthrosis and loss of motion, instability can be an even greater clinical problem, particularly in younger patients (12,95). Recurrent dislocation during cast immobilization has been reported (44). Therefore, some authors recommend a full 6 weeks of cast immobilization for young, active patients, whereas 4 weeks may be adequate for older patients. Symptomatic subtalar arthritis can be managed by subtalar or triple arthrodesis (44). Avascular necrosis occurs in less than 5% of these injuries (95).

### AUTHOR'S PERSPECTIVE

Decisions for treatment of displaced talar neck fractures are difficult. The nondisplaced neck fracture can be treated nonoperatively; however, serial radiographs must be frequently and closely examined. Minimal degrees of displacement affect adversely the force distribution in the subtalar joint. A minimally displaced type II fracture can be treated successfully by closed reduction and posterior screw placement. Laboratory studies have confirmed better mechanical stability by posterior screw placement, and, by placing the screws in the central axis of the bone, no medial or lateral gaping occurs. Types III and IV fractures are probably best treated by combined approaches and dual fixation. This technique allows anatomic reduction and debridement of the subtalar joint with placement of stable fixation. New miniplate constructs placed medially and laterally just inferior to the articular surface may provide the most rigid fixation.

Avascular necrosis in the presence of a healed talus fracture frequently is incomplete and asymptomatic. Positive imaging studies should not be of major concern. It has been shown that small areas of focal avascular necrosis are well tolerated by the joint and can result in an excellent, functional outcome.

Avascular necrosis with painful collapse and loss of joint function is still best treated with ankle arthrodesis. Creative hindfoot fusions are required because obtaining a fusion in the presence of avascular bone can be difficult. Therefore, techniques such as interpositional bone grafting, calcaneal–tibial arthrodesis, and bone transport techniques have all been described.

Finally, talar-dome defects are one indication for ankle arthroscopic techniques. Utilizing ankle distraction, visualization of the talus is excellent enough to allow drilling and fixation. Biodegradable pins are useful.

## CALCANEUS FRACTURES

***Technical Contributor: Michael W. Chapman***

Anatomic reduction is the goal of the operative treatment of fractures of the calcaneus whenever it is possible and advisable. However, frustration in treatment of these fractures has led many to abandon attempts at open reduction, and instead to treat these difficult fractures by elevation of the foot, compression dressing, and early motion. The end result is usually a bulbous heel that will not fit a shoe properly; a short heel in valgus with a relatively short heel cord; a mass of bone laterally producing impingement on the peroneal tendons; and disruption of the subtalar joint, which may result in traumatic arthritis.

Although not all these fractures have bad results, the results of treatment of calcaneus fractures over the years have not been good. It is logical to assume that patients are better off with an anatomic or near-anatomic reduction than to be left with the deformities. The more anatomic the reduction, the better the functional results you can expect. Regardless of the fracture type and method of treatment, always try to restore the normal width of the heel as well as the length and height of the calcaneus.

### PATHOLOGIC ANATOMY

The calcaneus is the largest of the tarsal bones and its articular surfaces are located on the dorsal aspect of its anterior half (58). The posterior half, the tuberosity, provides the site of insertion of the Achilles tendon. It inserts about midway down the posterior aspect of the tuberosity with a small bursa located between the tendon and the calcaneus in the superior portion. The plantar fascia originates from the medial and lateral processes located on the plantar aspect of the tuberosity. The calcaneal portion of the subtalar joint is made up of a posterior facet, which is the largest and is convex in shape; it is separated by the tarsal sinus and the tarsal ligament from the middle and anterior facets, which are concave in shape and usually contiguous with each other. The middle facet is located on the prominent medial projection of the anterior calcaneus, called the sustentaculum tali. The anterior surface provides a saddle-shaped articular surface for the cuboid. The calcaneus is composed of dense cancellous bone covered by a very thin cortical shell. On a lateral radiograph of the calcaneus (Fig. 110.20), two important angles are used to help determine the quality of reduction after fractures. Böhler's tuber angle, measured by a line drawn from the posterior superior prominence of the tuberosity to the superior apex of the posterior facet to the superior aspect of the anterior process, measures between 25° and 40° in most individuals. Gissane's angle, also known as the critical angle, is directly beneath the lateral process of the talus and is where axial compressive forces are applied by the talus during vertical loading, which is the most common mechanism of injury for fractures of the calcaneus.

***Figure 110.20.*** Lateral view of the calcaneus. **A:** Böhler's tuber angle. **B:** Crucial angle of Gissane.

The most common mechanism of injury in fractures of the calcaneus is a direct blow to the plantar aspect of the heel from either a fall or a severe deceleration injury such as in high-speed motor vehicle accidents. Twisting forces are more likely to produce extra-articular fractures such as those of the anterior process, the sustentaculum, and the medial process. Fractures of the tuberosity are usually caused by avulsion of the Achilles tendon insertion. Bilateral fractures are usually caused by vertical loading of both lower extremities. Remember that the calcaneal fractures are often associated with fractures of cancellous bone in other portions of the skeleton, particularly the thoracolumbar spine.

Essex-Lopresti (34) described two common types of intra-articular calcaneus fractures: tongue-type and joint depression–type fractures (15) (Fig. 110.21).

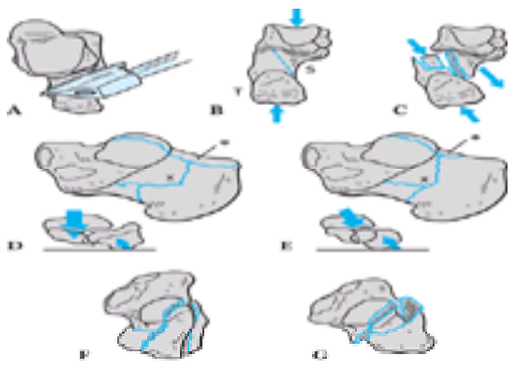

***Figure 110.21.*** **A:** Superior view of the talus and calcaneus, showing the sharp posterolateral edge of the talus that produces the fracture. **B:** Posterior view of the talus and calcaneus. **C:** Posterior view of the talus and calcaneus after fracture. The fracture line is along the *dotted line*, as shown in (B). **D:** The calcaneus seen from the medial side, showing a tongue-type fracture. **E:** Medial view of the calcaneus, showing a joint depression–type fracture. **F:** Superior view of a tongue-type fracture. **G:** Superior view of a joint depression–type fracture.

The oblique sharp posterolateral edge of the talus produces the fracture (Fig. 110.21*A*). It drives down across the calcaneus like an axe, producing a corresponding oblique fracture line through the calcaneus. The center of the tuberosity is slightly offset lateral to the center of the talus, so if a force is applied to the top of the talus with the tuberosity fixed to the ground, a shear line develops, as shown in Figure 110.21*B*. This shear line consistently produces a sustentacular fragment (*S* in Fig. 110.21*B*) and a tuberosity fragment (*T* in Fig. 110.21*B*).

The front half of the calcaneus is firmly bound to the underside of the talus by the talocalcaneal ligaments. Therefore, the sustentacular fragment remains attached to the talus and descends with it (Fig. 110.21*C*), while the tuberosity fragment, which has no ligamentous attachments, is unstable and moves laterally and upward. The *star* in Figure 110.21*C* shows production of either a tongue-type or a joint depression–type fragment by the descending posterolateral edge of the talus.

The tongue-type fragment is long and extends to the back of the tuberosity (*star* in Fig. 110.21*D*). The fracture line runs through the lateral part of the posterior facet. The fragment (*star*) is long and extends to the posterior part of the tuberosity. The joint depression–type fragment is short and extends just posterior to the posterior facet (*star* in Fig. 110.21*E*). The fractures are quite similar both in the shape of the sustentacular fragments and in the path of the fracture line through the lateral part of the posterior facet. The major difference in the fractures is the length of the superolateral fragments.

The sustentacular spike is shown by the *X* in Figure 110.21*D* and Figure 110.21*E*. The spike is important in locating the sustentacular fragment during surgery.

The small drawings below Figure 110.21*D* and Figure 110.21*E* show the displacement of the fragments. The tongue-type fragment is depressed in front and elevated to the rear, and the joint depression–type fragment is pushed straight down and rotated so that the articular cartilage of the fragment faces forward.

Figure 110.21*F* shows the tongue-type fracture from above. The fracture line runs through the lateral part of the posterior facet and parallels the posterolateral edge of the talus. The front of the tongue is depressed, leaving an offset in the posterior facet surface. Figure 110.21*G* shows the short joint depression–type fragment depressed into the body of the calcaneus, leaving an offset in the posterior facet surface. This fragment is also rotated downward in front.

***Radiographic Assessment***

The standard radiographic views obtained to assess calcaneus fractures are the lateral, tangential, and Broden's views. Broden's views are oblique views made with the leg internally rotated 45°. Four views are made, at 10°, 20°, 30°, and 40° distal to the perpendicular with the x-ray beam centered on the sinus tarsi. Figure 110.22*A*, Figure 110.22*B*, Figure 110.22*C* and Figure 110.22*D* show these views of a normal foot. The 10° view (Fig. 110.22*A*) shows the posterior aspect of the joint. The 20° and 30° views show the central part (Fig. 110.22*B* and Fig. 110.22*C*), and the 40° view shows the anterior aspect (Fig. 110.22*D*). The location of the fracture line in relation to the posterior facet can be determined from these views.

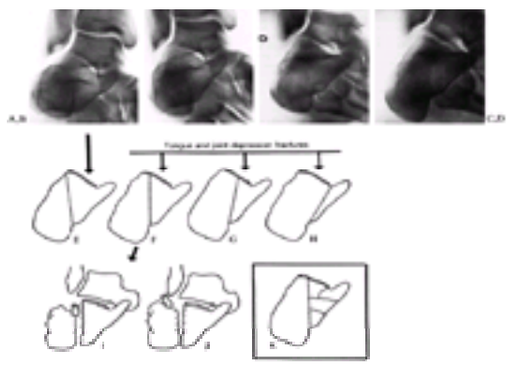

***Figure 110.22.*** **A:** Broden's view of a normal heel made at 10°. **B:** Broden's view of a normal heel made at 20°. **C:** Broden's view of a normal heel made at 30°. **D:** Broden's view of a normal heel made at 40°. **E–H:** Classification of the tongue-type and joint depression-type fractures is made according to the location of the fracture line in relation to the posterior facet, as shown in the 30° Broden's views. **I:** The fragment is depressed, leaving a step in the posterior facet surface. **J:** The fragment has slipped upward and from under the talus to lie at the tip of the lateral malleolus. **K:** Fracture with comminution of the sustentacular fragment.

Several authors (3,21,27,37,39,42,43,80,82) have investigated the usefulness of CT scans in evaluating calcaneus fractures. Allon and Mears (3) concluded that two-dimensional CT scans tend to overestimate the degree of comminution, whereas conventional radiographs provide an underestimation. Three-dimensional reconstructions from CT scans were superior, except in their somewhat poor resolution of intra-articular pathology. Carr et al. (21) proposed that three-dimensional CT reconstructions were most useful in preoperative planning to assist an inexperienced surgeon in learning to interpret the standard plain films. An experienced surgeon can analyze the fracture pattern and plan a procedure based on the standard lateral, tangential, and Broden's views without the need for CT. The surgeon must be familiar with Broden's views and must be able to interpret them, because they are used in surgery to determine whether the depressed fragment has been elevated properly; the CT scan cannot be used in surgery.

### *Classification*

Fractures of the calcaneus can be classified into extra-articular and intra-articular fractures. Extra-articular fractures make up 25% to 30% of all calcaneal fractures (25,26) and include fractures of the anterior process, beak or avulsion fractures of the tuberosity, medial process fractures, and fractures of the sustentaculum tali and body (Fig. 110.23).

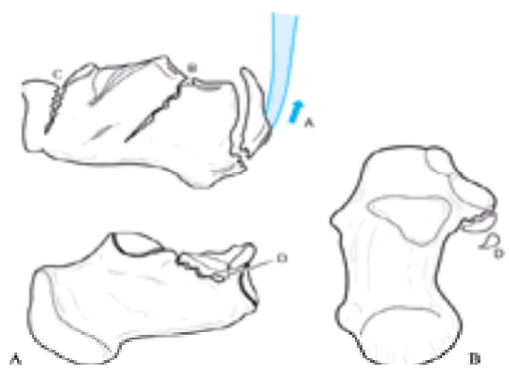

***Figure 110.23.*** **A:** Lateral and medial views of the calcaneus. **B:** Superior axial view of the calcaneus. *A*, avulsion fracture of tuberosity; *B*, body fracture; *C*, anterior process fracture; *D*, fracture of sustentaculum tali.

Classification of the joint depression–type and tongue-type fractures can be made according to the location of the fracture line in relation to the posterior facet (14). The fracture line may run lateral to the posterior facet (Fig. 110.22*E*), producing no damage to the joint. If the fracture line runs through the lateral part of the posterior facet (Fig. 110.22*F*), it produces a classic joint depression–type or tongue-type fracture, as described by Essex-Lopresti (34). Because the tongue-type or joint depression–type fragment is relatively small and contains only a small part of the articular facet, it is not always depressed into the body of the calcaneus (Fig. 110.22*I*). It may slip laterally out from under the talus and displace upward (Fig. 110.22*J*).

The fracture line may run through the center of the posterior facet (Fig. 110.22*G*), but it still produces a classic tongue-type or joint depression–type fracture, but with a larger fragment containing more of the posterior facet cartilage.

If the fracture line is far medial, it may miss the posterior facet and produce a large tongue- or joint depression–type fragment, which will contain the entire posterior facet (Fig. 110.22*H*).

Any of these fractures with sufficient displacement are candidates for open reduction (Fig. 110.22*E*, Fig. 110.22*F*, Fig. 110.22*G*, Fig. 110.22*H*, Fig. 110.22*I* and Fig. 110.22*J*). Before beginning surgery, obtain Broden's views or a CT scan so that you will know what type of fracture you are dealing with.

## PRINCIPLES OF TREATMENT

Calcaneus fractures are among the most difficult fractures to operatively reduce and internally fix. There has been great debate in the literature as to whether combinations of medial approaches, lateral approaches, or dual approaches provide the best opportunity to attain anatomic reduction (14,15,30,56,66,67,84). Treatment options for calcaneal fractures include the following:

- No reduction, with elevation of the foot, compression dressing, and early ROM.
- Closed reduction, with elevation of the foot, compression dressing, and early motion.
- Percutaneous reduction techniques such as Essex-Lopresti (34).
- Open reduction and internal fixation as popularized by Palmer (67) and McReynolds (56).
- Primary arthrodesis.

The goals of nonoperative treatment are to restore the overall shape of the calcaneus to as close to anatomic position as possible. Anatomic restoration of the articular surface is rarely possible by closed techniques, but it is worth trying as it is occasionally successful. The goals of ORIF are to safely restore the anatomy of the hindfoot. This includes anatomic reduction of the articular facets (61); reconstitution of hindfoot height, width, and length; and realignment of the tuberosity to appropriate axial alignment. The entire osseous morphology of the hindfoot must be anatomically reduced to provide the best chance of good long-term outcomes.

The difficulties of ORIF include the difficult exposure, the complex three-dimensional shape of the bone, ever-changing fixation devices, open fractures, and osteopenic bone disease. Patients with diabetes mellitus, hypertension, or peripheral vascular disease, and tobacco chewers and smokers, have an increased incidence of wound complications. Surgery in these patients may be contraindicated despite the degree of injury to the calcaneus.

McReynolds (56) popularized the medial approach to fixation and stated that the key to a successful reduction is restoration of the medial wall of the calcaneus by realigning the medial cortex of the tuberosity fragment with the medial cortex of the stable sustentacular fragment (14,15 and 16). Although this helps to restore height and axial alignment, it is difficult to reduce the posterior facet or address anterior calcaneal–cuboid pathology from the medial side.

The advantage of the lateral approach is the wide-open exposure (78). The calcaneal–cuboid joint and distal comminution can be addressed, as well as the reduction of the posterior facet, the axial tuberosity alignment, and the height and width of the hindfoot. Some surgeons (84) have advocated mini-open medial approaches to assist in the reduction of the tuberosity to the sustentacular fragment, then a more extensile exposure laterally for the remainder of the pathology, including bone grafting and lateral wall reduction. Because of the complications from open approaches, there has recently been increased interest in percutaneous reduction techniques with joysticks, small elevators, and percutaneous cannulated screws, which are modifications of the original Essex-Lopresti technique (34).

## SURGICAL TECHNIQUES

### *Closed Reduction*

Closed reduction of fractures of the calcaneus, without the insertion of any pins or fixation, is indicated in minimally displaced fractures or in displaced fractures where percutaneous reduction techniques or ORIF is contraindicated. Examples are in patients with massive swelling and blood-filled fracture blisters on the foot; for calcaneal fractures in patients with multiple injuries, where only the minimum can be done initially because of the patient's unstable condition; in patients with systemic disease contraindicating any type of intervention; or for local conditions of the foot, such as skin ulcers or active infection, that contraindicate any type of operative intervention. In addition, even when ORIF is anticipated to occur eventually, if it cannot be done immediately, then closed reduction under anesthesia may be useful to obtain initial alignment, which improves venous and lymphatic return from the foot, decompresses associated neurovascular structures, eliminates tenting of the skin, and generally improves the condition of the foot for the subsequent ORIF. However, remember that in general, except in neglected injuries or after extremely severe crushing type injuries with major soft-tissue damage, the earlier ORIF is carried out, the better the results. The technique is as follows:

- Administer a general or regional anesthetic and perform the reduction under fluoroscopic control with a C-arm. This is most easily done with the patient in the supine position and the C-arm positioned with the flat surface of the receiver at the foot of the table. By externally rotating the extremity at the hip, the foot then

can be placed in the lateral position on the C-arm for visualization of the reduction.

- If there is a tongue depression–type fracture, or the tuberosity is displaced superiorly, restoration of Böhler's angle and restoration of the tuberosity to its normal position is the first step. In displaced fractures, this requires grasping the tuberosity of the calcaneus in some manner. The simplest technique is to prepare the heel and grasp the tuberosity percutaneously through the skin with a large AO tenaculum-type bone-holding forceps, or large tenaculum pelvic-reduction clamps. An alternative is to temporally insert either a K-wire or a Steinmann pin and attach to it the appropriate bow for applying traction. To reduce the tuberosity and restore Böhler's angle, simultaneously pull plantarward the forefoot and the tuberosity of the calcaneus while visualizing the reduction on the fluoroscope. This also usually restores axial alignment.
- Next, grasp the calcaneus between the bases of both palms with your fingers interlocked beneath the heel. Apply strong manual compression to reduce the lateral wall fragments back into position, and position the tuberosity beneath sustentaculum tali. Ensure that axial alignment is restored.
- Small 2.0 mm K-wires can be placed temporarily or long term for stabilization.

Usually it is not possible with closed reduction alone to restore displaced articular fragments. Although occasionally with the maneuvers described here some intra-articular fractures will reduce if the intra-articular fragments are attached directly to the major fragments manipulated in the closed reduction.

Because of the soft-tissue swelling that usually follows these fractures, it is not feasible to hold reduction with a cast. Fortunately, a significant majority are reasonably stable after closed reduction if not subjected to forces that would displace them. After completion of the reduction, take AP, lateral, axial, and Broden radiographic views to document the reduction. Then apply a well-padded U-type short-leg splint along with a posterior splint to maintain the foot in a neutral position. Overwrap the splints with bias-cut stockinet.

Postoperatively, elevate the extremity 10 cm above the level of the heart and observe closely for excessive swelling. The dressings and splint often need to be split down to skin anteriorly within the first 24 hours because of excessive swelling. Once the swelling has resolved and prior to discharge from the hospital, overwrap the splint. Between 2 and 3 weeks after injury, the swelling will have subsided sufficiently, and a well-molded short-leg cast can usually be applied. When sufficient consolidation has occurred (usually by 6–8 weeks), the cast can be removed and the patient placed in a prefabricated orthosis such as a Cam-walker. At this point, institute ankle and foot joint ROM exercises. Delay weight bearing in most cases until 10–12 weeks after injury.

If patients have significant intra-articular involvement, they typically lose 50% or more of subtalar joint motion. If the overall external anatomy of the calcaneus has been restored, however, they will be able to successfully wear most types of shoes, and the average urban dweller who usually walks on flat surfaces will not complain of the loss of subtalar joint motion.

***Modified Essex-Lopresti Technique***

Essex-Lopresti in 1952 (34) described a percutaneous technique for the reduction of fractures of the calcaneus. It worked best for tongue-type fractures with minimal intra-articular involvement, and it utilized a spline inserted into the posterior aspect of the calcaneus to perform the reduction. Tornetta (92) described its use for tongue-type fractures of the calcaneus. I have modified this technique utilizing percutaneous manipulation of the fracture fragments and internal fixation with percutaneous K-wires and/or cannulated screws. This technique is indicated for displaced fractures of the calcaneus when there is minimal or no intra-articular involvement, or when formal ORIF is contraindicated. Elderly patients with displaced fractures, if they are sedentary and will place limited demands on their lower extremities, are excellent candidates for this technique, particularly if they have any associated systemic diseases or local extremity problems that would increase the rate of complications after open reduction.

Complete understanding of the anatomy of the fracture prior to surgery is essential. You must have a good feeling for the three-dimensional anatomy of the fracture, in particular the size and the position of the sustentaculum tali and the displaced intra-articular fragments. Stability is achieved by the insertion of a pin or cannulated fixation screw from an intact tuberosity fragment into the sustentaculum tali. This fixation usually enters on the posterolateral surface of the tuberosity of the calcaneus and passes across the fracture site in an anterior-to-medial direction into the sustentaculum. The preferred fixation is into the sustentaculum, as this avoids crossing the mid-foot joints. If the sustentaculum is too small or is comminuted, which is unusual, fixation can be extended into the talus, navicular, or cuboid. I try to avoid this, however, as it transfixes the intervening joints and damages somewhat the articular cartilage. This technique is difficult on the severely swollen foot, but it is achievable, particularly if the foot is overwrapped with a compression dressing and a foot pump applied preoperatively to “milk” edema out of the foot and heel. In addition, this technique is most successful when the fracture hematoma is liquid, so it should be done as soon as possible after the fracture occurs, preferably within the first 12 hours. As time passes, the effectiveness of this technique gradually diminishes; after 7 days, it may be ineffective because of the firm organization of the fracture hematoma.

The surgical technique follows:

- Administer a general or regional anesthetic and place the patient in a supine position on a radiolucent fracture table. Place a tourniquet on the upper thigh. This is usually not required but is handy to have in place in case there is excessive bleeding from the puncture wounds used for the technique. An alternative technique is to use the lateral decubitus position, particularly if implants will be inserted from the lateral side.
- As for the closed reduction technique previously described, position a C-arm adjacent to the side of the foot of the table on the affected side, with the large flat surface of the receiver head level with the tabletop. Prepare and drape the extremity from the tourniquet distally.
- First, perform a closed reduction as described previously, as the initial repositioning of the fragments makes the remainder of this procedure easier.
- Externally rotate the extremity at the hip and flex the knee to place the foot in the lateral position on the C-arm (49).
- Beginning 1 cm proximal to the insertion of the Achilles tendon into the calcaneus (note that this is about 50% distalward on the posterior aspect of the calcaneus), make a vertical midline posterior incision through the skin and subcutaneous fat approximately 2 cm in length.
- Under fluoroscopic control, insert a 1¼-inch (6 mm) threaded Steinmann pin at or somewhat distal to the proximal insertion of the Achilles tendon, slightly to the lateral side of the midline of the calcaneus. Drill this in slowly under fluoroscopic control, keeping the pin parallel to the superior surface of the tuberosity fragment and directing the pin in an anteromedial direction toward the sustentaculum tali. Since the fracture is not fully reduced, this is technically the most challenging part of the procedure. Insert the pin until it just exits the tuberosity fragment into the fracture site (Fig. 110.24*A*).

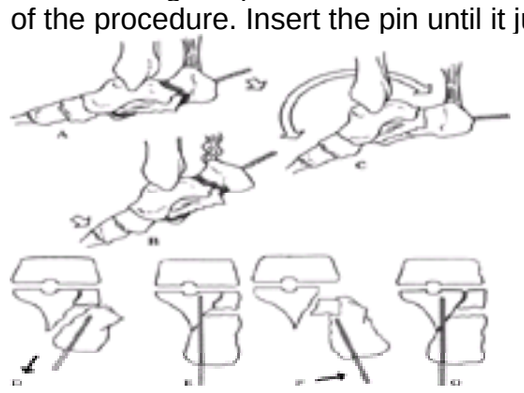

***Figure 110.24.*** Modified Essex-Lopresti technique. Reduction aided by plantar-flexing the foot. **A:** Insert a Steinmann pin into the tuberosity up to the fracture. **B:** Plantar-flex the forefoot. **C:** Distract and lever the tuberosity distalward while maintaining forefoot plantar flexion. **D:** Use the pin in the tuberosity to also correct the axial alignment. **E:** Line up the medial cortex and insert the pin across the fracture into the sustentaculum fragment. **F:** Where the lateral joint surface of the posterior facet is displaced, the pin–tuberosity fragment unit can sometimes be used to manipulate and elevate the articular surface. **G:** After reduction, insert the pin into the sustentaculum as described.

- If there is a depressed posterior facet fragment, it is often possible to reduce it now, by running this pin anteriorly under fluoroscopic control just beneath the displaced fragment (Fig. 110.24*F*, Fig. 110.24*G*).
- If there is a depressed posterior facet fragment that you feel cannot be reduced with the Steinmann pin, begin reduction by making a puncture wound medially so that a small elevator can be inserted percutaneously beneath the posterior facet fragment. Take care to avoid injury to medial neurovascular structures and tendons (Fig. 110.25).

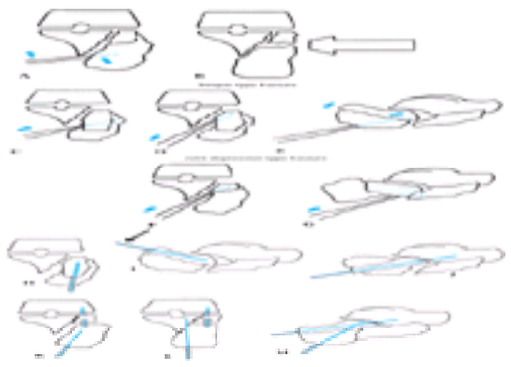

***Figure 110.25.*** Tricks for percutaneous reduction and fixation of more complex fractures. **A:** Percutaneously insert a small pin beneath the tenaculum into the tuberosity and use it to pry the tuberosity down. **B:** Then use lateral manual compression to reduce the lateral wall and restore axial alignment. **C:** Use an elevator to disimpact the lateral wall. **D,E:** Disimpact and derotate the tongue fragment. **F,G:** Use an elevator (can also be inserted from laterally) to elevate and derotate a depressed joint fragment. **H–M:** Reduce a tongue-type intra-articular fragment with Essex-Lopresti technique. Insert a pin into the tongue fragment **(H)**. Reduce the fragment **(I)**. Stabilize it by inserting the pin across the subtalar joint into the talus **(J)**. Insert a second pin into the tuberosity fragment and reduce it **(K)**. Stabilize the tuberosity by fixing it to the sustentaculum **(L)**. Lateral view of the fixation **(M)**.

- Next, perform a closed reduction. This usually requires two surgeons, one manipulating the foot and the other inserting the pins (Fig. 110.24*B*, Fig. 110.24*C*). If you do not feel that manipulation of the tuberosity fragment with the Steinmann pin alone will reduce the fragment, insert a second transverse K-wire or Steinmann pin attached to an appropriate bow just distal to the Essex-Lopresti pin. This will greatly aid in applying traction to the tuberosity fragment to reduce it. The reduction maneuver now involves traction on the tuberosity fragment to pull it distalward to restore Böhler's angle and to restore the length of the calcaneus, while the forefoot is plantar-flexed. While holding the foot in this position, pull the Essex-Lopresti pin plantarward to reduce the tuberosity and help reduce the posterior facet. If necessary, use an elevator beneath the facet to aid in the reduction (Fig. 110.25).
- Once the reduction is achieved on the lateral view, gently pick the foot up off the C-arm and compress the calcaneus laterally and medially to reduce the lateral wall and line up the tuberosity with the sustentaculum tali (Fig. 110.26).

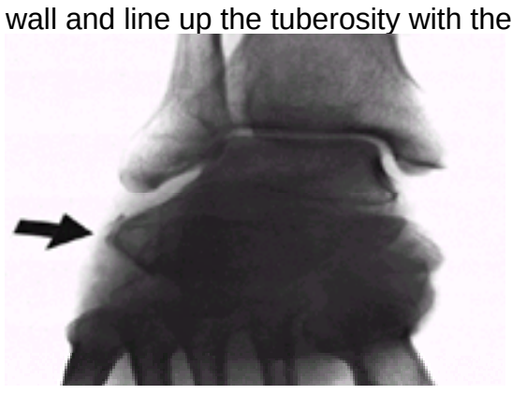

***Figure 110.26.*** The large bulge of the lateral wall of the calcaneus (*arrow*) impinges on the peroneal tendons and must be reduced.

- Under fluoroscopic control, drill the Steinmann pin forward into the sustentaculum fragment to secure the reduction. If at this point the posterior facet fragment or other components of the fracture are unstable and tend to redisplace percutaneously, insert guide pins for cannulated screws or K-wires or small Steinmann pins to control and fix the fragments (Fig. 110.24*F*, Fig. 110.24*G*).
- Once the guide pins, K-wires, and Steinmann pins have been inserted and stability achieved, carefully examine the calcaneus with the fluoroscope and plain radiographic images. A good axial view of the calcaneus is essential to assess the axial alignment of the calcaneus and to ensure that the primary Steinmann pin is in the sustentaculum. As mentioned before, if the sustentaculum does not offer sufficient fixation or is too difficult to hit with the pin, then running the pin forward into the midfoot bones or superiorly into the talus will achieve good fixation.
- Next, insert cannulated screws. Usually two 6.5mm screws are sufficient to stabilize the fracture. The temporary K-wire placement can be left to help stabilize the fracture.
- Close the posterior heel wound in the usual fashion. Apply sterile dressings and a bulky well-padded splint utilizing a medial lateral sugar-tong splint around the foot and a posterior splint to support the foot in a neutral position.
- Postoperatively, elevate the foot 10 cm above the heart. Observe closely for excessive swelling and expect to split the dressing anteriorly down to skin within the first 24 hours after the procedure. Maintain elevation of the foot at all times, except for the necessities of daily living until swelling has abated. Once the swelling is down, apply a well-padded short-leg cast protecting the protruding pins. Essex-Lopresti (34) advocated early motion of the subtalar joint, but in my experience this has led to wound complications and loss of fixation. Therefore, I immobilize the patient for 6 weeks in a short-leg cast. At 6 weeks, all the protruding wires and pins can be removed in an outpatient setting and an additional short-leg cast applied for 2 weeks more. At 6–8 weeks, remove the cast and apply a removable orthosis such as a cam-walker, and begin active ROM exercises for the foot and ankle. Delay weight bearing until 10–12 weeks. Neither the closed reduction technique described previously nor this one permits early motion in the subtalar joint, which is a disadvantage. The primary goal of this treatment is to restore the overall shape of the calcaneus as opposed to preserving subtalar joint motion.

In my experience, however, with closed reduction and the percutaneous techniques described, the need for subtalar joint fusion for subsequent subtalar joint pain and/or arthritis has been exceedingly rare. The subtalar joint, however, usually is quite stiff, with only a bit of motion remaining.

### *Open Reduction: Lateral Approach*

Most fracture surgeons today have adopted the extensile, lateral approach to ORIF of calcaneal fractures (see Chapter 3). The **J**, or lateral, approach with the subperiosteal dissection of a full-thickness flap off the lateral calcaneal wall is used for the exposure from the calcaneal tuberosity to the calcaneal cuboid joint. The principles of reduction include stabilization of the calcaneal–cuboid joint, the critical angle of Gissane, and the posterior facet; realignment of the calcaneal tuberosity to the sustentaculum; and finally replacement of the lateral wall. Bone grafts are used for large defects and fixation utilizes either a custom 3.5 or a 2.7 plate that has been specifically designed for calcaneal fracture fixation. The surgery can be difficult and tedious, but it is the best method for restoring the anatomy of the calcaneus, in particular the articular surfaces.

- Place the patient in a lateral decubitus position on a radiolucent fracture table with the foot to be operated uppermost. The surgery can be prolonged, so carefully position the upper extremities and pad bony prominences and neurovascular structures. Pad the down leg well and create a well-padded platform to operate on. With the legs in a slightly scissored position, lateral radiographs are easy to obtain. With external rotation, the tuberosity view can easily be obtained to check hindfoot alignment.
- Start the incision 6–7 cm above the lateral malleolus, and posterior along the lateral edge of the Achilles tendon. Extend it distally parallel to the Achilles tendon almost to the weight-bearing skin on the heelpad; then gently curve it forward and extend the transverse limb to the base of the fifth metatarsal (Fig. 110.27). Carry dissection directly down to the calcaneus, avoiding injury to sensory nerves. Then sharply elevate this entire full-thickness flap at a subperiosteal level, which includes the peroneal tendons, the calcaneal fibular ligaments, and the sural nerve. Full development of this exposure provides access to the calcaneal cuboid joint, the subtalar joint, the sinus tarsi, and the retrocalcaneal tuberosity. Place several folded towels under the tibia to allow the foot to be adducted, thereby increasing the exposure. For retraction of the flap, place K-wires in the lateral process of the talus, the fibula, and the cuboid, and bend them away from the surgical field to hold the flap. Avoid excessive tension and kinking of the flap, which can lead to marginal necrosis of the tip of the flap.

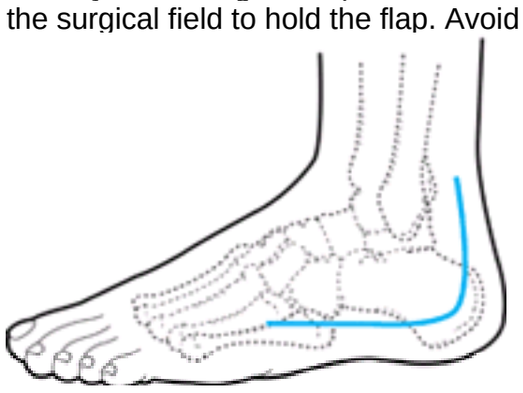

***Figure 110.27.*** Skin incision for open reduction of the calcaneus from a lateral approach.

- After this exposure, inspect the fractures and bulge of the lateral wall of the calcaneus. Reflect the lateral wall posteriorly to visualize the interior of the calcaneus and the facet joints. An osteotomy of the lateral wall is sometimes necessary. The lateral posterior facet usually is depressed deep into the midbody of the calcaneus and rotated clockwise as visualized in this approach. The tuberosity fragment is short and in varus. Anteriorly, expose and examine the calcaneal–cuboid joint for fracture or displacement, as the reduction generally starts from the anterior aspect of the calcaneus and progresses posteriorly.
- Address the anterior calcaneus and the calcaneal–cuboid joint first. Use multiple 1.6 or 2.0 K-wires to reduce and fix the anterior body of the calcaneus and then the calcaneal–cuboid joint.
- Reduce and temporarily fix with K-wires the depressed posterior facet fragment. If the fracture line is lateral and noncomminuted, fixation can be fairly easy, whereas a more medial fracture line or comminution can make this quite challenging. Access to the articular fragments can be improved by distracting the tuberosity fragment to restore the length of the calcaneus, which displaces the tuberosity fragment inferiorly, medially, and posteriorly. Reduction often requires a combination of techniques. Insert a small osteotome or elevator into the primary fracture line and displace the body of the calcaneal tuberosity. In addition, a “Gissane spike” (a 6.5 mm, fully threaded distraction bolt) or a transverse or a longitudinal Steinmann pin can be placed into the tuberosity to manipulate the tuberosity, provide traction, and aid with the reduction.
- Now elevate and rotate the depressed posterior facet joint fragments into anatomic position. Fix the posterior facet fragments to the intact portions of the facet and to the sustentaculum. Do all of this under fluoroscopic visualization to ensure anatomic reduction and appropriate placement of the wires. At this point, check Broden's views to be certain that the posterior facet joint is anatomically restored. It is usually best to complete the fixation of the articular surface by inserting 3.5 mm lag screws with washers prior to final reduction of the calcaneal tuberosity and placement of the calcaneal plate.
- Complete the reduction and fixation of the tuberosity. This is usually the most difficult part of the reduction and frequently takes more than one attempt before satisfactory hindfoot alignment is achieved.
- Use the pins or spike previously placed in the tuberosity to align it with the remainder of the calcaneus. Try to line up the medial cortex with the sustentaculum. At this point, a defect in the cancellous bone of the calcaneus beneath the posterior facet joint is usually evident. Stability of the reduction can be improved by packing this defect with autologous cancellous bone graft, morcelized allograft, or a synthetic bone graft substitute (90). Obtain temporary fixation of the reduction with K-wires.
- Reduce the lateral wall of the calcaneus back into position. If it is intact, it provides a good guide to reduction, as it should fit anatomically into place.
- Obtain final fixation by applying a specially designed calcaneus plate or a combination of mini-fragment or small fragment plates utilizing 2.7 and/or 3.5 mm screws.
- I prefer the AO calcaneal plate (Synthes, Paoli, PA), which must be carefully molded to fit the entire lateral surface of the calcaneus so that the fracture is not displaced with insertion of the screws. This plate provides many alternative locations for screws, not all of which need to be used. Insert screws where necessary to obtain as solid a fixation of the fracture as possible (45). Obtain final plain radiographs, including AP, lateral, tuberosity, and Broden's views (Fig. 110.28).

***Figure 110.28.*** **A:** Intra-articular fracture of the calcaneus. Note the reversal of Böhler's angle on this lateral radiograph. **B:** CT scan showing intra-articular stepoff. **C:** Postoperative lateral radiograph showing restoration of Böhler's angle and fixation with a low-profile titanium calcaneus plate. **D:** Axial view. (Courtesy of C. Finkemeier, Sacramento, CA.)

- The wound closure is critical to help prevent wound complications. Insert a small drain. Use interrupted figure-eight sutures from the periosteal flap to the deep tissues, including the fascia of the abductor digiti minimi. Place *all* deep sutures prior to tying and then tie from anteriorly to posteriorly. This provides even tension on the flap. Close subcutaneous fat and then the skin with either Allgöwer-type subcuticular vertical nylon mattress sutures or staples. Apply a well-padded short-leg splint incorporating bulk cotton to allow for swelling, holding the foot and ankle in a neutral position.

### *Open Reduction: Medial Approach*

A full medial approach can be used alone for fixation, or a small medial approach can be combined with a lateral approach to assist in the reduction of the calcaneal tuberosity to the sustentaculum tali, especially in fractures that are more than 3 weeks old.

- Begin the skin incision halfway between the medial malleolus and the bottom of the heel using a curvilinear incision that is parallel and posterior to the posterior tibial tendon and the neurovascular bundle. Reflect this flap in a subperiosteal manner superiorward to expose the calcaneus. Try to identify and preserve the sensory nerves.
- Identify the fracture lines, in particular the spike of bone of the sustentacular fragment, which is the key to the reduction.
- The techniques of reduction and fixation are similar to those already described for the lateral side. Lever the body of the tuberosity posteriorly and medially; the fracture fragments usually key into an anatomic position. Insert multiple K-wires through the calcaneal tuberosity into the sustentaculum or mid foot to hold the tuberosity fragment. Obtain fixation with staples, wires, screws, and/or small plates. As mentioned earlier, the lateral approach is necessary for reduction of the calcaneal–cuboid joint, the angle of Gissane, and the posterior facet joint.
- Wound closure is as described for the lateral side.
- Postoperatively, continue intravenous antibiotics for 24 hours. Keep the foot elevated 10 cm above the heart. Foot pumps may help to prevent edema (89). Discharge patients in the bulky dressing and splint, and see them for a follow-up at approximately 10 days. Continue elevation at home. If the flaps are healthy without drainage, convert to a removable splint to allow early ankle and hindfoot motion. Keep them non-weight-bearing. If the patients are unreliable, place the foot in a short-leg cast and see them regularly in the office for supervised active and passive ROM exercises. At 6–8 weeks, at least 50% of the motion should have returned to the ankle and hindfoot. If radiographs show healing, initiate partial weight bearing up to 50 pounds. By 12–14 weeks, allow full weight bearing, and begin strengthening exercises.

Have patients walk each day in good, well-cushioned shoes, using elastic hose to control edema. They must practice walking until they can walk across the room on tiptoe. If they fail to make sufficient progress, send them to a physical therapist for supervised exercises. They begin by walking on a combined treadmill–trampoline machine and progress as tolerated. Full recovery requires a full year, and some patients show additional improvement in the following year.

### *Primary Subtalar Arthrodesis*

When the articular facets on the calcaneus are so comminuted that anatomic reduction is not possible and posttraumatic arthritis is inevitable, some authors (13,78) advocate primary subtalar arthrodesis at the time of internal fixation of the calcaneus, feeling that the overall long-term recovery is shortened and a second operation avoided. In addition, this makes the fixation of the calcaneus easier as implants can be placed into the talus across the subtalar joint. To add subtalar arthrodesis to fixation of the calcaneus, remove the cartilage from the joint surfaces on the talus when the subtalar joint is exposed and curet the subchondral bone to expose bleeding cancellous bone. Be certain that the calcaneus is well aligned and in good position and pack autologous bone into the subtalar joint. Assuming the tuberosity of the calcaneus will provide good fixation, a long screw inserted from the plantar surface of the tuberosity through a stab wound on the heel can be angled up through the posterior facet joint into the body of the talus to obtain good fixation. Place a washer on the screw to prevent it from sinking into the calcaneus.

After swelling subsides, apply a short-leg cast, and keep it in place until union of the calcaneus and subtalar joint occurs. During this period, keep the patient non-weight-bearing. After 8 weeks, patients can be progressed toward full weight bearing either in a short-leg cast or with a removable orthosis such as a Cam-walker until solid union occurs, usually around 12 weeks.

## PITFALLS AND COMPLICATIONS

**Wound Necrosis** Necrosis of the superior wound margin can occur both medially and laterally. This is potentially very serious, as it can lead to secondary infection and exposure of the bone and fixation hardware (10,36). If not well managed, or if it occurs in the presence of peripheral vascular disease or systemic disease such as diabetes mellitus, deep bone infection can occur, which can result in amputation. Avoid this complication by careful patient selection, maintaining a full-thickness flap, using gentle retraction of the flap (which avoids the kinking of the flap), and avoiding prolonged operating times.

A tension-free closure utilizing suture techniques that preserve the blood supply to the skin is essential. If swelling occurs during surgery, so that a tension-free closure is not possible, leave the wound open; cover it with a biological dressing and return the patient to surgery for a delayed primary closure when the soft-tissue swelling has resolved. Necrosis of the tip of the superior flap of 5 mm or less can usually be treated by debridement on an outpatient basis, and with wet-to-dry dressing changes, allowing the wound to heal by secondary intention. If the wound necrosis is so large that bone and/or fixation will be exposed, consult with an orthopaedic or plastic surgeon with experience in local or free microvascularized flaps, so that the wound can be debrided back to viable tissue and closed as soon as possible.

**Infection** Deep infection, although uncommon, may manifest as a cellulitis, which can be treated with deep cultures and administration of appropriate intravenous bactericidal antibiotics. For deep infection with abscess formation, irrigate and debride the wound as soon as infection is detected, obtain deep cultures, and begin culture-specific bactericidal intravenous antibiotics. Usually, the wound needs to be left open, but it should be closed secondarily as soon as the acute infection resolves. If the construct remains stable and hardware fixation is solid, the implants can be left in place. If deep infection with osteomyelitis occurs with loosening of the implants, then removal of all implants and debridement of nonviable bone may be necessary to resolve the infection. This usually leads to an unsatisfactory outcome: a scarred, shortened heel with significant loss of function.

**Malreduction of the Fracture** Residual malposition of the calcaneus commonly occurs after any of the described methods of reduction because of the difficulty in treating these challenging fractures. The most frequent problem in my experience is residual shortening, with proximal migration of the tuberosity and residual valgus. This can lead to weakness in pushoff, difficulty with shoeware, and impingement on the peroneal tendons or tip of the fibula, which can lead to chronic pain and tendinitis. Reconstruction for late deformities of the calcaneus are very difficult and are beyond the scope of this chapter (see Chapter 115).

**Subtalar Joint Arthritis** Posttraumatic arthritis in the subtalar joint occurs to some extent in the majority of these fractures. It is primarily the result of the original trauma itself, although inadequate reduction can hasten the onset of arthritis. According to McReynolds (56), about 20% of calcaneal fractures will require subtalar arthrodesis for traumatic arthritis. This is much higher than in my experience, where less than 5% ever require arthrodesis, probably because many go on to stable pain-free fibrous ankylosis of the subtalar joint. If the overall anatomic shape and alignment of the calcaneus is restored, this minimizes the stresses on the subtalar joint and keeps the necessity for subsequent arthrodesis low. See Chapter 115 for a discussion of arthrodesis of the subtalar joint.

## AUTHORS' PERSPECTIVE

There have been few published randomized prospective studies comparing ORIF of calcaneal fractures to less invasive methods that have shown better functional outcomes with ORIF (87,91). There is an ongoing large randomized study in Canada, which is unpublished, that suggests that ORIF may provide a slightly better long-term result in certain displaced types of fractures. There is general agreement among fracture surgeons that anatomically reconstructing the calcaneus produces acceptable functional outcomes in the majority of selected patients, and that there is a tremendous advantage to subsequent reconstruction if the hindfoot anatomy is reasonably normal (87,91).

I prefer the extensile, lateral approach to the calcaneus. As mentioned, there are limited indications for small open medial approaches to assist in the reduction. Popularity is gaining for more aggressive percutaneous reduction techniques; however, these will probably not be universally applied in community practice settings until the techniques are better developed. Long-term results of this method are lacking. I prefer the lateral position using fluoroscopic control and the extensile lateral approach when the soft-tissue envelope is healthy. Calcaneal plate fixation with or without bone grafting provides the best opportunity for anatomic reconstruction by most general orthopaedic or fracture surgeons.

If patients eventually develop hindfoot arthritis, most can be well managed by using a rocker-bottom shoe and oral anti-inflammatories prior to recommending a hindfoot fusion. In the event of a failed calcaneal fracture, a reasonable salvage approach is a subtalar arthrodesis (22,88). Occasionally, the hindfoot will require bone block distraction to realign the hindfoot and the talonavicular joint with or without calcaneal osteotomy (79).

***Acknowledgments***

Portions of this chapter written in the second edition by Todd V. Swanson and B. D. Burdeau, Jr., are retained here in part.

### CHAPTER REFERENCES

Each reference is categorized according to the following scheme: *, classic article; #, review article; !, basic research article; and +, clinical results/outcome study.

# 1. Adelaar RS. Fractures of the Talus. *Instr Course Lect* 1990;34:147.

+ 2. Alexander AH, Lichtman DM. Surgical Treatment of Transchondral Talar Dome Fractures (Osteochondritis Dissecans): Long-Term Follow-up. *J Bone Joint Surg Am* 1980;62:646.

+ 3. Allon SM, Mears DC. Three-Dimensional Analysis of Calcaneal Fractures. Presented at the American Orthopaedic Foot and Ankle Society Meeting, 1988, Atlanta.

+ 4. Anderson IF, Crichton KJ, Grattan-Smith T, et al. Osteochondral Fractures of the Dome of the Talus. *J Bone Joint Surg Am* 1989;71:1143.

+ 5. Barger JR, Brucker JD, Haliburton RA. Peritalar Dislocation of the Foot. *Can J Surg* 1961;4:205.

+ 6. Bauer M, Jonsson K, Linden B. Osteochondritis Dissecans of the Ankle: A 20-Year Follow-Up Study. *J Bone Joint Surg Br* 1987;69:93.

+ 7. Berndt AL, Harty M. Transchondral Fractures (Osteochondritis Dissecans) of the Talus. *J Bone Joint Surg Am* 1959;41:988.

* 8. Blair HC. Comminuted Fractures and Fracture Dislocations of the Body of the Astragalus. *Am J Surg* 1943;59:37.

+ 9. Bonnin JG. Dislocations and Fracture-Dislocations of the Talus. *Br J Surg* 1940;28:88.

! 10. Borrelli J Jr, Lashgari C. Vascularity of the Lateral Calcaneal Flap: A Cadaveric Injection Study. *J Orthop Trauma* 1999;13:73.

+ 11. Boyd HB, Knight RA. Fractures of the Astragalus. *South Med J* 1942;35:160.

# 12. Brennan MJ. Subtalar Dislocations. *Instr Course Lect* 1990;34:157.

+ 13. Buch BD, Myerson MS, Miller SD. Primary Subtalar Arthrodesis for the Treatment of Comminuted Calcaneal Fractures. *Foot Ankle Int* 1996;17:61.

+ 14. Burdeaux BD. Reduction of Calcaneal Fractures by the McReynolds Medial Approach Technique and Its Experimental Basis. *Clin Orthop* 1983;177:87.

+ 15. Burdeaux BD. Calcaneus Fractures: Rationale for the Medial Approach of Reduction. *Orthopaedics* 1987;10:177.

+ 16. Burdeaux BD Jr. Fractures of the Calcaneus: Open Reduction and Internal Fixation from the Medial Side, a 21-year Prospective Study. *Foot Ankle Int* 1997;18:685.

+ 17. Butel J, Witvoet J. Les Fractures et les Luxations de L'Astragale. *Rev Chir Orthop* 1967;53:493.

# 18. Canale ST. Fractures of the Neck of the Talus. *Orthopaedics* 1990;13:1105.

+ 19. Canale ST, Belding RH. Osteochondral Lesions of the Talus. *J Bone Joint Surg Am* 1980;62:97.

+ 20. Canale ST, Kelly FB Jr. Fractures of the Neck of the Talus. *J Bone Joint Surg Am* 1978;60:143.

+ 21. Carr JB, Noto AM, Stevenson S. Volumetric Three-Dimensional Computed Tomography for Acute Calcaneus Fractures: Preliminary Report. *J Orthop Trauma* 1990;4:346.

+ 22. Chandler JT, Bonar SK, Anderson RB, Davis WH. Results of In-situ Subtalar Arthrodesis for Late Sequelae of Calcaneus Fractures. *Foot Ankle Int* 1999;20:18.

* 23. Coltart WD. Aviator's Astragalus. *J Bone Joint Surg Br* 1952;34:545.

+ 24. Comfort TD, Behrens F, Gaither DW, et al. Long-Term Results of Displaced Talar Neck Fractures. *Clin Orthop* 1985;199:81.

# 25. Connolly JF, ed. *The Management of Fractures and Dislocations*, 3rd ed. Philadelphia: Saunders, 1981.

# 26. Crenshaw AH, ed. *Campbell's Operative Orthopaedics*, 5th ed. St. Louis: Mosby, 1971.

+ 27. Crosby LA, Fitzgibbons T. Computerized Tomography Scanning of Acute Intra-Articular Fractures of the Calcaneus. *J Bone Joint Surg Am* 1990;72:852.

+ 28. Davidson AM, Steele HD, MacKenzie DA, Penny JA. A Review of 21 Cases of Transchondral Fracture of the Talus. *J Trauma* 1967;7:378.

+ 29. Davis FJ, Fry LR, Lippert FG, et al. The Patellar Tendon-Bearing Brace: Report of 16 Patients. *J Trauma* 1974;14:216.

# 30. Delee JC. Fractures and Dislocations of the Foot. In: Mann RA, ed.*Surgery of the Foot*, 5th ed. St. Louis: Mosby, 1986.

+ 31. Dennis MD, Tullos HS. Blair Tibiotalar Arthrodesis for Injuries to the Talus. *J Bone Joint Surg Am* 1980;62:103.

+ 32. Deyerle WM, Burkhardt B, Comfort T, Giles W. Displaced Fractures of the Talus—An Aggressive Approach. *Orthop Trans* 1981;5:465.

+ 33. Dunn AR, Jacobs B, Campbell RD Jr. Fractures of the Talus. *J Trauma* 1966;6:443.

* 34. Essex-Lopresti P. The Mechanism, Reduction Techniques and Results in Fractures of the Os Calcis. *Br J Surg* 1952;39:395.

+ 35. Fisher C, Loomer R, Amman W, et al. Osteochondral Lesions of the Talus: A New Classification, New Imaging Techniques and Surgical Approach. *Orthop Trans* 1989;13:681.

+ 36. Folk JW, Starr AJ, Early JS. Early Wound Complications of Operative Treatment of Calcaneus Fractures: Analysis of 190 Fractures. *J Orthop Trauma* 1999;13:369.

+ 37. Gilmer PW, Herzenberg J, Frank JL, et al. Computerized Tomographic Analysis of Acute Calcaneal Fractures. *Foot Ankle* 1986;6:184.

+ 38. Grob D, Simpson LA, Weber BG, Bray T. Operative Treatment of Displaced Talus Fractures. *Clin Orthop* 1965;199:88.

+ 39. Guyer BH, Levinsohn EM, Fredrickson BE. Computed Tomography of Calcaneal Fractures. *Orthop Trans* 1986;10:82.

+ 40. Hawkins LG. Fracture of the Lateral Process of the Talus: A Review of 13 Cases. *J Bone Joint Surg Am* 1965;47:1170.

* 41. Hawkins LG. Fractures of the Neck of the Talus. *J Bone Joint Surg Am* 1970;52:991.

+ 42. Heger L, Wulff K. Computed Tomography of the Calcaneus: Normal Anatomy. *Am J Radiol* 1985;145:123.

+ 43. Heger L, Wulff K, Seddiqi MSA. Computed Tomography of Calcaneal Fractures. *Am J Radiol* 1985;145:B1.

+ 44. Heppenstall RB, Farahvar H, Balderston R, Lotke P. Evaluation and Management of Subtalar Dislocations. *J Trauma* 1980;20:494.

+ 45. Jordan C, Mirzabeigi E, Williams S. Determining the Angle of Screw Placement for Internal Fixation of Calcaneal Fractures. *J Orthop Trauma* 1999;13:47.

! 46. Kelly PJ, Sullivan CR. Blood Supply of the Talus. *Clin Orthop* 1963;30:37.

+ 47. Leitner B. Obstacles to Reduction in Subtalar Dislocations. *J Bone Joint Surg Am* 1954;36:304.

+ 48. Lemaire RG, Bustin W. Screw Fixation of Fractures of the Neck of the Talus Using a Posterior Approach. *J Trauma* 1980;20:669.

+ 49. Levine DS, Malicky ES, Sangeorzan BJ. Intraoperative Axial Radiographs during Fixation of Fractures of the Calcaneus. *Am J Orthop* 1999;28:429.

+ 50. Lionberger DR, Bishop JO, Tullos HS. The Modified Blair Fusion. *Foot Ankle* 1982;3:60.

+ 51. Lorentzen JE, Christensen SB, Krogsoe O, Sneppen O. Fractures of the Neck of the Talus. *Acta Orthop Scand* 1977;48:115.

! 52. Manoli A II, Weber TG. Fasciotomy of the Foot: An Anatomical Study with Special Reference to Release of the Calcaneal Compartment. *Foot Ankle* 1990;10:267.

# 53. Mayo KA. Fractures of the Talus: Principles of Management and Techniques of Treatment. *Tech Orthop* 1987;3:42.

+ 54. McDougall A. The Os Trigonum. *J Bone Joint Surg Br* 1955;37:257.

+ 55. McKeever FM. Treatment of Complications of Fractures and Dislocations of the Talus. *Clin Orthop* 1963;30:45.

# 56. McReynolds IS. The Case for Operative Treatment of Fractures of the Os Calcis. In: Leach RE, Hoaglund FT, Riseborough EJ, eds.*Controversies in Orthopaedic Surgery.* Philadelphia: Saunders, 1982.

+ 57. Mindell ER, Cisek EE, Kartalian G, Dziob JM. Late Results of Injuries to the Talus. *J Bone Joint Surg Am* 1963;45:221.

+ 58. Miric A, Patterson BM. Pathoanatomy of Intra-articular Fractures of the Calcaneus. *J Bone Joint Surg Am* 1998;80:207.

+ 59. Morris HD, Hand WL, Dunn AW. The Modified Blair Fusion for Fractures of the Talus. *J Bone Joint Surg Am* 1971;53:1289.

+ 60. Mukherjee SK, Pringle RM, Baxter AD. Fracture of the Lateral Process of the Talus: A Report of 13 Cases. *J Bone Joint Surg Br* 1974;56:263.

! 61. Mulcahy DM, McCormack DM, Stephens MM. Intra-articular Calcaneal Fractures: Effect of Open Reduction and Internal Fixation on the Contact Characteristics of the Subtalar Joint. 1998;19:842.

* 62. Mulfinger GL. Trueta J. The Blood Supply of the Talus. *J Bone Joint Surg Br* 1970;52:160.

# 63. Müller ME, Allgöwer M, Schneider R, Willenegger H. *Manual of Internal Fixation. Techniques Recommended by the AO Group*, 2nd ed. New York: Springer, 1979.

+ 64. O'Donoghue DH. Chondral and Osteochondral Fractures. *J Trauma* 1966;6:469.

+ 65. O'Farrell TA, Costello BG. Osteochondritis Dissecans of the Talus: The Late Results of Surgical Treatment. *J Bone Joint Surg Br* 1982;64:494.

+ 66. Omoto H, Sakurada K, Sugi M, Nakamura K. A New Method of Manual Reduction of Intra-Articular Fractures of the Calcaneus. *Clin Orthop* 1983;177:104.

* 67. Palmer I. The Mechanism and Treatment of Fractures of the Calcaneus. Open Reduction with the Use of Cancellous Grafts. *J Bone Joint Surg Am* 1948;30:2.

+ 68. Paulos LE, Johnson CL, Noyes FR. Posterior Compartment Fractures of the Ankle: A Commonly Missed Athletic Injury. *Am J Sports Med* 1983;11:439.

+ 69. Pennal GF. Fractures of the Talus. *Clin Orthop* 1963;30:53.

+ 70. Penny JN, Davis LA. Fractures and Fracture-Dislocations of the Neck of the Talus. *J Trauma* 1980;20:1029.

! 71. Peterson L, Goldie IF. The Arterial Supply of the Talus: A Study of the Relationship to Experimental Talar Fractures. *Acta Orthop Scand* 1975;46:1026.

+ 72. Peterson L, Goldie IF, Irstam L. Fracture of the Neck of the Talus. *Acta Orthop Scand* 1977;48:696.

! 73. Peterson L, Goldie IF, Lindell D. The Arterial Supply of the Talus. *Acta Orthop Scand* 1974;45;260.

! 74. Peterson L, Romanus B, Dahlberg E. Fracture of the Collum Tali—An Experimental Study. *J Biomech* 1976;9:277.

+ 75. Pettine KA, Morrey BF. Osteochondral Fractures of the Talus. *J Bone Joint Surg Br* 1987;69:89.

+ 76. Ray RB, Coughlin EJ. Osteochondritis Dissecans of the Talus. *J Bone Joint Surg* 1947;29:697.

+ 77. Reckling FW. Early Tibiocalcaneal Fusion in the Treatment of Severe Injuries of the Talus. *J Trauma* 1972;12:390.

+ 78. Sanders RW. CT Scan Classification and Operative Lateral Approach for Internal Fixation of Calcaneal Fractures. *Video J Orthop* 1990; August.

# 79. Sangeorzan BJ. Salvage Procedures for Calcaneus Fractures. *Instr Course Lect* 1997;46:339.

+ 80. Segal D, Marsh JL, Leiter B. Clinical Application of CT Scanning of Calcaneus Fractures. *Clin Orthop* 1985;199:114.

# 81. Shelton ML, Pedowitz WJ. Injuries to the Talus and Midfoot. In: Jahss MH, ed.*Disorders of the Foot*. Philadelphia: Saunders, 1982:1463.

+ 82. Smith RW, Staple TW. CT Scanning Technique for the Hindfoot. *Clin Orthop* 1983;177:34.

+ 83. Sneppen O, Christensen SB, Krogsoe O, Lorentzen J. Fracture of the Body of the Talus. *Acta Orthop Scand* 1977;48:317.

+ 84. Stephenson JR. Treatment of Displaced Intra-Articular Fractures of the Calcaneus Using Medial and Lateral Approaches, Internal Fixation and Early Motion. *J Bone Joint Surg Am* 1987;69:115.

! 85. Swanson TV, Bray TJ, Holmes GB Jr. Talar Neck Fractures: A Mechanical Study of Fixation. *J Bone Joint Surg Am* 1992;74:544.

+ 86. Szyszkowitz R, Reschauer R, Seggl W. 85 Talus Fractures Treated by ORIF with 5 to 8 Years of Follow-up Study of 69 Patients. *Clin Orthop* 1985;199:97.

+ 87. Thermann H, Krettek C, Heufner T, et al. Management of Calcaneal Fractures in Adults: Conservative versus Operative Treatment. *Clin Orthop* 1998;353:107.

+ 88. Thermann H, et al. Long-term Results of Subtalar Fusions after Operative versus Non-operative Treatment of Os Calcis Fractures. *Foot Ankle Int* 1999;20:408.

+ 89. Thordarson DB, Greene N, Shepherd L, Perlman M. Facilitating Edema Resolution with a Foot Pump after Calcaneus Fracture. *J Orthop Trauma* 1999;13:43.

! 90. Thordarson DB, Hedman TP, Yetkinler DN, et al. Superior Compression Strength of a Calcaneal Fracture Construct Augmented with Remodelable Cancellous Bone Cement. *J Bone Joint Surg Am* 1999;81:239.

+ 91. Thordarson DB, Krieger LE. Operative vs. Non-operative Treatment of Fractures of the Calcaneus: A Prospective Randomized Trial. *Foot Ankle Int* 1996;17:2.

+ 92. Tornetta P III. The Essex-Lopresti Reduction for Calcaneal Fractures Revisited. *J Orthop Trauma* 1998;12:469.

+ 93. Trillat A, Bousquet G, Lapeyre B. Les Fractures-Separations Totales du Col ou du Corps de L'Astragale. Interet du Vissage par Voie Posterieure. *Rev Chir Orthop* 1970;56:529.

+ 94. Van Buecken K, Barrack RL, Alexander AH, Ertl JP. Arthroscopic Treatment of Transchondral Talar Dome Fractures. *Am J Sports Med* 1989;17:350.

+ 95. Zimmer TJ, Johnson KA. Subtalar Dislocations. *Clin Orthop* 1989;238:190.

# CHAPTER 111

# FRACTURES AND DISLOCATIONS OF THE MIDFOOT AND FOREFOOT

*Linda Ferris*

**L. Ferris:** Wakefield Orthopaedic Clinic, 270 Wakefield St., Adelaide, SA, 5000, Australia.

Introduction and General Considerations
- Anatomy
- Soft-tissue Management
- Neuropathic Midfoot Fractures
- Stress Fractures

Fixation Techniques in the Midfoot and Forefoot
- Kirschner Wires Versus Screws
- Bioresorbable Implants
- Role of External Fixation

Injuries to the Midfoot and Forefoot by Region
- Chopart's Joint-Fracture Dislocations
- Isolated Navicular Fractures
- Isolated Cuboid Fractures
- Isolated Cuneiform Fractures
- Tarsometatarsal (Lisfranc) Fracture Dislocations
- Metatarsal Fractures
- Metatarsophalangeal Joint Dislocations
- Sesamoid Fractures
- Phalangeal Fractures and Interphalangeal Joint Dislocations

Chapter References

## INTRODUCTION AND GENERAL CONSIDERATIONS

Recently, research on the impact of foot injuries in the rehabilitation of polytrauma patients has documented that patients with foot injuries often had more long-term morbidity (39). This research suggests that more attention needs to be paid to what may have been seen as less serious injuries. Recent publications provide excellent reviews of this important topic (1,18,29,30,37,40).

### ANATOMY

The bones discussed in this chapter include the navicular, cuboid, three cuneiforms, metatarsals, phalanges, and sesamoids. The joints discussed are Chopart's joint, Lisfranc complex, metatarsophalangeal (MTP) joints, and the interphalangeal joints. It is important to recognize the close relation of nerves and blood vessels to the bones and joints in the foot (33). In particular, the dorsalis pedis artery and the deep peroneal nerve are at risk in both injuries to and surgery for the Lisfranc complex. Incisional neuromas are relatively common complications of surgery in the foot and ankle. A variable number of compartments have been described in the foot (22,35) that must also be understood in these injuries. See Chapter 3 on surgical approaches to the lower extremity.

### SOFT-TISSUE MANAGEMENT

Although they are not limited to the foot, crush injuries and lawnmower injuries make up a significant subset of injuries to the foot and ankle (26). Crush injuries may be combined with degloving when the foot is run over by a heavy vehicle, but they also occur with direct impact such as dropping a heavy object on the foot. Lawnmower injuries are heavily contaminated open wounds with or without fractures and often some soft-tissue avulsion. These injuries not only damage bones and joints but also nerves and vascular structures, and can lead to skin necrosis, which is not evident acutely. Therefore, these wounds often need repeated debridements and delayed primary closure of the skin. Lawnmower injuries require urgent treatment, with thorough debridement and irrigation, and then reassessment of the viability of the affected part (26). Early administration of intravenous antibiotics is essential. The principles of management of open fractures are discussed in Chapter 12.

Vascular injuries, even forefoot gangrene, have been described following Lisfranc's injuries (6,13). This makes reduction of a displaced dislocation in this area urgent. Compartment syndrome in the foot has been well described by Manoli (22), Shereff (35), and others. Diagnosis and investigation of compartment syndrome are discussed in Chapter 13. Compartment syndrome can occur without bony injury in the foot, but when it is associated with a Lisfranc fracture dislocation, the surgical approach for decompression needs to take into consideration the approach for internal fixation of the underlying bony injury. Compartment syndrome release can be performed through a single medial incision, but my preference when it is associated with Lisfranc's fracture dislocation is to combine a medial incision with one or two dorsal incisions. There may be a role for foot pumps to decrease the incidence of foot compartment syndrome. Patients with calcaneal and more proximal fractures tolerate this treatment modality more readily.

Reflex sympathetic dystrophy (RSD) may be a complication of soft-tissue injuries as well as bony injuries of the foot (13). See Chapter 7 for more information of RSD.

### NEUROPATHIC MIDFOOT FRACTURES

It is important to recognize that in patients with peripheral neuropathy, particularly in diabetics, a forefoot or midfoot fracture can lead to the development of a Charcot arthropathy. This is discussed in detail in Chapter 116 and Chapter 124. In some acute injuries, the underlying neuropathy may not be recognized; in other cases, the patient may present with a well-established neuropathy and advanced deformity so that the diagnosis of neuropathy is obvious.

### STRESS FRACTURES

The principles of stress fractures are addressed in Chapter 96. In the midfoot and forefoot the most common sites for stress fractures are the navicular, the base of the fifth metatarsal, the shaft of the second and third metatarsals, and the sesamoids. Those most resistant to treatment are the navicular and base of the fifth metatarsal. Fractures of the sesamoid and middle metatarsals are addressed elsewhere in this chapter.

## FIXATION TECHNIQUES IN THE MIDFOOT AND FOREFOOT

The role of various fixation techniques is presented in Table 111.1.

| Fixation Techniques | Applications | Advantages | Disadvantages |
|---|---|---|---|
| Kirschner (K) Wires | Toe and metatarsal fractures and dislocations<br>Often injures as preliminary fixation<br>Preferred in children<br>Usually used for short-term fixation | Percutaneous insertion possible<br>Easily removed | May migrate<br>Limited strength<br>If left protruding, there is a risk of infection |
| Screws | Use independently or with plates<br>Allow compression techniques<br>Are buried and can be left over the long term<br>Displaced fractures of the navicular, first metatarsal, and others | If they are part of a cannulated system they can be inserted percutaneously. | May require a second operation to remove<br>Technically more challenging to use |
| Plates | 3.5 mm, 2.7 mm, or smaller mini plates are occasionally used on the first and other metatarsals.<br>First metatarsal phalangeal fusion<br>Usually left over the long term | Strongest fixation | Require open exposure<br>Increased soft tissue stripping<br>May require a second operation to remove<br>May be prominent or bothersome |
| Bioresorbable Implants | Potential replacement for K-wires or screws | No need to remove | Risk of inflammatory reaction |
| External Fixation | Used for unstable injuries too commonest for internal fixation<br>Open injuries where implants are not desirable<br>Helps maintain length during procedure or as definitive fixation<br>Temporary | No implants other than temporary fixation pins | Pin track infections<br>Adjustable postoperatively<br>May be shown soft tissues |

***Table 111.1. Applications, Advantages and Disadvantages of Foot Fixation Techniques***

## KIRSCHNER WIRES VERSUS SCREWS

Kirschner wires (K-wires) have been frequently used to stabilize forefoot fractures. They are particularly useful where their role is short-term fixation, particularly of a metatarsal or a toe. Their role in Lisfranc injuries remains controversial, however. The disadvantages of using smooth K-wires are migration if they are left buried and infection if they are left through the skin for prolonged periods. Therefore, when I repair primarily ligamentous injuries that require 3 months of immobilization, I prefer to use either a screw or a threaded K-wire and bury it beneath the skin.

The advantages of screws are the ability to provide compression and more solid fixation, which is particularly important for rigid stabilization of the medial three tarsal-metatarsal joints and for those fractures in which inadequate fixation is likely to lead to nonunion or delayed union. Cannulated screw systems allow percutaneous insertion of the implant. When a screw is placed across a joint, which is particularly relevant in Lisfranc's injuries, the other concerns are damage to the articular surface by the larger diameter and the need to remove the implant. If the screw is placed across a joint that is essential to the function of the foot, removal is indicated; otherwise, removal remains controversial unless the implant causes symptoms. Details of the recommended methods of fixation for individual injuries are discussed later in this chapter.

## BIORESORBABLE IMPLANTS

Pins and screws made of polylactic acid (PLA), polyglycolic acid (PGA), and substances that are absorbed over time are now available (5). These implants initially caused some concern because of local soft-tissue reactions, particularly seromas. The more recent implants produce less reaction and do have a role, especially for intra-articular fractures or for temporary (i.e., 6-week to 3-month) fixation of joints such as Lisfranc's injuries. Their role in long-term fixation of the foot and ankle, however, remains to be seen.

## ROLE OF EXTERNAL FIXATION

The midfoot contains a variety of small bones (e.g., the cuneiforms, navicular, and cuboid), which when fractured, may be comminuted and difficult to stabilize with internal fixation. It is occasionally useful to bridge the area with an external fixator, such as medially from the talar neck to the first metatarsal (Fig. 111.1*C*, Fig. 111.1*D*) (11,15) to restore the length of the column and reduce the fractures using ligamentotaxis. External fixation may be used as a temporary device to provide the reduction. The fracture can then be stabilized by internal fixation or percutaneous fixation as the definitive method of treatment, or the fixator can be left *in situ.* I have found this particularly helpful in a comminuted navicular fracture for which such extensive comminution occurred that stripping the soft tissues to allow adequate reduction might have led to avascular necrosis. The other role for external fixation is when the soft tissues are compromised, such as an open fracture or severe crushing, to provide temporary fixation while the soft-tissue situation is resolved.

***Figure 111.1.*** Lateral (**A**) and oblique (**B**) radiographs of a comminuted subtalar and talonavicular fracture dislocation. AP (**C**) and lateral (**D**) radiographs demonstrating external fixation to stabilize the medial column.

## INJURIES TO MIDFOOT AND FOREFOOT BY REGION

The algorithm for assessing injuries to the midfoot and forefoot is shown in Figure 111.2.

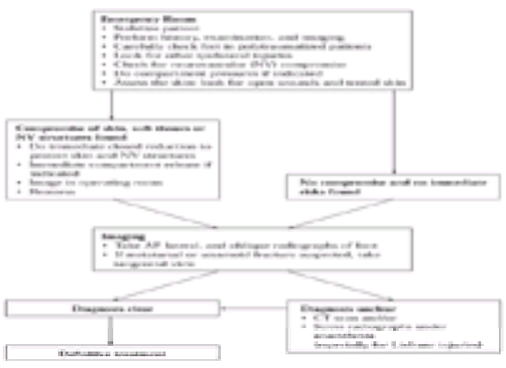

***Figure 111.2.*** Algorithm for assessment of midfoot and forefoot injuries.

## CHOPART'S JOINT-FRACTURE DISLOCATIONS

The algorithm for treatment of Chopart's joint injuries is shown in Figure 111-3.

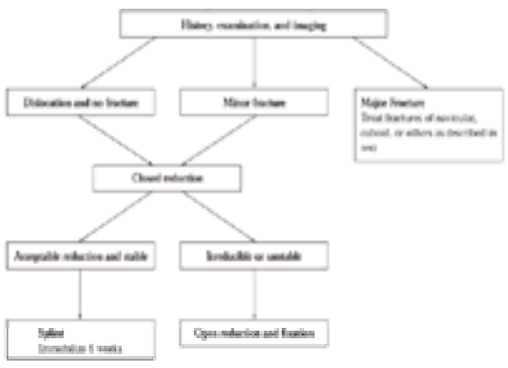


***Figure 111.3.*** Algorithm for Chopart's joint injuries.

### *Mechanism of Injury, Investigation, and Classification*

Chopart's joint is an unusual injury site, but because of its importance to the function of the foot, particularly in linking the hindfoot to the forefoot, damage in this area can have significant consequences to the function of the foot. Main and Jowett (21) classified midtarsal joint injuries based on the direction of the force of injury and the deformity that occurred. They described five patterns of injury; within each, the injuries varied in severity. However, their classification is not helpful in prognosis or management decisions.

The main concern is that the extent of the injury may be initially missed (10,21,27). A dislocation with spontaneous relocation may be associated with only minor avulsion fractures (10). Take a careful history, and ask about the amount of force applied, the direction of the force, and whether the patient felt a “clunk” as the joint dislocated or relocated. These injuries are often found in polytrauma patients, in whom the details of the injury may not be available; therefore, any polytrauma patient with a swollen foot needs careful assessment. Localize sites of maximum tenderness; test motor and sensory function, if possible, and gently stress the transverse tarsal joints to look for excessive mobility.

Take anteroposterior (AP), lateral, and a medial-oblique radiographs of the foot. Findings may include avulsion of the navicular tuberosity, fractures through the body of the navicular, compression of the cuboid, or anterior calcaneus. Hermel and Gershon-Cohen (17) applied the term “nutcracker fracture” to the compression fracture of the cuboid. True dislocations may be seen on plain radiographs, but most often, spontaneous reduction of the transverse tarsal joint has occurred. For this reason, examination under anesthesia is occasionally warranted if the patient is undergoing surgery for other injuries. Alternatively, if the patient does not have other major injuries and it is clinically indicated, local anesthetic injection may allow weight bearing or stress films to be taken. Further investigation such as computerized tomography (CT) may be warranted if a significant intra-articular fracture requires documentation or if the plain radiographs are not diagnostic. If the patient is seen late with persistent medial midfoot pain, a bone scan may be warranted to document an otherwise unrecognized injury (7,12).

### *Principles of Treatment*

The goal of treatment in the transverse tarsal joint is to restore the normal anatomy and stability without producing excessive stiffness. As shown in Figure 111.2, assess whether immediate treatment is warranted. Treatment may consist of closed reduction, external fixation, open reduction and internal fixation, or late reconstruction.

**Immediate Treatment** If the injury is primarily to soft tissues, or is a dislocation or subluxation, then treat immediately with closed reduction (Fig. 111.4*A* and Fig. 111.4*B*). If closed reduction is not possible owing to a trapped tendon, capsule, or bony fragments, perform an open reduction (Fig. 111.4*C* and Fig. 111.4*D*). Once the reduction is completed, assess the stability (Fig. 111.3).

***Figure 111.4.*** AP (**A**) and lateral (**B**) radiographs of residual subluxation following closed reduction of a Chopart's fracture and dislocation in a 9-year-old girl. AP (**C**) and lateral (**D**) radiographs of post-open reduction and K-wire fixation. The dorsal capsule was blocking reduction.

Most often, a transverse tarsal joint dislocation without a major fracture is relatively stable. Immobilize with a splint, and elevate (no weight bearing) for 1 to 2 weeks to allow pain to resolve. I recommend using a removable splint or removable cast to allow range of movement while protecting the foot from loading. If, however, there is a fracture associated with a dislocation, particularly a fracture of the navicular, then the injury may be unstable. If a fracture of the navicular is undisplaced and if closed reduction produces satisfactory alignment, splint until the swelling is reduced, followed by a period of immobilization in a short-leg cast for approximately 6 weeks. Weight bearing depends on the stability of the fracture. Then encourage range of movement.

For displaced fractures of the navicular, such as avulsion of the navicular tuberosity, open reduction and anatomic fixation are warranted. Immobilize for 6 weeks until fracture healing occurs. Weight-bearing status depends on the stability of the fracture and the fixation but is generally non-weight bearing for 6 weeks.

Fractures of the lateral column are less likely to be unstable, but a compression fracture of the cuboid may shorten the lateral column, which will have a long-term effect on foot function. When the lateral column fractures are minor avulsions, such as the anterior process of the calcaneus or the dorsal lip of the cuboid, treat symptomatically. Occasionally, late excision of bony fragments is necessary if they are problematic. If there is a crush injury of the lateral column with loss of height of the cuboid, however, then reduction and stabilization are indicated. The same pattern of cuboid injury may be seen with Lisfranc's dislocations. The principles of the different methods of treatment are discussed in relation to the different fracture patterns.

**External Fixation** I use external fixation on the medial side only when there is significant loss of medial column length, and when other methods of fixation are not an option. It is more common to have lateral column shortening. External fixation may be used if the fragments are too small to obtain stable reduction with internal fixation.

- Plan the insertion of two pins in the calcaneus and two in the fifth metatarsal.
- Make stab incisions in the skin; be careful to avoid injury to the sural nerve.
- Insert two pins in a half pin fashion into the calcaneus and two into the fifth metatarsal using the technique appropriate for the external fixator that is being used. Apply the fixator and distract the fracture.
- Expose the fractured bone through a short longitudinal incision and elevate the articular surface, which can usually be elevated and aligned to the remaining medial or plantar articular surface.
- Use a small amount of bone graft, which can be harvested locally from the calcaneus or malleoli, to fill any resulting defect and stabilize the fragment.
- Stabilize the fracture with one or two small threaded K-wires running in the subchondral bone into the remaining cuboid. Cut the wires off just outside the bone.

Postoperatively, leave the external fixator in place for at least 6 weeks to keep all compressive forces off the cuboid.

Occasionally the fragments are simply too small for any fixation, in which case simply elevate the fracture, pack in bone graft, and use external fixation to control the fracture. If the fracture fragments are large enough, a screw may be used to stabilize the fracture fragments. In this case, the external fixator may be removed or a plate may be applied (see the next section), depending on the stability of the construct.

**Open Reduction and Internal Fixation** On the medial column, open reduction and internal fixation are used for displaced fractures of the navicular tuberosity or displaced fractures of the body of the navicular. The most common injury is an avulsion fracture of the navicular tuberosity, which can be treated by the following technique:

- Make a longitudinal medial incision, centered over the navicular tuberosity. Dissect along the line of the incision straight down to the navicular.
- Identify the talonavicular and naviculocuneiform joints. Owing to the curved shape of the navicular, screws or pins placed from the medial aspect of the foot may inadvertently transgress one or both of these joints.
- If the fracture is not comminuted, reduction can often be achieved by inverting the foot. The navicular tuberosity is not primarily articular, so the main concern is restoration of the insertion of the tibialis posterior tendon and restoring medial stability.
- Once stabilization and reduction are achieved, insert a screw from proximal to distal using compression technique to stabilize the fracture.

Postoperatively, immobilize the foot in a splint in mild inversion and plantar flexion for 2 weeks and then reapply a splint or cast in neutral alignment. Time to weight bearing depends on the size of the fragment and the stability of the fixation, but most patients can bear full weight by 6 to 8 weeks.

Fractures that involve the body of the navicular, particularly those with severe comminution, are discussed in this chapter under the section titled Isolated Navicular Fractures, but in this context, it is important to note the initial aim in treatment is to restore normal forefoot–hindfoot alignment and to maintain the lengths of the medial and lateral columns. Many of these patients may require later arthrodesis, which will be much easier if the anatomy is preserved. Primary arthrodesis is occasionally indicated (11,12,15); however, my preference is to attempt to obtain healing in appropriate alignment in order to maintain the function of the transverse tarsal joints and perform arthrodesis only as a later reconstruction if symptoms cannot be controlled with nonoperative methods.

For lateral column injuries, open reduction and internal fixation are less frequently warranted.

- Make a longitudinal lateral approach to the anterior calcaneus, cuboid, and base of the fourth and fifth metatarsals with variations in the exposure depending on the fracture pattern in the cuboid and whether the anterior calcaneus is involved.
- The cuboid is generally crushed between the calcaneus and the metatarsals. The injury may be simply to the lateral half of the cuboid and often is primarily dorsal. Similar to tibial plateau fractures, the articular surface has been driven into the body of the cuboid with a thin rim of subchondral bone preserved.
- An alternative to using an external fixator for the previously discussed “nutcracker” fracture of the cuboid is to use a plate spanning from the calcaneus to the fifth metatarsal to distract and unload the cuboid fracture. Leave the plate *in situ* for approximately 3 months and then remove it (Fig. 111.5).

***Figure 111.5.*** **A:** Cuboid fracture with impaction of the proximal articular surface. **B:** Operative radiograph showing the use of a bridging plate, threaded K-wire, and bone graft.

- Application of a plate requires elevation of the peroneal tendons and protection of the sural nerve.
- Primary arthrodesis of the calcaneal cuboid joint is not generally indicated, but if necessary, loss of movement of the calcaneal cuboid joint results in about a 30% loss of subtalar motion (8).

**Late Reconstruction and Role of Arthrodesis** Late presentation of injuries to Chopart's joint injuries may be due to initial misdiagnosis of the injury as a minor sprain. The more severely displaced injuries are generally recognized immediately. Treat late presentation of a primarily soft-tissue injury with in-shoe devices combined with shoe modifications. Medial or lateral column shortening combined with degenerative changes in the affected joints is more serious and generally requires surgery.

For lateral column shortening and arthrosis of the calcaneocuboid joint and subluxation of the talonavicular joint, lengthen the lateral column and perform an arthrodesis of the calcaneocuboid joint.

In medial column shortening, generally both the talonavicular and naviculocuneiform joints are affected. Plan an arthrodesis for the entire medial column from the talus to the medial and intermediate cuneiforms. Quite commonly all three cuneiforms must be included in the arthrodesis to form a solid block with the navicular. There is relatively little motion between the cuneiforms, and it is easier to get a solid fusion by involving all three. If alignment is satisfactory, perform an *in situ* arthrodesis (20). If the medial column has been shortened, restoration of length is necessary and will require tricortical iliac crest graft (12). The aim is to restore the longitudinal axis of the foot so that the second metatarsal bisects the angle between talus and the calcaneus on an AP radiograph of the foot. Comparison radiographs of the other foot are helpful. Arthrodesis of the medial column is much more difficult to achieve than for the lateral column. Good-quality bone graft is essential, combined with rigid internal fixation, generally using multiple screws occasionally supplemented by a plate followed by non-weight bearing for 6 weeks and total immobilization of 3 months.

## ISOLATED NAVICULAR FRACTURES

Injuries to the navicular range from minor to severe. Stress fractures can be a complex problem and are discussed in Chapter 96.

### *Dorsal Avulsion Fractures*

Dorsal avulsion fractures are most commonly seen with a forced plantarflexion injury or a direct blow to the foot and are essentially a dorsal midfoot sprain (7,9,11,41). An avulsion fracture may be an indicator of a more serious fracture dislocation. If the mechanism of injury is relatively clear, symptoms and signs are localized at a small area on the dorsum of the foot, and there is no tenderness over the calcaneocuboid or navicular tuberosity, the fracture can be considered a localized injury. Check the function of the deep peroneal nerve, which generally lies immediately adjacent to this fracture. The tibialis anterior tendon does not insert in this area, but isolated ruptures of the tibialis anterior do occur, so look for this injury. Plain AP and lateral radiographs are usually sufficient. A typical avulsion fracture has sharp edges and irregular margins. Look for a fractured dorsal osteophyte. Do not mistake an accessory ossicle for a fracture.

Initially, manage the injury in a dorsiflexion splint for 1 to 2 weeks. Once the acute pain and swelling have resolved, apply a walking cast or removable orthosis (“cam-walker”) for another 3 to 4 weeks, followed by mobilization. Warn patients at the onset of treatment that the small fragment may not heal, and that the aim of the treatment is to allow the ligaments and soft tissues to heal. If the bony fragment is symptomatic, particularly irritation of the deep peroneal nerve, then surgical excision may be warranted at a later date. It may also be useful to teach the patient how to skip-lace their shoe.

### *Avulsion of the Navicular Tuberosity*

Avulsion of the navicular tuberosity may occur with resisted forceful contraction of the tibialis posterior or forced eversion (7,9,11,41). It is important to rule out a more complex associated injury. Take a good history to make sure the mechanism of injury is consistent with the clinical findings. Rule out other associated injuries, particularly to Chopart's and Lisfranc's joints. Assess the tibialis posterior tendon for continuity.

Take AP and lateral radiographs, but to visualize the navicular tuberosity, a reverse oblique will demonstrate a fracture better than the normal medial oblique view. It is

important to differentiate between an acute fracture and an accessory navicular. An accessory navicular usually has smooth edges rather than the sharper, irregular margins of an acute fracture. It is possible, however, for the fibrous syndesmosis between the accessory navicular and the navicular body to become disrupted, and that area may be symptomatic. An ultrasound scan may also be useful to assess the tendon at its insertion.

A fracture of the navicular tuberosity is often nondisplaced or minimally displaced. If so, initially splint the foot into slight inversion to take the tension off the posterior tibial tendon and ease pain, followed by a period of 4 to 6 weeks in a short-leg walking cast. Base the total treatment time on evidence of clinical and radiographic union. In athletes, some recommend simple bandaging (41). Because of the continuous pull of the tendon, nonunion may occur, but it is often asymptomatic.

An accessory navicular may become symptomatic, especially in the adolescent, in which case, 6 weeks in a short-leg walking cast is recommended to determine whether the syndesmosis will heal. If the nonunion of an accessory navicular produces persistent pain or loss of function of the tibialis posterior tendon, surgical intervention is indicated. For displaced fractures, surgical repair is warranted.

**Open Reduction and Fixation**

- Make a medial slightly curved longitudinal incision centered on the navicular tuberosity, curving proximally along the posterior tibial tendon and extending longitudinally distally along the plantar border of the medial cuneiform.
- By blunt dissection, expose the wide insertion of the tibialis posterior tendon with its extensive ligamentous insertion medially and plantarward.
- For acute fractures, clean the fracture ends, reduce the fracture, and generally fix it with a single compression screw.
- K-wire fixation may be necessary if the fracture is comminuted and no individual fragment is large enough to take screw fixation. If the bony fragment is small, an alternative is to excise the fragment and repair the remaining tibialis posterior tendon to the navicular.

Following any of these surgical procedures splint the foot in inversion and plantarflexion for 7 to 10 days, followed by a short-leg non-weight-bearing cast in neutral for 4 to 6 weeks and then a removable weight-bearing orthosis for up to 12 weeks.

***Fractures of the Navicular Body***

Acute fractures of the body of the navicular are seen frequently in the longitudinal stress pattern described by Main and Jowett (21). Typically, vertical splits occurring in line with the cuneiform. The pattern varies, depending on the amount of plantar flexion the foot is in at the time of injury. Sangeorzan (31) described three fracture patterns in 1989:

- Type I fractures have a fracture line parallel to the sole of the foot (i.e., the transverse plane separates it into dorsal and plantar fragments). This fracture pattern is usually benign with very little displacement of the forefoot in relationship to the hindfoot.
- Type II fractures are oblique fractures with fracture lines running dorsolateral to plantarmedial and the forefoot is displaced medially. More extensive comminution is noted.
- Type III fractures are comminuted with the main damage being centrally or laterally and the forefoot is displaced laterally.

Take AP, lateral, and oblique radiographs. A CT scan may be helpful in distinguishing type II and type III fractures if that influences the surgical decision making.

The talonavicular joint is one of the key joints maintaining the length of the medial column and foot function. Therefore, the goals of treatment are to restore an anatomic alignment of the talar articular surface of the navicular and to restore medial column length. Nonoperative treatment would be indicated only for an undisplaced fracture. If the fracture is a longitudinal split, consider a stress fracture.

**External Fixation** A mini-external fixator may be useful in medial column injuries for comminuted type II or III fracture patterns. For type II fractures in which there is primarily lateral comminution of the navicular with one relatively large dorsal medial fragment, two incisions may be indicated.

- Make a medial incision running from the navicular tuberosity toward the medial malleolus, above the tibialis posterior tendon, avoiding the saphenous nerves and veins, to expose the talar neck. The incision can be continuous, or separate incisions can be made distally over the medial cuneiform, or depending on the fracture pattern, the base of the first metatarsal.
- Then under direct vision, place external fixator pins in the talar neck and medial cuneiform, apply longitudinal traction, and tighten the external fixator while applying distracting forces across the navicular (Fig. 111.1). If the fracture is fixable, then either through the same medial incision or a second dorsal lateral incision, reduce and fix the fracture.
- If the lateral fragment is too comminuted for fixation, then reduce the dorsal medial fragment between the cuneiforms and transfix the talus in that position with either K-wires or fully threaded cortical screws. An alternative is to fix the fragments only to the cuneiforms to try and preserve talonavicular motion (11,15,31).
- For type III fractures in which the extent of comminution is such that stable internal fixation cannot be achieved, use the external fixator and apply longitudinal traction. By direct pressure, attempt to manipulate the fragments into satisfactory alignment, particularly aiming to align the forefoot to the hindfoot and maintain the medial column length.
- When there is widespread comminution of the fracture, do not expose it because it simply devascularizes the fracture fragments and may predispose the patient to avascular necrosis. Percutaneous fixation may add to the stability.

**Open Reduction and Internal Fixation** Open reduction and internal fixation is primarily used in the displaced type I and type II and some type III fractures. With comminuted type II and III fractures, open reduction and stable internal fixation are difficult to achieve and may need to be combined with some form of external fixation.

- Make a dorsomedial longitudinal incision through the tibialis anterior tendon sheath, down through the inferior margin of the sheath, and onto the navicular, being careful to identify the talonavicular joint and the medial cuneiform.
- Retract the tendon either medially or laterally to better visualize the fracture.
- Reduce the fracture and, if possible, fix it with screws inserted dorsally. It is important to remember the curve of the navicular and identify the joints on either side to avoid the screw impinging on either joint.

Postoperatively splint the foot and keep the patient non-weight bearing for at least 6 to 8 weeks and occasionally for 12 weeks. Patients, particularly those with type II and III fracture patterns, should be advised that there is a high likelihood of a fair to poor outcome (9,10,11 and 12,15,21,27,31) due to degenerative changes, malunion, nonunion, or avascular necrosis, and that even with good fracture healing, stiffness is a likely outcome.

**Late Reconstruction** Late reconstruction of fractures of the navicular are primarily for degenerative arthritis of the talonavicular joint due to avascular necrosis or shortening of the medial longitudinal arch causing dysfunction of the forefoot. The primary reconstruction option for all of these problems is arthrodesis, extending from the talar neck into the cuneiforms. If alignment is satisfactory, an *in situ* arthrodesis can be performed. Two techniques are described for this.

**Medial Column Arthrodesis**

- Expose the involved joints through a longitudinal medial incision.
- In the first technique, create a longitudinal channel in the bones and joints to be fused. Take iliac crest graft, split it, and reverse it so that the cancellous surfaces face out. Place them in the channel in the talar neck, navicular, and into the cuneiforms. Fix with either screws or K-wires.
- In the second technique, excise a portion of the navicular and replace it with tricortical iliac crest bone graft to lengthen the medial column and form a more solid wedge. Fix it with screws.

When alignment is not satisfactory and medial column lengthening is required, then the second technique is preferred because the tricortical iliac crest struts are strong enough to lengthen the medial column. Both of these techniques are described in the article by Ferris et al. (12).

**ISOLATED CUBOID FRACTURES**

Isolated cuboid fractures are rare. More commonly, cuboid injuries are associated with either Chopart's joint fracture dislocations or as part of a Lisfranc injury. Both of these injuries produce a “nutcracker” type of fracture (17), as described in the previous section. Isolated fractures can occur with a direct blow; these fractures are generally minimally displaced and can be treated in a short-leg cast. As long as the plantar and medical cortices are intact, a walking cast used for approximately 6 weeks is sufficient. Other isolated cuboid fractures are some of the minor avulsions seen with inversion or plantarflexion injuries (7). These fractures generally can be treated symptomatically. It is important to be aware of the os peroneum because it can be mistaken for a fracture of the cuboid. The os peroneum is a sesamoid bone

in the peroneus longus tendon as it curves around the cuboid. It can be painful.

There have been reports of calcaneocuboid subluxation as a source of pain in the lateral foot that is not usually due to acute trauma but is seen primarily in athletes and dancers (23).

**ISOLATED CUNEIFORM FRACTURES**

As an isolated entity, cuneiform fractures are most commonly an avulsion fracture due to plantar flexion force or from a direct blow. The most severe isolated cuneiform fractures are from direct trauma, particularly from gunshot wounds or propellers (26), which produce open fractures with bone loss. Otherwise, any injury to the cuneiform needs to be a warning sign to look for injury to the Lisfranc complex in particular. Note that Lisfranc's variants can extend to the intercuneiform joints (3,11,25). Isolated dislocations of the cuneiforms have been described (9,11). Charcot's arthropathy can result in isolated injuries as well.

Take AP, lateral, and oblique radiographic views of the foot. If there is suspicion of a Lisfranc injury, a CT scan may identify the small plantar fractures associated with disruption of the strong plantar ligaments. Manipulation of the foot under anesthesia may be necessary to detect instability.

Isolated fractures are treated according to the severity of the fracture. Treat isolated dorsal avulsion fractures with initial splinting, followed by a walking cast or a removable cast boot. Treat fractures of the body of the cuneiform non-weight bearing for at least 6 weeks and longer if severe comminution delayed healing, or undetected ligament injury (9,15). Treat open fractures as described in Chapter 12 and use external fixation if necessary to stabilize the foot (26). If bone loss has occurred, then late arthrodesis and bone grafting may be required. Even some apparently minor injuries may eventually require arthrodesis to treat a painful joint (12).

**TARSOMETATARSAL (LISFRANC) FRACTURE DISLOCATIONS**

The mechanisms for Lisfranc fracture dislocations have changed historically (2,3 and 4,6,9,11,13,14,15,16 and 17,21,24,25,28,32,36,41). The frequency of this injury is increasing owing to motor vehicle injuries and falls secondary to sports and work activities. Although it was thought to be a rare injury, this was because the injury is difficult to diagnose. Injuries that were previously undetected are now being recognized. Still today, approximately 20% of these injuries are undiagnosed at initial presentation, particularly in the polytrauma patient (13,39). Variants of the Lisfranc injury involving the cuneiforms has increased so that now the term “Lisfranc's complex” rather than “Lisfranc's joint” is more appropriate. Lisfranc's fracture-dislocations can include the tarsometatarsal (TMT) joints, cuneiforms, cuboid, and occasionally even the navicular.

Direct trauma, is less common. In significant crush injuries, management of the soft tissues may be the most challenging aspect of treatment. Indirect trauma is more common. Generally, a longitudinal or axial load is applied to a plantarflexed foot such as in a football player being tackled, or from windsurfing and snowboarding. More severe injuries result from the high-energy forces of motor vehicle or motorcycle accidents (39).

Knowledge of the anatomy of the Lisfranc complex is important to the investigation and classification of this injury (33). The base of the second metatarsal is the “keystone” of the Lisfranc complex, being inset so that the medial and lateral cuneiform bones provide support on either side of the base of the second metatarsal, locking it in place. The other four metatarsals have relatively little bony support. It is also important to understand that the dorsal TMT ligaments and capsule are relatively weak compared to the strong plantar ligaments. The Lisfranc ligament itself is a strong oblique ligament from the lateral aspect of the medial cuneiform to the base of the second metatarsal (33). Anatomically and radiographically, Stein (36) described five features that are radiographic constants and are helpful in assessing this area.

- The medial border of the fourth metatarsal always forms a continuous straight line with the medial border of the cuboid on the medial oblique view.
- The intermetatarsal space between the third and fourth metatarsals is continuous with that between the lateral cuneiform and the cuboid.
- On the medial oblique view, the intermetatarsal space between the second and third metatarsals is a continuous straight line with the open space between the lateral and medial cuneiform.
- On the AP view, the medial border of the second metatarsal forms an unbroken line with the medial border of the middle cuneiform.
- On the AP view, the space between the first and second metatarsals matches that between the medial and intermediate cuneiforms.
- On a lateral view, the base of the metatarsals should not be more dorsal than the adjacent cuneiform or cuboid (Fig. 111.6 and Fig. 111.7).

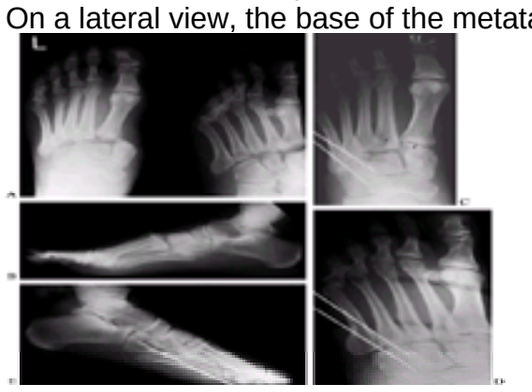

***Figure 111.6.*** Lisfranc's dislocations with predominantly ligamentous injuries. **A:** AP views. **B:** lateral view. **C:** Postoperatively on this AP view, two absorbable screws stabilize the medial column and two K-wires stabilize the lateral column. Arrows show the path of the screws from the medial cuneiform to the second and third metatarsals, which cannot be seen because they are radiolucent. **D:** Oblique view. **E:** lateral view.

***Figure 111.7.*** **AP** (**A**), oblique (**B**), and lateral (**C**) radiographs of bony Lisfranc's injury, fracture of second and third metatarsal necks, and displaced sesamoids due to a partly reduced first MTP dislocation. AP (**D**) and lateral (**E**) postoperative radiographs showing stainless steel screws to stabilize Lisfranc injury. The first MTP joint was reduced and stabilized with a K-wire. The second and third metatarsal neck fractures are well aligned.

Assessment must include a good history and physical examination because this injury may be missed, particularly in someone complaining of an “ankle sprain.” A history that suggests forced plantarflexion of the foot with axial loading needs to be examined very carefully. If there is tenderness dorsally over the TMT joints and it is not clear whether this is superficial or deep, then stress the Lisfranc complex by grasping the appropriate metatarsal head and applying plantarflexion and dorsiflexion forces to the metatarsal, with the hindfoot stabilized. Pain indicates TMT joint pathology. Similarly, rotational or mediolateral forces applied to the forefoot producing pain in the midfoot suggests injury to the Lisfranc complex. Take AP, lateral, and medial oblique radiographic views. In addition to the key features listed earlier, other significant signs include

- A small fracture from the base of the second metatarsal or intermediate cuneiform.
- Compression fracture of the cuboid on the AP or oblique radiograph (17).
- Any indication of overlap between the metatarsal bases and the adjacent tarsal bones, suggesting complete dislocation.

Stress views are generally painful in the acute circumstance but can be obtained under either general anesthesia or occasionally with an ankle block or local anesthetic

directly infiltrated into the TMT joints, depending on the clinical situation. A CT scan is not usually necessary to make the diagnosis, but if there are comminuted fractures, particularly of the cuboid, it may assist in assessing the fracture pattern.

Multiple injuries in the foot are not uncommon. Lisfranc's injuries can be associated with fractures of the shafts or necks of the metatarsals or dislocation of the MTP joints. Longitudinal forces can produce more proximal injuries, including navicular fracture. It is always important to visualize the entire foot radiographically in a patient with polytrauma with a swollen foot because an obvious fracture such as a calcaneus or ankle fracture may lead to missing a more subtle injury in the midfoot or forefoot (Fig. 111.8).

***Figure 111.8.*** Patient referred with persistent lateral foot pain 18 months after a calcaneal fracture and subtalar arthrodesis. There was a missed dislocation of tarsometatarsals 4 and 5. **A:** Lateral view of the hindfoot; note that the cuboid is plantar flexed. **B:** Oblique view showing overlap of the bases of the fourth and fifth metatarsals and the cuboid. **C,D:** CT scan sections through the midfoot, demonstrating chronic dislocations.

There are multiple classifications of Lisfranc's fractures in the literature. At present the most frequently quoted are Hardcastle et al. (16) and Myerson et al. (24,25). These classifications are primarily descriptive and do not alter treatment decisions. Myerson's work added to the understanding of the injury and led to the concept of the Lisfranc joint complex.

***Principles of Treatment***

The range of presentations of acute Lisfranc's injuries is from the “midfoot sprain” to severe displaced fracture-dislocation, occasionally with overlying soft-tissue injuries. In the polytrauma patient, the more subtle forms may be missed; therefore, clinical suspicion is important. See Figure 111.2 for an assessment algorithm.

**Immediate Treatment** When significant displacement exists, particularly when there is significant plantar or dorsal displacement of the metatarsal bases, neurovascular compromise is a possibility and urgent closed reduction should be attempted. Compartment syndrome is also possible with this injury, and fasciotomy is occasionally required. If fasciotomy is required, the incisions for the fasciotomy should be planned based on the incisions necessary for open reduction and internal fixation of the underlying injury. Other aspects of immediate treatment include assessing the rest of the foot for any associated injuries, particularly the MTP joints. If the major displacement cannot be reduced immediately, whether by direct manipulation or by application of toe traps and ankle traction, then perform immediate open reduction and internal fixation. This approach will decrease pressure on the skin and tension on the neurovascular bundle. Associated swelling is unlikely to resolve in the presence of persistent displacement.

For patients with more subtle or less severely displaced injuries who are not medically stable for immediate intervention, splinting, ice, and elevation are appropriate in the interim. Once the injury has been diagnosed and the patient otherwise stabilized, the choices for a displaced Lisfranc's fracture-dislocation are either closed reduction and percutaneous fixation or open reduction and internal fixation.

When the patient has symptoms and signs consistent with injury to the Lisfranc complex with no demonstrable displacement or fracture on plain x-ray studies, further investigation is warranted because a purely ligamentous injury may appear to be anatomic on plain x-ray studies and yet be unstable. Stress views or examination under anesthesia, or both, may demonstrate instability. If that is not possible, then splint the foot and do not allow the patient to bear weight for a few days until the foot can be reassessed clinically and radiographically. One method of obtaining a stress view in a patient who presents late (i.e., 2 weeks or more after injury) is to perform a weight-bearing x-ray and compare it with the opposite side, particularly looking at the gap between the first and second metatarsals and the medial and intermediate cuneiforms.

**Closed Reduction and Percutaneous Fixation** It is now widely agreed that anatomic reduction is essential in Lisfranc's injuries, even though the results are still disappointing (3,4,9,11,13,15,16,24,25,28). In the majority of cases in which significant displacement is visible on initial radiographs or intraarticular fractures exist, closed reduction is not sufficient. Closed reduction is feasible for subtle injuries that are detected only on stress views. Commonly, this is seen as a gap between the medial ray (first metatarsal and medial cuneiform) and the second ray. Closed reduction and percutaneous, cannulated screw fixation are an option.

- Use a large bone tenaculum, such as a pelvic reduction clamp placed through two small stab wounds to compress the medial cuneiform to the base of the second metatarsal under radiograph control.

**HINTS AND TRICKS**

Use of K-wires to stabilize minimally displaced Lisfranc's injuries has largely been superseded by percutaneous screw fixation (3) because it takes 3 months for the ligaments to heal. Smooth K-wires tend to cause problems with skin irritation or infection (4) and, therefore, generally are not suitable if they need to be left in place for longer than 6 weeks. They are frequently used for the lateral TMT joints in an effort to avoid stiffness.

Problems with cannulated screws include the fact that the guide pins are of small diameter and prone to shear off, leaving a portion *in situ.* Therefore, if you are using cannulated screws, it is safer to stabilize the construct with a parallel K-wire of at least 1.6 mm diameter so that when the screw hole is drilled and tapped, there is no micromotion between the bones. Guide pins can still break. An alternative when fluoroscopy is available is to use the drill bit for initial fixation; having stabilized the construct with a tenaculum, check the position under fluoroscopic control, and then insert a 3.5 mm cortical screw.

These injuries are a diastasis of a joint and, therefore, provided adequate reduction has been achieved, com pression is not necessary. A more recent option is that of bioabsorbable screws, which can be inserted in a similar fashion (Fig. 111.6).

- Position the image until it is perpendicular to the plane of the intercuneiform and intermetatarsal joint because that view is necessary to assess the reduction. Achieve an anatomic reduction.
- Then insert a screw from the medial cuneiform into the second metatarsal base, generally starting from plantar medial going to dorsal lateral. If the third metatarsal is also involved in the injury, then this screw can also fix the third metatarsal shaft. If the fourth and fifth metatarsal joints are not involved, then that single screw may be sufficient to stabilize the medial column. If in doubt, insert a second screw from the first metatarsal base into the second cuneiform to supplement the fixation. There are multiple options for internal fixation, depending on the pattern of injury (9,11,15).

**Open Reduction and Internal Fixation** This is my preferred option in the majority of injures in which significant displacement or articular fractures are evident on initial films. The majority of authors support this approach, although the choice of technique varies (3,4,9,11,13,15,16,24,25,28).

Careful preoperative assessment is important in planning the surgical incisions. A C-arm fluoroscope is useful. Before prepping the foot but after induction of anesthesia reassess the stability of each column of the foot under fluoroscopy. If the fourth and fifth tarsal metatarsal joints are stable to fluoroscopy, then an incision over these joints may be avoided. Much less commonly, the injury is isolated to the lateral TMT joints, sparing a medial incision. A variety of surgical approaches have been used (3,4,9,11,15,24,25). A frequent choice is a dorsal longitudinal incision just lateral to the extensor hallucis longus, extending to the first metatarsal space. Many authors supplement this incision with a second parallel incision extending from the third web space proximalward between the lateral cuneiform and the cuboid.

My preference to expose the complete Lisfranc complex is to use any combination of the following three incisions as the fracture pattern dictates (12) (Fig. 111.9*D*, Fig.

111.9*E* and Fig. 111.9*F*).

***Figure 111.9.*** **A:** I prefer two dorsal incisions for Lisfranc complex injuries. Vessel loops are around the neurovascular bundle. **B:** The neurovascular bundle is retracted laterally to demonstrate the base of the second metatarsal and intermediate cuneiform. **C:** The bases of the fourth and fifth metatarsals are dislocated dorsally. **D, E, F:** Medial and dorsal surgical incisions with an extended medial exposure and provisional fixation with K-wires.

- Make the first incision medially from the navicular tuberosity centered along the midportion of the medial cuneiform to the midpoint of the first metatarsal. Dissect down to bone, lifting an osteoperiosteal flap and being careful not to detach the tibialis anterior tendon insertion that wraps around the medial aspect of the medial cuneiform and first metatarsal base, which can, on occasion, be trapped in the fracture fragments.
- Make the second incision over the lateral aspect of the second metatarsal shaft and second interspace. Also carry this incision down to the bone, avoiding the medial branch of the superficial peroneal nerve.
- Once these two incisions are down to bone, then dissection allows elevation of a flap that contains the doralis pedis neurovascular bundle. Take particular care to protect the dorsalis pedis artery because it penetrates the first intermetatarsal space.
- Between these two incisions, identify and reduce the first and second TMT joints and, in particular, reduce the base of the second metatarsal to the lateral aspect of the medial cuneiform (Fig. 111.9*D*, Fig. 111.9*E* and Fig. 111.9*F*). The rationale behind the medial incision is to check the rotational reduction of the first metatarsal and to place screws from the medial aspect of the foot into the metatarsal bases and cuneiform.
- If necessary, place a K-wire from the dorsal incision to stabilize the fracture and then place a screw medially. The key screw is from the plantar medial aspect of the medial cuneiform to the base of the second metatarsal.

When the second metatarsal has a significant intra-articular fracture (e.g., the corner fracture of the medial aspect of the second metatarsal), the purpose of the screw is not to transfix that fracture but to stabilize the majority of the second metatarsal in appropriate alignment. An alternative fracture pattern, when there is a transverse fracture of the second metatarsal, leaves the base intact. Obviously, there are a wide variety of fracture patterns that can occur in the metatarsal, but these two are commonly seen.

- In the latter case, fix the screws into the base of the second metatarsal and a longitudinal K-wire can stabilize the shaft of the metatarsal to the base.
- When the second metatarsal shaft is extremely comminuted, a longitudinal K-wire to maintain the alignment is appropriate.
- If the articular surface is comminuted, remove any small fragments, particularly those without a blood supply. If there remain any articular fragments too small for a screw, then use a smooth or threaded K-wire for fixation.
- In some circumstances, it is possible to stabilize the second ray by placing screws on either side (i.e., the first and third rays). Occasionally, supplementary screws are needed from the medial cuneiform into the intermediate or through into the lateral cuneiform.

If the fourth and fifth TMT joints are involved, then curve the third incision to match to the steep angle of the fourth and fifth TMT joints (Fig. 111.9).

- Start distally in the fourth interspace and curve laterally and inferiorly proximalward to allow adequate exposure of the fourth and fifth TMT joints.
- For fixation across this joint, make a separate small stab wound over the base of the fifth metatarsal just distal to the flare. Again, there is a choice of K-wire or screw fixation in this area. More recently, there has been a move away from using screws across the fourth and fifth TMT joint because stiffness of these joints is more problematic. Therefore, insert a 0.062 in. (1.6 mm) threaded K-wire because it provides adequate stability with less damage to the articular surface than a 3.5 mm screw. This can be cut off to lie just under the skin. It generally is easily palpated and removed in clinic through a stab incision under local anesthetic at 3 months' follow-up. Document the fact that the K-wire is threaded so that needle-nose pliers or heavy-duty needle holders used to unscrew it.
- Make the two or three incisions to expose the area adequately (Fig. 111.7 and Fig. 111.9). Reduce the fracture dislocations working through the multiple exposures, and obtain temporary fixation with K-wires.
- Check the alignment with radiographs or fluoroscopy before placing any permanent fixation. Often, it is not possible to reduce each portion of the injury accurately until all of the joints have been approximately aligned.
- If the MTP joints are dislocated, it may be necessary to reduce the MTP joint before the metatarsal base can be anatomically relocated (Fig. 111.7). When metatarsal neck fractures have occurred they usually do not prevent reduction of the metatarsal base, but it is possible to extend the dorsal incisions distally to expose the metatarsal necks and transfix these fractures with longitudinal K-wires.
- Once all the fractures or dislocations are adequately reduced and stabilized, insert permanent fixation. My preference is fully threaded cortical screws, preferably not cannulated. Screws can be stainless steel, titanium, or bioresorbable. When screws are not possible because of comminution, then use either smooth or threaded K-wires (Fig. 111.6 and Fig. 111.7). Smooth K-wires are often satisfactory when stabilizing fractures with minimal ligamentous injury because generally by 6 weeks, fractures consolidate sufficiently to remove the K-wire.
- The pattern of screw fixation varies depending on the injury pattern. In particular, the injury may extend proximally between the cuneiforms or into the navicular, in which case transverse screws may be necessary to stabilize these injuries. The lateral cuboid may impact on the articular surface, particularly the dorsal lateral corner. If this is 25% or less of the articular surface, it is generally possible to stabilize the fourth metatarsal base to the medial half of the cuboid and insert a screw from the base of the fifth into the fourth metatarsal to stabilize the construct further. In this way, the articular surface of the cuboid can then be reduced, and occasionally bone grafted and fixed with a pin, a bridging plate, or an external fixator if the cuboid has a nutcracker-type injury that needs to be held out to length (Fig. 111.5).
- Once the entire construct is stabilized and any small loose bony fragments have been removed, close the wounds. If wounds cannot be closed owing to a compartment syndrome or massive swelling,, then apply dressings and bring the patient back for a delayed closure in 3 to 5 days.

The postoperative regimen includes rest, elevation, and splinting for 7 to 10 days and then the application of a non-weight-bearing cast. At approximately 6 weeks, remove any K-wires that have been left out through the skin for either a metatarsal neck or shaft fractures. Provided that the patient is reliable and will remain non-weight bearing, it is reasonable to place the patient in a removable cast to start range of movement to the ankle and subtalar joints. At 3 months, if clinical and radiographic findings show maintenance of the reduction and healing, the patient may commence weight bearing in a cam-walker. Schedule surgery for removal of the screws 3 to 4 weeks later. Whether removal of all of these screws is necessary is under review, but certainly any screw or hardware across the fourth and fifth TMT joints must be removed. I prefer to remove any screws that cross a joint. Some authors advocate leaving the screws in the medial three columns or even performing a primary arthrodesis (11,14,15,32). The use of bioresorbable implants eliminates the need for a second procedure.

**Late Reconstruction** If the injury is less than 6 weeks old and has significant displacement, then perform an open reduction and internal fixation as in an acute fracture. If the injury is between 6 weeks to 6 months old, base your decision of which procedure to perform on the patient's age and general health, the severity of displacement, activity level, and whether it is purely a soft-tissue or bony injury. In some cases, repair as for an acute injury may be successful. After 6 months, acute repair is unlikely to be successful, and the choices are nonoperative treatment or reduction and arthrodesis (11,12,15,32). Realignment and arthrodesis may lead to development of degenerative changes in adjacent joints (12). The presence of diabetes and, particularly, diabetic neuropathy makes success of any surgery less likely. Advise the patient that late treatment of a Lisfranc injury likely will result in long-term problems with persistent pain and possible progression of deformity.

## METATARSAL FRACTURES

The term “fracture of the metatarsals” covers a diverse group of injuries (7,9,15,19,34,38,41). The fifth metatarsal in particular is subject to a variety of injuries, including

- Fractures of the tuberosity, often associated with inversion ankle injuries
- Jones' fracture, which is a transverse fracture of the diaphysealmetaphyseal junction
- Spiral fractures of the shaft associated with rotational foot injuries

- Oblique or transverse fractures of the metatarsal neck

Management of the metatarsal must be appropriate to the site of the fracture in the metatarsal, especially whether the metatarsal is one of the middle metatarsals, which behave differently than the first and fifth. Similarly, multiple metatarsal fractures are treated differently than an isolated metatarsal fracture. Apart from Jones' fracture, there has not been much scientific study of metatarsal fractures, and authors have varied significantly in recommendations about management. A variety of opinions exist on the indications for reduction and internal fixation of these fractures (9,15,34,38).

***First Metatarsal Fractures***

The first metatarsal is less commonly fractured, but it does require special consideration. Any shortening of the first metatarsal or plantar or dorsal displacement of the metatarsal head will have an adverse affect on foot function as a whole. In addition, any articular fracture causing loss of movement in the first MTP joint will interfere with the normal progression of gait. Therefore, any displaced fracture of the first metatarsal that allows shortening or angular displacement or impacts the MTP joint requires reduction, either closed or open, and fixation. The choice between closed reduction and K-wire or external fixation versus open reduction and internal fixation depends on the site and comminution of the fracture and possibly related soft-tissue injuries.

***Fifth Metatarsal Fractures***

Fractures of the fifth metatarsal are common (23% of metatarsal injuries), particularly those associated with inversion injuries. Jones' fracture, although less common, is of clinical and academic interest because of its poor prognosis. The fifth metatarsal is the most mobile of the five, so a small amount of shortening or angular deformity may be less problematic because the fifth metatarsal itself is more adaptable.

Two common fracture patterns that usually do not require surgery are the fracture of the tuberosity of the fifth metatarsal, which is commonly an avulsion fracture, and the spiral fracture of the fifth metatarsal shaft. Nonoperative treatment of metatarsal fractures, include using a stiff-soled shoe, strapping, or a short-leg non-weight-bearing cast for 4 to 6 weeks.

I prefer to treat fractures of the styloid of the fifth metatarsal like an ankle sprain. Spiral fractures of the fifth metatarsal shaft produce significant pain and swelling, and benefit by a few days of rest, elevation, splinting, and crutches. Once the acute pain and swelling have subsided in both of these injuries, a removable cast device, preferably with some means to control swelling, will enable the patient to walk relatively pain free. A hard-sole shoe does not give sufficient support for the ankle and is moderately uncomfortable for walking.

Jones' fracture and stress fractures of the fifth metatarsal are discussed in Chapter 96. In brief, such fractures of the fifth metatarsal have a propensity for nonunion. For low-demand patients, if seen immediately after the injury, treat non-weight bearing for 6 weeks in a short-leg cast. Immobilization may be needed for 3 months or more with still no guarantee that the fracture will unite. For those patients with an established nonunion or those who are considered high demand, particularly athletes, it is recommended to peform intramedullary fixation of the fifth metatarsal shaft (9,15,34,38). In the acute instance, internal fixation alone may be sufficient. In established nonunions, opening the fracture site, debridement of the sclerotic bone, and bone grafting combined with internal fixation are warranted.

***Second, Third, and Fourth Metatarsal Fractures***

If a single metatarsal fracture occurs, it is usually of lower violence, and if the transverse metatarsal ligament is intact, most often there is minimal displacement and closed management is indicated. However, this is one area where authors differ widely. Shereff (34) believes that any displacement of more than 3 to 4 mm or more than 10° of angulation requires open reduction and internal fixation.

In cases of multiple metatarsal fractures, a higher level of energy has been dissipated in the foot. More than likely, the ligaments are disrupted and significant shortening or displacement will occur. These metatarsal fractures are often associated with other injuries in the foot and, as previously noted, the amount of morbidity associated with the metatarsal fractures has been underestimated. Dorsal displacement of the metatarsal head or shortening produces transfer metatarsalgia, which can lead to significant disability (Fig. 111.10). It is less clear cut whether medial or lateral displacement will cause interference with the adjacent metatarsal or interdigital nerve (34), although anatomically it is certainly feasible. If palpation of the forefoot demonstrates enough displacement of the affected metatarsal head to alter the mechanics of weight bearing, then reduction and fixation are indicated. Closed reduction of a metatarsal without some form of fixation is unlikely to be stable (15,34).

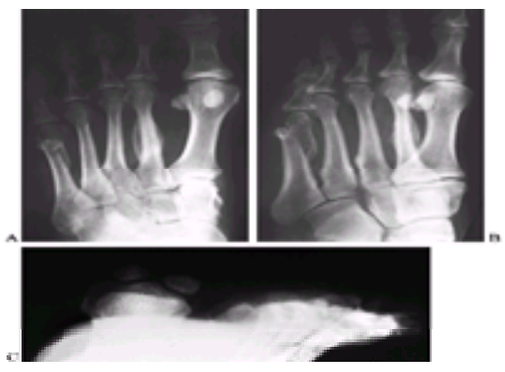

***Figure 111.10.*** Patient with persistent metatarsalgia after a “neuroma” was excised. AP (**A**), oblique (**B**), and sesamoid (**C**) views show healed metatarsal fractures. The fifth metatarsal is asymptomatic; pain is due to the overload of the third metatarsal from the dorsally angulated second metatarsal.

***Open Reduction and K-Wire Fixation***

Metatarsal shaft fractures often require open reduction and internal fixation. Fractures of the first metatarsal may require fixation with screws or a plate and screws.

Metatarsal neck fractures, particularly of the middle metatarsals, usually can be reduced and fixed with K-wires.

Closed reduction and pinning of multiple metatarsal fractures rarely results in anatomical position therefore I favor open reduction.

- Expose a fracture of the metatarsal neck through a 2 to 3 cm longitudinal dorsal incision. For multiple neck fractures, a somewhat larger incision over the first and third or second and fourth web spaces, depending on which metatarsals are fractured, provides adequate exposure. Identify and protect the extensor tendons and neurovascular structures.
- Expose the fracture and insert a 1.6 mm or 2 mm K-wire into the medullary canal of the distal fragment and exit on the plantar aspect of the foot. Keep the toe dorsiflexed to avoid penetration of the proximal phalanx.
- Then attach the drill to the exposed K-wire outside of the foot, reduce the fracture anatomically, and drill the wire retrograde into the medullary canal of the proximal shaft securing the fracture. Verify proper position radiographically.
- Cut the K-wire to leave 1 to 1.5 cm exposed and apply pin caps or bend the end of the wire to prevent migration.

Postoperatively, do not allow patients to bear weight in a splint. K-wires can be removed at 4 to 6 weeks, and weight bearing is then permitted. Sometimes, a cam-walker is useful for a couple of weeks.

Open fractures can be stabilized in a similar manner. Rarely is external fixation appropriate for the metatarsal (26).

**METATARSOPHALANGEAL JOINT DISLOCATIONS**

***First Metatarsophalangeal Joint and Sesamoid Injuries***

First MTP dislocation is generally associated with hyperextension and is an extreme example of the “turf toe” type injury. It can also occur with severe direct trauma, such as in motor-vehicle accidents. Jahss (19) classifies the injury as type I or II, depending on whether the intersesamoid ligaments are intact or whether one of the sesamoids has a transverse fracture. In the type I dislocation, the ligament and sesamoid are intact, and if the lesion is irreducible by closed means, it will require an open reduction and sometimes K-wire fixation. In the type II injury, there is either disruption of the intersesamoid ligament or a transverse fracture of one of the sesamoids. Closed reduction is usually successful, but when the sesamoid is fractured, the distal fragment usually requires excision. These are uncommon injuries. These can be approached dorsally, medially, or through a plantar incision. My preference is a direct medial approach, which allows access to both the dorsal and plantar aspects of the joint which avoids the neurovascular structures and a plantar scar (19). Be sure to preserve the continuity of the flexor hallucis brevis tendon if partial or complete excision of the sesamoid is indicated.

### *Lesser Metatarsophalangeal Dislocations*

Lesser MTP dislocations are easily missed, particularly in children. The most common mechanism is a hyperextension injury. The toe usually sits in a hyperextended position at the MTP joint with some associated clawing, the metatarsal head having button holed through the plantar plate. Closed reduction is often possible, but direct traction on the toe may further trap the metatarsal head and be ineffective. If closed reduction is ineffective, perform open reduction through a dorsal incision adjacent to the extensor tendon. These dislocations are usually stable after reduction. Chronic dislocations generally require open reduction and K-wire fixation through a dorsal approach. Sometimes, a metatarsal condylectomy is necessary to achieve reduction.

## SESAMOID FRACTURES

The medial sesamoid is more commonly injured or symptomatic. Although acute fractures of the sesamoids may occur with either direct trauma or hyperextension, it is also possible to have stress fractures of the sesamoids, symptomatic bipartite sesamoids, and also avascular necrosis of the sesamoids (7,9,15,19,41). Clinical and radiographic differentiation of these conditions may not be clear cut. A bone scan is not likely to differentiate between a stress fracture, an acute fracture, avascular necrosis, or even sesamoiditis. A bipartite sesamoid generally does not appear hot on a bone scan.

When acute injury is recognized, initial treatment includes no weight bearing and immobilization of the MTP joint for at least 4 to 6 weeks. This is followed by a further period of at least 4 to 6 weeks with protected weight bearing by relief padding or a removable cast-brace for a total of 3 months immobilization. Lack of healing is generally treated by sesamoidectomy. Occasionally, if one fragment is small, excision of a single pole is possible. The application of a bone graft to an undisplaced fracture site may encourage union.

## PHALANGEAL FRACTURES AND INTERPHALANGEAL JOINT DISLOCATIONS

Except for an intraarticular fracture of the proximal phalanx of the great toe, generally treat phalangeal fractures by strapping to the adjacent toe and using a stiff-soled shoe until pain and swelling settles. Similarly, generally treat dislocations of the interphalangeal joint, when closed, by closed reduction, strapping to an adjacent stable toe, and stiff-soled shoes (Fig. 111.11).

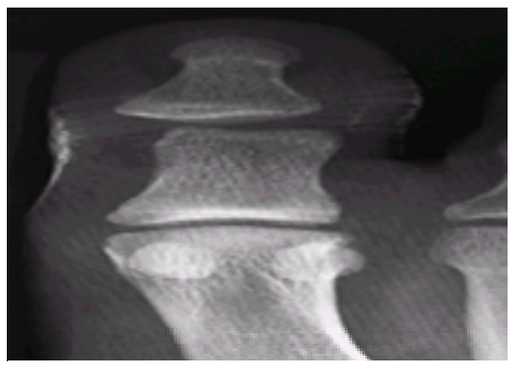

***Figure 111.11.*** Residual displacement after closed reduction of interphalangeal dislocation of the great toe. The patient declined further surgery.

Because of the importance of the great toe to foot function and the size of the bones that makes them more suitable for internal fixation, displaced intra-articular fractures are generally treated with open reduction and internal fixation with miniscrews. Treat shaft fractures of the proximal phalanx with a longitudinal K-wire, screws, or a miniplate if closed reduction and a splint or cast does not give adequate alignment and stability.

For noncontaminated open phalangeal fractures, debride and irrigate the wound, stabilize the fracture with an intramedullary K-wire running lengthwise down the toe to maintain length and medial and lateral stability, and give antibiotics. Interphalangeal joint dislocations are often open on the plantar aspect and, once they are reduced, are usually stable.

In lawnmower and similar high-energy injuries, the viability of the toe must be assessed in terms of neurovascular damage and the degloving component of the injury (26). Salvage of the toe risks infection, and poor function must be compared with the effects of loss of the toe through amputation on foot function.

## CHAPTER REFERENCES

Each reference is categorized according to the following scheme: *, classic article; #, review article; !, basic research article; and +, clinical results/outcome study.


# 1. Adelaar RS. Treatment of Tarsometatarsal Injuries. In: Adelaar RS, ed. *Complex Foot and Ankle Trauma.* Philadelphia: Lippincott-Raven Publishers, 1999:14.

+ 2. Aitken AP, Poulson D. Dislocation of the Tarsometatarsal Joint. *J Bone Joint Surg* 1963;45A:246.

# 3. Anderson RB. Lisfranc's Fracture-Dislocation. In Pfeffer GB, Frey CC, eds. *Current Practice in Foot and Ankle Surgery,* Vol 1. New York: Mcgraw-Hill, 1993:129.

+ 4. Arntz CT, Veith RG, Hansen ST Jr. Fractures and Fracture-Dislocations of the Tarsometatarsal Joint. *J Bone Joint Surg* 1988;70A:173.

+ 5. Blasier RD, Bucholz R, Cole W, et al. Bioresorbable Implants: Applications in Orthopaedic Surgery. *Instr Course Lect* 1997;46:531.

+ 6. Cassebaum WH. Lisfranc Fracture-Dislocations. *Clin Orthop* 1963;30:116.

# 7. Davis AW, Alexander IJ. Problematic Fractures and Dislocations in the Foot and Ankle of Athletes. *Clin Sports Med* 1990;9:163.

! 8. Deland JT, Lee KT, Hogle S, et al. *Range of Motion Before and after Calcaneocuboid Fusion with Lateral Column Lengthening.* Presented at the 10th Annual Summer meeting of the American Orthopaedic Foot and Ankle Society, 1994.

# 9. DeLee JC. Fractures and Dislocations of the Foot. In: Mann RA, Coughlin MJ, eds. *Surgery of the Foot and Ankle.* St. Louis: Mosby, 1993:1465.

* 10. Dewar FP, Evans DC. Occult Fracture-subluxation of the Midtarsal Joint. *J Bone Joint Surg* 1968;50B:386.

# 11. Early JS, Hansen ST Jr. Midfoot and Navicular Injuries. In: *Surgery of Disorders of the Foot and Ankle.* Philadelphia: Lippincott-Raven Publishers, 1996:731.

# 12. Ferris LR, Vargo R, Alexander IJ. Late Reconstruction of the Midfoot and Tarsometatarsal Region after Trauma. *Orthop Clin North Am* 1995;26:393.

+ 13. Goossens M, DeStoop N. Lisfranc's Fracture-Dislocations: Etiology, Radiology and Results of Treatment. *Clin Orthop* 1983;176:154.

+ 14. Granberry WM, Lipscomb PR. Dislocation of the Tarsometatarsal Joints. *Surg Gynecol Obstet* 1962;114:467.

# 15. Hansen ST. Foot Injuries. In: Browner BD, Jupiter JB, Levine AM, Trafton PG, eds. *Skeletal Trauma,* Vol 2. Philadelphia: W. B. Saunders, 1992.

* 16. Hardcastle PH, Reschauer R, Kutscha-Lissberg E, Schoffmann W. Injuries to the Tarsometatarsal Joint: Incidence, Classification and Treatment. *J Bone Joint Surg* 1982;64B:349.

* 17. Hermel MB, Gershon-Cohen J. The Nutcracker Fracture of the Cuboid by Indirect Violence. *J Radiol* 1953;60:850.

# 18. Herscovici D Jr, Sanders R. Fractures of the Tarsal Navicular. In: Sanders, R, ed. *Foot and Ankle Clinics: Concepts of Foot and Ankle Trauma,* Vols 3 and 4. Philadelphia: W. B. Saunders Company Publishers, 1999:587.

# 19. Jahss MH. Disorders of the Hallux and First Ray. In: Jahss MH, ed. *Disorders of the Foot and Ankle,* Vol 2. Philadelphia: W. B. Saunders, 1991:943.

+ 20. Johnson JE, Johnson KA. Dowel Arthrodesis for Degenerative Arthritis of the Tarsometatarsal (Lisfranc) Joints. *Foot Ankle* 1986;6:243.

* 21. Main BJ, Jowett RL. Injuries of the Midtarsal Joint. *J Bone Joint Surg* 1975;57B:89.

* 22. Manoli A II. Compartment Syndromes of the Foot: Current Concepts. *Foot Ankle* 1990;10:340.

+ 23. Marshall P, Hamilton WG. Cuboid Subluxation in Ballet Dancers. *Am J Sports Med* 1992;20:169.

+ 24. Myerson MS, Fisher RT, Burgess AR, et al. Fracture Dislocations of the Tarsometatarsal Joints: End Results Correlated with Pathology and Treatment. *Foot Ankle* 1986;6:225.

+ 25. Myerson MS. The Diagnosis and Treatment of Injuries to the Lisfranc Joint Complex. *Orthop Clin North Am* 1989;20:655.

# 26. Myerson MS, Sammarco VJ. Penetrating and Lacerating Injuries of the Foot. In: Sanders R, ed. *Foot and Ankle Clinics: Concepts of Foot and Ankle Trauma,* Vols 3 to 4. Philadelphia: W. B. Saunders Company Publishers, 1999:647.

# 27. Nyska M, Margulies JY, Barbarawi M, et al. Fractures of the Body of the Tarsal Navicular Bone: Case Reports and Literature Review. *J Trauma* 1989;29:1448

+ 28. Resch S, Stenstrom A. The Treatment of Tarsometatarsal Injuries. *Foot Ankle* 1990;11:117.

# 29. Romash MM. *Fractures of the Navicular and Cuboid: Complex Foot & Ankle Trauma.* Philadelphia: Lippincott-Raven Publishers, 1999:13.

# 30. Rutledge EW, Templeman DC, de Souza LJ. In: Sanders R, ed. *Foot and Ankle Clinics: Concepts of Foot and Ankle Trauma,* Vols 3 to 4. Philadelphia: W. B. Saunders Company Publishers, 1999:603.

* 31. Sangeorzan BJ, Benirschke SK, Mosca V, et al. Displaced Intra-Articular Fractures of the Tarsal Navicular. *J Bone Joint Surg* 1989;71A:1504.

+ 32. Sangeorzan BJ, Veitch RG, Hansen ST. Salvage of Lisfranc's Tarsometatarsal Joints by Arthodesis. *Foot Ankle* 1990;4:193.

* 33. Sarrafian SK. *Anatomy of the Foot and Ankle.* Philadelphia: J. B. Lippincott, 1983.

# 34. Shereff MJ. Fractures of the Forefoot. *Instr Course Lect* 1990;29:133.

# 35. Shereff MJ. Compartment Syndromes of the Foot. *Instr Course Lect* 1990;39:127.

* 36. Stein RE. Radiological Aspects of the Tarsometatarsal Joints. *Foot Ankle* 1983;3:286.

# 37. Thordarson D. Fractures of the Midfoot and Forefoot. In: Myerson M, ed. *Foot and Ankle Disorders.* Philadelphia: W. B. Saunders, 1999.

* 38. Torg JS, Balduini FC, Zelco RR, et al. Fractures of the Base of the Fifth Metatarsal Distal to the Tuberosity: Classification and Guidelines for Nonsurgical and Surgical Management. *J Bone Joint Surg* 1984;66A:209.

+ 39. Turchin D, Schemitsch E, Waddell J. The Outcome of Foot Injuries in Multiple Injured Patients. (Abstract.) American Orthopaedic Foot and Ankle Society 1998 Annual Winter Meeting.

# 40. Weber TG, Manoli A II. Compartment Syndromes of the Foot. In: Sanders R, ed. *Foot and Ankle Clinics: Concepts of Foot and Ankle Trauma,* Vols. 3 and 4. Philadelphia: W. B. Saunders Company, 1999:473.

# 41. Whittle AP. Fractures of the Foot in Athletes. In: Drez D Jr, DeLee JC, eds. *Operative Techniques in Sports Medicine,* Vol 2. Philadelphia: W. B. Saunders, 1994:1.

# CHAPTER 112

# HALLUX VALGUS

*Roger A. Mann and Jeffrey A. Mann*

**R. A. Mann and J. A. Mann:** 3300 Webster Street, Suite 608, Oakland, California, 94609.

Pathophysiology
Principles of Treatment
History
Physical Examination
Radiographic Evaluation
Conservative Management
Decision Making
Surgical Techniques
Akin Procedure
Chevron Procedure
Distal Soft-Tissue Procedure
Arthrodesis of the First Metatarsophalangeal Joint
Authors' Perspective
Chapter References

## PATHOPHYSIOLOGY

The hallux valgus deformity is characterized by lateral deviation of the proximal phalanx on the metatarsal head. In the majority of patients, the deformity is due to improper shoe wear. It occurs almost 10 times more frequently in women than in men.

As a result of this lateral subluxation of the proximal phalanx on the metatarsal head, several secondary changes occur:

- Contracture of the lateral joint capsule
- Attenuation of the medial joint capsule
- A medial eminence of varying size
- Pronation of the hallux as the deformity becomes more severe
- Medial deviation of the first metatarsal, giving rise to an increase in the intermetatarsal angle. This leads to an uncovering of the sesamoids, which are anchored in their lateralward position by the adductor hallucis.

As the hallux valgus deformity becomes more severe, the impingement of the hallux against the second toe can lead to destabilization of the second metatarsophalangeal joint, resulting in an overlapping of the hallux by the second toe. Occasionally, underlapping may occur.

As the deformity increases, the weight bearing of the hallux and first metatarsal is diminished, resulting in increased weight bearing by the second metatarsal head, which results in metatarsalgia, sometimes associated with a callus. The decreased weight bearing is due to the lack of plantar flexion of the first metatarsal in the last half of stance phase due to the decreased function of the windlass mechanism of the plantar fascia.

In 3% to 4% of cases, there is instability of the first metatarsocuneiform joint, resulting in hypermobility (9). When this condition is present, a first metatarsocuneiform joint fusion should be carried out in conjunction with the hallux valgus repair.

## PRINCIPLES OF TREATMENT

### HISTORY

It is important to obtain the patient's chief complaint with regard to the hallux valgus deformity. As a general rule, the chief complaint is pain over the medial eminence, although sometimes, despite a severe deformity, the patient's main complaint is a second toe deformity and associated symptoms.

Important aspects of the history involve degree of disability, lifestyle, and management of the disability. The history should answer questions such as the following:

- Is the primary problem that the patient cannot wear certain dress shoes or even a wide soft shoe?
- At work, how much time does the patient spend standing each day?
- Does the patient participate in athletics?
- Has the patient tried conservative care such as changing shoes or using a bunion splint?

Do not consider surgery unless the patient is significantly disabled from work or athletics.

### PHYSICAL EXAMINATION

- Begin with the patient standing.
- Observe the alignment of the foot and lower extremity. Note the deformity of the great toe and lesser toes.
- Seat the patient and measure the range of motion of the ankle, subtalar, and transverse tarsal joints with particular attention to the first metatarsophalangeal joint.
- Note any pain about the metatarsophalangeal joint, synovial thickening, or crepitation. If pain is persistent, it is important to localize this pain to the dorsal or plantar aspect of the joint because a sesamoid problem may be present.
- Carefully assess the neurovascular status of the foot. If there is any question about the vascularity, obtain an arterial Doppler study.

### RADIOGRAPHIC EVALUATION

- Always obtain anteroposterior (AP) and lateral radiographs of the foot weight bearing.
- Measure the first metatarsophalangeal joint angle, which should be less than 15°. The intermetatarsal angle should be less than 8°.
- Note the position of the sesamoids and the size of the medial eminence (Fig. 112.1).

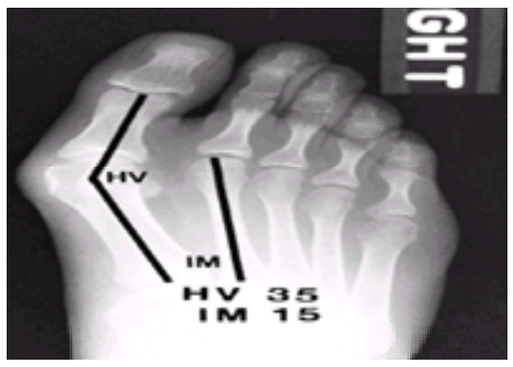


***Figure 112.1.*** The normal hallux valgus (*HV*) angle is less than 15°; the intermetatarsal (*IM*) angle less than 8°.

- Look for arthrosis in the first metatarsophalangeal joint and assess whether the joint is congruent or incongruent. A congruent joint is one with no lateral deviation of the proximal phalanx on the metatarsal head. An incongruent joint is one with lateral deviation of the proximal phalanx on the metatarsal head (Fig. 112.2).

***Figure 112.2.*** **A:** A congruent metatarsophalangeal joint is one in which there is no lateral subluxation of the proximal phalanx on the metatarsal head. **B:** An incongruent metatarsophalangeal joint is one in which there is lateral subluxation of the proximal phalanx on the metatarsal head.

- Measure the distal metatarsal articular angle (DMAA), which is the relationship of the articular surface to the long axis of the metatarsal. Normally, this should be less than 10° of lateral deviation (Fig. 112.3).

***Figure 112.3.*** Radiograph demonstrating the distal metatarsal articular angle, which measures the relationship between the articular surface of the metatarsal and the long axis of the first metatarsal. Normal should be less than 10° of lateral deviation.

## CONSERVATIVE MANAGEMENT

- Explain the nature of the problem to the patient. Try to talk the patient into using broad, soft-soled shoes, preferably with a low heel, that provide adequate room for the great toe and the medial eminence. Many patients can be made comfortable with just a change of shoe style. Some women, particularly young women, enjoy wearing stylish shoes and have difficulty with this type of conservative management; not infrequently, they will request surgery.
- Advise the patient that, after bunion surgery (in our experience), only two thirds of patients can wear shoes in an unrestricted manner, leaving a third requiring restricted shoe wear. People in this latter group typically have broad, wide feet, so that even after corrective surgery, even though they now have straight metatarsophalangeal joints, their feet still cannot fit into small, narrow, pointed-toe shoes.

## DECISION MAKING

One of the most important factors in the outcome of bunion surgery is the correct selection of the operative procedure. Not all bunion deformities are alike. Therefore, a single operative procedure will not result in a satisfactory outcome for all types of deformities.

The first consideration is whether the deformity is in a congruent or an incongruent joint. This is important because if the joint is congruent, the proximal phalanx cannot be rotated on the metatarsal head to correct the deformity; if the deformity is incongruent, however, the proximal phalanx can be rotated on the metatarsal head to correct the deformity. The algorithm in Table 112.1 can help in the decision-making process.

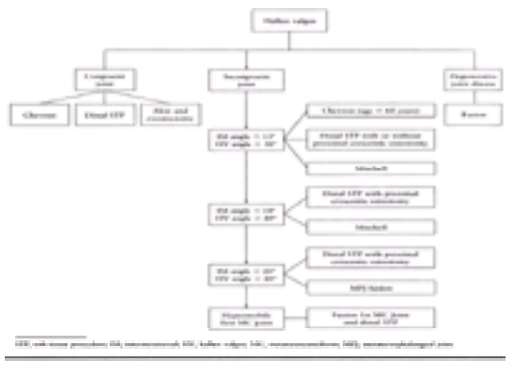

***Table 112.1. Algorithm for Treating Hallux Valgus***

In a congruent joint, use a chevron procedure to correct the deformity.

- If the DMAA is increased, use a medial closing wedge with a chevron osteotomy, rotating the metatarsal head medially and thereby correcting the DMAA (14).
- Other procedures include a distal soft-tissue procedure or an Akin procedure (osteotomy of the proximal phalanx) along with excision of the medial eminence.

If the hallux valgus deformity is associated with an incongruent joint, the operative procedure depends on the severity of the deformity. The numbers presented in Table 112.1 should be used as suggested values: They are not etched in stone.

- If the hallux valgus is mild with a hallux valgus angle of less than 30°, and the intermetatarsal angle is less than 13°, use a chevron osteotomy or distal soft tissue procedure to correct the deformity.
- If the deformity is moderate with a hallux valgus of 40° or less, and the intermetatarsal angle is 20° or less, use a distal soft-tissue procedure and a proximal metatarsal osteotomy to correct the deformity. Note that a chevron osteotomy cannot correct a deformity of this magnitude.
- If the deformity is severe with a hallux valgus angle of more than 40° and the intermetatarsal is greater than 20°, use a distal soft-tissue procedure with proximal osteotomy if there is minimal arthrosis. If arthrosis is present or the deformity is too severe, then consider an arthrodesis.
- If there is significant arthrosis of the metatarsophalangeal joint, an arthrodesis is probably the procedure of choice. Place the hallux at about 15° of valgus and 10° to 15° of dorsiflexion in relation to the ground.

## SURGICAL TECHNIQUES

### AKIN PROCEDURE

An Akin procedure is a medial closing-wedge osteotomy of the proximal phalanx (1) (Fig. 112.4). It can be utilized as an isolated procedure or in conjunction with excision of the medial eminence. Do not perform this procedure if the metatarsophalangeal joint is incongruent. It is a useful salvage procedure for a mild recurrent hallux valgus deformity with a stable metatarsophalangeal joint. It is the procedure of choice to correct a hallux valgus interphalangeus.

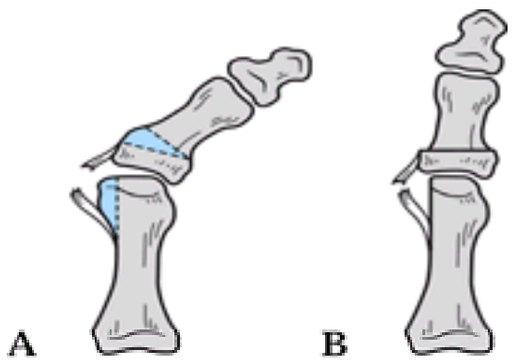


***Figure 112.4.*** The Akin procedure. **A:** Location of the osteotomy in the base of the proximal phalanx. Be sure the base of the osteotomy is distal to the concavity of the articular surface. **B:** Closure of the osteotomy site and plication of the medial capsule.

- Perform the Akin procedure through a medial incision starting along the medial aspect of the proximal phalanx and carried proximally to the metatarsal head. Create dorsal and plantar full-thickness skin flaps, exposing two thirds of the proximal phalanx and the medial eminence.
- Approach the metatarsophalangeal joint through a vertical capsulotomy and excise approximately 2–3 mm of capsule.
- Make a dorsomedial capsular incision to expose the medial eminence by hinging the capsule plantar medially.
- Expose the medial eminence by sharp dissection and excise it with a sharp thin osteotome. Begin at the sagittal sulcus in line with the medial aspect of the metatarsal shaft. Take care not to cut into the shaft.
- Close the capsule, pulling the toe into correct alignment. Avoid a varus position.

A valgus deformity is corrected by the Akin procedure in the proximal phalanx.

- Make the osteotomy of the proximal phalanx about 4–5 mm distal to the proximal articular surface. Keep in mind that the articular surface of the proximal phalanx is concave. Be certain that the osteotomy is distal to this concavity.
- Remove a wedge of proximal phalanx measuring 2–4 mm in thickness, depending on the deformity. Once the toe is straight, fix the osteotomy with crossed Kirschner (K-) wires or heavy suture material placed through drill holes in the proximal phalanx.

#### *Postoperative Care*

The postoperative management is important. Keep the foot in a dressing for 8 weeks, holding the hallux in a slight varus position. Use 2-inch Kling and half-inch adhesive tape to firmly hold the hallux in correct alignment. This permits the patient to ambulate more comfortably in a postoperative wooden shoe (Fig. 112.5).

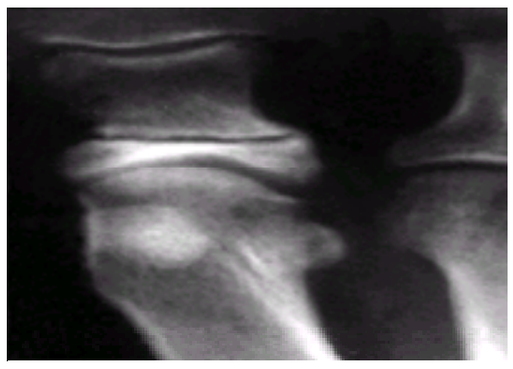

***Figure 112.5.*** Radiograph after an Akin procedure. The osteotomy site is often visible for many months, but it is clinically healed in 6–8 weeks.

#### *Complications*

The main complication following an Akin procedure is subluxation of the metatarsophalangeal joint. If the joint is subluxed preoperatively, as a rule it will tend to sublux even further following the procedure (18). Therefore, subluxation is the main contraindication to an Akin procedure. Only rarely does a nonunion occur in the proximal phalanx.

### CHEVRON PROCEDURE

Utilize the chevron procedure for mild to low-moderate hallux valgus deformity (2). If it is used for a deformity that is too severe, complete correction is not possible and a recurrence may develop.

- Make a medial midline incision starting at the medial side of the midportion of the proximal phalanx extending 1 cm proximally to the medial eminence.
- Develop full-thickness dorsal and plantar skin flaps. Retract the digital nerves out of the way.

- Having exposed the medial joint capsule, make a vertical capsulotomy with a #11 blade, excising a 3–5 mm piece of capsule. Then make an incision through the dorsal medial aspect of the capsule and strip the capsule off of the medial eminence.
- Remove the medial eminence with an osteotome starting at the sagittal sulcus on a slight oblique angle (Fig. 112.6*A*). This is in contradistinction to the plane of the osteotomy that is done to remove the medial eminence for the Akin or the distal soft-tissue procedure. This oblique angle is used to create a wide base for the chevron osteotomy, which is displaced laterally.

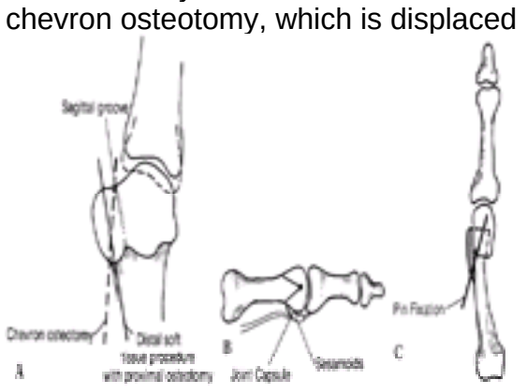


***Figure 112.6.*** Chevron procedure. **A:** The medial eminence is removed starting at the sagittal sulcus to the base of the medial eminence. **B:** The apex of the chevron osteotomy starts in the center of the metatarsal head and is brought proximally. The plantar aspect of the line of the osteotomy should be proximal to the joint capsule, thereby avoiding the sesamoid bones. **C:** The osteotomy site is displaced laterally 20% to 30% of the width of the shaft.

- Make the chevron cut by first drilling a horizontal hole in the middle of the metatarsal head, and then cutting the chevron with a small oscillating saw (Fig. 112.6*B*, Fig. 112.6*C*). It is important that the plantar limb of the osteotomy exit proximal to the sesamoid bones, so that they are not inadvertently damaged.
- Make the cut dorsally at about a 60° angle to the plantar cut. Do not cut too far through the lateral cortex, to avoid damage to the vessels along the lateral aspect of the metatarsal head.
- Once the osteotomy has been completed and the metatarsal head is free, displace it laterally 4–5 mm (3). Then secure it with an oblique pin passed from proximal to distal. Some surgeons advocate using a small screw with a larger dorsal bony cut, but we believe that a single 0.62-inch K-wire is adequate.
- Once this is achieved, remove the medial prominence of the metatarsal that remains by using the oscillating saw and buffing any sharp edges.
- Now hold the hallux in a completely neutral position. Plicate the medial joint capsule by using interrupted 2-0 chromic sutures. If insufficient capsule has been removed, remove more prior to plicating the capsule.
- After the capsule has been plicated and the hallux is released, it should stay in a neutral position. If it tends to drift into valgus, consider excising more joint capsule. If it is in a slight degree of varus, correct this with the postoperative dressings.

### *Postoperative Care*

Postoperative management consists of a postoperative shoe and a firm, spica-type dressing consisting of 2-inch Kling and half-inch adhesive tape holding the first metatarsophalangeal joint in satisfactory alignment. Change this dressing weekly for 8 weeks. When a K-wire is used to stabilize the metatarsal osteotomy, it can usually be removed after 4 weeks. Sometimes, premature removal is necessary because of a minor infection about the pin. After removing the dressings (at 8 weeks), begin exercises to restore motion in the metatarsophalangeal joint (Fig. 112.7).

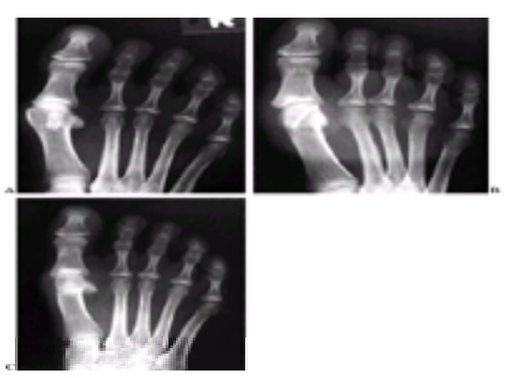

***Figure 112.7.*** **A:** Preoperative radiograph of a mild hallux valgus deformity. **B:** After a chevron procedure with pin fixation. **C:** Final result demonstrating satisfactory alignment of the metatarsophalangeal joint.

### *Complications*

Possible complications include arthrofibrosis, which is a stiffening of the metatarsophalangeal joint, and varus deformity, usually due to overplication of the medial joint capsule or inadvertent tilting of the metatarsal head into lateral deviation. This is possibly due to loss of fixation of the osteotomy site or a recurrence of the deformity because the preoperative deformity was too severe (10,11).

**HINTS AND TRICKS**

When there is an increased DMAA, the correction produced by the chevron procedure may be inadequate. To correct, remove more bone from the proximal limb of the chevron cut. Remove 2–3 mm of bone, which includes the width of the saw blade, from the medial aspect of the metatarsal, allowing the head to be angulated in a medialward direction, thereby correcting the abnormal DMAA. Some authors believe that release of the lateral joint capsule can be carried out with a chevron osteotomy, and the literature seems to support this (17,21). If a capsule release is carried out, it should be at the level of the joint and distally to avoid the blood supply coming into the metatarsal head through the joint capsule.

Avascular necrosis of the metatarsal head is an unusual complication but certainly can be disastrous. The incidence is low, probably 1% or 2%. Exactly why this occurs in some cases is unknown. It may be due to excessive stripping of the lateral joint capsule, thereby disrupting the blood supply to the metatarsal head (17,19,22). If there is complete avascular necrosis of the head associated with significant collapse, severe disability results. Minor radiographic changes are usually not of any clinical significance. If a patient develops avascular necrosis, treat it conservatively for as long as possible until a painful joint requires arthrodesis. Treat arthrofibrosis of the metatarsophalangeal joint with vigorous physical therapy.

Probably the most common complication is incomplete correction of the hallux valgus deformity. This results from treating too severe a hallux valgus deformity, or from failure to recognize an increased DMAA, so that it was not corrected at the time the chevron osteotomy was done.

## DISTAL SOFT-TISSUE PROCEDURE

The distal soft-tissue procedure with and without a proximal crescentic metatarsal osteotomy is indicated for a wide range of deformity from mild to severe. It is a procedure that is technically challenging and needs to be meticulously carried out to achieve the best clinical results (Fig. 112.8).

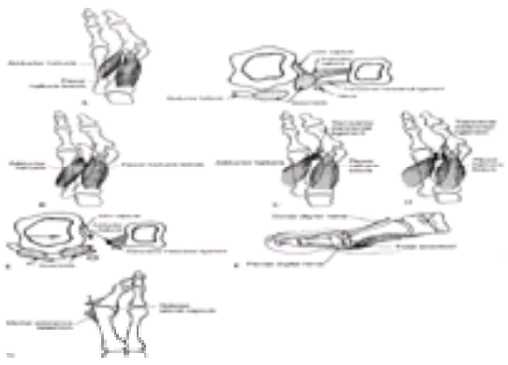

***Figure 112.8.*** Distal soft-tissue procedure. **A:** The adductor tendon inserts into the lateral aspect of the fibular sesamoid and into the base of the proximal phalanx. **B:** The adductor tendon is released from its insertion into the lateral side of the fibular sesamoid and the base of the proximal phalanx. **C:** The transverse metatarsal ligament passes from the second metatarsal into the fibular sesamoid. **D:** The transverse metatarsal ligament is transected. **E:** The three contracted structures on the lateral side of the metatarsophalangeal joint are released. **F:** The medial capsular incision begins 2–3 mm proximal to the base of the proximal phalanx, and a piece of tissue 3–8 mm is removed. A dorsal medial incision is then made to create a plantar proximally based flap. **G:** The medial eminence is removed in line with the medial aspect of the first metatarsal shaft. (From Mann RA, Coughlin MJ.*Video Textbook of Foot and Ankle Surgery.* St. Louis, MO: Medical Video Productions, 1991.)

- Make the initial incision on the dorsal aspect of the first web space in the midline, avoiding the superficial branches of the deep peroneal nerve.
- Through this incision, release the lateral joint capsule and the adductor hallucis tendon from its insertion along the lateral side of the fibular sesamoid and base of the proximal phalanx (Fig. 112.8*B*).
- Section the transverse metatarsal ligament, which inserts into the lateral aspect of the fibular sesamoid (Fig. 112.8*C*, Fig. 112.8*D*, Fig. 112.8*E*).
- Center the second incision over the medial aspect of the first metatarsophalangeal joint. Carry it down to the joint capsule and create a full-thickness dorsal and plantar flap. Take care to avoid the dorsomedial and plantar medial cutaneous nerves (Fig. 112.8*F*).
- Remove a wedge of capsule from the medial aspect of the metatarsophalangeal joint. Begin the initial capsular incision about 2–3 mm proximal to the base of the proximal phalanx. Make the second portion of the incision more proximal, between 4 and 8 mm, depending on the degree of the deformity that needs to be corrected. Dorsally, this incision ends about 1 cm medial to the extensor hallucis longus tendon and plantarly the passes through the abductor hallucis tendon, ending at the medial aspect of the tibial sesamoid.
- Expose the medial eminence either by carefully dissecting the medial joint capsule off the medial eminence or by making an incision along the dorsomedial aspect of the joint capsule to create a flap to expose the medial eminence.
- Remove the medial eminence about 1 mm medial to the sagittal sulcus and in line with the medial aspect of the metatarsal shaft (Fig. 112.8*G*). Smooth the edges with a rongeur.
- At this point, decide if the metatarsus primus varus can be corrected without a proximal metatarsal osteotomy. This is determined by pressing on the first metatarsal to see if it can be reduced to the second metatarsal. If this occurs without the first metatarsal springing medially again, then no osteotomy is necessary. If, however, there is a tendency for the two metatarsals to spring apart, then an osteotomy at the base of the metatarsal is required. We use an osteotomy in 80% to 90% of cases (Fig. 112.9) (7).

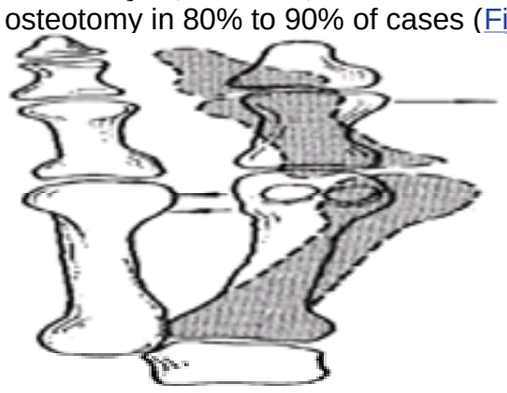

***Figure 112.9.*** To determine whether an osteotomy is necessary after the distal soft-tissue release has been done, push the first metatarsal head laterally. If there is any tendency for the metatarsal head to spring open, consider an osteotomy. We perform an osteotomy about 90% of the time.

- Expose the osteotomy site at the base of the metatarsal through a dorsal incision distal to the first metatarsocuneiform joint (Fig. 112.10). Do the osteotomy about 1 cm distal to the metatarsocuneiform joint. We prefer to use a crescentic osteotomy with the concavity directed proximally. The osteotomy is produced perpendicular to neither the metatarsal shaft nor the bottom of the foot, but halfway between. Cut the osteotomy with a crescentic blade by using an oscillating handpiece.

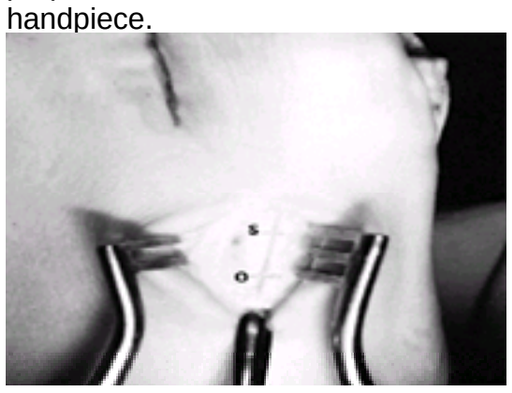

***Figure 112.10.*** The Freer elevator is pointing at the metatarsocuneiform joint. The osteotomy site (*O*) is about 1 cm distal. If a screw will be used for fixation of the osteotomy site, it is placed about 1 cm distal to the osteotomy site (*S*).

- Next, correct the hallux valgus by placing three sutures in the first web space between the first and second metatarsals, incorporating the adductor tendon. Pass the suture through the medial aspect of the capsule of the second metatarsophalangeal joint, through the adductor tendon, and then through the dorsal capsule on the lateral aspect of the first metatarsal. Tie these sutures after the proximal osteotomy has been fixed.
- Correct the increased intermetatarsal angle by freeing all the soft tissues around the osteotomy site, so the osteotomy can be easily moved. Place a Freer elevator on the proximal portion of the metatarsal and displace it medially as the metatarsal shaft is rotated laterally. Displacement of only 2–3 mm allows rotation of the metatarsal shaft at the osteotomy site, correcting the metatarsus primus varus (Fig. 112.11). We prefer to stabilize the osteotomy site with a 4.0 mm, cannulated AO screw, although an oblique $^{5}/_{64}$-inch Steinmann pin or multiple smaller K-wires may be used.

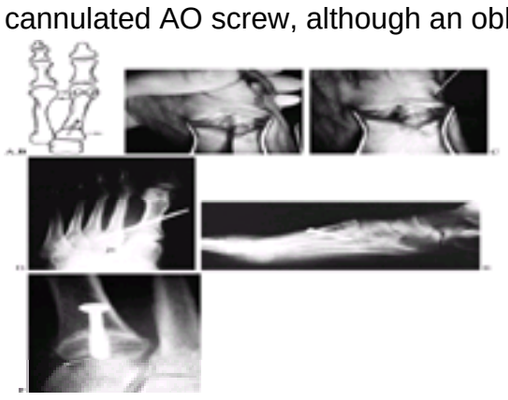

***Figure 112.11.*** The osteotomy site is reduced by completely freeing the soft tissue about the osteotomy, then pushing the proximal fragment medially with a small

Freer elevator while pushing the metatarsal head laterally. This locks the lateral aspect of the osteotomy site, and the internal fixation is inserted. **A:** Drawing shows the bones involved. **B,C,D:** Fixation of the osteotomy site using an oblique $^{5}/_{64}$-inch Steinmann pin. **E,F:** Fixation of the osteotomy site using a 4.0 mm screw.

- When using the cannulated screw, place the guide pin approximately 1 cm distal to the osteotomy site and at an angle of about 45° to the long axis of the metatarsal before cutting the osteotomy.
- After correction is obtained, drive the guide pin across the osteotomy site for fixation.
- Make a 4 mm drill hole over the guide pin because the self-tapping screw cannot cut through the cortical bone in this area at a 45° angle. Countersink the hole along its distal aspect to ensure that the head of the screw will not cam against the metatarsal and fracture the island of bone between the osteotomy site and the hole. Countersinking also lowers the profile of the screw. We usually use a 4.0 mm screw of 26 mm length. In a large person, use a 28–30 mm screw.
- Plicate the medial joint capsule using four to five sutures of 2-0 chromic. As the sutures are placed, an assistant must hold the first metatarsophalangeal joint in neutral position for dorsiflexion-plantarflexion and varus-valgus. The hallux must be rotated to correct any pronation, which rotates the sesamoids under the metatarsal head. Because the capsule on the plantar half of the metatarsophalangeal joint is the strongest, be certain that the suture line in this area is well secured. The alignment of the hallux should now be anatomic.

### *Postoperative Care*

Apply a compression dressing overnight. The patient can walk in a postoperative shoe. The next day, rewrap the foot into a firm dressing consisting of 2-inch Kling and half-inch adhesive tape. The postoperative dressing is extremely important. The main principles are to bind the metatarsal heads together to support the osteotomy site, to derotate the hallux to ensure that any pronation deformity is corrected, and to hold the toe in neutral alignment to correct any residual valgus or varus. While standing at the patient's foot, dress the right hallux counterclockwise and the left hallux clockwise to correct pronation, which maintains the sesamoid beneath the hallux (Fig. 112.12). Maintain dressing for 8 weeks and change it weekly. If a pin is used to fix the osteotomy site, remove it at 4 weeks.

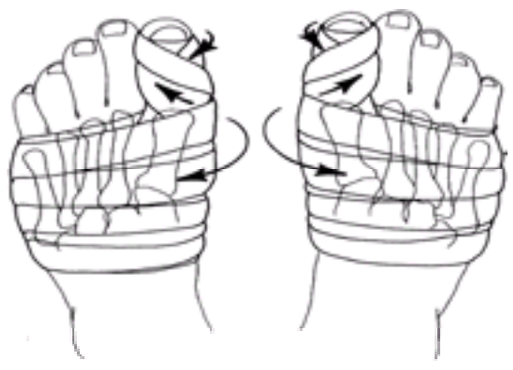

***Figure 112.12.*** The postoperative dressings are critical in maintaining proper alignment. Notice that the metatarsal heads are firmly bound with the gauze, and the great toe is rotated so as to keep the sesamoids aligned beneath the metatarsal head. This necessitates dressing the right toe in a counterclockwise direction and the left toe in a clockwise direction (from the point of view of someone standing at the foot of the bed).

The results after a distal soft-tissue repair are usually quite satisfactory (Fig. 112.13). In a review of 110 feet, 76% of the hallux valgus deformities were reduced to less than 16° (15). The hallux valgus angle was corrected from 30° to 9° and the intermetatarsal angle from 13° to 5°.

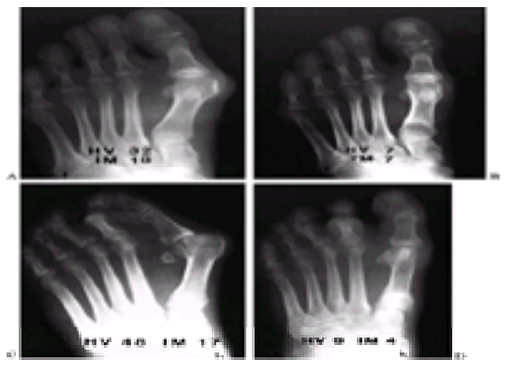

***Figure 112.13.*** Preoperative (**A**) and postoperative (**B**) radiographs demonstrating satisfactory correction of a moderate hallux valgus deformity using a distal soft-tissue procedure and proximal osteotomy. Notice satisfactory realignment of the sesamoids and minimal shortening of the first metatarsal. Preoperative (**C**) and postoperative (**D**) radiographs demonstrating satisfactory correction of a severe hallux valgus deformity using the distal soft-tissue procedure and proximal crescentic osteotomy.

### *Complications*

The main complication was hallux varus, which occurred in 14 cases and averaged 5.4°. Nine were less than 6°, which was of no clinical significance, and five were greater than 6°. Of these, two patients were dissatisfied with the result (7,16). Bear in mind that when a severe deformity is corrected, some loss of motion of the metatarsophalangeal joint may occur. If slight undercorrection of the hallux valgus occurs, and this is bothersome to the patient, an Akin procedure can be utilized in the future to complete the correction of the deformity. If overcorrection occurs and a hallux valgus deformity results, this may be corrected by an extensor tendon transfer, as described by Johnson and Spiegel (12) and modified by Mann (13).

**Hallux Varus Repair** The type of procedure chosen to repair a hallux varus deformity depends on several factors. If there is symptomatic arthrosis of the metatarsophalangeal joint, an arthrodesis is the procedure of choice. If there is no arthrosis present, then one might consider a soft-tissue reconstruction utilizing a split extensor hallucis longus repair. The principle of the repair is that all soft-tissue contracture along the medial aspect of the joint, which would include the joint capsule, abductor hallucis tendon, and the displaced tibial sesamoid, if present, needs to be sufficiently released to permit the proximal phalanx to be rotated laterally on the metatarsal head. The proximal phalanx is then stabilized in its normal position by transferring either a portion of or the entire extensor hallucis longus tendon beneath the transverse metatarsal ligament and suturing it into the base of the proximal phalanx through a transverse drill hole. If an interphalangeal joint contracture of more than 15° to 20° is present, usually an arthrodesis of the interphalangeal joint is added to the procedure.

The outcome of this procedure is usually quite satisfactory, although the patient does lose some motion at the metatarsophalangeal joint. If the alignment of the joint is satisfactory, however, the clinical problem of the hallux varus deformity is usually solved.

**Keller Procedure** The Keller procedure (20), once the most popular procedure for repair of hallux valgus deformity, is now used only in the patient who has limited ambulatory capacity, or possibly as an alternative to an arthrodesis in the more sedentary patient. The problem with the Keller procedure is that, in an active individual, the stability of the first metatarsophalangeal joint is lost and, as a result, a transfer lesion beneath the second metatarsal head often occurs. (Since the windlass mechanism of the first metatarsophalangeal joint, which brings about plantar flexion of the first metatarsal during the last half of stance phase, is disrupted, weight is transferred to the second metatarsal head, often resulting in a transfer lesion.) The great toe itself may drift into dorsiflexion, varus or valgus, because of its lack of ability to stabilize itself due to the excision of the proximal portion of the proximal phalanx.

The Keller procedure does play a limited role in management of foot problems, however. When utilized in the less active individual, it can bring about adequate

decompression of the metatarsophalangeal joint and relieve pressure on the skin on the medial side of the first metatarsal.

The Keller procedure is carried out through a medial approach, exposing the medial joint capsule. This is dissected off the metatarsal head, creating a distally based flap. The medial eminence is removed, and the proximal 20% of the proximal phalanx is removed. The metatarsophalangeal joint is then usually adequately decompressed, but, if the joint still remains somewhat tight, excise a little bit more of the proximal phalanx. If the deformity is severe, the adductor hallucis insertion into the lateral sesamoid sling is released. Try to reattach the sesamoid mechanism to the base of the proximal phalanx through small drill holes; if this is not possible, however, at least suture the sesamoid mechanism into the flexor hallucis longus tendon to help prevent dorsiflexion at the metatarsophalangeal joint. A longitudinal pin is then placed retrograde through the tip of the toe and back into the metatarsal head, after which the medial capsule is sutured closed. The pin is left in place for 3 weeks and the toe is kept dressed for approximately 6 weeks. During the postoperative period, the patient is permitted to ambulate in a postoperative shoe.

**ARTHRODESIS OF THE FIRST METATARSOPHALANGEAL JOINT**

Arthrodesis of the first metatarsophalangeal joint is performed for arthrosis of the joint or a failed hallux valgus repair. It is carried out routinely in the rheumatoid foot.

- Make an incision over the dorsal aspect of the first metatarsophalangeal joint. Dissect through subcutaneous fat to expose the extensor hallucis longus tendon.
- Retract the tendon medially or laterally to expose the underlying joint.
- Open the joint capsule and remove the osteophytes and the surrounding synovial tissue if present.
- Remove the distal portion of the metatarsal head and the base of the proximal phalanx with a sagittal saw, keeping the bone resection to a minimum. Make the bony cuts to produce 10° to 15° of valgus and about 30° of dorsiflexion in relation to the first metatarsal shaft, or 10° to 15° of dorsiflexion in relation to the plantar aspect of the foot (Fig. 112.14). If a medial eminence is present, remove it.

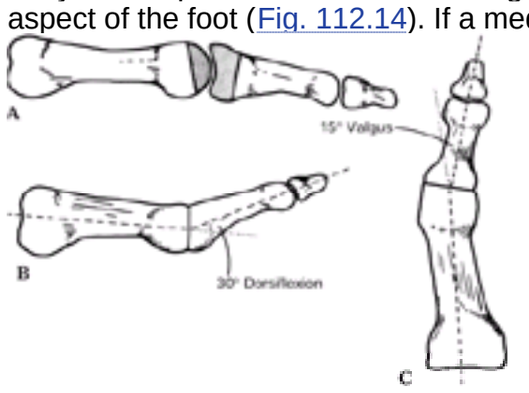


***Figure 112.14.*** Arthrodesis of a metatarsophalangeal joint. **A:** *Shaded area* represents amount of bone surface usually removed when arthrodesis is carried out. **B:** Lateral view of metatarsophalangeal joint demonstrating that the arthrodesis site should be placed in about 30° of dorsiflexion in relation to the metatarsal shaft. **C:** Anteroposterior view of metatarsophalangeal joint demonstrating that there should be about 15° of valgus at the arthrodesis site.

- I prefer to stabilize the fusion site with an interfragmentary compression screw, and a five- or six-hole quarter-tubular small fragment plate with 4.0-mm screws. After the bone cuts are made, stabilize the arthrodesis in proper alignment with 0.045-inch K-wires. Place the interfragmentary screw from the medial flare of the proximal phalanx obliquely into the metatarsal head. Usually a six-hole plate can be applied to the dorsal surface if adequate exposure is obtained; if not, use a five-hole plate. Although the plate is placed on the compression side of the fusion site, it is usually sufficient to neutralize the forces and permit fusion to occur. Secure the plate with 4.0 mm cancellous or cortical screws, depending on the quality of the bone (Fig. 112.15).

***Figure 112.15.*** AP **(A)** and lateral **(B)** radiographs demonstrating an arthrodesis of the first metatarsophalangeal joint in a patient with rheumatoid arthritis. The fusion site should be placed in approximately 15° of valgus, and at 10° to 15° of dorsiflexion in relation to the ground.

***Postoperative Care***

Apply a compression dressing and ambulate in a postoperative shoe with weight bearing as tolerated. Remove the sutures in 10–14 days. Use the postoperative shoe until fusion occurs, which usually is by 10–12 weeks. The plate needs to be removed in only about 10% of patients.

***Complications***

Most patients have few or no complaints. In fact, after an arthrodesis of the first metatarsophalangeal joint, patients are quite functional (4,8). Women can wear shoes with 1½-inch heels. Proper alignment of the joint must be achieved, however; otherwise, abnormal stress may be placed across the interphalangeal joint. Degenerative changes at the interphalangeal joint may occur in about 20% of patients. As a general rule, although radiographic changes occur in the interphalangeal joint, they rarely become clinically symptomatic if the alignment of the first metatarsophalangeal joint is correct. If insufficient valgus or too much plantar flexion is placed at the arthrodesis site, the patient tends to vault over the toe or externally rotate the foot to prevent excessive pressure across the great toe. Occasionally, a nonunion of the arthrodesis site occurs; if symptomatic, it should be repaired.

**HINTS AND TRICKS**

If bone stock is insufficient (e.g., after a Keller procedure, or in the case of severe rheumatoid arthritis with osteopenic bone), use Steinmann pins to stabilize the fusion site (6). Use two threaded double-ended $^{3}/_{32}$- or $^{1}/_{8}$-inch Steinmann pins. Drill each pin retrograde starting in the proximal phalanx, crossing the interphalangeal joint, and passing out through the tip of the great toe. Once the first pin has been drilled out completely, place a second pin parallel to it. Hold the cut bone surfaces in apposition and drill one Steinmann pin back across the metatarsophalangeal joint. As this is being done, place compression across the joint. The pin can usually be driven in 2–3 cm. Cut the pin, leaving it protruding from the tip of the toe by about 4–5 mm. Carefully check the toe for alignment and rotation by aligning the toenails, and then drill the second pin across the metatarsophalangeal joint (Fig. 112.16). Place the patient in a compression dressing and permit walking in a postoperative shoe until the arthrodesis heals, usually 10–12 weeks. Remove the pins under digital block using a Craig pin remover.

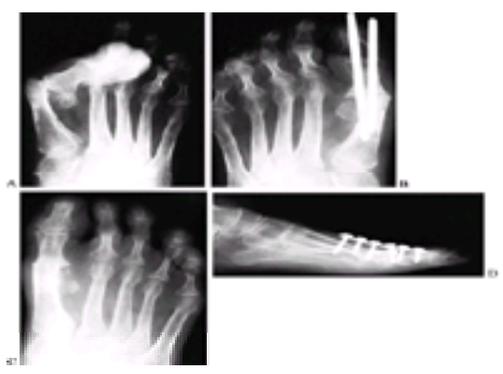

***Figure 112.16.*** Preoperative and postoperative radiographs of first metatarsophalangeal joint arthrodesis. **A:** Severe recurrent hallux valgus deformity. **B:** Fixation with $^{1}/_{8}$-inch threaded Steinmann pins. **C:** Postoperative result following satisfactory arthrodesis. **D:** Fixation of arthrodesis site using minifragment plate and interfragmentary screw.

## AUTHORS'S PERSPECTIVE

Hallux valgus surgery should result in satisfactory correction of the deformity and a painless functional first metatarsophalangeal joint. The surgical procedure must be carefully selected; if one attempts to use a procedure such as a chevron when the deformity is too severe, it will provide less than an optimal result. It is extremely important to carefully select the indicated procedure and not to “stretch' indications (5).

Postoperative management must be meticulous: It is an integral part of the procedure if a satisfactory outcome is to be achieved.

If a complication such as a mild hallux varus occurs, it usually is not symptomatic. When the hallux varus is greater than 8° to 10°, it may be symptomatic and surgical correction utilizing a split extensor hallicus longus transfer may be indicated.

Fully inform the patient about possible complications of the foot surgery. This prevents surprises for the patient, which makes for a much better physician–patient relationship.

## CHAPTER REFERENCES

Each reference is categorized according to the following scheme: *, classic article; #, review article; !, basic research article; and +, clinical results/outcome study.


* 1. Akin OF. The Treatment of Hallux Valgus: A New Operative Procedure and Its Results. *Med Sentinel* 1925;33:68.

+ 2. Austin DW, Leventen EO. A New Osteotomy for Hallux Valgus. *Clin Orthop* 1981;157:25.

+ 3. Badwey TM, Dutkowsky JP, Graves SC, Richardson EG. An Anatomical Basis for the Degree of Displacement of the Distal Chevron Osteotomy in the Treatment of Hallux Valgus. *Foot Ankle Int* 1997;18:213.

+ 4. Coughlin MJ. Arthrodesis of the First Metatarsophalangeal Joint with Minifragment Plate Fixation. *Orthopedics* 1990;13:1037.

# 5. Coughlin MJ. Hallux Valgus. *J Bone Joint Surg Am* 1996;78:932.

+ 6. Coughlin MJ, Mann RA. Arthrodesis of the First Metantarsophalangeal Joint as a Salvage for Failed Keller Procedure. *J Bone Joint Surg Am* 1987;69:68.

+ 7. Easley ME, Kiebzak GM, Davis WH, Anderson RB. Prospective, Randomized Comparison of Proximal Crescentic and Proximal Chevron Osteotomies to Correct Hallux Valgus Deformity. *Foot Ankle Int* 1996;17: 307.

+ 8. Fitzgerald JAW. A Review of Long Term Results of Arthrodeses of the First Metatarsophalangeal Joint. *J Bone Joint Surg Br* 1969;51:488.

! 9. Fritz GR, Prieskorn DW. First Metatarsocuneiform Motion: A Radiographic and Statistical Analysis. *Foot Ankle Int* 1995;16:117.

+ 10. Hattrup SJ, Johnson KA. Chevron Osteotomy: Analysis of Factors in Patient Dissatisfaction. *Foot Ankle* 1985;5:327.

+ 11. Johnson JE, Clanton TO, Baxter DE, et al. Comparison of Chevron Osteotomy and Modified McBride Bunionectomy for Correction of Mild to Moderate Hallux Valgus Deformity. *Foot Ankle* 1991;12:61.

+ 12. Johnson KA, Spiegel PV. Extensor Hallucis Longus Transfer for Hallux Varus Deformity. *J Bone Joint Surg Am* 1984;66:681.

+ 13. Mann RA. Hallux Varus. In: Couglin MJ, Mann RA, eds. *Surgery of the Foot and Ankle*, vol. 1, 7th ed. St. Louis: Mosby. 1999:258.

+ 14. Mann RA, Donatto MD. The Chevron Osteotomy: A Clinical and Radiographic Analysis. *Foot Ankle Int* 1997;18:255.

+ 15. Mann RA, Rudicel S, Graves SC. Hallux Valgus Repair Utilizing a Distal Soft Tissue Procedure and Proximal Metatarsal Osteotomy: A Long Term Followup. *J Bone Joint Surg Am* 1992;74:124.

+ 16. Markbreiter LA, Thompson FM. Proximal Metatarsal Osteotomy and Hallux Valgus Correction: A Comparison of Crescentic and Chevron Procedures. *Foot Ankle Int* 1997;18:71.

+ 17. Peterson DA, Zilberfarb JL, Greene MA, Colegrove RC. Avascular Necrosis of the First Metatarsal Head: Incidence and Distal Osteotomy Combined with Lateral Softtissue Release. *Foot Ankle Int* 1994;15:59.

+ 18. Plattner PF, VanManen JW. Results of Akin Type Proximal Phalangeal Osteotomy for Correction of Hallux Valgus Deformity. *Orthopedics* 1990;13:989.

+ 19. Pochapko DJ, Schlehr FJ, Murphey MD, Hamilton JJ. Distal Chevron Osteotomy with Lateral Release for Treatment of Hallux Valgus Deformity. *Foot Ankle Int* 1994;15:457.

+ 20. Richardson EG. Keller Resection Arthroplasty. *Orthopedics* 1990;13:1049.

+ 21. Richardson EG, Graves SC, McClure JT, Boone RT. First Metatarsal Head-shaft Angle: A Method of Determination. *Foot Ankle* 1993;14:181.

+ 22. Thomas RL, Espinosa FJ, Richardson EG. Radiographic Changes in the First Metatarsal Head after Distal Chevron Osteotomy Combined with Lateral Release Through a Plantar Approach. *Foot Ankle Int* 1995;15(6):285.

# CHAPTER 113

# LESSER TOE DISORDERS

*Mark S. Mizel*

**M. S. Mizel:** Department of Orthopaedics and Rehabilitation, University of Miami, Miami, Florida, 33136.

Anatomy and Physiology
Rigid Hammer Toe
Surgical Correction of Rigid Hammer Toe
Complications
Flexible Hammer Toe
Surgical Correction of Flexible Hammer Toe
Complications
Deformities of the Metatarsophalangeal Joint
Arthroplasty of the Metatarsophalangeal Joint
Complications
Crossover Second Toe
Surgical Repair of a Crossover Toe
Complications
Claw Toe
Surgical Correction of Claw Toe
Complications
Mallet Toe
Surgical Correction of Mallet Toe
Complications
Hard Corns
Surgical Correction of a Hard Corn
Complications
Soft Corns
Condylectomy for a Soft Corn
Complications
Chapter References

## ANATOMY AND PHYSIOLOGY

Each of the lesser toes consists of three phalanges, the proximal, middle, and distal phalanx. In the case of the fifth toe, sometimes the middle and distal phalanx fail to separate (7). Barriers to deformities include the medial and lateral collateral ligaments of the metatarsophalangeal (MP) joints, as well as of the proximal and distal interphalangeal joints. The plantar plate helps to passively return the MP joints to a neutral position when the joints are dorsiflexed during ambulation.

Active motion of the joints of the lesser toes is accomplished with both the intrinsic and the extrinsic musculature (11). Dorsiflexion of the MP joint is accomplished by the extensor digitorum longus tendon, whereas flexion of that joint is accomplished by the intrinsic lumbrical and interossei musculature. The interossei attach to the dorsal hood over the proximal phalanx, and through this they work to act as extensors of the proximal and distal interphalangeal joints. The proximal interphalangeal (PIP) joint is plantar flexed by the flexor digitorum brevis, and the distal interphalangeal joint is plantar flexed by the flexor digitorum longus (FDL) tendon. Because the strength of the extrinsics is significantly greater than that of the intrinsics, deformities are most commonly that of dorsiflexion at the MP joint and plantar flexion at the proximal and distal interphalangeal joints.

The etiology of a flexible hammer toe is often a tight FDL tendon; if the deformity persists for a sufficient duration, it can become fixed. A disproportionately long lesser toe or a shoe with a tight toe box can also cause a fixed hammer-toe deformity. Further causes of hammer-toe deformity can be poor shoe wear or the formation of a hallux valgus deformity, which can push the second toe into a “hammered” or overlapped position.

## RIGID HAMMER TOE

A rigid hammer toe is defined as a fixed flexion deformity of the PIP joint (10). This deformity can cause symptoms over the dorsum of the PIP joint where the toe rubs against the top of the toe box (Fig. 113.1), or at the tip of the toe where the toe hits the sole of the shoe. If the hammer toe produces sufficient distal migration of the plantar fatty cushion, pain under the metatarsal head can result. Shoe modifications, including extradepth shoes, soft insoles, and metatarsal pads, can help to alleviate symptoms.

***Figure 113.1.*** A patient with a symptomatic second hammer toe. **A:** Oblique view. **B:** Top view.

Evaluation of the entire foot for related deformities, such as a tight FDL tendon or a hallux valgus deformity, is important prior to any surgical treatment. A hallux valgus deformity can reduce the space lateral to the hallux, which prevents reduction of a second toe into a reduced position. If this condition exists, a hallux valgus repair should be strongly considered as a concomitant surgical procedure.

### SURGICAL CORRECTION OF RIGID HAMMER TOE

A PIP joint arthroplasty, such as described by DuVries (3,6), consists of the resection of the distal condyle of the proximal phalanx. It results in a fibrous ankylosis that allows approximately 15 ° or 20° of motion. An alternative is bony arthrodesis of the PIP joint.

- Make a dorsal elliptical incision over the PIP joint. Sharply remove the skin, extensor tendon, and capsule (Fig. 113.2).

***Figure 113.2.*** Removal of an ellipse of skin above the proximal interphalangeal joint.

- Release the medial and lateral collateral ligaments, and, after exposing the distal condyle of the proximal phalanx, remove the condyle using a bone cutter (Fig. 113.3). Take care to remove the entire condyle and make the cut so that it is perpendicular to the shaft of the proximal phalanx.

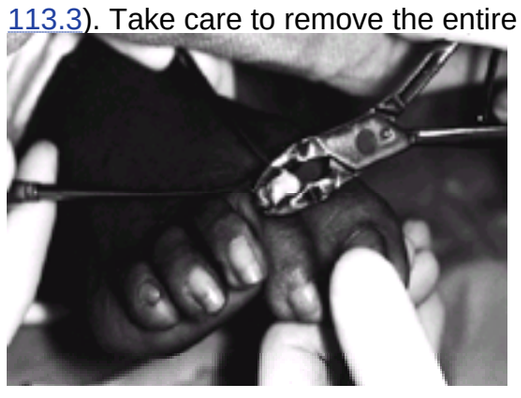

***Figure 113.3.*** The soft tissues have been elevated off the distal condyle of the proximal phalanx, and a bone cutter is about to remove the distal condyle. Note that the blades are perpendicular to the shaft of the phalanx.

- Then stabilize the toe with a 0.045-inch, double-ended Kirschner (K-) wire brought out distally from the PIP joint and then advanced in a retrograde fashion across the joint into the shaft of the proximal phalanx (Fig. 113.4). If stabilization of the MP joint is also desired, use a 0.062-inch K-wire to decrease the chance of breakage of the K-wire.

***Figure 113.4.*** A K-wire has been placed from the PIP joint out through the tip of the distal toe, and it will be brought into the proximal phalanx in a retrograde fashion.

- Close the skin with vertical mattress sutures (Fig. 113.5).

***Figure 113.5.*** The K-wire has been advanced to the proximal phalanx, bent, and cut. The extensor mechanism of the toe has been repaired as well as the skin.

Remove the sutures at 3 weeks, along with the K-wire. Allow the patient to ambulate with full weight bearing in a postoperative shoe 3 weeks after surgery. Splint the toe into neutral with tape for 3 weeks after removal of the pin. Advise the patient to use an open-toed shoe or one with a roomy toe box.

### COMPLICATIONS

Swelling is the most common complication following hammer-toe surgery. This usually decreases over the course of 6 months. Recurrence of a hammer-toe deformity is sometimes noted, and a floppy toe can result if too much of the shaft of the proximal phalanx is removed along with the distal condyle. Migration of the intermedullary pin can occur if the end is not bent or if a fixation device is not attached to the distal aspect of the pin.

## FLEXIBLE HAMMER TOE

A flexible hammer-toe deformity can decrease or be completely eliminated with plantar flexion of the MP joint or of the ankle. These deformities are usually caused by tightness of the FDL tendon. Treat a flexible hammer toe with a Girdlestone-Taylor (11) flexor tendon transfer if surgery is indicated. This transfer, often combined with the release of deforming forces at the MP joint, can produce satisfactory results. An arthroplasty of the PIP joint is sometimes combined with the tendon transfer if there is some element of a fixed component.

### SURGICAL CORRECTION OF FLEXIBLE HAMMER TOE

- Make a transverse incision under the proximal aspect of the proximal phalanx and carry dissection bluntly down to the flexor tendon sheath. Then open the flexor tendon sheath with a longitudinal incision using a #11 blade.
- Identify the FDL tendon and apply gentle traction by placing a curved hemostat beneath the tendon.
- Then make a second plantar transverse incision at the level of the distal plantar flexion crease at the distal interphalangeal joint.
- Free up the FDL tendon distally, transect it near its insertion, and bring it out through the proximal plantar transverse incision. Then split the tendon along its raphe.

- Make a longitudinal incision dorsally over the dorsal MP joint extending out to the distal condyle of the proximal phalanx, and release the extensor tendon and collateral ligaments if necessary.
- Excise the distal condyle of the proximal phalanx as in a fixed hammer-toe repair if there is noncorrectable deformity.
- Bring up each half of the FDL tendon from plantar to dorsal along both sides of the shaft of the proximal phalanx, and suture it into the extensor hood. Do this with the PIP joint of the toe extended and with the MP joint in slight flexion.
- Close all wounds and hold the toe in neutral position with a postoperative dressing. Fix the toe with a 0.062-inch K-wire if a fixed PIP joint deformity was treated.

Allow the patient to ambulate, with weight bearing as tolerated, with a postoperative shoe for 6 weeks.

### COMPLICATIONS

Complications include possible neurovascular injury from pressure or swelling around the area of the tendon transfer, producing vascular or neurologic compromise. Other difficulties, such as swelling and recurrence of deformity, can also occur. Minimize these risks with gentle precise surgical technique.

## DEFORMITIES OF THE METATARSOPHALANGEAL JOINT

Deformities or pain at the MP joint can exist along with a hammer toe (5,8,9,13). These usually consist of a fixed dorsiflexion deformity, although subluxation or dislocation of the joint can occur. Mild dorsiflexion deformities often can be treated with extensor tenotomy. Should the deformity be of such a magnitude that this treatment is not sufficient, however, an open release of the joint capsule may be necessary. An open extensor tenotomy and capsulotomy will correct many subluxation deformities, although it is important to ensure release of the medial and lateral collateral ligaments also. Take care to avoid injury to the neurovascular bundles on either side of the joint. After correcting the soft-tissue deforming forces, hold the toe in a neutral position and insert an intermedullary K-wire of at least 0.062 inches in diameter. Protect the foot with a wooden postoperative shoe until the pin is removed, 2–3 weeks after surgery.

When a severe deformity is present, a soft-tissue procedure is often not adequate, and an arthroplasty of the MP joint is necessary. Decompression of the joint will allow its reduction, and the conversion of a diarthrodial joint to a fibrous joint will provide stability.

### ARTHROPLASTY OF THE METATARSOPHALANGEAL JOINT

- Make a dorsal longitudinal incision over the MP joint and perform a dorsal capsulotomy with release of the collateral ligaments. Do a dorsal extensor tenotomy if necessary.
- Plantar flex the toe, and resect approximately 2–4 mm of bone off the distal metatarsal head. Use a rongeur, power saw, or osteotome to bevel the plantar and dorsal surfaces of the distal metatarsal head.
- Allow the toe to return to a neutral position, and repetitively move the ankle dorsally and plantarly to check the stability of the MP joint. The amount of bone that requires resection can be estimated by evaluating the overlap seen preoperatively on a lateral radiograph of the MP joint.
- After obtaining satisfactory stability, stabilize the joint with a K-wire of at least 0.062 inches. Position the wire by inserting it into the proximal phalanx and drilling it out the tip of the toe. Then align the joint and insert the wire across the joint into the metatarsal head in a retrograde fashion. Bend the pin to prevent its proximal migration, and cut it. Hold the toe in a slightly plantar-flexed position during pin fixation.

Postoperatively, treat the patient for 2–3 weeks in a wooden postoperative shoe. Remove the pin prior to return to regular shoes, after 3 weeks or so. There will be a loss of up to 50% of normal motion. This arthrofibrosis, however, helps to provide stability and prevent dislocation.

### COMPLICATIONS

Redislocation of the MP joint is the most common complication of this procedure. Thorough release of the soft tissues is the best method of preventing redislocation. Neurologic or vascular compromise can occur if the toe stays reduced without adequate soft-tissue release, or if the vascular supply is compromised prior to the procedure. Occasionally, removal of the K-wire may be necessary to improve postoperative vascular status. Redislocation often occurs after K-wire removal; however, this is preferable to necrosis of all or part of the toe.

## CROSSOVER SECOND TOE

A significant hallux valgus deformity can cause pressure on the second toe and lead to dorsal subluxation or dislocation of the second toe, placing the great toe adjacent to the third toe (1,2,3 and 4). This results in attenuation of the second MP joint's fibular collateral ligament, and possibly even the formation of a rent in it. The tibial collateral ligament can sometimes contract. As the deformity progresses, dorsal subluxation and possibly dislocation of the second MP joint can occur.

Evaluate instability of the joint using the anterior drawer sign of the lesser MP joint, as described by Thompson and Hamilton (13). Grasp the proximal phalanx of the lesser toe between the thumb and index finger and stabilize the metatarsal with the other hand. Then manipulate the toe in a vertical fashion. If instability exists, there is subluxation at the MP joint, and pain may exist.

Nonsurgical treatment includes taping the second toe in a reduced position or using open-toed or extra-depth shoes.

### SURGICAL REPAIR OF A CROSSOVER TOE

- Make a dorsal longitudinal incision over the second MP joint.
- Perform extensor tenotomy as well as dorsal capsulotomy and collateral ligament release as described in the previous paragraphs.
- Hold the toe in a reduced position with a 0.062-inch intramedullary K-wire for 4–6 weeks after surgery.
- For severe deformity, MP joint arthroplasty, as previously described, may be necessary to both decompress the joint and allow reduction of the proximal phalanx. A Girdlestone-Taylor (11) flexor tendon transfer may also be necessary. Reefing of the lateral capsule may also be used to strengthen the reconstruction and decrease the chances of recurrence of the deformity.
- Perform correction of the hallux valgus deformity at the same time as repair of the second toe to allow for proper placement and reduction of the toe, and to prevent the hallux from again displacing the second toe (see Chapter 112).

### COMPLICATIONS

The complications of treatment of the second toe include swelling of the toe as well as recurrence of the first and second toe deformity. Loss of motion at the MP joint from postsurgical scarring and fibrous arthrodesis is a common complication. Occasional neurovascular compromise from stretching of the neurovascular bundle with reduction of the toe at the MP joint is also a possibility. Avoid this by adequate soft-tissue release, avoiding overlengthening, and gentle surgical technique.

## CLAW TOE

A claw toe is a deformity of the MP joint that occurs together with a flexion deformity of either the proximal or distal interphalangeal joints. The PIP joint is involved much more frequently than the distal interphalangeal joint in a claw-toe deformity. When evaluating a claw toe, examine both the MP and the involved interphalangeal joint to determine whether the involved deformity is fixed or flexible at each joint. In addition, carefully evaluate the hallux for a valgus deformity, which could prevent reduction of the second toe into its normal position. If there is a hallux valgus deformity that might interfere with the second toe, correct it simultaneously.

### SURGICAL CORRECTION OF CLAW TOE

- At the PIP joint, make a dorsal elliptical incision and perform a resection of the distal condyle of the proximal phalanx with the creation of a fibrous arthroplasty as described for the surgical treatment of hammer toe.
- Then make a longitudinal incision over the MP joint, and perform extensor tenotomy and capsulotomy, with release of the medial and lateral collateral ligaments as necessary. This is often enough to correct all deformities; however, a flexor tendon transfer, as described in the treatment of flexible hammer toe, is sometimes also required.
- If severe subluxation or dislocation of the MP joint is present, release of the soft tissues will often not be sufficient to allow a stable reduction, and a resection arthroplasty of the MP joint might be necessary. Accomplish this by decompressing the joint with the removal of 2–3 mm of the distal metatarsal head as described previously. This is often adequate to allow reduction of the joint and produce postoperative stability. Some beveling of the dorsal and plantar condyles

with a rongeur produces a smoother surface, which permits easier dorsiflexion of the toe.
- Test the toe for stability in neutral position as well as during dorsiflexion. After treatment of all bony and soft-tissue deformities, stabilize the digit with a 0.062-inch K-wire. The technically least demanding method is to insert the K-wire from the PIP joint distally, out through the tip of the toe, and bring it back in a retrograde fashion through the proximal phalanx into the proximal metatarsal. Take care to ensure proper position of the toe while placing the internal fixation.
- Close all wounds and bend the K-wire protruding from the toe.

Remove the K-wire approximately 3 weeks after surgery. Allow the patient to ambulate with weight bearing as tolerated in a stiff postoperative shoe. At this point, begin gentle mobilization of the MP joint. Arthrofibrosis often occurs at the MP joint after this surgery, and loss of range of motion up to 50% is common. Avoid proximal phalangectomy. The stability offered by the presence of the wide base of the proximal phalanx is important. This flared area will help to form a stable fibrous joint, allowing articulation with the shortened and reshaped metatarsal head.

### COMPLICATIONS

Redislocation of the MP joint is an occasional complication of this procedure. It can result from inadequate shortening of the MP head or stiffness from inadequate rehabilitation after pin removal. Incomplete soft-tissue release may also be a factor contributing to recurrence. Compromise of the vascular supply at the toe can occur from tension or spasm of the interdigital vessels, and postoperative monitoring is strongly recommended. If vascular compromise appears to jeopardize the viability of the toe, removal of the K-wire will sometimes help to improve the digital blood supply. Unfortunately, this usually also allows dislocation of the MP joint.

## MALLET TOE

Mallet toe is a flexion deformity of the distal interphalangeal joint. It often causes pain because the tip of the toe rubs on the inner sole of the shoe. Mallet toe is usually a fixed deformity and is less common than hammer toe.

### SURGICAL CORRECTION OF MALLET TOE

- Mallet toes that are flexible can occasionally be treated with percutaneous tenotomy of the FDL tendon.
- With a fixed deformity, it is necessary to decompress the distal interphalangeal joint. Excise an ellipse of skin from the dorsal aspect of the distal interphalangeal joint, and after release of the extensor apparatus and the collateral ligaments, excise the distal condyle of the middle phalanx with a bone cutter. This technique is similar to that described for correction of rigid hammer toe.
- Hold the toe in a neutral position with a 0.045-inch K-wire.
- Close the skin with interrupted vertical mattress sutures.

Allow the patient to ambulate with a postoperative shoe for 3 weeks, and then remove the pin and sutures. Then hold the toe in a neutral position with a half-inch adhesive tape wrapping for another 3 weeks. Take care to avoid any injury to the proximal nail matrix.

### COMPLICATIONS

Complications are the same as for repair of hammer toe.

## HARD CORNS

A hard corn is a thickened area of skin usually found on the dorsolateral aspect of the fifth toe (Fig. 113.6). The thickened skin is a hyperkeratotic reaction to the increased pressure between the distal condyle of the proximal phalanx of the fifth toe and the side of the shoe. Nonsurgical treatment for this problem consists of protecting the skin with a donut device made of soft material. In addition to this, wider, roomy shoes that minimize or eliminate a confined toe box are also quite effective. Shaving of the keratotic lesion can also help alleviate symptoms. If surgery is necessary, the underlying principle is to remove the offending condyle to relieve pressure on the skin.

***Figure 113.6.*** **A:** A hard hyperkeratotic region over the PIP joint of the fifth toe. **B:** The radiograph of the toe.

### SURGICAL CORRECTION OF A HARD CORN

- When the hard corn is on the dorsolateral fifth toe, make a longitudinal incision over the fifth toe and dissect around the PIP joint to expose it.
- Release the collateral ligaments and resect the distal condyle of the proximal phalanx perpendicular to the shaft using a bone cutter (Fig. 113.7).

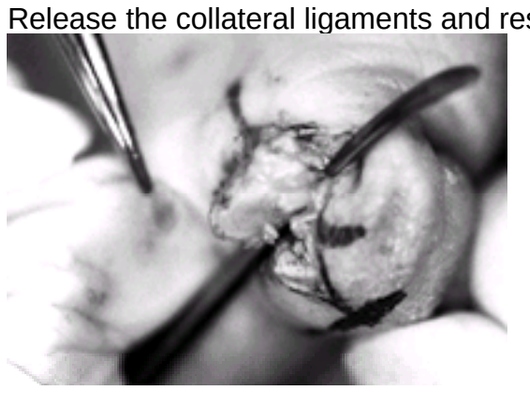

***Figure 113.7.*** The distal condyle of the proximal phalanx, which has been exposed. A freer elevator ensures that the soft tissues from underneath the proximal phalanx have been released.

- Make certain all remaining bony surfaces are smooth (Fig. 113.8). Use a rasp as necessary.

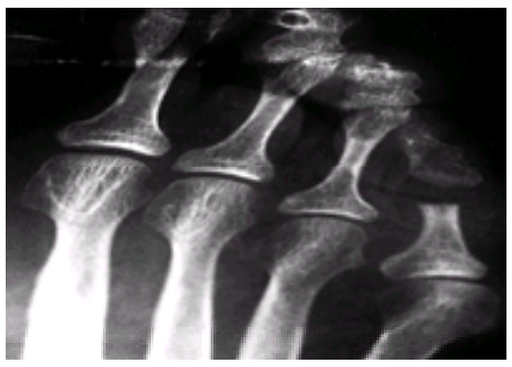

***Figure 113.8.*** Radiograph of the toe after removal of the bony prominence.

- Close the skin with interrupted sutures.

Protect the toe for approximately 3 weeks after surgery, allowing full weight bearing in a postoperative shoe. At approximately 3 weeks after surgery, allow the patient to go to wide, laced shoes, and stabilize the toe by buddy taping it to the fourth toe for approximately 3–4 weeks.

**COMPLICATIONS**

Swelling of the toe is not uncommon, but this will usually resolve over approximately 3–6 months. Stiffness of the PIP joint often occurs but is usually not symptomatic. If excess bone is removed, a floppy toe may result. If the condyle is resected at a significant angle to the shaft, a spike of bone may cause discomfort in the adjoining fourth toe.

## SOFT CORNS

A soft corn is a thickening of the skin between two lesser toes (Fig. 113.9). This hyperkeratotic skin reaction is caused by excess pressure in the web space between the toes, often caused by a constricted toe box. The moisture present in the region between the toes results in the maceration of the keratotic lesion. The location of the corn is usually at the area where one bony prominence is pushed into the adjoining toe.

***Figure 113.9.*** **A:** A soft corn between the fourth and fifth toes on the fibula side of the fourth toe. **B:** Area between the toes approximately 5 weeks postoperatively, with the soft corn almost completely resolved.

To treat, prescribe open-toed shoes or a wide toe box, and place a soft material such as lamb's wool between the toes. If this is not satisfactory, removal of the offending condyle can resolve the problem. If there is any question as to which is the offending condyle, identify it by placing a small lead marker over the soft corn, and obtain a radiograph (Fig. 113.10). This condyle may be on the toe with the lesion or on the adjacent digit.

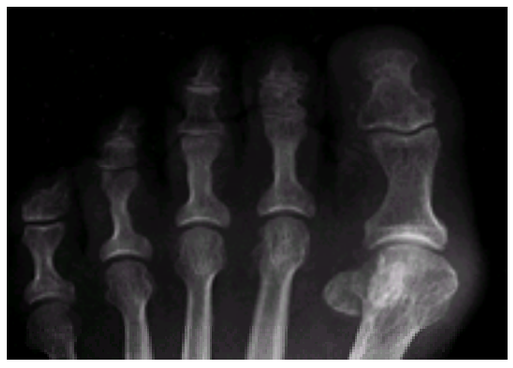

***Figure 113.10.*** A lead marker placed on the lesion demonstrates it to be at the level of the distal condyle of the proximal phalanx of the fifth toe.

**CONDYLECTOMY FOR A SOFT CORN**

Make a dorsal elliptical incision over the joint with the offending condyle, usually at the PIP joint.

- Resect the distal condyle as previously described for hammer toe.
- If surgery is done on the fifth toe, use a longitudinal incision. Surgery on two adjacent toes is occasionally necessary.

Postoperative treatment is identical to that described for hammer toe, mallet toe, or a hard corn, depending on which joint or digit is involved.

**COMPLICATIONS**

Swelling is not uncommon, but it often resolves within 3–6 months. Excessive resection of the proximal phalanx can result in a floppy toe, or if the remaining piece of bone is angulated, this can result in malalignment of the toe. Surgery on the wrong toe occasionally occurs; any doubt as to which digit is the offending toe should be resolved prior to surgery.

**CHAPTER REFERENCES**

Each reference is categorized according to the following scheme: *, classic article; #, review article; !, basic research article; and +, clinical results/outcome study.


+ 1. Coughlin MJ. Crossover Second Toe Deformity. *Foot Ankle* 1987;8:29.

# 2. Coughlin MJ. Subluxation and Dislocation of the Second Metatarsophalangeal Joint. *Orthop Clin North Am* 1989;20:535.

# 3. Coughlin MJ, Mann RA. Lesser Toe Deformities. In: Mann RA, Coughlin MJ, eds. *Surgery of the Foot and Ankle*, 6th ed. St. Louis: CV Mosby, 1992:341.

# 4. Mann RA, Coughlin MJ. Lesser Toe Deformities. *Instr Course Lect* 1987;36:137.

+ 5. Mann RA, Mizel MS. Monoarticular Nontraumatic Synovitis of the Metatarsophalangeal Joint: A New Diagnosis. *Foot Ankle* 1985;6:18.

+ 6. Mizel MS. Correction of Hammertoe and Mallet Toe Deformities. *Oper Tech Orthop* 1992;2:188.

# 7. Mizel MS. Anatomy and Pathophysiology of the Lesser Toes. In: Gould JS, ed. *Operative Foot Surgery*. Philadelphia: WB Saunders, 1993:76.

+ 8. Mizel MS, Michelson JD. Nonsurgical Treatment of Monarticular Nontraumatic Synovitis of the Metatarsophalangeal Joint. *Foot Ankle* 1997;7:424.

# 9. Mizel MS, Yodlowski M. Disorders of the Lesser Metatarsophalangeal Joints. *J Am Acad Orthop Surg* 1995;3:166.

+ 10. Myerson M, Sheref M. Pathological Anatomy of Claw and Hammertoes. *J Bone Joint Surg Am* 1989;71:45.

! 11. Sarrafian SK, Topouzian LK. Anatomy and Physiology of the Extensor Apparatus of the Toes. *J Bone Joint Surg Am* 1969;51:669.

+ 12. Taylor RG. The Treatment of Claw Toes by Multiple Transfers of Flexor into Extensor Tendons. *J Bone Joint Surg Am* 33:539.

+ 13. Thompson FM, Hamilton WG. Problems of the Second Metatarsophalangeal Joint. *Orthopaedics* 1987;10:83.

# CHAPTER 114

# PERIPHERAL NERVE LESIONS OF THE FOOT AND ANKLE

*Martin G. Mankey*

**M. G. Mankey:** Department of Orthopaedics, University of Washington, Seattle, Washington, 98195.

Interdigital Neuroma
- Pathophysiology
- Principles of Treatment
- Literature Review
- Diagnosis
- Preoperative Management
- Operative Technique
- Postoperative Care
- General Pitfalls and Complications
- Recurrent Neuromas

Author's Perspective
Tarsal Tunnel Syndrome
- Anatomy
- Pathophysiology
- Symptom Complex
- Physical Examination
- Diagnostic Studies
- Preoperative Management
- Operative Technique
- General Rehabilitation and Postoperative Principles
- Results
- General Pitfalls and Complications

Author's Perspective
Sural Nerve Entrapment
- Pathophysiology
- Assessment, Indications, Relative Results
- Preoperative Management
- Operative Technique

Deep Peroneal Nerve Entrapment
- Pathophysiology
- Assessment, Indications, Relative Results
- Preoperative Management
- Operative Technique

Superficial Peroneal Nerve Entrapment
- Pathophysiology
- Preoperative Management
- Operative Technique

Plantar Nerve Entrapment
- Pathophysiology
- Assessment, Indications, Relative Results
- Preoperative Management
- Operative Technique

Chapter References

## INTERDIGITAL NEUROMA

### PATHOPHYSIOLOGY

The term *neuroma* is actually a misnomer. Most recent literature supports the theory that the condition we call interdigital neuroma is an entrapment neuropathy of the common digital nerve beneath the transverse metatarsal ligament (26,38,39,44). These studies demonstrate that almost all the histologic changes in the nerve occur distal to the transverse metatarsal ligament, and that the nerve proximal to the ligament appears normal. The histologic changes are characterized by perineural fibrosis, degeneration of the nerve fibers, deposition of an amorphous eosinophilic material, and a decrease in both the number and the diameter of thick myelinated fibers (Fig. 114.1). Although these studies seem to support the theory that the main cause of an interdigital neuroma is an entrapment neuropathy, there are anatomic factors that need to be considered.

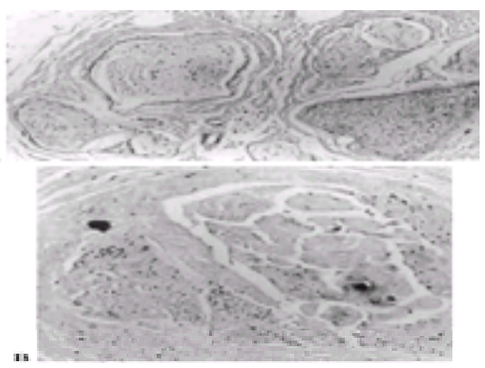

***Figure 114.1.*** Photomicrographs of an interdigital neuroma (trichrome stain). **A:** Low-power photomicrograph of a normal nerve. **B:** High-power photomicrograph of neuroma. Axonal degeneration and abundant vasculature are present.

Early reports regarding this painful entity, often referred to as Morton's syndrome, focused on the third interspace (9,46,48). Subsequent studies of the anatomy of the plantar nerves and their branches have demonstrated a communicating branch between the medial and lateral plantar nerves (9,32) (Fig. 114.2). This branch was noted to course from the common digital nerve in the fourth interspace to the third digital branch of the medial plantar nerve in the third interspace. Jones and Klenerman (32) found this communicating branch to be present in all 20 of the cadaver specimens dissected. In two of the female specimens, they found the communicating branch was enlarged, and they hypothesized that this enlargement may be a factor for the frequent involvement of the nerve to the third interspace. Mann and Reynolds (44) reported an equal distribution of interdigital neuromas in the second and third interspaces. They believed their data supported the theory that neuromas are caused by repetitive local trauma related to footwear (e.g., tight shoes, high heels, and thin soles) and shed doubt on the role of the communicating branch as the main cause of interdigital neuroma formation. Levitsky et al. (39) found the communicating branch was present in only 19 (26.8%) of 71 specimens dissected, and the incidence of third-interspace neuromas was no greater in those feet with the communicating branch as those without it. The information also questions the role of the communicating branch in the etiology of interdigital neuromas. Both Mann and Levitsky failed to identify a neuroma in the first and fourth

interspaces.

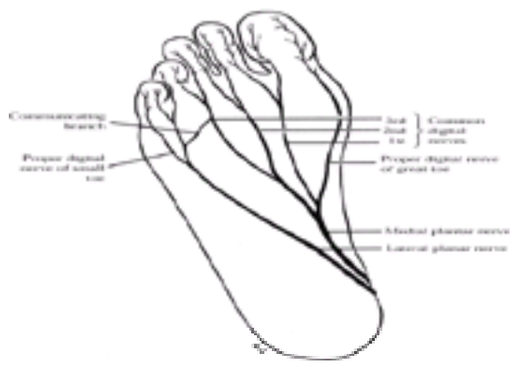


***Figure 114.2.*** Plantar nerves of the right foot.

Aside from finding a low incidence of the communicating branch in their study, Levitsky et al. (39) also measured the distance between the metatarsal heads and the diameter of the common digital nerve to each interspace. They found the intermetatarsal head distances in the second and third interspaces were significantly smaller than in the first and fourth. They then calculated a mean ratio of the intermetatarsal head distance to the diameter of the common digital nerve and found that ratio was significantly lower in the second and third interspaces compared to the first and fourth interspaces. They believed their data lent support to the theories that explain the formation of a neuroma in both the second and third interspaces on a mechanical basis.

The incidence of interdigital neuromas is 8–10 times more common in women than men. It is well known that with hyperextension of the metatarsophalangeal joints, along with the action of the plantar aponeurosis, the metatarsal heads are depressed. This exposes the interdigital nerve to increased pressure. In a woman's fashionable high heel shoe, the metatarsophalangeal joints are constantly hyperextended. This can cause the interdigital nerve to be tethered across the transverse metatarsal ligament, leading to an entrapment neuropathy. It is therefore realistic to consider a “neuroma” as an entrapment neuropathy caused by a combination of anatomic factors, such as a decreased ratio of the diameter of the intermetatarsal head to that of the digital nerve, combined with extrinsic factors, such as fashionable shoes and activity level.

## PRINCIPLES OF TREATMENT

The principles of treatment for interdigital neuroma are threefold:

1. Make the correct diagnosis.
2. Nonoperative treatment (shoewear alterations, metatarsal pad, corticosteroid injection, nonsteroidal anti-inflammatory medication)
3. Operative treatment (dorsal approach, plantar approach)

## LITERATURE REVIEW

A review of the literature about interdigital neuromas over a span of 120 years follows (13).

- 1876—Morton (48) coined the term *metatarsalgia* to describe a painful affliction of the forefoot suspected to involve the interdigital nerves.
- 1893. Hoadley (29) explored the digital nerves under the painful area, “found a small neuroma,” excised it, and claimed the patient obtained “prompt and perfect cure.”
- 1940. Betts (9) stated that “Morton's metatarsalgia is a neuritis of the fourth digital nerve.” He also noted branches of both the medial and lateral plantar nerves formed the nerve in the third interspace.
- 1979. Gauthier (22) speculated that the condition represented a nerve entrapment, a theory supported by Lassman (38) and later by Graham and Graham (26).
- 1983. Mann and Reynolds (44) found an equal number of interdigital neuromas in the second and third interspaces. They theorized that repetitive local trauma related to footwear was the main etiologic factor rather than the communicating branch.
- 1984. Jones and Klenerman (32) identified the communicating branch in all 20 cadaver feet studied. They suggested enlargement of this communicating branch may be responsible for the frequent involvement of the third interspace.
- 1993. Levitsky et al. (39) found the communicating branch in only 26.8% of specimens studied. They developed a ratio of the distance between the metatarsal heads to the diameter of the nerve and found it to be significantly smaller in the second and third interspaces, suggesting neuromas are caused by an entrapment neuropathy based on mechanical force.
- 1993. Thompson and Deland (66) coined the term “second neuroma, same foot,” or SNSF, to describe the occurrence of a second primary neuroma in the same foot. They placed the incidence at under 4%. They found it even more rare for the neuromas to occur simultaneously and suggested that both interspaces not be explored at the same time.
- 1995. Bennett et al. (7) presented a comprehensive staged treatment protocol for interdigital neuromas, along with their results.
- 1996. Benedetti et al. (6) reported on 19 feet that underwent simultaneous excision of two primary interdigital neuromas in adjacent interspaces. They found a 3% incidence. Patients had dense sensory loss. The authors recommended one single dorsal longitudinal incision in the second webspace to resect both neuromas.

## DIAGNOSIS

The key to a successful outcome from treatment of an interdigital neuroma is first making the correct diagnosis. The examiner needs to determine not only if the patient's symptoms are consistent with the diagnosis of a neuroma, but also at which interspace the neuroma is located. This can be very challenging. The diagnosis is made on the basis of a patient's symptoms and the physical examination. Certainly there are patients that present with classic symptoms and physical findings. Although magnetic resonance imaging (MRI) and ultrasound have been reported to be sensitive in diagnosing interdigital neuromas, they have not gained wide acceptance and should not take the place of a directed history and physical examination.

### *Symptom Complex*

The most common symptoms, in decreasing order of frequency, are presented in Table 114.1, which was adapted from Mann and Reynolds' study (44). Other studies present data without significant differences. A vast majority of the patients are women in their fifties. Most of the time, symptoms are unilateral, although bilateral neuromas occur about 15% of the time. Either the second or third interspace can be involved, with studies showing anywhere from equal involvement to predominance in the third interspace. The classic symptoms are burning plantar pain between the metatarsal heads with radiation into the toes, exacerbated by wearing tight toed, high heeled shoes and relieved by removing the offending footwear. Patients may feel a “lump” or “mass,” as if their sock is rolled up (but it is not). Some patients feel the need to “pop” their foot to obtain relief. Runners and athletes are a group being seen more often. They note the onset of their symptoms after a certain distance or period of activity. Their pain crescendos to a peak and does not subside until they stop and remove their athletic shoes.

| | |
|---|---|
| Plantar pain increased with walking | 91% |
| Relief of pain by resting | 89% |
| Plantar pain | 77% |
| Relief of pain by removing shoes | 70% |
| Pain radiating into toes | 62% |
| Burning pain | 54% |
| Aching or sharp pain | 40% |
| Numbness in the toes or foot | 40% |
| Pain radiating up the foot or leg | 34% |
| Cramping sensation | 34% |

***Table 114.1. Preoperative Symptoms***

### *Physical Examination*

A very thorough and detained examination of both feet is necessary to make the diagnosis of a neuroma. Look for positive findings consistent with a neuroma, but also rule out other causes of forefoot pain. First examine the foot in the weight-bearing position and look for deformity and swelling. In particular, note any hindfoot deformity, either varus or valgus, which affects the forefoot. Also note hammer toe, claw toe, or other angular deformities of the digits. Swelling or fullness in the interspaces or around the metatarsophalangeal joints is not a typical finding in a patient with an interdigital neuroma. Observe the patient's gait and look for any dynamic deformities or signs of pain. Then examine the non-weight-bearing foot. Document range of motion of all the joints of the foot and ankle, especially the metatarsophalangeal joints. Neurovascular assessment, skin condition, temperature, and color of the foot should be part of any foot examination and can give important information to direct the diagnosis. Check for Tinel's sign over the tarsal tunnel, because diffuse burning plantar foot pain can be caused by neuritis of the tibial nerve or a tarsal tunnel syndrome.

Perform a detailed palpitation and exam of the forefoot, specifically looking for signs of a neuroma. Palpitate carefully each metatarsophalangeal joint, under each metatarsal head, and in each interspace. Tenderness directly under the metatarsal heads or in the metatarsophalangeal joints is not a finding consistent with neuroma. When palpating in the interspace, start proximal to the metatarsal heads and work distally into the web space. This will often reproduce the patient's symptoms if a neuroma is present. Then reexamine the web spaces by applying dorsal–plantar pressure with the thumb and forefinger while squeezing the foot in a medial–lateral direction. This maneuver may produce a click or crunching feeling (called Mulder's sign) and may reproduce the patient's symptoms (49). If so, this is considered diagnostic for an interdigital neuroma. One can often feel a crunching or click without reproducing a patient's symptoms. In that case, the finding is not diagnostic for a neuroma. Table 114.2, also adapted from Mann and Reynolds (44), outlines the more common physical findings.

| | |
|---|---|
| Plantar tenderness | 95% |
| Radiation of pain into toes | 46% |
| Palpable mass | 12% |
| Numbness | 3% |
| Widening of interspace | 3% |

***Table 114.2. Physical Findings in Interdigital Neuromas***

### *Diagnostic Studies*

Obtain a weight-bearing radiograph of the foot to rule out any osseous abnormalities. Assess the metatarsophalangeal joints for arthritis, subluxation, or widening, or any other abnormalities such as a foreign body.

There are reports of the use of MRI to aid in the diagnosis of an interdigital neuroma (30,65). The authors note no false positives in the patients who eventually required surgery, but they cannot comment on false negatives without histologic verification of the diagnosis. Overall, the usefulness and cost-effectiveness of MRI have yet to be determined in the diagnosis of interdigital neuromas and directing treatment. Therefore, I do not recommend routine use of MRI.

Ultrasound has also been advocated by Shapiro and Shapiro (61) as a useful study in diagnosing neuromas. The authors accurately predicted the presence, location, and size of the neuroma in 98% of cases. They feel it is particularly useful in diagnosing adjacent neuromas in the same foot; this is the situation for which ultrasound may have its greatest usefulness. The authors also admit that the diagnosis is examiner dependent, and an experienced ultrasonographer interested in foot and ankle problems is essential.

### *Making the Diagnosis*

As mentioned earlier, some patients present with classic symptoms and physical findings, and the diagnosis seems straightforward. Many, however, are difficult to diagnose with enough confidence to suggest surgery. The best way to sort through the findings for the difficult patient is to perform a series of examinations over a period of time. Symptoms change, as do physical findings. You will either feel more confident about the presence of a neuroma or more sure that you are dealing with an entity different from a neuroma. During the time you are following the patient, different nonoperative treatments can be tried, and you may actually be able to come to a diagnosis based on the patient's response. A reasonable time period between assessments is 6–8 weeks.

One entity that can make the diagnosis and location of a symptomatic neuroma difficult is the presence (in 28% of feet) of adjacent neuromas (39), although this problem is becoming better understood. Thompson and Deland (66) suggest the use of 1–2 ml of Xylocaine into one of the suspected interspaces, with follow-up to determine its effect. If no or partial relief is obtained, the other interspace is similarly injected, with later follow-up. The authors suggest that if you feel strongly that the patient indeed has simultaneous adjacent neuromas, they should not be excised at the same time and the symptomatic one should be excised first. Benedetti et al. (6) reported on the surgical outcome of excision of adjacent neuromas, but they did not have any specific suggestions on how to diagnose them. They did stress the importance of ruling out any other condition that could cause more diffuse forefoot pain, such as peripheral neuropathy, double crush syndrome, and synovitis of the metatarsophalangeal joints.

To reiterate, if the diagnosis is not clear, treat nonoperatively, perform repeated examinations at appropriate intervals, and do *not* operate.

## PREOPERATIVE MANAGEMENT

Once the diagnosis is made, treat nonoperatively initially in all patients. Bennett et al. (7) developed a three-stage treatment protocol, the first two stages of which were nonoperative. The first stage included patient education about the condition. Footwear modifications were made to include a wider shoe, and a metatarsal pad was applied proximal to the involved interspace. A letter was sent to the patient to reinforce the program. If little or no improvement was seen within 3 months, the patient returned, and 2 ml of 1% Xylocaine and 1 ml of Aristocort (triamcinolone, 40 mg/ml) was injected into the interspace (stage 2). Immediate short-term pain relief was seen in all patients. They were encouraged to continue with the shoewear modifications. If satisfactory relief of the patient's symptoms was not seen 3 months later, surgical excision was carried out (stage 3). The authors' results are summarized in Table 114.3. They conclude that although the nonsurgical treatment was not successful in all patients, the protocol helped select those patients who might benefit most from surgery. They also felt that the injection was diagnostically helpful and that a positive response to the injection is a prerequisite to recommending surgical treatment.

| | Symptoms < 1 yr (N = 68) | Symptoms > 1 yr (N = 47) |
|---|---|---|
| Stage 1 (N = 115) | 26/68 | 18/47 |
| Improved | 43% | 39% |
| Stage 2 (N = 58) | 17/34 | 10/24 |
| Improved | 50% | 42% |
| Stage 3 (N = 24) | 12/12 | 11/12 |
| Improved | 100% | 92% |

Data from Bennett GL, Graham CE, Mauldin DM. Morton's Interdigital Neuroma: A Comprehensive Treatment Protocol. *Foot Ankle* 1995;16:760.

***Table 114.3. Patient Satisfaction with Treatment Program***

The treatment used by Mann and Reynolds (44) was similar to stage 1 of the preceding protocol. These authors found that although the patients responded well to nonoperative management, 70% to 80% were sufficiently symptomatic and dissatisfied with the change in shoewear that they opted for surgery. Anti-inflammatory medications or injections, with or without a steroid, did not provide long-term relief and was not part of their routine management. Rasmussen et al. (55) reported on 51 feet that received a single corticosteriod injection for treatment of third interspace neuromas. They concluded that injections generally did not provide a cure for interdigital neuromas, but they did provide temporary relief and did not preclude a good surgical outcome. After 4 years, only 11% of the feet had lasting improvement. The authors felt, as did Bennett et al. (7), that injection can be useful in confirming the diagnosis and as a predictor of operative success.

Local steroid injection into superficial areas with little subcutaneous tissue, such as the interspace in the foot, can cause subcutaneous atrophy, altered cutaneous pigmentation, alopecia, and telangectasia (56). The effects are more pronounced with the use of relatively insoluble preparations, such as triamcinolone. The more soluble preparations should be used in low volume if a corticosteroid is to be injected into the foot for treatment of an interdigital neuroma.

## OPERATIVE TECHNIQUE

If the surgeon feels confident that patient's symptoms are from an interdigital neuroma, and the patient has failed nonsurgical management, surgery is indicated. There are essentially three options for surgical treatment: (a) dorsal approach, (b) plantar approach, or (c) dividing the transverse metatarsal ligament and leaving the nerve intact.

### *Dorsal Approach*

The dorsal approach is the most common and widely used surgical treatment for interdigital neuroma. Overall, one can expect 80% to 85% good and excellent results with this surgical approach combined with the staged treatment protocol outlined previously (7,19,44). It is my preferred technique.

- Under tourniquet control, make a 3 cm incision starting in the involved webspace (Fig. 114.3). Place the incision between the metatarsals to avoid injury to a small dorsal sensory nerve. Carry out blunt dissection with a thumb or small scissors down through the subcutaneous tissue, avoiding injury to superficial nerves.

***Figure 114.3.*** Dorsal incision placed between the metatarsals.

- Place a Weitlander retractor or a small lamina spreader into the wound between the metatarsal heads, and open it, placing the transverse metatarsal ligament under tension (Fig. 114.4).

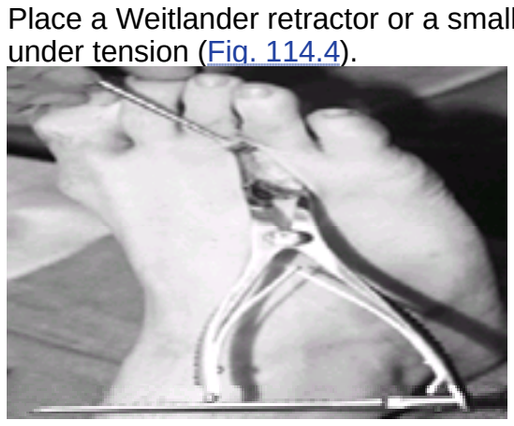

***Figure 114.4.*** Weitlander retractor placed between the metatarsals for exposure.

- Use a Freer elevator to bluntly dissect in line with the incision to identify the transverse metatarsal ligament and the normal interdigital nerve proximally. The nerve occasionally courses close to the metatarsal and is not always in the center of the interspace. Plantar pressure under the web space should reveal the enlarged neuroma protruding distal to the transverse metatarsal ligament (Fig. 114.5). Then sharply divide the metatarsal ligament.

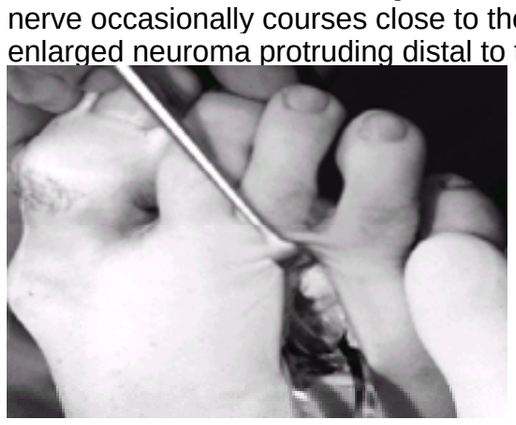

***Figure 114.5.*** Neuroma protruding distal to the transverse metatarsal ligament.

- Identify the nerve in the proximal part of the wound and trace it distally into the irregular mass. Look for any accessory branches coming from either metatarsal to join the common digital nerve. If one is identified, dissect it and clearly define it. I recommend leaving a divided accessory branch long and suturing the end into the interosseous muscle or capsule of the metatarsal head with a small suture. This prevents the nerve end from retracting and forming a potential painful

neuroma stump directly under the metatarsal head.

- Trace the common digital nerve and transect it in the most proximal aspect of the wound so the cut end does not end up between metatarsal heads. Then dissect the neuroma out distally and excise it (Fig. 114.6). Preserve as much plantar fat as possible.

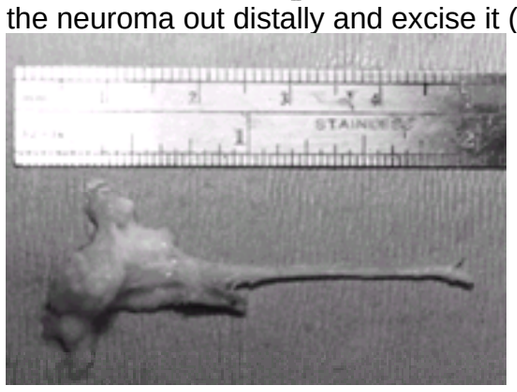

***Figure 114.6.*** Typical surgical specimen showing normal interdigital nerve (*right*) leading into irregular neuroma mass.

- Close the skin with an interrupted 4-0 nylon suture and apply a compressive dressing (Fig. 114.7).

***Figure 114.7.*** Wound is closed with interrupted nylon suture to prevent hematoma formation.

### *Plantar Approach*

The plantar approach is used less often. Karges (34) performed 57 primary interdigital neuroma excisions through a plantar approach. He felt that the improved exposure gave better results. He reported no wound problems. There are other reports, however, of painful plantar incisions from this approach. Because there is little recourse to remedy a painful plantar scar, and because the dorsal approach provides good exposure with less morbidity, the dorsal approach is preferred for excision of a primary interdigital neuroma (42,44). Some have advocated the plantar approach for treatment of recurrent neuromas. The following is a brief description of the technique.

- Palpate the metatarsal heads on each side of the involved interspace and draw them out with a skin marker.
- Place a small-gauge needle (25- or 27-gauge) from a dorsal to plantar direction in the interspace, piercing the plantar aspect of the foot. This identifies the interspace plantarward so the incision can be made accurately. Draw the incision in line with the interspace, but proximal to the metatarsal heads.
- Carry the incision through the subcutaneous tissue. Place a Weitlander retractor. Carry out dissection with a blunt scissors in line with the skin incision. Retract slips of the plantar fascia, exposing the interdigital nerve and neuroma. Transect the nerve proximally and continue dissection distal to the neuroma. Excise the neuroma as in the dorsal approach.
- Close the skin with interrupted 5-0 nylon and apply a compressive dressing.

### *Division of Transverse Metatarsal Ligament*

Good results have been reported by dividing the transverse metatarsal ligament and decompressing the interdigital nerve (22,24). When surgery has been performed for a recurrent neuroma, it appears that the transverse metatarsal ligament has completely reconstituted. This casts some doubt on the long-term outcome of an interdigital neuroma treated by this method, and it cannot be recommended at this time (42).

## POSTOPERATIVE CARE

The postoperative management for all surgical techniques is similar. Send the patient home the same day in a postoperative shoe. Instruct the patient to elevate the foot as much as possible to decrease swelling. Allow weight bearing, but the dressing should be reapplied and kept in place for up to 3 weeks after surgery. The patient may ambulate in the postoperative shoe during this time. After 3–4 weeks, the swelling and tenderness should subside enough for him to begin ambulating in a wide, sensible shoe. Start passive and active range-of-motion exercises of the foot and ankle at that time. The patient can then slowly increase activities as tolerated, but he may experience swelling and soreness for some months with vigorous activities.

## GENERAL PITFALLS AND COMPLICATIONS

There are many pitfalls awaiting the physician in the diagnosis and treatment of an interdigital neuroma. Making the correct diagnosis of a neuroma and its location can be challenging. Suggestions to avoid pitfalls in diagnosis have been given.

Be aware of the possibility of the presence of the second neuroma in the same foot. This condition is rare, but it could be the reason for unsatisfactory surgical outcomes. In addition, an incorrect diagnosis about the interspace in which the neuroma is located will lead to a poor surgical outcome. These two pitfalls have some overlap, which is difficult to sort through at times.

Too many injections of corticosteroids into one interspace can lead to atrophy of the fat pad and pigment changes of the skin. I recommend only one injection, if any, at this time, based on the previously presented data.

There have been few reported wound problems with the dorsal approach. If done incorrectly, or if the patient forms a keloid, it can lead to a painful incision that can be very difficult to cure. Dissection outside the line of the incision or overvigorous activities can lead to injury to the small dorsal cutaneous nerves, resulting in uncomfortable paresthesias or dysesthesias in the toes.

If surgery is carried out for excision of simultaneous neuromas in adjacent web spaces, the patient will experience dense sensory loss under the third toe that can be uncomfortable. Devascularization of the third toe due to injury to the digital arteries has been reported as well (Fig. 114.8).

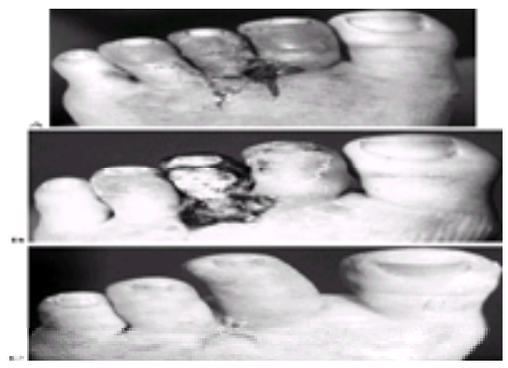

***Figure 114.8.*** **A:** Patient 8 days after excision of presumed adjacent neuromas. **B:** Same patient 20 days postoperatively with gangrene secondary to devascularization of third toe. **C:** Same patient 3 weeks after amputation of third toe.

### RECURRENT NEUROMAS

Certainly not every patient with persistent pain following neuroma excision has a “recurrent” neuroma. Beskin and Baxter (8) noted that two thirds of the 39 patients they treated for recurrent neuroma had symptoms within 12 months of the original procedure. The other one third noted symptoms 1–4 years later. Mann and Baxter (42) hypothesized that the group with recurrent symptoms within 12 months probably had surgery for the wrong diagnosis, and that the other third had the interdigital nerve transected too far distal, and the neuroma stump from the excision ended up between the metatarsal heads and took 1–4 years to become painful. In their own experience of 11 recurrent neuromas, Mann and Reynolds (44) noted the neuroma stump to be adherent to the plantar aspect of the metatarsal head in all cases. They reported that 81% of these patients were asymptomatic after surgery through a dorsal approach. The diagnosis, nonoperative management, and surgical approach are almost identical to those for the primary neuroma. At the time of surgery, you may need to extend the incision a little more proximally to get down to virgin tissue and nerve, then follow it distally into the neuroma stump. Also, postoperatively, patients should be allowed a little longer healing time before returning to vigorous activities.

## AUTHOR'S PERSPECTIVE

Interdigital neuromas can be very challenging to diagnose and treat. By following the guidelines for diagnosis, nonoperative management, and surgical treatment outlined in this section, you may be able to avoid the many pitfalls and complications. Nothing can take the place of experience. I cannot overstate the importance of patient history and physical examination. All the information needed to make the diagnosis is in the room with you and the patient—you just need to find it. Those of us who treat foot and ankle problems on a daily basis all too often see distressed patients who have had neuromas excised from multiple interspaces on both feet. Unfortunately, there is very little to offer them at that point. Remember that adjacent neuromas in the same foot are very rare. Neuromas occur bilaterally in about 15% of the patients, and even then rarely at the same time. If you think a patient has multiple neuromas, think again and again. If unsure as to the diagnosis or location, do not operate. That is the best advice I can give.

## TARSAL TUNNEL SYNDROME

### ANATOMY

The anatomy of the tarsal tunnel must be understood to understand tarsal tunnel syndrome. The tarsal tunnel is a fibro-osseous canal bounded by the tibia and medial malleolus anteriorly, the talus laterally, and the flexor retinaculum medially. The medial surface of the talus with the sustenaculum tali and the medial surface of the os calcis form the osseous floor. The tunnel is completed by the laciniate ligament (flexor retinaculum). The contents of the canal are, from medial to lateral, the tibialis posterior tendon and its sheath, the flexor digitorum longus tendon and its sheath, the posterior tibial neurovascular bundle, and the flexor hallucis longus muscle–tendon unit (Fig. 114.9).

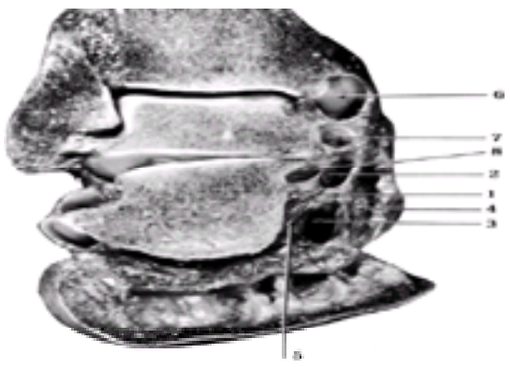

***Figure 114.9.*** The compartments of the tarsal tunnel as seen in a frontal cross section of the ankle and hindfoot. *1*, Interfascicular septum; *2*, upper chamber containing medial plantar neurovascular bundle; *3*, lower chamber containing lateral plantar neurovascular bundle; *4*, abductor hallucis muscle; *5*, quadratus plantae muscle; *6*, tibialis posterior tunnel; *7*, flexor digitorum longus tunnel; *8*, flexor hallucis longus tunnel.

The flexor retinaculum is triangular, with a proximal malleolar apex and an inferior base along the superior border of the abductor hallucis muscle. The anterior and posterior borders are difficult to define because they blend with the dorsal and superficial aponeuroses of the foot and leg, respectively. The tibial nerve divides into the medial and lateral plantar nerves and gives off its calcaneal branch within the tarsal tunnel in most cases. There is, however, great variation in this branching pattern (Fig. 114.10).

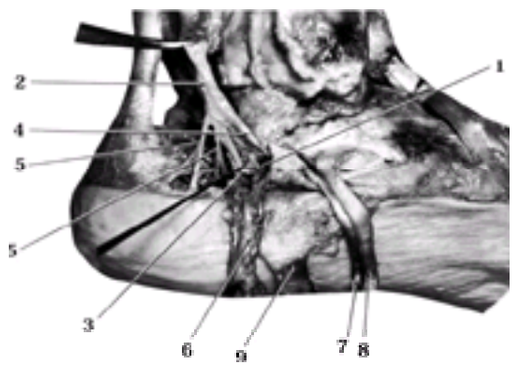


***Figure 114.10.*** Medial aspect of tarsal tunnel. *1*, Interfascicular ligament; *2*, posterior tibial nerve; *3*, lateral plantar nerve entering lower chamber; *4*, medial plantar nerve entering upper chamber; *5*, medial calcaneal nerves; *6*, posterior tibial vessels reflected downward; *7*, flexor digitorum longus reflected downward; *8*, tibialis posterior tendon reflected downward; *9*, reflected flexor retinaculum.

## PATHOPHYSIOLOGY

Tarsal tunnel syndrome is the result of compression of the posterior tibial nerve within the tarsal canal, or of one of its terminal branches distal to the canal. Along its course, the nerve is susceptible to compression from numerous sources, both intrinsic and extrinsic. In about 60% of the patients with a tarsal tunnel syndrome, a specific cause can be identified (41). Table 114.4 lists the differential diagnosis of tarsal tunnel syndrome (16).

| |
|---|
| Remote causes |
| Interdigital neuroma |
| Intervertebral disc lesion |
| Plantar fasciitis |
| Plantar fibromatosis |
| Intraneural causes |
| Peripheral neuritis |
| Peripheral vascular disease |
| Diabetic neuropathy |
| Leprosy |
| Neurofibromatosis |
| Neuroma |
| Extraneural causes |
| Ganglion |
| Nerve retracting |
| Fracture |
| Blunt trauma |
| Valgus hindfoot |
| Rheumatoid arthritis |
| Venous varicosities |
| Tenosynovitis |
| Ligament constriction |
| Abductor hallucis origin constriction |
| Tarsal coalition (middle or posterior facet) |
| Lipoma |

From Mann RA. Tarsal Tunnel Syndrome. Proceedings of the American Orthopaedic Foot Society. Orthop Clin North Am 1978;9:189.

***Table 114.4. Differential Diagnosis of Tarsal Tunnel Syndrome***

## SYMPTOM COMPLEX

The most common presenting complaint for tarsal tunnel syndrome is “burning” dysesthesias or paresthesias on the plantar aspect of the foot. The symptoms are aggravated by prolonged standing or activity and partially relieved at rest. Many patients describe worsening of their symptoms while in bed at night, making it difficult to fall asleep. Some patients describe the Valleix phenomenon, which is proximal radiation of the pain along the medial aspect of the leg to the midcalf (16). Often the symptoms are diffuse and vague and not very well localized. Take a carefully directed history to identify any of the alternative diagnoses listed in Table 114.4. Look for a history of previous trauma such as an ankle sprain or fractures about the ankle or hindfoot. It is very important to elicit a history of diabetes or peripheral vascular disease, which can cause a peripheral neuropathy and mimic some of the symptoms of a tarsal tunnel syndrome.

## PHYSICAL EXAMINATION

First, examine the foot in the weight-bearing position, looking for any deformity such as varus or valgus of the hindfoot. Perform gross examination for swelling, color, and temperature. Carry out a detailed neurovascular exam. Check pulses, warmth, and capillary refill. Gross sensory examination is usually not very localizing or helpful. Patients may note some subjective decrease in sensation on the plantar aspect of the foot, but it is difficult to quantify. Bailie and Kelikian (2) reported a significant increase in two-point discrimination (2-PD) of 7 mm in affected feet compared to normal controls. Postoperatively, they noted an improvement of 4 mm in 2-PD. They suggest using the patient's uninvolved foot as the control in unilateral disease because of the wide range of normal values (8–15 mm). Check the range of motion of the ankle, subtalar, and transverse tarsal joints for possible arthrofibrosis from an old injury, or the presence of a tarsal coalition.

Then palpate the entire course of the posterior tibial nerve, starting proximal to the tarsal tunnel and proceeding distally along the medial and lateral plantar nerves. In a patient with a tarsal tunnel syndrome, one can often demonstrate radiation of neuritic symptoms into the plantar aspect of the foot in the distribution of the medial or lateral plantar nerves or both (Tinel's sign). Carefully palpate the tarsal tunnel to identify the presence of any space-occupying lesion such as a ganglion cyst or tumor. Motor function of the intrinsic and extrinsic muscles of the foot rarely reveals weakness. Look for any subtle atrophy of the abductor hallucis or abductor digiti quinti muscles as compared to the opposite foot.

## DIAGNOSTIC STUDIES

### *Electrodiagnosis*

Carry out electrodiagnostic studies in all patients to support the diagnosis of tarsal tunnel syndrome. Only when these studies are abnormal, and combined with a history and physical examination consistent with a tarsal tunnel syndrome, can the diagnosis be made. Since Goodgold et al. (25) have established the electrodiagnostic criteria for tarsal tunnel syndrome, numerous authors have reported on the use of electrodiagnosis for tarsal tunnel syndrome (2,11,16,20,21,25,31,33,41,50,52). As work continues in this area, recommendations for the best method are constantly changing.

Electrodiagnostic tests fall into three broad categories: (a) nerve conduction studies of the medial and lateral plantar nerve, (b) measurement of motor-evoked potentials, and (c) sensory conduction velocity (42). Recent data suggest that the sensory nerve conduction velocity is the most accurate. Galardi et al. (21) found sensory action potential (SAP) to be abnormal in all affected limbs, thereby making it a very sensitive test. This coincides with the findings of Oh et al. (50), who found abnormal SAPs in 90.5% of their patients. Galardi et al. (21) were concerned about the poor specificity of pure sensory potentials. They studied mixed nerve action potentials (NAPs) and found them abnormal in 85.7% of the limbs with tarsal tunnel syndrome, with no abnormal studies in asymptomatic limbs or normal controls, making it very specific. They concluded that both SAPs and mixed NAPs are useful in the diagnosis of tarsal tunnel syndrome. They recommend that the coexistence of abnormal sensory and mixed nerve action potentials is highly sensitive and specific for diagnosis of tarsal tunnel syndrome.

### *Magnetic Resonance Imaging*

Magnetic resonance imaging can accurately depict the contents of the tarsal tunnel and the courses of the terminal branches of the posterior tibial nerve (17). Most studies report that surgical outcome for tarsal tunnel syndrome is best when a definite lesion is identified (11,17,18,51,64). Frey and Kerr (18) noted positive MRI findings in 88% of symptomatic feet studied. They also noted positive MRI findings in 85% of the feet with abnormal electrodiagnostic studies. They concluded that the information provided by MRI could enhance surgical planning by indicating the extent of decompression required. Pfeiffer and Cracchiolo (51) suggest that, unless there is an identifiable lesion on MRI near or within the tarsal tunnel preoperatively, surgical decompression of the posterior tibial nerve should be considered with caution. Again, the diagnosis of tarsal tunnel syndrome is based on clinical and electrodiagnostic data. MRI is a useful adjunct when a space-occupying lesion is suspected.

## PREOPERATIVE MANAGEMENT

Nonsurgical treatment depends heavily on the diagnosis and identification of a cause. Nonsteroidal anti-inflammatory medicines or an injection of a corticosteroid preparation can be tried if tenosynovitis is suspected. If a flexible foot deformity is found, an orthotic device can be helpful. If a lesion is found either on examination or on MRI, surgical decompression is indicated. If a patient's symptoms persist after nonsurgical treatment, and you strongly suspect compression or constriction of the posterior tibial nerve within the tarsal tunnel, surgery is also indicated.

## OPERATIVE TECHNIQUE

There is no controversy about the surgical technique for decompression of the posterior tibial nerve within the tarsal tunnel. Identify and decompress the distal branches (i.e., the medial and lateral plantar nerves) at the same time.

- Approach the tarsal tunnel through a curved incision starting 10 cm proximal to the tip of the medial malleolus and 2 cm posterior to the medial tibial border. Carry the incision distal to the tip of the medial malleolus, then gently curve it distally and plantarward. Deepen the incision through the subcutaneous tissue to the level of the flexor retinaculum (laciniate ligament).
- Identify the retinaculum proximally. Note the tibialis posterior tendon in its sheath. The flexor digitorum longus tendon and posterior tibial nerve lie directly posterior to it. Open the retinaculum from proximal to distal. As you dissect distally, the retinaculum becomes more thick and taut. Place a curved clamp under the retinaculum, and release it completely.
- Bluntly dissect the posterior tibial nerve from proximal to distal. Note the condition of the nerve as well as any compression along its course. If the normal amount

of perineural fat is present, it should be preserved.

- Trace the medial plantar nerve distally to where it enters into a fibrous tunnel. If the nerve is felt to be compressed at this point, open the tunnel and release the nerve.
- Then trace the lateral plantar nerve distally to where it courses deep to the abductor hallucis muscle. The dorsal portion of the muscle often requires release to decompress the nerve branch. Identify the first branch off the lateral plantar nerve, the nerve to the abductor digiti quinti, as it courses deep to the deep investing fascia encompassing the abductor hallucis muscle. This is discussed in more detail later in this chapter.
- Release the tourniquet to obtain hemostasis. Observe whether the nerve's normal color returns or if there is a pale area from chronic constriction. Note in the operative report if the nerve appears abnormal, for prognostic purposes. Then close the wound in layers, without repairing the retinaculum. Apply a sterile soft dressing and place a well-padded posterior splint.

### GENERAL REHABILITATION AND POSTOPERATIVE PRINCIPLES

Do not allow weight bearing for 3 weeks, then apply a removable walking cast for an additional 3 weeks. During that time, the patient may remove the cast and start early range-of-motion exercises. Physical therapy is rarely indicated. Patients may increase activities as tolerated after 6 weeks.

### RESULTS

Overall, superior results are seen when an obvious lesion is identified and treated. If no specific etiology can be identified, approximately 75% of patients obtain relief but 25% obtain little or no relief (42). It is rare for a patient to be more symptomatic following uncomplicated tarsal tunnel release. In 1990, Cimino (11) reviewed 24 articles and compiled the overall treatment results from these reports. Those data are summarized in Table 114.5.

| *Results* | *Patients (N)* |
|---|---|
| Surgery | |
| Good (resolution of symptoms) | 84 |
| Improved (mild residual symptoms) | 27 |
| Poor (symptoms unchanged or worsened) | 8 |
| Recurrent (symptoms returned) | 3 |
| Percentage of good and improved | 91% |
| Orthoses | |
| Good (resolution of symptoms) | 10 |
| Poor | 0 |
| Refused treatment or pending | 12 |
| Other methods | |
| Injection, resolution | 3 |
| Spontaneous resolution | 4 |
| Results not reported | 35 |
| Total | 186 |

From Cimino WR. Tarsal Tunnel Syndrome: Review of the Literature. Foot Ankle 1990;11:67.

***Table 114.5. Results of Tarsal Tunnel Treatment: Summary of 24 Reports***

Since Cimino's review, Bailie and Kelikian (2) reported 72% patient satisfaction following surgery. They also noted an overall less-satisfied patient group in the presence of a worker's compensation claim. Pfeiffer and Cracchiolo (51) reported only 44% patient satisfaction after surgery and cautioned against surgery unless an obvious lesion is identified.

### GENERAL PITFALLS AND COMPLICATIONS

Most of the pitfalls associated with tarsal tunnel syndrome are related to misdiagnosis. Tarsal tunnel syndrome is a rare entity. It implies compression of the posterior tibial nerve or its branches within the tarsal tunnel. Pain or neuritis along the course of the posterior tibial nerve is not a tarsal tunnel syndrome. Peripheral neuropathy, often in conjunction with diabetes, can mimic tarsal tunnel syndrome, but surgical decompression will rarely be of benefit. Additional nerve lesions in the same lower extremity can affect the treatment outcome of tarsal tunnel syndrome. These additional lesions, which can occur anywhere along the course of the sciatic, common peroneal, posterior tibial, or plantar nerves, can be detected with electrodiagnostic tests as well as with a thorough history and physical examination (58). As noted, the best results occur when a specific mass or lesion is identified, either clinically or on an MRI scan. When a lesion is not identified, surgical decompression can still be of benefit, but the patient needs to understand that satisfactory outcomes occur only 75% of the time on average, or even less.

Electrodiagnostic studies and the criteria for diagnosing tarsal tunnel syndrome are ever changing. Patients are often referred with an electromyogram and/or nerve conduction velocity study with an interpretation by the examiner of a tarsal tunnel syndrome. The diagnosis is not made on electrodiagnostic studies alone. These studies serve only to support the clinical impression.

Surgical complications have been infrequently reported in the literature. A single case report of posterior tibial tendon dislocation following decompression has been published (37). One series reported an overall 13% complication rate, consisting of a hematoma, suture abscesses, superficial wound infections, and hypertrophic sensitive scars (2).

Recurrent symptoms can occur after initial relief. They are believed to be secondary to adhesions or fibrosis around the nerve, rather than the formation of another lesion. An MRI may be quite useful to identify a possible surgical lesion. Revision surgery for tarsal tunnel syndrome is rarely beneficial and should be avoided if possible. This is especially true for the patient who did not obtain any relief from the first surgical decompression.

### AUTHOR'S PERSPECTIVE

I believe that tarsal tunnel syndrome is a rare and overdiagnosed condition. If, after a thorough history and physical examination, you feel strongly that the patient's symptoms are caused by compression of the posterior tibial nerve within the tarsal tunnel, obtain an electrodiagnostic study. Most recent reports indicate that a combination of SAPs and mixed NAPs is a highly sensitive and specific electrophysiologic indication for tarsal tunnel syndrome. Work closely with the person performing these tests and be familiar with their techniques and expertise. If the electrodiagnostic tests are consistent with the diagnosis, and a repeat history and physical examination are unchanged from the first ones, treat the patient for tarsal tunnel syndrome. If an extrinsic cause, such as varus or valgus of the hindfoot, is identified, carry out nonsurgical treatment accordingly. If after 3–6 months the treatment has not provided adequate relief, consider surgical decompression. If a lesion or mass is appreciated on physical examination, or is suspected, obtain an MRI to define the extent of the lesion. If a fracture or tarsal coalition is suspected, obtain a computed tomography scan to delineate the abnormality. Surgery is indicated if an expected lesion is identified. Revision tarsal tunnel surgery has poor results and I try to avoid it.

## SURAL NERVE ENTRAPMENT

### PATHOPHYSIOLOGY

The sural nerve is most often formed by the medial sural nerve, a branch of the tibial nerve. It may receive branches from the lateral sural nerve or the common peroneal nerve (Fig. 114.11). The sural nerve is accompanied by the short saphenous vein as they course lateral to the Achilles tendon. It passes 1.0–1.5 cm distal to the tip of the lateral malleolus. Readers interested in a detailed description of the anatomy and the many variations of the sural nerve are referred to Sarrafian's textbook (59).

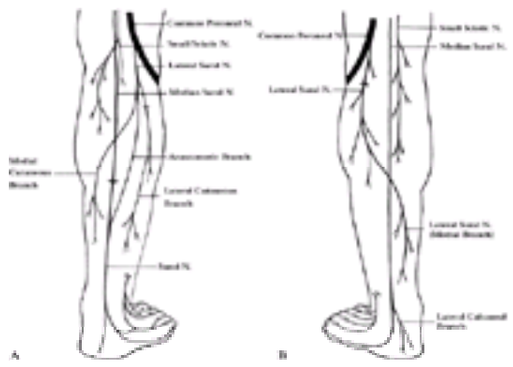

***Figure 114.11.*** **A:** Sural nerve type A (53%) formed by the medial sural nerve only. **B:** Sural nerve type B (40%) formed by two roots, the medial and lateral sural nerves, connected by an anastomotic branch.

The sural nerve is well protected throughout its course, being surrounded by subcutaneous tissue, and is not subjected to sharp fascial edges or tight constricting bands. Coert and Dellon (12) identified a potential site of entrapment of the lateral sural nerve as it pierces through the deep vein fascia near the knee. As the knee is extended, the fascia can exert a compressive force on the nerve. Most sural neuropathies, however, are either related to trauma (e.g., lacerations, fractures, ankle sprains) or external pressure (e.g., ganglia, Baker's cyst). There are few reports in the literature regarding this entity. In 1974, Pringle et al. (53) reported four cases of sural nerve entrapment. Their report found a fracture at the base of the fifth metatarsal, a recurrent ankle sprain, and ganglion cysts to be underlying causes. Also, external compression of the nerve at different levels has been reported (57).

### ASSESSMENT, INDICATIONS, RELATIVE RESULTS

The most reliable feature in making the diagnosis of sural nerve entrapment is a history of neurogenic pain in the distribution of the sural nerve. Often the symptoms occur only with athletic activities. Physical findings are often absent, so the history becomes paramount in making the diagnosis. On occasion one can palpate a mass or cyst, or identify an associated fracture, but more often the history is all there is to go on. Electrodiagnostic testing can be performed to help localize an area of compression if the physical examination is not helpful. Sensory nerve action potentials are reduced in the affected extremity and normal in the contralateral limb. If a mass is suspected, an MRI scan is useful to identify the extent and location of the mass.

### PREOPERATIVE MANAGEMENT

Treatment is directed based on the underlying cause. If a history of external compression is identified, the symptoms resolve 1–2 months after removal of the offending cause (57). If the symptoms are secondary to trauma, a combination of casting or rest, nonsteroidal anti-inflammatory medicines, and observation is indicated. If nonsurgical methods fail to resolve the symptoms, consider surgery. A trial injection of a local anesthetic agent around the involved area with temporary resolution of symptoms preoperatively will increase the chance that surgery may help. If a mass or ganglion cyst is noted, surgical excision is indicated.

### OPERATIVE TECHNIQUE

- Place the patient either supine or in the lateral position on the operating room table. A tourniquet may be used.
- Make a small incision over the involved area identified preoperatively. Carry out blunt dissection carefully down to the nerve. Excise the mass or release any compression.
- Transpose the nerve if external compression is the problem.
- At closure, cover the nerve with surrounding soft tissue and close the skin with interrupted suture. Apply a compressive dressing.

Postoperatively, the patient may increase activity as tolerated after the incision has healed.

## DEEP PERONEAL NERVE ENTRAPMENT

### PATHOPHYSIOLOGY

In the distal third of the leg, the deep peroneal nerve courses beneath the extensor hallucis longus muscle. As it approaches the ankle, it is located between the extensor hallucis longus tendon and the tendon of the extensor digitorum longus. It passes beneath the superior and inferior extensor retinacula, then divides into a medial and lateral branch. The medial branch accompanies the dorsalis pedis artery, and it divides into two dorsal branches that supply the first web space (Fig. 114.12). Just distal to the inferior retinaculum, the lateral branch penetrates and innervates the extensor digitorum brevis (EDB) muscle. These terminal branches of the peroneal nerve may become compressed beneath the inferior extensor retinaculum. Marinacci (45) called this entrapment the anterior tarsal tunnel syndrome. Since that time, there have been scattered case reports in the literature (1,10,23,35,54), with the largest series being reported by Dellon (14).

***Figure 114.12.*** Second layer of the dorsum of the foot and ankle. *1*, Anterior tibial artery; *2*, anterior medial malleolar artery; *3*, anterior lateral malleolar artery; *4*, dorsalis pedis artery; *5*, first dorsal metatarsal artery; *6*, arcuate artery; *7*, dorsal metatarsal arteries 2, 3, 4; *8*, medial tarsal artery; *9*,*10*, deep peroneal nerve; *11*, motor nerve branch to extensor digitorum brevis (EDB); *12*, inferior extensor retinaculum; *13*, superomedial band of inferior extensor retinaculum; *14*, inferomedial of inferior extensor retinaculum; *15*, superolateral band of inferior extensor retinaculum; *16*, superior extensor retinaculum; *17*, tibialis anterior tendon; *18*, extensor hallucis longus tendon; *19*, extensor digitorum longus tendon; *20*, EDB muscle to toes 2, 3, 4; *21*, extensor hallucis brevis muscle.

### ASSESSMENT, INDICATIONS, RELATIVE RESULTS

Most patients reported in the literature have been women. A history of trauma can often be elicited. Shoe straps or tight-fitting boots, such as ski boots, that cross the dorsum of the foot may irritate the nerve and lead to compression of the deep peroneal nerve (Fig. 114.13). Classically, patients complain of a deep ache over the dorsal and medial aspects of the foot, with paresthesias into the first web space. Symptoms can range from exacerbation with activities and relief with rest, to night pain that awakens the patient. Physical findings include decreased sensation in the first web space, a positive nerve percussion sign (Tinel's) over the course of the deep peroneal nerve, and atrophy of the EDB muscle. Often, however, only a few—if any—of these signs are present. There are a couple of reasons that atrophy of the EDB may be lacking despite the presence of a true anterior tarsal tunnel syndrome. If the entrapment occurs distal to the take-off of the motor branch, a pure sensory neuropathy occurs. If the motor branch is involved, atrophy and weakness of the EDB may be seen. Another reason is that in 22% of patients the accessory deep peroneal nerve, a branch of the superficial peroneal nerve, innervates the EDB (27,36,43). In these cases, entrapment of the deep peroneal nerve would not manifest as denervation of the EDB muscle.

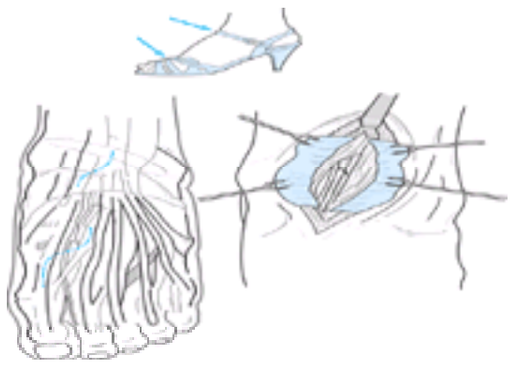

***Figure 114.13.*** Entrapment sites over dorsum of ankle and foot. Shoe straps may have a direct relationship to nerve compressions in this region. Notice the more proximal site for release of the anterior tarsal tunnel syndrome at the inferior retinaculum. The incision for the release of the deep peroneal nerve over the mid dorsum of the foot is outlined (*arrow*). Deeper view demonstrates extensor hallucis brevis tendon crossing the neurovascular bundle.

Electrodiagnostic abnormalities include prolonged distal latencies of the peroneal nerve (Table 114.6) and needle findings described as representing "denervation" changes confined to the EDB muscle. Gessini et al. (23) have suggested that a distal latency of greater than 5 msec confined to the deep peroneal nerve is important in making the diagnosis. Because abnormal needle findings in the EDB muscle have been reported in a high number of normal subjects (1), one must be cautious about using this as the sole criterion for making a diagnosis.

| | *Peroneal Motor Distal Latency (msec)* | | |
|---|---|---|---|
| *Author* | *Patients (N)* | *Right* | *Left* |
| Marinacci (1968) | 3 | 9.5 | 11.2 |
| Krause et al. (1977) | 1 | 7.0 | 4.0 |
| | 2 | 6.7 | — |
| | 3 | 4.3 | 8.4 |
| Borges et al. (1981) | 1 | 3.5 | 7.5 |
| | 2 | 5.4 | 8.6 |
| Gessini et al. (1984) | 1 | 8.2 | 7.6 |
| | 2 | 6.9 | — |
| | 3 | 7.4 | 5.5 |

From Andersen BL, Wersch JJ, Stewart WA. Anterior Tarsal Tunnel Syndrome. *Arch Phys Med Rehabil* 1972;73:1112.

***Table 114.6. Anterior Tarsal Tunnel Syndrome***

A helpful diagnostic maneuver is to inject 3 ml of 1% Xylocaine without epinephrine into the dorsal aspect of the foot proximal to the cuneiform bones. This should provide complete, but temporary, relief of symptoms. This nerve block is recommended prior to surgery in any patient for whom the diagnosis is not clear based on history and physical examination.

### PREOPERATIVE MANAGEMENT

Nonoperative management is directed toward the underlying cause. Whatever the treatment, it should be tried for at least 3 months before considering surgery. If shoewear is identified as the problem, alterations can help. Adjusting tight ski boots is possible and would be optimal compared to surgery. Providing relief from straps (e.g., over a bone prominence) should also be tried before surgery. Alteration in athletic or daily activities as well as nonsteroidal anti-inflammatory medications can provide relief of symptoms. If these treatment modalities fail, operative intervention is indicated.

### OPERATIVE TECHNIQUE

- Place the patient supine on the operating room table. Administer regional or general anesthesia. Operate with or without a tourniquet.
- Make a dorsal incision over the proximal first metatarsal, then curve it laterally between the junction of the first and second metatarsals with the cuneiforms. Extend the incision proximally to the level of the inferior extensor retinaculum.
- Identify the extensor hallucis brevis tendon crossing the nerve at this point. Release this tendon, identify the deep peroneal nerve, and dissect both proximally and distally until the medial and lateral branches are exposed (Fig. 114.14). Release only a portion of the inferior retinaculum to make sure the nerve is not compressed.

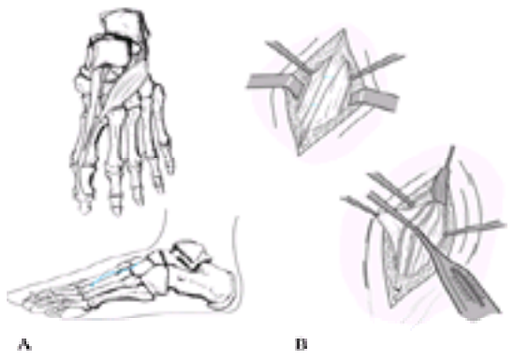


***Figure 114.14.*** Anatomy of staged surgical release of distal deep peroneal nerve entrapment. **A:** Notice extensor hallucis brevis tendon crossing deep peroneal nerve at junction of metatarsals and cuneiform bones. **B:** The initial operative management preserves the superficial peroneal nerves (vessel loops) and resects a segment of the extensor hallucis brevis tendon (between *dotted lines*). Subsequent release of the deep fascia permits neurolysis; take care to preserve the dorsalis pedis vascular bundle.

- Examine the nerve. If salvageable, perform a neurolysis. If crushed or not deemed salvageable, resect it. If the nerve is resected, dissect it proximally and bury the nerve end into the muscles of the anterolateral compartment and secure it with 5-0 nylon suture (15). This prevents traction on the nerve end with ankle motion.
- If there is an underlying exostosis or bone fragment, excise it.
- Close the skin with interrupted sutures and apply a compressive dressing.

## SUPERFICIAL PERONEAL NERVE ENTRAPMENT

### PATHOPHYSIOLOGY

The superficial peroneal nerve is a branch of the common peroneal nerve. It innervates the peroneus longus and brevis muscles in the lateral compartment of the leg. The nerve is most predictably found about 10.5 cm proximal to the tip of the lateral malleolus as it pierces the fascia in the distal anterolateral leg. Because of its subcutaneous position as it courses between the peroneal muscles and the extensor digitorum longus, it is especially prone to injury at this site. The superficial peroneal nerve then divides into two terminal sensory branches to form the medial dorsal cutaneous and intermediate dorsal cutaneous nerves (Fig. 114.15).

***Figure 114.15.*** Superficial layer of the dorsum of the foot and ankle. *1*, Superficial peroneal nerve; *2*, intermediate dorsal cutaneous nerve; *3*, medial dorsal cutaneous nerve; *4*, dorsal cutaneous nerve to fourth web space; *5*, dorsal cutaneous nerve to third web space; *6*, dorsal cutaneous nerve to second web space with branch to dorsum of big toe; *7*, dorsomedial cutaneous nerve to big toe; *8*, nerve branch from deep peroneal nerve to first interspace; *9*, sural nerve; *10*, saphenous nerve; *11*, dorsal venous arcade; *12*, lesser saphenous vein; *13*, greater saphenous vein; *14*, dorsal metatarsal veins; *15*, stem of inferior extensor retinaculum; *16*, superomedial band of inferior extensor retinaculum; *17*, inferomedial band of inferior extensor retinaculum.

Patients usually report paresthesias over the dorsum of the foot, sparing the first web space. The symptoms have typically been present for years and are worse with activities such as walking, jogging, or running. Patients also complain of pain over the lateral distal leg and lateral ankle. About 25% of the patients report a prior history of trauma, mostly ankle sprain. Injury to the nerve has also been reported following fibular shaft fractures, or compression by a lipoma (3,40,47,62).

As with all compression syndromes of the foot and ankle, start the physical examination with examination of the back, and look for any sciatic tension signs. Examine the common peroneal nerve around the fibula head for any swelling or a positive Tinel's sign that reproduces the location and quality of the patient's complaints. The most common area of entrapment is where the superficial peroneal nerve pierces the deep fascia approximately 10.5 cm proximal to the tip of the fibula. Point tenderness and a positive Tinel's sign is often elicited at this site. Styf and Morberg (63) described three provocative tests for detection of nerve compression, which are undertaken at rest and then again after exercise. In the first, pressure is applied over the anterior intermuscular septum while the patient actively dorsiflexes the ankle. In the second, the foot is passively plantar flexed and inverted at the ankle. The third test is performed by applying passive stretch with inversion, and percussing over the course of the nerve. Pain or paresthesia caused by any of these tests suggests entrapment of the superficial peroneal nerve. According to the authors' diagnostic criteria, entrapment of the superficial peroneal nerve is diagnosed when sensation over the dorsum of the foot is decreased and there is pain at rest or during exercise, and when at least two of the three provocative tests are positive.

### PREOPERATIVE MANAGEMENT

As with the other entrapment or compressive neuropathies, a trial of activity modification, anti-inflammatories, and an ankle strap or orthotic device may prove useful. If this fails, operative management is indicated.

Preoperatively, identify the etiology and site of compression or entrapment. If a mass is present, an MRI scan can help localize it. By examination, identify the area(s) of compression by the provocative tests and map this area out.

### OPERATIVE TECHNIQUE

- Place the patient in the supine position under general or regional anesthesia. Use a thigh tourniquet.
- Make a 6 cm incision just dorsal to the previously marked painful sites. Carry the incision bluntly through the subcutaneous tissue and identify the superficial peroneal nerve exiting the deep fascia.
- Incise the roof of the peroneal tunnel longitudinally until the nerve enters the muscle belly of the peroneal longus. Keep the incision close to the anterior intermuscular septum (Fig. 114.16).

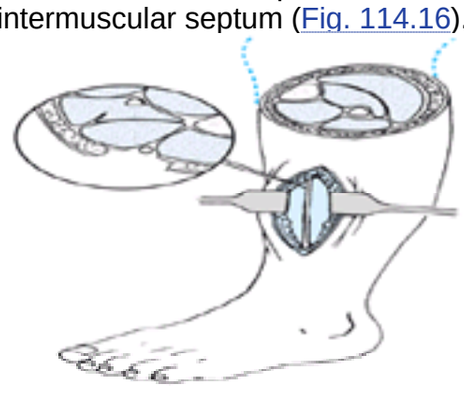

***Figure 114.16.*** Diagram of the anatomy of the superficial peroneal tunnel.

- Thoroughly decompress the nerve.
- After the nerve is freed from any surrounding pressure, close the skin with interrupted sutures.

Allow the patient to bear weight in a walking boot the following day.

## PLANTAR NERVE ENTRAPMENT

### PATHOPHYSIOLOGY

Painful conditions about the heel are common, and the differential diagnosis is extensive. One cause of a painful heel syndrome is an entrapment neuropathy of one of the branches of the tibial nerve (4,5,28). The first branch of the lateral plantar nerve has been implicated as a source of heel pain. It supplies the abductor digiti quinti muscle on the lateral side of the foot. Distal to the laciniate ligament (flexor retinaculum), the tibial nerve divides into four or five branches. There are one or two superficial branches, called the medial calcaneal nerves. The medial and lateral plantar nerves, as well as the nerve to the abductor digiti quinti, then course deep to the abductor hallucis muscle. The nerve to the abductor digiti quinti may be a separate branch of the tibial nerve or arise as a branch of the lateral plantar nerve (Fig. 114.17). It passes beneath the thick, inelastic, deep fascial edge of the abductor hallucis muscle, where it can become compressed. The nerve continues laterally, deep to the origin of the plantar fascia and flexor digitum brevis muscle, and terminates in the proximal portion of the abductor digiti quinti.

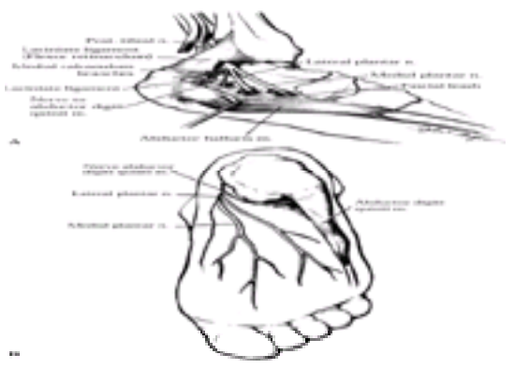

***Figure 114.17.*** **A:** Nerve to abductor digiti quinti muscle as it migrates under the deep fascia of the abductor hallucis muscle. This nerve is deeper than the more

superficial calcaneal nerve. **B:** Plantar view of nerve coursing to the abductor digiti quinti muscle.

## ASSESSMENT, INDICATIONS, RELATIVE RESULTS

Patients with painful heel syndrome typically complain of heel pain exacerbated by weight bearing. Pain is worse with the first step in the morning or on arising after a period of rest. The onset is often gradual, and a history of competitive sports is present in 50% of the cases. In contrast to other patients with heel pain who are generally older, heavier, and less active, those with nerve compression as the etiology are younger and more athletic. This patient often has had symptoms for many months or years before seeking medical attention. The pain normally starts medially but can radiate laterally. Rarely does the patient complain of numbness or paresthesias into the foot.

Physical examination reveals tenderness over the origin of the abductor hallucis muscle. Tenderness over the medial tubercle of the calcaneus is a common finding as well. A Tinel's sign is often lacking, but on occasion one can elicit radiation of pain to the lateral side of the foot. Electrodiagnostic studies can be useful as an adjunct to the history and physical examination for entrapment of the nerve to the abductor digiti quinti (60). However, the exact criteria and best method are yet to be determined.

## PREOPERATIVE MANAGEMENT

Even if entrapment of the nerve to the abductor digiti quinti is suspected as a cause of a patient's symptoms, treat nonoperatively for 6 to 12 months. The treatment is much the same as for heel pain syndrome caused by plantar fasciitis. This includes education, stretching, heel cups, over-the-counter or custom-molded orthoses, nonsteroidal anti-inflammatory medications, and alteration in athletic shoes and/or activity.

## OPERATIVE TECHNIQUE

Baxter and coworkers reviewed their experience with the operative results of 69 heels in 53 patients with recalcitrant heel pain who had failed a minimum of 6 months of conservative therapy. Their surgical technique is outlined below (4,5,42).

- Place the patient in the supine position on the operating table. Administer anesthesia, typically an ankle block. A tourniquet is not required but can be used.
- Make a 4 cm oblique incision on the medial aspect of the heel over the proximal abductor hallucis muscle. Center the incision over the course of the first branch of the lateral plantar nerve. The incision is oblique and placed distal to the medial calcaneal sensory nerves.
- Divide the superficial fascia of the abductor hallucis muscle with a #15 blade and retract the muscle superiorly with a small retractor.
- Remove a section of the deep fascia along the inferior border of the abductor hallucis directly over the area where the nerve is compressed between the taut fascia and the medial border of the quadratus muscle. A small portion of the medial plantar fascia may be removed to facilitate exposure and clearly define the plane between the deep abductor fascia and the plantar fascia (Fig. 114.18).

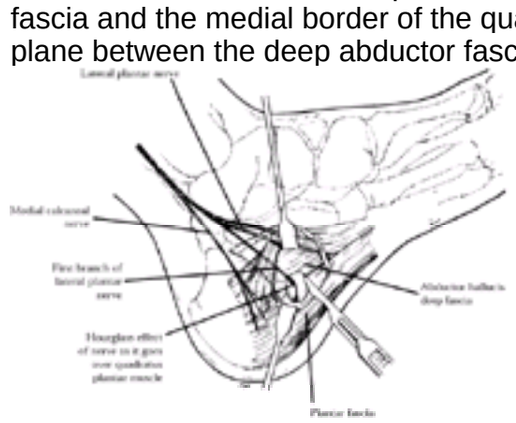

***Figure 114.18.*** A section of deep fascia of the inferior abductor abductor hallucis muscle is removed directly over the area where the nerve is compressed between this taut fascia and the medial border of the quadratus plantae muscle.

- Remove a heel spur, if present, taking care to protect the nerve that runs superiorly with a Freer elevator. Leave intact the abductor hallucis muscle belly and its superficial fascia.
- Do not perform an extensive plantar fascia release unless on direct examination there is evidence of pathology in the entire proximal portion of the plantar fascia.
- Close the wound with interrupted sutures and apply a bulky dressing.

Postoperatively, place patients on crutches, and do not allow weight bearing for 3–4 days. Then begin gradual weight bearing. Dress the wound daily with antibiotic ointment and apply gauze. One week postoperatively, the patient can try to put on an athletic shoe with a soft heel pad. The patient can resume light jogging by 4 weeks, but some symptoms persist for 3 months.

## CHAPTER REFERENCES

Each reference is categorized according to the following scheme: *, classic article; #, review article; !, basic research article; and +, clinical results/outcome study.


+ 1. Andresen BL, Wersch JJ, Stewart WA. Anterior Tarsal Tunnel Syndrome. *Arch Phys Med Rehabil* 1992;73:1112.

+ 2. Bailie DS, Kelikian AS. Tarsal Tunnel Syndrome: Diagnosis, Surgical Technique, and Functional Outcome. *Foot Ankle* 1998;19:65.

+ 3. Banerjee T, Koons DD. Superficial Peroneal Nerve Entrapment: Report of Two Cases. *J Neurosurg* 1981;55:991.

+ 4. Baxter DE, Pfefer GB. Treatment of Chronic Heel Pain by Surgical Release of the First Branch of the Lateral Plantar Nerve. *Clin Orthop* 1992;279:229.

+ 5. Baxter DE, Thigpen CM. Heel Pain: Operative Results. *Foot Ankle* 1984;5:16.

+ 6. Benedetti RS, Baxter DE, Davis PF. Clinical Results of Simultaneous Adjacent Neurectomy in the Foot. *Foot Ankle* 1996;17:264.

+ 7. Bennett GL, Graham CE, Mauldin DM. Morton's Interdigital Neuroma: A Comprehensive Treatment Protocol. *Foot Ankle* 1995;16:760.

+ 8. Beskin JL, Baxter DE. Recurrent Pain Following Interdigital Neurectomy: A Plantar Approach. *Foot Ankle* 1988;9:34.

+ 9. Betts LO. Morton's Metatarsalgia Neuritis of the Fourth Digital Nerve. *Med J Aust* 1940;1:514.

+ 10. Borges LF, Hallett M, Selkoe DJ, Welch K. The Anterior Tarsal Tunnel Syndrome: Report of Two Cases. *J Neurosurg* 1981;54:89.

# 11. Cimino WR. Tarsal Tunnel Syndrome: Review of the Literature. *Foot Ankle* 1990;11:47.

+ 12. Coert JH, Dellon AL. Clinical Implications of the Surgical Anatomy of the Sural Nerve. *Plast Reconstr Surg* 1994;94:850.

# 13. Coughlin MJ. Soft-tissue Afflictions of the Foot. In: Chapman MW, ed. *Operative Orthopaedics.* Philadelphia: JB Lippincott, 1993;2287.

+ 14. Dellon AL. Deep Peroneal Nerve Entrapment on the Dorsum of the Foot. *Foot Ankle* 1990;11:73.

+ 15. Dellon AL, Aszmann OC. Treatment of Superficial and Deep Peroneal Neuromas by Resection and Translocation of the Nerves into the Anterolateral Compartment. *Foot Ankle* 1998;19:300.

# 16. Edwards WG, Lincoln CR, Bassett FH III, Goldner JL. The Tarsal Tunnel Syndrome: Diagnosis and Treatment. *JAMA* 1969;207:716.

+ 17. Erickson EJ, Quinn SF, Kneeland JB, et al. MR Imaging of the Tarsal Tunnel and Related Spaces: Normal and Abnormal Findings with Anatomic Correlation. *AJR* 1990;155:323.

+ 18. Frey C, Kerr R. Magnetic Resonance Imaging and the Evaluation of Tarsal Tunnel Syndrome. *Foot Ankle* 1993;14:159.

# 19. Friscia DA, Strom DE, Parr JW, et al. Surgical Treatment for Primary Interdigital Neuroma. *Orthopedics* 1991;14:669.

+ 20. Fu R, DeLisa JA, Kraft GH. Motor Latencies through the Tarsal Tunnel in Normal Adult Subjects: Standard Determinations Corrected for Temperature and Distance. *Arch Phys Med Rehabil* 1980;61:243.

+ 21. Galardi G, Amadio S, Madera L, et al. Electrophysiologic Studies in Tarsal Tunnel Syndrome. *Am J Phys Med Rehabil* 1994;73:193.

+ 22. Gauthier G. Thomas Morton's Disease: A Nerve Entrapment Syndrome. *Clin Orthop* 1979;142:90.

+ 23. Gessini L, Jandolo B, Peitrangel A. The Anterior Tarsal Tunnel Syndrome: Report of Four Cases. *J Bone Joint Surg Am* 1984;66:786.

+ 24. Gillmore WN. Morton's Metatarsalgia. Proceedings of the Australian Orthopaedic Association. *J Bone Joint Surg Br* 1973;55:221.

+ 25. Goodgold J, Kopell HP, Speilholz NA. The Tarsal Tunnel Syndrome: Objective Diagnostic Criteria. *N Engl J Med* 1965;273:742.

+ 26. Graham CE, Graham DM. Morton's Neuroma: A Microscopic Evaluation. *Foot Ankle* 1984;5:150.

+ 27. Gutmann L. Atypical Deep Peroneal Neuropathy. *J Neurol Neurosurg Psych* 1970;33:453.

+ 28. Henricson AS, Westlin NE. Chronic Calcaneal Pain in Athletes: Entrapment of the Calcaneal Nerve? *Am J Sports Med* 1984;12:152.

+ 29. Hoadley AE. Six Cases of Metatarsalgia. *Chicago Med J* 1893;5:32.

+ 30. Hoskins CL, Sartoris DJ, Resnick D. Magnetic Resonance Imaging of Foot Neuromas. *J Foot Surg* 1992;31:10.

+ 31. Johnson EW, Ortiz PR. Electrodiagnosis of Tarsal Tunnel Syndrome. *Arch Phys Med Rehabil* 1980;61:243.

+ 32. Jones JR, Klenerman CM. A Study of the Communicating Branch between the Medial and Lateral Plantar Nerves. *Foot Ankle* 1984;4:313.

+ 33. Kaplan PE, Kernahan WT. Tarsal Tunnel Syndrome: An Electrodiagnostic and Surgical Correlation. *J Bone Joint Surg Am* 1981;63:96.

+ 34. Karges DE. Plantar Excision of Primary Interdigital Neuromas. *Foot Ankle* 1988;9:120.

+ 35. Krause KH, Witt T, Ross A. The Anterior Tarsal Tunnel Syndrome. *J Neurol* 1977;217:67.

+ 36. Lambert EH. The Accessory Deep Peroneal Nerve: A Common Variation in Innervation of Extensor Digitorum Brevis. *Neurology* 1969;19:1169.

+ 37. Langan P, Weiss CA. Subluxation of the Tibialis Posterior: A Complication of Tarsal Tunnel Decompression: A Case Report. *Clin Orthop* 1980;146:226.

+ 38. Lassmann G. Morton's Toe: Clinical, Light, and Electron Microscopic Investigations in 133 Cases. *Clin Orthop* 1979;142:73.

+ 39. Levitsky KA, Alman BA, Jevsevar DS, Morehead J. Digital Nerves of the Foot: Anatomic Variations and Implications Regarding the Pathogenesis of Interdigital Neuroma. *Foot Ankle* 1993;14:208.

+ 40. Mackey D, Colbert DS, Chater EH. Musculocutaneous Nerve Entrapment. *Irish J Med Sci* 1977;146:100.

+ 41. Mann RA. Tarsal Tunnel Syndrome. Proceedings of the American Orthopaedic Foot Society. *Orthop Clin North Am* 1974;5:109.

# 42. Mann RA, Baxter DE. Diseases of the Nerves. In: Mann RA, Coughlin MJ, eds. *Surgery of the Foot and Ankle*, 6th ed. St. Louis: Mosby, 1993:544.

# 43. Mann RA, Plattner P. Nerve Entrapment Syndromes of the Foot and Ankle. In: Szabo RM, ed. *Nerve Compression Syndromes: Diagnosis and Treatment.* New Jersey: Slack, 1989;273.

+ 44. Mann RA, Reynolds JC. Interdigital Neuroma: A Critical Analysis. *Foot Ankle* 1983;3:238.

+ 45. Marinacci AA. Neurological Syndromes of the Tarsal Tunnels. *Bull Los Angeles Neurol Soc* 1968;33:90.

* 46. McElvenny R. The Etiology and Surgical Treatment of Intractable Pain about the Fourth Metatarsophalangeal Joint (Morton's Toe). *J Bone Joint Surg* 1943;25:675.

+ 47. Mino DE, Hughes EC. Bony Entrapment of the Superficial Peroneal Nerve. *Clin Orthop* 1984;185:203.

* 48. Morton JG. A Peculiar and Painful Affliction of the Fourth Metatarsophalangeal Articulation. *Am J Med Sci* 1876;71:37.

+ 49. Mulder JD. The Causative Mechanism in Morton's Metatarsalgia. *J Bone Joint Surg Br* 1951;33:94.

+ 50. Oh SJ, Kim HS, Ahmad BK. The Near-Nerve Sensory Conduction in Tarsal Tunnel Syndrome. *J Neurol Neurosurg Psych* 1985;48:999.

+ 51. Pfeiffer WH, Cracchiolo A III. Clinical Results after Tarsal Tunnel Decompression. *J Bone Joint Surg Am* 1994;76:1222.

+ 52. Ponsford SN. Sensory Conduction in Medial and Lateral Plantar Nerves. *J Neurol Neurosurg Psych* 1988;51:188.

+ 53. Pringle RM, Protheroe K, Mukherjee SK. Entrapment Neuropathy of the Sural Nerve. *J Bone Joint Surg Br* 1974;56:465.

+ 54. Rash MR. Entrapment of the Anterior Tibial Nerve: Report of a Case Treated Surgically. *J Neurol Orthop Surg* 1980;1:153.

+ 55. Rasmussen MR, Kitaoka HB, Patzer GL. Nonoperative Treatment of Plantar Interdigital Neuroma with a Single Corticosteroid Injection. *Clin Orthop* 1996;326:188.

+ 56. Reddy PD, Zelicof SB, Ruotolo C, Holder J. Interdigital Neuroma. Local Cutaneous Changes after Corticosteroid Injection. *Clin Orthop* 1995;317:185.

+ 57. Reisen R, Pardal A, Ruggieri V, Gold L. Sural Neuropathy Due to External Pressure: Report of Three Cases. *Neurology* 1994;44:2408.

+ 58. Sammarco GJ, Cjhalk DE, Feibel JH. Tarsal Tunnel Syndrome and Additional Nerve Lesions in the Same Limb. *Foot Ankle* 1993;14:71.

# 59. Sarrafian SK. *Anatomy of the Foot and Ankle: Descriptive, Topographic, Functional.* Philadelphia: J.B. Lippincott, 1993.

+ 60. Schon LC, Glennon TP, Baxter DE. Heel Pain Syndrome: Electrodiagnostic Support for Nerve Entrapment. *Foot Ankle* 1993;14:129.

+ 61. Shapiro PP, Shapiro SL. Sonographic Evaluation of Interdigital Neuroma. *Foot Ankle* 1995;16:604.

+ 62. Sridhara CR, Izzo KL. Terminal Sensory Branches of the Superficial Peroneal Nerve: An Entrapment Syndrome. *Arch Phys Med Rehabil* 1985;66:789.

+ 63. Styf J, Morberg P. The Superficial Peroneal Tunel Syndrome. *J Bone Joint Surg Br* 1997;79:801.

+ 64. Takakura Y, Kitada C. Sugimoto K, et al. Tarsal Tunnel Syndrome. *J Bone Joint Surg Br* 1991;73:125.

+ 65. Terk MR, Kwong PK, Suthar M, et al. Morton's Neuroma: Evaluation with MR Imaging Performed with Contrast Enhancement and Fat Suppression. *Radiology* 1993;189:239.

+ 66. Thompson FM, Deland JT. Occurrence of Two Interdigital Neuromas in One Foot. *Foot Ankle* 1993;14:15.

# CHAPTER 115

# ARTHRODESES OF THE FOOT AND ANKLE

*Roger A. Mann and Jeffrey A. Mann*

**R. A. Mann and J. A. Mann:** Oakland, California 94609.

Introduction
Principles of Treatment
Preoperative Management
Preoperative Planning
Surgical Techniques
Ankle Arthrodeses
Subtalar Arthrodeses
Talonavicular Joint Fusion
Double Arthrodeses
Triple Arthrodeses
Tarsometatarsal Joint Arthrodeses
General Principles of Postoperative Management Following an Arthrodesis
Pitfalls and Complications
Authors' Perspective
Chapter References

## INTRODUCTION

The basic principle of an arthrodesis is to correct a painful, deformed, or unstable joint to produce a painless plantigrade foot. This is achieved by resecting the articular surfaces, correcting malalignment, and then using an appropriate method of internal fixation to provide interfragmentary compression at the arthrodesis site. The use of bone graft is usually not necessary in doing an arthrodesis unless a defect is present. Adequate postoperative immobilization is necessary to ensure that fusion occurs.

## PRINCIPLES OF TREATMENT

An arthrodesis is a surgical technique by which the articular surfaces of the bones comprising a joint are removed and bone union (fusion) is attempted, thereby effectively eliminating the motion that normally occurs in the joint. Mobility of the adjacent joints should be maintained whenever possible. Mobility of the joints of the foot and ankle aids in shock absorption at the time of initial ground contact and in producing stability within the foot at the time of heel rise and toe off. Shock absorption within the ankle occurs through dorsiflexion and plantar flexion, in the subtalar joint by eversion at the time of initial ground contact, and at the transverse tarsal joint by its flexibility at initial ground contact. Even the tarsometatarsal joints have some motion that helps to absorb stress.

Although a fusion is sometimes necessary to alleviate a patient's problem, the extent of the fusion should be minimized. If only the subtalar joint is involved, then only the subtalar joint should be fused rather than performing a triple arthrodesis. The motion of the subtalar joint depends on movement within the talonavicular and calcaneocuboid joints (transverse tarsal joint). If the talonavicular joint is arthrodesed, motion of the subtalar joint is effectively eliminated (10). An isolated calcaneocuboid joint arthrodesis still permits about two thirds of subtalar motion. An arthrodesis of the subtalar joint, however, permits motion to occur within the transverse tarsal joint (abduction–adduction). Although the degree of motion within the midfoot area, namely the intertarsal and tarsometatarsal joints, is minimal, arthrodesis in these joints creates a rigid midfoot and forefoot so that there is little or no accommodation of the forefoot to the ground during stance phase. Therefore, in attempting a fusion of this type, line up the forefoot as anatomically as possible to create a plantigrade forefoot.

The indications for an arthrodesis are to alleviate a painful joint, to correct a deformity, to produce stability, or a combination of these. The pain in the joint is usually caused by arthrosis, whether it be degenerative, traumatic, rheumatoid, or of undetermined etiology. When the articular surfaces are no longer congruent, or the articular cartilage has deteriorated, intractable pain often results. Because the foot is a weight-bearing structure with stress constantly applied to it, the pain may result in considerable disability. Although some of these problems can be managed conservatively with an orthotic device, eventually an arthrodesis is required.

An arthrodesis is often used to correct a deformity of the foot or ankle to produce a plantigrade foot. At times the deformity may cause pain resulting from an abnormal weight-bearing pattern that places too much stress on a localized area of the foot. Sometimes after trauma, such as a severe calcaneal fracture, an explosive-type fracture of the navicular, or a Lisfranc fracture-dislocation, a significant deformity may result that can be corrected with an arthrodesis.

A neurologic deficit such as peroneal weakness in Charcot-Marie-Tooth disease, a dropfoot secondary to a peroneal nerve palsy, or a deficit following a compartment syndrome or poliomyelitis may produce instability about the foot so that the foot cannot support the body weight. The instability may be produced by rupture of a tendon, such as the posterior tibial or the peroneal tendon. In such cases, a significant degree of instability and possibly a deformity may result that again may cause pain because of instability. In all of these cases, an arthrodesis may be used to realign the architecture of the foot to produce a plantigrade foot that will enable the patient to ambulate with increased stability and little or no pain.

When an arthrodesis about the foot and ankle is contemplated, several factors must be carefully considered. The soft tissue covering the foot and ankle is such that there is often little or no fatty tissue present. Therefore, the surgical approach must be as precise as possible to avoid having to place undue tension on the skin at the time of surgery, for fear that a slough might occur. The skin flaps created must be full thickness with as little undermining as possible. Keep in mind the location of the cutaneous nerves about the foot and ankle. A technically good arthrodesis may not satisfy the patient if a cutaneous nerve is caught up within the scar tissue or sensation is impaired distally as the result of a cut nerve, making it difficult for the patient to wear shoes comfortably. The major mixed nerves running into the foot are susceptible to being cut or stretched, resulting in loss of function.

When considering an arthrodesis, decide whether the arthrodesis should be an *in situ* fusion or one that requires realignment. In an *in situ* fusion, no change in the overall position of the extremity is made; when realignment is required, the deformed extremity must be carefully examined and compared with the normal side. In this way, the overall alignment of the limb (in regard to the varus–valgus alignment of the hindfoot and forefoot) and the degree of rotation (internal and external) of the extremity are determined. When an arthrodesis is performed, restore normal alignment as much as possible.

Bone preparation for an arthrodesis about the foot and ankle is the same as that for other joints: to ensure the best possible chance for fusion, broad surfaces of cancellous bone must be brought into apposition. When a realignment arthrodesis is being performed, achieving broad bony surfaces is not difficult because a sufficient amount of bone is removed during realignment of the joints. If, however, an isolated talonavicular or calcaneocuboid joint fusion is carried out and too much bone is removed from one side of the foot, a forefoot deformity could result because of shortening of the medial or lateral column. In this situation, adequate bony contact may be impossible without incorporation of some type of bone graft.

Some surgeons prefer to perform an arthrodesis by adding bone graft, obtained either locally or from the iliac crest. Local bone graft may be obtained just above the medial malleolus and from the calcaneus. This is preferable to an iliac crest bone graft. The graft may be in the form of a dowel or a rectangle of bone to be inlaid or fragments placed between the bone surfaces. Regardless of the type of fusion contemplated, the most important factor is careful surgical technique to remove the cartilage and subchondral bone so that there is good cancellous bone contact, which, with good internal fixation, should then proceed to a satisfactory fusion.

Once the bone work has been completed, some type of internal fixation is usually necessary, such as pins, plates, staples, or screws. The type of fixation depends on the surgeon's preference and the type of fusion. The following sections on each specific fusion discuss our own methods, but there are many ways to carry out an arthrodesis and insert internal fixation. Ours is based on our experience as foot and ankle surgeons.

## PREOPERATIVE MANAGEMENT

The preoperative management of an arthritic joint about the foot and ankle involves careful assessment of the patient's problem. After obtaining a history from the patient regarding the complaint, perform a physical examination to look at the alignment of the entire lower extremity. Assess the range of motion of the ankle, subtalar, transverse tarsal, and metatarsophalangeal joints. Observe the posture of the foot to see if the foot is plantigrade and, if not, the reason for the abnormality. There may be multiple joint involvement, as in the rheumatoid patient with involvement of the knee, ankle, subtalar, and transverse tarsal joints. Assess the quality of the skin because adherent skin or multiple scars may make it difficult to expose the arthrodesis site safely. Last, assess the neurovascular status of the foot and, if there are questions about the adequacy of the circulation, do arterial Doppler studies.

The conservative management of an arthritic joint usually requires an ankle–foot orthosis to immobilize a joint or accommodate a deformity. As a general rule, however, most patients with significant arthrosis are not comfortable in the long term with an orthotic device and will usually require fusion.

## PREOPERATIVE PLANNING

The preoperative planning of an arthrodesis is extremely important. Assess the involved joint or joints and decide on the extent of fusion required. Minimize the number of joints to be fused to maintain maximum flexibility of the foot and ankle. Decide whether an *in situ* fusion will be adequate or if some type of correction of a deformity needs to be achieved to create a plantigrade foot.

Last, inform the patient about the nature of the surgical procedure, including the possibility of failure of the procedure, particularly of a nonunion.

## SURGICAL TECHNIQUES

### ANKLE ARTHRODESES

An arthrodesis of the ankle joint is performed for arthrosis of the joint, malalignment, or both. There are many ways to carry out an arthrodesis of the ankle joint; the one we describe here is the transfibular approach, which we believe is the most utilitarian type of fusion (1,7,23,24 and 25). Some authors advocate doing an *in situ* fusion arthroscopically, but this should be attempted only by a very experienced arthroscopist (5,6,12,26). Most authors who initially touted this method of fusion now utilize a limited approach to the ankle joint rather than carrying it out arthroscopically. The most important factor in carrying out an ankle arthrodesis is the alignment. The alignment of the ankle joint should always be matched to the uninvolved normal side. The planes of alignment include (a) dorsiflexion–plantar flexion, (b) internal and external rotation, (c) varus–valgus, (d) medial–lateral displacement, and (e) anterior–posterior displacement (3). These five planes must be taken into consideration when carrying out an ankle arthrodesis.

- Approach the ankle joint through a transfibular approach, which starts over the lateral aspect of the fibula approximately 10 cm above the tip of the malleolus and carries distally along the lateral side of the foot toward the base of the fourth metatarsal (Fig. 115.1*A*). Create full-thickness dorsal and plantar flaps in this inter nervous plane down to bone. Continue subperiosteal dissection over the anterior aspect of the tibia and ankle joint to the neck of the talus.

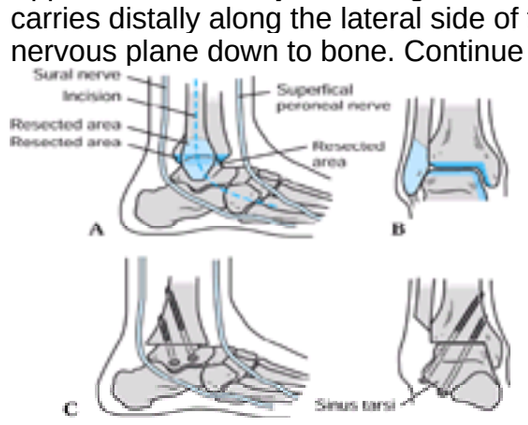


***Figure 115.1.*** Ankle arthrodesis. **A:** Placement of the incision between the superficial peroneal nerve and the sural nerve. Note that the incision ends near the base of the fourth metatarsal. **B:** Cuts made in the fibula, distal end of the tibia, and talus. This creates the flat, bony surfaces at the arthrodesis site. The fibular cut ends approximately 1.5 to 2.0 cm proximal to the level of the ankle joint. **C:** Placement of 6.5-mm screws across the arthrodesis site. Note that the screws are placed as longitudinally as possible and engage the cortex on the medial aspect of the tibia.

- Posteriorly expose the fibula, releasing the peroneal tendons.
- Distally identify the posterior facet of the subtalar joint as well as the tarsal sinus.
- Excise the distal fibula by making an oblique cut in the fibula ending 1.5 cm proximal to the joint line (Fig. 115.1*B*).
- Expose the posterior aspect of the tibia by making an incision along its posterior aspect. Strip the soft tissue along the posterior tibia distally to the calcaneus. Place malleable retractors anterior and posterior to the tibia.
- Use an oscillating saw to remove the articular surface of the tibia by transecting the tibia just proximal to the subchondral bone, remaining as perpendicular as possible to the long axis of the tibia. Cut from lateral to medial but not so far medially that the medial malleolus is fractured by using first a short wide and then a long wide saw blade.
- Remove approximately 2 to 3 mm of distal tibia, taking care to prevent fracturing the medial malleolus.
- If it appears that the cut fragment is too thick and a fracture of the medial malleolus may occur, make a second approach along the anterior medial aspect of the joint. Make an anterior medial longitudinal incision over the ankle joint and carry it distally and obliquely around the medial malleolus.
- Expose the ankle joint, avoiding injury to the saphenous vein and nerve.
- Use a 6-mm osteotome along the lateral aspect of the medial malleolus to free up the distal tibial fragment to prevent fracture of the medial malleolus when this bone fragment is removed. Return now to the lateral wound and remove the distal tibial fragment in its entirety. It is important that this cut be brought all the way across to the lateral aspect of the medial malleolus.
- Place the foot into a plantigrade position, insofar as dorsiflexion–plantarflexion and varus–valgus are concerned.
- If at this time there is a gap between the talus and the distal tibial cut, the medial malleolus is likely keeping the joint space from collapsing. In this situation, remove the distal 6 to 8 mm of medial malleolus by cutting all soft tissue attachments, avoiding injury to the posterior tibial tendon, artery, and nerve. Once this piece of medial malleolus has been removed, the joint space will readily collapse.
- With the foot held in neutral dorsiflexion–plantarflexion and about 5° of valgus, excise the dome of the talus with a saw cut that parallels the cut surface of the distal tibia. Excise approximately 3 to 4 mm of talus. Once this has been achieved, there should be a good bony apposition between the two cut surfaces, and the foot should be in a plantigrade position.
- Remove the remaining articular cartilage along the lateral side of the medial malleolus and medial side of the talus.
- If the bone in the distal tibia or talus is sclerotic, make multiple drill holes. Bring the two broad, flat surfaces of the tibia and talus together so that the anterior cut of the tibia matches the anterior aspect of the cut in the talus. In this way, the normal posterior contour of the heel is achieved.
- Check rotation by palpating the patella and rotating the foot into the predetermined degree of external rotation as well as the varus and valgus position of the hindfoot. Use two 0.062-in. K-wires for preliminary fixation of the arthrodesis.

### HINTS AND TRICKS

- Remove the two K-wires and stress the fixation. There should be little or no motion present.
- If there is some motion, insert a third screw from the tibia, either medially or laterally, into the talus. If the bone is soft, use washers.
- If there is lateral displacement at the ankle, remove the medial malleolus, center the talus on the tibia, and use multiple staples along the medial side for added internal fixation.

- For internal fixation, we prefer two interfragmentary screws, one starting in the sinus tarsi area and inserted obliquely into the medial aspect of the distal tibia and the other starting in the region of the lateral process of the talus almost paralleling the screw in the sinus tarsi and again exiting along the medial aspect of the tibia (20,21) (Fig. 115.1*C*).
- Insert the screw by first drilling a hole with a 3.2-mm drill bit in the sinus tarsi at as oblique an angle as possible to obtain the maximum amount of compression across the ankle. It is important that the medial aspect of the tibial cortex is drilled. Leave the drill bit in place and use a second drill bit to make the hole in the lateral process. Be certain to leave sufficient bone along the lateral side of the talus to provide adequate screw purchase in the bone. The second drill hole should almost parallel the first, and insert it at as longitudinal an angle as possible to gain the maximum amount of compression across the arthrodesis. Once these two

drill bits have been inserted, there is good stabilization of the arthrodesis site.
- Remove the first drill bit, measure and tap the hole, and insert a 6.5-mm long threaded screw. The screw must engage the medial cortex of the tibia to gain maximum interfragmentary compression.
- Next, remove the second drill bit and insert the next screw.

***Postoperative Care***

When closing the wounds, place a small drain and apply a short-leg compression dressing incorporating plaster splints. Approximately 10 days following surgery, remove the dressing. Remove the sutures and apply a short-leg, non-weight-bearing cast for 6 weeks. At 6 weeks, if on radiographs the arthrodesis site appears to be making satisfactory progress. Apply a short-leg weight-bearing fiberglass cast for another 6 weeks. As a general rule, the arthrodesis is solidly healed by 12 to 16 weeks (Fig. 115.2).

***Figure 115.2.*** Radiographs demonstrating ankle arthrodesis utilizing the technique described in the text. On the AP view **(B)**, note that the screws engage the medial cortex to maximize interfragmentary compression. It is also important that the threads are past the fusion site.

## SUBTALAR ARTHRODESES

Arthrodesis of the subtalar joint is used to treat arthrosis of the subtalar joint secondary to trauma, rheumatoid arthritis, or a subtalar coalition (19,22,27,29). Sometimes a subtalar arthrodesis is necessary to treat instability of the subtalar joint secondary to rupture of the posterior tibial or peroneal tendons or because of a marked valgus deformity secondary to collapse of the telonavicular joint as a result of rheumatoid arthritis.

When performing a subtalar arthrodesis for a calcaneal fracture, evaluate whether any lateral impingement is present between the calcaneus and fibula so that it can be corrected at the same time.

As a general rule, we prefer to perform a subtalar fusion without the addition of bone graft from another site, although sometimes when attempting to correct a severe valgus deformity of the subtalar joint, a bone graft may be required to fill the gap created along the lateral aspect of the joint. In the occasional patient with severe collapse of the calcaneus secondary to trauma, we insert a bone block to restore the anatomic relationship between the talus and calcaneus.

- Begin the skin incision at the tip of the fibula and carry it distally just proximal to the base of the fourth metatarsal (Fig. 115.3). The incision should be dorsal to the sural nerve, although a smaller anterior branch may be present that should be looked for and protected. Carry the incision down to the fascia overlying the extensor digitorum brevis muscle. Detach the origin of the muscle from the lateral aspect of the subtalar joint and reflect it distally to the level of the calcaneocuboid joint.

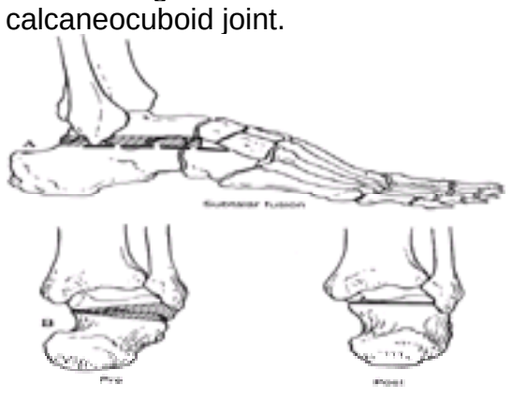

***Figure 115.3.*** **A:** Incision for subtalar fusion; *shaded area* indicates bone to be resected. **B:** Correction of varus deformity.

- Visualize the subtalar joint by removing the fat pad from the sinus tarsi and stripping the joint capsule along the lateral side of the posterior facet to delineate the posterior facet and posterior aspect of the subtalar joint.
- Facilitate exposure of the posterior facet by using a lamina spreader in the sinus tarsi to open the joint. Use a sharp curet to methodically remove the articular cartilage from the entire posterior facet and by reaching across the sinus tarsi, the middle facet.
- Remove the lamina spreader and assess the alignment of the subtalar joint. The fusion should place the subtalar joint in 5° to 7° of valgus in relation to the long axis of the lower extremity.
- If *in situ* fusion is to be achieved, feather the bone with a small osteotome and insert internal fixation. If a varus deformity needs to be corrected, remove a wedge of bone 3 to 5 mm in width from the lateral aspect of the posterior facet to realign the hindfoot. If a valgus deformity is to be corrected, a piece of iliac crest bone used as a strut in the subtalar joint may be necessary.
- When an *in situ* fusion is done, local bone graft can be acquired by harvesting the anterior process of the calcaneus, avoiding the articular surface of the calcaneocuboid joint. This can be morselized and packed into the sinus tarsi. If more bone graft is required, then we obtain the graft above the medial malleolus.
- Feather the bone surfaces of the posterior and middle facets and sinus tarsi with a 4- or 6-mm osteotome. This elicits a healing response, increases the bony surfaces, and increases the chances of successful fusion.
- For internal fixation, we prefer a 7.0-mm fully threaded cannulated screw inserted from the posterior aspect of the calcaneus just off the weight-bearing area to the neck of the talus. We overdrill the calcaneus with a 7.0-mm drill to create a glide hole to achieve intrafragmentary compression between the talus and calcaneus.
- Insert a guide pin from the posterior inferior aspect of the calcaneus about 1 cm above the weight-bearing area utilizing an anterior cruciate guide device to direct the guide pin into the posterior facet of the subtalar joint approximately in the midline and about 3 to 5 mm posterior to the anterior edge of the posterior facet. This ensures that the screw remains within the posterior facet rather than traversing the sinus tarsi.
- Once the guide pin has been placed in the calcaneus, remove the anterior cruciate guide, manipulate the calcaneus into 5° of valgus, and insert the guide pin into the neck of the talus. Use fluoroscopy to ensure proper placement of the guide pin. The guide pin should be entirely within the posterior facet of the subtalar joint and in the neck of the talus. The advantage of this technique is that with only a guide pin in place, the alignment of the subtalar joint can be checked to be certain that it is correct. If the alignment is not satisfactory, back out the guide pin, reposition the calcaneus, and reinsert the guide pin.
- Once the alignment is satisfactory, make a transverse incision on the heel along the pin in the calcaneus. Make this incision large enough to easily seat a washer without crushing the surrounding fatty tissue. Measure for screw length and then drill the guide pin through the skin on the anterior aspect of the ankle. This permits the guide pin to be gripped so that it is not accidentally withdrawn during the drilling of the hole. Use a 4.5-mm drill to drill a hole through the calcaneus and talus, following with a 7.0-mm drill to create the glide hole only in the calcaneus.
- Tap the talus and insert a 7.0-mm fully threaded screw with a washer, achieving excellent interfragmentary compression.
- If by chance there is any rocking or motion at the subtalar joint, insert a 1/8-inch smooth Steinmann pin for additional fixation. This is very rarely needed.
- Check the length of the screw by fluoroscopy, and if it is satisfactory, remove the guide pin.
- Pack bone graft into the sinus tarsi.
- Suture the extensor digitorum brevis back to its origin and close the skin.
- Apply a short-leg compression dressing incorporating plaster splints.

## HINTS AND TRICKS

- Under certain circumstances following a calcaneal fracture, when there is lateral impingement of the calcaneus against the fibula, the lateral wall of the calcaneus is removed in line with the lateral aspect of the articular surface of the talus. In this way, the peroneal tendons are decompressed. This bone can be utilized for bone graft if necessary.

***Postoperative Care***

Ten days following surgery, remove the postoperative cast. Remove sutures and apply a short-leg non-weight-bearing cast, which is kept in place for 6 weeks. At 6 weeks, if satisfactory healing of the arthrodesis is seen on radiographs, permit walking in the short-leg walking cast for another 6 weeks. Solid fusion usually occurs by 10 to 12 weeks (Fig. 115.4).

***Figure 115.4.*** Radiograph demonstrating a subtalar fusion utilizing the technique described in the text.

### TALONAVICULAR JOINT FUSION

Talonavicular joint fusion is performed for arthrosis of the talonavicular joint that may be caused by trauma or degenerative or rheumatoid arthritis (11). Subluxation of the talonavicular joint secondary to rheumatoid arthritis or posterior tibial tendon dysfunction is also an indication for an isolated talonavicular fusion (9,15). As a general rule, if the patient is older than 50 years of age, an isolated fusion is probably adequate. If the patient is younger than 50 years old or is very active, the calcaneocuboid joint should be included for increased stability. Careful evaluation is necessary to determine whether an isolated talonavicular fusion will achieve satisfactory realignment of the foot or whether the calcaneocuboid and/or subtalar joints should also be incorporated. If it seems that too much bone will be removed from the medial column when doing the talonavicular fusion, thereby producing an adducted position, always include the calcaneocuboid joint so that a balanced foot will result. Keep in mind that fusion of the talonavicular joint renders the subtalar joint nonfunctional. Therefore, it is essential that the subtalar joint be placed in 5° of valgus when the talonavicular joint is fused; otherwise a nonplantigrade foot will result.

- Approach the talonavicular joint medially. Start the incision about 1 cm distal to the tip of the medial malleolus and carry the incision along the midline of the foot to the naviculocuneiform joint (Fig. 115.5). In this area there are no superficial nerves of significant concern. Some surgeons prefer to make a slightly dorsally curved incision to approach the talonavicular joint, which is also satisfactory. When making a slightly dorsally curved incision, avoid injury to the saphenous nerve, which accompanies the saphenous vein.

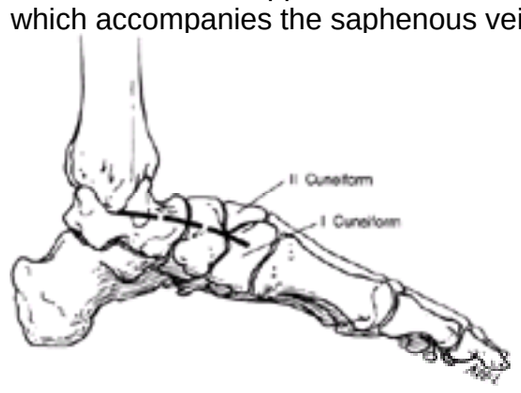


***Figure 115.5.*** Incision for talonavicular fusion.

- Palpate the talonavicular joint to be certain the proper joint is being exposed, because confusion can arise in this area. Once the talonavicular joint is identified, strip the capsular tissue along its medial aspect and then onto its dorsal and plantar aspects.
- If dorsal spurs are present, remove them. Decortication of the talonavicular joint is sometimes difficult because of limited exposure. It is often helpful to place a large towel clip into the medial aspect of the navicular and pull the foot into a slightly adducted position, which facilitates exposure of the joint.

## HINTS AND TRICKS

- In a large person, a 7.0-mm cannulated screw can be utilized.
- Where poor bone stock is present, multiple staples from a power stapilizer can be used.

- Meticulously remove all of the articular cartilage. Once this is achieved, heavily feather the talar head and the navicular.
- Manipulate the foot to assure that there will be adequate bony apposition when the foot is placed into a plantigrade position. If too much adduction will occur without bone grafting, insert bone graft or include the calcaneocuboid joint in the fusion.
- We prefer fixation with two 4.0-mm cannulated screws inserted from the naviculocuneiform joint. Place the foot in a plantigrade position with the subtalar joint in 5° of valgus and the forefoot in neutral abduction–adduction. Correct any forefoot varus by plantarflexing the navicular on the head of the talus.
- Insert a guide pin across the talonavicular joint and a second guide pin just inferior to it. Verify the position on fluoroscopy.
- Insert two 4.0-mm cannulated screws with washers, which produce good interfragmentary compression.
- Close the wound in layers and apply a short-leg compression dressing incorporating plaster splints.

***Postoperative Care***

Remove the postoperative dressing and sutures at approximately 10 days and place the patient into a short-leg non-weight-bearing cast, which is changed 6 weeks after surgery. If there is radiographic evidence of healing at that time, allow ambulation in a short-leg walking cast for another 6 weeks. As a general rule, fusion occurs by 12 to 16 weeks (Fig. 115.6).

***Figure 115.6.*** Talonavicular arthrodesis using 6.5-mm screw and two small staples. **A:** Arthrosis of the talonavicular joint. **B:** Method of internal fixation. **C:** Degenerative arthritis of the talonavicular joint, anteroposterior radiograph. **D:** Fixation of talonavicular joint using compression screw and staple.

## DOUBLE ARTHRODESES

A double arthrodesis is a fusion of the talonavicular and calcaneocuboid joints. It is indicated when there is deformity secondary to rupture of the posterior tibial tendon or after trauma in which the transverse tarsal joints (talonavicular and calcaneocuboid) have been disrupted without involvement of the subtalar joint (4,8). Consider doing a double arthrodesis when an active patient who otherwise would require only an isolated talonavicular or calcaneocuboid joint fusion will be placing a great deal of stress on the foot. A more stable foot results. A single arthrodesis can give a most satisfactory result, but we believe that in the higher-performance patient, adding the other joint enhances the stability of the foot and thus makes it more functional. Performing a double arthrodesis essentially eliminates all subtalar joint motion because subtalar motion depends on rotation of the navicular on the talus and to a lesser degree the calcaneocuboid joint. The advantages of a double arthrodesis over a triple arthrodesis are that the former has decreased morbidity and there is one less joint to fuse.

- Approach the talonavicular joint as previously described. Approach the calcaneocuboid joint through a longitudinal incision centered over the calcaneocuboid joint; make this incision cautiously because the sural nerve is in the area. Carefully identify and retract the sural nerve if possible. Deepen the incision to expose the calcaneocuboid joint and expose the joint subperiostially. Sometimes the lateral aspect of the talonavicular joint can be decorticated through this incision as well.
- If the procedure is to be done *in situ,* the alignment of the foot is not a significant problem, but if there is deformity, the joint surfaces must be realigned. Decorticate and feather the joint surfaces with a 4- or 6-mm osteotome, as previously described.
- Before internal fixation, a plantigrade foot must be achieved because there will be no functional subtalar joint motion following the double arthrodeses. Place the subtalar joint in 5° of valgus, place the forefoot in neutral abduction–adduction, and correct any forefoot abnormality, particularly varus, by plantarflexing the navicular on the head of the talus.
- Fix the talonavicular joint as described previously with two 4.0-mm cannulated screws or a 7.0-mm cannulated screw, or with multiple staples. We fix the calcaneocuboid joint with two 4.0-mm cannulated screws or multiple staples, depending on the quality of the bone.
- After surgery, keep the patient in a short-leg compression dressing incorporating plaster splints.

### *Postoperative Care*

Change the postoperative dressing at about 10 days, remove sutures, and apply a short-leg, non-weight-bearing cast for 6 weeks. At this point, if there is radiographic evidence of healing, place the patient into a short-leg walking cast for another 6 weeks. Fusion usually occurs by 12 to 16 weeks (Fig. 115.7).

***Figure 115.7.*** AP (**A**) and lateral (**B**) radiographs following a double arthrodesis utilizing 4.0-mm cannulated screws.

## TRIPLE ARTHRODESES

A triple arthrodesis is used to realign the hindfoot for instability secondary to a neurologic deficit, a tendon rupture, arthrosis, or a deformity caused by rheumatoid arthritis or trauma (2,13,14,30). The triple arthrodesis involves fusion of the subtalar, talonavicular, and calcaneocuboid joints. The fusion may be an *in situ* arthrodesis, which is relatively simple to achieve; however, when realignment of the foot is required, this procedure can be technically extremely difficult. It can be used to correct a cavus deformity as well as a flat foot deformity. It is not within the scope of this section, however, to discuss all of the various types of triple arthrodeses.

- Use two skin incisions to adequately expose the joints to be fused. Expose the subtalar and calcaneocuboid joints through a longitudinal incision starting at the tip of the fibula and carried toward the base of the fourth metatarsal (Fig. 115.8A). Expose the talonavicular joint through a longitudinal incision beginning at the tip of the medial malleolus and extended to the area of the naviculocuneiform joint (Fig. 115.5).

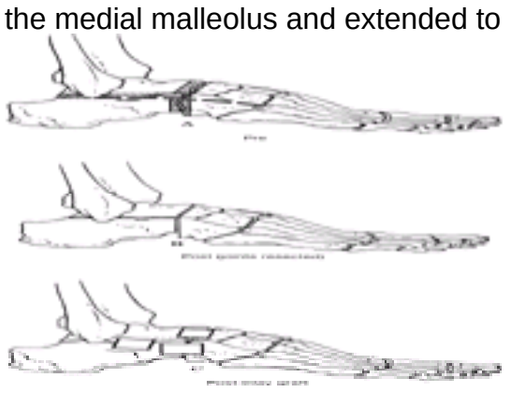

***Figure 115.8.*** Triple arthrodesis. **A:** *Dashed line* indicates incision; *shaded area* is bone to be resected. **B:** Appearance of the joint after preparation of the surfaces. **C:** An alternative technique involves stabilizing the joints with rectangular bone graft inlays; this may be combined with the procedure shown in Fig. 115.3*B*.

- Once the joints are exposed, decorticate them as previously described. As a rule, when performing a triple arthrodesis, we prefer to decorticate the surfaces to obtain good bony apposition; others, however, prefer to inlay dowels or rectangular pieces of bone from the iliac crest (Fig. 115.8*B*, Fig. 115.8*C*). Both techniques produce satisfactory results; however, we prefer not to use iliac crest bone graft if possible because of increased morbidity.
- If there is malalignment that needs correction, some bone may have to be resected to produce a plantigrade foot. The decortication of the subtalar joint is the same as previously described for subtalar joint fusion. The decortication of the talonavicular and calcaneal joints is the same as for a double arthrodesis.

- Once the joint surfaces have been prepared, place the foot into a plantigrade position with the hindfoot in 5° of valgus and the transverse tarsal joint in neutral abduction–adduction and correct any forefoot deformity, particularly forefoot varus, by plantar flexing the navicular on the head of the talus. If a plantigrade foot cannot be achieved, then resect bone as necessary to correct the deformity. Heavily feather and then internally fix the joints.
- Fix the subtalar joint with a 7.0-mm cancellous screw, as described previously, and then stabilize the talonavicular joint followed by the calcaneocuboid joint. After surgery, keep the patient in a short-leg compression dressing incorporating plaster splints for about 10 days, followed by a short-leg, non-weight-bearing cast.

### *Postoperative Care*

At 6 weeks, remove the postoperative cast, obtain radiographs, and, if early union is occurring, place the patient into a short-leg walking cast. Fusion usually occurs by 12 to 16 weeks (Fig. 115.9).

***Figure 115.9.*** Radiographs of a triple arthrodesis. **A:** Fixation of the triple arthrodesis utilizing screws. **B:** Triple arthrodesis utilizing staples and screws in a patient whose bone stock was not sufficient to obtain adequate fixation utilizing only screws.

### *Complications*

Occasionally, a nonunion occurs following a triple arthrodesis, usually at the talonavicular joint. If symptomatic, it should be surgically repaired. This is most easily accomplished by inlaying or rotating a block of bone within the nonunion site.

Malalignment can occur if the hindfoot is placed into too much varus or valgus or the forefoot is placed into too much adduction, abduction, pronation, or supination. This results in abnormal weight bearing, and it usually cannot be compensated for with an orthotic device or shoe modification, so a revision of the triple arthrodesis may be necessary. The revision is done with the same surgical approach as outlined for the triple arthrodesis. If the forefoot is in too much abduction or adduction, shorten the medial or lateral column of the foot by resecting more bone from the appropriate side to realign the foot. If a pronation or supination deformity of the forefoot also exists, realign by rotation through the transverse tarsal joint. Careful alignment of the forefoot to the hindfoot is needed to obtain a plantigrade foot.

## TARSOMETATARSAL JOINT ARTHRODESES

Arthrodesis of the tarsometatarsal joint is usually performed for primary arthrosis or posttraumatic arthrosis. Arthrodeses in the tarsometatarsal area may involve a single joint, such as the first metatarsocuneiform joint, or multiple joints (16). An *in situ* fusion may be all that is required. If there is deformity, correct it.

If only the tarsometatarsal joints are involved, then the arthrodesis need include only the metatarsal and cuneiform joints. If, however, the cuneiforms have also been disrupted, then a block fusion incorporating the cuneiforms and metatarsals is needed. Sometimes after a Lisfranc fracture dislocation, the fourth and fifth metatarsal cuneiform joints are involved, and thus, fusion of these joints must be included.

The main problems in performing a tarsometatarsal arthrodesis are that there is little soft-tissue coverage, and the nerves over the dorsum of the foot are extremely sensitive to pressure. Even when the nerves are identified during the surgical approach, the pressure from a retractor may cause a neuropraxia, which often will resolve.

There are several techniques for arthrodesis of a tarsometatarsal joint. These may involve decortication of the bony surfaces and internal fixation; others recommend using various types of dowels (17). We prefer to decorticate the bony surfaces, perform a reduction, and insert internal fixation (18,28).

- If only a first metatarsocuneiform arthrodesis is to be done, use a medial approach to expose the first metatarsocuneiform joint. Center the incision over the first metatarsocuneiform joint and carry it down through the subcutaneous tissue to expose the bone. There is no nerve in the way when a direct medial approach is used, but if a dorsal medial approach is used, carefully identify and retract the dorsal medial cutaneous nerve. Once the first metatarsocuneiform joint is identified, reflect the capsule along the dorsal, medial, and plantar aspects.
- Meticulously decorticate the first metatarsocuneiform joint, which is a sinusoidal shape so that sometimes debriding the plantar aspect of the joint is difficult. Once this has been achieved, place the joint in the same degree of abduction–adduction and plantarflexion as on the uninvolved foot. Usually the joint will fall into place once all of the soft tissues have been released and the joint surfaces are decorticated. If a deformity is present, some bone may need to be removed to realign the joint, but this is rarely necessary. Then heavily feather the joint surfaces with a 4-mm osteotome.
- There are several ways to fix the joint, but we prefer to utilize 4.0-mm cannulated screws, one from the metatarsal into the cuneiform and the other from proximally in the cuneiform into the first metatarsal. This pattern of screws gives rather rigid fixation of the joint.
- If multiple metatarsocuneiform joints need to be arthrodesed, or if the fusion mass needs to include the cuneiforms themselves, then two incisions are used. The first incision is the medial incision just described, and the second incision is placed just along the lateral aspect of the second metatarsal. The lateral approach to the second metatarsocuneiform region must be made cautiously because the neurovascular bundle lies just lateral to the extensor hallucis longus tendon. After the skin incision is made and the superficial fascia is opened, take care to expose the cutaneous nerves. We have found it simplest to approach this area by working through the medial incision and stripping the soft tissues over the dorsum of the foot as far as possible. Usually this dissection can be carried along the skeletal plane, thereby passing beneath the neurovascular bundle to about the lateral side of the middle cuneiform. When the lateral incision is deepened to the level of the skeletal plane, most of the soft tissues will have already been elevated, protecting the neurovascular bundle.
- Once the tarsometatarsal joints and intercuneiform joints that are to be arthrodesed are exposed, they should be meticulously decoricated with a thin rongeur or an osteotome. We have found that power tools usually remove too much bone.
- Once all the involved joints have been decorticated, reduce the first metatarsocuneiform joint. Following this, carefully check the alignment of the remainder of the joints to see whether any bone needs to be removed. Usually bone does not need to be removed because most deformities can be corrected by fully mobilizing the tarsometatarsal joints. Feather all of the joints to be arthrodesed with a 4-mm osteotome.
- Fix the first metatarsocuneiform joint with two crossed 4.0-mm cannulated screws as previously described.
- Next, reduce and fix the second metatarsocuneiform joint, starting the screw distally in the metatarsal and inserting it proximally across the metatarsocuneiform joint into the second cuneiform. If the cuneiform joints are included in the fusion mass, place a transverse screw from medial to lateral across the cuneiforms. If the third metatarsocuneiform joint is to be included, insert an oblique screw from distally in the third metatarsal and proximally into the third cuneiform. Occasionally, in a large person or one in whom some instability still seems to be present after the screws have been inserted, place a crossing screw from the first metatarsal into the cuneiform or occasionally a screw from the medial cuneiform into the third metatarsal base. Sometimes arthrosis is present at the naviculocuneiform joint, which then needs to be incorporated into the fusion.
- As a general rule, fusion of metatarsocuneiform joints 1, 2, and 3 is adequate. If the fourth and fifth metatarsal cuboid joints need to be arthrodesed, then try not to fuse from the cuboid to the lateral cuneiform so that motion can still be present between the medial and lateral arches of the foot. If, however, severe arthrosis is present in this area, then it must be included in the fusion, but a stiffer foot will result.
- On completion of the arthrodesis, the wounds need to be carefully closed because the skin over the dorsum of the foot is extremely thin and sensitive to pressure.
- After surgery, place the foot into a short-leg compression dressing incorporating plaster splints.

### *Postoperative Care*

Change the dressing in 10 days and apply a short-leg non-weight-bearing cast for approximately 1 month. If radiographic union seems to be occurring, use a short-leg walking cast until fusion is complete at 10 to 12 weeks (Fig. 115.10).

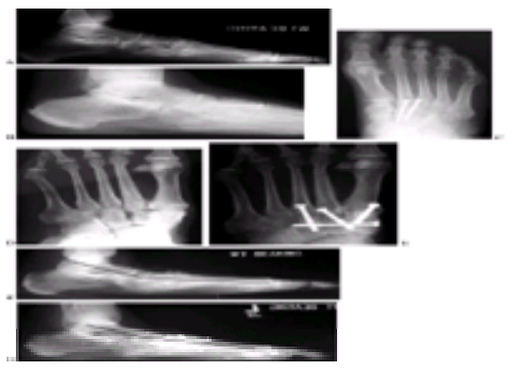

***Figure 115.10.*** Radiographs following tarsometatarsal fusions. **A:** Arthrosis of the second tarsometatarsal joint. **B,C:** Arthrodesis of the second tarsometatarsal joint utilizing 4.0-mm screws. **D:** Preoperative radiograph demonstrating primary arthrosis of the tarsometatarsal joints 1, 2, and 3. **E:** Postoperative radiograph demonstrating realignment and fusion. **F:** Preoperative radiograph demonstrating advanced arthrosis of the first tarsometatarsal joint. **G:** Postoperative radiograph following arthrodesis, demonstrating improvement in the height of the longitudinal arch.

## GENERAL PRINCIPLES OF POSTOPERATIVE MANAGEMENT FOLLOWING AN ARTHRODESIS

Before applying the dressings, infiltrate the site of the arthrodesis with 0.25% plain bupivacaine (Marcaine). This provides the patient with some initial postoperative analgesia. Once the patient is in the recovery room, have the anesthesiologist do a popliteal block. This provides the patient with anesthesia below the knee that lasts from 18 to 36 hours. Controlling the initial postoperative pain reduces narcotic requirements significantly. If the patient has too much pain the day following surgery, which occurs in about 10% to 15% of cases, do a second popliteal block. By utilizing this type of analgesia, most of our arthrodeses are carried out as outpatient procedures with a minimum amount of patient morbidity.

As a general rule, an arthrodesis results in a fair amount of trauma to the tissues, particularly in the hindfoot and midfoot. Unfortunately, there is not a great deal of soft tissue coverage in this area, so swelling must be carefully controlled with the postoperative dressing. Use a firm compression dressing along with splints for the immediate postoperative period. This firm dressing helps control the initial swelling but also permits expansion, which is important to accommodate the postoperative swelling. Following the initial postoperative period, after the sutures are removed, a firm, well-fitting cast may be applied. The patient should be kept from weight bearing on the foot until union is well under way in the presence of good internal fixation—about 6 weeks.

## PITFALLS AND COMPLICATIONS

The complications following an arthrodesis are infection, nonunion, malalignment, skin slough, and nerve entrapment, among others.

Appropriate perioperative antibiotics given when an arthrodesis is performed may help decrease the incidence of infection, but good surgical technique and careful handling of tissues are the most important factors in minimizing the risk of infection. Unfortunately, about 0.5% to 1% of cases become infected following surgery and need to be treated vigorously with debridement and antibiotic therapy.

Nonunion of an arthrodesis may occur at any joint. Minimize the risk by proper preparation of the bone surfaces and adequate internal fixation, using good postoperative immobilization. Sometimes dysvascularity of the bone prevents satisfactory arthrodesis. This may occur at the talonavicular joint if the navicular is avascular secondary to an old crush injury or when an ankle or subtalar arthrodesis is done if the body of the talus has avascular necrosis. Rather than attempting to fuse to a bone that appears avascular, excise the avascular bone and graft into bones that have normal blood supply. If a nonunion occurs and is symptomatic, revision is necessary with excision of the nonunion site and either bone grafting or reestablishing adequate bone apposition along with internal fixation.

A skin slough can be a significant problem. Because there is little soft tissue coverage about the foot and ankle, a skin slough may occur because of excessive pressure from retractors or because of marginal skin from previous surgery or trauma. Too tight a postoperative dressing can compromise skin as well. The best treatment is prevention. When a skin slough occurs, debridement may be necessary, followed by a skin graft or pedicle to close the defect if it is too large. Small marginal sloughs will heal on their own with serial dressing changes.

A nerve entrapment or neuroma can be very bothersome if the patient's shoe puts pressure against the involved area. The patient may then be unhappy in spite of a satisfactory arthrodesis. For persistent pain and disability, excise the neuroma and resect the nerve back to normal soft tissues if possible. Because there is little soft tissue coverage about the foot, it may be necessary to place the end of the nerve into the bone to relieve symptoms.

Malalignment following an arthrodesis can be frustrating for both patient and surgeon. Careful preoperative planning is necessary to prevent malalignment. Carefully assess the alignment of the entire lower extremity before attempting fixation of the arthrodesis site. Take into account the alignment of the foot with the patella because aligning the foot only to the distal tibia may result in mal alignment. Malalignment that cannot be compensated for by the use of an orthosis or shoe modification necessitates a revision of the arthrodesis site.

When performing a triple arthrodesis or other hindfoot procedures, take great care to realign the forefoot to the hindfoot. It is not enough to align the hindfoot with the leg and not take into account the alignment of the forefoot on the hindfoot.

## AUTHORS' PERSPECTIVE

An arthrodesis is an excellent procedure to provide pain relief and create a plantigrade foot. There are many pitfalls, unfortunately, along the way to obtaining a satisfactory fusion, but with careful preoperative planning, meticulous surgery, and rigid internal fixation, a satisfactory outcome can usually be achieved. In our experience, the patients who are least satisfied are the ones who have malalignment of the extremity resulting in a nonplantigrade foot. The possibility of nonunion is always present but can usually be avoided by good surgical technique.

## CHAPTER REFERENCES

Each reference is categorized according to the following scheme: *, classic article; #, review article; !, basic research article; and +, clinical results/outcome study.


+ 1. Abdo RV, Wasilewski SA. Ankle Arthrodesis: A Long-Term Study. *Foot Ankle* 1992;13(6):307.

+ 2. Adelaar RS, Dannelly EA, Meunier PA, et al. A Long-Term Study in Triple Arthrodesis in Children. *Orthop Clin North Am* 1976;7:895.

+ 3. Buck P, Morrey BF, Chao EY. The Optimum Position of Arthrodesis of the Ankle. *J Bone Joint Surg* 1987;69-A(7):1052.

+ 4. Clain MR, Baxter DE. Simultaneous calcaneocuboid and Talonavicular Fusion: Long-Term Follow-up Study. *J Bone Joint Surg* 1994;76-B:133.

+ 5. Crosby LA, Yee TC, Formanek TS, Fitzsgibbons TC. Complications Following Arthroscopic Ankle Arthrodesis. *Foot Ankle Int* 1996;17(6):340.

+ 6. Dent CM, Patil M, Fairclough JA. Arthroscopic Ankle Arthrodesis. *J Bone Joint Surg* 1993;75B:830.

+ 7. Dohm M, Purdy BA, Benjamin J. Primary Union of Ankle Arthrodesis: Review of Single Institution, Multiple Surgeon Experience. *Foot Ankle Int* 1994;15(6):293.

* 8. DuVries HL. *Surgery of the Foot.* St. Louis: CV Mosby, 1959.

+ 9. Elbaor JE, Thomas WH, Weinfeld NS, Potter TA. Talo navicular Arthrodesis for Rheumatoid Arthritis of the Hindfoot. *Orthop Clin North Am* 1976;7:821.

! 10. Elftman H. The Transverse Tarsal Joint and Its Control. *Clin Orthop* 1960;16(41).

+ 11. Fogel GR, Kato HY, Rand JA, Chao EY. Talonavicular Arthrodesis for Isolated Arthrosis: 9.5 Year Results and Gait Analysis. *Foot Ankle Int* 1982;3:105.

+ 12. Glick JM, Myerson MS, Morgan CD, et al. Ankle Arthrodesis Using an Arthroscopic Method: Long-Term Follow-up of 34 Cases. *Arthroscopy* 1996;12:428.

+ 13. Graves SC, Mann RA, Graves KO. Triple Arthrodesis in Older Adults. Results after Long-Term Follow-up. *J Bone Joint Surg* 1993;75-A:355.

+ 14. Haritdis JH, Kirkos JM, Provellegios SM, Zachos AD. Long-Term Result of Triple Arthrodesis: Forty-two Cases Followed for Twenty-Five Years. *Foot Ankle Int* 1994;15:548.

+ 15. Harper MC, Tisdel CL. Talonavicular Arthrodesis for the Painful Acquired Flat Foot. *Foot Ankle Int* 1996;17(11):658.

+ 16. Horton GA, Olney BW. Deformity Correction and Arthrodesis of the Midfoot with a Medial Plate. *Foot Ankle Int* 1993;14:493.

+ 17. Johnson JE, Johnson KA. Dowel Arthrodesis for Degenerative Arthritis of the Tarsometatarsal (Lisfranc) Joints. *Foot Ankle* 1986;6:243.

+ 18. Mann RA, Prieskorn D, Sobel M. Midtarsal and Tarsometatarsal Arthrodeses for Primary Degenerative Osteoarthrosis or Osteoarthrosis after Trauma. *J Bone Joint Surg* 1996;78A:1376.

+ 19. Mann RA, Beaman DN, Horton GA. Isolated Subtalar Arthrodesis. *Foot Ankle Int* 1998;19(8):511.

+ 20. Mann RA, Rongstad K. Arthrodesis of the Ankle: A Critical Analysis. *Foot Ankle Int* 1998;19(1):3.

+ 21. Mann RA, Van Manen JW, Wapner K, Martin J. Ankle Fusion. *Clin Orthop* 1991;268:49.

+ 22. Mann RA, Baumgarten M. Subtalar Fusion for Isolated Subtalar Disorders; Preliminary Report. *Clin Orthop* 1988;226:260.

+ 23. Marcus RE, Balourdas GM, Heiple KG. Ankle Arthrodesis by Chevron Fusion with Internal Fixation and Bone Grafting. *J Bone Joint Surg* 1983;65-A(6):833.

+ 24. Maurer RC, Cimino WR, Cox CV, Satow GK. Transarticular Cross-Screw Fixation. *Clin Orthop* 1991;268:56.

+ 25. Mazur JM, Schwarz E, Simon SR. Ankle Arthrodesis Long Term Follow-up with Gait Analysis. *J Bone Joint Surg* 1979;61-A(7):964.

+ 26. Myerson MS, Quill G. Ankle Arthrodesis. A Comparison of an Arthroscopic and an Open Method of Treatment. *Clin Orthop* 1991;268:84.

+ 27. Russotti GM, Cass JR, Johnson KA. Isolated Talocalcaneal Arthrodesis: A Technique Using Moldable Bone Graft. *J Bone Joint Surg* 1988;70-A:1472.

+ 28. Sangeorzan BJ, Veith RG, Hansen ST Jr. Salvage of Lisfranc's Tarsometatarsal Joint by Arthrodesis. *Foot Ankle* 1990;10:193.

+ 29. Swiontkowski MF, Scranton PE, Hansen S. Tarsal Coalitions: Long-Term Results of Surgical Treatment. *J Pediatr Orthop* 1983;3:287.

+ 30. Wetmore RS, Drennan JC. Long-Term Results of Triple Arthrodesis in Charcot-Marie-Tooth Disease. *J Bone Joint Surg* 1989;71-A:417.

# CHAPTER 116

# DIABETIC FOOT CARE

*Jason H. Calhoun and Jon T. Mader*

**J. H. Calhoun:** Professor and Chairman, The John Sealy Distinguished Centennial Chair in Rehabilitation Services, University of Texas Medical Branch, Galveston, Texas 77555.
**J. T. Mader:** Professor and Section Chief, Surgical Infectious Diseases, Department of Internal Medicine, University of Texas Medical Branch, Galveston, Texas 77555.

Overview
Goals of Diabetic Foot Care
Pathophysiology
Metabolic Mechanisms of Peripheral Neuropathy
Vascular Disease
Metabolic Control and Nutrition
Limited Joint Mobility Syndrome
Pathophysiology of Infections in Diabetics
Principles of Foot Care and Prevention
The Foot Care Team
Team Education and Assessment
Patient Education and Prevention
Principles of Diagnosis
Predisposing Factors
Physical Examination
Neurologic Examination
Vascular Examination
Imaging
Classification and Treatment of Infections
Cellulitis
Ulcers
Abscess and Osteomyelitis
Gangrene
Wound Closure
Role of Amputation
Principles of Foot Reconstruction
Neuropathy Control
Orthotics and Special Shoes
Treatment of Deformity
Vascular Management
Medical Management
Vascular Reconstruction
Neuropathic Arthropathy
Pathophysiology
Presentation
Treatment of Charcot Foot
Authors' Perspective
Suggested Readings
Chapter References

## OVERVIEW

The numbers of cases and problems associated with diabetic foot infections (DFI) have dramatically increased in recent years. The main reason for this increase is the growing diabetic population. For example, there were approximately 6 million diabetics in the United States in 1987 (59), and this number has grown at the rate of 9% per year to 16 million in 1997 (62). Four factors explain this dramatic growth in the number of diabetics.

1. *Heredity.* The at-risk populations such as Hispanics and Native Americans are increasing.
2. *Weight gain.* A higher percentage of people are overweight in the United States.
3. *Longevity.* Improved care for diabetics has decreased the mortality and morbidity rates for the diabetics.
4. *Reclassification.* The criteria for the diagnosis of diabetes were changed in the mid-1990s, reclassifying many patients who were formerly labeled “glucose intolerant” as diabetic.

Although the increased diabetic population is largely responsible for the elevated rates of problems associated with DFI, other factors play a role. Cases of diabetic ketoacidosis and hypoglycemia are less frequent, and the renal problems, cardiac problems and other comorbidities are better managed. Also, cases of DFI are better handled. These factors result in a reduction in the rate of amputation surgery. Hence, more diabetics are living longer, and with the decrease in amputations, there is an increase in foot problems.

Although the rate of amputation surgery is declining, diabetes is still the leading cause of amputation in the United States. In 1987, 560,000 lower extremity amputations were performed on diabetics (39). Also, diabetics are 40 times more likely that nondiabetics to have an amputation. A diabetic with an amputation has a 30% chance that the other leg will be amputated in 3 years or a 50% chance of this happening within 5 years.

### GOALS OF DIABETIC FOOT CARE

The primary goal in the management of DFI is to maintain functional ambulation through the prevention and treatment of neuropathy and infection. It is clear that development of peripheral neuropathy in the diabetic is related to high blood sugar levels (23,33). Frequent blood sugar tests for at-risk groups (e.g., overweight family members) will aid in early diagnosis. Recently, the level of hyperglycemia for the diagnosis of diabetes was lowered from 140 to 126 mg/dl (59), and at-risk group initial screening may be lowered from 40 to 25 years of age. Aggressive management of diabetes with patient education, diet, exercise, and medication yields the best blood sugar control, resulting in decreased complications of neuropathy and vasculopathy.

Many patients are unaware that they have diabetes, which is demonstrated by the fact that almost half (43%) of all diabetics have their first hospital admission or diagnosis of diabetes associated with a foot infection (7,42). Most patients, and many nurses and doctors, are unaware that neuropathy is a main contributing cause of DFI. Ninety percent of these patients have neuropathy that is associated with high blood sugar levels. Eye problems in diabetics (retinopathy) and foot problems (peripheral neuropathy) do not have the same etiology. Peripheral neuropathy is mainly a chemical neuropathy, whereas retinopathy is due to ischemic focal occlusion from plaques in athrosclerotic vessels. Although it was previously believed that proper glucose control would not affect diabetic retinopathy, it has been demonstrated that the diabetic patient under “intensive control” can dramatically reduce the progression of not only neuropathy and nephropathy but also retinopathy (20,23,34). Therefore, education of the patient, family, and health care team is the key strategy in the prevention of these diabetic-associated problems.

The American Orthopaedic Foot and Ankle Society has published a brochure, “The Diabetic Foot,” to help the physician with patient education.* One recommendation presented in this publication is that diabetic patients should wear shoes at all times, except in bed, to protect the feet from minor injury. Because DFIs start as ulcers in the insensate skin, normal or continual pressure on insensate skin causes the skin to break down. Therefore, diabetics must frequently check their feet to remove wrinkles in socks or foreign objects in shoes and vary pressure on the feet. They must always be cautious to avoid injury and to look for and immediately respond to any signs of infection in their feet. Insensate skin will also break down due to new shoes or a change in the level of use of the foot such as would occur in a new job requiring more walking. One patient of ours, a school teacher, presented with a cellulitic toe ulcer. When we showed him that his shoe had a roofing nail in the sole, he

said, “We are building a gazebo, but I visited the building site 10 days ago.” He had acquired the nail in his shoe then and had been walking on it since. The cellulitis was bad enough to require admission, intravenous antibiotics, and debridement, followed by a long course of oral antibiotics and wound care, with eventual healing. He returned five years later with a small ulcer in the other foot from another nail. He sheepishly took the nail out of his pocket to show us and commented, “I found this in my shoe shortly after I had been outside.” The second ulcer healed quickly with outpatient care and oral antibiotics. At least he knew to check his shoes and feet, and he knew the signs of infection. Even though his disease had progressed, he had less of a problem with the second infection than with the first.

## PATHOPHYSIOLOGY

Peripheral neuropathy is usually present in patients with DFIs (7,49). Although peripheral vascular disease can contribute to the severity of peripheral neuropathy, it is not the primary factor. Distal polyneuropathy is present in approximately 60% of diabetics and can be seen in any age group regardless of whether they require insulin or not (23). Nerve death in the diabetic is a result of metabolic, vascular, and histologic changes.

### METABOLIC MECHANISMS OF PERIPHERAL NEUROPATHY

In the diabetic, nerves undergo metabolic changes due to a build-up of sorbitol and fructose, and a decrease of *myo*-inositol and sodium-potassium-adenosine triphosphatase. These changes occur when increased tissue glucose is metabolized by an alternate pathway as a result of the lack of insulin, leading to decreased nerve cell function and disruption of the membrane-associated sodium pump. This factor, in turn, causes a reduction in the ability of the nerve cell to maintain a normal polarized state, and leads to demyelination, nerve injury, and eventually, nerve death (33). Loss of large sensory fiber and motor nerves causes a decrease in light touch sensation and proprioception, as well as ataxia and weakness. Loss of small sensory fibers causes a decrease in pain and temperature sensation. With decreased sensation, injuries may go unnoticed and repeated insults to the soft tissue and bone can occur (9). Also, loss of protective sensation in the joints often results in excessive forces applied to ligaments, cartilage, and bone, leading to joint erosions, dislocations, fractures, and Charcot's joint (common eponym for neuroarthropathy) development and necrosis (25,32). Neurovascular dysfunction and autonomic failure may also play roles in the development of the Charcot's joint (9,31).

### VASCULAR DISEASE

#### *Vascular Etiology*

Blood vessels in the diabetic are subject to accelerated atherosclerosis, and blood is characterized by increased viscosity, clotting, and thrombosis formation (18,65). This causes nerve death, ischemia, and embolization.

#### *Histologic Changes*

Histologic changes include paranodal and segmental demyelination in peripheral nerves, connective tissue build-up, and capillary basement membrane hypertrophy with capillary closure, resulting in the death of both large and small myelinated nerve fibers (25,32,33 and 34).

#### *Pathophysiology of Vascular Disease*

The concept that diabetic ischemia is due to small vessel disease has been challenged. It appears that there is minimal collateral vessel formation in the foot due to the rapid onset of diabetic arteriosclerosis and lack of angiogenesis (18,40). Although neuropathy is the cause of most ulcerations, vascular disease, either alone or superimposed on neuropathy, can cause DFIs (51).

#### *Susceptibility*

Diabetics are more susceptible to and have more severe arteriosclerosis than nondiabetics. Bilaterality is more often an expression of more aggressive disease progression. Calcification in diabetic arteries is diffuse and found in the media layer. In contrast, nondiabetics suffering from arteriosclerosis have a patchy distribution of plaques in the intimal layer of the diseased artery (40,53). Calcified small arteries of the foot are commonly seen on radiographs of diabetics suffering from this vascular process.

#### *Distribution*

Although diabetics get proximal occlusive disease in the iliac and femoral vessels requiring endarterectomies and proximal bypass, this disease differs from that seen in nondiabetics because diabetics tend to have a more distal distribution of disease. More distal vessel disease in the diabetic is thought to occur because the rapid progression overcomes the rate of distal collateral revascularization. Frequently, this disease has diffuse involvement of all three vessels below the trifurcation and may require a bypass that extends far more distally than that seen in nondiabetics (7).

#### *Risk Factors*

The major risk factors for development of arteriosclerosis in nondiabetics are cigarette smoking, lipoprotein abnormalities, and high blood pressure. Diabetics seem to be at greater risk for these factors, and blood pressure, triglycerides, and cholesterol are more frequently elevated and difficult to control in these patients (60).

### METABOLIC CONTROL AND NUTRITION

Multiple studies have shown a correlation between poor wound healing and poor nutrition.

Therefore, it is imperative that the diabetic patient learn to monitor blood sugars closely with visits to the endocrinologist, diabetologist, internist, and nutritionist. When an infection is present, blood sugar levels are more difficult to control, and may require several days or weeks to stabilize after the infection is controlled. A well-kept patient diary that records date, time, blood sugar levels, food, and medication is a useful tool.

### LIMITED JOINT MOBILITY SYNDROME

Limited joint mobility occurs in diabetics as the foot loses its sensation, proprioception, and intrinsic muscle function. Sensation and intrinsic muscle causes an “extrinsic plus” wide-based gait for balance that progresses to claw toes, midfoot valgus, and calcanealequinovalgus with decreased ankle and subtalar motion. Thus, a flat, stiff, insensate foot is more prone to injury, further breakdown, decreased mobility, and ulcer formation.

### PATHOPHYSIOLOGY OF INFECTIONS IN DIABETICS

#### *Immunology*

Diabetics have a poor response to infection. Decreased phagocytosis of bacteria and impaired cell-mediated immunity are noted and are worse when the serum glucose is poorly managed. Also, many antibiotics are ineffective in the resulting hypoxic, acidic environment and may be subtherapeutic in the ischemic tissue of diabetics. Blood flow is further decreased in the swollen, infected tissue seen in cellulitis, ulcers, abscesses, osteomyelitis, gangrene, and Charcot's joints. These complications often produce large dead spaces and necrotic tissue, making the local host response and antibiotic penetration even less effective.

#### *Bacteriology*

DFIs are polymicrobial and usually involve both aerobic and anaerobic species (63,64) (Table 116.1). Skin flora can cause deep infections in diabetics, occasionally making it difficult to determine the correlation between cultures taken from superficial ulcers or sinus tracts and the true pathogens causing deep infection (66). Therefore, the most meaningful cultures are those that are taken in the operating room from deep tissue underneath the ulcers or open wounds. Many of the acute soft tissue infections are caused by streptococci or *Staphylococcus aureus,* which may be found as the single pathogenic species (51). With an increase in the chronicity of the infection, or in the face of partial antibiotic treatment, polymicrobial infections are found in greater frequency. Infections may include Pseudomonas and anaerobic organisms, although it is uncommon to see a monomicrobic anaerobic infection (66).

| Superficial organisms | 1969–1973 (%) | 1974–1978 (%) | 1979–1983 (%) | 1984–1988 (%) | 1989–1992 (%) |
|---|---|---|---|---|---|
| *Streptococcus species* | 33 | 43 | 42 | 24 | 19 |
| *Staphylococcus aureus* | 44 | 28 | 43 | 33 | 29 |
| Gram-negative bacilli | * | * | * | * | 23 |
| *Staphylococcus epidermidis* | * | * | 36 | 27 | 19 |
| *Anaerobes* | * | * | 34 | 33 | 13 |
| *Enterococcus species* | * | 22 | 39 | 23 | 16 |
| Methicillin-resistant *Staphylococcus aureus* (MRSA) | * | * | 14 | 16 | 11 |
| Diphtheroids | 33 | 17 | 19 | 23 | 11 |
| *Pseudomonas species* | * | 6 | 22 | 19 | 12 |
| Gram-positive cocci | * | * | * | * | 8 |
| *Proteus species* | 33 | 17 | 37 | 20 | 8 |
| Fungi | * | * | * | * | 6 |
| Other | * | * | * | * | 6 |
| *Escherichia coli* | * | * | 16 | 9 | 4 |
| Methicillin-resistant *Staphylococcus epidermidis* (MRSE) | * | * | 17 | 2 | 4 |
| *Bacteroides species* | * | * | * | * | 2 |
| Species per patients | 1.66 | 1.31 | 3.39 | 2.44 | 2.33 |

* Too Gm-Gangrene add VR-PCN for Clostridia.
From Keogh T, Ernst S, Cullinane JD, Wanke JT: Treatment of Diabetic Foot Infections: The Common Classification, Therapy and Trends Presented at the Foot & Ankle Society Meeting, 1998, New Orleans, LA.

***Table 116.1. Bacterial Cultures***

# PRINCIPLES OF FOOT CARE AND PREVENTION

## THE FOOT CARE TEAM

The family physician, internist, orthopedic surgeon, vascular surgeon, plastic surgeon, nutritionist, diabetic nurse, and social worker need to work with the patient and the patient's family. Regular, urgent, and emergent clinics that the diabetic patient can easily access will prevent minimal problems from becoming major problems. The diabetic wound care nurse or physician's assistant plays a vital role as a part of the care team. Special training, either with a skilled local foot care team or at national courses, can give the nurse or physician's assistant the skills to organize a wound care clinic. This clinic should be open 5 days a week for dressing care, and a member of the foot care team must be readily available to answer telephone inquires from patients and for referrals. Education of local emergency rooms and primary care clinics regarding preventive care and the decision of when to refer is important. The most important members of this team are the patient and family because they must become knowledgeable and involved. If they are not or cannot be involved, then the prognosis of the patient is typically poor and they will require more care by the doctors and nurses in the clinic or hospital.

The treatment of DFIs is extremely important. Eighty percent of amputations and 20% of hospital admissions each year are due to DFIs (60). In a poorly treated foot ulcer, osteomyelitis increases the risk of amputation (3). A good treatment plan must address the underlying cause of the skin breakdown or infection and not just simply treat the ulcer itself.

## TEAM EDUCATION AND ASSESSMENT

We have found it helpful to teach the patient, family, and health care team the most common causes of (and terms for) infection and pathology in the diabetic foot. The team, which consists of the patient, family, doctors, nurses, and assistants, must be able to classify the infection and respond to it appropriately: “Is it more red?” (i.e., cellulitis); “Is there a skin sore?” (i.e., ulcer); “Is there a deep infection?” (i.e., abscess or bone infection); “Is there dead tissue?” (i.e., gangrene); “Is it getting better or worse?” (i.e., do we continue with this treatment or go to the clinic for a check-up or to the emergency room for admission?).

We have looked at diabetic infections in 1,752 cases over a 20-year period and have concluded that a simple, common classification system (Table 116.2) aids in consistent categorization and treatment for the best outcome (7,10,11). The simplicity of the classification also facilitates as ease of communication between the team and the patient. The best way to think about the type of infection in order of increasing severity and stage is cellulitis, ulcer, abscess, osteomyelitis, and gangrene. One or all of these infection grades can be present, but typically one predominates and the more severe type (i.e., the higher stages) determines treatment. Furthermore, the presence of neuropathy and ischemia make the treatment more involved.

| | |
|---|---|
| I, Cellulitis | Local redness, swelling, enlarged lymph nodes, fever, systemic illness |
| II, Ulcer | Blisters, hyperkeratotic lesions, superficial lesion to full thickness to deep tendon, bone or joint involvement |
| III, Abscess | Local blisters of the skin to deep plantar abscess with tendon or fascial involvement |
| IV, Osteomyelitis | Superficial to localized (sequestrum) to diffuse (entire bone) with intramedullary involvement |
| V, Gangrene | Dead tissue—dry, wet, gas, or necrotizing fasciitis |
| Neuropathy–(n) | Loss of protective sensation; loss of pain to pin prick |
| Ischemia–(i) | Lack of healing of an ulcer or surgical wound, slowed capillary refill<br>Blanch test > 7 minutes, $TCPo_2$ < 30 mm Hg |

$TCPo_2$, transcutaneous partial oxygen pressure.

***Table 116.2. The Common Types of Diabetic Foot Infections***

## PATIENT EDUCATION AND PREVENTION

Emphasize daily inspection of toes and feet. A mirror can be used for self-examination of the bottoms of the feet. Patients with impaired vision should have a family member inspect their feet daily. It is important to stress daily foot washing, careful drying between the toes, and daily application of a light water-based (not alcohol-based) cream without moisturizing between the toes. Caution patients to avoid exposure of feet to extremes of temperature. Have them test the temperature of bath water with the elbow before immersion. Patients also need to avoid using chemical agents or doing bathroom surgery to remove corns or calluses, and application of adhesive tape to the feet must be avoided. It is also important for the patient to inspect the insides of their shoes daily for foreign objects, nail points, and torn shoe linings. Wearing properly fitted stockings without seams or mended areas may prevent unnecessary irritation. Caution patients against wearing sandals or shoes without stockings. Patients should never walk barefoot, especially on hot sandy beaches or around swimming pools.

Appropriate activity modifications should be suggested. Last, patients should avoid wearing garters or sitting cross-legged.

### *Nail Care with Regular Follow-up by Trained Hands*

In general, it is safer to instruct patients to seek professional help for routine nail care. Hypertrophied nails colonized by fungi are potential infection sites, and trimming can be difficult if the patient's sight is poor and toes are insensate. Usually, a nurse or a physician's assistant can provide nail care in the office.

### *Footwear*

Most commercial insurance companies and most managed care plans now pay for extra-depth diabetic shoes. If the patient's insurance company does not cover the cost of these special shoes, send a letter of medical necessity or contact the insurance company with the recommendation that in order to try to prevent expensive surgery or greater disability, the patient needs extra-depth diabetic shoes. Many patients can be managed in the more “fashionably” acceptable jogging or walking shoes. Deformities such as ingrown toenails, claw toes, bunions, and hyperkeratotic areas can be managed with orthotics or shoewear modifications.

# PRINCIPLES OF DIAGNOSIS

## PREDISPOSING FACTORS

Factors that predispose diabetics for foot infections include patient noncompliance and poor visual acuity, making daily foot inspections unreliable. Patients with

peripheral neuropathy often have delays in diagnosis of infection owing to a failure to sense tissue damage. Also, autonomic dysfunction leads to anhydrosis and a loss of skin temperature regulation, which can result in dry, scaly, easy-cracking skin contributing to ulcer formation. These cracks and ulcers provide a portal for bacterial invasion that leads to infection. Poorly controlled diabetics have these problems in greater frequency (27). When ischemia or malnutrition is present, infection is also more likely to develop.

### PHYSICAL EXAMINATION

The focused orthopaedic examination of a DFI should begin with the evaluation of both lower extremities from the knee down. Owing to peripheral neuropathy, diabetics with infection may not have pain as a primary complaint. The patient and family will note fever, chills, and recent hyperglycemia despite a normal dose of insulin. On physical examination, look for erythema, swelling, induration, or fluctuance, and probe ulcers for depth and the presence of an abscess or exposed bone. Laboratory studies may show an elevated white blood cell (WBC) count with an increase in polymorphonuclear cells and elevated erythrocyte sedimentation rate, C-reactive protein, or glycosylated hemoglobin.

### NEUROLOGIC EXAMINATION

Neuropathy assessment includes an evaluation of sensory, autonomic, and motor functions. Although diabetics may have numbness, they may still feel pain. The so-called “stocking-glove” description of the sensory deficit distribution is not accurate. Although peripheral neuropathy is usually more severe distally, the proximal border of the neuropathic area is not, typically, a perfect cross section of the affected limb. The border is typically more distal directly over the major sensory nerves for evaluation of touch and more proximal farther from the major nerves for evaluation of painful stimuli. Some patients complain of severe paresthesia (spontaneous pain or burning) and dysesthesia (contact pain), which is thought to be a result of spontaneous depolarizations of injured or regenerating nerves (33). Light touch, the pin-prick test, two-point discrimination, and the Semmes-Weinstein monofilament can be used to document the sensory deficit. About 10% of patients who have already had ulceration still meet the supposed threshold criterion of feeling the 5.07% Semmes-Weinstein monofilament (7). The pinwheel test allows rapid cutaneous sensory mapping of fine point and pain perception. Clean the pinwheel well with alcohol between patients or use disposable pinwheels. Autonomic deficits present as dry, stiff skin that easily cracks owing to a loss of skin temperature regulation, abnormal sweating, and arteriovenous shunting (1,27). Clawing, pes planus, and equinus contracture occur from motor denervation of the intrinsics and compensation by the extrinsics. When combined with decreased sensation, the likelihood of ulceration increases dramatically.

### VASCULAR EXAMINATION

Patients with good capillary refill do not require additional diagnostic screening. Patients without pulses and good capillary refill may benefit from vascular consultation and screening with Doppler studies, transcutaneous oxygen measurements, or angiograms. Vasculopathy can be demonstrated by blanching normal skin and releasing the pressure. Normal blood flow results in capillary refill in less than 2 seconds. A mild decrease in the blood flow requires 7 seconds, moderate flow takes up to 13 seconds, and severe impairment greater than 13 seconds. Assess the temperature of the skin with the back of one's fingers. Some other signs of vascular insufficiency can be observed by skin changes that include loss of hair and smooth or edematous skin.

Wagner has used ankle brachial Doppler pressure ratios of less than 0.45 to indicate the potential for poor wound healing (10,54,69). For Doppler pressures, request toe pressures and pulse-volume recordings (PVR) at different locations along the limb. The PVR is normally triphasic, but when the vessel looses compliance, the waveform becomes monophasic or biphasic (7). Toe pressures less than 40 mm Hg are unlikely to result in healing of ulcers and are at a higher risk for requiring reconstructive procedures (2). We recommend the use of transcutaneous oxygen measurement ($TcP_{O_2}$) for evaluating vascularity, healing potential, and soft-tissue viability (3,11,29). Values of $TcP_{O_2}$ lower than 20 mm Hg often result in local surgical failure unless a vascular bypass is performed (13,14,70). Other useful studies are angiography or xenon clearance studies, but these procedures are more expensive and invasive.

### IMAGING

The clinical presentation and findings on physical examination determine the need for imaging studies. Imaging studies are often overused. Plain radiographs suffice in the vast majority of DFI cases. In all patients presenting with DFI, high-quality radiographs of the feet include anteroposterior (AP), lateral, and oblique views. Look for loss of soft-tissue planes, lucencies indicating gas, foreign bodies that may have precipitated the infection, and bony changes such as erosion and periosteal new bone formation that may indicate osteomyelitis. The osseous radiographic changes of neuroarthropathy can simulate osteomyelitis and the differential diagnosis can sometimes be difficult. Lytic changes in bone without overlying skin ulceration is usually not due to osteomyelitis but rather due to neuroarthropathy. Radionuclide scans, computed tomographic (CT) imaging, and magnetic resonance imaging (MRI) may be necessary to differentiate between osteomyelitis and Charcot's arthropathy, abscess, cellulitis, or early osteomyelitis (19,30,50,55,68). Although these studies are useful in certain instances, a sterile aspiration or biopsy in clinic or on the hospital floor is an easy, rapid, and painless procedure, because the patient has no sensation in the involved area.

## CLASSIFICATION AND TREATMENT OF INFECTIONS

Wagner's classification system for foot infection is quite explanatory and an excellent teaching tool for physicians and nurses; however, because it is complex it can make taking an accurate history and understanding by patients problematic. A commonly used classification that is simple is (in order of increasing severity and stage) cellulitis, ulcer, abscess, osteomyelitis, and gangrene.

### CELLULITIS

Cellulitis can range from mild redness around a callus or ulcer to full foot or leg involvement, with swelling and lymphedema. Underlying abscess, osteomyelitis, gas gangrene, or necrotizing fasciitis that can cause sepsis and death should be ruled out by examination and radiographs. Most mild cellulitis around a callus or ulcer can be managed on an outpatient basis with local skin care and oral antibiotics (Fig. 116.1). Mark the border of the red cellulitic skin with a permanent pen to establish a baseline before treatment is started. if the cellulitis worsens (extends 2 to 3 cm past the baseline) after 24 to 48 hours of oral antibiotics, the patient should be re-evaluated and treated with different oral antibiotics or hospital admission and intravenous antibiotics.

***Figure 116.1.*** **A:** Latino man, 52 years of age, who had non-insulin-dependent diabetes mellitus (NIDDM) for 10 years and was employed as head of housekeeping at the hospital. Admitted to the hospital with cellulitis and diabetic ulcer on the plantar aspect of left great toe. The $TcP_{O_2}$ was 38 mm Hg at the base of toe. The patient was discharged after 3 days of intravenous (IV) antibiotics [cephalexin (Keflex) and gentamicin], local wound care, and oral antibiotics (Keflex for 2 weeks); the wound healed at 2 months. **B:** Similar ulcer 3 years later treated without hospital admission, oral antibiotics for 2 weeks, and local wound care. Patient still works as chief of housekeeping 10 years later.

### ULCERS

It is imperative to determine whether or not an ulcer is infected before beginning wound care. Clinicians should diagnose ulcer infection by looking for drainage, depth, erythema, and cellulitis surrounding the wound; if infection is suspected, take wound cultures. Swab cultures from the surface of an ulcer or from sinus drainage have been shown to be poor indicators of the bacterial species below (64). Therefore, clinicians should curet and culture an ulcer from the base for aerobic and anaerobic organisms. Start with empirical antibiotics if infection is suspected, and modify them, if necessary, when the culture results and antibiotic sensitivities are available. The

bacterial species seen in DFIs are often multiple and range from streptococcus or staphylococcus species (the two most common) to gram-negative organisms and anaerobic organisms (Table 116.1). Bacterial infections usually can be treated with empiric oral antibiotics. We usually begin with first-generation cephalosporins and modify treatment based on the response to treatment, antibiotic sensitivities, and cultures. Quinolones may be added for gram-negative coverage and penicillin-VK for clostridial infections (Table 116.3). It the infection is arrested after 2 to 4 weeks of treatment, the antibiotic may be stopped or the dose decreased. In patients with advanced cellulitis, gas gangrene, or sepsis, treatment usually requires hospital admission, intravenous antibiotics, urgent surgical debridement, deep tissue cultures, and an infectious disease consultation.

| Organism | Antibiotic |
|---|---|
| *Staphylococcus* (methicillin-sensitive) | First-generation cephalosporin, β-lactamase-resistant penicillins (oxacillin, nafcillin), vancomycin, rifampin |
| *Staphylococcus* (methicillin-resistant) | Vancomycin |
| Enterococcus (group D *Streptococcus*) | Ampicillin, β-lactamase inhibitor (sibactam or ticarcillin-clavulanate), vancomycin |
| Gram-negative (*Pseudomonas* sp., Anaerobes (*Bacteroides* sp.) | Ciprofloxacin, L-Ofloxacin Clindamycin, metronidazol |

***Table 116.3. Antibiotic Selection***

In general, most ulcers can be treated on an outpatient basis with local wound care in conjunction with redistribution of pressure with total contact casts, orthotics, or diabetic shoes. The evolution of wound management and wound care products has created the need for standardized pathways for wound management. Accurately record the size of the ulcer in centimeters with an anatomic sketch in the patient's chart. An alternative method is to trace the ulcer on a glove or ziplock bag, then separate and dispose the side of the glove or bag that touched the ulcer and tape the tracing in the chart. Digital photographic prints of the wound are the easiest, most accurate means of documentation. Make note of the size and color of the wound bed, and look closely at the wound margins to identify sinus tracts, undermining or rimming. Describe the characteristics of the exudate by including the type, amount, color, consistency, odor, and the adherence to the wound base. These characteristics must receive ongoing assessment so that an appropriate dressing can be used that is based on the healing stage of the wound. The primary function of a wound dressing is to promote the moist healing environment necessary for tissue repair (72). The functions and indications of the most commonly used dressing materials are listed in Table 116.4. Ulcers with significant drainage require gauze dressings with frequent changes.

***Table 116.4. Characteristics of Some Available Wound Care Dressing Materials***

After healing, further ulceration can be prevented by using custom-molded, extra-depth, diabetic shoes. Deeper ulcers with hyperkeratotic edges or necrosis can be debrided in the clinic and successfully treated with the application of a total contact cast. Treatment with intravenous antibiotics based on a swab culture, or preferably, a deep culture, is helpful if significant cellulitis is present.

### *Total Contact Cast Technique*

The goal of total contact casting is the relief of pressure by distributing stresses over a large surface area.

- Apply a light dressing to the wound and hold it in place with a stockinette.
- Pad all bony prominences for protection while in the cast.
- Overlap cast padding only one-half width of the roll.
- Apply a layer of plaster, which is then overwrapped with fiberglass.
- Use a cast shoe.
- Excessive padding will allow movement in the cast and cause skin irritation or ulceration.
- The cast can be bivalved so dressing changes are easier and the cast will last longer.

Initially, casts are changed weekly to evaluate the skin and the wound. As the situation stabilizes, the cast may be changed less often.

## ABSCESS AND OSTEOMYELITIS

Treat abscesses and osteomyelitis with thorough debridement to remove all necrotic, infected tissue, followed by reconstruction (Fig. 116.2*C*, Fig. 116.2*D* and Fig. 116.2*E*). Surgery for diabetic abscess and osteomyelitis is more difficult than that for a nondiabetic because of the poor blood supply and insensate tissue. Toe amputations, ray resections, midfoot amputations, Syme's amputations, muscle flaps, or distal below-the-knee amputations (BKAs) require good blood flow to heal and adequate protective sensation to stay healed. If the area being treated is insensate, it allows more aggressive debridement with less general anesthesia, which is safer owing to the multiple system dysfunction (renal, cardiac, pulmonary) in the diabetic. Some anesthesiologists may be unfamiliar with diabetes-associated numbness and require guidance on the amount of analgesia to use during procedures. We test for lack of sensation at the incision site by squeezing with toothed tissue pick-ups before administration of anesthesia. Most distal debridement and amputation can be performed with a small amount of local or intravenous analgesia. The anesthesiologist must be present to monitor cardiac, pulmonary, and renal function. Amputation for the treatment of osteomyelitis is commonly used to remove a chronic nidus of infection and to get to the level of protective sensation for prosthetic wear. Antibiotic treatment for deep abscesses and osteomyelitis are based on cultures and antibiotic sensitivities. Only 2 weeks of antibiotics may be required if the infected bone and soft tissue are removed and good bleeding soft tissue is left. Up to 6 weeks may be required if there is osteomyelitis. Hyperbaric oxygen helps the patient with marginal oxygen levels to heal.

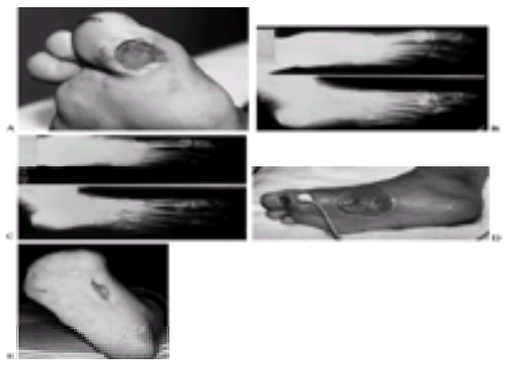

***Figure 116.2.*** **A:** White man, 37 years of age, who has NIDDM and works as welder. He has five children but no insurance. He presented with an ulcer on his toe. **B:** He had no osteomyelitis. He was not able to perform wound care or use total contact cast because of work. The ulcer progressed to osteomyelitis of the first metatarsophalangeal joint (**C**) and plantar abscess (**D**). He was treated with amputation of the toes and debridement of midfoot, IV antibiotics for 3 weeks, and second-stage closure with skin graft at 2 weeks (**E**). He still works 10 years later with same foot.

## GANGRENE

Gangrene or tissue necrosis can present as dry, wet, or gas gangrene, or necrotizing fascitis. Although all gangrenous tissue will eventually be removed, dry gangrene can be managed on an outpatient basis with local wound care for long periods until the odor, pain, or local infection requires surgical removal. Outpatient management for dry gangrene requires that the patient, family, or local care provider watch for signs of sepsis or gas gangrene. Although dry gangrene usually is painless, some patients have good sensation, and in this patient subset, the acid from the dead tissue can cause severe pain that is relieved only with amputation (Fig. 116.3). Outpatient management for forefoot gangrene can occasionally result in “auto-amputation,” in which the necrotic tissue breaks off spontaneously.

***Figure 116.3.*** White woman, 63 years of age, who had NIDDM for 3 years. She had normal sensation and a very painful gangrenous toe. $TcPo_2$ at foot of 12 mm Hg; at ankle, 21 mm Hg; at proximal tibia, 41 mm Hg. Treated with BKA.

The need for and level of amputation is determined by tissue viability and protective sensation (Fig. 116.4). We use $TcPo_2$ greater than 40 mm Hg as an indication of good perfusion and potential for healing. A patient with a $TcPo_2$ of less than 40 mm Hg has an increased failure rate, and healing can be helped with hyperbaric oxygen (52). If the patient refuses a higher amputation level or if the patient is healthy, we use the lowest amputation level that will help with ambulation and prescribe adjunctive hyperbaric oxygen therapy (Fig. 116.5). If the patient is ill or not able to use the lower amputation level for a prosthesis or ambulation and has a $TcPo_2$ of less than 40 mm Hg, we perform a higher amputation. To assess the patient's healing potential intraoperatively, we use William Wagner's (69) tourniquet technique. When a tourniquet above an amputation site is deflated and poor bleeding results after as much as 5 minutes, wound healing is unlikely. If bleeding begins 3 minutes after deflation, there is an 80% healing rate, and at 2 minutes or less, a 100% healing rate occurs (69) (Fig. 116.9*D*).

***Figure 116.4.*** White man, 40 years of age, who had insulin-dependent diabetes mellitus (IDDM) for 5 years. He had protective sensation at ankle and good blood flow. He was treated with amputation of all toes.

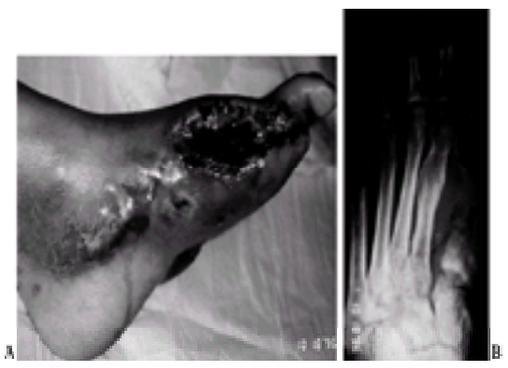

***Figure 116.5.*** **A,B:** White man, 51 years of age, who had IDDM for 7 years. The $TcPo_2$ at BKA site was 29 mm Hg, indicating gas gangrene. The patient was treated with BKA, hyperbaric oxygen treatment, and IV antibiotics.

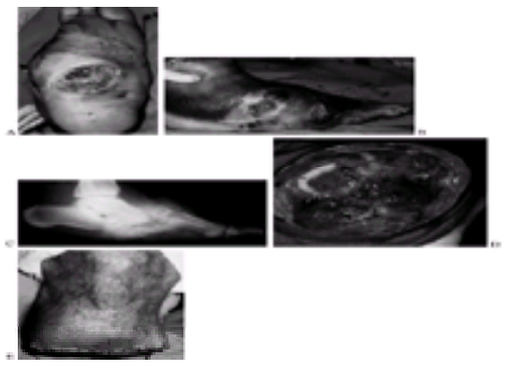

***Figure 116.9.*** **A,B:** White man, 46 years of age, had IDDM for 8 years and a Charcot midfoot for 6 months. **C:** The deformity progressed and he developed a plantar ulcer. The $TcPo_2$ at the foot was 11 mm Hg; at the ankle, 21 mm Hg; at the BKA site, 39 mm Hg. There was pain sensation in the proximal anterior tibia and posterior midcalf. A radiograph showed gas in the tissue. The patient was febrile and felt ill. He was admitted to the hospital and placed on penicillin, clindamycin, and ciprofloxacin. Cultures showed Staphylococcus, Streptococcus, Pseudomonas, and Diptheroids. **D:** Emergent guillotine amputation was performed; there was minimal

bleeding. Cultures at the amputation site showed Staphylococcus. The patient was treated for 3 days with triple antibiotics, wet-to-dry sterile saline dressings changed every 8 hours. **E:** The amputation was revised and completed 3 days after the guillotine procedure; cultures were then negative. IV antibiotics (clindamycin, ciprofloxacin) were administered for 2 weeks; oral antibiotics (clindamycin, ciprofloxacin) were administered for 4 weeks. The patient now wears a permanent BKA prosthesis, is ambulating, and has returned to work.

### WOUND CLOSURE

If the infection is not too severe and bleeding is adequate, all lower extremity wounds should be closed. If the degree of infection is too severe (i.e. purulence, cellulitis, or edema,), then perform a staged debridment and closure, returning the patient to the operating room in a few days for repeat debridement or wound closure, or both. The surgeon must debride or amputate to a level on the limb that produces sufficient bleeding indicative of adequate circulation for healing.

### ROLE OF AMPUTATION

Amputation can be lifesaving surgery if sepsis, gas gangrene, or necrotizing fasciitis is present (Fig. 116.6). It can cause a great deal of stress for patients, so they may need time and counseling before making a decision about an amputation. Of the “stressful events of life” amputation is second only to loss of a loved family member. Patients frequently go through the “stages of death and dying” of denial, anger, negotiation, depression, and acceptance. Some patients refuse to have an amputation for religious reasons or request that the amputated part be stored for the time of burial. We describe amputation to patients as a type of reconstructive surgery that is necessary to remove infected or dead tissue so that the a patient's health and function may improve. Most patients understand this and work very hard to rehabilitate. The design of prosthetic devices continues to improve, thereby increasing the percentage of patients that have a functional outcome. See Chapter 120 and Chapter 122 on amputation and prosthetics.

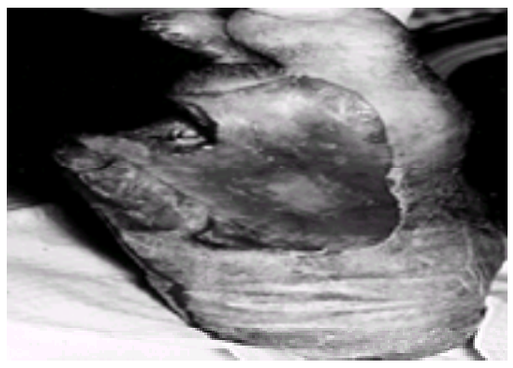

***Figure 116.6.*** Black man, 63 years of age, who had a foot with wet gangrene. The $TcPO_2$ at the BKA site was 21 mm Hg. The patient was treated with BKA, hyperbaric oxygen treatment, and IV antibiotics.

### PRINCIPLES OF FOOT RECONSTRUCTION

Realignment and restoration of normal foot mechanics with attention to nerve and vascular function are the main principles of foot reconstruction. After the infected, dead tissue is removed, wound closure with a good weight-bearing stump is essential. Do not leave bony prominences or less than five toes or metatarsals because this produces an unbalanced foot that almost guarantees further surgery in the next year. It is also of no value to perform inadequate debridement or close ischemic skin or muscle.

### NEUROPATHY CONTROL

Good glucose control and attempting to maintain HbA1c levels at less than 8% help prevent progression of neuropathy (20). Analgesics and other pharmaceuticals [e.g., amitriptyline (Elavil) 25 to 100 mg at bedtime for sleep, or fluphenazine (Prolixin)] can be helpful in controlling the paresthesias and dysesthesia (1,42,65).

### ORTHOTICS AND SPECIAL SHOES

Orthotics should be accommodating but not rigid, with adequate padding to relieve overloaded bones and tissue. Soft Plastazote is better than Pelite to avoid shear stress and give a firm underlayer of support. A wide toe box with extra-depth shoes is necessary to provide room for toe deformities. Shoes should fit well when purchased and should not be expected to stretch out with wear.

### TREATMENT OF DEFORMITY

Surgical treatment of the underlying deformity is often necessary to heal the ulcers or prevent recurrence. With good blood supply, an ostectomy may relieve the pressure of a bony prominence. Balancing of muscle forces such as percutaneous tendoachilles lengthening for tight heel cords, as well as procedures for intrinsic minus clawing can relieve excessive pressure on the metatarsal heads. Plastic surgery consultation may be needed when soft-tissue coverage is needed (46). See Chapter 112, Chapter 113, Chapter 114, Chapter 115 and Chapter 118 for details on foot reconstruction.

## VASCULAR MANAGEMENT

### MEDICAL MANAGEMENT

Studies have shown that pentoxifylline is effective in diabetic patients with chronic ulcerations that do not heal despite other treatment options. Pentoxifylline and its metabolites decrease the viscosity of blood, therefore improving its flow properties. It improves tissue oxygenation. In addition, pentoxifylline 800 mg/day was shown to improve walking distance, paresthesia, skin temperature, and subjective overall response (12).

### VASCULAR RECONSTRUCTION

For vascular insufficiency, consider vascular surgery for possible reconstruction. This procedure may range from a single vessel angioplasty to multiple by-pass arterial procedures. In the diabetic vessel, bypass operations are more distal owing to the higher number of diseased arteries below the trifurcation of the popliteal artery (58). Revascularization can heal ulcerations and allow more distal foot reconstructions or amputation (29).

## NEUROPATHIC ARTHROPATHY

Neuropathic arthropathy is joint destruction caused by a lack of protective sensation. The incidence of neuroarthropathy in diabetics ranges from 1% to 2.5% (27). Charcot's joint, the common eponym for neuropathic arthropathy, was coined from the description given in 1868 by J. M. Charcot for a patient with syphilitic joint destruction (41). Treatment is directed toward preventing progression and the sequelae of infection and amputation. See Chapter 124 for more details.

### PATHOPHYSIOLOGY

Diabetes is the most common cause of neuropathic arthropathy. It is believed to be caused by a loss of protective sensation about joints, allowing repetitive microtrauma to have additive effects on bone and joint destruction (21). The inflammatory changes of erythema and increased blood flow seen in Charcot's arthropathy may be due to autonomic neuropathy and can contribute to the bone and joint destruction that sometimes occurs despite adequate immobilization and rest (43). Neuropathic arthropathy is accelerated osteoarthritis that causes hypermobility of the joint. Typically, joint fragmentation and fractures occur with destruction of the

articular cartilage and bone, with accompanying synovitis and pannus formation (9).

Other diseases that can cause neuropathic arthropathy are syphilis, syringomyelia, alcoholism, stroke, congenital insensitivity to pain, spinal cord or peripheral nerve injury, and spina bifida (35). Patients with these diseases, however, usually do not have the severe vascular and immunologic changes that diabetics experience. Other severe problems might also be present (e.g., alcoholism, malnutrition, cord injury, and total paralysis), but the neuropathic arthropathy can be managed much like that for diabetics.

## PRESENTATION

Patients frequently complain of foot swelling, redness, and numbness. A recent increase in shoe size may also be reported. Pain is not typically a chief complaint, and when it is present, it is usually less than expected. Neuroarthropathy is commonly found in middle-aged diabetics with a history of poor glucose control. Fever, chills, nausea, and malaise are generally absent, but may be present with an infected Charcot joint. Capillary refill can be assessed with a blanch test or foot elevation, or both, and is typically normal in the Charcot foot. If the foot remains red and warm with elevation, infection may be present.

### *Laboratory Tests*

Without infection, the complete blood count is normal, but the erythrocyte sedimentation rate and glycosylated hemoglobin are usually elevated. Also, $TCPo_2$ is usually normal.

### *Radiographs*

Radiographs correspond to the stage of neuropathic arthropathy (15,16,26,38,41,71) (Table 116.5). Eichenholtz staging refers to the individual fracture's healing (Table 116.6). In the preneuropathic arthropathy stage, joints at risk for progression or deformities (e.g., hallux valgus or claw toes) can be seen, and muscular imbalances (e.g., tight heelcord and clawing) can be identified. Radiographs of patients with early neuropathic arthropathy show joint widening and stress fractures. In progressive and late stages, further destruction and multiple joint involvement are seen.

| Stage | Signs | X-ray findings | Result |
|---|---|---|---|
| Preneuropathic arthropathy | Stasis, wide-based gait, imbalance, intrinsic minus foot, toe clawing, flatfoot, valgus heel | Joints at risk—hallux valgus, toe clawing | Increased pressure in the joints, progressive bone, joint, and soft tissue destruction |
| Early neuropathic arthropathy | Specific joints are involved; inflammatory arthritis | Joint widening, stress fractures | Cartilage and subchondral bone destruction, dislocation, erosions |
| Progressive neuropathic arthropathy | Deformities of specifically dislocated joints; rapid bone destruction about joint | Joint dislocation; multiple fragmentation; progressive deformation | Fractures; hyperemia; demineralization; deformity of other joints |
| Late neuropathic arthropathy | "Rag-doll bones"; multiple joints involved; hemarthrosis; failure; ulcers, osteomyelitis, abscesses | Multiple joint and bone destruction; bony prominences; callus formation | Significant deformity, ulcers, infection |

Data from Brand PW. The insensitive foot (including Leprosy). In: Jahss MH, ed. *Disorders of the Foot*. Philadelphia: W.B. Saunders, 1992:1266; Brand PW. Repetitive Stress in the Development of Diabetic Foot Ulcers. In: Levin ME, O'Neal LW, eds. *The Diabetic Foot*. 4th ed. St. Louis: C.V. Mosby, 1990:63; Ordway DR, Thompson RC Jr. Fractures Associated with Neuropathic Arthropathy in Adults Who Have Juvenile-onset Diabetes. *J Bone Joint Surg (Am)* 1980;70:1192; Cofield RH, Morrison MJ, Beabout JW. Diabetic Neuropathy in the Foot: Patient Characteristics and Patterns of Radiographic Change. *Foot Ankle* 1983;4:15; Edmonds ME, Clarke MB, Newton S, et al. Increased Uptake of Bone Radiopharmaceutical in Diabetic neuropathy. *Q J Med* 1985;57:843; Eichenholtz SN. *Charcot Joints*. Springfield, IL: Charles C. Thomas, 1966; Mazzeo RS, Sharp RM. Charcot Joints of the Foot. *Contemp Orthop* 1987;14:17; and Chalkin MM, Fabricio M, Iannotti JJ, Hennela D. The Diabetic Foot. *Radiol Clin North Am* 1987;25:1091.

***Table 116.5. Neuropathic Arthropathy Stages***

| Stage | Signs |
|---|---|
| First Stage | Hyperemia<br>Inflammation<br>Fragmentation of joints<br>Rapid onset of fractures<br>Progression of deformity |
| Second Stage | Coalescence<br>Inflammation subsides<br>Healing begins |
| Third and Final Stage | Resolution of inflammatory condition<br>Considerable deformity |

Data from Cofield RH, Morrison MJ, Beabout JW. Diabetic Neuropathy in the Foot: Patient Characteristics and Patterns of Radiographic change. *Foot Ankle* 1983;4:15; Edmonds ME, Clarke MB, Newton S, et al. Increased Uptake of Bone Radiopharmaceutical in Diabetic neuropathy. *Q J Med* 1985; 57:843; Eichenholtz SN. *Charcot Joints*. Springfield, IL: Charles C. Thomas, 1966.

***Table 116.6. Eichenholtz Staging of Neuropathic Arthropathy***

Changes seen in the forefoot are dorsal dislocation of the toes, metatarsophalangeal joint destruction, and metatarsal stress fractures (6,17,43). In the midfoot, the arch becomes flattened, the distal segments dislocate dorsally, and fragments of the cuneiform or cuboid become prominent in the sole and can cause ulcers (48). The hindfoot is disrupted as the calcaneus or talus dislocate, allowing the talus or malleoli to become prominent and cause ulcers (56). Occasionally, entire bones, especially the talus, cuneiform, or cuboid, are crushed *in situ.*

The most common location for Charcot's arthropathy is Lisfranc's joint (Fig. 116.7). This can account for 70% of cases, whereas the forefoot and hindfoot each account for 15% (Fig. 116.8). Recurrence of the neuroarthropathic process is rare and is most commonly seen in renal transplant patients. Bilateral involvement has been seen in 35% of patients with diabetic Charcot's process (36).

***Figure 116.7.*** **A,B:** Black man, 55 years of age, who worked in hospital as a radiology technician. He had IDDM for 12 years before he noticed both feet swelling for 2 years before presentation. At presentation, he had minimal pain and was placed in extra-depth diabetic shoes for bilateral, midfoot, early Charcot's joints. The condition continued to progress on the right side, so he underwent bilateral midfoot and hindfoot fusions 2 years later. Six years later, the deformities have stabilized (**C–G**) and the patient is disabled.

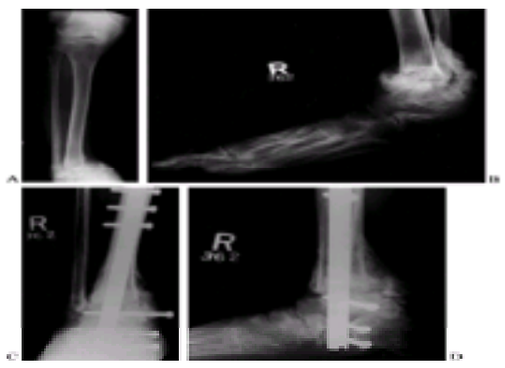

***Figure 116.8.*** **A,B:** White woman, 32 years of age, who had IDDM for 4 years secondary to renal failure and immunosuppression. She presented with a 2-month history of ankle deformity and an ulcer with purulent drainage. Cultures showed *Staphylococcus aureus* and Streptococcus, which was sensitive to penicillin. She was treated with a 6-week total contact cast and oral antibiotics until the cellulitis resolved and the wound healed. After healing she underwent **C,D:** debridement surgery and calcaneal, talar, and tibial fusion with a nail (no bone graft). She was treated with IV antibiotics for 2 weeks, oral antibiotics for 6 weeks, a cast for 3 months, a brace for 2 months. Solid union resulted.

### *Imaging*

Bone scans, CT, and MRI help differentiate early Charcot's joint changes from infection. A technetium bone scan will show increased uptake in neuropathic arthropathy but is not needed if infection is either obvious or not suspected (26,47). Gallium and indium scans can be helpful in diagnosing and defining the extent of infection. Arteriography is frequently used to determine if and where vascular bypass is indicated (37,44,45,67). Although an 111-indium WBC scan is preferable to MRI to rule out osteomyelitis, it is usually negative in patients with neuropathic arthropathy, although false-positive readings may occur. MRI is sensitive in showing the extent of infection that might be superimposed on Charcot's changes (30,50). If the 111-indium WBC scan is positive, biopsy confirmation is recommended (30).

## TREATMENT OF CHARCOT FOOT

### *Education*

Control of glucose is essential for the treatment of Charcot's foot. Patient behavior modifications are necessary to eliminate vascular disease risk factors such as smoking, and elevated blood cholesterol and triglycerides. Have patients avoid activities that cause repetitive stress on the feet. Frequent follow-up by the treating physician is essential.

### *Orthotics and Special Shoes*

It is imperative that patients with neuropathic arthropathy have custom-molded orthotics that accommodate the deformity and resist its progression. Rigid orthotics should be avoided because they will cause ulcers. Wide toe box, extra-depth shoes provide room for the abnormal forefoot. Rocker bottom soles decrease midfoot stresses (27). High-top, ankle lace-up shoes attached to molded lower leg braces resist ankle deformity.

### *Total Contact Casting and Bracing*

Total contact casting is useful for treating ulcers and to prevent deformity progression until consolidation occurs. Patellar tendon-bearing casts unload the foot and ankle (61). During phases of swelling, frequent cast changes are needed to prevent pressure ulcers caused by the cast. Likewise, bracing can be helpful both during and after progression of a deformity by placing the foot into optimal alignment and position and supporting it. This can be provided by a fairly restrictive orthosis such as a customized ankle-foot orthosis that is well padded to accommodate any structural abnormality.

### *Operative Treatment*

Treatment depends on soft-tissue viability and infection. For ischemia, vascular repair might be indicated, but most Charcot's joints have good to excellent blood flow (37,44,45,58,67). Infection is usually obvious with an ulcer, and drainage can be easily established with a sterile aspiration of the insensate foot in the clinic (Fig. 116.9). Infection in the Charcot joint is treated much the same way as DFIs outlined earlier. Establish the extent of infection—cellulitis, ulcer, abscess, osteomyelitis, and gangrene—and treat with culture and sensitivity-directed antibiotics, debridement, and reconstruction. Infection in the Charcot joint usually means there is an excellent blood supply (but not always!) so antibiotic delivery and the host's ability to fight the infection are good, but the bone and joint involvement is more severe, so the debridement and reconstruction are more difficult. Usually, an infected Charcot joint will need to be “staged.” In the first stage, identify the bacteria with sterile deep cultures and debride all infection and dead bone. In the second stage, reconstruct remaining tissue, usually with fusions (Fig. 116.7) or amputate if reconstruction is not possible owing to the patient's health and the local conditions.

**Ostectomy or Osteotomy** A cheilectomy, or “bumpectomy,” to remove protruding bones can treat or prevent ulceration (8). Realignment osteotomies and fusions after the hyperemic or osteopenic phase is over require extended immobilization (up to 1 year), but even a pseudoarthrosis may improve function, relieve pressure, and treat ulcers (4,24,48,57).

**Correction of Muscle Imbalance** Muscle imbalance due to an intrinsic minus foot with claw toes, flat foot, and valgus heel and calcaneal equinus can be corrected somewhat with a percutaneously lengthening of a tight heelcord.

**Amputation** Owing to the severity of many of these cases, especially those involving deep infections, amputation is often the most reasonable surgery.

## AUTHORS' PERSPECTIVE

DFIs and Charcot joints are increasing and can be treated in a straightforward way. Excellent treatment of the diabetic foot is gratifying for the surgeon and for the patient. A balanced foot care team with individuals with varied skills and roles is key. The team consisting of the patient, family, doctors, nurses, and clinical assistants needs to be educated about foot problems and be able to work together to provide the best care for these patients. Looking at the infection in common terms (cellulitis, ulcer, abscess, osteomyelitis, gangrene), with an understanding of neuropathy (pain or protective level for prosthesis and Charcot joint) and vasculopathy (level of healing and need for vascular repair), will empower the patient and team to deal effectively with these complex problems.

---

*Contact the American Orthopaedic Foot and Ankle Society, 901 Boren Ave., Suite 1300, Seattle, WA 98104 (1-800-235-4855) for copies of this brochure.

## SUGGESTED READINGS


Brodsky JW. The Diabetic Foot. In: Mann RA, Coughlin MJ, eds. *Surgery of the Foot and Ankle,* 6th ed. St. Louis, MO: Mosby, 1993:877.

Brodsky JW. Amputations of the Foot and Ankle. In: Mann RA, Coughlin MJ, eds. *Surgery of the Foot and Ankle,* 6th ed. St. Louis, MO: Mosby, 1993:959.

Edmonds ME. The Diabetic Foot: Pathophysiology and Treatment. *Clin Endocrinol Metab* 1986;15:889.

Heckman JD, ed. *Section II, Diabetic Foot: Instructional Course Lectures 42.* Rosemont, IL: American Academy of Orthopaedic Surgeons, 1993:115.

McDermott JE, ed. *The Diabetic Foot. Monograph Series.* Rosemont, IL: American Academy of Orthopaedic Surgeons, 1995:1.

## CHAPTER REFERENCES

Each reference is categorized according to the following scheme: *, classic article; #, review article; !, basic research article; and +, clinical results/outcome study.


+ 1. Ahmed ME, LeQuesne PM. Quantitative Sweat Test in Diabetics with Neuropathic Foot Lesions. *J Neurol Neurosurg Psychiatry* 1986;49:1059.

+ 2. Apelqvist J, Castenfors J, Larsson J, et al. Prognostic Value of Systolic Ankle and Toe Blood Pressure Levels in Outcome of Diabetic Foot Ulcer. *Diabetes Care* 1989;12:373.

+ 3. Bamberger DM, Daus GP, Gerding DN. Osteomyelitis in the Feet of Diabetic Patients: Long Term Results, Prognostic Factors, and the Role of Antimicrobial and Surgical Therapy. *Am J Med* 1987;83:653.

+ 4. Bono JV, Roger DJ, Jacobs RL. Surgical Arthrodesis of the Neuropathic Foot. A Salvage Procedure. *Clin Orthop* 1993;296:14.

# 5. Brand PW. The Insensitive Foot (Including Leprosy). In: Jahss MH, ed. Disorders of the Foot. Philadelphia: W.B. Saunders, 1982:1266.

# 6. Brand PW. Repetitive Stress in the Development of Diabetic Foot Ulcers. In: Levin ME, O'Neal LW, eds. *The Diabetic Foot,* 4th ed. St. Louis: C.V. Mosby, 1988:83.

# 7. Brodsky JW. Outpatient Diagnosis and Care of the Diabetic Foot. In: Heckman JD, ed. *Instructional Course Lectures 42.* Rosemont, IL: American Academy of Orthopaedic Surgeons, 1993:121.

+ 8. Brodsky JW, Rouse AM. Exostectomy for Symptomatic Bony Prominences in Diabetic Charcot Feet. *Clin Orthop* 1993;296:21.

+ 9. Brower AC, Allman RM. Pathogenesis of the Neurotrophic Joint: Neurotraumatic vs. Neurovascular. *Radiology* 1981;139:349.

+ 10. Calhoun JH, Cantrell J, Cobos J, et al. Treatment of Diabetic Foot Infections: Wagner Classification, Therapy, and Outcome. *Foot Ankle* 1988;9:101.

+ 11. Calhoun J, Keogh P, Koen S, Mader J. *Diabetic Foot Infections: 902 Cases. A Prospective Study of Protocol Versus Non-Protocol Treatment.* American Orthopaedic Foot and Ankle Society Winter Meeting, New Orleans, LA, February 1998.

+ 12. Campbell RK. Clinical Update on Pentoxifylline Therapy for Diabetes—induced Peripheral Vascular Disease. [Review]. *Ann Pharmacol* 1993;27:1099.

+ 13. Christensen KS, Klarke M. Transcutaneous Oxygen Measurement in Peripheral Occlusive Disease: An Indicator of Wound Healing in Leg Amputation. *J Bone Joint Surg [Br]* 1986;68:423

+ 14. Christensen KS, Falstie JN, Christensen ES, Brochner MJ. Results of Amputation for Gangrene in Diabetic and Non-diabetic Patients. *J Bone Joint Surg [Am]* 1988;70:1514.

+ 15. Clohisy DR, Thompson RC Jr. Fractures Associated with Neuropathic Arthropathy in Adults Who Have Juvenile-onset Diabetes. *J Bone Joint Surg [Am]* 1988;70:1192.

+ 16. Cofield RH, Morrison MJ, Beabout JW. Diabetic Neuropathy in the Foot: Patient Characteristics and Patterns of Radiographic Change. *Foot Ankle* 1983;4:15.

+ 17. Cohn BT, Brahms MA. Diabetic Arthropathy of the First Metatarsal Cuneiform Joint: Introduction to a New Surgical Fusion Technique. *Orthop Rev* 1987;16:465.

# 18. Colwell JA, Lopes-Virella MF, Winocour PD, Halushka PV. New Concepts about the Pathogenesis of Atherosclerosis in Diabetes Mellitus. In: Levin ME, O'Neal LW, eds. *The Diabetic Foot,* 4th ed. St. Louis: C.V. Mosby, 1988:51.

+ 19. Croll SD, Nicholas GG, Osborne MA, et al. Role of Magnetic Resonance Imaging in the Diagnosis of Osteomyelitis in Diabetic Foot Infections. *J Vasc Surg* 1996;24:266.

+ 20. The Diabetics Control and Complications Trial Research Group: The Effect of Intensive Treatment of Diabetes on the Development and Progression of Long-term Complications in Insulin-dependent Mellitus. *N Engl J Med* 1993;329:977.

+ 21. Doctor N, Pandya S, Supe A. Hyperbaric Oxygen Therapy in Diabetic Foot. *J Postgrad Med* 1992;38:112.

+ 22. Duckworth T, Boulton AJ, Betts RP, et al. Plantar Pressure Measurements and the Prevention of Ulceration in the Diabetic Foot. *J Bone Joint Surg [Br]* 1985;67:79.

# 23. Dyck PJ, Thomas PK, Lambert EH, et al, eds. *Peripheral Neuropathy.* Philadelphia: W.B. Saunders, 1975:956.

+ 24. Early JS, Hansen ST Jr. Surgical Reconstruction of the Diabetic Foot: A Salvage Approach for Midfoot Collapse. *Foot Ankle Int* 1996;17:325.

+ 25. Eaton RP, Sibbitt WL Jr, Harsh A. The Effect of Aldose Reductase Inhibiting Agent on Limited Joint Mobility in Diabetic Patients. *JAMA* 1985;253:1437.

+ 26. Edmonds ME, Clarke MB, Newton S, et al. Increased Uptake of Bone Radiopharmaceutical in Diabetic Neuropathy. *Q J Med* 1985;57:843.

# 27. Edmonds ME. The Diabetic Foot: Pathophysiology and Treatment. *Clin Endocrinol Metab* 1986;15:889.

# 28. Eichenholtz SN. *Charcot Joints.* Springfield, IL: Charles C Thomas, 1966.

+ 29. Gaylarde PM, Fonseca VA, Llewellyn G, et al. Transcutaneous Oxygen Tension in Legs and Feet of Diabetic Patients. *Diabetes* 1988;37:714.

# 30. Gold RH, Tong DJ, Crim JR, Seeger LL. Imaging of the Diabetic Foot [Review]. *Skeletal Radiol* 1995;24:563.

! 31. Gough A, Abraha H, Li F, et al. Measurement of Markers of Osteoclast and Osteoblast Activity in Patients with Acute and Chronic Diabetic Charcot Neuroarthropathy. *Diabet Med* 1997;14:527.

! 32. Greene DA. Adlose Reductase Inhibitors Promote Sural Nerve Fiber Regeneration and Repair in Patients with Diabetic Neuropathy. *Clin Res* 1987;35:623A.

# 33. Greene DA. Neuropathy in the Diabetic Foot: New Concepts in Etiology and Treatment. In: Levin ME, O'Neal LW, eds. *The Diabetic Foot,* 4th ed. St. Louis: C.V. Mosby, 1988;76.

! 34. Greene DA, Lattimer SA, Sima AAF. Sorbitol, Phosphoinositides, and Sodium-potassium-ATPase in the Pathogenesis of Diabetic Complications. *N Engl J Med* 1987;316:599.

# 35. Gupta R. A Short History of Neuropathic Arthropathy. *Clin Orthop* 1993;296:43.

# 36. Harrelson JM. The Diabetic Foot: Charcot Arthropathy. In: Heckman JD, ed. *Instructional Course Lectures 42.* Rosemont, Illinois, American Academy of Orthopaedic Surgeons, 1993:141.

+ 37. Harris HW, Rapp JH, Reilly LM, et al. Saphenus Vein Bypass to Pedal Arteries: An Aggressive Strategy for Foot Salvage. *Arch Surg* 1989;124:1232.

# 38. Herzwurm PJ, Barja RH. Charcot Joints of the Foot. *Contemp Orthop* 1987;14:17.

# 39. Incidence of Amputations in Diabetics. *MMWR* 1991;40:737.

+ 40. Irwin ST, Gilmore J, McGrann S, et al. Blood Flow in Diabetics with Foot Lesions due to “Small Vessel Disease.” *Br J Surg* 1988;75:1201.

# 41. Jacobs RL, Karmondy AM. Charcot Foot. In: Jahss MH 2nd, ed. *Disorders of the Foot.* Philadelphia: W.B. Saunders, 1991:2156.

# 42. Jacobs RL. Salvage of a Functional Lower Limb in Diabetic Patients after Amputation, in Diabetic Patients after Amputation. In: Heckman JD, ed. *Instructional Course Lectures 42.* Rosemont, IL: American Academy of Orthopaedic Surgeons, 1993:159.

+ 43. Johnson JT. Neuropathic Fractures and Joint Injuries: Pathogenesis and Rationale of Prevention and Treatment. J Bone Joint Surg 1967;49A:1.

# 44. Karmondy AM, Corson JD, Jacobs RL, et al. The Diabetic Foot. Curr Prob Surg 1986;23:729.

# 45. Karmondy AM, Jacobs RL. Vascular Diseases of the Foot. In: Jahss MH, ed. *Disorders of the Foot.* Philadelphia: W.B. Saunders, 1982:1301.

+ 46. Karp NS, Kasabian AK, Siebert JW, et al. Microvascular Free-flap Salvage of the Diabetic Foot: A 5-year Experience. *Plast Reconstr Surg* 1994;94:834.

+ 47. Knight D, Gray HW, McKillop JH, Bessent RG. Imaging for Infection: Caution Required with the Charcot Joint. *Eur J Nucl Med* 1988;13:523.

+ 48. Lesko P, Maurer RC. Talonavicular Dislocations and Midfoot Arthropathy in Neuropathic Diabetic Feet: Natural Course and Principles of Treatment. *Clin Orthop* 1989; 240:226.

# 49. Levin ME. The Diabetic Foot: Pathophysiology, Evaluation, and Treatment. In: Levin ME, O'Neal LW, eds. The Diabetic foot, 4th ed. St. Louis: C.V. Mosby, 1988:1.

+ 50. Levine SE, Neagle CE, Esterhai JL, et al. Magnetic Resonance Imaging for the Diagnosis of Osteomyelitis in the Diabetic Patient with a Foot Ulcer. *Foot Ankle Int* 1994;15:151.

+ 51. Lipsky BA, Pecoraro RE, Larson SA, et al. Outpatient Management of Uncomplicated Lower-extremity Infections in Diabetic Patients. *Arch Intern Med* 1990;150:790.

+ 52. Mader JT, Hicks CA, Calhoun JH. Bacterial Osteomyelitis: Adjunctive Hyperbaric Oxygen Therapy. *Orthop Rev* 1989;18:581.

# 53. Mann RA, Coughlin MJ, eds The Diabetic Foot. In: *Surgery of the Foot and Ankle,* 6th ed. St. Louis, MO: Mosby, 1993:877.

+ 54. Mooney V, Wagner FW Jr. Neurocirculatory Disorders of the Foot. *Clin Orthop* 1988;122:52.

+ 55. Morrison WB, Schweitzer ME, Wapner KL, et al. Osteomyelitis in Feet of Diabetics: Clinical Accuracy, Surgical Utility, and Cost-effectiveness of MR Imaging. *Radiology* 1995;196:557.

+ 56. Myerson MS. *Salvage of Severe Diabetic Neuroarthropathy with Arthrodesis.* Presented at the Fifth Annual Summer Meeting of the American Orthopaedic Foot and Ankle Society, Sun Valley, ID, August 3–6, 1989.

+ 57. Papa J, Myerson M, Firard P. Salvage, with Arthrodesis, in Intractable Diabetic Neuropathic Arthropathy of the Foot and Ankle. *J Bone Joint Surg* 1993;75A:1056.

+ 58. Pomposelli FB Jr, Marcaccio EJ, Gibbons GW, et al. Dorsalis Pedis Arterial Bypass: Durable Limb Salvage for Ishemia in Patients with Diabetes Mellitus. *J Vasc Surg* 1995;21:375.

# 59. Prevalence and Incidence of Diabetics. *MMWR* 1998;139:809.

# 60. Reiber GE. The Epidemiology of Diabetic Foot Problems. *Diabet Med* 1996;13(Suppl 1):56.

+ 61. Saltzman CL, Johnson KA, Goldstein RH, Donnelly RE. The Patellar Tendon Bearing Brace as Treatment for Neurotrophic Arthropathy: A Dynamic Force Monitoring Study. *Foot Ankle* 1992;13:14.

# 62. *San Antonio Heart Study.* 58th Annual Scientific Session of the American Diabetic Association, June 14, 1998.

+ 63. Sapico FL, Canawati HN, Witte JL, et al. Quanitative Aerobic and Anaerobic Bacteriology of Infected Diabetic Feet. *J Clin Microbiol* 1980;12:413.

# 64. Sapico FL, Witte JL, Canawati HN, et al. The Infected Foot of the Diabetic Patient: Quantitative Microbiology and Analysis of Clinical Features. *Rev Infect Dis* 1984;6(Suppl 1):S171.

# 65. Sargent WQ. Hemorrheology. In Levin ME, O'Neal LW, eds. *The Diabetic Foot,* 4th ed. St. Louis: C.V. Mosby, 1988:71.

+ 66. Sharp CS, Bessman AN, Wagner FW, et al. Microbiology of Deep Tissue in Diabetic Gangrene. *Diabetes Care* 1978;1:289.

# 67. Sicard GA, Walker WB, Anderson CB. Vascular Surgery. In: Levin MG, O'Neal LW, eds. *The Diabetic Foot,* 4th ed. St. Louis: C.V. Mosby, 1988:151.

+ 68. Spaeth HJ Jr, Dardani M. Magnetic Resonance Imaging of the Diabetic Foot. *Magn Res Imaging Clin N Am* 1994;2:123.

# 69. Wagner FW Jr. Infections of The Diabetic Foot. In: Chapman, MW, ed. *Operative Orthopaedics,* 2nd ed. Philadelphia: J.B. Lippincott Company, 1993:2299.

+ 70. Wyss CR, Harrington RM, Burgess EM, Matsen FA. Transcutaneous Oxygen Tension as a Predictor of Success after an Amputation. *J Bone Joint Surg [Am]* 1988;70:203.

# 71. Zlatkin MB, Pathria M, Sartoris DJ, Resnick D. The Diabetic Foot. *Radiol Clin North Am* 1987;25:1095.

# CHAPTER 117

# RHEUMATOID ARTHRITIS OF THE FOOT

*Michael J. Coughlin*

**M. J. Coughlin:** Oregon Health Sciences University, Portland, Oregon, 97201, and Treasure Valley Hospital, Boise, Idaho, 83706.

Pathophysiology
History, Physical Examination, and Radiographic Examination
Principles of Treatment
Preoperative Management and Planning
Surgical Techniques
Lesser Metatarsophalangeal Joint Synovectomy
Treatment of Hammer-Toe Deformities
Treatment of the Lateral Rheumatoid Forefoot
Treatment of the First Metatarsophalangeal Joint
Excisional Arthroplasty
Repair of the Rheumatoid Hindfoot
Chapter References

Rheumatoid arthritis is a systemic disease that affects up to 2% of the general population in the United States (73,77). Women are affected more frequently than men, with a peak onset noted in the third to fifth decade. Rheumatoid arthritis affects both small and large joints in the upper and lower extremities. Although its onset is typically insidious, an acute presentation is not uncommon. Chronic inflammatory changes of rheumatoid arthritis can cause significant disability of the foot. Initial involvement of the feet is noted in 16% of patients with acute manifestations of rheumatoid arthritis; however, the incidence of chronic foot deformities in patients with longstanding rheumatoid arthritis may approach 90% (65,89). In chronic rheumatoid arthritis, symmetric involvement is frequently reported, although early involvement may be asymmetric. Because of chronic inflammatory synovitis, the metatarsophalangeal joints become distended. This eventually leads to the loss of integrity of both the collateral ligaments of the metatarsophalangeal (MTP) joints and the supporting capsular structures, which sets the stage for progressive deformity due to loss of stability.

## PATHOPHYSIOLOGY

Progressive destructive articular changes are characterized by erosion of the metatarsal heads with cystic degeneration. As a patient continues to ambulate in the presence of incompetent ligamentous and capsular structures, subluxation and eventual dislocation can occur at the MTP joints (17). In the presence of an active synovitis, the intrinsic muscles are overpowered by the extrinsic flexor and extensor muscles, and clawing of the interphalangeal (IP) joints and dislocation of the MTP joints can occur (Fig. 117.1). This clawing leads to a distal displacement of the plantar fat pad and the formation of intractable plantar keratoses beneath prominent metatarsal heads (Fig. 117.2). Marked rigidity of the foot due to ankylosis of the ankle, hindfoot, or midfoot makes the foot less supple, which compounds forefoot symptoms.

***Figure 117.1.*** **A:** Rheumatoid arthritis with dislocated third metatarsophalangeal joint and chondrolysis of remaining lesser MTP joints. **B:** Seven years later, severe hallux valgus with dislocation of the second, third, fourth, and fifth MTP joints has occurred.

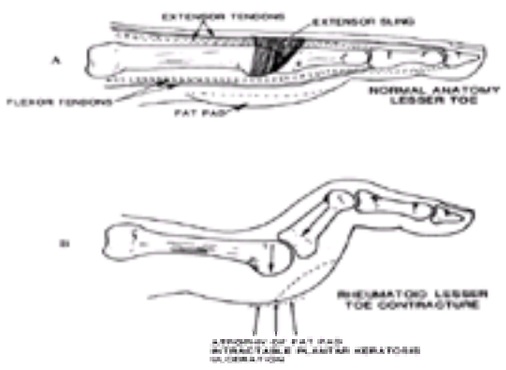


***Figure 117.2.*** **A:** Normal anatomy of the lesser toe. **B:** Pathophysiology of lesser toe deformity in rheumatoid arthritis. (From Coughlin M. The Rheumatoid Foot. Pathophysiology and Treatment of Arthritic Manifestations. *Postgrad Med* 1984;75:207, with permission.)

Vidigal et al. (93) reported that the forefoot had the greatest propensity for involvement with longstanding rheumatoid arthritis. Michelson et al. (65) observed that within the first 3 years following the onset of rheumatoid arthritis, two thirds of patients developed MTP synovitis. McGarvey and Johnson (63) and Spiegel and Spiegel (84) reported that approximately two thirds of patients with chronic rheumatoid arthritis develop subluxation and dislocation of the lesser MTP joints. Hammer-toe or claw-toe deformities of the lesser toes vary in frequency from 40% to 80% (63,65,89,93).

A hallux valgus deformity is more frequent and increases in severity in the chronic stages of rheumatoid arthritis (10), with a reported incidence of 59% to 90% (84,89,93). As progressive clawing of the lesser toes develops, little stability is afforded to the great toe, and gradual lateral migration occurs either beneath or above the second and third toes. This is associated with progressive articular destruction and resorption of subchondral bone, which destabilizes the great toe MTP joint. With progressive deformity, active weight bearing on the first ray lessens and a greater proportion of weight is borne beneath the lesser metatarsal heads (Fig. 117.3).

***Figure 117.3.*** **A:** A typical rheumatoid foot showing severe hallux valgus and overlapping and clawed lesser toes. **B:** The plantar surface of a foot, demonstrating prominent metatarsal heads, distal migration of the metatarsal fat pad, and an intractable plantar keratosis beneath the second metatarsal head. **C:** Postoperative appearance after the first metatarsophalangeal joint fusion and a resection arthroplasty of the lesser MTP joints with hammer-toe repairs. **D:** Postoperative photograph of the plantar aspect of the foot, demonstrating improved position of the foot and toes with resolution of the intractable plantar keratoses.

Clayton (15) reported that the forefoot was involved 10 times more frequently than the hindfoot in patients with chronic rheumatoid arthritis. Vidigal et al. (93) noted that two thirds of patients with chronic rheumatoid arthritis developed mid tarsal involvement, associated with flattening of the longitudinal arch in approximately 50% of patients. Often a valgus deformity of the hindfoot occurs in association with this, leading to a shuffling, flat-footed gait, and with the passage of time, the foot changes to a passive weight-bearing platform for ambulation. Chondrolysis associated with chronic synovitis eventually may lead to tarsometatarsal joint involvement. Likewise, the first metatarsocuneiform joint may develop hypermobility with resultant impaired gait. Transfer metatarsalgia may occur in association with this first-ray hypermobility. Vainio (89) noted that 59% of men and 72% of women with chronic rheumatoid arthritis developed either midtarsal or hindfoot arthritis. Typically, hindfoot degeneration occurs much later with chronic rheumatoid arthritis. Spiegel and Spiegel (84) reported that in patients with rheumatoid arthritis of a duration less than 5 years, only 8% developed arthritis of the hindfoot; however, of those with a duration greater than 5 years, 25% developed symptomatic hindfoot arthritis. Gold and Bassett (32) reported that the talonavicular joint is typically the first hindfoot joint to become involved, and Michelson et al. (65) reported that degenerative subtalar changes varied in incidence from 32% to 42%. As with the forefoot, the underlying pathophysiology is the destruction of the capsule and ligaments supporting the joints combined with concomitant progressive arthritis. Because the function of the subtalar joint is directly associated with transverse tarsal joint function, overall instability and deformity of these joints may lead to altered gait and function with a progressive pes planovalgus deformity. Likewise, posterior tibial tendon dysfunction can lead to a progressive unilateral flat-foot deformity (25,45). With the development of a severe hindfoot deformity, an Achilles tendon contracture may develop. Thus, at the time of corrective surgery, lengthening of the Achilles tendon may be necessary.

Ankle joint involvement in longstanding rheumatoid arthritis occurs mainly as synovitis. Spiegel and Spiegel (84) noted that 63% of patients with rheumatoid arthritis of less than 10 years' duration developed ankle synovitis. Benson and Johnson (7) and others (73,89,93) have reported the ankle joint to be involved with a frequency of 4% to 16%. Clearly, hindfoot involvement occurs much more frequently than involvement of the ankle joint (Fig. 117.4). Wagner (94) reported on 8,000 clinic visits to Rancho Los Amigos Hospital by patients with arthritis; in this group, 90 ankle arthrodeses were performed. Only three ankle arthrodeses were performed for patients with rheumatoid arthritis. Thus, a very small percentage of patients had rheumatoid arthritis of the ankle and progressed to surgery.

***Figure 117.4.*** Anteroposterior (AP) (**A**) and lateral (**B**) radiographs demonstrating ankle arthritis and spontaneous subtalar fusion in a patient with longstanding rheumatoid arthritis.

## HISTORY, PHYSICAL EXAMINATION, AND RADIOGRAPHIC EXAMINATION

Typically, the initial complaints of patients with inflammatory arthritis are ill-defined metatarsalgia and forefoot pain. These complaints are often associated with synovitis and concomitant intra-articular effusions that impair ambulation. Although ill-defined metatarsalgia may be misdiagnosed as an interdigital neuroma (90), in time chronic synovitis may make a diagnosis of rheumatoid arthritis more obvious. In the presence of forefoot problems, as time passes synovitis usually develops. Findings include nonspecific forefoot edema, swelling, tenderness to palpation, and impaired ambulation. In time, a hallux valgus deformity, subluxation or dislocation of the lesser MTP joints, and fixed hammer-toe or claw-toe deformities may develop (Fig. 117.5). Note any hindfoot deformities and especially posterior tibial tendon dysfunction, pes planovalgus, and Achilles tendon contracture.

***Figure 117.5.*** **A:** Dorsal view of a foot with longstanding rheumatoid arthritis, with hallux valgus and subluxation of the lesser toes and hammer-toe deformities. **B:** Severe intractable plantar keratoses associated with dislocation of the lesser metatarsophalangeal joints.

The radiographic findings of rheumatoid arthritis are typical of synovial inflammatory diseases associated with hyperemia, periarticular osteoporosis, and soft-tissue swelling. In time, marginal cortical erosions may develop that then progress to central erosions, joint-space narrowing, and eventual joint subluxation and dislocation as destruction of the articular cartilage develops. Rheumatoid arthritis tends to involve the first, fourth, and fifth metatarsal joints early on (32), specifically the medial aspect of the first, second, third, and fourth metatarsals and the lateral aspect of the fifth metatarsal. The IP joints of the toes are typically not involved except for the hallux. Hindfoot and midfoot deformities include midfoot collapse, pes planus, and subtalar sclerosis. Look for involvement of the knee and hip joints, because in general, involvement of these joints requires total joint arthroplasty before reconstructive foot surgery (20).

***Stages of Rheumatoid Arthritis***

Stage 1 Discomfort, synovitis without significant joint-space narrowing; no bony deformity
Stage 2 Minimal erosive articular changes; early involvement without fixed deformity
Stage 3 No significant joint erosion; soft-tissue deformity
Stage 4 Severe hallux valgus, lesser MTP-joint dislocation with fixed hammer-toe or claw-toe deformities, articular destruction, pes plano valgus, hindfoot arthritis

## PRINCIPLES OF TREATMENT

The principles of nonoperative treatment involve maintaining a good gait pattern and independent ambulation, or restoring adequate gait by minimizing inflammation, reducing pain, and supporting inflamed joints. In the presence of fixed deformity, surgical correction may be necessary, with arthrodeses and occasional excisional arthroplasty being the preferred treatments.

Use rest and limited weight bearing to relieve the swollen and inflamed joints of an acute rheumatoid flare-up. Application of a cast may be necessary. Roomy footwear, padding, and prefabricated or custom longitudinal arch supports may be efficacious. An important aspect of nonsurgical care involves proper shoes and the modification of shoes. A metatarsal pad placed proximal to an area of plantar keratoses may diminish tenderness and relieve discomfort associated with increased pressure. Many patients with early rheumatoid foot deformities can be adequately treated with a soft-soled and broad-toed shoe (85). An in-depth shoe with a custom-molded, a viscoelastic, or a soft insole may help to accommodate progressive deformities. Working with a pedorthist with skill in the use of specialized orthopaedic appliances helps to maintain function and prevent deformities. Orthotic devices help redistribute plantar weight-bearing forces, which may decrease discomfort associated with pressure areas, and support unstable joints. Shoes with low heels, increased depth, and soft leather uppers may be used to accommodate hammer-toe and claw-toe deformities. A soft-soled rocker-bottom shoe is helpful in the treatment of not only metatarsalgia but hindfoot deformities.

Instruct patients in appropriate foot care and show them how to look for potential breakdown areas in their skin. Patients with hindfoot and midfoot discomfort with minimal or no deformity can be adequately treated with a custom arch support or a polypropylene ankle or foot orthosis. As deformities increase, custom bracing may alleviate discomfort and provide support. A molded leather ankle lacer with steel stays can be used inside a shoe and provides significant hindfoot and ankle support. With progressive deformity or deformity associated with unrelenting pain refractory to conservative treatment, surgical intervention for forefoot, midfoot, or hindfoot dysfunction may be indicated.

The objective with conservative care or with surgery is to maintain or attain a plantigrade foot. The clinical course of a patient's rheumatoid arthritis determines the treatment program. Direct treatment toward correction of deformity, restoration of function, and pain relief. Pharmacologic treatment is an essential part of controlling the disease process, and involvement of a rheumatologist for medical management is most important. Rheumatologists often prescribe salicylates, nonsteroidal anti-inflammatory medications, gold salts, antimalarials, and immunosuppressive agents for the treatment of inflammatory arthritis, with the goals being reduction of inflammation and relief of pain. An occasional intra-articular corticosteroid injection may be helpful, but oral steroid therapy is employed less commonly because of the deleterious side effects associated with chronic use (24). I recommend that methotrexate be discontinued 1 week before and 1 week after surgery to avoid the diminished wound-healing capacity often associated with it. See Chapter 99 for more details on medical management. Cover patients who had previous total joint arthroplasty with perioperative antibiotics at the time of foot and ankle surgery.

Physical therapy on occasion may be helpful in treating forefoot and hindfoot deformities associated with rheumatoid arthritis. Stretching exercises for contracted Achilles tendon, manipulation of ankle and hindfoot joints to maintain or restore range of motion, muscle-strengthening exercises to assist in maintaining ambulatory capacity, and the use of ambulatory aids such as crutches, walkers, and canes may help in maintaining ambulation. With upper extremity involvement, platform crutches or canes may be necessary. Reduced ambulation during acute flare-ups, and stretching and exercises for involved joints are important elements of a physical therapy regimen to help maintain function in the patient with progressive rheumatoid arthritis.

## PREOPERATIVE MANAGEMENT AND PLANNING

Whereas medical management is critically important throughout the progression of the rheumatoid disease process, surgical intervention depends on the progression of the disease process and its severity. Individualize the timing of specific surgical procedures for each patient. Although sometimes conservative management provides relief of pain, making surgical intervention unnecessary, a synovectomy may be indicated to slow the progression of the inflammatory process. With increasing deformity, the ultimate goal is to prevent the loss of capacity to ambulate that may occur with progression of the arthritis. Surgical intervention may be interspersed with long periods of conservative care. In general, proximal joint surgery (total hip and knee arthroplasty) should precede foot and ankle surgery. Hindfoot surgery typically precedes forefoot surgery (22). The rationale for hindfoot surgery preceding forefoot surgery is that with a progressive pes planus deformity, a recurrent forefoot deformity may occur. I prefer to operate on one foot at a time, because the magnitude of surgery may diminish ambulatory capacity in the postoperative period.

## SURGICAL TECHNIQUES

### LESSER METATARSOPHALANGEAL JOINT SYNOVECTOMY

Synovectomy of the lesser MTP joints is indicated for the treatment of painful joints early in the disease process, before significant deformity has occurred (2,11,23,24,74,90). This procedure is contraindicated in the presence of MTP joint subluxation or dislocation, or with the formation of intractable plantar keratoses; in these cases, it achieves limited gains. Excision of hypertrophic synovial tissue may slow or arrest the degenerative process, decrease distention of MTP joints, and reduce the soft-tissue deformation that would lead in time to subluxation and dislocation. Success of surgery depends on the length of remission, but a patient should be informed that a synovectomy may provide only temporary relief. Nonetheless, it helps to maintain function of the lesser MTP joints and toes.

- Center a dorsal longitudinal incision over the involved MTP joint. With multiple joint synovectomies, use a second and/or fourth interspace incision to expose adjacent joints.
- Using the extensor tendon as a guide, carry the dissection down through the extensor hood and incise the capsule, exposing the MTP joint.
- Resect proliferative synovial tissue on the medial and dorsolateral aspects, taking care to remove any synovium beneath the collateral ligaments. Carry the resection as far in the plantar direction as possible.
- Close the joint capsule with absorbable sutures, and approximate the skin with interrupted sutures.
- Carry out a synovectomy of the first MTP joint through a dorsal longitudinal incision centered over it, using a technique similar to that described for the lesser MTP joints.

#### *Postoperative Care*

Apply a gauze-and-tape compression dressing at surgery, and change it weekly for 6 weeks. Initiate active and passive MTP range-of-motion exercises 3 weeks after surgery.

#### *Results and Complications*

Metatarsophalangeal joint synovectomy may diminish symptoms of metatarsalgia and reduce progression of deformity. Aho (2) and others (24,74,90) have reported good pain relief following synovectomy. Major complications include injury to the dorsal cutaneous nerve of the lesser toes. Take care to avoid injury to adjacent sensory nerves. In time, recurrence of synovial hypertrophy may lead to symptoms and require further surgery.

### TREATMENT OF HAMMER-TOE DEFORMITIES

With time, chronic rheumatoid arthritis may lead to hammer-toe and claw-toe deformities that occur in association with MTP subluxation and dislocation. Whereas a mild deformity may be treated with passive manipulation and intramedullary Kirschner wire (K-wire) fixation (closed osteoclasis) (14,23,49,60,70), more severe deformities need a proximal phalangeal condylectomy to achieve realignment with bony decompression (22,23,43,49,95).

- Center an elliptical incision over the dorsal proximal interphalangeal (PIP) joint of the lesser toe (Fig. 117.6). Excise the dorsal callus, extensor tendon, and joint capsule, exposing the PIP joint.

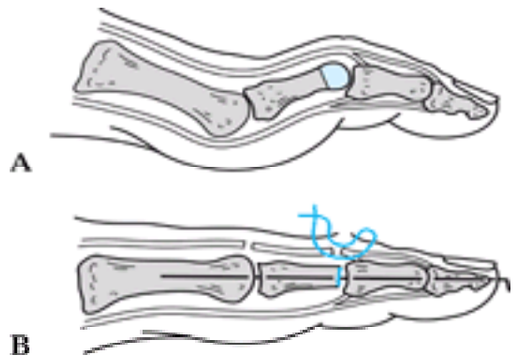


***Figure 117.6.*** Hammer-toe repair. **A:** Resection of the distal condyle of the proximal phalanx. **B:** Use of an intramedullary K-wire to stabilize the arthroplasty site.

- Sever the collateral ligaments on the medial and lateral aspects, allowing the condyles to be delivered into the wound. Take care to avoid injury to the adjacent neurovascular bundles.
- Resect the condyles of the proximal phalanx in the supracondylar region, and smooth them with a rongeur. As the toe is brought into correct alignment, if there appears to be any remaining tension at the PIP joint, resect more bone. You may resect the articular surface of the base of the middle phalanx with a rongeur to achieve arthrodesis, but this is optional.
- To stabilize the arthroplasty, introduce a 0.045 K-wire at the PIP joint, and drive it distally to exit the tip of the toe. With the toe aligned, drive the pin in a retrograde fashion, stabilizing the repair.
- If MTP joint arthroplasty is also done, advance the pin into the metatarsal shaft, stabilizing the arthroplasty site. Although the use of an intramedullary K-wire to stabilize the PIP arthroplasty site is a matter of preference, internal fixation appears to improve the cosmetic result by achieving and maintaining alignment postoperatively (33,52,59,95).

### *Postoperative Care*

Apply a gauze-and-tape dressing, and change it each 7–10 days. Remove sutures and K-wires 3 weeks after surgery, and support the toes with a gauze-and-tape dressing for 3 more weeks. Discontinue dressings 6 weeks after surgery. Avoid constrictive shoe wear for at least 3 months following surgery.

### *Results and Complications*

Although no long-term results of hammer-toe repairs in patients with rheumatoid arthritis have been reported, the goal of treatment is to achieve and maintain adequate alignment of the lesser toes. The major complication following surgery is recurrence of deformity, which in time may lead to hyperextension of the MTP joint. Recurrent deformity may be due to a lack of initial correction or to true recurrence. Other complications include prolonged swelling, which usually subsides in time; molding of the toe to the shape of the adjacent toes; and, on occasion, a painful arthroplasty site, for which injection with corticosteroids often gives lasting relief.

## TREATMENT OF THE LATERAL RHEUMATOID FOREFOOT

A forefoot arthroplasty is indicated for progressive rheumatoid arthritis associated with hallux valgus, metatarsalgia, and subluxation/dislocation of the lesser MTP joints. The choices of techniques include a Hoffman procedure (metatarsal head excision) (Fig. 117.7*A*) (38), a Fowler procedure (resection of the base of the proximal phalanx with beveling of the plantar metatarsal surface) (Fig. 117.7*B*) (30), and a Clayton procedure (partial proximal phalangectomy combined with metatarsal head resection) (Fig. 117.7*C*) (13,14 and 15). The choice of operative incisions depends on your preference. A transverse plantar incision, an elliptical plantar incision with resection of redundant skin and soft tissue, a transverse dorsal incision, and multiple longitudinal dorsal incisions are all alternatives (Fig. 117.8). I prefer three longitudinal dorsal incisions, with the medial incision centered over the first MTP joint and the two lateral incisions located over the second and fourth intermetatarsal spaces.

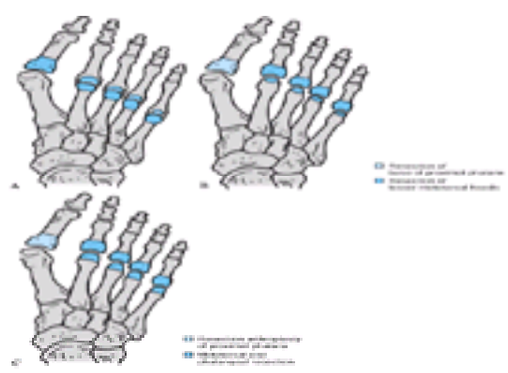

***Figure 117.7.*** Alternatives for forefoot arthroplasty. **A:** Hoffman procedure. **B:** Fowler procedure. **C:** Clayton procedure.

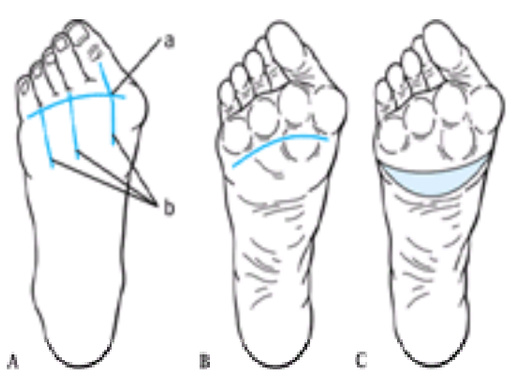


***Figure 117.8.*** Operative incisions. **A: (a)** Transverse dorsal incision. **(b)** Longitudinal dorsal incisions. **B:** Transverse plantar incision. **C:** Elliptical plantar incision.

On occasion, only one or two MTP joints are involved, and a decision must be made as to whether an entire forefoot arthroplasty should be performed. If one or two joints are involved, an arthroplasty may be performed on only these joints. However, alert the patient that the disease process will likely progress in time, eventually involving the other MTP joints. Rarely is the first MTP joint spared when the other lesser metatarsal joints are involved. When the entire forefoot is involved except for the fifth MTP joint, perform an arthroplasty of the fifth MTP joint as well. Whereas Thomas (85) recommended surgical resection for a single involved MTP joint, he recommended that an entire forefoot arthroplasty be performed if three joints were involved. Marmor (62) and others (9,52,66,72) recommended that an entire forefoot arthroplasty be performed when two MTP joints required resection. I support this procedure because it frequently eliminates the need for later additional surgery with further involvement of the remaining MTP joints.

- Through two longitudinal dorsal incisions centered in the second and fourth interspaces, expose the lesser MTP joints (Fig. 117.8). Commence the incisions at the webspace and extend them proximally 3 cm.
- With the skin flaps slightly undermined, dissect obliquely to each side to expose the adjacent MTP joints.
- Identify the extensor tendons, but leave them intact except in the presence of significant contracture.
- Identify the bases of the proximal phalanges by tracing the insertion of the long extensor tendon. Take care to protect the neurovascular bundles.

- With sharp dissection, incise the capsule and expose the metatarsal neck and head circumferentially. Plantar flexion of the phalanx often delivers the metatarsal head dorsally.
- Resect redundant synovium.
- With a bone-cutting rongeur, transect the metatarsal in the metaphyseal region. The amount of bone resection depends on the shortening that has occurred with the dislocation.
- Grasp and remove the metatarsal head. Removal of the entire metatarsal head in one piece avoids leaving remnants of bone, which may later lead to recurrent callosities.
- Bevel the plantar aspect of the metatarsal shaft to reduce any prominence. Resect any synovial cysts or bursa as well.
- I prefer to preserve the concave surface of the proximal phalanx (avoiding a partial proximal phalangectomy), because I believe the base of the proximal phalanx affords significant stability to the pseudoarticulation at the MTP joint. With decompression of the MTP joint, I have found that in time the fat pad routinely realigns, thereby eliminating the need for resection of the plantar skin (Fig. 117.9*A*). It is important that the excisional arthroplasty of the lesser MTP joints achieve decompression of the MTP joint; usually a space of 1 cm between the resected metatarsal surface and the base of the proximal phalanx is sufficient.

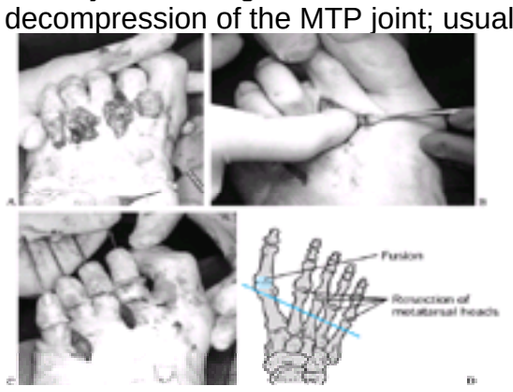


***Figure 117.9.*** Metatarsal head resection. **A:** Excision of the four lesser metatarsal heads through two longitudinal intermetatarsal incisions. **B:** Introduction of the index fingertip into the resection site. **C:** Stabilization of the digits with intramedullary K-wires. **D:** Second and third metatarsals of equal length, and fourth and fifth metatarsals progressively slightly shorter.

- With longitudinal tension on the toe, insert the tip of your index finger into the resection arthroplasty site and gauge the adequate amount of resection (Fig. 117.9*B*). There should be room for the tip of your finger to be placed comfortably in this interval. It is important to resect the metatarsal heads and metaphysis symmetrically. I prefer that the first and second metatarsals be of equal length, with the third, fourth, and fifth metatarsals being progressively shortened from medial to lateral. This helps to avoid an abnormally long metatarsal with consequent development of intractable plantar keratoses.
- Following metatarsal head resection, correct hammer-toe deformities with a closed osteoclasis or an open hammer-toe repair (see Chapter 113). Introduce an 0.045 K-wire at the PIP joint and drive it in a distal direction to exit the tip of the toe (Fig. 117.9*C*). Advance it proximally into the metatarsal diaphyses and metaphyses.
- Embed the K-wire in the proximal metatarsal base to give stability to the arthroplasty site. Bend the pin at the tip of the toe to prevent proximal migration.
- Approximate the arthroplasty sites with the skin closure (Fig. 117.9*D*).

### *Postoperative Care*

Apply a gauze-and-tape compression dressing at surgery. Change it weekly for approximately 6 weeks. Remove K-wires and sutures 3 weeks after surgery. Allow the patient to ambulate in a wooden-soled postoperative shoe. Immediately after surgery, observe the circulatory status of the toes. With severe deformities, vascular compromise may develop, necessitating removal of the K-wires.

### *Results and Complications*

In general, the results of lesser MTP joint arthroplasty are gratifying (Fig. 117.10). Mann and Thompson (60) showed 89% good and excellent results at final follow-up. Of 1,874 cases reported in many series using various surgical techniques, an overall satisfaction rate of 81% has been reported (4,5,9,13,16,26,30,35,44,54,55,59,60,62,63,66,68,79,80,91,92,95).

***Figure 117.10.*** **A:** Preoperative radiograph demonstrating hallux valgus and dislocation of lesser metatarsophalangeal joints. **B,C:** Radiographs taken after MTP fusion and lesser MTP joint forefoot arthroplasty.

Reports on partial proximal phalangectomy show a satisfaction rate of 65% (180 of 278 cases) (16,26,68,79). Partial proximal phalangectomy with combined beveling of the metatarsal head [Fowler procedure (30)] has a reported success rate of 65% (76 of 177 cases) (7,30,50,51,54,55,70,95). Partial proximal phalangectomy combined with metatarsal head resection [Clayton procedure (14)] has been reported to achieve a higher success rate, with 80% good and excellent results (507 of 636 cases) (4,5,9,17,30,35,49,55,57,59,60,62,63,70). Metatarsal head excision (Hoffman procedure) has achieved the highest published success rate—89% good and excellent results (748 of 843 cases) (4,5,9,24,28,33,37,38,43,44,49,66,80,85,91,92,95). I prefer metatarsal head resection to achieve decompression of the MTP joint.

The most common complication following forefoot arthroplasty is recurrence of intractable plantar keratoses or recurrent pain due to inadequate resection. Clayton (13,14) reported a 10% reoperation rate resulting from inadequate resection of the lesser metatarsal heads. Thus, adequate decompression at the MTP joint is extremely important to avoid recurrent deformity. While chronic swelling of the forefoot postoperatively is a frequent complaint, it usually subsides with time. On the other hand, isolated resection of one or two metatarsal heads should be avoided, as intractable plantar keratoses often develop beneath the remaining metatarsal heads. I believe that revision surgery for the rheumatoid forefoot becomes necessary most frequently for the following reasons: (a) irregular lesser metatarsal head resection, (b) limited surgery with resection of only one or two metatarsal heads, (c) bony regrowth in the area of the lesser metatarsal head resection, and (d) recurrent deformity following development of hindfoot or ankle joint problems.

Use careful and meticulous surgical technique, with special attention to the resection of the metatarsal heads in a line in which the first and second metatarsals are of equal length and the third, fourth, and fifth are progressively shorter, to help avoid recurrent plantar keratoses. Likewise, meticulous debridement in the area of the metatarsal head resection is necessary because complete removal of all bone fragments will minimize bony regrowth. All four lesser metatarsal heads should be resected: Avoid limited surgery in which only one or two metatarsal heads are resected. Likewise, in the presence of hindfoot or ankle joint dysfunction, treat these problems first. Reserve surgery to correct rheumatoid forefoot deformities for patients with significant pain and disability, because this is truly a salvage procedure, and after surgery the lesser toes will have little active function.

## TREATMENT OF THE FIRST METATARSOPHALANGEAL JOINT

Although in the past, resection arthroplasty of the first MTP joint was recommended concomitantly with forefoot reconstruction (4,5,7,30,38,50,62), McGarvey and Johnson (63) and others (36,67) have found that Keller resection arthroplasty for the rheumatoid forefoot frequently fails. McGarvey and Johnson (63) reported a 67% level of dissatisfaction after Keller arthroplasty combined with lesser MTP forefoot arthroplasty. They noted recurrent hallux valgus in 53% and forefoot instability in

27%, and only one third of their patients reported satisfactory results. They concluded that first-MTP-joint arthrodesis was preferable to resection arthroplasty. Later, van der Heijden et al. (91) reported that 71% of resection arthroplasties of the first MTP joint were unsatisfactory. Likewise, silastic implant arthroplasty of the first MTP joint has been recommended as an alternative treatment (23,41). However, silastic implants have been fraught with both long- and short-term complications, including implant fracture, synovitis, recurrent osteolysis, and recurrent pain (81). First-MTP-joint arthrodesis is recommended for the stability that it affords the first ray (17,26,53,57,58,60,67,95). A resection arthroplasty of the lesser MTP joints affords little lateral stability to the hallux, allowing lateral displacement. With an arthrodesis, the first ray bears increased pressure, and a permanently stable construct is created. Henry and Waugh (36) observed improved weight-bearing function of the great toe following first-MTP arthrodesis, and Watson (95) concluded that arthrodesis was the treatment of choice for correction of a forefoot deformity (Fig. 117.11).

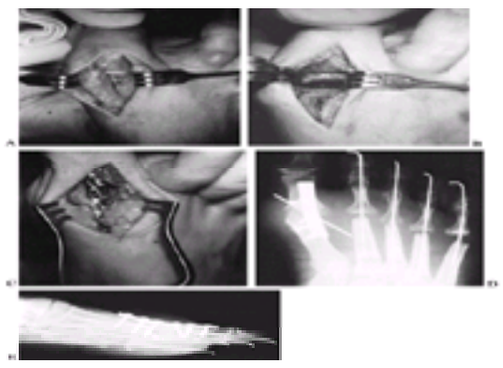

***Figure 117.11.*** Arthrodesis of the first metatarsophalangeal joint. A dorsal incision exposing the MTP joint of the hallux (**A**). Resection of the MTP articular surfaces (**B**). A small dorsal compression plate fixing the arthrodesis site (**C**). AP (**D**) and lateral (**E**) radiographs demonstrating compression-plate fixation of the first MTP joint arthroplasty. The excisional arthroplasty of the lesser MTP joints has been stabilized with K-wires.

To a large extent, the postoperative alignment and stability of the great toe determine the ultimate level of patient satisfaction. Fitzgerald (29) noted a high correlation between degenerative IP joint arthritis and the magnitude of MTP valgus, and he recommended arthrodesis for 20° of valgus or more. Recommendations for valgus alignment vary from 15° to 30°, and whereas a straight position (minimal valgus or slight varus) may lead to pain along the medial border of the hallux as it strikes the toe box, excessive valgus is often poorly tolerated as well. I usually recommend arthrodesis in 15° to 20° of valgus because it tends to attain a more acceptable first-ray alignment in relationship to the lesser metatarsals. Recommendations for dorsiflexion (in relationship to the plantar surface of the foot) vary from 10° to 30°, with 20° being the average recommendation. Women desiring to wear higher-heeled shoes may desire increased dorsiflexion. Minimal dorsiflexion (less than 10°) may leave the patient with a complaint of pressure at the tip of the toe with ambulation, and dorsiflexion greater than 40° may lead to increased pressure beneath the first metatarsal head. In measuring the dorsiflexion at the fusion site, take into account the average plantar inclination of the first metatarsal, which is 15°. Combined with dorsiflexion of the phalanx of 5° to 15°, this translates into 20° to 30° of dorsal angulation at the arthrodesis site.

Correct rotation of the great toe is important. Place the toe in neutral rotation when arthrodesed. Excessive pronation may lead to pressure on the medial border of the toenail, causing an ingrown toenail.

An increased intermetatarsal angle between the first and second is not a contraindication for MTP arthrodesis. Harrison and Harvey (34) and others (54,58,64,67) have reported significant reduction in the 1–2 intermetatarsal angle following fusion. Mann and Katcherian (58) and Humbert et al. (39) have noted an average decrease in the 1–2 intermetatarsal angle of approximately 6° following arthrodesis. Thus, a first metatarsal osteotomy is rarely indicated after MTP fusion.

- For an MTP arthrodesis, exsanguinate the foot and use a tourniquet.
- Center a 5 cm dorsal longitudinal incision over the first MTP joint and protect the adjacent neurovascular bundles. They are often ill defined in the presence of chronic soft-tissue inflammation or where previous surgery has been performed.
- Deepen the dissection along the medial aspect of the extensor hallucis longus tendon to the MTP joint (Fig. 117.11*A*). Enhance the exposure with a self-retaining retractor.
- Release the collateral ligaments and the adductor hallucis. Release the medial and lateral capsules, and resect the proliferative synovial tissue.
- Initially, soft-tissue release adequately decompresses the joint. The amount of bony resection depends on the shortening achieved with the lateral MTP joint arthroplasties.
- Use transverse osteotomies to resect the articular surfaces of the base of the proximal phalanx and the metatarsal head (Fig. 117.11*B*). Make these cuts with a small oscillating saw or osteotome. The first ray at the conclusion of surgery should not be significantly longer than the adjacent second ray. Usually, if the lateral forefoot arthroplasties have been performed before first-ray surgery, appropriate postoperative length is achieved. Frequently, you must resect additional bone to shorten the first ray. More bone is usually removed from the distal metatarsal than from the proximal phalanx.
- Resect the medial eminence of the metatarsal.
- The angle of the osteotomy of the articular surface of the proximal phalanx and first metatarsal determines the position of fusion. Valgus of 10° to 20° and dorsiflexion of 15° to 25° are most common. Usually, women prefer more MTP dorsiflexion than men. Determining the valgus position of the arthrodesis site can be difficult.
- Once the MTP joint has been decompressed, ascertain the flexibility of the metatarsocuneiform joint by compressing the transverse metatarsal joint. With adequate flexibility, fixation in 10° to 20° of valgus is appropriate (Fig. 117.11*C*, Fig. 117.11*D* and Fig. 117.11*E*).

  An alternative to preparing flat arthrodesis surfaces is to create curved, cup-shaped surfaces. I have designed cannulated reamers (18,19 and 20) that prepare the phalangeal and metatarsal surfaces so that rotation, valgus/varus, and dorsiflexion/plantar flexion can be varied independently without changing other alignment factors.

- First, employ a barrel-shaped reamer to shape the metatarsal metaphysis into a cylinder (Fig. 117.12*A*), and then use a cup-shaped reamer to create a convex metatarsal surface (Fig. 117.12*B*). Ream the base of the phalanx to create a concentric concave surface (Fig. 117.12*C*).

***Figure 117.12.*** Preparing the metatarsophalangeal arthrodesis site with power reamers. **A:** Shaping the metatarsal metaphysis into a cylinder. **B:** Creating a convex metatarsal surface. **C:** Reaming the base of the phalanx to create a concentric concave surface. **D:** Stabilizing the first MTP joint with a dorsal Vitallium plate. (From Coughlin M. Arthritis. In: Coughlin M, Mann R, eds. *Surgery of the Foot and Ankle*, 7th ed. St. Louis: CV Mosby, 1999, with permission.)

- Fixation is possible with crossed K-wires, compression screws, and multiple intramedullary Steinmann pins. Application of a Vitallium mini-fragment plate dorsally gives increased strength of fixation (Fig. 117.12*D*) (21). In younger patients who do not have significant osteoporosis, fix the arthrodesis site with a small Vitallium compression plate. Other methods may be necessary in older patients with osteoporotic bone.
- Once the MTP joint has been placed in the appropriate amount of valgus and dorsiflexion, stabilize the fusion site with an 0.062 K-wire. Introduce it from a plantar/medial direction and drive it proximally across the MTP joint. It may be used temporarily during the plate application, or it may be left in place for 3–4 weeks to augment fixation.
- Alternatively, replace the K-wire with a cross-compression screw. In using the dorsal six-hole mini-compression plate (Fig. 117.12*D*), bend it to 10° to 20° of dorsiflexion and fix it dorsally with six bicortical screws.
- Take biplanar radiographs to ensure that the IP joint has not been violated.

- Approximate the wound with interrupted subcutaneous and skin sutures.

### *Postoperative Care*

Apply a gauze-and-tape compression dressing at surgery, and change it weekly. Permit the patient to ambulate in a wooden-soled postoperative shoe, initially bearing weight on the heel and the outer aspect of the foot. A below-knee walking cast is an alternative. Discontinue dressings or casting 8–12 weeks after surgery, when there is radiographic evidence of successful arthrodesis.

### *Alternative Method of Fixation*

On occasion, either after a failed resection arthroplasty or in the presence of significant osteoporosis, intramedullary fixation may be necessary to stabilize an arthrodesis site. Use two double-pointed, threaded $^{1}/_{8}$-inch Steinmann pins for fixation (Fig. 117.13).

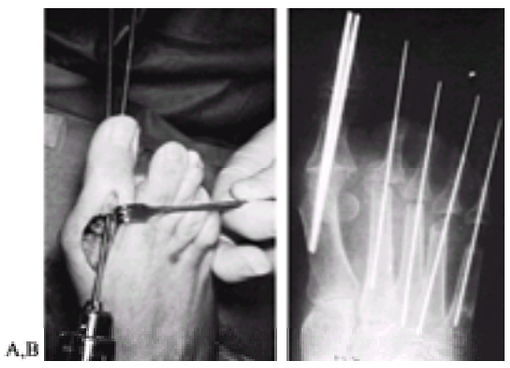


***Figure 117.13.*** Intramedullary fixation of first-MTP-joint arthrodesis. **A:** Introduction of double-pointed threaded Steinmann pins. **B:** Radiograph showing the pins stabilizing the MTP joint.

- After preparing the MTP joint surfaces, center a threaded Steinmann pin on the base of the proximal phalanx and drive it distally across the IP joint through the distal phalanx and out through the tip of the toe (Fig. 117.13*A*).
- Attach a drill to the distal end of the pin, and pull this pin, under power, farther distally until its proximal tip is flush with the prepared phalangeal surface. Use a pin cutter to remove 4 inches of the distal aspect of the pin so that it will not interfere when a second pin is drilled distally.
- Center a second double-pointed, threaded Steinmann pin just to the medial side of the first pin, and drive it in a similar fashion across the IP joint and out the tip of the toe.
- Attach the drill to the distal end of the second pin, and pull this pin distally until its proximal point is flush with the prepared phalangeal surface.
- Position the toe in the desired amount of rotation, valgus, and dorsiflexion. With axial compression pressure on the phalanx across the joint, drive the longest pin in a retrograde fashion across the MTP joint and into the metatarsal shaft. After it penetrates the proximal metatarsal plantar medial cortex, further advancement is not necessary. Use a pin cutter to sever the pin, leaving $^{1}/_{8}$ to ¼ inch extending beyond the tip of the toe for ease of removal after successful fusion occurs (Fig. 117.13*B*).
- Attach the power drill to the first pin that was placed, and drive it proximally in a similar manner.
- Following placement, cut the pin with $^{1}/_{8}$ inch protruding beyond the tip of the toe.
- Carry out the subcutaneous and skin closures as previously described. Apply a compression dressing.

Twelve to 16 weeks after surgery, when the arthrodesis is solidly healed, remove the pins under a digital nerve block in an office setting. Oral analgesics are helpful as well. Use a pin remover or power drill to remove the Steinmann pins.

### *Results and Complications*

A review of the literature reveals an overall fusion rate of 91% (1,394 of 1,536 arthrodeses; range, 77% to 100%) (6,8,12,19,21,22,29,31,34,36,39,40,42,56,60,64,75,76,78,83,86,87,96,97 and 98). Mann and Thompson (60) reported on MTP arthrodesis in 18 feet with an average 4-year follow-up. Their results were classified as good or excellent in 16 of 18. Seventeen of 18 went on to successful arthrodesis. Degenerative arthritis of the IP joint was noted radiographically but was not believed to be clinically significant (Fig. 117.14). A 92% fusion rate (1,074 of 1,164) with the use of conical reamers has been reported (8,19,21,29,40,42,61,64,75,76,82,96,98). Coughlin and Abdo (21) reported on 47 patients (58 feet) who were evaluated after first-MTP-joint fusion. Twenty-eight patients had rheumatoid arthritis. A 98% fusion rate was achieved. The average correction of the 1–2 intermetatarsal angle was to 9.5° and the hallux valgus angle was corrected to 17.1°.

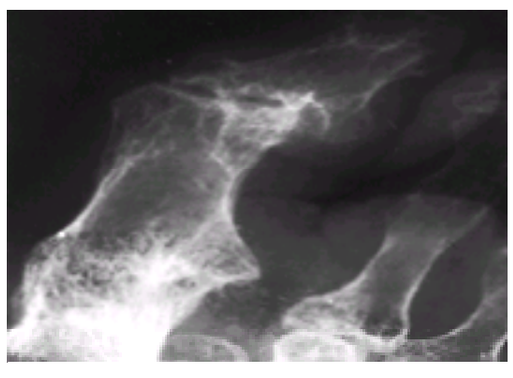

***Figure 117.14.*** Degenerative arthritis of the interphalangeal joint associated with first-MTP-joint arthrodesis in minimal valgus.

Complications after arthrodesis are uncommon and include nonunion and malunion. Unsuccessful arthrodesis does not necessarily lead to a painful pseudoarthrosis, and McKeever (64) noted that a nonunion may still give an acceptable result (Fig. 117.15). Results tend to vary depending on the method of internal fixation and operative technique utilized. The highest rate of nonunion (23%) (31) follows crossed K-wire fixation. Malunion in any plane—whether rotation, varus/valgus, or dorsiflexion/plantar flexion—is poorly tolerated. IP joint arthritis may develop following MTP fusion and has been reported to vary from 6% to 60% (6,12,21,22,36,67,76). Coughlin and Abdo (21) reported a 10% incidence of progressive IP joint arthritis, but only 2% were symptomatic.

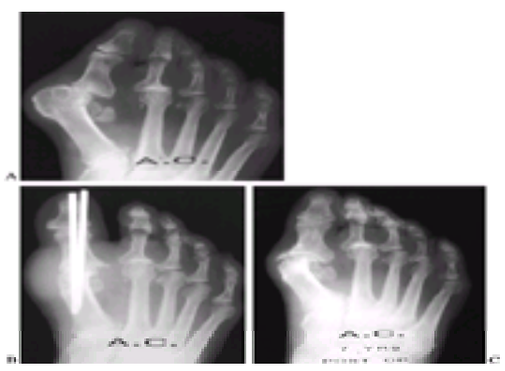

***Figure 117.15.*** Nonunion following arthrodesis. **A:** Dislocation of the first and second metatarsophalangeal joints with severe hallux valgus, associated with long-term rheumatoid arthritis. **B:** Attempted first-MTP-joint arthrodesis. **C:** Seven years after surgery, the result was successful: painless nonunion with marked improvement in alignment. (From Coughlin M. Arthritis. In: Coughlin M, Mann R, eds. *Surgery of the Foot and Ankle*, 7th ed. St. Louis: CV Mosby, 1999, with permission.)

Relative contraindications to MTP arthrodesis include degenerative arthritis of the IP joint and bony insufficiency due to previous excisional arthroplasty or severe osteoporosis. Arthrodesis in these situations can be more difficult to achieve.

## EXCISIONAL ARTHROPLASTY

Although I do not favor excisional arthroplasty, others do prefer this technique, which Keller described in 1904 (46). In an older patient who may have difficulty with the compliance required for MTP arthrodesis or in the presence of recurrent infection or atrophic skin, excisional arthroplasty may be a simple and expeditious procedure. Resection of the base of the proximal phalanx detaches both the intrinsic muscle insertions and the plantar aponeurosis. Although this salvage procedure allows correction of the deformity by decompression of the MTP joint, it shortens the toe and impairs strength and control of the hallux. Preoperative counseling is important to ensure that the patient is aware of these factors.

- Deepen a longitudinal incision on the dorsomedial aspect of the first MTP joint along the medial aspect of the extensor hallucis longus tendon. Take care to protect the dorsal and plantar neurovascular bundles.
- Incise the MTP joint capsule, and expose the base of the proximal phalanx.
- Elevate the capsule off the medial eminence, and resect the medial eminence.
- Dislocate the base of the proximal phalanx. With a power saw, resect approximately one third of the proximal phalanx (Fig. 117.16*A*). Excessive resection may lead to a weakened or flail toe or a cock-up deformity (22).

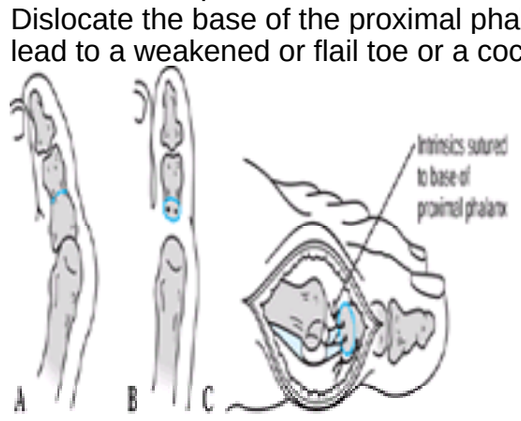


***Figure 117.16.*** An excisional arthroplasty of the hallux (Keller procedure). **A:** Removal of one third to one half of the proximal phalanx. **B:** Fixation holes in the base of the proximal phalanx for reattachment of the plantar plate. **C:** Reattachment of the plantar plate.

- I prefer to reattach the plantar plate and sesamoids to the base of the proximal phalanx. Place the drill holes 2–3 mm distal to the osteotomized surface (Fig. 117.16*B*). Reattach the plantar plate to the remaining proximal phalanx with interrupted nonabsorbable sutures (Fig. 117.16*C*).
- Introduce an 0.062 intramedullary K-wire at the MTP joint. Drive it distally through the tip of the toe, and then advance it in a retrograde fashion into the metatarsal head to stabilize the repair. Bend the pin at the tip of the toe to prevent proximal migration.
- Reapproximate the capsule and the subcutaneous tissues with several interrupted absorbable sutures. Approximate the skin with an interrupted closure.

### *Postoperative Care*

Apply a gauze-and-tape compression dressing at surgery, and change it weekly for approximately 6 weeks. Remove sutures and the intramedullary K-wire 3 weeks after surgery.

### *Results and Complications*

Shortening of the hallux, loss of power, and lateral metatarsalgia are major complaints following excisional arthroplasty. Henry and Waugh (36) reported lateral metatarsalgia following the Keller procedure and advocated MTP fusion. You may note a recurrence of hallux valgus after excisional arthroplasty, especially with progression of the inflammatory process (Fig. 117.17*A*). A cock-up or claw-toe deformity of the hallux, with detachment of the intrinsic muscle insertion on the base of the proximal phalanx, has also been reported as a postoperative result of excisional arthroplasty (Fig. 117.17*B*) (22).

***Figure 117.17.*** **A:** A postoperative recurrence of valgus deformity following a Keller procedure in a patient with rheumatoid arthritis. **B:** A cock-up deformity following a Keller procedure.

## REPAIR OF THE RHEUMATOID HINDFOOT

Involvement of the hindfoot in chronic rheumatoid arthritis is not uncommon. Vainio (89) reported that 72% of women and 59% of men with chronic rheumatoid arthritis had involvement of the subtalar (Fig. 117.18*A*) and midtarsal joints. Clayton and Giannestras (15) noted a tenfold incidence of forefoot involvement in relationship to the hindfoot.

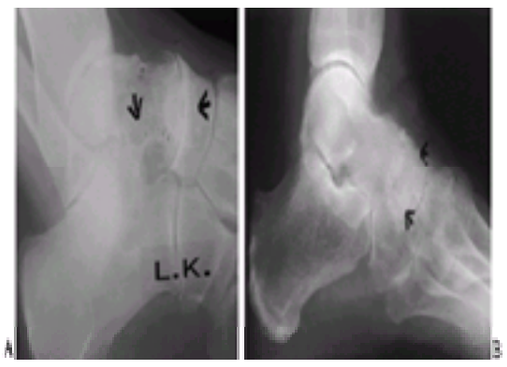


***Figure 117.18.*** **A:** Cystic changes of the inferior aspect of the talus associated with hindfoot rheumatoid arthritis. **B:** Isolated talonavicular arthritis may be one of the earliest findings with rheumatoid arthritis. (From Coughlin M. Arthritis. In: Coughlin M, Mann R, eds. *Surgery of the Foot and Ankle*, 7th ed. St. Louis: CV Mosby, 1999, with permission.)

The typical findings with chronic rheumatoid arthritis are midfoot and hindfoot pain, swelling, flattening of the longitudinal arch, and progressive valgus of the hindfoot. Again, conservative care includes proper footwear, rest to relieve swollen and inflamed joints from the stresses of weight bearing, padding, and longitudinal arch supports. When progressive deformity occurs or unrelenting pain is refractory to conservative treatment, surgery of the hindfoot may be necessary.

Prior to surgery, evaluate the vascular supply of the foot. Rheumatoid vasculitis, while uncommon, may present an increased risk to wound healing. Recognition of the degree of involvement of other joints necessitates planning various lower-extremity operations. With isolated forefoot involvement, occasionally a repair of the rheumatoid forefoot will precede total hip and knee arthroplasty to improve ambulatory capacity after surgery. Therefore, if the hindfoot is mobile and relatively uninvolved, forefoot reconstruction usually proceeds first. When the midfoot and hindfoot are significantly involved with rheumatoid arthritis, you may delay surgical intervention so that total knee and total hip arthroplasty may be performed first. Then align the hindfoot with respect to the overall axial alignment of the lower extremity. If both forefoot and hindfoot are involved, the hindfoot reconstruction should precede the forefoot reconstruction.

The involvement of specific joints and the deformities that are present help in decision making. When an isolated talonavicular joint is involved (Fig. 117.18*B*), arthrodesis of this joint may give good results. Early talonavicular fusion may arrest the progression of insidious pes planus and eliminate a later need for more extensive hindfoot correction (27,71). Involvement of the metatarsocunei form joint also may be treated with isolated arthrodesis of the Lisfranc joint.

When the talonavicular and calcaneocuboid joints are relatively uninvolved, and when the valgus deformity of the hindfoot can be passively corrected, subtalar fusion may be indicated. In this situation, where valgus is usually not excessive, an *in situ* fusion with an iliac crest graft can be performed without significant alteration of the transverse tarsal joint. The development of a valgus deformity of the hindfoot can occur because of various pathologic conditions. It may be associated with erosion of the lateral subtalar joint, hindfoot ligamentous laxity, or both. It may also be associated with a valgus deformity of the ankle. When a unilateral valgus deformity occurs suddenly, suspect a rupture of the posterior tibial tendon. Whether a soft-tissue reconstruction or hindfoot arthrodesis is preferable depends on the condition of other hindfoot joints and the severity of the deformity. See Chapter 118 for a discussion of the treatment of rupture of the posterior tibial tendon, and Chapter 115 for a description of hindfoot arthrodesis.

With progressive involvement of the transverse tarsal joint or with more severe and irreducible valgus of the hindfoot, perform a triple arthrodesis, not only to stabilize the hindfoot but also to correct the deformity (Fig. 117.19). In the patient with hindfoot involvement and a rigid forefoot (Fig. 117.20*A*), the objective is to obtain a plantigrade foot. Therefore, a triple arthrodesis is usually necessary (Fig. 117.20*B*) (1). However, after completion of the subtalar component of this fusion, you must pronate the forefoot or a plantigrade foot will not be obtained. This correction is achieved at the transverse tarsal joint.

***Figure 117.19.*** **A,B:** Triple arthrodeses performed for rheumatoid arthritis of the hindfoot.

***Figure 117.20.*** **A:** Preoperative radiograph demonstrating severe pes planovalgus deformity and forefoot deformity associated with rheumatoid arthritis. **B:** Radiograph following triple arthrodesis and forefoot arthroplasty with correction of deformity. (From Coughlin M. Arthritis. In: Coughlin M, Mann R, eds. *Surgery of the Foot and Ankle*, 7th ed. St. Louis: CV Mosby, 1999, with permission.)

If a severe valgus deformity is present with a supple forefoot, a subtalar fusion may be feasible, but in all probability a bone graft to realign the excessive valgus deformity will be necessary. The objective is to obtain heel valgus of 5° at the completion of the arthrodesis. Failure to perform a bone graft with a severe valgus deformity may lead to a recurrence of valgus.

Uncommonly, the ankle joint is involved in severe rheumatoid arthritis. When progressive hindfoot valgus has occurred, hindfoot stabilization is often indicated. The choice between subtalar and triple arthrodesis depends on several factors, including the severity of joint involvement, the degree of joint deformity, and the ankle involvement. Nonetheless, attention to the ankle joint is necessary, since subtalar or triple arthrodesis with concurrent ankle disease may eventually progress to a pantalar arthrodesis.

Wagner (94) noted that ankle fusion is rarely indicated in rheumatoid arthritis. When significant degeneration has occurred, surgical intervention may be necessary (Fig. 117.21). Whereas long-term evaluation of total ankle arthroplasty has revealed suboptimal results (47,69,88,99), newer uncemented components have yielded encouraging results (Fig. 117.22) (3,48). Ankle arthrodesis also may be an alternative for the treatment of end-stage ankle arthritis refractory to conservative care. On the rare occasion that subtalar and ankle joints are involved, perform pantalar arthrodesis. However, even with significant chondrolysis of the ankle joint, surprisingly

good function may be retained.

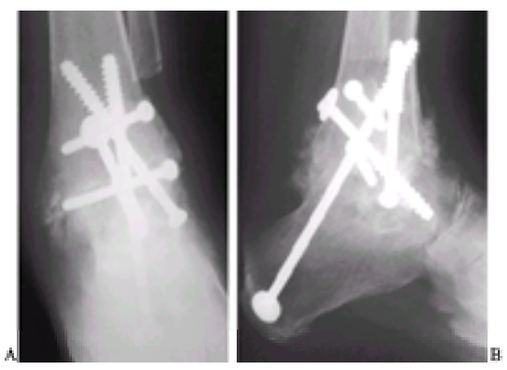

***Figure 117.21.*** AP (**A**) and lateral (**B**) radiographs demonstrating ankle arthrodesis in a rheumatoid patient following spontaneous subtalar arthrodesis at an early age.

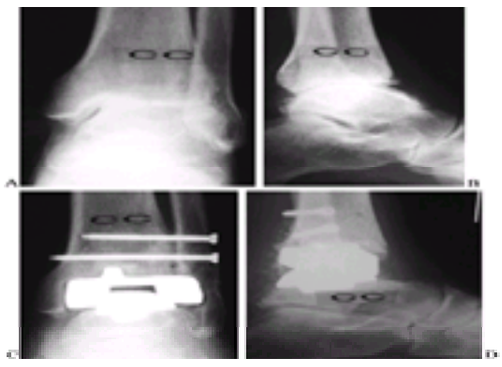

***Figure 117.22.*** Rheumatoid arthritis of the ankle. **A:** AP radiograph. **B:** Lateral radiograph. **C:** Postoperative lateral radiograph after total ankle arthroplasty. **D:** Lateral radiograph.

The techniques for talonavicular, subtalar, triple, and ankle arthrodeses are described in Chapter 115. The use of autogenous iliac crest graft depends on the deformity and the fusion that is attempted. If correction is desired, bone grafting may be necessary. Occasionally, a bone mill is used in the preparation of bone. This graft is then placed in the realigned subtalar joint, which is then stabilized with internal fixation.

## CHAPTER REFERENCES

Each reference is categorized according to the following scheme: *, classic article; #, review article; !, basic research article; and +, clinical results/outcome study.


# 1. Adam W, Ranawat C. Arthrodesis of the Hindfoot in Rheumatoid Arthritis. *Orthop Clin North Am* 1976;7:827.

+ 2. Aho H. Synovectomy of MTP Joints in Rheumatoid Arthritis. *Rheumatology* 1987;11:126.

+ 3. Alvine F. Total Ankle Arthroplasty: New Concepts and Approach. *Contemp Orthop* 1991;22:397.

+ 4. Amusco S, Wissinger H, Margolis H, et al. Metatarsal Head Resection in the Treatment of Rheumatoid Arthritis. *Clin Orthop* 1971;74:94.

+ 5. Barton N. Arthroplasty of the Forefoot in Rheumatoid Arthritis. *J Bone Joint Surg Br* 1973;55:126.

+ 6. Beauchamp C, Kirby T, Rudge S, et al. Fusion of the First Metatarsophalangeal Joint in Forefoot Arthroplasty. *Clin Orthop* 1984;190:249.

# 7. Benson G, Johnson E. Management of the Foot in Rheumatoid Arthritis. *Orthop Clin North Am* 1971;2:733.

+ 8. Bingold A. Arthrodesis of the Great Toe. *Proc R Soc Med* 1958;51:435.

+ 9. Brattstrom J, Brattstrom M. Resection of the Metatarsophalangeal Joints in Rheumatoid Arthritis. *Acta Orthop Scand* 1970;41:213.

+ 10. Calabro J. A Critical Evaluation of the Diagnostic Features of the Feet in Rheumatoid Arthritis. *Arthritis Rheum* 1962;5:19.

+ 11. Caputi R. Synovectomy. *Clin Podiatr Med Surg* 1988;5:249.

+ 12. Chana G, Andrew T, Cotterill C. A Simple Method of Arthrodesis of the First Metatarsophalangeal Joint. *J Bone Joint Surg Br* 1984;66:703.

+ 13. Clayton M. Surgery of the Forefoot in Rheumatoid Arthritis. *Clin Orthop* 1960;16:136.

* 14. Clayton M. Surgery of the Lower Extremity in Rheumatoid Arthritis. *J Bone Joint Surg Am* 1963;45:1517.

# 15. Clayton M; Giannestras N, ed. *Foot Disorders: Medical and Surgical Management*, 2nd ed. Philadelphia: Lea & Febiger, 1973.

+ 16. Conklin M, Smith R. Treatment of the Atypical Lesser Toe Deformity with Basal Hemiphalangectomy. *Foot Ankle* 1994;15:585.

# 17. Coughlin M. The Rheumatoid Foot. Pathophysiology and Treatment of Arthritic Manifestations. *Postgrad Med* 1984;75:207.

# 18. Coughlin M. Arthrodesis of the First Metatarsophalangeal Joint. *Orthop Rev* 1990;19:177.

+ 19. Coughlin M. Arthrodesis of the First Metatarsophalangeal Joint with Mini-fragment Plate Fixation. *Orthopedics* 1990;13:1037.

# 20. Coughlin M. The Rheumatoid Foot. In: Chapman M, ed. *Operative Orthopaedics*, 2nd ed. Philadelphia: JB Lippincott, 1993:2311.

+ 21. Coughlin M, Abdo R. Arthrodesis of the First Metatarsophalangeal Joint with Vitallium Plate Fixation. *Foot Ankle* 1994;15:18.

* 22. Coughlin M, Mann R. Arthrodesis of the First Metatarsophalangeal Joint as Salvage for the Failed Keller Procedure. *J Bone Joint Surg Am* 1987;69:68.

+ 23. Cracchiolo A. Management of the Arthritic Forefoot. *Foot Ankle* 1982;3:17.

# 24. Cracchiolo A. Rheumatoid Arthritis of the Forefoot. In: Gould J, ed. *Operative Foot Surgery.* Philadelphia: WB Saunders, 1994:141.

+ 25. Downey D, Simkin P, Mack L, et al. Tibilias Posterior Tendon Rupture: A Cause of Rheumatoid Flat Foot. *Arthritis Rheum* 1988;31:441.

# 26. DuVries H. Arthritides. In: DuVries H, ed. *Surgery of the Foot*, 2nd ed. St. Louis: CV Mosby, 1965:318.

+ 27. Elbaor J, Thomas W, Weinfeld M, Potter T. Talonavicular Arthrodesis for Rheumatoid Arthritis of the Hindfoot. *Orthop Clin North Am* 1976;7:821.

+ 28. Faithful D, Savill D. Review of the Results of Excision of the Metatarsal Head in Patients with Rheumatoid Arthritis. *Ann Rheum Dis* 1971;30:201.

+ 29. Fitzgerald J. A Review of Long-term Results of Arthrodesis of the First Metatarso-phalangeal Joint. *J Bone Joint Surg Br* 1969;51:488.

+ 30. Fowler A. A Method of Forefoot Reconstruction. *J Bone Joint Surg Br* 1959;41:507.

+ 31. Gimple K, Amspacher J, Kopta J. Metatarsophalangeal Joint Fusion of the Great Toe. *Orthopedics* 1978;1:462.

+ 32. Gold R, Bassett L. Radiologic Evaluation of the Arthritic Foot. *Foot Ankle* 1982;2:332.

+ 33. Gould N. Surgery of the Forepart of the Foot in Rheumatoid Arthritis. *Foot Ankle* 1982;3:173.

+ 34. Harrison M, Harvey F. Arthrodesis of the First Metatarsophalangeal Joint for Hallux Valgus and Rigidus. *J Bone Joint Surg Am* 1963;45:471.

+ 35. Hasselo L, Willkens R, Toomey H, et al. Forefoot Surgery in Rheumatoid Arthritis: Subjective Assessment of Outcome. *Foot Ankle* 1987;8:148.

+ 36. Henry A, Waugh W. The Use of Footprints in Assessing the Results of Operations for Hallux Valgus. A Comparison of Keller Operation and Arthrodesis. *J Bone Joint Surg Br* 1975;57:478.

+ 37. Hodor L, Dobbs B. Pan Metatarsal Head Resection. A Review and New Approach. *J Am Podiatr Med Assoc* 1983;73:287.

+ 38. Hoffman P. An Operation for Severe Grades of Contracted or Clawed Toes. *Am J Orthop Surg* 1911;9:441.

+ 39. Humbert J, Bourbonniere C, Laurin C. Metatarsophalangeal Fusion for Hallux Valgus: Indications and Effect on the First Metatarsal Ray. *Can Med Assoc J* 1979;120:937.

+ 40. Jeffery J, Freedman L. Modified Reamers for Fusion of the First Metatarsophalangeal Joint. *J Bone Joint Surg Br* 1995;77:328.

+ 41. Jenkin W, Oloff L. Implant Arthroplasty in the Rheumatoid Arthritic Patient. *Clin Podiatr Med Surg* 1988;5:213.

+ 42. Johansson J, Barrington T. Cone Arthrodesis of the First Metatarsophalangeal Joint. *Foot Ankle* 1984;4:244.

# 43. Joplin R. Surgery of the Forefoot in the Rheumatoid Arthritic Patient. *Surg Clin North Am* 1969;49:847.

* 44. Kates A, Kessel L, Kay A. Arthroplasty of the Forefoot. *J Bone Joint Surg Br* 1967;49:552.

+ 45. Keenan M, Peabody T, Gronley J, Perry J. Valgus Deformities of the Feet and Characteristics of Gait in Patients Who Have Rheumatoid Arthritis. *J Bone Joint Surg Am* 1991;73:237.

* 46. Keller W. The Surgical Treatment of Bunions and Hallux Valgus. *N Y Med J* 1904;80:741.

+ 47. Kitaoka H, Patzer G, Ilstrup D, Wallrichs S. Survivorship Analysis of the Mayo Total Ankle Arthroplasty. *J Bone Joint Surg Am* 1994;76:974.

+ 48. Kofoed H. Cylindrical Cemented Ankle Arthroplasty: A Prospective Series with Long-term Follow-up. *Foot Ankle* 1995;16:474.

+ 49. Kuhns J. The Foot in Chronic Arthritis. *Clin Orthop* 1960;16:141.

+ 50. Larmon W. Surgical Treatment of Deformities of Rheumatoid Arthritis of the Forefoot and Toes. *Northwest Univ Bull Med School* 1951;25:39.

# 51. Leavitt D. Surgical Treatment of Arthritic Feet. *Northwest Med* 1956;55:1086.

+ 52. Lipscomb P. Surgery for Rheumatoid Arthritis—Timing and Techniques: Summary. *J Bone Joint Surg Am* 1968;50:614.

+ 53. Lipscomb P. Arthrodesis of the First Metatarsophalangeal Joint for Severe Bunions and Hallux Rigidus. *Clin Orthop* 1979;142:48.

+ 54. Lipscomb P, Benson G, Sones D. Resection of Proximal Phalanges and Metatarsal Condyles for Deformities of the Forefoot due to Rheumatoid Arthritis. *Clin Orthop* 1972;82:24.

+ 55. MacClean C, Silver W. Dwyer's Operation for the Rheumatoid Forefoot. *Foot Ankle* 1981;1:343.

+ 56. Mankey M, Mann R. Arthrodesis of the First Metatarsophalangeal Joint Utilizing a Dorsal Plate. Presented at the 7th Annual Summer Meeting of the American Orthopaedic Foot and Ankle Society, Boston, Mass., July 17, 1991.

# 57. Mann R, Coughlin M. The Rheumatoid Foot. Review of the Literature and Method of Treatment. *Orthop Rev* 1979;7:105.

+ 58. Mann R, Katcherian D. Relationship of Metatarsophalangeal Joint Fusion on the Intermetatarsal Angle. *Foot Ankle* 1989;10:8.

+ 59. Mann R, Schakel M II. Surgical Correction of Rheumatoid Forefoot Deformities. *Foot Ankle Int* 1995;16:1.

+ 60. Mann R, Thompson F. Arthrodesis of the First Metatarsophalangeal Joint for Hallux Valgus in Rheumatoid Arthritis. *J Bone Joint Surg Am* 1984;66:687.

+ 61. Marin G. Arthrodesis of the Metatarsophalangeal Joint of the Big Toe for Hallux Valgus and Hallux Rigidus. A New Method. *Int Surg* 1968;50:176.

+ 62. Marmor L. Resection of the Forefoot in Rheumatoid Arthritis. *Clin Orthop* 1975;108:223.

+ 63. McGarvey S, Johnson K. Keller Arthroplasty in Combination with Resection Arthroplasty of the Lesser Metatarsophalangeal Joints in Rheumatoid Arthritis. *Foot Ankle* 1988;9:75.

* 64. McKeever D. Arthrodesis of the First Metatarsophalangeal Joint for Hallux Valgus, Hallux Rigidus, and Metatarsus Primus Varus. *J Bone Joint Surg Am* 1952;34:129.

# 65. Michelson J, Easley J, Wigley F, Hellmann D. Foot and Ankle Problems in Rheumatoid Arthritis. *Foot Ankle Int* 1994;15:608.

+ 66. Morrison P. Complications of Forefoot Operations in Rheumatoid Arthritis. *Proc R Soc Med* 1974;67:110.

+ 67. Moynihan F. Arthrodesis of the Metatarsophalangeal Joint of the Great Toe. *J Bone Joint Surg Br* 1967;49:544.

+ 68. Newman R, Fitton J. Conservation of Metatarsal Heads in Surgery of Rheumatoid Arthritis of the Forefoot. *Acta Orthop Scand* 1983;54:417.

# 69. Newton E. Total Ankle Arthroplasty. In: Jahss M, ed. *Disorders of the Foot and Ankle: Medical and Surgical Management.* Philadelphia: WB Saunders, 1982:816.

+ 70. Peterson L. Surgery for Rheumatoid Arthritis—Timing and Techniques: The Lower Extremity. *J Bone Joint Surg Am* 1968;50:587.

+ 71. Potter T. Talonavicular Fusion with Bone Graft for Spastic Arthritic Flatfoot. *Surg Clin North Am* 1969;49:883.

+ 72. Rana N. Juvenile Rheumatoid Arthritis of the Foot. *Foot Ankle* 1983;3:2.

# 73. Rana N. Rheumatoid Arthritis, Other Collagen Diseases and Psoriasis of the Foot. In: Jahss M, ed. *Disorders of the Foot and Ankle, Medical and Surgical Management*, 2nd ed. Philadelphia: WB Saunders, 1991:1719.

+ 74. Raunio P, Laine H. Synovectomy of the Metatarsophalangeal Joints in Rheumatoid Arthritis. *Acta Rheum Scand* 1970;16:12.

+ 75. Raymakers R, Waugh W. The Treatment of Metatarsalgia with Hallux Valgus. *J Bone Joint Surg Br* 1971;53:684.

+ 76. Riggs S, Johnson E. McKeever Arthrodesis for the Painful Hallux. *Foot Ankle* 1983;3:248.

# 77. Rodnan G, Schumacher H, eds. *Primer on the Rheumatic Diseases*, 8th ed. Atlanta: Arthritis Foundation, 1983:49.

+ 78. Salis-Soglio G, Thomas W. Arthrodesis of the Metatarsophalangeal Joint of the Great Toe. *Arch Orthop Trauma Surg* 1979;95:7.

+ 79. Saltzman C, Johnson K, Donnelly R. Surgical Treatment for Mild Deformities of the Rheumatoid Forefoot by Partial Phalangectomy and Syndactylization. *Foot Ankle* 1993;14:325.

+ 80. Schwartzmann J. The Surgical Management of Foot Deformities in Rheumatoid Arthritis. *Clin Orthop* 1964;36:86.

+ 81. Shereff M, Jahss M. Complications of Silastic Implant Arthroplasty in the Hallux. *Foot Ankle* 1980;1:195.

+ 82. Smith N. Hallux Valgus and Rigidus Treated by Arthrodesis of the Metatarsophalangeal Joint. *Br Med J* 1952;2:1385.

+ 83. Smith R, Joanis T, Maxwell P. Great Toe Metatarsophalangeal Joint Arthrodesis: A User-friendly Technique. *Foot Ankle* 1992;13:367.

+ 84. Spiegel T, Spiegel J. Rheumatoid Arthritis in the Foot and Ankle—Diagnosis, Pathology and Treatment. *Foot Ankle* 1982;2:318.

# 85. Thomas W. Surgery of the Foot in Rheumatoid Arthritis. *Orthop Clin North Am* 1975;6:831.

+ 86. Tupman S. Athrodesis of the First Metatarsophalangeal Joint. *J Bone Joint Surg Br* 1958;40:826.

+ 87. Turan I, Lindgren U. Compression-screw Arthrodesis of the First Metatarsophalangeal Joint of the Foot. *Clin Orthop* 1987;221:292.

+ 88. Unger A, Inglis A, Mow C, Figgie H. Total Ankle Arthroplasty in Rheumatoid Arthritis: A Long-term Follow-up Study. *Foot Ankle* 1988;8:173.

+ 89. Vainio K. The Rheumatoid Foot. A Clinical Study with Pathologic and Roentgenological Comments. *Ann Chir Gynaecol* 1956;45(suppl):1.

+ 90. Vainio K. Morton's Metatarsalgia in Rheumatoid Arthritis. *Clin Orthop* 1979;142:85.

+ 91. Van der Heijden K, Rasker J, Jacobs J, Dey K. Kates Forefoot Arthroplasty in Rheumatoid Arthritis. A 5-Year Followup Study. *J Rheumatol* 1992;19:1545.

+ 92. Van Loon P, Ariea R, Karthaus R, Steenaert B. Metatarsal Head Resection in the Deformed, Symptomatic Rheumatoid Foot. A Comparison of Two Methods. *Acta Orthop Belg* 1992;58:11.

+ 93. Vidigal E, Jacoby R, Dixon A, et al. The Foot in Chronic Rheumatoid Arthritis. *Ann Rheum Dis* 1975;34:292.

+ 94. Wagner F. Ankle Fusion for Degenerative Arthritis Secondary to the Collagen Diseases. *Foot Ankle* 1982;3:24.

+ 95. Watson M. A Long-term Follow-up of Forefoot Arthroplasty. *J Bone Joint Surg Br* 1974;56:527.

+ 96. Wilkinson J. Cone Arthrodesis of the First Metatarsophalangeal Joint. *Acta Orthop Scand* 1978;49:627.

+ 97. Wilson C. A Method of Fusion of the Metatarsophalangeal Joint of the Great Toe. *J Bone Joint Surg Am* 1958;40:384.

+ 98. Wilson J. Cone Arthrodesis of the First Metatarsophalangeal Joint. *J Bone Joint Surg Br* 1967;49:98.

+ 99. Wynn A, Wilde A. Long-term Follow-up of the Conaxial (Beck-Steffee) Total Ankle Arthroplasty. *Foot Ankle* 1992;13:303.

# CHAPTER 118

# TENDON DISORDERS OF THE FOOT AND ANKLE

*Mark M. Casillas and Roger A. Mann*

**M. M. Casillas:** Clinical Instructor of Orthopaedics, the University of Texas Health Sciences Center in San Antonio; and Orthopaedic Surgeon, Orthopaedic Surgery Associates of San Antonio 9150 Huebner Road, San Antonio, Texas, 78240.
**R. A. Mann:** Director, Orthopaedic Foot and Ankle Fellowship Program, Oakland, California, 94609.

Achilles Tendinosis and Rupture
- Pathophysiology
- Principles of Treatment
- Assessment
- Classification
- Preoperative Management
- Operative Techniques
- Complications
- Conclusions

Posterior Tibial Tendon Dysfunction
- Pathophysiology
- Principles of Treatment
- Assessment
- Classification
- Preoperative Management
- Operative Techniques
- General Rehabilitation
- Complications

Peroneal Tendon Subluxation, Dislocation, and Longitudinal Rupture
- Pathophysiology
- Principles of Treatment
- Assessment
- Classification
- Preoperative Management
- Operative Techniques
- General Rehabilitation
- Complications
- Conclusions

Chapter References

## ACHILLES TENDINOSIS AND RUPTURE

### PATHOPHYSIOLOGY

The gastrocnemius muscle and the soleus muscles combine in the posterior compartment of the leg to produce a common tendon, the Achilles tendon, which inserts into the posterior tuberosity of the calcaneus. The tendon does not have an accompanying synovial sheath, but it is surrounded by a peritenon or fibrous covering that is derived from the crural fascia. During steady-state walking, the primary function of the gastrocsoleus muscle group is to decelerate the tibia as it passes over the foot. This is accomplished with eccentric muscle contraction. Toe-off is a passive event during steady-state walking and an active event during steady-state running or acceleration (20).

Using pathologic criteria, the classification of Achilles tendon dysfunction is best divided into paratenonitis, tendinosis, and partial or complete rupture. Paratenonitis is defined by inflammation of the tissues surrounding, but not including, the Achilles tendon. Paratenonitis is commonly attributed to athletic training errors, such as ineffective stretching or warm-up and overuse. Mechanical factors, such as excessive foot pronation or a tight Achilles tendon, have also been implicated. Tendinosis is defined by degenerative changes within the substance of a tendon; these changes are probably age related and may represent a precursor to partial tears. Histologic examination of chronic Achilles tendinosis reveals abnormal fibrous structure, focal hypercellularity, and vascular proliferation. Curiously, inflammatory cells are not found (2). Angiographic and microangiographic examinations reveal a paucity of vasculature in the segment of tendon between 2 and 6 cm proximal to the insertion (18). Clinical findings suggest that this same area is susceptible to tendinosis and rupture.

### PRINCIPLES OF TREATMENT

The goal of treating Achilles tendinosis is to alleviate pain, prevent further degeneration, and preserve function. The goal of treating Achilles tendon ruptures is to restore the functional integrity to the gastrosoleus complex. For both conditions, surgical and nonsurgical methods are used in an effort to maximize outcome.

### ASSESSMENT

The patient with Achilles tendinosis presents with pain over the Achilles tendon that is aggravated by activity. Physical examination begins with gait analysis; moderate to severe tendinosis produces an antalgic pattern. Examine the patient in the standing position to evaluate swelling or fullness related to the Achilles tendon. Assess calf atrophy by comparison with the contralateral extremity. Have the patient perform a repeated single-heel rise test. This is accomplished by having the patient stand at a nearby wall using hands for balance. The patient lifts the unaffected extremity while performing repeated single-heel rises on the affected extremity. The test is positive if the patient is unable to perform the maneuver owing to pain or if the maneuver causes pain at the Achilles tendon. Then seat the patient and palpate the posterior leg to assess swelling and tenderness. Nodular or fusiform swelling typically accompanies tendinosis.

Diagnostic imaging for the patient with Achilles tendinosis begins with a lateral radiographic view of the distal leg and hind foot. Look for intratendinous calcification associated with tendinosis and check the topography of the posterior superior calcaneus. The presence of a hyperconvex superior tuberosity of the calcaneus may be associated with distal tendinosis. Although it is not required for evaluation of Achilles tendinosis or rupture, magnetic resonance imaging (MRI) is probably the most useful imagining modality. On a T2-image sequence, tendinosis shows increased signal activity within the tendon as well as localized thickening, cystic changes, and even partial tears.

Rupture of the Achilles tendon may occur without antecedent symptoms or may follow a period of pain associated with Achilles tendinosis. Rupture is associated with the acute onset of pain over the Achilles tendon and the loss of plantar flexion power, either subtle or overt. Occasionally, the patient recalls sensing or hearing a “pop” at the time of rupture. Examination of the standing patient may reveal subtle to massive swelling along the posterior leg. With the patient in a prone position, perform a Thompson's test by squeezing the calf at midsubstance and looking for the absence of foot plantarflexion. When foot plantarflexion is not observed, the test is considered positive and the diagnosis of ruptured Achilles tendon is established (41). Palpation of the Achilles tendon itself may reveal a defect. Failure to find this defect, however, does not rule out tendon disruption.

Complete tears of the Achilles tendon are easily identified on MRI, but the diagnosis is usually obvious on clinical examination as well. MRI is not required for the routine evaluation of Achilles tendon ruptures.

### CLASSIFICATION

Achilles tendinosis consists of a spectrum of injuries ranging from small focal areas of degeneration associated with mild pain and minimal dysfunction through significant areas of degeneration and partial tearing associated with significant discomfort and loss of function. Furthermore, tendinosis can be classified with an anatomic system based on the location of the degeneration relative to the insertion. Noninsertional tendinosis includes degenerative changes of the Achilles tendon between the musculotendinous junction to a point proximal to the insertion. Insertional tendinosis is limited to degeneration at the Achilles tendon insertion. This entity tends to be more focal, but similar treatment principles apply.

Achilles tendon ruptures may occur *de novo* through a section of healthy tendon or through a section of tendinosis. Lacerations, ruptures through previously healed tendon disruptions, and chronic ruptures are recognized as distinct entities.

## PREOPERATIVE MANAGEMENT

Treat Achilles tendinosis initially with rest, application of ice, and nonsteroidal anti-inflammatory medication. Patients with moderate to severe symptoms require immobilization with a weight-bearing cast or removable cast boot. Once the pain, swelling, and tenderness have resolved, institute a rehabilitation program. Place emphasis on stretching the gastrosoleus motor complex. Also correct training errors related to intensity or frequency of activity.

Patients with acute, complete Achilles tendon rupture may be treated by surgical or nonsurgical methods. The ideal treatment of the acute, complete Achilles tendon rupture remains controversial. Nonsurgical methods have the advantage of avoiding wound complications, but they appear to have a higher rerupture rate (14,29). Patients treated with surgical primary repair have a significantly lower rerupture rate and a higher degree of satisfaction; unfortunately, they are also prone to surgical complications such as deep infection, fistula, and skin or tendon necrosis (14,29)

For nonsurgical treatment of acute, complete Achilles tendon ruptures, use a non-weight-bearing equinus cast for 6 weeks, followed by a weight-bearing cast boot for a second 6-week period, then place a silicone heel wedge in the cast boot and subsequent shoewear. On the resolution of local warmth and swelling, begin a motion and strengthening program. Surgical treatment consists of primary repair of the Achilles tendon. Achilles tendinosis that is recalcitrant to a prolonged course of immobilization and conservative management requires surgical debridement and possible reconstruction. Although it is not required, an MRI may be obtained in order to better delineate the extent of tendon degeneration.

## OPERATIVE TECHNIQUES

### *Debridement of Achilles Tendinosis*

- Using general or regional anesthesia and a proximal thigh tourniquet, make a longitudinal incision parallel to and 1.5 cm anterior to the medial border of the Achilles tendon. Because the wound is prone to marginal necrosis and breakdown, exercise caution when handling soft tissues. By sharp dissection, expose the Achilles paratenon and incise it longitudinally, allowing complete inspection of the tendon.
- Degenerative changes are suggested by changes in local color, swelling, localized tissue edema, cystic changes, and partial tears. Sharply excise all degenerative sections. If the functional integrity of the tendon is compromised, perform a reconstructive procedure. If, however, the remaining tendon remains functionally competent, carefully repair the subcutaneous tissue with interrupted absorbable sutures and close the skin with nylon or skin clips.
- Apply a large, bulky, compression dressing with the foot in a neutral position.
- *Postoperative management:* Ten days after surgery, remove the sutures, place the leg in a removable cast, and begin a range-of-motion and strengthening program. After local swelling and warmth have resolved, gradually resume athletic activity.

### *Debridement of Achilles Tendinosis and Reconstruction with Transfer of the Flexor Hallucis Longus Tendon*

If systematic debridement of the Achilles tendon results in the loss of functional integrity, it must be reconstructed. The flexor hallucis longus (FHL) tendon transfer provides not only additional collagen but also an additional motor unit.

- Make an incision on the medial aspect of the forefoot from the navicular to the metatarsal head. Identify the abductor hallucis muscle and release its fascia longitudinally from the first metatarsal. Retract the muscle to visualize the plantar nerves as well as the FHL and flexor disitorum longus (FDL) tendons.
- Carefully release the flexor knot of Henry as well as all fascial connections between the FHL and FDL tendons. Tenodese the distal FHL tendon with a #2 nonabsorbable suture. Then divide it just proximal to the tenodesis.
- Then make an incision along the medial aspect of the Achilles tendon from the calcaneus for as proximal as necessary. Identify the FHL muscle and its tendon. Pull it into the proximal wound. Using a quarter-inch drill, make a tunnel through the superior tuberosity of the calcaneus, smoothing its edges (Fig. 118.1). Then pass the FHL tendon through the tunnel. With the foot in a plantarflexed position, carefully adjust the tension in an effort to approximate that of the contralateral Achilles tendon. Then suture the FHL tendon to itself and to the adjacent Achilles tendon with nonabsorbable suture. Typically, the remaining section of FHL tendon is woven across the Achilles tendon defect.

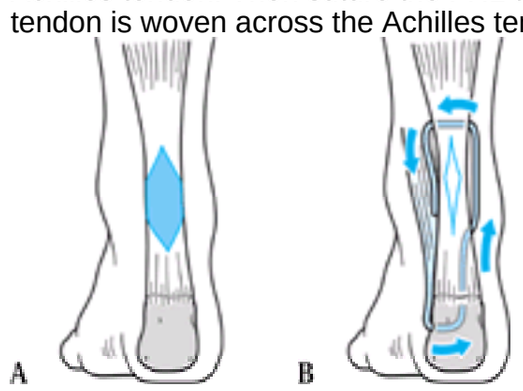


***Figure 118.1.*** Debridement and reconstruction of the Achilles tendon with the FHL tendon. **A:** The shaded area represents the area of tendinosis and debridement. **B:** Reconstruction with the FHL tendon. See text for details.

- If further reinforcement is required, perform a plantaris tendon weave, a turn-down of the central one third of the Achilles tendon, or a **V**-**Y** advancement of the musculotendinous junction.
- Close the subcutaneous tissue with interrupted absorbable sutures and close the skin with nylon or skin clips.
- Apply a large bulky compression dressing with the foot in a plantarflexed position.
- *Postoperative management:* Ten days after surgery, remove the sutures and apply another plantarflexed cast. Between 2 and 4 weeks after surgery, gradually bring the foot up to a plantigrade position and continue in a cast. At 5 weeks after surgery, use a removable cast boot so that range-of-motion and strengthening exercises can be instituted. At 12 weeks, discontinue immobilization. After local swelling and warmth have resolved, gradually resume athletic activity.

### *Achilles Tendon Turn-Down Flap*

The reconstruction of the Achilles tendon with a turn-down flap is shown in Figure 118.2.

***Figure 118.2.*** Reconstruction of Achilles tendon with turn-down flap. **A:** Abnormal segment of Achilles tendon has been excised, leaving normal ends proximal and distal. **B:** A segment of proximal tendon is harvested. The lateral edge of the tendon has been left intact proximally. **C:** The proximal end is tubularized and then pivoted downward. **D:** The graft has been passed through the calcaneal tunnel and sutured back to itself.

- With the patient in the prone position, make a longitudinal incision from the midportion of the calf in the midline, extending distally to the posteromedial heel. Expose the posterior calcaneus and Achilles tendon, and excise the scar in the defect.
- Using a 4.5 mm drill, make a transverse tunnel in the calcaneal tuberosity, and enlarge it as needed using curets.
- Divide the lateral half of the Achilles tendon tranversely at the proximal musculotendinous junction, just up to the lateral edge. Leave the lateral edge intact as a cuff. Split the proximal tendon longitudinally both laterally and in the midline. In the midline, turn the tendon down, stopping 1 inch proximal to the site of rupture. Separate this segment from the underlying muscle with a pair of scissors.
- Insert several stay stitches of 0 absorbable suture at the pivot point to prevent distal tearing.
- Form a tube of the now-distal end by sewing its medial and lateral sides together with a running 0 absorbable suture. Weave a #1 nonabsorbable suture through the end of the graft, and pass the suture through the calcaneal tunnel. Place the ankle in 20° of plantarflexion and tension the graft. Sew it back to itself with the nonabsorbable suture. Use multiple stitches of 0 absorbable suture to augment this repair and to secure the graft to the calcaneal periosteum at the medial and lateral ends of the tunnel.
- Divide the plantaris tendon proximally, leaving its calcaneal insertion intact, and fan it out as a covering for the reconstruction.
- Proximally repair the remaining medial half of the tendon to the remaining lateral cuff with interrupted 0 absorbable sutures.
- Close the subcutaneous tissue and skin of both wounds in layers. Apply a short-leg posterior splint with the ankle in 20° of plantarflexion.
- *Postoperative management:* Remove the skin sutures at one week and apply a short-leg non-weight-bearing cast, with the ankle in 20° plantarflexion, which is worn for 5 weeks. Then apply a removable orthosis with the ankle at neutral for 4 to 6 more weeks. Allow active ankle exercises for motion without resistance during this time. Begin passive motion and soft-tissue mobilization between 8 and 10 weeks after surgery. Swimming and cycling can begin 4 months after surgery, followed by plantarflexion-resistive exercises. A permanent loss of power must be expected, but running and jumping are possible. Return to sports requires a minimum of 12 months recovery.

***Repair of an Acute, Complete Achilles Tendon Rupture***

- Using general or regional anesthesia and a proximal thigh tourniquet, make a longitudinal incision parallel to and 1.5 cm anterior to the medial border of the Achilles tendon. Because these wounds are prone to marginal necrosis and breakdown, exercise caution when handling soft tissues.
- Sharply dissect directly to the Achilles paratenon. Incise the paratenon longitudinally, allowing complete inspection of the tendon rupture. Debride the rupture site of hematoma.
- Approximate the tendon ends and do a primary repair with a core suture of #3 nonabsorbable braided suture (Fig. 118.3). Follow with a circumferential peripheral tendon repair with braided nonabsorbable suture. Weave the plantaris across the repair site and secure it with 2-0 braided nonabsorbable sutures.

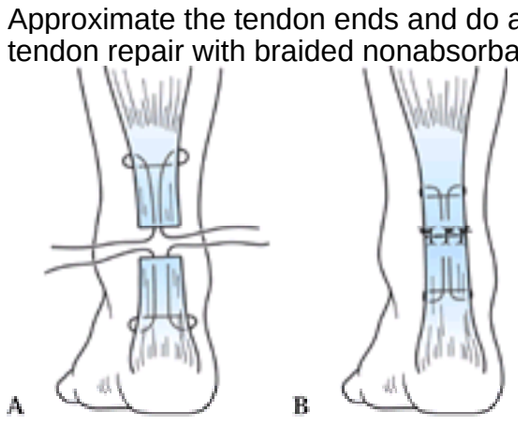


***Figure 118.3.*** Primary repair of an acute Achilles tendon rupture with a core suture. **A:** Insertion of sutures. **B:** Completed repair.

- Carefully repair the subcutaneous tissue with multiple absorbable sutures and close the skin with fine nylon or skin clips.
- Apply a large, bulky compression dressing with the foot in a plantarflexed position.
- *Postoperative management:* Remove the sutures 10 days after surgery and apply a non-weight-bearing cast, with the foot in a plantarflexed position. Over the next 4 weeks, gradually bring the position of the foot to a plantigrade position. At the 4-week postoperative visit, apply a removable cast boot and begin range-of-motion and low-resistance exercises. At the 8-week postoperative visit, begin weight bearing. At 12 weeks after surgery, immobilization can be discontinued. Gradually resume athletic activity once local warmth and swelling have resolved.
- Delay postsurgical stretching of the Achilles tendon until local swelling, warmth, and tenderness have resolved. Early and aggressive stretching may result in lengthening of the gastrosoleus complex with concomitant loss of power. Once local conditions permit, warm-up and stretching of the entire lower extremity remain important tools in the enhancement of performance and reduction of repeat injury.

### COMPLICATIONS

Rerupture is a complication of Achilles tendon rupture treated with either surgical or nonsurgical intervention. The rerupture rate appears to be higher in those patients treated with cast immobilization alone (14,29), particularly in those treated with less than 8 weeks of immobilization (19).

Skin slough and wound infection are serious complications because of the subcutaneous position of the tendon. Surgical technique requires preservation of full-thickness skin flaps, gentle soft-tissue handling, and tension-free closure. Before immobilization of the foot at surgery, verify the viability of the skin overlying the Achilles tendon, with the foot in the proposed position of immobilization.

### CONCLUSIONS

With regard to the controversy surrounding acute, complete Achilles tendon ruptures, we prefer early, primary repair for healthy, active individuals. We believe that this treatment modality allows a faster and more complete recovery.

## POSTERIOR TIBIAL TENDON DYSFUNCTION

### PATHOPHYSIOLOGY

From the deep posterior compartment of the leg, the posterior tibial muscle forms a tendon that courses behind the medial malleolus, turns anteriorly, and inserts directly into the navicular tuberosity. The tendon is surrounded by a synovial sheath. The position of the tendon relative to the ankle and subtalar joint axes of rotation defines its function as an invertor and plantarflexor of the foot (Fig. 118.4) (22). Insufficiency of the posterior tibial tendon (PTT) results in the production of an asymmetric flatfoot identified by heel valgus, midfoot collapse and abduction, and forefoot pronation. Insufficiency may be related to acute or chronic tenosynovitis or partial or complete rupture. It is unknown why the PTT is predisposed to injury, but it may be related to a zone of relative hypovascularity within the tendon located behind and distal to the medial malleolus (11). PTT dysfunction occurs more frequently in patients with diabetes, hypertension, and obesity compared with the general population (13).

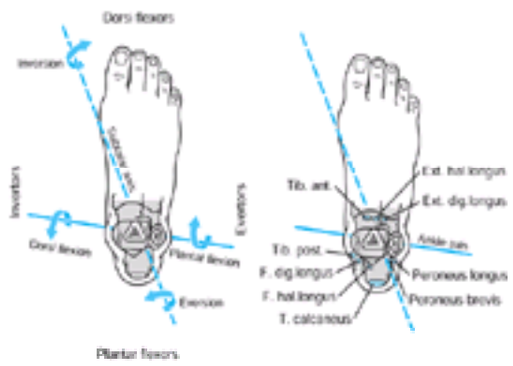


***Figure 118.4.*** Relationship of the tendons crossing the ankle relative to the axes of rotation for the ankle and subtalar joints. (Redrawn from Mann RA. Biomechanics of the Foot. In: *American Academy of Orthopaedic Surgeons: Atlas of Orthotics*. St Louis: Mosby–Year Book, 1985, with permission.)

## PRINCIPLES OF TREATMENT

The loss of PTT function results in significant impairment to the lower extremity. The primary goal of treatment is to re-establish the function of the PTT, when possible. For patients with advanced disease, the substitution or addition of the FDL tendon may be required. The most advanced stages of dysfunction are not amenable to soft-tissue reconstruction and require identification and treatment of fixed deformities.

## ASSESSMENT

Begin the physical examination with gait analysis. When viewed from behind, the patient with PTT dysfunction may have decreased heel inversion between flatfoot and toe-off, and in advanced cases, an antalgic gait may be noted. Examination of the standing patient may reveal varying degrees of swelling over the course of the PTT, as well as heel valgus, midfoot collapse, and abduction. Ask the patient to perform a repeated single-heel rise test. This is accomplished by having the patient stand at a nearby wall, using the hands for balance. The patient lifts the unaffected extremity while performing repeated single-heel rises on the affected extremity. Patients with tenosynovitis or mild degenerative changes are able to perform the maneuver repeatedly with evidence of good heel height and heel inversion, but this is typically a painful maneuver. In advanced stages, heel height and heel inversion decrease. Finally, patients with complete dysfunction of the PTT are unable to perform the maneuver. Then seat the patient and palpate the posterior leg to assess swelling over the PTT and associated tenderness. Tenderness at the sinus tarsi may indicate lateral impingement in advanced cases. Early findings include supple motion at the ankle, hindfoot, midfoot, and forefoot. With progression of the disorder, subtalar motion becomes limited and the heel eventually becomes fixed in a valgus position, midfoot abduction increases with a concomitant decrease in midfoot adduction, and forefoot pronation becomes fixed, which paradoxically produces fixed forefoot varus when the heel is held in a neutral position. In the most advanced cases, Achilles contracture produces equinus deformity, which is most easily appreciated when ankle motion is evaluated with the heel held in a neutral position. Manual motor testing reveals loss of function varying from slight weakness associated with tenosynovitis to complete loss of function associated with chronic tendinosis or complete rupture.

Begin the radiographic examination with weight-bearing views of the foot and ankle. Valgus tilt of the ankle mortise increases the amount of chronic stress across the posterior tibial tendon. Loss of ankle joint height, especially at the lateral joint line, is a risk factor for rapidly progressive arthrosis after hindfoot fusion. An enlarged or accessory tarsal navicular is a predisposition to PTT dysfunction. Assess foot alignment, with particular attention to midfoot collapse on the lateral view and midfoot abduction on the anteroposterior view. Advanced imaging of the PTT is best accomplished with MRI (4). The tendon is normally round to oval in shape with a low, homogenous signal. Tenosynovitis is easily identified by increased fluid surrounding the tendon. Degeneration and partial and complete tears are identified on the T2 sequence by thickening, increased signal activity, and cystic changes.

## CLASSIFICATION

PTT dysfunction can arbitrarily be divided into synovitis; tendinosis manifested by partial or complete tears, leading to loss of the functional integrity; tendinosis with supple hind foot valgus; and tendinosis associated with fixed deformity of the subtalar and transverse tarsal joints.

## PREOPERATIVE MANAGEMENT

Treat patients with posterior tibial tenosynovitis with reduction or modification in activity. For advanced or recalcitrant symptoms, immobilize the leg in a short-leg walking cast or removable cast boot. For risk factors such as excessive pronation, use orthotic devices.

Treat patients with tendinosis in a fashion similar to that discussed earlier. Immobilization for 6 to 8 weeks may be required. Occasionally, symptoms recur immediately on discontinuation of treatment. For patients unwilling to pursue surgical treatment, a custom ankle-foot orthosis is indicated.

For patients with a completely dysfunctional tendon, nonoperative treatment is predicated on the presence of hindfoot and forefoot deformity. Patients with mild to moderate deformity may be treated in a custom ankle-foot orthosis. Patients with severe deformity require more extensive bracing with a double upright brace and medial **T**-strap.

Evaluate patients with tenosynovitis and early tendinosis with MRI to evaluate the extent of tendon degeneration. Patients with advanced tendinosis with loss of PTT function do not require evaluation by MRI. The presence of hindfoot valgus, supple or fixed, along with the presence of any fixed deformity including Achilles tendon contracture, must be appreciated before surgical intervention.

## OPERATIVE TECHNIQUES

### *Debridement*

Patients with tenosynovitis who fail to respond to an adequate course of conservative management require debridement of the PTT sheath (40).

- Using general or regional anesthetic and a proximal tourniquet, make a linear incision over the course of the PTT from the tip of the medial malleolus to the navicular. Sharply dissect down to the tendon sheath, which is longitudinally divided throughout the length of the surgical wound.
- Synovitis is manifested by the presence of an effusion, synovial proliferation, and increased vascular activity. Systematically excise the synovium.
- Occasionally, proximal exposure of the PTT is required. Extend the skin incision proximally over the course of the PTT. Leave a 1 cm section of PTT sheath and flexor retinaculum intact at the medial malleolus. Once the tendon is completely exposed, carefully inspect it. The treatment of tendon tears is discussed later.
- On completion of the procedure, loosely close the tendon sheath, followed by subcutaneous tissue closure with interrupted absorbable suture and skin closure with nylon or skin clips. Immobilize the foot and ankle in a neutral position.
- *Postoperative management:* Remove sutures or skin clips 10 days after surgery and apply a removable cast. Begin range-of-motion exercises and allow weight bearing as tolerated. At 4 weeks after surgery, begin a strengthening program. Permit a gradual return to activities once local swelling and warmth resolve.

### *Debridement and Reconstruction with FDL Tendon Transfer*

Patients with posterior tibial tendinosis who fail conservative management require surgical intervention in a timely manner in order to reduce the risk of permanent structural changes.

- Expose the PTT sheath and debride as previously described. Using sharp resection, completely remove the degenerative portions of the tendon, which are indicated by color changes, thickening, loss of tendon consistency, cystic changes, and partial tears. If necessary, debride the entire tendon from the navicular to a point proximal to the degenerative changes.
- On completion of tendon debridement, inspect the deltoid and spring ligaments. Reconstruct excessive laxity in the spring ligament by excision and imbrication of redundant tissue.
- Harvest the FDL tendon by extending the incision to the medial forefoot. Identify the abductor hallucis muscle and release its fascia longitudinally from the first metatarsal. Plantar retraction of the muscle allows visualization of the plantar nerves as well as the FHL and FDL tendons. Carefully release the flexor knot of

Henry as well as all fascial connections between the FHL and FDL tendons. Perform a distal tenodesis with a #2 nonabsorbable suture. Divide the FDL tendon just proximal to the tenodesis.

- Now turn attention to the proximal aspect of the surgical exposure. Identify the FDL tendon posterior to the PTT sheath, where it is secured and retracted proximally.
- Make a quarter-inch drill hole through the medial portion of the navicular. Take care not to violate the adjacent articular surfaces. Pass the free end of the FDL tendon from the plantar to dorsal side of the navicular. No attempt is made to place the tendon transfer within the posterior tibial tendon sheath. Plantarflex and invert the foot and increase tension across the tendon transfer. Secure the transfer with multiple interrupted nonabsorbable sutures. Occasionally, the free end of the tendon can be sutured to a more proximal portion of the FDL tendon.
- Repair the abductor hallucis muscle to the first metatarsal. Close the subcutaneous tissue and close the skin with nylon suture or skin clips. Immobilize the foot and ankle in a plantarflexed and inverted position.
- *Postoperative management:* After 10 days, remove the sutures or skin clips. Apply a non-weight-bearing short-leg cast, with the foot maintained in a plantarflexed and inverted position. At 4 weeks, place the foot in the neutral position and fit a removable cast boot. At 6 weeks after surgery, start range-of-motion exercises for the foot and ankle, and allow weight bearing to tolerance with the cast boot. Institute a strengthening program with an elastic band after 8 weeks. Activities are gradually resumed once local warmth and swelling are resolved.

#### *Debridement and Reconstruction with FDL Tendon Transfer and Medial Displacement Calcaneal Osteotomy*

Persistent PTT dysfunction allows the hindfoot to assume a valgus position. Patients with posterior tibial tendinosis and flexible hindfoot valgus require debridement and reconstruction of the posterior tibial tendon, along with correction of the propensity for hindfoot valgus. This is accomplished with medial displacement calcaneal osteotomy as well as FDL tendon transfer (16,28,31). The osteotomy reduces the lateral displacement of the heel and decreases the valgus forces produced by weight bearing and the pull of the gastrosoleus complex.

- Approach the calcaneus through a lateral incision in line with the posterior border of the fibula with blunt dissection to localize the sural nerve. Expose the lateral border of the calcaneus from the posterior aspect of the posterior facet of the subtalar joint to the inferior border of the calcaneus.
- Use a sagittal saw to osteotomize the calcaneus just posterior to the posterior facet. Carefully approach and divide the medial cortex of the calcaneus. On completion of the osteotomy, use a broad osteotome to elevate the medial soft tissues carefully. At this point, translate the posterior tuberosity of the calcaneus medially approximately 1 cm.
- Temporarily fix the osteotomy with K-wires. Verify by examination that heel valgus has been corrected. Accomplish permanent fixation with a single partially threaded 7.0 mm screw advanced from the posterior tuberosity into the anterior process of the calcaneus.
- Then debride and reconstruct the posterior tibial tendon as previously described. Apply a bulky dressing and splint the foot and ankle in a plantarflexed and inverted position.
- *Postoperative management:* After 10 days, remove the sutures or skin clips. Apply a non-weight-bearing short-leg cast with the foot in a plantarflexed and inverted position. At 4 weeks, place the foot in the neutral position and apply a removable cast boot. At 6 weeks, repeat radiographs; if union appears eminent, allow weight bearing to tolerance with a cast boot. Institute a strengthening program with an elastic band after 8 weeks. Gradually resume activities once local warmth and swelling are resolved.

#### *Subtalar Arthrodesis*

PTT dysfunction associated with fixed hindfoot deformity is not amenable to soft-tissue reconstruction. When the deformity is limited to the subtalar joint, and the remainder of the foot remains supple (i.e., the absence of fixed forefoot varus), then treatment with an isolated subtalar arthrodesis is possible. The surgical technique for hindfoot arthrodesis is described in Chapter 115. Take care to produce a neutral heel and plantigrade foot before the placement of internal fixation.

#### *Double and Triple Arthrodesis*

Advanced PTT dysfunction associated with hindfoot valgus will eventually produce fixed forefoot deformities, namely, forefoot varus. The correction of the subtalar deformity alone will not produce a plantigrade foot. Fixed forefoot deformity is best addressed with a double or triple arthrodesis. The triple arthrodesis increases the likelihood of talonavicular fusion and is used in patients at risk for nonunion (e.g., those who smoke or who have diabetes, rheumatoid arthritis, or excessive bone loss). On completion of the arthrodesis, final assessment of foot position allows a true evaluation of Achilles tendon contracture. Occasionally, a triple hemisection, gastrocnemius recession, or an open Achilles tendon lengthening is necessary. Failure to identify Achilles tendon contracture results in inordinate stress across the transverse tarsal arthrodesis and increases the likelihood of talonavicular malunion and nonunion.

### GENERAL REHABILITATION

Patients who have been successfully managed with nonsurgical methods as well as those managed with soft-tissue reconstruction are placed on programs designed to maintain motion of the foot and ankle, and to increase strength of the posterior tibial muscle or the transferred FDL muscle. Orthotics designed to resist excessive pronation and hindfoot valgus are also prescribed as needed.

### COMPLICATIONS

Care must be taken not to allow the patient with early posterior tibial tendon dysfunction, synovitis, or mild tendinosis to progress to a more advanced stage requiring more invasive and more morbid intervention.

## PERONEAL TENDON SUBLUXATION, DISLOCATION, AND LONGITUDINAL RUPTURE

### PATHOPHYSIOLOGY

The peroneus brevis and longus muscles originate from the lateral compartment of the leg. Distally, they form individual tendons, which pass behind the lateral malleolus to turn anteriorly toward their respective insertions at the base of the fifth metatarsal and the base of the first metatarsal. At the lateral malleolus, the peroneus brevis tendon remains anterior to the peroneus longus tendon. The tendons are retained behind the lateral malleolus by the superior peroneal retinaculum (14), a structure that originates from the periosteum on the posterolateral ridge of the fibula (5). The peroneal groove or retromalleolar sulcus is a shallow bony groove (9) that is deepened by a fibrocartilaginous ridge (Fig. 118.5). The position of the tendons relative to the axis of rotation of the ankle and subtalar joints determine their function as plantar flexors and evertors of the foot (Fig. 118.4).

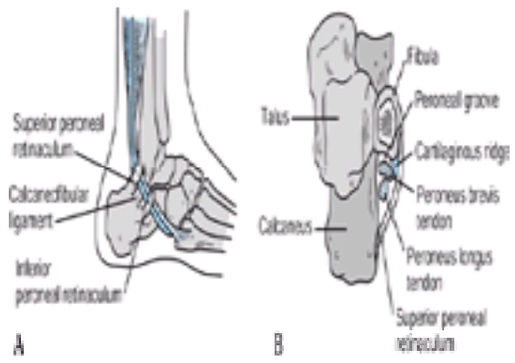


***Figure 118.5.*** Anatomic relationships at the lateral aspect of the ankle. Note on the cross section that the peroneal groove is supplemented by a fibrocartilaginous ridge.

The peroneal tendons (PTs) share a common synovial sheath (35) that bifurcates above and below the lateral malleolus. The tendons receive vascular supply through a posterolateral vincula (37). Unlike the Achilles and posterior tibial tendons, the PTs do not have a demonstrable zone of hypovascularity.

Perhaps because of the intrinsic lack of bony stability, the PTs have a propensity to dislocate out of the peroneal groove to a position anterior to the lateral malleolus.

The injury occurs as a result of sudden, forceful, passive dorsiflexion of the inverted foot with reflex contraction of the PTs (8,27,39); an association with chronic lateral ankle instability has also been reported (12). Dislocation of the peroneal tendons out of the peroneal groove is associated with a variety of underlying pathoanatomic findings, including a tear of the superior peroneal retinaculum, elevation of the superior retinaculum off the lateral border of the fibula with concomitant dissection of the tendon beneath the lateral fibular periosteum, and fracture of the posterolateral margin of the fibula.

Chronic subluxation of the peroneus brevis tendon onto the posterolateral border of the fibula may occur as a clinical or subclinic entity. This condition has been implicated as a major causative factor in the development of longitudinal tears of the peroneus brevis tendon (17,36). Anatomic factors associated with longitudinal tears of the peroneus brevis tendon include laxity of the superior peroneal retinaculum, compression of the peroneus brevis tendon by the overlying peroneus longus tendon (17,32,36), the presence of peroneal musculature at the peroneal groove, and finally, the presence of an anomalous peroneal muscle such as the peroneus quartus muscle (38). A longitudinal tear of the peroneal tendons has also been described after acute and chronic lateral ankle inversion injury (3,33).

## PRINCIPLES OF TREATMENT

When diagnosed acutely, the acute PT dislocation can be maintained in a reduced position by a cast. Recurrent or chronic dislocation requires surgical stabilization by soft-tissue or bony reconstruction, or both. Longitudinal ruptures associated with chronic subluxation of the peroneal tendons may respond to a period of immobilization. Surgical treatment requires the identification and correction of all pathoanatomic features in addition to the debridement and repair of the longitudinal tendon rupture.

PT pathology has a tendency to evade diagnosis, especially in the acute setting. Clinical findings are very similar to that of a lateral ankle ligament sprain. Furthermore, peroneal tendon injury can occur concomitantly with lateral ankle ligament injury.

## ASSESSMENT

The patient with acute PT dislocation complains of pain over the course of the PTs as well as the lateral border of the fibula. The patient may offer a history of forceful, passive, dorsiflexion of the foot and the detection of a “pop” at the time of injury. Many patients are able to describe accurately the translation of the tendon out of the peroneal groove. The tendon typically reduces spontaneously. Often, the patient presents after the condition becomes recurrent or chronic. Examination of the acute injury reveals swelling and tenderness behind the lateral malleolus (1,8,10,24,27). This is in contrast to the inversion lateral ankle sprain, which is associated with tenderness anterior to the lateral malleolus. Observation of the contralateral extremity may reveal asymptomatic physiologic subluxation. With the foot held in a plantarflexed and everted position, active dorsiflexion may result in apprehension, subluxation, and even dislocation. Dislocation is typically quite painful and is not elicited as a routine part of our examination. Gentle palpation of the PTs at the peroneal groove while the foot is taken through active circumduction may reveal the presence of nodule formation or snapping. Complete the examination with evaluation of lateral ankle ligament stability.

Patients with partial longitudinal tears of the peroneus brevis tendon associated with chronic subluxation present with acute or chronic lateral ankle pain localized to the retrofibular region. This pain may be associated with intermittent or persistent swelling, a recurrent “popping” sensation, or lateral ankle instability. Examination of the lateral ankle reveals mild to moderate swelling over the course of the peroneal tendons at the peroneal groove. Palpation of the region while the ankle is actively circumducted reveals nodule formation and possibly a “popping” phenomenon. Resisted ankle dorsiflexion may confirm the presence of physiologic subluxation of the peroneal tendons. Resisted manual motor testing may reproduce pain as well as weakness of the respective muscles. Once again, lateral ankle instability must be ruled out.

Routine radiographic evaluation after acute PT dislocation rarely demonstrates an avulsion fracture off the rim of the lateral malleolus (Fig. 118.6) (21). Obtain stress views if lateral ankle instability is an associated finding. For cases that present a diagnostic dilemma, use MRI to detect tenosynovitis, partial or complete ruptures, subluxation, dislocation, competency of the superior peroneal retinaculum, the presence of a large distal peroneus brevis muscle insertion, the competency of lateral ankle ligaments, and internal derangement of the ankle and subtalar joints.

***Figure 118.6.*** Oden type III peroneal tendon dislocation with the characteristic rim fracture.

## CLASSIFICATION

The pathoanatomic classification developed by Eckert and Davis (7) and subsequently modified by Oden (30) is based on the type of superior peroneal retinaculum injury (Fig. 118.7). In a type I injury, the superior peroneal retinaculum remains in continuity with the periosteum overlying the lateral border of the fibula; the tendons translate out of the peroneal groove and dissect beneath the periosteum, forming a false pouch. In the type II injury, the superior peroneal retinaculum is disrupted by an anterior tear. The type III injury is marked by an avulsion fracture off the posterior fibular margin. Finally, the type IV injury is defined by a posterior tear of the superior peroneal retinaculum.

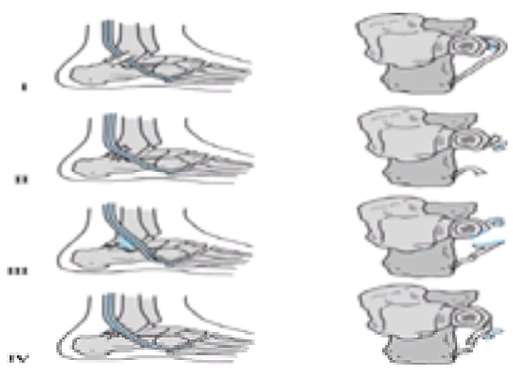

***Figure 118.7.*** Oden classification of peroneal tendon dislocation. (Redrawn from Oden RF. Tendon Injuries about the Ankle Resulting from Skiing. *Clin Orthop* 1987;216:63, with permission.)

## PREOPERATIVE MANAGEMENT

Treat a single, acute dislocation of the peroneal tendons with a well-fitted, non-weight-bearing, short-leg cast applied with the foot in slight plantarflexion. Window the cast over the peroneal tendons at the peroneal groove. Place one-quarter to one-half inch of felt padding over the tendons and reduce the window. Instruct the patient to adjust the thickness of the felt pad for comfort. Immobilize the foot for 6 weeks, at which time, the stability of the peroneal tendons should be checked. An additional 4 weeks of casting may be necessary. Rehabilitation focuses on motion, strength, and proprioception. Occasionally, the patient is able to detect recurrent dislocation within the cast. These patients, as well as all patients with recurrent or chronic dislocation, will not respond to nonsurgical treatment methods (1,15,23,24,25,26 and

27,34,42).

The treatment for partial longitudinal tear of the peroneal tendon is initially symptomatic. Treatment includes decreased activity, application of ice, and oral nonsteroidal anti-inflammatory agents. Patients that fail to respond require enforced rest with a weight-bearing cast. A taping program may allow continued athletic activity.

Before surgical exposure, the prediction of pathologic findings associated with peroneal tendon dislocation is very difficult. Therefore, it is impossible to anticipate the exact nature of the surgical repair and reconstruction. The patient must be prepared for debridement of the peroneal tenosynovium; excision of excessive distal peroneus brevis muscle insertion; resection of an anomalous peroneal tendon such as the peroneus quartus; deepening of the peroneal groove; imbrication and reconstruction of the superior peroneal retinaculum; and finally, debridement, repair, or tenodesis of the peroneal tendons. Failure to address contributing pathology or concomitant injury, may result in the persistence of symptoms. An MRI and a computed tomography (CT) scan can be used to delineate pathologic findings further, but these are not used for routine evaluation of peroneal dislocation or partial longitudinal tears.

## OPERATIVE TECHNIQUES

### *Repair and Imbrication of the Superior Peroneal Retinaculum*

- Utilizing a general or regional anesthetic and a proximal thigh tourniquet, make an **L**-shaped incision over the course of the peroneal tendons. Limit the initial exposure to 6 cm, with the majority of the incision proximal to the tip of the lateral malleolus. If dissection is carried distal to the lateral malleolus, take care to avoid the sural nerve and its communicating branch, which occasionally is found crossing the course of the peroneal tendons.
- Expose the superior peroneal retinaculum and verify its integrity by manipulation of the foot and ankle with significant digital pressure posterior and medial to the peroneal tendons. Sharply divide the retinaculum and synovial sheath in line with the posterior border on the lateral malleolus. Complete the exposure by systematic synovectomy and tenolysis of the peroneal tendons. If the dissection is carried distal to the tip of the lateral malleolus, leave a 1 cm cuff of superior peroneal retinaculum and underlying synovial sheath intact.
- Resect peroneus brevis muscle that lies within the peroneal groove off the tendon. At this point, dislocate the peroneal tendons. Debride and repair partial longitudinal tears as described below. If the bony peroneal groove appears shallow or convex, a deepening procedure is indicated (Fig. 118.8).

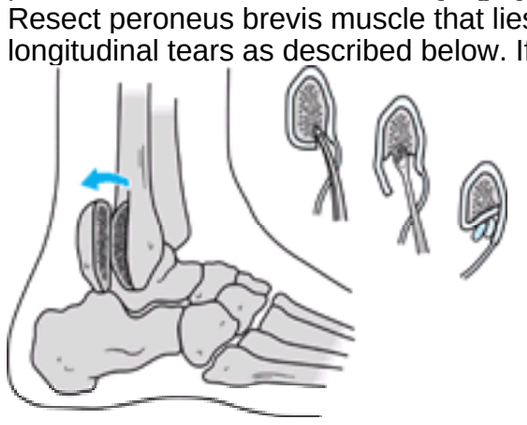

***Figure 118.8.*** Treatment of peroneal tendon dislocation with a groove-deepening procedure. (Redrawn from Arrowsmith SR, Fleming LL, Allman FL. Traumatic Dislocation of the Peroneal Tendons. *Am J Sports Med* 1983;11:142, with permission.)

- Make a longitudinal incision through the overlying periosteum and expose the underlying cancellous bone by elevating an osteoperiosteal flap. Deepen the bony groove by removing the cancellous bone, replacing the osteo-periosteal flap, and smoothing the remaining cancellous surfaces with bone wax. Reduce the tendons and their excursion and stability by passive motion of the foot and ankle.
- At this point, repair and imbricate tears of the superior peroneal retinaculum. In the more common situation in which the superior peroneal retinaculum and the lateral fibular periosteum are elevated off the lateral border of the fibula, several pathoanatomic features must be addressed. First, obliterate the false pouch created by elevation of the lateral fibular periosteum. Accomplish this by curettage of the overlying lateral fibula. Next, advance the superior peroneal retinaculum into multiple drill holes placed through the posterolateral border of the fibula. Use multiple nonabsorbable sutures to complete a tight reconstruction. Finally, advance the remaining superior peroneal retinaculum and lateral fibular periosteum posteriorly, and repair them over the underlying reconstruction. This procedure obliterates the false pouch, and advances and reconstructs the superior peroneal retinaculum.
- Once the repair is complete and its integrity verified, reapproximate the subcutaneous tissue with absorbable suture and close the skin with nylon or skin clips. Immobilize with the foot and ankle with a compression dressing in neutral position.
- *Postoperative management:* At 10 days after surgery, apply a removable cast boot for non-weight-bearing ambulation. Teach range-of-motion exercises. At 6 weeks after surgery, begin weight bearing, as well as proprioception and strengthening exercises. Gradually resume activities once local swelling and warmth have resolved.

### *Repair of Longitudinal Peroneal Tendon Rupture*

- Using a general or regional anesthetic and a proximal thigh tourniquet, expose the superior peroneal retinaculum as described in the previous section. Again, use provocative maneuvers to reproduce subluxation or dislocation.
- Next, incise the superior retinaculum posterior to the posterolateral border of the fibula. Leave a cuff of tissue attached to the fibula for subsequent repair and imbrication. Initially, complete the exposure to the tip of the fibula and perform a complete synovectomy and tenolysis. When present, resect a distal insertion of the peroneus brevis muscle. Carefully retracted and inspect each tendon.
- If the initial exploration is negative, extend the exposure distally over the course of the peroneal tendons. Leave a 1 cm cuff of superior peroneal retinaculum and synovium intact inferior to the tip of the fibula to act as a pulley.
- Debride partial longitudinal tears with associated fibrillation to normal tendon. After debridement, if the remaining tendon appears functional, repair the longitudinal tear with running Polydioxanone (PDS; Ethicon, Inc., Wayne, NJ) or nylon suture. If the tendon appears flattened, it may be tubularized with a running suture. If after debridement the remaining tendon does not appear to be functional, perform a tenodesis between the peroneus brevis and longus tendons proximal and distal to the peroneal groove, and sharply excise the pathologic section of tendon. At this point, take care to establish that the tendons demonstrate full excursion and stability within the peroneal groove. Instability must be addressed with the techniques described in the previous section.
- Close the peroneal sheath with a running nylon suture. Repair the subcutaneous tissue and close the skin with nylon suture or skin clips. Apply a compression dressing with the foot and ankle immobilized in a neutral position.
- *Postoperative management:* Ten days after surgery, apply a removable cast boot, and begin non-weight-bearing ambulation and range-of-motion exercises. At 6 weeks after surgery, progress to weight bearing to tolerance with the cast boot and institute a proprioception and strengthening program. Gradually resume activities when local warmth and swelling resolve.

## GENERAL REHABILITATION

After the completion of a nonoperative or operative treatment program, focus rehabilitation on ankle and subtalar range-of-motion, ankle and subtalar stability, peroneal motor strengthening, and finally, lower extremity proprioception. Resume full athletic activity only when local warmth and swelling have resolved and the patient demonstrates full pain-free range of motion without evidence of tendon or joint instability.

## COMPLICATIONS

Occasionally, surgical exploration of the peroneal tendons fails to reveal significant pathologic findings. At this point, do not hesitate to extend the exposure distally beyond the tip of the fibula. Again, take care to maintain a cuff of peroneal retinaculum and synovial sheath to function as a distal pulley.

When performing a stabilization procedure, if soft-tissue techniques fail to provide adequate stability, do not hesitate to perform a sliding osteotomy of the fibula (6) or a reconstruction using a lateral slip of the Achilles tendon (15).

## CONCLUSIONS

Early accurate diagnosis of PT pathology requires a high degree of suspicion. When it is detected, concomitant injury must be identified and treated in order to maximize the functional outcome. Individualize surgical treatment and address each identifiable pathologic condition.

## CHAPTER REFERENCES

Each reference is categorized according to the following scheme: *, classic article; #, review article; !, basic research article; and +, clinical results/outcome study.


+ 1. Arrowsmith SR, Fleming LL, Allman FL. Traumatic Dislocation of the Peroneal Tendons. *Am J Sports Med* 1983;11:142.

+ 2. Åstrom, M, Rausing, A. Chronic Achilles Tendinopathy. A Survey of Surgical and Histologic Findings. *Clin Orthop* 1995;316:151.

+ 3. Bassett FH, Speer KS. Longitudinal Rupture of the Peroneal Tendon. *Am J Sports Med* 1993;21:354.

+ 4. Conti, S, Michelson, J, Jahss, M. Clinical Significance of Magnetic Resonance Imaging in Preoperative Planning for Reconstruction of Posterior Tibial Tendon Ruptures. *Foot Ankle* 1992;13:208.

! 5. Davis WH, Sobel M, Deland J, et al. The Superior Peroneal Retinaculum: An Anatomical Study. *Foot Ankle* 1994;15:271.

* 6. DuVries HL. *Surgery of the Foot.* St. Louis: Mosby–Year Book, 1965:256.

+ 7. Eckert WR, Davis EA Jr. Acute Rupture of the Peroneal Retinaculum. *J Bone Joint Surg* 1976;58-A:670.

+ 8. Edwards ME. The Relationship of the Peroneal Tendons to the Fibula, Calcaneus, and Cuboideum. *Am J Anat* 1928;42:213.

+ 9. Escalas F, Figueras JM, Merino JA. Dislocation of the Peroneal Tendons. *J Bone Joint Surg* 1980;62-A:451.

! 10. Frey C, Shereff, M, Greenidge N. Vascularity of the Posterior Tibial Tendon. *J Bone Joint Surg* 1990;72-A:884.

! 11. Geppert MJ, Sobel M, Bohne WHO. Lateral Ankle Instability as a Cause of Superior Peroneal Retinacular Laxity: An Anatomic and Biomechanical Study of Cadaveric Feet. *Foot Ankle* 1993;14:330.

+ 12. Holmes GB, Mann RA. Possible Etiologic Factors Associated with Rupture of the Posterior Tibial Tendon. *Foot Ankle* 1992;13:70.

+ 13. Inglis AE, Scott WN, Sculco TP, Patterson AH. Rupture of the Tendo Achillis. An Objective Assessment of the Surgical and Non-surgical Treatment. *J Bone Joint Surg* 1976;58-A:990.

+ 14. Jones E. Operative Treatment of Chronic Dislocations of the Peroneal Tendons. *J Bone Joint Surg* 1932;14:574.

+ 15. Koutsogiannis E. Treatment of Mobile Flat Foot by Displacement Osteotomy of the Calcaneus. *J Bone Joint Surg* 1971;53-B:96.

+ 16. Krause JO, Brodsky JW. Peroneus Brevis Tendon Tears: Pathophysiology, Surgical Reconstruction, and Clinical Results. *Foot Ankle* 1998;19:271

! 17. Lagergren C, Lindholm Å. Vascular Distribution in the Achilles Tendon. An Angiographic and Microangiographic Study. *Acta Chir Scand* 1958;116:491.

+ 18. Lea R, Smith L. Non-surgical Treatment of Tendo-Achillis Rupture. *J Bone Joint Surg* 1972;54-A:1398.

# 19. Mann RA. Biomechanics of the Foot and Ankle. In: Mann RA, Coughlin MJ, eds. *Surgery of the Foot and Ankle,* 6th ed. p.18-19.

# 20. Mann RA. Biomechanics of the Foot and Ankle. In: Mann RA, Coughlin MJ, eds. *Surgery of the Foot and Ankle,* 6th ed. p. 1171.

# 21. Mann RA. Biomechanics of the Foot. In: *American Academy of Orthopaedic Surgeons: Atlas of Orthotics,* 2nd ed. St. Louis: Mosby–Year Book, 1985:121.

+ 22. Martens MA, Noyez JF, Mulier JC. Recurrent Dislocation of the Peroneal Tendons: Results of Rerouting the Tendons under the Calcaneofibular Ligament. *Am J Sports Med* 1986;14:148.

+ 23. McLennan JG. Treatment of Acute and Chronic Luxations of the Peroneal Tendons. *Am J Sports Med* 1980;8:432.

+ 24. Micheli LJ, Waters PM, Sanders DP. Sliding Fibular Graft Repair for Chronic Dislocation of the Peroneal Tendons. *Am J Sports Med* 1989;17:68.

+ 25. Miller JW. Dislocation of the Peroneal Tendons—a New Operative Procedure: A Case Report. *Am J Orthop* 1967;9:136.

+ 26. Murr S. Dislocation of the Peroneal Tendons with Marginal Fracture of the Lateral Malleolus. *J Bone Joint Surg* 1961;43-B:563.

+ 27. Myerson MS, Corrigan J, Thompso F, Schon L. Tendon Transfer Combined with Calcaneal Osteotomy for Treatment of Posterior Tibial Tendon Insufficiency: A Radiologic Investigation. *Foot Ankle* 1995;16:712.

+ 28. Nistor L. Surgical and Non-surgical Treatment of Achilles Tendon Rupture. *J Bone Joint Surg* 1981;63-A:394.

+ 29. Oden RR. Tendon Injuries about the Ankle Resulting from Skiing. *Clin Orthop* 1987;216:63.

+ 30. Pomeroy GC, Manoli A. A New Operative Approach for Flatfoot Secondary to Posterior Tibial Tendon Insufficiency: A Preliminary Report. *Foot Ankle* 1997;18:206.

+ 31. Purnell ML, Drummond DS, Engber WD, Breed AL. Congenital Dislocation of the Peroneal Tendons in the Calcaneovalgus Foot. *J Bone Joint Surg* 1983;65-B:316.

+ 32. Sammarco GJ, DiRaimondo CV. Chronic Peroneus Brevis Tendon Lesions. *Foot Ankle* 1989;9:163.

+ 33. Sarmiento A, Wolf M. Subluxation of the Peroneal Tendons: A Case Treated by Rerouting the Tendons under the Calcaneofibular Ligament. *J Bone Joint Surg* 1975;57-A:115.

! 34. Sarrafian SK. Tendon Sheaths and Bursae. In: *Anatomy of the Foot and Ankle,* 2nd ed. Philadelphia: J.B. Lippincott, 1993:284.

! 35. Sobel M, Geppert MJ, Hannafin JA, et al. Microvascular Anatomy of the Peroneal Tendons. *Foot Ankle* 1992;13:469.

+ 36. Sobel M, Geppert MJ, Olson EJ, Bohne WHO. The Dynamics of Peroneus Brevis Tendon Splits: A Proposed Mechanism, Technique of Diagnosis, and Classification of Injury. *Foot Ankle* 1992;13:413.

! 37. Sobel M, Levy ME, Bonhe WHO. Congenital Variations of the Peroneus Quartus Muscle: An Anatomic Study. *Foot Ankle* 1990;11:81.

+ 38. Stover CN, Bryan DR. Traumatic Dislocation of the Peroneal Tendons. *Am J Surg* 1962;103:180.

+ 39. Teasdall RD, Johnson KA. Surgical Treatment of Stage I Posterior Tibial Tendon Dysfunction. *Foot and Ankle International* 1994;15:646.

+ 40. Thompson TC. A Test for Rupture of the Tendo Achilles. *Acta Orthop Scand* 1962;32:461.

+ 41. Zoellner G, Clancy W Jr. Recurrent Dislocation of the Peroneal Tendon. *J Bone Joint Surg* 1979;61-A:292.

# CHAPTER 119

# MISCELLANEOUS DISORDERS OF THE FOOT

*Loretta B. Chou*

**L. B. Chou:** Department of Orthopaedic Surgery, Stanford University Hospital, Stanford, California, 94306.

Freiberg's Infraction
Pathophysiology
Nonoperative Treatment
Surgical Treatment
Postoperative Care
Pitfalls And Complications
Köhler's Disease
Pathophysiology
Treatment
Flexible Pes Planus
Pathophysiology
Conservative Treatment
Surgical Treatment
Postoperative Care
Pitfalls and Complications
Rigid Pes Planus
Pathophysiology
Nonoperative Treatment
Surgical Treatment
Postoperative Care
Pitfalls and Complications
Accessory Navicular
Pathophysiology
Nonoperative Treatment
Surgical Treatment
Postoperative Care
Pitfalls and Complications
Chapter References

## FREIBERG'S INFRACTION

### PATHOPHYSIOLOGY

Freiberg's infraction, caused by avascular necrosis of the epiphysis of the metatarsal head, was first reported in six cases in 1914 (3). It occurs in adolescence, mostly affecting girls. The etiology is assumed to be traumatic insult causing loss of vascularity. It usually involves the second metatarsal, and less frequently the third and fourth. The second metatarsal head is affected because it is the longest ray and is the least mobile, as it is the keystone of the transverse arch of the foot.

Pain with weight bearing is the most frequent symptom. There can be associated swelling and loss of motion. The pain diminishes with rest and increases with activity. Physical examination shows swelling, tenderness, and discomfort with movement of the joint. If the osteophytes are large, they may be palpated.

Radiographic changes include sclerosis followed by loss of joint space and collapse of the metatarsal head in the late stage. There can be new bone formed as the metatarsal attempts to heal. Smillie's classification is based on the anteroposterior and oblique radiographs (20, 21). In stage I, there is a fissure fracture of the ischemic epiphysis; in stage II, there is central depression of the head from bone resorption; in stage III, there is further collapse of the head with residual projections of the sides, and the plantar cartilage remains intact; in stage IV, the plantar portion of articular cartilage separates into a loose body; and stage V is the final stage, with arthritis, deformity, and flattening of the metatarsal head (Fig. 119.1).

***Figure 119.1.*** Radiograph showing the typical appearance of Freiberg's infraction, with a large metatarsal head, flattening, and osteophytes.

If the disease is suspected but the radiographs are negative, a bone scan will show increased uptake in the early stage (8).

### NONOPERATIVE TREATMENT

Most cases can be treated nonoperatively despite the radiographic appearance. In the early stages, cast immobilization for 4–6 weeks with protected weight bearing will decrease pain and swelling. Later, pressure under the affected metatarsal head can be reduced by a metatarsal pad, metatarsal bar, or a custom-molded orthosis.

The disease is self-limiting, and once the healing process begins, symptoms generally reduce. Sometimes the symptoms are present after complete healing. There can be residual pain and loss of motion from the bony prominence from the healed metatarsal head or the presence of loose bodies. In these cases, surgery may be indicated.

### SURGICAL TREATMENT

Many surgical procedures have been described for treatment of symptomatic Freiberg's infraction. These include debridement, cheilectomy, osteotomy, resection arthroplasty, and metatarsophalangeal joint implant (8,14).

If the articular cartilage is intact, debridement of the joint may be helpful to remove the synovitis, loose bodies, nand osteophytes. Excision of excess bone is indicated if

the bony prominence is symptomatic.

- Make a dorsal hockey-stick incision over the second metatarsophalangeal joint, and incise the extensor tendons longitudinally to expose the joint.
- Perform a modified DuVries condylectomy (see Chapter 113).
- Perform a synovectomy, and remove the excess bone of the metatarsal head.
- Remove the dorsal one fourth to one third of the metatarsal head with an osteotome, and use a rongeur to excise any remaining sharp edges.
- Remove the medial and lateral osteophytes to the level of the metatarsal diaphysis. Extend the second toe to 75° to 80° to confirm that enough bone has been removed.
- Repair the extensor mechanism and the skin, and apply a firm compression dressing.

In cases that do not have remaining articular cartilage, consider resection of the metatarsal head. This procedure is not generally recommended because it will result in shortening of the toe, possibly transferring pain to the third metatarsal head.

### POSTOPERATIVE CARE

Permit the patient to bear weight in a postoperative shoe. Remove the skin sutures at 2 weeks, and start the patient on passive and active range-of-motion exercises. An ordinary store-bought shoe may be worn once swelling has decreased. A metatarsal pad may be helpful during the first few weeks after resection to decrease the pressure under the metatarsal heads.

## PITFALLS AND COMPLICATIONS

The patient's expectations should be fully investigated prior to the operative procedure and realistic expectations established. The most common postoperative complaint is continuation of some of the preoperative symptoms of pain and stiffness. Because the metatarsal head is involved, it is likely that some pain and stiffness will persist that may require shoewear modifications or possibly a secondary procedure.

Shortening of the toe and subluxation or dislocation are other possible complications. These may be prevented by limiting the amount of resection, and by limiting motion of the toe for 3 weeks with a K-wire, depending on the amount of dissection and excision. After pin removal, tape the toe for 3 weeks, and have the patient continue to wear the postoperative shoe.

Avoid excessive resection because of the possibility of transferring pressure to the third metatarsal head or even developing an intractable plantar keratosis.

## KÖHLER'S DISEASE

### PATHOPHYSIOLOGY

Köhler's disease is an osteochondrosis affecting the pediatric population. It is more commonly seen in male patients, and the average age of onset is 5–6 years, during the time of ossification of the navicular (11). The exact etiology of this disease is unknown, but it may be traumatic.

Pain, swelling, the inability to bear weight, and limping are the most common symptoms. There may be swelling and tenderness of the medial midfoot, and discomfort with ranging the transverse tarsal joints.

Radiographs show a flattened, dense, sclerotic navicular with some fragmentation (Fig. 119.2). Despite the collapse, the space for the navicular remains the same, which may account for the lack of residual deformity (Fig. 119.3). Only the ossification center is affected. Because there are few, if any, surgical pathologic specimens, the true etiology remains unknown.

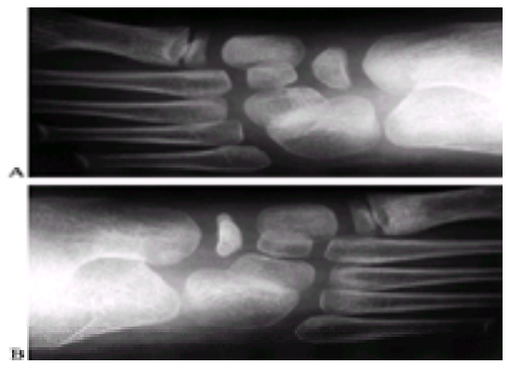

***Figure 119.2.*** Radiographs **(A,B)** of a patient with unilateral Köhler's disease show that the navicular on the affected side is flattened and sclerotic.

***Figure 119.3.*** Lateral radiograph of a patient with Köhler's disease showing preservation of the space for the navicular despite fragmentation and flattening of the bone.

### TREATMENT

The treatment of Köhler's disease is nonoperative and aimed at reducing symptoms. An arch support may be used, but cast immobilization for 6–8 weeks is more effective (11), especially when used initially with crutches. Follow-up radiographs are not necessary as these lesions heal, and by 6–13 months after onset the navicular has normal appearance and there are no known residual symptoms in adults.

## FLEXIBLE PES PLANUS

### PATHOPHYSIOLOGY

Flexible pes planus, also known as flexible flatfoot, is very common. Frequently seen in children, it is caused by ligamentous laxity and is considered a variation of normal (22). The medial longitudinal arch is determined by age and inheritable traits; it develops with age as the ligamentous laxity resolves and the subcutaneous fat decreases (23). Gould et al. (6) followed 125 toddlers from 11–14 months of age until 5 years of age. Initially, all the toddlers had pes planus, and arch development

occurred regardless of the type of footwear worn.

In a patient with flexible pes planus, the medial longitudinal arch is lost with weight bearing, but it reconstitutes with non-weight-bearing. Generally, a flexible flatfoot does not cause pain or disability. Even into adulthood, most patients do not develop pain or stiffness or require treatment. A flexible flatfoot can be associated with disability if there is an associated equinus contracture.

Symptomatic patients often complain of pain of the medial arch. Their arch can “feel tired.” They may complain of difficulty in finding comfortable shoes, or they experience abnormal or excessive shoe wear. Inspect both lower extremities undressed to check foot posture and function during gait, standing, and sitting. Assess motion of the foot and ankle, and look for abnormal bony prominences. Look for an Achilles tendon contracture by inverting the subtalar joint and forefoot to lock the calcaneus under the talus while dorsiflexing the ankle.

Weight-bearing radiographs show talonavicular sag on the lateral view. Also, the angle between the longitudinal axis of the talus and the first metatarsal is increased; 0° is normal, 0° to 15° is a mild deformity, 15° to 30° is moderate, and more than 30° is severe. The anteroposterior view may reveal abduction of the talonavicular joint, leaving the medial portion of the talar head uncovered.

## CONSERVATIVE TREATMENT

In the past, multiple treatment modalities have been tried for flatfoot deformity, but the current recommended treatment is observation in the asymptomatic child. The natural history of flexible pes planus is not changed by corrective shoes, orthotic devices, or exercises. Also, compliance was found to diminish with prolonged use of corrective shoewear (over 3 years) (23).

In the occasional case where the parents see a functional improvement in a treated symptomatic patient, a supportive medial arch may be used. If the Achilles tendon is tight, initiate heel cord stretching exercises. Occasionally, sequential casting is needed to treat a tight heel cord. Place the talonavicular joint in the corrected position by placing the forefoot in varus (correct the lateral subluxation), and apply the cast with the ankle in neutral. Allow the patient to bear weight. Change the cast 2–3 weeks later; usually three casts changes are required for correction (4).

## SURGICAL TREATMENT

Despite the large number of procedures performed for pes planus in the past, it is unusual that a surgical procedure is indicated. The operative options are a soft-tissue procedure, osteotomy, and fusion (4). If the disability is caused by an associated equinus contracture that does not respond to nonoperative measures, then a tendo Achillis lengthening is performed.

### *Tendo Achillis Lengthening*

- Perform tendo Achillis lengthening through three small incisions along the length of the tendon, two medial and one lateral. Expose the tendon at each incision and then cut from the midline of the tendon outward.
- Repair the tendon sheath to help prevent scarring of the tendon to the skin.
- Extend the knee, and bring the foot up to 10° to 15° of dorsiflexion, taking care not to overlengthen the tendon.
- Repair the skin and place the limb in a short-leg cast with the ankle in neutral.

In some patients, pain may be caused by the development of stiffness from adaptive changes of soft-tissue or bone. The symptoms can be from severe pronation and heel valgus. In the past, a triple arthrodesis yielded the most reliable results. Currently, other procedures can alleviate the symptoms without the dramatic loss of motion by sparing the joints. These are osteotomies aimed at correcting the hyperpronation.

### *Evans Procedure*

The Evans procedure involves lengthening the lateral column by placing a bone graft from the tibia into the anterior process of the calcaneus. It was described by Evans (2) as treatment of calcaneovalgus feet, in which the medial and lateral columns are equalized in length. This procedure preserves the calcaneocuboid joint and pushes the navicular bone medially in relation to the talus. The procedure has been popularized by Mosca (15).

- Perform the Evans procedure through a longitudinal incision over the lateral calcaneus, just superior and parallel to the peroneal tendons, and protecting the sural nerve. Expose the anterior calcaneus and calcaneocuboid joint (Fig. 119.4).

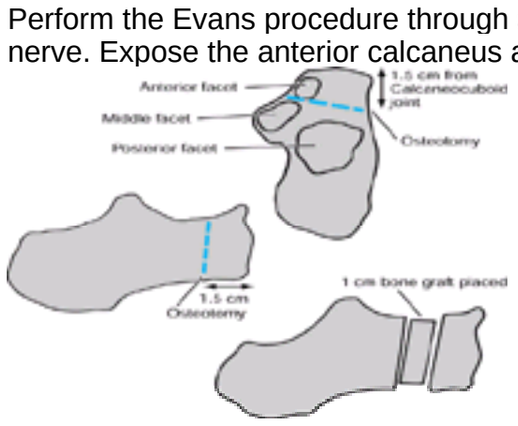


***Figure 119.4.*** The Evans procedure.

- Do a vertical osteotomy of the anterior end of the calcaneus, anterior to the peroneal tubercle and parallel to the calcaneocuboid joint, and about 1.5 cm away from the joint between the anterior and middle facets.
- Take a cortical bone graft from the tibia, a bicortical iliac crest graft, or a piece of cortical allograft measuring approximately 1 cm, depending on the desired amount of correction. Place it between the osteotomized fragments so that the hindfoot valgus deformity is corrected.
- Use 2 mm Kirschner (K) wires for fixation.

Evans reported the results of this procedure in 56 feet in 1975 (2). The procedure was successful in treating calcaneovalgus caused by polio, painful rigid flatfoot, and idiopathic calcaneovalgus. It slightly improved the shape of the foot and relieved pain in patients with rigid flatfeet.

### *Medial Displacement Osteotomy*

Alternatively, a medial displacement calcaneal osteotomy can be used to correct the deformity. The effect is to move the proximal calcaneus medially, which improves the excessive valgus, elevates the medial arch, and centralizes the motion of the subtalar joint (17).

- Make a lateral oblique incision over the lateral calcaneus above the peroneal tendons. Retract the tendons posteriorly and inferiorly with the sural nerve (Fig. 119.5).

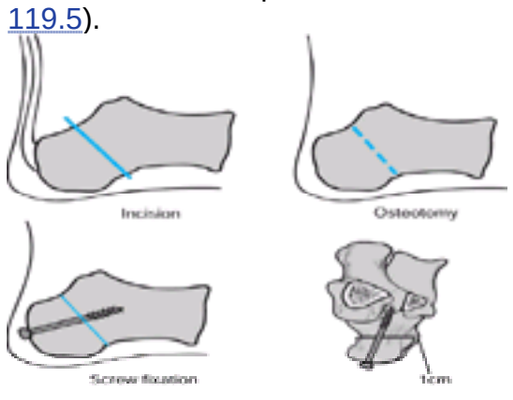

***Figure 119.5.*** Medial displacement osteotomy.

- Cut the calcaneus perpendicular to the body between the posterior facet and the posterior tuberosity.
- Perform the osteotomy with a saw; complete it with an osteotome at the medial cortex. Then bluntly strip the medial periosteum of the calcaneus.
- Open the osteotomy site with a lamina spreader, and then displace the proximal portion medially, one half of the width of the calcaneus, and tilt it to correct the valgus.
- Insert a bone graft to fill the gap and use two 2 mm K-wires (for a cannulated 7.3 mm screw), which are drilled from posterior to anterior, for fixation.

### POSTOPERATIVE CARE

After a tendo Achillis lengthening procedure, apply a short-leg walking cast in the neutral position and begin weight bearing as tolerated for a total of 6 weeks.

For osteotomies of the calcaneus, initially apply a bulky compression dressing and splints. Remove the sutures at 2 weeks, and apply a non-weight-bearing cast for an additional 4 weeks. Allow weight bearing in a walking cast at 4–6 weeks after surgery. Remove the K-wires as an outpatient surgical procedure 8 weeks after surgery. Once the osteotomy has healed and the cast is removed, progress weight bearing with limitations on athletics. At 6 months, allow full activity.

## PITFALLS AND COMPLICATIONS

Do not overlengthen a tight Achilles tendon. This procedure is rarely indicated in an adult because no growth potential remains. The presence of a fixed deformity in the hindfoot or midfoot or degenerative joint disease is a contraindication to a soft-tissue procedure or osteotomy. Perform arthrodeses for correction of deformity and alleviation of pain (see Chapter 115).

With a medial displacement osteotomy, take care at the medial aspect to strip but not cut the medial periosteum of the calcaneus, to avoid injury of the neurovascular structures and flexor tendons, which lie just on the periosteum.

## RIGID PES PLANUS

### PATHOPHYSIOLOGY

The etiology of rigid pes planus is different from that of a flexible deformity (Fig. 119.6). Usually, there is a bony abnormality, such as tarsal coalition, congenital vertical talus, or arthritis. Of these, tarsal coalition is the most common cause and can present as peroneal spastic flatfoot.

***Figure 119.6.*** Lateral radiograph of an adult patient with rigid pes planus demonstrating adaptive bony changes. The patient also had a tight heel cord.

The cause of tarsal coalition is a failure of mesenchymal segmentation, and the resulting connection of two tarsal bones may be fibrous (syndesmosis), cartilaginous (synchondrosis), or bony (synostosis) (10). Tarsal coalition was described as long ago as 1769 by Buffon and can involve any combination of the tarsal bones (5). The tarsal coalition is an inherited disease that is autosomal dominant.

The incidence is 2%, with a calcaneonavicular bar being most common (10,18). The calcaneonavicular type becomes symptomatic when the coalition ossifies at 8–12 years of age. The talocalcaneal coalition frequently involves the medial facet, and it ossifies at 12–16 years of age. In a study of 22 patients with suspected coalitions, Herzenberg et al. found that 14 had a coalition documented by computed tomography (CT) scans, of which six were bilateral (9). All of the talocalcaneal coalitions involved the middle facet joint, and these were composed of bony or mixed osteocartilaginous tissue.

Most coalitions are asymptomatic or have mild symptoms. Tarsal coalition should be suspected in adolescents with painful and stiff pes planus. The most common age of presentation is the teen years, but patients can develop initial symptoms in their twenties to forties. Most patients complain of pain about the tarsal area, and stiffness and tightness of the peroneal and toe extensor muscles. They complain of difficulty with sports activities or even with standing and walking. Physical examination shows a rigid hindfoot, loss of the medial longitudinal arch, and fixed forefoot abduction. Spasm of the peroneal tendons can be seen by placing the foot into inversion: The result is contraction of the peroneus brevis or longus, or both.

Radiographs may show a naviculocalcaneal coalition on the oblique view of the foot (Fig. 119.7). The Harris view (posterior axial) can show a talocalcaneal coalition, but CT scans are more helpful in demonstrating this (Fig. 119.8). They are superior to plain tomography and radiographs for visualizing the three subtalar facet joints, as well as the size, nature, and location of the coalition. To obtain coronal cuts of the subtalar joint, position the patient supine with the hips and knees flexed, and place the feet in maximum plantar flexion and flat on the table so that the subtalar joint is perpendicular to the x-ray beam.

***Figure 119.7.*** Oblique radiograph showing a complete bony coalition between the navicular and calcaneus.

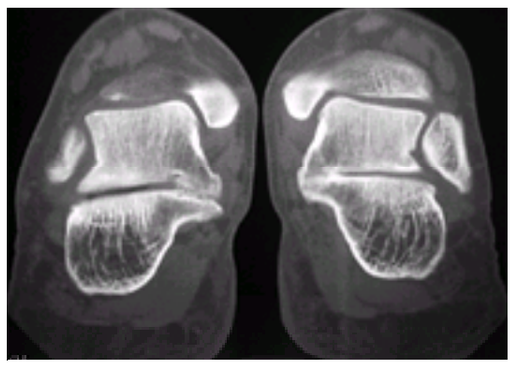

***Figure 119.8.*** Computed tomography scan showing bilateral talocalcaneal coalition of the middle facet.

### NONOPERATIVE TREATMENT

Only those patients with symptoms require treatment. Rest, nonsteroidal anti-inflammatory medication, and cast immobilization will be helpful to some patients. Use a cast for at least 3 weeks; usually 6–8 weeks are required for relief of symptoms. Later, a shoe modification, such as a heel cup, a medial arch support, or a medial heel wedge, may allow patients to return to weight-bearing activities.

In a report of 14 patients (23 feet) with symptomatic talocalcaneal coalition, Scranton (19) found that five feet in three patients became asymptomatic after immobilization in a cast.

### SURGICAL TREATMENT

Resection of tarsal coalition is the treatment of choice in a child with a middle facet coalition or a posterior facet coalition that comprises less than 25% of the joint surface and that is symptomatic and unresponsive to nonoperative treatment. Once symptomatic, the majority of patients do not respond to nonoperative treatment. Contraindications to coalition resection include degenerative arthritis, associated deformity, and involvement of greater than 50% of the posterior facet.

#### *Excision of a Calcaneonavicular Coalition*

- Make a lateral longitudinal or oblique incision over the sinus tarsi. Make full-thickness skin flaps, and identify and protect the sural nerve and peroneal tendons. Elevate the extensor digitorum brevis from its origin from proximal to distal to expose the coalition.
- Excise the coalition with an osteotome, ronguer, or motorized burr.
- Once the bar is completely removed, transfer the extensor digitorum brevis muscle into the defect of the excised coalition, holding it there with absorbable sutures. A convenient method is to use a pullout suture.
- Close the skin incision and apply a bulky dressing and well-padded splints.

#### *Excision of a Talocalcaneal Coalition*

- Make a medial longitudinal curvilinear incision 6 cm long, just plantar to the posterior tibial tendon.
- Develop the interval between the flexor digitorum longus and the flexor hallucis longus tendons, retracting the neurovascular bundle plantarward.
- Localize the coalition with two Keith needles on either side using fluoroscopy. Then excise about 5–7 mm of the bar with an osteotome or motorized burr until motion in the subtalar joint is restored.
- Apply bone wax to the cut bony surfaces to control bleeding. Then interpose fat harvested from the posterior aspect of the calcaneus into the gap.
- Repair the flexor digitorum and hallucis longus tendon sheaths, and then close the skin. Apply a bulky dressing and short-leg splints.

In adults, excision of the coalition is generally not recommended, although this is controversial. Excision alone is definitely contraindicated if degenerative changes are present. Note that talar beaking is a traction spur on the dorsum of the talus and not degenerative arthritis. In young adults with no or minimal degenerative changes or deformity, an excision may be attempted to delay fusion. Some authors advocate this treatment initially. Scranton (19) reported that of 14 feet that underwent resection of a talocalcaneal coalition, 13 had a good result and 1 a satisfactory result. No patient had a poor result. He found that once the coalition was excised, the anterior and posterior facet joints appeared normal. Olney and Asher (16) had satisfactory results in 8 of 10 feet after resection of talocalcaneal coalition, and all patients appeared to have increased in the range of motion in the subtalar joint.

A fusion yields the most reliable result. If the deformity can be corrected by fusing the subtalar joint, the transverse tarsal joints can be spared. This is my preferred method of surgical treatment if there are no degenerative changes of the talonavicular and calcaneocuboid joints. In the patient with severe deformity and disabling pain, a triple arthrodesis is the procedure of choice. If there is an associated equinus contracture, a tendo Achillis lengthening may be needed to fully correct the deformity.

### POSTOPERATIVE CARE

Remove the sutures about 2 weeks after coalition excision surgery, and begin range-of-motion exercises. Continue non-weight-bearing until ranging the subtalar joint does not cause pain, which is usually about 6 weeks. At that time, begin weight bearing.

Protect a subtalar or triple arthrodesis with a bulky compression dressing and splints in the first 2 weeks, and then remove the staples or sutures. Apply a non-weight-bearing cast, which is worn for 4 weeks, followed by a walking cast for the next 6 weeks until bony union occurs. After this, a well-cushioned wide shoe may be worn.

## PITFALLS AND COMPLICATIONS

Inadequate resection may cause impingement or continued limitation of motion. Gonzalez and Kumar (5) reported in 75 feet that only 22% had partial reformation of the coalition. In no patient did the coalition reform completely.

Older patients should be informed that their pain may persist, especially if there are degenerative changes. If excision is the initial treatment, a fusion later may be required. Talar beaking, however, is not a contraindication to resection of the coalition alone, and it may be resected at the time of surgery if symptomatic. Patients who have good to excellent early results continue to do well even at 10 years follow-up (5).

## ACCESSORY NAVICULAR

### PATHOPHYSIOLOGY

The accessory navicular is an accessory bone that is also called the accessory scaphoid, prehallux, os tibiale, os tibiale externum, naviculare secundarium, and navicular secundum. It was initially described by Bauhin in 1605 (7). The accessory navicular sits posteromedial to the navicular (Fig. 119.9), and it ossifies between 9 and 11 years of age. It is seen radiographically with much variation, small to large, round to triangular. Its connection to the navicular may be fibrous, cartilaginous, or bony.

***Figure 119.9.*** **(A)** Anteroposterior and **(B)** lateral radiographs of a patient with a symptomatic accessory navicular.

There are three types of accessory navicular, as determined by radiographic appearance. Type I is an ossicle that lies within the posterior tibial tendon, type II is connected to the navicular by a cartilaginous bridge, and type III is a cornuate-shaped navicular from fusion of the accessory bone to the navicular. Accessory navicular is quite common—2% to 14% of the population and is bilateral in 77% to 100% of cases (7,8).

There is some controversy as to whether the accessory navicular can cause pes planus. Generally, the patient has a flatfoot deformity and the accessory bone interferes with the normal mechanics of the posterior tibial tendon. Kidner (12,13) believed that removal of the accessory navicular would allow a straighter pull of the tendon and thus improvement of the flatfoot deformity.

Most cases of accessory navicular are asymptomatic, and less than 1% require surgical treatment (1). The source symptoms in an accessory navicular are not absolutely clear. Inflammation of the surrounding soft tissues from the prominence or trauma to the cartilaginous bridge may cause pain. Repetitive stresses on a cartilage bridge may result in a painful stress fracture (7).

Symptoms usually begin in the teen years, as pain in the mid-medial arch aggravated by weight bearing. In adults, initial symptoms may appear after a severe twisting injury, often occurring in sports.

Physical examination will reveal a bony prominence of the proximal medial border of the navicular with tenderness over the accessory bone. There can be associated local edema and erythema.

The accessory bone is usually visible on plain radiographs of the foot. A bone scan may help to localize and differentiate the pathologic cause of medial arch pain, but it is rarely necessary.

### NONOPERATIVE TREATMENT

Nonoperative treatment is generally effective and consists of rest from activity, nonsteroidal anti-inflammatory medication, and shoewear modification. A wider shoe will relieve the pressure over the bony prominence. With a flatfoot deformity, a medial arch in a custom orthotic device may reduce the stress on the medial longitudinal arch.

Acute symptoms associated with an injury, even a minor sprain, can be treated with a short course of cast immobilization for 3–6 weeks. After casting, usual activities can be resumed as symptoms allow.

### SURGICAL TREATMENT

In cases of disabling pain that is unresponsive to nonoperative treatment, excision of the accessory bone is indicated. Excision of the accessory bone with advancement of the posterior tibial tendon is known as the Kidner procedure. However, there is little advantage to advancing the tendon, and I do not recommend it. Bennett et al. (1) reported on 75 feet that were treated with excision of the accessory navicular only and simple reefing of the tibialis posterior tendon. Fifty-eight feet had excellent results, and 12 had good results. Grogan et al. (7) had excellent results in 16 of 17 patients by simple excision of the accessory navicular.

- Make a 3–4 cm medial longitudinal incision over the insertion of the posterior tibial tendon, incise the tendon longitudinally, and visualize the accessory navicular.
- Excise the accessory navicular. The remaining navicular tuberosity is usually prominent, so use a ronguer to create a smooth surface. Apply bone wax to the cut surface to decrease postoperative bleeding.
- Repair the posterior tibial tendon with interrupted absorbable sutures. If the defect is large, repair the tendon and advance it through a drill hole in the navicular; bring it out the dorsum and suture it onto itself.

### POSTOPERATIVE CARE

Immobilize the foot in some plantar flexion and minimal inversion in a bulky compressive dressing with splints. Remove the sutures at 2 weeks, and place the foot in the same position in a fiberglass cast until 3 weeks. Continue immobilization in a removable cast for an additional 3 weeks, and then begin weight bearing as tolerated.

Begin range-of-motion and strengthening exercises after removal of the cast, and prescribe a custom orthotic device with a molded arch if necessary.

## PITFALLS AND COMPLICATIONS

If some prominence of the navicular remains, symptoms of pressure against shoewear may persist. Sometimes tenderness persists over the medial eminence area, especially in adults. To prevent this problem, remove sufficient bone and smooth the remaining surface with a rongeur.

If the patient has another anatomic abnormality, including symptomatic flatfoot, equinus contracture, or a tarsal coalition, the treatment must address these problems as well.

### CHAPTER REFERENCES

Each reference is categorized according to the following scheme: *, classic article; #, review article; !, basic research article; and +, clinical results/outcome study.


+ 1. Bennett GL, Weiner DS, Leighley B. Surgical Treatment of Symptomatic Accessory Tarsal Navicular. *J Pediatr Orthop* 1990;10:445.

* 2. Evans D. Calcaneo-valgus Deformity. *J Bone Joint Surg Br* 1975;57:270.

* 3. Freiberg AH. The So-called Infraction of the Second Metatarsal Bone. *J Bone Joint Surg* 1926:257.

# 4. Glancy GL. Surgical Management of the Flatfoot. In: Bassett FH III, ed. *Instr Course Lect* 1988;37:111.

+ 5. Gonzalez P, Kumar SJ. Calcaneonavicular Coalition Treated by Resection and Interposition of the Extensor Digitorum Brevis Muscle. *J Bone Joint Surg Am* 1990;72A:71.

+ 6. Gould N, Moreland M, Alvarez R, et al. Development of the Child's Arch. *Foot Ankle* 1989;9:241.

+ 7. Grogan DP, Gasser SI, Ogden JA. The Painful Accessory Navicular: A Clinical and Histopathological Study. *Foot Ankle* 1989;10:164.

+ 8. Helal B, Gibb P. Freiberg's Disease: A Suggested Pattern of Management. *Foot Ankle* 1987;8:94.

+ 9. Herzenberg JE, Golner L, Martinez S, Silverman PM. Computerized Tomography of Talocalcaneal Tarsal Coalition: A Clinical and Anatomic Study. *Foot Ankle* 1986;6:273.

# 10. Huurman WW. Congenital Foot Deformities. In: Mann RA, Coughlin MJ, eds. *Surgery of the Foot and Ankle.* St. Louis: Mosby-Yearbook, 1993:1340.

+ 11. Ippolito E, Ricciardi Pollini PT, Falez F. Kohler's Disease of the Tarsal Navicular: Long-Term Follow-up of 12 Cases. *J Pediatr Orthop* 1984;4:416.

* 12. Kidner FC. The Prehallux (Accessory Scaphoid) in Its Relation to Flatfoot. *J Bone Joint Surg* 1929:831.

* 13. Kidner FC. The Prehallux in Relation to Flatfoot. *JAMA* 1933;101:1539.

+ 14. Kinnard P, Lirette R. Dorsiflexion Osteotomy in Freiberg's Disease. *Foot Ankle* 1989;9:226.

+ 15. Mosca VS. Calcaneal Lengthening for Valgus Deformity of the Hindfoot. Results in Children Who Had Severe, Symptomatic Flatfoot and Skewfoot. *J Bone Joint Surg Am* 1995;77:500.

+ 16. Olney BW, Asher MA. Excision of Symptomatic Coalition of the Middle Facet of the Talocalcaneal Joint. *J Bone Joint Surg Am* 1987;69:539.

# 17. Pedowitz WJ, Kovatis P. Flatfoot in the Adult. *J Am Acad Orthop Surg* 1995;3:293.

* 18. Sarrafian SK. *Anatomy of the Foot and Ankle*, 2nd ed. Philadelphia: JB Lippincott, 1993:94.

+ 19. Scranton PE. Treatment of Symptomatic Talocalcaneal Coalition. *J Bone Joint Surg Am* 1987;69:533.

* 20. Smillie IS. Freiberg's Infraction. *J Bone Joint Surg Br* 1957;39:580.

* 21. Smillie IS. Treatment of Freiberg's Infraction. *Proc R Coll Med* 1967;60:29.

* 22. Staheli LT, Chew DE, Corbett M. The Longitudinal Arch: A Survey of Eight Hundred and Eighty-two Feet in Normal Children and Adults. *J Bone Joint Surg Am* 1987;69:426.

+ 23. Wenger DR, Mauldin D, Speck G, et al. Corrective Shoes and Inserts as Treatment for Flexible Flatfoot in Infants and Children. *J Bone Joint Surg Am* 1989;71:800.

# CHAPTER 120

# AMPUTATIONS OF THE LOWER EXTREMITY

*Walther H.O. Bohne and Jan Paul Ertl*

**W. H. O. Bohne:** Hospital for Special Surgery, New York, New York, 10021.
**J. P. Ertl:** Sacramento, California, 95825.

Indications
Peripheral Vascular Disease
Trauma
Malignancies
Levels of Amputation
Tissue Management
Surgical Techniques
Open Amputation
Toe Disarticulation or Amputation
Ray Resection of the Foot
Transmetatarsal Amputation
Lisfranc and Chopart Amputations
Boyd Amputation
Syme's Amputation
Below-Knee Amputations
Knee Disarticulation
Above-Knee Amputation
Hip Disarticulation
Hemipelvectomy
Ertl Osteomyoplastic Lower Extremity Amputation Reconstruction (Primary and Secondary)
Postoperative Care and Rehabilitation
Pitfalls and Complications
Authors' Perspective
Chapter References

The number of lower extremity amputations performed in the United States annually has remained fairly steadily between 30,000 and 40,000 over the last 15 years (3). Most of the amputees are older people with ischemic disease of the lower extremities or diabetes of long standing. Amputations are a major social and economic burden to society. Moreover, the amputation of one lower extremity in the elderly all too frequently is followed by the amputation of the contralateral limb; this occurs in 15% to 28% of cases within 3 years. Only 50% of elderly amputees survive the first 3 years following an amputation. In spite of the advances in medicine these statistics have not improved significantly for the dysvascular amputee (9,12,14,59,63).

An amputation, however, does not have to be considered a failure of treatment. Frequently, it is the treatment of choice for a devastating injury to the lower extremity where reconstruction may be a long and costly undertaking that leads to the preservation of a functionally unsatisfactory extremity (33,34 and 35,65,72). It is important that amputation be done well and with adequate preoperative planning (4), so that the outcome results in a residual limb that can wear a prosthesis comfortably. With a prosthesis that fits well, the patient is most likely to become an active member of society and independent in his life-style.

Because of the complexity of the conditions that can lead to an amputation, a treatment team is required that includes the primary care physicians, the surgeons, a physical therapist, a prosthetist, and a social worker (53). The patient must be involved and committed to a successful outcome. In the case of patients with vascular disease, other organ systems are usually involved. An internist who is familiar with the patient's condition must be involved and should counsel the patient (5,13,52).

## INDICATIONS

### PERIPHERAL VASCULAR DISEASE

Vascular insufficiency is the most common problem requiring amputation and usually occurs in the geriatric patient. Since preservation of a functioning knee greatly improves the chances of rehabilitation of the amputee, consider reconstruction of occluded major proximal arteries, which may save the limb or at least allow amputation below the knee (1,25,58,67,71,72).

The largest subset of patients with peripheral vascular disease are those with diabetes mellitus (27,48,61). These patients have the added problems of peripheral neuropathy. Therefore, they are subject to trophic ulcers and Charcot osteoarthropathy. Indeed, frequently the amputation in patients with diabetes is performed because of osteomyelitis caused by a trophic ulcer that has exposed bones of the foot. Instability of the foot or ankle because of the osteoarthropathy may also require amputation (8,44,63).

### TRAUMA

When a patient requires an amputation for trauma, it is usually because of an irreparable acute vascular injury. Treatment of lacerations of the popliteal artery has improved: During World War II, amputation occurred in 72% of these cases (15), whereas 68% were successfully treated with vascular reconstruction in both the Korean War (39) and the Vietnam War. This rate of success has been reflected in the civilian experience (13,15,39,66).

Limb salvage in the severely injured lower extremity with an open fracture, a vascular injury requiring repair, or transection of the posterior tibial nerve is challenging, requiring a long and expensive course of treatment with numerous surgical procedures. Even if the limb can be saved, it is often painful and not as useful as a prosthesis. This, together with a protracted course of treatment, places an undue psychological burden on the patient (38,40,63). See Chapter 12 and Chapter 24 for a thorough discussion of these issues.

### MALIGNANCIES

The development of limb salvage procedures for malignant tumors of the extremities, combined with adjuvant therapy, has reduced the incidence of amputations for primary malignancies of the lower extremities (19,20,41,50,57,70,75). This is discussed in detail in Chapter 128 and Chapter 129.

## LEVELS OF AMPUTATION

The optimal stump is covered with durable, wellvascularized subcutaneous tissue and skin that will withstand pressure in weight-bearing areas, and friction in areas covered by the prosthesis. Stumps that allow end bearing are particularly desirable. Usually, end-bearing stumps retain a part of the sole pad or have a bony surface of sufficient size that it can bear the body weight for varying periods of time. These conditions are common in partial foot amputations.

Another means of creating an end-bearing stump is ankle or knee disarticulation. Disarticulation is particularly desirable in growing children and in the elderly. In children, overgrowth, which is seen often in diaphyseal amputations, is avoided by retaining the epiphysis (26,45). In the elderly, an end-bearing stump decreases problems with fitting and improves the chances for rehabilitation (37,64). The creation of a tibiofibular synostosis as described by Ertl (24) can create end-bearing conditions somewhat comparable to those of the disarticulation.

Because a well-vascularized and durable skin is so important for the healing of the amputation wound, several methods have been developed to predict at which level of the lower extremity the circulation in the skin is adequate for primary wound healing. One of these is the xenon-133 ($^{133}$Xe) clearance. After the ambient conditions have been regulated, radionuclide is injected intradermally. A gamma camera monitors the $^{133}$Xe activity for 10 minutes. The faster the $^{133}$Xe is cleared from the site of injection, the better the perfusion of the skin (34,46).

Of the noninvasive methods of predicting success in major amputations, the most accurate is probably the transcutaneous measurement of oxygen tension. The oxygen sensor is calibrated for temperature and atmospheric pressure and applied to the skin. The skin is heated to 45°C. The sensor stabilizes after approximately 20 minutes. The minimal desirable tension varies between 30 and 50 mm of mercury (7,47).

However, none of the methods for measuring blood flow in the affected extremity is entirely reliable for predicting success in healing of the amputation wound. Other conditions, such as nutrition, state of health, age, collateral circulation, and infection, play a role in the success or failure of the amputation.

The various levels of amputation are depicted in Figure 120.1. See Chapter 175 for amputations in children.

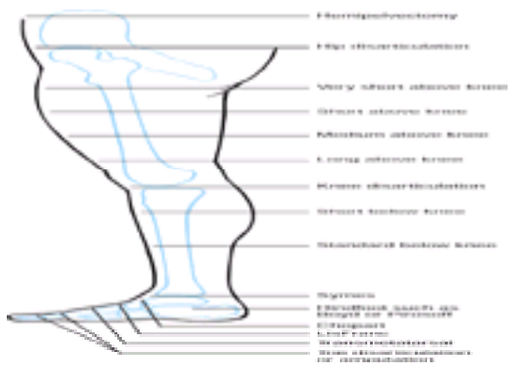

***Figure 120.1.*** Levels of lower extremity amputation.

## TISSUE MANAGEMENT

The skin is the most important tissue for the healing of the amputation wound. It is therefore important that it be handled with care. The use of skin hooks in particular is desirable in patients with dysvascular extremities.

Skin grafting, although for a long time frowned upon, is not entirely contraindicated in the lower extremity. As long as a split-thickness graft is over soft tissue and not adherent to bone or thick scars, it is likely to withstand the prosthetic wear. Pedicle grafts do even better as long as they are not in the immediate weight-bearing area of the residual extremity (74). Skin grafts are more successful in children than in adults.

The transected muscles should provide an adequate soft-tissue mantle for the residual extremity. This can be achieved best through myodesis (suturing the transected muscle end to drill holes in the bone) or myoplasty (suturing the cut ends of the antagonistic muscle groups and their fascias together). Under normal circumstances, the cut muscle ends have the greatest amount of capillary bleeding. Therefore, the suction drain should be in this layer of the amputation stump.

Where bones cannot be used for actual weight-bearing stumps, such as in partial foot amputations or disarticulations, bony prominence under this skin should be removed. Consider the possibility of an osteoplastic treatment of the bones, such as a tibiofibular synostosis (24).

Transection of the nerves during amputation leads without exception to the formation of neuromas. In the vast majority, these neuromas are painless. However, where the cut end of the nerve is within the weight-bearing area of the residual extremity, the neuroma can become painful. Therefore, during the amputation each nerve should be identified, dissected free to a level well above the amputation, and sharply transected. Where a concomitant vessel is expected, ligate the nerve before cutting it under minimal tension.

Dissect the larger veins and arteries free and doubly ligate them before transection. It is advisable not to catch neighboring veins and arteries in the same ligature, since this might lead to the development of aneurysms.

## SURGICAL TECHNIQUES

### OPEN AMPUTATION

When amputation becomes necessary in patients with overwhelming infections, particularly infection by gas-producing bacteria, an open amputation (43,66,69) may be indicated. The aim of this surgery is to eradicate the diseased area without creating a harbor for renewed infection. Although a straight guillotine transverse amputation is the simplest, we prefer to develop flaps as the secondary revision, and closure is then usually easier.

- Prepare the skin flaps that are necessary for the secondary closure of the amputation wound. You may want to make the initial skin flaps somewhat longer than usual, as some retraction will occur.
- Transect the soft tissues and bone in the usual fashion.
- Carry out hemostasis and transection of the nerves as described previously.
- To prevent the skin flaps from retracting, invert and suture the free skin edges to the subcutaneous fascia at the base of the flaps with nonabsorbable sutures to be unrolled at the time of secondary closure (Figure 120.2.). Only in patients with excellent circulation should you use skin traction to prevent skin retraction.



***Figure 120.2.*** Open amputation with preservation of flap length using inversion technique. See text for details. (From Bohne WHO.*Atlas of Amputation Surgery.* New York: Thieme Medical, 1987:36, Fig. 8-9, with permission.)

### TOE DISARTICULATION OR AMPUTATION

- Select the level of amputation depending on the pathology being treated. Preservation of some part of the toe helps prevent migration of the other toes into the void created by the missing toe.
- Develop equivalent-length dorsal and plantar full-thickness, fishmouth-type skin flaps, favoring the tougher plantar skin for the end of the stump.

- Transect the extensor tendon and let it retract.
- Work from dorsal to plantar. Disarticulate the joint or transect the bone at the appropriate level and smooth the end.
- Identify the neurovascular bundles. Cut the digital nerves back sharply and ligate the arteries and veins.
- Then transect the flexor tendons and let them retract.
- Close the skin flaps with interrupted absorbable sutures in the subcutaneous fat, and interrupted 5-0 nylon sutures in the skin. Do not resect “dog-ears,” as they will retract and assume a smooth contour.

**RAY RESECTION OF THE FOOT**

Ray resection of the foot is indicated when there is a perforating ulcer under one of the metatarsal heads that has not healed in spite of prolonged care, and when osteomyelitis involves the metatarsal.

- Make a racket-type incision circumferentially around the toe, with a single limb over the dorsum of the involved metatarsal, and including the area of the ulcer on the plantar surface (Figure 120.3.*A*).

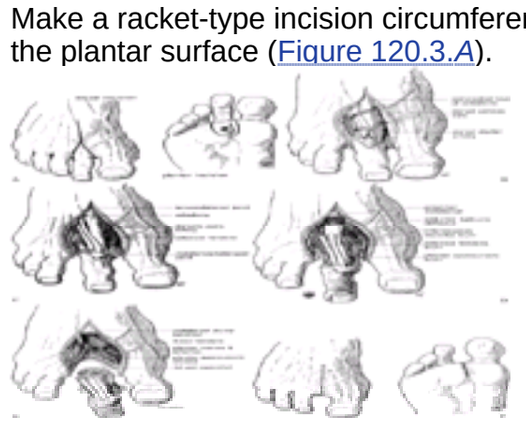

***Figure 120.3.*** Amputation of the second ray of the foot. See text for details. **A:** Skin incision. **B:** Dorsal soft-tissue dissection to expose the metatarsal. **C:** Osteotomy at the base of the metatarsal. **D:** Release of other soft tissues. **E:** The metatarsal and toe are now free. **F:** Skin closure. (From Bohne WHO. *Atlas of Amputation Surgery.* New York: Thieme Medical, 1987:40–42, Fig. 10-1, Fig. 10-2, Fig. 10-3, Fig. 10-4,Fig. 10-5 and Fig. 10-6 with permission.)

- Dissect open the skin on the dorsum of the foot like a double door. Follow the intermetatarsal space without incising the periosteum except at the very base of the metatarsal (Figure 120.3.*B*). Identify and transect the digital nerves to the amputated toe. Preserve the branches to the adjacent toes. Identify and ligate the digital arteries and veins.
- Transect the base of the metatarsal (Figure 120.3.*C*), lift up the distal end, and continue the dissection on the plantar surface, including the part of the plantar fascia belonging to the diseased ray. You can then lift the ulcer, the toe, and the surrounding skin out of the wound. Leave the surrounding intrinsic muscles attached to the metatarsal (Figure 120.3.*D*, Figure 120.3.*E*).
- Obtain hemostasis. Either leave the wound open until secondary closure, or close the intermetatarsal space with interrupted absorbable sutures and the skin with interrupted 5-0 nylon sutures (Figure 120.3.*F*) (15).

Resection of the first ray in insensate feet frequently leads to a transfer lesion on the second metatarsal. Therefore, in these cases a transmetatarsal amputation may be the better choice.

**TRANSMETATARSAL AMPUTATION**

The advantage of transmetatarsal amputation is the possibility of eradicating the disease processes that involve the toes and the metatarsal heads and necks. It requires a long plantar flap to cover the anterior part of the amputation wound. In general, it creates an excellent weight-bearing foot remnant. However, you must consider that the fifth metatarsal is more horizontal than the first metatarsal, so the shoe insert that is required after the rehabilitation has to provide sufficient medial support to distribute weight bearing evenly.

- This procedure requires transection of the dorsal skin slightly distal to the level of the bony amputation. The plantar flap must be long enough to cover the ensuing amputation wound. It must avoid any ulcerations that may be present on the plantar surface of the forefoot (Figure 120.4.*A*). Expose the metatarsals dorsally. Transect the extensor tendons, ligate the dorsal veins, and cut back sharply the cutaneous nerves (Figure 120.4.*B*).

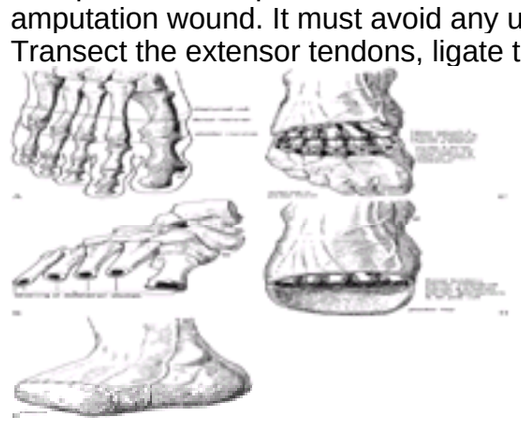

***Figure 120.4.*** Transmetatarsal amputation. See text for details. **A:** Dorsal and plantar skin incisions relative to level of transection of the metatarsals. **B:** Transection of the metatarsals produces a cascade in which the fifth metatarsal remnant is slightly shorter than the first. Bevel the prominent plantar edges of the metatarsal remnants as well as the lateral aspect of the fifth and medial aspect of the first. **C:** Plantar-flex the forefoot after transection of the metatarsals to gain access to the plantar structures. **D:** Completed amputation. **E:** Skin closure. (From Bohne WHO. *Atlas of Amputation Surgery.* New York: Thieme Medical, 1987:44–47, Fig. 11-2, Fig. 11-5, Fig. 11-6, Fig. 11-7 and Fig. 11-8, with permission.)

- Carry out bony transection from the dorsum of the foot. There should be a slight cascade, with the fifth metatarsal remnant being minimally shorter than the first one.
- Transect the metatarsals with a small oscillating saw. Deliver the distal ends of the metatarsal into the wound and expose the flexor tendons and plantar neurovascular bundles (Figure 120.4.*C*). Divide and ligate these in an orderly fashion with the techniques described previously, preserving the plantar flap (Figure 120.4.*D*).
- Where possible, tack down the plantar pad to the periosteum on the dorsum of the metatarsal remnants and approximate the edges of the skin of the plantar and dorsal aspects (Figure 120.4.*E*).

**LISFRANC AND CHOPART AMPUTATIONS**

The LisFranc amputation is carried out through the tarsometatarsal joints, whereas the Chopart amputation is a disarticulation through the talonavicular and calcaneocuboid joints. Both amputations sacrifice the insertions of the muscles that aid in the extension of the ankle joint; therefore, the anterior tibial tendon, the toe extensors, and the peroneal tendons must be reinserted into the tarsal bones. Even so, dorsiflexion of the ankle joints often is inadequate, requiring a transcutaneous Achilles tenotomy. These levels of amputations are less desirable than a transmetatarsal amputation, as the stump has a tendency to develop an equinus posture over time. Increased weight-bearing pressures over the plantar aspect of the end of the stump may lead to pain and/or ulceration. On the other hand, when one of these amputations is successful, its advantages are that it is end bearing, does not sacrifice leg length, and requires only a filler in a regular shoe in most cases.

The procedure in both amputations is somewhat similar to that of the transmetatarsal amputation.

- Transect the dorsal skin at the level of the disarticulation. The plantar skin flap must be long enough to cover the anterior aspect of the remaining limb.
- Transect the extensor tendons somewhat distal to the skin incision to allow their insertion into the tarsal bones.
- Transect the ligaments and joint capsules of the tarsometatarsal joints, in the case of the LisFranc amputation, and of the talonavicular and calcaneocuboid joints, in the case of the Chopart amputation. Sharply plantar-flex the forefoot. The capsule and plantar ligaments can be transected as well as the flexor tendons. Take

care not to injure the medial or lateral plantar artery and nerves.
- Dissect the part of the foot to be amputated off the plantar flap, which should not be debrided to allow full-thickness coverage of the anterior part of the stump.
- Leave the cartilage of the tarsal bones and the remaining limb intact. This cartilage presents an effective barrier against infections of the bone, and it decreases blood loss from bone bleeding. Nevertheless, introduce a drain into the amputation wound.
- Close the plantar flap to the dorsal incision, securing the deep fascia to the periosteum and deep fascia of the stump with absorbable sutures. Close the skin with interrupted 4-0 or 5-0 nylon or similar sutures.

The Chopart amputation is the highest level of amputation of the foot that allows the possibility of fitting with a shoe and shoe filler; however, frequently the patient prefers a formal prosthesis because the shoe is unstable (10).

**BOYD AMPUTATION**

The Boyd procedure provides a broad weight-bearing surface of the heel by creating an arthrodesis between the distal tibia and the tuber of the calcaneus (45). Compared to a Syme's amputation, it provides more length and better preserves the weight-bearing function of the heel pad. Its increased complexity and morbidity have made it less used now than the Syme's amputation. The Pirogoff amputation removes the anterior two thirds of the calcaneus (Figure 120.5.) but has no advantage over the Boyd amputation, which is described later.

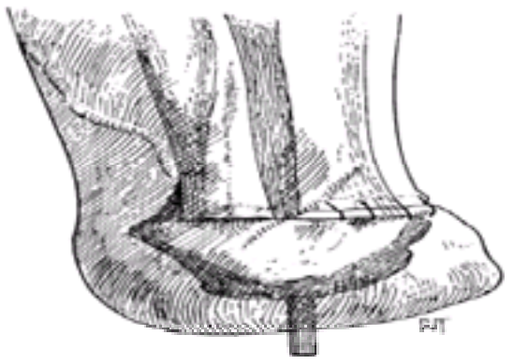

***Figure 120.5.*** Pirogoff amputation with fixation of the tuberosity of the calcaneus to the tibia.(From Bohne WHO. *Atlas of Amputation Surgery.* New York: Thieme Medical, 1987:53, Fig. 12-7, with permission.)

- Make the dorsal skin incision from the medial to the lateral malleolus across the anterior aspect of the ankle joint. Connect this to a plantar incision through the plantar fat pad at the midtarsal joint region. Take care not to injure the tibial neurovascular bundle. Plantar-flex the foot. Place a bone hook in the posterior talus and pull it forward. Excise the talus. The plantar pad remains attached to the undersurface of the calcaneus. Remove the portion of the foot to be amputated (Figure 120.6.*A*).

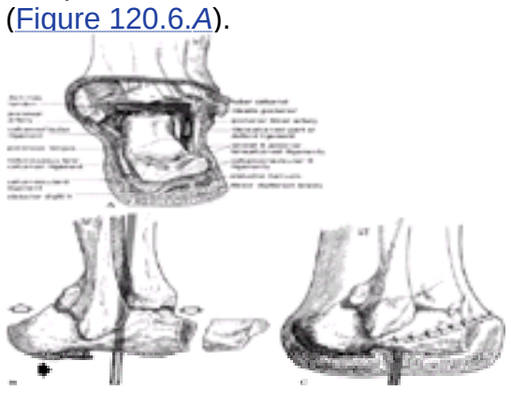

***Figure 120.6.*** Boyd amputation. See text for details. **A:** Anterior–dorsal skin incision and exposure with excision of the talus. **B:** Excise the anterior process of the calcaneus and remove cartilage from the articular facets. Fit the calcaneus into the ankle mortise, shifting it anteriorly. Secure it with a Steinmann pin. **C:** Completed amputation with skin closure. (From Bohne WHO. *Atlas of Amputation Surgery.* New York: Thieme Medical, 1987:56–57, Fig. 12-11, Fig. 12-13, Fig. 12-14, with permission.)

- Remove the anterior process of the calcaneus. Fashion the ankle mortise in such a way that the decorticated superior part of the tuber calcanei can be fitted into the ankle mortise with good bone apposition. Slide the calcaneus somewhat anteriorly.
- Fix the tuber calcanei into the ankle mortise with either a Steinmann pin or a partially threaded cancellous screw (Figure 120.6.*B*).
- Pull the plantar skin flap over the anterior aspect of the calcaneal remanent, and close it in layers at the anterior aspect of the ankle joint (Fig. 120.6*C*). Postoperative casting may be necessary to provide secure arthrodesis between the ankle mortise and the calcaneal remanent.

**SYME'S AMPUTATION**

The Syme's amputation provides an end-bearing stump that in many circumstances allows ambulation without a prosthesis over short distances. It is an excellent amputation for children, in whom it preserves the physes at the distal end of the tibia and fibula (26).

The Syme's amputation works well for tumors and trauma, assuming that the heel flap has been spared from the trauma. In the past, it has had a high failure rate in ischemic limbs because of failure of wound healing. Today, the success of amputation at this level has increased because local tissue perfusion is preoperatively determined with Doppler ultrasound measurement of blood pressures, with radioactive $^{133}$Xe clearance tests, and with transcutaneous measurement of oxygenation.

In infected limbs, particularly in diabetics, a two-stage amputation, where the wound is left open initially and the viability of the heel flap is established prior to definitive wound closure, has also increased success rates. The two most common problems with the Syme's amputation are skin slough due to trimming of the dog-ears of the skin flaps, which interferes with the blood supply to the heel pad, or late migration of the heel pad due to instability. The risk of both of these problems can be minimized by careful attention to surgical technique.

The only other objection to the Syme's amputation is that a below-knee prosthesis must be worn, which is rather bulky around the ankle because of the need to accommodate the flair of the distal tibial metaphysis. The prothesis consists of a molded plastic socket with a removable medial window through which the stump is inserted. Usually a solid-ankle, cushion-heel (SACH) foot is attached. For this reason, the Syme's amputation has not often been recommended for women, but active athletic women probably would prefer this level of amputation because it is much more functional for sports activities than a standard below-knee amputation.

- Make a dorsal skin incision from the medial to the lateral malleolus over the anterior aspect of the ankle joint. Continue the plantar incision around the anterior process of the calcaneus (Figure 120.7.*A*). Transect the extensor tendons and cut back sharply the cutaneous nerves. Ligate the dorsalis pedis artery and vein.

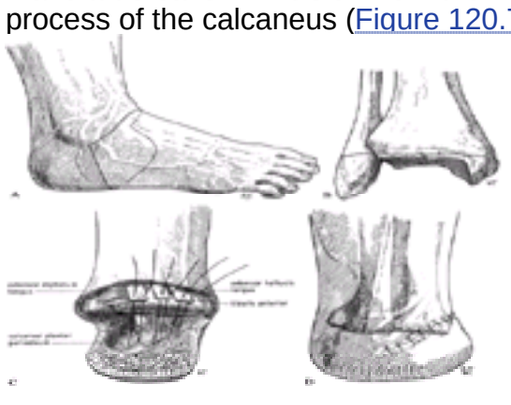

***Figure 120.7.*** Syme's amputation. **A:** Skin incisions. **B:** Level of bone transection in adults. **C:** Begin closure of the wound by attaching the extensor tendons to the calcaneal periosteum to help stabilize the heel pad. **D:** Skin closure. (From Bohne WHO. *Atlas of Amputation Surgery.* New York: Thieme Medical, 1987:58–62, Fig. 12-15, Fig. 12-21, Fig. 12-22 and Fig. 12-23, with permission.)

- Disarticulate the talus from the ankle mortise by transecting the medial and lateral collateral ligaments. Take care not to injure the tibial neurovascular bundle. Strip the calcaneus subperiosteally and remove it from the heel pad. This dissection can be difficult and is aided by placing a bone hook into the posterior aspect of the talus and pulling it and the calcaneus anteriorly. Then use a sharp scalpel to meticulously dissect the calcaneus free from the heel pad, at a subperiosteal level.
- When the calcaneus is free, transect the plantar tendons and neurovascular bundles, taking care to protect the vascular supply and sensory nerves to the heel pad.
- In a standard Syme's amputation in adults, remove the malleoli at the level shown in Figure 120.7.*B*. In children and for first-stage amputations in diabetics, leave the malleoli intact.
- Start closure of the wound by suturing the anterior tibial tendon as well as the extensor digitorum longus tendon into the anterior part of the heel pad. This prevents, at least to some extent, posterior migration of the heel pad (Figure 120.7.*C*). Complete a layered closure as described previously.
- Since the removal of the calcaneus from the heel pad creates a large empty space, insert a suction drain to prevent the formation of a large hematoma. There is a mismatch between the thin skin at the anterior aspect of the ankle joint and the thick plantar skin. However, the ridge that is created by the skin closure flattens out eventually. Large dog-ears are usually created by this closure. Do not trim these. They eventually flatten out.

## BELOW-KNEE AMPUTATIONS

Select a site of amputation that is at a level where good soft-tissue coverage of the bony stump end is possible. The minimal length of the bony stump for good function is about 12 cm, as measured from the medial tibial plateau distally, and the maximum length is 17 cm, depending on the height of the patient. Longer stumps require less energy consumption during gait and can be fitted with sockets without special suspension. Very short stumps often require knee hinges and a thigh lacer and are much less functional.

There are three common approaches to developing skin flaps. The first provides equal skin flaps medially and laterally (2); the second provides equal skin flaps posteriorly nand anteriorly; the third and most common approach provides a long posterior flap. The latter is most desirable in dysvascular patients and leaves the patient with a scar on the anterior aspect of the residual limb. However, other methods of skin closure have been successful (Figure 120.8.) (32,42,68).

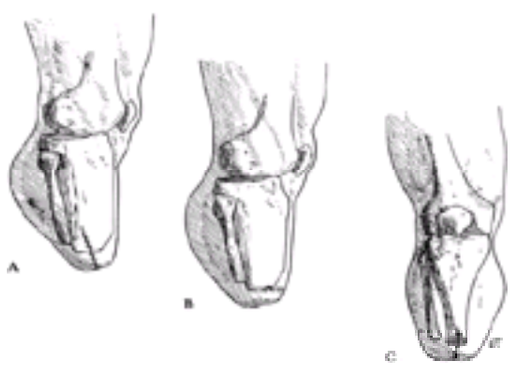

***Figure 120.8.*** Suture line in various types of below-knee amputations. **A:** In the nonischemic limb. **B:** Amputation of the ischemic limb in the coronal plane. **C:** Amputation of the ischemic limb in the sagittal plane. (From Bohne WHO. *Atlas of Amputation Surgery.* New York: Thieme Medical, 1987:69, Fig. 13-8, with permission.)

- Determine the level of transection of the tibia by direct measurement, or using the method depicted in Figure 120.9..

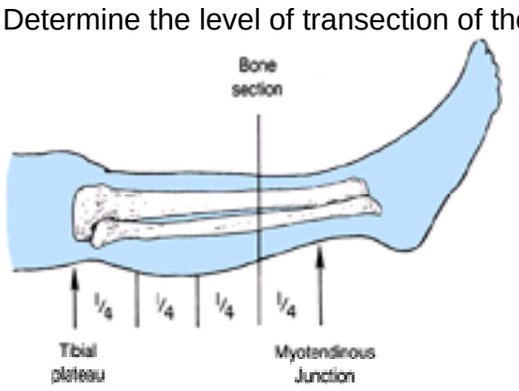


***Figure 120.9.*** Use a sterile marking pen to divide the leg into four equal quadrants from the tibial plateau to the myotendinous junction of the gastrocsoleus muscle. In most cases, transect the bone at the distal portion of the third quarter.

- In the long posterior flap method, make the skin incision at the anterior aspect of the tibia, 1.3 cm distal to the level of the bone transection. The posterior flap must be long enough to provide soft-tissue coverage without undue tension (Figure 120.10.). Extend the incision down to the deep fascia and periosteum of the tibia veering medially and laterally to point B on Figure 120.10., which is two thirds of the anteroposterior (AP) diameter of the calf. Then curve the incision directly distal for a distance of 1.3 cm before sloping posteriorly to create the posterior flap. The length of the posterior flap must be more than two thirds of the AP diameter of the calf at the level of the bone transection.

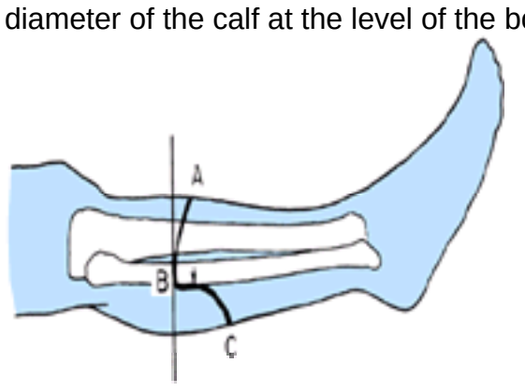


***Figure 120.10.*** Skin incision for a below-knee amputation as described by Mooney.

- Raise the periosteum of the tibia and transect it with an oscillating saw. Bevel the anterior aspect of the tibia. Transect the fibula with an oscillating saw 1–2 cm proximal to the level of the tibial transection.
- Working from anterior to posterior, transect the muscles and neurovascular bundles. Pulling the distal tibia anteriorly places the soft tissues under tension and facilitates dissection. Transect the muscles of the anterior, lateral, and deep posterior compartments just distal to the end of the tibia, so that when they retract they are even with the end of the tibia. Identify each neurovascular bundle. Cut the nerves back sharply and doubly ligate the arteries and veins independently.
- Bevel the posterior flap to produce adequate coverage for the end of the amputation stump. At the level of the skin, it should consist only of fascia.
- Carry out a myoplastic closure, suturing the fascia of the posterior flap to the anterior compartment and the periosteum of the tibia. Lead a drain out through the

skin laterally. Particularly in the dysvascular patient, avoid any tension in the skin closure (Figure 120.11.).

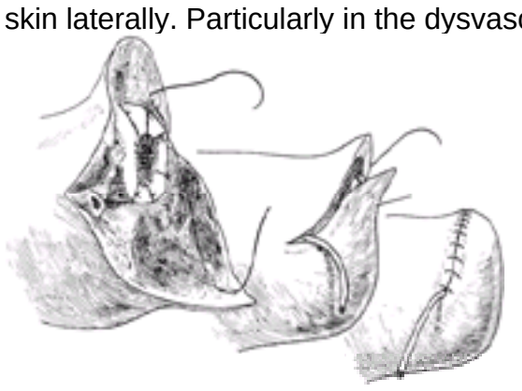

***Figure 120.11.*** Below-knee amputation. Myoplastic closure with approximation of the fascia of the posterior flap to the fascia of the anterior compartment and periosteum of the tibia, and subsequent closure of the subcutaneous tissues and skin over a drain placed at the level of the bone. (From Bohne WHO. *Atlas of Amputation Surgery.* New York: Thieme Medical, 1987:68, Fig. 13-7, with permission.)

**KNEE DISARTICULATION**

Amputation through the knee offers numerous advantages. The main advantage is the creation of an endbearing stump and preservation of the distal femoral physes, which is particularly desirable in children. Another advantage is the maintenance of a long active lever arm for control of the prosthesis, with excellent muscle attachments. The bulbous distal stump enhances suspension of the prosthesis. In elderly dysvascular patients, the longer stump helps prevent hip flexion contractures and it provides better balance for wheelchair activities. Knee disarticulation is most useful in young athletic amputees in whom a below-knee amputation is not feasible. Several modifications have been introduced by Mazet and Hennessy (60) and Burgess (6), and they are incorporated here.

- Equal anteroposterior or mediolateral skin flaps using a fishmouth type of incision are acceptable.
- Start the anterior skin incision approximately 2 cm below the tibial tubercle. The posterior incision is usually at the level of the distal popliteal flexion crease.
- Raise a skin and subcutaneous fat flap and transect the patellar ligament as far distally as possible.
- Open the anterior capsule and transect the collateral ligaments. Transect the cruciate ligaments at their insertion on the tibial plateau.
- Open the posterior capsule and doubly ligate the popliteal vessels distally to the level of the superior geniculate artery. Sharply transect the nerves well proximally to the skin incision.
- Transect the tendons of the knee flexors as far distally as possible.
- Using an oscillating saw, remove the femoral condyles 1.5 cm proximal to the knee joint.
- Shell the patella out of the patellar tendon. Suture the patellar tendon and the flexor tendons of the knee to the cruciate ligaments (Fig. 120.12).

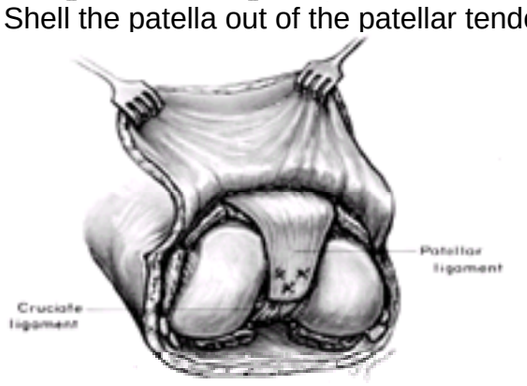


***Figure 120.12.*** Knee disarticulation. Suturing of the patellar ligament to the cruciate ligaments. Suturing of the hamstring tendons to the cruciate ligaments and resection of the distal femoral condyles as described by Burgess (6) is not illustrated.

- Although there is very little bleeding after this procedure, insert a drain into the wound. Complete the procedure with subcutaneous and skin sutures.

**ABOVE-KNEE AMPUTATION**

Whenever preservation of the knee joint is impossible, diaphyseal amputation through the femur becomes necessary. The soft-tissue coverage of the above-knee stump is excellent and usually provides good arterial perfusion to allow primary healing of the amputation. It is the most commonly used amputation for vascular disease because it heals reliably. The optional level for prosthetic fitting is at the junction of the distal and middle thirds.

Although patients with a stump length of 10 cm below the gluteal crease have been fitted successfully with prostheses, a longer amputation stump makes prosthetic fitting, as well as rehabilitation, easier and more successful. Equal anterior and posterior soft-tissue flaps are used most commonly, but atypical soft-tissue coverage is well tolerated in above-knee amputations.

- Make a fishmouth skin incision to create equal anterior and posterior flaps (Figure 120.13.*A*).

***Figure 120.13.*** Above-knee transdiaphyseal amputation. **A:** Skin incisions relative to the level of transection of the femur. **B:** Myodesis closure of the stump over a drain. (From Bohne WHO. *Atlas of Amputation Surgery.* New York: Thieme Medical, 1987:87–89, Fig. 14-4, 14-7, with permission.)

- After the skin incision, transect the quadriceps musculature anteriorly; this will leave the muscle even with the level of bone transection.
- Next, either cut the femur (as this permits the transection of tissues from anterior to posterior) or complete the soft-tissue work prior to cutting the bone. Cut the adductors and hamstrings so that they also lie even with the cut bone.
- If you have not done so already, transect the bone and round off the sharp edges.
- Obtain hemostasis and isolate and doubly ligate the large vessels with at least one suture ligature. Place a ligature on the sciatic nerve well above the level of amputation, prior to sharply transecting the nerve.
- Fashion the muscle flaps and do a myoplasty by approximating the anterior to the posterior myofascial flap (Figure 120.13.*B*). In younger active patients, place two drill holes in the bony stump end for each compartment, and do a myodesis by pulling the muscles out to length and securing them to the bone end with sutures. This improves the power and control over the stump and keeps the bone centralized in the stump.
- Place a drain and close the subcutaneous flap and skin loosely with interrupted sutures or staples.

**HIP DISARTICULATION**

Hip disarticulation is done today mainly to eradicate malignancies. Prosthetic fitting is quite possible, although rehabilitation is most successful in younger and more vigorous individuals, since the prosthetic gait requires considerable expenditure of energy. Very short above-knee amputations (Figure 120.1.) are fitted with a hip disarticulation prosthesis (Chapter 122), as is the short stump that cannot control an above-knee prosthesis even with a hip hinge and waist belt.

- Place the patient in the lateral decubitus position with the operated side uppermost, and prepare and drape the limb free, including the hip and groin.
- Make a racket-type incision down to the deep fascia, that starts at the anterior superior iliac spine, follows the inguinal ligament to a point 5 cm below the pubic tubercle, and curves around the medial and posterolateral aspects of the thigh approximately 5 cm below the ischial tuberosity. The incision then extends anteriorly to the greater trochanter and joins the beginning of the incision at the anterior iliac spine (Figure 120.14.*A*).

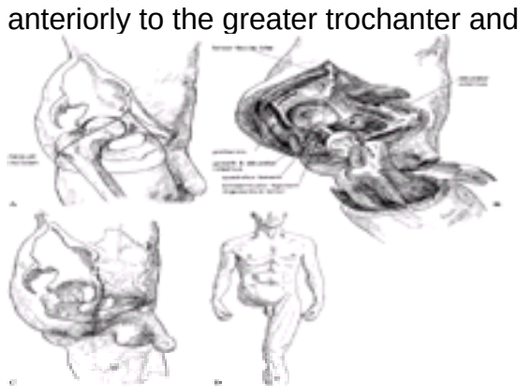

***Figure 120.14.*** Disarticulation of the hip. See text for details. **A:** Racket-type skin incision. **B:** The hip disarticulation is completed except for cutting the ligamentum teres. **C:** Skin closure. **D:** Frontal view of a patient after hip disarticulation. (From Bohne WHO. *Atlas of Amputation Surgery.* New York: Thieme Medical, 1987:106–111, Fig. 14-28, Fig. 14-31, Fig. 14-34, Fig. 14-35, with permission.)

- Anteriorly expose the femoral artery and vein. Isolate them and doubly ligate them. Dissect the femoral nerve free, ligate it, and transect it sharply farther proximally.
- Transect the muscles originating from the iliac spine and retract them distally. Transect the pectineus muscle a finger's breadth laterally to the pubic ramus. Externally rotate the hip and transect the psoas tendon. Next, detach the muscles from the pubic bone and the adductor magnus as it originates from the ischium.
- Between pectineus and the hip external rotators, dissect the obturator artery free and ligate it. Transect the obturator externus distal to the obturator foramen, because inadvertent transection of the obturator artery leads to retraction of the vessel into the inner pelvis, where it is difficult to recover for ligation.
- Then internally rotate the hip and transect the gluteus medius and minimus muscles at the greater trochanter.
- Divide the fascia lata either above or below the insertion of the tensor fasciae latae muscle.
- Next divide the lower fibers of the gluteus maximus and detach its tendon from its insertion into the linea aspera. Retract the gluteus maximus and identify and ligate the sciatic nerve and divide it as far proximally as possible, but outside the sciatic foramen. Then transect the external rotators of the hip and divide the origins of the hamstring muscles at the ischial tuberosity.
- Complete the amputation by transecting the joint capsule and intra-articular ligament as close to the acetabulum as possible (Figure 120.14.*B*). Ensure good hemostasis.
- Place large suction drains, one deep in the wound and one above the fascia.
- Begin the closure of the wound by suturing the tendons of the glutei medius and minimus to the transverse acetabular ligament. Suture the gluteus maximus forward to the origin of the pectineus, obturator externus, iliopsoas, and adductor muscles. Close the skin without tension.

## HEMIPELVECTOMY

The primary indication for hemipelvectomy, or hindquarter amputation, is the eradication of malignant tumors of the soft tissues or bone of the hip or pelvis. Occasionally, overwhelming infections such as gas gangrene or the consequences of trauma may require this operation. Prosthetic fitting is difficult and relies on weight bearing on the uninvolved side. Energy expenditure for prosthetic gait is considerable. Depending on the location of the tumor, an anterior-flap or a posterior-flap technique can be used. In an attempt to improve the prosthetic fitting, consider a conservative hemipelvectomy, which retains the ileum and its attachment to the sacroiliac joint. Another possibility is the excision of the hemipelvis, including the hip joint, while maintaining the lower extremity without its attachment to the pelvic girdle. Expect considerable blood loss during the operation.

A meticulous preoperative workup with imaging studies and sometimes anteriography is usually necessary to plan for safe margins for tumor resection and to determine what type of hemipelvectomy is appropriate.

- Insert a ureteral catheter for identification of the ureter and a Foley catheter to drain the bladder.
- Close the anus temporarily with a purse-string suture.
- Position the patient in the lateral decubitus position but make the supports loose, so he can be shifted from a more supine to a more prone position. Do a wide preparation and drape of the involved extremity, the pelvis, and the lower thorax.

### *Posterior-Flap Technique*

Maintenance of a posterior flap requires a three-step procedure with an anterior part, perineal portion, and posterior component.

- For the anterior portion, start the skin incision at the pubic tubercle and extend it along the inguinal ligament to the anterior superior iliac spine. From there, follow the anterior part of the iliac crest eventually to the mid ileum (Figure 120.15.*A*).

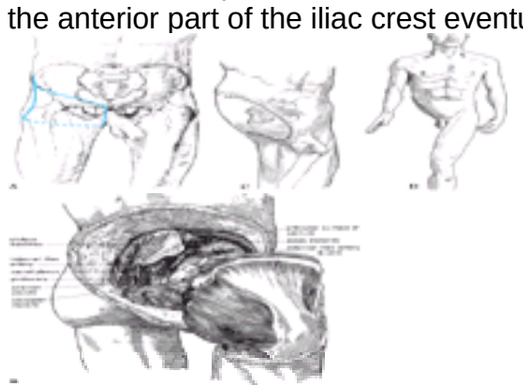

***Figure 120.15.*** Hemipelvectomy. See text for details. **A:** Skin incision. Start the incision at the anterior superior iliac spine (ASIS) and extend along the inguinal ligament to the pubic tubercle. Then extend vertically into the perineum to the ischial tuberosity, to the fold of the gluteus maximus. Follow the gluteal crease laterally to the greater trochanter and with a gentle anterior curve return to the ASIS. **B:** The hemipelvectomy has been completed and the hindquarter detached. **C,D:** Skin closure. (From Bohne WHO. *Atlas of Amputation Surgery.* New York: Thieme Medical, 1987:118–119, Fig. 15-1, Fig. 15-7, Fig. 15-8, with permission.)

- Detach the inguinal ligament as well as the abdominal muscles from the iliac crest, and develop the space between the peritoneum and the iliacus muscle.
- Then detach the inguinal ligament and the rectus abdominus tendon from the pubic bone. In men, retract the spermatic cord medially. Now enter the space of Retzius and retract the bladder into the pelvis.
- Doubly ligate and transect the external iliac artery and veins and cut the femoral nerve back sharply. Now pack the anterior wound to control hemorrhage and protect the soft tissues.
- For the perineal part, abduct the hip and extend the incision from the pubic tubercle vertically through the perineum to the ischial tuberosity. Expose the pubic and ischial rami, and detach subperiosteally the adductor, hamstring, and perineal muscles originating from them, as well as the corpus cavernosum. Then divide the symphysis pubis. Take care not to injure the urethra.
- To complete the posterior part, roll the patient somewhat forward, and while flexing and adducting the hip, complete the skin incision by extending it from the ischial tuberosity laterally along the gluteal crease to the greater trochanter, and from there superiorly to join the anterior incision at the midiliac crest (Figure 120.15.*A*). Expose the posteroinferior margins of the gluteus maximus, incise its aponeurosis in line with the skin incision, detach its femoral insertion, and reflect

it and the overlying fat and skin as a composite flap proximally. Identify the gluteus medius, the external rotators of the hip, and the sciatic nerve.

- Identify, ligate, and sharply transect the sciatic nerve and allow it to retract into the pelvis.
- Pass a Gigli saw through the greater sciatic notch; divide the sacrotuberous and sacrospinous ligaments and divide the ileum just lateral to the sacroiliac joint. This is easier than disarticulating the sacroiliac joint. The joint can be disarticulated or even a portion of the sacrum resected if required to establish a surgical margin.
- Then externally rotate the innominate bone, ligate and divide the obturator vessels and nerve, and transect the psoas muscle at the level of the sacroiliac joint. Divide the hip external rotator muscles close to the ischium.
- Transect the levator ani close to its origin on the ischium and the pubis. This will free the hindquarter (Figure 120.15.*B*).
- Place a deep and superficial suction drain and begin closure by bringing the posterior skin and muscle flap forward and suturing it to the lateral border of the abdominal muscles and the rectus abdominus muscle. Posteriorly, secure it to the psoas and quadratus lumborum muscles. Use #0 or #1 absorbable sutures.
- Then close the skin loosely (Figure 120.15.*C*, Figure 120.15.*D*).

### *Anterior-Flap Technique*

The anterior-flap technique for hemipelvectomy as described by Larsen and Liang (51) requires retention of the femoral nerve and vessels as well as the quadriceps musculature.

- Create the anterior flap by starting an incision at the anterior superior iliac spine, and extend it along the lateral aspect of the thigh to the level of the superior pole of the patella. Then continue the incision transversely across the quadriceps tendon and medially to the midline, and subsequently proximalward to the groin (Figure 120.16.*A*).

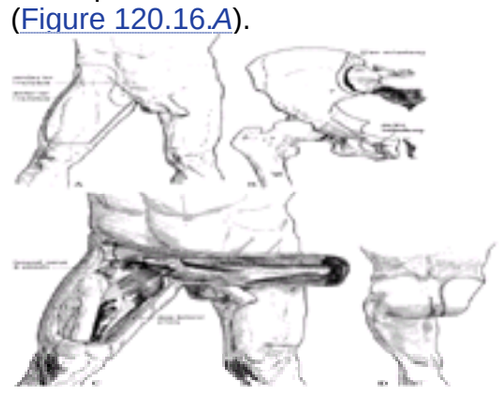

***Figure 120.16.*** Larsen and Liang (51) modified hemipelvectomy using an anterior quadriceps flap. See text for details. **A:** Skin incision. **B:** Remove the innominate bone with osteotomies of the pubic rami and the ileum. **C:** The anterior quadriceps musculocutaneous flap is supplied by the superficial femoral artery and vein, which are carefully preserved. **D:** The skin closure. (From Bohne WHO. *Atlas of Amputation Surgery.* New York: Thieme Medical, 1987:120–124, Fig. 15-9, Fig. 15-10, Fig. 15-13, with permission.)

- Develop the musculocutaneous flap from lateral to medial by incising the deep fascia and transecting the quadriceps tendon horizontally. Elevate the quadriceps muscle from the femur, developing the dissection along the vastus medialis.
- Find the adductor canal, transect the sartorius muscle and ligate, and transect the femoral vessels as far distally as possible so that their proximal ends remain with the musculocutaneous flap. With further proximal dissection, take care not to injure the femoral vessels. Only the profunda femoris artery is ligated farther proximally (Figure 120.16.*C*).
- Then complete the hemipelvectomy as described previously, but exclude the posterior flap, which is replaced by the anterior flap. Removal of the innominate bone can be made easier by osteotomy of the pubic rami rather than by disarticulation of the pubic symphysis (Figure 120.16.*B*).
- Closure of the amputation is as described previously (Figure 120.16.*D*).

## ERTL OSTEOMYOPLASTIC LOWER EXTREMITY AMPUTATION RECONSTRUCTION (PRIMARY AND SECONDARY)

Despite seemingly well-performed amputations, some patients experience persistent residual extremity pain, swelling, a sense of instability, and an inability to tolerate extended prosthetic ambulation. The residual extremity undergoes atrophy as a result of inactivity and becomes a passive participant in walking. This symptom complex is referred to as the inactive residual extremity syndrome. The Ertl osteomyoplastic lower extremity amputation reconstruction is directed at treating difficult transtibial and transfemoral amputee symptoms and reversing the inactive residual extremity syndrome (21,22,23 and 24). Patients in our transtibial and transfemoral series were surgically reconstructed after nonoperative and prosthetic modifications were exhausted (22,23,24).

### *Transtibial Technique*

- Utilize the previous amputation incision for exposure. Isolate the neurovascular structures, and ligate the arteries and veins separately. Distract the nerves and cut them well above the bone level, allowing them to retract into a soft-tissue bed.
- Separate the anterior and posterior muscle groups, exposing the distal tibia and fibula in preparation for forming osteoperiosteal cortical island flaps.
- Elevate the osteoperiosteal cortical island flaps with a 30° to 45° angled chisel from the medial and lateral borders of both the tibia and the fibula (Figure 120.17.*A*).

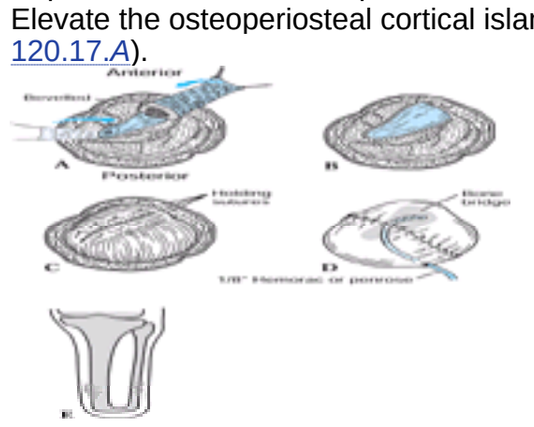


***Figure 120.17.*** Ertl osteomyoplastic transtibial amputation reconstruction. **A:** Transverse section of amputation level, with elevated osteoperiosteal flaps from the medial and lateral aspects of the tibia and fibula. The roof is created with the interior flaps. **B:** The outer osteoperiosteal flaps are folded over the medullary canals and sutured to one another as well as to the superior flap, forming a closed tubelike structure (osteoperiosteal bridge) and closing the medullary canal. **C:** The opposing muscle groups are sutured together forming the myoplasty. Muscle rotation may be necessary to completely cover the bridge and anterior tibia. **D:** The skin is contoured to the underlying myoplasty, avoiding dog-ear formation, creating a smooth surface and interface. **E:** Completed transtibial reconstruction with mature bridge and reestablishment of the medullary canal.

- Remove approximately 1.5–2 cm of the end of the tibia, and suture the retained osteoperiosteal flaps together in tubelike fashion, forming a bony bridge between the tibia and fibula (Figure 120.17.*B*).
- To complete the myoplasty, secure the ends of the opposing muscle groups to each other over the end of the bone and the underlying bridge, reestablishing some muscle tension (Figure 120.17.*C*, Figure 120.17.*D* and Figure 120.17.*E*).
- Contour the skin to the underlying myoplasty, forming a smooth, cylindrical residual extremity (Figure 120.17.*D*).

### *Transfemoral Technique*

The transfemoral approach is similar to that for transtibial reconstruction.

- Expose the distal femur through the previous surgical scar and treat the soft tissues and neurovascular structures as described.
- Elevate and suture together the osteoperiosteal cortical island flaps, covering the open-ended medullary canal. Remove minimal bone after flap elevation (Figure 120.18.*A*, Figure 120.18.*B*, Figure 120.18.*C*, Figure 120.18.*D* and Figure 120.18.*E*).

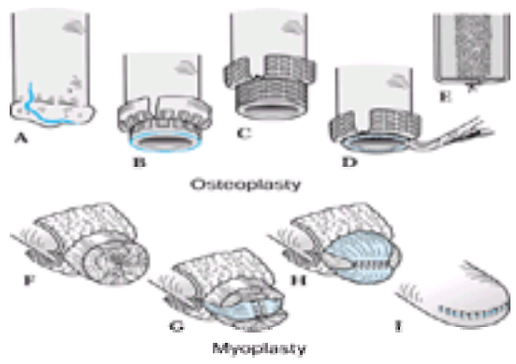


***Figure 120.18.*** Ertl osteomyoplastic transfemoral amputation reconstruction. **A:** A periosteal incision is made. **B:** Osteoperiosteal flaps are created and elevated. **C:** The femur is transected below the osteoperiosteal flaps. **D:** The exposed distal bone surface is freshened with a rongeur. **E:** The osteoperiosteal flaps are sutured to each other, closing the medullary canal. **F:** The four major muscle groups are isolated. **G:** The adductors are sutured to the abductors, incorporating sutures into the periosteal sleeve or through bone holes. **H:** The extensors are sutured to the flexors, circumferentially covering the medial/lateral myoplasty. **I:** The skin is contoured to the underlying myoplasty, avoiding dog-ear formation.

- Secure the opposing muscle groups to the distal periosteum and to each other to reestablish muscle length and to stabilize the femoral shaft within the muscle envelope (Figure 120.18.*F*, Figure 120.18.*G* and Figure 120.18.*H*).

### *Conclusion*

We have performed 150 transtibial reconstructions, with a mean follow-up of 9 years and a mean time to reconstruction of 9.5 years. We also performed 74 transfemoral reconstructions, with a mean follow-up of 9.8 years and a mean time to reconstruction of 13.3 years. A 30-point clinical assessment score was used to rate postoperative pain, function, stability, swelling, hours able to wear the prosthesis, and radiographic evaluation. A score of over 25 points was graded as excellent, 20–24 as good, 15–19 as fair, and less than 15 as poor. In the transtibial group, there were 73.3% excellent, 18.7% good, 5.3% fair, and 2.7% poor results, with an overall patient satisfaction of 97%. The transfemoral group had 70% excellent, 20% good, 4% fair, and 6% poor, with an overall patient satisfaction of 94% (23,24).

Closure of the medullary canal in amputated extremities has been shown to improve vascularity to the residual extremity and return an elevated intramedullary pressure to normal (23,24,29,49,54,55). In the transtibial population, medullary closure stabilizes the fibula by forming a bony bridge, thus improving the rotational control of the extremity within the prosthesis. The potential for tolerating end bearing is also enhanced with medullary closure for both transtibial and transfemoral patients. Myoplasty has been demonstrated to improve the arterial supply and venous return of the residual extremity, benefiting vascular amputees as well (21,22,28,30,31,62). Additionally, the osteomyoplasty improves extremity control and strength and can provide a greater surface area for prosthetic fitting. Other authors have demonstrated a more powerful residual extremity that is prosthetically more satisfactory (11,16,17 and 18,49,54,55).

Our efforts with the osteomyoplastic technique are directed at generating an active and functional residual extremity by reestablishing as normal a physiologic environment as possible. It is our feeling that the resultant residual extremity will provide the patient with a more durable limb with improved stability and proprioception. The residual limb is more powerful and prosthetically provides better adherence to the socket. No unnecessary bone length is removed to achieve the end result, but we do not hesitate to sacrifice length when an increase in function can be achieved. We have successfully applied this reconstruction to both primary and secondary amputations.

## POSTOPERATIVE CARE AND REHABILITATION

Four types of dressings have been recommended following amputation: soft dressings, soft dressings with pressure wrapping, semirigid dressings (56), and rigid dressings. Each has advantages and disadvantages. The rigid dressing leads to the most successful early maturation of the stump. Indeed, in well-vascularized amputation stumps, the rigid dressing can be combined with an immediate postoperative fitting that will allow early weight bearing (8). However, the rigid dressings do not allow easy access to the amputation wound.

The application of an immediate postoperative prosthesis (IPOP) can be considered for all levels of the lower extremity amputation. Use the IPOP with caution in dysvascular amputees, as excessive pressure may lead to wound necrosis. Potential advantages include decreased postsurgical edema, a decreased incidence of thromboembolic disease, less pain, protection of the stump wound, and earlier mobilization of the patient and fitting of a pylon prosthesis, which enhances rehabilitation and is psychologically good for the patient.

Apply the rigid dressing immediately postoperatively in the operating room. Cover the wound with a sterile dressing and a sterile stump sock. Fill the area between the amputation wound and the cast with either fluffed gauze or a premanufactured polyurethane foam cup. Pad bony prominences with strips of felt, and over this apply an elastic plaster-of-paris bandage to gently compress the area of the amputation wound. In the below-knee amputation, apply the cast to above the knee and keep the knee at approximately 10° to 20° of flexion. Incorporate into the cast a suspension strap for a waist belt as well as an attachment plate for the pylon that holds the prosthetic foot.

Experience in applying the IPOP is extremely important, not only for the surgeon and prosthetist but also for the physical therapist who has to supervise the early partial weight bearing (25). Delay weight bearing in dysvascular amputees. Removable rigid dressings have been devised. After 2 weeks at the most, remove the circular rigid dressing for wound inspection and reapplication.

The rigid dressing prevents excessive postoperative edema. This advantage is lost in soft dressing. If a soft dressing with pressure wrapping is used, apply the elastic bandage with care to avoid excessive compression and strangulation of the residual limb.

In a semirigid dressing, use the same inner sterile dressings as for the rigid dressing; however, the outer layer of this dressing consists of Unna paste bandages, which have to be held in place with a stockinet. This type of dressing has the same advantage of preventing excessive postoperative edema as the rigid dressing but does not allow any attachment of the provisional prosthesis.

## PITFALLS AND COMPLICATIONS

### *Infection*

Infection after amputations is uncommon and does not occur at a higher incidence than after normal elective surgery when amputations are performed in the absence of preexisting vascular disease or infection in the extremity. The incidence of infection, however, is much higher when amputation is performed in the presence of active infection in the extremity, particularly when the level of amputation is close to the site of infection. In dysvascular amputees, occasionally too distal a level of amputation is selected in spite of preoperative studies indicating that the level of amputation is appropriate.

In our experience, there is a significant incidence of stump complications in amputations performed for open fractures of the tibia secondary to high-velocity crush injuries, when the open fracture wound has gone on to progressive necrosis and infection. These tend to occur in young active patients, so there is a tendency to try to preserve a below-knee level, which may lead to amputation through marginal tissues. The risks of stump wound breakdown and infection in these cases can be minimized by careful preoperative workup to ensure that the amputation is occurring through viable tissue, and by performing staged amputations. The initial stage of the amputation can be a simple guillotine-type amputation, followed by definitive amputation with or without primary closure, or the initial amputation can be with the usual flaps but be left open and then closed secondarily when it is evident that the tissues are viable and infection is not present.

### *Stump-wound Breakdown*

The most common cause of stump-wound breakdown is infection, but necrosis of wound edges as well as of underlying muscle can occur in amputation for peripheral vascular disease because of inadequate vascularity at the level of amputation. Current techniques for evaluating extremity perfusion (as discussed previously) have lessened this risk, but in spite of the best of care breakdown still occasionally occurs. Closure of the wound under tension predisposes to breakdown. This can be

avoided by always closing stumps loosely, since this allows accommodation for postoperative swelling. If revision of the level of amputation to a more proximal level may result in loss of the knee joint or preclude the use of a prosthesis, then reconstructive options such as free microvascular transfer of tissues and Ilizarov bone transport methods may be indicated to preserve function in young active individuals.

***Neuromas***

All nerves that are transected form neuromas, but these are only occasionally painful. Isolating all superficial and deep nerves, gently applying traction to them, and cutting them with a sharp, fresh blade to allow them to retract into soft tissue where the prosthesis will not bear on the nerve end will avoid most problems with neuromas. Treat neuromas initially nonoperatively, with adjustments of the prosthesis and desensitizing techniques in physical therapy. If a neuroma is refractory to nonoperative treatment, explore the nerve, and transect it higher deep in soft tissues where it will not be a problem.

## AUTHORS' PERSPECTIVE

Amputation of any part of the body is a severe emotional as well as a physical trauma. One of my patients told me on the day after the operation, “Part of me has died. When is the rest to follow?” To overcome this feeling of depression and disability, the amputation should be undertaken with a view toward the postoperative life of the patient: The patient must be the most important member of the team that is undertaking the rehabilitation after the amputation.

Certain principles have emerged: Achieving an end-bearing limb remnant in the very young and the very old is important. In the growing individual, the reason for the end-bearing stump is to prevent bony overgrowth, which can require numerous revisions of the amputation. Also, in our experience, the patellar-tendon-bearing prosthesis in the growing individual often leads to the development of a patellar alta, which in turn, is frequently the cause for recurrent dislocation of the patella. In the very old, the end-bearing prosthesis makes rehabilitation considerably easier, and ultimately the prosthesis is more comfortable than after diaphyseal amputations.

Another principle is the preservation of the knee joint. The new prosthetic components have made the use of the below-knee prosthesis easier and more satisfactory than in times gone by. Indeed, many of our younger patients have returned to high-achievement sports. In older below-knee amputees, energy consumption is much more favorable than in above-knee amputees of similar age, allowing them to participate in physical activities with greater ease.

Thus, a conservative approach to amputation, saving as much of the limb as possible as long as the disease process allows, is highly desirable. In lower extremity amputations, this is particularly obvious when comparing internal hemipelvectomy with hindquarter amputation.

## CHAPTER REFERENCES

Each reference is categorized according to the following scheme: *, classic article; #, review article; !, basic research article; and +, clinical results/outcome study.


+ 1. Albrektsen SB, Henriksen BM, Holstein PE. Minor Amputaions on the Feet after Revascularization for Gangrene. A Consecutive Series of 95 Limbs. *Acta Orthop Scand* 1997;68:291.

+ 2. Au KK. Sagittal Flaps in Below-knee Amputations in Chinese Patients. *J Bone Joint Surg Br* 1989;71:597.

+ 3. Bodily K, Burgess E. Contralateral Limb and Patient Survival after Leg Amputations. *Am J Surg* 1983;146:280.

# 4. Bohne WHO. *Atlas of Amputation Surgery.* New York: Thieme Medical, 1987.

* 5. Boyd H. Anatomic Disarticualtion of the Hip. *Surg Gynecol Obstet* 1947;84:346.

* 6. Burgess E. Disarticulation of the Knee: A Modified Technique. *Arch Surg* 1977;112:1250.

+ 7. Burgess E, Matsen F, Wyss D, Simmons C. Segmental Transcutaneous Measurements of $PO_2$ in Patients Requiring Below the Knee Amputation for Peripheral Vascular Insufficiency. *J Bone Joint Surg Am* 1982;64:378.

+ 8. Burgess E, Romano R, Zettl J, Schrock R. Amputation of the Lower Extremity for Peripheral Vascular Insufficiency. *J Bone Joint Surg Am* 1971;53:74.

+ 9. Campbell WB, St. Johnston JA, Kernick VF, Rutter EA. Lower Limb Amputation: Striking the Balance (see comments). *Ann R Coll Surg Engl* 1994;76:205.

+ 10. Chang BB, Bock DE, Jacobs RL, et al. Increased Limb Salvage by the Use of Unconventional Foot Amputations. *J Vasc Surg* 1994;19:341 (disc., 348).

! 11. Condie DN. Electromyography of the Lower Limb Amputee. *Medicine and Sport*, vol 8: *Biomechanics* 482. Basel, Switzerland: Karger, 1973.

+ 12. Conkle D, Richie R, Sawyers J, Scott H. Surgical Treatment of Popliteal Artery Injuries. *Arch Surg* 1975;110:1351.

+ 13. Daugherty M, Sachatello C, Ernst C. Improved Treatment of Popliteal Arterial Injuries. *Arch Surg* 1978;113:1317.

+ 14. Dawson I, Keller BP, Brand R, et al. Late Outcomes of Limb Loss after Failed Infrainguinal Bypass. *J Vasc Surg* 1995;21:613.

* 15. Debakey M, Simeone F. Battle Injuries of the Arteries in World War II. *Ann Surg* 1946;123:534.

# 16. Deffer PA. Ertl Osteoplasty at Valley Forge General Hospital. *Amputee Clin* 1969;1.

# 17. Deffer PA. More on the Ertl Osteoplasty, Committee on Prosthetic-orthotic Education. *Amputee Clin* 1970;2.

+ 18. Deffer PA, Moll JH, LaNoue AM. The Ertl Osteoplastic Below Knee Amputation. *J Bone Joint Surg Am* 1971;53:1028.

+ 19. Eilber F, Muria J, Grant T, et al. Is Amputation Necessary for Sarcomas? A Seven Year Experience with Limb Salvage. *Ann Surg* 1980;192:431.

+ 20. Enneking W, Durham W. Resection and Reconstruction for Primary Neoplasms Involving the Innominate Bone. *J Bone Joint Surg Am* 1978;60:731.

* 21. Ertl JV. *Regeneration: Ihre Anwendung in der Chirurgie.* Leipzig: Verlag von Johann Ambrosius Barth, 1939.

* 22. Ertl J. Uber Amputationsstumpfe. *Chirurg* 1949;20:218.

+ 23. Ertl J. Ertl Osteomyoplastic Lower Extremity Amputation Reconstruction. Orthopaedic Transactions. *J Bone Joint Surg Am* 1997.

+ 24. Ertl J. Ertl Osteomyoplastic Lower Extremity Amputation Reconstruction: Technique and Long Term Results. Presented at the annual meeting of the American Association of Orthopaedic Surgeons, San Francisco, CA, Feb. 17, 1997.

+ 25. Folsom D, King T, Rubin JR. Lower-extremity Amputation with Immediate Postoperative Prosthetic Placement. *Am J Surg* 1993;164:320.

+ 26. Gaine WJ, McCreath SW. Syme's Amputation Revisited: A Review of 46 Cases. *J Bone Joint Surg Br* 1996;78:461.

+ 27. Goodson W, Hunt T. Wound Healing and the Diabetic Patient. *Surg Gynecol Obstet* 1979;149:600.

* 28. Hansen-Leth C. Muscle Blood Flow after Amputation with Special Reference to the Influence of Osseous Plugging of the Medullary Cavity. *Acta Orthop Scand* 1976;47:613.

! 29. Hansen-Leth C. Muscle Blood Flow after Amputation with Special Reference to the Amputation Level. *Acta Orthop Scand* 1977;48:10.

! 30. Hansen-Leth C. The Vascularization in the Amputation Stumps of Rabbits. A Microangiogrpahic Study. *Acta Orthop Scand* 1979;50:399.

! 31. Hansen-Leth C, Reiman I. Amputations With and Without Myoplasty on Rabbits with Special Reference to the Vascularization. *Acta Orthop Scand* 1972;43:68.

+ 32. Harrison JD, Southworth S, Callum KG. Experience with the “Skew Flap” Below-knee Amputation. *Br J Surg* 1987;74:930.

+ 33. Hartford JM, Abdu WA, Mayor MB. Reconstructive Amputation after Grade IIIC Open Tibial Fracture. One Method of Preserving residual Limb Length. *J Orthop Trauma* 1994;8:354.

+ 34. Helfet D, Howery T, Sanders R, Johansesn K. Limb Salvage versus Amputation: Preliminary Results of the Mangled Extremity Severity Score. *Clin Orthop* 1990;256:80.

+ 35. Hierner R, Betz AM, Cometet JJ, Berger AC. Decision Making and Results in Subtotal and Total Lower Leg Amputations: Reconstruction versus Amputation. *Microsurgery* 1995;16:830.

+ 36. Holstein P, Sager P, Lassen N. Wound Healing in Below Knee Amputations in Relation to Skin Perfusion Pressure. *Acta Orthop Scand* 1979;50:49.

+ 37. Houghton A, Allen A, Luff R, McColl I. Rehabilitation after Lower Limb Amputation: A Comparative Study of Above-Knee, Through-Knee, and Gritti-Stokes Amputations. *Br J Surg* 1989;76:622.

+ 38. Howe H, Poole G, Hansen F, et al. Salvage of Lower Extremities Following Combined Orthopedic and Vascular Trauma: A Predictive Salvage Index. *Am J Surg* 1987;53:205.

* 39. Hughes C. Arterial Repair during the Korean War. *Ann Surg* 1958;147:555.

+ 40. Johansen K, Darness M, Howey T, et al. Objective Criteria Accurately Predict Amputation following Lower Extremity Trauma. *J Trauma* 1990;30:568.

+ 41. Johnson J. Reconstruction of the Pelvic Ring following Tumor Resection. *J Bone Joint Surg Am* 1978;60:747.

+ 42. Kaufman JL. Alternative Methods for Below-knee Amputation: Reappraisal of the Kendrick Procedure. *J Am Coll Surg* 1995;181:511.

+ 43. Kerneck CB, Rozzi WB. Simplified Two-staged Below-knee Amputation for Unsalvageable Diabetic Foot Infections. *Clin Orthop* 1990;261;251.

+ 44. Kihn R, Warrem R, Becke G. The Geriatric Amputee. *Ann Surg* 1972;176:305.

+ 45. Kornah B. Modified Boyd Amputation. *J Bone Joint Surg Br* 1996;78:149.

+ 46. Kostuik J, Wood D, Hornby R, et al. The Measurement of Skin Blood Flow in Peripheral Vascular Disease by Epicutaneous Application of 133 Xenon. *J Bone Joint Surg Am* 1976;58:833.

+ 47. Kram H. Non-invasive Tissue Oxygen Monitoring in Surgical and Critical Care Medicine. *Surg Clin North Am* 1985;65:1005.

# 48. Kwasnick E. Limb Salvage in Diabetics: Challenges and Solutions. *Surg Clin North Am* 1986;66:305.

# 49. La Noue AM. More on the Ertl Tibiofibular Synostosis: Committee on Prosthetic-Orthotic Education. *Amputee Clin* 1973;5.

+ 50. Lane J, Harsh B, Boland P, Glasser D. Osteogenic Sarcoma. *Clin Orthop* 1986;204:93.

+ 51. Larsen D, Liang M. The Quadriceps Musculocutaneous Flap: A Reliable, Sensate Flap for the Hemipelvectomy Defect. *Plast Reconstr Surg* 1983;72:347.

+ 52. Larsen F, Christiansen J, Ebskov B. Prevention and Treatment of Ulceration of the Foot in Unilaterally Amputated Diabetic Patients. *Acta Orthop Scand* 1982;53:481.

+ 53. Larsson J, Agardh CD, Apelqvist J, Stenstrom A. Clinical Characteristics in Relation to Final Amputation Level in Diabetic Patients with Foot Ulcers: A Prospective Study of Healing Below or Above the Ankle in 187 Patients. *Foot Ankle Int* 1995;16:69.

* 54. Loon HE. Biological and Biomechanical Principles in Amputation Surgery. Prosthetics International. Proceedings of the Second International Prosthetics Course, Copenhagen, 1962.

# 55. Loon HE. Below Knee Amputation Surgery. (National Academy of Sciences–National Research Council.) *Artif Limbs* 1963;6:86.

+ 56. MacLean N, Fick GH. The Effect of Semirigid Dressings on Below-knee Amputations. *Phys Ther* 1994;74:668.

+ 57. Marcove R, Mike V, Hajek J, et al. Osteogenic Sarcoma under the Age of 21. A Review of 145 Preoperative Cases. *J Bone Joint Surg Am* 1970;52:411.

+ 58. Martin P, Frawle J, Barabus A, et al. On the Surgery of Atherosclerosis of the Profunda Femoris Artery. *Surgery* 1972;71:182.

# 59. Mazet R. The Geriatric Amputee. *Artif Limbs* 1967;11:33.

+ 60. Mazet R, Hennessy C. Knee Disarticulation: A New Technique and a New Knee Joint Mechanism. *J Bone Joint Surg Am* 1966;48:126.

+ 61. McMurray J. Wound Healing with Diabetes Mellitus: Better Glucose Control for Better Wound Healing in Diabetes. *Surg Clin North Am* 1984;64:769.

# 62. Medhat MA. Rehabilitation of the Vascular Amputee. *Orthop Rev* 1983;12:51.

+ 63. Ottemanm M, Stahlgrew L. Evaluation of Factors which Influence Mortality and Morbidity following Major Lower Extremity Amputation for Atherosclerosis. *Surg Gynecol Obstet* 1965;120:1217.

+ 64. Pinzur M, Smith D, Daluga D. Selection of Patients for Through the Knee Amputation. *J Bone Joint Surg Am* 1988;70:746.

+ 65. Purry NA, Hannon MA. How Successful is Below-knee Amputation or Injury. *Injury* 1989;20:32.

+ 66. Rich N, Baugh JR, Hughes C. Popliteal Artery Injuries in Vietnam. *Am J Surg* 1969;118:531.

+ 67. Rollins D, Towne J, Bernhard V, et al. Isolated Profundaplasty for Limb Salvage. *J Vasc Surg* 1985;2:585.

+ 68. Saleb M, Data D, Eastaugh-Waring SJ. Long Posteromedial Myocutaneous Flap Below-knee Amputation. *Ann R Coll Surg Engl* 1995;77:141.

+ 69. Senkowsky J, Money MK, Kerstein MD. Lower Extremity Amputation: Open versus Closed. *Angiology* 1990;41:221.

+ 70. Simon M. Limb Salvage for Osteosarcoma. *J Bone Joint Surg Am* 1988;70:307.

+ 71. Susak Z, Pikielny S, Najenson T. The Influence of the Deep Femoral Arterys on Wound Healing in Amputees. *Acta Orthop Scand* 1978;49:420.

# 72. Tornetta P 3rd, Olson SA. Amputation versus Limb Salvage. *Instr Course Lect* 1997;46:511.

+ 73. Towne J, Rollins D. Profundaplasty: Its Role in Limb Salvage. *Surg Clin North Am* 1986;66:403.

+ 74. Van der Way LP, Polder TW. Salvage of a Through-knee Amputation Level Using a Free Fillet Sole Flap. *Microsurgery* 1993;14:605.

+ 75. Winkler K, Bernon G, Katz R, et al. Neoadjuvant Chemotherapy for Osteogenic Sarcoma: Results of a Cooperative German/Austrian Study. *J Clin Oncol* 1984;2:617.

# CHAPTER 121

# AMPUTATIONS OF THE UPPER EXTREMITY

*Edward A. Athanasian*

**E. A. Athanasian:** Assistant Attending Orthopaedic Surgeon, Hospital for Special Surgery, Memorial Sloan-Kettering Cancer Center, New York, New York 10021.

Introduction
Indications
Trauma
Brachial Plexus Injury
Malignant Musculoskeletal Tumors
Surgical Techniques
Upper-Extremity Amputation
Below-Elbow Amputation
Elbow Disarticulation
Above-Elbow Amputation
Amputations About the Shoulder
Shoulder Disarticulation
Scapulothoracic Disarticulation
Resection Replantation
Postoperative Care and Rehabilitation
Chapter References

## INTRODUCTION

Upper-extremity amputations, excluding finger amputation, account for 15% to 20% of major extremity amputations. More than 90% of all upper-extremity amputations are a result of trauma, and most of these occur in men between the ages of 20 and 40 years (1). Limb-sparing surgery for primary bone and soft-tissue sarcoma of the upper extremity is possible in the majority of patients, although amputation may still be necessary for local control or palliation in 5% to 10% of patients with malignant tumors (18). Less common causes of upper-extremity amputation are peripheral vascular disease, congenital malformations, neurologic disorders, and severe infections.

The loss of an upper extremity has more devastating consequences than the loss of a lower extremity. Upper-extremity amputations are most common in young male trauma victims, in whom the loss profoundly affects function and self-image. Despite improvements in materials and design, long-term use of prosthetics by upper-extremity amputees is only about 50%. Prosthetic use is reduced in patients with higher levels of amputation, those with brachial plexus injury, and when initiation of prosthetic limb rehabilitation is delayed (4,12,13,23).

## INDICATIONS

Trauma is the most common indication for upper-extremity amputation. Acutely severed, crushed, or mangled limbs may require immediate amputation (19). Irreversible brachial plexus injuries resulting in a flail, useless limb may come to amputation following the acute injury period. Malignant bone or soft-tissue tumors that contaminate or encase major nerves or vessels may not be amenable to limb salvage. Tumors with extensive involvement of the carpal tunnel or antecubital fossa may require amputation to eradicate the tumor locally. Peripheral vascular disease that cannot be corrected or reconstructed may require amputation, particularly in the case of diabetes (10).

### TRAUMA

Before the development of optical magnification and microsurgical technique, proximal arm replantation was accomplished with limited success (14). Application of microsurgical vascular and nerve repair has allowed successful replantation of more distally severed arms and fingers. Preservation of the arm or hand even with limited sensation or function is often superior to an insensate prosthetic limb. Specific indications for digit replantation have been developed as limitations in function of the replanted part have become better appreciated (6,8,24). Absolute and relative contraindications for limb replantation are listed in Table 121.1. Limb replantation at the transhumeral level is valuable in recovering function of the elbow in most patients; however, more distal recovery is less predictable. Replantation at this level may permit conversion of an above-elbow amputation to a below-elbow amputation, thereby improving rehabilitation potential and success of prosthetic use (22). Short residual limbs following traumatic amputation in selected individuals can be lengthened using bone distraction techniques (20).

*Absolute*
- Severe concomitant life-threatening injuries
- Severe crush of the limb
- Severe chronic illness
- Inability to tolerate surgery
- Inability to tolerate morbidity of replantation

*Relative*
- Older than 50 years
- Avulsion injuries
- Warm ischemia time greater than 12 hours
- Severe contamination
- Previous surgery or injury to the amputated part

From Kleinart HE, Jablon M, Tsai TM. An Overview of Replantation and Results of 347 Replants in 245 Patients. *J Trauma* 1980;20:390, with permission.

***Table 121.1. Contraindications to Replantation***

### BRACHIAL PLEXUS INJURY

Brachial plexus injury most commonly occurs in young men following motor vehicle accidents or industrial or farming injuries. The prognosis for recovery depends the location of the injury and its extent. Nerve root avulsions are not reparable but may be reconstructed with distal neurotization and muscle transfer, provided sufficient donors are available. Extensive, multilevel nerve root avulsions may result in a flail limb with little potential for recovery. Computed tomography contrast myelography, axon response to intradermal histamine, electromyography, somatosensory evoked potentials, and magnetic resonance imaging may be useful means to identify nerve injury location (11,15). Early repair and intraoperative nerve conduction and stimulation have been advocated to improve results of brachial plexus repair (9,15).

Signs of irreversible complete brachial plexus injuries include (17)

- Absence of any clinical return of function after 1 year
- Three or more pseudomeningoceles on myelography
- Absence of voluntary action potentials in the area of C-5 to T-1 on repeated electromyographic examinations

- Positive histamine tests in the area of C-5 to T-1

If an irreversible injury occurs, consider early above-elbow amputation and prosthetic rehabilitation. Within 3 to 6 months after a complete brachial plexus injury the patient becomes a “one-handed” person, transferring most activities from the injured limb to the normal limb. More effective rehabilitation and better prosthetic compliance have been achieved with early above-elbow amputation and prosthetic training, avoiding the development of single-hand function patterns (13,16,17). Upper-extremity amputation for intractable pain following brachial plexus injury is not successful in the majority of patients (3) (see Chapter 60).

### MALIGNANT MUSCULOSKELETAL TUMORS

The majority of bone and soft-tissue sarcomas in the upper extremity, excluding the hand, can be resected with wide margins that spare the limb without adversely affecting survival (18). Bone and soft-tissue reconstruction using tendon transfers, nerve and vein grafts, and free microvascular tissue transfer allow both functional and cosmetic reconstruction in the majority of cases. Tumors that cannot be resected without the sacrifice of multiple major nerves, or without excessive risk of local recurrence, usually require amputation. The level of amputation must provide margins that preclude local recurrence regardless of the functional impairment that results from a more proximal level of amputation. See Chapter 126 and Chapter 128.

## SURGICAL TECHNIQUES

### UPPER-EXTREMITY AMPUTATION

- Perform upper-extremity amputations at the most distal level compatible with uncomplicated wound healing. Handle soft tissues atraumatically.
- Sharply divide nerves and allow them to retract to provide adequate soft-tissue coverage. Avoid electrocautery in the vicinity of nerves.
- A tourniquet may be used; however, exsanguination is contraindicated in limbs being amputated for infection or tumor.

### BELOW-ELBOW AMPUTATION

If the vascular status of the limb is satisfactory, amputation at the most distal level provides the optimal stump for prosthetic use. If the vascular status of the limb is compromised, healing at the distal third of the forearm may be impaired owing to the lack of well-vascularized muscle deep to the subcutaneous tissue. A tourniquet may be used.

- Fashion equal anterior and posterior skin flaps (Fig. 121.1), and ligate the radial and ulnar arteries.

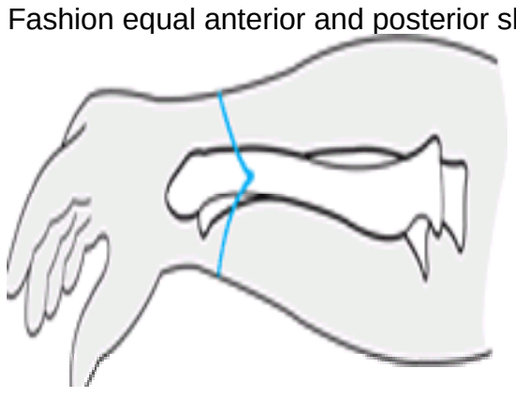

***Figure 121.1.*** A below-elbow amputation, demonstrating equal dorsal and volar flaps.

- Identify the major nerves (i.e., radial, ulnar, median), sharply divide them as far proximally as possible, and allow them to retract into the soft tissues.
- Section the radius and ulna proximal to the most proximal portion of the skin incision, and smooth the rough edges with a rasp or rongeur.
- Perform a myoplastic closure. If the amputation level is proximal to the myotendinous junction of the flexor and extensor tendons of the forearm, suture the palmar compartment muscles over the end of the bone to the extensor compartment.
- The most proximal level compatible with below-elbow prosthetic fitting is the level of the biceps tendon insertion on the radius. If circumstances require amputation at this level, releasing the distal 2.5 cm of the biceps tendon provides a longer stump for prosthetic fitting.
- If the level of amputation is in the distal one third of the forearm, bring the tendinous portion of the flexor digitorum superficialis over the end of the bone and suture it to the extensor compartment fascia.
- Obtain hemostatis. If necessary, use a drain. Close the wound without tension, and apply a bulky compressive dressing.

### ELBOW DISARTICULATION

Amputation through the elbow has the same advantages as a through-knee amputation in the lower extremity. The bulbous distal humerus allows suspension of a prosthesis. The long lever arm allows humeral rotation of the prosthesis, alleviating the need for the mechanical turntable required in more proximal brachial amputations. However, the soft tissue is thin at the elbow, and fitting of the prosthesis must be exact.

- A sterile tourniquet may be used. Fashion equal anterior and posterior flaps, with the posterior flap extending to a point 2.5 cm distal to the olecranon and the anterior flap extending to the biceps insertion on the radius.
- Ligate the brachial artery. Sharply divide the radial, ulnar, and median nerves proximally. Allow them to retract into soft tissue.
- Disarticulate the elbow by dividing the insertion of the biceps (i.e., radius) and the insertion of the brachialis (i.e., ulna) anteriorly and by dividing the triceps tendon at its olecranon insertion. Release the medial flexor and pronator mass from the medial epicondyle, and divide the extensors from the lateral humeral epicondyle.
- Perform an anterior capsulotomy, and remove the forearm, leaving the articular surface of the distal humerus intact.
- Bring the triceps tendon anteriorly and suture it to the tendons of the biceps and brachialis muscles over the trochlea of the humerus. Place a drain and close the wound without tension. Apply a bulky compressive dressing.

### ABOVE-ELBOW AMPUTATION

To allow fitting of an above-elbow prosthesis, which includes an elbow lock mechanism for flexion and extension and an elbow turntable for rotation, perform above-elbow amputations 3.8 cm proximal to the joint. Amputation at the level of the surgical neck of the humerus functions as a shoulder disarticulation; however, this level has the cosmetic advantage of preserving normal shoulder contour.

#### *Midarm Amputation*

- For amputations through the midbrachium (Fig. 121.2), fashion equal anterior and posterior flaps.

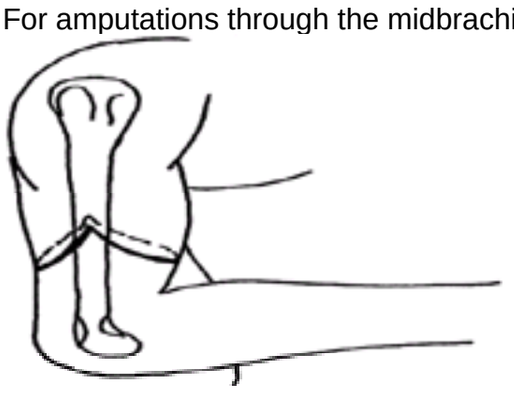

***Figure 121.2.*** An above-elbow amputation using equal anterior and posterior flaps.

- Identify and ligate the brachial artery.
- Divide the anterior compartment muscles approximately 1.3 cm distal to the intended level of bone transection. Divide the triceps 5 cm distal to the intended level of bone transection.
- Section the humerus and smooth its rough edges with a rasp.
- Perform a myoplastic closure, suturing the anterior compartment muscles to the triceps. Close the wound without tension over a drain. Apply a bulky compressive dressing.

***Proximal Third Amputation***

- For amputations through the surgical neck of the humer us, make an incision anteriorly from the coracoid process along the anterior border of the deltoid to the lateral insertion of the deltoid on the humerus. Extend the incision posteriorly along the posterior margin of the deltoid to the posterior axillary fold, and connect the two incisions by an axillary incision.
- Ligate the cephalic vein. Release the deltoid muscle from its humeral insertion, and reflect it proximally. Release the pectoralis major muscle from its humeral insertion, and reflect it medially (Fig. 121.3).

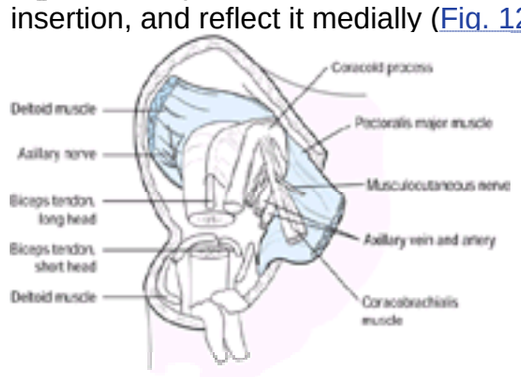


***Figure 121.3.*** A proximal humeral amputation using the anterior approach.

- Identify the neurovascular bundle, and ligate the axillary artery. Sharply divide the musculocutaneous, median, ulnar, and radial nerves, and allow them to retract proximally.
- Divide the teres minor and latissimus dorsi muscles close to their humeral insertion. At a point approximately 2 cm distal to the intended bone section, divide the coracobrachialis and biceps muscles, and reflect them distally.
- Amputate the humerus at the surgical neck. Suture the biceps and coracobrachialis muscles to the triceps muscle over the stump of bone. Trim the deltoid laterally, and suture it medially. Place appropriate drains, and close the skin without tension.

**AMPUTATIONS ABOUT THE SHOULDER**

Amputations about the shoulder, which include shoulder disarticulation and the forequarter or scapulothoracic amputation, are performed almost exclusively for tumors (2). A functional prosthesis is not available for these amputations. The Tikhor–Lindberg resection is performed for malignant tumors of the shoulder girdle if there is no involvement or limited tumor involvement of the neurovascular bundles. This resection resects the proximal humerus, scapula, and clavicle but preserves the brachium and distal arm (7). The anterior approach for forequarter amputation has the advantage of allowing early control of the major vessels under optimal visualization, whereas the posterior approach may be advocated due to the progressively improved exposure obtained while the weight of the arm acts to retract the major soft-tissue mass.

**SHOULDER DISARTICULATION**

- Begin an anterior incision at the coracoid process, and proceed distally along the anterior margin of the deltoid to its humeral insertion (5). Continue posteriorly along the posterior margin of the deltoid, and connect the anterior incision with a posterior incision across the axilla.
- Identify the neurovascular bundle in the interval between the coracobrachialis and the short head of the biceps, and ligate and divide the axillary artery and vein. Sharply divide the median, ulnar, and musculocutaneous nerves, and allow them to retract into soft tissue.
- Detach the deltoid from its humeral insertion, and retract it along with its overlying skin proximally. Release the coracobrachialis and short head of the biceps from their origin from the coracoid, and release the humeral insertion of the pectoralis major.
- Externally rotate the arm, and divide the anterior joint capsule and subscapularis muscle. Internally rotate the arm, and divide the short external rotators and the teres major.
- Divide the triceps and inferior capsule, and remove the arm.
- Suture the muscle ends into the glenoid to fill dead space. Bring the deltoid with its overlying skin inferiorly, and suture it inferior to the glenoid to the margin of the posterior axilla incision, completing the procedure.

**SCAPULOTHORACIC DISARTICULATION**

- Begin the incision lateral to the clavicular insertion of the sternocleidomastoid muscle, and extend the incision distally along the clavicle to the acromioclavicular joint over the acromion to the spine of the scapula and posteriorly along the vertebral border of the scapula (5,7).
- Begin the lower incision at the middle third of the clavicle. Proceed distally to the deltopectoral groove and cross the axilla horizontally, and join the first incision posteriorly at the spine of the scapula.
- Release the pectoralis major from the clavicle, and divide the clavicle lateral to the insertion of the sternocleidomastoid. Excise the clavicle to the level of the acromioclavicular joint.
- If necessary, ligate the external jugular vein and release the pectoralis major and minor from their insertions, exposing the neurovascular bundle.
- Ligate and divide the subclavian artery and vein. Section the components of the brachial plexus, and allow them to retract.
- Release the latissimus dorsi and axillary fascia from the humerus, allowing the limb to fall posteriorly. Hold the arm across the chest, and from superiorly to inferiorly divide the remaining muscles that fix the shoulder to the scapula. Divide the muscles that hold the scapula to the thorax, starting with the trapezius and continuing through the omohyoid, levator scapulae, rhomboid major and minor, and serratus anterior.
- Remove the arm and scapula.
- Suture the remaining muscle over the lateral chest wall, and close the skin flaps over suction drainage.

**RESECTION REPLANTATION**

- Resection replantation has been described by Windhager et al. (21) and is analogous to a Van Ness rotation plasty of the lower limb.
- Resect the tumor-bearing portion of the arm as a cylindric segment, including prior biopsy sites and all contaminated structures.
- Dissect uninvolved vessels or major nerves from the tumor-bearing segment through longitudinal incisions, if this can be done with wide margins (21).
- Accomplish reconstruction by limb shortening, osteosynthesis, and vascular, nerve, and soft-tissue repair. This is an effective procedure for malignant tumors that offers an alternative to amputation in carefully selected patients.

## POSTOPERATIVE CARE AND REHABILITATION

After surgery, a patient with an upper-extremity amputation may be treated with a rigid dressing and early prosthetic fitting, as described by Burkhalter (4). Approximately 50% of upper-extremity adult amputees are rehabilitated with functional prosthetics (23). Before initiating prosthetic fitting and training, consider the age, extremity dominance, occupation, and psychosocial status of the patient (12,13). Bilateral upper-extremity adult amputees should be fitted with at least one functional prosthesis, usually one that is externally powered.

There are two major categories of upper-extremity prostheses. The conventional body-powered prosthesis relies on proximal shoulder girdle muscles to provide the force to power a terminal grasp device through a system of harness and cables. Depending on the level of amputation, the elbow and wrist “joints” must be positioned manually by the contralateral normal limb. Myoelectric prostheses rely on electrical potentials in active muscles in the stump to activate electrodes in the prostheses,

which switch electrical motors on and off within the device. These prostheses are expensive, heavy, and require frequent maintenance.

Regardless of the type of prosthesis used, the timing of initial prosthetic fitting determines the ultimate success of rehabilitation. Malone demonstrated in a series of upper-extremity amputees that prosthetic fitting within 1 month of amputation resulted in a 93% success rate of prosthetic rehabilitation (26 of 28 patients) (12,13). Among upper-extremity amputees fitted later than 1 month after amputation, only 42% (9 of 19) achieved prosthetic rehabilitation. Although advocates of rigid postoperative dressings note higher rates of early prosthetic use, their use should be limited to those patients with normal sensation and well-vascularized soft tissues that have not been injured by trauma.

## CHAPTER REFERENCES

Each reference is categorized according to the following scheme: *, classic article; #, review article; !, basic research article; and +, clinical results/outcome study.


# 1. Baumgartner R. The Surgery of Arm and Forearm Amputation. *Orthop Clin N Am* 1981;12:805.

+ 2. Bhagia SM, Elek EM, Grimer RJ, et al. Forequarter Amputation for High-Grade Malignant Tumours of the Shoulder Girdle. *J Bone and Joint Surg* 1997;79B:924.

+ 3. Bruxelle J, Travers V, Thiebaut JB. Occurrence and Treatment of Pain After Brachial Plexus Injury. *Clin Orthop* 1988;237:87.

* 4. Burkhalter WE, Mayfield G, Carmona LS. The Upper-Extremity Amputee: Early and Immediate Post-surgical Prosthetic Fitting. *J Bone Joint Surg* 1976;58A:46.

# 5. Clippinger FW. Amputations and Limb Substitutions. In: Sabiston D, ed. *Textbook of Surgery,* 13th ed. Philadelphia: WB Saunders, 1986:1488.

# 6. Jager SH, Tsai TM, Kleinert HE. Upper Extremity Replantation in Children. *Orthop Clin North Am* 1981;12:897.

* 7. Janecki CJ, Nelson CL. En Bloc Resection of the Shoulder Girdle: Technique and Indications. *J Bone Joint Surg* 1972;54A:1754.

# 8. Kleinert HE, Jablon M, Tsai TM. An Overview of Replantation and Results of 347 Replants in 245 Patients. *J Trauma* 1980;20:390.

+ 9. Kline DG, Judice DJ. Operative Management of Selected Brachial Plexus Lesions. *J Neurosurg* 1983;58:631.

+ 10. Lagaard SW, McElfresh EC, Premer RF. Gangrene of the Upper Extremity in Diabetic Patients. *J Bone Joint Surg* 1989;71A:257.

# 11. Leffert R. Lesions of the Brachial Plexus Revisited. *Instr Course Lect* 1989;38:245.

+ 12. Malone J, Fleming L, Robertson J, et al. Immediate, Early, and Late Postsurgical Management of Upper-Limb Amputation. *J Rehabil Res Dev* 1984;21:33.

+ 13. Malone JM, Leal, JM, Underwood CPJ, Childers SJ. Brachial Plexus Injury Management Through Upper Extremity Amputation with Immediate Postoperative Prostheses. *Arch Phys Med Rehabil* 1982;63:89.

* 14. Malt RA, McKhann CF. Replantation of Severed Arms. *JAMA* 1964;189:114.

* 15. Marshall RW, DeSilva RDD. Computerised Axial Tomography in Traction Injuries of the Brachial Plexus. *J Bone Joint Surg* 1986;68B:734.

+ 16. Ransford AO, Hughes SPF. Complete Brachial Plexus Lesions: A Ten Year Follow-up of Twenty Cases. *J Bone Joint Surg* 59B:417, 1977.

+ 17. Rorabeck CH. The Management of the Flail Upper Extremity in Brachial Plexus Injuries. *J Trauma* 1980;20:491.

* 18. Rosenberg SA, Kent H, Costa J. Prospective Randomized Evaluations of the Role of Limb-Sparing Surgery, Radiation Therapy and Adjuvant Chemoimmunotherapy in the Treatment of Adult Soft Tissue Sarcomas. *Surgery* 1978;84:62.

* 19. Slauterbeck JR, Britton C, Moneim MS, Clevenger FW. Mangled Extremity Severity Score: An Accurate Guide to Treatment of the Severely Injured Upper Extremity. *J Orthop Trauma* 1994;8:282.

+ 20. Stricker SJ. Ilizarove Lengthening of a Posttraumatic Below Elbow Amputation Stump: A case report. *Clin Orthop* 1994;306:124.

* 21. Windhager R, Millesi H, Kotz R. Resection-Replantation for Primary Malignant Tumours of the Arm: An Alternative to Fore-quarter Amputation. *J Bone Joint Surg* 1995;77B:176.

+ 22. Wood MB, Cooney WP. Above Elbow Limb Replantation. Functional Results. *J Hand Surg* 1986;11A:682.

+ 23. Wright TW, Hagen AD, Wood MB. Prosthetic Usage in Major Upper Extremity Amputations. *J Hand Surg* 1995;20A:619.

# 24. Zhong-Wei C, Meyer VE, Kleinert HE, Beasley RW. Present Indications and Contraindications for Replantation as Reflected by Long-Term Functional Results. *Orthop Clin North Am* 1981;12:849.

# CHAPTER 122

# PRINCIPLES OF AMPUTEE PROSTHETICS

*Patricia G. Rossbach, Michael A. Joyce,*
*Eric Schaffer, and Joseph M. Lane*

**P. G. Rossbach, M. A. Joyce, and E. Schaffer:** The Joyce Center for Prosthetics and Rehabilitation, Manhasset, New York 11030.
**J. M. Lane:** Department of Orthopaedic Surgery, Weill Medical College of Cornell University; Metabolic Bone Disease Service, Hospital for Special Surgery, New York, New York 10021.

Lower-Extremity Amputations
- Amputation Site Versus Function
- Preprosthetic Care
- Immediate Postoperative Prosthesis
- Rationale for a Preparatory Prosthesis
- Prosthetic Fitting and Alignment
- Rehabilitation and Training
- Gait Analysis

Upper-Extremity Amputations
- Amputation Site Versus Function
- Preprosthetic Care
- Immediate Postoperative Prostheses
- Prosthetic Fitting
- Rehabilitation and Training

Pitfalls and Complications
- Skin Problems
- Choke Syndrome
- Pain
- Contractures
- Psychosocial Maladjustment

Resources
Chapter References

A prosthesis cannot come close to replacing a missing limb from either a functional or a cosmetic viewpoint. In the last decade, however, modern technology and improved materials have closed the gap considerably (1,3,4,11). The result is that motivated individuals with no additional health problems can now expect to regain a degree of function that will allow them to pursue an active life style of their choice. Limitation of the maximum performance possible should not be a consequence of either an inadequate prosthesis or negative expectations of the health care providers. Patients' cooperation and positive attitude are critical.

To regain an active life style, patients must be educated about the operative procedure, receive psychosocial support, be fitted with a comfortable prosthesis, and engage in aggressive rehabilitation. Good communication between members of the health care team and patients cannot be emphasized strongly enough. Encouragement and positive reinforcement go a long way toward helping patients achieve their goals (see Chapter 120 and Chapter 121 for discussion of the principles of lower- and upper-extremity amputations, respectively).

## LOWER-EXTREMITY AMPUTATIONS

### AMPUTATION SITE VERSUS FUNCTION

Some of the older rules for limb length no longer apply in determining the level of amputation for prosthetic fit (12,13,17). For instance, when a lower-limb prosthesis is fitted, adequate length of the residual limb plus modern components can often result in significantly better function than an amputation that results in a longer lever arm with the use of more basic and primitive components (16,18).

#### *Partial Foot Amputation*

The main advantage of a partial foot amputation is the ability to walk without a prosthesis. The disadvantages at this site include the difficulty in making a cosmetic prosthesis with “toe off” function, the uneven gait that results without toe-off function, the tendency to develop an equinovarus deformity in the residual foot stump, and the limited foot components available (Fig. 122.1).

***Figure 122.1.*** **A:** Midfoot amputation with a shoe insert prosthesis. **B:** An ankle–foot prosthesis for amputations through the hindfoot other than a Syme's amputation. (From Dee R, Mango E, Hurst LC. *Principles of Orthopaedic Practice.* New York: McGraw-Hill, 1989:365, with permission.)

#### *Syme's Amputation*

Syme's amputation retains the heel pad. The advantage of this technique is that limited ambulation is possible without a prosthesis. Its disadvantages include a less cosmetic prosthesis due to the thick ankle required to accommodate the stump, the limited foot components available, and the limited amount of energy storage within these components (Fig. 122.2).

***Figure 122.2.*** Syme's prosthesis with posterior cutout for donning the prosthesis. (Courtesy of the Joyce Center, Manhasset, NY.)

#### *Transtibial Amputation*

In elective surgery where the amputation site can be selected, it is preferable to have enough space distally to incorporate appropriate prosthetic components for best function and cosmesis, while maintaining adequate length of the residual limb. Ideally, the length of tibia from the mid-knee joint to the distal end should be no less than 4 in. (10 cm) and no more than 7 in. (17.75 cm). If the tibia is too long, the choice of components is limited and cosmesis may be compromised. The space from the floor to the end of the residual limb (after the incision is closed) should be at least 12 in. (30.5 cm), but not if it will leave the length of the tibia less than 4 in. (10 cm).

#### *Through-the-knee Amputation*

Through-the-knee amputation provides the potential of end bearing in the prosthesis, a long lever arm, and condylar suspension. A knee disarticulation is particularly good for patients with poor gait and neuromuscular control. It is important in children with growth potential who need their distal femoral epiphysis to retain stump length. The disadvantages of this technique include the limited knee components available (including a button rotator), the differences in the center of rotation of the two knees, poor cosmesis due to the large femoral condyles, and atrophy of the thigh that occurs with condylar suspension. High-performance function is better achieved with a long transfemoral amputation and a prosthesis with modern knee components.

#### *Transfemoral Amputation*

When there is a choice of amputation site, a space of 4 in. (10 cm) from the knee center to the distal end of the residual limb is optimum, as long as this is not greater than one-third the length of the femur. This space permits a greater choice of knee and other components, and function and cosmesis are improved (Fig. 122.3).

***Figure 122.3.*** A transfemoral socket shows a valve hole and one-way valve for suction application. This is a transfemoral prosthesis with a button rotator, hydraulic swing-stance knee, and carbon-composite ankle–foot system with shock-absorbing pylon. (Courtesy of the Joyce Center, Manhasset, NY.)

#### *Hip Disarticulation and Hemipelvectomy Amputation*

Lightweight components and flexible buckets/sockets have improved comfort and reduced the workload of patients wearing these types of prostheses (Fig. 122.4).



***Figure 122.4.*** Endoskeletal prosthesis with foam cover for a hip disarticulation. (Courtesy of the Joyce Center, Manhasset, NY.)

## PREPROSTHETIC CARE

The goals after surgery for lower-extremity amputations in which there is a residual limb are listed in Table 122.1. These can be achieved through one of several methods: an immediate postoperative prosthesis or serial wrapping of the residual limb with an elastic bandage or an elastic shrinker. The overall aim is to reduce postsurgical edema. This in turn reduces postsurgical pain, minimizes later phantom pain, increases circulation (therefore hastening healing), and prepares the operative site and residual limb for a preparatory prosthesis. Where possible, elevation of the affected limb can also help reduce edema, although this must be accompanied by immediate aggressive physical therapy to prevent contractures of the surrounding joints. When there is no residual limb, the postsurgical goals are fewer (Table 122.1). Methods to reduce postoperative edema and prevent breakdown of the incision in patients include turning the patient onto the sound side and early mobilization.

| *With residual limb* | *Without residual limb (hip disarticulation or hemipelvectomy)* |
|---|---|
| Promote wound healing | Promote wound healing |
| Reduce postsurgical edema | Reduce postsurgical edema |
| Mold the residual limb | Maintain muscle strength in unaffected limbs |
| Prevent flexion contractures in the surrounding joints | Maintain body symmetry |
| Maintain muscle strength in the affected limb | |
| Maintain muscle strength in the unaffected limb | |
| Maintain body symmetry | |

***Table 122.1. Goals of Preprosthetic Care***

**IMMEDIATE POSTOPERATIVE PROSTHESIS**

An immediate postoperative prosthesis (IPOP) is a specialized dressing covered by a plaster cast molded to provide weight-bearing areas to enable patients to ambulate as soon as it is practical. The IPOP incorporates an adapter into its distal end that has a removable pylon with a prosthetic foot attached.

An IPOP is intended to control edema, promote ambulation, and prevent flexion contractures, as well as to keep patients from “waking up without a leg.” The prosthetist applies a specially padded and molded cast in the operating room after the surgical dressings have been applied. The advantage of this technique is that the cast initially prevents postsurgical edema, promoting wound healing and reducing pain. The cast also protects the residual limb, prevents flexion contractures in the surrounding joints, and molds the residual limb while compression is maintained. The difficulties with this technique are that the cast loosens as soon as the edema subsides and the subsequent pistoning action can cause tissue breakdown. The cast must either be continually replaced or be removable so that additional socks or fillers can be used to maintain compression. Other difficulties involve the heaviness of the cast, which prevents movement of the contained joints, impedes walking, and leads to muscle atrophy. The cast must be removed to monitor wound healing, frequently needs to be reapplied to contain compression, and is not cosmetic. Auxiliary suspension may be required (Fig. 122.5).

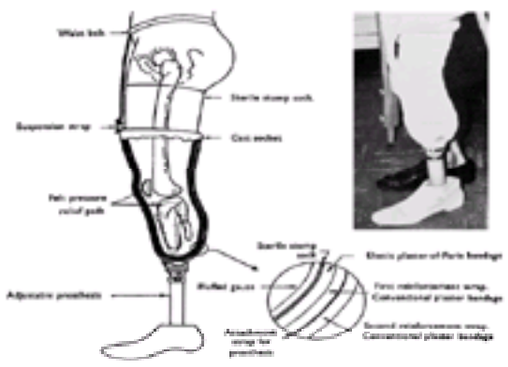

***Figure 122.5.*** IPOP after a below-knee amputation. Surgical dressings are applied first. The prosthetist then rolls a stump sock into place, pads the end of the stump and bony prominences with specially designed cushioning materials, and applies a well molded plaster cast that incorporates the knee, with a hole left for the patella, and extends up to the mid thigh. This is held in place by a suspension strap hooked to the stump sock and tied to a band around the waist. A connection for a pylon is incorporated into the end of the cast. The pylon is applied postoperatively when the patient is ready to be mobilized. (From Fulford GE, Hall MJ. *Amputation and Prostheses.* Philadelphia: Williams & Wilkins Co.: 14, with permission.)

The advantage of an elastic compression bandage is that it can be reapplied whenever it becomes loose and therefore compression can be kept constant. Patients can be taught to wrap the limb, and compression can be applied only in areas where it is needed (Fig. 122.6 and Fig. 122.7). The problem with a compression dressing is that it may be wrapped too tightly, causing pain or tissue breakdown, or too loosely to be effective. Patients may have difficulty wrapping it themselves, and it may cause window edema when applied incorrectly or unevenly.

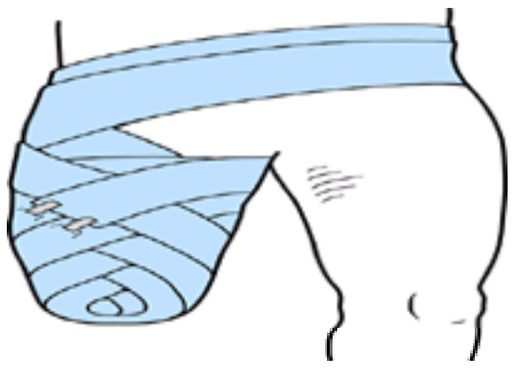

***Figure 122.6.*** Figure-eight wrap for a transfemoral amputation. The wrap is applied around the stump and subsequently around the waist, progressing from distal to proximal. The dressing is gently wrapped to avoid overconstriction, and more compression is applied distally than proximally.

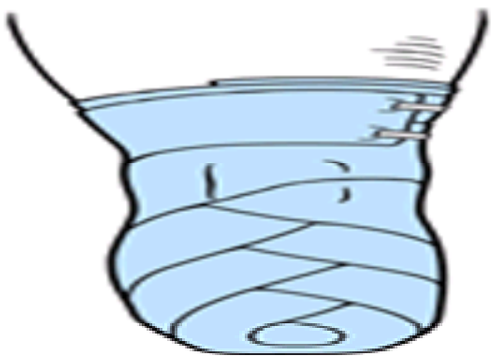

***Figure 122.7.*** Figure-eight elastic wrap for a below-knee amputation. The wrap is applied, progressing from distal to proximal, with the pressure graduated so that more compression is provided distally. The bandage should not be applied too tightly.

Elastic shrinkers, when applied correctly, provide overall compression and allow wound monitoring. They may be difficult to apply correctly in some individuals,

however, and may not put direct pressure over areas where it is needed (Fig. 122.8).

***Figure 122.8.*** Elastic shrinker for a transfemoral residual limb. (Courtesy of the Joyce Center, Manhasset, NY.)

The choice of these various techniques depends on the ability and cooperation of a patient, the length of the limb, and careful evaluation of the goals for the individual.

Secondary goals include the maintenance of range of motion in the surrounding joints (hip and knee), prevention of muscle atrophy, and elimination of pain. To achieve these, physical and occupational therapy consisting of range-of-motion, stretching, and strengthening exercises should be initiated as soon as possible. An early fit of the prosthesis will be beneficial.

## RATIONALE FOR A PREPARATORY PROSTHESIS

A preparatory prosthesis is fitted to a patient while the amputated limb undergoes normal maturational shape changes after surgery. Fitting should be started after the sutures or staples have been removed and the incision has healed.

In the lower limb, the primary purposes of a preparatory lower-extremity prosthesis include controlling postsurgical edema, minimizing the loss of muscle mass and strength, preventing joint contractures, and allowing patients to ambulate. Historically, preparatory prostheses were made with the simplest components, worn with prosthetic socks, and suspended with straps and belts. To accommodate postsurgical shrinkage and muscle atrophy of the residual limb, the ply of the socks was increased until the size of the limb stabilized, at which time the definitive prosthesis would be fabricated. However, new socket materials and designs, along with modern components and more aggressive training, promote the use of remaining muscle so that after postsurgical edema has subsided, there is often little or no muscle atrophy. If appropriate for an individual, one of several types of suction suspension can often be used as soon as the incision is completely healed, replacing the socks and belts. With the use of more sophisticated components, correct gait can be taught immediately to avoid retraining once the definitive prosthesis has been fit.

After the socket is carefully fitted and fabricated and the components are aligned, patients should be taught how to use the prosthesis. Limit ambulation to partial weight bearing, and check the residual limb frequently; graduate to total weight bearing as tolerated. How long this takes will depend on the fit of the prosthesis, as well as the strength, coordination, ability, and determination of the patient.

Although the residual limb will continue to mature and change shape for the lifetime of individuals, the most dramatic changes occur during the first 3–6 months. Constantly monitor and modify the socket, or change the sock ply to accommodate these changes to maintain fit. Make patients aware that this is quite normal. The definitive prosthesis is fabricated once these changes have stabilized.

## PROSTHETIC FITTING AND ALIGNMENT

When fitting a first prosthesis, the prosthetic team thoroughly examines a patient and evaluates the medical history. A detailed explanation of the process of prosthetic fitting, preferably accompanied by written materials, is given to the patient. A prescription recommendation is sent to the referring physician by the prosthetist with a request for a letter of medical necessity. The primary concerns are comfort, function, and cosmesis. The prescription recommendations depend on the patient's age, previous activity level, hoped-for outcome, length of residual limb, medical history, and reimbursement limitations. The prescription should include type of prosthesis (endoskeletal versus exoskeletal), type of suspension, socket design, materials, choice of components, and cosmetic finish.

The comfort of the socket is always the primary concern and depends on the skill of the person taking the measurements or the impression of the residual limb, as well as on the materials used. Initially, measurements are taken, and a negative wrap of the residual limb (or digitized equivalent; see below) is made. A positive model is produced from the impression and modified, and a clear diagnostic socket is formed over that mold. The diagnostic socket is fitted to the residual limb, the fit is checked, and any indicated changes are made to the positive model, with refitting of the socket if necessary. A flexible, total-contact socket is formed within a rigid frame, and the chosen components are aligned so that the foot, knee joint, and so on are in a neutral alignment. The prosthesis is then fitted and dynamically aligned, and initial gait training is performed while the alignment is fine-tuned. After the prosthesis is delivered to the patient for trial use, a protective cosmetic cover is fabricated, and further alignment and fitting changes are made, as necessary, on the basis of continued functional examination.

Although the majority of prosthetists take a cast of the residual limb and manually modify the positive mold to fabricate a socket, an alternative method is the computer-aided design/computer-aided manufacturing (CAD/CAM) system. With this system, information on the residual limb is converted into numerical data, read into the computer by a digitizer (usually from a negative mold), and converted into a three-dimensional image by commercially available software. Modifications to this image are made by the prosthetist; the information is then relayed to the attached carver, which produces the positive model. Thereafter, the processes are similar regardless of whether the manual or the CAD/CAM method is used: A hard, clear diagnostic socket is formed over the model and then fitted on the residual limb. Weight-bearing surfaces and bony or sensitive areas are checked, and any necessary modifications are made to the diagnostic socket before the definitive one is fabricated.

Once the components have been assembled and bench-aligned, a dynamic alignment must be done with the patient wearing the prosthesis. There are two schools of thought concerning alignment: According to one school, the prosthesis is aligned to accommodate any abnormalities in posture, such as flexion contracture, whereas with the second gradual corrections in alignment are made simultaneously with aggressive rehabilitation of the patient, until a more correct alignment can be obtained.

Frequent follow-up visits are necessary after delivery of the prosthesis to make the corrections and adjustments that will inevitably be needed as a patient progresses. It is important that patients understand that this is a normal process and that a plateau will eventually be reached where it will only be necessary to have routine check-ups, unless a new prosthesis needs to be fabricated. They must be informed of the importance of maintaining a stable body weight and a regular exercise program. Excessive gain or loss of weight compromises fit and function of a prosthesis. Many of today's components are designed for a weight range or activity level.

### *Endoskeletal versus Exoskeletal Prostheses*

A endoskeletal prosthesis is made with an internal skeleton of components and a foam outer cosmesis (Fig. 122.9). It is modular in design, thus permitting greater interchangeability. The advantages of the endoskeletal are that changes in alignment can be made with ease at any time during the life of the prosthesis to accommodate changes in posture, gait, or growth. In the modular design, individual components can be changed without remaking the prosthesis. The problems with this technique are that it is more expensive and may require more maintenance.



***Figure 122.9.*** Endoskeletal type of prosthesis, without socket. A Flex-Foot, Inc. prosthetic foot has a shank component composed of carbon fiber epoxy. This prosthesis stores energy during the stance phase and returns it to the amputee for push-off. A foam cover will be added for cosmesis.

The exoskeletal prosthesis is often made of wood or polyurethane with a laminated rigid outer shell (Fig. 122.10). Once fabricated, it has limited adjustability without being refabricated. It is less expensive and has a more durable cover than the endoskeletal type. Its disadvantages include no postdelivery accommodation–alignment changes, limited dynamic response capability, and limited component choices. In addition, it is frequently heavier than the endoskeletal prosthesis.

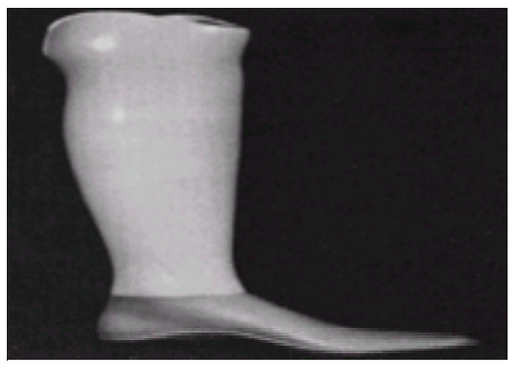

***Figure 122.10.*** Exoskeletal type of below-knee prosthesis. This patellar tendon–bearing type of below-knee prosthesis has a Pelite liner and supracondylar suspension. (From D'Astous J, ed. *Orthotics and Prosthetics Digest.* Canada: Edahl Productions Ltd., 1981:113 with permission.)

Suspension can be achieved with suction or a sleeve, belt, or cuff strap. The suction technique aims to reduce pistoning in the socket, thus requiring less energy expenditure during ambulation (Fig. 122.11). It promotes venous return and gives patients the feeling that the prosthesis is lighter. In addition, it eliminates the need for uncomfortable belts and straps.

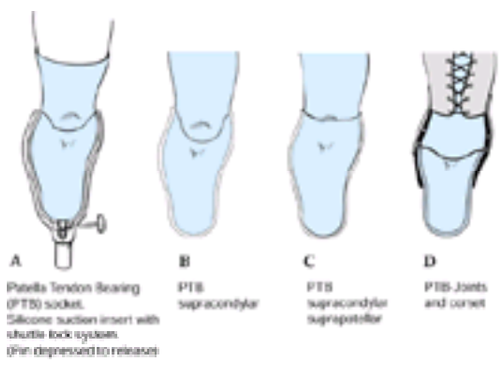


***Figure 122.11.*** Types of suspension for transtibial amputees. **A:** Traditional patellar tendon–bearing (PTB) total-contact socket with a silicone socket suspension system in which the suction unit attaches to the socket by a shuttle-lock system. If this is not used, a supracondylar suspension strap can be added. **B:** PTB supracondylar prosthesis. **C:** PTB supracondylar/suprapatellar socket. **D:** PTB prosthesis incorporating side hinges and joints with a thigh corset.

In the transfemoral amputation suction application, the residual limb is drawn into the socket with an elastic bandage or a type of pull sock until the air is displaced through the distal valve hole; a one-way valve is placed in the valve hole to prevent air from reentering the socket (Fig. 122.3). Although it seems easier to lubricate the residual limb and push it into the socket, the result is hammocking (stretching) of tissues on the distal end and failure to get all the proximal tissue into the socket.

In transfemoral or transtibial amputations, one of several silicone or gel liners with a distal locking mechanism can be used. These are rolled up onto the residual limb, with the liner holding onto it; and the distal locking mechanism attaches mechanically to the prosthesis, creating an alternative suction fit.

The sleeve technique is used for transtibial application. The distal end of the sleeve fits over the proximal portion of the prosthesis. The proximal end of the sleeve is then pulled up over the knee onto the patient's thigh. It can act as a suction device if it is made of nonporous material.

The belt suspension is used in transfemoral and transtibial applications when suction suspension is not an option. It can be used in conjunction with a socket interface, socks, or silicone gel liner that has no locking mechanism.

The supracondylar cuff strap in used for transtibial applications when suction is not an option. It is sometimes used in conjunction with a waist belt.

***Socket Design***

The shape and fit of the socket is the single most important factor in a successful outcome. Today's sockets are designed to fit more anatomically and to provide total contact with the residual limb. Increased suction on the distal end of the residual limb, due to lack of contact, results in verrucous hyperplasia, if left uncorrected. Under extreme circumstances, this can lead to localized infection or cellulitis.

The sockets are usually made of flexible plastic and surrounded by a rigid frame to support the weight-bearing areas. The quadrilateral socket for the transfemoral amputee is being replaced by one of several versions of ischium-containing designs. Containment of the ischium within this type of socket provides pelvic stability and promotes more normal femoral alignment and better function of the remaining intact musculature. Proprioception is also increased.

It is now possible to make more comfortable sockets for higher transfemoral, hip-disarticulation, or hemipelvectomy amputations. The bucket socket is made of laminated silicone or flexible plastic supported by a rigid frame (Fig. 122.4). The new families of silicone or gel socket liners have improved the comfort of sockets.

***Choice of Components***

Components that improve the comfort and function of the prosthesis should be used. It is our opinion that the more debilitated a patient is, the greater is the need for

help from the prosthesis. The question posed should be, “What can we provide to make walking easier and more efficient for a person?” rather than making the assumption that this person is not “a candidate for ambulation.” The components requiring consideration are the hips, the knees, and the feet.

The hip joints are limited to single-axis joints with an extension assist.

Several types of knee joints are available. The single-axis, constant-friction knee is the simplest design. The main drawback for this component is that ambulation is normal only at one speed for a set amount of friction. The safety knee with constant friction is designed so that the patient's weight locks the knee in the standing position. The polycentric knee joint has hinges external to the prosthesis and was originally designed for through-the-knee prostheses. It provides better control during standing and the stance phase of gait. The swing phase may be controlled mechanically or with a hydraulic cylinder. Hydraulic knee joints, which are the most sophisticated on the market to date, control both swing and stance phase and are velocity-sensitive. Table 122.2 specifies the indications for use of the various types of prostheses, together with advantages and disadvantages.

| Type | Typical patient | Advantages | Disadvantages |
|---|---|---|---|
| Single-axis, constant-friction | Sedentary<br>Poor access to maintenance | Inexpensive<br>Durable<br>Easy to maintain<br>Lightweight | No swing-phase control<br>Gait optimal at only one speed<br>Little inherent knee stability |
| Safety knee (weight-activated swing-phase control) | Elderly/Weak<br>Neurologic compromise | Inexpensive<br>Durable<br>Provides stability of the knee at heel strike and during stance | No swing-phase control<br>Gait optimal at only one speed<br>Sacrifices flexibility for safety and stability |
| Polycentric four-bar knee joint | Knee disarticulation amputation | Can be less expensive<br>Can incorporate hydraulic swing-phase control<br>Stable<br>Required for knee disarticulation<br>Inherent stability | Bulky<br>Poorer cosmesis<br>Increased weight<br>More frequent maintenance |
| Hydraulic or pneumatic swing-phase control | Active, young patients<br>Access to maintenance facility | Best swing-phase control<br>Adapts to speed of cadence<br>Best gait pattern<br>Normal phase | Expensive<br>More frequent and expensive maintenance<br>Heavier<br>Bulky |
| Manual locking knee | Elderly/weak<br>Unstable | Maximum stability<br>Very light | Unnatural gait<br>Must be unlocked to sit |

***Table 122.2. Knee Joints for Above-Knee Prosthesis***

The prosthetic ankle–foot systems comprise several main groups: articulated ankle joints, dynamic-response and energy-storing foot, and nondynamic-response and/or energy-storing feet. The simplest and cheapest combination is the nonarticulated ankle and the nondynamic-response foot, called the solid ankle-cushion heel (SACH) foot; it is also the least efficient.

The combination of a solid ankle and a dynamic-response foot allows maximum loading of the toe section of the foot during “rollover.” Similar to the action of a coiled spring, when the pressure or loading is removed, the toe section springs back to provide push-off. The most extreme version of this is found in a foot–ankle and shank made of carbon fibers, in which the loading action or energy storage is also carried out in the shank. The method of loading the toe must be taught, or the benefits will not be experienced. In fact, users may complain that the toe is too stiff, and reject the foot.

An articulated ankle joint, useful for people who spend considerable time walking on uneven ground, is heavier than other prosthetic feet and requires more maintenance. An added disadvantage is that even if it is combined with a dynamic-response foot, the action of the ankle precludes loading the toe to provide push-off. The various options for lower-extremity prosthetic components are shown in Figure 122.12.

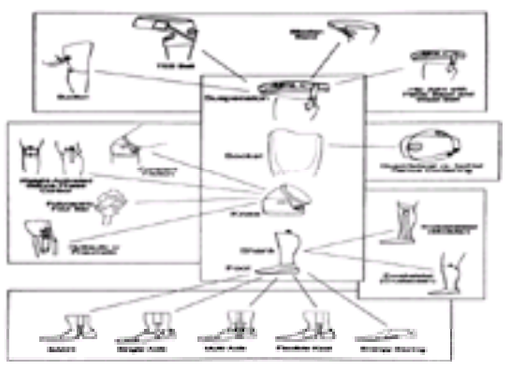

***Figure 122.12.*** Choice of components for the transfemoral amputee. (From Braddon RL. *Physical Medicine and Rehabilitation.* Philadelphia: W.B. Saunders, 1996:307, with permission, University of Texas Health Science Center at San Antonio.)

**REHABILITATION AND TRAINING**

A successful outcome depends as much on rehabilitation and training as it does on the fabrication and fitting of a prosthesis. Studies show that energy expenditure during ambulation is higher for amputees than for nonamputees (2,6,7,9,10,14,15,19). Factors affecting energy expenditure include the length of the residual limb, unilateral or bilateral amputation, the reason for amputation, the choice of prosthetic components, the weight of the prosthesis and whether the weight is concentrated distally or proximally, the efficiency of the suspension aids for the prosthesis, the symmetry of the gait, the state of the cardiovascular system, the patient's age, and the general state of physical fitness (5,11).

The net energy cost of ambulation, or the amount of oxygen required per kilogram of body weight per meter walked (ml $O_2$/kg/m), is higher than normal in most untrained amputees and increases as the amputation level gets higher. In addition, the preferred speed of walking becomes slower (8). The weight of the prosthesis can contribute to this increased energy cost, particularly if the extra weight is distal. Suction suspension can make a prosthesis feel lighter, while pistoning between residual limb and socket creates a pendulum effect. Careful choice of components is therefore very important. A less symmetric gait also requires more energy. Elderly individuals who have an amputation for vascular reasons are less efficient partly because of the aging process but also as a result of arteriosclerotic heart disease, peripheral vascular disease, or diabetes, which all inhibit the efficient transfer of oxygen to the muscles.

Start balancing, stretching, and muscle-strengthening exercises as soon as possible after amputation to maintain flexibility, prevent flexion contractures, and preserve muscle strength and mass. In addition, make an aerobic conditioning program a part of the rehabilitation process whenever possible. This combination will have the dual effect of strengthening the cardiovascular system so that there is more efficient transfer of oxygen and building up muscles to use that oxygen (8). Once a prosthesis has been fitted, patients should do all physical therapy and exercise programs with the prosthesis on.

Correct-gait training starts with the first step taken in the prosthesis. Even if only partial weight bearing is allowed, encourage amputees to stand up straight and take even strides. It is easier to teach someone correctly from the beginning than to try to correct a bad habit later, just as it is easier to prevent a flexion contracture than to correct it. Although walking frames are frequently used, particularly by the elderly, they have the disadvantage of encouraging users to walk unevenly. Typically, a long step is taken with the sound side to the front of the frame, and the prosthetic side is then only brought even with the sound side. If a walker must be used for stability, it should be moved forward before each footstep to allow room for the feet to be placed sequentially one in front of the other.

Fear of losing balance and falling is the main concern of new amputees. Functional muscle-strengthening exercises—those that are carried out standing on the prosthetic side while exercising the sound side—are as important as exercises carried out on the affected side.

We have observed that, unless taught otherwise, many amputees will stand and walk with their affected-side hip behind their sound-side hip, even though the shoulders will remain straight. The result is that the stride length is uneven, with the stride taken with the prosthesis being longer than that with the sound side. Use of an energy-storing/dynamic-response foot will in effect prevent loading of the toe and the resulting toe push-off. It has therefore been our practice to gait-train our clients in the following way:

- At heel strike on the affected side, contract the muscles on that side from the gluteals to the end of the residual limb and push down and back.
- Move the affected hip forward until the foot is flat on the floor while rolling forward (not up) onto the toe of the sound side and starting the sound-side swing phase.
- Move the affected hip farther forward, feeling the stretch in the hip flexors, compressing and loading the prosthetic toe while completing the swing phase of the sound side.
- At heel strike on the sound side, relax the muscles on the affected side. The prosthetic toe will push off, initiating a knee bend and affected-side swing-through.

In this way, the patient's own body weight is doing the work of loading the prosthetic toe. It is also important to maintain normal upper-body movement, that is, equal arm swing and torso rotation. Although it seems to be very difficult work initially, the result is a more even gait pattern and less work. Figure 122.13 and Figure 122.14 depict the appropriate activity of the muscles during gait for transtibial or transfemoral amputation.

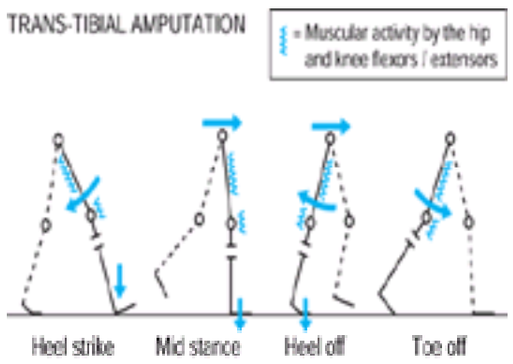


***Figure 122.13.*** Muscle activity in the flexors and extensors of the hip and knee during the gait cycle for a transtibial amputee.

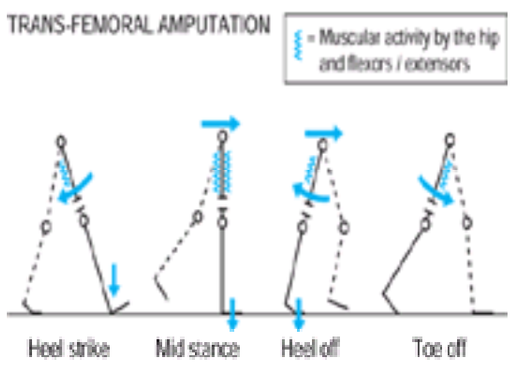


***Figure 122.14.*** Muscle activity flexors and extensors of the hip in a transfemoral amputee during the full-gait cycle.

Unless contraindicated, a supervised aerobic conditioning program will improve the endurance of all lower-extremity amputees—it is not only for athletes. In our experience, as long as a prosthesis fits well, a tailored exercise program can be undertaken by individuals with diabetes and circulatory insufficiency, and they will benefit. Stationary bicycles, rowing machines, or upper-body ergometers can all be used, although the treadmill is the piece of equipment of choice because it also improves walking. Ideally, in addition to stretching and muscle-strengthening exercises, these individuals should exercise for a minimum of 20 minutes at least three times per week at an elevated heart rate determined by their physicians.

**GAIT ANALYSIS**

After a patient has had some early experience in the prosthesis, members of the prosthetic team must observe the patient's gait on a straight-level walkway to be certain that gait abnormalities are not due to inadequate rehabilitation or improper fitting or alignment of the prosthesis. Table 122.3 and Table 122.4 provide an outline of commonly observed gait abnormalities, a description of their characteristics, and common causes that require correction.



***Table 122.3. Gait Analysis of the Transtibial Amputee***

***Table 122.4. Gait Analysis of the Transfemoral Amputee***

**UPPER-EXTREMITY AMPUTATIONS**

## AMPUTATION SITE VERSUS FUNCTION

Upper-extremity amputations include wrist disarticulation, below-elbow amputation, elbow disarticulation, above-elbow amputation, shoulder disarticulation, and forequarter amputation. Wrist disarticulation has the greatest range of extremity motion: flexion, extension, pronation, and supination. It also has a long lever arm for strength and support of distal components, and increased proprioception and function. However, it is more difficult to fit with a myoelectric hand and wrist, and the resulting fit is often longer than the sound side. The choice of components is limited.

The below-elbow amputation provides anatomic ability to pronate and supinate, has a wider range of components available, and can achieve equal length with the sound side. The choice of a myoelectric or body-powered prosthesis is available. This amputation has less range of motion, a shorter lever arm, and less proprioception and function than the wrist disarticulation. Anatomic pronation and supination decrease as the length of the residual limb decreases.

The elbow disarticulation has a long lever arm and potential increased prosthetic range of motion, for the shoulder-to-elbow portion, when fitted with a prosthesis, will be longer than the opposite extremity than with the above-elbow amputation. The increased length at the elbow is due to the components, but casual observers do not detect the discrepancy. Choice of elbow components is limited to body-powered devices.

The above-elbow amputation has a better choice of elbow components, either myoelectric or body-powered. It has a short lever arm to support distal components and a limited potential range of motion.

Shoulder disarticulation and forequarter amputation leave patients with significant disability. The shoulder disarticulation has a very limited range of motion, and the prosthesis is cumbersome and heavy. It is frequently used primarily for cosmesis. The forequarter amputation also has a limited range of motion. The prosthesis is even more cumbersome and heavy, and suspension is particularly difficult. The more distal the amputation in the upper extremity is, the more functional the outcome and the better the cosmesis will be.

## PREPROSTHETIC CARE

The goals of preprosthetic care for upper-extremity amputations are the same as those for lower-extremity amputations (Table 122.1).

## IMMEDIATE POSTOPERATIVE PROSTHESES

An IPOP applied to the upper-extremity controls postsurgical pain and edema, improving circulation through reduced edema. Patients benefit psychologically by “waking up with a hand and arm.”

In amputations with a residual limb, a preparatory upper-extremity prosthesis can protect the residual limb from injury, prevent and treat contractures in the contained joints, and initially mold the residual limb. Patients maintain some two-handed function and receive training in the use of a prosthesis. It also allows assessment of a patient's motivation. It can be removed for wound care and helps maintain body symmetry. The IPOP is usually worn only for 2–6 weeks after surgery. It is body-powered rather than myoelectric, and because of its weight, it uses a terminal hook device rather than a hand.

Nonetheless, the plaster cast of the IPOP is heavy and prevents movements of contained joints, resulting in muscle atrophy. If the cast becomes loose, it can cause tissue breakdown, particularly if it is resting on the transradial area or other proximal joint. The cast is also prone to fall off, particularly with transhumeral amputations, unless auxiliary suspension is used. Use of a cast also prevents monitoring of the incision. Another problem with this technique is that the terminal hook device is not cosmetic. An IPOP cannot be applied over extensive skin grafting and is not useful on very short residual limbs.

The rationale for upper-extremity preparatory prostheses is the same as that for lower-extremity preparatory prostheses.

## PROSTHETIC FITTING

Rejection of upper-extremity prostheses is more common than for lower-extremity prostheses, with rejection rates increasing the more proximal the amputation site is. If prosthetic fitting is not done early, the client can become so adept at doing tasks with one hand that a prosthesis may seem cumbersome and heavy.

Length, condition, strength, and range of motion of the residual limb are the determining factors in the choice of a prosthetic system. Personal preference and motivation also play a role.

Preservation of length of the residual limb in upper-extremity amputations is critical for maximum function. This differs from the principles for the lower-extremity, where components can be more functional and a long residual limb length is not always beneficial.

Upper-extremity prostheses involve several choices:

- Passive, in which the position of the terminal device or more proximal components is changed with a contralateral hand
- Body-powered, in which gross body movements activate cables for function
- Myoelectric, which is battery-powered and computer-driven
- Hybrid system, which is a combination of body-powered and myoelectric

Table 122.5 delineates the advantages and disadvantages of these various options.

| Type | Advantages | Disadvantages |
|---|---|---|
| Cosmetic (passive) | Most lightweight<br>Best cosmesis<br>Least harnessing | High cost if custom made<br>Least function<br>Low-cost gloves stain easily |
| Body-powered | Moderate cost<br>Moderately lightweight<br>Most durable<br>Higher sensory feedback | More body movement to operate<br>Most harnessing<br>Least satisfactory appearance |
| Externally powered (myoelectric and switch control) | Moderate or no harnessing<br>Least body movement to operate<br>Moderate cosmesis<br>More function proximal levels | Heavier<br>More expensive<br>More maintenance<br>Limited sensory feedback |
| Hybrid (cable elbow/electric TD) | All cable excursion to elbow<br>Increased TD pinch | Electric TD weight forearm (harder to lift)<br>Good for elbow disarticulation (or long above-elbow amputation) |
| Hybrid (electric elbow/cable TD) | All cable excursion to TD<br>Low effort to position TD<br>Low maintenance TD | Least cosmesis<br>Lower pinch force for TD |

TD, terminal device.

Modified from Engelman A, Leonard J.A. Jr., Meier RH, Sol, et al. Prosthetics, Orthotics, and Assistive Devices. J. Prosthetics. Arch Phys Med Rehabil 1989;70(Suppl 1):1297, with permission.

***Table 122.5. Advantages and Disadvantages of Various Upper-limb Prostheses***

### *Passive Prosthesis*

A passive prosthesis can be used for individuals who want nearly life-like cosmesis or who have a high-level amputation and want a lightweight arm for cosmetic reasons. Passive prostheses are lightweight and nonfunctional. Cost depends largely on cosmetic finish. Off-the-shelf cosmetic covers are relatively inexpensive, while nearly life-like silicone covers are expensive.

### *Body-powered Prosthesis*

In a body-powered prosthesis, the components are controlled by gross body movements through a system of straps and a harness that also doubles as a suspension aid. Stainless steel cables are attached to the straps proximally and to parts of the terminal device distally. If the amputation is proximal to the elbow joint, the cable will go through an elbow flexion attachment first. Body movements, such as a shoulder shrug or scapular abduction, put tension on a cable, causing a response. A series of

movements initiates flexion, extension, and locking of the elbow, after which the terminal device can be activated (Table 122.6). If distal, the cables merely control the terminal device. The body-powered prosthesis does not depend on a battery for power, has a quicker component reaction time, and is less expensive than the myoelectric. There is feedback from the cable, and it is more durable and easier to maintain. Conversely, a body-powered prosthesis is at risk for repetitive injury of the activating muscles and joints, has limited pinch-force control for an involuntary terminal device, and can cause irritation to the skin of the contralateral side from the harness.

| *Body motion* | *Prosthesis activation* |
|---|---|
| Scapular abduction | Terminal device activation |
| Chest expansion | Terminal device activation |
| Humeral flexion | Terminal device activation |
| Shoulder depression, extension, and abduction | Elbow lock activation |

From Braddon RL. *Physical Medicine and Rehabilitation.* Philadelphia: W.B. Saunders, 1996:284.

***Table 122.6. Body Control Motions Typically Used for Prosthesis Activation***

### *Myoelectric Prosthesis*

Myolectric prosthetic components are controlled by voluntary muscle action via an electronic signal. The signal is picked up and amplified by electrodes placed over the muscle fibers and then downloaded to a computer to provide a specific function.

To determine whether a patient is a candidate for this type of prosthesis, myoelectric testing is done, before the components are chosen, to determine the maximum threshold available from the muscles. A myoelectric prosthesis provides good cosmesis and does not require a harness to be activated. It has increased range of motion and avoids repetitive-movement injury; it also has increased anatomic function and voluntary wrist rotation. To its disadvantage, a myoelectric device has a slower response time and increased weight distally, as well as higher maintenance. It is battery-dependent and less durable and has a longer down time for repairs. In addition, myoelectric devices are expensive, require longer training, and are less adaptive and not waterproof (Fig. 122.15).



***Figure 122.15.*** Myoelectric prosthesis with a hand attachment shows a battery and electrodes (no socket). (Courtesy of Liberty Technology, Hopkinton, MA.)

### *Hybrid System*

The hybrid system has a combination of body-powered and myoelectric components, such as a body-powered elbow and a myoelectric hand. This combination reduces the weight of the prosthesis and the expense.

### *Choice of Components*

**Types of Suspension** The socket design depends on the type of suspension used—suction, bony lock, or harness—and the socket fit.

Full-suction suspension is used for wrist disarticulation and above- or below-elbow amputations. It is more secure, provides greater proprioception, reduces harnessing, and enables pronation and supination where anatomically possible. With full-suction suspension, the prosthesis feels lighter. However, it is more difficult to put on, especially for bilateral amputees, and difficult to fit for short above- or below-elbow limbs. In addition, it may be more expensive than other choices. A suction liner can be used for above- and below-elbow prostheses. It is easier to put on than full suction but may cause skin irritation. However, it is not as secure as full suction and is more expensive.

Bony-lock suspension can be used with or without socks for wrist disarticulation and below-elbow prostheses. It is easy to put on and remove. Its disadvantages are that it can cause muscle atrophy and prevents pronation and supination in below-elbow amputees (8).

Harness suspension can be used for all upper-extremity prostheses. It is less expensive and more reliable than other suspensions, and the only choice for a shoulder disarticulation or forequarter amputation. The problem is that it is irritating to wear and is less cosmetic.

**Terminal Devices** Apart from appearance, weight is a main factor to be considered in the choice of a terminal device. Hooks are lighter, have less of a pendulum effect, and are less tiring to use. One option is to use a hook for daily activities and to attach a hand whenever cosmesis is more important. The passive device is nonfunctional and for cosmesis only. Both the body-powered hook and body-powered hand are voluntary- or involuntary-closing devices. The myoelectric hand is battery-powered and computer-driven. It has specific adaptive equipment, such as for sports, tools, and so forth.

The main groups of wrist units are body-powered and myoelectric. Myoelectric devices can pronate and supinate and are motor-driven. In elbow units, the main groups include passive, body-powered, and myoelectric devices. In shoulder units, there is only a manual unit.

Typical transhumeral and transradial body-powered prostheses are depicted in Figure 122.16 and Figure 122.17.



***Figure 122.16.*** Typical body-powered prosthesis for a transhumeral amputee (harness not shown). (From D'Astous J, ed. *Orthotics and Prosthetics Digest,* Canada: Edahl Productions Ltd, 1981:153, with permission.)

***Figure 122.17.*** Typical body-powered prosthesis for a transradial level amputee.

### REHABILITATION AND TRAINING

Institute occupational therapy as soon as possible to maintain body symmetry, prevent flexion contractures, reduce surgical edema, and prepare the residual limb for the prosthesis. Early fitting of a prosthesis and promotion of two-handed function reduce the rejection rate. Strengthening exercises help counteract the pendulum effect of the terminal device. In addition, if myoelectric components are used, patients may need exercises to improve their ability to contract and cocontract the muscles chosen for the electrode site. Computer programs are used to aid in training patients. Activities of daily living must be taught before a patient becomes adept at doing these tasks single-handedly; otherwise the prosthesis may feel cumbersome.

For both upper- and lower-limb amputees, the resources necessary for success are not always available. Reimbursement issues continue to present considerable problems for both prosthesis and rehabilitation costs. In addition, a patient old enough to receive Medicare cannot learn to walk in the limited physical therapy sessions allowed for gait training at either outpatient or private physical therapy facilities. The reimbursement allowed by some insurance companies for one prosthesis per lifetime is not sufficient when the patient is a child born with a limb deficiency. Often, less functional components are used, purely on the basis of cost. In addition, prosthetists have different levels of skills.

## PITFALLS AND COMPLICATIONS

### SKIN PROBLEMS

Proper prosthetic fitting and a good training program to gradually accommodate amputees to their prosthesis and teach them how to care for it and their skin will avoid most skin problems. The residual limb and socket must be washed daily. Areas of split-thickness skin graft do not tolerate pressure, particularly if over bony prominences. They may eventually require revision if modification of the socket is not successful in preventing problems. Painful bursas can usually be managed by modifications of the socket, but occasionally problematic bony prominences will require removal.

Fungal skin infections are best avoided by cleanliness, keeping the socket and skin as dry as possible, and, when necessary, application of typical fungicides. Folliculitis usually results from sweating, poor hygiene, and pistoning in the socket caused by a poor fit. These problems usually respond to good skin care. If folliculitis progresses to abscess, it may require incision and drainage, with limited prosthesis use until healing occurs.

### CHOKE SYNDROME

Proximal restriction in the socket with lack of total contact can lead to edema in the stump, which can lead to hemosiderin deposition and the eventual development of verrucous hyperplasia. This problem is preventable through good prosthetic fitting that achieves total contact in the socket.

### PAIN

Pain over surgical scars or bony prominences or from neuromas should initially be addressed with socket modifications. If modifications are unsuccessful, then surgical intervention may be required (see Chapter 120 and Chapter 121). Nearly all adult amputees have an image and sensation of the amputated part known as “phantom sensation,” which usually declines with time. On occasion, this will be accompanied by pain in the phantom. Rule out any prosthetic or surgical causes of pain, as these may aggravate phantom pain. Referral to a pain management center for medicinal therapy, transcutaneous electrical stimulation, lumbar sympathic blocks, and other such interventions may be useful. Strong psychosocial support for patients is important.

### CONTRACTURES

It is important to emphasize to patients the critical role of early rehabilitation and exercises to build strength and prevent flexion contractures. Minor contractures of up to 10° can usually be accommodated in the prosthesis and require no special treatment. Hip and knee flexion contractures greater than 25° interfere with prosthesis fitting and will result in an unfavorable posture and gait pattern. Surgical release is sometimes necessary if these do not respond to nonoperative treatment.

### PSYCHOSOCIAL MALADJUSTMENT

Amputee support groups and peer counseling are very helpful for patients sustaining amputations in accepting their new body image and adjusting to their new situation. Open discussion of their problems and concerns in a group or mentor setting is helpful.

## RESOURCES

The Amputee Coalition of America and National Limb Loss Information Center (toll-free: 1-888-AMP-KNOW) is a national organization that is helpful for new amputees. This center has an information hotline and can help find a local support group and peer visitor, as well as providing appropriate pamphlets, magazines, and videos and a list of certified prosthetists in their area.

To be certified by The American Board for Certification in Prosthetics and Orthotics, Inc., today's prosthetists must meet certain educational and professional standards. These include a bachelor's degree and supervised internship, as well as passing a national certification examination followed by mandatory continuing education. As a result of constantly changing technology, better outcomes can be realized when prosthetists have input into the prescription request based on the initial prosthetic evaluation.

### CHAPTER REFERENCES

Each reference is categorized according to the following scheme: *, classic article; #, review article; !, basic research article; and +, clinical results/outcome study.


# 1. Braddon RL. *Physical Medicine and Rehabilitation.* Philadelphia: WB Saunders, 1996:284.

+ 2. Cammisa FP, Glasser DB, Otis JC, et al. The Van Nes Tibial Rotationplasty: A Functionally Viable Reconstructive Procedure in Children Who Have a Tumor of the Distal End of the Femur. *J Bone Joint Surg Am* 1990:72:541.

# 3. Dee R, Mango E, Hurst LC. *Principles of Orthopaedic Practice.* New York: McGraw-Hill, 1989.

# 4. DeLisa JA, Gans BM. *Rehabilitation Medicine: Principles and Practice,* 3rd ed. Philadelphia: Lippincott–Raven Publishers, 1998.

+ 5. English Rd, Hubbard WA, McElroy GK. Establishment of Consistent Gait after Fitting of New Components. *J Rehabil Res Dev* 1995;32:32.

+ 6. Harris IE, Leff AR, Gitelis S, Simona MA. Function after Amputation, Arthrodesis, or Arthroplasty for Tumors about the Knee. *J Bone Joint Surg Am* 1990;72:1477.

+ 7. Herbert LM, Engsberg JR, Tedford KG, Grimston SK. A Comparison of Oxygen Consumption during Walking between Children with and without Below-knee Amputations. *Phys Ther* 1994;74:943.

+ 8. Lane JM, Kroll MA, Rossbach PG. New Advances and Concepts in Amputee Management after Treatment for Bone and Soft Tissue Sarcomas. *Clin Orthop* 1990;256:22.

+ 9. McClenaghan BA, Krajbich JI, Pirone AM, et al. Comparative Assessment of Gain after Limb-salvage Procedures. *J Bone Joint Surg Am* 1989;71:1178.

+ 10. Otis JC, Lane JM, Kroll MA. Energy Cost during Gain in Osteosarcoma Patients after Resection and Knee Replacement and after Above-the-knee Amputation. *J Bone Joint Surg Am* 1985;67:606.

# 11. Pinzur MS. Current Concepts: Amputation Surgery in Peripheral Vascular Disease. *Instr Course Lect* 1997;46:501.

# 12. Rodriguez RP. Amputation Surgery and Prostheses. *Orthop Clin North Am* 1996;27:525.

+ 13. Steen Jensen J, Mandrup-Poulsen T. Success Rate of Prosthetic Fitting after Major Amputations of the Lower Limb. *Prosthet Orthot Int* 1983;7:119.

+ 14. Torburn L, Powers CM, Guiterrez R, Perry J. Energy Expenditure during Ambulation in Dysvascular and Traumatic Below-knee Amputation: A Comparison of Five Prosthetic Feet. *J Rehabil Res Dev* 1995;32:111.

+ 15. Traugh GH, Corcoran PJ, Reyes RL. Energy Expenditure of Ambulation in Patients with Above-knee Amputations. *Arch Phys Med Rehabil* 1975;56:67.

+ 16. van der Windt DA, Pieterson I, van der Eijken JW, et al. Energy Expenditure during Walking in Subjects with Tibial Rotationplasty, Above-knee Amputation, or Hip Disarticulation. *Arch Phys Med Rehabil* 1992;73:1174.

+ 17. Volpicelli LJ, Chambers RB, Wagner FW Jr. Amputation Levels of Bilateral Lower-extremity Amputees: Analysis of One Hundred and Three Cases. *J Bone Joint Surg Am* 1983;65:599.

! 18. Waters RL, Perry J, Antonelli D, Hislop H. Energy Cost of Walking of Amputees: The Influence of Level of Amputation. *J Bone Joint Surg Am* 1976;58:42.

+ 19. Zohman GL, Boardman DL, Eckardt JJ, Lane JM. Stride Analysis after Proximal Tibial Replacement. *Clin Orthop* 1997;339:180.

# CHAPTER 123

# ORTHOPAEDIC MANAGEMENT OF LOWER EXTREMITY DYSFUNCTION FOLLOWING STROKE OR BRAIN INJURY

*Mary Ann E. Keenan and Guy Alan Lee*

**Mary Ann E. Keenan**: Director, Neuro-Orthopaedics Program, Department of Orthopaedic Surgery, Albert Einstein Medical Center, 19140; Professor of Orthopaedic Surgery, Professor of Rehabilitation Medicine, Temple University School of Medicine, Philadelphia, Pennsylvania, 19140.
**Guy Alan Lee:** Department of Orthopaedic Surgery, Albert Einstein Medical Center, Philadelphia, Pennsylvania, 19141.

Introduction
- Orthopaedic Surgery as a Rehabilitation Tool
- Expectations and Timing of Orthopaedic Surgery

Stroke
- Pathophysiology of Stroke
- Neurologic Impairment Following Stroke
- Orthopaedic Management of Stroke

Traumatic Brain Injury
- Prognosis
- Orthopaedic Management of Brain Injury

Heterotopic Ossification
Reflex Sympathetic Dystrophy
General Considerations for Decision Making
- Degree of Spasticity
- Timing of Neurologic Recovery
- Pattern of Neurologic Recovery
- Temporary Management of Spasticity During the Period of Physiologic Recovery
- Phenol Blocks
- Botulinum Toxin Blocks
- Common Techniques of Nerve and Motor Point Blocks

Evaluation of Residual Limb Deformities
- Assessment of Cognition and Communication
- Sensory Evaluation
- Evaluation of Limb Deformity and Potential Functional Capability

Orthopaedic Management of Common Lower Extremity Deformities
- General Considerations
- Spastic Hip Deformities
- Spastic Knee Deformities
- Spastic Foot and Ankle Deformities

Pitfalls and Complications
Author's Perspective
Chapter References

## INTRODUCTION

Cerebrovascular accident (CVA) and traumatic brain injury (TBI) are distinct syndromes; however, the stroke patient and brain-injured patient share many features (4,12,13,16,20,22,23,25,26,28,40,42,45,49,50,55,57,78,80,89,91,94,95 and 96,99,100 and 101,103,106,115,122,127,144,147,148,156,162,163,164 and 165,174,176,177,178,179 and 180,215,216,224,230,231,237,238,241,250). Both patient groups exhibit upper motoneuron (UMN) syndromes with impairment of motor control, spasticity, and stereotypic patterns of movement (synergy). Cognitive, memory, and sensory deficits are also commonly seen in these patients. Because of the similarities between stroke and TBI, there is a great deal of overlap in terms of specific surgical and nonsurgical techniques for treating the lower extremity problems caused by these conditions.

Lesions of the central nervous system (CNS), the peripheral nervous system, and the musculoskeletal system, as well as lesions causing pain, may lead directly or indirectly to syndromes of restricted or excessive motion of the limbs. Syndromes of restricted limb motion are the most common types of movement impairment. Syndromes of excessive motion are less common. A distinction between restricted versus excessive motion is shown in Table 123.1 (147,148). The functional implications of each and the treatment of the problems they generate are very different.

| *Limbs with restricted motion* | *Limbs with excessive motion* |
|---|---|
| 1. Spasticity, stiffness, and contracture | 1. Cerebellar ataxia |
| 2. Upper motoneuron pattern of dysfunction | 2. Brain stem syndrome |
| 3. Heterotopic ossification | 3. Chorea |
| 4. Bony malalignment/ fracture malunion | 4. Ballismus |
| 5. Pain syndromes | 5. Chorea |
| 6. Pseudobulbar athetoid syndrome | 6. Tremors |
| 7. Brain stem syndrome | 7. Myoclonus |
| 8. Rigidity and bradykinesia | 8. Tics |
| 9. Dystonia, torticollis, bruxism, locked jaws | 9. Ligamentous and capsular instabilities |
| 10. Decorticate and decerticate rigidity | 10. Sensory disturbance |

Reference: 147,148.

***Table 123.1. Clinical Phenomena Associated with Impaired Movement that Functionally Lead to Restricted or Excessive Motion after TBI or CVA***

Syndromes of restricted limb motion are manifested by impaired access of the limb to targets in the environment during voluntary movement. Limbs are unable or are poorly able to move toward objects or places because motion across joints is restricted. An example is a patient with spastic hip and knee flexors who attempts to stand with a crouched posture. Another example seen after head injury is heterotopic bone formation about the hip, which restricts joint motion and impairs use of the lower extrem-ity even in the presence of voluntary muscle action. Limbs with restricted motion lose their operating range and are unable to be positioned adequately for function. The general treatment strategy for limbs with restricted motion is to identify and reduce sources of limb restriction.

Syndromes of excessive limb motion are manifested by impaired tolerances in the production of voluntary movement parameters such as movement amplitude, accuracy, timing, and force. Clinical conditions associated with excessive motion seen after head injuries include movement disorders such as hemiballismus, athetosis, tremors, and cerebellar ataxia. Biomechanical laxity in the musculoskeletal system may also be associated with excessive motion. For example, posterior subluxation of the knee may lead to excessive motion and instability during standing.

## ORTHOPAEDIC SURGERY AS A REHABILITATION TOOL

The effects of injury to the brain extend beyond the confines of the skull and the subsequent cognitive function of the brain. The musculoskeletal system is profoundly affected by brain dysfunction. Hypertonicity, the unmasking of primitive reflexes and impaired motor control all contribute to the abnormal limb positions, contractures,

and impaired mobility that are so frequently encountered in persons with brain injury.

The converse is also true. The brain is strongly affected by dysfunction of the musculoskeletal system. Just as the hip and knee position of the foot for walking, the musculoskeletal system gives mobility to the brain and positions it to interact with the world. Mobility of the individual is a key element of human life and of fundamental importance to our well-being.

Professionals working in the field of brain injury and stroke rehabilitation are knowledgeable about the cognitive and behavioral deficits that accompany brain injury. It has been our experience that less importance has been given to the musculoskeletal impairment that results from brain trauma or stroke. The penalties of musculoskeletal limitations for the individual can be devastating. Improving an individual's physical mobility is often therapeutic, leading to increases in cognitive, behavioral, and emotional capacities.

Wellness promotion has become an objective of medical care. This cannot mean the complete prevention of disease, injury, and disability. In the physically disabled population, wellness promotion means maximizing function and mobility in order to avoid the complications of their chronic incapacity. Potential complications of physical immobility include decubiti, infection, pain, social isolation, physical dependence, and emotional dependence. For society, this results in a costly loss of productivity for the patient and often family members as well.

### EXPECTATIONS AND TIMING OF ORTHOPAEDIC SURGERY

When evaluating patients with CNS dysfunction, questions commonly arise regarding the indications for surgery, the cost, what outcome to expect, and the practicality of this approach. These issues should be considered on an individual basis for each patient. The following general principles can serve as guidelines for decision making.

*1. Operate early, before deformities are severe and fixed.* Orthopaedic surgery is a powerful rehabilitation tool. It is often the *only* treatment that will correct a limb deformity or improve function. Surgery should not be considered a treatment of last resort when “conservative” measures have failed. Physical and occupational therapy cannot effect a permanent change in motor control. Drug therapy for increased muscle tone has generalized effects and cannot be targeted to specific offending muscles. Phenol blocks and botulinum toxin injections provide only temporary modulation of muscle tone. When a permanent treatment is needed to decrease muscle tone or redirect muscle force, consider surgery. The results of surgical intervention are improved when deformities are corrected early. Less muscle lengthening is needed when deformities are mild and there is little or no fixed contracture to overcome. Early surgery preserves maximum muscle strength, joint capsule and ligament flexibility, and articular cartilage integrity. In general, the patient will also be in better physiologic condition to undergo surgery if there has not been a period of several years of immobility.

*2. Better underlying motor control means better function for the extremity.* Orthopaedic surgery cannot impart control to a muscle. Lengthening a spastic muscle can improve its function by diminishing the overactive stretch response and uncovering any control that is present. Successful surgery depends on a careful evaluation preoperatively to determine the amount of volitional control present in each individual muscle that is affecting limb posture and movement.

Motor performance can be thought of as a continuous scale, with the totally disabled at the lower end and the elite athlete at the upper end. Infinitesimal improvements in the performance of elite athletes distinguish between the winner and loser. Incremental changes in limb function also result in performance improvements for the disabled individual. Surgery should not be reserved only for patients with severe impairment and deformity. Individuals with milder degrees of impairment can benefit greatly from relatively simple procedures such as lengthening of the Achilles tendon to regain a plantigrade foot for standing, transfers, and ambulation. The amount of improvement correlates best with the degree of underlying motor control and not the severity of the deformity.

*3. Distinguish between the function of the extremity and the function of the individual.* We commonly speak of “functional” and “nonfunctional” surgical procedures. These terms refer to the expected outcomes for a limb but do not indicate the outcome for the person as a whole. Surgical release of a leg contracted in a flexed and adducted position in a nonambulatory, quadriplegic patient often allows the person to sit comfortably in a wheelchair and become interactive with others.

*4. Consider the cost of not correcting limb deformities.* The cost of motor control evaluation using dynamic electromyography (EMG) is relatively modest for the benefits it provides. Dynamic EMG is a one-time expense. The cost of performing an incorrect surgical procedure that fails to correct or even worsens a limb deformity is much greater. The cost of performing a surgical procedure is likewise limited when compared with a lifetime of attendant care, spasticity medications, repeated blocks, orthotics to control limb position, complications such as skin ulceration and infection, and lost productivity for the patient and caretakers.

## STROKE

Stroke is the leading cause of acquired hemiplegia and long-term disability in the United States (27,80,115,139,142,180,217,227,248). It is also the third leading cause of death. Roughly 600,000 people suffer a new or recurrent stroke each year. Management of the stroke patient has become a major priority for physicians who treat the elderly population. There are 4,000,000 stroke survivors today. The average patient who survives beyond the first few months after a stroke has a life expectancy of more than 6 years (12,82,83). In general, stroke victims survive long enough and achieve adequate function to justify aggressive rehabilitation.

### PATHOPHYSIOLOGY OF STROKE

Cerebral function depends on a continuous supply of oxygen. Any significant interruption of oxygenation by thrombosis, emboli, or hemorrhage will result in neuron death and subsequent deficits in cognitive, sensory, and motor functions. Thrombosis is the most common cause of infarction and accounts for nearly three fourths of all CVAs (82,83). Arteriosclerosis is the most significant predisposing factor.

Cranial hemorrhage accounts for approximately one sixth of all CVAs, and includes spontaneous intracerebral hemorrhage and subarachnoid hemorrhage. Hypertension is commonly present in these patients. Isolated cerebral emboli account for less than 10% of CVAs.

Predisposing factors to CVAs include:

- atherosclerosis
- increasing age
- genetic predisposition
- hypertension
- hyperlipidemia
- hypercholesterolemia
- obesity
- cardiac anomalies (arrhythmias, myocardial infarction, hypotension, mural thrombosis)
- diabetes mellitus
- collagen vascular disease (vasculitis, polyarteritis)
- hyperviscosity states (polycythemia, sickle cell anemia)
- oral contraceptive use
- tobacco smoking
- severe cerebrovascular spasm secondary to migraine headaches
- septic vasculitis (tuberculosis, syphilis, and mucormycosis).

### NEUROLOGIC IMPAIRMENT FOLLOWING STROKE

Distinct clinical syndromes arise from insults to specific areas of the cerebral cortex. CVAs involving the middle cerebral artery are the most common and produce the typical hemiplegic picture of greater impairment in the upper extremity, face, and speech compared with lower extremity involvement. The middle cerebral artery supplies the largest area of cerebral cortex. This area controls sensory and motor function of the trunk, upper extremity, and face, as well as the functions of speech.

The anterior cerebral artery supplies the mid cortex in the sagittal plane. This area of cerebral cortex controls sensory and motor function predominantly in the lower extremity. CVAs involving the anterior cerebral artery result in a hemiplegic picture of sensory and motor deficits chiefly involving the lower extremity.

The posterior cerebral artery supplies the visual cortex in the occipital region. Involvement of this artery typically results in visual impairment. Bilateral cortical

involvement may lead to severe mental impairment, frontal release signs, loss of short-term memory, and inability to learn.

CVAs in the vertebral basilar system are rare. Deficits in balance and coordination arise from interruption of afferent and efferent pathways between the brain and spinal cord. Balance reactions also depend on limb control and proprioception (96,115,144,198).

***Cognitive Impairment***

Cognitive deficits commonly follow CVAs. Impairment of mentation, decreased learning ability, and loss of short-term memory may occur (12,16,20,22,25,28,33,42,50,80,82,83,93,104,106,144,151,160,161,164,179,217,228,251). The ability to cooperate with treatment affects rehabilitation potential. In patients with extensive frontal lobe deficits, these deficits may be severe. Patients with extensive frontal lobe pathology exhibit clinical features similar to those of senility, with lack of attention span and little motivation for recovery. Their prognosis for rehabilitation is poor.

Aphasia is a loss of ability to communicate. It may be receptive or expressive in nature; it usually involves both components. Aphasia occurs with lesions of the left hemisphere, usually without regard to hand dominance. A receptive aphasia hinders rehabilitation most strongly because the patient cannot understand instructions. A patient with persistent receptive loss has a poor prognosis. On the other hand, expressive aphasia may be compatible with rehabilitation, allowing a patient to comprehend and follow instructions. Expressive aphasia may resolve significantly.

Apraxia, or impairment of execution (motor planning), is characterized by a loss of ability to perform a previously learned action, such as tying shoelaces or waving goodbye. Apraxia is not the result of motor or sensory loss. It occurs more commonly with right hemispheric involvement (left hemiparesis). The apraxia, however, occurs on both sides of the body. The prognosis for patients with severe apraxia is generally poor. Some improvement with practice and repetition may occur. If impairment persists after 3 months, further improvement is unlikely (12).

***Sensory Impairment***

A wide span of sensory loss can occur following stroke. Sensory perception occurs in the cerebral cortex and is most often affected by lesions of the middle cerebral artery. Sensory loss may be manifest by impairment of touch, pinprick, two-point discrimination, proprioception, discrimination of size, shape, texture, or point localization, or the presence of astereognosis. Impairment of sensory function in the extremities is a poor prognostic sign, even though motor function may be intact or only minimally impaired (4,12,16,20,22,25,26,27 and 28,40,42,60,73,78,80,89,94,106,110,115,122,127,129,134,143,144,147,148,150,151,156,162,163,164 and 165,176,179,180,184,194,203,226,227,230,237,238,246,250,251). Lesions of the parietal lobe of the nondominant hemisphere may result in a lack of awareness of the involved side of the body (neglect). A failure to recognize and use the involved side may occur despite minimal motor involvement.

Disturbances of vision may occur. These disturbances include hemianopia (blindness in one eye), disturbance of perception, poor perceptual organization, loss of geometric sense, inability to copy figures, and failure to perform tasks involving spatial analysis. Hemianopia is likely to be permanent, but it usually has little impact on rehabilitation potential. Disturbances in visual perception are more significant and may result in failures of activities of daily living (209).

***Motor Impairment***

Motor impairment is commonly the most obvious sequela of stroke. Recovery follows a fairly typical pattern. A period of flaccid paralysis occurs lasting from 24 hours to several weeks. This is followed by a period of increasing muscle tone. In general, the longer the period of flaccidity, the poorer the prognosis for functional recovery. In the leg, either a flexor or externsor pattern may predominate. With a flexor pattern, the hip and knee are flexed. With an extensor pattern, the hip is adducted and extended, the knee is extended, and the foot is in equinovarus (Table 123.2). These changes are usually evident within 48 hours after the stroke. Any paralysis remaining after 3 months will usually persist, although some slight improvement may occur over a 6-month period (16,20,22,25,26,27 and 28,30,31,33,34,42,50,53,70,80,82,83,87,92,93,97,104,106,109,115,120,121,127,139,140,142,144, 151,154,160,161,162,163 and 164,172,179,180,187,194,197,198,202,215,216,217 and 218,227,228,235,237,241,248,250,251,256,257). Functional improvement may continue as a result of further sensorimotor re-education. Increasing muscle tone usually leads to muscle spasticity. Hyperactive deep tendon reflexes and clonus may appear.

| Problem | Cause |
|---|---|
| Scissoring thighs | Hip adductor spasticity |
| Crouched gait | Hip and knee flexion (static or dynamic) |
| Stiff-knee gait | Quadriceps spasticity during swing |
| Equinovarus foot | Gastrocsoleus and tibialis anterior spasticity |
| Hitchhiker toe | Extensor hallucis longus spasticity |
| Claw toes or cavus foot | Extrinsic and intrinsic toe flexor spasticity |
| Valgus foot | Peroneal muscle spasticity |

References 145.

***Table 123.2. Common Lower Extremity Limb Deformities***

Voluntary movement returns first in the most proximal muscle groups of the limbs and follows in a proximal-to-distal direction or pattern of recovery. Voluntary movement should be sought and examined during the early recovery phase when flaccidity is present.

Grade motor control in the extremity using the clinical scale shown in Table 123.3 (116,147,148). The extremity may be hypotonic or flaccid and without any volitional movement. A spastic extremity may be held rigidly without any volitional or reflexive movement. Patterned or synergistic motor control is defined as a mass flexion or extension response involving the entire extremity. Mass flexion in the lower extremity consists of hip and knee flexion with dorsiflexion of the ankle. Mass extension in the lower extremity consists of extension of the hip and knee with equinovarus of the foot and ankle. Synergistic movement may be reflexive and in response to a stimulus but without volitional control. Some patients can also volitionally initiate the synergistic movement. Selective motor control with pattern overlay is defined as the ability to move a single joint or digit with minimal movement in the adjacent joints when performing an activity slowly. Rapid movements or physiologic stress make the masspattern more pronounced. Selective motor control is the ability to volitionally move a single joint or digit independently of the adjacent joints. Spasticity can mask underlying motor control.

| | Motor control | Description |
|---|---|---|
| Grade 1 | Flaccid | Hypotonic, no active motion |
| Grade 2 | Rigid | Hypertonic, no active motion |
| Grade 3 | Reflexive mass pattern (synergy) | Mass flexion or extension in response to stimulation |
| Grade 4 | Volitional mass pattern | Patient-initiated mass flexion or extension movement |
| Grade 5 | Selective with pattern overlay | Slow volitional movement of specific joints. Physiologic stress results in mass action |
| Grade 6 | Selective | Volitional control of individual joints |

References 105, 112, 117, 125, 147, 148.

***Table 123.3. Clinical Scale of Motor Control***

Patterned movement, even when initiated volitionally, is a primitive form of motor control and of no functional use in the upper extremity. The hand requires some selective control for functional use. The lower extremity can more successfully use synergistic motions for functional activities, such as transfers or walking. For

example, the patient can be taught to use the flexion movement to advance the limb and the extension pattern to provide limb stability during stance.

The final processes in sensory perception occur in the cerebral cortex, where basic sensory information is integrated to complex sensory phenomena such as proprioception, spatial relationships, shape, sight, and texture. A patient with severe parietal dysfunction and sensory loss may lack sufficient perception of space and awareness of the involved segment of his or her body to ambulate. A patient with severe perceptual loss may lack balance to sit, stand, or walk.

### ORTHOPAEDIC MANAGEMENT OF STROKE

#### *The Period of Acute Injury*

Direct initial efforts toward the medical stabilization of the patient. The orthopaedic surgeon is rarely involved in the acute care of the stroke patient. In some situations, the orthopaedic surgeon may be asked to assist with splinting extremities to prevent limb deformities.

#### *The Period of Physiologic Recovery*

Spontaneous neurologic recovery occurs primarily during the first 6 months following a stroke. This is particularly true for recovery of muscle function. During the subacute phase, limb flaccidity changes to spasticity. The patient is commonly in a rehabilitation facility for a portion of this time. Muscle weakness can result in joint subluxation or ligamentous laxity if the limb is not protected. When spasticity becomes pronounced, temporary measures are used to prevent contracture formation until spontaneous neurologic recovery has ceased. It is important to prevent the complications associated with limb spasticity (Table 123.4) (121,122,147,148).

| |
|---|
| Contractures |
| Decubitus ulcers |
| Hygiene difficulties |
| Fracture malunion |
| Joint subluxation or dislocation |
| Heterotopic ossification |
| Peripheral neuropathy |
| References: 121, 122, 147, 148. |

***Table 123.4. Complications of Spasticity***

#### *The Period of Functional Adaptation to Residual Deficits*

Generally the patient is neurologically stable after 6 months. Decisions can then be made regarding surgery to correct limb deformities and rebalance the muscle forces. This is the time of greatest contribution by the orthopaedic surgeon.

## TRAUMATIC BRAIN INJURY

Injury to the brain is a leading cause of disability and death in the United States (68,99,100,141,165,209,211,219,224,258). An epidemiologic study of physician-documented cases of TBIs occurring in San Diego County, California, in 1981 determined an annual incidence of 180 per 100,000 population (141).

Extrapolating this rate to the entire United States population provides an estimate of 410,000 new cases of TBI cases each year. Eleven percent of these patients will die shortly after the injury. Approximately 80% of the survivors will have a good or moderate neurologic recovery. Most traumatic injuries to the brain are in individuals who are younger than 45 years of age, and those who survive have a normal life span despite the injury.

### PROGNOSIS

Prognosis following TBI has traditionally been predicted relative to the Glasgow Coma Scale (GSC) (Table 123.5) (99,100,219). The GCS is the total of the scores of a patient's responses to eye opening, motor responses, and verbal responses. Obtained within 24 hours of the patient's admission to the hospital, a GCS of 11 or greater is associated with an 82% probability of moderate or good neurologic recovery. Lower scores have a significantly higher incidence of severe sequelae. The Glasgow Outcome Scale (Table 123.6) is frequently used to grade long-term recovery following TBI.

| | | |
|---|---|---|
| Eye opening: | Spontaneous | 4 |
| | Speech | 3 |
| | Pain | 2 |
| | None | 1 |
| Motor response: | Obeys | 6 |
| | Localizes | 5 |
| | Withdrawal | 4 |
| | Abnormal flexion | 3 |
| | Extension | 2 |
| | None | 1 |
| Verbal response: | Oriented | 5 |
| | Confused | 4 |
| | Inappropriate | 3 |
| | Incomprehensible | 2 |
| | None | 1 |
| References: 99, 100, 219. | | |

***Table 123.5. Glasgow Coma Scale Components***

| |
|---|
| Dead |
| Persistent vegetative state |
| Severely disabled |
| Moderately disabled |
| Good recovery |
| References: 99, 100, 219. |

***Table 123.6. Glasgow Outcome Scale***

Age is an important factor in neurologic outcome following brain injury regardless of the severity of injury. As a group, patients younger than 20 years of age at the time

of brain injury experience a 62% chance of moderate or good neurologic recovery. Patients between 20 and 30 years of age can expect a 46% chance of moderate or good neurologic recovery. In a series of pediatric patients with brain injury, overall 90% achieved a moderate or good neurologic recovery and only 8% expired or remained in a persistent vegetative state (95,96). Young children with a GCS of 5 or better have a good prognosis for recovery. In addition to having a poorer prognosis for recovery, the cost and time required for rehabilitation of older patients is higher than that for younger patients (40).

Although the GCS has been demonstrated to predict mortality accurately, recent studies have suggested the GCS as a single variable may have limited value as a predictor of functional outcome, and many trauma centers are now using the Revised Trauma Score (RTS) to assist with triage of multitrauma patients. The RTS combines the GCS with the systolic blood pressure and respiratory rate, and is used to predict both mortality and disability (254,255).

The duration of coma is another prognostic indicator. If emersion from coma occurs within the first 2 weeks of brain injury, 70% of patients can be expected to achieve a good recovery. If the coma persists beyond 4 weeks, the chance of good recovery is much diminished. Brain stem involvement, as indicated by the presence of decerebrate or decorticate posturing, has a poor prognosis for outcome. If decerebrate posturing occurs and resolves within the first week after injury, 40% of patients will receive a good neurologic recovery. If decerebrate posturing persists beyond the first week, only 9% of patients will achieve a good neurologic recovery. In a similar manner, the duration of posttraumatic confusion can also be an indicator of prognosis. If the period of posttraumatic confusion persists for more than 4 weeks, one third of patients will have a poor neurologic outcome. It should be remembered, however, that prognosis is a probability statement, and although various factors can be used as guidelines, none is an absolute indicator in the individual patient.

## ORTHOPAEDIC MANAGEMENT OF BRAIN INJURY

The orthopaedic management of TBI can be divided into three distinct time periods (73,78,122,147,148):

- the period of acute injury
- the period of physiologic recovery
- the period of functional adaptation to residual deficits

### *The Period of Acute Injury*

The initial phase of management occurs immediately following the injury in the acute care hospital. The majority of TBIs are the result of a motor vehicle accident. Multiple trauma is common. The orthopaedic surgeon is a consultant with a critical role. Aggressive treatment of orthopaedic injuries at an early stage is important to functional outcome.

The first priority is to diagnose all injuries accurately (1,8,21,23,39,58,61,63,68,71,73,76,85,98,113,145,166,168,186,188,189,204,205,209,210 and 211,253,255). It is common for injuries such as fractures or major peripheral nerve injuries to go undetected. Garland reported an 11% incidence of delayed diagnosis of fractures, with an average time to diagnosis of 57 days (68,209). In the comatose patient, obtain radiographs of all major joints and any other areas suspected of injury. It is important not to assume that all neurologic deficits present are from the CNS injury. Stone and Keenan (209) reported that 34% of brain-injured patients have missed peripheral nerve injuries. Especially in the presence of a limb fracture, suspect a peripheral nerve injury (68,209).

After head injury, pain is often caused by reflex sympathetic dystrophy, deep vein thrombophlebitis, spasticity, occult fracture, and the formation of heterotopic ossification (HO) (37,63,64,84,85,166,204,209,210,224). If pain is treated promptly (and this depends on accurate and early diagnosis), prolonged restriction of motion may be prevented. HO, fracture, and fracture malunion restrict motion due to lost structural integrity. Many brain-injured patients who recover cognitive function have residual spasticity and impaired balance, and consequently, are less able to compensate for such structural impediments (63,156). Peripheral nerve injury produces weakness and pain, both potential causes of restricted motion.

The second rule of orthopaedic care is to assume that the patient will make a good neurologic recovery. Treat all orthopaedic injuries promptly and appropriately. When possible, internal fixation is best. Spasticity develops, and casting a spastic joint in a flexed position may result in a joint contracture or an unsatisfactory reduction. Fracture healing is accelerated, presumably by the same humoral factors that contribute to heterotopic bone formation (10,111,190,222). Fracture malunion is a common and potentially avoidable complication (Fig. 123.1).

***Figure 123.1.*** **A:** Radiograph showing a malunited subtrochanteric fracture of the femur in a 27-year-old man. The fracture was not treated initially because the patient was not expected to survive. **B:** Radiograph showing the corrective osteotomy required to treat the malunion.

The third principle is to expect lack of patient cooperation. The patient emerging from coma may go through a period of agitation and confusion. Fracture care should be made as foolproof as possible because patient cooperation cannot be expected. In anticipating a possible period of agitation, avoid, where possible, traction and external fixators for treatment of extremity fractures (63,71,73,76,79,81,156,224,243,253).

### *The Period of Physiologic Recovery*

Following TBI, neurologic recovery can proceed for a prolonged period of time. The majority of improvement in motor control occurs within the first 6 months following injury. Cognitive improvement occurs most rapidly in the early phases following brain injury but can continue for a very prolonged period of time, often years (Table 123.7) (90). Because the period of potential neurologic recovery following head injury is prolonged, definitive surgical procedures are avoided during the transitional stage. There is no exact time that must elapse before considering surgery to improve musculoskeletal function. Consider the rate of continued improvement in motor control when deciding at what point to intervene surgically. If the additional improvement in motor control will be overridden by the complications of contracture formation, osteopenia, peripheral nerve compression, and muscle atrophy, then early surgical intervention is appropriate.

| | |
|---|---|
| I | No response |
| II | Generalized response |
| III | Localized response |
| IV | Confused, agitated |
| V | Confused-inappropriate, nonagitated |
| VI | Confused-appropriate |
| VII | Automatic-appropriate |
| VIII | Purposeful-appropriate |

Reference: 90.

***Table 123.7. Rancho Levels of Cognitive Functioning***

During the period of physiologic recovery, the patient is commonly in a rehabilitation facility. Serious head injury is usually complicated by UMN syndrome (9,19,74,104,105,112,117,137,148). Spasticity is commonly severe and prevents adequate joint range of motion. Spasticity also interferes with the maintenance of limb position despite the most conscientious and aggressive treatment. Even in those situations in which joint motion can be maintained by a knowledgeable therapist, it commonly requires much force, which is painful for the patient, potentially harmful, and very time consuming. Lesser degrees of spasticity can also impede a patient's function or require the use of positioning devices that interfere with the use of an extremity.

Multiple complications can occur in the presence of spasticity (see Table 123.4). Contractures are common. Limited positioning and myostatic contractures combined with the patients diminished nutritional status can result in pressure sores or hygiene problems. When fractures are present, malunions can occur in the face of uncontrolled muscle tone and accelerated fracture healing. Joint subluxation can also occur from prolonged spasticity or the attempts to range a joint in the face of severe spasticity. If a ligamentous injury occurred at the time of injury, frank dislocation of a joint can be caused by hypertonicity. Spasticity also appears to be one of several etiologic factors in the formation of HO in periarticular location (Fig. 123.2) (13,18,41,44,62,63,64 and 65,67,69,72,73,86,87,98,111,113,128,135,149,153,157,159,167,173,188,190,222,223). An-other common complication of spasticity is acquired peripheral neuropathy (39,47,51,61,68,166,209). The most common peripheral neuropathies acquired with severe spasticity and contracture formation are ulnar neuropathy at the elbow from severe flexion and continuous pressure on the ulnar nerve and carpal tunnel syndrome secondary to severe wrist flexion and pressure of the median nerve against the leading edge of the transverse carpal ligament (166,209). In the lower extremity, sciatic neuropathy can result from trauma such as a hip dislocation or acetabular fracture. Sciatic neuropathy can be caused by the pronounced inflammation associated with heterotopic bone formation posterior to the hip joint. In some cases, the bone can encase the sciatic nerve. During the period of physiologic recovery, the temporary control of spasticity is the major focus of treatment. Prevention of additional complications, such as disuse muscle atrophy, joint contractures, HO, and peripheral neuropathies, is critical to a good functional outcome (5,13,18,36,37,39,41,44,47,48,54,58,61,62,63,64 and 65,67,69,72,73,77,86,87,98,111,113,128,135,149,153,157,159,173,174,181,185,188,190,191 and 192,199,204,205,206 and 207,209,210,212,213,222,223,243,245,253,256,257). Early joint contractures are also best corrected during this phase of treatment. This is accomplished by first reducing spasticity and then correcting contractures by splinting, casting, and range-of-motion therapy.

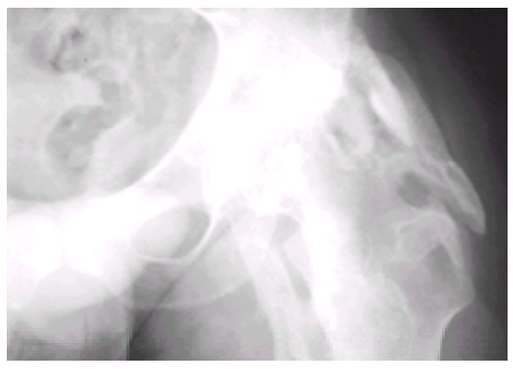

***Figure 123.2.*** Radiograph of a hip showing periarticular heterotopic ossification posterior and lateral to the joint.

***The Period of Functional Adaptation to Residual Deficits***

When physiologic neurologic recovery has ceased, the brain-injured patient is commonly left with residual limb deformities from spasticity, contractures, and muscle imbalance. It is at this time that definitive orthopaedic surgical procedures are performed to rebalance the muscle forces and correct the residual deformities.

## HETEROTOPIC OSSIFICATION

HO presents clinically with an intense inflammatory reaction about the joint seen as redness, warmth, severe pain, and rapidly decreasing range of motion (5,13,18,36,37,39,41,44,48,54,61,62,63,64 and 65,67,69,72,73,77,86,87,98,111,113,128,135,149,153,157,159,173,188,190,191 and 192, 199,204,205,206 and 207,210,212,213,222,223,243,245) (see Fig. 123.2).Although the time of initial occurrence is variable, HO is usually detected 2 months following the onset of TBI. Generally, radiographs show evidence of the heterotopic bone in the form of spotty periarticular calcification.

The incidence of periarticular HO following TBI is 11%; the hips are most commonly involved, followed by shoulders and elbows (69,111,135,222). The exact etiology of HO is not known, and it is likely multifactorial. It clearly has a predilection, however, for joints surrounded by spastic or paretic muscle (63,64,69,72,111,222). A dramatic increase in incidence to 85% is seen in patients who have concomitant musculoskeletal injury. Because of this increased incidence, consider prophylactic treatment. Several modalities have been used with varying success. High-dose diphosphonates (Didronel) and nonsteroidal anti-inflammatory drugs, particularly indomethacin, have been used in the early postinjury period (5,65,68,136,193,207,212,243). Radiation (800 cGy limited field) can be used within several days following the injury (5,48,64,65,149,153,199). Joint manipulation has also been used, but the benefit of this is unclear if the heterotopic bone has already begun to form (77,212). Formation of HO can be followed radiographically and by following serial alkaline phosphatase measurements. The HO is mature when the alkaline phosphatase has returned to a normal value and the radiographs show a well-defined, corticated bone mass. Technetium bone scans show increased uptake for many years and are of little value in this situation. Studies have found that measuring the serum osteocalcin levels is an unreliable method to diagnose HO or determine its maturation (159). Surgical excision is thought to carry a higher risk of recurrence if it is attempted before maturation. This factor has been noted in work with HO in spinal cord–injury patients and has not been shown to be applicable to TBI patients (36,37,64,65,72,87,135,157,191,212). Early excision should be considered in cases in which the HO is causing progressive nerve or vascular compromise, or is threatening joint ankylosis. Early excision of HO is technically more demanding because the planes of dissection are less clear. There is also a much greater blood loss when resecting immature HO.

## REFLEX SYMPATHETIC DYSTROPHY

Reflex sympathetic dystrophy (RSD) is characterized by “constant, spontaneous, severe, burning pain and is usually associated with hypo- and hyperesthesia, hyperpathia, and allodynia, along with vasomotor and sudomotor disturbances that, if persistent, result in trophic changes” (85). RSD commonly develops following CVAt (posthemiplegic dystrophy), TBI, and surgery. It may be associated with trauma that occurred concurrently with TBI, although the severity of the initial injury is unrelated to the severity of the ensuing symptoms.

Onset following trauma is usually within the first several weeks; however, with stroke and brain injury, the onset may be delayed and atypical. Because of this, RSD may remain undiagnosed in the stroke or brain-injured population until it becomes irreversible.

Radiographs showing patchy demineralization of involved epiphyses even during the first phase suggest the diagnosis. Subperiosteal resorption, tunneling of the cortex, and striation may be evident on good-quality films. Unfortunately, none of these changes are specific for RSD. A triple-phase bone scan may help with diagnosis. The pattern seen varies with the phase of the disease. In the acute phase, the flow (immediate), blood pool (early), and delayed (static) scan patterns all show increased uptake, usually in a periarticular distribution. False-negative results are frequent in the dystrophic phase, in which the flow and blood pool scans are normal, and the delayed scan shows a somewhat less prominent periarticular increase in uptake. In the atrophic phase, both the flow and early scans show decreased uptake, whereas the delayed phase is normal.

Treatment includes several modalities. Physical therapy, particularly active and active assisted range of motion, gentle muscle strengthening and conditioning, massage, and heat therapy have been effective. Tricyclic antidepressants (amitriptyline) may have an effect because of their inhibition of serotonin uptake at pain-suppressing neurons, prolonging the serotonin effect at the receptor. Narcotics have a role in low-dose epidural infusions in combination with local anesthetics. Systemic corticosteroids and adrenergic blocking agents have both been advocated. Use of nerve blocks, including stellate ganglion blocks, Bier blocks, surgical sympathectomy, and chemical sympathectomy, have been reported resulting in improvement in a high percentage of patients. At present, we use a regimen of amitriptyline, physical therapy, and percutaneous sympathetic blockade.

## GENERAL CONSIDERATIONS FOR DECISION MAKING

### DEGREE OF SPASTICITY

The majority of stroke patients have a period of limb flaccidity before the gradual onset of increasing muscle tone or spasticity (resistance to quick stretch). Because these patients are generally older than brain-injured patients, their muscles are also weaker. This, combined with the shorter period of spontaneous neurologic recovery (6 months), makes the temporary control of spasticity an easier task in stroke patients. The use of phenol nerve blocks or intramuscular botulinum toxin injection is therefore less common than in the TBI patient.

**TIMING OF NEUROLOGIC RECOVERY**

The prolonged period of physiologic recovery, the intense level of spasticity (response to fast stretch), the presence of rigidity (resistance to slow stretch), and the strong muscles found in young TBI patients make the temporary control of spasticity much more difficult. Phenol nerve blocks, botulinum toxin injections, and casting are used more commonly and aggressively.

**PATTERN OF NEUROLOGIC RECOVERY**

The majority of stroke patients (middle cerebral artery infarcts) have hemiplegic involvement with a nonfunctional upper extremity and a lower extremity with greater potential for function. The surgical procedures used to correct residual deformities in the upper extremity are more likely to be for the correction of contractual deformities than to improve function. Even when functional procedures are employed, the gains from these procedures are more modest than those in the brain-injured patient.

In contrast, the young brain-injured patient is more likely to have quadriplegic involvement, concomitant peripheral nerve injuries, residual deformities from fractures, and joint limitation from HO but better return of motor control. Functional surgical procedures are more common in these patients.

**TEMPORARY MANAGEMENT OF SPASTICITY DURING THE PERIOD OF PHYSIOLOGIC RECOVERY**

The treatment of spasticity depends on the time since injury and the prognosis for further recovery. In the period of physiologic recovery, temporizing interventions are used because permanent changes may result in chronic imbalance of forces across joints (14,15,17,29,46,52,73,74 and 75,102,104,107,118,119,131,132 and 133,155,158,197,202,225,247,249). Prevention of additional complications, such as disuse muscle atrophy, joint contractures, HO, and peripheral neuropathies, is critical to a good functional outcome. Several choices are available for treatment.

A combination of peripheral nerve blocks and casting or splinting techniques are commonly used to give temporary relief of spasticity. Casting maintains muscle fiber length and diminishes muscle tone by decreasing sensory input (14,73). Local anesthetic nerve blocks are very helpful when they are administered before cast application because relieving the spasticity allows for easier limb positioning (Fig. 123.3). Casts are used primarily for the correction of contractual deformities by applying a cast on a weekly basis. Serial casting is most successful when a contracture has been present for less than 6 months.

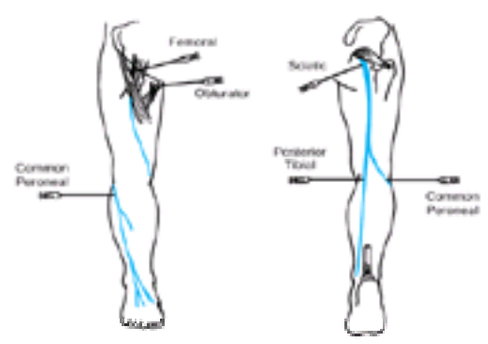


***Figure 123.3.*** The most commonly performed local anesthetic nerve blocks in the lower extremity. (From Keenan MAE. The Orthopaedic Treatment of Spasticity. *The Journal of Head Trauma Rehabilitation* 1987;2:62.)

Oral antispastic agents may be used during this period. Antispastic agents that have sedating properties, such as baclofen, diazepam, and clonidine, may compromise patients with attention deficits or memory disorders. Even a drug such as dantrolene sodium, which has a peripheral mechanism of action, may also cause drowsiness. Other serious side effects such as hepatotoxicity can occur. Continuous infusion of intrathecal baclofen has been reported to be useful in managing spasticity secondary to spinal cord injury. Such delivery avoids the cognitive side effects seen with oral delivery. Early studies have shown that intrathecal bolus infusions of baclofen via a catheter placed in the lumbar space may also be capable of reducing spastic hypertonia associated with brain injury (2,3,152).

Focal injection with neurolytic or chemodenervating agents is the most suitable approach for treating restricted motion secondary to spasticity. Neurolytic agents such as phenol and chemodenervation agents such as botulinum toxin A are used during this period because their effects are temporary, lasting only 3 to 5 months (15,17,29,46,73,74 and 75,101,102,104,107,118,119,131,132 and 133,155,158,225,249). These agents are used when restricted motion occurs as a result of focal spasticity. When these agents “wear off,” the patient is re-evaluated to determine whether additional recovery has taken place and whether there is further indication for reblocking. It is critical that the functional problems of the patient be accurately ascribed to specific muscles. This is done by evaluation using multichannel dynamic EMG (60,105,109,112,117,125,136,137,147,148,176,183). Even if many muscles in a limb are involved, a number of focal injections are possible, and by doing so, CNS side effects can be avoided. For patients with pathologies causing excessive motion, environmental modification weights, bracing, and oral medications may be considered during the period of physiologic recovery.

**PHENOL BLOCKS**

Phenol, a derivative of benzene, in aqueous concentrations of 5% or more denatures the protein membrane of peripheral nerves. When phenol is injected in or near a nerve bundle, its neurolytic action on the myelin sheath or the cell membranes of axons with which it makes contact serves to reduce neural traffic along the nerve. The onset of the destructive process with higher concentrations of phenol may begin to show effects several days after injection. The denaturing process induced by phenol extends biologically on the order of weeks but eventually regeneration occurs. A phenol block is used as a temporizing measure rather than a permanent intervention. In our clinical experience and the experience of others, the effect of a phenol block typically lasts 3 to 5 months.

Histologically, it has been shown that phenol destroys axons of all sizes in a patchy distribution but more so on the outer aspect of the nerve bundle onto which the phenol is dripped. When phenol is percutaneously injected, it is likely that the nerve block will be incomplete. This is especially useful in situations in which a spastic muscle also has volitional capacity, because under these circumstances, it is desirable to reduce spasticity while still preserving volitional capacity of a given muscle or muscle group.

The technique of phenol injection is based on electrical stimulation. Motor branches are injected close to the offending muscle or muscle group. These branches are referred to as motor points. A surface stimulator is briefly used to approximate the percutaneous stimulation site in advance. A 25-gauge Teflon-coated hypodermic needle is advanced toward the motor nerve. Electrical stimulation is adjusted by noting whether muscle contraction of the index muscle takes place. As the electrode gets closer to the motor nerve, less current intensity is required to produce a contractile response. The motor nerve is injected when minimal current produces a visible or palpable contraction of the muscle. Generally, 4 to 7 ml of 5% to 7% aqueous phenol is injected at each site. As with any injection, care must be taken not to inject the agent into a blood vessel; this is done by aspirating before the injection (15,17,29,46,73,74 and 75,101,102,104,107,118,119,131,132 and 133,147,148,155,158,225).

**BOTULINUM TOXIN BLOCKS**

Botulinum toxin is a newer agent used in the localized treatment of spasticity. Ordinarily, an action potential propagating along a motor nerve to the neuromuscular junction triggers the release of acetylcholine (ACh) into the synaptic space. The released ACh causes depolarization of the muscle membrane, activating a biochemical sequence that leads to muscle contraction. Botulinum toxin type A is a protein produced by *Clostridium botulinum* that inhibits this calcium-mediated release of ACh at the neuromuscular junction. Botulinum toxin A attaches to the presynaptic nerve terminal and divides into a light and a heavy component. The light component gets into

the nerve cell and interferes with “fusion proteins” affiliated with vesicles of ACh, thereby preventing the release of ACh from their storage vesicles.

Botulinum toxin injection has been used to treat a variety of dystonias and has been approved by the U.S. Food and Drug Administration for the treatment of blepharospasm, facial spasm, and strabismus. A number of studies have reported its use in treating spasticity in individuals with cerebral palsy, stroke, head trauma, and multiple sclerosis (38,52,60,147,148,197,202,247). The clinical benefit lasts 3 to 5 months but may be more variable. Botulinum toxin is injected directly into an offending muscle and, depending on the size of the muscle being injected, dosing has ranged between 10 and 200 units (U). Current practice is to wait at least 12 weeks before reinjection and not to administer a total of more than 400 U in a single treatment session. Because this upper limit of 400 U may be reached rather quickly, a different strategy is needed for the limb requiring many proximal and distal injections. Botulinum toxin A and phenol may be combined, with botulinum toxin A being injected into smaller distal muscles and phenol aimed at larger proximal ones. A 3- to 7-day delay between injection of botulinum toxin A and the onset of clinical effect is typical. Effects are not seen immediately by the patient, and usually a follow-up visit is arranged to check the result. The amount of toxin given for a particular muscle is variable.

The technique of botulinum toxin injection varies. Some physicians inject through a syringe attached to a hypodermic needle that doubles as a monopolar EMG-recording electrode. Patients may be asked to make an effort to contract the targeted muscle, or the muscle may contract involuntarily as in dystonia. After inserting the needle electrode, injection is made when EMG activity is recorded. For deep or small spastic muscles (e.g., extrinsic toe flexors), electrical stimulation is preferred to localize the muscle before injection.

Botulinum toxin injections have gained much popularity in the past several years. The advantages of botulinum toxin are its ease of injection and the lack of residual scarring after injection. The disadvantages of botulinum toxin are its high cost and the stimulation of antibody formation, which requires higher doses for repeated injections. Phenol, by contrast, requires more technical expertise to localize the nerve or motor points for injection. Phenol is caustic and causes localized scarring of the nerve and muscle. On the other hand, phenol is inexpensive and readily available.

## COMMON TECHNIQUES OF NERVE AND MOTOR POINT BLOCKS

### *Hip Adductor Spasticity*

Severe spasticity of the hip adductor muscles causes multiple problems (73,78,103,122,127,147,148,155,158,176,178,184,226). These include limited access to the perineum resulting in poor hygiene, limited positioning of the patient, and the formation of decubitus ulcers. In more functional patients, the increased adductor tone causes scissoring of the legs when the patient is upright. Scissoring interferes with balance, transfers, and ambulation by narrowing the base of support (Fig. 123.4).

***Figure 123.4.*** Limb scissoring caused by spasticity of the hip adductor muscles produces a narrow base of support and difficulty with balance during ambulation.

There are several techniques for controlling spasticity on a temporary basis in a patient who is still in the period of physiologic recovery (Table 123.8). A phenol block of the obturator nerve can be performed percutaneously to decrease the hip adductor tone. Because the sensory component of the obturator nerve is small, direct injection of the nerve is not problematic. It is advisable to administer an anesthetic nerve block first to rule out a myostatic contracture. Locate the obturator nerve as it emerges from the obturator canal by using a nerve stimulator and insulated needle electrode. Then inject 2 to 5 ml of 5% phenol in saline. The block will gradually take effect over the following 24 hours, and the effects will last for approximately 2 months. While the hip adductor tone is decreased, use gentle range of motion exercises to stretch out any contracture. Transfer and gait training can be continued.

| *Disorder* | *Corrective technique* |
|---|---|
| Hip flexion | Paraspinal phenol lumbar blocks |
| Hip adduction | Obturator nerve phenol blocks |
| Knee extension | Femoral nerve phenol block |
| Knee flexion | Sciatic nerve anesthetic block<br>Application of long leg-cast |
| Equinus foot | Botulinum toxin injection of calf muscles |
| Varus foot | Botulinum toxin injection of the tibialis anterior muscle |
| Valgus foot | Botulinum toxin injection of the personal muscles |

***Table 123.8. Techniques for the Temporary Management of Spasticity***

Botulinum toxin injections of the hip adductor muscles can also be administered. If many large muscles in the lower extremity require treatment for control of spasticity, phenol is a more practical choice.

### *Hip Flexor Spasticity*

Severe spasticity of the hip flexor muscles not only causes hip flexion contractures but may also contribute to knee flexion deformities (Fig. 123.5). When hip flexor spasticity cannot be controlled by the use of a long-leg cast, prone lying, or positioning devices, then percutaneous paraspinal blocks of the upper lumbar nerve roots can be performed to diminish hip flexor spasticity.

***Figure 123.5.*** Patient with severe, longstanding flexion contractures of both the hips and knees. The patient developed multiple pressure sores and had a flap

procedure to cover a decubitus ulcer over the left greater trochanter.

Localize the nerve roots by using an insulated spinal needle and nerve stimulator. Then inject 1 to 2 ml of 5% phenol in saline. The hip flexor tone can be expected to decrease gradually over the following 24 hours. Then begin a physical therapy program to stretch out any fixed hip flexion contracture.

Botulinum toxin injections of the hip flexor muscles can be administered but are technically difficult given the deep location of the muscles and the proximity of the large femoral vessels.

***Hip Extensor Spasticity***

Severe spasticity of the hip extensor muscles can occur with a brain stem or anoxic injury. Lack of adequate hip flexion range of movement will greatly interfere with a patient's ability to sit in a chair (Fig. 123.6) (60,132,133,147,148). Sitting is a crucial step in rehabilitation because it allows a person to begin interacting with people and objects in the environment.

***Figure 123.6.*** Spasticity of the hip and knee extensor muscles in a brain-injured patient results in difficulty while sitting. This young patient requires the use of a seat belt and a semireclining wheelchair to maintain her position.

Percutaneous phenol injection of the inferior gluteal nerve as it enters the muscle belly of the gluteus maximus is an effective technique in reducing hip extensor tone and maintaining the ability to flex the hip. The inferior gluteal nerve enters the gluteus maximus muscle at the center of the muscle belly just proximal to the piriformis tendon. Carefully localize the nerve with an electrode needle and a nerve stimulator before injection. Inject 2 ml of 5% phenol in saline into the muscle at the motor point. The muscle tone can be expected to diminish over the following 24 hours. Then begin passive range-of-motion exercises to increase hip flexion range. A continuous passive motion machine is helpful to supplement the physical therapy program. Botulinum toxin injections of the hip extensor muscles can also be administered.

***Knee Flexor Spasticity***

When severe hamstring spasticity is present, knee flexor contractures develop very rapidly (Fig. 123.5). Because of the large sensory component of the sciatic nerve, direct injection with phenol is undesirable. The dissection required to identify the multiple motor branches of the hamstring muscles is extensive and often impractical. Phenol motor point injections or botulinum toxin injections of the hamstring muscles can be administered. Prevention of knee flexion contractures can also be achieved by performing repeated anesthetic nerve blocks of the sciatic nerve and casting the limb in extension (73,78,80,88,101,103,120,122,127,147,148,169,174,178,194,201). Take care to observe the knee very closely during the casting program to avoid posterior subluxation of the knee joint. Using a sciatic nerve block at the time of casting diminishes the likelihood of this complication. An anesthetic block of the sciatic nerve will also temporarily eliminate calf spasticity and allow for serial casting of an equinus contracture of the foot, if present.

When serial casting and sciatic nerve blocks fail to correct a knee flexion deformity or when posterior subluxation of the tibia occurs secondary to the hamstring tightness, a lengthening of the hamstring muscles can be performed even in the early stages following injury. The biceps femoris, gracilis, and the semimembranosus muscles have myotendinous junctions that permit a fractional lengthening. The semitendinosus muscle is either divided or **Z** lengthened (Fig. 123.7). Casting is still commonly needed following hamstring lengthening to correct the residual flexion deformity.

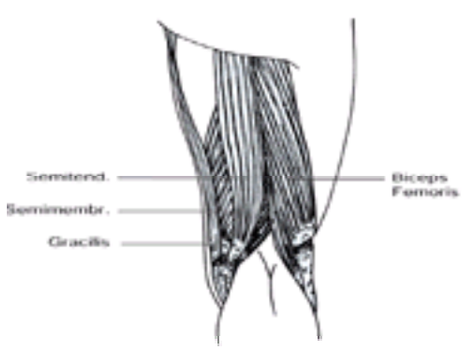


***Figure 123.7.*** Lengthening of the biceps femoris, semimembranosus, and gracilis muscles at the musculotendinous junction. The semitendinosus is released.

***Knee Extensor Spasticity***

Severe spasticity of the quadriceps muscles may be seen in brain stem injuries or anoxic brain damage (Fig. 123.6). When knee range of motion cannot be maintained because of quadriceps tone, a percutaneous phenol block of the femoral nerve can be performed (15,38,46,60,73,101,102,131,132,147,148,155,158,247,249). This block, in combination with the use of a continuous passive motion machine, is then used to regain and maintain adequate knee range of motion. Even in a severely injured patient, knee and hip flexion range should be preserved to permit adequate sitting in a chair.

The femoral nerve has a minimal sensory component and can therefore be directly injected using a percutaneous technique. Localize the nerve in the groin lateral to the femoral vessels by using an electrode needle and nerve stimulator. Then inject 2 ml of 5% phenol in saline. Relaxation of quadriceps muscle tone can be expected to last 2 to 3 months. Use physical therapy and continuous passive motion to regain knee flexion range.

It is also possible to locate the motor points of the individual muscles of the quadriceps and perform motor point blocks using phenol. Use a surface stimulator to find the general vicinity where the motor branches of the femoral nerve enter each muscle belly. These are located at the proximal end of the muscles. Then use a needle electrode and stimulator to localize the motor nerve more accurately.

Botulinum toxin injections of the knee extensor muscles can also be administered. Because the quadriceps are large muscles, a large volume of botulinum toxin would be needed. It would also require injections to be given on several occasions. For these reasons, phenol is a more practical choice.

### *Ankle Plantarflexor Spasticity*

Excessive spasticity of the gastrocnemius and soleus muscles causing equinus posturing of the foot is very common. When the spasticity is mild, it can generally be contained and an equinus contracture prevented by using a rigid ankle-foot orthosis (AFO). At times the muscle tone is too severe to be adequately controlled by a brace. The patient may exhibit ankle clonus while in the upright position, causing the foot to piston up and down in the brace.

Some rehabilitation specialists do percutaneous phenol injections of the posterior tibial nerve. We do not recommend this procedure because of the large sensory component of the nerve. Phenol is a caustic substance, and its injection into a mixed nerve can result in severe painful dysesthesia and loss of sensation on the plantar aspect of the foot. A phenol block of the motor branches of the posterior tibial nerve can be performed as a surgical procedure to preserve sensation to the plantar aspect of the foot (Fig. 123.8) (73,75,78,103,108,122,127,147,148).

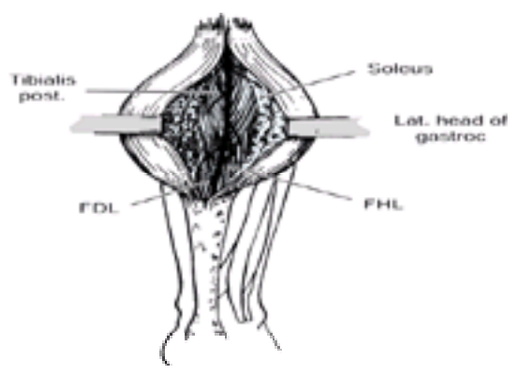


***Figure 123.8.*** The branches of the posterior tibial nerve as exposed at the time of surgery. The individual motor branches of the nerve are injected with a 5% phenol and glycerin solution under direct vision. This procedure provides 6 months of relief of spasticity without interfering with sensation to the leg. *FDL,* flexor digitorum longus; *FHL,* flexor hallicus longus; *gastroc,* gastrocnemius.

- Make an incision on the posterior aspect of the calf at the midline beginning just distal to the popliteal crease.
- Identify the posterior tibial nerve between the heads of the gastrocnemius muscle and trace it distally. Use a nerve stimulator to identify the motor branches. When all of the motor branches have been identified to the gastrocnemius, soleus, posterior tibialis, flexor hallucis longus, and flexor digitorum muscles, protect each from the surrounding tissue with a moistened gauze sponge.
- Then inject the motor branches with a 5% phenol solution in glycerin. Glycerin is used for surgical phenol blocks because it allows the phenol to be released more slowly and therefore prolongs the effect of the block for 6 months. The glycerin solution is too viscous for percutaneous use.

Postoperatively, protect the patient with an AFO to maintain the ankle at a neutral position to protect the calf muscles while the block is in effect.

Since the advent of botulinum toxin injections, surgical phenol blocks of the posterior tibial nerve are rarely needed. It is much more practical to inject the gastrocnemius and soleus muscles with botulinum toxin. It isusually necessary to inject the flexor hallucis and flexordigitorum muscles simultaneously because they both contribute to the equinus. Use an AFO after botulinum toxin injections because of the muscle weakness caused by the blocks.

### *Ankle Invertor and Evertoe Spasticity*

Spasticity of the tibialis anterior muscle has been shown to be a primary muscle responsible for the varus deformity of the foot in both stroke and brain-injured patients (Fig. 123.9 and Fig. 123.10) (16,20,22,25,26,28,43,59,60,78,80,103,105,106,108,109,122,127,138,147,148,163,174,175,176,177 and 178,180,184,194,195,226,227,230,241). Most frequently, this deformity can be controlled initially with the use of an AFO. In the event that a brace does not control the foot, a phenol block of the motor branch of the deep peroneal nerve in the proximal leg can be performed percutaneously to decrease the spasticity. Localize the nerve by using a stimulator and needle electrode before injection with 1 ml of 5% phenol in saline. Alternatively, inject the muscle with botulinum toxin. The extensor hallucis longus (EHL) muscle and the tibialis posterior muscle can significantly contribute to a varus foot deformity. Phenol motor point or botulinum toxin injections of these muscles are often needed as well. Use an AFO to maintain a neutral foot position after the blocks.

***Figure 123.9.*** Patient with a spastic equinovarus deformity of the foot following a cerebrovascular accident.

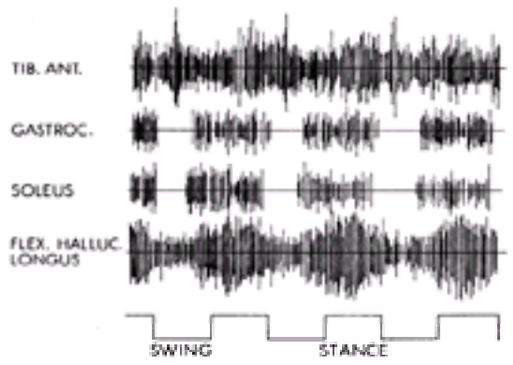


***Figure 123.10.*** Dynamic electromyogram (EMG) obtained during walking from a stroke patient with a spastic equinovarus foot deformity. The foot switches on the baseline indicate the swing and stance phases of gait. The tibialis anterior shows continuous activity in a nonphasic manner throughout (class IV EMG activity; see Table 123.9). The gastrocnemius shows class II EMG activity, which begins prematurely during the late swing phase and continues throughout the stance phase. The soleus muscle also shows class II activity with premature firing in late swing, continuing throughout the stance phase. The flexor hallucis longus exhibits class IIIC activity. The activity is continuous, but some phasic element can be seen with increased amplitude in midstance.

| | | |
|---|---|---|
| Class I | | Normal phasic activity |
| Class II | | Premature prolonged activity |
| Class III | | Phasic prolonged activity |
| | IIIA | Mild prolongation activity |
| | IIIB | Moderate prolongation activity |
| | IIIC | Severe prolongation activity |
| Class IV | | Continuous activity |
| Class V | | Stretch response activity |
| Class VI | | Absent activity |

References: 105, 112, 117, 126, 147, 148.

***Table 123.9. Classification of EMG Activity***

Although less common, spastic valgus foot deformities can occur. Phenol motor point or botulinum toxin injections of the offending peroneal muscles temporarily control the deformity.

## EVALUATION OF RESIDUAL LIMB DEFORMITIES

### ASSESSMENT OF COGNITION AND COMMUNICATION

Extremity function requires that complex and highly sophisticated mechanisms work together in unison. Improving lower extremity function requires careful systematic evaluation before surgery. The goals of surgery must be practical and clearly understood by the patient and the family. Assessment includes an evaluation of cognition and communication skills (4,20,22,25,26,28,78,80,101,105,106,109,115,122,138,147,148,150,151,156,178,184,194,195,226,241). This is done during the physical examination. The patient must be capable of following simple commands and should also be able to cooperate with a postoperative therapy program. In addition, the patient should have sufficient cognition to incorporate the improved motor function into their use of the extremity. Adequate memory is needed to retain what is taught during postoperative therapy.

### SENSORY EVALUATION

The ability to maintain balance and ambulate depends on adequate sensation in the foot and ankle. The basic modalities of light touch and pain sensation are essential. Proprioception must be present at the level of the ankle joint for good balance reactions. If proprioception is impaired at the ankle, an AFO may be needed during ambulation to prevent a compensatory knee extension thrust (115,175,178,180).

### EVALUATION OF LIMB DEFORMITY AND POTENTIAL FUNCTIONAL CAPABILITY

Diffuse axonal injury, multifocal vascular pathology, and diffuse hypoxic encephalopathy lead to a large variety of posttraumatic motor phenomena, many of which are functionally significant. Lesions affecting the corticospinal system, the cerebellum and its pathways, and the extrapyramidal system are common. Hemiparesis is the most common long-term residual of head injury. Many patients, however, have a brain stem syndrome consisting of ipsilateral ataxia and contralateral spastic hemiparesis. A small percentage have a pseudobulbar athetoid type of picture. Patients can also have residuals of bilateral hemiparesis, ataxia involving both sides of the body, and severe dystonic decerebrate posturing or rigidity. Many patients, especially during the early recovery stage from head injury, reveal mixed signs such as spasticity combined with tremor and ataxia. Peripheral neuropathy is common after head injury, and focal dystonia, although unusual, is also seen. Because so many different aspects of the motor control system may be affected by a head injury, we present a way of organizing the unwieldy array of symptoms that emerge from a damaged nervous system (147,148). Our perspective is a practical one, namely taking into account the impact of movement disorders on the patient's ability to function in real life.

Treatment of spasticity is most effective when functional problems are formulated and described in focal rather than diffuse terms. Treatment of focal problems lends itself well to surgical intervention, which can target particular muscles. Surgical lengthening, transfer, or release of targeted muscles can provide very effective solutions to problems of function that are clearly identified from the outset. The localizing approach is useful because it forces the clinician to indicate the desired outcome in advance. The outcome is based on an analysis that identifies the specific spastic muscles responsible for the problem. For example, if the clinical problem is an equinovarus foot that inhibits walking, surgically lengthening or transferring the tibialis posterior will not solve the problem if tibialis anterior and gastrocsoleus muscles are really the culprits responsible for the problem. Identifying the specific offending muscles is critically important to localized strategies of intervention (59,101,105,129,175,176 and 177,179,180,231,232,241).

In a neurologically impaired patient, it is frequently difficult to distinguish between the many potential causes of limited joint motion. The possibilities include increased muscle tone, a myostatic contracture, the presence of periarticular HO, an undetected fracture or dislocation, joint subluxation, pain, or the lack of patient cooperation secondary to diminished cognition. Bony deformities may not exhibit an obvious clinical deformity but can be detected by radiography.

#### *Clinical Evaluation of Motor Control*

Evaluation of spasticity focuses on identification of three factors: (1) the clinical pattern of motor dysfunction, (2) the patient's ability to control muscles involved in the clinical pattern, and (3) the role of muscle stiffness and contracture in relation to the functional problem. For purposes of convenience, we identify seven clinical patterns of lower extremity motor dysfunction that are most commonly seen (Table 123.2).

Other variations of motor dysfunction occur but are less common. Various muscles may contribute to motor dysfunction across joints and limb segments in these clinical patterns. Evaluation focuses on the following characteristics of the involved muscles: voluntary or selective control, spastic reactivity, rheologic stiffness, and contracture. Ask five specific questions:

- Does the patient have voluntary control over a given muscle?
- Is the muscle spastic to passive stretch?
- Is the muscle, as an antagonist, activated during active movement generated by an agonist?
- Does the muscle have increased stiffness when stretched?
- Does the muscle have fixed shortening (contracture)?

When many muscles cross a joint, the characteristics of each muscle may vary. Because each muscle may contribute to motion and movement of the joint, information about each muscle's contribution is useful to the assessment as a whole. Treatment depends on such information (60,147,148).

Spasticity often masks underlying motor control. In the lower extremity, the most common pattern of spasticity is one of flexion. First, establish passive range of motion of each joint. Test by slow extension of the joint to avoid the velocity-sensitive response of the muscle spindle. When spasticity is significant and passive joint motion is incomplete, it is necessary and advisable to perform an anesthetic nerve block to assess whether a myostatic contracture is present (Fig. 123.3) (104,105,121,125,126). To evaluate passive joint motion in the entire lower extremity, perform combined femoral and sciatic nerve blocks by using a local anesthetic. Alternatively, examine the patient while he or she is under general anesthesia. This is usually done only when the patient is going to surgery for another reason.

Unmasking of primitive patterning reflexes further contributes to the motor impairment. Spasticity (hyperactive response to quick stretch), rigidity (resistance to slow movement), or movement dystonias may be present. The degree of spasticity within selected muscles can be graded clinically in response to a quick stretch as mild, moderate, or severe. There is surprising consistency between observers using this simple grading system. Another method of quantifying muscle tone, which is readily accessible and easily performed at the bedside, is to measure the amount of intramuscular pressure generated by a passive quick stretch or during functional use of the limb. Intramuscular pressure can be measured by using a wick or slit catheter technique. The pressure generated within the muscle is proportional to the force of contraction (7,181).

Motor control can be graded in the extremity using a clinical scale (see Table 123.3) (112). The extremity may be hypotonic or flaccid and without any volitional movement (grade 1). A spastic extremity may be held rigidly without any volitional or reflexive movement (grade 2). Patterned or synergistic motor control is defined as a mass flexion or extension response involving the entire upper extremity. This mass patterned movement may be reflexive in response to a stimulus but without

volitional control (grade 3). It is also possible for a patient to initiate mass patterned movement volitionally (grade 4). Although patterned movement can often be volitionally initiated, it is a neurologically primitive form of motor control and of no functional use in the upper extremity. Selective motor control with pattern overlay is defined as the ability to move a single joint or digit with minimal movement in the adjacent joints when performing an activity slowly (grade 5). Rapid movements or physiologic stress make the mass pattern more pronounced. Selective motor control is defined as the ability to move a single joint or digit volitionally independently of the adjacent joints (grade 6). Observe the patient clinically in a variety of functional tasks.

Differentiating between the relative contributions of pain, increased muscle tone, and contracture to a limb deformity can be difficult. Anesthetic nerve blocks are extremely useful in assessing joint range of motion. The blocks can be easily performed without the use of special devices. By temporarily eliminating pain and muscle tone, patient cooperation is gained and the amount of myostatic contracture can be determined. By using local anesthetic blocks, the strength and motor control of the antagonistic muscle group can also be evaluated (Fig. 123.3).

***Laboratory-Assisted Assessment of Gait and Motor Control***

Clinical examination supported by laboratory studies is the mainstay of evaluation. The clinical questions of interest regarding a given muscle include the following: Does the patient have selective voluntary control over the given muscle? Is the muscle activated dyssynergically (i.e., in antagonism to movement) when the patient attempts to move the relevant joint? Is the muscle resistive to passive stretch (i.e., spastic)? Does the given muscle have fixed shortening (i.e., contracture)? Given the degree of clinical effort, patient morbidity, and procedural costs involved in treating complicated movement dysfunction in patients with CVA and TBI, clinical examination alone may not be sufficient to answer these questions with a high degree of confidence.

Technology-driven laboratory assessments that include formal gait and motion analysis, dynamic EMG studies, and nerve blocks are helpful (7,11,24,25,26 and 27,35,43,52,59,60,89,94,108,109 and 110,114,115,127,129,138,143,147,148,175,176,177,178,179 and 180,198,203,214,220,229,231,232,233 and 234,236,239,240,241 and 242). Perform laboratory gait analysis preoperatively on all patients using a standard laboratory protocol. This consists of bidirectional, slow-motion video recordings. Ground reaction forces are displayed using a laser vector superimposed on the video. Ground reaction forces are recorded from a force plate mounted into the walkway. The force plate consists of a rigid platform suspended on strain gauge transducers fitted with strain gauges. Each supporting corner has three sensors set at right angles to one another, and the vertical load, horizontal shear force, and forces in the mediolateral direction are measured. Temporospatial parameters obtained include walking velocity, cadence, stride time, and measurements of symmetry of gait. Dynamic multichannel EMG is acquired with simultaneous measurements of joint motion (kinematics) in the lower extremity while walking. Joint motion is recorded using electrogoniometers. Surface electrodes are used for the superficial lower limb muscles and wire electrodes for the deep muscles such as tibialis posterior and long toe flexors.

Kinetic, kinematic, and dynamic EMG data assist the clinician in interpreting whether voluntary function (effort-related initiation, modulation, and termination of activity) is present in a given muscle and whether that muscle's behavior is also dyssynergic (sometimes referred to as “out of phase” behavior). In addition, responses to different rates of passive stretch of the muscle before and after a local anesthetic nerve block can help the clinician distinguish between the dynamic, velocity-sensitive reflex resistance of spasticity versus passive muscle tissue stiffness and contracture. Somatosensory-evoked potentials (SEPs) and motor evoked potentials (MEPs) provide information on the integrity of the sensory and motor pathways and may be helpful in predicting recovery of motor function after stroke (93). Combined with clinical information, laboratory measurements of muscle function often provide the degree of detail and confidence necessary for making conservative and surgical treatment decisions.

By combining the findings in several previous studies of spastic patients from our institution the following classification of EMG activity was devised to standardize terminology and may be used for either the upper or lower extremity (Table 123.9) (105,112,117,125,126).

- Class I constitutes a normal phasic pattern with appropriate on and off EMG activity.
- Class II consists of EMG activity that, although phasic, begins prematurely and continues for a short period beyond the normal duration of activity for that muscle. This pattern is more commonly seen in the lower extremity.
- Class III consists of phasic activity with prolongation beyond the normal timing of the muscle. Class III activity can be further subdivided into three patterns, depending on the degree of prolongation.
- Class IIIA consists of phasic activity with a short period of low-intensity EMG activity extending into the next phase of the flexion-extension cycle secondary to mild spasticity.
- Class IIIB consists of phasic activity, with prolongation extending for at least half of the next phase of motion. This is indicative of a moderate amount of spasticity.
- Class IIIC represents a severely spastic muscle and consists of phasic activity with severe prolongation in which EMG activity is continued throughout the next phase of motion at a high intensity but the underlying phasic nature of the muscle activity is still distinguishable.
- Class IV consists of continuous EMG activity without phasic variations.
- Class V consists of EMG activity seen only in response to a quick stretch by the antagonist muscles. There is no volitional activation of the muscle. This pattern is common in the finger extensors.
- Class VI consists of absent EMG activity.

Clinical examples of common deformities follow.

**Equinovarus Foot Deformity** Dynamic EMG performed during walking illustrates the motor pattern responsible for the spastic equinovarus deformity (Fig. 123.10) (105,109,175,176 and 177,179,180,226,227,230,231,237,241). The gastrocnemius and soleus muscles are spastic, causing the equinus posture of the foot. The tibialis anterior muscle is also spastic, resulting in the varus position of the forefoot. In stroke and brain injury, the tibialis posterior muscle is less commonly an offending force. When the tibialis posterior is overactive, excessive heel varus is seen (Fig. 123.11). The flexor digitorum longus (FDL), flexor hallucis longus, and intrinsic muscles of the foot are also spastic, resulting in curled toes.

***Figure 123.11.*** Patient with an equinovarus deformity of the foot with pronounced inversion of the heel. This marked heel inversion usually indicates spasticity in the tibialis posterior muscle. Spasticity in the tibialis posterior muscle is seen in 10% of patients with UMN syndrome from stroke or brain injury.

**Spastic Valgus Foot** Spastic valgus deformities of the foot are less common in stroke and brain-injured patients but can easily be missed (Fig. 123.12). The valgus deformity may occur alone as a result of overactivity of the peroneus longus or brevis muscle (Fig. 123.13) (252). It may also occur during stance phase in combination with an equinovarus deformity that occurs during the swing phase of gait.

***Figure 123.12.*** Patient with a spastic valgus deformity of the foot secondary to spasticity of the peroneus longus muscle.

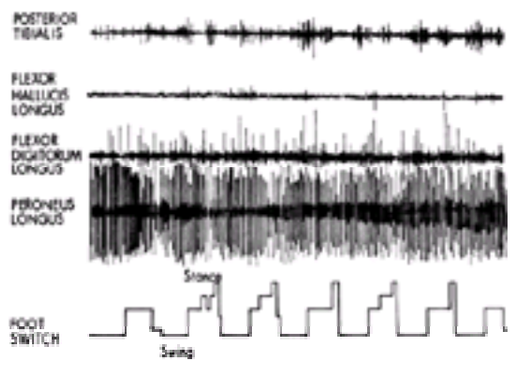


***Figure 123.13.*** Dynamic electromyographic record of a patient with a spastic valgus deformity of the foot. The foot switch tracing represents swing phase at the baseline of the tracing. Stance phase is indicated by the rise in the tracing. The tibialis posterior and flexor hallucis longus muscles show minimal activity throughout both swing and stance phase. The flexor digitorum longus muscle shows mild continuous activity throughout swing and stance. The peroneus longus muscle shows severe spasticity with no phasic pattern. All four muscles have class IV activity.

**Stiff-Knee Gait** Inadequate knee flexion during the swing phase of gait causes the patient to hike the hip and circumduct the leg in order to clear the foot. This is a very energy-consuming gait deviation. Because equinus of the ankle will result in an extension thrust at the knee, it is first necessary to rule out either static contracture or dynamic equinus posturing as a cause.

Normally, the knee begins to flex in the preswing phase of gait, which is marked by the point at which the opposite foot contacts the ground and double stance begins. Knee flexion is a passive event caused by the forward momentum of the body rather than by contraction of the knee flexor muscles. Dynamic EMG studies during gait have shown that patients with a spastic stiff-legged gait exhibit inappropriate activity of the quadriceps during early swing, which blocks knee flexion (16,20,22,59,101,105,127,147,170,171,178,184,194,203,214,232). In 13% of head-injured patients, there is isolated firing of the rectus femoris during early swing. There is no clinical test to determine the pattern of muscle activity within the quadriceps. Dynamic EMG gait analysis is required for surgical decision making (Fig. 123.14).

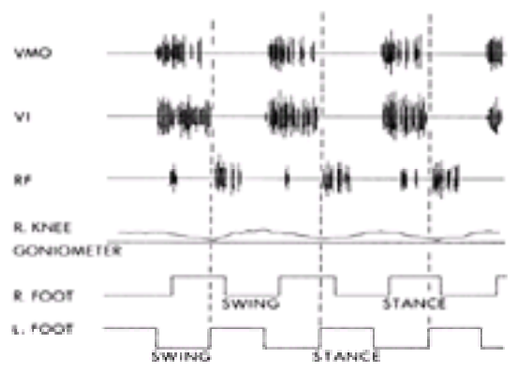


***Figure 123.14.*** Dynamic electromyogram of a patient with a stiff-knee gait abnormality. The muscle activity was recorded from the right leg. The knee goniometer baseline represents full knee extension, with upward deflections indicating knee flexion. Maximum knee flexion for this patient was 10°. The initiation of stance on the contralateral left foot represents the beginning of double limb support and the preswing stance period for the right leg. The vastus medialis obliqus (VMO) and the vastus intermedius (VI) show normal class I activity. The rectus femoris (RF) muscle shows activity in the preswing phase. This normal activity in the rectus femoris assists hip flexion and forward advancement of the limb. The spasticity in the leg triggers an overactive response that, in turn, blocks knee flexion. This patient is a candidate for transfer of the rectus femoris to the gracilis.

## ORTHOPAEDIC MANAGEMENT OF COMMON LOWER EXTREMITY DEFORMITIES

### GENERAL CONSIDERATIONS

The patterns of limb spasticity seen following stroke and TBI are very similar. The same orthopaedic procedures can be used in both patient populations. The orthopaedic treatment interventions are described together. These procedures, however, are not applied equally to both patient groups. The degree of spasticity, the timing of neurologic recovery, and the pattern of spontaneous neurologic recovery are different between stroke and brain-injured patients. These differences account for the variation in the need for specific treatments between the two groups.

Patients who have had TBI or stroke present unique challenges to the surgical team. The patients may have behavioral deficits or cognitive limitations that would make them difficult to manage with regional anesthesia and sedation. Therefore, general anesthesia is preferred (70,208). These patients have often previously had tracheostomy performed; therefore, an anesthesia team familiar with airway difficulties caused by this procedure is important. Take great care when positioning these patients for long procedures because contractures of other portions of their bodies may increase the risk of pressure ulcer formation.

#### *Fracture Malunion*

Fracture malunions are common in the TBI patient (58,63,68,71,73,76,79,81,145,204,243,253) owing to a combination of factors. Trauma concurrent with the brain injury may cause complex fractures, which are predisposed to malunion. Injuries may be missed in the initial resuscitation, leading to malunion. The prognosis of the braininjury may be so poor that optimal internal fixation offractures is not sought or obtained. Hemodynamic or pulmonary instability may cause optimal fracture fixation to be delayed. Poor patient compliance, agitation, and spasticity may alter the initial reduction. If these problems are not anticipated, malunion may result.

**Pelvis and Hip** Pelvic malunion can occur following unreduced unstable pelvic fractures. Patients usually present with rotational deformities, leg-length discrepancy, pain, and gait abnormalities (23,63,145,253). The need for surgical correction must be individualized to each patient's symptoms. For example, a small leg-length discrepancy without pelvic pain may be best managed with a shoe lift.

Malunions of both intertrochanteric and subtrochanteric hip fractures can be seen in TBI patients. They usually present with leg-length discrepancy, gait abnormalities,

and pain (see Fig. 123.1). These deformities can be managed with a corrective osteotomy after careful preoperative planning (196).

**Femur** There is no consensus on what represents a malunion of the shaft of the femur (12). An anterior bow is better tolerated than either a varus or a valgus alignment. Malalignment of fracture may lead to early degenerative arthritis at the knee joint secondary to increased pressure along the tibial plateau (130). Most deformities can be managed with a corrective osteotomy and intramedullary fixation.

**Tibia** Tibial malunions can lead to abnormal stresses across the ankle and knee. This malalignment can lead to degenerative changes at both the knee and ankle (130). Like the femur, corrective osteotomies can be performed to restore balance. External fixators can be employed for more complex deformities if intramedullary fixation is not possible.

**Ankle** Ankle malunions can also be seen in the TBI patient. The most common malunion of the ankle is shortening and malrotation of the fibula (221). A corrective osteotomy can be performed to restore length and re-establish alignment (244).

***Heterotropic Ossification***

The etiology of periarticular HO is unknown, but several factors have been implicated. A genetic predisposition is suspected (63,67,145,245). Unidentified humoral factors that cause enhanced osteogenesis have been demonstrated in the sera of patients with brain injury (10,66,190). Other contributing factors include soft-tissue trauma and spasticity (5,13,18,36,37,39,41,44,48,54,61,62,63,64 and 65,67,69,72,73,77,86,87,98,111,113,128,135,149,153,157,159,173,188,190,191 and 192,199,204,205,206 and 207,210,212,213,222,223,243,245).

HO is commonly detected 2 months after injury. The clinical picture of ensuing HO is increasing pain and decreasing range of motion about a joint. The bone forms in association with spastic muscles. The alkaline phosphatase is elevated. Bone scans may aid in early diagnosis, and radiographs confirm diagnosis. There is an intense inflammatory reaction that occurs while the HO is forming. The swelling and inflammation commonly impinge on adjacent nerves, causing severe dysesthesia and pain. HO can also be associated with reflex sympathetic dystrophy. Treatment of the nerve irritation using steroids, amitriptyline, or gabapentin can be useful.

Clinically significant HO is seen in 11% of adult head-injured patients. It is virtually unheard of in children with TBIs. Patients develop HO in one joint or at multiple sites. The overall rate of joint ankylosis is 16% (69). The heterotopic bone forms between the joint capsule and the overlying muscle. Unlike myositis ossificans, HO does not form within the muscle tissue itself.

The early treatment of HO consists of drug therapy using diphosphonates (diphosphonate 20 mg/kg/day) to inhibit calcium crystal deposition in the underlying collagen matrix. Anti-inflammatory agents (indomethacin 50 mg tid) are used to control the intense inflammatory process that occurs secondary to the formation of HO. Spasticity is aggressively treated using medication, phenol nerve blocks, or botulinum toxin injections. Physical therapy with gentle range-of-motion exercises is used to maintain joint motion.

HO occurs more frequently in the proximal joints and limbs. HO around the hip is seen in 44% of the patients who form ectopic bone. When there has been a fracture or dislocation of the hip or pelvis associated with TBI, the incidence of HO is 55% (63,69,72,79,81). Bilateral involvement and joint ankylosis are common. Heterotopic bone is less common about the knee joint but does occur (37).

Surgical excision is the definitive treatment of heterotopic bone, but it should be delayed until the heterotopic bone is fully mature to prevent recurrence. A true bone cortex should be visible radiographically. The serum alkaline phosphatase level should be normal. The patient should have sufficient cognitive recovery to cooperate with the physical therapy program after surgery (Table 123.10) (72). Surgical excision of functionally significant periarticular HO often results in significant improvements in range of motion, independence, and quality of life. Radiographically immature lesions have a higher rate of recurrence (62,64,65,72,135,157,191). It may not be feasible or desirable to allow the HO to reach maturity before resection because although the risk of recurrence is higher, ankylosis of the joint and subsequent contracture worsen the overall functional result. HO may be detected earlier by obtaining a bone scan, which can identify clinically silent lesions. After excision of the HO, give prophylactic treatment to prevent recurrence. The drug therapy we employ is diphosphonate 20 mg/kg/day combined with indomethacin 50 mg tid. If there are contraindications to these medicines, low-dose radiation therapy can be employed.

| *Class* | *Cognitive deficit* | *Physical disability* |
|---|---|---|
| I | Minimal | Mild |
| II | Minimal | Moderate |
| III | Minimal | Severe |
| IV | Moderate/Severe | Mild/Severe |
| V | Moderate/Severe | Severe |

Reference: 72.

***Table 123.10. Functional Classes of the Brain-Injured Adult***

**Pelvis and Hip**

*Anterior Hip (Flexor)* After TBI, HO typically occurs along the lines of tension caused by the spastic muscles. Anterior HO is seen to follow the iliopsoas muscle. Anterior HO usually extends from the anterior superior iliac spine (ASIS) and inner aspect of the pelvis to the proximal femur in the region of the lesser trochanter.

- When resecting anterior hip HO, perform a standard anterior approach to the hip, but also dissect the femoral triangle and its contents (see Chapter 2 and Chapter 3).
- Take care to identify all major divisions of the femoral artery, nerve, and vein. It is prudent to place vascular loops around all major vessels proximally to ensure easier control of bleeding should a major vessel be damaged during the procedure. A wide exposure and meticulous hemostasis are needed.
- Although all the neurovascular structures may be encased in HO, it is more common for the nerve to be entrapped (65). The femoral nerve is already dividing into its many branches within the femoral triangle. The motor branches are small in diameter; carefully identify them.
- Because it is difficult to mobilize the neurovascular structures, remove the heterotopic bone in small segments. It is difficult to distinguish normal from abnormal bone. The morphology of the normal bone and the HO must be closely observed. Preoperative CT scans with three-dimensional reconstruction can be extremely helpful in understanding the morphology. Also use intraoperative radiographs or fluoroscopy to guide the resection (63,64 and 65,72,73,111,135,157,191).

*Medial Hip (Adductor)* Heterotopic bone seen inferomedial to the hip joint follows the adductor muscles from the pubis and extends toward the medial aspect of the femur.

- Use a medial approach to the hip for resection. If there is a significant hip adduction contracture, release of the hip adductors may also be needed.
- Often, HO is seen both anterior and medial to the hip. In these cases, it is necessary to make two separate incisions and work between both.

*Posterior Hip (Extensor)* Posterior HO lies immediately posterior to the femoral head and neck (see Fig. 123.2). Although posterior bone forms in conjunction with hip extensor spasticity, it is usually associated with a flexion contracture of the hip.

- Use a posterior approach to the hip for resection.
- Identify the sciatic nerve distally and dissect it proximally. It is common for the sciatic nerve to be encased within the mass of heterotopic bone. Significant scarring may also be seen around the sciatic nerve secondary to the intense inflammatory reaction that happens during the intermediate stages of bone formation. A neurolysis of the sciatic nerve may be needed.
- Once the sciatic nerve is identified, begin a more aggressive resection of the bone.
- If a significant hip flexion contracture persists after excision of the posterior HO, an anterior soft-tissue release may be necessary (63,64 and

65,72,73,111,135,157,191).

*Lateral Hip (Abductor)* When HO is seen in the abductor region, it is usually a result of trauma or surgical stimulation.

- Use a straight lateral or posterior incision.
- It is important to separate the heterotopic bone from the abductor muscles and preserve as much muscle function as possible. The abductor muscles are usually very atrophic.

**Thigh and Knee** HO is less common in the thigh and the knee. When it does occur, it usually is seen medially and may appear as a Pellegrini-Stieda lesion. Even when the medial HO does not bridge the joint, it commonly causes a knee flexion contracture by placing tension on the surrounding tissues. When there has been knee extensor spasticity, the HO can be found along the distal shaft of the femur beneath the quadriceps muscle. It often wraps around both the medial and lateral sides of the femur and greatly restricts knee motion (63,64 and 65,72,73,111,135,157,191). Posterior HO is uncommon after head injury but can occur in conjunction with hamstring spasticity (37,69,87,98,153,192,212).

Perform surgical resection of the HO if knee motion is limited. The choice of the surgical approach depends on the location of the HO.

- When a medial approach is needed, split the collateral ligament longitudinally and strip it from its insertion. Use a hinged brace postoperatively until the medial collateral ligament has reattached and the knee is stable.
- When there is extensive HO beneath the quadriceps, it is often necessary to make both medial and lateral incisions and remove the ectopic bone from beneath the muscle. Preserve the integrity of the quadriceps to allow for immediate mobilization after surgery.
- If a posterior approach is chosen, first identify the neurovascular structures proximally and dissect down to the HO. Continuous passive motion devices are helpful postoperatively.

## SPASTIC HIP DEFORMITIES

### *Adduction Deformity*

**Obturator Neurectomy** Scissoring of the legs in an ambulatory patient gives the patient a narrow base of support while standing and results in poor balance. A preoperative obturator nerve block eliminates the adductor spasticity and allows assessment of the adduction contracture (127). Alternatively, the patient can be examined at the time of surgery while under anesthesia to determine if a fixed myostatic contracture is present. When no fixed adduction contracture is present, transection of the anterior branches of the obturator nerve will denervate the adductors and allow the patient a broader base of support (16,25,26,28,78,89,108,123,127,138,151,156,169,179,184,203,226,227). Commonly, a small contracture is found and the adductor longus muscle is released at the time of the obturator neurectomy.

- Make a longitudinal incision directly over the adductor longus muscle.
- Release and retract the adductor longus muscle.
- Transect the anterior branch of the obturator nerve over the muscle belly of the adductor brevis.

**Hip Adductor Tenotomy** A hip adduction contracture that interferes with nursing care and hygiene in a nonambulatory patient or excessive limb scissoring during attempted transfers and ambulation in a patient with active function are indications for surgical release (16,25,26,28,78,89,108,123,127,138,151,156,169,179,184,203,226,227).

In a severely spastic patient, a flexion contracture of the hip and knee commonly occurs in conjunction with an adduction contracture. As for any contracture, obtain preoperative radiographs before performing soft-tissue releases to rule out the presence of HO or an underlying bony deformity that would prevent correction.

- With the patient in the supine position, make a longitudinal incision over the adductor longus muscle.
- Place the incision distal to the groin crease to position the incision in a more hygienic location.
- Use a longitudinal incision to decrease tension on the wound edges as the leg is brought into a corrected position after surgery.
- Dissect the adductor longus muscle free and transect it using electrocautery.
- Identify and transect the anterior branches of the obturator nerve.
- Release the adductor brevis and gracilis close to their pelvic origin (Fig. 123.15).

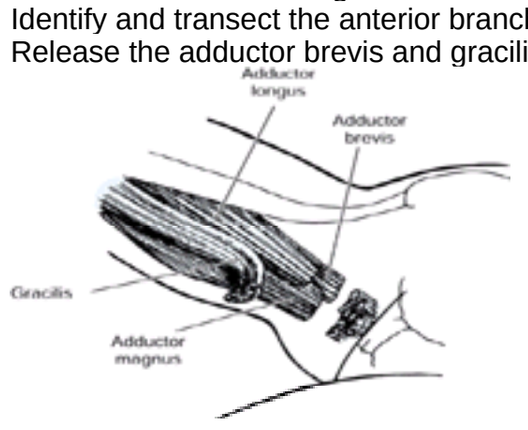


***Figure 123.15.*** Release of the spastic hip adductor muscles. The adductor longus, adductor brevis, and gracilis muscles are released through a medial groin incision. The adductor magnus is rarely released.

- Close the wound over a drain.

Daily wound care is essential to prevent infection in this potentially contaminated area. Keep the hips in abduction for 4 weeks using casts or an abduction pillow splint to prevent recurrence of the deformity during wound healing.

### *Flexion Deformity*

**Functional Release—Pectineus Release with Iliopsoas Recession** Spasticity of the hip flexors can result in a crouched gait with compensatory knee flexion to maintain balance. This is a very costly deformity because it requires constant use of the quadriceps, hip extensor, and calf muscles to maintain upright posture. The energy requirement for the continuous firing of these muscles is extremely high. Few patients are able to remain ambulatory with this deformity.

The hip flexor muscles are needed to advance the limb during gait. Avoid complete release of the hip flexors in any patient with the potential to ambulate. Because the iliopsoas has capsular insertions, release of the iliopsoas tendon from the lesser trochanter of the femur does not provide a complete release. Release of the tendon from the lesser trochanter permits the iliopsoas to recess proximally, thereby diminishing its pull but retaining its function.

- Use a medial approach to the hip. Make a longitudinal incision overlying the adductor longus tendon beginning 3 cm distal to the pubic tubercle.
- Bluntly develop a plane between the adductor longus and gracilis muscles.
- Continue the dissection between the adductor brevis and adductor longus muscles.
- Identify and protect the anterior division of the obturator nerve.
- If an adduction deformity is also present, perform division of the adductor longus muscle. This facilitates exposure of the deeper muscles.
- Identify the pectineus muscle as it lies deep to the femoral vessels and medial to the adductor longus.
- Divide the pectineus muscle using electrocautery. The lesser trochanter of the femur can be palpated in the depth of the wound.
- Visualize the tendon of the iliopsoas by placing narrow reverse retractors above and below the lesser trochanter.
- Divide the iliopsoas tendon from the trochanter and allow it to retract proximally (Fig. 123.16).

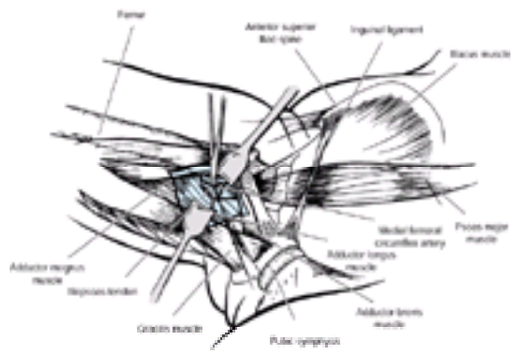

***Figure 123.16.*** Iliopsoas release from the lesser trochanter. The iliopsoas recedes but remains attached to the anterior hip joint capsule. The pectineus is released through its belly using electrocautery. (From Keenan MAE, Kozin SH, Berlet, AC. *Manual of Orthopaedic Surgery for Spasticity.* New York: Raven Press, 1993, with permission.)

- Close the wound over a drain.

Postoperatively, have the patient begin range-of-motion exercises and full weight-bearing gait training as tolerated. Prone lying and electrical stimulation of the gluteus maximus muscle are helpful to correct any residual hip flexion deformity.

**Nonfunctional Release—Complete Hip Release for Severe Contracture** A hip flexion contracture or severe spasticity in a nonambulatory patient that causes poor hygiene or pressure sores that cannot be healed secondary to limited positioning of the patient are indications for surgical release (16,25,26,28,78,89,108,123,127,138,151,156,169,179,184,203,226,227).

An adduction contracture of the hip and a flexion deformity of the knee are commonly associated with a hip flexion contracture in the severely spastic patient. These deformities are common in persons with TBI, stroke, cerebral anoxia, and multiple sclerosis. As for any contracture, obtain preoperative radiographs before performing soft-tissue releases to rule out the presence of HO or an underlying bony deformity that would prevent correction.

When a severe adduction contracture of the hip is present, it may be necessary to perform a percutaneous release of the adductor longus tendon in the groin in order to position the patient adequately and prep for further surgery. Simultaneously correct any flexion contracture of the knee to prevent the leg from positioning in flexion and causing a recurrent and more resistant contracture.

- With the patient in the supine position, make an anterior incision beginning 2.5 cm distal to the anterior superior iliac spine. Carry it distally following the sartorius muscle for a short distance. The incision should not extend over the iliac crest because the patient will be expected to lie in the prone position postoperatively to gain further correction of the deformity.
- Identify the lateral femoral cutaneous nerve as it passes distal to the anterior superior iliac spine and protect it.
- Detach the sartorius muscle from its origin on the anterior superior iliac spine.
- Release the rectus femoris muscle from its origin on the anterior inferior spine of the pelvis.
- Gently retract the femoral nerve and vessels medially to expose the iliopsoas muscle on the anterior aspect of the hip.
- Carefully divide the iliopsoas and pectineus muscles over the pelvic brim by using electrocautery to diminish postoperative bleeding. Because the iliopsoas has capsular insertions, release of the iliopsoas tendon from the lesser trochanter of the femur does not provide a complete release. The tensor fascia lata and the anterior portion of the gluteus medius and gluteal aponeurosis may be released from the iliac crest if necessary. The hip joint capsule is not released (Fig. 123.17).

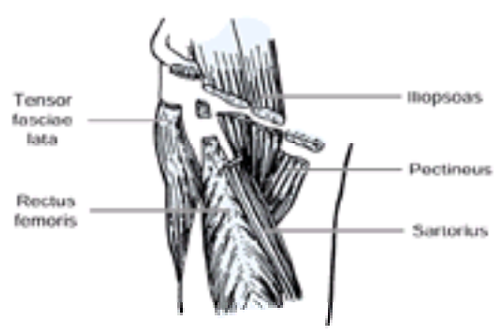


***Figure 123.17.*** Complete release of the hip flexor muscles for a severe spastic flexion deformity in a nonambulatory patient. The sartorius, tensor fascia lata, and rectus femoris muscles are released from their origins. The iliopsoas and pectineus muscles are transected through their midsubstance at the rim of the pelvis.

- In a severely contracted patient, take care to identify all structures before release because the anatomy is frequently distorted by the longstanding deformity. A large dead space is left after releasing the hip flexor muscles, and a drain should be used.
- Carefully close the wound and apply a compressive dressing, which is helpful in preventing postoperative infection.

As with release of other contracted joints, approximately 50% of the deformity will be corrected at the time of surgery. Daily wound care will help prevent infection in this area where bacterial contamination is likely. Place the patient in a prone position three times a day for increasing periods and institute gentle stretching exercises to assist in correcting any residual hip flexion deformity. When a release of a knee flexion contracture has been performed simultaneously, the weight of the long-leg cast will also provide a correcting force. Allow sitting in a wheelchair for short periods.

On occasion, a patient is seen with chronic hip subluxation or dislocation from severe and very longstanding hip flexion and adduction spasticity. Both problems are most common with anoxic encephalopathy. The hip joint has advanced osteoarthrosis and is painful. The hip pain increases the spasticity, which, in turn, causes more pain and so on in a circular fashion. In these cases, it is usually necessary to resect the femoral head at the same time as performing a complete muscle release. It is not advisable merely to resect the femoral head because this approach will not treat the spasticity and a more severe leg deformity can occur. After this surgery, it is very important to maintain the leg in a neutral position for at least 3 months while soft-tissue healing occurs. This can be done with bilateral short-leg casts connected with a bar to hold the legs in neutral rotation and slight abduction. If the hip is allowed to position in flexion, abduction, and external rotation while healing occurs, the ability to sit in a chair may be severely compromised.

***Extension Deformity***

**Proximal Hamstring Release** Following a severe brain stem injury, spasticity of the extensor muscles of the leg may result in a hip extension contracture (Fig. 123.18). Although this problem is uncommon, an extension contracture will interfere with a person's ability to sit. When good sitting posture cannot be obtained, a release of the proximal origin of the hamstring muscles is indicated (56,123,200,201).

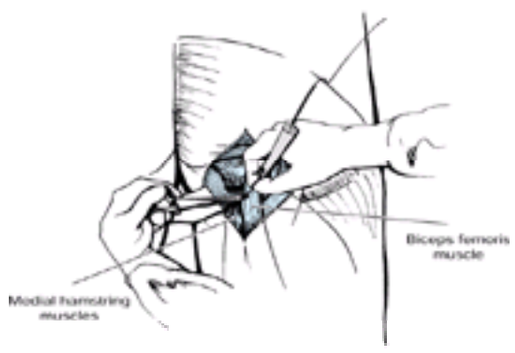

***Figure 123.18.*** Proximal release of the hamstring muscles from the ischium. (From Keenan MAE, Kozin SH, Berlet, AC. *Manual of Orthopaedic Surgery for Spasticity.* New York: Raven Press, 1993, with permission.)

- Place the patient in the prone position for surgery.
- Make a longitudinal incision over the posterior thigh beginning at the gluteal fold.
- Identify and protect the posterior femoral cutaneous nerve.
- Lift the distal edge of the gluteus maximus proximally to expose the underlying hamstring muscles.
- Then detach the biceps femoris, semimembranosus, and semitendinosus muscles from their origins on the ischial tuberosity and allow them to retract distally.

Postoperatively, start the patient on gentle passive range-of-motion exercises to regain hip flexion.

## SPASTIC KNEE DEFORMITIES

### *Flexion Deformity*

**Distal Hamstring Lengthening** A knee flexion deformity is caused by overactivity of the hamstring muscles (6,88,105,120,241). When the knee flexion deformity is less than 60° and the patient has documented volitional activity in the hamstring muscles, perform a lengthening procedure. This approach will correct the flexion deformity while preserving the function of the hamstrings.

- With the patient in the supine position, make a longitudinal incision of approximately 8 cm on the lateral aspect of the distal thigh just proximal to the knee joint (see Fig. 123.7).
- Isolate and protect the peroneal nerve and divide the biceps femoris tendon obliquely as it overlies the muscle belly. This allows the tendon to slide distally while still maintaining continuity of the muscle.
- Also divide the portion of the iliotibial band that is posterior to the axis of knee flexion transversely.
- Then make a longitudinal incision on the medial aspect of the distal thigh.
- Isolate the tendons of the gracilis and semimembranosus and fractionally lengthen them at the myotendinous junction by making an oblique cut in the tendon as it overlies the muscle belly (see Fig. 123.7). The semitendinosus tendon has a very short myotendinous junction, which does not permit fractional lengthening. Simply transect this tendon.

After surgery, immobilize the extremity in a long-leg cast. Approximately 50% correction of the knee flexion deformity can be expected at the time of surgery. Further correction is limited due to tethering of the neurovascular structures. Cast the extremity in the position of knee extension it assumes while being supported under the heel, without attempting forced extension. Forced knee extension can result in limb ischemia. Change the long-leg cast weekly until full knee extension has been obtained. Use splints at night for an additional 4 weeks to maintain correction.

**Distal Hamstring Release** In a nonambulatory patient with a marked increase in hamstring muscle tone, knee flexion contractures result (103,105,108,120,122,123,127,169,174,184,203,230). Spasticity is frequently present. When severe spasticity of the hamstring muscles or a knee flexion contracture of greater than 60° is present, attempts to correct the knee position with casting or bracing may result in posterior subluxation of the tibia. Distal release of the hamstring tendons does not prevent a patient from becoming ambulatory. If the hip flexion contracture or spasticity is not corrected at the same time as the hamstring release, a recurrent knee flexion contracture is likely to develop that is very resistant to surgical correction.

- With the patient in the supine position, make a longitudinal incision of approximately 8 cm on the lateral aspect of the distal thigh just proximal to the knee joint (Fig. 123.19).

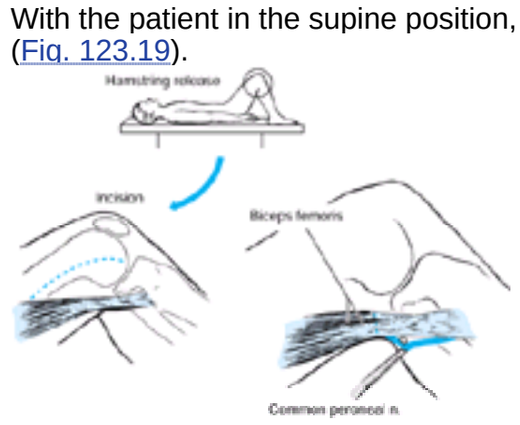


***Figure 123.19.*** Release of the lateral hamstring muscles is performed through a lateral incision, with the patient in the supine position.

- Isolate and protect the peroneal nerve and divide the biceps femoris muscle and tendon just proximal to its insertion using electrocautery.
- Also, divide the portion of the iliotibial band that is posterior to the axis of knee flexion transversely.
- Then make a longitudinal incision on the medial aspect of the knee, and isolate and divide the tendons of the gracilis, semimembranosus, and semitendinosus muscles (Fig. 123.20). The semitendinosus tendon is usually surrounded by a layer of fat and can closely resemble the posterior tibial nerve. Dissect the fatty tissue from the tendon to confirm its identity before transection.

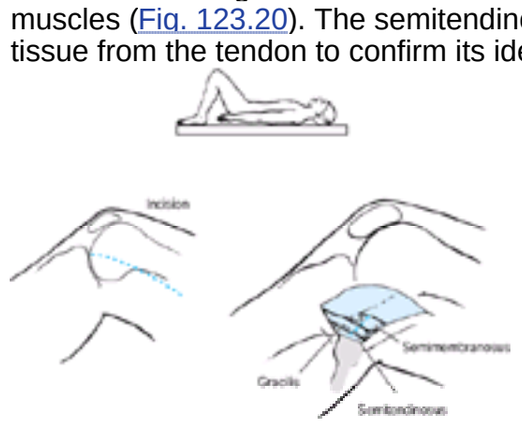


***Figure 123.20.*** Release of the medial hamstring muscles is performed through a medial incision with the patient in the supine position.

- In severe contractures, also perform release of the sartorius muscle. By using electrocautery, the procedure is easily performed without a tourniquet, which facilitates localization and protection of the posterior tibial artery, vein, and nerve.
- Following localization of the neurovascular bundle, divide any remaining restricting bands as required. The posterior fascia at the knee is often thickened, which limits extension and may require release. The posterior joint capsule may need to be released in longstanding contractures.
- Strip the joint capsule from the distal posterior femur using a periosteal elevator. Do not divide the cruciate ligaments.
- If more correction is required, a closing wedge osteotomy can be performed. A closing wedge will allow for some shortening of the femur and release some tension from the neurovascular structures and posterior skin.

After surgery, immobilize the extremity in a long-leg cast. Approximately 50% correction of the knee flexion deformity can be expected at the time of surgery. Further correction is limited due to tethering of the neurovascular structures. Cast the extremity in the position of knee extension it assumes while being supported under the heel, without attempting forced extension. Forced knee extension can result in limb ischemia. Postoperatively, change the long-leg cast weekly until full knee extension has been obtained. Have the patient use splints or a knee immobilizer at night for an additional 4 weeks to maintain correction.

### *Extension Deformity*

**Rectus Femoris to Gracilis Transfer for Dynamic Stiff-knee Gait** Patients with a stiff-knee gait are unable to flex the knee during the swing phase of gait. The deformity is a dynamic one, meaning that it only occurs during walking. There is no restriction of passive knee motion, and the patient does not have difficulty sitting. Usually, the knee is maintained in extension throughout the gait cycle (Fig. 123.21). Toe drag, which is likely in the early swing phase, may cause the patient to trip; thus balance and stability are also affected (105,108,147,148,170,171,176,214,232). The limb appears to be longer functionally. Circumduction of the involved limb, hiking of the pelvis, or contralateral limb vaulting may occur as compensatory maneuvers.

***Figure 123.21.*** A stiff-knee gait is caused by inappropriate activity in the quadriceps muscles, which inhibits knee flexion. The patient must hike the hemipelvis and circumduct the leg to clear the foot during swing. (From Keenan MAE, Kozin SH, Berlet, AC. *Manual of Orthopaedic Surgery for Spasticity.* New York: Raven Press, 1993, with permission.)

Preoperatively, conduct a gait study with dynamic EMG to document the activity of the individual muscles of the quadriceps (see Fig. 123.14). Dyssynergic activity is commonly seen in the rectus femoris muscle from preswing through terminal swing throughout the gait cycle. Abnormal activity is also common in the rectus intermedius muscle. If knee flexion is improved with a block of the rectus femoris or vastus intermedius muscle, the rationale for surgical intervention is strengthened. Any equinus deformity of the foot should be corrected before evaluation of a stiff-knee gait because equinus causes a knee extension force during stance. The amount of knee flexion during swing is directly related to the speed of walking, so the patient should be able to ambulate with a reasonable velocity in order to benefit from surgery. Hip flexion strength is also needed for a good result because it is the forward momentum of the leg that normally provides the inertial force to flex the knee. In the past, a selective release of the rectus femoris muscle or rectus and vastus intermedius muscles was performed to remove their inhibition of knee flexion. On average, a 15° improvement in peak knee flexion was seen after surgery. Transfer of the rectus femoris to a hamstring tendon not only removes it as a deforming muscle force, it also converts the rectus into a corrective (flexion) force. This procedure provides improved knee flexion over selective release.

- Make a longitudinal incision on the anterior thigh from 10 cm above the patella to the middle aspect of the patella.
- Dissect the rectus femoris muscle free from the other vasti muscles both proximally and distally.
- Carry the dissection distally to the patella and also remove a strip of periosteum from the patella to gain additional length. If significant spasticity was seen in the vasti muscle on the dynamic EMG study, these muscles are fractionally lengthened by transecting their tendons as they overly the muscle belly.
- Make a second incision over the medial hamstrings just proximal to the knee.
- Identify the gracilis tendon.
- Then make a subcutaneous tunnel between the two incisions and through the intermuscular septum.
- Pass the distal end of the rectus femoris tendon through the tunnel to the medial wound, with the knee flexed 90° and the femur externally rotated.
- Sew the rectus femoris tendon to the gracilis tendon (Fig. 123.22) by means of a Pulvertaft weave. We prefer to use the gracilis as our transfer site as opposed to the sartorius because of the strong tendon repair possible. The gracilis also provides a more posterior attachment of the transfer, which, in turn, increases the flexor moment created.

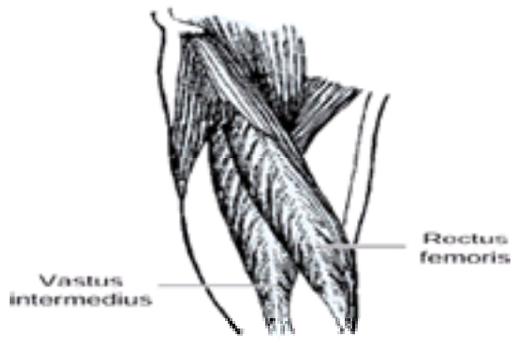


***Figure 123.22.*** The rectus femoris is transfered to the gracilis tendon to improve knee flexion during the swing phase of gait.

- Transfer the rectus muscle under considerable tension.
- Then gently extend the knee to be certain that full knee extension can still be obtained. The location of the transfer has not been shown to affect range of motion of the knee (170,171).

Postoperatively, place the patient in a knee immobilizer splint for 1 week to prevent a knee flexion deformity from occurring secondary to the tension and to prevent discomfort of the transfer. The patient can begin gait training in the immobilizer on the first postoperative day. Because of the good fixation into the gracilis tendon, start knee range of motion and ambulation without the splint 1 week later. Stress a marching gait pattern during therapy to facilitate knee flexion during swing.

**Quadriceps Lengthening** After a brain stem injury, extensor spasticity can cause a knee extension contracture. This is usually seen in combination with a hip extension contracture. Both deformities result in problems with sitting. The knee extension deformity can be corrected by lengthening the quadriceps. Quadriceps weakness is not a problem in these patients because they are not ambulatory. In the past, V-Y lengthening of the quadriceps tendon was routinely performed (123,169). We have more recently been performing a fractional lengthening of the individual muscles of the quadriceps. This procedure is more easily performed and has a lower morbidity rate than the **V-Y** lengthening. It also does not cause a patella baja deformity. Even severe hyperextension knee deformities can be corrected with this procedure.

- Make a longitudinal incision over the anterior thigh at the junction of the middle and distal third of the quadriceps muscle.
- Dissect the rectus femoris tendon free from the vasti at this level. This is easily done.
- There is a long overlap of the rectus muscle and tendon on the undersurface of the muscle belly. Sharply transect the tendon over the muscle belly, leaving the underlying muscle intact. The rectus tends to be the most contracted muscle and two cuts are often made in the tendon.
- Beneath the rectus femoris muscle, locate the myotendinous junctions of the vastus intermedius, medialis, and lateralis muscles. Individually transect each tendon over the muscle belly.
- Then gently and slowly flex the knee to at least 120°. The quadriceps muscles can be seen to lengthen as the knee is flexed.
- Close the wound in a routine manner.

Postoperatively, have the patient perform passive knee flexion several times daily to maintain knee flexion. Permit the patient to sit as much as tolerated. Immobilization is not needed.

## SPASTIC FOOT AND ANKLE DEFORMITIES

### *Equinus*

**Achilles Tendon Lengthening** Equinus is the most common spastic deformity that causes gait difficulty (Fig. 123.23) (4,101,105,109,110,140,143,174,175,176,177 and 178,180,182,195,231,241). Equinus results from the overactivity or premature activity of the gastrocnemius and soleus muscles. Surgical lengthening of the Achilles tendon is indicated when the patient's foot and ankle position is not adequately controlled by an orthosis or when attempting to make the patient brace free. Adequate lengthening of the Achilles tendon can be performed using the Hoke triple hemisection technique percutaneously (Fig. 123.24).

***Figure 123.23.*** Patient with a spastic equinovarus deformity of the foot.

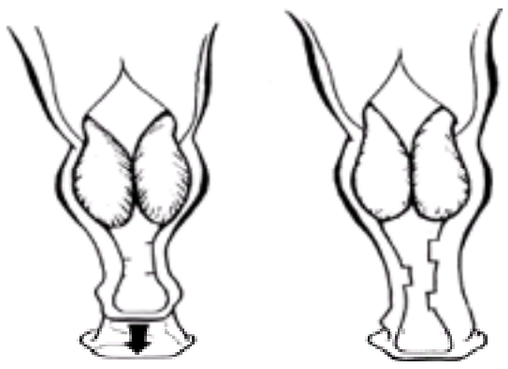

***Figure 123.24.*** Hoke technique for Achilles tendon lengthening. (From Keenan MAE, Kozin SH, Berlet, AC. *Manual of Orthopaedic Surgery for Spasticity.* New York: Raven Press, 1993, with permission.)

- With the foot held in maximum dorsiflexion, make three percutaneous hemitransections of the Achilles tendon using a #11 knife blade.
- If a varus deformity of the foot is present, make the proximal and distal cuts in the medial half of the tendon, and place the center cut laterally.
- Then push the foot into dorsiflexion, allowing the tendon to lengthen.

Postoperative management requires 6 weeks of rigid immobilization. We begin by using a short-leg walking cast for 2 weeks. We then use a cam walker boot for the next 4 weeks. At this time, we allow the patient to remove the boot once daily for bathing and skin care, provided that the patient does not stand or walk without the boot. After this, the patient uses an AFO for an additional 6 weeks.

***Varus***

**Split Anterior Tibial Tendon Transfer** Varus deformities most commonly occur as the result of increased and innappropriate activity of the tibialis anterior muscle (see Fig. 123.10). When the tibialis anterior has been documented by dynamic EMG to be a cause of varus, the deformity can be corrected by a split anterior tibial tendon transfer (SPLATT). The SPLATT maintains the half of the tendon on the medial aspect of the foot and transfers the other half of the tibialis anterior tendon to the lateral side of the foot (Fig. 123.25) (4,101,105,109,127,184,203,226,230,241).

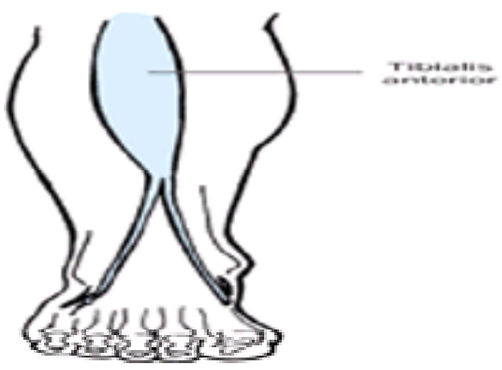


***Figure 123.25.*** The split anterior tibialis tendon transfer for correction of varus caused by overactivity of the tibialis anterior muscle.

Equinus and toe curling usually accompany the varus deformity, so a lengthening of the Achilles tendon should be performed first and the toe flexor tendons divided.

- Make an incision over the distal insertion of the tibialis anterior tendon on the medial aspect of the foot.
- Sharply divide the lateral half of the tendon from its insertion. Place a nonabsorbable suture in the cut end of the tendon as a tag for ease of handling. The suture can be used later to help secure the tendon in its new location in the cuboid bone.
- Make a second incision approximately 10 cm proximal to the ankle joint, just lateral to the crest of the tibia over the tibialis anterior muscle.
- Make an opening in the fascia overlying the tibialis anterior.
- We use a long twisted wire loop as a tendon passer. Pass the wire loop under the fascia and follow the tibialis anterior tendon to the incision on the medial foot. Pass the suture in the free end of the tendon through the wire loop and pull it into the proximal wound. Use this suture to pull the free end of the tendon into the proximal wound, thereby splitting the tibialis anterior tendon and a portion of the muscle belly.
- Wrap the tendon in a saline moistened sponge temporarily.
- Then make a third incision on the lateral aspect of the foot. Expose the lateral face of the cuboid subperiosteally.
- Use a drill to make a tunnel through the cuboid for anchoring of the lateral portion of the tendon.
- Create a subcutaneous tunnel from the proximal wound to the lateral incision using a long forceps.
- Pass the lateral arm of the tibialis tendon through this subcutaneous passage to protrude from the lateral incision.
- Secure the tibialis anterior tendon on the lateral side of the foot through the tunnel in the cuboid bone and suture it to itself to hold the foot in a neutral position. When there is marked osteoporosis, the cuboid bone may be too weak to use for the transfer. In this situation, the tibialis anterior tendon can be interwoven into the peroneus brevis using a Pulvertaft technique.
- Place the patient in a short-leg walking cast at surgery to hold the foot in a neutral position.

Start gait training on the first postoperative day, allowing the patient to bear full weight on the foot as tolerated. Keep the cast on the foot for 2 weeks, then remove the cast and sutures. Then place the patient in a cam walker boot for the next 4 weeks. With reliable patients, we allow the cam boot to be removed once daily for washing

and skin care. The foot must be maintained in a neutral position while the boot is off and no weight bearing is allowed. Six weeks after surgery, use a nonarticulated, moderately rigid AFO for an additional 6 weeks. The patient must sleep wearing the AFO during this time to protect the foot from inadvertent stretch. At 3 months after surgery, the brace can be removed for sleeping and gait training. Discontinue the AFO if and when the patient has established sufficient strength in the calf muscles to permit safe walking.

**Tibialis Anterior Lengthening** Occasionally, a mild varus deformity is seen during walking that is due to a moderate increase in tibialis anterior activity. In this situation, a myotendinous lengthening is sufficient to control the varus deformity.

- Make an incision over the tibialis anterior muscle approximately 10 cm proximal to the ankle joint.
- Open the fascial sheath of the tibialis anterior and transect the tendon over the muscle belly of the tibialis anterior, thereby allowing the muscle to lengthen fractionally.

If this is the only procedure performed, no immobilization is needed after surgery. Allow full weight-bearing ambulation immediately.

**Tibialis Posterior Lengthening** In approximately 10% of stroke and brain-injured patients the tibialis posterior muscle is also spastic and can contribute to the varus deformity (105,109,231). Clinically, this is evidenced by the increased heel varus in addition to the forefoot varus caused by the tibialis anterior muscle (see Fig. 123.11).

When spasticity of the tibialis posterior muscle is present, perform a myotendinous lengthening by transecting the tendon as it overlies the muscle belly, posterior and slightly proximal to the medial malleolus. Complete release of the tibialis posterior tendon is not recommended because a secondary planovalgus deformity may occur.

**Extensor Hallucis Longus Lengthening** With the equinovarus deformity, the patient may also have a hitchhiker's great toe secondary to spasticity of the EHL tendon (59,60,147,148). The EHL also contributes to the varus deformity of the forefoot. Many patients with this condition complain of shoe wear problems from pressure of the hallux against the shoe.

- Make a 3 cm incision over the anterior leg, beginning 10 cm proximal to the ankle joint. Identify the EHL muscle and fractionally lengthen it by transecting the tendon as it overlies the muscle belly.

If no other surgical procedures are needed, then no immobilization is needed after surgery. Most commonly, the EHL is lengthened in combination with a SPLATT procedure. In this situation, follow the postoperative protocol of the SPLATT.

***Valgus***

**Peroneal Lengthening** Spastic valgus foot deformities are less common in the stroke and brain injury population. The deformity can result from overactivity of the peroneus longus, peroneus brevis, or both (252). Use dynamic EMG to determine which muscles are causing the deformity.

If the deformity is not severe, consider a myotendinous lengthening.

- Make an incision over the lateral leg, approximately 10 cm above the ankle joint.
- Open the fascia of the lateral compartment and fractionally lengthen the offending peroneal muscles.

If no other procedures are performed simultaneously, no immobilization is needed after surgery. Allow unrestricted ambulation.

**Peroneus Longus Transfer** A spastic valgus deformity may result from overactivity of the peroneus longus muscle. This problem can occur as an isolated deformity but more commonly occurs in combination with spastic equinovarus (123,252). In the “spastic combination foot” deformity, equinovarus is observed during swing phase from premature and prolonged firing of the tibialis anterior and gastroc-soleus muscles. The planovalgus deformity occurs during stance from the inappropriate activity of the peroneus longus muscle. The pronation deformity may be accentuated by a premorbid tendency to flat foot or by the presence of an equinus contracture.

When a severe spastic valgus occurs, the peroneus longus tendon is transferred through the interosseous membrane to the tarsal navicular bone to support the longitudinal arch of the foot during stance.

- Make a small incision on the lateral border of the foot just proximal to the base of the fifth metatarsal (Fig. 123.26).

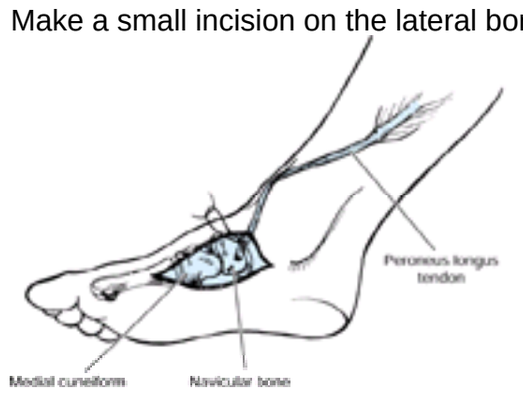


***Figure 123.26.*** Transfer of the peroneus longus tendon to the tarsal navicular for correction of a severe spastic valgus foot deformity caused by spasticity of the peroneus longus muscle. (From Keenan MAE, Kozin SH, Berlet, AC. *Manual of Orthopaedic Surgery for Spasticity.* New York: Raven Press, 1993, with permission.)

- Identify the peroneus longus and brevis tendons.
- Divide the peroneus longus tendon to obtain maximal length.
- Make a second incision over the lateral leg approximately 10 cm above the ankle.
- Identify the peroneus longus muscle and pull the distal end of the tendon proximally into this wound.
- Make a third incision over the anterior leg 10 cm proximal to the ankle.
- Carry the dissection down to expose the interosseus membrane.
- Make a window in the interosseus membrane and pass the peroneus longus tendon through to the anterior leg wound.
- Make a final incision over the navicular bone on the medial side of the foot.
- Use a drill to create a tunnel through the navicular bone.
- Then pass the peroneus longus tendon subcutaneously to the medial foot using a long forceps.
- Pass the end of the tendon through the tunnel in the navicular and secure it back to itself using nonabsorbable sutures. Secure the tendon to hold the foot in a neutral alignment.
- Place the patient in a short-leg walking cast at surgery, holding the foot in a neutral position.

When a combined deformity is present, perform a split anterior tibial tendon transfer along with an Achilles tendon lengthening and toe flexor release to correct the swing phase abnormalities.

Start gait training on the first postoperative day, allowing the patient to bear full weight on the foot as tolerated. Keep the cast on the foot for 2 weeks, and then remove the cast and sutures. Then place the patient in a cam walker boot for the next 4 weeks. With reliable patients, we allow the cam boot to be removed once daily for washing and skin care. The foot must be maintained in a neutral position while the boot is off, and no weight bearing is allowed. Six weeks after surgery, use a nonarticulated, moderately rigid AFO for an additional 6 weeks. The patient must sleep wearing the AFO during this time to protect the foot from an inadvertent stretch. At 3 months after surgery, the brace can be removed for sleeping and gait training. Discontinue the AFO if and when the patient has established sufficient strength in the calf muscles to permit safe walking.

### *Cavus*

**Steindler Stripping** A cavus deformity is defined as an elevated arch that does not flatten with weight bearing. The deformity is probably a result of muscle imbalance of both the intrinsic and extrinsic muscles of the foot (146). If the foot is supple, a soft-tissue procedure can be performed; however, if the foot is rigid, a bony fusion must be performed. Steindler stripping is the release of the plantar structures.

- Expose the plantar fascia through a medial foot incision. Take care to identify and preserve the medial calcaneal nerve branches to the heel pad.
- Release the origin of the fascia under direct vision.
- Identify the origin of the abductor hallucis and elevate it from the tuberosity of the os calcis.
- Also release the origin of the flexor brevis and intrinsic muscles of the foot.
- Then passively correct the foot and place it into a short-leg cast.

Keep the short-leg cast for 2 weeks. Start weight bearing on the first postoperative day. Because this procedure is usually done in combination with the SPLATT operation, the SPLATT protocol is generally followed.

**Triple Arthrodesis** For severe rigid bony deformities, a triple arthrodesis is performed to correct the foot (146). Most commonly, this procedure is performed in combination with a plantar release (Steindler stripping) and the SPLATT procedure.

- Make an incision over the lateral foot from the tip of the fibula to base of the fourth metatarsal.
- Elevate the extensor brevis and fat pad to expose the calcaneocuboid joint and the sinus tarsi. Remove the superior process of the distal calcaneus by using an oscillating saw to fascilitate exposure. Save the bone to use as graft later.
- Insert a lamina spreader between the talus and calcaneus to expose the joint surfaces further.
- Denude the posterior and middle facets of the subtalar joint of cartilage.
- Also expose the calcaneal cuboid joint and remove the cartilage.
- Expose the lateral talonavicular joint and prepare it through the same incision.
- Make a small medial incision over the talonavicular joint and remove the remaining cartilage. At this time, fix the three joints with three large-diameter cannulated screws and confirm their placement by fluroscopic guidance.

Postoperatively, place the patient in a short-leg walking cast for 6 weeks. With the rigid fixation provided by the screw fixation, weight bearing is permissable. If sufficient bony union is seen at 6 weeks after surgery, allow the patient to use a rigid, nonarticulated AFO for ambulation. Protect the fusion until full bony healing is seen.

### *Clawfoot*

**Toe Flexor Release** Toe clawing or curling is a common accompaniment of overactivity of the gastrocnemius muscles. Toe curling is caused by overactivity of the flexor hallucis longus and flexor digitorum muscle as well as the short toe flexor and occasionally the intrinsic muscles of the foot (110).

- Make a longitudinal incision on the plantar surface of each toe at the metatarsal phalangeal joint level. Identify the flexor tendons and release them under direct vision (Fig. 123.27). Also see Chapter 113.

***Figure 123.27.*** Release of the long and short toe flexor tendons at the base of each toe.

This procedure is commonly performed in combination with an Achilles tendon lengthening because bringing the foot into a plantigrade position will worsen the toe curling. When an Achilles tendon lengthening has been performed, immobilize the foot for 3 months as described for that procedure.

### *Calf Paresis*

**Transfer of the Flexor Digiturom Longus to Os Calcis** Muscle paresis (weakness) is an integral part of UMN syndrome. Lengthening the Achilles tendon to correct an equinus deformity weakens the gastrocnemius-soleus muscle group, which was already weak as a consequence of the underlying UMN syndrome. This calf paresis generally results in the need for an AFO during ambulation. Thus, transfer of the FDL muscle can be done to augment calf strength (Fig. 123.28). With this transfer, more patients eventually achieve brace-free ambulation (124). In prior studies of treatment of a spastic equinovarus foot deformity, 30% of patients were able to walk safely without an AFO (109). When the strength of the gastrocsoleus is augmented by transfer of the FDL to the os calsis, 70% of patients achieve brace-free ambulation (124).

***Figure 123.28.*** Transfer of the flexor digitorum longus tendon to the os calcis to augment the strength of the gastrocnemius and soleus muscles.

- Make a 4 cm incision on the medial border of the foot dorsal and parallel to the abductor hallucis muscle. Reflect the abductor hallucis plantarward from the base of the first metatarsal and isolate the flexor hallicus longus and FDL through the deep fascia at the master knot of Henry. At this level, the FDL has not yet split into four tendons and the FHL is easily dissected free.
- If the flexor brevis tendons are to be released simultaneously to correct toe curling, release them before transecting the FDL tendon.
- Dissect the FHL and FDL at the knot of Henry.
- Then make a 5 cm incision at the medial supramalleolar region, where the muscle belly of the FDL is isolated with its tendon and delivered through the medial supramalleolar incision.
- Make a 1 cm incision over the medial posterior superior os calcis.
- Use a $^{3}/_{8}$-inch drill to create a tunnel through the posterior superior calcaneus, exiting on the lateral side.

- Make a small incision over the lateral malleolus at the exit site of the drill.
- Place a suture ligature in the FDL and pass the tendon subcutaneously to the medial heel wound. Then pass the tendon medially to laterally through the tunnel created in the calcaneus.
- Use a twisted wire loop to first pull the suture ligature through the tunnel.
- Drill a Sta-tek (Zimmer; Warsaw, IN) suture anchor into the lateral os calcis and securely tie the transferred tendon with the foot in maximum dorsiflexion to prevent a recurrent equinus deformity.
- Place the patient in a short-leg walking cast at surgery, holding the foot in a neutral position.

Start gait training on the first postoperative day, allowing the patient to bear full weight on the foot as tolerated. Keep the cast on the foot for 2 weeks, then remove the cast and sutures. Then place the patient in a cam walker boot for the next 4 weeks. With reliable patients, we allow the cam boot to be removed once daily for washing and skin care. The foot must be maintained in a neutral position while the boot is off and no weight bearing is allowed. Six weeks after surgery, the patient begins using a nonarticulated, moderately rigid AFO for an additional 6 weeks. The patient must sleep wearing the AFO during this time to protect the foot from an inadvertent stretch. At 3 months after surgery, the brace can be removed for sleeping and gait training. The AFO can be discontinued if and when the patient has established sufficient strength in the calf muscles to permit safe walking.

***Foot Deformities in the Nonambulatory Patient***

Severe deformities of the feet are common in patients with spasticity. Even in the nonambulatory patient, these deformities cause significant problems. These complications include pressure sores, inability to wear shoes or protective footwear, and difficulty positioning the feet on wheelchair supports for improved sitting balance. Correct these deformities surgically to maintain a plantigrade foot.

The most common deformity is equinovarus with claw toes. As in the more functional patient, muscle balance must be achieved by performing the SPLATT, an Achilles tendon lengthening, and release of the toe flexor tendons and lumbrical insertions. Because the spasticity is often extreme and of long duration, it is commonly necessary to perform a release of the plantar fascia to correct a cavus deformity as well as a triple arthrodesis in conjunction with the tendon transfer.

## PITFALLS AND COMPLICATIONS

Throughout the text of this chapter, we have attempted to point out specific considerations to avoid complications and achieve a maximal outcome. There are a few general guidelines to consider.

The orthopaedic surgical techniques used to correct limb deformities from inappropriate muscle activity are release, denervation, and lengthening or transfer. No surgical manipulation of soft tissues will be successful if there is an underlying bony restriction. Preoperative radiographs are obtained to assess joint congruency, or to detect heterotopic bone or other deformity. Muscle or tendon release removes the deforming force of that muscle. Release is only used on muscles with no potential for function. A release corrects both active deformity and a static contracture. Denervation of a muscle removes the deforming force of that muscle and is useful when no fixed contracture is present.

Lengthening of a muscle-tendon unit diminishes the spastic response to quick stretch (spasticity) in a muscle that has volitional use. By removing the overactive stretch response of the muscle, its volitional use is significantly improved. Lengthening of a muscle tendon corrects both static and dynamic deformities. Lengthening is often performed exclusively to correct a dynamic deformity. When the patient is under general anesthesia and the muscles are relaxed, a purely dynamic deformity (e.g., an equinus foot deformity) appears corrected. It is a mistake to alter the surgical plan at this time and not lengthen the muscle in question. If a muscle exhibited dyssynergic activity during functional activity, it should still be lengthened to decrease its activity even in the absence of a fixed contracture.

Transfer of a muscle-tendon unit redirects a muscle force. It is not necessary for the muscle to have normal control. It is critical that the transferred muscle has a predictable, nonvariable action to achieve the desired result. Varying muscle activity, such as in athetosis, is a contraindication to tendon transfer.

Do not guess at which muscles are causing a deformity. Clinical assessment alone is unreliable to determine the causes of a spastic limb deformity. There are at least twenty different combinations of muscle activity that can cause an equinovarus foot posture. Dynamic poly-EMG studies or diagnostic nerve blocks are needed to assess the problem fully. The outcome of surgical correction depends on the accuracy of the preoperative assessment.

## AUTHOR'S PERSPECTIVE

Patients with complex UMN disorders can initially be overwhelming to an orthopaedic surgeon. However, the care of these patients follows standard, well-known orthopaedic principles. Considering the specific limb problems individually and then constructing a prioritization list is the most effective method of dealing with patients who have multiple problems. As a starting point, it is helpful to consider problems in functional categories and next to consider whether or how correction of a specific limb deformity is likely to improve the function. Examples of functional categories include dressing, eating, transfers, and walking.

Limb function can be either active or passive. Passive function refers to problems of passive manipulation of limbs to achieve functional ends. Problems of passive function typically relate to activities such as dressing, bathing, sitting, or transfers. Problems of active function refer to a patient's direct use of a limb to carry out the functional activity. It is a useful construct to categorize problems of function as being either passive or active in nature.

Walking is a commonly desired goal for patients and their caregivers. A patient with a severe equinovarus foot deformity often is unable to walk. If the patient has some active hip flexion to provide limb advancement and good sitting balance, then correction of the foot deformity is likely to make the patient ambulatory. It may also be necessary to correct a hand contracture for the patient to use a cane or walker to achieve this goal. If the patient lacks active hip flexion and has poor trunk balance, then correction of the foot deformity will not allow walking. Correction of the foot may still be useful to allow shoe wear or to improve sitting balance with the foot resting on the leg support of a wheelchair.

By using a systematic approach and dividing problems into both functional and anatomic categories, it is easier to sort through the numerous musculoskeletal issues faced by persons with neurologic disorders. A major improvement in function and quality of life is achieved for many, giving both the surgeon and the patient a feeling of satisfaction and accomplishment.

**CHAPTER REFERENCES**

Each reference is categorized according to the following scheme: *, classic article; #, review article; !, basic research article; and +, clinical results/outcome study.


+ 1. Aboulafia AJ, Keenan MA, Stone L. An Uncommon Cause of Fever in a Brain Injured Patient. *Brain Inj* 1990;4:307.

+ 2. Albright AL. Neurosurgical Treatment of Spasticity: Selective Posterior Rhizotomy and Intrathecal Baclofen. *Stereotact Funct Neurosurg* 1992;58:3.

+ 3. Albright AL, Barron WB, Fasick MP, et al. Continuous Intrathecal Baclofen Infusion for Spasticity of Cerebral Origin. *JAMA* 1993;270:2475.

# 4. Anmuth C, Esquenazi A, Keenan MAE. Lower Extremity Surgery for the Spastic Patient. In: Katz R, ed. *Spasticity,* Vol 8. Philadelphia: Hanley & Belfus, 1994:547.

+ 5. Ayers DC, Pellegrini VD, Evalts CM. Prevention of Heterotopic Ossification in High-risk Patients by Radiation Therapy. *Clin Orthop* 1991;263:87.

+ 6. Bauman JU, Ruetsch H, Schurman K. Distal Hamstring Lengthening in Cerebral Palsy. *Int Orthop* 1980;3:305.

! 7. Bauman JU, Sutherland DH, Hanggi A. Intramuscular Pressure During Walking: An Experimental Study Using the Wick Catheter Technique. *Clin Orthop* 1979;145:292.

+ 8. Beck ER, Bell KR. Deep Venous Thrombosis in the Spastic Upper Limb. *Brain Inj* 1995;9:413.

+ 9. Bell KR, Massagli TL. Subacute Brain Injury Rehabilitation: An Opportunity for Medical Education and Training. *Brain Inj* 1996;10:875.

+ 10. Bidner SM, Rubins IM, Desjardins JV, et al. Evidence for a humoral mechanism for enhanced osteogenesis after head injury. *J Bone Joint Surg [Am]* 1990;72:1144.

+ 11. Blessey RL, Hislop HJ, Waters RL, Antonelli D. Metabolic Energy Cost of Unrestrained Walking. *Phys Ther* 1976;56:1019.

+ 12. Bloch R, Bayer N. Prognosis in Stroke. *Clin Orthop* 1978;131:10.

+ 13. Bontke CF, Cobble ND. Rehabilitation in Brain Disorders. Clinical Manifestations and Medical Issues. *Arch Phys Med Rehabil* 1991;72:S320.

+ 14. Booth BJ, Doyle M, Montgomery J. Serial Casting for the Management of Spasticity in the Head Injured Adult. *Phys Ther* 1983;63:1960.

+ 15. Botte MJ, Abrams RA, Bodine-Fowler SC. Treatment of Acquired Muscle Spasticity Using Phenol Peripheral Nerve Blocks. *Orthopaedics* 1995;18:151.

# 16. Botte MJ, Abrams RA, Keenan MAE, Mooney V. Limb Rehabilitation in Stroke Patients. *The Journal of Musculoskeletal Medicine* 1992;9:66.

+ 17. Botte MJ, Keenan MA. Percutaneous Phenol Blocks of the Pectoralis Major Muscle to Treat Spastic Deformities. *J Hand Surg [Am]* 1988;13:147.

+ 18. Botte MJ, Keenan MA, Abrams RA, et al. Heterotopic Ossification in Neuromuscular Disorders. *Orthopedics* 1997;20:335.

+ 19. Botte MJ, Keenan MA, Gellman H, et al. Surgical Management of Spastic Thumb-in-palm Deformity in Adults with Brain Injury. *J Hand Surg [Am]* 1989;14:174.

# 20. Botte MJ, Keenan MAE. Brain Injury and Stroke. In: Gelberman RH, ed. *Operative Nerve Repair and Reconstruction.* Philadelphia: JB Lippincott Publishers, 1991:1413.

+ 21. Botte MJ, Keenan MAE, Gelberman RH. Volkmann's Ischemic Contracture of the Upper Extremity. *Hand Clin* 1998;14:483.

# 22. Botte MJ, Keenan MAE, Jordan C. Stroke. In: Nickel VL, Botte MJ, eds. *Orthopaedic Rehabilitation.* New York: Churchill Livingstone, 1992:337.

+ 23. Botte MJ, Moore TJ. The Orthopaedic Management of Extremity Injuries in Head Trauma. *The Journal of Head Trauma Rehabilitation* 1987;2:13.

+ 24. Botte MJ, Nakai RJ, Waters RL, et al. Motor Point Delineation of the Gluteus Medius Muscle for Functional Electrical Stimulation: An In Vivo Anatomic Study. *Arch Phys Med Rehabil* 1991;72:112.

# 25. Botte MJ, Waters RL, Keenan MAE, et al. Orthopaedic Management of the Stroke Patient: Part I: Pathophysiology, Limb Deformity, and Patient Evaluation. *Orthop Rev* 1988;27:637.

# 26. Botte MJ, Waters RL, Keenan MAE, et al. Orthopaedic Management of the Stroke Patient: Part II: Treating Deformities of the Upper and Lower Extremities. *Orthop Rev* 1988;27:891.

+ 27. Bowman BR, Baker LL, Waters RL. Positional Feedback and Electrical Stimulation: An Automated Treatment for the Hemiplegic Wrist. *Arch Phys Med Rehabil* 1979;60:497.

# 28. Braun RM, Gellman H. Stroke and Brain Injury. In: Green DP, ed. *Operative Hand Surgery,* Vol 1. New York: Churchill Livingstone, 1993:225.

+ 29. Braun RM, Hoffer MM, Mooney V, et al. Phenol Nerve Block in the Treatment of Acquired Spastic Hemiplegia in the Upper Limb. *J Bone Joint Surg [Am]* 1973;55:580.

+ 30. Braun RM, Mooney V, Nickel VL. Flexor-Origin Release for Pronation-Flexion Deformity of the Forearm and Hand in the Stroke Patient. *J Bone Joint Surg [Am]* 1970;52:907.

+ 31. Braun RM, West F, Mooney V, et al. Surgical Treatment of the Painful Shoulder Contracture in the Stroke Patient. *J Bone Joint Surg [Am]* 1971;53:1307.

# 32. Bucholz RW, Brumback RJ. Fractures of the Shaft of the Femur. In: Rockwood CA, Green DP, Bucholz RW, eds. *Fractures in Adults,* Vol 2. Philadelphia: JB Lippincott, 1991:1653.

+ 33. Aldwell CB, Wilson DJ, Braun RM. Evaluation and Treatment of the Upper Extremity in the Hemiplegic Stroke Patient. *Clin Orthop* 1969:63.

+ 34. Carey JR. Manual Stretch: Effect on Finger Movement Control and Force Control in Stroke Subjects with Spastic Extrinsic Finger Flexor Muscles. *Arch Phys Med Rehabil* 1990;71:888.

+ 35. Cerny D, Waters R, Hislop H, Perry J. Walking and Wheelchair Energetics in Persons with Paraplegia. *Phys Ther* 1980;60:1133.

+ 36. Charnley G, Judet T, de Loubresse CG, Pirou P. Articulated Radial Head Replacement and Elbow Release for Post Head-injury Heterotopic Ossification. *J Orthop Trauma* 1996;10:68.

+ 37. Charnley G, Judet T, Garreau de Loubresse C, Mollaret O. Excision of Heterotopic Ossification Around the Knee Following Brain Injury. *Injury* 1996;27:125.

+ 38. Childers MK, Stacy M, Cooke DL, Stonnington HH. Comparison of Two Injection Techniques Using Botulinum Toxin in Spastic Hemiplegia. *Am J Phys Med Rehabil* 1996;75:462.

+ 39. Chua HC, Tan CB, Tjia H. A Case of Bilateral Ulnar Nerve Palsy in a Patient with Traumatic Brain Injury and Heterotopic Ossification. *Singapore Med J* 1997;38:447.

+ 40. Cifu DX, Kreutzer JS, Marwitz JH, et al. Functional Outcomes of Older Adults with Traumatic Brain Injury: A Prospective, Multicenter Analysis. *Arch Phys Med Rehabil* 1996;77:883.

+ 41. Citta-Pietrolungo TJ, Alexander MA, Steg NL. Early Detection of Heterotopic Ossification in Young Patients with Traumatic Brain Injury. *Arch Phys Med Rehabil* 1992;73:258.

# 42. Clifford B, Waters RL, Jordan C. Stroke: The Challenge. In: Sculco TP, ed. *Orthopaedic Care of the Geriatric Patient.* St Louis: CV Mosby, 1985.

+ 43. Close JR, Todd FN. The Phasic Activity of the Muscles of the Lower Extremity and the Effect of Tendon Transfer. *J Bone Joint Surg [Am]* 1959;41A:189.

+ 44. Cohen RB, Hahn GV, Tabas JA, et al. The Natural History of Heterotopic Ossification in Patients Who Have Fibrodysplasia Ossificans Progressiva. A Study of Forty-four Patients. *J Bone Joint Surg [Am]* 1993;75:215.

# 45. Cope DN. The Effectiveness of Traumatic Brain Injury Rehabilitation: A Review. *Brain Inj* 1995;9:649.

+ 46. Copp EP, Keenan J. Phenol Nerve and Motor Point Block in Spasticity. *Rheumatol Phys Med* 1972;11:287.

+ 47. Cosgrove JL, Vargo M, Reidy ME. A Prospective Study of Peripheral Nerve Lesions Occurring in Traumatic Brain-injured Patients [See Comments]. *Am J Phys Med Rehabil* 1989;68:15.

+ 48. Cullen JP, Pellegrini VD Jr, Miller RJ, Jones JA. Treatment of Traumatic Radioulnar Synostosis by Excision and Postoperative Low-dose Irradiation. *J Hand Surg [Am]* 1994;19:394.

+ 49. Davis CH, Fardanesh L, Rubner D, et al. Profiles of Functional Recovery in Fifty Traumatically Brain-injured Patients After Acute Rehabilitation. *Am J Phys Med Rehabil* 1997;76:213.

+ 50. De Quervain IA, Simon SR, Leurgans S, et al. Gait Pattern in the Early Recovery Period after Stroke. *J Bone Joint Surg [Am]* 1996;64-A:1506.

+ 51. Decq P, Filipetti P, Feve A, et al. Peripheral Selective Neurotomy of the Brachial Plexus Collateral Branches for Treatment of the Spastic Shoulder: Anatomical Study and Clinical Results in Five Patients. *J Neurosurg* 1997;86:648.

+ 52. Dengler R, Neyer U, Wohlfarth K, et al. Local Botulinum Toxin in the Treatment of Spastic Drop Foot. *J Neurol* 1992;239:375.

+ 53. Dimitrijevic MM, Stokic DS, Wawro AW, Wun CC. Modification of Motor Control of Wrist Extension by Mesh-glove Electrical Afferent Stimulation in Stroke Patients. *Arch Phys Med Rehabil* 1996;77:252.

+ 54. Djurickovic S, Meek RN, Snelling CF, et al. Range of Motion and Complications After Postburn Heterotopic Bone Excision About the Elbow. *J Trauma* 1996;41:825.

+ 55. Dombovy ML, Olek AC. Recovery and Rehabilitation Following Traumatic Brain Injury. *Brain Inj* 1997;11:305.

+ 56. Drummond DS, Rogala E, Templeton J. Proximal Hamstring Release for Knee Flexion and Crouched Posture in Cerebral Palsy. *J Bone and Joint Surg [Am]* 1974;56-A:1598.

+ 57. Eames P, Cotterill G, Kneale TA, et al. Outcome of Intensive Rehabilitation after Severe Brain Injury: A Long-term Follow-up Study. *Brain Inj* 1996;10:631.

+ 58. Enderson BL, Maull KI. Missed Injuries. The Trauma Surgeon's Nemesis. *Surg Clin North Am* 1991;71:399.

# 59. Esquenazi A, Keenan MA. Gait Analysis. In: DeLisa JA, ed. *Rehabilitation Medicine: Principles and Practice.* Philadelphia: Lippincott Company, 1993:122.

+ 60. Esquenazi A, Keenan MA, Mayer N. Evaluacion y Manejo de Espasticidad, Contracturas y Disfuncion del Control Motor. *Kinesiologia* 1995;42:60.

+ 61. Fitzsimmons AS, O'Dell MW, Guiffra LJ, Sandel ME. Radial Nerve Injury Associated with Traumatic Myositis Ossificans in a Brain Injured Patient. *Arch Phys Med Rehabil* 1993;74:770.

+ 62. Frischhut B, Stockhammer G, Saltuari L, et al. Early Removal of Periarticular Ossifications in Patients with Head Injury. *Acta Neurol (Napoli)* 1993;15:114.

+ 63. Garland DE. Clinical Observations on Fractures and Heterotopic Ossification in the Spinal Cord and Traumatic Brain Injured Populations. *Clin Orthop* 1988;233:86.

+ 64. Garland DE. A Clinical Perspective on Common Forms of Acquired Heterotopic Ossification. *Clin Orthop* 1991;263:13.

+ 65. Garland DE. Surgical Approaches for Resection of Heterotopic Ossification in Traumatic Brain Injured Adults. *Clin Orthop* 1991;263:59.

+ 66. Garland DE. Evidence for a Humoral Mechanism for Enhanced Osteogenesis after Head Injury [Letter; Comment]. *J Bone Joint Surg [Am]* 1992;74:152.

+ 67. Garland DE, Alday B, Venos KG. Heterotopic Ossification and HLA Antigens. *Arch Phys Med Rehabil* 1984;65:531.

+ 68. Garland DE, Bailey S. Undetected Injuries in Head-injured Adults. *Clin Orthop* 1981;155:162.

+ 69. Garland DE, Blum CE, Waters RL. Periarticular Heterotopic Ossification in Head-injured Adults. Incidence and Location. *J Bone Joint Surg [Am]* 1980;62:1143.

+ 70. Garland DE, Capen D, Waters RL. Surgical Morbidity in Patients with Neurologic Dysfunction. *Clin Orthop* 1979;145:189.

+ 71. Garland DE, Dowling V. Forearm Fractures in the Head-Injured Adult. *Clin Orthop* 1983;176:190.

+ 72. Garland DE, Hanscom DA, Keenan MA, et al. Resection of Heterotopic Ossification in the Adult with Head Trauma. *J Bone Joint Surg [Am]* 1985;67:1261.

+ 73. Garland DE, Keenan MA. Orthopedic Strategies in the Management of the Adult Head-injured Patient. *Phys Ther* 1983;63:2004.

+ 74. Garland DE, Lilling M, Keenan MA. Percutaneous Phenol Blocks to Motor Points of Spastic Forearm Muscles in Head-injured Adults. *Arch Phys Med Rehabil* 1984;65:243.

+ 75. Garland DE, Lucie RS, Waters RL. Current Uses of Open Phenol Nerve Block for Adult Acquired Spasticity. *Clin Orthop* 1982;165:217.

+ 76. Garland DE, O'Hollaren RM. Fractures and Dislocations about the Elbow in the Head-Injured Adult. *Clin Orthop* 1982;168:38.

+ 77. Garland DE, Razza BE, Waters RL. Forceful Joint Manipulation in Head-injured Adults with Heterotopic Ossification. *Clin Orthop* 1982;169:133.

+ 78. Garland DE, Rhoades ME. Orthopedic Management of Brain-injured Adults. *Clin Orthop* 1978;131:111.

+ 79. Garland DE, Rathi B, Waters RL. Femoral Fractures in Head-injured Adults. *Clin Orthop* 1982;166:219.

+ 80. Garland DE, Waters RL. Orthopedic Evaluation in Hemiplegic Stroke. *Orthop Clin North Am* 1978;9:291.

# 81. Garland DE, Waters RL. Extremity Fractures in Head Injured Adults. In: Meyers MH, ed. *The Multiply Injured Patient with Complex Fractures.* Philadelphia: Lea & Febiger, 1984:134.

+ 82. Garraway WM, Whisnant JP, Drury I. The Changing Pattern of Survival Following Stroke. *Stroke* 1983;14:699.

+ 83. Garraway WM, Whisnant JP, Kurland LT, O'Fallon WM. Changing Patterns of Cerebral Infarction: 1945–1974. *Stroke* 1979;10:657.

+ 84. Gellman H, Keenan MA, Botte MJ. Recognition and Management of Upper Extremity Pain Syndromes in the Patient with Brain Injury. *The Journal of Head Trauma Rehabilitation* 1996;11:23.

+ 85. Gellman H, Keenan MA, Stone L, et al. Reflex Sympathetic Dystrophy in Brain-injured Patients. *Pain* 1992;51:307.

+ 86. Gennarelli TA. Heterotopic Ossification. *Brain Inj* 1988;2:175.

+ 87. Goodman TA, Merkel PA, Perlmutter G, et al. Heterotopic Ossification in the Setting of Neuromuscular Blockade [See Comments]. *Arthritis Rheum* 1997;40:1619.

+ 88. Grujic H, Asparisi T. Distal Hamstring Release in Knee Flexion Deformity. *Int Orthop* 1982;6:103.

+ 89. Guanche C, Keenan MAE. Principles of Orthopaedic Rehabilitation. *Phys Med Rehab Clin North Am* 1992;3:417.

# 90. Hagen C, Malkmus D, Durham P, Bowman. *Levels of Cognitive Functioning. Rehabilitation of the Brain Injured Adult: Comprehensive Physical Management.* Downey, CA: Professional Staff Association of Rancho Los Amigos Hospital, 1979:87.

+ 91. Harrison CL, Dijkers M. Traumatic Brain Injury Registries in the United States: An Overview. *Brain Inj* 1992;6:203.

+ 92. Haselkom JK, Mueller BA, Rivara FA. Characteristics of Drivers and Driving Record after Traumatic and Nontraumatic Brain Injury. *Arch Phys Med Rehabil* 1998;79:738.

+ 93. Hendricks HT, Hageman G, van Limbeek J. Prediction of Recovery from Upper Extremity Paralysis after Stroke by Measuring Evoked Potentials. *Scand J Rehabil Med* 1997;29:155.

+ 94. Hesse S, Bertelt C, Schaffrin A, et al. Restoration of Gait in Nonambulatory Hemipareitc Patient by Treadmill Training with Partial Body-weight Support. *Arch Phys Med Rehabil* 1994;75:1087.

+ 95. Hillier SL, Metzer J. Awareness and Perceptions of Outcomes after Traumatic Brain Injury. *Brain Inj* 1997;11:525.

+ 96. Hillier SL, Sharpe MH, Metzer J. Outcomes 5 Years Post-traumatic Brain Injury (with Further Reference to Neurophysical Impairment and Disability). *Brain Inj* 1997;11:661.

+ 97. Hummelsheim H, Maier-Lath ML, Eickhof C. The Functional Value of Electrical Muscle Stimulation for the Rehabilitation of the Hand in Stroke Patients. *Scand J Rehabil Med* 1997;29:3.

+ 98. Hurvitz EA, Mandac BR, Davidoff G, et al. Risk Factors for Heterotopic Ossification in Children and Adolescents with Severe Traumatic Brain Injury. *Arch Phys Med Rehabil* 1992;73:459.

+ 99. Jennett B, Teasdale G, Braakman R, et al. Prognosis of Patients with Severe Head Injury. *Neurosurgery* 1979;4:283.

+ 100. Jennett B, Teasdale G, Galbraith S. Severe Head Injuries in Three Countries. *J Neurol Neurosurg Psychiatry* 1977;40:291.

+ 101. Jordan C. Current Status of Functional Lower Extremity Surgery in Adult Spastic Patients. *Clin Orthop* 1988;233:102.

+ 102. Katz J, Knott LW, Feldman DJ. Peripheral Nerve Injections with Phenol in Management of Spastic Patients. *Arch Phys Med Rehabil* 1967;48:97.

# 103. Keenan MA. The Orthopaedic Management of Spasticity. *The Journal of Head Trauma Rehabilitation* 1987;2:62.

+ 104. Keenan MA. Management of the Spastic Upper Extremity in the Neurologically Impaired Adult. *Clin Orthop* 1988:116.

+ 105. Keenan MA. Surgical Decision Making for Residual Limb Deformities Following Traumatic Brain Injury. *Orthop Rev* 1988;17:1185.

# 106. Keenan MA. Stroke. In: Kasser JR, ed. *Orthopaedic Knowledge Update 5.* Rosemont, IL: American Academy of Orthopaedic Surgeons, 1996:689.

+ 107. Keenan MA, Botte MJ. Technique of Percutaneous Phenol Block of the Recurrent Motor Branch of the Median Nerve. *J Hand Surg [Am]* 1987;12:806.

# 108. Keenan MA, Botte MJ, Hsu J, et al. Symposium: Orthopaedic Management of Patients with Traumatic Brain Injuries. *Contemporary Orthopaedics* 1993;27:357.

+ 109. Keenan MA, Creighton J, Garland DE, Moore T. Surgical Correction of Spastic Equinovarus Deformity in the Adult Head Trauma Patient. *Foot Ankle* 1984;5:35.

+ 110. Keenan MA, Gorai AP, Smith CW, De, G. Intrinsic Toe Flexion Deformity Following Correction of Spastic Equinovarus Deformity in Adults. *Foot Ankle* 1987;7:333.

+ 111. Keenan MA, Haider T. The Formation of Heterotopic Ossification after Traumatic Brain Injury: A Biopsy Study with Ultrastructural Analysis. *The Journal of Head Trauma Rehabilitation* 1996;11:8.

+ 112. Keenan MA, Haider TT, Stone LR. Dynamic Electromyography to Assess Elbow Spasticity. *J Hand Surg [Am]* 1990;15:607.

+ 113. Keenan MA, Kauffman DL, Garland DE, Smith C. Late Ulnar Neuropathy in the Brain Injured Adult. *J Hand Surg [Am]* 1988;13:120.

+ 114. Keenan MA, Peabody TD, Gronley JK, Perry J. Valgus Deformities of the Feet and Characteristics of Gait in Patients Who Have Rheumatoid Arthritis. *J Bone Joint Surg [Am]* 1991;73:237.

+ 115. Keenan MA, Perry J, Jordan C. Factors Affecting Balance and Ambulation Following Stroke. *Clin Orthop* 1984:165.

+ 116. Keenan MA, Ahearn R, Lazarus M, Perry J. Selective Release of Spastic Elbow Flexors in the Patient with Brain Injury. *The Journal of Head Trauma Rehabilitation* 1996;11:57.

+ 117. Keenan MA, Romanelli RR, Lunsford BR. The Use of Dynamic Electromyography to Evaluate Motor Control in the Hands of Adults Who Have Spasticity Caused by Brain Injury. *J Bone Joint Surg [Am]* 1989;71:120.

+ 118. Keenan MA, Todderud EP, Henderson R, Botte M. Management of Intrinsic Spasticity in the Hand with Phenol Injection or Neurectomy of the Motor Branch of the Ulnar Nerve. *J Hand Surg [Am]* 1987;12:734.

+ 119. Keenan MA, Tomas ES, Stone L, Gersten LM. Percutaneous Phenol Block of the Musculocutaneous Nerve to Control Elbow Flexor Spasticity. *J Hand Surg [Am]* 1990;15:340.

+ 120. Keenan MA, Ure K, Smith CW, Jordan C. Hamstring Release for Knee Flexion Contracture in Spastic Adults. *Clin Orthop* 1988;236:221.

# 121. Keenan MA, Waters RL. Surgical Treatment of the Upper Extremity after Stroke or Brain Injury. In: Chapman M, ed. *Operative Orthopaedics.* Philadelphia: JB Lippincott Publishers, 1993:1529.

# 122. Keenan MAE, Botte MJ. Traumatic Brain Injury. In: Nickel VL, Botte MJ, eds. *Orthopaedic Rehabilitation.* New York: Churchill Livingstone Publishers, 1992:361.

# 123. Keenan MAE, Kozin SH, Berlet AC. *Manual of Orthopaedic Surgery for Spasticity.* New York: Raven Press, 1993.

+ 124. Keenan MAE, Lee GA, Tuckman AS, Esquenazi A. Improving Calf Muscle Strength in Patients with Spastic Equinovarus Deformity by Transfer of the Long Toe Flexors to the Os Calcis. *Journal Head Trauma Rehabil* 1999;14(2):163.

+ 125. Keenan MAE, Perry J. Evaluation of Upper Extremity Motor Control in Spastic Brain-injured Patients Using Dynamic Electromyography. *The Journal of Head Trauma Rehabilitation* 1990;5:13.

# 126. Keenan MAE, Perry J. Motion analysis: Upper Extremity. In: Nickel VLaB MJ, ed. *Orthopaedic Rehabilitation.* Churchill Livingstone Publishers, 1992:243.

# 127. Keenan MAE, Waters RL. Surgical Treatment of the lower Extremity after Stroke. In: Chapman M, ed. *Operative Orthopaedics.* Philadelphia: JB Lippincott Publishers, 1993:3449.

# 128. Keenan MA, Waters RL. Orthopaedic Rehabilitation. In: Skinner HB, ed. *Current Diagnosis and Treatment in Orthopaedics.* NJ: Appleton & Lange Medical Publishing, 1995:604.

+ 129. Kerrigan DC, Annaswamy TM. The Functional Significance of Spasticity as Assessed by Gait Analysis. *The Journal of Head Trauma Rehabilitation* 1997;12:29.

+ 130. Kettelkamp DB, Hillberry BM, MulTish D, Heck D. Degenerative Arthritis of the Knee Secondary to Fracture Malunion. *Clin Orthop* 1988;234:159.

+ 131. Khalili AA, Betts HB. Peripheral Nerve Block with Phenol in the Management of Spasticity. *JAMA* 1967;200:1155.

+ 132. Khalili AA, Harmel MH, Forster S, Benton JG. Management of Spasticity by Selective Peripheral Nerve Block with Dilute Phenol Solutions in Clinical Rehabilitation. *Arch Phys Med Rehabil* 1964;45:513.

+ 133. Kiwerski J. New Possibilities of Improving the Function of the Hand of Patients with Spastic Hemiplegia. *Int J Rehabil Res* 1984;7:293.

# 134. Kolessar D, Keenan MAE. Surgical Management of Upper Extremity Deformities Following Traumatic Brain Injury. In: Stone LR, ed. *Neurologic and Orthopaedic Sequelae of TBI,* Vol 7. Philadelphia: Hanley & Belfus, Inc., 1993:623.

+ 135. Kolessar DJ, Katz SD, Keenan ME. Functional Outcome Following Surgical Resection of Heterotopic Ossification in Pateints with Brain Injury. *The Journal of Head Trauma Rehabilitation* 1996;11:78.

+ 136. Koman LA, Gelberman RH, Toby EB, Poehling GG. Cerebral Palsy. Management of the Upper Extremity. *Clin Orthop* 1990;253:62.

+ 137. Kozin SH, Keenan MA. Using Dynamic Electromyography to Guide Surgical Treatment of the Spastic Upper Extremity in the Brain-injured Patient. *Clin Orthop* 1993;288:109.

# 138. Kozin SH, Keenan MAE. Principles of Surgery for Adult Brain Injury. *Current Orthopaedics* 1991;5:75.

+ 139. Kraft GH, Fitts SS, Hammond MC. Techniques to Improve Function of the Arm and Hand in Chronic Hemiplegia. *Arch Phys Med Rehabil* 1992;73:220.

+ 140. Kralj A, Acimovic R, Stanic U. Enhancement of Hemiplegic Patient Rehabilitation by Means of Functional Electrical Stimulation. *Prosthet Orthot Int* 1993;17:107.

+ 141. Kraus JF, Black MA, Hessol M, et al. The Incidence of Acute Brain Injury in a Defined Population. *Am J Epidemiol* 1984;119:186.

+ 142. Kumar R, Metter EJ, Mehta AJ, Chew T. Shoulder Pain in Hemiplegia. The Role of Exercise. *Am J Phys Med Rehabil* 1990;69:205.

+ 143. Lawrence SJ, Botte MJ. Current Topic Review: Management of the Adult Spastic Equinovarus Foot Deformity. *Foot Ankle Int* 1994;15:340.

+ 144. Loewen SC, Anderson BA. Predictors of Stroke Outcome Using Objective Measurement Scales. *Stroke* 1990;21:78.

+ 145. Malisano LP, Stevens D, Hunter GA. The Management of Long Bone Fractures in the Head Injured Polytrauma Patient. *J Orthop Trauma* 1994;8:1.

# 146. Mann RA, Pes Cavus. In: Mann RA, Coughlin M, eds. *Surgery of the Foot and Ankle.* St. Louis: CV Mosby, 1993:785.

+ 147. Mayer N, Esquenazi A, Wannstedt G. Surgical Planning for Upper Motoneuron Dysfunction: The Role of Motor Control Evaluation. *The Journal of Head Trauma Rehabilitation* 1996;11:37.

# 148. Mayer NH, Esquenazi A, Keenan ME. Analysis and Management of Spasticity, Contracture, and Impaired Motor Control. In: Horn LJ, Zasler ND, eds. *Medical Rehabilitation of Traumatic Brain Injury.* Philadelphia: Hanley & Belfus, 1996:411.

+ 149. McAuliffe JA, Wolfson AH. Early Excision of Heterotopic Ossification about the Elbow Followed by Radiation Therapy. *J Bone Joint Surg [Am]* 1997;79:749.

+ 150. McCollough NC III. Orthotic Management in Adult Hemiplegia. *Clin Orthop* 1978:38.

# 151. McCollough NC. The Role of the Orthopaedic Surgeon in the Treatment of Stroke. *Orthop Clin North Am* 1978;9:305.

+ 152. Meythaler JM, DeVivo MJ, Hadley M. Prospective Study on the Use of Bolus Intrathecal Baclofen for Spastic Hypertonia due to Acquired Brain Injury. *Arch Phys Med Rehabil* 1996;77:461.

+ 153. Meythaler JM, Tuel SM, Cross LL, Mathew MM. Heterotopic Ossification of the Extensor Tendons in the Hand Associated with Traumatic Spinal Cord Injury. *J Am Paraplegia Soc* 1992;15:229.

+ 154. Moberg E. Two-point Discrimination Test. A Valuable Part of Hand Surgical Rehabilitation, e.g. in Tetraplegia. *Scand J Rehabil Med* 1990;22:127.

# 155. Mooney V, Frykman G, McLamb J. Current Status of Intraneural Phenol Injections. *Clin Orthop* 1969;63:122.

# 156. Moore T. Traumatic Brain Injury. In: Kasser JR, ed. *Orthopaedic Knowledge Update 5.* Rosemont, IL: American Academy of Orthopaedic Surgeons, 1996:695.

+ 157. Moore TJ. Functional Outcome Following Surgical Excision of Heterotopic Ossification in Patients with Traumatic Brain Injury. *J Orthop Trauma* 1993;7:11.

+ 158. Moritz U. Phenol Block of Peripheral Nerves. *Scand J Rehabil Med* 1973;5:160.

+ 159. Mysiw WJ, Tan J, Jackson RD. Heterotopic Ossification. The Utility of Osteocalcin in Diagnosis and Management. *Am J Phys Med Rehabil* 1993;72:184.

+ 160. Nakayama H, Jorgensen HS, Raaschou HO, Olsen TS. Compensation in Recovery of Upper Extremity Function after Stroke: The Copenhagen Stroke Study. *Arch Phys Med Rehabil* 1994;75:852.

+ 161. Nakayama H, Jorgensen HS, Raaschou HO, Olsen TS. Recovery of Upper Extremity Function in Stroke Patients: The Copenhagen Stroke Study. *Arch Phys Med Rehabil* 1994;75:394.

+ 162. Nyberg L, Gustafson Y. Fall Prediction Index for Patients in Stroke Rehabilitation. *Stroke* 1997;28:716.

+ 163. O'Dwyer NJ, Ada L, Neilson PD. Spasticity and Muscle Contracture Following Stroke. *Brain* 1996;119:1737.

+ 164. Olsen TS. Arm and Leg Paresis as Outcome Predictors in Stroke Rehabilitation. *Stroke* 1990;21:247.

+ 165. Olver JH, Ponsford JL, Curran CA. Outcome Following Traumatic Brain Injury: A Comparison Between 2 and 5 Years After Injury. *Brain Inj* 1996;10:841.

+ 166. Orcutt SA, Kramer WGD, Howard MW, et al. Carpal tunnel syndrome secondary to wrist and finger flexor spasticity. *J Hand Surg [Am]* 1990;15:940.

+ 167. Otfinowski J. Heterotopic Induction of Osteogenesis in the Course of Neural Injury. *Patol Pol* 1993;44:133.

+ 168. Ouellette EA, Kelly R. Compartment Syndromes of the Hand. *J Bone Joint Surg [Am]* 1996;78:1515.

# 169. Ough JL, Garland DE, Jordan C, Waters RL. Treatment of Spastic Joint Contractures in Mentally Disabled Adults. *Orthop Clin North Am* 1981;12:143.

+ 170. Ounpuu MS, Muik E, Davis III RB, et al. Rectus Femoris Surgery in Children with Cerebral Palsy. Part II: A Comparison Between the Effect of Transfer and Release of the Distal Rectus Femoris on Knee Motion. *J Pediatr Orthop* 1993;13:331.

+ 171. Ounpuu MS, Muik E, Davis III RB, et al. Rectus Femoris Surgery in Children with Cerebral Palsy. Part I: The Effect of Rectus Femoris Transfer Location of Knee Motion. *J Pediatr Orthop* 1993;13:325.

+ 172. Panizza M, Balbi P, Russo G, Nilsson J. H-reflex Recovery Curve and Reciprocal Inhibition of H-reflex of the Upper Limbs in Patients with Spasticity Secondary to Stroke. *Am J Phys Med Rehabil* 1995;74:357.

+ 173. Perlmutter MN, Synder M, Miller F, Bisbal R. Proximal Femoral Resection for Older Children with Spastic Hip Disease. *Dev Med Child Neurol* 1993;35:525.

# 174. Perry J. Contractures. A Historical Perspective. *Clin Orthop* 1987;219:8.

# 175. Perry J. *Gait Analysis. Normal and Pathological Function.* Thorofare: Slack Inc., 1992.

# 176. Perry J. Determinants of Muscle Function in the Spastic Lower Extremity. *Clin Orthop* 1993;288:10.

+ 177. Perry J, Giovan P, Harris LJ, et al. The Determinants of Muscle Action in the Hemiparetic Lower Extremity. *Clin Orthop* 1978;131:71.

# 178. Perry J, Keenan MAE. Rehabilitation of the Neurologically Disabled Patient. In: Aminoff MJ, ed. *Neurology and General Medicine.* New York: Churchill Livingstone Publishers, 1989:747.

# 179. Perry J, Waters RL. Orthopaedic Evaluation and Treatment of the Stroke Patient. Part III. Upper Extremity Management and Surgery. *Instr Course Lect* 1975;24:51.

+ 180. Perry J, Waters RL, Perrin T. Electromyographic Analysis of Equinovarus Following Stroke. *Clin Orthop* 1978;131:47.

+ 181. Peter KS, Hsu JD, Keenan MA, Romansky SG. Histology and Intramuscular Pressure in Spastic Muscles. *The Journal of Head Trauma Rehabilitation* 1996;11:1.

+ 182. Piccioni L, Keenan MA. Surgical Management of the Spastic Equinovarus Foot Deformity. *Operative Techniques in Orthopaedics* 1992;2:146.

+ 183. Pinzur MS. Dynamic Electromyography in Functional Surgery for Upper Limb Spasticity. *Clin Orthop* 1993;288:118.

+ 184. Pinzur MS. Surgical Correction of Lower Extremity Problems in Patients with Brain Injury. *The Journal of Head Trauma Rehabilitation* 1996;44:69.

+ 185. Pomerance JF, Keenan MA. Correction of Severe Spastic Flexion Contractures in the Nonfunctional Hand. *J Hand Surg [Am]* 1996;21:828.

+ 186. Poulin de Courval L, Barsauskas A, Berenbaum B, et al. Painful Shoulder in the Hemiplegic and Unilateral Neglect. *Arch Phys Med Rehabil* 1990;71:673.

+ 187. Prochazka A, Gauthier M, Wieler M, Kenwell Z. The Bionic Glove: An Electrical Stimulator Garment that Provides Controlled Grasp and Hand Opening in Quadriplegia. *Arch Phys Med Rehabil* 1997;78:608.

+ 188. Ragone DJ Jr, Kellerman WC, Bonner FJ Jr. Heterotopic Ossification Masquerading as Deep Venous Thrombosis in Head-injured Adult: Complications of Anticoagulation. *Arch Phys Med Rehabil* 1986;67:339.

# 189. Raj P, Caloodney A, Janisse T, Cannella J. Reflex Sympathetic Dystrophy. In: Browner BD JJ, Levine AM, Trafton PG, eds. *Skeletal Trauma: Fractures, Dislocations, Ligamentous Injuries,* Vol 1. Philadelphia: WB Saunders, 1992:471.

+ 190. Renfree KJ, Banovac K, Hornicek FJ, et al. Evaluation of Serum Osteoblast Mitogenic Activity in Spinal Cord and Head Injury Patients with Acute Heterotopic Ossification. *Spine* 1994;19:740.

+ 191. Ritter MA. Indomethacin: An Adjunct to Surgical Excision of Immature Heterotopic Bone Formation in a Patient with a Severe Head Injury. A Case Report. *Orthopedics* 1987;10:1379.

+ 192. Rocke DM, Zasloff M, Peeper J, et al. Age- and Joint-specific Risk of Initial Heterotopic Ossification in Patients Who Have Fibrodysplasia Ossificans Progressiva. *Clin Orthop* 1994:243.

+ 193. Rogers RC. Heterotopic Calcification in Severe Head Injury: A Preventive Programme. *Brain Inj* 1988;2:169.

# 194. Roper BA. The Orthopedic Management of the Stroke Patient. *Clin Orthop* 1987;219:78.

+ 195. Roper BA, Wilhims A, King JB. The Surgical Treatment of Equinovarus Deformity in Adults with Spasticity. *J Bone Joint Surg [Br]* 1978;60-B:533.

# 196. Russell TA, Taylor JC. Subtrochanteric Fractures of the Femur. In: Browner BD, Jupiter JB, Levine AM, Trafton PG, eds. *Skeletal Trauma: Fractures, Dislocations, Ligamentous Injuries,* Vol 2. Philadelphia: WB Saunders, 1992:1485.

+ 197. Sampaio C, Ferreira JJ, Pinto AA, et al. Botulinum Toxin Type A for the Treatment of Arm and Hand Spasticity in Stroke Patients. *Clin Rehabil* 1997;11:3.

+ 198. Sandin KJ, Smith BS. The Measure of Balance in Sitting in Stroke Rehabilitation Prognosis. *Stroke* 1990;21:82.

+ 199. Schaeffer MA, Sosner J. Heterotopic Ossification: Treatment of Established Bone with Radiation Therapy. *Arch Phys Med Rehabil* 1995;76:284.

+ 200. Seymour N, Sharrard WJW. Bilateral Proximal Release of the Hamstrings in Cerebral Palsy. *J Bone Joint Surg [Br]* 1968;50-B:274.

+ 201. Sharps CH, Clancy M, Steele HH. A Long Term Retrospective Study of Proximal Hamsting Release for Hamstring Contracture in Cerebral Palsy. *J Pediatr Orthop* 1984;4:443.

+ 202. Simpson DM, Alexander DN, O'Brien CF, et al. Botulinum Toxin Type A in the Treatment of Upper Extremity Spasticity: A Randomized, Double-blind, Placebo-controlled Trial. *Neurology* 1996;46:1306.

+ 203. Smith CW, Levanthal L. Surgical Management of Lower Extremity Deformities in Adult Head Injured Patients. *The Journal of Head Trauma Rehabilitation* 1987;2:53.

+ 204. Sobus KM, Alexander MA, Harcke HT. Undetected Musculoskeletal Trauma in Children with Traumatic Brain Injury or Spinal Cord Injury. *Arch Phys Med Rehabil* 1993;74:902.

+ 205. Sobus KM, Sherman N, Alexander MA. Coexistence of Deep Venous Thrombosis and Heterotopic Ossification in the Pediatric Patient. *Arch Phys Med Rehabil* 1993;74:547.

+ 206. Spencer RF. Heterotopic Ossification in a Finger Following Head Injury. *J Hand Surg [Br]* 1991;16:217.

+ 207. Spielman G, Gennarelli TA, Rogers CR. Disodium Etidronate: Its Role in Preventing Heterotopic Ossification in Severe Head Injury. *Arch Phys Med Rehabil* 1983;64:539.

# 208. Stiles CM, Patel M, Keenan MAE. Anesthesia for Rehabilitation Surgery. In: Nickel VL, Botte MJ, ed. *Orthopaedic Rehabilitation.* New York: Churchill Livingstone Publishers, 1992:105.

+ 209. Stone L, Keenan MA. Peripheral Nerve Injuries in the Adult with Traumatic Brain Injury. *Clin Orthop* 1988;233:136.

+ 210. Stone LR, Keenan MA. Deep-venous Thrombosis of the Upper Extremity after Traumatic Brain Injury. *Arch Phys Med Rehabil* 1992;73:486.

+ 211. Stone LR, Keenan MA, Shin DY. Acquired Limb Loss in Patients with Traumatic Brain Injury. *Am J Phys Med Rehabil* 1990;69:135.

+ 212. Subbarao JV. Pseudoarthrosis in Heterotopic Ossification in Spinal cord–injured Patients. *Am J Phys Med Rehabil* 1990;69:88.

+ 213. Summerfield SL, DiGiovanni C, Weiss AP. Heterotopic Ossification of the Elbow. *J Shoulder Elbow Surg* 1997;6:321.

+ 214. Sutherland DH, Santi M, Abel MF. Treatment of Stiff-Knee Gait in Cerebral Palsy: A Comparison by Gait Analysis of Distal Rectus Femoris Transfer Versus Proximal Rectus Release. *J Pediatr Orthop* 1990;10:433.

+ 215. Swaine BR, Sullivan SJ. Longitudinal Profile of Early Motor Recovery Following Severe Traumatic Brain Injury. *Brain Inj* 1996;10:347.

+ 216. Swaine BR, Sullivan SJ. Reliability of Early Motor Function Testing in Persons Following Severe Traumatic Brain Injury. *Brain Inj* 1996;10:263.

+ 217. Swanson AB, de Groot Swanson G. Evaluation and Treatment of the Upper Extremity in the Stroke Patient. *Hand Clin* 1989;5:75.

+ 218. Taub E, Miller NE, Novack TA, et al. Technique to Improve Chronic Major Deficit after Stroke. *Arch Phys Med Rehabil* 1993;74:347.

+ 219. Teasdale G, Jenne'dt B. Assessment of Coma and Impaired Consciousness: A Practical Scale. *Lancet* 1974;2:81.

+ 220. Teng EL, McNeal DR, Kralj A, Waters RL. Electrical Stimulation and Feedback Training: Effects on the Voluntary Control of Paretic Muscles. *Arch Phys Med Rehabil* 1976;57:228.

# 221. Trafton PG, Bray TJ, Simpson LA. Fractures and Soft Tissue Injuries of the Ankle. In: Browner BD JJ, Levine AM, TrafLon PG, eds. *Skeletal Trauma: Fractures, Dislocations, Ligamentous Injuries,* Vol 2. Philadelphia: WB Saunders, 1992:1871.

+ 222. Tsur A, Sazbon L, Latem M. Relationship Between Muscular Tone, Movement and Periarticular New Bone Formation in Postcoma-unaware (PC-U) Patients. *Brain Inj* 1996;10:259.

+ 223. van der Linden AJ. Spontaneous Regression of Neurogenic Heterotopic Ossification. *Int Orthop* 1984;8:25.

+ 224. Vara-Thorbeck R, Ruiz-Morales M. Severe Head Injury Combined with Orthopedic and Vascular Trauma of the Limbs. Langenbecks. *Arch Surg* 1998;383:252.

+ 225. Wainapel SF, Haigoey D, Labib K. Spastic Hemiplegia in a Quadriplegic Patient: Treatment with Phenol Nerve Blocks. *Arch Phys Med Rehabil* 1984;65:786.

+ 226. Waters R, Montgomery J. Lower Extremity Management of Hemiparesis. *Clin Orthop* 1974;0:133.

+ 227. Waters R, Rhoades M, Montgomery J. Improvement of Physical Function after Stroke: Surgical and Orthotic Management. *J Am Geriatr Soc* 1975;23:248.

# 228. Waters RL. Upper Extremity Surgery in Stroke Patients. *Clin Orthop* 1978:30.

+ 229. Waters RL, Campbell J, Perry J. Energy Cost of Three-point Crutch Ambulation in Fracture Patients. *J Orthop Trauma* 1987;1:170.

+ 230. Waters RL, Clifford B, Jordan C. Surgical Correction of Spastic Lower Extremity Deformities. *Acta Orthop Belg* 1984;50:172.

+ 231. Waters RL, Frazier J, Garland DE, et al. Electromyographic Gait Analysis before and after Operative Treatment for Hemiplegic Equinus and Equinovarus Deformity. *J Bone Joint Surg [Am]* 1982;64:284.

+ 232. Waters RL, Garland DE, Perry J, et al. Stiff-legged Gait in Hemiplegia: Surgical Correction. *J Bone Joint Surg [Am]* 1979;61:927.

# 233. Waters RL, Hislop HJ, Perry J, Antonelli D. Energetics: Application to the Study and Management of Locomotor Disabilities. Energy Cost of Normal and Pathologic Gait. *Orthop Clin North Am* 1978;9:351.

+ 234. Waters RL, Hislop HJ, Perry J, et al. Comparative Cost of Walking in Young and Old Adults. *J Orthop Res* 1983;1:73.

# 235. Waters RL, Keenan MA. Surgical Treatment of the Upper Extremity after Stroke. In: Chapman M, ed. *Operative Orthopaedics,* Vol 1. Philadelphia: JB Lippincott Publishers, 1988:1449.

+ 236. Waters RL, Lunsford BR, Perry J, Byrd R. Energy-speed Relationship of Walking: Standard Tables. *J Orthop Res* 1988;6:215.

+ 237. Waters RL, McNeal DR, Clifford B. Correction of Footdrop in Stroke Patients via Surgically Implanted Peroneal Nerve Stimulator. *Acta Orthop Belg* 1984;50:285.

+ 238. Waters RL, McNeal DR, Faloon W, Clifford B. Functional Electrical Stimulation of the Peroneal Nerve for Hemiplegia. Long-term Clinical Follow-up. *J Bone Joint Surg [Am]* 1985;67:792.

+ 239. Waters RL, Perry J, Antonelli D, Hislop H. Energy Cost of Walking of Amputees: The Influence of Level of Amputation. *J Bone Joint Surg [Am]* 1976;58:42.

+ 240. Waters RL, Perry J, Conaty P, et al. The Energy Cost of Walking with Arthritis of the Hip and Knee. *Clin Orthop* 1987;214:278.

+ 241. Waters RL, Perry J, Garland D. Surgical Correction of Gait Abnormalities Following Stroke. *Clin Orthop* 1978;9:54.

+ 242. Waters RL, Perry J, McDaniels JM, House K. The Relative Strength of the Hamstrings during Hip Extension. *J Bone Joint Surg [Am]* 1974;56:1592.

+ 243. Webb LX, Bosse MJ, Mayo KA, et al. Results in Patients with Craniocerebral Trauma and an Operatively Managed Acetabular Fracture. *J Orthop Trauma* 1990;4:376.

+ 244. Weber BG, Simpson LA. Corrective Lengthening Osteotomy of the Fibula. *Clin Orthop* 1985;199:61.

+ 245. Weiss S, Grosswasser Z, Ohri A, et al. Histocompatibility (HLA) Antigens in Heterotopic Ossification Associated with Neurological Injury. *J Rheumatol* 1979;6:88.

+ 246. Whitlock JA, Hamilton BB. Functional Outcome After Rehabilitation for Severe Traumatic Brain Injury. *Arch Phys Med Rehabil* 1995;76:1103.

+ 247. Wilson DJ, Childers MK, Cooke DL, Smith BK. Kinematic Changes Following Botulinum Toxin Injection after Traumatic Brain Injury. *Brain Inj* 1997;11:157.

+ 248. Wolf SL, Binder-MacLeod SA. Electromyographic Biofeedback Applications to the Hemiplegic Patient. Changes in Upper Extremity Neuromuscular and Functional Status. *Phys Ther* 1983;63:1393.

+ 249. Wood KM. The Use of Phenol as a Neurolytic Agent. *Pain* 1978;5:205.

+ 250. Yamamoto H, Olumara S, Morita S, et al. Surgical Correction of Foot Deformities After Stroke. *Clin Orthop* 1992;282:213.

+ 251. Yekutiel M, Guttman E. A Controlled Trial of the Retraining of the Sensory Function of the Hand in Stroke Patients. *J Neurol Neurosurg Psychiatry* 1993;56:241.

+ 252. Young S, Keenan MA, Stone LR. The Treatment of Spastic Planovalgus Foot Deformity in the Neurologically Impaired Adult. *Foot Ankle* 1990;10:317.

# 253. Young S, Keenan MAE. Extremity Fractures in the Brain-injured Patient. In: Publishers CL, ed. *Orthopaedic Rehabilitation.* New York: Churchill Livingstone Publishers, 1992:401.

+ 254. Zafonte RD, Hammond FM, Mann NR, et al. Relationship between Glasgow Coma Scale and Functional Outcome. *Am J Phys Med Rehabil* 1996;75:364.

+ 255. Zafonte RD, Hammond FM, Mann NR, et al. Revised Trauma Score: An Additive Predictor of Disability Following Traumatic Brain Injury? *Am J Phys Med Rehabil* 1996;75:456.

+ 256. Zorowitz RD, Hughes MB, Idank D, et al. Shoulder Pain and Subluxation after Stroke: Correlation or Coincidence? *Am J Occup Ther* 1996;50:194.

+ 257. Zorowitz RD, Idank D, Ikai T, et al. Shoulder Subluxation after Stroke: A Comparison of Four Supports. *Arch Phys Med Rehabil* 1995;76:763.

+ 258. Zuhosky JP, Dugan SA, Young JL, et al. A Retrospective Review of the Incidence and Rehabilitation Outcome of Concomitant Traumatic Brain Injury and Ligamentous Knee Injury. *Arch Phys Med Rehabil* 1998;79:805.

# CHAPTER 124

# HETEROTOPIC OSSIFICATION AND CHARCOT NEUROARTHROPATHY

*Gary Shapiro and Mathias Bostrom*

**G. Shapiro and M. Bostrom:** Hospital for Special Surgery, New York, NY, 10021.

Heterotopic Ossification
- Definition
- Etiology
- Laboratory Assessment
- Classification
- Overview of Prevention Modalities
- Total Hip Arthroplasty
- Acetabular Fractures
- Elbow
- Traumatic Head Injury and Spinal Cord Injury

Charcot's Neuroarthropathy
- Pathogenesis
- Clinical Presentation
- Imaging
- Foot and Ankle
- Hip
- Knee

Authors' Perspective
Chapter References

## HETEROTOPIC OSSIFICATION

### DEFINITION

Formation of mature lamellar bone in nonosseous tissue is termed heterotopic ossification (HO) or heterotopic bone. Histologically, it differs from soft-tissue calcification in terms of its osteoblastic activity. Myositis ossificans is histologically identical to HO but, by definition, forms in inflammatory muscle. Periarticular calcification does not manifest the radiologic features of organized bone and is usually limited to distinct structures, such as the collateral ligaments. HO is metabolically active and histologically similar to native bone, with increased numbers of osteoblasts and osteoclasts.

### ETIOLOGY

The pathogenesis of HO is not fully understood, although it is clearly associated with certain clinical situations. HO can result in severe limitation of motion and ankylosis. Chalmers et al. (19) proposed three conditions necessary for HO formation: an osteogenic precursor cell, an inducing agent, and an environment conducive to osteogenesis. Mesenchymal cells, which have the ability to differentiate to osteogenic stem cells, are found in the soft tissues surrounding joints. Osteoinductive substances are probably released as a result of the insult, and they may cause a proliferation of mesenchymal cells. Growth factors, such as bone morphogenetic proteins (BMPs), are potential inducers of undifferentiated mesenchymal cells to proliferate and differentiate into cartilage and bone and may play a role in the formation of HO (125,126).

### LABORATORY ASSESSMENT

The preoperative identification of patients who are at risk has been investigated with bone scans and with laboratory tests, such as erythrocyte sedimentation rates (ESRs) and alkaline phosphatase levels. The results of these tests do not always correlate well with the development of the condition Theoretically, an immediate postoperative change in the serum level of substances related to osteoblast activity, such as osteocalcin, circulating growth factors, or the bone isoenzyme of alkaline phosphatase, might aid in the selection of high-risk patients needing prophylaxis. Most investigators have observed an increase in the serum alkaline phosphatase up to 3.5 times normal, beginning in the first month of HO and peaking at about 3 months (84). However, by the time these levels are noted to be elevated, the process is well established and prophylaxis is unlikely to be useful.

There has not been any conclusive evidence in the literature with regard to which test is the most accurate predictor of HO formation and maturation. Despite this, most surgeons usually allow a triple-phase bone scan and alkaline phosphatase to return to baseline before resecting heterotopic bone. Computerized tomography is often useful for operative planning.

### CLASSIFICATION

The most common classification scheme used clinically is the Brooker classification, which is based on the extent of HO seen on the AP radiograph of the hip (Table 124.1). Wright et al. (131) tested the reliability and validity of this grading system. The intraobserver reliability between two surgeons was 86% and 77%, and the interobserver reliability was 68%. Although it is useful in determining the radiographic appearance of the HO, the Brooker classification does not address its functional effect.

| Class | Criterion |
|---|---|
| I | Isolated bone islands |
| II | Greater than 1 cm of distance between opposing ossification configurations |
| III | Less than 1 cm of distance between opposing ossification configurations |
| IV | Apparent bony ankylosis |

***Table 124.1. Brooker Classification of Heterotopic Ossification (15)***

### OVERVIEW OF PREVENTION MODALITIES

HO prevention is based on preventing bone induction. The mainstays of this prevention are nonsteroidal anti-inflammatory agents (NSAIDs), ionizing radiation, and meticulous handling of surgical tissue.

The inhibitory action of NSAIDs on HO is probably related to their inhibition of the activity of prostaglandin synthetase. The resulting decrease in local concentrations of osteoactive prostaglandins may be key to the inhibition of formation of heterotopic bone. The change in environment tends to inhibit the proliferation and maturation of pluripotential osteogenic precursors and limits the development of heterotopic bone. Indomethacin has been shown in an animal model to be effective only if administered in the initial phase of bone induction (81). In studies of animals, NSAIDs have been shown to delay the healing of bone after local trauma. Rats that had been fed an aspirin-rich diet revealed a dose-dependent delay in fracture healing (4). Dahl (24) first reported on the use of indomethacin after total hip arthroplasty. Its use as an analgesic showed reduction of HO compared with the use of a placebo. Since that time, numerous studies have been conducted to compare the different anti-inflammatory agents with varying dosing and length of treatment. Because of the potential side effects of dyspepsia, bleeding, and inhibited bone healing, much emphasis has focused on finding the lowest dose and shortest length of treatment, without compromising the results of suppression of HO formation. Coumadin has been proven to be ineffective (103).

Numerous authors have investigated the use of radiation therapy. Most of their work centers around the use of such therapy after total hip replacement (23,25,43,47,48,51,59,71,74,78,86,106,107,127).

Careful handling of tissue during any surgical procedure, especially around the hip and elbow, is also of importance to minimize any trauma and subsequent inflammation. The role of proper surgical technique in the formation of heterotopic bone is difficult to quantitate.

Several unproved methods of prophylaxis have been studied. Riska and Michelsson (92) had encouraging results with the transplantation of fat after excision of HO, theorizing that filling the gap created in the soft tissues would prevent recurrence. Biphosphonates have been employed because they inhibit the transformation of amorphous calcium phosphate into hydroxyapatite and thereby the mineralization of osteoid matrix. Unfortunately, mineralization occurs when the medicine is discontinued. Thomas and Amstutz (120) found no difference when they compared biphosphonates to a placebo 2 years after the operation. Furthermore, the medication is expensive and can adversely affect calcium and phosphate metabolism, leading to conditions that include osteomalacia.

**TOTAL HIP ARTHROPLASTY**

HO is a frequent occurrence after a total hip arthroplasty (Fig. 124.1). Certain patients are at a higher risk for developing clinically significant HO: those with ankylosing spondylitis, osteoarthritis with large acetabular osteophytes, Forestier's disease, Paget's disease, bilateral disease, extensive operative trauma, formation of a hematoma, and those who have developed HO after a previous total hip arthroplasty. Men with osteoarthritis are at higher risk for HO than women (93). Ahrengart and Lindgren (3) concluded that men with osteoarthritis, men with fractures, women older than 65 with osteoarthritis, and women with hypertrophic osteoarthritis should be considered for prophylactic treatment.

***Figure 124.1.*** AP hip demonstrating Brooker IV heterotopic bone formation.

The roentgenographic incidence of HO after cemented total hip arthroplasty without prophylactic treatment approximates 30%, with a reported range from 5% (21) to 90% (99) (Table 124.2). Of those who develop HO, 3% to 10% have pain and decreased range of motion as a direct result of the HO. Maloney and Krushell (72) found a significant increase in the severity of HO with uncemented total hip arthroplasty as compared with hybrid arthroplasty. The rate of clinically significant HO in cementless total hip arthroplasty is approximately 30% (62).

***Table 124.2. Incidence of Heterotopic Ossification After Total Hip Arthroplasty***

HO usually becomes visible on radiographs 3 to 4 weeks after operation and matures by 3 to 6 months. Histologically, HO is of the membranous type and has a woven structure that is later transformed into a more organized trabecular bone. Six months to 1 year after the operation, the rate of remodeling decreases, and the tissue tends to stabilize (Fig. 124.2).

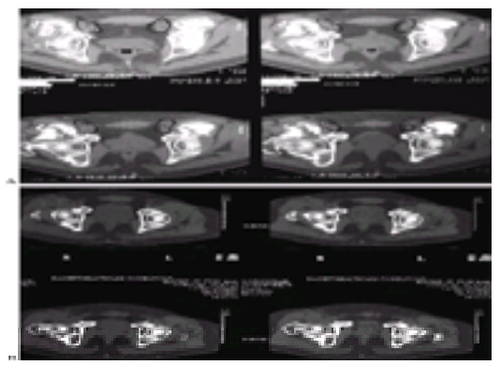

***Figure 124.2.*** CT scan of a patient with Brooker IV heterotopic bone formation before and after resection.

***Prevention***

**NSAIDs** Comparison of the effects of anti-inflammatory medications has been made in various studies with favorable results (Table 124.3) (33,103). Schmidt et al. (103) found 6 weeks of indomethacin to be highly effective; a subsequent study by Knelles et al. (63a) showed 7 days to be adequate. Cella et al. (18) found that 30% of their patients could not be treated with indomethacin because of side effects. Indomethacin has been the drug of choice by many physicians, although a recent study found no difference between enteric-coated aspirin and indomethacin (60). Because of animal studies showing decreased bone healing after NSAID use, several authors have studied cementless total hip arthroplasty results. Kjaersgaard-Anderson et al. (62) reported that NSAIDs had no effect on the clinical results of cementless total hip arthroplasty.

| Authors | Year | Dosage (mg, duration) | No. of patients | Incidence of HO (%) | Significant HO (%) |
|---|---|---|---|---|---|
| [illegible] | [illegible] | [illegible] | [illegible] | [illegible] | [illegible] |

*Table 124.3. Previous Studies of Indomethacin to Prevent Heterotopic Ossification After Total Hip Arthroplasty*

**Radiation Therapy** The results of radiation therapy have been extensively studied (Table 124.4). Radiation therapy is delivered locally and not systemically. Ionizing radiation exerts its greatest influence on rapidly dividing cells by altering nuclear DNA. It is believed that radiation therapy prevents the differentiation of the pluripotential mesenchymal cells into osteoblastic stem cells (32). Radiation therapy may effectively block one of the earliest steps in a series of events leading to H.O. It is imperative to begin the therapy immediately to block the differentiation of stem cells, which peaks at 48 hours. It is delivered through anteroposterior portals centered on the prosthesis, which exposes the periarticular tissue but not the surrounding radiosensitive organs.

| Authors | Year | Dosage (cGy, fractions) | No. of patients | Incidence of HO (%) | Significant HO (%) |
|---|---|---|---|---|---|
| [illegible] | [illegible] | [illegible] | [illegible] | [illegible] | [illegible] |

*Table 124.4. Incidence of Heterotopic Ossification After Prophylactic Irradiation*

Protect the skin incision during radiation to prevent wound breakdown. Single-dose protocols improve accuracy of radiation delivery to the specific field, and minimizes patient discomfort, transport, and scheduling issues. When irradiating a cementless total hip arthroplasty, exclude the areas of porous coating. The radiation portal is rectangular in shape, and the exposed field includes the area surrounding the prosthetic femoral neck, the region between the lesser trochanter and the ischium, and the lateral region between the greater trochanter and the ilium.

Postoperative radiation therapy does not cause delayed wound healing or wound complications, providing that the incision is excluded from the field of irradiation. Trochanteric nonunion after radiation therapy in several studies of revision total hip arthroplasty ranged from 25% to 43%. This compares with the incidence of trochanteric nonunion in the absence of radiation of 2% to 15%. A comparison is difficult to make because the bone quality in revision total hip arthroplasty is usually poorer. Longo et al. (70) studied bone ingrowth in rabbits after porous prostheses with radiation therapy. The greatest delay of bony ingrowth was at 2 weeks, but by 6 weeks, the control group and irradiated groups were similar. No radiation therapy protocol has been discontinued because of patient intolerance, as has been reported with anti-inflammatory agents.

The risk of sarcoma after radiation therapy has been investigated by many authors. No soft-tissue sarcomas have been reported with less than 3000 cGy (12). Radiation in low doses has been associated with the development of leukemia (109). Although no definitive statement can be made regarding the risk of development of sarcoma after prophylaxis with radiation therapy, this possible side effect must be considered. The resistance of peripheral nerves to radiation, combined with low-dose techniques, has led to no documented cases of radiation-induced neuritis (74).

It is important to note that a single dose has a greater effect on tissue than fractionating doses. This greater tissue effect is referred to as the time-dose relationship (79). Table 124.5 shows a comparison of the time-dose fractionation (TDF) of various protocols.

| *Radiation dose (cGy)* | *Fractions* | *TDF units* |
|---|---|---|
| 2000 | 10 | 33 |
| 1000 | 5 | 17 |
| 800 | 1 | 28 |
| 700 | 1 | 23 |
| 600 | 1 | 18 |

*TDF, time-dose fractionation.*

*Table 124.5. Tissue Effect from Radiation Therapy*

## ACETABULAR FRACTURES

HO is common after open reduction and internal fixation of acetabular fractures. It is seen in only about 5% of patients treated conservatively (87) but in as many as 90% after extensile approaches to acetabular fractures (66). Severe HO has been reported in approximately 24% of patients (56). Certain types of exposures, including the Kocher-Langenbeck, extended iliofemoral, and triradiate, have resulted in a high occurrence of HO, whereas the ilioinguinal exposure has not. The extended iliofemoral approach has the highest prevalence of HO (66). Postoperative HO prophylaxis is not required for fractures treated through the ilioinguinal exposure. Prophylaxis with either NSAIDs, single-dose local field radiation, or a combination should be used routinely early after open reduction and internal fixation with approaches other than the ilioinguinal approach. Moed and Letournel (78) reviewed 53 patients who underwent the posterior or extended iliofemoral approach and were treated with indomethacin and irradiation. Indomethacin was given for 3 weeks, and radiation therapy was given, either in divided or a single dose. Forty-four

fractures showed no HO, and 10 had grade I fractures. There was no difference between radiation doses.

**ELBOW**

From studies that have mostly focused on the hip, information about the incidence, pathophysiology, and treatment has been applied to the upper extremity. HO around the elbow is associated with local injury, electrical and thermal burns, and neurologic injury to the brain and spinal cord. The most frequent cause of heterotopic bone about the elbow is direct trauma (Fig. 124.3) (46). There appears to be a direct correlation between the frequency of HO and the magnitude of the injury. HO is usually seen in the collateral ligaments when it is associated with trauma.

***Figure 124.3.*** **A, B:** Twenty-one-year-old patient with head injury resulting from attempted suicide, with signs of heterotopic bone formation bilaterally. **C,D:** HO following fracture and fixation of a distal humerous fracture.

HO develops in approximately 1% of patients who have sustained burns, 3% of patients with a local injury of the elbow, and 11% of patients with a head injury (36,88,121). The elbow is the most frequent site after a burn. When a fracture combined with a dislocation occurs, the incidence rises to 15% to 20%. The incidence of HO about the forearm is approximately 2% to 4%, with high-energy and open fractures most at risk. HO around the elbow, associated with head injury, has been investigated by Garland and O'Hollaren (38). The incidence of HO increases fifteenfold when the neurotraumatized patient has an associated elbow injury.

The Brooker classification is insufficiently sensitive to describe the functional loss of motion in the elbow (74). Hastings and Graham (46) divided HO in the elbow and forearm after all types of trauma into three classes (Table 124.6). A treatment plan should be based on severity of HO (Table 124.7).

| | |
|---|---|
| Class I | Radiologic evidence of heterotopic bone without functional deficit |
| Class II | Restriction of motion in either flexion/extension, pronation/supination, or both |
| Class IIA | Limitation in elbow, flexion/extension plane |
| Class IIB | Limitation in forearm, pronation/supination plane |
| Class IIC | Limitation in both planes of motion |
| Class III | Complete ankylosis of the joint |

***Table 124.6. HO of Elbow and Forearm***

| | |
|---|---|
| Class I | Close observation, radiographs, physical therapy<br><6 weeks—radiation versus NSAIDs<br>6 weeks to 3 months—physical therapy and NSAIDs |
| Class IIA | Anterior heterotopic ossification—capsulotomy with resection<br>Posterior heterotopic ossification—posterior capsular release, triceps tenolysis, excision, partial olecranon excision, preservation of fat pad of the olecranon fossa |
| Class IIB | Resection ± interposition |
| Class IIC | Resection ± interposition |
| Class III | Resection ± interposition versus total elbow arthroplasty |

***Table 124.7. Treatment Algorithm For Elbow Heterotopic Ossification***

Early range of motion is essential to prevent stiffness. Early after injury, there is no completely effective prophylaxis. The difficulty with the elbow is its smaller size, compared with the hip; therefore, a small amount of bone results in more functional limitations. Bridging bone in one plane is amenable to excision with good results, whereas synostosis in two or more planes has poorer results. Most surgeons wait 12 to 18 months before excision, with recurrence demonstrated frequently in patients (Table 124.7) (37,88,97). There is an advantage to early excision, particularly in those with neurologic injury. This allows for early rehabilitation, enhancing function and independence. In a recent review of eight patients who had excision of HO at an average of 7 months followed by radiation therapy, there was no recurrence and significant improvement in arc of motion (74). This compares with previous reports of recurrence rates up to 30% (37). Because the preoperative testing for maturation of HO is not reliable for recurrence, individualize the decision for excision.

The most common site for HO about the elbow is the posterolateral aspect of the elbow, from the olecranon to the lateral humeral condyle. The elbow can be approached by various incisions dictated by the location of HO (see Chapter 1). Postoperatively, early motion is imperative, with the continuous passive motion device used commonly. Initiate irradiation and anti-inflammatory medications within 72 hours of surgery.

**TRAUMATIC HEAD INJURY AND SPINAL CORD INJURY**

The complication of HO around the joints of patients was first described in patients with spinal cord injuries in the late 1800s, whereas its association with traumatic brain injury was first reported by Roberts in 1968 (98). The incidence of HO in adults who have had an injury to the brain ranges from 11% to 76% (100). Garland et al. (34,35,36 and 37) have studied the traumatic brain injury patient in depth. The frequency of HO in the upper extremity parallels that in the lower extremity. The incidence of HO in the shoulder is similar to that in the elbow (Fig. 124.4). Involvement of the upper extremities is more frequent in patients who have had injuries to the brain than in those with spinal cord injuries (34).

***Figure 124.4.*** Brain-injured patient with ankylosed shoulder.

The incidence of HO in patients with spinal cord injury is reported to be 20% to 30% (34). Limitation of joint motion occurs in 18% to 37% of patients who develop HO (11,52). HO develops more often in patients with complete paralysis (102). Patients with spinal cord injuries usually present with HO anteromedial to the hip in the vicinity of the lesser trochanter, whereas in traumatic brain injury patients, the location is more variable. New bone formation in the head-injured patient is usually periarticular, whereas patients with spinal cord injury develop HO at a distance from the joint.

Whereas the hip is the most common location for HO in neurologically injured patients, the elbow most often becomes ankylosed. New bone formation in the hip and elbow correlate with the position of the extremity. It is thought that diffuse axonal injury often produces spasticity, which is known to be associated with HO (1). Patients with spastic quadriplegia and those with low levels of recovery are particularly prone to the formation of HO and recurrence after resection.

The exact timing for resection is better defined when the lesion occurs after a spinal cord injury. Resection is usually performed when serial alkaline phosphatase and bone scan have returned to baseline. Brain-injured patients have a high variability of neurologic involvement and severity, as well as variability in anatomic location of HO. In a review of 23 patients with resection of HO in 37 joints, a recurrence of HO was found in 56%. The recurrence was closely linked to the severity of cognitive deficit and physical disability (37).

Postoperatively, patients are irradiated or treated with NSAIDs. Biphosphonates are usually selected for prophylaxis if there is a contraindication to NSAIDs. The size of the initial HO mass may be the most important factor in predicting postoperative recurrence (116).

The site of the HO at the elbow or hip dictates the approach for resection. The shoulder is usually amenable to manipulation and only uncommonly requires resection. Most resections are carried out through a deltopectoral approach. The hip has three areas of possible development of new bone: anterior, inferomedial to the hip joint and distal to the lesser trochanter (associated with adductor spasticity), and posterior to the femoral head (associated with flexion contractures). The hip may be approached anteriorly or posteriorly.

## CHARCOT'S NEUROARTHROPATHY

Neuropathic osteoarthropathy, or Charcot's disease, is a chronic form of a degenerative arthropathy that is associated with decreased sensory innervation. It results in fragmentation, destruction, and dislocation of the joints. Its most common locations are the knee, ankle, and foot joints (Fig. 124.5 and Fig. 124.6).

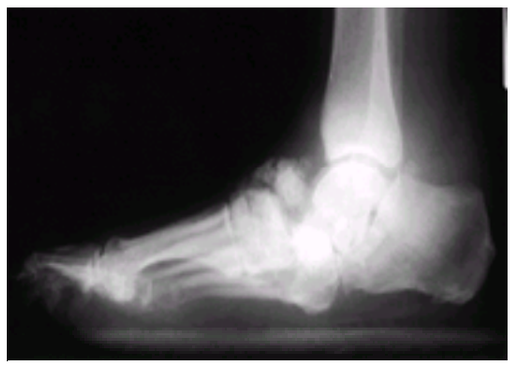

***Figure 124.5.*** Lateral radiograph of a diabetic patient with Charcot arthropathy.

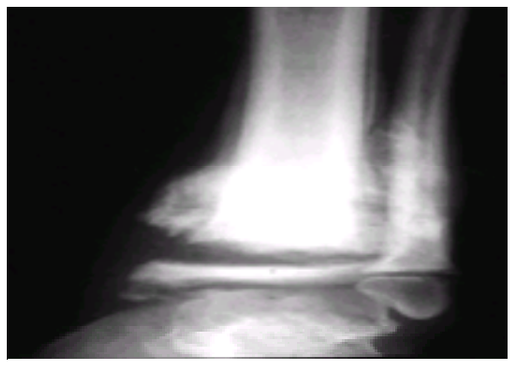

***Figure 124.6.*** AP radiograph of a Charcot ankle in a skeletally immature girl with spina bifida.

Eugene Martin Charcot, a French neurologist, first described neuropathic arthropathy in 1868 as a “trophic effect” in a patient with tabes dorsalis (20). He described a process of severe osteoarthritic changes, including swelling and instability of the knees. Prior to Charcot's description, Mitchell (77a) identified a destructive arthropathy associated with diseases involving peripheral nerves. Volkmann and then Virchow proposed that the underlying cause of the destruction was repeated traumatic events of varying degrees unperceived by the insensitive joint. Steindler (44) was one of the first to link together the destructive atrophic form and the hypertrophic proliferative form, and to suggest that there were many types and degrees of the condition. Before the advent of antibiotics, syphilis was the most common cause involving primarily the knee. The first report of arthropathy associated with diabetes was by Jordan in 1936 (54), and even in 1966, the knee was still reported as the most common site (Table 124.8) (29).

| | |
|---|---|
| Diabetes | Pernicious anemia |
| Tabes dorsalis | Paraplegia |
| Syringomyelia | Surgical cordotomy |
| Leprosy | Potts' disease |
| Spina bifida | Poliomyelitis |
| Repeated steroid injections | Congenital indifference to pain |
| Alcoholism | |

***Table 124.8. Etiology of Charcot's Neuroarthropathy***

Although there are many causes of Charcot's arthropathy, the three most common (in order) are diabetes, syphilis, and syringomyelia. There are approximately 10 million diabetics in the United States, with an incidence of Charcot arthropathy of 0.1% to 2.5% (77) usually occurring after 10 years of the disease. The most common diabetic complication requiring hospitalization is foot disease. There is equal prevalence in men and women and in type I and type II diabetes, and no correlation with glucose control. Those with concomitant renal disease have a higher risk of complications. Approximately 30% develop contralateral involvement (14). The incidence of HO associated with tabes dorsalis is 6% to 10%. The diabetic patient tends to have involvement of the tarsometatarsal joints, tarsal, and ankle joints, whereas in syphilitic patients, larger joints such as the knee are involved. The shoulder and elbow are afflicted most commonly in syringomyelia (Fig. 124.7).

***Figure 124.7.*** Patient with syringomyelia causing Charcot's arthropathy of the shoulder.

**PATHOGENESIS**

There are two theories of pathogenesis: neurotraumatic and neurovascular. The neurotraumatic theory proposed by Johnson in 1967 (53) involves repetitive trauma sustained by a joint unable to sense pain. In cats, a denervated immobilized limb does not produce a destructive arthropathy, but it can occur when the cats are allowed to freely walk (16). This does not account for the sensation of pain and neuroarthropathic changes that can occur after acute fractures. It also does not explain the gross destruction of joints that do not bear weight.

The neurovascular theory, suggested by Allman and Brower (5), refers to a sympathetic dysfunction with persistent hyperemia and active bone resorption by osteoclasts. As early as 1927, Leriche noted that lesions of the sympathetic nerve led to an increase in blood flow (5). Blood flow may actually increase up to five times the normal rate in diabetic neuropathy.

Joint destruction in the neuropathic joint is probably brought on by a combination of factors that include damage to the nociceptors of the joint and the periarticular tissues. This injury may initially be caused by mechanical trauma, chronic infections such as syphilis, or metabolic diseases such as diabetes associated with loss of pain and proprioception. This leads to stretched ligaments, and lax and subluxed joints. The activity of peptides such as substance P, calcium gene–related peptide, and vasoactive intestinal peptide (VIP) could result in increased vascularity and inflammation, contributing to further joint destruction. Substance P can enhance the cellular synthesis of collagenase and prostaglandin-E; activate T lymphocytes, monocytes, and neutrophils; and take an active part in inflammation. Glycolization of the supporting ligaments in the foot due to high glucose levels in the blood can increase the stiffness and cross-linking of the collagen fibers, making them brittle.

The initial pathologic changes occur in the underlying bone and cartilage. Recurrent effusions occur due to hyperplasia of the synovium. The articular cartilage is slowly destroyed by a pannus, which helps distinguish Charcot's joints from other forms of osteoarthritis. Histology of the fragments of cartilage and bone in synovium shows deeply embedded tissue with normal metachromatic staining. In contrast, in osteoarthritis the fragments are deposited superficially and have staining characteristics suggestive of degeneration (68).

Excess osteoclast activity is believed to be responsible for the early bone changes associated with Charcot's neuroarthropathy in diabetes mellitus. In a recent study by Gough et al. (41) the serum carboxyterminal telopeptide of type 1 collagen, a marker of osteoclastic bone resorption, had significantly increased levels in the acute Charcot foot. The lack of an associated increase in osteoblastic activity supports the idea that excess osteoclast activity is a feature of the early stages of Charcot's neuroarthropathy.

High-peak plantar pressures have been identified as a risk factor for ulceration in diabetics. In a study of 164 diabetic patients, higher peak plantar pressures occurred in those with Charcot's arthropathy and those with neuropathic ulcers than in those without. Measuring plantar pressures might be an effective means of screening large numbers of patients (8).

**CLINICAL PRESENTATION**

The most common presentation of neuroarthropathy in a diabetic patient is a single, painless, swollen, deformed foot and no specific history of trauma. The joint has a large effusion, ligamentous laxity, and increased warmth, but the peripheral white blood count (WBC) and the ESR are normal. The swelling and warmth may suggest an infection or pseudoseptic arthritis. The synovial fluid is clear, straw colored, and viscous, although it can be bloody. Usually, there is evidence of peripheral neuropathy in the presence of normal or bounding pulses. Joint changes frequently precede the neurologic deficit, and as many as one third of patients actually have pain at presentation (57). The deep tendon reflexes at the knee are absent in a majority of patients. Some patients present with nontraumatic dislocations or rapid joint destruction without any known trauma. The spine is involved in 6% to 21% of cases (40). Anand et al. (7) reported on a patient with neuropathic spinal arthropathy in Charcot-Marie-Tooth disease. Nonspiral fractures of the long bones should heighten concern, because considerable force would normally be necessary to cause such an injury. Rule out other disease processes such as avascular necrosis (AVN), infection, crystal-induced arthritis, hemophilia, and rheumatoid arthritis (RA).

**IMAGING**

Early radiographs may demonstrate changes very similar to those observed in early osteoarthritis. Nontraumatic dislocations may be an early sign. With time, there is radiographic evidence of joint distention caused by fluid, hypertrophic synovitis, osteophytes, and subluxation. The normal architecture of the joint is lost, with dislocation, fragmentation, attempted repair by osteophytes, and sclerosis. Various degrees of bone absorption have been observed, with margins resembling surgical amputation coupled with periarticular speckled calcification in the soft tissue. Infection usually produces indistinct margins of bone as opposed to the sharp ones seen in neuroarthropathy.

Osteomyelitis typically is secondary to infected ulcers or cellulitis, with direct infectious spread to and through the cortex of the adjacent bone. Establishing the diagnosis of osteomyelitis in the foot may be difficult (see Chapter 116). Use imaging studies to confirm the clinical suspicion of osteomyelitis. Lipman et al. (67) studied the diagnostic efficacy of combined three-phase bone scintigraphy and indium-111–labeled WBC scintigraphy, magnetic resonance imaging (MRI), and conventional

radiography in detecting osteomyelitis of the neuropathic foot. MRI was found to be comparable to conventional radiography. In the midfoot and hindfoot, three-phase or WBC scans were more specific than either MRI or conventional radiography. MRI was most accurate in the forefoot.

## FOOT AND ANKLE

### *Classification and Staging*

The staging of neuroarthropathy according to Eichenholtz (29) uses both clinical and radiologic criteria. Stage I consists of an acute, warm, swollen, erythematous foot. Radiographic changes of bony fragmentation may occur and are often confused with osteomyelitis. Stage II involves the beginning of the subacute process, in which swelling subsides and new bone formation occurs. Stage III is chronic; in it, the foot no longer is warm and swollen but is severely deformed. Schon and Marks (105) have added a stage 0: the diabetic patient at risk for neuroarthropathy after an injury.

Brodsky (13) has developed a classification of neuroarthropathic joints that allows for recognition of potential problems as well as helping to establish the prognosis after treatment.

- Type I neuropathy shows midfoot manifestations in 60% to 70% of cases. It is characterized by symptomatic medial and plantar bony prominences that may lead to ulceration. A substantial indirect bending force is applied to the ankle during the midstance and terminal-stance phases of gait.
- Type II involves the hindfoot, representing 20% of Charcot's joints; it is characterized by instability and requires long periods of immobilization.
- Patients with type IIIA neuropathy have an incidence of less than 10%. This type includes ankle injuries, and are the most unstable and take the longest time to heal.
- Type IIIB involves the os calcis, which presents clinically as a pathologic fracture of the tuberosity of the calcaneus. These patients risk progressive pes planus and tendo-Achilles incompetence. The Wagner classification (128) focuses on the progression of involvement of the soft tissue, which leads to eventual extension into the bone midjoints.

### *Treatment*

The goal of treatment is to restore a biomechanically sound, plantigrade foot. The treatment of the injury should depend on the timing, the stage of the injury, and the objective findings in the physical exam. A choice must be made between conservative and operative treatment based on the overall clinical scenario (Table 124.9). Education of the patient on the importance of foot care is of paramount importance. Successful treatment results in a braceable ankle without ulceration. The midfoot is afflicted most severely, followed by the hindfoot and the ankle. Midfoot Charcot's joints tend to become more stable over time, in contrast to the hindfoot and ankle joint, which become painful and prone to ulceration. Total-contact casts are helpful in the management of the ulcers, with 86% of them healing within 2 years (80).

| *Characteristics* | *Grade* | *Treatment* |
|---|---|---|
| Patients with intact skin | 0 | Skin care program |
| Superficial ulceration | I | Total-contact cast |
| Ulcers extending down to bone, ligament, tendon, joint capsule, or deep fascia without an abscess or osteomyelitis | II | Total-contact cast |
| Ulcers characterized by an abscess, pyarthrosis, or osteomyelitis | III | Debridement/IV antibiotics |
| Focal gangrene | IV | Local debridement or limited amputation |
| Gangrene of the entire foot | V | Amputation |

***Table 124.9. Wagner Classification of Neuropathic Ulcerations (128)***

Most authors agree that immobilization in plaster is the mainstay in managing this condition in the early stages of the disease process. Immobilization has been proven to slow down and sometimes arrest destruction (28). Early stability helps prevent bony prominences from causing ulceration. The length of immobilization varies with the clinical exam. Saltzman et al. (100) found that a properly fitted patellar tendon–bearing (PTB) brace can reduce load transmission to the Charcot hindfoot. Selby et al. (108) showed that biphosphonates can produce prompt reduction in the Charcot activity. Ultrasound has been successful in the treatment of 28 of 29 patients with Charcot's neuropathy of the foot and ankle (64). There are many who recommend protected weight bearing of the contralateral uninvolved foot and ankle (49). Some patients develop deformity despite proper treatment or present with significant deformity. This is especially true of patients who have a varus or valgus deformity associated with involvement of the ankle or subtalar joint. The foot is at risk for recurrent ulceration and infection.

Treat patients presenting with Eichenholtz I findings with serial-contact casting and avoidance of weight bearing until the acute edema has resolved. Surgery can be considered for severe dislocation that is unstable and manually reducible. Bone fragmentation is a contraindication for surgery.

Once the edema has resolved and the patient shows early healing (stage II), allow progressive weight bearing. Replace the cast with a brace once healing occurs. Johnson (53) has shown that bracing is frequently effective in the treatment of the deformed neuropathic foot. Bracing for ankle, hindfoot, and midfoot may include a Charcot restraint orthotic walker, a double upright metal foot orthosis, or a modified ankle-foot orthosis. The forefoot can be managed with well-padded total-contact inserts.

Once the patient progresses to a chronic stage or Eichenholtz III, he or she can be managed in a long-term brace or with continued use of the shoe insert. If the patient regresses back to the acute stage, he or she must be placed into a total-contact cast and weight bearing must be restricted. Bracing is successful in arresting the deformity and providing a stable ankle-foot complex, and it is the treatment of choice. It is imperative to evaluate the skin and soft tissues at regular intervals for evidence of breakdown. Once the deformity continues to progress with instability, the soft tissues overlying the bone may begin to break down. Although the ulceration and infection can be treated with local wound care and antibiotics, the underlying cause is the deformity. With continued use of the extremity, a cycle of breakdown and infection occurs. Bracing and foot and ankle appliances are frequently not effective at this point. The deformed limb ceases to be functional and requires surgery.

In a series of 221 neuropathic fractures, Schon et al. (104) noted that nondisplaced neuropathic ankle fractures typically healed uneventfully with casting and bracing. Closed reduction and casting for displaced fractures has often resulted in loss of reduction and progressive deterioration. Open reduction and internal fixation provides better results (122). Fracture stability may be enhanced by multiple syndesmotic screws.

Excellent surgical technique and prolonged immobilization are essential for proper fracture management. Connolly and Csencsitz (22) reported on six ankle fractures in five patients with longstanding diabetes. One patient needed an amputation 10 days after a closed injury, stressing that significant complications can occur.

Ankle fusion is difficult to achieve in Charcot's disease because of the poor quality of the bone and the difficulty in achieving a stable biomechanical construct with screws, plates, or external fixation. The goal is a plantigrade foot with the ankle at 90°, the hindfoot in 5° to 10° of valgus angulation, and external rotation of the foot with respect to the tibia equivalent to that of the contralateral foot (85). Results of surgery have varied between series. Bono et al. (11a) performed 11 arthrodesis procedures for Charcot's joint and achieved clinical union with good stability in 91%. Papa et al. (85) reported a 93% clinical success rate despite a 31% pseudarthrosis rate. Stuart and Morrey (117) reported on ankle arthrodesis procedures on 13 patients, with clinical union in seven patients. Pinzur and Kelikian (89) reported on the stabilization of patients with a retrograde intramedullary locked nail that had failed rigorous nonoperative measures. Nineteen of 21 ankles progressed to fusion at an average of 20 months.

When the talus is fragmented and avascular, perform a talectomy and a tibiocalcaneal arthrodesis. Consider ankle disarticulation (Symes amputation) before ankle fusion in the most severe cases to avoid progression to a more proximal amputation in the future. Postoperatively, do not allow weight bearing. Observe the patient closely for postoperative complications such as ulceration, infection, and pseudarthrosis.

The midfoot sometimes continues to progress with ulceration and deformity despite casting, bracing, and shoe modifications. Exostectomy is most effective in the chronic, midfoot deformity that is stable. If the foot is unstable, realignment and arthrodesis is the procedure of choice. Early and Hansen (27) reported on 21 patients with fusions who had midfoot collapse. Despite 50% postoperative complications and two amputations, 86% of patients had successful results.

The standard of care for hindfoot neuroarthropathy is nonsurgical. Harris and Brand (45) and Johnson (53) advocate immobilization in plaster. Consider arthrodesis for hindfoot valgus with subluxation of the subtalar joint or midtarsals to prevent ulceration and infection. Tisdel et al. (122a) reported on eight triple arthrodeses in seven patients with 100% union for peritalar neuroarthropathy. They stressed the principles outlined by Papa et al. (85):

- Careful removal of cartilage and debris.
- Thorough removal of sclerotic bone.
- Adequate fashioning of congruent bone surfaces for apposition.
- Rigid fixation of the arthrodesis site.
- Complete resection of fibrotic capsular tissue and synovium.

Amputation eliminates the immediate problem, but most patients develop limitation of function that necessitates a modification of their lifestyle (58). There is an increased energy requirement to walk after amputation, which can be a problem in diabetics with other comorbid conditions. There is also a risk of an amputation on the contralateral limb, so limb salvage should be attempted whenever possible.

**HIP**

Charcot neuroarthropathy in the hip is rare. As with any joint, the critical element in treating a patient with a neuropathic hip joint is to establish the diagnosis (Fig. 124.8) (9).

***Figure 124.8.*** AP hip demonstrating Charcot's arthropathy.

If the joint remains painless and functional, no intervention is required. If pain is present and function is impaired, pursue conservative treatment with protected weight bearing as long as possible before considering any type of surgical procedure. Treatment with hip arthrodesis results in a high rate of nonunion; historically, it has been as high as 100% (53). Total hip arthroplasty also has a high failure rate, especially in patients with significant neurologic findings or ataxia. The overwhelming evidence in the literature is that these patients do poorly with any type of prosthetic replacement. The number of patients treated with total hip arthroplasty reported in the literature is small, reflecting the relatively low incidence of neuropathic hips. They have universally done poorly (93,114). This limited evidence strongly indicates that prosthetic replacement of the Charcot hip joint is contraindicated. Of the dozen or so cases reported in the literature, only one patient was stated to have done well with a total hip joint arthroplasty (114). The remainder did poorly even when treated with a broad range of total hip designs. Resorting to a resection arthroplasty may be the only viable solution in the treatment of the painful hip in these patients.

The treatment of hip fractures in a Charcot hip joint also remains problematic. Johnson (53) found that over 50% of fractures of the femoral neck in diabetics developed Charcot's joints. Many times, the neuropathic nature of this fracture is not recognized, and hip nailing or a prosthesis is inserted, only to result in failure. Internal fixation has been documented to do as poorly as prosthetic replacements. Treatment with restricted weight bearing may be the most prudent option with a delayed resection arthroplasty if the joint subsequently becomes painful.

Complex fractures of the acetabulum in patients with diabetes are difficult to treat. Berg (10) reported on three patients who developed Charcot's changes after open reduction internal fixation for fractures of the acetabulum. None had any previous evidence of a neuropathy.

**KNEE**

Charcot's neuroarthropathy in the knee has previously been reported as the most common neuropathic joint problem secondary to syphilis and one of the most difficult to treat (53). There is tremendous leverage, predisposing to instability, and little soft-tissue envelope to cushion the joint. When the knee is painless, bracing is the treatment of choice. Johnson (53) recommends a corrective osteotomy to prevent shearing stress, followed by bracing for severely damaged knees, particularly with bilateral involvement. If only one knee is involved and destruction is severe, fusion is indicated. Bracing is imperative to promote a solid union.

Fractures in diabetics are best treated by prolonged immobilization and splinting until there is definite radiographic evidence of repair. The potential for complications with immobilization is high. Arthrodesis, usually the treatment of choice in advanced disease of the knee, may fail because of nonunion and breakage of fixation devices. Drennan (26) found a 55% clinically successful arthrodesis in his series of patients with knee fusion. Arthroplasty is generally considered contraindicated in Charcot's joints. Loosening and breakage of the prosthesis is more likely to occur secondary to lack of proprioception, although the results of nine total knee arthroplasties were considered excellent in eight knees after a 3-year follow-up (113). Correct ligamentous balancing, use of long-stemmed components, and meticulous surgical detail are imperative for good long-term results. Despite these good reported early results, total knee arthroplasty should be approached in these patients with great caution because the long-term results undoubtedly will not be as favorable.

## AUTHORS' PERSPECTIVE

Both HO and Charcot's neuroarthropathy represent distinct, potentially devastating pathologic conditions affecting joints. Although the two problems are different, the key to the successful treatment and outcome of each is early recognition of patients at risk and taking the appropriate preventive measures. Once the conditions have been established, their outcomes, regardless of treatment, are less favorable.

## CHAPTER REFERENCES

Each reference is categorized according to the following scheme: *, classic article; #, review article; ! basic research article; and +, clinical results/outcome study.


+ 1. Adams JH, Graham DI, Murray LS, Scott G. Diffuse Axonal Injury due to Nonmissile Head Injury in Humans: An Analysis of 45 Cases. *Ann Neurol* 1982;12:557.

+ 2. Ahrengart L, Lindgren U. Functional Significance of Heterotopic Bone Formation After Total Hip Arthroplasty. *J Arthroplasty* 1989;4:125.

+ 3. Ahrengart L, Lindgren U. Heterotopic Bone after Hip Arthroplasty. Defining the Patient at Risk. *Clin Orthop* 1993;293:153.

+ 4. Allen HL, Wase A, Bear WT. Indomethacin and Aspirin: Effect of Nonsteroidal Anti-inflammatory Agents on the Rate of Fracture Repair in the Rat. *Acta Orthop Scand* 1980;51:595.

+ 5. Allman RM, Brower AC, Kotlyarov EB. Neuropathic Bone and Joint Disease. *Radiol Clin North Am* 1988;26:1373.

+ 6. Almånsbakk K, Røysland P. Does Indomethacin (IMC) Prevent Postoperative Ectopic Ossification in Total Hip Arthroplasty. *Acta Scand* 1977;48:556.

+ 7. Anand N, Levine DB, Burke S, Bansal M. Neuropathic Spinal Arthropathy in Charcot-Marie-Tooth Disease. *J Bone Joint Surg* 1997;79-A:1235.

+ 8. Armstrong DG, Lavery LA. Elevated Peak Plantar Pressures in Patients Who Have Charcot Arthropathy. *J Bone Joint Surg* 1998;80-A:365.

+ 9. Baldini N, Sudanese A, Toni A. Total Prosthetic Replacement in Tabetic Arthroplasty of the Hip Joint. *Ital J Orthop Traumatol* 1985;11:193.

+ 10. Berg EE. Charcot Arthropathy After Acetabular Fracture. *J Bone Joint Surg [Br]* 1997;79:742.

+ 11. Blane CE, Perkash I. True Heterotopic Bone in the Paralyzed Patient. *Skeletal Radiol* 1981;7:21.

11a. Bono JV, Roger DJ, Jacobs RL. Surgical Arthrodesis of the Neuropathic Foot. A Salvage Procedure. *Clin Orthop* 1993;296:14.

+ 12. Brady L. Radiation-induced Sarcomas of Bone. Skeletal Radiol 1979;4:72.

+ 13. Brodsky JW. Management of Charcot Joints of the Foot and Ankle in Diabetes. *Semin Arthroplasty* 1992;3:58.

# 14. Brodsky JW. The Diabetic Foot. In: MRaC MJ, ed. *Surgery of the Foot and Ankle.* St. Louis: Mosby–Year Book, 1993:877.

+ 15. Brooker A, Bowerman J, Robinson R, Riley L. Ectopic Ossification following Total Hip Replacement. Incidence and a Method of Classification. *J Bone Joint Surg* 1973;55-A:1629.

# 16. Bruckner FE, Howell A. Neuropathic Joint. *Semin Arthritis Rheum* 1972;2:47.

+ 17. Brunner R, Morscher E, Hünig R. Para-articular Ossification in Total Hip Replacement: An Indication for Irradiation Therapy. *Arch Orthop Trauma Surg* 1987;106:102.

+ 18. Cella J, Salvati E, Sculco T. Indomethacin for Prevention of Heterotopic Ossification following Total Hip Replacement. *J Arthroplasty* 1988;3:229.

+ 19. Chalmers J, Gray D, Rush J. Observations on the Induction of Bone in Soft Tissues. *J Bone Joint Surg* 1975;57-B:36.

* 20. Charcot JM. Sur Quelques Arthropathies. Qui Paraissent Dependre d'Une Lesion. Du Cerveau on de la Moelle Epinere. *Arch Physiol* 1868;1:161.

* 21. Charnley J. The Long-term Results of Low-friction Arthroplasty of the Hip Performed as a Primary Intervention. *J Bone Joint Surg* 1972;54-B:61.

+ 22. Connolly JF, Csencsitz TA. Limb Threatening Neuropathic Complications from Ankle Fractures in Patients with Diabetes. *Clin Orthop* 1998;348:212.

+ 23. Coventry M, Scanlon P. The Use of Radiation to Discourage Ectopic Bone: A Nine-year Study in Surgery about the Hip. *J Bone Joint Surg* 1981;63-A:201.

# 24. Dahl H. *Clinical Observations.* Symposium on Arthrosis: Proceedings of a Conference, Norway, 1974.

+ 25. DeFlitch CJ, Stryker JA. Postoperative Hip Irradiation in Prevention of Heterotopic Ossification: Causes of Treatment Failure. *Radiology* 1993;188:265.

+ 26. Drennan DB, Fahey JJ, Maylahn DJ. Important Factors in Achieving Arthrodesis of the Charcot Knee. *J Bone Joint Surg* 1971;53-A:1180.

+ 27. Early JS, Hansen ST. Surgical Reconstruction of the Diabetic Foot: A Salvage Approach for Midfoot Collapse. *Foot Ankle Int* 1996;17:325.

# 28. Edmonds ME. The Diabetic Foot: Pathophysiology and Treatment. *Clin Endocrinol Metab* 1986;15:889.

# 29. Eichenholtz SN. *Charcot Joints.* Springfield, IL: Charles C Thomas, 1966.

+ 30. Elmstedt E, Lindholm TS, Nilsson OS, Tornkvist H. Effect of Ibuprofen on Heterotopic Ossification after Hip Replacement. *Acta Orthop Scand* 1985;56:25.

+ 31. Errico TJ, Fetto JF, Waugh TR. Heterotopic Ossification: Incidence and Relation to Trochanteric Osteotomy in 108 Total Hip Replacement. *Clin Orthop* 1984;190:138.

+ 32. Evarts CM, Ayers DC, Puzas JE. *Prevention of Heterotopic Bone Formation in High-risk Patients by Postoperative Irradiation, The Hip.* Proceedings of the 14th Open Scientific Meeting of the Hip Society, St Louis, CV Mosby, 1986.

+ 33. Freiberg A, Cantor R, Freiberg R. The Use of Aspirin to Prevent Heterotopic Ossification after Total Hip Arthroplasty. *Clin Orthop* 1991;267:93.

+ 34. Garland D. Clinical Observations on Fractures and Heterotopic Ossification in the Spinal Cord and Traumatic Brain Injured Populations. *Clin Orthop* 1988;233:86.

+ 35. Garland D. Surgical Approaches for Resection of Heterotopic Ossification in Traumatic Brain Injured Adults. *Clin Orthop* 1991;263:59.

+ 36. Garland D, Blum C, Waters R. Periarticular Heterotopic Ossification in Head Injured Adults. *J Bone Joint Surg* 1980;62-A:1143.

+ 37. Garland D, Hanscom M, Keenan M, et al. Resection of Heterotopic Ossification in the Adult with Head Trauma. *J Bone Joint Surg* 1985;67-A:1261.

+ 38. Garland D, O'Hollaren R. Fractures and Dislocations about the Elbow in the Head-injured Adult. *Clin Orthop* 1982;168:38.

+ 39. Gebuhr P, Soelberg M, Orsnes T, Wilbek H. Naproxen Prevention of Heterotopic Ossification after Hip Arthroplasty. *Acta Orthop Scand* 1991;62:226.

+ 40. Goldman AB, Freiberger RH. Localized Infections and Neuropathic Diseases. *Semin Roentgenol* 1979;14:19.

! 41. Gough A, Abraha H, Li F, et al. Measurement of Markers of Osteoclast and Osteoblast Activity in Patients with Acute and Chronic Diabetic Charcot Neuroarthropathy. *Diabet Med* 1997;14:527.

+ 42. Goutallier D, Colmar M, Penot P. Heterotopic Ossification of the Hip: The Influence of the Duration of Postoperative Treatment with Indomethacin on the Prevention of Ossification and the Effect of Uncemented Acetabular Implants on the Development of Ossification. *J Orthop Surg* 1993;7:144.

+ 43. Gregoritch S, Chadha M, Pellegrini V, et al. Randomized Trial Comparing Pre-operative Versus Post-operative Irradiation for Prevention of Heterotopic Ossification following Prosthetic Total Hip Replacement: Preliminary Results. *Int J Radiat Oncol Biol Phys* 1994;30:55.

# 44. Gupta R. A Short History of Neuropathic Arthropathy. *Clin Orthop* 1993;296:43.

+ 45. Harris JR, Brand PW. Patterns of Disintegration of the Tarsus in the Anaesthetic Foot. *J Bone Joint Surg* 1966;48-B:4.

+ 46. Hastings H, Graham T. The Classification and Treatment of Heterotopic Ossification about the Elbow and Forearm. *Hand Clin* 1994;10:417.

+ 47. Healy WL, Lo TCM, Covall DJ, et al. Single-dose Radiation Therapy for Prevention of Heterotopic Ossification after Total Hip Arthroplasty. *J Arthroplasty* 1990;5:369.

+ 48. Hedley AK, Mead LP, Hendren DH. The Prevention of Heterotopic Bone Formation following Total Hip Arthroplasty Using 600 Rad in a Single Dose. *J Arthroplasty* 1989;4:319.

+ 49. Holmes GB, Hill N. Fractures and Dislocations of the Foot and Ankle in Diabetics Associated with Charcot Joint Changes. *Foot Ankle Int* 1994;15:182.

+ 50. Holz U, Kraner F, Weller S. Periarticular Ossification following Replacement. *Z Orthop* 1977;115:146.

+ 51. Jasty M, Schutzer S, Tepper J, et al. Radiation-blocking Shields to Localize Periarticular Radiation Precisely for Prevention of Heterotopic Bone Formation around Uncemented Total Hip Arthroplasties. *Clin Orthop* 1990;257:138.

+ 52. Jensen LL, Halar E, Little JW, Brooke MM. Neurogenic Heterotopic Ossification. *Am J Phys Med* 1988;66:351.

+ 53. Johnson JTL. Neuropathic Fractures and Joint Injuries. *J Bone Joint Surg* 1967;49-A:1.

+ 54. Jordan WR. Neuritic Manifestations in Diabetes Mellitus. *Arch Intern Med* 1936;57:307.

+ 55. Jowsey J, Coventry MB, Robins PR. *Heterotopic Ossification: Theoretical Consideration, Possible Etiologic Factors, and a Clinical Review of Total Hip Arthroplasty Patients Exhibiting This Phenomenon.* The Hip: Proceedings of the Fifth Open Scientific Meeting of the Hip Society. St Louis: CV Mosby, 1977.

+ 56. Kaempffe F, Bone L, Border J. Open Reduction and Internal Fixation of Acetabular Fractures: Heterotopic Ossification and Other Complications of Treatment. *J Orthop Trauma* 1991;5:439.

+ 57. Katz IG, Dziadiw R. Early Changes in Charcot's Joints. *AJR Am J Roentgenol* 1961;86:965.

+ 58. Kegel B, Carpenter ML, Burgess EM. Functional Capabilities of Lower Extremity Amputees. *Arch Phys Med Rehab* 1978;59:109.

+ 59. Kennedy W, Gruen T, Chessin H, et al. Radiation Therapy to Prevent Heterotopic Ossification after Cementless Total Hip Arthroplasty. *Clin Orthop* 1991;262:185.

+ 60. Kjaersgaard-Anderson P, Ritter MA. Short-term Treatment with Nonsteroidal Antiinflammatory Medications to Prevent Heterotopic Bone Formation after Total Hip Arthroplasty: A Preliminary Report. *Clin Orthop* 1992;279:157.

+ 61. Kjaersgaard-Anderson P, Schmidt SA. Indomethacin for Prevention of Ectopic Ossification after Hip Arthroplasty. *Acta Orthop Scand* 1986;1986:12.

+ 62. Kjaersgaard-Anderson P, Sletgard J, Gjerloff C, Lund F. Heterotopic Bone Formation after Noncemented Total Hip Arthroplasty: Location of Ectopic Bone and the Influence of Postoperative Antiinflammatory Treatment. *Clin Orthop* 1990;252:156.

+ 63. Knahr K, Salzer M, Eyb R, et al. Heterotopic Ossification with Total Hip Endoprostheses in Various Models of Thrombosis Prophylaxis. *J Arthroplasty* 1988;3:1.

+ 63a. Knelles D, Barthel T, Karrer A, et al. Prevention of Heterotropic Ossification after Total Hip Replacement. A Prospective, Randomized Study Using Acetylsalicylic Acid, Indomethacin, and Fractional or Single-Dose Irradiation. *J Bone Joint Surg Br* 1997;79:596.

+ 64. Kristiansen TK. The Effect of Low Power Specifically Programmed Ultrasound on the Healing Time of Fresh Fractures Using a Colles' Model. *J Orthop Trauma* 1990;4:227.

+ 65. Lazansky MG. Complications Revisited: The Debit Side of Total Hip Replacement. *Clin Orthop* 1973;95:96.

# 66. Letournel E, Judet R. *Fractures of the Acetabulum.* New York: Springer-Verlag, 1993:558.

+ 67. Lipman B, Collier D, Carrera G, et al. Detection of Osteomyelitis in the Neuropathic Foot: Nuclear Medicine, MRI, and Conventional Radiography. *Clin Nucl Med* 1998;23:77.

+ 68. Lloyd-Roberts GC. The Role of Capsular Changes in Osteoarthritis of the Hip Joint. *J Bone Joint Surg* 1953;35-B:627.

+ 69. Lo TC, Healy WL, Covall DJ, et al. Heterotopic Bone Formation after Hip Surgery: Prevention with Single-dose Postoperative Hip Irradiation. *Radiology* 1988;168:851.

! 70. Longo JA, Hedley AK, Weinstein AM. Comparative Effects of EHDP, Indomethacin and Irradiation on Bone Ingrowth in a Porous Polyethylene Rabbit Model. *Eur Soc Biomat* 1985; 5:195.

+ 71. MacLennan I, Keys H, Evarts C, Rubin P. Usefulness of Postoperative Hip Irradiation in the Prevention of Heterotopic Bone Formation in a High-risk Group of Patients. *Int J Radiat Oncol Biol Phys* 1984;10:49.

+ 72. Maloney W, Krushell R. Incidence of Heterotopic Ossification after Total Hip Replacement: Effect of the Type of Fixation of the Femoral Component. *J Bone Joint Surg* 1991;73-A:191.

+ 73. Matos M, Amstutz HC, Finerman G. Myositis Ossifications following Total Hip Replacement. *J Bone Joint Surg* 1975;57-A:137.

+ 74. McAuliffe J. Early Excision of Heterotopic Ossification about the Elbow followed by Radiation Therapy. *J Bone Joint Surg* 1997;79-A:749.

+ 75. McLaren AC. Prophylaxis with Indomethacin for Heterotopic Bone after Open Reduction of Fractures of the Acetabulum. *J Bone Joint Surg* 1990;72-A:245.

+ 76. McMahon J, Waddell J, Morton J. Effect of Short-course Indomethacin on Heterotopic Bone Formation after Uncemented Total Hip Arthroplasty. *J Arthroplasty* 1991;6:259.

+ 77. Mills JL, Beckett WC, Taylor SM. The Diabetic Foot: Consequences of Delayed Treatment and Referral. *South Med J* 1991;84:970.

* 77a. Mitchell JC. On a New Practice in Acute and Chronic Rheumatism. *Am J Med Sci* 1831;8:55.

+ 78. Moed B, Letournel E. Low Dose Irradiation and Indomethacin Prevent Heterotopic Ossification after Acetabular Fracture Surgery. *J Bone Joint Surg* 1994;76-B:595.

# 79. Moss WT, Cox JD. *Radiation Oncology: Rationale, Technique. Results.* St. Louis: CV Mosby, 1989:20.

+ 80. Myerson M, Papa J, Eaton M, et al. The Total Contact for Management of Neuropathic Plantar Ulceration of the Foot. *J Bone Joint Surg* 1992;74-A:261.

+ 81. Nilsson OS, Bauer HC, Brosjo O, Tornkvist H. Influence of Indomethacin on Induced Heterotopic Bone Formation in Rats: Importance of Length of Treatment and of Age. *Clin Orthop* 1986;207:239.

+ 82. Nollen AJG, van Douveren FQMP. Ectopic Ossification in Hip Arthroplasty. *Acta Orthop Scand* 1973;64:185.

+ 83. Nollen AJG, van Douveren FQMP. Ectopic Ossification in Hip Arthroplasty: A Retrospective Study of Predisposing Factors in 637 Cases. *Acta Orthop Scand* 1993;64:185.

+ 84. Orzel JA, Rudd TG. Heterotopic Bone Formation: Clinical, Laboratory and Imaging Correlation. *J Nucl Med* 1985;26:125.

+ 85. Papa J, Myerson M, Girard P. Salvage, with Arthrodesis, in Intractable Diabetic Neuropathic Arthropathy of the Foot and Ankle. *J Bone Joint Surg* 1993;75-A:1056.

+ 86. Pellegrini VV, Konski AA, Gastel JA, et al. Prevention of Heterotopic Ossification with Irradiation after Total Hip Arthroplasty. *J Bone Joint Surg* 1992;74-A:186.

+ 87. Pennal GF, Davidson J, Garside H, Plewes J. Results of Treatment of Acetabular Fractures. *Clin Orthop* 1981;151:115.

+ 88. Peterson SL, Mani MM, Crawford CM, et al. Postburn Heterotopic Ossification: Insights for Management Decision Making. *J Trauma* 1989;29:365.

+ 89. Pinzur MS, Kelikian A. Charcot Ankle Fusion with a Retrograde Locked Intramedullary Nail. *Foot Ankle Int* 1997;18:699.

+ 90. Randelli G, Romano C. Prophylaxis with Indomethacin for Heterotopic Ossification after Chiari Osteotomy of the Pelvis. *J Bone Joint Surg* 1992;74-A:1344.

+ 91. Riegler HF, Harris CM. Heterotopic Bone Formation after Total Hip Arthroplasty. *Clin Orthop* 1976;117:209.

+ 92. Riska E, Michelsson J. Treatment of Para-articular Ossification after Total Hip Replacement by Excision and Use of Free Fat Transplants. *Acta Orthop Scand* 1979;50:751.

+ 93. Ritter MA, DeRosa GP. Total Hip Arthroplasty in a Charcot Joint. A Case Report with a Six-year Follow-up. *Orthop Rev* 1977;6:51.

+ 94. Ritter MA, Gioe TJ. The Effect of Indomethacin on Para-articular Ectopic Ossification after Total Hip Arthroplasty. *Clin Orthop* 1982;167:113.

+ 95. Ritter MA, Sieber JM. Prophylactic Indomethacin for the Prevention of Ectopic Bone Formation following Total Hip Arthroplasty. *Clin Orthop* 1985;196:217.

+ 96. Ritter MA, Vaughan RB. Ectopic Ossification after Total Hip Arthroplasty: Predisposing Factors, Frequency, and Effect on Results. *J Bone Joint Surg* 1977;59-A:345.

+ 97. Roberts JB, Pankratz DG. The Surgical Treatment of Heterotopic Ossification at the Elbow following Long-term Coma. *J Bone Joint Surg* 1979;61-A:760.

+ 98. Roberts P. Heterotopic Ossification Complicating Paralysis of Intracranial Origin. *J Bone Joint Surg* 1968;50-B:70.

+ 99. Rosendahl S, Christoffersen JK, Norgaard M. Para-articular Ossification following Hip Replacement. *Acta Orthop Scand* 1977;48:400.

+ 100. Saltzman CL, Johnson KA, Goldstein RH, Donnelly RE. The Patellar Tendon-bearing Brace as Treatment for Neurotrophic Arthropathy: A Dynamic Force Monitoring Study. *Foot Ankle Int* 1992;13:14.

+ 101. Sazbon L, Najenson T, Tartakovosky M, et al. Widespread Periarticular New Bone Formation in Long-Term Comatose Patients. *J Bone Joint Surg* 1981;63-B:120.

+ 102. Scher AT. The Incidence of Ectopic Bone Formation in Posttraumatic Paraplegic Patients of Different Racial Groups. *Paraplegia* 1976;14:202.

+ 103. Schmidt SA, Kjaersgaard-Anderson P, Pedersen NW, et al. The Use of Indomethacin to Prevent the Formation of Heterotopic Bone after Total Hip Replacement. A Randomized, Double-blind Clinical Trial. *J Bone Joint Surg* 1988;70-A:834.

# 104. Schon LC, Easley ME, Weinfeld SB. Charcot Neuroarthropathy of the Foot and Ankle. *Clin Orthop* 1998;349:116.

+ 105. Schon LC, Marks R. The Management of Neuroarthropathic Fracture-dislocations in the Diabetic Patient. *Orthop Clin North Am* 1995;26:375.

+ 106. Seegenschmiedt MH, Goldmann AR, Martus P, et al. Prophylactic Radiation Therapy for Prevention of Heterotopic Ossification after Hip Arthroplasty. *Radiology* 1993;188:257.

+ 107. Seegenschmiedt MH, Martus P, Goldmann AR, et al. Preoperative Versus Postoperative Radiotherapy for Prevention of Heterotopic Ossification. *Int J Radiat Oncol Biol Phys* 1994;30:63.

+ 108. Selby PL, Young MJ, Boulton AJM. Biphosphonates: A New Treatment for Diabetic Charcot Neuroarthropathy? *Diabet Med* 1994;11:28.

+ 109. Smith PG, Doll R. Mortality among Patients with Ankylosing Spondylitis after a Single Treatment Course with X-rays. *Br Med J* 1982;284:449.

+ 110. Soballe K, Christensen F, Kristensen SS. Ectopic Bone Formation after Total Hip Arthroplasty. *Clin Orthop* 1988;228:57.

+ 111. Sodemann B, Persson P, Nilsson O. Prevention of Heterotopic Ossification by Nonsteroid Antiinflammatory Drugs after Total Hip Arthroplasty. *Clin Orthop* 1988;237:158.

+ 112. Sodemann B, Persson PE, Nilsson OS. Periarticular Heterotopic Ossification after Total Hip Arthroplasty for Primary Coxarthrosis. *Clin Orthop* 1988;237:150.

+ 113. Soudry M, Binazzi R, Johanson NA, et al. Total Knee Arthroplasty in Charcot and Charcot-like Joints. *Clin Orthop* 1986;208:199.

+ 114. Sprenger TR, Foley CJ. Hip Replacement in a Charcot Joint: A Case Report and Historical Review. *Clin Orthop* 1982;165:191.

+ 115. Steenmeyer A, Slooff T, Kuypers W. The Effect of Indomethacin on Para-articular Ossification Following Total Hip Replacement. *Acta Orthop Belg* 1986;52:305.

+ 116. Stover SL, Niemann KM, Tulloss JR. Experience with Surgical Resection of Heterotopic Bone in Spinal Cord Injury Patients. *Clin Orthop* 1991;263:71.

+ 117. Stuart MJ, Morrey BF. Arthrodesis of the Diabetic Neuropathic Joint. *Clin Orthop* 1990;253:209.

+ 118. Sundaram NA, Murphy JCM. Heterotopic Bone Formation Following Total Hip Arthroplasty in Ankylosing Spondylitis. *Clin Orthop* 1986;207:223.

+ 119. Taylor AR, Kamdar BA, Arden GP. Ectopic Ossification Following Total Hip Replacement. *J Bone Joint Surg* 1976;58-B:134.

+ 120. Thomas BJ, Amstutz HC. Results of the Administration of Diphosphonate for the Prevention of Heterotopic Ossification After Total Hip Arthroplasty. *J Bone Joint Surg* 1985;67-A:400.

+ 121. Thompson HC, Garcia A. Myositis Ossificans: Aftermath of Elbow Injuries. *Clin Orthop* 1967;50:129.

+ 122. Thompson RC, Clohisy DR. Deformity following Fracture in Diabetic Neuropathic Osteoarthropathy. *J Bone Joint Surg* 1993;75-A:1765.

122a. Tisdel CL, Marcus RE, Heiple KG. Triple Arthrodesis for Diabetic Peritalar Neuroarthropathy. *Foot Ankle Int* 1995;16:332.

! 123. Tonna E, Cronkite E. Autoradiographic Studies of Cell Proliferation in the Periosteum of Intact and Fractured Femora of Mice Utilizing DNA Labeling with H3-thymidine. *Proc Cos Exper Biol Med* 1961;107:719.

+ 124. Tözün R, Pinar H, Yesiller E, Hamzaoglu A. Indomethacin for Prevention of Heterotopic Ossification after Total Hip Arthroplasty. *J Arthroplasty* 1992;7:57.

+ 125. Urist MR, DeLange RJ, Finerman GA. Bone Cell Differentiation and Growth Factors. *Science* 1983;220:680.

+ 126. Urist MR, Lietze A, Mizutani H, et al. A Bovine Low Molecular Weight Bone Morphogenic Protein (BMP). *Clin Orthop* 1982;162:219.

+ 127. van der Werf GJ, van Hasselt NG, Tonino AJ. Radiotherapy in the Prevention of Recurrence of Paraarticular Ossification in Total Hip Prostheses. *Arch Orthop Trauma Surg* 1985;104:85.

+ 128. Wagner FW. A Classification and Treatment Program for Diabetic, Neuropathic, and Dysvascular Foot Problems. *Instr Course Lect* 1979; 28:143-165.

+ 129. Wahlström O, Risto O, Djerf K, Hammerby S. Heterotopic Bone Formation Prevented by Diclofenac. *Acta Orthop Scand* 1991;62:419.

+ 130. Warren SB. Heterotopic Ossification after Total Hip Replacement. *Orthop Rev* 1990;19:603.

+ 131. Wright JG, Moran E, Bogoch E. Reliability and Validity of the Grading of Heterotopic Ossification. *J Arthroplasty* 1994;9:549.

+ 132. Wurnig C, Eyb R, Auersperg V. Indomethacin for Prevention of Ectopic Ossification in Cementless Hip Arthroplasties: A Prospective 1-year Study of 100 Cases. *Acta Orthop Scand* 1992;63:628.

# CHAPTER 125

# OSTEONECROSIS

*We gratefully acknowledge the contributions of Harlan C. Amstutz, M.D.; Paul E. Beaulé, M.E., F.R.C.S.C.; Jerilyn K. Higa, M.D.; Jonathan R. Perryman, M.D.; Yoichi Sugioka, M.D., Ph.D.; and James R. Urbaniak, M.D.*

*Marvin E. Steinberg and Michael A. Mont*

**M. E. Steinberg:** Professor and Vice Chairman, Department of Orthopaedic Surgery, Hospital of the University of Pennsylvania, Philadelphia, Pennsylvania, 19104.
**M. A. Mont:** Associate Professor, Department of Orthopaedic Surgery, Johns Hopkins University School of Medicine, Baltimore, Maryland, 21239.

Etiology, Pathophysiology, and Pathogenesis
- Etiology
- Pathophysiology
- Pathogenesis
- Transient Osteoporosis of the Hip

Early Diagnosis
- Clinical Features
- Laboratory Tests
- Functional Exploration of Bone
- Imaging Modalities

Classification and Staging
Early Management
- Prevention
- Medical Management
- Protected Weight Bearing
- Electrical Stimulation
- Core Decompression
- Osteotomies
- Grafting Procedures

Late Management
- Protected Weight Bearing
- Cup Arthroplasty
- Surface Replacement Arthroplasty
- Hemisurface Replacement
- Femoral Endoprosthetic Replacement
- Total Hip Replacement
- Resection Arthroplasty
- Arthrodesis

Other Sites and Types of Involvement
- The Knee: Distal Femur and Proximal Tibia
- The Humeral Head
- The Foot and Ankle
- The Elbow
- Miscellaneous Conditions

Authors' Perspective
Chapter References

Osteonecrosis, also referred to as avascular necrosis (AVN), aseptic necrosis, and ischemic necrosis, is not a specific disease but rather a condition in which a circum-fcscribed area of bone becomes necrotic as a result of a loss of its blood supply. The femoral head is the site most often affected, and the most frequent cause is a displaced fracture through the femoral neck. Posttraumatic osteonecrosis is best dealt with in a section on fractures; therefore, this chapter focuses on nontraumatic osteonecrosis of the adult hip. It also includes a brief description of other areas that may be involved.

In 1962, Mankin and Brower (73) reported five new cases of bilateral idiopathic osteonecrosis of the hip and stated that only 22 additional cases could be found in the English literature. Since that time, this diagnosis has been made with increasing frequency because of both an increased incidence and improved methods of diagnosis. It is currently estimated that 15,000 to 20,000 new cases are diagnosed annually in the United States alone and that osteonecrosis accounts for approximately 10% of the total hip replacements (THRs) performed.

Despite growing interest in this condition, there is much yet to learn about its etiology, pathogenesis, and treatment. A number of etiologic factors have been implicated, although the exact mechanisms by which they act have not been completely determined. The most commonly identified are high doses of corticosteroids and chronic, excessive alcohol intake. In most series, approximately 15% of the cases are considered to be idiopathic; however, as we learn more about etiologic factors, the number of patients placed in this category will diminish. For example, it has recently been shown that in approximately 70% of “idiopathic” cases, subtle coagulopathies are present (47).

The clinical picture is nonspecific. The presenting symptom is usually unilateral hip pain, which may be followed by a limp and a decreased range of motion (ROM). Young adults between the ages of 30 and 40 are most frequently affected, and the condition is bilateral in more than 50% of patients. Diagnosis is usually made from plain radiographs, but in the earlier, asymptomatic stages, magnetic resonance imaging (MRI) may be required.

Although we have improved our ability to diagnose osteonecrosis early, we still do not have completely satisfactory methods for treating this condition. Our goal is to preserve and not replace the femoral head. A number of procedures have been described to accomplish this. Although an accurate comparison of their relative effectivenesses is not yet available, surgical treatment of osteonecrosis in general yields better results than protected weight bearing and symptomatic management. Whichever procedure is selected, a better outcome will be achieved if the condition is diagnosed and treated early, well before femoral head collapse. Patients with advanced stages of osteonecrosis are generally treated symptomatically until such time as hip arthroplasty or other reconstruction is indicated.

## ETIOLOGY, PATHOPHYSIOLOGY, AND PATHOGENESIS

### ETIOLOGY

Because of the limited biological response of different organ systems, various etiologic factors can lead to similar pathologic changes. In most cases of osteonecrosis, a specific etiologic factor or factors can be identified. In traumatic cases such as hip dislocation and femoral neck fracture, there is a clear cause-and-effect relationship between the insult, mechanical damage to the vessels that supply the femoral head, and the resulting osteonecrosis. A number of etiologic factors can be identified in patients with nontraumatic osteonecrosis. These include intraosseous marrow displacement disorders that lead to increased pressure in the femoral head and neck, such as Gaucher's disease, leukemia, and myeloproliferative disorders (52,58,85,144). Other conditions, such as radiation and chemotherapy, lead to bone necrosis by direct cell toxicity. Mechanical blockage of vessels may be caused by emboli composed of abnormal red blood cells, such as in sickle cell disease and thalassemia; or nitrogen bubble emboli, such as in caisson disease, or dysbarism (59,60).

In many cases of osteonecrosis, the etiology is less clear. In these cases, one can often identify specific factors known to be frequently associated with osteonecrosis, although the exact mechanisms by which they act have not been completely delineated (Table 125.1). For example, high doses of corticosteroids and excessive alcohol intake have been identified in nearly 80% of cases of nontraumatic osteonecrosis (30,52,53,61,84,85,87,144). However, a one-to-one relationship between these factors and this disorder has not been established, because most patients exposed to steroids or alcohol do not develop osteonecrosis (30,84,85). Although the entity of idiopathic osteonecrosis most likely does exist, as we learn more about the etiology of this condition, the number of patients who will be relegated to this

category will diminish (61).

| |
|---|
| Trauma |
| Femoral neck fracture |
| Dislocation |
| Corticosteroids |
| Alcohol |
| Coagulation disorders |
| Thrombophilia |
| Hypofibrinolysis |
| SLE and connective tissue disease |
| Hyperlipidemias |
| Altered red blood cells |
| Sickle cell anemia |
| Thalassemia |
| Organ transplants |
| Renal |
| Cardiac |
| Liver |
| Dysbarism |
| Rheumatoid arthritis |
| Gastrointestinal disorders |
| Myeloproliferative disorders |
| Leukemia |
| Gaucher's disease |
| Radiation |
| Pregnancy |
| Smoking |
| Hyperuricemia |
| Chemotherapeutic agents |
| Hypersensitivity reactions |
| Idiopathic |
| SLE, systemic lupus erythematosus. |

***Table 125.1. Factors and Conditions Associated with Osteonecrosis***

## PATHOPHYSIOLOGY

There have been many mechanisms proposed to explain the pathogenesis of osteonecrosis. They can be categorized into six groups: (a) direct cellular toxicity, (b) extraosseous arterial, (c) extraosseous venous, (d) intraosseous extravascular, (e) intraosseous intravascular, and (f) multifactorial (Table 125.2).

| |
|---|
| Direct Cellular toxicity |
| Chemotherapeutic agents |
| Radiation |
| Thermal injury |
| ? Alcohol |
| ? Corticosteroid |
| Accumulated cell stress |
| Extraosseous arterial |
| Femoral neck fractures |
| Hip dislocation |
| Postsurgery (iatrogenic) |
| Congenital arterial abnormality |
| Extraosseous venous |
| Venous abnormalities |
| Venous stasis |
| Intraosseous extravascular |
| Hemorrhage |
| Elevated bone marrow pressure |
| Cellular hypertrophy and marrow infiltration |
| Bone marrow edema |
| Displaced femoral neck fracture |
| Intraosseous intravascular |
| Sickle cell disease |
| Dysbarism |
| RBC emboli |
| Lipid emboli |
| Thrombosis and coagulation disorders |
| Thrombophilia |
| Hypofibrinolysis |
| Hypersensitivity reactions |
| Multifactorial |
| RBC, red blood cell. |

***Table 125.2. Pathogenic Mechanisms***

### *Direct Cellular Toxicity*

Exposure to radiation, chemotherapy, or thermal injuries can cause injury to and death of marrow cells and osteocytes and lead to osteonecrosis of the femoral head. It has been proposed that corticosteroids and alcohol have direct cytotoxicity; however, *in vitro* studies have indicated no direct cytotoxic effect with alcohol at physiologically tolerated concentrations. In certain animal studies, fat accumulation in the marrow and within osteocysts after exposure to corticosteroids has been implicated as a cause of bone cell death; however, no animal model has developed the collapse that is characteristic of the human disease (59,60,141).

### *Extraosseous Arterial*

Osteonecrosis that occurs after femoral neck fractures and hip dislocation is a direct result of injury to the arteries and veins that supply a significant portion of the femoral head. Angiographic studies in cases of nontraumatic osteonecrosis have demonstrated a high incidence of ab-bnormalities in major vessels about the hip, including the retinacular arteries (14,15). Superselective microangiographic studies of preclinical and contralateral “normal” hips have been consistent with a diagnosis of intraosseous vascular occlusion (115). Osteonecrosis may be encountered after various surgical procedures about the hip, as well as after forceful manipulation and casting in extreme positions. These are related to iatrogenic trauma to regional vessels.

### *Extraosseous Venous*

Venous abnormalities and stasis have been shown to occur in all stages of osteonecrosis (55,144). However, as with other purported mechanisms, it is unclear whether this is an inciting factor or a consequence of the disease. In cases of posttraumatic osteonecrosis, direct venous injuries also accompany arterial trauma.

### *Intraosseous Extravascular*

**Hemorrhage** Paul Ficat (52) observed the presence of intramedullary hemorrhage in the osteonecrotic lesion of core biopsy specimens. Saito et al. (103,104) also reported evidence of old hemorrhage in areas of necrosis without microfractures. Using a rabbit model of hypersensitivity vasculitis, one study (141) found that in 7 of 20 animals that were injected with both horse serum and methylprednisolone acetate, there was histologic evidence of vascular lesions and fresh intramedullary hemorrhages. Perfusion studies have demonstrated narrowing and a decrease in the number of vessels supplying the femoral head with formation of fine new anastomotic arterioles around areas of infarct in the bone of transplant patients treated with corticosteroids (112). Saito et al. (103,104) found areas of fresh hemorrhage in association with arterial damage adjacent to microfractures and necrotic trabeculae. They concluded that multiphasic episodes of intramedullary hemorrhages are an important element in the pathogenesis of osteonecrosis. However, other investigators have proposed that the necrotic lesions resulted from a single rather than multiple events.

**Elevated Bone Marrow Pressure** Several investigators have found elevated bone marrow pressures and abnormal stress tests in hips with osteonecrosis (52,144). Core biopsy specimens from patients with early stages of osteonecrosis have shown histologic changes taking place in the marrow before bony abnormalities appear (11). This observation has led to the theory that the bone acts like a Starling resistor (52), in which thin-walled vessels traverse the space within a rigid outer cortex. Any increase in the pressure within this compartment would tend to cause the vessel walls to collapse, thus leading to decreased blood flow. Although it is well established that increased intraosseous pressure is present in and around areas of osteonecrosis, it is uncertain whether this is an initial event causing the osteonecrosis or whether it takes place after some other etiologic factor and then contributes to the pathogenesis.

**Cellular Hypertrophy and Marrow Infiltration** Since marrow elements and trabeculae of cancellous bone exist within a closed compartment made up of cortical bone, it is possible that hypertrophy of fat cells and infiltration of the marrow within this compartment can cause an occlusion of vessels and place abnormal pressure on osteocytes and marrow cells. There are several circumstances in which this might be implicated in the pathogenesis of the ischemia: (a) corticosteroid therapy, (b) Gaucher's disease, (c) leukemia, or (d) caisson disease or dysbarism.

**Bone Marrow Edema** Intraosseous edema is a finding common to osteonecrosis. This has been documented histologically and by MRI (85). However, edema can occur without the subsequent development of osteonecrosis, as noted in transient osteoporosis of the hip or bone marrow edema syndrome. Thus, the role of marrow edema in the pathogenesis of osteonecrosis remains unclear (18).

### *Intraosseous Intravascular*

**Sickle Cell Disease and Dysbarism** A strong association exists between osteonecrosis and both sickle cell disease and dysbarism (59,60). This is believed to be related to emboli composed of clumps of abnormal red blood cells or to nitrogen bubbles, which can lodge within vessels and can also accumulate in the fatty marrow

surrounding vessels.

**Lipid Emboli** Emboli of intravascular fat have been proposed as another etiologic factor that may lead to osteonecrosis (59,60). The association of hyperlipidemia with gout, alcoholism, and corticosteroid therapy is believed by some to support this hypothesis.

**Thrombosis and Coagulation Disorders** With the development of more sophisticated laboratory tests, the possibility that hypofibrinolysis and thrombophilia may play roles in the pathogenesis of osteonecrosis has gained support (38,84,85,87,138). In thrombophilia, there is an increased tendency to form intravascular thrombi, whereas in hypofibrinolysis, thrombi that have already formed are less readily lysed and removed. Abnormal levels of the specific factors associated with these conditions have been documented in more than 70% of patients with osteonecrosis—in those previously diagnosed as having "idiopathic" osteonecrosis as well as in those in whom other predisposing factors have been identified. However, as is the case for other etiologic factors, not all individuals with these abnormalities develop osteonecrosis.

These can be autosomal dominant disorders and a high familial incidence has been demonstrated. It may therefore be possible to detect patients at risk before osteonecrosis develops. Because these disorders can in part be reversed by the use of anticoagulants, a pharmacologic treatment might theoretically be effective both in preventing the development of osteonecrosis and in lessening its severity once it has occurred. Therefore, consider testing for these abnormalities in patients with clinically diagnosed osteonecrosis and in their close relatives as described in the later section, "Laboratory Tests." A consultation with a hematologist might be indicated in certain cases.

**Hypersensitivity Reactions** Recently, it has been suggested that intravascular coagulation might be a result of pathophysiologic mechanisms such as the Schwartzman phenomenon, in which immune complex deposition may lead to vascular damage and ultimately osteonecrosis. Several animal models have been developed that demonstrate this phenomenon. When corticosteroids were added, bone necrosis can be produced. However, the overall picture was quite different from osteonecrosis as it occurs in humans, and there is no proof that this mechanism plays a clinical role in the development of the human disorder.

### *Multifactorial Etiology*

Osteonecrosis may be multifactorial in etiology—that is, not one but several precipitating factors may act simultaneously or in sequence (64). There are several ways this can develop. For example, a patient may have an underlying abnormality, such as a subtle coagulation defect, but may not develop osteonecrosis until one or more additional factors are present. These might include excessive alcohol intake or chronic steroid administration. Under other circumstances, a specific etiology factor may evoke more than a single mechanism to cause vascular injury. For example, excess corticosteroid use can cause hyperlipidemias that result in intravascular lipid emboli. These in turn cause intravascular coagulation. In addition, steroids may cause direct cellular toxicity and may lead to abnormalities in marrow fat, thus causing increased pressure on local vessels. In addition to the factors identified to date, it is quite possible that other factors that predispose patients to the development of osteonecrosis have yet to be identified.

## PATHOGENESIS

Although several different etiologic factors can lead to vascular impairment in osteonecrosis, the sequence of events that follow the initial insult or insults is similar. The resultant hypoxia rapidly leads to increased cell membrane permeability, which allows fluid and electrolytes to enter the cell, causing it to swell. Intracellular lysosomal enzymes are released, resulting in autodigestion or coagulation necrosis and cell rupture. Vascular injury leads to tissue edema and hemorrhage. An inflammatory response ensues, marked by the appearance of neutrophils and macrophages.

Death of bone is more difficult to diagnose than marrow necrosis and is predicated on the disappearance of osteocytes from within their lacunae, a process that takes several days to develop (Fig. 125.1). The center of the necrotic lesion remains avascular and repair is not possible. Bone and soft-tissue detritus accumulate. As a result of repeated stresses, dead trabeculae undergo microfractures that cannot be repaired.

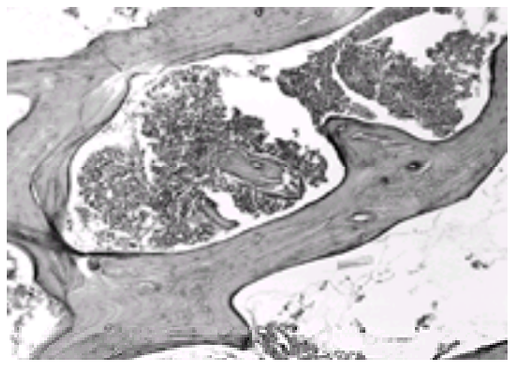

***Figure 125.1.*** Necrotic bone and marrow from the center of the ischemic area (hematoxylin and eosin, ×50).

Toward the periphery of the necrotic area where sufficient vascularity is present, the transition zone, an active process of repair begins. Macrophages and osteoclasts remove dead marrow elements and bone. Granulation and fibrous tissue are formed. Osteoblasts form new bone, much of which is laid down directly on remnants of dead trabeculae (Fig. 125.2). The resulting trabeculae are much thicker than normal and are responsible for the sclerotic margin that surrounds the lesion and that is one of the radiographic hallmarks of osteonecrosis (Fig. 125.3).

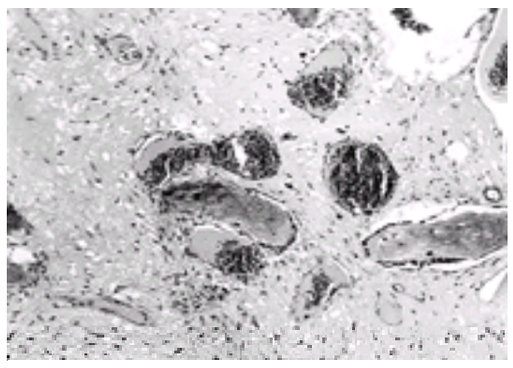

***Figure 125.2.*** Tissue taken from the periphery of the lesion (transition zone) shows active bone resorption and formation, and the presence of macrophages, lymphocytes, and fibrous tissue (hematoxylin and eosin, ×100).

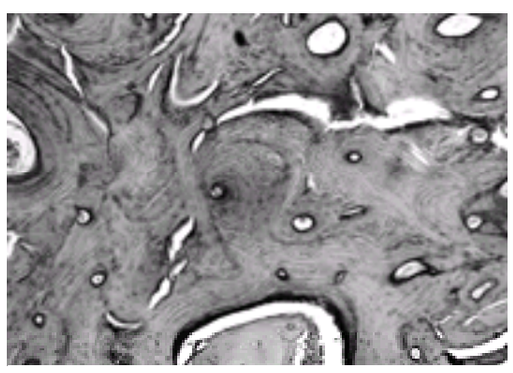

***Figure 125.3.*** Trabeculae in the transition zone may become markedly thickened due to new bone apposition to old, dead trabeculae (hematoxylin and eosin, ×50).

If the lesion is small, and particularly if it is not in a major weight-bearing region of the femoral head, it may undergo revascularization and be completely replaced with viable bone. Alternatively, it may remain as a small sequestrum surrounded by a wall of new bone. In either case, femoral head collapse does not occur, the hip continues to function normally, and the patient remains asymptomatic.

Larger lesions, particularly those in a region of major weight bearing, have a poor prognosis. The attempt at repair is only partially effective. Bone resorption is more rapid than formation. There is a gradual collapse of cancellous bone beneath the bony endplate of the weight-bearing aspect of the femoral head. If the contour of the articular surface remains intact, a fluid-filled space beneath the cortical subchondral bone develops, which gives the appearance of a crescent sign on radiographs (Fig. 125.4). With flattening and collapse of the articular surface, this space is obliterated and the crescent disappears. Gross flattening of the femoral head is now apparent (Fig. 125.5).

***Figure 125.4.*** Transected femoral head shows the area of necrosis, which is collapsed from beneath the articular surface, leaving a space that appears as a crescent sign on radiographs. Note that the articular cartilage appears grossly intact.

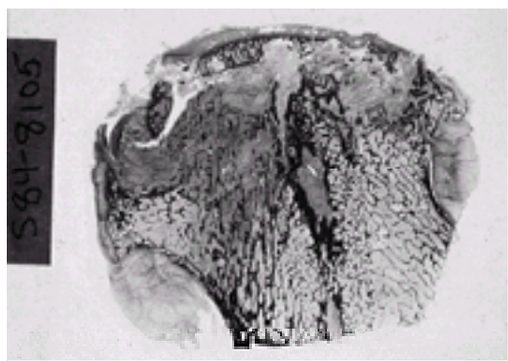

***Figure 125.5.*** Low-power photomicrograph of a sectioned femoral head. The articular surface is flattened. Several elements of necrosis and repair can be identified in more than half of the specimen (hematoxylin and eosin, ×0.5).

Articular cartilage derives its nourishment from synovial fluid within the joint rather than from vessels in the cancellous bone, so it remains viable while the attached subchondral bone dies. The mechanical stresses on the collapsed and irregular articular surface eventually result in damage to and death of chondrocytes (Fig. 125.6). These abnormal stresses are transferred to the otherwise normal cartilage of the acetabulum, which undergoes secondary degenerative changes. Joint line narrowing becomes obvious on radiographs. As the processes of degeneration continue, the underlying acetabular bone becomes affected. Typical changes of degenerative joint disease appear and include sclerosis, cyst formation, and marginal osteophytes. End-stage arthritis of the hip eventually ensues (18,28,55,56,58,76,113,114).

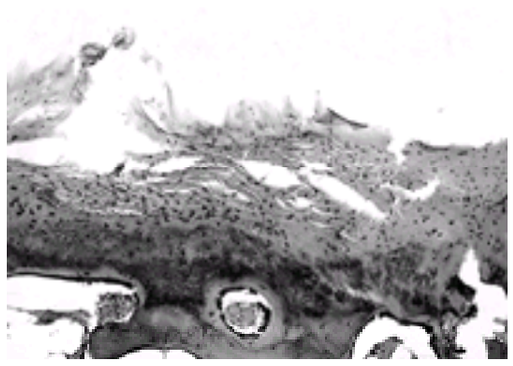

***Figure 125.6.*** Articular cartilage overlying an area of femoral head collapse. The cartilage remains viable but is undergoing severe degenerative changes as a result of the mechanical stresses that result from subchondral collapse and flattening (hematoxylin and eosin, ×100).

**TRANSIENT OSTEOPOROSIS OF THE HIP**

Osteonecrosis is quite different histologically from transient osteoporosis (or osteopenia) of the hip (TOH) (39,42), although these two conditions can be confused. In TOH, there are no findings of bone infarction or repair, which are the hallmarks of osteonecrosis. The pathologic picture is primarily one of marrow edema, hence TOH is also referred to as bone marrow edema syndrome (BMES). Some of the pathologic features of TOH, such as the presence of edema fluid, have also been found in early stages of osteonecrosis, and this has led some authors to conclude that these two entities are at different ends of the spectrum of the same disorder (49).

Clinically, transient osteoporosis also behaves differently from osteonecrosis. The onset of pain is usually more sudden and it is often more severe. To minimize the chance of fracture, place patients on crutches until there is clinical, radiographic, and MRI evidence of resolution. This may require 4–6 months. This condition affects men more often than women, and these patients have no associated risk factors as in osteonecrosis. In women, it classically develops during the third trimester of pregnancy, and the incidence of fracture is greater than in men. The disease rarely involves both hips at the same time. Occasionally, the opposite hip is affected months or years later. It is difficult to make a definitive diagnosis on the basis of standard radiographs because the only abnormality is mild osteopenia of the femoral head and neck. However, the diagnosis can be made readily based on MRI in most cases.

It is essential to distinguish transient osteoporosis from osteonecrosis, because the natural histories, prognoses, and treatments of these two conditions are quite different. Because TOH is usually self-limited, it is treated with protected weight bearing to prevent fracture. Infrequently, core decompression may be indicated if a patient has an inordinate amount of pain or if the diagnosis is in doubt. Osteonecrosis, on the other hand, is a progressive disorder if untreated, and in most instances early diagnosis and treatment are required (18,48,49).

## EARLY DIAGNOSIS

The diagnosis of established osteonecrosis of the femoral head is usually not difficult because the radiographic picture is often pathognomonic. Our goal, however, is to make the diagnosis as early as possible, ideally before characteristic changes appear on radiographs. This will allow early treatment with procedures that may help retard or reverse progression of this condition and save the femoral head. This, in turn, requires a familiarity with its etiology, pathogenesis, and clinical features, as well as with the laboratory tests and imaging studies that enable us to make the diagnosis early.

### CLINICAL FEATURES

The signs and symptoms of osteonecrosis are nonspecific. For weeks and perhaps even months after the initial vascular insult, the involved area may be entirely asymptomatic. When symptoms develop, they usually do so gradually. This may be due to a buildup of intraosseous pressure initially and later perhaps to microfractures of affected trabeculae. The pain is usually localized to the inguinal region but may involve the buttock or the upper thigh. Rarely does it radiate as far as the knee. It may be present at rest but is often exacerbated by activity. Later, a limp and a slight decrease in ROM, associated with pain, may develop.

Although both hips are affected in more than 50% of the cases, the involvement is usually not simultaneous. Therefore, the patient will normally present initially with symptoms on only one side. If the contralateral hip is afflicted, symptoms will usually develop within 3 to 6 months. Approximately 80% of asymptomatic hips with MRI-proven osteonecrosis eventually become symptomatic. The incidence is much less in the case of small lesions. When the asymptomatic contralateral hip of a patient with osteonecrosis on the opposite side appears normal on the initial MRI, there is less than a 10% incidence that this hip will develop osteonecrosis at a later date (32). In a small number of cases of advanced osteonecrosis, the patient may develop a positive Trendelenburg sign and have shortening of the limb, due both to collapse of the femoral head and to a limited range of hip motion resulting in a functional shortening.

In approximately 15% of cases of hip involvement, other areas will also develop symptomatic osteonecrosis. These include knees, shoulders, wrists, feet, and, rarely, elbows and facial bones. Accordingly, these areas should be evaluated by history and physical examination. If there is any question of involvement, plain radiographs and perhaps a bone scan or an MRI should be obtained. Recently, MRI studies have indicated that the incidence might be considerably higher than expected.

Take a careful history, looking for possible etiologic or associated factors. High doses of corticosteroids and prolonged, excessive alcohol intake are most often implicated, but a number of other factors should also be considered, as discussed earlier. The quantities of alcohol or steroid required to cause osteonecrosis have not been exactly determined, and it is clear that there is a tremendous variation in the sensitivity of patients to these agents. For example, it has been shown that patients on corticosteroids who develop Cushingoid features are much more likely to develop osteonecrosis than individuals taking the same dose of steroid who do not become Cushingoid (120).

### LABORATORY TESTS

In most instances, routine laboratory tests are within normal limits. In selected cases, serologic testing can be used to rule out or diagnose other possible causes of hip pain. Although these tests do not diagnose osteonecrosis per se, they may identify certain risk factors, thus helping to support the diagnosis. These include sickle cell disease, systemic lupus erythematosis, hyperuricemia, abnormal amounts of circulating lipids, and subtle coagulopathies.

Abnormalities in coagulation factors have recently been identified in more than 70% of patients with previously diagnosed “idiopathic” osteonecrosis (45,46). They have also been identified in a large number of patients with osteonecrosis in whom other inciting factors, such as alcohol or steroids, are present. It is thus felt that either alone or in combination with other agents, these coagulation abnormalities may predispose to or cause osteonecrosis.

These abnormalities cannot be detected on standard measurements of coagulation, such as prothrombin time, partial thromboplastin time, and bleeding time, which are usually within normal limits. A more complete coagulation profile is therefore required to identify these factors. Thrombophilia may be associated with decreased levels of protein C, protein S, and antithrombin III (AT III); increased resistance to activated protein C (RAP-C); and elevated antiphospholipid antibodies. Hypofibrinolysis may be associated with increased plasminogen activator inhibitor activity (PAI-1), increased lipoproteins, and decreased stimulated plasminogen activator activity. Unfortunately, at the present time these tests cannot be performed in all facilities, and they are expensive.

### FUNCTIONAL EXPLORATION OF BONE

The earlier literature recommended that certain invasive tests, referred to as “functional exploration of bone,” be performed in patients suspected of having osteonecrosis despite normal radiographs (12,38,39,52). These included intraosseous venography, intraosseous pressure measurements, and histologic examination of core biopsy specimens taken from the femoral head. Although these tests can often lead to the diagnosis of osteonecrosis prior to the development of radiographic changes, they are seldom indicated if MRI is available. Rarely, histologic evaluation may be useful in distinguishing between osteonecrosis and certain other conditions affecting the femoral head, such as TOH (18,39,45,48,49).

### IMAGING MODALITIES

#### *Plain Radiographs*

The most important modality for the diagnosis of osteonecrosis is high-quality anteroposterior (AP) and lateral radiographs of both hips. Initially, these will be within normal limits because it takes a period of weeks to months after the initiating event for changes to appear on radiographs. The first changes to be noted are areas of radiolucency and sclerosis within the femoral head, usually in the anterior superior quadrant. These result from bone resorption and new bone formation. Infrequently, the earliest finding is diffuse osteopenia. If present, this must be differentiated from other conditions, including inflammatory arthritis, reflex sympathetic dystrophy, and TOH. If the involved area is small, and particularly if it is not in a region of major weight bearing, spontaneous healing may occur. Once radiographic changes are present, however, they rarely disappear completely, and the involved area can usually be identified by its sclerotic appearance.

Most untreated hips will not heal spontaneously but will show evidence of progression. Once established radiographically, the lesion will rarely enlarge in size, but microfractures through weakened, dead trabeculae will occasionally result in the presence of a crescent sign. This is seen in only a small percentage of hips with osteonecrosis and represents an area in which the supporting trabeculae have collapsed from beneath the subchondral bony endplate prior to flattening of the articular surface. Gross flattening of the femoral head later develops (Fig. 125.5), and, when this occurs, the crescent sign is usually obliterated. Fragmentation of bone in the necrotic region can often be identified. Usually the collapse progresses and the majority of the weight-bearing surface of the femoral head becomes flattened. Occasionally, the process seems to stabilize after only a small amount of flattening has occurred. In these instances, the joint line may be preserved for months to years, although secondary arthritic changes eventually develop. These are manifested by progressive joint-line narrowing, cystic and sclerotic changes within the acetabulum, and the development of marginal osteophytes. In longstanding cases, nearly complete obliteration of the joint line may eventually develop.

It must be emphasized that osteonecrosis is a disorder initially involving the subchondral bone of the femoral head. Joint-line narrowing and acetabular changes are secondary phenomena and usually develop only after femoral head collapse. An awareness of this fact will usually help in radiographically differentiating between osteonecrosis and a variety of arthritides, which, in the end stage, may look quite similar.

#### *Magnetic Resonance Imaging*

If osteonecrosis is suspected despite normal-appearing plain radiographs, MRI of both hips should be obtained because more than 50% of cases are bilateral. If the diagnosis in one hip has already been established by plain radiographs, then MRI will add little to the evaluation of this hip, and the study may be performed on the contralateral hip only. However, the usual procedure is to obtain coronal sections of the pelvis, including both hips. The MRI picture of osteonecrosis is usually quite characteristic and, if both heads are involved, it may be pathognomonic (Fig. 125.7). The anterior superior quadrant of the head is usually affected, although changes may be seen involving nearly all of the head. Very rarely do these extend into the neck. If a significant amount of edema has developed adjacent to the necrotic lesion, this may occasionally lead to an abnormal MRI signal extending well into the femoral neck. In such cases, you must be cautious to differentiate osteonecrosis from TOH. The latter condition routinely involves both the femoral head and neck down to the intertrochanteric line and is manifested by a homogeneous, decreased signal intensity on the T1-weighted images and an increased intensity on the T2-weighted images, reflecting the presence of large amounts of edema fluid (Fig. 125.8 and Fig. 125.9). In osteonecrosis, the changes are usually limited to the superior portion of the femoral head, and the signal is most commonly decreased or irregular in both the T1- and the T2-weighted images. When present, the double-line sign on T2-weighted images is essentially pathognomonic for osteonecrosis (Fig. 125.7).

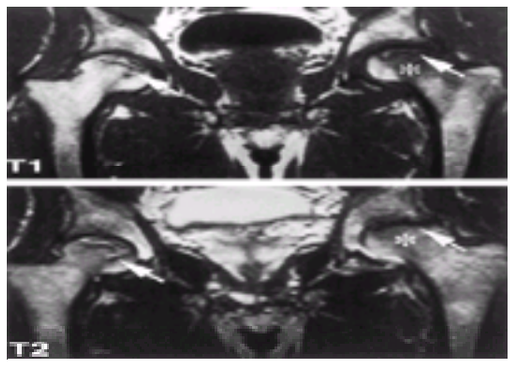


***Figure 125.7.*** MRI images of a patient with bilateral osteonecrosis seen on plain radiographs. The T1-weighted image (**top panel**) shows subchondral lesions bilaterally composed of alternating areas of low and high signal intensity. The T2-weighted image (**bottom panel**) shows a high signal line inside the low signal on the right (*double line sign*). On the *left*, the lesion in the proximal portion of the femoral head has diffuse low signal intensity whereas the area below the necrotic lesion (*asterisks*) is isointense, indicating coexisting edema. (Courtesy of Dr. S. Hoffman, Danube Hospital of Vienna, Austria. From Bauer T, Plenk H. The Pathology of Early Osteonecrosis. *Semin Arthroplasty* 1998;3:192, with permission.)

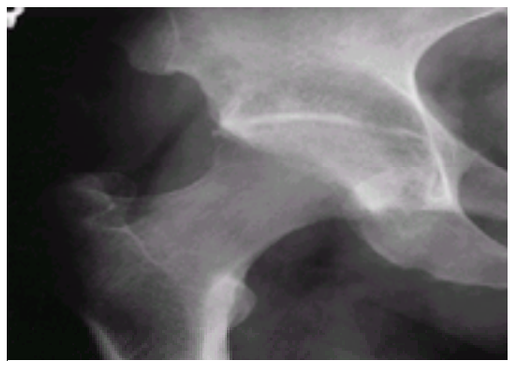

***Figure 125.8.*** Radiograph of a hip with transient osteoporosis. Note the marked osteopenia of the head and neck.

***Figure 125.9.*** MRI of patient with transient osteoporosis or bone marrow edema syndrome of the right hip. Radiographs were normal. The right femoral head and neck show a diffuse low signal intensity in the T1-weighted image (**top panel**) and a high intensity in the T2-weighted image (**bottom panel**). (Courtesy of Dr. S. Hoffman, Danube Hospital of Vienna, Austria. From Bauer T, Plenk H. The Pathology of Early Osteonecrosis. *Semin Arthroplasty* 1998;3:192, with permission.)

### *Other Imaging Modalities*

If high-quality AP and lateral radiographs are available, computed tomographic (CT) scans usually add little to the diagnosis of osteonecrosis. In selected instances, CT may better visualize a small lesion not easily seen on routine radiographs, and it may demonstrate small areas of articular surface collapse that are not apparent on plain films. It may also be used to help quantitate the extent of femoral head involvement.

Technetium bone scans have been used infrequently since the development of MRI. They are nonspecific and less sensitive than MRI and are only rarely positive if the MRI is normal. In such instances, other diagnoses should be considered. Bone scans may be of value when the MRI picture is atypical and further confirmation of the diagnosis is required, when a single screening test is desired to rule out the presence of multiple joint involvement, or when MRI is not available.

Limited studies have been reported with the use of single photon emission computerized tomography (SPECT), positron emission tomography (PET), and gadolinium-enhanced MRI. The roles of these studies in evaluating osteonecrosis have not yet been determined and they are currently not in routine use for this purpose (30,44,80,97,116,118,123,131).

## CLASSIFICATION AND STAGING

Once osteonecrosis has been diagnosed, the radiographic appearance of the hip is a good indicator of both the type and extent of the pathologic changes present. An effective method for classification and staging, based primarily on radiographs and other imaging modalities, serves many important roles. It helps establish a prognosis, follow improvement or progression of the condition, compare the effectiveness of different methods of treatment, and determine the best method of management for patients with different stages of osteonecrosis. Uniform use of such a system of classification should eliminate much of the current confusion about both the natural history and the treatment of osteonecrosis.

At this time, several different systems of staging are in use, some of which will be specifically described. In the 1960s, Arlet and Ficat in France (12) described a three-part staging system, and in the 1970s a fourth stage was added (39) (Table 125.3). This form is perhaps the one most widely used now, despite the fact that a stage 0 and a transitional stage were added later (38). Bone and marrow scans were mentioned but did not appear to be an integral part of the staging system, and MRI was not described. Certain invasive tests, such as intraosseous pressure measurements and femoral head biopsy, were deemed necessary to make the diagnosis in the earliest stages. Patients' symptoms and physical findings were correlated with the stage. There was no attempt made to measure or quantitate the extent of involvement.

| | Stage | Jointline | Femoral head contour | Trabecular | Diagnosis by X-ray | Diagnosis by functional exploration for bone |
|---|---|---|---|---|---|---|
| Simple necrosis | I | N | N | N or very slight osteoporosis | Impossible | Hemodynamic probable |
| | II | N | N | Osteoporosis, mixed sclerosis/ porosis | Probable | Histopathologic certain |
| Necrosis complicated by collapse | III | N | Flattened subchondral infraction collapse | Sequestrum formation | Certain | Confirmation |
| | IV | Narrowed | Collapsed | Destruction of superior pole | Very difficult between arthrosis, inflammatory arthritis, and necrosis | Hemodynamic insufficiency, combined biopsy necessary |

N, normal.
From Ficat RP, Arlet J. Necrosis of the Femoral Head In: Hungerford DS, ed. Ischemia and Necrosis of Bone. Baltimore: Williams & Wilkins, 1980:168, with permission.

***Table 125.3. Ficat and Arlet Four-stage Classification of Osteonecrosis***

In 1973, Marcus et al. (74) identified six stages of osteonecrosis and described the radiographic picture for each. These were correlated with gross and histologic findings as well as with the patient's symptoms and physical examination. Bone scans were not specifically described and MRI was not available at that time. No preradiographic stages were included and no attempt was made to quantitate the size of the lesion.

In 1974, Kerboul et al. (65) noted that the results of osteotomies performed for osteonecrosis depended on both the location and the extent of the lesion. This latter was expressed in degrees after measuring the arc of the articular surface involved as seen on both AP and lateral radiographs of the femoral head. Similar observations were reported by Wagner and Zeiler (139), Sugioka et al. (128), and Koo and Kim (66).

In 1987, the Japanese Investigation Committee for Avascular Necrosis described a new roentgenographic classification (94,95). It focused on hips with Ficat and Arlet stages II and III, and it grouped them by the type and location of the lesion as well as the amount of articular surface involved. This system has not gained popularity outside of Japan. The Committee on Nomenclature and Staging of the Association Research Circulation Osseous (ARCO) in 1991 endorsed the staging system developed at the University of Pennsylvania in the early 1980s. In 1992, location of the lesion, as described in the Japanese system (10,42), was added, and in 1993, stages III and IV were combined, as were stages V and VI.

The University of Pennsylvania staging system identified seven distinct stages, incorporated both technetium scans and MRI, and included a measurement of lesion size in both early and late stages. Symptoms and physical findings were considered important in determining treatment but were not specifically included as part of the staging (Table 125.4) (Fig. 125.10, Fig. 125.11, Fig. 125.12, Fig. 125.13, Fig. 125.14 and Fig. 125.15). This system of staging was compared in clinical use to older, nonquantitative systems and was found more effective in following the progression or resolution of the condition, evaluating the results of treatment, and establishing a prognosis (117,118,122). It is now generally recognized that the size or extent of the necrotic lesion is an important indicator of prognosis and determinant of the management, and it should be included in staging. Use of this staging system in conjunction with a clinical evaluation as described has enabled us to develop an algorithm that has proven helpful in determining treatment for patients with osteonecrosis (Table 125.5). It outlines treatment in general categories only because there are a number of specific options to be considered in each category.

| Stage | Criteria |
|---|---|
| 0 | Normal or nondiagnostic x-ray, bone scan, and MRI |
| I | Normal x-ray, abnormal bone scan and/or MRI<br>A. Mild (<15% of femoral head affected)<br>B. Moderate (15%–50%)<br>C. Severe (>50%) |
| II | "Cysts" and sclerotic changes in femoral head<br>A. Mild (<15% of femoral head affected)<br>B. Moderate (15%–50%)<br>C. Severe (>50%) |
| III | Subchondral collapse (crescent sign) without flattening<br>A. Mild (<15% of articular surface)<br>B. Moderate (15%–50%)<br>C. Severe (>50%) |
| IV | Flattening of femoral head<br>A. Mild (<15% of surface and <2 mm depression)<br>B. Moderate (15%–50% of surface or 2–4 mm depression)<br>C. Severe (>50% of surface or >4 mm depression) |
| V | Joint narrowing and/or acetabular changes<br>A. Mild<br>B. Moderate<br>C. Severe<br>} Average of femoral head involvement, as determined in stage IV, and external acetabular involvement |
| VI | Advanced degenerative changes |

MRI, magnetic resonance imaging.
From Steinberg ME, Hayden CT, Coscia A. Osteonecrosis of the Femoral Head: Results of Core Decompression and Grafting with Thermal Sensitivity. Clin Orthop 1989;249:100, with permission.

***Table 125.4. University of Pennsylvania System for***

***Figure 125.10.*** Images of a young patient with stage I, steroid-induced osteonecrosis of the right femoral head. **A:** The plain radiograph is within normal limits. **B:** The T1-weighted MRI shows a decreased signal intensity in the femoral head, characteristic of osteonecrosis.

***Figure 125.11.*** Stage II osteonecrosis showing areas of sclerosis and radiolucency within the femoral head.

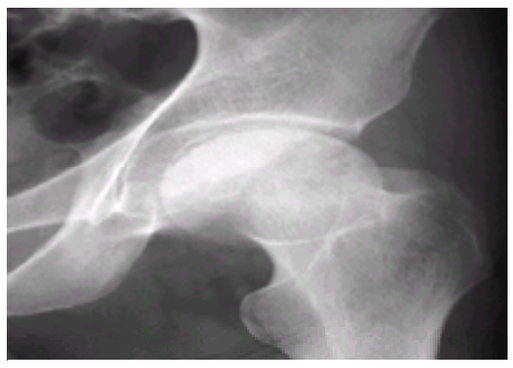

***Figure 125.12.*** Stage III osteonecrosis. Note the crescent sign, indicating subchondral collapse without flattening of the articular surface.

***Figure 125.13.*** Stage IV osteonecrosis. Marked flattening of the femoral head is present without radiographic evidence of acetabular involvement.

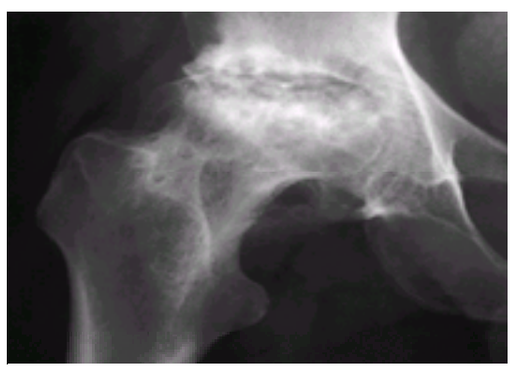

***Figure 125.14.*** Stage V osteonecrosis. The femoral head is markedly flattened. The joint line is narrowed, and the acetabulum shows irregularity, sclerosis, and radiolucency.

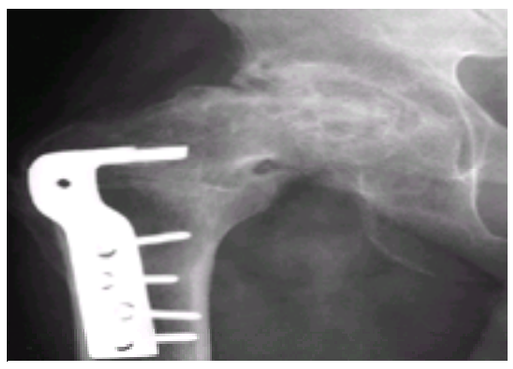

***Figure 125.15.*** Stage VI osteonecrosis showing advanced degenerative changes that have taken place in the hip joint secondary to osteonecrosis of the femoral head, treated by intertrochanteric osteotomy.

| *Stage* | *Treatment* |
|---|---|
| I-A, II-A | Close observation or prophylactic treatment |
| I-B/C, II-B/C | Prophylactic treatment |
| III–IV-A/B | Prophylactic treatment *if* signs and symptoms are minimal |
| IV-B/C | Total hip replacement or hemiarthroplasty |
| V–VI | Total hip replacement when clinically indicated |

***Table 125.5. Treatment Algorithm for Osteonecrosis of the Femoral Head***

## EARLY MANAGEMENT

In this section, *early* is meant to include hips with little or no evidence of femoral head collapse and minimal or no symptoms or physical findings. Considerable controversy exists regarding the early management of osteonecrosis. Several different procedures have been described, and in general most give results better than nonoperative or symptomatic treatment. It is, however, difficult to compare the effectiveness of each of these or to determine their specific indications and contraindications. This is because of the many variables included in these studies and the significant differences in techniques, inclusion criteria, radiographic evaluation, outcome measurements, and criteria for determining success or failure. A coordinated series of prospective studies is required to determine the effectiveness and indications for each of these techniques, but this is not yet available.

No method for treating early osteonecrosis of the femoral head is completely satisfactory. The natural history of this condition after clinical diagnosis is one of progression in most instances, except perhaps where lesions are small and in an area of relative non-weight-bearing. Thus, a procedure that retards this progression

and provides an increased period of survivorship of the femoral head before arthroplasty is required should be considered at least partially successful.

## PREVENTION

Even more important than the treatment of a disease state is its prevention. In osteonecrosis, certain specific risk factors have been identified and these should be eliminated or minimized to the extent possible. This applies particularly to alcohol ingestion and steroid administration, the two leading causes of osteonecrosis, as well as to smoking. In regard to steroid use, altered dosage schedules and the substitution of other agents have already led to a decrease in the incidence of osteonecrosis under circumstances in which the use of corticosteroids has not yet been completely eliminated. Established guidelines for divers and those working under hyperbaric conditions must be followed. When they become generally available, medications shown to be effective in combating some of the known causes of osteonecrosis should be appropriately utilized in those patients particularly at risk.

## MEDICAL MANAGEMENT

Certain systemic disorders have been associated with an increased incidence of osteonecrosis. These include coagulopathies, hyperlipidemias, and the presence of specific antibodies. Screen patients with osteonecrosis for the presence of these disorders, with coagulation studies, liver function tests, lipid profiles, and tests for anticardiolipin antibodies and lupus anticoagulant. If definite abnormalities are found, decide whether to treat them and which agents to use. Limited studies have shown a possible role for stanozolol, an anabolic steroid that alters lipoproteins and suppresses clotting factors; nifedipine, a vasodilator; agents that lower circulating lipids; and long-term anticoagulation to treat coagulopathies. A limited number of patients in this latter category have been treated to date. Anticoagulation is not a benign form of treatment, and the appropriate dose and duration of treatment has not been established. In general, neither the effectiveness nor the safety of these agents has been determined, nor do we have appropriate guidelines for their use at present. We can hope they will prove to be effective and will be available for the prevention and treatment of osteonecrosis in the not too distant future (46).

## PROTECTED WEIGHT BEARING

When a patient is diagnosed with osteonecrosis of a weight-bearing joint, there is a natural desire on the part of the treating physician to protect the involved area from excessive stress by using some form of limited weight bearing. Thus, canes or even crutches are frequently prescribed. Although these may decrease the degree of discomfort in patients who are symptomatic, they have not been shown to alter the natural course of this disorder.

Protected weight bearing may be used empirically as an alternative to surgical management in cases with a good prognosis. These cases include small, asymptomatic lesions and those in regions of relatively low weight bearing, such as the medial aspect of the femoral head. However, it has not been established that limited weight bearing improves the already favorable course in such instances. Symptomatic management, including protected weight bearing, may be the treatment of choice when the patient's age, general prognosis, and associated medical conditions, or the patient's own wishes, contraindicate surgical intervention.

Protected weight bearing is mandated following certain types of surgical procedures, such as core decompression, grafting, and osteotomies, where it is used as an adjunct to the basic operative approach. Here it serves to protect the weakened regions from fracture, and perhaps protects the femoral head as well, until the healing processes have progressed satisfactorily. Perhaps the most important role for protected weight bearing is in the patient with relatively advanced stages of osteonecrosis, when it is felt that prophylactic procedures are of little avail. Here the use of a cane or perhaps crutches can diminish symptoms and improve function considerably until such time as a reconstructive procedure is indicated (3,81,85,94).

## ELECTRICAL STIMULATION

Various types of electrical stimulation have demonstrated an ability to enhance bone formation and fracture healing. It was thus natural for electrical stimulation to be applied to patients with osteonecrosis, either alone or as an adjunct to other surgical procedures, in the hope that it would stimulate healing of the necrotic regions. Three specific signals have been used: direct current (DC), capacitive coupling (CC), and pulsing electromagnetic fields (PEMF). The latter two are transmitted to the involved bone by means of surface electrodes or coils placed on the skin over the involved region. Thus they can be used alone or in conjunction with surgical procedures. DC stimulation requires the insertion of an electrode directly into the bony region to be stimulated, and therefore it has been used as an adjunct to core decompression rather than as an independent treatment modality.

Only limited studies have been reported using these techniques (18). Capacitive coupling, with the specific signal utilized, failed to show any enhancement of the effects of core decompression and bone grafting alone. DC stimulation, despite indications of an early response, did not show a long-term effect. Results with PEMFs, both in individual studies and in a multicenter study, were promising (1,4). They were shown to be more effective than symptomatic management in precollapsed and minimally collapsed hips; as effective as core decompression in precollapsed lesions; and more effective in hips with early collapse, both as determined by radiographic progression and delaying the need for arthroplasty. A special signal, different from that used to treat fractures, was used to treat osteonecrosis. At present, this is not generally available for routine use in the United States. If further evaluation by other investigators confirms these early positive findings, PEMF may be added to the treatment modalities available for this condition (1,4,119).

## CORE DECOMPRESSION

During the early 1960s, Arlet and Ficat (12,38,39) used core decompression to examine the pathologic changes in femoral heads of patients who were suspected of having AVN. This procedure caused a decrease in the abnormally elevated intraosseous marrow pressures and frequently produced immediate relief of preoperative pain. Subsequently, this approach was used as a therapeutic rather than a diagnostic procedure. It is presumed to work by decreasing the abnormally high intraosseous pressures present in osteonecrotic lesions, by opening up channels for vascular ingrowth, and by stimulating the natural processes of repair. This technique can be utilized as initially described or it can be supplemented with loosely fitted cancellous or cortical grafts, electrical stimulation, or various agents with the potential to stimulate bone healing, such as bone morphogenetic protein (BMP) and demineralized bone matrix (DBM) (2).

Investigators do not completely agree as to the safety or the effectiveness of this procedure. In 1985, Ficat and Arlet (38) reported on 133 hips in stages I and II treated with core decompression. They noted “good and very good results” in 90% of hips clinically and in 79% of hips radiographically. In 1986, Camp and Colwell (26) retrospectively reviewed 40 core decompressions performed by 13 surgeons in their area. Sixty percent of hips treated before collapse failed either radiographically or clinically, and all hips treated after collapse were considered clinical failures. Four patients sustained postoperative fractures.

Although opinion remains somewhat divided on the efficacy of core decompression, most studies report a low incidence of complications and results significantly better than with symptomatic management. In an extensive review of the literature published in 1996, Mont et al. (81) reviewed 42 reports of 2,025 hips, of which 1,206 were treated by core decompression and 819 by nonoperative means. Satisfactory results were found in 64% of hips treated by core decompression, compared with only 23% of hips treated nonoperatively. In the hips treated before collapse, good results were obtained in 71% with core decompression and 35% treated nonoperatively. The best results were achieved at centers doing the greatest numbers of procedures (37,81,85,110,124).

### *Operative Technique*[1]

We have modified the surgical technique somewhat from that originally described by Ficat, Arlet, and Hungerford (12,38,88). Our technique is as follows:

- Use a standard fracture table with a biplane image intensifier in place.
- Expose the lateral femoral cortex through a short linear incision.
- Divide fascia and muscles in line with their fibers in routine fashion, and identify the flare of the greater trochanter.
- Place a small drill hole in the mid-lateral cortex at the point where the bone begins to flare laterally. Insert a small guide wire through this hole into the center of the lesion in the femoral head, using the image intensifier.
- Then open the lateral femoral cortex with a conical reamer or cannulated drill, to a diameter of 10 mm. Insert an 8 mm Michele trephine over the guide wire and manually advance to within approximately 5 mm of the articular surface. Take care not to perforate the joint.
- Bone from the intertrochanteric region is considered essentially normal; put it aside to be used later for grafting. The necrotic segment can be identified because of the sclerotic bone encountered and the resistance to advancement of the trephine.
- Advance the trephine slowly, in stages, into the lesion, removing bone from the trephine with an obturator as soon as significant resistance is met and further progression of the trephine ceases. Do not strike the instrument with a mallet. On occasion, it is difficult or impossible to remove all of the necrotic specimen from the proximal portion of the femoral head using the trephine. In such cases, remove the last few millimeters of bone with either a cannulated or a solid drill.
- Send abnormal bone for histologic examination.
- After the large central channel has been created, make two additional channels with a 5 or 6 mm Michele trephine. These extend from the initial opening in the cortex into other segments of the necrotic lesion. Accomplish this simply by slightly changing the angle of insertion of the trephine. Additional holes through the cortex are not required (Fig. 125.16 and Fig. 125.17).



***Figure 125.16.*** Michele trephines, 6 mm and 8 mm, used in core decompression.

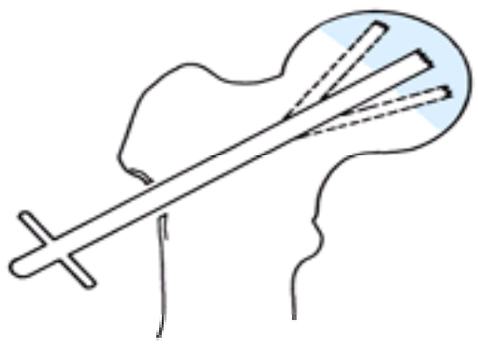

***Figure 125.17.*** Technique for performing core decompression. (From Steinberg ME, Brighton CT, Corces A, et al. Osteonecrosis of the Femoral Head. Results of Core Decompression and Grafting with and without Electrical Stimulation. *Clin Orthop* 1989;249:199, with permission.)

- Irrigate the wound and check the central channel to be sure that no debris is present.
- Thin the cancellous graft initially removed from the intertrochanteric region by using a rongeur or bone-cutting forceps. Place it very loosely into the central track extending from the relatively normal bone of the femoral neck into the depths of the lesion (Fig. 125.18). This can be accomplished easily by using the large trephine as a carrier for the graft and holding the graft in position with the obturator while the trephine is withdrawn. Then place additional cancellous bone at the cortical margin of the lateral femur to promote healing of the surgical defect. Leave the two smaller decompression channels open.

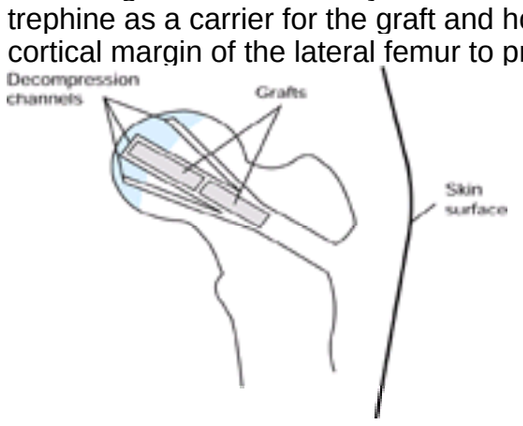


***Figure 125.18.*** Decompression channels with central bone grafts inserted.

This surgical technique varies somewhat from that used by most other investigators. Some surgeons make a single channel 8–10 mm in diameter, whereas others use two orbnperhaps three channels of varying sizes. Also, the procedure may be done on an ordinary operating table rather than a fracture table. In the classical core decompression, supplemental bone graft is not used. In all our cases, a loosely fitting cancellous graft was inserted into the central channel as a supplement to the core decompression. This was done on a strictly empirical basis in the hope that it would act as a stimulus to vascular ingrowth and bone healing. However, we have no evidence that this alters the results obtained by a classical core decompression done without bone graft.

Postoperatively, we advise our patients to use two crutches with partial weight bearing for 3 months, although some other surgeons use crutches for only 6 weeks without any obvious deleterious effects. At the end of this time, we allow patients to progress quickly to full weight bearing, but we caution them to avoid excessive stress and strain to the extremity, such as would be encountered in running and active sports, for 1 year from the time of surgery. If bilateral core decompression is indicated, it is performed sequentially under one anesthetic. Patients undergoing bilateral procedures are treated in a fashion similar to those undergoing the procedure unilaterally, except that they are instructed in a true four-point gait rather than a partial-weight-bearing gait. In most instances, however, they proceed spontaneously to a two-point gait within the first few weeks following surgery.

***Results***

Since 1981, more than 400 hips with osteonecrosis (University of Pennsylvania stages I–IV) were treated at the University of Pennsylvania with a modified core decompression using supplemental cancellous bone grafting. Results were determined by clinical evaluation, radiographic resolution or progression, and the need for THR. The results were compared to 55 hips treated nonoperatively prior to the start of this series and to results reported in the literature. Of 297 hips with a minimum 2-year follow-up, 64% did not require further surgery during the 2- to 14-year period of follow-up. This contrasted with only 23% of hips treated symptomatically. In the operative group, hips not requiring THR showed a mean improvement of 10 points on the Harris Hip Evaluation scale. A number of these hips showed a small degree of radiographic progression despite satisfactory clinical results; however, this was significantly less than in hips treated nonoperatively. Of hips in stages I and II undergoing decompression, 39% were radiographically stable, compared with only 19% of hips treated nonoperatively. THR was required in 31% of hips treated prior to femoral head collapse and in 48% of hips treated after collapse was apparent. There was a clear correlation between outcome and lesion size. In stages I and II, hips with small lesions involving less than 15% of the femoral head by volume required THR in only 22% of cases, compared with 40% of the hips with medium to large lesions involving more than 15% of the head. We noted no clear correlation with etiology except for patients in whom both corticosteroids and alcohol were implicated. These did slightly worse than other groups.

The complication rate was low. Five complications were recorded in 420 hips. Two patients sustained transcervical fractures after falling during the first month following surgery, one patient had a massive but nonfatal pulmonary embolism, one developed pneumonia, and one was diagnosed with proximal thrombophlebitis of the thigh.

Our results corresponded closely with those reported from a review of the literature by Mont et al. (81,119). We concluded that compared to nonoperative or symptomatic management, core decompression with or without a cancellous bone graft was a safe and effective procedure for the treatment of AVN. At present, we recommend core decompression, with or without cancellous grafting, as a treatment for most hips with earlier stages of osteonecrosis, including those with a small to moderate degree of femoral head collapse but without acetabular involvement or significant pain or disability (stages I to IV-B) (Fig. 125.19). This procedure is used in both symptomatic and asymptomatic hips, as we found no correlation between symptoms and outcome in hips treated prior to femoral head collapse. Results in hips with very small lesions, especially those not in a region of major weight bearing, were considerably better than in the group as a whole, and the question has been raised as to how much the operative procedure adds to the outcome. Accordingly, these patients are now given the option of nonoperative management with close observation. Surgery is recommended, however, at the first sign of progression.

***Figure 125.19.*** Radiographs of the left hip of an active young man with alcohol-related avascular necrosis. **A:** Preoperative radiographs show a large area of sclerosis and radiolucency within the femoral head. **B:** Radiographs taken 1 year following core decompression and bone grafting show that the lucent areas have begun to fill in with bone. The patient remained essentially asymptomatic and was clinically doing well 12 years after the surgery.

## OSTEOTOMIES

Various types of osteotomies have been utilized in the treatment of osteonecrosis of the femoral head over the past 30 years (13,33,65,72,76,83,106,133). These are technically demanding procedures that are not frequently employed in North America. Results vary considerably, and subsequent arthroplasty may be compromised. The most commonly cited rationale for their efficacy is the biomechanical effect of moving the necrotic segment of the femoral head from the principal weight-bearing area of the hip to an area that bears less weight, and replacing it with relatively normal bone and cartilage. Others have suggested that the beneficial effects of osteotomies are secondary to the procedure effecting a reduction in venous hypertension and intramedullary pressure (13).

Two general types of osteotomies have been described: varus or valgus osteotomies, usually combined with flexion or extension, and transtrochanteric rotational osteotomies. The varus or valgus osteotomies have been associated with variable rates of success after short-term follow-up of approximately 5 years (13,72). Recent reports also include a prospective study of valgus-extension osteotomies combined with curettage and bone-grafting of the necrotic segment in a group of non-corticosteroid-associated hips (106). These authors reported a good or excellent clinical result in 36 of 45 hips (80%) at a mean follow-up of 65 months (range, 32 to 126 months). In a recent study of varus osteotomies combined with flexion or extension (83), there were 28 of 37 good and excellent outcomes (76%) at a mean follow-up of 11.5 years (range, 5 to 18 years). In patients without a corticosteroid association in this study, there were 17 of 20 successful clinical outcomes (85%).

The indications for varus or valgus osteotomies depend on the location and size of the lesion. Osteotomies may be utilized for both pre- and postcollapse lesions, but they should usually not be performed if there is acetabular involvement. Osteotomies work best when the lesions are small or medium sized with a combined necrotic angle of less than 200° (Fig. 125.20) (65) or with less than 30% of femoral head involvement. For varus osteotomies, there should be at least 20° of the superolateral femoral head not involved with disease, because this area of cartilage will be shifted into weight bearing after the osteotomy. Likewise, a valgus osteotomy requires normal bone and cartilage in the central or medial aspect of the head. Guidelines for when to add a flexion or extension component to the osteotomy are similarly based on the location of the lesion. Extension can be added when the necrotic segment is posterior and flexion can be added if the lesion is anterior.

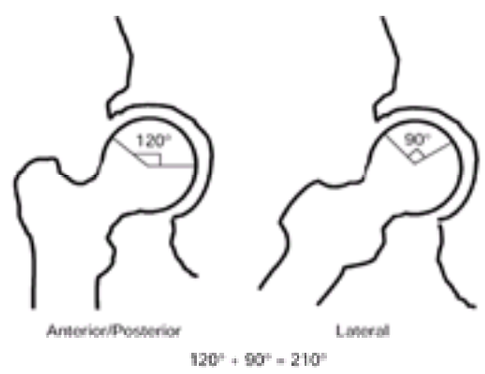


***Figure 125.20.*** The angular measurements of the lesion on the AP and lateral radiographs are added together to give the “combined necrotic angle,” as described by Kerboul et al. (From Kerboul M, Thomine J, Postel M, Merle D'Aubigné R. The Conservative Surgical Treatment of Idiopathic Aseptic Necrosis of the Femoral Head. *J Bone Joint Surg Br* 1974;56:291, with permission.)

### *Valgus Osteotomy with Flexion and Bone Grafting*

Valgus osteotomy with flexion and bone grafting (106) is utilized in hips with Ficat Stage III when the osteonecrotic segment is confined to the anterosuperior part of the femoral head (less than 20% posterior involvement). Optimally, patients are less than 45 years of age and are not on steroids or chemotherapy.

- Expose the hip joint through an anterolateral approach, with an anterior capsulotomy permitting visualization of the femoral head.
- Insert guide wires to obtain the desired valgus and flexion.
- Cut the initial osteotomy perpendicular to the femoral shaft at the intertrochanteric level 1.5–2.0 cm inferior to the seating chisel.
- Make the bone wedge with a power saw and excise the anterior and lateral bone wedge.
- Use an AO right-angle or 95° blade-plate to fix the osteotomy.
- After fixation of the osteotomy, fenestrate the femoral neck anteriorly, just inferior to the head.
- Curet out the necrotic bone and elevate the collapsed subchondral area with a punch if necessary.
- Firmly pack cancellous bone graft from the iliac crest into the cavity created.

Postoperatively, allow patients toe-touch weight bearing (15 kg) for 3–4 months or until radiographs show healing of the osteotomy. Partial weight bearing may be continued for 6 months or longer, depending on the rate of healing of the femoral head.

### *Varus Osteotomy with Flexion or Extension*

Varus osteotomy with flexion or extension (83) is utilized for small- or medium-sized lesions with a combined necrotic angle of less than 200°. There should be no radiographic evidence of acetabular involvement, and an arc of at least 20° on the lateral aspect of the femoral head should be free of underlying necrotic bone. The femoral head is moved into abduction and the femoral shaft is brought into adduction and flexion. This brings the necrotic area anteriorly, inferiorly, and medially.

- Place the patient supine on a radiolucent operating table with a small bump under the hip. Use a lateral approach to the proximal femur with the fascia lata and vastus lateralis split adjacent to the intermuscular septum. Expose the hip joint only if a flexion osteotomy is being performed. This is to facilitate an anterior capsulotomy to allow extension of the hip if necessary.
- Obtain the desired angular correction by two osteotomies that remove a triangular segment of bone. Determine the amount of varus correction desired by preoperative AP radiographs. Use lateral radiographs to determine flexion or extension components of the osteotomy.
- Perform the osteotomy with a power saw and hand-held osteotomes. Start the first cut on the lateral cortex at the vastus ridge. Use a fixed-angle AO blade plate or sliding hip screw to fix the osteotomy.

Postoperatively, keep the patient at toe-touch weight bearing for 2 months and then advance to a cane until union is visible on radiographs (Fig. 125.21), usually 4–6 months after the procedure.

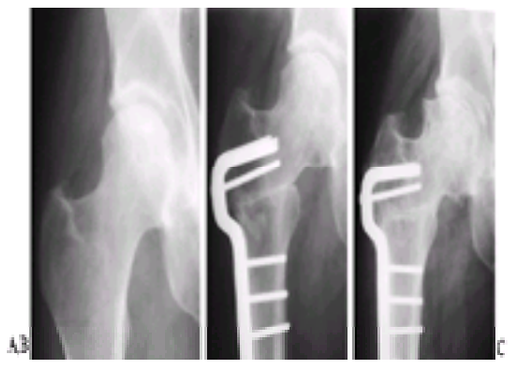

***Figure 125.21.*** Radiographs of a hip that underwent a varus osteotomy for osteonecrosis. **A:** Preoperative status. **B:** Six months after osteotomy. **C:** Ten years after surgery. The hip continues to function satisfactorily, although degenerative changes were eventually present.

### *Rotational Osteotomies*[2]

The primary goal of osteotomy in the treatment of osteonecrosis is to shift the necrotic segment of bone out of the region of major weight bearing and to replace it with normal bone and cartilage. The effectiveness of conventional angulation osteotomies is necessarily quite limited by the amount one can alter the normal neck–shaft angle without impairing motion and function of the hip. However, this is not encountered when performing rotational osteotomies. The head can be rotated 90° or more around the head–neck axis without interfering with hip function. Thus, these osteotomies should be more effective in shifting normal bone and cartilage into the major weight-bearing region.

In 1967, Wagner described a double intertrochanteric osteotomy to accomplish this. However, by 1977 he concluded that the clinical results with this procedure were no better than with conventional angulation osteotomies and abandoned it (139). In 1973, Sugioka (125,127) reported on a different type of transtrochanteric anterior rotation osteotomy. More than 500 of these procedures were performed since 1972, and Sugioka's results, especially in hips treated before significant femoral head collapse, were quite gratifying (50,129). Unfortunately, these results could not be consistently duplicated by other investigators (33,36,132). In some instances, this might be explained by deviation from the specific indications for the procedure, the complicated operative technique, or the postoperative regimen outlined by Sugioka.

In most instances, osteonecrosis involves the anterosuperior aspect of the femoral head, leaving the posteroinferior portion relatively intact. By rotating the femoral head anteriorly, the necrotic segment is removed from the region of major weight bearing and replaced with relatively normal bone and cartilage. Occasionally, rotation posteriorly rather than anteriorly will more effectively accomplish this goal. Varus or valgus can be added to the rotation. The exact plane and alignment of the osteotomy can be determined from a careful measurement of preoperative radiographs. It is essential that the indications and contraindications be clearly understood and that the details of this difficult operative technique and postoperative care be closely adhered to. A critical point is the absolute necessity of maintaining the blood supply to the femoral head by preserving the vascular pedicle of the medial circumflex femoral vessels, which is located beneath the quadratus femoris.

**Indications** Rotational osteotomy is indicated for the treatment of early to intermediate stages of osteonecrosis of the femoral head in which the acetabular cartilage is relatively unaffected. There must be sufficient normal bone and cartilage in the femoral head so that after rotation the intact segment occupies at least 36% of the weight-bearing surface of the acetabulum. Contraindications include whole-head necrosis, significant degenerative changes in the femoral head or acetabulum, and poor general health.

**Operative Technique** Preoperatively, good-quality AP and lateral radiographs must be evaluated and measured to determine the plane of the osteotomy and to be certain that the basic goals of the procedure can be met. (This procedure is described in greater detail in references 126 and 129.)

- Make a modified Ollier's incision and expose the capsule of the hip joint through a lateral approach.
- Osteotomize the greater trochanter and reflect it proximally with the attached tendons of the gluteus medius and minimus and the piriformis.
- Expose the lesser trochanter carefully to allow safe transverse osteotomy of the lesser trochanter; the adipose tissue, which contains the vascular pedicles of medial circumflex femoral vessels, is close to the osteotomy site.
- Transect the piriformis tendon and the short external rotator muscle–tendon units attached to the intertrochanteric fossa, and widely expose the capsule anteriorly and posteriorly.
- Dissect the quadratus femoris muscle carefully and leave some of the deepest fibers of the muscle intact, to avoid vascular pedicle injury. No attempt should be made to expose or identify the vessels of the pedicle.
- Divide the obturator externus muscle sufficiently during dissection; otherwise, the inferior portion of the joint capsule cannot be adequately visualized for capsulotomy. Also, incomplete transection of the obturator externus muscle will produce compression of the vessel pedicle during anterior rotation.
- Place Kirschner wires (K-wires) in the cut surface of the greater trochanter from lateral to medial; insert the first K-wire 1 cm distal to the intertrochanteric crest and perpendicular to the long axis of the femoral neck in the AP view (coronal plane) and direct it toward the inferior aspect of the lesser trochanter at the posterior margin of the cut surface of the greater trochanter.
- Insert the second K-wire at the anterior margin so that a line drawn between the insertion points of the two wires is perpendicular to the femoral shaft axis (not the neck axis) in the lateral view (sagittal plane). The second wire is parallel to the first K-wire.
- Place the third K-wire distal and parallel to the second wire. Make the K-wires different lengths for easy identification on radiographs.
- To confirm the sites of the wires and of the planned osteotomy, take a true AP radiograph of the hip in the neutral position in all planes with the knee flexed to 90°. On this AP view, the first and second K-wires should be superimposed and at 90° to the neck axis. When the first and second K-wires are not superimposed on the radiograph, the second K-wire insertion should be corrected forward or backward in the proper length, judging from the distance between the second and third K-wire.
- After performing the circumferential capsulotomy using special forceps, subluxate the femoral head to see the extent of necrosis and to evaluate the remaining intact surface of the head for its weight-bearing capability.
- Blood flow in the femoral head can be evaluated using a laser Doppler speckled method during surgery.
- Using a reciprocating saw, make a transtrochanteric osteotomy at 90° to the long axis of the femoral neck. Use the inserted K-wires as a guide for the osteotomy. As described previously, when the lesion is extensive so that the varus position requires a greater angle of anteversion, incline 10° to 15° more vertically.
- Then make a second osteotomy at the superior edge of the lesser trochanter. The angle between the first and secondary osteotomies in the AP view should be greater than 90°. This will help the proximal fragment contact the distal fragment after rotation.
- Place a 3 mm Steinmann pin in the superolateral corner of the proximal fragment from posterior to anterior, and then insert a second pin (a 2 mm K-wire) parallel and adjacent to the first pin in the distal fragment.
- Cut the psoas tendon, the remaining fibers of the obturator externus, and the vastus lateralis and capsule, which cross between the fragment anteriorly.
- Using the proximal pin as a handle, rotate the femoral head anteriorly (Fig. 125.22 and Fig. 125.23). In the case of posterior rotation, place a Steinmann pin in the superolateral corner of the proximal fragment from anterior to posterior. The second K-wire serves as a reference point for measurement of the angle of rotation.

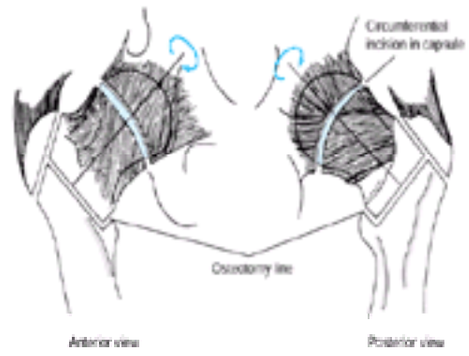


***Figure 125.22.*** Schematic of the Sugioka transtrochanteric rotational osteotomy of the femoral head. (Courtesy of Professor Y. Sugioka.)

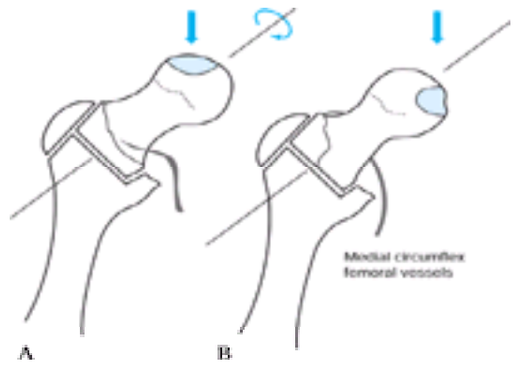


***Figure 125.23.*** Transposition of necrotic focus of femoral head anteroinferiorly away from weight-bearing area as a result of anterior rotation of the femoral head. (**A**) before rotation and (**B**) after rotation. (From Sugioka Y, Mohtai M. Osteonecrosis of the Femoral Head: A Conservative Surgical Solution. In: Sedel L, Cabanela M, eds. *Hip Surgery: Materials and Developments.* London: Martin Dunitz, 1998, with permission.)

- Flex and adduct the distal fragment to oppose it with the rotated proximal fragment.
- Check for bleeding at the osteotomy site and check the color of the synovium of the proximal fragment.
- Then fix the osteotomy internally with three Venable screws with or without a side plate attached.
- Trim the lateral aspect of the proximal fragment carefully to adjust the level to the osteotomy site of the greater trochanter in the distal fragment. (In the case of anterior rotation, this area is occupied by the intertrochanteric crest, and the vascular pedicle is at risk during this trimming.) Also trim the anteromedial corner of the proximal fragment if it impinges on the rectus femoris, which could inhibit hip extension. When trimming the proximal fragment, check for the presence of good bone bleeding. Fix the greater trochanter with heavy wires.
- Make AP and lateral radiographs before wound closure to confirm the proper placement of the screws, the position of the transposed joint surface, and the alignment of the osteotomy.
- After placing anterior and posterior suction drains, close the wound in layers.

**Postoperative Management** Apply skin traction of 2 kg continuously for the first week and for an additional 2 weeks at night only. Begin hip ROM exercises after the first postoperative week. Patients can perform their own active assisted ROM exercises throughout the day using a pulley system attached to the overhead frame on the bed to achieve hip flexion. Flexion over 90° should be achieved by 3 weeks postoperatively, after which allow the patient up in a wheelchair and to begin ROM exercises in the Hubbard tank.

About 6–8 weeks postoperatively, begin ambulation in a water tank, with the water level at the nipple line. The timing of this progression depends on the inherent stability of the osteotomy line. Progression to partial weight bearing with crutches proceeds as indicated by healing, but do not begin full weight bearing before 6 months postoperatively.

**Results** Kaplan-Meier survivorship analysis of 295 hips with a follow-up of 3 to more than 20 years was performed. At 15 years following surgery, 80% of hips did not require additional operative intervention. The need for a second procedure was significantly greater in patients in whom less than 20% of intact femoral head was repositioned within the acetabulum and in those with advanced stages of femoral head collapse preoperatively. Seven percent of hips in stage 2, 21% in stage 3, and 24% in stage 4 required prosthetic replacement [Japanese Investigation Committee for Idiopathic Femoral Head Necrosis staging system (95)].

Satisfactory clinical results were achieved in 82% of stage 2, 72% of stage 3, and 52% of stage 4 hips. The incidence of recollapse of the femoral head was 15% within 3 years and 21% within 10 years of osteotomy. In hips with more than 36% of normal head within the acetabulum, only 7% collapsed; in hips with 21% to 35%, 35% collapsed; and in hips with less than 20%, 72% collapsed (125,126,127,128 and 129).

## GRAFTING PROCEDURES

Bone-grafting procedures can be divided into two general categories: nonvascularized (19,20,23,35,41,56,76,82,98,102,109,114,142) and vascularized (16,22,57,77,134,135,143). Most of these procedures are designed to provide some degree of structural support to prevent collapse of the articular cartilage surface. There are several different types of nonvascularized bone-grafting procedures, and they differ considerably. The graft may be introduced through the femoral head, the neck, or the intertrochanteric area. Either cancellous or cortical bone can be used, and this can be obtained from the patient's own iliac crest, proximal femur, tibia, or fibula, or from the bone bank.

There are also various techniques for performing vascularized bone grafting. The graft may be taken from the ilium, fibula, or greater trochanter. It may involve a muscle pedicle, which contains its own vascular supply, or a microvascular anastomosis can be performed using regional vessels. These procedures have been used both before and after femoral head collapse but work best for precollapse lesions. They should not be utilized when there are obvious degenerative changes in the acetabulum.

### *Structural Grafts*

Structural bone grafting was first described by Phemister (98) for posttraumatic osteonecrosis. The technique was later modified by Bonfiglio and Bardenstein (20) and Boettcher et al. (19), who also used it to treat nonunions and nontraumatic osteonecrosis. In these cases, nonvascularized autogenous tibial, fibular, or iliac crest bone grafts were introduced through a core track, which extended from the lateral femoral cortex through the neck and into the head at an angle of 45° after the necrotic bone had been removed. The rationale for this procedure was that this bone graft would lend structural support to the articular surface while the femoral head was healing. Initial results were favorable (19,20), but longer-term follow-ups indicated lower success rates (35,109). Buckley et al. (23) described the results after core decompression combined with tibial autografts and fibular autografts or allografts. They reported successful clinical outcomes in 18 of 20 hips (90%) that had precollapse disease, stage I or II, at a mean follow-up of 8 years (range, 2–19 years). Their surgical technique for *free nonvascularized bone graft* follows.

- Perform a core decompression as previously described with a 9 mm cannulated drill bit.
- Drill the infarct up to the subchondral bone.
- Then prepare the graft with a rounded proximal end and tapered distally to be press-fit through the lateral femur up into the head. The graft utilized can be autogenous ipsilateral tibial corticocancellous strips or intact fibula. Alternatively, an allogeneic fibular graft can be used.
- Confirm the appropriate placement of the graft by fluoroscopic imaging with its rounded proximal end within the lesion just underneath the subchondral bone.

Postoperatively, keep the patient non-weight-bearing with crutches for a variable period up to 1 year (Fig. 125.24).

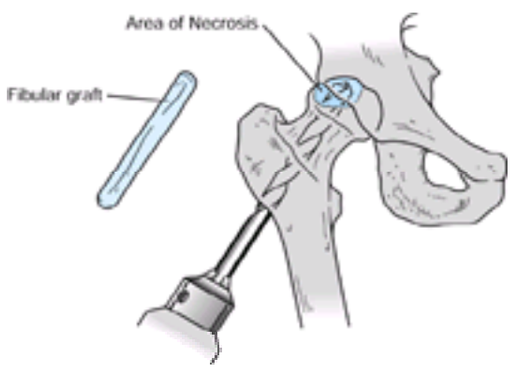


***Figure 125.24.*** Technique for grafting using an intact fibular allograft. (From Buckley PD, Gearen PF, Petty RW. Structural Bone Grafting for Early Atraumatic Avascular Necrosis of the Femoral Head. *J Bone Joint Surg Am* 1991;73:1361, with permission.)

### *Cancellous and Cortical Grafting through the Neck or Head*

A number of authors have used cancellous bone grafting through a window in the femoral neck. A procedure reported by Ganz and Buchler (41) combined this with an osteotomy, similar to that later described by Scher and Jakim (106). Japanese investigators described a technique whereby autogenous iliac crest strut grafts were inserted through a window into the neck and were impacted into position, thus elevating the collapsed femoral head to its former sphericity. The necrotic lesion was partially curetted and the strut grafts were supplemented with cancellous bone. They reported good or excellent results in 23 of 38 hips (61%), at a mean follow-up of 9 years (range, 2–15 years) (56,142). Rosenwasser et al. (102) replaced the necrotic bone with cancellous autograft and reported good to excellent clinical outcomes in 13 of 15 stages II and III hips followed for a mean of 12 years (range, 10–15 years).

In the so-called light bulb procedure of Rosenwasser et al. (102), the femoral head is approached through a window in the anterior aspect of the femoral neck. The necrotic material is excavated up to the subchondral bone. This cavity is then packed with autogenous cancellous bone harvested from the ilium. Postoperatively, patients remain non-weight-bearing for 6 months (Fig. 125.25).

***Figure 125.25.*** Lightbulb procedure as described by Rosenwasser et al. (From Rosenwasser MP, Garino JP, Kiernan HA, Michelsen CB. Long-Term Follow-up of Thorough Debridement and Cancellous Bone Grafting of the Femoral Head for Avascular Necrosis. *Clin Orthop* 1994;306:17, with permission.)

Another method of introducing bone graft is through a trapdoor made in the articular cartilage of the femoral head. This was first described in detail by Meyers et al. (77,78), who utilized autogenous iliac cancellous bone grafting. Mont et al. (82) combined autogenous iliac cancellous and cortical bone grafting with demineralized bone matrix using this approach. They reported 22 of 30 good and excellent clinical outcomes at a mean follow-up of 4.7 years. Their *trapdoor surgical procedure* follows.

- Perform an arthrotomy using either an anterolateral or a posterolateral approach. Perform a capsulectomy and dislocate the hip.
- Using thin, sharp osteotomes, make a “trapdoor” in the articular surface over the collapsed segment by outlining three quarters of circle. Then hinge this osteochondral trapdoor back on the remaining one quarter of the osteochondral surface, revealing the sequestrum beneath.
- Use high-speed burrs and curets to remove all the necrotic bone until bleeding cancellous bone is encountered.
- Impact two to three iliac cortical struts into the base of the cavity.
- Surround the struts with cancellous bone to which demineralized bone matrix has been added.
- Replace the trapdoor and fix it with two to three absorbable pins.
- Relocate the hip and close the wound routinely. Keep patients at toe-touch weight bearing for 3 months and then advance to full weight bearing over the next 1–2 months (Fig. 125.26).

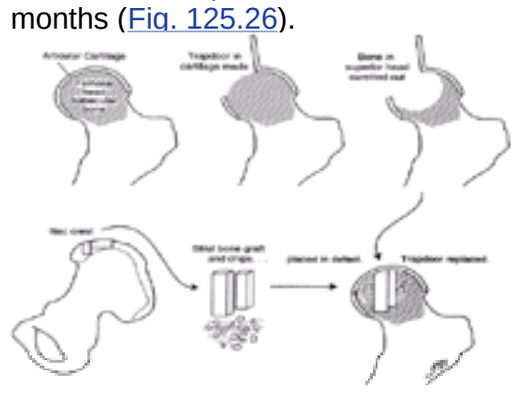

***Figure 125.26.*** Trapdoor procedure as modified by Mont et al. (From Mont MA, Einhorn TA, Sponseller PD, Hungerford DS. The Trapdoor Procedure Using Autogenous Cortical and Cancellous Bone Grafts of Osteonecrosis of the Femoral Head. *J Bone Joint Surg Br* 1998;80:57, with permission.)

### *Osteochondral Grafts*

There are only a few reports about the use of osteochondral allografts to replace the necrotic segment of the femoral head in the treatment of hips that have femoral head flattening combined with degenerative changes in the overlying cartilage (77,78). The hip is usually dislocated posteriorly, the depressed segment of articular cartilage and subchondral bone is removed, and the necrotic bone is then excavated down to a margin of viable bone. The cavity is first packed with autogenous, cancellous graft taken from the ilium. Osteochondral allograft is then placed over this, restoring the articular surface. Meyers and Convery (78) reported good and excellent clinical outcomes in 8 of 9 Ficat stage III hips with a mean follow-up of 3 years (range, 1–9 years). However, there are no long-term reports of this procedure.

There are several technical difficulties inherent in this procedure. It can be extremely difficult to obtain a properly fitting osteochondral allograft in a timely fashion, because these grafts must be obtained from the donor within hours of the implantation and cannot be stored for prolonged periods. It is necessary to have an almost exact match in size between the donor femoral head and the head that is to receive the tissue. In addition, there are certain risks of infection as well as possible graft–donor mismatches that can lead to rejection.

### *Muscle-Pedicle Bone Grafts*

As previously stated, there are multiple methods of utilizing muscle-pedicle bone grafts (16,57,78). The rationale for all of these procedures is that the muscle-pedicle bone graft will bring a blood supply to replace that lost by the necrotic tissue that is removed. This technique was first described by Meyers et al. (79), who used it in posttraumatic osteonecrosis. After the hip is exposed by a posterior approach, a capsulotomy is performed and the head–neck junction is identified. A segment of cortical bone with its attached quadratus femoris muscle is elevated and retracted. A longitudinal window is then made in the posterior aspect of the femoral neck. Through this window, necrotic bone from the femoral head is curetted out. The segment of cortical bone with its attached muscle is then placed into this channel, which extends through the neck and into the head. Cancellous bone is packed about this cortical graft as required. The cortical strut may be fixed in place using a single screw (Fig. 125.27).

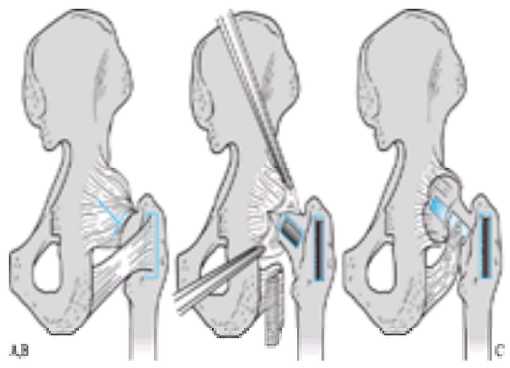

***Figure 125.27.*** Technique for performing muscle-pedicle bone grafting to the femoral head, modified after Meyers et al. **A:** Surgical exposure with bone graft outlined. **B:** Procurement of graft and preparation of bed in femoral neck and head. **C:** Graft inserted into the femoral head through a window in the posterior aspect of the neck. (From Meyers MH, Harvey JP, Moore TM. Treatment of Displaced Subcapital Transcervical Fractures of the Femoral Neck by Muscle-Pedicle-Bone Graft and Internal Fixation. *J Bone Joint Surg Am* 1973;55:261, with permission.)

Other investigators have reported the use of muscle pedicles using bone taken from the ilium. Most of the studies report satisfactory short-term results in 70% to 90% of precollapsed lesions at a mean follow-up of less than 5 years. It should be noted, however, that very few of these procedures have been reported to date, and these techniques are not in general use at this time. See Chapter 29 for a description of this technique as used for nonunion of the femoral neck.

### *Free Vascularized Fibular Grafting*[3]

During the past few years, there has been increasing interest in the role of free vascularized fibular grafting (FVFG) as a treatment for osteonecrosis of the femoral head. Only a few centers have significant experience with this technique, but they have reported encouraging results. This procedure is technically demanding, is ideally performed by two teams operating simultaneously, and requires assistance of a well-trained microvascular surgeon. Considerable experience is required before optimal results can be anticipated, and initially one should allow several hours for the procedure. The complication rate is significant, even in experienced hands, and stress fractures of the tibia have been reported. At the present time, it is difficult to determine if this procedure yields better results than simpler techniques, and if it does, how much better. The specific indications for it have yet to be established.

The goals of FVFG are (a) to decompress the femoral head, thereby relieving intraosseous pressure and reversing the ischemia; (b) to remove a significant portion of necrotic bone; (c) to fill the necrotic defect with osteoinductive cancellous bone graft; and (d) to support the subchondral bone and enhance the revascularization process by means of a vascularized cortical bone strut (102,134). This procedure has been criticized by some for the added morbidity of harvesting the ipsilateral fibula and for the complexity of the procedure as compared with performing a standard core decompression and bone grafting. We feel, however, that the improved potential for healing and joint-space preservation with FVFG justifies its use for treating osteonecrosis of the femoral head.

**Indications** We now perform this procedure in patients 20–40 years of age with symptomatic stage II to IV avascular necrosis of the femoral head. For patients younger than 20 years of age, the indications have been expanded to include stage V disease, given the limited treatment options in this age group. For those people 40–50 years of age, the indications have narrowed, so individuals with stage IV disease and greater than 50% femoral head involvement are not candidates for the procedure (135).

Ongoing corticosteroid use is not a contraindication for the procedure at our institution, but continued ethanol abuse and vascular compromise to the lower extremity are contraindications. At present we do not perform FVFG on asymptomatic patients, but we have found that a large proportion of individuals who are asymptomatic at initial presentation will progress to have symptoms within 5 years. This raises the question as to whether a prophylactic procedure should be performed even in patients with asymptomatic osteonecrosis, to help prevent progression. This issue continues to be debated.

**Operative Procedure on the Hip** Two surgical teams working concurrently shorten the duration of the procedure considerably. One surgeon operates on the lower leg while the other works on the hip. The average operating time at our institution is less than 3 hours.

- Place the patient on the operating room table in the lateral decubitus position with the use of a bean bag. General anesthesia or spinal anesthesia is generally utilized.
- Prepare and drape the entire lower extremity including the hip area. Make a curvilinear incision over the anterolateral aspect of the proximal femur (Fig. 125.28). Carry the incision down through the subcutaneous tissue, exposing the interval between the tensor fascia lata and the gluteus medius.

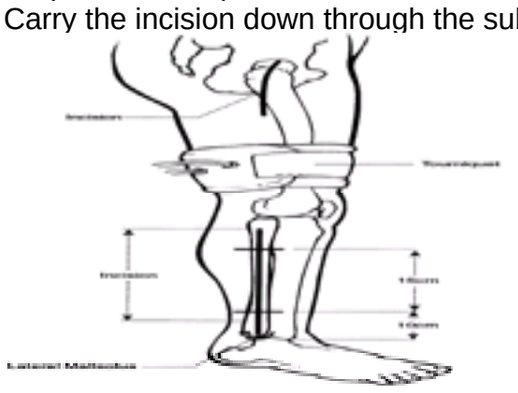

***Figure 125.28.*** Location of the tourniquet on the leg, and the location of the incisions for the approach to the hip and for harvesting the fibula.

- Split this interval and place a self-retaining retractor deep to the fascia.
- The vastus lateralis can then be seen; reflect it distally to expose the lateral aspect of the femur. Pull the vastus lateralis distally and, with the use of a knife, cut it transversely in the avascular plane of its origin on the vastus ridge.
- Posteriorly, reflect approximately 5 cm of posterior lateralis off the linea aspera and sweep it distally using a periosteal elevator.
- Anteriorly, detach the origin of the vastus intermedius carefully with a right-angle dissector and a knife, to create a trough that provides a shorter route for the ascending vessels and to eliminate tension on the vascular anastomosis (Fig. 125.29). Halt the dissection once the fat layer is encountered medial to the intermedius, to prevent injury to the vessels and the femoral nerve.

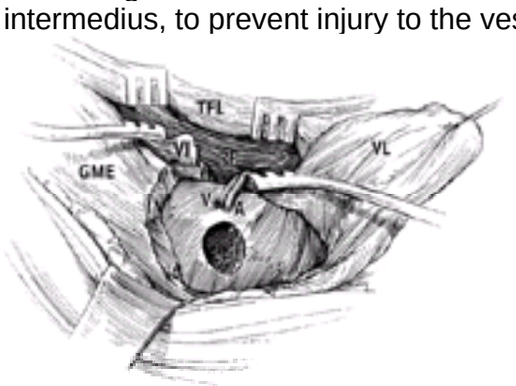


***Figure 125.29.*** Plane of dissection showing freed vastus lateralis (*VL*) swept distally, with a trough created in the vastus intermedius (*VI*). Ascending vein (*V*) and artery (*A*) are also shown. GME, gluteus medius; RF, rectus femoris; TFL, tensor fascia lata. (From Urbaniak JR, Coogan P, Gunneson E, Nunley J. Treatment of Osteonecrosis of the Femoral Head with Free Vascularized Fibular Grafting. A Long-Term Follow-Up Study of One Hundred and Three Hips. *J Bone Joint Surg Am* 1995;77:681, with permission.)

- The deep plane of dissection is between the rectus femoris and the vastus intermedius. Hold the plane open using the self-retaining retractor. The donor vessels for the anastomosis with the fibula are the ascending branches of the lateral femoral circumflex artery and vein. These ascending branches consist of a central artery and two veins. The other branches of the lateral femoral circumflex vessels are the transverse and descending.
- For better visualization, release the aponeurotic bridge between the rectus femoris and the anterolateral femur. Expose the underlying fat and sweep it away with a sponge stick to reveal the ascending branches. These branches are consistently found 8–10 cm distal to the anterosuperior iliac spine.
- Then take down the vessels in a cephalad to caudad direction, starting at the first major division of the artery and veins. Clip the vessels with small vascular clips just distal to this bifurcation. This ensures adequate length of the vessels (about 4 cm), and the bifurcation affords a larger potential lumen size for anastomosis to help prevent vessel mismatch.
- Dissect each vessel back to its origin, placing small hemostatic vessel clips on any small branches. It is technically easier to expose the vessels down individually rather than as a group.
- Now remove the retractor for the bony preparation of the proximal femur.
- Place a sterile drape over the C-arm fluoroscopy unit. Position the C-arm to obtain an AP projection of the hip. Obtain a frog-leg lateral projection simply by flexing and externally rotating the hip.
- Beginning about 2 cm distal to the vastus ridge at the junction of the posterior and middle thirds of the exposed lateral femur, and using fluoroscopy, direct a 3 mm guide pin up the femoral neck and into the center of the necrotic area in the femoral head. The orientation of the guide pin should also be rather steep in an effort to place the graft in a position that optimally supports the subchondral area of the defect. On the frog-leg lateral view, take special care to ensure adequate room in the neck to accommodate a 19 mm reamer if needed. By this time, the fibular graft should have already been removed so that the leg can be moved freely to obtain a frog-leg projection.
- Progressively use cannulated reamers over the guide pin, starting with a 10 mm reamer. The average female and male patients require final reamings of 16 mm and 19 mm, respectively, although this may vary depending on the size of the largest diameter of the donor fibula. The reaming extends to within 3–5 mm from the articular surface of the femoral head. It is safer to do the final part of the reaming using fluoroscopy.
- If the necrotic region involves greater than 25% of the femoral head, use a ball reamer to remove the remaining necrotic bone, which is depicted on fluoroscopy as a cyst. The relationship of the remaining cyst to the bone tunnel can be better depicted by placing renograffin in the tunnel. Then use the ball reamer under fluoroscopic guidance. Reintroduce renograffin into the tunnel to check that the necrotic bone is completely removed.
- Then remove the cancellous bone from both the greater and the lesser trochanter with an upgoing and straight curet, respectively, through the bone tunnel opening. The cancellous bone reamings harvested from between the flutes of the reamers, both directly and by using a filtered suction tip (KAM Super Sucker; Anspach, Palm Beach Gardens, FL), can also be utilized as bone graft. However, take care to avoid using the reamings from the necrotic area.
- Then place the cancellous bone graft into the reamed cavity with the use of a custom-made impaction device. Use the scale on the surface of the device to measure the depth of the bone tunnel so that the length of the fibular graft can be determined. The impactor has side windows at the area of the subchondral bone, and their position can be changed by rotating the impactor.
- Then place the bone obtained from the trochanter first, followed by the reamings.
- Confirm the completeness of the grafting by placing renograffin in the canal and seeing obliteration of the necrotic cavity, using fluoroscopy in the AP and frog-leg lateral projections.

**Operative Procedure on the Fibula**

- Approach the fibula via a lateral incision, simultaneously with the hip approach. Mark the line of the incision longitudinally in line with the fibula. Make the fibular bone cuts 15 cm apart, with the distal cut 10 cm proximal from the distal fibular tip. The incisional length should coincide with the level of the bone cuts (Fig. 125.28). The technical details of fibular removal have been described elsewhere (134,135) (see Chapter 36).
- Final preparation of the fibula occurs on the back table. Immediately inject 40 ml of heparinized lactated Ringer's solution into both veins and the artery of the pedicle to inspect for leaks. Reflect the pedicle from the proximal fibula until a large nutrient vessel is found entering the cortex. If the pedicle is not at least 5 cm long, dissect the bundle farther from the fibula. If the pedicle branches before 5 cm of pedicle can be mobilized, preserve both branches with subperiosteal dissection.
- When the feeder vessel is located, cut the fibula at that point with a reciprocating saw, and use copious irrigation.
- Prepare the end of the pedicle with microsurgical dissection.
- Choose one vein as the recipient and place a small hemostatic clip on the end of the other. Use the final measurement from the calibrated bone impactor to determine the second distal bone cut.
- To prevent stripping of the pedicle during insertion into the core in the femoral neck and head, use absorbable sutures to bind the pedicle to the distal end of the fibula.

**Placement of the Fibular Graft into the Femoral Head**

- After complete removal of the contrast material from the core, insert the fibula with the pedicle located superiorly and anteriorly on the fibula. Position the pedicle into the fibular sulcus for better protection from the walls of the femoral tunnel. Placement of the fibular graft at the posterior border of the core allows the pedicle to be free from compression. The fit should be snug, but not tight, to ensure that the vessels are not being compromised.
- Check the location of the fibular graft with fluoroscopy. If the graft is not fully seated, it can be tamped into place.
- Use a 0.062-inch wire to hold the graft in place; it crosses both cortices of the fibula and inserts into the medial cortex of the lesser trochanter. Take care to protect the pedicle during this step. Then cut the wire and bend it with a needle driver.
- Remove the fluoroscopic unit. Place the hip retractor back into the hip wound with the four claw retractors attached to retract all four quadrants of the wound.
- Bring in the microscope and place it in an optimal position for performing the vascular anastomoses.
- Couple the vein first to diminish bleeding, which could obscure the field if the artery were anastomosed first. Use of a coupling device for the vein anastomosis decreases operative time. However, we prefer to anastomose the artery with interrupted 8-0 nylon sutures because of problems with intimal cracking upon placing the coupler on the artery. A disposable suction mat of contrasting color is helpful in performing the microsurgery (Fig. 125.30).

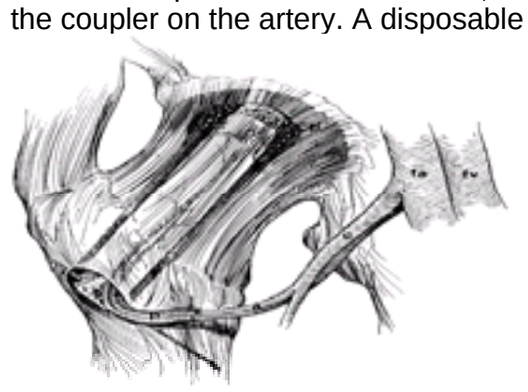

***Figure 125.30.*** Fibular graft inserted into femoral head and surrounded by cancellous bone (*CB*) taken from greater trochanter. The peroneal artery and vein (*p*) have been anastomosed to the ascending branches (*a*) of the lateral femoral circumflex artery (*c*) and vein, which arise from the femoral artery (*fa*) and vein (*fv*). (From Urbaniak JR, Coogan P, Gunneson E, Nunley J. Treatment of Osteonecrosis of the Femoral Head with Free Vascularized Fibular Grafting. A Long-Term Follow-Up Study of One Hundred and Three Hips. *J Bone Joint Surg Am* 1995;77:681, with permission.)

- After the vessels have been anastomosed, endosteal bleeding must be observed from the end of the fibula to confirm vascularization of the fibula. Postoperative angiograms have shown good blood flow in the anastomosed vessels. To prevent compromise of the vascular pedicle, do not reattach the vastus lateralis and intermedius origins.
- Close the gluteal fascia and the tensor fascia lata over a drain.

**Postoperative Care** On the first day after surgery, get the patient out of bed and begin ROM exercises for the ankle and toes to prevent a flexion contracture of the great toe, which can result from scarring of the dissected flexor hallucis longus (FHL) muscle. Continue non-weight-bearing ambulation for 6 weeks, followed by progressive weight bearing. At 6 months, allow full weight bearing. If both sides are being treated in staged procedures, the second operation is done 3 months after the first.

**Results** Successful outcomes with FVFG have been reported by many researchers. Yoo et al. (143) reported a 90% success rate at a follow-up interval of 3–10 years. Brunelli and Brunelli (22) achieved 78% good to excellent results with a follow-up of more than 5 years. Our initial 103 hips treated with FVFG were studied in detail, all with a minimum 5-year follow-up. We found a conversion to total hip arthroplasty (THA) in 11% of stage II hips, 23% of stage III hips, 43% of stage IV hips, and 32% of

stage V hips that had undergone free vascularized bone grafting. Kaplan-Meier survivorship analyses of the initial 103 hips demonstrated that the probability of conversion to THA within 5 years after FVFG was 11% for stage II hips, 23% for stage III hips, 29% for stage IV hips, and 27% for stage V hips. No association was found between the etiology of the osteonecrosis and the likelihood of conversion to THA. The average postoperative Harris hip scores for those hips not converted to THA at 5 years follow-up were 80 for stage II hips, 85 for stage III hips, 76 for stage IV hips, and 75 for stage V hips (134).

Since this study, we have looked at our experience with 646 consecutive grafts with a follow-up of 1–17 years. The expected survival or time to conversion to THA of the vascularized fibular graft for all stages of osteonecrosis (including stage V) was more than 10 years (as determined by the Kaplan-Meier method of survivorship analysis). The overall survival in this series (all stages included) was 82.7%. There was, however, a greater failure rate for stage V osteonecrosis than for any other stage. Overall, excluding hips with stage V disease, the failure rate was 16.1% (93/579). The median time to failure, if it occurred, was 2.3 years. These relatively long-term results suggest that FVFG is a viable option for the treatment of advanced osteonecrosis of the femoral head (Fig. 125.31).

***Figure 125.31.*** AP radiographs of a 46-year-old man with stage III osteonecrosis of the femoral head. **A:** Preoperative radiograph. **B:** Radiograph obtained 8 years postoperatively, showing preservation of the femoral head and joint space.

**Complications** The majority of complications with this procedure are related to donor site morbidity (22,134,143). In a study by Vail and Urbaniak (137), the donor site morbidity from harvesting a free fibular graft was studied in 247 consecutive grafts in 198 patients. With a minimum 5-year follow-up, 24% of the lower legs were found to have donor site complications. These complications included a sensory deficit in 11.8% of the limbs, motor weakness in 2.7%, pain at the ankle in 11.5%, and pain at other sites in the leg in 8.9%. Two percent of the limbs had a contracture of the FHL. The FHL contracture was felt to be avoidable with careful stretching of the toes in extension during the first few postoperative days.

In 822 FVFG procedures of the hip performed at our institution, two patients had a deep vein thrombosis and one patient had a massive pulmonary embolus 6 weeks postoperative. Generally, patients are maintained on one enteric-coated aspirin a day and persantine 50 mg three times a day for 6 weeks. Other complications included two superficial wound infections, one transient deep peroneal nerve paralysis, and one injury to a branch of the superficial peroneal nerve.

## LATE MANAGEMENT

*Late* is defined as after significant femoral head collapse has occurred, with or without evidence of joint-line narrowing or acetabular involvement. It is usually associated with at least a moderate degree of pain and disability, although not infrequently patients with significant radiographic involvement (stages IV-B to VI) have relatively little discomfort. Under these circumstances, it is usually concluded that there is little chance of preserving the femoral head by the procedures previously described, and that some type of arthroplasty or hip reconstruction is virtually inevitable.

Most of the time it will be apparent whether the patients fits into the early or the late category. At times, however, the patient will fall someplace between these two. In such cases, the experience and clinical judgment of the surgeon is paramount. The patient must be informed of his options and should enter into the decision as to whether to attempt to retard progression and postpone reconstructive surgery by some type of prophylactic surgery, or to accept the fact that reconstruction is inevitable and treat the hip symptomatically until arthroplasty is indicated.

### PROTECTED WEIGHT BEARING

As mentioned earlier, protected weight bearing does not alter the natural progression of this condition. Thus, it should not be considered an alternative method of prophylactic management. In the later stages, however, it is a useful adjunct for symptomatic management of a patient who is not yet ready for a definitive arthroplasty. Intermittent use of a single cane or perhaps even two crutches at the discretion of the patient, together with a reasonable limitation of activities and the use of mild analgesics, will often decrease pain and enhance function.

### CUP ARTHROPLASTY

Prior to the development of THR, cup arthroplasty was often considered the standard reconstructive procedure for patients with late stages of osteonecrosis, degenerative arthritis, and other arthritides. The postoperative regimen was lengthy and complicated, the results were inconsistent, and even relatively good results were generally not completely satisfactory by today's standards. Accordingly, conventional cup arthroplasty was essentially abandoned with the advent of THR.

Because osteonecrosis initially affects the femoral head and involves the acetabulum only much later, a number of surgeons have advocated performing arthroplasty on the femoral side alone, provided that the acetabulum is still relatively normal. This can be accomplished by using a modified cup arthroplasty or a femoral endoprosthetic replacement arthroplasty (25,53,67,93,108,116,132).

Investigators in France (65) modified the standard cup arthroplasty and referred to it as an adjusted cup arthroplasty. In this procedure, the femoral head is reamed and a snugly fitting metallic cup is impacted over it. The articular cartilage of the acetabulum is left intact. Kerboul et al. (65) reported on 80 hips treated by this operation and followed for 1–6 years. At follow-up, 66% were felt to be successful, 16% somewhat improved but still experiencing pain and a limp, and 16% failures. The failures were related to rotation of the cup on the femoral head, femoral head resorption and collapse, and acetabular erosion. The authors felt that with more rigid indications and improvements in techniques, the results could be improved.

Sedel et al. (108) reported satisfactory short-term results with the adjusted cup arthroplasty but later abandoned this procedure in favor of ceramic THR arthroplasty. In the United States, Nelson and Walz (93) modified the cup arthroplasty by cementing the cup onto the femoral head, leaving the relatively normal acetabulum intact. They reported satisfactory intermediate-term results (17,65).

### SURFACE REPLACEMENT ARTHROPLASTY

Surface replacement arthroplasty (SRA) was popularized in the 1970s as an alternative to conventional THR. It was thought to be especially suited for the young adult. Several different designs were available, and a number of procedures were performed in patients with osteonecrosis. Despite the theoretical advantages of this approach, the clinical results were unacceptable, with a high 5-year failure rate. The procedure was therefore virtually abandoned. However, McMinn et al. (75), Amstutz (5,9), and others have continued their work to eliminate the problems inherent in the original designs, which used thin polyethylene acetabular components cemented into place. Newer devices incorporate metal-on-metal articulations with acetabular components adapted for both cemented and cementless fixation. To date, results have been variable and we must await further reports with larger numbers and longer follow-ups to determine the roles that these components will eventually play in the treatment of patients with osteonecrosis (5,9,75,107,140).

### HEMISURFACE REPLACEMENT[4]

Hemisurface replacement, also known as cup hemiarthroplasty, is a direct descendant of cup arthroplasty, which was originally conceived by Smith-Petersen (111). Because it involves resurfacing the femoral head only, it is a viable treatment option for patients with osteonecrosis of the femoral head when bone quality is adequate and when acetabular cartilage is relatively normal. Because the femoral canal is not violated, nor is the femoral intramedullary diaphyseal bone compromised, as it is with THA, hemisurface replacement preserves bone stock, affording potential for easy revision. With normal transfer of stress to the proximal femur, proximal bone loss

due to stress shielding may be mitigated. Cartilage durability is enhanced by optimizing contact of the hemispherical bearing to the acetabular cartilage. An added advantage of this technique is that the larger ball size ensures greater joint stability than with THA (7).

### *Indications and Contraindications*

Hemisurface replacement is best performed in patients with adequate bone stock and relatively intact acetabular cartilage (Ficat stage III and early stage IV). It is especially suited for young and physically active patients as a way to postpone the need for THR (Fig. 125.32). Once collapse has occurred, we recommend that patients refrain from weight bearing from the point of identification onward, to minimize further damage to the acetabular cartilage. Patients with advanced osteonecrosis in which both sides of the joint are severely damaged are not candidates for hemisurface replacement, and full-surface or total hip replacement should be considered instead. In our practice, the underlying cause of osteonecrosis has not been a contraindication when considering patients for hemisurface replacement.

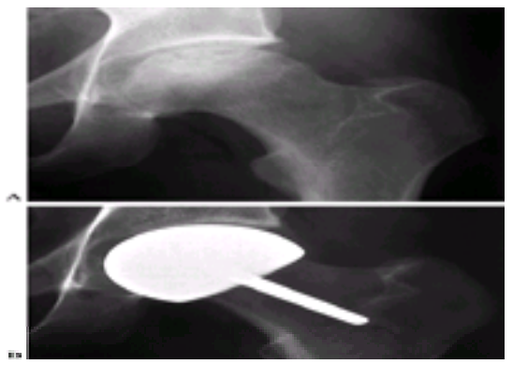

***Figure 125.32.*** Case illustration: A 31-year-old man with Ficat stage III osteonecrosis. Risk factors included steroid use, mild alcohol consumption, and trauma. **A:** Preoperative radiograph. **B:** Postoperative radiograph taken 9 months after hemisurface replacement.

### *Operative Technique*

Currently, we are using the CONSERVE (Wright Medical Technology, Arlington, TN) surgical system for hemisurface replacement. Available in millimeter increments from 42 to 54 mm for precision fitting, the CONSERVE prosthesis is made of cobalt chrome (Fig. 125.33). It has greater sphericity than other hemisurface designs to provide more coverage around the reamed bone, it has an expanded fixation area, and it employs a short stem to ensure accurate alignment with a uniform cement mantle around the resurfaced femoral head. These new design features enable us to deal with extensive bone stock abnormality or deformity, such as seen in Gaucher's disease and perhaps sickle cell anemia.



***Figure 125.33.*** The CONSERVE hemisurface femoral component, designed for increased coverage of reamed bone and more accurate alignment than with other hemisurface prostheses.

A schematic diagram of femoral preparation for hemisurface replacement appears in Figure 125.34. A cylindrical reamer, an oscillating saw, and a chamfered cutter are used to remove necrotic areas and contour the femoral head. Instrumentation of the system is designed for nontrochanteric approaches, although the best surgical approach is the one with which the surgeon feels most comfortable. The anterior, modified lateral, and posterior approaches have been successfully performed.

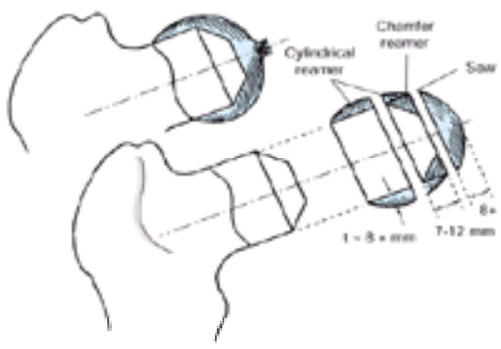


***Figure 125.34.*** Preparing the femoral head for hemiresurfacing. A cylindrical reamer, oscillating saw, and chamfered reamer are used in succession to give the head its final shape before the component is affixed.

Preoperatively, determine the approximate size and orientation of the prosthesis by using templates (Fig. 125.35), with final selection of prosthesis size made at the time of surgery. With adequate preoperative planning, there should never be a need to notch the neck.

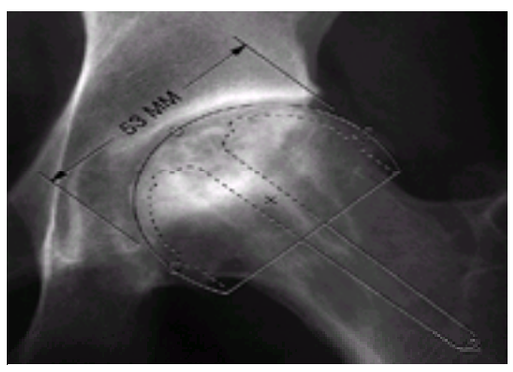

***Figure 125.35.*** Selecting the target component size. Scaled templates are superimposed on preoperative radiographs to estimate the final component size.

- We no longer use the transtrochanteric approach for surgical exposure, preferring the posterolateral approach, in which the circumference of the femoral head and neck can be assessed and the entire acetabulum can be completely visualized. This allows accurate assessment of the articular cartilage and optimizes our ability to precision-fit the prosthesis to the cartilage where it is best preserved, whether centrally or around the periphery. Section the gluteus maximus tendon at the point where it inserts into the linea aspera.
- Next, divide the short rotators, the piriformis tendon, and the quadratus femoris. Tag the piriformis tendon for later repair.
- To mobilize the femoral head, section the ligamentum teres with a ligamentum teres sectioner and complete the capsulotomy. The entire capsule must be removed to improve visualization of the articulating cartilage. We do not attempt to preserve the labrum.
- Rotate the hip internally so that the femoral head can be inspected and so that pin placement down the central axis of the neck can be facilitated. Then use sizing ring gauges to estimate femoral head size, trying to obtain a tight fit at the widest part of the head.
- Begin preparation of the femoral head. First, place the pin-centering guide firmly about the superior and inferior femoral neck, and insert a 3.2 mm Steinmann pin to a depth of approximately 10–20 mm.
- Assess pin alignment in the femoral neck axis visually in two planes. Note that pin placement does not correspond to the center of the head; with the posterior approach, the pin-centering guide often must be forced anteriorly to correct the tendency to retrovert the pin.
- Then check correct positioning of the pin using the cylindrical reamer gauge by rotating it around the pin to confirm that there is equal clearance around the femoral neck. By using the cylindrical reamer gauge, proper pin placement can be achieved, and selecting a reamer that is smaller than the femoral neck should be prevented. Moreover, displacement of the cylindrical reamer from the neck axis, which could result in notching of the femoral neck during reaming, can also be prevented.
- Initially, select an oversized cylindrical reamer (generally two sizes larger than the target size) to remove a small amount of bone. Attach this to the power source and advance it over the femoral head, using the Steinmann pin as a guide and taking care to clear debris and to stop reaming at the femoral head–neck juncture. Make successive reamings with appropriately smaller-size reamers until the final reamed head diameter is reached. Because each reamer has an intrinsic dome stop anthropometrically designed to prevent notching, the cutting teeth will not penetrate the bone of the intertrochanteric area. These stops are effective when the largest cylindrical reamer used is no more than two sizes greater than the target reamer size (based on the templated neck dimensions of the contralateral, normal neck, or measurement of the abnormal neck). However, as the reamer is advanced, regular visual inspection and finger palpation is advised to avoid neck invasion.
- For the femoral dome resection, secure a cutoff guide, which corresponds to the size of the last cylindrical reamer used, onto the femoral head with one or two pins. Then resect the dome of the femoral head with a saber or oscillating saw.
- Make the hole for the short neck stem of the component at this time by mounting the tower alignment guide assembly onto the cutoff guide.
- Use a tapered stem reamer to ream distally to the sizing mark on the reamer corresponding to the target size of the component.
- Then insert the chamfer guide into the central hole. Use the chamfer cutter that corresponds to the size of the final component to give the femoral head its final shape, significantly increasing the available fixation area.
- Remove all remaining friable, yellow, nonviable necrotic bone with a curet or high-speed burr. We do not remove the dense reactive sclerotic bone.
- Confirm the size of the femoral head by using the component template that matches the inner dimension of the femoral component (Fig. 125.36). By rotating the template, the uniformity of the cement mantle can be assessed. Mark the bone at the distal tip of the template to indicate complete seating of the femoral component during impaction.



***Figure 125.36.*** Checking the femoral head preparation. The femoral head template, when placed on the resurfaced area, is used to assess the accuracy of the bone preparation.

- Residual areas of poorly vascularized, sclerotic bone may be drilled using a 1.5 mm drill bit into more vascular bone to a depth of 3–5 mm.
- Curet out any remaining cysts, and clean the bone with saline using pulsatile lavage. Then apply the translucent head protector.
- Insert the acetabular sizing gauge into the acetabulum and press it against the acetabular cartilage to visualize the contact areas. To optimize contact with the best remaining cartilage, perform several trials with larger or smaller acetabular gauges. Then select a target component size, ensuring a preparation with a cement mantle of 1 mm. Generally, we recommend using the next larger size when the dimensions fall between millimeter increments, to provide peripheral or rim contact.
- Before cement is applied, thoroughly clean both the reamed head and the acetabulum with pulsatile lavage to make certain all bone fragments and soft tissue have been removed.
- Perform a trial reduction with the precision fit component. A radiograph at this point may be helpful to assess and verify correct component size. Check ROM before proceeding.
- Mix the acrylic bone cement and pour it in a low-viscosity state into the component up to the circumferential recess. The timing of cement application onto the femoral head depends on bone density. If the bone is very compact and dense, cement should be applied in a less viscous state; if the bone is osteopenic, the cement should be applied when it has become more viscous to avoid deep penetration of the acrylic.
- Where there is good bone quality, we prefer to avoid cementing the stem of the implant by reinserting the chamfer guide temporarily into the dome hole for the stem during initial application; instead, we use finger pressurization of bone cement into the cancellous bone, especially the cylindrically reamed bone. Press the femoral component containing the doughy cement onto the prepared femoral surface and hold it rigidly until polymerization is complete.
- Then reduce the hip and check it for ROM and stability.
- Reattach the gluteus maximus and piriformis tendon and close the wound with one or more suction drains in place.

Begin ambulation on the first postoperative day, allowing weight bearing as tolerated. Have the patient use crutches for 4–6 weeks and a cane, if desired, for an additional 2–3 weeks. Permit sports at 4 months postoperatively. (See references 8 and 9 for additional details of the surgical technique.)

### *Results*

Our experience with hemisurface replacement began with a series of precision-fit titanium alloy shells (6,132) in 1980 and has gradually evolved into studies with ceramic and cobalt chrome shells (8,9). A total of 33 hips in 29 patients, with a mean age of 33.8 years at the time of surgery and an average follow-up of 5.1 years, were reviewed at our center. All had a diagnosis of osteonecrosis; 20 were classified as Ficat stage III and 13 as stage IV. Four have undergone revisions to either surface or total hip replacement. In the 29 remaining hips, the average UCLA hip scores are 8.1 for pain, 8.5 for walking, 7.5 for function, and 5.5 for activity. Radiographic analysis showed no cases with loosening; in fact, one case even had bone fill in the acetabular fossa (9). To date, no dislocations have occurred with this group, due in large part to the stability provided by the larger ball size.

Although long-term results have largely depended on the quality of acetabular cartilage, some are continuing to perform well at more than 15 years. Survivorship of this group is 81% at 5.1 years and 61% at 10 years (9). Revisions, when necessary, were all the result of acetabular cartilage wear; however, some cases with rather advanced articular cartilage fibrillation at the time of surgery remain intact. Morbidity has been minimal, and no instances of sepsis, nerve palsy, thromboembolic events, or other complications have occurred. There have been no cases of prosthetic loosening, and bone stock has been well preserved and well maintained (8,9).

Retrieval studies of the titanium alloy implants have shown that although significant burnishing of the components occurred, the histologic response was benign (6). Some metallic debris and a few macrophages were found scattered throughout the tissue, located mostly in loose connective tissue. A change to cobalt chrome was precipitated by these findings, under the premise that a harder bearing-surface might extend the life of the cartilage and the durability of the prosthesis. Based on our own retrieval studies, we have established that the viability of the femoral head after hemiresurfacing is preserved (8,51).

Whenever reoperation has been necessary, bone stock preservation and intact intramedullary canals have made revision to either full-surface or total hip replacement much like a primary replacement. No debris-induced granulomata were encountered. Because acetabular cartilage will undergo accelerated degenerative changes from articulating with metal, revision will eventually become necessary.

***Conclusions***

Based on our results and on a review of the literature, hemiresurfacing arthroplasty for Ficat stage III and early stage IV osteonecrosis is a reliable and successful time-buying procedure for young and active patients. Using this approach, only the diseased portion of the joint is surgically removed, and osteolysis and other complications such as dislocations are eliminated by avoiding the use of either bipolar or total hip replacement. Furthermore, the results of THA after hemisurface replacement are not compromised, and complete resurfacing can still be achieved.

Although we favor hemisurface replacement arthroplasty for patients with osteonecrosis who meet the indications outlined, there are many surgeons who prefer primary THR when an arthroplasty is required. A greater number of cases with a longer follow-up will be required to help determine which is the more successful approach.

**FEMORAL ENDOPROSTHETIC REPLACEMENT**

The rationale for using a femoral endoprosthesis rather than a THR for osteonecrosis once again stems from the fact that initial changes are in the femoral head and not the acetabulum. It was thus felt by some investigators that replacing only the femoral head would be more conservative than THR (25,116). The early procedures used solid press-fit femoral components that employed neither cement nor bone ingrowth for fixation of the stem into the femoral canal. The heads were sized rather crudely to the acetabulum because the importance of an exact fit was not realized at that time. The long-term results with these prostheses when used in younger patients with osteonecrosis were generally poor (Fig. 125.37), although some good to excellent results did occur (Fig. 125.38).

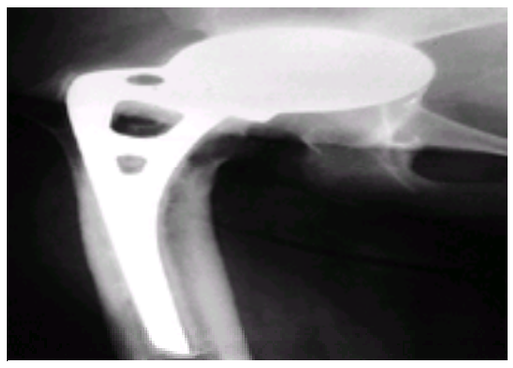

***Figure 125.37.*** Radiograph of the right hip of a patient with avascular necrosis treated with the insertion of an Austin Moore noncemented femoral endoprosthesis 12 years earlier. The femoral component remains well fixed within the shaft, whereas the ball has eroded superiorly and medially into the acetabulum. The patient required revision to a total hip arthroplasty.

***Figure 125.38.*** Fourteen-year follow-up of a cemented unipolar endoprosthesis. The patient has little pain and excellent function.

More recently, endoprostheses have been rigidly fixed into the femoral canal either by cement or by biological ingrowth. Modular components came into use and both unipolar and bipolar devices were employed. Initially it was felt that the use of a bipolar component would yield better results than a unipolar in that there would be less frictional wear on the acetabulum and thus a lower incidence of acetabular failure. Unfortunately, other problems with the bipolar prostheses developed, and there is currently little evidence of the superiority of the bipolar over the unipolar device (Fig. 125.39).

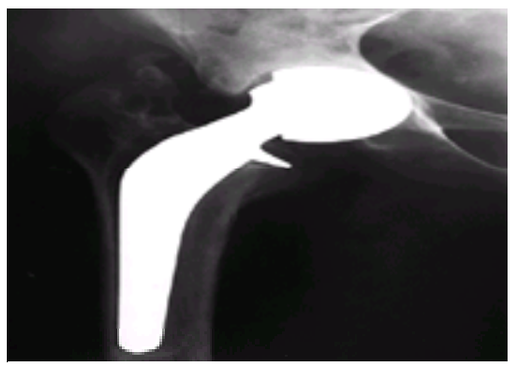

***Figure 125.39.*** Radiograph of the right hip of a patient who underwent a cemented bipolar endoprosthetic replacement 5 years earlier. Note the loosening of the femoral component in addition to the medial erosion of the acetabular component into the pelvis.

Although a number of surgeons continue to use femoral endoprostheses in patients with osteonecrosis, the current trend is away from these devices and toward THR arthroplasty or other procedures.

When the results of endoprosthetic replacement, using current techniques and components, are compared to THR, most reports indicate better results with THR. Because the stem design and the fixation of endoprostheses and total hips are now similar, it is probable that the difference in results can be attributed to problems within the acetabulum. A metallic femoral head places abnormal stress on the acetabular cartilage and creates a situation that is far from physiologic. This is not consistently well tolerated, even by normal articular cartilage, and it has been noted that the acetabular cartilage in osteonecrosis is no longer normal by the time arthroplasty is needed (24,25,31,67,130).

**TOTAL HIP REPLACEMENT**

Although THR is by far the most commonly used procedure for the treatment of patients with advanced stages of arthritis and other disorders of the hips, there has been a certain reluctance to advise this procedure for patients with AVN. This is because these patients are much younger than patients with degenerative joint disease at the time that arthroplasty is required, and it is generally accepted that the survivorship for THR in young patients is less than in older patients. In addition, patients with osteonecrosis seem to have a higher complication rate and earlier incidence of failure than patients of a similar age but with other disorders of the hip (96). In five reports published between 1981 and 1984 on THR arthroplasty in younger patients, the mean incidence of revision was 13%, and results were rated as good to excellent in 81% with a 5-year follow-up (3). Salvati and Cornell (105) reviewed their experience with THR in patients with osteonecrosis from 1972 through 1975. They found that 11 of 28 arthroplasties failed at a mean of 8 years (range, 5–10 years), for an overall failure rate of 37%. Of the remaining 18 THRs, 16 had good to excellent ratings. It was their opinion that the failure rate in osteonecrosis was four times greater than in osteoarthritis.

More recent literature, however, indicates improved results at short- and medium-term follow-up times with more modern components and techniques (21,25,40,43,54,62,71,92,99). In 1994, Piston et al. (100) reported on 35 hips with AVN treated with porous-coated THR arthroplasty. Follow-up ranged from 5 to 10 years with a mean of 7.5 years. They encountered one femoral and two acetabular revisions, for an overall revision rate of 6%. There was, however, significant remodeling in six hips and osteolytic reactions in six others. In 1997, Garino and Steinberg (43) reported on 123 THAs in patients with osteonecrosis. The follow-up was 2–10 years with a mean of 4.6 years. All femoral stems and 71 sockets were fixed with acrylic cement. Fifty-two sockets were designed for bone ingrowth. The average Harris hip score improved from 45 points preoperatively to 92 points at the time of last follow-up. Of the 246 components used, 6 acetabular and 4 femoral prostheses (4%) were revised. The incidence of revision for aseptic loosening was 2.5%. None of the noncemented acetabular components were either radiographically loose or revised. Fifty-two hips had a minimum follow-up of 5 years (mean, 6.6 years). In this group, five components (5%) were revised and four (4%) were radiographically loose. The revision rate for hybrid hips with a minimum 5-year follow-up was 2%. These results seem significantly better than reports of older series. The authors concluded that using modern techniques and components in THR arthroplasty can give excellent results over a period of 2–10 years, even in young patients with osteonecrosis. They felt that this procedure was the treatment of choice when reconstructive surgery was required (Fig. 125.40 and Fig. 125.41).

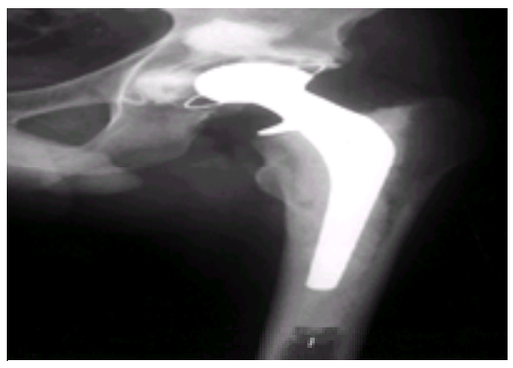

***Figure 125.40.*** Radiograph of the left hip of a husky young man with alcohol-related avascular necrosis, treated 11 years earlier with a cemented total hip replacement arthroplasty. The patient continues to do well clinically with minimal radiographic changes since the time of surgery.

***Figure 125.41.*** A 19-year follow-up of a Muÿller total hip replacement in a young man with alcohol-related osteonecrosis. The prosthesis continues to function well.

## RESECTION ARTHROPLASTY

Resection arthroplasty, also referred to as a Girdlestone pseudarthrosis, was used as a primary arthroplasty for both septic and nonseptic hips prior to the advent of THR. Today it is used most frequently as a salvage for the failed and usually infected THR or endoprosthesis. Under certain selected circumstances, however, it can be used as a primary arthroplasty. In the patient with end-stage osteonecrosis whose pain and disability require some type of operative intervention, but in whom prosthetic replacement or THR is contraindicated, the resection arthroplasty may be a reasonable alternative. This procedure may be considered to treat the osteonecrotic hip complicated by sepsis, and the patient in whom THR arthroplasty has a high potential for complications and failure. Patients with chronic recurrent septicemia, those on renal dialysis, and individuals with active sickle cell disease may fit into this category. Resection arthroplasty might also be considered in the individual who is felt to be too unreliable to take proper precautions following THR, such as the chronic alcoholic, drug abuser, and mentally retarded. It also might be used for the individual who is confined to a bed/chair existence due to neurologic or medical problems and who simply needs pain relief and satisfactory motion rather than stability and the ability to ambulate.

Resection arthroplasty must be considered a compromise. If this is clear from the outset to both the patient and physician, and if there is an understanding of the advantages and disadvantages of this procedure, then most patients will be satisfied with the outcome. A resection arthroplasty will eliminate sepsis if present, provide pain relief, give a good ROM, and not deteriorate with the passage of time. At the same time, the joint will be unstable, the limb will be an average of 1–1.5 inches short, and most patients will require both a shoe lift and the use of at least one cane or possibly two crutches for ambulation (Fig. 125.42) (27,121). Resection arthroplasty may be used as a definitive procedure or as an intermediate step, such as in the case of infection, until a THR can be safely performed.

***Figure 125.42.*** Radiographs of the left hip of a 22-year-old man who developed a septic nonunion with avascular necrosis following open reduction and internal fixation of a displaced femoral neck fracture. **A:** Radiographs show the nonunion and loosening of the fixation device within the femoral head. **B:** Radiographs taken 3 years after a resection arthroplasty (Girdlestone pseudarthrosis). The patient is doing well clinically and has declined total hip replacement arthroplasty.

### ARTHRODESIS

In the patient with significant pain and disability, who is no longer responsive to conservative management, and in whom prosthetic replacement or THR is contraindicated but stability of the hip rather than motion is required, arthrodesis rather than resection arthroplasty might be considered. Most of the indications described for resection arthroplasty also apply to hip fusion. This procedure might also be considered in the large, young, active man who desires a single “permanent” procedure rather than a THR with the need for more than a single revision during his lifetime. Before embarking on this procedure, the individual must be fully aware of the possibility that the attempt at fusion may not be successful, and of the permanent limitations that a fusion will impose. At times the use of a pantaloon spica as a trial will help the patient make an informed decision. The usual contraindications for hip fusion apply here as well and include pathology in the knees, lumbar spine, or contralateral hip. Because of the known high incidence of bilaterality of osteonecrosis, it is essential that involvement of the opposite hip be ruled out prior to embarking on a fusion. If, despite these precautions, osteonecrosis does develop in the contralateral hip, THR can be performed with a satisfactory outcome. The incidence of nonunion in osteonecrosis is somewhat higher than in patients with other disorders because of the necrotic bone present in the femoral head.

## OTHER SITES AND TYPES OF INVOLVEMENT

### THE KNEE: DISTAL FEMUR AND PROXIMAL TIBIA

Osteonecrosis can involve both distal femoral condyles or the proximal tibia (85,89,91). This is probably the second most common site of involvement after the femoral head, with one report (91) finding an incidence of knee involvement in 9% of patients with osteonecrosis. Two entirely separate entities can affect this region: One is known as spontaneous osteonecrosis of the knee (or SPONK), and the other, which will be referred to as avascular necrosis, is the disorder that can also affect the hip and other areas of the skeleton (Fig. 125.43). SPONK occurs in patients over 55 years of age, and it typically involves one femoral condyle or tibial plateau without other joint involvement. The risk factors commonly found in osteonecrosis of the hip have not been identified. AVN of the knee, on the other hand, is typically found in patients younger than 45 years of age, may involve several sites about the knee itself, is associated with hip involvement 90% of the time, has a different appearance on radiographs and MRI, and is often associated with corticosteroid use or alcohol intake.

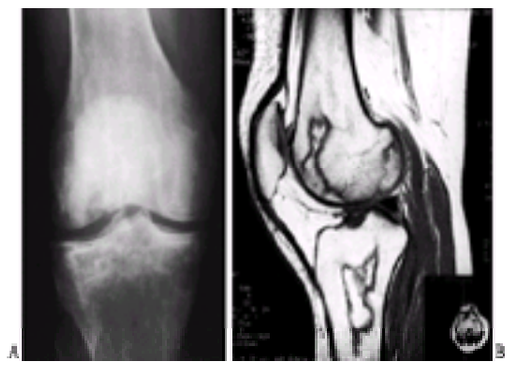


***Figure 125.43.*** Avascular necrosis of the knee with involvement of both femoral condyles and the tibial plateau. **A:** AP radiograph. **B:** MRI in sagittal projection.

#### *Spontaneous Osteonecrosis of the Knee*

In the SPONK disorder, patients have a sudden onset of pain, usually about the medial aspect of the knee. Radiographs are within normal limits initially, but the bone scan or MRI shows abnormalities involving the medial aspect of the knee more often than the lateral, with the femoral condyle being more frequently affected than the tibial plateau. The prognosis is based on the size of the lesion. When the involvement is greater than 50% of the transverse diameter of the condyle, the prognosis is worse than when the lesion is smaller. Initially, patients should be treated symptomatically with protected weight bearing. The condition often resolves over the course of the next several months. It is important to separate this entity from other conditions such as meniscal tears, so that unnecessary arthroscopic surgery is avoided.

Patients with larger lesions have a poorer prognosis and often go on to collapse despite protected weight bearing. A small number of cases have been treated with osteotomies, but the results have generally been unsuccessful, and larger lesions often lead to either hemiarthroplasty or total knee replacement. The results have been generally favorable. There is little experience with core decompression in these cases and there is no evidence that it affects the prognosis (101).

#### *Avascular Necrosis of the Knee*

Small lesions of the knee are usually treated nonoperatively with restricted weight bearing and analgesics. Larger lesions are more often symptomatic and have occasionally been treated by core decompression with moderate success. A recent study revealed satisfactory outcomes in 61 of 77 cases (79%), at a mean follow-up of 7 years (range, 2–16 years) (91).

There have been only a few reports of arthroscopic debridement or bone grafting for lesions about the knee (86). The results of total knee replacement in this group of patients have been disappointing. A recent report of 31 primary total knee arthroplasties followed for 8 years (range, 2–16 years) revealed only 17 good to excellent results (55%). These poor results may be related to the fact that the procedure was performed in young patients with high activity levels and with bone that was metabolically and structurally compromised (89).

### THE HUMERAL HEAD

Involvement of the humeral head has been reported in 5% to 12% of patients with osteonecrosis (29,69,86). Involvement is bilateral in 50% of the patients when associated with corticosteroids. The initial treatment of this entity is symptomatic and includes gentle exercises to preserve strength and ROM and the avoidance of excessive stresses on the joint. There have been relatively few reports of core decompression; however, the best results have been obtained when the procedure was performed prior to humeral head collapse (88). A recent study (69) reported good to excellent results in 47 of 62 shoulders (76%) with a mean follow-up of 8.5 years (range, 2–18 years). Some shoulders may continue to function reasonably well even after humeral head collapse has occurred. In some, however, the pain and disability is sufficient to warrant either hemiarthroplasty or total shoulder replacement. These are described in only a few reports, and there is mixed opinion as to which of the two procedures should be utilized, even if radiographs do not demonstrate changes in the glenoid (63).

### THE FOOT AND ANKLE

Although osteonecrosis of the talus is most often seen following fracture, atraumatic osteonecrosis is occasionally seen in association with involvement of the hip and other regions (34,86,90,136). Talar involvement is seen in approximately 2% of patients with osteonecrosis. Eighty percent of the patients are women and the disorder is noted bilaterally 50% of the time (Fig. 125.44). Other bones of the foot and ankle are also involved occasionally. These include the distal tibia, calcaneus, medial cuneiform, metatarsal heads, and distal fibula (Fig. 125.45). Treatment options include analgesics, bracing, or casting. Core decompression of the talus has been performed in a small number of cases. A recent report (90) noted satisfactory results in 29 of 32 cases. If these measures fail and the talus goes on to collapse, significant pain and disability may result, requiring tibiotalar arthrodesis or possibly pantalar arthrodesis (86). Fusion can be difficult to obtain. In one report (86), there were 8 of 9 nonunions (89%) following the first attempt. In another report (136), 9 of 11 ankles (82%) eventually went on to fusion, but multiple procedures were often required; these included autogenous bone grafting, crossed cancellous screws, tibial struts, the insertion of a blade plate, and prolonged casting.

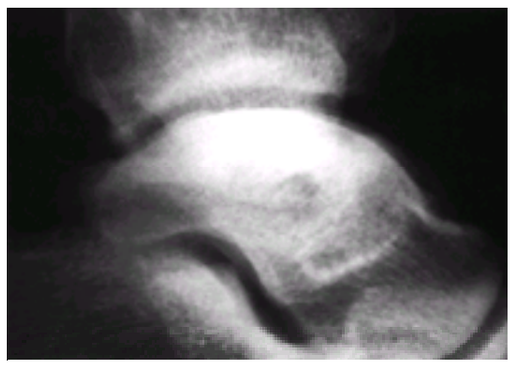

***Figure 125.44.*** Lateral radiograph of the ankle, demonstrating nontraumatic osteonecrosis of the talus.

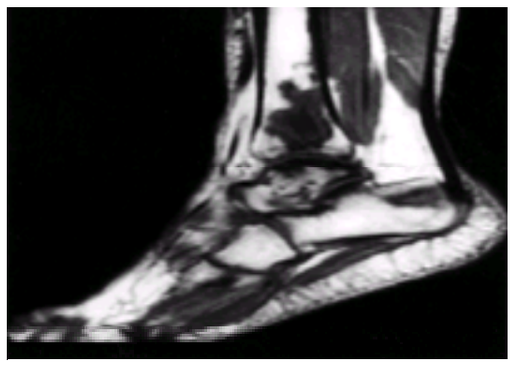

***Figure 125.45.*** MRI of the foot and ankle of a patient with steroid-related osteonecrosis of the distal tibia and talus.

## THE ELBOW

Osteonecrosis of the adult elbow is encountered infrequently (70). One recent report (68) described eight adult patients with atraumatic osteonecrosis of the elbow. These included four men and four women with a mean age of 35. Four patients had an associated autoimmune disease, all had involvement of other joints, and all were on corticosteroid therapy. Four cases involved the capitellum, three the trochlea, and three the lateral condyle. Four elbows presented in the precollapsed stage radiographically and responded well to nonoperative management. Two patients with collapse failed nonoperative treatment and underwent core decompression for pain relief. One elbow with advanced disease required a total elbow arthroplasty. In contrast to the pediatric form of osteonecrosis, Panner's disease, osteonecrosis of the adult elbow can lead to endstage arthritis.

## MISCELLANEOUS CONDITIONS

Osteonecroses involving various bones in children and adolescents were previously grouped together with a variety of skeletal disorders collectively known as the osteochondroses. These include Perthes disease, Freiberg's disease, Koöhler's disease, and Kienboöck's disease. With the exception of Perthes disease, these conditions are rarely encountered (120).

### *Perthes Disease*

Perthes disease, or Legg-Calveé-Perthes disease, is the pediatric form of osteonecrosis involving the capital femoral epiphysis. It is usually found in patients between 4 and 10 years of age, affects boys 80% of the time, and is unilateral in 70% to 80% of patients. Pathologically, the disease is quite similar to the adult form, with dead bone and marrow always present. Subchondral fractures are common. As in the adult, evidence of repair occurs from granulation tissue that grows into the area of necrosis with new bone deposition upon dead trabeculae. The repair process is more successful in the pediatric patient than in the adult, with complete repair occurring often. The prognosis depends both on the age of onset and on the extent of epiphyseal involvement. Patients younger than 6 years generally have a good prognosis, as do patients in whom less than 50% of the femoral head is involved.

### *Freiberg's Disease*

Osteonecrosis of the metatarsal head, usually the second, is known as Freiberg's disease or Freiberg's infarction. This condition affects adolescent girls in 75% of cases. It has been postulated to occur after trauma to an elongated and more rigidly fixed second metatarsal. Treatment consists of a short-leg walking cast for 4 weeks, followed by metatarsal supports. The condition is usually self-limited and the prognosis is good. Occasionally patients do not have symptomatic relief and require operative treatment consisting of curettage and bone grafting, metatarsal osteotomy, or resection of the metatarsal head.

### *Koöhler's Disease*

Osteonecrosis of the tarsal navicular is known as Koöhler's disease. It usually affects boys under 10 years of age, with one third occurring bilaterally. The cause of this disorder is unknown but it may be secondary to repetitive shear forces applied to the ankle joint. It may also be related to late ossification of this important weight-bearing bone. It is usually treated with arch supports and heel wedges unless severe symptoms warrant the application of a short-leg cast. The prognosis is excellent and the navicular becomes fully ossified in most cases.

### *Kienboöck's Disease*

Osteonecrosis of the lunate, or Kienboöck's disease, usually affects the dominant wrist of young adults. It has been related to repeated trauma as well as to a genetic predisposition to a shortened ulna. In the early stages, treatment options include immobilization and symptomatic management. Radial shortening or ulnar lengthening have also been employed with some success. For more advanced stages with collapse of the lunate, surgical procedures include excision of the lunate, replacement with a synthetic implant or biological tissue, and wrist fusion.

### *Preiser's Disease*

Atraumatic osteonecrosis of the scaphoid is an uncommon condition that may be related to steroid administration or repetitive minor trauma, or it may be idiopathic. It often remains asymptomatic for quite some time before presenting as wrist pain and limitation of motion. Sclerosis and cyst formation often give way to fragmentation and eventually degenerative arthritis of the wrist. Treatment is similar to that for Kienboöck's disease.

### *Osteonecrosis of the Capitate*

Osteonecrosis of the capitate is a rare condition of uncertain etiology, although corticosteroids and minor repetitive trauma have been implicated. The clinical course, radiographic picture, and treatment are similar to those described for osteonecrosis of the lunate and scaphoid.

## AUTHORS' PERSPECTIVE

This chapter has focused on nontraumatic osteonecrosis of the adult hip because this is the region most frequently affected. Although the incidence of osteonecrosis is much lower than that of other disorders affecting the hip joint, it can no longer be considered a rare condition. Despite an increased interest over the past several years,

there is much yet to be learned about its etiology and pathogenesis. As with many conditions, prevention is perhaps more important than cure. We must therefore be aware of factors that contribute to the development of osteonecrosis and eliminate or minimize them to the extent possible. Recent studies have indicated that subtle coagulopathies are often involved, and this information may lead to more effective methods of treatment and prevention.

Although the prognosis for a hip with a small necrotic lesion may be relatively good, especially if the area of involvement is not in a region of major weight bearing, most clinically diagnosed cases will progress to femoral head collapse without specific treatment. The majority of these will eventually require some type of arthroplasty. Symptomatic treatment, including protected weight bearing, is generally not successful. Our goal is therefore to institute some type of definitive treatment as early as possible. This, in turn, requires early diagnosis, which is now possible due to a heightened awareness of osteonecrosis in the medical community and to newer diagnostic modalities, particularly MRI.

Among the operative procedures available for the treatment of early cases of osteonecrosis are core decompression, various types of osteotomies, and several different grafting procedures. These have been described in some detail in this chapter. Unfortunately, it is difficult to compare accurately the results of these procedures and to determine their relative indications because of the many variables that exist in reports published to date.

Once significant collapse of the femoral head has occurred, prophylactic measures are far less effective. At this stage, patients are generally treated symptomatically until pain and disability necessitate some type of arthroplasty. Although THR is currently the procedure most often selected, other choices include femoral endoprosthetic replacement and modified cup arthroplasty or hemisurface replacement, if the acetabulum is relatively uninvolved. It has yet to be determined whether it is best to perform this type of limited procedure to buy time before THR is required, or to proceed directly with THR.

If the acetabulum has undergone secondary degenerative changes, THR is usually the procedure of choice. This is a reliable operation that yields excellent pain relief and function. The major concern is with long-term survivorship, because most patients with osteonecrosis are young. However, recent studies indicate improved durability with newer techniques and devices.

Our future goals include learning more about the etiology and pathogenesis of this condition so as to prevent it from occurring when possible. Research must continue on medical approaches to prophylaxis and treatment. Methods for early diagnosis will continue to improve, and the medical community at large must be made even more aware of the importance of early diagnosis and early treatment. The search should continue for better techniques to treat early cases of osteonecrosis. Controlled, prospective studies should be instituted to evaluate and compare the various procedures available so as to determine the relative effectiveness and the specific indications for each. These must include uniform inclusion criteria and effective methods of evaluation and staging.

For hips with femoral head collapse but without significant acetabular involvement, we should continue to evaluate and develop better types of limited arthroplasties.

For hips in the later stages, where acetabular changes are already well established, we must improve the durability of THR arthroplasty. With advances in surgical technique and in component design, materials, and manufacturing, it is quite possible that the useful life of a THR arthroplasty will be extended considerably so that these components may last a lifetime, not only in the older patient, but also in the younger patient with osteonecrosis. When this occurs, there will be a dramatic improvement in our ability to handle patients with even the most advanced stages of this frustrating condition.

---

By Marvin E. Steinberg, M.D.
By Yoichi Sugioka, M.D., Ph.D.
By Jonathan R. Perryman, M.D., and James R. Urbaniak, M.D.
By Harlan C. Amstutz, M.D., Paul E. Beaulé, M.E., F.R.C.S.C., and Jerilyn K. Higa, M.D.

## CHAPTER REFERENCES

Each reference is categorized according to the following scheme: *, classic article; #, review article; !, basic research article; and +, clinical results/outcome study.


+ 1. Aaron RK, Ciombor DM. Electrical Stimulation, Demineralized Bone Matrix, and Bone Morphogenic Protein. *Semin Arthroplasty* 1998;9:221.

+ 2. Aaron RK, Ciombor DM, Lord CF. Core Decompression Augmented with Human Decalcified Bone Matrix Graft for Osteonecrosis of the Femoral Head. In: Urbaniak JR, Jones JP, eds. *Osteonecrosis: Etiology, Diagnosis, and Treatment.* Chicago: American Academy of Orthopaedic Surgeons, 1997;301.

! 3. Aaron RK, Lennox D, Stulberg BN. The Natural History of Osteonecrosis of the Femoral Head and Risk Factors for Rapid Progression. In: Urbaniak, JR, Jones JP, eds. *Osteonecrosis: Etiology, Diagnosis, and Treatment.* Chicago: American Academy of Orthopaedic Surgeons, 1997;261.

+ 4. Aaron RK, Steinberg ME. Electrical Stimulation of Osteonecrosis of the Femoral Head. *Semin Arthroplasty* 1991;2:214.

+ 5. Amstutz HC, Grigoris P. Metal-On-Metal Bearings in the Hip Arthroplasty. *Clin Orthop* 1996;329S:11.

+ 6. Amstutz HC, Grigoris P, Safran MR, et al. Precision Fit Surface Hemiarthroplasty for Femoral Head Osteonecrosis: Long Term Results. *J Bone Joint Surg Br* 1994;76:423.

+ 7. Amstutz HC, Kody MH. Dislocation and Subluxation. In: Amstutz HC, ed. *Hip Arthroplasty.* New York: Churchill Livingstone, 1991;429.

+ 8. Amstutz HC, Noordin S, Campbell PA, Schmalzreid TP. Precision Fit Surface Hemiarthroplasty for Femoral Head Osteonecrosis. In: Urbaniak JR, Jones JP, eds. *Osteonecrosis: Etiology, Diagnosis, and Treatment.* Chicago: American Academy of Orthopaedic Surgeons, 1997;373.

+ 9. Amstutz HC, Sparling EA, Grigoris P. Surface and Hemi-Surface Replacement Arthroplasty. Semin Arthro- plasty 1998;9:261.

# 10. ARCO (Association Research Circulation Osseous).: Committee on Terminology and Classification. *ARCO News* 1992;4:41.

* 11. Arlet J, Durroux R, Fauchier C, Thieéchart C. Histopathology on the Non-Traumatic Necrosis of the Femoral Head: Topographic and Evolutive Aspects. In: Arlet J, Ficat P, Hungerford DS, eds. *Bone Circulation.* Baltimore: William and Wilkins, 1984;296.

* 12. Arlet J, Ficat RP. Forage-Biopsie de la Teête Femorale dans l'Osteonecrose Primative. Observations Histo-pathologiques Portant sur Huit Foranes. *Rev Rhum Ed Fr* 1964;31:257.

* 13. Arnoldi CC. Vascular Aspects of Degenerative Joint Disorders. A Synthesis. *Acta Orthop Scand Suppl* 1994;65:1.

! 14. Atsumi T, Kuroki Y. Role of Impairment of Blood Supply of the Femoral Head in the Pathogenesis of Idiopathic Osteonecrosis. *Clin Orthop* 1992;277:22.

! 15. Atsumi T, Kuroki Y, Yamano K. A Microangiographic Study of Idiopathic Osteonecrosis of the Femoral Head. *Clin Orthop* 1989;246:186.

+ 16. Baksi DP. Treatment of Osteonecrosis of the Femoral Head by Drilling and Muscle-Pedicle Bone Grafting. *J Bone Joint Surg Br* 1991;73:241.

+ 17. Barnes CL, Collins DN, Nelson CL. Cup Arthroplasty, Surface Replacement Arthroplasty, and Femoral Head Resurfacing for Osteonecrosis. *Semin Arthroplasty* 1991;2:222.

! 18. Bauer TW, Plenk H. The Pathology of Early Osteonecrosis of the Femoral Head. *Semin Arthroplasty* 1998;9:192.

+ 19. Boettcher WG, Bonfiglio M, Smith K. Non-Traumatic Necrosis of the Femoral Head. Part II. Experiences in Treatment. *J Bone Joint Surg Am* 1970;52:322.

+ 20. Bonfiglio M, Bardenstein MB. Treatment by Bone-Grafting of Aseptic Necrosis of the Femoral Head and Non-Union of the Femoral Neck (Phemister Technique). *J Bone Joint Surg Am* 1958;40:1329.

+ 21. Brinker MR, Rosenberg AG, Kull L, Galante JO. Primary Total Hip Arthroplasty Using Non-Cemented Porous-Coated Femoral Components in Patients with Osteonecrosis of the Femoral Head. *J Arthroplasty* 1994;9:457.

+ 22. Brunelli G, Brunelli G. Free Microvascular Fibular Transfer for Idiopathic Femoral Head Necrosis: Long-Term Followup. *J Reconstr Microsurg* 1991;7:285.

+ 23. Buckley PD, Gearen PF, Petty RW. Structural Bone-Grafting for Early Atraumatic Avascular Necrosis of the Femoral Head. *J Bone Joint Surg Am* 1991;73:1357.

+ 24. Cabanela ME. Hip Arthroplasty in Osteonecrosis of the Femoral Head. In: Urbaniak JR, Jones JP, eds. *Osteonecrosis: Etiology, Diagnosis, and Treatment.* Chicago: American Academy of Orthopaedic Surgeons, 1997;385.

+ 25. Cabanela ME. Femoral Endoprostheses and Total Hip Replacement for Avascular Necrosis. *Semin Arthroplasty* 1998;9:253.

+ 26. Camp JF, Colwell CW. Core Decompression of the Femoral Head for Osteonecrosis. *J Bone Joint Surg Am* 1986;68:1313.

# 27. Carangelo RJ, Schutzer SF. Resection Arthroplasty. In: Callaghan JJ, Rosenberg AG, Rubash HE, eds. *The Adult Hip.* Philadelphia: Lippincott-Raven, 1998;737.

* 28. Catto M. Pathology of Aseptic Bone Necrosis. In: Davidson JK, ed. *Aseptic Necrosis of Bone.* Amsterdam: Excerpta Medica, 1976.

* 29. Cruess RL. Steroid Induced Avascular Necrosis of the Head of the Humerus. *J Bone Joint Surg Br* 1976;58:313.

* 30. Cruess RL. Steroid Induced Osteonecrosis: A Review. *Can J Surg* 1981;24:567.

! 31. Dalldorf PF, Banas MP, Hicks DG, Pellegrini VD. Rate of Degeneration of Human Acetabular Cartilage after Hemiarthroplasty. *J Bone Joint Surg Am* 1995;77:877.

! 32. Davidson JL, Coogan PG, Gunneson EE, Urbaniak JR. The Asymptomatic Contralateral Hip in Osteonecrosis of the Femoral Head. In: Urbaniak JR, Jones JP, eds. *Osteonecrosis: Etiology, Diagnosis, and Treatment.* Chicago: American Academy of Orthopaedic Surgeons, 1997;231.

+ 33. Dean MT, Cabanela ME. Transtrochanteric Anterior Rotational Osteotomy for Avascular Necrosis of the Femoral Head. Long-Term Results. *J Bone Joint Surg Br* 1993;74:597.

# 34. Delanois R, Mont MA, Yoon TR, et al. Atraumatic Osteonecrosis of the Talus. *J Bone Joint Surg Am* 1998;80:529.

+ 35. Dunn AW, Grow T. Aseptic Necrosis of the Femoral Head. Treatment with Bone Grafts of Doubtful Value. *Clin Orthop* 1977;122:249.

+ 36. Eyb R, Kotz R. The Transtrochanteric Anterior Rotational Osteotomy of Sugioka: Early and Late Results in Idiopathic Aseptic Femoral Head Necrosis. *Arch Orthop Trauma Surg* 1987;106:161.

+ 37. Fairbank AC, Bhatia D, Jinnah RH, Hungerford DS. Long-Term Results of Core Decompression for Ischemic Necrosis of the Femoral Head. *J Bone Joint Surg Br* 1995;77:42.

+ 38. Ficat RP. Idiopathic Bone Necrosis of the Femoral Head: Early Diagnosis and Treatment. *J Bone Joint Surg Br* 1985;67:3.

! 39. Ficat RP, Arlet J. Treatment of Bone Ischemia and Necrosis. In: Hungerford DS, ed. *Ischemia and Necroses of Bone.* Baltimore: Williams & Wilkins, 1980;171.

+ 40. Fye MA, Huo MH, Zatorski LE, Keggi KJ. Total Hip Arthroplasty Performed without Cement in Patients with Femoral Head Osteonecrosis Who Are Less Than 50 Years Old. *J Arthroplasty* 1998;13:876.

+ 41. Ganz R, Buchler U. Overview of Attempts to Revitalize the Dead Head in Aseptic Necrosis of the Femoral Head: Osteotomy and Revascularization. In: *The Hip: Proceedings of the Eleventh Open Scientific Meeting of the Hip Society.* St. Louis, MO: CV Mosby, 1983;296.

# 42. Gardeniers JWM. The ARCO Perspective for Reaching One Uniform Staging System of Osteonecrosis. In: Schoutens A, Arlet J, Gardeniers JWM, Hughes SPF, eds. *Bone Circulation and Vascularization in Normal and Pathological Conditions.* New York: Plenum Press, 1993;375.

+ 43. Garino JP, Steinberg ME. Total Hip Arthroplasty in Patients with Avascular Necrosis of the Femoral Head: A 2 to 20 Year Followup. *Clin Orthop* 1997;334:108.

! 44. Glickstein MF, Burk DL Jr, Schiebler ML, et al. Avascular Necrosis versus Other Diseases of the Hip. Sensitivity of Imaging. *Radiology* 1988;169:213.

! 45. Glueck CJ, Freiberg R, Glueck HI, et al. Hypofibrinolysis: A Common, Major Cause of Osteonecrosis. *Am J Hematol* 1994;45:156.

! 46. Glueck CJ, Freiberg R, Gruppo R, et al. Thrombophilia and Hypofibrinolysis: Reversible Pathogenetic Etiologies of Osteonecrosis. In: Urbaniak JR, Jones JP, eds. *Osteonecrosis: Etiology, Diagnosis, and Treatment.* Chicago: American Academy of Orthopaedic Surgeons, 1997;105.

! 47. Glueck CJ, Freiberg R, Tracy T, et al. Thrombophilia and Hypofinbrinolysis: Pathophysiologies of Osteonecrosis. *Clin Orthop* 1997;344:43.

# 48. Guerra JJ, Steinberg ME. Distinguishing Transient Osteoporosis of the Hip from Avascular Necrosis. *J Bone Joint Surg Am* 1995;77:616.

+ 49. Hofmann S, Engel A, Neuhold A, et al. Bone-Marrow Edema Syndrome and Transient Osteoporosis of the Hip: An MRI Controlled Study of Treatment by Core Decompression. *J Bone Joint Surg Br* 1993;75:210.

+ 50. Hosokawa A, Mohtai M, Hotokebuchi T, et al. Transtrochanteric Rotational Osteotomy for Idiopathic and Steroid-Induced Osteonecrosis of the Femoral Head: Indications and Long-Term Follow-up. In: Urbaniak SR, Jones JP, eds. *Osteonecrosis: Etiology, Diagnosis and Treatment.* Rosemont, IL. American Academy of Orthopaedic Surgeons, 1997;309.

! 51. Howie DW, Cornish BL, Vernon-Roberts B. The Viability of the Femoral Head after Resurfacing Hip Arthroplasty in Humans. *Clin Orthop* 1993;291:171.

! 52. Hungerford DS. Pathogenic Considerations in Ischemic Necrosis of Bone. *Can J Surg* 1981;24:583.

* 53. Hungerford MW, Mont MA, Scott R, et al. Surface Replacement Hemiarthroplasty for the Treatment of Osteonecrosis of the Femoral Head. *J Bone Joint Surg Am* 1998;80:1656.

+ 54. Huo MH, Salvati EA, Browne MG, et al. Primary Total Hip Arthroplasty in Systemic Lupus Erythematosus. *J Arthroplasty* 1992;7:51.

! 55. Inoue A, Ono K. A Histological Study of Idiopathic Avascular Necrosis of the Head of the Femur. *J Bone Joint Surg Br* 1979;61:138.

+ 56. Itoman M, Yamamoto M. Pathogenesis and Treatment of Idiopathic Aseptic Necrosis of the Femoral Head. *Clin Immunol* 1989;21:713.

+ 57. Iwata H, Torii S, Hasegawa Y, et al. Indications and Results of Vascularized Pedicle Iliac Bone Graft in Avascular Necrosis of the Femoral Head. *Clin Orthop* 1993;295:281.

# 58. Jacobs B. Epidemiology of Tramuatic and Non-Traumatic Osteonecrosis. *Clin Orthop* 1978;130:51.

! 59. Jones JP Jr. Alcoholism, Hypercortisonism, Fat Embolism, and Osseous Avascular Necrosis of the Femoral Head. In: Zinn WM, ed. *Idiopathic Ischemic Necrosis of the Femoral Head in Adults.* Stuttgart, Germany: Georg Thieme, 1971;112.

! 60. Jones JP Jr. Intravascular Coagulation and Osteonecrosis. *Clin Orthop* 1992;277:41.

! 61. Jones JP. Etiology and Pathogenesis. *Semin Arthroplasty* 1998;9:184.

+ 62. Katz RL, Bourne RB, Rorabeck CH, McGee H. Total Hip Arthroplasty in Patients with Avascular Necrosis of the Hip. Follow-up Observations on Cementless and Cemented Operations. *Clin Orthop* 1992;281:145.

+ 63. Kay SP, Amstutz HC. Shoulder Hemiarthroplasty at UCLA. *Clin Orthop* 1988;288:42.

! 64. Kenzora JE, Glimcher MJ. Accumulative Cell Stress: The Multifactorial Etiology of Idiopathic Osteonecrosis. *Orthop Clin North Am* 1985;16:669.

+ 65. Kerboul M, Thomine J, Postel M, Merle D'Aubigneé R. The Conservative Surgical Treatment of Idiopathic Aseptic Necrosis of the Femoral Head. *J Bone Joint Surg Br* 1974;56:291.

! 66. Koo KH, Kim R. Quantifying the Extent of Osteonecrosis: A New Method Using MRI. *J Bone Joint Surg Br* 1995;77:875.

+ 67. Lachiewicz PF, Desman SM. The Bipolar Endoprosthesis in Avascular Necrosis of the Femoral Head. *J Arthroplasty* 1988;3:131.

# 68. LaPorte D, Mont MA, Jones LC, et al. Multifocal Osteonecrosis: Demographic, Clinical and Radiographic Characterization. *J Rheumatol* 1998 (in press).

+ 69. LaPorte D, Mont MA, Mohan V, et al. Osteonecrosis of the Humeral Head Treated with Core Decompression. *Clin Orthop* 1998;355:254.

+ 70. Le T-B, Mont MA, Laporte D, Hungerford DS. Demographic, Radiographic and Clinical Presentation of Adult Osteonecrosis of the Elbow. Chicago: *Proceedings of the American Academy of Orthopaedic Surgeons*, 1999;202.

+ 71. Lins RE, Barnes BC, Callaghan JJ, et al. Evaluation of Uncemented Total Hip Arthroplasty in Patients with Avascular Necrosis of the Femoral Head. *Clin Orthop* 1993;297:168.

+ 72. Maistrelli G, Fusco U, Avai A, Bombelli R. Osteonecrosis of the Hip Treated by Intertrochanteric Osteotomy. A Four- to Fifteen-Year Follow-Up. *J Bone Joint Surg Br* 1988;70:761.

* 73. Mankin HJ, Brower TD. Bilateral Idiopathic Aseptic Necrosis of the Femur in Adults: “Chandler's Disease.” *J Hosp Joint Dis* 1962;23:42.

* 74. Marcus ND, Enneking WF, Massam RA. The Silent Hip in Idiopathic Aseptic Necrosis: Treatment by Bone Grafting. *J Bone Joint Surg Am* 1973;55:1351.

+ 75. McMinn DJW, Treacy RBC, Lin K, et al. Metal-on-Metal Surface Replacement of the Hip. Experience with the McMinn Prosthesis. *Clin Orthop* 1996;329S:89.

* 76. Merle D'Aubigneé R, Postel M, Mazabraud A, et al. Idiopathic Necrosis of the Femoral Head in Adults. *J Bone Joint Surg Br* 1965;47:612.

+ 77. Meyers MH. The Treatment of Osteonecrosis of the Hip with Fresh Osteochondral Allografts and with the Muscle Pedicle Graft Technique. *Clin Orthop* 1978;130:202.

+ 78. Meyers MH, Convery FR. Grafting Procedures in Osteonecrosis of the Hip. *Semin Arthroplasty* 1991;3:189.

+ 79. Meyers MH, Harvey JP, Moore TM. Treatment of Displaced Subcapital Transcervical Fractures of the Femoral Neck by Muscle-Pedicle Bone Graft and Internal Fixation. *J Bone Joint Surg Am* 1973;55:261.

! 80. Mitchell DG, Rao VM, Dalinka MK, et al. Femoral Head Avascular Necrosis: Correlation of MR Imaging, Radiographic Staging, Radionuclide Imaging, and Clinical Findings. *Radiology* 1987;162:709.

# 81. Mont MA, Carbone JJ, Fairbank AC. Core Decompression versus Nonoperative Management for Osteonecrosis of the Hip. *Clin Orthop* 1996;324:169.

+ 82. Mont MA, Einhorn TA, Sponseller PD, Hungerford DS. The Trapdoor Procedure Using Autogenous Cortical and Cancellous Bone Grafts in the Treatment of Osteonecrosis of the Femoral Head. *J Bone Joint Surg Br* 1998;80:56.

+ 83. Mont MA, Fairbank AC, Krackow KA, Hungerford DS. Corrective Osteotomy for Osteonecrosis of the Femoral Head. The Results of a Long-Term Follow-Up Study. *J Bone Joint Surg Am* 1996;78:1032.

! 84. Mont MA, Glueck CJ, Wang P, et al. Risk Factors for Osteonecrosis in Systemic Lupus Erythematosus. *J Rheumatol* 1997;24:654.

# 85. Mont MA, Hungerford DS. Current Concepts Review: Non-Traumatic Avascular Necrosis of the Femoral Head. *J Bone Joint Surg Am* 1995;77:459.

# 86. Mont MA, Hungerford DS. Osteonecrosis of the Shoulder, Knee and Ankle. In: Urbaniak J, Jones JP, eds. *Osteonecrosis: Etiology, Diagnosis and Treatment.* Rosemont, IL: American Academy of Orthopaedic Surgeons, 1997;429.

! 87. Mont MA, Jones LC, Einhorn TA, et al. Osteonecrosis of the Femoral Head: Potential Treatment with Growth and Differentiation Factors. *Clin Orthop* 1998;355S:314.

+ 88. Mont MA, Maar DC, Urquhart M, et al. Results of Core Decompression for Avascular Necrosis of the Humeral Head. Average 7.4-Year Follow-Up. *J Bone Joint Surg Br* 1993;75:785.

+ 89. Mont MA, Myers TH, Krackow KA, Hungerford DS. Total Knee Arthroplasty for Corticosteroid Associated Avascular Necrosis of the Knee. *Clin Orthop* 1997;338:124.

+ 90. Mont MA, Schon LC, Hungerford MW, Hungerford DS. Avascular Necrosis of the Talus Treated by Core Decompression. *J Bone Joint Surg Br* 1996;78:827.

+ 91. Mont MA, Tomek I, Hungerford DS. Core Decompression for Avascular Necrosis of the Distal Femur. Long-Term Follow-Up. *Clin Orthop* 1997;334:124.

+ 92. Murzic WJ, McCollum DE. Hip Arthroplasty for Osteonecrosis after Renal Transplanation. *Clin Orthop* 1994;299:212.

+ 93. Nelson CL, Walz BH. Resurfacing of Only the Femoral Head in Young Patients Who Have Osteonecrosis with Collapse, Delamination, and Significant Head Involvement. In: Urbaniak JR, Jones JP, eds. *Osteonecrosis: Etiology, Diagnosis, and Treatment.* Chicago: American Academy of Orthopaedic Surgeons, 1997;405.

! 94. Ohzono K, Saito M, Takaoka K, et al. Avascular Necrosis of the Femoral Head. *J Bone Joint Surg Br* 1991;73:68.

* 95. Ono K, ed. *Annual Report of Japanese Investigation Committee for Avascular Necrosis of the Femoral Head* (in Japanese). 1987;331.

+ 96. Ortiguera CJ, Pulliam IT, Cabanela ME. Total Hip Arthroplasty for Osteonecrosis. Matched-Pair Analysis of 188 Hips with Long-Term Follow-Up. *J Arthroplasty* 1999;14:21.

! 97. Owen RS, Dalinka MK. Imaging Modalities for Early Diagnosis of Osteonecrosis of the Hip. *Semin Arthroplasty* 1991;2:169.

* 98. Phemister DB. Treatment of the Necrotic Head of the Femur in Adults. *J Bone Joint Surg Am* 1949;31:55.

+ 99. Phillips FM, Pottenger LA, Finn HA, Vandermolen J. Cementless Total Hip Arthroplasty in Patients with Steroid-Induced Avascular Necrosis of the Hip. A 62-Month Follow-up Study. *Clin Orthop* 1994;303:147.

+ 100. Piston RW, Engh CA, De Carvalho PI, Suther K. Osteonecrosis of Femoral Head Treated with Total Hip Arthroplasty without Cement. *J Bone Joint Surg Am* 1994;76:202.

+ 101. Pollack M, Dalinka M, Kressel H, et al. Magnetic Resonance Imaging in the Evaluation of Suspected Osteonecrosis of the Knee. *Skeletal Radiol* 1987;16:121.

+ 102. Rosenwasser MP, Garino JP, Kiernan HA, Michelson CB. Long-Term Followup of Thorough Debridement and Cancellous Bone Grafting of the Femoral Head for Avascular Necrosis. *Clin Orthop* 1994;306:17.

! 103. Saito S, Inoue A, Ono K. Intramedullary Hemorrhage as a Possible Cause of Avascular Necrosis of the Femoral Head. The Histology of 16 Femoral Heads at the Silent Stage. *J Bone Joint Surg Br* 1987;69:346.

! 104. Saito S, Ohzono K, Ono K. Early Arteriopathy and Postulated Pathogenesis of Osteonecrosis of the Femoral Head. The Intracapital Arterioles. *Clin Orthop* 1992;277:97.

+ 105. Salvati EA, Cornell CN. Long-Term Follow-up of Total Hip Replacement in Patients with Avascular Necrosis. *Instr Course Lect* 1988;37:67.

+ 106. Scher MA, Jakim I. Intertrochanteric Osteotomy and Autogenous Bone-Grafting for Avascular Necrosis of the Femoral Head. *J Bone Joint Surg Am* 1993;75:1119.

+ 107. Schmalzried TP, Fowble VA, Ure KJ, et al. Metal-on-Metal Surface Replacement of the Hip: Technique, Fixation and Early Results. *Clin Orthop* 1996;329S:106.

+ 108. Sedel L, Travers V, Witvoet J. Spherocylindric (Luck) Cup Arthroplasty for Osteonecrosis of the Hip. *Clin Orthop* 1987;219:127.

+ 109. Smith KR, Bonfiglio M, Montgomery WJ. Non-Traumatic Necrosis of the Femoral Head Treated with Tibial Bone-Grafting. A Follow Up Note. *J Bone Joint Surg Am* 1980;62:845.

+ 110. Smith SW, Fehring TK, Griffin WL, Beaver WB. Core Decompression of the Osteonecrotic Femoral Head. *J Bone Joint Surg Am* 1995;77:674.

* 111. Smith-Petersen MN. Evolution of Mold Arthroplasty of the Hip Joint. *J Bone Joint Surg Br* 1948;30:59.

! 112. Spencer JD, Brookes M. Avascular Necrosis and the Blood Supply of the Femoral Head. *Clin Orthop* 1988;235:127.

! 113. Spencer JD, Humphreys S, Tighe JR, Cumming RR. Early Avascular Necrosis of the Femoral Head. *J Bone Joint Surg Br* 1986;68:414.

+ 114. Springfield DS, Enneking WJ. Surgery for Aseptic Necrosis of the Femoral Head. *Clin Orthop* 1978;130:175.

! 115. Starklint H, Lausten GS, Arnoldi CC. Microvascular Obstruction in Avascular Necrosis: Immunohistochemistry of 14 femoral heads. *Acta Orthop Scand* 1995;66:9.

# 116. Steinberg ME. Management of Avascular Necrosis of the Femoral Head: An Overview. *Instr Course Lect* 1988;37:41.

* 117. Steinberg ME, Hayken GD, Steinberg DR. A Quantitative System for Staging Avascular Necrosis. *J Bone Joint Surg Br* 1995;77:34.

# 118. Steinberg ME, Hayken GD, Steinberg DR. Early Diagnosis, Evaluation, and Staging. *Semin Arthroplasty* 1998;9:203.

+ 119. Steinberg ME, Larcom PG, Stafford BB, et al. Treatment of Osteonecrosis of the Femoral Head by Core Decompression, Bone Grafting, and Electrical Stimulation. In: Urbaniak JR, Jones JP, eds. *Osteonecrosis: Etiology, Diagnosis, and Treatment.* Chicago: American Academy of Orthopaedic Surgeons, 1997;293.

# 120. Steinberg ME, Steinberg DR. Osteonecrosis. In: Kelley WN, Harris ED, Ruddy S, Sledge CB, eds. *Textbook of Rheumatology*, 3rd ed. Philadelphia: W.B. Saunders, 1989;1749.

+ 121. Steinberg ME, Steinberg DR. Resection Arthroplasty of the Hip. In: Steinberg ME, ed. *The Hip and Its Disorders.* Philadelphia: W.B. Saunders, 1991;770.

* 122. Steinberg ME, Steinberg DR. Evaluation and Staging of Avascular Necrosis. *Semin Arthroplasty* 1991;2:175.

! 123. Steinberg ME, Thickman D, Chen HH, et al. Early Diagnosis of Avascular Necrosis (AVN) by Magnetic Resonance Imaging (MRI). In: Arlet J, Mazieres B, eds. *Bone Circulation and Bone Necrosis.* New York: Springer-Verlag, 1990;281.

+ 124. Stulberg BN, Davis AW, Bauer TW, et al. Osteonecrosis of the Femoral Head: A Prospective Randomized Treatment Protocol. *Clin Orthop* 1991;268:140.

* 125. Sugioka Y. Transtrochanteric Rotational Osteotomy in the Treatment of Idiopathic and Steroid-Induced Femoral Head Necrosis, Perthes Disease, Slipped Capital Femoral Epiphysis, and Osteoarthritis of the Hip: Indications and Results. *Clin Orthop* 1984;184:12.

* 126. Sugioka Y. Transtrochanteric Rotational Osteotomy of the Femoral Head. In: Macnicol MF, ed. *Osteotomy of the Hip.* London: Mosby-Wolfe, 1996;145.

+ 127. Sugioka Y, Hotokebuchi T, Tsutsui H. Transtrochanteric Anterior Rotational Osteotomy for Idiopathic and Steroid-Induced Necrosis of the Femoral Head: Indications and Long-Term Results. *Clin Orthop* 1992;277:111.

+ 128. Sugioka Y, Katsuki I, Hotokebuchi T. Transtrochanteric Rotational Osteotomy of the Femoral Head for the Treatment of Osteonecrosis: Follow-up Statistics. *Clin Orthop* 1982;169:115.

+ 129. Sugioka Y, Mohtai M. Osteonecrosis of the Femoral Head: A Conservative Surgical Solution. In: Sedel L, Cabanela ME, eds. *Hip Surgery: Materials and Developments.* London: Martin Dunitz, 1998;105.

+ 130. Takaoka K, Nishina T, Ohzono K, et al. Bipolar Prosthetic Replacement for the Treatment of Avascular Necrosis of the Femoral Head. *Clin Orthop* 1992;277:121.

! 131. Takatori Y, Kokubo T, Ninomiya S, et al. Avascular Necrosis of the Femoral Head: Natural History and Magnetic Resonance Imaging. *J Bone Joint Surg Br* 1993;75:217.

+ 132. Tooke SMT, Amstutz HC, Delauney C. Hemiresurfacing for Femoral Head Osteonecrosis. *J Arthroplasty* 1987;2:125.

+ 133. Tooke SM, SMT, Amstutz HC, Hedley AK. Results of Transtrochanteric Rotational Osteotomy for Femoral Head Osteonecrosis. *Clin Orthop* 1987;224:150.

+ 134. Urbaniak JR, Coogan PG, Gunneson EB, Nunley JA. Treatment of Osteonecrosis of the Femoral Head with Free Vascularized Fibular Grafting. *J Bone Joint Surg Am* 1995;77:681.

* 135. Urbaniak JR, Harvey EJ. Revascularization of the Femoral Head in Osteonecrosis. *J Am Acad Orthop Surg* 1998;6:44.

+ 136. Urquhart MW, Mont MA, Michelson JD, et al. Avascular Necrosis of the Talus: Treatment by Ankle Fusion. *Foot Ankle* 1996;17:1.

+ 137. Vail TP, Urbaniak JR. Donor-site Morbidity with Use of Vascularized Autogenous Fibular Grafts. *J Bone Joint Surg Am* 1996;78:204.

! 138. Van Veldhuizen PJ, Neff J, Murphey MD, et al. Decreased Fibrinolytic Potential in Patients with Idiopathic Avascular Necrosis and Transient Osteoporosis of the Hip. *Am J Hematol* 1993;44:243.

* 139. Wagner H, Zeiler G. Idiopathic Necrosis of the Femoral Head: Results of Intertrochanteric Osteotomy and Joint Resurfacing. In: Weil UH, ed. *Segmental Idiopathic Necrosis of the Femoral Head.* Berlin: Springer-Verlag, 1981;87.

+ 140. Wagner M, Wagner H. Preliminary Results of Uncemented Metal-on-Metal Stemmed and Resurfacing Hip Replacement Arthroplasty. *Clin Orthop* 1996;329S:78.

! 141. Wang TY, Avlonitis EG, Relkin R. Systemic Necrotizing Vasculitis Causing Bone Necrosis. *Am J Med* 1988;84:1085.

+ 142. Yamamoto M, Itoman M, Sagamoto N, Morita M. Strut Bone Graft for Aseptic Necrosis of the Femoral Head: Theory and Surgical Technique. *Orthop Surg* 1983;34:902.

+ 143. Yoo MC, Chung DW, Hahn CS. Free Vascularized Fibular Grafting for the Treatment of Osteonecrosis of the Femoral Head. *Clin Orthop* 1991;277:128.

# 144. Zizic TM, Hungerford DS. Avascular Necrosis of Bone. In: Kelley WN, Harris ED, Ruddy S, Sledge C, eds. *Textbook of Rheumatology*, 2nd ed. Philadelphia, W.B. Saunders, 1985;1689.

# CHAPTER 126

# PRINCIPLES OF LIMB SALVAGE SURGERY

*Steven Gitelis, Martin Malawer, Douglas MacDonald, and Gordon Derman*

**S. Gitelis:** Rush Medical College, Chicago, Illinois, 60612.
**M. Malawer:** Washington Cancer Institute and George Washington University School of Medicine, Washington, D.C. 20010.
**D. MacDonald:** Barnes Hospital at Washington University School of Medicine, St. Louis, Missouri, 63110.
**G. Derman:** Department of Plastic and Reconstructive Surgery, Rush Medical College, Chicago, Illinois, 60612.

History of Limb Salvage Surgery
Natural History of Bone Tumors
Surgical Margins and Staging
Tumors of the Knee
Tumors of the Distal Femur
Resection of the Upper End of the Tibia
Indications and Contraindications For Limb Salvage About the knee
Reconstruction of the Knee After Resection
Soft-Tissue Coverage About the knee After Limb-Sparing Tumor Resection
Operative Technique
Complications
Tumors of the Shoulder Girdle
Overview and History
Tumor Involvement of the Shoulder—Unique Surgical and Anatomic Considerations
Preoperative Evaluation and Imaging Studies
Indications and Contraindications For Shoulder-Girdle Resection
Biopsy Technique
Rehabilitation After Shoulder-Girdle Resection
Tumors of the Scapula and Periscapular Area
Clinical Characteristics
Operative Techniques
Tumors of the Proximal Humerus
Preoperative Imaging Studies
Biopsy Technique
Management of Specific Tumors of the Proximal Humerus
Reconstruction for Tumors of the Proximal Humerus
Operative Techniques
Tumors of the Hip and Pelvis
Anatomic Considerations
Evaluation and Biopsy
Operative Techniques
Oncologic Outcome of Pelvic Lesions
Proximal Femoral Resections and Reconstructions
Chapter References

## HISTORY OF LIMB SALVAGE SURGERY

Limb salvage surgery is defined simply as removal of a neoplasm that otherwise would be treated by amputation. Limb salvage usually requires two separate but equally important procedures: (a) “adequate” removal of the tumor and (b) bone and soft-tissue reconstruction. Although the technique of limb preservation for bone tumors has only recently been popularized, isolated reports of various forms of limb salvage were published 40 years ago. At that time, low-grade tumors such as giant cell tumor and chondrosarcoma were treated by removal of the bone followed by osseous reconstruction. Usually the only options were autogenous arthrodesis and allografts. Resection arthrodesis of the knee was one of the earlier techniques described. The femoral “turn-down” or tibial “turn-up” arthrodesis was a procedure used to fuse the knee after resection of tumors involving the lower end of the femur or the upper tibia. When successful, this procedure led to knee fusion, but it was also associated with a significant complication rate.

During the 1960s, several reports on the use of human bone allografts were published. Three separate centers for this surgical procedure developed, with Ottolenghi working in Argentina (99,100), Parrish in the United States (104), and Volkov in the Soviet Union (138). These surgeons reported variable outcomes with the use of allografts for limb salvage following tumor resection. Approximately one third of their patients had an excellent outcome, one third failed, and the remaining third had reasonable results. The enthusiasm for the use of allografts increased after several reports by Mankin et al. from Boston (82,83,84 and 85), who showed that allografts could be used successfully and recommended that the mechanical and biological issues be studied.

During the late 1970s and the 1980s, limb salvage surgery became a very popular technique. This was the result of several advances. First, the imaging of bone and soft-tissue tumors improved dramatically. With the use of computed tomography (CT) scans, radioisotope scans, and magnetic resonance imaging (MRI), these tumors could be visualized precisely, and this allowed for adequate removal (26). Second, Enneking (34) carefully studied the natural history of mesenchymal tumors so that surgeons could better understand how these tumors progress and the natural barriers to their progression. In addition, Enneking et al. (40) further defined surgical margins by developing staging systems for both benign and malignant tumors. These staging systems and margin definitions are still used today.

Also during the 1970s and 1980s, there were developments in chemotherapy for bone malignancies, including osteosarcoma, malignant fibrous histiocytoma, and Ewing's sarcoma (90,111). At that time, several drugs that are effective in treating these tumors were identified and their use was well defined. Neoadjuvant chemotherapy was developed—the delivery of cytotoxic drugs prior to removal of the tumor, which leads to tumor necrosis and better oncologic outcomes. When used prior to limb salvage surgery for osteosarcoma, such drugs have been shown not only to improve patient survival, but also to reduce the risk of local recurrence to a level comparable to that for amputation (89). Simon et al. (123) compared survival data for limb salvage surgery to that for amputation and found comparable results. This further increased the enthusiasm for limb-preserving techniques, particularly because surgeons realized that patient survival would not be jeopardized.

The final technological advancement that improved the results of limb salvage surgery was the development of better reconstructive options. Allograft techniques improved during the 1980s and 1990s, and modular prosthetic replacements were developed. In addition, a combination of implants and allografts were tried with success. All of this has led to limb salvage surgery with better functional outcome and fewer complications.

## NATURAL HISTORY OF BONE TUMORS

Much of our knowledge of the natural history of orthopaedic neoplasms can be attributed to Enneking (34) and his colleagues. They studied many whole-mount surgical specimens and thereby were able to determine the natural progression of bone tumors, which led to improved surgical procedures with better oncologic outcomes. High-grade sarcomas progress in a centripetal fashion. Bone sarcomas start either within the medullary space or toward the surface of the bone. Surface tumors can be either periosteal or parosteal, originating from either the periosteum or the surface of the bone.

As malignant tumors progress, they do not respect natural barriers. They have a tendency to destroy the medullary cancellous bone. In addition, bone sarcomas can extend up the medullary space involving marrow and can be associated with “skip” lesions (37). Skip lesions are defined as discontinuous extensions of tumor within the medullary space of the bone with a disease-free interval. As the tumor progresses within the medullary space, the cortex is ultimately destroyed, frequently leading to soft tissue extension. Nearly 90% of osteosarcomas have both bone and soft-tissue extension at the time of presentation (Fig. 126.1). The host is unable to marginate a bone sarcoma, and an inflammatory and vascular zone—typically an infiltrative margin and a pseudocapsule—develops in the margin between the normal tissue and tumor. The pseudocapsule is a zone that is contaminated by microscopic islands of tumor, and therefore it does not represent a true barrier.

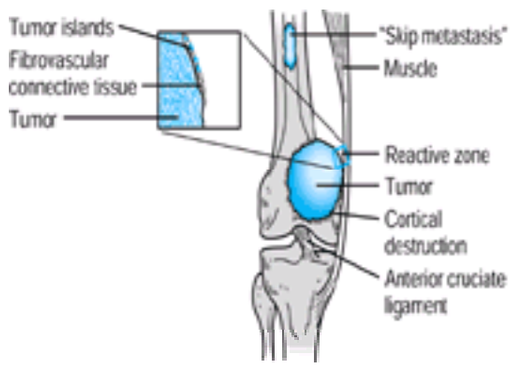


***Figure 126.1.*** Stage IIB sarcoma.

Early on, sarcomas such as osteosarcoma that involve the distal femur will respect cartilaginous barriers such as the growth plate or articular cartilage. Later, however, penetration through these structures occurs (125). Rarely, osteosarcoma will even enter the knee joint at cruciate ligament attachments.

Note that during the process of bone destruction, there is significant weakening of the bone, which may lead to a pathologic fracture. The exact mechanisms of osteolysis are not fully known. The process may be the result of proteolytic enzymes or a prominent osteoclastic response. During the process of tumor progression, the tumor outgrows its blood supply and spontaneous necrosis occurs. This necrosis reflects aggressive tumor biology and should not be misinterpreted as a chemotherapeutic response.

Finally, bone sarcomas can metastasize. As many as 80% of osteosarcomas have either microchmetastatic or macrochmetastatic disease at the time of presentation, as Link et al. (72) demonstrated in a clinical review. Rarely will a bone sarcoma metastasize to regional lymph nodes. The bone itself is another potential metastatic site, and it should be screened by radioisotope image scans. This understanding of the natural progression of bone sarcomas is useful conceptually when discussing surgical margins, because in surgical resection the interface between the tumor and the host is so important. Also, the effect of adjuvant therapy such as radiation, chemotherapy, or both on tumor progression has a significant impact when determining the appropriate surgical procedures.

## SURGICAL MARGINS AND STAGING

Enneking et al. (40) can also be credited with our current definition of surgical margins. Four types of margins have been described. The first is intralesional: The surgical dissection enters the tumor, leaving gross residual tumor within the bed. This type of margin is inadequate for bone sarcomas unless effective adjuvants are used to eradicate the residual tumor. There have been some isolated reports combining intralesional excision of bone sarcomas with adjuvants such as liquid nitrogen. These procedures should be considered experimental and reserved only for low-grade bone sarcomas.

The second margin is described as a “marginal” margin: removal of the tumor *en bloc*, but with the plane of dissection passing through the reactive zone surrounding the tumor (Fig. 126.2). This margin conceivably will leave microscopic disease in the tumor bed and by itself is not adequate for most bone sarcomas. When combined with adjuvants, however, it may be an adequate margin that is associated with a relatively low local recurrence rate. Some authors have shown this to be the case with effective neoadjuvant chemotherapy for osteosarcoma. For example, Picci et al. (107) have shown that effective chemotherapy marginates an osteosarcoma; at least conceptually, the reactive zone around the tumor becomes a true capsular margin. For the most part, oncologic surgeons try to obtain more than a marginal margin when removing bone sarcomas.

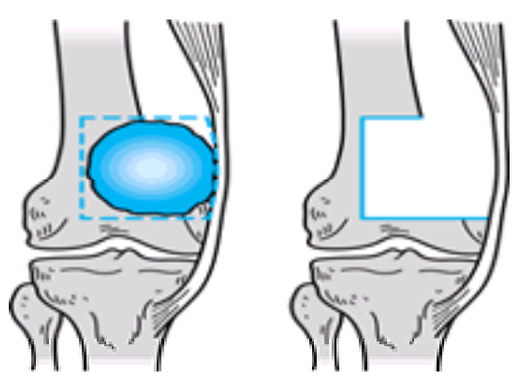

***Figure 126.2.*** Marginal surgical margin.

The next margin is called wide: *en bloc* removal of the bone tumor along with a cuff of normal tissue completely encircling the tumor (Fig. 126.3). This type of margin completely removes not only the tumor but also the reactive zone surrounding the tumor. It is considered the gold standard for most bone sarcomas and should be effective unless there is a skip lesion.

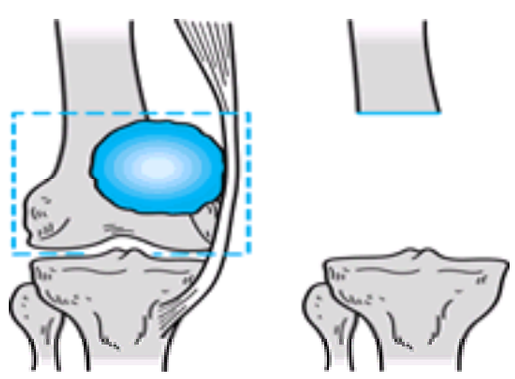

***Figure 126.3.*** Wide surgical margin.

Finally, there is the radical margin: *en bloc* removal of the tumor along with the bone from joint to joint and muscle from origin to insertion. This type of margin is rarely necessary. If there are skip lesions, a radical margin will remove both the primary tumor and the skip neoplasm. However, with aggressive adjuvant therapy for bone sarcomas, radical margins are less frequently needed.

In summary, most bone sarcomas are removed by wide *en bloc* resection. Margins, however, are getting “closer” as a result of better tumor imaging as well as effective neoadjuvant chemotherapy, which creates a barrier around the tumor. With the use of CT and MRI, it is possible to evaluate the tumor more precisely. The surgeon can then plan the resection preoperatively and decrease the need for removal of extensive amounts of normal tissue. With less normal tissue resected, functional outcomes are improving without the sacrifice of acceptable oncologic results.

The most common staging system for bone sarcoma is known as the Enneking system (40), which consists of three stages. Stage I includes low-grade bone sarcomas. Examples of stage I tumors are parosteal osteosarcoma, low-grade medullary osteosarcoma, and low-grade chondrosarcoma. Stage II tumors are

histologically high grade. Examples include conventional osteosarcoma, malignant fibrous histiocytoma, and high-grade chondrosarcoma; all of these tumors have a significant risk of metastases. Stage III sarcomas are tumors that have already metastasized. Metastasis can be to any site, including lung, lymph nodes, bone, and viscera. Tumors are further characterized as being intracompartmental (A) or extracompartmental (B). For a bone sarcoma, the bone is the compartment. If the tumor is confined to the bone, it is an A lesion, and if it extends outside the bone, it is a B lesion. For example, a nonmetastatic, high-grade conventional osteosarcoma of the distal femur with soft-tissue extension would be stage IIB. The Enneking staging system has been shown to prognosticate survival for bone sarcomas and as such is quite useful.

In this chapter, we approach limb salvage by anatomic site. We cover the workup and treatment of primary bone tumors. Factors such as patient evaluation, biopsy, surgical resection, and alternatives of reconstruction are covered, as well as some special features such as the influence of skeletal growth, and reconstructive options including complications and functional limitations. Also included is the Enneking stage for each site.

The three most common sites for malignant bone tumors are (a) the knee, (b) the shoulder girdle, and (c) the pelvic girdle. These anatomic sites account for nearly 80% of all bone tumors. Each site has its own special features that need to be considered when planning a limb-sparing surgical procedure.

## TUMORS OF THE KNEE

The distal femur and proximal tibia are common sites for both benign and malignant tumors. As an example, in the Schajowicz series of osteosarcoma published in 1994 (114), 347 out of 621 (56%) of osteosarcomas occurred in the lower end of the femur or the upper end of the tibia. The distal femur was the more common site, accounting for 229 patients. Malignant fibrous histiocytoma also commonly occurs about the knee. In the Huvos series (53), the femur accounted for 32% of the malignant fibrous histiocytomas. With a potential malignancy about the knee, it is necessary to perform appropriate staging biopsy.

The lesion is usually imaged with anteroposterior and lateral radiographs. This gives the first clue as to the type of neoplastic process occurring. A typical “conventional” osteosarcoma is a medullary tumor that involves the metaphysis or epiphysis, or both, of the lower end of the femur or upper end of the tibia. This tumor is characterized by bone destruction and frequently is associated with soft-tissue extension (Fig. 126.4). Variable amounts of ossification are seen in osteosarcoma except for the telangiectatic variant. Radiologic features such as “sunburst” or Codman's triangle, which is bone formation as a result of periosteal elevation, can be seen on plain radiographs.

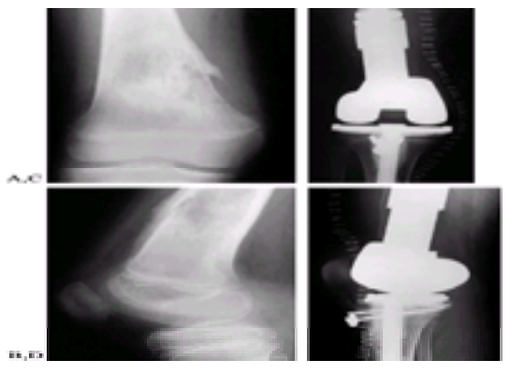


***Figure 126.4.*** **A:** Anteroposterior (AP) radiograph of an 8-year-old girl with osteosarcoma of distal femur. **B:** Lateral radiograph of osteosarcoma. Note the bone destruction and periosteal reaction. **C:** AP radiograph after resection of the distal femur. The knee is reconstructed with an expandable custom prosthesis. The articulation is a constrained condylar device. The expansion mechanism is at the top of the prosthesis. **D:** Lateral radiograph of an expandable knee prosthesis.

The next step in the imaging workup includes a technetium-99 diphosphonate bone scan and three-dimensional imaging. The technetium-99 diphosphonate bone scan is typically “hot” in osteosarcoma and will pick up multicentric disease (63). The three-dimensional imaging can be either a CT scan or an MRI (7,8,25,116). An MRI is particularly useful in determining the soft-tissue extension of the tumor and its relationship to the neurovascular bundle. This is important for tumors about the knee where posterior extension toward the neurovascular bundle is common. Usually, a pushing-type margin occurs that is readily seen with an MRI. An MRI is also useful in determining the intramedullary extent of the tumor; in addition, it picks up skip lesions. It can also determine the presence of transphyseal extension of the tumor and joint penetration, both of which are important when planning limb salvage surgery. Rarely is angiography necessary. Perform chest radiographs and a CT scan of the chest to determine the presence of metastatic disease to the lungs (19).

Once the imaging has been completed, perform a biopsy. Biopsies of the lower end of the femur or upper end of the tibia need to be performed carefully because their execution will critically affect ultimate limb salvage surgery (12,33,84,122,124). The biopsy can be either by needle or open. Needle biopsy with a skinny needle provides limited histology, and diagnosis is made primarily by cytologic features. Only an experienced pathologist can make an accurate diagnosis from a skinny needle. A core needle, on the other hand, provides more tissue for histologic diagnosis (27,28,99,114,115). The most dependable procedure for diagnosis, however, is open biopsy, which provides adequate amounts of tissue for extensive pathologic examinations and makes it possible to perform a frozen section to confirm that diagnosable tissue has been obtained.

Placement of the biopsy is important. The biopsy incision or needle puncture must be placed in an anatomic location that can be totally excised at the time of definitive limb salvage. Incisions must be longitudinal, and it is preferable to enter the tumor by passing through muscle rather than anatomic planes. It is best to biopsy the soft-tissue component of the tumor. Perform immunohistochemistry on all suspected round cell tumors as well as potential metastases. The biopsy is an important step during the sequence of events leading to limb salvage and is not without its hazards, as Mankin et al. reported (84). They found that inappropriate biopsies can lead to a false diagnosis or complications such as hematomas and bone fractures, and might possibly preclude the possibility of limb salvage. Therefore, this procedure needs to be carefully planned, preferably by the tumor surgeon contemplating limb salvage, so that no opportunities are lost.

### TUMORS OF THE DISTAL FEMUR

Once patient evaluation, staging, and biopsy have been completed, many patients are placed on neoadjuvant chemotherapy, particularly those with osteosarcoma and Ewing's sarcoma. This delivery of cytotoxic drugs for a period of time prior to resection of a tumor facilitates limb salvage by tumor shrinkage, tumor margination, and tumor necrosis. Some tumors, such as chondrosarcoma, are not sensitive to chemotherapy, and currently surgical resection represents the only means of eradicating them.

Tumors of the distal femur can be resected by either an intra-articular or an extra-articular procedure. The latter is reserved for those tumors where there is evidence of joint contamination. This contamination can be demonstrated by MRI or by joint aspiration and cytologic examination of fluid. With extra-articular resection, the quadriceps mechanism is disrupted, significantly limiting reconstructive options. The most reliable reconstruction after extra-articular resection of the distal femur is knee arthrodesis.

Fortunately, most tumors of the distal femur are amenable to intra-articular resection, which can be performed through either an anteromedial or an anterolateral extensile approach (Fig. 126.5). We prefer to use a long anteromedial longitudinal approach with a tibial tubercle osteotomy, using a sterile tourniquet after gentle gravity exsanguination.

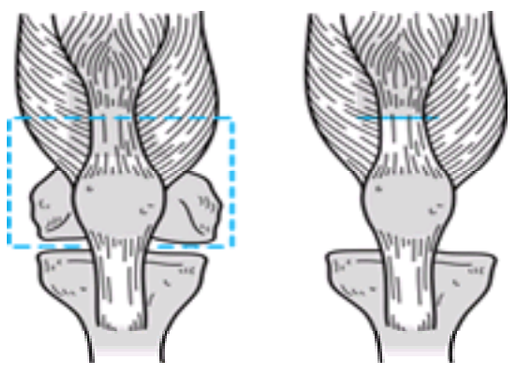

***Figure 126.5.*** Intra-articular resection of the distal femur.

- On the skin, draw out a long anteromedial longitudinal approach, elipsing out the prior biopsy site. Take this site *en bloc* with the tumor.
- On reaching the deep fascia, perform a medial parapatellar arthrotomy along with a tibial tubercle osteotomy to evert the patellar mechanism and displace it laterally.
- Perform the tibial tubercle osteotomy with a power-oscillating saw, taking a block of bone approximately 3 cm in length and 1 cm in depth, which includes the tubercle. Some predrill the fragment for replacement and fixation with a screw. This leaves an ample cancellous bed for reattachment at the end of the operative procedure.
- After everting the patellar mechanism, flex the knee and inspect the joint. Determine of the amount of resection of the quadriceps based on soft-tissue tumor extension.
- Take a cuff of normal tissue encircling the soft-tissue component of the tumor to achieve wide margins. This usually requires taking the vastus intermedius muscle along with a portion of either the medialis or the lateralis, depending on the anatomic location of the tumor. Preserve the remaining quadriceps mechanism by careful dissection.
- At this point, flex the knee acutely and perform the intra-articular dissection. Divide the anterior cruciate ligament close to the tibia, and divide the medial collateral ligament and posterior medial joint capsule.
- Divide the iliotibial band laterally by Gerdy's tubercle, and also divide the lateral collateral ligament at the joint line. Similarly, release the posterolateral capsule.
- Divide the medial and lateral heads of the gastrocnemius muscle along with the posterior cruciate ligament and then finally the posterior capsule, which allows the knee to be readily subluxed anteriorly.
- The next part of the dissection is to identify the femoral artery and vein in Hunter's canal, and dissect them carefully away from the tumor. There are numerous perforating vessels that need to be ligated to allow the vascular bundle to fall away from the posterior distal femur.
- Sharply divide the attachments to the linea aspera.
- Cut the femoral shaft with a power-oscillating saw.
- An MRI coronal image is frequently used and measured to determine the resection length. Select a clear margin beyond the tumor based on the MRI and divide the bone. Cut the remaining soft-tissue attachments and remove the distal femur. We prefer at least a 3 cm margin beyond the tumor.
- It is desirable to bisect the specimen either in an isolated area of the operating room or in the pathology lab to check for gross margins. If the margins are adequate, then perform the reconstruction with new gowns, gloves, and instruments.

If an extra-articular resection of the distal femur is necessary because of joint contamination, the procedure is different (Fig. 126.6). A tibial tubercle osteotomy is not performed, and the joint is not opened during the operative procedure.

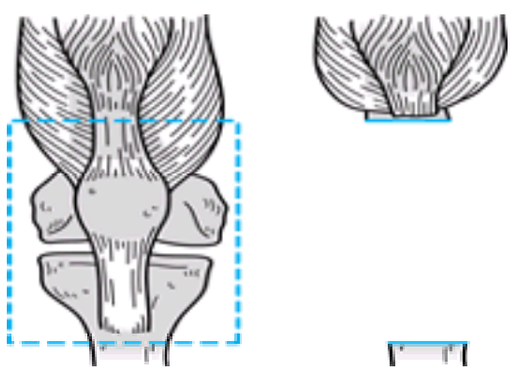

***Figure 126.6.*** Extra-articular resection of the distal femur.

- Take the patella, patellar ligaments, and tibial tubercle *en bloc* with the specimen. The soft-tissue extension of the tumor determines the amount of quadriceps mechanism to be resected.
- Dissect the vascular bundle from Hunter's canal to the upper end of the calf, and tie off perforating vessels so the vascular bundle falls posterior to the knee joint.
- The gastrocnemius muscle can either be detached from the femur with preservation of the posterior joint capsule or be taken with the specimen.
- Preserve the sciatic nerve by dissecting it free from the knee joint down to its division into tibial and peroneal components.
- Divide the quadriceps mechanism circumferentially around the femur, based on the desired length as determined by MRI. Also divide the upper end of the tibia or fibula (or both) below the joint line at an extracapsular site.
- Once this is done, divide the remaining soft-tissue attachments sharply so that the knee joint can be removed *en bloc* in an extra-articular manner. Because the quadriceps mechanism is sacrificed with an extra-articular resection, knee arthrodesis is usually performed.

**RESECTION OF THE UPPER END OF THE TIBIA**

Tumors of the upper end of the tibia pose a special problem because of the lack of soft-tissue coverage and the necessity of sacrificing the tibial tubercle and patellar mechanism. As with resection of the femur, resection of the upper end of the tibia can be either intra-articular or extra-articular, with intra-articular resection reserved for those tumors that do not contaminate the knee joint (Fig. 126.7, Fig. 126.8). With this procedure, the tibial tubercle is sacrificed, but the patellar ligament and patella can be preserved, although these need to be reconstructed by muscle and tendon transfer.

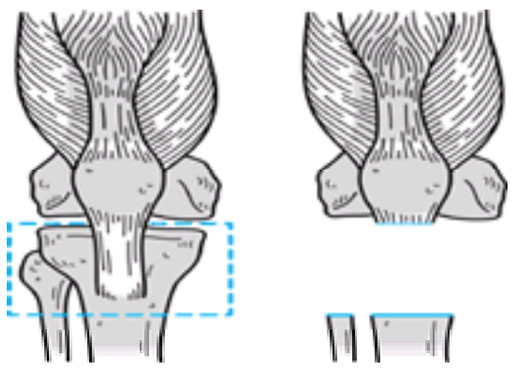

***Figure 126.7.*** Intra-articular resection of the tibia.

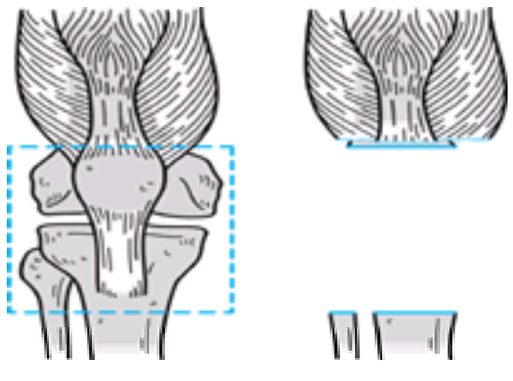

***Figure 126.8.*** Extra-articular resection of the tibia.

- The surgical approach to resection of the upper end of the tibia is usually performed through an anteromedial longitudinal incision, elipsing out the prior biopsy site.
- Raise fascial cutaneous flaps medially and laterally.
- Perform a median parapatellar arthrotomy, and divide the patellar ligament away from the tibial tubercle.
- At this point, evert the patellar mechanism laterally and flex the knee acutely. Perform the intra-articular dissection by dividing the anterior cruciate ligament, the medial collateral ligament, the posterior medial capsule, the posterior cruciate ligament, the iliotibial band, and the remaining posterior capsule.
- Divide the gastrocnemius muscle origin off of the femur.
- Divide the pes anserine tendons.
- Resect the tibia either alone or *en bloc* with the fibula. If the tibia is resected alone, identify the peroneal nerve and dissect down to its division into deep and superficial portions. Preserve the anterior compartment musculature if possible; otherwise, take it with the tibia to establish an adequate margin.
- Posteriorly, either reflect the soleus and deep posterior compartment musculature off the tibia or take it for margin as necessary.
- Dissect and preserve the popliteal artery and vein. It is frequently necessary to dissect the vessel down to its bifurcation into anterior and posterior tibial arteries. The former will pierce the interosseous membrane and enter the anterior compartment. It is necessary to dissect it into this interosseous space.
- Finally, divide the tibia at the desired length based on MRI and the remaining soft-tissue attachments, including the proximal tibiofibular joint.
- If it is necessary to take the fibula with the tibia, do not divide this joint, but rather divide the fibula at the same site as the tibia and remove these bones together *en bloc*.

## INDICATIONS AND CONTRAINDICATIONS FOR LIMB SALVAGE ABOUT THE KNEE

In recent years, there has been increased enthusiasm for limb salvage for tumors about the knee. As previously mentioned, Simon et al. (123) have demonstrated that limb salvage can have oncologic outcomes similar to those for amputation, as, for example, in their study reviewing osteosarcoma. There are, however, relative contraindications for limb salvage. Tumors involving the knee are frequently associated with a soft-tissue mass. If the mass involves the neurovascular bundle, then limb salvage should be reconsidered, particularly if the nerve is involved. The vascular bundle can be resected with the tumor and later reconstructed, but resection of the knee joint and sciatic nerve is a relative contraindication to limb salvage. Extensive skin involvement is also undesirable for limb salvage. Yet another relative contraindication is the presence of large bulky sarcomas that do not respond to chemotherapy. Joint contamination by sarcoma can be considered for limb salvage, but it usually requires extra-articular resection of the knee. Reconstruction is an important issue when determining the feasibility of limb salvage. The lifestyle or vocational demands of some patients are also relative contraindications for limb salvage. Consider durability of the reconstruction when deciding the advisability of limb salvage.

Finally, skeletal maturity is a critical feature. Sixty percent of limb growth occurs at the distal femoral and proximal tibial physes. Resection of these growth plates in very young children will lead to significant inequality of limb length. Generally patients under the age of 10 are not good candidates for limb salvage. Special techniques that allow for skeletal growth, such as an expandable prosthesis, are still experimental.

A surgical technique that has been well described for young children is the rotationplasty (13,65,89). This is not a form of limb salvage because the foot is used as a knee joint and the patient is fitted with a prosthesis. This procedure, however, leads to better function than conventional above-the-knee amputation. In 1966, Winkelmann (145) described the indications for rotationplasty. He included children under 10 years of age for whom wide margins with limb salvage were not possible. For this procedure, the sciatic nerve needs to be intact in the thigh. Winkelmann reported on 121 rotationplasties of various types; from this group there was only one local recurrence. He felt the oncologic results were similar to amputation, and the functional results exceeded conventional amputation. Complications included loss of limb circulation in seven patients, development of nonunion in four patients, and malrotation in five.

A promising technique for skeletally immature patients with tumors involving the distal femur or upper tibia is the option of intercalary resection with joint preservation. More specifically, tumors involving the metaphysis of the distal femur with an open growth plate that respond well to chemotherapy can potentially be treated by a transphyseal resection, preserving the articular surface with intercalary reconstruction. It is critical to determine whether the tumor crosses the physis, which would be a contraindication for this type of limb salvage. This type of resection can also be done for tumors involving the upper end of the tibia.

## RECONSTRUCTION OF THE KNEE AFTER RESECTION

There are two options for knee reconstruction after resection of the upper end of the tibia and lower end of the femur: arthrodesis and arthroplasty. Each procedure has advantages and disadvantages, and these need to be carefully discussed with the patient prior to making a management decision.

### *Arthrodesis*

A successful arthrodesis is a durable, stable limb. Because there are no moving parts, the physical restrictions are fewer. Manual labor is possible after knee fusion, and impact-sports activities are also possible, especially if the arthrodesis is obtained with living bone. However, late fractures have been reported for arthrodesis achieved by intercalary allograft. The disadvantages of a knee fusion are the technical difficulty in achieving a solid fusion and the loss of knee motion. The latter makes ambulating on uneven terrain difficult. It is also difficult to rise from a sitting position, and activities that require stooping are impossible. Knee arthrodesis may also cause problems with the ipsilateral hip and spine. Despite these limitations, patients can be quite functional and even participate in some sports.

There are several ways to achieve knee arthrodesis. One way is to use an intercalary allograft (Fig. 126.9). After the tumor has been resected, a properly screened frozen bone allograft can be placed in the osseous defect. Generally, the same type of bone that is removed is selected, and the articular cartilage is removed from the allograft so that the cut surface of the allograft coapts with the cut surface of the upper tibia (28,142). This creates a large cancellous bone surface for fusion to occur. It is important to fix the allograft rigidly at both ends (Fig. 126.10). This is accomplished either by a long intramedullary rod from the greater trochanter to the ankle, supplemented with a compression plate to prevent rotation, or by an osteosynthesis with two dynamic compression plates. This graft can be supplemented with a vascularized fibular bone graft to aid in healing.

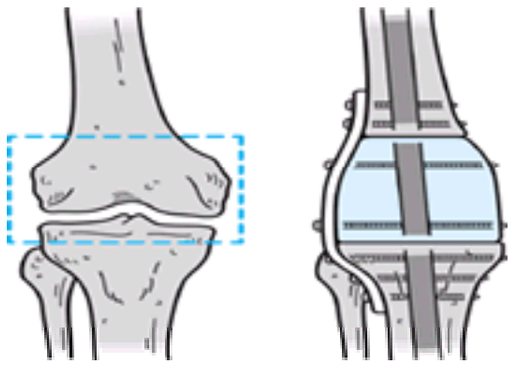

***Figure 126.9.*** Intercalary allograft arthrodesis.

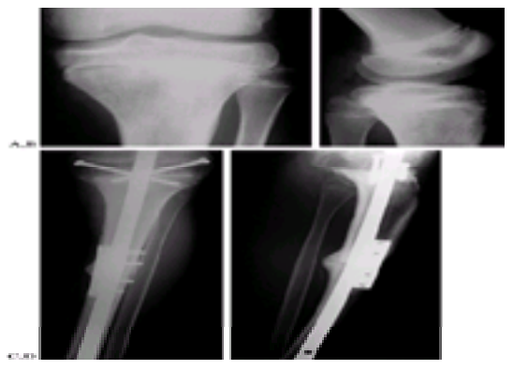

***Figure 126.10.*** **A:** AP radiograph of the knee and proximal tibia from a 15-year-old boy. An osteosarcoma involves the upper tibia. **B:** Lateral radiograph of tibial osteosarcoma. **C:** AP radiograph after resection of the upper tibia (intra-articular) and allograft arthrodesis. Note the intramedullary rod and screws for fixation. **D:** Lateral radiograph showing fusion of the knee.

Another technique is the use of a dual fibula autograft to fuse the knee after resection of the lower femur or upper tibia (Fig. 126.11). The problem with these grafts is that they are prone to stress fracture and usually need to be supplemented with autogenous iliac graft. They do not present the same broad cancellous surface for arthrodesis that an allograft affords. When a vascularized fibular autograft is used, hypertrophy of the fibula has reportedly occurred, especially with stress fractures of these grafts. Enneking and Shirley (39) described the use of local bone grafts along with an intramedullary rod to fuse the knee. The anterior cortex of the tibia is removed and placed in the resection gap. In addition, a vascularized or nonvascularized fibula can supplement the fusion.

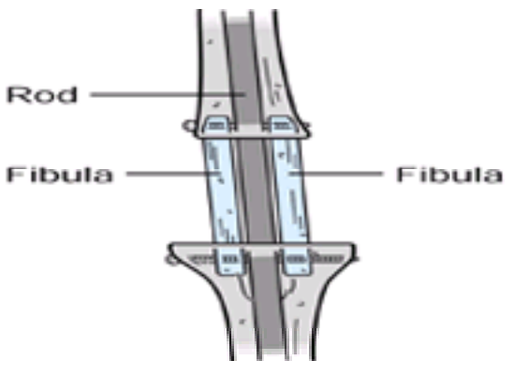


***Figure 126.11.*** Dual fibula arthrodesis.

Femoral turn-down (or tibial turn-up) arthrodesis has been described. This procedure uses half the distal femur or proximal tibia, which is transferred into the resection gap to fuse the knee. Implant arthrodesis has also been described with an intercalary prosthesis. Kuo et al. (66) published their account of a successful experience in fusing the knee with an intercalary porous titanium prosthesis.

***Arthroplasty***

Arthroplasty of the knee after resection of the femur or tibia is an alternative that has recently become popular. This reconstructive technique preserves functional knee motion. The biggest problem with this technique is durability. There are three ways to perform an arthroplasty of the knee after resection: (a) osteoarticular allograft arthrochplasty, (b) allograft prosthetic composite arthrochplasty, and (c) modular prosthetic arthroplasty. Each has advantages and disadvantages that need careful consideration.

The first two reconstructive techniques (Fig. 126.12) use biological tissue to restore either bone stock or bone stock with an articular surface. The osteoarticular allograft replaces the missing bone and, in addition, serves as a joint surface (22,43,82,83,84 and 85,91,121,147) (Fig. 126.13). Typically, these are frozen grafts from an accredited tissue bank (132). It is critical to screen all biological tissue for both viral and bacterial contamination (43,133). Frozen osteoarticular allografts are procured from donors that meet the guideline(s) of the American Association of Tissue Banks. At the time of procurement from an acceptable donor, the allografts are cultured and viral screens are performed. There is some attempt to cryopreserve the articular cartilage of the donated joint using either glycerol or dimethylsulfoxide. The cartilaginous portion of the graft is immersed in one of these cryoprotective agents. Conceivably, at least, these chemicals will decrease the water crystal formation at the time of graft freezing, because crystal formation is believed to kill the chondrocytes and limit their preservation. With cryopreservation, at least a portion of the chondrocytes survive and can continue to produce proteoglycans and other cartilaginous matrix proteins after transplantation (132).

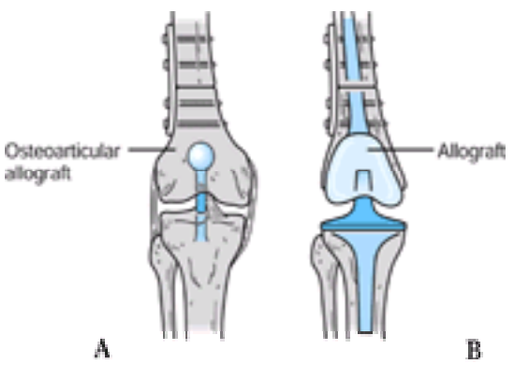


***Figure 126.12.*** Reconstructive techniques. **A:** Osteoarticular allograft. **B:** Allograft prosthetic composite.

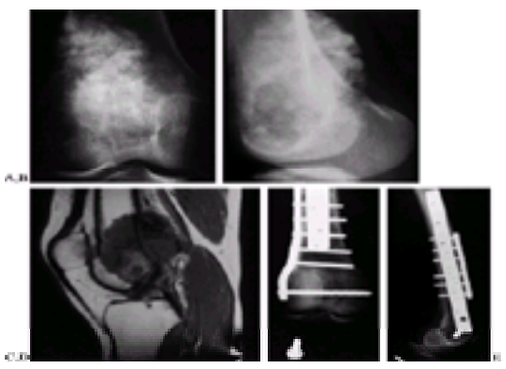

***Figure 126.13.*** **A:** AP radiograph of a 25-year-old woman with osteosarcoma of the distal femur. **B:** Lateral radiograph of osteosarcoma. The blastic lesion extends outside the bone. **C:** MRI (T1-weighted) showing both medullary and soft-tissue extension of the tumor. **D:** AP radiograph after resection of the distal femur (intra-articular) and osteoarticular allograft. **E:** Lateral radiograph of osteoarticular allograft.

The sizing of an osteoarticular allograft is critical. Prior to resection of the distal femur or proximal tibia, take radiographs with a ruler to ensure proper fitting. CT scans may be useful for measurement purposes. It is important to achieve congruity within a tolerance of 2–4 mm. No attempt at immunologic matching is performed because of the limited availability of large osteoarticular allografts. These grafts remain deep frozen at 60° to 80° in the tissue bank until their viral and bacterial screens have been reviewed and no evidence of contamination is seen (42). At the time of the surgical resection, the graft is brought into the operating room and then thawed at room temperature in lactated ringer solution.

- After removing the tumor, perform reconstruction with a new surgical setup. Fit the osteoarticular allograft into the joint to determine if it is properly sized.
- Next, fix the allograft to the host bone with either an intramedullary locked rod or dynamic compression plates. A step cut at the allograft–host bone junction can ensure rotational stability. A step cut, however, must be done precisely, especially in terms of rotation. It does increase the surface area of union and is a stable construct.

Some authors believe that the medullary canal of the allograft should be completely cleaned of all marrow- containing elements by reaming and then washing (142). In addition, some recommend the use of methylmethacrylate to strengthen the allograft. If methylmethacrylate is to be used, inject it into the medullary canal of the allograft.

Wilkins (143) recommended the intramedullary use of methylmethacrylate. He felt that it had several advantages, including increased graft strength, diminished immunogenicity, and better internal fixation. No adverse ef- fects on graft healing were observed with methylmethacrylate. Straw et al. (128) demonstrated this further in a canine model.

- With this technique, dynamic compression plating is usually chosen over intramedullary rodding. If dynamic compression plating is performed, use two plates at 90° to improve the strength of the construct. Distal femoral allografts are usually fixed with plates placed laterally and anteriorly. Try to obtain six to eight cortices of screw fixation in each fragment through each plate.
- Fill any drill hole in the allograft with a metallic screw, because empty holes tend to be sites of revascularization and resultant stress fracture.
- After fixing the allograft to the host bone, restore the joint ligaments. It is important when requesting the graft from the tissue bank to specify grafts with joint capsule and collateral ligaments.
- Perform a circumferential repair of the capsular and collateral ligaments with nonabsorbable sutures or staples.

Cruciate ligament reconstruction is a controversial issue. Some authors believe that joint stability is markedly enhanced with anterior and posterior cruciate ligament reconstruction, whereas others believe it is not necessary when a solid circumferential capsular and collateral ligament repair is done. Standard cruciate ligament reconstructive procedures can be performed on osteoarticular allografts as described in Chapter 89 and Chapter 90.

**Complications with Osteoarticular Allografts** Osteoarticular allograft is a pure biological solution to the problem of joint restoration after tumor surgery. As a result, it avoids implant complications and potentially restores bone stock. There are, however, numerous complications associated with osteoarticular allografts (74). First, a significant nonunion rate (approximately 10%) at the allograft–host bone junction has been reported, especially in patients receiving chemotherapy. For example, Capanna et al. (16) published the Rizzoli experience with allograft nonunion. The highest incidence of nonunion was at diaphyseal junctions (50%). More than 90% of the cortical cancellous junctions healed. The authors observed that a gap between allograft and host bone was a contributing factor to nonunion. Autogenous grafting of the allograft–host bone junction was also recommended. If a nonunion develops, autogenous grafting at the allograft–host bone junction is usually necessary.

Another complication associated with an osteoarticular allograft is fracture (131); the reported incidence of allograft fracture is around 10%. Berrey et al. (9) classified the types of fractures seen with allografts: type I is rapid graft dissolution, type II is diaphyseal fracture, and type III is joint fragmentation. They successfully treated 80% of their allograft fractures without removing the graft. These fractures can occur at any time after implantation, and they are prone to occur at sites of revascularization or screw holes. These fractures can be either joint surface, metaphyseal, or diaphyseal. Although some allograft fractures can be managed nonoperatively, the majority require either bone grafting or a repeat osteoarticular allograft procedure.

Joint degeneration is another problem with osteoarticular allografts. Although there is a potential for maintenance of the viability of some chondrocytes during the freezing process, joint degeneration will inevitably occur. This can be minimized by avoiding incongruity of the joint with proper fitting. But even with a well-fitted allograft, joint degeneration occurs and is sometimes asymptomatic. Some degeneration may be the result of ligament instability. The symptomatic patients with joint degeneration will require a repeat arthroplasty. If the joint degenerates, it is feasible to use the osteoarticular allograft bone stock and simply do a resurfacing arthroplasty.

**Allograft Prosthetic Composite Arthroplasty** Allograft prosthetic composite arthroplasty of the knee is a combination of biological and implant reconstruction (Fig. 126.14, Fig. 126.15). This procedure replaces the resected bone tissue with a frozen allograft but, in addition, resurfaces the joint with a metallic prosthetic device (44,50). The allograft–host bone junction needs to be rigidly stabilized, as in an osteoarticular allograft. This can be accomplished either with a long-stemmed femoral prosthetic component that bridges the junction or with the use of dynamic compression plating. The choice of prosthetic device can range from a constrained rotating hinge to a less constrained device. The latter requires careful soft-tissue reconstruction, as in an osteoarticular allograft, but it does not require cruciate ligament reconstruction.

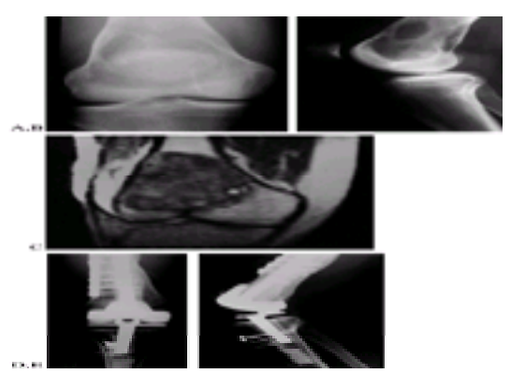

***Figure 126.14.*** **A:** AP radiograph of the distal femur in a 24-year-old man. A low-grade osteosarcoma is present in the distal femur. **B:** Lateral radiograph. Note the marked bone destruction. **C:** MRI scan, coronal image (T1-weighted). The tumor involves the lower end of the femur. **D:** AP radiograph after resection of the distal femur (intra- articular). The knee is reconstructed with an allograft and rotating hinge knee prosthesis. **E:** Lateral radiograph of knee reconstruction.

***Figure 126.15.*** **A:** AP radiograph of an 18-year-old man with a malignant fibrous histiocytoma of the upper tibia. **B:** Lateral radiograph demonstrates bone destruction. **C:** AP radiograph after resection (intra-articular) of the upper tibia. The knee is reconstructed with an allograft and rotating hinge prosthesis. Note the staples repairing the patellar ligament.

The advantage of an allograft prosthetic composite arthroplasty is the restoration of bone stock by the allograft and the maintenance of the medullary canal of the host bone without bone cement. This is an advantage over the modular oncology device, which is fixed by a long medullary stem in bone cement. Theoretically, at least, an allograft prosthetic composite arthroplasty is easier to revise than a modular oncology device because there is no cement in the femoral medullary canal. Still, healing at the allograft–host bone junction can be a problem, especially with chemotherapy, but it provides better joint stability than an osteoarticular allograft because of the bearing surfaces of the prosthesis.

Modular oncology implants are now available (10,64), and they can replace the missing bone with metallic components that can be assembled in the operating room, but they have a constrained knee articulation (Fig. 126.16, Fig. 126.17 and Fig. 126.18). Most of these are a variation of the kinematic rotating hinge knee. This type of articulation allows for varying amounts of rotational freedom through a tibial bearing, and for flexion and extension through a hinge axle mechanism between the tibial and femoral components. These devices are usually fixed to the host bone with cemented intramedullary stems. They do have the option of a porous collar where extracortical bone fixation can occur. Their primary method of initial fixation, however, is the cemented intramedullary stem. The femoral modular oncology device can replace any amount of femur resected. In fact, these devices can replace the entire femur with both a hip articulation and a knee articulation.

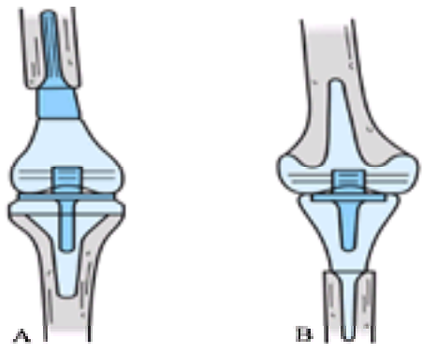


***Figure 126.16.*** Modular oncology prostheses. **A:** Femur. **B:** Tibia.

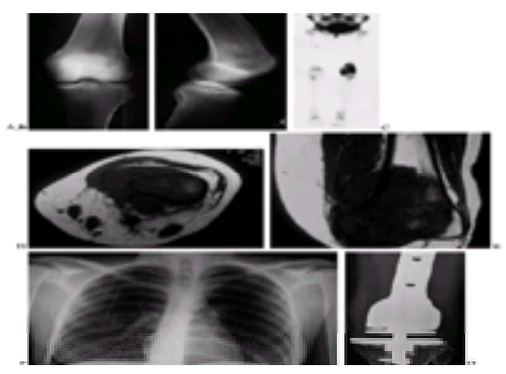

***Figure 126.17.*** **A:** AP radiograph of distal femur of an 18-year-old woman. The osteosarcoma is difficult to see. There is an area of sclerosis by the medial femoral condyle. **B:** Lateral radiograph. There is medullary sclerosis and loss of the anterior cortex. **C:** Technetium bone scan shows intense activity in the distal femur. **D:** Transverse MRI (T1-weighted). The osteosarcoma replaces the medullary bone with a large soft-tissue mass. **E:** Coronal MRI (T1-weighted). The medullary extent of the tumor is precisely visualized. **F:** AP chest radiograph. Note the intravenous catheter for chemotherapy. **G:** AP radiograph after resection of the distal femur (intra-articular) and modular oncology prosthesis.

***Figure 126.18.*** **A:** AP radiograph of 17-year-old girl with osteosarcoma of the proximal tibia. Note the sclerotic tumor in the medial tibial condyle. **B:** Lateral radiograph of the tibial osteosarcoma. **C:** AP radiograph after resection of the proximal tibia (intra-articular) and modular oncology tibial prosthesis. **D:** AP radiograph of the tibial shaft. Note the cemented intramedullary stem.

The modular oncology prosthesis has the fewest short-term complications. It provides for immediate bone restoration and stability (17,110). Bone healing does not need to occur. The modular oncology prosthesis allows early restoration of function with immediate weight bearing. In addition, joint stability is provided by the rotating hinge mechanism. Its potential disadvantage is long-term disability. Any part of the articulation can break by either yield failure or fatigue failure. The intramedullary stems can loosen and also can fracture.

Kawai et al. (58) reviewed 40 patients with prosthetic replacement of the knee after resection for malignant bone tumors. Their median follow-up was 8 years (range, 5–17 years). Implant survivorships were 85%, 67%, and 48% (at 3, 5, and 10 years). The complication rate was 45%, with aseptic loosening of the femoral component being the most common problem. Others (21,31,51,93,147,148) have reported 5-year implant survivorships ranging from 63% to 90%. These reports, however, had shorter follow-ups (34–77 months, mean). Despite potential problems, modular oncology prostheses represent the most popular method of performing a knee arthroplasty after resection of the knee.

The options for tibial reconstruction are identical to femoral reconstruction (139). There are, however, two major differences (11). First, soft-tissue coverage of a tibial reconstruction is critical. Soft-tissue coverage can be accomplished by either local rotation flaps or free flaps. Relying simply on skin to cover a tibial reconstruction is associated with a high complication rate. A second difference for tibial reconstruction is the problem of restoring the quadriceps mechanism (41,52,106). Because the upper end of the tibia is resected, the patellar ligament needs to be reattached to restore the function of the quadriceps mechanism. This can be accomplished either by the use of an allograft to which the patellar ligament can be reattached or by a local muscle rotation flap to which the patellar ligament can be reattached. This latter procedure is frequently performed for patients reconstructed with a modular oncology prosthesis.

An expandable prosthesis is available for skeletally immature patients (60,61,136) (Fig. 126.4). This metallic device allows a lengthening expansion as needed for skeletal growth (69). However, children have to return to the operating room on a fairly regular basis to lengthen the device, and this follow-up surgery can be associated with significant morbidity. Frequently, scar needs to be released to allow the lengthening mechanism to work. Complications such as infection, loosening, implant breakage, and flexion contractures have been reported with the expandable knee prosthesis (59,60 and 61,134). Kenan and Lewis (61) reviewed their experience with an expandable endoprosthesis for 40 children with bone tumors. Of these 40 patients, 20 were followed at least 5 years, and 18 of the 21 required revision. The mean implant survivorship was 68 months for cemented devices. There was a high complication rate in this series, and most patients developed stiffness of the knee. Ward et al. (140) reported similar results with an expandable prosthesis. It should be considered experimental, and more time is needed to prove its safety

and effectiveness.

In conclusion, limb salvage about the knee is an effective procedure and a viable alternative for the treatment of malignant tumors. There are several options of reconstruction, each with advantages and disadvantages. The long-term durability of these reconstructions is still questionable. It is important to pay very careful attention to technical detail to ensure an acceptable outcome. Complications need to be anticipated and treated aggressively. Patient satisfaction with limb salvage for tumors about the knee appears to be good, and this in turn encourages oncologic surgeons to continue with this form of treatment.

## SOFT-TISSUE COVERAGE ABOUT THE KNEE AFTER LIMB-SPARING TUMOR RESECTION

### *Principles of Soft-Tissue Reconstruction*

Unlike limb-sparing surgery about the knee region, which has had many new developments and changes in surgical techniques, the principles of soft-tissue reconstruction remain remarkably constant. The main goal is to promote uncomplicated primary wound healing. The wide oncologic resection of the tumor and subsequent orthopaedic reconstruction of the bone or joint defect interrupts major regional blood vessels, depriving the wound margin of its axial blood supply (105). The tenuous vascularity of these flaps and the creation of a large defect with potential dead space, combined with the superficial location of the prosthesis, demands reliable, well-vascularized, durable, and flexible soft-tissue coverage. It is important to emphasize that tension-free closure of the defect must be obtained and dead space obliterated, which makes it necessary to add more tissue. To achieve this, local muscle transposition has been the mainstay of soft-tissue reconstruction, with distant microvascular free tissue transfer and fasciocutaneous flaps used when necessary (52).

The most common and potentially limb-threatening complications of these limb-sparing procedures include failure of wound healing, flap necrosis, and infection, which can ultimately lead to exposure of the prosthesis or loss of the limb (79,109). Many patients receive preoperative adjuvant chemotherapy or radiation therapy, and they are therefore immunosuppressed and have decreased wound-healing capabilities at the time of surgery (29). Satisfactory postoperative soft-tissue healing is absolutely required to resume chemotherapy and/or radiation if necessary. Obviously, serious complications involving soft-tissue coverage can have serious effects. Problems such as infection; exposure of the implant; and withholding of chemotherapy, radiation therapy, or antithrombotics threaten a successful result from the limb-sparing surgery and even the patient's life. Complications increase the length of hospital stay and delay ambulation and range-of-motion (ROM) exercises, increasing the possibility of loss of some limb function.

To obtain stable, well-vascularized, and, in select cases, even functional soft-tissue reconstruction, total muscular envelopment of the exposed bone and the joint prosthesis (metal, plastic, allograft, or homograft) is necessary. Local muscle flaps using the medial and lateral gastrocnemius, soleus, portions of tibialis anterior, flexor digitorum longus, and flexor hallucis longus are most commonly used for this soft-tissue reconstruction. The medial gastrocnemius muscle serves as the mainstay of muscle reconstruction (46,88,113). The muscle is readily available in the operative field, has a reliable vascular supply (one of the most predictable of all lower extremity muscle flaps), and is of sufficient size to cover the majority of knee defects (79). It is possible to enlarge coverage by scoring the fascia of the muscle; splitting the muscle; augmenting the muscle envelope with adjacent muscles such as portions of the tibialis anterior, soleus, and flexor digitorum longus; or a combination of these methods. If necessary, converting to a medial gastrocnemius island flap can enhance the versatility of coverage, size, and location (3). The gastrocnemius muscle has the additional benefit of providing a well-vascularized segment of tendon that can be used for extensor reconstruction about the knee. In our own patients, using the gastrocnemius muscle for reconstruction has been very successful in providing excellent knee extension with normal gait.

We use free-muscle transfer flaps readily when larger defects dictate their use (117,146). The latissimus dorsi is the first choice for free-muscle transfer because of its size, reliable vascular supply, ease of harvesting, and large, lengthy pedicle (141). It also has an optional, extremely predictable skin paddle that offers good protection from radiation and trauma. The tendinous portion of this muscle also can be used for extensor reconstruction about the knee. Other free-transfer options include the rectus abdominus and the gracilis muscles. All of these muscle flaps, both local and distant, have been successfully used without causing significant donor site functional deficits. This is especially true of the medial and lateral gastrocnemius muscles, the soleus muscle, and the tibialis anterior and flexor digitorum muscles when partially transferred in the proper fashion. In the pediatric age group, there have been no deleterious effects at either the donor or recipient sites with subsequent growth and development.

The majority of defects are covered with muscle and split-thickness skin grafts, which give an acceptable cosmetic result. We discourage the use of a composite myocutaneous flap of the gastrocnemius muscle. Donor site closure is extremely difficult, it limits the use of the muscle in tendon reconstruction, and it decreases its excursion and coverage area. Finally, lateral fasciocutaneous flaps can be used selectively to cover smaller areas or in patients whose local muscle flaps are insufficient for total coverage and whose medical conditions contraindicate a lengthy microvascular free muscle transfer (48,108). See Chapter 8 and Chapter 35 for more details.

## OPERATIVE TECHNIQUE

### *Preoperative Planning*

Cooperative preoperative planning that involves both oncologic and reconstructive surgeons is essential to determine the amount of tissue to excise and how to deal with scars and zones of irradiated and injured tissues (4). The timing of surgery and dosages of chemotherapy and radiation therapy must be coordinated with the oncologist and radiation therapist as well, particularly concerning the dates when platelet, red blood cell, and white blood cell counts reach their lowest points. Perform angiograms (a necessity for free-tissue transfer and atypical cases) at least 48 hours prior to surgery, and catheterization entrance sites must be through an uninvolved alternate extremity. Administer appropriate preoperative antibiotics, insert a Foley catheter, and take care to protect peripheral nerves and pressure points (especially the heels) with padding during this long operative procedure.

### *Intraoperative Procedure*

- Widely excise all areas of involved skin and incision sites, taking special attention to elevate the adjacent skin as fasciocutaneous flaps to decrease ischemia (79).
- After excising the tumor and bone completely, examine the knee region for its remaining blood supply.
- Dissect the nicely exposed deep portion of the gastrocnemius muscle at this time, if desired (Fig. 126.19). Identify the sural arteries and veins and dissect them back to their popliteal artery takeoff to enhance pedicle length or if using an island flap. Take care to preserve and protect these structures, as 3–5 mm vessels are the main vascular pedicles to the gastrocnemius muscles.

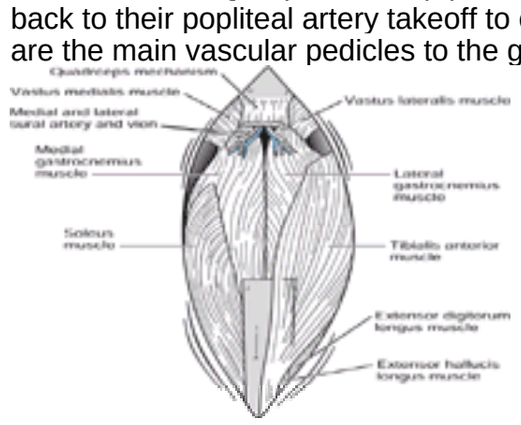


***Figure 126.19.*** Exposed defect of the knee region after tumor resection.

- At this point, if possible, close the soft tissues posterior to the prosthesis or arthrodesis. This includes the origins of the gastrocnemius muscles proximally, and the tibialis posterior to the soleus muscles more distally (78).
- Obtain hemostasis, and irrigate the tissues with antibiotic solution.
- After the prosthesis is in place, dissect the remainder of the gastrocnemius muscle. If necessary, a second, “stocking seam” longitudinal incision midposteriorly can be helpful during harvesting of the medial gastrocnemius muscle (46). The most tenuous blood supply is to the medial fasciocutaneous flap, and this can be improved if the stocking seam incision is made parallel and distal, leaving as wide a skin bridge as possible.
- To reconstruct the extensor mechanism, attach the patellar tendon remnant to the loop on the tibial component using heavy #5 nonabsorbable sutures.
- With the knee at neutral flexion, attach the tendon snugly to set proper quadriceps tension (Fig. 126.20*A*). This sutured reattachment now serves as the foundation for the extensor reconstruction.

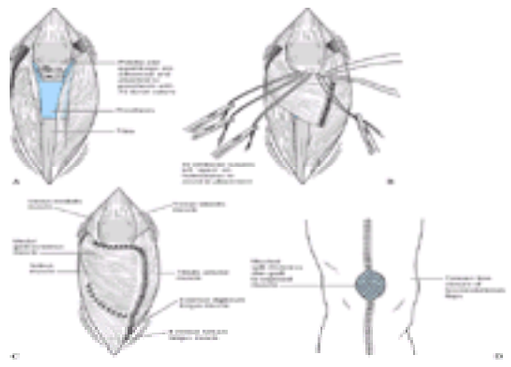

***Figure 126.20.*** **A:** Advancement reconstruction of joint capsule and quadriceps extensor mechanism. **B:** Medial gastrocnemius muscle transposition for extensor mechanism reconstruction. **C:** Completed muscular encasement of external tendon reconstruction, prosthesis, and bone. **D:** Completed tendon and soft-tissue reconstruction of defect.

- Next, rotate the medial gastrocnemius muscle into position, scoring the muscle's overlying anterior fascia so the muscle spreads to fill the defect. Suture the tendinous portion of the muscle underneath (now posterior) proximally (along the top) to the loop and to the remnants of the patellar tendon in a “vest-over-pants” fashion using #2 nonabsorbable interrupted sutures. Leave the suture ends open and secured by hemostats to assist in placement. Suture the medial hamstrings to this tendon as well, with the final portion of the gastrocnemius muscle sutured to the remaining lateral tibial periosteum and ligaments (Fig. 126.20*B*).
- After the proper distribution of sutures is complete, tie the #2 nonabsorbable sutures, reinforcing proper quadriceps tension.
- If additional tendon graft is required to aid in extensor mechanism reconstruction, use an extended medial gastrocnemius flap, including the medial portion of the Achilles tendon (54). All remaining portions of the prosthesis or arthrodesis are now covered with the adjacent muscles, thereby forming a complete muscular envelope.
- Laterally, portions of the tibialis anterior can be advanced or even split off to preserve function if the tendon and a sufficient portion of muscle are left attached. On the medial side of the tibia, the soleus muscle chproximally—portions of the flexor digitorum longus and flexor hallucis longus muscles distally, if necessary—can be sutured to the lateral musculature, completing the muscular encasement (Fig. 126.20*C*).
- Advance the fasciocutaneous flaps developed at the beginning of the surgery and suture them free of tension into position, tucking the muscle flaps underneath with tie-over bolsters if necessary. Because uncomplicated primary wound healing is of paramount importance, we have found it best to resect any questionably viable flap edges, releasing tension from these flaps whenever possible, even if it means grafting larger portions of muscle.
- Graft the remaining exposed muscle with meshed split-thickness (0.012 inches thick) skin grafts harvested from the lateral upper thigh region and sutured in place with 5-0 rapidly absorbing sutures (Fig. 126.20*D*).
- Using two large hemovac drains to prevent hematoma, dress the grafts and flaps, and apply a posterior splint from toes to upper thigh.

#### *Postoperative Care*

Check pulses before leaving the operating room, and temporarily discontinue epidural catheter solutions in the postanesthetic recovery room to assess motor function. The muscle flaps are sensitive, and patients do feel referred pain posteriorly when the transposed gastrocnemius muscle is palpated. If the pain is extreme, take down the dressings to rule out hematoma, pressure on the flap, or muscle ischemia. Keep the patient at strict bed rest with the leg slightly elevated and the posterior splint in place for approximately 5 days while postoperative wound checks and dressing changes are performed. If the flaps are viable, there is no bleeding, and the swelling is resolving, place the knee in nearly full extension in a windowed cast and discharge the patient at 5–7 days postoperatively. If possible, fit a knee–ankle foot orthosis prior to discharge for later use. Allow the patient up out of bed at 2 weeks postoperatively, and chemotherapy or radiation therapy may start 3 weeks postoperatively if primary healing is complete or if there is no drainage and only small superficial wounds remain.

Following this particular knee arthroplasty, it is important to prevent an extensor lag; therefore, avoid immediate postoperative motion (78). Start knee flexion exercises at 8 weeks postoperatively if wound healing is uncomplicated. If an extension lag develops, then immobilize in extension for another 4–6 weeks. Use a knee–ankle–foot orthosis until adequate active extension of the knee is present, which is usually at 4–6 months.

### COMPLICATIONS

The most common and one of the most deleterious complications is wound necrosis (18,30,109). At times the diagnosis can be difficult. In our experience, violaceous discoloration of the large fasciocutaneous flaps is an ominous sign and uniformly leads to necrosis. Intraoperative marking of the level of the prosthesis or the allograft on the skin surface can help future management decisions. Surgical debridement with secondary reconstruction is recommended as soon as the necrosis diagnosis is established. Perform all significant debridements in the operating room; they should not be taken lightly. Debridement, if performed during the first several days, can have excellent results (46,87). If the necrosis extends down to the prosthesis or allograft, copiously irrigate with antibiotic solution using a pulsatile evacuator. Then do a new reconstruction with flap readvancement, skin grafting, or new muscle flaps, including free-tissue transfer if necessary.

Additional complications include nerve injuries, which in most cases are a neurapraxia and resolve with time (109). In some cases, arterial spasm is present. If pulses remain absent postoperatively, and arteriograms may be required during the first 6 hours to rule out vascular injury or thrombosis. During the course of tumor extirpation, if nerve segments or blood vessels require resection, immediate reconstruction is recommended. Saphenous vein and sural nerve grafts are readily available in the operative field; take care to cover all grafts with well-vascularized muscle. Pressure necrosis can be problematic, and meticulous padding of pressure points is necessary, starting with the preoperative period through the postoperative cast and splinting. The operative limb has altered blood and nerve supply and is more susceptible to pressure necrosis.

In our group of patients, infection has been conspicuously absent. This could be explained by the use of perioperative antibiotics, vertical laminar airflow operating rooms with personal exhaust suits for all members of the surgical team, and full muscular closure over the prosthesis and development of fasciocutaneous flaps, with prompt treatment of zones of wound necrosis (109).

## TUMORS OF THE SHOULDER GIRDLE

Each bone of the shoulder girdle—the proximal humerus, the scapula, and the distal third of the clavicle—can give rise to a primary malignant bony tumor or be involved by an adjacent soft-tissue sarcoma (23). The proximal humerus is one of the most common sites for high-grade malignant bony tumors in both adults and children, and it is the third most common site for osteosarcomas. Chondrosarcomas, which commonly involve the shoulder girdle, often arise from the scapula or the proximal humerus. The bones of the shoulder girdle may also be involved secondarily by high-grade soft-tissue sarcomas that often require resections similar to that used in the surgical treatment of high-grade primary bony sarcomas with an extraosseous component.

Metastatic tumors often involve the shoulder girdle, and because of the extent of bony destruction and the presence of large extraosseous components, the treatment is sometimes similar to that for primary malignant bony sarcomas. This pattern is most common with the hypernephromas (renal cell carcinomas), which have a unique propensity to involve the proximal humerus, often as a solitary metastasis.

The resection of a malignant bony tumor of the shoulder girdle with subsequent shoulder-girdle reconstruction consists of three stages (75):

1. Wide surgical resection of the tumor using the principles already discussed
2. Reconstruction of the skeletal defect following the principles of orthopaedic skeletal reconstruction
3. Multiple muscle transfers to cover the skeletal reconstruction and to provide stability of the shoulder girdle and support for the extremity

The aim is to provide a stable shoulder girdle with a functioning elbow. The various surgical techniques currently in use for reconstruction of a segmental defect of the humerus or shoulder girdle all offer some degree of stability, function, durability, ROM, and preservation of motor power.

### OVERVIEW AND HISTORY

Initial reports of shoulder-girdle resections were confined to the individual bones or portions of the scapula. The first mention of a scapular resection in the literature is a partial scapulectomy that Liston performed in 1819 for an ossified aneurysmal tumor (73). In 1837, Mussey treated a recurrent chondrosarcoma by glenohumeral disarticulation (94). Syme performed a near-total scapulectomy with resection of the clavicle for a tumor in 1856 (129). This is the first reported total scapulectomy. In

1909, De Nancrede published a detailed review of “the end results after total excision of the scapula for sarcoma” (25). He concluded that anything less than a forequarter amputation for shoulder-girdle tumors was inadequate, thereby bringing scapular resections into disrepute for half a century.

Pack and Baldwin are credited with the revival of the procedure (102). In 1965, Papioannou and Francis reported on 26 scapulectomies and described the indications and limitations of the procedure (103). Today the indications are quite limited. Nonetheless, the first limb-sparing attempts involved tumors of the scapula.

The Tikhoff-Linberg interscapulothoracic resection is the first modern attempt at a total *en bloc* shoulder-girdle resection, and subsequently many shoulder-girdle resections have been inappropriately called Tikhoff-Linberg procedures (5,86,87,112). Two surgeons described the Tikhoff-Linberg intrascapulothoracic resection, or triple bone resection: Baumann, a Russian surgeon who worked with Tikhoff, described it in 1914 (5), and Linberg, an English surgeon, in 1928 (71). Between 1908 and 1913, Tikhoff and Baumann performed three scapula resections with the proximal humerus (that is, extra-articular resections of the glenohumeral joint). When Linberg published his classic paper in English in 1928, he named Tikhoff as the originator of the operation (71).

Since then, a number of new procedures and modifications of shoulder-girdle resections have been developed. Most have been reported as Tikhoff-Linberg resections or modified Tikhoff-Linberg resections (47,87,102), inaccurate eponyms for the procedures performed. The Tikhoff-Linberg resection was never intended to refer to resections of major tumors of the humerus; its originators intended it to be used only with intrascapulothoracic resections for sarcomas of the scapula and the periscapular soft tissues.

In 1965, Papioannou and Francis (103) described a three-part classification for scapulectomies: (a) total scapulectomy and nearly total scapulectomy, (b) radical subtotal scapulectomy, and (c) subtotal or partial scapulectomy. In 1968, Samilson et al. (112) revised this classification, adding the classical intrascapulothoracic resection (Tikhoff-Linberg procedure) and forequarter amputation, thereby establishing a universal classification system that covered virtually all major shoulder-girdle operations (resections and amputations) as of that date.

These two classification systems, however, are purely descriptive and refer almost exclusively to the bone resected. They do not accommodate or reflect the new concepts and new terminology that have developed in orthopaedic oncology during the past two decades. To fill this gap, Malawer et al. have described a six-stage surgical classification system (75,77,80,81). This system is based on current concepts of surgical margins, the relationship of the tumor to anatomic compartments (i.e., intracompartmental versus extracompartmental), the status of the glenohumeral joint (intra-articular versus extra-articular), the magnitude of the individual surgical procedures, and the presence or absence of the abductor mechanism (deltoid muscle, rotator cuff muscle, or both). The six-stage classification is as follows. (Fig. 126.21*A* illustrates the classifications, and Fig. 126.21*B* shows the distribution of 72 shoulder-girdle resections.)

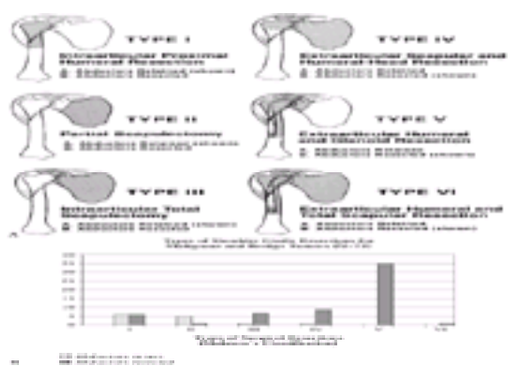

***Figure 126.21.*** **A:** Classification of shoulder-girdle resections. **B:** Distribution of 72 shoulder-girdle resections for bone tumors. (From Malawer MM, Meller I. A New Surgical Classification System for Shoulder Girdle Resection: Analysis of 38 Patients. *Clin Orthop* 1981;267:33, with permission.)

Type I: Intra-articular proximal humeral resection
Type II: Partial scapular resection
Type III: Intra-articular total scapulectomy
Type IV: Intra-articular total scapulectomy and humeral head resection
Type V: Extra-articular humeral and glenoid resection
Type VI: Extra-articular humeral and total scapular resection

Each type is further modified according to a major variable: the presence or absence of the main motor group, the abductor mechanism (deltoid and rotator cuff muscle). The abductors are present (subtype A) or partially or completely resected (subtype B). The abductor mechanism is almost always resected when there is extraosseous extension of a bone tumor in this area. The loss of any component of the abductor mechanism (deltoid muscle or rotator cuff) tends to create a similar functional disability. Regardless of histology or primary bone involvement, subtype A generally entails an intracompartmental resection, and subtype B an extracompartmental resection.

**TUMOR INVOLVEMENT OF THE SHOULDER—UNIQUE SURGICAL AND ANATOMIC CONSIDERATIONS**

The shoulder joint appears to be more prone than other joints to intra-articular or pericapsular involvement by high-grade bone sarcomas. Figure 126.22 shows the mechanisms of tumor spread. Direct capsular extension, direct tumor tracking along the long head of the biceps, a poorly planned biopsy, and pathologic fracture are mechanisms of glenohumeral contamination and make intra-articular resection for high-grade sarcomas a higher risk than extra-articular resection for local recurrence. (This is in contrast to most clinical experience with resections of the distal femur, which tend to be intra-articular.) Therefore, extra-articular resections are recommended for most high-grade sarcomas of the proximal humerus and scapula.

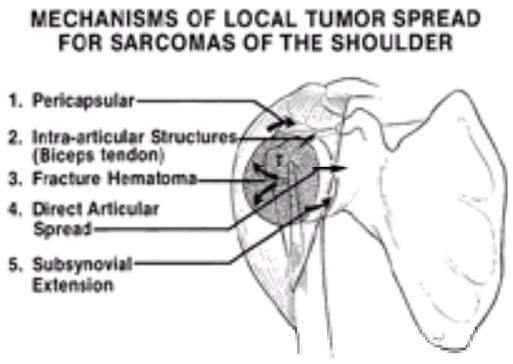


***Figure 126.22.*** Mechanisms of local tumor spread for sarcomas of the proximal humerus. There are five mechanisms of tumor spread to the capsule, synovium, and cartilage of the glenohumeral joint. An extra-articular resection is often required to perform a safe limb-sparing procedure. (From Sugarbaker PH, Malawer MM.*Musculoskeletal Surgery for Cancer: Principles and Techniques.* New York: Thieme Medical, 1992: Chapter 27, with permission.)

Frequently, the local anatomy of a sarcoma determines the extent of the operative procedure required. The following discussion addresses unique considerations of shoulder-girdle surgical anatomy (Fig. 126.23).

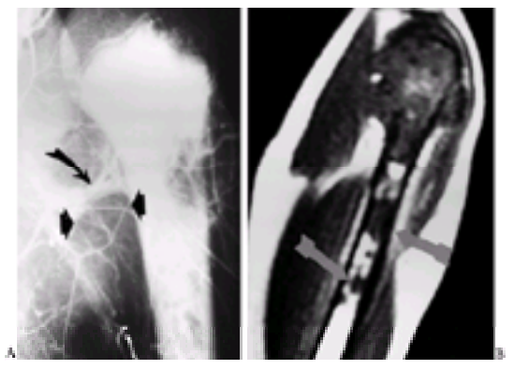

***Figure 126.23.*** Osteosarcoma of the proximal humerus. **A:** Angiogram of the proximal humerus showing large circumflex vessels supplying the tumor (*arrows*), which must be ligated prior to resection. **B:** MRI scan showing “skip” metastases (*arrows*) distal and not in continuity with the main mass. Skip lesions are seen in less than 5% of osteosarcomas and are best detected by MRI.

Often the glenohumeral joint is ineffective as a barrier to tumor spread. A lesion may cross the joint by direct extension or by other mechanisms, as shown in Fig. 126.24. It is often necessary to perform an extra-articular resection for high-grade bone sarcomas of the proximal humerus or the scapula (glenoid region).

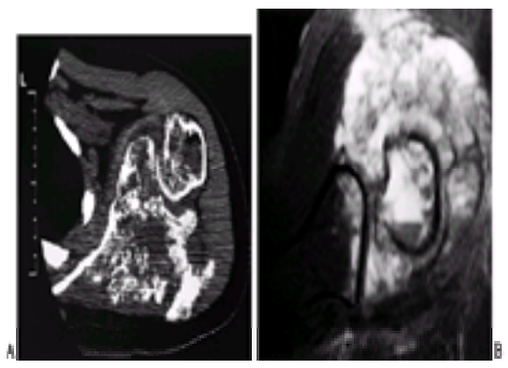

***Figure 126.24.*** Tumor involvement of the glenohumeral joint. **A:** CT scan of a large osteosarcoma of the scapula, which shows extensive involvement of the soft tissues with involvement of the glenohumeral joint. **B:** MRI scan of the same area, which shows marked involvement by the tumor surrounding and within the glenohumeral joint (*white area*, T2 pattern).

The three major cords of the brachial plexus are in close proximity to the subscapularis muscle, glenohumeral joint, and proximal humerus. Tumors involving the upper scapula, the clavicle, and the proximal humerus often displace the infraclavicular component of the brachial plexus, which then may make it necessary to sacrifice some of the major nerves.

The musculocutaneous and axillary nerves are often in contact with or in close apposition to tumors around the proximal humerus, and before proceeding with resection it is necessary to clearly identify both. The musculocutaneous nerve generally comes from beneath the coracoid and passes through the conjoined tendon or coracobrachialis muscle within a few centimeters of its origin. The position of this nerve does vary, however, and it may lay within 6–8 cm of the coracoid. It then passes through the short head of the biceps and into the long head of the biceps before innervating the brachialis muscle.

The axillary nerve is closest to most large tumors of the proximal humerus. It arises from the posterior cord and, along with the circumflex vessels, courses around the subscapularis muscle and the head and neck of the humerus to innervate the deltoid posteriorly. In patients who have large malignant tumors of the proximal humerus, the axillary nerve usually must be resected because of tumor proximity or involvement, and because it is necessary to remove the deltoid muscle to provide a satisfactory margin. With large, stage IIB bone sarcomas of the proximal humerus, it is rare that the axillary nerve and deltoid muscles can be preserved.

The brachial artery is surrounded by the three major cords of the brachial plexus and is tethered to the proximal humerus by the anterior and posterior circumflex vessels. A presurgical angiogram is extremely useful to localize the brachial artery and identify the level of the circumflex vessels. Occasionally, one finds anomalous brachial and axillary arteries that would be difficult to identify and explore if not recognized preoperatively. In general, the circumflex vessels are ligated during the initial dissection; this allows the entire brachial artery and the vein and nerves to fall away from the tumor mass. Early ligation of the circumflex vessels is key to the resection of proximal humeral sarcomas.

The radial nerve courses along the posterior aspect of the axillary sheath and exits from the posterior cord at the inferior border of the latissimus dorsi muscle. Fortunately, most sarcomas are located in the proximal third of the humerus and do not involve this nerve. However, to avoid injury the radial nerve must be isolated and protected prior to tumor resection. Sacrifice of the radial nerve is rarely necessary.

**PREOPERATIVE EVALUATION AND IMAGING STUDIES**

Appropriate imaging studies are crucial to successful resection of tumors of the shoulder girdle (75,77,80,81). The most useful preoperative evaluations are CT scans, MRI, arteriography, and three-phase bone scans (Fig. 126.25). For large tumors of the proximal humerus, a venogram may be warranted if there is evidence of distal obstruction.

***Figure 126.25.*** Osteosarcoma of the proximal humerus: staging studies and intraoperative management by resection and modular prosthetic replacement. **A:** Plain radiographs showing a typical sclerosing osteosarcoma (*arrows*) of the proximal humerus. **B:** Bone scan demonstrating extent of the tumor. Note: There are no other bony sites of involvement. **C:** Angiogram after chemotherapy showing the axillary artery and the circumflex vessels without any evidence of tumor blush. The absence of tumor vascularity is an excellent indication of response of the tumor, with marked tumor necrosis. **D:** Intraoperative photograph showing the Modular Replacement System (MRS, Howmedica, Rutherford, NJ). **E:** The postoperative radiograph following an extra-articular resection of the proximal humerus and the glenohumeral joint (type V resection).

A CT scan is more useful than an MRI in determining cortical bone changes, and it is considered complementary to an MRI in evaluating the chest wall, clavicle, and

axilla. Furthermore, the CT scan is more reliable than an MRI in the restaging of patients prior to surgery to determine the effects of induction chemotherapy, especially the bony response and the amount of tumor necrosis. It is also useful in determining the potential planes of tumor resection.

Use an MRI to determine the extent of soft-tissue involvement, especially around the glenohumeral joint, or of tumor extension along the chest wall or posterior scapula. It is often difficult to visualize the suprascapular area in patients with large tumors, which may infiltrate below the subscapularis muscle and exit near the coracoid. An MRI is especially useful in identifying the extent of intraosseous tumor, which is necessary to determine the length of the resection. Skip metastases rarely occur in this area. However, an MRI is not effective in determining the preoperative tumor response to induction chemotherapy.

The main purpose of a bone scan is to determine the intraosseous extent of the tumor defect and to evaluate for metastases. Both bone scan and MRI data are necessary to accurately evaluate intraosseous tumor extension.

Angiography is extremely useful and should be done with the arm abducted to determine the relationship of the brachial plexus and the vessels to the major tumor, the level of the circumflex vessels, and the presence of any anomalies. This is also the most reliable means of determining the response to neoadjuvant chemotherapy. The absence of vessels in the tumor or decrease in tumor vascularity indicates tumor necrosis. If there is a very good angiographic response (i.e., decrease or absence of tumor blush), it is safe to proceed with a limb-sparing resection, preserving as much normal tissue as possible and accepting close margins as long as they are negative.

If venous thrombosis or a mural thrombosis is expected, perform venography. The most suspicious finding is extremity edema. Brachial vein thrombosis is most common with large shoulder osteosarcomas and chondrosarcomas.

**INDICATIONS AND CONTRAINDICATIONS FOR SHOULDER-GIRDLE RESECTION**

Because it is possible to treat approximately 95% of high-grade shoulder-girdle malignancies safely by limb-sparing surgeries (75), forequarter amputation is now rare. The decision to proceed with limb-sparing surgery is based on the location of the cancer and a thorough understanding of its natural history. Major contraindications are tumor involvement of either the neurovascular bundle or the chest wall. Relative contraindications include pathologic fracture, extensive involvement of the shaft of the humerus, infection, and tumor contamination of the operative area from hematoma following biopsy or unwise placement of the biopsy incision. These contraindications are described next in greater detail (80).

The brachial artery is rarely involved by a tumor, although it may be in close proximity. The subscapularis and the short head of the biceps muscles often separate tumors of the proximal humerus and scapula from the vascular structures. Occasionally, however, the brachial veins are directly invaded by a tumor and may be the site of tumor thrombi.

Involvement of the musculoskeletal nerve by the tumor is rare, as is involvement of the three major cords to the brachial plexus, which follow the brachial vessels. Two of its major branches, the axillary nerve and the musculocutaneous nerve, however, may be involved, and resection of the axillary nerve is almost always required for large (stage IIB) tumors of the proximal humerus. Direct tumor extension into the brachial plexus requires a forequarter amputation. Direct tumor extension into the plexus occurs most often with axillary or chest wall sarcomas.

If an inappropriate biopsy contaminates the shoulder girdle, limb-preserving resection is often inadvisable. Today, one of the major causes for amputation of the shoulder girdle is inappropriate biopsy resulting in contamination of the pectoralis major, the chest wall, and the neurovascular structures.

Another contraindication is infection. Even with adequate resection, reconstruction of an infected field by arthrodesis, prosthesis, or allograft replacement reconstruction is extremely risky, considering that all patients with high-grade sarcomas must receive postoperative adjuvant chemotherapy. If an infection cannot be eradicated with the primary resection, amputation is advisable.

Previous surgeries also affect the feasibility of a limb-sparing procedure. The local recurrence rate is increased if a wide resection is attempted following a previous resection around the shoulder girdle.

On rare occasions, tumors of the scapula or proximal humerus with large soft-tissue components may invade the chest wall and intermingle with the intracostal muscles and the ribs. This situation usually requires a resection of the adjacent chest wall, but it is not an absolute indication for forequarter amputation because limb-sparing resection may be combined with chest wall resection.

In the rare instance of lymph node involvement documented by biopsy, a forequarter amputation may be the best way to remove all the axillary nodes as well as the proximal sarcoma. On the other hand, it is not unreasonable to proceed with a limb-sparing resection and an axillary node dissection. This method can provide long-term cure and local control.

**BIOPSY TECHNIQUE**

Because 95% of bone sarcomas have a soft-tissue component, a small needle or core biopsy is possible (Fig. 126.26). One exception may be the young patient with a suspected round cell tumor for whom more tissue for cytogenetic and immunohistochemical stains may be required. Another exception would be an older patient in whom a solitary metastatic lesion is suspected, and the pathology supports either metastatic carcinoma or a spindle cell sarcoma. This differentiation most often occurs with metastatic renal cell carcinoma. In such a case, a significant amount of tissue may be required to obtain immunohistochemical stains that will differentiate the metastatic tumor from a primary sarcoma.

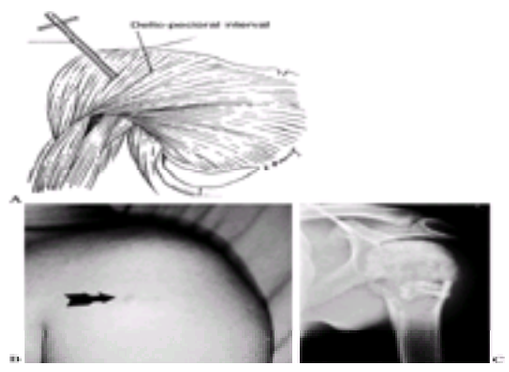

***Figure 126.26.*** Technique of biopsy of tumors of the proximal humerus. **A:** Schematic diagram showing a core needle biopsy through the anterior one third of the deltoid. Note: The axillary nerve comes in posteriorly, so the deltoid can be preserved if necessary. This does not contaminate the deltopectoral interval and thus the brachial vessels if a resection is required. **B:** Clinical photograph showing puncture site following a core needle biopsy (*arrow*). This patient had a high-grade osteosarcoma and was treated by an extra-articular shoulder-girdle resection. **C:** Plain radiograph showing the technique utilized if a small incisional biopsy is required. A 1 inch incision is utilized. A curet removes a small amount of tumor and the defect in the bone is filled with polymethylmethacrylate. The bone cement acts like a cork to prevent contamination following an open biopsy.

Most shoulder-girdle soft-tissue sarcomas are easily palpable. Multiple core needle biopsies performed through one puncture site under local anesthesia are recommended. If the mass is not palpable, perform all needle or core biopsies under fluoroscopic or CT guidance. To obtain multiple cores with only one puncture site, reintroduce the needle through the same puncture site, but vary the angle to obtain cores from several different areas. Obtain cultures routinely, regardless of the suspected diagnosis, because infection may simulate any malignancy. Touch-preps, frozen sections, or both confirm that lesional tissue has been obtained.

When an open (incisional) biopsy of the proximal humerus is required, perform it through the anterior third of the deltoid, not through the deltopectoral interval (75,81). A biopsy through the anterior third of the deltoid results in a limited hematoma that is confined by the deltoid muscle and can be resected with the tumor *en bloc*. On the other hand, an open biopsy through the deltopectoral interval will contaminate the pectoralis major muscle and provide a plane for the hematoma to dissect to the chest wall along the brachial vessels. This makes a local resection more difficult and increases the possibility of local recurrence.

Perform biopsies of scapular tumors along the lateral or axillary border of the scapula or along the intended site of the resection incision, and perform biopsy of the clavicle along the length of the clavicle. Unless there is a soft-tissue component, a small biopsy is advisable because a needle in this location could injure the brachial plexus and the neurovascular bundle.

### REHABILITATION AFTER SHOULDER-GIRDLE RESECTION

Patients undergoing shoulder-girdle resection retain hand function and good elbow function, but they lose some shoulder function, mainly abduction. From a rehabilitation perspective, the outcome of resection is clearly superior to that of a forequarter amputation or shoulder disarticulation. Furthermore, shoulder-girdle resection is less disfiguring and is associated with only minimal pain and edema. Generally, patients' acceptance of the outcome of their surgery is good to excellent.

Rehabilitation begins with an orientation program that often features pictures of patients who have undergone the procedures, and demonstrations of what one can do postoperatively. Preoperatively, a shoulder mold is fashioned using the involved shoulder, provided its contours are not distorted. The cosmetic shoulder helps to preserve the symmetry and appearance of the shoulder contour and can support a bra strap or heavy overcoat.

Have the patient use a sling postoperatively, and restrict motion until the incision is healed. Remove sutures after about 2 weeks. Control edema with an elasticized glove or elastic stockinet. At the same time, have the patient begin active, maximal head motion to preserve strength and range and to help mobilize edema.

If the incision heals per primam, start assistive elbow motion within the confines of the sling as soon as the suction catheters have been removed. At about 2 weeks, remove the sling for passive shoulder ROM and pronation and supination of the wrist. Have the patient continue to use the sling intermittently after the incision is healed, primarily for upright activities in which arm support increases comfort. Once his arm is out of the sling, have him perform full ROM of elbow (flexion, extension, pronation, and supination). He should also begin passive ROM to the shoulder (flexion, abduction, and external and internal rotation and pendulum exercise) with the help of a family member or physical therapist.

Rehabilitation depends on the type of reconstructive technique. In general, patients with endoprosthetic intra-articular allografts or composite allograft reconstruction undergo the same rehabilitation program. Those treated by arthrodesis, by allograft, or by autograft reconstruction are immobilized for 4–5 weeks to allow early bony union to take place.

## TUMORS OF THE SCAPULA AND PERISCAPULAR AREA

### CLINICAL CHARACTERISTICS

Tumors of the scapula present with pain, a mass, or both, and they may become quite large before they are brought to your attention. The most common primary malignancy of the scapula is the chondrosarcoma. Secondary chondrosarcomas occur from an underlying osteochondroma, but fewer than 2% of osteosarcomas arise from the scapula. In children, the most common malignant scapular tumor is Ewing's sarcoma. Soft-tissue sarcomas may involve the suprascapular or the infraspinous musculature and, secondarily, the scapula. Most soft-tissue sarcomas of the scapular region occur in adults. In very rare cases, radiation sarcomas of the scapula may develop secondary to radiotherapy for breast carcinoma.

Among the unique anatomic considerations is the fact that during the early stages of development, a cuff of soft tissue surrounds tumors arising within the scapula (75,78,80,81). As sarcomas enlarge, they may develop a large axillary component and invade the axillary vessels and brachial plexus. Tumors arising from the neck or glenoid usually involve the periscapular tissue and the glenohumeral joint; this is especially true of chondrosarcomas, osteosarcomas, and Ewing's sarcoma. Important anatomic areas to evaluate for extension are the chest wall, the axillary vessels, the proximal humeral and periscapular tissues, and the rotator cuff. Also, examine the axillary lymph nodes carefully, even though they are usually negative. Large suprascapular tumors extend into the anterior and posterior triangles of the neck, making resection difficult or contraindicated except for palliation.

A CT scan and MRI are the most valuable means of determining the size and extent of extraosseous disease and its relationship to the chest wall, whereas arteriography is important to determine vascular involvement. Displacement of the axillary vessels indicates anterior (axillary) extension of a tumor. Bone scans may show rib involvement or proximal humeral extension.

The biopsy site is a crucial factor in determining the final operative procedure, because inadvertent contamination of the neurovascular structures or chest wall must be avoided. For tumors arising within the body of the scapula, perform a posterior needle biopsy or a biopsy along the anterior axillary border of the scapula. With lesions involving the scapula and neck, choose a posterior approach directly through the posterior deltoid and teres minor; avoid an anterior approach. If an open biopsy is required, we recommend a small longitudinal incision in line with the incision that will be used for resection. Most operative approaches involve an incision along the axillary border of the scapula.

Certain specific tumors of the scapula and periscapular area require special management (Table 126.1) (75). Chondrosarcomas, for example, commonly arise from the scapula. Therefore, approach any large cartilaginous lesion of the scapula in an adult with a high index of suspicion. These lesions tend to be low grade with a large extraosseous component, and they are usually an Enneking stage IB. Cartilage tumors approaching the glenohumeral joint may directly involve the joint space and readily implant on the articular cartilage. In such cases, an extra-articular resection is generally recommended, with no attempt to perform an intra-articular resection. Usually a Tikhoff-Linberg resection (type IV) is curative.

| *Type of tumor* | *Scapula* | *Proximal humerus* | *Total* |
|---|---|---|---|
| Chondrosarcoma | 4 | 13 | 17 |
| Osteosarcoma | 4 | 24 | 28 |
| Ewing's sarcoma | 1 | 1 | 2 |
| Giant cell tumor | 1 | 0 | 1 |
| Osteochondroma | 2 | 0 | 2 |
| Fibrosarcoma | 2 | 0 | 2 |
| Fibromatosis | 3 | 0 | 3 |
| Hemangiopericytoma | 2 | 0 | 2 |
| Synovial sarcoma | 0 | 1 | 1 |
| Leiomyosarcoma | 0 | 1 | 1 |
| Malignant fibrous histiocytoma | 1 | 3 | 4 |
| Hypernephroma | 1 | 3 | 3 |
| Hemangiosarcoma | 0 | 1 | 1 |
| Pleomorphic sarcoma | 1 | 1 | 2 |
| Paget's sarcoma | 0 | 1 | 1 |
| Osteoblastoma | 0 | 1 | 1 |
| Total | 22 | 50 | 72 |

***Table 126.1. Histogenesis and Anatomic Site of Tumor in 72 Patients Treated by Limb-Sparing Surgery of the Shoulder Girdle***

Osteosarcomas (72), of which about 1.5% occur in the scapula, require a limb-sparing resection (type IV) or forequarter amputation. The limiting factors in performing a limb-sparing procedure are the size and extent of the extraosseous component. Neurovascular involvement requires a forequarter amputation. Evaluate chest wall involvement before surgery; if present, a partial chest wall resection *en bloc* with ablation of the primary tumor is necessary.

The traditional treatment for Ewing's sarcoma arising in the scapula has been radiation therapy in conjunction with chemotherapy, with excellent functional results. However, the treatment of Ewing's sarcoma is undergoing reevaluation. Recently, total scapulectomy (type IIIA or B), with or without prosthetic replacement, has been recommended in lieu of radiation therapy (24). Surgery has become increasingly common with the hope of increasing local control, decreasing the morbidity of radiation (especially of late secondary osteosarcomas), and increasing patient survival. Plan the surgery after induction chemotherapy, and stage the patient and the local tumor area as with patients who have other high-grade sarcomas.

It is usually possible to treat soft-tissue sarcomas arising in the periscapular musculature satisfactorily by removing the adjacent tissue *en bloc* while preserving the scapula, then following with radiotherapy. Occasionally, a soft-tissue sarcoma arising from the deeper structures will involve or encase the scapula, requiring combined scapular resection. If the tumor is distal to the scapular spine, a partial (type IIB) or total (type IIIB) scapulectomy may be adequate. Involvement of the suprascapular musculature or rotators requires an extra-articular resection (type IV).

Giant cell tumors and aneurysmal bone cysts often cause marked ballooning and destruction of the scapula. Small lesions may be treated by intralesional curettage. If the neck of the scapula is not involved, it is possible to perform a partial scapulectomy with minimal loss of function. Treat large lesions with total scapulectomy (type

IIIA) while preserving most adjacent muscles. Reconstruction involves suspending the scapula from the clavicle by a static and dynamic reconstruction. This is an excellent indication for scapular prostheses, which have recently been developed.

**OPERATIVE TECHNIQUES**

The Tikhoff-Linberg procedure (extra-articular total scapular proximal humeral resection, type IV) consists of *en bloc* removal of the scapula, clavicle, and proximal humerus and preservation of the arm (75,77,80,86) (Fig. 126.27). Indications for the procedure are low- and high-grade scapular sarcomas and periscapular and suprascapular soft-tissue sarcomas. A careful preoperative evaluation is imperative. A CT scan and MRI can help to determine possible chest wall involvement, and angiography is crucial to determine axillary vessel involvement. Contraindications to the Tikhoff-Linberg procedure are involvement by the tumor of the neurovascular bundle and of the chest wall, both requiring forequarter amputation. It is important to evaluate the interval between the tumor and vessels very carefully, and this may require surgical exploration prior to resection.

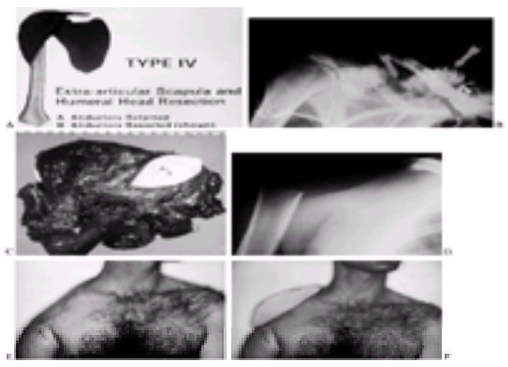


***Figure 126.27.*** **A:** Schematic of the classical Tikhoff-Linberg resection (type IV). This is an extra-articular scapular and proximal humeral resection with the abductors and deltoid removed *en bloc*. (From Malawer MM, Meller I. A New Surgical Classification System for Shoulder Girdle Resection: Analysis of 38 Patients. *Clin Orthop* 1981;267:33, with permission.) **B:** Preoperative angiogram showing a chondrosarcoma (*arrows*) arising from the superior aspect of the scapula and involving the entire suprascapular area. **C:** Operative specimen showing the resected scapula and glenohumeral joint covered by muscles in all directions. Note: The biopsy site and skin is removed *en bloc* with the tumor. **D:** Postoperative radiograph showing a resection of the scapula and glenohumeral joint *en bloc*. The remaining humerus is suspended to the clavicle by multiple muscle transfers and by the use of dacron tape (Genzyme Surgical Product Company, Fall River, Massachusetts) (see text). **E:** Clinical photograph following a Tikhoff-Linberg (type IV) resection for a high-grade soft-tissue sarcoma involving the scapula and glenohumeral joint. The extremity is suspended by the use of multiple muscle transfers and Dacron tape from the remaining clavicle. **F:** A cosmetic shoulder pad in place. The opposite shoulder was used to make a mold.

- Explore the axillary vessels, and if this interval is clear, proceed with the resection. Be prepared to convert from a limb-sparing procedure to a forequarter amputation should tumor involving the neurovascular bundles be encountered. Explore the most medial margin, the paraspinal muscles, and the base of the neck only if there is any possibility of their involvement. It is difficult to evaluate these anatomic areas thoroughly from preoperative studies alone. A forequarter amputation will not improve on this margin.
- Resection includes all the muscles arising from the scapula and inserting on the proximal humerus and an extra-articular resection of the glenohumeral joint. Occasionally, it is possible to preserve the deltoid muscle and the axillary nerve. Preserve the deltoid muscle whenever possible because it facilitates reconstruction; soft-tissue reconstruction is essential for a good functional outcome—a stable shoulder.
- The reconstruction consists of both static and dynamic support: suspension of the proximal humerus from the remaining clavicle by dacron tape (Genzyme Surgical Product Co., Fall River, MA) and muscle transfers. Suture the long and short heads of the biceps and coracobrachialis through drill holes to the remaining clavicle, and rotate the pectoralis muscle to cover the defect and to provide stability. Recent reconstructions have used a scapula and proximal humeral replacement.

In general, functional results are the same as those following a Tikhoff-Linberg resection (type IVB) and total scapulectomy (type IIIA/B): patients retain hand function and good elbow function. The shoulder should be stable and no external orthosis required. A molded shoulder pad improves cosmesis.

Total scapulectomy (73,77,83,86,94) is indicated primarily for low-grade sarcomas (stage IA/B) of the body of the scapula that involve the suprascapular area, low-grade sarcomas of the glenoid, or soft-tissue sarcomas that involve the scapula. Preoperative considerations are similar to those for a Tikhoff-Linberg resection. The neurovascular structures and chest wall must be free of disease. If the tumor extends anteriorly or laterally and involves the rotator cuff or the glenoid, perform an extra-articular resection (type IVB).

- The skin flaps are similar to those obtained from the posterior limb during a Tikhoff-Linberg resection.
- Transect all muscles away from the bone, starting at the lowest point inferiorly. Approach the neurovascular structures from the back, as the scapula is retracted away from the chest in a cephalad direction. Take care to avoid injuring the musculocutaneous and axillary nerves near the coracoid and around the subscapularis muscle.
- Be prepared to convert this approach (type III resection) to a Tikhoff-Linberg resection (type IVB) if the anterior or medial margins are questionable.
- Soft-tissue reconstruction is mandatory to provide stability and to avoid a flail extremity.
- Employ a dual suspension technique using Dacron tape from the clavicle for static support and reattaching the biceps and triceps muscles through drill holes. Tenodesing the deltoid to the pectoralis major and trapezius muscles is essential to provide stability.

The functional results are similar to those with the standard Tikhoff-Linberg resection. This defect occasionally can be reconstructed with a total scapula prosthesis if significant soft tissue remains. The important muscles for this are the latissimus dorsi, rhomboids, and trapezius.

***Scapula and Tikhoff-Linberg Resections***

The surgical exposure, resection, and reconstruction are similar for total scapulectomy (type III) and the Tikhoff-Linberg resections (type IV; interscapulothoracic) (25,75,77). Fig. 126.28 illustrates the technique of a total scapulectomy together with the modifications for performing a Tikhoff-Linberg resection.

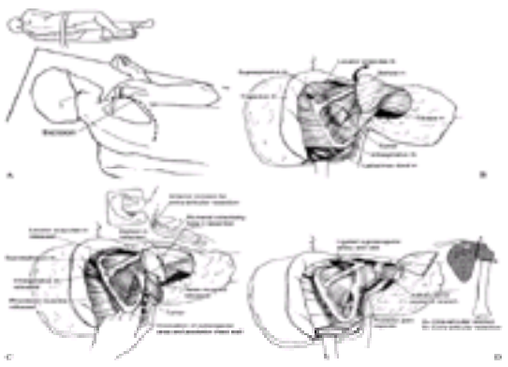

***Figure 126.28.*** Technique of Tikhoff-Linberg resection (type IV) and a total scapulectomy (type III). **A:** Make a long, curved incision over the scapula. Develop large fasciocutaneous flaps that permit easy visualization of all muscles attaching to the vertebral and axillary borders. **B:** Exposure of all three borders of the scapula. The rhomboids and latissimus dorsi muscles are detached. **C:** Muscle releases. Release all muscles attaching to the scapula. Place your hand between the scapula and chest wall to make sure there is no involvement of the underlying ribs. Then detach the serratus anterior. **D:** If an intra-articular resection (type III) is to be performed, release the joint capsule (*line A*). If an extra-articular resection is to be performed, osteotomize the proximal humerus below the capsular attachments (*line B*).

- Place the patient in the semilateral position. Drape the arm so that an assistant can move it as required during the operation.
- Make a curved skin incision (Fig. 126.28*A*), encompassing the tumor and extending from the tip of the acromion superolaterally to the paravertebral region inferomedially. The lower end of the incision can be extended to the midline.
- Develop large fasciocutaneous flaps that permit easy visualization of all muscles attaching to the vertebral and axillary borders.
- Raise the medial and lateral skin flaps, and then identify the superficial dorsal muscular attachments to the scapula. Resect the attachment of the trapezius muscle completely and retract it superomedially, exposing the supraspinatus muscle. The attachment of the deltoid muscle to the scapular spine is similarly reflected laterally. It is then possible to identify the rhomboid major muscle at the vertebral border, the latissimus dorsi inferiorly, the teres major and minor muscles laterally, and the infraspinatus muscle. Figure 126.28*B* shows construction of skin flaps and release of the trapezius and deltoid muscles.
- Incise the insertion of the latissimus dorsi muscle at the tip of the scapula and retract the muscle downward, exposing the tip. Have an assistant hold the scapular tip and pull, providing traction on the muscles at the vertebral border for incision of their scapular attachment.
- Then detach the muscular attachments at the superior angle of the scapula along the vertebral border of the scapula (Fig. 126.28). The levator scapulae and the rhomboids are easily delineated and then cut. If the assistant maintains constant upward traction of the scapula, this maneuver can be quite simple.
- For an *axillary exposure*, rotate the inferior tip of the scapula and apply a medial pull while the arm is abducted. This permits easy access to and identification of the axillary contents. Retract the contents out of the operating field after bluntly dissecting and identifying them.
- If an *alternate exposure* is needed, for example for a large axillary component to the tumor, make a separate anterior incision similar to that used in the Tikhoff-Linberg (type IV) resection to explore the axillary vessels. The anterior utilitarian approach is best.
- For an *anterior approach*, use the deltoid–pectoralis muscle interval to expose the anterior aspect of the scapula, coracoid, axilla, and brachial plexus. Safe dissection of all anterior structures as well as osteotomy of the proximal humerus is now possible (for an extra-articular resection or an intra-articular transarticular resection). The key to this approach is to detach the pectoralis major from its insertion onto the humerus and clavicle, and to reflect it toward the sternal origins to expose the axilla, coracoid, brachial plexus, and chest wall. Direct visualization of all anterior structures is now possible.
- It is our preference to make an anterior deltoid– pectoral incision to release the subscapularis and the muscles (short head of the biceps and the pectoralis minor) attaching to the coracoid. The axillary vessels can be retracted to avoid damage through the anterior incision after the pectoralis major is released (Fig. 126.28*C*).
- Cut the lateral muscles, teres major and minor, and the long head of the triceps. Release the supraspinatus and infraspinatus tendons and the attachment of serratus anterior muscles from the scapula (Fig. 126.28*D*).
- Next, *release the subscapularis*, the only muscle remaining that is attached to the scapula, humerus, and shoulder joint. Guide the resection with your fingers, protecting the axillary nerve at the lower border. Then transect the acromioclavicular ligaments under direct vision, with your fingers protecting the axillary vessels.
- For *soft-tissue reconstruction*, tenodese the deltoid and trapezius muscles, as well as the teres and latissimus muscles. The reconstruction provides shoulder stability. Figure 126.29 shows the technique for a custom scapular prosthesis.

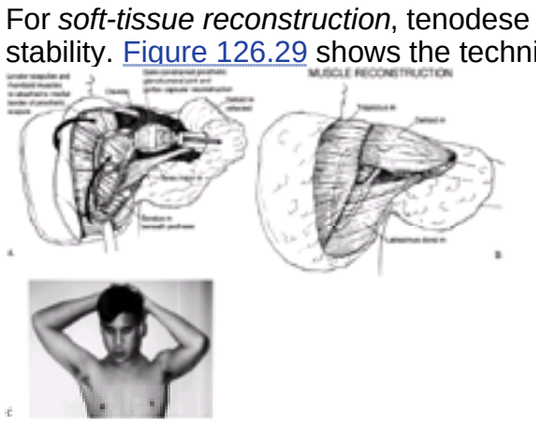


***Figure 126.29.*** Technique of scapular and proximal humeral replacement. A scapular replacement may be used if there are significant muscles remaining after a total scapular resection (type III) or an extra-articular resection (Tikhoff-Linberg procedure). The prosthesis has holes on the vertebral, axillary borders, and medial to the glenoid for attachments of the muscles with Dacron (Genzyme Surgical Product Company, Fall River, Massachusetts) tape and reconstruction of the glenohumeral joint with a Gore-Tex graft. **A:** Place the scapula prosthesis above the serratus muscle. Attach the rhomboids to the vertebral border of the scapula. Replace the proximal humerus with a corresponding prosthetic component. Reconstruct the glenohumeral joint with a Gore-Tex graft to restore stability. **B:** Rotate the latissimus dorsi and the trapezius muscles to close over the prosthesis. Tenodese the deltoid to the superior portion of the trapezius muscle. **C:** After a total scapular and proximal humeral resection for a hemangiosarcoma of the scapula, this patient has almost a full ROM. The deltoid and trapezius muscles were tenodesed to restore active abduction.

- Close the wound and continue suction drainage for 3–5 days.

### *Partial Scapulectomy*

A partial scapulectomy (75,77) is indicated for low-grade or benign lesions involving only the body of the scapula. It preserves a cuff of infraspinatus, subscapularis, and serratus anterior muscle. Reconstruction consists of suturing these muscles together to close the dead space, and reconstituting the points of origin and insertion of these muscles. A sling is required for 5–7 days.

There is minimal functional loss after a partial scapular resection (type II); in fact, shoulder motion and strength are nearly normal. Total scapular resection (type IIIA/B) causes loss of significant shoulder motion, but elbow and hand function are normal; the major limitation is the loss of shoulder abduction. Shoulder-girdle function is similar following total scapular resection and a Tikhoff-Linberg resection (type VB). Soft-tissue reconstruction is the key to establishing shoulder stability. A compressive arm stocking should be worn immediately after surgery to prevent swelling. Encourage the patient to flex the elbow but to avoid extension until there is good wound healing. The patient also needs a sling for 2–4 weeks, by which time the transferred muscles provide a stabilizing force to the entire upper extremity. Forward and backward flexion of approximately 30° to 45° is obtained. The goal of rehabilitation is to strengthen the transferred pectoralis major, latissimus dorsi, and trapezius muscles around the shoulder as well as the elbow flexors. A shoulder pad contributes to cosmesis and restores symmetry.

### *Total Scapular and Shoulder Joint Replacement*

Experience with total scapular replacement (75), although still limited, is increasing. Generally, if most of the musculature is retained (type IIIA), it is possible to reconstruct the defect with a custom scapular prosthesis (Fig. 126.30). The most common indications for this procedure are large (stage III) giant cell tumors, low-grade chondrosarcomas, and Ewing's sarcomas following induction chemotherapy. Successful reconstruction poses three primary challenges: (a) replacing the humeral joint, (b) stabilizing the scapula prosthesis within the humeral component (i.e., creating a new glenohumeral joint), and (c) providing soft-tissue attachments to both the scapular and humeral components to ensure stability as well as active motion.

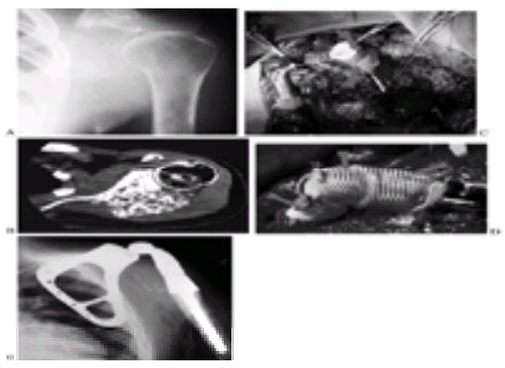

***Figure 126.30.*** High-grade osteosarcoma of the scapula with glenohumeral extension. **A:** Plain radiograph showing marked destruction and absence of the scapula. This was a high-grade osteosarcoma prior to induction chemotherapy. **B:** CT scan of the same tumor following induction chemotherapy showing marked reossification of the tumor. This indicates excellent tumor response and a high rate of tumor necrosis. A total scapular and proximal humeral resection in lieu of a forequarter amputation therefore was used to treat this patient. **C:** Intraoperative photographs following resection and the reconstruction. The proximal humerus is ready to be articulated with the polyethylene component of the total scapula. Note the Gore-Tex graft (W. L. Gore & Associates, Flagstaff, Arizona) around the scapula to the proximal humerus, which acts as a normal capsule maintaining stability and preventing subluxation. **D:** Intraoperative photograph showing the completion of the Gore-Tex reconstruction of the new shoulder capsule (*arrows*). The *central arrow* represents the level of the prosthetic joint. **E:** Postoperative photograph showing the

scapular and proximal humeral prosthetic replacement. The polyethylene glenoid cup and Gore-Tex graft are not visualized.

- Reconstruct the glenohumeral joint by sewing an aorta Gore-Tex (W. L. Gore & Associates, Flagstaff, Arizona) graft over the scapula neck and the proximal humerus (Fig. 126.30*D*). This permits stabilization of the joint and provides additional stability.
- Reattach and tenodese the remaining rhomboids, latissimus dorsi, and teres muscle to the prosthesis and to themselves to achieve reliable and functional soft-tissue reconstruction.
- Advance the preserved deltoid proximally and suture it to the trapezius; then close the pectoralis major muscle anteriorly over the new joint.

The function is superior to that of a flail shoulder. Shoulder stability is excellent, and there is good internal, and some external, rotation. If the deltoid and portions of the rotator cuff musculature are retained, between 60° and 110° of shoulder abduction can be obtained.

For information about rehabilitation following shoulder procedures, see Rehabilitation Following Shoulder-Girdle Resection in the previous section.

## TUMORS OF THE PROXIMAL HUMERUS

Resection and reconstruction of the proximal portion of the humerus is a challenging undertaking (75,77,80,81,86,87). The surgeon should be experienced in shoulder surgery and intimately familiar with the entire anatomy of the shoulder girdle, including the brachial plexus and axillary and brachial vessels, as well as the nerves innervating the shoulder girdle, particularly the musculocutaneous nerve, axillary nerve, radial nerve, and the cords of the plexus. Despite the complexity of these cases, limb-sparing surgery for both high- and low-grade sarcomas of the proximal humerus is possible in approximately 95% of cases (Fig. 126.31). Forequarter amputation is indicated mainly for large fungating tumors, tumors with secondary infections, cases in which there is chest wall involvement, and patients who have had a failed attempt at limb-sparing resection (Fig. 126.32). Preoperative neoadjuvant chemotherapy may allow fracture healing if there is significant tumor necrosis (Fig. 126.33).

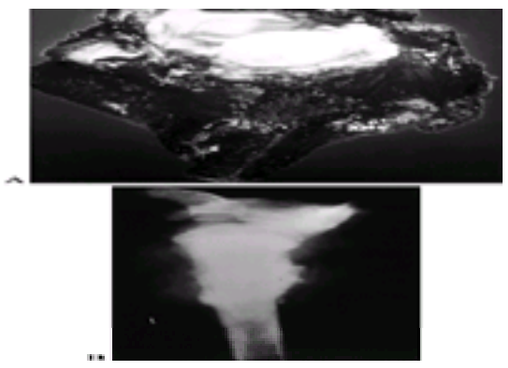

***Figure 126.31.*** Osteosarcoma of the proximal humerus. **A:** Gross specimen of osteosarcoma showing the proximal humerus and the glenohumeral joint *en bloc*. The joint had been exposed following the resection. **B:** Plain radiograph of the resected specimen demonstrating a complete glenohumeral resection with removal of the proximal half of the humerus.

***Figure 126.32.*** A large telangiectatic osteosarcoma of the proximal humerus. **A:** Clinical photograph prior to treatment of an extremely large telangiectatic osteosarcoma with secondary bleeding into the tumor, which made a limb-sparing procedure impossible. This patient required a forequarter amputation. **B:** Gross specimen forequarter amputation.

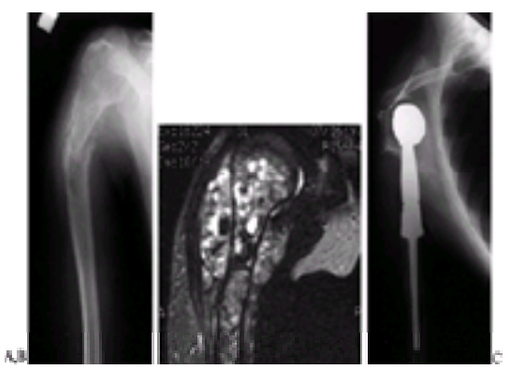

***Figure 126.33.*** Osteosarcoma of the proximal humerus with pathologic fracture. **A:** Plain radiograph prior to treatment demonstrates a moderately displaced fracture through an osteolytic osteosarcoma of the proximal humerus. **B:** MRI prior to induction chemotherapy shows the extent of the tumor within the medullary space and beneath the deltoid muscle. **C:** Postoperative radiograph following an extra-articular resection (type V) that included half of the proximal humerus, the glenohumeral joint, the abductors, and rotator cuff musculature. This was reconstructed with a Modular Replacement System (MRS) proximal humerus. This fracture healed following induction chemotherapy, which permitted a safe resection in lieu of a forequarter amputation.

Today, limb-sparing surgery is not contraindicated if a pathologic fracture heals during the course of induction chemotherapy. Immobilize the arm during this treatment period. However, approximately 5% to 10% of patients with osteosarcomas cannot be treated by a limb-sparing resection because of their extremely large size or because of vascular or neurologic involvement, infection, or pathologic fracture that does not respond to treat- ment.

Stage I (low-grade) sarcoma of the proximal humerus can be treated by type I excision with minimal functional deficit. High-grade sarcomas require a modified Tikhoff-Linberg resection (type V). Intra-articular and synovial involvement is more common with high-grade chondrosarcomas and osteosarcomas of the shoulder girdle than at other anatomic sites. Thus, extra-articular, rather than intra-articular, resections are recommended for high-grade tumors of the proximal humerus. Take care not to contaminate the anterior structures when performing a biopsy. Prosthesis, allograft, or dual fibula autograft can be used for reconstruction following a marginal resection (type I) for a low-grade lesion. Following resection of a high-grade lesion (stage IIB), the aim is a stable shoulder with minimal motion to preserve function in the elbow and hand. Regardless of the type of reconstruction, the magnitude of the surgical resection depends on the grade of the tumor and its anatomic

extent. Specific anatomic and surgical considerations are summarized next.

Tumors of the proximal humerus often grow large and present with an extraosseous component, particularly with most high-grade osteosarcomas, chondrosarcomas, and Ewing's sarcomas. The relatively small size of the glenohumeral joint in comparison to the knee or hip joint almost always mandates an extra-articular resection to obtain negative surgical margins. The recommended procedure is to treat most stage IIB bone sarcomas by an extra-articular resection. Usually, this requires a resection of the deltoid muscle as well as the axillary nerve. Any attempt to preserve either structure is risky and not recommended unless there has been a very good response to induction chemotherapy.

Arterial involvement rarely occurs, but often there is displacement of the vessel. The subscapularis muscle protects the brachial vessels and major nerves. The relationship of the axillary vessels and the brachial vessels must be evaluated preoperatively and routinely explored, and these vessels must be dissected free during the initial surgical exposure prior to the resection. Occasionally the brachial veins or axillary veins may be the site of mural (tumor) thrombi. Significant arm swelling and edema are important signs of vascular compression or involvement, or tumor thrombosis.

The musculocutaneous nerve, which travels between the brachialis and biceps muscles, is rarely involved unless the tumor extends to the coracoid. To avoid damage, it is imperative to identify this nerve before exploring the brachial vessels and mobilizing the arm muscles. Similarly, the tumor rarely involves the radial nerve, which arises from the posterior cord and passes posterior to the humerus at the inferior border of the latissimus dorsi muscle. However, the radial nerve is often displaced and can be easily damaged. It is also necessary to identify it before performing a humeral osteotomy.

A major consideration in the preoperative evaluation and surgical planning is the intraosseous extension of the tumor within the bone marrow. The humerus is shorter than the femur and tibia, the two most common sites of sarcomas, and large tumors of the humerus often require resection of a significant portion of the bone. It is not unusual to resect 50% to 80% of the humerus. Tumors arising within the diaphysis may require a total humeral resection and replacement of the glenohumeral and elbow joints. Be prepared with various lengths and diameters of intramedullary stems. Base the final decision of bone length on the frozen section of the osteotomized humerus at the time of resection.

The abductor mechanism, that is, the deltoid muscle and the rotator cuff, normally cover the shoulder joint. With high-grade proximal humeral sarcomas, these structures are usually resected. Following the resection, joint coverage and stability are essential to eliminate dead space, decrease the risk of infection, and maintain good elbow and hand function. The key muscle transfers in the reconstruction are the pectoralis major muscle and the latissimus dorsi muscle; these must be identified and preserved during the resection.

**PREOPERATIVE IMAGING STUDIES**

Magnetic resonance imaging and bone scan studies accurately demonstrate the soft-tissue extension as well as the intraosseous extent of the tumor (75,77,80,81). Pay careful attention to the level of marrow extension and thus the level of humeral resection, as well as to the extension of tumor along the shoulder joint, rotator cuff, and axillary space. Evaluate the scapula for transarticular skip metastases. Also evaluate the possibility of tumor extension along the subscapularis and the other rotator cuff muscles; if it is present, a wider resection is required.

A CT scan complements the MRI and bone scan by providing the best demonstration of bony disease and cortical involvement. At this point, evaluate the chest wall, axilla, and ribs for tumor involvement.

Angiography is required prior to resection to evaluate the brachial and circumflex vessels, which are often displaced. A decrease of tumor blush correlates with the tumor response to induction chemotherapy. A minimal tumor blush indicates a high degree of tumor necrosis, which may permit less tissue to be resected and may alter the necessary margins. The venous flow phase is useful to demonstrate venous occlusion or tumor thrombi. If there is any suggestion of occlusion, perform a brachial venogram.

**BIOPSY TECHNIQUE**

As always, it is essential to plan and perform the biopsy carefully because an inappropriate biopsy is a common cause of forequarter amputation (Fig. 126.27). In a patient with a tumor of the proximal humerus, a core or needle biopsy through the anterior third of the deltoid muscle is recommended (75,77,80). Open biopsies are rarely required and may lead to excessive local contamination. If there is a soft-tissue component, which occurs 95% of the time, there is no need to enter the bone. It is possible to perform multiple biopsies through one puncture site to obtain adequate material. Take care to avoid the deltopectoral groove: Contaminaton of this groove leads to contamination of the pectoralis muscle and potentially of the brachial vessels and axillary space. The axillary nerve innervates the deltoid muscle posteriorly, so the muscle can be partially resected without any loss of function if the muscle is to be preserved.

**MANAGEMENT OF SPECIFIC TUMORS OF THE PROXIMAL HUMERUS**

Specific tumors of the proximal humerus demand special treatment. The proximal humerus is the third most common site for osteosarcoma. Osteosarcomas in this area tend to have a poorer prognosis than those around the knee, and most have a significant extraosseous component. Plain radiographs suggest the correct diagnosis. Perform all staging studies prior to biopsy. If the axillary vessels are free of tumor, a limb-sparing procedure is generally indicated—preferably an extra-articular resection (type IB). A modified Tikhoff-Linberg procedure (type V) provides adequate resection of the proximal humerus for high-grade bone sarcomas. This includes *en bloc* removal of 15–20 cm of the humerus and shoulder joint, with the deltoid, rotator cuff, and portions of the biceps and triceps muscles. Reconstruction involves suspension of the arm, motor reconstruction, and provision of adequate soft- tissue coverage.

Primary (central) and secondary (peripheral) chondrosarcomas commonly occur in the proximal humerus. The peripheral lesions tend to be large but low grade, whereas the central lesions tend to be a higher grade. Stage I tumors of the proximal humerus can be treated by excision (type I) with minimal functional deficit.

High-grade sarcomas require a modified Tikhoff- Linberg resection (type V) or, rarely, a forequarter amputation. Intra-articular and synovial involvement with high-grade cartilaginous lesions are more common in this location than in other sites. Take care not to contaminate the anterior structures when performing the biopsy. An allograft prosthesis accomplishes the reconstruction following a marginal resection (type I) for a low-grade sarcoma.

Although this is the third most common site for osteosarcomas, fewer than 10% of Ewing's sarcomas involve the proximal humerus. The flat bones, specifically the scapula and clavicle, are the most common sites for Ewing's sarcomas. The treatment follows the guidelines for other high-grade bone sarcomas of the humerus. Surgery should never precede induction chemotherapy. Evaluate by CT scan, MRI, bone scan, and angiography when deciding whether to perform a limb-sparing resection. If a round cell tumor is suspected, first perform a small core biopsy. Because the patient may receive radiation therapy, it is important not to make a large hole in the underlying bone that might not heal. As previously mentioned, resection of Ewing's sarcoma is increasingly replacing radiation therapy. Ewing's sarcomas, unlike osteosarcomas, may dramatically decrease in size following induction chemotherapy, in which case the deltoid and axillary nerve may be preserved. For this reason, intra-articular resections are recommended. However, do not use radiation therapy in patients treated with a prosthesis or an allograft because it often leads to several local complications, such as restriction of motion, infection, and secondary amputation.

All carcinomas can metastasize to the proximal humerus. In specific situations, large metastatic tumors with marked bony destruction may be resected by a primary resection and prosthetic replacement. Hypernephroma, which is extremely vascular and has a predilection to this location, may present a unique problem of uncontrollable bleeding. Radiography often reveals marked destruction and ballooning, much like an aneurysmal bone cyst or primary sarcoma. Simple biopsy, even with a needle, may lead to severe hemorrhage. Preoperative angiography with embolization is recommended. Ligate the anterior and posterior circumflex vessels prior to any surgical procedure. If curettage and cementation are not feasible, a resection with prosthetic replacement (type I) is indicated.

**RECONSTRUCTION FOR TUMORS OF THE PROXIMAL HUMERUS**

Endoprosthetic replacement for reconstruction of the proximal humerus (75,77,80,81), which has been in use since 1973, is the most common technique for reconstructing large proximal humeral defects. It may be used for both intra-articular and extra-articular defects (i.e., when retaining the glenoid as well as when resecting it with the tumor specimen) (Fig. 126.34).

***Figure 126.34.*** Types of prostheses utilized for replacement and reconstruction of the proximal humerus. **A:** The initial vitallium prosthesis used in the 1940s. **B:** A long-stem Neer prosthesis (Howmedica, Rutherford, NJ) first used by Dr. Ralph Marcove at Memorial Sloan-Kettering Cancer Center during the 1960s. **C:** A proximal humeral modular replacement prosthesis (the MRS) developed by Howmedica (Rutherford, NJ) in 1988. This design is popular today.

Originally, each patient received a custom-made prosthesis. In 1988, Howmedica (Rutherford, NJ) developed the Modular Replacement System (MRS), which has since undergone several technological improvements. The present system is shown in Figure 126.35. Modular prosthetic systems are now widely available (from Howmedica; Biomet, Warsaw, IN; and Sulzermedical, Austin, TX) and obviate the need for custom devices. These prostheses have proven to be very durable. The reported rates of fracture, infection, nonunion, tumor recurrence, reoperation, and time of immobilization are all lower following endoprosthetic replacement than with allografts or composite reconstruction. Low-grade tumors are treated by an intra-articular resection and preservation of the abductor mechanism.




***Figure 126.35.*** The current MRS for the proximal humerus. **A:** The components of the modular system. There are various sizes of stems, bodies, and heads. Trial components are illustrated (note holes in the bodies denoting trial prostheses). **B:** Schematic of the MRS (courtesy of Howmedica, Rutherford, NJ).

An MRS is used for both intra- and extra-articular reconstructions. The reconstruction is combined with multiple muscle transfers to reconstruct the soft tissues that have been resected. For high-grade bone sarcomas, this is the method of choice. The deltoid and axillary nerves are routinely removed along with the glenohumeral joint. High-grade tumors often cross the glenohumeral joint and are a source of local tumor recurrence; therefore, intra-articular resections and reconstructions with osteoarticular allografts are not recommended. Treat low-grade tumors with an intra-articular resection and preservation of the abductor mechanism.

Soft-tissue reconstruction is essential to cover the prosthesis and create shoulder stability in a patient who has undergone resection of the proximal humerus (Fig. 126.36). This is accomplished through a technique of dual suspension that entails static and dynamic reconstruction. Use Dacron tape to secure the prosthesis horizontally, and secure the Dacron tape by drill holes in the remaining bony structures (i.e., clavicle and scapula or clavicle alone). The two sets of Dacron tape provide mediolateral and craniocaudal stability. Dynamic suspension, provided by transfer of the short head of the biceps muscle to the stump of the clavicle, allows elbow flexion.

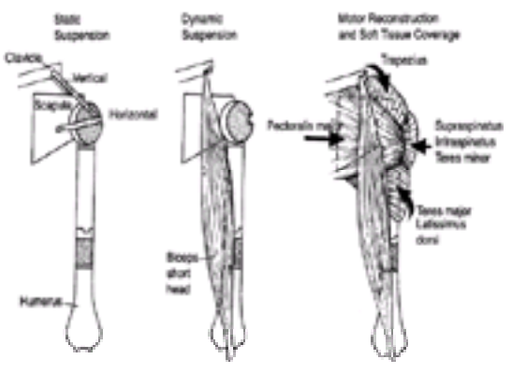


***Figure 126.36.*** Schematic technique of static and dynamic reconstruction with multiple muscle transfers following resection of high-grade sarcomas of the proximal humerus. This schematic demonstrates the use of dacron tapes (Genzyme Surgical Product Company, Fall River, Massachusetts) for static suspension and the transfers of the pectoralis major, biceps, and trapezius muscles for active dynamic motor reconstruction and soft-tissue coverage. It is important that a prosthesis not be permitted to remain subcutaneously. Muscle coverage is essential to avoid secondary infection following potential wound problems or flap necrosis. (From Sugarbaker PH, Malawer MM.*Musculoskeletal Surgery for Cancer: Principles and Techniques.* New York: Thieme Medical, 1992: Chapter 27, with permission.)

Preservation and transfer of the pectoralis major, trapezius, supraspinatus, infraspinatus, teres minor, teres major, and latissimus muscles provide mobility of the shoulder. These muscle groups offer dynamic support, assist in suspension of the prosthesis, and provide soft-tissue coverage, which is essential in preventing skin problems and secondary infection.

Endoprosthetic replacement is highly predictable and successful. There are minimal problems with subluxation following adequate soft-tissue reconstruction. Malawer et al. (75,76,80,81), who have the most extensive experience with replacing the proximal humerus with the MRS, report 95% survival of the prosthesis as determined by Kaplan-Meier analysis at 10 years (Fig. 126.37). Type I resections are routinely reconstructed with the prosthesis and the soft-tissue transfers described; extra-articular resections are reconstructed with the proximal humeral prosthesis lying anterior to the scapula. A Gore-Tex graft reconstruction of the joint may provide stability following a type I resection, even when normal soft tissues are retained. The most common problem is temporary nerve palsy, which occurs in approximately 10% of patients, usually involving the radial nerve and musculocutaneous nerves. Infections and skin flap necrosis occur rarely (1% to 2%) after endoprosthetic replacement around the shoulder.

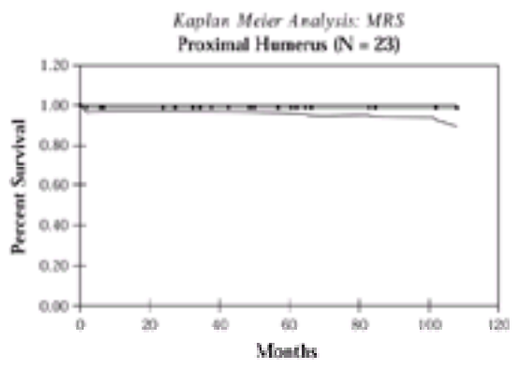


***Figure 126.37.*** Kaplan-Meier survival curve of modular proximal humeral replacement for high-grade bone sarcomas. The 5- and 10-year survival rates are between 95% and 100%. There were no infections, aseptic loosening, or local tumor recurrences. All patients were treated by a type V resection (extra-articular glenohumeral resection).

Osteoarticular (allograft) replacements were widely used for segmental joint replacements in the 1960s and 1970s, but they have become less popular in the past two decades. The rate of complications, which include infections, fracture through an allograft, nonunions, pain, and instability, is significantly higher than with endoprosthetic replacements for stage IIB bone sarcomas. Today, there are few indications for the use of either osteoarticular or composite allograft. The most common indications are for low-grade or aggressive benign bone tumors when most of the adjacent soft tissue can be preserved. Osteoarticular replacement is not indicated following high-grade tumor resection because of the need to retain the rotator cuff, deltoid, and axillary nerve, and the corresponding high rate of recurrence.

In 1991, among 20 cases of osteoarticular allografts out of 450 allografts performed at Massachusetts General Hospital, there were seven fractures, three infections, and one nonunion (83). Three of the allografts had to be removed and replaced, and flexion was seldom above 45°. Most of the allografts were for low-grade sarcomas or benign tumors (e.g., giant cell tumors). Two of the three stage IIB osteosarcomas recurred locally and required amputation. Only seven patients had no complications. We do not recommend osteoarticular allografts for stage IIB sarcomas (i.e., high-grade tumors with extra-articular components). One can generalize these concerns to composite allografts.

## OPERATIVE TECHNIQUES

### *Osteoarticular Allograft*

- For an osteoarticular allograft for the proximal humerus, carefully size the allograft preoperatively.
- When performing the procedure (Fig. 126.38), place the allograft into the patient and fix it with a cortical plate, intramedullary rod, or both. Cement the intramedullary fixation into the allograft and impact it into the remaining humerus before affixing the plate. The technique of intramedullary fixation with a small derotation plate decreases the rate of fracture and nonunions. To avoid subluxation and pain, it is essential to perform the soft-tissue reconstruction of the joint and capsule tightly.
- Suture the subscapularis and rotator cuff to the corresponding soft-tissue components on the allograft.

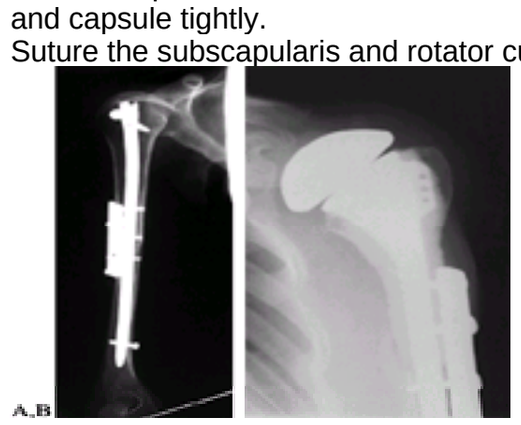


***Figure 126.38.*** Plain radiographs demonstrating the technique of osteoarticular allograft reconstruction. **A:** The technique of osteoarticular allograft to reconstruct the proximal humerus following an intra-articular resection with an osteochondral allograft. **B:** Plain radiograph of a composite allograft prosthesis following a proximal humeral resection.

- Then abduct the allograft into 90° of abduction for fixation of the plate onto the remaining humerus. Adequate soft-tissue coverage is essential.
- The allograft cannot be left subcutaneously; therefore, if there is not enough musculature, rotate the latissimus dorsi and the pectoralis major to cover the allograft.

**Notes on Allograft Technique** Composite allografts have been developed to decrease the complications of an osteoarticular replacement. The technique of combining a prosthesis with an allograft is to provide a stable joint surface and to avoid articular collapse, which is extremely common following osteoarticular replacement alone. This entails cementing a long-stem humeral prosthesis [Neer type (Howmedica, Rutherford, NJ)] into the allograft and fixating it into the remaining humerus. Although it is still popular, it offers no advantage over endoprosthetic replacements and has higher infection and complication rates (e.g., nonunions and instability). The main indications for allograft reconstructions are low-grade tumors in which the deltoid and rotator cuff musculature can be retained and adjuvant chemotherapy is not required.

The surgical technique of reconstruction for composite allograft is similar to that of noncomposite allograft replacements. The main difference is the use of a long or short endoprosthetic proximal humerus component (Neer type) to replace the humeral head. This is done to avoid subchondral fractures, which have been reported with allografts alone. The fixation of the long stem into the remaining bone appears to decrease the nonunion rate. Usually, plate fixation is added, although this remains an issue of debate. The soft-tissue reconstruction following composite allograft fixation is identical to that of osteoarticular replacements.

There have been several attempts to develop an intercalary arthrodesis using an allograft fixed to the remaining distal humerus and scapula or glenoid. This is an extremely difficult, time-consuming procedure. Complications are numerous and include nonunion, skin necrosis, and metal or plate breakage. In addition, many patients who have undergone arthrodesis complain about the lack of rotation, which other reconstructive techniques preserve. In general, the maximal abduction is only 30° to 45°. We do not recommend arthrodesis.

The oldest surgical technique is resection leaving a flail shoulder. Before endoprosthetic and allograft reconstruction, the shoulder girdle was left unreconstructed after resection. The patient needed a large, bulky, external orthosis to support the upper extremity and prevent the arm from pulling on the brachial plexus and vascular structures. This approach does not permit any type of stability and, moreover, it does not afford a stable fulcrum, which is necessary for elbow function. This procedure is recommended only following failed reconstruction, usually in patients with infections that cannot be resolved.

One technique that is no longer used is arthrodesis with dual fibular strut grafts (Fig. 126.39). The original procedure, described using autogenous fibula bone grafts in the 1970s (before modern endoprosthetic and composite allograft reconstruction), was to remove both fibulas from the patient, screw them together proximally to form a pseudohumeral head, and then fix this to the adjoining host bone. It is a reliable method of reconstruction, but it has an extremely high morbidity and is not in common use now.

***Figure 126.39.*** Dual fibular arthrodesis of the humerus to the scapula following proximal humeral resection.

During the 1980s, the development of microvascular anastomosis techniques in free tissue and bone transplants permitted surgeons for the first time to transplant a single fibula with its attached blood supply to reconstruct the proximal humerus. This technique, which involves the end-to-side anastomosis of the peroneal artery (supplying the fibula) to the brachial artery, is extremely time-con- suming, and there is minimal evidence that the fibular transplants remain viable. Bone scans and angiography have been used to show postoperative patency of the vascular anastomosis. Single fibulas, even when vascularized, have high incidences of stress fractures, subluxation, and dislocation. This technique has recently been combined with osteoarticular allograft arthrodesis to reinforce the allograft and promote its incorporation in the glenoid and scapula and the remaining humeral bone. It has not been demonstrated that this technique has a higher incorporation rate than nonvascularized fibula transplants to humeral defects. Although appealing, it has not been widely used.

***Extra-articular Proximal Humeral Resection and Prosthetic Reconstruction***

The technique of extra-articular proximal humeral resection and prosthetic reconstruction (Fig. 126.40) permits modification for an intra-articular resection (75,77,80). We recommend an extra-articular (type V) resection. This method may be modified if an intra-articular resection is to be performed for low-grade sarcomas. The method of soft-tissue reconstruction and prosthetic suspension was described previously. In general, the deltoid muscle and axillary nerve cannot be preserved for high-grade sarcomas. Three osteotomies are required for an extra- articular resection.

***Figure 126.40.*** Surgical technique of resection of the proximal humerus for high-grade bone sarcomas. (From Sugarbaker PH, Malawer MM.*Musculoskeletal Surgery for Cancer: Principles and Techniques.* New York: Thieme Medical, 1992: Chapter 27, with permission.) **A:** Make an anterior incision to permit wide exposure of the axilla, axillary and brachial vessels, shoulder joint, and anterior scapula. **B:** The key to the exposure of the axilla and its contents is the release of the pectoralis major muscle and the short head of the biceps and pectoralis minor from the coracoid. **C:** Expose the anterior neck of the scapula. Transect the subscapularis muscle. The capsule attaches lateral to the coracoid. Make the scapula osteotomy (*dotted line*) lateral to the coracoid so as not to enter the joint. Perform this osteotomy after the posterior exposure. **D:** Posterior incision. The anterior incision is now a **T** to permit exposure of the posterior aspect of the shoulder musculature and to allow the scapular osteotomy to be performed safely. If an intra-articular resection is performed, steps (D) and (E) are omitted. **E:** Palpate the glenoid and transect the covering muscles. This permits direct exposure of the posterior scapula and glenoid neck. **F:** Reconstruction with a modular prosthesis. **G:** Major muscle reconstructions.

- Place the patient in a lateral position, allowing some mobility of the upper torso.
- Prepare the skin down to the level of the midline anterior and posterior to the umbilicus, and cranially past the hairline.
- Start the incision over the junction of the inner and middle thirds of the clavicle, continue along the deltopectoral groove, and then move down the arm over the medial border of the biceps muscle (Fig. 126.40*A*).
- Excise the biopsy site, leaving a 2–3 cm margin of normal skin. Do not open the posterior incision until the anterior dissection is complete.
- For exploration of the axilla, open the skin through the superficial fascia.
- Dissect the skin flap anteriorly off the pectoralis major muscle to expose its distal third, and uncover the short head of the biceps muscle. The key to exposure of the anterior shoulder girdle and axilla is the detachment and mobilization of the pectoralis major muscle with partial mobilization medially toward the chest wall (Fig. 126.40*B*).
- Dissect the pectoralis major muscle overlying the axilla free of fat, so that its insertion on the humerus can be visualized. Then divide this muscle just proximal to its tendinous insertion on the humerus, and use a suture to tag the portion of muscle remaining with the patient.
- Identify the axillary sheath and visualize the coracoid process. To expose the axillary sheath along its full extent, divide the pectoralis minor, short head of the biceps, and coracobrachialis muscles at their insertion on the coracoid process. Tag all proximal muscles with a suture for later identification and use in reconstruction.
- Before exploring the neurovascular bundle, develop the skin flaps just minimally. If the patient's tumor is found unsuitable for limb-salvage surgery, more extensive flap dissection would lead to tumor contamination of the skin needed for forequarter amputation.
- In dissecting the neurovascular bundle, pass vessel loops around the neurovascular bundle near the proximal and distal ends of the dissection. Medial traction on the neurovascular bundle allows visualization of the axillary nerve, posterior circumflex humeral artery, and anterior circumflex humeral artery. (It is rare to preserve the axillary nerve in large stage IIB sarcomas of the proximal humerus, but if the tumor is small and intraosseous, the nerve can be preserved.) Ligate these three structures and divide them.
- If the neurovascular bundle is tumor free, proceed with dissection for a limb salvage procedure.
- Isolate and preserve the musculocutaneous nerve, although it is occasionally necessary to sacrifice this nerve to preserve tumor-free margins of resection.
- Divide the deep fascia between the short and long heads of the biceps muscle; this permits easy visualization of the musculocutaneous nerve.
- Identify the radial nerve at the lower border of the latissimus dorsi muscle, where it passes around and behind the humerus in its midportion (spiral groove) into the triceps muscle group.
- Pass a finger around the humerus to bluntly move the nerve away from the bone.
- Trace the ulnar nerve down the arm; you must divide the intermuscular septum between the biceps and the triceps over the nerve to see it clearly.
- It is necessary to divide the muscle groups anteriorly to expose the neck of the scapula if performing an extra-articular resection (Fig. 126.40*C*). Separate the short and long heads of the biceps to expose the humerus. Determine the site for the humeral osteotomy, and transect the long head of the biceps and brachialis muscles at this level.
- Identify the inferior border of the latissimus dorsi muscle, and make a fascial incision that makes it possible to pass a finger behind the latissimus dorsi and teres major muscles several centimeters from their insertion.
- Transect the latissimus dorsi and teres major muscles using electrocautery.
- External rotation of the humerus exposes the subscapularis muscle, which is transected at the level of the coracoid process. Take care not to enter the joint space. Tag the portions of these muscles that will remain with the patient for future reconstruction. Transecting these muscles exposes the anterior portion of the neck of the scapula.
- Now move to the posterior aspect of the patient. Rotate the table, if desired, to provide better visualization.
- Begin the posterior incision anteriorly over the junction of the middle and lateral thirds of the clavicle and continue down over the lateral third of the scapula past the lower edge of this bone.
- Develop a skin flap by dissecting the skin and subcutaneous tissue between the anterior and posterior incision from the underlying deltoid muscle down to the level of the midhumerus.

- If removing the entire scapula (type VI resection), make the posterior incision longer and curve it posteriorly to allow the skin flap to expose muscle over the entire scapula.
- Next, divide the posterior muscle group (Fig. 126.40*D*). Divide the thick fascia that joins the posterior border of the deltoid muscle to the infraspinatus muscle and scapular spine. Leave the deltoid muscle intact to cover the tumor mass.
- Transect the trapezius muscle from its insertions on the scapular spine and acromion.
- Pass your index finger beneath the teres minor up to the area of the planned scapular osteotomy. Transect the supraspinatus, infraspinatus, and teres minor muscles over the neck of the scapula, thus allowing the plane of transection through the neck of the scapula to be exposed. Tag all transected muscles proximally (Fig. 126.40*E*).
- While shielding the radial and ulnar nerves, transect the triceps muscles at the level selected.
- Perform clavicular, scapular, and humeral osteotomies as follows. Divide the clavicle at the junction of its middle and inner thirds. This is usually accomplished with a Gigli saw.
- Divide the scapula through its surgical neck medial to the coracoid process, also using a Gigli saw.
- Perform the clavicular and scapular osteotomies before the humeral osteotomy.
- Remove the entire specimen, taking care to protect all the neurovascular structures at each osteotomy site.
- If resecting the entire scapula, take the skin flap back to the medial edge of the scapula.
- Divide the rhomboid, levator scapula, and trapezius muscles from their insertions on the scapula. It is unnecessary to divide the teres major, teres minor, supraspinatus, infraspinatus, and subscapularis muscles when performing a full scapular resection.
- Transect the humerus 4–6 cm distal to the tumor, as determined by preoperative bone scan.
- Obtain frozen sections of tumor margins and touch preparations for cytologic examination of the marrow at the site of the osteotomy.
- Measure the section of humerus removed and select a prosthesis 1–2 cm shorter. Some shortening of the extremity facilitates soft-tissue coverage and closure.
- Reconstruct the defect with a modular prosthesis (Fig. 126.40*F*). The head of the prosthesis sits anterior to the remaining scapula, which has a normal concavity.
- Place the head in 30° to 45° of retroversion.
- The soft-tissue reconstruction consists of static and dynamic supports. Use dacron tapes (static) to suspend the prosthesis from the remaining scapula as well as from the clavicle.
- The major muscle reconstructions (Fig. 126.40*G*) are the pectoralis major to the lateral border of the scapula, thus covering and supporting the prosthesis. The reaming muscles, the trapezius, supraspinatus, infraspinatus, and latissimus dorsi are tenodesed to the transferred pectoralis muscle.
- The final closure is to tenodese the biceps and triceps to each other and to the pectoralis proximally. This establishes a very stable shoulder girdle.

### *Reconstruction*

Once the specimen has been removed, a generous amount of soft tissue should still cover the tumor. The long and lateral heads of the triceps muscle remain on the humerus. The upper portion of the long head of the biceps and the upper portion of the brachialis muscle remain with the specimen. The entire deltoid muscle covers the tumor. The insertions of the supraspinatus, infraspinatus, pectoralis major, latissimus dorsi, teres major, teres minor, and subscapularis muscles remain covering the tumor and constitute the free margins.

### *Total Humeral Resection*

Total humeral resection as shown in Figure 126.41 (i.e., removal of the shoulder and elbow joints) and replacement is an unusual procedure (75). It is indicated when the tumor involves a large component of the medullary shaft. In such cases, an endoprosthesis or allograft would not be successful because only a short distal segment remains following resection. A second and more common indication for total humeral resection is Ewing's sarcoma of the humeral diaphysis. Induction chemotherapy will often shrink the large extraosseous component frequently associated with Ewing's sarcomas, making a resection possible.

***Figure 126.41.*** Plain radiograph of a total humeral prosthesis following resection of the entire humerus, glenohumeral joint, and elbow joint for a large diaphyseal osteosarcoma that extended both proximally and distally.

Anatomic considerations relative to the proximal humeral component are similar to those previously described. Considerations relating to the midshaft and distal humerus center on the relationship of the tumor to the brachial artery and nerves. Angiography is required to determine the relationship to the brachial vessels medially and the antecubital fossa. Use MRI and bone scan to determine the extent of the humeral involvement, which determines whether total humeral resection is required. Remove the entire humerus in patients who have round cell tumors of the humerus and diaphysis.

- The surgical approach is similar to that of a type V resection using multiple muscle transfers and dacron tape (Fig. 126.42).

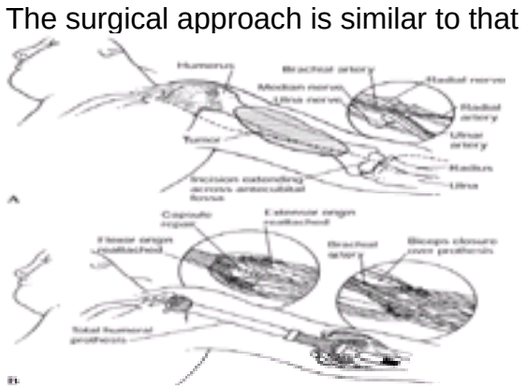


***Figure 126.42.*** Technique of total humeral resection and replacement. **A:** Continue the anterior incision to the elbow and across the joint to permit exposure to the brachial vessels, and the median, ulnar, and radial nerves, which all must be identified and retracted. **B:** A modular distal humeral body—a component of the MRS. Insert the olecranon component anteriorly. Attach the flexors and extensors to suture holes in the prosthesis with dacron tape (Genzyme Surgical Product Company, Fall River, Massachusetts). Then repair the biceps to adjacent soft tissues.

- Explore the vessels proximally, release the circumflex vessels proximally, and identify the musculocutaneous, axillary, and radial nerves.
- In addition, mobilize the brachial vessels throughout the length of the arm into the antecubital space to protect them and the accompanying medial nerve. The ulnar nerve passes posteriorly through the intramuscular septum and can easily be identified in the mid arm.
- Likewise, identify the radial nerve as it passes around the humerus and into the interval between the biceps and brachioradialis muscle, where it becomes the posterior interosseous nerve. It is necessary to identify and to initially preserve all of these nerves, as well as the brachial artery and vein (Fig. 126.42*A*).
- The resection is similar to that of the proximal humerus lesions, but continue it down to the elbow joint, which is opened anteriorly after mobilizing the brachial vessels and the median nerve through the antecubital fossa. Avoid a posterior approach to the elbow. Keep the triceps tendon attached to the olecranon.
- Open the capsule of the elbow joint circumferentially; this makes it possible to fit the elbow component and seat it into the olecranon. Detach the flexor and extensor muscles from their respective origins on the humeral condyles. Retract the biceps, but do not detach it from its insertion onto the radial tuberosity.
- Use one of the several elbow devices available (Fig. 126.42*B*). An intramedullary stem fixed with polymethylmethacrylate (PMMA) is widely used.
- Soft-tissue reconstruction of the elbow consists of reattaching the forearm flexor and extensor muscles to holes in the prosthesis.
- The ulnar nerve is routinely transposed anteriorly to avoid irritation from the prosthesis. Then repair the biceps to the adjacent soft tissue.

- Take care to interpose the capsule between the prosthesis and the neurovascular structures.

Experiences with total humeral prostheses are limited, but the duration of these prostheses is reliable. The most critical consideration following total humeral replacement is the potential for arterial thrombosis and occlusion, nerve compression, or neurapraxia. A sling or plaster splint is needed for a longer time than for proximal humeral resection to allow for soft-tissue healing around the elbow and the shoulder girdle. Elevation is required for the first 72 hours. Rehabilitation must focus on both the shoulder and the elbow joints. Fortunately, it is possible to preserve most of the musculature of the shoulder girdle, which allows for an extremely stable shoulder girdle as well as preservation of most of the elbow musculature.

## TUMORS OF THE HIP AND PELVIS

Anatomic complexity and reconstructive challenges of limb salvage make the hip and pelvis one of the most difficult areas of musculoskeletal oncology surgery. Prior to the development of effective techniques for management of pelvic girdle malignancies, the best patients could hope for was an oncologically sound hip disarticulation or hemichpelvectomy. The resulting emotional and functional impact for these patients, however, was considerable. Even as limb salvage techniques developed for other anatomic areas, management of pelvic lesions was still fraught with higher complication rates and less satisfactory functional results (32,35,56,126,127). The recognition that the surgical margin that could be obtained with amputation for large lesions was often no better than an effective limb salvage procedure provided the impetus to extend the indications for limb salvage to include even large pelvic lesions, provided some sort of functioning extremity could be preserved. Anatomic approaches and reconstructive techniques eventually became more standardized, and a limb salvage approach for many pelvic lesions developed. Furthermore, the development of a more uniform system for the evaluation of functional results allowed better comparison of reconstructive techniques (36). With more recent improvements in spinal fixation techniques, reconstruction for lesions involving the sacroiliac area and even some lesions requiring resection of the portion of the spine are possible in selected patients.

### ANATOMIC CONSIDERATIONS

An understanding of the complexity of pelvic anatomy, and to a lesser degree proximal femoral anatomy, is key to successful limb salvage. The bony pelvis forms a complete ring, with the two hemipelvi adjoined anteriorly at the symphysis pubis and posteriorly to the sacrum by the sacroiliac (SI) joints. Although portions of the SI joints are true diarthrodial joints, the close proximity of the ilium to the sacrum, as well as dense ligamentous attachments, distinguish them from other large synovial joints. This has important implications in tumor surgery because these joints, and for that matter the symphysis pubis, do not present the same relative barrier to tumor spread as do other joints. Extensions of tumor across the SI joints are not uncommon, with large masses of tumor from the ilium frequently extending across the SI joint anteriorly in front of the sacrum.

Each hemipelvis comprises the ilium, ischium, and pubis, with each of these bones contributing to the acetabulum. Because these bones fuse at skeletal maturity, resections of the pelvis tend to be classified not simply according to the bone that is removed, but rather by the zone of the pelvis involved.

The large iliac wing serves primarily as a site of muscle attachment, along both the iliac crest and the iliac and gluteal fossas. Tumors arising within the ilium, even with soft-tissue extension, are almost completely surrounded by muscle, which can aid in developing surgical margins. The ilium is not simply a site of muscle attachments, however. The posterior medial portion from the pelvic brim to the sciatic notch is very thick and forms the structural continuity between the acetabulum and the sacrum. Resections of the iliac wing that can preserve even a part of this portion of the ilium will leave a structurally intact pelvic ring and often require no significant reconstruction.

The ischium contributes a large part of the posterior portion of the acetabulum, as well as a portion of the structural posterior column of the pelvis. It has important ligamentous and muscle attachments as well. The sacrospinous and sacrotuberous ligaments are dense structures connecting the ischium to the sacrum, and they serve to define the greater and lesser sciatic notches. Muscle attachments such as the coccygeus, levator ani, and obturator internus help form the floor of the true pelvis. Furthermore, the ischial tuberosity serves as the origin for the hamstrings. Not only the ischium's important bony function, but also the important soft-tissue attachments and proximity of other important neurovascular structures make tumors arising within the ischium difficult to manage.

The pubis is the smallest of the three pelvic bones and, in some ways, the most expendable. It contributes to a part of the anterior aspect of the acetabulum, but a structurally less significant part. At the midline it joins with the pubis on the opposite side to form the symphysis pubis, thus completing the pelvic ring. Provided the posterior SI joints are intact, however, resection of the symphysis pubis does not significantly compromise pelvic stability. Therefore, from a purely structural standpoint, the entire pubis is considered expendable. Its importance from a surgical standpoint lies more with its soft-tissue attachments and its proximity to other neurovascular and urogenital structures. The rectus abdominus is an important muscle attachment forming a portion of the anterior abdominal wall. The ilioinguinal ligament and ilioinguinal ring complex also attach near the pubic tubercle, as do the origins of the medial thigh muscles. Directly anterior to the pubis, near its midportion, lie the femoral vessels within their own vascular sheath. Lateral to the femoral sheath lies the confluence of the iliacus and psoas muscles and the accompanying femoral nerve. Just inferior to the pubis, traveling through the superolateral aspect of the obturator foramen, are the obturator vessels and nerve. Similarly, important urogenital structures are intimately related with the pubis and symphysis pubis. These include the bladder directly posteriorly, the urethra inferiorly, and, in males, the spermatic cord, which is just superior to the pubis traveling through the inguinal ring. Tumors of the pubis, particularly if any soft-tissue mass exists, can often be intimately associated with these structures, making preservation sometimes difficult.

Although an understanding of the bony pelvis is important in determining levels of resection and structural continuity of the limb, it is the soft-tissue anatomy, in terms of muscles and neurovascular structures, that most greatly contributes to the ultimate function of the limb. Of primary importance in assessing patients for potential limb salvage is determining which nerves need to be sacrificed and which can be preserved.

Clearly, the sciatic nerve is the most important of all, and inability to save the sciatic nerve is considered an indication for amputation. The sciatic nerve has nerve root contributions from the L-4, L-5, S-1, S-2, S-3 levels. The L-4 and L-5 roots form a conjoined root traveling anterior to the sacrum at the S-1 level that is intimately associated with the sacrum and the anterior portion of the SI joint before diving posteriorly to enter the sciatic notch. The sacral contributions exit the sacral foramen anteriorly at their respective levels, transversing laterally to join with the L-4, L-5 root within the sciatic notch. Malignancies of the ilium and ischium with extensive soft-tissue extension either extrapelvically or intrapelvically near the sciatic notch usually require sacrifice of the entire sciatic nerve. This renders the lower leg functionless and insensate, and it also sacrifices the neurologic function to all of the gluteal muscles. Lesions involving the lower portion of the ischium or proximal femur may also have soft-tissue extensions near the sciatic nerve. Fortunately, the farther the nerve gets from the sciatic notch, the more mobile it becomes, making a greater latitude of nerve displacement possible. In many cases, although the nerve is displaced, it still can be preserved. This is certainly in contrast to the tight anatomic confines of the nerve within the sciatic notch itself.

Lesions that involve the anterior portion of the pelvis, including those tumors arising within the pubis or anterior portion of the acetabulum or ilium, potentially involve the femoral nerve. Within the pelvis, the femoral nerve lies between the iliacus and iliopsoas muscles, and there is a certain amount of potential for it to be displaced by masses in this area. It is most tightly confined where it passes beneath the inguinal ligament and over the pubis near the iliopectineal eminence. Large lesions in this area may require sacrifice of the femoral nerve, but in contrast to sacrifice of the sciatic nerve, this is not necessarily a contraindication to limb salvage.

Lesions of the proximal femur also may have soft-tissue extensions toward the femoral nerve. Fortunately, almost immediately after the femoral nerve passes beneath the ilioinguinal ligament, it begins to branch, and often only a portion of the nerve needs to be sacrificed. The final significant nerve exiting the pelvis with functional implications is the obturator nerve, which is formed from nerve roots exiting the L-2, L-3, and L-4 levels. It courses along the lateral side wall of the pelvis, just over the pelvic brim, and exits the pelvis through the obturator foramen. It can also easily be involved with periacetabular lesions or pubic lesions and may require sacrifice. This certainly denervates the adductor muscles of the thigh, but it does not significantly compromise gait. Its preservation, therefore, is not a requirement for limb salvage.

The vascular anatomy of the pelvis is complex, but it can be simplified for the purposes of limb salvage to that of an anterior, or external, iliac artery distribution and a posterior or internal iliac artery distribution. The external system has no significant branches within the pelvis until it gets to the level of the inguinal ligament. There it gives rise to the deep circumflex iliac and inferior epigastric arteries. The inferior epigastric artery is important in terms of potential soft-tissue reconstruction because it is the main pedicle to the lower portion of the rectus abdominus muscle, which can be used as a rotational flap for soft-tissue coverage. Once the artery passes under the inguinal ligament, it becomes the common femoral artery and eventually the superficial and profunda portion. The medial and lateral femoral circumflex arteries generally arise from the profunda branch. They not only provide much of the blood supply to the proximal portion of the femur, but they also contribute to the rich anastomosis around the hip with terminal branches from the internal iliac system. Within the pelvis, the internal iliac vessels lie posterior to the external iliac vessels as they traverse toward the sciatic notch. They become tightly adherent to the pelvic side wall as they course over the sacrum and pelvic brim and begin to divide into multiple terminal branches: superior and inferior gluteal, internal pudendal, and obturator, as well as branches providing blood supply to the intrapelvic contents such as the bladder and, in the female, the uterus. Tumors of the pelvis, with soft-tissue extensions inferior to the pelvic brim, can often involve these vessels or significantly displace them. Ligation of the internal iliac artery is often necessary but, due to the rich anastomosis both within the pelvis and outside the pelvis, this in itself does not cause a significant vascular problem. Thus, vascular involvement itself is rarely a contraindication to limb salvage; the external iliac system can be bypassed, and the internal iliac system is unnecessary.

Finally, a basic understanding of the urogenital anatomy is important in dealing with pelvic lesions with significant intrapelvic masses. In the retroperitoneum, the ureter

courses over the top of the psoas muscle and, at the level of the bifurcation of the great vessels, lies lateral to them. It crosses anterior to the common iliac vessels near the origin of the external and iliac branches, and from there the ureter lies in a medial position and begins to deviate from the vessels as it courses to the bladder. It is important to identify the ureter in any retroperitoneal dissection in this area. It is possible to identify it intraoperatively by testing for peristalsis, but for lesions with larger intrapelvic masses, preoperative placement of a ureteral stent can help, particularly if you suspect it may be displaced from its normal anatomic position. The bladder itself can be involved with larger intrapelvic masses, although more often than not it tends to be displaced and easily separated from tumor masses. Certainly, with distinct bladder involvement, a urologic surgeon's assistance is required because portions of the bladder can also be resected *en bloc* with the lesion.

**EVALUATION AND BIOPSY**

As with other malignancies of the musculoskeletal system, patients with pelvic neoplasms usually present with pain, a mass, or both. The development of a mass may go undetected for long periods of time, particularly if it is in an intrapelvic location, but even an extrapelvic mass or proximal femoral mass can go undetected. In contrast to lesions occurring more distally in the extremity, where peripheral nerves are more mobile, neurologic symptoms arising from pelvic lesions are not uncommon. Radicular pain from compression of the sciatic nerve or lumbosacral nerve roots can arise from lesions posterior to the hip joint or in the sacroiliac area due to the anatomic confines of the nerves in these locations. Often these symptoms are mistaken for low back pain or lumbar disc disease. It is certainly not uncommon for a patient with a pelvic neoplasm to have undergone previous lumbar discectomy without relief of symptoms before the true etiology of the pain is identified.

When performing physical exams on patients with suspected pelvic neoplasms, the objective is to localize the area of pain and tenderness, identify soft-tissue masses, and evaluate the neurologic function of the extremity. The presence of a mass either intrapelvically or extrapelvically in patients with pelvic pain is usually a sign of malignancy and should be evaluated accordingly. The identification of neurologic compromise, particularly if it corresponds to a particular level, is helpful in directing further studies. Bowel and bladder compromise is rare in patients with lesions of the pelvis because sufficient innervation from the contralateral side will maintain neurologic function. Significant alteration in bowel or bladder function suggests a higher lesion, one involving the sacrum or spine itself.

A good-quality plain radiograph is the first step in the radiographic evaluation. The fact that interpretation of plain films is sometimes difficult because of the complex anatomy, as well as overlying bowel and gas, is no reason not to obtain them. An initial diagnostic impression and reasonable differential diagnosis can generally be made after examining the plain radiographs. In patients under 30 years of age, destructive lesions of the pelvis and proximal femur are generally the result of osteosarcoma or Ewings' sarcoma. Benign lesions, such as aneurysmal bone cyst and giant cell tumor, are also possible and occasionally can have an aggressive appearance that warrants further radiographic evaluation. Large osteochondromas can also arise from the proximal femur and pelvis and may even produce a palpable mass. These patients are often already aware of the presence of an osteochondroma. If they have the impression that it is enlarging, though, malignant degeneration is a concern. As patients become older, the possibility of metastasis from carcinoma or myeloma is more likely. Certainly if one suspects metastasis, the diagnostic strategy should include looking for other lesions or other primary lesions.

Chondrosarcoma is one of the more common primary malignancies of the pelvis, particularly in patients over 40 years of age. These malignancies can present as intramedullary lytic lesions within the pelvis or proximal femur and are not necessarily associated with the distinctive calcific pattern generally attributed to these lesions. Certainly with patients having destructive lesions of the pelvis associated with a large soft-tissue mass containing fluffy and flocculent calcifications, a chondrosarcoma should be suspected. In fact, it is possible to confidently diagnose many of these lesions solely from plain film findings.

However, the identification of sacral lesions on plain films can be particularly difficult, even with good-quality radiographs. If you suspect a sacral lesion, further diagnostic imaging is in order. CT scans are particularly helpful in evaluation of pelvic lesions. Like the plain film, CT images are best at defining bony abnormalities and less effective in determining soft-tissue or intramedullary disease. As such they complement the plain film in determining the extent of cortical destruction and the presence of soft-tissue calcification. A CT scan is more often used for pelvic and spinal lesions than for extremity lesions because it is so difficult to visualize the complex three-dimensional anatomy of the pelvis and spine from plain films alone. Once again, certain lesions can be diagnosed with certainty from CT findings. For example, the calcific pattern associated with cartilage lesions can be identified effectively with a CT scan. Other lesions, such as aneurysmal bone cysts, can be effectively diagnosed with CT imaging if typical fluid levels are identified.

An MRI is essential in evaluating potential primary malignancies of the pelvis or proximal femur. The intraosseous or medullary extent of lesions can be accurately identified and often will be more extensive than one might presume from examining plain film or CT findings. Soft-tissue extension, both intrapelvically and extrapelvically, is well assessed with an MRI, especially the proximity to neurovascular structures. Furthermore, the MRI is excellent at assessing lesions that may involve the sacrum or lower spine because it can accurately image the spinal canal and potential involvement of nerve roots. In general, plain film and the CT scan give the most information regarding the actual character or histologic diagnosis of a lesion, whereas the MRI gives the most information regarding anatomic staging or the resectability of a lesion.

Systemic evaluation for patients with pelvic malignancies is similar to other anatomic areas. Technetium-99 bone scans can identify the source of other bony lesions, but they tend not to give any further information regarding the local disease. A thorough evaluation of the chest with chest radiographs and a CT scan is important in determining potential pulmonary involvement. Specialized tests that may be unique to pelvic neoplasms include angiography and tests to determine urologic involvement. Angiography usually is not required to assess vascular involvement, which can be predicted based on an MRI. Certainly if the specific diagnosis would benefit from embolizations, such as a large aneurysmal bone cyst, angiography can be an important tool. Similarly, angiography can play a role in assessing response to a preoperative chemotherapy.

The evaluation of urologic function is done either with an intravenous pyelogram (IVP) or more directly with cystoscopy. Prior to CT and MRI, the IVP was perhaps more valuable in determining displacement of the ureter or bladder. For these purposes, the MRI and CT scan are currently used more often. Cystoscopy can be helpful in determining actual bladder involvement, as it provides direct visualization. It is also helpful if a ureteral stent is placed to aid in the intraoperative localization of the ureter.

Once the patient has been evaluated radiologically, a biopsy is indicated to establish histologic diagnosis. There are many biopsy techniques available, and the actual technique used depends on the size and location of the lesion and, to some degree, on its suspected histologic diagnosis. For a patient with a known primary lesion and suspected metastasis, a simple fine-needle aspirate with or without CT guidance is acceptable. If the lesion is indeterminate, however, and certainly if you suspect a primary malignancy of the pelvis, the specific biopsy technique employed should allow for potential limb salvage.

The biopsy location in the pelvis is somewhat more complex than for lesions in the long bones. It is mandatory to have an understanding of the incisions and surgical approaches required for a pelvic limb salvage prior to biopsy of any of these lesions. An inappropriately placed biopsy, particularly one directly through the midportion of the gluteus muscle to get at an iliac or ischial lesion, can compromise the large gluteal flap that is often used in pelvic resections. In general, for lesions in the ilium, place the biopsy track along the iliac crest from the posterior superior iliac spine anteriorly up to the anterosuperior iliac spine. For lesions of the sacrum, a biopsy track close to the midline posteriorly is preferable. The biopsy track for lesions involving the anterior pelvis in the area of the pubis or symphysis should be along the line of the ilioinguinal ligament, either lateral to the femoral nerve or medial to the femoral vessels near the pubic tubercle or symphysis pubis. If the mass is in the interpelvic portion of the ilium or pubis, try to keep the biopsy track in an extraperitoneal location, which again means staying close to the iliac crest line. Biopsy lesions involving the obturator foramen, inferior pubic rami, or ischium from an anteroinferior direction, are shown as shaded regions in Figure 126.43. Lesions of the proximal femur can be biopsied directly lateral on a line anywhere from the tip of the greater trochanter down the shaft of the femur.

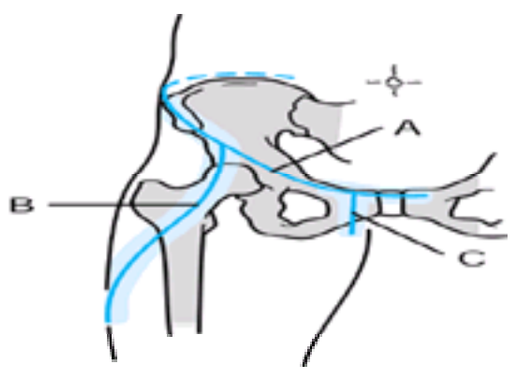


***Figure 126.43.*** Anterior view of incisions used for pelvic resections. The overlying *shading* shows general areas where it is safe to perform biopsies for the anterior lesions. **A:** Ilioinguinal portion. **B:** Iliofemoral portion. **C:** Inferior rami portion.

Depending on the location of the soft-tissue mass or the extent of resection needed, it is also possible to biopsy lesions along a line corresponding to the Smith-Peterson interval. This extends from the anterosuperior iliac spine, anteriorly and laterally across the thigh, in the interval between the tensor fascia muscle laterally and the sartorius and rectus medially. Lesions located along the medial acetabular wall and sciatic notch are in a very difficult area to biopsy, at least with sound oncologic principles. Unless extension of the mass occurs anterior to the level of the pelvic brim, it can be very difficult to reach from an intrapelvic biopsy placed along the wing of the ilium. Posteriorly directed biopsies through the sciatic notch potentially contaminate important neural structures. Under such circumstances, a consultation with an orthopaedic oncologist is indicated to determine the biopsy path that has the least anatomic and oncologic complications.

## OPERATIVE TECHNIQUES

### *Classification of Resections*

Enneking and Dunham (35) classified pelvic resections into three basic types, I, II, and III (Fig. 126.44). As previously mentioned, the classification is based on the zones of the pelvis that are removed rather than on actual anatomic bones. Type I resections are iliac wing resections, type II resections are acetabular resections, and type III are pubic rami or obturator resections. Enneking and Dunham initially used the letter **A** to further classify more extended resections. For example, a type IA resection includes the iliac wing plus the gluteal muscles, a type IIA resection includes the acetabulum as well as the proximal femur as an extra-articular resection of the hip, and a type IIIA resection includes the iliopsoas and femoral nerve. Since their original article, this basic classification system has been modified. A type IV resection has been added that is used to classify those resections that also include a portion of the sacrum, such as an iliosacral resection. These classifications not only provide a more uniform system for describing the resections, but also help to determine the optimal position for the patient for surgery and the surgical incision required.

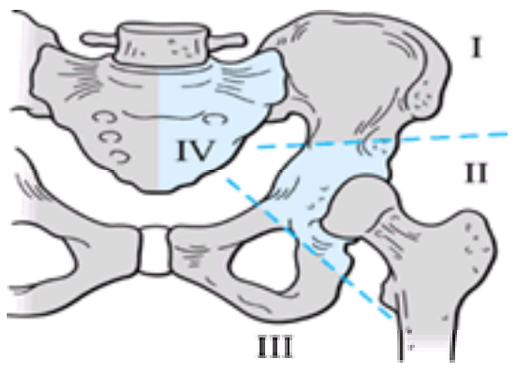


***Figure 126.44.*** Classification of pelvic resections.

The classification of proximal femoral resections is somewhat simpler and for the most part is based on the length of the proximal femur removed and whether the resection is performed as an intra-articular or extra articular resection. If a proximal femoral resection necessitates complete removal of the acetabulum, the anatomic and reconstructive challenges are virtually identical to those of the type II acetabular resections.

### *Surgical Exposure*

Despite its anatomic complexity, virtually all of the pelvis can be safely exposed and removed through a fairly basic set of incisions (Figure 126.43, Figure 126.45). The standard or utilitarian incision is useful for most iliac and acetabular resections. The incision is similar to that used for an extended iliofemoral approach (67).

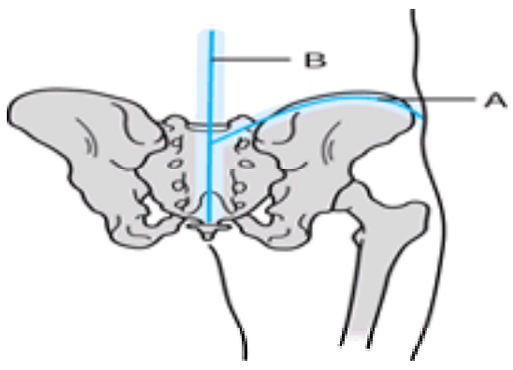


***Figure 126.45.*** Posterior view of incisions for pelvic resections. **A:** The posterior limb of the iliofemoral and ilioinguinal incision. **B:** The midline spine incision. The overlying *shading* shows the areas where biopsy track should be placed.

- Begin the incision at the posterosuperior iliac spine and extend it along the iliac crest to the anterosuperior iliac spine.
- Extend it then distally and laterally down the thigh, over the interval between the tensor fascia lata muscle laterally and the sartorius and rectus muscles medially.
- End the incision near the mid-lateral position of the thigh, 10–15 cm distal to the tip of the greater trochanter. It is possible to easily expose both the intrapelvic and extrapelvic portions of the iliac wing through this incision, as well as most of the acetabulum and hip joint.
- To expose any desired amount of femur, extend the incision distally down the thigh.
- For posterior exposure of the pelvis, use a large gluteal flap. Detach the origin of the gluteus maximus muscle and fascia from the iliac crest, and incise the fascia between the gluteus maximus and tensor fascia lata from the level of the iliac crest distally to the midportion of the iliotibial track, just past the level of the gluteus insertion. Turn the gluteus maximus itself posteriorly with its inferior gluteal neurovascular bundle. This exposes the interval between the gluteus maximus and the gluteus medius and minimus.
- Often with malignancies of the wing of the ilium, it is necessary to resect all or a portion of the gluteus medius and minimus with the specimen; this can easily be done through this approach. Structures exiting the greater sciatic foramen are accessible, as is the entire posterior column of the hemipelvis.
- Intrapelvic exposure of the iliac wing of the ilium is also possible through this incision. Detach the abdominal wall, including the external oblique, internal oblique, and transversalis muscles, from the wing of the ilium, generally 1–2 cm away from the iliac crest. The retroperitoneal space is entered quite easily over the top of the iliacus muscle, which allows for an oncologically safe plane of dissection for lesions involving the ilium. Exposure of the pelvis is readily achieved from the sacroiliac joint to the level of the iliopectineal eminence through this incision alone.
- If the lesion involves only the iliac wing (type I), develop the space within the iliacus and psoas muscles by retracting the femoral nerve and the psoas medially. Identify the pelvic brim and carry the dissection posteriorly to expose the intrapelvic portion of the sciatic notch.
- Depending on the size of the intrapelvic mass or the extent of the desired resection, further medial retroperitoneal dissection may be required. The external iliac vessels within their vascular sheath are aligned along the medial edge of the psoas muscle. It is possible to trace these proximally to their common iliac origin and, generally, to identify the internal iliac vessels as well. Through this standard iliofemoral approach, however, more extensive retroperitoneal exposure is difficult without a more formal ilioinguinal incision.
- Begin the ilioinguinal portion of the incision at the anterosuperior iliac spine and extend it medially along the ilioinguinal ligament to the pubic tubercle and symphysis pubis. This **T** extension of the incision does not normally have an adverse effect on wound healing.
- Incise this superficial ilioinguinal fascia from the level of the anterosuperior iliac spine to the pubic tubercle, and expose the ilioinguinal ligament itself. The ligament can be detached laterally or incised along its length as described by Letournel (68) for the ilioinguinal approach in trauma.
- Once the ligament is detached or incised, reflect it proximally and medially along with the abdominal wall, thus entering the retroperitoneal space. The femoral sheath and inferior epigastric pedicle are located midway between the anterosuperior iliac spine and the pubic tubercle.
- Ligate and cut the inferior epigastric vessels. Along the medial third of this dissection, identify the spermatic cord as it exits through the superficial external ring.
- Detach the ligamentous attachments of the ring from the pubis inferiorly, allowing the spermatic cord to be retracted proximally and medially. This approach allows adequate exposure of virtually all the important retroperitoneal anatomy previously alluded to.

- Alternatively, use the extended ilioinguinal approach as the primary incision, with the **T** extension as the distal lateral portion of the iliofemoral approach. The exposure is identical and merely a matter of the primary intent of the exposure and personal preference.
- For a more extensive exposure of the pubis, extend the ilioinguinal excision across the midline, reproducing the exposure on the contralateral side.
- For inferior pubic rami exposure, another incision or extension of the standard ilioinguinal incision is required. Figure 126.43 shows this limb of the exposure, which requires an incision from the pubic tubercle distally in the proximomedial thigh, along the line of the inferior pubic rami. This can be used alone, but more generally it is used in combination with at least a portion of the ilioinguinal approach and provides exposure to the entire obturator ring. Thus it is useful for type III pelvic resections.
- Finally, for more extensive posterior exposure of the pelvis and sacrum, as is required in iliosacral resection, use a midline spinal incision. Together with the posterolateral portion of the pelvic incision, this represents another **T**-type of incision, but it also has excellent healing qualities. The deep exposure gives access to the entire sacrum for laminectomy, nerve root exposure, and ultimate resection. The incision can be extended superiorly along the midline as far as necessary for further posterior spinal exposure.

### *Type I Resections and Reconstructions*

Type I resections of the ilium are indicated for lesions that involve the iliac wing and the immediate adjacent soft-tissue structures. Type I resections tend to be used with small lesions because a clear bony margin must exist in the supra-acetabular area to allow for a line of resection. The posterior resection is made at or near the sacroiliac joint. An important factor for these resections is whether a posteromedial strut of bone can be preserved, thereby maintaining structural continuity between the acetabulum and the sacrum. Figure 126.46 is an example of such a resection: Under the circumstances illustrated, no reconstruction is needed. If a complete resection is done through the sciatic notch, reconstructive options include (a) doing nothing, or (b) attempting to restore pelvic continuity with either autograft or allograft. Without reconstruction or with only minimal attempts at reconstruction—hinging the pelvis on the symphysis and approximating the remaining ischium to the sacrum—patients will develop a pseudarthrosis in this area. Most patients will have only minimal pain, but they will be left with a slightly shortened extremity. A better functional result can be achieved by reconstructing continuity of the pelvic ring (4,35,98). Autograft or allograft struts, either of fibula or, perhaps, iliac crest, can be wedged into the defect with internal fixation in the form of plate and screws to stabilize the pelvis until the graft heals (Figure 126.47).

***Figure 126.46.*** Type I pelvic resection with no reconstruction. **A:** Preoperative AP radiograph illustrating a chondrosarcoma located in the anterior ilium. **B:** Postoperative radiograph showing a line of resection from the superior acetabular lip to the posterior ilium. A strut of bone was left in continuity between the acetabulum and the sacrum, and therefore no reconstruction was required.

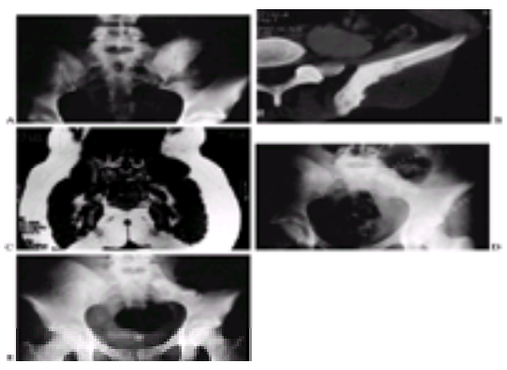

***Figure 126.47.*** Type I pelvic resection requiring reconstruction. **A:** AP radiograph of the pelvis showing a dense sclerosis within the posterior ilium in a 19-year-old woman. **B:** CT scan of the posterior ilium showing sclerosis as well as bony disruption and a soft-tissue mass. **C:** T1-weighted coronal MRI showing a large soft-tissue mass on the posterior ilium. The biopsy showed a Ewing's sarcoma. **D:** Immediate postoperative radiograph showing almost complete resection of the posterior ilium and a portion of the sacrum. A fibular allograft strut was placed between the sacrum and the ilium to aid in stability. **E:** One-year postoperative radiograph showing a consolidation of the bone graft. The patient was pain free with an excellent gait.

In the experience of Enneking and Dunham (35), 10 of 13 patients with type I or IA resections had a good functional result, although if pelvic continuity was lost, only 2 of 4 had a good result. The experience at the Mayo Clinic was similar: Out of 17 iliosacral resections, the best results were in the 12 patients who were left with a stable pelvis or who had a solid arthrodesis—and none of them had less than a good result. On the other hand, only 1 of the 5 patients with a pseudarthrosis or without reconstruction had a good result (98).

With more extensive resections of the sacrum, simple iliosacral fusion can be difficult because there is sacral bone loss. Extending the arthrodesis to the lumbar spine may be necessary. In these circumstances, spinal fixation instrumentation can be used with special modifications to allow fixation out to the ilium (Figure 126.48).

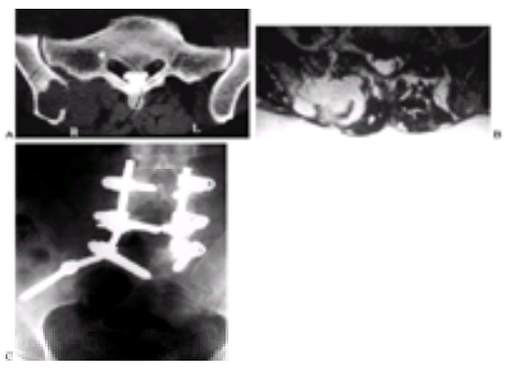

***Figure 126.48.*** Iliosacral resection with spinal instrumentation. **A:** CT scan in a 46-year-old man showing a destructive lesion in the posterior ilium involving the sacrum. **B:** T2-weighted axial MRI showing the soft-tissue mass involving the ilium. The lesion proved to be a hemangiopericytoma, and wide resection required removal of the entire posterior ilium, the lateral portion of the sacrum, and a portion of L-5. **C:** Reconstruction with an iliolumbar fusion with spinal instrumentation. A defect was bone grafted with morcelized allograft bone.

### *Type II Resections and Reconstructions*

Resections of the pelvis involving removal of the acetabulum **en bloc** are the most challenging not only from a surgical removal standpoint, but also from a

reconstructive standpoint. Whereas one can expect a reasonably good functional result after type I or type III resections alone, any resection involving the acetabulum generally has significant functional implications.

A type II resection is indicated for those lesions that involve all or a portion of the acetabulum and for those lesions that involve the hip joint proper, whether the lesion arises primarily within the pelvis, soft tissue, or proximal femur. For lesions that do arise within the pelvis itself, it is unusual to be able to do only a type II resection. Most type II resections are done either in combination with the iliac wing as a type I/II or in combination with the anterior arch of the pelvis as a type II/III.

Exposure for type II resections is generally obtained through the extensile ilioinguinal and iliofemoral approaches, using the **T**-type incision anteriorly. Adequate exposure of the intrapelvic and retroperitoneal structures is gained through the ilioinguinal portion of the dissection. The degree of soft-tissue extension into the pelvis determines the difficulty of dissection as well as the need to sacrifice important structures. In general, it is possible to preserve the external iliac vessels, as well as the femoral nerve; dissect them carefully away from any tumor mass. Ligation of the internal iliac vessels is often necessary, not only for adequate oncologic margins, but also to aid in getting the external iliac vessels away from any tumor mass. Once the tethering effects of the internal iliac vessels are removed, the external iliac vessels can easily be displaced medially.

- Divide the iliacus and psoas muscles near the intended level of bony resection, and identify the superior aspect of the sciatic notch.
- Use the lower portion of the ilioinguinal approach to identify the superior pubic rami and its intended resection level. The obturator nerve and vessels are generally sacrificed, particularly if there is any intrapelvic extension of tumor. The iliofemoral portion of the exposure completes the extrapelvic portion of the exposure. Not only are the lines of the iliac and ischial osteotomies determined, but exposure of the entire hip capsule circumferentially is possible.
- For intra-articular resection, make a circumferential capsular arthrotomy and dislocate the hip. A complete dissection of the sciatic nerve, from its exit through the sciatic notch to the proximal thigh, is possible.
- Complete removal of the acetabulum also requires a sectioning of the sacrospinous ligament. Take care to preserve the pudendal nerve, if possible, and the internal pudendal vessels.

Reconstruction after type II resection depends primarily on the actual amount of bone stock remaining. In principle, just as in other anatomic areas, the options include a flail joint, a stable arthrodesis, or a functioning arthroplasty. Early experiences with limb salvage of periacetabular lesions, before the development of effective reconstructive techniques, generally resulted in a flail hip joint (3,126). This also left the patient with a shortened extremity and a somewhat unstable hip, but it was preferable to a hemipelvectomy. There may still be indications for no reconstruction or an attempt to achieve a stable pseudarthrosis with minimal reconstruction. Normally this would occur when all or most of the hemipelvis was removed. Most authors agree that functional results are certainly improved and pelvic continuity can in some way be restored (38,98,130).

***Arthrodesis***

Arthrodesis of the proximal femur to a remaining portion of the pelvis can be an effective way of restoring function. Depending on the amount of bone removed, fuse the proximal femur either to the ilium as an iliofemoral fusion or, if the majority of the ilium has been resected, the proximal femur to the remaining ischium as an ischiofemoral arthrodesis. With an iliofemoral arthrodesis, fit the proximal femur onto the remaining ilium and, in most cases, secure it in a place with a 4.5 mm cobra plate (Figure 126.49). The greater trochanter of the femur can be osteotomized so that the plate fits more in line with the femur. The iliac fixation is, generally, on the outer table of the ilium, but it can be on the inner table if need be. Although this results in a shortened extremity, it produces a good functional result if successful.

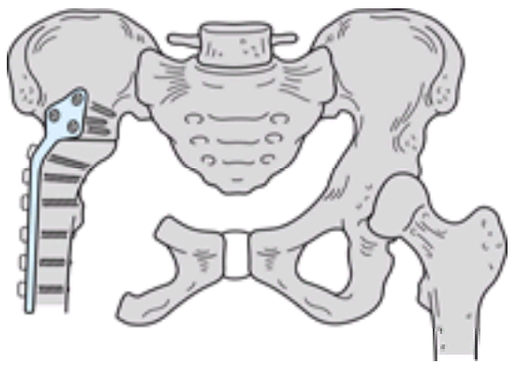

***Figure 126.49.*** Iliofemoral arthrodesis after type II pelvic resection. The proximal femur is fixed to the remaining ilium with a large cobra plate and screw fixation.

Unfortunately, fusion can be difficult, with a pseudarthrosis rate of at least 50%. In some patients, the pseudarthrosis is stable and minimally painful, and they may end up with a reasonably functional result. Experience from the Rizzoli Institute actually suggests that the functional result from a stable pseudarthrosis was very similar to that of a solid arthrodesis (14). These results suggested that minimal internal fixation, in the form of wiring the femur to the remaining ilium, may be preferable. This generally led to a firm pseudarthrosis and minimized the overall complication rate associated with failed fixation. To avoid the invariable limb shortening associated with a direct iliofemoral arthrodesis or attempted pseudarthrosis, an intercalary allograft can be used. Fusion, however, is still difficult, with a high rate of ultimate failure through nonunion or infection (15,98).

Ischiofemoral fusion can also result in a good functional outcome for patients who require periacetabular resections along with the majority of the iliac wing. In this instance, the proximal femur is fixed to the remaining ischium, generally with large fragment screws or wire cerclage (Figure 126.50). Successful patients generally have a good functional result, with less limb shortening than would be associated with an iliofemoral arthrodesis. The difficulty lies in actually obtaining the arthrodesis. The fusion rate is lower than that seen with iliofemoral arthrodesis. Additionally, postoperative pain at the symphysis pubis from the high stresses in this area combined with a very poor functional outcome if a pseudarthrosis occurs have led many physicians to avoid the ischiofemoral arthrodesis.

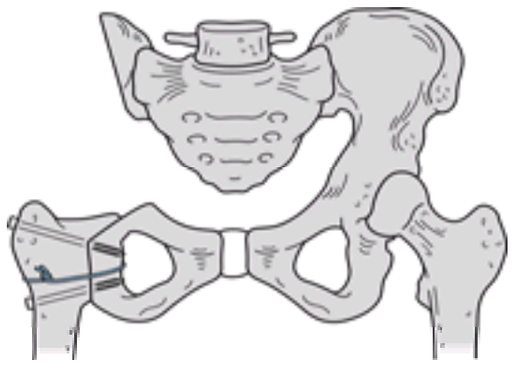

***Figure 126.50.*** Ischiofemoral arthrodesis after type I/II pelvic resection. The proximal femur is fused with the remaining ischium, a combination of interfragmentary screws, and a cerclage cable.

***Arthroplasty***

Hip arthroplasty for type II periacetabular resection can be achieved with either an endoprosthesis osteoarticular pelvic allograft or prosthetic bone graft composites. The type of arthroplasty performed is based on remaining bone stock, as well as physician and patient preferences.

***Endoprosthesis***

Perhaps the most straightforward endoprosthetic reconstruction, as long as adequate ilium remains, is the use of saddle prosthesis. The saddle prosthesis was

designed in Germany and consists of a **U**-shaped or saddle-shaped articulating piece, which is fit into a notch in the ilium (Figure 126.51). This articulating piece is connected to a relatively standard femoral prosthesis on the femoral head taper. Body segments can also be added in between to restore adequate limb length. Abduction and flexion/extension are achieved at the prosthesis–bone interface, with rotation achieved within the articulating prosthetic segment itself. Soft-tissue reconstruction is critical to provide stability of the prosthesis within the iliac notch. The early experience of Nieder et al. (96,97) with this prosthesis was primarily for patients with massive bone loss due to failed total joint arthroplasty. More recently, the prosthesis has been used in patients after periacetabular resections. Aboulafia et al. (1) reported on their experience with 17 patients, of whom 12 had overall good to excellent functional outcomes. In general, the functional level result is certainly not as good as a conventional hip arthroplasty, but it is much better than a flail hip and more predictable than attempts at iliofemoral arthrodesis.

***Figure 126.51.*** Type II/III pelvic resection with reconstruction using a saddle prosthesis. **A:** AP radiograph of the hip showing a large chondrosarcoma involving the entire obturator foramen. The lesion is primarily situated within the superior pubic rami, but it clearly extends to the acetabulum. **B:** CT scan illustrating extensive destruction of the medial acetabulum along with soft-tissue masses both within the pelvis and extending through the obturator foramen. **C:** A resection required removal of the entire acetabulum, and the reconstruction was performed with a saddle prosthesis.

A more complex method of pelvic reconstruction after acetabular resection involves the use of the pelvic endoprosthesis incorporating an actual hip joint near the anatomic center of the native joint (2,45,95,135,144). This prosthesis can be made as a custom implant or as a modular implant, allowing some intraoperative flexibility. By reproducing the normal hip center, Windhager et al. (144) felt their functional results were better than their experience with the saddle prosthesis. The advantage of these systems over using allografts or attempting to obtain an arthrodesis is a tendency toward fewer early complications, less morbidity, and an earlier functional return. This is particularly important in a patient with a high-grade malignancy of the pelvis who may have limited survival.

### *Biologic Arthroplasty*

Hemipelvic allografts or autoclaved autografts is another method of reconstruction for periacetabular resections (6,28,49,92). These techniques again have the advantage of reproducing a more normal hip center and limb length, but they are also associated with a longer operative time and increased morbidity. The use of a hemipelvic or whole acetabular allograft requires being able to procure a graft, normally from a large regional or a national bone bank, of the appropriate size to match the defect created after resection. The graft is normally fixed to the remaining host bone with a combination of plates and screws or large Steinmann pins. Perform a conventional hip arthroplasty, creating an allograft–prosthesis composite (Figure 126.52). Keep reaming of the acetabulum to a minimum to avoid excessive weakening of the graft. Now cement the acetabular component into place. Alternatively, use a bipolar prosthesis, thus eliminating any reaming of the allograft bone. It is certainly possible to replace the entire hip joint, including a segment of proximal femur, as a complete osteoarticular graft, although experience with this has generally led to failure, and most authors suggest using a prosthesis for the hip joint itself.

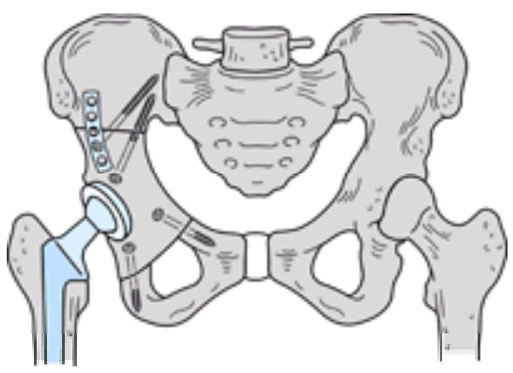

***Figure 126.52.*** Reconstruction of a type II pelvic resection with a whole acetabular allograft. Fix the allograft to the ilium and pubis with plate and screw fixation and interfragmentary screws as necessary. Then perform a total hip arthroplasty, cementing the acetabular cup into the allograft bone.

Some centers use the technique of autoclaving the resected specimen and reimplanting it. After resecting the specimen, clean it of any soft tissue and tumor and autoclave it at 135°C for approximately 10 minutes. Reinsert it into the original bed and fix it securely with plates or threaded Steinmann pins. The advantage of this technique is that it requires no allograft procurement or sizing. The fit is exact and therefore achieves excellent bone-to-bone contact. Clearly, if the tumor itself has already destroyed a lot of the actual bone, the technique would not be useful. Therefore, it is generally reserved for those lesions with minimal bone destruction.

Many of the published reports on the use of allografts or autoclaved autografts suggest a number of potential problems, including infection, dislocation, and graft failure through resorption, fracture, or prosthetic loosening (17,49,95,101). Harrington (49) reported on 14 patients, 10 of whom had reconstruction with an allograft and 4 of whom had the autoclaved autograft technique. Although he reported only one infection and one local recurrence, there were still three patients with late fracture of the grafts. The experience reported by Bell et al. (6), on 17 patients with pelvic allografts, also points out the potential difficulties with these reconstructions. They noted a local recurrence in three patients, deep infection in two, and dislocation of the hip in five. Overall, these results are not dramatically different from those achieved with reconstructions by other methods and serve to illustrate the difficulty of restoring function in periacetabular resections. In spite of the morbidity, attempts at reconstruction are generally worthwhile because the functional results are considerably better than leaving the hip flail.

### *Type III Resections and Reconstructions*

Obtain exposure for resection of lesions involving the pubic rami and obturator foramen through the ilioinguinal incision, with or without its posterior extension along the inferior pubic rami.

- After completing the intrapelvic and extrapelvic dissection, determine the lines of bony resection.
- The osteotomy through the symphysis pubis or even the contralateral side is generally made with a Gigli saw. Take care to protect the urethra from injury.
- Laterally, the superior pubic rami can be cut at any level, even to the point of resecting a portion of the anteroinferior acetabulum. Provided this is a minor amount of acetabulum, it will not compromise hip stability. It is usual to be able to preserve and protect the femoral vessels and femoral nerve throughout the dissection. It is very common, however, to have to sacrifice the obturator nerve, as mentioned previously.
- Make the posterior osteotomy anywhere along the inferior pubic rami as determined by the tumor extent, even to the point of making the resection through the posterior column just inferior to the acetabulum (Figure 126.53).

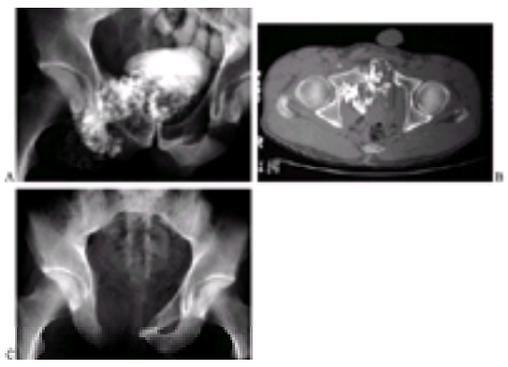

***Figure 126.53.*** Type III pelvic resection. **A:** AP radiograph of the lower pelvis showing a chondrosarcoma located within the superior pubic rami. **B:** CT scan showing a lesion primarily within the superior pubic rami with apparent sparing of the acetabulum. **C:** Type III resection of the pelvis. A small portion of the anterior acetabular wall was removed, but no reconstruction was necessary.

- You can usually palpate the sulcus just inferior to the acetabular lip, and this serves as a landmark to the inferior portion of the acetabulum.
- Expose the posterior column circumferentially through the lesser sciatic notch, using either a Gigli saw or an osteotome to make the cut. Generally, the resection can be made without dislocation of the hip, but if need be, dislocate the hip temporarily.

Reconstruction after type III resections is generally unnecessary because continuity between the femur and the sacrum is maintained (Figure 126.53). This is borne out by the experience of most authors, who show that functional results are generally good to excellent in the absence of any reconstruction (14,35,38,98). Soft-tissue closure after type III resections is particularly important. You must reconstruct the lower abdominal wall, normally by suturing the ilioinguinal detachment to the adductor muscles of the thigh. Be careful during the repair to allow plenty of room for the superficial femoral vessels as well as the spermatic cord. Because the pelvic floor is disrupted, there does tend to be a settling and a slight shift of abdominal contents into the area and, potentially, even into the upper thigh, but ths is generally asymptomatic.

**ONCOLOGIC OUTCOME OF PELVIC LESIONS**

The overall oncologic outcome of pelvic lesions depends on a number of factors, including the location and grade of the lesion as well as the ability to achieve a wide surgical margin. These principles are similar to those for malignancies that occur in other areas, and they are discussed in Chapter 128, Chapter 129 and Chapter 130. The pelvis is somewhat unique in that its anatomic complexities tend to make it more difficult to achieve a wide surgical margin. This is particularly evident in lesions that occur in the iliosacral area, because the margin for either may be similar, whether an amputation or a limb salvage procedure was done. Local recurrence rates after pelvic resections do tend to be higher than for extremity lesions. Overall, reports show local recurrence rates for lesions occurring in the pelvis to be in the range of 5% to more than 30% (6,14,35,58,98,118). The highest local recurrence rates are generally for iliosacral lesions. If you can achieve wide margins, the local recurrence rate is distinctly lower, usually less than 20%. When a marginal or lesional margin is achieved, the local recurrence rate tends to be closer to 50% or even higher.

Overall survival of patients with pelvic lesions depends primarily on the grade of the lesion. In general, patients with high-grade lesions of the pelvis tend to have a poorer prognosis than those with extremity lesions. In the series by both Shin et al. (118) and Kawai et al. (57), overall survival in patients with high-grade sarcoma of the pelvis was less than 35%.

**PROXIMAL FEMORAL RESECTIONS AND RECONSTRUCTIONS**

The proximal end of the femur is one of the more common locations for primary bone tumors. In children and young adults, the most common lesions include osteosarcoma and Ewings' sarcoma, whereas in patients over 40 years old chondrosarcoma is more likely. The proximal femur is also a common site for metastasis and myeloma, and, occasionally, proximal femoral resections are required to manage these lesions as well. Most lesions of the proximal femur are amenable to limb salvage because only with the most extensive soft-tissue involvement are any important neurovascular structures involved. The femoral vessels lie far enough anterior and medial to the femur itself that they are not normally a problem and, as mentioned earlier, the sciatic nerve at this level is not only well away from the femur but also mobile enough to make tumor involvement rare. Furthermore, because the functional results of hip disarticulation or hemipelvectomy are so poor, any reconstruction that provides a hip stable enough to allow reasonable knee and foot function would be worthwhile.

Proximal femoral resections are generally classified as intra-articular or extra-articular. For intra-articular resection, the acetabulum is preserved in its entirety, and reconstruction with a functional arthroplasty is generally possible. In an extra-articular resection, the entire joint is removed, including the acetabular articular surface. If this can be done by removing only a shell of the acetabulum without totally disrupting pelvic continuity, reconstruction with arthroplasty is also possible. If the entire acetabulum is removed, thereby disrupting pelvic continuity, the reconstructive challenges are similar to those encountered with type II pelvic resection.

- It is usual to do the resection in a lateral position with a long, straight, lateral incision that incorporates the biopsy track.
- Split the tensor fascia lata lengthwise; it can generally be preserved.
- Detach the gluteus medius and minimus from the greater trochanter, preserving as much length as possible depending on tumor extent. The origin of the vastus lateralis muscle is normally left with the specimen, but often a significant amount of the muscle itself can be preserved. Provided a cuff of the muscle is left adjacent to the femur, reflect the more superficial portion of the vastus lateralis anteriorly; it can be very useful in soft-tissue reconstruction.
- Expose the anterior aspect by externally rotating the femur. Variable amounts of rectus femoris will need to be resected or released, depending on tumor extent. The sartorius muscle spans the area of resection and therefore can generally be preserved.
- It is usual to transect the iliopsoas muscle at the level of the hip capsule. Only with very large lesions will you need to expose the femoral vessels themselves.
- By internally rotating the hip, expose the posterior aspect of the femur. Detach the short external rotators, quadratus femoris, and gluteus maximus from the femur, leaving a cuff of tissue.
- You can generally palpate the sciatic nerve, and often it is not necessary to expose it directly.
- Osteotomizing the femur at the intended level of resection facilitates medial exposure of the femur. The proximal femur becomes much more mobile, and it is possible to transect the adductor muscles appropriately.
- If the resection is to be intra-articular, incise the hip capsule circumferentially.
- Cut the ligamentum teres and remove the specimen.
- The options for reconstruction after proximal femoral resection depend primarily on whether the resection has been done with intra-articular or extra-articular margins. Intra-articular resections are generally amenable to arthroplasty, and patients generally prefer this. Perform the arthroplasty with an osteoarticular allograft, an allograft prosthesis composite, or an endoprosthetic reconstruction.
- When an osteoarticular allograft is planned, it is important to select a graft of the appropriate size, particularly the femoral head dimensions. Test the femoral head articulation within the acetabulum intraoperatively to ensure that it is the proper size. A femoral head too large or too small generally leads to problems, and one can decide to reconstruct with an allograft prosthesis composite if need be.
- To do the soft-tissue reconstruction around the hip, suture the remnant of the patients' capsule to the capsule that is attached to the allograft.
- Also suture the abductor muscles to the stump of tendon that was harvested with the graft.
- Bony fixation to the host bone is generally done with the large fragment plate and screw fixation.

The results of osteoarticular allograft reconstruction of the proximal femur are somewhat unpredictable (120). With 15 patients treated with osteoarticular allograft, Jofe et al. (55) noted nonunion and fracture in five patients, infection in four, and an unstable hip in one. Of the 15 patients, 10 required reoperation for complications.

Generally, reconstruction with an allograft prosthesis composite provides a better functional result with fewer complications than an osteoarticular allograft alone. The composite reconstruction provides the advantages of the allograft in terms of soft-tissue attachment, and also the more predictable return of function with fewer of the complications associated with an endoprosthesis. The specifics of the composite construct depend on the length of femur resected. From a biomechanical standpoint, it is considered unwise to have the tip of the prosthesis at or near the allograft–host junction.

- If the femoral resection is long, cement a standard hip component into the allograft, then fix the entire composite to the distal femur with a plate and screws. The plate should be long enough to overlap the stem by a few centimeters to attempt to alleviate any stress riser effect near the tip of the femoral stem.
- If the resection length is shorter, use a long-stem femoral component. Once again, cement the allograft to the proximal portion of the stem, and insert the entire composite into the distal femur.
- A press-fitting of the stem in a noncemented fashion achieves fixation in the host bone. If needed, add a plate to the allograft host junction for additional stability.

The articular portion of the reconstruction can be done with a standard acetabular component or as a bipolar arthroplasty.

The allograft prosthesis composite reconstruction typically fares better than the osteoarticular graft. Jofe et al. (55) reported on 13 patients with allograft prosthesis composite reconstruction. These patients had a much lower incidence of graft-related complications and had an overall better functional result than did the osteoarticular grafts. In addition, in a number of their patients, failures of osteoarticular graft were salvaged with allograft prosthesis composites. Gitelis and Piasecki (44) reported on their experience with allograft prosthesis composite and 11 reconstructions of the hip. In an average follow-up of almost 4 years, they reported overall good functional results and no implant revisions as a result of loosening.

Probably the most common method of reconstruction after proximal femoral resection uses an endoprosthetic device (Figure 126.54) (119). The prosthesis is either a one-piece design or a more recent, modular system, which allows intraoperative customization of length. This makes some intraoperative flexibility possible, as does an allograft prosthesis composite. The fixation stems can vary in length and diameter, and they can be straight or bowed to accommodate whatever remains of the patients' femur. These prostheses are generally cemented in place, although noncemented designs have shown effectiveness as well. Once the prosthesis is in place, soft-tissue reconstruction is critical in minimizing complications and improving function.

***Figure 126.54.*** Proximal femoral resection and endoprosthetic reconstruction. **A:** AP radiograph of the proximal femur showing a lytic lesion within the femoral neck and head in a 19-year-old woman. **B:** T1-weighted coronal MRI showing a lesion within the proximal femur, which eventually proved to be osteosarcoma. **C:** AP radiograph of the proximal femur after proximal femoral resection and endoprosthetic resection with a modular proximal femoral prosthesis.

- Secure whatever capsular structures remain around the neck of the prosthesis, generally in purse-string fashion, to improve stability.
- Pull the abductor muscles and tendons distally as far as possible and secure them to the prosthesis with a loop or other fixation at a point near the old greater trochanter.
- Use the remaining muscles of the thigh to cover up the entire prosthesis with healthy, viable muscle.
- Pull the vastus lateralis proximally and laterally as far as possible and secure it either to the abductor muscle or to the underside of the tensor.
- Farther down the thigh, suture the vastus lateralis to a hamstring, if it has been mobilized, or to the lateral intramuscular septum.
- Pull the gluteus maximus muscle anteriorly and suture it to the remaining vastus as well.
- With some diligence, the prosthesis can generally be covered, which aids in preventing deep infection and improves function by getting the muscle back out to a more physiologic length.

The experience with these megaprostheses has generally been favorable. Multiple series have been reported with various prosthetic designs (32,51,62,70,76,121,126,134,137). The most common complication seems to be dislocation, which is reported in up to 25% of patients. Reoperation for mechanical failure or loosening has been very low, less than 15%, and failure due to deep infection was also low, usually less than 5%. The functional results of endoprosthetic devices are quite good in terms of pain relief. The main functional problem is still the relative lack of abductor strength. This is certainly quite variable and depends on the number of abductors that are still available for reconstruction and the ability of the surgeon to get satisfactory healing into the surrounding soft tissues. In this regard, the allograft prosthetic devices may have a benefit.

## CHAPTER REFERENCES

Each reference is categorized according to the following scheme: *, classic article; #, review article; !, basic research article; and +, clinical results/outcome study.


+ 1. Aboulafia AJ, Buch R, Mathews J, et al. Reconstruction Using the Saddle Prosthesis following Excision of Primary and Metastatic Periacetabular Tumors. *Clin Orthop* 1995;314:203.

+ 2. Abudu A, Grimer RJ, Cannon SR, et al. Reconstruction of the Hemipelvis after the Excision of Malignant Tumours. Complications and Functional Outcomes of Prostheses. *J Bone Joint Surg Br* 1997;79:773.

+ 3. Arnold PG, Mixter RC. Making the Most of the Gastrocnemius Muscles. *Plast Reconstr Surg* 1983;72:38.

+ 4. Barwick WJ, Goldberg JA, Scully SP, Harrelson JM. Vascularized Tissue Transfer for Closure of Irradiated Wounds after Soft Tissue Sarcoma Resection. *Ann Surg* 1992;216:591.

+ 5. Baumann PK. Resection of the Upper Extremity in the Region of the Shoulder Joint. *Khirurgh Arkh Velyaminova* 1914;30:145.

+ 6. Bell RS, Davis AM, Wunder JS, et al. Allograft Reconstruction of the Acetabulum after Resection of Stage-IIB Sarcoma: Intermediate-Term Results. *J Bone Joint Surg Am* 1997;79:1663.

+ 7. Berger PE, Kuhn JP. Computed Tomography of Tumors in the Musculoskeletal System in Children. *Radiology* 1978;127:171.

+ 8. Berquist TH. Magnetic Resonance Imaging of Musculoskeletal Neoplasm. *Clin Orthop* 1989;244:101.

+ 9. Berrey BH Jr, Lord CF, Gebhardt MC, Mankin HJ. Fractures of Allografts: Frequency, Treatment, and End-Results. *J Bone Joint Surg Am* 1990;72:825.

+ 10. Bradish CF, Kemp HBS, Scales FT, et al. Distal Femoral Replacement by Custom Made Prostheses. *J Bone Joint Surg Br* 1987;69:276.

+ 11. Brien EW, Terek RM, Healey JH, Land JM. Allograft Reconstruction after Proximal Tibial Resection for Bone Tumors: An Analysis of Function and Outcome Comparing Allograft to Prosthetic Reconstruction. *Clin Orthop* 1994;303:116.

+ 12. Broström L, Harris MA, Simon MA, et al. The Effect of Biopsy on Survival of Patients with Osteosarcoma. *J Bone Joint Surg Br* 1979;61:209.

+ 13. Cammisa FP, Glasser DB, Otis JC, et al. The Van Nes Tibial Rotationplasty: A Functionally Viable Reconstructive Procedure in Children Who Have a Tumor of the Distal End of the Femur. *J Bone Joint Surg Am* 1990;72:1541.

# 14. Campanacci M, Capanna R. Pelvic Resections: The Rizzoli Institute Experience. *Orthop Clin North Am* 1991;22:65.

# 15. Capanna R, Donati D, Fazioli F, et al. Iliofemoral Arthrodesis with Intercalary Allograft. In: Brown KLB, ed. Complications of Limb Salvage. Proceedings of the International Symposium on Limb Salvage (ISOLS), Montreal, Canada, 1991:205.

+ 16. Capanna R, Donati D, Masetti C, et al. Effect of Electromagnetic Fields on Patients Undergoing Massive Bone Graft following Bone Tumor Resection: A Double Blind Study. *Clin Orthop* 1994;306:213.

+ 17. Capanna R, Morris HG, Campanacci D, et al. Modular Uncemented Prosthetic Reconstruction after Resection of Tumours of the Distal Femur. *J Bone Joint Surg Br* 1994;76:178.

+ 18. Catton C, Fornasier VL, Langer F. Wound-Healing Complications after Soft-Tissue Sarcoma Surgery. *Plast Reconstr Surg* 1994;93:980.

+ 19. Change AE, Schaner EG, Conkle DM, et al. Evaluation of Computed Tomography in the Detection of Pulmonary Metastases: A Prospective Study. *Cancer* 1979;43:913.

# 20. Chao EYS. A Composite Fixation Principle for Modular Segmental Defect Replacement (SDR) Prostheses. *Orthop Clin North Am* 1991;22:439.

+ 21. Choong PF, Sim FH, Pritchard DJ, et al. Megaprostheses after Resection of Distal Femoral Tumors. A Rotating Hinge Design in 30 Patients Followed for 2–7 Years. *Acta Orthop Scand* 1996;67:345.

+ 22. Clohisy DR, Mankin HJ. Osteoarticular Allografts for Reconstruction after Resection of a Musculoskeletal Tumor in the Proximal End of the Tibia. *J Bone Joint Surg Am* 1994;76:549.

# 23. Dahlin DC. *Bone Tumors: General Aspects and Data on 6,221 Cases*, 3rd ed. Springfield, IL: Thomas, 1978.

# 24. Das Gupta TK. Scapulectomy. Type III Shoulder Girdle Resection. In: Sugarbaker PH, Malawer MM, eds. *Musculoskeletal Surgery for Cancer: Principles and Techniques*, 3rd ed. New York: Thieme, 1992:338.

25. DeNancrede CB.

+ 26. DeSantos LA, Goldstein HM, Murray JA, et al. Computed Tomography in the Evaluation of Musculoskeletal Neoplasms. *Radiology* 1978;128:89.

+ 27. DeSantos LA, Murray JA, Ayala AG. The Value of Percutaneous Needle Biopsy in the Management of Primary Bone Tumors. *Cancer* 1979;43:735.

# 28. Donati D, Capanna R, Caldora P, et al. Internal Hemipelvectomy of the Acetabular Area Using Different Methods of Reconstruction. In: Tan SK, ed. *Limb Salvage, Current Trends. Proceedings of the International Symposium on Limb Salvage (ISOLS), Singapore*, 1993:185.

+ 29. Donati D, Capanna R, Campanacci D, et al. The Use of Massive Bone Allograft for Intercalary Reconstruction and Arthrodesis after Tumor Resection: A Multicentric European Study. *Chir Organi Mov* 1993;78:81.

+ 30. Drake DB, Oishi SN. Wound Healing Considerations in Chemotherapy and Radiation Therapy. *Clin Plastic Surg* 1995;22:31.

+ 31. Eckardt JJ, Eilber FR, Rosen G, et al. Endoprosthetic Replacement for Stage IIB Osteosarcoma. *Clin Orthop* 1991;270:202.

# 32. Eckardt JJ, Pignatti G, Eilber FR, et al. Management of Failed Endoprosthetic Implants: The UCLA Experience. In: Langlais F, Tomeno B, eds. Limb Salvage—Major Reconstruction in Oncologic and Nontumoral Conditions. Berlin: Springer-Verlag, 1991:479.

* 33. Enneking WR. The Issue of the Biopsy [editorial]. *J Bone Joint Surg Am* 1982;64:1119.

# 34. Enneking WF. General Principles of Musculoskeltal Tumor Surgery—Natural History. In: Enneking WF, ed.*Musculoskeletal Tumor Surgery*, vol. 1. New York: Churchill Livingstone, 1983:3.

* 35. Enneking WF, Dunham WK. Resection and Reconstruction for Primary Neoplasms Involving the Innominate Bone. *J Bone Joint Surg Am* 1978;60:731.

+ 36. Enneking WF, Dunham W, Gebhardt MC, et al. A System for the Functional Evaluation of Reconstructive Procedures after Surgical Treatment of Tumours of the Musculoskelatal System. *Clin Orthop* 1993;286:241.

+ 37. Enneking WF, Kagan A. The Implications of “Skip” Metastases in Osteosarcoma. *Clin Orthop* 1975;111:33.

# 38. Enneking WF, Menendez LR. Functional Evaluation of Various Reconstructions after Periacetabular Resection of Iliac Lesions. In: Enneking WF, ed.*Limb Salvage in Musculoskeletal Oncology.* New York: Churchill Livingstone, 1987:117.

+ 39. Enneking WF, Shirley PD. Resection Arthrodesis for Malignant and Potentially Malignant Lesions about the Knee Using Intramedullary Rod and Local Bone Grafts. *J Bone Joint Surg Am* 1997;59:223.

* 40. Enneking WF, Spanier SS, Goodman MA. A System for the Surgical Staging of Musculoskeletal Sarcomas. *Clin Orthop* 1980;153:106.

+ 41. Feldman JJ, Cohen BE, May JW Jr. The Medial Gastrocnemius Myocutaneous Flap. *Plast Reconstr Surg* 1978;61:531.

! 42. Friedlaender GE, Strong DM, Sell KW. Studies on the Antigenicity of Bone: I. Freeze-Dried and Deep-Frozen Bone Allografts in Rabbits. *J Bone Joint Surg Am* 1976;58:854.

+ 43. Gebhardt MC, Flugstad DI, Springfield DS, Mankin HJ. The Use of Bone Allografts for Limb Salvage in High-Grade Extremity Osteosarcoma. *Clin Orthop* 1991;270:181.

+ 44. Gitelis S, Piasecki P. Allograft Prosthetic Composite Arthroplasty for Osteosarcoma and Other Aggressive Bone Tumors. *Clin Orthop* 1991;270:197.

+ 45. Gradinger R, Reichl H, Hipp E. Pelvic Osteosarcoma. Resection, Reconstruction, Local Control, and Survival Statistics. *Clin Orthop* 1991;270:149.

+ 46. Greenberg B, LaRossa D, Lotke PA, et al. Salvage of Jeopardized Total-Knee Prosthesis: The Role of the Gastrocnemius Muscle Flap. *Plast Reconstr Surg* 1983;83:85.

+ 47. Guerra A, Capanna R, Biagini R, et al. Extra-Articular Resection of the Shoulder Girdle. *Clin Orthop* 1961;19:148.

+ 48. Guzman-Stein G, Fix RJ, Vasconez LO. Muscle Flap Coverage for the Lower Exremity. *Clin Plast Surg* 1991;18:545.

+ 49. Harrington KD. The Use of Hemipelvic Allografts or Autoclaved Grafts for Reconstruction after Wide Resections of Malignant Tumors of the Pelvis. *J Bone Joint Surg Am* 1992;74:331.

+ 50. Harris AI, Gitelis S, Sheinkop MB, et al. Allograft Prosthetic Composite Reconstruction for Limb Salvage and Severe Deficiency of Bone at the Knee or Hip. *Semin Arthroplasty* 1994;5:85.

+ 51. Horowitz SM, Glasser DB, Lane JM, Healey JH. Prosthetic and Extremity Survivorship after Limb Salvage for Sarcoma: How Long Do Reconstructions Last? *Clin Orthop* 1993;293:280.

+ 52. Horowitz SM, Lane JM, Healey JH. Soft-Tissue Management with Prosthetic Replacement for Sarcomas around the Knee. *Clin Orthop* 1992;275:226.

+ 53. Huvos AG, Heilweil M, Bretsky SS. The Pathology of Malignant Fibrous Histiocytoma of Bone: A Study of 130 Patients. *Am J Surg Pathol* 1985;9:853.

+ 54. Jaureguito JW, Dubois CM, Smith SR, et al. Medial Gastrocnemius Transposition Flap for the Treatment of Disruption of the Extensor Mechanism after Total Knee Arthroplasty. *J Bone Joint Surg Am* 1997;49:866.

+ 55. Jofe MH, Gebhardt MC, Tomford WW, Mankin HJ. Reconstruction for Defects of the Proximal Part of the Femur Using Allograft Arthroplasty. *J Bone Joint Surg Am* 1988;70:507.

+ 56. Johnson JTH. Reconstruction of the Pelvic Ring following Tumor Resection. *J Bone Joint Surg Am* 1978;60:747.

+ 57. Kawai A, Huvos AG, Meyers PA, Healey JH. Osteosarcoma of the Pelvis: Oncologic Results of 40 Patients. *Clin Orthop* 1988;348:197.

+ 58. Kawai A, Muschler GF, Lane JM, et al. Prosthetic Knee Replacement after Resection of a Malignant Tumor of the Distal Part of the Femur. *J Bone Joint Surg Am* 1998;80:636.

+ 59. Kenan S, Bloom N, Lewis MM. Limb-Sparing Surgery in Skeletally Immature Patients with Osteosarcoma: The Use of an Expandable Prosthesis. *Clin Orthop* 1991;270:223.

+ 60. Kenan S, Lewis MM. Limb Salvage in Pediatric Surgery: The Use of The Expandable Prosthesis. *Orthop Clin North Am* 1991;22:121.

+ 61. Kenan S, Lewis MM. Limb Sparing Surgery in Children. The Expandible Prosthesis. Current Trends and Controversies after the First 10 Years. Eighth International Symposium on Limb Salvage (ISOLS), Florence, Italy, 1995;124.

# 62. Khong KS, Chao EYS, Sim FH. Long-Term Performance of Custom Prosthetic Replacement for Neoplastic Disease of the Proximal Femur. In: Yamamuro T, ed.*New Developments for Limb Savage in Musculoskeletal Oncology.* Tokyo: Springer-Verlag, 1989;403.

+ 63. Kirchner PT, Simon MA. Radioisotopic Evaluation of Skeletal Disease. *J Bone Joint Surg Am* 1981;63:673.

+ 64. Kneisl JS, Finn HA, Simon MA. Mobile Knee Reconstructions after Resection of Malignant Tumors of the Distal Femur. *Orthop Clin North Am* 1991;22:105.

+ 65. Kotz R, Salzer M. Rotationplasty for Childhood Osteosarcoma of the Distal Femur. *J Bone Joint Surg Am* 1982;64:959.

+ 66. Kuo KN, Gitelis S, Sim FH, et al. Segmental Replacement of Long Bones Using Titanium Fiber Metal Composite following Tumor Resection. *Clin Orthop* 1983;176:108.

# 67. Langlais F, Thomazeau H, Kerbrat P. Reconstruction of the Hip Joint after Large Pelvic Allografts. In: Brown KLB, ed. *Complications of Limb Salvage. International Symposium on Limb Salvage* (ISOLS), Montreal, Canada, 1991;201.

# 68. Letournel E. Acetabulum Fractures: Classification and Management. *Clin Orthop* 1980;151:81.

+ 69. Lewis MM. The Use of the Expandable and Adjustable Prosthesis in the Treatment of Childhood Malignant Bone Tumors of the Extremities. *Cancer* 1986;57:499.

+ 70. Lewis MM, Chekofsky KM. Proximal Femur Replacement for Neoplastic Disease. *Clin Orthop* 1982;171:72.

* 71. Linberg BE. Interscapulo-Thoracic Resection for Malignant Tumors of the Shoulder Girdle Region. *J Bone Joint Surg* 1928;10:344.

+ 72. Link MP, Goorin AM, Miser AW, et al. The Effect of Adjuvant Chemotherapy on Relapse-Free Survival in Patients with Osteosarcoma of the Extremity. *N Engl J Med* 1986;314:1600.

+ 73. Liston R. Ossified Aneurysmal Tumor of the Subscapular Artery. *Ediul Med J* 1820;16:66.

+ 74. Lord CF, Gebhardt MC, Tomford WW, Mankin HJ. Infection in Bone Allografts. Incidence, Nature, and Treatment. *J Bone Joint Surg Am* 1988;70:369.

+ 75. Malawer MM. Tumors of the Shoulder Girdle: Technique of Resection and Description of a Surgical Classification. *Orthop Clin North Am* 1991;22:7.

+ 76. Malawer MM, Chou LB. Prosthetic Survival and Clinical Results with Use of Large-Segment Replacements in the Treatment of High-Grade Bone Sarcomas. *J Bone Joint Surg Am* 1995;77:1154.

# 77. Malawer MM, Link M, Donaldson S. Sarcomas of Bone. In: Devita VT, Hellman S, Rosenberg SA, eds. *Cancer: Principles and Practice of Oncology*, vol. 2, 3rd ed. Philadelphia: Lippincott, 1989:1418.

+ 78. Malawer MM, McHale KA. Limb-Sparing Surgery for High Grade Malignant Tumors of the Proximal Tibia. *Clin Orthop* 1989;239:231.

+ 79. Malawer MM, Price WM. Gastrocnemius Transposition Flap in Conjunction with Limb-Sparing Surgery for Primary Bone Sarcomas around the Knee. *Plast Reconstr Surg* 1984;73:741.

# 80. Malawer MM, Sugarbaker PH. Shoulder Girdle Resections: The Tikhoff-Linberg Procedure and Its Modification. In: Sugarbaker PH, Malawer MM, eds. *Musculoskeletal Surgery for Cancer: Principles and Techniques*, 3rd ed. New York: Thieme, 1992;346.

# 81. Malawer MM, Sugarbaker PH, Lamber MH, et al. The Tikhoff-Linberg Procedure and Its Modifications. In: Sugarbaker PH, ed. *Atlas of Sarcoma Surgery.* Philadelphia: Lippincott, 1984.

# 82. Mankin HJ, Doppelt SH, Sullivan TR, Tomford WW. Osteoarticular and Intercalary Allograft Transplantation in the Management of Malignant Tumors of Bone. *Cancer* 1982;50:613.

+ 83. Mankin HJ, Gebhardt MC, Jennings LC, et al. Long-Term Results of Allograft Replacement in the Management of Bone Tumors. *Clin Orthop* 1996;324:86.

* 84. Mankin HJ, Lange TA, Spanier SS. The Hazards of Biopsy in Patients with Malignant Primary Bone and Soft Tissue Tumors. *J Bone Joint Surg Am* 1982;64:1121.

# 85. Mankin HJ, Springfield DS, Gebhardt MC, Tomford WW. Current Status of Allografting for Bone Tumors. *Orthopedics* 1992;15:1147.

# 86. Marcove RC. Neoplasms of the Shoulder Girdle. *Orthop Clin North Am* 1975;6:541.

+ 87. Marcove RC, Lewis MM, Huvos AG. *En Bloc* Upper Humeral Interscapulothoracic Resection. The Tikhoff-Linberg Procedure. *Clin Orthop* 1977;124:219.

+ 88. Markovich GD, Dorr LD, Klein NE, et al. Muscle Flaps in Total Knee Arthroplasty. *Clin Orthop* 1995;321:122.

+ 89. Merkel KD, Gebhardt M, Springfield DS. Rotationplasty as a Reconstructive Operation after Tumor Resection. *Clin Orthop* 1991;270:231.

+ 90. Meyers PA, Heller G, Healey J, et al. Chemotherapy for Nonmetastatic Osteogenic Sarcoma: The Memorial Sloan-Kettering Experience. *J Clin Oncol* 1992;10:5.

+ 91. Mnaymneh W, Malinin TI, Lackman RD, et al. Massive Distal Femoral Osteoarticular Allografts after Resection of Bone Tumors. *Clin Orthop* 1994;303:103.

+ 92. Mnaymneh W, Malinin T, Mnaymneh LG, Robinson D. Pelvic Allograft: A Case Report with a Follow-Up Evaluaton of 5.5 Years. *Clin Orthop* 1988;255:128.

+ 93. Morris HG, Capanna R, Campanacci D, et al. Modular Endoprosthetic Replacement after Total Resection of the Femur for Malignant Tumor. *Int Orthop* 1994;18:90.

* 94. Mussey RD. Removal by Dissection of the Entire Shoulder Blade and Collar Bone. *Am J Med Sci* 1837;21:390.

# 95. Mutschler W, Burri C, Kiefer H. Functional Results after Pelvic Resection with Endoprosthetic Replacement. In: Enneking WF, ed. *Limb Salvage in Musculoskeletal Oncology.* New York: Churchill Livingstone, 1987;156.

+ 96. Nieder E, Elson RA, Engelbrecht E, et al. The Saddle Prosthesis for Salvage of the Destroyed Acetabulum. *J Bone Joint Surg Br* 1990;72:1014.

# 97. Nieder E, Keller A. The Saddle Prosthesis Mark II, Endo-Modell. In: Yamamuro T, ed. *New Developments for Limb Salvage and Musculoskeletal Tumors.* Tokyo: Springer-Verlag, 1989;481.

+ 98. O'Connor ML, Sim FH. Salvage of the Limb in the Treatment of Malignant Pelvic Tumors. *J Bone Joint Surg Am* 1989;71:481.

* 99. Ottolenghi CE. Aspiration Biopsy of the Spine: Technique for Thoracic Spine and Results of Twenty-Eight Biopsies in This Region and Over-All Results of 1050 Biopsies of Other Spinal Segments. *J Bone Joint Surg* 1969;51:1531.

+ 100. Ottolenghi CE. Massive Osteo and Osteo-Articular Bone Grafts: Technique and Results of 62 Cases. *Clin Orthop* 1972;87:156.

+ 101. Ozaki T, Hillman A, Bettin D, et al. High Complication Rates with Pelvic Allografts. Experience of 22 Sarcoma Resections. *Acta Orthop Scand* 1996;67:333.

+ 102. Pack GT, Baldwin JC. The Tikhoff-Linberg Resection of the Shoulder Girdle. Case Report. *Surgery* 1955;38:755.

+ 103. Papioannou AN, Francis KC. Scapulectomy for the Treatment of Primary Malignant Tumors of the Scapula. *Clin Orthop* 1965;41:125.

+ 104. Parrish FF. Allograft Replacement of All or Part of the End of a Long Bone Following Excision of a Tumor. *J Bone Joint Surg Am* 1973;55:1.

+ 105. Peat BG, Bell RS, Davis A, et al. Wound-Healing Complications after Soft-Tissue Sarcoma Surgery. *Plast Reconstr Surg* 1994;93:980.

+ 106. Petschnig R, Baron R, Kotz R, et al. Muscle Function after Endoprosthetic Replacement of the Proximal Tibia: Differential Techniques for Extensor Reconstruction in 17 Tumor Patients. *Acta Orthop Scand* 1995;66:266.

+ 107. Picci P, Bacci G, Campanacci M, et al. Histologic Evaluation of Necrosis in Osteosarcoma Induced by Chemotherapy: Regional Mapping of Viable and Nonviable Tumor. *Cancer* 1985;56:1515.

+ 108. Ponten B. The Fasciocutaneous Flap: Its Use in Soft Tissue Defects of The Lower Leg. *Br J Plast Surg* 1981;34:215.

+ 109. Quill G, Gitelis S, Morton T, Piasecki P. Complications Associated with Limb Salvage for Extremity Sarcomas and Their Management. *Clin Orthop* 1990;280:242.

+ 110. Roberts P, Chan, D, Grimer RJ, et al. Prosthetic Replacement of the Distal Femur for Primary Bone Tumours. *J Bone Joint Surg Br* 1991;73:762.

+ 111. Rosen G, Caparros B, Groshen S, et al. Primary Osteosarcoma of the Femur: A Model for the Use of Preoperative Chemotherapy in High Risk Malignant Tumors. *Cancer Invest* 1984;2:181.

+ 112. Samilson RL, Morris JM, Thompson RW. Tumors of the Scapula. A Review of the Literature and an Analysis of 31 Cases. *Clin Orthop* 1968;58:105.

+ 113. Sanders R, O'Neill T. The Gastocnemius Myocutaneous Flap Used as a Cover: The Exposed Knee Prosthesis. *J Bone Joint Surg Br* 1981;63:383.

# 114. Schajowicz F. Bone Forming Tumors—Osteosarcoma. In: Schajowicz F, ed. *Tumors and Tumorlike Lesions of Bone.* Berlin: Springer-Verlag, 1994;71.

* 115. Schajowicz F, Derqui JC. Puncture Biopsy in Lesions of the Locomotor System: Review of Results in 4,050 Cases, Including 941 Vertebral Punctures. *Cancer* 1968;21:531.

+ 116. Schreiman JS, Crass JR, Wick MR, et al. Osteosarcoma: Role of CT in Limb-Sparing Treatment. *Radiology* 1986;161:485.

+ 117. Senyuva C, Yucel A, Aydin Y, et al. Coverage of Knee-Tumor-Resection Prostheses with Free Flaps. *J Reconstr Micro* 1997;13:277.

+ 118. Shin KH, Rougraff BT, Simon MA. Oncologic Outcome of Primary Bone Sarcoma of the Pelvis. *Clin Orthop* 1994;304:207.

+ 119. Sim FH, Chao EYS. Hip Salvage by Proximal Femoral Replacement. *J Bone Joint Surg Br* 1981;63:1228.

+ 120. Sim FH, Frassica FJ. Use of Allografts following Resection of Tumors of the Musculoskeletal System. *Instr Course Lect* 1993;42:405.

# 121. Sim FH, Frassica FJ, Chao EY. Orthopaedic Management Using New Devices and Prostheses [Review]. *Clin Orthop* 1995;312:160.

# 122. Simon MA. Current Concepts Review: Biopsy of Musculoskeletal Tumors. *J Bone Joint Surg Am* 1982;64:1253.

+ 123. Simon MA, Aschliman MA, Thomas N, Mankin HJ. Limb-Salvage Treatment versus Amputation for Osteosarcoma of the Distal End of the Femur. *J Bone Joint Surg Am* 1986;68:1331.

+ 124. Simon MA, Biermann JS. Biopsy of Bone and Soft Tissue Lesions. *J Bone Joint Surg Am* 1995;75:616.

+ 125. Simon MA, Hecht JD. Invasion of Joints by Primary Sarcoma in Adults. *Cancer* 1980;50:1649.

+ 126. Steel HH. Partial or Complete Resection of the Hemipelvis: An Alternative to Hindquarter Amputation for Periacetabular Chondrosarcoma of the Pelvis. *J Bone Joint Surg Am* 1978;60:719.

+ 127. Stephenson RB, Kaufter H, Hankin FM. Partial Pelvic Resection as an Alternative to Hindquarter Amputation for Skeletal Neoplasms. *Clin Orthop* 1989;242:201.

! 128. Straw RC, Powers BE, Withrow SJ, et al. The Effect of Intramedullary Polylmethylmethacrylate on Healing of Intercalary Cortical Allografts in a Canine Model. *J Orthop Res* 1992;10:434.

* 129. Syme J. Excision of the Scapula. Edinburgh: Edmonston and Douglas, 1864.

# 130. Tait RJ, Selmer K, Neff JR. Pelvic Resection: Oncologic and Functional Outcome. In: Tan SK, ed.*Limb Salvage, Current Trends.* Singapore: Proceedings of the International Symposium on Limb Salvage (ISOLS), 1993;299.

+ 131. Thompson RC Jr, Pickvance EA, Garry D. Fractures in Large-Segment Allografts. *J Bone Joint Surg Am* 1993;75:1663.

# 132. Tomford WW, Mankin HJ, Friedlaender GE, et al. Methods of Banking Bone and Cartilage for Allograft Transplantation. *Orthop Clin North Am* 1987;18:241.

+ 133. Tomford WW, Thongphasuk J, Mankin HJ, Ferraro MJ. Frozen Musculoskeletal Allografts: A Study of the Clinical Incidence and Causes of Infection Associated with Their Use. *J Bone Joint Surg Am* 1990;72:1137.

# 134. Toni A, Sudanese A, Capanna R, et al. Custom-made Prosthesis: The Italian Experience. In: Enneking WF, ed. *Limb Salvage in Musculoskeletal Oncology.* New York: Churchill Livingstone, 1987;207.

+ 135. Uchida A, Myoui A, Araki N, et al. Prosthetic Reconstruction for Periacetabular Malignant Tumors. *Clin Orthop* 1996;326:238.

+ 136. Unwin PS, Walker PS. Extendable Endoprosthesis for the Skeletally Immature. *Clin Orthop* 1995;322:179.

+ 137. Veth RPH, et al. Megaprosthesis in the Treatment of Primary Malignant Metastatic Tumors in the Hip Region. *J Surg Oncol* 1989;40:214.

+ 138. Volkov M. Allotransplantation of Joints. *J Bone Joint Surg Br* 1970;52:49.

+ 139. Ward WG, Johnston KS, Dorey FJ, Eckhardt JJ. Extramedullary Porous Coating to Prevent Diaphyseal Osteolysis and Radiolucent Lines around Proximal Tibial Replacements: A Preliminary Report. *J Bone Joint Surg Am* 1993;75:976.

+ 140. Ward WG, Yang RS, Eckardt JJ. Endoprosthetic Bone Reconstruction following Malignant Tumor Resection in Skeletally Immature Patients. *Orthop Clin North Am* 1996;27:493.

+ 141. Weinberg H, Kenan S, Lewis MM, et al. The Role of Microvascular Surgery in Limb-Sparing Procedures for Malignant Tumors of the Knee. *Plast Reconstr Surg* 1993;92:692.

+ 142. Weiner SD, Scarborough M, Vander Griend RA. Resection Arthrodesis of the Knee with an Intercalary Allograft. *J Bone Joint Surg Am* 1996;78:185.

# 143. Wilkins RM. Complications of Allograft Reconstruction. In: Simon MA, Springfield D, ed. *Surgery for Bone and Soft-Tissue Tumors.* Philadelphia: Lippincott-Raven, 1998;487.

+ 144. Windhager R, Karner J, Kutschera HP, et al. Limb Salvage in Periacetabular Sarcomas: Review of 21 Consecutive Cases [Review]. *Clin Orthop* 1996;331:265.

# 145. Winkelmann WW. Rotationplasty. *Orthop Clin North Am* 1996;27:503.

+ 146. Yuen JC, Zhou AT. Free Flap Coverage for Knee Salvage. *Ann Plast Surg* 1996;37:158.

+ 147. Zatespin ST, Burdygin VN. Replacement of the Distal Femur and Proximal Tibia with Frozen Allograft. *Clin Orthop* 1994;303:95.

+ 148. Zwart HJ, Taminiau AH, Schimmel JW, van Horn JR. Kotz Modular Femur and Tibial Replacement: 28 Cases Followed for 3 (1–8) Years. *Acta Orthop Scand* 1994;65:315.

# CHAPTER 127

# BENIGN BONE TUMORS

*Carol D. Morris, Francis Y. Lee, and Mark C. Gebhardt*

**C. D. Morris:** Department of Orthopaedic Surgery, Memorial Sloan-Kettering Cancer Center, New York, New York, 10021.
**F. Y. Lee:** Department of Orthopaedic Surgery, Columbia-Presbyterian Medical Center, College of Physicians and Surgeons of Columbia University, New York, New York, 10032.
**M. C. Gebhardt:** Department of Orthopaedic Surgery, Children's Hospital, Massachusetts General Hospital Boston, Massachusetts, 02115.

Staging
Osteoid Osteoma
- Clinical and Radiographic Presentation
- Preoperative Management and Planning
- Operative Technique

Osteoblastoma
- Clinical and Radiographic Presentation
- Preoperative Management and Planning
- Operative Technique

Giant Cell Tumor
- Clinical and Radiographic Presentation
- Preoperative Management and Planning
- Operative Technique

Fibrous Cortical Defect and Nonossifying Fibroma
- Clinical and Radiographic Presentation
- Preoperative Management and Planning
- Operative Technique

Unicameral (Simple) Bone Cyst
- Clinical and Radiographic Presentation
- Preoperative Planning and Management
- Operative Techniques

Aneurysmal Bone Cyst
- Clinical and Radiographic Presentation
- Preoperative Planning and Management
- Operative Technique

Osteochondroma
- Clinical and Radiographic Presentation
- Preoperative Management and Planning
- Operative Technique

Chondroblastoma
- Clinical and Radiographic Presentation
- Preoperative Management and Planning
- Operative Technique

Chondroma
- Clinical and Radiographic Presentation
- Preoperative Management and Planning
- Operative Technique

Fibrous Dysplasia
- Clinical and Radiographic Presentation
- Preoperative Management and Planning
- Operative Technique

Langerhans's Cell Histiocytosis (Eosinophilic Granuloma of Bone)
- Clinical Presentation and Radiographic Findings
- Preoperative Management and Planning
- Operative Technique and Treatment

Chapter References

Benign tumors of the musculoskeletal system represent a diverse group of clinical entities, varying greatly in their behavior and thus treatment requirements. Some lesions may simply be observed indefinitely, while others demand wide resection and reconstruction. While benign bone tumors do not as a rule metastasize, they may at times act very aggressively locally and be mistaken for malignant tumors. On rare occasions, benign tumors may be multifocal or associated with pulmonary metastases. It is incumbent upon the treating orthopaedic surgeon to be familiar with the spectrum of benign bone tumors and tumor-like conditions in order to provide the appropriate management (Table 127.1). In this chapter, the most common benign, primary tumors and tumor-like conditions of bone across all age groups will be discussed as to their general and surgical management.

1. Bone-forming tumors
   a. Osteoma
   b. Osteoid osteoma
   c. Osteoblastoma
2. Cartilage-forming tumors
   a. Chondroma
   b. Osteochondroma
   c. Chondromyxoid fibroma
3. Giant cell tumor
4. Vascular tumors
   a. Hemangioma
   b. Lymphangioma
   c. Glomus tumor
5. Connective tissue tumors
   a. Desmoplastic fibroma
   b. Fibrous histiocytoma
   c. Lipoma
   d. Neurilemmoma
   e. Neurofibroma
6. Tumor-like lesions
   a. Unicameral bone cyst
   b. Aneurysmal bone cyst
   c. Eosinophilic granuloma
   d. Metaphyseal fibrous defect
   e. Fibrous dysplasia
   f. Osteofibrous dysplasia
   g. Myositis ossificans
   h. Brown tumor of hyperparathyroidism
   i. Intraosseous epidermoid cyst
   j. Giant cell reparative granuloma

***Table 127.1. Classification of Benign Bone Tumors***

## STAGING

Enneking et al. (46,47) described the most widely used staging system for benign bone tumors (Table 127.2). The stages are denoted by the Arabic numerals 1, 2, and 3, whereas malignant bone tumors are classified by Roman numerals (I, II, III). As will be detailed later, many benign bone tumors have the potential to present at, and progress through, various stages during their disease course.

| Stage | Description |
|---|---|
| 1 | Latent |
| 2 | Active |
| 3 | Aggressive |

***Table 127.2. Staging of Benign Bone Tumors***

Stage 1 or latent tumors are often discovered incidentally and usually do not progress. They may even spontaneously resolve. These tumors are noninvasive with distinct margins. Latent tumors can often be treated with observation alone. When surgical intervention is necessary, intralesional excision or simple curettage will suffice. Examples of stage 1 tumors are nonossifying fibroma, enchondroma, unicameral bone cyst, osteochondroma, osteoid osteoma, eosinophilic granuloma, and fibrous dysplasia.

Stage 2 or active tumors differ from latent tumors in that they usually are not self-limiting and tend not to resolve without intervention. These lesions expand or deform the host bone but remain contained in the bone. They have the potential to destroy the cortex, invade the surrounding soft tissues, and recur if residual tumor is left behind. Active lesions are most often treated with intralesional curettage. The procedure may be augmented with some type of adjuvant therapy to extend the margins if deemed necessary. Examples of stage 2 tumors are enchondroma, osteochondroma, osteoid osteoma, giant cell tumor, chondromyxoid fibroma, fibrous dysplasia, eosinophilic granuloma, aneurysmal bone cyst, osteofibrous dysplasia, and unicameral bone cyst.

Stage 3 or aggressive tumors extend beyond the bone into the adjacent soft tissues. These lesions can be so destructive that they mimic malignant tumors. Because of their extensive cortical destruction, it is not uncommon for stage 3 tumors to present with pathologic fracture. Aggressive tumors are best treated with *en bloc* resection when possible, or a very aggressive and thorough curettage. When these tumors are treated by intralesional excision because of anatomic restraints, they will almost always require some form of adjuvant therapy and are associated with a fairly high recurrence rate. Examples of stage 3 tumors are giant cell tumor, osteoblastoma, chondroblastoma, and aneurysmal bone cyst.

Benign lesions may “recur.” In general, recurrence refers to the persistence and subsequent growth of microscopic disease left over from the initial procedure.

## OSTEOID OSTEOMA

### CLINICAL AND RADIOGRAPHIC PRESENTATION

Osteoid osteoma is a benign tumor consisting of a well-demarcated bone-forming lesion called a nidus, surrounded by a radiodense, reactive zone of host woven or lamellar bone. The surrounding secondary bony reactive zone represents a reversible change that remodels and regresses after the nidus is removed. The nidus has limited growth potential and rarely exceeds 1 cm in diameter. Lesions larger than 1.5 cm in diameter have been arbitrarily designated osteoblastomas. Osteoid osteoma accounts for 10% to 13% of all benign bone tumors and 2% to 3% of all primary bone neoplasms (51,65,164). It is most commonly seen in the second and third decades of life, with a male to female predominance of approximately 3 to 1. Over half of these lesions occur in the long bones of the lower extremity, with the proximal femur being the most common location. In the spine, osteoid osteomas almost exclusively occur in the posterior elements of the lumbar vertebrae, namely the pedicular region of the posterior arch. In addition, they may occur in juxta-articular bone within the confines of the synovial cavity, where they are termed intra-articular osteoid osteomas. Osteoid osteomas are most commonly located in the cortex of the bone, but they may be located in the medullary cavity or periosteum of the bone. They are usually diaphyseal or metaphyseal, but on rare occasion they are epiphyseal.

The most common presenting symptom is a dull or sharp pain, usually worse at night, dramatically relieved by aspirin or other nonsteroidal anti-inflammatory drugs (NSAIDs). The duration of pain prior to presentation can vary from weeks to years. The second most common symptom is a limp. In lesions with relatively subcutaneous locations, such as the tarsal bones or phalanges of the hand, soft-tissue swelling may be present. Spine involvement may present as a painful scoliosis and unilateral muscle spasticity, with the concave part of the curve toward the side of the lesion (79). When the lesions occur near the physis, leg-length discrepancies may be observed with the affected extremity being longer. Other common signs on physical exam include muscle atrophy and structural (bowing) deformities.

The radiographic features of osteoid osteoma are highly characteristic and the diagnosis can often be made by plain roentgenograms alone. Conventional radiographs reveal a small, round radiolucent area within the cortex surrounded by a variable sclerotic zone (Fig. 127.1*A*). The tumor may exhibit different stages of mineralization and therefore display different degrees of density. The reactive periosteal lamination may mimic Ewing's sarcoma. Epiphyseal lesions often demonstrate a lack of sclerosis. Further imaging studies are indicated when typical plain film findings are not yet evident, when the exact location of the nidus is obscured because of extensive cortical thickening, when the lesion arises in an atypical location, or in anatomic sites that are difficult to image, such as the spine. The radionuclide bone scan is almost always positive for osteoid osteoma. Cross-sectional studies such as a computed tomography (CT) and magnetic resonance imaging (MRI) are especially helpful for areas that are difficult to image on plain films, such as the spine (Fig. 127.1*B*, Fig. 127.1*C* and Fig. 127.1*D*). CT appears to be a more accurate diagnostic tool than MRI because this modality displays the bony nidus and surrounding reactive bone in contrast to the normal cortex more clearly (7). The nidus is also less likely to be obscured by the edema associated with the lesion on CT scans than with MRI. It is important to get thin cuts through the area of a suspected nidus.

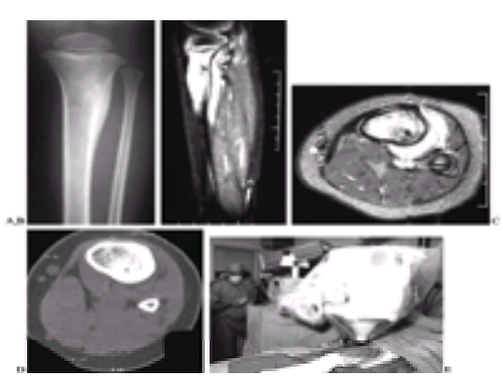

***Figure 127.1.*** AP radiograph (**A**) of the tibia in a patient with osteoid osteoma. Note that the nidus is not well visualized although there is thick, mature periosteal elevation and some medullary reactive bone in the lateral aspect of the proximal tibial metaphysis. The sagittal (**B**) and axial (**C**) MRI show extensive marrow edema and soft-tissue edema surrounding the proximal tibia. The edema extends well beyond the lesion. The nidus is visualized as a low signal (*dark area*) in the midst of the bright edema, which is present both in the soft tissues and in the medullary cavity. A CT scan (**D**) more clearly shows the radiodense nidus in the lateral aspect of the tibia. In this case, the nidus is in the medullary cavity and the thickness of the cortex is readily apparent. There is also thickening of the trabecular bone surrounding the lesion. The adjacent fibula is normal, and the soft tissues do not appear abnormal as they did on the MRI. The portable scanner used for intraoperative bone scans (**E**) allows precise intraoperative imaging of the area of abnormality and helps to plan the surgical approach. Disappearance of the area of increased uptake following excision of the nidus helps to confirm that it has been completely excised.

### PREOPERATIVE MANAGEMENT AND PLANNING

The standard treatment for osteoid osteoma is *en bloc* resection of the nidus (65). Important aspects of the preoperative management include planning the most appropriate surgical approach, selecting a method for intraoperative localization of the nidus, and determining if a less invasive method is a reasonable alternative to wide excision. A CT scan is often useful in helping to plan the most direct operative approach. The method by which intraoperative localization of the nidus is to be

accomplished must be determined prior to surgery. Intraoperative bone scintigraphy, tetracycline labeling, CT guidance, and conventional radiography have all been used (85,155). Intraoperative nuclear scanning takes advantage of the lesion's ability to concentrate radioisotopes following preoperative administration. The area in question is sequentially scanned intraoperatively until activity is appreciably diminished (Fig. 127.1*E*) (85). This indicates that the lesion has been completely removed.

Similarly, tetracycline labeling also relies on the ability of the nidus to concentrate this compound. After oral administration 24–48 hours preoperatively, an ultraviolet lamp is used to demonstrate the presence of uptake in the resected specimen. Tetracycline labeling should be reserved for patients over the age of 8 years because of its affinity for developing dentin and associated tooth discoloration.

CT-guided placement of probes is helpful in localization of the nidus but does not quantitate the adequacy of resection. Plain radiographs can be used in conjunction with intraoperative markers for immediate postresection imaging of the host or specimen. The exact perioperative method to determine complete removal of the nidus is chosen based on the surgeon's experience and the imaging modalities available.

For some patients, complete excision of the osteoid osteoma may require excessive bone resection, or it may not be possible because of anatomic considerations. Proper preoperative planning will identify those patients in whom a significant amount of bone must be removed to reach the lesion or to ensure adequate margins, and it will allow the surgeon to anticipate the need for bone grafting and internal fixation. Alternatively, a variety of percutaneous procedures for osteoid osteoma removal have been described. Percutaneous treatments have obvious advantages, including minimal invasiveness, relative safety, cost-effectiveness, and earlier return to normal activities. Bone trephination under CT guidance has been reported by several investigators with varying degrees of success (163). Percutaneous radiofrequency ablation has met with success and in a number of tumor centers and has become the procedure of choice in some institutions for lesions outside the spine (8,119,131). The technique involves introducing a radiofrequency probe over a biopsy needle, placed under CT control (Fig. 127.2). A 1 cm area containing the nidus is subjected to thermal necrosis after obtaining tissue for pathology. When comparing this approach to the more traditional open procedure, recurrence rates are essentially equivalent. The results from these percutaneous techniques appear encouraging.

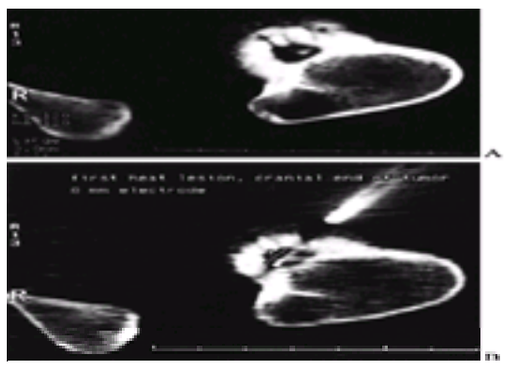

***Figure 127.2.*** **A:** The CT of another patient with an osteoid osteoma on the cortex of the proximal femur. The nidus is mostly radiolucent with a central radiodensity, and there is thick periosteal new bone around it. **B:** The trochar being placed into the lesion for radiofrequency heat ablation under CT control. The patient is under general anesthesia.

Nonsurgical management of osteoid osteomas has been suggested by some authors (80). Their experience argues that there are circumstances in which operative treatment may cause complications and disability more severe than those associated with the original condition. The medical management of osteoid osteoma involves a prolonged course of NSAIDs. Patients treated successfully by this regimen were administered medication for an average of 33 months. Contraindications to medical management include drug hypersensitivity, progressive deformities, and uncertain diagnosis. While nonoperative management may have a role, the subset of patients in which this treatment plan is preferred has yet to identified.

### OPERATIVE TECHNIQUE

#### En Bloc *Resection*

The classic surgical procedure for osteoid osteoma is a marginal or wide excision. The goal of surgery is to remove the entire nidus, as incomplete excision is associated with high recurrence rates and persistent pain. The amount of the surrounding reactive bone that is removed varies: The intent is to leave as much bone as possible to reduce the risk of pathologic fracture. To limit the amount of bone removed, one of the intraoperative imaging modalities just described should be utilized. As mentioned, bone grafting and internal fixation may be required to restore adequate structural integrity. This is especially true of femoral and tibial diaphyseal lesions in which extensive cortex may need to be excised. Excise lesions about the femoral neck using a fracture table, or a radiolucent table to allow for fluoroscopic imaging and internal fixation if needed.

#### *Burr-Down Technique*

The burr-down technique was described to avoid the possible complications of an extensive excision, which weakens the bone and predisposes it to fracture and the morbidity associated with autogenous or allogeneic bone graft.

- After intraoperative localization, identify the reactive cortex visually by its characteristic elevation and roughening, and expose it subperiosteally.
- Use a high-speed burr or osteotomes in a successive sweeping motion over the reactive cortex until the nidus is encountered (164).
- Remove the nidus of tissue by curettage and submit it for histologic confirmation. Then burr the cavity in all directions for 1–2 mm and smooth the edges. Bone grafting is usually not necessary.

Postoperative management depends on the degree of resection. Wide excisions often require prolonged periods of immobilization, a longer hospital stay, and protected weight bearing. Patients treated by the burr-down technique reportedly require fewer activity restrictions. Percutaneous techniques are often performed as an out-patient procedure and may not require weight-bearing precautions.

## OSTEOBLASTOMA

### CLINICAL AND RADIOGRAPHIC PRESENTATION

Benign osteoblastoma is an uncommon benign bone-forming tumor accounting for less than 1% of all primary bone tumors. It has been called by some authors giant osteoid osteoma, and these two lesions are often histologically indistinguishable (44,76). The microscopic appearance is characterized by benign-appearing osteoblasts producing woven bone and osteoid in varying shapes and amounts. Despite their similar microscopic patterns, their respective growth potentials and hence clinical courses differ remarkably (76). Osteoid osteomas rarely exceed 1.5 cm, whereas osteoblastomas often exceed 2 cm. In addition, patients with osteoblastoma do not typically describe night pain, a hallmark feature of osteoid osteoma. Radiographically, osteoblastomas often lack the peripheral sclerosis seen with osteoid osteoma. Despite these differences, it may still be difficult to distinguish between these two entities. In such instances, size greater than 1.5 cm has arbitrarily been chosen as the determining factor to make the diagnosis of benign osteoblastoma. Osteoblastoma typically presents during the second decade of life. Most patients are between the ages of 5 and 45. There is a male to female ratio of 3 to 1, which is similar for the sex distribution encountered in osteoid osteoma.

An entity referred to as aggressive osteoblastoma has been identified. These tumors are borderline lesions whose radiographic and histologic characteristics fall between benign osteoblastoma and osteosarcoma. Radiographically, aggressive osteoblastomas extend beyond the cortical margins of the bone, resembling an aneurysmal bone cyst. Microscopically, areas of epithelioid osteoblasts are present. Neither malignant transformation nor metastases of these lesions has been reported. However, these tumors are more likely to recur following incomplete or intralesional excision. The true incidence of this subset of osteoblastomas is not known.

The skeletal distribution for osteoblastoma is unique and distinguishes it from other benign bone lesions, including osteoid osteoma. Osteoblastoma has a predilection for the spine, particularly the posterior vertebral elements (84). In large series, up to a third of cases were located in the spine with near equal distributions in the cervical, thoracic, lumbar, and sacral spine (112). The second most frequent site of involvement is the long bones, followed by the bones of the hands and feet.

Pathologic fractures through the lesions have not been reported.

Clinically, pain is the most common presenting symptom. The pain increases in severity with time and has an unpredictable response to anti-inflammatory agents. Swelling and atrophy of the affected area may be present on physical exam. When the spine is involved, the patient often presents with a painful scoliosis and limitation of motion secondary to paraspinal muscular spasm. The lesion is usually located at the apex of the concavity of the curve (112). The scoliosis usually resolves following removal of the offending lesion. Persistent structural deformity may ensue if there is a significant delay in diagnosis. Neurologic deficit as the presenting complaint is not uncommon with spinal lesions. While the symptoms are typically mild, severe neurologic compromise has been reported (117).

Several radiographic studies may be used to evaluate osteoblastoma. Standard biplanar radiographs are typically capable of detecting lesions outside the sacrum. They reveal a round osteolytic lesion often greater than 2 cm in diameter, containing varying amounts of internal mineralization and surrounded by reactive bone. The lesions may be intramedullary, but the majority are intracortical. In addition, osteoblastomas may arise in the diaphysis, metaphysis, or epiphysis. When epiphyseal lesions do exist, they most often occur in the hands and feet. The lesion may expand through the involved cortex, but it seldom has an associated soft-tissue mass. In the spine, at least 90% of the lesions involve the posterior elements, namely the spinous process and arches. Although the tumor may extend into the vertebral body, it rarely arises in or exclusively involves the anterior spine. Details of spine lesions, such as the extent of mineralization and degree of rim sclerosis, are more easily discernible on CT scan. As spine lesions are often expansile, CT scan is superior to plain films in evaluating the relationship of the tumor to adjacent neurologic structures and for the purposes of staging and preoperative planning. If evidence of spinal cord or nerve root compression is apparent, obtain an MRI, as it provides exceptional imaging of the neural elements. Radionucleotide studies will demonstrate intense focal accumulation of the isotope. This study is perhaps most useful to help localize the origin of the lesion in patients with back pain in whom the diagnosis of osteoblastoma is suspected. Multicentric involvement has not been reported.

### PREOPERATIVE MANAGEMENT AND PLANNING

As with other benign bone tumors, the threat of recurrence must be balanced against the complications associated with aggressive resections, given the nonmalignant nature of the lesion. Treatment of the osteoblastoma largely depends on its location and behavior. When possible, perform a complete or marginal excision. Recurrence following incomplete intralesional curettage occurs in up to 15% (75,98). Margins can be extended using cryotherapy or phenol as described in the section on management of giant cell tumors.

The spine deserves special consideration, since the same treatment protocols for managing aggressive benign lesions in the extremities often are impractical given the anatomic restrictions and potential neurologic complications associated with spinal surgery. Such tumors may prove to be unresectable or even lethal in the spine. Employ the methodical approach to all spine neoplasms as described by Weinstein et al. (166).

- Perform a complete clinical and imaging workup before biopsy.
- Decide the most appropriate medical and surgical treatments, as well as possible adjuvants depending on the patient's overall condition and tumor stage.
- Plan the surgery according to a standardized spinal surgical staging system (165).
- Make every effort to preserve neurologic function.
- Maintain spinal column stability. Treat osteoblastoma according to its oncologic staging. Stage 2 lesions can probably be managed adequately with intralesional curettage. Stage 3 lesions are best treated with marginal resection. When marginal resection is not feasible, adjuvant radiation therapy may have a role, although its efficacy has yet to be demonstrated (18).

### OPERATIVE TECHNIQUE

In the extremities, do a complete excision when possible. When *en bloc* excision is not possible because of anatomic considerations, such as proximity to the physes, intralesional curettage is acceptable, especially for stage 1 and 2 lesions.

- Curet the tumor with conventional hand curets, mechanically extending the margins to normal tissue with the use of a high-speed motorized burr.
- For aggressive osteoblastomas, some authors advocate the use of adjuvants such as cryotherapy and phenol (65,157). Use these agents judiciously as their complications have been well documented and experience in treating osteoblastomas is limited.
- Small defects can be filled with bone graft. Larger defects may require internal fixation to achieve adequate structural integrity.
- In the spine, intralesional curettage is often used, as complete excision is frequently not possible. In such cases, perform an extralesional dissection as far as possible. As these lesions are usually extremely vascular, ligate identifiable feeder vessels as they are encountered.
- Then remove the tumor in piecemeal fashion. Curet or burr the walls of the cavity. All of the perilesional sclerotic reaction need not be removed.
- Take care to preserve stability of the spine; internal fixation may be required.

## GIANT CELL TUMOR

### CLINICAL AND RADIOGRAPHIC PRESENTATION

Giant cell tumor (GCT) is a rare bone tumor accounting for only 4% to 5% of all primary bone tumors in the United States. In Southeast Asian regions, GCT accounts for approximately 20% of all primary bone tumors (156,176). The peak age of incidence is in the third decade of life, with 70% of the cases diagnosed in persons 20–40 years old. Although there have been numerous reports of GCT arising in patients with open growth plates, this presentation is the exception. When it occurs in children with open growth plates, the lesion is metaphyseal. In skeletally mature patients, it is found most often in the epiphyseal ends of long bones, especially the distal femur, proximal tibia, and distal radius. Approximately 60% of the cases occur about the knee. It is uncommon in the axial skeleton with the exception of the sacrum (133). When it does occur in the spine, the vertebral body is most frequently involved. A slight female to male predominance exists. Multicentric involvement has been reported but is rare.

The clinical presentation of GCT is consistent with its active and locally aggressive tendency to increase pressure within the bone or break through the cortex and stretch the periosteum. As such, the predominant presenting symptoms are pain and swelling of variable severity. In addition, patients may present with decreased joint range of motion or pathologic fracture. On physical exam, a tender, hard mass is typically found. The involved extremity may display muscle atrophy secondary to disuse, joint effusion, and elevated temperature of the overlying skin.

Radiographically, GCT appears as an eccentric, juxtacortical, expanding zone of radiolucency at the epiphyseometaphyseal end of a long bone (Fig. 127.3*A*, Fig. 127.3*B*). The tumor is a well-delineated lesion with irregular endosteal margins. There is usually no reactive host bone at the periphery of the lesion. According to the staging system for benign bone tumors, the lesion most typically presents as an active (stage 2) or aggressive (stage 3) tumor. The tumor frequently extends to the subchondral bone of the articular surface and destroys the surrounding cortex, extending into the soft tissue. Because of the rapid expansion, a periosteal reaction is seldom seen. The combination of substantial destruction and poor margination may suggest malignancy.

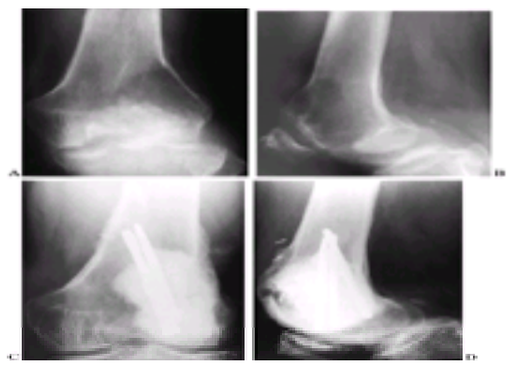

***Figure 127.3.*** AP radiograph (**A**) of a giant cell tumor (GCT) of bone shows a radiolucent lesion of the lateral distal femur involving the epiphysis and the metaphysis. It has destroyed the cortex although the periosteum is intact, and it is well delineated although not well marginated. In the lateral film (**B**), it is apparent that the lesion extends down to the subchondral bone distally and along the patellofemoral joint. This has the typical appearance of a GCT of bone. AP (**C**) and lateral (**D**) radiographs show the postoperative findings in this patient who was treated with extensive curettage, burring of the cavity, and packing with PMMA bone cement and reinforcing metal rods.

Although GCT is considered a benign neoplasm, a number of well-documented cases of pulmonary metastases have been reported in the literature (22,29). These so-called pulmonary implants are believed to occur in only 1% to 2% of patients with GCT. They are to be distinguished from true metastases secondary to malignant degeneration of GCT. Malignant degeneration of GCT is a phenomenon that usually occurs secondary to treatment of the original lesion, most typically radiation therapy (22). Pulmonary involvement in GCTs typically has a good prognosis, although up to 25% of patients die from the disease. Occasionally, the metastatic lesions may even spontaneously regress. The histology of the primary lesions of patients with pulmonary involvement (unlike that of patients without pulmonary involvement) fails to demonstrate any significant predicative features (29). In fact, histologic material from the lung is identical to that of the primary lesion. Chest radiographs should be obtained at regular intervals as part of the patient's management. Early detection is important given the unpredictable nature of pulmonary lesions. Complete resection is recommended (29,78).

## PREOPERATIVE MANAGEMENT AND PLANNING

Because of the aggressive nature of this lesion, establish a firm diagnosis. Malignant lesions must be ruled out by tissue biopsy prior to surgical treatment.

Giant cell tumors have a high potential for local recurrence. Adequate removal of the tumor leads to the lowest risk of recurrence (16). Aggressive resections, which may necessitate allograft or prosthetic reconstruction with their associated complications, must be weighed against the fact that GCT is almost always a benign neoplasm (125). Several methods for the treatment of GCT have been described and used with varying degrees of success: curettage alone, curettage combined with adjuvant therapies, *en bloc* resection, amputation, and radiation.

In general, an operative plan can be developed by considering three factors: (a) the type of resection, (b) the use of adjuvant therapy, and (c) the type of material to be used to fill the resultant defect. The first of these considerations involves deciding whether to do an intralesional or *en bloc* resection. Most GCTs are treated by intralesional curettage. The recurrence rate using curettage alone has been reported to be as high as 50%. The risk of local recurrence is greatly diminished by *en bloc* resection, so this is advocated for expendable bones such as the proximal fibula or portions of the ilium (55). Other indications for *en bloc* resection include circumstances in which reconstruction after intralesional curettage is not possible, such as some patterns of pathologic fracture and massive involvement with an incomplete cortical shell that is insufficient to contain cement. In these instances, reconstruction must be achieved with osteoarticular allograft or metal prosthetic replacements.

Use adjuvant therapy to eliminate microscopic disease following intralesional curettage. The most commonly used adjuvants alone or in combination are cryotherapy, phenol, and polymethylmethacrylate (PMMA). All have distinct advantages and disadvantages. Cryotherapy using liquid nitrogen has the ability to advance the resection margins because it creates a 1–2 cm zone of tissue necrosis (96). Complications of liquid nitrogen include fracture and local skin necrosis. Phenol also causes tumor cell necrosis, and reduced penetration results in only 1–2 mm of osteonecrosis, providing a theoretical advantage over liquid nitrogen by reduction of fracture rates. Phenol, however, can cause local chemical burns and exert systemic toxic effects on other organ systems. Both of these agents must be used with considerable caution: Their potential local toxicity can be difficult to control because of leakage. PMMA causes local necrosis in as much as 2–3 mm of bone by its thermal effects during polymerization (107). A major advantage of PMMA is its immediate structural stability; also, radiographic detection of local recurrence is easier (15,114). The long-term risk of early degenerative changes in an adjacent joint secondary to the stiffness induced by subchondral PMMA, while yet to be substantiated, remains a concern.

After adequate removal of the tumor, fill the resultant cavity if the defect is of substantial size, which it will be in the majority of cases. The two most commonly used bone fillers for this purpose are PMMA and bone graft. The results of autogenous or allogenic bone graft, when used in conjunction with phenol or liquid nitrogen, appear to be comparable to cementation (125). The risks of donor-site morbidity for autogenous graft and the possibility of disease transmission for allogenic graft must be considered.

## OPERATIVE TECHNIQUE

### *Intralesional Excision*

Intralesional curettage is usually the treatment of choice and should be performed in systematic manner.

- After exposing the bone over the tumor, make a large cortical window the size of the longest longitudinal dimension of the tumor to provide adequate visualization of the entire tumor cavity (Fig. 127.4) (13). Make the window elliptical, with its axis parallel to the long axis of the bone to reduce the stress-riser effect. Incorporate an already thinned or destroyed area of cortex to minimize additional bone loss.

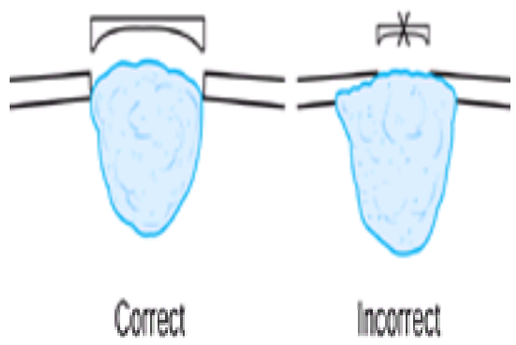


***Figure 127.4.*** The correct approach for creating a window for adequate curettage of an aggressive lesion such as a giant cell tumor. It is important to be able to directly visualize the entire cavity, so a small window such as that shown on the right is inadequate.

- Remove the soft-tissue portion of the tumor and thoroughly curet the walls, breaking down septae and getting into all the nooks and corners. Then thoroughly remove any residual tumor with a power burr.
- If the tumor extends into the soft tissues, excise the entire pseudocapsule. Take care to minimize contamination of surrounding tissues. Then thoroughly irrigate the cavity with pulsed lavage using saline.

### *Cryotherapy*

- If cryotherapy is chosen as the adjuvant of choice, before the introduction of liquid nitrogen, identify any bony perforations and seal then to prevent damage to the surrounding soft tissues and neurovascular bundles.
- Use a tourniquet. This maximizes the freezing by minimizing heat exchange due to 2° blood flow.
- Use the direct pour technique described by Marcove (96). Place a stainless steel funnel in the bony defect, which is insulated with Gelfoam (Fig. 127.5). Pour liquid nitrogen (–196°C) through the funnel, filling the entire cavity.

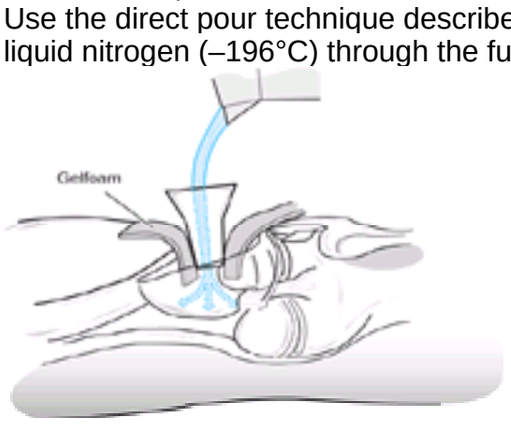


***Figure 127.5.*** The technique of liquid nitrogen as an adjuvant for a GCT of the lateral femoral condyle. Following thorough curettement of the tumor, totally protect the soft tissues surrounding the cavity with a layer of gelfoam. Do not let the gelfoam rest on the soft tissues. Instill liquid nitrogen through a stainless steel funnel.

- Use a warm saline solution to irrigate the surrounding soft tissues to minimize thermal injury.
- Leave the liquid nitrogen in the cavity until it evaporates completely, which typically takes 1–2 minutes followed by 3–5 minutes of spontaneous thawing. Repeat this freeze and thaw cycle 3 times. Some authors advocate the use of liquid nitrogen in a spray form, claiming better control over the chemical's dispersal. Irrigate the cavity with saline between cycles.

***Phenol***

Phenol exerts its cytotoxic effects by protein coagulation. It has the capacity to penetrate only 1 or 2 mm, behaving more like a surface agent.

- After thorough intralesional excision, apply phenol to the bony surface using cotton-tip applicators. Usually, a concentration of 12% to 50% phenol is used. Treat the entire surface, including crevices.
- Wash the cavity with alcohol to dissolve the phenol and minimize its local adverse effects. Follow with pulsative lavage.
- Following adjuvant treatment, reconstruct the defect using bone graft, bone graft substitute, or PMMA (130). Pack PMMA from the articular surface outward (Fig. 127.3*C*,*D*). As the PMMA sets, use iced saline lavage to help control the temperature at the subchondral bone–cement interface to prevent thermal damage to the articular surface. Use radiopaque cement to facilitate follow-up examinations for recurrence. If cryotherapy has not been used autogenous and/or allogenic bone graft may be used as an alternative to PMMA (16).

Depending on the size of the defect, internal fixation may be necessary to protect the bone until bone healing and remodeling occurs. Several standard internal fixation devices are available, including plates and screws, Steinmann pins, or flexible intramedullary devices. In one large, long-term series, fracture following cryosurgery occurred only in those patients whose construct was not augmented with internal fixation (93).

Recurrent GCTs can be very challenging to manage. They most often arise in stage 2 or 3 lesions, or in anatomic sites that are difficult to treat aggressively. Small local recurrences can be treated with repeat curettage. More extensive local recurrence is probably best treated with wide excision, which often necessitates an extensive reconstructive procedure, such as arthrodesis or total joint replacement for a periarticular tumor.

## FIBROUS CORTICAL DEFECT AND NONOSSIFYING FIBROMA

### CLINICAL AND RADIOGRAPHIC PRESENTATION

Of the benign lesions within the bone, the fibrous cortical defect (FCD) and nonossifying fibroma (NOF) are common lesions in childhood, perhaps representing 5% of benign bone tumors (159). These benign conditions have many designations. The World Health Organization (WHO) prefers the term *metaphyseal fibrous defect* and describes the lesion as “a well-defined nonneoplastic bone lesion” containing “spindle-celled fibrous tissue with a storiform pattern and containing a variable number of multinucleated giant cells, hemosiderin pigment, and lipid-bearing histiocytes” (138). *Nonossifying fibroma* is probably the most commonly applied term, but lesions confined to the cortex are called fibrous cortical defects. The terms *histiocytic xanthogranuloma*, *histiocytic fibroma*, and *nonosteogenic fibroma* also have been used. The distinction between NOF and benign fibrous histiocytoma is subtle, and some pathologists use the terms interchangeably (11).

The etiology is unclear, but most authors consider it to be a nonneoplastic process probably of histiocytic origin (97,138). It may be a developmental defect or hamartoma, associated with a vascular disturbance or related to intraosseous hemorrhage. The relationship to the growth plate and metaphysis suggests an alteration in the remodeling process (12,128). The lesion is usually solitary, but it may involve multiple bones (17). Most often they slowly involute and fill in with host bone over time. Some may enlarge in the adolescent years (177).

Both NOF and FCD are located in the metaphysis of the long bones, especially the distal femur and the proximal and distal tibia, but they may also occur in the upper extremities (proximal humerus, distal radius, and ulna). They occur primarily in the first two decades and are rarely seen in adults. Boys are affected slightly more than girls (138,159). Caffey (21) found one or several of these lesions to be present in early childhood on skeletal surveys in 36% of individuals studied. Although occasionally persisting into adulthood, most of these lesions disappear soon after late adolescence and generally produce no symptoms unless a fracture occurs (5).

Their radiographic appearance is sufficiently characteristic to make biopsy unnecessary. They are oval, elongated, purely radiolucent areas that align themselves along the cortex of the metaphysis and metadiaphysis (Fig. 127.6A, Fig. 127.6B) (24,38). They are well marginated by host reactive bone and frequently exhibit bony septations. Ritschl et al. (128,129) observed that they are most frequently seen at sites of ligament, tendon, or intraosseous membrane attachment to the bone. The cortex may be thinned, but the periosteum is intact. However, axial imaging with CT or MRI may show areas of incomplete periosteal containment. By adulthood, the epiphysis has migrated away from the lesion and it appears as a dense osseous cortical scar or occasionally involves the medullary cavity (now called NOF). No metastases have ever been reported, and spontaneous regression of these lesions is the rule.

***Figure 127.6.*** AP (**A**) and lateral (**B**) radiographs of a typical nonossifying fibroma. It is a “bubbly” lesion aligned with the cortex, which is well marginated. The lateral cortex is thinned, but the periosteum is intact. The lesion itself is purely radiolucent, although septa of reactive bone transgress the lesion.

The lesion is often an incidental finding following an injury to the ankle or knee in an otherwise asymptomatic child. It is seldom the cause of pain, although in rare instances an NOF may be painful for unknown reasons. In about 20% of the cases, the lesion presents as a pathologic fracture.

### PREOPERATIVE MANAGEMENT AND PLANNING

The perplexing dilemma for the orthopaedist is to decide whether the lesion is weakening the bone sufficiently to warrant surgical intervention. For patients who present without a fracture, decide whether or not to recommend surgical treatment. If left alone, these lesions will regress and heal, usually at about the time of skeletal maturity. In a young, athletically active child, however, the risk of fracture may be significant. It is difficult to convince the child to be careful for several years while the lesion heals.

We generally recommend curettage and bone grafting for lesions that appear to be significantly weakening the bone. Unfortunately, there are no clear guidelines to make this determination. One recommendation is to graft lesions that occupy more than half the diameter of the bone (5,21,122). However, other authors have observed low fracture rates in NOFs of the femur and tibia involving more than 50% of the long-bone diameter (45). More recently, CT scans obtained by a special protocol using density phantoms have been used. A biomechanical analysis of the CT data using the density of the involved bone and the thickness of the cortex compared to the uninvolved side yields a prediction of bone strength in various loading conditions (68,104). If the bone appears to be significantly weakened, we are more likely to recommend operation.

In the patient who presents with a fracture, we usually recommend allowing the fracture to heal with cast immobilization, followed by observation. In a fracture of a major long bone, such as the femur, internal fixation may be necessary initially. At times, the lesion will heal after fracture. If it does not, it seems prudent to curet and graft the lesion to prevent subsequent fracture.

### OPERATIVE TECHNIQUE

Expose the bone overlying the lesion. The curettage does not have to be as aggressive as that for GCT, but the entire lesion should be curetted. It may be useful to complete the curettage with a high-speed burr.

For lesions of the femur or hip region, internal fixation and grafting of the fracture may be indicated. The choice of autograft or freeze-dried allograft to fill the defect is decided by the patient and treating physician (39,120). Local recurrence is unusual.

## UNICAMERAL (SIMPLE) BONE CYST

### CLINICAL AND RADIOGRAPHIC PRESENTATION

The simple or unicameral bone cyst (UBC) is a lesion of unknown etiology that is common in the first two decades of life, primarily between the ages of 5 and 15 years. Boys are affected three times more commonly than girls (23,138,159). The cysts most commonly occur in the proximal humerus (50% to 60%) or proximal femur (25% to 30%) of a growing child, but other bones may be affected (23,138). In older children and adults, cysts occur most commonly in the calcaneus or flat bones (147).

Bone cysts are asymptomatic unless there has been a fracture. They may occasionally be discovered by serendipity on radiographs obtained for other reasons. There is no mass or tenderness unless there is a fracture. There may be angulation of the limb secondary to the fracture, or shortening if the adjacent growth plate is involved. Occasionally, a cyst that has fractured will heal and disappear as the fracture heals, but this is the exception.

The lesion is not a true cyst because it is not lined by endothelial cells but rather by a thin fibrous lining of compressed fibrous tissue and blood vessels. The fluid is either serous fluid similar to extracellular fluid or blood filled if there has been a fracture (33). The cause is completely unknown (26). Many authors have proposed theories, but a definitive explanation has not been forthcoming. Some presume it to be either a disorder of the growth plate or a transient circulatory compromise resulting from a developmental anomaly of the veins of an affected bone (31,33,34,67,77,138). The role of trauma has been postulated but not proven. Increased intraosseus pressure has been noted, and recently prostaglandins, free radicals, and other bone-resorbing factors have been noted in the fluid of the cyst (81,82,144). This may explain the success of steroid injection in the treatment of these lesions. The cysts may occasionally cross the growth plate and destroy it over time, which leads to shortening (19,23,26). In the humerus, this is not a major problem for function, but it may produce a cosmetic problem if it occurs early in childhood. Angular deformities are also rarely noted (109).

On radiographs, the cyst appears as a central, radiolucent lesion on the metaphyseal side of the growth plate of a long bone (Fig. 127.7*A*). The bone is widened but usually not to more than the width of the epiphyseal plate (86). The cortex is thinned but intact, and the lesion is usually well demarcated. The cavity is filled with a fluid similar to serum and extracellular fluid, which may be bloody if fracture has occurred. Some authors classify cysts as active when they are juxtaposed to the growth plate, and latent when the growth plate has migrated away from the cyst (23,26,110). Presumably latent cysts are more likely to heal following treatment. A “fallen fragment” sign may be present, indicating that the lesion is fluid filled rather than solid. This sign is seen when a fragment of cortical bone becomes dislodged and gravitates to the dependent portion of the unicameral bone cyst. It is seen in 10% to 20% of cysts and only in the presence of a fracture (86,102,126,153).

***Figure 127.7.*** **A:** A unicameral bone cyst of the left proximal humerus is purely radiolucent and thins the cortex. It is not wider than the width of the growth plate, although it extends up to it. There is a suggestion that it crosses the growth plate and enters the epiphysis, which is somewhat unusual. **B:** An MRI of this patient's humerus shows the fluid-filled nature of the lesion and clearly demonstrates that it crosses the growth plate. This patient developed a limb-length inequality despite treatment of the cyst with injections.

Other diagnostic tests are usually not required except in unusual locations such as the pelvis. In such locations, a CT scan or MRI can document the extent of the lesion and its cystic nature. The MRI shows low signal on T1- and high signal on T2-weighted scans (Fig. 127.7*B*) (26). It can be helpful in distinguishing unicameral cysts from aneurysmal cysts, GCT, fibrous dysplasia, and other benign lesions. Unless there has been a recent fracture, UBCs do not have fluid–fluid levels (20,89). A bone scan usually shows uptake at the periphery of the lesion, and a cold central area.

### PREOPERATIVE PLANNING AND MANAGEMENT

Treatment has traditionally consisted of curettage and bone grafting (111,148,149). Despite this aggressive approach, recurrence rates from 20% to 45% have been reported. Because of this, subtotal resection with grafting (with recurrence rates in the 10% range) has been advocated by some, but at the expense of a much larger operation (49,53,103). More recently, Scaglietti et al. (135,136) in Italy proposed needle aspiration and instillation of methylprednisolone acetate into these cysts. Although multiple injections were often required, they reported success in more that 90% of their cases.

Although randomized comparisons of these techniques have not been performed, most reports have indicated that steroid injections are as successful as curettage, if not more so (19,50). Injection is associated with the least morbidity, so operative treatment is reserved for those who do not respond to steroid injection. It usually requires several steroid injections to achieve healing of the cyst, and the mechanism of action of the steroid remains uncertain. One suggestion has been that the steroids reduce the levels of prostaglandin within the cyst fluid, thus retarding bone resorption (144). Campanacci et al. (23) compared the results of curettage and bone grafting with steroid injection in a large series of patients. They also defined radiographic criteria for complete and incomplete healing. Complete healing rates from curettage and grafting (46%) and steroid injection (42%) were comparable. Partial healing was noted in another 26%. Multiple injections led to complete healing in 50% and incomplete healing in another 25%. Repeat curettage in the surgically treated group was associated with a high recurrence rate. Risk of recurrence in the curettage group was related to the proximity of the growth plate; recurrence after steroid injection depended on the size of the cyst, contiguity with the growth plate, and the multilocular appearance of the cyst.

Recently, injections with bone marrow and demineralized bone gel have been reported to be successful in preliminary, unpublished reports (26). Other authors have employed high-porosity hydroxyapatite cubes (27,72) or tricalcium phosphate to fill the cavities (4,27), with variable success. Another approach has been to inject the cavities with a sclerosing agent similar to that used for soft-tissue hemangiomas (1). Calcaneal cysts appear to respond better to curettage and grafting than they do to steroid injection (59) and therefore are usually treated with surgery.

### OPERATIVE TECHNIQUES

#### *Curettage*

- Use standard surgical approaches to expose the wall of the cyst in the involved bone (see Chapter 1, Chapter 2 and Chapter 3).
- Make a window in the bone and aspirate the fluid. Completely curet the lining tissue, taking care to prevent injury to the growth plate. Then pack the lesion with autograft or allograft bone chips or other bone graft substitutes.

#### *Injection*

- Inject methylprednisolone acetate into the lesion under general anesthesia and fluoroscopic control. Place two spinal or bone marrow biopsy needles into the cyst; aspirate the fluid and send it for cytology.
- Inject radiographic contrast into the cyst to ensure that the entire lesion has been filled. Sometimes contrast will be seen to rapidly fill the draining veins.
- If there is relatively clear fluid initially and the lesion fills with contrast, inject 80–200 mg (2–5 ml) of methylprednisolone acetate (Depo-medrol) and remove the needles.
- Reinject the cyst at 2-month intervals until adequate healing is noted (19,23,26).

Recently, 2–4 cc of bone marrow obtained from the iliac crest has been mixed with demineralized bone gel and injected into these cysts. There are no published reports yet, but some surgeons believe this is a more reliable method to treat the cysts. In our early experience, no definite difference has been observed between this method and steroid injection, but the technique deserves proper study in a controlled study.

Another technique is to drill multiple holes in the cyst, and in some instances to leave wires in place, to allow continued drainage. The successful results suggest that venous obstruction may play an important role in the etiology of UBCs, and drilling may decrease the intracystic pressure (30,31 and 32,145). We have no experience with this technique. It is not yet used much in North America.

## ANEURYSMAL BONE CYST

An aneurysmal bone cyst (ABC) is a benign vascular tumor-like condition of unknown origin that accounts for approximately 1.5% of primary bone tumors (141). It is a multiloculated, radiolucent, eccentric lesion that expands the bone, giving it a “blown out” appearance. Histologically, it shows mesenchymal tissue–lined cysts containing blood. ABCs are believed to be reactive lesions caused by some hemodynamic disturbance in the rich capillary network of the host bone resulting in an expansile destructive process. This hypothesis was based on the observation that intracystic manometric pressure measurements were similar to arterial pressure (14).

Controversy exists as to whether ABCs are truly a distinct pathologic entity or a secondary phenomenon superimposed on a preexisting lesion (83). In up to about 50% of cases, a preexisting lesion can be identified. The most common of these is GCT, followed by osteoblastoma and chondroblastoma (99). Other underlying lesions include fibrous dysplasia, NOF, chondromyxoid fibroma, solitary bone cyst, eosinophilic granuloma, osteosarcoma, fibrosarcoma, trauma, and metastatic carcinoma. Although the lesion is benign, it is locally destructive with a high propensity for recurrence. The reactive lesion can also be solid in the form of a giant cell reparative granuloma, and then it is called a solid ABC (134). ABC is diagnosed by exclusion, as many tumors both benign and malignant can have a similar clinical and radiographic presentation.

### CLINICAL AND RADIOGRAPHIC PRESENTATION

Primary ABCs typically occur in the second decade of life. They have been reported to arise in almost every bone of both the axial and the appendicular skeleton, most often about the knee and in the vertebral column. Patients complain of pain and swelling of variable duration (weeks to years). Occasionally, a palpable mass may be identified. In the spine, compression may cause radicular symptoms, neurologic deficits, or even paraplegia. Patients may present with a pathologic fracture through the cyst, but this is uncommon given the eccentric nature of the lesion.

Aneurysmal bone cysts most often present as stage 2 or stage 3 disease. The radiographic appearance of an ABC is quite distinctive and almost diagnostic (Fig. 127.8*A*). The characteristic features include a subperiosteal lytic expansile lesion inflating and thinning the cortex. In the early stages, periosteal reaction is scarce, giving the appearance of a malignant tumor. The lesion typically involves the metaphysis, and occasionally the epiphysis, and it may even cross the physis. Because the periosteal response may extend along the shaft of the bone beyond the lesion, it may have the appearance of a finger in a balloon. Most often the lesion is eccentric, but it can be central. In the spine, the lesion typically involves the posterior elements but may expand to involve the vertebral body as well as adjacent vertebrae. CT and MRI are useful imaging modalities, especially in the axial skeleton. They are particularly helpful in confirming the diagnosis by demonstrating the characteristic fluid levels within the cyst (Fig. 127.8*B*). It should be stressed, however, that the presence of these fluid–fluid levels is not pathognomonic for ABC. Other lesions, including GCT, unicameral bone cyst with fracture, and osteosarcoma, may have this finding.

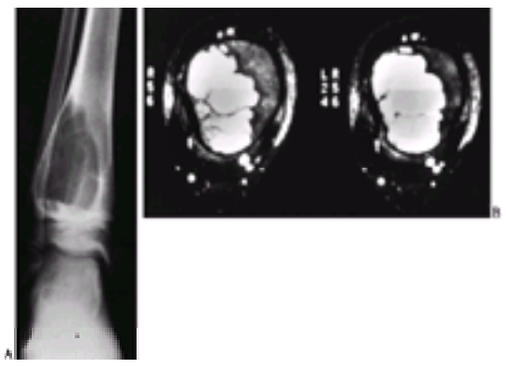

***Figure 127.8.*** **A:** AP radiograph of an aneurysmal bone cyst (ABC) shows an expanded radiolucent lesion in the metaphysis of the right distal tibia. The periosteum is intact and well marginated. There are some internal septations within the lesion. **B:** An MRI of this lesion shows the classic fluid–fluid levels. This was biopsied and proved to be an ABC.

### PREOPERATIVE PLANNING AND MANAGEMENT

The treatment of ABCs is surgical. Several details of the management must be carefully considered prior to surgery. Although the diagnosis of ABC can usually be made based on the imaging and clinical findings, malignant conditions, namely telangiectatic osteosarcoma, may mimic an ABC. As such, the initial surgical approach must take into account the possibility of encountering a malignant tumor and the need to perform a future limb-sparing procedure (see Chapter 126). Because of the vascular nature of the lesion, a large blood loss should be anticipated. Use tourniquets when possible and plan for blood replacement. In addition, certain lesions may benefit from preoperative selective arterial embolization. The extent of bony destruction must be fully appreciated in order to restore adequate bony stability with or without internal fixation. Because the majority of these cysts arise in skeletally immature individuals, the proximity of the physis must also be fully appreciated to prevent premature growth arrest.

Finally, plan to have the various adjuvants available to be used in conjunction with intralesional excisions (curettage) as discussed for GCTs. ABCs have a high incidence of recurrence after incomplete excision. The recurrence rates after curettage alone have been reported to be from 20% to 59% (14). Numerous investigators have used bone graft, PMMA, or cryotherapy (alone or in conjunction with bone grafting or PMMA) in an effort to reduce the rate of recurrence (95,115,140).

Special considerations in the management of spinal ABCs include difficult accessibility, intraoperative bleeding, proximity of the spinal cord and roots, necessity of removing the entire lesion to prevent recurrence, and potential bony instability (118). The posterior elements are usually involved, and the majority of these lesions extend into the vertebral body. An axial imaging study such as CT or MRI is essential in the preoperative evaluation of spinal lesions. Most spinal ABCs can be treated through a posterior approach. Some extensive lesions may require an anterior or combined anterior and posterior approach (see Chapter 151 and Chapter 152).

There are instances in which a spinal ABC may not be amenable to surgery, such as when the extent of involvement is so great that excision or curettage would risk neural compromise, or reconstruction would be technically dangerous. Both radiation and arterial embolization have been used with success in these instances. While radiation has demonstrated efficacy, it is used infrequently because of the concern for secondary radiation-induced sarcoma (146). Arterial embolization was first explored as a neoadjuvant therapy to decrease vascularity and hence intraoperative blood loss. However, its usefulness as a definitive treatment method has been demonstrated (42,43). Because spinal cord ischemia is a potential complication after arterial embolization, perform angiography followed by a provocative arterial infusion test with amobarbital sodium, with the patient awake or using somatosensory evoked potential monitoring (118). If no adverse changes are observed, selective arterial embolization can be done using polyvinyl-alcohol particles.

### OPERATIVE TECHNIQUE

Aneurysmal bone cysts can be treated by curettage, marginal excision, or, rarely, wide excision. In bones deemed expendable, such as ribs or the fibula, wide excision

is recommended. While marginal excision has been performed with low recurrence rates, it is difficult to justify aggressive bone resection given that ABC is a nonneoplastic lesion with the potential for spontaneous healing and complete recovery after incomplete excision (141). The most common method for treating ABCs is aggressive curettage followed by reconstruction of the tumor cavity with bone graft or PMMA.

- Expose the lesion under tourniquet control whenever possible. Create a wide window by removal of part of the expanded cortical shell. Send a biopsy specimen for frozen section to confirm the diagnosis.
- Remove the cyst by thorough curettage until all fibrous tissue has been excised. The cessation of bleeding usually indicates that the lesion has been completely excised. The margins of the excision may be further extended using a motorized burr or a chemical adjuvant. Then assess the extent of the cavitary defect and choose an appropriate method of reconstruction. Cancellous bone grafting is preferred over PMMA for pediatric patients and small contained defects.

## OSTEOCHONDROMA

### CLINICAL AND RADIOGRAPHIC PRESENTATION

Osteochondroma, or osteocartilaginous exostosis, is by far the most common benign tumor of bone, accounting for 35% to 50% of benign bone neoplasms and 10% to 15% of all primary bone tumors (69). The actual incidence is probably much higher, as most lesions are asymptomatic and never discovered. They may occur as solitary lesions or much less commonly as multiple hereditary exostoses (MHE), which is most often inherited as an autosomal dominant trait although it can also occur sporadically. MHE lesions show significant variability in size, number, and distribution.

Osteochondromas are not truly neoplasms but rather a developmental enchondromatous hyperplasia resulting in the formation of a cartilage-capped bony protrusion on the surface of a bone. They may occur in any bone that develops by enchondral ossification, most often in the distal femur, proximal tibia, and proximal humerus. In the axial skeleton, they most commonly arise in the ilium. There is a male to female predominance of up to 2 to 1, with most during the second and third decades of life.

An osteochondroma that continues to grow after skeletal maturity should raise the suspicion of malignant transformation. Malignant transformation almost never occurs in childhood. In adults, consider malignant transformation of the cap when there is such growth, and when the patient reports pain, especially in the setting of MHE. The malignancy associated with osteochondromas is most often chondrosarcoma, although malignant fibrous histiocytoma and osteosarcoma have been reported (52,113,172). It is estimated that the rate of sarcomatous change is approximately 1% per osteochondroma, although it is probably less. Central lesions (pelvis, scapula, ribs, spine) are at greatest risk for malignant transformation. Chondrosarcomas arising from osteochondromas have a better prognosis than other chondrosarcomas and rarely metastasize.

Patients usually complain of a hard, painless lump of long duration on the involved bone. Pain may be present resulting from impingement on or tethering of neighboring structures such as a tendon, muscle, or nerve. Pain may also arise from overlying bursal inflammation or a fracture through the stalk of the osteochondroma. On physical examination, a palpable mass is usually the only finding. Angular deformities or limb-length discrepancies may be present. Juxta-articular lesions may cause limitations of joint motion. Spine lesions may give rise to a variety of neurologic signs and symptoms secondary to cord or root compression (2,143). The most frequent sign of sarcomatous transformation is a sudden enlargement of a preexisting lesion in an adult. Pain is also a common, worrisome finding in these patients.

Radiographically, osteochondromas can be sessile or pedunculated (Fig. 127.9*A*,*B*). The roentgenographic picture of a pedunculated osteochondroma is so characteristic that it is virtually pathognomonic. A pedunculated lesion typically arises from the metaphysis of a long bone, with a stalk that is continuous with the adjacent cortex and is oriented away from the epiphysis. Sessile lesions demonstrate a flat, plateau-like protuberance, and have a wider differential diagnosis. The outline of the lesion is usually well demarcated, but it can vary from smooth to irregular. Prominent cartilaginous caps produce surrounding areas of calcification. CT and MRI are excellent imaging modalities to evaluate any questionable lesion, as they very nicely establish continuity with the cortex and underlying spongiosa of the host bone (Fig. 127.9*C*) (57). This is an important finding to document, especially in sessile osteochondromas that may be mistaken for parosteal osteosarcomas. When considering chondrosarcomatous degeneration, suspicious radiographic signs include loss of a distinctive bony margin, an adjacent soft-tissue mass, and areas of variable mineralization within the lesion. Historically, a cartilaginous cap larger than 1.5 cm in an adult is considered suspicious, although there is no absolute thickness specific for malignancy (52). While MRI and ultrasound have comparable detection rates and measurement accuracies for cap thickness determinations, MRI has the added ability to evaluate the surrounding soft tissues (94).

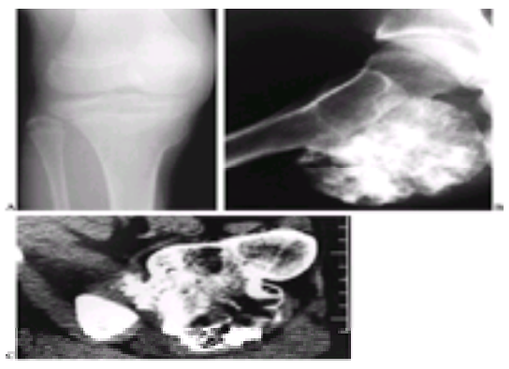

***Figure 127.9.*** **A:** AP radiograph of the tibia in a 10-year-old girl shows a small sessile osteochondroma of the right medial tibial metaphysis. It is adjacent to the growth plate. **B:** Another patient with a huge pedunculated osteochondroma arising from the posterior femur. At times, a lesion like this can be confused for a chondrosarcoma, which would be very rare in a child. **C:** The CT scan confirms that there is continuity between the cortex of the lesion and the cortex of the host bone and that the medullary cavities communicate.

### PREOPERATIVE MANAGEMENT AND PLANNING

There are numerous indications for surgical intervention in patients with osteochondromas. Complications associated with osteochondromas are listed in Table 127.3. In general, osteochondromas need not routinely be removed. In one series examining elective excision of these lesions, a 12% complication rate following excision was reported (170). When possible, it is best to avoid removing these lesions in skeletally immature individuals when the lesion is in proximity to the physis. In this circumstance, incomplete excision is likely to result in recurrence. The primary indications for removal are pain, fracture, nerve irritation, continued growth in a skeletally mature patient, and concern about cosmetic appearance. Osteochondromas adjacent to major vessels have on occasion led to pseudoaneurysm and may need to be prophylactically removed in that instance. The important principle in treating benign osteochondromas is to completely excise the cartilage cap and perichondrium.

| |
|---|
| Mechanical |
| Locking knee |
| Muscular restriction |
| Compression |
| Musculotendinous |
| Neurologic |
| Paresthesias |
| Paralysis |
| Vascular |
| Vessel displacement |
| Stenosis/occlusion |
| Pseudoaneurysm |
| Growth |
| Angular deformity |
| Cosmetic deformity |
| Trauma |
| Fracture |
| Nonunion |
| Infarction of cartilage cap |
| Ischemic necrosis |
| Bursitis |
| Malignant degeneration |

Reprinted with permission from Davids JR, Glancy GL, Filbert RE. Fracture through the Stalk of Pedunculated Osteochondromas. Clin Orthop 1991;271:26.1.

***Table 127.3. Osteochondroma: Associated Complications***

When malignant change is suspected, obtain adequate imaging studies, such as those previously mentioned, to fully appreciate the extent of the lesion. Treat these patients as you would those with conventional chondrosarcoma, including staging studies (151). A wide excision is the treatment of choice. Biopsy is usually not performed preoperatively, as the risk of seeding the biopsy track outweighs the possibility of obtaining a representative specimen, considering that low-grade cartilage lesions are difficult to interpret histologically. Most (85% in one series) of these secondary lesions are grade 1 chondrosarcomas (see Chapter 128).

For patients with MHE, corrective osteotomies are sometimes necessary to address functional impairment, angular deformities, and limb-length inequality (121). The three most common locations for involvement are the forearm, the ankle, and the knee. The most common of these is forearm deformity, resulting in ulnar deviation of the wrist associated with relative ulna shortening, bowing of both the ulna and the radius, and late dislocation of the radial head (6). These deformities usually progress, leading to functional impairment and cosmetic deformity. While a discussion of the exact surgical techniques to correct these complex malalignments is out of the scope of this chapter, it is worth mentioning that early recognition and intervention may prevent progression and reduce disability. Structural ankle valgus and genu valgum are not uncommon and benefit from corrective measures such as hemiepiphyseal stapling (see Chapter 165, Chapter 169, and Chapter 180).

### OPERATIVE TECHNIQUE

When surgical intervention is elected, the most common procedure performed is excision of the osteochondroma. Osteochondromas are nearly always cured by complete excision. It is important to remove the entire cartilaginous cap and overlying perichondrium (137). Be careful not to violate the cartilaginous cap, as cutting into it increases the rate of local recurrence. Remove the tumor flush with the underlying bone. Incomplete excision of these elements is associated with recurrence, although for benign lesions in adults this rate is about 2%.

Complete removal of sessile lesions poses a greater challenge. Fortunately, these lesions tend to cause fewer symptoms necessitating surgery. For these lesions, it may occasionally be necessary to leave behind part of the cortical stalk to avoid compromising bony stability or the need to bone graft. Be certain to remove the cartilage cap at the exostosis–host bone junction.

The management of fractured osteochondromas is somewhat controversial (41). The majority of fractures through osteochondromas will heal with activity restriction. Painful fibrous nonunions, particularly about the knee, do occur. In such instances, the osteocartilaginous loose body can be excised, usually without incident.

Excise enlarging osteochondromas in adults because of the possibility of sarcomatous degeneration. Use the surgical principles for managing primary bone sarcomas (Chapter 128), performing resection with a wide margin to minimize the risk of local recurrence. In one large series from the Mayo clinic, intralesional excision led to a 78% recurrence rate compared to only 15% in those who underwent wide resection (52). For patients with low-grade (grade 1) chondrosarcoma, wide resection is almost always curative. Those with higher grades are at much higher risk for local recurrence and distant metastasis. All patients, regardless of grade, require long-term surveillance. For patients with MHE, although they are at higher risk for malignant transformation than patients with solitary lesions, the same criteria for excision apply.

## CHONDROBLASTOMA

### CLINICAL AND RADIOGRAPHIC PRESENTATION

Chondroblastomas are primary tumors of bone that account for less than 1% of all primary bone tumors. They are composed of immature cartilage, multinucleated giant cells, and areas of thin calcifications with a “chicken wire” pattern. These tumors classically arise in the epiphysis of a long bone, although they can appear in any secondary center of ossification. Typical sites include the distal femur, proximal humerus, and proximal tibia in tubular bones, and the acetabulum and iliac crest in flat bones. There is a slight male to female predominance. The majority of patients are in the second decade of life at presentation. Although the lesion most commonly presents in individuals with an open physis, tumors have occurred in skeletally mature patients. Chondroblastoma is one of the few benign bone tumors that has the potential to develop pulmonary metastases (152,160). The pulmonary nodules have the same histologic characteristics as the primary lesion, without evidence of malignant differentiation.

As with other benign bone lesions, the presenting symptoms can be nonspecific. The majority of patients describe pain in the affected extremity, usually of several months duration. The pain at times may be quite severe and sharp, similar to that of osteoid osteoma. Patients may also complain of swelling, joint stiffness, and limp. On physical examination, approximately 50% of patients will have tenderness to palpation over the lesion. Occasionally, a palpable inflammatory mass will be found, raising the suspicion of a malignant tumor. Decreased range of motion of the involved joint and muscle wasting are also common. The lesion rarely presents with a pathologic fracture.

On plain radiographs, the lesion is typically an eccentric, round, radiolucent lesion contained within the epiphysis (Fig. 127.10*A*,*B*). Chondroblastomas commonly cross the physis and extend into the metaphysis. Rarely is the lesion purely metaphyseal. The lesion may also arise in an apophysis. A well-demarcated rim of sclerosis surrounds the lytic area. Areas of calcification scattered throughout the lesion are present in approximately one third. When these intrinsic calcifications are not present on conventional radiographs, a CT scan may confirm their presence, lending support to the diagnosis of chondroblastoma. CT scans or MRI images are also of assistance in determining the exact proximity of the tumor to the physis and articular surface. An MRI will demonstrate the surrounding inflammatory host response to the lesion (Fig. 127.10*C*,*D*). Some chondroblastomas may exhibit an aggressive radiographic appearance with erosion or even expansion of the adjacent cortex. Histologically, these aggressive lesions often have an ABC component. Secondary ABC is found in approximately 15% to 20% of chondroblastomas.

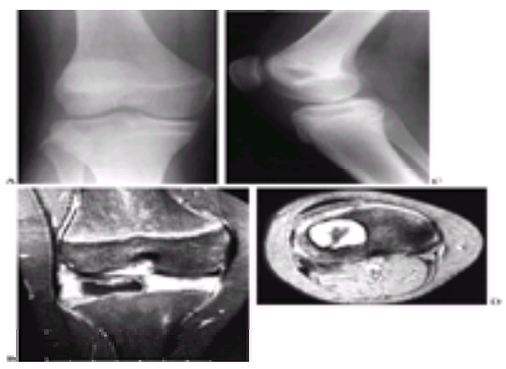

***Figure 127.10.*** AP (**A**) and lateral (**B**) radiographs of the right knee show a radiolucent lesion in the lateral tibial epiphysis, which extends from the growth plate to the subchondral bone. In this case, there is no stippled calcification, but this location is typical for a chondroblastoma in this age group, and biopsy confirmed this. Frontal plate (**C**) and cross-sectional (**D**) MRI images nicely delineate the extent of this lesion within the epiphysis. On the frontal plate image, surrounding edema of the epiphysis is evident. In the axial image, there is a central dark area that represents mineralization within the lesion.

### PREOPERATIVE MANAGEMENT AND PLANNING

Intralesional treatment of chondroblastoma is usually curative and the prognosis good. The standard treatment is biopsy followed by curettage and bone grafting. With this method, approximately 10% will recur within the bone or adjacent soft tissue, although up to a 20% recurrence rate has been reported (71,150). Biopsy is an important part of the treatment plan. While the differential diagnosis of epiphyseal lesions in childhood and early adulthood is somewhat limited (osteomyelitis and histiocytosis in rare instances), osteosarcoma may originate in the epiphysis (epiphyseal osteosarcoma) (158). In the adult, GCT, which is more accurately described as epiphyseometaphyseal, is more likely; less frequently is clear-cell chondrosarcoma seen. Clear-cell chondrosarcoma presents as an epiphyseal lesion and looks very similar to a chondroblastoma. The misdiagnosis of chondroblastoma in these instances would clearly result in inadequate treatment. In general, tumors involving the epiphysis in adolescents are usually chondroblastomas, whereas in the adult, GCT is more likely.

Perhaps the most important aspect of planning the surgical procedure is appreciating the close proximity of the tumor to the physis and articular cartilage. It is important to avoid entering the adjacent joint, as synovial membrane and articular recurrences may follow transarticular spillage of the tumor. Most authors agree that if the physis cannot be spared without compromising the margins of resection, it should be sacrificed, as overly conservative curettage is an invitation for tumor recurrence (71). Most of the time, the child is near skeletal maturity so that growth considerations are of lesser importance.

In the pelvis, we advise *en bloc* resection. For aggressive lesions, consider adjuvant therapy with phenol or liquid nitrogen to minimize recurrence. Finally, decide if autogenous or allogenic bone is necessary to fill the defect. Consider the morbidity of harvesting autograft as compared to the risk of disease transmission with allograft (58). For small defects, autograft and allograft have similar healing rates. For larger defects, autograft displays superior rates and completeness of healing. This increased efficacy presumes that an adequate amount of autogenous bone is available. Freeze-dried allograft bone is safe and generally works quite well.

While chondroblastoma is relatively radiosensitive, radiotherapy is contraindicated because of the average patient's age and the risk of secondary sarcoma. Irradiation of skeletally immature bones leads to a reduction in bone growth, abnormal bone remodeling, and increased propensity to fracture (60).

### OPERATIVE TECHNIQUE

In most cases, intralesional curettage will be the treatment of choice (56). When possible, perform curettage in an extra-articular manner. For most long-bone locations, standard surgical approaches can be utilized. Intraoperative fluoroscopy is extremely helpful. Bone graft the resultant cavitary defect. Avoid subchondral PMMA in children, as its long-term effects on articular cartilage have yet to be determined. For lesions not directly adjacent to subchondral bone, PMMA has been used with success. In instances where the tumor has eroded through the articular surface, reconstruction of the joint surfaces with an osteoarticular allograft may be necessary. Recurrent lesions are probably best treated by wide excision when possible.

The proximal femur is not an uncommon location for chondroblastoma and presents unique considerations. While this lesion has historically been treated by anterior capsulotomy, an extra-articular approach has been described (152).

- With the patient on a radiolucent or fracture table, make a lateral approach to the greater trochanter.
- Under fluoroscopic guidance, introduce a guide wire from the lateral femoral cortex, through the femoral neck, into the center of the lesion in the epiphysis.
- Using a coring device or cannulated drill, drill a tunnel of sufficient diameter (approximately 1 cm) into the tumor.
- Remove the tumor with long curets with narrow shanks and pituitary rongeurs.
- Use an arthroscope to verify that all of the tumor has been removed and to be certain that the articular surface has not been violated.
- After thorough curettage, pack the cavity with bone graft and replace the original autograft core back into the metaphyseal window if possible. Prevention of fracture can be achieved with interval fixation or spica case immobilization.

## CHONDROMA

### CLINICAL AND RADIOGRAPHIC PRESENTATION

Chondromas are benign hyaline cartilage tumors that can be one of two types depending on their location within a bone. Intramedullary lesions are called enchondromas, and subperiosteal lesions that form external to the cortex of a bone are termed periosteal chondromas. Some authors prefer the term *juxtacortical chondroma* instead of *periosteal chondroma*, since these lesions can arise in areas not covered by periosteum such as the femoral neck.

Chondromas are usually located centrally within the medullary cavity of short, long, or flat bones and are the most common bone tumor of the hand. From 35% to 58% occur in the hands and feet (159). Common locations are the proximal humerus, the distal and proximal femur, and the ribs. The lesions may occur at any age and are often asymptomatic unless accompanied by pathologic fracture. They presumably grow in size until maturity and then stabilize. In adults, an increase in size, especially if associated with pain, may herald sarcomatous change. Chondromas account for 25% of benign bone lesions, most of which are enchondromas (69). Periosteal chondromas are much rarer. Men and women are equally affected, most commonly in the third or fourth decades of life. Periosteal chondromas appear slightly earlier, probably because they are palpable and detected by the patient.

Secondary chondrosarcoma is a well-recognized complication of chondromas. Distal lesions, such as those of the phalanges, almost never undergo malignant change, whereas more proximal lesions, such as those of the pelvis or shoulder girdle, have a higher propensity to do so (9). The rate of malignant transformation for solitary enchondromas for all locations combined is less than 1%.

Enchondromas may be polyostotic in associated syndromes. Ollier's disease is characterized by multiple skeletal enchondromatoses. Maffucci's syndrome is multiple enchondromatosis with the additional component of hemangiomas. Both are nonheritable diseases in which proliferating masses of benign cartilage afflict the bones formed by enchondral ossification. These diseases tend to affect men twice as often as women and are evident in childhood. The hands are most commonly affected. Secondary chondrosarcoma is more common in both Ollier's and Maffucci's syndrome. It has been estimated that approximately 25% of patients with Ollier's disease will develop secondary chondrosarcoma, although this figure may be an overestimation reflecting a bias of those patients presenting to a cancer center. It is estimated that the incidence of malignant transformation of enchondromas in Maffucci's syndrome is higher, but the true incidence is unknown because many of these patients die from complications related to other malignancies (106).

Most typical solitary enchondromas are asymptomatic and are found incidentally as part of the workup for another condition or coincidental local trauma. Patients may present with pain or fracture through a weakened area of a longstanding tumor. Lesions in the proximal humerus are often detected when the patient is being evaluated for rotator cuff tears or tendinitis. This presents the difficult dilemma of determining whether the symptoms are due to malignant degeneration of the cartilage tumor or some other traumatic or inflammatory cause. Distal phalanx lesions may lead to ruptures of the flexor digitorum profundus tendon. Occasionally, painless swelling of a digit may be the chief complaint. Few patients will complain of pain related to the enchondroma in the absence of fracture. Pain in the lesion that is sharp, immediate, and severe following some type of strenuous or athletic activity is most likely a stress fracture through the enchondroma. Pain referable to the lesion that is vague and of longer duration is more likely to be associated with chondrosarcoma. Although chronic pain is thought to be an important aspect of the clinical history when assessing a patient for secondary chondrosarcoma, up to 50% of patients with biopsy-proven chondrosarcoma did not complain of pain (9).

Juxtacortical chondromas present with pain and overlying swelling and often a palpable mass. The pain is usually described as dull and aching, and it varies in duration from weeks to years. The swelling tends to be localized and may gradually increase with time. More frequently, these lesions are completely asymptomatic and especially in children can be followed with periodic radiographic evaluation (88).

In Ollier's disease and Maffucci's syndrome, clinical manifestations include gradual enlargement of the fingers, bowing deformities, shortening of the extremities, and limitations of joint motion. Patients with Maffucci's syndrome also present with subcutaneous hemangiomas. The phenotypic penetrance of these two entities is variable, with mild forms not detected until early adulthood and severe forms obvious in the first year of life.

The radiographic appearance of an enchondroma is usually that of a centrally placed, lucent lesion within the metaphysis or diaphysis, with mild forms not detected until early adulthood and severe forms obvious in the first year of life.

The radiographic appearance of an enchondroma is usually that of a centrally placed, lucent lesion within the metaphysis or diaphysis of the bone. Thinning or scalloping of the cortex may occur, but there is usually a moderate amount of radiodense margination. Rounded or stippled calcification is a frequent finding in adults (Fig. 127.11, Fig. 127.12). Some lesions may show well-circumscribed areas of relative radiolucency, with scattered amorphic calcifications centrally located in the medullary cavity of the bone. This picture is common for an enchondroma in the phalanges. Other lesions, such as those in the long bones, show large granular or flocculent collections of calcifications, with variable cortical thickening. Fractures through the thin cortices of the lesions in phalanges may be evident. Most lesions show an increased uptake on bone scans.

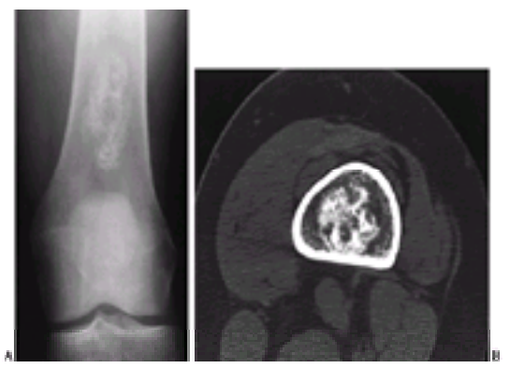

***Figure 127.11.*** **A:** Radiograph of the distal femur of a 30-year-old woman with an incidental finding of an enchondroma of the distal femur. Note the typical “popcorn”

type of calcification with small rings and arcs. There is no evidence of cortical erosion. **B:** The CT scan from this patient confirms these findings. The cortex is intact and the mineralization of this lesion in arcs and amorphous rings is readily apparent within the medullary cavity.

***Figure 127.12.*** A typical enchondroma in the proximal phalanx of the thumb of a 20-year-old man. It has enlarged the bone slightly, although the cortex is intact. There has been no mineralization, but the enchondroma has a characteristic appearance.

Juxtacortical (periosteal) chondromas present as a juxtacortical radiolucent mass, surrounded by peripheral periosteal host reaction at its base (Fig. 127.13). The base of the lesion is framed by a layer of cortical reactive bone and usually does not extend into the medullary cavity. There may be areas of stippled calcifications throughout the cartilaginous portion of the lesion.

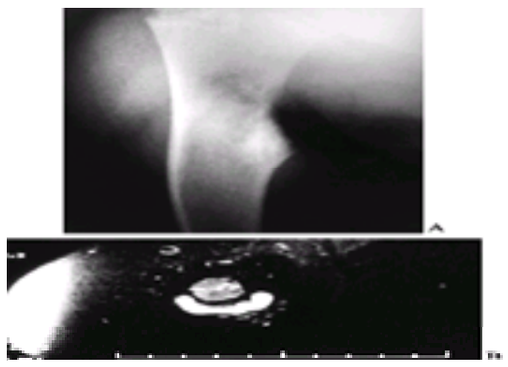

***Figure 127.13.*** **A:** AP radiograph of an 11-year-old boy shows a surface lesion of the right proximal humerus. Note “dish shaped” appearance and some periosteal elevation. **B:** MRI of this patient more clearly shows a cartilaginous mass sitting on the cortex of the bone. Unlike in osteochondroma, there is no communication of the medullary cavity with the lesion.

The radiographic appearance of Ollier's disease and Maffucci's is characteristic (Fig. 127.14). The multiple enchondromas are expansive and bubbly. The cortical margins are substantially thinned and may even be absent. The degree of calcification is variable. In the long bones, the remodeling deformities are manifested by bowing, shortening, and metaphyseal widening.

***Figure 127.14.*** AP radiograph of the hands shows findings characteristic of a patient with Ollier's disease. Multiple enchondromas can be seen in the phalanges and metacarpals of the hands, with gross distortion of the bones and enlargement of portions of many of the bones. Also typical is the relative increase in severity of the disease on this patient's left hand compared to his right.

## PREOPERATIVE MANAGEMENT AND PLANNING

Asymptomatic enchondromas can be observed. In the adult, follow these lesions with serial radiographs and CT to monitor changes in size and cortical destruction if the possibility of malignant change is a concern. The frequency of radiographic evaluation, which is necessary, has not been firmly established. We recommend that lesions that have characteristics associated with higher rates of chondrosarcoma, such as those in the axial skeleton, those larger than 5 cm, and those that involve more than 90% of the medullary cavity as visualized on axial tomography, be reevaluated every 6 months (35,54). Smaller, more peripherally localized lesions can be followed yearly or biannually.

Perhaps the greatest challenge in managing these tumors is distinguishing between benign enchondroma and low-grade chondrosarcoma. There are no clear-cut ways to do this radiographically, and even after histologic evaluation the distinction may be difficult. Signs indicating possible malignancy include new pain, soft-tissue mass, increase in size, cortical destruction, periosteal reaction, an area of radiolucency within a previous area of calcification, and marked increase in activity on bone scan (66,151). CT is a useful imaging modality for evaluating cortical scalloping, periosteal reaction, and soft-tissue mass (54). We feel that all adult patients with an enchondroma in a bone outside the hand should have a baseline CT scan or MRI.

## OPERATIVE TECHNIQUE

- Expose the lesion through standard approaches. Treatment is principally by curettage and packing the defect with autogenous or allograft bone.
- If you are concerned about malignancy, use recommended techniques for primary bone malignancies (see Chapter 128). Make a direct and limited approach, allowing for a wide resection of the tumor should it prove to be malignant. Make a small window in the cortex to obtain tissue for diagnosis.
- Obtain tissue for a frozen section. If there is doubt about the diagnosis, obtain enough to avoid a sampling error—and wait for a permanent section diagnosis before definitive treatment. It is advisable to plug the biopsy defect with PMMA to prevent the spread of hematoma and tumor cells.
- For lesions that are clearly benign, make a window in the cortex, outlining it with multiple drill holes and an osteotome or a high-speed burr (Fig. 127.15). Do a complete curettage to ensure complete removal. Submit all removed tissue for histologic examination to rule out low-grade chondrosarcoma.

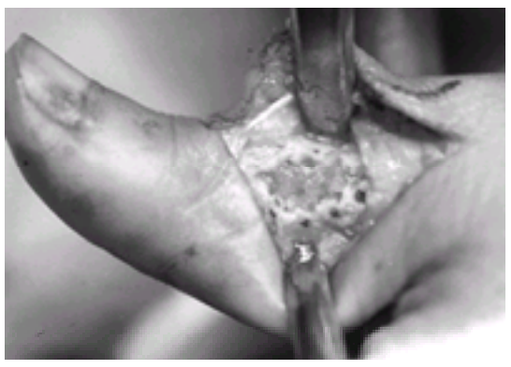

***Figure 127.15.*** Intraoperative photograph of the patient whose radigraph appears in Figure 127.12. The lesion has been exposed through a cortical window that has been removed. The glistening, glasslike appearance of the hyalin cartilage that forms this lesion can be seen clearly. This lesion was completely curetted and packed with bone graft, with a good result.

- Use adjuvants such as phenol, liquid nitrogen, or PMMA if you are concerned about recurrence. Pack the lesion with autograft or allograft chips. In locations where the bone is expendable, complete local excision.

## FIBROUS DYSPLASIA

Fibrous dysplasia is a disorder of fibro-osseous tissue that more likely represents a developmental abnormality of bone than a true neoplasm. No consistent familial or hereditary factors have been identified, but recently, activating missense mutations of the *Gs* alpha gene leading to overactivity of adenylyl cyclase have been identified in patients with McCune-Albright syndrome (127). This mutation can result in independent cell proliferation. The mutation in this syndrome is a missense point mutation in exon 8 that results in the substitution of either histidine or cysteine for arginine at position 201. Recently, four cases of monostotic fibrous dysplasia were demonstrated to have such a missense mutation, whereas other fibrous lesions and uninvolved tissue did not contain a mutation (3). The presence of somatic activating mutations of *Gs* may differentiate fibrous dysplasia from the other lesions and may be responsible for the loss of control of local proliferation and growth factor expression. Increased expression of the c-*fos* proto-oncogene has recently been noted in patients with McCune-Albright syndrome and may also be important in the pathogenesis of the bone lesions in patients with fibrous dysplasia (25).

### CLINICAL AND RADIOGRAPHIC PRESENTATION

The diagnosis can often be made in childhood, but recognition may not occur until adult life. Three clinical syndromes exist: monostotic fibrous dysplasia, polyostotic fibrous dysplasia, and McCune-Albright syndrome (61). The monostotic form occurs at any age, with the second and third decades predominating. The sexes are equally involved, and the bone lesions are most commonly located in the proximal femur, tibia, rib cage, and facial bones (138,159). Symptoms are usually related to deformity or pathologic fracture, although cranial lesions may cause progressive visual impairment or hearing loss. The polyostotic form usually presents at a younger age because of the greater involvement of the skeletal systems, and unlike the monostotic form, females outnumber males.

The lesion can be limited to a segmental defect in one extremity (monomelic form), but 25% of patients have polyostotic involvement of more than half of the skeletal system (64). About 85% of patients with this form sustain pathologic fractures, and deformities and limb-length inequality are common. Skin lesions may be present. In McCune-Albright syndrome, polyostotic fibrous dysplasia is associated with areas of cutaneous pigmentation and endocrine dysfunction (40,87,91,100,167). The skin lesions are flat and light to dark brown; sometimes, extensive areas of pigmentation with irregular margins present as café-au-lait lesions. Precocious puberty is the most common endocrinopathy, but acromegaly, hyperparathyroidism, vitamin D–resistant rickets, hyperthyroidism, and Cushing's syndrome may be present. Short stature secondary to premature physeal closure is common.

Radiographically, the lesions of fibrous dysplasia have a lucent or “ground glass” appearance and cause thinning of the cortex and endosteal scalloping (Fig. 127.16) (61). The bone may be enlarged or deformed (e.g., “shepherd's crook” deformity of the proximal femur), and it may be involved from one end to the other (Fig. 127.17). Tiny purposeless trabeculae are noted within the lesion.

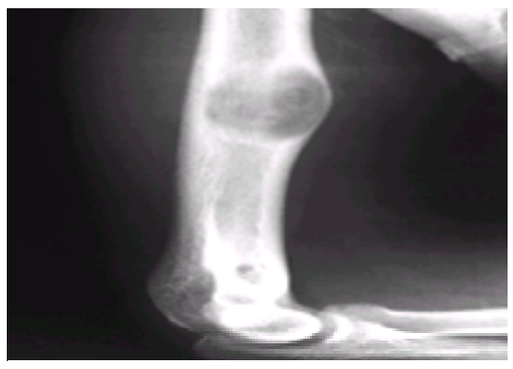

***Figure 127.16.*** Radiograph of an 18-year-old man with a typical lesion of fibrous dysplasia of his right humerus. He had monostotic fibrous dysplasia, which in this case involves a diaphysis with thinning of the cortex. There is a typical ground glass appearance and the lesion is relatively well marginated.

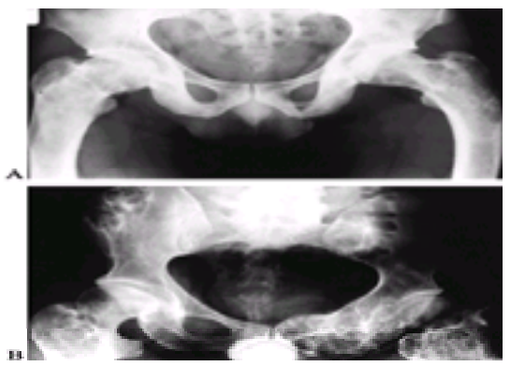

***Figure 127.17.*** **A:** A typical patient with polyostotic fibrous dysplasia and shepherd's crook deformities of both femurs. The medullary cavities of both the proximal femora have been replaced with a radiolucent, ground glass lesion, which has thinned the cortex and led to the typical varus deformities seen in this condition. **B:** This AP pelvis radiograph is from another patient with polyostotic fibrous dysplasia. It shows more extensive involvement with gross distortion and enlargement of the bones of both the pelvis and the proximal femora.

Malignant degeneration is extremely rare, occurring in 0.5% to 1% (61,70,74,132,173,174). When malignant degeneration occurs, it is usually in fibrous dysplasia that has received irradiation. Do not irradiate the bone lesions of fibrous dysplasia.

Nonsurgical management of fibrous dysplasia using bisphosphonates is currently under investigation. Intravenous pamidronate has been shown to alleviate bone pain, reduce bone turnover, and improve the radiographic appearance in one series of patients with fibrous dysplasia. While these data are preliminary, bisphosphonates look promising as an effective and well-tolerated treatment (28).

### PREOPERATIVE MANAGEMENT AND PLANNING

It is technically difficult to totally eradicate the disease in the absence of complete excision. Bone grafting is a temporary measure, as grafts are eventually replaced by fibrous dysplasia bone. Frequently, the goal of intervention is to maintain bone strength and integrity, or to correct deformity, not to cure the lesion. Symptomatic lesions can be treated by closed methods (splinting), curettage and bone grafting, internal fixation, and wide excision (rarely including amputation). Asymptomatic lesions do not require treatment.

Lesions in the upper extremity are usually observed or treated by closed methods. When operative intervention is necessary, internal fixation is rarely required.

Lower extremity lesions, especially involving the proximal femur, are particularly challenging and associated with significant morbidity. The patient's age at the time of symptomatic presentation seems to play a significant role in outcome. In patients older than 18 years, curettage and bone grafting appear to provide satisfactory results. In contrast, patients less than 18 years old treated by this method often sustain additional fractures, develop progressive deformity, and require additional procedures. The use of internal fixation in this group leads to a more favorable outcome (Fig. 127.18).

***Figure 127.18.*** AP radiograph of a patient with polyostotic fibrous dysplasia who had pain in his hip. To prevent a shepherd's crook deformity, he was treated with internal fixation using a dynamic hip screw device and an allograft cortical strut to strengthen the proximal femur and femoral neck region.

As with other aggressive benign entities, biopsy may occasionally be necessary to distinguish fibrous dysplasia from malignant lesions.

### OPERATIVE TECHNIQUE

The proximal femur is prone to develop complex varus deformities (the shepherd's crook deformity) that are difficult to correct. In severe cases, multiple osteotomies may be necessary. Patients with McCune-Albright syndrome are a special challenge and may require multiple operative procedures to stabilize fractures, correct deformity, and graft lesions (Fig. 127.19) (116). It may be necessary to excise parts of the bone and replace them with allograft segments, but we prefer to use fibular allograft struts within the medullary cavity whenever possible.

***Figure 127.19.*** **A:** This 21-year-old woman with precocious puberty, café-au-lait spots, and polyostotic fibrous dysplasia has classic McCune-Albright syndrome. She complained of bilateral hip pain and has had recurrent pathologic fractures through the large cystic lesion seen in the shaft of the left femur. This AP radiograph of the right femur shows classic findings of polyostotic fibrous dysplasia with a shepherd's crook deformity. **B:** AP radiograph of the left femur shows a more severe deformity. **C:** AP radiograph of the right femur after correction of the varus deformity of the hip and femoral shaft with double osteotomies and fixation with a Zickel nail. **D:** Lateral radiograph right femur. **E:** AP radiograph of the left femur after a similar procedure done at the same time as the right side. **F:** Lateral postoperative radiograph of the left femur. Her osteotomies healed without difficulty and she experienced significant pain relief. Her wide perineum, caused by the bilateral hip deformities, returned to normal and her gait improved substantially. At the 17-year follow-up, she has had no refractures of the femurs, has married, and has had a family. Her current problems are mainly pain in the left hip due to degenerative arthritis. (Courtesy M. W. Chapman)

## LANGERHANS'S CELL HISTIOCYTOSIS (EOSINOPHILIC GRANULOMA OF BONE)

### CLINICAL PRESENTATION AND RADIOGRAPHIC FINDINGS

Although probably not a true neoplasm, Langerhans' cell histiocytosis of bone presents with bony lesions that may be confused with benign bone tumors. It is a disorder of unknown etiology that presents with a variety of manifestations, and the tumor cells are believed to be derived from histiocytic cells resembling nonpigmented dendritic cells in the epidermis known as Langerhans' cells (162). This group of disorders is now termed Langerhans' cell histiocytosis, or granulomatosis, although traditionally it was divided into three distinct clinical entities.

The first, eosinophilic granuloma is a mild, localized, self-limited disorder of bone seldom involving more than two or three osseous sites (90,92,101,105). It occurs most commonly in the first two decades of life, but it may be seen up to the age of 50 years or beyond. Local pain or pathologic fracture calls the lesion to the patient's attention. Lytic, punched out, irregular defects are seen on radiographs. In the spine, however, a wafer-like appearance of the collapsed vertebral body is seen, which accounts for the majority of cases of vertebra plana (Calvé disease).

The second, Hand-Schüller-Christian disease, is a disease of the first and second decades with multiorgan involvement (90,154,162). Shortness of stature, diabetes insipidus, proptosis, exophthalmus, and abnormal dentition (“floating teeth”) are part of this complex. Lymphadenopathy, pulmonary infiltrates, and eczematoid weeping skin lesions at the hairline, abdomen, and extensor surfaces of the extremities are often seen. One third of the patients have involvement of the liver and spleen. The occurrence of skull lesions, exophthalmus, and diabetes insipidus is termed Christian's triad and occurs in about one third of the patients.

The third syndrome, Letterer-Siwe disease, is a fulminant disease occurring mostly in the first two years of life (92,162). It is characterized by hepatosplenomegaly, lymphadenopathy, failure to thrive, severe anemia, leukopenia, and thrombocytopenia. Marrow replacement and pulmonary infiltrates often result in death.

In each of these disorders, the bone lesions are usually “punched out” radiolucencies in the medullary cavity of the bone (48,92,162). They have a wide range of radiographic presentation and may mimic a variety of other tumors, especially round cell tumors such as Ewing's sarcoma and lymphoma (Fig. 127.20*A*, Fig. 127.21). In children under 5 years, exclude metastatic neuroblastoma and Wilms's tumor. It is wise to consider the diagnosis of histiocytosis for any unexplained bone lesion in a child. This and fibrous dysplasia have a wide variety of presentations. Often, histiocytosis is mistaken for Ewing's sarcoma. This can be made more confusing by the MRI appearance, which can show large areas of inflammation and edema in the surrounding marrow and soft tissues, mimicking the soft-tissue mass of Ewing's sarcoma (Fig. 127.20*B*,*C*). On careful inspection, however, the distinction between the edema of histiocytosis and the mass of Ewing's sarcoma can usually be made.

The pathologic findings are similar in all involved sites and in all three variants.

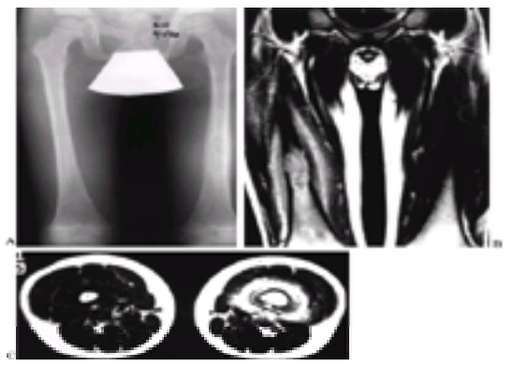

***Figure 127.20.*** **A:** AP radiograph of both femora of a 6-year-old boy with a punched-out radiolucent lesion of the left femur. There is periosteal elevation and thinning of the cortex. We were concerned about histiocytosis, Ewing's sarcoma, or infection. **B:** MRI shows the extent of the lesion within the medullary cavity and considerable soft-tissue swelling on this coronal image. **C:** Axial T1-weighted MR image shows considerable edema in the surrounding tissues. This should not be mistaken for Ewing's sarcoma, as histiocytosis commonly has significant edema surrounding the bone. After a biopsy proved that this was Langerhans' cell histiocytosis, the patient was treated with curettage. Alternatively, this lesion could have been managed with a needle biopsy and an injection of corticosteroids.

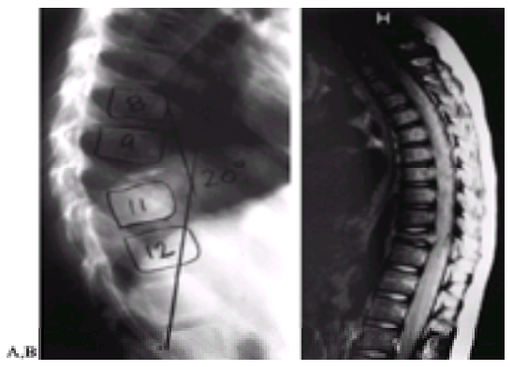

***Figure 127.21.*** **A:** Lateral radiograph of the spine of a 10-year-old patient with typical vertebra plana involving T-10. This patient had a 20° kyphosis through the area. **B:** An MRI of this patient shows reduced height of the vertebral body at T-10 but maintenance of the disc space. There is no encroachment on the thoracic spinal cord. This patient was managed with a needle biopsy to confirm the diagnosis and treated in a brace with resolution of symptoms.

## PREOPERATIVE MANAGEMENT AND PLANNING

Evaluate a patient suspected of having histiocytosis with a thorough history and physical examination. Inquire about polyuria and nocturia, eczematoid skin rashes, and otitis-like symptoms. Evaluate the bone lesion(s) with plain radiographs, and sometimes with MRI. Obtain a skeletal survey to search for other lesions. A bone scan is also useful, but on rare occasions, the bone scan may not detect lesions present on plain films. There is debate in the literature over whether bone scans or skeletal surveys are best to evaluate these patients (37,139,161,168,169). Both are useful. Obtain a first-void urine sample for specific gravity to exclude the possibility of diabetes insipidus. In a very young child, urinary catecholamines and an abdominal CT scan may be necessary to exclude the possibility of metastatic neuroblastoma or Wilms's tumor.

Biopsy lesions in the spine to exclude lymphoma, leukemia, infections, and Ewing's sarcoma. CT-directed needle biopsy is frequently possible and avoids a surgical procedure.

Vertebra plana, although frightening in appearance, seldom causes neurologic defects, and the compressed bony segment will at least partially reconstitute in height with time (73). Manage with bracing until the symptoms resolve. Opinion is divided as to whether these lesions require low-dose radiotherapy (450–900 cGy) or whether the same results might not be achieved by observation alone (63,108,142,171).

For disseminated disease, consult a pediatric oncologist. Management is frequently by chemotherapy, usually starting with vinblastine. In some patients, steroids and a variety of chemotherapy regimens, rarely necessitating bone marrow transplantation, are necessary over a protracted time to control the disease (36,92,105,108,124,142,162,171).

## OPERATIVE TECHNIQUE AND TREATMENT

Treatment is nonspecific and many of the lesions of eosinophilic granuloma will disappear if left alone. Open biopsy of solitary lesions is indicated to establish the diagnosis, and this alone is frequently curative, although autogenous or allograft bone graft of the curetted cavity is advisable if a large bony defect is created. At times, internal fixation or a spica cast will be necessary to avoid fracture until the lesion heals.

Steroid injections have also been shown to be successful in the management of the bony lesions (10,142,171,175). In our experience, this can be performed at the time of CT-directed needle biopsy of long-bone lesions and is much easier for the patient.

## CHAPTER REFERENCES

Each reference is categorized according to the following scheme: *, classic article; #, review article; !, basic research article; and +, clinical results/outcome study.


+ 1. Adamsbaum C, Kalifa G, Seringe R, Dubousset J. Direct Ethibloc Injection in Benign Bone Cysts: Preliminary Report on Four Patients. *Skeletal Radiol* 1993;22:317.

+ 2. Albrecht S, Crutchfield S, SeGall G. On Spinal Osteochondromas. *J Neurosurg* 1992;77:247.

+ 3. Alman BA, Greel DA, Wolfe HJ. Activating Mutations of Gs Protein in Monostotic Fibrous Lesions of Bone. *J Orthop Res* 1996;14:311.

+ 4. Altermatt S, Schwobel M, Pochon JP. Operative Treatment of Solitary Bone Cysts with Tricalcium Phosphate Ceramic. A 1 to 7 Year Follow-up. *Eur J Pediatr Surg* 1992;2:180.

+ 5. Arata MA, Peterson HA, Dahlin DC. Pathological Fractures through Non-ossifying Fibromas. Review of the Mayo Clinic Experience. *J Bone Joint Surg Am* 1981;63:980.

+ 6. Arms D, Strecker W, Manske P, Schoenecker P. Management of Forearm Deformity in Multiple Hereditary Osteochondromatosis. *J Pediatr Orthop* 1997;17:450.

+ 7. Assoun J, Richardi G, Railhac J, et al. Osteoid Osteoma: MR Imaging versus CT. *Radiology* 1994;191:217.

+ 8. Barei, D, Moreau, G, Scarborough, M. Percutaneous Radiofrequency Thermal Ablation of Osteoid Osteoma. *Oper Tech Orthop* 1999;72.

+ 9. Bauer H, Brosjo O, Kreicsbergs A, Lindholm J. Low Risk of Recurrence of Enchondroma and Low-grade Chondrosarcoma in Extremities: 80 Patients Followed for 2–25 Years. *Acta Orthop Scand* 1995;66:283.

+ 10. Bernstrand C, Bjork O, Ahstrom L, Henter JI. Intralesional Steroids in Langerhans Cell Histiocytosis of Bone. *Acta Paediatr* 1996;85:502.

+ 11. Bertoni F, et al. Benign Fibrous Histiocytoma of Bone. *J Bone Joint Surg Am* 1986;68:1225.

+ 12. Bertoni F, Unni KK, McLeod RA, Sim FH. Xanthoma of Bone. *Am J Clin Pathol* 1988;90:377.

+ 13. Bickels J, Rubert C, Meller I, Malawer M. Cryosurgery in the Treatment of Bone Tumors. *Oper Tech Orthop* 1999;79.

+ 14. Biesecker J, Marcove R, Huvos A, Mike V. Aneurysmal Bone Cyst: A Clinicopathologic Study of 66 Cases. *Cancer* 1970;26:615.

+ 15. Bini S, Gill K, Johnston J. Giant Cell Tumor of Bone: Curettage and Cement Reconstruction. *Clin Orthop* 1995;321:245.

+ 16. Blackley H, Wunder J, Davis A, et al. Treatment of Giant-cell Tumors of Long Bones with Curettage and Bone-grafting. *J Bone Joint Surg Am* 1999;81:811.

+ 17. Blau RA, Zwick DL, Westphal RA. Multiple Non-ossifying Fibromas. A Case Report. *J Bone Joint Surg Am* 1988;70:299.

+ 18. Boriani S, Capanna R, Donati D, et al. Osteoblastoma of the Spine. *Clin Orthop* 1992;278:37.

# 19. Bovill DF, Skinner HB. Unicameral Bone Cysts. A Comparison of Treatment Options. *Orthop Rev* 1989;18:420.

+ 20. Burr BA, Resnick D, Syklawer R, Haghighi P. Fluid–fluid Levels in a Unicameral Bone Cyst: CT and MR Findings. *J Comput Assist Tomogr* 1993;17:134.

# 21. Caffey J. In: Levine S, ed. *Advances in Pediatrics.* Chicago: Year-Book 1955:7;13.

+ 22. Campanacci M, Baldini N, Boriani S, Sundanese A. Giant Cell Tumor of Bone. *J Bone Joint Surg Am* 1987;69:106.

+ 23. Campanacci M, Capanna R, Picci P. Unicameral and Aneurysmal Bone Cysts. *Clin Orthop* 986;204:25.

+ 24. Campbell C, Harkess J. Fibrous Metaphyseal Defect of Bone. *Surg Gynecol Obstet* 1957:104;329.

+ 25. Candeliere GA, Glorieux FH, Prud'homme J, St-Arnaud R. Increased Expression of the C-*fos* Proto-oncogene in Bone from Patients with Fibrous Dysplasia [Comments]. *N Engl J Med* 1995;332:1546.

# 26. Capanna R, Campanacci DA, Manfrini M. Unicameral and Aneurysmal Bone Cysts. *Orthop Clin North Am* 1996;27:605.

+ 27. Capanna R, Manfrini M, Tigani D, Giunti A. Tricalcium Phosphate and Hydroxyapatite Ceramics in the Surgery of Bone Tumors: Preliminary Results. *Chir Organi Mov* 1991;76:245.

+ 28. Chapurlot R, Delmas P, Liens D, Mevnier P. Long-term Effects of Intravenous Pamidronate in FD of Bone. *J Bone Miner Res* 1997;12:1746.

+ 29. Cheng J, Johnston J. Giant Cell Tumor of Bone: Prognosis and Treatment of Pulmonary Metastases. *Clin Orthop* 1997;338:205.

+ 30. Chigira M, et al. A Case of Multiple Simple Bone Cysts. With Special Reference to Their Etiology and Treatment. *Arch Orthop Trauma Surg* 1987;106:390.

+ 31. Chigira M, Maehara S, Arita S, Udagawa E. The Aetiology and Treatment of Simple Bone Cysts. *J Bone Joint Surg Br* 1983;65:633.

+ 32. Chigira M, Shimizu T, Arita S, et al. Radiological Evidence of Healing of a Simple Bone Cyst after Hole Drilling. *Arch Orthop Trauma Surg* 1986;105:150.

+ 33. Cohen J. Simple Bone Cysts. Studies of Cyst Fluid in Six Cases with a Theory of Pathogenesis. *J Bone Joint Surg Am* 1960;42:609.

+ 34. Cohen J. Etiology of Simple Bone Cyst. *J Bone Joint Surg Am* 1970;52:1493.

+ 35. Colyer R, Sally P, Buckwalter K, Van Bastelaer F. MRI Assessment of Chondroid Matrix Tumors. In: Limb Salvage: Current Trends. Proceedings of the 7th International Symposium. 1993:89.

+ 36. Conter V, et al. Bone Marrow Transplantation for Refractory Langerhans' Cell Histiocytosis. *Haematologica* 1996;81:468.

+ 37. Crone-Munzebrock W, Brassow F. A Comparison of Radiographic and Bone Scan Findings in Histiocytosis X. *Skeletal Radiol* 1983;9:170.

+ 38. Cunningham J. Metaphyseal Fibrous Defects. *J Bone Joint Surg Am* 1956;38:797.

+ 39. Czitrom AA, Gross AE, Langer F, Sim FH. Bone Banks and Allografts in Community Practice. *Instr Course Lect* 1988;37:13.

+ 40. Danon M, Robboy SJ, Kim S, et al. Cushing Syndrome, Sexual Precocity, and Polyostotic Fibrous Dysplasia (Albright Syndrome) in Infancy. *J Pediatr* 1975;87:917.

+ 41. Davids J, Glancy G, Eilbert R. Fracture through the Stalk of Pedunculated Osteochondromas: A Report of Three Cases. *Clin Orthop* 1991;271:258.

+ 42. DeCristofano R, Biagini R, Boriani S. Selective Arterial Embolization in the Treatment of Aneurysmal Bone Cyst and Angioma of Bone. *Skeletal Radiol* 1992;21:523.

+ 43. DeRosa G, Granziano G, Scott J. Arterial Embolization of Aneurysmal Bone Cyst of the Lumbar Spine: A Report of Two Cases. *J Bone Joint Surg Am* 1990;72:777.

# 44. Dorfman H, Czerniak B. *Bone Tumors.* St Louis: Mosby, 1998.

+ 45. Easley ME, Kneisl JS. Pathologic Fractures through Nonossifying Fibromas: Is Prophylactic Treatment Warranted? *J Pediatr Orthop* 1997;17:808.

* 46. Enneking WF. A System of Staging Musculoskeletal Neoplasms. *Clin Orthop* 1986;153:9.

* 47. Enneking WF, Spanier SS, Goodman MA. A System for the Surgical Staging of Musculoskeletal Sarcoma. *Clin Orthop* 1980;204:106.

+ 48. Ennis JT, Whitehouse G, Ross FG, Middlemiss JH. The Radiology of the Bone Changes in Histiocytosis X. *Clin Radiol* 1973;24:212.

+ 49. Fahey JJ, O'Brien ET. Subtotal Resection and Grafting in Selected Cases of Solitary Unicameral Bone Cyst. *J Bone Joint Surg Am* 1973;55:59.

+ 50. Farber JM, Stanton RP. Treatment Options in Unicameral Bone Cysts. *Orthopedics* 1990;13:25.

# 51. Frassica F, Waltrip R, Sponseller P, et al. Clinicopathologic Features of Osteoid Osteoma and Osteoblastoma in Children and Adolescents. *Orthop Clin North Am* 1996;27:559.

+ 52. Garrison RC, Unni KK, McLeod RA, et al. Chondrosarcoma Arising in Osteochondroma. *Cancer* 1982;49:1890.

+ 53. Gartland JJ, Cole FL. Modern Concepts in the Treatment of Unicameral Bone Cysts of the Proximmal Humerus. *Orthop Clin North Am* 1975;6:487.

+ 54. Geirnaerdt M, Hermans J, Bloem J, et al. Usefulness of Radiography in Differentiating Enchondroma from Central Grade I Chondrosarcoma. *AJR Am J Roentgenol* 1997;169:1097.

+ 55. Gitelis S, Mallin B, Piasecki P, Turner F. Intralesional Excision Compared with *en Bloc* Resection for Giant-cell Tumors of Bone. *J Bone Joint Surg Am* 1993;75:1648.

# 56. Gitelis S, Wilkens R, Conrad E. Benign Bone Tumors. *Instr Course Lect* 1996;45:425.

# 57. Giudici M, Moser R, Kransdorf M. Cartilaginous Bone Tumors. *Radiol Clin North Am* 1993;31:237.

+ 58. Glancy G, Brugioni D, Eilbert R, Chang F. Autograft versus Allograft for Benign Lesions in Children. *Clin Orthop* 1991;262:28.

+ 59. Glaser DL, Dormans JP, Stanton RP, Davidson RS. Surgical Management of Calcaneal Unicameral Bone Cysts. *Clin Orthop* 1999;360:231.

+ 60. Goldwein J. Effects of Radiation Therapy on Skeletal Growth in Childhood. *Clin Orthop* 1991;262:101.

# 61. Grabias SL, Campbell CJ. Fibrous Dysplasia. *Orthop Clin North Am* 1977;8:771.

+ 62. Green JA, Bellemore MC, Marsden FW. Embolization in the Treatment of Aneurysmal Bone Cysts. *J Pediatr Orthop* 1997;17:440.

+ 63. Greis PE, Hankin FM. Eosinophilic Granuloma. The Management of Solitary Lesions of Bone. *Clin Orthop* 1990;257:204.

+ 64. Harris W, Dudley H, Barry R. The Natural History of Fibrous Dysplasia. An Orthopaedic, Pathological, and Roentgenographic Study. *J Bone Joint Surg Am* 1962;44:207.

# 65. Healey J, Ghelman B. Osteoid Osteoma and Osteoblastoma: Current Concepts and Recent Advances. *Clin Orthop* 1986;204:76.

+ 66. Healey J, Lane J. Chondrosarcoma. *Clin Orthop* 1986;204:119.

+ 67. Hecht AC, Gebhardt MC. Diagnosis and Treatment of Unicameral and Aneurysmal Bone Cysts in Children. *Curr Opin Pediatr* 1998;10:87.

+ 68. Hipp JA, Springfield DS, Hayes WC. Predicting Pathologic Fracture Risk in the Management of Metastatic Bone Defects. *Clin Orthop* 1995;312:120.

# 69. Huvos A.*Bone Tumors: Diagnosis, Treatment, and Prognosis*, 2nd ed. Philadelphia: Saunders, 1991.

+ 70. Huvos AG, Higinbotham NL, Miller TR. Bone Sarcomas Arising in Fibrous Dysplasia. *J Bone Joint Surg Am* 1972;54:1047.

+ 71. Huvos A, Marcove R. Chondroblastoma of Bone. A Critical Review. *Clin Orthop* 1973;95:300.

+ 72. Inoue O, Ibaraki K, Shimabukuro H, Shingaki Y. Packing with High-porosity Hydroxyapatite Cubes Alone for the Treatment of Simple Bone Cyst. *Clin Orthop* 1993;293:287.

+ 73. Ippolito E, Farsetti P, Tudisco C. Vertebra Plana. Long-term Follow-up in Five Patients. *J Bone Joint Surg Am* 1984;66:1364.

+ 74. Ishida T, Machinami R, Kojima T, Kikuchi F. Malignant Fibrous Histiocytoma and Osteosarcoma in Association with Fibrous Dysplasia of Bone. Report of Three Cases. *Pathol Res Pract* 1992;188:757.

# 75. Jackson R. Recurrent Osteoblastoma: A Review. *Clin Orthop* 1978;131:229.

+ 76. Jackson R, Reckling F, Mants F. Osteoid Osteoma and Osteoblastoma: Similar Histologic Lesions with Different Natural Histories. *Clin Orthop* 1977;128:303.

# 77. Jaffe H.*Tumors and Tumorous Conditions of the Bones and Joints.* Philadelphia: Lea and Febiger, 1968.

+ 78. Kay R, Eckardt J, Seeger L, et al. Pulmonary Metastasis of Benign Giant Cell Tumor of Bone. Six Histologically Confirmed Cases, Including One of Spontaneous Regression. *Clin Orthop* 1994;302:219.

+ 79. Keim H, Renia E. Osteoid Osteoma as a Cause of Scoliosis. *J Bone Joint Surg Am* 1975;57:159.

+ 80. Kneisl, J, Simon, M. Medical Management Compared with Operative Treatment for Osteoid Osteoma. *J Bone Joint Surg Am* 1992;74:179.

+ 81. Komiya S, et al. Simple Bone Cyst. Treatment by Trepanation and Studies on Bone Resorptive Factors in Cyst Fluid with a Theory of Its Pathogenesis. *Clin Orthop* 1993;287:204.

+ 82. Komiya S, Tsuzuki K, Mangham DC, et al. Oxygen Scavengers in Simple Bone Cysts. *Clin Orthop* 1994;308:199.

+ 83. Kransdorf MJ, Sweet DE. Aneurysmal Bone Cyst: Concept, Controversy, Clinical Presentation, and Imaging. *AJR Am J Roentgenol* 1995;164:573.

+ 84. Kroon H, Schurmans J. Osteoblastoma: Clinical and Radiologic Findings in 98 New Cases. *Radiology* 1990;175:783.

+ 85. Lee D, Malawer M. Staging and Treatment of Primary and Persistent (Recurrent) Osteoid Osteoma. Evaluation of Intraoperative Nuclear Scanning, Tetracycline Fluorescence, and Tomography. *Clin Orthop* 1992;204:229.

+ 86. Lee JH, Reinus WR, Wilson AJ. Quantitative Analysis of the Plain Radiographic Appearance of Unicameral Bone Cysts. *Invest Radiol* 1999;34:28.

+ 87. Lee PA, Van Dop C, Migeon CJ. McCune-Albright Syndrome. Long-term Follow-Up. *JAMA* 1986;256:2980.

+ 88. Lewis M, Kenan S, Yabut S, et al. Periosteal Chondroma: A Report of Ten Cases and Review of the Literature. *Clin Orthop* 1990;256:185.

+ 89. Maas EJ, Craig JG, Swisher PK, et al. Fluid–fluid Levels in a Simple Bone Cyst on Magnetic Resonance Imaging. *Australas Radiol* 1998;42:267.

+ 90. Mackenzie WG, Morton KS. Eosinophilic Granuloma of Bone. *Can J Surg* 1988;31:264.

+ 91. MacMahon HE. Albright's Syndrome—Thirty Years Later. (Polyostotic Fibrous Dysplasia). *Pathol Annu* 1971;6:81.

+ 92. Makley JT, Carter JR. Eosinophilic Granuloma of Bone. *Clin Orthop* 1986;204:37.

+ 93. Malawer M, Bickels J, Meller I, et al. Cryosurgery in the Treatment of Giant Cell Tumor: A Long Term Followup Study. *Clin Orthop* 1999;359:176.

+ 94. Malghem J, Vande Berg B, Noel H, Maldague B. Benign Osteochondromas and Exostotic Chondrosarcomas: Evaluation of Cartilage Cap Thickness by Ultrasound. *Skeletal Radiol* 1992;21:33.

+ 95. Marcove R, Sheth D, Takemoto S, Healey J. The Treatment of Aneurysmal Bone Cyst. *Clin Orthop* 1995;311:157.

+ 96. Marcove R, Weis L, Vagaiwalla M, et al. Cryosurgery in the Treatment of Giant Cell Tumor of Bone: A Report of 52 Consecutive Cases. *Cancer* 1978;41:957.

# 97. Marks KE, Bauer TW. Fibrous Tumors of Bone. *Orthop Clin North Am* 1989;20:377.

+ 98. Marsh BW, Bonfiglio M, Brady LP, Enneking WF. Benign Osteoblastoma: A Range of Manifestations. *J Bone Joint Surg Am* 1975;57:1.

+ 99. Martinez V, Sissons H. Aneurysmal Bone Cyst: A Review of 123 Cases Including Primary Lesions and Those Secondary to Other Bone Pathology. *Cancer* 1988;61:2291.

+ 100. Mauras N, Blizzard RM. The McCune-Albright Syndrome. *Acta Endocrinol* 1986;279(suppl):207.

+ 101. McCullough CJ. Eosinophilic Granuloma of Bone. *Acta Orthop Scand* 1980;51:389.

+ 102. McGlynn FJ, Mickelson MR, El-Khoury GY. The Fallen Fragment Sign in Unicameral Bone Cyst. *Clin Orthop* 1981;156:157.

+ 103. McKay DW, Nason SS. Treatment of Unicameral Bone Cysts by Subtotal Resection without Grafts. *J Bone Joint Surg Am* 1977;59:515.

+ 104. Michaeli DA, Inoue K, Hayes WC, Hipp JA. Density Predicts the Activity-dependent Failure Load of Proximal Femora with Defects. *Skeletal Radiol* 1999;28:90.

+ 105. Mickelson MR, Bonfiglio M. Eosinophilic Granuloma and Its Variations. *Orthop Clin North Am* 1977;8:933.

+ 106. Mirra J. Intramedullary Cartilage- and Chondroid-produing Tumors. In: Mirra J, ed. *Bone Tumors: Clinical, Radiologic, and Pathologic Crorrelations.* Philadelphia: Lea and Febiger, 1989;439.

+ 107. Mjoberg B, Petterson H, Rosenquist R, Rydholm A. Bone Cement, Thermal Injury and Radiolucent Zone. *Acta Orthop Scand* 1984;55:597.

+ 108. Morgan G. Myeloablative Therapy and Bone Marrow Transplantation for Langerhans' Cell Histiocytosis. *Br J Cancer* 1994;23(suppl):S52.

+ 109. Nasca RJ. Unicameral Bone Cyst of the Tibia Complicated by Genu Valgum. *South Med J* 1988;81:1301.

# 110. Neer CS, Francis KC, Johnston AD, Kiernan HA Jr. Current Concepts on the Treatment of Solitary Unicameral Bone Cyst. *Clin Orthop* 1973;97:40.

+ 111. Neer C, Francis K, Marcove R, et al. Treatment of Unicameral Bone Cyst. A Follow-up Study of One Hundred Seventy-five Cases. *J Bone Joint Surg Am* 1966;48:731.

+ 112. Nemoto O, Moser R, Van Dam B, et al. Osteoblastoma of the Spine: A Review of 75 Cases. *Spine* 1990;15:1272.

+ 113. Nojima T, Yamashiro K, Fujita M, et al. A Case of Osteosarcoma Arising in a Solitary Osteochondroma. *Acta Orthop Scand* 1991;62:290.

+ 114. O'Donnell R, Springfield D, Motwani H, et al. Recurrence of Giant-cell Tumors of the Long Bone after Curettage and Packing with Cement. *J Bone Joint Surg Am* 1994;76:1827.

+ 115. Ozaki T, Hillmann A, Lindner N, Winkelmann W. Cementation of Primary Aneurysmal Bone Cysts. *Clin Orthop* 1997;337:240.

+ 116. Ozaki T, Sugihara M, Nakatsuka Y, et al. Polyostotic Fibrous Dysplasia. A Long-term Follow Up of 8 Patients. *Int Orthop* 1996;20:227.

+ 117. Paige M, Michael A, Brodin A. Case Report 647: Benign Osteoblastoma Causing Spinal Cord Compression and Spastic Paresis. *Skeletal Radiol* 1991;20:54.

+ 118. Papagelopoulos P, Currier B, Shaughnessy W, et al. Aneurysmal Bone Cyst of the Spine: Management and Outcome. *Spine* 1998;23:621.

+ 119. Parlier-Cuau C, Champsaur P, Nizard R, et al. Percutaneous Removal of Osteoid Osteoma. *Radiol Clin North Am* 1988;36:559.

+ 120. Perry CR. Bone Repair Techniques, Bone Graft, and Bone Graft Substitutes. *Clin Orthop* 1999;360:71.

+ 121. Peterson H. Multiple Hereditary Osteochondromata. *Clin Orthop* 1989;239:222.

+ 122. Peterson HA, Fitzgerald EM. Fractures through Nonossifying Fibromata in Children. *Minn Med* 1980;63:139.

+ 123. Pettine K, Klassen R. Osteoid-osteoma and Osteoblastoma of the Spine. *J Bone Joint Surg Am* 1986;68:354.

+ 124. Raney RB Jr. Chemotherapy for Children with Aggressive Fibromatosis and Langerhans' Cell Histiocytosis. *Clin Orthop* 1991;262:58.

+ 125. Renard A, Veth R, Pruszczynski M, et al. Giant Cell Tumor of Bone: Oncologic and Functional Results. *J Surg Oncology* 1994;57:243.

+ 126. Reynolds J. The “Fallen Fragment Sign” in the Diagnosis of Unicameral Bone Cysts. *Radiology* 1969;92:949.

+ 127. Riminucci M, et al. Fibrous Dysplasia of Bone in the McCune-Albright Syndrome: Abnormalities in Bone Formation [Comments]. *Am J Pathol* 1997;151:1587.

+ 128. Ritschl P, Karnel F. Pathogenesis of Fibrous Cortical Defect and Non-ossifying Bone Fibroma. *Z Orthop* 1986;124:682.

+ 129. Ritschl P, Karnel F, Hajek P. Fibrous Metaphyseal Defects—Determination of Their Origin and Natural History Using a Radiomorphological Study. *Skeletal Radiol* 1988;17:8.

+ 130. Rock M. Adjuvant Management of Benign Tumors, Basic Concepts of Phenol and Cement Use. *Chir Organi Mov* 1990;75(suppl 1):195.

+ 131. Rosenthal D, Hornicek F, Wolfe M, et al. Percutaneous Radiofrequency Coagulation of Osteoid Osteoma Compared with Operative Treatment. *J Bone Joint Surg Am* 1998;80:815.

+ 132. Ruggieri P, Sim FH, Bond JR, Unni KK. Malignancies in Fibrous Dysplasia. *Cancer* 1994;73:1411.

+ 133. Sanjay B, Frassica F, Frassica D, et al. Treatment of Giant-cell Tumor of the Pelvis. *J Bone Joint Surg Am* 1993;75:1466.

+ 134. Sankerin N, Molt M, Roylance J. An Unusual Intraosseous Lesion with Fibroblastic, Osteoclastic, and Fibromyxoid Elements: “Solid” Varient of Aneurysmal Bone Cyst. *Cancer* 1983;51:2278.

+ 135. Scaglietti O, Marchetti PG, Bartolozzi P. The Effects of Methylprednisolone Acetate in the Treatment of Bone Cysts. Results of Three Years Follow-Up. *J Bone Joint Surg Br* 1979;61:200.

+ 136. Scaglietti O, Marchetti PG, Bartolozzi P. Final Results Obtained in the Treatment of Bone Cysts with Methylprednisolone Acetate (Depo-medrol) and a Discussion of Results Achieved in Other Bone Lesions. *Clin Orthop* 1982;165:33.

# 137. Scarborough M, Moreau G. Benign Cartilage Tumors. *Orthop Clin North Am* 1996;27:583.

# 138. Schajowicz F. In: Sundaram M, Gitelis S, McDonald C, eds. *Tumors and Tumor-like Lesions of Bone.* Berlin: Springer-Verlag, 1994.

+ 139. Schaub T, et al. Bone Scanning in the Detection and Follow-up of Skeletal Lesions in Histiocytosis X. *Ann Radiol* 1983;26:407.

+ 140. Schreuder HWB, Veth RPH, Pruszczynski M, et al. Aneurysmal Bone Cysts Treated by Curettage, Cryotherapy and Bone Grafting. *J Bone Joint Surg Br* 1997;79:20.

+ 141. Scully SP, Temple HT, O'Keefe RJ, Gebhardt MC. Case Report 830: Aneurysmal Bone Cyst. *Skeletal Radiol* 1994;23:157.

+ 142. Sessa S, Sommelet D, Lascombes P, Prevot J. Treatment of Langerhans-cell Histiocytosis in Children. Experience at the Children's Hospital of Nancy [Comments]. *J Bone Joint Surg Am* 1994;76:1513.

+ 143. Shapiro S, Javid T, Putty T. Osteochondroma with Cervical Cord Compression in Hereditary Multiple Exostoses. *Spine* 1990;15:600.

+ 144. Shindell R, Connolly JF, Lippiello L. Prostaglandin Levels in a Unicameral Bone Cyst Treated by Corticosteroid Injection. *J Pediatr Orthop* 1987;7:210.

+ 145. Shinozaki T, Arita S, Watanabe H, Chigira M. Simple Bone Cysts Treated by Multiple Drill-Holes. 23 Cysts Followed 2–10 Years [Comments]. *Acta Orthop Scand* 1996;67:288.

+ 146. Sim F, Cupps R, Dahlin D, Ivins J. Postradiation Sarcoma of Bone. *J Bone Joint Surg Am* 1972;54:1479.

+ 147. Smith RW, Smith CF. Solitary Unicameral Bone Cyst of the Calcaneus. A Review of Twenty Cases. *J Bone Joint Surg Am* 1974;56:49.

+ 148. Spence KF Jr, Bright RW, Fitzgerald SP, Sell KW. Solitary Unicameral Bone Cyst: Treatment with Freeze-dried Crushed Cortical-Bone Allograft. A Review of One Hundred and Forty-four Cases. *J Bone Joint Surg Am* 1976;58:636.

+ 149. Spence KF, Sell KW, Brown RH. Solitary Bone Cyst: Treatment with Freeze-dried Cancellous Bone Allograft. A Study of One Hundred Seventy-seven Cases. *J Bone Joint Surg Am* 1969;51:87.

+ 150. Springfield D, Capanna R, Gherlinzoni F, et al. Chondroblastoma: A Review of Seventy Cases. *J Bone Joint Surg Am* 1985;67:748.

+ 151. Springfield D, Gebhardt M, McGuire M. Chondrosarcoma: A Review. *J Bone Joint Surg Am* 1996;141.

+ 152. Stricker S. Extraarticular Endoscopic Excision of Femoral Head Chondroblastoma. *J Pediatr Orthop* 1995;15:578.

+ 153. Struhl S, Edelson C, Pritzker H, et al. Solitary (Unicameral) Bone Cyst. The Fallen Fragment Sign Revisited. *Skeletal Radiol* 1989;18:261.

+ 154. Stull MA, Kransdorf MJ, Devaney KO. Langerhans Cell Histiocytosis of Bone. *Radiographics* 1992;12:801.

+ 155. Sty J, Simons G. Intraoperative 99m Technetium Bone Imaging in the Treatment of Benign Osteoblastic Tumors. *Clin Orthop* 1982;165:223.

+ 156. Sung H, Kuo D, Shu W, et al. Giant Cell Tumor of Bone: Analysis of 208 Cases in Chinese Patients. *J Bone Joint Surg Am* 1982;64:755.

+ 157. Tonai M, Campbell CJ, Ahn GH, et al. Osteoblastoma: Classification and Report of 16 Patients. *Clin Orthop* 1982;167:222.

+ 158. Tsuneyoshi M, Dorfman H. Epiphyseal Osteosarcoma: Distinguishing Features from Clear Cell Chondrosarcoma, Chondroblastoma, and Epiphyseal Enchondroma. *Hum Pathol* 1987;18:644.

# 159. Unni K. *Dahlin's Bone Tumors: General Aspects and Data on 11,087 Cases.* Philadelphia: Lippincott-Raven, 1996.

+ 160. Van Horn J, Vincent J, Wiersma-van Tilburg A, et al. Late Pulmonary Metastases from Chondroblastoma of the Distal Femur: A Case Report. *Acta Orthop Scand* 1990;61:466.

+ 161. Van Nieuwenhuyse JP, et al. Radiographic Skeletal Survey and Radionuclide Bone Scan in Langerhans Cell Histiocytosis of Bone. *Pediatr Radiol* 1996;26:734.

+ 162. Velez-Yanguas MC, Warrier RP. Langerhans' Cell Histiocytosis. *Orthop Clin North Am* 1996;27:615.

+ 163. Voto SJ, Cook AJ, et al. Treatment of Osteoid Osteoma by Computed Tomography Guided Excision in the Pediatric Patient. *J Pediatr Orthop* 1990;10:510.

+ 164. Ward W, Eckardt J, Shayestehfar S, et al. Osteoid Osteoma Diagnosis and Management with Low Morbidity. *Clin Orthop* 1993;291:229.

# 165. Weinstein J. Surgical Approach to Spine Tumors. *Orthopaedics* 1989;12:897.

# 166. Weinstein J, Boriani S, Phillips F, Wetzel T. Management of Benign Tumors of the Spine. In: Simon M, Springfield D, eds. *Surgery for Bone and Soft-tissue Tumors.* Philadelphia: Lippincott-Raven, 1998:207.

+ 167. Weinstein LS, et al. Activating Mutations of the Stimulatory G Protein in the McCune-Albright Syndrome [Comments]. *N Engl J Med* 1991;325:1688.

+ 168. Westra SJ, van Woerden H, Postma A, et al. Radionuclide Bone Scintigraphy in Patients with Histiocytosis X. *Eur J Nucl Med* 1983;8:303.

+ 169. Wilson ES. Positive 99m-Technetium Polyphosphate Bone Scan in Eosinophilic Granuloma. *J Med Soc N J* 1977;74:247.

+ 170. Wirganowicz P, Watts H. Surgical Risk for Elective Excision of Benign Exostoses. *J Pediatr Orthop* 1997;17:455.

+ 171. Womer RB, Raney RB Jr, D'Angio GJ. Healing Rates of Treated and Untreated Bone Lesions in Histiocytosis X. *Pediatrics* 1985;76:286.

+ 172. Wuisman P, Jutte P, Ozaki T. Secondary Chondrosarcoma in Osteochondromas. *Acta Orthop Scand* 1997;68:396.

+ 173. Xu D, et al. Spontaneous Malignant Transformation of Fibrous Dysplasia. *Chin Med J* 1996;109:941.

+ 174. Yabut SM Jr, Kenan S, Sissons HA, Lewis MM. Malignant Transformation of Fibrous Dysplasia. A Case Report and Review of the Literature. *Clin Orthop* 1988;228:281.

+ 175. Yasko AW, Fanning CV, Ayala AG, et al. Percutaneous Techniques for the Diagnosis and Treatment of Localized Langerhans-Cell Histiocytosis (Eosinophilic Granuloma of Bone). *J Bone Joint Surg Am* 1998;80:219.

+ 176. Yip K, Leung P, Kumta S. Giant Cell Tumor of Bone. *Clin Orthop* 1996;323:60.

+ 177. Young JW, Levine AM, Dorfman HD. Case Report 293. Diagnosis: Nonossifying Fibroma (NOF) of the Upper Tibial Diametaphysis, with Considerable Increase in Size over a Three-Year Period. *Skeletal Radiol* 1984;12:294.

# CHAPTER 128

# MALIGNANT BONE TUMORS

*Kristy L. Weber and Franklin H. Sim*

**K. L. Weber:** Assistant Professor of Orthopaedic Oncology, University of Texas, M.D. Anderson Cancer Center, Houston, Texas, 77030.
**F. H. Sim:** Professor of Orthopaedic Surgery, Mayo Clinic, Rochester, MN, 55905.

Osteosarcoma
- Clinical Features
- Pathologic Features
- Radiographic Features
- Treatment
- Limb Salvage
- Results of Treatment

Chondrosarcoma
- Clinical Features
- Pathologic Features
- Radiographic Features
- Treatment
- Results of Treatment

Ewing's Sarcoma
- Clinical Features
- Pathologic Features
- Radiographic Features
- Treatment
- Results of Treatment

Fibrosarcoma
- Clinical Features
- Pathologic Features
- Radiographic Features
- Treatment
- Results of Treatment

Malignant Fibrous Histiocytoma
- Clinical Features
- Pathologic Features
- Radiographic Features
- Treatment

Myeloma
- Clinical Features
- Pathologic Features
- Radiographic Features
- Treatment
- Results of Treatment

Malignant Lymphoma of Bone
- Clinical Features
- Pathologic Features
- Radiographic Features
- Treatment

Chordoma
- Clinical Features
- Pathologic Features
- Radiographic Features
- Treatment
- Results of Treatment

Adamantinoma
- Clinical Features
- Pathologic Features
- Radiographic Features
- Treatment
- Results of Treatment

Chapter References

## OSTEOSARCOMA

### CLINICAL FEATURES

Osteosarcoma is a high-grade primary bone neoplasm with an aggressive pattern of local growth and a marked propensity to metastasize (39,129,155). It is the second most common primary malignant bone tumor after myeloma, and accounts for 20% of all bone sarcomas. The majority of patients are in their second decade, and men and women are affected equally. Although this tumor can occur in any bone, the appendicular skeleton is most frequently involved; approximately 50% of lesions occur about the knee (138). In long bones, it tends to occur in the metaphysis. Multifocal involvement is extremely rare. Most patients present with a short history of pain and swelling in the involved limb. The pain may be intermittent at first, becoming constant later, and often accentuated at night. Because these patients are generally young and active, pain around the knee is often mistaken as a sports injury and is not recognized until the tumor has grown. Patients may present with a pathologic fracture. The majority of hematogenous metastases occur in the lungs and develop in approximately half of the patients.

Osteosarcoma has a wide range of appearances, and it is important to classify them in order to predict prognosis and design treatment (27) (Table 128.1). The classic lesion is a high-grade intramedullary osteosarcoma, which occurs in 85% of cases. Approximately 1% of cases are low-grade, well-differentiated central osteosarcomas, which have a better prognosis (9). A variant known as small-cell osteosarcoma may be difficult to distinguish histologically from Ewing's sarcoma (140). There are three types of surface osteosarcomas, including high-grade, periosteal, and parosteal lesions (10,18,108,124,130). Parosteal osteosarcoma accounts for 3% of tumors, and it has a tendency to arise on the posterior aspect of the distal femur. Its prognosis is distinctly better than the conventional lesion. Rarely, a parosteal osteosarcoma can dedifferentiate into a higher grade tumor if it is neglected or incompletely excised. The telangiectatic subtype is a high-grade, intramedullary lesion with a separate histologic appearance that must be differentiated from benign lesions such as aneurysmal bone cyst (94,120). It occurs in 3% of cases and has a prognosis similar to that of conventional osteosarcoma.

A. Conventional high-grade osteosarcoma
B. Low-grade central osteosarcoma
C. Surface osteosarcoma
   1. High-grade surface osteosarcoma
   2. Periosteal osteosarcoma
   3. Parosteal osteosarcoma
D. Telangiectatic osteosarcoma
E. Small-cell osteosarcoma
F. Multicentric osteosarcoma
G. Secondary osteosarcoma
   1. Postirradiaton osteosarcoma
   2. Osteosarcoma arising in Paget's disease
   3. Dedifferentiated chondrosarcoma
H. Soft-tissue osteosarcoma

***Table 128.1. Classification of Osteosarcoma***

Most lesions appear to arise *de novo,* but secondary lesions may occur after irradiation, in Paget's disease, or as the highly sarcomatous portion of a dedifferentiated chondrosarcoma (44,45,157). Transformation should be suspected in patients with known Paget's disease who develop a sudden increase in pain. Rarely, osteosarcoma develops at the site of a pre-existing benign lesion such as fibrous dysplasia or a bone infarct. Primary osteosarcoma can also occur in the soft tissues (77).

**PATHOLOGIC FEATURES**

Osteosarcoma is defined by the presence of malignant cells producing osteoid (Fig. 128.1; see also Color Fig. 128.1). Grossly, varying amounts of soft friable tissue, firm fibrous tissue, cartilaginous tissue, and foci of ossification may be present in any given tumor. The cortex is frequently destroyed by the tumor, with extension into the surrounding soft tissues. Telangiectatic osteosarcoma is a large blood-filled tumor that may grossly appear similar to an aneurysmal bone cyst (ABC). Depending on the predominant pattern, three histologic variants of conventional osteosarcoma exist: osteoblastic, chondroblastic, and fibroblastic. However, all of these histologic subtypes of high-grade osteosarcoma have a similar prognosis. The small cell variant can be mistaken for Ewing's sarcoma under light microscopy, but current immunohistochemical and cytogenetic studies can help differentiate the two lesions. Periosteal osteosarcoma has a chondroblastic histologic pattern, whereas the parosteal variant tends to be heavily ossified and have a well-differentiated fibroblastic appearance. Telangiectatic osteosarcoma has large blood-filled spaces, but a careful search reveals the characteristic malignant cells producing osteoid that differentiates it from an ABC.

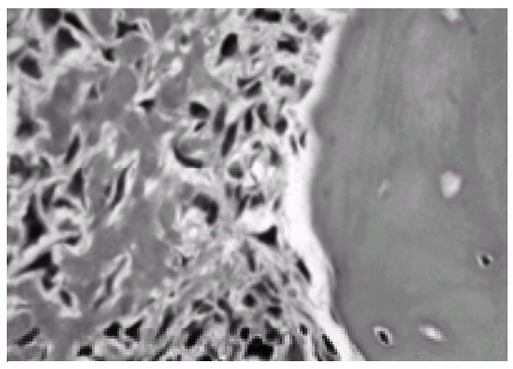

***Figure 128.1.*** (See Color Fig. 128.1.) Osteoblastic osteosarcoma showing malignant spindle cells with lacelike osteoid. Trabeculum of normal bone is on the right.

Recent studies have concentrated on cytogenetic abnormalities and mutations associated with osteosarcoma (166). A subset of patients with osteosarcoma have mutations in the p53 and retinoblastoma tumor suppressor genes, although there is no consensus on whether having the mutation affects the prognosis (96).

**RADIOGRAPHIC FEATURES**

On plain radiographs, osteosarcoma is usually a mixed lytic and sclerotic lesion (Fig. 128.2). The tumor is aggressive with indistinct margins and evidence of cortical destruction. An extensive extraosseous mass is common. New bone formation occurs in a typical sunburst appearance of the periosteum. Some lesions may be purely lytic, particularly the telangiectatic subtype. Other lesions may be heavily ossified, such as the parosteal type, which must be differentiated from myositis ossificans. Magnetic resonance imaging (MRI) is the most useful modality for determining local soft-tissue boundaries and proximity to adjacent structures. An MRI is particularly helpful in determining the intraosseous extent of a lesion when planning surgery. The low intramedullary signal seen on T1-weighted images corresponds closely to the gross tumor extent (146). Radionuclide scans can be helpful in identifying skip lesions.

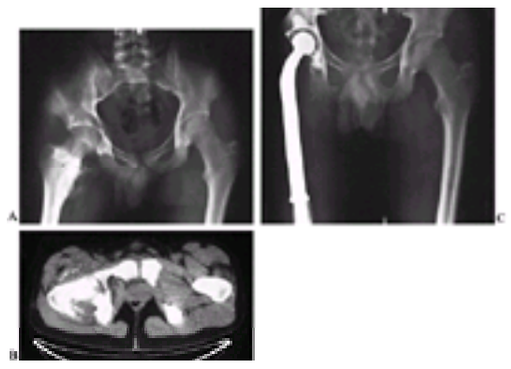

***Figure 128.2.*** **A:** AP radiograph of the pelvis in a patient with osteosarcoma demonstrating a bone-producing lesion in the right proximal femoral metaphysis. **B:** CT scan showing the extraosseous extension of the osteosarcoma. **C:** Neoadjuvant chemotherapy was administered, followed by wide resection and reconstruction using a proximal femoral replacement prosthesis. (From Sim FH, Bowman WE Jr, Wilkins RM, Chao EYS. Limb Salvage in Primary Malignant Bone Tumors. *Orthopedics* 1985;8:574, with permission.)

**TREATMENT**

Historically, the standard treatment for high-grade osteosarcoma was amputation. This treatment was associated with an overall 5-year survival of approximately 20%. The amputation was usually performed 8 to 10 cm proximal to the most proximal extent of the lesion, as determined by local staging studies. Despite the excellent local control achieved with amputation, pulmonary metastases developed in many patients (68,138). More effective treatment for systemic disease was needed to improve survival.

Enthusiasm for adjuvant chemotherapy was generated in the early 1970s with reports of 5-year survival increasing to between 45% and 60% (76). Other controlled trials showed no apparent survival benefits compared with surgery alone (34). However, the benefits of adjuvant chemotherapy soon became apparent, and there is now a strong consensus that it improves survival. Chemotherapy is now a component of all major osteosarcoma treatment protocols (3,82,91,98,163). The most effective agents have been methotrexate, cisplatin, doxorubicin, and ifosfamide. All standard protocols use preoperative (neoadjuvant) chemotherapy. This was historically done to allow time for the manufacture of a custom prosthesis, but preoperative chemotherapy is now used to allow more patients to undergo limb-salvage surgery and because it serves as an *in vivo* efficacy test of the chemotherapy itself. The extent of tumor necrosis at the time of definitive resection is used as a

measure of the tumor's response to chemotherapy, and this has been correlated with patient survival (3,116,164).

A recent multi-institutional trial for newly diagnosed, nonmetastatic osteosarcoma included high-dose methotrexate, doxorubicin, cisplatin, with or without ifosfamide and the immunostimulant MTP/PE (74). Future chemotherapy trials will incorporate the use of carboplatin. Of note, parosteal osteosarcoma is a well-differentiated low-grade tumor with a good prognosis after wide resection alone; therefore, chemotherapy is generally not used in its treatment protocol. However, periosteal osteosarcoma is intermediate in its biologic behavior, and in general, chemotherapy is included in the treatment protocol of this tumor.

Current research focuses on finding a way to predicting tumor response to chemotherapy before surgical resection. Then the operation can be tailored for the individual patient. Studies using various imaging modalities such as dynamic MRI and thallium scans have shown promising results (40,107). In addition, work continues on the molecular level to identify predictive biologic markers (158).

**LIMB SALVAGE**

The increased success of chemotherapy combined with improved techniques of oncologic reconstruction have allowed the majority of patients with osteosarcoma to undergo limb salvage, as outlined in Chapter 126. A surgical margin can often be achieved with a limb-sparing resection that is comparable to the margin achieved with an amputation. A large multi-institutional study compared amputation with limb salvage for lesions of the distal femur and found no significant difference in local recurrence rates, as long as a wide surgical margin was achieved (141). Other investigators confirmed a low incidence of local recurrence (approximately 5%) after limb salvage (3,33). The functional results achieved with limb salvage are generally superior to those after an amputation. Most medical centers active in the management of osteosarcoma report that as many as 85% of their patients are now being treated with limb-salvage surgery (3,33), compared with fewer than 20% before 1980.

A multidisciplinary approach is necessary for treating the patient with osteosarcoma. Careful preoperative staging, including a well-planned, adequate biopsy, forms the basis of the overall treatment plan. Despite significant advances in limb salvage surgery, there remains a role for amputation. Extremely large lesions with obvious neurovascular involvement, pathologic fracture with associated contamination of multiple tissue compartments, lesions of the distal portions of the extremities, local recurrences, and lesions in the very young are situations in which the best treatment may be amputation.

The techniques used for reconstruction after resection depend on the location of the tumor and the resulting limb function expected by the patient. The alternatives after resection of all or part of a major joint include custom prosthesis, osteochondral allograft, allograft prosthetic composite, or an arthrodesis (41,134,138). Limb salvage is important for lesions of the pelvis because of the severe functional impairment after hemipelvectomy, and because the surgical margin that is achieved often may be the same as that achieved by amputation. The use of current techniques depends on the location and extent of pelvic resection. With complete iliosacral joint resection, fusion of the remaining ilium to the sacrum can be achieved by hinging the pelvis on the symphysis pubis. After periacetabular resection, the proximal femur can be fused to the ilium or pubis. This construct is enhanced by the use of vascularized fibular grafts or intercalary allograft segments. The resultant large discrepancy in limb length can be corrected by bone transport of the femur in selected cases. A saddle prosthesis is an option if enough ilium remains to obtain a stable attachment (1). Some patients function quite well after periacetabular resection without reconstruction by developing a painless pseudarthrosis. Allograft reconstruction of the pelvis combined with prosthetic hip replacement has been successful, but this complicated technique is often fraught with postoperative complications such as allograft fracture, prosthetic loosening, or infection.

Prosthetic replacement has been particularly effective in restoring function of the hip joint after resection of a proximal femoral osteosarcoma (135) (Fig. 128.2). A custom prosthesis or an allograft prosthetic composite are good choices, with an allograft prosthetic composite used more often in younger patients to restore bone stock for future needs.

There are multiple options for reconstruction after resection of an osteosarcoma around the knee joint. Extra-articular resection and arthrodesis provide a durable limb and are an option in a very young patient (128). Techniques can be used to lengthen the limb after completion of chemotherapy to avoid a large limb-length discrepancy (112). Segmental arthrodesis can be accomplished by various methods. An effective method is use of hemicylindrical femoral turn-down or tibial turn-up grafts combined with ipsilateral fibular grafts and a long intramedullary rod with small antirotational plates at the host–graft junction for stabilization. At present, more surgeons use an intercalary allograft segment to span large defects and facilitate the arthrodesis. Use of an osteoarticular allograft has the advantage of being a biologic solution in a young patient; however, there is a high likelihood of complications in the first several years after surgery (89) (Fig. 128.3). At present, our preferred limb-salvage technique is a modular total knee replacement using a rotating hinge design. This provides immediate functional restoration and long-term durability, which has been improved with modern implants (19,23,33,86). Difficulty arises when the proximal tibia is replaced with a metal prosthesis because there is still no ideal method for reattaching the extensor mechanism to the prosthesis. (See Chapter 126 for some alternatives.) An allograft prosthetic composite is an effective procedure to provide restoration of bone stock and allow improved extensor function (62). The extensor mechanism is reattached to the allograft tendon and a rotational gastrocnemius flap is used to cover the allograft bone and tendon.

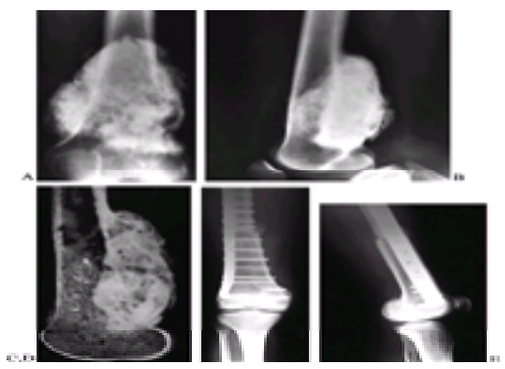

***Figure 128.3.*** **A, B:** AP and lateral views of the right distal femur in a 35-year-old woman demonstrating a heavily mineralized lesion consistent with a parosteal osteosarcoma emanating from the posterior cortex. This particular subtype of osteosarcoma is less aggressive than its conventional counterpart. **C:** Sagittal section through the gross specimen. The majority of the medullary cavity is free of tumor. **D, E:** AP and lateral radiographs of the distal femur after wide resection and reconstruction using an osteoarticular allograft.

Osteosarcoma of the upper extremity commonly involves the shoulder. Resection of the proximal humerus often requires sacrifice of the rotator cuff muscles, overlying deltoid, and axillary nerve (85,90). Reconstructive options include prosthetic replacements that use a modular design with a porous coating for potential bone ingrowth. Arthrodesis using dual fibular grafts, vascularized fibular grafts, or allografts has also been successful (89) (Fig. 128.4). If the axillary nerve and a portion of the deltoid can be maintained, an osteoarticular allograft or allograft prosthetic composite allows the patient to achieve reasonable function. If the scapula is involved by the tumor along with the proximal humerus, a Tikoff-Lindberg procedure is required, with placement of a metal spacer attached to the remaining chest wall to provide shoulder stability (see Chapter 126).

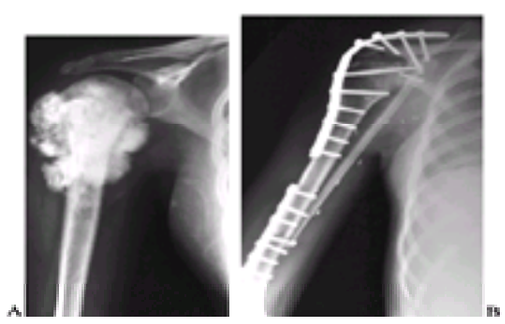

***Figure 128.4.*** **A:** AP view of the proximal end of the right humerus in a 15-year-old girl with an extensive osteosarcoma. She has no evidence of metastatic disease. **B:** Postresection arthrodesis in which an intercalary allograft was combined with a vascularized fibular graft. The soft-tissue extent of the tumor necessitated sacrifice of

the axillary nerve.

In very young patients, when resection or reconstruction of a limb involves the physeal plate, the limb-length discrepancy at adulthood may be substantial. Options that allow limb salvage for young patients include the use of an expandable prosthesis or a rotationplasty (81,152,162). The Ilizarov technique for limb lengthening and bone transport may have a role in the management of skeletal defects in young patients (112). Innovative methods of physeal distraction to improve the marginal resection and preserve the articular surface have been described.

### RESULTS OF TREATMENT

With advances in chemotherapy and surgical techniques, the outlook for patients with osteosarcoma continues to improve. The increase in limb-sparing surgery has not adversely affected survival. The multi-institutional study that looked at lesions in the distal part of the femur found no difference in survival among patients treated by limb salvage and those treated by amputation (141). Sim and colleagues (139) also found no adverse effects of limb-sparing surgery when compared with amputation. Current 5-year survival rates after a multidisciplinary approach are between 65% and 70%. The survival rate is as high as 80% in patients with extremity lesions who have an apparent good response (greater than 90% necrosis) to preoperative chemotherapy (3). In patients using multiple chemotherapeutic agents, one recent study showed a 10-year survival of 68% (95). The Mayo Clinic pilot study using ifosfamide-based chemotherapy showed an actuarial survival rate of greater than 90% at 2.5 years (98). For patients with metastases at diagnosis, only 40% remained free of progression of their disease at 2 years. The outlook in patients with systemic disease remains poor, although there are reports of long-term survival for patients treated with an aggressive surgical approach, including multiple thoracotomies and systemic chemotherapy (21) (Fig. 128.5). Patients who develop local recurrence of their osteosarcoma have a poor prognosis (119,141,149).

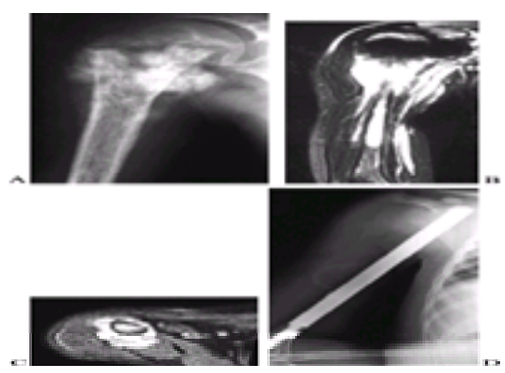

***Figure 128.5.*** **A:** AP radiograph of the right shoulder and humerus in a 10-year-old girl with osteosarcoma. Note the mineralized lesion in the proximal humeral metaphysis. **B, C:** Coronal and axial MRI views showing the extensive soft tissue and intramedullary component of the osteosarcoma. There was some decrease in the extraosseous component after neoadjuvant chemotherapy. **D:** Extraarticular resection of the proximal humerus, followed by placement of an intercalary metal spacer. This patient had systemic metastases at presentation, which were resected via bilateral thoracotomies.

## CHONDROSARCOMA

### CLINICAL FEATURES

Chondrosarcoma of bone is a malignant tumor of proliferating cartilage tissue (39,63,129,155) (Table 128.2). It accounts for approximately 10% of malignant bone tumors and tends to occur in older adults; the peak incidence is in the fifth to sixth decades of life. More than 75% of these lesions are located in the trunk or proximal portions of the femur or humerus. The inner wall of the acetabulum is a particularly common site. When it is found in the extremities, chondrosarcoma occurs centrally within the intramedullary portion of the bone. The lesions tend to grow slowly, and pain may be experienced for months or years before a mass or swelling is detected. Metastasis is generally to the lung but is rare in low-grade lesions and often occurs late in the course of the disease. However, the tumor has a tendency to recur locally (50,121).

A. Conventional chondrosarcoma
B. Periosteal chondrosarcoma
C. Mesenchymal chondrosarcoma
D. Clear cell chondrosarcoma
E. Secondary chondrosarcoma arising in
   1. Solitary osteochondroma
   2. Solitary enchondroma
   3. Hereditary multiple osteochondromas
   4. Ollier's disease
   5. Maffucci's syndrome
F. Dedifferentiated chondrosarcoma
G. Soft-tissue chondrosarcoma

***Table 128.2. Classification of Chondrosarcoma***

Mesenchymal chondrosarcoma is an extremely rare, highly malignant cartilage lesion with a bimorphic histologic appearance (66,102). It tends to occur in patients who are in their second or third decade. Two thirds of the lesions occur within the bone, and the remainder arise in the soft tissues. Clear cell chondrosarcoma is the least common of the chondrosarcoma subtypes. It is a low-grade malignant tumor with a predilection for the ends of long bones, particularly the proximal femur and humerus (11). Patients are usually in the third or fourth decades of life, and symptoms of vague pain can be present for years before discovery of the lesion. Dedifferentiated chondrosarcoma is a highly malignant variant that accounts for approximately 10% of chondrosarcomas. It is a high-grade noncartilaginous sarcoma that arises within a pre-existing low-grade chondrosarcoma (45,93).

Chondrosarcoma may arise *de novo* as a primary lesion, or it may occur secondarily at the site of a previous benign lesion such as an osteochondroma or enchondroma (47,103). More than 75% are primary tumors. Patients with multiple benign cartilage tumors, such as in Ollier's disease, Maffucci's syndrome, or multiple hereditary osteochondromas, are more likely to develop a secondary chondrosarcoma than are patients with solitary lesions.

### PATHOLOGIC FEATURES

Chondrosarcoma tends to be lobular with a matrix of varying consistencies (Fig. 128.6, ; see also Color Fig. 128.6). The center of the lobules often undergoes myxoid degeneration. Cortical destruction with soft-tissue extension is common, and calcific densities are frequently found within the chondroid matrix. This tumor has been divided into three histologic grades. Approximately 90% are well-differentiated (grade 1 or 2) tumors. In general, the grade of the tumor correlates with its cellularity (87,88). It is important to differentiate high-grade chondrosarcoma from chondroblastic osteosarcoma. Chondroblastic osteosarcoma has marked cytologic atypia and osteoid production. It is also often difficult to differentiate a low-grade chondrosarcoma from an enchondroma. Therefore, it is extremely important to correlate the clinical, radiographic, and histologic presentations before rendering a final diagnosis. Usually, a chondrosarcoma has more pleomorphic cells and may have myxoid changes within the chondroid matrix. Binucleation of the cells is not a distinguishing feature because it can be seen in both lesions. Chondrosarcoma of the small bones of the hand and foot is rare, and clinical and radiographic correlation is necessary to differentiate it from a benign cartilage lesion. Enchondromas in these sites are very common, but they have a much more aggressive histologic appearance than their long-bone counterparts. This makes the diagnosis difficult based on histology alone.

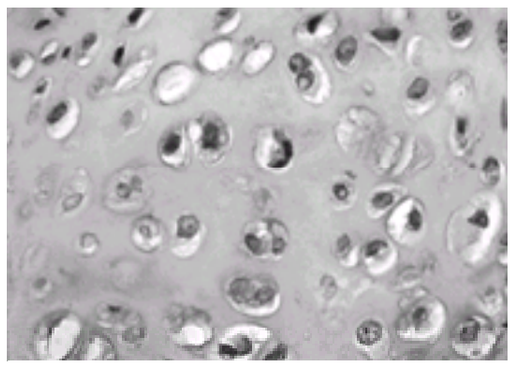

***Figure 128.6.*** (See Color Fig. 128.6.) Grade I chondrosarcoma. The lesion is quite cellular, the nuclei are enlarged and irregular, and double nucleated cells are present.

An important subtype of chondrosarcoma is the dedifferentiated lesion. Grossly, there is an abrupt transition from the centrally located hyaline component to the spindle cell portion. Histologically, it is characterized by sheetlike regions of highly anaplastic spindle cell sarcoma immediately adjacent to lobules of well-differentiated chondrosarcoma. The spindle cell component may show features of osteosarcoma, fibrosarcoma, or malignant fibrous histiocytoma. Another subtype, clear cell chondrosarcoma, has a cartilagenous matrix and is variably lobulated under low power. There are areas of mononuclear and multinucleated giant cells. The tumor cells have abundant clear cytoplasm and distinct boundaries. Mesenchymal chondrosarcoma is grossly well defined, with calcific foci scattered throughout the tumor. The low-power pattern is bimorphic, with islands of benign-appearing hyaline cartilage among highly cellular areas of uniform, small, round, or spindled cells. There are numerous branching vessels with a pattern reminiscent of hemangiopericytoma.

**RADIOGRAPHIC FEATURES**

Chondrosarcoma appears as a predominantly lytic lesion that arises in the medullary cavity but usually involves the cortex as well. (See Figure 128.7, Figure 128.8 and Figure 128.9.) Eventually it extends through the cortex and forms a large soft-tissue mass. Matrix calcification is present in the majority of tumors and appears as rings of mineral. Endosteal scalloping and cortical expansion are characteristic of a chondrosarcoma, as opposed to a benign enchondroma. In long bones, the tumor is usually metaphyseal or metadiaphyseal in location. Periosteal chondrosarcoma is a rare variant that arises *de novo* on the surface of the bone. A tumor arising in the pelvis is less distinct on plain films but is often associated with a characteristic large soft-tissue mass and mottled mineralization. Computed tomography (CT) and MRI can help define soft-tissue margins and cortical destruction in pelvic tumors. Both are useful in detection of recurrent lesions. If the cartilage cap on an osteochondroma exceeds 2 cm on MRI or CT scan in a patient with clinical symptoms, consider secondary chondrosarcoma.

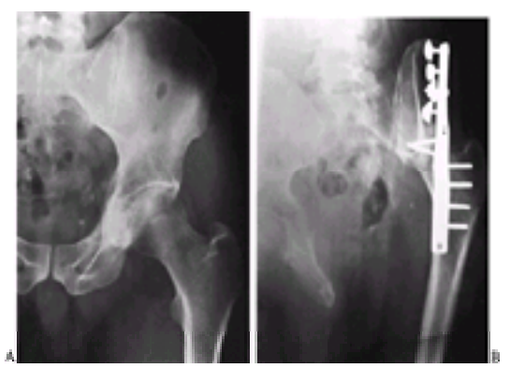

***Figure 128.7.*** **A:** AP radiograph of the left hemipelvis showing a chondrosarcoma of the ilium and acetabulum. Note the stippled calcification. **B:** *En bloc* resection, followed by iliofemoral arthrodesis. (From Sim FH, Bowman WE Jr, Chao EYS. Limb Salvage and Reconstructive Techniques. In: Sim FH, ed. *Diagnosis and Treatment of Bone Tumors: A Team Approach.* Thorofare, NJ: Slack, 1983:75, with permission of the Mayo Foundation.)

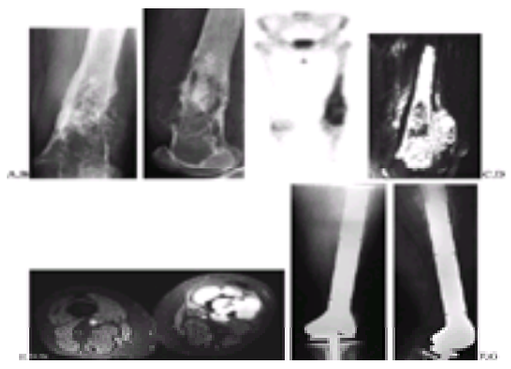

***Figure 128.8.*** **A, B:** AP and lateral radiographs of the left distal femur in a 61-year-old woman with chondrosarcoma showing a calcified intramedullary lesion with destruction of the surrounding cortex. **C:** Bone scan showing the extent and activity of the tumor. **D, E:** Coronal and axial MRI images further define the soft tissue and intramedullary extent to assist in preoperative planning. **F, G:** Wide resection of the distal femur followed by reconstruction using a custom rotating hinge knee prosthesis.

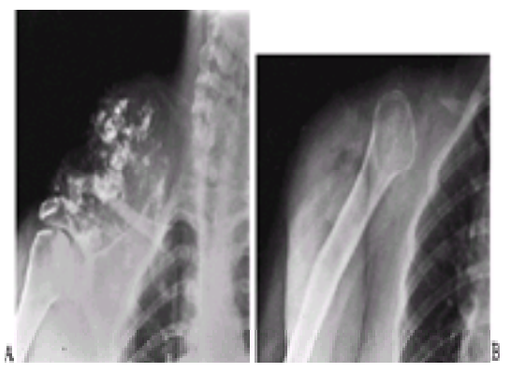

***Figure 128.9.*** **A:** Anteroposterior view of right shoulder showing an extensive chondrosarcoma arising from the upper scapula. **B:** After scapulectomy.

A dedifferentiated chondrosarcoma has the radiographic appearance of a conventional chondrosarcoma. However, 25% have an aggressive destructive area adjacent to the cartilage lesion. Clear cell chondrosarcoma has an appearance similar to chondroblastoma, with sharp margins and a sclerotic rim at the end of a long bone. There may be some mineralization and slight expansion of the cortex. Late in the course of the disease, there is extensive cortical destruction. Mesenchymal

chondrosarcoma has the appearance of a conventional chondrosarcoma when it arises in bone. Matrix calcification is present when it occurs in the soft tissues.

### TREATMENT

Surgical resection remains the mainstay of therapy for chondrosarcoma (12,121,133). Two important principles apply in surgical management. First, a well-planned and adequate biopsy that is representative of the entire tumor is necessary. Second, a wide margin must be achieved at initial resection to ensure the best chance of cure for this tumor, which is notorious for local recurrence. Accurate preoperative staging with determination of the histopathologic grade and regional tumor extent dictates the aggressiveness needed at operation. For lesions of higher grade with extensive soft-tissue and neurovascular involvement, amputation may be required to ensure local control. Even lower grade lesions that have recurred in the pelvis often involve the neurovascular bundle and necessitate external hemipelvectomy. When a limb-sparing procedure is feasible, the reconstructive techniques described for osteosarcoma apply equally well for chondrosarcoma (1,19,23,35,41,62,85,90,128,134) (Fig. 128.7, Fig. 128.8, and Fig. 128.9). Internal hemipelvectomy and iliofemoral fusion for pelvic lesions have yielded satisfactory results. For lesions involving the proximal femur, a custom prosthetic replacement or an allograft prosthetic composite is an effective reconstructive option after proximal femoral resection. In general, chondrosarcoma is resistant to chemotherapy and radiation.

Of the chondrosarcoma variants, clear cell chondrosarcoma is curable after wide resection. Mesenchymal chondrosarcoma also necessitates an aggressive surgical approach to achieve a wide resection margin. One report found radiation and chemotherapy to be beneficial in a subset of these tumors (66). Dedifferentiated chondrosarcoma has a dismal prognosis, despite radical surgical resection and adjuvant therapy.

### RESULTS OF TREATMENT

The overall survival rate for a patient with conventional chondrosarcoma is highly dependent on the histologic grade (12). A survival rate of 94% for grade 1, 61% for grade 2, and 44% for grade 3 at 5 years was reported in one study (50). Because local recurrence affects survival adversely and late recurrences are common, 5-year survival rates are unreliable indicators of long-term results. A 10-year survival rate of 77% for grade 1, 59% for grade 2, and 36% for grade 3 lesions was documented in another study (121). Local recurrence occurs in 20% and pulmonary metastases in 15% (12).

A wide resection of clear cell chondrosarcoma is generally curable. Patients treated with intralesional curettage have an 80% risk of local recurrence, with metastases to the lung and other skeletal sites (11). Patients with mesenchymal chondrosarcoma have a survival rate of 50% at 5 years and 28% at 10 years (66,102). Results of treatment of highly malignant, dedifferentiated chondrosarcoma are poor despite radical surgery. The 5-year survival rate is approximately 10% (45,93).

## EWING'S SARCOMA

### CLINICAL FEATURES

Ewing's sarcoma of bone is a highly anaplastic, small, round cell tumor of neuroectodermal origin (39,54,129,155,156) (Table 128.3). Ewing's sarcoma is the second most common primary malignant bone tumor in children and the fourth most common malignant bone tumor in all ages. It occurs slightly more often in male patients and almost never in the black population. The tumor occurs typically in the first and second decades of life; more than 90% of patients are younger than 30 years of age. It can arise in any bone of the body, but more than 60% of the lesions occur in the pelvic girdle and lower extremities. When it occurs in the long bones, the diaphysis is usually involved. Ewing's sarcoma can also occur primarily in the soft tissues (126).

| |
|---|
| Ewing's sarcoma |
| Primitive neuroectodermal tumor (PNET) |
| Metastatic neuroblastoma |
| Metastatic rhabdomyosarcoma |
| Lymphoma/leukemia |
| Small Cell osteosarcoma |
| Mesenchymal chondrosarcoma |

***Table 128.3. Small Round Cell Tumors of Bone***

Pain and swelling are the most common symptoms, and they may exist for several months before diagnosis. Occasionally, there are systemic signs and symptoms such as low-grade fever, increased erythrocyte sedimentation rate, leukocytosis, and anemia, which may be difficult to differentiate from an infection. Only 1% of lesions occur in the mobile spine, and these frequently present with a neurologic deficit (56). Pathologic fractures are the presenting feature in approximately 10% of patients. Fifty percent of the metastatic lesions are found in the lungs, although other skeletal sites, including the skull and vertebral column, are common.

### PATHOLOGIC FEATURES

The tumor is characteristically gray or white and has a semiliquid consistency that suggests purulence (Fig. 128.10; see also Color Fig. 128.10). Microscopically, it is a cellular sheetlike proliferation of small round cells without matrix production. However, fibrous strands may be identified traversing the lesion. The cells have indistinct cytoplasmic borders with round or oval nuclei. It may be difficult to differentiate Ewing's sarcoma from other round cell tumors such as lymphoma, embryonal rhabdomyosarcoma, metastatic neuroblastoma, and small cell osteosarcoma by light microscopy alone. In recent years, great strides have been made using immunohistochemical and molecular genetic methods to differentiate Ewing's sarcoma from other small round cell tumors (Table 128.4). Cytogenetic studies have revealed a reciprocal translocation (11;22) (q24;q12) found in both Ewing's sarcoma and primitive neuroectodermal tumor (PNET). Reverse transcriptase polymerase chain reaction (RT-PCR) assays can be used to look for this translocation even if traditional cytogenetic testing is unsuccessful (28,131). Other translocations have also been identified. In addition, these tumors have a cell surface glycoprotein called p30/32 MIC2, which is a product of the MIC2 gene located on the shorearms of the X and Y chromosomes. This glycoprotein can be recognized by commercially available monoclonal antibodies.

| |
|---|
| Histochemical stains |
| Reticulum stain |
| PAS |
| Immunohistochemistry |
| Panel including CD99 |
| Cytogenetics |
| Molecular genetics |
| RT-PCR for fusion product of translocation |
| EWS-FLI-1 (11;22)(q24;q12) |
| EWS-ERG (21;22)(q22;q12) |

***Table 128.4. Ewing's Sarcoma—Ancillary Studies***



***Figure 128.10.*** (See Color Fig. 128.10.) Small uniform nuclei with marked hyperchromasia typical of Ewing's sarcoma.

### RADIOGRAPHIC FEATURES

Ewing's sarcoma usually originates in the intramedullary cavity and commonly involves an extensive portion of the diaphysis of a long bone (Fig. 128.11). Lytic destruction in a mottled or moth-eaten pattern is the most common radiographic appearance. The margins are indistinct and the actual bone involvement seen on plain films may be subtle. Cortical destruction with periosteal elevation and multiple layers of subperiosteal new bone gives the classic “onion skin” appearance; however, this is not pathognomonic for Ewing's sarcoma. Radiating spicules of new bone in a sunburst pattern can also occur, making radiographic differentiation from osteosarcoma difficult. In rare lesions with little or no intramedullary involvement (e.g., subperiosteal Ewing's sarcoma), saucer-shaped destruction of the exterior cortex is a fairly characteristic feature. As in other malignant tumors, MRI is most helpful in defining the soft-tissue extension that is common in Ewing's sarcoma (140).

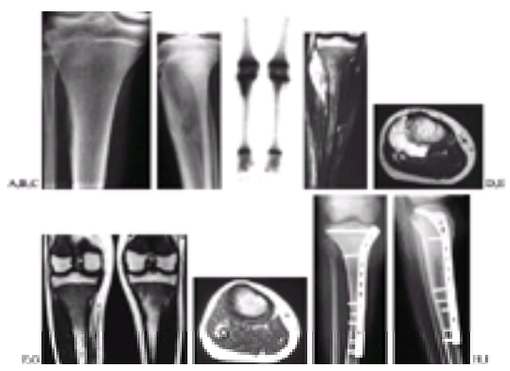

***Figure 128.11.*** **A, B:** AP and lateral radiographs of the right tibia in a 13-year-old girl with Ewing's sarcoma. Note the periosteal elevation along the lateral tibial cortex. **C:** Bone scan demonstrates increased activity throughout the metadiaphysis. **D, E:** Coronal and axial MRI images before neoadjuvant chemotherapy. Note the large soft-tissue mass extending to the surface of the fibula. **F, G:** Coronal and axial MRI images after chemotherapy. The soft-tissue mass has resolved. **H, I:** Transepiphyseal resection of the tibia followed by reconstruction using an intercalary allograft. The extensor mechanism was reconstructed from allograft tissues.

### TREATMENT

The mainstay of treatment for Ewing's sarcoma is multiagent chemotherapy. Over the past 20 years, multi-institutional chemotherapy studies have greatly enhanced our ability to increase the long-term survival rates in patients with this disease (54,156). In 1981, the first Intergroup Ewing's Sarcoma Study Group (IESS-I) demonstrated that adding doxorubicin (Adriamycin) to the standard regimen of vincristine, cyclophosphamide, and actinomycin-D increased survival (104). IESS-II showed that dose intensification of the four-drug regimen gave a significant improvement in disease-free and overall survival. Seventy-three percent of patients with nonmetastatic, nonpelvic disease were relapse free at a median follow-up of 5.6 years (16,142). IESS-III compared the intensified four-drug regimen with a similar protocol with the addition of ifosfamide and etoposide. There was an overall improvement in disease-free survival with the six-drug regimen that was most striking in the young age group and in patients with pelvic tumors (55,99). Current national cooperative studies are comparing the standard six-drug regimen with use of these agents over a shorter time course with intensification of ifosfamide and cyclophosphamide.

As a small round cell tumor, Ewing's sarcoma is considered to be radiosensitive. In the past, radiotherapy protocols consisting of 4000 to 6000 cGy were delivered to the affected bone to provide the primary means of local control along with chemotherapy. However, radiation inconsistently controlled the primary tumor, and local recurrence rates were 15% to 20% after treatment. Microscopically viable tissue was found in 65% of these patients in autopsy studies (156). The late morbidity associated with irradiation includes limb-length inequality, pathologic fracture, fibrosis, and ankylosis. The increased possibility of radiation-induced sarcoma led to a renewed interest in the role of surgical treatment for local control of Ewing's sarcoma (51,77,106,153).

Initially, surgery in Ewing's sarcoma was limited to the resection of expendable bones, such as the proximal fibula or rib lesions. The role of surgery expanded dramatically with reports of increased survival associated with a wide surgical margin (111,161). The current philosophy is use of intense neoadjuvant chemotherapy to decrease the size of the primary lesion, followed by wide resection (Fig. 128.11). Radiation is added postoperatively if the surgical margin is intralesional or marginal. The use of modern imaging techniques such as MRI has improved the surgeon's ability to define the lesion and make better decisions about the feasibility of resection with and without reconstruction. MRI scans are performed before and after completion of neoadjuvant chemotherapy. Many studies have shown a survival advantage for patients treated with surgical excision of their primary tumor compared with those treated with radiation for local control. Studies looking specifically at surgical resection of pelvic tumors reveal mixed conclusions (37,42,132,161). In general, these studies are retrospective with limited numbers of patients, and thus, the results must be evaluated with caution. However, there does seem to be a trend for prolonged survival as well as a decreased recurrence rate for patients who undergo surgery for local control of their tumor. Surgery should be considered in all cases in which the surgeon believes that the primary tumor can be completely removed with a wide margin.

In most cases, limb salvage is possible (29,81,86,89,112,134,152,162). Reconstruction options exist similar to those discussed for osteosarcoma. The same challenges of limb salvage in pediatric patients exists in Ewing's sarcoma. Limb lengthening by an expandable prosthesis or through bone transport are options for young patients when wide resection necessitates loss of the physis (see Chapter 126). Complicated surgical reconstructions that may necessitate a prolonged chemotherapy-free interval should be avoided, or else the entire course of chemotherapy should be given before surgery. The latter approach is encouraged in the management of patients with Ewing's sarcoma of the spine, in whom surgical procedures are frequently staged and often complicated.

### RESULTS OF TREATMENT

Before effective chemotherapy was available, Ewing's sarcoma was considered one of the most lethal sarcomas, with a 5-year survival rate of less than 20%. With a modern, multidisciplinary approach to treatment, the overall 5-year survival rate has improved to greater than 70% (4,16,69,104). As with osteosarcoma, a favorable response to preoperative chemotherapy is a good prognostic sign (118). Survival rates as high as 80% to 90% have been reported for patients with extremity lesions who have more than 90% necrosis after neoadjuvant treatment (69). In addition, patients with distal tumors have an improved prognosis compared with those with central lesions in the pelvis or sacrum. Poor prognostic variables include large tumor size, pelvic location, metastatic disease at initial presentation, and poor response to preoperative chemotherapy (4,36,69,161). In a review of 140 patients at the Mayo Clinic, 25% presented with metastatic disease. The 2-year survival rate of this subset was 39% compared with those with nonmetastatic disease, who had a 2-year survival rate of 69% (161).

## FIBROSARCOMA

### CLINICAL FEATURES

Fibrosarcoma of bone is a rare malignancy characterized by the proliferation of spindle cells without any discernible matrix production (39,129,155). This tumor

accounts for less than 4% of primary osseous malignancies and occurs in patients from the second through sixth decades of life. Patients with fibrosarcoma have an age distribution different from those with fibroblastic osteosarcoma, although the tumors may be similar histologically. Men and women are affected equally. The skeletal distribution is similar to that of osteosarcoma, with more than 50% occurring in long bones, usually the femur or tibia. Most of these lesions arise *de novo,* but 25% can be considered secondary, arising at sites of pre-existing disease or after irradiation. Symptoms of fibrosarcoma include pain and swelling, which may exist for a long time before diagnosis. Fifteen percent of patients present with a pathologic fracture. Fibrosarcoma metastasizes to the lungs in a high proportion of cases.

## PATHOLOGIC FEATURES

Fibrosarcoma varies in gross appearance (Fig. 128.12; see also Color Fig. 128.12). Some well-differentiated lesions may be firm, dense, and seemingly well circumscribed. Poorly differentiated lesions tend to be soft and friable with regions of myxoid degeneration. Areas of hemorrhage and necrosis are frequently evident. Cortical destruction is common, and soft-tissue involvement may be extensive. Fibrosarcoma has the same histologic features as its soft-tissue counterpart; however, it infiltrates through and destroys the bone (8). It is characterized by spindle cells arranged in a herringbone pattern. The cells form interlacing bundles of collagen fibers. They show varying degrees of cytologic atypia and stroma production. Some lesions are so well-differentiated that they can be confused with benign fibrous lesions such as desmoplastic fibroma (155). Other tumors are highly anaplastic, with little or no recognizable collagenous stroma. Approximately 68% of the lesions are grade 3 or 4.

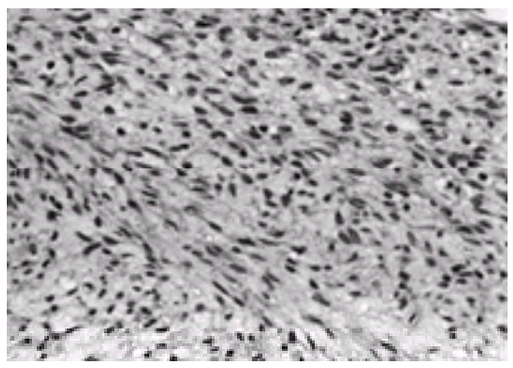

***Figure 128.12.*** (See Color Fig. 128.12.) Well-differentiated fibrosarcoma with fascicles of spindle cells without pleomorphism.

## RADIOGRAPHIC FEATURES

There are no pathognomonic radiographic features for fibrosarcoma (Fig. 128.13). There is osteolytic bone destruction with cortical and soft-tissue extension suggesting a malignant process, but it is difficult to differentiate from other malignancies such as osteosarcoma (Table 128.5). The absence of calcification or ossification can be helpful in ruling out other lesions. Periosteal new bone formation is uncommon. Most lesions are eccentrically located, with permeative or moth-eaten patterns of destruction evident well beyond the principal area of lysis. A fibrosarcoma can originate on the periosteal surface, but most lesions appear to arise from the intramedullary portion of the bone, with frequent extension into the adjacent soft tissues. MRI aids in determining osseous extent and in defining regional margins.

| *Benign* | *Malignant* |
|---|---|
| Desmoplastic Fibroma | Malignant Fibrous Histiocytoma |
| Chondromyxoid Fibroma | Telangiectatic Osteosarcoma |
| Giant Cell Tumor | Lymphoma |
| | Solitary Myeloma |
| | Metastatic Carcinoma |

***Table 128.5. Fibrosarcoma of Bone—Differential Diagnosis***

***Figure 128.13.*** **A, B:** AP and lateral radiographs of the right distal femur in a 25-year-old woman with fibrosarcoma. There has been cortical destruction along the medial femoral cortex. **C, D:** Extra-articular resection, followed by allograft arthrodesis, which is solidly healed three years later.

## TREATMENT

Adequate treatment requires wide surgical resection. If it is apparent that a wide margin cannot be obtained to achieve local control, an amputation is required. The principles and techniques of limb-sparing surgery to preserve function yet achieve local tumor control have been previously discussed (19,23,134). The reconstructive choices are similar to those for osteosarcoma and chondrosarcoma (Fig. 128.13).

Radiation therapy is usually ineffective, although it may have a palliative role in lesions deemed unresectable. Neoadjuvant multidrug chemotherapy programs similar to those used for osteosarcoma are being recommended for treatment of systemic disease, although long-term results are not available (8,65).

## RESULTS OF TREATMENT

Fibrosarcoma of bone portends a poorer prognosis than those of the soft tissues (122,150,151). It behaves similar to malignant fibrous histiocytoma of bone. In recent studies, the 5-year survival rate for fibrosarcoma is approximately 45% with or without adjuvant treatment (113). This reflects the improved preoperative staging and sophisticated imaging modalities compared with those of prior eras (65). As with other spindle cell sarcomas, the prognosis relates to the histology with low-grade, well-differentiated lesions having a distinctly better prognosis than high-grade tumors (65,122). Other factors associated with a poorer prognosis for survival include age greater than 40 years and location of the tumor in the axial skeleton. Metastases, primarily to the lung, are reported in up to 75% of patients with this rare tumor. Therefore, development of effective adjuvant chemotherapy protocols is a priority. Treatment of the metastatic lesions with aggressive thoracotomy has been reported

(147).

## MALIGNANT FIBROUS HISTIOCYTOMA

### CLINICAL FEATURES

Malignant fibrous histiocytoma of bone is a highly malignant neoplasm. It has previously been difficult to differentiate from fibrosarcoma and fibroblastic osteosarcoma, but it is now recognized as a distinct clinicopathologic entity. The histiogenesis of this tumor is debated, but many believe that it is derived from primitive mesenchymal cells. It is similar to its soft-tissue counterpart but much less common, accounting for approximately 5% of malignant bone tumors. Arising in patients of any age, it reaches its peak incidence in the fourth and fifth decades, and it occurs slightly more frequently in male patients (20,39,67,129,155). Malignant fibrous histiocytoma occurs as a metaphyseal lesion in the appendicular skeleton, particularly around the knee, but it can also be found in the pelvis and axial skeleton. Patients present with pain with or without swelling. Occasionally, a pathologic fracture is noted at initial presentation (Fig. 128.14).

***Figure 128.14.*** **A, B:** AP and lateral radiographs of the left distal femur in a 66-year-old woman with malignant fibrous histiocytoma of bone. Note the extensive metaphyseal involvement, with thinning of the cortices and a pathologic fracture. **C, D:** Coronal and axial MRI images reveal the large soft-tissue component of the tumor, along with the hematoma from the pathologic fracture. This patient was treated with an above-knee amputation.

Approximately 25% of malignant fibrous histiocytomas arise as secondary tumors in pre-existing conditions such as bone infarcts or Paget's disease (26,46,157). They also occur as the predominant histologic type in postirradiation sarcomas and the sarcomatous portion of dedifferentiated chondrosarcomas (45,64).

### PATHOLOGIC FEATURES

The tumors vary in consistency from firm to soft, depending on the amount of fibrous tissue they contain (Fig. 128.15; see also Color Fig. 128.15) They are typically gray to yellow, with areas of necrosis and hemorrhage. Cortical destruction and soft-tissue extension are prominent features. Malignant fibrous histiocytoma has a pleomorphic pattern at low magnification. The tumor contains both malignant spindle cells and malignant histiocytic cells. The spindle cell regions have a matted or storiform pattern reminiscent of primary soft-tissue lesions. Considerable cytologic variation is identifiable at high magnification. Histiocytic appearance is characterized by indentation of nuclei and large, well-defined cytoplasm. Other cells show a spindle cell arrangement with ovoid to ellipsoid nuclei. The vast majority of lesions are high grade. Osteoid or chondroid matrix production by the tumor cells precludes a diagnosis of malignant fibrous histiocytoma. Differentiation from fibrosarcoma may be difficult. The particular histologic features of this tumor have no prognostic significance.

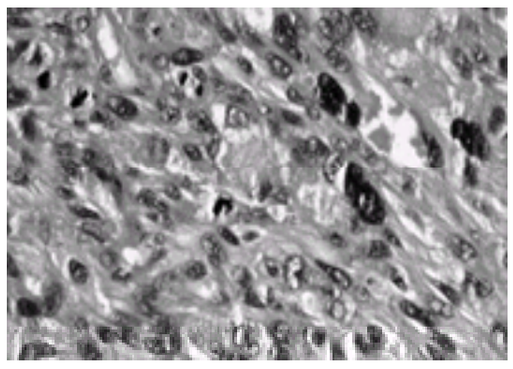

***Figure 128.15.*** (See Color Fig. 128.15.) High-grade malignant fibrous histiocytoma. There is marked pleomorphism.

### RADIOGRAPHIC FEATURES

Malignant fibrous histiocytoma is radiographically characterized by geographic lysis, but occasionally, there is a permeative picture. Cortical destruction and indistinct margins suggest an aggressive malignancy. There is a wide zone of transition from normal to abnormal bone. Little reactive periosteal or sclerotic bone is seen. Radionuclide scans are helpful in detecting other lesions. CT and MRI scans confirm the cortical destruction and aid in determining soft-tissue margins and the relation of the tumor to adjacent neurovascular structures.

### TREATMENT

The treatment of malignant fibrous histiocytoma is similar to that of other high-grade bone tumors. Surgery is the mainstay of treatment, and the goals of adequate surgical control with maximal preservation of limb function determine the feasibility of limb-sparing surgery (134). Often, a pathologic fracture or extremely large soft-tissue mass that comprises neurovascular function will necessitate amputation (Fig. 128.14). Lesions that cannot be adequately excised or present in problematic axial skeleton locations may be treated with adjuvant or primary radiotherapy. Occasional long-term survivors have been reported after treatment with radiation only (105).

Because this is such a rare tumor, few reports documenting the effect of chemotherapy have been published (32,117). Picci et al. (117) report an increased disease-free survival rate of 67% at median 7 years using a neoadjuvant chemotherapy protocol similar to that used for osteosarcoma. However, effective tumor necrosis was seen in only 25% of patients. The overall survival rate for patients treated surgically in the Mayo study is approximately 52% at 5 years and 41% at 10 years (105). Inadequate surgical margins, metastatic disease at presentation, age greater than 40 years, and axial tumor location have been correlated with a poorer prognosis (105). Local recurrence is increased after inadequate surgical margins. There is debate on whether the prognosis is worse in patients with a secondary malignant fibrous histiocytoma (20,64,105). Metastasis occurs hematogenously, usually to the lungs but also to other osseous sites. Patients occasionally can be cured with aggressive resection of pulmonary lesions.

## MYELOMA

### CLINICAL FEATURES

Myeloma is a neoplastic disease of plasma cells that involves the bone marrow (78,155) (Table 128.6). It has a wide clinical spectrum of disease, accounting for the variety in its presentation. It is most commonly manifested by widespread skeletal involvement with marked overproduction of monoclonal immunoglobulins. Myeloma is the most common primary malignancy of bone, accounting for approximately half of all bone tumors. Most patients are between 50 and 70 years old. The most common tumor locations are in bones that contain active hematopoietic elements; more than 85% of the lesions involve the axial skeleton and proximal portions of the

femur and humerus.

A. Monoclonal gammopathies of unknown significance
B. Malignant monoclonal gammopathies
  1. Multiple myeloma
    a. Overt multiple myeloma
    b. Smoldering multiple myeloma
    c. Plasma cell leukemia
    d. Nonsecretory myeloma
    e. IgD myeloma
    f. Osteosclerotic myeloma
  2. Plasmacytoma
    a. Solitary
    b. Extramedullary
C. Cryoglobulinemia
D. Pyroglobulinemia
E. Primary amyloidosis

***Table 128.6. Plasma Cell Proliferative Disorders***

Pain is a prominent feature of myeloma, particularly if a pathologic fracture occurs. Systemic symptoms of weakness and fatigue, along with abnormal laboratory findings, are helpful in establishing a diagnosis. Systemic amyloidosis occurs in 15% of patients with multiple myeloma. Patients have a characteristic immunoglobulin profile that can be demonstrated with immunoelectrophoresis. This particular finding is one part of a set of specific criteria necessary to diagnose myeloma accurately. Diagnosis of multiple myeloma is based on one major and one minor, or three minor, diagnostic criteria, as outlined in Table 128.7. It is important to differentiate this tumor from metastatic disease, which occurs in a similar age group and causes similar clinical symptoms. The classic staging system of Durie and Salmon (31) identifies patients at risk for shortened survival.

| *Major criteria* | *Minor criteria* |
|---|---|
| I. Plasmacytoma on tissue biopsy | I. Bone marrow plasmacytosis (10–30% plasma cells) |
| II. Bone marrow plasmacytosis (>30% plasma cells) | II. Monoclonal spike—low level |
| III. Monoclonal spike exceeding: 3.5 g/dl for G Peaks 2.5 g/dl for A Peaks | III. Lytic bone lesions |
| | IV. Residual normal IgM<50mg/dl IgA<100mg/dl IgG<600mg/dl |

***Table 128.7. Multiple Myeloma—Diagnostic Criteria***

Presentation with a solitary osseous lesion (plasmacytoma), which is defined as the concurrent finding of a positive biopsy of an isolated lesion, a negative bone marrow aspirate, and a negative skeletal survey, occurs in approximately 25% of patients (43). Subsequent dissemination of the disease occurs in more than 50% of these patients by 10 years. More than half of the solitary osseous lesions are located in the vertebral column (78). Solitary extramedullary plasmacytomas, often located in the upper airway passages, can occur alone or in patients in whom multiple myeloma later develops.

Osteosclerotic myeloma occurs in 1% of cases and can be associated with POEMS syndrome (Table 128.8). These patients have an increased incidence of peripheral neuropathy (73). In general, osteosclerotic myeloma occurs in younger patients and has a more indolent course.

Polyneuropathy
Organomegaly
Endocrinopathy
  Hyperthyroidism
  Glucose intolerance
  Impotence
M-Component
  Monoclonal protein
  Amyloid
Skin changes
  Thickening
  Hyperpigmentation

***Table 128.8. Multiple Myeloma—Poems Syndrome***

## PATHOLOGIC FEATURES

Myeloma is typically soft, gray to red, and friable (Fig. 128.16; see also Color Fig. 128.16). The gross boundaries are indistinct, and often the medullary and extraosseous involvement is greater than anticipated. Microscopically, the tumor consists of sheets of closely packed plasma cells. The cells are homogenous, with eccentric nuclei having a clumped chromatin pattern. There is abundant granular cytoplasm, and multinucleated cells are occasionally seen. A variable amount of pink, amorphous amyloid is present in 10% to 15% of myelomas (144).

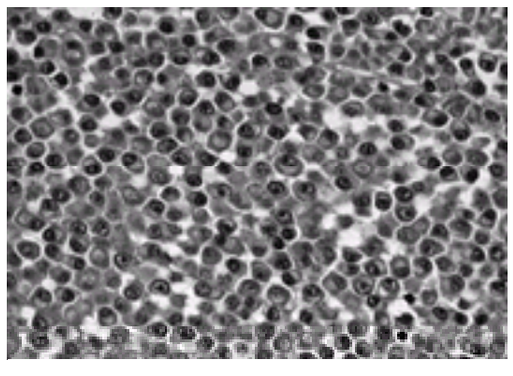

***Figure 128.16.*** (See Color Fig. 128.16.) Sheets of plasma cells typical of myeloma. There is abundant pink cytoplasm, and the nuclei are structured eccentrically.

### RADIOGRAPHIC FEATURES

The classic plain film appearance is of purely lytic “punched-out” areas of bone destruction (Fig. 128.17). The lesions are small and uniform. Typically, there is no reactive zone of sclerosis. A balloonlike expansion of bone may occur, particularly in rib lesions. Osteosclerotic lesions are either osteoblastic or mixed in appearance (123). In 15% to 25% of patients, no discrete lysis occurs, and diffuse osteopenia and osteoporosis are the only skeletal manifestations. MRI can help define the lesion when there is nothing definite on plain films. Technetium 99m bone scans are less reliable in identifying myeloma lesions because of a lack of osseous response to the tumor. A skeletal survey with plain tomography or CT is more helpful in finding additional lesions or defining the extent of osseous destruction. Sixty percent of patients develop pathologic fractures, with the majority being vertebral compression fractures.

***Figure 128.17.*** **A:** AP radiograph of the left hip in a 66-year-old woman with multiple myeloma. The patient has widespread lytic lesions throughout the proximal femur with a pathologic fracture of the femoral neck. **B:** A cemented long-stemmed hip replacement was quickly able to restore the patient's ambulatory function.

### TREATMENT

Standard treatment for multiple myeloma aims at control of the lesion; complete cure is rare. The primary systemic modality for patients with multiple myeloma is chemotherapy. Most protocols include the use of melphalan (L-phenylalanine mustard) and prednisone (52). Combination chemotherapy has not been definitively shown to prolong overall survival compared with the above-mentioned agents in randomized trials (109,115). A positive response to treatment can be monitored objectively by observing a decrease in M-type proteins, the rate of hematologic recovery, and occasionally, resolution of the skeletal disease. No single test can be reliably used to follow multiple myeloma, but serial serum protein electrophoresis or test for quantitative immunoglobulins is probably the most reasonable. Recent work using interventions such as interferon and peripheral stem cell transplantation is promising (5). In addition, biologic substances such as interleukin-6 are being targeted in cytokine growth factor–directed treatment (53). Despite this and other exciting new molecular work, there has been only minimal improvement in the overall survival of the patient in the last 20 years.

Radiation is very effective for localized lesions that are causing disabling pain or limitation of activity. Radiation tends to slow the growth of the tumor, which allows microfractures to heal. Occasionally, the lesion reossifies with a return of structural integrity. This, along with occasional bracing, is the standard treatment for patients with vertebral involvement. A more aggressive approach to therapy is warranted for patients with solitary myeloma. A radiation dose of 4500 cGy to the solitary lesion has been shown to prevent local recurrence (43). Localized extramedullary disease of the upper respiratory tract can be cured with radiation (58).

Surgical intervention in multiple myeloma is indicated for patients with vertebral involvement who have compressive paraplegia and for patients with impending or actual pathologic fractures. Decompressive laminectomy is indicated if radiation does not cause resolution of symptoms, and moderate to excellent return of function can be expected. Spinal stabilization is occasionally warranted, and recent advances in the techniques of anterior and posterior instrumentation have improved the effectiveness in restoring stability (79).

Pathologic fractures require aggressive surgical management to relieve pain and maintain ambulatory status (Fig. 128.17). The indications for prophylactic internal fixation of an impending pathologic fracture are the same as those used in metastatic disease (57,79,97,136,137). The principles of open reduction and internal fixation, often using supplemental methylmethacrylate, can achieve skeletal stability in most of these fractures (167). For those involving the femoral neck, resection and prosthetic replacement are effective (114,135). For subtrochanteric lesions, our preferred technique is the use of a reconstruction nail with methylmethacrylate augmentation. If there is extensive involvement of the proximal femur, a standard sliding hip screw and side plate has been shown to fail with progression of the disease; therefore, more extensive reconstruction techniques, including proximal femoral replacement, may be indicated. A more aggressive surgical approach is warranted in a patient with a solitary plasmacytoma because survival may be prolonged.

### RESULTS OF TREATMENT

The overall prognosis for patients with multiple myeloma is poor because patients tend to die within 3 years of diagnosis. The 5-year survival rate is 18% for multiple myeloma, with a median survival time of 20 months and a 1-year survival rate of 66% (78). Chemotherapy improves the median survival time to 3 years in the 50% to 60% who respond to treatment. Poor prognostic variables include the presence of M-proteins, pancytopenia, hypercalcemia, diffuse skeletal lesions, and renal failure. New biologic assays are emerging that identify patients who are likely to have long-term survival. Young patients with a low b2M level and a low plasma cell labeling index have a better prognosis, according to recent studies (51).

The overall survival rate of patients with solitary plasmacytoma is 74% at 5 years and 45% at 10 years. Fifty percent of patients progress to multiple myeloma (6,43).

## MALIGNANT LYMPHOMA OF BONE

### CLINICAL FEATURES

Malignant lymphoma of bone is a neoplasm of the reticuloendothelial system. It accounts for approximately 3% of primary osseous malignancies; an equal number of cases represent secondary osseous involvement. Non-Hodgkin's lymphoma is three times more likely to have bone involvement compared with Hodgkin's disease. There are well-described and useful classification and staging systems for both types of lymphoma (17). Any age group can be affected, but it is rare in the very young and peaks in the fifth to seventh decades of life. In primary lymphoma of bone, the lesions tend to be diaphyseal or metadiaphyseal, occurring in the proximal femur, proximal humerus, and distal femur. In disseminated disease, the bony involvement is commonly in the axial skeleton, including the pelvis and spinal column (15,155). Pain, often present for many months or years, is a constant feature. Neurologic symptoms are common with spinal lesions, as are pathologic fractures. Systemic disease is either via hematogenous spread or direct, contiguous extension from the nearby soft tissues or lymph nodes.

### PATHOLOGIC FEATURES

Gross inspection reveals a gray-white tumor with an infiltrative growth pattern and frequent soft-tissue extension (Fig. 128.18; see also Color Fig. 128.18). The tumor is generally soft if it has completely destroyed the bone but is firm if residual osseous trabeculae exist. Areas of necrosis may be present. Extraosseous masses are usually soft and friable. Microscopically, the tumor consists of an admixture of large and small cells amid a fine reticulin meshwork. It is composed of a proliferation of histiocytes and lymphoid cells at various stages of differentiation. Most common is the diffuse large-cell, B-cell phenotype. Varying degrees of fibrosis may be present. Histologically, primary malignant lymphoma of bone is indistinguishable from a lymphoma originating elsewhere. Immunohistochemical markers can help identify and subclassify these tumors.

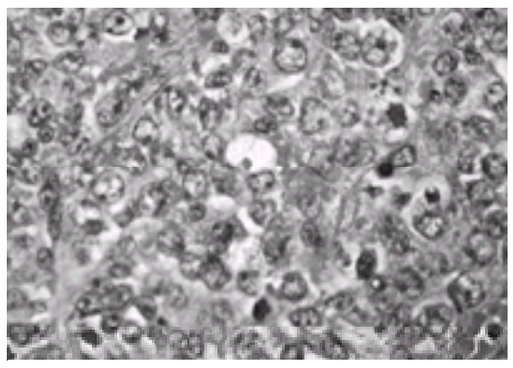

***Figure 128.18.*** (See Color Fig. 128.18.) Malignant lymphoma demonstrating proliferation of large cells with irregular nuclei. There is no matrix.

### RADIOGRAPHIC FEATURES

Primary lymphoma of bone tends to be located in the metadiaphyseal region, although 25% to 100% of the bone may be involved in a mottled or patchy fashion on plain radiographs. The margins are indistinct, with marked cortical destruction and soft-tissue extension. In some lesions, there is cortical thickening. There is usually no matrix mineralization. At times, plain radiographic changes may be subtle, but MRI scans show diffuse marrow signal change. Differentiation from Ewing's sarcoma, metastatic carcinoma, osteomyelitis, and Paget's disease may be difficult.

### TREATMENT

It is extremely important to obtain accurate clinical staging of the patient with lymphoma. In the past, inadequate staging has confused the analysis of clinical outcome. Routine blood counts and chemistries, chest radiograph, chest/abdomen/pelvis CT scan, and bilateral bone marrow biopsies are required. The primary treatment of lymphoma of bone is radiation (Fig. 128.19). The entire bone is treated with 4000 cGy, with a boost to the affected region of 4500 to 5000 cGy. Local control up to 85% has been reported (30). Chemotherapy is generally advocated for systemic disease, and different regimens are used for Hodgkin's and non-Hodgkin's lymphoma (92). The use of chemotherapy in the treatment of lymphoma with a single bony focus (stage 1E) is debated but appears to show some benefit in small series (2,38). Surgery is reserved for impending or actual pathologic fractures that cannot be managed reasonably by other means. Surgery is also indicated for isolated, uncontrolled lesions of an extremity that have failed to respond to radiation treatment.

***Figure 128.19.*** **A, B:** AP and lateral radiographs of the left distal femur in an 18-year-old man with lymphoma of bone. Note the lytic destruction with extensive periosteal reaction. **C:** Radiographs of the left distal femur 5 years after treatment with radiation and chemotherapy.

The overall survival rate of patients with primary bone lymphoma is 58% at 5 years and 53% at 10 years (15,110). Metastasis or recurrence may occur many years later, making 5-year survival values less reliable. The clinical staging of lymphoma has important prognostic significance (148).

## CHORDOMA

### CLINICAL FEATURES

Chordoma is a rare malignant bone tumor that occurs in the midline of the axial skeleton (35,39,61,63). It is a lesion that originates from primitive notochord remnants and accounts for 1% to 4% of primary osseous malignancies. It arises primarily at the cephalad and caudad regions of the spine, with the remainder within the cervical, thoracic, and lumbar vertebral bodies. Sacrococcygeal lesions comprise 50% of the tumors. The vast majority of sacral lesions present in patients between 50 and 70 years of age and are extremely unlikely in those younger than 30 years of age (155). Chordomas are slow-growing, locally invasive tumors, but they metastasize in 10% of patients (22). Symptoms depend on the location. The lesions arising at the base of the skull present a decade earlier than their sacral counterparts because they have less space to grow before causing symptoms. Vertebral chordomas cause symptoms as a result of pressure on nerve roots or the spinal cord (13). Patients may have numbness in an extremity, followed by pain. Many develop motor weakness, and paralysis is a late complication. The sacrococcygeal lesions can become quite large before discovery and may be associated with a long history of vague lower back pain. This may be referred to the hip or knee with further neoplastic progression. The mass usually displaces but does not invade the rectum and may cause constipation. Bladder symptoms such as urinary frequency are common, and incontinence is a late finding. If the chordoma originates caudal to the S-1 level, there is rarely any sensory or motor disturbance to the lower extremities. Late in the course, pain may become severe and intractable. Sacral lesions often arise as a fixed, palpable presacral mass noted on rectal examination.

### PATHOLOGIC FEATURES

On gross inspection, a chordoma may be lobulated and deceptively well circumscribed, but the tumorous tissue often extends beyond visible boundaries (Fig. 128.20; see also Color Fig. 128.20). It is soft, gray, and has a gelatinous consistency. Translucent areas may give it the appearance of a chondrosarcoma or mucinous carcinoma. The tumor can be focally cystic or hemorrhagic. The periosteum of the affected bone may be elevated, and a large soft-tissue mass is common.

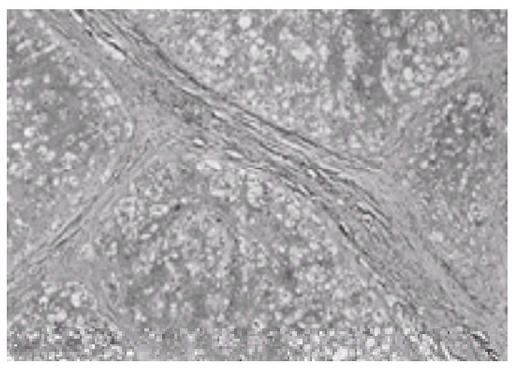

***Figure 128.20.*** (See Color Fig. 128.20.) Typical appearance of chordoma. The tumor is divided into lobules with fibrous septa. Tumor cells float in a blue myxoid background.

Microscopically, the tissue resembles fetal notochord. Lobules are separated by fibrous septa. Abundant basophilic extracellular matrix contains mucin and stains positively for glycogen. The cells are arranged in cords rather than being isolated in individual lacunae. Occasional islands of bone or cartilage are visible. On higher magnification, the cells are noted to be of various sizes and shapes with indistinct boundaries. The most classic type, called a physaliforous cell, has a round nucleus with multivacuolated cytoplasm, giving it a bubbly appearance. The vacuoles may displace the nucleus to the periphery of the cell. The differential diagnosis includes liposarcoma, metastatic carcinoma, and myxoid chondrosarcoma.

**RADIOGRAPHIC FEATURES**

The plain radiographic hallmark of a chordoma is midline bony destruction with a large associated soft-tissue mass (Fig. 128.21). The anterolateral mass is usually more extensive than the bony involvement. The lesions are poorly marginated and may be difficult to discern in the sacrococcygeal region. In the vertebral body, the chordoma is lytic, centrally located, and slowly expansile. Areas of sclerosis due to reactive bone formation are seen. Adjacent vertebral bodies and the intervening disc space can be involved.

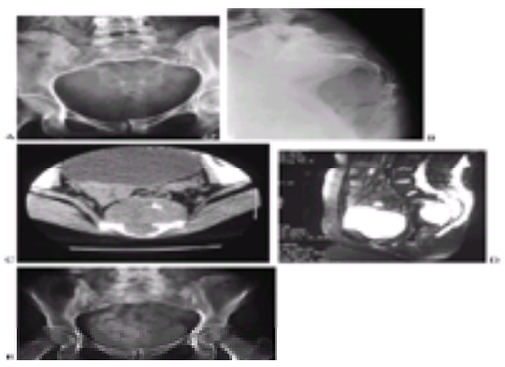

***Figure 128.21.*** **A, B:** AP and lateral radiographs of the sacrum in a 47-year-old woman with a chordoma. It is often difficult to see the lucency on plain radiographs. **C:** CT scan through the distal sacrum reveals a large presacral mass with characteristic flecks of calcification. There is midline destruction of the sacrum. **D:** Sagittal MRI scan with a T2-weighted sequence reveals the large mass to be pressing on the rectum and extending proximally to the S2–S3 junction. **E:** Postoperative radiograph of the sacrum after *en bloc* resection at S2–S3.

Reports vary as to the activity of a chordoma on bone scan, and accumulation of isotope in the bladder can obscure the sacral area. CT scans and MRI have been extremely helpful in determining the extent of the lesion and determining its proximity to vital structures. This is essential in preoperative planning. CT scans identify calcified areas that are not evident on plain films. Along with myelography, CT is helpful in planning resection of a vertebral lesion. MRI is useful in discovering recurrent nodules after surgical resection. Angiography is only occasionally indicated to identify the proximity of a cervical chordoma to the vertebral arteries. The radiographic differential diagnosis includes metastatic disease, multiple myeloma, giant cell tumor, and neurogenic tumors.

**TREATMENT**

After discovering a midline destructive lesion thought to be a chordoma, perform a biopsy after all staging studies are completed. A posterior needle biopsy can be used in collaboration with an experienced bone pathologist. On the other hand, most biopsies are performed through an open posterior approach. Under no circumstances should a transrectal biopsy be performed due to contamination of intervening tissue planes.

The mainstay of treatment and best hope for long-term survival is *en bloc* resection of the tumor with a wide margin and a surrounding cuff of normal tissue (Fig. 128.21. This resection is easier to perform in sacrococcygeal lesions because the anatomy of the skull base often precludes complete excision (48,165). The sacral nerve roots must be sacrificed, if necessary, to obtain an adequate margin. Given the large size, poorly accessible location, and tendency to adhere to the bowel, a wide margin is difficult to achieve, so a marginal resection is often the best that can be done. There is a high recurrence rate with inadequate resection, and recurrent lesions carry a poor prognosis because they often infiltrate the surrounding tissues.

Preoperatively, perform a complete bowel preparation and intravenous antibiotic prophylaxis to decrease the chance of wound infection. Intraoperatively, suture the anus to prevent possible fecal contamination of the surgical field. Close the wound primarily only if this can be done without undue tension. The operative time can be prolonged with difficult resections; therefore, attention to blood loss is critical. Greater blood loss can be expected in higher sacral lesions from the middle sacral vessels and branches of the internal iliac veins. Control hemorrhage by ligation of one or both of the internal iliac vessels, particularly in lesions above S-3. Postoperatively, administer antibiotics and provide prophylaxis for deep venous thrombosis. Resection of lesions below the third sacral level can be accomplished through a posterior approach, as described by MacCarty and colleagues (84; see also references 25 and 83). Lesions more cephalad often need a combined anterior and posterior approach in the same operative setting. For high sacral lesions, sacrifice of involved nerve roots and plans for a colostomy should be anticipated. Surgical resection in this location is associated with high morbidity. Full sacral resection can be performed when necessary to achieve a wide margin. Current advances in skeletal reconstruction can maintain stability after extensive resections (see Chapter 126). Thoracic lesions should be approached via thoracotomy, although combined anterior and posterior reconstruction and stabilization is often required after vertebral body excision. A retroperitoneal approach is usually adequate for midlumbar to lower lumbar lesions.

Chordomas are generally radioresistant, but adjuvant treatment has been used for contaminated surgical margins or surgically inaccessible lesions. Given the increased recurrence rate of large lesions, attention has focused on new preoperative and postoperative irradiation approaches to improve the chance of local control (125,145). The amount of irradiation is limited by the sensitivity of the spinal cord in the cranial and cervical regions and by the pelvic organs, colon, rectum, and overlying sacral skin in more caudal lesions. To facilitate the use of high local radiation doses without structural damage, proton beam and photon beam radiation techniques have been successful, but their long-term effectiveness is yet to be established (145). Wound healing problems contribute to high morbidity after radiation therapy. In addition, there have been reports of postirradiation high-grade sarcomas after treatment of a chordoma (147). Although this is a rare occurrence, radiation therapy should not be routinely prescribed to all patients with this tumor without careful consideration. Chemotherapy has no current role in the management of chordoma.

**RESULTS OF TREATMENT**

In general, the results for long-term survival depend on the adequacy of the initial surgical resection. Multiple studies have shown increased rates of recurrence with intralesional margins compared with wide excision. One report showed an increased recurrence rate from 28% after *en bloc* resection of a chordoma to 64% if the tumor was exposed during resection (70).

Function after surgery depends on both the level of resection and on which sacral roots remain. If the S-1 level is preserved, loss of motor function is minimal (71). Stener and Gunterberg (143) reported on extirpation of high sacral tumors that no deficit of urogenital or anorectal function occurs if there is only unilateral sacrifice of all sacral nerves. If only the first sacral roots are preserved, no sphincter control will remain, and the patient will need routine bladder self-catheterization. If bilateral S-2 roots are maintained, up to 50% of patients may retain partial bowel and bladder control with need for catheterization. If at least one S-3 root is saved, sphincter control will most likely be retained. Conversely, if the tumor is left untreated, 100% of patients will eventually have complete incontinence. Reconstruction is not needed if pelvic continuity can be maintained through preservation of half of the first sacral body (143).

A recent study examined 21 cases of sacrococcygeal chordoma (127). All lesions were approached posteriorly, and 14 had adjuvant radiotherapy. Four patients died, and 15 of the remaining 17 were disease-free at average 4.5-year follow-up. There was a 19% local recurrence rate, which compares well with the available literature, especially because a combined operative approach was not used. It was suggested that preoperative or postoperative radiation therapy allowed a better result after a marginal resection. There was a 5% incidence of metastases at 5 years, which increased to 50% at 10 years.

Another study reviewed 47 patients who had a reaction of sacrococcygeal chordomas with a 9-year average follow-up (24). Eighty-one percent were approached posteriorly, and only 19% were resected with a wide margin. Fifty-two percent received adjuvant postoperative irradiation. The cumulative probability of local recurrence was 51% at 5 years and 75% at 10 years. When the lesion extended to the S-1 level, there was 100% recurrence in seven cases. There was a 24% probability of

metastases at 5 years and 58% at 10 years. All but one patient with distant metastases also had local recurrence.

Chordomas are known to metastasize late, with the likelihood ranging from 5% to 40% in the literature. They can be found from 1 to 16 years after initial diagnosis. This finding is limited to sacral, or less likely vertebral, chordomas; the intracranial types rarely metastasize. Accurate prediction of which tumors will metastasize is not yet possible. The spread is to the regional lymph nodes, as well as the skin, lung, liver, and bone. Almost all patients die as a result of complications from local treatment failure rather than metastases, which are commonly asymptomatic. Studies show survival of patients with chordoma to be 45% to 77% at 5 years and 28% to 50% at ten years.

## ADAMANTINOMA

### CLINICAL FEATURES

Adamantinoma is an extremely rare primary malignant bony neoplasm (39,63,129,155). Half of the lesions occur in the second and third decades, and the remainder present throughout life. There is a slight male predominance. Ninety percent are found in the diaphysis of the tibia. Ten percent of patients have an ipsilateral fibular adamantinoma. The etiology of these tumors is not clear (59). They may have their origin in cells capable of differentiating into either epithelial or mesenchymal components, or else they are primarily an epithelial malignancy with a reactive fibrous stroma.

An adamantinoma presents as swelling with or without pain. It is a slow-growing lesion, and symptoms may be present from a few weeks to 50 years. More than one third of patients have symptoms for more than 5 years before diagnosis. A mass is the only finding on physical examination. An associated local traumatic event occurs in half of the patients, but no causal effect has been documented. There is slow but progressive bony destruction throughout adulthood. Metastases occur late, most often to the lungs, and account for 70% of the reported deaths from adamantinoma (100).

Adamantinoma is often confused with osteofibrous dysplasia, a benign tumor that presents in a similar location. However, the clinical presentation of osteofibrous dysplasia is in the first decade and generally asymptomatic. It is a self-limited process that does not progress or metastasize (75,101).

### PATHOLOGIC FEATURES

Grossly, an adamantinoma can be firm or soft, granular or fibrotic, or smooth or lobulated (Fig. 128.22; see also Color Fig. 128.22). It is grayish white and may have areas of necrosis, hemorrhage, or cystic spaces. It is well marginated and easily distinguishable from the surrounding normal tissue. Most are greater than 5 cm in length and can often involve the entire tibial shaft.

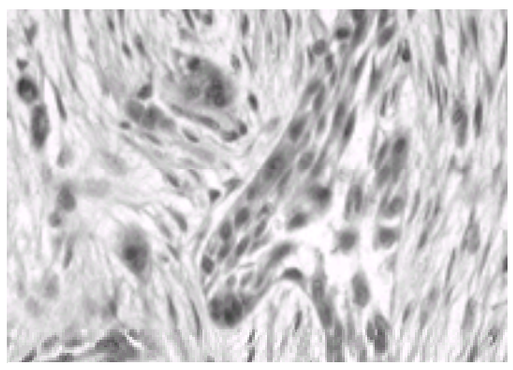

***Figure 128.22.*** (See Color Fig. 128.22.) Clusters of epithelial cells surrounded by fibrosis diagnostic of adamantinoma.

Histologically, an adamantinoma has a biphasic appearance with epithelial and fibrous areas. There are multiple appearances of the epithelial components in the adamantinoma; however, all of the epithelial cells stain strongly for keratin (7,159). Disorganized bony fragments may be seen within the stroma. The stroma can look strikingly similar to fibrous dysplasia. The nuclei are bland with minimal atypia in only 15%. Usually, no mitotic figures are seen, but they can be present without causing alarm. Electron microscopy and immunohistochemical staining for cytokeratin or other epithelial markers will confirm the lesion as an adamantinoma. The histologic differential diagnosis includes metastatic carcinoma, vascular neoplasms, synovial sarcoma, and osteofibrous dysplasia.

### RADIOGRAPHIC FEATURES

Plain radiographs are characteristic, demonstrating lobulated, lytic areas surrounded by sclerotic reactive bone (Fig. 128.23). A “soap bubble” appearance is classically described, with the tumor centered in the diaphysis of the tibia and asymmetrically expanding the anterior cortex. The lytic areas are sharply defined and may extend into the metaphysis but never occur in the epiphysis. Penetration of the cortex occurs in 15% of cases. Although there is a dominant central lesion, the eccentric lucent areas can occur throughout the shaft, separated by areas of sclerosis and having a multiloculated appearance. There may be bowing of the tibia in longstanding lesions. A bone scan is usually intensely positive because of the extensive bony reaction, but no uptake is seen past the edges of the lesion as defined on plain films. CT scans demonstrate whether or not the cortical lesion has penetrated into the soft tissues or medullary canal. MRI scans do not aid in the diagnosis but are valuable for preoperative planning. The radiographic differential diagnosis includes fibrous dysplasia and osteofibrous dysplasia (14).

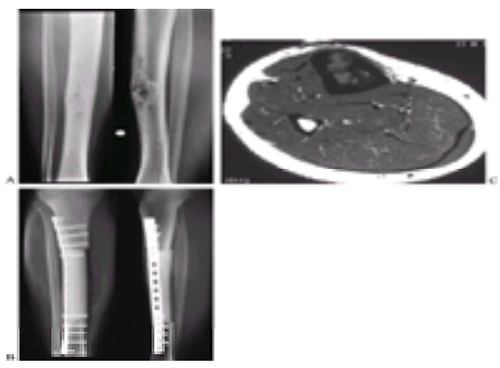

***Figure 128.23.*** **A:** AP and lateral radiographs of the tibia in a 23-year-old man with adamantinoma. Note the characteristic bubbly appearance of the anterior cortex in the tibial diaphysis. **B:** Axial MRI scan reveals medullary involvement of the tibia with expansion of the cortex but no soft-tissue mass. **C:** Following wide resection of the adamantinoma and reconstruction with an intercalary allograft.

### TREATMENT

Surgery is the primary method of treatment for adamantinoma. In the past, the malignant potential of this tumor was underestimated, and numerous cases were treated by local excision or curettage. This approach is associated with a 60% chance of local recurrence (72). It is now recognized that a wide margin is required by resection or amputation (49). All of the satellite lesions must be removed to minimize recurrence. Reconstruction after resection of a tibial lesion can be achieved by using intercalary allografts or vascularized fibular bone grafts (Fig. 128.23). If the entire shaft is involved, wide resection may not be practical, and amputation may be necessary. Amputation is also considered for recurrent lesions or those with extensive soft-tissue involvement when a wide margin cannot be obtained. Mankin and colleagues (49) described excellent early results after treatment by large segmental tibial resection followed by intercalary allograft replacement. Adjuvant radiation or chemotherapy has no role in the initial management of adamantinoma.

## RESULTS OF TREATMENT

In an excellent review of all documented cases of adamantinoma by Moon and Mori (100), the mortality rate was 18%, and known metastases were present in 70% of the patients who died. Metastases develop in 15% to 20% of patients and are more common following an inadequate initial resection with recurrent disease. Given the slow-growing nature of this tumor, an aggressive approach to pulmonary or lymph node metastases is warranted. Local recurrence and metastases may occur months to decades after treatment of the primary lesion; therefore, long-term follow-up is necessary (60). It is important not to underestimate the malignant potential of this tumor. Strict adherence to the principles of oncologic surgery ensure an optimal result.

## CHAPTER REFERENCES

Each reference is categorized according to the following scheme: *, classic article; #, review article; !, basic research article; and +, clinical results/outcome study.


+ 1. Aboulafia AJ, Buch R, Mathews J, et al. Reconstruction Using the Saddle Prosthesis Following Excision of Primary and Metastatic Periacetabular Tumors. *Clin Orthop* 1995;314:203.

+ 2. Bacci G, Jacce N, Emiliani E, et al. Therapy for Primary Non-Hodgkin's Lymphoma of Bone and a Comparison with Ewing's Sarcoma. *Cancer* 1986;57:1468.

+ 3. Bacci G, Picci P, Ferrari S, et al. Primary Chemotherapy and Delayed Surgery for Nonmetastatic Osteosarcoma of the Extremities: Results in 164 Patients Preoperatively Treated with High Doses of Methotrexate Followed by Cisplatin and Doxorubicin. *Cancer* 1993;72:3227.

+ 4. Bacci G, Toni A, Avella M, et al. Long Term Results in 144 Localized Ewing's Sarcoma Patients Treated with Combined Therapy. *Cancer* 1989;63:1477.

# 5. Barlogie B, Jagannath S, Vesole D, Tricot G. Autologous and Allogeneic Transplants for Multiple Myeloma. *Semin Hematol* 1995;32(Suppl 1):31.

+ 6. Bataille R, Sany J. Solitary Myeloma: Clinical and Prognostic Features of a Review of 114 Cases. *Cancer* 1981;48:845.

! 7. Benassi M, Campanacci L, Gamberi G, et al. Cytokeratin Expression and Distribution in Adamantinoma of the Long Bones and Osteofibrous Dysplasia of Tibia and Fibula. An Immunohistochemical Study Correlated to Histogenesis. *Histopathology* 1994;25:71.

+ 8. Bertoni F, Capanna R, Calderoni P, et al. Primary Central (Medullary) Fibrosarcoma of Bone. *Semin Diagn Pathol* 1984;1:185.

+ 9. Bertoni F, Bacchini P, Fabbri N, et al. Osteosarcoma, Low Grade Intraosseous Type, Histologically Resembling Parosteal Osteosarcoma, Fibrous Dysplasia, and Desmoplastic Fibroma. *Cancer* 1993;71:338.

+ 10. Bertoni F, Present D, Hudson T, et al. The Meaning of Radiolucencies in Parosteal Osteosarcoma. *J Bone Joint Surg* 1985;67A:901.

+ 11. Bjornsson J, Unni K, Dahlin D, et al. Clear Cell Chondrosarcoma of Bone: Observations in 47 Cases. *Am J Surg Pathol* 1984;8:223.

+ 12. Bjornsson J, Unni K, McLeod RA, et al. Primary Chondrosarcoma of Long Bones and Limb Girdles. *Cancer* 1998;83:2105.

+ 13. Bjornsson J, Wold L, Ebersold M, Laws E. Chordoma of the Mobile Spine. A Clinicopathologic Analysis of 40 Patients. *Cancer* 1993;71:735.

! 14. Bloem J, van der Heul R, Schuttevaer H, Kuipers D. Fibrous Dysplasia vs Adamantinoma of the Tibia: Differentiation Based on Discriminate Analysis of Clinical and Plain Film Findings. *AJR Am J Roentgenol* 1991;156:1017.

* 15. Boston HC Jr, Dahlin DC, Ivins JC, Cupps RE. Malignant Lymphoma (So-Called Reticulum Cell Sarcoma) of Bone. *Cancer* 1974;34:1131.

+ 16. Burgert EO Jr, Nesbit EM, Garnsey LA, et al. Multimodal Therapy for the Management of Nonpelvic Localized Ewing's Sarcoma of Bone: Intergroup Study IESS-II. *J Clin Oncol* 1990;8:1517.

* 17. Byrne GE Jr. Rappaport Classification of Non-Hodgkin's Lymphoma: Histologic Features and Clinical Significance. *Cancer Treat Res* 1977;61:935.

+ 18. Campanacci M, Picci P, Gherlinzoni F, et al. Parosteal Osteosarcoma. *J Bone Joint Surg* 1984;66B:313.

+ 19. Cannon SR. Massive Prostheses for Malignant Bone Tumors of the Limbs. *J Bone Joint Surg* 1997;79B:497.

+ 20. Capanna R, Bertoni F, Bacchini P, et al. Malignant Fibrous Histiocytoma of Bone: The Experience at the Rizzoli Institute: Report of 90 Cases. *Cancer* 1984;54:177.

+ 21. Carter SR, Grimer RJ, Sneath RS, et al. Results of Thoracotomy in Osteogenic Sarcoma with Pulmonary Metastases. *Thorax* 1991;46:727.

! 22. Chambers PW, Schwinn CP. Chordoma: A Clinicopathologic Study of Metastasis. *Am J Clin Pathol* 1979;72:765.

+ 23. Choong PFM, Sim FH, Pritchard DJ, et al. Megaprostheses after Resection of Distal Femoral Tumors. A Rotating Hinge Design in 30 Patients followed for 2–7 Years. *Acta Orthop Scand* 1996;67:345.

+ 24. Choudhury S, Emmanuel R, Unni K, Sim F. Treatment of Sacrococcygeal Chordoma: A Review of 47 Cases. Presented at the AAOS meeting February, 1995, Orlando, Florida.

* 25. Cody HS III, Marcove RC, Quan SH. Malignant Retrorectal Tumors: 28 Years' Experience at Memorial Sloan-Kettering Cancer Center. *Dis Colon Rectum* 1981;24:501.

+ 26. Cossetto D, Nade S, Blackwell J. Malignant Fibrous Histiocytoma in Paget's Disease of Bone: A Report of Seven Cases. *Aust N Z J Surg* 1992;62:52.

* 27. Dahlin DC, Unni KK. Osteosarcoma of Bone and Its Important Recognizable Varieties. *Am J Surg Pathol* 1977;1:61.

! 28. Delattre O, Zucman J, Melot T, et al. The Ewing Family of Tumors—A Subgroup of Small Round Cell Tumors Defined by Specific Chimeric Transcripts. *N Engl J Med* 1994;331:294.

+ 29. Damron TA, Sim FH, O'Conner MI, Pritchard DJ. Ewing's Sarcoma of the Proximal Femur. *Clin Orthop* 1995;316:189.

+ 30. Dosoretz, DE, Murphy GF, Raymond AK, et al. Radiaton Therapy for Primary Lymphoma of Bone. *Cancer* 1983;51:44.

* 31. Durie BGM, Salmon SE. A Clinical Staging System for Multiple Myeloma. Correlation of Measured Myeloma Cell Mass with Presenting Clinical Features, Response to Treatment, and Survival. *Cancer* 1975;36:842.

+ 32. Earl HM, Pringle J, Kemp H, et al. Chemotherapy of Malignant Fibrous Histiocytoma of Bone. *Ann Oncol* 1993;4:409.

+ 33. Eckardt JJ, Eilber FR, Rosen G, et al. Endoprosthetic Replacement for Stage IIB Osteosarcoma. *Clin Orthop* 1991;270:202.

+ 34. Edmonson JH, Green SJ, Ivins JC, et al. A Controlled Pilot Study of High-Dose Methotrexate as Postsurgical Adjuvant Treatment for Primary Osteosarcoma. *J Clin Oncol* 1984;2:152.

# 35. Enneking WF. *Musculoskeletal Tumor Surgery,* Vol 2. New York: Churchill Livingstone, 1983.

+ 36. Evans R, Nesbit M, Askin F, et al. Local Recurrence, Rate and Sites of Metastases, and Time to Relapse as a Function of Treatment Regimen, Size of Primary and Surgical History in 62 Patients Presenting with Nonmetastatic Ewing's Sarcoma of the Pelvic Bones. *Int J Radiat Oncol Biol Phys* 1985;11:129.

+ 37. Evans RG, Nesbit ME, Gehan EA, et al. Multimodal Therapy for the Management of Localized Ewing's Sarcoma of Pelvic and Sacral Bones: A Report from the Second Intergroup Study. *J Clin Oncol* 1991;9:1173.

+ 38. Fairbanks RK, Bonner JA, Inwards CY, et al. Treatment of Stage 1E Primary Lymphoma of Bone. *Int J Radiat Oncol Biol Phys* 1994;28:363.

# 39. Fechner R, Mills S. *Atlas of Tumor Pathology. Tumors of the Bones and Joints,* 3rd series. Washington, DC: Armed Forces Institute of Pathology, 1993.

+ 40. Fletcher BD, Hanna SL, Fairclough DL, Gronemyer SA. Pediatric Musculoskeletal Tumors: Use of Dynamic, Contrast-enhanced MR Imaging to Monitor Response to Chemotherapy. *Radiology* 1992;184:243.

# 41. Frassica F, Chao EYS, Sim FH. Special Problems in Limb Salvage Surgery. *Semin Surg Oncol* 1997;13:55.

+ 42. Frassica FJ, Frassica DA, Pritchard DJ, et al. Ewing's Sarcoma of the Pelvis. *J Bone Joint Surg* 1993;75A:1457.

* 43. Frassica DA, Frassica FJ, Schray MF, et al. Solitary Plasmacytoma of Bone: Mayo Clinic Experience. *Int J Radiat Oncol Biol Phys* 1989;16:43.

+ 44. Frassica FJ, Sim FH, Frassica DA, et al. Survival and Management Considerations in Postirradiation Osteosarcoma and Paget's Osteosarcoma. *Clin Orthop* 1991;270:120.

* 45. Frassica FJ, Unni KK, Beabout JW, Sim FH. Dedifferentiated Chondrosarcoma: A Report of the Clinicopathologic Features and Treatment in Seventy-Eight Cases. *J Bone Joint Surg* 1986;68-A:1197.

+ 46. Galli SJ, Weintraub HP, Proppe KH. Malignant Fibrous Histiocytoma and Pleomorphic Sarcoma in Association with Medullary Bone Infarcts. *Cancer* 1978;41:607.

+ 47. Garrison R, Unni K, McLeod R, et al. Chondrosarcoma Arising in Osteochondroma. *Cancer* 1982;49:1890.

+ 48. Gay E, Sekhar L, Rubinstein, E, et al. Chordomas and Chondrosarcomas of the Cranial Base: Results and Follow-up of 60 Patients. *Neurosurgery* 1995;36:887.

+ 49. Gebhardt M, Lord F, Rosenberg A, Mankin H. The Treatment of Adamantinoma of the Tibia by Wide Resection and Allograft Bone Transplantation. *J Bone Joint Surg* 1987;69-A:1177.

+ 50. Gitelis S, Bertoni F, Picci P, Campanacci M. Chondrosarcoma of Bone: The Experience at the Instituto Orthopedico Rizzoli. *J Bone Joint Surg* 1981;63A:1248.

# 51. Goldwein JW. Effects of Radiation Therapy on Skeletal Growth in Childhood. *Clin Orthop* 1991;262:101.

# 52. Greipp PR. Advances in the Diagnosis and Management of Myeloma. *Semin Hematol* 1992;29(Suppl 2):24.

# 53. Greipp PR, Witzig T. Biology and Treatment of Myeloma. *Curr Opin Oncol* 1996;8:20.

# 54. Grier HE. The Ewing's Family of Tumors. Ewing's Sarcoma and Primitive Neuroectodermal Tumors. *Pediatr Clin North Am* 1997;44:991.

+ 55. Grier H, Krailo M, Link M, et al. Improved Outcome in Nonmetastatic Ewing's Sarcoma and PNET of Bone with the Addition of Ifosfamide and Etoposide to Vincristine, Adriamycin, Cyclosphosphamide, and Actinomycin: A Children's Cancer Group and Pediatric Oncology Group report. (Abstract.) *Proc Am Soc Clin Oncol* 1994;13:421.

+ 56. Grubb MR, Currier BL, Pritchard DJ, Ebersold MJ. Primary Ewing's Sarcoma of the Spine. *Spine* 1994;19:309.

* 57. Harrington KD, Sim FH, Enis JE, et al. Methylmethacrylate as an Adjunct in Internal Fixation of Pathological Fractures: Experience with Three Hundred and Seventy-Five Cases. *J Bone Joint Surg* 1976;58-A:1047.

+ 58. Harwood AR, Knowling MA, Bergsagel DE. Radiotherapy of Extramedullary Plasmacytoma of the Head and Neck. *Clin Radiol* 1981;32:31.

+ 59. Hazelbag H, Hogendoorn P. Adamantinoma of Long Bones: Current Perspectives on Clinical Behaviour, Histology and Histogenesis. *The Cancer Journal* 1996;9:26.

+ 60. Hazelbag H, Taminiau A, Fleuren G, Hogendoorn P. Adamantinoma of the Long Bones. *J Bone Joint Surg* 1994;76-A:1482.

# 61. Healey J, Lane J. Chordoma: A Critical Review of Diagnosis and Treatment. *Orthop Clin North Am* 1989;20:417.

+ 62. Hejna MJ, Gitelis S. Allograft Prosthetic Composite Replacement for Bone Tumors. *Semin Surg Oncol* 1997;13:18.

# 63. Huvos AG. *Bone Tumors: Diagnosis, Treatment and Prognosis,* 2nd ed. Philadelphia: W.B. Saunders, 1991.

+ 64. Huvos AG, Heilweil M, Bretsky SS. The Pathology of Malignant Fibrous Histiocytoma of Bone: A Study of 130 Patients. *Am J Surg Pathol* 1985;9:853.

+ 65. Huvos AG, Higinbotham NL. Primary Fibrosarcoma of Bone. A Clinicopathologic Study of 130 Patients. *Cancer* 1975;35:837.

+ 66. Huvos AG, Rosen G, Dabska M, Marcove R. Mesenchymal Chondrosarcoma: A Clinicopathologic Analysis of 35 Patients with Emphasis on Treatment. *Cancer* 1983;51:1230.

+ 67. Huvos AG, Woodard HQ, Hellweil M. Postradiation Malignant Fibrous Histiocytoma of Bone: A Clinicopathologic Study of 20 Patients. *Am J Surg Pathol* 1986;10:9.

# 68. Jaffe N, Patel SR, Benjamin RS. Chemotherapy in Osteosarcoma. Basis for Application and Antagonism to Implementation; Early Controversies Surrounding its Implementation. *Hematol Oncol Clin North Am* 1995;9:825.

+ 69. Jurgens H, Exner U, Gadner H, et al. Multidisciplinary Treatment of Primary Ewing's Sarcoma of Bone: A 6-Year Experience of a European Cooperative Trial. *Cancer* 1988;61:23.

+ 70. Kaiser T, Pritchard D, Unni K. Clinicopathologic Study of Sacrococcygeal Chordoma. *Cancer* 1984;53:2574.

+ 71. Karakousis C. Sacral Resection with Preservation of Continence. *Surg Gynecol Obstet* 1986;163:271.

+ 72. Keeney G, Unni K, Beabout J, Pritchard D. Adamantinoma of Long Bones. A Clinicopathologic Study of 85 Cases. *Cancer* 1989;64:730.

+ 73. Kelly JJ, Kyle RA, Miles JM, et al. Osteosclerotic Myeloma and Peripheral Neuropathy. *Neurology* 1983;33:202.

+ 74. Kleinerman ES. Biologic Therapy for Osteosarcoma Using Lipsome Encapsulated Muramyl Tripeptide. *Hematol Oncol Clin North Am* 1995;9:927.

! 75. Knapp RH, Wick MR, Scheithauer BW, Unni KK. Adamantinoma of Bone: An Electron Microscopic and Immunohistochemical Study. *Virchows Arch* 1982;398-A:75.

+ 76. Krailo M, Ertel I, Makley J, et al. A Randomized Study Comparing High-Dose Methotrexate with Moderate-Dose Methotrexate as Components of Adjuvant Chemotherapy in Childhood Nonmetastatic Osteosarcoma: A Report from the Children's Cancer Study Group. *Med Pediatr Oncol* 1987;15:69.

+ 77. Kuttesch JF, Wexler LH, Marcus RB, et al. Second Malignancies After Ewing's Sarcoma: Radiation Dose-Dependency of Secondary Sarcomas. *J Clin Oncol* 1996;14:2818.

* 78. Kyle RA. Multiple Myeloma: Review of 869 Cases. *Mayo Clin Proc* 1975;50:29.

+ 79. Laha RK, Rao S. Replacement of Vertebral Body With Acrylic in Plasma Cell Myeloma. *Int Surg* 1979;64:59.

+ 80. Lee JY, Fetsch JF, Wasdhal DA, et al. A Review of 40 Patients with Extraskeletal Osteosarcoma. *Cancer* 1995;76:2253.

+ 81. Lewis MM. The Use of an Expandable and Adjustable Prosthesis in the Treatment of Childhood Malignant Bone Tumors of the Extremity. *Cancer* 1986;57:499.

+ 82. Link MP, Goorin AM, Horowitz M, et al. Adjuvant Chemotherapy of High-Grade Osteosarcoma of the Extremity: Updated Results of the Multi-institutional Osteosarcoma Study. *Clin Orthop* 1991;270:8.

+ 83. Localio SA, Eng K, Ranson JHC. Abdominosacral Approach for Retrorectal Tumors. *Ann Surg* 1980;191:555.

+ 84. MacCarty CS, Waugh JM, et al. The Surgical Treatment of Presacral Tumors: A Combined Problem. *Proc Mayo Clin* 1952;27:73.

+ 85. Malawer MM. Surgical Technique and Results of Limb Sparing Surgery for High-Grade Bone Sarcomas of the Knee and Shoulder. *Orthopedics* 1985;8:597.

+ 86. Malawar MM, McHale KA. Limb-Sparing Surgery for High-Grade Malignant Tumors of the Proximal Tibia: Surgical Technique and a Method of Extensor Mechanism Reconstruction. *Clin Orthop* 1989;239:231.

! 87. Mankin HJ, Cantley KP, Lippiello L, et al. The Biology of Human Chondrosarcoma. I. Description of the Cases, Grading, and Biochemical Analyses. *J Bone Joint Surg* 1980;62A:160.

! 88. Mankin HJ, Cantley K, Schiller AL, Lippiello L: The Biology of Human Chondrosarcoma. II. Variation in Chemical Composition Among Types and Subtypes of Benign and Malignant Cartilage Tumors. *J Bone Joint Surg* 1980;62A:176.

* 89. Mankin HJ, Gebhardt MC, Jennings LC, et al. Long Term Results of Allograft Replacement in the Management of Bone Tumors. *Clin Orthop* 1996;324:86.

+ 90. Marcove RC, Lewis MM, Huvos AG. En Bloc Upper Humeral Interscapulo-Thoracic Resection: The Tikhoff-Linberg Procedure. *Clin Orthop* 1977;124:219.

+ 91. Marti C, Kroner T, Remagen W, et al. High-Dose Ifosfamide in Advanced Osteosarcoma. *Cancer Treat Rep* 1985;69:115.

+ 92. Mauch P, Leonard R, Skarin A, et al. Improving Survival Following Combined Radiation Therapy and Chemotherapy for Unfavorable Prognosis Stage I–II non-Hodgkin's Lymphoma. *J Clin Oncol* 1985;3:1301.

+ 93. Mercuri M, Picci P, Campanacci L, Rulli E. Dedifferentiated Chondrosarcoma. *Skeletal Radiol* 1995;24:409.

+ 94. Mervak TR, Unni KK, Pritchard DJ, et al. Telangiectatic Osteosarcoma. *Clin Orthop* 1991;270:135.

+ 95. Meyers P, Heller G, Vlamis V, et al. Osteosarcoma of the Extremities: Chemotherapy Experience at Memorial Sloan-Kettering. Cancer *Treatment Res* 1993;62:309.

+ 96. Miller CW, Aslo A, Won A, et al. Alterations of the p53, Rb, and MDM2 genes in osteosarcoma. *J Cancer Res Clin Oncol* 1996;122:559.

* 97. Mirels H. Metastatic Disease in Long Bones. *Clin Orthop* 1989;249:256.

+ 98. Miser J, Arndt C, Smithson W, et al. Long Term Follow-Up of High Grade Osteosarcoma Treated with Preoperative Ifosfamide, Adriamycin and High Dose Methotrexate with Cisplatin Added Postoperatively for Poor Histologic Responders. (Abstract 2054.) *Proc Am Soc Clin Oncol* 1998;17:535a.

+ 99. Miser JS, Krailo M, Myers P, et al. Metastatic Ewing's Sarcoma and Primitive Neuroectodermal Tumor of Bone; Failure of New Regimens to Improve Outcome. (Abstract.) *Proc Am Soc Clin Oncol* 1996;15:467.

* 100. Moon NF, Mori H. Adamantinoma of the Appendicular Skeleton—Updated. *Clin Orthop* 1986;204:215.

! 101. Mori H, Yamamoto S, Hiramatsu K, et al. Adamantinoma of the Tibia: Ultrastructural and Immunohistochemical Study with Reference to Histogenesis. *Clin Orthop* 1984;190:299.

+ 102. Nakashima Y, Unni KK, Shives TC, et al. Mesenchymal Chondrosarcoma of Bone and Soft Tissue. A Review of 111 Cases. *Cancer* 1986;57:2444.

+ 103. Nelson DL, Abdul-Karim FW, Carter JR, Makley JT. Chondrosarcoma of Small Bones of the Hand Arising from Enchondroma. *J Hand Surg* 1990;15A:655.

+ 104. Nesbit ME, Gehan EA, Burgert EO, et al. Multimodal Therapy for the Management of Primary, Nonmetastatic Ewing's Sarcoma of Bone: A Long Term Follow-Up of the First Intergroup Study. *J Clin Oncol* 1990;8:1664.

+ 105. Nishida J, Sim FH, Wenger D, Unni KK. Malignant Fibrous Histiocytoma of Bone: A Clinicopathologic Study of 81 Patients. *Cancer* 1997;79:482.

# 106. O'Conner MI, Pritchard DJ. Ewing's Sarcoma. Prognostic Factors, Disease Control, and the Reemerging Role of Surgical Treatment. *Clin Orthop* 1991;262:78.

+ 107. Ohtomo K, Terui S, Yokoyama R, et al. Thallium-201 Scintigraphy to Assess Effect of Chemotherapy in Osteosarcoma. *J Nucl Med* 1996;37:1444.

+ 108. Okada K, Frassica FJ, Sim FH, et al. Parosteal Osteosarcoma: A Clinicopathologic Study. *J Bone Joint Surg* 1994;76A:366.

# 109. Oken MM. Standard Treatment of Multiple Myeloma. *Mayo Clin Proc* 1994;69(Suppl 8):781.

+ 110. Ostrowski ML, Unni KK, Banks PM, et al. Malignant Lymphoma of Bone. *Cancer* 58:2646; 1986.

+ 111. Ozaki T, Hillmann A, Hoffmann C, et al. Significance of Surgical Margin on the Prognosis of Patients with Ewing's Sarcoma. A Report from the Cooperative Ewing's Sarcoma Study. *Cancer* 1996;78:892.

# 112. Paley D. Problems, Obstacles, and Complications of Limb Lengthening by the Ilizarov Technique. *Clin Orthop* 1990;250:81.

+ 113. Papagelopoulos P, Galanis E, Frassica F, et al. Primary Fibrosarcoma of Bone: Outcome after Primary Surgical Treatment. *Clin Orthrop* 2000;373:88.

+ 114. Papagelopoulos P, Galanis E, Greipp PR, Sim FH. Prosthetic Hip Replacement for Pathologic or Impending Pathologic Fractures in Myeloma. *Clin Orthop* 1997;341:192.

+ 115. Peest D, Deicher H, Coldewey R, et al. Induction and Maintenance Therapy in Multiple Myeloma: A Multicenter Trial of MP versus VCMP. *Eur J Cancer Clin Oncol* 1988;24:1061.

! 116. Picci P, Bacci G, Campanacci M, et al. Histologic Evaluation of Necrosis in Osteosarcoma Induced by Chemotherapy: Regional Mapping of Viable and Nonviable Tumor. *Cancer* 1985;56:1515.

+ 117. Picci P, Bacci G, Ferrari S, Mercuri M. Neoadjuvant Chemotherapy in Malignant Fibrous Histiocytoma of Bone and in Osteosarcoma Located in the Extremities: Analogies and Differences between the Two Tumors. *Ann Oncol* 8:1107; 1997.

! 118. Picci P, Rougraff BT, Bacci G, et al. Prognostic Significance of Histopathologic Response to Chemotherapy in Nonmetastatic Ewing's Sarcoma of the Extremities. *J Clin Oncol* 1993;11:1763.

+ 119. Picci P, Sangiorgi L, Rougraff BT, et al. Relationship of Chemotherapy-induced Necrosis and Surgical Margins to Local Recurrence in Osteosarcoma. *J Clin Oncol* 1994;12:2699.

+ 120. Pignatti G, Bacci G, Picci P, et al. Telangiectatic Osteogenic Sarcoma of the Extremities: Results in 17 Patients Treated with Neoadjuvant Chemotherapy. *Clin Orthop* 1991;270:99.

+ 121. Pritchard DJ, Lunke RJ, Taylor WF, et al. Chondrosarcoma: A Clinicopathologic and Statistical Analysis. *Cancer* 1980;45:149.

+ 122. Pritchard DJ, Sim FH, Ivins JC, et al. Fibrosarcoma of Bone and Soft Tissues of the Trunk and Extremities. *Orthop Clin North Am* 1977;8:869.

+ 123. Resnick D, Greenway GD, Bardwick PA, et al. Plasma-Cell Dyscrasia with Polyneuropathy, Organomegaly, Endocrinopathy, M-Protein, and Skin Changes. The POEMS Syndrome. *Radiology* 1981;140:17.

+ 124. Ritts GD, Pritchard DJ, Unni KK, et al. Periosteal Osteosarcoma. *Clin Orthop* 1987;219:299.

+ 125. Romero J, Cardenes H, la Torre A, et al. Chordoma: Results of Radiation Therapy in Eighteen Patients. *Radiother Oncol* 1993;29:27.

+ 126. Rud NP, Reiman HM, Pritchard DJ, et al. Extraosseous Ewing's Sarcoma. A Study of 42 Cases. *Cancer* 1989;64:1548.

+ 127. Samson I, Springfield D, Suit H, Mankin H. Operative Treatment of Sacrococcygeal Chordoma. *J Bone and Joint Surg* 1993;75-A:1476.

+ 128. Scarborough MT, Helmstedter CS. Arthrodesis after Resection of Bone Tumors. *Semin Surg Oncol* 1997;13:25.

# 129. Schajowicz, F. *Tumors and Tumorlike Lesions of Bones: Pathology, Radiology, and Treatment,* 2nd ed. Berlin, Springer-Verlag, 1994.

+ 130. Schajowicz F, McGuire MH, Araujo ES, et al. Osteosarcomas Arising on the Surfaces of Long Bones. *J Bone Joint Surg* 1988;70-A:555.

! 131. Scotlandi K, Serra M, Manara MC, et al. Immunostaining of the p30/32 MIC2 Antigen and Molecular Detection of EWS Rearrangements for the Diagnosis of Ewing's Sarcoma and Peripheral Neuroectodermal Tumor. *Hum Pathol* 1996;27:408.

+ 132. Scully SP, Temple HT, Keefe RJ, et al. The Role of Surgical Resection in Pelvic Ewing's Sarcoma. *J Clin Oncol* 1995;13:2336.

+ 133. Shives TC, McLeod RA, Unni KK, Schray MF. Chondrosarcoma of the Spine. *J Bone Joint Surg* 1989;71-A:1158.

# 134. Sim FH, Bowman WE Jr, Wilkins RM, Chao EYS. Limb Salvage in Primary Malignant Bone Tumors. *Orthopedics* 1985;8:574.

+ 135. Sim FH, Chao EYS. Hip Salvage by Proximal Femoral Replacement. *J Bone Joint Surg* 1981;63-A:1228.

+ 136. Sim FH, Daugherty TW, Ivins JC. The Adjunctive Use of Methylmethacrylate in Fixation of Pathological Fractures. *J Bone Joint Surg* 1974;56-A:40.

# 137. Sim FH, Frassica FJ, Chao EYS. Orthopaedic Management Using New Devices and Prostheses. *Clin Orthop* 1995;312:160.

# 138. Sim FH, Frassica FJ, Miser JS, Unni KK. Current Concepts in the Evaluation and Treatment of Osteosarcoma of Bone. *Adv Operative Orthop* 1993;1:345.

+ 139. Sim FH, Ivins JC, Taylor WF, Chao EYS. Limb-Sparing Surgery for Osteosarcoma: Mayo Clinic Experience. *Cancer Treat Symp* 1985;3:139.

+ 140. Sim FH, Unni KK, Beabout JW, et al. Osteosarcoma with Small Cells Simulating Ewing's Tumor. *J Bone Joint Surg* 1979;61A:207.

+ 141. Simon MA, Aschliman MA, Thomas N, Mankin HJ. Limb-Salvage Treatment Versus Amputation for Osteosarcoma of the Distal End of the Femur. *J Bone Joint Surg* 1986;68-A:1331.

+ 142. Smith MA, Ungerleider RS, Horowitz ME, et al. Influence of Doxorubicin Dose Intensity on Response and Outcome for Patients with Osteogenic Sarcoma and Ewing's Sarcoma. *J Natl Cancer Inst* 1991;83:1460.

* 143. Stener B, Gunterberg B. High Amputation of the Sacrum for Extirpation of Tumors: Principles and Technique. *Spine* 1978;3:351.

! 144. Strickler JG, Audeh MW, Copenhaver CM, Warnke RA. Immunophenotypic Differences Between Plasmacytoma/Multiple Myeloma and Immunoblastic Lymphoma. *Cancer* 1988;61:1782.

+ 145. Suit HD, Goitein M, Munzenrider J, et al. Definitive Radiation Therapy for Chordoma and Chondrosarcoma of Base of Skull and Cervical Spine. *J Neurosurg* 1982;56:377.

+ 146. Sundaram M, McGuire MH, Herbold DR, et al. Magnetic Resonance Imaging in Planning Limb Salvage Surgery for Primary Malignant Tumors of Bone. *J Bone Joint Surg* 1986;68-A:809.

+ 147. Sundaresan N, Huvos AG, Krol G, et al. Postradiation Sarcoma Involving the Spine. *Neurosurgery* 1986;18:721.

+ 148. Sweet DL, Mass DP, Simon MA, Shapiro CM. Histiocytic Lymphoma (Reticulum-Cell Sarcoma) of Bone: Current Strategy for Orthopaedic Surgeons. *J Bone Joint Surg* 1981;63-A:79.

+ 149. Tabone M, Kalifa C, Rodary C, et al. Osteosarcoma Recurrences in Pediatric Patients Previously Treated with Intensive Chemotherapy. *J Clin Oncol* 1994;12:2614.

! 150. Taconis WK, Mulder JD. Fibrosarcoma and Malignant Fibrous Histiocytoma of Long Bones: Radiographic Features and Grading. *Skeletal Radiol* 1984;11:237.

+ 151. Taconis WK, van Rijssel TG. Fibrosarcoma of Long Bones. A Study of the Significance of Areas of Malignant Fibrous Histiocytoma. *J Bone Joint Surg* 1985;67-B:111.

+ 152. Tillman RM, Grimer RJ, Carter SR, et al. Growing Endoprostheses for Primary Malignant Bone Tumors. *Semin Surg Oncol* 1997;13:41.

+ 153. Toni A, Neff JR, Sudanese A, et al. The Role of Surgical Therapy in Patients with Nonmetastatic Ewing's Sarcoma of the Limbs. *Clin Orthop* 1993;286:225.

+ 154. Turnage WS, Gill-Murdoch C, McKeown PP, Conant P. Bilateral Thoracoscopy and Limited Thoracotomy. A Combined Approach for the Resection of Metastatic Fibrosarcoma. *Chest* 1994;106:935.

# 155. Unni KK. *Dahlin's Bone Tumors: General Aspects and Data on 11,087 Cases,* 5th ed. Philadelphia, Lippincott-Raven, 1996.

# 156. Vlasek R, Sim FH. Ewing's Sarcoma. *Orthop Clin North Am* 1996;27:591.

+ 157. Weatherby RP, Dahlin DC, Ivins JC. Postradiation Sarcoma of Bone: Review of 78 Mayo Clinic Cases. *Mayo Clin Proc* 1981;56:294.

! 158. Weber KL, Bolander ME, Rock MG, et al. Evidence for the Upregulation of Osteogenic Protein-1 mRNA Expression in Musculoskeletal Neoplasms. *J Orthop Res* 1998;16:8.

! 159. Weiss S, Dorfman, H. Adamantinoma of Long Bone. An Analysis of Nine New Cases with Emphasis on Metastasizing Lesions and Fibrous Dysplasia-like Changes. *Hum Pathol* 1977;8:141.

+ 160. Wexler LH, DeLaney TF, Tsokos M, et al. Ifosfamide and Etoposide plus Vincristine, Doxorubicin, and Cyclophosphamide for Newly Diagnosed Ewing's Sarcoma Family of Tumors. *Cancer* 1996;78:901.

+ 161. Wilkins RM, Pritchard DJ, Burgert EO Jr, Unni KK. Ewing's Sarcoma of Bone: Experience with 140 Patients. *Cancer* 1986;58:2551.

* 162. Winkelman WW. Rotationplasty. *Orthop Clin North Am* 1996;27:503.

+ 163. Winkler K, Bielack S, Delling G, et al. Effect of Intraarterial versus Intravenous Cisplatin in Addition to Systemic Doxorubicin, High-Dose Methotrexate, and Ifosfamide on Histologic Tumor Response in Osteosarcoma (Study COSS-86). *Cancer* 1990;66:1703.

+ 164. Winkler K, Bieling P, Bielack S, et al. Local Control and Survival from the Cooperative Osteosarcoma Study Group Studies of the German Society of Pediatric Oncology and the Vienna Bone Tumor Registry. *Clin Orthop* 1991;270:79.

+ 165. Wold LE, Laws ER Jr. Cranial Chordomas in Children and Young Adults. *J Neurosurg* 59:1043; 1983.

! 166. Yamaguchi T, Toguchida J, Yamamuro T, et al. Allelotype analysis in osteosarcomas: Frequent allele loss on 3q, 13q, 17p, and 18q. *Cancer Res* 1992;52:2419.

+ 167. Yazawa Y, Frassica FJ, Chao EYS, et al. Metastatic Bone Disease. A Study of the Surgical Treatment of 166 Pathologic Humeral and Femoral Fractures. *Clin Orthop* 1990;251:213.

# CHAPTER 129

# SOFT-TISSUE SARCOMAS AND BENIGN SOFT-TISSUE TUMORS OF THE EXTREMITIES

*Terrance D. Peabody and Michael A. Simon*

**T. D. Peabody and M. A. Simon**: University of Chicago Hospitals and Clinics, Department of Surgery, Section of Orthopaedic Surgery and Rehabilitation Medicine, Chicago, Illinois, 60637.

Evaluation of the Patient with a Soft-Tissue Mass
- History
- Examination
- Imaging Studies
- Biopsy

Operative Planning
Surgical Techniques
- Wide Excision of a Subcutaneous Sarcoma
- Wide Excision of a Thigh Sarcoma
- Marginal Resection of an Intramuscular Encapsulated Benign Tumor (Lipoma)

Common Soft-Tissue Tumors
- Classification
- Fibrous Lesions
- Lipomatous Soft-Tissue Tumors
- Smooth Muscle Neoplasms
- Striated Muscle Tumors
- Vascular Neoplasms
- Synovial Neoplasms
- Neural Lesions
- Staging of Malignant Soft-Tissue Tumors
- Complications

Chapter References

## EVALUATION OF THE PATIENT WITH A SOFT-TISSUE MASS

In stark contrast to bone tumors, soft-tissue masses of the extremities are a common physical finding. Whereas most are posttraumatic or inflammatory in nature, a certain number later prove to be benign or malignant soft-tissue neoplasms. Soft-tissue masses present a diagnostic and therapeutic challenge to the treating surgeon. Some require only observation, whereas others should be imaged with appropriate methods and subsequently undergo pathologic evaluation. The difficulty is knowing what features of the patient's soft-tissue mass—for example, size, depth, or texture—are important in differentiating benign from malignant disease. A consistent, comprehensive, and educated approach to the evaluation and treatment of a soft-tissue mass will allow the surgeon to overcome this difficulty and provide optimal care as well as avoid an inaccurate diagnosis and excessive or inadequate treatment.

### HISTORY

Unfortunately, the patient's medical history is rarely of value. Cognitive and emotional issues, especially anxiety, denial, or ignorance, often cloud a patient's memory and reporting of events related to the tumor. Patients usually are unable to give an accurate estimate as to how long the mass has been present or its growth characteristics. Often, there is a history of trauma to the region that has brought the mass to the patient's attention. Symptoms may or may not be present in both malignant and benign tumors; however, you are more likely to investigate and eventually treat masses that are symptomatic.

A patient's medical history rarely gives keys to the diagnosis, except for patients with multifocal disease or those who have an established clinical syndrome. Exceptions include a familial history of lipomatosis, neurofibromatosis, Gardner's syndrome (colonic polyposis and desmoid tumor), Li-Fraumeni syndrome (familial breast cancer and soft-tissue sarcoma) (16), and Maffucci's disease (hemangiomas noted in conjunction with multiple bone enchondromas).

### EXAMINATION

Similarly, physical findings are rarely accurate or diagnostic. Tumor size, depth, and consistency can only be approximated in all but very small subcutaneous masses. It is uncommon for a mass to be pulsatile, indicating an underlying vascular neoplasm, or for Tinel's sign to be present in association with peripheral nerve sheath tumors.

Because of these factors, the difficult part of the evaluation of a patient with a soft-tissue mass is discerning which lesions should simply be observed and which should undergo further evaluation with imaging studies and possible biopsy. A suggested strategy is delineated in Figure 129.1 (19). As can be seen, tumor size and tumor depth are important features (18,24). Large or deep tumors should be considered malignant until imaging studies or biopsy prove otherwise.

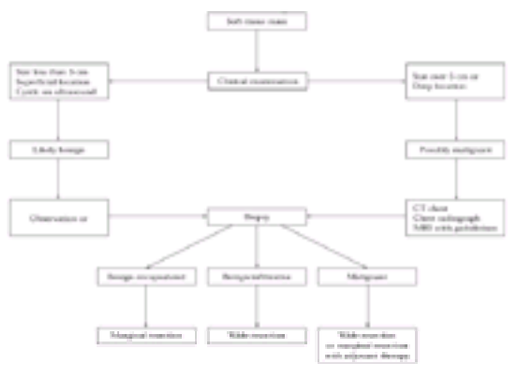

***Figure 129.1.*** Flow diagram of a suggested strategy for the evaluation and treatment of a patient with a soft-tissue mass.

### IMAGING STUDIES

Radiographs for soft-tissue masses, unlike bone tumors, are rarely diagnostic. Occasionally, a relative radiolucency is seen in the soft tissues compared with the surrounding tissues. This would suggest the presence of fat and an intramuscular lipoma. Phleboliths may be seen with hemangiomas; however, other forms of mineralization in the form of calcification or ossification are nonspecific and may suggest either underlying myositis ossificans, atypical infection (parasitic), or synovial sarcoma.

An ultrasound examination of the mass is particularly helpful in locations about joints (ganglion or popliteal cysts) and in the evaluation of the fluid content of a soft-tissue mass. Purely cystic masses are not likely to be malignant. Ultrasound is also useful in guiding the performance of an aspiration or biopsy, with cyst contents

sent for cytologic evaluation.

Small masses (smaller than 5 cm) that are superficial can be observed at intervals of several months to detect any change in size. Even if the underlying lesion proves to be malignant, the prognosis for survival as well as for local control is excellent (20,30). If the mass grows or symptoms develop, perform a magnetic resonance imaging (MRI) scan, followed by biopsy and possible excision.

Obtain an MRI of deep, larger masses (more than 5 cm) of the extremities. If the mass has signal characteristics identical to those of subcutaneous fat on all sequences and does not enhance with gadolinium, it is most likely to be a lipoma. Heterogeneous, large, or deep masses, especially those with a low signal on T1-weighted images and a higher signal on T2-weighted images, or those with gadolinium enhancement, should be suspected to be soft-tissue sarcomas. Additional imaging tests may be indicated, depending on the clinical diagnosis. Note that any local imaging study will have real and artifactual changes introduced by the performance of any operative procedure, including a biopsy; this will make their interpretation difficult. Therefore, perform all local imaging studies before any operative intervention.

Computed tomography (CT) is useful in identifying the location of soft-tissue tumors in the extremities but is more valuable in the pelvis. In many cases, CT scans reveal the proximity of the tumor to bone, nerve, and vascular structures; they also accurately indicate fat density. Lipomas usually can be differentiated from other tumors. CT scans are also important in the staging of malignant soft-tissue tumors in that the most common site of metastases from soft-tissue sarcomas is to the lungs. In comparison to plain radiography, CT has superior resolution in the imaging of metastatic disease in the lungs. Perform a CT scan of the retroperitoneum in the evaluation of extremity myxoid liposarcomas because, on occasion, patients will have concomitant disease in the retroperitoneum and extremities.

## BIOPSY

Biopsy is the final step in the evaluation of a patient with a soft-tissue mass. The biopsy is a technically simple procedure, but it requires extensive training and experience. A well-planned and executed biopsy provides an accurate diagnosis and facilitates treatment. A poorly performed biopsy, on the other hand, may fail to provide a diagnosis and, more important, may have a negative impact on patient survival and treatment options, especially the potential to preserve a limb (17). For these reasons, if a soft-tissue mass may be malignant, the biopsy should be performed by the surgeon who will ultimately be responsible for the full care of the patient.

Biopsies may be open (incisional or excisional) or closed (needle or trephine). The method is determined by the experience and preference of the surgeon and the pathologist, the differential diagnosis, and the anatomic location of the lesion. Closed procedures are less invasive, require smaller doses of anesthetic and analgesic agents, and carry a smaller risk in most instances. There is a lower risk of tumor contamination, hemorrhage, and infection than with open biopsies. When the procedures are supervised by the treating surgeon, they may be done under ultrasound or a CT scan visualization in order to localize the site of the biopsy better. Needle or trephine biopsies are usually performed in an outpatient or office setting whereas open biopsies require a full operating facility; therefore, they are less costly than open procedures (29).

The disadvantage of closed biopsy is the small amount of material obtained for pathologic review. For this reason, it is most important that the pathologist who reviews the material be trained in and have experience with needle biopsies. Highly accurate results are seen with closed technique biopies in large medical centers that have a large volume of musculoskeletal neoplasms (1). The accuracy of a closed biopsy is further improved by tumor homogeneity and the strength of supporting evidence provided by the surgeon regarding the clinical findings and the results of imaging studies. Closed biopsies are less reliable for cystic or myxoid tumors or heterogeneous-appearing neoplasms (29). With closed biopsy, there may not be enough pathologic material for additional studies such as cytogenetics or tissue culture, or for cellular research. Closed biopsies are more prone than open biopsies to sampling error, especially in heterogeneous tumors. The tissue architecture, which is important in determining tumor grade, may be more difficult to ascertain in a closed biopsy than in an open one.

Despite the increased morbidity, the anesthesia and analgesia required, and the greater cost of an open biopsy, it is the most reliable method for obtaining representative tissue. Open biopsies may be excisional or incisional. However, because of the technical difficulty in performing an incisional biopsy in the case of very small tumors, an open excisional biopsy is indicated for these tumors. In very small tumors, take a small cuff of surrounding tissue *en bloc* with the tumor (primary wide excision) because additional surgery may not be necessary, even in cases of malignancy.

### *Open Biopsy*

Biopsy placement is critical in that the biopsy site must be localized to obtain the best access to the tumor and it also must be in a position where the site can be excised *en bloc* with the tumor should it prove to be malignant.

- Perform the biopsy through a longitudinal incision. In the operative dissection, do not expose or contaminate important vascular or neural structures. Do not violate anatomic compartments other than those containing the tumor.
- Take special care around joints to prevent intraarticular contamination with tumor cells.
- Biopsies of soft tissue should not involve major tendons (e.g., the patellar tendon) or their insertion.
- In a biopsy, do not use intramuscular or intranervous planes, as in more standard orthopaedic approaches. Instead, use a direct approach with the smallest possible incision directly through skin, subcutaneous tissue, fascia, and muscle down to the tumor.

### *Fine-Needle Aspiration*

Pathologic diagnosis of a soft-tissue mass based on fine-needle aspiration is based on a pathologist's cytologic interpretation of single cells aspirated through a 0.6 to 1.0 mm—diameter needle. Fine-needle aspiration is more accurate in diagnosing homogeneous tumors than inhomogeneous tumors.

- After preparation of the skin, use the needle to make serial aspirations of the tumor bed through a single entry site. This site is agreed on by both the surgeon and the pathologist; ideally, mark it with any method that will allow future identification.
- This specimen is prepared immediately by the cytology technician, and the tissue is fixed according to the cytologist's preference. Often, the slides can be evaluated immediately.
- Maintain pressure on the biopsy site so that hematoma formation is minimized.

### *Tru-cut Needle Biopsy*

A Tru-cut (Baxter Health Care Corporation, Valencia, CA) needle biopsy is a trephine biopsy in which a 14-gauge cannula and trocar system are used that allow cores (approximately 1.75 mm) of tissue to be obtained with preservation of the architecture of the specimen.

- After preparation of the skin and infiltration with local anesthesia, use a #11 blade to incise the skin 2 to 3 mm.
- Then place the Tru-cut needle into the tumor bed. It is helpful to introduce the Tru-cut with the outer cannula sheath retracted, exposing the inner trocar tip and specimen notch.
- Sharply advance the outer cannula once the needle tip is placed within the tumor mass itself, so that an inner core of tissue is trapped.
- Repeat this procedure until multiple cores are available for pathologic review.
- Process the specimens with fixation in formalin or in gluteraldehyde.
- Maintain pressure on the site for several minutes to minimize hematoma formation.

An accurate diagnosis is obtained in approximately 80% of soft-tissue masses undergoing a Tru-cut biopsy (29).

### *Open Incisional Biopsy*

An open, incisional biopsy is a reliable means of making the diagnosis in soft-tissue tumors. Make the incision as small as is compatible with obtaining an adequate tumor specimen. Except for regions over the iliac crest or clavicle, longitudinal incisions are recommended.

- Proceed sharply through subcutaneous fat, fascia, and muscle. For intramuscular tumors, a color change in muscle from red to salmon often heralds the approaching tumor pseudocapsule. Malignant tumors are usually gray or white.
- Sample diagnostic tissue at the periphery of the tumor, which typically is the most viable region. A biopsy of necrotic appearing tissue is usually not of benefit.
- Perform frozen sections in all cases, if possible, for confirmation of the presence of tissue from which the pathologist may make a diagnosis. This is true even if definitive surgery is not planned at the same time.
- Meticulous hemostasis is essential so tumor spread by hematoma is prevented.

- Drains may be used, but they should be placed close to and in line with the incision to allow the future excision of the drain site along with the biopsy site. An outside-in technique for introduction of the drain, when the drain site is made with a scalpel and the drain is placed retrograde into the wound, is preferable to the use of a trocar from the deeper wound through the skin.
- Caution: Do not use widespread infiltration of local anesthetic or place sutures at a distance from the wound. A tourniquet may be applied for the procedure, but it must be deflated before wound closure. Do not exsanguinate the limb before biopsy.
- As with all surgical procedures, minimize postoperative limb swelling, edema, and bleeding through the use of sterile compressive dressings. Limb immobilization and elevation may also be required.

## OPERATIVE PLANNING

The decision to proceed with operative resection and the specific type of procedure performed depend on many factors, including the diagnosis, the local and distant extent of disease, the tumor location, the functional consequences of resection, and the patient's symptoms. An estimation of the growth pattern and malignant potential of the tumor will ultimately dictate treatment. Some benign tumors (e.g., lipomas) grow slowly in a centrifugal fashion and are bounded by surrounding anatomic structures such as fascia, bone, nerve, or vessels. A compressed area of fibrous adventitial and vascular structures forms a true capsule surrounding these neoplasms. In contrast, other benign tumors, such as intramuscular hemangiomas or desmoid tumors, lack a true capsule and often have permeative and infiltrative borders. Even malignant soft-tissue tumors, at least early on, respect anatomic borders but, instead of a true capsule, are surrounded by a “pseudocapsule” or reactive zone (7). This zone and the area surrounding it contain microscopic extensions or satellites of malignant tumor. An understanding of the growth characteristics is important in the selection of the most effective operative procedure for obtaining local control.

Enneking et al. (7,8) defined surgical resections as intralesional, marginal, wide, or radical.

- An *intralesional* resection is performed within the reactive zone of the tumor and includes debulking procedures. This form of resection is likely to leave both macroscopic and microscopic residual disease and to be associated with a high incidence of local relapse.
- A *marginal* resection is performed through the tissue plane of the capsule or reactive zone. This procedure is indicated for many benign tumors, but it is associated with an unacceptable risk of local recurrence in the case of malignant tumors because of residual microscopic peripheral satellite disease. For this reason, in the treatment of sarcomas, an effective adjuvant, most often radiation therapy, is administered in combination with a marginal operative resection for obtaining local control.
- A *wide* resection, performed in normal tissue peripheral to the reactive zone, is preferred for a soft-tissue sarcoma. With modern imaging for accurate determination of the tumor extent, this operative procedure is associated with a low incidence of local relapse and is recommended for most infiltrative benign and malignant tumors.
- A *radical* resection is one in which the entire anatomic compartment of tumor origin is removed. This procedure carries little, if any, advantage over wide resection in minimizing the prevalence of local recurrence and is now only rarely performed.

Amputations performed for malignant soft-tissue tumors may also be defined as marginal, wide, or radical according to the above-mentioned definitions. The indications for amputation are sepsis, extensive contamination of tumor from hemorrhage, a poorly performed biopsy, or extensive tumor involvement of vital neurovascular structures. Amputation may also be considered when the functional results after an ablative procedure would be superior to those following resection and adjuvant therapy. Additional indications may be the presence of multifocal disease, intractable pain, or local relapse.

Suggested resections for selected diagnoses are indicated in Table 129.1.

| *Tumor type* | *Examples* | *Recommended resection* | *Adjuvant treatment* |
|---|---|---|---|
| Benign encapsulated | Lipoma<br>Neurilemmoma | Marginal resection | NA |
| Benign infiltrative | Desmoid<br>Hemangioma | Wide resection | *Radiation |
| Malignant | Malignant fibrous histiocytoma<br>Liposarcoma<br>Synovial sarcoma | Wide resection | Low-grade radiation<br>High-grade radiation with or without chemotherapy |

* Radiation is commonly administered as an adjuvant therapy in the treatment of desmoid tumors. Rarely would it be recommended in the treatment of other benign neoplasms.

***Table 129.1. Operative Procedures in the Treatment of Soft-Tissue Neoplasms***

The diagnosis, the anatomic location of the tumor, and the functional consequences of resection determine the operative strategy. Asymptomatic benign tumors may be treated nonoperatively in an area where function after surgery is likely to be compromised. Benign tumors in easily accessible sites are often removed even in the absence of symptoms. For sarcomas located in the distal leg or foot, amputation may be preferable for tumor control, given the relatively good function and oncologic results after distal lower extremity amputations. A malignant tumor adjacent to a major nerve or artery may dictate that a marginal resection, in addition to some form of adjuvant therapy, be administered.

The extent of disease at the time of diagnosis influences the surgeon's decision as to what procedure to perform. In patients with malignant disease, it is important to determine the local and distant extent (metastases) of the tumor. Soft-tissue sarcomas most commonly metastasize to the lungs, and chest radiography and CT are indicated as a part of the initial evaluation. Metastases to lymph nodes and bone are unusual, and the additional value of technetium bone scanning, gallium scanning, or positron-emission tomography (PET) scanning is not clear. Adults with metastatic soft-tissue sarcomas at the time of diagnosis, or with severe comorbid medical conditions, have a very poor prognosis, and surgery may not be indicated except for palliation. Similarly, in some benign tumors, such as plexiform neurofibromas or extensive intramuscular hemangiomas, the tumor may be so extensive locally that resection would be associated with severe functional disability. In such cases, it may be in the patient's best interest not to attempt to resect all disease.

## SURGICAL TECHNIQUES

### WIDE EXCISION OF A SUBCUTANEOUS SARCOMA

Approximately one third of all soft-tissue sarcomas are located subcutaneously (25). Most are small (smaller than 5 cm) and are presumed, before operative resection, to be benign neoplasms. Therefore, most subcutaneous sarcomas are referred to surgical oncologists after excision. On reexcision of the tumor bed, focal residual sarcoma has been noted in more than one half of the patients treated (12,20). For this reason, surgical reexcision of the operative field is recommended in the treatment of patients with subcutaneous sarcomas. With such treatment, excellent rates of local control can be obtained (10).

A wide margin for subcutaneous sarcoma is defined as a normal cuff of skin and subcutaneous fat in continuity with fascia and muscle. Because there is no anatomic barrier to the spread of a subcutaneous sarcoma, the surgeon must determine, by palpation and careful review of imaging studies, the extent of a resection that will be necessary to encompass the entire previous operative field while remaining in normal tissue. Fortunately, in a subcutaneous location, major neurovascular structures are rarely involved.

For a wide excision, resect an area of skin approximately 3 to 5 cm about the biopsy site, as well as any obvious hematoma (Fig. 129.2).

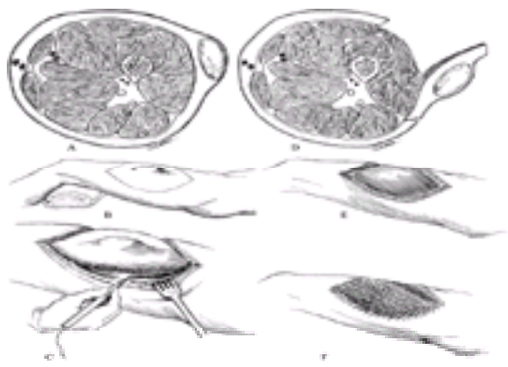

***Figure 129.2.*** Operative technique for a wide excision of a subcutaneous sarcoma in the midlateral aspect of the thigh. **A:** Cross section of the thigh; the lesion is completely contained within the subcutaneous tissue and does not involve the underlying fascia. **B:** The planned margin of resection of the previously biopsied tumor is indicated by the dotted line. **C:** A sharp dissection is performed through the subcutaneous tissue away from the mass, with use of the underlying fascia as the deep margin. **D:** The wide margin, including the deep fascia, seen in cross section. **E:** The muscle bed after resection. **F:** The defect is covered with a split-thickness skin graft.

- Dissect directly through skin, subcutaneous tissue, and fascia.
- Take a small amount of superficial muscle deep to the fascia in continuity with the resected specimen. In most instances, a split-thickness skin graft is required to close the defect over the remaining muscle. Occasionally, in certain anatomic locations such as in the inguinal region or in obese patients, elliptical incision may be made allowing resection of the tumor and primary closure of the wound.
- Take care not to compromise the amount of soft-tissue resected in order to obtain primary closure. Infrequently, a rotational or free flap is required for closure over bony surfaces such as the tibia.

**WIDE EXCISION OF A THIGH SARCOMA**

Unlike subcutaneous sarcomas, most deep sarcomas are large (larger than 5 cm) and are suspected to be malignant before operative resection. The most common site of a soft-tissue sarcoma is the thigh, and the tumor may be located in the anterior, posterior, or adductor compartment. In some cases, the tumor may be located in more than one anatomic compartment, or it may be extracompartmental (popliteal fossa). Often, the femur, superficial femoral artery and vein, femoral nerve, or sciatic nerve may be adjacent to the tumor mass. It is unusual for a soft-tissue sarcoma to invade neurovascular structures directly.

For malignant tumors, a wide resection is preferred to a marginal resection so that the occurrence of local relapse is minimized. However, if the tumor is immediately adjacent to bone, the sciatic nerve, or in some cases, the superficial femoral artery, a marginal resection is all that can be accomplished without severe compromise of limb function. In these cases, adjuvant therapy, most commonly in the form of radiation therapy, either external beam or brachytherapy, can be administered preoperatively or postoperatively to minimize the chance of local recurrence.

- Make the skin incision longitudinally over the extent of the tumor, ellipsing any previous biopsy site (Fig. 129.3). Dissect sharply through the subcutaneous tissue. Bevel the dissection outward at a 45° angle to the skin to increase the width of the resection further.

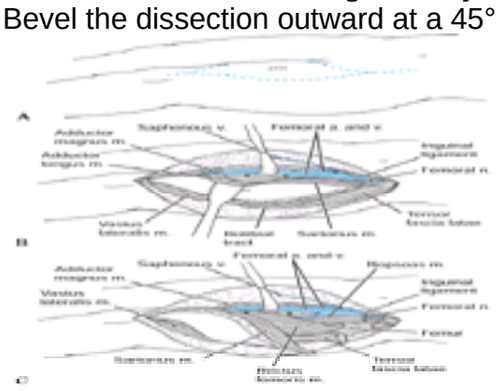

***Figure 129.3.*** Wide resection of a deep sarcoma of the thigh. **A:** Skin incision from the anterior superior iliac spine to the superior pole of the patella, including the site of elliptically excised biopsy specimen, for a deep intracompartmental tumor of the anterior thigh. **B:** Creation of skin flaps and dissection of superficial femoral vessels. **C:** Transection of muscle circumferentially around the tumor mass.

- Based on palpation and imaging studies, make a circumferential fascial incision, often in the form of an ellipse, 2 to 3 cm away from the tumor mass. It is important that skin, subcutaneous fat, and fascia remain attached to the underlying tumor mass.
- At this time, locate the superficial femoral artery and vein proximally and dissect them from proximal to distal. Ligate multiple branches in the region of the tumor. In cases of anterior thigh sarcomas, the femoral nerve must often be sacrificed proximally. Once the artery and vein have been freed from the underlying soft tissue, retract them medially and proceed with the resection.
- Transect muscle fibers on the periphery of the tumor for preservation of a cuff of normal tissue around the tumor pseudocapsule. Make every effort to avoid visualizing or penetrating the tumor pseudocapsule.
- If the tumor is immediately adjacent to the femur, it may be necessary to perform a subperiosteal dissection and include the periosteum as a deep margin. Be aware, however, that such subperiosteal dissection in the face of adjuvant radiation therapy may predispose a patient to a pathologic fracture of the femur due to the radiation therapy (15).
- Then sever surrounding muscle attachments, and remove the tumor from the thigh. Additional effort to remove entire muscles from origin to insertion (a radical resection) is not necessary in the treatment of most soft-tissue sarcomas.
- Irrigate the wound and close over suction drains. Leave the drains in place for a prolonged period to evacuate any dead space.

Postoperative immobilization of the knee is recommended to allow for optimal wound healing and to minimize seroma formation. In some cases, a rotational free flap may be necessary to provide vascularized tissue deep to the skin and to assist in wound healing.

**MARGINAL RESECTION OF AN INTRAMUSCULAR ENCAPSULATED BENIGN TUMOR (LIPOMA)**

A marginal resection differs from the procedures described earlier in that no effort is made to preserve a normal cuff of tissue about the tumor. In these cases, dissection proceeds through the capsule of the tumor itself without removal of additional soft tissue. This procedure is most commonly carried out for deep intramuscular lipomas. It is not recommended for the treatment of malignant disease.

- Make a longitudinal incision, slightly longer than the underlying tumor mass, directly over the most prominent portion of the tumor. The skin, subcutaneous tissue, and, in some cases, muscle must be longitudinally divided and bluntly dissected to reveal the underlying capsule of the tumor.
- Then carry out blunt dissection out along this margin. Frequently, digital dissection is very effective in mobilizing the tumor at its most proximal or distal extent.
- Then deliver the tumor mass from the wound, again working in the adventitial layer covering the tumor, dissecting circumferentially around the tumor mass. Then remove the tumor.
- Irrigate the wounds and close over drains if necessary.

Postoperatively, immobilization may be required, depending on the extent of resection.

## COMMON SOFT-TISSUE TUMORS

Enzinger and Weiss have defined soft-tissue tumors as “non-epithelial extra-skeletal tissue of the body exclusive of the reticuloendothelial system, glia, and supporting tissue of various mesenchymal organ” (9). Benign soft-tissue neoplasms are believed to be at least 100 times more common than their malignant counterparts,

soft-tissue sarcomas. Soft-tissue sarcomas may arise in any part of the body but are most common in the extremities, specifically the thigh and buttock. Common benign deep soft-tissue tumors include intramuscular lipomas, extraabdominal fibromatosis (desmoid tumors) hemangiomas, and benign nerve sheath tumors.

## CLASSIFICATION

In contrast to previous systems in which tumors were believed to arise from normal cells of a similar histologic appearance, the current histologic classification of soft-tissue tumors is based on the apparent differentiation of the tumor cell. Most tumors arise from an undifferentiated precursor cell and acquire phenotypic traits of various normal cells during neoplastic transformation. It is this appearance by which the tumors are classified rather than by the tissue of origin. The tumors are classified as benign, intermediate, or malignant based on their perceived capability of metastasis. Malignant tumors are subcategorized as low grade or high grade based on their histologic characteristics including tumor necrosis, cellular anaplasia, and the number of mitotic figures. Patients with high-grade tumors are at an increased risk for developing metastatic disease compared with those with low-grade tumors.

The most common soft-tissue tumors are noted in Table 129.2 (11). This table is based largely on the classification of soft-tissue tumors by the World Health Organization, with subsequent modification as described by Enzinger and Weiss. Again, this classification of tumors does not imply that the histologic appearance of the tumor is related to the tissue of origin. In addition, one must be careful not to assume that malignant soft-tissue tumors of one histologic type are the result of malignant degeneration of a benign neoplasm. Malignant degeneration of an underlying benign soft-tissue neoplasm is very rare.

***Table 129.2. Histologic Classification of Soft-Tissue Tumors***[11]

## FIBROUS LESIONS

These spindle cell neoplasms whose histologic appearance resembles fibrous tissue are common and may be reactive (nodular fasciitis), benign (fibroma of tendon sheath), infiltrative (desmoid tumor), or malignant (fibrosarcoma). Fibrous neoplasms of infancy and childhood should be considered separately because of their unique and often self-limiting behavior.

### *Nodular Fasciitis*

Nodular fasciitis is a benign proliferation of fibroblasts often mistaken for a malignant soft tissue tumor because of its rapid onset of growth, mitotic activity, and cellularity. It is most likely a self-limiting reactive process rather than a true neoplasm. Most patients present with a rapidly growing mass with associated tenderness. It is often located in the upper extremities, especially in the volar aspect of the forearm. In infants and children, it may be found in the head and neck region. It is usually small (smaller than 5 centimeters). It may be subcutaneous, intramuscular, or fascial based. It is usually treated by marginal excision and has a low recurrence rate (4). Spontaneous regression has been observed.

### *Palmar Fibromatosis*

This condition is known as Dupuytren's disease or Dupuytren's contracture and is the most common type of fibromatosis. Its etiology is unclear. It is seen most commonly in people older than 65 years of age. It may be associated with other forms of fibromatosis including plantar fibromatosis and penile fibromatosis (Peyronie's disease). It is also noted to be of increased incidence in patients with epilepsy and diabetes. It has also been known to be associated with chronic alcoholism and liver cirrhosis.

The onset of the disease is slow and insidious. Often, a firm nodule is palpable in the palmar aspect of the hand affecting the ulnar aspect of the hand. It may be associated with joint contracture. A single small nodule or an ill-defined conglomerate of several nodules is found on examination. Pathology consists of spindle-shaped fibroblasts and variable amounts of dense collagen. Treatment may include nonoperative therapy including physical therapy and topical treatment, but rarely do these measures have a significant effect on the disease. Operative resection, however, remains the treatment of choice in the patient with impairment secondary to flexion contractures of the digits. Fasciectomy is usually recommended as the treatment of choice (23). Local recurrence may result in recurrent contracture.

### *Plantar Fibromatosis*

This disease is similar to palmar fibromatosis and is identified by nodular fibrous proliferation arising with the plantar aponeurosis. Unlike disease in the hand, it is usually not associated with contractures of the digits. Usually, a single subcutaneous thickening or nodule that adheres to skin and is located in the middle or medial portion of the foot is found on examination. It may be painful and may be bilateral. The lesion is more common in men than women. It occurs in younger individuals than palmar fi- bromatosis. Pathologic findings are identical to palmar fibromatosis. Treatment is directed at the patient's symptoms, and nonoperative therapy consists of shoe pads and modified shoe wear. Radical fasciectomy is considered for patients with intractable pain but is associated with local recurrence in a number of cases (6).

### *Desmoid Tumor*

Desmoid tumor or extraabdominal fibromatosis is a difficult problem for those caring for patients with soft-tissue neoplasms. It has the potential to attain a large size, often recurs despite operative resection, and is infiltrative in nature. It may be associated with colonic polyposis (Gardner's syndrome). Clinical findings are usually a soft-tissue mass in the young adult. It is common about the shoulder, flank, and the muscles of the thigh. It may be multifocal within an extremity. Histologically, fibromatosis is benign in appearance with spindle-shaped fibroblasts and dense collagen. Imaging studies reveal that the tumor is typically of low signal on both T1- and T2-weighted images because of the large collagen content. Operative resection is considered for tumors in expendable locations (3). However, despite complete surgical resection, it is associated with recurrence in a number of cases. Adjuvant treatment in the form of radiation therapy is often considered for these individuals. Medical treatment in the form of estrogen blockade or chemotherapy may be considered in selected circumstances.

### *Fibrosarcoma*

Fibrosarcoma is a malignant tumor of soft tissue whose cells resemble fibroblasts but with significant cellular atypia, frequent mitoses, and increased cellularity compared with its benign counterparts. Before the subclassification of malignant fibrous histiocytoma, fibrosarcomas were the most common soft-tissue malignancies. Fibrosarcomas are often low grade. The recommended treatment is wide resection or marginal resection combined with adjuvant radiation therapy.

### *Malignant Fibrous Histiocytoma*

This tumor is composed of cells characterized by a storiform or cartwheel-type growth pattern. The actual histogenesis of the tumor may not be from a histiocyte but more closely related to the fibroblast. This tumor is also known as an adult spindle cell sarcoma. These neoplasms may be low grade or high grade based on their cellularity, atypia, and the presence or absence of mitotic figures and necrosis. They are commonly located in the subcutaneous tissue or the deep soft tissues of the thigh. Like other soft-tissue sarcomas, they are best treated with wide resection. Marginal resection can be combined with adjuvant radiation therapy. Patients with large, high-grade soft tissue sarcomas may, in addition, benefit from adjuvant chemotherapy (26).

## LIPOMATOUS SOFT-TISSUE TUMORS

### *Lipoma*

Lipoma is the most common soft-tissue tumor arising virtually anywhere in the body. The tumor is usually a soft, mobile, and asymptomatic mass with a very large range of sizes noted. The magnetic resonance images of a lipoma show signal characteristics similar to surrounding fat on all sequences. It is the one tumor that can usually be diagnosed by MRI. Asymptomatic lesions do not require treatment. Malignant transformation is rare. Symptomatic tumors are usually treated with local excision. Local recurrence is rare.

### *Liposarcoma*

Liposarcoma is the second most common malignant soft-tissue tumor seen in the extremities. It is also very common in the retroperitoneum. Liposarcomas may be low grade or high grade. The characteristic cell is the lipoblast, which consists of a cell containing large amounts of clear cytoplasm but with several septated vacuoles that secondarily indent the nucleus. This is different from the signet ring cell, a cell with a large clear cytoplasm and a thinned eccentric nucleus at one pole. Signet ring cells can be seen in both benign and malignant lipomatous soft tissue tumors. The lipoblast is characteristic of a malignant tumor. Higher grade liposarcomas may be difficult to differentiate from other soft-tissue sarcomas such as malignant fibrous histiocytoma because of the dense cellularity obscuring those cells that resemble fat. It should be noted that liposarcomas do not have an appearance similar to lipomas on MRI, that is, they tend to be of low signal on T1-weighted images and of bright signal on T2-weighted images. The management of liposarcoma is identical to other soft-tissue sarcomas, that is, wide resection when possible or marginal resection with adjuvant radiation therapy. Unlike other soft-tissue sarcomas, however, liposarcomas (especially the myxoid type) of the extremity may be associated with disease in other, nonpulmonary sites (e.g., retroperitoneum) (21).

## SMOOTH MUSCLE NEOPLASMS

### *Leiomyomas and Leiomyosarcomas*

These are relatively infrequent soft-tissue neoplasms seen in the extremities. Benign neoplasms may be managed with marginal resection. Malignant soft-tissue sarcomas require wide resection or marginal resection and adjuvant radiation therapy.

## STRIATED MUSCLE TUMORS

### *Rhabdomyoma and Rhabdomyosarcoma*

These tumors are rare soft-tissue neoplasms. A benign rhabdomyoma is exceptionally unusual and of variable presentation. The diagnosis is usually made on the basis of an open biopsy. Rhabdomyosarcoma, although unusual, is the most common soft-tissue malignancy of children. When it is located in an extremity, it is often of the alveolar histologic type. The characteristic tumor cell of a rhabdomyosarcoma is the rhabdoid cell, which is a large, irregularly shaped cell with an eccentric nucleus and eosinophillic cytoplasm. These high-grade tumors are often associated with metastatic disease at the time of presentation and are treated with systemic chemotherapy (5). The role of operative intervention is unclear and controversial. Radiation therapy may be considered. These tumors may actually be more closely related to soft-tissue Ewing's or soft-tissue primitive neuroectodermal tumor.

## VASCULAR NEOPLASMS

### *Hemangioma*

Hemangiomas are benign neoplasms resembling normal blood vessels. Some actually represent vascular malformations rather than true neoplasms. They are often seen in infants and may spontaneously regress. They may be localized or multifocal, in which case they are known as angiomatosis (22). The majority of hemangiomas are superficial lesions with a predilection for the head and neck but may also occur internally. Tumors may be responsive to circulating hormones, and changes in size may be seen during pregnancy. Based on the histologic appearance, they are subclassified as capillary hemangiomas, which are often seen in children. Cavernous hemangiomas are large with thin-walled veins. Hemangiomas may be seen in conjunction with dyschondroplasia, also known as Maffucci's syndrome. When the tumor is located in a subcutaneous or dermal location, there often are characteristic color changes to the skin. There is no such skin change found with deeper situated tumors. Radiographs may demonstrate phleboliths within the lesion. Vascular studies and ultrasound may show vascular flow but may be difficult to distinguish from other vascular neoplasms.

The treatment of a localized hemangioma, as long as the diagnosis is known, is based on symptoms. Again, many grow slowly if at all. This is especially true in children, in whom lesions are often known to regress spontaneously. Localized disease may be marginally resected, with an approximate 20% local recurrence rate. More difficulties are encountered with the extensive hemangiomas and multifocal hemangiomas. Angiographic embolization has been used to treat many afflicted individuals with variable success. Radiation therapy has been considered in the past but should be used with great caution in young people.

### *Angiosarcoma*

These malignant soft-tissue tumors resembling blood vessels are rare. Significant is the association of angiosarcoma with chronic lymphedema, for example, in patients following mastectomy and lymph node resection. Operative wide resection is the treatment of choice, and multifocal disease is commonly encountered.

## SYNOVIAL NEOPLASMS

### *Tenosynovial Giant Cell Tumor*

These tumors may be localized or diffuse and located in juxtaarticular or intraarticular locations. Intraarticular disease is known as pigmented villonodular synovitis and, again, may be localized or diffuse (27). Tenosynovial giant cell tumor affecting the tendon sheath is known as giant cell tumor of the tendon sheath. These tumors are believed to be benign neoplasms that may actually be reactive in etiology. Localized disease is usually treated with marginal resection. Diffuse disease, especially intraarticular disease in a large joint, such as the knee, may require synovectomy, and intraarticular or external beam radiation therapy.

### *Synovial Sarcoma*

This is the third most frequently seen soft-tissue sarcoma in adults and the second most frequently seen soft-tissue sarcoma in children. It is typically not located within a joint but within the structures about a joint. Many are located in the hand or foot. These tumors may be monophasic or so-called biphasic, consisting of plump synovial cells arranged in a glandular pattern with other fibroblastic areas around it. Radiographs of these lesions may reveal mineralization in the form of calcification. Like other soft-tissue sarcomas, MRI studies usually show predominantly low signal on T1-weighted images and bright signal on T2-weighted images. These lesions usually enhance with gadolinium infusion.

As with all soft-tissue sarcomas, operative treatment is wide resection or marginal resection and radiation therapy. Some synovial sarcomas may respond well to systemic chemotherapy (28).

## NEURAL LESIONS

### *Neurofibromas*

Neurofibromas are benign neoplasms noted in variable locations and may be solitary or part of a neurofibromatosis or von Recklinghausen disease (13). Often, this disease is noted as an inherited dominant trait of variable penetration. It may be associated with scoliosis, congenital pseudarthrosis of the tibia or clavicle, and gigantism. Neurofibromas are often asymptomatic. People with von Recklinghausen's disease may develop malignant nerve sheath tumors as well. Sarcomatous degeneration should be suspected in patients with very large or rapidly growing tumors.

In contrast to the neurilemmoma, which tends to be localized, neurofibromas are often extensive and infiltrative in nature around the nerve of origin. For this reason, if it

is decided to remove these tumors, it is often necessary to resect the underlying nerve. Operative resection, however, is only indicated for symptomatic lesions or for those suspected of sarcomatous degeneration.

### *Neurilemmoma*

In contrast to neurofibromas, neurilemmomas are localized benign neoplasms that are often located within the nerve sheath itself. It is often a fusiform soft-tissue mass tapered at either end by the axons resuming their normal position within the nerve proximal and distal to the lesion. The MRI scan often shows that this tumor is of very bright signal on T2-weighted images and is usually homogeneous. Physical findings often reveal Tinel's sign or a radiating sensation with direct percussion. Marginal resections are associated with a low incidence of recurrence. Pathology reveals a biphasic appearance with compact (Antoni A) or densely cellular areas alternating with areas with relatively few cells (Antoni B). Small clusters of palisading cells around a central eosinophilic area are known as Verocay bodies. Operative excision is often carried out as a form of diagnostic biopsy in which the nerve sheath itself is split longitudinally in order to remove the lesion without harming the surrounding axons. It is usually encapsulated and freed relatively easily from the underlying nerve.

### *Malignant Nerve Sheath Tumors*

These tumors are often high-grade large neoplasms. Their behavior, however, is not unlike other high-grade soft-tissue sarcomas (14). Operative treatment is preferably wide resection or marginal resection with adjuvant treatment

## STAGING OF MALIGNANT SOFT-TISSUE TUMORS

Systems have been developed for the staging of malignant soft-tissue tumors in an effort to predict the prognosis and evaluate the effect of therapeutic intervention by stratifying similar tumors according to various prognostic factors. Commonly used factors are tumor grade, size, compartmentalization of the tumor, and the presence or absence of metastases.

For soft-tissue sarcomas in adults, the two staging systems that are used at present were developed by the American Joint Committee on Cancer (AJCC; Table 129.3) (2) and by Enneking (Table 129.4) (8). In both systems, the variables used in the assignment of an appropriate stage include tumor grade, location, and the relative extent of the tumor, as well as the presence or absence of metastases.



***Table 129.3. American Joint Committee Staging Protocol for Sarcoma of Soft Tissue (2)***



***Table 129.4. Enneking System for Staging of Soft-Tissue Sarcomas***

Both systems agree that the presence of metastases is a very poor prognostic factor. This is true if metastases occur either to the lungs or to lymph nodes. The differences between the systems is that, first, the AJCC system is based on a grading system containing four variables, whereas the Enneking system considers only high and low grades. Second, the AJCC system uses tumor size as an important prognostic variable as opposed to compartmental location as described by Enneking. Third, the AJCC system considers tumor depth to be an important prognostic factor.

The staging systems available are based on histologic and clinical observations, and they serve to guide therapeutic strategies. However, these systems are based on variables that are crude and of limited usefulness. New discoveries in the fields of molecular and cellular biology are being made and will be correlated with the clinical course and outcome. These findings almost certainly will change the manner in which tumors are classified and staged, and will predict more accurately the behavior of a given tumor in a particular patient. Operative treatment, chemotherapy, and radiation therapy can then be used in a rational and effective manner to improve the functional and oncologic outcome (19).

## COMPLICATIONS

The complications of surgery to remove soft-tissue tumors are the same as those encountered for all orthopaedic surgery, as discussed in Chapter 5 and Chapter 8. The two most significant complications of the management of soft-tissue tumors of the extremities are improper performance of a biopsy, which leads to either misdiagnosis or compromise of the definitive method for surgical treatment, or recurrence after resection of an aggressive benign tumor or malignant tumor. Small benign-appearing tumors in the distal portions of the extremities are commonly removed by general orthopaedic and other surgeons by excisional biopsy with marginal resection. When histology reveals a malignant tumor, it is prudent to have the next stage of treatment management performed by an experienced oncology team consisting of a surgeon, medical oncologist, and radiation therapy specialist. In the case of lesions in which a malignant tumor is an obvious part of the prebiopsy differential diagnosis, biopsy should be performed only by a surgeon experienced in the treatment of malignant tumors who is prepared to carry out definitive treatment in conjunction with an oncology team. This approach will minimize the risk of local recurrence and enhance the long-term survival of patients with these troublesome tumors. In performing biopsy and subsequent resection of these tumors, the principles discussed in this chapter must be meticulously followed.

## CHAPTER REFERENCES

Each reference is categorized according to the following scheme: *, classic article; #, review article; !, basic research article; and +, clinical results/outcome study.


! 1. Akerman M, Rydholm A, Persson BM. Aspiration Cytology and Soft-Tissue Tumors. The 10-year Experience at an Orthopaedic Oncology Center. *Acta Orthop Scand* 1985;56:407.

+ 2. American Joint Committee on Cancer—Soft-Tissues. In: Fleming ID, Cooper JS, Hensen DE, et al., eds. *American Joint Committee on Cancer (AJCC) Cancer Staging Manual,* 5th ed. Philadelphia: Lippincott-Raven, 1997:149.

# 3. Ballo M, Zajars G, Pollack A, et al. Desmoid Tumor: Prognostic Factors and Outcome after Surgery, Radiation Therapy, or Combined Surgery and Radiation Therapy. *J Clin Oncol* 1999;17:158.

# 4. Bernstein KE, Lattes R. Nodular (Pseudosarcomatous) Faciitis, a Non-recurrent Lesion: Clinicopathologic Study of 134 Cases. *Cancer* 1992;49:1668.

# 5. Crist W, Gehan E, Rajeb A, et al. The Third Intergroup Rhabdomyosarcoma Study. *J Clin Oncol* 1995;13:610.

# 6. Curtin JW. Fibromatosis of the Plantar Fascia: Surgical Technique and Design of Skin Incision. *J Bone Joint Surg* 1965;47A:1605.

* 7. Enneking WF. *Musculoskeletal Tumor Surgery.* New York: Churchill Livingstone, 1983.

* 8. Enneking WF, Spanier SS, Goodman MA. A System for the Surgical Staging of Musculoskeletal Sarcomas. *Clin Orthop* 1980;153:106.

* 9. Enzinger FM, Weiss SW. *Soft-Tissue Tumors.* St. Louis: Mosby, 1995:1.

10. Gibbs CP, Peabody TD, Mundt AS, et al. Oncologic Outcomes of Operative Treatment of Subcutaneous Soft-Tissue Sarcomas of the Extremities. *J Bone Joint Surg* 1991;79A:888.

# 11. Gibbs CP, Peabody TD, Simon MA. Mini-Symposium: Soft Tissue Tumors of the Musculoskeletal System (i). Classification, Clinical Features, Preoperative Assessment, and Staging of Soft Tissue Tumors, *Current Orthopaedics* 1997;11:75

! 12. Giulano AE, Eilber FR. The Rationale for Planned Reoperation after Unplanned Total Excision of Soft Tissue Sarcomas. *J Clin Oncol* 1985;3:1344.

# 13. Hajdu S. Peripheral Nerve Sheath Tumors. *Cancer* 1993;72:3549.

# 14. Hruban R, Shiu M, Senie R, Woodruff J. Malignant Peripheral Nerve Sheath Tumors of the Buttock and Lower Extremity. A Study of 43 Cases. *Cancer* 1990;66:1253.

! 15. Helmstedter C, Boebel M, Scarborough MD. *Pathologic Fracture of the Femur after Radiation and Surgical Excision of Soft-Tissue Sarcomas of the Thigh.* Transactions International Society for Limb Salvage, 9th International Symposium, 1997:92.

* 16. Li FP, Fraumeni JF Jr. Soft-Tissue Sarcomas, Breast Cancer, and Other Neoplasms: A Familial Syndrome? *Ann Intern Med* 1969;71:747.

# 17. Mankin HJ, Mankin CJ, Simon MA. The Hazards of the Biopsy Revisited. For the Members of the Musculoskeletal Tumor Society. *J Bone Joint Surg* 1996;78A:656.

! 18. Mykre-Jenson O. A Consecutive 7-Year Series of 1,331 Benign Soft-Tissue Tumors. Clinicopathologic Data. Comparison with Sarcomas. *Acta Orthop Scand* 1981;52:287.

# 19. Peabody TD, Gibbs CP, Simon MA. Evaluation and Staging of Musculoskeletal Neoplasms. *J Bone Joint Surg* 1998;80A:1204.

! 20. Peabody TD, Monson D, Montag A, et al. A Comparison of the Prognosis for Deep and Subcutaneous Sarcomas of the Extremities. *J Bone Joint Surg* 1994;76A:1167.

# 21. Pearlston D, Pisters P, Bold R, et al. Patterns of Recurrence in Extremity Liposarcoma. *Cancer* 1999;85:85.

# 22. Rao V, Weiss S. Angiomatosis of Soft-tissue: An Analysis of the Histologic Featues and Clinical Outcome in 51 Cases. *Am J Pathol* 1992;16:764.

# 23. Rodrigo JJ, Neibauer JJ, Brown RL, et al. Treatment of Dupuytren's Contracture. Long-term Results after Fasciotomy and Fascial Excision. *J Bone Joint Surg* 1976;58A:380.

! 24. Rydholm A, Berg NO. Size, Site, and Clinical Incidence of Lipoma. Factors in the Differential Diagnosis of Lipoma and Sarcoma. *Acta Orthop Scand* 1983;54:333.

! 25. Rydholm A, Gustafson P, Rooser B, et al. Subcutaneous Sarcoma: A Population-Based Study of 129 Patients. *J Bone Joint Surg* 1991;73B:662.

# 26. Salo J, Lewis J, Woodruff J, et al. Malignant Fibrous Histiocytoma of the Extremity. *Cancer* 1999;58:1765.

# 27. Schwartz H, Unni K, Pritchard D. Pigmented Villonodular Synovitis: A Retrospective Review of Affected Large Joints. *Clin Orthop* 1989;247:243.

# 28. Singer S, Baldini E, Demetri G, et al. Synovial Sarcoma: Prognostic Significance of Tumor Size, Margin of Resection and Mitotic Activity for Survival. *J Clin Oncol* 1996;14:1201.

! 29. Skrzynski MC, Biermann JS, Montag A, Simon MA. Diagnostic Accuracy and Charge-Savings of Outpatient Core Needle Biopsy Compared with Open Biopsy of Musculoskeletal Tumors. *J Bone Joint Surg* 1996;78A:644.

! 30. Suit HD, Mankin HJ, Wood WC, et al. Treatment of the Patient in the Stage M0 Soft Tissue Sarcoma. *J Clin Oncol* 1988;6:854.

# CHAPTER 130

# METASTATIC BONE DISEASE

*Frank J. Frassica, Deborah A. Frassica, Steven A. Lietman, Edward F. McCarthy, and James F. Wenz*

**F. J. Frassica:** Professor of Orthopaedic Surgery and Oncology, Johns Hopkins University, Baltimore, MD, 21287.
**D. A. Frassica:** Assistant Professor of Radiation Oncology, Johns Hopkins University, Johns Hopkins Radiation Oncology at Greenspring Station, Lutherville, MD.
**S. A. Lietman:** Assistant Professor of Orthopaedic Surgery, Johns Hopkins University, Baltimore, MD, 21287.
**E. F. McCarthy:** Associate Professor of Pathology and Orthopaedic Surgery, Johns Hopkins University, Baltimore, MD, 21287.
**J. F. Wenz:** Assistant Professor of Orthopaedics and Oncology, Johns Hopkins University, Baltimore, MD, 21287.

Evaluation
Clinical Scenarios
Decision Making
Nonoperative Treatment
Operative Treatment
Preoperative Evaluation and Considerations
Upper Extremity
Lower Extremity
Postoperative Care
Postoperative External Beam Irradiation
Postoperative Complications
Chapter References

Metastatic bone disease is the most common cause of bone destruction in the adult skeleton. Each year in the United States there are approximately 1.3 million new cancer cases (16). The most common carcinomas, those of the breast, lung, prostate gland, and kidney, are also the most common cancers that metastasize to bone (9,10,11). The common distribution of bone metastases is to the spine, ribs, pelvis, and proximal limb girdles (1). Lung carcinomas and melanomas have the ability not only to occur in the axial skeleton but also to spread peripherally to the hands and feet (13,14). It is important for the clinician to remember that virtually every known cancer may metastasize to bone and that any bone in the body can be involved.

The goals of treatment of primary bone sarcomas are to both achieve local control of the tumor and reconstruct a limb that will be functional. In contrast, the goals of treatment of patients with metastatic bone disease are to stop progression of the tumor, control pain, and maintain the quality of the remaining life of the patient. Virtually all patients with metastatic bone disease will die of their cancer. Patients and their families greatly appreciate the clinician's expertise and commitment to maintain the patient's independence in ambulation and the activities of daily living. Uncontrolled pain, confinement to bed, pathologic fractures, and neurologic compromise lead to despair and must be avoided.

The purpose of this chapter is to provide the clinician with a working knowledge of the evaluation, decision making, operative treatment, and postoperative care of the patient with metastatic bone disease.

## EVALUATION

Bone pain is common in cancer patients. Carefully evaluate the patient to determine the source of the pain and to plan treatment. The essential steps in evaluation are history, physical examination, and plain radiographs (11).

Take a careful history. Determine the nature of the patient's pain. Pain at rest; severe pain; pain not responsive to anti-inflammatory medications and narcotics such as Tylenol with codeine, Tylox, and Darvocet; and pain at night are common complaints of patients with bone metastases. The pain often begins as a dull ache and then becomes constant. Activity-related pain is common with lower extremity metastases. Patients with lower extremity metastases will often relate a decrease in their ability to ambulate accompanied by fatigue, pain, and weakness. Patients with vertebral metastases often have pain and weakness, and they may have bladder and bowel dysfunction.

Patients with metastatic bone disease may have no prominent physical findings. Atrophy is common with lower extremity metastases, and the clinician can often elicit tenderness with deep palpation. Perform a careful neurologic examination of the upper and lower extremities. If the patient has back pain or reports bowel or bladder dysfunction, perform a rectal examination to exclude cauda equina syndrome.

Take plain radiographs in two planes of the painful areas. Many times, it is difficult to localize pain exactly in the upper extremity, back, or pelvis. In these areas, it is often necessary to obtain a combination of radiographs (Table 130.1). Carefully review the radiographs because the initial findings may be very subtle. The key features to look for are:

| *Type of pain* | *Combination of radiographs* |
|---|---|
| Pelvis pain | AP pelvis<br>AP/lat lumbosacral spine<br>AP/lat hip |
| Shoulder pain | AP/scapular axillary view<br>AP/lat cervical spine<br>Chest radiograph |
| Lower back pain | AP/lat lumbosacral spine<br>AP pelvis |

AP, anteroposterior.

***Table 130.1. Combinations of Radiographs for Bone Pain in Cancer Patients***

1. Cortical bone destruction: In metastatic bone disease, one may see the bone destruction on the endosteal or periosteal surface.
2. Periosteal reaction: Small areas of periosteal reaction are often the only evidence that the tumor has left the medullary cavity.
3. Permeative pattern of bone destruction: In contrast to bone sarcomas, which cause large areas of cortical bone destruction, in metastatic bone disease there are often very subtle areas of permeative bone destruction in the cortex.
4. Destruction of the vertebral pedicle: In the spine, the cortical destruction in the pedicle is an early radiographic sign of metastatic bone disease. This finding is often subtle and must be looked for carefully.

### CLINICAL SCENARIOS

After completing the initial history, physical examination, and plain radiographs, there are generally four different clinical scenarios:

1. Patients with advanced metastatic disease, including diffuse visceral and bone metastases. In this scenario, the orthopaedic surgeon is not called on to make a diagnosis but rather to evaluate and manage either a fracture or an impending fracture.

2. Patients with a history of cancer and a single destructive bone lesion. In this scenario, perform a very careful evaluation because you cannot simply assume that an undiagnosed bone lesion is necessarily related to the patient's prior cancer. Plan the evaluation as if you were evaluating the patient without the history of the prior cancer. The staging evaluation includes a technetium bone scan, chest radiograph, computerized tomographic (CT) scan of the chest and abdomen, and serum laboratory studies (complete blood count, erythrocyte sedimentation rate, chemistry group, and serum protein electrophoresis) (Table 130.2).

| Type of evaluation | Description |
|---|---|
| Technetium bone scan | Used to screen for multiple bone lesions (as would be seen in diffuse bone metastases, some cases of multiple myeloma, and other polyostotic lesions such as hyperparathyroidism and Paget's disease.) |
| Chest radiograph | Used to screen for parenchymal pulmonary metastases and pleural effusions. |
| CT scan chest/abdomen | Used to screen for visceral metastases from any prior malignancies, visceral primaries such as lung cancer and renal carcinoma, as well as lymphoma. |
| Serum laboratory studies | Complete blood count and sedimentation rate are abnormal in up to two thirds of patients with multiple myeloma. The serum protein electrophoresis is an excellent modality to detect a monoclonal spike in patients with multiple myeloma. The chemistry group screen for Paget's disease by noting an elevation in the alkaline phosphatase level and hyperparathyroidism by detecting an elevated serum calcium and decreased inorganic phosphate level. |

***Table 130.2. Staging Evaluation for Patients with a Single Destructive Bone Lesion with and without a History of Cancer (22)***

3. Patients without a history of cancer and a single destructive lesion. Many patients with metastatic bone disease present with a destructive lesion without a history of cancer. Skeletal pain or fracture heralds the presence of an occult primary malignancy (sentinel metastasis). A sentinel metastasis is common in carcinomas of the kidney, lung, and melanoma. The evaluation of the patient with a single destructive lesion is exactly the same as the scheme for the patient with a known cancer with a single destructive lesion.
4. Patients with a history of cancer, bone pain, and normal radiographs. Primary care physicians, medical and radiation oncologists, and orthopaedic surgeons often evaluate cancer patients with bone pain and normal radiographs. This scenario is tricky. Do a careful history and physical examination to avoid both undertreatment and overtreatment. If the plain radiographs do not show a destructive lesion, try to establish the cause of the pain. For example, if the patient has shoulder pain, look for a degenerative, traumatic, or other anatomic problems such as rotator cuff tendinitis, cervical spondylolysis, acromioclavicular joint arthritis, and glenohumeral arthritis. If a reasonable working diagnosis cannot be established, then search for bone metastases with other imaging techniques. A technetium bone scan is very sensitive; it will detect an occult metastatic focus in about 95% of patients (25). Magnetic resonance imaging (MRI) is also highly sensitive and can pinpoint the site of the pain. If the patient's shoulder pain is secondary to a cervical vertebral metastasis, however, an MRI of the shoulder will not detect the lesion.

Rougraff, Kneisel, and Simon have developed a strategy to evaluate patients with an unknown primary tumor that has metastasized to bone (22). This plan is based on the knowledge that the two most common occult primary carcinomas that metastasize to bone are lung and kidney cancers. When one wishes to search for the occult primary malignancy, a CT scan of the chest is used to look for either a primary lung carcinoma and a CT scan of the abdomen, or abdominal ultrasound is used to detect a renal cell carcinoma. Serum studies are used to detect multiple myeloma. Patients with multiple myeloma have a decreased hemoglobin level or an increased erythrocyte sedimentation rate, or both, in approximately 60% to 70%. This simple staging evaluation identifies the primary carcinoma in up to 85% of patients. In contrast, biopsy of the bone lesion alone identifies the primary in less than 5% of patients.

If this staging study is negative, we generally do not pursue further tests such as gastrointestinal contrast studies or endoscopy. We designate the patient as having an unknown primary carcinoma.

**DECISION MAKING**

When faced with a patient with a destructive lesion, decide whether the patient should be treated with both surgery and radiation or radiation alone. Virtually all patients with complete fractures need surgery unless their medical condition is too precarious or their life expectancy is very short (less than 2 to 4 weeks). Fracture risk is multifactorial, and there are no absolute criteria, although there have been a number of criteria described in the literature (2,5,15,19). For most patients, the decision must be individualized, and there are several criteria that should be considered.

The single most useful criterion to predict fracture is the amount of cortical bone destruction. Lesions that fill the medullary cavity but have not destroyed any of the cortical bone are at low risk for fracture. Many destructive lesions destroy bone eccentrically, with damage to a single cortex visible on anteroposterior and lateral radiographs. We try to quantify the amount of bone destruction by studying the two sets of radiographs. If three of the cortices are normal and a single cortex is 50% destroyed, then the amount of bone destruction would be 12.5%. When the amount of cortical bone destruction is assessed at less than 20% to 30%, the risk of fracture is small. When the cortical bone destruction is between 40% and 80%, the risk is much higher. Spontaneous fractures (without trauma) commonly occur in the lower extremity if there is greater than 75% cortical bone destruction (or the equivalent of three missing cortices).

The type of bone metastasis is as important as the amount of bone destruction. Lesions that are purely blastic seldom fracture. In contrast, lesions that are purely lytic are prone to fracture, especially when they are large or in high-stress regions. Lung and renal carcinoma often produce purely lytic metastases, which can progress rapidly. Many patients with prostate carcinoma have purely blastic metastases, which tend to progress slowly. Patients with breast cancer usually have one of three patterns: (a) purely lytic lesions, which are aggressive; (b) purely blastic lesions, which grow very slowly; and (c) a mixed pattern of bone destruction and bone formation.

The location of the metastasis is another factor that must be considered. Very proximal lesions in the metaphysis and epiphysis are less prone to fracture. In contrast, lesions that destroy greater than 50% of the cortical bone in the subtrochanteric, midshaft, or distal third regions of the femur are prone to fracture. In the upper extremity, similar sized lesions in the surgical neck, humeral shaft, and distal third of the humerus may fracture. Fortunately, most pelvic lesions do not fracture unless they become very large or invade the hip joint.

Weight-bearing pain in the lower extremity is another clue to impending fracture. Many patients describe marked pain with ambulation and none when they rest. Place patients on crutches or a walker if they have weight-bearing pain as they await treatment.

Mirels (19) developed a scoring system based on the degree of bone destruction, presence of lytic or blastic metastases, location of the lesion, and type of bone pain. For each of these four variables, there is a score of 0 to 3 for a 12-point grading system. Patients with a score of 9 or greater are prone to fracture, whereas those with a score of 7 or less are less likely to fracture. This system has not been widely accepted because of the overlap between the fracture and nonfracture groups and the subjectivity of the criteria.

We try to individualize the decision for each patient by explaining the risks and benefits of prophylactic fixation. The benefits include (a) an elective procedure that can be optimally timed between courses of chemotherapy, if necessary; (b) usually less blood loss; (c) avoidance of the pain of a pathologic fracture; (d) often a technically easier operation that can usually be performed using closed techniques; and (e) a quicker recovery. The risks are the usual ones for surgery with the potential for an anesthetic complication, bleeding, infection, and a delay in chemotherapy.

The following criteria lead us to recommend prophylactic fixation, particularly if they occur in combination:

1. Cortical bone destruction greater than 40% to 50%
2. Pure lytic metastases
3. Permeative pattern of bone destruction over a length of bone that exceeds two to three shaft diameters
4. Lesions in high-stress areas:

    Subtrochanteric region of the femur
    Shaft of the femur
    Supracondylar region of the femur
    Surgical neck of the humerus
    Shaft of the humerus
5. Weight-bearing pain

We employ these criteria without quantifying the factors. Take into consideration the patient's emotional needs, the anticipated loading of the bone, the need for

chemotherapy, and the medical condition of the patient.

## NONOPERATIVE TREATMENT

External beam irradiation and protected weight bearing are the mainstays of nonoperative treatment (8). Most patients are treated with a course of either 2,000 cGy in 5 fractions or 3,000 cGy in 10 fractions. In patients who are terminally ill, a single dose of 800 cGy often diminishes their pain. Patients with a solitary lesion and a relatively good prognosis can be treated with a longer course (4,000 to 5,000 cGy in 20 to 25 fractions). Patients with renal carcinoma are frequently treated with a higher dose (4,500 to 5,000 cGy) than those with other carcinomas because of the tendency for disease progression with lower doses.

Have patients with lower-extremity lesions use a walker or crutches during treatment and for 2 to 3 months following treatment. Take serial radiographs at 1-month intervals to judge healing of the lesion. Caution patients with upper-extremity disorders or injuries to avoid heavy loads such as changing a car tire, chopping wood, lifting items greater than 5 to 10 pounds, twisting the cap off a tight jar, carrying heavy suitcases, and so forth.

## OPERATIVE TREATMENT

The goal of operative treatment is to achieve immediate rigid fixation so that the patient can bear full weight following the operation. In contrast to the treatment of nonpathologic fracture, in which the surgeon depends on the bone to heal, there may or may not be healing of the fracture in metastatic disease because of the tumor itself or the postoperative radiation or chemotherapy. In patients who live for 5 years following treatment, the failure rates due to disease progression or inadequate fixation can be as high as 40% (26).

Internal fixation devices (intramedullary rods and plates) and prosthetic devices are the most commonly used surgical tools. Methyl methacrylate can be used to supplement the fixation and to fill in defects caused by the tumor (12). If rigid fixation cannot be achieved with an internal fixation device or if the joint surfaces have been destroyed, we prefer to use an endoprosthesis. When we use a prosthetic device we always add an aminoglycoside antibiotic (Tobramycin) to the cement. The risk of infection is higher in patients with metastatic bone disease, so we take the extra precaution.

In contrast to primary bone sarcomas, for which the goal of treatment is to remove the tumor with a wide margin, in metastatic disease, the cancer is controlled with external beam irradiation, hormonal treatment, or chemotherapy. When open surgery is performed, the metastatic tissue is curetted down to the cortex, and methyl methcrylate is usually used to fill the spaces that have been destroyed by the tumor.

Occasionally, metastatic lesions are treated by wide resection (23,24). There are two relative indications for wide resection:

1. A lesion in which there is disease progression despite one or two adequate courses of irradiation. If the patient has a good prognosis, we perform a wide resection to achieve local control and then reconstruct the limb as necessary.
2. In a patient who has renal cell carcinoma and an excellent prognosis, we sometimes perform a wide resection for local control. Many renal cell carcinomas are difficult to control with external beam irradiation alone, especially if the patient survives 3 to 5 years.

Methyl methacrylate is a useful adjunct to fill large defects and to supplement the fixation of internal fixation devices. When large defects are filled, the cement becomes load sharing in compression and helps reduce the deformation of the bone–implant construct. If large voids are left, there will be excessive bending forces on the implant with weight bearing. Metal fatigue failure was common before the use of the cement. The cement is an excellent adjuvant to enhance the fixation of intramedullary rods and screws. When applying the cement, one must be careful to confine the cement to the intramedullary cavity. If the cement leaks into the soft tissue, it can damage neurovascular structures; when large amounts are in the fracture site, the two bones ends will not unite. Most of the healing of pathologic fractures comes from the periosteal tissues.

The cement can be used to increase markedly the fixation of cortical and cancellous screws. The screw can be initially placed and then removed. The cement is injected into the screw hole with a 5-ml syringe, and then the screw is placed and the cement is allowed to harden. An alternative method is to place the cement and then drill and tap through it. Both methods work well.

## PREOPERATIVE EVALUATION AND CONSIDERATIONS

Careful preoperative evaluation of the cancer patient is necessary (9). Make an assessment of the entire skeleton. This can be done by either reviewing a recent technetium bone scan or asking the patient if there is more than one site of bone pain. If you suspect cervical vertebral involvement, study an anteroposterior or lateral view of the cervical spine to make sure that the spine is stable before surgery. When lower extremity surgery is planned, make sure that there are no large lesions in the humeri. Humeral lesions may fracture in the postoperative period while the patient is using a walker or crutches.

Anemia is common in the cancer patient due to multiple factors: marrow replacement by tumor cells, prior irradiation and chemotherapy, and anemia of chronic disease. We generally transfuse patients preoperatively if their hemoglobin levels are below 10 mg/dl. For complex procedures or procedures in which major blood loss is anticipated, we transfuse to a hemoglobin level of 13 mg/dl or higher. Leukopenia is also common. Ascertain if the patient's white blood cell count is rising or falling if he has received recent chemotherapy. We avoid operating if the absolute white blood cell count is below 500 cells/$mm^3$ at the time of surgery or below that within 2 weeks of surgery. Thrombocytopenia is also common. If the platelet count is below 50,000/$mm^3$, transfuse the patients with 8 units of platelets on the morning of surgery. Depending on the blood loss, platelets may also be needed intraoperatively.

Hypercalcemia is also common in cancer patients (4). Lung and breast carcinomas, lymphoma, and myeloma are the most common malignancies with associated hypercalcemia. Symptoms from hypercalcemia are relative to the serum calcium level and the acuteness of the rise. A rapid small rise may precipitate symptoms, whereas a slow rise to a higher value may not. Early symptoms of hypercalcemia include anorexia, fatigue, nausea, and vomiting. These symptoms may mimic the common cold, so keep a high index of suspicion in the cancer patient. Late symptoms include coma and other neurologic symptoms. Correct hypercalcemia before surgery. Hydration and saline diuresis are the first steps in treatment. Intravenous pamidronate is very effective in lowering the serum calcium level (usually within 24 hours).

### UPPER EXTREMITY

In the upper extremity, there can be a wide variety of metastatic lesions. Destructive lesions are more common in the proximal limb girdle—in the scapula, clavicle, and proximal one-half of the humerus. Most lesions of the clavicle, scapula, forearm, wrist, and hand can be treated nonoperatively. Occasionally, a pathologic fracture occurs in the radius and ulna that requires open reduction with a dynamic compression plate with methyl methacrylate augmentation as necessary.

The humerus is the most common bone in the upper extremity to require operative treatment.

#### *Prosthetic Arthroplasty of the Proximal Humerus*

There are four indications for prosthetic arthroplasty of the proximal humerus:

1. The humeral articular joint surface has been destroyed.
2. A pathologic fracture of the anatomic neck is present.
3. A large destructive lesion is present so that rigid internal fixation is not feasible.
4. There is progressive disease despite external beam irradiation.

- Perform prosthetic arthroplasty through a deltopectoral approach in a manner similar to arthroplasty for nonpathologic conditions.
- Take the subscapularis off the humerus and address the tumor according to the particular problem.
- If a fracture has occurred through the anatomic neck, resect the proximal fragment with the articular surface and curet the tumor from the distal fragment with straight and angled curets.
- Then prepare the humerus with reamers and broaches and perform a trial reduction.
- Then cement the humeral component into place and test the appropriate head with the humeral endoprosthesis.
- Close the wound in a routine fashion.

### *Closed Rodding of the Humerus*

Closed rodding of the humerus is most frequently used for prophylactic fixation of impending fractures. Usually, at least one cortex (on the anteroposterior and lateral views) is intact. The intact cortices and the intramedullary nail result in a rigid construct, so the patient has use of the upper extremity immediately postoperatively without restriction. Closed rodding can also be used once a fracture has occurred if the amount of bone destruction is small. If there is a large destructive lesion, then it is unlikely that rod fixation alone will result in a rigid construct. In this scenario, we prefer open rodding with methyl methacrylate augmentation.

- Place the patient supine on a radiolucent table with a bump under the affected shoulder. Before prepping the patient, use the image intensifier to ensure visualization of the humeral articular surface and the entire humerus. Some fluoroscopy tables must be turned around 180° to image the upper extremity because they are designed for imaging the lower extremity.
- Prep the limb from the fingers to the angle of the jaw proximally. Include the anterior chest wall to the midline and the posterior shoulder to the vertebral border of the scapula.
- Cover the image intensifier with a sterile drape and maintain sterility throughout the procedure. If the sterile drape is contaminated at some point, change it.
- For closed nailing, make a 5 to 8 cm longitudinal incision from the acromion distally just posterior to the greater tuberosity. Incise the subcutaneous tissue and fascia over the deltoid muscle.
- Divide the deltoid muscle longitudinally with electrocautery down to the rotator cuff.
- Make a 3 cm incision into the rotator cuff about one finger breadth posterior to the greater tuberosity.
- Bring the image intensifier into the field and use a sharp pointed awl to enter the proximal humerus just medial and posterior to the greater tuberosity.
- Use a pointed T-handled reamer to both enlarge the entry point and develop a track in the proximal humerus for the guide wire. Bend the tip of the guide wire at 30° over a 3 cm length to facilitate passage of the guide across the fracture site.
- Then pass the guide wire into the proximal fragment to the level of the fracture site under image guidance.
- Reduce the fracture under the image intensifier and pass the guide wire across the fracture site. Then advance the guide wire as far distally as possible.
- Measure the length of the intramedullary rod by placing a second guide wire of the same length along the intramedullary guide wire and placing the tip at the entry site with the image intensifier.
- Place a Kocher clamp on the measuring guide at the proximal end of the intramedullary guide wire. Use a nail gauge to measure the difference, which represents the length of the guide that is in the intramedullary cavity. An alternate and equally effective method is to use the nail itself as a reference.
- Then sequentially ream the humerus in 0.5 mm increments. The diameter of the nail chosen is the largest nail that will reasonably fit in the intramedullary cavity. We generally choose a nail diameter 1.0 mm less than the last intramedullary reamer.
- Exchange the ball-tipped guide wire for a smooth guide wire, and place the nail over the guide wire into the proximal fragment under image intensification. With the help of the image intensifier, pass the rod across the fracture site. By alternately checking the entry site and the elbow, advance the rod until the proximal end is buried in the humeral head. Then place a proximal interlocking screw.
- If the destructive lesion is small and rigid fixation has been achieved with the rod and proximal locking screw, a distal interlocking is not necessary. When in doubt, add the distal locking screw to the fixation.

### *Open Rodding of the Humerus*

We perform open rodding of the humerus for large destructive lesions and in most pathologic fractures in which we do not believe that we can obtain rigid fixation with closed rodding (Fig. 130.1). The rodding procedure is exactly the same as for closed rodding with the following modifications.

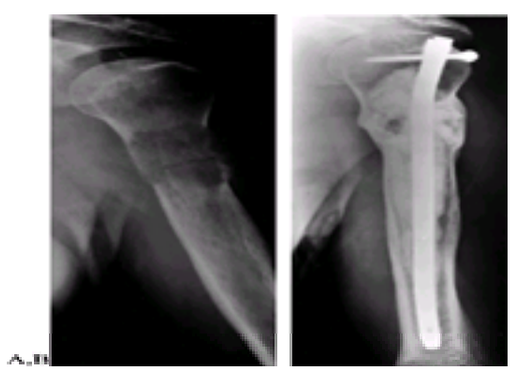

***Figure 130.1.*** Anteroposterior radiograph of the proximal humerus showing a purely lytic lesion with a pathologic fracture. **B:** Anteroposterior radiograph following open reduction internal fixation with an intramedullary rod augmented with methyl methacrylate. Note the mature periosteal healing around the cement augmentation.

- Use a deltopectoral approach to expose the proximal humerus and an anterolateral approach for lesions of the diaphysis. For large lesions that involve both the proximal and mid humerus, we combine the two approaches.
- Curet the tumor from the medullary canal through a large cortical window in the patients who do not have a fracture and through the fracture site in patients with fractures.
- Then prepare the humerus to accept the intramedullary rod. We rehearse placement of the nail across the fracture site and verify satisfactory reduction and position of the nail before placing the cement in the intramedullary cavity. Be sure that the exposure is adequate and the instruments and nail are ready.
- Withdraw the nail into the proximal fragment proximal to the destructive lesion. We generally remove the guide wire at this point. If the field is very bloody or the exposure is less than adequate, you can leave the guide wire in place; however, that makes it more difficult to inject the cement.
- Mix the cement and inject it with a cement gun using a small nozzle into the distal fragment first and then into the proximal fragment. Hand pressurize the cement to fill all the defects.
- Drive the nail into place and then image the humerus from the shoulder to the elbow to make sure the nail placement is adequate and that there is not excessive cement in the soft tissues.
- Place the proximal locking screws and close the wound in layers with a suction drain.

## LOWER EXTREMITY

The pelvis, hip, and femoral shaft are the most common sites of metastatic bone disease (6). Most destructive lesions in the pelvis can be managed with external beam irradiation alone. The most common lesions that require surgery are lesions in the hip and femoral shaft.

### *Hip*

Destructive lesions in the hip can be very disabling. The pattern of disease can be very diffuse with destructive lesions involving the femoral head, neck, or intertrochanteric and subtrochanteric regions alone or in various combinations. In addition, there may be destructive lesions in the shaft of the femur that are separated from the hip lesions by many centimeters. Preoperative planning requires a high-quality plain radiograph of the entire femur. Base the treatment plan on the location of the lesions.

**Femoral Neck Lesions** We generally perform bipolar hemiarthroplasty for most femoral neck lesions (3,17,18,21) (Fig. 130.2). The advantage of arthroplasty is that the patient can bear full weight within a month of surgery and pain relief is excellent and reproducible. Occasionally, if the patient has a small femoral neck lesion (less than 40% cortical bone destruction), we perform cancellous screw fixation with three screws followed by external beam irradiation. Most metastatic lesions in the proximal femur are very diffuse, however, and the screw fixation protects only the discrete femoral neck lesions. We often treat patients with femoral neck lesions with external beam irradiation alone and with crutches. Many patients wish to avoid surgery but if the femoral neck fractures, the surgical procedure remains the same—bipolar hemiarthroplasty.

***Figure 130.2.*** **A:** Anteroposterior radiograph of the hip with extensive lytic and blastic areas in a woman with breast cancer. There is a minimally displaced femoral neck fracture. **B:** Anteroposterior radiograph of the hip following reconstruction with a long-stem bipolar endoprosthesis. Note the lytic lesion in the medial cortex of the midshaft of the femur. This lytic area is well bypassed by the femoral stem.

- Bipolar arthroplasty can be performed equally well through anterior or posterior approaches. We prefer the Hardinge approach because it provides excellent access to the entire femoral shaft if curettage, wiring, or other procedures are also necessary. It is important to choose a femoral stem that will adequately bypass any lesions in the femoral shaft.
- Have available both head and neck replacement prostheses and long-stem prostheses. The head and neck prostheses are very useful if the proximal femoral disease is found to be greater at surgery than what the radiographs showed. Many lesions will progress while the patient waits for surgery. The long-stem prostheses are very useful if an intraoperative fracture occurs. When a long-stem prosthesis is used, it is very important not to pressurize the cement because fat embolization may occur and result in intraoperative cardiac arrest. To prevent this problem, vent the intramedullary canal with a Silastic tube or drill one or two holes in the proximal anterior cortex.
- Place the patient in the lateral decubitus position and pad all pressure points.
- Using the Hardinge approach, incise the skin and subcutaneous tissues directly down to the fascia and place a Charnley self-retaining retractor to retract the deep fascia.
- Excise the trochanteric bursa and release the anterior one third to one half of the gluteus medius and minimus from the proximal femur.
- For bipolar arthroplasty, incise the hip capsule with a T-type incision with the horizontal limb parallel to the intertrochanteric line. Place no. 2 Ethibond sutures (Ethicon, Inc., Somerville, NJ) in the capsule to facilitate retraction. Take the vertical limb of the T to the acetabular labrum without cutting the labrum.
- Be careful when dislocating the femoral head. If the proximal femur is severely compromised by several destructive lesions and you apply a large amount of force to dislocate the head, the femur may fracture and significantly increase the magnitude of the surgical problems. Three techniques can be used to minimize the risk of fracture (we always employ the first two):
  1. Release the capsule anteriorly from the proximal femur around the medial side by flexing and externally rotating the hip while releasing the capsule. This can be accomplished around the medial side and for a short distance posteriorly.
  2. Place a bone hook around the femoral neck to facilitate dislocation.
  3. Osteotomize the femoral neck *in situ* and remove in a manner similar to that for a patient who has had femoral neck fracture. Be careful not to injure the acetabular cartilage while removing the femoral head.

- Once the femoral head has been removed, inspect the articular cartilage visually and by palpation. If there are no defects, then trial the acetabulum for the appropriate diameter femoral head. We also measure the femoral head diameter with a caliper.
- Then ream and broach the proximal femur to accept the femoral component. When cementing the component, do not pressurize the cement as for nonpathologic cases.
- Close the wound in layers over suction drain.

Before cementing standard or long-stem prostheses, be sure to advise the anesthesiologist so that proper precautions can be taken. These precautions include (a) decreasing the amount of inhalation agent, (b) ensuring that the patient is not hypovolemic, and (c) maximizing the oxygenation of the patient. The femoral canal is not pressurized as is done in nonneoplastic cases.

**Intertrochanteric Lesions**

- Treat intertrochanteric lesions in a fashion similar to femoral neck lesions.
- Always use the anterior Hardinge exposure.
- Remove the compromised cortex and shape the intertrochanteric region to accept the head and neck prostheses.
- Use straight and angled curets to remove the gross disease. Do not be overly aggressive and thus destroy the remaining cortical shell or there will not be sufficient bone stock to perform the arthroplasty.
- Perform a trial reduction and cement the prosthesis as previously described.

**Extensive Proximal Femoral Lesions and Salvage of Failed Internal Fixation Devices** In some patients, it is not feasible to save the proximal femur. In this scenario, we resect the proximal femur and reconstruct the defect with a modular custom prosthesis. There are three common situations in which this procedure is necessary:

1. There is extensive proximal femoral disease and the bone stock is so poor that a standard prosthesis, head and neck prosthesis, or an internal fixation device is not suitable.
2. The patient has undergone one or two courses of external beam irradiation to the hip and has progressive disease. Here, the only way to halt progression is to resect the lesion.
3. The patient has a failed internal fixation device (the metal has fractured, the device has cut out of the bone, or there is disease progression around the implant with loss of fixation).

- The positioning of the patient and the surgical approach is exactly the same as for bipolar hemiarthroplasty.
- Divide the abductor mechanism longitudinally into two equal anterior and posterior halves. When the anterior half is dissected, release the gluteus medius and minimus from the femur in longitudinal continuity with the vastus lateralis (it is important for postoperative function not to separate them transversely).
- Remove the posterior flap from the proximal femur in a similar fashion, although it is much more difficult to maintain the continuity with the vastus lateralis. Also, release the short external rotators.
- Release the hip capsule in a fashion similar to that for bipolar arthroplasty, except now release the entire capsule from the femur. Be very careful not to sever the acetabular labrum because it is important for the stability of the prosthesis.
- Then osteotomize the femur at the desired level and place a Verbrugge clamp on the end of the proximal fragment. The Verbrugge is useful to position the proximal fragment as the soft tissues are released.
- By placing the proximal fragment in external rotation, abduction, and internal rotation, release the adductors muscles, psoas tendon and all other soft tissues from the femur. Having released all the soft tissues, dislocate the femoral head from the acetabulum and section the ligament of the head. A hip skid is often helpful to dislocate the head; however, be careful not to injure the acetabular cartilage. Inspect the acetabular cartilage and determine the bipolar head size.
- Then assemble the modular trial prosthesis based on the amount of proximal femur removed. If the trial modular components are too long, use a smaller body segment (decrease by 20 mm increments). If only the stem and proximal trunnion are used and the reduction is too tight, then resect 1 or 2 cm of femoral shaft from the remaining femur. Tag the hip capsule at four to six points along its 360° circumference to prevent soft-tissue entrapment during the trial reductions of the bipolar component.
- Once the proper size is found, prepare the femoral shaft with a flexible reamer so that a 1.0 to 1.5 mm cement mantle can be achieved (the stem diameters are 9, 11, and 13 mm; reaming would then be 11 mm for the 9 mm stem, 13 mm for the 11 mm stem and 15 mm for the 13 mm stem).
- Then bring the actual prosthesis to be used onto the field and assemble it. Cement the stem into the femur with modern cement technique.
- Close the hip capsule carefully with no. 5 Ethibond sutures.
- Close the anterior and posterior sleeves of the abductor and vastus lateralis muscles carefully with a combination of no. 5 Ethibond and no. 1 Vicryl sutures (Ethicon, Inc., Sommerville, NJ).
- Close the remainder of the wound in layers over a suction drain.

Postoperatively, place the patient in a hip abduction brace for 3 to 6 months, allowing full weight bearing immediately following surgery.

**Subtrochanteric and Femoral Shaft Lesions** Intramedullary nailing with locked intramedullary nails has evolved as an excellent modality to internally fix both impending and complete fractures of the femur (20) (Fig. 130.3). In contrast to the procedure with the humerus, we usually do not open femoral shaft fractures to supplement the fixation with methyl methacrylate. Rigid fixation can usually be achieved with proximal and distal interlocking. We study anteroposterior and lateral radiographs of the entire femur to identify sites of bone destruction. If there are substantial lesions in the subtrochanteric region (within 10 cm of the lesser trochanter), we prefer to fix the femur with a reconstruction nail. We use the standard femoral nail for lesions in the femoral shaft to the supracondylar region. We do not routinely use the reconstruction nail for all femoral lesions because the nail is more difficult to insert than the standard nail. See Chapters 11 and, in particular, Chapter 20 for a description of closed intramedullary nailing. Specific details of the technique for metastatic lesions follows:

***Figure 130.3.*** **A:** Anteroposterior radiograph of the hip showing a large subtrochanteric lytic lesion and diffuse disease in the intertrochanteric region. **B:** Anteroposterior radiograph following stabilization with a reconstruction nail. The femoral shaft fractured while placing the nail. Note the prominent periosteal healing.

- We prefer the supine position on the fracture table. For reconstruction nailing, place the entry point a little anterior to the exact midline. If the entry point is too posterior with reconstruction nailing, you will not be able to place the proximal interlocking screws into the femoral head.
- When advancing the guide pin in femoral shafts with large destructive lesions, be careful because the guide can penetrate the remaining cortex and enter the soft tissues. Avoid this problem by turning the angle of the distal guide wire away from the destructive lesion as the guide wire is advanced under image control. In patients with complete fractures, advance the guide wire in the proximal fragment until the fracture site is reached. With image guidance, reduce the fracture and pass the guide wire across the fracture site and advance it to the physeal scar.
- Plan to ream about 1 to 2 mm larger than the first reamer that obtains good cortical contact.

Fat, marrow, and tumor cells may embolize from the intramedullary cavity to the lungs during reaming and insertion of the femoral nail. We do not routinely vent the femur by placing more holes in the already compromised bone. Instead, we choose an intramedullary nail that is 1.5 to 2.0 mm smaller than the last reamer. With this technique, the nail can be advanced by hand or with gentle hammer taps. The proximal and distal interlocking screws provide the rotational stability. If one has to drive the nail with sharp hammer blows, then the femur should be reamed an additional 0.5 to 1.00 mm or a smaller diameter nail chosen.

***Destructive Lesions in the Metaphysis***

Destructive lesions in the metaphysis of the distal femur and proximal tibia are usually managed by curettage of the lesion, cement augmentation, and plate fixation (Fig. 130.4). It is more difficult to achieve rigid fixation with intramedullary rods when the lesion approaches the articular surface. For the distal femur we use a dynamic compression screw, whereas in the tibia we use lateral tibia plateau plates or medial buttress plates, depending on the location of the bone destruction. We avoid removing intact cortical bone and generally do the exposure and plate fixation on the side of the greatest bone destruction.

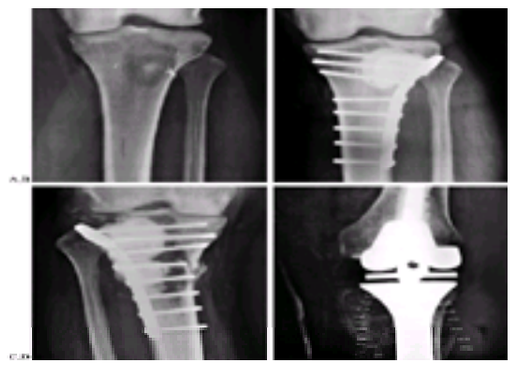

***Figure 130.4.*** **A:** Anteroposterior radiograph of the tibia showing a destructive lesion in a patient with renal cell carcinoma. **B:** Anteroposterior radiograph of the tibia following curettage and methyl methacrylate augmentation and plate fixation. **C:** Anteroposterior radiograph of the tibia showing progressive bone destruction following two courses of external beam irradiation and plate fixation with cement augmentation. **D:** Anteroposterior radiograph demonstrating resection of the proximal tibia and reconstruction with a custom modular knee replacement.

## POSTOPERATIVE CARE

The goals of postoperative care are to (a) halt progression of the bone destruction, (b) avoid postoperative complications, and (c) control pain.

### POSTOPERATIVE EXTERNAL BEAM IRRADIATION

External beam irradiation following surgery plays a crucial role in halting disease progression (7,8). Without postoperative irradiation, 20% to 30% of patients will have disease progression with failure of the surgical procedure. In addition, pain control can be achieved only when the tumor cells stop destroying the bone. Begin radiation therapy at 2 to 3 weeks following surgery, when the wound has healed. In noncomplicated wounds, we often close the wound with staples. Nylon sutures are used if we anticipate leaving the sutures in place for a prolonged period because most radiation oncologists hesitate to radiate over metal staples because of possible skin reaction. The dose of radiation depends on the clinical situation and the general health of the patient, according to the following guidelines:

1. Patients who are terminally ill and cannot tolerate 2 weeks of daily treatments can be treated with a single treatment 800 cGy in a single fraction.
2. The most common prescription is 2,000 to 3,000 cGy in 5 to 10 fractions; this regimen is excellent for achieving pain control and decreasing the risk of disease progression.
3. For a solitary metastasis in a patient with a good prognosis (survival greater than 12 to 24 months), 4,000 to 4,500 cGy in 20 to 25 fractions is often recommended. Patients with renal cell carcinoma are also treated with higher doses because it is often difficult to control metastatic renal cell carcinoma with lower doses.

Medical treatment can play an important role in stabilizing bone disease in patients with metastatic bone disease. Hormonal therapy plays a key role in appropriate patients with metastatic breast and prostate carcinoma. Chemotherapy has less of an effect on the healing of bone disease.

Diphosphonate therapy has become a pivotal therapy in treating widespread bone metastases in patients with metastatic breast cancer and multiple myeloma. The diphosphonates stop the osteoclasts from resorbing bone, and this action helps to halt the relentless cycle of bone destruction and further activation. Intravenous pamidronate is the most commonly used agent. It is given over a 3-hour period, usually on a monthly basis.

## POSTOPERATIVE COMPLICATIONS

Complications are common in cancer patients following surgery because many of the patients are immunocompromised, poorly nourished, and prone to deep vein thrombosis and hypercalcemia. The following are some general guidelines to employ:

1. In patients who are immunocompromised, administer intravenous cephalosporin and aminoglycoside for 3 days following surgery. Continue with oral cephalosporin if the wound continues to drain.
2. Provide nutritional supplements to patients who have low albumin levels or lymphocyte counts.
3. Give low-dose warfarin (Coumadin) for 4 to 6 weeks following surgery to patients who have lower extremity surgery. Encourage them to wear their thromboembolic disease (TED) hose for 6 weeks when they are out of bed and ambulating.
4. Check serum calcium levels postoperatively in patients who exhibit any early symptoms of hypercalcemia. Check the serum calcium routinely in patients who have a history of hypercalcemia.

### CHAPTER REFERENCES

Each reference is categorized according to the following scheme: *, classic article; #, review article; !, basic research article; and +, clinical results/outcome study.


* 1. Batson OV. The Function of the Vertebral Veins and Their Role in the Spread of Metastases. *Ann Surg* 1940;112:138.

+ 2. Beals RK, Lawton GD, Snell WE. Prophylactic Internal Fixation of the Femur in Metastatic Breast Cancer. *Cancer* 1971;28:1352.

+ 3. Behr JT, Dobozi WR, Badrinath K. The Treatment of Pathologic and Impending Fractures of the Proximal Femur in the Elderly. *Clin Orthop* 1985;198:173.

# 4. Colgan JP. Hematologic Considerations. In: Sim FH, ed. *Diagnosis and Management of Metastatic Bone Disease. A Multidisciplinary Approach.* New York: Raven Press, 1988:153.

+ 5. Fidler, M. Prophylactic Internal Fixation of Secondary Neoplastic Deposits in Long Bones. *Br Med J* 1973;1:341.

# 6. Finn HA. Hip and Proximal Femur. In: Simon MA, Springfield D, eds. *Surgery for Bone and Soft Tissue Tumors.* Philadelphia: Lippincott-Raven, 1998:683.

# 7. Frassica DA, Frassica FJ, Sim FH. Supportive Measures for Patients. In: Simon MA, Springfield D, eds. *Surgery for Bone and Soft Tissue Tumors.* Philadelphia: Lippincott-Raven, 1998:625.

# 8. Frassica DA, Frassica, FJ. Nonoperative Management. In: Simon MA Springfield D, eds. *Surgery for Bone and Soft Tissue Tumors.* Philadelphia: Lippincott-Raven, 1998:633.

# 9. Frassica FJ, Gitelis S, Sim FH. Metastatic Bone Disease: General Principles, Pathophysiology, Evaluation, and Biopsy. *Instr Course Lect* 1992;I:293.

# 10. Frassica FJ, Sim FH. Pathogenesis and Prognosis. In: Sim FH, ed. *Diagnosis and Management of Metastatic Bone Disease. A Multidisciplinary Approach.* New York: Raven Press, 1988:1.

# 11. Frassica FJ, Sim FH. Bone Pain. In: Taylor R, ed. *Difficult Diagnoses II.* Philadelphia: WB Saunders, 1992:52.

+ 12. Harrington KD, Sim FH, Enis JE, et al. Methylmethacrylate as an Adjunct in Internal Fixation of Pathologic Fractures: Experience with Three Hundred and Seventy Five Cases. *J Bone Joint Surg [Am]* 1976;58:1047.

+ 13. Hattrup S, Amadio PC, Sim FH, Lombardi, RM. Metastatic Tumors of the Foot and Ankle. *Foot Ankle* 1988;8:243.

+ 14. Healey JH, Twinbull AD, Miedema B, Lane JM. Acrometastases: A Study of Twenty Nine Patients with Osseous Involvement of the Hands and Feet. *J Bone Joint Surg [Am]* 1986;68:743.

+ 15. Hipp JA, Springfield DS, Hayes WC. Predicting Pathologic Fracture Risk in the Management of Metastatic Bone Defects. *Clin Orthop* 1995;312:120.

# 16. Landis SH, Murray T, Bolden S, Wingo PA. Cancer Statistics, 1998. *CA Cancer J Clin* 1998;48:6.

+ 17. Lane JN, Sculco TP, Zolan S. Treatment of Pathologic Fractures of the Hip by Endoprosthetic Replacement. *J Bone Joint Surg* 1980;62a:954.

+ 18. Levy RN, Sherry HS, Siffert RS. Surgical Management of Metastatic Disease of Bone at the Hip. *Clin Orthop* 1982;169:62.

+ 19. Mirels H. Metastatic Disease in Long Bones: A Proposed Scoring System for Diagnosing Impending Pathologic Fractures. *Clin Orthop* 1989;249:256.

# 20. Peabody TD, Finn HA. Femoral Diaphysis and Distal Femur. In: Simon MA, Springfield D, eds. *Surgery for Bone and Soft Tissue Tumors.* Philadelphia: Lippincott-Raven, 1998;705.

+ 21. Rinkes IH, Wiggers T, Bouma WH, et al. Treatment of Manifest and Impending Pathologic Fractures of the Femoral Neck by Cemented Hemiarthroplasty. *Clin Orthop* 1990;260:220.

+ 22. Rougraff BT, Kneisel JS, Simon MA. Skeletal Metastases of Unknown Origin: A Prospective Study of a Diagnostic Strategy. *J Bone Joint Surg* 1993;75A:1276.

# 23. Sim FH. Metastatic Bone Disease of the Pelvis and Femur. *Instr Course Lect* 1992;41:317.

+ 24. Sim FH, Frassica FJ, Chao EYS. Orthopaedic Management Using New Devices and Prostheses. *Clin Orthop* 1995;312:160.

# 25. Wahner HW, Brown ML. Role of Bone Scanning. In: Sim FH, ed. *Diagnosis and Management of Metastatic Bone Disease. A Multidisciplinary Approach.* New York: Raven Press, 1988:51.

+ 26. Yazawa Y, Frassica FJ, Chao EYS, et al. Metastatic Bone Disease: A Study of the Surgical Treatment of 166 Pathologic Humeral and Femoral Fractures. *Clin Orthop* 1990;251:213.

# CHAPTER 131

# METABOLIC BONE DISEASE

*William F. Flynn, Joseph M. Lane, and Charles N. Cornell*

**W. F. Flynn:** Waterbury, CT, 06708.
**J. M. Lane and C. N. Cornell:** Hospital for Special Surgery, New York, New York, 10021.

Calcitropic Hormones
Calcium Phosphate Metabolism
Paget's Disease
Diagnosis
Treatment
Orthopaedic Implications
Paget's Sarcoma
Elective Orthopaedic Surgery
Rickets and Osteomalacia
Renal Osteodystrophy
Osteoporosis
Prevention
Treatment
Orthopaedic Problems
Chapter References

Orthopaedic surgeons tend to think of the skeleton primarily in its mechanical role as the body's framework, often overlooking its metabolic aspects. Bone is dynamic tissue, and disturbances in its metabolic activity may have significant consequences for the skeleton and the body as a whole. In this chapter, we will explore the implications for orthopaedic surgery of bone metabolism.

## CALCITROPIC HORMONES

Parathyroid hormone (PTH) is synthesized and released when the body's serum ionized calcium concentration is low; the net effect of PTH is an increase in serum calcium. PTH causes bone resorption by indirect activation of the osteoclasts (increased number and activity) through osteoblast coupling factors. At high concentrations of PTH, osteoblast activity is inhibited, and at low concentrations, bone formation is stimulated. In the kidney, PTH causes decreased resorption of phosphate in the proximal tubule and increased distal resorption of calcium. PTH also increases renal conversion of 25-hydroxy vitamin D to active 1,25-dihydroxy vitamin D, resulting in increased calcium absorption from the gut (see later).

Vitamin D, a sterol hormone, is also of vital importance in calcium metabolism. It is synthesized from 7-dihydrocholesterol in the skin under the influence of ultraviolet light. As little as 15 minutes a day of direct sunlight exposure on a Caucasian person will produce the daily requirement of vitamin D, but many people, particularly in northern cities, do not meet this requirement during the winter (28). The cytochrome P450 system forms 25-hydroxy vitamin D, which has a 3-day half-life, from vitamin D in the liver. The kidney then converts this into the active form, 1,25-dihydroxy vitamin D, which has a half-life of 8 hours. This step is under the influence of PTH.

The effect of vitamin D on calcium metabolism is primarily to increase the concentration of calcium. Vitamin D enhances PTH-stimulated bone resorption and promotes increased intestinal absorption of calcium. In the gut, 1,25-dihydroxy vitamin D acts to mature the intestinal villi and to induce the formation of calcium-binding protein by the villi. This binding protein is responsible for active transport of calcium across the gut. In high dietary calcium situations, it is absorbed across the gut by passive diffusion. Vitamin D also promotes the differentiation of cells in the monocyte–macrophage line, which should increase the number of osteoclasts. The possible effect of vitamin D on osteoid mineralization may be mediated through alterations in osteoblasts, enhanced osteocalcin production, or modification of phospholipid metabolism. Vitamin D, however, does not directly stimulate bone formation.

Calcitonin is another peptide hormone active in calcium metabolism. It produces potent and rapid hypocalcemic activity through inhibition of the activity and number of osteoclasts. Calcitonin binds directly to receptors on osteoclasts, resulting in detachment of osteoclasts from the bone and disappearance of the ruffled border. Continued administration of calcitonin produces a gradually smaller response in the osteoclasts. It stimulates bone formation, but this effect wanes as the number of osteoclasts decreases. Calcitonin also acts in the kidney to decrease resorption of calcium from the proximal tubules. It also appears to inhibit production of the active 1,25-dihydroxy vitamin D.

Estrogen has recently been demonstrated to have an effect on calcium metabolism through estrogen receptors on the surface of osteoblasts (17). Although the mechanisms of estrogen's effect on bone metabolism have not been clearly identified, accelerated loss of bone following natural, chemical, or surgical oophorectomy is well established (57,72). Administration of estrogen with calcium has been shown to slow the accelerated loss of skeletal calcium following menopause (14,18,32,33,39,57).

## CALCIUM PHOSPHATE METABOLISM

Dietary calcium is absorbed primarily in the duodenum and upper gut; about 15% to 40% of the dietary dose is absorbed, depending on the patient's age and hormonal status. The body's requirement for calcium changes with age (Table 131.1). Children need 400–700 mg/day ingested calcium (two or three dairy equivalents daily). During the peak acquisition of skeletal bone mass, between adolescence and age 25, daily intake of about 1,300 mg of calcium (five dairy equivalents) is required. Healthy adults generally require 500 mg/day, pregnant women 1,500 mg/day, and lactating women 2,000 mg/day. Postmenopausal women generally require 1,500 mg/day, as do patients who have had a major fracture.

| *Age group* | *Daily requirement (mg)* |
|---|---|
| Young children | 400–700 (2 or 3 dairy equivalents) |
| Growing adolescents to age 25 | 1300 (5 dairy equivalents) |
| Premenopausal women | 800 |
| Pregnant women | 1500 |
| Lactating women | 2000 |

***Table 131.1. Daily Calcium Requirements***

Calcium absorption is facilitated by the appropriate gastric pH, adequate 1,25-dihydroxy vitamin D, and a calcium-to-phosphate ratio of 1:1 or 1:2. Achlorhydria; decreased vitamin D; increased phosphates; increased fat, phytates, or oxylates in the diet; sprue; blind-loop disorders; and renal disorders can decrease the

absorption of calcium.

Phosphate is absorbed primarily in the lower bowel and excreted in the urine. The daily requirement is about 1,000–1,500 mg and is rarely a limiting factor in American diets. Aluminum and beryllium can decrease the absorption of phosphate; PTH increases its excretion.

## PAGET'S DISEASE

Paget's disease is a disorder characterized by a disturbance in the rate of bone turnover, initiated by an early increase in bone resorption by osteoclasts and followed by excessive and pathologic bone formation by osteoblasts. The result is distorted bones with thickened cortices, coarse trabeculations, and an immature woven appearance. Paget's disease can affect any bone but most commonly afflicts the femur, spine, pelvis, and cranium. Paget's disease may be monostotic or polyostotic, and it may or may not be symptomatic.

The etiology of Paget's disease remains unknown. There appears to be a familial clustering, with a positive family history in 14% to 30% of patients with Paget's disease. A correlation of Paget's disease and certain human leukocyte antigen (HLA) patterns has been noted (83). In addition, a viral etiology for Paget's disease has been proposed (64,65,78). Inclusions resembling viral nuclear capsules have been described in osteoclasts in pagetic bone; these are not seen in osteoclasts or osteoblasts in normal sites in the same patient. These viruslike particles resemble paramyxovirus or measles virus (65). Viral etiology has not been definitively proved, but it is possible that a susceptible host may contract a slow type of virus, predisposing the host to Paget's disease later in life.

Paget's disease afflicts men more commonly than women by a 3:2 ratio, and it is seen most often in patients over age 50. It is estimated that 3% to 4% of people over age 45 and as many as 8% of those over age 80 in the United States may have Paget's disease, a total of more than 3 million people (84). This disease is most common in Europe, North America, Australia, and New Zealand, and it appears more common in people of northern European ancestry than of southern European ancestry, although Scandinavians have a particularly low rate. The disease is uncommon in Asians and blacks, although most clinical series in North America have black patients.

### DIAGNOSIS

Perhaps 10% to 20% of patients with Paget's disease are asymptomatic when diagnosed incidentally through radiology or laboratory work (e.g., by an elevated alkaline phosphatase). In symptomatic Paget's disease, patients experience bone pain either with rest or with motion. Pagetic bone also has increased vascularity, leading to a warmth of the bone or of the skin over the bone. Back pain is common in patients with Paget's disease, secondary to spinal stenosis or vertebral compression fractures. Paraplegia can occur acutely, often in association with a giant-cell tumor secondary to Paget's. Paget's disease may cause an increase in the size of the skull, with or without frontal bossing. Hearing loss may also occur.

Radiographically, pagetic bone may have small transverse lucencies or pseudofractures, typically on the convex surfaces of the weight-bearing long bones. Bowing of the femur or tibia may also occur, either with or without pseudofracture. Typical radiologic appearance includes areas of focal bone resorption and formation and a disordered trabecular pattern (Fig. 131.1, Fig. 131.2). Bone size is expanded and the cortices are thickened. A flame-shaped osteolytic wedge may be seen, as may bony deformities, incomplete pseudofractures, and frank pathologic fractures.

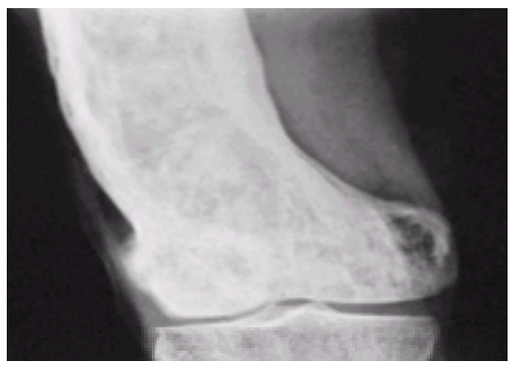

***Figure 131.1.*** Paget's disease. Notice coarse trabeculation.

***Figure 131.2.*** Paget's disease. Notice enlargement of bone and coarse trabeculation.

Classically, in Paget's disease, involvement at one end of the bone progresses toward the other end. A bone scan is more useful than a skeletal survey to discover the extent of the disease. A gallium scan will differentiate tumor from Paget's disease (only tumor is positive). Elevated serum alkaline phosphatase and bone collagen products (*N*-telopeptide, pyridinoline) are typical findings. The alkaline phosphatase level is more useful as a screening tool. Either alkaline phosphatase or collagen breakdown products may also be used to monitor response to treatment, with a 50% reduction considered to be a good clinical response.

Histologic examination of pagetic bone shows marked abnormalities. There is an increase in the cellular activity of both osteoblasts and osteoclasts, with fibrosis and fibrovascular invasion of the marrow. The osteoclasts seen in Paget's disease have extremely numerous nuclei with very large nucleoli (Fig. 131.3). Active Paget's disease as just described presents a classic histologic appearance. “Burned-out” sclerotic pagetic bone, however, is more difficult to diagnose definitively because the bone reverts to near normal, although a mosaic-type bone pattern can be seen microscopically with polarized light.

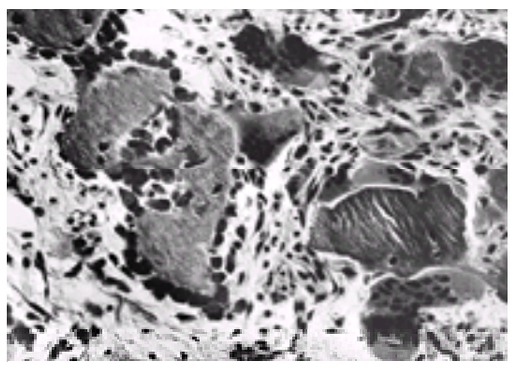

***Figure 131.3.*** Photomicrograph shows resorption by large osteoclasts with numerous nuclei, as well as bone formation by osteoblasts (hematoxylin and eosin, ×80).

## TREATMENT

Asymptomatic patients with Paget's disease, especially those who do not have the disease in the weight-bearing bones in the lower extremity, do not require intervention other than periodic monitoring. In patients with symptomatic Paget's disease, the primary indication for treatment is pain (Table 131.2). Bone pain, excessive warmth over bones, headaches, and some low back pain secondary to vertebral changes are most likely to be relieved with drug treatment. Secondary arthritic pain is less likely to be relieved by antipagetic agents. Treatment is also indicated when it is felt that suppression of the disease would be beneficial to the patient (e.g., in the presence of neurologic deficits, fracture, proposed elective skeletal surgery, congestive heart failure due to polyostotic disease, and severe polyostotic disease itself). A third indication is an alkaline phosphatase or bone biomarker level twice normal, with the disease in weight-bearing bones.

| Indication | Treatment |
|---|---|
| Pain | Nasal Calcitonin |
| Deformity | Alendronate 40 mg/day for 6 months |
| Increased alkaline phosphatase or collagen breakdown (>2 times normal) | Etidronate 400 mg/day for 6 months |
| Pathologic fracture | IV Pamidronate 30 mg for 3 days |
| Congestive heart failure | Risedronate 30 mg/day for 2 months |
| Pending elective surgery | Tiludronate 400 mg/day for 3 months |
| Paget's paraplegia | IV mithramycin 15 mg/kg/day for 10 days |

***Table 131.2. Management of Paget's Disease***

The main agents used for the treatment of Paget's disease in the United States are calcitonin, bisphosphonates such as etidronate, and occasionally mithramycin. Calcitonin is available as salmon or human calcitonin; the salmon calcitonin is more potent by weight. Calcitonin is a peptide and is currently given by an intranasal spray. In patients with painful pseudofracture or frank fractures, calcitonin is given initially at 200 units/day until there is evidence of decreased bone pain or fracture healing, and the alkaline phosphatase level falls. The dose can then be decreased to three times a week to maintain the alkaline phosphatase at a lower level. Side effects of nasal calcitonin include dry nares (2%).

The preferred method of treatment for Paget's disease is bisphosphonate. Several compounds that have shown excellent efficacy are oral alendronate, residronate, and tulidronate, as well as intravenous pamidronate. These agents essentially inhibit bone resorption with no significant inhibition of bone formation. Etidronate affects both aspects of bone turnover.

Mithramycin is an extremely cytotoxic agent that is a strong inhibitor of both osteoclasts and osteoblasts. It can rapidly relieve bone pain in Paget's disease, but because of its significant side effects it is recommended only in Paget's paraplegia (62,79). In this case, it is given intravenously in doses of 15 mg/kg/day for 10 days.

## ORTHOPAEDIC IMPLICATIONS

Fractures, particularly pathologic fractures, are the most common complication in Paget's disease. An estimated 10% of patients with extensive Paget's disease will suffer pathologic fracture, usually of the femur, tibia, or forearm (62). Nonunions are common, particularly with femoral neck and subtrochanteric fractures (5,15,24,69).

Fractures occurring through secondary sarcomas account for 5% to 20% of fractures in pagetic bone (70). Pseudofractures in Paget's disease occur most commonly in the tibia and the proximal femur, typically on the convex side of the bone, although they may be seen on the medial concavity of the femur as well. Treatment includes bracing and protected weight bearing in addition to pharmacologic treatment until the patient becomes pain free. Radiologic healing often lags behind clinical healing.

Actual fractures in Paget's disease are often short, oblique, or transverse. If they fail closed management, they are best treated by an intramedullary device. Passage of an intramedullary device may be technically difficult because of the disordered architecture of the pagetic bone.

Femoral neck fractures are a particular problem and often do not heal in patients with Paget's disease; the reported rate of nonunion is 75% to 90% (62). If these fractures are displaced, perform prosthetic replacement. Intertrochanteric fractures, on the other hand, usually unite after fixation with a sliding screw-plate device.

Subtrochanteric fractures are particularly difficult to handle in patients with Paget's disease. Intramedullary fixation is preferable from a biomechanical standpoint but may be difficult because of excessively soft or sclerotic bone and because of bony deformity of the femur. Sometimes a corrective osteotomy in addition to intramedullary fixation may be required (Fig. 131.4). Femoral shaft fractures are typically managed in a similar way, but tibial fractures can often be managed by closed means because of the transverse configuration of the fracture. Surgical treatment of a fracture, however, may provide an opportunity to correct a deformity.

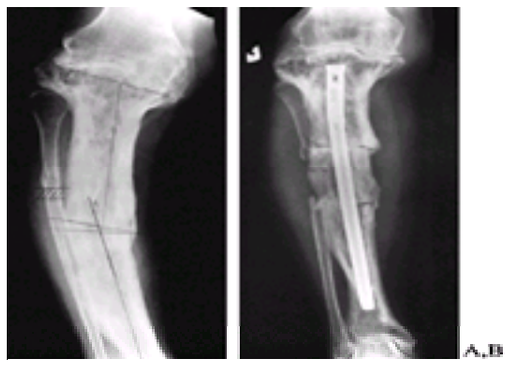


***Figure 131.4.*** Corrective osteotomy with intramedullary fixation. **A:** Preoperative. **B:** Postoperative.

With these exceptions, fractures in Paget's disease tend to heal with abundant callus. Delayed union or nonunion is more common in the sclerotic burned-out phase of the disease. Even after successful union, protective bracing may be needed for 3–6 months to allow for remodeling, which is slow.

## PAGET'S SARCOMA

In symptomatic patients with Paget's disease, the incidence of tumors is about 2% to 4%; however, when all patients who have Paget's disease of any variety are included, the incidence is usually about 0.1% (62). The most commonly seen benign tumors are giant-cell tumors, which are common in patients with an ancestry from Arolina, Italy. They contain viral particles and are exquisitely sensitive to corticosteroid therapy (84). The most common malignant tumors are osteogenic sarcomas, although fibrosarcoma and chondrosarcoma may be seen as well.

The prognosis for patients with Paget's disease and osteogenic sarcoma is poor despite radical surgery and chemotherapy (34). At Memorial Sloan-Kettering Cancer

Center, there have been no survivors for axial tumors, but 23% of appendicular tumors have a 5-year survival. Any patient with Paget's disease who develops new pain in a previously pain-free area of Paget's disease, or a lytic area in sclerotic Paget's bone, must be evaluated for a possible tumor.

### ELECTIVE ORTHOPAEDIC SURGERY

Patients with Paget's disease not only have bone pain but may also have arthritis associated with either biomechanical factors or pagetic involvement of the joints. For patients with severe disabling arthritis of the hip, total joint replacement may be considered, but several technical considerations should be noted. There is often significant varus deformity of the proximal femur, and the medullary canal may be distorted. The bone may also be extremely sclerotic, making reaming difficult.

In patients with active Paget's disease, increased blood loss may be expected, and postoperatively the patients have a higher incidence of heterotopic ossification. On the acetabular side, about 25% of patients may have a protrusio acetabuli (27). Because many patients with Paget's disease also have involvement of the lumbar spine, it is extremely important to carefully separate possible lumbar spine pain from hip pain before undertaking arthroplasty of the hip. Local instillation of anesthesia into the hip may help determine the primary cause of pain.

Long-term follow-up of cemented total hip replacement in patients with Paget's disease shows a slightly increased incidence of revision for aseptic loosening, but otherwise good or excellent results (55,58,61). These studies reviewed cemented total hip arthroplasty; there have been no long-term studies of porous ingrowth implants in patients with Paget's disease. Because of the modeling and remodeling disorders in Paget's, uncemented total hip replacement is not recommended. Treat patients undergoing total joint arthroplasty with calcitonin, 50 units three times a week, beginning 1 month preoperatively and continuing for about 5–6 months postoperatively, so as to decrease perioperative bleeding and postoperative hypercalcemia.

Total knee replacement has also been reported in patients with Paget's disease, with up to a 12-year follow-up. No unusual technical difficulties were encountered (7,9).

The other type of orthopaedic surgery that may be required in Paget's disease is osteotomy to correct malalignment in the leg. Osteotomy, particularly of the femur and tibial shaft, is indicated for symptomatic and recurrent or recalcitrant pseudofractures. Surgery is usually performed with an interlocking intramedullary rod after one or more closing-wedge osteotomies. If the intramedullary canal is obstructed, double plating with bone grafting can be used.

## RICKETS AND OSTEOMALACIA

Rickets and osteomalacia are respectively the childhood and adult consequences of a failure to mineralize either physeal cartilage (children) or osteoid (adults) due to disorders in vitamin D metabolism.

The classic clinical description of a child with rickets is of an apathetic, irritable child who is shorter than usual and has a positive Gower's sign, frontal bossing, and an enlarged epiphysis. He also may have a rachitic rosary or Harrison's groove. The radiologic findings in rickets include a wide epiphyseal plate with cupping, and an indistinct zone of provisional calcification (Fig. 131.5). Long-bone bowing, genu valgum or genu varum, and stress fractures (Looser's lines) are also seen (Fig. 131.6).

***Figure 131.5.*** Rickets: Notice the widened, cupped physes on the AP (**A**) and the lateral (**B**) radiographs.

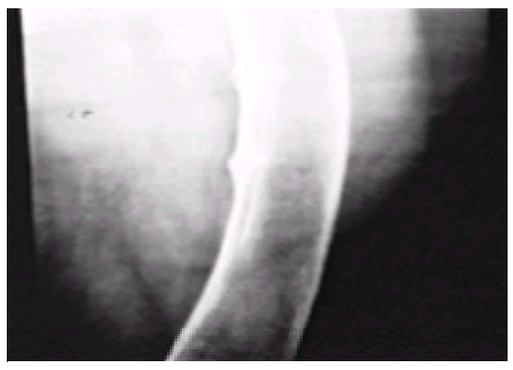

***Figure 131.6.*** Looser's lines in osteomalacia.

The adult patient with osteomalacia may have localized bone pain and muscle weakness. Radiologic findings may be identical to those seen in osteoporosis, except that Looser's lines appear in patients with osteomalacia. Other radiologic findings, such as “rugger jersey spine,” have also been described in patients with osteomalacia.

Laboratory findings in rickets and osteomalacia may vary, depending on the etiology of the problem. Phosphorus is decreased, alkaline phosphatase is increased, and 25-hydroxy vitamin D is decreased in patients who have a vitamin D deficiency syndrome (Table 131.3). Vitamin D deficiency may be secondary to decreased exposure to ultraviolet light or to a vitamin D deficiency in the diet. Although milk and dairy products in the United States are typically fortified with vitamin D, certain people are at risk because of their dietary habits. A significant number of American blacks are lactose intolerant and therefore avoid dairy products. Strict vegetarians who do not eat any dairy products are at risk for rickets or osteomalacia.

| Disorder | Ca | $PO_4$ | PTH | Alk Ph | $25(OH)_2$ | $1,25(OH)_2$ | U-Ca |
|---|---|---|---|---|---|---|---|
| Vitamin D deficiency | Nl, Dec | Dec | Inc | Inc | Dec | Any | Dec |
| Vitamin D resistant | Nl | Dec | Nl | Inc | Nl | Nl, Dec | Nl |
| Renal osteodystrophy | Dec | Inc | Inc | Inc | Nl | Dec | Dec |
| Hyperparathyroidism | | | | | | | |
| 1 | Inc | Dec | Inc | Inc, Nl | Nl | Nl, Inc | Inc |
| 2 | Dec | Dec (Inc RTO) | Inc | Inc, Nl | Dec, Nl | Any | Dec |
| Hypophosphatasia | Inc | | | Dec | | | * |
| Paget's disease | Nl | Nl | Nl | Inc | Nl | Nl | Nl, Inc |
| Osteoporosis | Nl | Nl | Nl | Nl | Nl | Nl | Nl, Dec |

Nl, normal; Dec, decreased; Inc, increased; RTO, renal osteodystrophy.
* Phosphoethanolamine is increased in the urine.

***Table 131.3. Disorders of Mineral Metabolism***

Treatment depends on the etiology. Vitamin D deficiency is typically treated with 50,000 units of vitamin D plus calcium. Vitamin D–resistant rickets (a proximal tubular defect in excretion of phosphorus) requires increased phosphate in the diet plus 1,25-dihydroxy vitamin D in low doses.

Rickets and osteomalacia are typically very responsive to treatment once the diagnosis is made. Patients may consult an orthopaedic surgeon because of bone pain or bony deformity. Specific orthopaedic intervention is rarely necessary, but bracing of the extremities or spine may be required, particularly in children. In addition, a patient with significant bony deformity may need an osteotomy. With appropriate pharmacologic treatment, such a patient can produce appropriate amounts of osteoid, and the osteotomy should heal well.

## RENAL OSTEODYSTROPHY

Renal osteodystrophy encompasses a continuum of diseases, ranging from a low-turnover bone disease resembling osteomalacia to a high-turnover disease resembling secondary hyperparathyroidism. In renal disease, the physiologic PTH–vitamin D axis is altered. Phosphate retention and hyperphosphatemia occur as a result of impaired renal phosphorus clearance. Hypocalcemia occurs, partly as a result of increased calcium excretion. In addition, hydroxylation to form 1,25-dihydroxy vitamin D is diminished, which in turn impairs calcium absorption across the gut. The effect of PTH on the kidney is also diminished.

In patients with the high-turnover form of the disease, hyperphosphatemia is an important factor in the development of the secondary hyperparathyroidism. There is abundant histologic evidence of active bone resorption, including increased number and size of osteoclasts, increased percentage of bone surface covered with osteoclasts, and increased number of Howship's lacunae. Patients may develop osteitis fibrosa, in which fibrous tissue accumulates in the bone. Osteoblast activity also increases in patients with osteitis fibrosa (80,82). Moderate increases in the amount of osteoid may be seen, and the osteoid often appears woven because of the increased bone turnover. Clinically, bone pain, brown tumors, and ulcers may be seen. On radiographs, the classic salt-and-pepper skull, soft-tissue calcifications, osteopenia next to osteosclerosis, and erosions of the phalangeal tuft and distal clavicle may be seen. These changes parallel those seen in patients with primary hyperparathyroidism.

In children, metaphyseal changes and epiphyseal plate changes are common and have been described as rickets-like. Unlike patients with congenital rickets, patients with renal osteodystrophy prematurely develop genu valgum deformities. In addition, slipped capital femoral epiphysis (SCFE) is a common complication of the disease in children (59). Epiphyseal slippage may also occur in the lower femoral epiphysis or the distal tibial epiphysis.

The opposite extreme of renal osteodystrophy may be seen as a low-turnover bone disease similar to osteomalacia and aplastic bone disease. Initially thought to be the result of vitamin D deficiency, it is now clear that aluminum toxicity can account for osteomalacia seen with renal osteodystrophy (Fig. 131.7). Aluminum contamination of water used in dialysis solutions has been identified as a source; a decrease in the aluminum in the filtrate reduces the prevalence of the osteomalacia (53,71,76).

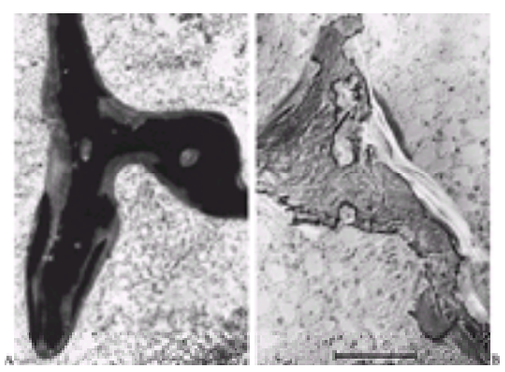

***Figure 131.7.*** **A:** Photomicrograph shows extensive hyperosteoidosis with smudged mineralization front (Von Kossa, ×80). **B:** Photomicrograph shows aluminum deposition at the mineralization front. Patient has renal osteodystrophy (aurin tricarboxylic acid stain, ×80).

In addition, patients with renal osteodystrophy use aluminum-containing phosphate binders to prevent hyperphosphatemia and secondary hyperparathyroidism. These buffers can substantially increase the aluminum load in the body. Aluminum is known to deposit along the mineralization front, which may impair the calcification of the osteoid (22,56). Aluminum is also associated with a substantial decrease in the number of osteoblasts. Histologically, patients who have a low-turnover type of bone disease have bone characterized by excessive osteoid or unmineralized collagen. The osteoid seams are widened and often multilamellar in appearance, with more of the bone surface covered by osteoid. Osteoblastic activity is markedly reduced. Aluminum can be demonstrated in these areas by staining. The use of calcium carbonate to buffer high phosphate has largely prevented this disorder.

Patients rarely display one extreme or the other of renal osteodystrophy. Typically they have some type of mixed pattern characterized by secondary hyperparathyroidism as well as evidence of osteomalacia. The most common clinical manifestations of renal osteodystrophy are bone pain, muscle weakness, skeletal deformities, ectopic calcification, and growth retardation in children.

Bone pain is common in renal osteodystrophy and is usually aggravated by weight bearing. It is most common in the lower back, hips, and legs, although heel and ankle pain may also be noted. Bone pain is more common in patients with aluminum-related bone disease than in those with osteitis fibrosa (54). Muscle weakness, often of a proximal myopathy type, may also be noted with severe renal disease. In some cases, a favorable clinical response has been seen after treatment with 1,25-dihydroxy vitamin $D_3$ and with deferoxamine chelators for treatment of aluminum-related bone disease (12,68).

Skeletal deformities are a major clinical feature of renal osteodystrophy. They are more common in children and may affect either the axial or the appendicular skeleton. In adults, particularly those with aluminum toxicity, deformities are predominantly confined to the axial skeleton.

In children up to age 4, abnormalities seen in renal disease resemble those of vitamin D–deficiency rickets. In children between ages 4 and 10, deformities of the long bones, particularly bowing of the tibia and femur, are common; genu valgum is particularly common. SCFE is common in pediatric patients, particularly those with secondary hyperparathyroidism. Despite vitamin D treatment, 20% to 25% of pediatric patients treated with long-term dialysis require orthopaedic intervention to correct bony deformities (23).

Patients with renal disease also often have ectopic calcification, often in a periarticular location. These calcifications are most common when the calcium–phosphorous ion products exceed 75 (23). Ectopic calcifications are more common in adults but can also occur in children with severe end-stage disease.

Another complication of long-term renal disease is amyloidosis. The most common presenting syndrome is carpal tunnel syndrome, but pathologic fracture or scapulohumeral periarthritis may also be present (23,44). Arthritis may involve the metacarpophalangeal and interphalangeal joints, hand, shoulder, wrist, and knees. Bone cysts may be found in the femoral head, acetabulum, humerus, radius, carpal bones, tibial plateau, and pubis; these may resemble brown tumors (44). Distinctive changes may occur in the bone with sites of amyloid deposition, and fractures can occur through such cysts. There is no clear treatment for this problem.

Primary initial treatment of renal osteodystrophy is medical and dietary. Restrict phosphorus intake in the diet to 400–800 mg/day. Phosphate-binding antacids may be required to decrease the absorption of phosphorus. Calcium supplements are useful; calcium carbonate not only increases the amount of calcium available for absorption but also acts as a phosphate-binding agent. Do not, however, give calcium supplements until the serum phosphorus levels are reduced to about 6.5 mg/dl or less or until the calcium–phosphorous ion product is below 75, to minimize the risk of extraskeletal calcification (23). If calcium carbonate is to be used to bind phosphate, it should be taken with a meal to increase its phosphate-binding efficiency.

Vitamin D derivatives and 1,25-dihydroxy vitamin D have also been used in the treatment of renal osteodystrophy. Oral calcitriol (0.25 to 1.5 µg/day) in patients with renal osteodystrophy has improved muscle strength, decreased bone pain, and increased growth in uremic children (12). The major side effect of this treatment is hypercalcemia. Hypercalcemia developing within the first few weeks of treatment may indicate either a limited amount of bone disease or autonomous

hyperparathyroidism.

If secondary hyperparathyroidism is a prominent manifestation of the renal disease, parathyroid surgery can be considered, especially if patients have persistent hypercalcemia, intractable pruritus, progressive ectopic calcifications, severe skeletal pain, or fractures.

The management of aluminum toxicity in renal disease is difficult. The chelator deferoxamine substantially increases the removal of aluminum with both hemodialysis and peritoneal dialysis, which may improve symptoms and bone histology (26,29,63). Currently, it is recommended that deferoxamine be given only to patients with symptomatic aluminum toxification. The dose should not exceed 1–2 g/week; measure aluminum levels and plasma regularly.

Several orthopaedic complications in renal bone disease have already been mentioned. In children, SCFE and deformities of the long bones are most prominent. SCFE requires pinning and appropriate medical treatment. Bowing of the extremities can sometimes be treated with bracing but often require osteotomy. In both adults and children, bone pain may be due to pseudofractures seen as Looser's lines, and these may progress to frank fractures. The treatment of bone pain associated with pseudofractures should be medical management combined with decreased weight bearing until the pain has resolved. An actual fracture should be treated as any other fracture, with the expectation that healing will be delayed.

Carpal tunnel syndrome resulting from amyloid deposition is unlikely to be successfully managed by conservative treatment alone, and surgery may be required. There are no good long-term studies available for total joint replacement in patients with renal osteodystrophy, but because of the severe derangement of bone metabolism, uncemented arthroplasty cannot be recommended. Dialysis patients have a high rate of prosthesis loosening, but patients who have undergone transplantation do well.

If you are contemplating surgery on a patient with renal osteodystrophy, do an extensive medical workup first. Patients with severe renal disease may have clotting abnormalities and often have severe anemia. They also have arteriovenous fistulae from dialysis, which require careful management in the hospital. Infections can be particularly severe in patients with renal osteodystrophy; make every effort to minimize any chance of contamination. Overall, the patient's medical condition must guide any decisions about elective orthopaedic surgery, and in emergency situations optimize the patient's medical status before doing any surgery.

## OSTEOPOROSIS

Osteoporosis has been defined by the National Institutes of Health (NIH) Consensus Conference as an age-related disorder characterized by decreased bone mass and increased fracture risk in the absence of other recognizable causes of bone loss (69). The fractures most commonly seen in osteoporosis involve the vertebral body, proximal femur, wrist, humerus, pelvis, and ankle and foot.

Osteoporosis is a major public health problem in the United States, where it is estimated that more than 20 million people have it. As the population ages, this number will increase dramatically. More than 1.2 million fractures a year are attributed to osteoporosis, including about 535,000 vertebral fractures, 172,000 wrist fractures, and 200,000 hip fractures (39). The financial cost of osteoporosis in 1982 was over $6 billion annually (60).

Risk factors for osteoporosis include having low body weight, and being postmenopausal, white, and of northwestern European descent (77). Other factors include poor calcium intake, a sedentary lifestyle, cigarette and alcohol use, and, most prominently, any history of premature menopause or amenorrhea. Factors that increase risk for hip fracture besides osteoporosis include falls, lack of weight gain since age 25, greater height, poorer self-rated health status, history of hyperparathyroidism, use of long-acting benzodiazepines, inability or unwillingness to stand each day (4 min), inability to rise from a chair, impaired vision, heart rate over 80, and a history of a fragility fracture (15,64). In addition, family history may be important. At the Hospital for Special Surgery Osteoporosis Center, one third of patients with osteoporosis have been found to have a strong family history of the disease.

Peak bone mass is typically achieved by age 30 for both men and women. Men have a peak bone mass about 30% higher than women, and blacks 10% higher than whites, although nutrition, exercise, and general health can affect the peak bone mass (13,19,69). Declining bone mass after the age of 30 may represent an inescapable part of the aging process.

After the fifth decade, two patterns of bone loss are generally identified, slow and accelerated. The slow phase is loss of bone that occurs at a nearly constant rate of 0.3% to 0.5% per year (85). It affects men and women equally and is thought to be due to continuous negative calcium balance. Rapid or accelerated bone loss begins after natural or surgical menopause and can result in the loss of 2% to 3% of bone mass per year (8% per year trabecular and 0.5% per year cortical). From 6 to 10 years after menopause, the rate returns to the slow phase (51,52,57,72,74,75).

These two patterns of bone loss have been characterized by Riggs and Melton: Type I is the rapid postmenopausal loss, and type II is the slow loss (Table 131.4) (79). The type I pattern is most common in recently postmenopausal woman, predominantly age 51 to 65. It involves rapid bone loss primarily from areas of trabecular bone and is characterized by vertebral and wrist fractures. Men make up about 16% of patients manifesting this pattern of osteoporosis. In about half of these men, hypergonadism may be a contributing factor to osteoporosis.

| *Parameter* | *Finding* |
|---|---|
| | *Type I: Postmenopausal Osteoporosis* |
| Age* | 51–65 |
| Sex | F/M ratio 6:1 |
| Bone loss | Rapid trabecular bone loss up to 8% per year, 0.5% per year cortical bone loss |
| Fractures | Distal radius, vertebra |
| Etiology | Changing hormonal milieu postmenopause |
| | *Type II: senile osteoporosis* |
| Age* | >70 |
| Sex | F/M ratio 2:1 |
| Bone loss | Trabecular and cortical loss, 0.3%–0.3% per year |
| Fractures | Hip, pelvis, humerus, tibia, vertebra |
| Etiology | Aging: calcium deficiency, decreased vitamin D activity, increased parathormone activity |

* The age limits are guidelines only. Some patients may exhibit rapid loss after age 65, and others may have low-turnover disease early. A bone biopsy is essential to differentiate low- and high-turnover osteoporosis. (From Riggs BL, and Melton LJ, III. Involutional Osteoporosis. *New Engl J Med* 1986; 314: 679.)

***Table 131.4. Types I and II Osteoporosis***

Type II or senile osteoporosis involves the loss of both cortical and trabecular bone, typically seen in men and women over age 75. Typical fractures resulting from this type of osteoporosis include those of the hip, pelvis, humerus, and tibia. Type II bone loss is related to aging and chronic calcium deficiency as well as decreased vitamin D activity, increased PTH, and decreased bone formation. Women age 65 to 75 may manifest elements of both types of bone loss. Several laboratory tests can differentiate between high- and low-turnover osteoporosis. These tests measure the level of bone resorption by elevating bone collagen breakdown products. The most common tests are *N*-telopeptide, pyridinoline, and dehydroxypyridinoline tests (22).

Two types of osteoporosis correlate well with the timing and patterns of the various fracture syndromes seen in osteoporosis. The incidence of vertebral fractures and Colles' fractures rises soon after menopause, as these areas derive much of their mechanical strength from trabecular bone (73). The incidence of hip fractures, in which cortical bone loss is more important, increases slowly with age until late in life. One third of women who live to age 90 suffer a hip fracture (69).

The radiologic findings in osteoporosis include osteopenia, seen when more than 30% of mineral is absent; loss of horizontal trabeculae of the vertebral bodies; wedge fractures to the thoracic spine; end-plate fractures or crush fractures of the lumbar spine; stress fractures of the pelvis; and fractures of the humerus, wrist, hip, supracondylar femur, and tibial plateau. In pure osteoporosis, laboratory studies are normal except for a slight increase in alkaline phosphatase after new fractures. Although osteoporosis is the number one cause for fractures in these locations, other possible metabolic abnormalities must be ruled out before making the diagnosis of osteoporosis.

Hormone excess can lead to osteoporosis. Hyperparathyroidism is a relatively common cause of osteopenia, and patients with the condition typically have an increased PTH level, hypercalcemia, and hypophosphatemia. Most of the patients are identified by incidental laboratory findings.

Hyperthyroid patients may also be osteoporotic. The $T_3$ and $T_4$ values may be elevated or may be within the high-normal limits. Iatrogenic hyperthyroidism is common in women who are slightly obese and have been placed on thyroid medication. The key diagnostic tests for patients with suspected hyperthyroidism is the thyroid stimulating hormone–radioimmunometric assay (TSH-IRMA). Other endocrinopathies associated with osteoporosis are unstable diabetes and Cushing's disease. Over 99% of cases of Cushing's disease leading to osteoporosis are iatrogenic, with patients on doses of prednisone exceeding 7.5 mg/day. Diabetes can cause

osteoporosis by hypercalciuria and negative nitrogen balance.

Neoplastic disorders can also account for osteopenia and should be sought in patients with localized vertebral fractures. Two percent of osteopenic patients have bone-marrow abnormalities; 50% of these are multiple myeloma. Typical laboratory findings for these patients are decreased hemoglobin, increased sedimentation rate, and abnormal serum or urinary protein electrophoresis. In about 15% of patients with multiple myeloma, the serum electrophoresis may be normal. Osteopenic patients with abnormal blood parameters may require a bone-marrow biopsy. Once endocrinopathy and bone-marrow pathologies have been eliminated as causes for osteopenia, the differential diagnosis is between osteomalacia and osteoporosis.

About 8% of our patients with osteopenia display various degrees of osteomalacia. About half of these patients have abnormal blood studies—most notably decreased urinary calcium, decreased to low-normal serum calcium, decreased 25-hydroxy vitamin D, low phosphorus, and elevated alkaline phosphatase. The remaining patients with osteomalacia can be differentiated from those with true osteoporosis only by evaluating a transilial bone biopsy.

A double tetracycline labeling program provides the maximum information. Patients whose biopsies demonstrate more than 5% osteoid volume are considered to have osteomalacia, and the source should be sought. The bone biopsy can also help distinguish between high-turnover and low-turnover forms of osteoporosis. With the biopsy demonstrating less than 5% osteoid volume and less than 0.5% of the trabecular surface with active resorption, the patient is classified as having quiescent or low-turnover osteoporosis; this accounts for about two thirds of the patients with osteoporosis. Patients with more than 0.5% active resorption on the trabecular surface and less than 5% osteoid volume are classified as having high-turnover osteoporosis.

Treatment differs for these two types of osteoporosis. Treatments for the other forms—osteopenia and osteomalacia—should be individualized to the underlying etiology (Table 131.5).



***Table 131.5. Workup of Osteoporosis***

Once the diagnosis of osteoporosis is clinically made, quantification of bone mass is necessary for confirmation of the diagnosis and longitudinal follow-up. Plain radiographs are of little use in measuring a patient's bone mass. A decrease or loss of the horizontal trabecular pattern on spinal radiograph suggests osteopenia; such a finding is, however, somewhat technique dependent, and up to 40% of spinal bone mass can be lost before this finding is noted. Dual-energy x-ray absorption uses an x-ray source that emits two different energies, allowing the soft-tissue component to be subtracted. This technique permits assessment of fracture risk of the vertebral bodies and the femoral neck. The radiation dose is low (about 5–15 mrad), and the precision is 1% to 2% for the vertebral body and 2% to 4% for the femoral neck (43). Compression fractures, scoliosis, and soft-tissue calcifications may distort the data.

Total body bone mass or local bone mass determinations can also be made. New studies using this method in a lateral position appear to improve its sensitivity by 50% (85) (Table 131.6).

| *Group* | *Diagnostic criteria* |
|---|---|
| Normal | Bone mineral density within 1 standard deviation of the mean of a young adult reference population |
| Osteopenia (low bone mass) | Bone mineral density between 1.0 and 2.4 standard deviation below the mean of a young adult reference population |
| Osteoporosis | Bone mineral density 2.5 or more standard deviation below the mean of a young adult reference population |
| Severe osteoporosis | Osteoporosis with one or more fragility fractures |

Glaser DL, Caplan FS. Osteoporosis Definition and Clinical Presentation. *Spine* 1997;22:245S:12S–16S. World Health Organization. Assessment of Fracture Risk and Its Application to Screening for Postmenopausal Osteoporosis. Report of a WHO Study Group. *WHO Technical Report Series* 1994;843:1–129.

***Table 131.6. World Health Organization Diagnostic Criteria for Osteoporosis***

Quantitative computed tomography (CT) scanning permits the measurement of spinal trabecular bone density and is very sensitive to change; its precision is 3% to 15% (43). There is about 20 times as much radiation involved as in dual-energy x-ray absorptiometry. The CT scan may be affected by artifacts caused by marrow fat or vertebral veins.

Both dual-energy x-ray absorptiometry and quantitative CT scanning are used to identify patients with low initial bone mass, or to monitor patients longitudinally to evaluate decreasing bone mass. Other methods to identify osteopenic patients include radiographic wedge, single-beam absorptiometry, and ultrasound. Although these measures can be used to identify a population at risk for fracture (those with spinal density below 1 g/cm$^3$), they have proved to be of little value in predicting whether a particular patient will suffer a fracture during a specific period of time.

**PREVENTION**

The most effective way to deal with osteoporosis is to prevent it (Table 131.1), but uniform preventative measures have not been widely adopted. Clearly, patients who develop a high peak bone mass by age 25, maintain adequate calcium intake, and perform weight-bearing exercises will have a decreased risk of developing symptomatic osteoporosis. During the period of maximum bone accretion (age 13 to 25), we recommend a dietary regimen of about 1,200 mg/day elemental calcium with 400 units vitamin D, as well as an impact-type exercise program.

Teenagers, particularly girls, often do not eat enough protein, carbohydrates, and calcium. Girls who develop amenorrhea or oligomenorrhea at an early age are at particular risk for developing osteoporosis later, because they never attain sufficient peak bone mass. These patients can actually develop a negative calcium balance and lose bone mass while young. Although some have suggested that exercise causes both amenorrhea and bone loss, it has been shown that girls who maintain normal menstrual cycles while exercising are at no increased risk for osteoporosis. Young athletes who do develop amenorrhea or oligomenorrhea should be considered for cyclic estrogen/progesterone or birth-control pills in an effort to reestablish normal menstrual cycles.

Premenopausal women age 25 and older (and men of similar age) should be maintained on a calcium intake of about 800 to 1,000 mg/day with 400 units of vitamin D, as well as a reasonable exercise program.

**TREATMENT**

Table 131.7 summarizes the many possible treatments once the diagnosis of osteoporosis is established. Recommend behavior modification, such as the cessation of smoking and decreasing alcohol intake, for all patients, but do not expect a high level of compliance. Another nonpharmacologic intervention is to increase the level of

exercise. It is well known that immobilization leads to increasing bone resorption (67). Prospective studies have shown that 1 hour of exercise two or three times a week is effective in increasing lumbar spine density and total body calcium in postmenopausal women compared with sedentary control groups (1,47). Spinal extension, abdominal muscle strengthening, and impact-loading exercises such as walking, square dancing, or weight lifting may be very beneficial for patients with osteoporosis.

***Table 131.7. Updated Protocol for Treatment of Osteoporosis at the Hospital for Special Surgery***

### *Calcium*

Although a dietary calcium deficiency is known to adversely affect the skeleton, the role of calcium supplementation in preserving or augmenting skeletal mass is unclear. Menopausal status may determine whether calcium therapy will be effective in osteoporotic patients.

At a study at the Hospital for Special Surgery, osteoporotic women were put on 1.5 g/day calcium, 800 units/day vitamin D, and an exercise program. The patients were divided into three age groups: premenopausal, early postmenopausal (within 10 years of menopause), and late postmenopausal (65 years or older). Serial dual-photon absorptiometry measurements were obtained from the lumbar spine and femoral neck. Calcium therapy (with exercise and vitamin D) resulted in a significant 3% to 5% increase in bone mass of the femoral neck among all three groups tested in the first and second year of therapy.

In the spine, premenopausal patients showed no change in density instead of the expected 0.3% to 0.5% decrease per year. Late postmenopausal patients showed a slight increase in bone density. Early postmenopausal patients, however, lost vertebral bone density at the rate of 2.2% per year, the rate of loss reported elsewhere (18,75).

This study suggests that although calcium supplementation was beneficial in the younger and oldest patients, calcium supplementation alone will not reverse or significantly slow the rate of acute postmenopausal bone loss. Women with calcium intake below 400 mg/day, however, can be significantly aided by calcium. We currently recommend that all women over age 35 take 1,200 mg/day of calcium; postmenopausal women should take 1,500 mg/day. Give vitamin D, 400–800 units/day, to all patients.

### *Estrogen*

Estrogen replacement therapy (ERT) has also been used effectively in the treatment of osteoporosis (16,46). Many studies demonstrate that low-dose estrogen therapy, particularly when begun shortly after menopause, can arrest or decrease spinal bone loss, and decrease by 50% the incidence of radial, vertebral, and proximal femoral fractures (18,32,33,42,51,52). Postmenopausal patients with a strong family history of osteoporosis, those with a bone mass more than 1.5 standard deviations below the mean, or those who demonstrate a loss of 4% or more of bone per year on serial bone-density measurements are strong candidates for estrogen therapy or other antiresorptive programs.

Although there is an increased risk of endometrial cancer in women taking only exogenous estrogens, low-dose estrogens combined with progesterone actually lower the incidence of endometrial cancer (10). Of somewhat greater concern is the possibility of an increased risk of breast cancer in patients on estrogen. Several studies of combined treatment with low-dose estrogen and progesterone indicate that the risk of breast cancer may not be appreciably increased (19,38,91). The general consensus, however, is that estrogen, even in combination, may marginally increase breast-cancer risk. Unopposed estrogen therapy appears to have a beneficial effect on atherosclerotic heart disease and mental function (20).

Patients in whom estrogen therapy is absolutely contraindicated include those with preexisting breast cancer, regardless of receptor status, and patients with a history of thromboembolic disease on hormonal therapy (95). Excess uterine bleeding, hypertriglyceridemia, liver disease, and cholelithiasis may also be contraindications to therapy.

At the Hospital for Special Surgery (53), about 90% of women eligible for estrogen therapy were reluctant to undertake it because of the perceived risk of cancer. Clearly, it is the orthopaedist's responsibility to educate the patient on relative risks and benefits of estrogen therapy. If hormonal therapy is chosen, we recommend a minimum dose of 0.625 mg of conjugated estrogen cycled with appropriate medroxyprogesterone acetate. Mammograms and gynecologic evaluations must be done at least yearly.

### *Tamoxifen/SERMs*

Tamoxifen and selective estrogen receptor modulators (SERMs) such as relaxofen provide ERT-like bone benefits without the associated breast and endometrial cancer risk. Preliminary data suggest that spinal fractures decrease by 50% and the risk of breast cancer decreases similarly. There are no data regarding hip fracture.

### *Calcitonin*

Calcitonin directly inhibits osteoclast function, and chronic administration may decrease the number of osteoclasts. Calcitonin is a strong antiresorptive agent particularly useful for patients with high-turnover osteoporosis who will not take estrogen or progesterone. Currently, calcitonin must be given subcutaneously by injection; in some patients, flushing accompanies injection. Although 40% of patients develop an antibody to the calcitonin, this circumstance does not preclude its use. Patients on calcitonin have shown increases in total body calcium, iliac crest bone volumes, and bone content of the lumbar spine and femoral diaphysis (21,24,25). Most of the increase occurs in the first 6 months.

Calcitonin has been shown to decrease the incidence of vertebral fracture by 37% (91). Nasal calcitonin is similarly effective, with few or no side effects (11). Calcitonin may also be particularly useful in patients with acute recent spinal fractures, as there is evidence that it functions as a neuropeptide and has an analgesic effect. It is also helpful in steroid osteoporosis, in which it counteracts the secondary hyperparathyroidism. The usual dose is 200 units daily nasally for 18 months, with concomitant calcium and vitamin D.

### *Bisphosphonate*

The bisphosphonates, particularly etidronate, have been used for decades in the treatment of Paget's disease; recently, they have been used successfully to treat osteoporosis (92,94). The cyclic use of etidronate, 400 mg/day for the first 14 days of each quarter, significantly increased bone mass by 1% to 2% per year and decreased the spinal fracture rate when compared with calcium alone (87,89). Appendicular bone mass increased less, and there was no clear effect on prevention of hip fractures. Some of the newer bisphosphonates, the so-called third-generation bisphosphonates, including pamidronate and alendronate, lead to a greater increase in spinal mass and may enhance formation and decrease resorption more effectively than the first-generation bisphosphonates such as etidronate (15). Alendronate use is supported by a large number of clinical trials using fracture as an end point (42). Like ERT, alendronate increases bone mass and decreases fracture risk for all bones by 50%. The major side effect is esophagitis. Alendronate appears to have similar efficacy on osteoporosis in men.

Prolonged use of first-generation bisphosphonates inhibits bone formation and resorption and can lead to osteomalacia, which is the reason for using short cycles. The

newer bisphosphonates do not affect formation and are quite safe.

**ORTHOPAEDIC PROBLEMS**

Fractures in patients with osteoporosis may entail increased morbidity and mortality. Economic consequences of these fractures can also be quite severe. Cornell has developed the following principles guiding the management of fractures in patients with osteoporosis (14):

- Elderly patients are best served by rapid definitive fracture care aimed at early restoration of mobility and function. Often patients are in their best health on the day of the injury; if so, perform surgery at that time. Judicious medical management of patients with coexisting medical problems can minimize postoperative morbidity and mortality. Choose surgical procedures that require minimal operative time and result in minimal blood loss while providing definitive care.
- The operative procedure should allow stable fracture fixation with early weight bearing or early return of function. Intra-articular fractures should be anatomically restored, but metaphyseal and diaphyseal fractures are best managed by achieving primary stability rather than anatomic reduction.
- In osteoporotic patients, the primary mode of failure of fracture repair is failure of the bone rather than failure of the implant. Choose fracture fixation to allow stable compaction of fracture fragments and to minimize stress shielding of regional bone.
- Osteoporotic patients go through the early stages of fracture healing by endochondral repair normally. However, the last stage of remodeling is slowed in these patients. Hip fractures can remain positive on bone scan as long as 3 years. In addition, elderly patients often are malnourished at the time of injury, and their diets are deficient in calcium, calories, and protein. Administer 1,500 mg/day of calcium and physiologic vitamin D to patients in the hospital, as well as a diet sufficient in calories and protein to overcome malnutrition.
- Evaluate patients with fractures fully for the type of osteoporosis they have, and initiate treatment on the basis of the pathology.

Although not the most common osteoporotic fracture, hip fractures are the major cause of morbidity and mortality in patients with osteoporosis (45). About 32% of women and 17% of men suffer a hip fracture before age 90, and 40% of noninstitutionalized patients die within 2 years of the injury (4,30,31,35,36,40,90). A return to preinjury level of function is seen in only 25% of patients who suffer a hip fracture, and 50% of these patients have a significant social deterioration (36,86).

Other nonmetabolic causes of hip fractures have been noted. It has been suggested that the common use of tranquilizing medication in this population results in poorer reaction time and an increased incidence of falls (88,93). Hayes has suggested that only falls that result in a direct blow to the region of the greater trochanter result in hip fracture (31). Recent incidence studies by Cummings and Hayes now place falls as the primary etiology in 65% to 95% of cases (15). Osteopenia is almost universally found in patients with hip fractures.

Femoral neck fractures are a particular problem in patients with osteoporosis because of the high incidence of nonunion and avascular necrosis. Closed reduction and internal fixation have been associated with an incidence of about 14% nonunion and 15% avascular necrosis (11). While these complications can be minimized by accurate reduction, patients with severe osteopenia have a higher incidence of failure secondary to loss of bone fixation (3).

The basic treatment options for femoral neck fracture are closed reduction with internal fixation, and hemiarthroplasty. Hemiarthroplasty would seem an ideal procedure, as nonunion and avascular necrosis would not occur, but it is associated with its own complications (dislocation, loosening and breakage of implants, late infection). In addition, hemiarthroplasty does not provide hip function equal to that of an intact hip joint. We recommend primary hemiarthroplasty using a cemented bipolar prosthesis for patients who are physiologically 70 years of age and who are active household or community ambulators. Patients with severe osteopenia and those with neurologic disorders who cannot comply with partial weight-bearing are also selected for hemiarthroplasty.

For patients who do not fit these criteria, perform closed reduction with internal fixation using cannulated screws, Knowles pins, or compression screws. A study from New York Hospital–Cornell Medical Center and the Hospital for Special Surgery showed that among 251 patients undergoing this procedure between 1979 and 1981, 80% of those with grades III and IV fractures had good to excellent results at 6 months when good reduction was obtained in the operating room, compared with 95% good-to-excellent results for hemiarthroplasty. The survival rate at 6 months was 96% for patients with Knowles pins and 95% with hemiarthroplasty (Fig. 131.8) (2,6).

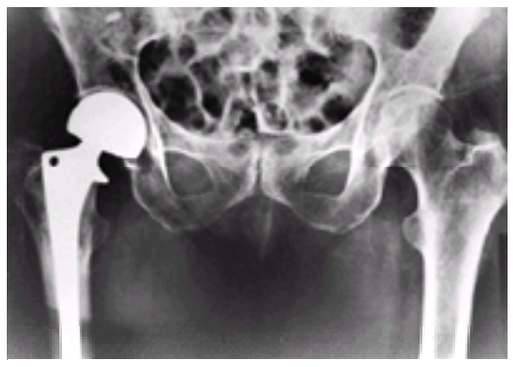

***Figure 131.8.*** Hemiarthroplasty (bipolar) for treatment of displaced femoral neck fracture.

Intertrochanteric fractures are common in patients with osteoporosis. These fractures do not have the same rate of nonunion and avascular necrosis as do femoral neck fractures, but malunion with varus and shortening in external rotation is a risk. Nail side-plate devices, such as the Jewett nail, have been associated with loss of fixation. This device is a load-bearing, not a load-sharing, device. Use of these fixators in patients with poor bone quality often results in loss of fixation or pin penetration into the joint.

Sliding hip screws are load-sharing devices that allow controlled impaction. The sliding hip screw has been our primary means of treatment of intertrochanteric fractures. Several technical points should be noted. Place the screw in the center of the femoral head to engage subchondral bone. A screw with a side-plate angle more than 140° is optimal for biomechanical reasons. New screws with extra-large threads have been introduced to improve fixation in poor-quality bone. In patients with grossly unstable fractures in which a large amount of impaction is anticipated, use short-barrel side plates (Fig. 131.9). Some authors have recommended lag-screw fixation for large posterior medial fragments to improve the stability for three- and four-part intertrochanteric fractures (48).

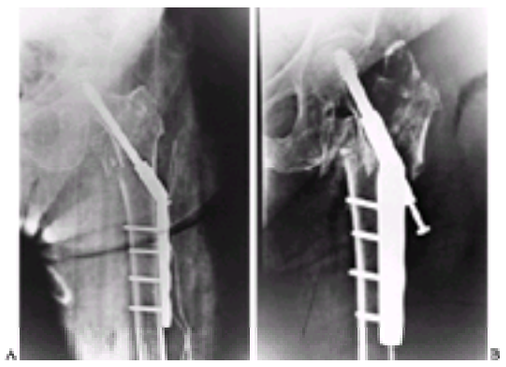

***Figure 131.9.*** **A:** Intertrochanteric hip fracture fixed with sliding hip screw. **B:** Further impaction. Patient went on to union in this position.

Supracondylar fractures of the distal femur and fracture of the tibial plateau are also seen in patients with osteoporosis, because they occur in areas of thin cortex and abundant trabecular bone. In general, gear treatment toward producing early range of motion in the knee and quadriceps rehabilitation. In debilitated patients with limited ambulatory capacity preoperatively, or limited life expectancy, either a long-leg cast or cast-brace may be the best treatment. If surgery is necessary, the standard principles of anatomic restoration and rigid fixation apply as in any fracture.

For supracondylar femur fractures, use a 95° condylar blade plate or screw side plate device (Fig. 131.10); in extremely comminuted fractures, a condylar buttress

plate can be substituted. Autogenous bone graft can be applied to areas of comminution. Rigid fixation will allow early knee rehabilitation, including continuous passive motion (CPM). Ideally, in a stable situation ambulation can be started, although a cast-brace may be required.

***Figure 131.10.*** **A:** Supracondylar femur fracture. **B:** Fixation of supracondylar fracture.

Minimally displaced tibial plateau fractures that have less than 5 mm of depression and are stable on examination can be treated by a short period of knee immobilization, followed by active knee motion. No weight should be put on the site until fracture healing has occurred. CPM may be used after the injury; apply a hinged knee brace for protection. Patients with displaced fractures of more than 8 mm or with an associated varus or valgus instability require open reduction and internal fixation (66) (Fig. 131.11).

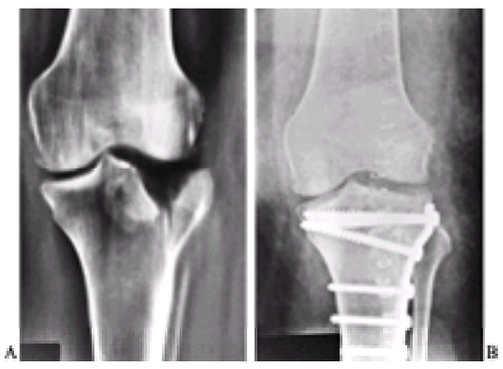

***Figure 131.11.*** **A:** Tibial plateau fracture. **B:** Fixation of tibial plateau fracture.

A longitudinal midline incision provides excellent exposure; it is the incision of choice in elderly patients who may later need a total knee arthroplasty. Use CPM and a cast-brace postoperatively, and delay weight bearing for 8–10 weeks.

Treat fractures of the ankle in patients with osteoporosis by the same principles as for ankle fractures in younger patients. In osteoporotic bone, which often provides poor screw purchase, Rush rods or tension band techniques may be superior. Antiglide plate fixation of the lateral malleolus also offers advantages in the elderly (8,81). Pay close attention in the postoperative period to the wound. Generally, use splints for 10–14 days; keep the fracture site elevated and permit no weight bearing. Then apply a short-leg cast for 4–6 weeks, and begin joint range-of-motion and strengthening exercises.

Perhaps the most common osteoporotic fracture is the fracture of a vertebral body. In 90% of the population, radiographic evidence of a vertebral injury is discernible by age 75 (37). The classic “dowager's hump” is the result of compression and wedge fractures primarily of the thoracic and lumbar spine, resulting in kyphosis and diminished height. To maintain upper body posture, a hyperlordotic curve can develop in the lumbar spine, resulting in mechanical low-back pain.

Generally, vertebral body fractures are identified by loss of height of the vertebral body or anterior wedging of the vertebral body, in addition to clinical symptoms of pain and tenderness. Often, though, the fractures may be relatively asymptomatic and discovered only on radiograph. As previously mentioned, a patient with one isolated vertebral fracture must be fully evaluated to exclude the diagnosis of malignancy. In addition, as with all osteoporotic fractures, do a full evaluation of the underlying metabolic bone disease.

Medical treatment of osteoporosis has already been discussed, and additional orthopaedic intervention may be required. Pain may be a prominent finding in patients with vertebral body fractures, and analgesics may be necessary. Narcotic analgesics are unsuitable because of the potential for respiratory depression and the effect of sedation on the patient's ability to ambulate without falling.

Bracing or mechanical support of the spine is controversial. Nachemson (73) and others believe that bracing should be avoided, because further osteoporosis will result if the brace functions as a load-bearing device. Studies by Krag et al. suggest that corset spinal braces do not significantly reduce the load on the spine but do restrict motion (49,50). These braces may allow the patient to ambulate while restricting motion enough to minimize pain.

A total-contact orthosis probably significantly unloads the spine and is undesirable in patients with severe osteoporosis. A light hyperextension type of orthosis may be helpful in relieving pain in some patients; however, patient compliance can be a problem. In these cases, a very short period of bed rest followed by ambulation and mobilization as tolerated may be sufficient.

Osteoporotic spine fractures are rarely treated by operative means, except for the rare patient in whom significant neurologic compromise develops. Patients who suffer a high-energy type of burst fracture with a resultant unstable spine require posterior fixation.

## CHAPTER REFERENCES

Each reference is categorized according to the following scheme: *, classic article; #, review article; !, basic research article; and +, clinical results/outcome study.


+ 1. Aloia JF, Cohn SH, Ostuni JA, et al. The Prevention of Involutional Bone Loss by Exercise. *Ann Intern Med* 1978;89:356.

+ 2. Arnold WD. The Effect of Early Weight-Bearing on the Stability of Femoral Neck Fractures Treated with Knowles Pins. *J Bone Joint Surg Am* 1974;56:254.

+ 3. Arnold WD, Lyden JP, Minkoff J. The Treatment of Intracapsular Fractures of the Femoral Neck. *J Bone Joint Surg Am* 1974;56:254.

+ 4. Avioli LV. Postmenopausal Osteoporosis: Prevention and Cure. *Fed Proc* 1981;40:2418.

+ 5. Barry HC. Fracture of the Femur in Paget's Disease of Bone in Australia. *J Bone Joint Surg Am* 1967;49:1359.

+ 6. Bochner R, Pellicci PM, Lyden JP. The Treatment of Intertrochanteric Fractures with a Sliding Nail Plate. *J Trauma* 1982;22:205.

+ 7. Broberg MA, Cass JR. Total Knee Arthroplasty in Paget's Disease of the Knee. *J Arthroplasty* 1986;1:139.

# 8. Brunner CF, Weber BG. *Special Techniques in Internal Fixation.* New York: Springer-Verlag, 1982.

# 9. Cameron HU. Total Knee Replacement in Paget's Disease. *Orthop Rev* 1989;18:206.

+ 10. Cancer and Steroid Hormone Study of the Centers For Disease Control and the National Institutes of Child Health and Human Development. Combination Oral Contraceptive Use and the Risk Of Endometrial Carcinoma. *JAMA* 1987;257:796.

+ 11. Cardona JM, Pastor E. Calcitonin Versus Etidronate for the Treatment of Postmenopausal Osteoporosis. *Osteoporosis* 1997;7:165.

# 12. Coburn JW, Slatopolsky E. Vitamin D, Parathyroid Hormone, and Renal Osteodystrophy. In: Brenner B, Rector F, eds. *The Kidney.* Philadelphia: W.B. Saunders, 1981.

+ 13. Cohn SH, Abesamis C, Yasumura S, et al. Comparative Skeletal Mass and Radial Bone Mineral Content in Black and White Women. *Metabolism* 1977;26:171.

# 14. Cornell CN. Management of Fractures in Patients with Osteoporosis. *Orthop Clin North Am* 1990;21:125.

+ 15. Cummings SR, Nevett MC, Browner WS, et al. Risk Factors for Hip Fractures in White Women. Study of Osteoporotic Fractures Research Group. *N Engl J Med* 1995;332:767.

+ 16. Defazio J, Speroff L. Estrogen Replacement Therapy: Current Thinking and Practice. *Geriatrics* 1985;40:32.

+ 17. Delmas PD, Bjarnason NH, Mitlak BH, et al. Effects of Raloxifene on Bone Mineral Density, Serum Cholesterol Concentrations, and Uterine Endometrium in Postmenopausal Women. *N Engl J Med* 1997;337:1641.

+ 18. DeVolgelaer JP, Nagent de Deuxchaisnes C. The Treatment of Involutional Osteoporosis with the Bisphosphonate APD (Disodium Pamidronate): Nonlinear Increases in Lumbar Bone Mineral Density. *J Bone Miner Res* 1990;5(suppl 2):5251.

+ 19. Dove J. Complete Fractures of the Femur in Paget's Disease of Bone. *J Bone Joint Surg Br* 1980;62:12.

+ 20. Eriksen EF, Berg NJ, Graham ML, et al. Evidence of Estrogen Receptors in Human Bone Cells. *J Bone Miner Res* 1987;2(suppl 1):238.

+ 21. Ettinger B, Genant HK, Cann CE. Postmenopausal Bone Loss Is Prevented with Low-Dose Estrogen with Calcium. *Ann Intern Med* 1987;106:40.

+ 22. Eyre D. Bone Biomarkers as Tools in Osteoporosis Management. *Spine* 1997;22:24S:17S.

# 23. Gallagher JC, Riggs BL. Current Concepts in Nutrition: Nutrition and Bone Disease. *N Engl J Med* 1978;298:193.

+ 24. Gambrell RD Jr. The Menopause: Benefits and Risks of Estrogen-Progestogen Replacement Therapy. *Intern Med Specialist* 1985;6:136.

+ 25. Gennari C, Chierichetti SM, Bigazzi S, et al. Comparative Effects on Bone Mineral Content of Calcium and Calcium plus Salmon Calcitonin Given in Two Different Regimens in Postmenopausal Osteoporosis. *Clin Ther Res* 1985;38:455.

# 26. Goodman WG, Coburn JW, Slatopolsky E. Renal Osteodystrophy in Adults and Children. In: *Primer on Metabolic Bone Disease and Disorders of Mineral Metabolism.* Kelseyville: ASBMR, 1990.

+ 27. Goodman WG, Henry DA, Horst R, et al. Parenteral Aluminum Administration in the Dog. II. Induction of Osteomalacia and Effect on Vitamin D Metabolism. *Kidney Int* 1984;25:370.

+ 28. Gruber HE, Ivey JL, Baylink DL. Long-Term Calcitonin Therapy in Postmenopausal Osteoporosis. *Metabolism* 1984;33:295.

+ 29. Grundy M. Fracture of the Femur in Paget's Disease of Bone. *J Bone Joint Surg Br* 1970;52:252.

+ 30. Harris WH. Paget's Disease Involving the Hip Joint. *J Bone Joint Surg Br* 1971;53:650.

+ 31. Hayes W. Fall Biomechanics as Determinants of Osteoporotic Hip Fracture Risk. Presented at the Steenbock Symposium on Osteoporosis, June 1989.

+ 32. Heaney RP, Recker RR, Saville PD. Calcium Balance and Calcium Requirements in Middle-Aged Women. *Am J Clin Nutr* 1977;30:1603.

+ 33. Hercz G, Salusky IB, Nomis KC, et al. Aluminum Removable Peritoneal Dialysis: Intravenous vs. Intraperitoneal Desferoxamine. *Kidney Int* 1986;30:944.

# 34. Holbrook TL, Grazier K, Kelsey JF, et al. *Human and Economic Impact of Injuries and Crippling Disorders of the Musculoskeletal System.* Chicago: American Academy of Orthopaedic Surgeons, 1984.

# 35. Holbrook TL, Grazier K, Kelsey JF, et al. *Frequency of Occurrence, Impact, and Cost of Selected Musculoskeletal Conditions in the US.* Chicago: American Academy of Orthopaedic Surgeons, 1984.

+ 36. Horsman A, Gallagher JC, Simpson M, et al. Prospective Trial of Estrogen and Calcium in Postmenopausal Women. *Br Med J* 1977;2:789.

+ 37. Hutchinson TA, Polansky SM, Feinstein AR. Postmenopausal Oestrogens Protect against Fractures of the Hip and Distal Radius: A Case Control Study. *Lancet* 1979;2:705.

+ 38. Huvos AG, Butter A, Bletsky SS, et al. Osteogenic Sarcoma Associated with Paget's Disease of Bone. *Cancer* 1983;52:1489.

# 39. Jensen JS, Tondevold E. Mortality after Hip Fracture. *Acta Orthop Scand* 1979;50:161.

# 40. Jette AA, Harris BA, Clearly PD, et al. Functional Recovery after Hip Fracture. *Arch Phys Med Rehabil* 1987;68:735.

# 41. Kane WJ. Spinal Osteoporosis, Spinal Deformity: What's the Latest, What's the Best? Presented at meeting of American Academy of Orthopaedic Surgeons, Baltimore, 1988.

+ 42. Karpf DM, et al. Prevention of Non-Vertebral Fracture by Alendronate. *JAMA* 1997;277:1159.

+ 43. Kaufman DW, Miller DR, Rosenberg L, et al. Non-Contraceptive Estrogen Use and the Risk of Breast Cancer. *JAMA* 1984;252:63.

# 44. Kelsey JF. Osteoporosis: Prevalence and Incidence. In: *Proceedings of the NIH Consensus Development Conference*, Bethesda, MD, 1984.

+ 45. Kenzora JE, McCarthy RE, Lowell JD, et al. Hip Fracture Mortality. *Clin Orthop* 1984;186:45.

+ 46. Kiel DP, Felson DT, Anderson JJ, et al. Hip Fracture and the Use of Estrogen in Postmenopausal Women. *N Engl J Med* 1987;317:1169.

+ 47. Kimmel PL. Radiologic Methods to Evaluate Bone Mineral Content. *Ann Intern Med* 1984;100:908.

+ 48. Kleinman KS, Coburn JW. Amyloid Syndromes Associated with Hemodialysis. *Kidney Int* 1989;35:567.

! 49. Krag MH, Byrne KB, Gilbertson LG, et al. Intra-Abdominal Pressurization: Failure to Reduce Erector Spinae Loads During Lifting Tasks. Presented to the International Society for Study of the Lumbar Spine, Dallas, 1986.

! 50. Krag MH, Gilbertson LG, Pope MH. Intra-Abdominal and Intrathoracic Pressure Effects upon Load-Bearing of the Spine. Presented at meeting of Orthopaedic Research Society, Las Vegas, 1985.

+ 51. Krolner, B, Toft B, Pors Neilsen S, et al. Physical Exercise as Prophylaxis against Involutional Vertebral Bone Loss: A Controlled Trial. *Clin Sci* 1983;64:541.

+ 52. Kyle RF, Gustilo RB, Premer RF. Analysis of 622 Intertrochanteric Hip Fractures. *J Bone Joint Surg Am* 1976;61:216.

# 53. Lane JM. Osteoporosis. *Spine* 1997;22:24S, 32S.

+ 54. Lewinnek GE, Kelsey J, White AA, et al. The Significance and a Comparative Analysis of the Epidemiology of Hip Fractures. *Clin Orthop* 1980;152:35.

+ 55. Lindsay R, Hart DM, Aitken JM, et al. Long-Term Prevention of Postmenopausal Osteoporosis by Oestrogen. *Lancet* 1976;1:1038.

+ 56. Lindsay R, Hart DM, Forrest C, et al. Prevention of Spinal Osteoporosis in Oophorectomized Women. *Lancet* 1980;2:1151.

+ 57. Llach F, Felsenfeld AJ, Coleman MD, et al. Natural Course of Dialysis Osteomalacia. *Kidney Int* 1986;29:574.

# 58. Llach F, Felsenfeld AJ, Coleman MD, et al. Prevalence of Various Types of Bone Disease in Dialysis Patients. In: *Proceedings of the 9th International Congress of Nephrology.* New York: Springer-Verlag, 1984.

+ 59. Ludkowski P, Wilson-MacDonald J. Total Arthroplasty in Paget's Disease of the Hip: A Clinical Review and Review of the Literature. *Clin Orthop* 1990;255:160.

! 60. Maloney NA, Ott SM, Alfrey AC, et al. Histologic Quantification of Aluminum in Iliac Bone from Patients with Renal Failure. *J Lab Clin Med* 1982;99:206.

+ 61. McDonald DJ, Sim FH. Total Hip Arthroplasty in Paget's Disease. *J Bone Joint Surg Am* 1987;69:766.

+ 62. Meema S, Bunker ML, Meema HE. Preventative Effect of Estrogen on Postmenopausal Bone Loss: A Follow-Up Study. *Arch Intern Med* 1975;135:1436.

# 63. Mehls O. Renal Osteodystrophy in Children: Etiology and Clinical Aspects. In: Fine RN, Grushkin AB, eds. *End Stage Renal Disease in Children.* Philadelphia: W.B. Saunders, 1984.

+ 64. Melton LJ III. Epidemiology of Osteoporosis. *Spine* 1997;22:24S.

# 65. Melton LJ III, Riggs BL. Epidemiology Of Age-Related Fractures. In: Avioli L, ed. *The Osteoporotic Syndrome.* New York: Grune & Stratton, 1987.

# 66. Merkow RL, Lane JM. Paget's Disease of Bone. *Orthop Clin North Am* 1990;21:177.

+ 67. Merkow RL, Pellicci PM, Hely DP, et al. Total Hip Replacement for Paget's Disease of the Hip. *J Bone Joint Surg Am* 1984;66:752.

+ 68. Milliner DS, Hercz G, Miller JH, et al. Clearance of Aluminum by Hemodialysis: Effect of Desferoxamine. *Kidney Int* 1986;28:5108.

+ 69. Mills BG, Singer FR. Nuclear Inclusions in Paget's Disease of Bone. *Science* 1976;194:201.

+ 70. Mills BG, Weiner LP, Sutton SC, et al. Evidence for Both Respiratory Syncytial Virus and Measles Virus Antigens in Osteoclasts of Patients with Paget's Disease of Bone. *Clin Orthop* 1984;183:303.

+ 71. Minaire P, Meunier P, Eduoard C, et al. Quantitative Histological Data on Disuse Osteoporosis: Comparison with Biological Data. *Calcif Tissue Res* 1974;17:57.

# 72. Müller ME, Allgöwer M, Schneider R, et al. *Manual of Internal Fixation*, 2nd ed. New York: Springer-Verlag, 1979.

+ 73. Nachemson AL. Orthotic Treatment for Injuries and Diseases of the Spinal Column. *Phys Med Rehabil* 1987;1:11.

# 74. National Institutes of Health Consensus Development Conference Statement on Osteoporosis. *JAMA* 1984;252:799.

+ 75. Nicholas JA, Killoran P. Fracture of the Femur in Patients with Paget's Disease: Results of Treatment in 23 Cases. *J Bone Joint Surg* 1965;47:450.

+ 76. Platts MM, Goods GC, Hislop JS. Composition of Domestic Water Supply and Incidence of Fractures and Encephalopathy in Patients on Home Dialysis. *Br Med J* 1977;2:657.

+ 77. Richelson LS, Wahner HW, Melton LJ III, et al. The Relative Contributions of Aging and Estrogen Deficiency to Postmenopausal Bone Loss. *N Engl J Med* 1984;311:1273.

+ 78. Riggs BL, Melton LJ III. Evidence for Two Distinct Syndromes of Involutional Osteoporosis. *Am J Med* 1983;75:899.

+ 79. Riggs BL, Melton LJ III. Involutional Osteoporosis. *N Engl J Med* 1986;314:676.

+ 80. Riggs BL, Wahner HW, Melton LJ III, et al. Rates of Bone Loss in Appendicular and Axial Skeletons of Women: Evidence of Substantial Vertebral Bone Loss before Menopause. *J Clin Invest* 1981;67:328.

+ 81. Ryan WG, Schwartz TB. Mithramycin Treatment of Paget's Disease of Bone. *Arthritis Rheum* 1980;23:1155.

! 82. Saleppi KP, Stulberg B, Vigorita VJ, et al. Bone Histomorphometry in Femoral Neck Fractures. *Surg Forum* 1981;3:543.

+ 83. Salusky IB, Coburn JW, Brill J, et al. Bone Disease in Pediatric Patients Undergoing Dialysis with CAPD or CCPD. *Kidney Int* 1988;33:975.

+ 84. Schoffer JJ, Manoli A. The Antiglide Plate for Distal Fibular Fixation. *J Bone Joint Surg Am* 1987;69:596.

+ 85. Seeger LL. Bone Density Determination. *Spine* 1997;22:24S:49S.

# 86. Sherrard DJ, Ott SM, Maloney NA, et al. Uremic Osteodystrophy: Classification, Causes and Treatment. In: Frame B, Potts J, eds. *Proceedings of the Symposium on Clinical Disorders of Bone and Mineral Metabolism.* Amsterdam: Excerpta Medica, 1984.

+ 87. Singer FR. Paget's Disease of Bone: A Slow Virus Infection? *Calcif Tissue Int* 1980;31:185.

# 88. Siris E. Paget's Disease of Bone. In: Favus ML, ed. Primer on Metabolic Bone Disease and Disorders of Mineral Metabolism. Kelseyville: ASBMR, 1990.

+ 89. Smith DM, Khairi MRA, Johnston CC Jr. The Loss of Bone Mineral with Aging and Its Relationship to the Risk of Fracture. *J Clin Invest* 1975;56:311.

+ 90. Steen-Jensen J, Bagger J. Long-Term Social Prognosis after Hip Fracture. *Acta Orthop Scand* 1982;53:97.

+ 91. Stock JL,Avioli LV, Baylink, et al. Calcitonin—Salmon Nasal Spray Reduces the Incidence of New Vertebral Fracture. *J Bone Miner Res* 1998;12:S149(abstract 187).

+ 92. Storm T, Thamsborg G, et al. Effect of Intermittent Cyclical Etidronate Therapy on Bone Mass and Fracture Rate in Women with Postmenopausal Osteoporosis. *N Engl J Med* 1990;322:1265.

+ 93. Tinetti M, Speehley M, Ginter SF. Risk Factors for Falls among Elderly Persons Living in the Community. *N Engl J Med* 1988;319:1701.

+ 94. Watts N, Harris ST, Gennant H, et al. Intermittent Cyclical Etidronate Treatment of Postmenopausal Osteoporosis. *N Engl J Med* 1990;323:73.

+ 95. Wingo PA, Layde PM, Lee NC, et al. The Risk of Breast Cancer in Postmenopausal Women Who Have Used Estrogen Replacement Therapy. *JAMA* 1987;257:209.

# CHAPTER 132

# PRINCIPLES OF TREATMENT OF INFECTION AND ANTIMICROBIAL THERAPY

*Ashkan Lahiji and John L. Esterhai, Jr.*

**A. Lahiji:** Resident, Hospital of the University of Pennsylvania, Department of Orthopaedics, Philadelphia, Pennsylvania, 19104.
**J. L. Esterhai, Jr.:** Associate Professor of Orthopaedic Surgery, Hospital of the University of Pennsylvania, Department of Orthopaedics, Philadelphia, Pennsylvania, 19104.

Overview
Common Infections
Factors Influencing Infection
- Bacteria-Determined Factors
- Patient-Determined Factors
- Surgeon-Dependent Factors

Diagnosis of Infection
- Signs and Symptoms
- Laboratory Investigation
- Radiologic Investigation
- Culture Investigation
- Molecular Investigation

Antibiotic Intervention
- *B*-Lactam Antibiotics
- Drugs Effective Against Mycobacteria
- Drugs Effective Against Fungi
- Streptogramin Antibiotics
- Prolonged Antibiotic Use

Chapter References

## OVERVIEW

This chapter covers the etiology of musculoskeletal infection, diagnostic options, and antimicrobial treatment. No attempt is made to discuss the specific management of individual infectious problems such as acute or chronic osteomyelitis, infectious arthritis, or infected total joint arthroplasty, because these issues are covered in Chapter 73, Chapter 133, Chapter 134, Chapter 135, Chapter 150, and Chapter 176. Nor does this chapter include information on universal precautions and protection of the health care worker.

Important issues bearing on the etiology of musculoskeletal infection include an understanding of normal human skin flora, bacterial virulence factors, antibiotic resistance, nonspecific and specific immunity factors, and immune deficiency states. Also important are the impact of surgical technique, skin preparation, and antibiotic prophylaxis.

Diagnostic evaluations involve laboratory studies including erythrocyte sedimentation rate (ESR), C-reactive protein (CRP), and the newer polymerase chain reactions (PCR). Roentgenographic imaging tools include plain x-ray studies, tomograms, computer-assisted tomography (CT scans), magnetic resonance imaging (MRI), and nuclear medicine studies (99m Tc bone scans, gallium- and indium-labeled white blood cell scans, and IgG). Culture, antibiotic susceptibility testing, and biopsy are also discussed.

Antimicrobials are discussed on the basis of their classification and properties including dosing, adverse effects, toxicities, and interactions. New antibiotic options, novel delivery systems, and issues surrounding long-term suppressive antibiotic therapy are discussed.

## COMMON INFECTIONS

**Postoperative Wound Infection** Incisional wound infection is a relatively uncommon complication of an orthopaedic surgical procedure. Because most procedures are considered “clean,” the expected incidence of infection is approximately 2%. The most common offending pathogens in these types of infection are *Staphylococcus aureus* and *Staphylococcus epidermidis*. Because of the morbidity associated with these infections, the benefits of routinely using prophylactic antibiotics are believed to outweigh the risks to the patient. These risks can be reduced by obtaining a detailed history of adverse reactions to medication. Prophylaxis may be further enhanced with a good understanding of the antibiotic sensitivities of the organisms in a given institution (24).

**Cellulitis** Cellulitis is a spreading infection of the subcutaneous tissues, and it is usually due to streptococcus, although a significant number of cases are caused by *S. aureus.* Often, the patient has experienced a minor trauma, or an insect sting or bite. This event may have allowed bacteria to gain entry into the subcutaneous tissues. The findings of tenderness, erythema, and lymphangitis or lymphadenopathy will allow you to make the diagnosis. Most cases of uncomplicated cellulitis can be simply treated with oral antibiotics. Admit patients to the hospital whose cellulitis is complicated by immunodeficiency, high fever, or systemic toxicity for administration of intravenous (IV) antibiotics and observation.

**Paronychia and Felon** Paronychia is the most common infection of the hand and involves the soft-tissue fold that surrounds the fingernail. It is commonly caused by the introduction of *S. aureus* into this paronychial tissue by a hangnail, manicure instrument, or tooth. Early use of warm soaks and oral antibiotics, as well as resting of the involved digit can halt the infection. As the condition progresses, there may be a need for incision and drainage of the abscess, followed by parenteral or oral antibiotics, depending on the extent of the infection.

A felon is a subcutaneous abscess in the distal pulp of a finger or thumb. Numerous fibrous septae tether the skin to the bone and compartmentalize the pulp space; thus, a felon is composed of a series of small closed-space infections, which must be individually incised and drained. Pain and swelling in the finger develop quickly as the abscess enlarges. The expanding felon can break down the septae and extend proximally up the finger, in some cases producing osteitis or osteomyelitis. Treatment involves incision and drainage as well as systemic antibiotic therapy (see Chapter 73).

**Bite Injuries** Injuries caused by human bites are commonly seen in the emergency room. The most common infective organisms are normal flora of the mouth such as *Streptococcus viridans, Bacteroides, S. epidermidis, S. aureus,* and *Peptostreptococcus.* Irrigate and debride bite wounds adequately, and leave them open. Direct antibiotic therapy at the most common infecting organisms.

Dog bites may harbor S. viridans, Pasteurella multocida, Bacteroides, and *Fusobacterium.* Treatment of dog bites may be complicated by the threat of rabies. All efforts should be made to discover the rabies status of the dog. Prophylactic antirabies treatment must be considered.

Cat bites may be more dangerous than those of dogs, because feline teeth allow deeper penetration of tissue and the wounds are more difficult to drain adequately. It is estimated that more than 80% of cat-bite wounds become infected compared with 5% of dog bites. In cat bites, the common infecting organisms include *P. multocida* and *S. aureus* (Table 132.1).

| Source of bite | Suspected organisms | Primary therapy | Secondary therapy |
|---|---|---|---|
| Human | S. viridans, S. epidermidis, S. aureus, Bacteroides, Peptostreptococcus | Ampicillin/clavulanate 875/125 mg tid if no signs of infection | Ampicillin/sulbactam 1.5 gm qdh IV Cefoxitin 2.0 g qdh IV if infected |
| Dog | S. viridans, P. multocida, S. aureus, Bacteroides | Ampicillin/clavulanate 500/125 mg tid | Clindamycin and ciprofloxacin (adults) clindamycin and TMP SMX (children) |
| Cat | P. multocida, S. aureus | Ampicillin/clavulanate 500/125 mg tid or Penicillin V 500 mg qid | Cefuroxime or doxycycline |

tid, three times daily; qid, four times daily; q, every; IV, intravenous; TMP/SMX, Bactrim.

***Table 132.1. Antimicrobial Therapy for Bite Wounds***

**Gangrene** Gas gangrene is classically caused by the gram-positive anaerobe *Clostridium perfringens* but may also be the result of enteric gram-negative rod infections. Clostridial spores germinate in the anaerobic environment of necrotic tissue. *C. perfringens* ferments carbohydrates and produces large amounts of carbon dioxide. The gas causes high pressure locally that, in turn, limits blood flow to the area and further enhances the anaerobic environment. The presentation includes progressive pain and edema of the involved extremity with a foul-smelling serosanguineous discharge. Plain-film radiographs or CT scan may show gas in the soft tissues. Treatment includes widespread irrigation and debridement, high-dose administration of antibiotics, and hyperbaric oxygen.

**Necrotizing Fasciitis** Necrotizing fasciitis is a relatively rare infection with high mortality (40%) and morbidity rates. Most cases of necrotizing fasciitis follow minor trauma or recent surgery, with the highest incidence seen among patients with small-vessel diseases such as diabetes mellitus. The clinical manifestations include extensive dissection and necrosis of the superficial and often deep fascia. The infection undermines adjacent tissue and leads to marked systemic toxicity. Thrombosis of the subcutaneous blood vessels leads to necrosis of the overlying skin. Numbness or analgesia replaces the initial local pain as the infection involves the cutaneous nerves. It is most commonly associated with Group A streptococcus but may also be the result of infection by staphylococcus, or gram-negative enteric bacteria. With careful use of bacteriologic techniques, anaerobes, such as *Peptostreptococcus, Bacteroides,* and *Fusobacterium* sp, can be isolated in 50% to 60% of cases. It is an emergency situation, and treatment involves wide surgical debridement of the infected area and administration of IV antibiotics.

**Tetanus** Tetanus is a potentially deadly yet easily avoidable neuroparalytic disease that is caused by the exotoxin of the gram-positive anaerobe *Clostridium tetani.* Treatment involves proper wound care and prophylactic treatment with formalin-inactivated tetanus toxoid. Immunization for tetanus has a well-established schedule, and indications for reimmunization can be easily determined on the basis of the wound sustained and the patient's immunization history. Patients with no previous history of immunization or very severe wounds may benefit from the administration of tetanus immune globulin (Table 132.2).

| | Clean, minor wounds | | Other wounds | |
|---|---|---|---|---|
| History of tetanus immunization (doses) | Give Td | Give tetanus immune globulin | Give Td | Give tetanus immune globulin |
| Unknown or <3 doses | Yes | No | Yes | Yes |
| 3 or more doses | No (unless last dose >10 years ago) | No | No (unless last dose >5 years ago) | No |

Td, tetanus toxoid.

***Table 132.2. Tetanus Immunization Recommendations***

**Foot Infections** Foot infections are common in patients with diabetes because of the prevalence of vascular insufficiency, neuropathy, and immune deficiency. Cultures of these infections generally reveal them to be polymicrobial in nature.

Puncture wounds of the foot through the sole of a shoe are commonly associated with Pseudomonas. Pseudomonas infection is serious and requires aggressive debridement and antibiotic therapy.

## FACTORS INFLUENCING INFECTION

Numerous factors determine the incidence of infection, its progression, and ultimate response to intervention in a given patient. They can be separated into factors relating to the infecting organism, the patient, the surgeon, and the choice of optimal therapy.

### BACTERIA-DETERMINED FACTORS

#### *Normal Human Flora*

Multiple factors influence the ability of bacteria to cause infection and disease. One of the most commonly neglected yet important concepts to understand is the fact that a diverse flora is associated with the normal skin, mucous membranes, and the respiratory, urogenital, and gastrointestinal mucosa from birth until death. The human body harbors numerous bacteria, with the composition of this flora remaining relatively stable within body regions during a person's lifetime. In some instances, the flora may aid the host by competing for microenvironments with other pathogenic bacteria, but in other circumstances, if given the opportunity, these bacteria may be the actual cause of disease. The main influences determining the composition of the natural flora of the human body are pH, temperature, redox potential, and oxygen, water, and nutrient levels.

The most important normal flora to be considered in orthopaedic surgical infections are skin flora. The variety of microenvironments provided by skin allows for the wide diversity of dermal flora. Different bacteria characterize the following four regions: (1) the axilla, perineum, and toe webs; (2) hand, face, and trunk; (3) upper arms and legs; and (4) fingernails and toenails. Sites with more potential for occlusion, such as the axilla or perineum, harbor more bacteria than open areas like the arm or trunk. It is believed that the increased moisture, temperature, and skin surface lipids allow for the higher numbers of organisms. These more occluded regions may also have higher levels of gram-negative bacteria.

*S. epidermidis* is the most abundant bacteria of the skin surface, comprising up to 90% of the aerobic flora in some areas. *S. aureus* is found most abundantly in the nasal cavity and perineum, with levels ranging from 10% to 40%. Its prevalence rises to 67% on vulvar skin. In those individuals with dermatologic conditions, such as psoriasis or atopic dermatitis, the prevalence may be more than 80%. Propionibacteria are common in areas rich in sebaceous glands and are associated with trichomycosis axillaris and acne vulgaris. *Propionibacterium acnes* is the most common offending species. Other bacteria seen less commonly on the skin include streptococci, micrococci, and gram-negative rods.

The flora of the nails is similar to that of skin, but in addition to bacteria, various species of fungi can also be isolated, including Aspergillus, Penicillium, Cladosporium, and *Mucor.* The conjunctival and respiratory mucosal flora when cultured can show *Corynebacteria, Neisseriae, Moraxellae, Streptococcus,* and *Staphylococcus.* The primary organisms of the oral flora are *Streptococcus viridans* and b-hemolytic streptococcal species that are often involved in periodontal disease and dental caries. Studies have shown that a transient bacteremia of these species occurs during dental procedures and up to 25% of the time after brushing one's teeth. This bacteremia may be of concern in those patients with implanted prosthetic devices, which may become seeded during these events. The bowel and bladder also acts as reservoirs for a wide variety of disease-causing gram-negative bacilli, enterococci, anaerobes, and the gram-positive rod *C. perfringens,* which may be involved in gas gangrene of the extremities (24).

### *Bacterial Virulence Factors*

Bacterial virulence, defined as the pathogenicity of a microorganism, is affected by such factors as the number of infecting organisms, route of entry into the body, and virulence factors that bacteria have evolved to invade, cause disease, and evade the host's defenses. Virulence can be measured experimentally by determining the dosage of bacteria required to cause death or disease in a given subject. These calculations refer to the inoculum required to cause death or symptoms in at least 50% of the population, the so-called lethal dose (LD50) or effective dose (ED50) respectively.

Virulence factors may be specific to each bacterial species or may be found in a broad range of organisms. One such factor is the presence of pili or fimbria that allow bacterial adherence to host cells or aid the bacteria in escaping host defenses. The pili of *Streptococcus pyogenes* and *Escherichia coli* allow the organisms to attach to the mucosa, whereas the pili of *Neisseria gonorrhoeae* also function as an inhibitor of phagocytosis.

Bacterial cell surface receptors also play a part in the disease process. *S. aureus, Yersinieae,* and *S. pyogenes* isolated from patients suffering from septic arthritis possess a cell surface collagen receptor (48). *Rickettsia* sp and *Mycobacterium tuberculosis* invade host cells and, as obligate or facultative intracellular pathogens, avoid the host immune response.

Capsule formation has long been recognized as a bacterial protective mechanism. These capsules act to interfere with opsonization by immunoglobulins, phagocytosis, and intracellular killing of the bacteria. There are numerous bacteria that produce such capsules including *Streptococcus pneumoniae, E. coli, Bacteroides, Salmonella,* and *Haemophilus influenzae.* Protein A, expressed by *S. aureus,* is antiphagocytic and binds to the Fc portion of IgG, preventing complement binding and opsonization. Protein M of *S. pyogenes* inhibits phagocytosis.

Endotoxin is most commonly produced by gram-negative organisms. It is a naturally occurring bacterial outer-cell membrane component that has systemic effects on the host, causing a generalized sepsis that can progress to shock. Exotoxins are specifically produced for release by bacteria, generally exerting their effects over a limited site of action or on particular cell types or receptors. There are multiple classes of exotoxins, including neurotoxins, cytotoxins, and enterotoxins.

The classic neurotoxin is that of *C. tetani* that affects only the inhibitory neurons in the central nervous system (CNS). The result is unopposed firing of motor neurons, leading to violent muscle contractions and a spastic paralysis known as tetanus. *S. aureus* produces a leukocidin that destroys polymorphonuclear cells as well as an a-toxin that functions to cause lysis of monocytes and platelets, resulting in the formation of pus and abscesses.

Other bacteria secrete enzymes as a virulence factor. *Pseudomonas aeruginosa* secretes elastase, collagenase, and lecithinase, as well as an exoprotease that cleaves and inactivates immunoglobulins. *S. pyogenes* produces the clot-lysing enzyme streptokinase, as well as the enzymes streptolysin O and S. IgA protease, produced by *S. pneumoniae, N. gonorrhoeae,* and *H. influenzae,* destroys the secretory immunoglobulins.

A specific virulence factor related to the pathogenesis of prosthetic joint infections involves adhesion of the organism to the biomaterial. The implant elicits a host response that results in the coating of the prosthetic material and potential pathogen in a layer of proteins including fibronectin, vitronectin, collagen, and fibrinogen. This “extracellular slime” acts to bind the organism and foreign body together. The adhesion of *S. aureus* to bioprosthetic materials is also mediated by adhesin molecules belonging to the microbial surface components recognizing adhesive matrix molecules (MSCRAMM) family of microbial cell surface proteins. The organism further encases itself in glycocalyx that probably includes glycerol techoic acid. This extracellular slime isolates bacteria from the immune surveillance of the host. Furthermore, the glycocalyx stimulates monocytes to produce prostaglandin $E_2$, which acts to inhibit T lymphocyte proliferation, B-lymphocyte blastogenesis, and immunoglobulin production. It interferes with white cell chemotaxis and degranulation, as well as immunoglobulin opsonization, and inhibits antimicrobial therapy from locally reaching effective levels to exert their actions.

**Antibiotic Resistance** The final microbial factor that influences the course of infection is the presence of antibiotic resistance. The issue of resistance is an ever-growing problem in medicine and is discussed in detail as it relates to each specific antibiotic.

## PATIENT-DETERMINED FACTORS

The human immune system is charged with resisting the onslaught of invading organisms and keeping the body free from infection. This process involves the two distinct arms of the immune system, innate or nonspecific immunity and acquired or specific immunity (Table 132.3).

| *Systemic factors* | *Local factors* |
|---|---|
| Malnutrition | Major vascular compromise |
| Renal or hepatic failure | Chronic lymphedema |
| Diabetes mellitus | Vasculitis |
| Malignancy | Extensive scar tissue |
| Immunosuppressive therapy | Radiation fibrosis |
| Chronic hypoxia | Small vessel disease |
| Immunodeficiency | Venous stasis |
| Extremes of age | Neuropathic extremity |
| Alcohol abuse | |

***Table 132.3. Systemic and Local Factors That Affect Host Response to Infection***

### *Innate Immunity*

Innate immunity is based on the normal physical and physiologic barriers of the human body, as well as the inflammatory reactions that begin once these barriers are compromised. This nonspecific immune system protects from all invasion nondiscriminately.

**Physical Barriers** Innate immunity starts at the simplest level of the physical barrier of the skin and mucous membranes. These surfaces provide an effective barrier to the entry of most microorganisms. In addition, the sebaceous glands, associated with the hair follicles, produce sebum, lactic and fatty acids, maintaining the skin pH between 3 and 5, inhibiting the growth of most bacteria. Even small breaks in the skin resulting from wounds or abrasions are potential routes for infection. Biting insects harboring pathogenic organisms may also introduce these pathogens subcutaneously or systemically as they feed. This is the mechanism of spread for such diseases as malaria, bubonic plague, and Lyme disease.

**Physiologic Barriers** Physiologic barriers include lysozyme, interferon, and the complement system. Lysozyme enzymatically cleaves bacterial cell wall peptidoglycan and is capable of killing invading bacteria. Interferon exerts systemic effects that generally induce an antiviral state throughout the entire body. Complement is a group of serum proteins circulating in an inactive proenzyme state. Once activated, the cascade amplifies a nonspecific immune reaction that ultimately destroys the invading organism.

**Phagocytosis** Nonspecific phagocytosis is mediated by antigen-recognizing cells of the immune system that are on constant surveillance. Once confronted by any foreign particle or organism, these cells, best characterized by macrophages, internalize these particles and degrade them through lysozymal enzymes into macromolecular pieces. These pieces can then be presented to lymphocytes to begin the process of developing acquired immunity.

**Inflammation** The final and most important aspect of innate immunity is the inflammatory response to local tissue damage. The four cardinal signs of inflammation—rubor, tumor, calor, and dolor—have classically described this response. The events taking place during inflammation are (1) local tissue damage, (2) vasodilation, (3) increased capillary permeability, and (4) an influx of phagocytic cells. These responses are mediated by the release of local inflammatory mediators such as histamine, kinins, prostaglandins, leukotrienes, and chemotactic factors.

### *Acquired Immunity*

The acquired immune system is composed of humoral and cell-mediated responses. Unlike innate immunity, the acquired immune system exhibits specificity, diversity, memory, and self and non-self recognition. A discussion of the mechanism of this specific immunity is beyond the scope of this chapter; it is important, however, to understand the factors that may affect the ability of the body to mount an adequate immune response.

**States of Immune Compromise** In order to fight infection, the body must have functional reticuloendothelial and polymorphonuclear cells, as well as competent B and T lymphocytes. Patients with deficiencies in any of these cell lines are particularly vulnerable to infection. Deficiencies may be present in patients with neoplasia involving the bone marrow, those receiving certain medications (including patients taking corticosteroids or immunosuppresives in the case of transplant or rheumatoid arthritis), and patients with systemic illnesses such as sickle cell disease. Tannenbaum et al. (50) followed the clinical progress of 19 patients who had undergone both transplant and arthroplastic procedures. Their findings suggested that patients who had undergone orthopaedic procedures before transplant surgery had the same rate of infection as the general population. Patients who underwent orthopaedic procedures following transplantation, however, were at a significantly higher risk of developing infection in the prosthetic joint. Their study concluded that this increased risk was most evident in those patients whose immunosuppressive protocol included the use of cyclosporine A (50).

The prevalence of human immunodeficiency virus (HIV) infection continues to spread in the United States and throughout the world. The virus has a trophism for CD4, or so-called “helper” T lymphocytes, infecting and ultimately destroying them. The CD4 lymphocytes play a crucial role in orchestrating the activation and actions of both humoral and cell-mediated immunity. When patients have lost significant activity of their CD4 cells, they are no longer immunocompetent and are given the diagnosis of acquired immunodeficiency syndrome (AIDS). These patients are at risk of developing opportunistic infections as well as infections seen in healthy individuals. Corticosteroid use, lymphomas, nutritional deficiencies, obesity, uremia, and widespread radiation therapy, as well as the other factors, may all be causes for immunocompromise in patients. In the case of patients with longstanding diabetes, vascular compromise along with neuropathy can allow small wounds in the distal lower extremities, in the absence of proper care and adequate inflammatory and immune responses, to become limb-threatening infections.

Patients with diabetes, alcoholism, patients on cytotoxic medication, and those with hematologic malignancies may develop neutropenia, with absolute neutrophil counts below 500 cells/ml. At this point, such patients are vulnerable to infections from *S. aureus* and gram-negative enterobacteria, as well as certain fungi. These patients may not have high fever or appear toxic because of their lack of immune response. The index of suspicion should be very high in such patients, and a fever of 38°C (100.5°F) or higher should warrant a thorough evaluation.

Patients with congenital or qualitative defects of their humoral or complement systems are vulnerable to infection as well, particularly with encapsulated organisms such as *N. meningitidis, H. influenzae,* and *S. pneumoniae*. The same holds true for patients who have undergone splenectomy. Nonfunctional complement also predisposes for infections from *S. aureus* and gram-negative enterobacteriae.

**Nutritional Status** Malnutrition may affect wound healing, humoral and cell-mediated immunity, serum complement levels, and neutrophil chemotaxis and bactericidal activity. The basal metabolic requirements of patients who have undergone major mechanical trauma or severe burns may rise to 200% of normal levels.

The most important component of a patient's nutritional evaluation is the history and physical examination. Measure weight and height, assess caloric intake, and evaluate medical conditions that may affect nutritional status. On physical examination, look for evidence of weight loss, loss of subcutaneous fat, muscle wasting, and the presence of sacral or tibial edema or ascites. Anthropomorphic measurements such as skin-fold thickness and muscle circumference are often not useful. Clinical palpation of the triceps muscle, however, can often provide an excellent estimate of nutrition, because extensors tend to lose muscle mass faster than flexors.

Laboratory investigation may also contribute to nutritional evaluation. Measurement of visceral proteins, renal and liver function, serum electrolytes and minerals, and hematologic evaluation, as well as delayed cutaneous hypersensitivity testing, may all play a role in developing the overall nutritional assessment of a patient. Malnourishment has been defined in the past by laboratory values of serum albumin levels below 3 to 4 mg/dl, serum transferrin below 150 mg/dl, and total lymphocyte counts below 1500 cells/$mm^3$. Additionally, the absence of significant immune reaction to skin testing may indicate a malnourished state.

**Distant Infections** Finally, the presence of infection at a distant site at the time of surgery has been associated with prosthetic joint infections. Patients with such infections may continue to have episodes of transient bacteremia, seeding the entire body with bacteria, and increasing their risk for developing infection. Screen patients thoroughly for the presence of pulmonary, genitourinary, skin, and dental infections preoperatively. Treat and eliminate the infection before proceeding with any orthopaedic procedures.

**SURGEON-DEPENDENT FACTORS**

**Surgical Technique** The actions and decisions the surgeon makes in treating a patient play a tremendous role in the development and subsequent progression of infection. When treating a patient with an open wound after trauma or infection, be certain to irrigate the wound adequately, removing the greatest load of bacteria and foreign debris possible. At the same time, debride the wound well, and remove all nonviable tissue, making certain that the remaining tissue has an adequate blood supply. In the case of open fractures, the use of prophylactic antibiotics with early irrigation and debridement can minimize the risk of an infection that may jeopardize healing. The length of surgery may also influence the incidence of infection. In addition, orthopaedic techniques, such as reaming, can disrupt local blood supply and alter host–cell, humoral factor, and antibiotic penetration to the site.

In addition, foreign materials like polymethylmethacrylate cement (PMMA) can contribute to the potential for infection. PMMA significantly increases the likelihood for infections with *S. epidermidis* and *S. aureus. In vitro* studies have shown the toxicity of PMMA monomer on the bactericidal serum factors, terminal complement components, phagocytosis, lymphocyte function, and intracellular killing by polymorphonuclear cells. PMMA monomers may reach toxic concentrations surrounding implanted prostheses. When closing the wound, it is important to eliminate dead space, have satisfactory drainage of hematomas, and provide adequate soft-tissue coverage.

**Skin Preparation** Preparation of the skin for surgery can play a role in the incidence of infection, because infection may occur whenever the protective barrier of the skin is broken. Proper preparation of the skin before incision can decrease the risk of contamination significantly (7).

The purpose of preoperative skin preparation is to remove the soil and transient flora found on skin, to reduce resident microbial counts to subpathogenic levels in a short period of time with the least amount of tissue irritation, and to inhibit the rapid rebound growth of microorganisms. Although the normal flora of the skin and hair can never be eradicated, the total number of organisms can be markedly reduced through the use of agents such as iodine iodophors, alcohol, hexachlorophene, and chlorhexidine. These preparation agents have excellent activity against gram-positive bacteria and good activity against gram-negative bacteria and fungi, reducing microbial activity 100-fold within minutes. It must be kept in mind that the sebaceous glands and hair follicles of normal skin where bacteria reside and multiply can never be sterilized because of the poor penetration of these agents.

The transient skin flora is easier to remove than the resident flora that may be attached or absorbed into the epidermal layers. Studies have measured that approximately 20% of resident skin flora is not removed by standard preparation techniques. A recent study comparing clean and sterile prep kits showed no difference between the efficacy of either kit, a fact that has significant financial implications for medical centers. The cost of prep kits assembled in the hospital is significantly less than that of disposable kits provided by vendors. When necessary, perform hair removal in the operating room. Studies have shown that shaving of the operative site the night before surgery can produce conditions optimal for the reproduction of bacteria, increasing the risk of infection (43).

**Operating Room Environment** Despite the use of ultra-clean air, airborne bacteria in the operating room environment remain a source for contamination. Bacteria may enter the wound directly or indirectly through gloves or instruments that may become contaminated during skin preparation and patient draping. These bacteria are believed to be mostly gram-positive and shed by personnel in the room, particularly during periods of increased activity. Conventional operating rooms may have as many as 10 to 15 bacteria per cubic foot. Lidwell reported the development of infection following 1.5% of total hip arthroplasties performed in conventional operating rooms and only 0.6% of procedures performed in ultra-clean air operating rooms. Sir John Charnley advocated the use of rapid air-change systems, along with multiple instrument trays in orthopaedic operating rooms. Studies have found the number of airborne bacteria can be reduced by approximately 50% in such ultra-clean air rooms, and perhaps again by 50% with the use of body exhaust suits. Other studies have shown no benefits to the use of ultra-clean air, and one series examining the use of horizontal laminar flow actually revealed an increase in the rate of infection in total knee arthroplasty (6,41,45,51,56).

Rates of infection have been found to be directly related to airborne bacterial levels. Standards have been recommended for ultra-clean air operating rooms: fewer than 10 colony-forming units per cubic meter (CFU/$m^3$) within 30 cm of the wound and 20 CFU/$m^3$ at the level of the operating table within the remaining clean-air enclosure (6,45).

A recent study examined the airborne bacterial counts during skin preparation and patient draping. Airborne bacterial counts were found to be 4.4 times higher during prepping and draping of the extremity with an unscrubbed, ungowned leg holder, and 2.4 times higher with a scrubbed and gowned leg holder as compared with intraoperative levels. Another study examined the levels of bacterial contamination in two layers of latex gloves during operative procedures. It was found that the outer

glove used exclusively for draping is the most significantly contaminated, and that changing this outer glove at appropriate times during surgery greatly minimizes the rates of contamination (34). The use of ultraviolet light in operating rooms has also been shown to decrease the incidence of wound infection by reducing airborne bacteria.

**Antibiotic Prophylaxis** The issue of administration of prophylactic antibiotics is another important decision for the treating surgeon. The incidence of infection in clean surgery should be less than 2%. For clean surgery that involves the implantation of foreign material, grafts, polymethylmethacrylate cement, or prosthetic devices, prophylaxis is well accepted and justified, because this practice provides benefits that outweigh the expected risks. Prophylactic antibiotics should also be used in cases of major devascularization, impaired host defenses, or suspected wound contamination.

Ideally, any prophylactic antibiotic given to a patient should be bactericidal, have low toxicity and good tissue penetration, be low in cost, and effective against the most commonly suspected infecting agents. *S. aureus* and *S. epidermidis* are the most common pathogens involved in at least half of prosthetic joint infections and 70% to 90% of wound infections in clean surgery. Gram-negative bacilli are involved to a much lesser extent. First-generation cephalosporins have been favored in this country for a variety of reasons. They are nontoxic, inexpensive, and effective against the potential infective organisms. The administration of antimicrobial agents for a short duration (24 to 48 hours) postoperatively is effective in preventing infection (44).

Intravenous cefazolin, given as 1 g within 2 hours of entering the operating room has been shown to be effective in this capacity. Ideally, the infusion should be completed 30 minutes before surgery to ensure adequate antibiotic levels at the time of skin incision. An additional 1-g dose should be administered if the duration of surgery is longer than 4 hours. Cefazolin 500 mg every 8 hours can be continued for 24 hours postoperatively.

In institutions with a high incidence of methicillin-resistant *S. aureus* or coagulase-negative staphylococcus, vancomycin alone or in combination with another agent, such as gentamicin, has been shown to be effective. Patients with a history of severe allergic reaction (urticaria, angioedema, anaphylaxis) to a penicillin or cephalosporin should receive 1 g of vancomycin 2 hours before incision and every 12 hours thereafter for 24 hours. Recent studies investigating prophylactic use of the glycopeptide antibiotic teicoplanin against methicillin-resistant staphylococcus species in patients unable to tolerate vancomycin have shown it to be as efficacious as any other regimen (31,37,44,57,59).

Alternatively, the prophylactic use of antibiotics in cemented arthroplasty as well as antibiotic-impregnated polymethyl methacrylate beads has been shown to be effective in reducing the risk of infection. Josefsson et al. (22) followed a prospective randomized group of 1688 consecutive total hip arthroplasties comparing the use of gentamicin-impregnated bone cement with systemic antibiotics. They found a decreased risk of deep infection in those patients with antibiotic-impregnated cement, but this effect was limited to the first year after operation.

Espehaug et al. (12) retrospectively looked at 10,905 total hip arthroplasties performed in Norway from 1987 to 1995. They compared patients who had received no prophylactic antibiotics, systemic antibiotic prophylaxis only, cement antibiotic prophylaxis only, and both systemic and cement antibiotic prophylaxis. The lowest rate of revision arthroplasty was found among those patients who had received both systemic and cement antibiotic prophylaxis. Those receiving only systemic antibiotic prophylaxis had a revision rate 4.3 times higher, those with only antibiotic bone cement 6.3 times higher, and those with no prophylaxis having a rate of revision surgery 11.3 times higher (6,8,12,19,51,52).

Antibiotic-impregnated cement beads have been used extensively in the management of open fractures and chronic osteomyelitis (42). These beads have been found to be cheaper than systemic antibiotics yet provide the same efficacy. They are able to keep local antibiotic concentration at levels that would be toxic systemically (29). Keating et al. (23) showed a decrease from 16% to 4% in infection rates among open tibia fractures. Cho et al. (10) followed 54 patients with chronic osteomyelitis of the long bones treated with local antibiotics and bone grafting an average of 4 years, finding that 55% of these patients were completely free of infection.

The use of antibiotic prophylaxis in arthroplasty patients who undergo dental procedures is controversial. A recent survey has shown that a majority of orthopaedists (n = 44) and dentists (n = 36) believe that patients with prosthetic joints should receive prophylactic antibiotics before dental procedures (81% and 66%, respectively) (47). Three approaches have been outlined in the literature.

The first approach does not recommend prophylactic antibiotic use based on the cost, the adverse effects from antibiotic agents, the potential for the emergence of antibiotic resistance, and the lack of a clear cause-and-effect relationship. Others suggest routine prophylaxis before dental and other procedures known to cause transient bacteremia for at least 2 years after arthroplasty. Yet others recommend the use of prophylaxis only in those patients with conditions that predispose for infection (27,53).

Ainscow and Denham (1) reported on 1,000 patients who had undergone 1,112 joint replacements and were followed an average of 6 years. Their arthroplastic procedures were performed between 1966 and 1980. The patients in this series were never advised to take antibiotic prophylaxis before dental or surgical procedures. Of these 1,000 patients, only three were found to have developed prosthetic joint infections, and two of these patients suffered from rheumatoid arthritis. Waldman et al. (54) retrospectively looked at 3,490 patients who had had total knee arthroplasty between 1982 and 1993. Of these patients, 62 developed late infections of the prosthetic joint. Of these cases, seven were strongly associated with prior dental procedures, representing 11% of these late infections. The study concluded that the majority of infections after dental procedures occurred in those patients with systemic illnesses such as rheumatoid arthritis and diabetes mellitus.

When prophylaxis is used for dental procedures, an oral first-generation cephalosporin is an appropriate choice because its antimicrobial spectrum includes most organisms found in the oral cavity. Cephalexin 1 to 2 g 1 hour before the procedure and 0.5 to 1 g at 4 to 6 hours is recommended. Alternatively, 3 g of amoxicillin 1 hour before the procedure and 1.5 g 6 hours after the initial dose is effective as well. Patients with allergy to penicillin should receive 600 mg of clindamycin 1 hour before the procedure and 6 hours later or erythromycin 0.5 to 1 g 1 hour before the procedure and 0.5 g 4 to 6 hours after the first dose.

**Antibiotic Irrigation** Antibiotic irrigation is commonly used in orthopaedic procedures, although its true value has never been established. In vitro systems have shown that colony counts of *S. aureus*, *S. epidermidis, E. coli,* and *Pseudomonas* sp can be reduced 12% to 56% with saline irrigation alone. Several studies have shown a decrease in colony counts in wounds and a decrease in infection rates for general surgical procedures with the use of antibiotic devices. It has been shown, however, that the use of power irrigation increases the removal of bacteria by a factor of at least 100 over bulb-syringe irrigation of the same volume, regardless of the solution used (2,5).

Topical antibiotics used in irrigation should have a wide spectrum of activity and have low toxicity. The addition of polymyxin, bacitracin, neomycin, or a combination of these agents is most effective for this purpose (19).

## DIAGNOSIS OF INFECTION

### SIGNS AND SYMPTOMS

In the initial evaluation of orthopaedic infections, the patient's history plays a key role in guiding further diagnostic procedures and what intervention is most suitable. A history of systemic illness or medication use that may lead to immune depression are important clues as to the environment in which an infection has developed and what microorganisms may be responsible. A history of prior surgery, infections at other sites, open fracture, or instrumentation can also point to a likely etiology of infection.

The symptoms classically associated with most infections, such as fever, chills, redness, nausea, swelling, and tenderness, may not be present in the context of an orthopaedic-related infection. The most reliable symptom in these situations is pain in the affected region, but this finding may be very subtle and easily missed, perhaps presenting as an innocuous chronic ache. When examining the involved musculoskeletal component, note local signs of stasis, hypoxia, drainage, edema, erythema, warmth, induration, tenderness, painful range of motion, and evidence of previous trauma or surgery. Evaluate joint range of motion above and below the involved region and perform a full neurovascular examination (15).

### LABORATORY INVESTIGATION

The first diagnostic procedures undertaken usually consist of a complete blood count (CBC), ESR, and CRP. In evaluating the CBC, the classic finding of a leukocytosis (white count greater than 12,000) is associated with the presence of infection. This finding may not be consistent, especially in infections with a more indolent course. When leukocytosis is present, however, the differential cell count will show an increase in the relative number of neutrophils, as well as a shift to more immature polymorphonuclear cells in circulation.

The ESR is a widely used test in orthopaedic practice. It is not a specific test for infection and may be elevated in a number of systemic conditions such as advanced age, pregnancy, morbid obesity, and while a patient is using certain medications such as heparin and oral contraceptives. It is also elevated in a variety of pathologic conditions including infection, inflammation, collagen vascular diseases, recent surgery or fracture, certain malignancies, myocardial infarction, gastrointestinal, thyroid,

and renal diseases (11). The ESR reflects an increase in the acute-phase reactants produced by the liver in response to inflammation or infection.

Fibrinogen has been found to be the strongest promoter of the aggregation of erythrocytes, followed by other serum proteins. These positively charged proteins coat red blood cells (RBC), which normally repel each other because of their negative surface charges. The coated RBCs assume rouleaux formations and settle in the patient's blood sample, with the rate measured as the ESR in millimeters per hour. Normal values by the Westergren method are less than 16 mm/hour for men and 25 mm/hour for women (11).

As many as 85% to 100% of patients with lumbar disc space infections, 84% to 100% of patients with proven infection about a total hip replacement, and 71% to 97% of children with hematogenous osteomyelitis have an elevated ESR (46). The ESR has been found to rise within 2 days of infection in children with infectious arthritis of the hip. The value of ESR is in following the response of infection to therapy through serial observations. Return of the ESR to normal may take many weeks, despite effective treatment of the infection.

CRP is another acute-phase reactant produced by the liver that is also a nonspecific marker of inflammation and infection. Its temporal relationship to infection, however, makes it a much more useful tool in the diagnosis of infection as well as its response to intervention. Levels of CRP rise within 6 hours of infection, reaching their peak within 48 hours, and fall to near-normal levels within 1 week of proper intervention (26).

Other laboratory investigations in the acute setting may include a cell count and Gram stain of joint fluid or localized collection aspirates. These immediate procedures can determine the presence of septic arthritis as well as quickly yielding a likely pathogen. Cell counts greater than 100,000 with a differential greater that 75% neutrophils increases the likelihood of infectious arthritis.

**RADIOLOGIC INVESTIGATION**

Begin with plain roentgenograms of the affected region. These images may show soft-tissue swelling, localized bone destruction, periosteal thickening, or loosening of fracture fixation hardware or total joint arthroplasty. The findings of bone destruction are rarely present until 2 to 3 weeks into the course of an infection, after a significant proportion of bone matrix has been lost. The value of such plain films is limited but can be helpful in following the course of a patient's illness. If the suspicion of infection remains high even after this initial evaluation, the use of other imaging modalities that are able to detect disturbances of normal soft-tissue architecture, joint inflammation, or the presence of fluid collections may be necessary.

Although CT can be used to visualize effectively the bone and soft-tissue architecture of an axial and appendicular skeleton, one disadvantage is the scatter phenomenon that occurs when metal is present in or near the area of bone visualized. This scatter results in a significant loss of image resolution (38,49).

MRI has developed a tremendous role in orthopaedic surgical practice, mainly because of its superior ability to evaluate soft-tissue structures. Any infectious or inflammatory process produces localized edema in the affected area, which will be readily detected by T2 images. The fat of the marrow cavity that normally appears bright white on T1 images loses its intensity in cases of intramedullary osteomyelitis, whereas the marrow cavity signal is increased in T2 images. This finding reflects the replacement of the marrow fat with edema and inflammatory cell infiltrates. MRI may also detect bony destruction earlier than plain x-ray studies and CT scans because these signal changes reflect the earlier processes of bone destruction that may not be visible by conventional radiographic studies. As with CT scans, metallic implants in the region of interest may produce focal artifacts, thereby decreasing the usefulness of the image (38,49).

Conventional tomography is useful for identifying sequestra and subtle hardware loosening in cases of osteomyelitis or involvement of subchondral bone in septic arthritis. Ultrasound can be used to localize abscesses or fluid collection and may aid in its proper drainage. Arthrography can be used in cases of infectious arthritis after initial synovial fluid samples have been taken. The contrast material once visualized allows determination of whether the joint was properly aspirated.

Radionuclide scanning plays a significant role in the diagnosis of infection. Contrary to the previously discussed imaging modalities, which give structural or anatomic representations of the patient, isotope scanning attempts to deliver functional or physiologic information. Radionuclide scanning cannot directly show infection or the structural changes that may be associated, but it can reveal inflammatory processes throughout the body and the bone's attempt to heal. It is for this reason that radionuclide scanning has lower specificities in differentiating infection, because any source of inflammation or bone turnover can yield a false-positive result (26).

The three radionuclide tests classically used in the detection of infection include technetium 99m, gallium citrate, and indium-labeled leukocyte scans. Technetium 99m is by far the most commonly employed bone-scanning procedure and depends on uptake of the technetium by active osteoblasts. Any physiologic process that causes rapid turnover of bone appears as an area of increased uptake on the technetium bone scan, including infection, inflammation, metastatic tumor, degenerative joint disease, and postsurgical and posttraumatic changes. Photopenia reflects areas of minimal uptake of isotope and may be associated with decreased area blood flow, certain tumors, vasospasm, and impingement of the local blood supply by soft-tissue swelling.

Technetium 99m is usually administered as part of a three-phase bone scan that acts to improve the overall specificity of the test. The three phases consist of the flow phase, the equilibrium phase, and the delayed phase. The initial flow phase reflects blood flow throughout a region and large vessel patency. The equilibrium phase shows the passage of technetium into the smaller vessels of a given area and its subsequent diffusion throughout the tissues, revealing the relative blood supply to that area. The delayed phase of bone scanning is measured at a time of 3 to 4 hours after injection, when most of the remaining isotope has been taken up by osteoblasts.

By interpreting the findings at the various phases of bone scanning, you can determine the true location of increase physiologic activity. Osteomyelitis will show increased uptake of technetium 99m at flow, equilibrium, and delayed phases of bone scanning. Conversely, in the case of cellulitis, the findings at initial flow and equilibrium phases show increased activity but low or normal activity at the delayed phase. At the same time, osteoarthritis shows decreased uptake of isotope at initial flow and equilibrium phases but increased uptake at the delayed phase (32,33).

Indium-111 can be added to the patient's incubating leukocytes in vitro. These cells are then reinjected into the patient, with imaging taking place 24 to 48 hours later. When a focal area of bone shows increased uptake relative to the surrounding bone, the scan is considered positive. Indium scanning has found a significant role in the diagnosis of acute osteomyelitis. However, the presence of chronic infections, in which the predominant inflammatory cell type is lymphocytic, indium has a much lower sensitivity.

Indium-labeled leukocyte scintigraphy has been found to be 100% sensitive in the diagnosis of acute osteomyelitis and 60% sensitive in chronic osteomyelitis. A negative indium scan usually means that osteomyelitis is not present. Combining the indium scan with a technetium 99m scan can increase the specificity of the test. A number of conditions including fractures, arthritis, osteosarcoma, eosinophilic granuloma, pigmented villonodular synovitis, and neuropathic arthropathy have been found to show false-positive results on indium-111—labeled leukocyte scans (20,30,58).

Gallium citrate is believed to be taken up directly by leukocytes, thus reflecting the increased numbers of white blood cells that migrate into infected areas. It was hoped that the use of gallium citrate, when used in concert with technetium 99m scanning, could distinguish infection from other processes. Despite the initial promising results, sequential technetium-gallium scanning has demonstrated only 50% sensitivity, 78% specificity, and an accuracy rate of only 62% in the detection of low-grade musculoskeletal sepsis. These values are far inferior to the 83% sensitivity, 94% specificity, and 88% accuracy found with indium-111—labeled leukocyte scanning alone (36).

A newer radionuclide imaging modality involves indium-111—labeled monoclonal immunoglobulin directed toward granulocyte cell surface antigens (Leukoscan). Becker et al. (4) performed scintigraphy in 53 patients at 1 to 6 hours and at 24 hours after injection of the labeled antibody. The overall sensitivity of Leukoscan and indium-111—labeled leukocytes was found to be 90% and 83.9%, respectively, the specificity 84.6% and 76.5%, respectively, and the accuracy 87.9% and 81.3%, respectively. Hakki et al. (18) prospectively compared the efficacy of Leukoscan, indium-111—labeled white blood cell scabs, and technetium 99m bone scans in diagnosing 74 patients with suspected musculoskeletal infections. Their findings showed a sensitivity of 93%, 85%, and 92% for Leukoscan, indium-111—labeled white cells, and technetium 99m bone scans, respectively. Specificity was 89%, 75%, and 52%, and accuracy was 90%, 79%, and 74%, respectively.

**CULTURE INVESTIGATION**

The diagnostic modalities discussed thus far show the physiologic and structural changes caused by infection. These modalities, however, are not capable of giving an actual bacteriologic diagnosis that can aid in developing a treatment plan and proper choice of antibiotic chemotherapy. By properly using the laboratory evaluations available, the surgeon can isolate the responsible pathogen and determine its susceptibility to antibiotics (3).

Superficial wound or sinus tract cultures are seldom useful because they are usually polymicrobial and generally reflect the normal flora of the skin in the area. Mousa (40) prospectively compared sinus tract cultures with those obtained intraoperatively. The samples were found to be of value provided that they were obtained by deep probing of the tract and aspiration with a syringe. Swabbing of the sinus tract as well as the findings of *S. epidermidis* were found to be unreliable in the diagnosis. Of the 115 operative samples taken, 102 sinus tract isolates were identical to the operative cultures, with a specificity of 95.7% and predictive value of 90.3%. Lee (25)

retrospectively reviewed the wound cultures of 245 open fractures. Only 8% of organisms grown on predebridement cultures eventually caused infections. Among culture-negative patients, 7% went on to develop infection. Only 22% of the organisms cultured ultimately caused infection. These results suggest that culturing open fracture wounds is essentially of no medical value.

The most immediate diagnostic tests that can be performed on samples are a Gram stain or intraoperative frozen section (9). Gram stains allow for quick determination of gram-positive or gram-negative bacteria, as well as their morphology. Gram stains help select early appropriate broad-spectrum antibiotic therapy. More specific antibiotics can be used when sensitivity results have returned.

Feldman et al. (13) investigated the predictive value of intraoperative frozen sections in detecting infection in patients undergoing revision total joint arthroplasty. Infection was defined as five polymorphonuclear cells per high-power field in at least five distinct microscopic fields. Their investigation showed a 100% sensitivity, with all patients found to have positive intraoperative cultures also having positive frozen sections. In addition, their investigation showed a specificity of 96%.

Several types of media are available for culturing bacteria and fungi. Culture the initial specimens taken for aerobic, facultative anaerobic, and obligate anaerobic bacteria. If these specimens fail to yield any growth or there is little response from the patient to antibiotic intervention, other cultures may be considered to detect unexpected infectious agents such as mycobacteria and fungi.

Once these bacteria have been cultured, test for their antibiotic susceptibility. Testing may include the use of *in vitro* methods, testing for the patients' serum bactericidal activity while on antibiotic therapy, and direct measurement of serum antibiotic levels. *In vitro* methods include serial dilutions of antibiotic and antibiotic disc diffusion. These tests attempt to determine the concentration of antibiotic necessary to inhibit further growth of bacteria on an agar gel medium or in broth.

The serial dilution method tests multiple concentrations of antibiotic incubated with bacteria attempting to determine the concentration at which the growth of bacteria is halted. This concentration is termed the minimum inhibitory concentration (MIC). If bacterial growth is stopped by serum levels of an antibiotic when given in normal dosages and routes, the bacteria are said to be sensitive. After determination of the MIC, the minimal bactericidal concentration (MBC) can be determined, reflecting the lowest concentration of antibiotic at which 99.9% of all bacteria are killed. Ideally, an antibiotic will have an MIC that is equal to the MBC—that is, the antibiotic most effective in eradicating the pathogen will have the lowest toxicity (28).

Alternatively, the disc diffusion method uses antibiotic-impregnated discs placed in the broth or agar gel medium to determine the susceptibility of bacteria. By measuring the zone of inhibited bacterial growth, the MIC may be determined when compared with a standardized reference. The results of this test are reported as susceptible, intermediate, or resistant, depending on the size of the inhibited growth zones (28).

The patient's own serum can also be used in determining the effectiveness of the chemotherapeutic treatment. Samples of the patient's serum at peak and trough antibiotic levels are used. Peak serum titers of greater than 1:8 have been associated with good outcomes in the resolution of infection.

Use direct measurement of antibiotic levels in the patient's blood to assist in determining whether the levels are within the reference range for effectiveness, as well as in below levels.

**MOLECULAR INVESTIGATION**

The classic methods for the detection of musculoskeletal infection have their shortcomings and limitations. Culture investigation remains the only definitive modality for the identification of the pathogenic organism. However in 7% to 15% of patients with periprosthetic infections, no pathogen can be cultured (16). With the increasing availability of molecular biologic techniques, the surgeon has gained a valuable tool in detecting and differentiating pathogens in orthopaedic infections. The predominant molecular technique available in this capacity is PCR. PCR depends on the activity of the heat-stable Taq polymerase, which through repeated sequences of DNA replication, can tremendously amplify even minute samples of bacterial DNA.

Using RNA probes created to specifically recognize DNA sequences in bacteria, it is now possible to identify a pathogen based solely on its DNA. In patients with suspected infection, this molecular technique can be used to prove infection and provide the likely organism when all other diagnostic modalities have failed. In addition to PCR, other molecular techniques under investigation include ligase chain reaction, reverse transcriptase PCR, branched-chain DNA reaction, monoclonal antibodies directed against unique bacterial proteins, direct detection of target RNA through Northern blotting, *in situ* hybridization of RNA with labeled complementary DNA sequences, Southern blotting of DNA, and Western blotting of proteins.

## ANTIBIOTIC INTERVENTION

### *B*-LACTAM ANTIBIOTICS

The b-lactam antibiotics are the most commonly prescribed agents in the treatment of infections of bones, joints, and soft tissue. Included in this class are the penicillins, cephalosporins, carbapenems, and monobactams. Penicillins consist of a thiazolidine ring coupled with a b-lactam ring, to which is attached a side chain. The nucleus of this molecule is the chief structural requirement for biologic activity, and any chemical or metabolic alteration of this portion causes a loss of all significant antibacterial activity. The side chain determines many of the antibacterial and pharmacologic characteristics of the particular penicillin.

#### *Penicillins*

Penicillins are bactericidal and act by inhibiting bacterial cell wall synthesis (Fig. 132.1). These cell walls are composed of murein (peptidoglycan) and are essential for the normal growth and development of bacteria. Peptidoglycan is a heteropolymeric component of the cell wall that provides rigid mechanical stability by virtue of its highly cross-linked latticework structure. In gram-positive bacteria, the thickness of this cell wall may be as much as 100 molecules, compared with a thickness of only 1 or 2 molecules in gram-negative organisms. Synthesis involves an *N*-acetylglucosamine-*N*-acetylmuramic acid (GlcNAc-MurNAc) disaccharide unit that is attached to a bactoprenyl lipid carrier molecule in the cytoplasmic membrane. Autolytic enzymes open sites in the existing cell wall where the new disaccharide units will be placed.

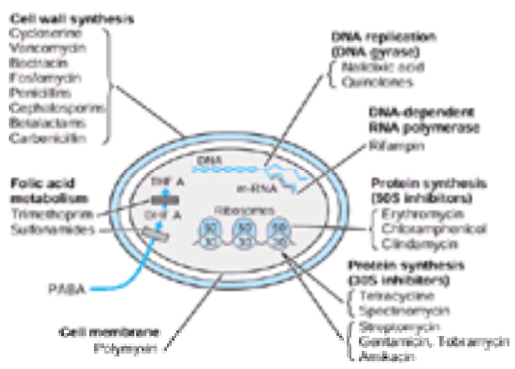


***Figure 132.1.*** Location of antibiotic activity in bacterial cell.

Once these molecules are donated by the lipid carrier and oriented, transpeptidase enzymes cross-link the peptide of the new GlcNAc-MurNAc moiety with that of another. The key targets of the penicillins in this process are the transpeptidases. By binding tightly to the active site of these enzymes, they inhibit the cross-linking of the cell wall components and reduce the overall tensile strength these cells need to resist osmotic lysis.

The enzymes that bind to penicillins are collectively referred to as penicillin-binding proteins (PBP), because their initial identification was based on their ability to bind with more complex and varied forms of penicillin. The PBP are a diverse group of transpeptidases and carboxypeptidases that are involved in various aspect of cell wall synthesis, and as such, each b-lactam antibiotic may have different affinities for selected PBP. Once the formation of the bacterial cell wall is inhibited, two normally expressed classes of autolysins seem to be responsible for the cidal action of b-lactam antibiotics.

The natural penicillins, penicillin G (benzylpenicillin) and penicillin V (the phenoxymethyl derivative), are very similar in their antimicrobial spectrum for aerobic

gram-positive organisms (Table 132.4 and Table 132.5). They remain the agents of choice in gonococcal and streptococcal arthritis and soft-tissue infections. Penicillin G is five to 10 times more active than penicillin V against gonococcus sensitive to penicillin. The sole virtue of penicillin V in comparison to penicillin G is its stability in an acid environment. Therefore, it is better suited for absorption from the gastrointestinal tract. On an equivalent oral dose, penicillin V may yield plasma concentrations two to five times greater than those provided by penicillin G. Once absorbed, both penicillin G and penicillin V are widely distributed in the body and excreted by the kidneys.

***Table 132.4. Dosing of Parenteral Antibiotics Commonly Used in Orthopaedic Infections***

***Table 132.5. Pathogenic Organism and Selected Treatment Options***

Intramuscular injection of penicillin G yields peak plasma concentrations within 15 to 30 minutes, but this value declines rapidly because of its short half-life (30 minutes). Many attempts have been made to maintain the concentration of penicillin G doses given parenterally. Probenicid has been found to block renal tubule secretion of penicillin, but it is rarely used in this capacity. Instead, repository preparations of penicillin may be used, the two favored compounds being procaine penicillin G and benzathine penicillin G. These preparations allow for slow release of antibiotic from the site of injection, while maintaining bactericidal blood concentrations over an extended period of time.

Newer penicillins grew from discoveries regarding the medium in which *Penicillium* mold was grown, and the realization that changing the side chain moiety could yield a wide variety of new properties. Investigators soon found a highly reactive precursor of penicillin, 6-aminopenicillanic acid, could be obtained by treating penicillin with an amidase. At that point, an almost infinite number of synthetically generated organic acids could then be fused with 6-aminopenicillanic acid to produce the semisynthetic penicillins.

Three major goals propelled the investigation of novel penicillin antibiotics. First, there was the need for a more acid-stable penicillin that was orally available. Second, penicillin G and V were effective against gram-positive aerobes but effective only against a handful of gram-negative bacteria. Finally, the issue of penicillin-resistant strains of bacteria had already begun to become a matter of great concern.

The semisythentic aminopenicillins (ampicillin, amoxicillin, and bacampicillin) were developed to extend the spectrum. These antibiotics are effective against many gram-negative bacteria but are only about one-half as effective against gram-positive bacteria as is penicillin G. Their amino group allows them to traverse the charged outer membrane of gram-negative bacteria easily and reach bactericidal concentrations. They are also acid stable and readily bioavailable through oral dosing. Their main limitation is that they are readily hydrolyzed by b-lactamase enzymes and are not effective against *P. aeruginosa.* The aminopenicillins are effective against non-b-lactamase—producing strains of *E. coli, H. influenzae, Proteus, Salmonella,* and *Shigella*.

The carboxypenicillins, ureidopenicillins, and piperazine penicillins were all developed to treat infections of *P. aeruginosa.* The carboxypenicillins carbenicillin and ticarcillin were the first antipseudomonal agents developed. They are ineffective against gram-positive organisms but have excellent activity against enteric rods and *Pseudomonas.* Piperazine penicillins, such as piperacillin, and the ureidopenicillins, such as mezlocillin and azlocillin, are even more effective against enteric bacteria and *Pseudomonas,* as a result of their high affinity for gram-negative PBP. Unfortunately, all of the antipseudomonal penicillins are sensitive to b-lactamase, are generally more toxic than their predecessors, and must be provided parenterally.

Bacterial resistance to penicillins can be mediated through a variety of means: Chromosomal changes in the affinity of PBP for penicillins, reduced antibiotic uptake, and decreased activities of bacterial autolysins are all possible mechanisms. The most commonly encountered resistance to penicillins, however, is based on the enzymatic destruction and inactivation of the b-lactam ring. Different microorganisms elaborate a number of distinct b-lactamases, although most bacteria are capable of producing only one form of the enzyme. The substrate specificities of these enzymes are relatively narrow, and they can often be described as either penicillinases or cephalosporinases. Other “broad-spectrum” enzymes may also be found that are capable of hydrolyzing a variety of b-lactam antibiotics.

In general, gram-positive bacteria produce large amounts of b-lactamase, secreting it extracellularly. In staphylococcus, the information for penicillinase is encoded on a plasmid that can be readily transferred by bacteriophage to other bacteria. In gram-negative bacteria, b-lactamases are found in much lower concentrations; their location in the periplasmic space, however, between the inner and outer cell membranes makes them ideally located for maximal protection of the microbe. In gram-negative organisms, b-lactamases are encoded in either a plasmid or the chromosome, allowing it to be transferred by conjugation with another bacterium as well. Whereas the staphylococcal enzyme is inducible by substrates, the gram-negative b-lactamases may be inducible or constitutive (35).

The b-lactamase—resistant penicillins include methicillin, nafcillin, and the isoxazolyl penicillins (oxacillin, cloxacillin, and dicloxacillin). These penicillins are more toxic and have less activity than penicillin G against gram-positive cocci, but it is their ability to resist hydrolysis by the b-lactamases produced by staphylococci that allows them to remain the drug of choice in most staphylococcal disease.

Clinical microbiology laboratories do not typically use the term “methicillin-resistant Staphylococcus.” Most often, the laboratory will test staphylococci with an oxacillin-impregnated disk, reporting the organism as “resistant to oxacillin.” Oxacillin is the commonly used class-disk for all penicillinase-resistant penicillins. Although it is not specifically stated, this use indicates a resistance of the organism to all other penicillinase-resistant penicillins including methicillin, dicloxacillin, nafcillin, and cloxacillin. These resistant organisms are also usually resistant to all available cephalosporins (17).

*S. aureus* is less likely to be methicillin resistant than the coagulase-negative staphylococci (including *S. epidermis*). In one institution's experience, 12% of outpatient and 32% of inpatient *S. aureus* isolates were methicillin resistant compared with 72% and 65%, respectively, for coagulase-negative staphylococci.

Another strategy to extend the usefulness of the penicillins has been the development of penicillin-like molecules that carry little antibacterial activity but can act to inactivate b-lactamases. The b-lactamase is able to cleave the b-lactam ring of the penicillin analog but in the process forms a stable but inactive complex with the cleaved ring, a process referred to as suicide inactivation. The commercially available combinations of penicillins and analogs include ampicillin/sulbactam, amoxicillin/clavulanic acid, ticarcillin/clavulanic acid, and piperacillin/tazobactam. In the cases of the ampicillin/sulbactam and amoxicillin/clavulanic acid, the combination has extended the antibiotic spectrum to include b-lactamase—producing strains of *Bacteroides fragilis, Enterobacter, E. coli, Haemophilus ducreyi, H.*

*influenzae, Klebsiella, Moraxella catarrhalis, N. gonorrhoeae, Proteus, Providencia, S. epidermis,* and methicillin-sensitive *S. aureus*.

### *Cephalosporins*

The cephalosporins and related cephamycins constitute the largest group of b-lactam antibiotics. The cephalosporins are semisynthetic penicillin derivatives of 7-aminocephalosporanic acid, consisting of a b-lactam ring coupled with a six-membered dihydrothiazine ring (compared with the five-membered ring of penicillins). In contrast to penicillins, cephalosporins can have up to three side chains attached to the nucleus of the molecule. The R1 group is attached to the same site as the R group of penicillin and determines the antibacterial properties of the molecule. The R2 group determines the metabolic and pharmacokinetic properties of the molecule, and the R3 group acts to increase the resistance of cephalosporins to the action of b-lactamase.

The cephalosporins have been divided into three major groups, referred to as generations, depending on their efficacy against gram-negative bacteria. Some of the more recently developed cephalosporins are referred to as “fourth generation,” but this classification has yet to achieve widespread acceptance.

The first-generation cephalosporins are effective primarily against gram-positive bacteria including pneumococci, streptococci, *C. perfringens, Corynebacterium diphtheriae, S. epidermidis,* and methicillin-sensitive *S. aureus.* The relevant spectrum of activity against gram-negative bacteria for these first-generation cephalosporins is limited to *E. coli, Klebsiella,* and *Proteus mirabilis.* It is important to note that most of the orally available cephalosporins are from this first-generation group (17,21,24) (Table 132.6).

| Antibiotic | Dose | Interval | Peak serum concentrations |
|---|---|---|---|
| Amoxicillin | 500 mg | 8 hours | 7 μg/ml |
| Ampicillin | 1–2 g | 4–6 hours | 4 μg/ml |
| Amoxicillin/Clavulanate (Augmentin) | 500 mg | 8 hours | 7 μg/ml |
| Cephalexin (Keflex) | 0.5–1.0 g | 6 hours | 15 μg/ml |
| Ciprofloxacin (Cipro) | 750 mg | 12 hours | 4 μg/ml |
| Clindamycin (Cleocin) | 300–450 mg | 6 hours | 4 μg/ml |
| Dicloxacillin (Dynapen) | 125–500 mg | 6 hours | 10 μg/ml |
| Cloxacillin (Cloxapen) | 500–1000 mg | 6 hours | 10 μg/ml |
| Metronidazole (Flagyl) | 500 mg | 6 hours | 10 μg/ml |
| Rifampin | 300 mg | 12 hours | — |
| TMP/SMX (Bactrim) | 160/800 mg | 6 hours | 240 μg/ml |

TMP/SMX, trimethoprim and sulfamethoxazole.

***Table 132.6. Dosing of Oral Antibiotics Commonly Used in Orthopaedic Infections***

Second-generation cephalosporins show more activity against gram-negative bacteria, whereas they have comparable to slightly less efficacy against gram-positive organisms compared with first-generation cephalosporins. Second-generation cephalosporins are not generally recommended for treatment of infections caused by gram-positive organisms because they are more expensive, often need to be given parenterally, and offer no real advantage over first-generation cephalosporins. Cefuroxime is highly effective against b-lactamase—producing strains of *H. influenza* and *N. meningitidis,* two major causes of meningitis in children and young adults. Other second-generation cephalosporins such as cefotetan and cefoxitin can provide good coverage against *N. gonorrhoeae,* including b-lactamase—producing strains, as well as enteric rods such as *E. coli, Klebsiella,* and *Proteus.* Second-generation cephalosporins are not effective against *P. aeruginosa*.

Third-generation cephalosporins are highly resistant to the actions of b-lactamase because of their unusually large R groups. Although these antibiotics have an excellent spectrum of coverage for gram-negative bacteria, they have very poor efficacy against gram-positive bacteria. Third-generation cephalosporins are highly effective against b-lactamase—producing strains of *N. gonorrhoeae, N. meningitidis, H. influenzae, M. catarrhalis,* and most enteric bacteria including *Citrobacter* strains, *E. coli, Klebsiella, Morganella, Proteus, Providencia, Salmonella, and Shigella.* Their excellent coverage is believed to be a result of the strong affinity for gram-negative PBP and resistance to b-lactamase. Of the third-generation cephalosporins, ceftazidime has the strongest activity against *P. aeruginosa.*

Newer cephalosporins, such as cefepime and cefpirome, exhibit activity against gram-negative bacteria similar to that of the third-generation cephalosporins while having the efficacy of first-generation cephalosporins in their activity against certain gram-positive bacteria. This trait has prompted some clinicians to refer to these antibiotics as fourth-generation cephalosporins, whereas others view them as only extended-coverage third-generation cephalosporins.

### *Carbapenems*

The carbapenems are synthetically derived antibiotics from thienamycin. Although thienamycin is not suitable for human use, its formimidoyl derivative imipenem has been shown to be the broadest spectrum b-lactam antibiotic available. Imipenem is resistant to most b-lactamases, can penetrate well into gram-negative bacteria, and is also active against anaerobes. Thus, it is active against b-lactamase—producing strains of *Acinetobacter, Listeria, N. gonorrhoeae, N. meningitidis, P. aeruginosa, S. pneumoniae,* gram-negative rods, and a number of strict anaerobes. Although it does not act as a cidal agent against *Enterococcus faecalis,* imipenem can act as a static agent against this organism.

Imipenem is inactivated by dihydropeptidase-1, which is located on the brush border of proximal renal tubules. Cilastatin, a specific inhibitor of dihydropeptidase-1 is given in a 1:1 ratio with imipenem to block inactivation and decrease the risk of renal tubular necrosis. Do not administer imipenem-cilastatin to individuals with CNS lesions (such as strokes or head injuries), a history of convulsions, or renal insufficiency. Reports have indicated that as many as 12% to 32% of these patients may develop convulsions as a consequence of this treatment. Because of this propensity to cause seizures and its high cost, imipenem is generally reserved for gravely ill patients with multiple-pathogen nosocomial infections. Meropenem is a newly approved carbapenem with a similar spectrum of activity as imipenem. It does not require dosing of cilastatin and carries a lower risk of seizures (17,21).

### *Monobactams*

Monobactams, as their name indicates, are composed solely of a single ring. The first such antibiotic created was aztreonam. In contrast to imipenem, aztreonam is a narrow-spectrum antibiotic, having good activity against only *N. gonorrhoeae, N. meningitidis, P. aeruginosa,* and most gram-negative enteric bacteria. Aztreonam is resistant to gram-negative b-lactamase but is readily inactivated by plasmid-encoded b-lactamase. The spectrum of aztreonam can be broadened with the addition of a penicillin with gram-positive activity, such as nafcillin or cloxicillin, or alternatively with an aminoglycoside. It also appears that patients with allergy to penicillin show no such reaction to aztreonam (17,21).

**Adverse effects** Refer to Table 132.7 and Table 132.8.

***Table 132.7. Selected Adverse Effects of Antibiotic***

| Drug | Minimum laboratory monitoring | Clinical monitoring |
|---|---|---|
| β-lactams | CBC with differential every 1–2 weeks. Baseline serum creatinine to determine dosage. | Diarrhea, rash, drug fever |
| Oxacillin | Liver function tests every 1–2 weeks | Signs and symptoms of hepatitis (nausea, vomiting, abdominal pain, jaundice, dark urine, fever, fatigue). |
| Vancomycin | Baseline serum creatinine to determine dosage. CBC every 1–2 weeks. Serum concentrations at steady state | Hearing loss, rash, drug fever, phlebitis |
| Fluoroquinolones | Baseline serum creatinine to determine dosage. Baseline anticonvulsant drug level is applicable | Drug interactions, diarrhea, rash, drug fever, CNS side effects, insomnia |
| Clindamycin | None | Diarrhea |
| Metronidazole | None | Disulfiram reactions with alcohol, neuropathy |

CBC, complete blood count; CNS, central nervous system.

***Table 132.8. Minimum Monitoring for Drug Toxicity***

One of the main concerns in the use of penicillin is the presence of an allergic response in a significant proportion of the population, estimated to be between 1% and 5% of adults. The commercially available preparations of penicillin act as excellent allergens. What is actually the allergenic component in these preparations is not the penicillin G itself but the incomplete penicillin molecules present in the mixture. Some molecules are the result of breakdown of penicillin while in storage, whereas others are incomplete molecules secreted by the fungus on production. These molecules act as haptens combining with the patient's own serum proteins to create an antigen capable of eliciting a vigorous response.

The most dramatic of these responses are IgE mediated, ranging from a wheal and flare at the site of injection to massive and immediate anaphylaxis that may result in death if it is not properly treated. Systemic anaphylaxis is life threatening. It is for this reason that physicians regularly ask their patients about a history of penicillin sensitivity, keep patients in the office after administering the antibiotic, and have emergency equipment and medications available. Such a reaction requires the attachment of IgE immunoglobulin to mast cells in the subcutaneous tissue of patients, therefore necessitating a previous exposure to penicillin. It must also be kept in mind that all penicillins are cross-sensitizing and cross-reacting.

Another adverse reaction to penicillin includes a serum sickness—type reaction that may produce urticaria, pruritis, joint swelling, and respiratory complications up to 2 weeks after the patient has received penicillin. This particular reaction can occur on the patient's first exposure to penicillin. IgG-mediated hemolytic anemia can also occur in some patients, caused by complement-mediated lysis of red blood cells coated with penicillin.

When taking histories, carefully question all patients about reactions to penicillin administration in the past. For those patients with an unclear history who must receive penicillin, penicillin breakdown products are commercially available that can be injected intradermally. A wheal and flare will be seen in those patients with an allergy to penicillin, necessitating the use of an alternative antibiotic. In cases in which the choice is between penicillin administration and death, patients can be desensitized to penicillin by sequential oral or parenteral administration of small doses over several hours.

About 5% of patients allergic to penicillins are also allergic to cephalosporins. In those patients whose reactions are not mediated by an IgE mechanism, cephalosporins can safely be used, but in those patients with a clear history of IgE-mediated penicillin allergy, cephalosporins are best avoided.

Other evidence of toxicity seen with the use of penicillins includes nausea, vomiting, and diarrhea. These effects are more pronounced with the broad-spectrum penicillins, such as ampicillin and amoxicillin. In cases in which massive doses of penicillin are administered, there can be direct cation toxicity ($Na^+$, $K^+$). Methicillin, nafcillin, and other penicillins have been known to cause granulocytopenia occasionally, especially in children.

Methicillin causes interstitial nephritis more commonly than does nafcillin. The antibiotic binds to the basement membrane of the renal tubules and becomes a target of antibody binding that, in turn, activates complement. Carbenicillin can cause hypokalemic alkalosis and transaminase elevation in serum and can induce hemostatic defects, leading to bleeding tendencies. Ampicillin frequently causes skin rashes, some of which are not related to allergic reaction.

The cephalosporins cefamandole, moxalactam, cefmetazole, cefotetan, and cefoperazone frequently cause hypoprothrombinemia and bleeding disorders. Administration of vitamin K, 10 mg twice weekly, can prevent such an outcome. Moxalactam can also interfere with platelet function and has induced severe bleeding. Its use has been largely abandoned. Cephalosporins can cause severe disulfiram-like reactions in patients who ingest alcohol or alcohol-containing products.

***Aminoglycoside Antibiotics***

The aminoglycosides include gentamicin, amikacin, tobramycin, and kanamycin. They exert their action by binding to the 30s ribosomal subunit in bacteria, disrupting the conformation of mRNA, and forcing erroneous tRNA binding to the codon. At high concentrations, aminoglycosides can bind to both the ribosomes and mRNA, disrupting protein translation beyond initiation as well as permanently altering the ribosome, rendering it functionally useless.

The aminoglycosides have a broad spectrum but are limited by several factors. First, because they require active protein production in the bacteria to exert their effect, they cannot be used with agents that reversibly interfere with protein synthesis. It is for this reason that aminoglycosides are not bactericidal in the presence of chloramphenicol. Second, the rate of bacterial killing by an aminoglycoside increases with the drug concentration, with the limiting factor being the rate at which the antibiotic enters bacterial cells. Third, aminoglycosides are effective only under aerobic conditions, thus they are ineffective against obligate anaerobic bacteria. Fourth, aminoglycosides are ineffective in areas of high acid or salt concentrations. Fifth, because of their poor penetration into the host cells, they offer little activity against intracellular bacteria. Finally, aminoglycosides are relatively toxic with a limited therapeutic window. High trough levels of aminoglycosides are classically associated with ototoxicity and nephrotoxicity.

The use of aminoglycosides is primarily for aerobic gram-negative rods. By administering aminoglycosides with a b-lactam, the antibiotics work synergistically to reduce the dosage, increase the therapeutic margin, and broaden the spectrum of the aminoglycosides. Through this combination therapy, clinicians can avoid the toxicities associated with this antibiotic.

Resistance to aminoglycosides can be due to two major mechanisms. In order to create sufficient concentrations in bacteria, the aminoglycosides must be transported intracellularly by means of a specific carrier protein. Bacteria that generate lower levels or weakly binding transport protein are innately resistant to aminoglycosides. Another mechanism that confers resistance to bacteria is the presence of a number of enzymes that deactivate the antibiotic by means of acetylation, phosphorylation, or adenylation. These chemical modifications do not allow the aminoglycoside molecule to interact with bacterial ribosomes to exert their bactericidal activity (35).

Aminoglycoside antibiotics are associated with nephrotoxicity, and their dosage must be adjusted on the basis of the patient's baseline renal function. Ototoxicity is another adverse effect of the antibiotic, manifesting mainly as vestibular dysfunction owing to the destruction of hair cells by prolonged drug trough levels in excess of 10 mg/ml. Loss of hearing can occur as well, and it is occasionally extensive and irreversible (17,21).

***Bacitracin***

Bacitracin is a cell wall synthesis inhibitor that is fairly toxic when administered systemically. The bactericidal action of bacitracin works by blocking the dephosphorylation of the bactoprenyl carrier molecule after it has donated its GlcNAc-MurNAc disaccharide to the growing peptidoglycan chain. As a result, no bactoprenyl phosphate is left available to receive to new disaccharide monomeric subunits to be incorporated into the existing murein, halting cell wall synthesis.

Bacitracin is an extremely toxic compound when administered parenterally, and therefore, it is restricted to topical and oral use. It can be found in topical creams for use in treating eye and skin infections caused by staphylococci and streptococci, as well as oral preparations for the treatment of pseudomembranous colitis caused by *Clostridium difficile*. Its use in this capacity is possible because of its poor absorption from oral intake.

Bacitracin is markedly nephrotoxic if absorbed, producing proteinuria, hematuria, and nitrogen retention. Its systemic use has been virtually abandoned. Topical application rarely causes hypersensitivity reactions or systemic toxicity.

***Chloramphenicol***

Chloramphenicol is a bacteriostatic antibiotic that interferes with the action of peptidyl transferase, inhibiting the formation of a peptide bond and arresting peptide chain elongation. Because of its bacteriostatic nature, it is generally not administered in combination with a bactericidal antibiotic. Chloramphenicol's ability to penetrate host cells is at the same time a great advantage and a drawback. Its accumulation in the host cell's cytoplasm allows the antibiotic to be used against intracellular organisms. At the same time, these cytoplasmic concentrations interfere with ribosomal protein synthesis, depressing bone marrow activity and causing a pancytopenia.

In infants, ineffective hepatic clearance of the medication leads to toxic levels, and leads to the condition known as gray-baby syndrome, with vomiting, flaccidity, hypothermia, gray color, shock, and collapse. One idiosyncratic reaction to the medication is the development of an aplastic anemia. It is not related to dosage or length of use, but the odds of developing this condition are increased by extended use of the medication. It is for these reasons that clinicians in the United States have limited its use.

The antibiotic remains an effective treatment for infections caused by *H. influenzae* and *Rickettsia* sp. Resistance to chloramphenicol is mostly limited to enteric bacteria. Three modes of resistance have been described in these organisms. The mechanism most commonly found is a gene coding for an enzyme that is able to acetylate both chloramphenicol and tetracylines, thereby inactivating them. The second method of resistance involves the ability of certain bacteria to limit their permeability to the antibiotic. The final resistance factor discovered is a mutation in the 50s subunit of the bacterial ribosome that results in poor recognition of the antibiotic by its target (35).

Other adverse reactions to chloramphenicol include GI upset with nausea, vomiting, and diarrhea. Chloramphenicol may also prolong the half-lives of many drugs including phenytoin, tolbutamide, chlorpropamide, and warfarin. This effect is attributed to the inhibition of liver microsomal enzymes by the antibiotic.

***Fluoroquinolones***

The fluoroquinolones are a group of synthetic quinolones developed with broad-spectrum effectiveness against most gram-negative and some gram-positive bacteria. Their proposed mechanism of action is through binding to the a-subunit of bacterial DNA gyrase (topoisomerase II), inhibiting the process of DNA supercoiling, a necessary step in the replication of DNA. The fluoroquinolones can be used to treat infections in most parts of the body including the urinary tract and to treat gonorrhea, bacterial diarrhea, and infections of the skin, bones, and joints as well. They are generally effective against *N. gonorrhoeae* and *S. aureus,* and they are usually effective against *P. aeruginosa.*

The most prominent adverse effects of the fluoroquinolones are nausea, vomiting, and diarrhea. Occasionally, headache, dizziness, insomnia, abnormal liver function tests, or skin rash may develop. Concomitant administration of theophylline and fluoroquinolones can lead to elevation of theophylline levels with increased risk of toxic effects, especially seizures (Table 132.9). Fluoroquinolones have been shown in animal models to damage immature cartilage, but no study has documented this finding in the human pediatric population.

***Table 132.9. Selected Important Drug Reactions***

***Glycopeptide Antibiotics***

The glycopeptide antibiotics vancomycin and teicoplanin have become extremely important tools against methicillin-resistant staphylococci. These antibiotics are macromolecules, consisting of seven amino acids at their core, with all glycopeptides sharing a homology of five of these amino acids. Because of their size, the glycopeptide antibiotics cannot effectively penetrate the outer membrane of the gram-negative bacteria and therefore can have no effect on these organisms. Their inability to penetrate the cytoplasmic membrane of gram-positive bacteria restricts their activities to the metabolic processes of the microbe occurring outside this membrane.

Each glycopeptide antibiotic possesses a ring-like configuration, with a central cleft binding tightly to its target. The active sites of vancomycin and teicoplanin have been shown to recognize tripeptides with a stereochemical configuration of L-D-D. This configuration can be found only within the MurNAc pentapeptide, where an L-amino acid can be found at position 3 with two terminal D-alanines. When vancomycin is administered to susceptible gram-positive bacteria, it first attaches to all available L-D-D residues in the cell wall.

Once these sites are saturated, the glycopeptide antibiotic attaches to the L-D-D of GlcNAc-MurNAc moeities that are attached to the bactoprenyl transferring lipid. Once in this position, the glycopeptide acts as a steric hindrance, blocking peptidoglycan transglycosidase from transferring the disaccharide unit to the peptidoglycan growth point. Moreover, the attachment of vancomycin to the acyl-D-alanine-D-alanine of non-cross-linked dipeptides already incorporated in the cell wall interferes with their ability to be cross-linked.

Vancomycin and teicoplanin are used to treat severe infections caused by *C. difficile,* multiply resistant *S. aureus,* coagulase-negative staphylococci, and penicillinase-producing strains of *S. pneumoniae* and *S. pyogenes.* A glycopeptide antibiotic can also be used in combination with an aminoglycoside to treat infections caused by highly resistant *E. faecalis.*

Adverse reactions are rare with vancomycin use. Although the use of vancomycin has occasionally been associated with ototoxicity and nephrotoxicity, the highly purified preparations of vancomycin that are now commercially available are generally considered safe for most patients and make these toxicities mild. Vancomycin is an irritant to tissue, and patients may develop phlebitis at the site of injection as well as a nonimmune-mediated histamine release referred to as the “red man syndrome.” This reaction can largely be prevented by the administration of antihistamine and slow infusion. Vancomycin is excreted through the kidneys, and in patients with altered renal function, peak and trough blood levels of the antibiotic should be checked to avoid any of the previously mentioned toxicities.

Resistance to glycopeptide antibiotics has been found mainly among *Enterococcus* sp primarily owing to the production of a membrane-bound protein known as VanA. VanA is a D-alanine-D-alanine ligase that synthesizes other mixed dipeptides, replacing the D-alanine-D-alanine within MurNAc. These VanA-containing enterococci no longer express the L-D-D target for the binding of glycopeptide antibiotics and are therefore rendered resistant to its actions. VanA has been found to be transferred to other bacteria via conjugation. Less commonly, *Entercoccus* sp express VanB or VanC proteins whose modes of action are most likely similar to that of VanA but have not been found to be transferred by conjugation (17,21,35,37,57,59).

***Lincosamide Antibiotics***

The lincosamides include the antibiotics clindamycin and lincomycin. The difference between these two antibiotics is the presence at position 7 of a chlorine group on clindamycin that is a hydroxyl group on lincomycin. This difference allows clindamycin to be more easily absorbed orally and more active against anaerobic bacteria. The lincosamides have the same receptor on the 50s subunit of the bacterial ribosome as chloramphenicol. Lincosamides, however, are able to cause a more rapid dissociation of the ribosome into its constituent 50s and 30s subunits.

The spectrum of action for clindamycin is similar to that of penicillin G and erythromycin, but it is used primarily in the treatment of infections caused by the strict anaerobe *B. fragilis*, especially in patients with known reactions to penicillin. It is sometimes used to treat abscesses or sepsis caused by other *Bacteroides* sp, *Actinobacillus, Actinomyces, Capnocytophaga, Clostridium, Flavobacterium, Fusobacterium, or Peptostreptococcus.* Most of these bacteria are anaerobic or

microaerophilic.

Clindamycin can also be used for deep staphylococcal infections, and in combination with gentamicin to treat complicated pelvic inflammatory disease. Although the development of pseudomembranous colitis is seen with prolonged use of any antibiotic, it is most commonly associated with clindamycin. Clindamycin effectively eradicates the normal flora of the colon, leaving it prone for superinfection by *C. difficile*. The newly dominant *C. difficile* elaborates a potent exotoxin responsible for the colitis. The colitis can be treated with either metronidazole or vancomycin.

Resistance to clindamycin is seen in organisms that also exhibit resistance to macrolide antibiotic. The resistance appears linked to the same mechanisms that alter the bacterial 50s ribosomal subunit and produce resistance to the macrolides (17,35).

***Macrolide Antibiotics***

Macrolide antibiotics are large, cyclic molecules that contain a lactone ring. Until recently, erythromycin was the only macrolide antibiotic available. The increasing incidence of resistant strains has led to the development of the newer macrolides azithromycin and clarithromycin. These antibiotics are bacteriostatic at low concentration and bactericidal at high concentration. Macrolides bind to ribosomes, allowing the initiation and formation of a short peptide sequence, but inhibit the process of translocation and elongation soon thereafter. This blocked complex becomes unstable, and eventually the ribosomal fragments are released from the mRNA strand.

The popularity of the macrolides is based on their spectrum of action similar to that of penicillin G, resistance to b-lactamase, oral availability, and absence of major toxicity. Most adverse reactions are related to disturbances of the gastrointestinal tract. Erythromycin is used in treating Legionnaires' disease, diptheria, pertussis, and atypical pneumonia cause by *Mycoplasma* or *Chlamydia.* The newer macrolides have broadened the spectrum of this class of antibiotics. Azithromycin has also been shown to be effective against *Borrelia burgdorferi,* the causative agent of Lyme disease; *H. influenzae;* and *Toxoplasma gondii.* Clarithromycin is unusual in its effectiveness against *Mycobacterium avium-intracellulare* and several of the atypical mycobacteria.

Resistance to macrolides is conferred by genetic changes of the 50s ribosomal subunit in the bacteria resulting in an inability of these subunits to recognize the antibiotic (35).

Adverse effects of macrolide antibiotics given orally include anorexia, nausea, vomiting, and diarrhea. Erythromycin can also produce acute cholestatic hepatitis (fever, jaundice, impaired liver function), probably as a hypersensitivity reaction. Other allergic reactions include fever, eosinophilia, and rashes. Erthyromycins can also inhibit cytochrome P450 and increase the effects of anticoagulants, digoxin, cyclosporine, and antihistamines.

***Polymyxins***

Polymyxin antibiotics are large polypeptide antibiotics that contain fatty acids, multiple positive charges, and a long alkyl side chain. These properties allow polymyxins to act as cationic detergents, binding avidly to lipopolysaccharide and phosphotidylethanolamine in gram-negative outer membranes but poorly to phosphatidylcholine, a constituent of human cell membranes. Therefore, polymyxins are effective against gram-negative bacteria.

Two polymyxins are available in the United States, polymyxin B and polymyxin E. Because of their toxicity, polymyxins are not the drug of choice in the treatment of any bacterial infection. Instead they can be used as a second-line drug to treat severe or life-threatening infections caused by *P. aeruginosa* or other gram-negative rods when such infections have not responded to standard therapies.

Local reactions and hypersensitivity to topical administration are rare. Systemic levels of polymyxins can cause paresthesias, dizziness, and lack of coordination, which disappear when the drug has been excreted. Very high blood levels (greater than 30 mg/ml) can cause respiratory paralysis. Polymyxins may also cause proteinuria and hematuria.

***Rifampin***

Rifampin is a transcriptional inhibitor that binds to the b-subunit of DNA-dependent RNA polymerase in bacteria. It allows the creation of the first phosphodiesterase bond to form in the RNA but then blocks any subsequent bond formation, and effectively terminates chain initiation in RNA synthesis. Resistance to rifampin is based on a mutation of the gene coding for the b-subunit of the bacterial DNA-dependent RNA polymerase that will not allow for proper binding of rifampin. Because of the high rate of spontaneous mutations that create resistance to rifampin, its use has been limited to (1) long-term treatment of tuberculosis and leprosy, (2) prophylaxis for those exposed to patients with meningitis due to *H. influenzae* type b or *N. meningitidis,* and (3) combination therapy with vancomycin, nafcillin, and ciprofloxacin in the treatment of endocarditis or osteomyelitis caused by *S. aureus* or *S. epidermidis.*

Rifampin imparts a harmless orange color to urine, sweat, tears, and contact lenses of which patients should be warned. Occasional adverse reactions include rashes, thrombocytopenia, nephritis, and impairment of liver function. Rifampin induces the cytochrome P450 system of the liver and increases the elimination of anticoagulants and contraceptives. Likewise, administration of rifampin with ketoconazole, cyclosporine, or chloramphenicol results in significantly lower serum levels of these medications.

***Tetracyclines***

Tetracyclines are broad-spectrum bacteriostatic agents that are capable of penetrating well into host cells. They are most effective against rapidly multiplying bacteria. This group of antibiotics include tetracycline, doxycycline, demeclocycline, and minocycline. The tetracyclines exert their action by binding to the 30s bacterial ribosomal subunit and inhibiting the correct positioning of the incoming tRNA, thereby inhibiting peptide elongation. The earlier tetracylines were not well absorbed from the intestinal tract and, as a result killed much of the normal flora, resulting in colitis. However, with the development of the more lipophilic semisynthetic tetracyclines doxycycline and minocycline, intestinal absorption has increased and reduced the incidence of colitis.

Nausea, vomiting, and diarrhea are the most common reasons for discontinuing tetracycline. These symptoms can usually be controlled by administering the antibiotic with food. Use in children under the age of 12 can impair bone development and stain developing teeth. Tetracyclines can probably impair hepatic function and may also result in liver necrosis, especially in pregnant patients. Renal tubular acidosis and other renal injuries resulting in nitrogen retention have been attributed to the administration of outdated tetracycline preparations. Intravenous injection of tetracycline can lead to venous thrombosis, whereas intramuscular injection produces painful local irritation and should be avoided. Administration of systemic tetracycline, especially demeclocycline, can induce sensitivity to sunlight or ultraviolet light, particularly in fair-skinned individuals. Dizziness, vertigo, nausea, and vomiting have been particularly noted in patients receiving minocycline.

Tetracyclines are used primarily in the treatment of infections caused by intracellular organisms such as *Chlamydia, Rickettsia,* and pneumonia caused by *M. pneumoniae*. Resistance to tetracyclines is based on a plasmid-encoded active efflux system. Although tetracycline entry into the cell is not altered, an active system for pumping the antibiotic out of the bacteria is established (35).

***Metronidazole***

Metronidazole is a nitroimidazole antiprotozoal drug that also has striking bactericidal effects against most anaerobes, including *Bacteroides* and clostridia. It exerts its antibacterial effect through the formation of short-lived, highly cytotoxic intermediates that develop in anaerobic conditions. It is well absorbed when taken orally, metabolized by the liver, and may accumulate in patients with hepatic insufficiency. Metronidazole is considered for use in anaerobic and protozoal infections, and antibiotic-associated enterocolitis. Adverse effects of the medication include nausea, diarrhea, stomatitis, and peripheral neuropathy with prolonged use. Advise patients to avoid alcohol ingestion because of metronidazole's disulfiram-like effect.

***Trimethoprim-Sulfamethoxazole***

Trimethoprim and sulfamethoxazole (TMP/SMX) act at different points in the chemical pathway that produces dihydrofolic acid for bacterial cells. Dihydrofolic acid acts as a reducing agent in bacteria and is necessary for normal cellular processes. Because of their actions on the same pathway, TMP/SMX act synergistically against susceptible bacteria as well as some parasites. Resistance to TMP/SMX develops when enzymes in the dihydrofolic acid pathway mutate and no longer bind these medications as avidly. Because of the use of two medications on the same chemical pathway, however, the development of resistant strains is somewhat hampered (35).

Sulfonamides can cause a wide variety of untoward effects owing partly to allergy and partly to direct effects. The most common adverse effects include fever, skin

rashes, photosensitivity, urticaria, nausea, vomiting, and diarrhea. Other effects include stomatitis, conjunctivitis, arthritis, hepatitis, exfoliative dermatitis, polyarteritis nodosa, Stevens-Johnson syndrome, and psychosis. Sulfonamides can produce anemia (hemolytic or aplastic), granulocytopenia, thrombocytopenia, or leukemoid reactions. These are rare except in certain high-risk patients. Sulfonamides cause hemolytic anemia in patients with glucose-6-phosphate dehydrogenase deficiency, and sulfonamides taken near the end of pregnancy increase the risk of kernicterus in the newborn infant.

Trimethoprim produces the predictable adverse effects of an antifolate drug, especially megaloblastic anemia, leukopenia, and granulocytopenia. These effects can be prevented by the simultaneous administration of folinic acid.

## DRUGS EFFECTIVE AGAINST MYCOBACTERIA

### *Isoniazid*

Isoniazid (INH) is a bactericidal antibiotic that interferes with the synthesis of mycolic acid, an essential component of the cell wall complex of *Mycobacterium tuberculosis.* When used as prophylaxis for tuberculosis, it can be given as monotherapy. With the rise of multidrug-resistant TB, however, INH must be given in combination with other antimycobacterial drugs. Another antimycobacterial drug ethionamide is closely related to INH and has the same mode of action.

The most common side effects of INH use, seen in 10% to 20% percent of patients, are on the peripheral nervous system and CNS. These are related to a relative pyridoxine deficiency and include peripheral neuritis, insomnia, restlessness, muscle twitching, urinary retention, and even convulsions or psychotic episodes. Most of these complications can be avoided by the administration of pyridoxine (vitamin $B_6$). Isoniazid has been associated with hepatotoxicity with abnormal liver function tests, clinical jaundice, and multilobular necrosis.

### *Pyrazinamide*

Pyrazinamide is a relative of nicotinamide and strongly inhibits the growth of tubercle bacilli and other mycobacteria. Pyrazinamide is well absorbed from the gastrointestinal tract and widely distributed throughout the body. Tubercle bacilli develop resistance to pyrazinamide fairly readily, but there is no cross-resistance with INH or other antimycobacterial drugs. The major adverse effects of pyrazinamide include hepatotoxicity (in 1% to 5% of patients), nausea, vomiting, drug fever, and hyperuricemia.

### *Rifampin*

The use of rifampin for bacterial infections has been discussed earlier. It is also used as a front-line chemotherapeutic agent against mycobacterial infections.

### *Ethambutol*

Ethambutol is a bactericidal antibiotic that inhibits the synthesis of cellular metabolites by an unknown mechanism. In combination with other medication, it is used in the short-term treatment of tuberculosis. Ethambutol may cause reduced visual acuity, optic neuritis, and perhaps retinal damage in about 0.8% of patients but rarely in patients with normal renal function.

### *Cycloserine*

Cycloserine acts as an analog of D-alanine-D-alanine, and inhibits the formation of peptidoglycan cross-links by acting as a competitive inhibitor of the transpeptidase enzymes. Cycloserine is indicated primarily as a second-line agent in the treatment of tuberculosis. Its use has been associated with convulsions, other serious CNS dysfunction, and psychotic reactions.

### *Streptomycin*

Streptomycin is identical in action to the aminoglycosides previously discussed and possesses the same adverse effects. Most tubercle bacilli are inhibited by streptomycin, but the drug can exert its effects only on extracellular bacteria because only 10% of the antibiotic can penetrate cells that harbor the intracellular pathogen.

### *Dapsone*

Dapsone is a sulfone antibiotic with an identical mode of action and adverse effects as the sulfonamides. For many years, dapsone was the treatment of choice against *Mycobacterium leprae.* With the rise of dapsone resistance among leprosy bacilli during the past few years, standard treatment of leprosy now combines dapsone with other antimycobacterial drugs.

## DRUGS EFFECTIVE AGAINST FUNGI

Because of the eukaryotic nature of fungi, the problem of developing a selectively toxic antifungal agent has been difficult. It has been solved by the use of agents that inhibit the synthesis of unique fungal cell wall or membrane. Thus, most antifungal agents act by binding or inhibiting the synthesis of ergosterol, a steroid found only in fungal cell membranes. In high concentrations, however, these antibiotics can have toxic effects on human cells as well, making the treatment of systemic fungal disease difficult.

### *Polyene Antibiotics*

Amphotericin B and nystatin are polyene antibiotics. They are selectively toxic to fungi because of their ability to preferentially bind ergosterol. This binding disorganizes the lipid bilayer, and fungal metabolites leak out of the damaged cell. In addition to their ability to bind ergosterol, the polyenes can bind to cholesterol in the human cell membrane. It is for this reason that amphotericin B is toxic when used IV, and high-dose therapy may damage renal basement membranes. This is not a problem with nystatin, because it is not given intravenously. Regardless of its toxic effects, amphotericin remains the drug of choice in the treatment of systemic aspergillosis, blastomycosis, candidiasis, coccidiomycosis, cryptococcosis, histoplasmosis, mucormycosis, and sporotrichosis. Nystatin is used in the treatment of cutaneous and mucocutaneous Candida infections. Because nystatin is not absorbed well from the gut, it is often used in the treatment of gastrointestinal candidiasis.

Intravenous injection of amphotericin B usually produces chills, fever, vomiting, and headache. The severity of these reactions may be diminished by reducing the dosage temporarily; administering aspirin, phenothiazines, antihistamines, or corticosteroids; or stopping injections for several days. Therapeutically active amounts of amphotericin B commonly impair renal and hepatocellular function, and produce anemia.

### *Azole Antibiotics*

The azole antibiotics are fungistatic and exert their antifungal effect by blocking the synthesis of ergosterol through the inhibition of the cytochrome P-450 enzyme lanosterol-14-demethylase. When the available ergesterol for cell growth is depleted and there is no additional supply of ergesterol produced, fungal growth ceases. The azole antifungals can be used topically in the treatment of dermatophyte infections, chronic mucocutaneous candidiasis, candidiasis in immunodepressed individuals, chromoblastomycosis, paracoccidiomycosis, and cutaneous or lymphatic sporotrichosis.

Adverse effects of the azole antifungal drugs include vomiting, nausea, diarrhea, rashes, and sometimes impairment of hepatic function. Fluconazole and ketoconazole inhibit cytochrome P450 and may increase serum concentrations of phenytoin, cyclosporine, oral hypoglycemic drugs, and anticoagulants.

### *Nucleoside Analogs*

Flucytosine is the only nucleoside analog used in the treatment of fungal infections. In fungal cells, flucytosine is enzymatically converted to fluorouracil, and acts to terminate RNA replication, and thus protein synthesis. Flucytosine can be used as a single agent to treat Candida infections of the urinary tract, and is used in combination with amphotericin B in the treatment of systemic candidiasis or cryptococcosis. As much as 15% of fungal isolates, however, rapidly develop resistance to flucytosine when it is used as a single agent. In addition, flucytosine may be toxic in some patients, with prolonged serum levels causing bone marrow depression with

leukopenia or thrombocytopenia, hair loss, and abnormal liver function.

### *Griseofulvin*

Griseofulvin is a fungistatic antibiotic produced by *Penicillium* and is used to treat dermatophyte infections that are not responsive to topical antibiotics. It may also be administered orally to eradicate infections that are localized in the stratum corneum. It is believed that griseofulvin acts as a colchicine-like agent, interfering with cellular microtubule assembly and inhibiting fungal mitosis. Although griseofulcin is effective against dermatophytes, it has limited effectiveness for the treatment of tinea versicolor or tinea nigra. It is well tolerated, with headache being the most commonly reported adverse reaction.

### *Allylamine Antibiotics*

Naftifine and terbinafine are two members of the newer allylamine class of antifungal agents available. They are used mostly to treat dermatophyte infections, such as athlete's foot and ringworm. These antibiotics are fungicidal and work through allosteric inhibition of squalene epoxidase, leading to an accumulation of high levels of squalene and inhibition of ergosterol synthesis (39).

## STREPTOGRAMIN ANTIBIOTICS

The streptogramin antibiotics are members of the macrolide-lincosamide-streptogramin family and function to inhibit protein synthesis by interfering with bacterial ribosomal function. Pristinamycin is a naturally occurring antibiotic whose existence has been known for several years. The novel antibiotic Synercid is composed of two synthetic derivatives of pristinamycin, quinupristin, and dalfopristin mixed in a 30:70 ratio, respectively. Either component used alone has a bacteriostatic effect, but when they are combined, the antibiotic is a powerful bactericidal agent. Consequently, quinupristin/dalfopristin has improved activity against pathogens resistant to macrolides and lincosamides. In addition, quinupristin/dalfopristin is also active against pathogens resistant to b-lactams and glycopeptide antibiotics owing to its differences in chemical structure and mode of action. This and other novel antibiotics in development will be important against emerging strains of resistant bacteria in the future (14,17,39).

## PROLONGED ANTIBIOTIC USE

Infections of the bone and joints, because of their severity and in many instances the relative lack of blood supply, may require high doses of antibiotic over prolonged periods of time. This antibiotic therapy may begin in the operating room but will need to continue throughout the patient's stay at the hospital and while at home. With the introduction of the Hickman, Broviac, and PICC types of indwelling catheters, one of the obstacles to home antibiotic therapy has been conquered. In addition, the training of visiting home nurses to educate patients and supervise the infusion of antibiotics, as well as the efforts of pharmaceutical services to provide adequate resources, has made this goal of long-term therapy far more achievable (14).

Some problems that are unique to the use of long-term antibiotic remain, however. For those antibiotics with known toxicities, such as the aminoglycosides or vancomycin, blood-level monitoring is necessary to avoid toxic side effects. Audiology testing is needed for a baseline before beginning therapy and may be needed at some point during the course of treatment to avoid vestibular and cochlear damage. Other forms of antibiotics may require serial complete blood counts and liver function tests to avoid toxicity. As mentioned earlier, serum bactericidal concentrations (SBC) can be measured to ensure that the antibiotic concentrations remain effective. An SBC greater than 1:16 at peak concentrations and greater than 1:2 at trough concentrations correlate with successful treatment of deep-seated infections (39).

## CHAPTER REFERENCES

Each reference is categorized according to the following scheme: *, classic article; #, review article; !, basic article; and +, clinical results/outcome study.


+ 1. Ainscow DA, Denham RA. The Risk of Hematogenous Infection in Total Joint Replacements. *J Bone Joint Surg [Br]* 1984;66-B:580.

! 2. Anglen JO, Apostoles S, Christensen G, et al. The Efficacy of Various Irrigation Solutions in Removing Slime-Producing Staphylococcus. *J Orthop Trauma* 1994;8:390.

+ 3. Barrack RL, Jennings RW, Wolfe MW, et al. The Value of Preoperative Aspiration before Total Knee Revision. *Clin Orthop* 1997;345:8.

+ 4. Becker W, Palestro CJ, Winship J. Rapid Imaging of Infections with a Monoclonal Antibody Fragment (Leukoscan). *Clin Orthop* 1996;329:263.

+ 5. Benjamin JB, Volz RG. Efficacy of a Topical Antibiotic Irrigant in Decreasing or Eliminating Bacterial Contamination in Surgical Wounds. *Clin Orthop* 1984;184:114.

+ 6. Brien WW, Salvati EA, Klein R, et al. Antibiotic-impregnated Bone Cement in Total Hip Arthroplasty. An In Vivo Comparison of the Elution Properties of Tobramycin and Vancomycin. *Clin Orthop* 1993;296:242.

+ 7. Brown AR, Taylor GJS, Gregg PJ. Air-Contamination During Skin Preparation and Draping in Joint Replacement Surgery. *J Bone Joint Surg [Br]* 1996;78-B:92.

+ 8. Calhoun JH, Mader JT. Treatment of Osteomyelitis with a Biodegradable Antibiotic Implant. *Clin Orthop* 1997;341:206.

+ 9. Chimento GF, Finger S, Barrack RL. Gram Stain Detection of Infection During Revision Arthroplasty. *J Bone Joint Surg [Br]* 1996;78-B:838.

+ 10. Cho SH, Song HR, Koo KH, et al. Antibiotic-impregnated Cement Beads in the Treatment of Chronic Osteomyelitis. *Bull Hosp Jt Dis* 1997;56:140.

+ 11. Covey DC, Albright JA. Clinical Significance of the Erythrocyte Sedimentation Rate in Orthopaedic Surgery. *J Bone Joint Surg [Am]* 1987;69-A:148.

+ 12. Espehaug B, Engesaeter L, Vollset SE, et al. Antibiotic Prophylaxis in Total Hip Arthroplasty: Review of 10,905 Primary Cemented Total Hip Replacements Reported to the Norwegian Arthroplasty Register, 1987 to 1995. *J Bone Joint Surg [Br]* 1997;79-B:590.

+ 13. Feldman DS, Lonner JH, Desai, P, et al. The Role of Intraoperative Frozen Sections in Revision Total Joint Arthroplasty. *J Bone Joint Surg [Am]* 1995;77-A:1807.

+ 14. Graninger W, Presterl E, Wenisch C, et al. Management of Serious Staphylococcal Infections in the Outpatient Setting. *Drugs* 1997;54:21.

# 15. Greene WB. Instr Course Lect 1990;39.

# 16. Gristina AG, Kolkin J. Current Concepts Review: Total Joint Replacement and Sepsis. *J Bone Joint Surg [Am]* 1983;65-A:128.

# 17. Gruneberg RN. Anti-Gram-Positive Agents. What We Have and What We Would Like. *Drugs* 1997;54:29-38.

+ 18. Hakki S, Harwood SJ, Morrissey, MA, et al. Comparative Study of Monoclonal Antibody Scan in Diagnosing Orthopaedic Infection. *Clin Orthop* 1997;335:275.

# 19. Henry SL, Galloway KP. Local Antibacterial Therapy for the Management of Orthopaedic Infections: Pharmacokinetic Considerations. *Clin Pharmacokin* 1995;29:36.

+ 20. Iles SE, Ehrlich LE, Saliken JC, et al. Indium-111 Chloride Scintigraphy in Adult Osteomyelitis. *J Nucl Med* 1987;28:1540.

+ 21. Isiklar ZU, Darouiche RO, Landon GC, et al. Efficacy of Antibiotics Alone for Orthopaedic Device Related Infections. *Clin Orthop* 1996;332:184.

+ 22. Josefsson G, Gudmundsson G, Kolmert L, et al. Prophylaxis with Systemic Antibiotics Versus Gentamicin Bone Cement in Total Hip Arthroplasty: A Five-year Survey of 1688 Hips. *Clin Orthop* 1990;253:173.

+ 23. Keating JF, Blachut PA, O'Brien PJ et al. Reamed Nailing of Open Tibial Fractures: Does the Antibiotic Bead Pouch Reduce the Deep Infection Rate? *J Orthop Trauma* 1996;10:298.

# 24. Kloos WE, Bannerman TL. Update on Clinical Significance of Coagulase Negative Staphylococci. *Clin Microbiol Rev* 1994;7:117.

+ 25. Lee J. Efficacy of Cultures in the Management of Open Fractures. *Clin Orthop* 1997;339:71.

+ 26. Levine SE, Esterhai JL Jr, Heppenstall, RB et al. Diagnoses and Staging. Osteomyelitis and Prosthetic Joint Infections. *Clin Orthop* 1993;295:77.

+ 27. Little JW. Managing Dental Patients with Joint Prostheses. *J Am Dent Assoc* 1994;125:1374.

+ 28. Loveless MO. The Role of Susceptibility Testing in Appropriate Selection of Antibiotics. *Lab Med* 1986;17:75.

+ 29. Mader JT, Calhoun J, Cobos J. In Vitro Evaluation of Antibiotic Diffusion from Antibiotic-impregneted Biodegradable Beads and Polymethylmethacrylate Beads. *Antimicrob Agents Chemother* 1997;41:415.

+ 30. Magnuson JE, Brown ML, Hauser ME, et al. In-111-Labeled Leukocyte Scintigraphy in Suspected Orthopaedic Prosthetic Infection: Comparison with Other Imaging Modalities. *Radiology* 1988;168:235.

# 31. Marchese A, Debbia EA, Bacca D, et al. Multidrug-Resistant Gram-Positive Pathogens. An Update on Current Microbiological Patterns. *Drugs* 1997;54:11.

+ 32. Maurer AH, Chen DCP, Camargo EE, et al. Utility of Three-Phase Skeletal Scintigraphy in Suspected Osteomyelitis. *J Nucl Med* 1981;22:941.

+ 33. McAfee JG, Thakur ML. Survery of Radioactive Agents for In Vitro Labeling of Phagocytic Leukocytes. *J Nucl Med* 1976;17:480.

+ 34. McCue SF, Berg EW, Saunders EA. Efficacy of Double-Gloving as a Barrier to Microbial Contamination During Total Joint Arthroplasty. *J Bone Joint Surg [Am]* 1981;63-A:811.

# 35. McManus M. Mechanisms of Bacterial Resistance to Antimicrobial Agents. Am J Health Syst Pharm 1997;54:1420.

+ 36. Merkel KD, Brown ML, Dewanjee MK et al. Comparison of Indium-Labeled-Leukocyte Imaging with Sequential Technitium-Gallium Scanning in the Diagnosis of Low-Grade Musculoskeletal Sepsis. *J Bone Joint Surg [Am]* 1985;67A:465.

+ 37. Mini E, Nobil S, Periti P. Methicillin-Resistant Staphylococci in Clean Surgery. Is There a Role for Prophylaxis? *Drugs* 1997;54:39.

+ 38. Modic MT, Pflanze W, Feiglin DHI, et al. Magnetic Resonance Imaging of Musculoskeletal Infections. *Radiol Clin North Am* 1986;24:247.

# 39. Moellering, RC Jr. Past, Present and Future of Antimicrobial Agents. *Am J Med* 1995;99:11S.

+ 40. Mousa HA. Evaluation of Sinus-Track Cultures in Chronic Bone Infection. *J Bone Joint Surg [Br]* 1997;79-B:567.

# 41. Nasser S. Prevention and Treatment of Sepsis in Total Hip Replacement Surgery. *Orthop Clin North Am* 1992;23:265.

+ 42. Ostermann PAW, Seligson D, Henry SL. Local Antibiotic Therapy for Severe Open Fractures: A Review of 1085 Consecutive Cases. *J Bone Joint Surg [Br]* 1995;77-B:93.

+ 43. Pearce BA, Miller LH, Martin MA, et al. Efficacy of Clean Versus Sterile Surgical Prep Kits. *AORN J* 1997;66:464.

+ 44. Periti P, Mini E, Mosconi G. Antimicrobial Prophylaxis in Orthopaedic Surgery: The Role of Teicoplanin. *J Antimicrob Chemother* 1998;41:329.

+ 45. Salvati EA, Robinson RP, Zeno SM, et al. Infection Rates after 3175 Total Hip and Total Knee Replacements Performed with and without a Horizontal Unidirectional Filtered Air-flow System. *J Bone Joint Surgery [Am]* 1982;64:525.

+ 46. Schulak DJ, Rayhack JM, Lippert FG, III et al. The Erythrocyte Sedimentation Rate in Orthopaedic Patients. *Clin Orthop* 1982;167:197.

+ 47. Shrout MK, Scarbrough F, Powell BJ. Dental Care and the Prosthetic Joint Patient: A Survey of Orthopaedic Surgeons and General Dentists. *J Am Dent Assoc* 1994;125:429.

+ 48. Stout RD, et al. Staphylococcal Exopolysaccharides Inhibit Lymphocyte Proliferative Responses by Activation of Monocyte Prostaglandin Production. *Infect Immun* 1992;60:922.

+ 49. Tang JSH, Gold RH, Bassett LW, et al. Musculoskeletal Infection of the Extremities: Evaluation with MR Imaging. *Radiology* 1988;166:205.

+ 50. Tannenbaum DA, Matthews LS, Grady-Benson JC. Infection around Joint Replacements in Patients Who Have Renal or Liver Transplantation. *J Bone Joint Surg [Am]* 1997;79-A:36.

+ 51. Taylor GJS, Bannister GC. Infection and Interposition Between Ultraclean Air Source and Wound. *J Bone Joint Surg [Br]* 1993;75:503.

+ 52. Trippel SB. Antibiotic-impregnated Cement in Total Joint Arthroplasty. *J Bone Joint Surg [Am]* 1986;68-A:1297.

+ 53. Wahl MJ. Myths of Dental-Induced Prosthetic Joint Infections. *Clin Infect Dis* 1995;20:1420.

+ 54. Waldman BJ, Mont MA, Hungerford DS. Total Knee Arthroplasty Infections Associated with Dental Procedures. *Clin Orthop* 1997;343:164.

+ 55. Wininger DA, Fass RJ. Antibiotic-impregnated Cement Beads for Orthopaedic Infections. *Antimicrob Agents Chemother* 1996;40:2675.

+ 56. Whyte W, Hodgson R, Tinkler J. The Importance of Airborne Bacterial Contamination of Wounds. *J Hosp Infect* 1982;3:123.

+ 57. Wood MJ. The Comparative Efficacy and Safety of Teicoplanin and Vancomycin. *J Antimicrob Chemother* 1996;37:209.

+ 58. Wukich DK, Abreu SH, Callaghan JJ, et al. Diagnosis of Infection by Preoperative Scintigraphy with Indium-labeled White Blood Cells. *J Bone Joint Surg [Am]* 1987;69-A:1353.

+ 59. Zeckel ML. A Closer Look at Vancomycin, Teicoplanin, and Antimicrobial Resistance. *J Chemother* 1997;9:311.

# CHAPTER 133

# MANAGEMENT OF ACUTE AND CHRONIC OSTEOMYELITIS

*Michael J. Patzakis*

**M. J. Patzakis:** Department of Orthopaedic Surgery, University of Southern California School of Medicine, Los Angeles, California, 90033.

Pathogens
Systemic Antibiotic Therapy
Topical Antibiotic Therapy
Classification of Osteomyelitis
Diagnosis
Principles of Treatment of Infected Ununited Fractures and Nonunions
Surgical Considerations
Tourniquets
Debridement
Irrigation
Wound Management
Drains
Wound Packing
Antibiotic Bead Pouch
Surgical Techniques
Hematogenous Osteomyelitis
Osteomyelitis Following Open Fractures
Dead-Space Management
Osteomyelitis in the Presence of Internal Fixation for Fracture Stabilization
Osteomyelitis of the Metatarsal Heads and Phalanges Following Puncture Wounds of the Foot
Osteomyelitis of the Metatarsal
Osteomyelitis of the Calcaneus
Osteomyelitis of the Fibula
Osteomyelitis of the Patella
Osteomyelitis of the Femur
Osteomyelitis of the Ilium
Osteomyelitis of the Ischium and Pubis
Osteomyelitis of the Radius and Ulna
Osteomyelitis of the Humerus
Ilizarov Procedure
Acknowledgment
Chapter References

The portals of entry for osteomyelitis, or inflammation of the bone, can result from hematogenous seeding, from direct inoculation (i.e., following open fractures or open reduction and internal fixation of fractures), or from the contiguous spread of bacteria from infected structures. Early diagnosis and effective surgical and antibiotic management can control the infection; suppression of infection may last a lifetime.

Since the early 1980s, limb salvage with good functional outcome has been enhanced by the addition of microvascular and local muscle transfers, bone grafting techniques, bone transport for large bone defects, newer antibiotics, and local antibiotic delivery systems. The treatment of osteomyelitis requires the work of a team, consisting of the orthopaedic surgeon, an infectious disease physician, and, in complex cases involving soft-tissue defects or inadequate soft-tissue coverage, a plastic surgeon. In many institutions, some orthopaedic nurses are specially trained in the care of patients with orthopaedic infections.

## PATHOGENS

The organisms that cause osteomyelitis vary depending on the portal of entry and the type, age, and associated medical conditions of the host. Unfortunately, it is usually not possible to accurately predict the specific pathogen on the basis of clinical presentation alone. In the past, the most common causes of osteomyelitis were *Staphylococcus aureus* and various streptococcal species. Gustilo et al. (22) and Patzakis et al. (48) reported that *S. aureus* and coagulase-negative staphylococci were the most common organisms causing infections in open fractures. However, the microbiology of musculoskeletal sepsis has been changing in recent years. While *S. aureus* remains the predominant cause of osteomyelitis, there has been an increase in the frequency of infections caused by gram-negative organisms (52,53).

The portal of entry is an important consideration in the determination of the microbiology. Hematogenous osteomyelitis is most commonly caused by *S. aureus*. In the past, *Haemophilus influenzae* type B (HiB) was a common organism in children, but the advent of HiB vaccine has made it a rare cause (3). Causes of osteomyelitis due to direct inoculation, such as into an open fracture, will be influenced by the environment in which the injury occurred. For example, injuries occurring in water may lead to infection with *Aeromonas* or *Plesiomonas*. Nail puncture wounds of the foot, particularly through a tennis shoe, are associated with infection with *Pseudomonas aeruginosa* (28,50).

Underlying medical conditions of the host also influence the expected microbiology. Intravenous drug users may have *P. aeruginosa* and other gram-negative bacilli as causes of their osteomyelitis (18,39,61). Patients with sickle cell disease are prone to the development of *Salmonella* osteomyelitis. Osteomyelitis caused by fungal infections is more likely to be seen in immunocompromised hosts. Diabetic foot infections leading to osteomyelitis often are polymicrobial, often involving anaerobes and gram-positive and gram-negative aerobic bacilli. Patients infected with the human immunodeficiency virus (HIV) are at risk for a variety of unusual infections, including atypical mycobacteria.

One of the greatest problems for the future is the growing frequency of antimicrobial resistance in bacteria. Methicillin-resistant *S. aureus* has been known for decades, but its incidence is growing, even among nonhospitalized patients. Multidrug-resistant gram-negative bacteria are increasingly becoming a problem, limiting treatment options. Vancomycin-resistant *Enterococcus faecium* has become a major problem in nosocomial infections in the United States, but thus far has been rarely seen in osteomyelitis. The greatest concern is the development of vancomycin-resistant *S. aureus*, which has now been identified in patients in Japan, the United States, and Europe. Although this has not yet been reported as a cause of osteomyelitis, bone infections with this organism could be catastrophic, as no effective antibiotics for this infection are yet available.

## SYSTEMIC ANTIBIOTIC THERAPY

Antibiotic therapy is an adjunct to good surgical management, which includes adequate debridement and wound management. There has been a recent surge in the number of antibiotics available for the treatment of osteomyelitis. The beta-lactam antibiotics, such as penicillin and cephalosporin, are effective and relatively safe antimicrobials that can cover a wide range of gram-positive and gram-negative infections. The quinolones, however, have changed the treatment of osteomyelitis by providing oral drugs that achieve excellent serum levels and have good bone penetration.

The questions most often asked about the use of antimicrobials concern the choice of agent, the optimal route (intravenous, oral, or local), and the length of administration. The Gram stain, culture, and antimicrobial sensitivity tests are important guides in determining the specific antimicrobials to be used. Sensitivity testing not only helps to identify resistant organisms but also to guide the selection of the most active antimicrobial for the specific infection.

*Staphylococcus aureus* remains the most common cause of osteomyelitis. A semisynthetic penicillin (such as nafcillin) is the drug of choice for most staphylococcal infections. Alternative choices could include a first-generation cephalosporin [such as cefazolin (Ancef)], clindamycin, or a quinolone. Vancomycin is less active against *S. aureus* than the penicillins and should not be used except in the case of patient allergy to the beta-lactams or for the treatment of methicillin-resistant *S. aureus*.

Rifampin may be used in combination with one of the other agents for synergy.

Infections with the gram-negative bacilli can be treated with a penicillin plus beta-lactamase inhibitor combination [such as piperacillin-tazobactam (Zosyn)], a cephalosporin [such as cefotaxime (Claforan) or ceftriaxone (Rocephin)], an aminoglycoside, or a quinolone. For infections with *P. aeruginosa*, treatment with an antipseudomonal beta-lactam (such as piperacillin, ceftazidime, or cefipime) together with an aminoglycoside (such as tobramycin, which is the most effective against *Pseudomonas*) still represents the gold standard of therapy. Although successful treatment with a single agent, such as ceftazidime, has been reported (1,16), treatment failures with single-agent therapy have been noted, including some cases associated with the emergence of resistance.

The quinolones are a major addition to the antimicrobials available for the treatment of osteomyelitis. Currently available quinolones that may be useful in the treatment of osteomyelitis include ciprofloxacin, ofloxacin, and levofloxacin. They have a broad spectrum of activity including *S. aureus* and streptococci (with the newer quinolones such as levofloxacin having much better activity against the gram-positive organisms than ciprofloxacin), the aerobic gram-negative enteric bacilli, and *P. aeruginosa*.

One of the most important advantages of the quinolones is the fact that oral administration results in levels similar to those obtained with intravenous administration, suggesting that oral therapy can replace intravenous therapy, at least in some instances (17,58). Since the incidence of adverse reactions to these drugs is low, they may be used in place of more toxic antimicrobials such as the aminoglycosides.

The treatment of osteomyelitis caused by *Mycobacterium tuberculosis* has been influenced by the rise in drug-resistant organisms. The current treatment recommendations are starting with three or four drugs (isoniazide, rifampin, pyrazinamide, and ethambutol), depending on the level of isoniazide resistance in the community. If cultures show that the organism is sensitive to isoniazide and rifampin, therapy can continue with isoniazide and rifampin for a minimum of 6 months, although longer regimens (9–12 months) are probably required (55).

Fungal infections have traditionally been treated with amphotericin B, which was the only agent effective against deep fungal infections. Although it is often effective, there are significant adverse effects associated with the administration of amphotericin B, including fever, chills, and nausea during administration, and renal insufficiency or failure with potassium and magnesium wasting. Newer agents such as fluconazole and itraconazole have excellent activity against many of the fungal organisms and far fewer side effects.

Because of the large number of new antimicrobials available, the problem of increasing resistance among organisms, and the potential for significant adverse reactions with many of the drugs, it is imperative that an infectious disease consultant help with the selection of specific antibiotic therapy and the monitoring of the patient for adverse reactions. Table 133.1 lists commonly used antimicrobials (also see Chapter 132).

***Table 133.1. Commonly Administered Antimicrobials***

## TOPICAL ANTIBIOTIC THERAPY

Topical antibiotic therapy is an old concept. Hippocrates and later Galen used medicinal ointments that included honey, a bactericidal agent, in the treatment of open fractures. In the early 1900s, Lord Lister, with good success, used phenol-soaked compresses to combat the microorganisms believed to be responsible for infection (35). He later introduced the use of carbolic acid as an antiseptic. Following the discovery of the sulfonamides, sulfa powder in wounds was popular among war surgeons. The major changes of today are the choice of the agent used and the development of new vehicles for delivery.

Most orthopaedic surgeons use a topical antibiotic solution for irrigation of infected wounds at the time of surgery. Although any antimicrobial could be used, the most commonly used agents are polymyxin (1 million units/L of saline) and bacitracin (50,000 units/L of saline).

Closed-suction antibiotic, high-volume irrigation systems have been used for ingress and egress, usually administered for a period of 3 to 21 days. The main deterrent to this mode of administration has been the emergence of new organisms, usually hydrophilic gram-negative organisms (10,29,47). The overall success for antibiotic irrigation has been shown to be the same as for antibiotic-impregnated polymethylmethacrylate (PMMA) beads (62). Therefore, tube-suction irrigation has been abandoned by many surgeons. If this system is used, adhere to every means possible to prevent contamination. The risk of secondary contamination increases with the length of usage of the irrigation system. It is advisable to use Silastic drains and to place the tubes on suction or egress for 24 hours before removing the system. This procedure will remove all of the fluid and hematoma present and will collapse the dead space, thereby precluding the possibility of abscess formation. I do not recommend the use of suction-irrigation systems.

Antibiotic-impregnated PMMA can be used to achieve local delivery of high concentrations of antibiotics. Among the advantages of antibiotic beads are low systemic levels of antibiotics, resulting in a lower potential of systemic toxicity, decreased need for systemic intravenous therapy, and decreased length of hospital stay. The disadvantages are that it requires a closed wound for the development of high local levels of antibiotics. Moreover, it may act as a foreign body, especially in the presence of resistance to the antibiotic in the vehicle, such as gentamicin or tobramycin.

The use of antibiotic-impregnated PMMA in total hip implants has been advocated (4,5,41). Klemm and other investigators have reported good results with the use of gentamicin-impregnated methylmethacrylate beads (Septopal) for the treatment of chronic osteomyelitis (30,31). Unfortunately, the United States Food and Drug Administration (FDA) approval of factory-made gentamicin beads (Septopal) has been indefinitely delayed, leading many surgeons to make their own beads using bead molds (13).

Numerous studies have evaluated the *in vitro* elution characteristics of PMMA combined with antibiotics. The majority of studies have evaluated gentamicin, but as it is no longer commercially available in powder form for injection in the United States, physicians now use tobramycin and vancomycin since they are active against the most common organisms leading to prosthetic joint infections and osteomyelitis. Antibiotic elution from antibiotic-impregnated PMMA is proportional to the surface area of the cement (68,69) and affected by the type and concentration of the antibiotic used, the brand of PMMA cement, and the amount and turnover of the surrounding fluid (66). Studies have shown that antibiotics elute better from beads than from spacers, and better from palacos cement than from simplex cement, and tobramycin achieves better levels than vancomycin (20,33,36).

Overall, the results of treatment with antibiotic-impregnated PMMA beads are encouraging, so the use of these in selected cases seems appropriate (Fig. 133.1). A different vehicle for the delivery of local antibiotic therapy may improve results and lessen the disadvantages associated with this therapy. Various biodegradable antibiotic delivery systems are now being evaluated but are still in the investigational stage.

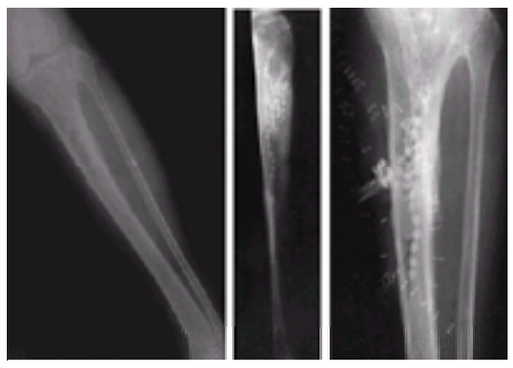

***Figure 133.1.*** Anteroposterior roentgenograms of a 46-year-old man with chronic osteomyelitis. The patient was treated with debridement followed by insertion of aminoglycoside-impregnated methylmethacrylate beads and a local muscle flap.

## CLASSIFICATION OF OSTEOMYELITIS

Cierney et al. proposed a staging system for adult osteomyelitis based on anatomic type and physiologic class (7,8). The four anatomic types are type I, medullary osteomyelitis; type II, superficial osteomyelitis; type III, localized osteomyelitis; and type IV, diffuse osteomyelitis.

The three physiologic classes deal with the condition of the host. An “A” host has good systemic defenses with good local vascularity and a normal physiologic response to infection and surgery. A “B” host is a compromised host with either local, systemic, or combined deficiency in wound healing and infection response. A “C” host is a patient who is not a surgical candidate, requires suppressive or no treatment, who has minimal disability, or for whom the treatment or results of treatment are more compromising than the disability caused by the disease itself.

## DIAGNOSIS

A diagnosis of acute osteomyelitis should be considered an emergency. The presenting signs and symptoms may vary with the severity of the infection. Symptoms include fever and chills, general malaise, irritability, pain, and swelling. With lower extremity involvement, there is either a limp or an inability to bear weight. An infant with upper extremity involvement may exhibit pseudoparalysis; older children and adults with upper extremity involvement complain of pain on movement or use of the extremity.

It is important to localize the point of maximum tenderness, which is usually warm and swollen. In children it is generally in the metaphyseal region. It is also important to evaluate the adjoining joint for evidence of septic arthritis, which can occur as an extension of the adjoining osteomyelitis. Osteomyelitis involving the neck of the femur, talus, and humeral head often leads to sepsis of the joint because these foci are located within the joint capsule.

Once the point of maximum tenderness is localized, aspirate the area, and send the pus or fluid obtained for Gram stain, culture, and sensitivity studies. If tuberculosis or a fungal infection is suspected, obtain an acid-fast stain and tuberculosis and fungal cultures. When a joint effusion is present or joint involvement is suspected, aspirate the joint and confirm with an arthrogram. The arthrogram helps document the location of the aspiration and is useful for positive as well as for negative aspirations, since it may also identify joint capsule rupture. Aspiration of the hip joint under ultrasound guidance is very helpful in children and adults.

The white blood cell count is generally elevated, depending on the severity of the infection, with an increase in immature or band cells. The erythrocyte sedimentation rate and the C-reactive protein are usually elevated. Obtain blood cultures in all cases of acute hematogenous osteomyelitis and in chronic osteomyelitis exacerbated by fever and bacteremia.

Roentgenograms taken early in the disease process generally show soft-tissue swelling. Bony changes are not present until 7–10 days after the onset of infection. Radionuclide bone scanning using radioactive-labeled isotopes, such as technetium-99m and, more specifically, gallium citrate-67 and indium-111-labeled white blood cells, is helpful in localizing the area of involvement and in helping diagnose the condition.

Plain technetium, sequential technetium-gallium imaging, and indium-labeled leukocyte scintigraphy are the studies most commonly used. Indium 111-labeled leukocytes have been reported by a number of investigators as being more useful than other imaging in osteomyelitis complicated by fractures and nonunions (11,38,40,63) (see Chapter 132). Aspiration is used for the diagnosis, especially when there is no drainage or sinuses, and in some cases bone biopsy may be necessary.

Magnetic resonance imaging (MRI) has added a new dimension to the diagnosis, localization, and characterization of the extent of infection. MRI has been reported by Modic et al. to have a 94% accuracy in diagnosing spine infections (40). T1- and T2-weighted images are the initial screening techniques for diagnosing osteomyelitis. The MR finding in osteomyelitis on T1-weighted image sequences is a low signal intensity due to a dark marrow signal and an increased signal intensity due to a bright marrow signal on the T2-weighted image sequences (Fig. 133.2, Fig. 133.3). MRI has decreased the need for bone scanning and provides more useful information. Do sinograms whenever there is a sinus tract or open draining area from which the depth and extent of the infection can be determined (Fig. 133.4). Do abscessograms whenever an abscess is present and frank pus is aspirated. The abscessogram will help outline the extent of the abscess cavity (Fig. 133.5). MRI, computed tomographic scanning, and radiographic tomogram are all useful tools in evaluating osteomyelitis.

***Figure 133.2.*** These are T1-weighted images of a 44-year-old woman with systemic lupus erythematosis and hematogenous osteomyelitis. There is decreased signal within the distal third of the tibia and a serpiginous area of low intensity consistent with osteonecrosis. A biopsy had been performed previously. At surgery, she had an abscess with sequestra.

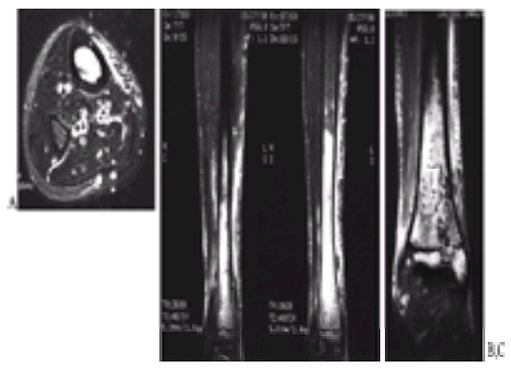

***Figure 133.3.*** These T2-weighted images of a 15-year-old boy show increased signal from the ankle to the mid tibia. There is increased signal in the adjacent soft tissues about the ankle and tibia. There is a minimal ankle effusion present. At surgery, the patient had an intramedullary abscess of the metaphysis and distal tibia.

***Figure 133.4.*** Anterior (**A**) and posterior (**B**) roentgenograms of a sinogram in a 21-year-old man with chronic osteomyelitis that tracks into the intramedullary cavity.

***Figure 133.5.*** Lateral radiograph (**A**) of a 15-year-old boy shows a subperiosteal abscess that was aspirated and injected with contrast material. Anteroposterior (**B**) and lateral (**C**) radiographs of a 9-year-old child show contrast material in the subperiosteal area and within the medullary cavity after pus had been aspirated. The contrast material demonstrates the extent of the abscess.

## PRINCIPLES OF TREATMENT OF INFECTED UNUNITED FRACTURES AND NONUNIONS

The principles of treatment are infection control, stabilization of the fracture, soft-tissue coverage, and bone graft of ununited fractures and large bone defects.

Infection control includes irrigation and debridement, culture and sensitivities, and antibiotic therapy. In chronic osteomyelitis, obtain aerobic, anaerobic, and fungal cultures. Recent studies have advocated taking of multiple deep cultures from purulent material, soft tissue, and bone (51,56). Marrie and Costerton postulated that different organisms may be growing in isolated microenvironments. Sampling differences and bacterial viability may influence the culture results (37).

Stabilization of the ununited fracture or nonunion is essential. Soft-tissue coverage may require the use of local muscle flaps and free vascularized muscle flaps for soft-tissue defects or an inadequate soft-tissue envelope after control of the osteomyelitis. Local muscle flaps and free vascularized muscle transfers also help by bringing in a new blood supply, which is important in host defense mechanisms, antibiotic delivery, and osseous and soft-tissue healing (46). For the tibia, use the gastrocnemius muscle for proximal-third defects, the soleus for middle-third, and for the distal-third, free vascularized muscle transfers.

For local muscle transfers, it is important to assess the muscle preoperatively and not to transfer damaged muscle. Also avoid using crushed or badly damaged muscle, as flap necrosis or flap complications may result. In these cases, use free vascularized tissue transfer. Do preoperative angiograms on patients whose vascular status has been altered from any cause.

## SURGICAL CONSIDERATIONS

### TOURNIQUETS

Apply a tourniquet whenever possible except in patients with sickle cell disease or significant peripheral vascular disease. The tourniquet improves hemostasis and thus facilitates identification of the infection process. In acute cases with swelling, cellulitis, or abscess formation, elevate the extremity for several minutes before inflating the tourniquet. In chronic osteomyelitis without significant cellulitis or abscess formation, use an elastic bandage to extravasate the extremity before inflating the tourniquet.

### DEBRIDEMENT

Thorough debridement of all sequestra and necrotic and desiccated bone is essential. Do not remove viable infected bone, so as not to create large bony defects. It is not necessary to debride viable infected bone. Dyes and tetracycline labeling have been used as a means of identifying necrotic bone, but I have not found these techniques to be useful.

Clinically dried out, exposed, desiccated bone is darker than normal and should be debrided. Necrotic bone that has not been exposed may appear at surgery more yellowish than viable bone, which is whitish. The main finding is that viable bone bleeds, whereas necrotic bone does not.

Use of an osteotome to superficially shave the outer cortex of the questionable bone results in small areas of punctate bleeding. Some bone that may have been exposed to air may be viable; in these cases, the exposed outer cortex should be debrided with an osteotome down to good bleeding bone. Evacuate all pus and abscess, and remove all necrotic and infected soft tissue.

### IRRIGATION

Use copious amounts of irrigating fluid, which cleanses the area of purulent exudate, loose soft tissue, and bony fragments, and decreases the bacterial count. I use 10 L of irrigating fluid for most infected wounds. I use 2 L of antibiotic solution containing 50,000 units of bacitracin and 1 million units of polymyxin per liter as the final irrigating solution. Other antibiotics can be used for topical irrigation as well.

### WOUND MANAGEMENT

The decision to leave a wound open or to close it requires careful judgment. In the majority of acute infections, and in all cases in which there is associated abscess formation with cellulitis and swelling, the wound should be left open. In some cases of early postoperative infection, the wound may be closed over drainage tubes, as long as the wound is thoroughly clean and the infection is not anaerobic.

In cases of chronic osteomyelitis in which there is no significant cellulitis or abscess formation and in which the wound has been adequately debrided and converted to

a clean wound, the wound may be closed over drainage tubes. In some cases in which bone or metal will be exposed if the wound is left open, a partial closure over the bone or metal may be desirable, as long as an adequate pathway has been provided for drainage. When there is any doubt, it is safest to leave the wound open. If the wound is closed, the wound site must be examined daily for any signs of infection; if such signs appear, the wound must be opened.

Many wounds heal nicely by secondary intention. In the case of large wounds or when delayed closure is preferable, do not attempt closure until two criteria are met. First, the wound should appear clinically healthy, with clean granulating tissue and without any purulent exudate or necrotic tissue. If infected necrotic tissues are present, redebride the wound until it appears healthy. Second, once the clinical appearance of the wound is clean, take quantitative tissue cultures and do Gram stains. Wounds with either a positive Gram stain or quantitative tissue cultures with a bacterial count greater than $10^{-5}$ organisms should never be closed. (A positive Gram stain implies a bacterial count of greater than $10^{-5}$ organisms.)

These wounds should be considered infected and reassessed for further surgical debridement and the appropriateness of the systemic antibiotic therapy. With experienced surgical teams, tissue cultures are not routinely performed. It has been our practice to do a thorough initial debridement followed by an *en bloc* excision of the wound at closure or muscle transfer.

In secondary closure of wounds, it is important to redebride the wound at the time of closure and to do *en bloc* resection of the granulating tissue for several reasons. First, although the bacterial count is low, these tissues should still be considered contaminated; debridement will further reduce the bacterial count and thereby diminish the chance of infection. Second, debridement allows for cleaner, healthier tissue to be approximated by wound closure or covered by muscle transfer.

### DRAINS

When the wounds are closed, Silastic (Jackson-Pratt) or polyethylene (Hemovac) drains may be used. I prefer the Jackson-Pratt drains. Penrose drains, made of rubber, are the most reactive, and if left in for long periods can cause foreign-body granulomas. Do not use Penrose drains in orthopaedic infection management.

Remove the suction drain in 48–72 hours. The drain allows the removal of all hematoma and tissue fluid, and the collapse of the potential dead space. The drains should be removed under sterile conditions and the tip cut off and sent for culture and sensitivity tests.

The drain tends to attract whatever bacteria are present because it is a foreign body and because tissue fluids are removed through it. In general, a positive culture of the drain tip is a bad prognostic sign: It means that bacteria remain behind. Monitor the clinical course and wound site closely; if any clinical signs of wound infection reappear, it may be necessary to consider redebridement and reassessment of antibiotic therapy.

### WOUND PACKING

The purpose of leaving a wound open is to allow drainage. Make certain, therefore, when packing wounds with gauze or other materials, that packing does not obstruct drainage. If it does, the purulent exudate will be retained in the wound, possibly causing tissue breakdown and necrosis with secondary cellulitis or even abscess formation. It is best to put wicks perpendicular to the open wound to allow free drainage. Wicks can be either povidone-iodine (Betadine)-soaked gauze, plain gauze, or fine-mesh gauze. The size varies with the size of the wound. The ends of the wicks should always protrude through the skin edges to allow easy access and removal and to prevent retention.

### ANTIBIOTIC BEAD POUCH

Antibiotic-loaded beads were first introduced by Klaus Klemm for use in osteomyelitis (30,31). Henry, Seligson, and Ostermann introduced a physician-made antibiotic bead pouch for use in open fractures (25,43). This concept has been expanded, and I now use a physician-made antibiotic bead pouch during the interval between the initial debridement and the time of muscle transfer, a median of 4 days. Microbe-specific antibiotic(s) can be added to either Palacos or Simplex PMMA. I prefer Palacos: The antibiotic elution has been reported by some investigators to be better them Simplex. Although most antibiotics may be added to PMMA depending on the microbial sensitivity results, tobramycin and other aminoglycosides are the most commonly used antibiotics.

I use 2.4 g tobramycin to 40 g Palacos PMMA, an amount sufficient to make enough bead chains to fill large defects. I use a mold to make 6- or 7-mm beads strung on 24- or 26-mm wire. For those surgeons who make beads without a mold, the bead size should be small because increased surface area allows for better antibiotic elution. The beads are then covered by Tegaderm, Opsite, or an equivalent material. The advantages of the antibiotic bead pouch used in this fashion are high local antibiotic levels with low systemic toxicity and less chance for secondary contamination because the wound is covered. Also important is patient comfort, as dressing changes are not required, and there are decreased requirements for wound care.

## SURGICAL TECHNIQUES

### HEMATOGENOUS OSTEOMYELITIS

Hematogenous osteomyelitis is most often seen in infants, children, drug abusers, and immunosuppressed hosts. In 1894, Lexer injected laboratory animals with *S. aureus* organisms and then traumatized a bony area, causing infection to appear at that site (34). Hobo explained that the predilection for the metaphysis in acute osteomyelitis was due to the fact that the arteries in this location are end arteries, that there is slowing of the venous flow in the sinusoids, and that phagocytosis is defective in this area (27).

Trueta later expanded on Hobo's work (65). Once the metaphyseal region is seeded and exudate or pus forms, the suppurative process may then travel under pressure through the Volkmann canals into the subperiosteal region, extend itself within the medullary cavity, or spread into the epiphysis (Fig. 133.6). It is not uncommon for the joint to be involved secondarily, especially a joint in which the metaphysis is intra-articular, such as the hip or shoulder. Often the abscess extends into the soft tissues as well (42,67).

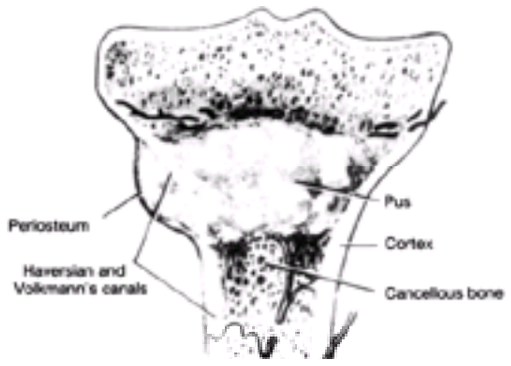


***Figure 133.6.*** Outline of the pathophysiology of hematogenous seeding. When under pressure, the exudate or abscess can extend through the Volkmann canals into the subperiosteal region, and from there into the intramedullary cavity or the epiphysis. (Modified from Hobo T. Zur Pathogenese der Akuten Haematogene Osteomyelitis, mit Berucksichtigung der Vitalfarbungslehre. *Acta Sch Med Univ Imper Kioto* 1921;4:1.)

In cases in which the disease is not diagnosed promptly or in which either inadequate or no treatment is given, the disease enters the subacute stage (Fig. 133.7). Because of the introduction of antibiotics and improved diagnostic and surgical techniques, the chronic stage and its sequelae are no longer seen as frequently as they used to be.

***Figure 133.7.*** **A:** A frog-leg lateral view shows a lytic area in the metaphysis of a 7-year-old boy with a 6-month history of pain and a limp. **B:** Anteroposterior radiograph taken at the time of biopsy. The lesion was found to be a subacute osteomyelitis caused by a *Staphylococcus aureus* organism.

One question that arises in the treatment of acute hematogenous osteomyelitis is whether to treat all patients surgically. Unless clinical evidence of an abscess is present, I treat patients with systemic antibiotics and without surgery. However, the clinical situation must be repeatedly assessed during treatment. Many osteomyelitic processes are seen early in the disease process or represent a cellulitic process of the bone, and pus or the abscess phase may not occur.

Although some authors have not found it necessary to drill a window in cases of subperiosteal or soft-tissue-extended osteomyelitis, I routinely window the cortical bone for better debridement of the residual intramedullary abscess and necrotic bone and tissue (Fig. 133.8) (see Chapter 176).

***Figure 133.8.*** **A:** Anteroposterior radiograph in a child shows destructive lytic changes in the metaphyseal region with periosteal reaction. **B:** Lateral film shows the extent of the cortical window made for debridement of the medullary abscess. **C:** Lateral film taken 7 months later shows healing of both the cortical window and the osteomyelitic process.

***Cortical Windowing for an Acute Intramedullary Abscess of the Tibia***

- Using tourniquet control, make a longitudinal incision along the posterior border of the medial tibia and over the affected part of the tibia. If a subperiosteal abscess is present (more likely in a child than in an adult), incise the periosteum longitudinally over the abscess.
- If no subperiosteal abscess is found, observe the status of the cortex. The infected area is often soft and may be pitted, with or without obvious cortical destruction.
- Drill several holes through the cortex into the medullary canal. Unless the intramedullary abscess has already decompressed itself into the subperiosteum or soft tissues, pus will exude through these holes.
- Outline with a drill an elongated cortical window extending along the extent of the intramedullary abscess. The outlined elongated window should be centered in the posterior half of the anteroposterior diameter of the bone to allow for dependent drainage. The length of the window depends on the extent of the intramedullary abscess, and the width depends on the diameter of the bone. For children, use a 1- to 2-cm-wide window. After debridement of any obvious sequestrum and copious irrigation, insert a Betadine gauze into the wound and leave it open. A similar type of window of the femur is made for osteomyelitis of the femur.

**OSTEOMYELITIS FOLLOWING OPEN FRACTURES**

For acute osteomyelitis following an open fracture, it is important to assess the extent of the infection and to obtain a Gram stain, culture, and sensitivity test. Start appropriate systemic antibiotics, and take the patient to surgery for irrigation, debridement, and stabilization of the fracture if it is not already adequately stabilized (Fig. 133.9). The majority of fractures in the tibia can be stabilized with half-pin external fixation devices. Use a biplanar or delta frame for more stability if required.

***Figure 133.9.*** **A:** A 28-year-old man with an infected open fracture. **B:** There is a clean granulating wound 12 days after the fracture had been irrigated, debrided, and stabilized with an external fixator and the patient given systemic antibiotic. At this time, biplanar fixation with half-pins rather than full-length pins would be performed.

Once the open fracture infection has been controlled and the fracture stabilized, perform cancellous autogenous bone grafting, particularly for fractures with bone deficiency and type III open fractures. Fracture healing, which facilitates infection control, is an important principle in the management of infected nonunited fractures and nonunions. Although many fractures heal in the presence of infection, infection interferes with the osteogenic process and may lead to nonunion by a number of mechanisms: The bacteria compete with osteogenic cells for oxygen and nutrients, activate enzymes deleterious to the osteogenic process, lower the pH, affect oxygen potential, interfere with the differentiation of osteogenic cells, and retard tissue maturation.

For both unstable infected open tibial fractures and type III infected open tibial fractures, I recommend early autogenous cancellous bone grafting through a posterolateral approach. Alternatively, if a muscle flap has been made anteriorly for soft-tissue coverage, an autogenous cancellous bone graft can be done anteriorly 6 weeks later, provided there is no evidence of recurrent infection.

## HINTS AND TRICKS

- Avoid making a cortical window directly under the skin incision; the soft tissues will not granulate over a cortical defect, and skin coverage therefore will not occur. A muscle transfer may then be necessary.
- Make the cortical window in the dependent one half of the anteroposterior diameter of the bone to allow for adequate drainage.
- Avoid making too large a cortical window, which can lead to pathologic fractures, especially if the width is excessive.
- In children, in whom the usual location for hematogenous osteomyelitis is the metaphysis, be careful not to damage the epiphyseal plate. Use roentgenograms intraoperatively to help locate the physis.
- If follow-up cultures are positive or if pus continues to drain, consider performing a second irrigation and debridement.
- Postoperatively, apply a posterior splint. A wound left open generally closes by secondary intention within 3 weeks.
- Recommend protected weight bearing in a cast or orthosis for 6–12 weeks whenever a cortical window is used.

***Posterolateral Bone Grafting of the Tibia***

Posterolateral bone grafting is particularly useful in achieving union of an infected nonunion or an infected fracture of the tibia. Freeland and Mutz have reported a 100% union rate in 26 patients with infected nonunions treated in this manner (14). I have achieved a union rate of approximately 91% in the treatment of 61 infected tibial nonunions (49).

The approach is used for the distal two thirds of the tibia. It was described by Harmon and is also used for tibia-pro-fibula grafting (23) (Also, see Chapter 3).

- Place the patient in either a prone or a lateral decubitus position. Identify the posterior border of the fibula and the lateral border of the gastrocnemius muscle. Using tourniquet control, begin an incision of appropriate length along the lateral border of the gastrocnemius and posterior to the fibula.
- Once you have cut through the subcutaneous structure, identify the peroneal muscles anteriorly and develop a plane between the peroneals and the posterior muscles consisting of the gastrocnemius, the soleus, and the flexor hallucis longus muscles.
- Now reflect the soleus and flexor hallucis longus posteriorly and medially to expose the posterior aspect of the fibula.
- Elevate the origin of the tibialis posterior muscle from the posterior aspect of the interosseous membrane. Locate the posterolateral border of the tibia and, using sharp dissection, expose the posterior surface of the tibia by stripping the muscles subperiosteally off the tibia. In the distal one third of the tibia, approximately four to five fingerbreadths above the tip of the lateral malleolus, an interosseous arteriole branch from the peroneal artery perforates the interosseous membrane and travels anteriorly to anastomose with the anterior tibial artery. Take care to protect this vessel. The posterior tibial neurovascular bundles lie between the tibialis posterior and flexor hallucis longus muscles and are not visible. The muscular branches of the peroneal artery lie within the peroneal muscles.
- Once the posterior aspect of the tibia is exposed (Fig. 133.10), prepare the tibia and the posterior aspect of the fibula for bone grafting by roughening up the cortex with either a burr or an osteotome. Be extremely careful not to disturb the fracture site so as to avoid contamination posteriorly.

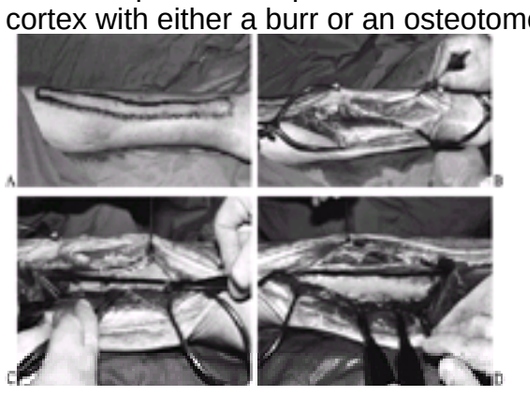

***Figure 133.10.*** **A:** A cadaveric specimen outlining the fibula. A skin incision varying with the exposure desired is made just posterior to the fibula along the lateral border of the gastrocnemius and soleus muscles. **B**,**C:** The peroneal muscles are retracted anteriorly and the border of the fibula is exposed. The tibialis posterior and the flexor hallucis muscles are dissected from the interosseus membrane and the posterior tibia and retracted posteriorly. The posterior tibialis neurovascular bundle is protected by the tibialis posterior and flexor hallucis longus muscles, which it lies between. **D:** The posterior aspect of the fibula is now exposed, and the posterior border of the fibula and interosseous membranes are visible.

- Lay cancellous bone grafts posteriorly several inches above and below the fracture site and between the tibia and fibula across the interosseous membrane. The objective is to achieve not only union of the fracture site, but also a tibial–fibular synostosis (Fig. 133.11). A 1.5–2 oz medicine glass filled with cancellous bone is generally sufficient to repair a nonunion without bone loss.

***Figure 133.11.*** Anteroposterior and lateral films show healing of the fracture following the posterolateral bone graft. Note the synostosis between the tibia and fibula.

- At this point, release the tourniquet and achieve hemostasis. Insert a Silastic drain. Allow the peroneal muscles and posterior muscle mass to return to their anatomic positions. Do not close the deep fascia.
- Close the subcutaneous tissues and skin with interrupted sutures.
- Remove the Silastic drains in approximately 48 hours and elevate the leg for 72 hours.
- Start full weight bearing to tolerance 7 days postoperatively if the patient is immobilized in a cast.
- If an external fixator is used for an unstable fracture, it can generally be removed at 6–8 weeks and a walking cast applied.
- Union generally occurs in 4–7 months, median time being 6 months.

**HINTS AND TRICKS**

- An arteriogram obtained before this procedure is performed can help determine what vessels are patent and where they are.
- Be aware of the location of the neurovascular structure.

**DEAD-SPACE MANAGEMENT**

It is important that soft-tissue and bony defects be filled to reduce the chance of continued infection and loss of function. Advances in microvascular techniques have made possible the transfer of muscle, myocutaneous, osseous, and osteocutaneous flaps to the soft-tissue and bony defects. Fitzgerald et al. reported a 93% success rate in the treatment of chronic osteomyelitis with local muscle flaps combined with thorough debridement and specific antimicrobial therapy (12). Our results using this technique have also been encouraging (46).

In general, for soft-tissue defects involving the proximal third of the tibia, use the gastrocnemius muscle; for those involving the middle third, use the soleus muscle; and for those involving the distal third, use a free-tissue transfer.

In cases of bony defects, perform autogenous cancellous bone grafting six or more weeks later. The muscle flap can be elevated and cancellous bone grafting performed underneath, provided there are no signs of infection (Fig. 133.12).

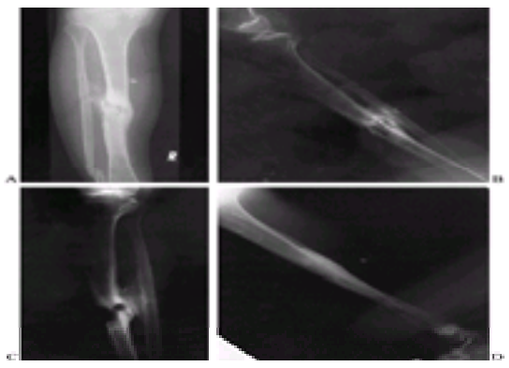

***Figure 133.12.*** Anteroposterior (**A**) and lateral (**B**) radiographs of the tibia and fibula in a 21-year-old man who had a previous posterior bone graft and now shows the presence of a large sequestrum. Lateral film (**C**) shows debridement of the infection and sequestra. Lateral film (**D**) taken 10 months after a local flap was performed and an autogenous cancellous bone graft was performed.

According to Weiland et al., the highest rate of recurrence of infection in free-tissue transfer in osteomyelitis is found in cases associated with a segmental bone defect (70). It has been our experience that the fibula is the key factor in treating osteomyelitis with segmental bone loss of the tibia. If there is a bony defect or segmental loss of both the fibula and tibia with chronic osteomyelitis, an amputation is advisable. If the fibula is intact or without a bony defect, reconstruction of the bony defect is more likely to be successful. For defects up to 6 cm, autogenous cancellous bone grafting can be done (Fig. 133.13).

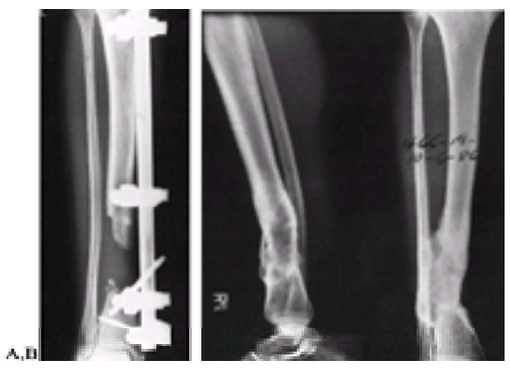

***Figure 133.13.*** **A:** Anteroposterior radiograph of a 34-year-old woman with approximately a 6 cm defect. **B:** Anteroposterior and lateral films taken 1 year following performance of an autogenous cancellous bone graft to fill dead space caused by bony defects.

In larger defects, use a free vascularized osseous graft. A tibia-pro-fibula synostosis using the previously described posterolateral approach can be done when a free vascularized osseous graft or autogenous cancellous bone grafting of the defect is not possible (Fig. 133.14). The fibula hypertrophies with time, allowing for functional weight bearing.

***Figure 133.14.*** **A:** Anteroposterior and lateral radiographs of a 48-year-old man who developed clostridial myonecrosis after an open fracture of the tibia and treatment with a tibia-pro-fibula synostosis. The distal synostosis site was bone grafted first and is seen here 10 weeks postoperatively. **B:** Radiographs taken 4 years after the tibia-pro-fibula synostosis for the segmental defect. Note the synostosis proximally and distally, and the hypertrophy of the fibula. **C:** Healed wounds show no evidence of recurrence of infection. Notice the area of defect in the middle calf area.

Another procedure for dead-space management is the open cancellous bone grafting procedure described by Rhinelander (57) and by Papineau et al. (45). This procedure is useful when tissue transfer is not possible.

***Open Cancellous Bone Grafting***

Open cancellous bone grafting has been effective in the treatment of infected bone defects. Papineau et al. (45), Roy-Camille et al. (59,60), Rhinelander (57), Higgs (26), Knight and Wood (32), Coleman et al. (9), Bickel et al. (2), and Green and Dlabal (19) have all reported favorable results. However, because of the associated long hospitalization time, long healing time, high complication rate, meticulous care required, and resulting unstable scar skin, I use it only if local muscle transfers or free-vascular tissue transfers with secondary cancellous bone grafting cannot be done.

There are three stages to this technique:

- Thorough debridement of all infected tissues, repeated as necessary; stabilization of the fracture with an external skeletal fixator
- Cancellous autogenous bone grafting into a defect lined with clean uninfected granulation tissue
- Skin coverage either by secondary epithelialization or, in larger defects, by split-thickness skin grafting

- Debride all infected soft tissue and sequestra, and debride all necrotic bone to bleeding osseous tissue. Perform stabilization using an external skeletal fixator.
- When exposed surfaces are covered with clean granulation tissue, pack finely morcelized autogenous cancellous bone into the defect created by the bone debridement or previous bone loss. The diameter of the graft should be slightly larger than the diameter of the bone being replaced, since the graft will tend to contract. Rhinelander recommends that the maximum graft thickness be 1.5 cm from the nearest granulation surface (57).
- Dress the wound with gauze and keep it moist with a physiologic irrigating solution such as Ringer's lactate, either by intermittent soaking of the dressings or by a slow intravenous drip. The dressing, which should be changed daily, is to be soaked with physiologic solution until the wound is covered by epithelialization or, in some cases, by secondary split-thickness skin grafting (Fig. 133.15).

***Figure 133.15.*** **A:** Lateral radiograph of the tibia and fibula in a 37-year-old woman with loss of the tibia following an infection that developed after the patient sustained a type III open fracture. **B:** Anteroposterior photograph shows the soft-tissue and bone loss and exposed tibial shaft. **C:** Photograph taken at the time of autogenous cancellous bone grafting of the dead space. **D**,**E:** Anteroposterior and lateral radiographs, taken after the grafts had consolidated, show healing of the fracture. **F:** Lateral photograph, taken 3 years after the procedure, shows knee flexion and the appearance of the leg. The patient has been free of infection.

**HINTS AND TRICKS**

- Make sure all necrotic soft tissue and bone are debrided.
- Stabilize the fracture.
- There must be a clean granulating base before autogenous cancellous bone grafting is performed. Do a quantitative tissue culture and Gram stain. If the quantitative tissue culture yield is greater than $10^{-5}$ organisms, or if the Gram stain is positive (implying the presence of more than $10^{-5}$ organisms), do not perform the cancellous bone grafting. A count greater than $10^{-5}$ organisms is consistent with infection, in which case redebridement is necessary.

**OSTEOMYELITIS IN THE PRESENCE OF INTERNAL FIXATION FOR FRACTURE STABILIZATION**

Osteomyelitis in conjunction with internal fixation for fracture stabilization poses a special problem for the surgeon. Should the metal be removed or left in? The answer to this question is guided by such factors as the stage of fracture healing, the amount of stability provided, the amount of time since surgery, and the location of the fracture.

Gristina and Costerton reported that in 76% of prosthesis-related infections, microorganisms grew in a biofilm or glycocalyx that adhered to the surfaces of the biomaterials present (21). They suggested that infections in the presence of orthopaedic implants may be more resistant than normal to host defense mechanisms and to antimicrobial therapy.

If osteomyelitis develops in the presence of metal with a healed fracture, remove the metal. If the fracture is not united and the metal is not providing stability, remove the metal and restabilize the fracture. In the immediate postoperative period (within the first 1–6 weeks), retain the internal fixation device if it is stable and is required.

If the internal fixation device is stabilizing a nonunited articular fracture, retain it (Fig. 133.16). In general, for late infected nonunion of tibial shaft fractures with internal fixation, I recommend removal of the internal fixation device and stabilization with an external fixator. For late nonunion infections of the femur with plate fixation, I recommend removal of the plate and eventual stabilization with an intramedullary rod.

***Figure 133.16.*** **A:** Anteroposterior radiograph of the distal tibia and fibula showing a comminuted fracture of the tibia and plafond. **B**,**C:** Anteroposterior and lateral films taken following open reduction and internal fixation show fractures nonunited at the time of infection. **D:** Anterior photograph of the ankle shows exposed metal and ankle joint with a necrotic anterior tibialis tendon after an acute postoperative infection. **E:** There is no evidence of infection 9 months following removal of metal and a free-vascularized latissimus dorsi muscle transfer.

In femoral infections with intramedullary rods, an exchange rodding is preferred. If an extensive intramedullary abscess with cellulitis is present, it may be necessary to insert antibiotic beads into the medullary canal, treat the patient in traction for several days, and then redebride the femur and stabilize the fracture with an intramedullary locked nail. I prefer intramedullary nail stabilization over external fixation in most cases because of the propensity for pin loosening, infections, and binding down of muscles with external fixation.

At the time of debridement, it is important to remove the infected membrane from within the canal by reaming followed by copious pulsatile irrigation. In the case of infected intramedullary nails involving the femoral shaft (unless there is an extensive associated intramedullary abscess), the metal does not adversely affect eradication of the infection, provided the infection has been appropriately treated with surgical debridement and parenteral antibiotics followed by fracture healing with or without autogenous cancellous bone grafting (54).

**OSTEOMYELITIS OF THE METATARSAL HEADS AND PHALANGES FOLLOWING PUNCTURE WOUNDS OF THE FOOT**

*Pseudomonas* has been reported to be the most common organism causing infection following nail puncture wounds of the foot. The treatment that produces the best results consists of surgical drainage, debridement, and curettage of the puncture wound in the bone, and debridement of all necrotic bone, along with specific antibiotic therapy. The antibiotic of choice for *Pseudomonas* infections is generally tobramycin, in combination with either piperacillin or a third-generation cephalosporin, depending on the sensitivity reports. Continue systemic antibodies for approximately 3 weeks (Fig. 133.17, Fig. 133.18).

***Figure 133.17.*** The plantar aspect of the foot of a 5-year-old child has swelling, erythema, and abscess formation following a nail puncture wound to proximal phalanx of the second toe.

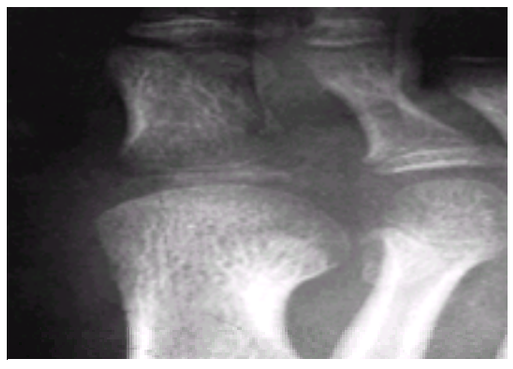

***Figure 133.18.*** Anteroposterior radiograph of a 6-year-old child shows osteomyelitic changes of the proximal metaphysis with involvement of the first metatarsal phalangeal joint.

In most cases, use a plantar approach. A dorsal incision can be used when there is joint involvement, provided that debridement of the plantar surface of the metatarsal head or proximal phalanx is accomplished.

***Plantar or Hoffman Approach***

- Make a plantar transverse incision distal to the weight-bearing area of the metatarsal heads but proximal to the web space of the toes. Carry the incision down through the subcutaneous tissues and identify the flexor tendons, which should be retracted to expose the involved metatarsal head.
- Incise the periosteum and elevate it to expose the proximal metatarsal; generally, the periosteum has been destroyed and this latter step is not necessary.
- Identify the area of osteomyelitis, and curet and debride the lytic infected bone. If there has been extensive destruction of the metatarsal head, the head can be excised through this approach.

**HINTS AND TRICKS**

- Be certain to debride all necrotic tissue.
- Always curet the bony puncture site when it is identifiable because this site could be a source of continued infection.

***Dorsal Incision***

- Make a longitudinal incision over the affected joint. Retract the extensor tendons. Identify the joint capsule and incise it longitudinally. Debride the joint of any necrotic tissue.
- Next, free the soft tissue from the plantar surface of the metatarsal, debride any necrotic bone and tissue, and curet the puncture site.
- Finally, irrigate the wound with copious amounts of irrigating fluid, and leave a small Betadine gauze or wick in the wound.

**OSTEOMYELITIS OF THE METATARSAL**

The metatarsals are most likely to be infected in diabetic patients or persons who have open fractures. Depending on the extent of the infection, local debridement of all soft tissue and bone may be satisfactory. In more extensive infections in which the entire metatarsal is necrotic, it may be necessary to remove it.

- Make a longitudinal incision over the involved bone extending from just distal to the distal row of tarsal bones to the middle of the proximal phalanx of the involved toe.
- Identify the extensor tendons and retract them.
- Identify the involved metatarsal, incise the periosteum longitudinally, and strip it and all soft tissues from the bone.
- Resect the entire shaft or part of the shaft as indicated. In children, avoid injury to the physis.

**HINTS AND TRICKS**

Infrequently, especially following open fracture infections, there may be extensive soft-tissue loss with exposed viable bone. In such a case, it may be necessary to perform tissue transfers, including free-vascularized tissue transfers, for coverage.

- Irrigate the wound with copious amounts of irrigating fluid. Pack the wound loosely with a Betadine gauge or a fine-mesh gauze and leave a wick protruding from the wound. When the infection is more localized, use a smaller longitudinal incision over the involved metatarsal.
- Apply a below-the-knee splint and dress the wound.

**OSTEOMYELITIS OF THE CALCANEUS**

Osteomyelitis of the calcaneus can be extremely difficult to eradicate and requires adequate, thorough debridement. In early involvement, extensive local debridement and curettage are usually sufficient. With extensive involvement of the calcaneus, resection of the diseased area is necessary to eradicate or control the infection. Osteomyelitis occurring either medially or laterally in the calcaneus usually follows pin-track infections, gunshot wounds, or open fractures.

Medial and lateral approaches to the calcaneus are useful in draining a localized abscess, curetting the infected bone tissue, doing a local resection, and windowing the bone cortex for an osteomyelitic abscess.

In osteomyelitis involving the plantar surface of the calcaneus, use the approach described by Gaenslen (15), with modifications. Gaenslen divided the calcaneus with an osteotome from posterior to anterior, thereby exposing the inside of the bone. He used this technique primarily to treat hematogenous osteomyelitis.

The technique has a very serious drawback, however, in that it creates a fracture, which could cause an infection to continue, leading to extensive bone loss. Therefore, avoid splitting the calcaneus when you plan to preserve it. Excision of the calcaneus through this approach, especially when there is a wound or fistula on the weight-bearing surface of the heel, works well.

- With the patient prone, make a longitudinal incision centered in the midline of the heel. Start the incision just inferior to the insertion of the Achilles tendon on the tuberosity, and extend it plantarward approximately to the level of the base of the fifth metatarsal.
- Incise the plantar aponeurosis in a plane between the abductor digiti quinti and flexor digitorum brevis muscles. Visualize the lateral plantar artery and nerve in the distal aspect of the wound and retract them medially.
- Expose the quadratus plantar muscle and split both it and the long plantar ligament longitudinally. The plantar surface of the calcaneus is now exposed. For localized infection use a curet to remove sequestra, infected tissue, and sinuses. For more extensive involvement use an osteotome to resect the involved bone parallel to the plantar surface of the foot (Fig. 133.19). After debridement and copious irrigation, place a Betadine-soaked gauze dressing in the wound and leave the wound open.

***Figure 133.19.*** Lateral radiograph of a 42-year-old man demonstrates extensive destruction of the calcaneus by osteomyelitis. A marking pen outlines the area of bones to be resected.

- Postoperatively, change dressings daily. Permit weight bearing after the incision has healed.

**OSTEOMYELITIS OF THE FIBULA**

Depending on the extent of the infection, it is safe to excise the proximal three fourths of the fibula, provided the fibular collateral ligament and the biceps femoris tendons are inserted into the tibia when this area of bone is sacrificed. The distal one fourth should not be excised, because excision would lead to impaired function of the ankle, and deformity. If it is necessary to remove this part, a tibial–talar fusion will be necessary later.

- Make a longitudinal incision, starting on the posterior border of the fibula from the head of the fibula and extending distalward as needed. This incision can be carried down the entire length of the fibula.
- Identify the common peroneal nerve in the proximal part of the wound; it crosses under the peroneus longus just distal to its attachment to the lateral surface of the head of the fibula. Identify the fascial plane between the soleus muscle and the peroneal muscles anteriorly, and carry the dissection down to the fibula.
- Retract the peroneal muscles anteriorly, and expose the fibula by incising the periosteum. Take care not to injure the branches of the deep peroneal nerve, which lie on the deep surfaces of the peroneal muscles at the neck of the fibula and proximal 5 cm of the fibula. Now expose the fibula, and debride or resect the infected area.

**HINTS AND TRICKS**

- Debridement is the key. Don't be hesitant to resect all infected necrotic bone.
- Be careful of the lateral plantar neurovascular structures.

- The distal one fourth of the fibula is subcutaneous and can be easily exposed by a longitudinal incision along the posterior border of the fibula.
- A Betadine-soaked gauze strip can be loosely placed in the wound.
- Apply a long posterior molded splint. Dress the wound daily.

**OSTEOMYELITIS OF THE PATELLA**

- Expose the patella through a longitudinal skin incision that starts just proximal to the patella and extends distally to the inferior pole. Carry the incision down through the subcutaneous tissue and fascia to the periosteum.
- Incise the periosteum and elevate it with a periosteal elevator. Curette and debride the involved area of bone.
- In cases of extensive involvement of the patella, either part or all of the patella can be removed. In cases in which the knee joint is involved, irrigate the knee with 10 L of irrigating fluid. Close the joint capsule over Silastic drainage tubes, which are removed in 48–72 hours.

**OSTEOMYELITIS OF THE FEMUR**

The predisposing factors leading to osteomyelitis of the femur are very important in its management. For hematogenous osteomyelitis, windowing of the cortex as described in this chapter is the preferred method of treatment.

***Posterolateral Approach***

- Use either a lateral decubitus position or turn the patient slightly to elevate the involved extremity. This approach provides access to the entire femoral shaft.
- Make an incision from the base of the greater trochanter distally to the lateral femoral condyle, depending on the desired length of exposure. Incise the superficial fascia and the fascia lata along the anterior border of the iliotibial band.
- Expose the vastus lateralis muscle and retract it anteriorly. Continue along the anterior surface of the lateral intermuscular septum, which attaches to the linea aspera.
- Expose the periosteum and incise it longitudinally. Then use a periosteal elevator to expose the bone. Debride the area of infected necrotic tissue and bone.
- In cases of nonunion in which a plate is present and the infection is seen late, remove the plate and apply an external fixation device. Follow with an autogenous cancellous bone-grafting procedure when the infection is controlled.
- In the middle third of the thigh, take care to identify and ligate the second perforating branch of the profunda femoris artery and vein, which travel transversely from the biceps femoris to the vastus lateralis. Avoid damaging the sciatic nerve and profunda femoris artery and vein by not dividing the long and short heads of the biceps femoris muscle.

**OSTEOMYELITIS OF THE ILIUM**

Infection involving the ilium can occur on the medial, or inner, cortex and on the lateral, or outer, cortex, or on both. Hematogenous seeding is more common in young persons. In adults, osteomyelitis usually occurs following open fractures, bone-grafting procedures, or, in debilitated patients confined to bed, secondary to pressure sores.

- Make an incision along the crest of the ilium extending the length of the infected area. Extend the dissection through the subcutaneous tissues to the crest.
- Incise the periosteum over the top of the crest and subperiosteally strip the muscles from the lateral cortex of the iliac wing. Identify the abscess, if one is present, and the extent of bone involvement. Drain the abscess and debride all necrotic bone. Window the cortex as necessary. Be careful of the lateral femoral cutaneous nerve, which normally lies just medial to the anterior superior iliac spine. Perform local resection of the ilium for extensive local involvement, especially in chronic osteomyelitis (Fig. 133.20).

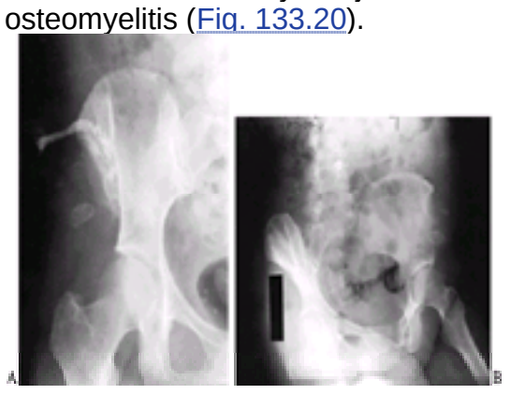

***Figure 133.20.*** **A:** Anteroposterior view of the ilium and hip showing a sinogram tract down to the ilium. This 44-year-old woman developed chronic osteomyelitis of the ilium following an open fracture. She had undergone multiple previous procedures. **B:** Radiograph after local resection of the ilium.

### OSTEOMYELITIS OF THE ISCHIUM AND PUBIS

Osteomyelitis involving the ischial tuberosity is usually encountered in paraplegics or patients who are bedridden and develop pressure sores with secondary infection, necrosis, and osteomyelitis. In these infections, it is necessary to debride all necrotic tissue, after which the infected ischial tuberosity can be resected with an osteotome and mallet. Irrigate the wound copiously and leave it open, with Betadine-soaked gauze inserted into it to allow for drainage. In paraplegic patients, soft-tissue transfers are often necessary following infection control.

Abscesses in the ischiorectal fossa or beneath the obturator externus or internus often develop with osteomyelitis of the pubis and ischium.

### OSTEOMYELITIS OF THE RADIUS AND ULNA

The ulna and the radius are most likely to become infected after open reduction and plating of fractures.

- Because the posterior surface of the ulna lies subcutaneously essentially throughout its length, expose the ulna by a skin incision carried down through the fascia and periosteum.
- Approach the radius in its distal third by the anterior approach, as described by Henry (24). Expose the proximal fourth of the radius with an anterior Henry incision or an extended Thompson approach.
- The middle two thirds of the radius can then be exposed by the Thompson approach (64) (see Chapter 1).

### OSTEOMYELITIS OF THE HUMERUS

In adults, osteomyelitis of the humerus most commonly follows internal fixation of the humerus. Often, draining sinuses are present (Fig. 133.21).



***Figure 133.21.*** A sinogram tract down to metal and bone. The patient had persistent drainage for 7 months following open plating of the humerus. Notice that the fracture is healed.

- After assessing the extent of the infection, expose the humeral shaft through an anterolateral approach (see Chapter 1). Make a skin incision along the anterior border of the deltoid muscle, extending it distally along the lateral border of the biceps muscle to within several inches of the elbow joint. Identify the cephalic vein and ligate it.
- Retract the deltoid laterally and the biceps medially to expose the proximal shaft. Distal to the deltoid insertion, identify the brachialis and split it longitudinally to the bone, retracting the lateral half laterally and the medial half medially. The radial nerve is protected by the lateral half of the brachialis muscle. In the distal third of the exposure, identify the radial nerve, which lies between the brachioradialis and brachialis muscles, and protect it. Avoid injury to the musculocutaneous nerve.
- Debride all infected and necrotic bone and soft tissue. If the humerus is unstable, remove the internal fixation and stabalize with external fixation. Leave the wound open.

### ILIZAROV PROCEDURE

In osteomyelitis, the Ilizarov procedure has been found to be useful for the treatment of extensive bone loss problems or for angulatory nonunions (44) (Fig. 133.22). A more extensive discussion of the Ilizarov technique is presented in Chapter 32.

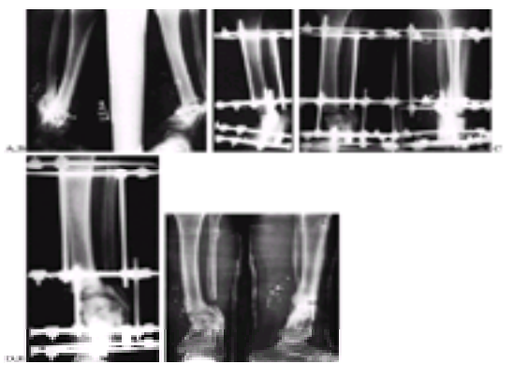

***Figure 133.22.*** Correction of deformity and subsequent healing process in a 29-year-old man with an infected nonunion of the tibia in marked varus, treated with the Ilizarov technique.

## ACKNOWLEDGMENT

I want to thank Dr. Paul Holtom, Associate Professor of Clinical Medicine and Orthopaedic Surgery, section of Infectious Disease, University of Southern California School of Medicine, for his technical assistance in the antibiotic section of this chapter.

### CHAPTER REFERENCES

Each reference is categorized according to the following scheme: *, classic article; #, review article; !, basic research article; and +, clinical outcome study.

+ 1. Bach MC, Cocchetto DM. Ceftazidime as Single-agent Therapy for Gram-negative Aerobic Bacillary Osteomyelitis. *Antimicrob Agents Chemother* 1987;31:1605.

+ 2. Bickel WH, Bateman JG, Johnson WE. Treatment of chronic osteomyelitis by means of saucerization and bone grafting. *Surg Gynecol Obstet* 1953;96:265.

+ 3. Bowerman SG, Green NE, Mencio GA. Decline of Bone and Joint Infections Attributable to *Haemophilus influenzae* Type b. *Clin Orthop* 1997;341:128.

* 4. Bucholz HW, Elson RA, Heinen K. Antibiotic-loaded Acrylic Cement: Current Concepts. *Clin Orthop* 1984;190:96.

* 5. Bucholz HW, Engelbrecht H. Uber die Depotwirkunk Einiger Antibiotica bei Vermischung mit dem Kunstharz Palacos. *Chirurgie* 1970;41:511.

# 6. Canale ST, ed. *Campbell's Operative Orthopaedics*, 9th ed. St. Louis, MO: CV Mosby, 1998.

+ 7. Cierney G III. Chronic Osteomyelitis—Results of Treatment. In: Green WB, ed. *Instr Course Lect* 1989;39:495.

* 8. Cierney G III, Mader JT, Penninck JJ. A Clinical Staging System for Adult Osteomyelitis. *Contemp Orthop* 1985;10:17.

+ 9. Coleman HM, Bateman JE, Dale GM, Starr DE. Cancellous Bone Grafts for Infected Bone Defects. *Surg Gynecol Obstet* 1946;83:392.

+ 10. Dombrowski ET, Dunn AW. Treatment of Osteomyelitis by Debridement and Closed Wound Irrigation—Suction. *Clin Orthop* 1965;43:215.

+ 11. Esterhai JL, Goll SR, McCarthy KE, et al. Indium-111 Leukocyte Scintigraphic Detection of Subclinical Osteomyelitis Complicating Delayed and Nonunion of Long Bone Fractures: A Prospective Study. *J Orthop Res* 1987;5:1.

+ 12. Fitzgerald RH Jr, Ruttle PE, Arnold PG, et al. Local Muscle Flaps in the Treatment of Chronic Osteomyelitis. *J Bone Joint Surg Am* 1985;67:175.

! 13. Flick AB, Herbert JC, Goodell J, Kristiansen T. Noncommercial Fabrication of Antibiotic-impregnated Polymethylmethacrylate Beads. *Clin Orthop* 1987;223:282.

+ 14. Freeland AE, Mutz B. Posterior Bone Grafting for Infected Un-united Fractures of the Tibia. *J Bone Joint Surg Am* 1976;58:653.

+ 15. Gaenslen FJ. Split-heel Approach in Osteomyelitis of the Os Calcis. *J Bone Joint Surg* 193l[w]:759.

+ 16. Gentry LO. Treatment of Skin, Skin Structure, Bone, and Joint Infections with Ceftazidime. *Am J Med* 1985;79(suppl 2A):67.

+ 17. Gentry LO, Rodriguez GG. Oral Ciprofloxacin Compared with Parenteral Antibiotics in the Treatment of Osteomyelitis. *Antimicrob Agents Chemother* 1990;34:40.

+ 18. Gifford GB, Patzakis MJ, Ivler D, Swezey RL. Septic Arthritis due to *Pseudomonas* in Heroin Addicts. *J Bone Joint Surg Am* 1975;57:63l.

+ 19. Green SA, Dlabal TA. The Open Bone Graft for Septic Non-union. *Clin Orthop* 1983;180:117.

! 20. Greene N, Holtom PD, Warren CA, et al. In Vitro Elution of Tobramycin and Vancomycin Polymethylmethacrylate Beads and Spacers from Simplex and Palacos. *Am J Orthop* 1998;27:201.

+ 21. Gristina AG, Costerton JW. Bacterial Adherence to Bio-materials and Tissue. *J Bone Joint Surg Am* 1985;67:264.

+ 22. Gustilo RB, Simpson L, Nixon RA, Indeck W. Analysis of 511 Open Fractures. *Clin Orthop* 1969;66:148.

+ 23. Harmon PH. A Simplified Surgical Approach to the Posterior Tibia for Bone Grafting and Fibular Transference. *J Bone Joint Surg* 1945;27:496.

# 24. Henry AK. Exposures of Long Bones and Other Surgical Methods. Brisol, UK: John Wright & Sons, 1927.

+ 25. Henry SL, Ostermann PAW, Seligson D. The Antibiotic Bead Pouch Technique: The Management of Severe Compound Fractures. *Clin Orthop* 1993;295:54.

+ 26. Higgs SL. The Use of Cancellous Chips in Bone Grafting. *J Bone Joint Surg* 1946;28:1.

* 27. Hobo T. Zur Pathogeneses der Akuten Haematogene Osteomyelitis, mit Berucksichtigung der Viratfarbungslehre. *Acta Sch Med Univ Imper Kioto* 1921;4:1.

+ 28. Jacobs RF, McCarthy RE, Elser JM. *Pseudomonas* Osteochondritis Complicating Puncture Wounds of the Foot in Children. A 10-year Evaluation. *J Infect Dis* 1989;160:657.

+ 29. Kelly PJ, Wilkowske CJ, Washington JA II. Musculoskeletal Infections due to *Serratia marcescens*. *Clin Orthop* 1973;96:76.

* 30. Klemm K. Die Behandlung Chronischer Knocheninfektionen mit Gentamycin-PMMA-Kugeln. *Unfallchirurgie* 1977;1:20.

+ 31. Klemm K. Indikation und Techhik zur Einlage von Gentamicin- PMMA-Kurgeln bei Knochen- und Wechteilinfekten. *Aktuelle Probl Chir Orthop* 1979;12.

+ 32. Knight MP, Wood GO. Surgical Obliteration of Bone Cavities Following Traumatic Osteomyelitis. *J Bone Joint Surg* 1945;27:547.

! 33. Kuechle, D.K, Landon, G.C, Musher, D.M, Noble, P.C. Elution of Vancomycin, Daptomycin, and Amikacin from Acrylic Bone Cement. *Clin Orthop* 1991;364:302.

+ 34. Lexer E. Zur Experimentellen Erzeugung Osteomyelitischer Herdde. *Langenbechs Arch Klin Chir* 1894;48:181.

+ 35. Lister J. On the Antiseptic Principle in the Practice of Surgery. *Br Med J* 1867;2:246.

+ 36. Marks KE, Nelson CL, Lautenschlager EP. Antibiotic-impregnated Acrylic Bone Cement. *J Bone Joint Surg Am* 1976;58:358.

! 37. Marrie TJ, Costerton JW. Mode of Growth of Bacterial Pathogens in Chronic Polymicrobial Human Osteomyelitis. *J Clin Microbiol* 1985;22:924.

! 38. Merkel K, Brown M, Dewanjee M, Fitzgerald R. Comparison of Indium-labelled-leukocyte Imaging with Sequential Technetium-gallium Scanning in the Diagnosis of Low-grade Musculoskeletal Sepsis. *J Bone Joint Surg Am* 1985;67:465.

+ 39. Miskew DBW, Lorenz MA, Pearson RL, Pankovich AM. *Pseudomonas aeruginosa* Bone and Joint Infection in Drug Abusers. *J Bone Joint Surg Am* 1983;65:829.

! 40. Modic MT, Pflanze W, Freiglin DH, Belhobek G. Magnetic Resonance Imaging of Musculoskeletal Infections. *Radiol Clin North Am* 1986;24:247.

+ 41. Murray WR. Use of Antibiotic-containing Bone Cement. *Clin Orthop* 1984;190:89.

+ 42. Nade S. Acute Hematogenous Osteomyelitis in Infancy and Childhood. *J Bone Joint Surg Br* 1983;65:109.

+ 43. Ostermann PAW, Seligson D, Henry S. Local Antibiotic Therapy for Severe Open Fractures: A Review of 1085 Consecutive Cases. *J Bone Joint Surg Br* 1995;77:93.

+ 44. Paley D, Catagni M, Arganani F, et al.. Ilizarov Treatment of Tibial Nonunions with Bone Loss. *Clin Orthop* 1989;241:146.

+ 45. Papineau LJ, Alfageme A, Delcourt JP, Pilon BL. Chronic Osteomyelitis of Long Bones—Resection and Bone Grafting with Delayed Skin Closure. *J Bone Joint Surg Br* 1976;52:138.

+ 46. Patzakis MJ, Abdollahi K, Sherman R, et al. Treatment of Chronic Osteomyelitis with Muscle Flaps. *Orthop Clin North Am* 1993;24:505.

+ 47. Patzakis MJ, Dorr DL, Iver D, et al. The Early Management of Open Joint Injuries. *J Bone Joint Surg Am* 1974;57:1065.

* 48. Patzakis MJ, Harvey JP Jr, Ivler D. The Role of Antibiotics in the Management of Open Fractures. *J Bone Joint Surg Am* 1974;56:532.

+ 49. Patzakis MJ, Watkins R, Harvey JP Jr. Posterolateral Bone Grafting for Infected Non-unions of the Tibia. In: Moore TM, ed. *American Academy of Orthopaedic Surgeons Symposium on Trauma to the Leg and Its Sequelae*. St. Louis, MO: CV Mosby, 1981:235.

+ 50. Patzakis MJ, Wilkins J, Brien WW, Carter VS. Wound Site as a Predictor of Complications Following Deep Nail Punctures to the Foot. *West J Med* 1989;150:545.

+ 51. Patzakis MJ, Wilkins J, Kumar J, et al. Comparison of the Results of Bacterial Cultures from Multiple Sites in Chronic Osteomyelitis of Long Bones. *J Bone Joint Surg Am* 1994;76:664.

+ 52. Patzakis MJ, Wilkins J, Moore TM. Considerations in Reducing the Infection Rate in Open Tibial Fractures. *Clin Orthop* 1983;178:36.

+ 53. Patzakis MJ, Wilkins J, Moore TM. Use of Antibiotics in Open Tibial Fractures. *Clin Orthop* 1983;178:31.

+ 54. Patzakis MJ, Wilkins J, Wiss D. Infection Following Intra-medullary Nailing of Long Bones. *Clin Orthop* 1986;212:182.

# 55. Perez-Stable EJ, Hopewell PC. Current Tuberculosis Treatment Regimens: Choosing the Right One for Your Patient. *Clin Chest Med* 1989;10:323.

+ 56. Perry CR, Pearson RL, Miller GA. Accuracy of Cultures of Material from Swabbing of the Superficial Aspect of the Wound and Needle Biopsy in the Preoperative Assessment of Osteomyelitis. *J Bone Joint Surg Am* 1991;73:745.

+ 57. Rhinelander FW. Minimal Internal Fixation of Tibial Fractures. *Clin Orthop* 1975;107:188.

+ 58. Rissing JP. Antimicrobial Therapy for Chronic Osteomyelitis in Adults: Role of the Quinolones. *Clin Infect Dis* 1997;25:1327.

+ 59. Roy-Camille R, Reignier B, Saillant G, Berteaux D. Resultants de l'Operation de Papineau. *Rev Chir Orthop* 1976;62:347.

+ 60. Roy-Camille R, Reignier B, Saillant G, Berteaux D. Technique et Histoire Naturelle de l'Intervention de Papineau. *Rev Chir Orthop* 1976;62:337.

+ 61. Sapico FL, Montgomerie JZ. Vertebral Osteomyelitis in Intravenous Drug Abusers: Report of Three Cases and Review of the Literature. *Rev Infect Dis* 1980;2:196.

+ 62. Schmidt J, Hackenbroch MH, Kumm D, Taravati V. Is Instillation Drainage for the Treatment of Infected Joints, Bones and Soft Tissues Still up to Date? *Arch Orthop Trauma Surg* 1996;115:149.

+ 63. Seabold JE, Nepola JV, Conrad GR, et al. Detection of Osteomyelitis at Fracture Nonunion Sites. Comparison of Two Scintigraphic Methods. *Am J Roentgenol* 1989;152:1021.

* 64. Thompson JE. Anatomical Methods of Approach in Operations on the Long Bones of the Extremities. *Ann Surg* 1918;68:309.

* 65. Trueta J. The Three Types of Acute Hematogenous Osteomyelitis: A Clinical and Vascular Study. *J Bone Joint Surg Br* 1959;41:671.

! 66. Wahlig H, Dingledein E. Antibiotics and Bone Cements. Experimental and Clinical Long-term Observations. *Acta Orthop Scand* 1980;51:49.

* 67. Waldvogel FA, Medoff G, Swartz MN. Osteomyelitis: A Review of Clinical Features, Therapeutic Considerations and Unusual Aspects. *N Engl J Med* 1970;282:198, 316.

! 68. Wallenkamp G. Small PMMA Beads Improve Gentamicin Release. *Acta Orthop Scand* 1989;60:668.

! 69. Wallenkamp GHIM, Vree TB, Van Rens TJG. Gentamicin-PMMA Beads. Pharmokinetics and Nephrotoxicological Study. *Clin Orthop* 1986;205:171.

+ 70. Weiland AJ, Moore JR, Daniel RK. The Efficacy of Free Tissue Transfer in the Treatment of Osteomyelitis. *J Bone Joint Surg Am* 1984;66:181.

# CHAPTER 134

# MANAGEMENT OF PYARTHROSIS

*Stuart B. Goodman, Loretta B. Chou and David J. Schurman*

**S. B. Goodman:** Chief of Orthopaedic Surgery, Stanford University Medical Center, Stanford, CA, 94305.
**L. B. Chou:** Assistant Professor, Orthopaedic Surgery, Stanford University Hospital, Stanford, CA, 94306.
**D. J. Schurman:** Professor, Orthopaedic Surgery, Stanford Medical Center, Stanford, CA, 94305.

Pathophysiology
Clinical Presentation
Diagnosis
Microbiology
Treatment
Aspiration Versus Surgical Drainage Versus Arthroscopy
Antibiotics
Rehabilitation
Prognosis and Complications
Chapter References

The term pyarthrosis is a fusion of two Greek words—*pyon,* meaning pus, and *arthrosis,* meaning joint (110). Therefore, pyarthrosis by definition denotes a suppurative arthritis. In common medical usage, the term refers to pyogenic infections involving the synovial joints. Septic arthritis accounts for 0.2% to 0.7% of hospital admissions and continues to be a cause of an orthopedic emergency that can lead to morbidity and mortality (83).

## PATHOPHYSIOLOGY

Organisms may infect joints through several different mechanisms, including hematogenous spread from a distant source and spread from an adjacent focus of infection, for example contiguous osteomyelitis (6). Direct inoculation through a penetrating injury is another means, as is intra-articular injection and or a surgical procedure.

Infection of a synovial joint is an interaction between the host and the infecting organism. Factors important to this interaction include general host factors, local host factors, and the quantity and virulence of the infecting organism. General host factors that predispose individuals to septic arthritis include defects in the immune system (e.g., hypogammaglobulinemia), quantitative and qualitative white blood cell deficiencies, cancer, immunosuppression caused by chemotherapeutic agents, and severe chronic illness such as liver and kidney disease, rheumatoid arthritis, systemic lupus erythematous, diabetes mellitus, sickle cell anemia, and alcoholism (5,20,71,78,86,87,117). Any distant focus of infection that induces recurrent bacteremia may predispose a patient to joint sepsis; sources include chronic sinusitis, bronchiectasis, and intravenous drug abuse (91).

Local joint factors are also important. Septic arthritis is more common after previous joint trauma, and a history of prior arthritis increases the risk of septic arthritis in the same joint (31,71,87,103). In rheumatoid arthritis, the increased risk of superimposed pyogenic arthritis is related to local factors (e.g., chronic hyperemia, a protein-rich inflammatory exudate within the joint, or local steroid injection), as well as generalized host factors (e.g., humoral and white blood cell deficiencies, the use of systemic immunosuppressive agents, and general debility) (5,36,66,69,71,85,114,117).

Other localized arthritides that have been associated with an increased incidence of septic arthritis include degenerative joint disease, Charcot arthropathy, and crystal-induced arthritis (gout and pseudogout) (22,61,64). The incidence of local infection is also increased after the implantation of various biomaterials commonly used in orthopaedic surgery (82). In particular, methylmethacrylate has been shown to have profound effects on local polymorphonuclear leukocyte chemotaxis and phagocytosis (81,82).

Synovial infection depends not only on host factors but also on the quantity and virulence of the infecting organism. Important factors in this respect include exotoxin, endotoxin, and enzyme production by the bacteria and the synovial membrane. These by-products, as well as bacterial debris, may also play a role by stimulating the host's immune system to produce the postinfectious arthritis syndrome (31,37).

Once the bacteria have reached the synovium, an acute inflammatory response ensues. Proteolytic enzymes are produced that degrade the proteoglycan matrix of the cartilage ground substance and the collagen. These enzymes are released by the polymorphonuclear leukocytes and the lysosomes within the synovium (18,19,113,118). The bacteria themselves may also contribute to this depletion of cell matrix, even in the absence of inflammation (108).

If the septic process can be terminated before collagen loss has begun, the proteoglycan losses may be reversed. Enzymes released by the polymorphonuclear leukocytes and synovium, including collagenase, elastase, cathepsins, and other proteases, remove the proteoglycan matrix from the cartilage, destroy the collagen superstructure, and subject the chondrocytes to increased mechanical stress. As cartilage cells die, matrix formation is decreased, and a vicious circle ensues. The articular cartilage is eroded away, and the synovium becomes hyperplastic. A pannus of chronic granulation tissue may cover the joint surface. Fibrous or bony ankylosis may be the final result (46) (Fig. 134.1).

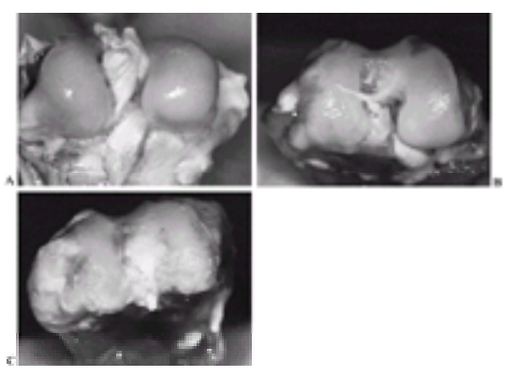

***Figure 134.1.*** **A:** Photograph of the distal femoral articular surface in a normal rabbit. **B:** Photograph of distal femur of rabbit infected with *Staphylococcus aureus* and having antibiotic treatment started at 48 hours. Notice the irregularity and pitting in the weight-bearing portion of the articular cartilage. **C:** Distal femoral articular surface of a rabbit that was infected with *S. aureus* but did not receive antibiotics. Notice the severe degenerative arthritis that has developed.

## CLINICAL PRESENTATION

Septic arthritis may affect any age group but has a propensity for neonates and infants, older adults, and patients who have a chronic, systemic disease, or a compromised immune system. Although virtually any joint may be involved, the large weight-bearing joints of the lower extremity are most at risk (5,6,29,31,46). The joints most commonly involved are the knee, hip, ankle, shoulder, wrist, and elbow (32). Usually, only a single joint is involved, but multiple joint involvement has been documented (5,31,52,74).

Patients with septic arthritis usually have a single joint that demonstrates the signs of acute inflammation: pain, swelling, heat, erythema, and loss of function. In

patients with chronic arthritis (e.g., rheumatoid arthritis), the diagnosis may be delayed because either the patient or the physician assumes that the clinical picture is a manifestation of an acute exacerbation of the chronic disease. Such was the case in 4 of 13 rheumatoid patients reported by Gristina et al. (36) In these instances, the physician must maintain a high index of suspicion of septic arthritis superimposed on a chronic illness.

Nongonococcal suppurative arthritis is most commonly secondary to hematogenous spread from a distant focus (5,70). Therefore, signs of systemic sepsis, such as fever and tachycardia, may be present. In one study, during the first 24 hours of hospitalization, 78% of patients with septic arthritis were febrile. Chills and rigors are uncommon, and the temperature infrequently goes above 39°C (102.2°F) (31,70). The original focus of infection may be discovered after a careful history and physical examination. Special attention should be paid to the ears, nose, throat, and chest, as well as the integumentary, genitourinary, and gastrointestinal systems.

Gonococcal arthritis is probably the most common cause of bacterial septic arthritis (76). Whereas nongonococcal septic arthritis affects the very young, the elderly, or the immunocompromised, gonococcal arthritis affects healthy persons, usually younger than 40 years of age. The increasing female preponderance appears to be related to the asymptomatic carrier status. Women are often seen during pregnancy or just after beginning the menstrual period, implicating local gynecologic and physiologic factors in the production of disseminated disease (70). Systemic signs and symptoms are variable (10,17,42,51,109).

The clinical picture is classically a migratory polyarthritis, which may eventually become monoarticular. The knees, wrists, ankles, and hands are most often affected, and there may be an associated tenosynovitis. This classic clinical presentation of a migratory polyarthritis, tenosynovitis, and the characteristic vesicopapular skin lesions of gonorrhea is rarely seen in cases of nongonococcal septic arthritis. Look for other manifestations of gonorrhea, including signs of heart (endocarditis or myocarditis), central nervous system (meningitis), and liver involvement and conjunctivitis. Undertake an examination and cultures of the genitalia, rectum, oral pharynx, and other possible lesions (e.g., of the skin). Whereas joint aspiration and blood cultures are frequently positive in nongonococcal arthritis, this is not so in the case of gonorrhea.

The pediatric patient poses a special diagnostic problem. Whereas adults with septic arthritis can verbalize their pain, neonates and infants cannot. The child with a septic joint is generally systemically ill (34,35). Pseudoparalysis of the limb and resistance to passive range of motion are frequently present and often suggest to the unwary that the child has a fracture. It is only after a more in-depth examination that the signs of inflammation are noted and focused to a single joint. The physician must always be suspicious of septic arthritis, especially in the immunocompromised child, the neonate who is small for gestational age, and at any age when invasive monitoring techniques are being used (34,35,68).

## DIAGNOSIS

The history and physical examination pointing to a monoarticular inflammation should suggest septic arthritis. A white blood cell count from the peripheral blood is greater than 10,000 cells/mm$^3$ in only 50% of patients and is occasionally helpful. The key diagnostic study is analysis and culture of the synovial fluid (31,46,70). Aspirate the fluid under strictly sterile conditions, and perform the following tests: gross examination of appearance, viscosity, and color; a white blood cell count; the percentage of polymorphonuclear leukocytes; the glucose concentration of the aspirate; Gram's stain; and culture. Tables have been published to differentiate the characteristics of normal synovial fluid from those associated with degenerative joint disease, inflammatory arthritis, and septic arthritis (91). Send all specimens to the laboratory promptly for immediate analysis. Culture the arthrocentesis fluid aerobically and anaerobically, and incubated in 5% to 10% $CO_2$ on chocolate agar plates if gonococcal arthritis is suspected. If tuberculous arthritis is a possibility, order a Ziehl-Neelsen stain and appropriate culture. Fungal infections may be viewed microscopically with potassium hydroxide preparations and cultured on Sabouraud's medium. If the synovial fluid is centrifuged, the concentrated sediment often improves the yield of a Gram stain or other stain.

In the typical acute bacterial arthritis, the synovial fluid is purulent, being gray, yellow, or green, and usually opaque (Fig. 134.2) (91,97). The viscosity of the fluid is variable; however, the mucin clot is usually very friable. The synovial fluid white blood cell count is usually more than 50,000 cells/mm$^3$ and is often over 100,000. Polymorphonuclear leukocytes constitute at least 75% of the cellular population and frequently make up more than 90%. Synovial fluid glucose concentration is usually lower than the blood glucose level. Frequently, the fasting blood minus synovial fluid glucose level is more than 50 mg/dl (97). In tuberculous and fungal arthritis, the findings are similar, except there is usually a higher proportion of mononuclear cells (30% to 50%). Look for the presence of crystals under polarized light to rule out gout or pseudogout in afebrile adults. See Chapter 99 for more details on synovial fluid analysis.

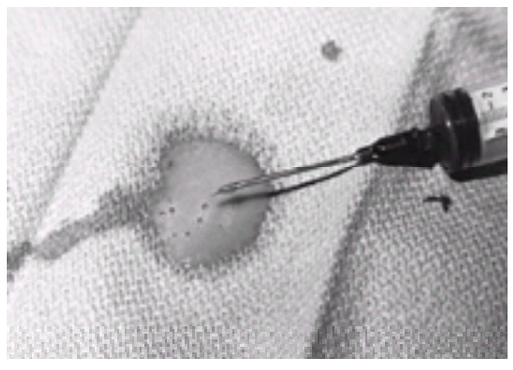

***Figure 134.2.*** Pus aspirated from a knee joint infected with *Staphylococcus aureus*.

Take cultures of the blood and other possible portals of entry. This may include any suspicious skin lesion or wound, the nasal pharynx, sputum, urine, and stool. Approximately 50% of patients with nongonococcal bacterial arthritis have a positive blood culture, whereas the frequency of positive synovial fluid cultures ranges from 25% to 97% (38). If the patient was treated with antibiotics before the synovial culture was obtained, the yield is much lower.

Various specialized diagnostic studies have been used to detect bacterial antigens (94), metabolites (11), and monoclonal antibodies (84) in the synovial fluid in cases of septic arthritis. These procedures are sometimes costly and in practice have had only limited application. Immunodiagnosis employs monoclonal antibodies in patients with culture-negative infections, especially those who have been previously treated with antibiotics. The method employs immunoassays with counterimmunoelectrophoresis or latex particle agglutination to detect antibodies or bacterial antigens in synovium, including *Streptococcus pneumoniae, Neisseria meningititis,* and *Haemophilus influenzae* type b.1 (38,111). If the antibody to a bacterial antigen is found, then the patient has been previously exposed and the immune response has been activated; however, the test does not differentiate between a recent exposure or a remote one. These tests have been shown to be positive in 75% of patients with *H. influenzae* infection (63).

Always take radiographs of the involved joint. The film may show evidence of pre-existing disease and may alert the physician to the possibility of a superimposed septic arthritis. Usually, however, the radiographs show soft-tissue swelling and synovial distention and little more. Later radiographs (1 to 2 weeks) may show osteopenia in the subchondral area or evidence of a coexisting osteomyelitis. Subluxation or dislocation of the joint may be seen early or late. It is more common in the hip of the infant and may be accompanied by exuberant new periosteal bone formation (57). Septic arthritis associated with subluxation of the glenohumeral joint has been documented in the adult (62). If a gas-forming organism (e.g., some gram-negative organisms and anaerobes) is the cause of septic arthritis, the radiograph may disclose gas in the joint and surrounding tissues (9,65). Late radiographic changes in untreated cases of septic arthritis include progressive joint narrowing and destruction. Fibrous or bony ankylosis may be the final result.

Postoperative hip infections are of particular interest because the appearance of the “classic” radiographic signs may be altered (54). In a series of proven hip infections after surgical treatment of hip fractures with internal fixation, Lewis and Norman found that pericapsular edema was absent in 50% of patients. Joint space narrowing was the initial and most reliable radiographic sign and was recognized as early as 4 weeks after surgery. Later acetabular destruction superiorly in the weight-bearing area was often accompanied by subluxation. If septic arthritis is suspected in a prosthetic joint, radiographs should be taken to assess whether there is evidence of new periosteal bone formation, bone lysis, or loosening of the arthroplasty (88). This subject is discussed in more detail in Chapter 135.

Joint scintigraphy using technetium phosphate, gallium citrate, indium, or other radioisotopes is sometimes helpful in the diagnosis of difficult cases of septic arthritis (55,93). The scan may localize septic areas that are difficult to examine clinically and may help differentiate cellulitis from septic arthritis or osteomyelitis. Further localization of difficult joints (e.g., the sacroiliac or sternoclavicular joints) may also be afforded by plain or computed tomography (CT) (67).

Monoclonal antibodies can be labeled with technetium 99m to help detect infection. This test is 95% sensitive, but the specificity is lower at 85% because the test

cannot distinguish between infection and inflammation (3).

Magnetic resonance imaging (MRI) can show the presence of infection earlier than radiographs, because MRI is sensitive for detecting fluid in joints and is able to show abnormalities within 24 hours (13,49,60). MRI has low specificity because it cannot distinguish fluid from infectious, inflammatory, or hemorrhagic causes. MRI is useful in showing infection of the soft-tissue and bony involvement of the spine and pelvis or chronic osteomyelitis. It also shows marrow changes, contrast between bone and soft tissue, and anatomic detail. Generally, T1-weighted images show decreased signal intensity, whereas increased signal intensity is seen on T2-weighted imaging because of marrow edema, ischemia, or exudation. Chronic cases show well-defined soft-tissue abnormalities, and thickened cortices, whereas an acute infection shows poorly defined soft-tissue planes, no cortical thickening, and poor distinction between normal and diseased marrow.

MRI with gadolinium enhances the visualization of osteomyelitis and the presence of an abscess. MRI is also useful in cases that may need surgical treatment, especially of the spine or pelvis. A study by Hovi et al. (43) found that persistent pathologic findings on MRI were seen in some patients despite normal C-reactive protein (CRP) levels and a low erythrocyte sedimentation rate (ESR). The investigators suggested that antimicrobial therapy continue even in the absence of clinical signs of infection and normal CRP levels and ESR if there are MRI abnormalities consistent with infection.

Rarely, a synovial biopsy is required to distinguish a case of infectious from noninfectious arthritis or to provide material for culture and histologic analysis in difficult, perplexing cases (30).

## MICROBIOLOGY

Gonococcal arthritis caused by *N. gonorrhoeae* is the most common cause of septic arthritis in the healthy adult population younger than 40 years of age. It has been estimated that two to three cases of gonococcal arthritis are seen for every case of bacterial arthritis (24).

*S. aureus* continues to be the most common agent responsible for nongonococcal bacterial arthritis, appearing in about 60% of cases (15). In a series from Boston University Medical Center published between 1965 and 1982, *S. aureus* accounted for 40% of cases of nongonococcal bacterial arthritis (31). Various streptococcal species constituted 27% of infections. Recently, gram-negative bacillary septic arthritis has become more prevalent, constituting 23% of cases in the above-mentioned series. *Diplococcus pneumoniae* (6%) and *S. epidermidis* (4%) accounted for the remainder. In two other large series, staphylococcal infections played an even more prominent role. Staphylococci made up 77% (108 of 141, and 80 of 104 cases) of all bacteria isolated in nongonococcal septic arthritis in adults (52,74). These bacteria are showing increasing penicillin resistance (103), necessitating the use of alternative chemotherapeutic agents.

Streptococcal species, including *S. pneumoniae* (pneumococcus), almost always cause septic arthritis through hematogenous spread from the upper or lower respiratory tracts or skin; other rare sources have been noted (12,32,53). Gram-negative bone and joint infections appear to be on the increase (51), a fact related to the rise in intravenous drug abuse and to chronic medical problems such as diabetes, cancer, and the use of chemotherapeutic agents (28,90,104,117). Whereas *Pseudomonas aeruginosa* and *Serratia marcescens* septic arthritis are usually associated with intravenous drug abuse, *Escherichia coli* and *Proteus mirabilis* infections often stem from urinary sepsis (28,90,104,116). Many other gram-negative organisms have also been implicated in cases of septic arthritis (28,103).

Septic arthritis in neonates, infants, and children has a slightly different bacteriology. For the first few months of life, the neonate attains passive immunity from maternal antibodies. In this age group, the most common bacteria causing septic arthritis include gram-positive cocci (staphylococcal and b-streptococcal species) and gram-negative rods (70,102). These bacteria may emanate from the maternal vaginal flora or from invasive procedures such as intravenous catheters introduced in the hospital nursery. Gonococcal arthritis should always be kept in mind in this age group. Infants older than 6 months of age and children up to several years of age have an increased incidence of *H. influenzae* infections in addition to the common neonatal organisms. Frequently, septic arthritis due to *H. influenzae* is resistant to ampicillin. In children older than 2 years of age, *S. aureus* is the usual bacterial organism cultured; however, *H. influenzae,* streptococcal, gonococcal, and other organisms may be the cause (34,35,68,70). In older children, infection associated with a foreign body in the joint (e.g., the knee) should always be suspected.

Mycobacterial (typical and atypical) and fungal septic forms of arthritis are rare. In general, appropriate cultures should be made to exclude these agents, especially in the case of an immunocompromised host (33,56). The atypical mycobacteria, including *Mycobacterium kansasii, Mycobacterium marinum, Mycobacterium intracellulare,* and others, usually cause a monoarticular-pauciarticular arthritis of the hands or knees (41). Mycotic septic arthritis may include infection with *Sporothrix schenckii, Candida* species, the maduromycoses, *Cryptococcus neoformans, Coccidiodes immitis, Blastomyces dermatitidis, Aspergillus fumigatus,* and others (41).

Viral-associated arthritis may occur during infection with any of the more common or uncommon viruses (96). It frequently appears with infection due to rubella, hepatitis B, and alphavirus, and less commonly with infection due to mumps, adenovirus, herpesvirus, and enterovirus. Joint symptoms are transient, often polyarticular, and nondestructive. The etiology of the arthralgia or arthritis may be due to direct synovial invasion of the virus or to a virus–host interaction involving stimulation of the immune system (96).

Predisposing factors are the major etiology of nongonococcal bacterial arthritis, with the most important being total joint arthroplasty. The rate of infection following total joint arthroplasty of the hip and knee is 1% to 5%, with *S. aureus* being the most common cause (15,75).

Factors associated with hip infections include slow convalescence from an illness or surgery, urinary tract infection, failure of fixation of a hip fracture, and diabetes mellitus. Factors associated with knee joint infections include antibiotics given for wound infections, increased pain and limited motion, and rheumatoid arthritis (26). Sickle cell disease continues to be an important predisposing factor for pyarthrosis, especially due to salmonella. Human immunodeficiency virus (HIV) infection is becoming a more common predisposing factor, with *S. aureus* as the most common organism and the knee the most common site (83).

Postoperative infections after orthopaedic procedures are usually due to one predominant organism. Gram-positive bacteria (i.e., *S. aureus* and *S. epidermidis*) comprise 60% to 80% of the organisms cultured (1,2,18,93). Gram-negative and multiple organisms occur less frequently. After joint replacement, staphylococcal infections take on a new significance (96,105). *S. epidermidis* infection becomes as common as *S. aureus* and appears to be more difficult to eradicate (105). In one large series of 137 infected total hip replacements, 68% of cultures grew gram-positive organisms, 18% grew gram-negative organisms, one hip was infected with multiple organisms, and 11% of cultures were sterile (results in two cases were not available) (45). Most authors agree that infection with gram-negative organisms or mixed organisms yield the poorest results (14,44,45,105). This subject is discussed in greater detail in Chapter 135.

## TREATMENT

Any suspicion of the diagnosis of septic arthritis demands an immediate thorough workup, including history, physical examination, appropriate blood work, radiography, joint aspiration with Gram's stain and culture, and an intense search for a primary infective focus.

The principles of treatment of septic arthritis include the following:

- Sterilize the joint by providing adequate drainage and appropriate antibiotics in sufficient dosages to kill the pathogen.
- Prevent the occurrence of deformity.
- Fully rehabilitate the joint and limb (37).

### ASPIRATION VERSUS SURGICAL DRAINAGE VERSUS ARTHROSCOPY

Perhaps the most controversial aspect in the treatment of septic arthritis is the method of drainage. All agree that adequate drainage is of paramount importance. It mitigates the ongoing degradation of the cartilage ground substance by the enzymes of the polymorphonuclear leukocytes and lysosomes within the synovium (18,19,118). The debate centers around the method of drainage–in other words, whether repeated aspiration or surgical drainage is indicated.

Whereas virtually all physicians believe that septic arthritis of the hip and other less accessible joints requires surgical drainage, the method of treatment in other joints is less clear. In general, internists and pediatricians favor repeated aspiration of an infected joint; most surgeons favor surgical drainage (5,27,31,35,52,57,74,79,91). Arthroscopy is the method of choice for the knee, and when the surgeon is experienced, it is also the method of choice for the shoulder, elbow, wrist, and ankle (23,41). Indeed, Paterson has stated, “It is suggested that aspiration has no place in the treatment of suppurative arthritis of the hip, and it is not considered a safe method for any other joint” (79). However, there have been no randomized, prospective studies to document the superiority of one form of treatment over the other. Several retrospective studies, including those by Goldenberg et al. (27) and Rosenthal et al. (92) compared the two methods of treatment and concluded that patients undergoing needle aspiration did better than those undergoing surgical drainage and debridement. However, the controversy has not been settled. Other issues are also involved; for example, consider how difficult it is to convince a pleading, crying child with septic arthritis that he or she must undergo aspiration once (or more) per day. See Chapter 176 for more details about pyarthrosis in children.

### *Aspiration*

If aspiration is the chosen treatment, aspirate the joint frequently enough to prevent the stagnation and loculation of pus, initially, aspirate once or twice each day (28,31,91). Careful sterile technique is mandatory.

- Use a large-bore (at least an 18-gauge) needle for larger joints. Culture the aspirate every 1 to 2 days after antibiotic treatment has commenced to assess the efficacy of therapy. Continue aspirations until little exudate is retrieved and repeat joint fluid cultures are negative.
- Monitor the clinical status closely. It is sometimes useful to lavage the joint with saline after the aspiration to wash the debris and chondrolytic enzymes from the joint.
- The specific location of the needle insertion for aspiration is not important, as long as adequate drainage is attained and the joint and important structures around it (i.e., vessels, nerves, tendons) are not injured (27,77,91).
- We find it easiest to aspirate the shoulder either anteriorly or posteriorly. In the anterior approach, direct the needle posteriorly, superiorly, and laterally from a point slightly inferior and lateral to the coracoid process. This maneuver is often facilitated by external rotation of the shoulder. For the posterior approach, enter the shoulder joint 1.5 inches (3.75 cm) inferior and medial to the acromial angle.
- Approach the elbow joint posterolaterally, just below the midpoint connecting the lateral epicondyle and the lateral edge of the olecranon. Keep the elbow flexed 90° during the aspiration.
- Approach the wrist dorsally. This provides excellent access while avoiding many of the critical structures in the area.
- Enter the finger joints through a posteromedial or posterolateral stab, just volar to the extensor mechanism using a smaller bore needle.
- The carpometacarpal joint of the thumb is more difficult because of the large number of tendons, nerves, and vessels passing in the vicinity. It is approached most safely by flexing the thumb across the palm and directing the needle at the base of the first metacarpal volar to the radial artery and anatomical snuff box, aiming for the fourth metacarpal base.
- The hip joint is one of the most difficult to aspirate. All physicians involved in the treatment of pyarthrosis must know the proper technique. Aspiration of the hip is best performed in the radiology suite or operating room, where good radiographic imaging with fluoroscopy is available. Place the patient in the supine position on a radiolucent table. In the anterior approach, extend and externally rotate the hip. Introduce the needle 1 inch (2.5 cm) below the anterosuperior iliac spine and 1 inch (2.5 cm) lateral to the palpable pulsations of the femoral artery. Direct the needle into the joint posteromedially at a 60° angle. For the lateral approach to the hip, position the hip in extension and internal rotation. Identify the greater trochanter. Direct the aspiration needle along the anterior portion of the greater trochanter, parallel to the femoral neck, then medially and cephalad toward the middle of the inguinal ligament.
- The *knee* joint is the easiest joint to aspirate because it is superficial and contains the largest synovial cavity in the body. With the patient in the supine position and the knee fully extended, insert the needle from a midlateral or midmedial parapatellar location and direct it posteriorly and inferior to the patella. Take care not to scratch or scuff the articular surfaces.
- The *ankle* may be approached easily either anteromedially or anterolaterally. In the anteromedial approach, insert the needle just distal to the tibial plafond, between the lateral edge of the medial malleolus and the medial edge of the tibialis anterior tendon. For the anterolateral approach, enter the ankle joint just lateral to the extensor digitorum communis tendons.
- Enter the subtalar joint either just below the tip of the lateral malleolus or at the level of the sinus tarsi. The sinus tarsi is found just below and anterior to the lateral malleolus. If a septic arthritis of this joint is noted, the normal “pitting” landmark of the sinus tarsi may be replaced by bulging synovium.
- Approach the small joints of the foot and toes in a fashion similar to that used for the small joints in the hand.

### *Surgical Drainage*

Although the indications for surgical drainage of various joints remain controversial, there is general agreement that deeper joints such as the hip and sacroiliac joints, which are less accessible to aspiration, should be treated surgically. Another indication for surgical drainage is thick purulence or loculations within the joint. Also, drain surgically any joint that does not respond to repeated aspirations and appropriate systemic bactericidal antibiotics within 48 hours.

Surgical drainage of a septic hip joint is almost always recommended in the child because of the difficulty in aspiration of this deeply seated joint, the risk of inadvertent damage to the joint surface during the procedure, and the risk of avascular necrosis to the head of the femur. The avascular necrosis of the head of the femur may result from compromise of the retinacular vessels caused by increased intracapsular pressure (35,57,79).

If open surgical drainage of a septic joint is indicated, perform the operation promptly. The aims of surgery are to debride the joint thoroughly; excise all dead, infected, nonviable tissue; and assess the articular surface with respect to the possible need for future reconstructive procedures. Some investigators believe that a concomitant synovectomy is indicated, especially if there has been any delay in diagnosis or a poor response to antibiotic treatment and drainage by closed means (25,112). In one study, synovectomy helped prevent late joint destruction in cases of septic arthritis involving the knee joint but not the hip (112). At a minimum, the joint should be thoroughly debrided of all nonviable tissue. During arthrotomy, always take appropriate specimens for microbiologic and pathologic studies.

Choose a surgical approach that allows wide drainage and complete inspection of the joint. We believe that the joint should not be left open to the environment for fear of colonization of the dressings (and joint) with other organisms. We close the debrided joint over suction tubes, which are removed after several days, depending on the patient's clinical response and the amount and type of drainage.

### *Tube-suction Drainage*

- Occasionally, suction drainage has been combined with an irrigation system, particularly when a great deal of thick, purulent material has been excised (16,50).
- Depending on which joint is involved, establish a suitably sized inflow catheter on one side of the joint, and one or two larger bore outflow catheters on the opposite side of the joint. (For example, a central venous pressure tubing or small Hemovac drain may be used for inflow irrigation of the knee joint, and a larger bore Hemovac drain may be used for outflow.) Place the drains far enough apart so that distention of the joint and circulation of the fluid will be accomplished.
- Keep the system entirely closed, and secure all tubing joints with adhesive tape.
- A physiologic saline solution may be infused at a rate sufficient to provide a constant outflow. Antibiotics need not be added to the irrigant because sufficient joint levels are attained with systemic antibiotics (73,98,99,100,101 and 102)
- Leave the irrigation tubes in place for 2 to 3 days and then remove them. Leave the effluent tubes in place for approximately 24 hours after the inflow tubes are removed.
- These time periods have been selected because of experimental evidence that has demonstrated changes in the articular cartilage glycosaminoglycan staining after 3 days of constant saline irrigation (50); these changes reflect deprivation of the nutrients in the synovial fluid that normally bathes the articular cartilage. Furthermore, if drains are left in much longer than several days, they may serve as a portal of entry for bacteria and may contribute to the formation of a synovial fistula (59,115).

Arthroscopic debridement has been used in conjunction with systemic antibiotics to debride infected joints, most notably the knee. Although most of the reported series are small, this method appears to allow adequate drainage and visualization of the joint with minimal morbidity (23,47,48).

**Approaches for Specific Joints** Specific surgical approaches for open arthrotomy include the standard approaches outlined in Chapter 1, Chapter 2 and Chapter 3. If the joint is to be left open, then dependent drainage can be facilitated by the surgical approach selected and appropriate postoperative positioning techniques. We routinely close arthrotomy incisions and use suction (with or without irrigation), so the actual approach may be of less importance because joint dependency is not necessary.

- The *shoulder* joint may be decompressed either anteriorly or posteriorly; we usually select the anterior approach. We use a deltopectoral approach and identify the shoulder joint beneath the subscapularis muscle, which is reflected medially, allowing a cuff of tendon to remain on the lesser tuberosity for closure.
- The *elbow* joint is most easily debrided posterolaterally through an oblique incision between the extensor carpi ulnaris and anconeus muscles. If a posteromedial approach is selected, identify and protect the ulnar nerve.
- Approach the *wrist joint and carpus* dorsally, with the forearm pronated. Make a central incision and enter the wrist joint between the third (extensor pollicis longus) and fourth (extensor digitorum communis) compartments. Reconstruct the extensor retinaculum before closure.
- Use a midlateral or midmedial longitudinal approach for the *finger* joints. Avoid injury to the digital nerves and vessels.
- Arthrotomy of the *hip* joint may be performed through a number of different approaches. We prefer the standard anterior iliofemoral approach in children and the posterolateral, gluteus maximus–splitting approach in adults. If the hip joint is to be left open, we recommend the posterolateral approach because it allows dependent drainage with the patient supine. A child may be placed in the prone position after an iliofemoral approach.
- For the *knee,* either the anteromedial or anterolateral parapatellar approach allows excellent surgical decompression and visualization of the knee joint. The anteriomedial approach is most often used. Use the posteromedial approach just posterior to the medial collateral ligament if dependent drainage is required.
- The *ankle* joint may be exposed by numerous approaches (anteromedial, anterolateral, posteromedial, or posterolateral). We use the anterolateral exposure lateral to the extensor digitorum longus) or posterolateral exposure (between the fibula and the Achilles tendon) most often. In the posterolateral approach, identify and protect the sural nerve. This approach allows dependent drainage in the supine position if the wound is left open.

- Approach the small joints in the *foot and toes* dorsally (talus) or midlaterally or midmedially (toes), through exposures similar to those used in the hand.
- In each case, thoroughly irrigate, debride, inspect, and loosely close the joint over suction tubes. Irrigation tubes may be added if the purulent material is thick. Close skin and subcutaneous tissues loosely. If the infection is particularly worrisome (loculated with thick pus, severe joint destruction), leave the joint open to granulate. Change dressings three to four times per day for open wounds, using hydrogen peroxide or another antiseptic solution.

After surgery, we splint septic joints in the functional position and begin active assisted and gentle passive range-of-motion exercises when the inflammatory response subsides, usually after 24 to 48 hours. We have not used postoperative continuous passive motion, but experimental evidence suggests that this modality may prove useful in maintaining joint range of motion and minimizing loss of cartilage glycosaminoglycan (95). Certainly, prolonged immobilization appears to be contraindicated because it leads to intra-articular adhesions, more cartilage destruction, stiffness, atrophy, and poor rehabilitation.

With respect to lower extremity joints, use protected weight bearing until inflammation has ceased, range of motion is pain free, and rehabilitation is well under way. In general, do not perform extensive bony or soft-tissue reconstructive procedures during the acute phase of septic arthritis; postpone these procedures until the infection has resolved and the joint has been fully rehabilitated.

**ANTIBIOTICS**

The proper selection of antibiotic therapy is an integral part of the treatment of septic arthritis (29,28,31,41,52,70,74) (see Chapter 132). The immediate Gram stain of the synovial fluid aspirate may identify specific microorganisms, which will determine the choice of antibiotics. If no organisms are seen on Gram's stain but pus cells are identified in the aspirate, administer antibiotics according to the “best guess principle,” as described later. Continue them until the results of the synovial aspirate and blood cultures become available, which is usually within 24 to 48 hours.

Administer antibiotics intravenously. Bactericidal antibiotics are generally preferred over bacteriostatic agents. Intra-articular injection of antibiotic is not necessary because adequate levels are achieved in synovium and bone with parenteral use; also, a chemical synovitis may result from direct intra-articular inoculation (31,71,73,98,99,100,101 and 102). In difficult cases, the blood and synovial fluid may be monitored to ensure that antibiotic levels are above the minimal inhibitory concentration for a specific microorganism.

There is no general agreement as to how long to treat a patient with septic arthritis with antibiotics. In general, we treat with parenteral antibiotics until systemic toxicity and local swelling are under control. We monitor the white blood cell count and the ESR in peripheral blood, and perform repeated synovial fluid aspirations in patients treated with needle drainage. We culture the aspirate every 1 to 3 days and perform a Gram stain. A glucose concentration, white blood cell counts, and polymorphonuclear leukocyte counts may be performed as well. We continue antibiotics orally an additional 2 to 3 weeks after the course of parenteral antibiotics. This may be done on an outpatient basis with close supervision. Longer courses are recommended for patients with a concomitant osteomyelitis, for gram-negative infections, multiple microorganisms, or in the immunocompromised patient. We frequently confer with our infectious disease colleagues, especially in the more complex situations.

If gram-positive cocci are noted on the initial Gram stain, staphylococcal or streptococcal species are the usual microorganism. We use a semisynthetic, penicillinase-resistant penicillin (e.g., nafcillin, oxacillin, cloxacillin; 8 to 12 g/day, given every 4 to 6 hours in adults; 150 to 200 mg/kg daily, given in four to six divided doses in children) until cultures are available. Alternate choices include a cephalosporin (e.g., cefazolin, 1 to 2 g intravenously every 6 hours in adults; 100 to 200 mg/kg daily in children), or vancomycin (2 g/day in divided doses in adults; 40 mg/kg daily in two divided doses in children). We continue the above-mentioned regimen if penicillinase-producing staphylococci are cultured. In penicillin-sensitive cases (e.g., some *S. aureus* and streptococcal infections), we switch to penicillin G (10 million units, given in four divided doses in adults; 100 to 200 mg/kg daily, given in six divided doses in children). Vancomycin may be substituted in patients who are allergic to penicillin.

Gram-negative cocci in a septic joint in an adult usually signify gonorrheal infection. We recommend the use of parenteral penicillin therapy (penicillin G, 10 million units daily, in four divided doses). The patient can be switched to oral penicillin therapy when signs and symptoms abate, for a 2-week course. Spectinomycin is recommended in patients with penicillinase-producing gonococcal infection (89). Third-generation cephalosporins can be extremely effective, and long-acting agents such as ceftriaxone are being used with increasing frequency.

Gram-negative coccal organisms in an infant's or young child's synovial aspirate may signify *H. influenzae* infection. Whereas we used to give a combination of ampicillin and chloramphenicol, these drugs are presently less used because of ampicillin resistance and the very close monitoring of serum concentrations and side effects that is necessary with chloramphenicol. At present, we use cefuroxime, a second-generation cephalosporin (100 mg/kg daily, given every 8 hours). Other alternatives include cefotaxime and ceftriaxone. The clinical response is monitored closely, and a final choice is made when cultures are available.

Gram-negative bacilli seen on Gram's stain of the joint aspirate require immediate treatment and close observation. Look for infection of the urinary tract and biliary tract, for generalized debilitating disease, and for the possibility of drug abuse (28,90,103,104,116). We use tobramycin (5 mg/kg daily, given in three divided doses), gentamicin (same dose), or amikacin (15 mg/kg daily) until the cultures are returned. Ticarcillin (300 mg/kg daily given every 4 to 6 hours) is frequently prescribed by our infectious disease colleagues in addition to one of the above-mentioned drugs, especially for *Pseudomonas* infections. If aminoglycosides are used, monitor renal and vestibuloauditory function, at least on a weekly basis. Obtain antibiotic peak and trough blood levels in the first few days and repeat later if clinical response is not appropriate, or if aminoglycosides are used.

If the Gram stain does not show the presence of any bacteria, a “best guess” must be made until the cultures return. The physician must consider the patient's age, associated disease, and immunocompetence. In the neonate, the most common bacteria causing septic arthritis include gram-positive cocci (staphylococcal and b-streptococcal species) and gram-negative rods (70,104). Until the cultures are available, a semisynthetic penicillinase-resistant penicillin should be combined with tobramycin, gentamicin, or amikacin. In infants and children from 6 months to 3 years of age, *S. aureus* and *H. influenzae* are the most likely pathogens. In such cases, we generally use cefuroxime either alone or in combination with nafcillin. The results of the cultures and sensitivities will dictate which drug will be continued. In older children and adults, a semisynthetic penicillinase-resistant penicillin active against *S. aureus* or a cephalosporin may be used. In the immunocompromised host, we combine an anti-staphylococcal agent with tobramycin, gentamicin, or amikacin. A consultation with an infectious diseases specialist can be very helpful.

In adults, ciprofloxacin, a fluoroquinolone antibiotic, may prove useful for the continuation of oral therapy, after a course of intravenous antibiotics with another drug. Ciprofloxacin is bactericidal against most gram-negative aerobic bacteria (including *P. aeruginosa*), some strains of *S. aureus* and *S. epidermidis,* and enterococcus. Ciprofloxacin has poor activity against anaerobes. Perform sensitivity testing. This drug is a useful adjunct because it requires oral administration only twice per day. It is not recommended for children. Absorption of ciprofloxacin is markedly decreased by aluminum- and magnesium-containing antacids. Ciprofloxacin administration also increases the serum theophylline level in patients taking these drugs simultaneously. Monitor serum theophylline levels closely.

In the treatment of tuberculous septic arthritis (41), combination therapy is most commonly prescribed, including two or more of the following: isoniazid (300 mg/day in adults; 3 to 5 mg/kg daily in children), ethambutol (1.5 to 2 g/day in adults; 15 to 25 mg/kg daily in children), and rifampin (600 mg/day in adults; 10 mg/kg daily in children). Pyridoxine is given to prevent neuritis if isoniazid is used. Liver function should be closely monitored with isoniazid, and one should be aware of the lupus syndromes associated with its use. Thrombocytopenia, hepatitis, and flulike syndromes may be associated with the use of rifampin, and visual disturbances may be associated with ethambutol. Continue therapy for at least 18 months. Other drugs that may be useful include streptomycin and aminosalicylic acid.

Antifungal chemotherapy with intravenous amphotericin B (0.6 to 1.0 mg/kg daily) must be performed with great caution because of the toxicity of this drug. Monitor renal, hematologic, gastrointestinal, and other side effects closely.

## REHABILITATION

Spasm of the muscles surrounding an infected joint often accompanies the signs of inflammation, which may lead to pathologic subluxation or dislocation, or the development of contractures (79). After adequate drainage and the institution of appropriate antibiotic therapy, position the limb to encourage retention of the joint in a position of function while avoiding subluxation or the development of contractures. Position the hip joint in abduction and neutral rotation. We have used skin traction in a Thomas splint or a hip spica cast to maintain this position. After drainage, position the knee in full extension and place the ankle in neutral dorsiflexion and plantar flexion. A long- or short-leg plaster cast works well for the knee and ankle. After drainage of the shoulder, a sling, a collar and cuff, or Velpeau dressing provides adequate immobilization. We recommend splintage of the elbow in a 90-degree cast, with the forearm in neutral or mild supination. Splint the wrist in slight dorsiflexion and place the hand in the functional “apple-holding position.”

The concept of early joint motion in the treatment of septic arthritis is not a new one. Before the use of antibiotics, Willems in 1919 advocated surgical decompression and early active motion for septic joints (116). This concept was further put to use by Ballard et al. (8), who combined arthrotomy, systemic antibiotics, and early, active range-of-motion exercises in the treatment of septic arthritis of the knee. They demonstrated an 82% fair or good result rate despite a difficult population composed primarily of prior treatment failures. Perhaps the most elegant experimental study was performed by Salter's group (95). Using a model of staphylococcal septic arthritis

of the rabbit knee, they combined arthrotomy and antibiotic treatment with either plaster immobilization of the knee joint, cage activity, or continuous passive motion (CPM) on a specially designed machine. The CPM group fared the best, showing decreased cartilage ground substance losses compared with the other treatment methods. Our current treatment protocol emphasizes proper splintage during the early stages of treatment, with the institution of active assisted and gentle passive range-of-motion exercises after 24 to 48 hours, when the inflammation and pain subside. We delay weight bearing on septic joints of the lower extremity until range of motion and strength are virtually normal.

## PROGNOSIS AND COMPLICATIONS

Denis Paterson of the Adelaide Children's Hospital has emphasized that “every hour that an acute suppurative process continues within a joint is of urgent significance to prognosis” (79). Lloyd-Roberts agreed that Paterson did “not exaggerate the sense of urgency required of us when confronted by either the certainty, probability or even the possibility of this affection” (57).

Numerous studies have demonstrated a negative correlation between the length of time from onset of symptoms to documentation of a sterile joint and the quality of the outcome (7,29,31,39,58). Other factors associated with a poor outcome include immunodeficiency in the host (e.g., malignancy, rheumatoid arthritis, or prematurity in neonates), concomitant osteomyelitis, infection involving the hip joint or any prosthetic joint, the presence of positive blood cultures, and infection with *S. aureus* or multiple organisms, especially anaerobes or gram-negative rods (40), symptoms greater than 1 week before treatment, involvement of more than four joints, and positive cultures with repeat aspiration after 7 days of antibiotic treatment (107). In general, gonococcal arthritis has a much better prognosis if treatment is instituted promptly (5,17,24,42,51,76,109).

Complications associated with septic arthritis include death, variable destruction of the joint with residual joint stiffness and functional limitation, subluxation and dislocation, avascular necrosis, local growth disturbance (Fig. 134.3), osteomyelitis, and postinfection synovitis (5,7,21,29,39,57,58,72,79,92,106).

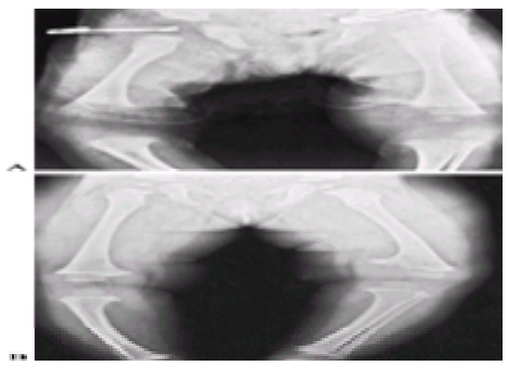

***Figure 134.3.*** **A:** Radiograph of lower extremities in a 2-year-old child with a painful left knee of 2 months' duration. The child was febrile. Notice the soft-tissue swelling over the left distal thigh. Aspiration of the knee joint demonstrated *Staphylococcus aureus.* **B:** This septic arthritis of the left knee led to premature closure of the medial half of the left distal femoral epiphysis, resulting in growth abnormality and a varus deformity of the left knee.

The incidence of death from septic arthritis has ranged from 8% to 15% in three series published since 1975 (29,39,92).

Mortality rates are highest in people with one or more of the poor outcome factors mentioned earlier.

The consequences of septic arthritis of a joint, especially the hip, in a growing child can be disastrous (7,21,57,58,70,72,80,106). Avascular necrosis, sequestration and absorption of the femoral capital epiphysis, chondrolysis of the articular cartilage, destruction of the epiphyseal plate with growth disturbance or arrest, and subluxation or dislocation of the epiphysis or entire hip joint can occur. These complications have a profound effect on a child of any age and may herald a long course of repeated reconstructive surgeries. In the adult, degenerative arthritis with fibrous or bony ankylosis may be the result. These complications may occur in virtually any septic joint but are most profound in the hip (Fig. 134.4).

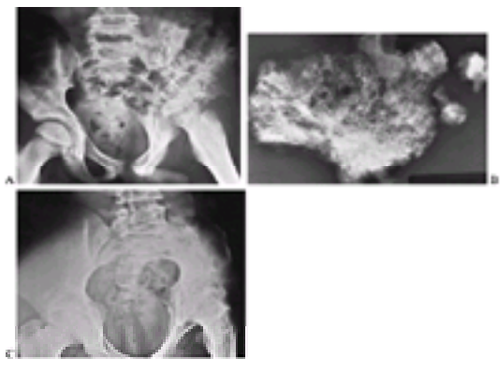

***Figure 134.4.*** A 16-year-old patient developed severe pain in the left hip girdle and a temperature of 104°F (40°C). **A:** He developed osteomyelitis of the left iliac wing, as well as septic arthritis of the left hip joint. **B:** A sequestrectomy of the left ilium was performed and the wound was packed open. **C:** The patient's extremity was placed in a hip spica cast, which resulted in bony ankylosis of the left hip. (Note: This case is from 1939, the preantibiotic era). (Radiographs courtesy of Dr. Henry Jones, Radiology Department, Stanford University Medical Center.)

Recurrent synovitis may persist despite the eradication of microorganisms from the joint. This complication is most common after intra-articular antibiotic injection (5). Nonsteroidal anti-inflammatory drugs may aid in the treatment of this puzzling residuum.

Overall, the fact that septic arthritis has a favorable outcome in approximately 50% to 80% of cases (29,39,92) emphasizes the need for a heightened index of suspicion of this disease and the immediate institution of appropriate diagnostic and treatment procedures.

## CHAPTER REFERENCES

Each reference is categorized according to the following scheme: *, classic article; #, review article; !, basic research article; and +, clinical results/outcome study.


# 1. Abbas AK, Lichtman AH, Pober JS. Antibodies and Antigens. In: *Cellular and Molecular Immunology,* 3rd ed. Philadelphia: W.B. Saunders, 1997.

+ 2. Ahlbert A, Carlsson A, Lindberg L. Hematogenous Infection in Total Joint Replacements. *Clin Orthop* 1978;137:69.

# 3. Alazradi N. Radionuclide Techniques. In: Resnick, D, ed. *Diagnosis of Bone and Joint Disorders,* 3rd ed. Philadelphia: W.B. Saunders, 1995.

+ 4. Andrews HJ, Arden CP, Hart GM, et al. Deep Infection After Total Hip Replacement. *J Bone Joint Surg* 1981;63-B:53.

+ 5. Argen RL, Wilson CH, Wood P. Suppurative Arthritis. Clinical Features of 42 Cases. *Arch Intern Med* 1966;117:661.

+ 6. Atcheson SG, Ward LR. Acute Hematogenous Osteomyelitis Progressing to Septic Synovitis and Eventual Pyarthrosis: The Vascular Pathway. *Arthritis Rheum* 1978;21:968.

+ 7. Baitch A. Recent Observations of Acute Suppurative Arthritis. *Clin Orthop* 1962;22:157.

+ 8. Ballard A, Burkhalter WE, Mayfield GW, et al. The Functional Treatment of Pyogenic Arthritis of the Adult Knee. *J Bone Joint Surg* 1975;57-A:1119.

+ 9. Bliznack J, Ramsey J. Emphysematous Septic Arthritis Due to *Escherichia coli. J Bone Joint Surg* 1976;58-A:138.

# 10. Brandt KD, Cathcart ES, Cohen AS. Gonococcal Arthritis. *Arthritis Rheum* 1974;17:503.

+ 11. Brook I, Reza MJ, Bricknell KS, et al. Abnormalities in Synovial Fluid of Patients with Septic Arthritis Detected by Gas Liquid Chromatography. *Ann Rheum Dis* 1980;39:168.

+ 12. Brosseau JD, Mazza JJ. Group A Streptococcal Sepsis and Arthritis. Origin from an Intra-uterine Device. *JAMA* 1977;238:2178.

# 13. Brower AC. Septic Arthritis. *Radiol Clin North Am* 1996;34:293.

+ 14. Buchholz HW, Elson RA, Engelbrecht E, et al. Management of Deep Infection of Total Hip Replacement. *J Bone Joint Surg* 1981;63-B:342.

# 15. Cimmino MA. Recognition and Management of Bacterial Arthritis. *Drugs* 1997;54:50.

+ 16. Compere EL, Metyger WI, Mitra RN. The Treatment of Pyogenic Bone and Joint Infections by Closed Irrigation (Circulation) with a Non-toxic Detergent and One or More Antibiotics. *J Bone Joint Surg* 1967;49-A:614.

# 17. Cook CL, Owen DS Jr, Irby R, Toone E. Gonococcal Arthritis. *JAMA* 1971;217:204.

! 18. Curtiss PH Jr, Klein L. Destruction of Articular Cartilage in Septic Arthritis. I. In Vitro Studies. *J Bone Joint Surg* 1963;45-A:797.

! 19. Curtiss PH Jr, Klein L. Destruction of Articular Cartilage in Septic Arthritis. II. In Vivo Studies. *J Bone Joint Surg* 1965;47-A:1595.

+ 20. Ebong WW. The Treatment of Severely Ill Patients with Sickle Cell Anemia and Associated Arthritis. *Clin Orthop* 1980;149:145.

+ 21. Eyre-Brook AL. Septic Arthritis of the Hip and Osteomyelitis of the Upper End of the Femur in Infants. *J Bone Joint Surg* 1960;42-B:11.

+ 22. Fitzgerald RH, Nolan DR, Ilstrup DM, et al. Deep Wound Sepsis Following Total Hip Arthroplasty. *J Bone Joint Surg* 1977;59-A:847.

+ 23. Gainor BJ. Instillation of Continuous Tube Irrigation of the Septic Knee at Arthroscopy: A Technique. *Clin Orthop* 1984;183:96.

+ 24. Garcia-Kutzbach A, Masai AT. Acute Infectious Agent Arthritis (IAA): A Detailed Comparison of Proved Gonococcal and Other Blood Borne Bacterial Arthritis. *J Rheumatol* 1974;1:13.

+ 25. Gerard Y, Lamarque B, Segal PH, et al. La Place de la Synovectomie dans le Traitement des Arthrites Aigues a Pyogenes. *Rev Rhum Mal Osteoartic* 1977;44:741.

# 26. Goldenberg DL. Bacterial Arthritis. *Curr Opin Rheumatol* 1994;6:394.

+ 27. Goldenberg DL, Brandt KD, Cohen AS, Cathcart ES. Treatment of Septic Arthritis. Comparison of Needle Aspiration and Surgery as Initial Modes of Joint Drainage. *Arthritis Rheum* 1975;18:83.

+ 28. Goldenberg DL, Brandt KD, Cathcart ES, Cohen AS. Acute Arthritis Caused by Gram-negative Bacilli: A Clinical Characterization. *Medicine* 1974;53:197.

+ 29. Goldenberg DL, Cohen AS. Acute Infectious Arthritis: A Review of Patients with Non-gonococcal Joint Infections (with Emphasis on Therapy and Prognosis). *Am J Med* 1976;60:369.

+ 30. Goldenberg DL, Cohen AS. Synovial Membrane Histopathology in the Differential Diagnosis of Rheumatoid Arthritis, Gout, Pseudogout, Systemic Lupus Erythematosus, Infectious Arthritis and Degenerative Joint Disease. *Medicine* 1978;57:239.

+ 31. Goldenberg DL, Reed JJ. Bacterial Arthritis. *N Engl J Med* 1985;312:764.

+ 32. Good AE, Hague AM, Kauffman CA. Streptococcal Endocarditis Initially Seen as Septic Arthritis. *Arch Intern Med* 1978;138:805.

+ 33. Greene JB, Sidhu GS, Lewin S, et al. *Mycobacterium avium-intracellulare:* A Cause of Disseminated Life-threatening Infection in Homosexuals and Drug Abusers. *Ann Intern Med* 1982;97:539.

# 34. Griffin PP. Bone and Joint Infections in Children. *Pediatr Clin North Am* 1967;14:533.

# 35. Griffin PP. *Septic Arthritis in Children. Orthopedic Surgery Update Series.* Princeton: Continuing Professional Education Center (CPEC), 1982.

+ 36. Gristina AG, Rovere GD, Shoji H. Spontaneous Septic Arthritis Complicating Rheumatoid Arthritis. *J Bone Joint Surg* 1974;56-A:1180.

+ 37. Hadler NM, Granovetter DA. Phlogistic Properties of Bacterial Debris. *Semin Arthritis Rheum* 1978;8:1.

+ 38. Hamed KA, Tam JY, Prober CG. Pharmacokinetic Optimisation of the Treatment of Septic Arthritis. *Clin Pharmacokinet* 1996;31:156.

# 39. Ho G Jr, Su EY. Therapy for Septic Arthritis. *JAMA* 1982;247:797.

# 40. Ho G Jr, Toder JS, Zimmermann B. An Overview of Septic Arthritis and Septic Bursitis. *Orthopaedics* 1984;7:1571.

# 41. Hoffman GS. Mycobacterial and Fungal Infections of Bones and Joints. In: Kelley WN, Harris ED, Ruddy S, Sledge CB, eds. *Textbook of Rheumatology.* Philadelphia: W.B. Saunders, 1985:1527.

+ 42. Holmes KK, Counts GW, Beaty HN. Disseminated Gonococcal Infection. *Ann Intern Med* 1971;74:979.

+ 43. Hovi I, Valtonen M, Korhola O, Hekali P. Low-field MR Imaging for the Assessment of Therapy Response in Musculoskeletal Infections. *Acta Radiol* 1995;36:220.

+ 44. Hunter GA. The Results of Reinsertion of a Total Hip Prosthesis After Sepsis. *J Bone Joint Surg* 1979;61-B:422.

+ 45. Hunter GA, Dandy D. The Natural History of the Patient with an Infected Total Hip Replacement. *J Bone Joint Surg* 1977;59-B:293.

# 46. Rodnan GP, Schumacher HR: Infectious Arthritis. In: Rodman GP, Schumacher RH, eds. *Primer on the Rheumatic Diseases,* 8th ed. Atlanta: Arthritis Foundation, 1983.

+ 47. Ivey M, Clark R. Arthroscopic Debridement of the Knee for Septic Arthritis. *Clin Orthop* 1985;199:201.

+ 48. Jackson RW, Parsons CJ. Distention Irrigation Treatment of Major Joint Sepsis. *Clin Orthop* 1974;96:160.

+ 49. Jaramillo D, Treves ST, Kasser JR, et al. Osteomyelitis and Septic Arthritis in Children: Appropriate Use of Imaging to Guide Treatment. *Am J Roent Ray Soc* 1995;165:399.

! 50. Johnson RG, Herbert MA, Wright S, et al. The Response of Articular Cartilage to the In Vitro Replacement of Synovial Fluid with Saline. *Clin Orthop* 1983;174:285.

+ 51. Keiser H, Ruben FL, Wolinsky E, Kushner L. Clinical Forms of Gonococcal Arthritis. *N Engl J Med* 1968;279:234.

# 52. Kelly PJ. Bacterial Arthritis in the Adult. *Orthop Clin North Am* 1975;6:973.

+ 53. Kluge R, Schmidt M, Barth WF. Pneumococcal Arthritis. *Ann Rheum Dis* 1973;32:21.

+ 54. Lewis MS, Norman A. The Earliest Signs of Postoperative Hip Infection. *Radiology* 1972;104:309.

+ 55. Lisbona R, Rosenthal L. Observations on the Sequential Use of 99m Tc-Phosphate Complex and 67Ga Imaging in Osteomyelitis, Cellulitis, and Septic Arthritis. *Radiology* 1977;123:123.

+ 56. Lloveras J, Peterson PK, Simmons RL, Najarian JS. Mycobacterial Infections in Renal Transplant Recipients: Seven Cases and a Review of the Literature. *Arch Intern Med* 1982;142:888.

# 57. Lloyd-Roberts GC. Septic Arthritis in Infancy. *Int Orthop* Société Internationale de Chirurgie Orthopédique et de Traumatologie 1978;2:97.

+ 58. Lunseth PA, Heiple KG. Prognosis in Septic Arthritis of the Hip in Children. *Clin Orthop* 1979;139:81.

+ 59. Magee C, Rodeheaver GT, Golden GT, et al. Potentiation of Wound Infection by Surgical Drains. *Am J Surg* 1976;131:547.

+ 60. Mandell GA. Imaging in the Diagnosis of Musculoskeletal Infections in Children. *Curr Probl Pediatr* 1996;26:218.

+ 61. Martin JR, Root HS, Kim SO, Johnson LG. Staphylococcus Suppurative Arthritis Occurring in Neuropathic Knee Joints: A Report of Four Cases with a Discussion of the Mechanisms Involved. *Arthritis Rheum* 1965;8:389.

+ 62. Master R, Weisman MH, Armbuster TG, et al. Septic Arthritis of the Glenohumeral Joint. *Arthritis Rheum* 1977;20:1500.

# 63. Matan AJ, Smith JT: Pediatric Septic Arthritis. *Orthopedics* 1997;20:630.

+ 64. McConville JH, Potosky RS, Calia FM, Pachas WN. Septic and Crystalline Joint Disease. *JAMA* 1975;231:841.

+ 65. Meredith HC, Rittenberg GM. Pneumoarthropathy: An Unusual Radiographic Sign of Gram-negative Septic Arthritis. *Radiology* 1978;128:642.

+ 66. Mills LC, Boylston BF, Green JA, Mayer JH. Septic Arthritis as a Complication of Orally Given Steroid Therapy. *JAMA* 1957;164:1310.

+ 67. Morgan GJ Jr, Schlegelmilch JG, Spiegel PK. Early Diagnosis of Septic Arthritis of the Sacroiliac Joint by the Use of Computed Tomography. *J Rheumatol* 1981;8:979.

# 68. Morrissy RT. *Joint Sepsis in the Pediatric Patient: Prevention and Management of Sepsis in Orthopaedic Surgery.* Lecture, San Francisco. August 17, 1985. Unpublished data.

+ 69. Mowat AG, Baum J. Chemotaxis of Polymorphonuclear Leukocytes from Patients with Rheumatoid Arthritis. *J Clin Invest* 1971;50:2541.

# 70. Myers AR. Septic Arthritis Caused by Bacteria. In: Kelley WN, Harris ED, Ruddy S, Sledge CB, eds. *Textbook of Rheumatology.* Philadelphia: W.B. Saunders, 1985:1507.

+ 71. Myers AR, Miller LM, Pinals RS. Pyarthrosis Complicating Rheumatoid Arthritis. *Lancet* 1969;2:714.

+ 72. Nade S. Acute Septic Arthritis in Infancy and Childhood. *J Bone Joint Surg* 1983;65-B:234.

+ 73. Nelson JD. Antibiotic Concentrations in Septic Joint Effusion. *N Engl J Med* 1971;284:349.

# 74. Newman JH. Review of Septic Arthritis Throughout the Antibiotic Era. *Ann Rheum Dis* 1976;35:198.

# 75. Norman DC, Yoshikawa TT. Infections of the Bone, Joint, and Bursa. *Clin Geriatr Med* 1994;10:703.

+ 76. O'Brien JP, Goldenberg DL, Rice PA. Disseminated Gonococcal Infection: A Prospective Analysis of 49 Patients and a Review of Pathophysiology and Immune Mechanisms. *Medicine* 1983;62:395.

# 77. Owen DS Jr. Aspiration and Injection of Joints and Soft Tissues. In: Kelley WN, Harris ED, Ruddy S, Sledge CB, eds. *Textbook of Rheumatology.* Philadelphia: W.B. Saunders, 1985:546.

+ 78. Palmer DW. Septic Arthritis in Sickle-Cell Thalassemia: Pathophysiology of Impaired Response to Infection. *Arthritis Rheum* 1976;18:339.

+ 79. Paterson DC. Acute Suppurative Arthritis in Infancy and Childhood. *J Bone Joint Surg* 1970;52-B:474.

! 80. Petty RW. The Effect of Methylmethacrylate on Chemotaxis of Polymorphonuclear Leukocytes. *J Bone Joint Surg* 1978;60-A:492.

! 81. Petty W. The Effect of Methylmethacrylate on Bacterial Phagocytosis and Killing by Human Polymorphonuclear Leukocytes. *J Bone Joint Surg* 1978;60-A:752.

+ 82. Petty W, Spanier S, Shuster JJ, Silvenhome C. The Influence of Skeletal Implants on Incidence of Infection. *J Bone Joint Surg* 1985;67-A:1236.

# 83. Pioro MH, Mandell BF. Septic Arthritis. *Rheum Dis Clin North Am* 1997;3:239-258.

+ 84. Polin RA, Kennett R. Use of Monoclonal Antibodies in an Enzyme-linked Inhibition Assay for Rapid Detection of Streptococcal Antigen. *J Pediatr* 1980;97:540.

+ 85. Pryzanski W, Leers WD, Wardlow AC. Bacteriolytic and Bactericidal Activity of Sera and Synovial Fluid in Rheumatoid Arthritis and Osteoarthritis. *Arthritis Rheum* 1974;17:207.

+ 86. Quie PG, Mills EL. Microbial-Phagocytic Interactions. *Clin Rheum Dis* 1978;4:15.

+ 87. Quismorio FP, Dubois EL. Septic Arthritis in Systemic Lupus Erythematosus. *J Rheumatol* 1975;2:73.

+ 88. Rand JA, Morrey BF, Bryan RS. Management of the Infected Total Joint Arthroplasty. *Orthop Clin North Am* 1984;15:491.

+ 89. Rinaldi RZ, Hartison WO, Fan PT. Penicillin-Resistant Gonococcal Arthritis. *Ann Intern Med* 1982;97:43.

+ 90. Roce RP, Yoshikawa TT. Primary Skeletal Infections in Heroin Users: A Clinical Characterization, Diagnosis and Therapy. *Clin Orthop* 1979;144:238.

# 91. Rodman GP, Schumacher MR. *Primer on the Rheumatic Diseases,* 8th ed. Atlanta: Arthritis Foundation, 1983:187.

+ 92. Rosenthal J, Bole GG, Robinson WD. Acute Non-gonococcal Infectious Arthritis: Evaluation of Risk Factors, Therapy and Outcome. *Arthritis Rheum* 1980;23:889.

+ 93. Rosenthal L, Hawkins D. Radionuclide Joint Imaging in the Diagnosis of Synovial Disease. *Semin Arthritis Rheum* 1977;7:49.

+ 94. Rytel MW. Microbial Antigen Detection in Infectious Arthritis. *Clin Rheum Dis* 1978;4:83.

! 95. Salter RB, Bell RS, Keeley FW. The Protective Effect of Continuous Passive Motion on Living Articular Cartilage in Acute Septic Arthritis: An Experimental Investigation in the Rabbit. *Clin Orthop* 1981;159:223.

# 96. Schnitzer TJ. Viral Arthritis. In: Kelley WN, Harris ED, Ruddy S, Sledge CB, eds. *Textbook of Rheumatology.* Philadelphia: W.B. Saunders, 1985.

# 97. Schumacher RH. Synovial Fluid Analysis. In: Kelley WN, Harris ED, Ruddy S, Sledge CB, eds. *Textbook of Rheumatology.* Philadelphia: W.B. Saunders, 1985:561.

+ 98. Schurman DJ, Burton DS, Kajiyama G. Cefoxitin Antibiotic Concentration in Bone and Synovial Fluid. *Clin Orthop* 1982;168:64.

+ 99. Schurman DJ, Hirshman HP, Burton DS. Cephalothin and Cefamandole Penetration into Bone, Synovial Fluid, and Wound Drainage. *J Bone Joint Surg* 1980;62-A:1981.

+ 100. Schurman DJ, Hirshman HP, Kajiyama G, et al. Cefazolin Concentration in Bone and Synovial Fluid. *J Bone Joint Surg* 1978;60-A:359.

! 101. Schurman DJ, Kajiyama G. Antibiotic Absorption from Infected and Normal Joints Using a Rabbit Knee Joint Model. *J Orthop Res* 1985;3:185.

! 102. Schurman DJ, Kajiyama G, Nagel DA. *Escherichia coli* Infections in Rabbit Knee Joints. *J Bone Joint Surg* 1980;62-A:620.

! 103. Schurman DJ, Mirra J, Ding A, Nagel DA. Experimental *E. coli* Arthritis in the Rabbit: A Model of Infectious and Post-infectious Inflammatory Synovitis. *J Rheumatol* 1977;4:118.

# 104. Schurman DJ, Wheeler R. Gram-negative Bone and Joint Infections. *Clin Orthop* 1978;134:268.

# 105. Schurman DJ, Woolson ST. Prophylactic Antibiotics in Orthopaedic Surgery. *Orthopaedics* 1984;7:1603.

# 106. Sharrard WJW. *Paediatric Orthopaedics and Fractures.* Edinburgh: Blackwell Scientific Publications, 1971.

# 107. Smith JW, Piercy EA: Infectious Arthritis. *Clin Infect Dis* 1995;20:225.

+ 108. Smith RL, Merchant TC, Schurman DJ. In Vitro Cartilage Degradation by *Escherichia coli* and *Staphylococcus aureus. Arthritis Rheum* 1982;25:441.

+ 109. Spink WW, Keefer CS. Diagnosis, Treatment and End Results in Gonococcal Arthritis: Study of Seventy Cases. *N Engl J Med* 1938;218:453.

# 110. *Stedman's Medical Dictionary,* 25th ed. Baltimore: Williams & Wilkins, 1972:1048.

# 111. Stiehm ER. Passive Immunization. In: Feigin RD, Cherry JD, eds. *Textbook of Pediatric Infectious Diseases,* 4th ed. Philadelphia: W.B. Saunders, 1998: 2769.

+ 112. Tarholm C, Hedstrom S, Sunden G, Lidgren L. Synovectomy in Bacterial Arthritis. *Acta Orthop Scand* 1983;54:748.

+ 113. Tesar JT, Dietz F. Mechanisms of Inflammation in Infectious Arthritis. *Clin Rheum Dis* 1978;4:51.

+ 114. Turner RA, Schumacher HR, Myers AR. Phagocytic Function of Polymorphonuclear Leukocytes in Rheumatic Diseases. *J Clin Invest* 1973;52:1632.

+ 115. Waugh TR, Stinchfield FE. Suction Drainage of Orthopaedic Wounds. *J Bone Joint Surg* 1961;43-A:939.

+ 116. Williams C. Treatment of Purulent Arthritis by Wide Arthrotomy Followed by Immediate Active Mobilization. *Surg Gynecol Obstet* 1919;28:546.

+ 117. Willkens RF, Healey LA, Decker JL. Acute Infectious Arthritis in the Aged and Chronically Ill. *Arch Int Med* 1960;106:354.

+ 118. Ziff M, Gribetz HJ, Lospalluto J. Effect of Leukocyte and Synovial Membrane Extracts on Cartilage Mucoprotein. *J Clin Invest* 1960;39:405.

# CHAPTER 135

# MANAGEMENT OF INFECTED IMPLANTS

*Kevin L. Garvin, Matthew A. Mormino, and Theresa M. McKillip*

**K. L. Garvin:** Director, Adult Reconstructive Surgery, University of Nebraska Medical Center, Omaha, Nebraska, 68198.
**M. A. Mormino:** Assistant Professor, University of Nebraska Medical Center, Department of Orthopaedic Surgery, Omaha, Nebraska, 68198.
**T. M. McKillip:** University of Nebraska Medical Center, Department of Orthopaedic Surgery, Omaha, Nebraska, 68198.

Pathogenesis and Pathophysiology
Diagnosis
Infected Total Hip Arthroplasty
Classification
Early Infections of Total Hip Arthroplasty
One-Stage Reimplantation Versus Two-Stage Reimplantation
Resection Arthroplasty
Infected Total Knee Arthroplasty
Pathogenesis and Pathophysiology
Diagnosis
Treatment
Amputation
Antibiotic Prophylaxis for Patients with Total Joint Replacement
Infection After Internal Fixation
Early Infection After Internal Fixation
Late Infection After Internal Fixation
Late Infection with a Healed Fracture
Chapter References

Infection has been a major nemesis for orthopaedic surgeons for as long as medical history has been recorded. Its frequency and severity have lessened considerably, but occasionally it is still responsible for compromising an otherwise good outcome for the patient. The recent emergence of bacteria that are resistant to antibiotics are of increasing concern. The purpose of this chapter is to present the principles of treatment for infection involving prosthetic joints and internal fixation devices for long bones.

## PATHOGENESIS AND PATHOPHYSIOLOGY

The initial event of infection occurs when bacteria successfully lodge on or near the implanted prosthesis. The easiest and most common access for bacteria is the surgical wound. They flourish in this environment because trauma to the tissues by the surgery, causes some tissue necrosis is due to direct trauma, compromises the blood flow to the tissues and results in hematoma formation. The presence of the large foreign body provides a surface for the bacteria to adhere to.

The other routes bacteria may take to reach the area are hematogenous seeding and contiguous spreading from adjacent areas of infection. The hematogenous spread of bacteria to a prosthetic joint has been associated with chronic skin lesions, dental manipulation, urinary infection, diabetes, and other chronic diseases. One of several scenarios may take place once the bacteria have gained entry to the area. Bacteria may be destroyed by the host, live in symbiosis with the host, or flourish, causing local infection, host sepsis, and even death.

The body's first response to bacterial invasion is an acute inflammatory reaction. A myriad of components are involved in this process, including polymorphonuclear cells, chemotactic factors, and the immune system. Leukocyte diapedesis occurs, followed by infiltration of polymorphonuclear cells to the area. The process in which polymorphonuclear cells are attracted to the area by chemical substances is known as chemotaxis. Boyden originally discovered that chemotaxis occurred if serum was incubated with precipitates of antigens of antibiotics (9).

The immune system is composed of cell-mediated and humoral components. Both cell-mediated and humoral responses are activated to fight bacterial infections. Once the polymorphonuclear cells attack bacteria, some may be damaged, thus releasing additional chemotactic molecules that attract even larger numbers of polymorphonuclear cells. When the polymorphonuclear cells are in proximity to the bacteria, the particles are phagocytosed. For phagocytosis to occur, opsonins or components in the serum must coat the bacteria, making them more attractive for the macrophage.

Elderly patients, the population most commonly managed with joint replacement, may be particularly susceptible to infection because their immune systems are compromised. With increasing age, the immune becomes less competent. These changes include atrophy of the thymus (the site of T-cell maturation), a decreased ability to mount a delayed-type hypersensitivity to various stimuli, and a generalized decreased ability of lymphocytes response to respond to foreign stimuli.

The nonspecific immune response can be affected not only by activation of the complement system but also by certain medications. Nonsteroidal anti-inflammatory agents, steroids, and aspirin are common medications that suppress the immune response (55).

Although the list of potential pathogens is virtually limitless, coagulase-negative staphylococci and *Staphylococcus aureus* dominate the list of pathogens (Table 135.1). In a combined study from the Mayo Clinic and The Hospital for Special Surgery, 97 pathogens were isolated from 76 patients who had periprosthetic hip infections (20,21). *Staphylococcus epidermidis* and *S. aureus* were identified 36 and 18 times, respectively, accounting for more than one half of the pathogens. *Streptococcus viridans,* group-D Streptococcus or Enterococcus, and beta-hemolytic serogroups, also gram-positive organisms, accounted for an additional 14 pathogens. These gram-positive organisms as well as gram-positive anaerobic bacteria accounted for a total of 76% of the 97 pathogens. Gram-negative aerobic and facultative organisms accounted for 11% of the 97 organisms and included *Escherichia coli, Proteus mirabilis, Pseudomonas aeruginosa, Salmonella choleraesuis,* and *Campylobacter intestinalis.*

| |
|---|
| Gram positive |
| *Staphlococcus aureus* |
| *Staphlococcus epidermidis* |
| *Streptococcus viridans* |
| Enterococcus |
| Gram negative |
| *Escherichia coli* |
| *Proteus mirabilis* |
| *Pseudomonas aeruginosa* |
| *Salmonella* spp. |
| *Klebsiella* spp. |
| Anaerobic |
| *Peptococcus* spp. |
| *Mycobacterium* |
| *Clostridium bifermentans* |

***Table 135.1. Common Bacteria Involved in Periprosthetic Infections***

Other gram-negative organisms that are commonly reported but were not found in this study are Klebsiella, Serratia, Acinetobacter species, and other Pseudomonas species. Finally, anaerobic bacteria were identified 12 times (12%) in the study and included *Propionibacterium acnes, Peptococcus asaccharides, Peptococcus magnus, Peptostreptococcus microsphore,* and *Clostridium bifermentans.* Other anaerobic bacteria that are commonly reported but were not found in this study are

those of the Bacteroides genus and Mycobacterium. A single organism rather than multiple organisms was isolated in most patients.

## DIAGNOSIS

Pain is the presenting symptom of most patients who have a periprosthetic infection. Pain that is present while the patient is at rest suggests an inflammatory process. Drainage after surgery is the second most common symptom and is strongly suggestive of an infection if it is still present several weeks after the operation.

Drainage can occur within the first few days after the operation or weeks later. If it occurs within the first few days, it is typically either sanguineous, originating from a hematoma, or is serous, originating from inflamed subcutaneous tissue. Drainage that occurs several days to weeks later is typically serous and, if it is left untreated or allowed to progress, will result in formation of a sinus tract. Sinus tracts generally form within or adjacent to the operative incision, but rarely they occur in other locations.

A history of prolonged drainage after the operation in a patient who has persistent pain can be very helpful in establishing the correct diagnosis. Fever is not a common presenting complaint, because only 5% of patients with an infected joint replacement have a temperature of 37.8° C or more (18). A history of the joint replacement having “never been right” raises the clinical suspicion of infection. After knee replacement, joint stiffness may be present, and although it is not diagnostic, this symptom raises the suspicion of infection (42).

Laboratory tests that are helpful in establishing the diagnosis of an infected implant include a complete blood cell count with differential, determination of the erythrocyte sedimentation rate (ESR), and C-reactive protein (CRP). Of these tests, the CRP may be the most useful for evaluating and monitoring the patient's response to therapy. After surgery, the CRP rises with a peak usually on the second or third day, but by 3 weeks, it is usually back to normal (54).

Sanzen and Carlsson (52) examined a series of 23 patients with proven deep infections of hip replacements and found that the CRP was elevated (greater than 20 ug/L) in 19 patients. By comparison, 7 of the patients had an ESR of 20 mm/h or less. The CRP and the ESR were not elevated in only one of the 23 patients. The investigators also report that infection should be suspected if an elevated CRP has been recorded on several occasions (52).

Begin imaging studies with conventional radiographs, which may show radiolucent lines, focal osteolysis, or periosteal bone formation, which suggest infection. Unfortunately, the presence of periprosthetic lucencies is not specific for nor most commonly the result of infection. Mechanical loosening and foreign body histiocytic reaction are more common causes of lucencies and osteolysis.

Bone destruction and irregular periosteal reaction are uncommon manifestations but are strongly suggestive of an infected joint prosthesis (3). Typically, radiographs of infected prostheses are normal, show only a joint effusion, mimic mechanical loosening, or resemble aggressive granulomatosis. Unfortunately, the absence of any findings does not rule out the presence of an infection. Investigate further if infection is suspected clinically.

Nuclear medicine imaging can be extremely valuable in diagnosing periprosthetic infections. In patients without prostheses or other complicating factors, a three-phase bone scan using technetium-99m methylene diphosphonate (Tc-99m MDP) is highly sensitive and specific for osteomyelitis. In evaluation of suspected periprosthetic infections, however, bone scans retain their sensitivity but become nonspecific.

Increased uptake may occur normally with aseptic loosening or with infection (15,50,58). If abnormal increased uptake is present in the clinical setting of a painful prosthesis, perform leukocyte scintigraphy (LS), which is the preferred nuclear imaging method for identifying infected prostheses. LS involves labeling a patient's white blood cells (WBCs) with radioisotopes (Indium-111 or Tc-99m complexed to hexamethyl propyleneamine oxide), reinjecting the WBCs, and then imaging the patient approximately 24 hours later. Especially when correlated with bone scans, indium leukocyte scintigraphy has a sensitivity of about 90% and specificity of about 85% for periprosthetic infections (33,40). Major drawbacks to the routine use of LS are the extensive time, labor, and cost of the technique.

Ultrasound, computed tomography (CT), and magnetic resonance imaging (MRI) have traditionally played a very limited role in the evaluation of patients with suspected deep infections. MRI is extremely useful in evaluating bone and soft-tissue infections of the spine and appendicular skeleton of patients without orthopaedic devices. Its use is limited, however, when metallic implants are present because of localized signal loss. CT is also hampered by artifact caused by the metal prosthesis and is less sensitive to musculoskeletal infections when compared with MRI.

If clinical or radiographic evidence suggests that an infection is present, the next step in the diagnostic workup is aspiration of the joint. Positive culture results confirm the diagnosis of infection as well as identify the organism and thus direct the course of treatment.

It is important to use joint aspiration selectively and understand its limitations. Barrack and Harris (3) reviewed the results of routine aspiration before 270 consecutive revision operations of the hip. An infection was identified at surgery in six hips, four of which had been successfully aspirated. In the other two hips, aspiration failed to yield any fluid. Thirty-two (13%) of the 254 patients who did not have an infection but had been successfully aspirated had a false-positive result on culture of the aspirated fluid (3).

Overall, Hamblen reports that only about 50% of aspirations from infected joint replacements are positive (29). This finding emphasizes the importance of hip aspiration for patients whose history suggests infection or for those with radiographs showing focal osteolysis, aggressive nonfocal osteolysis, or periostitis; but not for all patients whose hips are scheduled for revision surgery.

## INFECTED TOTAL HIP ARTHROPLASTY

### CLASSIFICATION

In 1975, Coventry described the most widely accepted classification of periprosthetic infections of the hip (13) (Table 135.2). According to this system, stage I infections are acute, fulminating infections that develop within 3 months after the operation. They are clinically apparent wound infections or infections of hematomas that have progressed to deep infections. Stage I infections have become increasingly rare after modern-day hip replacement as a result of improved operative techniques, a better operating room environment, the routine use of prophylactic antibiotics, and the generalized awareness of measures to prevent infection.

| *Stage* | *Features* |
|---|---|
| Stage I | Acute<br>Clinically apparent wound or superficial infection that progresses to deep infection<br>Occur within 3 months postoperatively |
| Stage II | Delayed<br>Indolent<br>Occur between 3 months and approximately 2 years postoperatively |
| Stage III | Hematogenous<br>Period of normal function followed by increasing pain and functional impairment.<br>Can occur at any time after joint replacement. |

From Coventry MB. Treatment of Infections Occurring in Total Hip Surgery. Orthop Clin North Am 1975;6:991.

***Table 135.2. Coventry Classification of Periprosthetic Hip Infections***

Stage II, or delayed, infections are more indolent and may not become apparent until several months after the hip replacement. Typically, patients who have a stage II infection have never had a pain-free interval after the operation. A timetable for how late the infection may be diagnosed has not been well established, but the range for the diagnosis is 3 months to approximately 2 years after surgery.

Stage III infections are frequently hematogenous. The hip may function very well after the operation, but later, the patient has increasing symptoms of pain and impaired function. The symptoms may be associated with a previous infection remote to the hip joint (respiratory, dental, urinary tract, or skin lesion) and may develop soon after the remote infection or as late as 2 or even several years after the hip replacement.

Coventry's classification system has been clinically useful but has been modified to facilitate further the management of patients with prosthetic hip infections. The modification is more closely aligned with current consensus and treatment guidelines for infected total hip arthroplasties (57). The newer classification comprises four categories as follows (Table 135.3).

| Type | Definition | Treatment |
|---|---|---|
| Positive intraoperative cultures | Two or more positive cultures from surgical site | Appropriate parenteral antibiotics |
| Early postoperative infection | Infection occurs within the first month after arthroplasty | Debridement with prosthesis retention and appropriate parenteral antibiotics |
| Late chronic infection | Chronic indolent clinical course or infection apparent one month after operation | Debridement and removal of prosthesis and appropriate antibiotics |
| Acute hematogenous infection | Hematogenous seeding of a previously well functioning arthroplasty | If prosthesis is loose, then remove prosthesis plus antibiotics. If prosthesis is well fixed, then debridement with prosthesis retention and antibiotics. |

***Table 135.3. Updated Classification of Periprosthetic Infections***

#### *Positive Intraoperative Culture*

The infection is diagnosed after two or more samples of fluid or tissue, obtained intraoperatively from different sites of the hip, have been cultured and found to be positive for the same organism. The problem is typically identified in revision hip patients when cultures are obtained but infection is not grossly evident during surgery. Treat the infection with 6 weeks of intravenous antibiotics and no operative intervention.

#### *Early Postoperative Infection*

The infection is apparent within 1 month after implantation of the prosthesis. Treat early postoperative infection with debridement, exchange of the polyethylene liners, retention of the components, and intravenous administration of antibiotics for 4 weeks.

#### *Late Chronic Infection*

The infection is apparent more than 1 month after the operation and has an insidious clinical onset. Treat it with debridement, removal of the components, and appropriate antibiotics for 4 to 6 weeks. This may be followed by implantation of a new prosthesis after the patient has been free of infection.

#### *Acute Hematogenous Infection*

The acute infection is characterized by the precipitous onset of clinical symptoms in a previously well-functioning hip. The patient is often able to recall the exact timing of the onset of severe pain, which is often associated with constitutional symptoms such as fever, chills, leukocytosis, and an elevated ESR (19). If the prosthesis is well fixed, treat the infection in the same manner as for an early postoperative infection; if the prosthesis is loose, treatment should be the same as for a late chronic infection.

### EARLY INFECTIONS OF TOTAL HIP ARTHROPLASTY

Retention of the components is an alternative for a small percentage of patients who have an early infection or for those with an acute hematogenous infection with symptoms present for a short period of time (less than 1 to 2 weeks). Surgically debride the infected site to remove infected and necrotic tissue, as soon as possible after the patient is deemed an appropriate candidate for surgery.

- Use the previous surgical skin incision, and if necessary, excise it to remove any adjacent scar tissue. Dissect down to the prosthesis using the same surgical approach used for the initial surgery. This minimizes additional unnecessary bone and soft-tissue devitalization and permits removal of any previously placed deep nonabsorbable sutures that may be a nidus for infection.
- Obtain several tissue cultures from the pseudocapsular and intra-articular regions of the hip joint during debridement.
- Completely expose the prosthesis–bone or cement–bone interfaces to remove any granulation tissue or extension of the purulent process. Removal and exchange of the polyethylene liner of the acetabular component is particularly important because it allows more complete debridement of the metal shell–polyethylene interface.
- Irrigate the area extensively and close the wound in layers over deep drains.

Once the surgical procedure is completed, initiate parenteral antibiotic therapy to treat any microscopically retained bacteria and modify as necessary on the basis of culture results. Guidelines have been suggested for initial component retention in infected prosthesis and include:

- a short (less than 3- to 4-week) duration of symptoms
- a culture showing gram-positive organisms that are sensitive to antibiotics
- no loosening of the prosthesis
- an absence of excessive scar tissue from previous operative procedures (14,16,32)

Gustilo and Tsukayama (28) reported the results after retention of the components, debridement, and treatment with antibiotics in 41 patients. Of the 35 patients who had had an early postoperative infection, 26 (74%) had a successful result, compared with only three of the six patients who had had an acute hematogenous infection. These authors suggest that early intensive debridement can be successful in carefully selected patients.

### ONE-STAGE REIMPLANTATION VERSUS TWO-STAGE REIMPLANTATION

Although most surgeons agree that removal of hardware is necessary for adequate treatment of a deep infection with a compromised prosthesis, issues regarding reimplantation are less clear. Reimplantation can be performed after debridement and removal of a prosthesis during the same procedure (one-stage procedure) or weeks to months later (two-stage procedure). The indications for use of one technique as opposed to the other are not very clear and have varied considerably among different centers and experts who manage a large number of patients with hip infections.

The generally accepted criteria for a direct-exchange (one-stage) arthroplasty include the presence of a pathogen that is very sensitive to antibiotics. These include aerobic and anaerobic, gram-positive cocci, which are methicillin or oxacillin sensitive and are non-glycocalyx-elaborating pathogens. Examples are some *S. aureus, S. epidermidis,* and Streptococcus—and some antibiotic-sensitive gram-negative bacteria. The host should be healthy with few or none of the risk factors for infection (which include rheumatoid arthritis, diabetes, chronic skin lesions, and obesity). The joint to be operated on must have adequate bone and soft tissues to support reconstruction and prosthetic reimplantation. Another candidate for one-stage reimplantation may be an elderly or infirm patient who will not tolerate prolonged bed rest and a second major operation.

Buchholz et al. (10) have had extensive experience with the direct-exchange technique and have used it for all patients who have a prosthetic joint infection. They reported a successful result in 77% of 583 patients. The technique included debridement or excision of the necrotic soft tissues, removal of the implant and cement, replacement with an appropriate implant with use of Palacos (Smith & Nephew, Memphis, TN) acrylic cement loaded with an appropriate antibiotic, and, more recently, systemic administration of antibiotics. Follow-up of these patients at 8 years showed that approximately 50% remained free of infection (51).

Wroblewski (61) reported his experience with a prospective study of one-stage revision of infected cemented total hip arthroplasty in 102 consecutive patients using gentamicin-impregnated acrylic cement with systemic and oral antibiotics. Thirty percent had had a sinus tract at some stage before the revision surgery. The most common infecting organism was coagulase-negative *Staphylococcus*. The success rate was 91%, with an average follow-up of 3 years. Of the nine patients in whom

deep infection persisted, three had had a sinus tract before the revision and a sinus tract reappeared within 3 months of the revision surgery. In three patients, the radiologic evidence of the persistence of infection first became obvious at the junction of the old and new cement within the medullary canal. The author concluded that adequate debridement and removal of all of the cement is essential. The use of antibiotic-impregnated cement cannot be advocated to the exclusion of all other aspects of revision (61).

If a one-stage procedure or direct exchange is chosen, it is recommended that antibiotics be added to the cement at the time of the reimplantation (22). The infecting organisms must be sensitive to the antibiotic used. It must be stable when it is exposed to heat so that its efficacy is not degraded by the polymerization of the cement. Geometric dilution of the powdered antibiotic and cement, or mixing equal amounts until all of the antibiotic powder and cement are mixed, ensured even distribution of the antibiotic, allowing for high levels of the antibiotic and adequate strength of the acrylic cement.

The advantages of direct-exchange arthroplasty include fewer operations, lower cost, and less inconvenience to the patient. The risks and consequences, if the technique is unsuccessful, however, are substantial and include sepsis, disarticulation at the hip, and operative mortality. Buchholtz et al. (10) reported 13 deaths (1.6%) as a result of 798 operations performed for the treatment of deep infection after prosthetic replacement.

Two-stage reimplantation is most commonly used for patients who have a deep periprosthetic infection of the hip. Reimplantation is performed after the patient has received 4 to 6 weeks of parenteral therapy with antibiotics, but it is often delayed for several weeks after completion of antibiotic treatment as well. Reports have shown that, for patients who have a deep infection of the hip, a two-stage reimplantation results in the highest rate of success, and most surgeons believe that two-stage reimplantation is the procedure of choice (21,22).

The exact timing of the reimplantation varies from center to center, but if the operative site has been treated appropriately during the first procedure, it is rare that the reimplantation cannot be performed after 6 weeks. At the time of reimplantation, the tissues are redebrided and specimens are sent for histopathologic analysis and culture. If the histopathologic analysis (frozen section) is positive (more than 5 polymorphonuclear neutrophils per high power field [PMNS/HPF]), the surgeon may elect to postpone joint reimplantation in favor of a second debridement. It is critical to work with an experienced pathologist and have experience treating infected joints. The use of antibiotic-impregnated cement is also encouraged for a two-stage reimplantation, because it has been associated with the best overall results.

### RESECTION ARTHROPLASTY

Resection arthroplasty is a treatment option for some patients who have a periprosthestic hip infection. The decision to perform a permanent resection arthroplasty without reimplantation of a second prosthesis is based on multiple factors, including:

- Infection with multiple organisms or bacteria resistant to antibiotic therapy
- Poor quality local soft tissues
- Unacceptable complexity of the reconstruction
- Refusal by the patient to have another operation after removal of the implant
- Patients with systemic disease and poor overall health
- Inadequate bone stock
- Combinations of these factors

Patients who have a resection arthroplasty can expect to have less pain than they did when the infection was present, but their functional recovery will be significantly impaired. These patients need aids to walk, have a noticeable limp, and must use a shoe lift to equalize the leg-length discrepancy and improve gait (1,6,26,34,45).

## INFECTED TOTAL KNEE ARTHROPLASTY

### PATHOGENESIS AND PATHOPHYSIOLOGY

From the inception of prosthetic joint replacement, total knee arthroplasty has been associated with a greater risk of infection than total hip arthroplasty. Although the rate of infection following total hip arthroplasty is less than 1%, the rate of infection following total knee arthroplasty is approximately 2%. The reason for this discrepancy remains unclear but may be related to the fact that the implants are more superficial in the knee, and the limited amount of well-vascularized muscle and tissue surrounding the knee impairs local defense mechanisms.

As was previously discussed, a variety of pathogens may be responsible for an infected total knee arthroplasty. The most common organisms, however, are *S. aureus* (50% to 65%) and *S. epidermidis* (25% to 30%). Other bacteria, fungi, and mycobacterium accounted for only 10% to 15% of the infections (53,59).

Other risk factors for infection are rheumatoid disease, open skin lesions, a previous history of surgery about the knee, and a previous history of infection (48,59,60). The risks associated with open skin lesions and other systemic infections are modifiable. Any medical condition that impairs the well-being of the patient, such as diabetes mellitus, poor nutrition, advanced age, or obesity, may increase the potential for infection.

Careful preoperative evaluation and treatment before an elective total knee arthroplasty can minimize the risk for postoperative complications. The greatest risk for infection is associated with a previous infection of the knee. Wilson et al. (59) reported a rate of infection of 3.1% in a study of 1,857 osteoarthritic knees that had had a revision total knee arthroplasty because of an infection around the previous implant (59). Rheumatoid disease, in addition to being associated with the risk of acute infection, is also associated with a risk of late infection secondary to hematogenous bacterial seeding of the knee. The risk of late infection in these patients is high; Wilson et al. (59) reported that late infections accounted for 45 of the 67 infections in a series of 4,171 total knee arthroplasties.

### DIAGNOSIS

A patient who has an infection at the site of a total knee arthroplasty usually presents with a painful, warm, swollen, and stiff joint. The differential diagnosis of pain at the site of a knee replacement includes mechanical loosening of the components, reflex sympathetic dystrophy, heterotopic ossification, and arthrofibrosis. Evaluate patients in whom infection is suspected with pertinent physical exam, plain film radiographs, and laboratory evaluations, as discussed earlier. The key to diagnosis of infection in a total knee replacement is usually aspiration of the joint and analysis of the fluid with a Gram stain, complete and differential cell counts, and cultures.

In a study of a consecutive series of 69 knees in 67 patients, Barrack et al. (4) reported that the results of aspiration had a sensitivity of 75%, specificity of 96%, and accuracy of 90%. These results support the routine use of preoperative aspiration before revision of a total knee prosthesis.

The major problem encountered in this study was the relatively common occurrence of antibiotic use among patients with symptomatic total knee replacements, which can increase the risk of false-negative results. Patients should be carefully questioned about their use of antibiotics. Delay or repeat aspiration 2 weeks after discontinuation of antibiotics. Aspirate the joint under meticulously sterile conditions to minimize the risk of contamination with skin flora. Local anesthetics are not recommended because of their bacteriostatic properties.

Sometimes it is not possible to identify an organism definitively in spite of a suspicious or convincing clinical course characterized by pain and loosening of the components. In these cases, staged reconstruction is commonly performed, and it is only with direct culture of the tissue membrane beneath the implant or material obtained by swabbing of the component that an organism is identified.

### TREATMENT

Once the diagnosis of infection has been established, determine the most appropriate treatment regimen. The issue is often a complex one, because the surgeon must weigh the anticipated quality and longevity of life and expected function against the extensive surgery and course of treatment required to eradicate the infection. Removal of the infected implants, treatment with appropriate antibiotic therapy, and eventual reimplantation of a prosthesis, is the ideal.

A variety of circumstances might require an alternative treatment plan, however. The patient may be quite elderly, have multiple medical problems that would increase surgical risk, have other conditions that cause functional impairment, or have a well-fixed prosthesis. In these types of patients, the morbidity associated with removal of the prosthesis may be greater than that associated with chronic antibiotic suppression with preservation of the knee joint.

#### *Retention of the Prosthesis*

Retention of the prosthesis is generally feasible only in the setting of an acute infection with an onset within 10 to 21 days of the operation, with a susceptible

gram-positive bacteria and no evidence of mechanical loosening. If antibiotic therapy alone is initiated within 48 hours of onset, a success rate of 6% to 10% has been reported in several large studies. Rates of success may be improved to approximately 23% by performing open debridement and synovectomy (53). This approach, however, requires long-term antibiotic suppression in an effort to contain the infection indefinitely. Rates of success are generally even lower in patients who develop infection more than 21 days after initial implantation.

#### *Removal of the Prosthesis*

Resistance of implant infections to treatment has been attributed to the environment of the implant surface and adherent bacteria that produce a biofilm (27). This biofilm provides an environment for the bacteria that is resistant to antibiotics and host defenses. Surfaces covered with biofilm may be surgically inaccessible to even the most aggressive debridement. Therefore, it is widely accepted that removal of the prosthesis is imperative when eradication of the infection is a primary goal. Surgical options include resection arthroplasty, arthrodesis, reimplantation in either one or two stages, and amputation.

Although resection arthroplasty is rarely selected as the definitive treatment, it remains a reasonable option for patients such as those who have rheumatoid arthritis and may have involvement of multiple joints. It is also reasonable for those with limited functional goals and a prospect for walking only with the assistance of a walker or local risk factors precluding a reoperation about the knee. In such patients, modest motion is preserved, usually in the range of 45%. It allows function for activities of daily living, although a brace is usually needed for ambulation. In a study by Falahee et al., overall patient satisfaction approached 80% and most patients had good or excellent relief of pain (17).

#### *Arthrodesis*

Arthrodesis of the knee is an option that can provide a more stable lower extremity at the expense of motion at the knee. After an arthrodesis, the ability to walk independently depends on good function of neighboring joints of the lower extremity. Relative contraindications to arthrodesis include ipsilateral ankle or hip disease, severe segmental bone loss, contralateral leg amputation, and bilateral knee disease.

- Expose the prosthesis through the previous surgical approach.
- Remove the prosthesis, and thoroughly excise all scarred and infected tissues; carefully contour the bone ends. Consider placing cancellous bone grafts about the periphery of the arthrodesis.
- Place the knee in slight flexion of no more than 20°.
- Apply a rigid biplanar external fixator to obtain a compression arthrodesis, which is combined with prolonged immobilization. Time to union can vary considerably and depends on multiple factors.

An alternative is intramedullary nailing performed in a staged fashion, with removal of the prosthesis and debridement of the infected area, followed by antibiotic therapy and placement of the intramedullary nail at a later date. This alternative carries risks similar to those of reimplantation, namely multiple surgeries and the risk of continuation and spread of infection. The problems inherent with arthrodesis are bone loss, shortening, and gait disturbance. Knee arthrodesis also results in an increased energy expenditure for ambulation (47).

#### *Single-stage Exchange*

As noted above, removal of the infected prosthesis along with antibiotic therapy is the ideal initial treatment for infected total knee arthroplasty. Reimplantation of a new total knee prosthesis is the most acceptable option after removal of the infected prosthesis for providing the patient with a functional joint. Historically, reimplantation was done in a single operation, with success rates ranging from 50% to 75% (48,60). More recently, two-stage or delayed reimplantation has become the accepted procedure. The use of antibiotic cement, however, aggressive surgical debridement, and newer antibiotic regimens have led to the development of more protocols for immediate or early exchange of an infected knee replacement.

Goksan and Freeman (24) reported successful eradication of infection at 5 years in 17 of 18 patients treated by a single-stage protocol, which included aggressive debridement, the use of antibiotic-impregnated cement, and a 3-month course of antibiotics. The only recurrence was in a patient with severe rheumatoid disease with multiple joint involvement. All of the patients in this group were infected with gram-positive organisms and had no systemic signs of sepsis. Such studies suggest that one-stage reimplantation may be a reasonable alternative in carefully selected patients and has the advantage of avoiding the added morbidity of another operation (24).

#### *Two-stage Reimplantation*

Removal of the implant, radical debridement, and an interval period of intravenous antibiotics followed by reimplantation remains the standard treatment of the infected total knee arthroplasty in most cases. It is commonly accepted that this approach gives the patient the best chance of eradication of infection. As previously noted, all foreign material, including the implant and all bone cement, must be removed at the time of the initial debridement.

Clean the bone meticulously and insert an antibiotic-impregnated cement spacer between the femur and the tibia. The antibiotic spacer preserves the joint space for later reimplantation, permits stability with weight bearing across the resected knee joint, and provides local antibiotics. The disadvantages of the spacer are the potential for erosion of adjacent bone, and after the elution of antibiotics ceases, it may act as a foreign body.

Continue administration of the appropriate parenteral antibiotic for at least 6 weeks. Controversy still exists regarding the total duration of antibiotic treatment, with some advocating the administration of an additional 6 weeks of oral antibiotics (2). Discontinue antibiotics at least 6 weeks before reaspirating the pseudoarthrosis. Consider reimplantation if the culture is negative. Repeat arthroplasty is usually performed between 12 weeks and 1 year after resection. The technical aspects of delayed reimplantation are more complex than those of standard revision due to problems of exposure, bone loss, ligamentous balance, and restoration of flexion.

Although staged reimplantation is plagued with numerous potential problems and requires careful management, results can be quite rewarding. Goldman et al. (25) reported on a series of 64 infected total knee replacements in 60 patients who were followed for an average of 7.5 years. At follow-up, six knees (9%) had become reinfected, but only two with the same organism, yielding an infection eradication rate of 97%. Most patients were satisfied with their function and outcome following surgery. The authors concluded that two-stage reimplantation with a 6-week course of parenteral antibiotics is an effective means of eradicating deep infection and providing a functional knee. The long-term functional results, reinfection rate, and survivorship are comparable with those found in revision total knee arthroplasty without infection.

### AMPUTATION

The alternative of amputation is usually reserved as a final option in the treatment of life-threatening infection or in the setting of a particularly virulent or resistant organism. It is only infrequently required but can provide an expeditious resolution to a very difficult problem. Unfortunately, a poor functional result is the rule, with only one third of patients retaining the ability to walk, even with assistive devices, and the remaining two thirds confined to a wheelchair (46). Above-knee amputation (AKA) is seldom necessary and prosthetic fitting of an AKA prosthesis is rarely successful in these elderly patients.

## ANTIBIOTIC PROPHYLAXIS FOR PATIENTS WITH TOTAL JOINT REPLACEMENT

The incidence of deep postoperative total joint arthroplasty infection has been dramatically reduced over the past 25 years with the use of prophylactic antibiotics, careful surgical technique, maximizing the patient's health before surgery, and controlling bacterial contamination of the wound. Of these factors, prophylactic antibiotic therapy used routinely for patients undergoing total joint replacement is the most important. Several studies have documented the efficacy of prophylactic antibiotic therapy compared with placebo in preventing deep postoperative infection in total joint arthroplasty patients.

Carlsson et al. (11) published the results of a double-blind investigation of the value of prophylactic antibiotic therapy in early and late infections after total hip replacement (11). The early (2.5-year) follow-up of 118 patients showed no infection in the 60 patients who received prophylactic antibiotics compared with seven infections in the 58 patients who did not receive prophylactic antibiotics. The 5-year follow-up of the same patients also showed a difference, with two infections in the 60 patients who received prophylactic antibiotics and 14 infections in the 58 patients who did not receive the antibiotics.

A second study by Hill et al. (31) also documented the reduction of infection in patients administered prophylactic antibiotics compared with patients administered a placebo. The criticism of their review was that other factors were not controlled, such as the type of operating room used. It is known that laminar air flow, body exhaust suits, careful patient selection, ultraviolet light, and limiting operating room traffic all contribute to a decrease in the infection rate.

Cephalosporins remain the antibiotic of choice to prevent infection after total joint arthroplasty. Administer the antibiotic intravenously one-half hour before the incision is made to achieve bactericidal levels at the time of the initial incision. If the operative procedure is prolonged or exceeds the half-life of the antibiotic selected for prophylaxis, administer an additional dose. Continuing prophylactic antibiotics beyond 24 hours after surgery has not been shown to increase efficacy. This practice increases cost and may contribute to the emergence of resistant organisms. One exception to the routine use of cephalosporins may be in hospitals with a high percentage of methicillin-resistant strains of staphylococcus. Otherwise, the prophylactic use of vancomycin and other second-line antibiotics is discouraged to reduce the emergence of resistant bacteria.

The role of prophylactic antibiotics in preventing late or hematogenous infections is less clear. If prophylactic antibiotics are not used and the artificial joint becomes infected, the complication is catastrophic. The risk of such an occurrence in healthy patients, by contrast, is very small. Factors that argue against the use of prophylactic antibiotics include the very high cost of administering antibiotics to hundreds of thousands of patients per year, the possibility of anaphylactic reaction from the antibiotics, and the resistant strains of bacteria that emerge because of the overuse of prophylactic antibiotics.

It is likely that bacteremias associated with acute infection in the oral cavity, skin, respiratory, gastrointestinal, and urogenital systems and other sites can and do cause late implant infections. Two important factors to be considered are the amount of expected bacteremia from mucosal injury and the integrity of the patient's host defense mechanisms. In general, administer prophylactic antibiotics appropriate to the endogenous flora immediately before any procedure that has a significant risk of mucosal injury, such as peridontal surgery, or in patients with host defense impairment such as collagen diseases.

After careful consideration and review of all available data by an expert panel of dentists, orthopaedic surgeons, and infectious disease specialists, the American Academy of Orthopaedic Surgeons issued an advisory statement regarding the need for prophylactic antibiotics in dental patients who have undergone total joint arthroplasties. They concluded that antibiotic prophylaxis is not indicated for dental patients with pins, plates, and screws, nor is it routinely indicated for most dental patients with total joint replacements. It is advisable, however, to consider premedication in a small number of patients who may be at potential increased risk of hematogenous total joint infection (Table 135.4). The Academy also modified antibiotic regimens to eliminate the need for second doses (Table 135.5).

| |
|---|
| Immunocompromised/immunosupressed patients |
| Inflammatory arthropathies |
| Rheumatoid arthritis |
| Systemic lupus erythematosus |
| Disease, drug, or radiation-induced immunosuppression |
| Other patients |
| Insulin-dependent (type I) diabetes |
| First 2 years following joint placement |
| Previous prosthetic joint infections |
| Malnourishment |
| Hemophilia |

***Table 135.4. Patients at Potential Increased Risk of Hematogenous Total Joint Infection***

| *Patient Characteristic* | *Drug* | *Dosage* |
|---|---|---|
| Patients not allergic to penicillin | Cephalexin<br>Cephradine<br>Amoxicillin | 2 g orally 1 hour before dental procedure |
| Patients not allergic to penicillin and unable to take oral medications | Cefazolin 1 g or ampicillin 2 g | IM/IV 1 hour before the dental procedure |
| Patients allergic to penicillin | Clindamycin | 600 mg orally 1 hour before the dental procedure |
| Patients allergic to penicillin and unable to take oral medications | Clindamycin | 600 mg IM/IV 1 hour before the procedure |

No second doses are recommended for any of these dosing regimens.

***Table 135.5. Suggested Antibiotic Prophylaxis Regimens for Patients with Total Joints Undergoing Invasive Procedures***

## INFECTION AFTER INTERNAL FIXATION

A patient with an infected internal fixation device usually has increasing or new onset of pain that may be located at the implant insertion site or at the fracture site. The pain is often described as dull and deep within the extremity and exacerbated by activity. Local signs may include cellulitis, abscess formation, and wound drainage. Constitutional symptoms include fever, chills, night sweats, tachycardia, and anemia. Past medical history may reveal risk factors such as cigarette smoking, diabetes, alcohol abuse, previous open fracture, or previously draining wound (35). Several recent studies have shown a high infection rate in patients undergoing delayed intramedullary fixation following external fixation, particularly if there has been an infected pin site (38,39,56).

In suspected infections, the patient's ESR or CRP may be elevated. A CBC may show a leukocytosis with a left shift or anemia of chronic disease. Aspiration of the site of maximal tenderness or fluctuance or deep culture of a wound that shows organisms on Gram's stain or grows organisms on culture generally confirms the diagnosis of infection.

Obtain radiographs as soon as the diagnosis is suspected to assess the stability of the fixation construct. Radiolucency around the fixation devices suggests loose hardware. Assess fracture healing as well. Do not confuse periosteal reaction from the infection with fracture callus (Fig. 135.1). Plain tomography may assist in the assessment of fracture healing. Finally, classic signs of osteomyelitis with involucrum or sequestrum may be present.

***Figure 135.1.*** A 27-year-old man sustained an open fracture of the shaft of the right femur secondary to a low-velocity gunshot wound. **A:** AP radiograph of the fractured right femur. **B:** Postoperative AP radiograph. This wound was treated with irrigation and debridement, and immediate locked intramedullary nailing as well as parenteral antibiotics. **C:** Postoperative lateral radiograph. **D:** This fracture healed nicely, but 4 months later, the patient developed a localized abscess at the fracture site. This AP radiograph shows periosteal reaction at the healed fracture site. **E:** Lateral radiograph showing periosteal new bone at the fracture site. **F:** This was treated with incision and drainage of the abscess, removal of the intramedullary nail, cross-screws and reaming of the intramedullary canal to debride it, as well as administration of parenteral bactericidal antibiotics. This AP radiograph taken 4 months later shows the healed fracture with resolution of the bone infection. **G:** Lateral radiograph 4 months after debridement.

## EARLY INFECTION AFTER INTERNAL FIXATION

The method of treatment of infection after internal fixation is based upon:

- The time of onset after internal fixation.
- The status of fracture healing.
- The stability of the implants and fracture.
- The extent of radiographic bone involvement.
- The type and virulence of the organism.
- The patients general condition and health (Fig. 135.2).

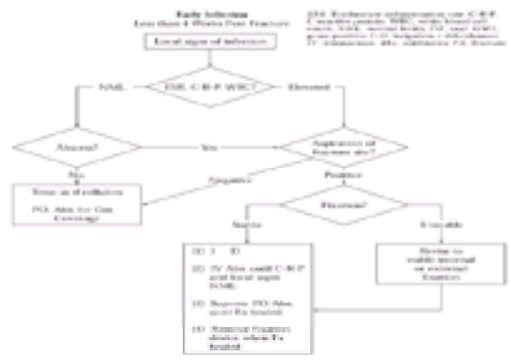

***Figure 135.2.*** Algorithm for treatment of acute infection after internal fixation.

Infections that arise in a patient within the first 4 weeks after internal fixation are generally considered early infections. Pain, fever, and wound drainage are the typical signs and symptoms. Plain radiographs usually show no signs of loosening or chronic osteomyelitis.

Acute infection may occur in the immediate postoperative period (i.e., the first 1 to 4 weeks) and may be characterized by either persistent drainage and an otherwise unremarkable appearing wound or by acute cellulitis, sometimes with systemic signs of infection. The differential diagnosis is a large hematoma and sometimes thrombophlebitis. If other signs of thrombophlebitis are present, perform a Doppler ultrasound examination first. Otherwise, immediately return the patient to surgery. Open the surgical wound down to the bone and implants. Send any fluid found and selected specimens of the deep soft tissues and a small biopsy of bone for immediate Gram's stain, culture, and sensitivity tests. Thoroughly debride and irrigate the wound. Ensure that the implants are stable. If a bone graft was placed at the time of the initial surgery, and gross purulence is not found, leave it in place. If gross purulence is found, most likely it will need to be removed, because it is a significant nidus for infection.

As soon as specimens are obtained, begin intravenous antibiotics. The choice of antibiotics is based on the results of the Gram stain or on what are the most likely infecting organisms in your hospital and in the patient you are treating, taking into account his or her clinical condition.

In most cases the wound can be closed in a routine fashion, unless gross purulence and poor conditions of the soft tissue contraindicate closure.

Most trauma surgeons close over antibiotic-impregnated beads without the use of suction or suction irrigation. If beads are not used, place closed suction drainage. Depending on the virulence of the infection and the patient's clinical response, returning the patient to surgery for repeat irrigation and debridement may be necessary on one or more occasions until the acute local infection is resolved. If antibiotic beads are used, insert a new set of beads at the time of each repeat irrigation and debridement.

If the wound has a benign appearance, or just a hematoma or seroma is found and cultures are negative, systemic antibiotics can usually be stopped when the wound is healed, the CRP level has returned to normal, and there is no further evidence of infection. If cultures are positive, then intravenous antibiotics, perhaps followed by oral antibiotics, are recommended for periods ranging from 4 to 8 weeks. In some cases, oral suppressive medication may be necessary until the fracture is healed and implants are eventually removed (12,41).

The treatment of acute infections varies depending on the type of implant in place. If external fixation is present, then simply ensure that all of the fixation pins are tight in the bone and not directly involved in the fixation suffices. External fixation is the most ideal type of fixation in the presence of infection because it minimizes the surface areas available for glycocalyx-forming bacteria to adhere to. In the case of plates and screws, the procedure is performed as described earlier, as long as the implants are solid in bone.

In the case of intramedullary nails, a decision must be made as to whether the infection involves just the outside of the bone or whether it has invaded the intramedullary canal. This decision can be difficult to make. If there is no gross purulence and the intramedullary canal does not seem to be involved, then leaving the rod in place and following the patient clinically is usually advisable. It may be impossible to irrigate around a solid nail, but exchange nailing may be necessary to debride the canal adequately (12,63; see Fig. 135.3).If there is gross purulence, however, and the implant appears to be loose or the medullary canal involved, then removal of the nail and cross-screws and conversion to external fixation is usually prudent. Another alternative would be to maintain the patient in a cast or traction, hoping that if the infection shows an excellent response to treatment that early reimplantation of the rod may be possible. If the rod is removed, debride the canal by reaming somewhat larger than the nail used. Culture the medullary contents.

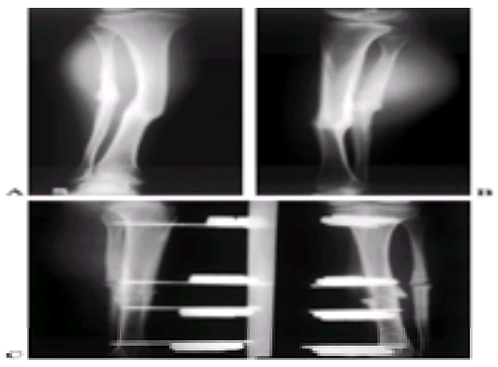

***Figure 135.3.*** A 15-year-old girl with type I diabetes mellitus had a varus malunion of the right midshaft tibia due to a closed tibial fracture treated in a plaster cast. This AP radiograph shows the healed malunion. **B:** This problem was treated with open osteotomy of the tibia and fibula, and insertion of a locked medullary nail. This AP radiograph of the tibia shows excellent correction of fixation. **C:** Unfortunately, 3 weeks postoperatively, the patient developed an acute wound infection. Initially, this wound was irrigated and debrided, and the nail was left in place. Because of inability to control the infection, the nail and cross-screws were subsequently removed and the patient was converted to a single plane external fixator. These AP radiographs show excellent maintenance of correction and good bone apposition at the fracture site. Fortunately, this wound healed and her infection has resolved

## LATE INFECTION AFTER INTERNAL FIXATION

In patients with subacute or late infections, symptoms may be less obvious (Fig. 135.4). Often, the only symptoms are vague, deep pain with minimal signs of local inflammation. Others may present with classic signs of acute inflammation and abscess formation. Laboratory values may be consistent with acute inflammation with elevated ESR and CRP levels. Radiographic signs of infection are often present. Frequently there is evidence of hardware loosening with bone resorption, screw backout, and implant failure, sequestrum formation, resorption of bone ends, and permeative cortical lysis. Again, an assessment of fracture healing is paramount and can be aided by tomography.

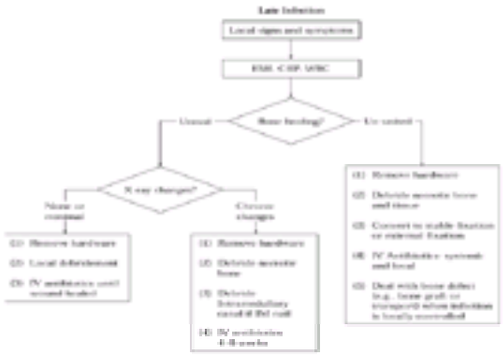

***Figure 135.4.*** Algorithm for treatment of late infection after internal fixation.

In fractures with delayed union or nonunion that are infected, surgical treatment is nearly always necessary and begins with debridement of bone and soft-tissue abscesses, removing all infected and nonviable tissues. In the presence of delayed union or nonunion, implants are almost always loose. Convert unstable fixation to stable external fixation, and administer culture-directed parenteral antibiotics (12,41,63). Remove infected intramedullary implants, and debride the medullary canal by reaming.

The sequence of serial wound debridements, leaving the wound open, or managing it with close suction irrigation or antibiotic impregnated beads is performed as described for acute infection earlier. Administration for at least 6 weeks of parenteral antibiotics to which the organism is sensitive is nearly always necessary.

After local control of the infection is achieved, repeat internal fixation may be possible but the vast majority of cases are managed with external fixation. In the case of intramedullary nails, it may be possible to reinsert a statically locked new larger nail if the infection is of low virulence and the organisms are sensitive, but a majority of cases will require definitive management in stable external fixation.

Now direct your attention to achieving bone union. In most cases, application of autologous cancellous bone graft is best. When segmental bone deficiency is present, a microvascularized bone transfer or bone transport using Ilizarov's technique may be necessary. Electrical stimulation has little role in these cases but can be used as a supplemental treatment.

Traditionally, bone grafting has been delayed until the wound is drainage free for 3 to 6 months, except in the Papineau technique, in which grafting can be carried out as soon as the bone is covered by a clean granulating bed (43). Patzakis et al. (44) challenged the delayed bone grafting concept by treating 32 patients with septic nonunions of the tibia with a protocol of irrigation, debridement, external fixation, and bone grafting at an average of 8 weeks after wound coverage. With this protocol, they achieved infection control in all of their patients and union in all but three patients. Union was achieved in these three patients after additional bone grafting.

The decision to persist with reconstruction of a septic nonunion must be weighed against the economic and human cost of such a complicated operative course. Lerner and others have shown the impact of such a treatment course on the patient's quality of life (5,23,30).

## LATE INFECTION WITH A HEALED FRACTURE

In some patients, infection persists despite bone union. Generally, infections are the result of hematogenous seeding or result from a prior infection harbored in a retained sequestrum or the secretion of the glycocalyx on the fixation device. In the absence of a prior infection, it can be assumed that the hematogenous seeding is the cause of the infection.

To treat, drain any abscess, debride necrotic bone and soft tissue, and remove all fixation devices. In the case of intramedullary fixation, ream the canal to complete the debridement. Significant bone involvement requires prolonged antibiotic therapy. Patients with minimal bone involvement and simple hardware removal can generally be treated with a short course of antibiotics until their wounds are healed and their CRP levels have returned to normal. The vast majority of these infections resolve after hardware removal.

### CHAPTER REFERENCES

Each reference is categorized according to the following scheme: *, classic article; #, review article; !, basic article; and +, clinical results/outcome study.


+ 1. Ahlgren SA, Gudmundsson G, Bartholdsson E. Function After Removal of a Septic Total Hip Prosthesis. A Survey of 27 Girdlestone Hips. *Acta Orthop Scand* 1980;51:541.

+ 2. Ayers DC, Dennis DA, Johanson NA, Pellegrini VD. Common Complication of Total Knee Arthroplasty. Instructional Course Lecture. *J Bone Joint Surg Am* 1997;790A:278.

+ 3. Barrack RL, Harris WH. The Value of Aspiration of the Hip Joint Before Revision Total Hip Arthroplasty. *J Bone Joint Surg* 1993;75-A:66.

+ 4. Barrack RL, Jennings RW, Wolfe MW, Bertot AJ. The Value of Preoperative Aspiration Before Total Knee Revision. *Clin Orthop* 1997;345:8.

+ 5. Bondurant FJ, Cotler HB, Buckle R, et al. The Medical and Economic Impact of Severely Injured Lower Extremities. *J Trauma* 1988;28:1270.

+ 6. Bourne RB, Hunter GA, Rorabeck CH, Macnab JJ. A Six Year Follow-up of Infected Total Hip Replacements Managed by Girdlestone Arthroplasty. *J Bone Joint Surg Br* 1984;66-B:340.

+ 7. Boyd HB. Symposium: Treatment of Ununited Fractures of the Long Bones. *J Bone Joint Surg Am* 1965;47-A:167.

+ 8. Boyd HB, Lipinski SW, Wiley JH. Observations on Non-Union of the Shafts of the Long Bone with a Statistical Analysis of 842 Patients. *J Bone Joint Surg Am* 1961;43-A:159.

! 9. Boyden S. Chemotactic Effect of Mixtures of Antibody and Antigen on Polymorphonuclear Leukocytes. *J Exp Med* 1962;115:453.

+ 10. Buchholz HW, Elson RA, Engelbrecht E, et al. Management of Deep Infection of Total Hip Replacement. *J Bone Joint Surg* 1981;63-B:342.

* 11. Carlsson AS, Lidgren L, Lindberg L. Prophylactic Antibiotics Against Early and Late Deep Infections after Total Hip Replacements. *Acta Orthop Scand* 1977;48:405.

+ 12. Court-Brown CM, Keating JF, McQueen MM. Infection after Intramedullary Nailing of the Tibia. *J Bone Joint Surg* 1992;74-B:770.

+ 13. Coventry MB. Treatment of Infections Occurring in Total Hip Surgery. *Orthop Clin North Am* 1975;6:991.

* 14. Del Sel J, Charnley J. Total Hip Replacement Following Infection in the Opposite Hip. *Clin Orthop* 1979;141:138.

+ 15. Duus BR, Boeckstyns M, Stadeager C. The Natural Course of Radionuclide Bone Scanning in the Evaluation of Total Knee Replacement. *Clin Radiol* 1990;41:341.

+ 16. Estrada R, Tsukayama D, Gustilo R. Management of THA Infections. A Prospective Study of 108 Cases. *Orthop Trans* 1993;17:1114.

+ 17. Falahee MH, Matthews LS, Kaufer H. Resection Arthroplasty as a Salvage Procedure for a Knee with Infection after a Total Arthroplasty. *J Bone Joint Surg Am* 1987;69-A:1013.

+ 18. Fitzgerald RH, Jones DR. Hip Implant Infection. Treatment with Resection Arthroplasty and Late Total Hip Arthroplasty. *Am J Med* 1985;78(Suppl 6B):225.

+ 19. Fitzgerald RH, Nolan DR, Ilstrup DM, et al. Deep Wound Sepsis Following Total Hip Arthroplasty. *J Bone Joint Surg Am* 1977;59-A:847.

* 20. Fitzgerald RH, Randall KR, Brown WJ, Nasser S. Treatment of the Infected Total Hip Arthroplasty. *Curr Opin Orthop* 1994;5:26.

* 21. Garvin KL, Fitzgerald RH, Salvati EA, et al. Reconstruction of the Infected Total Hip and Knee Arthroplasty with Gentamicin Impregnated Palacos Bone Cement. *Instr Course Lect* 1993;42:293.

# 22. Garvin KL, Hanssen AD. Current Concepts Review: Infection after Total Hip Arthroplasty. *J Bone Joint Surg Am* 1995;77:1576.

+ 23. Georgiadis GM, Behrens FF, Joyce MJ, et al. Open Tibial Fractures with Severe Soft Tissue Loss: Limb Salvage Compared with Below the Knee Amputation. *J Bone Joint Surg Am* 1993;75-A:1431.

+ 24. Goksan SB, Freeman MA. One Stage Reimplantation for Infected Total Knee Arthroplasty. *J Bone Joint Surg Am* 1992;74-B:78.

+ 25. Goldman RT, Scuderi GR, Insall JN. Two Stage Reimplantation for Infected Total Knee Replacement. *Clin Orthop* 1996;331:118.

+ 26. Grauer JD, Amstutz HC, O'Carroll PF, Dorey FJ. Resection Arthroplasty of the Hip. *J Bone Joint Surg Am* 1989;71-A:669.

! 27. Gristina AS, Costerton JW. Bacterial Adherence and the Glycocalyx and Their Role in Musculoskeletal Infection. *Orthop Clin North Am* 1984;15:517.

+ 28. Gustilo RB, Tsukayama D. Treatment of Infected Cemented Total Hip Arthroplasty with Tobramycin Beads and Delayed Revision with a Cemented Prosthesis and Bone Grafting. *Orthop Trans* 1988;12:739.

+ 29. Hamblen DL. Diagnosis of Infection and the Role of Permanent Excision Arthroplasty. *Orthop Clin North Am* 1993;24:743.

+ 30. Hansen ST Jr. Overview of the Severely Traumatized Lower Limb. *Clin Orthop* 1989;243:17.

+ 31. Hill C, Flamant R, Mazas F, et al. Prophylactic Cefazolin versus Placebo in Total Hip Replacement. Report of a Multicentre Double-blind Randomized Trial. *Lancet* 1981;1:795.

! 32. Inman RD, Gallegos KV, Brause BD, et al. Clinical and Microbial Features of Prosthetic Joint Infection. *Am J Med* 1984;77:47.

+ 33. Johnson JA, Christie MJ, Sandler MP. Detection of Occult Infection Following Total Joint Arthroplasty Using Sequential Technetium-99m HDP Bone Scintigraphy and Indium-111 WBC Imaging. *J Nucl Med* 1988;29:1347.

+ 34. Kantor GS, Osterkamp JA, Dorr LD, et al. Resection Arthroplasty Following Infected Total Hip Replacement Arthroplasty. *J Arthroplasty* 1986;1:83.

+ 35. Kwiatkowski TC, Hawley EN Jr, Ramp WK. Cigarette Smoking and Its Orthopedic Consequences. *Am J Orthop* 1996;25:590.

+ 36. Magnuson JE, Brown ML, Hauser MF. In-111 Labelled Leukocyte Scintigraphy in Suspected Orthopaedic Prosthesis Infection: Comparison with Other Imaging Modalities. *Radiology* 1988;168:235.

+ 37. Masri BA, Kendall RW, Duncan CP, et al. Two-Stage Exchange Arthroplasty Using a Functional Antibiotic-Loaded Spacer in the Treatment of the Infected Knee Replacement: The Vancouver Experience. *Seminars in Arthroplasty* 1994;5:122.

* 38. Maurer DJ, Merkow RL, Gustilo RB. Infection After Intramedullary Nailing of Severe Open Tibial Fractures Initially Treated with External Fixation. *J Bone Joint Surg Am* 1989;71A:835.

+ 39. McGraw JM, Lim EV. Treatment of Open Tibial Shaft Fractures. *J Bone Joint Surg Am* 1988;70-A:900.

+ 40. Merkel KD, Brown ML, Dewanjee MK, et al. Comparison of Indium-labeled Leukocyte Imaging with Sequential Technetium-gallium Scanning in the Diagnosis of Low-grade Musculoskeletal Sepsis. *J Bone Joint Surg Am* 1985;67:465.

+ 41. Miller ME, Ada Jr, Webb LX. Treatment of Infected Nonunion and Delayed Union of Tibia Fractures with Locking Intramedullary Nails. *Clin Orthop* 1989;245:233.

* 42. Morrey BF, Westholm F, Schoifet S, et al. Long-term Results of Various Treatment Options for Infected Total Knee Arthroplasty. *Clin Orthop* 1989;248:12.

* 43. Papineau LJ, Alfageme A, Dalcourt JP, Pilon L. Osteomyelite Chronique: Excision et Greffe de Spongieux a l'Air Libre Apres Mises a Plat Extensives. *Int Orthop* 1979;3:165.

+ 44. Patzakis MJ, Scilanis TA, Chan J, et al. Results of Bone Grafting for Infected Tibial Nonunion. *Clin Orthop* 1995;315:192.

+ 45. Petty W, Goldsmith S. Resection Arthroplasty Following Infected Total Hip Arthroplasty. *J Bone Joint Surg Am* 1980;62-A:889.

+ 46. Pring DJ, Marks L, Angel JC. Mobility After Amputation for Failed Knee Replacement. *J Bone Joint Surg Br* 1988;70-B:770.

+ 47. Rand JA. Knee Arthrodesis. *Instr Course Lect* 1986;25:325.

+ 48. Rand JA. Evaluation and Management of Infected Total Knee Arthroplasty. *Seminars in Arthroplasty* 1994;5:178.

+ 49. Rand JA, Bryan RS. Reimplantation for the Salvage of an Infected Total Knee Arthroplasty. *J Bone Joint Surg Am* 1983;65-A:1081.

+ 50. Rosenthall L, Lepanto L, Raymond F. Radiophosphate Uptake in Asymptomatic Knee Arthroplasty. *J Nucl Med* 1987;28:1546.

+ 51. Rottger J. Symposium: Antibiotic-Impregnated Acrylic Composites. *Contemp Orthop* 1986;12:85.

+ 52. Sanzen L, Carlsson AS. The Diagnostic Value of C-Reactive Protein in Infected Total Hip Arthroplasties. *J Bone Joint Surg Br* 1989;71-B:638.

+ 53. Schoifet SD, Morrey BF. Treatment of Infection After Total Knee Arthroplasty by Debridement with Retention of the Components. *J Bone Joint Surg Am* 1990;72-A:1383.

# 54. Scuderi GR, Insall JN. Total Knee Arthroplasy. Current Clinical Perspectives. *Clin Orthop* 1992;276:26.

! 55. Sochacki M, Garvin KL. An Immunocompromised Osteomyelitis Model. *Transaction of the 41st Annual Meeting of the Orthopaedic Research Society* 1995;20:258.

+ 56. Tornetta P, DeMarco C. Intramedullary Nailing After External Fixation of the Tibia. *Bull Hosp Jt Dis* 1995;54:5.

+ 57. Tsukayama DT, Estrada R, Gustilo RB. Infection After Total Hip Arthroplasty. A Study of the Treatment of One Hundred and Six Infections. *J Bone Joint Surg Am* 1996;78-A:512.

+ 58. Utz JA, Lull RJ, Galvin EG. Asymptomatic Total Hip Prosthesis: Natural History Determined Using Tc99m MDP Bone Scans. *Radiology* 1986;161:509.

+ 59. Wilson MG, Kelley K, Thornhill TS. Infection as a Complication of Total Knee Replacement Arthroplasty. Risk Factors and Treatment in Sixty-seven Cases. *J Bone Joint Surg Am* 1990;72-A:878.

* 60. Windsor RE, Insall JN, Urs WK, et al. Two-stage Reimplantation for the Salvage of Total Knee Arthroplasty Complicated by Infection. Further Follow-up and Refinement of Indications. *J Bone Joint Surg Am* 1990;72-A:272.

+ 61. Wroblewski BM. One Stage Revision of Infected Cemented Total Hip Arthroplasty. *Clin Orthop* 1986;211:103.

+ 62. Wymenga AB, Van Horn JR, Theeuwes AD, et al. Perioperative Factors Associated with Septic Arthritis After Arthroplasty. *Acta Orthop Scand* 1992;63:665.

+ 63. Zych GA, Hutson JJ Jr. Diagnosis and Management of Infection After Tibial Intramedullary Nailing. *Clin Orthop* 1995;315:153.

# CHAPTER 136

# ORTHOPAEDIC MANAGEMENT OF HEMOPHILIC ARTHROPATHY

*James V. Luck Jr., Judith C. Lin, Carol K. Kasper and Laurence J. Logan*

**J. V. Luck Jr:** Chief of Orthopaedics, Hemophilia Center, Orthopaedic Hospital; Executive Vice Chairman, UCLA-Orthopaedic Hospital Department of Orthopaedics, University of California at Los Angeles, Los Angeles, California, 90007.
**J. C. Lin:** Staff Hematologist, Hemophilia Center, Orthopaedic Hospital, Los Angeles, California, 90060.
**C. K. Kasper:** Director of Research, Hemophilia Center, Orthopaedic Hospital; Emeritus Professor, Department of Medicine (Hematology), University of Southern California; Vice President, Medical, World Federation of Hemophilia, Los Angeles, California, 90060.
**L. J. Logan:** Medical Director, Hemophilia Center, Orthopaedic Hospital; Associate Clinical Professor, Department of Medicine (Hematology), University of Southern California, Los Angeles, California, 90060.

Pathophysiology
Nonoperative Management of Hemophilic Synovitis
Prophylactic Concentrate
Arthroscopic Synovectomy
Radiosynovectomy
Surgery for Hemophilic Arthropathy
Current Regimen of Clotting Factor Replacement
Surgical Synovectomy
Specific Joint Considerations
Impact of Hiv Infection on Elective Reconstructive Surgery
Recommendations for Surgery on the Hiv-Positive Patient
Authors' Perspective
Chapter References

Hemophilia is inherited as a sex-linked recessive trait, with an incidence in the United States of 1 in 10,000 male births. Factor VIII deficiency, or hemophilia A, represents about 85% of these cases, and factor IX deficiency, or hemophilia B, accounts for 15%. Cases with a negative family history are considered *de novo* occurrences and are the result of a recent genetic mutation that accounts for 25% of new hemophilia A cases. This mutation rate is one of the highest among genetic disorders.

The original article on hemophilic arthropathy is credited to Konig (39), who described the gross articular changes in 1892. Detailed descriptions of the microscopic pathology followed in 1925 by Freund (19) and in 1929 by Reineke and Wohlwill (62). The first papers in English were radiologic descriptions in 1921 by Klason (37) and in 1926 by Doub and Davidson (15). In 1932, J. Albert Key (34) presented the gross and microscopic findings in hemophilic arthropathy. His paper included a fascinating description of a 13-year-old boy who presented with a "tumor" about the knee. This patient had a negative family history for bleeders, but he had a history of easy bruising, nosebleeds, and periodic joint swelling. It was only after a synovectomy and stormy postoperative course that he was discovered to be a *de novo* hemophiliac. In 1936, Henry Thomas (70) described orthopaedic findings in 98 hemophiliacs. Over the last six decades, the volume of scientific literature on hemophilic arthropathy has greatly expanded with many excellent papers and several complete texts (6,13,14,17,26,66,72).

## PATHOPHYSIOLOGY

The course of hemophilic arthropathy is all too often unrelenting, progressing from hemarthrosis to chronic synovitis to extensive joint surface erosion and, ultimately, to end-stage joint destruction (Fig. 136.1, Fig. 136.2, Fig. 136.3, Fig. 136.4, Fig. 136.5 and Fig. 136.6; see also Color Fig. 136.2). End-stage arthropathy is complicated by severe loss of motion secondary to arthrofibrosis as the hypertrophic synovium is replaced by dense fibrous scar. Severe contractures, angular deformity, and loss of bone stock due to synovial cysts and mechanical abrasion are common. The pathophysiology has been intensely studied, but our understanding remains incomplete. Chronic synovitis and progressive arthropathy have been reproduced in rabbits and dogs by serial intra-articular injections of autologous blood (26,65). Gross and microscopic examination of hemophilic arthropathy reveals destruction of articular cartilage by direct synovial invasion and subchondral synovial and degenerative cysts. Biochemical studies have documented enzymatic degradation similar to other forms of inflammatory arthritis (6,66). Symmetry is common, and in that sense, the condition is similar to rheumatoid arthritis.

***Figure 136.1.*** AP **(A)** and lateral **(B)** x-ray study of a 14-year-old boy with severe hemophilia type A. The cartilage interval is well maintained. There are minor surface irregularities and an erosion on the posterior surface of the lateral femoral condyle.

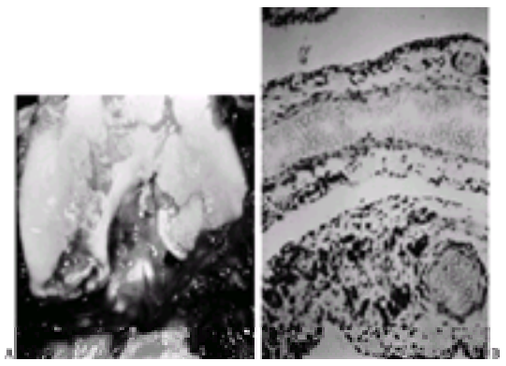

***Figure 136.2.*** **A:** Photograph of the knee of the patient in Figure 136.1 at the time of open synovectomy a few days after the x-ray studies were taken. There is extensive hyperplastic synovitis with full-thickness erosion of the articular surface of the weight-bearing surfaces of the medial and lateral condyles and the trochlea. This demonstrates the advanced destruction that can occur with chronic hemophilic synovitis despite a relatively benign-appearing x-ray study. **B:** Photomicrograph of the synovium from this patient showing hemosiderin pigment deposition on the surface taken up by the phagocytic synovial A cells. These cells migrate into the perivascular tissue of the subsynovial layer to return blood products to the general circulation. This patient was in the stage of chronic hemarthrosis, which is easy to understand with dilated venous channels immediately beneath the surface that are easily torn when the fragile, hypertrophic synovium gets caught between the eroded joint surfaces. (See also Color Fig. 136.2.)

***Figure 136.3.*** Eleven-year-old boy with a severe flexion contracture of his right knee secondary to recurrent hemorrhage and advanced arthrofibrosis.

***Figure 136.4.*** Thirteen-year-old boy with severe type A hemophilia. He demonstrates marked muscle atrophy and a lateral translation deformity of his left knee.

***Figure 136.5.*** AP **(A)** and lateral **(B)** radiographs showing moderately advanced hemophilic arthropathy with almost complete loss of cartilage interval. Note the synovial cyst in the medial femoral condyle, flattening of the anterior part of the trochlea resulting from lateral subluxation of the patella, and loss of the normal posterior tilt of the tibial articular surface, which results from a flexion contracture during growth. These changes are typical of hemophilic arthropathy.

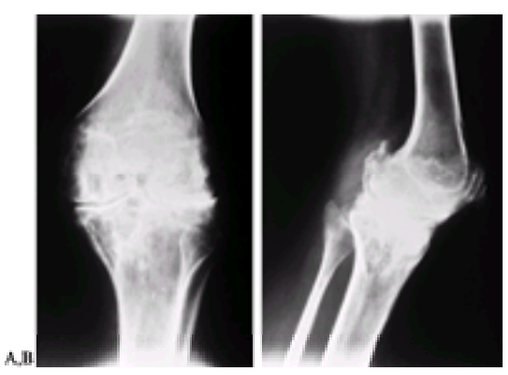

***Figure 136.6.*** AP **(A)** and lateral **(B)** radiographs showing end-stage arthropathy with large synovial cysts, complete loss of cartilage interval, flattening of the opposing joint surfaces, ossification of the posterior capsule, and nearly complete fibrous ankylosis.

The joints most commonly involved are knees, elbows, and ankles. Hips, shoulders, and subtalar joints are sometimes involved; wrists, fingers, and toes are rarely involved. Fortunately, hemophilic arthropathy of the spine does not occur. The prevalence of hemophilia arthropathy correlates with the level of circulating clotting factor. Polyarthropathy is common in severe hemophilia (defined as less than 1% of normal circulating clotting factor). Arthropathy is much less common in moderate hemophilia (1% to 4% of normal clotting factor) and rare in mild hemophilia (greater than 5% of normal clotting factor).

Susceptibility to target joint formation varies from joint to joint within the same patient. The first hemorrhage may initiate a smoldering, low-grade synovitis with recurrent, subclinical bleeding, which results in a steady progression to chronic synovitis and end-stage arthropathy. However, a major joint may remain normal through adulthood despite the occurrence of a few hemorrhages in childhood and adolescence. The biochemical and pathophysiologic reaction of the synovium to hemarthrosis varies even within the same patient and probably involves an element of autoimmune sensitivity.

## NONOPERATIVE MANAGEMENT OF HEMOPHILIC SYNOVITIS

### PROPHYLACTIC CONCENTRATE

Aggressive use of clotting factor concentrate in the early phases of hemophilic synovitis may reverse the progressive nature of this disease in some cases, but even with optimal management, many patients will progress. Chronic synovitis reaches a point at which the membrane becomes very friable, with dilated venous channels immediately beneath the surface. This is the stage of chronic hemarthrosis and is usually associated with joint surface erosions. With motion of this jagged joint, the friable, hyperemic synovium is torn, resulting in bleeding regardless of clotting factor level (Fig. 136.1, Fig. 136.2). Muscles atrophy, joint contractures develop, and the patient becomes severely disabled (Fig. 136.3, Fig. 136.4).

Because of the often inexorable course of hemophilic synovitis, management of initial hemarthroses is critical if a normal joint is to be preserved.

- Start clotting factor concentrate as soon as possible after the onset of bleeding.
- If the hemarthrosis is clinically significant, consider aspiration to reduce the magnitude of blood breakdown products to which the synovium is exposed as well as to reduce pain and facilitate recovery.

- Start the patient on prophylactic factor replacement with daily doses for the first few days, followed by every other day for at least 2 weeks or until the joint is nearly normal on careful examination with no evidence of effusion or synovial thickening.

Strengthening exercises may play a role in reducing hemarthroses. Several centers have documented a lower frequency of hemarthroses and arthropathy in severe hemophilia patients of mesomorphic habitus compared with endomorphs and ectomorphs. Even under optimal circumstances, chronic synovitis with “target joint” formation subject to recurrent hemarthroses without trauma may occur.

The initial bleed usually occurs during early childhood, most commonly in the ankle, followed by the elbow and knee. In recent years, several hemophilia centers (58) have begun programs of primary prophylaxis before the first bleed. Regular doses of clotting factor are begun at 1 to 3 years of age and continued into middle to late adolescence. This approach is based on the experience with moderate hemophiliacs with factor levels of 1% to 4% of normal who grow up with a paucity of joint hemorrhages and are often free of arthropathy when they reach adulthood (58). This approach is very costly and usually requires a venous access port with a significant risk of infection. Fortunately, recombinant factor is now available and free from viral contaminants.

On the horizon is gene therapy, which promises to be the ultimate answer for prevention of arthropathy. In the meantime, older children, adolescents, and adults continue to be plagued by chronic synovitis and progressive arthropathy. Early synovectomy holds some promise for the prevention of progressive arthropathy in target joints.

About 15% of factor VIII–deficient and fewer factor IX–deficient patients develop antibodies termed inhibitors to human clotting factor (4). Treatment with immune tolerance programs, in which patients are given large amounts of clotting factor to overwhelm and suppress the inhibitor, are often successful for these patients. Although these programs are costly, in the range of $200,000 to $800,000 per patient, immune tolerance is greatly beneficial to the patient and may be ultimately cost effective because it prevents hemorrhage and progressive arthropathy. Patients with persisting inhibitors are like hemophiliacs before the days of any effective treatment. They are extremely complex to manage, and major trauma or surgery creates a precarious situation; they are not candidates for surgery other than in life-threatening emergencies.

## ARTHROSCOPIC SYNOVECTOMY

Synovectomy is the treatment of choice for hemophilic synovitis, ideally before irreversible joint destruction has occurred. Synovectomy may be surgical, either open or arthroscopic, or through the injection of radioactive colloids. Open synovectomies were first performed in the late 1960s, when clotting factor concentrate (67) became available. Although these procedures were effective in reducing or eliminating hemarthroses, they were complicated by severe arthrofibrosis and loss of motion, and there was one report of arteriovenous fistula (11,12,24,48,60,72). Because of the complexity and prohibitive cost of the administration of concentrate for this procedure, most patients had significant joint surface erosion by the time synovectomy was eventually performed, and joint surface degeneration progressed over the ensuing years. In that era before arthroscopy and magnetic resonance imaging (MRI), findings at surgery showed a surprising degree of surface erosion that was unsuspected based on the plain radiographs (Fig. 136.1 and Fig. 136.2). With the advent of arthroscopic surgery, arthroscopic synovectomy replaced open procedures and was associated with much less loss in motion but was occasionally complicated by significant hemorrhage in the perioperative period (15,43,76). Massive amounts of factor replacement were still required for 2 weeks following surgery and before physical therapy for as long as the therapy was needed, so the prohibitive cost of administering concentrate remained about the same.

## RADIOSYNOVECTOMY

Radiosynovectomy, or radiosynoviorthesis, which is a term preferred by some, was introduced in 1963 and has been used extensively for rheumatoid arthritis (5). Over the last 20 years, several hemophilia centers outside the United States have used a variety of radiocolloids for chronic hemophilic synovitis (2,3,18,63). In 1988, with institutional review board approval, the Hemophilia Center at Orthopaedic Hospital in Los Angeles (OHHC), began a prospective study of radiocolloid synoviorthesis in the treatment of chronic hemophilic synovitis.

$^{32}$P chromic phosphate is the agent of choice for radiosynovectomy in the United States and Canada. The dosage protocol is also quite universal (Table 136.1). To date, the procedure has not been performed on hips at OHHC.

| | *Small Joints (e.g., elbows, ankles)* | *Large Joints (e.g., knees, shoulders)* |
|---|---|---|
| Children | 0.25 millicuries | 0.5 millicuries |
| Adults | 0.5 millicuries | 1.0 millicuries |

***Table 136.1. Dosage Protocol for Radiosynovectomy with $^{32}$P Chromic Phosphate***

All patients receive a dose of clotting factor just before the procedure that is aimed at attaining a plasma level of clotting factor of 50% of normal and are advised to self-infuse a second time 8 to 12 hours following the procedure. Patients with inhibitors receive the clotting factor that has been the most effective in controlling their bleeding episodes. They are observed overnight in the hospital. The procedure is as follows:

- Prep the involved joint with povidone-iodine and drape it with sterile towels.
- Infiltrate lidocaine 1% into the skin, subcutaneous tissue, and capsule with a 27-gauge needle. Buffered lidocaine is less painful and is especially useful in children. Lidocaine-prilocaine lotion applied to the skin 1 hour before injection also reduces pain.
- Insert a larger needle ranging in gauge from 23 to 18, depending on the amount of fluid to be aspirated, into the joint space. Needles larger than 22 gauge are not used in subcutaneous joints such as the elbow to avoid retrograde leakage of radiocolloid onto the skin. The intra-articular position of the needle is critical; confirm the position by the aspiration of blood or synovial fluid, or in cases in which that is not possible, confirm position by the injection of radiographic dye under image-intensifier visualization.
- After confirmation of needle position, inject the selected dose of radiocolloid in a volume of 1 ml through a separate syringe.
- Change syringes and partially inject a mixture of 5 ml lidocaine and 2 ml dexamethasone acetate into the joint. Use the remainder to flush the needle and needle tract as the needle is withdrawn to reduce the risk of radiocolloid leakage along the needle tract.
- Apply local pressure. followed by cleansing of the area with isopropyl alcohol, followed by more local pressure for a total of 3 to 5 minutes. While maintaining local pressure on the injection site, put the joint through range of motion to disperse the radiocolloid throughout the joint.
- When the puncture site is completely dry, apply a small adhesive bandage.
- Immobilize the treated joint for 2 days and have the patient avoid strenuous activities for 2 weeks.
- Perform biodistribution analysis using a small window Geiger-Muller counter to determine the counts per minute for the target joint, contralateral joint, regional nodes, and liver. In addition, perform a single photon emission computed tomography (SPECT) scan to determine the distribution of the radiocolloid within the joint. Check the biodistribution at the time of the procedure, and after 1 day, 1 week, and 1, 2, and 3 months. Because of the large particle size, escape of the colloid from the joint is much less frequent than with gold or yttrium. At our center, in 120 consecutive cases, only three patients demonstrated minute escape of the radioactive colloid, ranging from 0.5% to 2.5% of the total dose in the target joint (46).

Results from several centers have been remarkably consistent, with about a 75% rate of good and excellent results defined as complete cessation of hemarthroses (excellent) or greater than 75% reduction in frequency of hemarthroses (good) (1,46,47,64). This success rate remains stable at 10 years follow-up.

Safety is a function of the local and remote effects of the radiation, with particular concern for damage to local tissues, such as the growth plate or articular cartilage, and the late development of a secondary neoplasm. Because $^{32}$P chromic phosphate is a pure beta emitter, the penetration of radiation is limited to 3 to 5 mm; therefore, intra-articular injection should not reach the growth plate. To date, there have been no reported cases of growth plate disturbance (3,18). Furthermore, over the last 20 years, many centers have treated pediatric patients with $^{198}$Au radiocolloid, which has both beta and gamma radiation, without apparent growth plate disturbance. Articular cartilage is highly radioresistant, and although damage is theoretically possible, none has been reported. Progressive degeneration of treated

joints does occur, but the rate is equal to or slower than expected for the disease process (38,53,55,77).

The principal concern in radiosynovectomy is the potential of late radiation-induced neoplasia. External beam radiation has been extensively studied and carries a small risk of induction of bone sarcomas, principally osteosarcoma or fibrosarcoma. The peak incidence is 5 to 10 years after the procedure, but cases have been reported as early as 3 years (28,49). Because of the low penetration of $^{32}P$ chromic phosphate, bone exposure is minimal. Furthermore, intra-articular sarcomas of any type are extremely rare. For example, synovial sarcomas and chondrosarcomas are almost never intra-articular.

Probably the strongest argument for the safety of intra-articular radiocolloids, is the long-term follow-up of the more than 5,000 radiosynovectomies performed for rheumatoid arthritis, none of which have been reported to develop radiation-induced malignancies (41). Five to 10 millicuries of $^{198}Au$ were used on most of these patients since 1963. The small (20 mm) particle size of Au resulted in a 20% to 37% incidence of escape, usually to regional nodes (22,71,74). Yet, there have been no reports linking the use of this agent to hematogenous malignancies or sarcomas. In our series, the maximum escape was 2.5% of the target dose, which occurred in one patient (46). Winston et al. (79), using chromic phosphate in rheumatoid patients, reported a maximum escape in only one patient of 3.2%, which agrees closely with our results. Rivard (64), however, reported three patients with 7%, 9%, and 14% escape using chromic phosphate. Immobilizing the treated joint for 2 days and limiting activities for 2 weeks may reduce the risk of escape. The small amount of intra-articular steroids used in our series may account for the absence of postinjection inflammation and bleeding reported in other series. This approach may further reduce the risk of escape.

## SURGERY FOR HEMOPHILIC ARTHROPATHY

Before the release of factor VIII concentrate in 1966, major surgery for chronic synovitis or advanced hemophilic arthropathy was a rare undertaking fraught with an unacceptable rate of complications as a consequence of uncontrolled hemorrhage and systemic fluid overload from the transfusion of whole blood and fresh frozen plasma (31). Even with the availability of cryoprecipitate, surgery was mostly limited to the mild hemophiliacs with higher levels of circulating factor VIII or IX (13,14,57). With the availability of factor VIII concentrate in the United States in 1967, major hemophilia centers began performing elective surgery on their patients (14,16,17,30,57). During the past 30 years, an interdisciplinary team of physicians at OHHC has performed more than 700 major surgical procedures on hemophiliacs. Our surgical philosophy and recommendations are based on that experience and a substantial volume of published reports and presentations from hemophilia centers around the world.

Factor VIII deficiency, or hemophilia type A, accounts for about 85% of hemophilia. Almost all of our joint replacement patients fall into this group. For many years, we were reluctant to consider major surgery on patients with factor IX deficiency, or type B hemophilia, because of the increased risk of life-threatening thromboembolic complications related to activated clotting factors in factor IX concentrate previously reported by our center (30). When purified factor IX became available in 1990, however, these patients also became elective surgical candidates (31). Rarely, patients with Von Willebrand's syndrome and other clotting factor deficiencies will develop hemophilic arthropathy that requires joint replacement. Some will need joint replacement at an advanced age on the basis of osteoarthritis unrelated to their clotting disorder.

Kasper et al. (30) reported on a retrospective study of the first 15 years' experience with clotting factor concentrate in elective surgery. The amount of concentrate used tripled during the study period, but the incidence of postoperative bleeding was not significantly reduced by the additional factor VIII replacement. The frequency of postoperative bleeding correlated better with the site and type of surgery than with the factor levels at the time of the incident. For example, the incidence of postoperative, surgical site hemorrhage was 40% for knee surgeries and 15% for all other types. These findings were similar to those reported by Kay et al. (32).

### CURRENT REGIMEN OF CLOTTING FACTOR REPLACEMENT

- Preoperatively, carefully screen the patients for any evidence of a factor VIII inhibitor and any medical contraindications to elective reconstructive surgery.
- Elevate factor VIII levels to above 100% of normal 1 hour before surgery.
- Maintain factor levels at 60% by continuous infusion until the patient is discharged. This is cost effective because continuous infusion maintains a more consistent level and uses less total factor than bolus therapy (25).
- If further, vigorous physical therapy is required to increase range of motion, infuse the patient to a 50% level before each therapy session.

With the increased emphasis on cost containment, we allow selected patients to leave the hospital after the first week and continue intermittent self-infusion at home. This is possible only for lesser procedures, such as radial head excision and elbow synovectomy, and in patients who are on the self-infusion program, live close to the hospital, and are eminently reliable.

Orthopaedic surgical intervention for hemophilic arthropathy may be divided into two categories based on the degree of arthropathy: synovectomy with or without debridement for early to moderate arthropathy, and reconstructive surgery for advanced arthropathy.

### SURGICAL SYNOVECTOMY

The indications for surgical synovectomy vary among hemophilia centers depending on their interest in radiosynovectomy. Because radiosynovectomy is about 5% to 10% of the cost of surgical synovectomy and much easier for the patient, most centers favor that procedure for earlier cases. Surgical synovectomy is clearly indicated for patients who have very thick synovium (more than 5 mm) that would be beyond the penetration of beta-emitting radiocolliods, patients with significant arthrofibrosis requiring debridement, and patients in whom radiosynovectomy has failed. Arthroscopic synovectomy has almost completely replaced open synovectomy, except for the patient with severe arthrofibrosis and loss of motion.

The indication for synovectomy is recurrent or chronic hemarthrosis that is unresponsive to appropriate conservative management in a joint with minimal arthropathy. A trial of conservative treatment usually requires 3 to 6 months. However, by the time these patients come to surgery, there is often a significant amount of full-thickness articular cartilage erosion and the remaining articular surface has sustained significant mechanical and biochemical insult (Fig. 136.1, Fig. 136.2*A*). Under these circumstances, synovectomy is rarely curative but is often effective in resolving the chronic and recurrent hemarthroses, and possibly slowing the progression of arthropathy (52,54). Resolution of the chronic hemarthrosis allows the patient to resume therapeutic exercises, often with marked improvement in function as well as reduction in hemarthroses and the need for coagulation factor replacement.

There is increasing interest in considering synovectomy before irreversible damage to the articular cartilage occurs. Surface erosion occurs early in this process, even before the synovitis is noticeably symptomatic or clinically evident. Patients at this stage are often 3 to 8 years of age. If the safety of radiosynovectomy can be established for this age group, early intervention may become the standard. Early arthroscopic synovectomy is also an option because children are much more difficult to rehabilitate than adults after surgical synovectomy. The pediatric patient is not usually capable of exercising the knee if it is painful and often loses range of motion after open synovectomy and occasionally after arthroscopic synovectomy if hemarthrosis occurs. Small vessel hemostasis at the time of arthroscopic synovectomy is not possible with motorized shavers but would be possible with a laser. However, to date there is no large reported experience with laser synovectomy in hemophilia. For patients whose range of motion fails to progress postoperatively, consider closed manipulation 10 to 14 days postoperatively, followed by continuous passive motion. The injection of a nonsoluble steroid preparation, such as dexamethasone acetate, combined with long-acting local anesthetic at the time of manipulation has been helpful in reducing postmanipulation pain, inhibiting fibroplasia, and restoring range of motion, especially in children.

### SPECIFIC JOINT CONSIDERATIONS

Surgical experience and current recommendations from our center are presented in the order of the frequency of joint involvement: knee, elbow, ankle and subtalar joint, hip, and shoulder.

#### *Knee*

Arthropathy of the knee is the most common cause of pain and disability severe enough to require reconstructive surgery in hemophiliacs. Involvement of the ankle and elbow is about as common as that of the knee, but the ankle and elbow require surgical intervention less frequently. Historically, the range of procedures considered for hemophilic arthropathy of the knee included synovectomy, debridement, debridement with patellectomy, osteotomy, fusion, and total knee prosthetic arthroplasty. Today at OHHC, we perform only arthroscopic synovectomy, open debridement, total knee prosthetic arthroplasty, and fusion. Previously, we performed distal femoral extension osteotomy for severe flexion contractures that failed to respond to physical therapy or serial casting. Today, such deformities are much less common except in patients with advanced arthropathy and are corrected at the time of prosthetic arthroplasty. Preservation of the patella is especially important in this patient population who are prone to flexion contractures, especially following knee replacement. Patellectomy is occasionally indicated at the time of knee replacement when, either from erosion or prior surgery, there is inadequate bone stock for secure fixation of a prosthetic component.

Because of the complexity of postoperative rehabilitation and the risk of recurrent arthrofibrosis, patient motivation and careful preoperative counseling are very important. At OHHC, all patients are seen preoperatively by the surgeon, hematologist, physical therapist, and patient-care coordinator as a team for assessment and

counseling.

We use arthroscopic or open debridement to treat chronic synovitis and early to moderate arthropathy. The principal indications for debridement are recurrent hemarthrosis that is unresponsive to conservative management and impingement symptoms, usually associated with recent loss of extension. In some patients, impingement is intermittent, but in others, it cannot be overcome, and any attempt at vigorous exercise or passive range of motion results in hemarthrosis. Pain in this group of patients is usually intermittent and responds to nonsteroidal anti-inflammatory agents and analgesics. If pain is the principal symptom in a patient with moderately advanced to advanced arthropathy, debridement is rarely of lasting benefit. In our experience, at 7 to 21 years of follow-up, 6 of 18 patients who had undergone debridement had required total knee replacement, four of them within 1 year. These patients were older at the time of debridement (average age, 30.8 years) than those who obtained lasting benefit (average age, 16.5 years), and they had arthropathic pain as their principal complaint (43).

Open debridement is often complicated by loss in range of motion. Arthrofibrosis with loss of motion is one of the most significant complications of surgery for advanced hemophilic arthropathy (6,40,42,50,52,53,73,75). In our series, the average loss of range of motion in the nine patients undergoing arthroscopic debridement was only 9°, but they had a 50% incidence of postoperative hemarthrosis compared to none in the open debridement group. This difference is attributed to the inability to achieve adequate hemostasis with arthroscopic debridement. Open debridement has been performed for patients with arthrofibrosis. Although early improvement may be obtained, the arthrofibrosis often recurs with a poor end result. Occasionally, lasting improvement in range of motion has been obtained following the injection of a long-acting local anesthetic and a nonsoluble cortisone preparation at the time of knee manipulation 7 to 14 days after surgery.

Primary knee fusion may be indicated for patients with end stage arthropathy and fibrous ankylosis, severe deformity, or infection. Seven primary knee fusions have been performed at OHHC. Two of these patients had a history of infection, one from a hematogenous pyarthrosis with *Pseudomonas aeruginosa* and another with chronic *Staphylococcus aureus* osteomyelitis after an osteotomy. Five of the patients fused without problems and with good long-term results, including the one patient with *Pseudomonas* infection before surgery. One of the patients hemorrhaged from the denuded bone surfaces and swelled to such an extent that the external fixator crossing the knee had to be removed. He healed without infection but has a pseudarthrosis that is stable and painless. He is fully ambulatory with a cylinder orthosis. The patient with chronic osteomyelitis fused but has a draining sinus. Six of these patients have limited mobility of the opposite knee and bilateral ankle and elbow involvement but can rise from an armchair without assistive devices. No patient has developed associated ipsilateral hip or low-back problems. We have performed no primary knee fusions in the last 15 years because we now favor total joint replacement. Patients with end-stage arthropathy and fibrous ankylosis usually have minimal or no pain and do not require surgery if the knee is near-full extension and adequately aligned.

The knee is the most frequently reconstructed joint for hemophilic arthropathy. At OHHC, knee replacement represents about 10% of all surgeries on hemophiliacs. The indications for knee replacement are the same in hemophilia as in other arthropathies: pain and disability that is unresponsive to conservative management with end-stage radiographic changes (Fig. 136.6). End-stage arthropathy may develop by late adolescence. Severe pain and disability often exist by the third or fourth decade. The age range at surgery in our series was 21 to 62 years, which is typical. Most patients are in their forth or fifth decade at the time of operation.

Chronic synovitis and extensive arthrofibrosis requiring careful dissection and definition of normal tissue planes complicate the surgical approach for knee replacement in these patients. It is important to preserve the fat layer in the supracondylar area of the femur, which is an effective barrier to adhesions between the extensor mechanism and the distal femur. Many patients have flexion contractures that require modified cuts on the distal femur as well as posterior capsular release. Our preferred method of posterior release is under direct vision through the usual anterior approach to the knee, as follows:

- Carefully dissect the posterior capsule off the distal femur with the knee in maximum flexion. Interpose your nondominant hand and use it to apply pressure to the posterior capsule just below its attachment to the distal femur to protect the popliteal structures from inadvertent laceration while dissecting the capsule off the femur with a half-inch osteotome.
- Excision of popliteal synovitis as well as the posterior release are often facilitated by placing a self-retaining lamina spreader alternately in the medial and lateral compartments to separate the femur from the tibia and maintain tension on the capsule. Extensor mechanism contracture is also common. Quadricepsplasty may be required but often results in loss of full active extension, which gradually recovers over the ensuing few months.
- Take care to maintain full passive extension postoperatively. Partial release, rather than complete transection of the extensor mechanism, is preferable when it is adequate to allow 80° of flexion. A V-Y lengthening is performed for more severe cases. With diligent physical therapy, these patients often end up with 90° or more of motion.
- Close the wound in patients with limited preoperative flexion, with the knee in about 50° flexion.

The first knee replacements at OHHC were performed in 1974 and were of the two-compartment type. We began using three-compartment “total condylar” prostheses in 1978. Beginning in 1982, 18 bone ingrowth “cementless” prostheses were implanted. For the last decade, we have used cemented posterior stabilized knees exclusively. The age range at the time of surgery and pathology was very similar among these three groups. There has been no statistically significant difference between these groups in the survivorship of the prosthesis, which, without infection, is 96% projected to 20 years (43,44). However, the eight knee replacements of the two-compartment type had an average loss of 10 degrees of range of motion, and three patients had residual patellofemoral pain. After converting to three compartment replacements, range of motion improved an average of 30° for patients with a preoperative range of less than 80°. The probable reason for this gain in motion is inclusion of the patellofemoral joint replacement, but improved techniques, including the use of continuous passive motion postoperatively, also may have contributed. At present, we begin continuous passive motion the second postoperative day if the wound is doing well. We no longer use immediate postoperative continuous passive motion because it is associated with increased bleeding. Although the end results of the “cementless” knees were equivalent to our current cemented models, there was significantly increased blood loss postoperatively, as measured by Hemovac output.

Loss of bone stock is relatively common in hemophilic arthropathy owing to synovial cysts or mechanical erosion. Earlier solutions to this problem included filling defects with polymethylmethacrylate cement or the use of specially designed, stemmed components. During the past 18 years, bone grafting has been the procedure of choice. It is especially attractive because of the potential to improve bone stock if future revisions are needed in these relatively young patients. A minimum of bone is resected. Local autogenous bone is used for small and moderate-sized defects. Large defects require allograft. Autogenous iliac graft is not used because of the risk of hemorrhage and possible pseudotumor formation at the donor site.

**Complications** At OHHC, four types of significant early postoperative complications have occurred following knee replacement: hemarthrosis, Coombs-positive hemolysis, wound dehiscence at the time of manipulation, and component loosening (43). In one study, hemarthrosis in the perioperative period following knee surgery on hemophiliacs was reported in 40% of patients regardless of the factor level (30). Perioperative hemarthrosis tends to occur in the patients who still have active, hypertrophic synovitis and are in the stage of chronic hemarthrosis. The intra-articular blood is partially clotted and impossible to aspirate. It should be evacuated using arthroscopic cannulas, followed by thorough lavage and the placement of a suction drain.

Coombs-positive hemolysis has been identified in only one knee replacement patient and was probably the result of minor host-donor incompatibilities present in earlier clotting factor concentrates. Clotting factor preparations are now purified, and there have been no instances of this hemolysis in the last 12 years.

Wound dehiscence occurred in one patient at the time of manipulation in the early days of knee replacement. Today, manipulation is rarely used. However, the capsule is always closed with nonabsorbable suture to reduce this risk, especially in the patient with arthrofibrosis who will undergo fairly vigorous physical therapy beginning a few days after surgery. There were no perioperative infections, even in patients infected with the human immunodeficiency virus (HIV). Later complications have included hematogenous infection and component loosening.

Aseptic failure of fixation from any cause occurred in three patients, each with single-component loosening: tibial component, femoral component, or patellar component. The femoral component failed when the patient fell and fractured his distal femur near the component. The failed tibial component, a Geomedic two-compartment replacement performed in 1974, was inserted in a patient with severe bone stock deficiency resulting from a large pseudotumorous cyst in the upper tibia, which was filled with cement. The failed patellar component was inserted into a patella that had eroded down to a thin cortical shell and did not have adequate bone stock for cement intrusion and fixation. The loose femoral and tibial components were treated by revision surgery, and the patellar component was treated by patellectomy. These three revision surgery patients have done well. The patellectomy patient regained active range of motion of 0° to 90°. The tibial component failure was revised to a Total Condylar I (Zimmer) prosthesis and did well for 9 years, until he died of hepatic carcinoma, a consequence of chronic active hepatitis C. The patient with the femoral failure with the distal femur fracture was revised to a Total Condylar III (Zimmer) prosthesis and is doing well after 15 years. This represents an aseptic failure rate of 3 in 90, or 3.3%, at 2 to 24 years' follow-up, which despite the young ages of these patients at the time of prosthetic arthroplasty, is comparable to a reported series of knee replacements in patients with osteoarthritis and rheumatoid arthritis (27). The low aseptic failure rate for this relatively young population is probably due to their low activity level as a consequence of polyarthropathy. The principal mode of failure of prosthetic joints in hemophiliacs is late, hematogenous infection, which is discussed in a separate section of this chapter.

### *Elbow*

Elbow synovitis and arthropathy are common in hemophilia, but most patients are not symptomatic enough to warrant surgical intervention. Radionuclide synovectomy for persistent synovitis was effective in reducing hemarthroses in 78% of patients in our series (46). Under present protocols, at the time of radiosynovectomy, essentially all patients have some degree of joint surface changes. The synovectomy may forestall but will not prevent progression to advanced arthropathy. The only

open surgical procedure, in our experience, that is useful for patients with persistent synovitis and advanced arthropathy is radial head excision with synovectomy and debridement.

Indications for radial head excision with synovectomy and debridement include pain, chronic hemarthrosis unresponsive to nonoperative management, and loss of forearm rotation. The most disabling loss of motion in these patients is loss of supination on the dominant side. If it is less than 45°, it impairs the patient's ability to eat normally, accept change, and accomplish personal hygiene. The major source of pain, recurrent bleeds, and restricted forearm rotation is derangement of the proximal radioulnar joint secondary to hypertrophy and marginal irregularity of the radial head. Hemophilic arthropathy of the elbow often is associated with marked hypertrophy of the radial head, which impinges against the proximal ulnar facet, inhibiting forearm rotation and trapping fragile synovium, resulting in hemarthrosis (Fig. 136.7). The patient's pain is typically posterolateral. There is focal tenderness over the posterior aspect of the proximal radioulnar joint and increased pain with forearm rotation, especially supination.

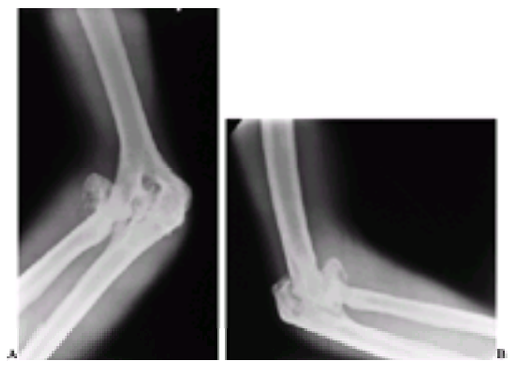

***Figure 136.7.*** **(A)** and lateral **(B)** radiographs showing advanced hemophilic arthropathy of the elbow with massive enlargement of the radial head and synovial cysts on both sides of the joint resulting in deepening of the trochlear groove.

The level of resection of the radial head is just below the ulnar facet, which eliminates impingement but preserves part of the annular ligament for stability. Later proximal migration of the radius, causing distal radioulnar joint symptoms, has not been observed in our patients, all of whom were at least in their third decade at the time of surgery. This procedure is not recommended for immature patients.

Use a posterolateral surgical approach along the border of the anconeus (see Chapter 1). Following radial head excision, dissect part of the common extensor origin from the lateral epicondyle, to expose the ulnohumeral articulation. This dissection is aided by varus stress. Posterior exposure may be enhanced with further dissection of the capsule from the posterolateral humerus.

Pain relief with this procedure has been excellent in spite of advanced changes in the medial side of the ulnohumeral articulation, which is only debrided. Cessation of recurrent or chronic hemarthrosis occurs in approximately 90% of patients. In patients with restricted forearm supination preoperatively, radial head excision has resulted in an average gain of 30°, which has made a significant difference in the ability to perform activities of daily living. Occasional patients will have significant pain at the ulnohumeral joint, usually on the medial side, and some will manifest symptoms of a tardy ulnar palsy as a result of synovial invasion of the ulnar groove. These patients can be helped with ulnar nerve transposition and debridement of the ulnar side of the elbow.

Flexion-extension range is a function of the pathology in the ulnohumeral joint, its capsule, and the musculotendinous units crossing the joint. Loss of this range in chronic hemophilic arthropathy is a long-term process and is not altered significantly by radial head excision, even with ulnohumeral joint debridement. Increased range may be accomplished at surgery but is rarely maintained postoperatively.

### *Ankle and Subtalar Joint*

The ankle is similar to the knee and elbow in frequency of involvement and is usually the first target joint in children after they begin to walk. Progressive arthropathy is the rule. End-stage ankle arthropathy is commonly manifested by severe joint surface erosion, valgus alignment, and opposing exostoses on the tibia and talus. Large synovial cysts occasionally invade the talus adjacent to the ankle joint (Fig. 136.8). The subtalar joint is also subject to hemophilic arthropathy, although involvement is less common than in the ankle (Fig. 136.9). Its involvement usually accompanies that of the ankle but can occur in isolation. Erosion of the posterior margin of the posterior facet, similar to that seen in rheumatoid arthritis, is the first manifestation of subtalar joint disease on plain radiographs. Many patients develop equinus deformities secondary to ankle arthropathy and calf bleeds with residual muscle contractures (Fig. 136.8, Fig. 136.10).

***Figure 136.8.*** Advanced arthropathy of the tibiotalar joint with surface irregularity, joint surface erosions, and abutting anterior exostoses.

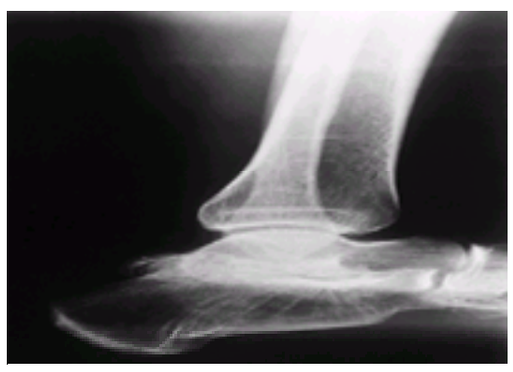

***Figure 136.9.*** Isolated advanced arthropathy of the subtalar joint without tibiotalar involvement.

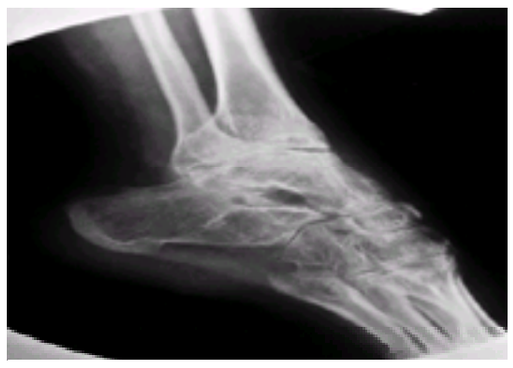

***Figure 136.10.*** Advanced arthropathy of the ankle involving both tibiotalar and subtalar articulations. This patient has a severe equinus deformity that resulted from a massive calf hemorrhage during his adolescence, which was before clotting factor was available.

Only a small percentage of ankles require surgery. The procedure of choice for the ankle or subtalar joint is arthrodesis. Over the years, a variety of fixation techniques has been used, including Charnley external fixation, anterior plate and screws, and crossed screws. Crossed screws are our favored technique. For combined ankle and subtalar arthrodesis, we drill two or three cancellous screws from the tibia across the talus into the oscalcis using a custom drill guide. The distal fibula often unites more slowly than the tibiotalar joint. A distal fibular osteotomy eliminates rotation stresses about the lateral malleolus. If the malleolus is unstable, the lateral malleolus may be compressed against the talus with a single transfixing screw into the tibia. In patients with moderate to severe equinus deformity and Achilles tendon contracture, a single-pin Charnley compression device may be placed through the anterior talus and tibia to maintain the foot in neutral and take stress off the internal fixation screws transfixing the ankle. Cast fixation alone may not be adequate in these patients without producing excessive pressure on the metatarsal heads.

The OHHC surgical experience includes 42 cases: tibiotalar arthrodesis, 34; tibiotalar and subtalar arthrodesis, 5; pantalar arthrodesis, 2; and tibiotalar prosthetic arthroplasty, 1. If the talonavicular and calcaneocuboid joints are normal, they are not included in the fusion. Fixation techniques included 39 internal fixation and 3 Charnley external fixators. External fixators are safe in hemophiliacs and do not require clotting factor replacement after the initial 2 weeks. This is similar to the experience reported by Wilson et al. (78) and Patel et al. (59), but different from that suggested on theoretical grounds by Trueta (72) and Arnold and Hilgartner (6).

**Postoperative Care** Place all patients in a non-weight-bearing short leg cast for 6 weeks, followed by a weight-bearing well-molded short leg cast or a polypropylene ankle-foot orthosis (AFO) depending on the degree of consolidation evident on radiographs at 6 weeks. At 12 weeks, even if the fusion appears solid, continue an AFO until the fusion is solid and can withstand all daily activities.

**Results** Over the last 16 years, we have not seen progressive degeneration of the unfused midfoot joints following combined ankle and subtalar arthrodesis.

One patient with a tibiotalar joint treated with external fixation developed a painless nonunion, and there was one patient with delayed union of a subtalar joint in which internal fixation was used. Gamble et al. (20) reported on 10 tibiotalar arthrodeses in eight patients using a variety of techniques. Two developed painless nonunions but continued to have bleeding episodes. There have been no early or late infections in our patients who underwent ankle fusion or in those reported by Gamble.

Because talonavicular and calcaneocuboid joint involvement is rare, primary pantalar arthrodesis has been required only twice in the OHHC series. One other case was reported in the literature (59). All three of these patients obtained solid fusions and can bear weight fully without orthoses. One tibiotalar joint replacement was performed in 1978; the patient moved away, but his brother reports that he is doing well, without pain or hemarthroses. In our opinion, the ankle and subtalar joints are better treated by arthrodesis than with prosthetic arthroplasty.

***Hip***

Arthropathy affects the hip less commonly than the knee, ankle, or elbow. It has two modes of onset. In childhood, rapidly progressive, severe arthropathy may result from a single hemarthrosis because of increased intracapsular pressure leading to osteonecrosis of the capital femoral epiphysis (Fig. 136.11). More often, hip arthropathy is the result of chronic synovitis, similar to that of the other joints (Fig. 136.12*A*). The first prosthetic arthroplasty of the hip in a hemophiliac in the United States was a cup arthroplasty performed at OHHC by J. Vernon Luck in 1968 (Fig. 136.12*B*).

***Figure 136.11.*** **A:** Frog lateral x-ray study in a 20-month-old boy with severe hemophilia B and a history of a hemarthrosis in his left hip at 6 months of age. **B:** The same patient at skeletal maturity. His capital femoral epiphysis never developed.

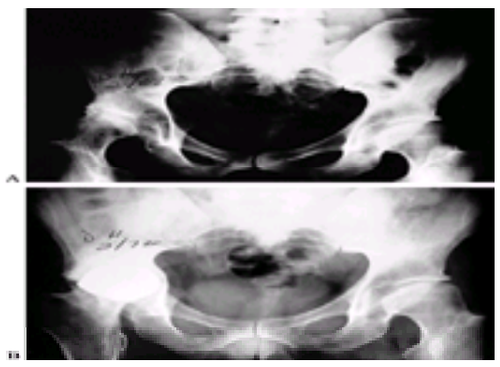

***Figure 136.12.*** **A:** Advanced hemophilic arthropathy of the hip resulting from chronic synovitis with typical joint surface erosions and lateral subluxation. The coxa valga is probably the result of inhibition of abductor function from hemarthroses during growth. **B:** Cup arthroplasty in the same patient. This was the first major reconstructive procedure performed on a hemophiliac at OHHC.

End-stage hip disease in hemophiliacs poses a dilemma. The patients are relatively young when they require hip replacement. They are not suitable candidates for fusion because of knee involvement. In our experience, primary cemented prostheses have a 33% aseptic failure rate at 8 to 18 years follow-up, which may be higher than expected in a comparable group of patients with another form of polyarthritis. The patients in the OHHC series were relatively young (30 to 61 years of age at the time of surgery) but not particularly active owing to multicentric arthritis. Hemophiliacs tend to be slender, and none of the hip replacement patients was overweight. With the exception of periarticular cysts, bone density is better than would be expected in a group of patients with rheumatoid arthritis in the same age range. Kelley et al. (33) reported a failure rate of 21% for cemented femoral components and 23% for cemented acetabulae, with a median follow-up of 8 years. In addition, 10 of 24

cemented femoral and 10 of 23 cemented acetabular components showed radiographic evidence of “definite” loosening. Within this group were three patients with late infection, all of whom were infected with HIV. Nelson et al. (56) reported on 22 total hip replacements, eight of which had been revised or showed definite signs of loosening radiographically, with an average follow-up of 7.6 years. There were two deep infections, but this factor was not correlated with HIV status.

A unique aspect of many patients with advanced hemophilic arthropathy is a remarkably stiff-legged gait due to severe arthrofibrosis of the knee and ankle. This causes increased forces on the hip due to a lengthened lever arm and loss of the normal shock-absorbing function of the knee and ankle. All of the patients in our series had bilateral knee and ankle arthropathy, and none had knee joint replacements. Part of the reason for loosening of cemented hip prostheses in hemophiliacs may be the increased stresses of a stiff-legged gait. Another consideration is the possibility of bleeding within the membrane that forms at the cement-bone interface. As a result of subclinical hemorrhage within and around this membrane, loosening may propagate more rapidly in hemophiliacs than other arthritis patients.

Since 1982, we have used porous-coated, uncemented hip prostheses to improve durability. Results in terms of pain relief and cessation of hemarthroses have been excellent, and none of the 12 cases have required revision for fixation failure. One HIV-positive patient developed a late infection requiring prosthesis removal. More cases are needed before we will know if this represents a significant improvement over cemented prostheses in the management of hemophilic arthropathy of the hip.

### *Shoulder*

Arthropathy of the shoulder deserves more attention than it has received. Shoulder pain, like hip pain, can be intractable, interrupting sleep and daytime function. Muscle atrophy and loss of motion occur early, often before the patient is aware of a significant problem. Attempts to restore range of motion and increase strength are usually thwarted by hemorrhage due to synovial hypertrophy that is friable and bleeds even with antihemophilic factor replacement.

Chronic synovitis of the shoulder frequently resists conservative measures. Open shoulder synovectomy has been abandoned because of unacceptable loss of motion and persistent pain. Shoulder arthroscopy is severely inhibited in these joints because of fibrosis and hyperplastic synovitis. The answer to this dilemma for all hemophilic joint involvement, but especially that of the shoulder, is early diagnosis by regular examination or at the time of initial hemorrhage. Early in the course of the disease, maintenance of strength and range of motion is still possible. Regular follow-up examinations are essential. Persistent synovitis, which is unresponsive to prophylactic concentrate, should be treated by synovectomy either with radiocolloids or arthroscopically before joint surface erosion and arthrofibrosis cause loss of motion.

Inexorable progression to end-stage arthropathy is the usual course. Hemarthrosis diminishes in the fibrotic end-stage joint. Pain is the primary indication for surgical intervention. Loss of shoulder motion in these patients does not cause enough impairment of activities of daily living to warrant surgery by itself. End-stage arthropathy of the shoulder may be treated by arthroplasty or arthrodesis. The traditional approach has been arthrodesis, which gives predictable and durable results but has the disadvantage of lesser range of motion, especially rotation. Impaired elbow motion in most of these patients makes loss of shoulder motion even more consequential. The patient must be involved in this decision after careful counseling.

Two of the first three patients treated by shoulder fusion at OHHC failed to obtain solid bony union, although the clinical results were good in terms of the absence of pain and hemarthroses because of a stable fibrous ankylosis. These nonunions seem to have occurred because of reactive sclerosis at the glenohumeral joint combined with the use of single-plane glenohumeral screw fixation. Our preferred method of fusion is the three-plane screw fixation method developed by Kauko Vainio (personal communication, 1974). This method includes the AO screw transfixion of the acromiohumeral and coracohumeral junctions in addition to the glenohumeral joint. Glenohumeral and acromiohumeral wire loops lend additional stability. The upper extremity is placed in a salute position, with the shoulder in 20° to 30° of abduction, 30° of forward flexion, and 30° to 40° of internal rotation. Postoperatively, we immobilize the shoulder in a modified Bateman foam support, which allows periodic elbow motion, until fusion is apparent radiographically. All of our fusion patients are able to reach the top of their heads with the help of neck flexion, and all can reach their sacrums. The five patients in whom three-plane screw fixation was used have all attained solid bony union.

Prosthetic shoulder arthroplasty has the advantage of increased rotation but does not improve abduction or forward flexion owing to the arthrofibrosis. During the last 15 years, we have performed six prosthetic shoulder arthroplasties in hemophiliacs using the Neer II prosthesis with cement fixation. All are satisfactory, and none has recurrent hemarthrosis. Five are pain free, and the other has occasional slight pain. Range of motion is improved in all compared with their preoperative status. Rotation is better than the fusion group but forward flexion and combined abduction are about the same.

## IMPACT OF HIV INFECTION ON ELECTIVE RECONSTRUCTIVE SURGERY

It is estimated that 90% of severe, type A hemophiliacs became infected with HIV between 1978 and the introduction of an effective antibody screen, the enzyme-linked immunosorbent assay (ELISA), in 1985. Mild and moderate type A and type B hemophiliacs use less clotting factor concentrate and thus fewer have seroconverted. This factor has added immensely to the complexity, morbidity, and mortality of an already medically challenged population. Fortunately, treatment of HIV infection has improved to the point at which patients who were severely debilitated are now stable and leading relatively normal lives. Many of these patients have advanced arthropathy and are potential candidates for reconstructive surgery.

We often are asked how the presence of HIV and acquired immune deficiency syndrome (AIDS) has affected indications for elective surgery in these patients. As always, the decision is based on the risks and benefits to the patient. No decision is made without a comprehensive team evaluation, team conference, and multiple discussions with the patient.

Surgery, elective or emergent, on the HIV-positive patient involves some special risks, which may be divided into two categories: risk to the patient, and risk to health care personnel. Both of these risks must be understood and considered in making a decision regarding the appropriateness of surgery for these patients. Because of concern about these issues, some orthopaedic surgeons may pursue nonoperative management of fractures that are usually treated surgically and are reluctant to recommend elective surgery in the HIV-positive patient.

Because of documented seroconversion of health care personnel following HIV-contaminated puncture injuries (8) and the frequency of parenteral and surface exposure to blood and body fluids in the operating room setting, there has been extensive study of the risks to health-care personnel. Recommendations of methodologies to reduce this risk in the practice of orthopaedics have been developed and published by the Task Force on AIDS and Orthopaedic Surgery of the American Academy of Orthopaedic Surgeons (AAOS) (69). To date, there have been 49 well-documented occupational seroconversions among health care workers. However, none have followed suture needle injuries, the most common surgical percutaneous injury (8). In a recent report from the Centers for Disease Control (CDC), zidovudine (ZVD) was shown to be effective in the prevention of seroconversion following percutaneous exposure to HIV-contaminated blood (9,10). Hepatitis C virus (HCV) transmission by percutaneous injury may pose a greater risk to health care personnel than HIV. HCV is about equally prevalent in this patient population and is estimated to be about 10 times more transmittible by percutaneous injury (35,51,54). We believe that if the AAOS/CDC recommendations are closely followed, the risk to health care personnel, although real, can be reduced to an acceptable level.

Risks to health care personnel can be significantly lessened but not totally eliminated by the vigorous application of universal precautions in the operating room and on the ward. The use of face masks, impervious gowns, and foot covers in the operating room is effective in preventing blood or body fluid contact with eyes or skin. If power equipment (e.g., saws, drills) that creates airborne blood droplets is used, we wear space suits with inflow and outflow high-efficiency particulate arrestance (HEPA) filters. Even more important than this is the prevention of puncture injuries from suture needles, bone spicules, and other sharp objects, which are common in orthopaedic surgery. Modified surgical technique and the routine use of triple gloves with a cloth intermediate glove can help reduce this risk. Research is under way on the development of a tougher, more protective glove material.

In addition to concern about the risk of HIV transmission in the health care setting, surgeons have expressed concern about the complications and outcome of operations on the HIV-infected patient. This risk may be divided into early and late postoperative complications. Early postoperative complications of greatest concern in the HIV-positive patient include sepsis and impaired healing. The late postoperative complication of primary concern in the HIV-positive orthopaedic patient is implant infection, which some authors have speculated is at increased risk (29,36). The risk of early and late septic complications is theoretically increased because of impaired cellular and humoral immunity. The estimated magnitude of increased risk is based on a series of reports of the outcome of surgery on HIV-positive patients and is less well delineated than the theoretical basis. These clinical studies also address our ability to prevent complications in the HIV-positive surgical patient successfully.

Buehrer et al. (7) studied surgical wound infection rates in HIV-positive and HIV-negative hemophiliacs by reviewing 169 procedures, 53 of which were orthopaedic. There were two wound infections but no statistically significant difference in the wound infection rate between the HIV-positive group (1.4%) and the HIV-negative group (0%). There were no wound infections in the seven procedures performed on patients with AIDS.

Greene et al. (23) reviewed 26 orthopaedic procedures on HIV-positive hemophiliacs performed between 1984 and 1988. There were no surgical site infections but there was one case of cellulitis at an intravenous site. Five patients had a protracted postoperative fever but did not develop clinical infection. The outcome and functional results were similar to the patients treated before 1982 who were presumed to be HIV negative.

In a mail survey of 115 hemophilia centers, Ragni et al. (61) studied the rate of early postoperative infection in 74 orthopaedic procedures performed on 66 HIV-positive patients with CD4 counts below 200 at the time of surgery. [Cluster designation (CD) identifies lymphocyte subsets.] A CD4 count of less than 200 qualifies these patients for the diagnosis of AIDS. Eliminating those patients with evidence of active infection preoperatively, the rate of postoperative infection was 7.5%. Thirty-four of the procedures were joint replacements, of which there were five postoperative infections without evidence of infection preoperatively. Except for the timing of infection, this rate of 6.7% is not different from reported series of joint replacements in HIV-negative hemophiliacs (21,43,53).

### RECOMMENDATIONS FOR SURGERY ON THE HIV-POSITIVE PATIENT

Based on current basic and clinical knowledge, a general philosophy or guideline may be developed for elective surgery on the HIV-positive hemophilia patient in various stages of disease. Most of the clinical studies available to date do not demonstrate an increased incidence of early postoperative complications in asymptomatic HIV-positive patients compared with the HIV-negative group. Furthermore, most of the orthopaedic studies and the more recent general surgery studies do not show an increased incidence of early complications in the symptomatic HIV positive patients with CD4 counts above 200 undergoing elective procedures. The basic science work establishes some impairment of defenses against common orthopaedic pathogens and the potential delay of wound healing (45). As the disease progresses and these impairments increase, the hazard of early complication increases. The risk of late prosthetic implant infection is increased in hemophiliacs regardless of HIV status. In view of all of these factors, special management of the HIV-positive hemophiliac patient undergoing surgery seems warranted. OHHC uses a protocol that serves as the basis for the following recommendations.

Informed decision making about the advisability of surgery is crucial. As a result of improved reverse transcriptase agents and third-generation protease inhibitors, high viral loads are treatable to undetectable levels, often resulting in elevation of the CD4 count. The prognosis and life expectancy for patients with AIDS has improved dramatically, making reconstructive surgery in these patients who require it an appropriate consideration. Following a thorough assessment of the patient's medical status, a thoughtful discussion of the risk–benefit ratio ensues between the patient and the multidisciplinary team. Quality of life issues are often a principal consideration in the patient's view and must be balanced against risk management.

The spectrum of disease in HIV infection is a continuum on which each patient may be positioned to assess risk properly. No single clinical factor is a reliable predictor of longevity or risk of surgery. Several components should be combined in determining a prognosis and assigning risk. The factors that seem to correlate best with surgical outcome are history of opportunistic infection, CD4 cell level less than 200, serum albumin less than 25 g/L, and cutaneous anergy (23,44,61). However, these studies antedated current HIV therapy. Today, viral load combined with CD4 counts are the primary indicators for surgery. Patient reliability and ability to cooperate with medical recommendations is essential to reduce the risk of late complications in the joint-replacement patient.

Once a decision is made to proceed with surgery, several steps can be taken to reduce the risk of perioperative complications further. Some of the measures are applicable to an emergent situation. Others require more time and are only feasible in elective surgery. The absolute polymorphonuclear leukocyte count should exceed 1,000 and the platelet count should exceed 50,000. In addition to HIV, platelet deficiency can result from chronic active hepatitis B or C, which is common in hemophiliacs. Acceptable platelet levels may vary from 30,000 to 60,000, depending on lever function status and other comorbidities. Platelet transfusions also may be used when needed. Chronic liver disease can also reduce vitamin K levels, which can further compound the coagulation disorder. In patients for whom surgery is essential, granulocyte-stimulating factor may also be used to elevate an unacceptably low white blood cell count. Low platelet and white blood cell counts may be indications that management of the patient's underlying infection with HIV or HCV, or both, is inadequate, which should be corrected before any elective surgery. Inadequate management may be an indication of patient noncompliance, which will place the patient in a higher risk category for postoperative complications if it cannot be reliably corrected. All patients should be carefully screened for opportunistic infections, including bacterial, mycobacterial, and fungal agents that might increase the risk of early or late postoperative infection.

Many of the symptomatic HIV-positive patients are chronically anemic as a consequence of disease and therapy, and may require transfusion before surgery. When clinically appropriate, marrow-suppressing drugs should be stopped a few days preoperatively and resumed after the first postoperative week. Some of the drugs used to suppress HIV, such as ZVD, didanosine (DDI), and zalcitabine (DDC), can cause various degrees of marrow suppression. However, the more recently developed reverse transcriptase inhibitors such as lamivudine (3TC) and stavudine (D4T) and the protease inhibitors are not likely to do this. Prophylactic antibiotics seem clearly indicated in this patient population. In the patients with advanced HIV infection, some authors have suggested continuation of prophylactic antibiotics longer than normal, but there are no data to demonstrate efficacy, and many studies show no increase in the incidence of early postoperative infection in this patient population.

The HIV-positive patient with a prosthetic implant may be at increased risk of late hematogenous implant infection as host defenses diminish. Patients are cautioned to use meticulous antisepsis technique for self-infusion. Regular medical attention, prophylactic antibiotics before dental work and any invasive procedures, and early evaluation and treatment of possible infections are especially important in this group. Rarely, a patient may require long-term venous access. Subcutaneous ports are less likely to become infected than external, percutaneous catheters. Tanner et al. (68) found a rate of infection in Hickman catheters of 50%, compared with 5% for implanted subcutaneous ports placed in the upper extremity. Avoid external catheters whenever possible in patients who have undergone joint replacement. Some clinicians have raised the issue of using chronic prophylactic antibiotics in symptomatic HIV-positive patients with a joint replacement. To date, there have been no studies demonstrating a reduction in the rate of late infection with chronic prophylactic antibiotics. Long-term use of trimethoprim-septra, which many patients with advanced HIV disease take as prophylaxis against *Pneumocystis* pneumonia, may offer some protection against *S. aureus* infection of prosthetic joints.

## AUTHORS' PERSPECTIVE

We have come a long way in the management of the devastating disease of hemophilia and its accordant form of arthritis, but much remains unanswered. Early treatment and prevention of chronic synovitis and progressive arthropathy are the key. Diagnosis of early synovitis before joint erosion is challenging but possible with close follow-up after an initial bleed. The role of radiosynovectomy versus arthroscopic synovectomy is being defined. When end-stage arthropathy does occur and is severely disabling, durable, functional reconstruction with minimal risk must be our goal.

As medical management of HIV infection continues to improve, so does the prognosis for HIV-infected hemophiliacs, many of whom will require reconstructive procedures. The unusually high risk of late prosthetic infection in this patient population may be reduced by careful attention to antisepsis for self-infusion, dental prophylaxis, and close medical monitoring. The ultimate prevention of hemophilic arthropathy will follow the correction of the underlying clotting disorder by primary prophylaxis and, eventually, gene therapy.

### CHAPTER REFERENCES

Each reference is categorized according to the following scheme: *, classic article; #, review article; !, basic research article; and +, clinical results/outcome study.


+ 1. Abshire T, Busch M, Rickles F. *Radionuclide Synovectomy in Hemophilia (RASH) Conference, Emory University.* Atlanta, Sept. 14, 1998.

+ 2. Ahlberg A. *Radioactive Gold in the Treatment of Chronic Synovial Effusion in Hemophilia.* In Excerpta Medica International Congress of Hemophilia, published 1973. Teheran, Iran, May 17–20, 1971.

+ 3. Ahlberg A, Pettersson H. Synoviorthesis with Radioactive Gold in Hemophiliacs: Clinical and Radiological Follow-up. *Acta Orthop Scand* 1979;50:513.

+ 4. Aledort L. Inhibitors in Hemophilia Patients: Current Status and Management. *Am J Hematol* 1994;47:208.

+ 5. Ansell BM, Crook A, Mallard J, et al. Evaluation of Intra-articular Colloidal Gold 198Au in the Treatment of Persistent Knee Effusions. *Ann Rheum Dis* 1963;22:435.

+ 6. Arnold WD, Hilgartner MW. Hemophilic Arthropathy. *J Bone Joint Surg* 1977;59A:287.

+ 7. Buehrer JL, Weber DJ, Meyer AA, et al. Wound Infection Rates after Invasive Procedures in HIV-1 Seropositive Versus HIV-1 Seronegative Hemophiliacs. *Ann Surg* 1990;211:492.

# 8. Centers for Disease Control and Prevention. *HIV/AIDS Surveillance Report* 1995;7:21.

+ 9. Centers for Disease Control and Prevention. Case-control Study of HIV Seroconversion in Health-care Workers after Percutaneous Exposure to HIV Infected Blood—France, United Kingdom, and United States, January 1988—August 1994. *MMWR* 1995;44:929.

+ 10. Chang HJ, Luck JV, Bell DM, et al. Transmission of Human Immunodeficiency Virus Infection in the Surgical Setting. *Journal of the American Association of Orthopaedic Surgeons* 1996;4:279.

+ 11. Clark MW. Knee Synovectomy in Hemophilia. *Orthopedics* 1978;1:285.

+ 12. Cohen B, Griffiths L, Dandy DJ: Arteriovenous Fistula after Arthroscopic Synovectomy in a Patient with Haemophilia. *Arthroscopy* 1992;8:373.

# 13. De Palma AF, Cotler J. Hemophilic Arthropathy. *Clin Orthop* 1956;8:163.

+ 14. De Palma AF. Hemophilic Arthropathy. *Clin Orthop* 1967;52:145.

* 15. Doub HP, Davidson EC. Roentgen-Ray Examination of the Joints of Hemophiliacs. *Radiology* 1926;6:217.

# 16. Duthie RB. Reconstructive Surgery in Hemophilia. *Ann N Y Acad Sci* 1975;240:295.

# 17. Duthie RB, Matthews JM, Rizza CR, Steel WM. *The Management of Musculo-Skeletal Problems in the Haemophilias.* Oxford, Blackwell Scientific Publications, 1972.

+ 18. Fernandez-Palazzi F, De Bosch NB, De Vargas AF. Radioactive Synovectomy in Haemophilic Haemarthrosis. Follow-up of Fifty Cases. *Scand J Haematol* 1984;40(Suppl):219.

* 19. Freund E. Die Gelenkerkrankungen der Bluter. Arch Pathol Physiol 1925;256:105.

+ 20. Gamble JG, Bellah J, Rinsky LA, et al. Arthropathy of the Ankle in Hemophilia. *J Bone Joint Surg* 1991;73-A:1008.

+ 21. Goldberg VM, Heiple KG, Ratnoff OD, et al. Total Knee Arthroplasty in Classic Hemophilia. J Bone Joint Surg 1981;63-A:695.

+ 22. Grahame R, Ramsey NW, Scott JT. Radioactive Colloidal Gold in Chronic Knee Effusions with Baker's Cyst Formation. *Ann Rheum Dis* 1970;29:159.

+ 23. Greene WB, DeGnore LT, White GC. Orthopaedic Procedures and Prognosis in Hemophilic Patients Who are Seropositive for Human Immunodeficiency Virus. J Bone Joint Surg 1990;72-A:2.

# 24. Greer RB. Operative Management of Hemophilic Arthropathy—an Overview. *Orthopedics* 1980;3:135.

+ 25. Hathaway WE, Christian MJ, Clarke SL, Hasiba U. Comparison of Continuous and Intermittent Factor VIII Concentrate Therapy in Hemophilia A. *Am J Haematol* 1984;17:85.

! 26. Hoagland FT. Experimental Hemarthrosis. *J Bone Joint Surg* 1967;67-A:285.

+ 27. Insall JN, Kelly M. The Total Condylar Prosthesis. *Clin Orthop* 1986;205:43.

# 28. Jaffe HL. *Tumors and Tumorous Conditions of the Bones and Joints*. Philadelphia: Lea & Febiger, 1958:492.

+ 29. Jellis JE. Orthopaedic Surgery and HIV Disease in Africa. *International Orthopaedics (SICOT)* 1996;20:253.

# 30. Kasper CK, Boylen AL, Luck JV, et al. Hematologic Management of Hemophilia A for Surgery. *JAMA* 1985;253:1279.

+ 31. Kasper CK, Lusher JM. Transfusion Practices Committee: Recent Evolution of Clotting Factor Concentrates for Hemophilia A and B. *Transfusion* 1993;33:422.

+ 32. Kay L, Stanisby D, Buzzard B, et al. The Role of Synovectomy in the Management of Recurrent Hemarthroses in Hemophilia. *Br J Haematol* 1981;49:53.

+ 33. Kelley SS, Lachiewicz PF, Gilbert MS, et al. Hip Arthroplasty in Hemophilic Arthropathy. J Bone Joint Surg 1995;77-A:828.

* 34. Key JA. Hemophilic Arthritis (Bleeder's Joints). *Ann Surg* 1932;95:198.

+ 35. Kiyosawa K, Sodeyama T, Tanaka E, et al. Hepatitis C in Hospital Employees with Needlestick Injuries. *Ann Intern Med* 1991;115:367.

+ 36. Kjaersgaard-Andersen P, Christiansen SE, Ingerslev J, Sneppen O. Total Knee Arthroplasty in Classic Hemophilia. *Clin Orthop* 1990;256:137.

* 37. Klason T. Hemophilia and Hemophilic Arthropathy. *Acta Radiol* 1921;1:26.

+ 38. Klein KS, Aland CM, Kim HC, et al. Long Term Follow-up of Arthroscopic Synovectomy for Chronic Hemophilic Synovitis. *Arthroscopy* 1987;3:231.

* 39. Konig F. Die Gelenkerkrankungen bie Blutern mit Besonderer Beruck Sichtigung der Diagnose. *Klin Vortr* 1892;36:233.

+ 40. Lachiewicz PF, Inglis AE, Insall JN, et al. Total Knee Arthroplasty in Hemophilia. *J Bone Joint Surg* 1985;67-A:1361.

+ 41. Lee P. The Efficacy and Safety of Radiosynovectomy. *J Rheumatol* 1982;9:165.

# 42. Luck JV Jr. Prosthetic Knee Arthroplasty for Advanced Hemophilic Arthropathy. In: Seligsohn U, Rimon A, Horoszowski H, eds. *Haemophilia.* Turnbridge Wells, Castle House Publications, 1981:183.

+ 43. Luck JV Jr, Kasper CK. Surgical Management of Advanced Hemophilic Arthropathy: An Overview of 20 Years' Experience. *Clin Orthop* 1989;242:60.

+ 44. Luck JV, Hansjaj KK, Dorey FJ, Kasper CK. Risk Factors for Late Infection in Hemophiliacs with Total Hip and Knee Arthroplasties. *Proceedings of the American Academy of Orthopaedic Surgeons,* 1994.

+ 45. Luck JV Jr, Logan LR, Benson DR, Glasser DB. Immunodeficiency Virus Infection: Complications and Outcome of Orthopaedic Surgery. *Journal of the American Association of Orthopaedic Surgeons* 1996;4:297.

+ 46. Luck, JV Jr, Siegel ME, et al. $^{32}$*P Chromic Phosphate Radiosynoviorthesis for Chromic Hemophilic Synovitis: An Analysis of Efficacy, Safety and Cost.* Presented at the Annual Meeting of the American Academy of Orthopaedic Surgeons, San Francisco, CA, February 12–17, 1997.

+ 47. Manco-Johnson M, Wiedel J. *Radiosynovectomy for Hemophilic Arthropathy.* Conference on Radionuclide Synovectomy in Hemophilia, Emory University, Atlanta, Sept. 14, 1998.

+ 48. Mannucci PM, De Franchis R, Torri G, Pietrogrande V. Role of Synovectomy in Hemophilic Arthropathy. *Israel J Med Sci* 1977;13:983.

# 49. Mirra JM, Picci P, Gold RH. *Bone Tumors: Clinical radiologic and Pathologic Correlations,* Vol 1. Philadelphia: Lea & Febiger, 1989:353.

+ 50. Marmor L. Total Knee Replacement in Hemophilia. *Clin Orthop* 1977;125:192.

+ 51. Marranconi F, Mecenero V, Pellizzer GP, et al. HCV Infection after Accidental Needlestick Injury in Health-care Workers. *Infection* 1992;20:111.

52. + Matsuda Y, Duthie RB. Surgical Synovectomy for Haemophilic Arthropathy of the Knee Joint: Long-term Follow-up. *Scand J Haematol* 1984;33:237.

53. + McCollough NC, Enis JE, Lovitt J, et al. Synovectomy or Total Replacement of the Knee in Hemophilia. *J Bone Joint Surg* 1979;61-A:69.

54. + Mitsui T, Iwano K, Masuko K, et al. Hepatitis C Virus Infection in Medical Personnel after Needlestick Accident. *Hepatology* 1992;16:1109.

55. + Montane I, McCollough NC, Lian EC-Y. Synovectomy of the Knee for Hemophilic Arthropathy. *J Bone Joint Surg* 1986;68-A:210.

56. + Nelson IW, Sivamurugan MB, Latham PD, et al. Total Hip Arthroplasty for Hemophilic Arthropathy. *Clin Orthop* 1992;276:210.

57. + Nilsson IM, Hedner U, Ahlberg A, et al. Surgery of Hemophiliacs—20 Years' Experience. *World J Surg* 1977;1:55.

58. + Nilsson IM, Berntorp T, Lofqvist T, et al. Twenty-five Years' Experience of Prophylactic Treatment in Severe Haemophilia A and B. *J Int Med* 1992;232:25.

59. + Patel MR, Pearlman HS, Lavine LS. Arthrodesis in Hemophilia. *Clin Orthop* 1972;86:168.

60. + Pietrogrande V, Dioguardi N, Mannucci PM. Short-term Evaluation of Synovectomy in Haemophilia. *Br Med J* 1972;13:378.

61. + Ragni MV, Crossett LS, Herndon JH. Postoperative Infection following Orthopaedic Surgery in Human Immunodeficiency Virus-infected Hemophiliacs with CD4 Counts 200/mm$^3$. J Arthroplasty 1995;10:716.

62. * Reinecke H, Wohlwill F. Üauber hämophilie Gelenkerkrankung. *Langenbecks Arch Klin Chir* 1929;154:425.

63. + Rivard GE, Girard M, Lamarre C, et al. Synoviorthesis with Colloidal $^{32}$P Chromic Phosphate for Hemophilic Arthropathy. *Arch Phys Med Rehabil* 1985;66:753.

64. + Rivard GE, Girard M, Belanger R, et al. Synoviorthesis with Colloidal $^{32}$P Chromic Phosphate for the Treatment of Hemophilic Arthropathy. *J Bone Joint Surg* 1994;76-A:482.

65. + Roy S, Gadially FN. Pathology of Experimental Hemarthrosis. *Ann Rheum Dis* 1966;25:402.

66. + Stein H, Duthie RB. The Pathogenesis of Chronic Haemophilic Arthropathy. *J Bone Joint Surg* 1981;63-B:601.

67. + Storti E, Traldi A, Tosatti E, Davoli P. Synovectomy a New Approach to Haemophilic Arthropathy. *Acta Haematol* 1969;41:193.

68. + Tanner AG, Skinner CJ, McBride MO. A Prospective Comparative Study between Externally Sited (Hickman), Chest Implanted (Port-O-Cath), and Arm Implanted (PASport) for Long Term Venous Access in AIDS Patients. (Abtract no. PB0888.) *Int Conf AIDS* 1994;10:219.

69. # Task Force on AIDS and Orthopaedic Surgery. *Recommendations for the Prevention of Human Immunodeficiency Virus (HIV) Transmission in the Practice of Orthopaedic Surgery.* Rosemont, IL: American Academy of Orthopaedic Surgeons, 1989.

70. * Thomas HB. Some Orthopaedic Findings in Ninety-Eight Cases of Hemophilia. *J Bone Joint Surg* 1936;38:140.

71. + Topp JR, Cross EG. The Treatment of Persistent Knee Effusions with Intra-articular Radioactive Gold: Preliminary Report. *Can Med Assoc J* 1970;102:709.

72. + Triantafyllou SJ, Hanks GA, Handal JA, Greer RB III. Open and Arthroscopic Synovectomy in Hemophilic Arthropathy of the Knee. *Clin Orthop* 1992;283:196.

73. # Trueta J. The Orthopaedic Management of Patients with Haemophilia and Christmas Disease. In: Biggs R, Macfarlane RG, eds. *Treatment of Haemophilia and Other Coagulation Disorders.* Philadelphia: F. A. Davis, 1966:303.

74. + Virkkunen M, Krusius FE, Heiskanen T: Experiences of Intra-articular Administration of Radioactive Gold. *Acta Rheumatol Scand* 1967;13:81.

75. # Wiedel JD, Gilbert MS, Berson BL, Hofmann A. Arthroscopy of the Knee in Hemophilia. In: Dohring S, Schulitz KP. *Symposium on Orthopaedic Problems in Hemophilia.* München, West Germany: W. Zuckschwerdt Verlag, 1986:121.

76. + Wiedel JD. Arthroscopic Synovectomy for Chronic Hemophilic Synovitis of the Knee. *Arthroscopy* 1985;1:205.

77. + Wiedel JD. Arthroscopic Synovectomy of the Knee in Hemophilia: 10- to 15-year followup. *Clin Orthop* 1996;328:46.

78. # Wilson FC, Mahew DE, McMillan CW. Surgical Management of Musculoskeletal Problems in Hemophilia. *Instr Course Lect* 1983;32:233.

79. + Winston MA, Bluestone R, Cracchiolo A III, Blahd WH. Radioisotope Synovectomy with $^{32}$P-chromic Phosphate-kinetic Studies. *J Nucl Med* 1973;14:886.

# CHAPTER 137

# BIOMECHANICS OF SPINAL INSTRUMENTATION

*Christian M. Puttlitz, Vijay K. Goel, and Robert F. McLain*

**C. M. Puttlitz:** Research Fellow, Departments of Biomedical Engineering and Orthopaedic Surgery, University of Iowa, Iowa City, Iowa, 52242.
**V. K. Goel:** Professor, Department of Biomedical Engineering; Professor, Department of Orthopaedic Surgery; Co-Director, Iowa Spine Research Center, University of Iowa, Iowa City, Iowa, 52242.
**R. F. McLain:** Director of Spine Research, Department of Orthopaedic Surgery, The Cleveland Clinic Foundation, Cleveland, Ohio, 44195.

Normal Motion
Instability
Fusion and Instrumentation
Posterior Devices
Anterior Devices
Interbody Fusion Devices
Biomechanical Evaluation of Instrumentation and Device Failure
Authors' Perspective
Chapter References

The spine is a mechanical entity. Its most important function is to protect the spinal cord from damage while allowing physiologic motions at each vertebral level. Many times, especially in disease states or in the case of trauma, vertebral motion may produce impingement on the spinal canal, resulting in elevated pressure on the spinal cord. Some spinal disorders may reduce mechanical stability, resulting in abnormal motion, pain, or deformity in the face of normal loads and activity. The primary goal of surgical intervention is to relieve extraneous spinal pressure, reduce the patient's pain, and obtain correct spinal alignment.

Obtaining a solid fusion of the affected levels is often the long-term goal of surgery. It is commonly achieved by open reduction and bone grafting, with the postoperative reduction maintained by fixation implants. Each stage in treatment has an associated biomechanical implication that cannot be overlooked.

## NORMAL MOTION

The normal motion of the spine is determined by the spinal structures, particularly the facet joints and intervertebral disc. The spine exhibits two types of motion: in-plane and “coupled” motion. Coupled motion is defined as movement that is out of the plane of the applied loads. The orientation of the facet joints primarily determines the magnitude of in-plane and coupled motion.

Range-of-motion (ROM) characteristics are determined partially by the intervertebral disc and ligaments. Hyperextension, for instance, is limited by the anterior longitudinal ligaments and the anterior portion of the annulus fibrosis (16). Flexion is limited primarily by the posterior ligamentous complex and capsules of the facet joints. The degree of lateral bending is usually checked by the capsular ligaments and facet joints. Axial rotation is regulated by the intervertebral discs including Luschka's joints (cervical spine), facet joints, and capsular, interspinous, and supraspinous ligaments. It has been demonstrated that 90% resistance to axial rotation in the lumbar spine is provided by the facet joints and intervertebral discs; the ligaments are responsible for the remaining 10% (10).

The upper cervical region, the occipitoatlantoaxial complex (C0–C1–C2), is the most mobile area of the spine (Fig. 137.1). Both the occipitoatlantal and atlantoaxial levels allow greater than 20° of flexion and extension. Also, the C1–C2 facets and the atlantodental articulation allow for 40° to 50° of axial rotation to each side. The lower cervical spine (C3–C7) exhibits more lateral bending than the occipitoatlantoaxial complex. Sagittal plane and axial rotation diminish from the C4–C5 level and below.



***Figure 137.1.*** Mapping of the normal ranges of motion in combined flexion and extension, lateral bending, and axial rotation as a function of spinal position. Note that these values should not be regarded as absolute and that considerable variation exists within the population. (From White AA, Panjabi MM. *Clinical Biomechanics of the Spine,* 2nd ed. Philadelphia: J.B. Lippincott Co., 1990:107, with permission.)

Because of its articulation with the rib cage, the thoracic region is the least mobile portion of the spine. The upper thoracic spine allows significant axial rotation (approximately 10°), but below T8–T9, the major motion of the thoracic spine is in flexion and extension. The lumbar spine permits a significant degree of flexion and extension across all levels. There is a sharp increase in the amount of lateral bending exhibited by the L3–L4 level, with a corresponding decrease at the L2–L3 and L4–L5 motion segments. Axial rotation in the lumbar spine is limited by the vertical orientation of the facet joints.

## INSTABILITY

Measurement of spinal stability (or instability) is integral to the diagnosis and treatment of the lumbar spine. Instability of the spine can be a result of a purely mechanical disorder or a disorder of another origin.

Incorrect judgments of spinal stability can lead to unnecessary surgery in some cases or inadequate treatment in others. Unrecognized and untreated instability exposes the patient to an increased risk of neurologic injury, pain, and in the upper cervical spine, mortality. White and Panjabi (54) define clinical instability as “the loss of the ability of the spine under physiologic loads to maintain its pattern of displacement so that there is no initial or additional neurological deficit, no major deformity, and no incapacitating pain.” The key phrase within this definition, for the purpose of understanding stability, is “to maintain its pattern of displacement.” Trauma, degeneration, and certain clinical procedures can severely alter the spine's normal pattern of displacement and lead to instability.

A checklist based on clinical and radiographic criteria has been developed to help the physician determine the degree of instability; see Table 137.1. (43) Radiographs of the spine are taken, whereupon the physician assigns a certain number of points depending on range of motion and condition of spinal elements. According to this system, a total of five points or more indicates a clinically unstable spine.

| Element | Point value |
|---|---|
| Anterior elements destroyed or unable to function | 2 |
| Posterior elements destroyed or unable to function | 2 |
| Radiographic criteria | 4 |
| Flexion-extension radiographs | |
| Sagittal plane translation >4.5 mm or 15%† | 2 |
| Sagittal plane rotation | |
| >15° at L1–L2, L2–L3, and L3–L4 | 2 |
| >20° at L4–L5 | 2 |
| >25° at L5–S1 | 2 |
| Resting radiographs | |
| Sagittal plane displacement >4.5 mm or 15%† | 2 |
| Relative sagittal plane angulation >22° | 2 |
| Cauda equina damage | 3 |
| Dangerous loading anticipated | 1 |

* A total of five points or greater indicates clinical instability of the spine. (Adapted from White AA, Panjabi, MM. *Clinical Biomechanics of the Spine*, Philadelphia: J.B. Lippincott Co., 1990, with permission.
† Of the anteroposterior diameter.

***Table 137.1. Checklist for the diagnosis of clinical instability of the lumbar spine****

Sagittal plane displacement greater than 4.5 mm or 15% of the anteroposterior diameter of the vertebral body or relative angulation greater than 22° denotes potential instability (45,50). Also, relative sagittal rotation greater than 15% at L1–L2, L2–L3, and L3–L4; greater than 20° at L4–L5; or greater than 25° at L5–S1 represents an abnormal range of motion and potential instability (54). The presence of a neurologic deficit is also diagnostic of spinal stability.

A theory that has gained some popularity in assessing spinal instability involves the idea of quantifying the “neutral zone” (43). Within the neutral zone, there is minimal resistance to intervertebral motion; minor changes in load result in considerable shifts in position. A patient in pain may reveal an increase in the neutral zone, allowing motion to occur beyond the pain-free zone under physiologic loads, while showing no change in the spine's overall range of motion. In contrast, when the spine is stabilized, pain may decrease because of a decrease in the range of the neutral zone as well as the overall range of motion.

At present, clinicians can quantify the degree of instability within the lumbar spine through the use of magnetic resonance imaging (MRI), computed tomography (CT) scans, and radiographs, which can indicate the spine's range of motion. (Take care to identify whether the data are based on active or passive range of motion, because there is a difference between the two.) Many recent studies have also postulated that a measurement of the time course of motion within the spine may be as important as range of motion in determining degrees of instability (34,40).

These studies suggest that both velocity and acceleration of movement give key insight into the patient's condition. Slow motion could indicate a patient's lack of confidence or pain. Jerky movements may be indicative of a lack of fine motor control. Some studies suggest that the dynamics behind the movement of the spine are subject to a great amount of variability depending on neuromuscular coordination, motivation, skill, physiologic strength and flexibility, and metabolic support (24).

How much each one of these factors contributes to the speed at which the patient moves is unknown. No conclusive evidence has indicated that velocity measurements are more sensitive to impairment than ROM measurements. The large amount of variability found in studies that examine movement velocity for diagnostic purposes has limited the clinical usefulness of such measurements. Therefore, a dynamic analysis of the spine should be used as a supplement to static radiographs for the determination of spinal instability; flexion and extension x-ray studies are the most widely used studies for this purpose.

Spinal instability can be the direct result of trauma, degeneration, tumor, infection, muscle dysfunction, surgical intervention, or any combination thereof. Damage to any portion of the functional spinal unit (vertebra-disc-vertebra assembly) can lead to instability. The most important spinal elements contributing to instability are the intervertebral disc, facet joints, and the perispinal ligaments. It is often necessary to dissect some or all of these components during spinal surgery. Just exposing the spine can damage fine nerves that contribute to muscle function and coordination (38,44). Nerve damage can upset the normal distribution and transmission of loading, leading to further instability. Thus, it is necessary to describe the biomechanical effects due to partial or complete spinal element removal. The three most common procedures involving spinal element resection are laminectomy, facetectomy, and partial or complete removal of the intervertebral disc.

Laminectomy involves partial or complete removal of the posterior vertebral arch to decompress the neural elements, cord and nerve roots. Partial laminectomy does not necessarily result in instability. Cadaver experiments show that partial laminectomy has a greater effect on the amount of flexion and axial rotation (approximately a 15% to 20% increase) than lateral bending (less than a 5% increase) (23). Controversy exists as to whether fusion is necessary following laminectomy procedures. Degenerative spondylolisthesis cohort studies suggest that laminectomy with fusion results in a decrease in pain, with increased stability. However, follow-up studies on patients who had laminectomies for spinal stenosis showed no difference in outcome whether or not a coincident fusion procedure was performed. It appears that an indication for fusion depends more on the evidence of pre-existing instability than on the decompression itself.

The geometry of the posterior facets is important in determining the relative amount of motion at each spinal level. In particular, the facets serve to resist axial rotation and extension motion. Farfan et al. (10) demonstrated that, in the lumbar region, the facets alone resist approximately 50% of the torsional loads experienced by the spine.

It would seem intuitive that partial or complete removal of these vertebral elements would result in an unstable spine. In fact, however, partial unilateral or bilateral facetectomy at one level results in greater motion but may not produce instability (23). Complete facetectomy (unilateral or bilateral) increased motion by 78% in extension, 63% in flexion, 15% in lateral bending, and 126% in axial rotation as compared with the intact controls, confirming that the degree of instability can be directly correlated with amount of facet removal.

Intervertebral disc disorders can produce instability. The intervertebral disc can degenerate, becoming dehydrated and fissured, resulting in nonphysiologic loading (18). The nucleus pulposus can evidence fibrous tissue formation, leading to nonhomogeneous stresses within the disc. The intervertebral disc, which may protrude or herniate, causing nerve root compression, has been implicated as common source of low back pain (“discogenic pain”). Thus, many surgical interventions involve removing part or all of an intervertebral disc, as do interbody fusion techniques.

Partial removal of the disc can lead to iatrogenic instability. It has also been shown that discectomy with minimal removal of the lamina does not produce instability. In fact, complete discectomy (partial laminectomy, partial facetectomy, partial annulus removal, and complete nucleotomy) results in an 80% increase in flexion, an increase of 60% in extension, a 38% increase in lateral bending, and a 62% increase in axial rotation (14). Postdiscectomy back pain may be associated with more extensive disc removal at the time of surgery.

## FUSION AND INSTRUMENTATION

Spinal stabilization and fusion procedures have been used to treat ailments ranging from fractures and tumors to spondylolisthesis and disc degeneration. Eliminating motion between the affected segments increases the likelihood of fusion and may reduce the degree of pain the patient experiences (41,53). Properly applied, spinal instrumentation maintains alignment and shares spinal loads until a solid, consolidated fusion is achieved.

As instrumentation procedures have become increasingly popular (9,30), the number of available fixation systems has grown. With few exceptions, these systems are used in combination with bone-grafting procedures and may be augmented by external bracing systems.

Most often, spinal instrumentation systems are described in terms of where the hardware is attached: anterior, posterior, or interbody.

- The “anterior” devices such as anterior plates and screw systems usually are classified as those systems that are designed to attach to the anterior or anterolateral aspect of the vertebral body. Typically, the plate or rod construct is transfixed to the involved vertebral segments by screws that pierce one or both cortices as well as gain purchase in the cancellous bone of the vertebral body.
- “Posterior” systems are affixed to the elements situated posterior to the vertebral body, the spinous processes, pedicles, facets, or laminae. These instrumentation systems use laminar hooks, pedicle screw systems, facet screws and wiring techniques.
- Finally, interbody fusion systems promote fusion between the vertebral bodies by the incorporation of a device or graft that spans the disc space. Although allograft and autograft spacers are routinely used in combination with other anterior or posterior instrumentation, a variety of “stand-alone” devices are now available and approved for implantation. Usually, the interbody systems are further classified by the surgical approach used during device implantation. The comingling of system and approach has given rise to such contemporary terminology as anterior lumbar interbody fusion (ALIF), transforaminal lumbar interbody fusion (TLIF), and posterior lumbar interbody fusion (PLIF) procedures.

## POSTERIOR DEVICES

The earliest form of spinal fusion was developed using the posterior fusion technique. The concept originated using the midline fusion technique wherein the graft material spanned adjacent spinous processes and lamellae (Fig. 137.2*A*). This technique is biomechanically disadvantageous. The graft material is situated far from the center of rotation and experiences tensile forces when the spine is put in flexion, both factors that may induce excessive motion and cause the graft to migrate before it can incorporate and consolidate. The measured stress increases as the distance from the center of rotation increases; thus, grafts placed at this distance may result in a nonunion due to resorption or material failure. In addition, tensile loads experienced by the graft also may cause it to fail because bone is inherently more stable in compression than in tension. The clinical outcome is delayed union or nonunion.

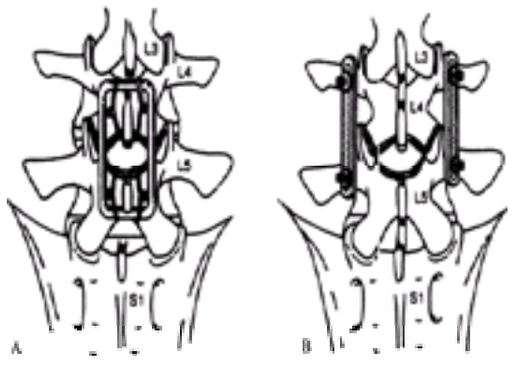

***Figure 137.2.*** Schema depicting two types of posterior fusion devices. **A:** The Luque Loop application is a midline procedure that uses wiring to achieve fixation to the spine. **B:** The posterolateral application of Steffee plates involves pedicle screw fixation (From Goel VK, Lim TH, Gwon J, et al. Biomechanics of Fusion. In: Andersson GBJ, NcNeill TW, eds. *Lumbar Spinal Stenosis.* Chicago: Mosby–Year Book, 1996:403, with permission.)

These mechanical disadvantages were manifested in the relatively high pseudoarthrosis rate with early posterior fusion techniques. The most commonly employed contemporary method of fusion, the posterolateral fusion technique (Fig. 137.2*B*), addresses many of these flaws. The posterolateral technique involves fusion of the transverse processes and the facet joints of adjacent vertebrae. The intertransverse fusion allows placement of the graft in closer proximity to the center of vertebral rotation than the midline fusion, thus reducing the tensile loads experienced by the graft and decreasing the risk of graft migration.

Both factors increase the probability of obtaining a solid fusion. Although aggressive removal of the facet cartilage does reduce the inherent stability of the motion segment, the increased surface area for fusion and close apposition of the facet joint surfaces facilitates the rate of fusion. Internal fixation using wiring, pedicle screw fixation, and hooks usually reduces the risk of graft displacement by decreasing displacement and the loads through the graft during the healing process.

Posterior implant systems have evolved from simple distraction devices, using hooks to force the laminae apart and straighten the spine. Sublaminar wires were the first implant used to provide “segmental” fixation, attaching the rod to the spine at multiple points along the length of the construct. They are still used in deformity surgery, but because they do not provide axial stability, they are a poor choice for stabilizing fractures or bone loss due to tumors. Sublaminar wires have greater leverage in directly pulling the displaced element to the correcting rod than the distraction systems could safely generate, but they cannot prevent these elements from sliding down the rod should adjacent levels collapse.

Contemporary segmental systems use a variety of hooks to attach to multiple points along the construct, and they offer a means of locking the hook to the rod at any given point to maintain axial distraction or compression forces after implantation. Pedicle screws, large fixation screws implanted through the lamina and pedicle into the vertebral body, allow segmental fixation even in areas where the laminae have been removed. Pedicle screws are the only devices available that provide fixation to all three vertebral columns. When used in combination with sublaminar wires and pedicle screws, contemporary posterior instrumentation systems are highly versatile and effective devices.

Pedicle screw systems in particular continue to gain use. These systems provide a high degree of construct stability as well as afford good fixation to the spine. Because pedicle screws are inserted into the vertebral body, these posterior devices can directly manipulate the intervertebral space. Pedicle screws also allow one to apply distraction, compression, lordosis, rotation, and anterolisthesis or retrolisthesis forces selectively. They are the most important factor that provides torsional stiffness in thoracolumbar spinal constructs. Pedicle screw systems provide a means to treat thoracolumbar instability after burst fracture or resection of a spinal tumor. However, they must be augmented with anterior column support to avoid exposing the screws to excessive cantilever loads that might cause bending failure or breakage.

As the indications for the use of pedicle screw systems have increased, additional modifications have become essential to increase their effectiveness and compensate for the shortcomings of the system for a given indication. For example, studies reported a high rate of screw failure when first-generation screws were used to treat thoracolumbar burst fractures (39). Implant failure, by either acute bending failure (postyield deformation) or acute fracture, was seen in young patients with axial instability due to trauma. Screw failure contributed to loss of alignment and fixation. Loosening, toggling, or backing out of the screw owing to failure of bone may occur, early or late, in older patients with weak, osteoporotic bone.

Fatigue failure, occurring after the bony healing period, often results in asymptomatic screw breakage and is usually not a problem clinically. To reduce screw-bone interface problems, augmentation of thoracolumbar constructs with offset laminar hooks has been recommended (51). Laminar hooks help decrease the load transmitted between the bone and pedicle screws, thereby protecting the screws and the bone. Injection of bone cement in the hole before insertion of the screw has also been suggested to increase the bone–screw interface strength, but this approach has limited effectiveness in severely osteoporotic patients and introduces some very real, if uncommon, risks.

Clinical failure in pedicle screws occurs two ways—by loosening and fixation failure and by acute or subacute bending failure or breakage. Loosening occurs as repetitive loading persists beyond the tolerance of the bone, which is usually due to delayed union or excessive activity. The screw is exposed to a combination of cantilever bending and axial pullout loads. Cantilever bending loads may also exceed the yield point of the screws, resulting in acute bending failure and breakage. Even in the degenerated and collapsed disc, axial loads impart small cyclic displacements that generate significant cantilever loads and bending moments. These are most pronounced around the screw hub, inside the pedicle. When the pedicle screws are forced to bear most or all of the anterior column's axial loads, as in burst fracture or tumor reconstruction, excessive bending moments predictably lead to screw failure and progressive kyphosis.

## ANTERIOR DEVICES

The advantage of the anterior approach to the spine is that it gives direct access to the area of disease, which is frequently the disc or vertebral body. The anterior approach allows the surgeon to decompress the neural structures, resect the disease, reduce deformity, and stabilize the injured segment. Fusion anteriorly has the mechanical advantage of being in closer proximity to the vertebral center of rotation, thus reducing the stresses on the graft and hardware, as well as being placed in compression.

Anterior reconstructions directly oppose the greatest forces acting on the thoracic and thoracolumbar spine—the anterior compressive forces generated by gravity, posture, activity, and muscular contraction. Unopposed, these forces lead to progressive and disabling kyphosis. Whereas posterior systems depend on long lever arms and cantilever forces to resist kyphotic collapse, anterior struts are loaded in nearly pure compression, the cortical bone's strongest aspect. Anterior instrumentation need only share the compressive load and resist translation and torsion to be effective.

Biomechanical animal studies (59) have demonstrated the efficacy of obtaining a solid fusion when anterior instrumentation is used. These studies also indicate that fusion mass consolidation is greater when anterior instrumentation is used, resulting in higher torsional stiffness of the fused levels. Most anterior fixation systems use screws placed into the vertebral body with rods or plates, or both (Fig. 137.3). The weak link in these constructs is most often the bone–screw interface, or fatigue failure of the implant occurs due to nonunion.

***Figure 137.3.*** An example of an anterior instrumentation device (applied to a cadaveric specimen). This device (ALC dynamized system, AcroMed, Inc., Cleveland, OH) uses screws driven into the vertebral body with bars spanning between the screws. These devices are commonly used in conjunction with vertebrectomy procedures.

Although rigidity of the implant seems to be the most important feature associated with immediate postoperative stability, the higher stiffness fixation systems can, in time, impart progressively deleterious effects. “Stress shielding” is a phenomenon that occurs with both anterior and posterior devices when a relatively stiff implant bears a disproportionately large amount of physiologic loads compared with the host bone. The biologic response of the bone to the reduction in load is resorption of the bone around the implant.

Stress shielding of the graft and surrounding bone by the implant can lead to progressive angular deformities and loss of fixation of the implant to the bone owing to weakening or resorption of the bone around the implant, which leads to migration of the implant in the bone. More rigid fixation, however, has been associated with greater degrees of immediate postoperative stability. Thus, the dilemma is that although higher implant rigidity is needed in the immediate postoperative period, it may contribute to stress shielding as time proceeds.

The clinical importance of stress shielding in any given construct remains unclear. Additionally, the controlled subsidence of the graft into the vertebral endplate may be a contributing factor to successful fusion, which stiffer implants may impair. At the extreme, resorption of the graft adjacent to a rigid implant may convert a “load-sharing” device to a “load-bearing” device, leading predictably to implant failure.

To overcome these perceived deficiencies, several new devices of more flexible design have come on the market (48). The flexible devices theoretically permit more load-bearing through the interbody bone graft. They may not, however, provide the same degree of immediate stability until fusion occurs. In newer implants the rigidity of the device decreases as a function of time, providing a rigid construct for the initial healing phase and thereafter permitting larger loads through the fusion site because of a gradual decrease in the rigidity of the device (20). The newer anterior as well as posterior “dynamized” systems seek to allow a preset degree of axial subsidence due to graft resorption and settling, thereby allowing temporal load-sharing as graft consolidation proceeds (28). These devices are quite new, however, and are still in evaluation and thus not accepted for general use.

### INTERBODY FUSION DEVICES

Total disc removal alone or in combination with other surgical procedures invariably leads to a loss of disc height and an unstable segment. Both allografts and autologous bone grafts have been used as interbody spacers. Autogenous bone grafts have the disadvantage of donor site morbidity, and both autografts and allografts are subject to dislodgement when used anteriorly, resulting in loss of alignment.

The use of disc space inserts fabricated from synthetic materials has gained popularity. These inserts may be implanted through an anterior or posterior approach.

Interbody cages composed of titanium or carbon fiber mesh promote fusion by imparting immediate postoperative stability, promoting fusion through the incorporation of bone chips packed inside the cage (29). Anterior procedures used to implant cages usually require extensive removal of the anterior portion of the annulus fibrosis and anterior longitudinal ligament. The strength of the construct relies in part on distraction, which produces tension in the remaining annulus (11).

Posterior interbody fusion procedures require removal of various posterior elements. Iatrogenic or acquired (spondylolytic) posterior column instability frequently requires posterior fixation. Combined anterior or posterior interbody fusion and posterior instrumentation and fusion in the lumbar spine usually requires partial or complete facetectomy, removal of the pars interarticularis, and partial or complete discectomy. These constructs require a significant amount of load-bearing by the graft (and cage) construct and posterior hardware to resist translation and torsion forces (47).

## BIOMECHANICAL EVALUATION OF INSTRUMENTATION AND DEVICE FAILURE

The development of various spinal devices has come, in large part, from a desire on the part of surgeons to improve success rates. The operative assumption is that better instrumentation will produce better surgical results, whether success is defined in terms of fusion rate, correction of deformity, pain relief, or hardware survival. Thus, it is no surprise that the engineering community, in concert with surgeons, is constantly evaluating the mechanical performance of spinal instrumentation.

Over the years, a vast number of biomechanical studies have appeared in peer-reviewed journals publishing data on a multitude of clinically relevant mechanical parameters, collected using an equally large and diverse number of *in vitro* and *in vivo* testing methods. The literature can be loosely divided into several distinct categories that outline the stepwise evolution that typically occurs in the design and development of spinal implants and subsequent release for clinical use (1,2,13,46). The majority of data deal with three mechanical parameters: construct stiffness, load to failure, and fatigue load (7,12,26,29,42,55,59,60).

Stiffness is the ratio of the applied load to the resultant displacement. The failure load defines the maximum load that can be applied to the construct before component or fixation failure occurs. Fatigue load is usually defined as the number of loading cycles, at physiologic loading levels, that can be applied to a given system before hardware or fixation failure.

The goal of most instrumentation systems is to minimize motion between the affected levels; thus knowledge of the construct stiffnesses in flexion, extension, lateral bending, and axial rotation is requisite for a complete understanding of a particular hardware system. Load-to-failure studies reveal how the implant is likely to behave when it is first applied. Fatigue studies give insight into the likelihood and type of failures to be expected when the system is exposed to normal loads over time. Several important categories of biomechanical testing modalities illustrate the nature and value of data obtained from each study type.

1. *Interconnection testing* of spinal instrumentation systems has become increasingly more common, owing to the complexity of contemporary designs. This type of testing seeks to characterize mechanically the slip and failure properties of the various interfaces within the device (Fig. 137.4). Interconnection testing performed for pedicle screw and rod systems can assess the failure load needed to produce appreciable slip at the screw-rod junction.



***Figure 137.4.*** Interconnection testing seeks to characterize mechanically the interfaces within an assembled device. Pictured are two examples: testing of the

hook–rod interface (**A**) and the screw–rod interface (**B**).

Because these tests are standardized as to configuration and loading, comparisons between various studies can be made. Figure 137.5, for example, shows the loads needed to produce failure slip under both axial and rotational forces for many contemporary lumbar designs (21).

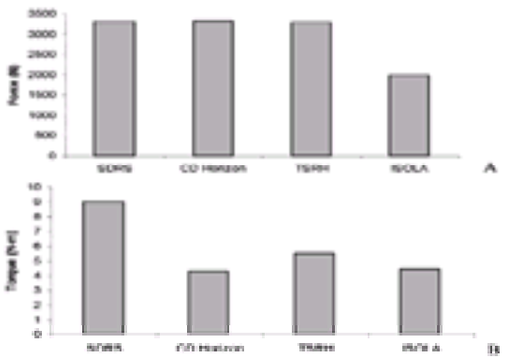

***Figure 137.5.*** Data from interconnection testing for both (**A**) axial load and (**B**) axial rotation. The four systems tested were the Surgical Dynamics Rodding System (SDRS), Cotrel-Dubousett Horizon (CD-Horizon), Texas Scottish Rite Hospital (TSRH), and ISOLA system.

2. *Plastic vertebrae (simulated corpectomy) models* are tests that mimic the performance of fixation devices under the worst possible clinical scenario, which is where an anterior gap is produced by vertebrectomy. Tests using plastic models standardize the bone-screw interface and, thus, highlight the performance of the assembled device as distinguished from the bone-screw interface. The devices are mounted onto molded plastic vertebral components (Fig. 137.6) (8,48) and subjected to axial compression, compression-flexion bending, and torsional modes, loading either statically or cyclically (fatigue testing).

***Figure 137.6.*** Instrumentation testing using the plastic vertebrae model. The construct is assembled with the two plastic blocks representing the vertebral bodies. The assembly depicted here is being subjected to a combined loading of flexion and compression.

Results show that most devices fail at up to 50% less load, when fatigue tested to 5 million cycles, as compared to the loads they can withstand when loaded statically (22). Failure always seems to occur at points of stress concentration, such as attachment of the rod to the screw, at threads in the rod, at the junction of the cross-links, and in the longitudinal members. These failure patterns are supported by pedicle-screw loading studies.

One such study (56) demonstrated that the maximum stresses are seen near the hub of the screw and decay nonlinearly to zero at the screw tip. Additionally, the stress concentrations introduced by the geometry of the screw hub–shaft junction increased the stresses experienced by the screw such that the screw would be at risk of fatigue failure. Biomechanical studies using analog models have shown that even small changes in screw orientation or insertion technique can affect screw bending moments (35,36 and 37). Thus, it seems that with the development of more versatile pedicle screw systems, the clinical ease for implanting the devices may improve but may introduce additional stress concentration sites. This type of testing clearly shows the need for coordination between implant design engineers and clinicians to ensure that the likely locations of failure will be the least problematic.

Tests of the compression strength of cortical and cancellous bone dowels and cortical femoral rings, inserted between plastic blocks having matching geometry and loaded in axial compression using a servohydraulic testing machine, have shown that fresh human cancellous bone fails at an average load of 863 N, whereas cortical bone dowel strength may exceed 24,000 N (4).

3. *The strength of the bone–implant interface* is as important as the strength of the implant in preventing failure. Axial pullout tests, which evaluate the fixation characteristics of different screw types (31), have led to optimization of screw placement (6) and thread design, producing instrumentation systems that are less likely to fail clinically owing to fixation failure. Use of offset hooks has been suggested as a supplement to pedicle screw fixation. Yerby et al. (57) demonstrated that hook augmentation to screw fixation decreased the bending moment experienced by pedicle screws by approximately 30%, leading to reduced screw migration during *in situ* contouring of the rods.

   The strength of pedicle screw fixation can be augmented by filling the screw holes with hydroxyapatite grouting material. This method can increase screw purchase in situations in which the bone quality is diminished.

   In an animal study, Spivak et al. (49) used hydroxyapatite as a grouting material for posterior screw placement. They showed that grouting significantly improved screw pullout strength 6 weeks following implantation. Histologic analysis showed that this was most likely due to new bone formation within the grout material around the screw.

   In an acute pullout study, Yerby et al. (58) performed similar testing to determine the potential improvement in fixation provided by hydroxyapatite augmentation for revision pedicle screws. They simu- lated revision by pulling out 6.0 mm screws and replacing them with 7.0 mm screws. The results showed that hydroxyapatite augmentation increased the pullout strength by 325%. They also showed that 7.0 mm screws that pulled out could be salvaged by augmention with hydroxyapatite.

   Pullout studies have also been used to study the parameters governing cage migration and extrusion in the immediate postoperative period. Brantigan and Steffee (5) reported that an average force of 342 N was required to dislodge their fiber cage, whereas a force of 122 N was required to extract rectangular PLIF bone plugs. Bagby and Kuslich (3) determined that a mean force of 569 N was needed to dislodge the BAK interbody fusion cage, compared with a mean force of 271 N for corticocancellous bone dowels.
4. *Cadaveric construct testing* (Fig. 137.7) provides important information about the effectiveness of a device in reducing intervertebral motion across the affected and adjacent segments during quasiphysiologic loading.

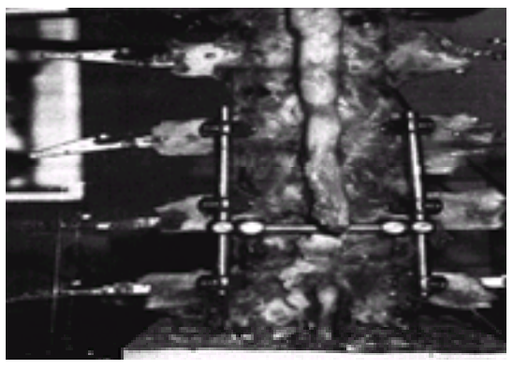

***Figure 137.7.*** Cadaver construct testing is an important evaluation in the testing protocol. In this example, a pedicle screw system is applied to the lumbar spine and pure moments are applied to the superiormost vertebra. The motion of each lumbar vertebra is tracked to determine the hardware's effectiveness in reducing motion at the affected and adjacent levels.

For example, a cadaver study (28) was used to compare the load-deformation characteristics of three different anterior devices: the Synthesis Anterior Thoracolumbar Locking Plate (ATLP, Synthes, Paoli, PA), the AcroMed Smooth Rod Kaneda System (SRK, AcroMed Corp., Cleveland, OH), and Z-Plate (Sofamor-Danek, Inc.). Loads of 0 to 6 Nm were applied in increments of 1.5 Nm to thoracolumbar spine segments from T9–L3. Following destabilization by L-1 corpectomy and removal of the adjoining discs, a wood dowel was placed between the T-12 and L-2 vertebral bodies to simulate the presence of an interbody bone graft to restore bony alignment and height.

Results showed that the SRK device provides greater stiffness than the ATLP, although neither is different from the intact spine (Fig. 137.8*A*). The Kaneda rod system provided the highest degree of immediate stability, which should provide the best chance of fusion. The stiffness of the construct obtained with the SRK and ATPL systems were equivalent to the intact spine. The SRK and Z-Plate systems withstood best fatigue loading in 5,000 cycles of flexion and extension (Fig. 137.8*B*). The data show that the SRK and Z-Plate system will maintain their structural integrity in the face of repeated physiologic loading, thus reducing the chance of failure. Most important, the stability of construct using existing anterior devices can, at best, only approach that of the intact spine.



***Figure 137.8.*** Rotational data of the intact spine and the spine stabilized using three devices: the Synthesis Anterior Thoracolumbar Locking Plate (ATLP, Synthes, Palo, PA), the AcroMed Smooth Rod Kaneda System (SRK, AcroMed Corp., Cleveland, OH), and Z-Plate (Sofamor-Danek, Inc.). **A:** Following stabilization, a significant difference was observed between the ATLP and both the SRK and Z-Plate in extension. **B:** After cyclic testing, the SRK was found to provide significantly more stability to the segment, as compared with the ATLP device, in flexion, extension, lateral bending, and right axial rotation. The Z-Plate was significantly more stable as well in flexion, extension, and axial rotation.

In flexion and extension, rigid posterior devices provide a 70% reduction in motion across the L4–L5 level, compared with the intact spine. Similar results were obtained for three different systems which were loaded in lateral bending and axial rotation as well (27).

Pedicle screw systems are effective, at least initially, in stabilizing the motion segment, irrespective of screw size, implant shape, or other variables. This finding is not surprising in that stainless steel and titanium implants are many orders of magnitude stiffer than the bony and ligamentous components of an intact spine. As a result, slight variations in the shapes and sizes of pedicle screw devices are not likely to affect the stability of constructs to any significant degree.

Flexible restraints have been tried. The Graf system is an extreme example of a flexible posterior system, in which bilateral polyester tension bands span the vertebral pedicle screws (51). After laminectomy, this system restored axial rotation to normal stiffness levels. It also significantly decreased the range of motion in flexion and extension and lateral bending. Flexible systems have not proven successful in restoring stability to a severely destabilized spinal segment such as after partial or total discectomy.

The major concern with dynamized systems is whether they can impart initial rigidity comparable to that of traditional systems using plates, bars, and screws. Hitchon et al. (28) evaluated the stiffness properties of one such anterior dynamized system, the Anterolateral Controlled Compression (ALC) device (AcroMed, Cleveland, OH). The implant can be applied as a dynamized device (ALC) or can be attached rigidly (ALCR). Both applications produced the same degree of stiffness in flexion, extension, lateral bending, and axial rotation (Table 137.2). There seems to be no loss of immediate stability using the implant as a dynamized device, which may reduce long-term, deleterious effects due to stress shielding.

| | Flex. | Ext. | RLB | LLB | RAR | LAR |
|---|---|---|---|---|---|---|
| Intact | 3.7 ± 1.1 | −1.1 ± 0.8 | 0.8 ± 1.0 | −12.2 ± 2.2 | 1.3 ± 0.5 | −1.5 ± 0.3 |
| ALC | 3.2 ± 1.0 | −1.0 ± 0.7 | 1.2 ± 0.3 | −1.6 ± 0.2 | 5.1 ± 1.3 | −8.4 ± 1.6 |
| ALCR | 1.0 ± 0.6 | −2.1 ± 1.5 | 0.6 ± 0.3 | −0.8 ± 0.1 | 2.9 ± 0.6 | −2.7 ± 0.4 |

Angular motion data in flexion (Flex.), extension (Ext.), right lateral bending (RLB), left lateral bending (LLB), right axial rotation (RAR), and left axial rotation (LAR) for the dynamized (ALC) and rigid (ALCR) Anterolateral Controlled Compression device. Each loading case represents 6.0 Nm of pure load applied to the L1 of the L3-L4 cadaveric spine. The data indicate that the dynamized device (ALC) was able to reduce significantly the motion seen in the intact case and closely approximate the motion reduction obtained with the rigid device (ALCR).

***Table 137.2. Angular Rotations (Degrees)***

In a similar study (48), this group compared the Segmental Spine Correction System (SSCS), which is a pedicle hinged screw-rod system (Osteotech, Inc. Eatontown, NJ), with its equivalent rigid screw system. The hinged screw allows 15° of movement, at which point the hinge mechanism engages the screw shaft; it then behaves like a rigid screw. The researchers showed a 65% reduction of motion in flexion and extension and 90% reduction in lateral bending across the destabilized segment for both devices when compared with the intact spine.

Interbody fusion cages have also been mechanically evaluated using cadaver models (42,52). Nibu et al. (42) studied the stabilizing effect of implantation of the BAK (Spine Tech Inc., Minneapolis, MN) interbody fusion device in human lumbrosacral specimens (L5–S1). They found that range of motion was reduced by 46% in flexion, 66% in lateral bending, and 40% in axial rotation after implantation of the device as compared with the intact spine. However, extension range of

motion increased by 14% after implantation of the device owing to the anterior approach, which required cutting the anterior longitudinal ligament and the anterior annulus, which compromises the stability in extension.

5. *Analytic modeling* (15,19), such as finite element (FE) analysis, is a valuable tool for determining how implant and intraosseous loading patterns change with varying parameters of the device design. FE modeling can also help predict bone remodeling in response to the implant; therefore, it helps in evaluating stress shielding. Goel et al. (13) have generated osteoligamentous one-segment (L3–L4) and two-segment (L3–L5) FE models of the intact lumbar spine. Using the L3–L4 model, they simulated bilateral fusion using unilateral and bilateral plating, and measured the magnitude and position of internal stresses in bone, ligament, and the implants. They normalized their data to an intact model. Bilateral plating models showed significantly reduced stresses in cancellous bone. In a simulated consolidated fusion mass, there was unloading of the cancellous bone, even after simulated removal of the device. This model predicts that removal of the fixation would not alleviate stress-shielding–induced osteopenia, which may be due to the fusion mass itself.

   Models of unilateral plating revealed higher initial trabecular bone stresses than were seen with bilateral plating. However, the degree of initial stability was reduced. Thus, the best appears to be a fixation system that allows the bone to bear greater load as fusion proceeds, which would offer higher initial stability and yet minimize the problem of long-term stress-shielding–induced bone resorption.

   FE modeling (17) of newer dynamic fixation systems shows that the load through the bone graft increases 10% compared with the rigid systems. Thus, it seems that the competing criteria can, in some part, be simultaneously satisfied with these dynamized devices.

   FE modeling coupled with adaptive bone remodeling algorithms has been used to predict temporal changes that may be associated with interbody fusion devices. Grosland et al. (25) studied the BAK device (Fig. 137.9) and showed that implantation of this interbody fusion device results in hypertrophy of bone directly overlying and underlying the implant, whereas lateral atrophy occurs due to the stress-shielding effects associated with the relatively high stiffness of the implant. The model also predicts that bone would be stimulated to grow into and around the larger holes in the implant, resulting in sound fixation of the device.

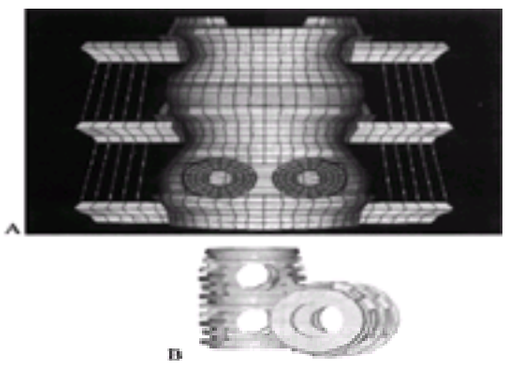

***Figure 137.9.*** Finite element (FE) modeling has proved to be an invaluable tool for determining the changes in load sharing associated with device implementation. The schematic depicts the implantation of an interbody fusion device into a three-vertebrae FE model. This model has been used to characterize not only the loading changes that will occur immediately in the postoperative period but also as consolidation of the graft proceeds.

   The value of FE modeling is that mapping of the stresses and strains in bone, ligaments, and instrumentation can be obtained in a relatively inexpensive and time-efficient manner. In addition, it yields important predictive data concerning temporal changes in bone in response to implantation of a device. It also facilitates quick assessment of the relative advantages and disadvantages of design iterations. Actual mechanical testing of constructs is still necessary, from time to time, to validate theoretical assumptions and confirm FE predictions.

6. *Animal studies* provide real-time *in vivo* data concerning the performance and associated biologic response to an implant. Temporal changes in both the host biologic tissue and associated instrumentation can be assessed with selective intermittent sacrificing of the animals.

   The usefulness of these tests is best illustrated by the animal studies performed by McAfee et al. (32,33). They investigated the effects of instrumentation on fusion consolidation and peri-implant bone density in 63 canines. The data confirmed a higher probability of achieving fusion when instrumentation was used. Mechanical testing of the fusion sites after sacrifice (and removal of all metal components) revealed that fusions achieved with instrumentation were more rigid than those that occurred without instrumentation. There was, however, an inverse correlation between volumetric density of bone and rigidity of the implant, implying that utilization of the implant resulted in an osteoporotic effect owing to stress shielding. These findings could not have been predicted by the FE models available at the time.

   The findings of animal models must be evaluated in terms of their inherent limitations. Most animal studies involve quadrupeds; thus, the loading imposed on the spinal instrumentation may not represent the loading that it would experience in patients.

   For example, in the study mentioned earlier, McAfee et al. used a complete corpectomy model, with the device spanning the vertebrectomy space. In patients, one would expect a degenerated disc or interbody bone graft between the vertebral bodies. Hence, in the experimental model, the device assumed 100% of the load in contrast to the load-sharing capabilities for which it was designed.

   The greatest value of animal studies is to provide bioengineers and clinicians with data as to how the osseous and soft tissues adapt to the altered loading environment produced by instrumentation. They also demonstrate the impact of normal and altered biology on the healing process.

   The biomechanical evaluation of spinal fusion and stability has produced a large knowledge base that has allowed for the design, development, and implementation of progressively more sophisticated devices. The preceding methods are used to demonstrate the safety and potential effectiveness of instrumentation. Of course, the ultimate measure of efficacy of any system is based on well-designed and selected studies.

## AUTHORS' PERSPECTIVE

The human disc, facets, and the ligaments of a spinal segment work in unison to transmit loads and permit motion. If the degenerative process, trauma, or any other factor affects an anatomic component, changes in loading and motion patterns result. Modern imaging techniques and clinical observations have adequately delineated morphologic changes in certain spinal structures that may precede degeneration of the spine. A surgeon combines this information with his or her experience to assess instability and the need for surgery, especially when conservative treatment options fail to produce satisfactory results.

The choice of technique, whether anterior, posterior, or interbody, and fixation system must be approached from a biomechanical perspective. The biomechanical data available can make the choice a more informed one. On a short-term basis, rigid fixation devices (both anterior and posterior) are capable of imparting stability to an injured or unstable segment. The degree of stability imparted, at least in the physiologic range of motion, does not vary significantly with the screw size, implant shape, or other variables.

The rigidity of the construct and the ability of a spinal fixation device to share a load with the maturing fusion mass are essential for fusion to occur. If the load transferred through the fusion mass is increased without sacrificing the rigidity of the construct, a more favorable environment for fusion may be created. Finally, although a host of experimental methods have enabled researchers to evaluate initial device performance and failure characteristics, the true measure of a device's effectiveness can be assessed only through properly designed clinical outcome studies.

### CHAPTER REFERENCES

Each reference is categorized according to the following scheme: *, classic article; #, review article; !, basic research article; and +, clinical results/outcome study.


! 1. Ashman RB. Mechanical Testing of Spinal Implants. *Seminars in Spine Surgery* 1993;5:73.

! 2. Ashman RB, Birch JG, Bone LB, et al. Mechanical Testing of Spinal Implementation. *Clin Orthop* 1988;227:113.

+ 3. Bagby GW, Kuslich SD. Arthrodesis of the Lumbar Spine Utilizing a Rigid Housing Containing Bone Graft—the BAK Interbody Fusion Method. In: Thalgott JS, Aebi, eds. *Manual of Internal Fixation of the Spine.* Philadelphia: Lippincott-Raven Publishers, 1996:156.

! 4. Brantigan JW, Cunningham BW, Warden K, et al. Compression Strength of Donor Bone for Posterior Lumbar Interbody Fusion. *Spine* 1993;18:1213.

! 5. Brantigan JW, Steffee A, Geiger J. A Carbon Fiber Implant to Aid Interbody Lumbar Fusion: Mechanical Testing. *Spine* 1991;16:S277.

! 6. Carlson GD, Abitbol JJ, Anderson DR, et al. Screw Fixation in the Human Sacrum—an In Vitro Study of the Biomechanics of Fixation. *Spine* 1992;17:S196.

! 7. Chang KW, Dewei Z, McAfee PC, et al. A Comparative Biomechanical Study of Spinal Fixation Using the Combination Spinal Rod-plate and Transpedicular Screw Fixation System. *J Spinal Disord* 1989;1:257.

! 8. Clausen JD, Goel VK, Sairyo K, Pfeiffer M. A Protocol to Evaluate Semi-rigid Pedicle Screw Systems. *J Biomech Eng* 1997;119:364.

+ 9. Davis H. Increasing Rates of Cervical and Lumbar Spine Surgery in the United States, 1979–1990. *Spine* 1994;19:1117.

+ 10. Farfan HF, Gracovetsky S. The Nature of Instability. *Spine* 1984;9:714.

+ 11. Fraser RD. Interbody, Posterior, and Combined Lumbar Fusions. *Spine* 1995;20:167S.

! 12. Glazer PA, Colliou O, Klisch SM, et al. Biomechanical Analysis of Multilevel Fixation Methods in the Lumbar Spine. *Spine* 1997;22:171.

# 13. Goel VK, Gilbertson LG. Basic Science of Spinal Instrumentation. *Clin Orthop* 1997;335:10.

! 14. Goel VK, Goyal S, Clark C, et al. Kinematics of the whole lumbar spine. *Spine* 1985;10:543.

! 15. Goel VK, Grosland NM, Grobler LJ, Griffith SL. Adaptive Internal Bone Remodeling of the Vertebral Body Following an Anterior Interbody Fusion—a Computer Simulation. The 24th Annual Meeting of the International Society for the Study of the Lumbar Spine, Singapore. 1997.

! 16. Goel VK, Grosland NM, Scifert JL. Biomechanics of the Lumbar Disc. *Journal of Musculoskeletal Research* 1997;1:81.

! 17. Goel VK, Konz RJ, Chang H-T, et al. Hinged-dynamic Posterior Device Permits Greater Loads on the Graft and Similar Stability as Compared to Its Equivalent Rigid Device—a Three-dimensional Finite Element Assessment. Submitted for publication, 1999.

! 18. Goel VK, Lim TH. Mechanics of Spondylolisthesis. *Seminars in Spine Surgery* 1989;1:95.

! 19. Goel VK, Lim TH, Gilbertson LG, Weinstein JN. Clinically Relevant Finite Element Models of a Ligamentous Lumbar Motion Segment. *Seminars in Spine Surgery* 1993;5:26.

! 20. Goel VK, Lim TH, Gwon J, et al. Effects of Rigidity of an Internal Fixation Device: A Comprehensive Biomechanical Investigation. *Spine* 1991;16:S155.

! 21. Goel VK, Scifert JL, Grosland NM. Evaluation of Surgical Dynamics Rodding System (SDRS) Using ASTM Standard Methodologies. (Personal Communication), 1998.

! 22. Goel VK, Winterbottom JM, Weinstein JN. A Method for the Fatigue Testing of Pedicle Screw Fixation Devices. *J Biomechanics* 1994;27:1383.

+ 23. Goel VK, Woodhouse J, Hitchon PW. Stability Considerations for the Lumbar Spine. In press, 1998.

! 24. Gomez T, Beach G, Cooke C, et al. Normative Database for Trunk Range of Motion, Strength, Velocity, and Endurance with the Isostation B-200 Lumbar Dynometer. *Spine* 1991;16:15.

! 25. Grosland NM, Goel VK, Grobler LJ, Griffith SL. Adaptive Internal Bone Remodeling of the Vertebral Body Following an Anterior Interbody Fusion—a Computer Simulation. 24th Annual Meeting of the International Society for the Study of the Lumbar Spine, Singapore, 1997.

! 26. Gurr KR, McAfee PC, Shih CM. Biomechanical Analysis of Anterior and Posterior Instrumentation Systems after Corpectomy. *J Bone Joint Surg* 1988;70-A:1182.

! 27. Gwon JK, Chen J, Lim TH, et al. In Vitro Comparative Biomechanical Analysis of Transpedicular Screw Instrumentations in the Lumbar Region of the Human Spine. *J Spinal Disord* 1991;4:437.

! 28. Hitchon PW, Goel VK, Serhan H, et al. Biomechanical Studies on a Dynamized Anterior Thoracolumbar Implant. *Spine* 2000;25:306.

+ 29. Hoshijima K, Nightingale RW, Yu JR, et al. Strength and Stability of Posterior Lumbar Interbody Fusion—Comparison of Titanium Fiber Mesh Implant and Tricortical Bone Graft. *Spine* 1997;22:1181.

+ 30. Katz JN. Lumbar Spinal Fusion—Surgical Rates, Costs and Complications. *Spine* 1995;20:78S.

! 31. Lieberman IH, Khazim R, Woodside T. Anterior Vertebral Body Screw Pullout Testing. A Comparison of Zielke, Kaneda, Universal Spine System, and Universal Spine System with Pullout-resistant Nut. *Spine* 1998;23:908.

+ 32. McAfee PC, Farey ID, Sutterlin CE, et al. Device-related Osteoporosis with Spinal Instrumentation. *Spine* 1989;14:919.

! 33. McAfee PC, Farey ID, Sutterlin CE, et al. The Effect of Spinal Implant Rigidity on Vertebral Bone Density: A Canine Model. *Spine* 1991;16:S190.

+ 34. McGregor AH, McCarthy ID, Hughes SFP. Motion Characteristics of the Lumbar Spine in the Normal Population. *Spine* 1995;20:2421.

! 35. McKinley TO, McLain RF, Yerby SA, et al. The Effect of Pedicle Morphometry on Pedicle Screw Loading in Unstable Burst Fractures: A Synthetic Model. *Spine* 1997;22:246.

! 36. McKinley TO, McLain RF, Yerby SA, et al. Effects of Pedicle Screw Insertion Techniques on Pedicle Screw Bending Moments: A Biomechanical Analysis. *Spine* 1999;24:18.

! 37. McLain RF, McKinley T, Sarigul-Klijn N, et al. The effects of Cancellous Bone Quality on Pedicle Screw Loading in Axial Instability: A Synthetic Model. *Spine* 1997;22:1454.

! 38. McLain RF, Pickar JG. Mechanoreceptor Endings in Human Thoracic and Lumbar Facet Joints. *Spine* 1998;23:168.

+ 39. McLain RF, Sparling E, Benson DR. Early Failure of Short-segment Pedicle Instrumentation for Thoraco-lumbar Fracture. *J Bone Joint Surg* 1993;75A:162.

! 40. Menezes AP, Davies KE, Hulkins DWL, Jayson MIV. Measurement of the Time Course of Bending of the Back in the Sagittal Plane. *Eur Spine J* 1995;4:24.

! 41. Nagel DA, Edwards WT, Schneider E. Biomechanics of Spinal Fixation and Fusion. *Spine* 1991;16:S151.

! 42. Nibu K, Panjabi MM, Oxland T, Cholewicki J. Multidirectional Stabilizing Potential of Bak Interbody Spinal Fusion System for Anterior Surgery. *J Spinal Disord* 1997;10:357.

# 43. Panjabi MM. Low Back Pain and Spinal Stability. In: Weinstein GS, ed. *Low Back Pain: A Scientific and Clinical Overview.* San Diego: American Academy of Orthopaedic Surgeons, 1996.

! 44. Pickar JG, McLain RF. Responses of Mechanosensitive Afferents to Manipulation of the Lumbar Facet in the Cat. *Spine* 1995;20:2379.

! 45. Posner I, White AA, Edwards WT, Hayes WC. A Biomechanical Analysis of the Clinical Stability of the Lumbar and Lumbosacral Spine. *Spine* 1982;7:374.

! 46. Puttlitz CM, Goel VK, Pope MH. Biomechanical Testing Sequelae Relevant to Spinal Instrumentation. *Orthop Clin North Am* 1998;29:571.

! 47. Rapoff AJ, Ghanayem AJ, Zdeblick TA. Biomechanical Comparison of Posterior Lumbar Interbody Fusion Cages. *Spine* 1997;22:2375.

! 48. Scifert JL, Sairyo K, Goel VK, et al. Stability Analysis of an Enhanced Load Sharing Posterior Fixation Device and Its Equivalent Conventional Device in a Calf Model. *Spine* 1999;24:2206.

+ 49. Spivak JM, Neuwirth MG, Labiak JL, et al. Hydroxyapatite Enhancement of Posterior Spinal Instrumentation Fixation. *Spine* 1994;19:955.

+ 50. Stagnara P, DeMauroy JC, Dran G, et al. Reciprocal Angulation of Vertebral Bodies in a Sagittal Plane: Approach to References for the Evaluation of Kyphosis and Lordosis. *Spine* 1982;7:335.

! 51. Strauss PJ, Novotny JE, Wilder DG, et al. Multidirectional Stability of the Graf System. *Spine* 1994;19:965.

! 52. Tencer AF, Hampton D, Eddy S. Biomechanical Properties of Threaded Inserts for Lumbar Interbody Spinal Fusion. *Spine* 1995;20:2408.

# 53. Traynelis VC, Goel VK, Gilbertson LG. Biomechanics of the Throracolumbar Spine. In: Sonntag MAAV, ed. *Principles of Spinal Surgery*. New York: McGraw-Hill, 1995:85.

# 54. White AA, Panjabi MM. *Clinical Biomechanics of the Spine,* 2nd ed. Philadelphia: J.B. Lippincott Co., 1990.

! 55. Wittenberg RH, Shea M, Edwards WT, et al. A Biomechanical Study of the Fatigue Characteristics of Thoracolumbar Fixation Implants in a Calf Spine Model. *Spine* 1992;17:S121.

! 56. Yerby SA, Ehteshami JR, McLain RF. Loading of Pedicle Screws within the Vertebra. *J Biomechanics* 1997;30:951.

! 57. Yerby SA, Ehteshami JR, McLain RF. Offset Laminar Hooks Decrease Bending Moments of Pedicle Screws during In Situ Contouring. *Spine* 1998;23:276.

! 58. Yerby SA, Toh E, McLain RF. Revision of Failed Pedicle Screws Using Hydroxyapatite Cement. *Spine* 1998;23:1657.

+ 59. Zdeblick TA, Shirado O, McAfee PC, et al. Anterior Spinal Fixation after Lumbar Corpectomy. *J Bone Joing Surg* 1991;73-A:527.

! 60. Zdeblick TA, Warden KE, Zou D, et al. Anterior Spinal Fixators—a Biomechanical In Vitro Study. *Spine* 1993;18:513.

# CHAPTER 138

# SURGICAL APPROACHES TO THE SPINE

*Robert G. Watkins*

**R. G. Watkins:** Los Angeles, California, 90033.

The Cervical and Thoracic Spine
Posterior Approach to C1–C2
Transoral Approach to C1–C2
Anterolateral Approaches to C-1, C-2, and C-3
Anteromedial Approach to the Midcervical Spine
Supraclavicular Approach
Third Rib Resection in the Transthoracic Approach
Thoracotomy Approach
The Thoracolumbar Junction
Tenth Rib Thoracoabdominal Approach
The Lumbosacral Spine
Pararectus Incision for L2–S1
Anterior Retroperitoneal Flank Approach to L2–L5
Retroperitoneal Exposure of L5–S1
Transperitoneal Exposure of L5–S1
Posterior Approach to L1–S1
Laminotomy
Laminectomy
Foraminotomy
Lateral Approach to the Disc
Chapter References

As late as 1980, spinal surgeons, and therefore spinal patients, were severely limited in the options available to them for surgical treatment. The source of this limitation was a combination of technology and the experience in surgical approaches. Very few spinal surgeons had the ability to approach every aspect of the spine with the optimal exposure. Spinal access surgeons were few and far between. The microscopic and endoscopic approaches that protect normal tissue and speed recovery were scarcely available to unavailable. The evolution of spinal surgery now allows the surgeon to approach their pathology so as to optimize the resection of a pathologic lesion and reconstruct the spine to optimal biomechanical advantage. Perfecting the approach is the first step to perfecting the surgery and a major step in protecting the patient.

## THE CERVICAL AND THORACIC SPINE

### POSTERIOR APPROACH TO C1–C2

- For the posterior cervical exposure of any level, position the patient's head in the self-retaining neurosurgical head fixation device that is attached to the surgical table. Attach the drapes to the patient's neck with stay sutures. Neck flexion will increase exposure, but flexion is limited by the type of pathologic process present, usually to a neutral, slightly flexed position. In the presence of spinal instability, confirm the position of the spine with radiographs.
- Incise the skin and subcutaneous tissue in the midline to the fascia, and obtain hemostasis with rapid application of hemostats and electrocautery. Insert self-retaining retractors.
- Deepen the incision with the cautery knife, staying within the thin white median raphe; avoid cutting muscle tissue. The medial raphe of the cervical spine is a tortuous structure that does not follow a straight path. Open the median raphe to the spinous processes of C-2 and C-3, the occiput, or any level needed. In children, expose no spinal levels unnecessarily to avoid spontaneous fusion at adjacent levels, including the occiput.
- With a #15 blade or cutting cautery, expose the bulbous bifid tips of the spinous processes. The ligamentous attachments to C-2 are very prominent. The large spinous process of C-7 and T-1 can be identified. Identify any spina bifida of the cervical spine on preoperative radiographs and be aware of these areas at surgery. Insert the Cobb elevator, first facing up to elevate the tip of the spinous process subperiosteally, then facing down to complete the subperiosteal elevation from medial to lateral for a width of approximately 1 inch (2.5 cm) at each level. At levels below C-2, identify the medial edge of the facet joint at the base of the lamina and pack each level as it is exposed. When necessary, expose the occiput with elevators. Insert the self-retaining retractors to expose the base of the skull and the dorsal spine of C-2. The area in between will contain the ring of C-1. This is often very deep compared with the spinous process of C-2.
- Maintaining firm lateral retraction of the wound, identify the posterior tubercle of C-1 longitudinally in the midline by probing with a sharp Cobb elevator. Begin the subperiosteal dissection to expose the bone.
- Often the C-1 ring is very thin, and direct pressure can fracture it or cause the instrument to slip off the ring and penetrate the atlantooccipital membrane. Elevation on this ring can be very dangerous if there is subluxation with constriction of the posterior dura under this ring. The dura may be vulnerable on both the superior and inferior edges of the ring of C-1.
- At the level of C-1, dissect laterally only approximately 1.5 cm. The second cervical ganglion is an important landmark on the ring of C-1 laterally; it lies approximately 1.5 cm laterally on the lamina of C-1 in the area of the groove for the vertebral artery. Carefully identify the most medial aspect of the groove for the vertebral artery and vein on the superior border of the C-1 ring. The bluish color of the vein is visualized first. By seeing the initial ridge or the vein, damage to the artery can be avoided. There is seldom any indication for dissection lateral to the groove of the vertebral artery on C-1. The vertebral artery and vein are vulnerable in the groove; in addition, as the artery passes from the foramen transversarium of C-2 to that of C-1, it is in close proximity laterally and posteriorly to the joint (29) (Fig. 138.1 and Fig. 138.2).

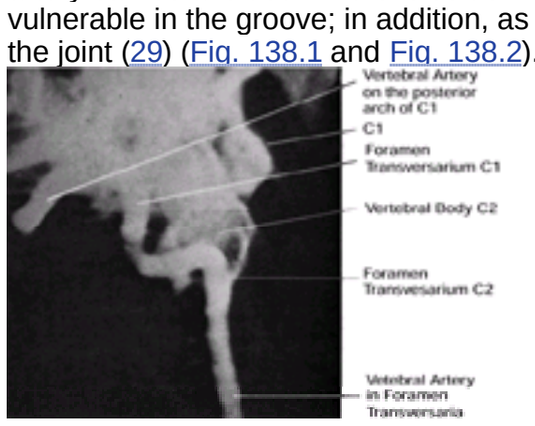


***Figure 138.1.*** The course of the vertebral artery is from the foramen transversarium of C-1 posteriorly in the region of the C1–C2 articulation through the transversarium of C-1, then posteromedially to the posterior rim of C-1.

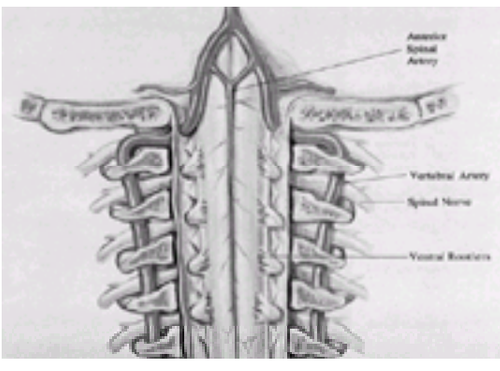

***Figure 138.2.*** The anterior view without vertebral bodies emphasizes the formation of the anterior spinal artery. There are numerous variations in this formation, ranging from a unilateral vertebral artery contribution to no contribution.

- The vertebral artery enters the foramen transversarium at the sixth vertebra and progresses cephalad. It exits through the foramen transversarium of C-1 and progresses posteriorly as well as medially in the groove of the superior border of C-1 toward the midline, then turns cephalad along the spinal cord to enter the foramen magnum. The vertebral artery can be damaged by penetrating the atlanto-occipital membrane off the superior border of the ring of C-1 more lateral than the usually safe 1.5 cm from the midline.
- Following exposure of the ring of C-1 and exposure to bone of the posterior occiput, different operative procedures require exposure of the dura under the edge of the foramen magnum (17,25,26). Never attempt to decompress the posterior fossa under the edge of the foramen magnum without sufficient visualization of the area cephalad to the foramen. This is best accomplished by placing two burr holes just off the midline of each side of the skull (Fig. 138.3). The caudal extent of the holes is usually determined by the angle of the drill on the skull as limited by the patient's shoulders.



***Figure 138.3.*** Posterior approach to the foramen magnum.

- In the posterior approach to the foramen magnum, first place burr holes in the occiput above the foramen magnum. Two parasagittal holes allow removal of bone from the dura with a Harrison-type rongeur. Careful dissection medially from the burr holes provides protection from the often significant fragile venous sinus, and dissection caudally approaches the foramen magnum. After removal of the occiput including the bony rim of the foramen magnum, which is a sharp-lipped structure projecting directly anterior in the transverse plane, the fibrous attachment of the inner periosteum of the skull to the dura at the rim of the foramen magnum is encountered. When a transverse venous sinus in this area is torn, bleeding can be significant. Attachment to the dura in this area produces a dural leak unless the area is carefully dissected.
- Penetrate to the inner periosteum and the bone edge with a small dissector. Expand the hole caudally to the foramen with rongeurs. The edge itself curves under and projects anteriorly. The periosteum of the skull at this point is often conjoined with the dura of the spinal cord. There is a median venous sinus in the midline, and the fascial attachment of the periosteum of the skull to the dura often contains a transverse sinus as well.
- Passing instruments under the edge of the foramen can produce dangerous bleeding in the posterior fossa with no means of control. Therefore, resect the bone down to this edge from above.
- For a more lateral approach to the C1–C2 facet joint, the vertebral artery between C-1 and C-2 must be identified. In rotatory dislocations of C1–C2, the artery is stretched tightly across the joint on the side that C-1 is anterior to C-2, and it is easily damaged (29).
- For nerve root exposure below C-2, identify the junction of the lamina and the inferior facet. Then identify the junction of the interlaminar area and the facet joint. Expanding these areas with a burr or a micro-Kerrison rongeur allows entry into the intervertebral foramen and exposure of the nerve root.

## TRANSORAL APPROACH TO C1–C2

For preoperative preparation, take oral and nasal cultures of the patient in case problems develop later (1). Use standard prophylactic antibiotics because no special antibiotic coverage for normal oral flora is needed. I do not use preoperative antiseptic gargles or tetracycline (7).

Always perform a tracheostomy, using a short-cuffed tube.

- Position the patient supine with the head slightly flexed on occipital pads, or put the head into a halo. A more upright position can be used with certain precautions.
- The Boyle-Davis or McIver ear, nose, and throat (ENT) retractor allows depression of the tongue and self-retaining retraction of the mouth. The lips and teeth should be adequately padded.
- Incise the soft palate with a curvilinear incision around the uvula, and retract the cut edges with stay sutures to the lateral walls of the oropharynx or to an especially bent, blunt-tipped Gelpi retractor (7,14). Prep the oropharynx with povidone-iodine (Betadine) solution and reculture it.
- Enhanced hemostasis by injecting the posterior pharyngeal tissue with a solution of 5% lidocaine and 1:500,000 epinephrine.
- After palpation and radiographic confirmation of the ring of C-1, make a vertical incision from approximately 1 cm cephalad to the tip of the odontoid to 2 cm distal to the anterior tubercle of C-1. Incise the four layers (posterior pharyngeal mucosa, superior constrictor muscle of the pharynx, the prevertebral fascia, and the anterior longitudinal ligaments) directly to the bone.
- Bluntly dissect the soft tissue off the body of C-2 below the odontoid and off the anterior tubercle of C-1.
- *Caution: The longus colli muscle inserts on the anterior tubercle of C-1, and sharp dissection may be needed to remove it. Venous bleeding may arise from the recesses just lateral to the base of the odontoid.*
- When necessary, the lateral masses of C1–C2 can be exposed by bluntly dissecting the bone both transversely and vertically.
- *Caution: Avoid plunging lateral to the facet joints. To avoid damage to the internal carotid, do not pass a stay suture too deeply into the lateral pharyngeal wall.*
- Remember, this is a deep wound, requiring long instruments with fine tips. Most operations done with this exposure require use of the microscope for lighting and magnification.
- After the bony work is completed and good hemostasis is obtained, close the posterior pharynx in a single layer with interrupted absorbable sutures.

## ANTEROLATERAL APPROACHES TO C-1, C-2, AND C-3

- Position the patient supine with the appropriate support for the cervical spine mentioned earlier. For two levels of pathology, it is a transverse incision, one fingerbreadth medial to the medial border of the sternocleidomastoid. Open layers in a fashion similar to that used with the standard cervical approaches.
- For higher anterior approaches to C-1, C-2, and C-3, identify the superior thyroid artery and vein. The superior thyroid artery arises from the external carotid artery at approximately the level of the hyoid bone. It crosses through the carotid triangle, arches deep to the strap muscles, and enters the lateral superior aspect of the thyroid gland. Retract the superior thyroid artery and vein inferiorly.
- Identify and retract the hypoglossal nerve. The hypoglossal nerve is found passing from lateral to medial superficial to the external carotid, lingual, and facial arteries (Fig. 138.4). It exits the skull in close proximity to the vagus nerve and courses beneath the internal carotid artery and internal jugular vein, becoming superficial at the angle of the mandible. After the usual point of identification of the hypoglossal nerve over the arteries, it passes deep to the tendon of the digastric muscle and stylohyoid muscle for distribution to the muscles of the tongue. Retract the hypoglossal nerve cephalad; usually, the superior thyroid artery and vein are retracted caudad.

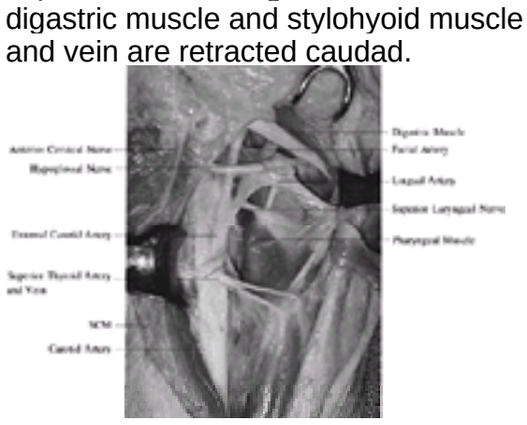

***Figure 138.4.*** Dissected anatomy of the carotid triangle and area just below emphasizes the importance of identification of the hypoglossal nerve before ligation of the arterial structures in this area. The most common approach is cephalad to the superior thyroid artery and caudad to the digastric muscle. SCM,

sternocleidomastoid.

- Be certain of the identification of the hypoglossal nerve before ligating any structure. It is a superficial structure, first coursing vertically and parallel to the carotid sheath, then horizontally, crossing medially over the carotid and its branches.
- Identify the lingual artery, which arises from the external carotid. From the level of the hyoid, it crosses under the digastric and stylohyoid muscles in its ascent to the oral pharynx.
- Identify and ligate the facial artery. The facial artery next leaves the external carotid artery, coursing under the ramus to the mandible within the carotid triangle. It passes deep into the digastric muscle and enters the face at the anterior edge of the mastoid after crossing on the submandibular gland.
- Identify the digastric muscle. This muscle is easily retracted cephalad with the hypoglossal nerve. When necessary, divide the stylofascial band running from the stylohyoid process to the posterior pharynx.
- Difficulties may be encountered with the superior laryngeal nerve, both external and internal branches, and the pharyngeal branches of the vagus nerve. These nerves should be identified and retracted, but they frequently suffer from the retraction. Continue to use finger palpation to identify the spine and the carotid artery.
- Retract the carotid sheath and the ligated stumps of the lingual and facial arteries laterally, and retract the musculovisceral column medially with deep right-angle, hand-held blunt retractors.
- With a Kittner dissector, make a careful, blunt dissection at this point, to identify the prevertebral fascia.
- Elevate the fibers of the longus colli muscle and fascia off the vertebral body in a lateral and cephalad direction. Insert the sharp claw blades of the Cloward retractor under the longus colli. The smooth-tipped blades can be used if firm fixation cannot be obtained under the longus colli (3). Deep hand-held retractors are also quite effective (Fig. 138.5).

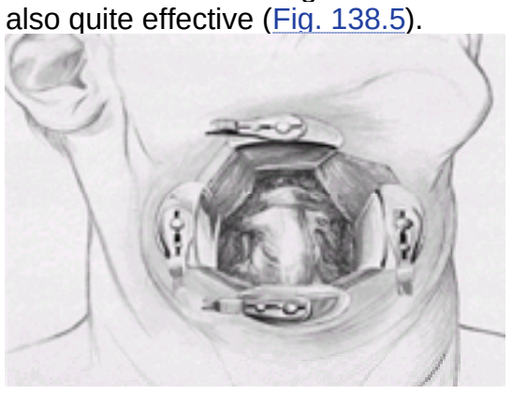

***Figure 138.5.*** The spine is exposed with deep retractor blades.

The external investing fascia forms the anterior and posterior sheaths of the sternocleidomastoid muscle and the fascial covering of the visceral structures of the neck (10). This investing layer of cervical fascia is attached inferiorly to the acromion, clavicle, and manubrium of the sternum in an outer and inner layer superiorly to the hyoid bone, posteriorly to the mandible and mastoid processes, and superior to the nuchal line. The interval between the two laminae of the external investing fascia is called the suprasternal space, or the space of Burns. This space, which contains the anterior jugular veins and sternal head of the sternocleidomastoid, is referred to as the cul-de-sac of Bruger. Communication between the anterior and external jugular veins is channeled through this inner laminar area.

The middle cervical fascia attaches to the carotid sheath and joins the external investing fascia at the posterior border of the sternocleidomastoid muscle. Inferiorly, the middle cervical fascia attaches to the posterior surface of the sternum, as do the muscles that they cover. It is the middle cervical fascia that attaches to the clavicle and forms the loop for the inferior belly of the omohyoid muscle.

The prevertebral fascia is continuous with the endothoracic fascia caudally, and laterally it covers the levator scapulae and splenius muscles. It extends posteriorly to attach to the spinous processes of the vertebrae. In the neck and throughout the spinal column, it covers the longus colli and capitus muscles and is secured to the tips of the transverse processes.

The origin of the anterior scalene muscle rises from the anterior tubercles of the transverse processes of C-3, C-4, C-5, and C-6. It inserts into the scalene tubercle on the inner border of the first rib and into the ridge on the cranial surface of the rib ventral to the subclavian groove. The scalenus medius originates from the posterior tubercle of the transverse processes of the last six cervical vertebrae and inserts into the first rib.

The scalenus medius is a muscular reinforcement of Sibson's fascia. These fascial connections and the scalenus minimus connect the transverse processes of the seventh cervical vertebra to the first rib. Sibson's fascia, as a portion of the prevertebral fascia, becomes continuous with the endothoracic fascia on the inner surface of the first rib. Extending medially between the anterior scalene muscle and the spine is the all-important retropharyngeal fascial cleft. This is the space beneath the visceral structures, superficial to the prevertebral fascia; it is in this space that retraction and work on the anterior portion of the spine takes place.

## ANTEROMEDIAL APPROACH TO THE MIDCERVICAL SPINE

- Position Gardner-Wells tongs or headhalter traction for cervical traction. Position the head in slight extension and rotation to the right. Contour a small, curved sand bag under the neck to support the spine. Drape off the entire neck with adhesive towel drapes. Select the level of the skin incision. Superficial landmarks are used to determine the appropriate placement of the skin incision over the appropriate level of the spine. For approaches to C-1, C-2, and C-3, start the incision midline extended to the lateral border of the carotid sheath, one fingerbreadth below the angle of the madible. For approaches to C2–C3 start the incision at the midline and extend it to the lateral border of the sternocleidomastoid at the level of the cephalad margin of the thyroid cartilage. For C4–C5, start the incision at the midline and extend it to the medial border of the sternocleidomastoid at the level half way between the cricoid cartilage and the superior border of the tyroid cartilage. For C5–C6, start the incision at the midline on the cephalad margin of the cricoid cartilage and extend it to the medial border of the sternocleidomastoid. For C6–C7, start the incision at the midline of the caudal margin of the cricoid cartilage and extend it to the medial border of the sternocleidomastoid. For C7–T1, start the incision at the midline; extend it just lateral of the medial border of the sternocleidomastoid, halfway between the cricoid cartilage and the clavicle. We prefer the midline starting point, because retraction of the medial muscular visceral column is the strongest structure requiring retraction. Having the skin open to the midline eases that retraction. The self-retaining retractor is placed in the midline. Having the skin open to the midline aids in that retraction.
- After making a transverse skin incision at the appropriate level (Fig. 138.6), dissect through the subcutaneous tissue to the platysma muscle. Elevate the platysma muscle with Adson forceps, and open it carefully, in the line of the fibers, when possible. Beware of damage to veins and the sternocleidomastoid muscle (2,21). Insert a spring retractor.

***Figure 138.6.*** The more cosmetically suitable transverse incision is made at the appropriate level and should allow exposure of up to two discs and three vertebrae. A vertical incision can be used for an even greater exposure.

- Open the superficial cervical fascia and identify the medial border of the sternocleidomastoid muscle (25). The first key to successful exposure is adequate identification of the medial border of the sternocleidomastoid so that it may be retracted laterally (23) (Fig. 138.7). With identification of this medial border, bluntly develop the interval between the sternocleidomastoid muscle and the sternohyoid muscles. Retract the posterior cutaneous nerves. Bluntly dissect the soft tissue and spread it vertically in this interval.

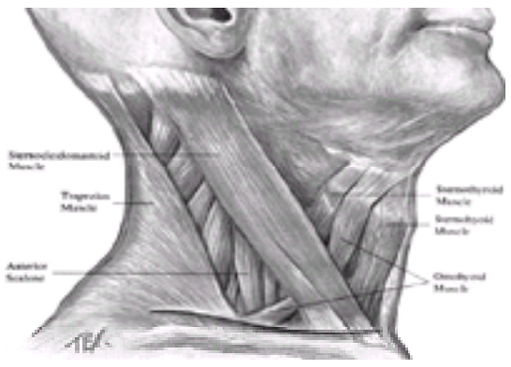

***Figure 138.7.*** The key to the dissection at this point is to identify the medial border of the sternocleidomastoid muscle. With lateral retraction of the sternocleidomastoid, the interval between this muscle and the medial strap msucles is delineated.

- Retract the sternocleidomastoid laterally and the strap musculature medially with angled retractors. Identify the middle cervical fascia. The omohyoid muscle crosses from proximal medial to lateral distal through the middle cervical fascia at C6–C7. Retract the omohyoid; when necessary, divide it and later repair it in its midportion.
- After retracting the sternocleidomastoid muscle laterally and the strap musculature medially, identify the arteriovenous structures of the middle cervical fascial layer (Fig. 138.8). Palpate the carotid pulse. Open the midline cervical fascia medial to the carotid artery. Ligate and tie the medial thyroid vein. Retract cephalad the superior thyroid artery and retract caudad the inferior thyroid artery to expose the midcervical spine.

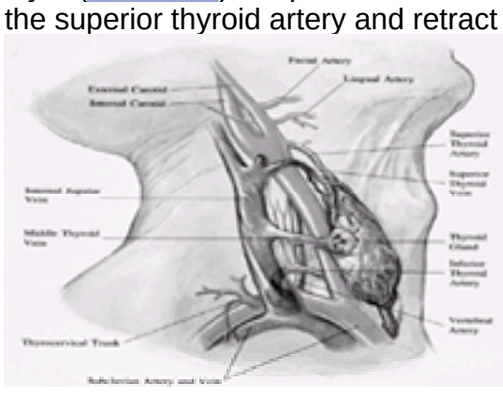

***Figure 138.8.*** Arteriovenous structures of the middle cervical fascial layer.

- Spread the middle cervical fascia just medial to the carotid sheath (23), with finger dissection spreading vertically and horizontally (3). Identify the inconstant middle thyroid vein crossing at approximately C-5, and ligate and divide it when needed. Identify the spine with finger palpation of the anterior surface of the vertebral body. Insert a blunt, nonlipped Cloward hand-held retractor into the wound directly down to the spine. Hold the retractor on the right longus colli. Beware of entering the tracheoesophageal groove (and thereby damaging the recurrent laryngeal nerve with the retractor tip) (19).
- Distally retract the inferior thyroid artery and vein at the C6–C7 level, and proximally retract the superior thyroid artery and vein with the superior laryngeal nerve at C3–C4.
- Do not mistake the transverse process for the anterior surface of the vertebral body because an incision deep in this area will damage the longus colli, the sympathetic chain, and possibly the vertebral artery. An incision into the longus colli produces bleeding.
- Palpate a disc in the midline of the spine and open the prevertebral fascia with a small dissector longitudinally until the disc can be identified. If the finger dissects directly to the spine and the retractor is then inserted, the esophagus cannot be seen. The empty esophagus is only a soft, flat ribbon-like structure simulating the musculature over the anterior portion of the spine. Always use either an esophageal stethoscope or a nasotracheal tube to identify the esophagus.
- Insert a needle into a disc for lateral radiographic confirmation of the level.
- Retract the esophagus, trachea, and anterior strap muscles medially and the carotid sheath and sternocleidomastoid muscle laterally.
- Incise the prevertebral tissue in the midline on the disc. Use a bipolar coagulator along the medial edge of the longus colli as needed. Using sharp periosteal elevators, fashion a flap of muscle under which the retractor can be inserted laterally from the midline. Insert the clawed blades of the Cloward deep self-retaining retractor under the longus colli on both sides of the spine. To expose the desired disc, use the blunt-tipped Cloward retractor vertically (3).
- Insert the clawed retractor first. Hold it down on the spine while inserting the near retractor. The Cloward curved periosteal elevator can lift up the flap for insertion of the blade retractor.
- After hemostasis has been achieved, close the deep wound by removing the retractors. Use subcuticular skin closure, and always use a closed suction wound drainage system.

## SUPRACLAVICULAR APPROACH

- Place the patient in the supine position with the neck slightly hyperextended and rotated away from the side of the approach. Use an inflatable cervical pillow for support; a small roll under the shoulder often helps to extend the neck.
- *Caution: Location of the thoracic duct and recurrent laryngeal nerve becomes even more important at this level. Approaches from the left for C6–T2 are directly in the vicinity of the thoracic duct. Identify the thoracic duct when possible and protect it. A large fatty meal the day before surgery will help. If the thoracic duct is inadvertently divided, double ligate both ends well. The approach to the right definitely requires identification and protection of the recurrent laryngeal nerve. I recommend the left supraclavicular approach to avoid risk to the recurrent laryngeal nerve.*
- Make a transverse incision approximately one fingerbreadth above the clavicle from the midline to the posterior border of the sternocleidomastoid muscle. After the skin and subcutaneous tissue are divided and small skin self-retaining retractors are placed, incise the playtsma muscle in the line of the incision. As in the higher approaches, identification of the medial border of the sternocleidomastoid muscle is imperative.
- In addition, identify and define the anterior and posterior borders of the sternocleidomastoid muscle. The external jugular vein, although somewhat variable, is usually directly in the operative field, and the anterior jugular vein is positioned more medially. Divide it, if necessary.
- Incise the external investing fascia. Pass a probe or finger laterally from the medial border of the sternocleidomastoid to clear off the venous structures underneath the clavicular head of the sternocleidomastoid.
- Divide the sternocleidomastoid laterally to medially 1 inch from its insertion, watching for the internal jugular vein (12). If required for visualization, remove the sternal head of the sternocleidomastoid muscle in the same fashion. Eventual reattachment depends on suturing the fascial covering of the muscle.
- Retract the divided sternocleidomastoid in a cephalad-caudad direction with self-retaining blunt retractors. The floor of the incision, at this point, consists of the middle cervical fascia, which contains the omohyoid and the sternohyoid muscles.
- Enter the middle cervical fascia lateral to the carotid sheath. Bluntly dissect to the surface of the anterior scalene muscle. The superficial surfaces of the anterior scalene are composed of the outer layer of prevertebral fascia, which is the third and deepest of the fascial layers dealt with in this approach. Lying on the surface of the anterior scalene muscle is the phrenic nerve. The phrenic nerve crosses from lateral to medial, and cephalad to caudad. Retract the phrenic nerve medially after freeing it from the surface of the anterior scalene muscle. Identify the large internal jugular vein medially and feel for the carotid pulse. Although retraction of the carotid sheath is possible laterally, attempt to retract the internal jugular vein and carotid sheath medially (24). Retract the phrenic nerve to obtain good visualization of the anterior scalene, which is between the phrenic nerve and the middle scalene. The brachial plexus and suprascapular nerves are more superficial at the lateral border of the anterior scalene.
- Delineate the medial and lateral borders of the anterior scalene muscle. The fascia on the deep surface of the anterior scalene is Sibson's fascia, a continuation of the prevertebral fascia that encloses this muscle. The apex of the parietal pleura and lung form the undersurface of Sibson's fascia.
- Retract the anterior scalene laterally. Now carry out blunt dissection medially under the retracted carotid sheath. Stay on the prevertebral fascia of the spine.
- If more exposure is needed, carefully approach under the anterior scalene without violating the major portions of Sibson's fascia, and divide the anterior scalene muscle. The scalene can be retracted cephalad to caudad with self-retaining blunt retractors. Sibson's fascia now makes up the floor of the wound; the large internal jugular vein and the carotid sheath are located medially; the apex of the lung is beneath Sibson's fascia in the floor of the wound; and laterally, the brachial plexus courses superficial to the scalenus medius. The proximal portion of the anterior scalenus muscle may be dissected from the anterior tubercle of the transverse processes to allow greater exposure of the spine or brachial plexus (22).
- Incise Sibson's fascia at the transverse processes and bluntly retract it inferiorly. This retracts the pleura of the lung, which is usually at the T-1 level. Mobilize the recurrent laryngeal nerve medially with the carotid sheath and medial visceral column. Expose the spine by opening the fascia in the midline over the body. The transverse processes and rib heads can be exposed (18).
- Dissect to the second and third rib heads. This produces a rather lateral exposure of the spine. From the rib heads, dissect medially to enter the retropharyngeal fascial cleft on the anterior surface of the spine without having to dissect the longus colli muscle. Identify the vertebral artery entering the spine at C-6. The

subclavian vein courses on the floor of the wound.

- If the approach is done from the left, the junction of the internal jugular veins and the subclavian veins will contain the thoracic duct. Identify the thoracic duct. In case of damage, double ligate it proximally and distally. Chylothorax can be prevented with proper ligation. Often, a more judicious approach involves blunt dissection, progressing cephalad to caudad, as has been described for the transverse processes of C-5, C-6, and C-7, to the rib head of the first rib down on the spine. This will sweep most of these structures cephalad to caudad. The danger, of course, lies in cutting restraining structures that cross the field. The sympathetic chain (stellate ganglion at C-7) lies on the rib heads in a lateral position. Avoid damage by dissecting more medially.

## THIRD RIB RESECTION IN THE TRANSTHORACIC APPROACH

Third rib resection is used for the transthoracic approach to the T1–T4 area. Resection of the third rib allows greater spreading of the intercostal area than does second rib resection (13). The cephalad extension of the exposure is enhanced with kyphosis deformity of the cervicothoracic junction area. The second rib can be removed if the operative exposure is inadequate.

- Place the patient in the lateral decubitus position, with the left side up. Prep and drape the entire left upper extremity in a sterile manner (Fig. 138.9).

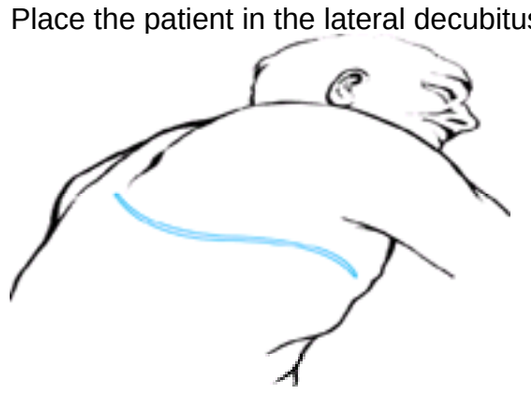

***Figure 138.9.*** Skin incision for third rib resection for the transthoracic approach.

- Incise the skin and subcutaneous tissue from the lateral paraspinous area at T-2, along the medial caudal border of the scapula, under the axilla to the costal cartilage of the third rib.
- Carefully divide each subsequent muscle layer down to the level of the rib, sectioning portions of the trapezius, latissimus dorsi, rhomboid major, and serratus posterior as needed. Careful dissection with electrocautery and meticulous cauterization of each muscle bleeding point allows exposure to the outer periosteum of the third rib with a minimal amount of bleeding. As the muscle layers are divided, retract the scapula cephalad and medially to tense the muscle tissue for easier cutting. Palpate the chest wall cephalad for identification of the third rib. Remember that the first rib is situated inside the second; this is important for reaching the correct rib level (Fig. 138.10).

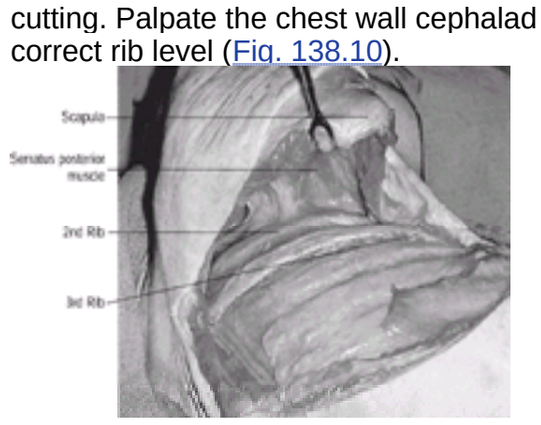


***Figure 138.10.*** Elevation of the scapula aids in the division of the muscles attached to the scapula and allows visualization of the third rib.

- Dissect the external periosteum off the third rib with periosteal elevators. Excise the third rib from the angle of the rib to the costal cartilage. Open the rib bed as in the standard thoracotomy approach (Fig. 138.11). The rib bed consists of periosteum, endothoracic fascia, and parietal pleura. Incise the parietal pleura, carefully avoiding damage to the underlying lung. Pick up the inner periosteum of the rib bed with Adson forceps and open the rib bed with scissor tips or fine dissection with a knife blade. To avoid lung and pleural adhesions just under the rib, complete the opening of the rib bed with semiclosed scissors, using a finger to clear lung from the undersurface.

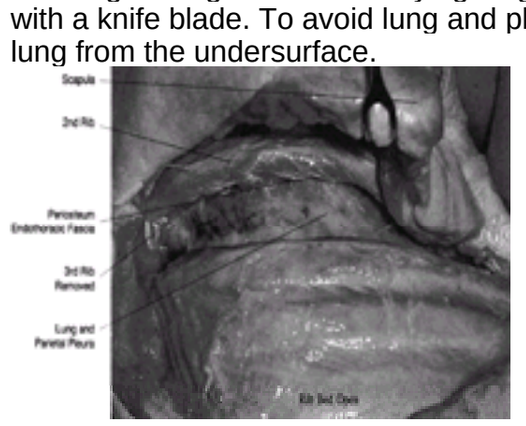


***Figure 138.11.*** Excise the third rib from the angle of the rib to the costal cartilage.

- Use the Feochetti rib spreader to open the intercostal area. Deflate or retract the lung with a spatula-type retractor (Fig. 138.12).

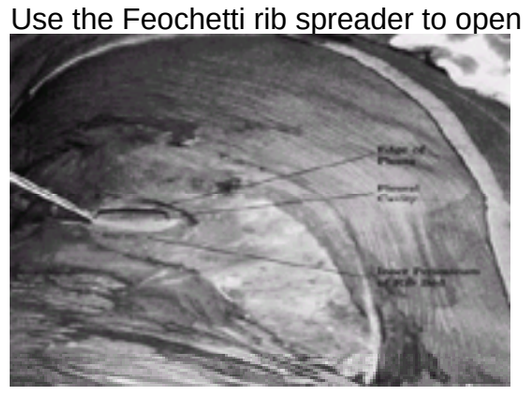

***Figure 138.12.*** With the rib bed open, place the Feochetti rib-separating retractor and retract the lung with a spatula lung retractor.

- Identify the aorta, spine, ribs, parietal pleura, and veins under the parietal pleura in the wound. The highest intercostal vein is usually seen.
- Use an Adson forceps and Metzenbaum scissors to open the parietal pleura delicately over the costovertebral articulations.
- Identify the prominent soft or white tissue of the intervertebral disc. This is a relatively avascular, safer plane for dissection than the surface of the vertebral body. Make an intraoperative radiograph to verify the level.
- Dissect each intercostal vessel, tying and ligating it over the vertebral body. Bluntly dissect the soft tissue from the vertebral body (Fig. 138.13).



***Figure 138.13.*** After the parietal pleura is opened, bluntly dissect its edges off the spine with a “peanut” or sponge. The parietal pleura may be sutured back laterally with stay sutures when necessary for continued retraction.

- Fully expand the lung and visualize in all areas before closure. Close the parietal pleura over the spine whenever possible. Place the chest tube through a separate aperture, preferably in the ninth intercostal space. Protect the lung during closure. Close the chest with the rib approximator. Close the rib bed with interrupted permanent braided Dacron sutures. The chest tube can usually be removed within 48 to 72 hours, depending on drainage and expansion of the lung.

## THORACOTOMY APPROACH

The standard thoracotomy approach is used for safe exposure of vertebral levels T-2 to L-2. Rib selection depends on the location and extent of the pathologic process. Anatomic variations at the cervicothoracic and thoracolumbar junction dictate the rib to be taken. Choose the rib to be resected for a certain vertebral level by one of two methods:

1. When the pathology dictates a direct anterior approach to the vertebral column (e.g., kyphotic tuberculous abscess), choose the rib directly horizontal to the vertebral level at the midaxillary line in an anteroposterior chest radiograph. The rib removed must be cephalad to the lesion to give adequate proximal exposure of the lesion (13).
2. When direct access to the spinal canal is needed at one disc (e.g., ninth rib to the T8–T9 disc), use a left approach because it is much easier to deal with the aorta and the segmental vessels from the left side. For patients with a large abscess in the right chest or in other circumstances that dictate a right thoracic approach, be prepared to mobilize the vena cava and associated veins from that side.

- Place the patient on the bean bag. Use a double-branched endotracheal tube into the right and left mainstem bronchi to allow selective collapse of the left lung. Center the midthorax of the patient over the break in the table. Pad the dependent axilla, and pad and protect the left arm. Stabilize the pelvis with a strap to the table. Place a pillow between the legs, and pad all the bony prominences. Flex the table to allow better exposure.
- Open the skin and subcutaneous tissue from the lateral border of the paraspinous musculature to the sternocostal junction over the rib to be resected. Inject the incision with 1:500,000 epinephrine. Place the thoracotomy incision slightly tangential to the rib to be resected, allowing easier resection of more than one rib if necessary.
- After inserting the self-retaining retractors, extend the wound with the electrocautery down through the muscle layers to the thorax. When necessary for full exposure, the latissimus dorsi, trapezius, and rhomboid major and minor muscles can be sectioned.
- After the chest wall is exposed, count the ribs from the twelfth up to the appropriate rib or from the first rib downward. The first rib appears to be inside the second when one is palpating from this angle, and it is often difficult to find. Each rib articulates with the superior portion of the body in the area of the disc space of the level above. Therefore, the twelfth rib inserts closer to the T11–T12 intervertebral disc space. Confirm identification of the rib with a radiograph.
- Expose the outer periosteum of the rib with the electrocautery and cut directly to the bone through the periosteum from the angle of the rib to the costal cartilage. Elevate the periosteum off the outer rib surface. Use the curved-tip rib elevator to strip the superior and inferior borders of the rib, maintaining an intact elevated periosteum. Elevate the inner periosteum of the undersurface of the rib with the Doyen elevator.
- *Caution: Avoid damaging the intercostal vessels that course on the inferior surface of the rib. Elevate the periosteum of the rib by cutting with the elevator directly on bone. Avoid plunges that might inadvertently enter the pleura.*
- With the intact periosteum freed from the rib, cut the rib with the rib cutter as far posteriorly as necessary between the costotransverse joint and the angle of the rib and anteriorly at the costal junction. Remove the rib and save it for bone graft. Lightly wax the bone on the end of the rib after rasping to make sure there are no ragged edges. Tie a sponge on the tip of the stump to protect the surgeon during the procedure.
- Pick up the inner periosteum of the rib bed with Adson forceps and open the rib bed with scissor tips. Avoid lung and pleural adhesions. Complete the opening of the rib bed with a semiclosed scissors after using a finger to clear lung from the undersurface. When pleural adhesions exist, first attempt to dissect the adhesions bluntly with the finger or sponge stick. If necessary, sharply dissect dense adhesions and ligate vascular structures.
- Retract the lung medially with a spatula lung retractor or deflate it. Retraction of the lung should be removed at least every 20 minutes to allow adequate expansion of the lung and to prevent postoperative atelectasis. Insert the Feochetti separator in the rib resection defect, with moist lap sponges over the edges. Expand the Feochetti separator to allow adequate visualization inside the thoracic cavity. Flexion of the table may be of benefit.
- The anatomy of the spine at this point is obscured by the reflection of the parietal pleura as it covers the soft-tissue structures over the spinal column. Elevate the parietal pleura with Adson forceps and open it with Metzenbaum scissors. Extend the opening of the parietal pleura cephalad and caudad on the spine by cutting over a peon dissected under the pleura. The presence of a large paravertebral abscess at this point means only that the abscess should be exposed just as the spine would be. When an abscess is present, cut its outer wall longitudinally and approach the spine through the abscess.
- The disc is the more prominent, softer, white structure of the spine. The discs are relatively avascular and a much safer area for dissection. An intercostal vein and artery cross the midportion of each vertebral body.
- Bluntly dissect the edges of the parietal pleura off the spine with a Kittner dissector or sponge. Elevate the pleura on the discs and lift it off the vessels on the vertebral body. Dissection begun over the disc is less likely to cause bleeding. Make a radiograph at this point to verify the level. After the parietal pleura is opened, it may be sutured back on itself laterally with two stay sutures.
- Separate, sever, and ligate each of the intercostal vessels over the vertebral body. If a large paravertebral abscess is present, the arteries enter the abscess. Take care to avoid clamping segmental arteries too close to the aorta so as to lose the tie or too close to the intervertebral foramen. Tie arteries and veins separately or together, depending on their size. Pass a right-angled clamp under the vessels, and use a braided 2-0 suture in a free tie to tie off first the medial and then the lateral exposed vessels; use vascular clamps in a similar fashion.
- *Caution: Take care to dissect adequately under the vessels. A common mistake is to have both ligature sutures in the same place under the vessel and not have adequate room for cutting between them. Handle every segmental vessel in the area of where bony work will be done in this manner. Paralysis due to ligation of a segmental artery on the vertebral body has not been a problem (13).*
- *Caution: Do not dissect into the intervertebral foramen.*
- Bluntly expose the outer surface of the spine after division of the segmental vessels. When bone and disc exposure is needed, cut with the cautery directly to bone. Use the periosteal elevator to dissect the annulus off the disc and the periosteum off the bone medially and laterally, exposing the entire disc and vertebral column. The tendency is not to dissect the soft tissue laterally enough off the spine. The rib head articulates with the cephalad half of its appropriate vertebral body and the disc space above. Access to the posterior disc and spinal column can be gained by resecting the rib head (Fig. 138.14). Removal of the head of the rib and its articulation allows excellent exposure of the posterolateral aspect of the intervertebral disc. After the rib head and disc are removed, identify the intercostal nerve, dural sac, posterior vertebral body wall, and spinal canal. The costal vertebral articulation is a major stabilizing structure in the thoracic spine. Identifying the left pedicle in a left-sided approach helps locate the spinal canal for orientation. The vertebral body can be completely exposed by resecting the disc above and below to identify the posterior body wall and spinal canal and dissected laterally to identify the pedicle and spinal canal.

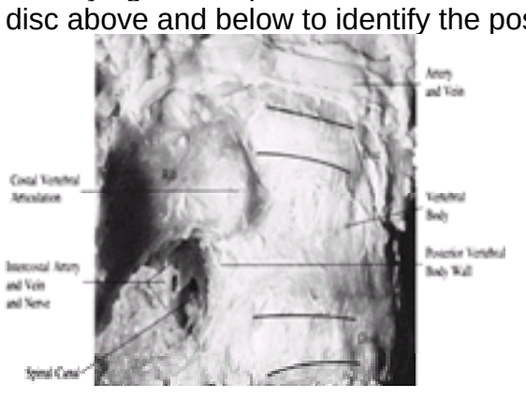

***Figure 138.14.*** The rib articulates with the cephalad half of its appropriate numbered vertebral body and with the disc space above. Therefore, the tenth rib articulates at T9–T10.

- Visualize the lung fully expanded in all areas before closure. Close the parietal pleura over the spine whenever possible. Place the chest tube through a separate aperture, preferably in the ninth intercostal space. Protect the lung during closure. Close the chest with the rib approximator. Close the rib bed with interrupted permanent braided Dacron sutures. The chest tube connects to the water seal. With the lung re-expanded, the chest tube can usually be removed within 48 to 72 hours, depending on drainage and expansion of the lung.

## THE THORACOLUMBAR JUNCTION

The rules for resecting the best rib for exposure of the thoracolumbar junction are much the same as in the rest of the thoracic spine. Hodgson and Rau (13,14) recommend a ninth rib resection for T10–L1. Dwyer et al. (6) recommend a tenth rib resection with the standard thoracolumbar approach for the T10–L1 area. For exposure of the T12–L1 area, Perry (19) recommends a tenth rib resection. Ideally, choosing the rib in the midaxillary line opposite the lesion or the apex of a curve allows adequate proximal exposure for working “down” or caudad on the lesion.

Transthoracic resection of the ninth rib is usually best for maximum exposure of T11–T12. A tenth rib thoracoabdominal approach is preferred for exposure of the T12–L1 area. Both techniques involve detaching the diaphragm at its circumference. A twelfth rib approach is used in cases in which less exposure is needed or when it is imperative that the diaphragm not be taken down. A twelfth rib extrapleural retroperitoneal approach is recommended for exposure of L1–L2.

The approach through the eleventh rib, a more demanding approach with less expansive exposure, is the highest practical, extrapleural, retroperitoneal anterior approach for the exposure of the T10–L2 area. It is ideally used in severely ill patients in whom avoiding opening the pleural cavity and cutting the diaphragm is an advantage. Another alternative for limited extrapleural exposure with low morbidity is the posterior costotransversectomy approach. The vertebral body and spinal canal can be exposed by following the twelfth subcostal nerve to T12–L1. Unless at least two levels are exposed with the approach, the visualization necessary to perform total discectomy, vertebrectomy, and strut grafting is extremely poor compared with the anterior approach.

A third approach that may be used in special situations is the tenth rib thoracolumbar approach for long exposures of the thoracic and lumbar spine. This approach allows proximal and distal extension for multilevel operations and optimum exposure for bony work.

### TENTH RIB THORACOABDOMINAL APPROACH

- Place the patient in the lateral decubitus position. Make the approach from the convexity of the scoliosis or from the left side, when possible (Fig. 138.15). A left-sided approach is preferred because of ease of mobilization of the aorta compared with the vena cava and because splenic retraction is easier than hepatic reconstruction. Open the skin and subcutaneous tissue from the lateral border of the paraspinous musculature over the tenth rib to the junction of the tenth rib and costal cartilage (20). Curve the incision anteriorly from the tip of the tenth rib to the lateral rectus sheath and distally down the edge of the sheath as far as necessary for exposure. Use electrocautery to slowly extend the incision through each muscle layer while an assistant aggressively picks up bleeders with two Adson forceps.

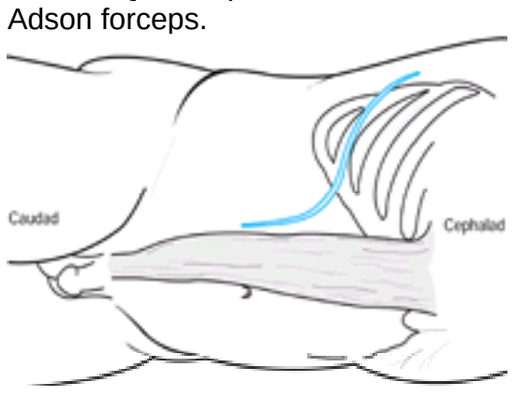


***Figure 138.15.*** Skin incision for a tenth rib thoracoabdominal approach.

- Open the superficial periosteum of the tenth rib to the costal cartilage. Use the sharp, curved periosteal elevator to remove the superficial and deep periosteum off the rib. Take care to avoid the neurovascular bundle on the inferior surface of the rib. Cut posteriorly at the angle of the rib, and cut at the junction of the rib and costal cartilage. Remove the rib. On opening the pleural space, retract the lung and fully open the rib bed with scissors (Fig. 138.16). At this point, the intrapleural cavity is opened and the retroperitoneal cavity is still closed.

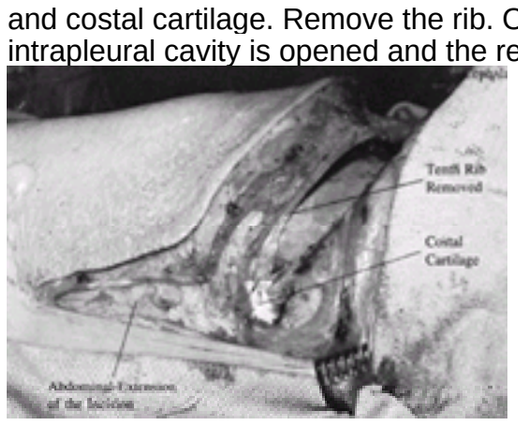


***Figure 138.16.*** With the rib removed, carefully delineate the costal cartilage.

- Split the costal cartilage with a knife along its length. Open the undersurface of the costal cartilage and retract the two tags of cartilage (5,6,20) (Fig. 138.17).

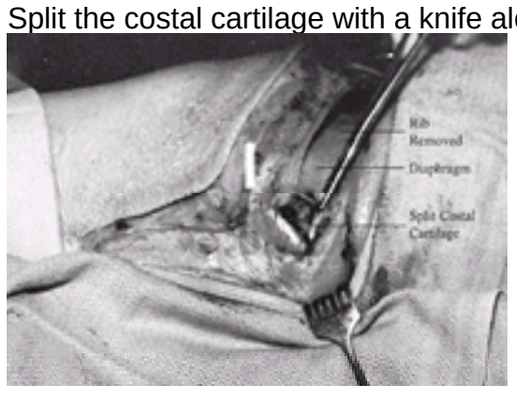


***Figure 138.17.*** Split the costal cartilage. Open the most superficial layer of soft tissue under the costal cartilage enough to allow retraction of the cartilage tips.

- Identify the peritoneum and retroperitoneal space by blunt dissection under the retracted split tips of the costal cartilage. The guide to the retroperitoneal space is the light areolar tissue of the retroperitoneal fat (Fig. 138.18).

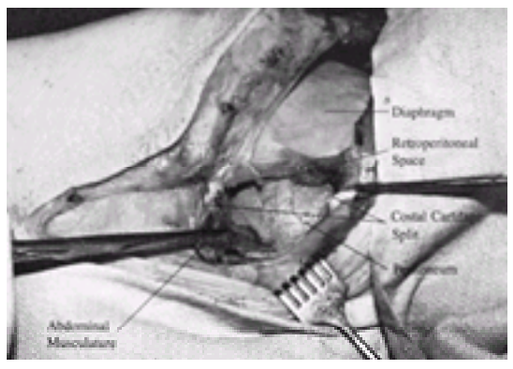


***Figure 138.18.*** Retract the split tips of costal cartilage. Identify the insertion of the diaphragm into the cephalad cartilage tip and the insertion of the abdominal musculature into the caudad cartilage tip.

- Bluntly dissect the peritoneum off the inferior surface of the diaphragm (Fig. 138.19). The peritoneum is swept, using a sponge, first from the undersurface of the diaphragm, then from the transversalis fascia, and finally from the abdominal wall.

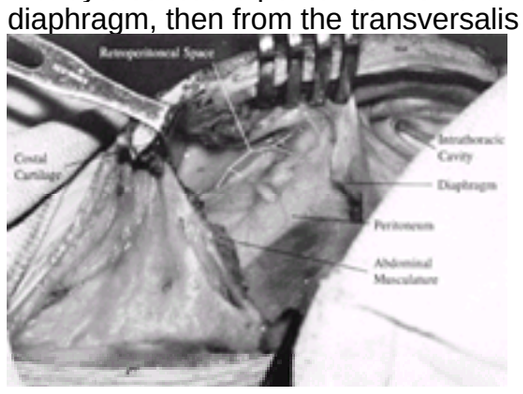


***Figure 138.19.*** Bluntly dissect the periosteum off the inferior surface of the diaphragm.

- After the peritoneum is retracted, carefully open the abdominal musculature (the external oblique, the internal oblique, and the transversus abdominis) one layer at a time, with complete hemostasis. At this point the chest and retroperitoneal space are open and the diaphragm is the intervening structure in the wound.
- Incise the diaphragm from inside the chest with clear visualization under the diaphragm in the retroperitoneal space. Extend the incision in the diaphragm circumferentially, 1 inch from its peripheral attachment to the chest wall (28). Use marker clips throughout the take-down of the diaphragm to allow accurate reapproximation.
- For work on T2–L1, resect the diaphragm to the spine. Cut the crus of the diaphragm and elevate it off the spinal column. Use protected Deaver retractors to retract the peritoneal sac anteriorly. Identify the psoas muscle with its most cephalad attachment to the transverse process of L, and protect the muscle because the lumbosacra plexus is under it. With a large rib retractor, such as the Feochetti, open the tenth rib incision in the chest. The spine will be visualized from approximately T-6 as far distally in the lumbar spine as necessary. In the lumbar spine, remove the crus of the diaphragm and the attachments of the psoas muscle, if needed, for proper visualization of the spine. In the thoracic spine, the parietal pleura is opened as in a standard thoracotomy approach. Tie and ligate the intercostal artery and vein to allow mobilization of the major vascular trunks. If it is identified as in the operative area, the thoracic duct, which usually crosses right to left around T4–T5, is tied off. Avoid the sympathetic plexus. After the intercostal vessels are removed, cut directly to the spine. Dissection is carried out on the spine, and soft tissue is removed laterally.
- The key to closure is the reapproximation of the costal cartilage. After the diaphragm is resutured with multiple interrupted sutures and the split cartilage is reapproximated, insert the chest tube in the eighth intercostal space and pass it posterosuperiorly. Attached to the cephalad half of the costal cartilage is the insertion of the diaphragm and the interthoracic fascia. Inserting into the distal split of costal cartilage is the transverse abdominal fascia and attachment for the abdominal musculature. With the costal cartilage reapproximated, the layers of the abdominal musculature are better defined. Close each layer of the abdominal wall separately when possible, and close the chest as in a standard thoracotomy.

## THE LUMBOSACRAL SPINE

### PARARECTUS INCISION FOR L2–S1

- Position the patient supine on the table with the lower lumbar spine at the level of the kidney rests.
- Make a lower abdominal pararectus incision through the skin and subcutaneous tissue. The most immediate layers are those of the external oblique with its transition into the linea semilunaris, which leads to the fascia of the rectus sheath. The linea semilunaris is composed of the aponeurosis of the three layers of the abdominal musculature and their fascia.
- Incise the fibers of the external oblique, the internal oblique, and the small thin layer of transversus abdominis muscles laterally to the semilunaris in line with the skin incision.
- Identify the transversalis fascia, which is the internal investing fascial layer of the abdominal cavity. Dissect the outer surface of the transversalis fascia to the edge of the rectus sheath. The transversalis fascia splits at this point to form the lamina of the rectus sheath. The posterior lamina of the rectus sheath forms the endoabdominal fascia in this area.
- Carefully incise the transversalis fascia laterally to the linea semilunaris, and identify the peritoneum through the incision.
- Begin the incision in line with the skin incision. Dissect the peritoneum with a sponge or gloved hand off the undersurface of the transversalis fascia. Open the abdominal wall after the peritoneum has been identified and cleared.
- Bluntly dissect the peritoneum from the lateral abdominal wall, progressing posteriorly. Identify the psoas muscle, as in any retroperitoneal approach to the spine. Retract the peritoneum off the left iliac artery and vein by use of the surgeon's hand, a padded deaver retractor, or sponge sticks. Sweep the peritoneum with the ureter from left to right, and expose the left common iliac artery and vein. Insert Freebody pins or special retractors.
- Palpate and identify the intervertebral disc. Remember that this is a relatively avascular area. With any approach to the L4–S1 area, identify the left iliolumbar vein and ligate it when necessary. Dissection within the bifurcation of the aorta should be blunt and as avascular as possible. Remember, the left common iliac vein lies in the bifurcation over the L4–S1 disc. The variation in inferior vena cava and lumbar veins often dictates the exact approach from this point.
- Bluntly retract and protect the hypogastric plexus.
- Allowing the peritoneal sac to fall into place, close the muscle layers with a running suture. The transversus abdominis and the internal oblique may be closed together.

## ANTERIOR RETROPERITONEAL FLANK APPROACH TO L2–L5

For the retroperitoneal exposure of the lumbar spine, an anterior pararectus vertical incision, a J-shaped renal incision, or a horizontal lateral abdominal incision can be used (Fig. 138.20). I prefer the horizontal oblique incision.

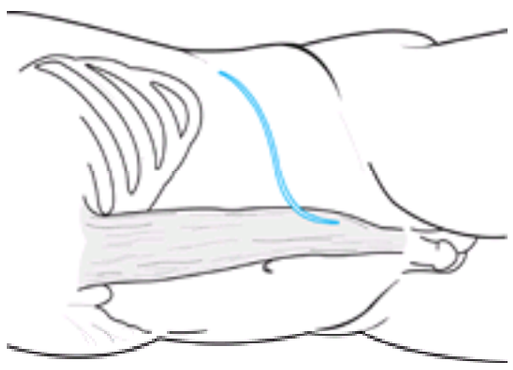

***Figure 138.20.*** For retroperitoneal exposure of the lumbar spine, an anterior pararectus vertical incision, a J-shaped renal incision, or a horizontal lateral abdominal incision can be used.

- Place the patient in the supine position over the kidney rests. For patients with a large abdominal pannus, the left lateral decubitus position can be used. In the lateral position, too much hip flexion at this point will limit the operative exposure anteriorly.
- Start the incision equidistant between the lowest rib and the superior iliac crest in the midaxillary line, and extend it approximately to the edge of the rectus sheath. The level of the incision varies according to the level of the spine approached: L5–S1 is in the lower half of the distance between umbilicus and symphysis, L4–5 is in the upper half, L3–4 is at the umbilicus, and L2–3 is above the umbilicus. The length of the incision can vary according to the surgeon's experience, the exposure needed, and the operation to be done.
- Muscle relaxation allows greater mobility to the abdominal wall and decreases the contractility of the muscle as it is incised. First, open the muscle layers as laterally as possible because they are thicker here and there is less chance of penetrating the peritoneum. The muscle layers thin out, and the layers of the fascia become almost joined medially. The peritoneum is very superficial. Inadvertent penetration of the peritoneum is most likely just lateral to the rectus sheath. Dissect through the external oblique and the internal oblique muscle. Inferior to the internal oblique is the transversus abdominis. Use care in inserting self-retaining retractors into the muscle layers so as not to damage the peritoneum. Often, the transversus abdominis muscle is a very thin or absent muscle layer. Bluntly spread this thin muscle in line with its fibers to expose the transversalis fascia.
- Open the transversalis fascia in the lateral portion of the wound (Fig. 138.21). Lift the transversalis fascia with Adson forceps and carefully open it with blunt scissors. The retroperitoneal fat allows room to enter the extraperitoneal space.

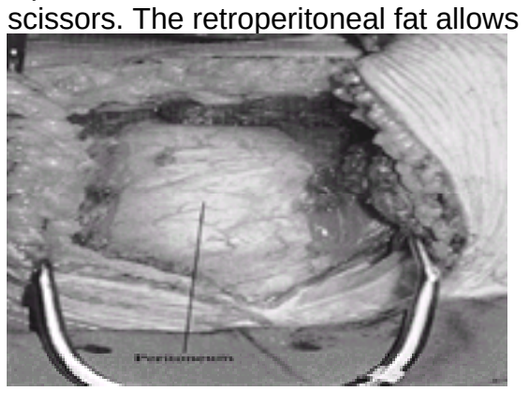

***Figure 138.21.*** Open the transversalis fascia in the lateral portion of the wound. Lift it with Adson forceps and carefully open it with blunt scissors.

- Enter the retroperitoneal space laterally. Identify the peritoneum and the fat of the peritoneal space. Remove the peritoneum from the remaining transversalis fascia with blunt dissection. Extend the incision after the peritoneum has been safely removed. The sheath may be incised for added exposure. Torn peritoneum should be repaired promptly (19).
- Identification of the psoas muscle is the key to the retroperitoneal approach. Pass your hand directly to the psoas. Avoid opening the retropsoas space, which is a blind pouch. The genitofemoral nerve can be identified on the psoas. The spine is immediately medial to the psoas and can be partially obscured by it. Palpate and identify the psoas muscle, the intervertebral disc, the aorta, and the vertebral body. The paravertebral sympathetic chain lies medial to the psoas muscle. The ureter will be reflected medially with the undersurface of the peritoneum. If a retroperitoneal abscess is well developed, open it and dissect inside the abscess to the spine.
- The key at this point is to identify the raised, white, softer disc by direct palpation with the finger, as opposed to the lower, concave vertebral body, where the lumbar vessels are found. The discs are the hills, and the vertebral bodies are the valleys. The vessels are in the valleys.
- Once the lumbar disc can be identified, insert a blunt elevator or padded small retractor to sweep the soft tissue from left to right across the disc space. The lumbar veins are a horizontal tether. Variations in formation of the inferior vena cava and lumbar veins are the rule rather than the exception (11). The most important of these veins is the iliolumbar vein, which crosses the body of L-5 from right to left and ascends in the left paraspinous area (13). This vessel is a direct tether to the left-to-right retraction of the aorta off the spine and is very vulnerable to avulsion.
- For operations on the L4–L5 disc space, identify the iliolumbar vein early in the dissection (Fig. 138.22). Ligate it after clamping the vein with angled tonsil clamps and passing two or three ligatures around the vein. These ligatures should not be tied too close to the vena cava because a sidewall injury can occur. Transect the vein after securing the permanent ties. Greater mobilization of the vena cava and venous structures, left to right, is thereby obtained. The iliolumbar vein consistently requires ligation.

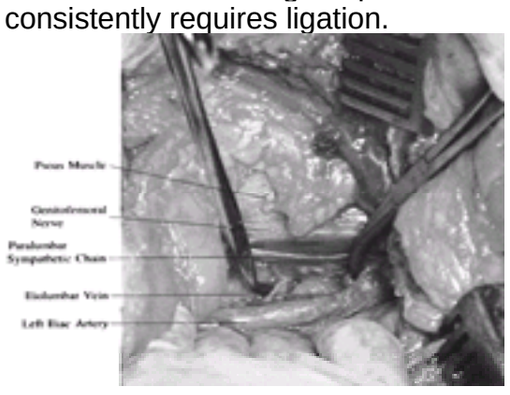


***Figure 138.22.*** For operations on the L4–L5 disc space, identify the iliolumbar vein early in the dissection.

- Lumbar veins of varying sizes at various positions are always present. Some may be directly posterior to the vena cava and of quite large diameter. Dissection on the anterior spine consists of gentle stretching and pulling of the structures, blunt dissection, direct pressure over many small bleeding areas with a sponge, and a minimum of electrocautery. The paraspinous sympathetic plexus between the spine and the psoas muscle varies in size and number of fibers. Branches course between the preaortic and paraspinous chains. Preserve paraspinous sympathetic fibers that do not impede dissection.
- Dissect with the fingertip and blunt elevators all the vascular structures from left to right to give adequate visualization of the end plate of the vertebral body above the disc (27).
- Use malleable Deaver-type retractors or blade spike retractors around the disc space. Alternatively, prepare four Freebody Steinmann pin retractors with rubber sleeves and mount them in a Steinmann pin holder (9). For any sharp stay-retractor that is driven into the body, stabilize the pin on the finger and engage the tip into the vertebral body under direct vision. The assistant taps the pin into the body while the surgeon maintains control of the pin. Avoid the tendency for the pin to enter the disc space by directing the tip of the pin horizontal to the disc space. Allow a sufficient distance from the endplate to allow work on the disc space without dislodging the pin. Place the superior and inferior right-sided pins before placing the left-sided pins.
- Expose the annulus of the disc (Fig. 138.23). There should have been minimal sharp dissection and cautery in this area. Now prepare the disc for the operative procedure. The vena cava and iliac artery and vein are held by the retractors.

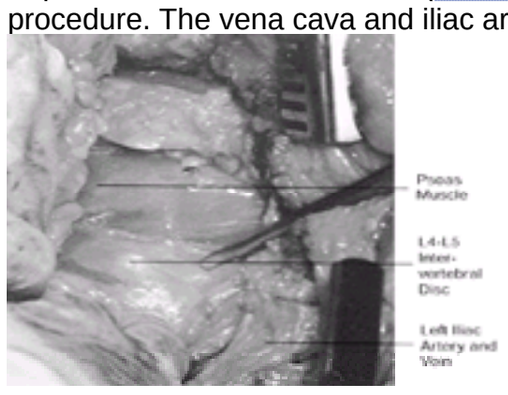


***Figure 138.23.*** Expose the annulus of the disc.

- Special curved or malleable retractors can be used between the stay retractors for protection of the vena cava.
- Extract the retractors with the same amount of care as when they were inserted. The sheath and a finger must guard the tip; otherwise the vena cava will be torn as the sharp tip passes the vessel that is tented around it.
- Remember:
  1. When making the incision, follow the skin guidelines for optimum spine exposure.
  2. Achieve careful hemostasis in the muscle layers.
  3. Incise the transversus abdominus muscle layer and the transversalis fascia in the lateral portion of the wound.
  4. Beware of thinning muscle layers and the peritoneum's superficial position medially near the rectus sheath.
  5. Pass directly to the psoas muscle.
  6. Identify the raised, soft, white disc.
  7. Identify, ligate, and divide the iliolumbar vein.
  8. Sweep prevertebral tissue left to right across the disc.
  9. Insert the Steinmann pin after placing it directly on bone with the fingertip.
- Retract the Steinmann pin, again with the fingertip preventing the tip of the pin from damaging the left iliac artery.

## RETROPERITONEAL EXPOSURE OF L5–S1

- Palpate the spine with a finger and find a disc for orientation. Usually, it is the L4–L5 disc. With identification of the L4–L5 disc, palpate the pulse of the left common iliac artery and the aortic bifurcation. The bifurcation of the aorta is critical in determining the exact approach from this point. The usual bifurcation at the L4–L5 disc level was present in 69% of anatomic dissections performed by Harmon (11), but great variation exists.
- Palpate the left common iliac artery and pass over it medially to the L5–S1 disc. By placement of the finger and a subsequent blunt retractor such as a sponge-covered elevator, develop a plane just to the right of the left common iliac artery.
- The left iliac vein lies within the aortic bifurcation. It often courses directly on the surface of the L5–S1 disc and may be flattened against the disc or L-5 body, with its venous character obscured. Mobilize it to the left and cephalad with the left iliac artery.
- The middle sacral artery and veins are present in the bifurcation. The key to handling these structures is blunt dissection just to the right of the left common iliac artery, sweeping from left to right the prevertebral tissue, including the middle sacral vessels and superior hypogastric plexus, off the lumbosacral disc. Occasionally, the middle sacral vessels are of formidable size, but seldom do they have to be ligated (4).
- An additional structure in the bifurcation is the superior hypogastric sympathetic plexus.
- The thoracolumbar sympathetic chain extends down anterior to the aorta and vertebral bodies in the retroperitoneal space as the preaortic sympathetic plexus. At approximately the L3–L4 level, the inferior hypogastric plexus extends to L4–S1 as the superior hypogastric plexus (Fig. 138.24). The structure of the superior hypogastric plexus varies considerably because the preponderance of the superior hypogastric plexus fibers is usually closer to the left iliac artery as they arch over the L5–S1 disc in the bifurcation of the aorta (Fig. 138.25) (16). There may be multiple strands or one predominant large simple nerve trunk. The superior hypogastric plexus contains the sympathetic function for the urogenital system. The S1–S4 nerve roots that contribute to the pelvic splenic nerves provide parasympathetic function for the urogenital system. The pudendal nerve covers somatic function from S-1, S-2, S-3, and S-4.

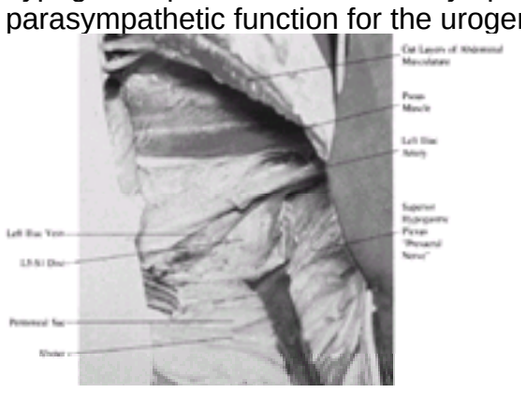

***Figure 138.24.*** Sweep the prevertebral tissue bluntly off the front of the L5–S1 disc. The superior hypogastric plexus may be a diffuse plexiform nerve formation that is retracted with the other tissue, or it can be a discrete well-defined presacral nerve.

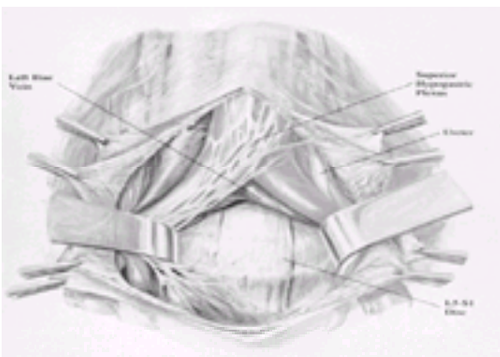

***Figure 138.25.*** The superior hypogastric plexus is within the bifurcation of the aorta.

- Ejaculation is predominantly a sympathetic function, whereas through control of the vasculature of the penis, erection is predominantly a parasympathetic function. Retrograde ejaculation and sterility result from disruption to the sympathetic plexus. The main effect of damage to the superior hypogastric plexus is improper closing of the bladder neck, with resultant retrograde ejaculation, although the sympathetic fibers also have some effect on the motility of the vas deferens, which is important in the transportation of the spermatozoa from the epididymis to the seminal vesicle (15).
- The prognosis for recovery from retrograde ejaculation is good (8). Sperm can be obtained in refractory cases by bladder aspiration techniques. Damage to the superior hypogastric plexus should not produce impotence or failure of erection. Avoid damaging the hypogastric plexus by doing the following (4):
  1. For the transperitoneal midline approach, carefully open the posterior peritoneum and bluntly dissect the prevertebral tissue from left to right (9).
  2. Visualize and retract the prevertebral tissues by opening the posterior peritoneum higher over the bifurcation and then extending the opening down over the sacral promontory (4,8,9,15).
  3. Remove the prevertebral tissue from the L5–S1 disc with blunt dissection, retraction, and spreading.
  4. Attempt to retract the middle sacral artery and vein without electrocautery by spreading and blunt dissection. Use vascular clips or tie ligation when this vessel is of considerable size.
  5. Until the annulus of the disc is clearly exposed, make no transverse scalpel cuts on the front of the L5–S1 disc.
  6. Do not use electrocautery within the aortic bifurcation.

- The key to avoid damaging the superior hypogastric plexus is to avoid transverse cuts on the face of the disc until all the prevertebral tissue has been elevated from the annulus and to avoid electrocautery on the surface of the L5–S1 disc. Small bleeding points are encountered when doing this dissection, but they are usually easily controlled by direct finger pressure or packing with hemostatic gauze. Usually, the left iliac artery and vein will be retracted to the left, but it may require retraction to the right on occasion.
- Locate and ligate the iliolumbar vein before any mobilization of the left iliac artery to the right.
- Always obtain radiographic confirmation of the level. It can be done easily by inserting a #22-gauge spinal needle and taking a radiograph. Because the L5–S1 disc and the sacrum are often angled very horizontally, the body of L-5 can be mistaken for the sacrum.
- Insert appropriate Freebody Steinmann pin stay-retractors, blade-point retractors, or hand-held retractors.

## TRANSPERITONEAL EXPOSURE OF L5–S1

- For the transperitoneal exposure, use either a vertical midline incision or a transverse “smile” incision. The “smile” is better cosmetically and gives excellent exposure, but it requires transection of the rectus abdominus sheath. Identify and open the rectus sheath, and transect the rectus abdominus muscle. The posterior rectus sheath, the abdominal fascia, and the peritoneum are conjoined in this area. Carefully open the posterior rectus sheath and abdominal fascia to

the peritoneum.

- Pick up the peritoneum. Open the length of the wound carefully, avoiding damage to the bowel. Identify the posterior peritoneum over the sacral promontory after packing off the bowel.
- Palpate the aorta and both iliac vessels through the posterior peritoneum. Feel the softer texture of the L5–S1 disc.
- Inject the retroperitoneal space with saline to achieve separation of the peritoneum from the vascular structures.
- Pick up the peritoneum with Adson forceps; handle it delicately.
- Avoid use of the electrocautery anterior to L5–S1 to prevent damage to the superior hypogastric plexus, despite the fact that there is bleeding in this area. The left common iliac vein often lies as a flat, white, bloodless ribbon across the L5–S1 disc within the aortic bifurcation.
- After the left common iliac artery and left common iliac vein are identified, use blunt dissection to the right of the left iliac artery and hypogastric plexus and soft tissue, moving from left to right (Fig. 138.26).

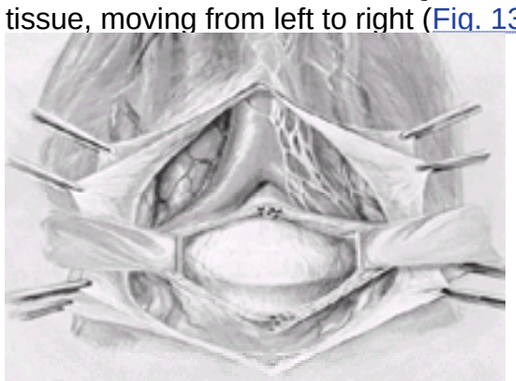

***Figure 138.26.*** Exposure of the L5–S1 disc. See text for a description of the technique.

- Bluntly dissect the middle sacral artery and vein from left to right without sacrifice at this point. Longitudinal blunt dissection allows better mobilization of these vascular structures. When bleeding is encountered, use direct finger and sponge pressure for a short time, followed by blunt dissection. Control hemorrhage with packing and pressure. Divide and tie the middle sacral artery and vein, if necessary.

## POSTERIOR APPROACH TO L1–S1

- Position the patient to allow full chest excursion, to maintain the neck in a safe position, and to allow the abdomen to hang completely free of pressure. Flex the hips and knees enough to relieve nerve root tension but not so much as to obstruct arterial flow to the legs or to produce any abdominal pressure. I prefer the Andrews frame.
- Obtain a skin marker radiograph by inserting two #20-gauge spinal needles perpendicular to the skin approximately three fingerbreadths lateral to the spine. Using the alignment of the needles, put the skin incision in the midline over the disc space. Paraspinous needles allow a more accurate skin incision than a spinous process marker.
- Use a skin marking pencil to draw a vertical, midline skin incision relative to the two needles over the disc space. Make a dermal skin incision only. The average length is 3.2 cm for a one-level microscopic discectomy, longer for a more extensive decompression. Inject 25 to 50 ml 1:500,000 epinephrine through the dermal incision into the subcuticular tissue and directly down to the lamina into the paraspinous muscle mass. Cut with a scalpel directly to the fascial layer. Preserve the lumbodorsal fascial attachments to the spinous process, the interspinous ligament, and the supraspinous ligaments by making a paraspinous fascial incision that can be sutured at closure without tension. This is preferable to removing all soft-tissue fascial attachments from the spinous process, unless a total laminectomy is to be done, in which the fascia is totally removed from the spinous process and lamina with the electrocautery.
- The lumbodorsal fascia is critical for stability of the spine. Maintaining the fascial attachments to the spine is important and should be done when possible. The abdominal, trunk, and gluteal muscles contract and tense the lumbodorsal fascia; the fascia attachment to the spine allows these muscles to stabilize the spine.
- Make an incision into the lumbodorsal fascia just lateral to the bulbous tips of the spinous processes. Lengthen the fascial incision. Insert a Cobb elevator, with the tip turned upward, onto the spinous process just under its bulbous tip, and start the subperiosteal dissection. Then turn the elevator bevel down. Dissect, identify by touch the cephalad and then the caudad lamina, and clear the interlaminar area. Take care not to cut through the outer cortex of the lamina. Sweep the superficial soft tissue off the interlaminar area laterally out to the facet joint capsule. Do not damage the capsule. Protect the facet joint capsule. Remember that the two laminae and their interlaminar areas are the only areas that need be exposed for an operation on one intervertebral disc.
- Following exposure of the intralaminar area, place a Williams self-retaining retractor with the blade retracting laterally over the facet joint capsule with the pointed tip placed medially. For larger, bilateral exposures, I use the Wiltse retractors with both sides exposed similarly.
- The superficial ligamentum flavum blends laterally into the facet joint capsule. Incise the superficial ligamentum flavum with the #15 blade or electrocautery laterally or at the junction of the superficial ligamentum flavum and the facet joint capsule. Use a curet to elevate the superficial ligamentum flavum from the deep ligament moving from lateral to medial. Remove the superficial ligament with a pituitary rongeur. The vertical striations of the yellow deep ligamentum flavum can be seen in the depths of the interlaminar area. Use an angled curet to clear under the caudal edge of the cephalad lamina and a straight curet to define the ligamentum flavum attachment to the caudad lamina (Fig. 138.27). Expose the deep portion of the ligamentum flavum's vertical striations.

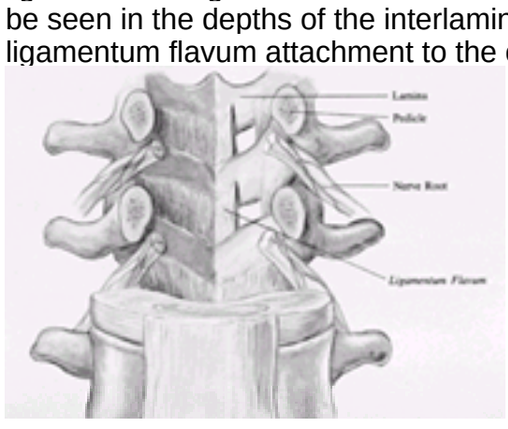


***Figure 138.27.*** This underview of the posterior elements from the intervertebral canal demonstrates the ligamentum flavum and its insertion on the lamina.

- Several factors concerning the anatomy of the ligamentum flavum are important:
  - It has a deep and superficial portion.
  - It blends with the facet joint capsule laterally.
  - It inserts over the caudal 50% of the undersurface of the cephalad lamina.
  - It inserts on the cephalad edge of the caudad lamina.
  - Its undersurface is the ideal dural covering.
  - It has a vertical, parasagittal orientation deep in the lateral recess under the superior facet that may contribute to lateral recess stenosis.
  - It is the main stabilizing ligament of the posterior column, and preservation of as much of it as possible will benefit spine stability at that motion segment.
  - It is the soft-tissue roof of the intervertebral foramina.

## LAMINOTOMY

- Perform as much of the lateral wall resection and laminectomy as possible before opening the ligamentum flavum. Estimate the size of the interlaminar area that will be needed for correcting the pathologic process. A portion of the caudad edge of the cephalad lamina can be removed if it is believed that exploration of the spinal canal will require greater cephalad exposure. The walls of the interlaminar area may be the area to be removed. Progressing from dorsal to ventral, the lateral wall of the interlaminar area is composed of the facet joint capsule, the inferior facet, the intra-articular space of the facet joint, the superior facet, the deep capsule and ligamentum flavum, the nerve root, the blood vessels, and the floor of the canal. The preoperative CT scan should determine the amount of lateral recess stenosis and how much of a medial facetectomy is needed. Remove as much bone as necessary. For a standard L5–S1 discectomy, I seldom remove any bone. At L3–L4, a centimeter of cephalad lamina is often removed. Evaluate the CT scan for cephalad migration of a disc fragment that would require the removal of more lamina. To allow a more lateral approach to a larger extruded disc fragment, remove a small portion of the medial facet. More extensive exposure may be required depending on the pathology.
- For a discectomy, make an incision with a #15 blade into the deep portion of the ligamentum flavum, approximately 50% of the width of the interlaminar area. Incise the ligamentum flavum by feathering the knife blade, allowing one to see the edge of the knife cutting into the ligamentum flavum. Make the incision by long cuts into the ligamentum flavum reaching from lamina to lamina with careful observation for any sign of the white undersurface of the ligamentum flavum, followed by the bluish hue of the dura. Once the undersurface is reached, use the handle of the knife or a Penfield 4 elevator to open the last few underlayers of the

ligamentum flavum. Use the Penfield 4 elevator to separate the entire length of the ligamentum flavum. Under the ligamentum flavum is usually a layer of epidural fat over the dura, but with a large space-occupying lesion in the canal, the dura may be immediately adjacent to the undersurface of the ligamentum flavum. Pass the Penfield 4 elevator under the lateral leaf of the ligamentum flavum, and retract the dura medially away from the lateral leaf of the ligamentum flavum. A cottonoid can be placed under the lateral leaf of the ligamentum flavum. With a Kerrison rongeur angled 40° in the dominant hand and the Penfield 4 elevator in the other hand, pass the Kerrison rongeur under the lateral ligamentum flavum and remove the lateral ligamentum flavum.

- The epidural fat, the dura, the nerve root, and the longitudinal blood vessels in the lateral recess can usually be identified after the lateral half of the ligamentum flavum is removed. The deep portion of the ligamentum flavum runs vertically in the lateral recess and attaches to the facet joint capsule. Position the cottonoid or Penfield 4 elevator between this portion of the ligament and the underlying nerve root. This stage of entering the canal is often an anxious one because of fear of bleeding and damaging the nerve root. The more delicate the approach, the less bone that is cut, and the less vigorous the removal of the lateral ligamentum flavum, the less bleeding there will be. Magnification is of tremendous value in identifying vessels and allowing safe, accurate retraction and bipolar coagulation, if needed. Removal of fat causes bleeding and later scarring. Bleeding often starts when exposing the disc or nerve root. When lateral exposure is obtained out to the pedicle, the longitudinal vessels lateral to the root can be identified and cauterized with the bipolar cautery. Cottonoids placed laterally at the cephalad and caudad extremes of the exposure can collapse the vessels and allow work in the area between the cottonoids.
- A transverse or horizontal vascular supply exits each intervertebral foramen. The most consistent vascular leash is found just caudad to the nerve root exiting in the caudal portion of the intervertebral foramen at the cephalad portion of the disc. For large exposures, when the dural sac needs to be retracted to the midline, identify and coagulate the vascular leash with a bipolar cautery. Minimize the use of electrocautery because the more that is used, the more scarring there will be. The use of cottonoids, Surgicel, and thrombin-soaked Gelfoam retards bleeding. I prefer not to leave Gelfoam and Surgicel packing in the spinal canal. Cottonoids remove epidural fat and should be used judiciously.
- The surgeon needs to know where the disc and root are without undue exploration. The key to intracanal anatomy is the pedicle (Fig. 138.28). The pedicle is deep to the caudad third of the inferior facet. After the ligamentum flavum is removed, palpate into the canal with a nerve hook or dental tool. Often, the pedicle is lateral under an overhanging roof of superior facet. In fact, the superior facet may be mistaken for the pedicle. To remove the roof of the lateral recess and to relieve lateral recess stenosis, remove the facet joint with the Kerrison rongeur medially to the parasagittal plane of the medial border of the pedicle.

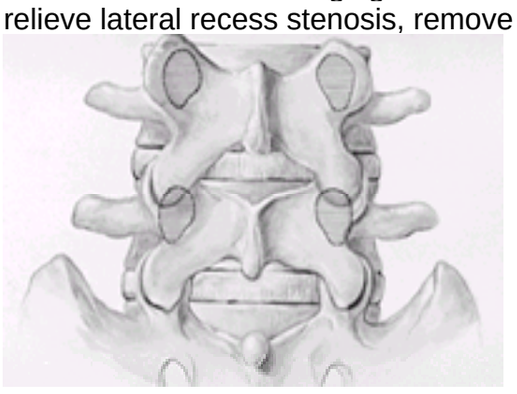

***Figure 138.28.*** The pedicle is the key to the intracanal anatomy. Identification of the pedicle will lead to the location of the disc and nerve root.

- Knowing the location of the pedicle tells you the following:
  - The disc space is less than 1 cm cephalad to the pedicle. It often appears to be immediately cephalad adjacent to the pedicle.
  - The intervertebral foramen above the pedicle is for the exiting nerve root and the intervertebral foramen below the pedicle is the foramen for the transversing nerve root.
  - Dorsal and immediately cephalad to the pedicle is the superior facet. The superior facet is the roof of the intervertebral foramen for the exiting nerve root.
  - Just medial to the pedicle is the traversing nerve root.
- Extensive probing should not be done in the medial pedicular area because the pedicular plexus will bleed. Remember, at higher lumbar levels, the disc is farther cephalad relative to the interlaminar space. Therefore, the L5–S1 disc is approximately at the level of the interlaminar space between L-5 and S-1. The L2–L3 disc space is well cephalad under the lamina of L-2 rather than at the level of the interlaminar space between L-2 and L-3. The ligamentum flavum covers the interlaminar area.
- Often, it is imperative to expose the disc space. The disc is a raised, white, soft structure that may be covered by epidural fat, veins, and the nerve root. Feel for the disc using the Penfield 4 elevator. It causes little bleeding and allows for palpation of the disc with the tip of the instrument. Reach out laterally and feel for the floor of the canal. Gently retract medially with the Penfield 4 elevator. Feel for obstruction to this medial retraction. Do not retract against a major obstruction. Retract gently, and insert the microsucker retractor. Lift the root up and medial with the nondominant hand; expose the disc with the Penfield 4 elevator in the dominant hand.
- When there is difficulty in finding the disc or retracting the nerve root, several methods have been used to prevent damage to the nerve root. Knowing the location of the pedicle in the canal is probably the most significant way to avoid major damage to the nerve root. Find the pedicle. The transversing nerve root is adjacent medially to the pedicle. Identify the nerve root medial to the pedicle. If the root cannot be retracted because it is tightly against the medial wall of the pedicle, proceed cephalad to a point slightly lateral to the medial wall of the pedicle. The transversing nerve root should not be lateral to the medial wall of the pedicle. Exposing the disc cephalad to the pedicle and lateral to the medial wall of the pedicle can avoid nerve damage. The nerve root exiting in this intervertebral foramen cephalad to the pedicle will usually be further cephalad, just under the pedicle above. The exiting nerve root runs obliquely across the intervertebral disc laterally in or lateral to the intervertebral foremen. The farther lateral on the intervertebral disc, the more likely the cephalad exiting nerve root is reached. A lateral disc herniation may trap the exiting nerve root in the intervertebral foramen. A conjoined root may totally fill the entire foramen from pedicle to pedicle. An exiting conjoined nerve root limits exposure of the disc. It can usually be identified preoperatively on the myelogram and contrast CT scan. The key to avoiding damage to a conjoined nerve root is recognition. This is facilitated by lateral exposure of the traversing root shoulder.
- For further exposure of the disc, determine the amount of tension in the nerve root. Do not retract the root against a solid obstruction. If it can be retracted easily, retract it medially with the nerve root retractor. If it is tight, it will feel like you are retracting against a solid wall.

  There are five common methods of dealing with a tight nerve root:

  1. Explore the axilla of the transversing root with the Penfield 4 elevator. The axilla is in the caudal part of the exposure between the root and the dural sac. If a fragment is found, remove it with the nerve hook. Bleeding may be encountered.
  2. Obtain more lateral exposure. Be sure you have identified the pedicle and have exposure lateral to the medial wall of the pedicle. The traversing nerve root should not be lateral to the medial wall of the pedicle.
  3. Enter the disc space lateral to the root, and try to decompress the disc and pull disc material from under the root through the disc space.
  4. Be sure that the root is free cephalad to the disc and that the ligamentum flavum or undersurface of the cephalad lamina is not a factor. Remove enough lamina and ligament cephalad to expose the shoulder of the nerve root.
  5. The nerve root may be tethered caudally in the foramen below the pedicle. Remove the roof (the junction of the caudad lamina and the superior facet) over the transversing root as it exits around the pedicle. A foraminotomy of the foramen below may allow better retraction of the root.

- Gently lift and retract the nerve root with a sucker retractor in the nondominant hand and explore the disc area with a nerve hook in the dominant hand. Take great care not to stretch the nerve root. Exploration underneath the dural sac may reveal a large fragment of herniated disc that can be pulled out from under the nerve root with the nerve hook. The lateral exposure allows this fragment of disc to be pulled laterally rather than vertically. Removing the fragment laterally from under the nerve root will decrease the nerve root tension and allow better visibility and protection for the nerve root. Large dilated vessels often decrease in size and not bleed when the fragment is removed, relieving vascular distention.
- Expose the annulus with the Penfield 4 elevator. Determine the texture of the annulus, amount of bulge, presence of herniation, or presence of a hole in the annulus, and perform a discectomy.
- More exposure is needed for significant spinal stenosis or central, lateral recess or foraminal stenosis.

## LAMINECTOMY

- When a total laminectomy is needed to expose the dura and nerve roots, remove the fascia entirely from the tip of the spinous process bilaterally. Extend the exposure laterally from the spinous process to the lamina with the Cobb elevators. Carefully protect the facet joint capsule. The exposure may be to the tips of the transverse processes if a fusion is to be done.
- *Note:* The most important structure that must be exposed and clearly seen is the pars interarticularis. Identification of the pars is imperative to prevent its transection with subsequent spinal instability. By continually visualizing the pars, removal of the lamina can be done quickly and safely. The bone cutters remove the spinous process. I prefer to use the Midas Rex AM1 (Medix Rex Pneumatic Tools, Inc., Fort Worth, TX) to remove all of the lamina over the ligamentum flavum and down to a 1 mm thin shell over the dura. Alternatively, I use the Luxel rongeur by inserting it under the caudad edge of the cephalad lamina and rotate the instrument cephalad, rolling a bite of lamina off. This allows visualization under the instrument to see a possible inadvertent dura pinch early. Before using the Midas Rex tool, I expose the pars by curetting the caudal tip of the inferior facet. Seeing the articular surface of the superior facet and the pars at each level allows full removal of lamina and medial portion of the facet without danger of cutting the pars. Identify the pedicle as soon as possible to avoid removing too

much facet.

- To expose the lateral portion of the spinal canal, remember that the lateral wall may protrude significantly into the spinal canal. If the partial medial facetectomy is to be done, use the Midas Rex AM1 or AM3, the Kerrison rongeur, the Cloward chisel, or the Pheasant discotome. Starting medially on the lamina, cut the caudal portion of the lamina and continue laterally onto the inferior facet. The amount of inferior facet removed varies according to the pathology. If the chisel is used, insert it to remove the appropriate amount of the medial portion of the inferior facet and twist the chisel, removing the bone medially. This allows visualization of the facet join space and the superior facet. The shiny cartilaginous floor is the superior facet. The ligamentum flavum inserts on the superior facet. The nerve root may be under this superior facet.
- The ligamentum should be opened at this point by one of numerous methods. Use the curet to detach the lateral ligamentum flavum from the edge of the superior facet. Position the Penfield 4 elevator, Penfield 3 elevator, or the cottonoid under the superior facet to protect the nerve. Use the Kerrison rongeur to remove the medial portion of the superior facet and the most lateral ligamentum flavum. The chisel is quite safe on the inferior facet because the superior facet provides a guard from possibly injuring the nerve root. With skill and experience, the superior facet likewise can be removed with a chisel by cutting over the pedicle with the Penfield elevator, protecting the nerve. With lateral recess stenosis, remove the medial facet to the parasagittal level of the medial wall of the pedicle.
- I prefer to use the Midas Rex bone cutter because it causes less splintering. Cut the lamina down centrally with the AM1. With the AM3, extend the bone removal laterally over the ligamentum flavum and foramen.
- After the lamina is burred down to a thin layer over the dura and totally off the ligamentum flavum, open the ligament with a Penfield 3 elevator and clasp it with a ligamentum flavum clamp. Pass a cottonoid between the ligament and the dura. Remove the major portion of the ligament with a large, straight curet from the opposite side of the table. The most lateral ligament is removed by undercutting with the angled kerrison chisel from across the table. Position the cottonoid and have the assistant remove the ligamentum flavum with a 45° Kerrison rongeur from the other side of the table. Remove the medial edge of the superior facet with the lateral-most ligamentum flavum. The assistant on the opposite side of the table also can position this cottonoid very effectively using the sucker and the bayonet. Use the 90° Kerrison rongeur to remove this lateral portion of the ligamentum flavum.
- The ligamentum flavum can be detached with a curet from its caudad and lateral attachments, and a curved osteotome can be used to free the cephalad attachment of the ligamentum flavum from the undersurface of the cephalad lamina. Use a nerve hook to pull the detached cephalad edge of the ligamentum flavum into the intralaminar area. Use a straight curet to detach the caudad edge of the ligamentum flavum from the edge of the caudad lamina and an angled curet to detach the lateral ligamentum flavum. With this detaching method, the ligamentum flavum can be retracted intact with a medial attachment to the ligamentum flavum from the opposite side, allowing access to the spinal canal without excision of the ligamentum flavum. Although the ligamentum flavum, being elastic, will shrink from its original attachment, it will still provide an excellent dural covering when reapproximated on closing. There is some danger in detaching this ligamentum flavum in the lateral recess because of the nerve root. Be careful over the “critical angle,” which is the junction of the base of the superior facet and the caudad lamina, because the nerve root exits under this angle.

## FORAMINOTOMY

- The key to a safe, effective foraminotomy is to expand the intervertebral foramen without damaging the pars interarticularis or the facet joint. A foraminotomy begins after removal of the lateral recess, identification of the pedicle, and identification of the pars interarticularis. The medial caudal aspect of the pedicle is the beginning of the intervertebral foramen. The pars forms part of the bony roof of the intervertebral foramen. The root exits around the pedicle, and it is the roof over that root as it exits that must be expanded first. I use the Midas Rex AM3 or M8 to an arc over the root, leaving a thin shell of bone over the root and plenty of the facet undersurface. Then insert the Kerrison rongeur on the root and remove the bone touching the nerve and any ligamentum flavum attached to it. Probe the foramen until it is clear. I use gallbladder probes up to 5 mm in diameter or a Woodson probe. Often, the tip of the superior facet compresses the nerve root from below. I routinely remove the cephalad tip of the superior facet with the Cloward chisel. The curved Kerrison rongeur removes more of the roof of the foramen laterally. Protect the pars. A portion of its undersurface can be carefully expanded to open the intervertebral foramen.
- Uncinate ventral spurs may arise from the caudal vertebral body, caudal to the pedicle, at the edge of the disc space below; they are seen on CT foraminal reconstructions. The root can be tented over the spur and tethered laterally by foraminal ligaments. Removing the roof is not enough to relieve this nerve root tension. The spur under the root should be removed. Although these spurs can be removed from cephalad to caudad by putting a chisel under the root, they are more easily approached from the level below. Remember, these spurs are under the annulus of the disc below and covered with soft tissue, making removal with a chisel more difficult. Putting a knife under the nerve root is dangerous.
- Expose the disc below. Working from caudad to cephalad, identify the exiting root. Open the disc with a knife laterally. Use the chisel and curet to burrow under the spur and then the endplate of the vertebra. Hollow out a space. Insert an angled curet between the root and the annulus-covered spur, and knock the spur into the hole. Leave it in the hole or remove it. It is safer to remove it after the root tension is relieved.
- The foraminotomy can be performed from the “outside in.” Move to a paraspinous position through the same incision. Identify the superior facet and transverse processes above and below the pars. Several tacks can be taken from this point. One is to remove the intertransverse ligament, identify the nerve, and follow it back into the canal, removing any obstructions for a foraminotomy. I prefer to expose the caudal surface of the pedicle above, using the pars and transverse process as guides. Identify the nerve there and expand the intervertebral foramen. If there is a foraminal herniated nucleus pulposus, expose the cephalad surface of the pedicle below, and work cephalad to identify the disc, the nerve, and the herniation.
- After the discectomy, the delicacy of the approach will determine how much fat is left covering the nerve root. Supplement this procedure with a free fat graft taken from the layer above the fascia in the caudal portion of the wound. When fat is not available, I use Depo-Medrol–soaked Gelfoam.
- After closing any dead space left by the fat graft, close the fascia with interrupted 0 Vicryl. When midline fascial structures have been removed from the spinous process, reattach them. The layers above the fascia are closed with multiple layers of interrupted 2-0 Vicryl. Close the subcutaneous fat in at least two layers, tacking each layer to the lower layer. I usually drain both the subfascial and suprafascial layers. Close the subcutaneous layer immediately adjacent to the subcuticular layer. Close the skin with subcuticular sutures, benzoin, and Steristrips. Retract and cut off the sutures after the Steristrips are applied.

## LATERAL APPROACH TO THE DISC

- Position the patient on a standard operating frame.
- Use skin-marking needles to identify the pedicles of the involved segment with a lateral radiograph. For L4–L5, align the needle markers over the pedicle at L-4 and the pedicle at L-5. Make the incision one fingerbreadth lateral to the spinous process, spanning between the pedicles of the involved segment (Fig. 138.29).

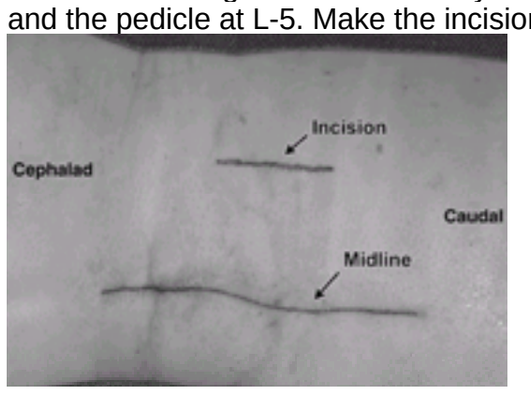


***Figure 138.29.*** Make the incision one fingerbreadth lateral to the spinous process, spanning between the pedicles of the involved segment.

- Carry the incision through the skin and subcutaneous tissue. Open the fascia enough to admit an index finger that dissects down in a muscle-splitting dissection to the cephalad transverse processes. Use a Penfield 1 instrument or a small Cobb elevator to identify the transverse processes, but do not carry out vigorous muscle dissection at this point. Use your finger to palpate medially on the cephalad-transverse process to the area of the pars interarticularis, just cephalad to the facet joint. Rest the Penfield 1 on the more cephalad transverse process and position the McCulloch blade-spike retractor by placing the blade laterally against the soft tissue, then placing the spike medially just dorsal to the pars interarticularis. Do not hook it under the pars interarticularis.
- By opening the retractor, visualize the transverse process. Obtain a lateral radiograph with a needle on the transverse process to confirm levels.
- Use the Bovie and curet to dissect the soft tissue off the pars interarticularis and the base of the transverse process.
- It is important to see the bone of the pars interarticularis. Too often, the dissection is carried out too far laterally. The transverse process is cleared off, but the actual location of the pedicle is more medial, and too much time is wasted in a more lateral position. Identify the pars and follow the bone of the transverse process back to the dorsal surface of the pedicle. At this point, there are times when a portion of the cephalad facet joint, or cephalad lateral portion of the inferior facet, has to be removed with Kerrison rongeur to provide proper exposure of the intertransverse area. For better exposure, laterally retract the muscle off the intertransverse ligament and hold it with the lateral blade retractor (Fig. 138.30).



***Figure 138.30.*** For better exposure of the intertransverse area, laterally retract the muscle of the intertransverse ligament. (Note: The illustration depicts a larger field of visualization than actually performed.) After opening the fascia, use finger dissection to clear the transverse process. Insert the retractor.

- Using a straight and an angled curet, detach the intertransverse ligament from the cephalad-transverse process, the dorsal surface of the pedicle, and the lateral surface of the pars interarticularis. Identify this ligament, hook it with a blunt nerve hook, pull it laterally, and free it up with the small Kerrison rongeur under direct visualization.
- *Caution: Sometimes, distinguishing the ligament from the nerve is not easy. Proceed carefully.*
- Identify the nerve as it exits around and just caudal to the cephalad pedicle (Fig. 138.31).

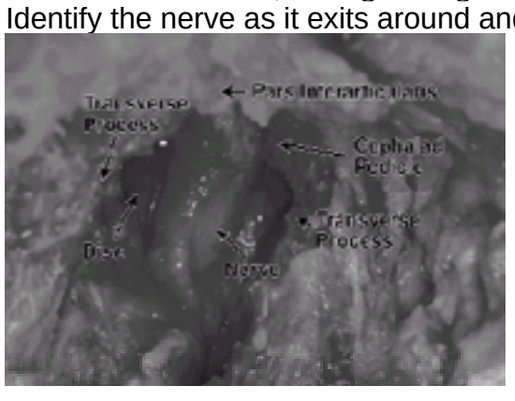


***Figure 138.31.*** Identify the cephalad transverse process, then expose the part interarticularis medially. Detach the intertransverse ligament. Identify the pedicle, then the nerve exiting just caudal to the pedicle. The disc is caudal to the nerve.

- Use the Penfield 4 elevator to palpate gently cephalad to the nerve, starting at the medial wall of the pedicle and progressing laterally. Beware of bleeding in this area.
- Identify the caudal aspect of the nerve and use the microsucker retractor to retract the nerve cephalad. Using the Penfield 4 elevator, identify the disc caudal to the nerve. Be aware that the dorsal ganglion of the nerve may feel like a disc fragment under the nerve. Carefully identify the nerve and the disc (Fig. 138.31). Follow the nerve laterally to insure removal of any lateral disc fragments.
- Remember:
  - Identify the cephalad transverse process.
  - Identify the pars interarticularis to stay medially.
  - The pedicle is the key landmark.
  - Laterally retract the intertransverse ligament.

## CHAPTER REFERENCES

Each reference is categorized according to the following scheme: *, classic article; #, review article; !, basic research article; and +, clinical results/outcome study.


+ 1. Apuzzo MJ, Weiss MH, Hyden JS. Transoral Exposure of the Atlanto-Axial Joint. *J Neurosurg* 1978;3:201.

+ 2. Bailey RW, Bagley CD. Stabilization of the Cervical Spine by Anterior Fusion. *J Bone Joint Surg Am* 1960;42:565.

+ 3. Cloward R. *Ruptured Cervical Intervertebral Discs. Codman Signature Series 4.* Codman and Shurtleff, 1974.

+ 4. Duncan HMM, Jonck LM. The Presacral Plexus in Anterior Lumbar Fusion of the Lumbar Spine. *S Afr J Surg* 1965;3:93.

+ 5. Dwyer AF. Experience of Anterior Correction of Scoliosis. *Clin Orthop* 1973;93:192.

+ 6. Dwyer AF, Newton NC, Sherwood AA. An Anterior Approach to Scoliosis. *Clin Orthop* 1969;62:192.

+ 7. Fang HSY, Ong BG. Direct Anterior Approach to the Upper Cervical Spine. *J Bone Joint Surg* 1962;44-A:1588.

+ 8. Flynn JC, Hoque A. Anterior Fusion of the Lumbar Spine. *J Bone Joint Surg* 1979;61-A:1143.

+ 9. Freebody D, Bedall R, Taylor RD. Anterior Transperitoneal Lumbar Fusion. *J Bone Joint Surg* 1971;53-B:617.

# 10. Goss CM, ed. *Gray's Anatomy of the Human Body,* 29th ed. Philadelphia: Lea & Febiger, 1973.

+ 11. Harmon PH. Anterior Extraperitoneal Lumbar Disc Excision and Vertebral Bone Fusion. *Clin Orthop* 1963;16:169.

# 12. Henry AK. *Extensive Exposure.* Baltimore, Williams & Wilkins, 1959.

# 13. Hodgson AR, Rau ACM. Anterior Surgical Approaches to the Spinal Column. In: Apley AG, ed. *Recent Advances in Orthopedics.* Baltimore, Williams & Wilkins, 1964:326.

+ 14. Hodgson AR, Rau ACM. Anterior Approach to the Spinal Column. *Recent Advances in Orthopaedics IX* 1969;9:289.

+ 15. Johnson RM, McGuire EJ. Urogenital Complications of Anterior Approaches to the Lumbar Spine. *Clin Orthop* 1981;154:114.

+ 16. LaBate JS. The Surgical Anatomy of the Superior Hypogastric Plexus-Presacral Nerve. *Surg Gynecol Obstet* 1938;67:199.

# 17. Logue V. Compressive Lesions at the Foramen Magnum. In: Ruge D, Wiltse L, eds. *Spinal Disorders: Diagnosis and Treatment.* Philadelphia, Lea & Febiger, 1977:249.

+ 18. Nanson EM. The Anterior Approach to Upper Dorsal Sympathectomy. *Surg Gynecol Obstet* 1957;104:118.

# 19. Perry J. Surgical Approaches to the Spine. In: Pierce D, Nichols V, eds. *The Total Care of Spinal Cord Injuries.* Boston: Little, Brown & Co., 1977:53.

+ 20. Riceborough EJ. The Anterior Approach to the Spine for Correction of the Axial Skeleton. *Clin Orthop* 1973;93:207.

+ 21. Riley L. Surgical Approaches to the Cervical Spine. *Clin Orthop* 1973;91:16.

+ 22. Riley L. Surgical Approaches to the Anterior Structures of the Cervical Spine. *Clin Orthop* 1973;91:10.

# 23. Robinson RA. *The Craft of Surgery,* 2nd ed. Boston: Little, Brown & Co., 1971.

# 24. Robinson RA. Approaches to the Cervical Spine C1-T1. In: Schmidek HH, Sweet WH, eds. *Current Techniques in Operative Neurosurgery.* New York: Grune & Stratton, 1978.

# 25. Robinson RA, Southwick WO. Surgical Approaches to the Cervical Spine. *Instr Course Lect* 1960;17:299.

# 26. Rothman R. *The Spine,* Vol I. Philadelphia: W.B. Saunders, 1975.

+ 27. Royal ND. A New Operative Procedure in the Treatment of Spastic Paralysis and Its Experimental Basis. *Med J Anat* 1924;77:30.

+ 28. Scott R. Innervation of the Diaphragm and Its Practical Aspects in Surgery. *Thorax* 1965;20:357.

# 29. Watkins RG, O'Brien JP. *Anatomy of the Cervical Spine (Sound/Slide Program).* Atlanta, American Academy of Orthopaedic Surgeons, 1980.

# CHAPTER 139

# UPPER CERVICAL SPINE FRACTURES AND INSTABILITY

*Claude Gelinas and Alan M. Levine*

**C. Gelinas:** Southwest Spine Center, Albuquerque, NM.
**A. M. Levine:** Director, Alvin and Lois Lapidus Cancer Institute, Professor of Orthopaedic Surgery and Oncology, Sinai Hospital of Baltimore, Baltimore, Maryland, 21215.

Introduction
Regional Anatomy
Evaluation and Management of Patients with Injuries to the Craniocervicum
Radiographic Evaluation
Emergent Immobilization of the Upper Cervical Spine
Classification, Pathology, and Treatment of Upper Cervical Spine Injuries
Pitfalls and Complications
Authors' Perspective
Chapter References

## INTRODUCTION

Upper cervical spine fractures include a wide spectrum of injuries whose patterns differ from those of injuries in the lower cervical, thoracic, and lumbar spine because of the unique anatomic configuration of the vertebral elements of the craniocervicum (45,57). The craniocervicum includes the base of the skull, the atlas, and axis, and is unique both in its bony as well as ligamentous structure. A variety of conditions can lead to upper cervical spine instability (infections, tumors, spondylosis, and congenital abnormalities), but the most common cause is direct trauma. Although upper cervical fractures occur as a result of mechanisms of injury that are similar to those causing other spine fractures (i.e., motor vehicle accidents, falls, diving, or direct trauma), they are nevertheless unique for several reasons. First, in autopsy series (2,13,17), many injuries to the upper cervical spine resulted in trauma to the brain stem and thus immediate death. In addition, in those patients surviving their initial trauma, the incidence of neurologic injury as a direct result of fractures and dislocations in the craniocervicum is proportionately less than the incidence in other areas of the cervical spine because of the relatively large area available for the spinal cord within the spinal canal. Again, because of the unique relationship of this spinal region to the skull, most fractures in the upper cervical spine result from a force applied through the skull, with resultant excessive motion of the head and upper cervical spine, creating the injury pattern. Although the fractures in the upper cervical spine may be survivable, some of these patients succumb as a result of associated severe head injury. In fact, many of the neurologic deficit patterns are a result not of the injuries to the spine but of direct head injuries. To understand the nature of these injuries and to be able to apply the most appropriate treatment methodologies, the physician must first thoroughly appreciate the anatomic considerations of the craniocervicum and then fully understand the mechanism associated with each injury pattern. Appreciation of the significance of the injury in relation to the immediate and subsequent potential instability is important in preventing both undertreatment and overtreatment of injuries in this location. It also may alert the physician to potential pitfalls in treatment modalities that may apply to the various injury types.

## REGIONAL ANATOMY

The term “craniocervicum” is generally applied to the area at the base of the skull, the atlas, and the axis. The area is unique because it is the junction between the skull and the cervical spine, and is characterized by extreme mobility (37). It is unique also because of the size, shape, and location of the joints that allow motion between the occiput and the atlas or the atlas and the axis. At the lower end of the craniocervicum (C2–C3), there is a transition in the size, shape, and location of the joints, transitioning to the more usual pattern seen in the lower cervical spine. Forces applied to the craniocervicum may result in injuries having far different patterns and resultant instabilities than those seen in the lower cervical spine.

The occipitocervical articulations lie anterolaterally with reference to the spinal canal in that area. Those joints are made up of convex-shaped lateral masses adjacent to the foramen magnum that articulate with the concave lateral masses of the atlas. The joints are trapezoidally shaped and are somewhat wider medially than laterally. In children, these joints are less concave and flatter, and therefore, they restrict motion to a less significant degree than they do in adults. Therefore, children have more mobility and are more predisposed to injury at this level (5). The normal range of motion at the occipitocervical junction is 21° of extension (which is in part limited by the occiput abutting on the posterior arc of the atlas) (89), 3° of flexion, 7° of rotation, and 5° of lateral bending (64).

The atlas is unique in that it has no distinct body, an element present in the remainder of the vertebrae of the cervical spine. Embryologically, the vertebral body of C-1 is absorbed into the formation of the dens process of C-2; therefore, the atlas has two lateral masses connected by an anterior and a posterior arch. The anterior arch is thicker and shorter than the posterior arch. The posterior arch has a tubercle in its posterior midportion and two relatively flatter areas just posterior to the lateral masses, over which the vertebral artery runs after it exits from the foramen in C-2. The shape of the lateral masses is important because it helps one understand how injuries to C-1 occur. The articular surfaces for C1–C2 and also occiput–C1 are concave, with that of the atlantoaxial joint being somewhat flatter than that of the occipitocervical joint. The resultant shape of the C-1 lateral mass is that it is thinner medially than laterally; thus, when axial loading forces are applied across the craniocervicum, there is a resultant force that serves to displace the lateral masses of C-1 in a lateral direction.

The axis is also unique in its relationship to the atlas because the atlantoaxial joint has two different sets of articulations. The first is the articulation of the slightly convex inferior articular process of the atlas with a slightly convex superior articular process of the atlas. Both joints are oriented in the horizontal plane with a medial inclination of approximately 35°. These joints permit rotation, accounting for nearly 50% of the rotation in the cervical spine (69). The odontoid process projects up inside the ring of the axis, forming a second joint with the anterior arch of the atlas. The dens generally is between 14 and 15 mm in height and thus is approximately 40% of the overall height of the axis (74). The overall diameter of the atlas is quite large in relation to the space necessary for the spinal cord (82). Generally, the midsagittal diameter of the cord is one third of the midsagittal diameter of the inner surface of the axis. Actual rotation between the occiput and C-1 is generally approximately 5° to 7°, with more than 8° being pathologic, and at the atlantoaxial joint, the amount of normal rotation is approximately 43°, with more than 50° representing hypermobility and approximately 65° of rotation required for atlantoaxial dislocation (20,38). At C-2, the isolation of the pedicles of the axis between the atlantoaxial joint anterior to them and the C2–C3 joint posterior to them contributes to the occurrence of fractures at the base of the pedicles. The relative stability of the craniocervicum as a unit isolates the pedicles of C-2, predisposing them to fractures. Finally, the large bifid process of C-2 is an anatomic landmark for physical examination as well as for anatomic dissection.

An understanding of the embryologic and postnatal development of the upper cervical spine is also helpful in further understanding injuries to this area. Although all other cervical vertebrae develop from at least three ossific nuclei, the atlas develops from only two centers of ossification, which usually fuse together between 3 and 5 years of age. Because there is an ossific center in each lateral mass, defects in both the anterior arch and posterior arch can occur. The axis has four centers of ossification, which also tend to fuse together between 3 and 6 years of age, with the exception of the junction between the odontoid process and the body, which may persist up to 11 years of age. The presence of persistent congenital defects in the ring of C-1 or C-2 in the adult and delayed fusion of ossific nuclei in children should not be confused with acute fractures.

The arterial supply to the dens initially comes from both the anterior and posterior ascending arteries from the vertebral arteries that anastomose to create a rich vascular network. The cartilage plate that separates the odontoid from the body of C-2, as previously mentioned, tends to ossify around 7 years of age, preventing direct vascularization from the rich plexus in the vascular body. There is also a zone of ossification at the tip of the dens, which appears between 3 and 6 years of age and can remain open until 12 years of age. Both of these delayed closures can be mistaken as fractures.

The relationship between the bony elements at each level of the craniocervicum is far different from that between the bony components of the lower cervical spine. The major difference is that there is no disc between occiput and C-1 or between C-1 and C-2 because there is no vertebral body at C-1. Therefore, without the stability provided by the intervertebral discs, the ligamentous integrity of the craniocervicum is provided by a structure quite different from that in the lower cervical spine. The central point of ligamentous stability in the upper cervical spine is the odontoid process. Affixed to it are several ligaments, which provide resistance to translation, flexion, extension, and rotation. The *transverse ligament* is fixed at the tubercle on the lateral mass at one side of the atlas and traverses just posterior to the odontoid process to attach to the tubercle of the contralateral lateral mass. It secures the anterior surface of the dens in close proximity to the posterior facet of the anterior arch of the atlas. The transverse ligament provides stability in flexion between the atlas and the axis, and also prevents anterior translation of the atlas on the axis (29). The

*alar ligaments* attach to the tip of the dens (Fig. 139.1). They actually arise from the medial aspect of the occipital condyles and insert along the tip of the odontoid. They function to prevent anterior translation at C1–C2 as well as to restrict rotation and lateral bending at that level (22,23). The *apical ligament* arises from the rim of the foramen magnum and inserts more centrally than the alar ligaments into the tip of the dens. Finally, the *accessory ligaments* arise from the lateral masses of C-2 and insert into the base of the dens. These three types of ligaments—the alar, apical, and accessory ligaments—act as important secondary restraints to C1–C2 translation, especially in the event of failure of the transverse ligament (29).

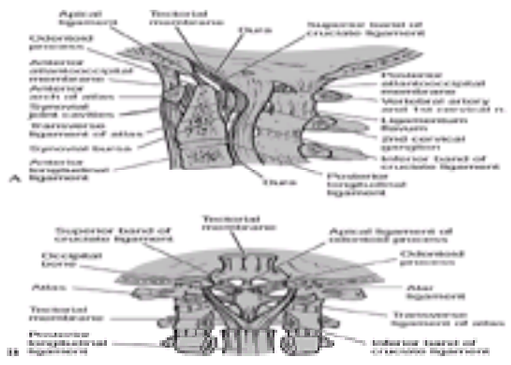

***Figure 139.1.*** **A:** A midsagittal section through the craniocervical junction. This figure shows the appropriate relationship of the basion or anterior aspect of the foramen magnum to the ring of C-1 and the odontoid process, and nicely illustrates the ligaments at the occipitocervical junction. **B:** A coronal section demonstrating the ligaments at the craniocervical junction. Note especially the alar ligaments and the tectorial membrane. (Redrawn from Martel W. The Occipito-atlantoaxial Joints in Rheumatoid Arthritis and Ankylosing Spondylitis. *AJR* 1961;86:223, with permission.)

The transverse ligament may become incompetent through two different mechanisms of injury. First, a severe flexion force between C-1 and C-2 may result in failure of the transverse ligament by impingement on the dens process, and this may also result in failure of the alar, apical, and accessory ligaments. In contrast, the transverse ligament can fail in tension with axial loading applied across C1–C2, resulting in failure of the accessory ligaments and transverse ligaments, but because of the direction of attachment, the alar and apical ligaments remain intact. Additional stability to this complex is imparted by the joint capsules, especially the C1–C2 capsules (16). These capsules function to limit rotation and, to a lesser degree, translation at the C1–C2 level. Posterior to the central ligamentous complex is the pectoral ligament. This is an attenuation of the interspinous ligament, which is a direct restraint to flexion. The final ligamentous component in the upper cervical spine is the continuation of the anterior longitudinal ligament. This, again, is somewhat attenuated, although it provides restraint to extension in the upper cervical spine.

The final anatomic element with a critical role in treating injuries of the craniocervicum is the vascular anatomy (66). There are three elements in the vascular anatomy of concern: the position and course of the vertebral arteries; the plexus of thin-walled vessels lying just posterior to the facet capsule at C1–C2; and the vascular supply surrounding the dens process. The vertebral arteries course upward through the foramen in C-2, then loop over the posterior arch of the atlas approximately 1.5 to 2 cm lateral to the tubercle of the posterior arch. The vertebral artery is vulnerable to injury during surgery in two separate areas. Dissection of the ring of C-1 more than 2 cm lateral from the midline may expose the vertebral artery to trauma. Also, the insertion of atlantoaxial screws exposes the vertebral artery to injury by direct trauma from a drill bit as it traverses the C-2 body. Because the location of the vertebral artery within C-2 varies, determine its position radiographically before screw fixation (65). It is, however, also important to know that because the vertebral arteries are paired structures (with one usually larger and, therefore, dominant over the other in terms of blood supply), injury to a single vertebral artery rarely results in significant neurologic deficit. In addition, as shown by Rauschning, there is a plexus of thin-walled vessels lying superficial to the facet capsule of C1–C2 with exposure of the C1–C2 articulation from a posterior direction. Sharp dissection through the soft tissue superficial to these vessels may result in profuse bleeding; there is less probability of injuring this vascular network by blunt dissection of the soft tissues caudal to rostral along the pedicle of C-2. Although the bleeding may be bothersome during the course of surgery, the consequences of disruption of the venous plexus is not significant.

Although it was originally thought that avascularity was the sole reason for the high rate of nonunion of the dens, it has since been found that in fact there is a significant endosteal and ligamentous blood supply (Fig. 139.2). The combination of the carotid arteries and vertebral arteries supply sufficient blood vessels to the dens process. Even the internal carotid supplies vessels to the dens through arteries that anastomose in a vascular arcade, and the dens may even have a direct blood supply through an ascending pharyngeal artery.

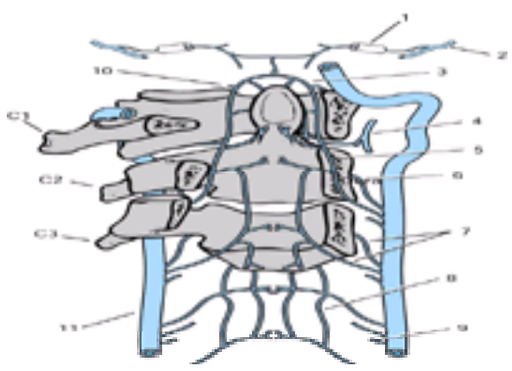

***Figure 139.2.*** The arterial supply to the upper cervical vertebrae and the odontoid process. 1, Hypoglossal canal containing the meningeal artery. 2, Occipital artery. 3, Apical arcade of the odontoid process. 4, Ascending pharyngeal artery giving a collateral branch beneath the anterior arch of the atlas. 5, Posterior ascending artery. 6, Anterior ascending artery. 7, Precentral and postcentral arteries to a typical cervical vertebral body. 8, Anterior spinal plexus. 9, Medullary branch of the vertebral artery. Radicular, prelaminar, and meningeal branches are also found at each level. 10, Collateral to the ascending pharyngeal artery passing rostral to the anterior arch of the atlas. 11, Left vertebral artery. (Redrawn from Parke WW. The Vascular Relations of the Upper Cervical Vertebrae. *Orthop Clin North Am* 1978;9:879, with permission.)

## EVALUATION AND MANAGEMENT OF PATIENTS WITH INJURIES TO THE CRANIOCERVICUM

Although it is vital that any patient with potential trauma to the cervical spine be first assessed for adequacy of airway, breathing, and circulation according to the American Trauma Life Support (ATLS) protocols, it is even more vital in patients with injuries to the upper cervical spine. Especially with injuries caused by distraction at the level of occiput–C1 or C1–C2, brain stem contusion is possible, resulting in cessation of spontaneous respiration. Emergent maintenance of airway and respiration may be the key to patient survival. Treat any patient with a head injury who is comatose or obtunded as if an injury is present until it is clearly ruled out. As with other spinal injuries, immobilize the entire spine on a backboard with a rigid collar. The physical examination of patients with upper cervical spine injuries begins with an evaluation of the skull for evidence of head trauma, including scalp or facial lacerations. Localizing signs, such as tenderness and especially the location of trauma to the skull, is helpful in the further evaluation of the patient as well as ultimately determining the mechanism of injury. In the awake, alert patient, palpate the entire spine for areas of localized tenderness or asymmetry.

In the initial neurologic examination, test for muscle function and strength; evaluate sensation with pinprick and light-touch; check the deep tendon reflexes, cranial nerves, and rectal tone and perianal sensation. Physical findings help in ordering proper radiographic evaluation of the patient.

In upper cervical spine injuries, dense incomplete neurologic injuries are rare. The most common neurologic patterns are Brown–Séquard syndrome resulting from rotatory injuries at the occiput–C1 or C1–C2 areas, or flexion injuries with rupture of the transverse ligament. Brain stem injuries with impairment of respiration most commonly occur in occipital–cervical dissociations and often result in sudden death because of lack of respiratory effort. Radicular injuries (aside from injury to the occipital nerve, which can occur with fractures at C-1 resulting in numbness in the posterior aspect of the skull) are infrequent in the craniocervicum. Because of the large area available for the spinal cord, incomplete spinal cord injury as seen in the lower cervical spine is uncommon. Neurologic deficit in patients with this type of injury is usually either severe or trivial. Fractures in patients without a neural deficit or with trivial deficits are usually diagnosed either on routine radiographic screening (especially in the elderly where pain may not be a significant component) or by the presence of pain in the upper cervical spine. Document the complete neurologic

examination on a form such as the American Spinal Injury Association (ASIA) Neurologic Assessment form.

The initial radiographic series obtained by most surgeons includes a lateral cervical spine roentgenogram and may also include an anteroposterior (AP) roentgenogram, and for the upper cervical spine, an open mouth view. Correlate the findings on the initial roentgenograms of the upper cervical spine with the initial physical examination to determine whether additional radiographic workup is necessary.

**RADIOGRAPHIC EVALUATION**

Radiographic evaluation of a patient suspected of having a spinal injury has two separate components. The first is to “clear” the cervical spine. The ultimate goal of this phase of evaluation is to ascertain as definitively as possible whether there is an injury in the cervical spine. The second phase is to define fully the nature of the spine injury once it has been shown to exist.

This evaluation ideally should be broken down into two separate approaches. In patients who are alert, oriented, nonintoxicated, and have no pain or neurologic symptoms, more than a single, lateral radiograph is unnecessary. The probability of finding significant injuries is very low in such patients. However, in patients with tenderness of the cervical spine or an altered state of consciousness, or in any polytrauma victim, perform a good quality lateral cervical spine film. An AP as well as an open mouth view may be indicated as part of the initial screening. It is clearly of no additional value to perform a five-view cervical spine radiograph (including two pillar views) unless you are trying to delineate a specific injury further. In patients with negative roentgenograms who are symptomatic and have no neurologic deficit, obtain physician-supervised flexion-extension lateral views in an awake, alert patient to rule out ligamentous instability.

There is also considerable controversy concerning what should contribute final clearance of the cervical spine in an obtunded patient. The opinions range from keeping the patient immobilized until responsive enough to undergo further radiographic evaluation to performing an magnetic resonance imaging (MRI) scan to look for ligamentous disruption. If all radiographs are negative, we prefer to keep the patient immobilized until he or she is responsive enough to cooperate with further testing.

Assess the lateral radiograph in an organized way:

- Assess overall alignment.
- Evaluate each vertebral level (base of the skull, C-1, and C-2) for orientation. If one level is true lateral and the next is oblique, a rotatory abnormality can be inferred.
- Look for translation or kyphosis on the lateral view. Assess routine parameters such as the anterior spinal line, the posterior spinal line, and the spinolaminar line for continuity.
- Identify the line forming the base of the clivus (known as Wachenheim's line) to verify the appropriate gleno-occipital relationships. Draw a line along the posterior surface of the clivus and extend it inferiorly; it should intersect or lie tangentially to the posterior cortex of the odontoid.
- The distance between the tip of the clivus (basion) and the odontoid process, the basion–dental interval, should be less than 1.2 cm in adults.
- The Powers' ratio (71) is also useful in assessing possible occipital–cervical dissociation (Fig. 139.3). This is the ratio of the distance between the basion and posterior arch of C-1 to the distance between the posterior margin of the foramen magnum (opisthion) and the anterior arch of C-1. A ratio of greater than 1.0 is abnormal and further imaging with a computed tomography (CT) scan is indicated.

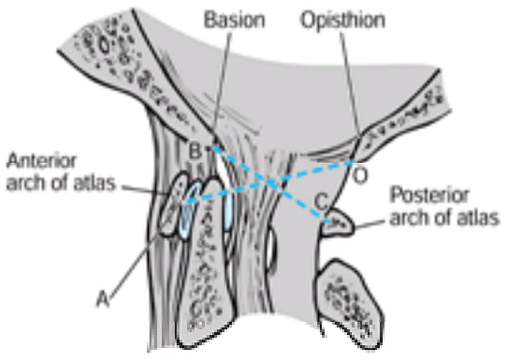


***Figure 139.3.*** Powers' ratio: if BC/OA is greater than 1, then an anterior occipitoatlantal dislocation exists. Ratios less than 1 are normal except in posterior dislocations, associated fractures of the odontoid process or the ring of the atlas, and congenital anomalies of the foramen magnum. (Redrawn from Jarrett PJ, Whitesides TE Jr. Injuries of the Cervicocranium. In: Browner BD, Jupiter JB, Levine AM, et al, eds. *Skeletal Trauma: Fractures, Dislocations, Ligamentous Injuries,* Vol 1. Philadelphia: W.B. Saunders Co., 1992:668, with permission.)

- The lateral roentgenogram also defines the atlanto–dens interval (ADI), which should be 3 mm or less in adults and 5 mm or less in children (32).
- Actual radiographic visualization of dens fractures may be difficult on the lateral roentgenogram. However, the angle of the dens with reference to the vertebral body of C-2 should be evaluated. Angles exceeding 20° should probably be considered abnormal or at least suggestive of a fracture and requiring additional evaluation.
- Fractures of the posterior arch of C-1 are generally visible on the lateral roentgenogram, but significant angulation of the posterior arch may be the only visible sign when the fracture line is in close proximity to the lateral mass of C-1.

Most types of traumatic spondylolisthesis in the axis can be visualized and fully defined on the plain lateral radiograph. Vertical distraction injuries at either occiput–C1 or at C1–C2 are easily visualized on the lateral roentgenogram and are most clearly defined on that study. Finally, the lateral roentgenogram can also be of some value in assessing the retropharyngeal soft-tissue shadow (68,85). The prevertebral soft tissue anterior to C-1 is clearly thicker than that more distal in the cervical spine. An increase in prevertebral soft-tissue shadow may not be present within the first hour or two of injury and is a quite unreliable sign in an uncooperative or screaming or crying patient. Soft-tissue shadows anterior to C-1 of greater than 10 mm in a cooperative patient suggest that there is some anterior column injury causing bleeding into the retropharyngeal space. This finding, in combination with a posterior arch fracture at C-1, would suggest that there is an anterior element injury as well.

The final critical element in evaluating lateral films is to look for contiguous or noncontiguous injuries in the cervical spine (55). Injuries in combination usually have the same mechanism of injury. The initial lateral roentgenogram may reveal an associated injury in 22% to 50% of patients, depending on the pattern and severity of the upper cervical injury.

The AP view contributes relatively less to the evaluation of the upper cervical spine than it does to the evaluation of the lower cervical spine. However, the posterior elements of C-1 and C-2 can be visualized with this view. One of the more critical features is to assess the orientation of the spinous processes. Loss of alignment of the spinous processes is highly suggestive of a rotatory injury in the upper cervical spine. In addition, an angular deformity on the AP roentgenogram may also be helpful, especially in patients with torticollis, for whom the lateral may be extremely difficult to assess. The AP is also helpful for assessing concurrent injuries in the lower cervical spine.

A well-oriented open mouth view defines the occipital condyles, may show evidence of a fracture of the occipital condyles, and also gives an excellent view of the lateral masses of C-1. Spreading of the lateral masses of C-1 is indicative of a fracture of the anterior arch of C-1, as seen in Jefferson's fractures. The total displacement of the lateral masses can be evaluated (80), providing an indication of rupture of the transverse ligament. The radiographic appearance of a rotatory subluxation at C1–C2 is often defined on the open mouth radiograph with the so-called “wink” sign [overlapping of the inferior edge of the lateral mass of C-1 and the superior edge of the lateral mass of C-2, thus apparently eliminating the joint space (31)]. The odontoid–lateral mass relationship (distance from lateral mass to dens on each side), which sometimes is cited as a pathologic sign, is, in fact, asymmetric in many normal individuals and is of little significance (52,67).

The primary use of CT scans is to enhance the anatomic delineation of fractures that have already been identified. Make the slices at a 1.5 or 2 mm interval to enhance coronal and sagittal reconstructions and three-dimensional reconstructions. In fractures of the atlas, the gantry of the CT scanner must be parallel to the arch of C-1. If care is not taken with the orientation, the views will be difficult to interpret and not add much information to the plain radiographs. At C-1, the CT scan is most helpful in defining the nature of injuries involving the ring. For injuries of the transverse ligament, CT scanning is of help where the disruption of the transverse ligament is with a bony avulsion. In those dens fractures in which the fracture line is not clearly visualized on either the AP or the lateral plain radiographs, but an angular deformity of the dens is noticed, a CT scan with midsagittal reconstructions may define the injury. CT scanning is also helpful for defining dens anatomy before screw fixation (44). It is excellent in defining abnormal C1–C2 relationships, especially in rotatory dislocations and subluxations (21,50,61,63), and as defined by Sonntag and Dickman (79), the CT scan with appropriate reconstruction may also help define the position of the vertebral artery and determine whether placement of an atlantoaxial screw is possible

in both sides.

MRI in upper cervical spine injuries is becoming more useful. It has recently been used to allow direct visualization of the transverse ligament, especially in patients with head injuries. The gradient echo MRI pulse sequence is of greatest value (18). Although MRI is helpful in delineating compression injuries to the brain stem and spinal cord in the upper cervical spine, it is of less value than the CT scan in defining bony anatomy. Because the majority of concerns in upper cervical spine trauma are about bony anatomic relationships, the role of MRI remains limited.

## EMERGENT IMMOBILIZATION OF THE UPPER CERVICAL SPINE

Patients who have sustained high-velocity vehicular injury, or those who are suspected of having a spine injury, will usually present to the emergency facility immobilized in a collar and on a spine board. Continue this immobilization until the spine has been cleared or until definitive immobilization and treatment can be instituted. Most upper cervical spine injuries in patients without neurologic deficit can be continuously immobilized in a collar until evaluation by CT scan and MRI is completed. Thus, a neurologically intact patient with a posterior arch fracture who is suspected of having a Jefferson fracture may undergo a CT scan using collar immobilization. In contrast, some place patients with transverse ligament rupture and a Brown–Séquard lesion in traction immobilization before initiating any further radiologic studies. It is our preference to keep the patient immobilized in a Philadelphia collar or Miami J collar and not to convert the patient to traction until the workup is completed. This makes transfer into the imaging machinery easier. With transfer in and out of a CT scanner or MRI machine, any traction will generally need to be discontinued several times, with some additional risk to the patient. Furthermore, it is critical with certain injuries, such as traction injuries to the upper cervical spine, that traction not be applied at all. If this mechanism is not recognized, even traction weights as small as 10 lb can cause stretching of the brain stem or cord with additional neurologic injury.

Next, decide what type of traction immobilization to apply once the radiologic examination is completed. The decision depends on two factors: What personnel are available to apply the traction device? What is the goal of applying the device to the patient? It is far simpler and more expeditious in the emergency setting to place Gardner–Well tongs, because this procedure can be done accurately by one person in a very short period of time and with minimal movement of the patient. Placement of a halo ring requires precise positioning of the patient and a surgeon and an assistant to make sure that the ring is applied properly. If the goal is simply to apply a traction force to either reduce or stabilize an injury before surgery, in which the surgical procedure will give definitive stabilization not requiring postoperative immobilization in a halo vest, Gardner–Wells tong traction is preferred. In contrast, in injuries that require initial reduction by traction and that will either be treated definitively in a halo vest or treated by surgery most likely will require additional postoperative immobilization in a halo vest, initial placement of a halo is appropriate. A third group of patients—those with distraction injuries to the cervical spine, such as occiput–C1 dissociations or type IIA traumatic spondylolisthesis of the axis—will be placed in a halo and then immediately in a halo vest for stabilization. No traction is indicated in either of those injuries but ensuring stability is important.

Decide whether the halo can be placed with the patient in a supine position or whether the erect position is safe, which simplifies the placement. Patients with grossly unstable injuries or multiple injuries cannot tolerate a sitting position, and thus require application in the supine position using a head-positioning apparatus and an open ring halo to allow accurate placement. In those patients who have an isolated upper cervical spine injury, such as a minimally displaced dens fracture, the halo ring can be applied by applying a cervical collar and placing the patient in the sitting position, for placement of the ring and, subsequently, the vest.

### *Application of Skull Tong Traction*

- Apply cervical tongs, such as Gardner–Wells tongs, in the supine position. Cleanse the hair directly above the external auditory meatus of the ear with povidone-iodine (Betadine) solution, but shaving the patient's hair is not necessary.
- Place the sterile pins through the ring and insert at a site directly superior to the external auditory meatus and one fingerbreadth above the pinna. Before application of the tong, inject the area down to the periosteum of the skull with 1% lidocaine, usually with epinephrine (1:100,000).
- Do not incise the skin. Tighten the pins simultaneously and, depending on the manufacturer's recommendations, bring the pressure indicators either to the level of outer surface of the pin or approximately 1 mm beyond.
- The initial traction weight in an adult is generally 10 lb, but before adding any weight, ascertain that the injury will not be made worse by traction.
- Increase the weights incrementally and obtain an appropriate radiograph between each increase to ensure that overdistraction is not occurring.

Although the general formula of 5 lb (2.3 kg) per cervical level above the fracture, with an initial 10 (4.6 kg) to 15 lb (6.8 kg) to overcome the friction of the head on the bed has been suggested, this is often not enough to reduce certain cervical spine injuries. The weight in certain types of traumatic spondylolisthesis as well as Jefferson's fractures will need to be increased to as much as 30 lb (13.6 kg) before an acute injury can be reduced. Between each 5 lb (2.3 kg) increment, however, appropriate radiographic evaluation is critical.

### *Application of a Halo Vest*

Placement of a halo and subsequently a halo vest is more difficult and requires at least two people.

- Before placing the ring, measure the head and torso and size for the halo and vest according to the manufacturer's instructions.
- Place the patient in the supine position or an operating table and use either a mechanical head holder or positioner, or apply the halo with the patient in the sitting position.
- Select the pin sites carefully; four pin sites are adequate in the adult, but more may be needed in the elderly patient with a thin skull or in the child.
- The preferred sites for halo insertion have been determined by a series of radiographic, cadaver, and clinical studies (36): Anteriorly place the pins approximately 1 cm superior to the orbital ridge, below the equator of the skull, and over the lateral two-thirds of the orbit. This will generally avoid the temporalis muscle, the supra-orbital branch of the trochlear nerve, and the frontal sinuses (Fig. 139.4).

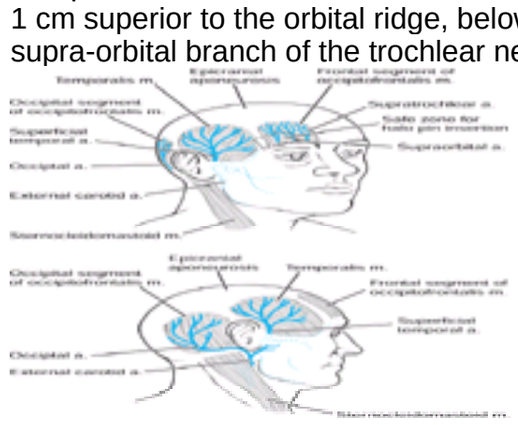


***Figure 139.4.*** The “safe zone” for placement of halo fixator pins. Place the anterior pins anterolaterally, approximately 1 cm above the orbital rim, below the equator of the skull, and cephalad to the lateral two thirds of the orbit. The safe zone avoids the temporalis muscle and fossa laterally, and avoids the supraorbital and supratrochlear nerves and the frontal sinus medially. (Redrawn from Ballock RT, Botte MJ, Garfin SR. Complications of Halo Immobilization. In: Garfin SR, ed. *Complications of Spine Surgery.* Baltimore: Williams & Wilkins, 1989, with permission.)

- Place the pins as far laterally as possible to minimize prominent scarring. Avoid placement within the temporalis muscle and fossa because it is particularly painful with motion and could cause significant bleeding; in addition, the area has a very thin cortical base, making perforation more common.
- The posterior sites are less critical and are generally placed at 180° on the contralateral side. Any area 2 to 3 cm posterior to the edge of the pinna of the ear is generally satisfactory. Shave the areas so that hair is not trapped as the pin is placed.
- Prepare and anesthetize each pin site by passing the needle for the local anesthetic through the selected hole or from above the halo to the exact contact point on the skin. Infiltrate the skin and deep tissues down to the skull.
- Ask the patient to close his or her eyes, and then make a small vertical incision with a #11 blade, directly in line with the selected screw holes. Some surgeons place the pins without using skin incisions (10). Place the four pins through the halo and screw them into the small incisions. Tighten the pins in a sequential fashion so that the halo is not shifted by overtightening one side before tightening the other.
- Tighten the pins in 2-inch-pound increments to a maximum of 8 inch-pounds in the normal adult skull. Tighten to lower levels when multiple pins are used in either the child or the osteoporotic elderly adult (9). Although 6 inch-pounds were initially used, 8 inch-pounds appears to have a lower rate of complications in terms of loosening and infection (9).
- Once the optimal torque is achieved with a torque screwdriver or a disposable wrench, place lock nuts over the pins and tighten them to prevent backing out of the pins.
- Apply traction through the halo ring using a bale, or the halo can now be connected to a vest. After applying a halo vest in the supine position, mobilize the patient to an upright position and recheck the halo vest.
- Now check the reduction of the cervical spine with a radiograph with the patient supine, if applied in the supine position, and then obtain a second radiograph in

the upright position to be certain that the reduction does not shift. Obtain another upright roentgenogram 24 hours after the patient is allowed to ambulate, to ensure the maintenance of position. Subsequent adjustments to the halo, in terms of position of the fracture, should be done in the upright position for optimal vest fit.

- With a torque wrench, retighten all four pins in the halo at 24 hours back to 8 inch-pounds. Teach the patient to cleanse the pin sites daily and to inspect for any problems.

## CLASSIFICATION, PATHOLOGY, AND TREATMENT OF UPPER CERVICAL SPINE INJURIES

Bony and ligamentous injuries can be classified in a number of different ways, although it is probably easiest to classify them by level as opposed to any type of mechanistic classification (Table 139.1).

| |
|---|
| • Occiput-cervical injuries |
| Occipital |
| Condyle fracture |
| Occipital-cervical ligamenteous injury |
| • C-1 injuries |
| Posterior ring fractures |
| Lateral mass fractures |
| Jefferson fracture |
| Avulsions of the anterior ring |
| • C1–C2 injuries |
| Rotational (atlanteoaxial rotatory) instability |
| Transverse ligament injuries (with atlantoaxial instability) |
| • C-2 injuries |
| Dens fracture |
| Traumatic spondylolisthesis |
| Extension teardrop fracture |

***Table 139.1. Classification of Injuries by Cervical Level***

### *Occipital–Cervical Injuries*

Injuries involving the occipital–cervical junction are extremely rare and often are fatal. This group of injuries includes dislocations that can occur with or without occipital condyle fractures, as well as occipital condyle fractures that occur without any subluxation. In addition, there are pure distraction injuries at the occipital–cervical junction. These are the most commonly fatal. These injuries may be overlooked in the acute emergency because they are uncommon and difficult to diagnose on plain roentgenograms. Many of these injuries are found only at autopsy (3). The injuries are commonly associated with other noncontiguous cervical spine fractures and with head injuries. The presence of a high-level neurologic deficit, often with involvement of all four extremities plus abnormal respiratory function, known as “pentaplegia,” is a tipoff to injury at the occipital–cervical junction. As a group, these injuries most commonly result from high-speed motor vehicle accidents or are found in pedestrians struck by motor vehicles (3,4,51,53,56,78,86). The cause of death may be due to the associated head injury or sudden loss of voluntary respiratory function because of brain stem injury from the occipital–cervical dissociation (53).

Patients with isolated occipital condyle fractures have a higher rate of survival than occipital–cervical dissociations or dislocations. Patients may present with cranial nerve involvement as well as persistent occipital headaches. The mechanism of injury of all occipital condylar fractures is believed to be either sudden deceleration or direct axial loading on the cranium. Occipital–cervical dislocations can occur as a result of violent hyperextension or distraction forces in which the torso is pinned in position and the distraction force applied to the neck by a force applied beneath the patient's chin. Occipital condyle fractures have been characterized by Anderson and Montesano (4) (Fig. 139.5). A type I fracture (Fig. 139.5*A*) is a unilateral undisplaced, comminuted fracture of the condyle, usually resulting from axial impact between the skull and the axis. The alar ligament may be disrupted on that side, but the segment is usually stable. A type II fracture (Fig. 139.5*B*) is a unilateral occipital condyle fracture that is associated with a basilar skull fracture on the same side. The mechanism is generally axial loading with lateral bending, and this injury is generally stable. Type I and II injuries can be treated nonoperatively using a rigid cervical orthosis for 6 to 8 weeks; halo mobilization is not generally required. The type III fracture (Fig. 139.5*C*) is a unilateral alar ligament avulsion from the occipital condyle. It occurs as a result of extreme lateral bending, rotation, or a combination of the two. This injury, because it has a ligamentous component, may be associated with atlanto-occipital dislocations. Type III fractures may be unstable. Treatment is based on the degree of instability, ranging from collar immobilization, to halo immobilization, to posterior occipital–cervical fusion if associated disruption of the occiput–C1 complex is significant. Perform flexion-extension radiographs at the end of nonoperative management to assess the degree of stability. At that point, abnormal motion can be considered evidence of either nonunion or nonhealing of the ligamentous injuries, which requires treatment with an occipital–cervical fusion. Occipital condyle injuries are commonly unilateral but may be bilateral as well.

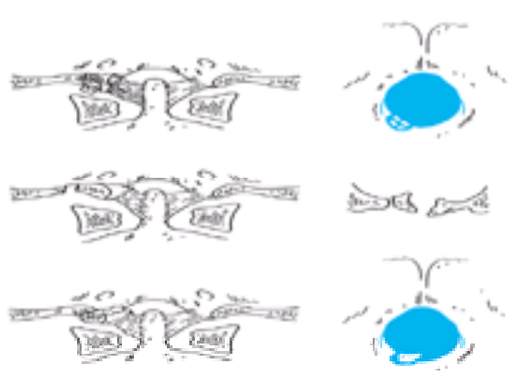

***Figure 139.5.*** The classification of Anderson and Montesano describes three basic types of occipital condyle fractures. **A:** An impaction-type fracture, which is usually the result of an asymmetrical axial load to the head; it may be associated with other lateral mass fractures in the upper cervical spine. **B:** A basilar skull-type occipital condyle fracture. **C:** An avulsion-type occipital condyle fracture, which may be the result of a distraction force applied through the alar and apical ligament complex. (Redrawn from Anderson P, Montesano P. Morphology and Treatment of Occipital Condyle Fractures. *Spine* 1988;13:731, with permission.)

Occipital–cervical subluxations and dislocations have been incorporated into a single classification described by Traynelis et al. (86) (Fig. 139.6). Type I injuries are anterior dislocations and generally have the highest survivability. Type II injuries demonstrate vertical displacement, usually from a distraction mechanism: type IIa injuries occur at the occipital–cervical junction, and type IIb injuries occur between the atlas and axis. In some cases, these injuries may be combined injuries. When there is greater than 2 mm of vertical displacement between the occiput and C-1 (IIa), a rupture of the tentorial ligament and alar ligaments must be suspected. At the C1–C2 level (IIb), the joint capsule is usually involved as well as the tentorial membrane and the alar ligaments. Injuries to the transverse ligament can also occur. Type II injuries should not be placed in longitudinal traction. Type III injuries are posterior dislocations and are often fatal, although accompanying fracture of the C-1 arch may increase the chance of survival. Types I and III injuries may be realigned initially using traction, although the degree of ligamentous disruption is difficult to assess initially. Traction should be used only in type I and type III injuries, with traction restricted to between 2 (0.9 kg) and 5 lb (2.3 kg). Interestingly, gravity itself is usually sufficient to reduce any translation. Increased survival has been reported with traction (26). After closed reduction is achieved, immediately place the patient in a halo vest and obtain a CT scan to identify any fractures. After this assessment, treat only patients with minimal ligamentous destruction and minimal bony disruption definitively in a halo vest for a period of 3 months. At the conclusion of that time, perform flexion-extension roentgenograms to check stability and decide whether a occipital–cervical fusion is necessary based on the degree of residual translation.

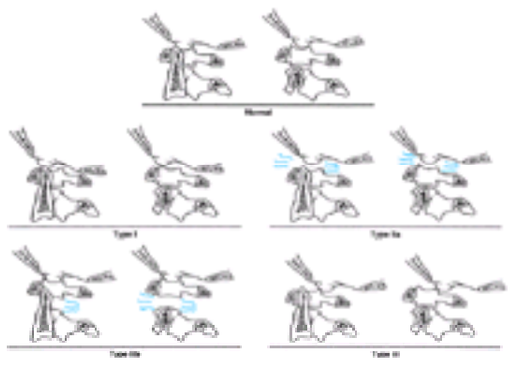

***Figure 139.6.*** The classification of Traynelis and others takes into account both the direction and level of upper cervical dislocation. Type I injuries (antero-occipital–cervical dislocations) are more common than type III, but both are easily missed on routine radiographs. Type II injuries are distraction types, with type IIa occurring predominantly at the occipitoatlantal level and type IIb occurring at the atlantoaxial level. Not accounted for in this classification are double-level distraction injuries, which are uniformly fatal. Type III injuries, which are quite infrequent, are posterior atlantooccipital dislocations. (From Levine AM, Eismont FJ, Garfin SR, Zigler JE. *Spine Trauma.* Philadelphia: W. B. Saunders Co., 1998, with permission.)

**Posterior Occipital Fusion** In most cases, however, these are extremely unstable injuries and a posterior occipital–cervical fusion is indicated. Various techniques have been used to achieve an occipital–cervical fusion. The most rigid fixation involves the use of a contoured plate secured with multiple occipital screws and a C1–C2 transarticular screw (24,38,39) (Fig. 139.7). Techniques for occipital–cervical wiring, described by Wertheim and Bohlman (90), require postoperative immobilization in a halo vest, but in their series, all 13 patients developed a solid arthrodesis. Other techniques using corticocancellous struts wired into the skull and beneath the spinous processes of C-1 and C-2 similarly have had high rates of union with minimal loss of fixation in patients treated postoperatively in a halo vest. A contoured occipital–cervical rod has also been described by a number of authors, giving additional stability that is not provided by bone graft alone (73,79). Irrespective of the type of construct, overall fusion rates for occipital–cervical fusions, when properly immobilized postoperatively, are in excess of 90%.

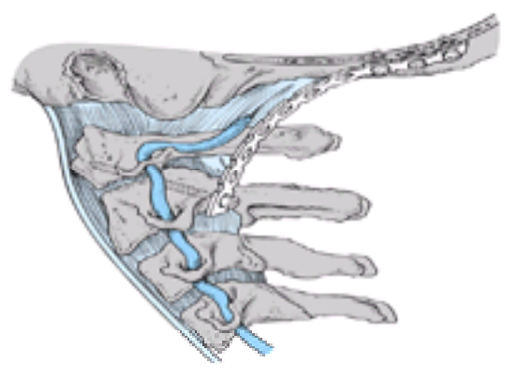

***Figure 139.7.*** Lateral view of the occipitocervical plating technique using C1–C2 transarticular screws and titanium reconstruction plates with bicortical cranial screws.

The advantage of occipital–cervical fusion with two plates and screws is that there is no need for halo immobilization.

- With the patient in the traction applied at the time of admission, perform an awake fiberoptic intubation. Then turn the patient into the prone position while still awake.
- Use a three-pin Mayfield (Ohio Medical Instrument Co., Inc., Cincinnati, OH) or halo modified headrest to secure the head. Induce general anesthesia once appropriate positioning is obtained and the patient's neurologic status is reassessed and found to be unchanged.
- Any manipulation of the head is done before inducing general anesthesia. Avoid extreme positions of flexion or extension because the plate fixation is rigid.
- Set up fluoroscopy so that AP and lateral images can be easily obtained, preferably simultaneously with two machines.
- Before incision, hold a guidewire alongside the neck and visualize it on a flouroscope to be sure that the C1–C2 transarticular screw can be placed with the patient as positioned. This technique generally cannot be accomplished in patients with an upper thoracic kyphosis or gibbous.
- Make a posterior incision from the occipital prominence and extend it to the midcervical spine. Elevate all soft tissue off the bone from the greater occipital prominence to the C2–C3 joint.
- Select two plates with appropriate hole spacing and then contour them to fit the occipital–cervical junction, with at least three fixation holes available in the occiput and extending far enough distally to allow a C1–C2 transarticular screw to be placed on each side.
- Take care in contouring the occipital portion of the plates so that the terminal end is not prominent and the screw fixation is on the undersurface of the occiput rather than on its most prominent posterior portion.
- After templating and drilling the C1–C2 transarticular screw according to the technique described by Magerl and Seemann (Fig. 139.7 and Fig. 139.12) (59), select the appropriate-length screw, place the plate into position, and pass the transarticular screw through the plate, tightening it so that the plate lies in the appropriate position against the occiput on one side.

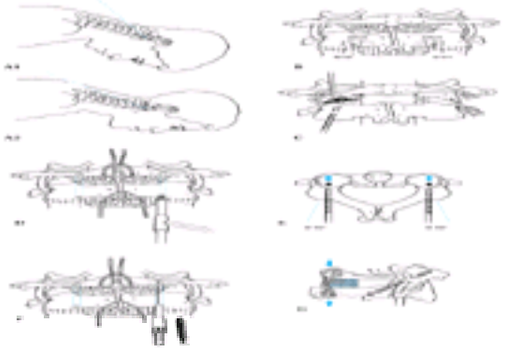

***Figure 139.12.*** The C1–C2 fusion technique of Magerl. **A1, A2, B to F:** The surgical technique; see text for details. **G:** Lateral view of the completed fixation. [Redrawn from (parts **C** and **G**) the Barrow Neurological Institute, Phoenix, AZ and (parts **A** and **B**, and **D** to **F**) from Levine AM, Eismont FJ, Garfin SR, Zigler JE. *Spine Trauma.* Philadelphia: W. B. Saunders Co., 1998, with permission.] The C1–C2 fusion technique of Magerl. **A1, A2, B to F:** The surgical technique; see text for details. **G:** Lateral view of the completed fixation. [Redrawn from (parts **C** and **G**) the Barrow Neurological Institute, Phoenix, AZ and (parts **A** and **B**, and **D** to **F**) from Levine AM, Eismont FJ, Garfin SR, Zigler JE. *Spine Trauma.* Philadelphia: W. B. Saunders Co., 1998, with permission.]

- Then place the occipital screws using three bicortical screws per side. The screws are typically between 6 and 12 mm in length. In older patients, the dura may be adherent to the inner surface of the skull, causing a small cerebrospinal fluid (CSF) leak, but this can be easily stopped by simply placing the screw in the hole.
- Then apply the second plate in a similar fashion.
- Fashion a corticocancellous graft to lie between the two plates, covering the posterior portion of the occiput, the posterior arch of C-1, and around the spinous process of C-2. Hold this graft in place using heavy suture or wire.
- If transarticular screw fixation cannot be achieved because of the patient's position, alternatively, a C-2 pedicle screw can be placed, generally in combination with a C-3 lateral mass screw and a wire or suture placed around the arch of C-1 and tied to the plate on either side.
- Immobilize the patient postoperatively in a rigid collar for 12 weeks. While the patient is in the collar, be certain that he does not develop an occipital decubitus either because of the cervical spine trauma resulting in anesthesia in the area of the greater occipital nerve or as a result of the surgical dissection.

***Fractures in the Atlas (C-1 Injuries)***

Almost 50% of fractures involving the atlas are associated with a second fracture, and approximately 25% of them are associated with noncontiguous second fractures. The two most common types of fractures associated with a fracture of the atlas are fractures of the dens (27,55,58) or type I traumatic spondylolisthesis (55). Because the majority of injury patterns for fractures of the atlas involve widening of the space available for the cord rather than narrowing of the canal area, these injuries are not generally associated with neurologic deficit. If a deficit is present, its etiology may be from another associated or nonassociated spine or head injury. Multiple types of fractures of the C-1 arch have been identified (Fig. 139.8). The initial description of fractures of the C-1 arch was by Jefferson (48,49). He described isolated fractures of the posterior arch as well as multiple fractures of the arch, although his name is most associated with the four-part fracture. Segal et al. (77) have actually identified six different fracture patterns. However, the most common injury type is the posterior arch fracture. This is thought to be the result of a hyperextension-axial loading injury in which the posterior arch is pinched between the occiput and the ring of C-2 (92). These fractures tend to occur at the area just behind the lateral mass where the vertebral artery passes over it. Associated with this hyperextension-axial load mechanism of injury are other fractures that have a similar mechanism, such as posteriorly displaced dens fractures, type I traumatic spondylolisthesis of the axis, and C-2 anterior extension teardrop fractures.

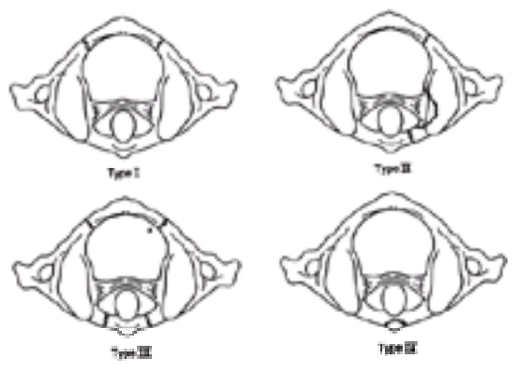

***Figure 139.8.*** Four major types of fractures can occur at the level of the atlas. Type I is the most common and is a posterior arch fracture, which is the result of hyperextension and axial loading. It may be associated with other injuries caused by the same mechanism, such as traumatic spondylolisthesis. Type II, or lateral mass fracture, is the result of axial loading and lateral bending. There is usually a fracture line anterior and posterior to the lateral mass, causing asymmetric spreading. A second fracture line can also be present in the contralateral posterior arch. Type III, or Jefferson's fracture, is a burst fracture resulting from axial loading of C-l. Two to five fracture lines can be present, although most commonly there are four fracture lines: two in the anterior arch and two in the posterior arch. The final category, type IV, is an avulsion fracture of the anterior tubercle of the atlas. (From Levine AM, Eismont FJ, Garfin SR, Zigler JE. *Spine Trauma.* Philadelphia: W. B. Saunders Co., 1998, with permission.)

The second most common type of injury, the lateral mass fracture, is generally composed of a fracture anterior to the lateral mass and one posterior to the lateral mass. In some instances, there may also be a fracture through the posterior arch on the contralateral side (42,55). These fractures have the same degree of instability, whether they are two-part or three-part injuries. The mechanism of injury is an axial load with lateral bending. The presence of a second fracture on the contralateral side would suggest at least some slight extension associated with this injury. In addition, the most common fracture occurring in association with this type is a lateral mass fracture in the lower cervical spine, which also has the same mechanism of extension, axial loading, and lateral bending.

The third type of fracture is what has been called the Jefferson fracture, which is a classic bursting injury of the ring of C-1. It has variably been described as having two fractures, one in the anterior arch and one in the posterior arch; or having three fractures, one in the anterior arch and two in the posterior arches; or having four or five fractures, with at least two in the anterior arch and two in the posterior arch. On open mouth radiograph view, this generally shows symmetric displacements of the lateral masses of C-1 (43,48,49,55,77). The injury is believed to be the result of axial loading applied to the skull. Because the lateral masses of C-1 are wider laterally than medially, they act like a wedge when they are axially loaded, driving the lateral masses laterally and disrupting the ring. Splaying of the lateral masses more than 6.9 mm on an open mouth view may indicate disruption of the transverse ligament (80).

The fourth type of fracture is an avulsion fracture off the inferior portion of the anterior tubercle of C-1, where the longest colli muscle inserts. It is generally the result of hyperextension and, therefore, is an avulsion injury. It is completely stable (83). The final type of injury is a transverse process fracture, which may be either unilateral or bilateral (15).

In general, isolated posterior arch fractures can be treated nonoperatively with 6 to 12 weeks of immobilization in a hard collar. Nonunion is exceedingly rare (55,77). Patients who have a dens fracture in association with a posterior arch fracture cannot be stabilized by standard C1–C2 wiring techniques. Without the integrity of the posterior arch, either an anterior dens screw or a posterior transarticular C-1 atlantoaxial arthrodesis may be necessary when operative treatment is indicated. Avulsions from the anterior tubercle and transverse process fractures can be treated symptomatically with simple collar immobilization until pain relief is achieved.

Lateral mass and Jefferson's fractures can be divided into two groups: those that are only minimally to moderately displaced (less than 7 mm total displacement on an open mouth view) and those that are more significantly displaced. Controversy remains concerning the most effective treatment for these injuries. For minimally to moderately displaced fractures, the transverse ligament is intact. Immobilization in a hard collar for less significantly displaced injuries or immobilization in a halo vest for more significantly displaced injuries appears to give adequate long-term results. The most common complications of treating these patients is symptomatic nonunion (77) in those patients who have displaced fragments of the ring that do not unite. If the fragments are symptomatic, they may require arthrodesis. Remember that the halo and vest cannot be expected to reduce the ring fragments, even with traction. Once traction is removed, the original displacement will recur. Thus, placing the patient in traction for several days before immobilizing the patient in a halo vest does not improve the degree of displacement (42,94).

Patients who have had rupture of the transverse ligament and, therefore, more than 7 mm displacement on an open mouth radiographic view can be treated in one of two ways. Although it was initially thought that these patients would have long-term instability without surgical intervention, on the basis of the apparent rupture of the transverse ligament (75), this has turned out not to be the case (51). Thus, if the patient can achieve union of the ring of C-1, the degree of instability, after treatment, is limited. As demonstrated earlier by Fielding (29), this is because only the transverse ligament is ruptured, and the alar, apical, and accessory ligaments as well as the joint capsule are still intact and providing sufficient stability. Thus, the degree of C1–C2 instability is minimal when the ring heals solidly (55). Therefore, patients can be treated with enough longitudinal traction to reduce the splaying of the lateral masses to anatomic position and then held in longitudinal traction until early healing takes place (approximately 6 weeks). Once preliminary healing has occurred, the patient can be mobilized in a halo vest for an additional 6 weeks without risk of loss of reduction.

If, however, the reduction is achieved initially and then the patient is immediately mobilized (within the first week), reduction will be lost. Because of the long hospitalization required, long-term traction is less popular than it was previously. In addition, if the patient cannot be left in a supine position on a Stryker (Stryker Corp., Kalamazoo, MI) frame for long periods of time, operative treatment for significantly displaced fractures may be indicated.

In that case, reduce the ring with axial traction and then perform a C1–C2 transarticular screw fixation (62).

**Posterior C1–C2 Arthrodesis, Modified Magerl Technique** The treatment of a widely displaced lateral mass or Jefferson's fracture is the modified Magerl transarticular C1–C2 screw fixation. The technique, however, has to be modified over that originally described by Magerl and Seemann (Fig. 139.9) (59) because a considerable portion of the stability of the technique is with the bone block that is usually placed between the intact posterior arch of C-1 and the spinous process of C-2. Because a Jefferson's fracture has an incompetent C-1 arch, additional stress is placed on the screws, risking early failure of fixation. Therefore, denude the cartilage of the facet joints, and pack bone directly into the posterior aspect of the C1–C2 joint. Also, place graft between the ring of C-1 and C-2, recognizing, however, that its structural integrity is compromised. Postoperatively, additional immobilization may be necessary in the form of a rigid collar or a halo vest, depending on the original degree of instability, the quality of the patient's bone, and the quality of the fixation.

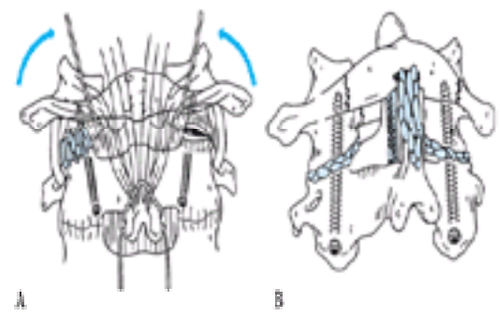

***Figure 139.9.*** An alternative method for the treatment of a widely displaced lateral mass or Jefferson's fracture is the Magerl transarticular C1–C2 screw fixation. See text for details.

- Reduce the fracture with halo traction using about 30 to 35 lb (13.6 to 15.9 kg) of traction to achieve an anatomic reduction, which makes placement of the screws relatively straightforward. Further reduction is not possible once operative stabilization has begun. Use a biplanar fluoroscope imaging.
- The only variation in the standard technique is that the joints are fully exposed (Fig. 139.9*A*) so that the cartilage can be curetted out for fusion, and no fixation of bone graft is possible between the fractured arch of C-1 and the lamina of C-2.
- Graft directly into the facet joints and also do an onlay graft from C-l to C-2 (Fig. 139.9*B*) so that as healing occurs, a solid arthrodesis will also occur. With satisfactory screw fixation, either the halo vest can be continued postoperatively or hard collar can be used.

In patients treated with arthrodesis who attain a satisfactory fusion, long-term results in terms of stability are excellent. In patients with relatively undisplaced lateral mass fractures and Jefferson's fractures treated only in a collar or halo vest, late instability is rare if union is achieved between all fragments (55,77). The motion between C1–C2 however rarely returns to normal. In the Levine and Edwards series (55), up to 80% of patients had some residual neck pain, although none required secondary fusions for neck pain (55). The significant joint incongruity and resultant degenerative changes in fractures that are significantly displaced at the conclusion of treatment will commonly lead to pain and secondary occipital cervical fusion. In one study, nonunions occurred in 17% of patients (77), and nonunion was directly related to the amount of displacement. Patients with a nonunion and displacement of the posterior arch could sustain neural compression on the basis of the displaced fragment, but this is a rare complication.

### *Atlantoaxial Instability (C1–C2 Injuries)*

Atlantoaxial instability may occur secondary to trauma, congenital abnormalities, infection, and arthritis. Traumatic atlantoaxial instability can be of two types. It can be related to flexion instability with anterior translation of the atlas on the axis resulting from rupture of the transverse ligament and disruption of the secondary stabilizers—the alar, apical, and accessory ligaments. The second type of atlantoaxial instability is a rotatory instability, which can be of several different types and be the result of both bony and ligamentous injuries. The transverse ligament is the primary stabilizer, preventing anterior translation of C-1 on C-2, but the alar, apical, and accessory ligaments, as well as the capsular ligaments, offer secondary stabilization. Posterior translation of C-1 on C-2 is prevented by the impingement of the anterior ring of C-1 on the dens. As shown by early work by Fielding et al. (29), a maximum of 3 mm of anterior translation of C-1 on C-2 can occur with an intact transverse ligament in the adult. Within the range of 3 to 5 mm of translation, catastrophic failure occurs, usually within the midsubstance of the ligament rather than at the bony attachments. No correlation has been made between the strength of the transverse ligament and age other than that children tend to be slightly more lax and, therefore, an ADI of 5 mm of translation can be accepted in children as normal. Simple experimental sectioning of the transverse ligament without disruption of the alar, apical, and accessory ligaments results in an ADI of only 5 mm in the adult in the experimental setting (29). In patients with gross instability with an ADI greater than 10 mm, not only does the transverse ligament need to be sectioned but all of the secondary restraints as well.

Most of these injuries are the result of significant trauma to the head, although they may occur in older patients with a simple fall and striking of the occiput. Patients may have varying neurologic involvement, from being neurologically normal with severe neck pain to a transient quadriplegia to a Brown–Séquard–type syndrome. The diagnosis of this injury is generally made on a lateral roentgenogram. If roentgenograms are taken in the supine position, the subluxation may reduce, especially in a patient whose chest is disproportionately large in relation to his or her head, thus placing the patient in extension, as is frequently the case with children. If the patient does not have neurologic deficit and injury is suspected, physician-supervised flexion-extension films in the alert, awake, neurologically intact, cooperative patient may be very helpful in making the diagnosis. In contrast, if the patient has severe neck pain and paraspinous muscle spasm, adequate-quality flexion-extension films may not be attainable. There may not be enough motion in the cervical spine to indicate whether the patient has instability. In that case, several options are available. The patient may be simply immobilized in a hard collar, and when the spasm subsides, adequate flexion-extension films can be obtained. Alternatively, under physician supervision, the amount of spasm in the paraspinous musculature can be reduced by intramuscular injection, allowing flexion-extension roentgenograms to be taken. An MRI may be used to investigate the integrity of the ligamentous complex.

Healing of the transverse ligament, even in the case in which its insufficiency is the result of the avulsion from its insertion on the lateral mass, is uncommon. This is one of the few injuries in the upper cervical spine that routinely requires surgical intervention. There are a variety of techniques to achieve C1–C2 arthrodesis. These are commonly done by posterior arthrodesis because it is infrequent to have a fracture of the posterior arch and a rupture of the transverse ligament from a flexion type injury. C1–C2 fusion, using either a Gallie (35), Brooks (12), or a Magerl (46) C1–C2 transarticular screw fixation, will give satisfactory results in this situation.

Until recently, the most common method for surgical stabilization for C1–C2 was either a Gallie (35) or a Brooks (12) fusion (Fig. 139.10). With any method, significant loss of rotation at the atlantoaxial joint will occur postoperatively because 50% of neck rotation normally occurs at this joint. In fact, because of compensatory motion at other joints, the loss is often less, as reported by Fielding et al. (30). Fielding demonstrated that an average loss of only 13% of rotational motion occurred in patients younger than 20 years of age; a 25% loss occurred in those in the 20-to-40-year-old age group, and a 28% loss occurred in those older than 40 years of age.

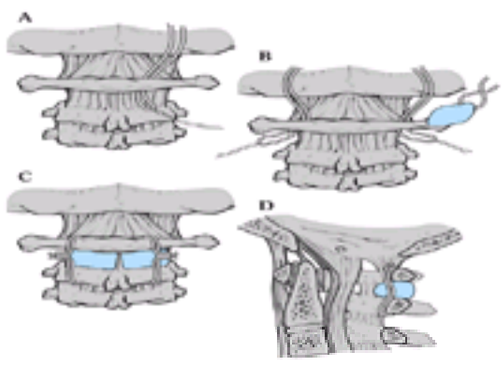

***Figure 139.10.*** Brooks fusion: The occipital nerves emerge through the interlaminar space between the atlas and the axis, the vertebral arteries are more lateral. See text for a description of the surgical technique. (Redrawn from Jarrett JP, Whitesides TE Jr. Injuries of the Cervicocranium. In: Browner BD, Jupiter JB, Levine AM, et al, eds. *Skeletal Trauma: Fractures, Dislocations, and Ligamentous Injuries,* Vol 1. Philadelphia, W. B. Saunders Co., 1992:689, with permission.)

**Modified Brooks Fusion** In both the Brooks' and Gallie's techniques, wires are passed beneath the arch of C-1, around the spinous process of C-2 in the Gallie technique and sublaminarly beneath the arch of C-2 in the Brooks technique. With the Gallie technique, a corticocancellous bone lock is laid on the arch of C-1 and notched to fit around the spinous process of C-2. There are a number of different modifications of the Brooks technique, ranging from two wedge-shaped blocks (Fig. 139.10), one on each side, with a single wire around them, to two wires around them, to instances of a single block in the center with wires that pass beneath the laminar at C-1 as well as sublaminar at C-2.

**Brooks Fusion** The occipital nerves emerge through the interlaminar space between the atlas and the axis; the vertebral arteries are more lateral.

- Make a midline approach. The arteries and nerves are fairly well protected by the neck muscles. Expose C-1 and C-2.

- On both the right and left, pass sutures under the posterior arch of the atlas (Fig. 139.10*A*). Then pass the sutures on the lamina of C-2. A twisted wire is then tied to the suture, which is used to guide the wire under the arch of the atlas and the lamina of the atlas (Fig. 139.10*B*).
- In the Figure 139.10*C* the wires are now in place and lie anterior to the anterior portion of the atlantoaxial membrane, which was not removed during exposure of the posterior elements of the atlas and axis.
- Harvest either two iliac crest corticocancellous grafts or one larger midline graft and fashion them to fit between the posterior arches of C-1 and C-2. Bevel edges to fit in the interval between the atlas and axis. Hold the graft in place with a towel clip. When they are wired in place, the beveled edges will be in contact with the arch of the atlas and the lamina of the axis.
- Secure the graft or grafts with the wires (Fig. 139.10*D*)

Several congenital anomalies are associated with atlantoaxial instability. These include Down's, Morquio's, and Klippel–Feil syndromes, as well as occipitalization of the atlas. The incidence of atlantoaxial instability in Down's patients has been reported to be as high as 20%. There is still controversy surrounding the need for prophylactic fusion in these individuals. Most recommend restriction of contact activities in patients with an ADI of less than 7 mm. Prophylactic fusion is recommended for displacement of greater than 7 mm.

### *Atlantoaxial Rotatory Deformities*

Atlantoaxial rotatory deformities have a number of different etiologies including trauma, tumors, and inflammatory conditions (31,54,93). They have been classified anatomically by degree of subluxation (31) and clinically by the duration of symptoms, response to treatment, or their underlying etiology. They are most commonly due to infection or trauma and have been reported in all age groups, with a higher incidence in children (70) and young adults, regardless of the etiology. The typical presentation is a sudden onset of torticollis in which the head is rotated away and tilted anteriorly toward the rotated side with associated spasm of the sternocleidomastoid muscle. The patients generally have significant neck pain and an inability to rotate the head past neutral. By palpating the posterior wall of the oropharynx, it is possible to feel the difference between the normal and abnormally rotated lateral masses. On the subluxed side, it is possible to appreciate a stepoff from the C-1 lateral mass to the C-2 lateral mass. Any motion produces significant discomfort. In long-standing cases, facial asymmetries may occur. Compensation for the torticollis may occur after some time as a result of counterrotation in the lower cervical spine or atlanto-occipital joint.

The most characteristic finding on the lateral radiograph is an obliquity in the orientation of the posterior arch of C-1 in comparison to the remaining lower spinous processes. A widened ADI may be seen. On the open mouth view, the anteriorly rotated lateral mass can appear wider and closer to the midline than the opposite side. However, the most pathognomonic sign on the open mouth view is the “wink” sign when the inferior edge of the lateral mass of C-1 on the affected side overlaps the lateral mass of C-2, obliterating the joint space. On an AP view the spinous process of C-2 may be rotated away from the side of the anterior displaced lateral mass, known as Sudeck's sign (84). A fixed subluxation can be easily seen on a thin-cut CT scan, which demonstrates the abnormal relationship of C-1 to C-2 (21,33,63). The dimensional reconstructions are also very useful for complete delineation of the injury. For reducible subluxations, a dynamic CT scan in maximal left and right rotation will generally reveal the deformity.

The classification is based on the integrity of the transverse ligament and the direction of the deformity (7,31). A type I deformity indicates an intact transverse ligament and a fixed C1–C2 position within a normal range of rotation. Type II deformities show mild deficiency of the transverse ligament with an ADI of 3 to 5 mm. Mild fixed rotation exceeds the normal motion of the C1–C2 joint. A type III deformity has an ADI greater than 5 mm, and both lateral masses of C-1 are displaced anteriorly, with one side rotated farther than the other. A type IV deformity describes a posterior subluxation of one or both lateral masses. Types III and IV have greater instability with increased neurologic risk, and decreased success with conservative management. Posttraumatic episodes of atlantoaxial deformity have a higher rate of instability and require more aggressive treatment. Rotatory dislocations of traumatic origin may have not only ligamentous disruption but also bony avulsions or fractures from the C-1 joint surfaces, increasing the degree of instability.

With an infectious etiology, treatment is initially geared toward eradicating the organism responsible with intravenous antibiotics. Treatment is then primarily based on the duration of the deformity at presentation. If the deformity has been present for less than 1 week, place the patient in a soft collar and put him on bed rest. If the deformity does not spontaneously reduce, institute halo traction. The weight initially used is based on the age of the patient: 7.7 lbs (3.5 kg) for younger children and up to 13 to 17.6 lb (6 to 8 kg) for adults. The weight may be increased in increments of 1.1 lb to 2.2 lbs (0.5 to 1 kg) every 3 to 4 days until reduction is achieved to a maximum limit of 13.2 lb (6 kg) in children (70) and 19.8 lb (9 kg) in adults. If the deformity has been present for more than 1 week, start halo traction immediately. Continue traction for up to 3 weeks, but if reduction is not accomplished, a surgical stabilization procedure in symptomatic individuals is indicated.

If reduction is achieved, continue immobilization to allow the capsules and ligaments to heal. Wetzel and La Rocca (91) devised a protocol for immobilization based on the type of deformity. They recommend a soft collar for type I, a rigid collar for type II, and a halo for types III and IV for a duration of up to 3 months. After treatment, obtain flexion-extension radiographs to document stability.

Surgical intervention is indicated when there is evidence of significant instability or neurologic deficits, when there is failure to achieve or maintain a reduction in an acute traumatic deformity, or if symptoms persist after conservative treatment. A posterior C1–C2 fusion is recommended. *In situ* fusion is recommended by some, but the passing of sublaminar wires is more difficult because of the narrowed space behind the posterior ring of C-1. Improvement in the cosmetic deformity is usually slow and often occurs through rotation at cephalad and caudal levels, which may become symptomatic in the future. Some surgeons recommend an attempt at open reduction.

#### Open Reduction

- Pass a sublaminar wire under the posterior arch of C-1 and gently applying traction in order to manually derotate the atlas.
- After reduction is achieved, incorporate the wire into a Gallie or Brooks C1–C2 fusion, or C1–C2 transarticular screw fixation can be done. The C1–C2 transarticular screw fixation is the most stable construction to prevent redisplacement if reduction can be achieved either preoperatively or intraoperatively.
- Screw placement is difficult when residual rotatory deformity exists at the time of screw passage.
- If neurologic deficit is present and reduction cannot be achieved, perform a decompression of the posterior arch of C-1, followed by an occipitocervical fusion.

### *C-2 Injuries*

**Fractures of the Odontoid (Dens)** Fractures of the odontoid account for approximately 15% of all cervical spine fractures. Neurologic deficits occur in approximately 25% of patients with fractures and can range from quadriplegia to slight neuralgias. There is a higher mortality rate associated with this fracture in elderly patients. In younger patients, these fractures tend to occur as a result of motor vehicle accidents; in older patients, they tend to result from falls. The mechanism is forceful flexion or extension with an axial load. Flexion results in anterior subluxation, whereas extension results in posterior subluxation.

The classification system for dens fractures was described by Anderson and D'Alonzo (3) (Fig. 139.11). A type I fracture is an avulsion fracture at the tip of the odontoid above the transverse ligament. A type II fracture occurs at the junction of the body and dens, and may be transverse or oblique. A type III fracture extends into the cancellous portion of the body of C-2.

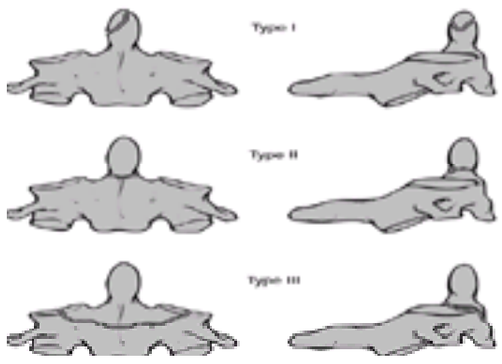


***Figure 139.11.*** Classification of odontoid fractures: Three types of odontoid fractures as seen on AP and lateral radiographs. Type I is an oblique fracture through the upper part of the odontoid process. Type II is a fracture at the junction of the odontoid process with the vertebral body of the second cervical vertebra. Type III is a fracture through the body of the axis. (Redrawn from Anderson LD, D'Alonzo RT. Fractures of the Odontoid Process of the Axis. *J Bone Joint Surg [Am]* 1974;56:1664, with permission.)

The treatment of type I fractures is a period of immobilization with a soft collar until symptoms resolve. However a type I fracture may be an indication of a distraction injury at C1–C2 and thus may be a grossly unstable injury requiring C1–C2 arthrodesis. Take flexion-extension radiographs to document stability because some instances of type I fractures are associated with other significant ligamentous injuries that can be grossly unstable. The outcomes are excellent, with few residual symptoms; even persistent nonunion of the avulsion fragment offers no long-term problems.

The treatment of type II fractures is somewhat controversial. The nonunion rate for nonoperative treatment is widely variable (1,3,6,14,40,41,60,88) and ranges up to 75% in some series. It appears to correlate with several factors:

- Posterior displacement (19)
- Initial displacement of greater than 5 mm (41)
- Inability to obtain or maintain an anatomic reduction
- Advanced patient age
- Pre-existing diabetes or rheumatoid arthritis in the injured patient

In these high-risk patients, initial surgical stabilization is recommended. In addition, the inability to achieve a reduction in traction or the inability to maintain a reduction in a halo vest is an indication for surgical stabilization.

Type III fractures have relatively low nonunion and malunion rates (less than 15%) when treated appropriately (14). Nondisplaced type III injuries can be treated in a rigid collar, but displaced injuries usually require halo vest immobilization for 12 weeks. If the fracture line is oblique, it is generally not possible to correct collapse, but angulation can be corrected and maintained to healing. Obtain flexion-extension radiographs at 12 weeks to document stability. Treat failures of halo treatment with a C1–C2 fusion. Loss of initial reduction is also an indication for fusion.

The most common method of treatment for dens fractures is C1–C2 arthrodesis by either the Gallie (35) or Brooks (12) methods, as previously described. The Gallie method is not indicated for posteriorly displaced fractures. Results of treatment of dens fractures uniformly demonstrate an arthrodesis rate of approximately 90% irrespective of the technique used.

When the posterior arch of C-1 is fractured or the dens fragment is so unstable that it translates both anteriorly and posteriorly, a C1–C2 transarticular screw (59) or a direct anterior osteosynthesis of the dens is necessary (Fig. 139.12). This technique provides increased initial stability when compared with wiring techniques but is technically challenging.

*Magerl Fusion C1–C2*

- Perform an awake fiberoptic intubation and turn the patient prone. Position the patient's head in a Mayfield three-pronged head holder. Verify the neurologic status and initiate general anesthesia.
- Set up fluoroscopy so that both AP and lateral images can be obtained, preferably simultaneously. Place the patient's neck in as much flexion as possible without displacing the dens. Place a guide wire along the neck and image to verify that the trajectory needed can be obtained.
- The position of the neck that can be achieved consistent with reduction of the deformity influences exposure. If the neck can be flexed (Fig. 139.12*A1*) and reduction achieved (as is the case with a posteriorly displaced dens fracture), then the drill insertion and instrumentation can usually be done through the primary surgical incision. If the neck cannot be significantly flexed and the position maintained, as is often the case with ruptures of the transverse ligament (Fig. 139.12*A2*), then use a shorter primary incision with the drills and taps passed percutaneously into the primary incision.
- Make a midline incision from occiput to the C-4 spinous process, exposing the posterior arch of C-1 to the C2–C3 facet joint. Carefully dissect with a Penfield elevator to expose the pedicle of C-2 all the way up to the posterior capsule of the C1–C2 joint. Remove the joint capsule. This dissection is done by elevating carefully along the proximal edge of the lamina of C-2 in a lateral direction until the pedicle is identified. Take care at this point to sweep the soft tissues proximally over the C-1 lateral mass rather than incise them because the greater occipital nerve and a very friable complex of thin-walled venous lakes overlie those structures. Significant bleeding may occur.
- Clearly dissect the medial aspect of the pedicle (Fig. 139.12*B*). The landmarks for the starting holes for the drill need to be near the medial edge of the facet and inferior margin of the lamina.
- Hold the soft tissue out of the way by placing a small K-wire below it drilled into the upper edge of the facet (Fig. 139.12*C*).
- Elevate the ligamentum flavum from under the posterior arch, and pass a sublaminar wire (Fig. 139.12*E*). Gentle traction on the wire may be needed to reduce any residual subluxation. The wire will be used later to secure the bone graft.
- Drill a guidewire under fluoroscopic visualization, entering the most inferior aspect of the C-2 lamina, 2 to 3 mm lateral to the medial border of the C-2 pedicle.
- The orientation of the drill should be from the medial starting hole to slightly lateral; do this by direct visualization of the path. It is important to monitor the position on the lateral image carefully so that the drill exits the C-2 lateral mass at its posterior aspect (Fig. 139.12*E*).
- Advance the wire slowly toward the posterior rim of the superior facet of C-2, across the joint, and into the middle or posterior third of the inferior articular process of C-1. Advance the wire toward the superior margin of the anterior arch of C-1. A percutaneous approach through the soft tissues at the C6–C7 level is sometimes necessary to obtain the correct trajectory.
- Use a cannulated screw system to simplify the remaining steps, but take great care because inadvertent advancement of the guidewire can cause significant injury. This method requires constant imaging.
- Drill and tap for 3.5 or 4 mm screw and determine the depth (Fig. 139.12*F*). A 3.5 mm fully threaded screw is most commonly used, with the length varying between 40 and 50 mm, depending on patient size and screw trajectory.
- Next, harvest a rectangular tricorticocancellous bone graft and notch it to fit between the decorticated spinous process of C-2 and posterior arch of C-1.
- Secure it in place with the sublaminar wire previously passed using Gallie technique.

Immobilize the patient postoperatively with a rigid collar for 6 to 8 weeks if no posterior arch fracture is present. If a posterior arch fracture is present or if the fixation is weak, immobilize the patient for 12 weeks in either a halo vest or suboccipital-mandibular immobilization (SOMI)-type brace.

In the interest of preserving as much rotational motion as possible, a direct anterior screw fixation technique has been recommended by some and has shown high union rates, requiring only limited postoperative immobilization (Fig. 139.13) (8,47). The complication rates, however, have been reported to be as high as 20%. The indications include acute type II fractures and very selected type III fractures without much C-2 body involvement. Contraindications include comminuted fractures, associated unstable ring fractures, atypical oblique coronal fractures, irreducible fractures, and nonunion with poor bone quality. It is essential that the fracture be reducible; reducibility must be verified preoperatively with either fluoroscopy or plain radiographs. A small amount of displacement significantly decreases the area available for insertion of the screw. Large amounts of cervicothoracic kyphosis make this procedure technically unfeasible because adequate space must be available for the correct screw trajectory. This procedure is technically difficult in posteriorly displaced fractures because reduction will be lost as extension of the cervical spine as is required to achieve access to C2. The postoperative range of motion has been shown to still be reduced, possibly secondary to adhesions and callus formation.

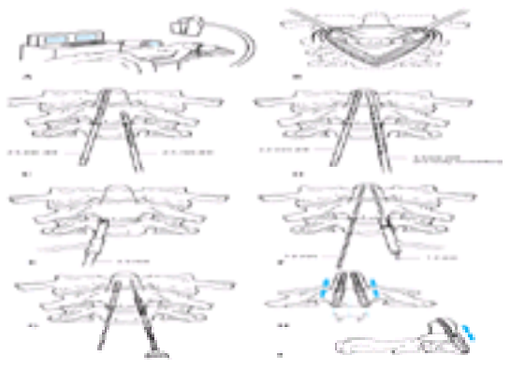

***Figure 139.13.*** Direct anterior screw fixation technique. See text for details. [Part (**A**) redrawn from Grob D, Magerl F. Operative Stabilisirrung bei Frakturen von C1 and C2. *Orthopade* 1987:16; parts (**B** to **I**) redrawn from Muller ME, Allgower M, Schneider R, et al., eds. *Manual of Internal Fixation Techniques Recommended by the AO-ASIF Group,* ed 3. Berlin: Springer-Verlag, 1991:638, with permission.]

*Anterior Screw Fixation of the Odontoid*

- Positioning of the patient for anterior dens osteosynthesis is critically important. Place the patient in the supine position with the neck extended so that exposure of the inferior edge of C-2 is possible. Rest the head on a Mayfield horseshoe head support. If fracture reduction is lost (as may happen with posteriorly displaced dens fractures), use less extension until provisional fixation has been achieved. Biplanar image intensification monitoring is essential (Fig. 139.13*A*). Perform an awake fiberoptic intubation and document the neurologic status. Aid reduction by placing a rolled towel under the neck for anterior displacement and under the head for posterior displacement.
- Set up fluoroscopy so that satisfactory AP and lateral views can be obtained; simultaneous imaging is preferred.
- When reduction is obtained, make a standard anterior lateral approach through a transverse incision centering the incision at the C5–C6 level (Fig. 139.13*B*)
- Make a retropharyngeal approach, as described by Smith-Robinson (see Chapter 138), at the C5–C6 disc space level and carry the dissection up to the C2–C3 disc space. Make an incision in the anterior longitudinal ligament at the level of the inferior portion of the C-2 body. A one- or two-screw technique can then be used.
- Starting 3 mm to either side of the midline and on the caudal edge of the body, medially insert a 1.5 mm K-wire to ascertain trajectory and stabilize the fragment (Fig. 139.13*C*). Insert it across the fracture into the center of the odontoid. Two K-wires can be placed and a cannulated system used, but inadvertent advancement of the wire is a complication; preferably, one wire is removed and replaced at a time with a solid 2.5 mm drill bit advancing to the tip of the dens.
- Pass the drill bit over the guidewire and advance it under fluoroscopic control. Take care—there have been instances in which the guidewire has been advanced into the spinal cord.
- Because a lag effect is desired, either a partially threaded screw can be used or one drill bit can be removed and the near fragment overdrilled with a 3.5 mm drill bit (Fig. 139.13*D*). Tap the near cortex only (Fig. 139.13*E*, Fig. 139.13*F* and Fig. 139.13*G*). Be sure that all threads of this lag screw are across the fracture site.
- Final screw fixation should have the screw slightly oblique toward the midline and optionally may perforate the cortex of the tip of the dens (Fig. 139.13*H* and Fig. 139.13*I*). Take care to begin the screw on the undersurface and not the anterior surface of the C-2 body to achieve the proper trajectory (Fig. 139.13*I*).

Studies have shown no significant increase in biomechanical stability with two screws, and anatomic studies have revealed that some odontoids are of inadequate size to accommodate two screws (1,8,28,59). Postoperative immobilization in a Philadelphia collar for 6 weeks is generally sufficient.

**Traumatic Spondylolisthesis of the Axis** Traumatic spondylolisthesis of the axis is a fracture that occurs through the pars interarticularis usually at its junction with the posterior aspect of the vertebral body. Such fractures are relatively uncommon and the mechanism of injury varies with the fracture type. These usually occur in motor vehicle accidents in which the head strikes the windshield or dashboard. The amount of displacement and angular deformity is related to the amount of rebound occurring from the associated acceleration and deceleration forces. These fractures are generally not associated with significant neurologic deficits because most of the injury patterns expand the canal diameter. As with fractures of the atlas, if a deficit is present, it may be related to a head injury or to some associated injury. Diligently search for associated injuries that can occur in up to 30% of patients with these fractures. Most of the concurrent injuries occur in the adjacent three cervical levels (56).

Several different classification systems have been used to describe traumatic spondylolisthesis of the axis. The systems have been based on either instability criteria (34), mechanism of injury (56), or anatomic or radiologic criteria (25,56,81). The classification most commonly used now is based on four patterns, each of which has both common radiographic and mechanistic characteristics (Fig. 139.14) (56).

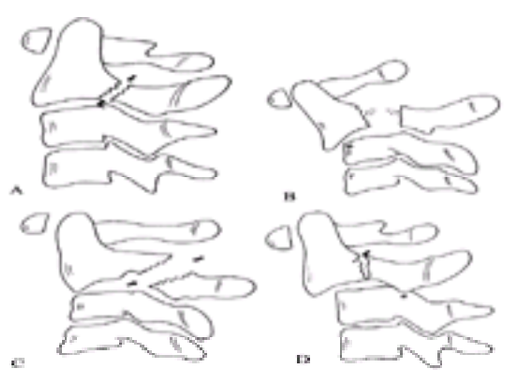

***Figure 139.14.*** Traumatic spondylolisthesis of the axis can be characterized by the amount of translation and angulation at the fracture site. **A:** In a type I injury, the fracture line is either vertical or slightly off vertical *(arrows)*. **B:** In a type II injury, the fracture line is relatively vertical with wide separation of the fragments *(arrows)*. These are characterized by more than 3 mm of translation and significant angulation as well. They frequently demonstrate a compression of the anterosuperior corner of the body of C-3 as a result of the flexion force that caused the anterior translation *(star)*. In this case, avulsion of the anterosuperior corner of the body has occurred. **C:** Type IIA traumatic spondylolisthesis is different in its mechanism from type I and II injuries. Frequently, the fracture lines are more oblique *(arrows)* and are not located as close to the junction of the body and the pedicle as in the type I and II injuries. **D:** Type III traumatic spondylolisthesis of the axis combines fractures of the neural arch with facet injuries at C2–C3. The first type is a bilateral facet dislocation at C2–C3 *(star)* with a type I Hangman's fracture at the base of the body–pedicle junction *(arrowhead)*. (From Levine AM, Eismont FJ, Garfin SR, Zigler JE. *Spine Trauma.* Philadelphia: W. B. Saunders Co., 1998, with permission.)

A type I injury has a fracture through the pedicles of C-2, just posterior to the junction of the body and the pedicles. A type I injury (Fig. 139.14*A*) is either a nondisplaced fracture or minimally displaced, with less than 3 mm of displacement and no angulation. It usually results from an axial load with an associated hyperextension moment. The type IA, or atypical hangman's pattern (81), involves a fracture between the junction of the pedicle and the body of C-2 in which, at least on one side, a portion of the posterior wall breaks off and remains attached to the pedicle. The significance of this pattern is that, if there is any displacement, the cord can be compressed between the ring of C-1 and the retained portion of the posterior wall. The fracture line frequently traverses the foramen for the vertebral artery and may result in intimal damage. A higher incidence of neurologic deficits is associated with this pattern.

The type II injury (Fig. 139.14*B*) involves displacement and angulation of C-2 on C-3. A type II injury is the result of a hyperextension axial load, which breaks the neural arch, followed by a flexion injury, which results in significant translation. The pattern of the fracture line is similar to that seen with a type I injury.

The type IIA injury (Fig. 139.14*C*) has only minimal translation of C-2 over C-3 but has severe angulation. The type IIA injury is characterized by minimal translation and significant angulation with widening of the posterior aspect of the disc space. With application of traction, these are the injuries that will demonstrate significant widening of the disc. The mechanism is different in that this type of injury occurs as a result of a flexion distraction force. The fracture line, instead of being vertical at the junction of the pedicle and the body is obliquely through pedicle. Traction may produce distraction, leading to potential neurologic injury.

The type III injury (Fig. 139.14*D*) is a pars fracture with an associated C2–C3 unilateral or bilateral facet dislocation. The mechanism most probably is initial flexion-distraction, which causes the dislocation, and then extension, which causes the traumatic spondylolisthesis. Reversing the mechanism would not permit the dislocation to occur, because the inferior facet of C-2 would then be detached from the cervicocranium, which serves as the lever for the dislocation. This pattern is associated with a higher incidence of neurologic deficits.

Radiologic evaluation and determination of the traumatic spondylolisthesis can usually be made on a lateral cervical spine roentgenogram. However, because most radiographs of this injury are performed in the supine position, the true nature of the injury may be obscured because any displacement may be reduced in the supine position. Thus, to ensure that the injury is indeed a type I, physician-supervised flexion-extension radiographs are necessary to differentiate it from a reduced type II. In order to undergo flexion-extension radiographs, patients must be awake, alert, and neurologically intact, and able to perform the flexion extensor maneuver themselves. Atypical hangman's fractures may require axial images from a CT scan to fully appreciate the direction and extent of the fracture lines. Finally, in type III injuries, a CT scan with reconstructions may be necessary to characterize the facet component of the injury.

Treat type I injuries nonoperatively with a rigid collar for 8 to 12 weeks. Late-onset degenerative arthritic changes can occur in up to 30% of patients because the initial injury causes severe impaction forces across the facet joint, which can be destructive to the articular cartilage. Patients with type I injuries do not go on to spontaneous ankyolsis across the C2–C3 disc, as is seen in type II injuries. Treat type II injuries with significant amounts of displacement or angulation initially by reduction using skeletal traction in a slight amount of extension followed by a halo vest for 12 weeks. It is not uncommon for some reduction to be lost in the halo vest, but this loss of reduction usually does not lead to any long-term consequences. If the displacement is in the range of 6 to 7 mm, alignment is maintained with a period of 4 to 6 weeks in halo traction, followed by another 6 weeks in the halo vest. Alternatively, after reduction in traction a direct osteosynthesis of the fracture can be accomplished with a lag screw. Treat type IIA injuries with a halo vest placed in compression and extension. This is achieved by placing the halo vest on the patient in a routine fashion and

then using the bolts on the uprights to compress the ring down toward the vest.

Type III fracture pattern injuries, in contrast, require immediate surgery. When this fracture pattern is identified, closed reduction should not even be attempted because it is rarely achieved and is potentially dangerous. Even if it is achieved, the remaining instability present is enough to warrant arthrodesis. A preoperative MRI is performed to evaluate the C2–C3 disc. The goal of surgical treatment is to stabilize the C2–C3 facet joint. This can be accomplished with a C2–C3 posterior plate with a C-2 pedicle screw and a lateral mass screw at C-3.

*Reduction and Stabilization of a Type III Hangman's Fracture*

- Carry out a fiberoptic, awake intubation and turn the patient prone on a Stryker frame. Check the patient's neurologic status and induce general anesthesia. Check lateral position on fluoroscopy or plain radiographs. High-quality biplanar flouroscopy is required to monitor the trajectory of the screws.
- Make a standard approach to the posterior cervical spine from the occiput down to C3–C4 level and expose the C2–C3 and C3–C4 facet joints. Use an elevator to dissect the medial aspect of the C-2 pedicle.
- The facet joint at C1–C2 does not need to be disrupted, but dissection from posterior to anterior toward the facet will usually demonstrate the fracture of the pedicle.
- Then carry out the reduction of the unilateral or bilateral facet dislocation at C2–C3. Place towel clips on the spinous processes of C-2 and C-3. Spread the spinous processes apart with a slight amount of flexion. This should unlock the jumped facets. Apply a posterior translation force to the C-2 spinous process as the towel clamps are brought together to achieve the final reduction.
- A bilateral subluxation is generally easier to reduce than a unilateral subluxation because of the increased ligamentous damage. Traction is not effective in this situation because the break in the pars of C-2 prevents any force from being transmitted to the C2–C3 joint level. Rarely, the C2–C3 facets need to be unlocked manually.
- Place a Freer or small Cobb elevator into the facet joint and gently elevate the C-2 facet until it becomes level with the C-3 facet. Then apply a posterior translation force to the towel clip on C-2 as the elevator is slowly removed to achieve reduction. After reduction is obtained, the C2–C3 joint must be stabilized. A standard interspinous process wiring or C2–C3 lateral mass plating can be used; however, the pedicle fracture would then be treated as a type II Hangman's fracture with 12 weeks in a halo vest.
- An alternative method of fixation is to insert a C-2 pedicle screw to secure the pedicle fracture (Fig. 139.15*A*, Fig. 139.15*B*, Fig. 139.15*C* and Fig. 139.15*D*) (72). If this technique is used, a partially threaded lag screw must be placed so that the threads are beyond the fracture site to prevent any distraction.

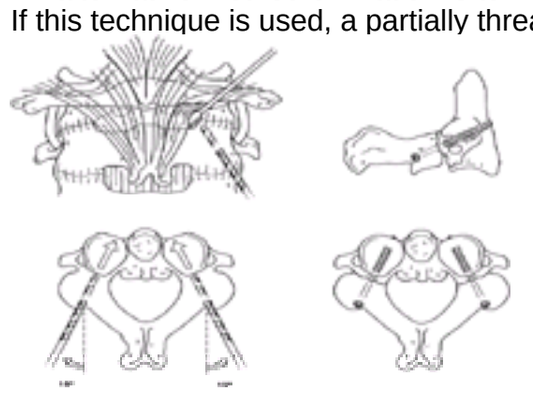

***Figure 139.15.*** **A:** The surgical technique for osteosynthesis of a traumatic spondylolisthesis of the axis. See the text for a description of the technique. **B:** Orientation of the drills along the pedicle in an axial plane. Slight convergence of the screws is desirable. **C:** Orientation across the fracture line from the posterior fracture to the anterior fragment. A partially threaded screw, with usually about 15 mm of thread and 20 mm of shank, is desirable. The proximal fragment can be overdrilled and lagged to the anterior fragment. **D:** The final axial view.

- Before beginning screw insertion, take care that the fracture is as reduced as possible and that a #4 Penfield elevator can be placed along the medial border of the pedicle for guidance.
- Verify the trajectory of the pedicle and the location of the vertebral arteries on a preoperative CT scan. Palpate the medial wall and gently retract the epidural soft tissue medially. The fracture site and posterior body should be seen. Then pass a drill, starting at the center of the facet and directed along the pedicle into the body beyond the fracture site.
- Select a plate of the appropriate length and contour to fit the lateral masses of C-2 and C-3.
- Place a partially threaded screw through the plate across the pedicle fracture. The threads should be beyond the fracture site, and no distraction of the pedicle fracture should be observed.
- Place a standard C-3 lateral mass screw through the plate.
- A rigid collar for 12 weeks is needed for postoperative immobilization.

Surgery is warranted for the other types of fracture patterns only if there is an associated cervical fracture that requires fixation, if conservative treatment fails, or if the use of a halo is contraindicated. A C-2 pedicle screw (Fig. 139.15*A*, Fig. 139.15*B*, Fig. 139.15*C* and Fig. 139.15*D*) can be used and offers immediate stability to the fracture. The starting point for the screw is just medial to the C2–C3 facet joint on the inferior edge of the lamina. Check the starting point on a lateral fluoroscopic view. A preoperative CT scan is necessary to identify the angle of the pedicle and the location of the vertebral artery. Use a rigid collar for 8 weeks for postoperative immobilization. Anterior arthrodesis for this injury has also been used with mixed results (40,41,87).

The results of treatment are related to the injury type. For type I fractures, union rates approach 98%. Recognition of other associated injuries is important because these fractures can occur with posterior arch fractures or odontoid fractures. The result of these combined injuries follows that of the associated fracture. The most common long-term problem of type I fractures is arthritic degeneration of the C2–C3 facet joint, which occurs in approximately 10% of injuries. For type IA fractures, the results are related to the fracture pattern but generally are similar to type I fractures. For type II fractures, displacement of 5 mm or more between the anterior and posterior fragments yields a high incidence of nonunion, although more than 70% go on to develop anterior fusions of the disc space. Injuries with symptomatic nonunion and large gaps are generally not amenable to C-2 pedicle screw fixation and require an anterior C2–C3 fusion. The results of type III fractures depend on the severity of the commonly associated head injuries and neurologic deficits. The overall success rate of fusion after reduction is achieved is quite high.

**Extension Teardrop Fractures** Although a number of different types of “teardrop fractures” have been described since the term was first used by Schneider and Kahn in 1956 (76) the two most common types are the flexion variant, which occurs in the lower cervical spine, and the extension type, which occurs predominantly in the upper cervical spine. The extension type of injury results from a hyperextension and axial loading mechanism and may be observed in combination with posterior arch fractures of the atlas and traumatic spondylolisthesis of the axis. The injury can be easily diagnosed on a lateral roentgenogram of the cervical spine. The triangular fragment usually comprises approximately 50% of the height and 50% of the width of the body. The vertebral body of C-2 remains in normal alignment with the body of C-3, but the avulsed fragment is rotated anteriorly (Fig. 139.16). This is in contradistinction to flexion teardrop injuries, in which the fragment remains in relatively normal orientation to the bodies above and below and the affected body is rotated posteriorly.

***Figure 139.16.*** Extension teardrop fracture.

These injuries are uniformly stable, although they may occur in combination with unstable contiguous injuries in the upper cervical spine. If they occur alone or in

combination with a stable injury collar, immobilization is sufficient to achieve a satisfactory result. If they occur in combination with an unstable injury, the treatment of the second injury determines the overall treatment.

## PITFALLS AND COMPLICATIONS

The most important aspect of the management of upper cervical spine fractures is diligent and thorough follow-up of the patients after treatment. Progressive deformities and neurologic deficits are more easily dealt with when recognized early. Union must always be verified with maximum flexion-extension radiographs after treatment.

Because the treatment of many of these fractures requires the use of a halo vest, take care in its proper placement and in follow-up. Complications include pin loosening, bone erosion, skull perforation, pin track infections, and cerebrospinal fluid leaks. If a circumferential collar is used, injury to the greater occipital nerve must be recognized because loss of sensation in this area can lead to occipital decubitus ulcers.

Although posterior wiring techniques are successful, the nonunion rates may be as high as 10%. Take care also with the passage of sublaminar wires because neurologic injuries have been reported. Mechanical testing has shown the transarticular screw to be more stable than wiring techniques. The procedure is difficult, but the early concerns of neurologic injury and the sequelae of perforation of one vertebral artery are not as formidable as they were previously thought to be. Clearly, if a vertebral artery injury does occur on one side, do not attempt screw placement on the other side for any reason. Screw malpositions have occurred in approximately 16% of cases, but complications attributable to this problem are rare (less than 2%) and include hypoglossal nerve irritation from excessive screw length, instability from the screws not crossing the joint, and screw breakage.

Anterior odontoid screws are extremely difficult to use and can cause spinal cord injury, cranial nerve injury, and loss of fixation. Other technical problems include incomplete fracture reduction with residual posterior angulation, incorrect screw entry site, and posterior screw angulation. Because of these problems, only experienced spine surgeons should use transarticular or anterior odontoid screws.

The occipitocervical fusion with plate and screws has added significant benefits to traditional wiring techniques. Complications are associated with the placement of the Magerl screw, as described previously. Leakage of CSF is not uncommon with the placement of bicortical occipital screws, but no persistent leaks or significant problems have been reported.

## AUTHORS' PERSPECTIVE

Injuries of the upper cervical spine encompass a wide spectrum of not only fractures but also patterns of instability that result from ligamentous disruption. The most critical features of the treatment of these injuries are to appreciate the true nature of the instability and the pertinent regional anatomy. Injuries of the upper cervical spine have often been treated more aggressively than necessary (e.g., halo vest for a posterior arch fracture or a Type I hangman's fracture). Surgery is often not necessary if appropriate use of nonoperative modalities are employed.

More recently, however, innovative surgical techniques have appeared that have been applicable to the upper cervical spine injuries. The Magerl C1–C2 transarticular screw fixation has simplified fixation for several different types of injuries. However, the rationale for surgery has sometimes been the desire not to use a halo as the immobilization device. Clearly, the risks and benefits have to be discussed with the patient in an objective fashion before the final treatment decision is made. For example, elderly patients have been reported to have difficult times tolerating a halo as an immobilization device, and physicians have resorted to operative procedures that also have high rates of morbidity. For example, the use of an anterior dens screw in the elderly patient with a Type II fracture without neurologic deficit may have more morbidity than halo immobilization. More recent studies suggest that less rigid immobilization may yield acceptable patient outcomes without either the risks of surgery or a halo. Accurate assessment of the true significance of the injury and its effect on spine stability will ultimately yield the best patient outcomes.

### CHAPTER REFERENCES

Each reference is categorized according to the following scheme: *, classic article; #, review article; !, basic research article; and +, clinical results/outcome study.


+ 1. Aebi M, Etter C, Cosica M. Fractures of the Dens: Treatment with Anterior Screw Fixation. *Spine* 1989;14:1065.

+ 2. Alker GH, Oh YS, Leslie FV, et al. Postmortem Radiology of Head and Neck Injuries in Fatal Traffic Accidents. *Radiology* 1975;114:611.

+ 3. Anderson LD, D'Alonzo RT. Fractures of the Odontoid Process of the Axis. *J Bone Joint Surg [Am]* 1974;56:1663.

+ 4. Anderson PA, Montesano PX. Morphology and Treatment of Occipital Condyle Fractures. *Spine* 1988;13:731.

+ 5. Apple JS, Kirks DR, Merten DF, et al. Cervical Spine Fractures and Dislocations in Children. *Pediatr Radiol* 1987;17:45.

+ 6. Apuzzo MLJ, Heiden JS, Weiss MH, et al. Acute Fractures of the Odontoid Process: An Analysis of 45 Cases. *J Neurosurg* 1978;48:85.

+ 7. Berkheiser EJ, Seidler F. Nontraumatic Dislocations of the Atlantoaxial Joint. *JAMA* 1931;96:517.

+ 8. Böhler J: Anterior stabilization for acute fractures and non-unions of the dens. J. Bone Joint Surg Am 64:18, 1982.

+ 9. Botte MJ, Byrne TP, Garfin SR. Application of the Halo Fixation Device Using an Increased Torque Pressure. *J Bone Joint Surg [Am]* 1987;69:750.

+ 10. Botte MJ, Byrne, TP, Garfin SR. Use of Skin Incisions in the Application of Halo Skeletal Fixator Pins. *Clin Orthop* 1989;246:100.

+ 11. Bracken MB, Shepard MJ, Holford PR, et al. Administration of Methylprednisolone for 24 or 48 Hours or Tirilizad Mesylate for 48 Hours in the Treatment of Acute Spinal Cord Injuries: Results of the Third National Acute Spinal Cord Injury Randomized Controlled Study—National Acute Spinal Cord Injury Study. *JAMA* 1997;277:1597.

+ 12. Brooks A, Jenkins E. Atlantoaxial Arthrodesis by the Wedge-compression Method. *J Bone Joint Surg [Am]* 1978;60:279.

+ 13. Bucholz RW, Burkhead WZ. The Pathological Anatomy of Fatal Atlanto-occipital Dislocations. *J Bone Joint Surg [Am]* 1979;61:248.

+ 14. Clark CR, White AA. Fractures of the Dens. *J Bone Joint Surg [Am]* 1985;67:1340.

+ 15. Clyburn TA, Lionberger DR, Tullos HS. Bilateral Fracture of the Transverse Process of the Atlas. *J Bone Joint Surg [Am]* 1982;64:948.

+ 16. Crisco JJ III, Oda T, Panjabi MM, et al. Transections of the C1-C2 Joint Capsular Ligaments in the Cadaveric Spine. *Spine* 1991;16(Suppl):S474.

+ 17. Davis D, Bohlman H, Walker AE, et al. The Pathological Findings in Fatal Craniospinal Injuries. *J Neurosurg* 1971;34:603.

+ 18. Dickman CA, Mamourian A, Sonntag VKH, et al. Magnetic Resonance Imaging of the Transverse Atlantal Ligament for the Evaluation of Atlantoaxial Instability. *J Neurosurg* 1991;75:221.

+ 19. Dunn ME, Seljeskog EL. Experience in the Management of Odontoid Process Injuries: An Analysis of 128 Cases. *Neurosurgery* 1986;18:306.

+ 20. Dvorak J, Hayek J, Zehnder R. CT-functional Diagnostics of the Rotatory Instability of the Upper Cervical Spine: II. An Evaluation on Healthy Adults and Patients with Suspected Instability. *Spine* 1987;12:726.

! 21. Dvorak J, Panjabi M, Gerber M, et al. CT-functional Diagnostics of the Rotatory Instability of the Upper Cervical Spine: I. An Experimental Study on Cadavers. *Spine* 1987;12:197.

! 22. Dvorak J, Panjabi M. Functional Anatomy of the Alar Ligaments. *Spine* 1987;12:183.

! 23. Dvorak J, Schneider E, Saldinger P, et al. Biomechanics of the Craniocervical Region: The Alar and Transverse Ligaments. *J Orthop Res* 1988;6:452.

! 24. Ebraheim NA, Lu J, Bijani A, et al. An Anatomic Study of the Thickness of the Occipital Bone: Implications for Occipitocervical Instrumentation. *Spine* 1996;21:1725.

+ 25. Effendi B, Roy D, Cornish B, et al. Fractures of the Ring of the Axis: A Classification Based on the Analysis of 131 Cases. *J Bone Joint Surg [Br]* 1981;63:319.

+ 26. Eismont FJ, Bohlman HH. Posterior Atlanto-occipital Dislocation with Fractures of the Atlas and Odontoid Process. *J Bone Joint Surg [Am]* 1978;60:397.

+ 27. Ersmark H, Kalen R. Injuries of the Atlas and Axis: A Follow-up Study of 85 Axis and 10 Atlas Fractures. *Clin Orthop* 1987;217:257.

+ 28. Etter C, Coscia M, Jaberg H, et al. Direct Anterior Fixation of Dens Fractures with a Cannulated Screw System. *Spine* 1991;16(Suppl 3):S25.

* 29. Fielding JW, Cochran GVB, Lawsing JF, et al. Tears of the Transverse Ligament of the Atlas. *J Bone Joint Surg [Am]* 1974;56:1683.

* 30. Fielding JW, Hawkins RJ, Ratzan SA. Spine Fusion for Atlantoaxial Instability. *J Bone Joint Surg [Am]* 1976;58:400.

* 31. Fielding JW, Hawkins RJ. Atlantoaxial Rotatory Fixation. *J Bone Joint Surg [Am]* 1977;59:37.

# 32. Fielding JW, Hawkins RJ. Roentgenographic Diagnosis of the Injured Neck. *Instruct Course Lect* 1976;25:149.

+ 33. Fielding JW, Stillwell WT, Chynn KY, et al. Use of Computed Tomography for the Diagnosis of Atlantoaxial Rotatory Fixation. *J Bone Joint Surg [Am]* 1978;60:1102.

+ 34. Francis WR, Fielding, JW, Hawkins RJ, et al. Traumatic Spondylolisthesis of the Axis. *J Bone Joint Surg [Br]* 1981;63:313.

* 35. Gallie W. Fractures and Dislocations of the Cervical Spine. *Am J Surg* 1939;46:495.

! 36. Garfin SR, Botte MJ, Centeno RS, et al. Osteology of the Skull as it Affects Halo Pin Placement. *Spine* 1985;10:696.

! 37. Goel VK, Winterbottom JM, Schulte KR, et al. Ligamentous Laxity Across C0-C1-C2 Complex: Axial-torque Rotation Characteristics Until Failure. *Spine* 1990;15:990.

+ 38. Grob D, Dvorak J, Panjabi MM, et al. Posterior Occipitocervical Fusion: A Preliminary Report of a New Technique. *Spine* 1991;16:17.

+ 39. Grob D, Dvorak J, Panjabi MM, et al. The Role of Plate and Screw Fixation in Occipitocervical Fusion in Rheumatoid Arthritis. *Spine* 1994;19:2545.

+ 40. Hadley MN, Browner C, Sonntag VKH: Axis Fractures: A Comprehensive Review of Management and Treatment in 107 Cases. *Neurosurgery* 1985;17:281.

+ 41. Hadley MN, Dickman CA, Browner CM, et al. Acute Axis Fractures: A Review of 229 Cases. *J Neurosurg* 1989;71:642.

+ 42. Han SY, Witten DM, Mussleman JP. Jefferson Fracture of the Atlas. *J Neurosurg* 1976;44:368.

+ 43. Hays MB, Alker GJ. Fractures of the Atlas Vertebra: The Two-part Burst Fracture of Jefferson. *Spine* 1988;13:601.

! 44. Heller JG, Alson MD, Schafler MB, et al. Quantitative Internal Dens Morphology. *Spine* 1992;17:861.

# 45. Jarrett PJ, Whitesides TE Jr. Injuries of the Cervicocranium. In Browner BD, Jupiter JB, Levine AM, et al, eds. *Skeletal Trauma: Fractures, Dislocations, Ligamentous Injuries,* Vol 1. Philadelphia: WB Saunders Co., 1992:668.

+ 46. Jeanneret B, Magerl F. Primary Posterior Fusion of Cl-2 in Odontoid Fractures: Indications Technique, and Results of Transarticular Screw Fixation. *J Spinal Disord* 1992;5:464.

+ 47. Jeanneret B, Vernet O, Frei S, Magerl F: Atlantoaxial Mobility after Screw Fixation of the Odontoid: A Computed Tomographic Study. *J Spinal Disord* 1991;4:203.

* 48. Jefferson G. Fracture of the Atlas Vertebra. *Br J Surg* 1920;7:407.

* 49. Jefferson G. Fractures of the First Cervical Vertebra. *Br Med J* 1927;July 30:153.

+ 50. Kowalski HM, Cohen WA, Cooper P, et al. Pitfalls in the CT Diagnosis of Atlantoaxial Rotary Subluxation. *AJR* 1987;149:595.

+ 51. Lee C, Woodring JH, Goldstein SJ, et al. Evaluation of Traumatic Atlanto-occipital Dislocations. *Am J Neuroradiol* 1987;8:19.

+ 52. Lee S, Joyce S, Seeger J. Asymmetry of the Odontoid-lateral Mass Interspaces: A Radiographic Finding of Questionable Clinical Significance. *Ann Emerg Med* 1986;15:1173.

+ 53. Lesoin F, Blondel M, Dhellemmes P, et al. Post-traumatic Atlanto-occipital Dislocation Revealed by Sudden Cardiorespiratory Arrest. *Lancet* 1982;2:447.

+ 54. Leventhal MR, Maguire JK Jr, Christian CA. Atlantoaxial Rotary Subluxation in Ankylosing Spondylitis: A Case Report. *Spine* 1990;15:1374.

+ 55. Levine AM, Edwards CC. Fractures of the Atlas. *J Bone Joint Surg [Am]* 1991;73:680.

+ 56. Levine AM, Edwards CC. The Management of Traumatic Spondylolisthesis of the Axis. *J Bone Joint Surg [Am]* 1985;67:217.

# 57. Levine AM, Edwards CC. Treatment of Injuries in the Cl-C2 Complex. *Orthop Clin North Am* 1986;17:31.

+ 58. Lipson SJ. Fractures of the Atlas Associated with Fracture of the Odontoid Process and Transverse Ligament Ruptures. *J Bone Joint Surg [Am]* 1977;59:940.

* 59. Magerl F, Seemann PS. Stable Posterior Fusion of the Atlas and Axis by Transarticular Screw Fixation. In: Kehr P, Weidner A, eds. *Cervical Spine.* Berlin: Springer-Verlag, 1986:322.

+ 60. Maiman DJ, Larson SJ. Management of Odontoid Fractures. *Neurosurgery* 1982;11:471.

+ 61. Martel W. The Occipito-atlantoaxial Joints in Rheumatoid Arthritis and Ankylosing Spondylitis. *AJR* 1961;86:223.

# 62. McGuire RA, Harkey HL. Unstable Jefferson's Fracture Treated with Transarticular Screws. *Orthopedics* 1995;18:207.

+ 63. Ono K, Yonenobu K, Fuji T, et al. Atlantoaxial Rotatory Fixation: Radiographic Study of its Mechanism. *Spine* 1985;10:602.

! 64. Panjabi M, Dvorak J, Duranceau J, et al. Three Dimensional Movements of the Upper Cervical Spine. *Spine* 1988;13:726.

+ 65. Paramore CG, Dickman CA, Sonntag V. The Anatomic Suitability of the C1-C2 Complex for Transarticular Screw Fixation. *J Neurosurg* 1996;85:221.

+ 66. Parke WW. The Vascular Relations of the Upper Cervical Vertebrae. *Orthop Clin North Am* 1978;9:879.

! 67. Paul LW, Moir WW. Non-pathologic Variations in Relationship of the Upper Cervical Vertebrae. *AJR* 1949;62:519.

+ 68. Penning L. Paravertebral Hematoma in Cervical Spine Injury: Incidence and Etiologic Significance. *AJR* 1981;136:553.

! 69. Penning L, Wilmink JT. Rotation of the Cervical Spine. A CT Study in Normal Subjects. *Spine* 1987;12:732.

+ 70. Phillips WA, Hensinger RN. The Management of Rotatory Atlantoaxial Subluxation in Children. *J Bone Joint Surg [Am]* 1989;71:664.

+ 71. Powers B, Miller MD, Kramer RS, et al. Traumatic Anterior Atlanto-occipital Dislocation. *Neurosurgery* 1979;41:12.

+ 72. Roy-Camille R, Saillant G, Bouchet T. Technique du Vissage des Pedicules de C2. In: Roy-Camille R, ed. *Cinquiemes Journees d'Orthopedie de la Pitie, Rachis Cervical Superieur.* Paris: Masson, 1986:41.

+ 73. Sakou T, Kawaida H, Morizino Y, et al. Occipitoatlantoaxial Fusion Utilizing a Rectangular Rod. *Clin Orthop* 1989;239:136.

! 74. Schaffler MB, Alson MB, Heller JG, et al. Morphology of the Dens: A Quantitative Study. *Spine* 1992;17:738.

+ 75. Schlicke LH. A Rational Approach to Burst Fractures of the Atlas. *Clin Orthop* 1981;154:18.

+ 76. Schneider RC, Kahn EA. Chronic Neurological Sequelae of Acute Trauma to the Spine and Spinal Cord, Part I: The Significance of the Acute Flexion or “Teardrop” Fracture Dislocation of the Cervical Spine. *J Bone Joint Surg [Am]* 1956;28A:985.

+ 77. Segal LS, Grimm JO, Stauffer ES. Non-union of Fractures of the Atlas. *J Bone Joint Surg [Am]* 1987;69:1423.

+ 78. Shkrum MJ, Green RN, Nowak ES. Upper Cervical Trauma in Motor Vehicle Collisions. *J Forensic Sci* 1989;34:381.

+ 79. Sonntag VK, Dickman CA. Craniocervical Stabilization. *Clin Neurosurg* 1993;40:243.

+ 80. Spence KF, Decker S, Sell KW. Bursting Atlantal Fracture Associated with Rupture of the Transverse Ligament. *J Bone Joint Surg [Am]* 1970;52:543.

+ 81. Starr JK, Eismont FJ. Atypical Hangman's Fractures. *Spine* 1993;18:1954.

! 82. Steel HH. Anatomical and Mechanical Considerations of the Atlantoaxial Articulations. *J Bone Joint Surg [Am]* 1968;50:1481.

+ 83. Stewart GC Jr, Gehweiler JA Jr, Laib RH, et al. Horizontal Fracture of the Anterior Arch of the Atlas. *Radiology* 1977;122:349.

* 84. Sudeck P. Torsion Dislocation of Atlas. *Dtsch Z Chir* 1924;183:289.

+ 85. Templeton PA, Young JWR, Mirvis S, et al. The Value of Retropharyngeal Soft Tissue Measurements in Trauma of the Adult Cervical Spine. *Skeletal Radiol* 1987;30:1.

+ 86. Traynelis VC, Marano GD, Dunker RO, et al. Traumatic Atlanto-occipital Dislocation. *J Neurosurg* 1986;65:863.

+ 87. Tuite GF, Papadopoulos MD, Sonntag VK. Caspar Plate Fixation for the Treatment of Complex Hangman's Fractures. *Neurosurgery* 1992;30:761.

+ 88. Wang G-J, Mabie KN, Whitehill R, et al. Nonsurgical Management of Odontoid Fractures in Adults. *Spine* 1984;9:229.

+ 89. Werne S. Studies in Spontaneous Atlas Dislocation. *Acta Orthop Scand* 1957;23(Suppl):1.

+ 90. Wertheim SB, Bohlman HH. Occipito-cervical Fusion. Indications, Techniques, and Results in 13 patient. *J Bone Joint Surg [Am]* 1987;69:833.

+ 91. Wetzel FT, La Rocca H. Grisel's Syndrome: A Review. *Clin Orthop* 1989;240:141.

# 92. White AA III, Panjabi MM. *Clinical Biomechanics of the Spine.* Philadelphia: JB Lippincott, 1991.

+ 93. White GM, Healy WI. Tumor-associated Atlantoaxial Rotatory Fixation: A Case Report. *Spine* 1987;12:406.

+ 94. Zimmerman E, Grant J, Vise WM, et al. Treatment of Jefferson Fracture with a Halo Apparatus. *J Neurosurg* 1976;44:372.

# CHAPTER 140

# FRACTURES AND DISLOCATIONS OF THE CERVICAL SPINE FROM C-3 TO C-7

*Michael J. Goebel, Charles Carroll, IV, and Paul C. McAfee*

**M. J. Goebel:** Blue Ridge Bone and Joint, Asheville, North Carolina, 28801.
**C. Carroll, IV:** Department of Clinical Orthopaedic Surgery, Northwestern University Medical School, Chicago, Illinois, 60611.
**P. C. McAfee:**Division of Spinal Surgery, St. Joseph's Hospital, Baltimore, Maryland, 21204.

Principles of Treatment
- Initial Care
- Radiographic Evaluation
- Anatomy
- Classification
- Criteria for Instability

Indications for Treatment
- Indications for Nonoperative Treatment
- Indications for Urgent Operative Intervention

Surgical Techniques
- Posterior Instrumentation Options
- Posterior Fusion
- Anterior Instrumentation
- Anterior Fusion

Pitfalls and Complications
- Neurologic
- Spinal Deformity
- Pulmonary
- Gastrointestinal
- Operative
- Bracing

Chapter References

Traumatic injuries to the cervical spine, a common cause of death and disability, range in severity from simple soft-tissue injuries to severe fractures or dislocations with paralysis or death. Cervical spine injuries are often first detected in the emergency room and must be carefully evaluated and managed to minimize adverse sequelae. Early diagnosis, immobilization, preservation or restoration of spinal cord function, and stabilization are the keys to successful management of these injuries.

As many as one third of all cervical spine injuries result from motor vehicle accidents, one third from falls, and the remainder from athletic injuries, falling objects, or fired projectiles (9). Most injuries occur to young and active persons in adolescence or early adulthood. The second-largest group comprises adults in their sixth or seventh decades. In this age group, preexisting spondylosis or stenosis may predispose these patients to severe injuries despite a relatively small amount of force being imparted to the cervical spine.

The formation of spinal cord injury centers has allowed progress in emergency care, medical and surgical intervention, and rehabilitation of the patient who has sustained a spine and/or spinal cord injury. A team approach is important to obtain optimal results. The therapeutic goals are to preserve life, maintain or restore neurologic function, provide stabilization of the cervical spine, and allow optimal rehabilitation. These goals are attainable if appropriate care is provided.

## PRINCIPLES OF TREATMENT

### INITIAL CARE

Care for a patient with a suspected cervical spine injury begins at the scene of the accident. Carefully move the patient to safety and then immobilize her on a long backboard and apply a rigid cervical collar. Stabilize the head by placing sandbags along each side or use tape to secure the forehead to the board. Paramedics or other emergency management team members often perform the initial assessment and resuscitation.

On arrival to the emergency department, continue resuscitation. Follow advanced trauma life support (ATLS) guidelines. If an airway needs to be secured, take care to prevent further cervical injury by utilizing fiberoptic nasotracheal intubation whenever possible. This technique minimizes movement of the injured cervical spine. Intravenous access is mandatory for fluid resuscitation in cases of neurogenic shock.

Obtain a history from the patient, the paramedics, or witnesses to determine the mechanism of injury and the circumstances surrounding the accident. A history of loss of consciousness is important, as the patient may not be able to accurately recall the events as they occurred. In addition, there is a high correlation between head trauma and cervical spine injuries. Make note of the initial neurologic assessment, with attention to any paralysis.

While the history is being obtained, perform a physical exam. The observation of craniofacial trauma can be important in the assessment of the mechanism of injury. If the patient is conscious, gently palpate the anterior and posterior cervical spine to determine the site of pain or swelling. Palpate the posterior elements in the midline posteriorly, noting any increase in the interspinous distance. Palpate the anterior vertebral bodies in the interval between the sternocleidomastoid and the trachea.

Perform a detailed neurologic examination. Note the general state of consciousness as well as respiratory status. The C-3 to C-5 levels innervate the diaphragm. Cord injury above the C-5 level may lead to respiratory failure. If the patient is conscious, perform motor, sensory, and reflex examination of the upper and lower extremities. The American Spine Injury Association (ASIA) spinal cord injury assessment form (Fig. 140.1) provides an excellent checklist to ensure completeness. Use rectal tone and perianal sensation to assess for the presence of sacral sparing. Document the absence or presence of the bulbocavernosis reflex for the determination of spinal shock.

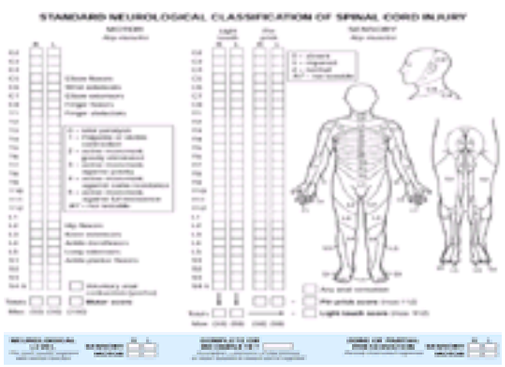

***Figure 140.1.*** American Spine Injury Association (ASIA) spinal cord injury assessment form. (Redrawn with permission from the American Spine Injury Association. *Standard Neurological Classification of Spinal Cord Injury*, revised. Chicago: American Spine Injury Association, 1992.)

In Bohlman's evaluation of 300 cervical spine injuries, 100 were initially missed at the time of presentation (7). Delay in diagnosis ranged from 1 day to 1 year. The common causes for lack of recognition were concomitant closed head injuries, multiple traumatic injuries, alcohol intoxication, and initial misdiagnosis such as cerebrovascular accidents. An alteration in consciousness contributed to the lack of proper evaluation and failure to take appropriate radiographs. Patients with these injuries often do not complain of pain, and facial and neck lacerations may detract from the evaluation of the cervical spine. Nevertheless, the physician always must suspect a cervical spine injury any time there is associated head trauma (7,18).

## RADIOGRAPHIC EVALUATION

As part of the initial trauma assessment, obtain the lateral view of the cervical spine, anteroposterior (AP) view of the chest, and AP view of the pelvis. Approximately 80% of cervical spine fractures can be diagnosed on the initial lateral view if it is adequately done (49,53). Once the patient is stabilized, complete the remaining views of the cervical spine trauma series. This includes the AP, open-mouth odontoid, and bilateral obliques or pillar views. The lateral view must extend to the C7–T1 level to be considered complete (7,36). A swimmer's view may be required to visualize the C7–T1 level in patients with short necks. If visualization still remains questionable, perform a computed tomography (CT) scan (59).

Scrutinize all radiographs carefully for abnormal alignment or fractures. The presence of retropharyngeal soft-tissue swelling is important and may indicate adjacent fractures or ligamentous injuries (20). Loss of facet parallelism, facet overlap, or widening of the distance between adjacent vertebrae may also indicate ligamentous injury. If abnormalities are noted, a CT scan is helpful in defining the compromised structures and the presence of bone or disc fragments within the spinal canal. Ligamentous injuries are best visualized by magnetic resonance imaging (MRI) performed within the first 72 hours (23,45).

## ANATOMY

The vertebrae from C-3 to C-7 are anatomically similar. Little inherent stability is achieved from the interrelationships of the osseous structures, and therefore the integrity of the supporting ligaments is very important (34,40). The anterior and posterior longitudinal ligaments span the length of this region and are firmly adherent to the annulus fibrosis at each level. These ligaments, along with the annulus, are the primary stabilizers of the anterior column. Posteriorly, the interspinous, supraspinous, and facet joint capsules comprise the primary ligamentous stabilizers. The ligamentum flavum becomes important at the extremes of motion (56).

The anterior structures, including the anterior longitudinal ligament and the annulus fibrosis, act as a tension band during extension. Similarly, the posterior longitudinal ligament, supraspinous and interspinous ligaments, and facet capsules act as a tension band in flexion (57). Flexion compresses the anterior column and tensions the posterior column, whereas extension tensions the anterior column and compresses the posterior column. Thus, the anterior and posterior columns are reciprocally affected by sagittal plane motion (27).

Approximately 50% of the flexion and extension arc of the cervical spine is achieved through the occipital cervical articulation. The remainder occurs through the lower cervical vertebrae, ranging from 8° to 17° at each motion segment. Rotation is equally shared between the atlantoaxial joint and the lower cervical vertebrae. Lateral bending in the subaxial region ranges from 4° to 11° at each segment (58).

## CLASSIFICATION

The most widely used classification system of lower cervical spine injuries was published by Allen et al. in 1982 (3). In a retrospective review of 165 cases of lower cervical spine injury, they developed a mechanistic system of classifying closed indirect fractures and dislocations.

Injuries are divided into six groups, each named according to the dominant force vector leading to failure and the position of the cervical spine at the time of injury (Fig. 140.2). The groups include compressive flexion, vertical compression, distractive flexion, compressive extension, distractive extension, and lateral flexion. The three most common groups are compressive flexion, distractive flexion, and compressive extension. The least common are distractive extension and lateral flexion, with vertical compression falling between. *Compressive* indicates that compression accounts for the initial structural failure in a motion segment, whereas *distractive* indicates that tension is the dominant force. The use of *flexion* or *extension* denotes the position of the cervical spine at the time of injury (3).

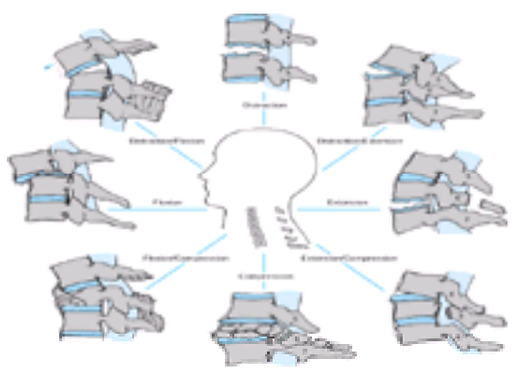

***Figure 140.2.*** Mechanistic classification of lower cervical spine injury. (Modified from Allen BL, Ferguson RL, Lehmann TR, O'Brien RP. A Mechanistic Classification of Closed, Indirect Fractures and Dislocations of the Lower Cervical Spine. *Spine* 1982;7:1, with permission.)

Each group is then classified into various stages, with the higher stages reflecting a greater degree of instability (3). Although the degree of neurologic injury cannot be correlated with the staging, the risk of injury is certainly greater in the advanced stages.

### *Compressive Flexion*

Five stages are recognized in the compressive flexion (CF) group. The force vector is directed anteriorly and inferiorly. In CFS1 injuries, mild blunting of the anterior-superior vertebral body is noted, caused by impression of the more superior vertebrae. In CFS2, the anterior vertebral body loses additional height and becomes wedged, but still without disruption of the posterior ligamentous structures. In CFS3, a fracture line passes obliquely from the anterior vertebral surface to the inferior endplate without displacement. CSF4 injuries have subluxation and displacement of the posterior vertebral wall into the spinal canal, but not exceeding 3 mm. CFS5 injuries involve severe displacement of the body fragment into the canal, as well as increased interspinous distance, facet subluxation, and posterior longitudinal ligament disruption (3).

CFS1 and CFS2 injuries are usually stable and can be treated nonoperatively (47). CFS3–5 injuries may be unstable, and operative intervention may be required to limit late instability (12,13).

### *Distractive Flexion*

Four stages are recognized within the distractive flexion (DF) group. The force vector is directed anteriorly, away from the trunk, with the neck flexed. In DFS1 injuries, posterior ligamentous disruption with facet subluxation and increased interspinous distance is noted. DFS2 represents a unilateral facet dislocation and DFS3 a bilateral facet dislocation. In DFS4, the superior vertebral body is displaced anteriorly, the full width of the body, creating a “floating” vertebra (3).

All distractive flexion injuries should be considered potentially unstable, although DFS1 injuries can commonly be treated nonoperatively. DFS2–4 commonly require operative intervention to prevent late instability (5,7,22,44).

### *Compressive Extension*

Five stages are recognized in the compressive extension (CE) group, although the distinction between the latter stages remains unclear. Unilateral vertebral arch fracture with or without displacement is found in CES1 injuries. Bilateral involvement distinguishes CES2. In CES3–5, comminution of the lamina and lateral masses

occurs with vertebral or disc space separation. In CES5, complete anterior displacement of the superior vertebral body is noted (3).

CES1 and some CES2 injuries may be treated nonoperatively. However, the higher stages, especially CES5, usually require operative stabilization.

#### *Vertical Compression*

Three stages are recognized in the vertical compression (VC) group, in which the force vector is axial. In VCS1 injuries, a fracture occurs through either the superior or the inferior endplate. VCS2 involves a fracture through both endplates, but with minimal displacement. In VCS3, further compression causes the fracture fragments to displace peripherally, possibly through a tear of the posterior longitudinal ligament (3).

The majority of these injuries have a high rate of healing when treated nonoperatively. However, VC3 injuries with canal compromise require operative decompression and stabilization (1,2).

#### *Distractive Extension*

Two stages are identified in the distractive extension (DE) group, in which the force vector is directed posteriorly, away from the trunk, with the head in extension. DES1 injuries involve either a transverse fracture through the vertebral body or disruption of the anterior ligamentous complex. DES2 consists of failure of the posterior ligamentous structures with displacement of the superior vertebral body into the canal (3).

DES1 injuries involving fracture of the vertebrae often heal nonoperatively without deformity. DES2 injuries, however, often require operative intervention.

#### *Lateral Flexion*

Two stages are identified in the lateral flexion (LF) group, in which the force vector is directed laterally. In LFS1 injuries, an ipsilateral vertebral body fracture and neural arch fracture are noted, without displacement. LFS2 progresses to displacement (3). Treatment depends on the extent of the injury, but most LFS1 injuries may be treated nonoperatively.

### CRITERIA FOR INSTABILITY

White and Panjabi (55) have defined clinical instability as the “loss of the ability of the spine under physiologic loads to maintain relationships between vertebrae in such a way that there is neither initial nor subsequent damage to the spinal cord or nerve roots, and in addition, there is neither development of incapacitating deformity nor severe pain.” In this definition, physiologic loads are those incurred during normal daily activity. Incapacitating deformity is defined as gross deformity that the patient finds intolerable. Severe pain is that which cannot be controlled by nonnarcotic medications.

In an effort to systemize this evaluation of clinical instability, White et al. (58) devised a checklist, incorporating both clinical and radiographic parameters. Radiographic parameters for ligamentous instability were established through biomechanical studies. Using fresh cadaveric specimens, serial sectioning of the posterior and anterior ligamentous structures was performed. Abnormal motion of the adjacent vertebrae was then measured. In an otherwise intact spine, instability was defined as translatory displacement of two adjacent vertebrae greater than 3.5 mm, or angulation greater than 11° compared with adjacent motion segments. Based on these and other results, a comprehensive checklist was developed for assessing traumatic instability.

According to this checklist, both clinical and radiographic findings are assigned point values. Assign two points each for anterior elements destroyed or unable to function, posterior elements destroyed or unable to function, relative sagittal plane translation greater than 3.5 mm, relative sagittal plane rotation greater than 11°, positive stretch test, or spinal cord damage. Assign one point each for nerve root damage, abnormal disc space narrowing, or dangerous loading anticipated. If the total point value is equal to or greater than five, assume instability of the motion segment (54).

Although checklists may be useful in the systematic determination of spinal instability, each case should be assessed individually; the importance of certain criteria may vary depending on the specific situation. Of prime importance is spinal cord integrity. When spinal cord injury is caused by extruded bone fragments, or deformity resulting from ligamentous disruption, assume instability. Evidence of isolated nerve root compromise is a weaker indicator of instability.

The stretch test can be particularly useful for evaluating the integrity of the ligamentous structures of the middle and lower cervical spine. This test is performed as follows:

- Apply traction through the use of secure skeletal fixation or a head halter device.
- To reduce frictional forces, place a roller under the patient's head.
- Place the radiographic plate 14 inches from the patient's spine and the tube 72 inches from the plate.
- Take an initial radiograph to ensure no occiput to C-1 to C-2 subluxation.
- Add a 10-pound weight and obtain a lateral radiograph.
- Repeat this process, increasing the traction by 10-pound increments until reaching one third of the body weight, or 65 pounds, whichever is less.
- After each additional weight application, check the patient for any change in neurologic status. If there is a change in status, stop the test. The test is then considered to be positive.

Radiographs are evaluated for any abnormal separation of the anterior or posterior elements. An abnormal test is indicated by differences either greater than 1.7 mm of interspace separation or 7.5° of change in the angle between vertebrae (35). An interval of at least 5 minutes should be allowed between incremental weight applications to allow for creep of the viscoelastic structures. The test is contraindicated in a spine with obvious clinical or radiographic instability.

## INDICATIONS FOR TREATMENT

Management of lower cervical spine injuries must proceed in an orderly fashion to minimize morbidity and mortality. At the time of initial evaluation and resuscitation, immobilize the injured spine as medical stabilization is implemented. Assess spinal alignment and correct it if necessary. Perform operative decompression if indicated and consider the long-term stability of the injured spine. If the injured segment or multiple segments are unstable, operative stabilization is necessary.

If significant malalignment is noted on initial radiographs, realignment is indicated to relieve any pressure on the neural elements, limiting ischemia and edema formation. Exactly what constitutes significant malalignment is debatable; however, sagittal translation greater than 3.5 mm or angulation greater than 11° would seem reasonable. In addition, realignment or traction would also be indicated in injuries in which extruded bone or disc fragments were contributing to spinal cord or nerve root compromise, even though no significant angulation or translation were present. Reduction can usually be established by skeletal traction with tongs in the skull (16).

- After the tongs are applied in a sterile fashion, apply an initial weight of 10 pounds of traction with appropriate analgesia.
- Perform a detailed neurologic examination and obtain a lateral radiograph.
- Perform careful evaluation of the occiput to C-1 to C-2 levels to ensure no concomitant injury to this region.
- If reduction is not achieved, add weight in 5-pound increments and repeat the process each time.
- Once reduction is obtained, reduce the weight to 15–20 pounds and obtain a repeat radiograph to confirm maintenance of reduction.
- Continue traction until a definitive treatment plan is chosen.

If closed treatment with traction of up to two thirds of body weight or 65 pounds (whichever is less) is unable to achieve adequate reduction, operative intervention is usually required. In cases of facet dislocation, closed manipulative reduction may be an option when traction alone fails to reduce the dislocation. This should be performed only by surgeons experienced in these techniques to minimize the risk of, or exaggeration of, neurologic injury.

Cervical vertebral body dislocations are associated with substantial disruption of the anterior and posterior ligamentous structures and clinical instability. Patients who are undergoing realignment in traction must be constantly monitored and examined to prevent iatrogenic injury to the neural elements resulting from excessive stretching across injured segments. Traction weights should begin at 5 pounds and progress cautiously in order to ensure that overdistraction does not occur.

### INDICATIONS FOR NONOPERATIVE TREATMENT

In patients with no compression of the neural elements and in whom the stability of the spine has not been jeopardized, a course of bracing in a rigid orthosis for 6–12 weeks may be appropriate. Injuries included in this category are mild compression fractures of the anterior elements and isolated fractures of the posterior elements or lateral masses. Mild vertical compression fractures may require halo immobilization. Follow-up radiographs must be obtained at regular intervals to assess healing. If instability is noted on follow-up radiographs, operative intervention is required.

### INDICATIONS FOR URGENT OPERATIVE INTERVENTION

In general, early operative intervention for lower cervical spine injuries is indicated in all cases for which decompression is necessary to restore or preserve spinal cord function, and if stabilization is required to prevent further cord or root injury (8,42). Schneider et al. (43) formulated their criteria for urgent operative intervention in patients who had sustained cervical spinal cord injuries. The criteria they deemed important included documented progression of neurologic signs and complete block of the subarachnoid space on myelography. Cooper and Ransohoff (15) included any myelographic evidence of spinal cord compression by hematoma or by bone or disc elements after alignment had been optimized.

Urgent operative intervention is not indicated in a patient with a complete neurologic deficit with loss of motor function distal to the injured segment. Such a patient is unlikely to achieve functional recovery, and operative intervention to stabilize the spinal column may be delayed until he is medically stable. However, urgent decompression of compromised nerve roots may be required in some such patients to preserve an additional neurologic level. Urgent stabilization of the spinal column may also be necessary to facilitate the treatment of other system injuries.

## SURGICAL TECHNIQUES

When operative intervention is required, the choice of the procedure depends on the nature of the injury and the goals of the surgeon. In general, approach the fracture from the site of major instability (47,51,55). If the injury involves the anterior longitudinal ligament, vertebral body, or disc, an anterior approach is most appropriate. If there is posterior ligamentous involvement or posterior element fractures, a posterior approach is preferred. Sometimes, combined anterior and posterior approaches are required (17). Perform a stabilization procedure at the site of decompression.

### POSTERIOR INSTRUMENTATION OPTIONS

The two most common posterior stabilization methods use posterior cervical wires or cables and lateral mass plates. In recent years, multistrand stainless steel or titanium cables have replaced traditional stainless steel wires. Multiple studies have shown that cables are stronger, more flexible, and more fatigue resistant than wires (19,28,46). However, the cables are also more expensive. In addition, the added bulk of the crimping device may detract from its use in certain situations. Most posterior wiring techniques require intact posterior arches and spinous processes across the levels to be fused. To provide sufficient spinal stability, the anterior column should be capable of weight bearing, and excessive rotational forces must be avoided (14,24). When these conditions are not present, lateral mass plates are preferred (31). However, it should be kept in mind that a real risk to the spinal cord, nerve roots, and vertebral arteries exists with lateral mass plating. Posterior cervical wiring techniques have fewer risks and years of proven success (11,52).

Most posterior wiring techniques used today have evolved from the interspinous technique reported by Rogers in 1942 (39). In his description, a wire was passed through and around the base of adjacent spinous processes. Corticocancellous bone grafts were placed under the wires, across the interlaminar space to facilitate fusion. Figure 140.3 diagrams the use of a flexible multistrand cable in a procedure similar to that presented by Rogers (see Rogers's technique in the next section).

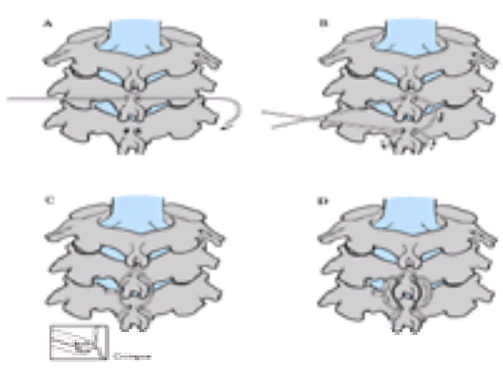

***Figure 140.3.*** Interspinous technique using flexible multiple cables. **A:** Pass cable 1, near to far, through the C-4 drill hole. Loop it around cephalad edge of the C-4 spinous process, and then pass through the hole again, near to far. **B:** Then pass cable 1, far to near, through the C-5 hole, loop it around the caudal edge of the C-5 spinous process, and then pass it through the hole again, far to near. **C:** Apply crimp to achieve single interspinous wiring. **D:** The bone is then in place under the parallel interspinous portions of the cable.

Bohlman's triple-wire technique is a modification of Rogers's, in which an additional two wires are used to secure the bone graft to the lamina and spinous processes (30). Bohlman's modification results in increased flexural and torsional stiffness that is superior to Rogers's wiring technique and to sublaminar wiring techniques (Fig. 140.4, Fig. 140.5 and Fig. 140.6).

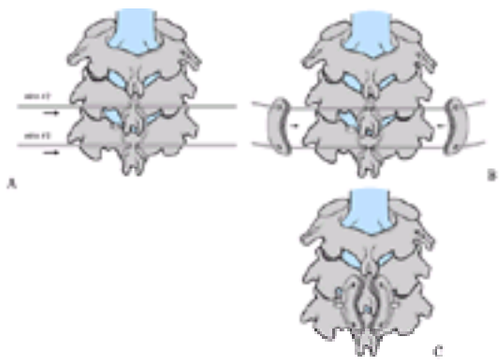

***Figure 140.4.*** Interspinous technique using two additional wires. **A:** Pass the upper and lower wires through the drill holes in the C-4 and C-5. **B:** Cinch the bone grafts simultaneously onto C-4 and C-5. **C:** The bone grafts are then in position.

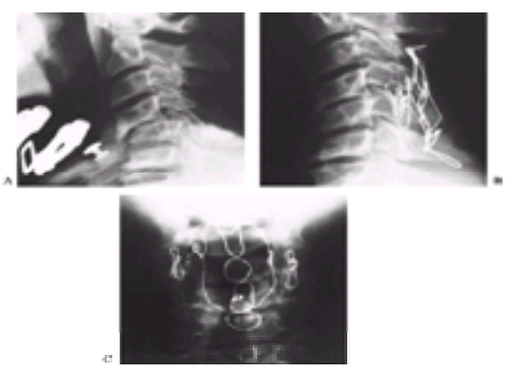

***Figure 140.5.*** **A:** Lateral radiograph of a 40-year-old lumberjack struck on the back of his neck by a falling tree. There is anterior subluxation of C-4 on C-5. The anterior subluxation was not adequately held despite the application of a halo vest. **B:** Lateral radiograph after posterior reduction and triple-wire stabilization from C-3 to C-6. Notice that there are two wires linking the facet joints at C4–C5 and a midline tethering wire bridging the base of the spinous processes from C-3 to C-6. There are no sublaminar wires. **C:** AP radiograph showing the lateral interfacet wires and the midline tethering wires. The patient at 1-year follow up was neurologically completely intact and his spine was completely fused. He returned to work as a lumberjack doing heavy manual labor.

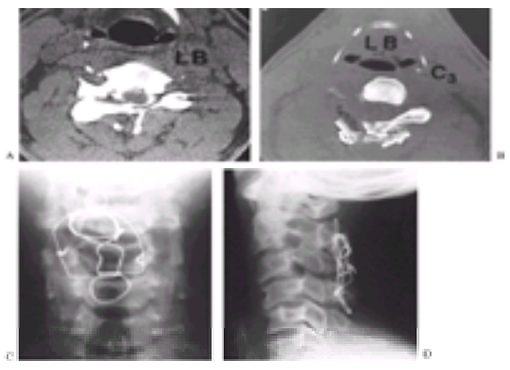


***Figure 140.6.*** **A:** Axial CT image of a 25-year-old man who sustained a diving injury. The patient has a fracture dislocation of the left C-3 facet joint. The inner aspect of the lamina is seen compressing the posterior aspect of the spinal cord. He had numbness on the left side of his neck in the C-3 nerve distribution. In addition, he was hyperreflexic throughout, secondary to a myelopathic lesion. **B:** The patient underwent a posterior decompression and triple-wire stabilization from C-2 to C-4. This axial postoperative CT image shows the posterior wiring and bone graft that stabilized the spine. Notice the adequacy of the decompression of the spinal canal. **C:** AP radiograph of the triple-wire stabilization technique from C-2 to C-4. The lateral wires hold two corticocancellous bone grafts in compression against the posterior aspects of the lamina at C-2 and C-4. **D:** Postoperative lateral radiograph shows a solid fusion from C-2 to C-4 with good spinal alignment aside from the patient's original 15% subluxation at C3–C4. The patient was neurologically completely intact, and his spine was stable at long-term follow-up.

When the lamina and spinous processes are compromised by injury or decompression, Rogers's and Bohlman's techniques cannot be used. An alternative to lateral mass plating is facet wiring, reported by Robinson and Southwick in 1960 (38), and modified by Callahan in 1977 (Fig. 140.7) (11). In this technique, the articular processes are denuded and wires are passed through the inferior articular processes, which are then secured to overlying bone graft. In the case of rotational instability, or when there is a one-level lamina fracture, oblique facet wiring is an option (Fig. 140.8) (10,21). Wires are placed through the inferior facet as described later in the facet wiring technique, but then secured to the next inferior spinous process instead of overlying bone graft. Bilateral wiring from the facets to the inferior spinous process is recommended.

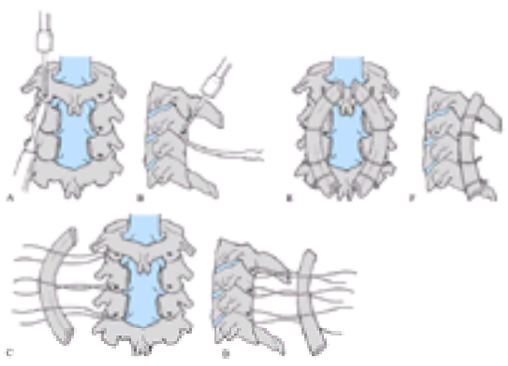

***Figure 140.7.*** Facet-wiring technique. **A and B:** Holes are drilled at a 90° angle to the articular surface. **A:** AP view. **B:** Lateral view. **C and D:** A curved rib graft or a portion of the iliac crest is used to create a cervical lordosis. **C:** AP view. **D:** Lateral view. **E and F:** Free wires emanate from the caudal end of the spinous process and are securely fixated to the graft or rod. **E:** AP view. **F:** Lateral view.

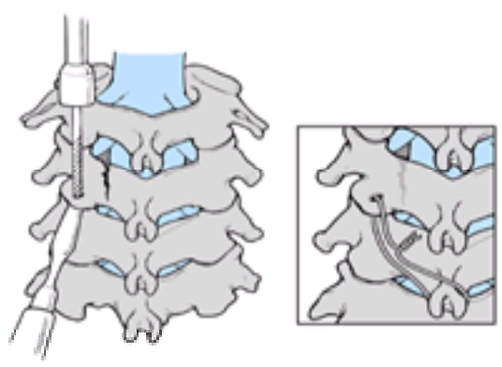

***Figure 140.8.*** Oblique facet wiring. A small drill is used to create a hole in the inferior articular process at a 90° angle to the articular surface. (*Inset*) Wires in place in the drill holes after being tightened and securely fixated.

Lateral mass plating is considerably more demanding than posterior wiring techniques. Plates are fixed to the lateral masses by screws placed at each level. Two methods of screw placement are commonly used, the original technique described by Roy-Camille et al. (41) and the Magerl technique (29). Of the two techniques, Magerl's is more commonly used because it provides a stronger and stiffer construct (Fig. 140.9) (32).

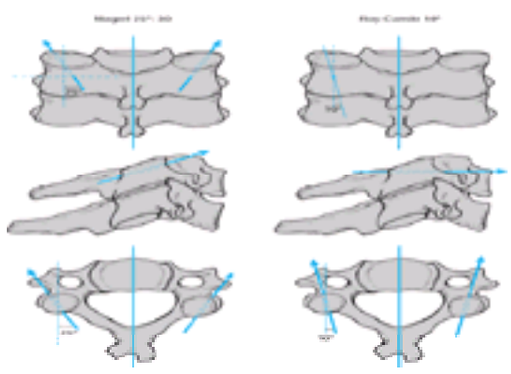

***Figure 140.9.*** Screw direction for the Magerl and Roy-Camille techniques.

## POSTERIOR FUSION

If the patient was previously placed in tongs, maintain traction throughout the case. Fiberoptic intubation is preferred to minimize any movement of the unstable spine.

- Following intubation, turn the patient prone on a spine-turning frame. If possible, keep her awake until after she is prone to monitor for any neurologic changes. Intraoperative neurologic monitoring [e.g., for somatosensory evoked potential (SSEP)], is helpful in identifying changes.
- Hold her face in a Mayfield head holder or other similar device.
- Tuck her arms at her sides. With 3-inch tape, secure her shoulders down to the foot of the bed with a gentle longitudinal pull. This permits radiographic visualization of the lower cervical spine.
- Obtain a preoperative radiograph in the prone position to verify spinal alignment.
- Shave and prepare the neck from the occiput to the midscapular region as well as the posterior iliac crest for bone graft harvesting.
- Make a midline incision overlying the injured area and use the cautery knife to expose the tips of the spinous processes.
- Dissect the subperiosteal soft tissues off the posterior elements to the lateral border of the articular masses.
- Take care to avoid undue pressure over the compromised levels.
- If the injured levels are difficult to identify intraoperatively, use radiographic localization.
- Decompress the areas dictated by the preoperative studies, and perform one of the following fusion techniques.
- After the stabilization procedure, obtain a radiograph to assess the reduction and to confirm the levels of fusion.
- Close the wound in layers over a drain.
- Continue prophylactic antibiotics for 24–48 hours.
- Continue postoperative traction for 24–48 hours, and then immobilize the neck with a hard collar or two poster orthosis, depending on the adequacy of the stabilization construct.

### *Rogers's Technique*

- Using a burr, make a hole in the midportion of the base of each spinous process to be included in the fusion. Avoid penetration of the laminae.
- Place a pointed towel clip through each hole to confirm adequate room for passage of the cable.
- Pass the cable through the hole in the most superior spinous process, and then wrap the cable around the spinous process and reenter the hole from the same direction (Fig. 140.3). This creates a tethering loop around the spinous process, decreasing the chance of the cable cutting out of the bone.
- From the opposite direction, pass the wire through the next spinous process to be included in the fusion, and follow a similar technique.
- Both ends of the cable should end on the same side of the patient. Tighten the construct and secure with the crimping device.
- Cut the cables flush with the crimp.
- Measure the length of the graft needed with a malleable probe.
- Harvest the corticocancellous graft from the posterior iliac crest. An oscillating saw minimizes the risk of microfractures in the graft. A piece that is the proper length and width can be split into two pieces for each side of the fusion.
- Using a saw, split the graft longitudinally.
- Before the graft is placed, remove all the soft tissue covering the lamina and roughen the bone surfaces with a burr to allow fusion to occur.
- Place the bone grafts underneath the cables, spanning the interlaminar space.

### *Bohlman's Triple-Wire Technique*

- Place the first cable as described for Rogers's technique.
- Place the remaining two cables through and around the most superior and inferior spinous processes to be included in the fusion (Fig. 140.4 and Fig. 140.6).
- Burr holes toward each end of the previously harvested corticocancellous grafts.
- In addition to roughening the surface of the lamina, include the portion of the spinous process that will be in contact with the graft as well.
- Place the cables through each end of the graft and tighten them simultaneously, orienting the graft into its most stable configuration.
- Crimp and cut the cables as in Rogers's technique.
- Pack extra bone along the sides of the grafts if needed.

### *Facet Wiring Technique*

- Identify each articular facet to be included in the fusion.
- Using a small, thin elevator, pry open the joint and rotate the elevator to maintain exposure of the joint surfaces (Fig. 140.7).
- Denude the surfaces with a burr to facilitate fusion.
- Drill a 3 mm hole at 45° off the horizontal through the inferior facet.
- Pass a cable through this hole from a posterior to anterior direction and grasp it from within the joint to deliver it into the field.
- Repeat this process bilaterally at each level to be included in the fusion.
- Use a burr to gently roughen the posterior surfaces of the lateral masses to be fused.
- Secure the corticocancellous grafts to the lateral masses by tightening and crimping the cables.
- Holes may be drilled though the grafts for more secure fixation.

### *Oblique Facet Wiring*

- Drill a hole through the inferior articular facet as described for facet wiring.
- Burr an additional hole through the base of the next inferior spinous process (Fig. 140.8).
- After passing the cable through the facet, pass it through and around the spinous process.
- Tighten and secure as previously noted for other techniques.
- Apply bone graft wherever possible.

### *Lateral Mass Plating*

- Using the Magerl technique, identify the four borders of each lateral mass to be included in the fusion. The medial border is the valley at the junction of the lamina and the facet. The lateral border is the far edge of the articular mass. The superior and inferior borders are the respective facet joints. The starting point is 1–3 mm medial to the center of the four borders of the lateral mass (Fig. 140.9).
- Direct the drill bit 30° to 40° superiorly, parallel to the facet joints, and 25° to 30° laterally. Use bicortical purchase and breach the far cortex by the “loss of resistance” technique with an oscillating drill. A depth gauge accurately assesses the length of screw needed, which is generally 16–22 mm. The vertebral artery is located directly anterior to the valley at the junction of the lamina and articular mass. Avoid this artery by aiming the screws laterally. Avoid the nerve roots by keeping the screws within the articular masses, aiming parallel to the articular surfaces.
- Place the most superior screw in the construct, as described for the Magerl oblique facet wiring technique.
- Drill the pilot hole with a 2 mm drill bit, aiming parallel to the articular surfaces and approximately 25° laterally.
- Place the appropriate-length plate over the lateral masses to be included in the fusion.
- Use the depth gauge to measure the length of the hole.
- Insert the appropriate-length screw and tighten moderately.
- Screw placement for the remaining articular masses will be somewhat dictated by the plate hole configuration. Place the remaining screws in a fashion similar to the first one.
- Tighten all screws securely at the end of the procedure.
- Denude the joints with a burr and apply local bone graft prior to plate placement.

In cases of spinal instability across the cervicothoracic junction, extension of the posterior plating construct to the upper thoracic vertebrae can be achieved. Fixation to the thoracic spine may be through the use of pedicle screws or hooks, depending on which plate or plate–rod construct is utilized. If pedicle screws are desired, the placement technique must be changed from that used for lateral mass screws (Fig. 140.10). Aim the upper thoracic pedicle screws 25° to 30° medially, with the starting point at the intersection of the midportion of the facet joint and the midportion of the transverse process. Thoracic pedicle screw placement is demanding and should be performed only by surgeons experienced in these techniques.

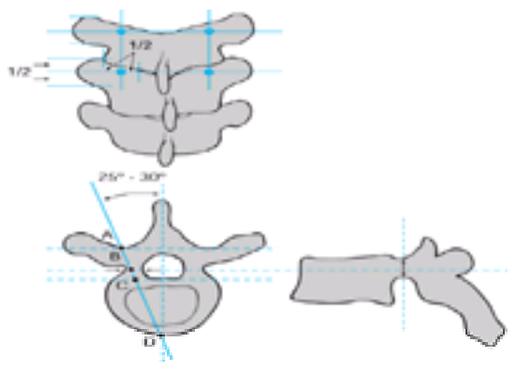


***Figure 140.10.*** Thoracic pedicle screw placement.

**ANTERIOR INSTRUMENTATION**

In the early 1950s, Robinson began his work on anterior approaches to the cervical spine in animals and cadavers (37). Currently, the Robinson anterolateral approach between the carotid sheath and the esophagus is optimally suited for access to levels C-3 to C-7. With exacting technique, it is possible to reach as superior as the second cervical vertebra and as inferior as the second thoracic vertebra. In fracture management, this approach is suited for decompression of herniated disc material and of retropulsed fragments from compressed vertebral bodies.

Anterior plates are commonly used for stabilization after decompression for traumatic injuries. Without instrumentation, loss of reduction and graft displacement occur in up to 64% of anterior decompression and strut graft reconstructions (2,6,26,48). The first-generation anterior cervical plates required bicortical purchase of the screws because there was no mechanism for locking the plate–screw interface. This problem was solved with the second-generation plates, which do not require bicortical purchase of the screws and have a rigid plate–screw interface. Morscher et al. (33) established the concept of the cervical locking plate—that is, a rigid plate–screw interface. A variety of second-generation systems are available today.

**ANTERIOR FUSION**

- If the patient has previously been placed in traction, maintain traction for the remainder of the case.
- Use fiberoptic equipment to insert a nasotracheal or endotracheal tube, avoiding manipulation of the unstable cervical spine during intubation.
- Position the patient carefully on the operative table. Tuck his arms at his sides and tape his shoulders down to the foot of the bed to permit radiographic visualization of the lower cervical levels.
- Obtain a preoperative lateral radiograph to check alignment.
- Prepare the skin aseptically from the chin to the nipple line bilaterally, as well as the anterior iliac crest for graft harvesting.
- Identify the carotid tubercle of the C-6 vertebra (Chassaignac's tubercle) for orientation purposes. If this is not palpable, the hyoid bone overlies C-3, thyroid cartilage is at C-4 to C-5, and cricoid cartilage localizes C-6. Use these landmarks to adjust the position of the skin incision in relation to the injured level.
- Make a transverse incision on the left or right side of the neck, whichever is preferred, extending from the midline to just past the anterior border of the sternocleidomastoid. Alternatively, use an oblique incision along the anterior border of the sternocleidomastoid to approach several levels (Fig. 140.11, Fig. 140.12). The rationale for approaching on the left side of midline is that the recurrent laryngeal nerve ascends in the neck on the left side between the trachea and the esophagus, having branched off from its parent nerve, the vagus, at the level of the arch of the aorta. On the other hand, the right recurrent laryngeal nerve travels alongside the trachea in the neck after passing beneath the right subclavian artery. In the lower part of the neck, the right recurrent laryngeal nerve is vulnerable to injury as it passes from the subclavian artery to the tracheoesophageal groove. Its course in the groove is also more variable on the right than on the left. Therefore, there is theoretically less risk to the recurrent laryngeal nerve by using the left-sided approach. However, the approach on the left has the possibility of injuring the thoracic duct, which enters the jugular vein–subclavian vein junction at the base of the neck on the left.

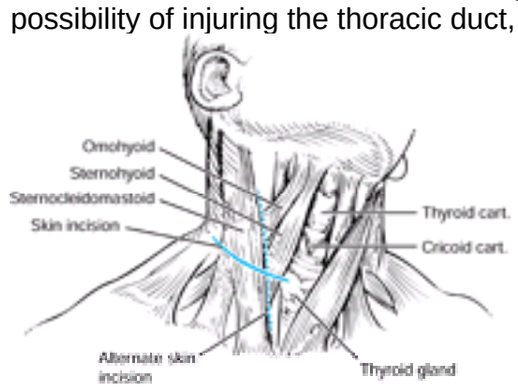


***Figure 140.11.*** Longitudinal and transverse incisions allow the necessary exposure to the anterior cervical spine.

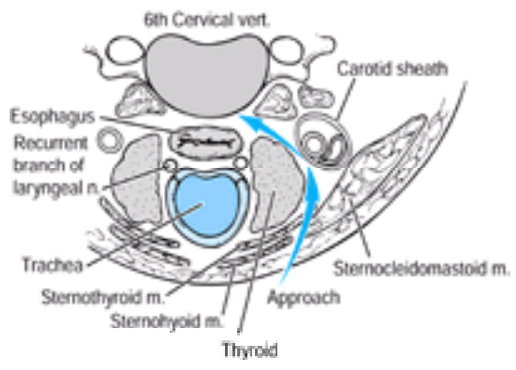


***Figure 140.12.*** The anterior spine can be visualized with dissection in the plane between the thyroid and the carotid sheath, which should be gently retracted laterally.

- Identify and elevate the platysma, incising it in line with the incision using Metzenbaum scissors.
- Next, incise the superficial layer of the deep cervical fascia along the anterior border of the sternocleidomastoid. Proper exposure is necessary to facilitate mobilization of the underlying structures. The omohyoid muscle traverses the field and can be retracted or divided as necessary.
- Palpate the arterial pulse to identify the carotid artery within its investing sheath.
- The middle layer of the deep cervical fascia is the next important layer to be divided. Divide it longitudinally, medial to the carotid sheath. Identify the carotid artery (by using your fingers), and protect it as this layer of fascia is divided. Retract the artery laterally, along with the internal jugular vein, vagus nerve, and phrenic nerve.
- Carry blunt dissection through the loose areolar tissue to the anterior cervical spine.
- Identify the esophagus medially, and retract it with a blunt Richardson retractor. Use a thyroid retractor to retract the carotid sheath and sternocleidomastoid laterally.
- Identify and protect the recurrent laryngeal nerve, which descends along the carotid sheath and ascends between the trachea and esophagus. This structure can be injured with sharp retractors or prolonged pressure.
- The midline of the anterior cervical spine can be palpated, as well as the anterior carotid tubercle at C-6. This landmark can be helpful in localizing the injured vertebrae. Transect the alar and prevertebral fascia vertically in the midline, revealing the underlying anterior longitudinal ligament. The longus colli is visible along the lateral aspects of the anterior cervical vertebrae.
- Perform subperiosteal dissection to the lateral edge of the vertebrae of the injured levels.

- Confirm the appropriate level with an intraoperative radiograph.
- After radiographic verification of the appropriate level, perform a decompressive procedure at the injured levels. Incise the disc with a #11 blade and remove it with curets and rongeurs. Complete excision of the disc is essential to gauge the proper depth to the posterior longitudinal ligament. If a corpectomy is required, excise each adjacent disc first and then remove the intervening bone. The posterior longitudinal ligament is usually disrupted in unstable injuries. Remove all bony fragments within the canal under direct visualization. Take care to avoid bone or disc excision lateral to the uncovertebral joints, to avoid injury to the vertebral arteries.
- After completing the decompression, use a burr to roughen the endplates to be included in the fusion to expose bleeding cancellous bone. Make a small trough in each endplate to accommodate pegs fashioned on either end of the tricortical iliac crest bone graft. Insert the graft with the pegs in the vertebral bodies with the cortical surfaces placed posteriorly to give maximal stability and to prevent collapse.
- After placement, obtain a radiograph to confirm reduction and placement (Fig. 140.13).

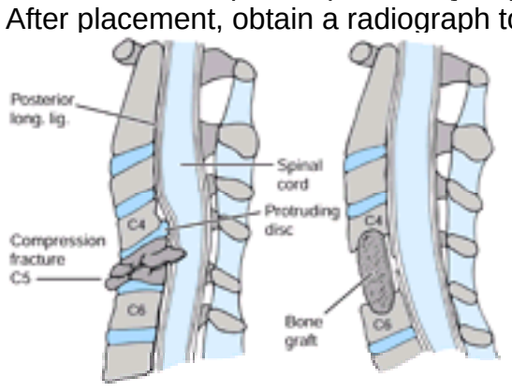


***Figure 140.13.*** Decompression of the cervical cord should include excision of the discs above and below the burst fracture and the appropriate vertebral body. **B:** The endplates should be undermined to allow the tricortical iliac crest graft to be countersunk.

- An anterior cervical plate may be added based on the amount of instability. Choose the length of the plate by using the provided template. Place the plate in the appropriate position, spanning the grafted area. Be sure that the longitudinal center of the plate is midline, not displaced to one side or another.
- Position the drill guide in its correct orientation, as dictated by the manufacturer's instructions. Usually, the drill guide is aimed medially 20°, with the sagittal angle determined by the position of the plate. Drill to a preselected depth, taking care to remain in bone at all times.
- After tapping, place the screw and tighten moderately. Place two screws in each vertebral body at the ends of the construct. Additional screws may be added in the graft. Tighten all screws and engage the locking mechanism. Radiographic confirmation of correct screw placement is advised.
- Place a large Penrose drain into the depths of the wound. Close the platysma with interrupted sutures and the skin with subcuticular sutures. Keep a tracheostomy set at bedside for 48 hours in case of hematoma formation, which may obstruct the airway. Remove drains at 48 hours.
- Keep the patient in traction overnight, and then place the neck into a hard cervical collar or halo, depending on the amount of instability and the stabilization achieved. Continue immobilization for 3 months or until union is achieved.

## PITFALLS AND COMPLICATIONS

Complications associated with the care of patients with lower cervical spine injuries can be numerous and involve many systems. Comprehensive care must be given to prevent or minimize these complications, especially those that may be iatrogenic in origin.

### NEUROLOGIC

It is essential to identify cervical spine injuries in trauma victims at the time of initial evaluation to prevent neurologic injury. Keep the patient immobilized at all times to prevent further injury to the spinal cord or nerve roots. Placement of an orthosis or halo apparatus must be done in an organized and efficient fashion to avoid further damage.

Ascending paralysis in the spinal cord–injured patient is rare. However, overdistraction in a circumferential injury pattern may be one cause. This is more common in patients with associated cervical spondylosis and ankylosing spondylitis. It can be seen at any time after injury and is usually secondary to ascending central necrosis of the gray matter, with an enlarging central syrinx. The diagnostic modality of choice is MRI.

### SPINAL DEFORMITY

Reduce any fractures and dislocations as expeditiously as possible by traction or operative means. If the deformity is not reduced, additional spinal cord or nerve root injury can occur by compression or edema. In addition, compression of the radicular arteries to the cord can precipitate ischemia and further worsen the neurologic injury.

Monitor the neurologic status of the patient at the time of the reduction because disc material and bone fragments may be pushed into the canal, causing further neural injury. If the reduction is performed nonoperatively, serial neurologic examinations provide adequate information regarding neurologic function. If operative reduction is required, neurologic monitoring (e.g., SSEPs or an electromyogram) is useful. Should a neurologic deficit occur following a closed or intraoperative reduction, operative decompression of the affected area is indicated.

If no neurologic deficit is noted initially with a unilateral or bilateral facet dislocation, a prereduction MRI is beneficial to identify extrusion of the disc material into the canal (22). If this is found, the authors recommend an anterior discectomy prior to reduction to minimize iatrogenic injury to the cord. A delay of reduction to perform imaging is of little benefit to the patient with a spinal cord injury (25). In cases with concomitant spinal cord injury, perform MRI after reduction. Carefully evaluate chronic dislocations with an intact neurologic status prior to any treatment. Operative fusion in the dislocated position may be required to prevent neurologic injury caused by reduction.

Carefully follow all fractures and dislocations treated nonoperatively or operatively to monitor for late instability and deformity. Should this occur, operative intervention is required.

### PULMONARY

In patients with high cervical lesions, hypoventilation may result from paralysis of the intercostal muscles and diaphragm. Hypoxia can ensue, requiring ventilatory support. Atelectasis and pneumonia are common causes of morbidity and mortality and must be treated aggressively.

Because patients with spinal cord injuries lose vasomotor tone and use of their upper and lower extremities, venous thrombosis and pulmonary embolism may be a problem. Emphasis should be placed on the prevention of venous thrombosis with compression pump stockings and other modalities. The use of prophylactic anticoagulants is controversial.

### GASTROINTESTINAL

In his review of 300 patients with cervical spine injuries, Bohlman (7) found gastrointestinal hemorrhage to be a common problem. This occurred most commonly 10–14 days after injury and was highly associated with the use of steroids. Recovery in the groups treated with steroids did not differ from that in the group treated without steroids.

Other factors play a role in gastrointestinal complications, including excessive gastric secretions, gastric stasis, and immobilization of the patients. Prophylactic care, including $H_2$ blockers, can be useful in the prevention of upper gastrointestinal hemorrhage.

### OPERATIVE

Bacterial contamination in anterior or posterior operations can cause sepsis or wound infections, which may result in cervical osteomyelitis, meningitis, and death.

In anterior procedures, the esophagus can be injured by retraction or with instrumentation such as drill bits or screws. This may result in dysphagia, fistula formation, and infection.

An injury to the carotid artery can produce massive hemorrhage.

Do not use methylmethacrylate in fractures other than those of pathologic bone. Bone cement does not fuse with bone, and fixation loosens with time, resulting in instability. Increased infection rates have been associated with the use of cement.

Decompressive laminectomy for relief of anterior compression is usually not helpful and may cause increased neurologic deficit. Laminectomy can decrease stability and does not permit retrieval of anterior fragments from the canal. Because sublaminar wires take up space within the canal and can injure the spinal cord, they are contraindicated in cervical spinal trauma.

If reduction of a dislocation is performed when the patient is asleep, spinal cord monitoring may help detect the rare complication of retropulsion of a ruptured disc causing spinal cord compression. If monitoring is not used, an intraoperative wake-up test may be performed. If there is a change in the neurologic status during or after a posterior procedure, perform anterior decompression without delay.

Nonunion with the posterior triple-wiring technique within the C-3 to C-7 levels is rare. In a review of 100 consecutive patients, no nonunions or increased neural deficits were noted (52). Similar rates of fusion have been reported with anterior instrumented fusions (4,33,50).

## BRACING

Patients who have neurologic deficits secondary to spinal cord injury must be followed for skin breakdown if they are placed in a two-poster orthosis or a halo jacket. Their insensate skin can break down easily. The two-poster orthosis and Philadelphia collar can cause breakdown over the chin region and therefore must be carefully applied and followed.

Potential complications of halo jackets are numerous. Pressure sores must be prevented. Pin placement and care are important when the ring is applied. Retorque the halo pins the day after application and check them for looseness periodically thereafter. Pay constant attention to the screws and rods to prevent loss of reduction.

Obtain radiographs periodically to assess the position of bone grafts and to look for loss of reduction. Before removing a halo jacket, obtain flexion and extension radiographs, after the connecting bars are loosened, to assess fusion and stability.

## CHAPTER REFERENCES

Each reference is categorized according to the following scheme: *, classic article; #, review article; !, basic research article; and +, clinical results/outcome study.


+ 1. Aebi M, Mohler J, Zach G, Morscher E. Indication, Surgical Technique and Results of 100 Surgically Treated Fractures and Fracture Dislocations of the Cervical Spine. *Clin Orthop* 1986;203:244.

+ 2. Aebi M, Zuber K, Marchesi D. The Treatment of Cervical Spine Injuries by Anterior Plating. *Spine* 1991;16:38.

* 3. Allen BL, Ferguson RL, Lehmann TR, O'Brien RP. A Mechanistic Classification of Closed, Indirect Fractures and Dislocations of the Lower Cervical Spine. *Spine* 1982;7:1.

# 4. Bassett T, Zdeblick TA. Complications of Cervical Spine Instrumentation. *Tech Orthop* 1994;9:8.

+ 5. Beyer CA, Cabanela ME, Bergquist TH. Unilateral Facet Dislocations and Fracture-Dislocations of the Cervical Spine. *Orthopedics* 1992;15:311.

+ 6. Boehler J, Gaudernak T. Anterior Plate Stabilization for Fracture-Dislocations of the Lower Cervical Spine. *J Trauma* 1980;20:203.

* 7. Bohlman HH. Acute Fractures and Dislocations of the Cervical Spine: An Analysis of 300 Hospitalized Patients and Review of the Literature. *J Bone Joint Surg Am* 1979;61:1119.

+ 8. Bohlman HH, Anderson PA. Anterior Decompression and Arthrodesis of the Cervical Spine. *J Bone Joint Surg Am* 1992;74:671.

# 9. Bohlman HH, Boada E. Fractures and Dislocations of the Lower Cervical Spine. In: The Cervical Spine Research Society, eds. *The Cervical Spine.* Philadelphia: JB Lippincott, 1983:232.

+ 10. Cahill DW, Bellegarrigue R, Ducker TB. Bilateral Facet to Spinous Process Fusion: A New Technique for Posterior Spinal Fusion after Trauma. *Neurosurgery* 1983;13:1.

+ 11. Callahan RA, Johnson RM, Margolis RN, et al. Cervical Facet Fusion for Control of Instability Following Laminectomy. *J Bone Joint Surg Am* 1977;59:991.

# 12. Capen DA, Nelson RW, Zigler J, et al. Surgical Stabilization of the Cervical Spine: A Comparative Analysis of Anterior and Posterior Spine Fusions. *Paraplegia* 1987;25:111.

+ 13. Capen DA, Zigler J, Garland DE. Surgical Stabilization in Cervical Spine Trauma. *Contemp Orthop* 1987;14:25.

! 14. Coe JD, Warden KE, Sutterlin CE, McAfee PC. Biomechanical Evaluation of Cervical Spinal Stabilization Methods in a Human Cadaveric Model. *Spine* 1989;14:1122.

# 15. Cooper PR, Ransohoff J. Surgical Treatment. In: The Cervical Spine Research Society, eds. *The Cervical Spine.* Philadelphia: JB Lippincott, 1983:305.

+ 16. Cotler JM, Herbison GJ, Nasuti JF, et al. Closed Reduction of Traumatic Cervical Spine Dislocation Using Traction Weights up to 140 Pounds. *Spine* 1993;18:386.

# 17. Cybulski GR, Douglas RA, Meyer PR, Rovin RA. Complications in Three Column Cervical Spine Injuries Requiring Anterior-Posterior Stabilization. *Spine* 1992;17:253.

+ 18. Davis D, Bohlman HH, Walker AE, et al. The Pathologic Findings in Fatal Craniospinal Injuries. *J Neurosurg* 1971;34:603.

! 19. Dickman CA, Sonntag VK. Wire Fixation of the Cervical Spine: Biomechanical Principles and Surgical Techniques. *BNI Quarterly* 1993;9:2.

# 20. Dunn EJ, Blazar S. Soft Tissue Injuries of the Lower Cervical Spine. *Instr Course Lect* 1987;36:499.

! 21. Edwards CC, Matz SO, Levine AM. The Oblique Wiring Technique for Rotational Injuries of the Cervical Spine. *Orthop Trans* 1986;10:455.

+ 22. Eismont FJ, Aruna MJ, Green BA. Extrusion of an Intervertebral Disc Associated with Traumatic Subluxation or Dislocation of Cervical Facets. *J Bone Joint Surg Am* 1991;73:1555.

+ 23. Forster BB, Koopmans RA. Magnetic Resonance Imaging of Acute Trauma of the Cervical Spine: Spectrum of Findings. *Can Assoc Radiol J* 1995;46:168.

+ 24. Gill K, Paschal S, Corin J, et al. Posterior Plating of the Cervical Spine. *Spine* 1988;13:813.

+ 25. Hadley MN, Fitzpatrick BC, Sonntag VK, Browner CM. Facet Fracture Dislocation Injuries of the Cervical Spine. *Neurosurgery* 1992;30:661.

+ 26. Hamilton A, Webb JK. The Role of Anterior Surgery for Vertebral Fractures With or Without Cord Compression. *Clin Orthop* 1994;300:79.

+ 27. Harris JH. Radiographic Evaluation of Spinal Trauma. *Orthop Clin North Am* 1986;17:75.

! 28. Huhn SL, Wolf AL, Ecklund J. Posterior Spinal Osteosynthesis for Cervical Freacture/Dislocation Using a Flexible Multistrand Cable System: Technical Note. *Neurosurgery* 1991;29:943.

+ 29. Jeanneret B, Magerl F, Haterward E. Posterior Stabilization of the Cervical Spine with Hook Plates. *Spine* 1991;16:56.

! 30. McAfee PC, Bohlman HH, Wilson WL. The Triple-wire Fixation Technique for Stabilization of Acute Fracture-Dislocations: A Biomechanical Analysis. *Orthop Trans* 1985;9:142.

! 31. McGuire R. Biomechanics of Cervical Spine Fixation. *Tech Orthop* 1994;9:30.

! 32. Montesano PX, Juach EC, Anderson PA, et al. Biomechanics of Cervical Spine Internal Fixation. *Spine* 1991;16:10.

+ 33. Morscher E, Sutter F, Jenny H, Olerud S. Die Vordere Verplattung der Halswirbelsaule mit dem Hohlschrauben-Plattensystem aus Titanium. *Chirurg* 1986;57:702.

# 34. Norton WL. Fractures and Dislocations of the Cervical Spine. *J Bone Joint Surg Am* 1962;44:115.

! 35. Panjabi MM, White AA, Keller D, et al. Stability of the Cervical Spine Under Tension. *J Biomech* 1978;11:189.

+ 36. Reid DC, Henderson R, Saboe L, Miller JD. Etiology and Clinical Course of Missed Spine Fractures. *J Trauma* 1987;27:980.

* 37. Robinson RA, Smith A. Anterolateral Cervical Disc Removal and Interbody Fusion for Cervical Disc Syndrome. *Bull Johns Hopkins Hosp* 1955;96:223.

+ 38. Robinson RA, Southwick WO. Indications and Techniques for Early Stabilization of the Neck in Some Fracture Dislocations of the Cervical Spine. *South Med J* 1960;53:565.

+ 39. Rogers WA. Treatment of Fracture-Dislocation of the Cervical Spine. *J Bone Joint Surg Am* 1942;24:245.

# 40. Rogers WA. Fractures and Dislocations of the Cervical Spine. *J Bone Joint Surg Am* 1957;39:341.

* 41. Roy-Camille R, Saillant G, Mazel C. Internal Fixation of the Unstable Cervical Spine by a Posterior Osteosynthesis with Plates and Screws. In: The Cervical Spine Research Society, eds. *The Cervical Spine*. Philadelphia: JB Lippincott, 1989:390.

+ 42. Schlegel J, Bayley J, Yuan H, Fredricksen B. Timing of Surgical Decompression and Fixation of Acute Spinal Fractures. *J Orthop Trauma* 1996;10:323.

+ 43. Schneider RC, Crosby EC, Russo RH, Gosch HH. Traumatic Spinal Cord Syndromes and Their Management. *Clin Neurosurg* 1972;20:424.

+ 44. Shapiro SA. Management of Unilateral Locked Facet of the Cervical Spine. *Neurosurgery* 1993;33:832.

+ 45. Silberstein M, Tress BM, Hennessy O. Prevertebral Swelling in Cervical Spine Injury: Identification of Ligament Injury with Magnetic Resonance Imaging. *Clin Radiol* 1992;46:318.

+ 46. Songer MN, Spencer DL, Meyer PR, Jayaraman G. The Use of Sublaminar Cables to Replace Luque Wires. *Spine* 1991;16:S418.

# 47. Stauffer ES. Management of Spine Fractures C3-C7. *Orthop Clin North Am* 1986;17:45.

+ 48. Stauffer ES, Kelley EG. Fracture-Dislocation of the Cervical Spine: Instability and Recurrent Deformity Following Treatment by Anterior Interbody Fusion. *J Bone Joint Surg Am* 1977;59:45.

+ 49. Streitwieser DR, Knopp R, Wales LR, et al. Accuracy of Standard Radiographic Views in Detecting Cervical Spine Fractures. *Ann Emerg Med* 1983;12:538.

+ 50. Suh PB, Kostuik JP, Esses SI. Anterior Cervical Plate Fixation with the Titanium Hollow Screw Plate System. *Spine* 1990;15:1079.

! 51. Ulrich C, Woersdoerfer O, Kalff R, et al. Biomechanics of Fixation Systems to the Cervical Spine. *Spine* 1991;16:S4.

+ 52. Weiland DJ, McAfee PC. Posterior Cervical Fusion with Triple-Wire Strut Graft Technique: One Hundred Consecutive Patients. *J Spinal Disord* 1991;4:15.

+ 53. West OC, Anbari MM, Pilgram TK, Wilson AJ. Acute Cervical Spine Trauma: Diagnostic Performance of Single-View Verses Three-View Radiographic Screening. *Radiology* 1997;204:819.

! 54. White AA, Panjabi MM. *Clinical Biomechanics of the Spine.* Philadelphia: JB Lippincott, 1978:223.

! 55. White AA, Panjabi MM.*Clinical Biomechanics of the Spine.* Philadelphia: JB Lippincott, 1990.

# 56. White AA, Panjabi MM, Posner I, et al. Spinal Stability: Evaluation and Treatment. *Instr Course Lect* 1983;32.

! 57. White AA, Panjabi MM, Saha S, Southwick WO. Biomechanics of the Axially Loaded Cervical Spine: Development of a Clinical Test for Ruptured Ligaments. *J Bone Joint Surg Am* 1975;57:582.

# 58. White A, Southwick W, Panjabi M. Clinical Instability in the Lower Cervical Spine: A Review of Past and Current Concepts. *Spine* 1976;1:15.

+ 59. Woodring JH, Lee C. The Role and Limitations of Computed Tomographic Scanning in the Evaluation of Cervical Trauma. *J Trauma* 1992;33:698.

# CHAPTER 141

# THORACOLUMBAR FRACTURES: EVALUATION, CLASSIFICATION, AND INITIAL MANAGEMENT

*Robert F. McLain and Daniel R. Benson*

**R. F. McLain:** Department of Orthopaedics, The Cleveland Clinic Foundation, Cleveland, Ohio, 44195.
**D. R. Benson:** Department of Orthopaedics, University of California, Davis Medical School, Sacramento, California, 95817.

Initial Assessment and the Fundamentals
The Chest
The Abdomen
The Extremities
The Head and Neck
Shock
Protecting the Patient
Initial Spinal Evaluation
Diagnostic Workup
Fracture Classifications
Compression Fractures
Burst Fractures
Flexion-Distraction Fractures
Fracture–Dislocations
Authors' Perspective
Chapter References

To treat spinal column injuries properly, the physician must recognize life-threatening injuries and treat them appropriately, provide initial supportive care at the same time diagnostic studies are initiated, and protect the neural elements until definitive treatment can be provided. Whether acting in concert with a team of trauma specialists or alone in the emergency department, an orderly, stepwise approach to assessment and management will improve overall outcome and ensure that serious injuries are not missed.

In providing initial care to a spine-injured patient, the physician must perform the following procedures:

- Assess vital functions—airway, bleeding, circulation.
- Protect the spine while managing initial shock or life-threatening injuries.
- Initiate a diagnostic workup for suspected spinal injury.
- Stabilize the spinal column to protect the neural elements during further evaluation and any emergency procedures.

Once the patient is hemodynamically stable and the fracture is identified and classified, the surgeon can prepare a treatment plan based on the fracture pattern, the severity of injury, and the patient's overall condition.

## INITIAL ASSESSMENT AND THE FUNDAMENTALS

In trauma management, the first priority is to preserve the patient's life. In some cases, the threat to life is evident (e.g., from hemorrhage, visceral trauma), but in others it is not.

Unstable thoracolumbar fractures are usually high-energy injuries. Anywhere from 40% to 80% result from motor vehicle accidents, involving drivers and passengers of automobiles, riders of motorcycles, and pedestrians (1,7,17,18,20,23,25,29). Other causes of spine fractures include falls from height, penetrating trauma, and crush injuries, such as those sustained by a worker caught beneath a collapsing structure. In these kinds of injuries, polytrauma is common (Fig. 141.1). In our experience, patients with unstable thoracolumbar fractures suffer an average of two other major injuries in addition to their spinal fracture; some patients may present with as many as six associated injuries (20).

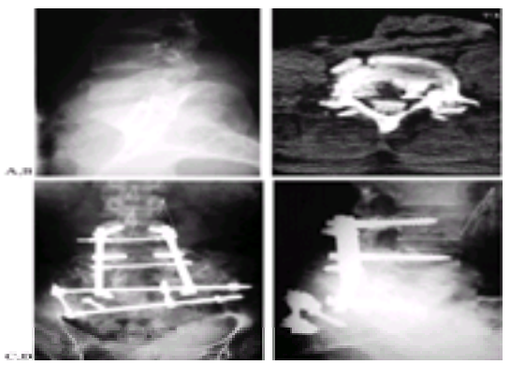

***Figure 141.1.*** Spinal trauma—a high-energy injury. **A:** Lateral radiograph of an 18-year-old man crushed under a wall, forced into extreme hyperflexion. He had massive thoracic injuries, a splenic laceration, and a progressive cauda equina injury. Radiograph demonstrates L-5 burst fracture. Pelvic radiographs also demonstrated bilateral sacroiliac fracture–dislocations. **B:** CT scan shows comminuted lumbar fracture, with retropulsed vertebral body fragment abutting the volar surface of the laminae. **C,D:** AP and lateral radiographs after emergent stabilization and resuscitation. The patient underwent multiple procedures under the initial anesthetic, including splenectomy, chest tube placement, L-5 vertebrectomy, cauda equina decompression, posterior spinal stabilization L-4 to sacrum, placement of vena caval filter, and posterior stabilization of the pelvic disruption. This aggressive approach provided enough spinal column stability to allow early mobilization and aggressive pulmonary toilet. Four years after this massive injury, the patient was ambulatory with an ankle–foot orthosis, had mild back pain, and had returned to college.

### THE CHEST

Common injuries associated with thoracolumbar and thoracic fracture reflect the forces of blunt trauma and rapid decelleration. Intrathoracic injuries include the following:

- Pneumo- and hemothorax associated with rib fractures or bronchial disruption
- Myocardial or pulmonary contusion
- Great vessel injury from blunt trauma or rapid deceleration
- Hemopericardium and cardiac tampanade
- Diaphragmatic rupture and acute hiatal hernia

A plain chest radiograph will confirm the presence of a hemo- or pneumothorax or a diaphragmatic rupture, and it may show widening of the mediastinum associated with a great-vessel injury. If multiple rib fractures are seen, particularly first rib and clavicle fractures, consider getting an angiogram to study the aortic arch.

Tension pneumothorax can be rapidly fatal, as can cardiac tampanade. Rapid placement of a chest tube will resolve the pneumo- or hemothorax, with immediate improvement of oxygenation and cardiac output. Pericardiocentesis will decompress the cardiac tampanade with rapid improvement in circulatory function. These injuries are often associated with thoracic fractures and fracture–dislocations. A quick assessment of bilateral breath sounds and heart sounds should identify either problem. In a tension pneumothorax, breath sounds are absent or diminished on the injured side, and the esophagus and trachea are displaced toward the normal lung. In cardiac tampanade, there are indistinct heart sounds, and the neck veins are distended. Cardiac output is impaired in either case, and the patient manifests signs of shock and cyanosis.

### THE ABDOMEN

Pay particular attention to patients with seat-belt injuries. The association of lap-belt abrasions with the classic flexion–distraction fracture should alert the physician to a high likelihood of intra-abdominal injury (12). Because this fracture occurs as the body is flexed forward over the lap-belt, visceral injuries are found in 40% to 60% of patients (10,27). Solid viscera may be injured directly when they are compressed between the body wall and the lap-belt, or they may be torn from their attachments when the body is suddenly and rapidly decelerated. Hollow viscera may be ruptured, perforated, or torn from their mesenteries. Obtain a general surgical assessment whenever a flexion–distraction injury is suspected. A rigid abdomen, falling hematocrit, and abdominal pain or tenderness are clear indications for emergent peritoneal lavage and laparotomy. In the stable patient with no symptoms of shock, an abdominal computed tomography (CT) scan may be used to rule out an abdominal injury. Intra-abdominal injuries are also common in thoracolumbar injuries.

### THE EXTREMITIES

Because most unstable thoracic and thoracolumbar fractures are high-energy injuries, it is not surprising that they are commonly associated with additional skeletal injuries:

- Fractures of the femurs, tibias, and feet are common.
- Fractures of humeri and forearm bones are less common.
- Major pelvic fractures are not common and are usually seen only after massive trauma.
- Hemorrhage from multiple long-bone fractures can be severe, resulting in shock (3).

### THE HEAD AND NECK

Injuries to the head and neck should be carefully assessed in the emergency room, and the cervical spine should be protected throughout the initial evaluation and emergency procedures (19). Unconscious, obtunded, or intoxicated patients cannot provide a dependable history or reliably report pain or numbness. These patients should be protected as though a cervical injury existed (2,24). Plain radiographs will demonstrate the majority of bony injuries but may not reveal soft-tissue disruptions; retropharyngeal hematoma indicates significant soft-tissue injury and mandates a formal cervical workup (30). Head injuries may be evaluated by a magnetic resonance imaging (MRI) or CT scan prior to anesthesia if surgery is needed, or they may be held under observation if otherwise stable.

### SHOCK

Shock may be seen for a variety of reasons. Hemorrhagic, hypovolemic shock is the most serious, and it must be recognized and corrected quickly. Young patients manifest tachycardia and peripheral vasoconstriction as primary symptoms; hypotension may not be seen until shock is severe and vascular collapse occurs. Older patients generally do not compensate well, and tachycardia and hypotension may both appear early on.

- Place a Foley catheter to monitor urine output.
- Rapidly assess common sites of blood loss—open wounds, intra-abdominal and intrathoracic hemorrhage, and long-bone and pelvic fractures.
- Institute fluid resuscitation immediately.

Neurogenic shock results from loss of normal vasomotor tone. Patients present with hypotension and tachycardia although they have warm, well-perfused skin and peripheral tissues. They may not respond to fluid bolus, and vasopressors may be needed.

Shock may result from any condition that reduces cardiac output, including cardiac tampanade, tension pneumothorax, myocardial injury, or myocardial infarction. In every case, rapid vascular access and fluid resuscitation are the vital initial treatments for spinal trauma patients.

## PROTECTING THE PATIENT

Once the potentially life-threatening injuries have been addressed or ruled out, the next priority is to stabilize and protect the patient's spine so that a more formal evaluation and workup can be carried out without injuring the spinal cord. This is particularly important in the polytrauma patient who may be unconscious, may require anesthesia and surgical care, and must be moved repeatedly to manage other life-threatening injuries. Plain radiographs of the cervical spine are mandatory before intubating the patient, and if injury is seen or suspected, a fiberoptic nasotrachial intubation is the safest.

Transfer of the patient is safest on a spine board or slide board, and it should always be done with sufficient personnel to make the transfer smoothly and without struggling. When log-rolling the patient, the team must coordinate efforts to see that the shoulders and pelvis move together as a unit. If the patient is hemodynamically stable and does not require emergency procedures, he may be transferred to a firm mattress and maintained under strict spinal precautions until the workup is completed. Precautions include strict supine positioning, log-rolling side to side every 2 hours for skin care, and periodic reexamination of neurologic status. Head-injured and combative patients may need to be sedated and intubated to avoid self-inflicted spinal cord injury.

## INITIAL SPINAL EVALUATION

With the patient hemodynamically and mechanically stabilized, return to the spinal injury assessment. Obtain a complete history, paying close attention to reports of transient paresthesias, acute back or neck pain, or temporary weakness or paralysis at the time of injury. Record the location and radiation of pain symptoms, as well as any radicular symptoms. Any history of previous injury, fracture, or pain symptoms should be noted. A global examination of motor and sensory function should rapidly focus on any areas of deficit. If the patient cannot cooperate with the exam, carefully observe and note spontaneous movements and withdrawal responses. Carry out a rectal exam to assess rectal tone, voluntary rectal control, and the bulbocavanosus reflex. If the patient is neurologically normal, log-roll him to one side so that the spine can be palpated for step-offs, tenderness, or kyphosis. Note the condition of the skin over the symptomatic area. If a neurologic deficit exists, obtain radiographs of the symptomatic level before moving the patient.

If a spinal cord injury is identified, start the patient on high-dose steroids to attempt to facilitate recovery (4). Steroids have been shown to improve spinal cord recovery relative to placebo and naloxone therapy, and they are thought to combat abnormal biochemical processes brought on by thromboxanes and prostaglandins released at the site of injury. Steroids must be given within 8 hours of injury to have any beneficial effect. Patients treated with high-dose steroids may be exposed to an increased infection rate and risk of gastrointestinal hemorrhage.

## DIAGNOSTIC WORKUP

A formal physical examination and history may not be possible until the patient has been stabilized hemodynamically and has recovered from initial resuscitation. When the patient is alert and cooperative, a formal motor, sensory, and reflex examination should be repeated, and a detailed history of the accident obtained.

The history should focus on three issues: mechanism of injury; presence or absence of neurologic symptoms, and past history of spinal trauma, surgery, or symptoms. In high-energy injuries, it is often difficult to determine exactly what forces acted on the spine to produce fracture, but knowledge of the injury mechanism can help identify associated injuries and provide clues to the level of instability to be expected. A lap-belted patient in a motor vehicle accident may present with a straightforward flexion–distraction injury, for instance, whereas a patient ejected from the vehicle or from a motorcycle frequently will present with a more complex fracture pattern consistent with the combination of torsional and axial loading forces experienced when striking the ground. If the forces involved in the fracture were rather low, an underlying pathologic process must be considered. If the forces involved were very high, and multiple injuries were sustained, the risk of prolonged

recumbency to the patient's life must be considered in timing a surgical procedure.

If the patient can recall the event, it is important to elicit any history of transient paresthesias or paralysis from the time of injury. Even if the patient's symptoms resolved quickly, they suggest that some level of root or cord injury occurred at the time of the injury; therefore, assume that the spinal fracture is unstable. If the patient cannot give the details of the event, careful scrutiny of field notes can provide important clues to whether the patient had abnormal findings at the accident site. These notes are often gross evaluations only, however, and a patient with a severe cauda equina injury can still “move all four extremities.”

A history of previous trauma, surgery, or symptoms is important to understanding the current injury. Lower extremity weakness due to old injury or spinal disease can confuse the diagnostic picture after an acute injury, and a preexisting deformity—compression fracture, spondylolisthesis, or kyphosis—can be difficult to differentiate from a new injury. Furthermore, the surgical approach to the multiply operated back will be more demanding and may require different instrumentation than for an ordinary fracture.

The physical examination for the spinal-injured patient centers around a careful, complete neurologic assessment. Having examined the musculoskeletal system in the emergency department, carefully reexamine the extremities for tenderness and pain, and examine the back again to determine the level of discomfort and the presence of step-offs or gaps between the spinous processes, and to assess the skin over the area of injury.

Document a complete motor and sensory examination. Test each motor group for the lumbar and sacral plexuses independently and compare to the contralateral group (Fig. 141.2). Motor strength is recorded on six-point scale:

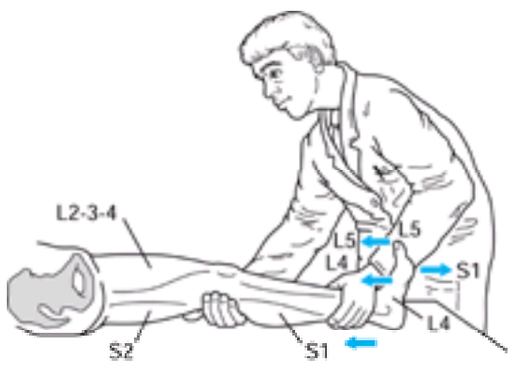


***Figure 141.2.*** Motor testing.

5full strength adequate to powerfully resist the examiner
4power to resist but not overcome the examiner
3power to overcome gravity
2power to move the joint but not to overcome gravity
1capacity to contract the muscle without functional power
0no motor function at all

When extremity injuries are present, make an educated assessment as to whether the patient is clinically weak or limited in effort by pain. Also determine whether the pattern of weakness is consistent with a cord lesion, a root lesion, or a peripheral nerve injury.

The sensory examination begins at the chest wall and seeks a level of anesthesia, root by root, down to the sacrum. Patients with thoracic cord injuries will have an anesthetic level at or just below their fracture. If the anesthetic level and the recognized fracture do not coincide, obtain an MRI to determine the actual cause of the cord impairment. Sensation in the lower extremities follows a dermatomal pattern; test each dermatome for light-touch and pin-prick sensation (Fig. 141.3).

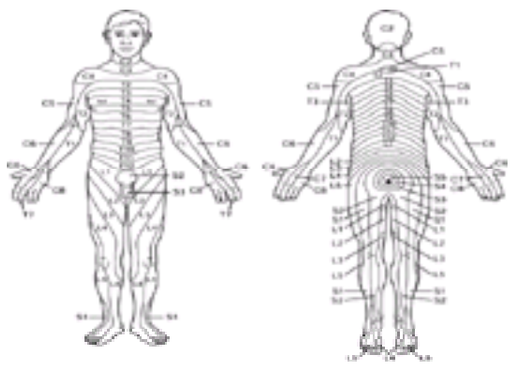

***Figure 141.3.*** Dermatomal patterns.

Check reflexes at both the knees and the ankles. The bulbocavernosus reflex, an involuntary contraction of the rectal sphincter, can be triggered either by gently squeezing the glans penis or glans clitoris or by gently tugging on the Foley catheter. If this reflex is absent, the patient either is in spinal shock or has suffered an injury to the caudal segments of the conus medullaris. Hyperactive reflexes suggest disinhibition due to a cord-level injury. Absent reflexes in an isolated distribution suggest an incomplete injury or root lesion. Complete absence of reflexes may be due to either spinal cord shock or a complete cauda equina injury. Spinal cord shock occurs at the time of injury and may persist for 72 hours. While the patient is in spinal cord shock, the neurologic examination remains unreliable—an incomplete injury may appear complete due to the overriding effects of cord shock. Once shock resolves and caudal reflexes return, the examination provides clear prognostic information: Incomplete injuries have potential for improvement, complete injuries have almost none. The bulbocavernosus reflex is the most reliable level for testing reflex return because it tests the most caudal segment of the spinal cord.

The rectal examination deserves special comment. The most caudal motor and sensory unit in the body is the rectum, the function of which is crucial to independent social activity. Carry out an independent examination of rectal tone, sensation, and reflex activity. Do not rely on emergency department records if there is any concern of neurologic injury. Explain the purpose of the examination to the patient, who may be anxious over repeated exams. Document resting tone, voluntary contraction, perianal sensation, and bulbocavernosus reflex.

Plain radiographs should include anteroposterior (AP) and lateral views of the thoracic spine and/or the lumbosacral spine, depending on the symptomatic level (16). On occasion, standard thoracic films will cut off T12–L1, and lumbosacral films will start at L-1, giving an inadequate view of the most frequently injured level. If fracture of the thoracolumbar junction is suspected, repeat AP and lateral radiographs, centered at the T-12 level. In stable fractures (compression fractures, mild burst fractures, and mild flexion–distraction injuries), plain radiographs are sufficient to allow definitive treatment, and no further diagnostic studies are needed. In unstable spine fractures, however, additional imaging studies are often indicated.

Unstable fractures (severe burst fractures, fracture– dislocations, significant flexion–distraction injuries, and any fracture with a neurologic deficit) require further study to assess the extent of bony disruption, spinal cord impingement, canal compromise, and/or cord injury. A CT scan provides the most definitive information on bony characteristics, such as fracture pattern and comminution (8,11,15). The axial cuts of the CT scan can completely miss flexion–distraction injuries, however. An MRI is superior for soft-tissue details such as cord injury, cord compression, disc herniation, and ligamentous disruption (28). The MRI has the added benefit of scanning the entire thoracolumbar spine, and it can pick up noncontiguous fractures, cord injury, and epidural hematoma at levels other than that of the primary fracture. Longitudinal MRI cuts show the soft-tissue disruption and bony separation of flexion–distraction injuries well.

Myelography, the gold standard for assessing neural compromise just a decade ago, is now replaced by the MRI in all but a few cases. When an MRI is contraindicated

(e.g., intraocular fragments, cardiac valves), CT myelography is an appropriate but more invasive alternative.

There are two absolute indications for ordering MRI or myelography in the acutely injured patient:

- Any patient with a progressive neurologic deficit needs emergent imaging.
- Any patient whose neurologic level does not coincide with the recognized injury needs further evaluation for an unrecognized fracture or disc disruption.

Plain tomography is sometimes useful for evaluating the cervicothoracic junction when a CT scan cannot be obtained immediately. Flexion–extension studies or nuclear medicine scans have little role in acute trauma. There is no role for electrodiagnostic testing in the acute management of spine trauma patients.

## FRACTURE CLASSIFICATIONS

Once the diagnostic evaluation is complete, the fracture can usually be classified according to one of a number of schemes. Holdsworth first characterized spinal fractures according to a two-column—anterior and posterior—model of the spinal column (13,14). This model has since given way to the three-column model of Denis, which considers the vertebral body, anulus, and posterior longitudinal ligament to be the middle column, a discrete unit separate from the anterior and posterior stabilizers (5,6,22) (Fig. 141.4).

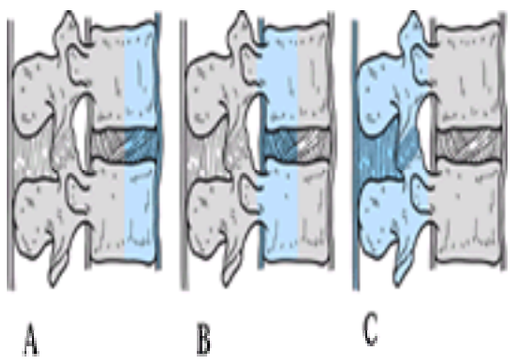


***Figure 141.4.*** Three-column model of Denis. **A:** Anterior column. **B:** Middle column. **C:** Posterior column.

The first consideration is whether to classify a specific injury as stable or unstable. Unstable injuries include all those with any of the following:

- Three-column disruption
- Greater than 50% collapse of anterior cortex
- Greater than 25° of focal kyphosis
- Any extent of neurologic deficit

Although all stable injuries may be treated nonoperatively, not all unstable injuries need to be treated operatively. A simple algorithm for treatment is indicated in Fig. 141.5.

***Figure 141.5.*** Treatment algorithm for thoracolumbar fractures.

After assessing the level of instability, classify the fracture according to fracture type and severity. The Denis fracture classification (Table 141.1) depends on information about the fracture pattern, the mechanism of injury, and the deforming forces that caused the fracture. The differences between severe burst fractures and rotational fracture–dislocations, and severe seat-belt injuries and flexion–distraction fracture–dislocations are subtle, and of limited importance: These severe injuries are all clearly unstable, and all require operative treatment.

| Fracture type | Subtype | Deforming forces | Columns injured | Stability |
|---|---|---|---|---|
| Compression | | Axial loading | 1: Anterior | Stable |
| Burst fracture | Type A | Axial loading | 2: Anterior and middle | Unstable |
| | Type B | Flexion, axial loading | 2: Anterior and middle | Possibly unstable |
| | Type C | Flexion, axial loading | 2: Anterior and middle | Possibly unstable |
| | Type D | Axial loading, rotation | 3: Anterior, middle, posterior | Unstable |
| | Type E | Lateral compression | 2–3: Anterior, middle, posterior | Possibly unstable |
| Seat-belt | | Flexion–distraction | 2: Posterior and middle | Unstable |
| Fracture-dislocation | Flexion–rotation | Hyperflexion–rotation | 3: Anterior, middle, posterior | Unstable |
| | Shear | Extension, translation | 3: Anterior, middle, posterior | Unstable |
| | Flexion–distraction | Hyperflexion–distraction | 3: Anterior, middle, posterior | Unstable |

***Table 141.1. Denis Fracture Classification***

### COMPRESSION FRACTURES

Compression fractures are common injuries, occurring with moderate trauma in young patients and minimal to no trauma in elderly, osteoporotic patients. The anterior column collapses under an axial or flexion load, with fracture of one or both endplates, but the middle and posterior columns are undamaged. These stable injuries are appropriately treated with a removable brace and symptomatic care. Observe patients with advanced osteoporosis for progressive collapse; severe compression fractures may warrant a CT examination to rule out a burst component.

### BURST FRACTURES

Burst fractures occur when the vertebral body is exposed to higher axial or flexural loads at a high loading rate. These fractures are commonly the result of motor vehicle accidents, falls from height, or crush injuries. The anterior cortex fails in compression, and either one or both endplates are fractured. The middle column is also fractured, and a portion of the posterior vertebral body is retropulsed backward into the canal. Depending on the severity of the fracture, the posterior elements may be fractured as well. Determine the need for surgical treatment by the extent of vertebral comminution, the extent of canal compromise, and the status of the posterior column structures (21). Burst fractures may be subdivided by fracture pattern:

- Type A fractures occur with axial loading, with fractures of both upper and lower endplates.
- Type B fractures are the most common (50%), with fracture of only the upper endplate.
- Type C fractures, with disruption of the lower endplate, are uncommon.
- Type D fractures have a rotational displacement of one body relative to the other on AP radiographs.
- Type E fractures are lateral compression injuries, with traumatic scoliosis (Fig. 141.6).

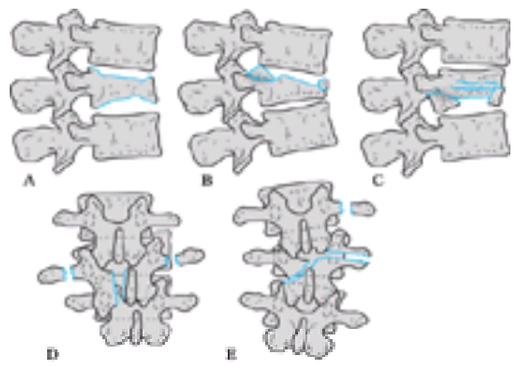


***Figure 141.6.*** Burst fracture patterns.

Canal compromise is most accurately assessed on a CT scan, by comparing the AP diameter of the normal spinal canal at an adjacent level to the reduced diameter at the level of the retropulsed fragment (26). The ratio of the injured to the intact diameters provides the percent compromise (Fig. 141.7). The greatest compromise occurs at the level of the pedicles and upper vertebral body. In type A and B burst fractures, the central portion of the posterior cortex and body is driven back into the canal between the two pedicles, which then prevent the fragment from reducing. Because of the differing volumes of neural tissue in the canal at different levels, compromise of greater than 50% may produce symptoms at the thoracolumbar junction, whereas compromise of 85% or more may be well tolerated at the lumbosacral junction (9). A CT scan will also demonstrate the presence and extent of posterior element disruptions (Fig. 141.8). Three-column injuries are inherently more unstable than two-column injuries, and the inability to load the posterior facet joints in a hyperextension cast may exclude nonoperative care for some patients.

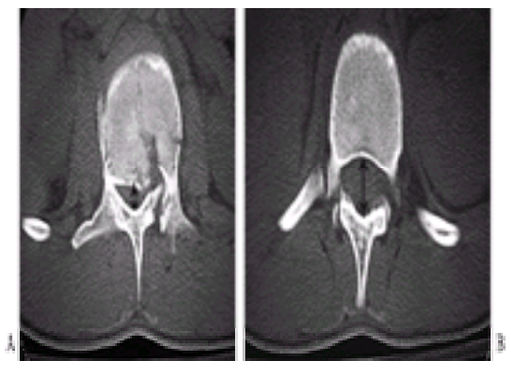


***Figure 141.7.*** Canal dimension at injured level (**A**) is compared to adjacent normal level (**B**) to determine percent canal compromise.

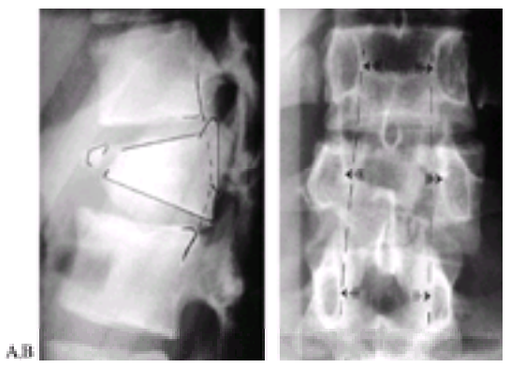


***Figure 141.8.*** Radiographic characteristics of burst fractures. **A:** Lateral view demonstrates fracture of anterior cortex and superior endplate, with resulting focal kyphosis. The posterosuperior portion of the vertebral body can be seen retropulsed into the spinal canal, with loss of normal concave contour of the posterior vertebral body. **B:** AP radiograph demonstrates the increased intrapedicular distance associated with a burst fracture; the distance between the L-1 pedicles is significantly greater than for the levels either above or below, indicating a complete disruption of anterior, middle, and posterior columns.

## FLEXION-DISTRACTION FRACTURES

Flexion-distraction, or seat-belt fractures may be either one- or two-level injuries (5,10,12,27). The classic one-level injury is the Chance fracture. The mechanism of injury involves the patient being thrown forward across an intact lap-belt, resulting in a hyperflexion force acting around a center of rotation *anterior* to the spinal column—at the belt itself. This results in distraction forces at all three columns of the spine: (a) The posterior elements are torn apart through either the facet joints or the bone itself, (b) the middle column is torn apart through either the posterior disc or the posterior vertebral body, and (c) the anterior column is either disrupted (in severe injuries) or left as a hinge that cannot resist either flexion or rotational displacement. Plain radiographs demonstrate the gap between the spinous processes and the disruption of the pedicle in most cases (Fig. 141.9) but may show minimal displacement when the patient is supine because the fracture tends to reduce in this position. An MRI shows the injury clearly.

***Figure 141.9.*** Radiographic characteristics of seat-belt fractures. **A:** Lateral radiograph of severe flexion–distraction injury, taken in sitting position. The patient was admitted following a head-on motor vehicle accident and treated for abdominal contusions, splenic rupture, and rupture of the colon. Injury was not apparent on supine radiographs. **B:** AP radiograph shows wide spacing between spinous processes at the level of injury. **C:** MRI confirms extensive soft-tissue disruption including rupture of the lumbodorsal fascia.

The violent compression of viscera between the spinal column and lap belt can rupture hollow viscera, lacerate solid viscera (liver and spleen), and avulse major vascular pedicles. Unrecognized, any of these injuries can prove rapidly fatal; it is therefore necessary that any patient with a seat-belt injury be carefully assessed by a general surgeon for acute or occult intra-abdominal injury.

Single-level injuries pass through the posterior ligamentous structures and the underlying disc at the same level, or through the posterior lamina, pedicle, and vertebral body in the same transverse plane (Fig. 141.10). These injuries disrupt only a single motion segment. Two-level injuries begin posteriorly at one level of lamina or facet joint, then proceed anteriorly in an oblique fashion so that the injury passes out of the vertebral body into an adjacent disc or through the disc into an adjacent body. In these injuries, two adjacent motion segments are disrupted, and stabilization requires addressing both levels of injury.

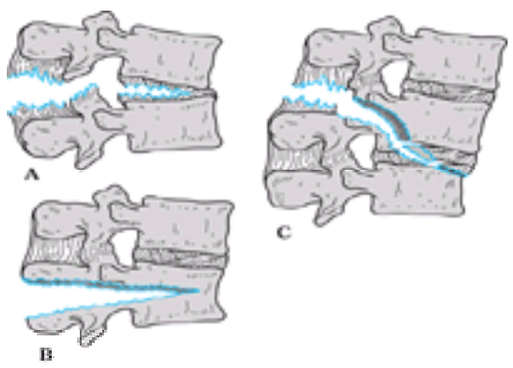


***Figure 141.10.*** Seat belt-fractures. **A:** Injury to soft-tissues only. **B:** Bony chance fracture. **C:** Mixed injury.

**FRACTURE–DISLOCATIONS**

Fracture–dislocations are, by definition, three-column injuries. They are highly unstable, usually associated with neurologic injury, and often associated with other musculoskeletal and visceral injuries. The neurologically intact patient must be carefully protected during any necessary testing or emergent operative procedures, and the spine must be stabilized at the first reasonable opportunity to allow mobilization and prevent paralysis. In the patient with neurologic deficit, postural reduction may improve alignment and reduce neural compression, and longitudinal traction may allow manual reduction of a displaced fracture–dislocation. Neither will reduce neural compression by retropulsed vertebral fragments, however, and direct decompression is indicated for those patients with an incomplete injury and hopes of improvement.

Flexion–rotation fracture–dislocations (Fig. 141.11) are caused by hyperflexion and rotation forces such as seen when a patient is ejected from a vehicle at high speed. When the vertebral body is fractured, this injury may be indistinguishable from a severe type D burst fracture. Shear fractures are more uncommon injuries and occur in the absence of axial loading or flexion–extension forces. Translational forces occurring when the subject is struck squarely from the side, front, or back act to shift one vertebral body relative to the next by shearing through bony articulations and ligamentous structures. Flexion–distraction fracture–dislocations occur when all three columns fail in hyperflexion. These injuries are often not distinguishable from severe seat-belt injuries.

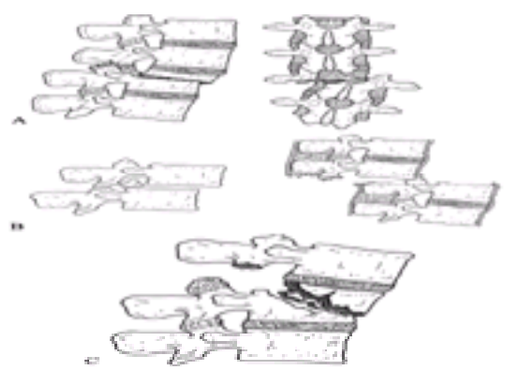

***Figure 141.11.*** Fracture dislocations. **A:** Flexion-rotation. **B:** Shear. **C:** Flexion-distraction.

A key consideration in fracture–dislocations is that all three columns are unstable in both axial loading *and in longitudinal traction*. Instrumentation systems that depend on distraction forces to secure hook purchase cannot be safely applied in these injuries, and any system incorrectly applied may overdistract the fracture and stretch the neurologic elements, precipitating or worsening the neurologic injury.

## AUTHORS' PERSPECTIVE

Successful fracture treatment begins with a careful and comprehensive initial evaluation. The key to success is, as always, to look at the whole patient—never allowing a single, dramatic injury to distract attention from more subtle, and potentially more dangerous, injuries. Once the patient is hemodynamically stable, and the fracture is recognized and classified, prepare a treatment plan based on the fracture pattern, the severity of injury, and the patient's overall condition. The options for nonoperative and operative treatment are extensive, and the correct choice for any patient must be determined by weighing all the above considerations, as well as the surgeon's experience, against the potential risks of treatment.

**CHAPTER REFERENCES**

Each reference is categorized according to the following scheme: *, classic article; #, review article; !, basic research article; and +, clinical results/outcome study.


+ 1. Benson DR, Burkus JK, Montesano PX, et al. Unstable Thoracolumbar and Lumbar Burst Fractures Treated with the AO Fixateur Interne. *J Spinal Disord* 1992;5:335.

* 2. Bohlman HH. Treatment of Fractures and Dislocations of the Thoracic and Lumbar Spine. *J Bone Joint Surg Am* 1985;67:165.

# 3. Bone LB. Management of Polytrauma. In: Chapman MW, ed. *Operative Orthopaedics*, 2nd ed. Philadelphia: JB Lippincott, 1993.

+ 4. Bracken MB, Shepard MJ, Collins WF, et al. A Randomized, Controlled Trial of Methylprednisolone or Naloxone in the Treatment of Acute Spinal Cord Injury. Results of the Second National Acute Spinal Cord Injury Study. *N Engl J Med* 1990;322:1405.

* 5. Denis F. The Three Column Spine and Its Significance in the Classification of Acute ThoracoLumbar Spinal Injuries. *Spine* 1983;8:817.

* 6. Denis F. Spinal Instability as Defined by the Three Column Spine Concept in Acute Trauma. *Clin Orthop* 1984;189:65.

+ 7. Dickson JH, Harrington PR, Erwin WD. Results of Reduction and Stabilization of the Severely Fractured Thoracic and Lumbar Spine. *J Bone Joint Surg Am* 1978;60:799.

+ 8. El-Khoury GY, Kathol MH, Daniel WW. Imaging of Acute Injuries of the Cervical Spine: Value of Plain Radiography, CT, and MR Imaging. *AJR Am J Roentgenol* 1995;164:43.

+ 9. Finn CA, Stauffer ES. Burst Fractures of the Fifth Lumbar Vertebra. *J Bone Joint Surg Am* 1992;74:398.

* 10. Gertzbein SD, Court-Brown CM. Rationale for the Management of Flexion Distraction Injuries of the Thoracolumbar Spine Based on a New Classification. *J Spinal Disord* 1989;2:176.

+ 11. Golimbu C, Firooznia H, Rafii M, et al. Computed Tomography of Thoracic and Lumbar Spine Fractures That Have Been Treated with Harrington Instrumentation. *Radiology* 1984;151:731.

* 12. Gumley G, Taylor TK, Ryan MD. Distraction Fractures of the Lumbar Spine. *J Bone Joint Surgery Br* 1982;64:520.

* 13. Holdsworth FW. Fractures, Dislocations, and Fracture-Dislocations of the Spine. *J Bone Joint Surg Br* 1963;45:6.

* 14. Holdsworth FW, Chir M. Fractures, Dislocations, and Fracture-Dislocations of the Spine. *J Bone Joint Surg Am* 1970;52:1534.

* 15. Keene JS. Radiographic Evaluation of Thoracolumbar Fractures. *Clin Orthop* 1984;189:58.

+ 16. Keene JS, Goletz TH, Lilleas F, et al. Diagnosis of Vertebral Fractures: A Comparison of Conventional Radiography, Conventional Tomography, and Computed Axial Tomography. *J Bone Joint Surg Am* 1982;64:586.

+ 17. McBride GG. Cotrel-Dubousset Rods in Spinal Fractures. *Paraplegia* 1989;27:440.

+ 18. McBride GG. Cotrel-Dubousset Rods in Surgical Stabilization of Spinal Fractures. *Spine* 1993;18:466.

+ 19. McLain RF, Benson DR. Missed Cervical Dissociation—Recognizing and Avoiding Potential Disaster. J Emergency Medicine, In Press, 1998.

+ 20. McLain RF, Benson DR. Thoracolumbar Fractures Treated with Segmental Fixation. Unpublished data.

* 21. McLain RF, Sparling E, Benson DR. Early Failure of Short Segment Pedicle Instrumentation for Thoracolumbar Fractures. *J Bone Joint Surg Am* 1993;75:162.

! 22. Panjabi MM, Oxland TR, Kifune M, et al. Validity of the Three-column Theory of Thoracolumbar Fractures. A Biomechanic Investigation. *Spine* 1995;20:1122.

+ 23. Place HM, Donaldson DH, Brown CW, Stringer EA. Stabilization of Thoracic Spine Fractures Resulting in Complete Paraplegia. A Long-term Retrospective Analysis. *Spine* 1994;19:1726.

# 24. Reid DC, Henderson R, Saboe L, Miller JDR. Etiology and Clinical Course of Missed Spine Fractures. *J Trauma* 1987;27:980.

# 25. Saboe LA, Reid DC, Davis LA, et al. Spine Trauma and Associated Injuries. *J Trauma* 1991;31:43.

+ 26. Shuman WP, Rogas JV, Sickler ME, et al. Thoracolumbar Burst Fractures: CT Dimensions of the Spinal Canal Relative to Postsurgical Improvement. *AJR Am J Roentgenol* 1985;145:337.

* 27. Smith WS, Kaufa H. Patterns and Mechanisms of Lumbar Injuries Associated with Lap Seat Belts. *J Bone Joint Surg Am* 1969;51:239.

+ 28. Tarr RW, Drolshagen LF, Kerna TC. MRI of Recent Spinal Trauma. *J Comput Assist Tomogr* 1987;11:412.

+ 29. Tasdemiroglu E, Tibbs PA. Long-term Follow-up Results of Thoracolumbar Fractures after Posterior Instrumentation. *Spine* 1995;20:1704.

+ 30. Vandermark RM. Radiology of the Cervical Spine in Trauma Patients: Practice, Pitfalls, and Recommendations for Improving Efficiency and Communication. *AJR Am J Roentgenol* 1990;155:465.

# CHAPTER 142

# OPERATIVE TREATMENT OF THORACIC AND THORACOLUMBAR FRACTURES

*Robert F. McLain and Daniel R. Benson*

**R. F. McLain:** Director, Spine Research, Department of Orthopaedics, The Cleveland Clinic Foundation, Cleveland, Ohio, 44195.
**D. R. Benson:** Department of Orthopaedics, University of California, Davis, Sacramento, California, 95817.

Introduction
Nonoperative Treatment
Indications
- Compression Fractures
- Burst Fractures
- Flexion-Distraction Injuries
- Fracture-Dislocations

Surgical Timing
Instrumentation Options
- Harrington Rods
- Hybrid Constructs
- Segmental Spinal Instrumentation
- Pedicle Screw Fixation
- Anterior Plates and Screws

Surgical Techniques
- Postural Reduction of Fracture
- Open Reduction of Fracture
- Fusion Technique
- Stabilization Techniques

Pitfalls and Complications
Summary
Chapter References

## INTRODUCTION

Since the early 1980s, operative treatment has moved to the forefront of fracture management in the spine. Techniques and implants have evolved to provide better results with decreased morbidity and mortality (1,9,11,13,17), and current operative management more rapidly returns the patient to work and satisfactory function (9,10,20,86). Changes in health care management and patient expectations have made prolonged bed rest or immobilization unacceptable (12). Improved imaging, a better understanding of fracture and implant biomechanics, and the introduction of a variety of new anterior and posterior fixation devices allow surgeons to plan definitive stabilizing procedures for any fracture pattern, allowing rapid mobilization and return to function. Hence, patients who cannot be mobilized in a cast or brace within a few days of their injury are often more reasonably treated with surgery.

The goals of treatment, operative or otherwise, remain to

1. Protect neural elements, restore/maintain neurological function;
2. Prevent or correct segmental collapse and deformity;
3. Prevent spinal instability and pain;
4. Permit early ambulation and return to function; and
5. Restore normal spinal mechanics.

## NONOPERATIVE TREATMENT

Only 20% to 30% of spine fractures require surgery. The rest can be treated nonoperatively in a brace, molded orthosis, or hyperextension cast. Single-column injuries (e.g., compression fracture, laminar fracture, spinous process fracture) are treated in an off-the-shelf brace that encourages normal spinal alignment and limits extreme motion (Fig. 142.1). More significant compression fractures may be treated in a molded orthosis. Two-column injuries, including severe compression fractures, mild to moderate burst fractures, and bony Chance fractures, are too unstable to be braced but may well be reduced and maintained at bed rest or in a hyperextension cast. Previous studies (84) have shown that even severe burst fractures can be treated with a regimen of bed rest, postural reduction, and casting. Bony remodeling reduces residual canal compromise by more than 50% over the course of a year (71) (Fig. 142.1), making surgical treatment unnecessary in many patients, including those with retropulsed fragments in the spinal canal. Recumbent treatment, although effective, is very expensive and rarely reimbursed or permitted in managed care systems. Hyperextension casting, on the other hand, allows immediate mobilization and early return to independent function.

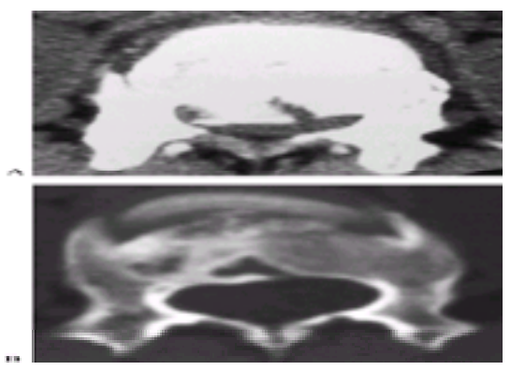

***Figure 142.1.*** Fracture remodeling. **A:** Thoracic level burst fracture. With nonoperative treatment, normal remodeling mechanisms tend to restore canal diameter compromised by retropulsed bony fragments. **B:** Resorption of the retropulsed vertebral body results in a “heart-shaped” canal with near-normal anteroposterior (AP) diameter 1 year later. (Courtesy Joseph Mumford, MD, Topeka, KS.)

The hyperextension cast can be used in many patients with severe compression fractures or burst fractures. Figure 142.2 shows an example of closed reduction and casting for thoracolumbar fractures.

***Figure 142.2.*** Closed reduction and hyperextension casting of thoracolumbar fractures.

- Place the patient on a modified fracture table (Fig. 142.2*A*). Suspend the patient on a narrow, midline, taut canvas support in cervical halter traction, with arms out to the side, knees flexed, and feet resting on the support to give the patient a sense of balance.
- Apply a vertically directed force that will achieve hyperextension at the fracture site (Fig. 142.2*B*). Once maximum hyperextension is achieved through this means, relax the horizontal canvas support and place additional traction on the iliac crests.
- After satisfactorily positioning the patient on the table, wrap the torso with Webril (Fig. 142.2*C*). Pad the bony prominences additionally with foam and apply the cast.
- Note the extreme hyperextension placed into the cast, as well as the large anterior abdominal hole that has been created (Fig. 142.2*D*, Fig. 142.2*E*). Send the patient to the x-ray department for postreduction and casting x-ray studies. If satisfactory alignment has been achieved, allow the patient to ambulate immediately.

If the posterior elements are intact, axial loads are transferred posteriorly through the facet joints, allowing immediate weight bearing and good restoration of sagittal alignment and vertebral body height. In Chance fractures, hyperextension closes the posterior defect and approximates the fracture margins. The cast cannot be placed until the abdomen is cleared and any ileus or distention has subsided, however, limiting its use in polytrauma patients. Patients with abdominal trauma, prolonged ileus, chest trauma, or multiple extremity fractures may not be suitable for casting for some time after admission. Once the abdomen is cleared and a well-molded cast is applied, the patient may begin transfers and ambulation. Braces and removable orthoses cannot generate the hyperextension forces necessary to maintain sagittal alignment and should not be considered substitutes for a well-molded hyperextension cast. Also see Chapter 10.

Operative treatment offers significant advantages over casting or recumbency (18,32,43,44,52,53). First, immediate spinal stability is provided for patients who can tolerate neither a cast or prolonged recumbency. Prolonged recumbency in multiply injured patients predisposes them to severe and life-threatening complications. Prompt surgical stabilization allows the patient to sit upright, transfer, and start rehabilitation earlier, with fewer complications (14,31,42). Second, surgical treatment more reliably restores sagittal alignment, translational deformities, and canal dimensions than does cast treatment. And, finally, surgical decompression more reliably restores neurologic function and decreases rehabilitation time (16,23,52,72).

## INDICATIONS

### COMPRESSION FRACTURES

Compression fractures are usually single-column injuries, are typically stable, and rarely cause neurologic injury. A hyperextension orthosis or chair-backed brace is sufficient to allow ambulation and return to limited activity. Fractures with more than 50% collapse of the anterior vertebral body or with more than 20° of sagittal angulation are considered potentially unstable. A computed tomography (CT) scan may be necessary to distinguish these injuries from a burst fracture. Severe compression fractures can be treated with a hyperextension cast, although some may require posterior instrumentation and fusion.

### BURST FRACTURES

Stable burst fractures (two-column injuries) may be treated in a hyperextension cast if the patient has no abdominal or thoracic injuries. Unstable injuries typically require operative reduction and stabilization.

- Burst fractures that are considered unstable include
- Greater than 50% axial compression.
- Greater than 20° angular deformity.
- Multiple contiguous fractures.
- Neurologic injury—complete, incomplete, or root.
- Three-column injuries and dislocations.
- Patients with extensive associated injuries.
- Greater than 50% canal compromise at L-1 and 80% compromise at L-5.

#### *Neurologically Intact*

In patients with no neurologic injury, treatment decisions are based on issues of mechanical stability and sagittal alignment primarily, and canal compromise secondarily. In the thoracic region, sagittal deformities are corrected by longitudinal distraction, which may also indirectly reduce some retropulsed vertebral fragments from the spinal canal. In the lumbar region, forceful distraction tends to reduce lumbar lordosis, introducing sagittal imbalance and a flat back. Forceful distraction in a patient with a three-column injury may inadvertently lengthen the spinal column and stretch the spinal cord, causing neurologic injury. Segmental spinal systems now allow segmental distraction within the construct while neutralizing construct length and sagittal alignment (Fig. 142.3). The segmental fixation system allows multiple points of fixation, to distribute reduction forces more evenly. Posterior systems cannot resist sagittal deforming forces if the anterior spinal column is deficient, however (70). Thoracolumbar and lumbar fractures with severe collapse and vertebral comminution tend to lose correction over time unless anterior instability is corrected. Patients with sagittal collapse tend to have more pain and may develop new neurologic symptoms if kyphosis progresses (27,70).

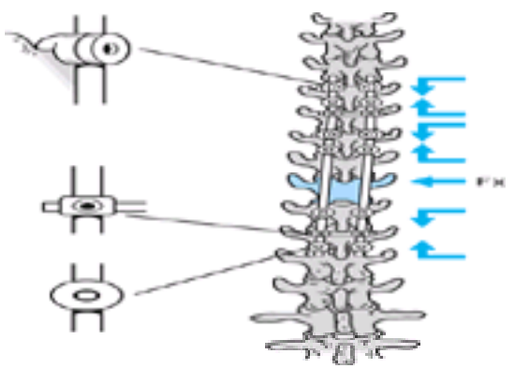

***Figure 142.3.*** Segmental fixation allows the surgeon to neutralize the overall length of the spinal segment, preventing overdistraction, and segmentally distract or compress segments within the construct to either decompress the fracture site or compress an anterior graft.

Canal compromise should be assessed in every burst fracture, but it becomes the primary concern only when a high degree of compromise is recognized. Residual compromise greater than 50% is worrisome at the T12–L1 level, where the conus medullaris and cauda equina fill the spinal canal (Fig. 142.4). Small increments of axial or sagittal collapse can compromise neurologic elements, and anterior decompression and stabilization should be considered for both mechanical and neurologic

reasons. On the other hand, 80% to 85% canal compromise may be well tolerated in the lower lumbar spine, where only a few roots remain in the otherwise capacious canal (40). Retropulsed bony fragments reabsorb and remodel over time, and do not need to be addressed in their own right (70). Sagittal collapse and kyphosis of a moderate degree is usually well tolerated in the thoracic region, and does not require aggressive reconstruction. Lower lumbar burst fractures are also well tolerated, and most have a satisfactory outcome without reconstruction. Canal compromise, sagittal imbalance, and segmental kyphosis are all poorly tolerated at the thoracolumbar junction, which is, unfortunately, the most common site of fracture.

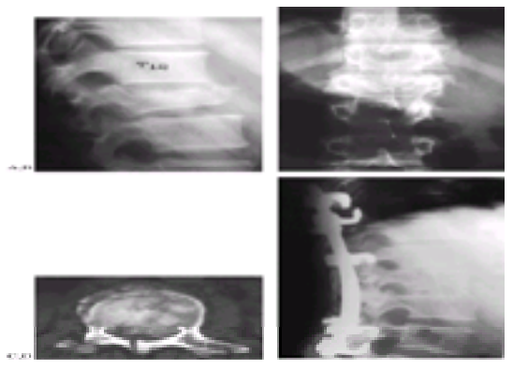

***Figure 142.4.*** Burst fracture: 32-year-old man fell 35 feet, sustaining severe L-1 burst fracture (Denis type B) and an open tibial shaft fracture. **A, B:** Lateral and AP radiographs demonstrate loss of vertebral height and widening of the pedicles, with little kyphosis. Cortical retropulsion is difficult to appreciate on plain radiograph. **C:** Computed tomography demonstrates severe comminution and canal compromise. A fracture of the lamina is also seen. Even though the patient was neurologically intact, the 75% compromise at the L-1 level seen here was considered too severe, and the spine, unstable. **D:** Anterior vertebrectomy was followed by strut graft reconstruction, restoring anterior column support and thoracolumbar alignment. Posterior segmental instrumentation stabilizes the spine; the intermediate, down-going hook compresses and entraps the anterior strut. The patient had a full recovery and returned to work and sports without restrictions.

***Neurologically Compromised***

In patients with a neurologic injury, operative treatment is carried out to protect residual function, restore neurologic deficits, and allow early mobilization and rehabilitation without a cast. If the cord or cauda equina injury is incomplete, neurologic decompression can significantly improve the eventual outcome (16,33,61), assuming that there is significant residual compression at the time of surgery (Fig. 142.5). If no residual compression exists, posterior stabilization is carried out alone. If the neurologic injury is complete, anterior surgery will not improve the chance of neurological improvement but may be indicated to treat sagittal deformity or instability. Posterior instrumentation is usually adequate to allow immediate transfers and early rehabilitation.

***Figure 142.5.*** Burst fracture-contiguous levels: 18-year-old man, status post motor vehicle accident, sustained L-2 and L-3 burst fractures with incomplete cauda equina injury. **A, B:** Lateral and AP radiographs. Multiple transverse process fractures suggest extent of soft-tissue trauma. **C:** CT of L-3 demonstrates greater than 80% canal compromise, laminar fractures, and extensive comminution. L-2 was less disrupted but unable to support an anterior strut. **D:** Lateral radiograph following L-2 partial and L-3 total vertebrectomy, followed by fibular autograft reconstruction. Construct was stopped at L-4 to spare the subjacent discs. At 4-year follow-up, the patient had normal neurologic function and minimal, intermittent back pain. **E:** Postoperative CT of patient following anterior decompression and reconstruction with autograft fibula and rib. The entire vertebral body has been removed from pedicle to pedicle, and all fragments have been removed from the canal. The patient had full neurologic recovery.

**FLEXION-DISTRACTION INJURIES**

Flexion-distraction injuries may occur through bone or soft tissue, and may involve one or multiple motion segments (24,25 and 26,44,79). Two-column injuries occurring through bone heal reliably and may well be treated in a hyperextension cast. Ligamentous injuries do not heal reliably and more often result in residual instability and pain. These injuries are best treated with a short compression construct and posterior fusion, as are patients with abdominal injuries in patients who cannot tolerate a cast (Fig. 142.6).

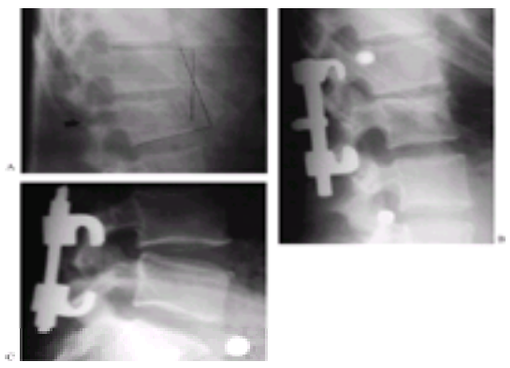

***Figure 142.6.*** Flexion-distraction injury—Chance fracture: 23-year-old with seat belt injury. The patient was neurologically intact but sustained severe internal injuries requiring colostomy. **A:** Lateral radiograph demonstrates focal kyphosis, expanded vertebral height, and transpedicular fracture line associated with Chance fracture. **B:** Because of abdominal injuries, casting was not possible. Operative reduction and fusion were carried out using a segmental fixation system. Reduction was obtained by positioning the patient in lordosis, manipulating the spinous processes to reduce displacement, and sequentially compressing the rod/hook construct until the fracture was closed and facets tightly compressed. **C:** A similar fracture treated with threaded Harrington compression rods.

Three-column flexion-distraction injuries are highly unstable. The incidence of spinal cord injury is high, as is the incidence of intra-abdominal injury, necessitating a more aggressive surgical approach. Pedicle instrumentation or extended segmental constructs are often needed to stabilize these fractures.

**FRACTURE-DISLOCATIONS**

Fracture-dislocations are the result of high-energy trauma (motor vehicle accidents and falls from height) and are typically associated with severe neurologic damage

and multiple associated injuries (67,74,75). Complete spinal cord lesions do not improve with surgery, but mortality and morbidity are both improved by early mobilization and rehabilitation. Cauda equina lesions are less predictable than thoracic lesions (some improvement may be seen), and restoration of spinal alignment is indicated to stabilize the spine and to decompress entrapped and compressed roots.

## SURGICAL TIMING

The patient's overall condition must be considered in making a surgical decision. Delaying treatment affords no benefit to the patient but may allow the surgeon to assemble a more skilled team of personnel. If the patient is stable, neurologically intact, and not suffering from multiple injuries, it is safe and reasonable to schedule surgery for the next elective opportunity. On the other hand, morbidity or mortality are not increased by taking the patient to the operating room on an emergent basis, and in some instances, an emergent stabilization may prove instrumental in the patient's overall management.

Patients with thoracic fracture-dislocation associated with severe chest trauma and pulmonary contusion may deteriorate rapidly after hospitalization. Recumbency frequently leads to hypoventilation, pneumonia, and sepsis, irrespective of antibiotic prophylaxis, making delayed stabilization impossible. Pneumonia and respiratory insufficiency will not clear until the patient can be set upright, so a vicious circle is initiated that may take weeks to resolve or may even take the patient's life. Early stabilization (12 to 24 hours) allows aggressive pulmonary toilet, upright positioning, and limits time on the ventilator and in the intensive care unite (ICU), reducing the likelihood of nosocomial infection. Indications for urgent or emergent stabilization include

- Severe chest trauma, pulmonary contusion.
- Polytrauma, with multiple injured systems or long-bone fractures.
- Progressive neurologic deficit.
- Fracture dislocation in a patient already undergoing emergency surgery.
- Fracture dislocation or deformity threatening skin breakdown.

In a recent review of polytraumatized spine fracture patients, perioperative and postoperative morbidity were not increased by emergent stabilization, but neurologic improvement was increased and life-threatening complications were reduced (70a) (Table 142.1). Note that overall mortality is this study was significantly less than predicted by the high Injury Severity Score (ISS), where an ISS of greater than 40 typically results in a 50% mortality rate in this age group.

| | *Emergent surgery (<24 hours after surgery)* | *Routine surgery (24–72 hours after surgery)* |
|---|---|---|
| N | 14 | 13 |
| Mean age, years | 27.5 (16–46) | 30.0 (18–58) |
| Mean ISS | 42 (27–75) | 36 (27–50) |
| Mean time to OR | 9.7 hours | 35.0 hours |
| Mean EBL, posterior | 1432 ml | 1600 ml |
| Perioperative mortality | 1/14 (7%) | 1/13 (7.7%) |
| ARDS, sepsis, DVT, PE | 0/14 | 1/13 |

ARDS, adult respiratory distress syndrome; DVT, deep venous thrombosis; EBL, estimated blood loss; ISS, Injury Severity Score; PE, pulmonary embolism.

***Table 142.1. Polytraumatized Patients Undergoing Surgical Decompression or Stabilization on an Emergent or Routine Basis***

## INSTRUMENTATION OPTIONS

Because the decision to operate is usually predicated on the presence of spinal instability, instrumentation is almost always incorporated into the surgical plan. The type of instrumentation used depends on the injured level, the fracture pattern, the need for anterior stabilization or decompression, and the surgeon's level of experience and training.

Options for instrumentation include

- Nonsegmental rod/hook systems (Harrington rod).
- Hybrid systems (Luque; Harrington rod with sublaminar wires).
- Segmental systems.
  - rod/hook constructs
  - extended pedicle screw constructs
  - short-segment pedicle instrumentation (SSPI)
  - compression instrumentation
- anterior screw/plate or screw/rod instrumentation

### HARRINGTON RODS

Harrington rods have been largely replaced by segmental spinal systems but can still play a role in fracture stabilization, primarily in the thoracic spine. Applied properly, Harrington distraction rods can reduce angular deformity, restore vertebral body height, and provide adequate stiffness to allow early mobilization (5,41,52,54). Fixation is dependent on strong distraction forces between the superior and inferior hooks, however, and constructs must span a number of vertebrae to provide optimal corrective forces. Constructs that span three levels above and two below the injury are biomechanically superior to shorter constructs. Three-column spinal injuries cannot resist the distraction forces of the Harrington rod, however, and rods placed in these injuries will either overdistract the spinal column or will not be firmly fixed.

Harrington rods also break in 7% to 10% of cases, usually at the junction of the ratchet and the main rod body (60). Because there are only two points of fixation on each rod, forces tend to concentrate at those points, and lamina fracture or hook dislodgement are frequent, leading to complete loss of fixation (32,36,82).

### HYBRID CONSTRUCTS

Adding sublaminar or spinous process wires significantly improves fixation of the Harrington rod and limits the risk of hook displacement (55). Spinous process wires are less likely to pull sublaminar hooks into the canal, but well-fitted hooks are unlikely to displace with either technique (Fig. 142.7). These constructs are best suited to fractures of the midthoracic spine, where extended fusions are relatively well tolerated. Although the addition of sublaminar segmental wires has improved the sagittal and torsional stiffness of Harrington constructs (3,19,63,81,85), it has not eliminated rod breakage. Luque instrumentation may prove useful in some thoracic fractures but does not provide sufficient axial stability to treat burst fractures.

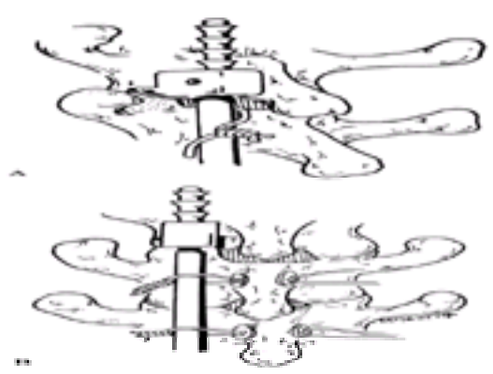

***Figure 142.7.*** Harrington rod fixation for thoracic fractures. Harrington rods, supplemented with sublaminar wires (**A**) or interspinous wires (**B**), provide sufficient rigidity

and stability to treat many thoracic level fractures and fracture dislocations.

### SEGMENTAL SPINAL INSTRUMENTATION

Segmental spinal instrumentation has improved treatment results for a variety of spinal disorders. Originally intended for scoliosis patients, segmental hook and rod systems have now been used to successfully treat trauma, infections, tumors, and degenerative disorders (51,59,76). Clinical series have documented the efficacy and technical demands of segmental systems in scoliosis, kyphosis, and congenital deformities, and have provided the clinician with enough information to develop rational and reliable treatment plans. Such principles have not been as well established for fracture treatment, however.

Segmental instrumentation is being used with increasing frequency for thoracic and thoracolumbar spine fractures, but only a handful of clinical studies have been published to support this application (47,64,80). McBride reported good results in thoracic and thoracolumbar fractures treated with longer hook and rod constructs (64,65), and SSPI constructs have been endorsed for treatment of lumbar fractures (7,20). Enthusiasm for SSPI has been tempered somewhat by recent studies identifying a high rate of screw failure in unstable fractures (4,8,69,70), however.

Segmental rod/hook constructs take advantage of three-point bending mechanics to reduce and maintain thoracic kyphosis and prevent translation of disrupted vertebral segments. The success of this strategy has been documented in nonsegmental systems (Harrington rods), and a number of construct patterns have been presented for segmental systems (64,65,80). Although they use the same basic reduction strategy as the Harrington rod, segmental rod/hook systems offer several unique advantages over first-generation instrumentation systems (6,39,49):

- Proximal and distal hook pairs (claws) provide more stable fixation than the Harrington hooks they replaced.
- Segmental systems are not dependent on strong distraction forces for purchase.
- Contact between the rod and the lamina still provides correcting forces in the sagittal plane.
- Segmental systems allow placement of intermediate hooks, thus distributing corrective forces over more laminae and reducing the likelihood of hook pull-out or fixation failure.
- Segmental constructs are stiffer than Harrington rods in both axial and torsional loading.

### PEDICLE SCREW FIXATION

Pedicle screws allow the surgeon to instrument vertebrae with absent or fractured laminae directly. They provide three-column fixation in unstable injuries and limit the length of fusion in the lumbar spine (50). Pedicle screws may be used exclusively or in combination with hook constructs to address a wide variety of fracture patterns. Combined (or “extended”) constructs are particularly useful at the thoracolumbar junction. Here, the thoracic spine is relatively immobile and tolerant of fusion. Extending the construct into these segments incurs little mechanical cost and provides more extensive fixation. This improved proximal fixation allows the surgeon to apply enough corrective force to restore sagittal alignment, an imperative at the thoracolumbar junction. Pedicle screws are then applied in the upper lumbar segment to limit the length of the construct, minimizing interference with lumbar motion segments. Extending fusion into the lower lumbar spine does alter mechanics and predisposes patients to junctional pain and subsequent degeneration.

The extended construct often incorporates an intermediate hook applied just above the fracture and just below the upper claw, and directed either cranially or caudally, depending on the situation. In most constructs, a narrow-width hook is placed up-going under the lamina of the vertebra two levels above the fracture. With the upper and lower fixation points locked in place to neutralize the construct length, this hook allows segmental distraction of the fracture to improve vertebral height and decompress the spinal canal indirectly without overdistracting the spine. In anterior and posterior reconstructions, this additional hook may be directed downward to compress and capture the anterior strut graft.

SSPI allows rigid fixation of short segments of the lumbar spine and provides sagittal, axial, and torsional stability superior to rod/hook constructs or sublaminar wiring (49,50). Fixation is not dependent on intact lamina, so there is no need to extend the fusion in cases of laminar fracture or laminectomy. Because distraction is not needed to correct the axial deformity, the risk of either overdistracting the disrupted segment or producing a flat-back syndrome is lessened. Both the surgical and mechanical disturbance to the adjacent lumbar segments is minimized. Nevertheless, SSPI is limited in its ability to maintain sagittal correction in severe burst fractures (7,69,70). If the anterior and middle spinal columns cannot share axial loads, the bending moments generated at the pedicle screw hub result in a high rate of bending failure or fracture. Once initial bending has occurred, progressive collapse is more likely, with progressive loss of lordosis in some patients.

### ANTERIOR PLATES AND SCREWS

A number of anterior fixation systems have been developed over the past 10 years, all based on the principle of anterolateral screw fixation coupled with longitudinal plates or rods (Fig. 142.8). These devices can span multiple segments and can be applied from the midthoracic region down to the L-5 vertebral body. They are intended to augment anterior column reconstruction, providing torsional and translational stability while sharing axial loads with a strut graft or cage (see Chapter 137). When posterior soft tissues and structures are intact, an anterior reconstruction and instrumentation may be adequate to stabilize the spine. If the posterior elements are disrupted, however, the anterior construct is likely to fail unless posterior instrumentation is carried out as well.

***Figure 142.8.*** Anterior instrumentation for burst fracture treatment.

## SURGICAL TECHNIQUES

Instrumentation provides little benefit unless the spinal alignment is corrected at the time of fixation. Failure to correct sagittal alignment will result in a fixed kyphotic deformity, predisposing the patient to dysfunction, pain, and instrumentation failure, and necessitating late revision and reconstruction. Failure to correct translational deformity will result in a residual stenosis at the level of offset, and may predispose the patient to nonunion and treatment failure.

### POSTURAL REDUCTION OF FRACTURE

The residual deformity in compression, burst, and many dislocation injuries is kyphosis. If this deformity is allowed to persist, it will become fixed and irreducible, but immediately after fracture, fragments are typically mobile and amenable to indirect reduction.

- If nonoperative treatment is planned, place the patient supine over a bolster until provisional healing has occurred (84) or until the patient is ready for casting. For operative care, accomplish reduction by properly positioning the patient on the surgical frame.
- Return fractures of the thoracic spine to normal kyphosis by placing the patient on a Wilson frame, adjusted to fit the patient's chest wall. Avoid hyperextension.
- Reduce fractures of the lower lumbar spine on either a Wilson or a fracture frame.

- Carry out instrumentation of the shortest possible segment with the hips extended and the torso positioned comfortably on the frame of choice.

Fractures at the thoracolumbar junction are most problematic for the following reasons: (1) The injured segments are junctional between the rigid thoracic spine and the well-supported lumbosacral vertebrae. (2) The neural elements at risk include the conus medullaris and entire cauda equina. (3) Residual deformity is poorly tolerated, and mechanical imbalance predisposes the patient to pain and construct failure.

- Position the patient gently and carefully in the prone position, with support under the iliac crests distally and the anterior chest wall proximally. Allow the abdomen and midtrunk to hang free.
- Options for positioning include transverse bolsters, the Relton-Hall type frame, and the Jackson turning frame. The Jackson turning frame allows the surgeon to position bolsters, arm boards, and headrest with the patient supine and awake, then turn the frame and patient as a unit without further repositioning (Fig. 142.9). A Wilson frame attachment is also available.

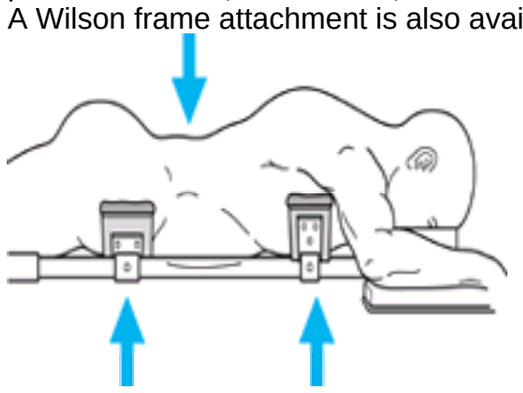

***Figure 142.9.*** Postural reduction of burst and flexion distraction injuries. Normal thoracolumbar lordosis can be restored by placing patient on a spinal frame supporting the torso and pelvis and allowing the abdomen to hang free. Further elevating the thighs will increase the lordosis in segments adjacent to the fracture, which helps in restoring normal alignment.

- As the abdomen and lower torso hang free, normal lumbar lordosis is accentuated, reducing the kyphotic deformity.
- Because postural reduction does not completely reduce the kyphosis of a severe burst fracture, it is incumbent on the physician to recognize residual deformity intraoperatively and manually restore thoracolumbar alignment at least to neutral position.

## OPEN REDUCTION OF FRACTURE

To complete reduction of a burst fracture, it may be necessary to manipulate the spine operatively. Two options are available. First, *in situ* contouring of the implants can restore lordosis to segments that are not completely reduced passively.

- Contour standard rod and screw or plate and screw constructs *in situ* to restore sagittal balance, or contour the rod before placement and then insert and rotate it into sagittal orientation to increase lordosis. Take care not to overpower and damage the implants, however.
- Supplement pedicle screws by offset laminar hooks before attempting vigorous contouring.
- Implants designed specifically for fracture reduction are available; they are designed to neutralize construct length at the same time that manipulation of the pins corrects sagittal collapse (7,30,37,38).

### *Short-Segment Pedicle Instrumentation*

Correction of residual kyphosis is important in the thoracolumbar region. Transpedicular instrumentation systems limit the extent of the spinal fusion to a few levels, and allow direct reduction of deformity. Figure 142.10 illustrates the use of SSPI:

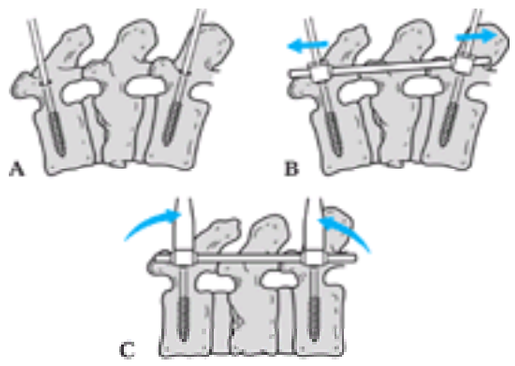


***Figure 142.10.*** Short-segment pedicle instrumentation. See text.

- After obtaining the best postural reduction, place screws according to anatomic landmarks and fluoroscopic control (step A).
- Apply the fixation rod and carry out gentle axial distraction to restore the normal height and alignment of the posterior elements (step B).
- Restore lordosis by levering the dorsal extensions of the screws together to distract the anterior and middle columns back to their normal height (step C). The sagittal rotation force applied at the screw-rod connection will further lengthen the posterior column as well, so avoid overdistraction during step B.
- Then tighten the locking nuts to fix both the axial and the sagittal correction.

### *Transpedicular Bone Graft*

The second option is to reduce the vertebral collapse directly through a posterolateral approach. Using this method, the surgeon elevates the depressed endplate through a transpedicular approach and reinforces the fracture site with a transpedicular bone graft (Fig. 142.11).

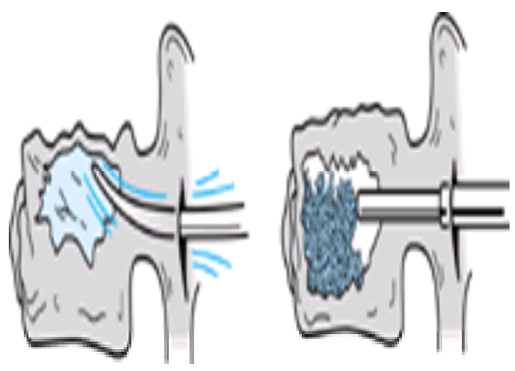

***Figure 142.11.*** Transpedicular bone graft. See text.

- To restore the anterior weight-bearing column without strut–graft reconstruction, carry out a transpedicular reduction and grafting.
- Using a specially designed instrumentation set (Synthes NA, Paoli, PA), directly elevate the fractured endplate using a transpedicular approach.
- Impact fracture fragments into the fracture defect or remove them through a transpedicular decompression.
- Impact additional graft, harvested from the pelvis using an acetabular reamer, into the anterior half of the vertebral body using a transpedicular funnel and stylet.

Irreducible facet dislocations may require an operative reduction to restore alignment. Fracture-dislocations are usually reduced easily because the soft tissues are completely disrupted. If part of the facet capsule or posterior longitudinal ligament is intact, manual reduction is more difficult. In such a case, in a neurologically intact patient, use a burr to take down the locked facet and allow a gentle reduction without overdistracting the spine (Fig. 142.12).

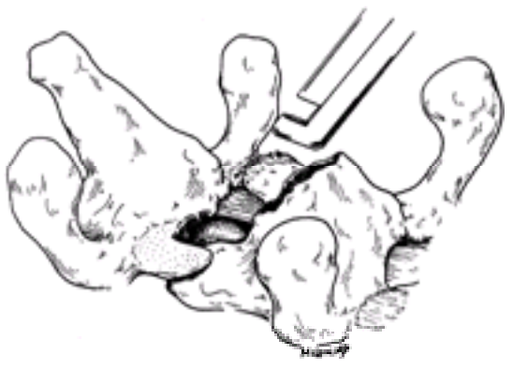

***Figure 142.12.*** Reduction of fracture-dislocation. When simple distraction cannot easily reduce a dislocated facet in a neurologically intact patient, resection of the overlapping articulation with a Kerrison rongeur or burr will allow gentle reduction.

## FUSION TECHNIQUE

Because segmental instrumentation allows the surgeon to instrument only those segments intended for fusion, the routine practice is to fuse all instrumented segments. Long rod/short fusion constructs have been only marginally successful at protecting lumbar segments in fracture patients (3), and newer systems allow surgeons to avoid instrumenting the lower lumbar spine altogether. This technique eliminates the need for a second surgery to remove the hardware and avoids concerns over degenerative changes seen in immobilized, unfused facet joints (21,56).

- Observe meticulous fusion technique to avoid pseudarthrosis.
- After stabilizing the fractured segment, decorticate laminae, and transverse processes, take down the facet joints, and liberally dress the lateral and dorsal surfaces with autologous iliac crest graft.
- Concentrate corticocancellous strips of autograft bone across the fractured segment and around the construct ends, which are typical areas of fusion failure.
- Take care to preserve the adjacent facet joints and avoid extending the fusion beyond the instrumented segments.

## STABILIZATION TECHNIQUES

### *Thoracic Spine*

- Stable thoracic compression and burst fractures may be treated in a Jewett brace or thoracolumbar sacral orthosis (TLSO) with good results.
- Multilevel compression or burst fractures will collapse into further kyphosis; instrument either with a Harrington rod and Drummond wires or with a segmental rod/hook construct. If the Harrington system is used, follow the old rule of “three above, two below,” with spinous process wires placed at each intact laminar level.
- Contour the rods to fit the thoracic kyphosis better but leave them somewhat straighter than the desired alignment to provide a third reduction force where the rod contacts the spinal laminae.

Segmental instrumentation can be placed in a variety of ways, depending on the fracture level and pattern.

- For compression fractures, place a simple transversopedicular claw (Fig. 142.13) above and below the fracture level.

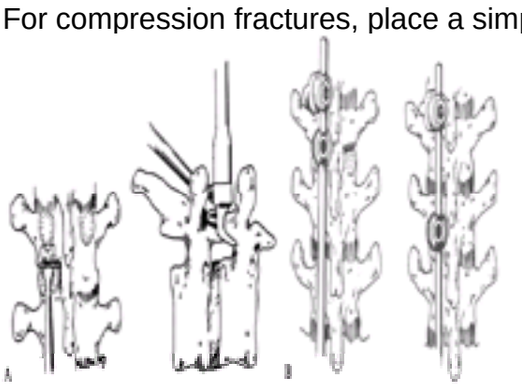

***Figure 142.13.*** Proximal fixation patterns. **A:** Proximal transversopedicular claw constructs mirror those applied in adult deformities. **B:** In osteoporotic bone, or when the transverse process has been broken, a laminolaminar claw can be substituted.

- In more severe fractures, use additional claws and intermediate hooks to provide secure fixation and allow intersegmental distraction.
- The rod/hook construct should take advantage of three-point bending mechanics to reduce and maintain thoracic kyphosis and prevent translation of disrupted vertebral segments.

The proximal and distal “claws” provide more stable fixation than the Harrington hooks they replace and are not dependent on strong distraction forces for fixation.

The additional hooks applied in segmental constructs distribute corrective forces over more laminae, reducing the likelihood of hook pull-out and fixation failure.

- Arrange hooks to accommodate the regional anatomy and the fracture pattern, as long as at least two hooks are applied on either side of the fracture (Fig. 142.14*A*, Fig. 142.14*B*, Fig. 142.14*C* and Fig. 142.14*D*).

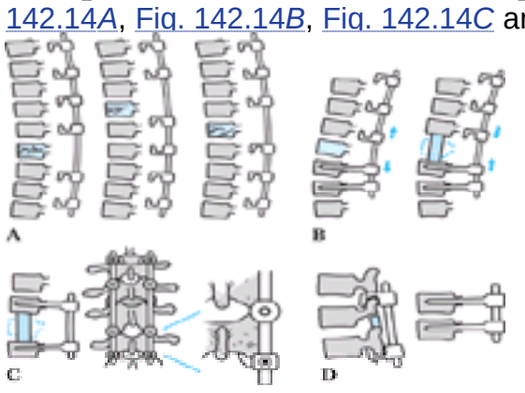

***Figure 142.14.*** Construct patterns for posterior instrumentation: Four basic construct patterns have been applied in thoracic, thoracolumbar, and lumbar

fractures, with or without anterior reconstruction. **A:** Upper and lower hook patterns used primarily in the thoracic segments but sometimes in the thoracolumbar segments. These consist of claw configurations above and below the fractured level, with supplemental hooks applied as an additional claw above the fracture in lower thoracic fractures (1), below the fracture in upper thoracic fractures (2), and across the fracture in the midthoracic region (3). **B:** Extended pedicle screw patterns used at the thoracolumbar junction. Pedicle screws placed below the fractured level are supported by offset laminar hooks or additional screw fixation at the level below. Proximal fixation is provided by a claw construct carried to the lower thoracic segment. A supplemental hook is placed above the fracture, providing distraction against the lumbar screws when an indirect reduction is desired (1), and compressing the anterior graft when a direct decompression has been performed (2). **C:** Short-segment pedicle instrumentation (SSPI) patterns used in thoracolumbar and lumbar fractures to limit fusion. Specifically designed constructs are available, or SSPI constructs can be designed from standard instrumentation sets. If the anterior column is unstable, protect posterior screws with an anterior strut (1), or with offset hooks applied above and below the screws (2). **D:** Compression construct patterns. Flexion distraction injuries are generally treatable with a simple posterior compression construct (1). If a fracture dislocation has occurred, pedicle screw instrumentation may be required to combat translational and rotational displacements (2).

- In upper thoracic fractures, place supplemental hooks caudal to the injury to avoid a bulky construct under the thinner soft tissues of the upper back.
- In lower thoracic injuries, place the supplemental hooks cranial to the fracture site.
- Never place supplemental hooks at the laminae just above the fractured vertebra, because this places the hook directly opposite any bone fragment retropulsed into the spinal canal.
- In osteoporotic bone or in face of transverse process fractures, substitute laminolaminar claws for transversopedicular claws.

### *Thoracolumbar Junction*

- SSPI allows direct reduction of sagittal deformity and translation while instrumenting the shortest possible segment of the lumbar spine.
- Treat thoracolumbar and lumbar fractures with pedicle screws placed immediately above and below the fractured segment.
- In cases of severe axial instability, place offset laminar hooks at the level above the cranial hooks and at the level of the caudal hooks.

If the anterior and middle columns cannot withstand axial loads, a large bending moment is generated at the pedicle screw hub, resulting in a high rate of bending failure. Acute bending failure occurs before a solid arthrodesis has occurred and before anterior column structures have regained enough strength to share compressive loads. Failure during this period results in progressive collapse of the spinal segment, progressive kyphosis, and clinical symptoms. Ebelke et al. (34) found that transpedicular bone grafting eliminated pedicle screw failure in their series (see the section entitled Transpedicular Bone Graft), and similarly, patients with an intact or restored anterior column do not experience screw-bending failure (70).

If care is taken to protect pedicle screws in patients with anterior column instability, SSPI is still an ideal approach for selected patients (Fig. 142.15*A*, Fig. 142.15*B*). Do not attempt *in situ* contouring of the rod unless offset laminar hooks are applied to supplement screw fixation. These hooks provide improved clinical results (4,39) and have been shown to improve construct stiffness and to reduce screw bending moments significantly both in sagittal loading and *in situ* contouring (22,83).

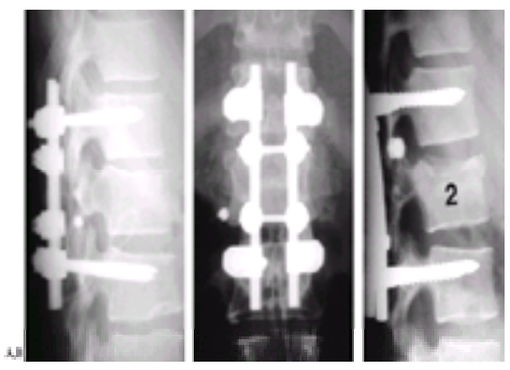


***Figure 142.15.*** Short-segment pedicle instrumentation. **A, B:** Lateral and AP views of 38-year-old patient with an L-1 burst fracture and marked sagittal collapse. Synthes Universal System fracture module was applied to correct kyphosis and anterior vertebral collapse. **C:** Similar fracture pattern treated with Cotrel-Dubousset segmental instrumentation. Because anterior column disruption was not severe, offset hooks were not applied.

Extended pedicle screw constructs are intended to address thoracolumbar fractures with as little alteration of lumbar spinal mechanics as possible (Fig. 142.16).

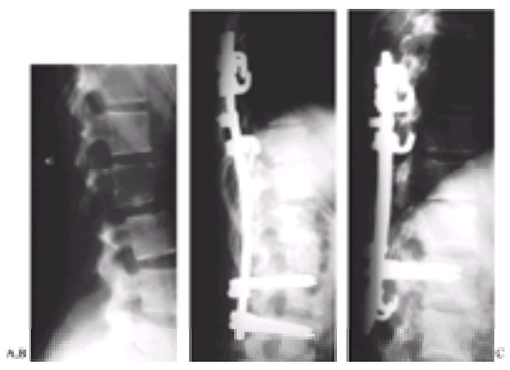

***Figure 142.16.*** Extended pedicle screw constructs. **A:** Lateral view of 18-year-old patient with L1–L2 fracture-dislocation and incomplete cauda equina syndrome. **B:** Extended construct using pedicle screws at L-2 and L-3 to stabilize the spinal column, with a down-going supplemental hook to compress the anterior strut graft. **C:** Extended pattern using supplemental offset hooks to protect pedicle screws. Intermediate hooks are directed cranially to decompress the fracture site indirectly.

- Extend the fixation construct into the lower thoracic region to apply sufficient corrective force to reverse sagittal deformity and restore neutral or lordotic alignment.
- Use pedicle screws just below the level of fracture to limit the extent of lumbar dissection and fusion (47,70). Pedicle screws may be supplemented with offset hooks.

The weak link in the extended construct, as in the short-segment construct, is the pedicle screw itself. Unless they are supplemented with an offset laminar hook, additional levels of fixation, or an anterior reconstruction, the pedicle screws are exposed to large cantilever bending loads (73,78). These forces are concentrated at the screw hub, a natural stress riser, and the contact point between the screw and the lamina (22,45,68,70). Screw breakage that occurs after healing is complete is often asymptomatic (62). Bending failure that occurs before the fracture has consolidated results in progressive material failure and sagittal collapse, and can occur even in braced patients (20,29,58). Patients treated with supplemental offset hooks or with an anterior reconstruction do not develop segmental collapse.

An incomplete neurologic deficit is a relative indication for anterior decompression. It should be recognized, however, that canal compromise can be improved through indirect reduction (77,86), and that bony remodeling improves canal diameter over time irrespective of treatment (71). Still, persistent neural compression can inhibit neurologic recovery (46), and anterior decompression can provide dramatic neurologic improvement in many patients (57,61). Because functional outcome is more clearly related to the residual neurologic deficit than to any other parameter, we continue to emphasize the need to maximize early neurologic recovery. This entails early recognition, rapid resuscitation, corticosteroid therapy, and surgical decompression when the patient is hemodynamically stable (12,15,23).

- Carry out anterior decompression at the thoracolumbar level through a combined thoracoabdominal approach, providing access to the entire thoracolumbar segment.

- A T-11 retroperitoneal approach may expose all of L-1 and most of T-12 but access to the fractured vertebra and, particularly, to the canal will be hampered by the intact diaphragm (see Chapter 138).
- After completing the surgical approach, identify the fractured vertebral body by inspection and confirm the level radiographically.
- After double-ligating the segmental vessels at the level of the fracture and both vertebral bodies to be instrumented, peel the psoas back from the vertebral body with a Cobb elevator.

  After elevating the psoas muscle back to the level of the neural foramen, completely debride the disc spaces above and below the fracture of disc material, removing the outer annulus circumferentially to the far side.

- Debride the posterior annulus back to the rim of the vertebral body and release it with a small curved curet. The discectomies should be relatively bloodless. Release as much of the fractured vertebra as is possible.
- Once the discs are gone, remove the fractured body piecemeal, taking the near and anterior cortices with double action rongeurs.
- Remove bone back to the posterior cortex with rongeurs and a high-speed burr, until the bell of the near pedicle is exposed and the posterior vertebral cortex has been identified.
- Usually, there will be one large fragment of bone locked between the pedicles, attached to the posterosuperior annulus. Insinuate a fine, curved curet between the bell of the pedicle and the back rim of this fragment to draw it out of the canal.
- Once this edge is freed from the overhanging pedicle, deliver the whole fragment anteriorly with the curet and pituitaries.
- Significant bleeding may be encountered as the posterior cortex is pulled away from the posterior longitudinal ligament (PLL) and the nutrient vessels (Fig. 142.17). Use bipolar cautery and thrombin-soaked gel foam to control this hemorrhage.

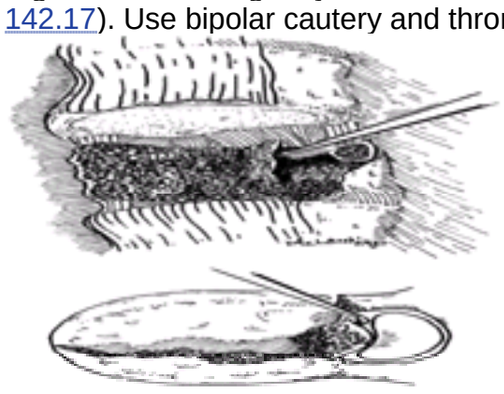

***Figure 142.17.*** Reduction of retropulsed fragments.

- On completion of the vertebrectomy, the dura should be visible from endplate to endplate and from pedicle to pedicle.
- Then prepare the endplates for reconstruction.

***Lumbar Spine***

Whether for simple stabilization or for instrumentation after decompression, SSPI performs well in fractures of the lumbar spine below L-2. Of the few burst fractures of the lower lumbar spine that require surgical treatment, half will undergo anterior decompression for cauda equina compression, followed by strut graft reconstruction (70). Patients with no neurologic injury typically require posterior SSPI alone. If there is severe vertebral comminution, however, anterior reconstruction may be needed to prevent progressive sagittal collapse (66).

Flexion-distraction injuries through soft tissues or multilevel injuries may benefit from internal fixation by one of two techniques: compression hook constructs or pedicle screw fixation.

- Reduce transverse disruptions by positioning the patient prone on transverse bolsters or the Jackson frame.
- Use a limited exposure of the fracture site, extending to the cranial rim of the first intact lamina above the injury and to the caudal rim of the intact lamina below the injury.
- Debride the disruption of bone fragments, hematoma, and disrupted ligamentum flavum, joint capsule, and muscle. This will prevent the soft tissues from infolding into the canal when the injury is reduced.
- After determining that the facet joints are reduced and the laminar edges aligned, apply a compression construct, with a hook above and one below the intact laminae.
- A Harrington compression rod may be used with two opposing laminar hooks, or a rod/hook combination from any segmental system (44,48,79).
- For more unstable injuries or frank dislocations, pedicle screw instrumentation provides three-column fixation to control axial, translational, and rotational displacements.

Anterior reconstruction of lumbar fractures may follow a decompressive procedure or may be carried out primarily to address axial instability. Anterior plate fixation may be adequate to immobilize the spine in some cases in which the posterior elements have not been injured. In cases in which laminar fractures or soft-tissue disruption have rendered the posterior column incompetent, reinforce anterior reconstruction with concomitant posterior instrumentation. Likewise, anterior reconstruction at the lumbosacral junction will require a posterior instrumentation, because no suitable fixation of the sacrum yet exists.

***Lumbosacral Junction***

Surgical treatment of L-5 burst fractures is rarely necessary (40); the spinal canal is large compared with the volume of its contents, and sagittal imbalance is more easily compensated for than at the thoracolumbar junction.

Traumatic spondylolisthesis is an uncommon injury, occasionally associated with sacral fractures or sacral facet fractures. Progressive deformity or onset of neurologic symptoms requires surgical stabilization, typically with lumbosacral pedicle screw instrumentation. Noninstrumented fusion is an option, but progression of the slip may occur even when fusion is successful.

Severe burst fractures are occasionally associated with pelvic and sacral injuries. These injuries are the result of high-energy trauma, and the patients are severely traumatized. Urgent spinal stabilization is indicated to allow safe treatment of multiple injuries, with early mobilization and aggressive pulmonary therapy. If decompression is needed anteriorly, blood loss may be severe.

- Repair dural tears primarily or with a fascial graft, and reconstruct the vertebrectomy with a tricortical strut or cage.
- Standard anterior instrumentation is not possible because screw fixation to the sacrum is both difficult and tenuous. Immediate posterior instrumentation to prevent graft displacement is indicated, when possible.
- Coordinate reconstruction of pelvic fractures or sacral disruptions with spinal care.

***Sacral Fractures***

Sacral fractures occur most often in patients with pelvic ring fractures, either in association with sacroiliac (SI) joint injuries or as discreet sacral fractures. The treatment of sacral fractures in the context of pelvic trauma is discussed in Chapter 17. There are six basic fracture patterns, as shown in Table 142.2.

| Fracture type | Description | Stability | Nerve injury (%) | Treatment |
|---|---|---|---|---|
| 1 | SI joint avulsion | Often highly unstable | 21 | Unstable—ORIF SI joint |
| 2 | Alae fracture | Stable if impacted | 10 | Protected weight bearing |
| 3 | Transforaminal | Unstable if displaced | 17 | Closed reduction, percutaneous SI screws |
| 4 | Transforaminal, extending into canal | Unstable if displaced | 60 | Closed reduction, percutaneous SI screws |
| 5 | Transverse | Highly unstable | 50 | Bed rest, decompression for neurologic deficit |
| 6 | Bilateral transforaminal | Highly unstable | 60 | Bed rest, decompression for neurologic deficit |

ORIF, open reduction and internal fixation.

***Table 142.2. Sacral Fracture Patterns***

Injuries of types 4, 5, and 6 have a high incidence of root and cauda equina injury. Residual compression may result in persistent neurologic deficit requiring surgical treatment. Patients with persistent radiculopathy following fracture should undergo a fine-cut CT scan of the sacrum. Neural foraminae with greater than 50% canal compromise may be indicated for surgical decompression (24,28,35).

- Position the patient prone with the abdomen free and a bolster under the pelvis.
- Expose the sacral lamina through a midline incision and perform an L5–S1 laminotomy.
- Then unroof the dural sac by laminectomy down to the S-3 level.
- Identify the involved root (typically S-1) and follow it laterally into the foramen.
- Take the interval between S-1 and S-2 down to the dorsal aspect of the ventral cortex.
- Debride the fracture fragments, fibrous tissue, and hematoma away from the undersurface of the nerve root using down-biting curets, pituitary rongeurs, and small osteotomes.
- Carry out debridement to the anterior aperture of the neuroforamen, or until the compression is relieved and the nerve root is free and mobile.
- Fixation of the fracture is usually not possible. Limit the patient's weight bearing until the fracture has united; patient should avoid sitting for up to 2 months.

**Transverse Sacral Fractures** When a transverse sacral fracture is encountered, laminectomy alone may not be enough to decompress the nerve roots, which are often tented over the kyphotic deformity. This bony prominence must be removed.

- To avoid injuring these roots, carry out a lateral approach to the anterior from between the exposed nerve roots at the level of fracture, usually between S-1 and S-2.
- Use narrow osteotomes and down-biting curets to fragment the retropulsed bone, and decompress the cauda equina.
- Once the kyphotic ridge has been removed, the nerve roots should be freely mobile.

## PITFALLS AND COMPLICATIONS

Unless basic biomechanical rules are understood and followed, serious complications can occur following spinal stabilization. Reduction of fractures and fracture dislocations through distraction is a routine manuever, but overdistraction can widely displace bony elements and stretch the spinal cord, causing serious neurological injury. Also, posterior reconstruction of severe burst fractures without restoring the anterior weight-bearing column exposes instrumentation systems to excessive cantilever-bending forces, resulting in acute pedicle screw-bending failure, or late collapse and fatigue failure. If the normal thoracolumbar lordosis is not restored at the time of surgery, the forces of weight bearing will fall anterior to the lumbar spine and pelvis, imparting an exaggerated flexion moment on the fracture and fixation construct, again predisposing to instrumentation failure. Finally, failure to expose the thecal sack completely—from pedicle to pedicle and endplate to endplate—during an anterior decompression may result in persistent neurologic impairment.

## SUMMARY

With newer, segmental instrumentation systems, our ability to address the individual “personality” of each spine fracture has improved. Segmental constructs and pedicle fixation have improved fixation strength and construct stiffness, allowing us to get patients out of bed, into rehabilitation, and home more rapidly and with better long-term results. Newer implant systems must still be applied with full attention to fracture type and biomechanical principles, or implant failure is sure to occur. Technique and implant design cannot alter the damage done to the spinal cord at injury either, and functional outcomes are most profoundly dependent on neurologic integrity. Further research in spinal cord recovery and regeneration holds the greatest promise for future victims of major spinal trauma.

### CHAPTER REFERENCES

Each reference is categorized according to the following scheme: *, classic article; #, review article; !, basic research article; and +, clinical results/outcome study.


# 1. Aebi M, Etter C, Kehl T, Thalgott J. The Internal Skeletal Fixation System: A New Treatment of Thoracolumbar Fractures and Other Spinal Disorders. *Clin Orthop* 1988;227:30.

+ 2. Akbarnia BA, Crandall DG, Burkus K, Matthews T. Use of Long Rods and a Short Arthrodesis for Burst Fractures of the Thoracolumbar Spine. A long-term follow-up study. *J Bone Joint Surg [Am]* 1994;76:1629.

+ 3. Akbarnia BA, Fogarty JP, Tayob AA. Contoured Harrington Instrumentation in the Treatment of Unstable Spinal Fractures. The Effect of Supplementary Sublaminar Wires. *Clin Orthop* 1984;189:186.

+ 4. Argenson C, Lovet J, de Peretti F, et al. The Treatment of Spinal Fractures with Cotrel-Dubousset Instrumentation. Results of the First 85 Cases. Scoliosis Research Society/European Spine Meeting. *Orthop Trans* 1990;14:776.

! 5. Ashman RB, Birch JG, Bone LB, et al. Mechanical Testing of Spinal Instrumentation. *Clin Orthop* 1988;227:113.

# 6. Benli IT, Tandogan NR, Kis M, et al. Cotrel-Dubousset Instrumentation in the Treatment of Unstable Thoracic and Lumbar Spine Fractures. *Arch Orthop Trauma Surg* 1994;113:86.

+ 7. Benson DR, Burkus JK, Montesano PX, et al. Unstable Thoracolumbar and Lumbar Burst Fractures Treated with the AO Fixateur Interne. *J Spinal Disord* 1992;5:335.

+ 8. Benzel EC. Short-segment Compression Instrumentation for Selected Thoracic and Lumbar Spine Fractures: The Short-rod/Two-claw Technique. *J Neurosurg* 1993;79:335.

+ 9. Bernard TN, Whitecloud TS III, Rodriguez RP, Hadad RJ Jr. Segmental Spinal Instrumentation in the Management of Fractures of the Thoracic and Lumbar Spine. *South Med J* 1983;76:1232.

* 10. Bohlman HH. Treatment of Fractures and Dislocations of the Thoracic and Lumbar Spine. *J Bone Joint Surg* 1985;67A:165.

# 11. Bohlman HH, Freehafer A, Dejak J. The Results of Treatment of Acute Injuries of the Upper Thoracic Spine with Paralysis. *J Bone Joint Surg Am* 1985;67:360.

* 12. Bone, LB. Management of Polytrauma. In: Chapman MW, ed. *Operative Orthopaedics,* 2nd ed. Philadelphia: J.B. Lippincott Co., 1993:299.

+ 13. Bosch A, Stauffer ES, Nickel VL. Incomplete Traumatic Quadriplegia: A Ten-year Review. *JAMA* 1971;216:473.

* 14. Bostman OM, Myllynen PJ, Riska EB. Unstable Fractures of the Thoracic and Lumbar Spine: The Audit of an 8-year Series with Early Reduction using Harrington Instrumentation. *Injury* 1987;18:190.

* 15. Bracken MB, Shepard MJ, Collins WF, et al. A Randomized, Controlled Trial of Methylprednisolone or Naloxone in the Treatment of Acute Spinal Cord Injury. Results of the Second National Acute Spinal Cord Injury Study. *N Engl J Med* 1990;322:1405.

+ 16. Bradford DS, McBride GG. Surgical Management of Thoracolumbar Spine Fractures with Incomplete Neurologic Deficits. *Clin Orthop* 1987;218:201.

# 17. Bradford DS, Thompson RC. Fractures and Dislocations of the Spine. *Minn Med* 1976;59:711.

# 18. Broom MJ, Jacobs RR. Current Status of Internal Fixation of Thoracolumbar Fractures. *J Orthop Trauma* 1989;3:148.

+ 19. Bryant CE, Sullivan JA. Management of Thoracic and Lumbar Spine Fractures with Harrington Distraction Rods Supplemented with Segmental Wiring. *Spine* 1983;8:532.

+ 20. Carl AL, Tromanhauser SG, Roger DJ. Pedicle Screw Instrumentation for Thoracolumbar Burst Fractures and Fracture-dislocations. *Spine* 1992;17(Suppl):S317.

* 21. Casey MP, Jacobs RR, Asher MA. *The Rod-Long-Fuse-Short Technique in Treatment of Thoracolumbar and Lumbar Spine Fractures.* Transactions of the 19th annual meeting of the Scoliosis Research Society, Orlando, 1984.

! 22. Chiba M, McLain RF, Yerby SA, et al. Short-segment Pedicle Instrumentation. Biomechanical Analysis of Supplemental Hook Fixation. *Spine* 1996;21:288.

+ 23. Clohisy JC, Akbarnia BA, Bucholz RD, et al. Neurologic Recovery Associated with Anterior Decompression of Spine Fractures at the Thoracolumbar Junction (T12–L1). *Spine* 1992;17(Suppl):S325.

* 24. Davis AG. Fractures of the Spine. *J Bone Joint Surg* 1929;11:133.

* 25. Denis F. The Three Column Spine and Its Significance in the Classification of Acute ThoracoLumbar Spinal Injuries. *Spine* 1983;8:817.

* 26. Denis F. Spinal Instability as Defined by the Three Column Spine Concept in Acute Trauma. *Clin Orthop* 1984;189:65.

+ 27. Denis F, Armstrong GWD, Searls K, Matta L. Acute Thoracolumbar Burst Fractures in the Absense of Neurological Deficit: A Comparison Between Operative and Non-operative Treatment. *Clin Orthop* 1984;189:142.

+ 28. Denis F, Davis S, Comfort T. Sacral Fractures: An Important Problem: Retrospective Analysis of 236 Cases. *Clin Orthop* 1988;227:67.

+ 29. Devito DP, Tsahakis PJ. *Cotrel-Dubousset Instrumentation in Traumatic Spine Injuries. The 6th Proceeding of the International Congress on Cotrel-Dubousset Instrumentation.* Montpellier, France: Sauramps Medical, 1989:41.

+ 30. Dick, W. The Fixateur Interne as a Versatile Implant for Spine Surgery. *Spine* 1987;12:882.

# 31. Dickman CA, Yahiro MA, Lu HT, Melkerson MN. Surgical Treatment Alternatives for Fixation of Unstable Fractures of the Thoracic and Lumbar Spine. A Meta-analysis. *Spine* 1994;19(Suppl):2266.

* 32. Dickson JH, Harrington PR, Erwin WD. Results of Reduction and Stabilization of the Severely Fractured Thoracic and Lumbar Spine. *J Bone Joint Surg [Am]* 1978;60:799.

+ 33. Dimar Jr 2nd, Wilde PH, Glassman SD, et al. Thoracolumbar Burst Fractures Treated with Combined Anterior and Posterior Surgery. *Am J Orthop* 1996;25:159.

* 34. Ebelke DK, Asher MA, Neff JR, Kraker DP. Survivorship Analysis of VSP Spine Instrumentation in the Treatment of Thoracolumbar and Lumbar Burst Fractures. *Spine* 1991;16(Suppl):428.

+ 35. Epstein NE, Epstein JA, Carras R. Unilateral S-1 Root Compression Syndrome Caused by Fracture of the Sacrum. *Neurosurgery* 1986;19:1025.

* 36. Erwin WD, Dickson JH, Harrington PR. Clinical Review of Patients with Broken Harrington Rods. *J Bone Joint Surg* 1980;62A:1302.

+ 37. Esses SI, Botsford DJ, Kostuik JP. Evaluation of Surgical Treatment for Burst Fractures. *Spine* 1990;15:667.

+ 38. Esses SI, Botsford DJ, Wright T, et al. Operative Treatment of Spinal Fractures with the AO Internal Fixator. *Spine* 1991;16(Suppl):S146.

! 39. Farcy J-P, Weidenbaum M, Michelsen CB, et al. A Comparative Biomechanical Study of Spinal Fixation Using Cotrel-Dubousset Instrumentation. *Spine* 1987;12:877.

* 40. Finn CA, Stauffer ES. Burst Fractures of the Fifth Lumbar Vertebra. *J Bone Joint Surg* 1992;74A:398.

+ 41. Flesch JR, Leider LL, Erickson DL, et al. Harrington Instrumentation and Spine Fusion for Unstable Fractures and Fracture-dislocations of the Thoracic and Lumbar Spine. *J Bone Joint Surg [Am]* 1977;59:143.

+ 42. Fletcher DJ, Taddonio RF, Byrne DW, et al. Incidence of Acute Care Complications in Vertebral Column Fracture Patients with and without Spinal Cord Injury. *Spine* 1995;20:1136.

+ 43. Gaines RW, Humphreys WG. A Plea for Judgement in Management of Thoracolumbar Fractures and Fracture-dislocations. *Clin Orthop* 1984;189:36.

# 44. Gertzbein SD, Court-Brown CM. Rationale for the Management of Flexion-distraction Injuries of the Thoracolumbar Spine Based on a New Classification. *J Spinal Disord* 1989;2:176.

+ 45. Gillet P, Meyer R, Fatemi F, Lemaire R. *Short Segment Internal Fixation Using CD Instrumentation with Pedicular Screws: Biomechanical Testing. The 6th Proceeding of the International Congress on Cotrel-Dubousset Instrumentation.* Montpellier, France: Sauramps Medical, 1989:19.

+ 46. Golimbu C, Firooznia H, Rafii M, et al. Computed Tomography of Thoracic and Lumbar Spine Fractures that Have Been Treated with Harrington Instrumentation. *Radiology* 1984;151:731.

+ 47. Graziano GP. Cotrel-Dubousset Hook and Screw Combination for Spine Fractures. *J Spinal Disord* 1993;6:380.

* 48. Gumley G, Taylor TK, Ryan MD. Distraction Fractures of the Lumbar Spine. *J Bone Joint Surg [Br]* 1982;64:520.

! 49. Gurr KR, McAfee PC, Shih C. Biomechanical Analysis of Posterior Instrumentation Systems after Decompressive Laminectomy. An Unstable Calf-spine Model. *J Bone Joint Surg* 1988;70A:680.

! 50. Gurr KR, McAfee PC, Shih C. Biomechanical Analysis of Anterior and Posterior Instrumentation Systems after Corpectomy. A Calf-spine Model. *J Bone Joint Surg* 1988;70A:1182.

+ 51. Gurr KR, McAfee PC. Cotrel-Dubousset Instrumentation in Adults. A Preliminary Report. *Spine* 1988;13:510.

+ 52. Jacobs RR, Asher MA, Snider RK. Thoracolumbar Spinal Injuries: A Comparative Study of Recumbent and Operative Treatment in 100 Patients. *Spine* 1980;5:463.

+ 53. Jacobs RR, Casey MP. Surgical Management of Thoracolumbar Spinal Injuries. *Clin Orthop* 1984;189:22.

+ 54. Jacobs RR, Nordwall A, Nachemson, A. Reduction, Stability, and Strength Provided by Internal Fixation Systems for Thoracolumbar Spinal Injuries. *Clin Orthop* 1982;171:300.

+ 55. Johnston CE, Ashman RB, Sherman MC, et al. Mechanical Consequences of Rod Contouring and Residual Scoliosis in Sublaminar Segmental Instrumentation. *J Orthop Res* 1987;5:206.

! 56. Kahanovitz N, Bullough P, Jacobs RR. The Effect of Internal Fixation without Arthrodesis on Human Facet Joint Cartilage. *Clin Orthop* 1984;189:204.

+ 57. Kostuik JP. Anterior Fixation for Burst Fractures of the Thoracic and Lumbar Spine with or without Neurological Involvement. *Spine* 1988;13:286.

+ 58. Kramer DL, Rodgers WB, Mansfield FL. Transpedicular Instrumentation and Short-segment Fusion of Thoracolumbar Fractures: A Prospective Study Using a Single Instrumentation System. *J Orthop Trauma* 1995;9:499.

+ 59. Markel DC, Graziano GP. A Comparison Study of Treatment of Thoracolumbar Fractures Using the ACE Posterior Segmental Fixator and Cotrel-Dubousset Instrumentation. *Orthopaedics* 1995;18:679.

+ 60. McAfee PC, Bohlman HH. Complications Following Harrington Instrumentation for Fractures of the Thoracolumbar Spine. *J Bone Joint Surg [Am]* 1985;67:672.

* 61. McAfee PC, Bohlman HH, Yuan HA. Anterior Decompression of Traumatic Thoracolumbar Tractures with Incomplete Neurological Deficits Using a Retroperitoneal Approach. *J Bone Joint Surg* 1985;67A:89.

! 62. McAfee PC, Weiland DJ, Carlow JJ. Survivorship Analysis of Pedicle Spinal Instrumentation. *Spine* 1991;16(Suppl):S422.

! 63. McAfee PC, Werner FW, Glisson RR. A Biomechanical Analysis of Spinal Instrumentation Systems in Thoracolumbar Fractures. Comparison of Traditional Harrington Distraction Instrumentation with Segmental Spinal Instrumentation. *Spine* 1985;10:204.

+ 64. McBride GG. Cotrel-Dubousset Rods in Spinal Fractures. *Paraplegia* 1989;27:440.

+ 65. McBride GG. Cotrel-Dubousset Rods in Surgical Stabilization of Spinal Fractures. *Spine* 1993;18:466.

! 66. McCormack T, Karaikovic E, Gaines RW. The Load Sharing Classification of Spine Fractures. *Spine* 1994;19:1741.

+ 67. McEvoy RD, Bradford DS. The Management of Burst Fractures of the Thoracic and Lumbar Spine. Experience in 53 Patients. *Spine* 1985;10:631.

! 68. McKinley TO, McLain RF, Yerby SA, et al. The Effect of Pedicle Morphometry on Pedicle Screw Loading in Unstable Burst Fractures: A Synthetic Model. *Spine* 1997;22:246.

+ 69. McKinley LM, Obenchain TG, Roth KR. *Loss of Correction: Late Kyphosis in Short Segment Pedicle Fixation in Cases of Posterior Transpeduncular Decompression. The 6th Proceeding of the International Congress on Cotrel-Dubousset Instrumentation.* Montpellier, France: Sauramps Medical, 1989:37.

* 70. McLain RF, Sparling E, Benson DR. Early Failure of Short Segment Pedicle Instrumentation for Thoracolumbar Fractures. *J Bone Joint Surg* 1993;75A:162.

+ 70a. McLain RF, Benson DR. Urgent Surgical Stabilization of Spinal Fractures in Polytraumatized Patients. *Spine* 1999;24:1646.

* 71. Mumford J, Weinstein JN, Spratt KF, Goel VK. Thoracolumbar Burst Fractures. The Clinical Efficacy and Outcome of Nonoperative Management. *Spine* 1993;18:955.

+ 72. Osebold WR, Weinstein SL, Sprague BL. Thoracolumbar Spine Fractures. Results of Treatment. *Spine* 1981;6:13.

! 73. Panjabi MM, Oxland TR, Kifune M, et al. Validity of the Three-column Theory of Thoracolumbar Fractures. A Biomechanic Investigation. *Spine* 1995;20:1122.

+ 74. Place HM, Donaldson DH, Brown CW, Stringer EA. Stabilization of Thoracic Spine Fractures Resulting in Complete Paraplegia. A Long-term Retrospective Analysis. *Spine* 1994;19:1726.

+ 75. Saboe LA, Reid DC, Davis LA, et al. Spine Trauma and Associated Injuries. *J Trauma* 1991;31:43.

+ 76. Sasso RC, Cotler HB. Posterior Instrumentation and Fusion for Unstable Fractures and Fracture-dislocations of the Thoracic and Lumbar Spine. A Comparative Study of Three Fixation Devices in 70 Patients. *Spine* 1993;18:450.

! 77. Shuman WP, Rogers JV, Sickler ME, et al. Thoracolumbar Burst Fractures: CT Dimensions of the Spinal Canal Relative to Postsurgical Improvement. *AJR Am J Roentgenol* 1985;145:337.

! 78. Slosar PJ Jr, Patwardhan AG, Lorenz M, et al. Instability of the Lumbar Burst Fracture and Limitations of Transpedicular Instrumentation. *Spine* 1995;20:1452.

+ 79. Smith WS, Kaufer H. Patterns and Mechanisms of Lumbar Injuries Associated with Lap Seat Belts. *J Bone Joint Surg* 1969;51A:239.

+ 80. Stambough JL. Cotrel-Dubousset Instrumentation and Thoracolumbar Spine Trauma: A Review of 55 Cases. *J Spine Disord* 1994;7:461.

+ 81. Sullivan JA. Sublaminar Wiring of Harrington Distraction Rods for Unstable Thoracolumbar Spine Fractures. *Clin Orthop* 1984;189:178.

+ 82. Tasdemiroglu E, Tibbs PA. Long-term Follow-up Results of Thoracolumbar Fractures after Posterior Instrumentation. *Spine* 1995;20:1704.

! 83. Yerby S, Ehteshami J, McLain RF. Offset Laminar Hooks Decrease Bending Moments on Pedicle Screws During In-Situ Contouring. *Spine* 1997;22:376.

* 84. Weinstein JN, Collalto P, Lehmann TR. Thoracolumbar “Burst” Fractures Treated Conservatively: A Long-term Follow-up. *Spine* 1988;13:33.

! 85. Wenger DR, Carollo JJ. The Mechanics of Thoracolumbar Fractures Stabilized by Segmental Fixation. *Clin Orthop* 1984;189:89.

+ 86. Willen J, Lindahl S, Nordwall A. Unstable Thoracolumbar Fractures. A Comparative Clinical Study of Conservative Treatment and Harrington Instrumentation. *Spine* 1985;10:111.

# CHAPTER 143

# CERVICAL DISC DISEASE

*Louis G. Jenis and Howard S. An*

**L. G. Jenis:** New England Baptist Spine Center, New England Baptist Hospital; and Department of Orthopaedic Surgery, Tufts University School of Medicine, Boston, Massachusetts, 02120.
**H. S. An:** Department of Orthopaedic Surgery, Rush–Presbyterian–St. Luke's Medical Center, Chicago, Illinois, 60612.

Cervical Anatomy/Pathoanatomy
- Soft Disc Herniation
- Spondylosis
- Ossification of the Posterior Longitudinal Ligament

Natural History of Cervical Disc Disease
- Neck Pain
- Radiculopathy
- Myelopathy

Clinical Evaluation
Diagnostic Testing
Nonoperative Treatment
Surgical Techniques
- Neck Pain
- Cervical Radiculopathy
- Cervical Myelopathy
- Spinal Instrumentation

Postoperative Management—Results
Pitfalls and Complications
Authors' Techniques
Conclusions
Chapter References

The pathoanatomy of disc degeneration or spondylosis of the cervical spine can be considered part of the normal aging process. The progressive deterioration that develops is commonly found in asymptomatic individuals but also may lead to neurocompression, radiculopathy, and myelopathy. The presentation of these syndromes depends on the specific structures compromised by the degenerative process. Treatments of axial neck pain, radicular arm pain, and myelopathy are based on a clear understanding of the natural history of the disorders and available therapeutic options. This chapter reviews the pathophysiology of cervical spondylosis and relates it to the development of clinical manifestations, including the evaluation as well as the nonoperative and operative management of such problems.

## CERVICAL ANATOMY/PATHOANATOMY

An understanding of normal and pathologic cervical anatomy is essential to appreciate the role of management of the symptomatic patient. The cervical spine comprises seven vertebrae, each possessing five articulations (Fig. 143.1). The cranial two vertebrae, the atlas and axis, are anatomically unique, whereas the third through the seventh (subaxial) vertebrae are more typical. The first two are rarely involved in the degenerative process and are more commonly affected by inflammatory processes such as rheumatoid arthritis (see Chapter 154).

The subaxial vertebral bodies increase in size from cephalad to caudad and are greater in the transverse than in the anteroposterior (AP) dimension (46). The superior endplate surface is concave, whereas the inferior surface is convex. Uncovertebral joints of Luschka or uncinate processes project from the superoposterior corner of each vertebral body and form a synovium-lined articulation with the corresponding vertebra (32). Short, small pedicles arise from the posterior vertebral body and extend posterolaterally to the lateral masses. The lateral masses are unique to the cervical spine and form superior and inferior articulations via synovium-lined facet joints. The laminae extend posteromedially from the lateral masses and form into the spinous process, which in the cervical spine are ordinarily bifid.

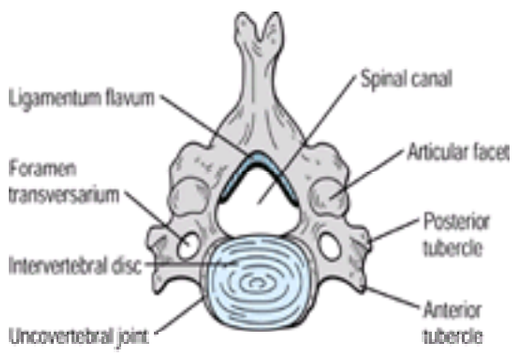


***Figure 143.1.*** Cross-sectional diagram of a normal cervical vertebra. Note the articulations of zygapophyseal facet joints and uncovertebral joints of Luschka.

### SOFT DISC HERNIATION

The lordosis typically seen in the cervical spine is achieved through the shape and configuration of the intervertebral discs. These discs make up nearly 22% of the overall length of the cervical spine (46). They are thicker in height in the anterior aspect of the intervertebral space supporting the lordotic curvature. The intervertebral discs increase range of motion between the vertebral bodies and distribute forces over the length of the spine (46).

The intervertebral disc consists of the central gelatinous nucleus pulposus, the outer annular fibrosis, and the superior and inferior endplate cartilage. The annulus is composed of alternating layers of collagen fibers running in oblique directions. A normal functioning disc will disperse forces by initial expansion of the nucleus pulposus and stretching of the annular fibers. This process essentially converts an axial load into horizontal forces absorbed by the annulus (46).

The neuroforamina are clinically important parts of the cervical spine. The neuroforamina are confined zones for the exiting nerve roots, bordered anteriorly by the lateral aspect of the intervertebral disc and the uncovertebral joint, superiorly and inferiorly by the pedicles, and posteriorly by the articular masses, notably the superior articular facet. Pathologic conditions involving these structures can lead to critical stenosis of the foramen and nerve root compression.

### SPONDYLOSIS

The change from normal anatomy to an aging spondylotic cervical spine is subtle and is part of the degenerative cascade. The initial alterations are suspected to occur within the intervertebral disc leading to secondary changes in the surrounding facet joints and soft-tissue structures. Diminished water content along with changes in the ratio of proteoglycan to collagen, and keratin sulfate to chondroitin sulfate are early manifestations of degeneration (60). Because of this, the nucleus pulposus no longer can generate the hydrostatic intradiscal force required to expand the annular fibers. This subjects the annular fibers to compression and shear forces, causing weakening and tearing in the outer layers. Disc protrusion or frank herniation may ensue, with or without neurocompression.

Disc dehydration also results in loss of height. This is more prominent in the anterior disc space because the uncovertebral joints impact on the posterior vertebral bodies as collapse occurs, preventing further posterior disc height loss. The combined effect leads to the characteristic loss of cervical lordosis on lateral plain

radiographs (48).

Approximation of the vertebral bodies alters the biomechanical forces placed on the uncovertebral joints and articular facet joints. Osteophytic spurring, often referred to as hard disc, may develop, leading to encroachment on the neuroforamina. Similarly, reactive bone forms along the posterior vertebral bodies as the margins come into greater contact when higher forces are applied. A spondylotic transverse bar may subsequently form, in combination with bulging of the posterior disc and stretching of the posterior longitudinal ligament. Further collapse of the anterior column height leads to buckling of the ligamentum flavum into the spinal canal, most notably during neck extension. This combination of events may lead to spondylosis-induced compromise of the AP diameter of the canal.

As the cervical discs degenerate, there are several potential sources of pain. Distortion of the intervertebral disc may lead to stretching or compression of the sinuvertebral nerve and finer nerve endings, with subsequent symptoms (54). Additionally, distortion or injury of innervated areas such as the apophyseal facet joints, ligamentous structures, and posterior musculature may produce pain.

There are several sites within the spinal canal where neurocompression may occur. Radiculopathy may occur from posterolateral soft disc herniation either contained by the posterior longitudinal ligament (PLL) or as free material extruded into and sequestered within the canal (Fig. 143.2). In addition, foraminal stenosis from the changes previously described may also lead to impingement on the exiting nerve root (Fig. 143.3).

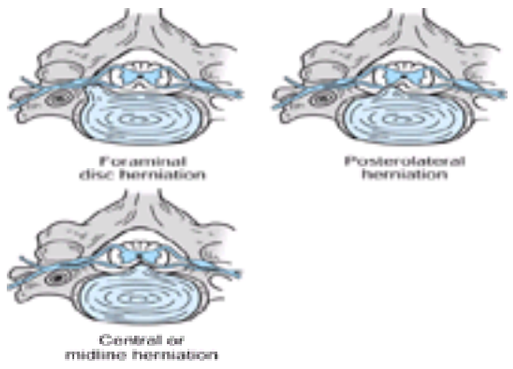


***Figure 143.2.*** Depiction of types of “soft disc” herniation causing impingement on the exiting nerve root or spinal cord.

***Figure 143.3.*** Nerve root impingement secondary to a “hard disc” from spondylosis and foraminal stenosis.

The pathophysiology of myelopathy involves many factors (7,8). The stenotic spinal canal may lead to neurologic dysfunction via compression of the anterior spinal artery with cord ischemia or mechanical deformation of the spinal cord from direct pressure, and/or dynamic compression (Fig. 143.4). Hyperextension may cause the lax and hypertrophied ligamentum flavum to buckle, compressing the spinal cord against the anterior spondylitic bar. Another mechanism of dynamic compression occurs in flexion, where the spinal cord is stretched over the anterior bony prominences. Occasionally, a midline soft disc herniation may cause cord compression and myelopathy combined with a degree of nerve root compression, leading to a myeloradiculopathy.

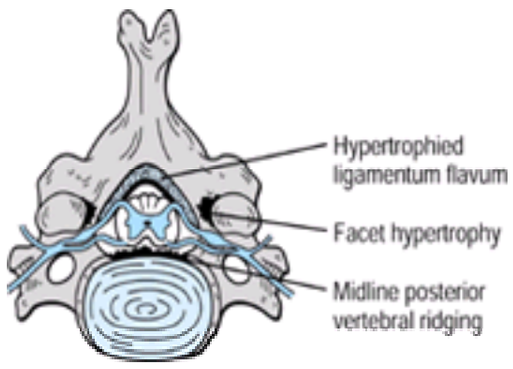


***Figure 143.4.*** Spondylosis leading to spinal cord compression secondary to hypertrophied ligamentum flavum and spondylotic ridging.

#### OSSIFICATION OF THE POSTERIOR LONGITUDINAL LIGAMENT

Finally, myelopathy may stem from cord compression secondary to ossification of the PLL (OPLL). The ossified mass arising from the PLL has been classified as *continuous*, extending over several vertebral bodies; *segmental*, ossification at the level of the posterior vertebral bodies only; *mixed* continuous and segmental; and *localized*, with ossification at the level of the disc only (13).

## NATURAL HISTORY OF CERVICAL DISC DISEASE

### NECK PAIN

Because of the numerous etiologies that can produce symptoms, establishing a prognosis for a patient with axial neck pain can be difficult. The natural history of neck pain has been evaluated by Gore et al. (30), who performed a retrospective review of patients with neck pain followed clinically and radiographically over a 10-year period. Of these patients, 79% had diminished pain and 43% had nearly complete relief of symptoms. However, nearly one third of the study group reported persistent moderate to severe pain. Outcome could not be correlated with radiographic or clinical findings, making outcome projections difficult for patients with neck pain.

### RADICULOPATHY

The natural history of cervical radiculopathy has been well described. Lees and Turner reported on the long-term follow-up of patients with spondylosis and confirmed that 30% experienced intermittent radicular symptoms and 25% had persistent pain (45). Progression from radiculopathy to myelopathy is unusual, and most likely these are distinct entities (25). In general, there is agreement that nonoperative treatment may alleviate symptoms of cervical spondylitic radiculopathy (CSR) in the short term, but over a long period of time symptoms frequently recur. Gore et al. retrospectively reviewed patients with cervical radiculopathy treated conservatively and

noted that 50% had persistent symptoms at 15-year follow-up (30).

### MYELOPATHY

Cervical spondylotic myelopathy (CSM) is associated with an insidious onset of symptoms and, in general, neurologic function undergoes episodes of worsening with intervening stable periods (42). However, there are no pathognomonic findings to predict the progression of symptoms (49). Clarke and Robinson evaluated the natural history of CSM prior to treatment and concluded that 75% in their cohort experienced episodic worsening of symptoms; 20% showed slow, steady progression without intervening stabilizing periods; and 5% experienced rapid onset of the disease process and progression (18). Progression to total disability is unusual, although slight incremental neurologic deterioration may occur with time, resulting in upper and lower extremity functional deficits. As the neurologic deficit worsens, improvement of disability becomes more unlikely and complete recovery even less likely.

## CLINICAL EVALUATION

The clinical evaluation of a patient with cervical degenerative disorders requires interpretation of the patient's complaints, meticulous examination, and appropriate selection of diagnostic tests. To perform a complete evaluation of a patient's complaints, first determine if the problem involves neck pain, arm pain, or a combination of both, or whether there is a myelopathic component. A detailed history is the initial step in evaluating a patient with cervical degenerative disc disease. Obtain a complete description of the symptomatology, including the onset, quality, and location of pain; inciting and alleviating factors; temporal nature; degree of impairment; and any associated symptoms.

Axial neck pain may be discogenic or musculogenic in origin, or it may be related to shoulder, occipitocervical, myofascial, or visceral pathology. To differentiate the potential multiple sources of neck pain, establish whether the symptoms are mechanical (increased with activity and diminished with rest or positioning) or nonmechanical (no relief with positional changes or rest). Nonmechanical neck pain may be related to tumor or infection, and such processes should be carefully sought out. A history of deep-seated aching pain that occurs only at night and is absent or markedly diminished during the day is suggestive of neoplasm or infection. Mechanical neck pain is commonly discogenic in origin and exacerbated with neck extension and rotation toward the side that is more symptomatic. Patients may describe pain referred to the shoulder, upper arm region, or interscapular area. Patients with upper cervical degeneration may also experience occipital or temporal pain, or retro-ocular headaches. Musculogenic pain, as from an acute or chronic muscle strain, is more often exacerbated with neck flexion and rotation, leading to increased symptoms on the opposite side of head rotation.

Radicular symptoms may be caused by a soft lateral disc herniation, chronic disc degeneration with osteophytic spurring, or segmental instability. The majority of patients present with a monoradiculopathy, although several roots can be involved. Symptoms consist of sharp, lancinating, radiating arm pain associated with various degrees of dysesthesia, paresthesia, and numbness along a dermatomal pattern consistent with distribution of the involved nerve root.

The symptoms may be exacerbated or relieved by several provocative tests. Typically, patients will describe an increase in pain with Valsalva activities and with neck extension or turning the head toward the symptomatic side. A Spurling's sign is indicative of radiculopathy. This is elicited by neck hyperextension and rotation toward the symptomatic side, resulting in reproduction of the pain. This maneuver serves to diminish the available area in an already compromised neuroforamen, leading to further nerve root compression. A less reliable provocative sign is the axial compression test, in which compression on the vertex of the skull may diminish the height of the foramen and also symptoms. The shoulder abduction sign is a test that relieves symptoms of compression by lessening nerve root stretch with placement of the ipsilateral hand on top of the head. Patients may present with this as the only upper extremity position that provides relief or comfort.

The history and examination identify the level of radiculopathy. Typically, the patterns of pain distribution that patients describe are imprecise because of anatomic variations, involvement of multiple levels, or the presence of chronic conditions. Upper cervical nerve root compression is less common than lower levels; however, it must be considered in the differential diagnosis of recalcitrant neck pain.

Radiculopathy of the C-3 or C-4 roots will manifest as neck pain radiating to the trapezial, shoulder, and anterolateral area of the chest. The symptoms are described as pain with variable degrees of paresthesia but without a specific motor deficit. A more classic presentation occurs with compression of the lower cervical nerve roots. A C-5 radiculopathy produces radiating pain down the lateral aspect of the shoulder and proximal arm with associated sensory changes and/or increased fatigue or weakness of shoulder abduction. The C-5 root solely innervates the deltoid, whereas the biceps has dual innervation from C-5 and C-6.

A C-6 radiculopathy produces neck pain radiating down the biceps and anterior arm to the radial aspect of the forearm and index finger and thumb. The biceps and wrist extensors may demonstrate weakness. The extensor carpi radialis longus and brevis are innervated by C-6, and the extensor carpi ulnaris is primarily C-7. Therefore, wrist extensor weakness may reflect compression of either C-6 or C-7. The brachioradialis reflex is most directly affected with C-6 compression with subtle changes noted in the biceps reflex due to its dual innervation.

Compressive pathology of the C-7 nerve root presents with pain along the posterior shoulder and arm, radiating to the posterolateral aspect of the forearm to the long finger. Inconsistent symptoms involving the index and ring digits as well as the first web space may also be detected. The triceps muscle is affected, resulting in a diminished reflex and elbow extensor weakness. Triceps weakness is an infrequent complaint, unless the patient is physically active.

A C-8 radiculopathy is characterized by pain referred to the ulnar aspect of the forearm, small finger, and ulnar half of the ring finger. The findings are primarily below the elbow, with most dysfunction noted as numbness along the ulnar digits and weakness in finger adduction, abduction, and flexion. In chronic C-8 root compression, intrinsic muscle atrophy may be seen.

The symptoms of cervical myelopathy are variable and complaints may be vague, so myelopathy is not easily picked up on the initial examination (17,23). Symptoms and findings can include gait difficulties, spasticity, decreased manual dexterity, paresthesias in the extremities, urinary urgency or frequency, and specific extremity or generalized weakness (52). In contrast to cervical radiculopathy, pain is not a common presenting finding. Depending on the site of anatomic spinal cord compression, the symptoms may be quite variable.

The gait disturbance may be an early presenting complaint. Patients describe insidious and slowly progressive stumbling or generalized gait disturbances. Patients may initially become aware of these changes from family members who note a shuffling gait or frequent falls. The characteristic stooped, wide-based gait of the elderly is the common end result. Involvement of the upper extremities may occur concomitantly or follow the gait changes, with complaints of clumsy or numb hands. Weakness of the hand manifests as decreased grip strength. Manual dexterity will often suffer and progress until the patient lacks the ability to complete routine activities such as buttoning a shirt, counting change, or writing. Several researchers have noted characteristic hand dysfunction in cervical myelopathy. For example, Ono et al. reported on the myelopathic hand syndrome, describing the finger escape sign and grip and release test (53). The finger escape sign is positive when the patient is asked to hold all the digits of her hand in an adducted and extended position and the two ulnar digits fall into abduction and flexion with time. In the grip and release test, the patient is asked to rapidly form a fist and then release all digits into extension repeatedly. A patient without myelopathy should be able to perform this test 20 times in a 10-second period.

Physical examination of a myelopathic patient consists of thorough neurologic and other special testing. The presence of lower extremity clonus and Babinski extensor plantar responses should be noted. The Hoffmann's reflex (finger and thumb interphalangeal flexion with sudden long finger distal interphalangeal joint extension) when present, and especially when asymmetrical, is strongly suggestive of cervical myelopathy (Fig. 143.5). Other tests that may be noted include an inverted radial reflex, a scapulohumeral reflex, and Lhermitte's sign (43).

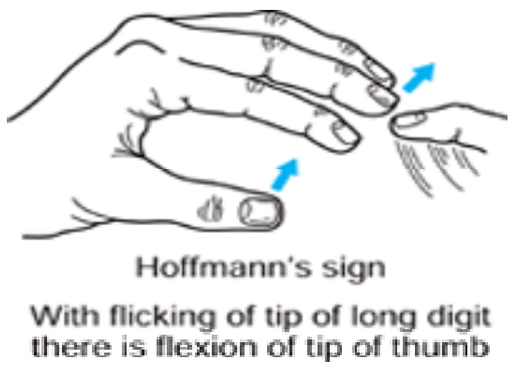


***Figure 143.5.*** Hoffmann's reflex is indicative of cervical cord impingement. The reflex is positive if the fingers and thumb react in flexion when the long finger distal

interphalangeal joint is flicked into extension.

## DIAGNOSTIC TESTING

Improved neuroradiologic imaging has led to a better understanding of the pathologic process of cervical radiculopathy and myelopathy. Several techniques are available for the evaluation of the symptomatic patient. Each modality has its own inherent strengths and weaknesses, and often combinations of examinations are required.

For initial radiographic evaluation, take AP, lateral, and oblique views and when instability is suspected, perform dynamic lateral images in flexion–extension. Evaluate findings such as disc space narrowing, developmental canal stenosis, subluxations and malalignments, and vertebral osteophtye formation in light of symptoms. Abnormal findings on plain radiographs may not be the cause of the clinical picture; therefore, further correlative studies may be necessary prior to recommending specific treatment. Changes on plain radiographs may also confirm the clinical suspicion of typical degenerative disease and reassure the clinician and the patient that appropriate therapy is being followed.

Water-soluble myelography has been used to evaluate cervical radiculopathy and myelopathy. The AP view demonstrates the exiting nerve roots to the level of the pedicle. A filling defect is a typical finding of nerve root compression. The lateral view may detect spinal cord compression by the disc or posterior vertebral osteophytes and/or hypertrophied ligamentum flavum. Current practice includes myelography followed by computed tomography (CT), which permits visualization of osseous compressive structures, especially in the neuroforamina (4). However, CT-myelography infers neural compression by deformity of the dural sac or nerve roots and cannot directly determine the etiology of contrast blockade.

Magnetic resonance imaging (MRI) does provide direct information about nerve root or spinal cord compression. The advantage of MRI in detecting direct compression is the intrinsic “contrast” available from the cerebrospinal fluid (CSF), as seen on T2-weighted images. This is the most sensitive modality for assessing the morphology of the spinal cord and its relation to the spinal canal. MRI also shows intramedullary cord changes, which may relate to disease prognosis (64). However, MRI is less sensitive in detecting foraminal stenosis and does not demonstrate cortical margins as well as CT-myelography.

Electromyography/nerve conduction studies (EMG/NCS) may be utilized to confirm suspected radiculopathy or may be used as an additional modality to further elucidate the cause of symptoms in a patient with atypical findings. These tests may be most useful when attempting to differentiate root compression and a peripheral neuropathy. Nuclear medicine bone scanning, local diagnostic injections, discography, and CSF analysis have a limited role in the diagnostic process.

## NONOPERATIVE TREATMENT

Most patients with symptoms of neck pain with or without radiculopathy can be managed nonoperatively. The initial treatment of moderate to severe symptoms should consist of a soft collar, nonsteroidal anti-inflammatory agents (NSAIDs), and physical therapy modalities, including traction, particularly when radicular signs are present. The limited use of a soft collar may help to decrease the dynamic compression of an irritated nerve root and permit the pain from fatigue or spasm in the paraspinal muscles to resolve. Prolonged use of a collar is not recommended because of the risk of paraspinal muscle atrophy. Restrict activities to avoid neck extension and heavy lifting during the acute period. Aspirin, ibuprofen, or NSAIDs may provide pain relief. Use narcotic pain medications sparingly, especially in elderly patients. Occasionally, a brief tapered course of oral cortisone may alleviate symptoms of radiculopathy. Physical therapy modalities such as heat and ultrasound may improve acute symptoms, but it is unclear whether they have any effect on natural history. Manual or home traction may provide relief of nerve root compression through distraction of the intervertebral foramen.

As in the lumbar spine, epidural steroid injections (ESI) may be recommended for treatment of the inflammatory component of cervical radiculopathy. The role of ESI is controversial, and the literature lacks well-designed studies documenting their efficacy. Before recommending ESI, weigh the short-term relief of symptoms against possible risks and complications of needle placement (15,65).

Patients with symptoms of myelopathy may be immobilized in a soft collar to prevent dynamic spinal cord compression. However, this is a temporizing measure only and is not definitive treatment.

## SURGICAL TECHNIQUES

### NECK PAIN

The indications for surgery in patients with neck pain secondary to spondylosis, canal stenosis, or discogenic neck pain are limited. Whitecloud and Seago reported 70% good-to-excellent results from anterior interbody fusion for patients with concordant neck pain on discography (68). However, others have found that fusion for discogenic neck pain based on provocative testing yields results that are not much improved from the natural history of the disorder (22). Conservative management for these individuals remains the treatment of choice.

Recalcitrant neck pain from degenerative spondylolisthesis or retrolisthesis is rare in the cervical spine. Instability suggested on dynamic flexion–extension radiographs may be managed by either anterior or posterior segmental fusion.

### CERVICAL RADICULOPATHY

The indications for operative intervention in cervical radiculopathy include (a) failure of a 3-month trial of nonoperative treatment to relieve persistent or recurrent radicular arm pain with or without neurologic deficit, and (b) a progressive neurologic deficit (9,27). Neuroradiographic findings must be consistent with the clinical signs and symptoms, and the duration and magnitude of symptoms must be sufficient to justify surgery.

The operative approaches utilized for radiculopathy include anterior decompression with discectomy [anterior cervical discectomy without fusion (ACD)] with or without interbody fusion (ACDF/ACD), anterior corpectomy with fusion (ACF), posterior laminotomy with foraminotomy, or laminectomy or laminoplasty with or without fusion (Table 143.1).

| |
|---|
| **Anterior cervical discectomy and fusion** |
| Radiculopathy with significant degenerative neck pain |
| Bilateral radiculopathy |
| Presence of localized kyphosis |
| Anterior plating recommended for three levels, or two levels with high risk for nonunion |
| **Anterior corpectomy with strut graft fusion** |
| As an alternative to two-level discectomy and fusion procedure, partial anterior corpectomy and strut graft fusion can be done to improve fusion rates with only two surfaces of fusion between the graft and the endplate |
| Posterolateral soft disc herniation at two levels |
| Spondylotic radiculopathy at two levels |
| Migrated disc fragment behind vertebral body, requires corpectomy to the dura |
| **Posterior laminotomy/foraminotomy** |
| Unilateral radiculopathy without significant neck pain |
| Absence of localized kyphosis |
| C7–T1 level that would be difficult to approach in certain patients with short necks |
| **Laminectomy** |
| Multiple-level radiculopathy |
| Bilateral radiculopathy at multiple levels |
| Maintenance of cervical lordosis |
| Absence of significant neck pain |
| Ankylosed or stiff spine |
| **Laminoplasty** |
| Unilateral, multilevel radiculopathy |
| Congenital cervical stenosis |
| Maintenance of cervical lordosis |
| Absence of significant neck pain |

***Table 143.1. Indications for the Operative Treatment of Cervical Radiculopathy***

### *Anterior Cervical Discectomy and Fusion*

Surgical exposure of the anterior aspect of the cervical spine is a relatively safe procedure that takes advantage of normal anatomic fascial planes during the approach

(55,56 and 57).

- Place the patient in the supine position with a small roll placed under the shoulder blades to drop the shoulders from the field and to present the anterior neck favorably. Strap the shoulders at the side with minimal traction to allow visualization of the lower cervical spine on lateral radiographs.
- Apply skull traction via a chin halter device or with Gardner-Wells tongs. Keep head rotation to a minimum because deep dissection will depend on identifying the vertebral midline to prevent inadvertent injury to adjacent structures. The reverse Trendelenburg position facilitates venous drainage and results in less bleeding during surgery.
- The superficial anatomic landmarks for incision include the hyoid bone overlying C-3, thyroid cartilage overlying the C4–5 interspace, and cricoid cartilage overlying the C-6 level. Use transverse incision for exposure in most cases when one or two discs are to be exposed. When three or more levels are approached, use a longitudinal incision along the anterior border of the sternocleidomastoid muscle. The transverse incision is preferred for its cosmetic appeal and access to the anterior spine, whereas the longitudinal incision serves to improve visualization of the region over multiple levels and avoids excessive retraction that may otherwise be necessary.
- Place the transverse incision along the anterior neck from the midline to the anterior border of the sternocleidomastoid in Langer's lines.
- Divide the superficial fascia and platysma muscle exposing the middle layer of the cervical fascia.
- Bluntly dissect the pretracheal fascia and palpate the carotid pulse.

Dissection through the pretracheal fascia places several structures at risk. The superior and inferior thyroid arteries extend through the pretracheal fascia from the carotid artery to the midline. The superior and inferior thyroid arteries travel at the C3–C4 and C6–C7 levels, respectively. The intervening area provides a relatively avascular plane for dissection. The recurrent laryngeal nerves are also at risk during the anterior approach. The right recurrent laryngeal nerve ascends in the neck after passing around the subclavian vessels and courses medially and cranially at the C6–C7 level, often along with the inferior thyroid artery. The left recurrent laryngeal nerve ascends after curving around the aortic arch along the tracheoesophageal groove in a more midline and protected position. A left-sided procedure may be safer, especially when lower cervical segments are approached. However, the thoracic duct is often visible on the left at the C7–T1 level and must be protected.

- Retract the sternocleidomastoid muscle and the carotid sheath along with its contents (common carotid artery, internal jugular vein, and vagus nerve) laterally, and retract the midline structures, including the trachea, esophagus, and thyroid gland medially.
- Complete blunt dissection through the deeper levels to the prevertebral fascia and vertebral bodies.
- Once the midline is identified, incise the prevertebral fascia and elevate the medial edges of the longus colli muscles.
- Place blunt self-retaining retractors under the leading edges of the muscle. Take care to avoid dissecting along the longus colli muscle because injury to the cervical sympathetic plexus is likely.
- Identify the vertebral bodies by their concave appearance and the discs by their more convex contour.
- Localize the disc space with a radiopaque marker and lateral radiograph.
- Incise the disc with an annulotomy blade and perform the decompression.
- Remove the disc contents and endplate cartilage to the PLL (Fig. 143.6*A*, Fig. 143.6*B* and Fig. 143.6*C*). The proper technique of discectomy involves removal of disc material in a posterior to anterior direction and lateral to medial away from the vertebral arteries. Use thorough evaluative preoperative imaging to determine the presence of a sequestered disc behind the PLL. Palpate the PLL for the presence of a rent that may also indicate a sequestered fragment. In the event that a rent is noted, or if an expected disc fragment is not identified, remove the PLL with Kerrison rongeurs or curets. Beware of routine removal of the PLL, because reports of postoperative epidural hematoma have been associated with this technique (70).

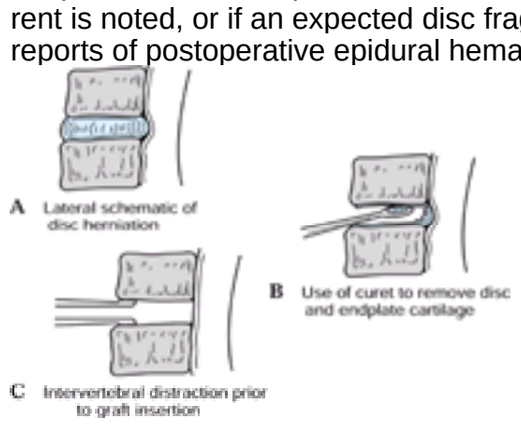


***Figure 143.6.*** Anterior cervical discectomy with distraction of the interspace and removal of disc to the posterior longitudinal ligament. See text for details.

- Removal of endplate and uncovertebral osteophytes is controversial. The proposed benefits of fusion without spur resection are that disc space distraction reduces ligamentum flavum buckling and increases neuroforaminal area. It is believed that fusion will arrest spur progression, and stability may allow for resorption over time. However, this is not a consistent phenomenon, and the location and size of the offending spur must be carefully considered when performing decompression for spondylitic radiculopathy. Exposure of the uncinate processes is critical to safely remove osteophytes.
- Utilize a high-speed burr to excise the spur from medial to lateral. Judge the adequacy of foraminotomy by the ability to place the tip of a curet anterior to the exiting nerve root without significant resistance.

Several techniques of anterior interbody fusion in the cervical spine have been described; they differ by graft configuration (Fig. 143.7).

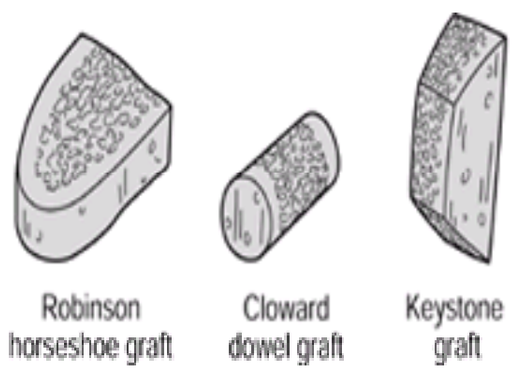


***Figure 143.7.*** Types of anterior cervical grafts used in interbody arthrodesis.

**Robinson Technique** The Robinson interbody fusion technique involves the placement of a tricortical iliac crest wedge graft into the disc space for bony healing.

- The graft height should be 2 mm greater than the preexisting disc height, or at least 5 mm, to obtain adequate compressive strength and to enlarge the neural foramina (1). Overdistraction of the disc space by greater than 4 mm of the preexisting height may result in graft collapse and pseudarthrosis (14). Achieve distraction of the disc space with skull traction, laminar spreader, vertebral screws, or combinations of these.
- Burr the endplates to create a flat surface on both sides of the intervertebral space. Additionally, small holes may be created in the endplates to promote vascularization of the graft.
- After measuring the depth and width of the disc space, harvest the tricortical graft from the anterior iliac region. Obtain the graft with an oscillating bone saw, because graft weakening has been associated with the use of osteotomes (37).
- Contour the graft to fit into the disc space and insert it with the leading cortical edge anteriorly and inset 2 mm beyond the vertebral bodies. The graft may also be inserted in the reverse position, with the leading cortex directed posteriorly, to maximize posterior disc space and foraminal distraction. This has been shown to be an acceptable alternative to the more traditional graft position. The graft should be stable with compression after removal of all traction devices.

**Cloward Technique** The Cloward technique utilizes a bicortical dowel-shaped graft (19). The technique requires the use of specialized instruments including drills, guards, and a dowel cutter.

**Simmons Technique** The Simmons technique for interbody fusion utilizes a keystone-shaped graft (59).

- After completion of the discectomy, remove bone from the inferior aspect of the superior vertebral body and the superior aspect of the inferior vertebral body with specialized osteotomes.
- The end of the vertebra is beveled to an angle of between 14° and 18°, as recommended by Simmons and Bhalla (59). Maximally distract the neck and measure the graft site.
- Harvest a rectangular iliac crest graft and contour to match the beveled surfaces of the vertebral bodies.
- After the graft is impacted in the host bed, release the traction, thus locking the graft in place.

**Bailey and Badgley Technique** The Bailey and Badgley technique involves developing an anterior trough in the vertebral bodies to accomplish fusion (3).

- Make a trough ½ inch wide and $^{3}/_{16}$ inch in depth along the full length of the vertebrae to be fused.
- Remove the intervening disc and endplate cartilage to a depth of $^{3}/_{16}$ inch and impact a unicortical iliac crest graft into place. Insert the graft with the neck in extension and, after placement, flex the neck to achieve stability.

The Cloward and the Bailey and Badgley techniques have the disadvantage of having no direct nerve root decompression, and thus are seldom used today.

Because iliac crest bone harvesting has an associated morbidity, the use of allograft bone has become a popular method of interbody fusion. In one study, although nonunion rates and graft collapse were more common in ACDF with freeze-dried tricortical iliac crest allograft, the clinical results were similar to ACDF with autogenous bone graft (77). Fibular allograft has also been shown to provide results similar to autograft, with acceptable single-level fusion rates and the absence of donor site pain (74). Other studies have found a higher radiographic nonunion rate with allograft and greater clinical improvement when autograft is used (44). Therefore, the results of using allograft bone are difficult to evaluate. One-level fusion with allograft may be acceptable, but graft collapse and radiolucencies may persist.

The presence of fusion following discectomy has not been uniformly correlated with a favorable clinical outcome, nor has nonunion consistently resulted in a clinical failure (16). The fact that a pseudarthrosis may be associated with a good clinical result led to the concept of ACD. A major advantage of ACD is the lack of donor site complications. However, the disadvantage is postoperative neck pain, which may become severe and is more common than when ACDF is performed (71). Postdiscectomy collapse and angular kyphosis may also occur, leading to recurrent nerve root compression if posterior osteophytes are not widely resected at the index procedure. Bilateral foraminotomies must be performed to prevent contralateral radiculopathy due to resultant disc space collapse. If ACD is to be performed, it most likely should be limited to soft disc herniations and avoided in patients with evidence of spondylosis who require disc space distraction.

### *Anterior Cervical Corpectomy*

A partial or complete anterior corpectomy and strut graft fusion (ACF) may be necessary in situations in which disc herniation is associated with a sequestered fragment that has migrated behind the vertebral body. Subtotal anterior corpectomy and fusion may also be performed when two-level disc disease is present. The theoretical advantage of ACF over two-level ACDF resides in the number of sites that must fuse.

- Accomplish anterior cervical corpectomy by discectomy above and below the vertebra in question. Then excise the vertebral body with rongeurs or a high-speed burr to the posterior cortex.
- Next, remove the posterior shell with angled curets directed away from the dura.
- Traction or distraction may then be applied to restore sagittal plane alignment at the decompressed level.
- Harvest an iliac crest strut graft and insert it into the prepared endplates, and countersink it slightly into the vertebral bodies. Assess stability of the graft with traction released and, if necessary, consider application of a rigid external orthosis, halo, or internal fixation such as an anterior cervical plate.

### *Posterior Decompression*

Posterior decompression for cervical radiculopathy can be performed with laminotomy and foraminotomy, laminectomy, or laminoplasty (Fig. 143.8, Fig. 143.9). Careful patient positioning is required to minimize the risk of neurologic injury and to maximize exposure of the required level.

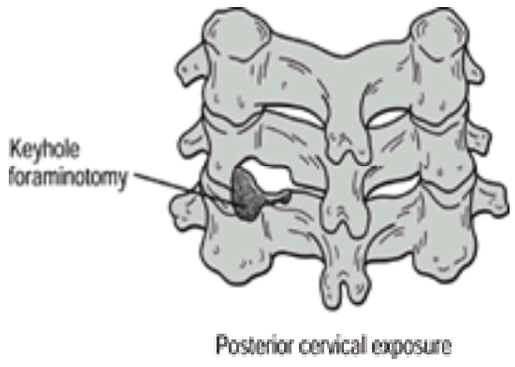


***Figure 143.8.*** Posterior laminotomy and foraminotomy depicting thinning of the lamina and facet joint with nerve root decompression.

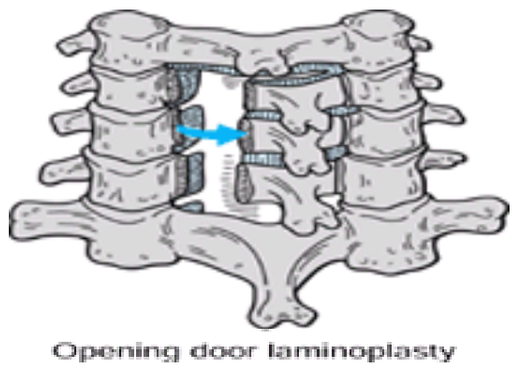


***Figure 143.9.*** Open-door laminoplasty depicting hinged lamina and spinal canal decompression.

**Laminoforaminotomy**

- Stabilize the head in the prone position with Mayfield skull tongs, leaving the face free without sources of pressure. The reverse Trendelenburg position promotes epidural venous drainage. The posterior approach to the cervical spine utilizes an internervous plane in the midline which separates the muscles from the segmental innervation supplied by the right and left posterior rami of the cervical nerves.
- Incise the ligamentum nuchae in the midline and carry the subperiosteal dissection down the spinous processes and corresponding laminae. In the cervical spine, the laminae do not override each other as much as in the thoracic spine; therefore, the interlaminar space may be inadvertently penetrated if caution is not taken during the exposure.
- Carry dissection out to the lateral edge of the lateral masses and preserve the facet joint capsule if no fusion is required or anticipated.
- Remove portions of the inferior and superior laminae at the level of the specific nerve root compression and perform partial facetectomy with a high-speed burr.
- To prevent iatrogenic instability, remove no more than 50% of the facet (78). The lamina and thinned bone should be gently lifted off the nerve and spinal cord

with small angled curets.
- Assess foraminotomy by placing a blunt probe or Woodson dental instrument into the neuroforamen to judge its patency.
- If disc removal is deemed necessary, expose the nerve root and cauterize the surrounding venous plexus. Gently retract the nerve root cephalad and remove the disc tissue.

**Laminectomy** Laminectomy is an option for treating multilevel spondylotic radiculopathy with anterior bony ankylosis when cervical lordosis has been preserved.

- Perform laminectomy by thinning the cortices at the junction of the laminae and lateral masses bilaterally with a power burr.
- Use a small Kerrison rongeur to complete the cut and a small angled curet to elevate the laminae.
- Cauterize the adherent underlying venous plexus to minimize epidural hematoma formation.
- Loss of the posterior structural support of the bony elements may increase the risk of subsequent vertebral subluxation and kyphotic deformity, especially in younger patients, in whom fusion should be considered at the time of decompression.

**Laminoplasty** Laminoplasty may be used in the treatment of multilevel spondylotic radiculopathy with predominantly unilateral symptoms. There are several methods of laminoplasty, which vary by location of the hinge and means of maintaining the open position (36).

- As in laminectomy, perform laminoplasty by thinning the cortex at the lamina and lateral mass junction with a high-speed burr bilaterally to the inner cortex.
- Thin the hinged side without completing the cut while completing the osteotomy on the opening side.
- Gently open the lamina either with towel clips placed through the respective spinous processes or with a vertebral spreader placed into the defect. Fracture the thinned inner cortex of the hinged side and hold the posterior elements open.

## CERVICAL MYELOPATHY

The surgical indications for the treatment of cervical myelopathy are not as well defined as they are for the treatment of cervical radiculopathy. A patient with mild, nonprogressive myelopathy that is long-standing and does not cause significant disability can be observed closely. Operative intervention is recommended for (a) progressive myelopathy, (b) moderate or severe myelopathy that is stable and of short duration (less than 1 year), and (c) mild myelopathy that affects routine activities of daily living. The age of the patient or severity of the disease should not serve as a contraindication for surgery; it must be conveyed to the patient that the goal of surgery is to prevent neurologic worsening.

Based on the clinical and radiographic evaluation, decide whether to approach the area of compression with an anterior technique, a posterior technique, or a combination (Table 143.2). The factors that are critical in this decision process are the site of compression, presence or absence of spinal stability, sagittal alignment of the cervical spine, and extent of the disease process (41).

| |
|---|
| Anterior cervical discectomy and fusion |
| Myelopathy with one- (or more) level disease due to disc herniation |
| Anterior plating recommended for multilevel cases |
| Anterior corpectomy with strut graft fusion |
| Myelopathy due to disc or osteophyte posterior to the vertebral body at multiple levels |
| Loss of cervical lordosis |
| Presence of significant neck pain |
| Laminectomy |
| Cord compression at three or more levels |
| Maintenance of cervical lordosis |
| Ankylosed, stiff spine |
| Absence of significant neck pain |
| Concomitant fusion recommended if there is vertebral subluxation or instability, or significant neck pain |
| Laminoplasty |
| Continuous OPLL at multiple levels |
| Congenital cervical stenosis |
| Maintenance of cervical lordosis |
| Absence of significant neck pain |

OPLL, ossification of the posterior longitudinal ligament.

***Table 143.2. Indications for the Operative Treatment of Cervical Myelopathy***

The presence of primarily anterior compression of the spinal cord limited to the intervertebral disc space without intervening stenosis of the canal at the vertebral body level indicates an anterior decompression. Anterior decompression can be performed with ACDF using the techniques described. Remove the spondylotic ridge, as well as any other areas of spur formation deemed clinically significant that may require hemicorpectomy. If multilevel disease is present, consider anterior corpectomy and strut graft fusion. When compressive pathology is present at the disc level as well as posterior to the vertebral body, as with OPLL, then an ACDF will increase the AP diameter at the disc level only and not the remainder of the spinal canal. Anterior corpectomy allows more complete decompression.

If myelopathy is present along with a kyphotic alignment, an anterior decompression is also indicated. This is best performed with ACF to realign and decompress the spine. When accompanied by significant subluxations, kyphosis may need to be approached from a combined anterior and posterior direction. In the presence of spondylotic spurring and a congenitally tight spinal canal over several segments, consider the posterior approach. A compression ratio of less than 0.5 (sagittal diameter divided by the transverse diameter of the spinal cord) may also indicate a posterior decompression (43). This can be performed with laminectomy or laminoplasty, as previously described.

Anterior corpectomy is performed through a transverse or longitudinal incision, based on the number of levels involved. Decompression of the spinal cord is accomplished by removal of the middle third of the vertebral body. Recommendations for safe decompression to within 5 mm of the transverse foramen allow removal of disc or bone 7.5 mm lateral to the midline at C-3 and 9.5 mm at C-6, which can be estimated intraoperatively (63). Because patient anatomy varies, evaluate this on an individual basis based on the preoperative imaging studies. In anterior decompression for OPLL, a “floating procedure” may be performed (72). The anterior ossified mass is not actually removed but rather is released from its surrounding attachments. The localized OPLL segment mass migrates anteriorly and allows decompression of the spinal cord. Because it is possible to encounter absence of the dura or coalescence of dura and PLL in the anterior approach to OPLL, this form of decompression is often recommended (61).

Strut graft fusion is performed with iliac crest when up to two vertebral bodies are removed, but because of its curvature this graft is less useful when longer struts are needed. In corpectomies of three or more levels, a fibular graft is indicated. The iliac crest graft has more exposed cancellous sites for incorporation, but the fibula is mechanically stronger.

## SPINAL INSTRUMENTATION

The role of instrumentation in the surgical management of cervical radiculopathy and myelopathy is less clear than in traumatic conditions (Fig. 143.10). In degenerative disc disease, various studies suggest that nonunion rates and graft dislodgement increase with the number of levels operated on (9,76). The goals of applying instrumentation are to provide immediate stability, increase fusion rate, prevent loss of fixation of the bone graft, improve postoperative rehabilitation, and possibly avoid the requirements for an external orthosis (34).

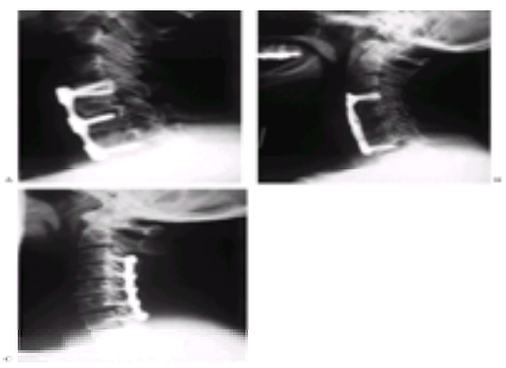

***Figure 143.10.*** **A:** Lateral radiograph shows interbody fusion at C5-6 and C6-7 with segmental plating from C-5 to C-7 (the Peak Polyaxial Anterior Cervical Plate,

Depuy-Acromed, Cleveland, OH). This patient, who had a history of cigarette smoking, underwent anterior fusion with plating for cervical radiculopathy with neck pain. The plate was used to improve fusion. **B:** Lateral radiograph shows strut grafting and anterior plating from C-4 to C-7 (the Orion Plate, Sofamor-Danek, Inc., Memphis, TN). This patient underwent anterior corpectomy and fusion for cervical spondylotic myelopathy. **C:** Lateral radiograph shows laminectomy and lateral mass plating from C-3 to C-7 (Axis Plate, Sofamor-Danek, Inc., Memphis, TN). This patient underwent the procedure for myelopathy due to multilevel cervical spondylosis.

Animal studies have not shown evidence of improved fusion rates of three-level ACDF with plating (76). Avascularity beneath the plate has also been detected, although its significance is unclear. It is doubtful that anterior plating for single-level ACDF increases fusion rate (21). The potential benefits of instrumentation may not outweigh the risks in these situations. Whether multiple-level ACDF fusion is improved by instrumentation remains to be determined, and presently no guidelines are available for their use. Two-level ACDF has a higher pseudarthrosis rate than single levels, and instrumentation is often used in certain situations such as patients who are actively smoking. Although rare, three-level ACDF may be accompanied by anterior plating; however, no scientific data support its use. The main use of anterior plating in ACF is to prevent graft dislodgement. When long graft constructs are used, a plate may be inserted at the inferior vertebra as a buttress where graft displacement most commonly occurs (75).

The role of posterior instrumentation in degenerative conditions is also controversial. Posterior decompressive laminectomy may require concomitant fusion in patients with preexisting instability based on imaging studies. Whether the addition of instrumentation such as lateral mass plating or facet joint wiring increases fusion rate while improving the postoperative course is unknown.

## POSTOPERATIVE MANAGEMENT—RESULTS

Patients who undergo anterior cervical spine surgery are allowed to gradually increase their postoperative activities and are encouraged out of bed with directed therapy as needed. Liquids are started with a gradual advance to solids as tolerated. Brace management is controversial and dealt with on an individualized basis. Patients recovering from one- or two-level ACDF may be treated in a rigid or soft orthosis based on their surgeon's preference. We recommend rigid external orthoses in ACDF, especially when multilevel decompression and fusion are performed in the absence of anterior plating. Such devices include Philadelphia collars or, in severely osteoporotic individuals, halo-vest immobilization. External wear may continue for 6–12 weeks based on radiographic progression of the fusion and the patient's comfort level. A gradual weaning process may follow from a rigid to a soft collar to no immobilization. A soft collar is all that is needed for posterior laminotomy, laminectomy, or laminoplasty when performed in the absence of fusion.

Postoperative results of surgical treatment of cervical radiculopathy and myelopathy vary, depending on the type of approach utilized and the severity of the disease. Literature review is depicted in Table 143.3 and Table 143.4. Limitations in drawing firm conclusions from previous reports stem from the lack of uniform patient population, inclusion of different disease processes in the same analysis (soft versus hard disc), and inconsistency of establishing successful results. Overall, the surgical treatment of radiculopathy yields satisfactory results in greater than 90% of patients. Although controversial, it appears that patients who attain a solid fusion do have better outcomes than those with a pseudarthrosis. The results of treatment of myelopathy also are variable, as depicted by the numerous techniques utilized to decompress the spinal cord. Overall, patients with greater neurologic deficits tend to experience less improvement in symptoms following surgery than those with more acute and less severe neurologic findings.

| Author (ref.) | Patients (N) | Technique | Results | Notes |
|---|---|---|---|---|
| [illegible] | [illegible] | ACDF | [illegible] | [illegible] |
| [illegible] | [illegible] | ACDF | [illegible] | [illegible] |
| [illegible] | [illegible] | ACDF | [illegible] | [illegible] |
| [illegible] | [illegible] | ACDF | [illegible] | [illegible] |
| [illegible] | [illegible] | ACDF | [illegible] | [illegible] |
| [illegible] | [illegible] | ACDF | [illegible] | [illegible] |
| [illegible] | [illegible] | ACDF | [illegible] | [illegible] |
| [illegible] | [illegible] | ACDF PLF | [illegible] | [illegible] |
| [illegible] | [illegible] | PLF | [illegible] | [illegible] |
| [illegible] | [illegible] | ACDF | [illegible] | [illegible] |
| [illegible] | [illegible] | ACDF | [illegible] | [illegible] |
| [illegible] | [illegible] | ACDF with anterior [illegible] | [illegible] | [illegible] |

[illegible]

*Table 143.3. Results of Surgical Treatment of Cervical Radiculopathy*

| Author (ref.) | Patients (N) | Technique | Results | Notes |
|---|---|---|---|---|
| Robinson 1957 (6) | 17 | ACDF | 82% improved | — |
| Lunsford et al. 1980 (67) | 31 | Ant. decompression | 80% improved | — |
| Zhang et al. 1983 (79) | 121 | ACDF, 3 or more levels | 90% improvement | — |
| Bazi et al. 1984 (10) | 29 | Ant. decompression, osteophyte removal | G-E 12% | — |
| Fisher et al. 1986 (31) | 30 | Ant. decompression, osteophyte removal | 5-point improvement on incontinency/ bladder scale | — |
| Yang et al. 1987 (75) | 114 | ACDF, 3 or more levels | 90% improvement | — |
| Bernard and Whitehead 1987 (3) | 21 | Ant. decompression, Shaker wear graft | 76% improved 1 grade | — |
| Scarden et al. 1991 (78) | 40 | Ant. decompression | 57.5% improved | 15% failure rate, 47.5% complication rate |
| Herzog et al. 1993 (34) | 84 | 51, laminectomy 33, ant. decompression | 68% improved 75% improved | Increased duration of symptoms Likely late deterioration |
| Kimura et al. 1993 (39) | 29 | Laminoplasty | G-E 14% | — |
| Nagata et al. 1996 (50) | 175 | 98, laminectomy 77, ant. decompression | Improvement in younger patients, fewer levels, milder disease | — |

[illegible]

*Table 143.4. Results of Surgical Treatment of Cervical Myelopathy*

## PITFALLS AND COMPLICATIONS

The anterior surgical approach to cervical disc disease involves dissection and retraction of numerous vital vascular, respiratory, neural, and intestinal structures. An overall 0.2% incidence of neck site complications based on an extensive review of published series has been reported in one series (67). It is with an understanding of the potential complications that may occur that improvements in techniques and results may follow.

The incidence of *vocal cord paralysis* from recurrent laryngeal nerve injury ranges from 1% to 11% of all neurologic injuries (33). The possible causes are traumatic division, stretch injury, compression from postoperative swelling, and injury from thermal necrosis. Injury is much more likely during a right-sided approach because the right subclavian is occasionally anomalous. In these cases, the right recurrent laryngeal nerve, having no vessel to follow, may cross the surgical field directly and may be easily injured during exposure to the mid-cervical spine. The injury is manifested as a hoarse, weak voice with a risk of aspiration due to the inability to completely close the larynx. When symptoms persist for longer than 6 weeks, referral to an otolaryngologist is recommended for evaluation and possible vocal cord injection.

*Sympathetic chain injury* is also uncommon and manifests as ipsilateral miosis, ptosis, and anhidrosis. Treatment options are limited.

Midline soft tissue injury to the trachea, esophagus, and pharynx are likewise unusual. *Dysphagia* following anterior cervical surgery is common and is estimated to occur transiently in 8% of patients. When persistent symptoms develop, evaluation should include a lateral radiograph to check bone graft position. *Esophageal lacerations* occur in 0.25% to 0.7% of patients (38). When identified, immediate primary repair should be performed, the wound appropriately drained, and the patient started on broad-spectrum antibiotics.

*Vascular injuries* during the surgical approach or decompression are rare but can have devastating sequelae. The structures that may potentially be injured include the carotid sheath contents, superior and inferior thyroid arteries, and vertebral artery. Avoid overzealous retraction and use blunt-edged retractors to reduce the risk of injury to these vessels. Knowledge of the anatomy of the vertebral artery and its relationship to the lateral disc space and vertebral body, as well as maintaining midline

orientation during decompression, all serve to minimize the risk of injury estimated to occur in 0.3% to 0.5% of patients (62). The thoracic duct is at some risk during left-sided approaches to the cervicothoracic junction. If a chylous effusion is encountered, injury to the duct must be suspected.

*Spinal cord injury* is perhaps the most devastating complication that can occur in anterior cervical surgery. An incidence of 0.1% to 0.64% has been reported in the literature (28). The literature indicates that the drill and dowel technique and the presence of myelopathy are the major risk factors for neurologic injury. In addition, neck manipulation during intubation, cervical malalignment following decompression and grafting, and postoperative epidural hematoma must all be considered in the evaluation of the patient with postoperative neurologic deterioration. Management should include maintenance of normotensive blood pressure, administration of steroids, and imaging studies to assess for possible graft dislodgement (28). If compressive pathology is identified, rapid reexploration and decompression are indicated.

*Pseudarthrosis* rates following anterior grafting procedures range from 0% to 26% (19,20,24,55,57,66,69). Estimates for fusion for single-level, two-level, and three-level ACDF are 88% to 90%, 73% to 80%, and 70%, respectively (9,76). Even though bony union may not occur, a stable fibrous union can develop and account for the lack of symptoms in some patients with pseudarthrosis. However, several reports have found better clinical results when solid fusion is attained (9,55,66).

*Bone graft site complications* are not infrequent, with a near 20% incidence reported (67). Injury to superficial nerves may result in numbness or pain with neuroma formation. Superior gluteal artery injury has also been reported in iliac crest bone harvest as well as iliac crest fracture.

Complications associated with the posterior approach to cervical degenerative disc disease may also occur. The risk of *hematoma* can be diminished with strict attention to dissection within the ligamentum nuchae and subperiosteally along the laminae. Reattachment of the paraspinal muscles, especially to the C-2 spinous process, may prevent loss of cervical lordosis following posterior decompression (51).

*Neurologic injuries* are rare during the posterior approach, although they are more common than with anterior surgery (28). Avoidance of placement of instruments into the spinal canal and thinning of the cortex with a high-speed burr followed by the use of curets during decompression may diminish the risk of neurologic injury.

## AUTHORS' TECHNIQUES

The clinical syndromes of neck pain, radiculopathy, and myelopathy require extensive preoperative evaluation, and when indicated, surgery must be directed at the specific pathology leading to symptoms (Table 143.1, Table 143.2). We manage cervical radiculopathy based on the number of levels involved and the degree of neck pain present. Significant neck pain and up to two levels of radicular symptoms are managed with anterior cervical discectomy and fusion. Radiculopathy without significant neck pain is managed with posterior laminoforaminotomy. In the uncommon situation in which a migrated disc fragment is located behind the vertebral body, a subtotal corpectomy followed by strut graft fusion is the preferred treatment. Radiculopathy involving three levels or greater is managed by laminoforaminotomy or laminoplasty for unilateral and laminectomy for bilateral symptoms. Laminectomy is frequently accompanied by lateral mass plating if there is associated instability. Another option is multilevel anterior discectomy and fusion with plating. For these multilevel cases, the anterior approach is preferred if there is loss of cervical lordosis, and the posterior approach is preferred if there is maintenance of lordosis.

Our approach to the treatment of myelopathy considers the site of spinal cord compression and the sagittal alignment of the cervical spine. Single- or two-level disease is treated with anterior decompression and fusion either with ACDF, if impingement is at the disc level, or with subtotal corpectomy if compression is behind the vertebral body. Multiple-level compression at greater than two levels is managed with anterior decompression and fusion or posterior decompression, depending on the pathology identified. Myelopathy with cervical kyphosis is approached with anterior decompression and strut graft fusion. Laminoplasty or laminectomy plus lateral mass plating and fusion is recommended for three- (or more) level disease with maintenance of cervical lordosis. If there is significant neck pain in addition to myelopathy, fusion is preferred over laminoplasty. Combined anterior and posterior decompression and fusion may be performed when severe circumferential cord compression is present.

## CONCLUSIONS

When evaluating patients with cervical degenerative conditions, the physician must be attentive to symptoms and signs of radiculopathy and myelopathy. Appropriate selection of imaging and other diagnostic tests is important for making the correct diagnosis and for cost-effectiveness. The treatment of patients with cervical disc disease is largely nonoperative. Only those patients who failed conservative treatment should undergo surgery for symptomatic relief of radicular arm pain or improvement of neurologic deficits. Patients with cervical spondylotic myelopathy should be treated more aggressively to prevent permanent loss of neurologic function. The choice of anterior versus posterior approach depends on the patient's symptoms, the location of neural compression, the sagittal alignment, the number of levels involved, and the surgeon's preference.

## CHAPTER REFERENCES

Each reference is categorized according to the following scheme: *, classic article; #, review article; !, basic research article; and +, clinical results/outcome study.


! 1. An H, Evanich C, Nowicki B, Haughton V. Ideal Thickness of Smith-Robinson Anterior Cervical Fusion. *Spine* 1993;18:2043.

+ 2. Aronson N. The Management of Soft Cervical Disc Protrusions Using the Smith-Robinson Approach. *Clin Neurosurg* 1973;20:253.

* 3. Bailey R, Badgley C. Stabilization of the Cervical Spine by Anterior Fusion. *J Bone Joint Surg [Am]* 1960;42:565.

# 4. Bell G, Ross J. The Accuracy of Imaging Studies of the Degenerative Cervical Spine: Myelography, Myelo-Computed Tomography, and Magnetic Resonance Imaging. In: Weisel S, ed.*Seminars in Spine Surgery— Cervical Disc Disease.* Philadelphia: WB Saunders, 1995:9.

+ 5. Bernard T, Whitecloud T. Cervical Spondylotic Myelopathy and Myeloradiculopathy—Anterior Decompression and Stabilization with Autogenous Fibula Strut Graft. *Clin Orthop* 1987;221:149.

* 6. Bohlman H. Cervical Spondylosis with Moderate to Severe Myelopathy: A Report of 17 Cases Treated by Robinson Anterior Cervical Discectomy and Fusion. *Spine* 1977;2:151.

# 7. Bohlman H. Cervical Spondylosis and Myelopathy. *Instr Course Lect* 1995;44:81.

# 8. Bohlman H, Emery S. The Pathophysiology of Cervical Spondylosis and Myelopathy. *Spine* 1988;13:843.

+ 9. Bohlman H, Emery S, Goodfellow D, Jones P. Robinson Anterior Cervical Discectomy and Arthrodesis for Cervical Radiculopathy. *J Bone Joint Surg [Am]* 1993;75:1298.

+ 10. Boni M, Cherubino P, Benazzo F. Multiple Subtotal Somatatectomy: Technique and Evaluation of a Series of Thirty-nine Cases. *Spine* 1984;9:358.

+ 11. Bosacco D, Berman A, Levenberg R, Dosacco S. Surgical Results in Anterior Cervical Discectomy and Fusion Using a Countersunk Interlocking Autogenous Iliac Crest Bone Graft. *Orthopedics* 1992;15:923.

+ 12. Brigham C, Tsahakis P. Anterior Cervical Foraminotomy and Fusion: Surgical Technique and Results. *Spine* 1995;20:766.

# 13. Brower R. Ossification of the Posterior Longitudinal Ligament: Clinical Manifestations and Surgical Treatment. In: Weisel S, ed. *Seminars in Spine Surgery—Cervical Disc Disease*. Philadelphia: WB Saunders, 1995:33.

! 14. Brower R, Herkowitz H, Kurz L. Effect of Distraction on the Union Rate of Smith-Robinson Type Anterior Cervical Discectomy and Fusion. Presented at the Cervical Spine Research Society Annual Meeting, Palm Desert, CA, 1992.

+ 15. Castagnera L, Maurette P, Pointillart V, et al. Long Term Results of Cervical Epidural Steroid Injection With and Without Morphine in Chronic Cervical Radicular Pain. *Pain* 1994;58:239.

# 16. Chestnut R, Abitol J, Garfin S. Surgical Management of Cervical Radiculopathy. Indications, Techniques, and Results. *Orthop Clin North Am* 1992;23:461.

# 17. Clark C. Cervical Spondylotic Myelopathy: History and Physical Findings. *Spine* 1988;13:847.

* 18. Clarke E, Robinson P. Cervical Myelopathy: A Complication of Cervical Spondylosis. *Brain* 1956;79:483.

* 19. Cloward R. The Anterior Approach for Removal of Ruptured Cervical Discs. *J Neurosurg* 1958;15:602.

+ 20. Connolly E, Seymore R, Adams J. Clinical Evaluation of Anterior Cervical Fusion for Degenerative Cervical Disc. *J Neurosurg* 1965;23:431.

+ 21. Connolly P, Esses S, Kostuik J. Anterior Cervical Fusion Outcome. Analysis of Patients Fused With and Without Anterior Cervical Plates. *J Spinal Disord* 1996;9:202.

+ 22. Connor P, Darden B. Cervical Discography Complications and Efficacy. *Spine* 1993;18:2035.

* 23. Crandall P, Batzdorf U. Cervical Spondylotic Myelopathy. *J Neurosurg* 1966;25:57.

* 24. DePalma A, Rothman R, Lewinneck R. Anterior Interbody Fusion for Severe Cervical Disc Degeneration. *Surg Gynecol Obstet* 1972;134:755.

# 25. Dillin W, Booth R, Cuckler J, et al. Cervical Radiculopathy—A Review. *Spine* 1988;11:988.

+ 26. Ebersold M, Pare M, Quast L. Surgical Treatment of Cervical Spondylotic Myelopathy. *J Neurosurg* 1995;82:745.

# 27. Fischgrund J, Herkowitz H. Anterior Surgical Procedures for Cervical Spondylotic Radiculopathy and Myelopathy. In: An H, ed. *Surgery of the Cervical Spine.* Baltimore: Williams and Wilkins, 1994:195.

# 28. Flynn T. Neurologic Complications of Anterior Cervical Interbody Fusion. *Spine* 1982;7:536.

+ 29. Gore D, Sepic S. Anterior Cervical Fusion for Degenerated or Protruded Discs. *Spine* 1984;9:667.

* 30. Gore D, Sepic S, Gardner G, Murray M. Neck Pain: A Long Term Follow-up of 205 Patients. *Spine* 1987;12:1.

+ 31. Hanai K, Fujiyoshi F, Kamei K. Subtotal Vertebrectomy and Spinal Fusion for Cervical Spondylotic Myelopathy. *Spine* 1986;11:310.

# 32. Hayashi K, Yabuki T. Origin of the Uncus and of Luschka's Joint in the Cervical Spine. *J Bone Joint Surg [Am]* 1985;67:788.

+ 33. Heeneman H. Vocal Cord Paralysis Following Approaches to the Anterior Cervical Spine. *Laryngoscope* 1973;83:17.

# 34. Herkowitz H. Internal Fixation for Degenerative Cervical Spine Disorders. In: Weisel S, ed. *Seminars in Spine Surgery—Cervical Disc Disease.* Philadelphia: WB Saunders, 1995:57.

+ 35. Herkowitz H, Kurz L, Overholt D. Surgical Management of Cervical Soft Disc Herniation: A Comparison between the Anterior and Posterior Approach. *Spine* 1990;15:1026.

+ 36. Hirabayashi K, Watanabe K, Wakano K, et al. Expansive Open-Door Laminoplasty for Cervical Spinal Stenotic Myelopathy. *Spine* 1983;8:693.

! 37. Jones A, Dougherty P, Sharkey N, Benson D. Iliac Crest Bone Graft: Osteotome Versus Saw. *Spine* 1993;18:2048.

+ 38. Kelley M, Rizzo K, Spigel J, Zwillenberg D. Delayed Esophageal Perforation: A Complication of Anterior Spine Surgery. *Ann Otol Rhinol Laryngol* 1991;100:201.

+ 39. Kimura I, Shingu H, Nasu Y. Long Term Follow-up of Cervical Spondylotic Myelopathy Treated By Canal Expansive Laminoplasty. *J Bone Joint Surg Br* 1995;77:956.

+ 40. Krupp W, Schatke H, Muke R. Clinical Results of the Foraminotomy as Described by Frykholm for the Treatment of Lateral Cervical Disc Herniation. *Acta Neurochir* 1990;107:22.

# 41. Kurz L, Herkowitz H. Surgical Management of Myelopathy. *Orthop Clin North Am* 1992;23:495.

# 42. LaRocca H. Cervical Spondylotic Myelopathy: Natural History. *Spine* 1988;13:854.

# 43. Law M, Bernhardt M, White A. Evaluation and Management of Cervical Spondylotic Myelopathy. *Instr Course Lect* 1995;44:99.

+ 44. Lee S, Connolly K, Incorvania B, et al. Anterior Cervical Fusion Using Allograft Versus Autograft Bone. Presented at the Cervical Spine Research Society Annual Meeting, Baltimore, MD, 1994.

* 45. Lees F, Turner J. Natural History and Prognosis of Cervical Spondylosis. *Br Med J* 1963;2:1607.

# 46. Lestini W, Weisel S. The Pathogenesis of Cervical Spondylosis. *Clin Orthop* 1989;239:69.

+ 47. Lunsford L, Bissoneete D, Zorub D. Anterior Surgery for Cervical Disc Disease. Part 2: Treatment of Cervical Spondylotic Myelopathy in 32 Cases. *J Neurosurg* 1980;53:12.

# 48. McNab I. Symptoms in Cervical Disc Degeneration. In: Sherk H, ed. *The Cervical Spine,* 2nd ed. Philadelphia: Lippincott, 1989:599.

# 49. Montgomery D, Brower R. Cervical Spondylotic Myelopathy—Clinical Syndrome and Natural History. *Orthop Clin North Am* 1992;23:487.

+ 50. Nagata K, Ohashi T, Abe J, et al. Cervical Myelopathy in Elderly Patients: Clinical Results and MRI Findings Before and After Decompression Surgery. *Spinal Cord* 1996;34:220.

! 51. Nolan J, Sherk H. Biomechanical Evaluation of the Extensor Musculature of the Cervical Spine. *Spine* 1988;13:9.

* 52. Nurick S. The Pathogenesis of the Spinal Cord Disorder Associated With Cervical Spondylosis. *Brain* 1972;95:87.

+ 53. Ono K, Ebara S, Fiji T, et al. Myelopathy Hand—New Signs of Cervical Cord Damage. *J Bone Joint Surg Br* 1987;69:215.

# 54. Parke W. Correlative Anatomy of Cervical Spondylotic Myelopathy. *Spine* 1988;13:831.

* 55. Riley L, Robinson R, Johnson K. The Results of Anterior Interbody Fusion of the Cervical Spine. *J Neurosurg* 1969;30:127.

# 56. Robinson R, Riley L. Techniques of Exposure and Fusion of the Cervical Spine. *Clin Orthop* 1975;109:78.

* 57. Robinson R, Walke A, Ferlic E, Wiecking D. The Results of Anterior Interbody Fusion of the Cervical Spine. *J Bone Joint Surg [Am]* 1962;44A:1569.

+ 58. Saunders R, Bernini P, Shireffs T, Reeves A. Central Corpectomy for Cervical Spondylotic Myelopathy: A Consecutive Series with Long Term Follow-up Evaluation. *J Neurosurg* 1991;74:163.

* 59. Simmons E, Bhalla S. Anterior Cervical Discectomy and Fusion. *J Bone Joint Surg Br* 1969;51:255.

! 60. Simpson J, An H. Degenerative Disc Disease of the Cervical Spine. In: An H, ed.*Surgery of the Cervical Spine.* Baltimore: Williams and Wilkins, 1994:181.

+ 61. Smith M, Bolesta M, Levanthal M, Bohlman H. Postoperative Cerebrospinal Fluid Fistula Associated with Erosion of the Dura. *J Bone Joint Surg [Am]* 1992;74:270.

+ 62. Smith M, Emery S, Dudley A, et al. Vertebral Artery Injury during Anterior Decompression of the Cervical Spine—A Retrospective Review of Ten Patients. *J Bone Joint Surg Br* 1993;75:410.

! 63. Vaccarro A, Ring D, Scuderi G, Garfin S. Vertebral Artery Location in Relation to Vertebral Body as Determined by Two-Dimensional Computed Analysis Evaluation. *Spine* 1994;19:2637.

+ 64. Wada E, Ohmura M, Yonenobu K. Intramedullary Changes of the Spinal Cord in Cervical Myelopathy. *Spine* 1995;20:2226.

+ 65. Waldman S. Complications of Cervical Epidural Nerve Blocks with Steroids: A Prospective Study of 790 Consecutive Blocks. *Reg Anesth* 1989;14:149.

* 66. White W, Southwick W, Deponte R. Relief of Pain by Anterior Cervical Spine Fusion for Spondylosis. *J Bone Joint Surg [Am]* 1973;55:525.

# 67. Whitecloud T. Complications of Anterior Cervical Fusion. *Instr Course Lect* 1978;30:223.

+ 68. Whitecloud T, Seago R. Cervical Discogenic Syndrome: Results of Operative Intervention in Patients with Positive Discography. *Spine* 1987;12:313.

+ 69. Williams J, Allen M, Harkess J. Late Results of Cervical Discectomy and Interbody Fusion: Some Factors Influencing Results. *J Bone Joint Surg [Am]* 1986;50:277.

+ 70. Wilson CUH. Postoperative Epidural Hematoma as a Complication of Anterior Cervical Discectomy. *J Neurosurg* 1978;49:288.

+ 71. Yamamoto I, Ikeda A, Shibuya R, et al. Clinical Long Term Results of Anterior Cervical Discectomy without Interbody Fusion for Cervical Disc Disease. *Spine* 1991;16:272.

+ 72. Yanagi T, Yamamura K, Ando K, Sobve I. Ossification of the Posterior Longitudinal Ligament of the Cervical Spine. *Clin Neurol* 1967;7:727.

+ 73. Yang K, Lu X, Cai Q, et al. Cervical Spondylotic Myelopathy Treated by Anterior Multilevel Decompression and Fusion. *Clin Orthop* 1987;221:161.

+ 74. Young W, Rosenwasser R. An Early Comparative Analysis of the Use of Fibular Allograft versus Autograft Iliac Crest Graft for Interbody Fusion after Anterior Cervical Discectomy. *Spine* 1993;18:1123.

+ 75. Zdeblick T, Bohlman H. Cervical Kyphosis and Myelopathy. Treatment by Anterior Corpectomy and Bone Grafting. *J Bone Joint Surg [Am]* 1989;71:170.

! 76. Zdeblick T, Cooke M, Wilson D, et al. Anterior Cervical Discectomy, Fusion, and Plating—A Comparative Animal Study. *Spine* 1993;18:1974.

+ 77. Zdeblick T, Ducker T. The Use of Freeze-dried Allograft Bone for Anterior Cervical Fusions. *Spine* 1991;16:726.

! 78. Zdeblick T, Zou D, Warden K, et al. Cervical Stability after Foraminotomy: A Biomechanical In Vitro Analysis. *J Bone Joint Surg [Am]* 1992;74:22.

+ 79. Zhang Z, Yin H, Yang K, et al. Anterior Intervertebral Disc Excision and Bone Grafting in Cervical Spondylotic Myelopathy. *Spine* 1983;8:16.

# CHAPTER 144

# LUMBAR DISC HERNIATION

*Dan M. Spengler*

**D. M. Spengler:** Vanderbilt University Medical Center, Department of Orthopaedics, Nashville, Tennessee, 37232.

Etiology of Lumbar Herniation
Natural History
Assessment and Diagnosis
Nonoperative Management
Author's Perspective
Surgical Techniques
Far Lateral and Intraforaminal Discs
Postoperative Care and Rehabilitation
Pitfalls and Complications
Chapter References

This chapter focuses on the evaluation and management of the patient with low back pain or sciatica, or both, that results from a herniation of a lumbar disc. The gold standard technique using open lumbar discectomy with loupe magnification is presented. In addition, the technical options for removing a lateral extraforaminal disc herniation are also discussed, as are pitfalls and complications. The most important concern regarding the management of lumbar disc herniation is selection of the appropriate patient for surgery than it is the technique for removal, assuming that a competent surgeon performs an adequate decompression.

## ETIOLOGY OF LUMBAR HERNIATION

This is a multifactoral problem and we still do not understand the precise cause for lumbar disc herniation in any given patient. Why is it that one person develops a lumbar disc herniation and another person does not? Patients with lumbar disc herniations are commonly seen in clinical practice. Fortunately, the majority of these patients respond to nonoperative management and do not require surgical removal of the disc. The reason for this improvement remains elusive, although recent work by Haro et al. (6) suggests that a local inflammatory process in the epidural space may stimulate host macrophages to resorb the displaced disc tissue.

From a biomedical perspective, Farfan (4) has shown that lumbar disc herniation may be reflective of high stresses at the posterolateral region of the disc secondary to torsion. These high loads cause fatigue failure of the annulus fibrosis that enables the inner nucleus pulposus to penetrate the laminations of the annulus gradually until a herniation occurs (4). Because the region of the disc with the highest torsional stresses is adjacent to the nerve root, these posterolateral herniations nearly always affect the exiting root or the central thecal sac. Less commonly, the disc may protrude into the extraforaminal area and produce compromise of the more proximal exiting root (e.g., L-4 for a lateral L4–L5 herniation).

Many authors have examined various factors that may represent predictors or risk factors for a lumbar disc herniation (2,3,9,15,16 and 17). The factors that seem to emerge as possibly being predictive include tall men, heavy women, individuals with a small spinal canal, and those who work in an environment with considerable vibration, such as that of airplane pilots and heavy equipment operators (2).

## NATURAL HISTORY

In a controlled, prospective long-term study, Weber (20) randomized 126 patients between surgical and nonsurgical treatments. At 1 year, those in the surgical group had fewer pain complaints. At 4 years, there was no statistically significant difference between the two groups. Weber was not a surgeon, and he had no bias toward the efficacy of surgery. One can conclude that surgical intervention should be limited to patients with a significant neurologic deficit or to those patients who are unable to engage in the lifestyle they desire because of sciatica. Weber (20) also demonstrated that less than 2% of the patients in both groups remained symptomatic at the end of 10 years.

## ASSESSMENT AND DIAGNOSIS

In patients with the acute onset of sciatica, perform a general history and physical examination. If no findings are identified that suggest another disease process, and the history and physical exam are consistent with a lumbar disc herniation without major neurologic compromise, initiate nonoperative treatment without imaging studies. Many patients improve rapidly and do not require further diagnostic testing. Those patients who do not improve within 30 days and who wish a prompt resolution to their problem warrant a thorough assessment. Plain radiographs with an anteroposterior (AP) and lateral flexion-extension views are useful to document hypermobility patterns or any spinal deformity. Obtain an magnetic resonance imaging (MRI) scan to characterize any disc pathology, localize any herniation, and exclude other conditions such as a spinal cord tumor or tethered cord. If the MRI reveals herniations at numerous disc levels, or if the patient has a contraindication to MRI (e.g., claustrophobia, intracranial vascular clips), obtain a computed tomography (CT) scan or myelogram.

I also request my patients to complete a pain drawing to evaluate the psychological characteristics of the patient. The pain drawing has been shown to correlate well with more formalized psychological testing (13). Psychological factors have been shown to be important predictors of outcome and, therefore, are of value to the surgeon (19).

I continue to formulate my surgical recommendation for patients by using the objective patient evaluation system (OPES) (19) (Table 144.1). If a patient has less than 50 points on this system, I recommend nonoperative management. More recently, we have found that even patients who have lumbar disc herniation with more than 50 points on the OPES will not necessarily achieve a “good outcome,” as we previously reported (11). If the patient has engaged an attorney to assist with a compensation claim or if the patient has an attorney who is involved in a civil claim, such as for a car accident, the likelihood for a good clinical outcome drops approximately 30% (11).

| Category | Maximum points allowed for category | Points assigned to patient |
|---|---|---|
| I. Neurologic signs | 17 | |
| Consistent evidence associated with positive results on EMG | | 15 |
| Normal EMG | | 10 |
| • Atrophy more than 2 cm | | 10 |
| • Absent or asymmetric reflex | | |
| Patients younger than 50 years of age (add 5 points if EMG results are positive) | | 10 |
| Patients older than 50 years of age (add 10 points if EMG results are positive) | | 10 |
| • No clinical signs: positive findings on EMG | | 15 |
| II. Sciatic stretch signs | 15 | |
| • Positive crossed straight leg-raising sign | | 20 |
| • Pelvic tilt (pelvic list) | | 15 |
| • Deadfulness of the lumbar paravertebral muscles with motion | | 15 |
| • Positive ipsilateral straight-leg raising | | 5 |
| III. Personality factors (MMPI Scores) | 15 | |
| • Normal (includes depression) | | 15 |
| • Abnormal (hypochondriasis/hysteria) | | 10 |
| • Elevated hysteria (score than 1 SD and less than 3 SD) | | 10 |
| • Conversion reaction or hysteria (more than 3 SD) | | 0 |
| IV. Lumbar myelography/CT scan/MRI | 20 | |
| • Positive results that correlate with clinical findings | | 25 |
| • Equivocal scans (not conclusive) | | 10 |
| • Positive results, but no correlation with clinical findings (includes spinal stenosis) | | 0 |
| • Normal | | 0 |
| Total | 100 | |

Adapted from Spengler DM, Freeman D, Fisher Schwim/Ser Lumbar Discectomy. Spine 1979;4:139, with permission.
EMG, Electromyogram; MMPI, Minnesota multiphasic personality inventory; SD, standard deviation; CT, computed tomography.

***Table 144.1. Objective Patient Evaluation System***

Patients who present with profound neurologic deficits, such as complete foot drop or cauda equina syndrome, require prompt imaging studies and early surgical decompression. These patients will not be discussed in this chapter because the focus here is on elective lumbar discectomy.

## NONOPERATIVE MANAGEMENT

In approaching patients with lumbar disc herniations, it is imperative to formulate a good nonoperative treatment plan. The initial goal is to control symptoms. Once symptoms are controlled, start an activation program. Such a program should include both an aerobic conditioning component and trunk muscle strengthening. In the majority of patients, symptoms can be controlled with nonsteroidal anti-inflammatory drugs (NSAIDs), acetaminophen (Tylenol), or salicylates. Narcotic medications are occasionally necessary in the first few days of the acute phase, but do not use narcotics for long-term pain control. Steroid dose packs have not been shown to be effective in a controlled study (5). Bed rest may be useful for 1 to 2 days but no longer. As the patient improves, implement a self-guided or supervised physical therapy program to enhance aerobic activity and to improve trunk strength. I prefer resistive exercise equipment such as Cybex, Nautilus, and therabands to strengthen both trunk flexors and extensors. Limit range of motion to 30° of flexion and 30° of extension if resistive equipment is used. If the patient demonstrates good progress, he or she can resume full activities at approximately 3 months after onset, assuming that there is full compliance with an activation program.

Although I do use epidural injections in selected patients with back or radicular pain, I avoid these injections in a patient with lumbar disc herniation, especially if a neural deficit is present. No prospective study has demonstrated success with the use of epidural injections in patients with a lumbar disc herniation.

## AUTHOR'S PERSPECTIVE

My indications for lumbar discectomy are based on the OPES (Table 144.1) (19). I recommend an elective discectomy only if the patient has failed to respond to a minimum of 30 days of nonoperative management. The patient must demonstrate that his or her quality of life is sufficiently impaired to warrant an elective spinal procedure. Finally, the patient must have a minimum of 50 points on the OPES (19). The technique that I select for surgery has nothing to do with the indications. Once I am comfortable that the patient understands the diagnosis and alternate treatment options, I select the optimal procedure for the patient based on the preoperative imaging studies as well as my knowledge and experience.

I believe that the gold standard surgical procedure for patient management remains open laminotomy with discectomy using loupe magnification (7,16). I perform the approach unilaterally if the symptoms are unilateral. If the patient has a central herniation with bilateral symptoms, I use a bilateral approach with bilateral removal of the disc nucleus. If a massive extruded disc is apparent on imaging studies, a hemilaminectomy may be necessary to provide sufficient longitudinal decompression to be able to safely mobilize the affected nerve root or thecal sac.

In the patient who demonstrates a far lateral or extraforaminal disc herniation, there are two options. An intervening hemilaminectomy may be performed so that the lateral herniation can be clearly visualized between the exiting nerve root above and the exiting nerve root below (18). Thus, for a far lateral disc herniation at L4–L5, expose both the L-4 and the L-5 nerve roots. Some surgeons prefer an extraforaminal approach (21,22). In this approach, make an incision lateral to the midline in the region of the transverse processes and facet joints. Carry the dissection through the intertransverse muscles and ligament to expose the lateral disc and exiting nerve root. Gain adequate exposure to understand the pathologic process clearly because the nerve root may be displaced from the normal course (3).

Microdiscectomy has been touted by several authors, most notably McCulloch and Young (12), who have written an entire text dealing with the nuances of this technique. Although lumbar microdiscectomy remains an appropriate technique to remove a lumbar disc herniation, I continue to prefer the open laminectomy approach with loupe magnification. Potential benefits of lumbar microdiscectomy would include a smaller incision, more focused lighting, and not wearing loupes and a fiberoptic headlight. Disadvantages include a higher incidence of dural tears and a more limited exposure, which might contribute to overlooking foraminal stenosis. Length of stay, blood loss, and time to full recovery are not different between the two procedures. I have no objection to these techniques but prefer the open-loupe technique. Our patients do not require blood transfusions. Our average hospital stay has been reduced to a 23-hour admission for the majority of patients with primary lumbar disc herniations.

Percutaneous techniques for lumbar disc removal are of interest and deserve our continued study to determine their usefulness once more clinical outcome studies are reported by noninventors. Kambin and Zhou (8) have demonstrated the clinical feasibility of a percutaneous approach by being able to remove the herniated portion of the disc and visually freeing the nerve root. This was a clear advance over the original automated percutaneous approach, which removed the central disc without addressing the posterolateral herniation. Revel et al. (14) demonstrated automated percutaneous lumbar discectomy to be ineffective in a randomized clinical trial. Treatment was considered successful in 61% of the 72 patients in the chymopapain group, with 44% of the 69 patients in the percutaneous discectomy group. At 1 year, overall success rates were 66% in the chemonucleolysis group and 37% in the automated percutaneous group. Within 6 months of treatment, 7% of the patients in the chemonucleolysis group and 33% in the discectomy group underwent subsequent open surgery. Although complication rates were low, 42% of the chemonucleolysis group continued to complain of significant low back pain.

More recently, Foley and Smith (4a) have described the MicroEndoscopic Discectomy (MED) system, which seems appropriately designed for patients with a soft herniation in close relationship to the nerve root. The visualization and lighting are superb. Before widespread endorsement, however, further clinical study is required to ascertain the indications, contraindications, and complications.

### HINTS AND TRICKS

The extent of the exposure depends on a number of factors: patient size, size and location of the lumbar herniation, and patient age. For a patient who is in excellent health and good physical condition, I recommend a unilateral approach. Place a small vertical incision over the appropriate vertebral interspace and perform only unilateral paraspinous stripping. Another option is to strip the paraspinal muscles bilaterally but to perform only a unilateral laminotomy. An older patient with significant degenerative changes may require bilateral stripping of the paraspinal muscles in addition to partial resection of the adjacent spinous processes. A patient with a large herniation and a neurologic deficit may require bilateral paraspinous stripping plus a partial or complete laminectomy to gain sufficient visualization to safely remove the herniation without incurring additional neurologic injury. No study has shown any adverse outcomes with a more generous exposure, so I believe that it is always better to err on the side of too generous rather than too small an approach. Greater retraction may be required when attempting to remove a large disc herniation through a small exposure. The technique that is illustrated describes a more generous exposure to illustrate better the anatomic details for an axillary lumbar disc herniation. A range of options exists regarding the extent of the exposure, depending on the above-mentioned parameters.

Chemonucleolysis with chymopapain continues to be used sparingly in various centers around the world, but few centers employ this technique in the United States. Although the concept makes some sense, the enzyme uses the central nucleus as the primary substrate without necessarily affecting the protruded portion of the disc. In addition, an enzymatic reaction is difficult to standardize with a set dosage because the composition of the substrate varies widely among patients. For example, the ratio of collagen to nucleus pulposus varies considerably among different age groups. Finally, as noted in the Rand (14) study, only 66% of the patients improved using chymopapain as compared with 85% to 90% in open discectomy (19).

Chemonucleolysis with chymopapain continues to be used sparingly in various centers around the world, but few centers employ this technique in the United States. Although the concept makes some sense, the enzyme uses the central nucleus as the primary substrate without necessarily affecting the protruded portion of the disc. In addition, an enzymatic reaction is difficult to standardize with a set dosage because the composition of the substrate varies widely among patients. For example, the ratio of collagen to nucleus pulposus varies considerably among different age groups. Finally, as noted in the Rand (14) study, only 66% of the patients improved using chymopapain as compared with 85% to 90% in open discectomy (19).

## SURGICAL TECHNIQUES

I perform all lumbar disc procedures under general inhalation anesthesia. Once anesthesia has been administered, place the patient prone on a Jackson table with slight hip flexion. This table enhances intraoperative positioning by accommodating a wide range of patient sizes. The abdominal viscera hang free without pressure on the venous plexus. The knees are well supported, and the lumbar spine can be flexed adequately. Transient paresthesias in the lateral femoral cutaneous nerve distribution are common postoperatively. In addition, some patients complain of mild postoperative discomfort over the greater trochanter. To prevent irritation of the brachial plexus, the arms must not be elevated excessively in relation to the trunk.

As an example, I describe the approach to the right L4–L5 disc level for the treatment of L-5 radiculopathy.

- Once the patient is properly positioned and carefully checked for pressure areas, especially the eyes, prepare and drape the lower back in sterile fashion.
- Palpate the iliac crests to locate the suspected L4–L5 level.
- Compare the clinically observed level of the iliac crests with preoperative radiographs, and label the level with a marking pencil.
- Make a vertical midline incision over the appropriate spinous processes.

- After the skin incision is made, complete the remaining portion of the dissection to the bony lamina using electrocautery.
- Extend the dissection to the lumbodorsal fascia. Identify the spinous processes of L-4 and L-5, and use the cautery unit to incise the fascia directly over the spinous processes. Use pickups to apply tension or a Cobb elevator as a gentle retractor.
- Dissect the fascia away from the spinous processes of L4–L5 and the inferior portion of L-3. By using Cobb elevators, carefully strip the paraspinous muscles from the spinous process to the lamina.
- Take care to maintain a subperiosteal approach. Blood loss is markedly reduced by avoiding the muscle envelope.
- Once the periosteum is stripped, insert a self-retaining retractor. Irrigate the wound and clearly identify the interlaminar space of L4–L5.
- Place a towel clip through a spinous process, and obtain a lateral radiograph to confirm the level.

- Once you are satisfied that you are operating at the proper level, continue dissection by partially resecting the inferior portion of the L-4 spinous process and the superior portion of the L-5 spinous process:
- Examine the interlaminar space. With a Penfield 1 elevator, strip the ligamentum flavum from the inferior and anterior surface of the lamina of L-4 (Fig. 144.1).

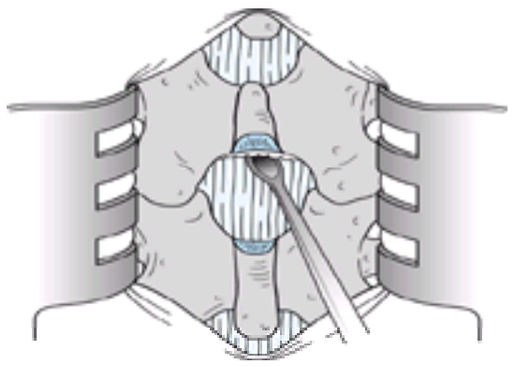

***Figure 144.1.*** Use a Penfield 1 elevator or curved curet to remove the ligamentum flavum from the anteroinferior surface of the lamina of L4.

- Use a Harper 45 rongeur to excise part of the middle portion of the L-4 lamina (Fig. 144.2).

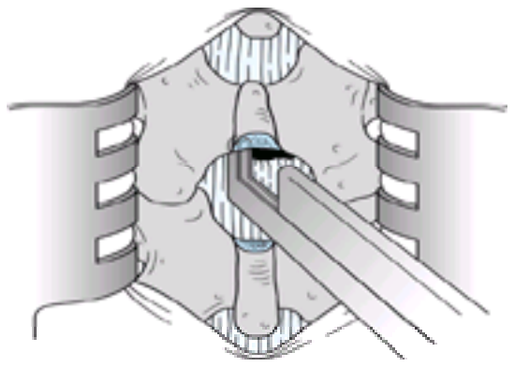

***Figure 144.2.*** Use an upbiting rongeur with a 45° angle to resect additional bone in the midline from the inferior portion of the L-4 lamina. Resect a section of bone that is approximately 2 to 3 mm in length superior to the midline raphe of the ligamentum flavum.

- Carry the dissection cephalad until the midline raphe of the ligamentum flavum can be identified.
- Insert a Penfield 3 elevator in the midline from proximal to distal immediately anterior to the ligamentum flavum (Fig. 144.3). Using a #15 blade knife, divide the ligamentum flavum in the midline.

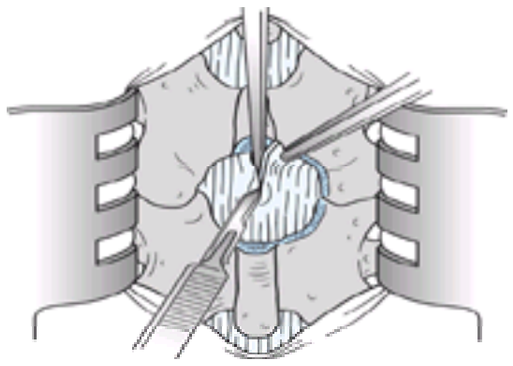

***Figure 144.3.*** Pass a Penfield 3 elevator from proximal to distal, and divide the ligamentum flavum on top of the elevator to minimize the possibility of injury to the dura.

- Carry the dissection laterally toward the lateral recess, again using the Penfield 1 or Penfield 3 elevator to protect the underlying dura (Fig. 144.4). Dissection can be accomplished using either a scalpel, curets, or a rongeur with a 45° angle.

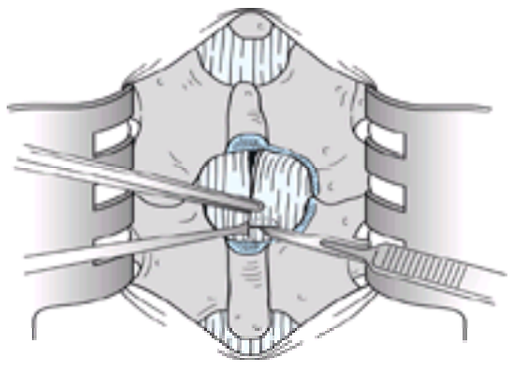

***Figure 144.4.*** After the midline division of the ligamentum flavum, use a Penfield 1 or 3 elevator to protect the contents of the spinal canal while the flavum is resected further using a #15 blade scalpel. Other options are to use a small curet or to elevate the flavum and remove it with an upbiting rongeur with a 45° angle.

- Once the bulk of the ligamentum flavum has been removed, examine the epidural fat and dura to determine the degree of lateral wall dissection necessary to identify and retract the displaced nerve root safely.
- In this chapter, I have chosen to depict a less common form of disc herniation to emphasize the pitfalls of root injury (Fig. 144.5). When the disc herniation is medial to the root, the lateral portion of the dura may be misinterpreted as being the lateral border of the nerve root. Such a misinterpretation can result in division of the nerve root or at least injury to the nerve root. Take extreme care to identify the nerve root.

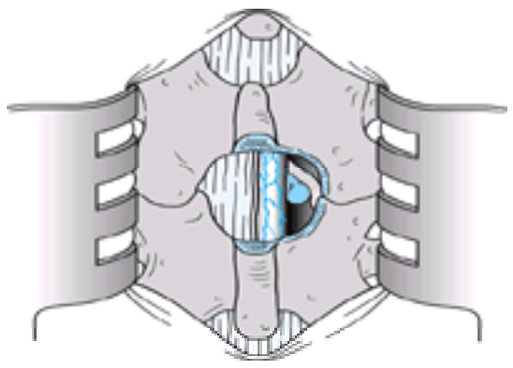

***Figure 144.5.*** Expose the contents of the vertebral canal after resection of the ligamentum flavum from the right side and after lateral wall resection using an upbiting rongeur with a 45° angle. A disc herniation medial to the nerve root was illustrated intentionally to emphasize the point that the surgeon can mistake the lateral border of the dura for the lateral border of the nerve root. The nerve root must be clearly visualized.

- Resection of the lateral wall of the spinal canal using a rongeur with a 45° angle is necessary in most cases.
- Once the nerve root is identified and the disc herniation is visualized, remove a portion of the herniation. Then medially displace the root and excise the remaining portion of the displaced disc (Fig. 144.6).

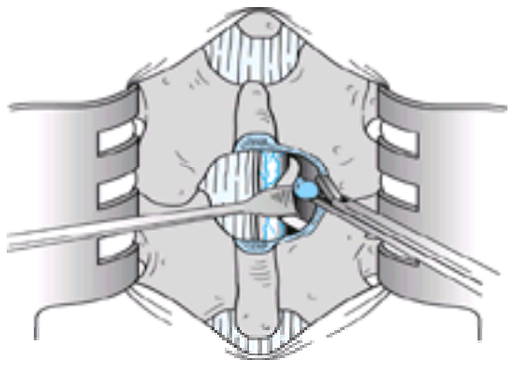

***Figure 144.6.*** Gently elevate the nerve root with a Freer elevator and a Penfield 4 elevator, and retract it medially over the displaced disc tissue. A Love root retractor can be used as illustrated to displace the root dura medially. Then remove the extruded disc with a small pituitary rongeur.

- A disc herniation is categorized as being extruded when the annulus is disrupted, and the herniated portion of the disc is categorized as being protruded when the annulus is intact but eccentrically displaced. The term sequestered is applied to a free fragment of intervertebral disc lying in the spinal canal with no defect evident in the annulus fibrosus. Seventy-five percent of lumbar disc herniations are of the extruded variety, whereas sequestered disc fragments are far less common (less than 5%).
- Dissect from the medial portion of the dura laterally, using a Penfield 4 elevator in the dominant hand and a Freer elevator in the other hand. Take extreme care to identify the displaced nerve root. Use of surgical loupes with 2.5 magnification and a fiberoptic headlight is essential for optimal visualization in this operation. Once the nerve can be displaced medially, insert a Love root retractor to displace the nerve root and dura gently medially, so that the extruded disc herniation can be excised (Fig. 144.6). A sharp incision into the annulus is seldom necessary because the pseudomembrane overlying an extruded disc can nearly always be dissected using a Penfield 4 elevator. In protruded disc herniation, however, the annulus must be incised.
- Once the disc has been removed, free the nerve root of tension and carefully inspect the neural foramina. The nerve root should be able to be displaced at least 1 cm medially (Fig. 144.7).

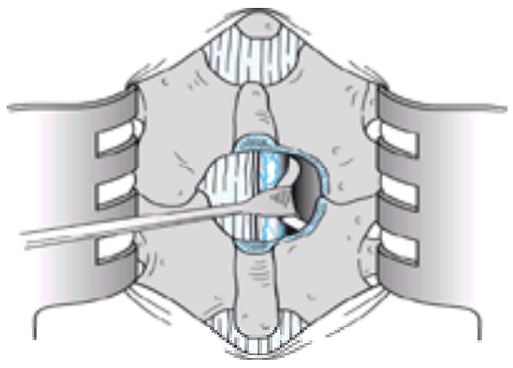

***Figure 144.7.*** After disc removal, it should be easy to displace the involved nerve root 1 cm medially. Should the root remain fixed, additional exploration of the foramina and the vertebral canal is necessary.

- Take care to ensure that no disc material is present between the annulus and the posterior longitudinal ligament.
- Once the disc has been excised, irrigate the wound and place an interposition membrane of Gelfoam or fat over the laminotomy. At present, I prefer to use Gelfoam (Fig. 144.8).

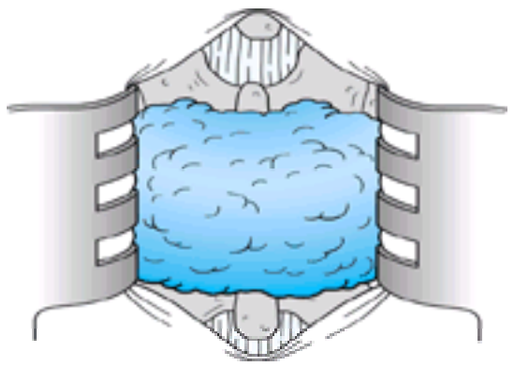

***Figure 144.8.*** An interposition membrane of Gelfoam; many surgeons prefer fat grafts.

- Then close the wound in layers. Use figure-8 sutures to achieve watertight closure of the fascia; I prefer subcuticular stitches for the skin.
- Apply a dry, sterile bandage.
- Gently straighten and rotate the patient onto the stretcher for extubation. Following extubation, take the patient to the recovery room. Blood transfusion is seldom necessary for a primary lumbar discectomy because blood loss usually averages less than 100 ml.

I have used this technique successfully for the past 15 years with no incidence of recurrent disc herniation over that reported by others (2%).

**FAR LATERAL AND INTRAFORAMINAL DISCS**

Far lateral and intraforaminal disc lesions cannot be easily removed through a midline approach (Fig. 144.9). Although taking down the entire facet is one alternative

advocated by some (1), the extraforaminal approach has been advocated by Wiltse (21,22). The proponents of going from the midline through the facets suggest that instability is not a subsequent problem and believe the nerve root can be more easily identified. Furthermore, they believe the surgeon can have greater confidence of complete decompression. However, many do not share this view.

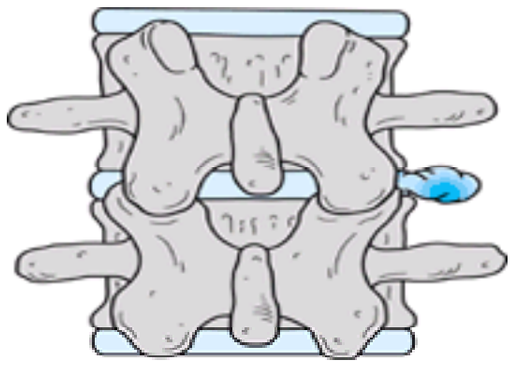

***Figure 144.9.*** Far lateral disc lesion. Note the relationship of the disc to the transverse processes.

The paramedian approach popularized by Wiltse (21,22) is a muscle-splitting approach.

- Make the incision 5 cm from the midline, followed by blunt dissection of the paraspinal muscles (Fig. 144.10).

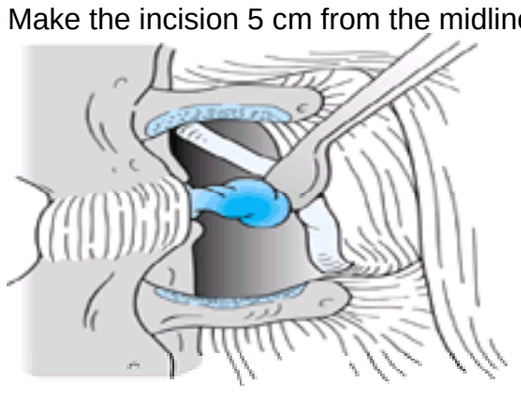

***Figure 144.10.*** The annulus is incised, the nerve root is retracted laterally, and the disc is removed with a pituitary rongeur.

- At this point, take radiographs to verify the level and clear the transverse processes of soft tissues.
- Enter the intertransverse ligaments and fascia with a knife or curet, then remove those structures between the transverse processes.
- Identify the nerve, which is usually 2 to 4 mm anterior to the fascia and directed at a 45° angle (Fig. 144.11).

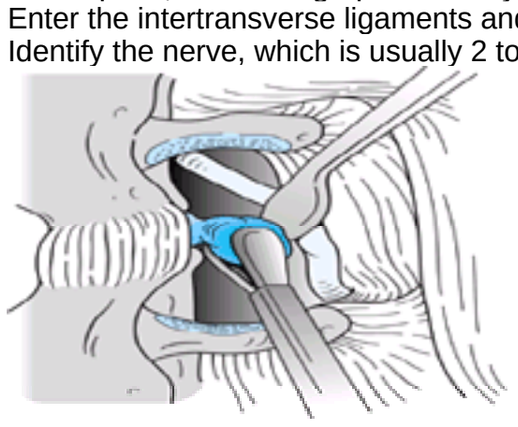

***Figure 144.11.*** Nerve identified and retracted at a 45° angle.

- Follow the nerve medially and identify the disc.
- If a free fragment is present, remove it. If only a bulge is present, incise the annulus and remove easily identifiable fragments. When the nerve root is easily mobile, sufficient disc has been removed.
- If the lesion is intraforaminal, take down a portion of the facet laterally to expose the nerve root canal. McCulloch and Young (12) point out, however, that this procedure is rarely necessary because of the the usual anatomic location of these lesions.
- Closure in both instances is routine, using a free fat graft or Gelfoam to cover the nerve.

## POSTOPERATIVE CARE AND REHABILITATION

In most patients, the preoperative radicular symptoms are improved when they awaken in the recovery room. On the evening of surgery, the patient is permitted to stand. By the first postoperative day, the patient is allowed to ambulate. If a dural leak occurs, ambulation is delayed by 24 to 48 hours. An abdominal binder is used for 4 weeks as partial protection for the patient. Rehabilitation is initiated 4 weeks after surgery and continued indefinitely. Patients are advised to maintain ideal weight and to develop good abdominal and trunk extensor muscle tone. Aerobic activity is encouraged and is initiated 4 weeks following surgery. Patients are discharged from follow-up approximately 12 months after surgery.

## PITFALLS AND COMPLICATIONS

The primary consideration is the selection of appropriate patients for surgical repair of lumbar disc herniations. The use of an objective method to accomplish this, as described in this chapter, will lessen the incidence of negative explorations (19), which is less than 2% in my experience. Although technical errors infrequently account for persistent pain after surgery, such errors invariably compromise the outcome. In a patient with established disc herniation, exploration at the wrong intervertebral level will not benefit the patient (10). Avoid this mistake by taking an intraoperative radiograph to confirm the appropriate level. If a disc herniation is not found, consider exploring additional levels after an intraoperative radiograph to confirm the proper level. Explorations at the wrong level are more common in patients who have transitional lumbar vertebrae.

Poor technique can prolong postoperative pain. Because excessive traction of neural tissue can cause irreversible nerve damage, use loupe magnification and fiberoptic lighting. These technologies have done much to minimize injury to neural tissue. Likewise, the use of an interpositional membrane (either free fat grafts or Gelfoam) at the completion of surgical exploration may minimize long-term perineural scar formation. Presently, newer antiadhesion barriers are being investigated in the United States. Experience in Europe has suggested that such barriers may lessen scarring within the spinal canal and perhaps even enhance clinical outcome. Additional evaluations are necessary to support these early but exciting assertions scientifically.

Technical errors can also result when the surgeon fails to detect a fragment of disc tissue that has migrated from the level of herniation, either cephalad in the canal or laterally into the extraforaminal area, trapping nerve roots (10). Because the only patients who should undergo surgery are those with objective findings, explore the canal thoroughly if no specific pathologic changes are encountered at the suspected level. Because the nerve root should be able to be displaced easily for a distance of approximately 1 cm medially, a nerve root that is tight in the canal and cannot be displaced suggests either a sequestered fragment along the nerve root or a stenotic lateral recess (10). Gently palpate the cauda equina to ensure that an intradural disc herniation is not present. Although a neoplasm involving the neural elements of the lumbar spine is always a possibility, it is distinctly uncommon. The most likely neoplastic lesion encountered in the lumbar vertebral canal is a

metastatic extradural lesion.

Hemostasis is essential in lumbar disc surgery. With proper technique, blood loss should be minimal, rarely exceeding 150 ml. Generally, epidural bleeding is easily controlled with bipolar coagulation, packing, or both.

Always be prepared to expand the surgical exposure. A straightfoward unilateral lumbar disc herniation rarely requires a complete laminectomy; however, when the surgical findings do not explain the preoperative symptoms, more open exposure is necessary.

Inadequate exposure can also present problems. Identify the dura and the nerve root, and expose the lateral wall adequately before examining the nerve root. Attempting to extract a large, extruded fragment through a small incision may traumatize the involved nerve root unnecessarily.

This point is especially important when dealing with a patient who presents with a cauda equina syndrome or a large central herniation without neurologic involvement. In these situations, remove the ligamentum flavum on both sides of the spine. Because the dura mater will be displaced posteriorly, a careful dissection is essential to avoid injury. A laminectomy may be the most appropriate exposure to ensure adequate visualization of the thecal sac and the exiting nerve roots on both sides. Often, the most appropriate beginning may be to perform an annulotomy and discectomy on the side with least herniation to debulk the herniation and to provide easier access to the root under maximal tension.

In patients older than 40 years of age, exploration of the neural canal must include a careful assessment of the lateral recess to interpret pathologic changes accurately. Performing a discectomy in a patient who also has lateral entrapment of the nerve root will not reduce the patient's symptoms. Careful probing of the neural foramina at the completion of the lumbar discectomy will locate the narrowing of the neural foramina. If stenosis of the lateral recess is the only manifestation, lumbar discectomy may not be necessary.

As with any surgical procedure, a list of potential complications that might occur would be exhaustive. Dural tears may occur during a lumbar discectomy. Such tears are more common in patients who undergo surgery for spinal stenosis or revision procedures. I recommend primary repair of dural tears with 5-0 Dermalon. Injuries to the iliac arteries and veins and viscera, including any structure from the appendix to the ureter, have been reported in association with a lumbar discectomy (15). Errors in diagnosis may occur. The patient may have symptoms suggestive of a lumbar disc herniation, which may, in fact, be related to intra-abdominal pathologic processes such as an aneurysm or a malignancy. Minimize these unusual complications by performing a thorough diagnostic assessment and decision analysis before a decision to operate on the spine. With proper patient selection and careful operative technique, lumbar disc surgery is highly successful and yields gratifying results for both the patient and the surgeon.

## CHAPTER REFERENCES

Each reference is categorized according to the following scheme: *, classic article; #, review article; !, basic research article; and +, clinical results/outcome study.


+ 1. Abdullah, AF, Wolber PG, Warfield JR, Gunadi IK. Surgical Management of Extreme Lateral Lumbar Disc Herniations: Review of 138 Cases. *Neurosurgery* 1988;22:648.

+ 2. Battie MC. *The Reliability of Physical Factors as Predictors of the Occurrence of Back Pain Reports.* Goteborg, 1989.

+ 3. Epstein JA. Discussion on Extreme Lateral Lumbar Disc Herniation. *J Spinal Disord* 1989;2:138.

# 4. Farfan H. *Mechanical Disorders of the Low Back.* Philadelphia: Lea and Febiger, 1973.

# 4a. Foley KT, Smith MM. Image-guided spine surgery. *Neurosurg Clin NAM* 1996;7:171.

+ 5. Haimonvic, IC, Beresford, HR. Dexamethasone Is Not Superior to Placebo for Treating Lumbosacral Radicular Pain. *Neurology* 1986;36:1593.

+ 6. Haro H, Shinomiya K, Komori H, et al. Unregulated Expression of Chemokines in Herniated Nucleus. *Spine* 1996;21:1647.

# 7. Holmes HE, Rothman RH. Technique of Lumbar Laminectomy. *Instr Course Lect* 1979;28:200.

+ 8. Kambin P, Zhou L Arthroscopic Discectomy of the Lumbar Spine. *Clin Orthop* 1997;337:49.

+ 9. Kane W. *Incidence of Lumbar Discectomy.* Presented at the 6th Annual Meeting of the International Society for the Study of the Lumbar Spine, New Orleans Louisiana, 1980.

+ 10. MacNab, I. Negative Disc Exploration. An Analysis of the Causes of Nerve Root Involvement in Sixty-eight Patients. *J Bone Joint Surg* 1971;53-A:891.

+ 11. Klekamp J, McCarty E, Spengler D. Results in Elective Lumbar Discectomy for Patients Involved in the Workers' Compensation System. *J Spinal Disord* 1998;II:277.

# 12. McCulloch J, Young P. *Essentials of Spinal Microsurgery.* Philadelphia: Lippincott-Raven, 1998.

+ 13. Ransford AO, Cairns D, Mooney V. The Pain Drawing as an Aid to the Psychological Evaluation of Patients with Low-back Pain. *Spine* 1976;1:127.

+ 14. Revel M, Payan C, Vallee C, et al. Automatic Percutaneous Discectomy versus Chemonucleolysis in the Treatment of Sciatica. *Spine* 1993;18:1.

+ 15. Spangfort EV The Lumbar Disc Herniation: A Computer-aided Analysis of 2,504 Operations. *Acta Orthop Scand* 1972;142(Suppl):1.

# 16. Spengler DM. Lumbar Discectomy. In: Chapman MW, ed. *Operative Orthopaedics,* Vol 3. Philadelphia: Lippincott, 1988:2055.

+ 17. Spengler DM, Freeman C, Westbrook R, Miller JW. Low Back Pain Following Multiple Lumbar Spine Procedures. *Spine* 1980;5:356.

# 18. Spengler DM, Frymoyer J., eds. Indications and Techniques. In: *The Adult Spine.* New York: Raven Press, 1991.

+ 19. Spengler, DM, Ouellette E, Battie M, Zeh J. Elective Discectomy for Herniation of a Lumbar Disc. *J Bone Joint Surg [Am]* 1990;72:230.

+ 20. Weber H. Lumbar Disc Herniation: A Controlled, Prospective Study with Ten Years of Observation. *Spine* 1983;8:131.

+ 21. Wiltse LL. Discussion on Extreme Lateral Lumbar Disc Herniation. *J Spinal Disord* 1989;2:134.

# 22. Wiltse LL, Watkins RG, Collis JC, eds. *Lumbar Discectomy and Laminectomy.* Rockville, MD: Aspen, 1987.

# CHAPTER 145

# DEGENERATIVE DISC DISEASE

*Eeric Truumees and Harry N. Herkowitz*

**E. Truumees and H. N. Herkowitz:** Section of Spinal Surgery, William Beaumont Hospital, Royal Oak, Michigan, 48073.

Pathophysiology and Pathomechanics
- Back Pain
- Nociception in the Disc
- Normal Age-Related Changes in the Disc
- Etiology
- Pathophysiology of DDD
- Types of DDD
- Natural History of DDD

Evaluation and Imaging
- History
- Physical Examination
- Plain Radiography
- Magnetic Resonance Imaging
- Discography
- Immobilization Techniques
- Psychological Assessment
- Summary of the Assessment Strategy

Nonoperative Treatment
Operative Treatment
- Posterolateral Spinal Fusion
- Anterior Lumbar Interbody Fusion
- Global Fusions
- Posterior Lumbar Interbody Fusion
- Summary of Treatment Options

Surgical Techniques
- Posterolateral Spinal Fusion
- Instrumented Posterior Spinal Fusion
- Sacral Fixation
- Posterior Lumbar Interbody Fusion
- Transforaminal Lumbar Interbody Fusion
- Rehabilitation and Postoperative Principles

Pitfalls and Complications
Authors' Perspective
Chapter References

The term *degenerative disc disease* (DDD) has been used to describe a wide variety of morphologic and radiographic changes in the adult lumbosacral spine. The North American Spine Society Consensus Committee on Nomenclature (16) defined disc degeneration as follows:

> Changes in a disc characterized by desiccation, fibrosis, or cleft formation in the nucleus; fissuring or mucinous degeneration of the annulus; defects and sclerosis of the endplates; and/or osteophytes at the vertebral apophysis.

The committee noted, “The term *degeneration* does not imply an etiology. Depending on age, degree, and type of change ... the changes of disc degeneration may be clinically insignificant.” Degenerative disc *disease,* on the other hand, is broadly defined as “a clinical syndrome characterized by manifestations of disc degeneration and symptoms thought to be related to those changes.” The authors point out that “causal connections between degenerative changes and clinical symptoms are often difficult clinical distinctions.”

In this chapter, *degenerative disc disease* refers to a continuum of nonradicular, mechanical pain disorders of presumably degenerative origin. Specifically excluded are those disc pathologies with neurologic impingement, such as disc displacement, spinal stenosis, and deforming degenerative conditions, such as degenerative scoliosis and spondylolisthesis.

Degenerative disc disease as a clinical entity remains controversial for five principal reasons:

1. A confusing and contradictory nomenclature
2. The similarity of “pathologic” changes to those of normal aging
3. The difficulty in accurately identifying the source of pain
4. Our limited understanding of the etiology and natural history of this process
5. Historically low success rates from surgical intervention for patients with DDD

## PATHOPHYSIOLOGY AND PATHOMECHANICS

### BACK PAIN

The social impact and suffering that results from back pain cannot be overestimated. With a lifetime incidence of 60% to 80%, low back pain (LBP) generates at least 15 million office visits per year (23). In fact, low back complaints are the leading compensable cause of injury in the workplace. In the United States, $24 billion a year is spent on the evaluation and direct management of patients with back pain. Indirect costs include work and productivity losses, and they account for an additional $27 billion annually (28).

Typically, back pain has a benign course. Within 3 months of the onset of symptoms, 95% of patients return to their previous employment. The 5% of patients with residual symptoms after 3 months, however, incur 85% of the costs. Moreover, the probability of returning to work falls with increasing duration of disability. After 2 years off work, less than 2% will return. Therefore, the early detection of those patients in whom LBP is more likely to become chronic would be of tremendous clinical and social benefit.

Adult LBP can arbitrarily be divided into five categories:

1. Referred back pain
2. LBP with radiculopathy or myelopathy
3. LBP with deformity, such as scoliosis, kyphosis, or spondylolisthesis
4. LBP in the context of fractures, tumors, or infections
5. Mechanical LBP without the features already noted

Before focusing on the spine and its related structures, consider other potential sources of referred pain. Included in the first LBP group are intra-abdominal and retroperitoneal pathologies such as abdominal aortic aneurysm and endometriosis. In groups 2 through 4, symptoms more readily correlate with evident spinal

pathology; as a result, treatment of these patients is satisfying and, overall, associated with good results.

The fifth group, patients with mechanical LBP only, includes several benign conditions, most likely representing ligamentous and muscular strain, mechanical stress from poor posture, or facet joint irritation. More chronic and disabling degenerative disc conditions, however, are included as well. In these patients, uncertain identification of the pain generator is associated with vague diagnostic groupings and failed surgical management. Included among these is DDD.

The multiple and synonymous terminology reflects an incomplete understanding of the pathophysiology and natural history of DDD. Moreover, because the "pathoanatomic" changes noted in DDD do not qualitatively differ from those of normal aging, the appropriateness of the appellation *disease* is intensely debated.

**NOCICEPTION IN THE DISC**

It is theorized that in DDD, pain arises in the disc. Historically, while the lumbar facets, posterior longitudinal ligament, dura, dorsal root ganglion, and myofascial structures of the lumbar spine have been recognized as pain-generating structures, the disc was felt to be aneural. More recently, however, nociceptive fibers have been identified in the outer annulus (22,30,47).

In one study, pain was generated by applying pressure to the disc during operations under local anesthesia (15). In another study, back pain resolved with procaine injection into the disc (75). Kuslich et al. (47) used a progressive local anesthesic technique to gauge pain response in different tissues in 193 consecutive laminectomies. Stimulation via blunt probe or unipolar electrocautery on the facet cartilage and synovium never caused pain. Also, no pain followed stimulation of the lamina, spinous process, ligamentum flavum, lumbar fascia, and uncompressed roots. Stimulation of the facet capsule, however, was associated with sharp, localized pain in 30%. This pain did not match the patient's preoperative symptoms. Stimulation of a compressed root resulted in sciatic pain in 79%. Finally, LBP similar to preoperative symptoms was noted in 70% of patients after stimulation of the posterior annulus or posterior longitudinal ligament (PLL). Local anesthetic injection obliterated the pain.

Nociceptive free nerve endings of the recurrent sinuvertebral nerve most likely carry these impulses. The sinuvertebral nerve, first described by Von Luschka, consists of a postganglionic derivative of rami communicantes that branches into segments. These segments ascend and descend into one or more adjacent levels (30,78) (Fig. 145.1). The branches accompany the venous plexus into the vertebral endplates and terminate in nociceptive free nerve endings in both the PLL and outer lamina of the annulus (51). In histometric studies, the outer third of the annulus has been found to contain nerve endings with nociceptive neurotransmitters [substance P, calcitonin, vasoactive intestinal peptide (VIP)] (54). Further, nociceptive fibers may *grow into* diseased discs (22). Theoretically, a small tear of the outer annulus may cause pain, even with a normal nucleus pulposus.

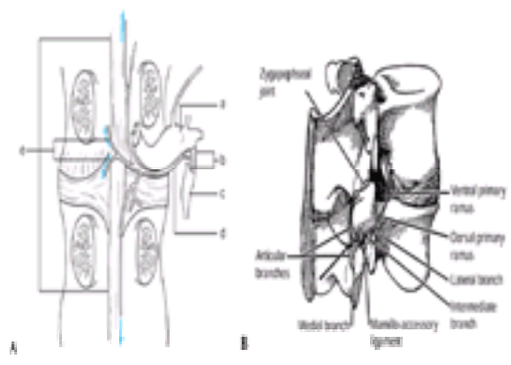

***Figure 145.1.*** The course of the sinuvertebral nerve (24,37). **A:** The sinuvertebral nerve shown on a cutaway drawing. **B:** The branches of the invertebral nerve shown on a lateral view of an intact spine. **a:** Dorsal root ganglion. **b:** Rami communicantes. **c:** Autonomic ganglion. **d:** Sinuvertebral nerve. **e:** Terminal branches of the nerve (may ascend or descend one or two vertebral levels).

Disc degeneration may indirectly stimulate pain receptors elsewhere. Disc height collapse may produce nociceptive signals from the facet mechanoreceptors by abnormal loading. Such mechanical derangement has been associated with abnormal intervertebral motion and has been termed *lumbar segmental instability.*

A degenerated disc may also indirectly cause pain by extrusion of nuclear material, a source of neural irritation and inflammation (54). The potential sources of pain in the lumbar spine are illustrated in Figure 145.2.

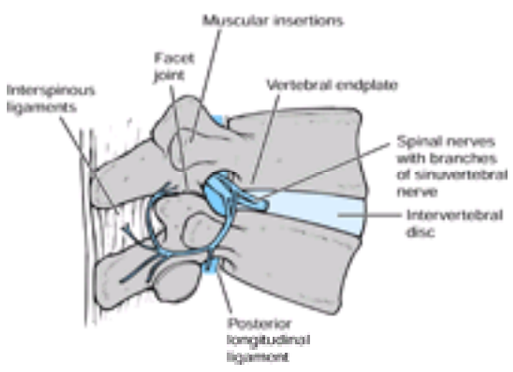


***Figure 145.2.*** Various potential pain generators in the lumbar spine.

**NORMAL AGE-RELATED CHANGES IN THE DISC**

During an individual's lifetime, intervertebral disc composition changes greatly. Given that certain degenerative phenomena may lead to pain, it is necessary to have a clear understanding of what changes constitute normal degeneration.

At birth, the disc surface area is 50% nucleus pulposus (NP) and 50% annulus. The notochordal cells of the NP are gradually replaced by chondrocytes throughout the early teenage years. This replacement is associated with annular thickening (Fig. 145.3). The demarcation between the annulus and the nucleus becomes less distinct. The older NP has a higher collagen content with more structured fibers. In these fibers, the ratio of type II to type I collagen increases (51).

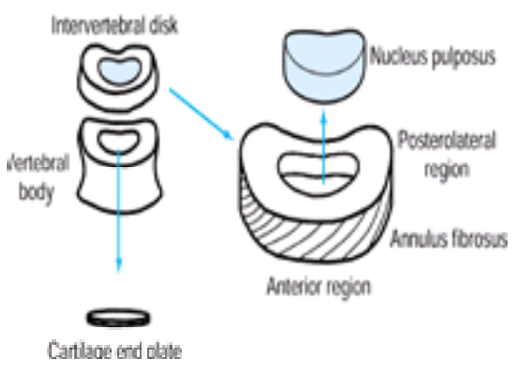

***Figure 145.3.*** Schematic of basic intervertebral disc anatomy.

Proteoglycan metabolism changes with age as well. Chondroitin-4-sulfate and chondroitin-6-sulfate concentrations decrease, and the ratio of keratin sulfate to chondroitin sulfate increases. Keratin sulfate has a smaller hydrophilic potential and a reduced tendency to form stable aggregates with hyaluronic acid. Dehydration, in turn, decreases the disc's resistance to axial loading (20).

As desiccation continues, clefts can be identified that originate in the central portion of the dehydrated NP. One hypothesis holds that these clefts eventually migrate toward the peripheral annulus and endplate and cause tears. Annular tears are classified by Vernon-Roberts (20) as peripheral, circumferential, and radiating. Circumferential and radiating tears are associated with degenerative changes in the endplate and NP.

With maturity, the vascular supply to the disc is obliterated. In adults, the disc is the largest avascular structure in the body. Thereafter, disc nutrition requires diffusion through the vertebral endplates (80%) and outer annulus (20%) (25).

Some authors have differentiated age related changes from pathological degeneration. One study found that altered collagen staining patterns and increases in lipofuscin and amyloid can be used to differentiate aged from degenerated discs (20). Further, this cycle of degeneration may be self-promoting, that is, small annular tears lead to further nuclear degeneration in animal models (47,54). Vascular ingrowth may also mark degenerated and herniated discal tissues (41).

At present, there is no clear boundary between these aging changes and disc degeneration. While some authors claim a quantitative if not qualitative difference between aged and degenerated discs, all discs degenerate with age. Miller et al. (55) reported evidence of disc degeneration by the age of 50 in 90% of 600 autopsy specimens. Holt (39) found evidence of disc degeneration on the plain radiographs of 80% of adults studied, although 53% had no history of LBP.

**ETIOLOGY**

While it appears that all intervertebral discs degenerate with age, the degree and rate of this degeneration vary significantly from individual to individual. The underlying reasons for this variability are only partly known.

The Hirsh theory of disc degeneration holds that insufficient nutrition, impaired waste transport, and traumatic mechanical factors combine with a genetic and hormonal proclivity to cause desiccation and annular tearing. Severe degeneration is associated with increased lactate metabolism, decreased pH, accumulation of proteolytic enzymes, and chondrocyte necrosis (Fig. 145.4) (37).

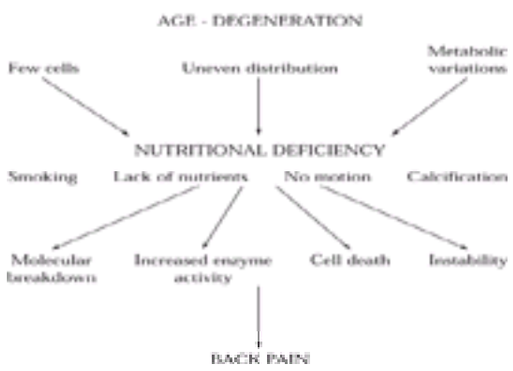


***Figure 145.4.*** The role of nutritional deficiency in the etiology of discogenic back pain. With advancing age, disc cells diminish in number and distribution and undergo metabolic variations. As a consequence, disc nutrition diminishes. These changes are accelerated by systemic factors such as overall nutritional status, smoking, motion, and endplate or disc calcification. Ultimately, cell death, increased enzyme activity, molecular breakdown, and instability ensue.

Various clinical factors have been implicated in precocious degeneration. Smoking and a familial tendency toward degeneration have long been established as contributing factors (68). Twins demonstrate similar degeneration patterns (3). In one study of 15-year-olds, LBP, decreased activity, and decreased spinal range of motion predicted later DDD (66). Anatomically, no association between DDD and facet tropism can be demonstrated (6). The endplate irregularities of thoracolumbar Scheuermann's disease, however, may be related to DDD (35).

**PATHOPHYSIOLOGY OF DDD**

If disc degeneration is a programmed, physiologic phenomenon influenced by heredity and environment, it is incumbent upon the clinician to ascertain when these changes constitute a disease. Benign age-related phenomena have been differentiated from pathologic phenomena on the basis of three factors: impaired function, structural changes, and an association with pain.

Yong-Hing and Kirkaldy-Willis (86) described a three-joint complex in the spinal column, with the disc anteriorly and the two facet joints posteriorly. They theorized that benign microscopic alterations progress to pathologic degeneration in stages. In this way, circumferential annular tears progress to radial tears. Radial tears, in turn, engender further disc degeneration or frank disc herniation. The ensuing loss of disc height alters facet joint mechanics, and facet cartilage disruption or destruction may take place. Coincidentally, the decrease in the intervertebral height causes buckling of the ligamentum flavum and facet overriding or enlargement. These changes may, singly or in combination, cause narrowing of the neuroforaminal and central canals. So, while disc degeneration manifests as mechanical LBP in some patients, others will experience neurologic claudication or radiculopathy from frank disc herniation (Fig. 145.5, Fig. 145.6).

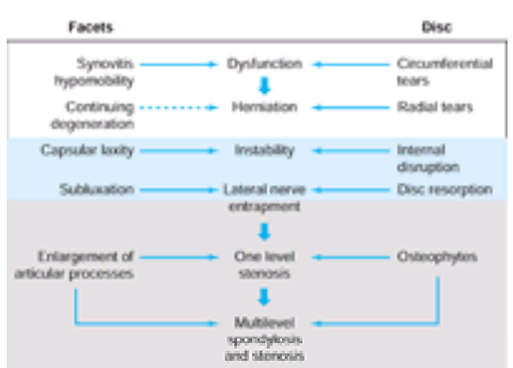


***Figure 145.5.*** The Kirkaldy-Willis (86) states of lumbar degeneration, including (left side) the events that occur in the facets and (right side) intervertebral discs and associated syndromes.

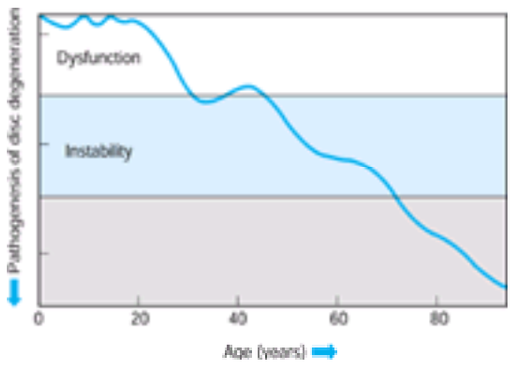


***Figure 145.6.*** The natural history of lumbar degeneration (Yong-Hing K, and Kirkaldy-Willis WH: The Pathophysiology of Disc degeneration of the Lumbar Spine. *Ortho Clin North Am* 1983;14:59).

Yong-Hing and Kirkaldy-Willis (86) then proposed three stages of degeneration of the intervertebral disc.

I. Microscopic alterations of disc consistent with aging
II. Increased spinal mobility
III. Stabilization of the functional spinal unit (discs anterior and facets posteriorly)

Vernon-Roberts (20) showed that many of these changes are present in nearly all middle-aged people and are not necessarily associated with back pain. Thus, the issue of when degenerative changes represent a disease remains unresolved. While data are lacking, it has been suggested that younger patients with relatively precocious disc degeneration do not tolerate these changes as well as older adults. Whether this perceived difference stems from higher functional demands or from a subtle difference in disc mechanics is not known. It is reasonable, however, to identify DDD as a chronic, mechanical LBP *syndrome* associated with changes in the structural and functional integrity of one or more intervertebral discs.

**TYPES OF DDD**

At present, DDD can be characterized by one of several associated terms, listed in Table 145.1. While some authors use these terms to refer to the same global discogenic pain syndrome, others view them as a means to differentiate among subgroups of patients. The divisiveness and misapplication of nomenclature further confuses any evidence-based appraisal of DDD, and its incidence, pathophysiology, and natural history.

| |
|---|
| Lumbar segmental instability |
| Degenerative disc disease |
| Black or dark disc disease |
| Discogenic back pain |
| Anterior column disease |
| Internal disc disruption |
| Isolated disc resorption |
| Lumbar spondylosis |

***Table 145.1. Named Discogenic Disorders***

Three subtypes may be identified as points in a continuum. First, *internal disc disruption* (IDD) refers to a painful annular tear in the absence of bony changes or disc height loss. As such, IDD must not be confused with disc protrusions, which are normal hydrodynamic findings (5).

Next, *lumbar spondylosis* (LS) refers to mechanical back pain in association with disc height loss, sclerosis, and osteophyte formation. LS is the most frequently described form of DDD, and it is the entity most authors are describing when they use the more global term *DDD*.

Finally, *lumbar segment instability* (LSI), which represents a progressive relaxation of facet capsules and ligamentous restraints, occurs in the context of chronically compromised disc biomechanics. White and Panjabi (83) define lumbar instability as more than 4.5 mm of translation, 15° to 25° of angular motion between adjacent segments on flexion–extension radiographs, or both (Fig. 145.7). It is not clear, however, that the chronic increase in intervertebral motion seen in degenerative lumbar diseases may be mechanically equated with traumatic spinal instability. Therefore, some authors classify this abnormality with degenerative spondylolisthesis and degenerative scoliosis, which have a similar pathogenesis. Others feel that all the subtypes of DDD represent a painful “microinstability” of the motion segment (48).

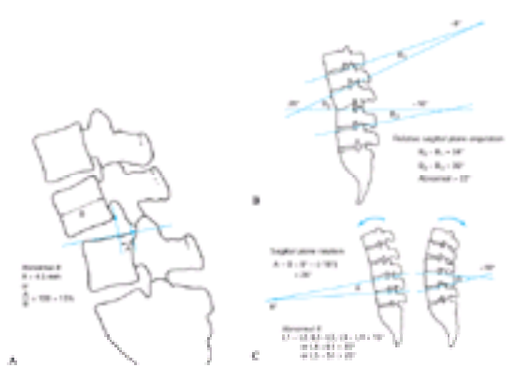

***Figure 145.7.*** **A:** The White and Panjabi (83) method for measuring sagittal plane translation. Greater than 4.5 mm (or 15% of vertebral body) of motion is considered abnormal. **B:** Method of measuring static sagittal plane angulation. Greater than 22° of relative angulation (i.e., angulation greater than that seen in the levels above and below) is considered abnormal. **C:** Method of measuring sagittal plane rotation on flexion–extension radiographs. Cobb measurements taken in extension are subtracted from those in extension. Abnormal values are greater than 15° at L1-2, L2-3, and L3-4, and greater than 20° at L4-5 and 25° at L5–S1.

**NATURAL HISTORY OF DDD**

The critical question of why most degenerated discs are asymptomatic remains to be answered. Even in those patients with degenerative changes, severe back pain, and positive discography, pain may spontaneously improve. In one series, 25 patients who had not had surgery were positive on a single-level discogram. When they were evaluated after an average of 4.9 years, 68% had improvement without surgery (70). Of the 32% who were unimproved, 66.7% had an underlying psychiatric diagnosis. In the absence of a more complete understanding of the natural history of this disorder, appropriate evaluation of surgical outcomes is extremely difficult.

In summary, while knowledge of the benign degeneration of the aging spine continues to grow, surprisingly little is known about disc degeneration as a disease process

(Table 145.2) (78).

| |
|---|
| Why are some people symptomatic and others are not? |
| What is the incidence and prevalence of disc degeneration as a disease? |
| Which disc level is the source of the problem in a given patient? |
| What is the natural history of disc disease in any given patient? |
| In which patients can the natural history of DDD can be reliably improved with surgical intervention? |

***Table 145.2. What We Do Not Know about Disc Degeneration as a Disease***

## EVALUATION AND IMAGING

### HISTORY

When evaluating a patient with chronic LBP, DDD remains a diagnosis of exclusion. A thorough history and physical examination are mandatory.

In patients with "red flags" such as very young or old age, nonmechanical pain, constitutional symptoms, and trauma, perform a thorough radiologic and serologic evaluation for infection, tumor, and fractures (Table 145.3). Other important considerations include intra-abdominal and intrapelvic pathology. Posterior penetrating ulcers, pancreatitis, renal disease, abdominal aortic aneurysm, and endometriosis are all known causes of severe, referred pain to the back.

| |
|---|
| Age <20 or >50 years |
| Progressive neurologic deficit |
| Gait disturbance, history of falls |
| Bowel or bladder difficulties |
| Cancer |
| Infection |
| Major trauma |
| Prior spine surgery |
| Immunocompromised status |
| History of intravenous drug abuse |
| Metabolic bone disease |
| Peripheral vascular disease |
| Genitourinary or gynecologic complaints |
| Nonmechanical pain pattern (worse when supine or at night) |
| Psychosocial overlay (e.g., depression, active legal proceedings) |
| Constitutional symptoms (malaise, fever, chills, weight loss) |

***Table 145.3. Historical Elements Requiring Thorough Evaluation ("Red Flags")***

Pay careful attention to historical clues as well as to significant social and psychological issues. Ask specific questions regarding drug and alcohol intake, mood, sleep disturbance, pending litigation, and job satisfaction.

In patients with pain of degenerative etiology, first exclude those with radicular or myelopathic signs and symptoms. Similarly, the evaluation of patients with significant thoracolumbar deformities such as scoliosis, hyperlordosis, and kyphosis is considered elsewhere (see Chapter 153, Chapter 155, Chapter 156, Chapter 159, Chapter 160 and Chapter 161). For example, spondylolisthesis, another disorder of genetic and environmental stress, is the most common structural abnormality in the adult spine (see Chapter 162). Spondylolisthesis is related to LBP in 5% of the population (21).

The evaluation of the remaining group of patients with isolated, mechanical LBP is challenging. The difficulty in identifying a specific pain generator accounts for the fact that only 15% of patients are given a definitive diagnosis. Physically and radiographically abnormal structures may not cause symptoms. On the other hand, grossly and radiographically normal structures may be associated with severe pain in certain individuals.

Muscular etiologies account for the vast majority of patients reporting acute LBP. Patients with myofascial pain are especially difficult to distinguish from those with "discogenic pain" when radiographic signs of disc degeneration are present. However, myofascial pain tends to have an acute onset and a relatively brief duration. The pain is localized to a specific paraspinal area, and muscle spasm is evident. In most cases, while some DDD patients identify a specific, traumatic event (such as bending, lifting, or twisting) with symptom onset, their pain is midline and does not resolve but rather worsens over time.

The pain described by patients with DDD is mechanical in that it is aggravated by activity, particularly flexion. Relative rest temporarily ameliorates symptoms. Patients with lumbar segmental instability may complain of a catch with flexion and extension (Fig. 145.8). DDD patients may also report having difficulty when getting up from a chair. In an attempt to splint the back, some will use upper extremity leverage, pressing their arms against their thighs, when arising.

***Figure 145.8.*** A suggested algorithm for the evaluation of discogenic back pain. *DDD,* degenerative disc disease; *F/E,* Flexion/Extension; *SX,* symptomatic.

Pain related to DDD may predate or postdate an episode of sciatica. Often, DDD patients report having had prior discectomy or chymopapain injections (20). Further, the disc collapse associated with LS may result in foraminal stenosis and mild radiculopathies (48). Other patients followed for axial spinal pain will later present with acute radicular complaints and imaging studies consistent with disc herniation. Diagnosis and treatment for these patients is discussed in Chapter 144.

Degenerative discs may be associated with referred, sclerotomal pain to the buttocks and posterior thigh. However, it is very difficult or impossible to localize the symptomatic disc level on the basis of history or physical exam alone.

### PHYSICAL EXAMINATION

The examination of DDD patients is generally nonspecific. These patients exhibit no point tenderness or paraspinal spasms. They often report pain or difficulty with flexion and rotation maneuvers of the spine, however. Normal neurologic findings including sensory, motor, and reflex exams are expected. Particular attention must be paid to Waddell's signs (Table 145.4) (79), which suggest psychological overlay.

| | |
|---|---|
| Tenderness: | pain at the tip of the tailbone; pain, numbness, or giving way of the whole leg; pain to light touch |
| Simulation: | pain with light axial loading of head or shoulders; pain with pelvic rotation through the hips; reproduction of pain with rolling of lumbar skin |
| Distraction: | no pain with a sitting straight-leg raise (SLR), pain with a supine SLR |
| Regional: | nonanatomic distributions of weakness or sensory changes (especially in a stocking distribution) |
| Overreaction: | moaning, trembling, collapsing, sweating, emergency admissions |

From Waddell G, McCullough JA, Kummel E, et al. Nonorganic Physical Signs in Low Back Pain. *Spine* 1980;5:117.

***Table 145.4. Waddell's Nonorganic Physical Signs***

Moreover, unexpected findings on physical examination such as anal sphincter laxity or major muscle weakness should be construed as red flags and investigated accordingly.

**PLAIN RADIOGRAPHY**

The ubiquity of painless LS limits the specificity of plain radiography in DDD. In the absence of red flags, radiographs are indicated only after a trial of symptomatic treatment. In patients failing to improve with these modalities, begin radiologic assessment with plain anteroposterior (AP) and lateral views of the lumbosacral spine. Oblique views and a lateral L5–S1 cone-down view are often helpful. The principal purpose of these studies in the early management of mechanical back pain is to exclude spondylolisthesis and the less benign entities mentioned previously.

Patients with internal disc derangement will have no plain radiographic changes. The cardinal findings of LS are endplate sclerosis and loss of disc space. Radiographs may also show a loss of lordosis, subluxations, vacuum phenomenon, and osteophytes (Fig. 145.9). Radiography, however, can be misleading: Frymoyer et al. (24) showed that signs suggestive of disc degeneration were present in 90% of adults studied, whereas 53% had no history of LBP (Table 145.5).

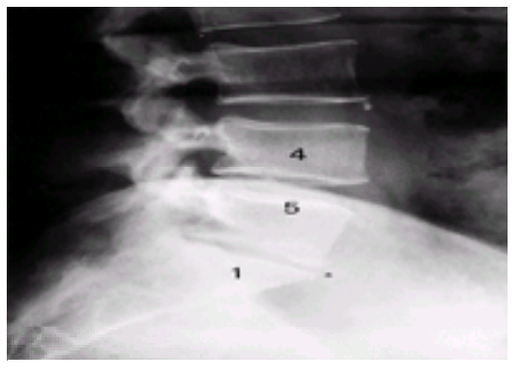


***Figure 145.9.*** Plain radiographic findings of DDD: disc space loss, endplate sclerosis, and osteophyte formation.

| *IDD* | *Lumbar spondylosis* | *Lumbar segmental instability* |
|---|---|---|
| None | Endplate sclerosis<br>Loss of disc space<br>Loss of lordosis<br>Vacuum phenomenon<br>Osteophytes | None, any, or all of those in lumbar spondylosis<br>Subluxations |

***Table 145.5. Plain Radiographic Findings of DDD***

It should be noted that the presence of nitrogen gas bubbles (the vacuum phenomenon) in degenerative discs probably excludes the diagnosis of discitis, as infection by gas-forming organisms are exceedingly rare.

In patients with normal findings on static radiography, obtain flexion–extension radiographs to exclude subtle instability patterns. Relatively subtly increased intervertebral motion can be associated with pain. In these patients, discography may be useful to establish a pain generator. Some authors assign no clinical importance to lumbar segmental motion (24,32).

Radionucleotide bone scans have only a minor role in the evaluation of disc degeneration by excluding other suspected pathologic processes, such as tumor, infection, or spondylolysis. Computed tomography (CT) may demonstrate degenerative changes in the lumbar spine, but is not particularly useful in the evaluation of patients with DDD.

**MAGNETIC RESONANCE IMAGING**

In the evaluation of DDD, magnetic resonance imaging (MRI) is the most commonly employed imaging modality. In that MRI can directly measure water content of the disc, it is the only imaging technique that can detect biochemical changes in the nucleus (56,61). The normal, hydrated NP has an increased proton signal on T2 images. With increasing desiccation, this signal blends with that of the surrounding annulus. With further degeneration, a dark, isointense signal may be seen on T2 (Fig. 145.10, Fig. 145.11). An increased T2 signal may be noted in some areas, where it is thought to represent free fluid in annular tears and fissures (87). Aprill and Bogduk (1) described a high-intensity zone (HIZ) representing a tear of the outer annulus. In their study, these HIZ lesions were associated with painful, concordant discography. Subsequent reports as to the significance of these lesions have been mixed (64).

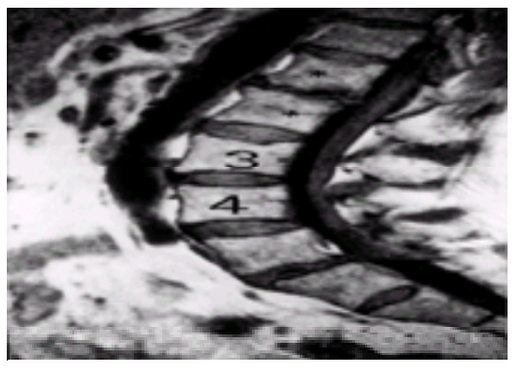


***Figure 145.10.*** Sagittal T1-weighted MRI depicting disc degeneration at L1–L2 with endplate sclerosis (*asterisk*).

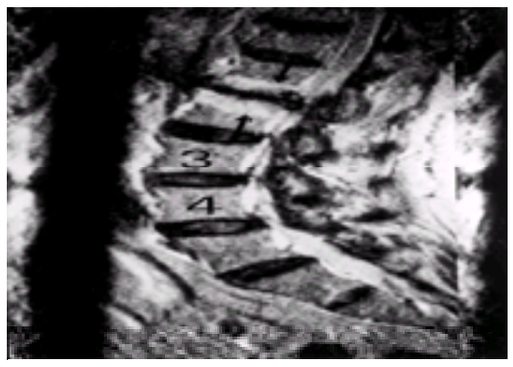


***Figure 145.11.*** Sagittal T2-weighted MRI depicting black disc at L1–L2 with typical endplate changes (*arrow*).

Aside from the discs themselves, changes in endplate morphology adjacent to degenerating discs may have clinical significance (56). These changes were first described by Modic et al. (57) and can be divided into three types. Type I reflects an acute disruption and fissuring of endplates, which leads to ingrowth of vascularized fibrous tissue into the adjacent vertebral body marrow. This tissue exhibits a diminished signal on T1 images and increased signal on T2 images.

In chronic degeneration, the hematopoietic (red) peridiscal marrow undergoes fatty degeneration. Here, a type II pattern is exhibited with an increased T1 and an isointense or slightly hyperintense T2 signal. While type II changes tend to remain stable, type I changes have been shown to develop into type II. Type III changes probably reflect extrinsic bone sclerosis as seen on plain radiographs. Dense bone in the vertebral endplates yields a hypointense signal on both T1 and T2 images (Table 145.6).

| | *MRI image* | | | |
|---|---|---|---|---|
| *Stage* | $T_1$ | $T_2$ | *Tissue* | *Clinical correlation* |
| I | D | I | Vascular fibrous tissue | Acute annular tearing, endplate fissure |
| II | I | D | Fatty replacement | Chronic marrow ol disuse |
| III | D | D | Endplate sclerosis | Chronic spondylosis |

D, decreased; I, increased; MRI, magnetic resonance imaging.
From Modic MT, Ross JS. Magnetic Resonance Imaging in the Evaluation of Low Back Pain. Orthop Clin North Am 1991;22:283.

***Table 145.6. Modic Changes***

Just as the pathologic changes of disc degeneration are likely to be a normal part of aging, the MRI findings associated with the changes described by Modic and Ross (56) frequently do not correlate with LBP. In 1990, Boden et al. (5) found that MRI evidence of degenerative discs was present in 34% of patients 20–29 years old, and in 93% of patients 60–80 years old.

**DISCOGRAPHY**

Although discography is controversial, it represents the only provocative method available to assess patients with a possible discogenic pain generator. In theory, fluid injected into the disc increases endplate pressures. These transferred pressures may cause pain (34). Abnormal pressure transmission may account for the small subset of patients with normal MRI findings and positive discography. Properly performed, discograms *may* be able to directly identify a cause-and-effect relationship between radiographic signs of degenerated discs and clinical symptoms of lumbar pain.

Morphologic information is available from the discogram or a postdiscography CT (Table 145.7, Fig. 145.12). Abnormal radiographic findings with leakage of dye were seen in 37% of an asymptomatic population, so the study is positive only if the radiographic changes correlate with a concordant pain response. A concordant response requires replication of the patient's usual pain with injection at the degenerated level, and no pain at adjacent, control levels (Table 145.8).

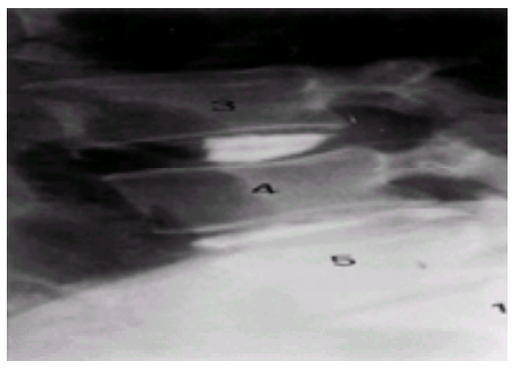

***Figure 145.12.*** Discography at the L3-4, L4-5, and L5–S1 interspaces. Note the normal appearance of the control L3-4 level and the abnormal morphology below.

| |
|---|
| Patient's pain response at the involved level |
| Pain response at control levels |
| Disc morphology |
| Disc pressure and injectant volume |

***Table 145.7. Information Available from Discography***

| |
|---|
| Nonirritating, radiopaque contrast |
| Nonsedated patients |
| Independent observer of pain response |
| Injection into both degenerated and one or two nondegenerated "control" levels |
| Paraspinal, not transdural, approach |

***Table 145.8. Key Elements of Discographic Technique***

In one large series, Holt (38), having found that a high percentage of previously asymptomatic volunteers had positive discography, considered the test unreliable. This study was later criticized by Simmons et al. (69), who noted that injections without fluoroscopic guidance often pressurize the sensitive annulus rather than the nucleus. Further, the contrast material used, diatrizoate meglumine, has been found to be irritating and painful. Later, the Holt study was repeated using modern techniques by Walsh et al. (80), who injected a nonionic, water-soluble contrast agent under fluoroscopic guidance. The study was considered positive only if the disc was radiographically abnormal and a concordant pain response reported. A false-positive rate of 0% with a specificity of 100% was noted in 10 asymptomatic volunteers.

Calhoun et al. (8) found that 89% of 137 patients with positive provocative discography had significant and sustained benefit from fusion at the indicated level. Of 20 patients fused without a positive discogram, only 52% enjoyed postoperative pain relief.

Given the overall controversy surrounding discography, it can be expected that recommendations regarding its role in patient assessment also vary. Some report that a negative MRI may miss clinically significant DDD (7). Others report that positive discography in the context of a negative MRI is associated with inferior results after fusion (27).

Schneiderman et al. (67) found a high correlation between MRI and discographic findings. They reported on 101 disc levels in 36 patients with LBP of longer than 2 months' duration. In each patient, both MRI and discography were performed and blindly reviewed by a neuroradiologist. MRI was accurate in predicting discographic disc morphology 99% of the time. Only one disc level with a normal MRI signal had an abnormal discogram. Of 49 levels with decreased signal on MRI, only two were normal on discogram. The authors found that concordant pain with discography was helpful in the assessment of abnormal discs identified by MRI, but they felt that discography was not indicated in the presence of a normal MRI. Simmons et al. (69), on the other hand, found only a 55% correlation between the tests. They wrote that discography is the only dynamic test available for disc evaluation and thus the only study that can determine which abnormal discs are truly symptomatic.

Horton and Daftari (40) found that, in many cases, MRI could not reliably predict or replace discography. They divided the MRI signal of lumbar discs into dark, white, and speckled patterns, and they characterized the posterior annulus as flat, bulged, or torn. Most dark or torn discs demonstrated positive discography, whereas white or flat discs were very likely to be negative on discography. The intermediate MRI patterns had uncertain correlation with discographic findings, however.

At present, we feel that discography should be performed only as a preoperative test in psychologically normal patients with positive MRI findings, and after aggressive, nonsurgical measures have failed. Discography is probably not warranted in patients with single-level changes. In patients with multilevel or equivocal MRI findings, we use a discogram to detect the symptomatic level.

**IMMOBILIZATION TECHNIQUES**

Various braces and supports have been recommended to provide pain relief in DDD (14,60,65). The underlying hypothesis is that bracing will simulate effects of fusion by restricting segmental motion. In general, such bracing is not justified, in that the braces most commonly recommended are unreliable in restricting lumbar spinal motion (17,65). Adequate immobilization of the lower lumbosacral spine requires a pantaloon brace.

**PSYCHOLOGICAL ASSESSMENT**

Ultimately, the treatment of DDD is directed only at pain, the perception of which is quite variable. Depression and anxiety are quite common in DDD patients and are associated with heightened pain perception (77). Historically, it has been difficult to establish whether the pain preceded the psychological disturbance. However, in a series of 200 patients with chronic back pain, 77% met the American Psychiatric Association's Diagnostic and Statistical Manual of mental disorders (DSM III-R) lifetime criteria for psychiatric illness, and 59% met criteria for current, active psychiatric illness (63). In this study, the authors concluded that psychiatric illness (particularly anxiety and substance abuse disorders) often preceded the onset of back pain.

Indications of somatic fixation on the Minnesota Multiphasic Personality Inventory (MMPI) include abnormal elevations of the hypochondriasis and hysteria scales, above that of the depression scale. On this inventory, somatic fixation tends to be predictive of poor surgical outcomes (84). Patients with low hypochondriasis and hysteria scores had 90% good to excellent results 1 year after surgery, while patients with higher scores had only a 10% rate of good to excellent results (84). Southwick and White (71) reported that patients in the latter category were more likely to have positive discograms at nondegenerated levels.

**SUMMARY OF THE ASSESSMENT STRATEGY**

While certain radiologic findings are consistent with disc degeneration, there are no findings pathognomonic for DDD. As in any degenerative condition of the spine, begin the evaluation with a complete history and physical exam. Pursue atypical pain and other red flags vigorously. Then, assuming limited findings on physical exam, commence further management with a rigorous nonoperative management regimen.

Only patients failing this management after a 2-month trial require plain radiographic evaluation. While the changes on plain radiographs associated with disc degeneration do not necessarily confer a diagnosis, use plain radiography to exclude other potentially serious causes of pain. If these radiographs are negative, obtain flexion–extension lateral radiographs to rule out subtle instability.

In all cases, pay careful attention to psychosocial factors. A long period of evaluation and nonoperative management affords the surgeon an opportunity to get to know the patient well. Obtain an MMPI if there are any doubts as to the psychological profile. A motivated, professionally satisfied patient is the ideal candidate for further evaluation and possible surgical treatment.

The MRI is the study of choice in the evaluating the intervertebral disc. In the context of unresponsive mechanical pain in a psychologically normal individual,

single-level degenerative changes may warrant consideration of operative treatment. Perform multilevel discography if several levels are involved or MRI findings are equivocal. Consider surgery only for those patients demonstrating one (possibly two) levels of concordant pain with no pain at control levels. Discography is at present not indicated in patients with a normal MRI.

## NONOPERATIVE TREATMENT

Treat the vast majority of patients with mechanical LBP nonoperatively (4). Begin treatment at the initial patient encounter and, should the pain fail to improve, continue it through the protracted evaluation period. During this period, optimize the patient's physiologic status through cessation of smoking, increasing spinal flexibility, and increasing aerobic exercise tolerance. Consider only patients actively participating in a surgeon-directed rehabilitation program for invasive presurgical testing, such as discography.

Specifically, institute a focused program of physical therapy including strengthening and stretching. Some have found that flexion exercises exacerbate discogenic pain. Specific abdominal strengthening and trunk-stabilizing exercises, such as abdominal crunches with flexed hips and knees, however, can be performed with limited lumbar flexion. Extension exercises and low-impact aerobic exercises, such as swimming and cycling, are often recommended and well tolerated.

For patients whose pain prevents them from being able to begin conditioning and strengthening exercises, start a course of acetaminophen or nonsteroidal anti-inflammatory drugs (NSAIDs). Muscle relaxants may be useful in the setting of acute LBP but are not recommended for patients with chronic difficulties (5).

Chiropractic care may also have a role in the management of acute LBP episodes, although no convincing evidence of efficacy in the context of chronic LBP is available. Further, as in acute back pain, extended periods of bed rest have no role in the management of DDD patients. Several clinical trials have studied the role of bracing. The Quebec Task Force on Spinal Disorders found insufficient scientific evidence to support the efficacy of a lumbar corset or support (5,14,89).

Other nonoperative modalities such as traction, massage, and acupuncture for chronic, mechanical LBP are not supported by the scientific literature (89).

Consider a multidisciplinary pain clinic for patients who fail to adequately participate in a nonoperative regimen. In such a setting, detoxification, psychological assessment, work hardening, work skills retraining, tricyclic antidepressant medication, and other modalities may be effectively applied to improve the patient's pain and functional status.

## OPERATIVE TREATMENT

In general, offer surgery only to those patients for whom operative results would represent an improvement over the natural history of DDD. Since the natural history of DDD remains to be elucidated, balance any recommendations for surgery carefully against surgical risks and the significant possibility of failure to obtain clinical improvement.

Presently, 50% to 80% clinical success rates are reported for the various operative modalities in DDD. There are no data to suggest that the various subtypes of DDD require different approaches to surgical management.

Different outcomes measures have been used in the past to quantify acceptable surgical results. Often, failures result from unrealistic expectations on the part of both physician and patient. One factor is “fusion disease,” described by Zdeblick (89). The stripping and retraction required for posterior spinal fusion procedures may cause permanent fibrosis and ischemic injury of the extensor musculature. Long periods of intense manual labor may be impossible even in the presence of a solid bony union.

While fusions for multiple-level DDD typically fail, single-level (and occasionally double-level) fusions for DDD may be considered if the following prerequisites have been met (36):

- Pain and disability are present for at least 1 year.
- There is failure of aggressive physical conditioning and conservative treatment of more than 4 months duration.
- There is single-level disc degeneration on MRI with concordant pain response on discography.
- There is absence of psychiatric or secondary gain issues.

The aim of surgery for DDD is to decrease pain by limiting mechanical stimuli across the painful motion segment. The least controversial procedures achieve this goal by solid arthrodesis. Several methods currently advocated to promote such a fusion will be described next.

### POSTEROLATERAL SPINAL FUSION

Posterolateral spinal fusion was previously the gold standard for the surgical treatment of discogenic back pain (36,62). The advantage of the posterior approach is that fusion can be performed in the absence of the posterior element; the risk of injury to the neural elements is low; and because the graft is placed away from midline, there is less risk of iatrogenic spinal stenosis.

Reported results of uninstrumented fusion have been contradictory. Stauffer and Coventry (73) reported 89% good results, and they achieved an 80% fusion rate by radiographic criteria; there was a high correlation between successful fusion and the clinical result. Dawson et al. (11) reported a 92% rate of solid fusion, with a 70% to 90% clinical success rate. Those undergoing a fusion above the lumbosacral motion segment were found to have a 45% pseudarthrosis rate, however.

Others have noted poor results with fusion. Finlayson et al. (18) performed a posterolateral fusion for DDD in 20 patients with concordant discography. While 11 felt the operation was worthwhile, only six had a good outcome as measured by impairment, disability, and work status. Parker et al. (62) reported a prospective, consecutive series of patients with discogenic LBP undergoing posterolateral fusion. They observed only 39% good to excellent results, with 13% fair and 48% poor results. Poor results were associated with workers' compensation status, pseudarthrosis, and being out of work longer than 3 months Greenough et al. (29) concluded that posterolateral fusion was an acceptable treatment for discogenic back pain only in very carefully selected patients.

Pedicle screw instrumentation has been added to posterolateral fusion procedures in an attempt to decrease pseudarthrosis rates (Fig. 145.13, Fig. 145.14). Data from fusion procedures for degenerative spondylolisthesis suggest increased fusion rates but no effect on clinical outcome (19). Instrumentation is associated with higher costs and complication rates. One recent series noted 10% of patients had instrumentation-related problems. Yet, biomechanical studies suggest that pedicle screw constructs are superior in stabilizing the nonosteoporotic spine (31). These constructs may confer immediate stability to motion segments and allow an expedited postoperative recovery. This added stiffness and faster recovery interval may be more important in the younger population with DDD than in the older patient with degenerative spondylolisthesis.



***Figure 145.14.*** Postoperative lateral radiograph depicting fusion with instrumentation at L3-4.

***Figure 145.13.*** Postoperative AP radiograph after single-level L4-5 posterior fusion with instrumentation.

Pseudarthrosis rates in noninstrumented fusions range from 35% to 68%. Instrumented fusions have pseudarthrosis rates reported from 0% to 33%. Increased rates of 75% to 95% significant clinical improvement are also reported in patients undergoing instrumented fusions, versus 59% to 70% in those fused without instrumentation (3,88). In patients undergoing fusion for discogenic pain, solid fusion is associated with increased return-to-work rates as well (11). Posterolateral fusions undertaken to treat DDD should probably be undertaken with rigid, transpedicular instrumentation, particularly in the revision situation (85).

**ANTERIOR LUMBAR INTERBODY FUSION**

There are two common approaches to anterior lumbar interbody fusion (ALIF). The first, the open retroperitoneal approach, employs a 5–10 cm incision to directly access the anterior spine. A complete discectomy may then be undertaken and a variety of implants, including allograft rings and threaded cages, placed into the disc space. Various endoscopic methods of threaded cage placement have been described as well. These approaches use relatively straightforward techniques for access, but they do not include a complete discectomy. Moreover, the threaded cage techniques require violation of the vertebral endplate. While these newer approaches may be less invasive, long-term data regarding fusion rates and implant stability are not available.

Historically, ALIF has been reserved as a salvage procedure for patients failing multiple posterior procedures (27). More recently, increased ease of access and concerns over extensor muscle retraction in a relatively young patient population have renewed interest in this approach. Moreover, some authors, citing the disc as the primary source of pain, recommend its complete extirpation (27,29,43,58,59,72,82,89,90).

The advantages of ALIF include the following:

- Complete excision of disc material
- Placement of the graft under compression
- Availability of a large surface area for graft incorporation
- Availability of a virgin operative site if there has been a prior posterior spinal fusion
- Avoidance of extensor muscle injury (“fusion disease”)

Advocates of ALIF report that even after solid posterior arthrodesis, flexion may occur through the fusion mass. This slight movement may cause continuing pain in the intervening degenerated discs. Weatherly et al. (81) reported complete relief of pain after ALIF in four patients with solid posterolateral fusion and concordant discograms at the previously fused level. Because ALIF places the fusion mass at the center of motion of the spine, it more rigidly immobilizes the spine once it is solid (33,90).

Results of ALIF have included highly variable fusion rates from 18% to 96% (26). However, the pseudarthrosis rate is generally felt to be lower than that for one-level posterolateral fusions or posterior lumbar interbody fusions (76,85). Similar variability in rates of pain relief and return to work have been reported. Ostensibly, this variability is caused by differences in surgical indications and techniques.

Several distinct operative techniques have been described for ALIF (see Chapter 146). Traditionally, corticocancellous bone from the iliac crest was placed in the disc space and maintained in position with a screw and washer. This approach was sometimes associated with graft collapse and pseudarthrosis. Allograft rings were then recommended and, subsequently, threaded cage techniques.

The cited advantages of threaded cages include structural support for the anterior column, indirect decompression of the foramina and nerve roots by distraction of the disc space, the potential for bony ingrowth through the cage, and the possibility of minimally invasive implantation (90). While clinical results are preliminary, early series demonstrate good mechanical stability with these constructs (52). Figure 145.15 shows sample cases.



***Figure 145.15.*** Case example. **A:** Preoperative AP radiograph of the lumbar spine depicting loss of disc space height and L5–S1. **B:** Lateral radiograph showing disc degeneration at L5–S1. **C1:** Sagittal T1-weighted MRI demonstrating disc degeneration at L4-5 and L5–S1 with an annular tear evident at L4-5 (*arrow*). **C2:** Sagittal T2-weighted MRI in the same patient. **D:** Discography was performed at the L3-4, L4-5, and L5–S1 levels. Concordant pain was noted at the L5–S1 level (*asterisk*). While the L4-5 annular tear is again appreciated on discography, this level was not painful to dye injection. **E:** Lateral radiograph demonstrating corticocancellous autograft ALIF at L5–S1 (*dots* outline the anterior and posterior extent of the graft). **F:** An immediately postoperative AP radiograph of another patient with allograft dowel placement via a mini-open ALIF approach. **G:** Lateral radiograph of another patient with BAK cage placement.

When considering the more recently described endoscopic methods of ALIF, it is important to remember that they represent only a new technique, not a new operation. Therefore, operative indications remain the same. There are proposed benefits of an endoscopic approach, however. Preliminary studies suggest shorter hospital stays, decreased morbidity, and earlier return to work with minimally invasive techniques (52,53).

At present, several endoscopic techniques are evolving. The transperitoneal approach with gas insufflation serves as a direct extension of conventional laparoscopic surgery (90). This technique allows direct access to L5–S1, L4–L5, and occasionally L3–L4. Proposed advantages include ease of organ retraction, more rapid exposure of the spine, increased working space, and decreased bleeding. Disadvantages include the requirement for expensive trocars with diaphragms and other special instruments, as well as the potential for air leakage and a carbon dioxide venous embolism.

A gasless approach has been devised wherein the working space is maintained by lifting the anterior abdominal wall with a fan-like retractor. This approach allows the use of conventional instruments and avoids carbon dioxide effects and expensive valves. The procedure is associated with increased time for exposure, limited lateral vision, and an overall more technically difficult approach. Therefore, an intermediate, combined insufflated and gasless technique was devised, in which insufflation is used for the initial spine exposure. Retractors and Steinmann pins are placed, and then conversion to gasless technique is undertaken.

For a retroperitoneal approach utilizing the potential space between the spine and the abdominal cavity, make a 2.5 cm flank incision by splitting the anterior lateral abdominal muscles. After an initial finger dissection, enlarge the space with a retroperitoneal balloon. Again, the laparoscopic retractor with a hydraulic arm is employed to create a tent-like effect. Further peritoneal reflection can then be carried out under direct vision. This procedure provides access from T-12 to S-1. Further, conventional instruments may be used and the procedure can be converted from a pure percutaneous endoscopic to an endoscopic-assisted anterior approach should the degree of difficulty be increased. Some authors report difficulty obtaining a direct frontal approach to the disc space with this technique, however.

**GLOBAL FUSIONS**

Global (360°) fusions were previously recommended for multilevel involvement and postlaminectomy patients. Kozack and O'Brien (44) reported a series of 69 patients with global fusions for DDD. Fusion levels were determined by provocative discograms. With one- and two-level procedures, 90% fusion rates were achieved. Three-level and greater procedures were associated with 77% fusion rates. Overall, 80% had acceptable clinical results. O'Brien et al. (59) described a global fusion procedure for 150 patients with severe disability due to back pain or with previous failed operations. With posterior instrumentation, they noted an 86% success rate.

Lower pseudarthrosis rates, usually 5% to 10%, were the principal justification for the added surgical morbidity of these combined procedures (44,76). More recently, concerns regarding the effectiveness of threaded cages as stand-alone devices has intensified the debate over the need for posterior stabilization.

A variation on this theme involves an endoscopic anterior fusion with a percutaneous posterior stabilization procedure with pedicle screws or translaminar facet screws, but there are no reports of long-term results.

**POSTERIOR LUMBAR INTERBODY FUSION**

A method of achieving an anterior arthrodesis with posterior stabilization in a single surgical approach is the posterior lumbar interbody fusion (PLIF). A wide posterior decompression is performed, allowing retraction of the dural sleeve and nerve roots for complete disc excision and anterior column fusion.

The PLIF was introduced by Cloward in 1945 to treat lumbar disc ruptures (9). He stated that PLIF was indicated for “the treatment of low back pain with or without sciatica due to lumbar disc disease.” This procedure has also been recommended for spondylolisthesis, lumbar scoliosis, osteomyelitis, lumbar kyphosis, and to increase posterior fusion rates in high-risk patients (e.g., smokers and diabetics).

In each case, the addition of an anterior load-sharing graft may enhance the fusion rate, stabilize the construct, and protect the posterior spinal implant by load sharing. In patients with deformity, the PLIF may aid in correction by partial anterior release. Most commonly, however, PLIF procedures are performed for discogenic back pain.

Cloward (9) summarized the PLIF as able to address “all sources of pathologic change of the motion segment in one operation, through one incision.” Yet, after initial enthusiasm, use of the PLIF declined due to high rates of pseudarthrosis and graft dislodgement. More recently, the advent of transpedicular instrumentation led to a resurgence of interest in PLIF. Steffee and Sitkowski (74) reported 104 fusions performed without graft dislocation, pseudarthrosis, or infection.

Reported advantages of PLIF include near total disc excision, restoration of disc height and normal sagittal contour, root decompression, solid mechanical arthrodesis, immediate load-sharing with structural support, large surface area for fusion between the vertebral endplates, fusion under compression, and avoidance of an additional anterior approach.

Disadvantages include graft displacement, pseudarthrosis, anterior and posterior destabilization, increased bleeding, dural tears, risk to nerve roots, and risk of epidural fibrosis from root retraction (36).

Ma (50) reported 100 consecutive PLIFs for back or leg pain, spondylolisthesis, or failed back syndrome. There was an 11% reoperation rate: six for pseudarthrosis, three for bone graft extrusion, one bone graft fracture, and one hematoma. Others have reported good to excellent results in 89%, with a fusion rates of 73% to 95% and an 82% return-to-work rate (49,76).

Of particular concern is the trauma to the nerve roots from wide retraction. Epidural fibrosis may develop into a chronic radiculopathy for which there is presently no satisfactory solution. Harms et al. (33) recently popularized a variant of the PLIF procedure that avoids significant retraction on the thecal sac. This posterolateral approach to the disc space relies on facet excision and has been termed the transforaminal lumbar interbody fusion (TLIF). While transpedicular instrumentation is recommended for the midline laminotomy version of the PLIF, it is mandatory here.

Transforaminal lumbar interbody fusion preserves the anterior and posterior ligamentous complex, thereby maintaining a tension band for compression of the graft and prevention of retropulsion. While long-term outcome reports are not yet available, some authors noted the proximity of the dorsal root ganglion and the potential for chronic, neurogenic pain after even minor trauma to this structure.

Posterior lumbar interbody fusion is contraindicated in patients with preexisting, significant epidural fibrosis and those with significant osteopenia. Aside from the more typical complications such as bleeding, infection, and pseudarthrosis (mentioned later), the unique complications possible with PLIF deserve special mention here. With standard PLIF procedures, damage to nerve roots remains a principal concern. The surgeon must be careful about overdistraction, particularly in patients with nerve root anomalies. New or increased deficits occur in 0.5% to 4% of patients after PLIF (48). The upper (exiting) root traverses the interspace just out of direct view in the lateral recess and can be damaged when grafts are inserted in the disc space.

Steffee and Sitkowski (74) report that a failed PLIF has “a worse outcome than failure of any other fusion procedure.” They report that exploration of patients with a post-PLIF chronic radiculopathy reveals epidural fibrosis for which there is no satisfactory salvage. Careful attention to the tension placed on the cauda and nerve roots may diminish the incidence of these problems.

Neural structures may also be injured with posterior bone graft migration. The subtotal discectomy required for a PLIF procedure risks penetration of the anterior annulus with attendant anterior vessel damage, a potentially catastrophic complication.

Revision options in failed PLIF are limited. A noninstrumented PLIF may be converted to an instrumented PLIF. A failed instrumented PLIF is most often revised with an attempted anterior fusion (82).

With the rising popularity of anterior approaches in the treatment of lumbar disc disease, the role of PLIF or TLIF is not entirely clear. For example, the importance of “fusion disease” in these relatively young patients remains to be established (42). Certain criteria, however, may reasonably aid in the selection between ALIF and PLIF (Table 145.9).

| *Situation* | *Relative preference* |
|---|---|
| Posterior decompression needed | PLIF |
| Previous retroperitoneal approach | PLIF |
| Pedicle screw instrumentation needed | PLIF |
| Male patient, to avoid retrograde ejaculation | PLIF |
| Previous laminectomy or discectomy | ALIF |
| Nerve root anomaly present (retraction more difficult) | ALIF |
| Loss of lumbar lordosis | ALIF |
| Technical ease at L5–S1 | ALIF |
| Foraminal stenosis without central or lateral stenosis | ALIF |
| Large cage needed for stabilization | ALIF |

ALIF, anterior lumbar interbody fusion; PLIF, posterior lumbar interbody fusion.

***Table 145.9. Soft Selection Criteria to Decide Between ALIF and PLIF***

Because PLIF is a relatively difficult surgery to revise, present recommendations for PLIF include lumbar disc disease with sciatica (10) and certain revision situations in which an anterior/posterior fusion through a single incision is desirable.

**SUMMARY OF TREATMENT OPTIONS**

We feel that a posterior fusion with instrumentation is the gold standard for the rare patient with true lumbar segmental instability. Those patients with painful lumbar spondylosis LS are best served with a disc ablative procedure such as ALIF and PLIF. Circumferential fusions should be reserved for patients with significant canal pathologies, where revision is required, and other situations in which additional stabilization is required.

We favor ALIF because of the destabilizing effects of PLIF and its potential for nerve root injury, epidural fibrosis, and “fusion disease.” The advent of transforaminal interbody fusion procedures may decrease the risk of the PLIF technique, but firm evidence is not available. As more information regarding the long-term results of interbody cage placement becomes available, treatment recommendations will no doubt be revised.

## SURGICAL TECHNIQUES

Two surgical procedures commonly employed to treat DDD in its various forms are discussed here: posterior lumbar fusion (with and without instrumentation) and PLIF. ALIFs, either through traditional open or laparoscopic techniques, are increasingly favored for patients with these disorders and are covered in Chapter 146.

**POSTEROLATERAL SPINAL FUSION**

Before undertaking a posterior spinal fusion for DDD, carefully review your patient selection criteria. Be sure the patient is well informed as to the risks and the potential for an unsatisfactory clinical outcome. Pay careful attention to patient physiology by the following measures:

- Discontinue aspirin and NSAIDs.
- Ensure a good nutritional status.
- Have the patient stop smoking and other tobacco use.
- Recommend preoperative blood donation and institute prophylactic antibiotics.

A posterolateral fusion begins with proper patient positioning. Choose a frame or bolsters that allow the abdominal contents to be free of compression and maintain proper lumbar lordosis (Fig. 145.16).

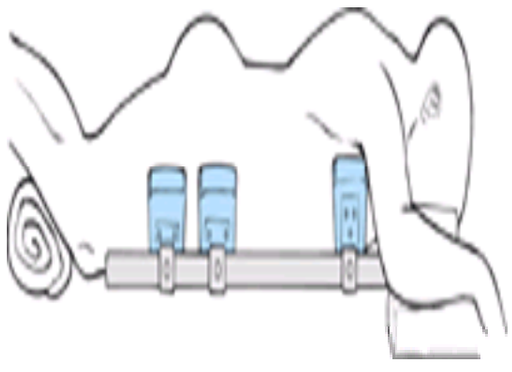

***Figure 145.16.*** Proper positioning on a frame that decompresses the abdomen and avoids pressure points is critical to the success of any lumbar fusion procedure.

- Freedom of abdominal contents will decrease epidural venous engorgement and blood loss.
- A Foley catheter similarly decreases intra-abdominal pressure by preventing bladder distention.
- Carefully pad all bony prominences and avoid pressure over the eyes.
- Use a radiolucent turning frame in procedures in which multiplanar image intensification is anticipated.
- Maintain the patient's core body temperature with ventral and lower-extremity air-circulating devices.

As in all spine surgery, a headlight and loupes increase the effectiveness of the exposure. Intraoperative neural monitoring may be used to stimulate pedicle screws during placement to detect pedicular penetration.

Spine fusion procedures may be associated with significant blood loss. Intraoperative blood salvage is occasionally useful. More important, anticipate and control bleeder sites as you encounter them. Three fairly constant bleeding points include the pars interarticularis artery, the artery of Macnab (transverse process artery), and the sacral arteries.

- The pars artery is encountered during the initial exposure. Emerging from a recess inferior to the facet, it wraps around the pars.
- A curved bayonet may help control the artery of Macnab, which lies on the upper aspect of the junction of the transverse process.
- The sacral arteries protrude from the posterior sacral foramina and are difficult to control without inserting bipolar cautery or forceps into the bony recess. Often, temporary packing with Gelfoam will provide adequate hemostasis.
- Begin the exposure by centering a 6–10 cm midline skin incision just cranial to the involved level (Fig. 145.17).

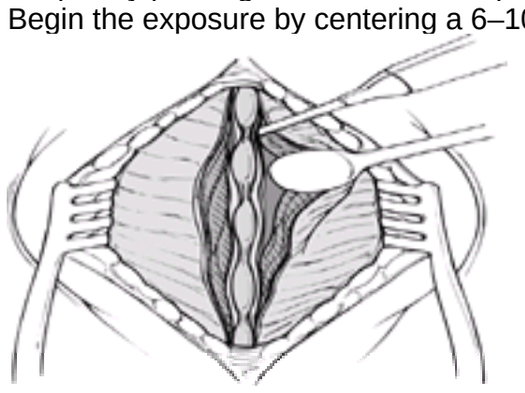

***Figure 145.17.*** Initiation of a midline subperiosteal approach.

- Inject a dilute epinephrine solution into the skin and subcutaneous tissue to decrease bleeding.
- Use electrocautery to proceed through the subcutaneous tissue to the fascia.
- Expose a 0.5 cm portion of the fascia on either side of the midline to aid subsequent closure. Avoid extensive fascial stripping, which increases dead space.
- Enter the deep space over the spinous processes in a subperiosteal fashion. Use the Cobb elevator for countertraction.
- Carry the subperiosteal dissection over the laminae to the facets with the electrocautery. Do not violate the facet capsules at this point.
- Insert a Penfield #4 elevator (Fig. 145.18) under a lamina and obtain a radiograph. Confirm operative levels and mark the superior level by resecting a portion of the spinous process with a rongeur.

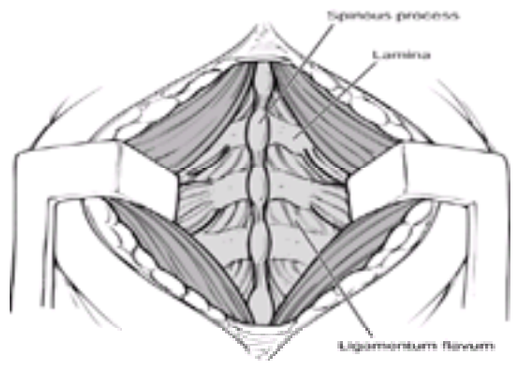


***Figure 145.18.*** Exposure of the facets.

- Expose the laminae one level above and one level below the anticipated level of fusion. Leave the facets intact at these levels. This additional dissection will reduce tension over the transverse process exposure at the operative level.
- Bluntly dissect over the facets with a Cobb elevator and a sponge at the operative level.
- Then expose the lateral pars interarticularis and transverse processes with electrocautery. The transverse processes lie immediately adjacent to the facets. Be careful not to penetrate the intertransverse membrane (Fig. 145.19).

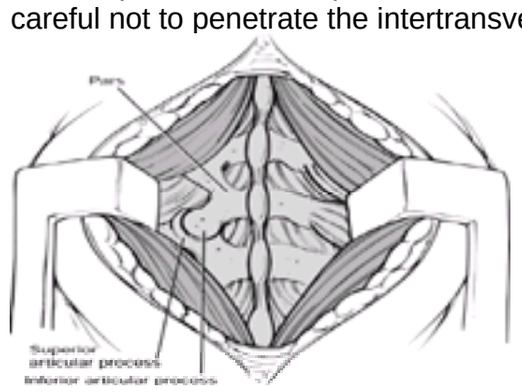


***Figure 145.19.*** Exposure of the transverse processes and pars interarticularis.

If no midline decompression is required, consider a bilateral Wiltse (paramedian) approach. A larger midline skin incision and subcutaneous dissection is required. Make the fascial incisions two finger breadths lateral to the midline bilaterally. Then bluntly dissect down to the lateral facets between the multifidus and longissimus muscles. This approach is covered more extensively in Chapter 138.

- Remove all soft tissue from the posterior aspect of the transverse processes, outer facets, and pars. If the fusion includes S-1, clear the sacral ala. Complete soft-tissue removal will double the area available for bone graft. Preparation of the graft bed is the most important part of any fusion procedure.
- Decorticate the lateral pars, the transverse process, and the lateral wall of the facets.
- Lay autologous cancellous bone into place and impact gently. Then add corticocancellous strips and compress gently into position.
- For each level to be included in the fusion, remove the entire facet joint capsule and denude the cartilage from the facet.
- Close the wound in layers to create a watertight fascial closure. Place a drain in the deep space.

**HINTS AND TRICKS**

To diminish operative morbidity in posterior approaches, do the following:

- Periodically release the retractor to reestablish muscle vascularity.
- Handle muscle carefully to minimize devascularization and necrosis.
- Make the exposure generous to minimize the required retractor tension.
- Use Gelfoam or bipolar cautery over the pars, transverse processes, neural foramen, and dorsal sacral foramen.
- Prevent overcauterization to minimize injury to nearby neural structures.

**INSTRUMENTED POSTERIOR SPINAL FUSION**

Employ the same initial steps as in a noninstrumented fusion. Do not insert pedicle screws prior to complete exposure of the posterior elements. Decortication of the transverse processes and bone graft insertion are more easily and completely accomplished prior to hardware insertion. Many surgeons, however, prefer to decorticate after instrumentation to diminish blood loss.

Several useful techniques for entry-point localization and pedicle-screw placement have been described. Thorough knowledge of pedicular anatomy is critical. Various radiographic techniques of localization are now available, but none replaces a firm grasp of the relationships of the posterior elements to one another.

The pedicle lies along the midline axis of the transverse process. The outer border of the facets describes a line roughly conforming to the lateral border of the pedicle. The lateral border of the pars defines the medial pedicular border. The accessory process is often identified at the junction of the facet and the transverse process. This process serves as a useful entry point (Fig. 145.20*A*).

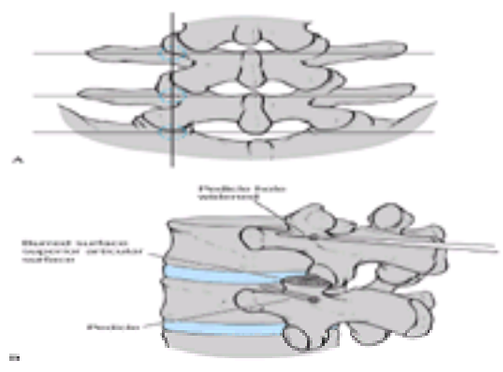

***Figure 145.20.*** **A:** Anatomy of pedicle location. See text for details. **B:** Sounding the pedicle with a probe or curret.

While multilevel fusions are generally not recommended for DDD, instrumentation in these cases is placed at each level in an effort to reduce micromotion. How much segmental stiffness is required to achieve fusion and eliminate pain is not established (45); however, given that micromotion has been hypothesized as a cause of pain in four screw micromotion-segment constructs (81), maximizing points of fixation is recommended. Screw placement is abandoned if preoperative imaging demonstrates thin pedicles. Similarly, if difficulties with cortical breech are noted intraoperatively, abandonment of that point of fixation is recommended.

- Carefully review the preoperative MRI or CT scan to confirm the extent of convergence of the pedicle at each level, as well as the length and size of screw

necessary.

- In general, screws should converge by 5° at the thoracolumbar junction. This convergence increases to 10° at L-2 and 15° at L-5.
- Use the localization lateral radiograph to define the proper attitude of the pedicle in the cranial and caudad planes.
- Most often, an L-3 pedicle screw is inserted perpendicular to the floor. Angle superior screws progressively more cranially. Angle inferior screws progressively more caudally.
- Decorticate the pedicle entry site with a burr.
- Enter the pedicle with a curet or pedicle probe. Gently work this device anteriorly into the vertebral body (Fig. 145.20*B*).
- Check for cortical penetration with a ball-tip probe. If a midline decompression has been performed, the pedicle may also be palpated from within the canal. If necessary, place markers and confirm radiographically.
- Tap the hole and insert the screw (Fig. 145.20*B*). The optimal depth of screw placement has not been determined, but pullout strength increases linearly with depth of penetration (46). We estimate 75% penetration using lateral fluoroscopy to increase purchase while minimizing risk to anterior vascular structures.
- Once the screws and bone graft have been placed, affix a plate or rod according to the manufacturer's instructions.
- Be careful to maintain proper lumbar lordosis.
- Undertake closure over a drain with watertight fascial closure, and follow with a layered closure of the subcutaneous tissues and skin.

## SACRAL FIXATION

Sacral fixation remains the weak link in posterior fixation systems (13). Large constructs extending to the sacrum require additional fixation. The combination of large forces transmitted to the sacrum and the size and bone content of the sacral pedicle may render S-1 screws inadequate as the sole point of inferior fixation. In the degenerative conditions described in this chapter, however, smaller, single-level constructs are recommended. In these cases, simple transpedicular instrumentation is usually successful. The sacral pedicle requires larger screws.

- Locate the S-1 pedicle at the intersection of a horizontal line connecting the inferior aspect of the lumbosacral facets, and a vertical line tangential to the lateral border of the superior facet.
- Insert the screws above and in line with the first sacral foramen. Converge the screws and incline them superiorly, parallel with the lumbosacral disc space.

Medial angulation allows longer screws with superior fixation strength, although iliac crest overhang may limit optimal screw trajectory. In the case of tenuous fixation, additional cortical purchase is recommended to prevent “windshield-wipering.” Options include careful perforation of the anterior cortex or of the L5–S1 disc space (Fig. 145.21).

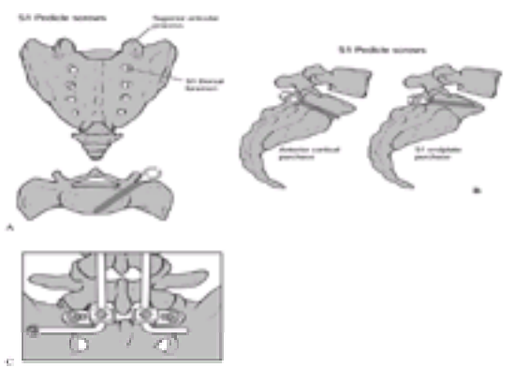

***Figure 145.21.*** **A:** Sacral screw placement. **B:** Lateral view of sacral screw placement. **C:** Iliac bolts.

When considering penetration of the anterior sacral cortex, recognize the possibility of significant individual anatomic variability (13). Differences in sacral bony anatomy are associated with differences in vascular tree branching patterns and in the location of the neural foramina. Assess the morphology and choose an optimal trajectory from preoperative CT or MRI scans.

The medial sacral promontory is the safest place to penetrate the anterior cortex. More lateral sacral screws may hit the lumbosacral plexus, which is affixed to the bone here. Lateral trajectories also risk injury to the iliac veins, particularly on the left.

Other options for fixation below the lumbosacral interspace include S-2 pedicle screws, sacroiliac bolts, and sacral rods. S-2 screws are easily inserted along the intermediate sacral crest midway between the first and second dorsal foramina, but they are considered biomechanically weak. Cortical penetration at this level risks injury to the sigmoid colon.

Postoperative bracing is not usually recommended, and genuinely effective bracing requires a pantaloon extension. Sacral fixation techniques are further discussed in Chapter 156, Chapter 159 and Chapter 160.

## POSTERIOR LUMBAR INTERBODY FUSION

Carry out the initial stages of PLIF (10,48,74) in the same manner as posterolateral fusion. Careful positioning is critical. Lumbar lordosis and abdominal decompression are important. Some authors feel the knee–chest position adequately maintains lordosis while maximizing hip and knee flexion. Hip and knee flexion ensure decreased tension on the nerve roots, which may allow greater thecal sac retraction for PLIF surgery.

Although PLIF was originally described without instrumentation, this is not recommended. The wide posterior exposure necessary for a safe PLIF produces increased instability with increased rates of pseudarthrosis and graft dislodgement.

Classically, a PLIF is performed in three steps: laminotomy, removal of the intervertebral disc, and spinal fusion.

- Perform a standard 10 cm midline exposure of the posterior elements (as described previously) with a wide laminotomy at the level of interest.
- Preserve the superior portion of the superior lamina and the inferior portion of the inferior lamina with portions of the spinous processes. Muscular attachment sites and interspinous ligaments to levels above and below operative level are thereby preserved.
- Remove the inferior third of the inferior facet, and the medial two thirds of the superior facet to the level of the pedicle. Visualize the lateral half of the intervertebral disc as well as the cranial and caudal nerve roots.
- The medial facet resection can be more aggressive if a combined posterior fusion and instrumentation is planned (Fig. 145.22).

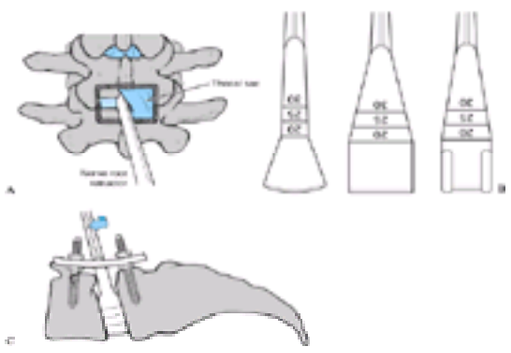

***Figure 145.22.*** **A:** Midline PLIF exposure. **B:** PLIG instruments. These instruments represent a sampling of those available for the purposes of complete discectomy and disc space distraction. **C:** Obtaining distraction through the disc space.

- Next, insert pedicle screws as described previously to allow placement of a working plate or rod.
- Distract the disc space with a lamina spreader and hold the distraction with the working plate. Minimize the force placed through the screws themselves.
- Retract and protect the dural sac and nerve roots. Take great care to prevent overdistraction of the neural structures. Ensure adequate mobilization of the thecal sac to the midline from either side.
- Meticulously cauterize the epidural venous plexus over the posterior annulus with bipolar cautery.
- Make box annulotomies with a knife, and aggressively clean the disc space on both sides of the thecal sac.
- Curet the endplates to remove the annulus and endplate cartilage.

A number of techniques are described for preparing the disc space. Specialized instruments are particularly useful. If they are not available, curets, pituitary rongeurs, and osteotomes may be used. The goal is to clear 80% to 90% of the disc space. Better preparation of the graft site yields a larger area of bony contact with the graft and increases the chance of successful fusion.

- Insert an 8 mm intradiscal shaper parallel to the endplates. The shaper has a blunt end to protect the annulus anterolaterally.
- Rotate the shaper to allow its side cutting flutes to remove disc material and cartilaginous endplate. Repeat this step on the opposite side.
- Increase the shaper size by increments of 1 mm. Although these instruments are graduated, the disc space depth varies from 25 to 35 mm and it is necessary to pay careful attention to the depth of insertion at all times.
- Avoid the anterior portion of the disc space beneath the anterior longitudinal ligament to minimize the chances of a catastrophic vascular injury.

Numerous techniques are also described for the posterior grafting of the anterior column (Fig. 145.23). With disc space distraction maintained, various graft materials may be inserted. These include dowels, corticocancellous ramps, titanium plugs, and metal or carbon fiber cages of the vertical (e.g., the Harms cage, DePuy-Acromed, Raynham, MA) or the horizontal variety (e.g., the BAK, Sulzer-Spinetech Minneapolis, MN) (12).

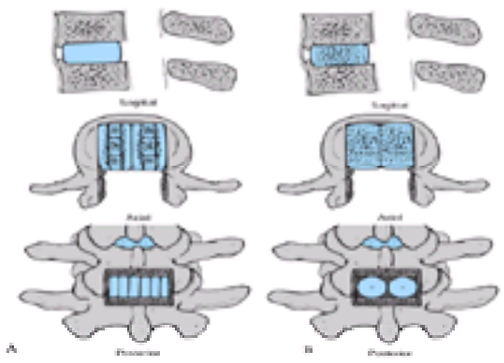

***Figure 145.23.*** Bone grafting options in PLIF. **A:** Sagittal, axial, and posterior views (from top to bottom) of Cloward's (9) tricortical rectangular graft technique. **B:** Similar views of threaded bone dowels used to obtain a PLIF.

Cages are designed to prevent postoperative collapse by providing a structural support to the interspace while the cancellous graft material becomes incorporated. The use of morcelized cancellous bone rather than corticocancellous pieces may minimize donor site morbidity. Specialized instrumentation has been developed for the posterior insertion of threaded interbody cages. While the specific instruments vary by the system used, the concepts are the same. The larger size of these implants requires a larger laminotomy or complete laminectomy and facetectomy. Base implant sizing on preoperative templating. Furthermore, the larger size of the instrumentation warrants a heightened awareness of the position of and tension on the dura and nerve roots.

- In some systems (e.g., the BAK), a drill tube is available to dock onto the disc space posteriorly. This allows insertion of the remainder of the instrumentation in a relatively safe fashion. The instrumentation includes distraction plugs or other devices to open the disc space, reamers to remove disc and endplate tissue, taps to prepare the threaded cage path, and cage inserters.
- When using this instrumentation, avoid long periods of traction on the dural sleeve with the tube in place.
- Remember to tightly pack the cage with autograft.
- Insert remaining autograft around the cage in the disc space. If individual bone pieces are used, pack the anterior disc space first, then pack medially under the thecal sac, then laterally.
- In all cases, countersink the graft material 3–5 mm to prevent canal encroachment.
- Some authors recommend placing a fat graft anteriorly between the dura and the grafts.
- Once maximal fill of the disc space has been achieved, remove the distractive forces to allow compression of the graft. With transpedicular instrumentation, further compression is achieved across the screws before final tightening. In all cases, make sure that appropriate lordosis is maintained.

**TRANSFORAMINAL LUMBAR INTERBODY FUSION**

The TLIF variant (33) of the standard PLIF procedure requires a wide, unilateral approach to the disc space at its posterolateral aspect.

- First remove the inferior facet of the superior vertebra with an osteotome. Then remove the superior facet of the inferior vertebra (Fig. 145.24).

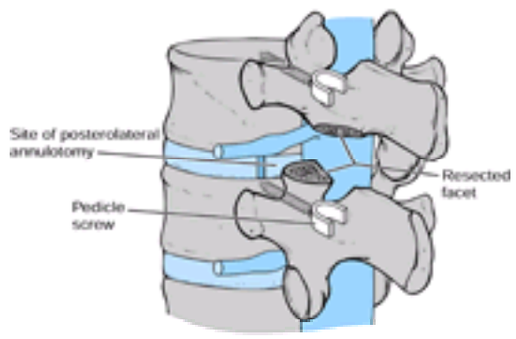


***Figure 145.24.*** Facet resection and interspace distraction through pedicle screws allows access to the disc without significant retraction of the thecal sac.

- Identify and protect the exiting and traversing nerve roots.
- After the pedicles have been identified, insert pedicle screws. Distract the disc space with an intervertebral spreader and maintain the distraction with working plates or rods affixed to the screws.
- Perform an annulotomy by creating a medially based annular flap. This flap may aid in thecal sac protection.
- Perform a complete discectomy, as described previously, and increase disc space distraction after the annulotomy.
- Tamp loose, morcelized, autogenous graft into the anterior disc space.
- Insert additional graft into an oblong 10–12 mm Harms cage (Fig. 145.25). Tamp the cage across the disc space to the contralateral side with either a straight or an angled impactor.

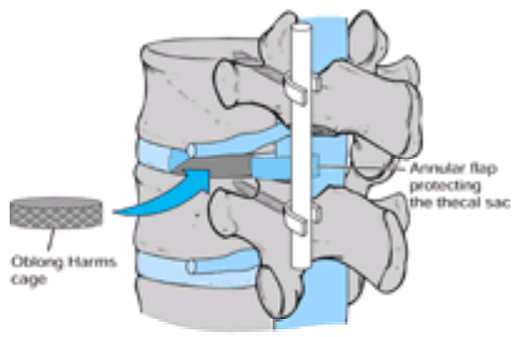


***Figure 145.25.*** Once a subtotal discectomy has been performed through a posterolateral annulotomy, bone graft is packed into the disc space anteriorly. Next, oblong, autogenous bone-graft-filled Harms cages are tamped across the disc space.

- Insert a second cage ipsilaterally.
- When packing extra bone graft around the insertion site, be sure that the nerve root is protected.
- Once grafting is completed, compress the posterior instrumentation.

### REHABILITATION AND POSTOPERATIVE PRINCIPLES

Regardless of the approach, early mobility is a prime postoperative goal.

- Mobilize patients to a chair the evening after surgery. No braces are employed.
- Request physical therapy assistance for ambulation and transfer techniques in the early postoperative period. Most patients can comfortably ambulate by the third day after surgery. Typically, young DDD patients rarely require assistive devices.
- Early postoperative restrictions include limitations on bending, lifting, and twisting, but other gentle activities are encouraged.
- After posterior fusion, remove drains and Foley catheters on the first postoperative day.
- At present, we use 24–48 hours of postoperative antibiotics.

Most patients are ready for discharge by the third postoperative day. See them for a wound check and staple removal at 7–14 days after surgery. Subsequent visits include 6- and 12-week checks. Obtained radiographs at these intervals to assess the status of the fusion.

The schedule for return to work and sporting activities is individualized on the basis of clinical status, radiographic union, and the nature of the activities involved. Early return with limited duty is preferred to lengthy sick leave.

After solid fusion is achieved, aerobic activities, spinal flexibility, and truncal strength and stability are important, life-long aspects of the patient's personal fitness regime. Further specific physical therapy is not usually needed, however.

Some patients may not be able to return to physically demanding occupations. Early intervention with skills retraining and a realistic outlook are crucial to optimal functional recovery.

## PITFALLS AND COMPLICATIONS

It is important to appreciate the scope and magnitude of potential pitfalls before selecting one of these procedures. Perisurgical problems include general surgical complications and specific procedure-related complications. The latter are detailed in their respective sections. Also, see Chapter 147.

General complications can be divided temporally into preoperative, intraoperative, and postoperative problems. Preoperative problems include the following:

- Wrong patient. Patient selection cannot be overemphasized.
- Wrong level. Correct identification of a pain generator amenable to surgical treatment is fraught with difficulty and remains the biggest hurdle in the treatment of patients with disc degeneration.
- Wrong surgery. Fusion procedures, particularly disc ablative procedures, are the only acceptable surgical modalities for DDD patients.
- Wrong doctor. Anterior and posterior spinal fusion procedures are technically demanding and should be practiced only by surgeons with special training.

Intraoperative complications are often site specific. Anterior and posterior approaches have a unique complement of attendant problems.

Adjacent segment degeneration is a significant problem in young, active patients with stiff spinal segments. While risks and pathomechanics are not entirely understood, some patients will require extension of fusion in the future for painful degeneration above or below the index fusion.

The risks of pseudarthrosis relative to each procedure have been discussed. In general, grafts under compression have lower pseudarthrosis rates. But anterior column applications require structural graft or cage support. Autogenous structural grafts have higher harvest morbidity. Allografts may have higher collapse potential. Further, autogenous bone harvest is recommended in each of these procedures. The morbidity of bone graft harvest, covered in Chapter 9, should not be underestimated.

Failure to improve despite solid fusion is most often related to poor patient selection or misidentification of the pain generator. In some cases, a solid posterior fusion may allow painful micromotion of the painful disc anteriorly (as described in the section on ALIF).

Benign postoperative urinary retention is common, but cauda equina syndrome and other postsurgical causes must be excluded. Further, indwelling catheters or repeated instrumentation of the genitourinary tract may lead to urinary tract infection and subsequent sepsis.

Ileus may be seen after posterior spine surgery, but it is more common after transperitoneal approaches or those retroperitoneal approaches that violate the peritoneum.

Deep vein thrombosis and pulmonary embolism, while less common than after hip and knee procedures, have rates similar to those in most general surgery procedures. Use of intermittent pneumatic compression stockings after surgery is recommended as a mechanical prophylaxis against this potentially fatal complication.

## AUTHORS' PERSPECTIVE

Recent studies demonstrate that the disc may be a source of back pain via nocireceptors and mechanoreceptors in the annulus and chemical irritants from the NP. The changes ascribed to DDD, however, are similar to the changes of normal aging. Moreover, a clear understanding of the pathophysiology and natural history of this pain complex is lacking. Given the ubiquity of back pain in society at large, isolating those symptom patterns and imaging findings consistent with a surgically treatable pain syndrome has been fraught with failure. A range of painful degenerative lumbar conditions exists. These entities have been grouped as degenerative disc disease or subclassified with names such as internal disc disruption, lumbar segmental instability, and lumbar spondylosis. These distinctions are largely conjectural and almost nothing is known about their natural histories.

Evaluation of DDD requires exclusion of other causes of pain. Begin investigation with a thorough history and physical examination. In the absence of red flags, a long trial of nonoperative treatment is indicated. Should symptoms continue, a progressive preoperative evaluation including MRI and psychosocial assessment is mandatory. Based on these studies, discography may be indicated to identify concordant pain at abnormal levels seen on MRI.

Then, only after rigorous selection criteria are fulfilled, may a patient be considered for surgery. Lumbar fusion remains the treatment of choice. In any operative

procedure, the known benefits must outweigh the risks. As the benefits of fusion for DDD have not been clearly established, a great deal of further study is required before routine operative intervention can be recommended for these patients.

In some circumstances, dual-level surgery may be justified. However, results of multilevel fusion for painful disc degeneration are abysmal, and it is best avoided. Multidisciplinary pain clinics remain a viable alternative.

Questions surrounding surgical approach are rapidly evolving. Presently, minimally invasive anterior approaches with threaded cages appear promising, but significant long-term data are lacking. PLIF techniques are also frequently employed. A transforaminal posterior interbody fusion may be a sensible approach in certain patients. As with any major posterior lumbar procedure, however, the long-term effects of “fusion disease” in an otherwise active patient population must be considered. With reasonable results reported for each of the various anterior and posterior procedures, the surgeon should ultimately choose that technique with which she is most comfortable. The most important factor in clinical success with this group of patients remains patient selection.

## CHAPTER REFERENCES

Each reference is categorized according to the following scheme: * classic article; #, review article; !, basic research article; and +, clinical results/outcome study.


+ 1. Aprill C, Bogduk N. High Intensity Zone. A Diagnostic Sign of Painful Lumbar Disc on Magnetic Resonance Imaging. *Br J Radiol* 1992;65:361.

! 2. Battie MC, Haynor DR, Fisher LD, et al. Similarities in Degenerative Findings on Magnetic Resonance Images of the Lumbar Spines of Identical Twins. *J Bone Joint Surg [Am]* 1995;77:1662.

+ 3. Bernhard M, Swatz D, Clothiaux P, et al. Posterolateral Lumbar and Lumbosacral Fusion With and Without Pedicle Screw Internal Fixation. *Clin Orthop* 1992;284:109.

# 4. Bigos SJ. A Literature-based Review as a Guide for Generating Recommendations to Patients Acutely Limited by Low Back Symptoms. In: American Association of Orthopaedic Surgeons, eds. *Orthopaedic Knowledge Update: Spine*. Rosemont, IL: AAOS, 1997:A15.

* 5. Boden SD, Davis DO, Dina TS, et al. Abnormal Magnetic Resonance Scans of the Lumbar Spine in Asymptomatic Subjects. A Prospective Investigation. *J Bone Joint Surg [Am]* 1990;72:403.

! 6. Boden SD, Riew KD, Yamaguchi K, et al. Orientation of the Lumbar Facet Joints. Association with Degenerative Disc Disease. *J Bone Joint Surg [Am]* 1996;78:403.

+ 7. Brightbill TC, Pile N, Eichelberger RP, Whitman M Jr. Normal Magnetic Resonance Imaging and Abnormal Discography in Lumbar Disc Disruption. *Spine* 1994;19:1075.

+ 8. Calhoun E, McCall I, Williams I, et al. Provocative Discography as a Guide to Planning Operations on the Spine. *J Bone Joint Surg Br* 1988;70:267.

* 9. Cloward R. The Treatment of Ruptured Lumbar Intervertebral Discs by Vertebral Body Fusion. *J Neurosurg* 1953;10:154.

* 10. Cloward R. Posterior Lumbar Interbody Fusion Updated. *Clin Orthop* 1982;193:16.

# 11. Dawson EG, Lotysch M, Urist MR. Intertransverse Process Lumbar Arthrodesis and Autogenous Bone Graft. *Clin Orthop* 1981;154:90.

+ 12. Enker P, Steffee A, McMillin C, et al. Artificial Disc Replacement. Preliminary Report with a Minimum 3 Year Follow-up. *Spine* 1993;18:1061.

! 13. Esses SI, Botsford DJ, Huler RJ, Raushning W. Surgical Anatomy of the Sacrum. A Guide for Rational Screw Fixation. *Spine* 1991;16:S283.

+ 14. Esses S, Botsford D, Kostuik J. The Role of External Spinal Skeletal Fixation in the Assessment of Low Back Disorders. *Spine* 1989;14:594.

! 15. Falconer M, McGeorge M, Begg A. Observations of the Cause and Mechanism of Symptom Production in Sciatica and Low Back Pain. *J Neurol Neurosurg Psychiatry* 1948;11:13.

# 16. Fardon DF, Herzog RJ, Mink JH, et al. Nomenclature of Lumbar Disc Disorders. In: In: American Association of Orthopaedic Surgeons, eds. *Orthopaedic Knowledge Update: Spine*. Rosemont, IL: AAOS, 1997:A3.

! 17. Fidler MW, Plasmans C. The Effect of Four Types of Support on the Segmental Mobility of the Lumbosacral Spine. *J Bone Joint Surg [Am]* 1983;65:943.

+ 18. Finlayson D, Birche M, Morris E, et al. Is There a Place for Fusion in Simple Backache? *J Bone Joint Surg Br* 1985;67:151.

+ 19. Fischgrund JS, MacKay M, Herkowitz HN, et al. Degenerative Lumbar Spondylolisthesis with Spinal Stenosis. A Prospective, Randomized Study Comparing Decompressive Laminectomy and Arthrodesis With and Without Instrumentation. *Spine* 1997;22:2807.

# 20. Fraser RD, Bleasel JF, Moskowitz RW. Spinal Degeneration: Pathogenesis and Medical Management. In: Frymoyer JW, Ducker TB, Hadler NM, et al., eds. *The Adult Spine: Principles and Practice*, 2nd ed. New York: Lippincott-Raven, 1997.

* 21. Frederickson BE, Baker D, McHolicle WJ, et al. Natural History of Spondylolysis and Spondylolisthesis. *J Bone Joint Surg [Am]* 1984;66:699.

! 22. Freemont AJ. Nerve Ingrowth into Diseased Intervertebral Disc in Chronic Back Pain. *Lancet* 1997;350:178.

! 23. Frymoyer J, Cats-Baril W. An Overview of the Incidence and Costs of Low Back Pain. *Orthop Clin North Am* 1991;22:263.

! 24. Frymoyer JW, Newberg JA, Pope MH, et al. Spine Radiographs in Patients with Low Back Pain. An Epidemiologic Study in Men. *J Bone Joint Surg [Am]* 1984;66:1048.

+ 25. Frymoyer JW, Selby DK. Segmental Instability. Rationale for Treatment. *Spine* 1985;10:280.

+ 26. Fujimaki A, Crock H, Bedbrook G. The Results of 150 Anterior Lumbar Interbody Fusion Operations Performed by Two Surgeons in Australia. *Clin Orthop* 1982;165:164.

+ 27. Goldner J, Urbaniak J, McCollum D. Anterior Disc Excision and Interbody Spinal Fusion for Chronic Low Back Pain. *Orthop Clin North Am* 1971;2:54.

# 28. Grazer K, Holbrock T, Kelsey J, Stauffer R, eds. *The Frequency of Occurrence, Impact, and Cost of Musculoskeletal Conditions in the United States.* Chicago, IL: American Association of Orthopaedic Surgeons, 1984.

+ 29. Greenough CG, Taylor LJ, Fraser RD. Anterior Lumbar Fusion. A Comparison of Noncompensation and Compensation Patients. *Clin Orthop* 1994;300:30.

! 30. Groen G, Baljet B, Drukker J. The Nerves and Nerve Plexuses of the Human Vertebral Column. *Am J Anat* 1990;188:282.

! 31. Guss K, McAfee P, Shih C. Biomechanical Analysis of Posterior Instrumentation Systems after Decompressive Laminectomy. *J Bone Joint Surg [Am]* 1988;70:680.

# 32. Hanley EN. The Indications for Lumbar Spinal Fusion With and Without Instrumentation. *Spine* 1995;20:143S.

# 33. Harms J, Jeszensky D, Stoltze D, Bohm H. True Spondylolisthesis Reduction and Monosegmental Fusion in Spondylolisthesis. In: Bridwell KH, DeWald RL, eds. *Textbook of Spinal Surgery,* 2nd ed. Philadelphia: Lippincott-Raven, 1997:1337.

! 34. Heggeness MH, Doherty BJ. Discography Causes End Plate Deflection. *Spine* 1993;18:1050.

! 35. Heithoff KB, Gundry CR, Burton CV, Winter RB. Juvenile Discogenic Disease. *Spine* 1994;19:335.

# 36. Herkowitz HN, Sidhu KS. Lumbar Spine Fusion in the Treatment of Degenerative Conditions. Current Indications and Recommendations. *J Am Assoc Orthop Surg* 1995;3:123.

! 37. Hirsh C, Ingelmark BE, Miller M. The Anatomical Basis for Lowback Pain. *Acta Orthop Scand* 1948;18:132.

* 38. Holt E. The Question of Lumbar Discography. *J Bone Joint Surg [Am]* 1968;50:720.

* 39. Holt L. Cervical, Dorsal and Lumbar Spinal Syndrome. *Acta Orthop Scand* 1954;17:65.

* 40. Horton W, Daftari T. Which Disc as Visualized by MRI is Actually a Source of Pain? *Spine* 1992;17:51.

! 41. Kauppila LI. Ingrowth of Blood Vessels in Degenerative Discs. Angiographic and Histochemical Studies of Cadaver Spines. *J Bone Joint Surg [Am]* 1995;77:26.

! 42. Kawaguchi Y, Matsui H, Tsuji H. Changes in Serum Creatine Phosphokinase MM Isoenzyme after Lumbar Spine Surgery. *Spine* 1997;22:1018.

+ 43. Knox BD, Chapman TM. Anterior Lumbar Interbody Fusion for Discogram Concordant Pain: *J Spinal Disord* 1993;6:242.

+ 44. Kozack J, O'Brien J. Simultaneous Combined Anterior and Posterior Fusion. An Independent Analysis of a Treatment for the Disabled Low Back Pain Patient. *Spine* 1990;15:322.

! 45. Krag MH. Biomechanics of Thoracolumbar Spinal Fixation. *Spine* 1991;16:584.

! 46. Krag MH, Beynnon BD, Decoster TA, Pope MH. Depth of Insertion of Transpedicular Vertebral Screws into Human Vertebrae: Effect upon Screw–Vertebra Interface Strength. *J Spinal Disord* 1988;1(4):287.

! 47. Kuslich S, Stephan D, Ulstrom C. The Tissue Origin of Low Back Pain and Sciatica. *Orthop Clin North Am* 1991;22:181.

# 48. Lanzino G, Shaffrey CI, Ray CD. Posterior Lumbar Interbody Fusion. In: Benzel E, ed *Spine Surgery: Techniques, Complication Avoidance, and Management*. Philadelphia: Churchill-Livingstone, 1999.

+ 49. Lin PM, Cautini RA, Joyce MF. Posterior Lumbar Interbody Fusion. *Clin Orthop* 1983;180:154.

+ 50. Ma G. Posterior Lumbar Interbody Fusion with Specialized Instruments. *Clin Orthop* 1985;193:57.

! 51. Malinsky J. The Ontogenetic Development of Nerve Terminations in the Intervertebral Discs of Man. *Acta Anat* 1959;38:96.

+ 52. Matthews HH, Evans MT, Molligan HJ, Long BH. Laparoscopic Discectomy with Anterior Lumbar Interbody Fusion. A Preliminary Review. *Spine* 1995;20:1797.

+ 53. McAfee PC, Regan JR, Zdeblick T, et al. The Incidence of Complications in Endoscopic Anterior Thoracolumbar Spinal Reconstructive Surgery. A Prospective Multicenter Study Comprising the First 100 Cases. *Spine* 1995;20:1624.

! 54. McCarron RF, Wimpee MW, Hudkins P, et al. The Inflammatory Effect of Nucleus Pulposus. A Possible Element in the Pathogenesis of Low Back Pain. *Spine* 1987;12:760.

! 55. Miller J, Schmatz C, Schultz A. Lumbar Disc Degeneration Correlation with Age, Sex, and Spine Level in 600 Autopsy Specimens. *Spine* 1988;13:173.

# 56. Modic MT, Ross JS. Magnetic Resonance Imaging in the Evaluation of Low Back Pain. *Orthop Clin North Am* 1991;22:283.

# 57. Modic MT, Steinberg PM, Ross JS, et al. Degenerative Disc Disease. Assessment of Changes in Vertebral Body Marrow with MR Imaging. *Radiology* 1988;166:193.

+ 58. Newman MH, Grinstead GL. Anterior Lumbar Interbody Fusion for Internal Disc Disruption. *Spine* 1992;17:831.

+ 59. O'Brien J, Dawson M, Heard C, et al. Simultaneous Combined Anterior and Posterior Fusion. *Clin Orthop* 1986;203:191.

+ 60. Orderburg G, Nskog J, Sjostrom L. Diagnostic External Fixation of the Lumbar Spine. *Acta Orthop Scand* 1993;64:94.

+ 61. Paajanen H, Erkintalo M, Kuusela T, et al. MR Study of Disc Degeneration in Young Low Back Pain Patients. *Spine* 1989;14:982.

+ 62. Parker LM, Murrell SE, Boden SC, Horton WC. The Outcome of Posterolateral Fusion in Highly Selected Patients with Discogenic Low Back Pain. *Spine* 1996;21:1909.

+ 63. Polatin PB, Kinney RK, Gatchel RJ, et al. Psychiatric Illness and Chronic Low Back Pain. The Mind and the Spine. Which Goes First? *Spine* 1993;18:66.

! 64. Raininko R, Manninen H, Battie MC, et al. Observer Variability in the Assessment of Disc Degeneration on Magnetic Resonance Images of the Lumbar and Thoracic Spine. *Spine* 1995;20:1029.

+ 65. Rask B, Dall BE. Use of the Pantaloon Cast for the Selection of Fusion Candidates in the Treatment of Chronic Low Back Pain. *Clin Orthop* 1993;288:148.

+ 66. Salminen JJ, Erkintalo M, Laine M, Pentti J. Low Back Pain in the Young. A Prospective Three-year Follow-up Study of Subjects With and Without Low Back Pain. *Spine* 1995;20:2101.

+ 67. Schneiderman G, Flannigan B, Kingston S, et al. Magnetic resonance Imaging in the Diagnosis of Disc Degeneration. Correlation with Discography. *Spine* 1987;12:276.

+ 68. Simmons ED Jr, Guntupalli M, Kowalski JM, et al. Familial Predisposition for Degenerative Disc Disease. A Case Control Study. *Spine* 1996;21:1527.

* 69. Simmons J, Aprill C, Dwyer A, Brodsky A. A Reassessment of Holt's Data on “The Question of Lumbar Discography.” *Clin Orthop* 1988;237:120.

+ 70. Smith SE, Darden BV, Rhyne AL, Wood KE. Outcome of Unoperated Discogram Positive Low Back Pain. *Spine* 1996;20:1997.

# 71. Southwick SM, White AA. The use of Psychological Tests in the Evaluation of Low Back Pain. *J Bone Joint Surg [Am]* 1983;65:560.

+ 72. Stauffer R, Coventry M. Anterior Interbody Lumbar Spine Fusion: Analysis of Mayo Clinic Series. *J Bone Joint Surg [Am]* 1972;54:756.

+ 73. Stauffer R, Coventry M. Posterolateral Lumbar Spine Fusion—Analysis of Mayo Clinic Series. *J Bone Joint Surg [Am]* 1972;54:1195.

+ 74. Steffee A, Sitkowski D. Posterior Lumbar Interbody Fusion and Plates. *Clin Orthop* 1988;227:99.

# 75. Steindler A, Luck J. Differential Diagnosis of Pain Low in the Back. *JAMA* 1938;110:106.

# 76. Steinmann JC, Herkowitz HN. Pseudarthrosis of the Spine. *Clin Orthop* 1992;284:80.

# 77. Sternbach R, Wolf SR, Murphy R, Akeson W. Aspects of Chronic Back Pain. *Psychosomatics* 1973;14:52.

# 78. Videman T, Battie MC. Epidemiology of Disc Disease. In: Weisel S, ed. *The Lumbar Spine*, 2nd ed. Philadelphia: Saunders, 1996:16.

* 79. Waddell G, McCullough JA, Kummel E, et al. Nonorganic Physical Signs in Low Back Pain. *Spine* 1980;5:117.

! 80. Walsh T, Weinstein J, Spratt K, Lehmann T. Lumbar Discography in Normal Subjects. *J Bone Joint Surg [Am]* 1990;72:1081.

* 81. Weatherly C, Prickett C, O'Brien J. Discogenic Pain Persisting Despite Solid Posterior Fusion. *J Bone Joint Surg Br* 1986;68:142.

+ 82. Wetzel FT, Larocca H. The Failed Posterior Lumbar Interbody Fusion. *Spine* 1991;167:83.

! 83. White AA, Panjabi MM, eds. *Clinical Biomechanics of the Spine*, 2nd ed. Philadelphia: Lippincott, 1990:345.

+ 84. Wiltse L, Rocchio P. Preoperative Psychological Tests as Predictors of Success of Chemonucleolysis in the Treatment of Low Back Pain Syndrome. *J Bone Joint Surg [Am]* 1975;57:478.

+ 85. Wood GW, Boyd RJ, Carothers TA, et al. The Effect of Pedicle Screw/Plate Fixation on Lumbar/Lumbosacral Autogenous Bone Graft Fusions in Patients with Degenerative Disc Disease. *Spine* 1995;20:819.

* 86. Yong-Hing K, Kirkaldy-Willis WH. The Pathophysiology of Disc Degeneration of the Lumbar Spine. *Orthop Clin North Am* 1983;14:59.

! 87. Yu S, Haugton VM, Sether LA, et al. Criteria for Classifying Normal and Degenerated Lumbar Intervertebral Discs. *Radiology* 1989;170:523.

+ 88. Zdeblick TA. A Prospective, Randomized Study of Lumbar Fusion—Preliminary Results. *Spine* 1993;18:983.

# 89. Zdeblick TA. The Treatment of Degenerative Lumbar Disorders. A Critical Review of the Literature. *Spine* 1995;20:126S.

+ 90. Zucherman JF, Zdeblick TA, Bailey SA, et al. Instrumented Laparoscopic Spinal Fusion. Preliminary Results. *Spine* 1995;20:2029.

# CHAPTER 146

# ANTERIOR LUMBAR INTERBODY FUSION

*Thomas A. Zdeblick*

**T. A. Zdeblick:** Professor and Chair, Orthopedic Surgery, University of Wisconsin, Madison, Wisconsin 53792.

Indications
- Degenerative Disc Disease
- Internal Disc Derangement
- Spondylolisthesis
- Deformity

Surgical Techniques
- Open Techniques
- Endoscopic Technique
- Fusion Options

Pitfalls and Complications
Author's Perspective
Chapter References

Perhaps no topic has generated as much interest in orthopaedic spine surgery over the past 10 years as anterior lumbar interbody fusion (ALIF). Although anterior fusions have been performed on the spine for more than 50 years, it is only recently that interest in the procedure has exploded. Traditionally, anterior or anterolateral approaches to the lumbar spine were performed for tumor, trauma, or infections. In these cases, debridement, strut grafting, and occasionally anterior fixation were used to decompress the spinal canal or stabilize the anterior spinal column. The advantages of these procedures included direct spinal canal decompression and reconstruction of the weight-bearing capability of the anterior column. Another advantage is that they avoid injury to posterior muscles.

The avoidance of posterior muscle dissection is important. Often, when posterolateral fusions were performed for degenerative disc problems, patients would have continued complaints of fatigue and weakness in the lumbar spine. Some of these symptoms may have been due to injury to the paraspinal muscles leading to “fusion disease” (19). In addition, over the past several decades, much research has pointed to the disc as a predominant source of chronic low back pain (see Chapter 144). Fusion procedures that eliminate discs entirely may offer advantages that more traditional posterior fusions do not. For both of these reasons, the indications for ALIF have greatly expanded over the last decade.

## INDICATIONS

Lumbar interbody fusion is indicated in selected patients with degenerative disc disease, internal disc derangement, spondylolisthesis, pseudarthrosis, and, occasionally, scoliosis, trauma, or infection. Each case must be evaluated on an individual basis to determine the appropriateness of surgical intervention.

### DEGENERATIVE DISC DISEASE

Degenerative disc disease shows radiographic changes of disc-space narrowing, endplate sclerosis, osteophyte formation, and occasionally vacuum phenomena within the disc space. Magnetic resonance imaging (MRI) corroborates this diagnosis, revealing “Modic” changes in the endplates surrounding the degenerative disc (14). Many of these changes can be traced to a previous episode of disc herniation that had been treated either with or without surgery. Often, in these cases, the sciatica has resolved but has been replaced by persistent chronic midline low-back pain.

Many patients with degenerative disc disease complain of pain over the sacroiliac joints, particularly if the L5–S1 disc space is involved. Most patients with degenerative disc disease can be successfully treated with an aggressive physical therapy program that includes trunk stabilization exercises and nonimpact aerobics. In the majority, symptoms improve, and patients decide to live with a low-level midline low-back ache. Other modalities that may be helpful include short-term periods of bracing, administration of nonsteroidal antiinflammatory medication, and occasionally manipulation. Epidural steroid injection, prolonged bed rest, transcutaneous electrical nerve stimulation units, and passive modalities such as heat, massage, or ice have not been proven to be of benefit.

Before offering surgery, evaluate a patient's psychological profile. Office findings of pain behaviors, Waddell's signs, chronic narcotic use, or excessive secondary gain are contraindications for surgical treatment (see Chapter 144). In addition, evaluate the adjacent discs. Ideally, only a one- or two-level fusion should be performed for degenerative disc disease. Fusion of more than two levels leads to less satisfactory clinical results. MRI of the adjacent disc is an excellent screening test. With normal MRI findings, it is safe to assume that the adjacent disc can be left unfused. If MRI is abnormal, then discography may be indicated to evaluate adjacent levels for fusion.

### INTERNAL DISC DERANGEMENT

Patients with a normal radiographic examination but abnormal MRI may have internal disc derangement (IDD). The MRI abnormalities of IDD include decreased signal intensity within the disc nucleus on T2-weighted images, annular tears (with or without enhancement), and high-intensity-zone lesions. In these cases, initiate a similar nonoperative treatment program before considering surgical therapy. Should patients satisfy diagnostic criteria and fail to improve with adequate conservative measures over 3–4 months, then discography is indicated for confirmation of the diagnosis. A positive discogram should include reproduction of the patient's symptoms upon injection, abnormal morphology with dye leakage through annular disruptions, and normal adjacent-level injections without pain reproduction (3). A patient who meets all of these criteria may be a candidate for ALIF surgery (1,6).

Other treatment modalities may include steroid injection within the disc, thermal repair of the disc annulus, or annular debridement. ALIF surgery, however, has the longest history of successful results in the treatment of this condition. It must always be kept in mind, however, that success is not universal in the treatment of patients with IDD. Many clinical reports document success rates in the 50% to 70% range (1,6,7,8 and 9). Patient selection is critical. Offer ALIF only to highly motivated patients with single-level disease who have no psychological overlay, secondary-gain issues, or chronic narcotic use. Only strict selection criteria will lead to an acceptable success rate from surgery.

### SPONDYLOLISTHESIS

Often, degenerative spondylolisthesis with spinal stenosis does not require ALIF. Most patients with this condition can be successfully treated with posterior decompression and posterolateral fusion techniques (19). In adult isthmic spondylolisthesis, however, ALIF plays an important role (see Chapter 162).

My approach to adult isthmic spondylolisthesis has evolved over the years. In patients in whom reduction of a spondylolisthesis is planned, anterior interbody support is necessary to prevent late hardware failure or pseudarthrosis. In patients with spondylolisthesis with a well preserved disc space and translational motion on flexion–extension films, anterior interbody support in addition to posterior fixation is necessary to achieve a high incidence of solid fusion. In patients with a collapsed disc space with degenerative changes, as well as isthmic spondylolisthesis, fusion with either anterior procedures alone or posterior procedures alone may be successful. Interbody fusion cages alone have successfully been used in this subset of spondylolisthesis patients. Exercise caution, however, when using cages alone for a spondylolisthesis patient who has a preserved disc space and hypermobility. In these cases, it is often difficult to obtain stability through the use of anterior cages alone.

### DEFORMITY

In selected cases of scoliosis and kyphosis in which correction will be performed, anterior release and interbody fusion are indicated. In addition, for patients with

traumatic endplate disruption or disc space infection, debridement and interbody fusion are helpful. Finally, in cases of previous pseudarthrosis of a posterolateral fusion, interbody fusion is often the only means of obtaining a solid arthrodesis. In addition, it avoids dissection through a previously scarred posterior paraspinal muscle approach.

## SURGICAL TECHNIQUES

Anterior lumbar interbody fusion surgery can be performed through a variety of surgical approaches. Open approaches include the transperitoneal, anterior retroperitoneal, and retroperitoneal flank approaches. For endoscopic techniques, the anterior transperitoneal laparoscopic approach has become popular, as has the retroperitoneal endoscopic approach using balloon insufflation or gasless techniques. All of these approaches require an excellent knowledge of the anatomy surrounding the middle and low lumbar spine (Fig. 146.1).

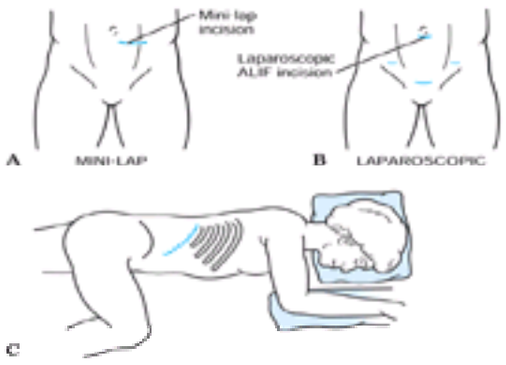


***Figure 146.1.*** Skin incisions utilized in anterior lumbar surgery. **A:** A skin incision utilized in the minilap retroperitoneal approach. A vertical paramedian incision may also be used. In this approach, the anterior rectus sheath is divided in line with the skin incision, the rectus abdominis muscle protected, and the preperitoneal space developed lateral to the peritoneal contents. **B:** The laparoscopic transperitoneal technique utilizes small skin incisions for the placement of the viewing camera (periumbilical portal), 5 mm incisions for lateral retractors, and a 15–20 mm incision for the placement of the fusion cages. This incision is typically placed in the suprapubic location for the L5–S1 disc space. **C:** Approach the lumbar interbody spaces laterally through a flank approach. Position the patient laterally with the ipsilateral hip flexed to relax the psoas muscles. Make a flank incision paralleling the twelfth rib. The position will vary, depending on the level for the fusion. For L-1 burst fractures, a typical incision will overly the eleventh rib. For L-2 or L-3 access, a twelfth rib incision is useful, and an incision midway between the iliac crest and the twelfth rib is useful for the L3–4 space.

Surgeons must be familiar with the vascular anatomy, including the bifurcation of the aorta and vena cava and the surrounding veins such as the iliolumbar vein or segmental vessels, as well as the path of the ureters and the left-sided placement of the sigmoid colon. In addition, the locations of the nerve roots as they exit the foramina and of the presacral parasympathetic plexus should be well known. Surgeons unfamiliar with this vascular anatomy or unwilling to handle complications from injuries to these and other important structures should enlist the help of a vascular or general surgeon in exposing the anterior lumbar spine (see Chapter 138).

### OPEN TECHNIQUES

#### *Open Transperitoneal Approach*

The open transperitoneal approach is the oldest and most traditional approach to the anterior lumbar spine.

- Make a midline vertical skin incision, and split the fascia between the rectus abdominis muscles (Fig. 146.2).

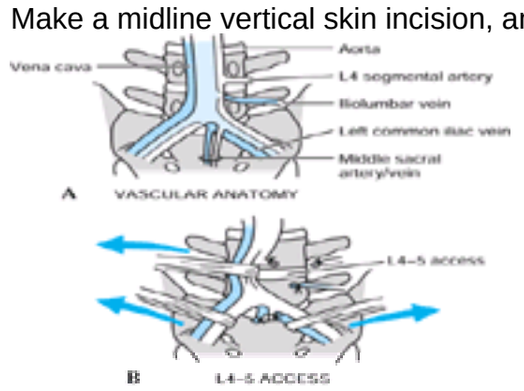


***Figure 146.2.*** **A:** Normal vascular anatomy of the anterior lumbar spine. Typically, the vena cava bifurcates at a higher point than the aorta. Usually, it bifurcates at the L4–5 disc space, and the aorta bifurcates over the L-5 body. The iliolumbar vein is a branch of the left common iliac vein and runs in an inferior direction at approximately 40°. **B:** Access to the L5–S1 disc space is typically between the bifurcation of the vessels. Ligation and control of the middle sacral artery and vein is necessary for complete disc exposure. At L4–5, the most common access pathway is to the left of both of the great vessels, with retraction in a left-to-right direction. This requires control and ligation of the iliolumbar vein for complete vessel mobility. Use blunt dissection only at both levels to prevent damage to the presacral nerve plexus.

- Enter the peritoneal cavity, and retract the small bowel superiorly and the sigmoid colon to the left laterally.
- Typically, the aorta and vena cava bifurcate at the level of the L-5 vertebra. There is considerable variation, however, so check the preoperative MRI to confirm the level.
- To expose the L5–S1 disc space, incise the posterior peritoneum vertically overlying the disc space. This incision can be safely made between the bifurcation of the aorta and vena cava.
- The presacral plexus of nerves runs directly over the L5–S1 annulus at this level. To minimize damage to this plexus, infiltrate the retroperitoneal space with saline, using a fine needle, before dividing the posterior peritoneum.
- Cut the peritoneum without cautery, and dissect over the disc space bluntly to minimize the risk of damage to the nerve plexus. In men, retrograde ejaculation may result if this plexus of nerves is damaged.
- Ligate the middle sacral artery and vein, which are adherent to the annulus, before exposing the disc.
- At L4–5, access to the disc space is more difficult. Study the vascular anatomy preoperatively on the patient's MRI scan (Fig. 146.2). Occasionally, the L4–5 disc space can be approached between the bifurcation of the vessels. Most commonly, however, a left-to-right path to the L4–5 disc space is recommended. In this manner, the aorta and vena cava are both retracted from the left to the right across the L4–5 disc space. This retraction is only possible after the iliolumbar vein is ligated. This vein descends at a 45° angle from the vena cava, angling toward the psoas muscle on the left side.
- Once it is ligated, adequate mobility of the great vessels is usually obtained. If possible, avoid dissection between the aorta and vena cava.
- The presacral plexus nerves are particularly vulnerable during dissection between the great vessels.
- At L3–4 disc space, the aorta and vena cava are more mobile, although segmental vessels need to be ligated to obtain exposure.
- After exposure is obtained, it is mandatory that the vascular structures be protected throughout the fusion procedure. I prefer to drive four Steinmann pins covered with a red rubber catheter into the endplates above and below the disc space to be worked on. These four pins serve as self-retaining retractors, providing a safe zone in which to perform the fusion. Other retraction systems are available, as well as self-retaining blades that may be staked through the vertebral endplates.
- Take particular care to avoid injury to the vena cava and common iliac veins. Once exsanguinated by the retraction, they are difficult to visualize and are prone to injury.

***Figure 146.3.*** Anteroposterior (**A**) and lateral (**B**) radiographs of a 39-year-old man with persistent low-back pain. He had a history of remote sciatica, which resolved but has now developed into persistent low-back pain despite maximal physical therapy. These radiographs show classic changes of degenerative disc disease: a narrowed disc space, sclerotic endplates, and marginal osteophyte formation. The L4–5 disc was normal on MRI, and thus no discography was indicated.

- Transperitoneal exposures of the lumbar spine above L-3 are difficult because of the renal and mesenteric vessels. At these levels, the flank retroperitoneal approach offers a lateral exposure of the lumbar vertebral bodies. This approach is most useful when debridement for infection, trauma, or tumor is required. When corpectomy is necessary, a lateral plate device is useful for stability and can best be placed from a lateral approach. If debridement and grafting alone are being performed, the anterolateral or anterior approach is adequate.

***Flank Approach***

The flank approach involves an oblique incision centered over the area of pathology of the lumbar spine. It parallels the twelfth rib and is anywhere from 4 to 8 in (10–20 cm) long, depending on the size of the patient.

- Use fluoroscopy to center this incision directly over the level of pathology.
- Should exposure of the low lumbar spine be required as well, curve the incision across the lateral aspect of the abdomen.
- After incising the skin, divide the external oblique, internal oblique, and transversalis muscle layers in line with the incision.
- Take care when dividing the transversalis to ensure that the reflection of the peritoneum is free.
- Once the transversalis fascia is divided, enter the retroperitoneal space, which is behind the fascia surrounding the kidney and thus is truly behind Girota's fascia.
- After entering the retroperitoneal space, identify the psoas muscle, and take care to preserve the ilioinguinal nerve lying on its surface.
- The origin of the psoas muscle is usually at the L-1 body, and each of the lumbar nerve roots as they exit the foramina run in the substance of the psoas muscle. For this reason, the psoas must be retracted in an anterior-to-posterior direction to expose the appropriate disc space.
- Perform this exposure, using elevators and cautery, controlling segmental vessel as needed.

This approach gives excellent visualization of the lateral aspect of the disc and vertebral body; it is limited posteriorly by the level of the nerve at the foramen and anteriorly by the great vessels. If necessary, dissect the anterior longitudinal ligament free from the vertebral bodies, and carry out subperiosteal dissection around to the opposite side of the vertebral body. This maneuver permits complete release of all soft-tissue structures in cases of deformity.

***Anterior Rectus–sparing Retroperitoneal Approach***

My preferred approach for ALIF is the anterior rectus-sparing retroperitoneal approach. In this approach, none of the muscles of the abdominal wall is divided, and therefore quick recovery is possible. I prefer a transverse incision.

- Begin in the midline, and extend the incision to the left for approximately 3–4 in (7.5–10 cm).
- Divide the anterior rectus sheath, and retract the rectus muscle from the midline to the left.
- Identify the posterior rectus sheath and the arcuate line.
- Use blunt dissection beneath the arcuate line to enter the preperitoneal space, and continue the dissection laterally to the left until you are lateral to the peritoneal contents and the psoas muscle can be identified.
- Place a retractor to pull the peritoneal contents toward the midline to expose the retroperitoneal space overlying the spine.
- Identify the left ureter, and protect it throughout the procedure. In general, in cases involving the L3-4 or L4-5 disc space, the ureter will be retracted toward the midline with the visceral peritoneum. At the L5-S1 space, the ureter will usually be on the left side of the incision and will be retracted laterally.
- Identify the sympathetic chain running on the psoas muscle and protect it.
- The dissection at this point proceeds in much the same fashion as previously described (see “Open Transperitoneal Approach” above).
- Bluntly dissect the tissues lateral to the aorta and vena cava at the L4–5 space or between the great vessels at L5–S1.
- At L4–5, ligate the iliolumbar vein to allow exposure.
- At L5–S1, ligate the middle sacral artery and vein to allow blunt dissection to proceed along the annulus.
- Several self-retaining retraction systems are available for use through this “minilaparatomy (minilap)” approach.

**ENDOSCOPIC TECHNIQUE**

In 1993, I began performing laparoscopic transperitoneal fusion of the lumbar spine and developed this approach along with Dr. David Mahvi, my general surgery colleague (13,20). The L5–S1 level lends itself to an endoscopic approach because of its easy accessibility between the bifurcation of the great vessels (Fig. 146.4).

***Figure 146.4.*** Laparoscopic transperitioneal fusion access route. Surgery consisted of anterior discectomy at L5–S1, distraction, and insertion of two tapered (LT) cages (Lumer Tspered, Sofamon Danek, Memphis, TN) at the L5–S1 disc space. Note the restoration of foraminal height and sagittal contour.

- Give a light bowel preparation the night before surgery.
- Facilitate exposure by placing the patient in the Trendelenburg position and allowing abdominal insufflation, which causes the small bowel to drift toward the diaphragm. It precludes the need for retraction of the abdominal contents; thus postoperative ileus is eliminated.
- Usually, the laparoscopic camera is placed in a periumbilical incision.
- Place two 5 mm portals laterally, midway between the umbilicus and the pubis, to allow retraction or suction as needed.
- Finally, place a suprapubic portal in line with the disc space. At the L5–S1 level, this is often two to three fingerbreadths above the pubic symphysis. At L4–5, it is usually midway between the umbilicus and pubic symphysis.
- Drain the bladder with a Foley catheter before placing this portal.
- The sigmoid colon may need to be retracted toward the left and will usually stay in this position throughout the procedure. The remainder of the dissection proceeds in much the same fashion as previously described (see “Open Transperitoneal Approach” above).

- Incise the posterior peritoneum vertically overlying the disc space. For the L5–S1 space, it is done just to the right of the midline or, for L4–5, just to the left of the aorta.
- Bluntly dissect the tissues in the retroperitoneal space. Often, the presacral plexus of nerves can be visually identified. Bluntly retract the nerves.
- At L5–S1, the middle sacral artery and vein lie in a plane adherent to the anterior annulus. Coagulate them with bipolar cautery.
- At L4–5, identify the iliolumbar vein coming off the vena cava at a 45° angle and heading inferiorly and laterally toward the psoas muscle. Ligate this vein, and retract the great vessels in a left-to-right direction to expose the annulus of the disc. Specially made vein retractors placed laparoscopically through the portals facilitate retraction of the great vessels.

The advantages of endoscopy are better visualization with magnification of the vascular structures and rapid patient recovery. Contraindications to the transperitoneal endoscopic technique include multiple abdominal adhesions, previous anterior spine surgery, and severe sacral tilt such that the L5–S1 disc space is not accessible. It is strongly recommended that this surgery be done with a general surgeon who has laparoscopic experience.

Endoscopic techniques utilizing retroperitoneal dissection have also been performed. Transfeldt et al. (18) and Thalgott et al. (17) described techniques whereby a small lateral incision is made through the oblique muscles and a balloon is placed in the retroperitoneal space. This balloon is then inflated, dissecting free the retroperitoneal cavity. Once the peritoneal reflection is dissected toward the midline, an anterolateral skin incision is made to expose the disc space.

This approach can also be carried out without balloon dissection, using a gasless system in which the anterior abdominal wall is lifted with a retractor system. My experience with this technique is that it can cause abdominal wall discomfort and slower patient recovery. In all of these endoscopic systems, the cost of disposable equipment and the time required for surgeons to learn the procedure must be balanced against the more traditional open or mini-open approaches. My current approach is as follows:

- At L5–S1 disc space, the laparoscopic transperitoneal approach is safe and quick and allows excellent visualization of the space.
- For multilevel fusions or fusion at L4–5, I now prefer a minilap-type open retroperitoneal exposure. It gives more reliable control of the bifurcation of the great vessels at the L4–5 space.

**FUSION OPTIONS**

Interbody fusion of the lumbar spine can be performed with a variety of methods. Most surgeons prefer to remove the entire disc before fusion. This requires a rectangular block-style incision of the annulus, removal of the annulus, and removal of all disc material including endplate cartilage through the use of a combination of curets, rongeurs, and elevators. In general, the annulus is left intact laterally and posteriorly. In some endoscopic techniques, trephine-style discectomies are preferred because it is risky to use curets and elevators in endoscopy. These techniques also preserve more of the anterior annulus, which helps ensure cage stability.

Surgical options for fusion include iliac crest or other autogenous bone graft, allograft bone consisting of femoral rings or fibula, and processed allografts consisting of threaded cortical dowels combined with autograft cancellous bone. Metallic options include the placement of a lateral plate overlying the disc space and bone graft, as well as devices placed within the disc space itself. These devices include anteriorly placed threaded cylindrical cages, anteriorly placed threaded tapered cages, laterally placed cages, lateral cages plus lateral plates, and upright cages placed within the disc space (Fig. 146.5). Other materials that have been used include carbon fiber cages and ceramic spacers.

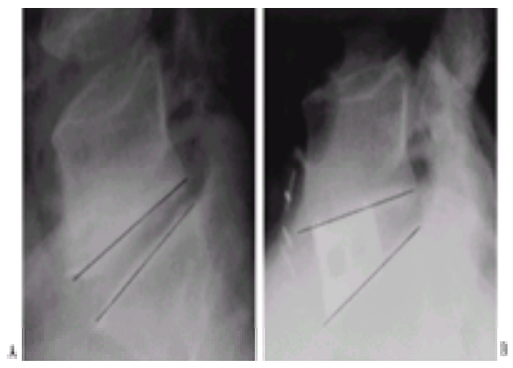

***Figure 146.5.*** The use of tapered interbody fusion cages at L5–S1 permits the restoration of both height and lordosis. Preoperative (**A**) and postoperative (**B**) lateral radiographs demonstrate the lordosis obtained in a 48-year-old man with degenerative disc disease.

The principles of cage interbody fusion include the following:

- Disc space distraction to cause tension in surrounding ligamentous structures, which increases stability
- Preparation of the endplates to expose cancellous bone, as well as providing an endplate substrate for weight bearing
- Provision of enough bony surface area to heal from one endplate through the bone graft to the other endplate
- Realignment of the spine to its optimal lordotic sagittal balance
- Production of a solid, long-term arthrodesis.

With current short-term follow-up, it appears that cage interbody fusion is successful in meeting these goals (13).

Several principles must be kept in mind, however, when interbody fusion cages are used. Disc spaces that have not undergone any degree of collapse are difficult to further distract. Therefore, the tall mobile disc space may not be an ideal candidate for cage-only fusion procedures. In addition, forceful distraction is required, and if the endplate bone is not strong enough to resist the distractive force, subsidence and instability will result. For this reason, do not use cages in patients with osteoporosis. Finally, most cage systems are designed for two cages to be implanted side by side. Although some biomechanical studies suggest that a single cage may lead to short-term stability, it is my feeling that there is inadequate surface area to ensure long-term arthrodesis.

The RAY cage (Surgical Dynamics, Minneapolis, MN) and the BAK device (Spinetech, Minneapolis, MN) were the initial threaded interbody fusion cages (10). They have been used with both posterior and anterior interbody fusion techniques. When used anteriorly, these systems restore lordosis through patient positioning and the placement of a tapered distraction plug.

- After the disc space is distracted, prepare the endplate on each side of the disc by passing a reamer to remove endplate cartilage, bone, and disc material. Then tap each side and place two threaded devices.
- Take great care, when placing cages, to identify the midline of the spine so that cages are not placed eccentrically.
- Determine the appropriate size cages from the radiographs and preoperative templates.
- A tapered threaded device has been designed that more accurately matches the anatomy of the L5–S1 disc space. It appears that a greater amount of lordosis can be obtained through the use of tapered cages with a minimal amount of endplate resection (16).

In general, threaded cages placed anteriorly can restore the stability of the lumbar spine without the need for supplementary posterior fixation. They have successfully been used in patients with degenerative disc disease or spondylolisthesis with a degenerated disc space. I do not recommend the use of cages alone in cases of spondylolisthesis with a tall mobile disc space.

Lateral cages have been placed both openly and endoscopically in the lumbar spine. Often, a single threaded cylindrical lateral cage is utilized. Although some authors have had success with this technique, others have shown that additional bone grafting is necessary to provide an adequate surface area for healing. In addition, LeHuec (11) designed a combined lateral cage and plate system to increase the rate of fusion.

Harms first introduced upright titanium mesh cages. Typically, two upright cylinders of titanium mesh are cut to fit the disc space and then driven into the space to provide support for the endplate and for healing potential. Harms recommended that posterior instrumentation be used to supplement ALIF with upright cages. Brantigan and Steffee (2) designed upright carbon fiber cages. While these were also met with worldwide acceptance and a high degree of success, most authors would agree that the upright carbon fiber cage is not stable enough to be used as a stand-alone device. Fraser (5) recommends that posterior fusion, as well as facet

screw instrumentation, be utilized to augment the interbody carbon fiber cage.

The use of spinal cages is evolving rapidly. Surgeons must evaluate each patient on an individual basis to determine which particular device is most appropriate.

## PITFALLS AND COMPLICATIONS

Anterior lumbar surgery is never easy and requires adequate surgical planning and preoperative preparation. An accurate understanding of the vascular and neurologic anatomy is a requirement for the performance of these procedures. The assistance of a general or vascular surgeon may be necessary to obtain adequate and safe exposure. Preoperative preparation consisting of a light bowel regime (e.g., GOLYTELY and Fleet enema) will make retraction of intestinal structures easier. Preoperative examination of the patient's abdomen and flank for prior incisions and potential adhesions is necessary. Preoperative evaluation of MRI or computed tomography to assess variations in the vascular anatomy is important, as it directs which approach will used for the portion of the spine to be fixed.

Vascular complications are certainly the most serious and life-threatening. The incidence of injury to the aorta, vena cava, or iliac vessels is estimated at 1% to 3% for anterior approaches (7,9). These injuries may be life-threatening and need to be dealt with calmly and with assistance. Obtain immediate control with tamponade. If the procedure is being done endoscopically, immediate laparotomy is recommended.

The assistance of a vascular surgeon is highly recommended for repair of the great vessels. The most common areas of vascular injury are the left common iliac vein at the L5–S1 level and the left side of the vena cava at the L4–5 level. At L4–5, there are several small perforating veins that may come from the posterior surface of the vena cava. They may need to be coagulated and divided before the vena cava is retracted, to prevent their avulsion. As mentioned earlier, control and ligation of the iliolumbar vein will greatly assist in vena cava mobilization.

Arterial occlusion due to embolization of plaques has also been reported (18). Anterior approaches to the lumbar spine in elderly patients are hazardous and must be done only when absolutely necessary and with caution. In many of these patients, the arterial system is much less mobile, and retraction may dislodge plaques. Always do a postoperative vascular examination, and if pulses are absent or the limb is cool, obtain an immediate consultation with a vascular surgeon. Routine anticoagulation has not been found to be necessary in ALIF surgery. However, if a major vessel must be repaired, postoperative anticoagulation may be necessary.

Neurologic complications include damage to the presacral plexus, nerve root injury, and violation of the spinal canal. As mentioned, the parasympathetic nerves that run within the presacral plexus are vulnerable to injury. They run along the aorta and vena cava and then between the bifurcation as they pass distally. For work along the L4-5 or L5–S1 disc spaces, it is mandatory that only blunt dissection be used and that no monopolar electrocautery be used. The incidence of retrograde ejaculation following ALIF has been estimated to be from 1% to 4%.

It appears that the incidence of neurologic injury is slightly higher in endoscopic procedures than in the open retroperitoneal approach. Early in any surgeon's experience, there is certainly a higher incidence of retrograde ejaculation. Fortunately, most cases of retrograde ejaculation are temporary and resolve within 4–6 months. It is assumed that they are due to stretch injury that occurs during exposure of the disc space. Should the patient not recover from retrograde ejaculation, urologic consultation is recommended.

The nerve roots are vulnerable after they exit the neuroforamina and proceed toward the psoas muscle. If the midline is not adequately evaluated and fusions are performed far lateral to the disc space, the nerve root is vulnerable to injury. Bone grafts or cages that are placed too laterally or too deeply may impinge on the neuroforamen of the level above. It is imperative to use fluoroscopy at some point to locate the midline of the disc space and maintain orientation as to the right and left margins of the disc space.

Cages or grafts that are placed too deeply may impinge on the spinal canal, causing cauda equina injury. Once again, fluoroscopic control of the implantation of interbody fusion devices should help eliminate this complication.

Abdominal-wall complications related to the approach may occur. The epigastric vessels must be either retracted or controlled, or a postoperative abdominal-wall hematoma may occur. Overzealous retraction of the rectus abdominis may lead to a stretch injury and cause weakness of the abdominal wall. During a flank approach, repair each layer independently to prevent weakening of the abdominal wall.

Pseudarthrosis of an ALIF may occur. Although the incidence of a pseudarthrosis after a 360° fusion is performed is exceedingly low, ALIF alone does carry a risk of pseudarthrosis. With the use of only iliac crest autograft, the pseudarthrosis rate was estimated at 30% to 35% (4,7). Femoral allograft rings have shown to have a pseudarthrosis rate approaching 20% (12). Threaded cortical bone dowels appear to have a much lower pseudarthrosis rate, but follow-up is too short to be conclusive.

Threaded interbody fusion cages have been reported to have a 90% fusion rate in the early BAK and RAY cage studies (10). Recent reports show a higher pseudarthrosis rate, however, which may be secondary to poor surgical indications or poor surgical technique (15). Should pseudarthrosis occur and the cages or bone dowels remain in an acceptable position, I recommend proceeding with a posterior instrumented fusion at that level. It will often resolve the patient's symptoms and may lead to healing of the interbody fusion. If a cage or bone dowel should migrate and cause neurologic symptoms, it should be removed at the time of revision surgery. Revision anterior interbody surgery is dangerous and should be approached with caution. Vascular structures often become adherent to the previously operated disc space, and the presence of a vascular surgeon is necessary for these challenging cases.

Finally, the incidence of persistent pain after ALIF has been estimated to be 10% to 20%. The exact cause is unknown and may be related to patient selection. This fact alone indicates that the treatment of low-back pain with interbody fusion is evolving. Keep in mind that the exact cause of each patient's low-back pain may be unknown.

## AUTHOR'S PERSPECTIVE

The use of ALIF techniques provides numerous advantages. Restoration of the weight-bearing column, provision of a greater surface for fusion to occur, and the ability to recreate the normal sagittal position of the spine are among its greatest advantages. If complications should occur, however, many of these advantages are lost. To obtain a high clinical and radiographic success rate, strict adherence to the details of the surgical approach and the fusion technique are required.

### CHAPTER REFERENCES

Each reference is categorized according to the following scheme: *, classic article; #, review article; !, basic research article; and +, clinical results/outcome study.


+ 1. Blumenthal SL, Baker J, Dossett A, Selby DK. The Role of Anterior Lumbar Fusion for Internal Disc Disruption. *Spine* 1988;13:566.

+ 2. Brantigan JW, Steffee AD. A Carbon Fiber Implant to Aid Interbody Lumbar Fusion: Two-year Clinical Results in the First 26 Patients. *Spine* 1993;18:2106.

+ 3. Crock HV. Internal Disc Disruption: A Challenge to Disc Prolapse Fifty Years on. *Spine* 1986;11:650.

+ 4. Dennis S, Watkins R, Landaker S, et al. Comparison of Disc Space Heights after Anterior Lumbar Interbody Fusion. *Spine* 1989;18:876.

+ 5. Fraser R. Personal communication.

+ 6. Gill K, Blumenthal SL. Functional Results after Anterior Lumbar Fusion at L5-S1 in Patients with Normal and Abnormal MRI Scans. *Spine* 1992;17:940.

+ 7. Goldner J, Urbaniak J, McCollum D. Anterior Disc Excision and Interbody Spinal Fusion for Chronic Low Back Pain. Orthop Clin North Am 1971;2:544.

+ 8. Knox BD, Chapman TM. The Anterior Lumbar Interbody Fusion for Discogram Concordant Pain. *J Spinal Disord* 1993;6:242.

+ 9. Kozak JA, Heilman AE, O'Brien JP. Anterior Lumbar Fusion Options: Technique and Graft Materials. *Clin Orthop* 1994;300:45.

+ 10. Kuslich SD, Dowdle JA. Two-year Follow-up Results of an Interbody Fusion Device. Presented at the Ninth Annual Meeting of the North American Spine Society, Minneapolis, MN, October 19–21, 1994.

+ 11. LeHuec JC. Lateral Cage Endoscopic Fusion. Presented at the Thirteenth Annual Meeting of the North American Spine Society, San Francisco, CA, October 27, 1998.

+ 12. Loguidice VA, Johnson RG, Guyer RD, et al. Anterior Lumbar Interbody Fusion. *Spine* 1988;13:366.

+ 13. Mahvi DM, Zdeblick TA. A Prospective Study of Laparoscopic Spinal Fusion. *Ann Surg* 1996;224:85.

+ 14. Modic MT, Steinberg PM, Ross JS, et al. Degenerative Disc Disease: Assessment of Changes in Vertebral Marrow. *Radiology* 1988;166:193.

+ 15. O'Dowd JK, Lam K, Mulholland RC, BAK Cage: Nottingham Results. Presented at the Thirteenth Annual Meeting of the North American Spine Society, San Francisco, CA, October 28, 1998.

+ 16. Orr RD, Andres B, Checovich M, Zdeblick TA. Results of Anterior Spinal Fusion with the Tapered Interbody Fusion (TIF) Device. Presented at the Thirteenth Annual Meeting of the North American Spine Society, San Francisco, CA, October 28, 1998.

+ 17. Thalgott JS, Chin AK, Ameriks JA. Minimally Invasive 360° Fusion. Presented at the Thirteenth Annual Meeting of the North American Spine Society, San Francisco, CA, October 28, 1998.

+ 18. Transfeldt E, Escobar G, Garvey T. Complications of View-assisted Spine Surgery. Presented at the Thirteenth Annual Meeting of the North American Spine Society, San Francisco, CA, October 28, 1998.

+ 19. Zdeblick TA. A Prospective Randomized Study of the Surgical Treatment of L5-S1 Degenerative Disc Disease. Presented at the Tenth Annual Meeting of the North American Spine Society, Washington, DC, October 20, 1995.

+ 20. Zuckerman JF, Zdeblick TA, Bailey SA, et al. Instrumented Laparoscopic Spinal Fusion: Preliminary Results. *Spine* 1995;20:2029.

# CHAPTER 147

# SPINAL STENOSIS

*Gordon R. Bell*

**G. R. Bell:** Vice-Chairman, Department of Orthopaedic Surgery, Head, Section of Spinal Surgery, Cleveland Clinic Foundation, Cleveland, Ohio, 44195.

Assessment
Classification
Clinical Evaluation
Natural History
Surgical Techniques
Comorbidity and Surgical Outcome
Laminectomy
Hemilaminectomy
Results of Decompressive Laminectomy
Alternatives to Laminectomy
Laminectomy and Fusion for Spinal Stenosis
Spinal Stenosis with Degenerative Spondylolisthesis
Results of Decompression without Fusion
Results of Decompression with Noninstrumented Fusion
Results of Decompression with Instrumented Fusion
Author's Preferred Treatment
Pitfalls and Complications
General Complications
Deep Venous Thrombosis and Pulmonary Embolus
Specific Complications Related to Posterior Decompression for Spinal Stenosis
Inadequate Neural Decompression
Recurrent Stenosis
Durotomy
Nerve Root Injury
Scar Tissue
Superficial Wound Infection
Deep Wound Infections
Epidural Abscess
Epidural Hematoma
Compression by Fat Grafts or Synthetic Scar Barriers
Vascular Complications
Postoperative Instability
Author's Perspective
Chapter References

Spinal stenosis describes a clinical syndrome of back, buttock, or leg pain with characteristic provocative and palliative features. The term “stenosis” denotes a narrowing or constriction of a tubular structure. Sachs and Fraenkel (103a) were among the first to relate symptoms of sciatica to neural compression within the spinal canal. Subsequent descriptions of this condition described acquired (degenerative) bony compression and congenital narrowing of the spinal canal. Van Gelderen (114a) proposed hypertrophied ligamentum as a potential cause of spinal stenosis and reported on two patients with this condition. The clinical features of the syndrome of spinal stenosis and its relationship to congenital narrowing were described in detail by the Dutch surgeon Verbiest, who also demonstrated mechanical compression of neural structures by myelography (116). Kirkaldy-Willis et al. further defined the pathoanatomy of spinal stenosis and helped correlate pathologic changes with symptoms (62).

## ASSESSMENT

### CLASSIFICATION

The etiology of spinal stenosis is most commonly either congenital (developmental), acquired (degenerative), or a combination of both (Table 147.1) (2). The majority of cases of spinal stenosis are acquired, being caused by degenerative changes occurring in the three-joint complex consisting of the intervertebral disc and the two facet joints. In some cases, such degenerative changes may be superimposed on a pre-existing congenital stenosis. Variations in the shape, as well as the size, of the spinal canal may predispose the patient to spinal stenosis, with a trefoil canal being associated with lateral recess stenosis more commonly than a round or oval canal.

I. Congenital/developmental stenosis
   A. Idiopathic (hereditary)
   B. Achondroplastic
II. Acquired stenosis
   A. Degenerative
      1. Central
      2. Peripheral (lateral recess, neural foramen)
      3. Degenerative spondylolisthesis
   B. Combined congenital and degenerative stenosis
   C. Spondylolytic/spondylolisthetic
   D. Iatrogenic
      1. Postlaminectomy
      2. Postfusion
      3. Postchemonucleolysis
   E. Posttraumatic
   F. Metabolic
      1. Paget's disease
      2. Flourosis

From Arnoldi C, Brodsky A, Cauchois J, et al. Lumbar Spinal Stenosis and Nerve Root Entrapment Syndromes. Clin Orthop 1976;115:4, with permission.

*Table 147.1. Classification of Spinal Stenosis*

### CLINICAL EVALUATION

#### *History*

*Spinal stenosis* is an anatomic description that should not be confused with *neurogenic claudication,* although the two terms are often used interchangeably. Spinal stenosis refers to morphology, not symptoms. Neurogenic claudication, also known as *pseudoclaudication,* is a clinical syndrome with symptoms of leg pain that are associated with walking (116). Neurogenic claudication should also be distinguished from vascular claudication, which has a different etiology and slightly different clinical features (Table 147.2).

| Evaluation | Vascular | Neurogenic |
|---|---|---|
| Walking distance | Fixed | Variable |
| Palliative factors | Standing at rest | Sitting/bending |
| Provocative factors | Walking/exercise | Walking/standing |
| Walking uphill | Painful | Painless |
| Bicycle test | Positive (painful) | Negative (painless) |
| Pulses | Absent | Present |
| Skin | Loss of hair/shiny | Normal |
| Weakness | Rarely | Occasionally |
| Back pain | Occasionally | Commonly |
| Back motion | Normal | Limited |
| Pain character | Cramping/distal-to-proximal | Numbness/aching/proximal-to-distal |
| Atrophy | Uncommon | Occasionally |

***Table 147.2. Vascular Versus Neurogenic Claudication***

Spinal stenosis is a condition of middle age and older, and is typically due to age-related degenerative changes of the lumbar spine (Table 147.3). The onset of symptoms is usually insidious and without associated trauma. A history of antecedent low back pain (LBP) is common, partly because of age-related spondylosis.

| | Lumbar disc herniation | Lumbar spinal stenosis |
|---|---|---|
| Age (years) | <50 | >50 |
| Sex | Male | Female |
| Onset | Acute | Insidious |
| Pain | Radicular/dermatomal | Referred/diffuse |
| Provocative factors | Sitting | Standing/walking |
| Palliative factors | Standing | Sitting |
| Weakness | Common | Uncommon |
| Sensory changes | Common | Uncommon |
| Tension sign | Present | Absent |
| Neurological findings | Present | Absent |

***Table 147.3. Comparative Features of Lumbar Disc Herniation versus Spinal Stenosis***

Neurogenic claudication is defined as lower extremity pain, paresthesias, or weakness associated with walking or standing (57). Pain is the predominant symptom, being present in up to 94% of patients, with numbness (63%) and weakness (43%) being less common. Bilateral involvement is common. Patients with neurogenic claudication may present with either unilateral radicular pain or with diffuse, nondermatomal symptoms beginning in the buttocks and extending a variable distance into the legs. Radicular pain is typically dermatomal in distribution and is often unilateral. It is the presenting type of symptom in 6% to 13% of symptomatic patients. It is often seen with lateral recess stenosis, foraminal stenosis, or with concomitant disc herniation. The presence of a symptomatic disc herniation in a patient with a narrowed spinal canal and spinal stenosis is not uncommon. Patients with either developmental or degenerative stenosis are more likely to develop symptomatic radiculopathy in the presence of a small disc herniation or even disc bulging (42,94).

Symptoms are typically produced by standing or walking and are relieved by sitting or bending forward (Table 147.2). Patients may preferentially assume a stooped-over posture when walking, or even standing, in order to ameliorate symptoms (5). Other leg symptoms such as weakness or numbness may also occur in association with prolonged standing or walking. Night pain is uncommon, although it has been described in patients with lateral recess stenosis (54). Unusual symptoms, such as priapism associated with intermittent claudication during walking, have also been reported.

The relationship of symptoms to posture can be explained by the variation of canal size with posture (5,47,122). Cadaveric studies have demonstrated that the spinal canal cross-sectional area, midsagittal diameter, and subarticular sagittal diameter are significantly reduced in extension (standing) and are increased with flexion (sitting) (47). Associated neural compression was also found to be greater in extension than in flexion (47).

*In vivo* studies relating posture to epidural pressure measurements have shown that epidural pressures at the level of stenosis were higher in the standing posture compared with those in the lying and sitting postures. Furthermore, local epidural pressures were increased with extension and decreased with flexion (47).

Neurogenic claudication should be distinguished from vascular claudication (Table 147.2). Although both conditions may present with leg pain associated with walking, it is only patients with neurogenic claudication who have leg pain resulting from standing. Leg pain associated with neurogenic claudication is highly position dependent. Vascular claudication, on the other hand, is unaffected by positions of lumbar flexion or extension. Leg pain from vascular claudication may be produced by cycling in a sitting position (27). Patients with vascular claudication typically have leg pain while walking uphill, whereas patients with a neurogenic etiology do not have this pain owing to the slightly flexed posture of the lumbar spine associated with this activity. Patients with neurogenic claudication may actually have increased leg pain when walking down an incline owing to increased associated lumbar lordosis.

A summary of the pertinent historical features of spinal strenosis are listed below:

- Demographics
  - Typically middle aged or older, unless congenital
  - Female > male (3:1 to 5:1)
- Leg pain > LBP
- May have long history of antecedent LBP
- Leg pain
  - Referred or radicular
  - Pseudoclaudication (neurogenic claudication)
    - Provoked by standing or walking
    - Relieved by sitting or leaning (“grocery cart sign”)
- Differential diagnosis
  - Peripheral neuropathy (not activity related; burning dysesthesia)
  - Vascular claudication versus neurogenic claudication (Table 147.2)
  - Hip arthropathy (“Hip-spine syndrome”)

### *Physical Examination*

Begin the examination of the patient with spinal stenosis by observing the patient, both at rest and during walking. Because symptoms are typically induced by the normal lordotic posture associated with walking or standing, the patient often preferentially assumes a slightly flexed posture in order to relieve neural compression causing leg pain. Flattening of the lower lumbar spine, owing to reduction in lumbar lordosis, may also be observed. With progressive ambulation, the patient may become increasingly more kyphotic in posture. This represents a conscious, or subconscious, attempt to decrease root compression by increasing canal or foraminal size. Back range of motion will likely be reduced as a result of age-related arthrosis.

Lumbar spinal stenosis is usually unaccompanied by hard neurologic signs (Table 147.3) (5,57,102). Tension signs, such as straight leg raising sign or femoral nerve stretch test, are uncommon with spinal stenosis unless it is associated with a disc herniation. Deep tendon reflexes, particularly at the ankle, may be normal, symmetrically reduced, or absent in the older patient. Therefore, the presence of diminished reflexes is usually not clinically significant unless it is asymmetric. Sensory findings, such as diminution of pinprick sensation, are uncommon with spinal stenosis. The presence of paresthesias should raise the suspicion of an underlying peripheral neuropathy.

The pathology of spinal stenosis comprises both a *fixed,* anatomic lesion as well as a *dynamic* component. Because of the dynamic nature of spinal stenosis,

symptoms or objective neurologic findings are not usually elicited until these dynamic factors are invoked. Therefore, resting neurologic examination is usually normal. The most common neurologic finding is weakness of the extensor hallucis longus (EHL). Patient symptoms may sometimes be provoked by either walking or lumbar hyper-extension. Indeed, reproduction of leg pain by hyperextension of the back may be the only objective finding (5). Signs and symptoms may also occasionally be elicited by examining the patient immediately after walking to the point of producing leg pain. Under such circumstances, mild muscle weakness or diminution of a tendon reflex may be detected. Profound muscle weakness is uncommon unless stenosis is accompanied by concomitant disc herniation. Long tract findings of spasticity, hyperreflexia, and clonus suggest superimposed cervical or thoracic myelopathy.

When examining the patient, rule out other potential causes for leg pain such as hip arthropathy or peripheral vascular disease. Include an examination of peripheral pulses and an examination of the hip. In addition to reproduction of the patient's pain by hip range of motion, the presence or absence of a hip flexion contracture should also be determined because its presence may not only help explain a patient's symptoms but also has therapeutic implications.

***Radiographic Evaluation***

Correlate the objective clinical findings with the radiographic findings in order to determine the significance, if any, of the radiographic finding and the patient's symptoms. Precise correlation between objective clinical findings and diagnostic imaging has been shown to have a high positive predictive value for good clinical outcome in patients undergoing surgery for symptomatic lumbar disc herniation. This poses somewhat of a problem in the diagnosis of lumbar spinal stenosis, in which objective neurologic findings are usually absent and the clinical diagnosis is made by patient symptoms rather than clinical findings (53).

Overemphasis on the radiographic component of patient evaluation can lead to a poor outcome following surgery, because radiographic abnormalities, including neural compression, are found in a significant proportion of asymptomatic individuals (13,45a,50,120). Unless there is concern for the presence of tumor or infection, avoid diagnostic imaging when the history or objective clinical findings do not support a compressive or mechanical cause for the patient's pain. Extensive diagnostic imaging can be delayed until the patient is a clear candidate for surgery.

**Conventional Radiography** Plain radiography is insensitive in predicting symptoms of either LBP or radicular leg pain (37,71). It has been estimated that only one in 2,500 lumbar radiographs yields clinically unsuspected findings in patients 20 to 50 years of age. Numerous studies have reported age-related degenerative x-ray changes to be present equally in both asymptomatic and symptomatic populations (37). Only the study by Frymoyer et al. (37) reported a statistically significant correlation between symptoms and any degenerative finding, that being an association between LBP and disc space narrowing or traction spurs at the L4–L5 interspace only.

Plain radiography is still an important preoperative tool. Obtain radiographs in all patients undergoing surgery for spinal stenosis. Look for unsuspected bony pathology, such as spina bifida occulta, on plain radiographs of patients undergoing lumbar surgery. In addition, the presence of transitional vertebrae should be identified when present, thereby alerting the surgeon to the possibility of errors in intraoperative localization.

Obtain *standing* lumbar x-ray studies for all patients undergoing surgical decompression for spinal stenosis to identify unrecognized degenerative spondylolisthesis or degenerative scoliosis, which could be undetectable on supine films. Preoperative identification of such pathology may influence the type of the planned surgery, such as the need for concomitant fusion with decompression. Furthermore, failure to identify a pre-existing degenerative spondylolisthesis preoperatively might lead to the erroneous conclusion that a slip seen on a postoperative x-ray study is iatrogenic.

**Dynamic Radiography (Flexion-extension X-ray Studies)** Many authors believe that dynamic radiographs are more useful than static x-ray studies in making a radiographic diagnosis of instability (14,41,81). Even with these radiographs, however, there is no uniformly accepted method of measurement of such instability (105). Shaffer et al. reported that the Morgan and King method of measuring from the anterior aspect of the vertebral body was the most reproducible method to measure translation (105). Other authors have described angulation, in addition to translation, as being indicative of radiographic instability (14,41).

As with routine radiographs, there exists a spectrum of normal translation and angulation that can exist in the absence of symptoms (14,41). Over 90% of asymptomatic volunteers exhibit between 1 and 3 mm of translation on flexion extension radiographs, and the mean dynamic sagittal rotation from flexion to extension ranges from 7.7° to 9.4° at each lumbar level (14). For translation, a dynamic change of greater than 4 mm is considered abnormal. Because plain radiographs do not visualize neural structures, they generally fail to provide an explanation for radicular pain.

**Myelography** As opposed to computed tomography (CT) or magnetic resonance imaging (MRI), both of which *directly* visualize neural compression, myelography provides *indirect* evidence of nerve root compression by demonstrating changes in the contour of normal contrast-filled structures. As such, the exact nature of compression may be unclear and could, therefore, result in diagnostic confusion. For example, lateral indentation of the dye column due to facet arthropathy could easily be confused with that due to a lateral disc herniation or to a ganglion cyst from a facet joint.

Current myelographic techniques employ *water-soluble* agents that permit better visualization of subtle pathology than did older *oil-based* agents. Myelography is superior to routine CT in its ability to image the entire thoracolumbar spine, thereby revealing unsuspected lesions at the thoracolumbar junction. This is particularly important with conditions such as spinal stenosis, in which compressive findings are often present diffusely throughout the lumbar spine, including the upper lumbar region, which is not routinely imaged by conventional CT.

Another advantage of myelography over CT or MRI is its superior ability to visualize neural compression associated with scoliosis afforded by its coronal imaging capabilities. The presence of a three-dimensional deformity such as scoliosis makes visualization of neural compression by CT or MRI more difficult than with myelography.

Because the dura ends at the level of the dorsal root ganglion (DRG) (21), which is located at the level of the pedicle, myelographic dye cannot extend beyond that point and myelography is unable to detect foraminal disc herniations, lateral stenosis, or the so-called far out syndrome, which is diagnosed more accurately by CT or MRI (121). The far-out syndrome typically occurs in the elderly patient with degenerative scoliosis or in the younger patient with a grade II or higher isthmic spondylolisthesis. The L-5 nerve root is compressed far laterally by either the L-5 transverse process or kinking beneath the L-5 pedicle.

Another disadvantage of myelography over CT is its inability to detect pathology below the level of a complete block to dye flow (43). This may occur in cases of severe spinal stenosis, such as with a high-grade L4–L5 degenerative spondylolisthesis. Under such circumstances, dye must be introduced both below and above the level of the block, or as is more commonly done, an adjunctive study such as MRI or CT must be used (43).

Postoperative imaging of the instrumented spine by CT or MRI is difficult owing to significant metal artifact associated with the use of stainless steel spinal instrumentation. This problem is partially obviated by the use of myelography, which is not associated with image distortion.

Hitselberger and Witten reported that 24% of asymptomatic patients undergoing oil-based contrast studies for suspected acoustic neurilemmoma had abnormal lumbar myelography (45a). This finding underscores the importance of correlating radiographic abnormalities with clinical findings.

The reported accuracy of water-soluble nonionic lumbar myelography in the diagnosis of lumbar nerve root compression ranges from 67% to 100%, depending on the criteria employed for diagnosing nerve root compression, whether or not surgical confirmation of compression was used as the standard, and whether or not the tests were interpreted without knowledge of clinical symptoms or objective neurologic findings (10,41,48,49,112). Most studies report the diagnostic accuracy of myelography for spinal stenosis to be between 70% and 90%.

**Computed Tomography and Postmyelography Computed Tomography** Unlike myelography, CT visualizes the neural structures *directly,* and therefore provides more accurate knowledge of the nature of the compressing lesion. Advantages of CT over myelography include its noninvasive nature, less ionizing radiation, and a better ability to visualize lateral pathology such as lateral or foraminal disc herniation or foraminal stenosis. Because CT is usually performed without sagittal reformation, it provides imaging in only one plane and routinely images only a limited segment of the spine. Therefore, CT misses proximal lumbar pathology, such as a high lumbar disc herniation, proximal stenosis, or other significant pathology (e.g., a thoracolumbar tumor) unless it is specifically oriented to those levels. Because spinal stenosis is a global condition, commonly involving upper lumbar segmental levels as well as lower lumbar levels, routine use of only CT as the primary imaging tool would result in some missed diagnoses.

As with routine radiography and myelography, lumbar CT abnormalities are common in asymptomatic subjects. Wiesel et al. (120) reported that 35.4% of asymptomatic individuals in their study group had an abnormal CT scan. Reported accuracy of CT in the diagnosis of nerve root compression from disc herniation or stenosis ranges from 72% to 100% (10,48,49,112).

The accuracy of CT can be enhanced by the simultaneous use of water-soluble contrast agents (intrathecal contrast-enhanced CT or myelo-CT). The incremental benefit provided by combining both procedures is so great that they are usually performed sequentially as part of a single study for spinal stenosis. Postcontrast CT

allows distinction between the disc margin, thecal sac, and ligamentum flavum, three structures that can blend together in a tight spinal canal in which normal tissue-separating fat is absent. It is invaluable in visualizing a stenotic spine associated with a complete myelographic block, as in severe lumbar stenosis associated with degenerative spondylolisthesis (43). Correlation between contrast-enhanced CT and myelography ranges between 75% and 96%, with myelo-CT invariably being the more accurate study (43,48,49,112).

**Magnetic Resonance Imaging** MRI images the spine by a matrix of numbers that have been assigned a shade of gray based on the intensity of a radio wave signal emanating from the tissue (7,8). In the lumbar spine, T1-weighted sagittal and axial sequences of approximately 4 mm slice thickness and sagittal gradient echo (GE) sequences are performed most commonly. Typically, osseous structures appear as areas of relative signal void, with cortical bone having a low intensity on MRI, and cancellous bone having a higher signal intensity owing to its fat content. The distinction between a small cortical bone osteophyte and a small disc herniation on T1-weighted sagittal image may be difficult, and precise differentiation between the two features may require CT. The nucleus pulposus is best visualized by T2-weighted spin echo (SE) sequences, which reflect the degree of hydration of the disc. With aging and disease, there is decreased signal intensity due to changes in total hydration within the disc (13). The T2 image tends to overemphasize the size of a disc herniation and, therefore, can overestimate its potential significance.

MRI, like myelography, can image the entire spine and can detect unsuspected pathology such as high-lumbar disc herniation, proximal stenosis, or thoracolumbar spinal tumor. MRI is noninvasive and eliminates the potential risk and associated discomfort associated with myelography. Like CT, MRI visualizes the spine *directly,* providing detail as to the etiology of neural compression and can accurately image lateral pathology. Unlike routine CT, however, MRI provides sagittal visualization of the spine and, therefore, provides imaging in orthogonal planes. Furthermore, MRI uses parasagittal views, which provide sequential visualization of neural foramina and can detect foraminal entrapment better than routine CT. This feature is particularly valuable for imaging spinal stenosis, in which neural entrapment within or beyond the neural foramen can be well visualized. MRI distinguishes between the disc and neural tissue better than nonenhanced CT but generally does not distinguish between bony and soft-tissue compression as well as CT. When this distinction is deemed important, as it sometimes is in cases of spinal stenosis, CT or contrast-enhanced CT is sometimes needed.

As with plain radiography and CT, abnormal MRI findings are common in asymptomatic individuals. In one study of asymptomatic subjects, the lumbar MRI images of 22% of those younger than age 60 and 57% of those older than age 60 were abnormal, showing disc herniation or spinal stenosis (13). Approximately 90% of those older than 80 years of age showed some element of lumbar disc degeneration, as demonstrated by decreased signal on T2-weighted images. The reported accuracy of MRI, when compared with documented intraoperative lumbar nerve root compression, is comparable to that of contrast-enhanced CT (myelo-CT) (9,49).

## NATURAL HISTORY

The true natural history of spinal stenosis is unclear, because good studies documenting the course of nontreatment are lacking. This is partly because most patients with this condition receive some form of conservative or surgical treatment, and those with severe stenosis are ultimately operated on (12). Several reported studies have described the clinical features of spinal stenosis, or its surgical treatment, and have included some patients who received no treatment (51). Approximately 20% of those receiving no treatment experienced progression of their symptoms.

The largest and best study of the natural course of lumbar spinal stenosis was published by Johnsson et al. (52), who reported on 32 patients with spinal stenosis followed for an average of 49 months. These patients were described as having “conservative treatment (i.e., no treatment)” because either the patient refused to undergo surgery or the anesthesiologist refused to administer anesthesia. Therefore, these patients had indications for surgery but were not operated on. At final follow-up, based on the clinical examination, 41% of patients were improved and 18% were worse. Based on subjective symptoms, only 15% were improved and 15% were worse. Changes in the patients' walking capacities were equally distributed among improved, worse, and unchanged (Table 147.4). When the final outcome was compared with the anteroposterior (AP) diameter of the dural sac, as measured on water-soluble contrast myelography, patients with narrow AP diameters had a tendency not to improve. This study concluded that the majority of patients with spinal stenosis who did not undergo surgery remained unchanged at 4 years of follow-up and severe progression was unlikely.

| | *Worse (%)* | *Unchanged (%)* | *Improved (%)* |
|---|---|---|---|
| VAS | 15 | 70 | 15 |
| Clinical exam | 18 | 41 | 41 |
| Walking capacity | 30 | 33 | 37 |

[a] VAS, Visual analog scale.
From Johnsson K, Rosen I, Uden A. The Natural Course of Lumbar Spinal Stenosis. *Clin Orthop* 1992;279:82, with permission.

***Table 147.4. Final Outcome for Untreated Spinal Stenosis by VAS[a], Clinical Exam, and Walking Capacity***

Johnsson et al. (51) compared the outcome of a group of 44 patients treated with surgical decompression with that of 19 patients treated without surgery (Table 147.5). The authors referred to the nonsurgical group as both *untreated* and *conservatively treated,* leaving unanswered what, if any, treatment this group did receive. Nevertheless, the authors found that only 32% of the nonsurgical patients had improved at an average follow-up of 31 months. In the *surgical* group, 59% of the patients reported improvement. Although 59% of the group who had received surgery improved, a greater percentage of the surgical group were worse at follow-up compared with patients who had not undergone surgery (25% versus 10%). This study concluded that nonsurgical treatment produced reasonably good results in approximately one third of patients, with only a 10% chance of deterioration during the 2- to 3-year follow-up period. This study, however, was not prospective nor randomized, making comparison between the two groups difficult. In the absence of randomization, it is not known whether the conservatively treated patients were comparable to the surgical group.

| | *Worse (%)* | *Unchanged (%)* | *Improved (%)* |
|---|---|---|---|
| No surgery | 10 | 58 | 32 |
| Surgery | 25 | 16 | 59 |

From Johnsson K, Uden A, Rosen I. The Effect of Decompression on the Natural Course of Spinal Stenosis. A Comparison of Surgically Treated and Untreated Patients. *Spine* 1991;16(6):615, with permission.

***Table 147.5. Comparison of Surgical Versus Nonsurgical Treatment of Lumbar Spinal Stenosis***

A recent attempt at meta-analysis of the literature on surgery for spinal stenosis failed to identify a single randomized trial comparing surgery with conservative treatment (113). A recent report evaluating the outcome of patients treated with aggressive nonsurgical measures (therapeutic exercises and epidural steroids, if necessary) suggested that such treatment could be very effective (103). Fifty-two patients were followed for 2 to 8 years. Thirty-three patients (63%) reported a tolerable pain level without major restriction in daily activities or use of narcotic analgesics; 36 patients (69%) reported “no or minimal restriction in walking tolerance,” although 25 patients (48%) reported “difficulty in standing for long periods.” None of the patients experienced any neurologic loss. Four of the 52 patients (8%) required surgery for presumed failure of nonsurgical measures. The exclusion criteria for this study included patients with pre-existing disease (comorbid conditions) or with a “compliance issue that prevented participation in a therapeutic exercise program.” In addition, it did not compare conservative treatment methods with surgery and could not, therefore, offer any comparative data regarding optimal treatment of this condition.

Standard modalities commonly employed to treat spinal stenosis include nonsteroidal anti-inflammatory medications, analgesics, oral and epidural steroids, physical therapy, bracing, and calcitonin (109).

## SURGICAL TECHNIQUES

Surgery for lumbar spinal stenosis may be broadly divided into decompressive procedures without concomitant fusion and decompression with fusion. Surgical decompression may vary from limited procedures, such as single-level unilateral laminotomy for focal neural compression, to global procedures, such as multilevel bilateral laminectomy with bilateral facetectomies. Types of fusion procedures include anterior lumbar interbody fusion (ALIF), posterior lumbar interbody fusion (PLIF), posterior fusion, posterolateral (also known as intertransverse or bilateral lateral) fusion, or combinations of these procedures (see Chapter 145 and Chapter 146). Indirect neural decompression may occur following ALIF or PLIF if disc-space distraction occurs, thereby enlarging the central or foraminal canal. Fusion may be augmented by the use of spinal instrumentation, either anterior fixation devices or posterior devices such as those using pedicle screw fixation.

### COMORBIDITY AND SURGICAL OUTCOME

Comorbidity refers to the presence and severity of conditions other than the disorder under study or treatment (56). The relationship between comorbidity and outcome is more commonly applied to surgical than medical outcomes. Comorbidity typically increases with age and is associated with a poor outcome for many medical and surgical conditions (20,25,107). Sick people have a higher mortality rate, a higher complication rate, and a lower level of function than do healthy patients. It is imperative to take this factor into account when assessing and comparing outcomes between treatment groups. If such factors are not taken into account, differences in outcome between treatment groups could reflect differences in patient comorbidities rather than differences as a result of treatment.

Rates of hospital morbidity and mortality following lumbar spinal surgery are greater with increasing age of the patient (25). Complications are more frequent with advancing patient age, increasing the complexity of both diagnosis and surgical treatment. The study by Deyo et al. (25) reported an overall mortality of 0.07% for 18,122 hospitalizations between 1986 through 1988. The mortality increased with age, increasing to 0.6% (ninefold increase) in patients older than 75 years of age. The overall complication rate of 9.1% increased to 17.7% in patients 75 years of age or older.

As would be expected, an increase in comorbidity is often associated with more in-hospital complications and perioperative mortality. This finding is independent of age alone. Oldridge et al. (86) found an age-related increase in mortality only for patients older than 80 years of age. There was, however, a significant increase in in-hospital and 1-year cumulative mortality associated with increasing number of comorbidities.

In a retrospective review of 88 patients undergoing laminectomy for spinal stenosis, Katz (56) concluded that the long-term outcome was generally less favorable than had been previously reported (Table 147.6). By 1 year after surgery, 6% of patients had a second operation and, by the time of the last follow-up, 17% had a repeat surgery. Only 40% of patients with the highest comorbidity score had a good outcome at the time of final follow-up compared with 75% of patients who had the lowest comorbidity score (P = 0.004). The most common comorbidities were osteoarthritis (32%), cardiac disease (22%), rheumatoid arthritis (10%), and chronic pulmonary disease (7%). Their data suggested that the effect of comorbidities was additive, because no single comorbidity was significantly associated with worse outcome. In a subsequent study by the same authors, comorbidity was found to be the second most important determinant of disability in lumbar canal stenosis, with complaints of predominantly LBP (as opposed to leg pain) preoperatively being the most important contributor to disability (55,58).

| | *One-year follow-up (%)* | *Final follow-up (%)* |
|---|---|---|
| Poor outcome | 11 | 43 |
| Severe pain | 7 | 30 |
| Reoperation | 6 | 17 |
| Limited function | 8 | 35 |
| Inability to walk 50 feet | 8 | 21 |

From Katz, Lipson S, Larson M, et al. The Outcome of Decompressive Laminectomy for Degenerative Lumbar Stenosis. *J Bone Joint Surg* 1991;73A:809, with permission.

***Table 147.6. Long-Term Outcome Following Surgery for Spinal Stenosis***

### LAMINECTOMY

The gold standard surgical procedure for spinal stenosis is decompressive laminectomy. This procedure may involve either *bilateral laminectomy* or *hemilaminectomy.* For bilateral laminectomy, the lamina and ligamentum flavum are removed on both sides of the stenotic level or levels to the lateral recess. Decompression begins at the most distal extent of neural compression and proceeds in a caudal-to-cranial direction. Although the L5–S1 level is rarely compressed centrally, owing to the capacity of the spinal canal at that level, decompression is most safely initiated at that level rather than at L4–L5, the most commonly involved level, which is often severely stenotic. Perform decompression sequentially, from medial to lateral.

- Position the patient in a kneeling position to allow the abdomen to hang freely in order to reduce abdominal compression and thereby reduce epidural bleeding. Prepare and drape the lumbosacral spine and expose the posterior elements from facet joint to facet joint laterally along the entire length of the intended decompression.
- Begin with a midline decompression. This is generally performed from the left side of the operating table (i.e., on the patient's left side) for a right-handed surgeon and on the right side by a left-handed surgeon.
- Use either 45° or 90° Kerrison rongeurs. In areas where stenosis is not severe, use a relatively large rongeur, such as a 4 mm Kerrison rongeur, to remove the thickened lamina.
- In areas of severe stenosis, however, use of such large instruments risks injury to underlying neural structures. Under these circumstances, it is safer to first thin the lamina with either a Lexsell rongeur or a high-speed power burr. Then use smaller instruments, such as 2 mm or 3 mm Kerrison ronguers, to complete the midline decompression.
- Maintain proper orientation during the procedure by identifying the level of the pedicle, because this defines the level of the nerve root. If in doubt as to the proper level, confirm with an intraoperative radiograph with a bent probe beneath the pedicle, within the neural foramen.
- Decompress the lateral recess next. Extend the decompression laterally until the lateral edge of the root is visualized and determined to be free of pressure. Take care to preserve the pars interarticularis to minimize the risk of producing instability by inadvertent sacrifice of the superior articular facet. Preserve the facet joint by using oblique-angled (45°) Kerrison rongeurs or by the use of osteotomes to undercut the facet joint (39,104).
- Finally, perform lateral decompression of the foraminae. Once the shoulder of the nerve root is identified and decompressed, follow it from its origin through the neural foramen.
- It is generally safer to proceed in a cranial-to-caudal manner in order to minimize risk of inadvertently cutting across the root, which can occur when performing the lateral decompression from a distal-to-proximal direction. Occasionally, the use of a right- or left-angled Kerrison rongeur can be helpful for foraminal decompression.
- Assess the adequacy of decompression within the neural foramen both visually and by palpation. Use a bent probe, such as a bent #4 Penfield elevator or a properly contoured ball probe, to determine the presence or absence of nerve root compression within the neural foramen. Decompression is generally complete when a bent probe can be passed out the foramen both dorsal and ventral to the nerve root, and the root can be gently retracted approximately 1 cm medially.

Following midline and lateral decompression, check for the presence or absence of a concomitant disc herniation, which might contribute to neural compression. Such herniations may be located either posterolaterally, foraminally, or extraforaminally. Unless the disc is contributing to definite neural compression, it is generally best to avoid discectomy in the presence of laminectomy because subsequent instability is more likely to occur when both anterior and posterior supporting structures are violated. When laminectomy is accompanied by discectomy, consider performing an arthrodesis at the time of surgery.

Because spinal stenosis is a global degenerative process, encompassing multiple levels and involving nerve roots bilaterally, multilevel bilateral laminectomy is commonly required. There is, however, some debate as to whether it is more appropriate to decompress only the symptomatic level and side, or whether all stenotic

levels should be decompressed. The argument against decompression of asymptomatic root levels or sides is the risk of producing symptoms at a previously asymptomatic level or side. On the other hand, failure to decompress a stenotic but asymptomatic level or side risks progression of the degenerative process with the development of more severe and potentially symptomatic stenosis. In addition, the natural tendency for degenerative changes to progress over time makes it possible that, in time, asymptomatic stenotic levels will eventually become stenotic. Indeed, several studies have reported long-term deterioration following initially successful surgical decompression (18,19,56,60,90,91 and 92).

**HEMILAMINECTOMY**

*Hemilaminectomy* involves unilateral, rather than bilateral, removal of bone and ligamentum flavum. Because the spinous processes, interspinous ligaments, and supraspinous ligaments are preserved medially, normal stabilizing structures are retained with less risk of development of postoperative instability. Take care to preserve the pars interarticularis laterally in order to minimize risk of postoperative instability (16,106). Hemilaminectomy is appropriate for patients with unilateral symptoms from stenosis. A disadvantage of this procedure is the relative difficulty of performing contralateral decompression and also in obtaining enough medial exposure to perform an adequate ipsilateral decompression in patients with foraminal stenosis. The presence of an intact spinous process and interspinous or supraspinous ligament complex makes it difficult to angle the Kerrison rongeur laterally enough to insert the jaw of the rongeur into the depths of the neural foramen. Under such circumstances, removal of the midline spinous process and interspinous or supraspinous ligament complex may be necessary in order to allow the proper angulation of the rongeur to perform the foraminal decompression. In addition to preserving midline stabilizing structures, hemilaminectomy also avoids exposure of, and potential injury to, the contralateral facet joint. Because the integrity of the unexposed contralateral facet is maintained, more aggressive decompression of a nerve root by partial, or even total, ipsilateral facetectomy need not necessarily be accompanied by a fusion.

Contralateral nerve root decompression may be accomplished through a unilateral hemilaminectomy approach by tilting the table away from the operating surgeon (Fig. 147.1). Particularly when used in conjunction with an operating microscope, which provides excellent illumination and which can be angled to visualize the opposite side, contralateral decompression can be accomplished without the need for removal of stabilizing midline structures (spinous processes and interspinous or supraspinous ligaments). The contralateral neural foramen can be visualized and decompressed, and its more distal portion can be palpated with a long bent probe such as a #4 Penfield elevator or a contoured probe. Although offering the advantage of preserving normal, noncompressing midline structures and minimizing scar tissue on the opposite side, this technique is more demanding than bilateral laminectomy because decompression is performed through a more limited exposure and the determination of adequate foraminal patency is more dependent on feel (palpation) than by direct visualization. In addition, there is a greater potential for dural laceration from the Kerrison rongeur when working through a small opening. Should such a dural tear occur, its repair often necessitates complete (bilateral) laminectomy with adequate exposure of the dural rent.

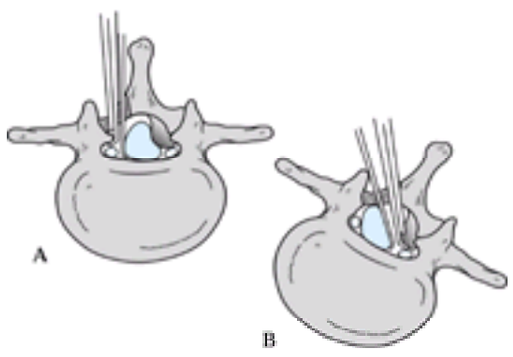


***Figure 147.1.*** **A:** Axial representation of hemilaminotomy showing ipsilateral decompression of the nerve root. The operating table can be tilted toward the surgeon to facilitate visualization of the contralateral spinal canal. A Kerrison rongeur is shown decompressing the nerve root within the lateral recess, while a Penfield retractor is protecting the common dural sac medially. **B:** Axial representation of hemilaminotomy showing contralateral decompression of nerve root. The operating table is tilted away from the surgeon. The Kerrison rongeur is shown decompressing the opposite nerve root, while the Penfield retractor is gently moving the common dural sac medially to facilitate visualization of the contralateral nerve root.

**RESULTS OF DECOMPRESSIVE LAMINECTOMY**

A recent review of the literature for spinal stenosis surgery failed to identify even a single randomized trial comparing surgery and conservative treatment (Table 147.7) (113). Turner et al. (113) attempted a meta-analysis of the literature on surgical outcomes for spinal stenosis, but the poor scientific quality of the literature precluded the authors from conducting the intended meta-analysis. Even using the authors' own ratings, the average proportion of good-to-excellent outcomes was only 72%. This study found no statistically significant relationship between outcome and patient age, gender, presence of prior back surgery or number of levels operated on. In those studies reporting on only patients with degenerative spondylolisthesis, the outcome was better. There was no statistically significant difference in outcome between decompression with or without associated fusion. This observation is particularly significant in light of the reported increased morbidity associated with lumbar fusion (114).

| *Total no. of patients* | *Satisfactory* | *Unsatisfactory* | *Progressive slip* |
|---|---|---|---|
| 216 | 140 (69%)[b] | 75 (31%)[b] | 67 (31%)[a] |

[a] Reported in only 9 of 11 Articles.
[b] Weighted pooled proportion.
From Maedjetko SM, Connolly PJ, Short S. Degenerative lumbar Spondylolisthesis. A Meta-Analysis of Literature 1970–1993. *Spine* 1994;19(20S):2556S, with permission.

***Table 147.7. Results of Decompression of Spinal Stenosis without Fusion: Meta-Analysis of Literature 1970–1993 (11 Articles)***

In contrast, the prospective cohort study of Atlas et al. (3) reported the 1-year outcome of patients with spinal stenosis treated surgically or nonsurgically in the state of Maine and found that at 1 year, 55% of the surgical patients reported definite improvement in their predominant symptom, compared with only 28% of the nonsurgical group. Surgery was found to increase the relative odds of “definite improvement” 2.6 fold compared with nonsurgical treatment.

In a large retrospective series Katz et al. (60) followed 88 patients for a period of 2.8 to 6.8 years (Table 147.6). Outcome assessment included a questionnaire in which the patients rated their outcomes in terms of pain and function. The authors reported a surprisingly high failure rate, with 11% of patients reporting a poor outcome at 1 year and 43% reporting poor outcome at final follow-up. Six percent of patients had repeat lumbar surgery within the first year and 17% had additional surgery by the time of last follow-up. The authors concluded that the long-term outlook for patients undergoing decompressive laminectomy for spinal stenosis is guarded owing to progressive deterioration of the results over time. They suggested that more extensive bone removal may be indicated at the time of initial surgery.

The authors also reported a high initial success rate following surgery, but by 5 years, the failure rate had reached 27%, with a predicted failure rate of 50% within the anticipated life expectancy of most patients. More than half (62%) of these failures were due to subsequent neurologic symptoms, with an equal incidence of recurrent stenosis at the same level and stenosis at a new level. Because of the high rate of failure from recurrent stenosis, the authors recommended that all levels of impending stenosis be decompressed along with the symptomatic levels.

**ALTERNATIVES TO LAMINECTOMY**

Despite the fact that some studies report deterioration of standard bilateral decompressive laminectomy over time, more limited alternatives to decompressive

laminectomy and hemilaminectomy have been espoused in order to avoid removal of normal, noncompressing structures and thereby minimize risk of postoperative instability (18,54,60,91). Such procedures include *hemilaminotomy, wide fenestration,* and *laminoplasty.* Hemilaminotomy involves a more limited decompression than hemilaminectomy (Fig. 147.2). Rather than removing an entire hemilamina, hemilaminotomy removes only the ligamentum flavum and adjacent portions of two hemilaminae responsible for neural compression. This procedure is more commonly performed in younger patients with unilateral focal stenosis in whom extensive laminectomy carries the risk of instability. It may also be considered in older patients who do not have extensive global stenosis.

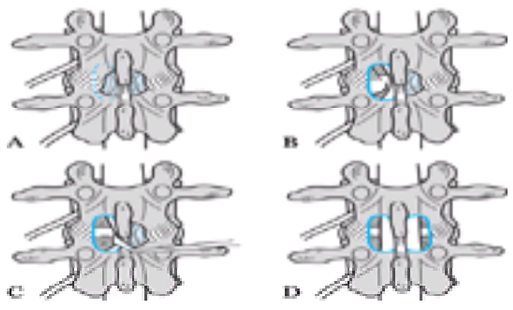


***Figure 147.2.*** Posterior view of a hemilaminotomy to decompress nerve root. **A:** Dotted line on left represents the inferior portion of the superior lamina, which is resected in order to decompress the dural sac. This allows identification of the origin of the ligamentum flavum, which attaches approximately half way up the deep surface of the lamina. **B:** Diagram showing the resected distal portion of the superior lamina and ligamentum flavum to reveal the underlying dura. The common dural sac is deviated medially by an underlying disc herniation. **C:** The common dural sac is gently retracted medially to facilitate lateral decompression of the facet joint or disc. **D:** Diagram showing bilateral hemilaminotomies with preservation of midline laminae and ligamentous complex.

- In the absence of significant underlying congenital stenosis, neural compression is generally due to buckling of the ligamentum flavum, which is usually secondary to collapse of the intervertebral disc, and to hypertrophy of the facet joint, which occurs as a result of subsequent instability. Decompression of only these structures should, therefore, relieve symptoms of neural compression.
- Because the superior attachment of the ligamentum flavum is approximately at the midpoint of the deep surface of the superior hemilamina, resect the distal half of the superior hemilamina in order to remove the proximal extent of the ligamentum (Fig. 147.2*A*).
- Remove the inferior portion of the superior hemilamina and the superior portion of the inferior hemilamina, together with the intervening ligamentum flavum (Fig. 147.2*B*).
- Perform lateral decompression by partial facetectomy as with bilateral laminectomy or hemilaminectomy (Fig. 147.2*C*).
- Like hemilaminectomy, contralateral decompression with preservation of spinous processes and midline supraspinous or interspinous ligaments can be performed by tilting the operating table away from the surgeon and by undercutting the medial and contralateral ligamentum flavum with a 45° Kerrison ronguer.

*Wide fenestration* is a procedure described for central stenosis in which only the medial portion of the inferior facets and adjacent ligamentum flavum is removed (69,83,123). Care is taken to remove only pathologic anatomy and to preserve the interspinous or supraspinous ligament complex and spinous processes, which make up the midline stabilizing structures. This may be performed by using bilateral laminotomies at one or more segmental levels, removing the ligamentum flavum (Fig. 147.2*D*). In a 5-year follow-up study of this procedure, 82% of patients had good or excellent early surgical outcomes, but results deteriorated to 71% satisfactory by 4 years postoperatively (83).

*Laminoplasty* is an alternative to laminectomy that was originally advocated for active manual workers (76,77). This procedure is similar to cervical laminoplasty and involves hinging open the lamina on one side and inserting the excised spinous processes into the open hinge in order to keep it patent. There is not sufficient experience with this technique to provide outcomes assessment.

**LAMINECTOMY AND FUSION FOR SPINAL STENOSIS**

The role of fusion in the treatment of spinal stenosis is somewhat controversial. For stenosis not associated with degenerative spondylolisthesis or other deformity, most studies report that simple decompression is the preferred method of surgical treatment. For patients with associated degenerative spondylolisthesis, concomitant fusion is generally recommended (30,44). The issue of using supplementary spinal instrumentation is yet unresolved (32,125).

In a recent prospective, randomized study of 45 patients undergoing either decompression alone or decompression with fusion for spinal stenosis without associated instability, there was no significant difference in outcome between fused and unfused groups (Table 147.8) (40). Overall, 78% of patient-reported and 80% of examiner-rated results were rated very good or good. When broken down by type of procedure performed, there were no significant differences in outcome between the three groups with regard to pain relief. The authors concluded that surgical decompression changed the natural history of spinal stenosis, resulting in generally favorable outcome and improved quality of life in the majority of patients. They further concluded that arthrodesis was not justified in the absence of radiographically proven segmental instability because there was no statistical difference in outcome between the three treatment groups.

| Evaluator | Decompression without fusion (%) | Decompression and fusion (most stenotic segment only) (%) | Decompression and fusion (all decompressed levels) (%) |
|---|---|---|---|
| Patient | 13/15 (87) | 12/15 (80) | 10/15 (67) |
| Examiner | 13/15 (87) | 12/15 (80) | 11/15 (73) |

From Grob D, Humke T, Dvorak J. Degenerative Lumbar Spinal Stenosis: Decompression with and without Arthrodesis. *J Bone Joint Surg* 1995;77A:1036, with permission.

***Table 147.8. Comparison of Decompression, Decompression and Fusion, and Limited Decompression and Fusion in Spinal Stenosis: Percentage of Good to Excellent Results***

**SPINAL STENOSIS WITH DEGENERATIVE SPONDYLOLISTHESIS**

Degenerative spondylolisthesis was first described in 1930 by Junghanns who coined the term *pseudospondylolisthesis* to describe the presence of forward slippage of a vertebral body in the presence of an intact neural arch (54a). The clinical and pathologic features of this entity were further defined by Macnab, who described the condition as “spondylolisthesis with an intact neural arch” (70). The term *degenerative spondylolisthesis* was originally used by Newman and Stone and is the terminology most commonly used to describe the anterior slippage of one vertebral body on another in the presence of an intact neural arch (84a).

Degenerative spondylolisthesis may be a source of both LBP and leg pain and may contribute to radicular or referred leg pain in a characteristic pattern of neurogenic claudication (36). The diagnosis is typically made on lateral radiographs, but it may have a dynamic component to it such that the slip may reduce in the supine position and, therefore, may be readily apparent only on stress radiographs. Such radiographs may include standing lateral views, sitting or standing flexion-extension views, or distraction compression radiography (14,41).

As with spinal stenosis generally, little is known of the natural history of degenerative spondylolisthesis. Mardjetko et al. (74) attempted a meta-analysis of the literature from 1970 to 1993. Only three papers, reporting on 278 patients, described the natural history of degenerative spondylolisthesis (33,78,96). Overall, 90 of these 278 patients (32%) achieved satisfactory results untreated (Table 147.9). Matsunaga et al. (78) presented a study of 40 patients who received no treatment and who were followed for at least 5 years (range: 5 to 14 years.; mean: 8.25 year). Progressive slip was noted in 12 patients (30%), although no correlation was noted between slip

progression and worsening of symptoms. Only 4 of 40 patients (10%) showed clinical deterioration over the course of the study, all of whom were in the group of 28 patients showing no slip progression over the follow-up period. Interestingly, none of the 12 patients with slip progression deteriorated clinically. Therefore, the majority of the patients in this study showed a slight improvement in their clinical symptoms over time, although only 1/3 were felt to have satisfactory function at final follow-up.

| *No. of patients* | *Satisfactory* | *Unsatisfactory* | *Progressive* |
|---|---|---|---|
| 278 | 90 (32%) | 188 (68%) | 12[a] |

[a] Reported in only one of three studies.
From Mardjetko S, Connolly P, Shott S. Degenerative Lumbar Spondylolisthesis. A Meta-Analysis of Literature 1970–1993. *Spine* 1994;19:2256S, with permission.

***Table 147.9. Non-Operative/Natural History of Degenerative Spondylolisthesis (Three Studies Reviewed)***

**RESULTS OF DECOMPRESSION WITHOUT FUSION**

Although current thinking generally favors concomitant fusion for spinal stenosis associated with degenerative spondylolisthesis, decompression without fusion is also a viable therapeutic option (Table 147.10) (74). Overall, 69% of patients from Mardjetko's meta-analysis reported satisfactory outcome with decompression without fusion, with 31% having an unsatisfactory result and 31% having progression of their slip. There was generally no correlation between clinical outcome and amount of slip progression except in the study by Bridwell et al., which showed a positive correlation between the two (15).

| *Total no. of patients* | *Satisfactory* | *Unsatisfactory* | *Progressive slip* |
|---|---|---|---|
| 216 | 140 (69%)[b] | 75 (31%)[b] | 67 (31%)[a] |

[a] Reported in only 9 of 11 articles.
[b] Weighted pooled proportion.
From Mardjetko SM, Connolly PJ, Shott S. Degenerative Lumbar Spondylolisthesis. A Meta-Analysis of Literature 1970–1993. *Spine* 1994;19:2556S, with permission.

***Table 147.10. Results of Decompression without Fusion: Meta-Analysis of Literature 1970–1993 (11 Articles)***

A recent report by Epstein and Epstein (29) reviewed 290 patients undergoing decompression without fusion for degenerative spondylolisthesis. Only patients with a “stable” slip, as defined by a slip having less than 4 mm translation and less than 10° to 12° angulation on dynamic lateral radiographs, were included. Two hundred and fifty patients had one-level listhesis and 40 had a two-level slip. Decompressive procedures included laminectomy in 249 patients and fenestration procedures in 41 patients. Fenestration procedures typically involved bilateral laminotomy with partial medial facetectomy and foraminotomy. At an average 10-year follow-up (range: 1 to 27 years), 69% of patients exhibited excellent, 13% good, 12% fair, and 6% poor outcome. The authors concluded that 82% excellent or good outcome was very acceptable in their elderly population (average age: 67 years old), in whom fusion is associated with higher morbidity and mortality (26).

Poor surgical outcome following laminectomy without fusion was reported in the prospective randomized study by Herkowitz and Kurz (44) comparing decompression alone with combined decompression and noninstrumented fusion (Table 147.11). In the decompression group, only 11 of 25 patients (44%) had a satisfactory result. This group of patients was found to have significantly more LBP and leg pain than their fused counterparts. Furthermore, the mean slip increased from an average of 5.3 mm preoperatively to 7.9 mm postoperatively. Other authors have reported a similar experience (15,30).

| *Result* | *Arthrodesis (no. = 25)* | *No arthrodesis (no. = 25)* |
|---|---|---|
| Excellent | 11 (44%) | 2 (8%) |
| Good | 13 (52%) | 9 (36%) |
| Fair | 1 (4%) | 12 (48%) |
| Poor | 0 (0%) | 2 (8%) |
| Mean Increase in Slip (preop to postop) | 0.5 mm | 2.6 mm (P = 0.002) |

From Herkowitz HN, Kurz LT. Degenerative Lumbar Spondylolisthesis with Spinal Stenosis. A Prospective Study Comparing Decompression with Decompression and Intertransverse Process Arthrodesis. *J Bone Joint Surg* 1991;73A:802, with permission.

***Table 147.11. Prospective, Randomized Comparison of Decompression versus Decompression and Noninstrumented Spinal Fusion for Degenerative Spondylolisthesis***

**RESULTS OF DECOMPRESSION WITH NONINSTRUMENTED FUSION**

The role of fusion in the surgical treatment of spinal stenosis associated with degenerative spondylolisthesis is less controversial than the role of fusion in the treatment of other degenerative back conditions (80,115). Caputy and Luessenhop (18) reported a retrospective review of 96 patients undergoing decompressive surgery for spinal stenosis who were followed for at least 5 years. The treatment failed in 16 patients because of recurrent neural involvement, and it failed in 10 patients because of LBP (total failures = 26). The authors concluded that because of the higher incidence of recurrent symptoms in patients with pre-existing degenerative spondylolisthesis, all patients with an associated slip should undergo fusion of the listhetic level.

In their prospective and randomized study comparing decompression alone with decompression and noninstrumented spinal fusion in the treatment of degenerative spondylolisthesis with spinal stenosis, Herkowitz and Kurz (44) reported superior results when concomitant fusion was performed with the decompression (Table 147.11). The reported outcome for the arthrodesis group was excellent in 44% and good in 52% (96% excellent or good total results), whereas in the nonarthrodesis group, only 8% reported an excellent outcome and 36% reported a good outcome (44% excellent or good total results) (P = 0.0001). There was a significant increase in the preoperative slip in patients not receiving an arthrodesis compared with those undergoing fusion (P = 0.002). Interestingly, 36% of those undergoing attempted arthrodesis were noted to have a pseudarthrosis, all of whom had either an excellent or a good result. This study concluded that the results of surgical decompression with *in situ* arthrodesis are superior to those of decompression alone. The authors further concluded that the decision for concomitant arthrodesis should be based purely on the presence or absence of a preoperative slip rather than on other preoperative factors, such as the age or sex of the patient or the disc height, or on intraoperative factors such as the amount of bone resected during the decompression.

The prospective randomized study by Bridwell et al. (15) included a subgroup of 11 patients undergoing decompression and noninstrumented fusion. Of the 10 patients

available for follow-up, only 3 (30%) reported improved functional outcome and seven had an increase in their preoperative spondylolisthesis.

Postacchini and Cinotti (90) reported on bone regrowth occurring an average of 8.6 years after surgical decompression for spinal stenosis (92). Although all 16 patients with degenerative spondylolisthesis showed some bone regrowth, the degree of regrowth was more severe in the six patients who did not undergo arthrodesis. Furthermore, the proportion of satisfactory results was significantly higher in patients who had spinal fusion (Table 147.12). Although this study was nonrandomized and retrospective, it suggested that arthrodesis stabilizes the spine, resulting in less bone regrowth and superior long-term results.

| | *No. of patients* | *Excellent* | *Good* | *Fair* | *Poor* |
|---|---|---|---|---|---|
| Fusion | 10 | 3 | 5 | 2 | 0 |
| No Fusion | 6 | 0 | 2 | 1 | 3 |

From Postacchini F, Cinotti G. Bone Regrowth After Surgical Decompression for Lumbar Spinal Stenosis. *J Bone Joint Surg* 1992;74B:862.

***Table 147.12. Relationship Between Outcome and Fusion in Patients with Degenerative Spondylolisthesis***

**RESULTS OF DECOMPRESSION WITH INSTRUMENTED FUSION**

Zdeblick (125) reported a prospective and randomized study of 124 patients undergoing either instrumented or noninstrumented fusion for a variety of diagnoses. The overall fusion rate for the noninstrumented group was 65%; for the semirigid fixation group, the fusion rate was 77%; and for the rigid fixation group, it was 95%. A trend for better clinical outcome with increasing rigidity of fixation was also observed. Seventy-one percent of the noninstrumented patients, 89% of the semirigid group, and 95% of the rigid group reported excellent or good results. For the subgroup of patients with degenerative spondylolisthesis, 65% of the noninstrumented patients fused compared with 50% of the semirigid fixation group, and 86% of the rigid fixation group had a good or excellent result. Subsequent studies have also reported superior results with concomitant arthrodesis and decompression for spinal stenosis with degenerative spondylolisthesis (18,44,60,90).

The historical cohort study of spinal fusion using pedicle screw fixation reported by Yuan et al. (124) involved a retrospective, multicenter study of 2,684 patients with degenerative spondylolisthesis. Solid radiographic fusion was noted in 89% of patients undergoing pedicle screw fixation compared with 70% of those without instrumentation. Clinical outcome was also better in the group of patients undergoing instrumented fusion.

Nork et al. (85) reported a retrospective study of 30 patients undergoing decompression and instrumented fusion for degenerative spondylolisthesis. Outcome was determined by fusion rate, a functional questionnaire, and the SF-36 survey. Both the rate of fusion and patient satisfaction was 93%. Thirteen patients (43%) had complications, including dural tears (three patients), excessive blood loss (two patients), pseudarthrosis (two patients), pulmonary embolus (PE) (one patient), deep infection (one patient), urinary tract infections (3 patients), and unstable angina (one patient).

A recent randomized prospective study of posterolateral lumbar fusion, with and without pedicle screw instrumentation, for a variety of conditions concluded that the addition of instrumentation did not produce an incremental clinical benefit to that obtained from noninstrumented fusion, although there was a slight nonsignificant trend toward a higher fusion rate in the instrumented fusion group (34). This study, involving a mean clinical follow-up of 40 months, prospectively examined 71 patients undergoing posterolateral fusion for either failed back surgery syndrome (FBSS), degenerative disc disease, isthmic spondylolisthesis, or degenerative spondylolisthesis. For the 10 patients who had degenerative spondylolisthesis, five underwent instrumented fusion and five underwent fusion *in situ.* Eighty percent of the patients with degenerative spondylolisthesis undergoing instrumented fusion achieved an excellent or good outcome, compared with 40% of those without instrumentation. For the small subgroup of 10 patients with degenerative spondylolisthesis, the clinical outcome appeared to be better than that of the overall population studied, although this subgroup was too small to establish statistical significance.

There does not appear to be a clear consensus as to the optimal way to treat the patient with degenerative spondylolisthesis. Most studies suggest that patients undergoing concomitant fusion do better when decompression is accompanied by fusion (44). It is less clear, however, whether or not the fusion should be augmented with instrumentation (32). It would seem reasonable that if there is clear evidence of instability on flexion-extension radiographs, the immediate stability provided by instrumentation would warrant the additional time, expense, and potential morbidity associated with its use. On the other hand, the indication for its use in the patient with a collapsed disc space and no motion at the spondylolisthetic level is less clear.

## AUTHOR'S PREFERRED TREATMENT

As noted earlier, the optimal surgical treatment of spinal stenosis, particularly when it is associated with degenerative spondylolisthesis, is still somewhat controversial. One area of controversy is the recommended extent of surgical decompression. Because spinal stenosis is a *global* degenerative condition, there are frequently many segmental levels showing radiographic central stenosis, with bilateral foraminal stenosis also being common. Clearly, decompression of every level showing any degree of radiographic stenosis is not always required. Obviously, all symptomatic levels should be decompressed. The extent of surgical decompression of asymptomatic levels, however, depends on many factors. As described earlier, many long-term studies suggest that restenosis at previously decompressed levels, or the development of symptomatic stenosis at previously nonoperated stenotic levels, is a common reason for failure of surgery for spinal stenosis. Therefore, when in doubt, it is generally more prudent to decompress a suspicious segmental level than not to decompress. I generally decompress all moderately and severely stenotic levels. When diffuse degenerative changes produce moderate or severe multilevel stenosis, I prefer to decompress the involved levels by unilateral or bilateral laminotomies, rather than by complete laminectomies. This approach reduces the need for concomitant fusion, and it preserves the uninvolved laminae and ligamentous structures, thereby and minimizing the risk of developing late instability.

During the course of surgery, it is sometimes unclear to the surgeon whether or not to decompress an adjacent level above or below the operated level. When this occurs, the degree of central stenosis of the adjacent segment can be gauged by passing a small catheter proximally or distally beneath the lamina. Difficult passage of the catheter mandates decompression of the involved level.

The decision of whether or not to perform fusion on a patient with stenosis associated with degenerative spondylolisthesis can be difficult in the elderly patient with multiple comorbidities. As noted previously, many studies suggest that patients have better clinical outcomes when decompression is accompanied by arthrodesis. The issue of whether or not to augment the fusion with segmental (pedicle) instrumentation is not yet resolved (32,34,125). The decision to fuse must be balanced against the increased morbidity associated with arthrodesis in the elderly patient (26). In the younger, healthy patient with spinal stenosis associated with degenerative spondylolisthesis, I will generally fuse the listhetic level, usually with segmental fixation. In elderly, debilitated, or low-demand patients, arthrodesis may not be required. This is particularly true when the listhetic level is associated with decreased disc height, spur formation, subchondral sclerosis, or ligament ossification. These degenerative changes may help stabilize the listhetic level and minimize the risk of slip progression. Under such conditions, I consider unilateral or bilateral laminotomies in order to preserve uninvolved stabilizing structures.

There are several techniques for orienting the pedicle screws for segmental fixation (Fig. 147.3). Roy-Camille et al. (99,100) described a *straight-ahead* method, in which the entry point of the pedicle screw is at the junction of a line bisecting the transverse axis of the transverse process and a line bisecting the facet joint (Fig. 147.3*A*). The pedicle screw is oriented parallel to both the sagittal plane and the superior and inferior vertebral end plates. Another technique is the *inward* method described by Magerl (72,73), in which the pedicle screw entry point is slightly more lateral than that described by Roy-Camille. The entrance point is at the junction of a line intersecting the transverse axis of the transverse process and a line along the lateral aspect of the facet joint (Fig. 147.3*B*). The screw orientation is parallel to the superior and inferior vertebral end plates but is oriented medially so that it is oblique to the sagittal plane.

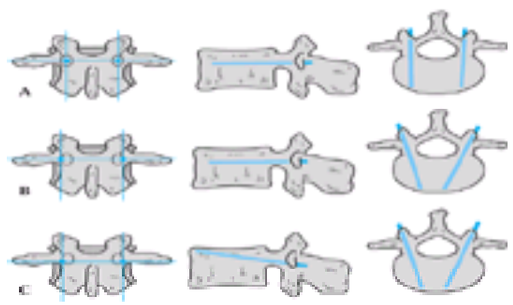

***Figure 147.3.*** Three techniques of pedicle screw insertion. **A:** The straight-ahead method of Roy-Camille. With this technique, the screw is inserted at the junction of a line bisecting the transverse axis of the transverse process and a line bisecting the facet joint. The pedicle screw is oriented parallel to both the sagittal plane and the superior and inferior vertebral endplates. **B:** The inward method of Magerl. The pedicle screw entry point is slightly more laterally located than that described by Roy-Camille. The screw entry point is at the junction of a line intersecting the transverse axis of the transverse process and a line along the lateral aspect of the facet joint. The screw orientation is parallel to the superior and inferior vertebral end plates but is oriented medially so that it is oblique to the sagittal plane. **C:** The author's preferred up-and-in method, as described by Krag. The entry point for the pedicle screw is at the junction of a line running slightly inferior to the transverse axis of the transverse process and a line along the lateral aspect of the facet joint. The screw is oriented slightly cephalad and is angled medially to the sagittal plane. By making the pedicle screw entry point slightly more caudal than with the other methods, this technique minimizes damage to the superior facet joint by the head of the screw and reduces the risk of subsequent adjacent level degeneration. The screw must be angled superiorly in order to maintain its path within the pedicle.

The method I prefer is the *up-and-in* method described by Krag and others (Fig. 147.3*C*) (64,65,68). The entry point for the pedicle screw is at the junction of a line running slightly inferior to the transverse axis of the transverse process and a line along the lateral aspect of the facet joint. The screw is oriented slightly cephalad and is angled medially to the sagittal plane. The up-and-in method is particularly useful in minimizing damage to the superior facet joint. By making the pedicle screw entry point slightly more caudal than the other methods, damage to the facet joint by the head of the screw is minimized and the risk of subsequent adjacent level degeneration is theoretically less. The screw must be angled superiorly in order to maintain its path within the pedicle.

In summary, I favor decompression and fusion with pedicle fixation in active, healthy, physiologically young patients with spinal stenosis associated with degenerative spondylolisthesis who have relatively few degenerative changes promoting stability at the level of the slip. I usually manage the elderly, low-demand patient with multiple comorbidities who has significant associated degenerative changes at the listhetic level by limited decompression without fusion.

## PITFALLS AND COMPLICATIONS

Complications related to surgical decompression for spinal stenosis may be either *general* in nature, sharing features in common with all types of spinal surgery, or they may be *specific* and related only to spinal stenosis decompression. Those that are specific to only spinal stenosis decompression include complications related to posterior approaches for spinal stenosis decompression and those complications associated with spinal fusion.

### GENERAL COMPLICATIONS

All lumbar spine surgery, and indeed all surgeries generally, share certain broad groups of potential complications, which can be thought of as occurring either *preoperatively, intraoperatively, or postoperatively.*

#### *Preoperative Complications*

Preoperative factors that are important determinants of surgical outcomes involve primarily surgical decision making, and therefore, complications of this process can be thought of as being judgment errors of patient selection. In general, surgery is more reliable in producing relief of leg pain than LBP. The difficulty with surgery for LBP lies not with the technical aspects of the surgical procedures but with the difficulty in determining the genesis of the back pain. Discography has been advocated as a diagnostic test for determining the source of pain (22). The role of discography is controversial and may not accurately predict the painful level, even when the pain might be coming from the disc (46). See Chapter 144 and Chapter 145 for more details.

#### *Intraoperative Complications*

Anesthetic complications related to spinal surgery are comparable to the complications associated with other nonspinal surgery. These complications include airway complications; fluid management problems, including shock, fluid overload, and transfusion reactions; pulmonary complications; cardiac risks related to perioperative myocardial infarction, cardiogenic shock, or congestive heart failure; and vascular complications related to blood loss, hypertension, hypotension, and thrombotic or embolic phenomena.

Posterior decompression for spinal stenosis poses particular problems related to positioning of the patient in the prone position, which is the least physiologic position for the patient under general anesthesia (118). These problems include potential difficulties with ventilation and airway management. In addition, there is the risk of pressure to sensitive structures such as the eyes, which can result in blindness. Pressure can result in compression of various neural structures, which can result in temporary or permanent nerve palsies. These structures include the sciatic nerve or its branches from prolonged pressure of the buttocks against a buttress while in the kneeling position, the ulnar nerve at the elbow, the anterior interosseous nerve in the cubital tunnel, the axillary nerve (84), brachial plexus from excessive shoulder abduction (23), and cervical area from prolonged positioning of the neck in a rotated position.

The optimum patient position for surgery is one in which the abdomen is hanging free in order to reduce inferior vena cava (IVC) pressure and thereby minimize intraoperative bleeding. This may be accomplished by placing the patient in a kneeling or a knee-chest position, or by placing the patient prone with the abdomen hanging freely. *In vivo* IVC pressure measurements have shown that pressure in the IVC is 1.5 times greater when the patient is in the prone position than when the patient is on a frame that allows the abdomen to hang freely. Problems associated with the kneeling position include sciatic nerve palsy, deep venous thrombosis (DVT), and compartment syndrome. Ophthalmic complications associated with spinal surgery have only recently been recognized and reported (66,82). Such complications include posterior optic nerve ischemia (66,82), occipital lobe infarcts, central retinal vein thrombosis (82), and cerebral ischemia (82). Although the etiology of the diminished visual acuity or blindness associated with these conditions is not always clear, identifiable causes include prolonged operative time, hypotension, blood loss, and direct pressure on the eye.

Anesthetic problems related to spinal anesthesia include persistent spinal fluid leak from spinal needle puncture and hypotension from venous pooling of blood in the lower extremities. The advantage of spinal anesthesia in posterior spinal surgery is that some of the positioning complications previously described can be obviated by having the patient remain awake and in control of the head and upper extremities. This approach minimizes the risk of pressure on the eyes, compression to the ulnar nerve at the elbow, and brachial plexus palsies.

The syndrome of inappropriate antidiuretic hormone (SIADH) secretion is a condition characterized by the release of antidiuretic hormone (ADH) from the posterior pituitary gland in the absence of the usual osmometric or volumetric stimulus of dehydration or hypovolemia. This results in failure to excrete free water, resulting in dilutional hyponatremia. SIADH is known to occur in many conditions, including surgery, and has also been reported during and following spinal surgery (7). It is thought that ADH secretion reaches its maximum during surgery, and that the syndrome gradually resolves by approximately the third postoperative day. It is imperative to distinguish between SIADH and hypovolemia as a cause of low urine output because SIADH demands treatment by fluid restriction whereas low urine output from hypovolemia requires fluid administration. SIADH should always be considered as a cause of low urine output and dilutional hyponaetremia during and immediately after surgery.

#### *Postoperative Complications*

Some postoperative complications are common to many surgical procedures, including spinal surgery. These include *metabolic* problems such as postoperative confusional states and SIADH, *pulmonary* conditions such as atelectasis and pneumonia, *genitourinary* complications such as urinary retention, and *gastrointestinal*

problems such as ileus and stress ulcer.

Although they are uncommon, some spinal conditions such as cauda equina syndrome may predispose the patient to urinary retention owing to impairment in function of the nervous supply to the bladder. When urinary retention is due to acute cauda equina compression, prompt surgery is imperative. Chronic urinary retention may require either intermittent straight catheterization or an indwelling catheter. The presence of a urinary catheter, particularly a long-standing indwelling catheter, may predispose the patient to a urinary tract infection requiring treatment with antibiotics.

Postoperative ileus is a condition that can occur following any surgery, and is common following large posterior spinal procedures such as multilevel decompressions for spinal stenosis and instrumented lumbar fusions. When the intertransverse membrane is violated during posterolateral fusion, bleeding into the retroperitoneal space may occur, and ileus is more likely.

**DEEP VENOUS THROMBOSIS AND PULMONARY EMBOLUS**

PE is the third most common cause of death in the United States, accounting for up to 200,000 deaths annually. In hospitalized patients, PE is the most common preventable cause of hospital death with pulmonary emboli detectable in more than one quarter of all routine autopsies. The etiology of pulmonary embolism includes the immobilization associated with hospitalization as well as factors related to surgery itself, which produce a hypercoagulable state. DVT is the precursor to PE in 90% of cases and is common in hospitalized patients. The risk of DVT following general surgery ranges between 5% and 63% and is particularly high with certain orthopaedic conditions, such as fracture of the hip, and following some orthopedic procedures, particularly total hip and total knee arthroplasty, in which the incidence of DVT following unprotected joint replacement is as high as 60% to 80%.

Although it is uncommon, DVT has been reported to occur following scoliosis surgery. DVT following routine spinal decompressions, however, was thought to be a rare occurrence. More recently, DVT has been recognized following spinal surgery (108,119). Using postoperative duplex scanning, the incidence of DVT in unprotected patients undergoing posterior lumbar surgery has been reported to be 14% (119). The use of elastic compression stockings or intermittent pneumatic compression stockings (PCS) has been shown to reduce the incidence of DVT diagnosed by duplex scanning to 0.9% to 6% (108). Bell et al. reported the incidence of venographically proven DVT following unprotected surgery for lumbar disc herniation or spinal stenosis performed under spinal anesthesia to be 25.8% (6A). This rate is significantly higher than that reported using duplex scanning as the method of diagnosis, thereby reflecting the greater accuracy of venography in diagnosing DVT (30a,30b,119). Prophylaxis with PCS reduced the incidence to 4.5% in patients receiving spinal anesthesia. PCS seemed to provide no significant protection from DVT in patients receiving general anesthesia, in whom the incidence of DVT was 13.6% in unprotected spinal surgery and 8.1% with PCS protection. This study suggested that the best combination of type of anesthesia and DVT prophylaxis in terms of prevention of DVT was spinal anesthesia with PCS. The worst combination was spinal anesthesia without PCS. See Chapter 5 for more details as well as recommendations for treatment

**SPECIFIC COMPLICATIONS RELATED TO POSTERIOR DECOMPRESSION FOR SPINAL STENOSIS**

Both laminectomy and laminotomy share common bony, soft-tissue, and neural anatomy, and therefore, share a common list of potential complications. These complications include inadequate neural decompression, recurrent stenosis, incidental durotomy, neural injury, epidural hematoma, neural compression from either fat grafts or other barriers to scar formation, vascular injury, and late instability.

**INADEQUATE NEURAL DECOMPRESSION**

Although it is not a complication in the usual sense of the term, failure to obtain symptomatic relief of radicular leg pain that is not due to an error in surgical decision making should be considered at least an adverse effect of surgery. Its avoidance requires precise correlation of the preoperative imaging study with the clinical picture and surgical anatomy, and demands that surgery be continued until the offending neural compression is found. It also requires a thorough knowledge of surgical anatomy and of the potential sources and sites of neural compression, as described by MacNab (70). In addition, it is imperative that the surgeon have a precise understanding of the potential anatomic variations in the location of disc herniations so that he will know precisely where to look for neural compression, particularly when the predicted pathology is not found (110).

It is important for the surgeon to recognize and look for additional sites of neural compression that may account for inadequate relief following decompression of only one site. This condition is sometimes referred to as a “double crush phenomenon” and is thought to be at least partially due to venous congestion of the neural segment located between the two sites of compression resulting in a compartment syndrome–like condition of the intervening segment. Multiple sites of compression are common with spinal stenosis, which is a global condition frequently involving multilevel, bilateral neural compression. Sites of compression include central compression of the cauda equina and lateral compression, either within the lateral recess, within the neural foramen, or extraforaminally. It is important to identify all clinically significant sites of neural compression and to decompress those levels adequately.

**RECURRENT STENOSIS**

Distinguishing recurrent symptoms due to neural compression from those due to scar formation is a complex decision-making process that requires a precise history and high-quality radiographic imaging. Failure to obtain even temporary pain relief following decompressive lumbar surgery suggests either inadequate neural decompression, irreversible neural damage already present at the time of surgery, or a nonspinal cause for the pain. A short pain-free interval of less than 6 months suggests development of scar formation as the cause of recurrent pain. Recurrence of pain following a long pain-free interval of more than 6 to 12 months suggests a new process such as a recurrent disc herniation or recurrent stenosis.

Because spinal stenosis may occur in association with disc herniation, recurrence of symptoms following decompression involving discectomy could be due to recurrent disc herniation. The overall reported incidence of recurrent disc herniation is approximately 3% (38). Its incidence following laminectomy or laminotomy associated with discectomy is unknown but could be even greater if decompression involved destabilization from facetectomy and resulted in instability (31).

Several studies have reported that the surgical results of spinal stenosis surgery deteriorate over time (18,56,60,91). Although this may be due to many factors, such as associated comorbidity and advanced patient age, surgical and pathologic factors are also important. These factors include progression of degenerative changes at unoperated levels (60), regrowth of bone at the operated levels (90,91), pre-existing instability (degenerative scoliosis or spondylolisthesis) (35), and development of postoperative instability [for example, due to resection of one or more facets at a single segmental level (1) or development of a facet fracture at the level of decompression during or following decompression (95)]. All of the above-mentioned factors can lead to recurrent LBP or radicular leg pain following decompressive surgery for spinal stenosis.

**DUROTOMY**

Incidental violation of the dura (durotomy) is a well-recognized complication of spinal surgery that has a reported incidence of 0.3% to 13%. It most commonly occurs when the edge of a biting instrument, such as a Kerrison rongeur, inadvertently grabs the dura and produces either a punctate hole in the dura or a frank laceration. Usually, the injury is noted immediately by the sudden appearance of cerebrospinal fluid (CSF) within the wound. Occasionally, however, the tear is not noted until sometime later by the clinical appearance of persistent spinal headache, the presence of CSF drainage from the wound, or by the onset of an obvious swelling in the patient's back suggesting a pseudomeningocele (75). The incidence of the latter complication has been estimated between 0.07 and 2 per cent.

***Repair of Durotomy***

When the durotomy is noted intraoperatively, repair the dura primarily (75,117).

- It is imperative that there be adequate exposure to visualize the full extent of the laceration and that adequate illumination and magnification be available with either an operating microscope or headlight and loupe magnification. This often requires wide decompression.
- To facilitate closure of the defect, place the patient in a slightly head-down (Trendelenberg) position in order to minimize the amount of CSF in the operative field. This approach not only provides a drier operative field but also minimizes the tendency for the individual roots of the cauda equina to float to the surface, which can result in their inadvertent injury during dural repair.
- For safe closures of large tears, place a small cottonoid patty over the exposed nerve roots for the initial portion of the repair and then remove it just before dural closure (28). For tears associated with loss of tissue, or for tears in difficult to repair locations, an autologous fat graft, a piece of autograft fascia (thoracolumbar fascia or fascia lata), or a freeze-dried fascia allograft may be required to close the defect (28). Perform a watertight closure with a running 5-0 or 6-0 nonabsorbable suture (e.g., silk or nylon).
- After meticulous closure, return the patient to a neutral or slightly head-up (reverse Trendelenberg) position and perform a Valsalva maneuver in order to assess the integrity of the closure. The use of a fibrin glue may also be considered for additional strength and integrity of the repair.
- The remainder of the surgical wound closure proceeds as usual, except that a drain is often not employed in order to minimize risk of development of a CSF

fistula. Oversew the fascial closure with a running stitch to maintain a watertight closure of the fascia. Perform routine interrupted skin closure.
- If the dural closure is watertight, the patient may be ambulatory the day following surgery. If there is any doubt about the integrity of the closure, keep the patient on bed rest for 3 to 5 days (28).

If a postoperative dural leak is suspected due to persistent spinal headache or a pseudomeningocele, confirm the diagnosis by myelography or MRI, and return the patient to the operating room for dural repair and watertight closure (75). Alternatively, a subarachnoid drain can be inserted at the bedside and the patient placed on bed rest until the leak subsides. This generally involves removal of approximately 300 ml of CSF in a sterile blood collection bag daily. The volume and rate of CSF removal is titrated by adjusting the height of the bag to produce the appropriate rate of CSF flow (63).

The long-term outcome of spinal surgery complicated by incidental durotomy is generally favorable (117). When identified intraoperatively and repaired primarily, perioperative surgical morbidity and long-term outcome is comparable to that of surgery not associated with incidental durotomy (117).

**NERVE ROOT INJURY**

Neural injury may occur due to direct trauma to the nerve root itself during surgery. This injury may be due to excessive neural retraction, contusion, laceration, or electrocauterization (111). The incidence of neurologic complications following lumbar spine surgery has been estimated to be 0.2%. Such injury may be suspected postoperatively by the presence of a new or increased objective neurologic deficit, or by the onset of new parasthesias. This condition, sometimes referred to as the “battered root,” may occur either as an unavoidable consequence of severe neural compression or as a result of indelicate surgery (11). Meticulous surgical technique, therefore, is of paramount importance in order to minimize such complications. Adequate surgical exposure is imperative in order to minimize excessive neural retraction. In cases of a large midline disc herniation or a disc herniation associated with spinal stenosis, for example, a bilateral laminectomy rather than a keyhole laminotomy may be required in order to remove the disc fragment safely.

It is important to perform an anteroposterior x-ray study of the lumbar spine in order to identify bony anatomy that might be of surgical significance. Note the presence of spina bifida occulta or a pre-existing laminectomy defect, for example, on the preoperative radiograph because the presence of either of these features mandates cautious surgical exposure in order to minimize risk of damage to underlying dura and nerve roots. Carefully examine other pre-operative studies to identify other potentially significant anatomic variants, such as anomalous nerve roots, that could be injured during surgical decompression (111).

It is important always to visualize the lateral edge of the nerve root during surgical decompression to be sure that exposure is not inadvertently being performed in the axilla of a nerve root where accidental dural laceration and neural injury could occur and where repair of such injuries is particularly difficult. This is also important during revision lumbar surgery, in which dissection should usually be performed lateral to the root along the lateral edge of the bony canal to avoid a potentially dangerous midline scar. When performing lateral nerve root decompressions, work parallel, rather than perpendicular, to the long axis of the nerve root in order to minimize risk of cutting across a root.

**SCAR TISSUE**

Although scarring is a common event following all surgeries, it has been implicated as a potential cause for continued pain following spinal surgery. Postoperative scar tissue may be located either intradurally *(arachnoiditis)* or extradurally *(epidural fibrosis).* Arachnoiditis is an inflammation of the pia-arachnoid membrane that surrounds the cauda equina or spinal cord (17). It can result in surgical failure and continued pain following decompressive surgery. Its etiology is often unclear, but it has been associated with many conditions, including oil-based myelographic contrast agents and prior surgery (93). The exact mechanism by which arachnoiditis occurs following surgery is not completely understood, but it is thought to be more likely to occur following dural laceration in which blood gains entry into the dural sac and mixes with neural elements. It is also associated with intraoperative trauma to neural structures. Arachnoiditis exists as a spectrum of severity, from mild pia-arachnoid thickening to severe scarring with complete blockage of the flow of contrast agents or spinal fluid. Diagnosis can be made by water-soluble myelography, MRI, or post-contrast CT in which the individual nerve roots of the cauda equina appear clumped together rather than as well-defined structures. Surgical treatment of arachnoiditis is not indicated because surgery rarely produces any significant pain relief and may be complicated by further damage to neural structures and more scarring (17).

Epidural fibrosis is extradural, rather than intradural, scar tissue in which adhesive constrictions can form around neural tissue. It commonly arises from contact with the paraspinal musculature and is probably a relatively frequent event following spinal surgery. Although such scar tissue can result in postoperative pain, symptoms are relatively infrequent. When postoperative pain exists, the primary differential diagnosis is between scar and recurrent disc herniation. Radiographic distinction between these two conditions is best made with gadolinium-enhanced MRI or post-contrast CT (97).

Efforts to prevent postoperative scar formation include delicate surgical technique with adequate illumination and magnification, meticulous hemostasis and drainage, and the use of some form of an interposition membrane as a barrier to scar formation. These barriers include a thin layer of fat or synthetic agents such as an absorbable gelatin sponge. The use of a free fat graft has been considered the gold standard interposition membrane, although use of large grafts has been associated with postoperative cauda equina syndrome (79).

**SUPERFICIAL WOUND INFECTION**

Postoperative spine infections may be divided into either *superficial* or *deep* infections. Although the treatment for both types of infections is often similar (i.e., debridement and antibiotic therapy), it is useful to make this distinction because duration of treatment (e.g., short-term antibiotics for superficial infections versus long-term intravenous antibiotics for deep infections), morbidity, and long-term outcome are often very different for the two types.

Superficial wound infections are located beneath the dermis and subcutaneous tissue but superficial to the deep thoracolumbar fascia and are characterized by tenderness and localized erythema. They usually have associated drainage and fluctuance, although in milder cases consisting only of cellulitis these may be absent. Patients may be febrile but usually show no other systemic signs of illness (67). Laboratory data usually show elevation of the erythrocyte sedimentation rate (ESR) and C-reactive protein (CRP), although the white blood cell count (WBC) is usually within normal limits.

Treatment of superficial wound infections consists of local wound care, ranging from simple packing of a small area of localized infection, followed by a short course of oral antibiotics, to more aggressive surgical debridement of necrotic tissue with short-term parenteral antibiotics. In cases requiring surgery, the wound can usually be closed primarily, although delayed closure is an option if there is any question about the adequacy of the debridement. The use of short-term suction-irrigation tubes is at the discretion of the surgeon, although they are usually not required.

**DEEP WOUND INFECTIONS**

As opposed to superficial infections, in which the diagnosis is usually readily apparent, deep infections may be difficult to diagnose and a high index of suspicion is often required (67). Because delay in diagnosis is common, the amount of tissue necrosis is often extensive. Symptoms include disproportionate back pain or leg pain. This may follow a relatively painless and uneventful immediate postoperative period. The patient may feel and look ill and may exhibit generalized malaise. Fever is often present but may be deceptively low grade. If an epidural abscess is present, radicular leg pain and neurologic deficit may occur. Although the patient may exhibit a leukocytosis, elevation of the WBC count is frequently absent. The ESR and CRP are usually elevated.

Radiographic imaging studies are usually required to confirm the diagnosis. MRI provides the best and most useful information by revealing both the presence and extent of a deep abscess. Typically, an abscess is demonstrated by the presence of a well-demarcated area of increased signal intensity on the T2-weighted image. When MRI is not available, diagnosis may be confirmed radiographically by the presence of a circumscribed area of fluid density visualized by CT. If a deep abscess is strongly suspected, diagnosis may be confirmed by aspiration, with subsequent culture and sensitivity of any fluid obtained (61).

Treat deep wound infection aggressively with surgical debridement of all necrotic tissues, followed by appropriate parenteral antibiotics. Begin surgical exposure of the affected area with careful sequential debridement, and irrigate each layer before proceeding to the next deeper layer to avoid inadvertent contamination of potentially unaffected deeper tissues. If the infection extends deeply into the laminectomy site, take care to remove any fat graft or absorbable gelatin sponge material. Following removal of infected or suspicious tissues, thoroughly irrigate the wound with pulsatile lavage. Do not remove rigid fixation and bone graft from an instrumented spinal fusion because this may increase the risk of subsequent pseudarthrosis. Loose hardware, on the other hand, no longer performs its function of providing stability to the spine and, therefore, should be removed and thoroughly debrided. Place a drain and close the wound meticulously. Tightly close the deep fascia with interrupted absorbable suture oversewn with a continuous running stitch. Close the wound primarily, particularly in the presence of spinal fixation hardware, unless there is infection from a particularly virulent organism. This may require extensive undermining of wound margins in order to avoid tension on friable wound edges. It is usually advisable to close the wound using large throws of a sturdy, nonabsorbable suture rather than staples. Use of suction-irrigation tubes for a few days may be considered, although this is usually not necessary.

## EPIDURAL ABSCESS

Epidural abscess, because of its risk of paresis or frank paralysis, is one of the most feared complications of spinal surgery. Fortunately, it is a rare occurrence following spinal surgery, with only 16% of epidural abscesses resulting from postoperative infection (4). Signs and symptoms are obvious and constitute a typical presentation (4). Patients nearly always have significant back pain, and often present with obvious neurologic findings such as nuchal rigidity and weakness or paralysis of the lower extremities. The patient appears to be much sicker than with either postoperative discitis or vertebral osteomyelitis and typically has a fever. Both the WBC and acute phase reactants are elevated. MRI is the diagnostic imaging modality of choice and clearly visualizes the abscess as a discreet, well-circumscribed entity within the subarachnoid space. It clearly delineates the upper and lower extent of the abscess and, therefore, is invaluable in the preoperative planning of the extent of decompression.

Treatment of an epidural abscess must be prompt and decisive: surgical evacuation of the abscess and any adjacent necrotic tissue, followed by parenteral antibiotics. The preferred surgical approach is generally posterior, although an anterior approach may be indicated in the presence of a significant kyphotic deformity in which bony collapse has compromised the neural structures and simultaneous anterior reconstruction and bone grafting are required to restore stability.

## EPIDURAL HEMATOMA

Epidural hematoma causing symptomatic neurologic compression is another devastating complication of spinal surgery. Fortunately, the risk of this complication can be minimized by meticulous attention to preoperative, intraoperative, and postoperative detail. *Preoperatively,* advise the patient to stop all nonsteroidal anti-inflammatory drugs (NSAIDS) for approximately 1 week before surgery. In addition, it is important that the patient is not hypercoagulable. When indicated, check the prothrombin time (PT), partial thromboplastin time (PTT), bleeding time, platelet count, and platelet function. *Intraoperatively,* position the patient with the abdomen hanging freely in order to minimize epidural venous congestion. Keep the blood pressure below 100 mm Hg systolic, if possible, in order to minimize bleeding. Use electrocautery, and seal raw bone surfaces with bone wax to minimize bleeding during the surgical exposure. Control epidural bleeding with bipolar electrocoagulation. At the end of the surgery, when the deep paraspinal muscle retractors are removed, check the muscle walls for persistent bleeding, because prolonged muscle retraction may temporarily occlude potentially significant muscle bleeders that could begin bleeding after muscle layer closure. In general, I prefer to use a drain postoperatively in order to minimize the formation of postoperative hematoma. *Postoperatively,* leave the drain in place for 24 to 48 hours or until the amount of collected blood is less than approximately 30 ml per 8-hour shift. I do not prescribe NSAIDS during the immediate postoperative period (during the first 48 hours) in order to minimize bleeding from the fresh wound.

A characteristic clinical feature of epidural hematoma is the presence of severe pain that appears out of proportion to what is normally expected. This is usually associated with a progressive neurologic deficit. Depending on the extent and location of the surgical exposure and the magnitude of the hematoma, the neurologic deficit may be focal and unilateral, or it may be widespread and may involve multiple muscle groups in both legs.

The key to diagnosis of this condition is having a high index of suspicion. Confirm the diagnosis with MRI, myelography, or CT. Once the diagnosis is suspected, immediately return the patient to the operating room for decompression and drainage of the hematoma.

## COMPRESSION BY FAT GRAFTS OR SYNTHETIC SCAR BARRIERS

Postoperative neurologic compression may be due to structures other than epidural hematoma. The use of free fat grafts as a barrier to scar formation has been associated with symptomatic neurologic compression mimicking epidural hematoma (79). Although this risk can be minimized with the use of a smaller (3 to 5 mm thick) piece of fat, the fear of epidural compression by fat graft has led some surgeons to abandon fat grafts in favor of other synthetic scar barrier substances. Even these substitutes, however, may cause neural compression if proper care is not exercised. For multilevel laminectomy requiring the use of a lengthy piece of scar barrier material, I prefer an absorbable gelatin sponge material rather than fat because the fat could theoretically become balled up and exert focal compression on the underlying dura, and result cauda equina syndrome.

## VASCULAR COMPLICATIONS

Vascular injuries associated with posterior lumbar spinal procedures are nearly always associated with surgical discectomy, rather than laminectomy. Vascular injury occurs most commonly at L4–L5, followed by L5–S1 (24). Although to some extent this reflects the most common levels of spinal surgery, regional differences in vascular anatomy of the lower lumbar spine also play a role. Injury of a major abdominal vessel typically occurs from aggressive use of the pituitary rongeur, with penetration through the anterior annulus.

Such injuries may be recognized early or late. Brisk bleeding from acute laceration of a major abdominal vessel presents early as hypotension and abdominal distention and is associated with a high mortality rate. The mortality rate from arterial injuries has been reported to be 78%, whereas that for venous injuries is 89% (24). Vascular injuries may be recognized late by the development of high-output cardiac failure or abdominal bruits from formation of an arteriovenous fistula. Arteriovenous fistula formation is the most common result of a vascular injury. It occurs most commonly between the right common iliac artery and vein (29.1%), between the left common iliac artery and vein (25.5%), the right common iliac artery and the IVC (21.8%), and the right common iliac artery and left common iliac vein (12.7%). Late arteriovenous fistula formation is more compatible with long-term survival, with mortality reported between 9% and 11% (24).

## POSTOPERATIVE INSTABILITY

Instability following surgical decompression is usually an iatrogenic complication of spinal surgery. Such instability can occur in either the anteroposterior plane (spondylolisthesis), in the mediolateral plane (lateral listhesis and scoliosis), or in both planes simultaneously. In general, the risk of postoperative anteroposterior instability can be minimized by maintaining the integrity of at least one facet joint at the level decompressed (1). In other words, if a unilateral complete facetectomy is performed on one side, then the integrity of the opposite facet must be maintained. Similarly, if half of one facet is removed during a surgical decompression, then at least half of the contralateral facet joint should be spared. If a total of more than one facet is removed during a decompression, consider prophylactic fusion of that level.

When decompressing a stenotic level associated with a degenerative spondylolisthesis, concomitant fusion should generally be performed because surgical outcome has been shown to be better with fusion than with decompression alone (44). This seems to occur even in the absence of solid bony arthrodesis, suggesting that even the presence of a stable pseudarthrosis results in better clinical outcome than when no fusion is attempted. This is thought to be due to a reduced risk of a subsequent increase in the slip, although a direct relationship between increase in magnitude of a subsequent slip and poorer surgical outcome has not been demonstrated. Although the use of segmental spinal fixation with pedicle screws has been shown to increase the rate of fusion compared with posterolateral fusion without instrumentation, there is no convincing evidence that such instrumentation leads to better clinical outcome (32).

Isthmic spondylolisthesis with frank fracture of the pars interarticularis may also occur in the absence of prior slip as a result of surgical decompression. In such cases, the patient presents with evidence of a *de novo* spondylolisthesis occurring either at one of the levels decompressed or at a level above the level of decompression. The presumed mechanism is either a mechanical stress fracture or perhaps an impairment of the blood supply to the affected level (16,106). Instability may also occur as a result of fracture of the facet joint following decompressive surgery.

## AUTHOR'S PERSPECTIVE

Spinal stenosis is a common pathologic clinical entity that is largely degenerative in nature, although it may have a predisposing congenital component to it. It may be accompanied by other structural changes (degenerative spondylolisthesis) producing instability. The natural history of spinal stenosis is unclear, but it appears that approximately 20% of patients worsen over time, 40% improve slightly, and 40% remain unchanged.

The surgical treatment of spinal stenosis involves decompression of the symptomatic level or levels. At the time of decompression of symptomatic levels, the role of surgical decompression of clinically asymptomatic levels that show compression on imaging studies is controversial. However, because long-term failures are frequently characterized by restenosis at previously decompressed levels, or by the development of symptoms at levels that were previously stenotic but asymptomatic, it is better to decompress any questionable levels. Such decompression may be performed through laminectomy or may be more limited in extent by multilevel laminotomies.

The role of fusion depends on whether or not there is associated spondylolisthesis. In general, fusion is indicated for spinal stenosis associated with degenerative spondylolisthesis. The indications for the use of concomitant segmental (pedicle) fixation are unclear, but we use fixation more commonly in relatively young, active,

healthy patients who lack significant degenerative changes at the level of the slip. Patients with more severe degenerative changes, particularly if they are elderly and of low demand, may do well with focal decompression (laminotomies) without fusion.

## CHAPTER REFERENCES

Each reference is categorized according to the following scheme: *, classic article; #, review article; !, basic research article; and +, clinical results/outcome study.


! 1. Abumi K, Panjabi M, Dramer K, et al. Biomechanical Evaluation of Lumbar Spinal Stability after Graded Facetectomies. *Spine* 1990;15:1142.

* 2. Arnoldi C, Brodsky A, Cauchoix J, et al. Lumbar Spinal Stenosis and Nerve Root Entrapment Syndromes. Definition and Classification. *Clin Orthop* 1976;115:4.

+ 3. Atlas S, Deyo R, Keller R, et al. The Maine Lumbar Spine Study, Part III. *Spine* 1996;21:1787.

+ 4. Baker AS, Ojemann RG, Swartz MN, et al. Spinal Epidural Abscess. *N Engl J Med* 1975;293:463.

# 5. Bell GR. Diagnosis of Lumbar Disc Disease. *Seminars in Spine Surgery* 1994;6:186.

# 6. Bell GR. Degenerative Lumbar Spinal Stenosis: Natural History and Results of Simple Decompression and Decompression and Fusion for Degenerative Spondylolisthesis. In *Low Back Pain: A Scientific and Clinical Overview.* 1996,663.

+ 6a. Bell GR, Boumphrey F, Piedmont M, et al. The Incidence and Prophylaxis of Deep Venous Thrombosis (DVT) Following Spinal Surgery. Presented at 20th Annual Meeting of the International Society for the Study of the Lumbar Spine. Marseilles, France 1993.

! 7. Bell GR, Gurd AR, Orlowski JP, et al. The Syndrome of Inappropriate Antidiuretic Hormone Secretion Following Spinal Fusion. *J Bone Joint Surg* 1986;68A:720.

# 8. Bell GR, Modic MT. Radiology of the Lumbar Spine. In: Rothman RH, Simeone FA, eds. *The Spine,* 3rd ed. Philadelphia: W.B. Saunders Company, 1992:125.

# 9. Bell GR, Ross JS. Imaging Studies of the Spine. In: *Orthopaedic Knowledge Update: Spine. American Academy of Orthopaedic Surgeons (AAOS).* Rosemont, IL: 1997:41.

+ 10. Bell GR, Rothman RH, Booth RE, et al. A Study of Computer-assisted Tomography. *Spine* 1984;9:552.

* 11. Bertrans G. The Battered Root Problem. *Orthop Clin North Am* 1975;6:305.

+ 12. Blau J, Logue V. Intermittent Claudication of the Cauda Equina. An Unusual Syndrome Resulting from Central Protrusion of a Lumbar Intervertebral Disc. *Lancet* 1961;1:1082.

! 13. Boden SD, Davis DO, Dina TS, et al. Abnormal Magnetic-resonance Scans of the Lumbar Spine in Asymptomatic Subjects. A Prospective Investigation. *J Bone Joint Surg* 1990;72A:403.

! 14. Boden SD, Wiesel SW. Lumbosacral Segmental Motion in Normal Individuals: Have We Been Measuring Instability Properly? *Spine* 1990;5:571.

+ 15. Bridwell K, Bridwell KH, Sedgewick TA, O'Brien MF, et al. Role of Fusion and Instrumentation in the Treatment of Degenerative Spondylolisthesis. *J Spinal Disord* 1993;6:461.

+ 16. Brunet J, Wiley J. Acquired Spondylolysis after Spinal Fusion. *J Bone Joint Surg Br* 1984;66:720.

+ 17. Burton C. Lumbosacral Arachnoiditis. *Spine* 1978;3:24.

* 18. Caputy A, Luessenhop A. Long-term Evaluation of Decompressive Surgery for Degenerative Lumbar Stenosis. *J Neurosurg* 1992;77:669.

+ 19. Chen Q, Baba H, Kamitani K, et al. Postoperative Bone Re-growth in Lumbar Spinal Stenosis. A Multivariate Analysis of 48 Patients. *Spine* 1994;19:2144.

+ 20. Cinotti G, Postacchini F, Weinstein J. Lumbar Spinal Stenosis and Diabetes. Outcome of Surgical Decompression. *J Bone Joint Surg Br* 1994;76:215.

! 21. Cohen MS, Wall EJ, Brown RA, et al. Cauda Equina Anatomy. II: Extrathecal Nerve Roots and Dorsal Root Ganglia. *Spine* 1990;15:1248.

+ 22. Collis JS, Gardner WJ. Lumbar Discography—an Analysis of One Thousand Cases. *J Neurosurg* 1962;19:452.

+ 23. Cooper DE, Jenkins RS, Bready L, et al. The Prevention of Injuries of the Brachial Plexus Secondary to Malposition of the Patient During Surgery. *Clin Orthop* 1988;228:31.

+ 24. DeSaussure RL. Vascular Injury Coincidence to Disc Surgery. *J Neurosurg* 1959;16:222.

+ 25. Deyo R, Cherkin D, Loeser J, et al. Morbidity and Mortality in Association with Operations on the Lumbar Spine. *J Bone Joint Surg* 1992;74A:536.

+ 26. Deyo R, Ciol M, Cherkin D, et al. Lumbar Spinal Fusion. A Cohort Study of Complications, Reoperations, and Resource Use in the Medicare Population. *Spine* 1993;18:1463.

+ 27. Dyck P, Doyle JB. “Bicycle test” of Van Gelderen in Diagnosis of Intermittent Cauda Equina Compression. *J Neurosurg* 1977;46:667.

+ 28. Eismont FJ, Wiesel SW, Rothman RH. Treatment of Dural Tears Associated with Spinal Surgery. *J Bone Joint Surg* 1981;63A:1132.

+ 29. Epstein N, Epstein J. Decompression in the Surgical Management of Degenerative Spondylolisthesis: Advantages of a Conservative Approach in 290 Patients. *J Spinal Disord* 1998;11:116.

+ 30. Feffer H, Weisel S, et al. Degenerative spondylolisthesis: To fuse or not to fuse. *Spine* 1985;10:286.

+ 30a. Ferree B, Stern P, Jolson R, et al. Deep Venous Thrombosis after Spinal Surgery. *Spine* 1993;18:315.

+ 30b. Ferree BA, and Wright AM. Deep Venous Thrombosis Following Posterior Lumbar Spinal Surgery. *Spine* 1993;18:1079.

+ 31. Finnegan WJ, Tenlin JM, Mavel JP, et al. Results of Surgical Intervention in the Multiply Operated Back Patient. *J Bone Joint Surg* 1979;61A:1077.

+ 32. Fischgrund J, Mackay M, Herkowitz H, et al. Degenerative Lumbar Spondylolisthesis with Spinal Stenosis: A Prospective, Randomized Study Comparing Decompressive Laminectomy and Arthrodesis with and without Spinal Instrumentation. *Spine* 1997;22:2807.

+ 33. Fitzgerald J, Newman P. Degenerative Spondylolisthesis. *J Bone Joint Surg* 1976;58B:184.

+ 34. France JC, Yaszemski MJ, Lauerman WC, et al. A Randomized Prospective Study of Posterolateral Lumbar Fusion. Outcomes with and without pedicle screw instrumentation. *Spine* 1999;24:553.

+ 35. Frazier D, Lipson S, Fossel A, et al. Associations between Spinal Deformity and Outcomes after Decompression for Spinal Stenosis. *Spine* 1997;22:2025.

# 36. Frymoyer J. Degenerative Spondylolisthesis: Diagnosis and Treatment. *J Am Acad Orthop Surg* 1994;2:9.

! 37. Frymoyer JW, Newberg A, Pope MH, et al. Spine Radiographs in Patients with Low-back Pain. *J Bone Joint Surg Am* 1984;66A:1048.

+ 38. Garfin SR, Glover M, Booth RE, et al. Laminectomy: A Review of the Pennsylvania Hospital Experience. *J Spinal Disord* 1988;1:116.

+ 39. Getty C, Johnson J, Kirwan E, et al. Parial Undercutting Facetectomy for Bony Entrapment of the Lumbar Nerve Root. *J Bone Joint Surg* 1981;63B:330.

+ 40. Grob D, Humke T, Dvorak J. Degenerative Lumbar Spinal Stenosis Decompression with and without Arthrodesis. *J Bone Joint Surg* 1995;77A:1036.

! 41. Hayes MA, Howard TC, Gruel CR, et al. Roentgenographic Evaluation of Lumbar Spine Flexion-extension in Asymptomatic Individuals. *Spine* 1989;14:327.

! 42. Heliovaara M, Vanharanta H, Korpi J, et al. Herniated Lumbar Disc Syndrome and Vertebral Canals. *Spine* 1986;11:433.

+ 43. Herkowitz H, Garfin S, Bell G, et al. The Use of Computerized Tomography in Evaluating Non-visualized Vertebral Levels Caudal to a Complete Block on a Lumbar Myelogram. *J Bone Joint Surg* 1987;69A:218.

+ 44. Herkowitz H, Kurz L. Degenerative Lumbar Spondylolisthesis with Spinal Stenosis: A Prospective Study Comparing Decompression with Decompression and Intertransverse Process Arthrodesis. *J Bone Joint Surg* 1991;73A:802.

* 45. Hirsch C, Nachemson A. The Reliability of Lumbar Disc Surgery. *Clin Orthop* 1963;29:189.

+ 45a. Hitselberger WE, Witten RM. Abnormal Myelograms in Asymptomatic Patients. *J Neurosurg* 1968;28:204.

* 46. Holt EP. The Question of Lumbar Discography. *J Bone Joint Surg* 1968;50A:720.

! 47. Inufusa A, An H, Lim T, et al. Anatomic Changes of the Spinal Canal and Intervertebral Foramen Associated with Flexion-extension Movement. *Spine* 1996;21:2412.

+ 48. Jackson RP, Becker GJ, Jacobs RR, et al. The Neuroradiographic Diagnosis of Lumbar Herniated Nucleus Pulposus: I. A Comparison of Computed Tomography (CT), Myelography, CT-myelography, Discography, and CT-discography. *Spine* 1989;14:1356.

+ 49. Jackson RP, Cain JE Jr, Jacobs RR, et al. The Neuroradiographic Diagnosis of Lumbar Herniated Nucleus Pulposus: II. A Comparison of Computed Tomography (CT), Myelography, CT-myelography, and Magnetic Resonance Imaging. *Spine* 1989;14:1362.

! 50. Jensen MC, Brant-Zawadzki MN, Obuchowski N, et al. Magnetic Resonance Imaging of the Lumbar Spine in People without Back Pain. *N Engl J Med* 1994;331:69.

+ 51. Johnsson K, Uden A, Rosen I. The Effect of Decompression on the Natural Course of Spinal Stenosis. A Comparison of Surgically Treated and Untreated Patients. *Spine* 1991;16:615.

* 52. Johnsson KE, Rosen I, Uden A. The Natural Course of Spinal Stenosis. *Clin Orthop* 1992;279:82.

+ 53. Jonsson B, Annertz M, Sjoberg C, et al. A Prospective and Consecutive Study of Surgically Treated Lumbar Spinal Stenosis. Part I: Clinical Features Related to Radiographic Findings. *Spine* 1997;22:2932.

+ 54. Jonsson B, Stromqvist B. Symptoms and Signs in Degeneration of the Lumbar Spine. A Prospective, Consecutive Study of 300 Operated Patients. *J Bone Joint Surg* 1993;75:381.

+ 54a. Junghanns H. Spondylolisthesen Ohne Spalt in Zwischengelenksteuck. *Archiv fuer Orthopadische Unfallchirurgie* 1930;29:118.

! 55. Katz J. Lumbar Spinal Fusion. Surgical Rates, Costs and Complications. *Spine* 1995;20(Suppl):78S.

+ 56. Katz J. Comorbidity and Outcome in Degenerative Lumbar Spinal Stenosis. Low Back Pain: A Scientific and Clinical Overview. 1996;41:689.

+ 57. Katz J, Dalgas M, Stucki G, et al. Degenerative Lumbar Spinal Stenosis. Diagnostic Value of the History and Physical Examination. *Arthritis Rheum* 1995;38:1236.

+ 58. Katz J, Lipson S, Brick G, et al. Clinical Correlates of Patient Satisfaction after Laminectomy for Degenerative Lumbar Spinal Stenosis. *Spine* 1995;20:1155.

+ 59. Katz J, Lipson S, Chang L, et al. Seven- to 10-year Outcome of Decompressive Surgery for Degenerative Lumbar Spinal Stenosis. *Spine* 1996;21:92.

+ 60. Katz J, Lipson S, Larson M, et al. The Outcome of Decompressive Laminectomy for Degenerative Lumbar Stenosis. *J Bone Joint Surg [Am]* 1991;73:809.

+ 61. Keller RB, Pappas AM. Infections after Spinal Fusion Using Internal Fixation Instrumentation. *Orthop Clin North Am* 1972;3:99.

* 62. Kirkaldy-Willis W, Paine K, Cauchoix J, et al. Lumbar Spinal Stenosis. *Clin Orthop* 1974;99:30.

+ 63. Kitchel SH, Eismont FJ, Green BA. Closed Subarachnoid Drainage for Management of Cerebrospinal Fluid Leakage after an Operation on the Spine. *J Bone Joint Surg* 1989;71A:984.

# 64. Krag MH. Lumbosacral Fixation with the Vermont Spinal Fixator. In: Lin PM, Gill K, eds. *Lumbar Interbody Fusion: Principles and Techniques of Spine Surgery.* Rockville, MD: Aspen, 1988.

! 65. Krag MH. Spinal Instrumentation. Biomechanics of Transpedicle Spine Fixation. In: *The Lumbar Spine,* 2nd ed. Philadelphia: W.B. Saunders Company, 1996:1177.

+ 66. Lee A. Ischemic Optic Neuropathy Following Lumbar Spine Surgery. Case Report. *J Neurosurg* 1995;83:348.

# 67. Lestini WF, Bell GR. Spinal Infections: Patient Evaluation. *Seminars in Spine Surgery* 2:244-256; 1990.

# 68. Levine AM, Edwards CC. Low Lumbar Burst Fractures. *Orthopaedics* 1988;11:1427.

+ 69. Lin PM. Internal Decompression for Multiple Levels of Lumbar Spinal Steonosis: A Technical Note. *Neurosurgery* 1982;11:546.

* 70. MacNab I. Spondylolisthesis with an Intact Neural Arch—the So-called Pseudo-spondylolisthesis. *J Bone Joint Surg* 1950;32B:325.

# 71. MacNab I. The Traction Spur: An Indication of Segmental Instability. *J Bone Joint Surg Am* 1971;53A:663.

# 72. Magerl F: External Spinal Skeletal Fixation. In: Weber BG, Magerl F, eds. *The External Fixator.* New York: Springer-Verlag, 1985.

# 73. Magerl FP. Stabilization of the Lower Thoracic and Lumbar Spine with External Skeletal Fixation. *Clin Orthop* 1984;189:125.

+ 74. Mardjetko S, Connolly P, Shott S. Degenerative Lumbar Spondylolisthesis: A Meta-analysis of Literature, 1970–1993. *Spine* 1994;19(Suppl):2256S.

# 75. Marshall LF. Cerebrospinal Fluid Leaks: Etiology and Repair. In: Rothman RH, Simeone FA, eds. *The Spine,* 3rd ed. Philadelphia: W.B. Saunders, 1992.

+ 76. Matsui H, Kanamori M, Ishihara H, et al. Expansive Lumbar Laminoplasty for Degenerative Spinal Stenosis in Patients below 70 Years of Age. *Eur Spine J* 1997;6:191.

+ 77. Matsui H, Tsuji H, Seido H, et al. Results of Expansive Laminoplasty for Lumbar Spinal Stenosis in Active Manual Workers. *Spine* 1992;17(Suppl):S37.

+ 78. Matsunaga S, Sakou T, et al. Natural History of Degenerative Spondylolisthesis: Pathogenesis and Natural Course of the Slippage. *Spine* 1990;15:1204.

+ 79. Mayer P, Jacobsen F. Cauda Equina Syndrome after Surgical Treatment of Lumbar Spinal Stenosis with Application of Free Autogenous Fat Graft. A Report of Two Cases. *J Bone Joint Surg* 1989;71:1090.

+ 80. McCulloch J. Microdecompression and Uninstrumented Single-level Fusion for Spinal Canal Stenosis with Degenerative Spondylolisthesis. *Spine* 1998;23:2243.

! 81. Morgan FP, King T. Primary Instability of Lumbar Vertebrae as a common Cause of Low Back Pain. *J Bone Joint Surg Am* 1957;39B:6.

+ 82. Myers M, Hamilton S, Bogosian A, et al. Visual Loss as a Complication of Spine Surgery. A Review of 37 Cases. *Spine* 1997;22:1325.

+ 83. Nakai O, Ookawa A, Yamaura I. Long-term Roentgenographic and Functional Changes in Patients Who Were Treated with Wide Fenestration for Central Lumbar Stenosis. *J Bone Joint Surg* 1991;73A:1184.

+ 84. Nambisan RN, Karkousis CP. Axillary Compression Syndrome with Neurapraxia due to Operative Positioning. *Surgery* 1989;105:449.

* 84a. Newman P, Stone K. The Etiology of Spondylolisthesis. *J Bone Joint Surg* 1963;45B:39.

+ 85. Nork SE, Serena SH, Workman KL, et al. Patient Outcomes after Decompression and Instrumented Posterior Spinal Fusion for Degenerative Spondylolisthesis. *Spine* 1999;24:561.

+ 86. Oldridge N, Yuan Z, Stoll J, Rimm A. Lumbar Spine Surgery and Mortality among Medicare Beneficiaries, 1986. *Am J Public Health* 1994;84:1292.

! 87. Olmarker K, Rydevik B, Holm S. Edema Formation in Spinal Nerve Roots Induced by Experimental, Graded Compression. An Experimental Study on the Pig Cauda Equina with Special Reference to Differences in Effects between Rapid and Slow Onset of Compression. *Spine* 1989;14:569.

! 88. Parke WW, Watanabe R. The Intrinsic Vasculature of the Lumbosacral Spinal Nerve Roots. *Spine* 1985;10:508.

! 89. Parke WW. The Significance of Venous Return Impairment in Ischemic Radiculopathy and Myelopathy. *Orthop Clin North Am* 1991;22:213.

+ 90. Postacchini F, Cinotti G. Bone Regrowth after Surgical Decompression for Lumbar Spinal Stenosis. *J Bone Joint Surg* 1992;74B:862.

+ 91. Postacchini F, Cinotti G, Gumina S, et al. Long-term Results of Surgery in Lumbar Stenosis. 8-year Review of 64 Patients. *Acta Orthop Scand* 1993;251(Suppl):78.

+ 92. Postacchini F, Cinotti G, Perugia D, et al. The Surgical Treatment of Central Lumbar Stenosis. Multiple Laminotomy Compared with Total Laminectomy. *J Bone Joint Surg* 1993;75B:386.

+ 93. Quiles M, Marchisello PS, Tsairis P. Lumbar Adhesive Arachnoiditis: Etiologic and Pathologic Aspects. *Spine* 1978;3:45.

! 94. Ramani P. Variations in Size of the Bony Lumbar Canal in Patients with Prolapse of Lumbar Intervertebral Discs. *Clin Radiol* 1976;27:301.

+ 95. Rosen C, Rothman S, Zigler J, et al. Lumbar Facet Fracture as a Possible Source of Pain after Lumbar Laminectomy. *Spine* 1991;16(Suppl):S234.

+ 96. Rosenberg N. Degenerative Spondylolisthesis: Surgical Treatment. *Clin Orthop* 1976;117:112.

+ 97. Ross JS, Masaryk TJ, Modic MT. MR Imaging of Lumbar Arachnoiditis. *Am J Neuroradiol* 1987;8:885.

+ 98. Rothman S, Glenn W Jr, Kerber C. Postoperative Fractures of Lumbar Articular Facets: Occult Cause of Radiculopathy. *AJR Am J Roentgenol* 1985;145:779.

# 99. Roy-Camille R. *Experience with Roy-Camille Fixation for the Thorocolumbar and Lumbar Spine. Acute Spinal Injuries: Current Management Techniques. University of Massachusetts Continuing Medical Education Course.* Sturbridge, MA: University of Massachusetts, 1987.

# 100. Roy-Camille R, Saillant G, Mazel C. Internal Fixation of the Lumbar Spine with Pedicle Screw Plating. *Clin Orthop* 1986;203:7.

! 101. Rydevik BL, Brown MD, Lundborg G. Pathoanatomy and Pathophysiology of Nerve Root Compression. *Spine* 1984;9:7.

! 102. Rydevik BL, Pedowitz RA, Hargens AR, et al. Effects of Acute, Graded Compression on Spinal Nerve Root Function and Structure. An Experimental Study of the Pig Cauda Equina. *Spine* 1991;16:487.

# 103. Saal JA, Saal JA, Parthasarathy R. *The Natural History of Lumbar Spinal Stenosis. The Results of Non-operative treatment.* Presented at Tenth Annual Meeting of the North American Spine Society (NASS). Washington, D.C., 1995.

* 103a. Sachs B, Fraenkel J. Progressive ankylotic rigidity of the spine (spondylose rhizomelique). *J Nerve Ment Dis* 1900;27:1.

+ 104. Sanderson P, Getty C. Long-term Results of Partial Undercutting Facetectomy for Lumbar Lateral Recess Stenosis. *Spine* 1996;21:1352.

! 105. Shaffer WO, Spratt KF, Weinstein J, et al. The Consistency and Accuracy of Roentgenograms for Measuring Sagittal Translation in the Lumbar Vertebral Motion Segment: An Experimental Model. *Spine* 1990;15:741.

+ 106. Sienkiewicz P, Flatley T. Postoperative Spondylolisthesis. *Clin Orthop* 1987;221:172.

+ 107. Simpson J, Silveri C, Balderston R, et al. The Results of Operations on the Lumbar Spine in Patients Who Have Diabetes Mellitus. *J Bone Joint Surg* 1993;75:1823.

+ 108. Smith M, Bressler E, Lonstein J, et al. Deep Venous Thrombosis and Pulmonary Embolism after Major Reconstructive Operations on the Spine. A Prospective Analysis of Three Hundred and Seventeen Patients. *J Bone Joint Surg* 1994;76:980.

# 109. Spivak J. Current Concepts Review. Degenerative Lumbar Spinal Stenosis. *J Bone Joint Surg* 1998;80A:1053.

# 110. Stambough JL. Surgical Technique for Lumbar Discectomy. *Seminars is Spine Surgery* 1989;1:47.

# 111. Stambough JL, Simeone FA. Neurogenic Complications in Spine Surgery. In: Rothman RH, Simeone FA, eds. *The Spine,* 3rd ed. Philadelphia: W.B. Saunders, 1992.

+ 112. Tchang SP, Howie JL, Kirkaldy-Willis WH, et al. Computed Tomography Versus Myelography in Diagnosis of Lumbar Disc Herniation. *J Can Assoc Radiol* 1982;33:15.

# 113. Turner J, Ersek M, Herron L, et al. Surgery for Lumbar Spinal Stenosis: Attempted Meta-analysis of the Literature. *Spine* 1992;17:1.

# 114. Turner JA, Ersek M, Herron L, et al. Patient Outcomes after Lumbar Spinal Fusions. *JAMA* 1992;268:XX.

+ 114a. Van Gelderen C. Ein orthotisches (Lordotisches) Kaudasyndrom. *Acta Psychiatr Neurol* 1948;23:57.

+ 115. Vaccaro A, Garfin S. Degenerative Lumbar Spondylolisthesis with Spinal Stenosis, a Prospective Study Comparing Decompression with Decompression and Intertransverse Process Arthrodesis: A Critical Analysis. *Spine* 1997;22:368.

* 116. Verbiest H. A Radicular Syndrome from Developmental Narrowing of the Lumbar Vertebral Canal. *J Bone Joint Surg* 1954;36B:230.

+ 117. Wang JC, Bohlman HH, Riew KD. Dural Tears Secondary to Operations on the Lumbar Spine. Management and Results After a Two-Year-Minimum Follow-up of Eighty-eight Patients. *J Bone Joint Surg* 1998;80A:1728.

+ 118. Ward CF. Complications of Positioning for Spine Surgery. In: Garfin SR, ed. *Complications of Spine Surgery.* Baltimore: Williams & Wilkins, 1989.

+ 119. West J, Anderson L. Incidence of Deep Vein Thrombosis in Major Adult Spinal Surgery. *Spine* 1992;17(Suppl):S254.

! 120. Wiesel SW, Tsourmas N, Feffer HL, et al. A Study of Computer-assisted Tomography: I. The Incidence of Positive CAT Scans in an Asymptomatic Group of Patients. *Spine* 1984;9:549.

+ 121. Wiltse LL, Guyer RD, Spencer CW, et al. Alar Transverse Process Impingement of the L5 Spinal Nerve: The Far-out Syndrome. *Spine* 1984;9:31.

! 122. Yoshida M, Shima K, Taniguchi Y, et al. Hypertrophied Ligamentum Flavum in Lumbar Spinal Canal Stenosis. Pathogenesis and Morphologic and Immunohistochemical Observation. *Spine* 1992;17:1353.

+ 123. Young S, Veerapen R, O'Laoire S. Relief of Lumbar Canal Stenosis Using Multilevel Subarticular Fenestrations as an Alternative to Wide Laminectomy: Preliminary Report. *Neurosurgery* 1988;23:628.

+ 124. Yuan HA, Garfin SR, Dickman CA, Mardjetko SM. A Historical Cohort Study of Pedicle Screw Fixation in Thoracic, Lumbar, and Sacral Spinal Fusions. *Spine* 1994;19(Suppl):2279S.

+ 125. Zdeblick T. A Prospective, Randomized Study of Lumbar Fusion: Preliminary Results. *Spine* 1993;18:983.

# CHAPTER 148

# FAILED AND REVISION CERVICAL SPINE SURGERY

*Eeric Truumees and Robert F.Mclain*

**E. Truumees:** Department of Spinal Surgery, William Beaumont Hospital, Royal Oak, Michigan, 48073.
**R. F. McLain:** Department of Orthopaedics, The Cleveland Clinic Foundation, Cleveland, Ohio, 44195.

Cause of Failure
Patient-Related Factors
Surgeon-Related Factors
Preoperative Assessment and Planning
Presentation
History and Physical Examination
Imaging Studies
Treatment
Nonoperative Treatment
Operative Planning and Treatment
General Rehabilitation and Postoperative Principles
Pitfalls and Complications
Chapter References

Cervical spine surgery is usually successful. The population of chronic, failed cervical spine surgery patients is smaller than for the lumbar spine. However, cervical spine surgery is becoming more common. Fusion procedures increased 70% between the periods of 1979–1981 and 1988–1990 (11). With this increase, more complications will be encountered and the need for revisions will rise. This chapter will focus on pseudarthrosis, residual compression, postlaminectomy kyphosis, hardware failure, and progressive or adjacent segment degeneration.

## CAUSE OF FAILURE

### PATIENT-RELATED FACTORS

Patients with active medicolegal issues or complex, unresolved psychosocial problems are less likely to achieve a satisfactory outcome from primary cervical spine surgery. Unrealistic expectations and poor compliance with postoperative care also reduce the chances for successful post-surgical outcome. Nutrition, smoking, diabetes, and steroid use all have implications in wound healing, bony fusion, and recovery.

Poor patient selection will predispose to failure of primary cervical surgery and will make revision surgery even more difficult. When failure is the result of, or compounded by, any of these factors, the issues must be addressed before surgical revision is likely to succeed.

### SURGEON-RELATED FACTORS

Preoperative factors leading to poor outcome include errors in diagnosis, surgical timing, and intended procedure. Common errors of surgical judgment include choosing the wrong approach, selecting improper fusion levels, or recommending improper postoperative care. These errors will be considered in terms of their outcome: deformity, pseudarthrosis, or inadequate decompression. Perioperative events, including infection, dural leak and pseudomeningocele, and hematoma are not uncommon causes of clinical failure and must be evaluated before planning a revision procedure.

#### *Pseudarthrosis*

Pseudarthrosis complicates both anterior and posterior fusion procedures, but it is not always the cause of postoperative neck pain. Anterior cervical discectomy (ACD), without fusion, relieves radicular and axial neck pain in many patients. The success of ACD highlights the fact that nonunion is not always painful (26). Nonetheless, the most common cause of axial pain or radicular symptoms after anterior cervical discectomy and fusion (ACDF) is still pseudarthrosis (36,41). Published reviews of ACDF outcomes report pseudarthrosis in up to 26% of patients (13,22,32,36). Patients at increased risk for pseudarthrosis after ACDF include those undergoing multilevel, individual fusions and those fused with allograft (20,48).

In their analysis of anterior cervical fusion, Lowery et al. (22) defined pseudarthrosis as having the following components:

- Continued or worsening axial pain 6 months after the index procedure
- Complete radiolucency at the host–graft interface
- Vertebral body motion of >2 mm on flexion–extension films

Symptomatic pseudarthroses were seen mainly at the interface between the graft and the vertebral body below. Only 9% of patients with pseudarthrosis felt better after their initial surgery; 27% felt the same, and 64% felt worse.

The literature regarding pseudarthrosis after posterior cervical fusion is relatively sparse. Posterior fusions do not enjoy the biological advantage of grafting under compression, but overall, fusion rates are felt to be high. Reported pseudarthrosis rates following traditional wiring techniques range from 0% to 50% (16), but it can be expected in 10% of patients. Outcomes after rigid posterior plating are reported with rates of 0% to 1.4% pseudarthrosis (16).

#### *Residual Compression*

Residual compression of the neural elements is a common cause of failure in both anterior and posterior cervical spine procedures (29). The diffuse nature of degenerative changes in the cervical spine sometimes requires more global or comprehensive procedures than the surgeon is initially willing to entertain. Residual compression after an index spine procedure may result from any of the following:

- Failure to perform a complete decompression at the injured/involved level
- Failure to decompress adjacent involved levels
- Migration of graft or fixation materials into the canal or foramen
- Wrong-level surgery

After ACDF, posterior osteophytes in the region of the posterior longitudinal ligament (PLL) may be a significant source of residual compression (44). Some surgeons feel that posterior osteophytes will resorb after successful fusion. Therefore, they avoid PLL resection and the dangers of operating near the spinal cord. However, the extent of osteophyte resorption is controversial. Recent studies have noted little remodeling or resorption after solid ACDF (32,38). Some authors have advocated more complete decompression in this area through PLL resection and direct visualization with an operating microscope or loupes (19).

Similarly, persistent neural compression following fracture may impair neurologic recovery. While stabilization alone affords some protection of neurologic tissues, adequate decompression of bony and soft-tissue elements increases neurologic recovery (31).

#### *Postlaminectomy Kyphosis*

Postlaminectomy kyphosis is a focal and often dramatic angulation of the cervical spine occurring after posterior decompression (21). Wide decompression necessarily sacrifices all or part of the facet and eliminates the attachments for the posterior spinal musculature. Bilateral facetectomy of more than 25% of the facet increases cervical motion in all planes and should prompt posterior fusion to prevent deformity (27,28). After extensive laminectomy, glacial progression toward scoliosis or kyphosis occurs in 30% to 50% of younger patients, and fusion is indicated (39).

Risk factors for postoperative kyphosis include (21) the following:

- Young age (into third decade)
- Preoperative deformity [particularly **S**-shaped or kyphotic deformities (25)]
- Removal of more than four laminae
- Destruction of facets
- Tumors
- Removal of C-2 posterior elements (major semispinalis insertion)
- Paralysis with paraspinal muscle weakness
- Anterior instability following fracture

#### *Hardware Failure*

If due consideration is given to the biomechanical status of the cervical spine and its relationship to the construct employed, the likelihood of failure of most modern instrumentation is small. Fixation failure reflects the types of failure already described:

- Persistent pseudarthrosis results in fatigue failure or failure at the host–hardware interface.
- Underestimated or unrecognized biomechanical loads cause acute failure.
- Aggressive postoperative mobilization, particularly in osteopenic bone, causes acute or progressive hardware loosening.
- Noncompliant patients can accelerate all these processes, particularly when smoking retards the healing process.
- Progressive destruction by tumor or infection further destabilizes the spine.

#### *Progressive or Adjacent-Segment Degeneration*

Cervical spine fusion may accelerate degeneration of neighboring, unfused levels (3). These changes may reflect local biomechanical alterations that result from an existing fusion (adjacent segment degeneration) or may simply reflect the natural history of that patient's cervical spondylosis. As such, this degeneration may take the form of recurrent stenosis, recurrent disc herniation, or degenerative disc disease. Up to 89% of ACDF patients report symptomatic degeneration at long-term follow-up (17,43). Anecdotal evidence suggests that fusions ending at C-5 or C-6 are particularly associated with recurrent axial neck pain, perhaps because of the increased segmental motion at these levels (40).

In patients with continued pain despite a solid arthrodesis, rule out inadequate decompression first. Then evaluate radicular or myelopathic symptoms for evidence of foraminal or canal stenosis or recurrent disc herniation. In patients with predominantly axial pain, assessment of the cervical discs above and below the fusion mass remains controversial. Some authors recommend cervical discography with anterior fusion for concordant pain (33).

## PREOPERATIVE ASSESSMENT AND PLANNING

### PRESENTATION

#### *Failed Cervical Spine Surgery*

Patients with failed cervical spine surgery present with the following:

- Residual axial pain
- Recurrent or residual myelopathy
- Recurrent or residual radiculopathy
- Development or progression of deformity

Evaluation algorithms are presented in Figure 148.1, Figure 148.2, Figure 148.3.

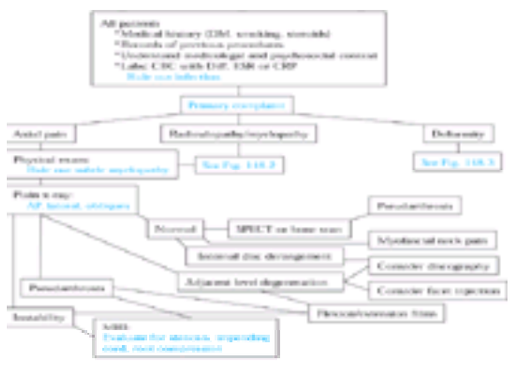

***Figure 148.1.*** Evaluation algorithm for patients with failed cervical spine surgery

***Figure 148.2.*** Evaluation algorithm for radiculopathy and myelopathy.




***Figure 148.3.*** Evaluation algorithm for postsurgical deformity.

#### *Pseudarthrosis*

Patients with pseudarthrosis typically present with the following:

- Axial neck pain
- Recurrent radiculopathy or myelopathy from regrowth of posterior osteophytes
- Deformity from failure of intended fusion after wide posterior decompression

#### *Inadequate Decompression or Adjacent-level Degenerative Disc Disease*

Patients with inadequate decompression or progressive or adjacent-level degenerative disc disease present with the following:

- Neural compression after cervical spine surgery, most commonly related to inadequate decompression, recurrent disc herniation, or recurrent stenosis
- Radicular pain (radiculitis), one of the earliest symptoms of neural compression; often relieved by distraction and increased with axial loading
- Weakness and sensory changes, presenting in a radicular pattern (radiculopathy) with increasing compression
- In advanced cases, lower motor neuron findings, including weakness and diminished reflexes, at the level of compression; below the compression, upper motor neuron signs, including hyperreflexia and spasticity
- Ataxia, clumsiness, diffuse lower extremity weakness, and bowel and bladder problems (i.e., myelopathy) after cervical spine surgery, often related to the following:

    Large central disc (less common)
    Severe, unaddressed osteophytosis (with normal or stenotic canal)
    Hardware displacement
    Postoperative deformity

#### *Postlaminectomy Kyphosis*

Patients with postlaminectomy kyphosis present with a history of prior posterior cervical spine surgery and an often subtle, progressive pattern of pain and neurologic change (18):

- Neck pain (75%)
- Severe neck deformity (30%)
- Progressive myelopathy (90%)
- Radiculopathy (50%)

#### *Hardware Failure*

Hardware failure may result in any of the symptoms described in this section. In dramatic cases, patients complain of tracheal or esophageal impingement. Sudden changes in alignment, neurologic status, or pain often indicate failure of hardware. Patients may be aware of a “pop” or acute onset of instability. However, slow pull-out of lateral mass plates, for example, can present with slowly increasing deformity, such as is seen in postlaminectomy kyphosis.

### HISTORY AND PHYSICAL EXAMINATION

Understand the patient's spine thoroughly before making treatment decisions. First, obtain complete records of previous procedures and determine the following:

- What types of postoperative immobilization were employed?
- What was the condition of the bone?
- Was allograft or autograft employed?
- Was the PLL resected?

A complete motor and sensory examination is critical. Patients with prior cervical spine surgery are likely to demonstrate complex abnormalities. Perform a detailed and stepwise assessment of sensory, motor, and reflex abnormalities, as well as a careful search for evidence of myelopathy to define new or residual neurologic deficits. Note bowel or bladder changes, gait disturbance, and the unilaterality or bilaterality of symptoms. The following may be a useful checklist:

- Recognize possible aberrant innervation patterns (23).
- Map complex sensory deficits on the skin with a skin marker.
- Chart complex motor and reflex changes.
- Distinguish cervical problems from those of shoulder, cardiac, cranial, or peripheral origin.
- Assess the location and healing of the prior incision(s).
- Assess cervical range of motion (ROM) and neck and body posture.
- Note areas of tenderness and spasticity of paravertebral and anterior strap muscles.

### IMAGING STUDIES

Compare plain anteroposterior (AP), lateral, and oblique views with prior studies to assess progression of spondylosis, fusion, deformity, or hardware migration. New degeneration most often presents with narrowing of adjacent disc heights and increase in osteophyte formation. Space available for the cord, from the posterior vertebral body to its lamina, is normally over 17 mm; an AP diameter of less than 13 mm suggests spinal cord compression (12). Oblique views assess the fusion mass, intervertebral foramina, pedicles, and facets, and they show persistent compression due to uncovertebral joint spurring.

If postoperative instability or pseudarthrosis is suspected, flexion–extension lateral films are useful. Dynamic x-rays are also helpful in evaluating new instability secondary to adjacent-level degenerative disc disease. In a patient with postoperative deformity, 5 pounds of axial traction may be used to determine reducibility (15).

Correlate radiographic findings with presenting complaints and physical exam. For example, pseudarthrosis is often difficult to identify. As in the lumbar spine, shingling of the bone mass may obscure the fusion defect (5). Therefore, clinical criteria (intractable neck pain with or without radicular symptoms) must be correlated with radiographic criteria (6). Radiographic signs of pseudarthrosis include the following (6):

- Gross motion at previous fusion site on dynamic radiographs

- Persistence of disc-space lucency
- Graft displacement or failure to incorporate
- No dissolution of endplates
- Hardware failure

Advanced imaging modalities may also prove useful. Single photon emission computed tomography (SPECT) scanning employs a tomographic camera to remove three-dimensional superimposition from scintigraphic images, thereby improving image contrast and offering more complete spatial information than conventional bone scans. It is increasingly being used to demonstrate increased focal uptake at sites of pseudarthrosis (37).

Computed tomographic myelography demonstrates neural compression indirectly through contour of the dural sac. While myelography is invasive, it is helpful in the presence of spinal deformity. Further, it offers information on conjoint nerve roots and other pathologies not readily appreciated with magnetic resonance imaging (MRI) (23). When spinal instrumentation is in place, myelography may be the only way to visualize neural structures.

Magnetic resonance imaging elucidates disc degeneration and intrinsic changes in the cord. However, major abnormalities are commonly encountered in asymptomatic patients (1). In postoperative patients, gadolinium enhancement reveals recurrent discs as nonenhancing space-occupying lesions, which scar enhances.

Some authors advocate cervical discography for patients with undetermined axial pain, reporting 70% good to excellent results with anterior fusion after concordant discography (41). However, others cite higher failure rates, including one report of 54% fair to poor results (8). These authors cite a 13% complication rate with cervical discography, including one case of acute epidural abscess resulting in quadriplegia. Discography is likely to remain controversial for some time.

Finally, root injections are occasionally used to determine painful levels. Resolution or mitigation of pain indicates specific root-level pathology and the likelihood of surgical relief of symptoms following surgery.

## TREATMENT

Principles and operative indications are the same as for patients requiring primary treatment. Early operative treatment should be considered in any patient demonstrating the following:

- Progressive motor or gait impairment
- Persistent disabling pain and weakness (3 months)
- Progressive deformity
- Instability
- Static neurologic deficits with significant axial or radicular pain

Surgery should not be contemplated in patients without consistent findings in both clinical examination and imaging studies. Pseudarthrosis alone, for example, is not an indication for revision surgery. Nonoperative treatment should be fully explored in the majority of “failed neck” patients.

### NONOPERATIVE TREATMENT

A trial of nonoperative treatment (Fig. 148.4) is useful even in those patients for whom later surgery is felt to be unavoidable. During this period, develop rapport with the patient, document compliance with prescribed treatment, maximize medical status, and optimize nutritional and smoking status. In certain patients, urine nicotine levels may be obtained.

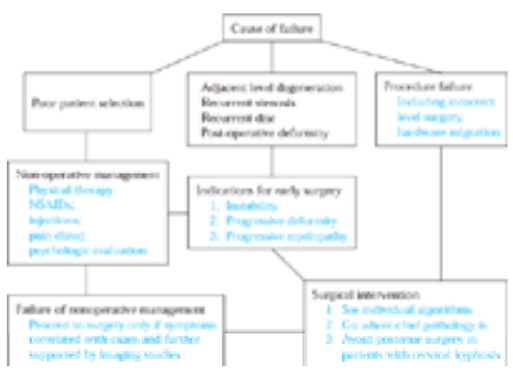


***Figure 148.4.*** Algorithm for treatment of patients with failed anterior surgery.

### OPERATIVE PLANNING AND TREATMENT

The operated neck is different in many ways from the “untouched” spine:

- Prior decompression may have rendered the spine unstable.
- Prior fusions create significant lever arms that must be considered in any subsequent construct.
- Surgical soft-tissue injury from the prior surgery interferes with blood supply, healing potential, and local biomechanics.

While many authors report acceptable results with allograft use in both index and revision cervical spine procedures, the decreased vascularity and altered biomechanics of the revision situation are an indication for autograft bone (14).

#### *Anterior Pseudarthrosis*

**Posterior Repair of Cervical Pseudarthrosis** Posterior fusion for symptomatic anterior pseudarthrosis was proposed by Riley and Robinson (30). The additional stabilization offered by posterior wiring encourages the anterior fusion mass to consolidate. This approach remains the gold standard today, with 94% to 100% union rates reported (4,13,20,34) (Fig. 148.5).

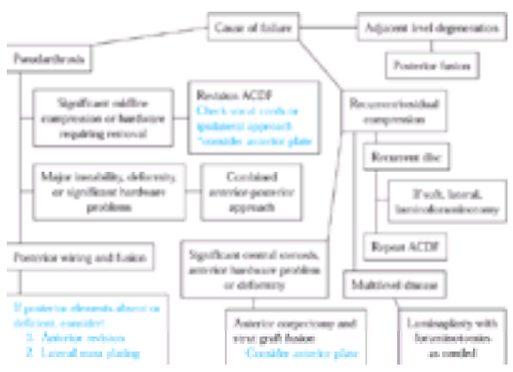


***Figure 148.5.*** Treatment algorithm for failed anterior surgery.

Several randomized, prospective series have been undertaken to compare anterior and posterior treatment of anterior pseudarthrosis (4,22,29). Interestingly, while over 80% of patients treated posteriorly felt better than before surgery, only 70% of those treated circumferentially reported symptomatic improvement. These results argue for a posterior approach unless specific hardware concerns require an anterior approach.

- Use a standard, midline approach to the involved level.
- Several wiring methods may be employed. If the spinous processes are intact, a triple wire technique provides good resistance to torsional and flexion forces (Fig. 148.6).

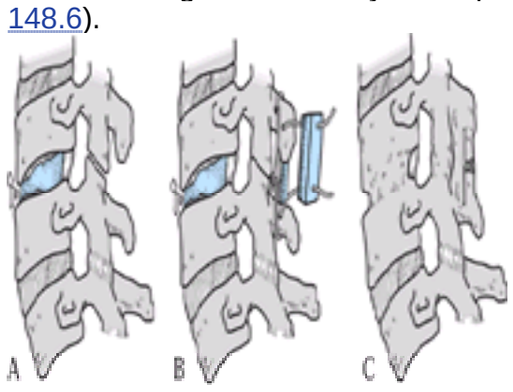


***Figure 148.6.*** Posterior stabilization for failed anterior cervical discectomy and fusion. **A:** Graft collapse and pseudarthrosis result in focal kyphosis, fragmentation, and instability. **B:** Posterior instrumentation and fusion are carried out without disturbing the anterior graft. The simplest approach is a triple wire technique using autograft bone. Approximate the spinous processes using an 18-gauge interspinous wire applied in a modified Rodger's technique. Apply the split autograft to either side of the intact spinous processes and compress the “sandwich” with a pair of 22-gauge wires. **C:** Posterior wiring will most often cause the anterior graft to consolidate at the same time the posterior fusion is healing.

- If the posterior elements are absent or inadequate, lateral mass plates provide greater resistance to torsional and extension forces.
- Use lateral mass plates for multisegmental fusions as well.
- Postoperative immobilization includes a Philadelphia collar for 6–12 weeks.

**Anterior Repair of Cervical Pseudarthrosis** An anterior approach to failed anterior cervical fusion is often required in cases of residual radiculopathy, or failed or migrated hardware. Although repeat anterior surgery was felt to have lower success rates than posterior surgery, recent authors, citing modern anterior osteosynthesis techniques, report increased fusion rates with excellent and good results in 83% (9).

Proponents of the repeat anterior approach cite lower rates of wound problems, the biomechanical advantages of anterior column grafting, and the ability to explore the decompression site and to remove any remaining osteophytes. Anterior repair is being increasingly recommended for patients with collapse of a previous anterior graft in conjunction with pseudarthrosis.

Some authors recommend using a contralateral approach to avoid operating through the scarring on the previously approached side. Contralateral exposure should not be carried out until laryngoscopic evaluation of the vocal cords has confirmed that both cords are functioning normally. This approach limits the risk of sequential injury to both recurrent laryngeal nerves.

- Use a transverse incision to approach the cervical spine in the standard fashion (see Chapter 138).
- Locate the failed fusion intraoperatively by x-ray.
- Next, place distraction pins into the superior and inferior vertebral bodies.
- Once slight distraction is applied, excise residual graft, scar, and fibrous tissue with curets, rongeurs, and a high-speed burr.
- Carefully contour the superior and inferior endplates with the burr.

For revision surgery, a tricortical block iliac crest autograft is preferred to dowel techniques.

- Carefully measure the disc space for height, depth, and width.
- Fashion the graft to fit the distracted disc space by cutting it 2–4 mm longer than the interspace is high.
- The graft should be at least 5 mm thick to prevent resorption and restore disc space height.
- To prevent microfracture, cut the iliac crest with a saw rather than osteotomes.
- Carefully remeasure the graft depth. In smaller patients, a graft depth of 12–14 mm may cause cord impingement. Contour the graft so that it can be countersunk 2 mm below the anterior cortex without impinging on the back rim of the vertebral body.

Revision ACDF is a strong indication for anterior plate osteosynthesis. We use a unicortical fixation system with screws that lock to the plate.

- Measure the sagittal depth of the vertebral body and preset the drill depth.
- When drilling, be aware of the endplate angle to avoid penetrating the intervertebral disc space above or below the intended body.
- Immediately mobilize the patient in a Philadelphia collar (usually worn for 6–12 weeks).
- When plate fixation is impractical or bony purchase is tenuous, longer postoperative immobilization in a rigid collar or a four-poster brace is advocated. In some circumstances, adjuvant posterior fixation may be employed as well, as mentioned.

***Inadequate Decompression***

The principles of treatment of residual compression are fairly straightforward. If significant compression remains anteriorly, the approach must be anterior. If significant compression remains posteriorly, the approach must be posterior. Similarly, posterior hardware problems are addressed posteriorly, and so on.

Anterior decompression of residual or recurrent cervical spine disease is indicated in patients with less than three levels of disease. Occasionally, large central osteophytes will militate against posterior decompression in even multilevel spondylosis.

In patients with prior posterior procedures, an anterior procedure for recurrent or residual radiculopathy or myelopathy most often involves anterior corpectomy with strut graft fusion (Fig. 148.7). The likelihood of posterior instability represents a strong indication for anterior plate osteosynthesis in conjunction with well-fashioned struts. In patients with single-level and radicular findings, standard ACDF is recommended. Plate fixation may be helpful in these patients as well (7). Preoperative flexion–extension radiographs will better define the stability of the cervical spine.

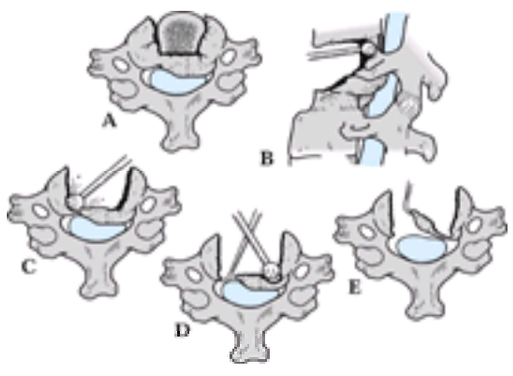


***Figure 148.7.*** Treatment of residual cord compression after inadequate decompression. **A:** In patients who have undergone previous but inadequate surgical treatment, the original compressive lesion is densely consolidated, and access may be hindered by surgical scarring, old hardware, and, often, a well-integrated strut graft. **B:** Remove the strut graft with rongeurs and a high-speed burr, back to the posterior vertebral cortex. Study the preoperative CT scan to determine whether there

is a distinct interval between the back of the graft and the residual vertebral body. **C:** Use a burr and microcurets to thin the posterior cortex in the lateral recess of the side with least compression. **D:** Enter the canal with a small curet or elevator directed toward the neural foramen and away from the cord. Thin the compressive mass with the burr, and use a diamond tip burr to thin the lateral recess to eggshell thickness. **E:** Use a small elevator or curet to reflect the residual bone fragments directly away from the canal and spinal cord. Dural adhesions may be divided with a fine Penfield elevator or microcuret.

**Anterior Decompression** Techniques for ACDF are discussed in Chapter 143. Anterior cervical corpectomy in the revision situation is discussed in the context of postlaminectomy kyphosis later. Key elements of the anterior decompression procedure include the following:

- Incise the annulus and remove adjacent discs with a pituitary rongeur and a small, angled curet.
- Remove the anterior portion of the vertebral body with rongeurs.
- Carefully thin the posterior cortices with a burr.
- Use a micro-Kerrison rongeur or curets to decompress the cord.
- Fashion a strut graft with iliac crest (two or fewer levels) or use allograft or autograft fibula.
- Contour and apply a plate.
- Use standard closure and postoperative immobilization (as described previously).

***Postlaminectomy Kyphosis***

Several approaches to postlaminectomy kyphosis have been described. They include anterior corpectomy and fusion, posterior fusion with lateral mass plates, and circumferential procedures (Fig. 148.8).

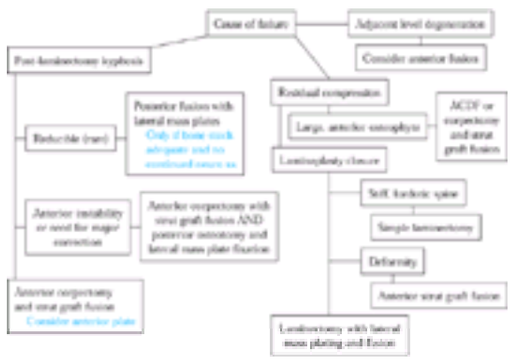


***Figure 148.8.*** Algorithm for treatment of failed posterior cervical spine surgery.

Correction of postlaminectomy kyphosis begins with preoperative traction. In most cases, moderate correction of the deformity is achieved and fusion is planned to the next normal level above and below the deformity (24,35).

A repeat posterior approach is often limited by inadequate bone stock, and corrective osteotomy through this approach is generally ineffective (2). Anterior cervical corpectomy with strut graft fusion and plating has become the favored approach in all cases without new posterior pathology (35,42,47).

A circumferential approach includes anterior corpectomy with posterior osteotomy and internal fixation (Fig. 148.9). This approach is particularly beneficial in patients with significant anterior instability as well. Generally, the circumferential approach allows for greater correction of the sagittal plane deformity. While reasoning of this surgical approach is sound, the added risks of a second operation make its use less compelling in the majority of postlaminectomy kyphosis patients (10,35).

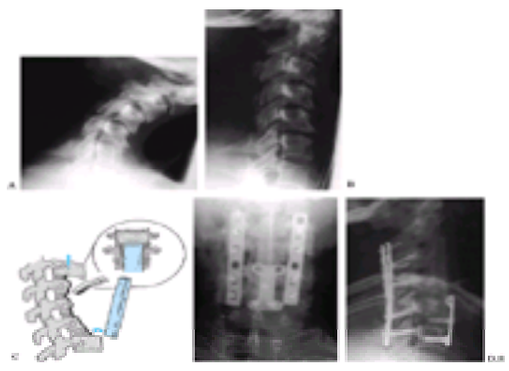

***Figure 148.9.*** Postlaminectomy kyphosis. **A:** This patient presented with progressive pain and deformity 3 months after multilevel cervical laminectomy. The deformity was passively correctable, to a degree, and the patient was neurologically intact. **B:** After 48 hours in halo traction, significant correction was obtained and surgical treatment was initiated. **C:** A staged anteroposterior reconstruction was planned. A five-level anterior vertebrectomy was performed initially, reconstructed with an autograft fibular strut. **D,E:** Five days later, we performed a posterior instrumentation and fusion using lateral mass plates. The slight increase in cervical lordosis produced by the plates caused the anterior strut to loosen and shift. During the same surgical procedure, the graft was repositioned and a short anterior plate placed to buttress the distal pole of the graft. Fusion was successful and the excellent sagittal correction was fully maintained. Figures D & E show anteroposterior and lateral views 1 year after surgery.

Herman and Sonntag (18) found that anterior corpectomy and plate yielded a mean correction of only 16° of kyphosis, but that 95% of these patients reported improvement of their presenting complaints. The authors report limited correction of the deformity due to fusions of the remaining levels at the facet and posterior element levels. Moreover, the goals of stabilization and prevention of further progression having been met, 10% reported complete relief of their symptoms and 55% noted substantial improvement.

**Combined Approach for Postlaminectomy Kyphosis**

- Begin the anterior approach with the patient supine. Tape the shoulders caudally and turn the head slightly away from the operative side. Place a bolster between the shoulders to provide mild hyperextension. A bolster may not be useful in patients with a fixed-flexion deformity due to the wedging of the vertebral bodies.
- A transverse incision may be used in most cases up to five levels. In longer procedures, an extensile incision along the anterior border of the sternocleidomastoid muscle can be used instead. A standard, left-sided approach is recommended.
- Use blunt, finger dissection to dissect the platysma from overlying and underlying tissues.
- Carefully develop the intervals between the tissue planes. This will increase the extensibility of the incision.
- The omohyoid may cross the surgical field, depending on the level of dissection. Division for increased exposure is rarely required.

A variable amount of scar may be seen anteriorly at the apex of the kyphosis (15). This scar may exert a tethering effect. Debridement of the scar will allow increased exposure of the anterior bodies. Overly aggressive lateral dissection threatens the sympathetic chain.

- To achieve correction of the deformity, completely excise the intercalary discs to the level of the PLL.
- Use a rongeur to remove large portions of the intervening bodies.

- Next, use a dental burr to remove bone laterally and posteriorly to the posterior cortex of the body.
- Use fine Kerrisons to remove the cortical wafer from the PLL.
- Once adequate decompression and visualization have been achieved, obtain radiographs to assess correction. Adjust the alignment and traction to achieve lordosis.
- Next, fashion an allograft or autograft fibular strut in the Whitecloud-LaRocca method with an H-shape. For less than two or three levels, iliac crest struts may be used. While crest graft offers a faster incorporation time, fibular graft is stronger in compression.
- Prior to insertion, undercut the endplates of the cranial and caudal vertebra with the burr. This allows the graft to be pushed into position cranially and, with a concurrent extension force on the neck, impacted into the caudal vertebra.
- Release the extension moment provided by traction to lock the graft into place.
- Anterior plate osteosynthesis is recommended. In long constructs, a short anterior plate can be applied at the caudal vertebra to buttress the inferior pole of the graft.
- Screws are not placed into the graft because of the risk of graft fracture. A heavy suture may be passed around the graft and the plate to keep the graft from shifting posteriorly.

Once the anterior reconstruction is completed, the patient is turned and prepared for posterior instrumentation and fusion. While this procedure is not necessary in two- or three-level fusions, we routinely add posterior fusion to reconstructions of four or more levels, and to those with poor bone quality, translational instability, or risk factors for pseudarthrosis.

- Expose the posterior cervical spine in the usual fashion, taking care to document levels and protect levels not instrumented anteriorly.
- Use a burr to decorticate the laminae and facets, and remove articular cartilage from the facets with a small curet.
- Use a 2.0 mm drill to prepare pilot holes for lateral mass plating.
- Contour the lateral mass plate to *neutralize* the alignment obtained during the anterior procedure. Increasing lordosis at this point will tend to loosen the anterior construct.
- Graft the facet joints and apply the plates over the graft.
- Close in layers and apply a sterile dressing.

A hard cervical collar is used for 8–12 weeks. Halo immobilization for 12 weeks may be useful in patients with poor bone, previous failures, or multiple-level procedures. These patients may also benefit from a posterior stabilization procedure, often with lateral mass plates.

***Hardware Failure***

As in pseudarthrosis, not all failed hardware requires surgical intervention. In some cases, external immobilization can be used until fusion occurs. However, when failed hardware results in neurologic or soft-tissue compression, instability, or progressive deformity, surgical treatment is offered.

Anterior hardware impinging on anterior structures must be approached anteriorly. Failed posterior hardware may be approached posteriorly. However, in cases of poor bone quality, deformity, or three-column destabilization, circumferential stabilization procedures are recommended.

Take care when approaching displaced anterior hardware. The inflammation and tissue reaction around the old hardware will make the exposure difficult and will distort tissue planes. Inadvertent entry into the carotid sheath, esophagus, or thoracic duct can result in potentially lethal complications.

After hardware removal, spinal instability must be addressed. In some cases, postoperative halo immobilization suffices. Typically, however, revision internal fixation is employed in conjunction with postoperative immobilization (7).

Failed spinous process wires are easily removed and replaced with lateral mass plates. Sublaminar wires are more problematic, and they may be retained or removed. In cases where dense scar makes dissection difficult, the broken wire may be retightened around the intact lamina and left in place. If monofilament wire must be removed, contour the end to be pulled through the canal so that it can be pulled out smoothly. Place a Woodson or Penfield elevator between the wire and the thecal sack and extract the wire by winding the free end up with a needle-holder. Cut braided wires close to the lamina to remove as much of the frayed portion as possible before trying to remove them.

***Adjacent-Level Degeneration and Recurrent Stenosis or Disc Herniation***

Adjacent-level degeneration in the cervical spine is related to recurrent compression. Recurrence of stenosis or disc herniation often reflects the same global nature of cervical spondylosis seen in patients with recurrent axial symptoms. Whether or not surgical intervention accelerates degenerative changes at neighboring levels, principles regarding their treatment remain the same.

Treatment options for recurrent disc herniation include ACDF of the new level or posterior keyhole foraminotomy. There are proponents of each approach. In the patient with a previously operated neck, the same principles apply, with the caveat that repeat anterior surgery requires special attention to the status of the recurrent laryngeal nerves and vulnerable soft-tissue structures of the neck (as previously discussed).

When recurrent or residual root compression is the result of soft disc pathology at one or two levels, keyhole foraminotomy may be indicated. Most often, this is seen in patients with a prior ACDF and an incompletely excised disc, or with recurrent soft disc pathology at a neighboring level.

The advantages of keyhole foraminotomy include the avoidance of fusion-related problems and the need for only minimal laminar resection to expose the lateral edge of the dura. Disadvantages include its failure to decompress the cord and stabilize the spine. Laminoforaminotomy is contraindicated in patients with cervical kyphosis or major anterior cord compression (17).

As in primary cervical spine procedures, debate continues as to the best method to treat multilevel recurrent or residual stenosis. Laminaplasty is recommended for recurrent stenosis above and below a previously, anteriorly fused level, or in the case of disease affecting more than three levels (28). Others report success with vertebrectomy and strut graft fusion techniques (42).

Laminaplasty preserves the cervical facets and decreases the incidence of instability associated with multiple-level laminectomies. However, decompression may be incomplete if foraminal stenosis is not addressed. Contraindications include cervical deformity (especially kyphosis) and major anterior cord compression.

Anterior vertebrectomy and strut graft fusion is recommended for patients with recurrent or residual stenosis after laminectomy and in those patients who are not candidates for posterior decompressive laminaplasty.

In patients with no evidence of stenosis and predominantly axial pain, the possibility of adjacent-segment disc degeneration must be considered. Advocates of cervical discography recommend anterior fusion for concordant pain (41).

**Keyhole Foraminotomy for Recurrent or Residual Disc Herniation**

- With the patient prone, obtain precise radiographic localization prior to skin incision. Employ a standard midline approach with careful, unilateral exposure to the lateral aspect of the facet capsule.
- Thin the lateral portion of the lamina and the medial portion of the facet with a burr.
- Carefully develop the interval between the medial facet capsule and the ligamentum flavum with a fine curved curet or Penfield.
- Remove the medial 25% of the facet with Kerrison rongeurs. Remove the volar facet capsule to visualize the root and the lateral margin of the thecal sack.
- Expand the laminotomy over the junction of the root and dura taking care to preserve over 50% of the facet.
- If a contained herniation is found, incise the PLL to retrieve the fragment.
- Apply a collar for comfort for the first 2–3 weeks after surgery. If more than 50% of both facets, or more than 75% of one facet, is removed, consider fusion with lateral mass plates.

**Laminaplasty for Multilevel Residual or Recurrent Stenosis** Open-book laminoplasty requires a wide exposure of the posterior elements and lateral masses of the involved cervical spine, as well as exposure of at least one normal level above and below the compression. The surgeon must elevate laminae at the margins of stenosis as well as those directly over the narrowed segment.

- Through a standard, midline approach, carefully elevate the paraspinal musculature to the lateral edges of the facets.
- Use a high-speed burr to cut longitudinal bone troughs through the lamina–facet junction.
- Use a fine Kerrison punch to complete the trough on the side of primary compression (i.e., at the greatest narrowing or most significant radiculopathy).
- Excise the ligamentum flavum and interspinous ligaments at the proximal and distal junctions of the laminaplasty segment with the normal spine.
- Apply gentle, sustained pressure on the spinous processes and upward on the open laminotomy to elevate the laminar flap on its intact cortical "hinge." Allow the intact lamina to deform plastically, being careful not to snap it off by applying too much force.
- Release dural adhesions to the lamina with a Penfield elevator.
- The lamina flap is then hinged wide open on the intact lamina in a staged fashion, moving cranially from the inferiormost hinged lamina. An elevation of 10–15 mm on the open side increases the sagittal diameter of the canal by 4–5 mm.

There are a number of techniques to keep the laminar flap open (Fig. 148.10). The laminae may be open with cadaver rib graft, as follows.

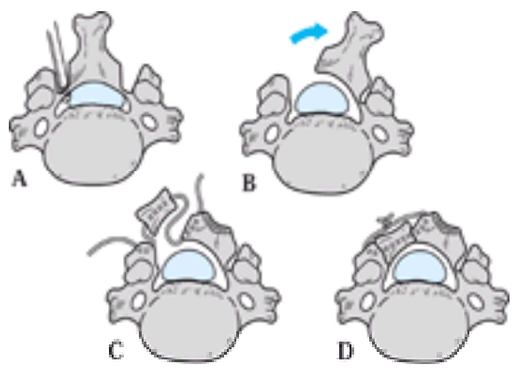


***Figure 148.10.*** Trap-door laminoplasty for extensive stenosis or adjacent-level degeneration. **A:** Cut longitudinal troughs through the involved laminae using a high-speed burr. Troughs should be centered over the medial edge of the facet so that penetration exposes the lateral recess and not the cord. Complete the defect on the side of most compression using a small Kerrison. **B:** Thin the opposite lamina down to the volar cortex, then gradually elevate the opened side up and away from the facet, allowing time for the intact hinge to deform plastically. If the hinge is too stiff, thin it further. **C:** Use the spinous processes or an allograft bone strut to hold the laminoplasty open. Groove both ends of the graft to capture the cut edges of the lamina and the lateral mass. Use a small drill to make holes at the margins of both, and pass a heavy suture through the drill holes and lengthwise through the graft. **D:** Position the strut and allow the lamina to close down slightly to capture the strut. Tie the heavy suture over the outside of the graft to prevent it from migrating into the canal or dislodging and allowing the laminaplasty to close.

- Cut three grafts to length (12–14 mm).
- Cut a trough into each end of the graft.
- One graft is inserted between the lamina and lateral mass at C-3, C-5, and C-7.
- To avoid inadvertent fusion, care must be taken to avoid bone graft touching another level.

Often, the cervical spinous processes can be used for this purpose as well, as follows.

- To keep the graft from displacing, pass a heavy suture longitudinally through the cancellous bone of each spinous process or rib allograft. Pass the suture through a small drill hole in the laminar margin and through the medial edge of the facet, and tie it tightly to compress the graft strut between the lamina and the facet margin. The secured strut will keep the flap from closing.
- Supplemental foraminotomies may then be carried out to treat radiculopathy, as needed.
- Close the posterior wound over drains. Reattach the deep layer to the spinous processes at the margins of the laminaplasty. Immobilize in a Philadelphia collar for 6–12 weeks. Some authors recommend a CT scan at 8 weeks to check healing on the hinge side and ensure canal patency. Once healing is complete, physical therapy emphasizing cervical extension exercises is recommended.

## GENERAL REHABILITATION AND POSTOPERATIVE PRINCIPLES

Most patients have already been immobilized from their prior cervical spine procedure. Significant deficits in extensor muscle strength and flexibility are common. Therefore, a supervised isometric strengthening and ROM program is indicated prior to returning to unlimited activity. At 12 weeks, or when x-rays demonstrate adequate bony union, prescribe a twice-daily regimen of 10 minutes of neck muscle ROM and isometric strengthening. Weekly physical therapy supervision to monitor progress and add incremental exercises until functional strength and ROM are regained may be recommended.

## PITFALLS AND COMPLICATIONS

Prior surgery increases the likelihood of complications (Table 148.1). The hypovascular scar bed predisposes to infection or failure of healing. Some authors have reported complication rates for anterior surgery following failed posterior procedures similar to those reported in index anterior procedures (42,46,47). However, hardware problems are more likely in osteopenic bone and when normal anatomic landmarks are distorted.

| | |
|---|---|
| Vocal cord paralysis | 15% |
| Pneumonia | 10% |
| Deep venous thrombosis | 5% |
| Reintubation | 5% |
| Graft site problems | 5% |
| Hardware failure | 5% |

From Coric D, Branch CL Jr, Jenkins JD. Revision of Anterior Cervical Pseudarthrosis with Anterior Allograft Fusion and Plating. *J Neurosurg* 1997;86(6):969, and Lowery GL, Swank ML, McDonough RF. Surgical Revision for Failed Anterior Cervical Fusions. Articular Pillar Plating or Anterior Revision? *Spine* 1995;20(22):2436.

***Table 148.1. Complications of Revision Anterior Surgery***

Repeated dissection through anterior soft tissues increases the possibility of transient sore throat or swallowing difficulty. Further, dissection through scar requires meticulous attention to detail and great caution. Perforation of the esophagus is a life-threatening injury, and only one third are recognized at the time of surgery. Mortality for injuries recognized early is 15%. If recognized late, mortality rises to 30% (30,36).

The literature regarding incidence of vocal cord paralysis after revision anterior cervical spine surgery is varied (9,22). Although the ipsilateral operative approach requires dissection through scar, the contralateral approach should not be undertaken without confirming the function of both vocal cords through laryngoscopy.

Other problems related to anterior surgery could be increased in the revision situation as well. Horner's syndrome from injury to the sympathetic chain and overretraction of the longus colli is ostensibly more likely if the longus muscles are encased in scar, or the dissection difficult.

The most common complications of revision posterior cervical spine surgery are wound infection (1.2%) and failure of healing. Correction of identifiable nutritional

deficiencies may decrease these problems. The incidence of dural tear also rises when dissecting through posterior scar (16).

## CHAPTER REFERENCES

Each reference is categorized according to the following scheme: 7, classic article; #, review article; !, basic research article; and +, clinical results/outcome study.


+ 1. Boden SD, McCoun PR, Davis DO, et al. Abnormal Magnetic Resonance Scans of the Cervical Spine in Asymptomatic Subjects. *J Bone Joint Surg Am* 1990;72:1178.

# 2. Bohlman HH, Dabb B. Anterior and Posterior Cervical Osteotomy. In: Bradford DS, ed. Master Techniques in Orthopaedic Surgery: The Spine. Philadelphia: Lippincott-Raven, 1997:75.

+ 3. Bohlman HH, Emery SE, Goodfellow DB, et al. Robinson Anterior Cervical Discectomy and Arthrodesis for Cervical Radiculopathy. Long-term Follow-up of One Hundred and Twenty-two Patients. *J Bone Joint Surg Am* 1993;75:1298.

+ 4. Brodsky AE, Khalil MA, Sassard WR, Newman BP. Repair of Symptomatic Pseudarthrosis of Anterior Cervical Fusion. Posterior versus Anterior Repair. *Spine* 1992;17:1137.

+ 5. Brodsky AE, Kovalsky ES, Khalil MA. Correlation of Radiologic Assessment of Lumbar Spine Fusions with Surgical Exploration. *Spine* 1991;16(suppl 6):S261.

+ 6. Brown MD, Malanin TI, Davis PB. A Roentgenographic Evaluation of Frozen Allografts vs Autografts in Anterior Cervical Spine Fusions. *Clin Orthop* 1976;199:231.

+ 7. Connolly PJ, Esses SJ, Kostuik JP. Anterior Cervical Fusion: Outcome Analysis of Patients Fused With and Without Anterior Cervical Plates. *J Spinal Disord* 1996;9:202.

+ 8. Connor PM, Darden BV II. Cervical Discography Complications and Clinical Efficacy. *Spine* 1993;18:2035.

+ 9. Coric D, Branch CL Jr, Jenkins JD. Revision of Anterior Cervical Pseudarthrosis with Anterior Allograft Fusion and Plating. *J Neurosurg* 1997;86:969.

+ 10. Cybulski GR, Douglas RA, Meyer PR Jr, et al. Complications in Three-column Cervical Spine Injuries Requiring Anterior-posterior Stabilization. *Spine* 1992;17:253.

+ 11. Davis H. Increasing Rates of Cervical and Lumbar Spine Surgery in the United States, 1979–1980. *Spine* 1994;19:1117.

+ 12. Epstein BS, Epstein JA, Jones MD. Cervical Spinal Stenosis. *Radiol Clin North Am* 1977;15:215.

+ 13. Farey ID, McAfee PC, Davis RF, Long DL. Pseudarthrosis of the Cervical Spine after Anterior Arthrodesis. *J Bone Joint Surg Am* 1990;72:1171.

+ 14. Fernyhough JC, White JI, LaRocca H. Fusion Rates in Multilevel Cervical Spondylosis Comparing Allograft Fibula with Autograft Fibula in 126 Patients. *Spine* 1991;16(suppl 10):S561.

+ 15. Fielding WJ, Tolli TC. Surgical Management of Postlaminectomy Kyphosis. *Semin Spine Surg* 1989;1:271.

+ 16. Heller JG, Silcox DH III, Sutterlin CE III. Complications of Posterior Cervical Plating. *Spine* 1995;20:2442.

+ 17. Herkowitz HN, Kurz LT, Overholt DP. Surgical Management of Cervical Soft Disc Herniation. A Comparison between Anterior and Posterior Approaches. *Spine* 1990;15:1026.

+ 18. Herman JH, Sonntag VK. Cervical Corpectomy and Plate Fixation for Postlaminectomy Kyphosis. *J Neurosurg* 1994;80:963.

+ 19. Kozak JA, Hanson GW, Rose JR, et al. Anterior Discectomy, Microscopic Decompression and Fusion. A Treatment for Cervical Spondylotic Radiculopathy. *J Spinal Disord* 1989;2:43.

+ 20. Lindsey RW, Newhouse KE, Leach J, Murphy MJ. Nonunion following Two-level Anterior Cervical Discectomy and Fusion. *Clin Orthop* 1987;223:155.

+ 21. Lonstein JE. Post-laminectomy Kyphosis. *Clin Orthop* 1977;128:93.

+ 22. Lowery GL, Swank ML, McDonough RF. Surgical Revision for Failed Anterior Cervical Fusions. Articular Pillar Plating or Anterior Revision? *Spine* 1995;20:2436.

! 23. Marzo JM, Simmons EH, Kallen F. Intradural Connections between Adjacent Cervical Spinal Roots. *Spine* 1987;12:964.

+ 24. Mikawa Y, Shikata J, Yamamuro T. Spinal Deformity and Instability after Multilevel Cervical Laminectomy. *Spine* 1987;12:6.

+ 25. Miyakazi K, Tada K, Matsuda T, et al. Posterior Extensive Simultaneous Multisegment Decompression with Posterior Lateral Fusion for Cervical Myelopathy with Cervical Instability and Kyphotic and/or S-shaped Deformities. *Spine* 1989;14:1160.

+ 26. Murphy MG, Gado M. Anterior Cervical Discectomy without Interbody Bone Graft. *J Neurosurg* 1972;37:71.

! 27. Nolan JP, Sherk HH. Biomechanical Evaluation of the Extensor Musculature of the Cervical Spine. *Spine* 1988;13:9.

+ 28. Nowinski GP, Visarius H, Nolte LP, Herkowitz HN. A Biomechanical Comparison of Cervical Laminaplasty and Cervical Laminectomy with Progressive Facetectomy. *Spine* 1993;18:1995.

+ 29. Raynor R. Anterior or Posterior Approach to the Cervical Spine. An Anatomical and Radiographic Evaluation and Comparison. *Neurosurgery* 1983;12:7.

+ 30. Riley LH, Robinson RA, Johnson KA, Walker E. The Results of Anterior Interbody Fusion of the Cervical Spine. *J Neurosurg* 1969;30:127.

+ 31. Robertson PA, Ryan MD. Neurologic Deterioration after Reduction of Cervical Subluxation. Mechanical Compression by Disc Tissue. *J Bone Joint Surg Br* 1992;74:224.

+ 32. Robinson RA, Walker AE, Ferlic DC, et al. The Results of an Anterior Interbody Fusion of the Cervical Spine. *J Bone Joint Surg Am* 1962;44:1569.

+ 33. Schellhaus KP, Smith MD, Gundry CR, Pollei SR. Cervical Discogenic Pain. Prospective Correlation of Magnetic Resonance Imaging and Discography in Asymptomatic Subjects and Pain Sufferers. *Spine* 1994;21:300.

+ 34. Shinomiya K, Okamoto A, Kamikozuru M, et al. An Analysis of Failures in Primary Cervical Anterior Spinal Cord Decompression and Fusion. *J Spinal Disord* 1993;6:277.

+ 35. Sim FH, Svien HJ, Bickel WH, et al. Swan-neck Deformity following Extensive Cervical Laminectomy. A Review of Twenty-one Cases. *J Bone Joint Surg Am* 1974;56:564.

+ 36. Simmons EN, Bhalla SK. Anterior Cervical Discectomy and Fusion. *J Bone Joint Surg Br* 1969;51:225.

+ 37. Slizofski WJ, Collier BD, Flatley TJ, et al. Painful Pseudarthrosis following Lumbar Spinal Fusion. Detection by Combined SPECT and Planar Bone Scintigraphy. *Skeletal Radiol* 1987;16:136.

+ 38. Stevens JM, Clifton AG, Whitiar P. Appearance of Posterior Osteophyte After Sound Anterior Interbody Fusion in the Cervical Spine. A High Definition CT Study. *Neuroradiology* 1993;35:227.

+ 39. Tachdjian MO, Matson DD. Orthopaedic Aspects of Intraspinal Tumors in Infants and Children. *J Bone Joint Surg Am* 1965;47:243.

# 40. White AA, Panjabi MM. *Clinical Biomechanics of the Spine*, 2nd ed. Philadelphia: JB Lippincott, 1990.

+ 41. Whitecloud TS, Seago RA. Cervical Discogenic Syndrome: Results of Operative Intervention in Patients with Positive Discography. *Spine* 1987;12:313.

+ 42. Whitecloud TS III. Anterior Surgery for Cervical Spondylotic Myelopathy. Smith-Robinson, Cloward and Vertebrectomy. *Spine* 1988;13:861.

+ 43. Winter CY, Brannstein EM, Bailey WR. Radiographic Changes following Anterior Cervical Fusion. *Spine* 1980;5:399.

+ 44. Wu W, Thuomas KA, Hedlund R, et al. Degenerative Changes following Anterior Cervical Discectomy and Fusion Evaluated by Fast Spin-echo MR Imaging. *Acta Radiol* 1996;37:614.

+ 45. Yonenobu K, Okada K, Fuji T, et al. Causes of Neurologic Deterioration following Surgical Treatment of Cervical Myelopathy. *Spine* 1986;11:818.

+ 46. Zdeblick TA, Bohlman HH. Cervical Kyphosis and Myelopathy. Treatment by Anterior Corpectomy and Strut-grafting. *J Bone Joint Surg Am* 1989;71:170.

+ 47. Zdeblick TA, Ducker TB. The Use of Freeze-dried Allograft Bone for Anterior Cervical Fusions. *Spine* 1991;16:726.

# CHAPTER 149

# MANAGEMENT OF THE PATIENT WITH FAILED LOW-BACK SURGERY

*William C. Lauerman and Sam W. Wiesel*

**W. C. Lauerman:** Associate Professor, Department of Orthopaedic Surgery, Chief, Division of Spine Surgery, Georgetown University Hospital, Washington, D.C., 20007.
**S. W. Wiesel:** Professor and Chairman, Department of Orthopaedic Surgery, Georgetown University Hospital, Washington, D.C., 20007.

Evaluation and Imaging
Differential Diagnosis
Nonorthopaedic Considerations
Herniated Intervertebral Disc
Lumbar Spinal Stenosis
Segmental Instability
Discogenic Back Pain
Arachnoiditis and Epidural Fibrosis
Discitis
Lumbar Pseudarthrosis
Nonoperative Treatment
Indications for Surgery
Instrumentation
Surgical Techniques
Repeat Laminectomy
Repeat Discectomy
Fusion Exploration and Revision
Postoperative Management
Pitfalls and Complications
Dural Tear
Authors' Perspective
Chapter References

Management of the patient with recurrent or residual back pain following previous surgery on the lumbar spine is a complex challenge. It is estimated that, in the United States alone, more than 300,000 lumbar laminectomies and 70,000 fusions are performed annually; at least 15% of these patients fail to achieve long-lasting pain relief (15,36).

An individual in whom prior surgery has failed represents a unique challenge and opportunity; many patients can be made better with appropriate operative or nonoperative treatment, but there is a great chance of succumbing to the assumption that another operation, in the absence of objective indications, will be the solution to the patient's problem. The inherent complexity of these cases necessitates an approach to evaluation that is precise and unambiguous—one that, it is hoped, will lead to accurate identification of the source of the patient's pain and to appropriate treatment.

The best solution for failed low-back surgery is prevention. Although the technical aspects of performing surgery on the lumbar spine are very important, proper patient selection is probably the most important factor in avoiding postoperative failure (see Chapter 144). Long et al. (25) reviewed 78 patients with so-called failed back surgery syndrome (FBSS) in a chronic pain program. They noted that, when original records were reviewed from before the first operation, 68% of these patients failed to fulfill any objective criteria available in either the orthopaedic or neurosurgical literature for surgery. Fifty-six percent were found to have an underlying psychiatric abnormality.

They concluded that improper patient selection was the most common factor associated with failure. Thus, it is clear that the initial decision to operate is the most important one and should be arrived at only when clear identification of the source of the patient's pain is made and objective criteria for the proposed surgery are met. See the objective patient evaluation system in Chapter 144. Once low-back surgery has failed, the potential for a solution is limited.

In evaluating recurrent symptoms following surgery, distinguish between a mechanical source for the complaint from nonmechanical causes. The types of mechanical conditions that respond, in select cases, to revision surgery include recurrent disc herniation, discogenic pain, segmental instability of the spine, and spinal stenosis. Nonmechanical entities that can lead to recurrent symptoms include local scar tissue formation (either arachnoiditis or epidural fibrosis), abdominal or pelvic disorders, systemic medical diseases, or psychosocial instability. These nonmechanical problems will not be helped by additional spinal surgery.

The keystone of successful treatment is to obtain an accurate diagnosis. Although this factor is seemingly obvious, this essential step is often neglected and the rehabilitation of the patient is therefore inadequate.

## EVALUATION AND IMAGING

A structured approach to the evaluation of the patient with recurrent symptoms following previous lumbar spine surgery is essential. Use a standardized form to detail the medical history and to list any and all previous back operations, including dates and the type of operation performed. Consider obtaining previous operative notes. The symptom complex before the original operation can help to determine the appropriateness of the procedure itself.

It is also useful to know the extent of postoperative pain relief and the length of the pain-free interval to determine the source of the patient's current pain. No relief of preoperative sciatica suggests failure to relieve root compression, which may be due to a retained disc fragment, surgery at the wrong level, or an improper original diagnosis. If the patient relates that the preoperative sciatica was relieved, note the percentage of relief and duration of that improvement. A pain-free interval of more than 6 months, and certainly more than 12 months, suggests that the patient's pain may be caused by recurrent disc herniation. A pain-free interval lasting only 2 to 6 months, particularly with the gradual recurrence of symptoms, suggests that epidural fibrosis may be the cause of the pain (13).

Also, record the number of previous operations on the lumbar spine. It is well documented that each subsequent operation, almost regardless of the diagnosis or procedure, carries a poorer prognosis for an eventual good result. This fact alone does not mean that a patient's fifth or even sixth operation, in the presence of clear-cut objective indications of nerve root compression or instability, might not be beneficial. The surgeon and patient need to be aware, however, of the diminishing statistical likelihood of success with each successive surgery. It has been shown that second operations have only, on average, a 50% chance of success, and in patients undergoing a third or more operation, symptomatic worsening is as likely as symptomatic improvement (37).

Finally, evaluate the patient's pain pattern. If leg pain predominates, a herniated disc or spinal stenosis is most likely, although scar tissue is also a possibility. Predominance of back pain suggests segmental instability, discogenic back pain, or perineural scar tissue. Mechanical symptoms—with clear-cut worsening of the pain with sitting and standing, and relief at rest—point more toward instability or discogenic back pain, whereas pain at rest suggests scar tissue, or the remote possibility of tumor or infection. The presence of back and leg pain may be due to spinal stenosis or scar tissue.

On physical examination, note the neurologic findings and the existence of any tension signs, such as a positive straight-leg raise test or femoral nerve stretch test. Obtain the results of any dependable previous examination and compare the patient's preoperative and postoperative status. If the neurologic picture is unchanged from before the previous surgery, and tension signs are negative, mechanical pressure is unlikely. If, however, a new neurologic deficit has occurred since the last surgery, or if tension signs are present, nerve root compression is often found. The presences of a tension sign is not necessarily pathognomonic for mechanical nerve root compression because epidural or perineural fibrosis can result in a tension sign.

Finally, review previous imaging studies, including, when possible, those that led to the original decision for surgery. These studies may give valuable information as to the appropriateness of the original procedure, as well as the etiology of the current problem.

The most helpful initial study is plain radiography, which may reveal the extent of the laminectomy defect, the level of the previous operation, changes consistent with spinal stenosis, and evidence of instability on dynamic films. Perform plain films and dynamic films with the patient standing (weight bearing). Assess any evidence of abnormal motion, progressive deformity, or progressive anterolisthesis (Fig. 149.1). Plain radiographs, including dynamic views, also help assess the quality of any fusion mass that may be present. On a lateral view, a successful interbody fusion is indicated by the continuity of bone between the outer margins of the adjacent vertebral bodies. A posterior fusion mass can be difficult to evaluate, particularly at L5–S1; a Ferguson anteroposterior (AP) view (with the x-ray beam tilted cephalad 30° to run parallel to the L5–S1 disc space) highlights the fusion mass between the L-5 transverse processes and the sacral alae.

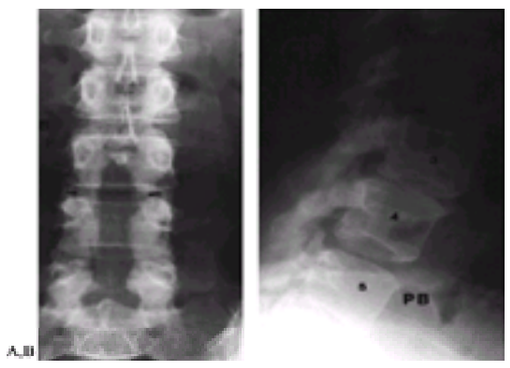

***Figure 149.1.*** A 49-year-old woman approximately 1 year after a decompressive laminectomy, with worsening low-back pain and recurrent leg pain. **A:** The AP view demonstrates the extent of the laminectomy defect (*arrows*). **B:** On the lateral view, subluxation of L-3 on L-4, not present before surgery, is seen, demonstrating postlaminectomy instability.

Indirect evidence of nonunion includes hardware failure such as screw loosening or breakage, rod breakage, progressive deformity across the fused levels, and evidence of motion on lateral flexion and extension views. Plain radiographs are relatively sensitive (90% to 95%) but fairly nonspecific (37% to 60%) in detecting pseudarthrosis following lumbar spine fusion (2,6).

In this setting, metrizamide myelography can still be of value. Although extradural compression is well seen on myelography, distinction between the presence of disc material and epidural scar formation is limited (8). Myelography is most helpful in confirming the diagnosis of arachnoiditis when it is otherwise uncertain.

Postmyelographic computed tomography (CT) has increased sensitivity for demonstrating changes of arachnoiditis. We still use it quite frequently in assessing spinal stenosis in a patient who has undergone previous surgery. The size of the spinal canal, the presence of bony defects and the extent of posterior element resection, and hypertrophic bony changes causing stenosis are all well visualized (Fig. 149.2) (34).

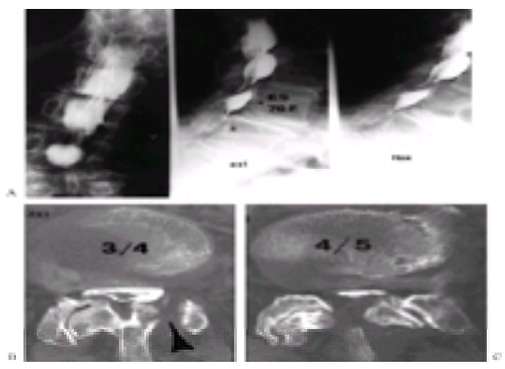


***Figure 149.2.*** A 76-year-old woman, 9 months after a left L3–L4 hemilaminectomy, with persistent back and leg pain. This shows AP and lateral flexion and extension views with myelography (**A**) Multi-level stenosis, most severe at L3–L4 and L4–L5; (**B** and **C**) axial postmyelogram CT images, which clearly define the pathologic anatomy. The failure of the previous decompression to address the pathology is appreciated (*arrowhead*).

CT scanning is quite useful in evaluating postoperative hardware placement. Although metallic scatter diminishes the quality of the images, careful scrutiny of the bony windows following plain CT scanning can usually establish whether or not a screw has broken out of the pedicle (usually medial) and is causing nerve root compression.

Magnetic resonance imaging (MRI) is, with rare exception, the most helpful diagnostic tool for imaging the lumbar spine that has previously undergone surgery. The most noteworthy use of MRI has been in the diagnosis of recurrent disc herniation, using images obtained before and after the injection of intravenous paramagnetic contrast material (Gadolinium-DTPA). MRI has 100% sensitivity, 71% specificity, and 89% accuracy (19). A nonenhancing soft-tissue mass causing nerve root compression is strongly suggestive of recurrent disc herniation, whereas Gd-DTPA enhancement suggests the presence of scar tissue (Fig. 149.3).

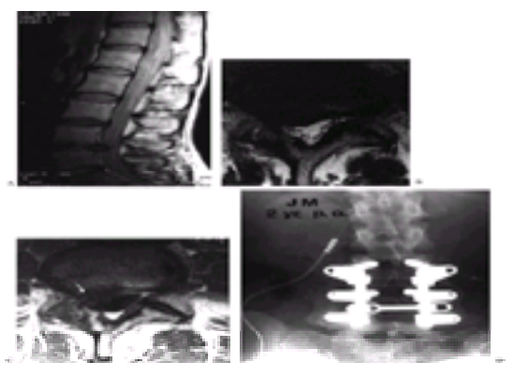

***Figure 149.3.*** A 37-year-old woman with a history of three previous discectomies who had recurrent, severe right leg pain, numbness, and a positive straight-leg raising sign. (**A**) The sagittal MRI demonstrates an apparent disc herniation at L4–L5; (**B**) the axial T2 image, without contrast, through the L4–L5 disc space demonstrates a soft-tissue mass consistent with disc herniation; (**C**) the T1 image, following contrast administration. The absence of contrast-enhancement of the mass (*white arrow*) is diagnostic of recurrent disc herniation, rather than epidural fibrosis; (**D**) a solid fusion 2 years following repeat discectomy and fusion; the patient continued to have significant back pain.

It should be noted that in the first 6 months following surgery, gadolinium-enhanced MRI frequently demonstrates pathologic changes and may suggest recurrent disc herniation, despite a good clinical result. Take care not to overinterpret gadolinium MRI in the early postoperative period; overreliance on this study may lead to negative findings on repeat surgical exploration (4).

MRI is also extremely sensitive for identifying inflammatory processes such as discitis, and in fact, it is the test of choice when a postoperative disc space infection is suspected. Decreased signal intensity in the disc on the T1-weighted images and increased signal on the T2-weighted images, particularly with enhancement following

Gd-DTPA injection, all suggest an inflammatory process (28).

A final use for MRI is for the definition of noninflammatory degenerative changes in the lumbar discs. Although the significance of disc degeneration in the lumbar spine remains controversial, MRI unquestionably gives the best picture of the discs involved with degenerative changes, the extent of disc desiccation, bulging, and reactive changes in the vertebral bodies. It may be beneficial in the evaluation of a patient with persistent mechanical back pain following a lumbar discectomy in whom discogenic back pain is considered a potential diagnosis (18).

Discography is occasionally used in the evaluation of the patient whose previous back surgery has failed. The indication for discography is to assess the reproduction of the patient's characteristic pain on disc injection and to compare it with the injection of control levels above and below. It should be stressed that, although discography gives a clear picture of abnormal disc morphology, this information rarely contributes meaningfully to surgical decision making and should not be used except in the context of reproduction of the patient's pain.

The role of discography in identifying the pain generator continues to be debated. Proponents believe that reproduction of pain during disc injection, in a manner and distribution concordant with the patient's characteristic pain complaints, identifies that disc as the source of the pain (Fig. 149.4). Conflicting reports regarding the specificity of discography have appeared, with Holt in 1968 reporting a false-positive rate of 37% (17), compared with Walsh et al., who recently noted no false-positive results in their study of normal subjects (38).

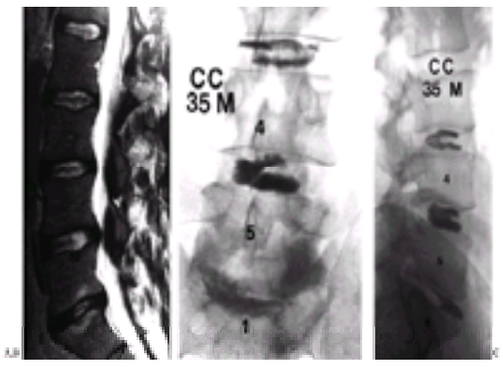


***Figure 149.4.*** A 35-year-old man, 3 years following right L5–S1 discectomy, with persistent incapacitating back and right buttock pain. (**A**) This is a T2-weighted MRI demonstrating degeneration of the disc, with reactive changes in the adjacent vertebrae; (**B** and **C**) AP and lateral discographic images. Injection of the L5–S1 disc reproduced the patients characteristic back and buttock symptoms, whereas injection at L4–L5 and L3–L4 discs was only minimally uncomfortable.

Suffice it to say that discography remains controversial, with its ability to predict the pain generator as well as to predict the results of surgical intervention still unproven. We agree with the North American Spine Society position statement on discography, which advocates discography only in the evaluation of a patient with unremitting spinal pain of more than 4 months' duration and only when the patient and physician have decided that surgical treatment is under consideration (29).

## DIFFERENTIAL DIAGNOSIS

Burton et al. (7) have described the conditions that contribute to FBSS, including recurrent or persistent disc herniation (12% to 16%), lateral (58%) or central (7% to 14%) stenosis, arachnoiditis (1% to 16%), epidural fibrosis (6% to 8%), and instability (5%). Superimposed on many of these conditions is discogenic back pain, a relatively common cause of back or leg pain following surgery.

### NONORTHOPAEDIC CONSIDERATIONS

First, rule out nonorthopaedic or systemic causes of pain such as pancreatitis, diabetes mellitus, or an abdominal aortic aneurysm. Other systemic disorders to be considered include fibromyalgia, ankylosing spondylitis, and osteoporosis or osteomalacia.

Also, assess the patient's psychosocial makeup. Identify specific factors such as alcoholism, drug dependence, depression, and the presence of compensation or litigation issues. Strongly weigh such factors when calculating the risk–benefit ratio of surgery. People with profound emotional disturbances and those involved in litigation rarely derive significant benefit from additional surgery (37). Even in the face of a specific orthopaedic diagnosis, make every attempt to address psychosocial problems such as drug dependence and depression before considering further surgery; in many cases, once a patient's underlying problem has been successfully treated, the somatic back complaints and disability improve.

### HERNIATED INTERVERTEBRAL DISC

Three possibilities exist if the patient's pain is caused by a herniated disc. First, the disc that caused the original symptoms may not have been completely removed, as can occur if the surgery was performed at the wrong level, if inadequate decompression was performed, or if a fragment of disc material was simply left behind. The predominant complaint is leg pain, and the neurologic findings, tension signs, and radiographic pattern remain unchanged from presurgical findings. The distinguishing feature is that there is typically no pain-free interval; this patient will have awakened from surgery complaining of the same pain that he or she had preoperatively. Patients in this group are helped by a correctly performed discectomy.

A second possibility is a recurrent disc herniation at the previously decompressed level. In this case patients complain of recurrence of sciatica and have similar neurologic findings and tension signs. The distinguishing characteristic in this group is the presence of a well-defined pain-free interval that is usually of 6 months' duration or longer. The diagnosis is confirmed with gadolinium-enhanced MRI; a recurrent disc herniation is avascular, with only a thin enhancing rim at the periphery of the lesion (19). If nonoperative treatment fails, repeat discectomy is indicated in this group of patients.

Finally, a disc herniation may occur at a completely different level or on the opposite side. In this case, patients will also describe a pain-free interval of 6 months or longer following their original surgery. Otherwise the development of their symptoms, with leg pain predominating, is similar to that for a typical disc herniation. A tension sign is usually present, as are appropriate neurologic findings. A neurologic deficit should be different from that associated with the original operation, because the source of the pain is compression of a different nerve root. Repeat surgery in these patients has the same prognosis as a primary discectomy.

### LUMBAR SPINAL STENOSIS

Lumbar spinal stenosis (LSS) in patients who have had previous back surgery can result in either back or leg pain but typically causes both. The etiology may be progression of the patient's underlying degenerative spine disorder, failure to decompress the patient's stenosis adequately at the time of the original operation, overgrowth of a previous posterior fusion mass, or transition syndrome.

Transition syndrome refers to the development of degenerative changes and frequently instability at a level adjacent to a previous lumbar fusion. The patient's report of a pain-free interval will vary when LSS is the cause of the symptoms; failure to recognize and relieve stenosis at the time of the original procedure may result in no pain-free interval whatsoever. Alternatively, a period of months or even many years may pass before stenosis develops in a patient who has undergone an otherwise successful operation.

In general, the history and physical examination of patients with postoperative LSS do not differ significantly from those of patients without prior surgery. Back and leg pain are typically seen. Worsening of the leg symptoms with walking or standing is a common finding, but not essential to the diagnosis, and many patients with LSS do not report neurogenic claudication. A normal neurologic examination is common, and neurologic findings, when present, are usually subtle. Tension signs are usually negative (14,33).

The plain radiographs can be suggestive of LSS, and they may display facet degeneration, decreased interpedicular distance, decreased sagittal canal diameter, and disc degeneration. Degenerative spondylolisthesis and degenerative scoliosis are commonly seen in patients with stenosis of the spinal canal and lateral recesses.

Neuroradiographic imaging of the postoperative patient with suspected LSS may be accomplished using plain CT, postmyelographic CT, or MRI.

Advantages of MRI include the ability to image sagittal and parasagittal views of the thecal sac and foraminal narrowing, and to identify disc degeneration, which may be helpful in planning for a fusion. Its sensitivity in identifying other causes of back pain in this population, including metastatic disease and occult infection, is also an advantage. State-of-the-art technology in MRI has provided sufficient bony detail to diagnose adequately facet overgrowth, osteophyte formation, and other causes of LSS in most patients. This is our routine test of choice (Fig. 149.5). In some patients with previous surgery, however, it is helpful to use postmyelographic CT scanning, which still provides better bony detail and shows encroachment on the thecal sac and on the nerve roots in the lateral recesses and foramina. Postmyelographic CT is not as specific as MRI in identifying and differentiating postoperative scar tissue from normal soft tissue, when differentiation is a consideration (5).

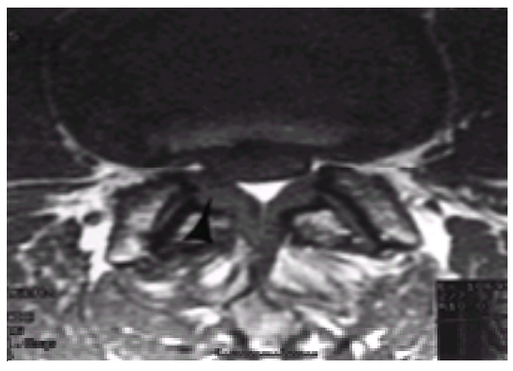

***Figure 149.5.*** A 52-year-old man with recurrent back and right leg pain 8 years following a lumbar decompression and fusion from L4–S1. On T1-weighted axial MR images, right lateral recess stenosis at L2–L3 (*arrows*) is clearly demonstrated. Following repeat decompression and extension of his fusion to L-2 he had near-complete pain relief.

The properly selected patient with symptomatic LSS, having failed nonoperative treatment, has at least a 70% chance of obtaining satisfactory results following surgery. If nonoperative treatment is unsuccessful, thorough decompression of any bony or soft-tissue compression is likely to relieve symptoms significantly. If, however, a significant component of the compression is due to epidural fibrotic scar, then the results of surgery are far less predictable. Patients undergoing repeat decompression who have either pre-existing instability or in whom instability may result from the decompression should also undergo a posterolateral fusion at the involved levels (20).

**SEGMENTAL INSTABILITY**

Lumbar instability is a poorly understood condition that can cause mechanical back pain following previous surgery. Instability results from the spinal motion segment's inability to bear physiologic loads; the result is abnormal motion between two vertebrae (42). Most commonly, it causes back pain, but leg pain or neurologic findings from dynamic stenosis may also be seen.

The diagnosis can be made on the basis of excessive motion on flexion and extension radiographs or by the development or worsening of spinal deformity (Fig. 149.6). Instability following lumbar spine surgery may be the result of a pre-existing condition, as in a patient with spondylolisthesis treated with decompression alone, or it may be the result of an excessively wide or aggressive decompression. It is not uncommon to see either frontal or sagittal plane instability occur in a patient who has had unilateral thinning of the inferior facet and pars, resulting in facet fracture (16). Unilateral facet resection is commonly believed to be benign, but this degree of resection in the presence of an incompetent disc, particularly after an extensive discectomy, may lead to instability. Another sign of instability would be painful motion occurring at the site of a pseudarthrosis.

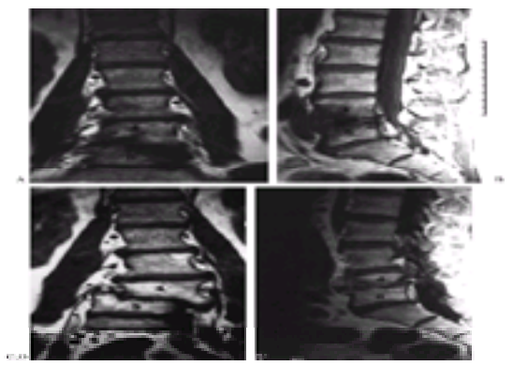

***Figure 149.6.*** A 53-year-old man 18 months following a decompressive laminectomy at L4–L5, with discectomy, for degenerative stenosis. (**A** and **B**) Coronal and sagittal MRIs demonstrating the alignment of his lower lumbar spine before surgery; (**C** and **D**) similar images taken 16 months later, demonstrating progressive development of deformity, indicative of instability.

Patients with instability complain predominantly of back pain, although 20% to 25% report radiating leg symptoms with weight bearing. The physical examination is frequently negative, although some patients have a characteristic reversal of normal spinal rhythm on return from forward bending (30). A key to diagnosis in these patients is the plain radiograph. Weight-bearing lateral flexion and extension views are diagnostic for instability when they demonstrate

- Sagittal plane translation greater than 12% of the AP diameter of the vertebral body,
- Relative sagittal plane rotation greater than 11°,
- Sagittal translation greater than 25% at L5–S1,
- Relative rotation greater than 19° (4).

Although these criteria represent absolute evidence of instability, indirect evidence may be seen in the patient who following surgery has developed

- Progressive deformity in either the sagittal or frontal planes;
- Short-segment angular collapse at the level of the decompression.

Frontal plane segmental collapse is seen commonly with postoperative instability and may result in dynamic stenosis, with leg pain resulting from root compression in the concavity of the collapse (Fig. 149.7). Scrutinize the plain AP radiograph for evidence of extensive or excessive resection of the posterior elements, such as the pars interarticularis and facet joints, which can lead to instability.

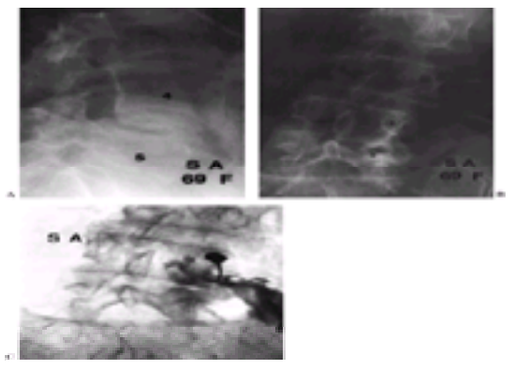

***Figure 149.7.*** A 69-year-old woman who underwent two prior laminectomies at L4–L5 with no relief of her right buttock pain. (**A** and **B**) Lateral and PA views of the lumbar spine. The frontal view demonstrates asymmetric collapse on the right at L4–L5; (**C**) a captured image during selective nerve root infiltration of the L-4 root, which completely relieved her pain, strongly suggesting that L-4 root compression was the cause of the symptoms.

If there is radiographic evidence of instability in a symptomatic patient, spinal fusion, facet injections, or discography may help clarify the precise origin of the patient's symptoms. Rule out other possible causes of back pain before performing repeat surgery.

**DISCOGENIC BACK PAIN**

Degeneration of the disc may result in ongoing back pain in as many as 14% of patients who have had previous back surgery (15). Although the exact etiology of this pain may vary, a certain subset of patients is believed to suffer from primary disc-related or discogenic pain. The existence of this entity continues to be debated, as does a reliable method of diagnosis. The difficulty in arriving conclusively at the diagnosis of discogenic back pain is magnified in the patient who has had prior back surgery because of the potential contributions of instability, epidural fibrosis, and generalized deconditioning.

In our experience, the typical patient with discogenic back pain following previous surgery had a history of leg pain as well as significant back pain before the initial operation. A period of improvement in leg pain following the surgery is noted, but very often the back pain continues unabated or even worsens. Gradual worsening of the leg pain is frequently reported, although this symptom may be related to epidural fibrosis. The pain is typically relieved by rest. Generalized limitation of motion of the lumbar spine is seen on examination, but otherwise the physical examination is usually unremarkable.

Evaluate the patient radiographically with plain films including dynamic views to rule out instability. MRI, with or without gadolinium, may demonstrate disc degeneration at the previous surgical site, and possibly at other levels of the lumbar spine.

Modic et al. (27) have described three types of signal changes in the vertebral bodies adjacent to a degenerated disc degeneration. Type I changes show decreased T1 intensity and increased T2 intensity, which correlates histologically with disruption and fissuring of the endplate and vascularized fibrous tissue within the marrow of the vertebral body. These changes, which can be suggestive of vertebral osteomyelitis, can be differentiated from infection by the absence of increased signal intensity on T2-weighted images.

Type II changes have strong signal intensity on both T1- and T2-weighted images. Histologically, these changes represent yellow marrow replacement in the vertebral body. Finally, Type III changes show decreased signal intensity on both T1- and T2-weighted images, reflecting relative absence of marrow in the vertebral body; this finding correlates with bony sclerosis seen on plain radiographs. The significance of these discogenic changes in the vertebral bodies, as seen on MRI, has not been clearly defined; such changes, when present, would suggest that the intervening disc is the source of the pain.

Next, perform pain provocation discography. Because of the invasive nature of the procedure and the potential risks, in particular discitis, perform discography only in patient's in whom you are considering fusion and they have agreed to proceed. The morphologic picture seen with contrast injection typically correlates closely with the MRI of disc degeneration, but it is the patient's report of reproduction of his or her characteristic pain that is essential in attempting to determine that a given disc is the pain generator. Do not use extensive sedation during the test because it renders the patient's feedback meaningless. It is also important to inject three or even four levels to find at least one control level. If every level injected reproduces the patient's pain pattern, then the test result is unreliable, and surgery based on this discogram is less likely to result in adequate pain relief.

If one or two degenerated levels can be identified as clearly reproducing the patient's characteristic pain pattern, then the patient may be a candidate for surgery. It should be noted there is no conclusive evidence that a confirmatory discography can predict surgical success. The patient and surgeon should be aware that no spine-fusion technique for discogenic back pain has been conclusively shown to have a high success rate.

In the carefully selected patient, we favor interbody fusion (see Chapter 146) rather than relying solely on posterolateral fusion. These techniques are in evolution, but success depends on using abundant autologous iliac bone graft with adequate graft–endplate contact, adequate stabilization provided by the implant, and a minimum of destruction of normal anatomy. Available techniques include

- Transforaminal interbody fusion (TLIF) combined with transpedicular instrumentation,
- Anterior lumbar interbody fusion (ALIF), or
- Posterior lumbar interbody fusion (PLIF) with fusion cages packed with autologous bone, and
- ALIF with structural allograft replacement.

As of this writing, all of these procedures should be considered investigational. These are discussed in further detail in Chapter 146.

**ARACHNOIDITIS AND EPIDURAL FIBROSIS**

Arachnoiditis and epidural fibrosis are nonmechanical causes of back or leg pain in patients who have had previous back surgery. Scar tissue occurring beneath the dura is commonly referred to as arachnoiditis. Scar tissue can also form extradurally, compressing either the cauda equina or the nerve root, and is referred to as epidural fibrosis.

Arachnoiditis is strictly defined as an inflammation of the pia-arachnoid membrane surrounding the spinal cord or cauda equina (31). The condition may be present in varying degrees of severity, from mild thickening of the meninges to solid adhesions. The scarring may be severe enough to obliterate the subarachnoid space and block the flow of contrast agents. The etiology of this condition has been attributed to many factors; prior surgery and particularly a history of myelography with oil-based contrast are frequent precipitating factors. A dural tear with blood mixing with cerebrospinal fluid (CSF) or a postoperative infection may also play a role in its pathogenesis. The exact mechanism by which arachnoiditis develops from these events is not clear. There is no uniform clinical presentation for arachnoiditis.

The patient's history usually reveals more than one previous operation and a pain-free interval lasting from 1 to 6 months. Often, the patient complains of back and leg pain. Physical examination is inconclusive; alteration in neurologic status may be on the basis of a previous operation. Myelography, CT, and MRI can all be helpful in confirming the diagnosis (43).

There is no effective treatment for arachnoiditis. Reconstructive or decompressive surgery has not proven effective in eliminating the scar tissue or significantly reducing the pain. Salvage procedures such as spinal cord stimulation or implantation of a morphine pump have been advocated, with some promising results reported (40).

Use nonoperative measures for most patients. Epidural steroids, transcutaneous nerve stimulation, operant conditioning, bracing, and patient education have all been tried. None leads to a cure, but all can provide symptomatic relief for varying periods of time. Patients should be detoxified from narcotics and encouraged to pursue physical activity as much as possible. Gabapentin (Neurontin) and amitriptyline (Elavil) are pharmacologic adjuncts that may be effective. Treating patients with arachnoiditis is a real challenge, and the physician must be willing to devote time and patience to achieve optimal results.

Formation of scar tissue outside the dura on the cauda equina or directly on the nerve roots is a common occurrence. This epidural scar tissue can act as a constrictive force around the neural elements and may cause postoperative pain. Although most patients have radiographic evidence of epidural scar tissue formation, only an

unpredictable few become symptomatic.

Patients with epidural fibrosis may become symptomatic at almost any time, from several months to years after surgery. The onset is typically gradual, with complaints of back pain, leg pain, or both. Commonly the neurologic examination is normal, but the presence of a tension sign may occur due to nerve root constriction from fibrotic changes. The diagnosis is best differentiated from recurrent disc herniation or LSS by gadolinium-enhanced MRI.

As with arachnoiditis, there is no definitive treatment for epidural fibrosis. Prevention may be the best answer, and fat, Gelfoam, and other interpositional membranes have been suggested to minimize the formation of scar tissue following laminectomy (22). Once scar has formed, decompressive surgery with the goal of resecting scar tissue has not proven successful because of the almost inevitable recurrence of even worse fibrosis. It is our experience, however, that a fibrosed nerve root may be more susceptible to the deleterious effects of instability or stenosis than a nerve that has not been surgically treated.

**DISCITIS**

Discitis is an uncommon but debilitating complication of lumbar disc surgery. Its pathogenesis is postulated to be direct inoculation of the avascular disc space at the time of discectomy, but it is not completely understood (1,9). The onset of symptoms usually occurs 2 to 4 weeks following surgery.

Most patients complain of rapid onset of severe back pain. Pain is unremitting, even at rest, and sometimes extends to the buttocks. Pain does not usually follow a dermatomal pattern down the leg. The patient may have a low-grade fever. Physical examination usually reveals marked paraspinal spasm and rigidity, and pain is present with any type of motion. Straight-leg raising may be limited, but the presence of a true tension sign or new neurologic abnormality is unusual. Occasionally, a superficial wound infection is seen, but in most cases, wound healing has been uneventful.

If you suspect discitis, obtain blood cultures, a white blood cell count with a differential, erthrocyte sedimentation rate (ESR), and a C-reactive protein level. Plain radiographs are usually normal in the early stages; later, endplate erosion may be seen, but it may not be present for several weeks. Contrast-enhanced MRI is the test of choice in suspected disc space infection. Increased signal intensity in the disc space on T2-weighted images suggests discitis, which can be confirmed by enhancement of the disc space with use of gadolinium.

Treatment options include bed rest, bracing, antibiotics, or combinations thereof. Initially, place the patient on bed rest to immobilize the lumbar spine, with or without a brace or corset. Begin empiric antibiotic treatment and continue it for 6 to 12 weeks. Cefepime, a third-generation cephalosporin with improved staphylococcal coverage as well as pseudomonicidal properties, is administered, giving 1 to 2 g every 12 hours. If the patient fails to respond rapidly to antibiotics and immobilization or manifests constitutional signs and symptoms, perform a needle biopsy of the affected disc space. Open biopsy is reserved for patients who fail to respond to treatment, as evidenced by improvement in pain and decline of the ESR, or for patients with neurologic compromise (9). Once the patient is comfortable at bed rest and is afebrile, institute progressively increasing activity as symptoms allow. Most authors report good long-term results with resolution of infection and adequate pain control.

**LUMBAR PSEUDARTHROSIS**

Nonunion following fusion of the lumbar spine has been reported to occur in as many as 40% of cases. Risk factors include a history of cigarette smoking, multiple-level fusion, and instability that has not been adequately addressed with either internal or external immobilization at the time of fusion (32). Nonunion may occur with or without instrumentation, although the presentation may be somewhat delayed in cases in which rigid internal fixation is initially used. Patients with persistent symptoms due to pseudarthrosis complain primarily of back pain. Leg pain may be present, but direct causes of nerve root compression should be sought, and an assumption that the pseudarthrosis is the cause of the leg pain is frequently unwarranted.

A pain-free interval following surgery may be variable; patients may say that their symptoms never improved following surgery, or they may report many months or even years of relatively good pain relief. It should be noted that unlike a simple discectomy, in which it is not uncommon for the patient to describe truly complete relief of pain, patients who have undergone spine-fusion surgery, even when it is successful, rarely describe complete relief of their symptoms. Patients who have undergone internal fixation, however, are more likely to describe a clear-cut pain-free interval that begins to deteriorate when the implant either loosens (the most common mode of failure) or breaks.

Pseudarthrosis may result in instability and mechanical back pain. It has long been recognized, however, that the correlation between radiographic failure of fusion and symptoms is uncertain. It is very difficult to identify accurately the source of the patient's pain following lumbar fusion; solid fusion is no guarantee of pain relief, and many patients with an obvious nonunion do remarkably well.

It is essential to think twice before offering patients with a pseudarthrosis revision fusion. Undertaking repeat surgery for pseudarthrosis repair in the absence of motion at the affected level and without a thorough search for alternative causes for the patient's symptoms has limited chances for success. Most authors report compromised results after such surgery, particularly when leg pain is noted in the absence of a compressive etiology (24).

Begin evaluation of the patient with a possible pseudarthrosis with plain radiographs, including Ferguson AP and weight-bearing, dynamic lateral radiographs. Solid fusion, either posteriorly or anteriorly, should eliminate virtually all motion on flexion and extension views. Although the landmarks may be somewhat difficult to identify, careful scrutiny of dynamic views can usually identify whether or not motion is taking place (Fig. 149.8).

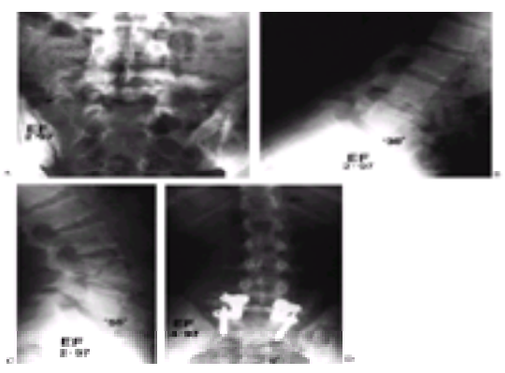

***Figure 149.8.*** A 17-year-old man, 18 months following L5–S1 fusion for spondylolysis, who now reports worsening low-back pain. (**A**) A Ferguson AP view shows abundant fusion mass on the right, although a defect can be seen (*arrowhead*), whereas on the left, most of the graft has been resorbed (*arrow*). Lateral flexion and extension radiographs demonstrate 17° of angular motion; (**B**) clear-cut evidence of pseudarthrosis, which was confirmed at surgery; (**C**), clear-cut evidence of pseudarthrosis, which was confirmed at surgery; (**D**) revision fusion posteriorly, with transpedicular instrumentation, led to complete pain relief.

The AP views may be difficult to interpret, but many times, a serpiginous cleft in the fusion mass can be visualized. Although a number of other radiographic modalities, including CT scanning and single photon emission computed tomography (SPECT) scanning, have been suggested to diagnosis nonunion, we rely almost exclusively on plain radiographic findings of motion or progressive deformity to identify the patient who is likely to benefit from repeat surgery.

In many cases, it is difficult to identify a pseudarthrosis clearly; additionally, the correlation between pseudarthrosis and symptoms in a given patient is uncertain. For these reasons, an aggressive attempt at nonoperative treatment is indicated. When the nonsurgical approach is unsuccessful, revision surgery may be undertaken. A failure rate as high as 50%, both clinically and radiographically, has been reported, however. Lauerman et al. (24) reported improved results in patients who had undergone only one prior operation on the lumbar spine and in patients who had a clear-cut original indication for fusion, such as spondylolisthesis.

## NONOPERATIVE TREATMENT

It is axiomatic that, for the patient with pain following previous surgery on the lumbar spine, there is always another operation that can be considered. Experience tells us, however, that the results following revision surgery on the lumbar spine are frequently unsatisfactory, and particularly when there is a history of two or more previous operations, the patient has a significant chance of being made worse rather than better with another surgery (37). In light of this, treat nonoperatively most

patients who have failed prior surgery, even when it is possible to identify an etiology of their pain that is potentially amenable to surgery.

Nonoperative treatment involves generalized back care as well as some more specific interventions. Realistic goals for pain relief are essential. Close questioning of the patient often reveals that he or she is significantly better now than before the previous operation; any consideration of further surgery simply to “get rid of all of the pain” is likely to be unsuccessful and is unwarranted. Furthermore, it is apparent on questioning some patients that there has been almost no postoperative attempt at rehabilitation. These patients respond quite readily to a generalized back exercise and aerobic exercise program with judicious use of medication.

A generalized back treatment program consists of

- Weight reduction when appropriate;
- A defined program of aerobic exercise, particularly involving walking, riding an exercise bicycle, or swimming;
- A supervised program of active physical therapy consisting of specific back stretching and strengthening exercises; and
- Use of nonsteroidal anti-inflammatory medications.

Make every attempt to detoxify the patient from chronic narcotic usage. Elavil is useful for the patient with chronic pain and sleep disturbance, as are several other antidepressants. Neurontin, an antiepileptic, appears to be beneficial in some patients with chronic radicular pain.

Other psychopharmacologic agents are available for use in the patient with chronic pain and are becoming increasingly popular. It is up to the individual physician to decide to what extent his or her practice includes prescribing these medicines. The authors find it more effective, in most cases, to refer such patients to a pain management center for pharmacologic management. A final adjunct that is occasionally useful is external immobilization, which may be provided by something as simple as a lumbar corset or as elaborate as a custom-made polypropylene lumbosacral orthosis. It is widely believed that these devices decondition the lumbar musculature, although there is little objective evidence to document this belief. Corsets and orthotics do, however, provide significant pain relief for many patients, and they are particularly effective in elderly patients.

In patients with leg pain and evidence of epidural fibrosis or recurrent mechanical compression from stenosis or disc, a trial of lumbar epidural steroids is worthwhile. The long-term benefits are quite variable, but a certain percentage of patients will obtain lasting relief or will tolerate a more aggressive program of rehabilitation once the inflammatory radicular symptoms are controlled. Local trigger-point injections, facet joint blocks, and sacroiliac injection may also be tried, although none of these methods has consistently proven effective.

## INDICATIONS FOR SURGERY

The principal indication for surgery in the patient with failed prior low-back surgery is persistent, unacceptable pain that has failed to respond to aggressive and persistent nonoperative treatment. In addition, it is explained by and correlates with either objective evidence of instability, mechanical nerve root compression, or both. The challenge in managing patients who have had prior back surgery, and the primary reason for the increased rate of failure with further surgeries, is the difficulty of clearly correlating the patient's pain with the radiographic findings. Adherence to guidelines that are as strict as or stricter than those used for primary surgery is essential. Our experience has been that attempts to extend these indications leads to consistently unsatisfactory results. Further, viewing fusion as a generically applicable salvage procedure for previously unsuccessful back surgery rarely results in significant and long-lasting pain relief.

Surprisingly good results can be obtained by operating on patients who fit into one of three categories. These include patients who have

1. Radicular leg pain and confirmatory evidence of nerve root compression on high-quality neuroradiographic imaging that demonstrates either recurrent disc herniation or LSS not caused by epidural fibrosis;
2. Back pain due to radiographically documented instability, as confirmed either by progressive deformity (scoliosis or spondylolisthesis), excessive motion on flexion and extension lateral radiographs, or a failed fusion with motion demonstrated on dynamic radiographs;
3. Back pain believed to be emanating from one or two painful degenerated discs, confirmed on pain-provocation discography.

Although the results are generally good when operating on this subset of patients, it should be stressed that only a relatively small percentage of patients with FBSS fit into one of these three categories.

Other indications for surgery in this patient population include the presence of a clearly documented progressive neurologic deficit. Although this condition is uncommon, it does occasionally occur, more often in elderly patients with severe stenosis. A progressive neurologic deficit is an indication for urgent surgery. Cauda equina syndrome, a distinctly rare occurrence in patients who have had unsuccessful back surgery, merits emergent imaging and surgical treatment. Finally, one occasionally encounters the patient with radiographic evidence of progressive spondylolisthesis or progressive collapsing scoliosis, which itself suggests the need for surgical stabilization. It rarely occurs in the absence of concurrent incapacitating pain but might be a situation in which a more aggressive approach is called for.

## INSTRUMENTATION

Since the early 1980s, transpedicular instrumentation has gained increasing popularity in North America as an adjunct to lumbar fusion. This trend has, in several ways, complicated the approach to the treatment of patients whose back surgery has failed. First, an increasing number of patients are undergoing lumbar spine fusion, and unfortunately, in many cases, it has been carried out in the absence of traditional, objective indications. The usual result is failure. The presence of the implant itself raises several technical considerations relating to the possible need for repeat surgery, including the significance of screw breakage, implant loosening, infection, and malposition of one or more screws. Finally, adverse publicity related to these devices has led to a climate in which either medicolegal concerns or, at the least, undue patient anxiety further clouds a complicated clinical picture.

Pedicle screw instrumentation systems are composed of metal alloys that have a very low incidence of true allergy; therefore, allergy is rarely, if ever, the cause of pain. Failure can occur in one of several ways, but mechanical failure does not necessarily represent an indication for removal of the implant or revision surgery. Screw breakage is the most dramatic mode of failure, but with current technology, it is quite rare. A broken screw does not preclude the possibility of a successful fusion and, therefore, is not an absolute indication of clinical failure (26,39).

On the other hand, the patient who, having had good relief of back pain following an instrumented lumbar fusion, now has the sudden recurrence of pain and is noted to have new screw breakage may well have had a nonunion that was adequately stabilized when the implant was intact. Such a patient would benefit from revision fusion.

Another mechanism of failure is screw loosening in the pedicle and vertebral body. This is much more common than screw breakage. The loosening is seen as a small zone of radiolucency about the screw on routine radiographs. There is no clear-cut relationship between screw loosening and symptoms, and unless failure of fusion and motion on flexion and extension views are demonstrated, continued observation is indicated.

Finally, the risk of infection appears to be increased with the use of these bulky implants, and the rate of infection has been reported to be from 2% to 5% (35). Acute and subacute infection is readily diagnosed, but late infection may represent the source of recurrent back pain after a relatively long pain-free interval. Consider infection when evaluating the patient with the late onset of pain after an otherwise successful fusion. On CT scan, look for a fluid collection around the implant. Aspirate the wound to look for purulent fluid. Send any fluid aspirated for Gram's stain and culture.

In addition to disc herniation or stenosis adjacent to the fused levels, another possible source of nerve root compression in patients who have implants in place is a misplaced screw. Although most patients have symptoms early from a misplaced screw, it is not uncommon for radicular pain to develop weeks, months, or even years later (Fig. 149.9).

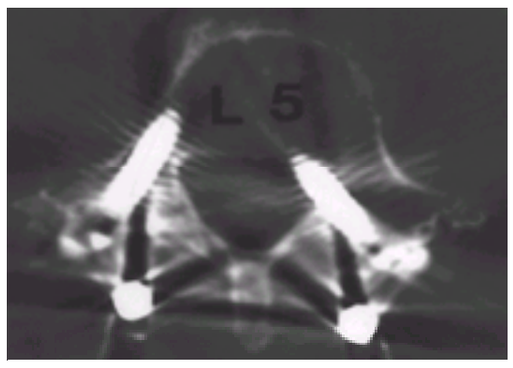


***Figure 149.9.*** A 59-year-old woman who, 1 month following revision fusion with transpedicular instrumentation, reported worsening left leg pain and weakness. A plain CT scan demonstrates, on the bone windows, medial placement of the L-5 screw, correlating with her symptoms. Prompt screw removal led to complete resolution of her leg pain, although she had mild residual weakness.

Thin-cut plain CT scanning of the lumbar spine, using bony windows, is a sensitive modality for identifying a screw placed outside the pedicle. Because screw misplacement is asymptomatic in as many as 20% of patients, close correlation between the patient's signs and symptoms and the root compromised by the screw in question is essential before deciding on repeat surgery (41). The most common location for screw impingement is medial to the pedicle, particularly at L-5, but it is important to check for the possibility of an S-1 screw placed through the sacral ala, lateral to the sacral body, which brings it into proximity to the L-5 root, passing over the brim of the sacrum. Once the diagnosis of screw malposition, which is causing symptoms, has been made, screw removal is indicated.

Although transpedicular instrumentation may lessen the risk of pseudarthrosis, it certainly does not eliminate it (35). A rigidly fixed pedicle screw implant may temporarily provide stability to an unstable motion segment, but if solid bony fusion is not achieved, loosening commonly occurs. Therefore, mechanical back pain may recur after a pain-free interval. No radiographic modality has consistently proven accurate in diagnosing nonunion in the presence of a transpedicular implant (23). We rely on the presence or absence of motion on flexion and extension lateral views to decide whether further surgery in indicated.

One final indication for surgery in patients in whom pedicle screw instrumentation is present is routine implant removal. It is unusual for a patient to be so thin that the implants are palpable or cause pressure problems with sitting in a hard-backed chair. The role of routine implant removal is uncertain, and significant pain relief, if a solid fusion is present, occurs in only about one patient out of three (10). To the patient requesting implant removal, we explain the uncertainty regarding the chances for improvement of their pain as well as the fairly significant surgery required to remove these devices. If the patient wishes to proceed under these circumstances, we will remove the implants and explore the fusion. We inform our patients that if a pseudarthrosis is found, further bone grafting and revision instrumentation will be carried out.

## SURGICAL TECHNIQUES

Operating on the lumbar spine after one or more previous surgeries can be a challenge. The technique of a repeat laminectomy or a repeat fusion is somewhat different from first-time surgery. The risk of complications is certainly greater, with the ever-present danger of a dural tear or neurologic injury.

### REPEAT LAMINECTOMY

The goal of a laminectomy in repeat back surgery is the same as that for the initial procedure—to decompress the neural elements without injury or excessive hemorrhage. Unfortunately, once the spine has already undergone surgery, the anatomy is not as clear and a great deal of scar tissue can be present. Thus, several technical aspects of a repeat laminectomy are different from those of a primary procedure.

The first difference involves the operative approach: It is not possible to strip the paraspinal muscles away with impunity because of absence of the spinous processes, lamina, or ligamentum flavum at the sites of previous surgery.

- Begin the approach at a new level with normal anatomy and normal protection of the cauda equina. Find the normal depth of the posterior elements and cauda equina, and carefully extend the dissection into the area of the laminectomy defect.
- Working laterally, identify and expose the facet joints.
- Proceeding distally, define the pars interarticularis at the caudal base of the superior articular facet; follow the pars further distally and medially onto the remaining lamina and inferior articular facet of the next-lower facet joint.
- Carefully scrutinize the preoperative plain radiographs, CT scan, and MRI scan to determine the extent of previous resection. It is not uncommon to encounter a pars or facet fracture unexpectedly.
- Beginning at each facet joint, use sharp curets and a Penfield dissector to subperiosteally expose the remaining normal posterior elements while minimizing risk of injury to the dura and underlying cauda equina.

The surgeon may also be tempted, once the depth of the neural elements is determined, to remove the extradural scar tissue directly over the dura. This is a technically difficult procedure with the potential for a great deal of hemorrhage and a strong possibility of dural injury. Even if the scar tissue can be successfully removed, there is no reliable means available to prevent its regrowth. We recommend, for the most part, that extradural scar tissue be left intact; remove only the tissue covering the area of previously documented nerve root compression.

The object of the surgical procedure is to visualize the nerve roots laterally and remove any mechanical (nonscar) tissue pressure from them. Do so by extending the laminectomy from the new level down the lateral gutters, leaving the central scar tissue as is:

- Use sharp curets to follow the medial border of the laminectomy defect ventrally, developing a plane between the epidural scar tissue and the residual bone.
- Once this plane is developed, introduce a Kerrison rongeur at a 45° angle, and undercut the bony encroachment, usually arising from the medial overhang of the superior articular facet.
- Carry this decompression out proximally, distally, and laterally until all bony overgrowth has been removed back to the medial wall of the pedicle.
- You may also use an osteotome to remove the most medial portion of the facet, thereby gaining entry to the spinal canal and nerve roots.
- If the goal of the repeat procedure is decompression of recurrent stenosis, extend the laminectomy laterally to the pedicle on either side at whatever levels are radiographically involved.
- Leave the midline epidural fibrosis intact.
- If a central laminectomy is required either proximal or distal to the previous laminectomy, proceed in standard fashion, first developing the interval between the caudad half of the lamina and the underlying ligamentum flavum. Then resect the lamina piecemeal.
- Once normal dura is encountered proximally, reverse direction, working caudally to remove the intervening ligamentum flavum from the underlying dura.
- If, at the junction of the previous decompression and the ligamentum flavum, you find adherent scar tissue, leave a small amount of ligamentum flavum over the thecal sac if it cannot be safely dissected free.
- Address the nerve roots laterally, as previously described.

### REPEAT DISCECTOMY

The use of Repeat surgery for a recurrent disc herniation is common. Many of the same caveats as described for repeat decompressive laminectomy apply. Usually, a recurrent disc herniation occurs in a patient who has had a previous relatively limited hemilaminotomy, with the majority of the posterior elements being preserved.

- Expose the affected side only by carefully dissecting along the involved laminae and following them laterally as they join to become the facet joint. Place a retractor lateral to the facet joint to visualize the previous laminotomy.
- As with a more extensive laminectomy, bear in mind at all times the risk of a dural tear when performing a repeat discectomy. This risk can be minimized, and safe entry into the canal achieved, by using sharp curets to define clearly the remaining bony landmarks around the prior laminotomy.
- Scar tissue that is encountered can be thinned out, but as with a decompressive laminectomy, attempts to remove epidural fibrosis from the dura completely increase the risk of injury and are not indicated in most cases.

- Once the hemilaminotomy has been completely defined, use either a Kerrison rongeur or osteotome to remove a small portion of residual bone, first from the inferior facet of the cephalad level and then from the medial aspect of the superior facet of the caudad level.
- This new entry into the spinal canal and lateral recess is slightly more lateral to the original hemilaminotomy site. Extend the exposure until you are flush with the medial wall of the pedicle.
- The traversing nerve root is usually encased in a layer of scar tissue of variable thickness, but can be palpated with a Penfield dissector.
- Carefully dissect along the lateral border of the root to mobilize it and retract it medially. Expose the underlying disc.
- Although it can be fairly time consuming, careful mobilization of the nerve root is essential to avoid root injury.
- Once the root is safely retracted medially, expose the underlying disc and resect it in standard fashion.
- Whether or not to fuse in the face of a recurrent disc herniation is a highly controversial decision; we favor fusion when the patient has significant back pain or when there is any suggestion of instability. We are more inclined to fuse at the L4–L5 level than at L5–S1.
- A second recurrence (third disc herniation) merits strong consideration of fusion.

### FUSION EXPLORATION AND REVISION

Do not undertake repeat surgery on the lumbar spine with the specific goal of repairing a nonunion unless other potential causes of pain have been excluded. We rarely undertake nonunion repair in cases in which evidence of motion on dynamic lateral x-ray studies or progressive deformity has not been documented. Once the decision has been made to proceed with revision fusion, several technical points facilitate the procedure.

- If there has been a prior laminectomy, expose carefully, starting at normal levels as described above.
- Carry the exposure lateral to the facet joints and out all the way to the tips of the transverse processes on each side.
- In cases in which there is a laminectomy defect from previous surgery and no further decompression is planned, use a paraspinal muscle-splitting approach, which affords excellent visualization of the facet joints, pars interarticularis, and laterally placed fusion mass. It also facilitates pedicle screw placement.
- After exposure, carefully explore the fusion mass.
- In places where fixation devices are still in place, it is very difficult to determine whether the fusion is solid until the instrumentation is completely removed. Therefore, once exposure has been obtained, disassemble the implant and remove it piecemeal.
- Remove the fibrous scar tissue to visualize the fusion mass clearly.
- Use Cobb elevators and sharp curets to remove all soft tissue from the dorsal cortex of the fusion mass extending from cephalad to caudad and from the most medial extent to the lateral margins of the transverse processes and fusion mass.
- A well-consolidated fusion is easy to strip, although it is not uncommon to find islands of fibrous tissue surrounded by bridging trabecular bone. Soft tissues are attached strongly to nonunions and are difficult to strip.
- Once the fusion has been completely exposed, check not just for continuity but for adherence as well to the proximal and distal spinal elements; occasionally, well-formed bone is not adherent to the transverse process or, more commonly, the sacral ala.
- In order to verify the adequacy of fusion, take an osteotome and carefully remove the dorsal cortex of the fusion mass to verify that there is underlying cancellous bone in continuity with the transverse processes and alae.
- When a defect in the fusion mass is found, it is frequently narrow and wanders in a serpiginous fashion through the fusion. It can take fairly extensive exploration of a defect to document that it does indeed track through the entire fusion mass and allows motion.
- If the fusion is found to be solid, close the wound in standard fashion. If a defect in the fusion mass is found, use curets and a high-speed burr to remove all soft tissue from the dorsal aspect of the defect.
- Complete excision of all soft tissue is not necessary; remove the accessible dorsal soft tissue and decorticate the area around the defect. Then apply abundant autologous bone graft to the nonunion.
- Then stabilize the nonunions with a pedicle screw system and apply compression across the nonunion.
- Identification of the normal landmarks for pedicle screw placement can be difficult. Use interoperative fluoroscopy for identification of the appropriate starting point and path for the screws.

In addition to discovering a defect in an otherwise well formed fusion mass, nonunion is seen in many patients in whom there has been complete or near-complete resorption of the previously placed bone graft. It is more common in patients in whom an allograft is used and in smokers. In these patients, it is usually readily apparent that the original fusion has failed.

- Thoroughly expose out to the tips of the transverse processes.
- Carefully decorticate the transverse processes and sacral ala.
- Apply a massive bone graft to provide the best chance for successful repair.
- In these cases, in which there is no stabilization from the original fusion, rigid internal fixation is essential.

Another alternative when considering repair of a previously failed fusion is interbody fusion. It can be performed through a transforaminal or posterior approach or, more commonly, through an anterior approach.

- Use allograft, if desired, as a block graft to provide stability, but supplement it with autologous bone from the iliac crest or from the adjacent vertebral body.
- We consider performing a combined posterior and anterior fusion in patients in whom a previously well-done fusion with rigid fixation has led to nonunion, in smokers, or in cases in which it is determined, at the time of posterior exploration, that there has been sufficient attenuation of the bone posteriorly to suggest that the chances of obtaining a solid fusion are minimal (Fig. 149.10).

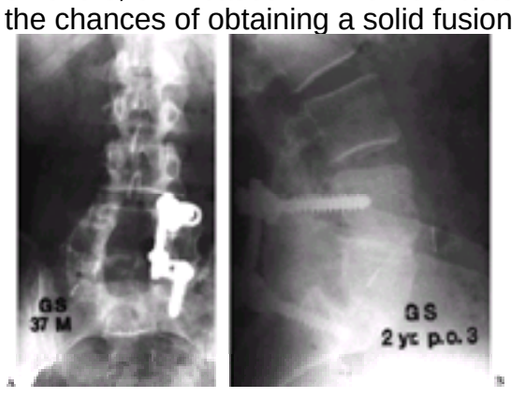


***Figure 149.10.*** A 37-year-old man 2 years following his third attempt at L4–L5 and L5–S1 fusion for isthmic spondylolisthesis. **A:** At the last posterior surgery, malpositioned left L-4 and L-5 screws were removed and it was elected only to instrument the right side. Because of the recurrent pseudarthrosis, and the ability to instrument only one side, it was elected to proceed with anterior interbody fusion, using a femoral ring allograft at both levels. **B:** At 2 years follow-up, solid fusion is seen, and the patient, who had not worked in 3 years, is minimally symptomatic and back to full-time employment.

## POSTOPERATIVE MANAGEMENT

For the most part, postoperative management of patients undergoing revision low-back surgery is similar to that for primary surgery. Although the hospital stay is usually unchanged, the overall length of recovery can be prolonged compared with first-time surgery. The patient should be prepared for an extended time away from work or other pressing duties. Fixation after revision fusion may be less than ideal; therefore, we commonly supplement fixation with a brace. We use a physical therapist to mobilize the patient after surgery by facilitating transfers and ambulation; otherwise, we delay back rehabilitation for 3 to 4 months following surgery.

Try to detoxify patients from narcotics before surgery. The early postoperative period following a revision operation is not the time to withdraw narcotic medication. Work with a pain management specialist to lessen narcotic usage gradually with a goal of discontinuing narcotic medication altogether by 6 to 12 months postoperatively. Although this is an extended period of time, it is impractical to assume that quicker withdrawal is possible.

## PITFALLS AND COMPLICATIONS

### DURAL TEAR

The risk of encountering a dural tear is definitely greater in the patient who has undergone previous back surgery. Although each dural tear is different, certain basic principles always apply and certain steps should be followed.

A dural tear usually occurs as the surgeon is gaining visualization of, and entry into, the spinal canal. Although a large majority of dural tears do not result in any long-term morbidity, the repair of an intraoperative tear is time consuming and bears with it the potential for persistent CSF leakage, wound problems, and nerve root injury. The risk of dural tear is increased in repeat surgery because previous resection of the posterior elements obliterates the usual landmarks. Other risks include the difficulty of separating scar tissue from the dura to develop a plane between the thecal sac and nerve root, and the pathologic anatomy related to whatever is causing recurrent neural compression.

- Lessen the risk of dural injury by beginning the deep exposure of the posterior elements, proximally and distally, where there are retained normal spinous processes and laminae.
- Dissect proximally and distally along a normal lamina to the facet joints and then work caudally from the proximal end and distally from the cephalad end to expose the length of the entire laminectomy defect safely.
- Expose the preserved facet joints and pars interarticularis susperiosteally, and leave a layer of scar tissue over the dura.
- Use a curet to define the medial border of the retained posterior elements.
- Rather than try to directly peel off or resect scar tissue from the dura, resect a small amount of normal, retained lamina or medial facet to expose an area of spinal canal, thecal sac, or nerve root uninvolved with scar tissue. Entry to the canal in such a way usually permits decompression without dural injury.

If the goal of surgery is to remove epidural scar tissue that is contributing to the nerve root or thecal sac compression, then the technique described earlier is less likely to be adequate and the risk of a dural tear is increased.

Once a tear occurs, the wound usually fills quickly with CSF, obscuring the extent of the damage. The surgeon's first impulse is to try to see the tear by using suction in the approximate area of the problem. This is a mistake, because the individual nerve roots may be sucked out of the thecal sac, causing significant neurologic damage. Suction should be used only over a cottonoid so that no further damage to the nerve roots is done. After visualizing the tear, place a piece of Gelfoam over the injury site, cover it with a large cottonoid, and complete the original procedure. The patient's head may be tilted downward into the Trendelenburg position to decrease the flow of CSF into the wound.

Once the definitive procedure is completed, refocus on repair of the dural tear. The goal is to achieve a watertight closure; if not, a CSF fistula can form, raising the risk of meningitis or a subarachnoid cyst. A dry operative field with hemostasis maintained throughout the repair is essential. Similarly, achieve adequate exposure in both the cephalocaudad and mediolateral directions in order to define the extent of the tear adequately and to allow access for repair. Failure to maintain hemostasis and to obtain adequate exposure are the two most common causes of difficulty in repairing a dural tear. Magnification loupes and adequate lighting also facilitate the repair.

The actual technique of closure used depends on the size and location of the tear:

- For simple dural lacerations, we prefer 4-0 or 5-0 silk sutures on a tapered one-half circle needle. A running locking suture or simple sutures incorporating a free fat graft provide a watertight closure.
- If a tear is large or irreparable, harvest a fascial graft from the lumbodorsal fascia and suture it around the periphery of the defect with interrupted silk sutures.
- If the defect is in an inaccessible area, introduce a small tissue plug of muscle or fat through a second midline durotomy, pulling the tissue plug into the tear, thereby obliterating the tear from inside the dura (12).
- Use Fibrin glue to reinforce the dural repair if there is any question about the adequacy of the repair.
- Test the repair by placing the patient in the reverse Trendelenburg position and performing a Valsalva maneuver to increase intrathecal pressure. Close the fascia with a heavy, nonabsorbable suture, which must be watertight.

Most authors prefer not to use drains to avoid the possibility of the development of a draining fistula if there is persistent CSF leakage. Keep the patient on bed rest for at least 3 or 4 days to reduce pressure on the repair while it heals.

The diagnosis of a CSF leak in the postoperative period can be difficult to make. If relatively clear drainage occurs, consider the possibility of a dural leak. Similarly, a history of headaches when the patient sits or stands suggests CSF leakage. No completely reliable noninvasive diagnostic technique is available at present. The presence of glucose in the fluid draining from an incision is not a reliable determinant, because glucose is normally present in both noninflammatory and inflammatory exudates. The best diagnostic test, a myelogram performed with water-soluble contrast medium, is recommended if a dural leak is suspected but the diagnosis is uncertain. Once a postoperative CSF leak is diagnosed, pursue aggressive treatment. In the early postoperative period, placement of a subarachnoid drain for 4 to 5 days has been reported with good results (21). If this procedure is unsuccessful or a leak is diagnosed late, timely return to the operating room for dural repair is in order.

## AUTHORS' PERSPECTIVE

We stress that an organized methodical approach to the evaluation of the patient who has had previous back surgery is essential. In many cases, the problem resulted from inadequate or incorrect indications for the original surgical procedure. In such patients, further exploratory surgery is not warranted and would lead only to further disability. Another surgery is indicated only when objective findings for a specific diagnosis are present.

In the few patients who do require an additional operation, it must be appreciated that the surgery is usually more extensive than the original operation with certain inherent risks. One must approach the spine at a new level to identify the normal anatomy of the neural elements and visualize the appropriate nerve root or roots laterally, leaving the midline epidural scar tissue intact.

If the dura is injured during the course of the procedure, repair it in a watertight fashion. If nonunion of a prior fusion is suspected, then carefully explore the fusion mass when a nonunion is found, perform a thorough decortication, removal of scar tissue, massive bone grafting, and rigid fixation.

Those involved with treatment of patients undergoing repeat back surgery must realize that the chance of returning these patients to a pain-free status is low. Depending on the type of previous surgery and the patient's symptoms, usually some form of permanent impairment persists. These patients need counseling and must be strongly encouraged to resume as functional a role as possible in society.

### CHAPTER REFERENCES

Each reference is categorized according to the following scheme: *, classic article; #, review article; !, basic research article; and +, clinical results/outcome study.


+ 1. Bircher MD, Tasker T, Crashaw C, et al. Discitis Following Lumbar Surgery. *Spine* 1988;13:98.

+ 2. Blumell SC, Gill K. Can Lumbar Spine Radiographs Accurately Determine Fusion in Postoperative Patients? *Spine* 1993;18:1186.

+ 3. Boden SD, Davis DO, Dina TS, et al. Contrast-enhanced MR Imaging Performed After Successful Lumbar Disc Surgery: Prospective Study. *Radiology* 1992;182:59.

+ 4. Boden SD, Wiesel SW. Lumbosacral Motion in Normal Individuals: Have We Been Measuring Instability Properly? *Spine* 1990;12:571.

+ 5. Bolender NF, Schonstrom NSR, Spengler DM. Role of Computed Tomography and Myelography in the Diagnosis of Central Spinal Stenosis. *J Bone Joint Surg [Am]* 1985;67:240.

+ 6. Brodsky AE, Kovalsky ES, Khalil MA. Correlation of Radiographic Assessment of Lumbar Spine Fusions with Surgical Exploration. *Spine* 1991;16:261.

+ 7. Burton CV, Kirkaldy-Willis WH, Yong-Hing K, Heithoff KB. Causes of Failure of Surgery on the Lumbar Spine. *Clin Orthop* 1981;157:191.

+ 8. Byrd SE, Cohn ML, Biggers SL, et al. The Radiographic Evaluation of the Symptomatic Post-operative Lumbar Spine Patient. *Spine* 1985;10:652.

+ 9. Dall BE, Rowe DE, Odette WG, et al. Postoperative Discitis; Diagnosis and Management. *Clin Orthop* 1987;224:138.

+ 10. Davne SH, Meyers DL. Results Following Removal or Revision of Lumbar Pedicle Screw Instrumentation. *Orthop Trans* 1994;18:257.

+ 11. Edwards CC, Weigel MC, Levine AM. Improved Results Treating Lumbosacral Nonunions with Compression Instrumentation. *Orthop Trans* 1988;12:131.

+ 12. Eismont FJ, Wiesel SW, Rothman RH. Treatment of Dural Tears Associated with Spinal Surgery. *J Bone Joint Surg* 1981;63-A:1132.

+ 13. Finnegan WJ, Fenlin JM, Marvel JP, et al. Results of Surgical Intervention in the Symptomatic Multiply-operated Back Patient. *J Bone Joint Surg* 1979;61-A:1077.

+ 14. Hall S, Bartleson JD, Onofrio BM, et al. Lumbar Spinal Stenosis: Clinical Features, Diagnostic Procedures, and Results of Treatment in 68 Patients. *Ann Int Med* 1985;103:271.

+ 15. Hanley EN, Shapiro DE. The Development of Low Back Pain After Excision of a Lumbar Disc. *J Bone Joint Surg* 1989;71-A:719.

+ 16. Hazlett JW, Kinnard P. Lumbar Apophyseal Process Excision and Instability. *Spine* 1982;7:171.

+ 17. Holt E The Question of Lumbar Discography. *J Bone Joint Surg* 1968;50A:720.

+ 18. Horton W, Daftari T. Which Disc as Visualized by MRI Is Actually a Source of Pain? A Correlation Between MRI and Discography. *Spine* 1992;17:S164.

+ 19. Hueftle MG, Modie MT, Ross JS, et al. Lumbar Spine: Postoperative MRI with Gadolinium-DTPA. *Radiology* 1988;167:817.

+ 20. Johnsson KE, Wilner S, Johnsson K. Postoperative Instability After Decompression for Lumbar Spine Stenosis. *Spine* 1986;11:107.

+ 21. Kitchel SH, Eismont FJ, Green BA. Closed Subarachnoid Drainage for Management of Cerebrospinal Fluid Leakage After an Operation on the Spine. *J Bone Joint Surg* 1989;71-A:984.

+ 22. Langenskydd A, Kiviluoto O. Prevention of Epidural Scar Formation After Operations on the Lumbar Spine by Means of Free Fat Transplants. *Clin Orthop* 1976;115:92.

+ 23. Larsen JW, Rimoldi RL, Nelson RW, et al. Identification of Pseudarthrosis in the Presence of Pedicle Screw Instrumentation. *Orthop Trans* 1995;18:983.

+ 24. Lauerman WC, Bradford DS, Ogilvie JW, et al. Results of Lumbar Pseudarthrosis Repair. *J Spinal Discord* 1992;5:149.

+ 25. Long DM, Filtzer DL, BenDebba M, et al. Clinical Features of the Failed-back Syndrome. *J Neurosurg* 1988;69:61.

+ 26. McAfee PC, Farey ID, Sutterlin CE, et al. Device-related Osteoporosis with Spinal Instrumentation. *Spine* 1989;14:919.

# 27. Modic MT, Masaryk T, Paushter D. MRI of the Spine. *Radiol Clin North Am* 1986;24:A229.

+ 28. Modic MT, Pflanze W, Feiglin DH, et al. Magnetic Resonance Imaging of Musculoskeletal Infections. *Radiol Clin North Am* 1986;24:247.

+ 29. Mooney V. Position Statement on Discography. *Spine* 1988;13:1343.

+ 30. Paris SV. Physical Signs of Instability. *Spine* 1985;10:277.

+ 31. Quiles M, Marchisello PJ, Tsairis P. Lumbar Adhesive Arachnoiditis: Etiologic and Pathologic Aspects. *Spine* 1978;3:45.

# 32. Reilly JP, O'Leary PF. Complications of Lumbar Spine Surgery. In: White AH, Rothman RH, Ray CD, eds. *The Lumbar Spine.* New York: Raven Press, 1987:357.

# 33. Spengler DM. Degenerative Stenosis of the Lumbar Spine. Current Concepts Review. *J Bone Joint Surg Am* 1987;69:305.

+ 34. Teplick JG, Haskin ME. CT of the Postoperative Lumbar Spine. *Radiol Clin North Am* 1983;21:395.

+ 35. Vaccaro AR, Garfin SR. Pedicle Screw Fixation in the Lumbar Spine. *J Am Acad Orthop Surg* 1995;3:263.

+ 36. Waddell G. Failures of Disc Surgery and Repeat Surgery. *Acta Orthop Belg* 1987;53:300.

+ 37. Waddell G, Kummel EG, Lotto WN, et al: Failed Lumbar Disc Surgery and Repeat Surgery Following Industrial Injuries. *J Bone Joint Surg* 1979;61:201.

+ 38. Walsh T, Weinstein J, Spratt K, et al. Lumbar Discography in Normal Subjects. A Controlled Prospective Study. *J Bone Joint Surg* 1990;72-A:1081.

+ 39. West JL, Bradford DS, Ogilvie JW. Results of Spinal Arthrodesis with Pedicle Screw-plate Fixation. *J Bone Joint Surg Am* 1991;73:1179.

# 40. Wetzel FT, LaRocca SH. Surgical Procedures for the Control of Chronic pain. In: Rothman RH, Simeone FA, eds. *The Spine,* 3rd ed. Philadelphia: W.B. Saunders, 1992:1982.

+ 41. Weinstein JN, Spratt KF, Spengler D, et al: Spinal Pedicle Fixation: Reliability and Validity or Roentgenogram-based Assessment and Surgical Factors on Successful Screw Placement. *Spine* 1988;13:1012.

# 42. White AA, Panjabi MM, Posner I. *Spinal Stability: Evaluation and Treatment. AAOS ICL XXX.* St. Louis: Mosby, 1981.

# 43. Wilkinson HA. Adhesive Arachnoiditis. In: Weinstein JN, Wiesel SW, eds. *The Lumbar Spine.* Philadelphia: W.B. Saunders, 1990;1872.

# CHAPTER 150

# PYOGENIC AND GRANULOMATOUS INFECTIONS OF THE SPINE

*Munish C. Gupta and Daniel R. Benson*

**M. C. Gupta:** Department of Orthopaedics, University of California, Davis, Sacramento, California 95817.
**D. R. Benson:** Department of Orthopaedics, University of California, Davis, Sacramento, California 95817.

Etiology: Hematogenous Spread
Risk Factors
Pathophysiology: Tuberculosis of the Spine (Pott's Disease)
Diagnosis
History and Physical Examination
Laboratory Data
Organisms
Imaging Studies
Biopsy
Disease-Specific Treatment
Granulomatous Infections
Fungal Infections
Postoperative Spinal Infections
Epidural Abscess
Drainage and Debridement of Spinal Abscesses
Lumbar Spine
Thoracic Spine
Pitfalls and Complications
Intraoperative Complications
Early Postoperative Complications
Late Complications
Chapter References

Tuberculosis played an important role in our learning about the treatment of infections of the spine. Tuberculosis patients with deformity and paralysis forced us to address this devastating process with aggressive surgical and medical treatment. Even with the decrease of tuberculosis in developed countries, the principles of treating infections, pyogenic or granulomatous, have been influenced by the experience of treating tuberculosis.

Pyogenic infections have a spectrum of presentation from discitis in children, to osteomyelitis in adults, to postsurgical infections. The infection usually affects the vertebral body and disc and, less commonly, the posterior elements, except in cases of postsurgical infection (Fig. 150.1). The lumbar spine is the most common location of infection, followed by the thoracic spine; cervical spine infection is least common (132). The least common sites for spinal osteomyelitis are the occiput, atlas, and axis, with only a few isolated cases reported (178).



***Figure 150.1.*** Hematogenous osteomyelitis most commonly invades first the anterior portion of the vertebral body, just adjacent to the endplate. Radiographic changes take time to appear and the usual picture is that of simultaneous involvement of two adjacent endplates with narrowing of the intervertebral disc space. This tomogram of the lumbar spine shows endplate destruction of the lower vertebral combine with loss of a good deal of the body of the upper vertebra.

Hematogenous pyogenic osteomyelitis is characteristically a disease of men 50 years of age and older and is usually caused by *Staphylococcus aureus.* An increased incidence in younger male intravenous drug abusers has been noted. Pyogenic spinal osteomyelitis is usually monomicrobial, unless it is secondary to a systemic disease, in which case a polymicrobial infection is more common. There has been an increase in gram-negative infections compared with the more common gram-positive infections (19). The increased infection rates from gram-negative organisms may be due to wide use of broad-spectrum antibiotics.

Granulomatous infections of the spine, tuberculosis being the most common, readily infect the vertebral bodies and discs, with more than 50% of tuberculosis infections of bone occurring in the spine. The onset is insidious, with destruction of the vertebral bodies, discs, and ligaments if the disease progresses unchecked by medical and surgical treatment. As structural stability is destroyed, kyphosis combined with inflammatory debris and necrotic material can cause progressive paraplegia. Therefore, in the treatment of spinal infections, it is critical to make the diagnosis early so that antibiotic therapy or surgical debridement and fusion can be done before bony collapse and neurologic compromise occur.

## ETIOLOGY: HEMATOGENOUS SPREAD

Hematogenous inoculation provides the most common source of organisms for both discitis and vertebral osteomyelitis. Other etiologies include surgery, direct spread from a pulmonary abscess, penetrating trauma, and soft-tissue deficits, such as a decubitus ulcer. Batson (10) demonstrated venous return from the pelvis into the venous plexus of the vertebral column. He theorized that the paravertebral venous reservoir could allow continued venous return and mixing in the setting of changing abdominal and intrathoracic pressures. In his view, these interconnecting venous systems provided an explanation for the presence of vertebral metastases in the absence of lung metastases.

Wiley and Trueta (168) doubted the importance of Batson's venous plexus, demonstrating by injection studies an arterial system of nutrient vessels that supplies the vertebral bodies under physiologic arterial pressures. They found that the richly vascular metaphyseal bone near the anterior longitudinal ligament correlates with the most common site of infections.

Ratcliffe (126) emphasized metaphyseal cancellous infarction caused by a septic embolus. The vascular anatomy of the spine, which changes as a child matures, provides the most likely explanation for the differences in spinal infections in children and adults, as well as for the characteristic locations of infections in the vertebral unit. The interosseous arteries in children are anastomotic; therefore, occlusion of a single nutrient artery leads to destruction of only a small portion of bone because of collateral flow. In adults, a larger portion of bone is destroyed because the interosseous arteries are end arteries, and septic thrombus spreads into peripheral interosseous arteries. The disc is avascular and is attacked by infection equally in all ages.

A process related to vertebral osteomyelitis is spinal epidural abscess (Fig. 150.2). Hlavin et al. (68) reported an incidence of this infection of 1.9 per 10,000 admissions per year. Spinal epidural abscess tends to occur in an older, more medically debilitated population and to be monomicrobial, despite its frequent occurrence in a more medically complex environment. The most common organism is *S. aureus.* Epidural abscess may be due to direct seeding from invasive procedures, such as spinal anesthesia or epidural steroid injection, may form adjacent to an area of osteomyelitis, or, less commonly, may occur from spontaneous hematogenous spread (2,27,107). The distribution of this infection parallels the distribution of vertebral osteomyelitis: It is more common in the lumbar spine and less common in the thoracic and cervical segments (41).

***Figure 150.2.*** Epidural abscess formation occurs in about 15% of vertebral infections. MRI shows an epidural abscess compressing the thecal sac. **A:** Lateral view. **B:** Transverse section.

While there are case reports of spinal infection following abdominal stab wounds and, rarely, gunshot wounds, the National Spinal Cord Injury Model System reported no cases of spinal infection in a series of 90 patients, despite a 20% incidence of alimentary perforation (64,65,118,164).

## RISK FACTORS

Risk factors for spinal osteomyelitis include diabetes mellitus; chronic steroid use; drug and alcohol abuse; rheumatoid arthritis; urinary, respiratory, or abdominal sepsis; previous surgery; dental infection or extraction; urinary tract manipulation; and any type of spinal needle procedure: acupuncture, spinal anesthesia, epidural catheters, or steroid injections (10,22,27,63,103,112,118,124,145,148,165,166). Increasing age may be an independent risk factor, with the increasing incidence of gram-negative or anaerobic infections in elderly patients, often in the absence of any concomitant risk factors (23).

Malnutrition, urban overcrowding, and immunocompromising disease are prominent risk factors for granulomatous infection. Tuberculosis is found most commonly in underdeveloped nations. Big cities in Western countries still have cases of tuberculosis in higher risk patients such as the homeless, immigrants, alcoholics, and other immunocompromised individuals such as those with human immunodeficiency virus infection (97). Other granulomatous infections have geographic risk factors, such as coccidioidomycosis in the San Joaquin Valley of California or histoplasmosis in the central United States.

## PATHOPHYSIOLOGY: TUBERCULOSIS OF THE SPINE (POTT'S DISEASE)

Like any other osteoarticular tubercular lesion, spinal tuberculosis is the result of hematogenous dissemination from a primary infected visceral focus. The primary focus can be active or quiescent, apparent or obscure, and located in the lung, lymphatic system, kidney, or other viscus. In a typical lesion, the tuberculous bacilli find their way to the paradiscal area of two contiguous vertebrae, which supports the concept that the spread is via the arterial blood supply. Anterior extension of the lesion, with involvement of multiple vertebral bodies, is caused by extension of the abscess beneath the periosteum and anterior longitudinal ligament. The anterior and posterior longitudinal ligaments and periosteum are stripped from the vertebral bodies, which results in loss of periosteal blood supply and destruction of the anterolateral surfaces of several contiguous vertebrae.

Vertebral destruction takes place by bone lysis. Periosteal stripping combined with arterial occlusion due to endarteritis causes ischemic infarction leading in turn to necrosis of the involved bone. The body of the vertebra is thus softened and yields to compressive forces. The intervertebral disc is not involved primarily because it is avascular. However, involvement of the paradiscal regions of the vertebra compromises disc nutrition. A disc may then be invaded by the infectious process and destroyed. Radiographically, it is typical to see more than one vertebra involved (average, 3.4 vertebrae) (71). The most common finding is narrowing of the disc space and vertebral osteolysis. In more advanced disease, a paravertebral shadow is produced by extension of the tuberculous granulation tissue and formation of an abscess in the paravertebral region (Fig. 150.3); later, vertebral collapse and angulation of the spine occur.



***Figure 150.3.*** **A,B:** This patient with osteomyelitis has complete loss of the disc space with partial destruction of the contiguous vertebral bodies. The lateral x-ray (**B**) shows kyphotic angulation of L-4 in relation to L-5. This 70-year-old woman was having severe pain and muscle spasm. The physical examination revealed loss of L-5 nerve root function on the right. **C:** The patient elected nonoperative care. After a needle biopsy revealed the causative organism, she was treated with antibiotics and a body jacket. At 4 months, a tomogram of the involved level shows osteophyte formation that is starting to bridge the disc space. **D:** A lateral x-ray taken at 4 months reveals correction of the kyphotic angulation. After 2 months of bed rest, a body jacket was applied and molded in hyperextension. **E,F:** Radiographs taken after 1 year show fusion of L-4 to L-5. She returned to work as a farm wife, pain free and with resolution of the foot drop due to the L-5 root lesion. This patient shows that nonoperative treatment can be successful.

## DIAGNOSIS

The workup for suspected vertebral infection includes a history and physical examination, a complete blood cell count and erythrocyte sedimentation rate (ESR), venous blood cultures if temperature spikes are noted, nuclear medicine imaging (technetium Tc 99m or gallium Ga 65), plain radiographs, and magnetic resonance imaging (MRI) if symptoms are present for more than 1 month. Computed tomography (CT) may be useful for delineating bony destruction and can be used to guide needle biopsy. Lateral tomograms may also be indicated for preoperative evaluation, particularly to delineate bony destruction in the thoracic spine.

### HISTORY AND PHYSICAL EXAMINATION

A significant delay of weeks to months is common in the diagnosis of vertebral osteomyelitis (46,163). This delay may be due to a lack of any distinctive early physical or radiographic findings or to a failure to look for spinal infection. Dramatic regional pain that is worsened by motion or compression is the most common symptom. The pain persists despite bed rest and is classically exacerbated with motion. Pain, particularly at night, may not be relieved with analgesics. Fever is not a consistent finding. Anorexia and weight loss have been noted, and although the presentation may be acute, the most typical presentation is subacute or chronic. Chills, night

sweats, hemoptysis, or chronic bronchial cough are also suggestive of infection.

On physical examination, the most common finding is severe paraspinal muscle spasm associated with marked tenderness to palpation. A pseudoscoliosis due to spasm may be present. Loss of spinal motion is typical. Patients tend to splint and guard in an attempt to decrease pain; they may be unwilling to bear weight, particularly children. There may also be a mass and a concomitant deformity visible in the area of infection. Neurologic findings may vary from meningeal signs to mild weakness and, finally, paraplegia. One of the earliest findings of spinal cord involvement from tuberculosis is sustained clonus in the ankle.

**LABORATORY DATA**

The most consistent laboratory finding in the diagnosis of vertebral osteomyelitis is an elevated ESR, usually greater than 40 mm/h (Westergren method). However, Schofferman et al. (135) reported normal values for the ESR in seven of nine patients with occult infections by indolent organisms, such as diphtheroid or coagulase-negative staphylococci. Serial ESR readings are valuable for following a patient's response to intravenous antibiotic therapy (121). C-reactive protein (CRP) is an acute-phase protein synthesized by hepatocytes. An elevated CRP level is seen in various conditions, including infection, inflammation, and malignancy, as a response to tissue injury. Healthy individuals show only trace amounts of CRP. CRP levels rise after surgery but also drop quickly thereafter. An elevated CRP is more helpful for determining postoperative infection during the immediate postoperative period because the ESR can remain elevated at that time (96,151).

The peripheral white blood cell (WBC) count is unreliable. In a series of 38 patients with documented spinal infection, the average WBC count was only slightly increased over the usual high-normal value of 10,000 cells/$mm^3$ (162).

Blood cultures are an important part of the workup of vertebral osteomyelitis, particularly if the blood culture is obtained during a febrile episode (47,123). Negative culture results are common, however. The tuberculin purified protein derivative (PPD) test is usually positive in patients with tuberculosis. Before administering a PPD test, do an anergy battery to detect immune compromise.

**ORGANISMS**

By far the most common organism encountered in vertebral osteomyelitis is *S. aureus.* There has been a relative increase in other organisms over the last few years, particularly gram-negative organisms (163). *Pseudomonas aeruginosa* infections are often seen in the setting of intravenous drug abuse, trauma, or immune compromise (19). *Staphylococcus epidermidis* and *Enterococcus* species have also been noted with increasing frequency in postoperative infections (43). At least 27 other organisms have been found to cause vertebral osteomyelitis (Table 150.1). The most common granulomatous infection is tuberculosis.

| |
|---|
| *Arcanobacterium haemolyticum* |
| *Clostridium perfringens* |
| *Corynebacterium xerosis* |
| *Eikenella corrodens* |
| *Haemophilus aphrophilus* |
| *Haemophilus influenzae* |
| *Kingella kingae* |
| Microorganism group Ve-1 |
| *Neisseria sicca* |
| *Pasteurella multocida* |
| *Peptostreptococcus* spp. |
| *Propionibacterium* spp. |
| *Pseudomonas cepacia* |
| *Salmonella* spp. |
| *Salmonella virchow* |
| *Serratia marcescens* |
| *Staphylococcus warneri* |
| *Streptococcus agalactiae* |
| *S. bovis* |
| *S. milleri* |
| *S. mutans* |
| *S. pneumoniae* |
| *S. sanguis* |
| *S. viridans* |
| *Tsuglopis glabrata* |
| *Treponema pallidum* |
| *Yersinia enterocolitica* |

***Table 150.1. Unusual Organisms Causing Pyogenic Vertebral Osteomyelitis***

Immunocompromised patients may present with uncommon or exotic pathogens, and often with multiple organisms. Oral flora is commonly cultivated from intravenous drug abusers and patients with dental abscesses or extensive oral surgery. Resistant strains of bacteria are of particular concern in chronically ill or hospitalized patients.

**IMAGING STUDIES**

The radiographic findings in pyogenic vertebral osteomyelitis tend to differentiate it from tuberculous involvement of the spine, which classically shows relative sparing of the disc space. With pyogenic vertebral osteomyelitis, the earliest x-ray finding is usually disc-space narrowing, which is noted at about 2–3 weeks after the onset of infection. Disc-space narrowing is followed by endplate erosion, then by progressive vertebral body destruction (Fig. 150.3) (121).

The next roentgenographic change seen is vertebral endplate sclerosis, with increased density noted in the subchondral bone secondary to deposition of new bone on the existing trabeculae and new subperiosteal bone formation (162). This subchondral sclerosis may be preceded by a period of relative radiolucency at about 6 weeks postinfection. The process of increasing postinfection sclerosis will then proceed and can ultimately lead to spinal fusion at about 6 to 24 months.

In tuberculous vertebral osteomyelitis, plain radiographs may not reveal disc-space narrowing until 24–36 months after the onset of the disease process. There may be loss of vertebral density, but reactive new bone is rarely seen and fusion is rarely noted. With tuberculous vertebral infection, a common finding is a large paravertebral soft-tissue mass with calcifications, which is often noted on plain radiographs and CT. This is relatively pathognomonic for tuberculosis. Vertebral pyogenic osteomyelitis, as well as vertebral discitis, tends to be more common in the lumbar spine, less common in the thoracic spine, and least common in the cervical spine. In contrast, tubercular spondylitis is most common in the thoracic spine and at the thoracolumbar junction.

Lateral tomograms may be useful to highlight subtle plain radiographic findings. They can be particularly helpful in imaging the thoracic spine and cervicothoracic junction (Fig. 150.4).

***Figure 150.4.*** Lateral tomogram illustrates endplate destruction in this thoracic infection. Without special studies such as tomography, these lesions can be difficult to visualize.

Computed tomography also has an important role in diagnosis (1,95,161) and is particularly useful when used with myelography (Fig. 150.5) (18). However, in infected patients, myelography carries the risk of possible intrathecal spread of the infection. Bone density can be followed with CT and may give some clue as to whether the infection is progressing or resolving. Increasing bone density has been noted after successful treatment of vertebral body osteomyelitis with antibiotics (83).

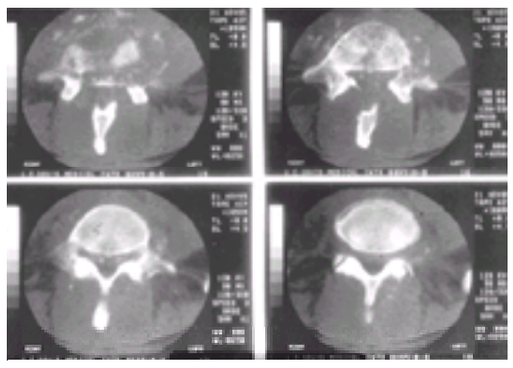

***Figure 150.5.*** CT of an L4-5 infection gives a better picture of the actual bony loss. The cut in the upper right hand corner shows virtually no anterior bony support; the spine is expected to be unstable. This is the same patient described in Figure 150.3. The vertebral angulation can be appreciated on the original lateral x-ray (Fig. 150.3*B*).

CT-guide needle biopsy allows accurate placement within the vertebral body and disc in both pediatric and adult patients (58,72,111). The yield of needle biopsy in producing infectious organisms, however, has been reported to be as low as 50% (6).

Technetium bone scintigraphy is positive in most patients with active vertebral osteomyelitis, but false-positive results have been reported, particularly in the elderly population (3,134). Gallium scan has also been used to image pyogenic vertebral osteomyelitis. Haase et al. (62) described a butterfly appearance of pyogenic vertebral osteomyelitis on gallium scan; the butterfly shape, reflecting soft-tissue uptake, appears on either side of the spine on an anteroposterior view. Bruschwein (21a), reporting on a review of 100 consecutive patients with spinal infections studied with gallium scanning, found a sensitivity of 89%, a specificity of 85%, and an accuracy of 86% (9). Indium-labeled leukocyte imaging of the spine has an accuracy of only 31% (167,174).

Modic et al. (114) reported a sensitivity of 96%, a specificity of 92%, and an accuracy of 94% for MRI in diagnosing spinal infections. In a study of 27 patients with pyogenic vertebral osteomyelitis, MRI accurately detected abnormalities in all patients; radiography did so only in 48%, CT in 65%, technetium bone scan in 71%, and gallium scan in 86%. The most consistent finding on MRI was increased signal intensity, particularly on T2-weighted images (Fig. 150.6).

***Figure 150.6.*** MRI provides a means for earlier diagnosis of vertebral osteomyelitis. This T2-weighted image shows increased signal uptake in the involved vertebral bodies. In addition, it yields information about the amount of soft-tissue and spinal cord involvement.

T1-weighted MR images show characteristic findings of disc-space narrowing, low signal intensity in the marrow of at least two adjacent vertebrae, subligamentous or epidural soft-tissue masses, and erosion of cortical bone (152). T2-weighted images demonstrate narrowed discs with variable signal changes, abnormal high signal intensity in the marrow of at least two adjacent vertebrae, high-signal subligamentous or epidural masses, and cortical bony erosion. MRI demonstrates disc sparing in patients with tuberculous spondylitis, as well as the extraosseous soft-tissue extensions.

Gadolinium enhancement of MRI is useful in distinguishing epidural abscesses from the adjacent compressed thecal sac, as well as identifying a paraspinal mass most likely to yield a positive percutaneous biopsy (125,142). Gadolinium contrast also helps distinguish active infection from an infection that has adequately responded to antibiotic therapy (125).

**BIOPSY**

If the diagnosis is still in question after the above examinations, the differential diagnosis will usually include infection, primary neoplasm, and metastatic involvement of the spine. Tissue from a biopsy is required to differentiate these entities. If the diagnosis is not in question but the causative organism has not been identified, aspiration or biopsy for culture is still required. For the cervical spine, we recommend an anterior approach with a formal operative exposure to avoid the high risk of inadvertently perforating neck structures with a biopsy needle if a percutaneous technique is used. Biopsy samples of the posterior cervical elements may be obtained percutaneously, although formal open exposure facilitates visualization. In the thoracic and lumbar spine, we recommend a posterior CT-guide needle biopsy technique. If additional tissue is required, a Craig needle biopsy can be performed under regional or general anesthesia (Fig. 150.7).

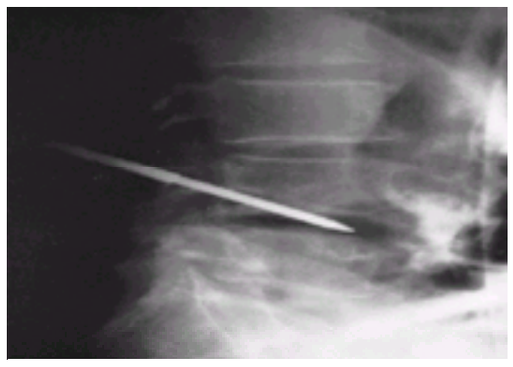

***Figure 150.7.*** A radiograph demonstrates a Craig needle in the L4-5 disc space. Usually, a needle of this size can be used percutaneously in the lumbar spine. In the cervical spine, open techniques are safer. In the thoracic spine, a CT-guided needle biopsy or an open procedure is safer.

Obviously, the chances of obtaining positive culture results are increased if a patient has not been treated with antibiotics before the biopsy. If a patient's condition permits, discontinue antibiotic therapy for 2 weeks and then proceed with biopsy and culture. Although the clinical presentation and the corroborating radiographic evidence and histology from a biopsy can confirm the presence of infection, culture results are required to prescribe a specific antibiotic regimen. Histology is adequate to diagnose tuberculosis and most fungal infections.

## DISEASE-SPECIFIC TREATMENT

### Pyogenic Infections

The treatment of most infections of the spine include intravenous antibiotics, rest, and spinal immobilization. In pediatric discitis, this is the treatment of choice. Generally, a regimen of 6 weeks of an intravenous antibiotic followed by 6 weeks of an oral antibiotic is suggested (Table 150.2). Some recommend continuing antibiotic treatment until 3 months after the ESR has returned to normal (163). This presumes that a patient is responding well to treatment and that the response is followed by monitoring the ESR weekly, WBC counts daily (initially) and then every third day, daily temperature reading, and complaints of pain. A Hickman catheter or other long-term indwelling intravenous catheter allows outpatient administration of intravenous antibiotics. We prefer to discontinue antibiotics when a patient is afebrile, pain has nearly resolved, and the ESR is normal. When back pain improves, we allow patients to ambulate in a custom-made thoracolumbar sacral orthosis or, occasionally, in an off-the-shelf brace.

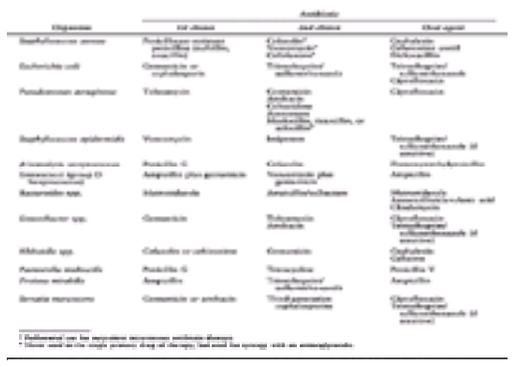

***Table 150.2. Intravenous Antibiotics of Choice for Some of the More Common Organisms Causing Pyogenic Infections of the Spine***

#### *Indications for Surgery*

If 2–3 weeks of immobilization and an intravenous antibiotic produce no abatement of fever or decrease in the ESR or WBC count, then consider a thorough anterior debridement and strut grafting (Fig. 150.8). Other indications for surgical intervention include the following:

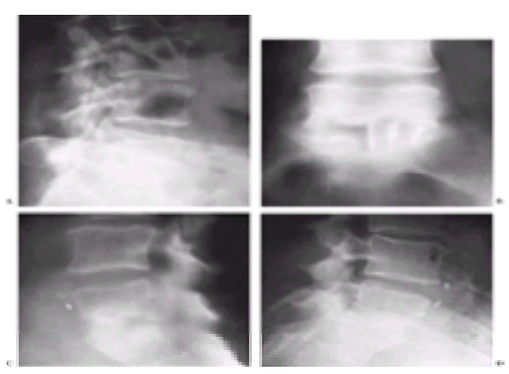

***Figure 150.8.*** **A:** Lateral radiograph shows disc-space narrowing of L5-S1 due to *Escherichia coli* infection. Antibiotics failed to lower the ESR, and the patient continued to have pain. Anteroposterior (**B**) and lateral (**C**) radiographs show the site after surgical debridement and strut grafting. Two bicortical iliac grafts fill the debrided area of the vertebral bodies. **D:** One year after surgery, the L5–S1 disc space is fused. The patient has no back pain symptoms.

Large abscess, for which an intravenous antibiotic is usually ineffective

Neurologic compromise, particularly if it is progressive

Progressive kyphosis with osseous involvement

Failure to obtain bacterial cultures by needle biopsy

Neurologic deficits from mechanical failure of the anterior column, which results in kyphosis, are best treated by anterior debridement and mechanical reconstruction with strut grafting (26,46,48,100,105,110). Although several bones may be used for strut grafting, including rib and fibula, tricortical iliac crest autograft is preferred. The cortical portion provides immediate stability, and early union is enhanced by the cancellous component. Before debridement, we recommend a 2-week course of an intravenous antibiotic, if possible, to decrease purulence and surrounding inflammation (153).

Laminectomy for the treatment of spinal infection has been condemned because of its resultant complications (86). The infection decreases the mechanical strength of the anterior and middle bony columns. A laminectomy then destabilizes the remaining (bony–ligamentous) posterior column, adding to instability and increasing the potential for progressive kyphosis. Laminectomy may be appropriate in treating an isolated epidural abscess (29). In this setting, early aggressive laminectomy may be the treatment of choice, permitting decompression and evacuation of the epidural abscess, in conjunction with appropriate antibiotic therapy (68,130).

Several investigators have reported successful anterior bone grafting in the face of infection (26,48,105,110). Safran et al. (131) reported good success with combined same-day simultaneous and sequential anterior decompression and posterior spinal instrumentation. In addition, Hopf et al. (74) recommended anterior debridement and anterior instrumentation as a single-stage procedure. Rath et al. (127) demonstrated success with posterolateral debridement of the infection and posterior instrumentation and autograft, which represents an alternative way to treat osteomyelitis and disc-space infection. Percutaneous drainage combined with percutaneous placement of pedicle screws for an external fixator has also been used by Jeanneret and Mageral (78). Fusion with bone grafting and instrumentation should be added if a large laminectomy involving multiple segments is performed. This is especially true in children, in whom spinal growth will lead to a progressive kyphotic deformity if fusion is not performed.

#### *Conclusion*

Bone grafting and instrumentation in the face of infection is usually successful when performed under the coverage of intravenous antibiotics. The decision to proceed with this major surgery in the face of infection is based on what is best for a patient in the context of a surgeon's abilities and available support services. Anterior debridement and strut grafting followed by posterior instrumentation and grafting work best in our hands and others (59). If one or more vertebral bodies are to be resected to gain adequate anterior decompression and strut grafting, we recommend subsequent posterior stabilization with instrumentation to provide immediate mechanical stability and protection for the neural elements. A spanning segmented instrumentation construct is appropriate (Fig. 150.9).

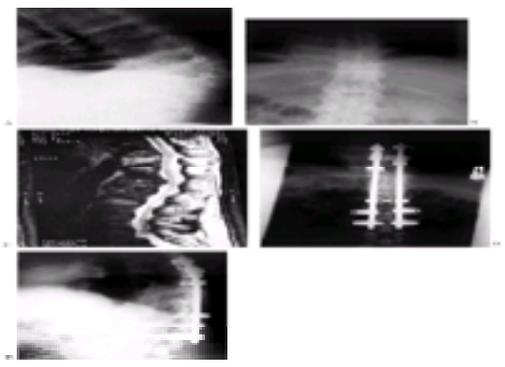

***Figure 150.9.*** A 52-year-old white man had a history of weight loss, fevers, chills, and progressive loss of lower extremity function over 8 months. He presented to the emergency department with weakness in both lower extremities. He had an obvious kyphotic deformity with pain at the apex of the kyphosis as seen on lateral (**A**) and AP (**B**) radiographs, and MRI (**C**). Anterior debridement of T-10 and T-11 vertebral bodies was performed, with subsequent anterior strut grafting with autogenous iliac crest bone graft. Posterior segmental instrumentation and fusion were performed the same day as seen on AP(**D**) and lateral (**E**) radiographs. Intraoperative cultures revealed *S. aureus,* and the patient underwent long-term intravenous antibiotic treatment. He recovered and walked without any assistive devices.

## GRANULOMATOUS INFECTIONS

### *Historical Background*

In the past, tuberculosis was treated by rest, by encouraging patients to spend time in the fresh air, and by relying on patients' natural recuperative powers (67,80). Abscesses were drained when necessary, and the vertebral column was debrided if the patient became paraplegic. In 1895, Menard (113) decompressed an abscess surrounding the spinal cord and was delighted to find that the patient recovered neurologically. This led him and other surgeons to decompress the spinal cord through a variety of posterolateral and anterolateral approaches (17,139). The combination of rest, fusion, and debridement allowed the paraspinal abscesses to regress spontaneously (81). Some patients, however, demonstrated progressive bony destruction, paralysis, and spread of the disease.

Antituberculous drugs changed the surgical approach to spinal tuberculosis. With drugs as the only treatment, patients could be cured not only of active disease but also of paralysis (170). Operative treatment was reserved for failure of drug therapy, recrudescence of disease, Pott's paraplegia that did not resolve after 4–6 weeks of treatment, progressive or worsening paraplegia, or the development of spinal cord involvement or other complications. In 94% of patients without neurologic compromise, clinical healing of the lesion occurred without surgery (154). However, with neurologic involvement, only 38% recovered completely with drug treatment alone, while 69% had complete recovery after surgical decompression.

Martin (109) studied the results of treatment before and after the development of antituberculous drugs and with and without surgical fusion. Of 227 adult patients treated without antibiotics or surgery, bony ankylosis occurred within an average of 5.7 years. Children treated without antibiotics or surgery took even longer to stabilize, requiring on average 9 years to bony ankylosis. Patients treated nonoperatively with antibiotics experienced fusion in 4.9 years. Martin's impression was that antibiotics and surgical fusion produced a more stable spine within a shorter time; he reported a 96.2% fusion rate.

In a later study of patients with Pott's paraplegia (120 of the 740 patients in his total series), Martin (108) found that antibiotics improved patients' general condition and made the surgery safer. It did not, in his opinion, prevent paraplegia or promote recovery from it. He found that 24 (48%) of 50 patients recovered with antibiotics alone, while 60% of patients who underwent surgical decompression recovered. He suggested that an early surgery might prevent or abort the onset of paralysis.

Guirguis (60) reported on 60 patients with Pott's paraplegia, one half of whom were operated on and the other one half treated conservatively. He found better results in the surgically treated patients, with 28 (93%) of 30 patients showing improvement and many being completely cured of any neurologic compromise. Many patients were relieved of their painful flexor spasms.

Neville and Davis (119) also studied patients treated with or without surgery, with emphasis on the fusion rate. In the nonsurgical group, 50% had autofusion at an average of 15.2 months. The surgical group had a fusion rate of 92%.

Arct (7) found that patients older than 60 years of age in Poland could tolerate and benefit from surgical fusion. Of 133 patients, 61 had conservative treatment, while 72 underwent surgical decompression with or without fusion. Only 13 of the conservatively treated patients returned to their regular lifestyle; none could return to work as a farmer or laborer. Of the surgically treated patients, 41 (57%) of 72 had complete clinical and radiographic recovery; 21 patients returned to agricultural work.

In summary, the medical treatment of tuberculosis has been highly effective in controlling bony tuberculosis and even curing it. The newer drugs have been more effective in preventing recurrence of disease due to resistant organisms. However, for at least the first 6 months of chemotherapy, further bony destruction and collapse may occur, causing increased vertebral angulation and cord compression. This is particularly true if a significant amount of kyphotic angulation is already present when drug therapy is started. Without chemotherapy, there will be progressive thinning of the intervertebral space, atrophy of osseous tissue, and decalcification, which can persist for an average of 2–3 years (61). In properly selected patients, medical treatment is adequate and can be expected to yield a relatively high rate (up to 79% in one series) of solid bony fusion (88).

### *Current Medical Recommendations*

Current therapeutic regimen recommended for treating acute tuberculosis of the spine includes the following:

Rifampin: adults, 600 mg daily in a single oral dose 1 hour before or 2 hours after a meal; children, 10–20 mg/kg per day (not to exceed 600 mg)

Isoniazid: adults, 5 mg/kg orally (up to 300 mg per day) in a single dose

Ethambutol: adults only, 15 mg/kg orally in a single dose

Pyrazinamide: 20 mg/kg

Rifampin, isoniazid, and pyrazinamide are each given for 12 months. A four-drug regimen for 12 months or a three-drug regimen for 18 months is appropriate for eradicating difficult infections (115). Initiate antibiotics at least 2 weeks before surgery and, if possible, continue them postoperatively. In cases of acute paraplegia requiring emergency decompression, begin antibiotics before spinal surgery.

### *Surgical Management*

Although antibiotics can medically treat Pott's disease, most orthopaedic surgeons continue to favor surgical debridement. Hodgson et al. (71) proposed that debridement be done as soon as possible after the diagnosis is established for the following reasons:

In the early stages of the disease, extirpation of the infected focus is easier, and fusion without deformity is possible.

Secondary deformities occur as the disease progresses, impairing the patient's cardiopulmonary function.

The patient's general condition improves markedly after evacuation of the abscess.

The patient requires less extended hospitalization and can return to work earlier, often within 4–6 months.

Late recurrence of the disease is less common.

Rapid progression of the abscess along the spine is prevented.

Surgical exploration of the tuberculous lesion is the only way to ensure that the disease is indeed active or healed.

Hodgson et al. (69) also confirmed that tuberculosis can penetrate the covering of the spinal cord (dura), causing irreversible paraplegia; therefore, they felt an urgent need for surgical drainage to prevent this complication. In their hands, early anterior debridement and fusion of the spine resulted in 4% mortality, but the fusion rate was 93% and 26 of 35 patients with paraplegia recovered complete function. There was a close correlation between the duration of neurologic symptoms before operation and the time required to recover from paraplegia (69). In tuberculosis, bone grafting is safe, even in the presence of drainage (4,5).

While anterior decompression and fusion of the spinal column is reliable and effective in treating neurologically compromised patients, posterior laminectomy is not effective and may lead to neurologic deterioration (15). Infectious destruction is usually anterior, causing the involved vertebral body to collapse and angulate into kyphosis. Laminectomy destabilizes the spine further and aggravates this progression into kyphosis. Hence, there is no question as to the superiority of the anterior approach (8,45).

In children, Bailey et al. (8) noted that anterior tuberculous disease was almost always more widespread than demonstrated on radiographs. Even late decompression, when symptoms have been present for an extended period, can produce neurologic recovery. Bone grafting leads to an acceptable risk of fusion in both children and adults (4,79,85).

In the immature spine, there may be progressive kyphosis despite a solid fusion (50), as continuing growth in the posterior spine may create further deformity (79). Schulitz et al. (138) studied anterior fusion, anterior debridement, and combined anterior and posterior fusion in children followed for at least 10 years. Anterior fusion alone had the worst prognosis in terms of progression of kyphosis. Combined anterior and posterior fusion decreased the incidence of kyphosis. On the other hand, Upadhyay et al. (156,157,158,159 and 160) showed that a short anterior spinal arthrodesis done at a early age was not associated with progression of deformity during growth and development from disproportionate posterior spinal growth. Therefore, they did not recommend a posterior fusion to stop posterior growth. They also reported that patients who had reduction of kyphosis at the time of the fusion showed a difference only at the sixth month of follow-up, compared with patients who had only debridement. At final follow-up, however, they found no difference in kyphosis between the groups and stressed the importance of achieving complete reduction and fusion to prevent kyphosis. In summary, our preferred approach to the treatment of children is a combined anterior and posterior fusion when multiple levels of radical debridement are required; we use the anterior approach only when only a short fusion is necessary.

In a long-term controlled trial comparing radical debridement and anterior fusion, simple debridement, and medical treatment alone, the Medical Research Council showed radical debridement and fusion to be superior in the following ways (31,32,50,150):

Anterior bony fusion occurs earlier and in a higher percentage of patients (70% versus 20% and 26% at 5-year follow-up).

Kyphotic angulation was less common at 5 years.

At 10 years, kyphotic angulation increased further in the simple-debridement group, whereas it actually decreased in the radical-debridement and fusion group.

Others have agreed with this philosophy, although none has had the experience or stated the case so eloquently as the group from Hong Kong (25,51,70,71,79,85,89,90,144,147,169,175,176). While the surgery is technically demanding and risky, the alternative seems to be worse. Yau and Hodgson (175) reported on the penetration of the lung by vertebral abscesses and on irreversible paraplegia from tuberculous infection passing through the dura and directly involving the spinal cord (61,69).

The bony destruction, collapse, and angulation that can occur while under medical treatment are undesirable and preventable (91). Adding internal fixation to the treatment of tuberculosis of the spine diminishes the incidence of kyphosis and pain, reduces the incidence of bedsores, pulmonary infections, and recurrence rates and shortens hospital stay (73). Moon et al. (116,117) described similar findings in which anterior debridement and posterior fixation provided early fusion, prevented progression of kyphosis, and achieved correction of kyphosis. Other authors have suggested using anterior instrumentation routinely at the time of debridement (74,93). Therefore, if proper facilities and expertise for surgical drainage and grafting of the infected vertebral column are available, surgical fusion and stabilization are indicated (14,25,28,57,87,101,116,129,160). Nonoperative treatment with antibiotics and orthotic support continues to be an option for patients without significant destruction and kyphosis (125).

Even though anterior instrumentation has successfully been used for pyogenic and granulomatous infections, we have not routinely used it. Anterior instrumentation may be used in these situations if immediate stability is needed or posterior instrumentation cannot be performed in a timely manner.

Even late cases with severe kyphotic deformity can be candidates for surgery. Spinal osteotomy, halo–pelvic distraction, and anterior and posterior surgery have been used to correct these deformities (176). Although the complication rate associated with halo–pelvic traction and the multiple surgical procedures was high, the average amount of correction was 28.3% in 30 patients; more important, further progression of the deformity was halted. Halo–pelvic traction is still a viable technique and sometimes safer than immediate correction with anterior and posterior osteotomies. In these cases, a modest correction of the spinal deformity balanced with prevention of further progression is the goal.

In the cervical spine, Lifeso (99) refined the staging of atlantoaxial tuberculosis, describing three stages with progressive bone destruction. In stage I, there is minimal bony destruction, and a transoral biopsy and decompression can be used to surgically treat the infection, followed by halo orthosis. In stage II, there is minimal bony destruction, but anterior displacement of C-1 and C-2 is present. For this, he advised transoral biopsy and decompression followed by reduction with a halo orthosis and a posterior surgical fusion of C1–2. In stage III, marked bony destruction with displacement of C-1 and C-2 occurs. For this stage, an anterior decompression is performed, followed by halo-traction reduction and posterior fusion from the occiput to C-2 or C-3. We endorse this step-by-step approach as a practical way to approach this difficult problem.

In the lower cervical spine, Hsu and Leong (75) found a high incidence of neurologic compromise and recommended anterior decompression and fusion in all cases of tuberculosis of the cervical spine (see Chapter 151). Other authors have reported similarly on lower cervical spine tuberculosis, noting a high incidence of neurologic compromise requiring surgical treatment with bone grafting and anterior plating combined with antibiotic treatment (102,104).

***Conclusion***

The major anatomic feature characteristic of all granulomatous diseases is destruction of the anterior column. This is the area that usually needs to be drained or, if weakened by bony destruction, supported by grafting. In most cases, posterior procedures are supplemental to the anterior operation. For Pott's paraplegia, the preferred procedure is anterolateral decompression. Arthrodesis of the spine is usually necessary to support the weakened anterior column. Strut grafting is difficult through a costotransversectomy, so anterolateral decompression, debridement, and fusion are best accomplished through this approach. Posterior decompression further weakens the spinal column and can cause further collapse and neurologic deterioration (106). We prefer anterior decompression and strut grafting followed by a posterior stabilization procedure (Fig. 150.10). We debride infected and weakened bone and reconstruct the anterior column with rigid bone strut grafting, which we then augment by posterior instrumentation using a neutralization construct and fusion.

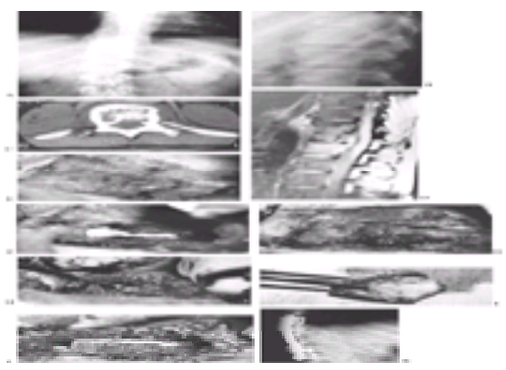

***Figure 150.10.*** Anteroposterior (**A**) and lateral (**B**) radiographs from a 30-year-old baker who had back pain after stepping into a hole. He had an ESR of 120 mm/h, a positive PPD with 10 mm of induration, and a negative coccidioidin titer. The lateral film demonstrates loss of height of the T-11 body and endplate destruction. **C:** CT demonstrates destruction of the vertebral body with extension posteriorly into the neural canal. **D:** MRI reveals the amount of vertebral destruction and compression of the spinal cord. Because of the amount of vertebral body involvement, it was elected to debride and strut-graft this lesion anteriorly and to fuse and stabilize the spine with instrumentation posteriorly. **E:** An anterolateral thoracic approach through the tenth rib was used to expose the T-11 vertebra. This photograph demonstrates the abscess over the vertebral body expanding the parietal pleura. The aorta lies just anterior to the spinal column. **F:** The abscess is incised along the posterolateral border of the spinal column parallel to it. Gross purulence exudes from the incision. **G:** A second incision is made perpendicular to the first from posterior to anterior, forming a T, and the corners can be elevated off the vertebral body and anchored anteriorly with skip sutures. Later, these flaps can then be used as closure over the grafted area. The segmental vessels to the vertebral bodies have been ligated. **H:** The necrotic bone and abscess material are removed by curettage or drilling with a high-speed burr. The involved bone, disc, and other debris are removed until good bleeding bone is located at each end of the lesion. If decompression of the spinal cord or cauda equina is needed, it is done at this time. The amount of material removed can be impressive. **I:** Bicortical bone can be removed from the ilium. This should be done with a separate draping and surgical setup so as not to contaminate the graft site. The graft is measured before it is cut to ensure an adequate length to strut the defect. **J:** The strut is impacted into the defect created by the debridement. The table, which had previously been flexed to provide access to the chest, is now straightened, locking the graft in place. If an acute kyphosis is present, additional strut grafts may be needed to bridge it completely. These are placed more anteriorly and should also be implanted into the bony portion of the vertebra. **K:** A postoperative lateral radiograph shows the iliac strut graft to span the infected level extending into the vertebrae above and below. Cotrel-Dubousset instrumentation extends an additional level above and below the T-11 vertebra. A posterior fusion supplements this instrumentation. The patient was ambulatory and taking tuberculosis medication when he left the hospital 2 weeks after the second surgery. He will continue his medication for 1 year after surgery.

### *Atypical Mycobacterial Infections*

Atypical mycobacterial disease usually occurs in the extremities, but cases of spinal involvement have been reported. Diagnosis depends on identification of acid-fast bacilli, as granuloma formation is not necessarily a feature of the disease (106,133,137). In the presence of a persistent inflammatory process, ask about a history of contact with shellfish and other sea life, gardening, or trauma. Surgical excision of the infected focus and antibiotic administration are the mainstays of therapy (54,133).

## FUNGAL INFECTIONS

### *Coccidioidomycosis*

Coccidioidomycosis is caused by *Coccidioides immitis,* the most infectious of all fungi capable of producing systemic disease. The localized form is usually benign, but the disseminated form is progressive and potentially lethal. Of those with disseminated disease, 20% have osseous lesions. The fungus is endemic to the southwestern United States, Central America, and parts of South America. It is particularly prevalent in central California, where it carries the name San Joaquin Valley fever (171). Although the disease occurs in all ages, it is most prevalent in individuals 25–55 years of age, and dissemination is greater in men. Disseminated disease is 10 times more common in blacks than whites and is of even greater hazard to Filipinos (171).

The organisms enter the body via the respiratory tract and are spread hematogenously. If respiratory symptoms and fever develop in a patient in an endemic region and last longer than 1 month, disseminated disease should be suspected. In an endemic area, 50% to 84% of the population will have a positive coccidioidin skin test. It takes 3–6 weeks for an exposed patient to test positive. Because of anergy, the test is unreliable when systemic disease is present. A serologic complement fixation titer of 1:64 or higher is thought to be diagnostic of disseminated disease (154).

Most bone lesions are lytic in nature and indiscriminately involve the vertebrae and other bony elements of the spine (Fig. 150.11). Often, multiple spinal lesions are found. Although the discs are spared, paraspinal masses are seen with contiguous rib involvement (35). Treatment with amphotericin B or fluconazole (Diflucan) is recommended (39,133). Indications for surgical procedures are similar to those recommended for tuberculosis.

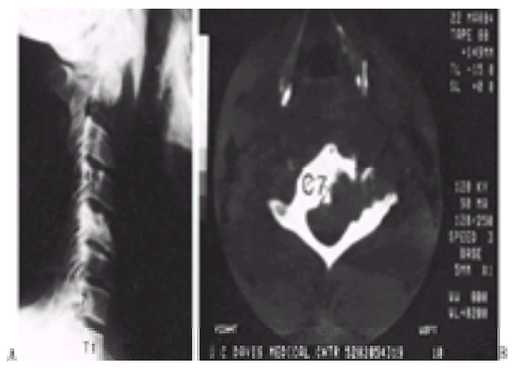


***Figure 150.11.*** Coccidioidomycosis can occur anywhere in the spine. In this case, the body and left lateral mass of the C-7 vertebra are destroyed. It is not as clearly seen on the lateral radiograph (**A**), but CT reveals the amount of vertebral destruction (**B**). During anterior debridement and strut grafting, the vertebral artery was identified. This 40-year-old man preoperatively received large amounts of amphotericin b with little effect on the bone disease.

### *Blastomycosis*

Blastomycosis (North American) is caused by *Blastomyces dermatitidis,* a fungus causing chronic systemic infection that is respiratory in origin but capable of dissemination. It is endemic in the southeastern and midwestern United States. Men are affected nine times more often than women; all ages may be affected, although there is a higher frequency in the third and fourth decades.

The disease usually begins as a mild respiratory infection, but as it disseminates hematogenously, generalized symptoms of fever, night sweats, anorexia, and weight loss develop. Skin tests are often negative early in the disease, but a culture of the skin or lesion will reveal budding yeast cells. Serologic tests may show a high titer only to *Histoplasma capsulatum.*

Osteomyelitis is common in disseminated blastomycosis, and it has a greater tendency than coccidioidomycosis for fistula formation and erosion into joints. The disc cartilage is usually involved early, and large paravertebral masses involving ribs may be seen. Hilar adenopathy may be noted on the chest radiograph, as in tuberculosis (56). Treatment for blastomycosis is oral ketoconazole (Nizoral) or itraconazole (Sporanox), but amphotericin B may be needed in immunocompromised patients. Indications for surgery and the procedures are similar to those for tuberculosis.

### *Cryptococcosis*

Cryptococcosis, caused by *Cryptococcus neoformans,* is a chronic systemic fungal disease originating in the respiratory tract. It may affect all ages, but is most prevalent between 40 and 60 years of age and is twice as common in men. Cryptococcosis is commonly seen in patients with leukemia, Hodgkin's disease, or sarcoidosis in whom central nervous system findings develop. The pulmonary disease is rarely symptomatic. Spread is by the hematogenous route and often results in a cryptococcal meningitis, with 10% of disseminated cases involving bone. The bony lesions are heralded by pain, swelling, and progressive loss of spine motion (34).

Blood, spinal fluid culture, or cultures from bony lesions may reveal the organism. India ink capsule stain is helpful, especially in spinal fluid specimens. Cryptococcal antibodies may be measured, and some authors believe that their presence indicates a good prognosis. Radiographically, the findings are indistinguishable from coccidioidomycosis (34).

Similar to all the fungal diseases, cryptococcosis is treated medically with amphotericin B or fluconazole plus flucytosine (Ancobon) (79). Guidelines for surgery are

similar to those for tuberculosis.

### *Brucellosis*

Brucellosis is a systemic infectious disease caused by small, nonmotile, non-spore-forming, gram-negative rods of the genus *Brucella.* Farm animals are primary sources of infection, but many other animals may harbor the bacteria (172). Human infection occurs primarily from ingestion of improperly prepared animal tissues or products or from skin wound contamination from infected animal tissues. Infection via inoculation of the conjunctiva has been demonstrated, and there is some evidence that inhalation of aerosols containing bacteria can lead to the disease (11,12).

Brucellar infections are often asymptomatic. Initial infection leads to immunity in about 90% of cases (12,172). Men are affected more often than women, probably because of a higher rate of occupational exposure. Initial symptoms may include fever, sweats, weakness, weight loss, headache, myalgia, lymphadenopathy, and hepatosplenomegaly. Late complications are multisystemic and may include septic arthritis, central nervous system involvement, osteomyelitis, and spine involvement (172). Of patients with spinal involvement, about 12% will have spinal cord compromise.

Brucellae can be cultured from the blood during a bacteremic episode and from involved lymph nodes or granulomas later in the course of the disease. The organisms are dangerous to laboratory personnel, and any suspected materials should be clearly identified (172). The *Brucella* agglutination test is quite reliable, and about 97% of infected patients will become positive within 3 weeks of exposure. Brucellosis is a reportable disease.

Radiographic changes to the spine occur relatively late in the course of the disease and are similar to but less severe than those seen in tuberculosis (11,172). A paravertebral abscess usually is not present, as in tuberculosis, and the spinal involvement usually is in the lumbar area (11,172).

The mainstay of treatment for brucellosis is antibiotic therapy, usually with doxycycline and rifampin, for at least 6 weeks. Surgical intervention is usually limited to a biopsy to obtain a tissue diagnosis. Occasionally, stabilization of the spine or decompression of the cord may be necessary. The indications and techniques are identical to those proposed for treatment of the tuberculous spine. Brucellosis is a completely curable infection. The primary pitfall is a delay in diagnosis of more than 1 month, which can lead to multisystem involvement with severe sequelae (11,12,172).

### *Aspergillosis*

Aspergillosis is a rare form of fungal spinal osteomyelitis (Fig. 150.12) (49,77,140,141,143). It is most common in immunosuppressed patients but has also been reported in cases of postoperative disc-space infection and after invasive monitoring (17,21,76,77,143,146). The radiographic appearance is not pathognomonic but is distinctive, generally demonstrating dense reactive new bone, a small lytic region, and the absence of sequestration. Histologic diagnosis is usually made with a potassium hydroxide preparation. Recommended treatment is amphotericin B alone or together with itraconazole; rifampin may be added (42,94). Surgery is recommended in accordance with the previously outlined guidelines for tuberculosis (40,88,133,136).

***Figure 150.12.*** Aspergillosis can infect the spine in immunocompromised patients, including those with acquired immunodeficiency syndrome (AIDS) or AIDS-related complex, intravenous drug abusers, or patients receiving cancer chemotherapy. This and other unusual organisms (e.g., *Candida*) are appearing with increasing frequency. This young man had aspergillosis that destroyed the T-2 and T-4 vertebral bodies with acute collapse and angulation. **A:** Tomography demonstrates the amount of destruction and angular deformity. **B:** Myelography reveals a blockage of the spinal cord canal created by granulation tissue and the deformity. The patient was paraplegic and required anterior debridement and posterior stabilization. There was complete recovery of neurologic function after anterior decompression.

### *Candidiasis*

Along with aspergillosis, candidal infections are becoming increasingly common, primarily in the settings of immune compromise or secondary overgrowth following antibiotic usage (44,52,55,67,82,120,146). Systemic candidiasis may be diagnosed with positive sputum, urine, or blood cultures. Medical treatment is amphotericin B or fluconazole, and surgery is indicated within the guidelines described for tuberculosis.

### *Actinomycosis*

Actinomycosis is often confused with fungal infection (33). However, the cause is an anaerobic, gram-positive, branching, filamentous bacterium. In actinomycosis, granulomatous suppurative lesions form and often develop sinus tracts, particularly in the head and neck region (79,136). The infection can be treated medically with penicillin (133). The need for surgery is determined in accordance with the previously delineated recommendations for spinal stabilization.

## POSTOPERATIVE SPINAL INFECTIONS

Infection after spinal surgery is a significant complication. Postoperative infection following disc penetration is most likely due to direct inoculation (37,38,122,177). Therefore, the routine use of prophylactic antibiotics is recommended whenever the intervertebral disc is entered (including procedures such as minor discography) or other spinal surgery is undertaken (122). Infection rates increase with the extent or complexity of spinal surgery. The lowest rates (0.7% to 0.8%) are reported with intervertebral disc surgery without fusion (37). For patients undergoing spine fusion without instrumentation, the rates range from 0.9% to 6%. The highest rates are reported with the use of spinal instrumentation (0.5% to 15%); the average is about 8% (149).

### *Postoperative Discitis*

Postoperative discitis has decreased with the use of microsurgical techniques, probably because of decreased soft-tissue injury (37). Patients with discitis will usually be pain-free for 1–2 weeks after surgery, and then progressively increasing low-back pain develops. This may be accompanied by temperature elevation, an increased ESR, elevated CRP and WBC counts, increasingly tender paravertebral musculature, increasing muscle spasm, and decreased lumbosacral range of motion. The neurologic status usually does not change from the immediate postoperative examination. Plain radiographs are rarely definitive in this period, but may demonstrate disc-space narrowing and evidence of endplate involvement by 2–3 weeks after the onset of infection. Nucleotide bone scan will be positive because of the surgery, and so are not useful in differentiating infection. If the presentation is delayed, MRI may demonstrate the characteristic findings of a spinal infection (Fig. 150.13). The definitive procedure for accurate diagnosis of postoperative discitis is CT-guide neddle biopsy followed by culture of the organism from the disc space (Fig. 150.14).

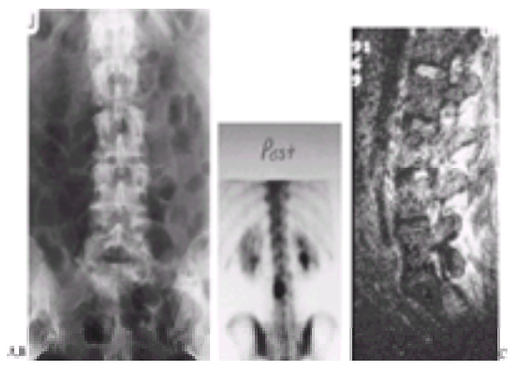


***Figure 150.13.*** **A:** Back pain and spasms developed in this patient 8 months after a percutaneous discectomy of the L3-4 disc. Percussion at the level of the discectomy produced severe, localized pain. The ESR was 120 mm/h. This anteroposterior radiograph shows only slight disc-space narrowing. **B:** Tc 99m bone scan demonstrates increased uptake at the level of the previous discectomy. This is much too intense to be due to postoperative changes. **C:** T2-weighted MRI shows increased signal uptake in the L3-4 disc space, indicative of infection. A Craig needle biopsy confirmed the diagnosis of disc-space infection; *S. aureus* was cultured. The patient recovered after 6 weeks of immobilization in a body jacket and intravenous antibiotic treatment.

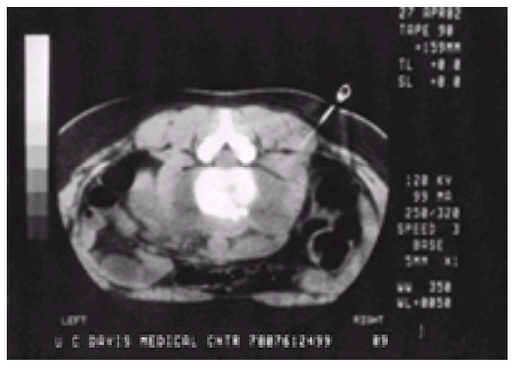

***Figure 150.14.*** CT shows a needle being directed into a paravertebral abscess surrounding an infected vertebra.

With the organism identified, an appropriate antibiotic can be given; most patients can be successfully treated with an intravenous antibiotic, bed rest or immobilization in a brace, and serial monitoring of the ESR and CRP level. We follow the guidelines for surgery discussed previously for primary infection of the disc space if medical treatment fails.

### *Postoperative Infections with Spinal Implants*

A multicenter study by Thalgott et al. (149) resulted in a classification of patients with spinal instrumentation and postoperative infections into three groups on the basis of a clinical staging system for adult osteomyelitis developed by Cierny. Group 1 patients had a single-organism infection, either superficial or deep; group 2 had multiple-organism deep infections; and group 3 had multiple organisms with myonecrosis. Host response was also ranked into three classes: Class A included patients with normal systemic defenses and normal metabolic capabilities and vascularity; class B patients demonstrated local or multiple systemic diseases, including cigarette smoking; and class C patients were immunocompromised or severely malnourished.

Group 1 patients could generally be treated with a single irrigation and debridement, and closure over suction drainage tubes without the use of inflow irrigation (43). Group 2 patients required an average of three irrigations and debridements and had a higher percentage of resolution of the infection when a closed inflow–outflow suction irrigation system was used (53). Group 3 patients were difficult to manage and tended to have a poor outcome. Patients with diminished host defenses (classes B and C) demonstrated an increased risk for postoperative wound infection.

Metallic implants were generally left in place for spinal stability during treatment. Bone graft, if loose, grossly infected, and surrounded by purulence, should be debrided; otherwise the bone graft can be left in place.

Delayed infections following posterior spinal instrumentation have been reported at an average of 25 months after surgery (128). It is not entirely clear whether this drainage and infection are due to primary inoculation with low-virulence organisms or prominence of implants causing formation of bursal sacs that become infected secondarily. *Propionibacterium* species, *S. epidermidis,* and *Micrococcus* species have been found to be the organisms most responsible for causing these late infections. Treatment requires removal of the implants, debridement, and intravenous antibiotics.

The most important aspect of treating postoperative infections is to be aggressive in irrigating and debriding such wounds, rather than treating them with antibiotics alone. Multiple debridements may be necessary to achieve formation of granulation tissue before primary closure can be performed. Wounds that have gross purulence or failed closure may be managed with dressing changes and healing by secondary intention. At times, latissimus dorsi or rotational flaps may be needed to obtain coverage. In our experience, suction–irrigation and multiple debridements have worked well in treating most infections postoperatively. Antibiotic beads placed at the time of each debridement have also shown promise in terms of adding a concentrated antibiotic locally to the infection.

## EPIDURAL ABSCESS

Epidural abscess is a potentially devastating condition. Patients complain of local pain, tenderness over the spine, generalized malaise, and fever. The symptoms may be highly variable in immunocompromised patients. Heusner (66) described four phases of neurologic involvement from epidural abscess. In early phases I and II, there is localized pain with the development of radicular pain and early neurologic changes, such as diminished reflexes. In phase III, progressive neurologic symptoms occur, including evidence of upper motor neuron impairment such as hyperflexia. Motor weakness may eventually develop, with impaired bowel and bladder function. Finally, in phase IV, complete paralysis develops. Epidural abscesses may occur from either metastatic seeding or direct extension (20,66). Spinal cord dysfunction is probably due to a combination of mechanical compression and anterior spinal artery thrombosis, which can cause ischemia and direct infection of the cord (20,66). Multiple reports have described many conditions that can lead to an epidural abscess, including intravenous drug abuse, lumbar puncture, and urinary tract and upper respiratory tract infections (9,13,36,92). Unfortunately, the diagnosis is frequently delayed (9). The ESR will be elevated, and blood cultures may be positive. MRI is the best tool for diagnosing epidural abscess. Radionuclide studies (technetium or gallium scan) may not be helpful.

Differential diagnosis includes metastatic disease to the epidural space and abscess in the subdural space, which is rare. Only 45% of the patients with an epidural abscess are infected by *S. aureus* (41). Gram-negative rods, anaerobes, mycobacteria, and fungi are responsible for the remaining 55%.

Treatment should be emergent. Start intravenous antibiotics immediately. A penicillinase-resistant penicillin or vancomycin will provide coverage for *S. aureus,* and an aminoglycoside for other suspected organisms, until the Gram stain and culture results are available (84). Posterior compressive lesions should be treated with surgical drainage by laminectomy, with maintenance of mechanical stability by preservation of the facets. The wound may be closed over drains or packed open in cases in which there is gross purulence. If an epidural abscess occurs anteriorly, particularly with a disc-space infection with extension into the epidural space, anterior debridement and decompression of the anterior epidural space are necessary.

Although management of epidural abscess with intravenous antibiotics alone without surgery has been reported, the risk of progression of neurologic compromise is high (16,30,98). The current treatment of choice for patients with cord compromise is surgical debridement and antibiotics. In patients without neurologic involvement who are poor surgical candidates, antibiotics may be used initially, with monitoring of neurologic status. Surgery may be necessary if significant neurologic findings develop.

## DRAINAGE AND DEBRIDEMENT OF SPINAL ABSCESSES

### LUMBAR SPINE

Abscesses secondary to tuberculosis or fungal disease may present as masses that can be palpated externally. Pyogenic abscesses rarely reach this extent without proving lethal. In the lumbar spine, an abscess will generally follow the course of the psoas muscle, although it can also appear as a paravertebral mass. An abscess that dissects along the psoas may extend below Poupart's ligament and present on the anteromedial surface of the thigh (adductor region) or in the gluteal region. Occasionally, an abscess will appear over the crest of the ilium in Petit's triangle.

#### *Paravertebral Abscess*

- To drain a paravertebral mass posteriorly, make an incision 4–8 cm lateral to the vertebral spinous processes in a line parallel to the spine.
- Use a Cobb elevator or even finger dissection to bluntly dissect around the erector spinae muscles until the transverse processes of the vertebrae are reached.
- Usually, the abscess is entered immediately. If not, puncture the thoracolumbar fascia that separates the quadratus lumborum muscle from the erector group.
- Locate the abscess by working under the transverse process, and then debride and drain it (173). Send purulent material and tissue for Gram stain, culture, sensitivities, and histology.
- After drainage, close the tissues in layers over a drain, or pack the wound open. This is determined by the local conditions and surgeon preference (71,85).

#### *Psoas Abscess*

**Posterior Approach** Psoas abscesses are extraperitoneal and can be drained posterolaterally through Petit's triangle or anteriorly beneath Poupart's ligament. Petit's triangle is bordered by the lateral margin of the latissimus dorsi muscle, the medial border of the external oblique abdominal muscle, and inferiorly by the crest of the ilium.

- Make an incision 2.5 cm above the crest of the ilium and parallel to it. Begin the incision lateral to the erector spinae muscle group.
- Bluntly dissect through the internal oblique abdominal muscle to gain access to the abscess cavity.
- The incision may be also made directly over the iliac crest, in which case detach the internal and external oblique abdominal muscles from the ilium and expose its inner surface.
- Palpate the abscess extraperitoneally, and then open and drain it.
- Manage the wound as described above.

**Anterior Approach**

- Make an incision from the anterosuperior iliac spine extending distally and medially for about 6 cm roughly parallel to the inguinal ligament.
- Identify the sartorius muscle, and carry the dissection medial to it to the level of the anteroinferior iliac spine. Protect the femoral nerve, artery, and vein, which lie just medial to this dissection.
- Identify the abscess on the medial surface of the wing of the ilium under Poupart's ligament (173). If the psoas abscess presents medially in the adductor region of the thigh, drain it through a Ludloff approach.
- For the Ludloff approach, make a longitudinal incision on the medial aspect of the thigh, starting 2–3 cm below the pubic tubercle. Develop the interval between the gracilis and adductor longus muscles.
- Develop a plane between the adductor longus and brevis muscles anteriorly and the gracilis and adductor magnus muscles posteriorly.
- Protect the posterior branch of the obturator nerve and the neurovascular bundle to the gracilis.
- The psoas muscle, attaching to the lesser trochanter, and the floor of the hip joint are located in the base of the wound.
- Drain the abscess through this wound (106).

### THORACIC SPINE

#### *Abscess Drainage via Costotransversectomy*

In the thoracic spine, abscesses are frequently drained through a costotransversectomy approach (Fig. 150.15).

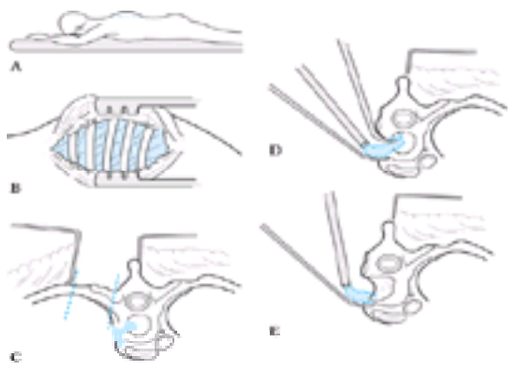

***Figure 150.15.*** **A:** Incision for a costotransversectomy (as described by Capner). With the patient in the prone position, make a curved incision 10 cm above the lesion, curving 7.5 cm laterally and ending 10 cm below. **B:** Reflect the skin and fascial layers medially as a flap. **C:** Remove a portion of the rib and transverse process of the vertebra over the abscess cavity. Expose the ribs and transverse processes of several vertebrae. **D:** The lateral surface of the abscess can be elevated free by working anterior and lateral to the vertebral body, usually without entering the pleural cavity. Curet and debride the abscess as well as possible. **E:** Decompression of the canal is possible if the pedicle and posterior surface of the vertebral body are removed. All debris is curetted and suctioned out of the cavity. It is difficult to insert a strut graft with this approach.

- Make a midline spinal incision extending over two or three spinous processes.
- Reflect the muscle and soft tissues away from the spinous processes and the vertebral laminae on the side of the abscess.
- Widely expose the middle transverse process, and resect it at its base.
- Reflect the periosteum from the contiguous rib, and resect the medial portion of the rib by dividing it 5 cm lateral to the tip of the transverse process. Do not enter the pleural cavity.
- Follow the rib medially, and enter the abscess by bluntly dissecting down the lateral side of the pedicle close to the vertebral body.
- Remove more than one transverse process and rib, if necessary, to completely debride the abscess.
- The neurovascular bundles between the ribs must be dissected free, ligated, and sacrificed (24).

Seddon (139) described a similar approach using a semicircular incision lateral to the spine that starts superior to the kyphotic deformity and ends inferior to it.

- Elevate the skin flap and muscles medially to expose the medial 8 cm of three or more ribs and their transverse processes.
- Subperiosteally resect the rib judged to be in the center of the abscess, being careful to stay outside the pleura.
- Remove at least 7 cm of the medial rib in an adult, freeing the medial end with a periosteal elevator.
- When the rib is teased free, pus should pour out of the gap created.
- Explore and debride the abscess cavity. Remove the necrotic material and any sequestered bone, and thoroughly irrigate the cavity.

#### *Debridement and Arthrodesis*

In addition to evacuating the necrotic debris of a granulomatous infection, many authors recommend immediate arthrodesis of the spine. This requires a more

extensive approach than for simple drainage. When neurologic compromise is present, the spinal cord or cauda equina may have to be decompressed by removing additional bone or soft tissue. This is usually the result of bony collapse with the development of an acute gibbus.

Anterior surgical approaches to the thoracic and lumbar spine are described in Chapter 138. The removal of diseased tissue is the same in all areas of the spine.

- Remove the debris, pus, sequestered bone, and disc, using curets and pituitary rongeurs. Some of this material can be removed with a large sucker tip.
- Remove the tissue across the entire breadth of the vertebral body.
- Remove diseased bone or areas where graft will be inserted, using double-action rongeurs, a drill, or an osteotome.
- Expose the spinal canal for the entire length of the diseased area, decompressing the neural elements. Granulation tissue, fibrous tissue, or the posterior longitudinal ligament may require sharp incision to expose the dura mater.
- Remove the disc at each end of the cavity to expose the endplates of the vertebrae above and below.
- Scrape the cartilage off the endplates, revealing bleeding cancellous bone.
- Place the strut graft into the endplates, keying the grafts into mortises made with a drill or curet to prevent dislodgement. The strut graft should correct the deformity as much as possible and hold the vertebrae apart.
- The strut grafts should be strong yet osteogenic in nature; autologous cortical or bicortical iliac crest graft is ideal, but the area to be grafted may be too large for the iliac grafts available. Longer struts can be obtained from the fibula or ribs. These should be supplemented with iliac bone because the fibula is strong but mostly cortical bone and the rib is osteogenic but relatively weak and will fail if stressed.
- The best source of bone is the patient's own ilium, but cadaver bank bone is a good second alternative, especially when a long segment of bone is needed.
- In the thoracic and lumbar spine, we usually supplement anterior struts with a second-stage posterior instrumentation and fusion. With this technique, there is less chance of graft dislodgement anteriorly. Anterior instrumentation may also be used successfully if immediate stability is needed and posterior fixation cannot be done in a timely manner.

**Anterior Decompression and Fusion**

*Thoracic Spine, C7 to T4*

- Place the patient in a left lateral position on a regular operating table with the right shoulder flexed to 120° and placed on an arm rest.
- Stand on the spinal side of the patient, tilting the table toward you to afford better visualization.
- Approach the upper thoracic spine through a right thoracotomy, using the bed of the third rib. If significant kyphosis is present, a costotransversectomy might be better.
  - Make a curved incision around the medial and inferior aspects of the scapula. After dividing the parascapular muscles, retract the scapula forward and upward.
  - Excise the third rib, and enter the pleural cavity through its bed. To improve visualization, cut the insertion of the scalenus posterior muscle and remove the second rib. The level is decided by following the rib head into the vertebral body. The third rib head articulates with the junction between the T-2 and T-3 vertebral bodies (71).

If more cervical vertebrae are involved, a sternum-splitting operation may be indicated. The procedure is an extension of the exposure for the cervicothoracic junction.

- Extend the incision in the midline down the sternum to the xiphoid process.
- Clear the anterior mediastinal tissues by blunt dissection behind the manubrium, working distally from the suprasternal notch. Work proximally from the xiphoid process in the same manner.
- Divide the sternum with an oscillating saw, and retract the two halves laterally. With this approach, the vessels and midline structures can be retracted more widely.
- Mobilize the recurrent laryngeal nerve so that it will lie obliquely across the operative field. Protect it during the procedure with a moist sponge to prevent paralysis of the vocal cords.
- Identify the vertebral artery behind the carotid sheath. The artery passes upward and laterally to enter the foramen in the C-6 vertebra.
- Approach the spine from the right because the innominate artery on that side takes off from the aorta at a lower level than the left subclavian vessels. In addition, the left innominate vein runs obliquely and distally to join the right innominate vein. The thoracic duct is also avoided.
- Anterior access to the distal cervical and proximal thoracic vertebrae is fairly good when the vessels are retracted.
- After decompression and any stabilization are complete, insert a suction drain, and close the sternum with stainless-steel wire or staples. If the pleura was opened, drain the chest with a large chest tube attached to underwater suction for at least 48 hours (85).

*Approach to Lower Thoracic Spine* The chest may be opened from either the left or the right side. In early disease without kyphosis, the right side is best because fewer important structures are present. In more severe or chronic disease when kyphosis is present, the left side is preferable because the vena cava or aorta can become incorporated in the abscess wall. The side of the larger abscess or lung penetration may also determine the side of approach.

- Use a bean bag to hold the patient in the lateral decubitus position, and flex the table at the level of the lesion to facilitate exposure.
- Make an incision along the rib to be excised. It should be two levels higher than the lesion. Additional ribs can be removed for better exposure. Divide muscle layers in line with the incision, and resect the rib subperiosteally.
- Enter the pleural cavity and divide the adhesions (if present), freeing the lung as completely as possible. If thick adhesions between the lung and the abscess are present, portions of the lung inevitably will be left adherent to the abscess cavity in order to mobilize the lung and gain exposure. Open the lung abscess, and remove any caseous material (60). Close the cavity with absorbable suture. A thoracic surgeon often performs this portion of the procedure.
- After the parietal pleura covering the abscess is exposed, mobilize the aorta so that an interval is developed between the two. Ligate and cut the segmental intercostal vessels traversing this segment. If severe kyphosis exists, the aorta will be acutely angulated and the segmentals bunched together at the apex of the curve. Take great care in developing the plane between the vertebral body and aorta: Adhesions can compromise the integrity of the aortic wall.
- After the aorta is mobilized and protected, open the abscess with a T-shaped incision. Make the transverse portion of the T on the anterior portion of the vertebral body parallel to the aorta. Retract the triangular flaps created by the T incision, and attach them by stay sutures to the muscles at the wound edges. Work from proximal and distal to the mid portion of the kyphosis, particularly if cord compression is present.
- Radically excise all bony sequestra, sequestered disc, granulation tissue, and avascular bone.
- The posterior longitudinal ligament forms the posterior limit of the abscess cavity and is just anterior to the spinal cord. Carefully, incise the ligament and remove it with pituitary rongeurs. Allow the dura to slide or prolapse forward into the area vacated by the debridement.
- Debride the bone until bleeding cancellous bone surfaces are exposed. Cut or drill slots into the exposed cancellous bone of the end vertebrae.
- Apply posterior pressure on the kyphosis to open the interval so that it can be measured with a caliper. Place several ribs or an iliac bicortical graft into the slots, and gently impact the graft into place.
- Release the posterior pressure on the spine, and the grafts will be firmly held in compression. It is wise to supplement the impacted bone with additional struts, although these will not be under compression. Usually, five to six ribs or two bicortical iliac crest grafts can be fitted into the thoracic spine (71,85).
- Complete closure of the abscess cavity flaps is unnecessary. In Hong Kong, streptomycin, 1 g, and isoniazid, 200 mg, are placed in the abscess cavity before closure (Fig. 150.10 and Fig. 150.16) (71).

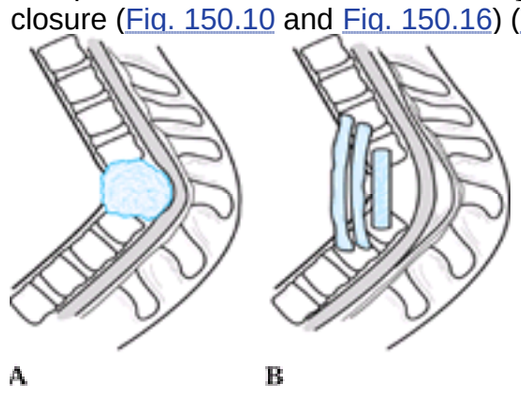


***Figure 150.16.*** **A:** An anterior thoracolumbar approach is best for thoracic or lumbar involvement. With the patient in the lateral decubitus position, make an incision over the rib just superior to the apex of the kyphosis. The rib can be removed for use as a strut graft. Remove the tuberculous debris, devascularized disc, and avascular vertebral body by curettage or use of a power burr. **B:** If the cord is compressed, completely expose it anteriorly to remove any pressure. Place strut grafts of bicortical ilium and rib or fibula to bridge the angular kyphosis from good vertebrae to good vertebrae. Sometimes, correction of the kyphosis can be obtained during the grafting procedure. This anterior fusion will need posterior instrumentation to stabilize the spine and keep the anterior strut grafts from displacing.

**Posterior Procedures for Combined Approaches and Reconstruction** If debridement has required the use of a strut graft, usually a second-stage posterior procedure is planned to provide immediate stability, to support the strut anteriorly, and to prevent later collapse and angulation. In the cervical spine, we use a posterior wiring technique; in the thoracolumbar spine, we most often use segmental instrumentation. In both cases, we combine the instrumentation with a posterolateral spinal fusion. In the cervical spine, the levels of the instrumentation extend from the first good vertebra superiorly to the first good vertebra inferiorly. In the thoracolumbar spine, it is important to include vertebrae at least two levels above and below the resected vertebral bodies.

After patients begin to recover, mobilize them, using external immobilization. Use a halo orthosis vest to control motion in the cervical spine and a polypropylene fitted body jacket for the thoracolumbar area. Continue external immobilization for 3 months in the cervical spine and up to 6 months in the thoracolumbar spine. The patient may get out of bed as soon as the external immobilization device is applied and may ambulate, if not paraplegic, as early as tolerated.

Use radiographs and tomograms to confirm graft incorporation and consolidation of the fusion. The vertebral column is also monitored for any angulation or vertebral collapse during the later stages of recovery. Good nutrition and antibiotics complete the treatment program.

## PITFALLS AND COMPLICATIONS

The following complications are specific to the treatment of infections.

### INTRAOPERATIVE COMPLICATIONS

The lungs can be penetrated during thoracotomy procedures. This is usually of no special concern and can be ignored, unless there is a significant air leak. This will generally scar and seal in time. Use a chest tube if a pneumothorax develops.

The dura can be opened accidentally during the decompression. Always try to close the rent. If closure is unsuccessful, a spinal fluid fistula may result. These eventually heal but may persist for up to 3–4 months.

Injury to the sympathetic nerves in the cervical region will produce Horner's syndrome, which usually is only temporary. In the lumbar area, the extremity of the operated side will be warmer. This too will usually resolve with time.

If there is excessive retroperitoneal scarring, the ureter can be cut accidentally. If so, this must be recognized and a reanastomosis performed at once. If you suspect preoperatively that the ureter might be involved in the abscess, place a stent into the ureter on the side being operated on. This will make the ureter easier to palpate and therefore less likely to be cut. A stent with a fiberoptic light can even allow the ureter to be visualized among the debris and bleeding as the abscess is incised and cleaned out.

Occasionally, the vena cava, aorta, or a common iliac vessel is cut or torn during mobilization of the great vessels. This is most likely to occur at the lumbosacral junction, where the main structure preventing access and mobilization of the common iliac vessels is the iliolumbar vein. Locate this vessel before it is torn. If it cannot be safely moved, ligate and cut it. If the vena cava or aorta is injured, do an immediate vascular repair. Usually, a stitch or two will control the problem, but occasionally a friable vena cava will be impossible to repair and will need to be ligated.

### EARLY POSTOPERATIVE COMPLICATIONS

After anterior or even posterior spinal surgery in the thoracolumbar or lumbar area, a paralytic ileus is common. Patients should not be fed until bowel sounds are actively present, and they have noticed some flatus. Even oral fluids, if given too early, can aggravate the ileus and prolong final recovery.

Chest complications are also common, particularly after a thoracotomy. The most common is atelectasis, which will respond to deep breathing, coughing, and use of the inspirometer. However, if left untreated, this can develop into pneumonia. If a chest tube is improperly placed or if it becomes blocked, pleural effusion or hemothorax can occur with lung collapse and subsequent pneumonia.

The most catastrophic complication is deterioration of neurologic status after anterior decompression. This is probably the result of excessive trauma to the already jeopardized spinal cord, particularly if the paraparesis is of long duration and the surgical approach is difficult. It is likely to resolve because the spinal cord in Pott's paraplegia is resilient and can withstand a great deal of trauma without permanent damage. On the other hand, if worsening of paraplegia is caused by spasm of or injury to the anterior spinal artery, then the prognosis for recovery is bleak. There is no good way to know which condition is causing the problem, and treatment for either condition is not very effective. If arterial spasm is suspected, administer intravenous methylprednisolone. Image the strut-grafted area with radiography or CT, or both, to ensure that a graft has not slipped posteriorly into the spinal cord. If this is suspected, reoperate and reinsert the graft into a firm bony bed so that it will not impinge on the cord. Hematoma or abscess is unlikely to cause compression of the spinal cord, because most of the abscess has been removed and the area around the debridement cannot contain the hematoma.

### LATE COMPLICATIONS

If the inserted grafts are reabsorbed, usually the infection is not being sufficiently controlled by the antibiotic. This is usually evident 6–12 weeks after surgery, and culture and sensitivity reports will help in modifying the drug regimen. Usually, the grafts need not be replaced, but if destruction is severe, reoperation should be considered.

Long grafts, particularly fibula, are subject to late fracture. Fractures occur 12–18 months after surgery, when the bone is weakened by resorption and replacement by new bone. These resemble stress fractures and will heal with immobilization and rest. Fracture of the graft is best recognized with tomography in the sagittal (lateral) plane.

In 7% to 8% of patients, the spinal fusion will fail. If this is thought to be secondary to persistent infection, it must be dealt with medically. When further spinal collapse and increase in kyphosis occur, restabilization of the vertebral column is required. If the disease is judged to be quiescent, the kyphotic angle is stable, and the patient is asymptomatic, a nonunion can be ignored. If symptoms do occur, a revision posterolateral fusion with instrumentation can be performed.

## CHAPTER REFERENCES

Each reference is categorized according to the following scheme: *, classic article; #, review article; !, basic research article; and +, clinical results/outcome study.


+ 1. Abbey D, Rosea S. Diagnosis of Vertebral Osteomyelitis in a Community Hospital by Using CT. *Arch Intern Med* 1989;149:2029.

+ 2. Abdel-Magid R, Korb H. Epidural Abscess after Spinal Anesthesia: A Favorable Outcome. *Neurosurgery* 1990;27:310.

+ 3. Adatepe M, Powell O, Isaacs G, et al. Hematogenous Pyogenic Vertebral Osteomyelitis: Diagnostic Value of Radionuclide Bone Imaging. *J Nucl Med* 1986;27:1680.

+ 4. Allen A, Stevenson A. The Results of Combined Drug Therapy and Early Fusion in Bone Tuberculosis. *J Bone Joint Surg Am* 1957;39:32.

+ 5. Allen A, Stevenson A. A 10-year Follow-up of Combined Drug Therapy and Early Fusion in Bone Tuberculosis. *J Bone Joint Surg Am* 1967;49:1001.

+ 6. Amir J, Shockelford P. *Kingella kingae* Intervertebral Disk Infection. *J Clin Microbiol* 1991;29:1083.

+ 7. Arct W. Operative Treatment of Tuberculosis of the Spine in Old People. *J Bone Joint Surg Am* 1968;50:255.

* 8. Bailey J, Gabriel M, Hodgson A, Shin J. Tuberculosis of the Spine in Children. *J Bone Joint Surg Am* 1972;54:1633.

+ 9. Baker A, Ojemann R, Swartz M, Richardson E. Spinal Epidural Abscess. *N Engl J Med* 1975;293:463.

* 10. Batson O. The Vertebral Vein System as a Mechanism for the Spread of Metastases. *Am J Roentgenol Radium Ther* 1942;48:75.

# 11. Bennett J. Brucellosis. In: Wyngaarden J, South L, eds. *Cecil Textbook of Medicine.* Philadelphia: WB Saunders, 1985:1614.

# 12. Benson D. Orthopaedic Disorders: The Spine and Neck. In: Gershwin M, Robbins D, eds. *Musculoskeletal Diseases of Children.* New York: Grune & Stratton, 1983:494.

+ 13. Bergman I, Wald E, Meyer J, Painter M. Epidural Abscess and Vertebral Osteomyelitis Following Serial Lumbar Punctures. *Pediatrics* 1983;72:476.

# 14. Boachie-Adjei O, Squillante R. Tuberculosis of the Spine. *Orthop Clin North Am* 1996;27:95.

+ 15. Bohlman H, Freehafer A, Dejak J. The Results of Treatment of Acute Injuries of the Upper Thoracic Spine with Paralysis. *J Bone Joint Surg Am* 1985;67:360.

+ 16. Bouchez B, Arnott G, Delfosse J. Acute Spinal Epidural Abscess. *J Neurology* 1985;231:343.

+ 17. Brandt S, Thompson R. Mycotic Pseudoaneurysm of an Aortic Bypass Graft and Contiguous Vertebral Osteomyelitis Due to *Aspergillus fumigatus. Am J Med* 1985;79:259.

+ 18. Brant-Zawadzki M, Burke V, Jeffrey R. CT in the Evaluation of Spine Infection. *Spine* 1983;8:358.

+ 19. Brelt R, Nade S. *Pseudomonas* Osteomyelitis of the Spine: Report of a Case Not Associated with Drug Abuse. *Aust N Z J Surg* 1987;57:871.

+ 20. Browder J, Meyers R. Infections of the Spinal Epidural Space: An Aspect of Vertebral Osteomyelitis. *Am J Surg* 1937;37:4.

+ 21. Brown D, Musher D. Hematogenously Acquired *Aspergillus* Vertebral Osteomyelitis in Seeming Immunocompetent Drug Addicts. *West J Med* 1987;147:84.

+21a. Bruschwein DA, Brown ML, McLeod RA. Gallium Scintigraphy in the Evaluation of Disk-Space Infections: Concise Communication. *J Nucl Med* 1980;21:925.

+ 22. Cabezudo M, Olabe J, Bacci F. Infection of the Intervertebral Disc Space after Placement of a Percutaneous Lumboperitoneal Shunt for Benign Intracranial Hypertension. *Neurosurgery* 1990;26:1005.

+ 23. Cahill D, Love L, Rechtine D. Pyogenic Osteomyelitis of the Spine in the Elderly. *J Neurosurg* 1991;74:878.

+ 24. Capener N. The Evolution of Lateral Rachitomy. *J Bone Joint Surg Br* 1957;36:173.

+ 25. Chahal A, Jyoti S. The Radical Treatment of Tuberculosis of the Spine. *Int Orthop* 1980;4:93.

+ 26. Chan K, Leung P, Lee S, et al. Pyogenic Osteomyelitis of the Spine: A Review of 16 Consecutive Cases. *J Spinal Disord* 1988;1:224.

+ 27. Chan S, Leung S. Spinal Epidural Abscess Following Steroid Injection for Sciatica: Case Report. *Spine* 1989;14:106.

+ 28. Chen W, Chen C, Shih C. Surgical Treatment of Tuberculous Spondylitis: 50 Patients Followed for 2–8 Years. *Acta Orthop Scand* 1995;66:137.

+ 29. Clark R, Carlisle J, Valainis G. *Streptococcus pneumoniae* Endocarditis Presenting as an Epidural Abscess. *Rev Infect Dis* 1989;11:338.

+ 30. Colle I, Peeters P, Le Roy I, et al. Epidural Abscess: Case Report and Review of the Literature. *Acta Clin Belg* 1996;51:412.

* 31. A Controlled Trial of Ambulant Out-patient Treatment and In-patient Rest in Bed in the Management of Tuberculosis of the Spine in Young Korean Patients on Standard Chemotherapy: A Study in Masan, Korea. First Report of the Medical Research Council Working Party on Tuberculosis of the Spine. *J Bone Joint Surg Br* 1973;55:678.

* 32. A Controlled Trial of Anterior Spinal Fusion and Debridement in the Surgical Management of Tuberculosis of the Spine in Patients on Standard Chemotherapy: A Study in Hong Kong. Fourth Report of the Medical Research Council Working Party on Tuberculosis of the Spine. *J Brit Surg* 1974;61:853.

+ 33. Cope V. Actinomycosis of Bone with Special Reference to Infection of Vertebral Column. *J Bone Joint Surg Br* 1951;33:205.

+ 34. Cowan N. Cryptococcosis of Bone: Cost Report and Review of the Literature. *Clin Orthop* 1969;66:174.

+ 35. Dalinka M, Dinnenberg S, Greendyke W, Hopkins R. Roentgenographic Features of Osseous Coccidioidomycosis and Differential Diagnosis. *J Bone Joint Surg Am* 1971;53:1157.

# 36. Danner R, Hartman B. Update of Spinal Epidural Abscess: 35 Cases and Review of the Literature. *Rev Infect Dis* 1987;9:265.

+ 37. Dauch W. Infection of the Intervertebral Space Following Conventional and Microsurgical Operation on the Herniated Lumbar Intervertebral Disc: A Controlled Clinical Trail. *Acta Neurochir (Wien)* 1986;82:43.

+ 38. Deeb ZL, Schimel S, Daffner R, et al. Intervertebral Disk-space Infection after Chymopapain Injection. *AJR* 1985;144:671.

+ 39. DeFelice R, Galgian J, Campbell S, et al. Ketoconazole Treatment of Nonprimary Coccidioidomycosis. *Am J Med* 1982;72:681.

+ 40. Dehring D, Tucker R. Treatment of Invasive Aspergillosis with Intrathecal Ketoconazole. *Am J Med* 1985;86:791.

+ 41. Del Curling OJ, Gower D, McWhorter J. Changing Concepts in Spinal Epidural Abscess: A Report of 29 Cases. *Neurosurgery* 1990;27:185.

+ 42. Denning D, Tucker R, Hanson L, Stevens D. Treatment of Invasive Aspergillosis with Itraconazole. *Am J Med* 1989;86:791.

+ 43. Dernbach P, Gomez H, Hahn J. Primary Closure of Infected Spinal Wounds. *Neurosurgery* 1990;26:707.

# 44. Edwards J, Lehrer R, Stiehm E. Severe Candida Infections: Clinical Perspective, Immune Defense Mechanisms and Current Concepts of Therapy. *Ann Intern Med* 1978;89:91.

+ 45. Eismont F, Bohlman H, Soni P, et al. Pyogenic and Fungal Vertebral Osteomyelitis with Paralysis. *J Bone Joint Surg Am* 1983;65:19.

+ 46. Emery S, Chan D, Woodward H. Treatment of Hematogenous Pyogenic Vertebral Osteomyelitis with Anterior Debridement and Primary Bone Grafting. *Spine* 1989;14:284.

+ 47. Endress C, Guyot D, Fata J, Salciccioli G. Cervical Osteomyelitis Due to Intravenous Heroin Use: Radiologic Findings in 14 Patients. *AJR* 1990;155:333.

+ 48. Fang D, Cheung K, Dos Remedios I, et al. Pyogenic Vertebral Osteomyelitis: Treatment by Anterior Spinal Debridement and Fusion. *J Spinal Disord* 1994;7:173.

+ 49. Ferris B, Jones J. Paraplegia Due to Aspergillosis. *J Bone Joint Surg Br* 1985;67:800.

* 50. Five-year Assessments of Controlled Trials of Ambulatory Treatment, Debridement and Anterior Spinal Fusion in the Management of Tuberculosis of the Spine: Studies in Bulawayo (Rhodesia) and Hong Kong. Sixth Report of the Medical Research Council. *J Bone Joint Surg Br* 1978;60:163.

+ 51. Fountain S, Shu L, Yau A, Hodgson A. Progressive Kyphosis Following Solid Anterior Spine Fusion in Children with Tuberculosis of the Spine. *J Bone Joint Surg Am* 1975;57:1104.

+ 52. Friedman B, Simon G. Candida Vertebral Osteomyelitis: Report of Three Cases and Review of the Literature. *Diagn Microbiol Infect Dis* 1987;8:31.

+ 53. Garrido E, Rosenwasser R. Experience with the Suction-Irrigation Technique in the Management of Spinal Epidural Infection. *Neurosurgery* 183;12:678.

+ 54. Garvey T, Eismont F. Tuberculous and Fungal Osteomyelitis of the Spine. *Semin Spine Surg* 1990;2:295.

+ 55. Gather J, Harris R, Garland B, et al. Candida Osteomyelitis: Report of Five Cases and Review of the Literature. *Am J Med* 1987;82:927.

+ 56. Gehweiler J, Capp M, Chick E. Observations on the Roentgen Patterns in Blastomycosis of Bone. *AJR* 1970;108:497.

+ 57. Ghobadi F, Potenza A, Dibenedetto A. Spinal Tuberculosis: Treatment by Debridement and Anterior Spine Fusion. *N Y State J Med* 1975;75:1527.

+ 58. Golimbu C, Firooznia H, Rafil M. CT of Osteomyelitis of the Spine. *AJR* 1984;142:159.

+ 59. Graziano G, Sidhu K. Salvage Reconstruction in Acute and Late Sequelae from Pyogenic Thoracolumbar Infection. *J Spinal Disord* 1993;6:199.

+ 60. Guirguis A. Pott's Paraplegia. *J Bone Joint Surg Br* 1967;49:658.

+ 61. Guri J. Pyogenic Osteomyelitis of the Spine. *J Bone Joint Surg Am* 1946;28:29.

+ 62. Haase D, Martin R, Marrie T. Radionuclide Imaging in Pyogenic Vertebral Osteomyelitis. *Clin Nucl Med* 1980;5:533.

+ 63. Hadden W, Swanson A. Spinal Infection Caused by Acupuncture Mimicking a Prolapsed Intervertebral Disc: A Case Report. *J Bone Joint Surg Am* 1982;64:624.

+ 64. Hales D, Duffy K, Dawson E, Delamarter A. Lumbar Osteomyelitis and Epidural and Paraspinous Abscesses: Case Report of an Unusual Source of Contamination from a Gunshot Wound to the Abdomen. *Spine* 1991;16:380.

+ 65. Harries T, Licktman D, Swafford A. Pyogenic Vertebral Osteomyelitis Complicating Abdominal Stab Wounds. *J Trauma* 1981;21:75.

+ 66. Heusner A. Nontuberculous Spinal Epidural Infections. *N Engl J Med* 1948;239:845.

+ 67. Hirschmann J, Everett E. Candida Vertebral Osteomyelitis. *J Bone Joint Surg Am* 1976;58:573.

+ 68. Hlavin M, Kaminski J, Ross J, Ganz E. Spinal Epidural Abscess: A 10-year Perspective. *Neurosurgery* 1990;27:177.

* 69. Hodgson A, Skinsnes O, Leong C. The Pathogenesis of Pott's Paraplegia. *J Bone Joint Surg Am* 1967;42:295.

* 70. Hodgson A, Stock F. Anterior Spine Fusion for the Treatment of Tuberculosis of the Spine. *J Bone Joint Surg Am* 1960;42:295.

* 71. Hodgson A, Stock F, Fang H, Ong G. Anterior Spinal Fusion: The Operative Approach and Pathological Findings in 412 Patients with Pott's Disease of the Spine. *Br J Surg* 1960;48:172.

+ 72. Hoffer F, Strand R, Gebhardt M. Percutaneous Biopsy of Pyogenic Infection of the Spine in Children. *J Pediatr Orthop* 1988;8:442.

+ 73. Hong Z, Zisheng W, Jianziong S, et al. Application of Internal Fixation in the Treatment of Tuberculosis of the Spine. *Chin Med Sci J* 1994;9:179.

+ 74. Hopf C, Meurer A, Eysel P, Rompe J. Operative Treatment of Spondylodiscitis: What is the Most Effective Approach. *Neurosurg Rev* 1998;21:217.

+ 75. Hsu L, Leong J. Tuberculosis of the Lower Cervical Spine (C-2 to C-7). *J Bone Joint Surg Br* 1984;66:1.

+ 76. Ingwer I, McLeish D. *Aspergillus fumigatus* Epidural Abscess in a Renal Transplant Recipient. *Arch Intern Med* 1978;138:153.

+ 77. Jack K, Rhame F. Aspergillus Osteomyelitis: Report of Four Cases and Review of the Literature. *Am J Med* 1982;73:296.

+ 78. Jeanneret B, Mageral F. Treatment of Osteomyelitis of the Spine Using Percutaneous Suction/Irrigation and Percutaneous External Spinal Fixation. *J Spinal Disord* 1994;7:185.

+ 79. Johnson R, Hillman J, Southwick W. The Importance of Direct Attack upon Lesions of the Vertebral Bodies, Particularly in Pott's Disease. *J Bone Joint Surg Am* 1953;35:17.

# 80. Jones A. The Influence of Hugh Owen Thomas on the Evolution of Skeletal Tuberculosis. *J Bone Joint Surg Br* 1953;35:309.

+ 81. Karlen A. Early Drainage of Paraspinal Tuberculosis Abscess in Children. *J Bone Joint Surg Br* 1959;41:491.

+ 82. Kashimoto T, Kitagawa H, Kachi H. *Candida tropicalis* Vertebral Osteomyelitis and Discitis: Case Report. *Spine* 1986;11:57.

+ 83. Kattapuram S, Phillips W, Boyd R. CT in Pyogenic Osteomyelitis of the Spine. *AJR* 1983;140:1199.

+ 84. Kaufman D, Kaplan J, Litman N. Infectious Agents in Spinal Epidural Abscesses. *Neurology* 1980;30:844.

+ 85. Kemp H, Jackson J, Cook J. Anterior Fusion of the Spine for Infective Lesions in Adults. *J Bone Joint Surg Br* 1973;55:715.

+ 86. Kemp H, Jackson J, Shaw N. Laminectomy in Paraplegia Due to Infection Spondylosis. *Br J Surg* 1974;61:66.

+ 87. Khan M. The Place of Anterior Spinal Fusion in Treatment of Tuberculosis of the Spine. *Clin Orthop* 1964;35:139.

+ 88. King D, Mayo K. Infective Lesions of the Vertebral Column. *Clin Orthop* 1973;96:248.

+ 89. Kirkaldy-Willis W, Thomas T. Anterior Approaches in the Diagnosis and Treatment of Infections of the Vertebral Bodies. *J Bone Joint Surg Am* 1965;47:87.

+ 90. Kondo E, Yamada K. End Results of Focal Debridement in Bone and Joint Tuberculosis and its Indications. *J Bone Joint Surg Am* 1957;39:27.

+ 91. Konstam P, Blesovsy A. The Ambulant Treatment of Spinal Tuberculosis. *Br J Surg* 1962;50:26.

+ 92. Koppel B, Tuchman A, Mangiardi J, et al. Epidural Spinal Infection in Intravenous Drug Abusers. *Arch Neurol* 1988;45:1331.

+ 93. Korkusuz F, Islam C, Korkusuz Z. Prevention of Postoperative Late Kyphosis in Pott's Disease by Anterior Decompression and Intervertebral Grafting. *World J Surg* 1997;21:524.

+ 94. Korovessis P, Repanti M, Katsardis T, Stamatakis M. Anterior Decompression and Fusion for Aspergillus Osteomyelitis of the Lumbar Spine Associated with Paraparesis. *Spine* 1994;19:2715.

+ 95. Larde D, Mathieu D, Frija J, et al. Vertebral Osteomyelitis: Disk Hypodensity on CT. *AJR* 1982;139:963.

+ 96. Larsson S, Thelander U, Friberg S. C-reactive Protein (CRP) Levels after Elective Orthopaedic Surgery. *Clin Orthop* 1992;275:237.

+ 97. Leibert E, Schluger N, Bonk S, Rom W. Spinal Tuberculosis in Patients with Human Immunodeficiency Virus Infection: Clinical Presentation, Therapy and Outcome. *Tuber Lung Dis* 1996;77:329.

+ 98. Leys D, Lesoin F, Viaud C, et al. Decreased Morbidity from Acute Bacterial Spinal Epidural Abscesses Using Computed Tomography and Nonsurgical Treatment in Selected Patients. *Ann Neurol* 1985;17:350.

+ 99. Lifeso R. Atlanto-axial Tuberculosis in Adults. *J Bone Joint Surg Br* 1987;69:183.

+100. Lifeso R. Pyogenic Spinal Sepsis in Adults. *Spine* 1990;15:1265.

+101. Lifeso R, Weaver P, Harder E. Tuberculous Spondylitis in Adults. *J Bone Joint Surg Am* 1985;67:1405.

+102. Loembe P. Tuberculosis of the Lower Cervical Spine (C3-C7) in Adults: Diagnostic and Surgical Aspects. *Acta Neurochir (Wien)* 1994;131:125.

+103. Lowe J, Kaplan L, Liebergall M, Floman Y. Serratia Osteomyelitis Causing Neurological Deterioration after Spine Fracture: A Report of Two Cases. *J Bone Joint Surg Br* 1989;71:256.

+104. Lukhele M. Tuberculosis of the Cervical Spine. *S Afr Med J* 1996;86:553.

+105. Malawski S, Lukawski S. Pyogenic Infection of the Spine. *Clin Orthop* 1991;272:58.

+106. Marchevsky A, Damslar B, Green S. The Clinicopathological Spectrum of Non-tuberculous Mycobacterial Osteoarticular Infections. *J Bone Joint Surg Am* 1985;67:925.

+107. Markus H, Allison S. *Staphylococcus aureus* Meningitis from Osteomyelitis of the Spine. *Postgrad Med* 1989;65:941.

+108. Martin N. Pott's Paraplegia: A Report of 120 Cases. *J Bone Joint Surg Br* 1971;53:596.

+109. Martin N. Tuberculosis of the Spine: A Study of the Results of Treatment during the Last 25 Years. *J Bone Joint Surg Br* 1970;52:613.

+110. Matsui J, Hirano N, Sakaguchi Y. Vertebral Osteomyelitis: An Analysis of 38 Surgically Treated Cases. *Eur Spine J* 1998;7:50.

+111. McGahan J, Dublin A. Evaluation of Spinal Infections by Plain Radiographs, CT, Intrathecal Metrizamide, and CT-guided Biopsy. *Diagn Imaging Clin Med* 1985;54:11.

+112. McGrath HJ, McCormick C, Carey M. Pyogenic Cervical Osteomyelitis Presenting as a Massive Prevertebral Abscess in a Patient with Rheumatoid Arthritis. *Am J Med* 1988;84:363.

* 113. Menard V. *Etude Practique sur le Mal de Pott.* Paris: Masson et Cie, 1900.

+114. Modic M, Feiglin D, Piraino D. Vertebral Osteomyelitis: Assessment Using MR. *Radiology* 1985;157:157.

+115. Moon M. Tuberculosis of the Spine: Controversies and a New Challenge. *Spine* 1997;22:1791.

+116. Moon M, Ha K, Sun D, et al. Pott's Paraplegia: 67 Cases. *Clin Orthop* 1996;323:122.

+117. Moon M, Woo Y, Lee K, et al. Posterior Instrumentation and Anterior Interbody Fusion for Tuberculous Kyphosis of Dorsal and Lumbar Spines. *Spine* 1995;20:1910.

+118. Myllynen P, Klossner O. Pyogenic Vertebral Osteomyelitis as a Complication of an Abdominal Stab Wound. *Ann Chir Gynaecol* 1982;71:344.

+119. Neville C, Davis W. Is Surgical Fusion Still Desirable in Spinal Tuberculosis? *Clin Orthop* 1971;75:179.

+120. Noble H, Kyne E. Candida Osteomyelitis and Arthritis from Hyperalimentation Therapy. *J Bone Joint Surg Am* 1974;56:825.

+121. Osenbach R, Hitchon P, Menezes A. Diagnosis and Management of Pyogenic Vertebral Osteomyelitis in Adults. *Surg Neurol* 1990;33:266.

+122. Osti O, Fraser R. Discitis after Discography: The Role of Prophylactic Antibiotics. *J Bone Joint Surg Br* 1990;72:271.

+123. Patzakis M, Rao S, Wilkins J, et al. Analysis of 61 Cases of Vertebral Osteomyelitis. *Clin Orthop* 1991;264:178.

+124. Pinckney L, Currarino G, Highgenboten C. Osteomyelitis of the Cervical Spine Following Dental Extraction. *Radiology* 1980;135:335.

+125. Post M, Sze F, Quencer R, et al. Gadolinium-enhanced MR in Spinal Infection. *J Comput Assist Tomogr* 1990;14:721.

+126. Ratcliffe J. Anatomic Basis for the Pathogenesis and Radiologic Features of Vertebral Osteomyelitis and its Differentiation from Childhood Discitis: A Microarteriographic Investigation. *Acta Radiol Diagn* 1985;26:137.

+127. Rath S, Neff U, Schneider O, Richter H. Neurosurgical Management of Thoracic and Lumbar Vertebral Osteomyelitis and Discitis in Adults: A Review of 43 Consecutive Surgically Treated Patients. *Neurosurgery* 1996;38:926.

+128. Richards B. Delayed Infections Following Posterior Spinal Instrumentation for the Treatment of Idiopathic Scoliosis. *J Bone Joint Surg Am* 1995;77:524.

+129. Richardson J, Campbell D, Grover F, et al. Transthoracic Approach for Pott's Disease. *Ann Thorac Surg* 1976;21:552.

+130. Rockney R, Ryan R, Knuckey N. Spinal Epidural Abscess: An Infectious Emergency Case Report and Review. *Clin Pediatr* 1989;28:332.

+131. Safran O, Rand N, Kaplan L, et al. Sequential or Simultaneous, Same-day Anterior Decompression and Posterior Stabilization in the Management of Vertebral Osteomyelitis of the Lumbar Spine. *Spine* 1998;23:1885.

# 132. Sapico F, Montgomerie J. Vertebral Osteomyelitis. *Infect Dis Clin North Am* 1990;4:539.

+133. Savonia M. An Overview of Antibiotics Useful in the Treatment of Bacterial, Mycobacterial, and Fungal Osteomyelitis. *Semin Spine Surg* 1990;2:309.

+134. Schlaeffer F, Mikolich D, Mates S. Technetium (Tc-99m) Diphosphonate Bone Scan: False-normal Findings in Elderly Patients with Hematogenous Vertebral Osteomyelitis. *Arch Intern Med* 1987;147:2024.

+135. Schofferman L, Schofferman J, Zucherman J. Occult Infections Causing Persistent Low-back Pain. *Spine* 1989;14:417.

# 136. Schroeder S, Krupp M, Tierney L Jr, eds. *Current Medical Diagnosis and Treatment.* Norwalk, CT: Appleton & Lange, 1989.

+137. Schulak D, Rayhack J, Lippert F. The Erythrocyte Sedimentation Rate in Orthopedic Patients. *Clin Orthop* 1982;167:197.

+138. Schulitz K, Kothe R, Leong J, Wehling P. Growth Changes of Solidly Fused Kyphotic Bloc after Surgery for Tuberculosis: Comparison of Four Procedures. *Spine* 1997;22:1150.

* 139. Seddon J. Pott's Paraplegia and its Operative Treatment. *J Bone Joint Surg Br* 1953;35:487.

+140. Seligson R, Rippon J, Lerner S. *Aspergillus terreus* Osteomyelitis. *Arch Intern Med* 1977;137:918.

+141. Seris J, Ono H. Aspergillosis Presenting as Spinal Cord Compression. *J Neurosurg* 1972;36:221.

+142. Sharif H. Role of MR Imaging in the Management of Spinal Infections. *AJR* 1992;158:1333.

+143. Shaw F, Warthen H. Aspergillosis of Bone. *South Med J* 1963;29:1070.

+144. Shaw T, Thomas T. Surgical Treatment of Chronic Infective Lesions of the Spine. *Br Med J* 1963;1:162.

+145. Silverthorn K, Gillespie W. Pyogenic Spinal Osteomyelitis: A Review of 61 Cases. *N Z Med J* 1986;99:62.

+146. Simpson M, Nerz W, Kurlinski J. Opportunistic Mycotic Osteomyelitis: Bone Infections Due to Aspergillosis and *Candida* Species. *Medicine* 1977;56:475.

+147. Stern W, Balch R. Surgical Aspects of Nonspecific Inflammatory and Suppurative Disease of the Vertebral Column. *Am J Surg* 1966;112:314.

+148. Tami T, Burkus J, Strom C. Cervical Osteomyelitis: An Unusual Complication of Tonsillectomy. *Arch Otolaryngol Head Neck Surg* 1987;113:992.

+149. Thalgott J, Cotler H, Sasso R, et al. Postoperative Infections in Spinal Implants: Classification and Analysis—A Multicenter Study. *Spine* 1991;16:981.

+150. A 10-year Assessment of a Controlled Trial Comparing Debridement and Anterior Fusion in the Management of Tuberculosis of the Spine in Patients in Standard Chemotherapy in Hong Kong. Eighth Report of the Medical Research Council. *J Bone Joint Surg Br* 1982;64:393.

+151. Thelander U, Larsson S. Quantitation of C-reactive Protein Levels and Erythrocyte Sedimentation Rate after Spinal Surgery. *Spine* 1992;17:400.

+152. Thrush A, Enzmann D. MRI of Infectious Spondylitis. *Am J Neuroradiol* 1990;11:1171.

+153. Thurston A, Gillespie W. *Torulopsis glabrata* Osteomyelitis of the Spine: A Case Report and Review of the Literature. *Aust N Z J Surg* 1981;51:374.

+154. Tuli S. Results of Treatment of Spinal Tuberculosis by “Middle Path” Regime. *J Bone Joint Surg Br* 1975;57:13.

+155. Tuli S, Srivastava T, Varma B, Sinha G. Tuberculosis of the Spine. *Acta Orthop Scand* 1967;38:445.

+156. Upadhyay S, Saji M, Sell P, et al. The Effect of Age on the Change in Deformity after Anterior Debridement Surgery for Tuberculosis of the Spine. *Spine* 1996;21:2356.

+157. Upadhyay S, Saji M, Sell P, et al. Longitudinal Changes in Spinal Deformity after Anterior Spinal Surgery for Tuberculosis of the Spine in Adults: A Comparative Analysis between Radical and Debridement Surgery. *Spine* 1994;19:542.

+158. Upadhyay S, Saji M, Sell P, et al. Spinal Deformity after Childhood Surgery for Tuberculosis of the Spine: A Comparison of Radical Surgery and Debridement. *J Bone Joint Surg Br* 1994;76:91.

+159. Upadhyay S, Saji M, Sell P, Yau A. The Effect of Age on the Change in Deformity after Radical Resection and Anterior Arthrodesis for Tuberculosis of the Spine. *J Bone Joint Surg Am* 1994;76:701.

+160. Upadhyay S, Sell P, Saji M, et al. Surgical Management of Spinal Tuberculosis in Adults: Hong Kong Operation Compared with Debridement Surgery for Short- and Long-term Outcome of Deformity. *Clin Orthop* 1994;302:173.

+161. Van Lom J, Kellerhouse L, Pathria M. Infection versus Tumor in the Spine: Criteria for Distinction with CT. *Radiology* 1988;166:851.

# 162. Vincent K, Benson D. Differential Diagnosis and Conservative Treatment of Infectious Disease. In: Frymoyer J, ed. *The Adult Spine: Principles and Practice.* New York: Raven Press, 1991.

+163. Vincent K, Benson D, Voegeli T. Factors in the Diagnosis of Adult Pyogenic Vertebral Osteomyelitis. *Orthop Trans* 1988;12:523.

+164. Waters R, Adkins R. The Effects of Removal of Bullet Fragments Retained in the Spinal Canal: A Collaborative Study by the National Spinal Cord Injury Model System. *Spine* 1991;16:934.

+165. Wayne D, Muizelaar P. Acute Lumbosacral Epidural Abscess after Percutaneous Transluminal Angioplasty. *Am J Med* 1989;87:478.

+166. Wenningsted-Torgard K, Heyn J, Willumsen L. Spondylitis Following Epidural Morphine: A Case Report. *Acta Anaesthesiol Scand* 1982;26:649.

+167. Whalen JL, Brown ML, McLeod R, Fitzgerald RJ Jr. Limitations of Indium Leukocyte Imaging for the Diagnosis of Spine Infections. *Spine* 1991;16:193.

+168. Wiley A, Trueta J. The Vascular Anatomy of the Spine and its Relationship to Pyogenic Vertebral Osteomyelitis. *J Bone Joint Surg Br* 1959;41:796.

+169. Wiltberger B. Resection of Vertebral Bodies and Bone Grafting for Chronic Osteomyelitis of the Spine. *J Bone Joint Surg Am* 1952;34:215.

+170. Wimmer C, Ogon M, Sterzinger W, et al. Conservative Treatment of Tuberculous Spondylitis: A Long-term Follow-up Study. *J Spinal Disord* 1997;10:417.

+171. Winter W, Larson R, Hoenggar M, et al. Coccidioidal Arthritis and its Treatment. *J Bone Joint Surg Am* 1975;57:1152.

+172. Wise R. Brucellosis in the United States. *JAMA* 1980;244:2318.

# 173. Wood G. Infections of the Spine. In: Crenshaw A, ed. *Campbell's Operative Orthopaedics.* St Louis, MO: Mosby, 1987:1323.

+174. Wukich D, Van Dam B, Abreu S. Preoperative Indium-labeled White Blood Cell Scintigraphy in Suspected Osteomyelitis of the Axial Skeleton. *Spine* 1988;13:1168.

+175. Yau A, Hodgson AR. Penetration of the Lung by the Paravertebral Abscess in Tuberculosis of the Spine. *J Bone Joint Surg Am* 1968;50:243.

* 176. Yau A, Hsu L, O'Brien J, Hodgson A. Tuberculous Kyphosis: Correction with Spinal Osteotomy, Halo Pelvic Distraction, and Anterior and Posterior Fusion. *J Bone Joint Surg Am* 1974;56:1419.

+177. Zeiger HJ, Zampella E. Intervertebral Disc Infection after Lumbar Chemonucleolysis: Report of a Case. *Neurosurgery* 1986;18:616.

+178. Zigler J, Bohlman H, Robinson R, et al. Pyogenic Osteomyelitis of the Occiput, the Atlas, and the Axis: A Report of Five Cases. *J Bone Joint Surg Am* 1987;69:1069.

# CHAPTER 151

# TUMORS AND INFECTIONS OF THE CERVICAL SPINE

*Kamshad Raiszadeh and Behrooz A. Akbarnia*

**K. Raiszadeh:** Clinical Instructor, University of California–San Diego School of Medicine, Department of Orthopaedics, San Diego Center for Spinal Disorders, San Diego, California, 92123.
**B. A. Akbarnia:** Clinical Professor, University of California—San Diego School of Medicine, Department of Orthopaedics, San Diego Center for Spinal Disorders, San Diego, California, 92123.

Cervical Tumors
Diagnostic Evaluation
Biopsy and Aspiration
Treatment of Cervical Tumors
Exposure, Excision, and Reconstruction of Cervical Destructive Lesions
Infection
Vertebral Osteomyelitis
Epidural Abscess
Chapter References

This chapter focuses on the surgical management of destructive lesions of the cervical spine. For cervical tumors, the indications and techniques for biopsy are reviewed, followed by the exposure and reconstruction of destructive lesions. Tumor classification and details on the various tumors are presented in Chapter 126, Chapter 127, Chapter 128, Chapter 129 and Chapter 130. Many of the general principles of spinal tumors are covered in Chapter 152, Tumors of the Thoracic and Lumbar Spine. This chapter focuses solely on the management of these tumors in the cervical spine. Similarly, the general principles of management of bone infection are covered in Chapter 132 and Chapter 133, and the details of the various types of infections are covered in Chapter 150. In this chapter, we focus on the management of cervical infections. The evaluation of osteomyelitis and epidural abscess are reviewed, followed by a discussion of the outcome of different treatments.

## CERVICAL TUMORS

### DIAGNOSTIC EVALUATION

In the preoperative workup for tumors of the cervical spine, the surgeon should first determine the oncologic stage and evaluate for local and systemic disease. The Enneking system of staging for musculoskeletal neoplasms (see Chapter 126) has been adapted to neoplasms of the axial skeleton (4). As with extremity neoplasms, spinal tumors are staged according to histologic grade, compartmental location, and the presence or absence of metastases. There is a major difference between surgical staging of spinal neoplasms compared with neoplasms of long bones; the Weinstein-Boriani-Biagini (WBB) classification addresses the unique anatomy of the spine (25). In the transverse plane, the vertebra is divided into 12 zones, numbered 1 to 12 clockwise starting on the left half of the spinous process. The layers are further divided from paravertebral extraosseous to dura, denoted as layers A through E, with a further layer F for the vertebral artery canal (Fig. 151.1). Recording the spinal segments involved defines the longitudinal extent of tumor involvement. A simpler method of categorizing the level of involvement is to divide the vertebral body into four zones, I through IV. Tumor extension is designated as A, B, and C for interosseous, extraosseous, and distant tumor spread, respectively (Fig. 151.2). This classification is helpful because the zones of tumor involvement correspond to the surgical approach: tumors involving zones I and II are usually resected and, if necessary, stabilized posteriorly. Zone III lesions are usually approached anteriorly. Zone IV lesions that require a complete or *en bloc* excision must be managed through a combined anterior and posterior approach. Zone IIIB lesions should be carefully analyzed preoperatively to anticipate possible invasion of or adherence to critical neural elements, esophagus, or trachea. The general workup of tumors of the cervical spine and the different tumor types are covered in Chapter 152.

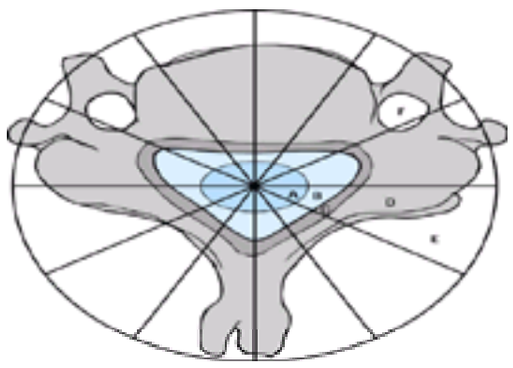

***Figure 151.1.*** Weinstein-Boriani-Biagini classification–surgical staging of spinal neoplasms. There is a major difference between surgical staging of spinal neoplasms compared with neoplasms of long bones. **A:** Intradural. **B:** Epidural. **C:** Involving bony canal. **D:** Intraosseous. **E:** Paravertebral, extraosseous. **F:** Vertebral artery canal.

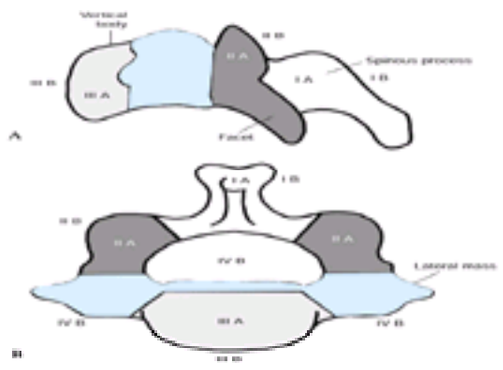

***Figure 151.2.*** Cervical spine tumor staging system, modified from the thoracolumbar staging system of Weinstein and McLain. The vertebral body is divided into zones I to IV. Zones I and II: lamina, facets, and pedicle. Zone III: vertebral body. Zone IV: epidural space, dural contents, and posterior vertebral body and annulus. **A:** Interosseous. **B:** Extraosseous. **C:** Designates distant metastatic spread, not shown. (Modified from McLain RF, Weinstein JN. Tumors of the Spine. *Seminars in Spine Surgery* 1990;2:157.)

Long-term survival and decreased recurrence rates in patients with primary spinal malignancy correlate significantly with tumor type and the extent of the initial surgical procedure. Hart et al. (25) and Boriani et al. (4) showed decreased recurrence rates of giant cell tumor and chordoma, respectively, using the WBB and the Enneking surgical staging systems with *en bloc* excision performed at a tertiary referral center. Although they have not been specifically studied, it is reasonable to extrapolate the results obtained in other areas of the spine to cervical tumors.

The incidence and presentation of cervical disease is different from other regions, however. The reported frequency of cervical metastatic disease is much less than

thoracic or lumbar metastases. Also, the presentation of cervical metastatic disease differs from metastatic disease at the thoracic and lumbar levels (49). A review of the natural history shows the average life expectancy to be 14.7 months after cervical metastatic disease is diagnosed (52). Pain with cervical metastatic disease is more frequent (93%), whereas neurologic deficit is less frequent than when disease is present at the thoracic or lumbar levels (5–14% cervical versus 50% thora co-lumbar) (52,53). The prevalence of upper cervical neurologic deficit is lower than that of the lower cervical spine, possibly related to the wider canal in the upper region.

## BIOPSY AND ASPIRATION

Conditions such as osteoid osteoma and osteoblastoma can be diagnosed solely on the basis of the radiologic workup of plain radiographs and computed tomography (CT) scans. By recognizing the benign or inactive lesions that, by their self-limiting nature, do not require biopsy, an unnecessary procedure can be avoided. Also, in cases such as spinal metastases from a known primary carcinoma, no biopsy is necessary. A similar situation involves the patient with multiple myeloma and spinal involvement with impending or actual cord compression. In patients with multiple myeloma, the laboratory tests provide the diagnosis. Because the myelomas are sensitive to radiation therapy, proceeding directly with radiation rather than performing a biopsy or other surgery is most appropriate.

If the benign or malignant nature of a spinal neoplasm is uncertain, one must make a definitive diagnosis with a complete workup and a biopsy or aspiration. It is important to realize, however, that planning the biopsy should be the last step, after appropriate staging and other workup. The benefit of performing the biopsy at the end of the staging and evaluation are

- Unnecessary biopsy can be avoided (e.g., multiple myeloma)
- Other more accessible sites may be found for biopsy (e.g., a metastatic lesion)
- Prebiopsy embolization can be performed, if necessary (e.g., renal cell metastasis or other vascular lesion).

The biopsy, although seemingly simple, is a difficult procedure with possible complications that can change the course of treatment and significantly alter the treatment outcome (40). *The orthopaedist who is responsible for the definitive treatment and subsequent care should be responsible for performing the initial biopsy.* The recommendations regarding performance of biopsies, either open or percutaneous, are

- Place the biopsy tract where it will be fully removed at the time of definitive treatment. This may not be possible during anterior biopsies.
- Ensure minimal tissue contamination by avoiding excessive dissection of tissue planes.
- Obtain adequate tissue for diagnosis (may require confirmation by frozen section).
- Maintain adequate hemostasis.
- Use drains only through the wound or in proximity so that the track is removed with the definitive resection. The drain can provide a track along which malignant cells can pass, which may increase the margin necessary for subsequent resection.

An adequate amount of tissue must be obtained regardless of whether an aspiration, needle biopsy, or open biopsy is performed. Coexistent infection and tumor have been reported (16); therefore, we recommend routine microbiologic culture. Biopsy techniques include percutaneous (aspiration, fine-needle, or large-bore), open incisional biopsy, or excisional biopsy. When normal marrow elements are present, aspiration effectively rules out metastatic malignancy. Needle aspiration and fine-needle biopsy, however, provide only a small specimen and, therefore, introduce a sampling error. Simple aspiration or fine-needle biopsy should be used predominantly in the cervical spine to rule out infection, confirm suspected metastatic disease, or diagnose recurrence of a known lesion. Because aspiration biopsy may fail to provide definitive diagnosis in up to 20% of cases (6), large-needle or open biopsy is often necessary.

For lesions in the posterior aspect of the cervical spine, large-needle trocar biopsy is relatively easy to perform under CT guidance. If a benign lesion such as osteoid osteoma or osteoblastoma is suspected, however, open biopsy followed by excision often provides the easiest solution. We also do not favor routine needle or trocar biopsy of suspected aneurysmal bone cysts. Most of these lesions, when well-demonstrated radiologically, are typical and do not require biopsy. Some lesions can have a clinical and radiographic appearance similar to that of a malignant tumor and, in fact, may also contain malignant portions; therefore, a gross pathologic specimen may be needed for diagnosis. Additionally, the small amount of tissue obtained with needle or trocar biopsy often creates confusion in the diagnosis or may not include the pre-existing lesion (50). Open biopsy with curettage or excision, or both, on the other hand, provides the entire lesion for pathologic examination. Furthermore, there have been reports that extradural bleeding of aneurysmal bone cysts of the spine following needle biopsy cause neurologic deficit (26). Finally, because open excisional biopsy can cure the condition, there seems to be little justification for needle or trocar biopsy, which may be negative and possibly risky (1).

Biopsy of anterior lesions is performed either laterally or anterolaterally following the standard surgical approach (see the discussion of surgical approaches, later). It is often not possible to entirely excise the biopsy tract with anterolateral and lateral biopsies due to the multiple tissue planes in the anterior neck and the presence of the carotid sheath. Avoid transverse posterior skin incisions. Plan the incision so that it will not compromise subsequent surgical procedures.

For planning the management of suspected metastatic disease, divide the cervical spine into three regions: the upper cervical vertebral bodies (C1–C3), the lower cervical vertebral bodies (C4–C7), and the posterior elements and posterior epidural space. Biopsies of the C1–C3 vertebral bodies can be performed through a transoral approach, with the patient under general nasotracheal anesthesia, or through a high lateral approach. The C4–C7 vertebral bodies can be accessed through a lateral or anterolateral approach (see the discussion of surgical approaches, later) or with open biopsy. Closed biopsy techniques of the cervical spine are technically demanding and often fraught with neurologic and vascular complications. If metastasis is suspected and the lesion is extensive enough to require surgical stabilization, we recommend an open biopsy to confirm the diagnosis by immediate frozen section, followed with a definitive surgical procedure. A fine-needle biopsy is possible under CT guidance, especially if surgical reconstruction is not deemed necessary.

## TREATMENT OF CERVICAL TUMORS

An individualized approach is necessary, focusing on the concurrent goals of relief of pain, and the maintenance of spinal stability and neurologic integrity.

### *Benign Tumors*

For benign cervical tumors, these general principles are relevant:

- Differentiate “latent” or “active” (i.e., stage 1 or 2 based on the Musculoskeletal Tumor Society surgical staging system) from “aggressive” or stage 3 lesions.
- Treat stage 1 or 2 lesions with intralesional curettage.
  - Precisely localize the tumor.
  - Protect structural and neurologic integrity.
  - In children, perform a posterior arthrodesis if performing a laminectomy.
- Treat stage 3 lesions with marginal or *en bloc* excision.
  - Be prepared for excessive bleeding.
    - Control bony bleeding with liberal application of bone wax and Gelfoam.
    - Preoperative embolization may be helpful to avoid excessive bleeding, especially in the case of aneurysmal bone cysts.
    - Be prepared to ligate or bypass the vertebral artery if necessary.
    - Perform preoperative angiography to assess collateral blood flow.
    - Consider packing the wound and embolizing the tumor or the vertebral artery if uncontrolled bleeding is encountered.
  - If the anterior part of the vertebra is severely involved, perform a posterior stabilization first to establish stability.

Certain tumors, such as osteoid osteoma and osteoblastoma, are common in children and have a predilection for the posterior elements. For characteristic osteoid osteoma and small osteoblastomas, excisional biopsy and intralesional curettage is sufficient treatment. The key to operative management is precise localization of the osteoid osteoma before surgery. If the lesion is located in the lamina, remove the posterior cortex of the lamina using a power drill to expose the nidus. While removing the nidus, take care not to damage the dura, because the anterior cortex is usually thin.

Larger lesions such as osteoblastomas can involve the soft tissue as well as the vertebral body and, similar to giant cell tumors and aneurysmal bone cysts (ABCs), have the potential for local recurrence. Because of the size and expansile nature of these tumors, surgical excision is more radical and often leads to spinal instability, necessitating spinal fusion. “Active” stage 2 lesions are positive on a bone scan and have a well-marginated sclerotic border. These lesions can be treated by curettage and have a low local recurrence rate (5% to 10%) (3). The “aggressive” stage 3 lesions are surrounded by a large pseudocapsule, which can be observed on a contrast-enhanced CT scan. Intralesional curettage has been associated with a 20% rate of local recurrence (36). Although *en bloc* excision is the treatment of choice, owing to anatomic restraints in the cervical spine, selected stage 3 benign tumors can be treated by incisional biopsy and frozen section confirmation of tumor type, followed at the same surgery with marginal excision.

*En bloc* excision in the cervical spine is a challenge and, owing to the increased surgical risks, should be reserved for the aggressive stage 3 lesion or recurrent tumors.

- Dissect the tumor outside its wall, leaving some of the soft tissue attached to the thin wall.
- If the tumor is next to the dura, dissect the wall with a Freer elevator, taking care not to compress the spinal cord.
- Be prepared to ligate or bypass the vertebral artery, if necessary.
- If a significant part of the esophagus is encased in tumor, an esophagectomy and gastric pull-up or colon interposition is indicated (8).

Radiation therapy may be considered as adjuvant therapy in the case of ABCs but is generally discouraged because of the potential for cord damage, induced sarcoma, and growth retardation (5). Low-dose radiotherapy may be considered for the well-circumscribed recurrent ABC lesion. Embolization may be effective for decreasing vascularity and making surgical resection and decompression less morbid, and may eliminate symptoms from expansive hemangioma.

After removing the larger posterior benign lesions, consider reconstructing the potentially destabilized spine. The extent of this destabilization depends on the age of the patient as well as the amount of posterior element resection. In children, laminectomy frequently results in secondary kyphosis that is difficult to correct. Therefore, in skeletally immature children, perform a posterior arthrodesis traversing the extent of the laminectomy (37). In the adult, when resection of any part of the lateral mass or pedicle is necessary, simultaneously arthrodese and instrument the affected levels using the remaining posterior spinal elements. Harvest an autologous graft through a separate incision, using a separate setup to avoid cross-contamination of the donor site.

### *Primary Malignant Tumors*

Surgical treatment of primary cervical malignancies is predicated on the tumor type and the extent of local and systemic spread. Avoid surgery for primary malignant spinal tumors unless there is a good chance the surgery can offer significant palliation or a cure. Marginal or intralesional resection of the tumor, followed by radiation therapy, is an appropriate palliative approach to an intermediate-grade osteosarcoma with soft-tissue involvement. A wide resection for a low-grade chondrosarcoma in the vertebral body represents an attempt to cure by surgery alone.

The treatments for solitary plasmacytoma and multiple myeloma should necessarily be somewhat different owing to their different prognoses, although they are a continuum of the same disease and most cases of solitary plasmacytoma progress to multiple myeloma. Radiation is the initial treatment of choice in either case. Prophylactic laminectomy and stabilization before radiotherapy can be used if cord compromise or spinal instability is present. In the rare instance of a cervical solitary plasmacytoma, prognosis is enhanced by surgical excision reducing the tumor burden. In such cases, perform an intralesional excision and stabilization, followed by radiation therapy.

Chordomas pose a difficult problem owing to their high local recurrence rates and the difficulty in accessing this lesion in the cervical spine. Unlike sacral chordomas, in which sacral nerve roots can be sacrificed, cervical chordomas often involve the clivus and upper cervical spine, in which, at best, only decompression and marginal excision is possible. Often, the only option for surgical treatment is posterior stabilization and fusion, followed by anterior intralesional or marginal excision and decompression.

### *Metastatic Tumors*

In the adult population, metastatic tumors are the most common tumors in the cervical spine with a predilection for the anterior column. In the cervical spine, the weight-bearing axis falls at or posterior to the vertebral body, and the articular processes support the weight of the skull. For this reason, destruction of the vertebral body results in some loss of vertebral body height, but kyphotic deformity is uncommon. Instability is also an uncommon. Destruction of the lateral masses as well as the vertebral body must occur to permit rotatory instability. Except for extensive lysis in one or more contiguous bodies, or the involvement of the spinous process of C-2, where the nuchal fascia inserts, metastatic involvement of the upper cervical spine rarely results in kyphosis or true flexion instability (49).

In the upper cervical spine, the prevalence of neurologic deficit is much lower owing to the space available for the cord. The development of neurologic deficit here is usually due to extension of the tumor rather than to angular kyphosis. The sudden onset or rapid progression of neurologic deficit is usually due to a vascular accident rather than vertebral collapse and usually has a poor prognosis. Reporting on all locations of spinal tumors, Harrington (23) noted 62% of initially paraplegic patients regained enough neurologic function to ambulate after surgical intervention, but patients with rapid paraplegia exhibited a poor prognosis for recovery.

Appropriate treatment is selected dependent on life expectancy, type of tumor, location of tumor (accessibility), radiosensitivity, degree of instability, and neurologic status of the patient. Because the primary goal is to improve the patient's quality of life, thoroughly consider the patient's personal preference and family situation. Metastasis of lung carcinoma has a 7- to 9-month mean survival time, whereas breast carcinoma has a survival exceeding 30 months. Consider embolization of tumors with hemorrhagic tendencies, such as renal and thyroid. Treat radiosensitive tumors such as lymphoma, myeloma, and prostate with nonoperative management: Radiate with doses up to 4,000 cGy as long as there is no instability, neurologic threat, or significant deformity. Doses in excess of 5,000 cGy may cause acute or chronic radiation myelitis. Radiation therapy is compatible with internal fixation devices and methacrylate but may cause failure of supporting bone graft struts. Radiation therapy alone is rarely effective in relieving a well-established neural deficit, especially in the presence of a collapsed vertebral body and bony impingement.

With normal neurologic function, consider surgery when there is severe pain, instability, or impending kyphotic collapse, or when the tumor is known to be radioresistant. Tumors with greater than 50% involvement of the vertebral body and greater than 50% destruction of the ipsilateral middle and posterior columns require prophylactic surgical stabilization. Kyphotic deformity and amount of subluxation should also be considered, but the assessment of instability is still somewhat subjective. The goal of surgery is to prevent neurologic compromise, but severe neurologic deficit is not a contraindication for surgery.

Location of the tumor is a major consideration for treatment with immobilization versus early radiation therapy versus surgery.

- Treat patients with tumors in the posterior C-2 arch with early radiation therapy so that progressive kyphosis does not develop.
- For destruction of the lateral mass of C-1, perform an occiput to C-3 fusion with adjunctive radiation therapy because rotatory instability is common (49).
- For destruction of the dens with instability, perform a C1–C2 fusion. If cord compression is impending, remove the arch of C-1 and perform an occiput to C-3 fusion.
- In the lower cervical spine, consider early combined anterior and posterior stabilization owing to the difficulty of fixation and the increased stress at the cervicothoracic junction.

Plan surgery so that it is appropriate for the tumor's stage and extent. Determine what anatomic structures may need to be sacrificed to perform the resection. Sacrifice of one vertebral artery can be tolerated if cure is a reasonable goal, but obtain a preoperative angiogram to assess collateral flow. If the cervical esophagus or a significant part of the thoracic esophagus is involved by tumor, total esophagectomy and gastric pull-up or colon interposition can be performed (8).

The results of surgery for cervical spine metastasis have shown a high rate of pain relief (94% to 95%), motor recovery (64% to 92%), and ambulation (87%). The results of surgery are usually maintained until the terminal stage, with local recurrences in 30% (2,48). In an elderly population with a mean age of 73, a mortality rate of 16% was reported within 7 days after surgery (60).

## EXPOSURE, EXCISION, AND RECONSTRUCTION OF CERVICAL DESTRUCTIVE LESIONS

### *Anterior Approaches*

The different incisions for the anterior approaches are shown in Figure 151.3 and are discussed in detail in Chapter 138. The different techniques employ three separate deep paths to the cervical spine: transpharyngeal, lateral and posterior to the carotid sheath, or anterior to the carotid sheath.

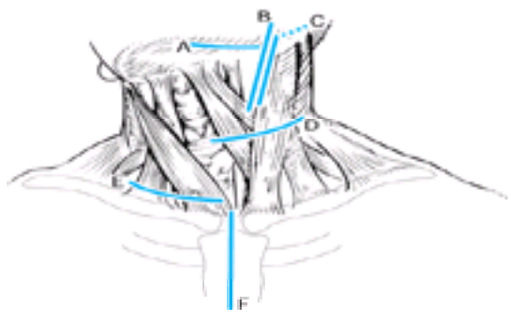


***Figure 151.3.*** Incisions for the anterior approaches to the spine. **A:** Submandibular approach, described by McAfee et al. (43). This approach is retropharyngeal and prevascular (medial to carotid sheath). The incision is 1 cm below the jaw. **B:** Extension of the prevascular approach. This approach is a cephalad extension of the standard anterolateral approach to the midcervical spine, and when it is combined with the submandibular approach, it allows direct exposure from the tip of the clivus and can be extended caudal to the lower cervical spine. **C:** Retrovascular, lateral approach (lateral and posterior to carotid sheath), popularized by Whitesides and Kelly (64). This approach allows direct exposure of one side or the other only at the level of the C1–C2 articulation. **D:** Standard anterolateral approach to the midcervical spine, medial to the carotid sheath. **E:** Exposure to lower cervical spine, which may require clavicular osteotomy for cervicothoracic exposure. **F:** Sternal splitting approach to the cervicothoracic spine.

**Exposure for Upper Cervical Anterior Lesions** The upper cervical spine can be approached through the transoral approach. Routine tracheostomy is necessary only if a tongue or mandibule-splitting approach is used. See Chapter 138 for a detailed description. The standard transoral approach can be used for exposure of C1–C2 (Fig. 151.4*A*), and this can be enlarged by the tongue-splitting (Fig. 151.4*B*) or transmandibular (Fig. 151.4*C*) approach, for decompression from the level of the clivus to C-4 (31). If division of the soft palate becomes necessary (only during extensile approaches), it is incised on one side of the midline to avoid the uvula. This approach allows for tumor resection, but the risk of sepsis makes placing implants impractical.

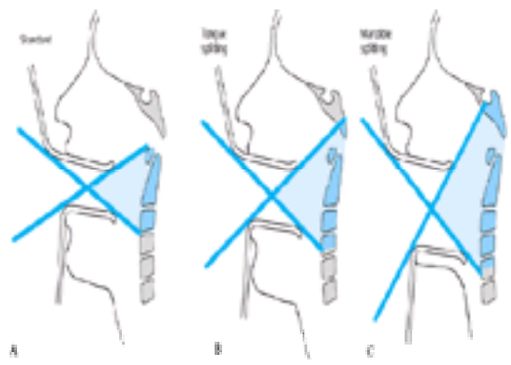

***Figure 151.4.*** Transpharyngeal approaches. **A:** Standard transoral approach: can expose tip of odontoid to C-2. **B:** Tongue-splitting approach: can expose tip of clivus to C-3. **C:** Mandible-splitting approach: can expose clivus to C-4.

The upper cervical spine can be alternatively approached through the submandibular approach, which is prevascular and retropharyngeal (incision: Fig. 151.3*A*; deep dissection: Fig. 151.5*A*). This approach is a cephalad extension of the standard approach to the midcervical spine (34,43).

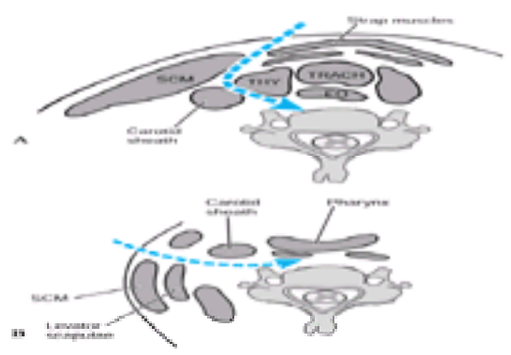

***Figure 151.5.*** Standard anterior approaches to the spine. **A:** Anterolaterally: medial to the carotid sheath. **B:** Lateral: lateral to the carotid sheath.

- Make a transverse incision 1 cm below the jaw line, which can be extended into a longitudinal incision if more extensile exposure is needed (Fig. 151.3*A* and Fig. 151.3*B*).
- Recruit the assistance of a head and neck surgeon familiar with radical neck dissections to decrease the incidence of complications.
- Develop the interval medial to the sternocleidomastoid by preserving the mandibular branch of the facial nerve and by dividing the submandibular salivary gland and the vascular leashes of the superior thyroid, lingual, and facial arteries.
- Keep the patient intubated at least overnight due to the upper pharyngeal edema common with this approach.

This approach permits extensile exposure of the anterior cervical spine. The visualization is similar to that obtained by the transmucosal route. This approach allows decompression up to the clivus and reconstruction of the anterior column with strut graft and internal fixation. We prefer this prevascular extraoral approach to the upper cervical spine owing to the excellent extensile exposure and decreased risk of infection compared with those of the transpharyngeal approach, especially if instrumentation is used. There is a reported 40% incidence of mostly transient palsies of the marginal mandibular branch of the facial nerve (34).

A third approach is the retrovascular, lateral approach popularized by Whitesides and Kelly (incision: Fig. 151.3*C*; deep dissection: Fig. 151.5*B*) (64). Owing to the restriction in mobilizing the carotid sheath, this approach allows direct exposure of one side or the other only at the level of the C1–C2 articulation and, therefore, is best suited for fusion and even instrumentation but not decompression. Lans (34) reported on 10 cases of C1–C2 arthrodesis through this bilateral, lateral approach first described by Barbour, with instrumentation using bilateral transarticular screws.

**Exposure for Midcervical Anterior Lesions** Corpectomy and stabilization through the standard anterior prevascular approach (see Chapter 138) is usually the surgical treatment of choice for lesions from C-3 to C-7. Rarely, if a lateral biopsy was obtained and the goal of surgery was a wide margin with excision of the biopsy tract, the exposure would need to begin from the lateral approach and proceed posterior to the neurovascular bundle (22).

**Exposure for Cervicothoracic Anterior Lesions** Inferior extension of the exposure in the cervical spine may be limited by the diameter of the thoracic inlet, the height of the clavicles and manubrium anteriorly, and the extent of cervicothoracic kyphosis. Obtain a preoperative radiograph to compare the upper margin of the clavicles and manubrium with the level of the vertebral body. If clearance of the clavicle and manubrium is not possible, we prefer the sternal splitting approach (62) to clavicular osteotomy (33). The sternal splitting approach is very familiar to cardiothoracic surgeons (only the superior portion of the sternum needs to be split) and can be easily extended into the neck. This allows an extensile approach to the cervicothoracic junction, and the exposure can be further enhanced by ligation of the brachiocephalic vein. Such ligation produces significant edema in the upper extremity.

**Reconstruction of Anterior Lesions** In the cervical spine, the resultant corpectomy defect can be replaced in several ways. In patients with benign lesions, or lesions with which there is long life expectancy, we prefer to use autograft or allograft struts to replace the anterior defect, followed by anterior instrumentation. If massive resection of the vertebral bodies is necessary at multiple levels, we perform posterior stabilization before anterior resection and reconstruction. The different scenarios for upper cervical, midcervical, and lower cervical reconstructions are shown in Figure 151.6, Figure 151.7 and Figure 151.8.

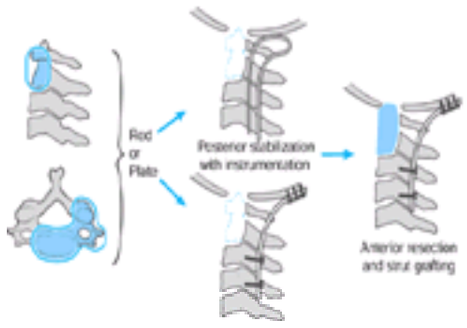


***Figure 151.6.*** Scenario for upper cervical reconstruction. For extensive destruction of C1–C2, perform a posterior stabilization first with instrumentation, with next-stage anterior resection and strut grafting as needed.

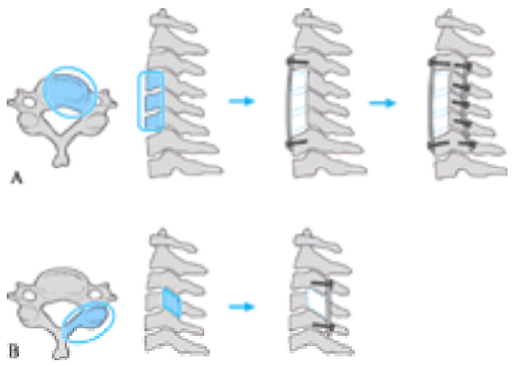


***Figure 151.7.*** Scenario for midcervical reconstruction. **A:** For extensive anterior destruction and fixed kyphosis in the midcervical spine, perform anterior decompression, strut grafting, and instrumentation, followed by posterior instrumentation. Perform the posterior instrumentation can be performed first if there is no significant deformity or if there is severe instability. **B:** For posterior destruction of the facets, perform a posterior-only reconstruction with plating or wiring.

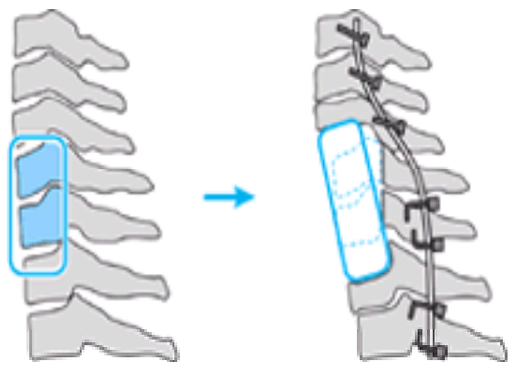

***Figure 151.8.*** Scenario for cervicothoracic reconstruction. For extensive cervicothoracic destruction, perform a posterior stabilization followed by anterior reconstruction.

In the case of giant cell tumor and other aggressive stage 3 lesions, some advocate use of methylmethacrylate (PMMA) anteriorly, with or without posterior arthrodesis or plating (36). Similar to its use in the extremities, PMMA has the advantage of immediate stability, local control due to the heat of polymerization, and rapid recognition of early recurrence. Despite the advantages of PMMA, we recommend reconstruction with autograft or allograft to provide a biologic reconstruction in these patients who usually have a long life expectancy. The benefits of a biologic reconstruction must be weighed against the risk of failure if radiation is used. Use of titanium or carbon fiber cages is controversial, and recognition of early recurrence with use of titanium is more difficult. Postoperative radiation therapy may be used if resection is incomplete, and in these cases, we would recommend use of PMMA.

For metastatic disease, when survival is anticipated to be less than 6 to 12 months, we use PMMA combined with metal implants to give immediate stable fixation (25). Radiation therapy can be used with PMMA without fear of impacting the healing of bone graft. Stabilization of the spine with PMMA can be fraught with major complications, however (42). Take care to avoid spinal cord injury, which can be caused by direct mass effect or by heat generated from the exothermic reaction of cement solidification.

- Protect the cord with Gelfoam, wire mesh, silicon sheets, or various plastics positioned anterior to the dura.
- As the cement begins to harden, irrigate with cooled saline to reduce its temperature. When multiple level corpectomies are performed, most authors agree that anterior plating is best (24,35).
- Do not use PMMA alone for anterior fixation. The average length of time to failure of PMMA fixation anteriorly used alone was 194 days (42).
- Perform posterior fixation for cases of multiple level corpectomies. In cases of massive anterior instability without rigid kyphosis, we recommend posterior fixation before anterior resection. Owing to different anatomy, the upper, mid-, and lower cervical spine require different strategies for stabilization and fixation (Fig. 151.6, Fig. 151.7 and Fig. 151.8, respectively).

### *Posterior Approach and Stabilization*

The posterior approach may be preferred in the upper cervical spine or the cervicothoracic junction owing to the difficulties inherent in anterior approach and stabilization in these areas. Laminectomy alone is contraindicated in the presence of anterior compression and kyphosis. If the posterior elements can be left intact, then standard wiring techniques can be used. In the case of a laminectomy, lateral mass plates may be used for stabilization. Special techniques are available for occipitocervical and cervicothoracic instrumentation.

Options for occipitocervical instrumentation are

- Use of a contoured rod with wires for occipital and cervical laminar fixation (Fig. 151.9).

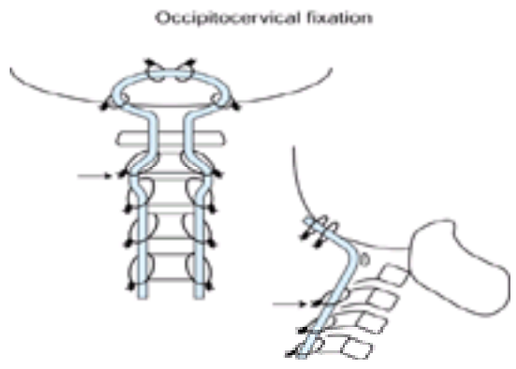


***Figure 151.9.*** Preferred method for occipitocervical instrumentation. Use a contoured rod as shown. Wiring to the occiput is performed through four drill holes through the occiput and passage of the two superior-most wires. The next set of wires are inserted from two occipital drill holes through the foramen magnum. A total of six occipital drill holes are necessary. After wiring of the lamina, the loop resists settling (arrow).

- Plating with use of lateral mass screws in the cervical spine and screws in the occiput
- Combination of the above-mentioned techniques

Options for cervicothoracic instrumentation are

- Use of rods and wires if posterior elements are intact.
- Use of a one-piece plate and rod combination with screws in the cervical lateral masses and hooks in the thoracic spine (Acromed/DePuy/Johnson and Johnson, Rahnam, MA) (Fig. 151.10*A*).

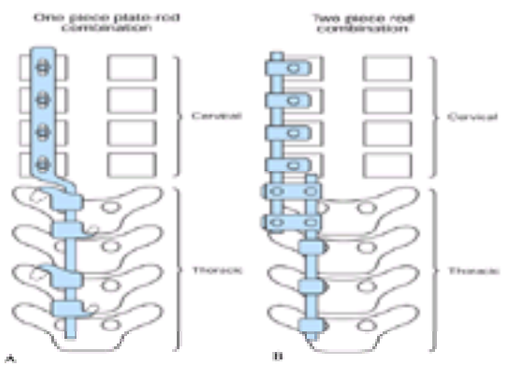

***Figure 151.10.*** Options for cervicothoracic fixation. **A:** Use of a one-piece plate and rod combination. Lateral mass screws in the cervical spine and hooks in the thoracic spine. **B:** Use of two different diameter rods—the cervical rod affixed to the cervical spine via lateral mass screws, and the thoracic rod affixed via thoracic screws or hooks. Use rod-to-rod connectors to attach the two rods together.

- Use of a two-piece cervical plate with cervical lateral mass screws and thoracic rod using thoracic hooks or pedicle screw (Danek, Memphis, TN, or Acromed/DePuy/Johnson and Johnson, Rahnam, MA)
- Use of two different diameter rods spanning the cervical and thoracic spine segments, affixed separately to cervical lateral mass screws and thoracic screws or hooks and connected by rod-to-rod connectors (Synthes, Paoli, PA) or (Acromed/DePuy/Johnson and Johnson, Rahnam, MA) (Fig. 151.10*B*).

The use of methacrylate for posterior stabilization should be condemned unless it is used to augment the lateral mass screws. We do not recommend augmentation of lateral mass screws with PMMA if the anterior cortex has been breached due to risk of vertebral artery injury. In cases in which the patient's life expectancy is more than 2 years (plasmacytoma or breast carcinoma), or in cases in which global instability exists where anterior stabilization alone is insufficient, a combined anterior and posterior approach should be used.

## INFECTION

### VERTEBRAL OSTEOMYELITIS

#### *Diagnostic Evaluation*

Infections can be classified as hematogenous or contiguous and postoperative. See Chapter 150 for a general discussion of infections of the spine. Hematogenous spine infections are less common in the cervical spine than in the thoracic or lumbar spines, but they do have a predilection for the anterior compartment of the spine. The most common complaint of patients with cervical infections is neck pain (18). Because of the nonspecific nature of cervical infections, delayed diagnosis is common. Radionuclide studies can detect spinal infection before plain films can and have the advantage of revealing other foci of infection, which occur in 4% of cases (46). Gallium scans have been shown to detect infection earlier in the course of the disease than technetium scans, and they are more useful for following the response to treatment (47). Gallium scans become normal during the resolution of the infection, whereas technetium scans remain positive for many months after the disease has resolved. Single-photon emission computed tomography (SPECT) allows the advantage of three-dimensional localization with higher sensitivity as compared with planar technetium scintigraphy or gallium scintigraphy (17). Indium scans are not helpful owing to their low sensitivity (17%) (63).

When cervical infection is suspected, gadoliniumenhanced MRI is the modality of choice. MRI has 96% sensitivity, 93% specificity, and 94% accuracy in detecting vertebral osteomyelitis and becomes positive at about the same time as the gallium scan (46). Eismont (14) noted some degree of neurologic deficit in 80% of patients with cervical osteomyelitis, and the MRI can also help identify the site and extent of compression.

Despite the accuracy of MRI, the diagnosis is confirmed by bacteriologic or histologic examination of tissue or an aspirate. The only circumstances in which a diagnosis can be made without tissue biopsy are in pediatric discitis (rare in the cervical spine) and when there is a positive blood culture with a patient who has typical signs and symptoms of spinal infection.

#### *Biopsy and Aspiration*

A definite diagnosis of the infection is possible with a closed-needle biopsy in 68% to 86% of cases (9,44). In the cervical spine, open biopsy is often performed as part of the definitive surgical procedure.

#### *Treatment*

**Hematogenous Vertebral Osteomyelitis and Disk-Space Infection** The goals of treatment are to

- Establish diagnosis
- Relieve pain
- Prevent or reverse neurologic deficit
- Establish or maintain spinal stability
- Eradicate infection

Cervical discitis or osteomyelitis can be treated with external immobilization and appropriate antibiotics if there is no abscess formation, neurologic deficit, or vertebral collapse and instability. Associated conditions that compromise wound healing or immune response should be managed aggressively. Bring diabetes or other systemic diseases under control, and address proper nutrition and reversal of hypoxia and metabolic deficits. Compared with thoracic and lumbar spine infections, infections of

the cervical spine have a higher risk of complications and surgical treatment is often required in addition to antibiotic therapy.

- Choose the antibiotic according to culture and sensitivity results.
- Withhold antibiotics in cases in which a biopsy is done, in case a second biopsy is required.
- In patients who have systemic toxicity or neurologic deficit, start maximum-dose broad-spectrum bacteriocidal antibiotics as soon as biopsy is obtained.
- If the patient does not respond clinically to antibiotics, or the sedimentation rate does not decrease to one half or two thirds by completion of treatment, perform a repeat biopsy.
- Immobilize patients for pain control and to prevent deformity or deterioration of neurologic status.

Surgical indications include the following:

- The need for tissue and bacteriologic diagnosis
- To drain an abscess that is clinically significant (fevers or sepsis)
- Cases refractory to nonoperative treatment
- Presence of neurologic deficit
- Prevention or correction of spinal deformity or instability

In nearly all cases of hematogenous cervical osteomyelitis, if surgery is deemed to be necessary, a solely anterior surgical approach with discectomy and debridement of pus and strut grafting from healthy bone above to below is sufficient. Laminectomy is contraindicated except for the rare case of associated posterior epidural abscess. If there is evidence of epidural extension, excise the posterior longitudinal ligament to ensure decompression and removal of infected tissue.

Autogenous bone grafting after vertebral body resection in the presence of active infection has been shown to be safe and effective (44). Iliac bone is preferable to that of the fibula because it has more cancellous bone. Revascularization of cortical graft may not be complete even after 1 year (57). Experience has shown that instrumentation and even allograft may also be placed anteriorly in situations of active infection, as long as adequate debridement has been performed back to healthy, bleeding bone (55,57). Dietze et al. (13) reported no recurrence of cervical infection with a 37-month follow-up after debridement and use of allograft and instrumentation, but they presented information on only five patients. In cases of significant kyphosis, or to avoid halo immobilization, the anterior strut graft can be safely followed by second-stage posterior instrumentation.

Infections involving the midcervical spine can be addressed with standard surgical approaches. The occipitocervical junction is difficult to treat owing to anatomic and mechanical constraints. Upper cervical osteomyelitis is rare but generally requires fusion because of associated instability. Stabilization of the upper cervical spine should be performed in cases of instability as defined by traction or flexion-extension radiographs, odontoid and transverse ligament resection or destruction, or clivus and odontoid resection or destruction in the presence of basilar invagination. The principle of debridement to healthy bone still applies. For high cervical infections that require drainage owing to abscess formation or cord compression, we recommend a transoral drainage and posterior stabilization. Many authors recommend posterior stabilization due to the nonsterile environment of the posterior pharynx and devitalized bone (21,39). Zigler et al. (65) described five patients with pyogenic osteomyelitis of the occipitocervical region treated by operation and antibiotics. The options used were anterior debridement and occipitocervical fusion, transoral drainage, posterior occipitocervical fusion, and posterior C1–C2 fusion; and all five patients recovered. The surgical procedure must be individualized in each case according to the degree of bony destruction and instability.

**Treatment of Posterior Infection** Most posterior infections result from previous surgery. Treat by irrigation, debridement, and administration of culture-specific intravenous antibiotics. If more than 50% of the facet joint is resected during debridement (very rare), then perform a fusion. Autogenous bone graft placed in a thoroughly debrided bed will usually result in a successful arthrodesis because of the abundant blood supply. We recommend a halo brace for immobilization after debridement of posterior infection and bone grafting. Stabilization with bone screws and plate or wire techniques is possible in spite of the infection, but the use of posterior cervical instrumentation in the presence of active infection is controversial. The length of time of administration of postoperative intravenous antibiotics will depend on the causative organism, but they should be given for at least 6 weeks; however, 4-week courses have been reported with good results (12).

### *Outcome of Treatment*

Cervical infections have a higher rate of spontaneous fusion compared with thoracic and lumbar infections. Almost all cases of cervical infection that can be treated nonoperatively fuse spontaneously (45), as compared with only 50% of all patients with thoracic and lumbar vertebral osteomyelitis treated nonoperatively (19). Human immunodeficiency virus (HIV) status (27) and intravenous drug abuse (59) do not appear to affect the neurologic outcome of patients with spinal infections adversely. Infants with vertebral osteomyelitis (15), elderly patients, and those with underlying disease (58) have a high recurrence rate and a poorer prognosis. Factors that predispose to paralysis include increased age, a subaxial level of infection, and a concomitant disease (diabetes or rheumatoid arthritis) (14). Relapse of infection occurs in up to 25% of cases but is much less common when antibiotics are administered for more than 4 weeks (14,58).

Eismont et al. (14) found that the prognosis for patients with paralysis from cervical spine infection is better with an anterior surgical procedure than with the posterior approach; three of seven patients deteriorated and four remained unchanged after laminectomy. Stone et al. (61) reported that all surgical patients with myelopathy and radiculopathy achieved solid fusion, and at final follow-up, they were ambulatory and neurologically intact. When doubt exists regarding the reversibility of a spinal cord lesion, perform a decompression. Recovery from paralysis has been noted in patients who underwent decompression as late as 5 months after the onset of weakness (47).

## EPIDURAL ABSCESS

### *Diagnosis*

Epidural abscess is rare but potentially devastating. In a series of 25 epidural infections, the cervical spine was noted to be involved in 13. Three were multifocal (cervical and thoracic) (54). Cervical epidural abscess may occur via hematogenous spread from a remote location or from a contiguous focus of vertebral osteomyelitis, or by direct inoculation at the time of operation or injection.

The peak incidence of spinal epidural abscess is in the sixth and seventh decade of life, and there is a high incidence in patients who are intravenous drug abusers, so comorbid conditions may impair immunocompetence (29). Even though most epidural abscesses are seen after invasive processes that violate the epidural space, there are reports of multifocal abscesses when systemic infection is the cause of the abscess (7).

Anatomically, the epidural space is not a uniform space (10). Some areas are filled with fat and veins, and others are in direct contact with bone or ligament, creating individual metameric segments. In the cervical spine, except for a space dorsal to the origin of the spinal nerves, the epidural space is mostly a potential space. Individual metamers are septated, preventing free communication between the anterior and posterior epidural space (30). Because the majority of epidural abscesses from hematogenous spread are located posteriorly (29), they do not involve the anterior epidural space or circumferentially surround the thecal sac. Conversely, postsurgical cases or cases associated with discitis or vertebral osteomyelitis not only involve the anterior epidural space but may be circumferential because of the common postsurgical disruption of normal anatomic septations (41).

To diagnose epidural abscess, MRI with contrast is the modality of choice. False-negative results may occur with nonenhanced MRI, especially with extensive abscesses that do not have a discrete proximal or distal extent (20). Concomitant meningitis may also cause signal changes in the abscess that may be similar to infected cerebral spinal fluid, resulting in a false-negative magnetic resonance imaging MRI scan (51). Myelography and CT are sensitive for confirming the presence and extent of an extradural compressive lesion but should be avoided if epidural abscess is suspected because dural puncture risks spreading the infection to the intrathecal compartment. There is also a small but real risk of causing an acute neurologic deterioration owing to resultant spinal coning if lumbar puncture is performed caudal to a spinal block (41). Owing to the frequently rapid evolution of the disease process and associated illnesses, the mortality rate is as high as 20% (29). In cases in which MRI is not readily available, CT with myelography should be performed because, despite the increased risk, confirmation of the diagnosis should not be delayed.

### *Treatment*

Management of spinal epidural abscess is based on the clinical condition of the patient. Medical management is often successful in the treatment of lumbar epidural abscess, but cervical epidural abscess presents an increased risk to the spinal cord. Indications for nonoperative treatment of spinal epidural abscess are

- Poor surgical candidates due to severe concomitant medical problems
- Patients with abscess involving a considerable length of the spinal canal (cervical to lumbar) and who have epiduritis but a normal neurologic examination
- Patients with normal spinal cord or cauda equina function

- Patients with complete paralysis for more than 3 days (38)

Medical treatment involves 8 to 12 weeks of intravenous antibiotics. Close monitoring with hospitalization and numerous MRIs is needed. The disadvantages of medical treatment are that neurologic deterioration can be precipitous, and once present, the deficits may be irreversible. We recommend aggressive surgical management of cervical epidural abscesses. When surgical drainage is performed and osteomyelitis is not present, shorter courses of intravenous antibiotics (less than 4 weeks) have been successful (11).

When epidural abscesses are located posteriorly, laminectomy is the most effective approach for decompression. The extent of the exposure is determined by the operative findings. If purulent material is found (acute infection), a limited approach can be used (see case example, Fig. 151.11). In chronic infection, dense granulation tissue is present; decompress the full extent of the abscess. Stabilization is usually not necessary.

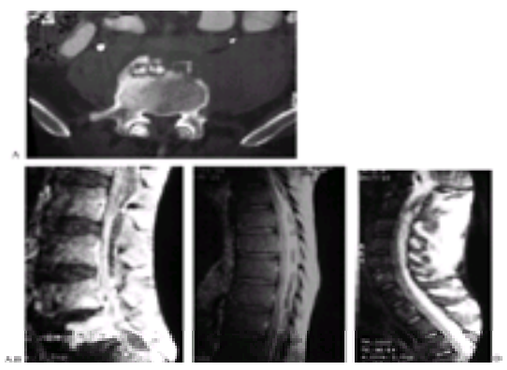

***Figure 151.11.*** A case of epidural abscess formation leading to severe cervical spinal cord impingement. A 45-year-old homeless patient with increasing low back pain for months, fevers, and chills. The patient failed to seek treatment and finally presented with severe progressive neurologic deficit and respiratory difficulties. **A:** Lumbar spine CT scan showing anterior sequestra. **B:** Lumbar MRI showing vertebral osteomyelitis and massive epidural abscess. **C:** Thoracic MRI showing massive posterior epidural abscess involving at least 50% of spinal canal. **D:** Cervical MRI showing massive posterior epidural abscess with almost 75% involvement of the spinal canal at the level of C-2. The probable start of the infection was lumbar discitis and vertebral osteomyelitis that progressed to epidural extension and eventual marked spinal cord compression. Treatment was limited cervical laminectomy. After the cervical laminectomy, the patient was placed in Trendelenberg position, with massive drainage of the thoracic and lumbar pus. Postoperatively, the patient had significant but partial neurologic recovery. The patient was lost to follow-up.

Anterior epidural infections are usually associated with discitis or osteomyelitis and should be approached anteriorly (29). If the patient has discitis, osteomyelitis, and instability, anterior debridement and reconstruction can be carried out without formal excision of the granulation tissue formed by the abscess. Incise the posterior longitudinal ligament to allow evacuation of purulent material. If cord compression is symptomatic, complete exposure of the granulating abscess is necessary to allow excision of this dense, tenacious material from the thecal sack. Extreme caution is advised.

- Remove necrotic disc and endplate material, and resect diseased bone back to healthy, bleeding vertebral bone. If only the endplate and less than half of the body remain at any level, resect the remnant and extend to the next disc space.
- Use a micropituitary and small curet to fenestrate the posterior longitudinal ligament (PLL) laterally. Use small Kerrison rongeur to expand the window, and resect a portion of posterior vertebral rim.
- If there are no signs of cord compression, drain any purulent material, gently irrigate, and proceed with stabilization. If there are signs of cord compromise, carefully resect the posterior vertebral cortex and PLL over the length of the lesion to provide full decompression.
- If the thickened granulation tissue is to be removed from the surface of the cord, magnification is necessary.
- Carefully develop the interval between the abscess and thecal sack with Roton dissectors and a nerve hook.
- Monitor spinal cord function constantly.
- Once the mass is debulked and cultures obtained, irrigate with antibiotic solution and stabilize the resected segment with an autograft strut.
- Stabilize in a halo. Do not use implants in the presence of deep infection.

### *Outcomes of Treatment of Epidural Infection*

As previously stated, the prognosis for patients with cervical epidural abscess is not as favorable as that for thoracic and lumbar infections. The mortality rate with cervical abscess was reported to be as high as 38% despite aggressive treatment, and the neurologic deficits were more severe and refractory to treatment (20). Diabetes, HIV infection (20,33), and vertebral osteomyelitis (28) are associated conditions that carry a poor prognosis. Reporting on predominantly cervical and cervicothoracic epidural abscesses, Redekop and Del Maestro (54) reported a 20% mortality rate, and only 56% retained or recovered ambulation. They attribute the high morbidity and mortality rates to delay in diagnosis and treatment, which has been shown to be a factor in all epidural abscesses. Reporting on all locations of epidural abscesses, no patients with paralysis for longer than 36 hours recovered significant neurologic function (22,28,29), and only 40% of patients who initially had less than antigravity strength were eventually ambulatory and continent despite surgical intervention within 36 hours (56). If rapid acute progressive paraplegia occurs within the first 12 hours, prognosis is poor, presumably secondary to spinal cord infarction rather than mechanical compression (33).

## CHAPTER REFERENCES

Each reference is categorized according to the following scheme: *, classic article; #, review article; !, basic research article; and +, clinical results/outcome study.


# 1. Akbarnia BA, Merenda JT. Benign Tumors of the Spine. In: *Spine: State of the Art Reviews,* Vol 10, No 1. Philadelphia: Hanley & Belfus, 1996.

+ 2. Atanasiu JP, Badatcheff F, Pidhorz L. Metastatic Lesions of the Cervical Spine. A Retrospective Analysis of 20 Cases. *Spine* 1993;18:1279.

# 3. Boriani S, Capanna Donati D, Levine A. Osteoblastoma of the Spine. *Clin Orthop* 1992;278:37.

# 4. Boriani S, Chevalley F, Weinstein JN, et al. Spine Update: Primary Bone Tumors of the Spine: Terminology and Surgical Staging. *Spine* 1997;22:1036.

+ 5. Capanna R, Albisinni U, Picci P, et al. Aneurysmal Bone Cyst of the Spine. *J Bone Joint Surg [Am]* 1985;67:527.

+ 6. Carson HJ, Castelli MJ, Reyes CV, Gattuso P. Fine-needle Aspiration Biopsy of Vertebral Body Lesions: Cytologic, Pathologic, and Clinical Correlations of 57 Cases. *Diagn Cytopathol* 1994;11:348.

+ 7. Chow GH, Gebhard JS, Brown CW. Multifocal Metachronous Epidural Abscesses of the Spine. A Case Report. *Spine* 1996;21:1094.

+ 8. Coleman JJ. Reconstruction of the Pharynx and Cervical Esophagus. *Semin Surg Oncol* 1995;3:208.

# 9. Currier BL, Heller JG, Eismont FJ. Cervical Spinal Infections. In: *The Cervical Spine,* 3rd ed. The Cervical Spine Research Society Editorial Committee. Philadelphia: Lippincott-Raven, 1998.

+ 10. Dandy WE. Abscesses and Inflammatory Tumors in the Spinal Epidural Space (So-called Pachymeningitis Externa). *Arch Surg* 1926;13:477.

# 11. Danner RL, Hartman BJ Update of Spinal Epidural Abscess: 35 Cases and Review of the Literature. *Rev Infect Dis* 1987;9:265.

+ 12. Del Curling O Jr, Grower DJ, McWhorter JM. Changing Concepts in Spinal Epidural Abscess: A Report of 29 Cases. *Neurosurgery* 1990;27:185.

# 13. Dietze DD Jr, Fessler RG, Jacob RP. Primary Reconstruction for Spinal Infections. *J Neurosurg* 1997;86:981.

* 14. Eismont FJ, Bohlman HH, Soni PL, et al. Pyogenic and Fungal Vertebral Osteomyelitis with Paralysis. *J Bone Joint Surg [Am]* 1983;65:19.

+ 15. Eismont FJ, Bohlman HH, Soni PL, et al. Vertebral Osteomyelitis in Infants. *J Bone Joint Surg [Br]* 1982;64:32.

+ 16. Eismont FJ, Green BA, Brown MD, GhandourMnaymneh L. Coexistent Infection and Tumor of the Spine. A Report of Three Cases. *J Bone Joint Surg [Am]* 1987;69:452.

+ 17. Feiglan D, Modic M, Piraino D, et al. Evaluation of MRI and Nuclear Medicine in Spinal Infection—a Reappraisal. *J Nucl Med* 1985;26:672.

# 18. Forsythe M, Rothman RH: New Concepts in the Diagnosis and Treatment of Infections of the Cervical Spine. *Orthop Clin North Am* 1978;9:1039.

* 19. Frederickson B, Yuan H, Orlans R. Management and Outcome of Pyogenic Vertebral Osteomyelitis. *Clin Orthop* 1978;131:160.

* 20. Gardner RD, Cammisa FP, Eismont FJ, Green B. Nongranulomatous Spinal Epidural Abscesses. *Orthop Trans* 1989;13:562.

* 21. Ghanayem AJ, Zdeblick TA. Cervical Spine Infections. *Orthop Clin North Am* 1996;27:53.

+ 22. Hakin RN, Burt AA, Cook JB. Acute Spinal Epidural Abscess. *Paraplegia* 1979;17:330.

+ 23. Harrington KD. Current Concepts Review—Metastatic Disease of the Spine. *J Bone Joint Surg [Am]* 1986;68:1110.

+ 24. Harrington KD. The Use of Methylmethacrylate for Vertebral Body Replacement and Anterior Stabilization of Pathological Fracture Dislocations of the Spine due to Metastatic Disease. *J Bone Joint Surg* 1981;63A:36.

* 25. Hart RA, Boriani S, Biagini R, et al. A System for Surgical Staging and Management of Spine Tumors. A Clinical Outcome Study of Giant Cell Tumors of the Spine. *Spine* 1997;22:1773.

# 26. Hay MC, Patterson D, Taylor TKF. Aneurysmal Bone Cysts of the Spine. *J Bone Joint Surg* 1978;60A:406.

+ 27. Heary RF, Hunt CD, Krieger AJ, Vaid C. HIV Status Does Not Affect Microbiologic Spectrum or Neurologic Outcome in Spinal Infections. *Surg Neurol* 1994;42: 417.

# 28. Heusner AP. Nontuberculosis Spinal Epidural Infections. *N Engl J Med* 1948;239:845.

# 29. Hlavin ML, Kaminski HJ, Ross JS, Ganz E. Spinal Epidural Abscess: A 10-year Prospective. *Neurosurgery* 1990;27:177.

! 30. Hogan QH: Lumbar Epidural Anatomy: A New Look by Cryomicrotome Section. *Anesthesiology* 1991;75:767.

+ 31. Honma G, Murota K, Shiba R, Hidemaru K. Mandible and Tongue-splitting Approach for Giant Cell Tumor of Axis. *Spine* 1989;14:1204.

+ 32. Koppel BS, Tuchman AJ, Mangiardi JR. Epidural Spinal Infection in Intravenous Drug Abusers. *Arch Neurol* 1988;45:1331.

+ 33. Kurz L, Pursel S, Herkowitz H. Modified Anterior Approach to the Cervicothoracic Junction. *Spine* 1991;16(suppl):2.

+ 34. Laus M, Pignatti G, Malaguti MC, et al. Anterior Extraoral Surgery to the Upper Cervical Spine. *Spine* 1996;21:1687.

# 35. Levine AM. Operative Techniques for Treatment of Metastatic Disease of the Spine. *Semin Spine Surg* 1990;2:21.

# 36. Levine AM, Boriani S. Benign Tumors of the Cervical Spine, 3rd ed. The Cervical Spine Research Society Editorial Committee. Philadelphia: Lippincott-Raven, 1998:621.

* 37. Levine AM, Boriani S, Donati D, Campanacci M. Benign Tumors of the Cervical Spine. *Spine* 1992;17:S399.

+ 38. Leys D, Lesion F, Viaud C, et al. Decreased Morbidity from Acute Bacterial Spinal Epidural Abscesses Using Computed Tomography and Nonsurgical Treatment in Selected Patients. *Ann Neurol* 1985;17:350.

* 39. Manasse AM, Van Gilder JC. Transoral-transpharyngeal Approach to the Anterior Craniocervical Junction. *J Neurosurg* 1988;69:895.

* 40. Mankin HJ, Mankin CJ, Simon MA. The Hazards of the Biopsy, Revisited. *J Bone Joint Surg [Am]* 1996;78:656.

# 41. Martin RJ, Yuan HA. Neurosurgical Care of Spinal Epidural, Subdural, and Intramedullary Abscesses and Arachnoiditis. *Orthop Clin North Am* 1996;27:125.

* 42. McAfee PC, Bohlman HH, Ducker T, Eismont FJ. Failure of Stabilization of the Spine with Methacrylate. A Retrospective Analysis of Twenty-four Cases. *J Bone Joint Surg [Am]* 1986;68:1145.

* 43. McAfee PC, Bohlman HH, Riley LH, et al. The Anterior Retropharyngeal Approach to the Upper Part of the Cervical Spine. *J Bone Joint Surg [Am]* 1987;69:1371.

+ 44. McGuire RA, Eismont FJ. The Fate of Autogenous Bone Graft in Surgically Treated Pyogenic Vetebral Osteomyelitis. *J Spinal Disord* 1994;7:206.

+ 45. Messer HD, Litvinoff J. Pyogenic Cervical Osteomyelitis. Chondro-osteomyelitis of the Cervical Spine Frequently Associated with Parenteral Drug Use. *Arch Neurol* 1976;33:571.

+ 46. Modic MT, Feiglin DH, Piraino DW. Vertebral Osteomyelitis: Assessment Using MR. *Radiology* 1985;157: 157.

! 47. Norris S, Ehrlich MG, McKusick K. Early Diagnosis of Disk-space Infection with 67Ga in an Experimental Model. *Clin Orthop* 1979;144:293.

+ 48. Ono K, Yonenobu K, Ebara S, et al. Prosthetic Replacement Surgery for Cervical Spine Metastasis. *Spine* 1988;13:817.

# 49. Phillips E, Levine AM. Metastatic Lesions of the Upper Cervical Spine. *Spine* 1989;14:1071.

# 50. Pollack MR, Seiman LP. Aneurysmal Bone Cyst in the Pediatric Spine. *Orthop Grand Rounds* 1986;3:2.

+ 51. Post MJD, Quencer RM, Montalvo BM, et al. Spinal Infection: Evaluation with MR Imaging and Intraoperative US. *Radiology* 1988;169:765.

* 52. Rao S, Badani K. Cervical Metastases. *J Bone Joint Surg* 1994;53A:5511.

# 53. Rao S, Davis RF. *Cervical Spine Metastases,* 3rd ed. The Cervical Spine Research Society Editorial Committee. Philadelphia: Lippincott-Raven, 1998:603.

# 54. Redekop GJ, Del Maestro RF. Diagnosis and Management of Spinal Epidural Abscess. *Can J Neurol Sci* 1992;19:180.

+ 55. Redfern RM, Miles J, Banks AJ, et al. Stabilization of the Infected Spine. *J Neurol Neurosurg Psychiatry* 1988;51:803.

+ 56. Rigamonti D, Liem L, Wolf AL, et al. Epidural Abscess in the Cervical Spine. *Mt Sinai J Med* 1994;61:357.

# 57. Rothman-Simeone XX. Infections, 4th ed. In: Herkowitz et al. *The Spine.* Philadelphia: W. B. Saunders Co., 1999:1224. Infections chapter 1207-1258. Tumors p1171-1206.

+58. Sapico FL, Montgomerie JZ. Pyogenic Vertebral Osteomyelitis: Report of Nine Cases and Review of the Literature. *Rev Infect Dis* 1979;1:754.

+59. Sapico FL, Montgomerie JZ. Vertebral Osteomyelitis in Intravenous Drug Abusers: Report of Three Cases and Review of the Literature. *Rev Infect Dis* 1980;2:196.

+ 60. Seifert V, van Krieken FM, Bao SD, et al. Microsurgery of the Cervical Spine in Elderly Patients. Part 2: Surgery of Malignant Tumorous Disease. *Acta Neurochir (Wien)* 1994;131:241.

# 61. Stone JL, Cybulski GR, Rodriguez J, et al. Anterior Cervical Debridement and Strut-grafting for Osteomyelitis of the Cervical Spine. *J Neurosurg* 1989;70:879.

+ 62. Sundaresan N, Shah J, Feghall J. The Trans-sternal Approach to the Upper Thoracic Vertebra. *Am J Surg* 1984;198:473.

+ 63. Whalen JL, Brown ML, McLeod R, Fitzgerald RH Jr. Limitations of Indium Leukocyte Imaging for Diagnosis of Spine Infections. *Spine* 1991;16:193.

* 64. Whitesides TE Jr, Kelly RP. Lateral Approach to the Upper Cervical Spine for Anterior Fusion. *South Med J* 1966;59:879.

+ 65. Zigler JE, Bohlman HH, Robinson RA, et al. Pyogenic Osteomyelitis of the Occiput, the Atlas, and the Axis: A Report of Five Cases. *J Bone Joint Surg [Am]* 1987;69:1069.

# CHAPTER 152

# TUMORS OF THE SPINE

*Robert F. McLain*

**R. F. McLain:** Department of Orthopaedics, The Cleveland Clinic Foundation, Cleveland, Ohio, 44195.

Diagnosis
- Incidence and Presentation
- Presenting Symptoms

Evaluation
- Imaging
- Biopsy

Tumor Types
- Primary Tumors
- Benign Primary Tumors
- Malignant Primary Tumors
- Metastatic Disease
- Pediatric Tumors

Treatment
- Indications for Surgery
- Treatment of Metastatic Spinal Tumors
- Treatment of Benign Tumors
- Treatment of Primary Malignant Tumors

Author's Perspective
Chapter References

Appropriate, timely surgical treatment can increase survival and improve the quality of life for many patients with spinal column tumors. The goals of treatment are pain relief, improved function, and the best possible chance of local control and cure of the disease. Aggressive surgical approaches, combined with improved adjuvant therapy, now offer good short-term and long-term outcomes for many lesions previously thought untreatable or unresectable.

## DIAGNOSIS

### INCIDENCE AND PRESENTATION

Spinal column tumors, malignant and benign, occur in all age groups and at all levels of the spine. Primary tumors can arise from any of the hard or soft tissues of the spinal column, or they can extend directly to the spinal column from contiguous paraspinal lesions. Metastatic tumors, which migrate from distant sites by either lymphatic or hematogenous routes, account for 97% of all spinal column tumors.

Spinal metastases are common among patients with adenocarcinoma. Between 50% and 70% of all patients with carcinoma develop skeletal metastases during the course of their disease, as do 85% of women with breast cancer (9,25,34). The spine is the most common site for these metastases. The most common metastatic lesions are adenocarcinomas from the following:

- Lung
- Breast
- Prostate
- Kidney
- Gastrointestinal tract
- Thyroid

Certain primary tumors, such as chordoma, osteoblastoma, and plasmacytoma, show a preference for the spinal column, but they represent a small proportion of all spinal lesions.

Because of the preponderance of metastatic disease, spinal lesions in all age groups are more likely to be malignant than benign. This is particularly true in adult patients, where an increasing incidence of metastatic disease, an increased risk of systemic diseases such as myeloma and lymphoma, and a greater likelihood of having a malignant primary tumor combine to present a particularly grim prognosis. Seventy percent of primary spine tumors in patients over 25 are malignant, compared with only 30% in patients under 21 years of age (73).

Both primary and metastatic malignancies tend to originate in the vertebral body, involving one or both pedicles. The vertebral body contains most of the bone, hematogenous marrow, and cartilage from which primary lesions arise, and the notochordal rests that give rise to chordoma. Most of the *hematogenous* marrow is also contained in the bodies. Finally, retrograde flow through the venous drainage of the spinal column (Batson's plexus) permits tumor cells from the abdominal cavity to seed the vertebral bodies directly (29). Lesions of the posterior elements are more commonly benign.

### PRESENTING SYMPTOMS

Back pain is common and nonspecific, and it is ubiquitous in the age group most at risk for spinal tumors. Whereas idiopathic back pain is typically mechanical, activity related, and self-limiting, neoplastic pain is more often

- progressive and unrelenting,
- unrelated to activity and unresponsive to rest,
- well localized to the spinal segment involved,
- reproduced by palpation or percussion over the involved area,
- and more severe or disturbing at night.

Pain and neurologic dysfunction are the most common presenting symptoms and usually arise from one of the following causes:

- Pathologic fracture
- Expansion of the vertebral cortex and surrounding tissues by tumor
- Compression or invasion of nerve roots
- Segmental instability
- Spinal cord compression

Rapid progression of pain or neurologic symptoms occurs with more aggressive, malignant tumors, whereas symptoms that progress over years are typical of slow-growing and often benign processes. Spine tumor patients most often present with pain. Common presenting symptoms occur as follows:

- Eighty-five percent of spine tumor patients present with pain.
- Back pain is the only symptom in 30%.

- Leg pain is the only symptom in 10%.
- Twenty-eight percent present with a combination of pain and neurologic deficit.
- Forty-two percent of all patients have a neurologic deficit at presentation.
- Sixteen percent have a mass or deformity.
- Spinal tumor is an incidental finding in 2% of patients.

Although radicular symptoms may simulate herniated nucleus pulposis, symptoms from lumbar and sacral neoplasms do not respond to rest and recumbency, and they tend to progress relentlessly (62).

Spinal deformity is rarely associated with spinal neoplasia, except when vertebral collapse results in severe kyphosis. Osteoid osteoma and osteoblastoma may produce a scoliosis that is typically painful, with localized pain, muscle spasm, and limited motion. Deformities associated with tumors may come on suddenly and progress rapidly. Unless addressed early on, these curves will become structural and difficult to manage (35). If the primary lesion is addressed in a timely manner, the curve will often resolve with observation or bracing. However, if the deformity is allowed to persist, surgical correction may be necessary (50).

To make the diagnosis before neurologic symptoms arise, the physician must be alert to any patient with persistent, nonmechanical back pain, age- or activity-related risk factors, or, particularly, a previous history of malignancy (23). Although neurologic injury is rarely the first sign of a spinal neoplasm, it may be present in as many as half of patients by the time they seek medical attention, and they may be recognized in more than 70% by the time a diagnosis is made.

The basic workup of any spine tumor includes the following:

- Complete blood cell count (CBC), differential, sedimentation rate, urinalysis, electrolytes, calcium, and basic chemistry panel
- Serum and urine protein electrophoresis; if positive, bone survey and bone marrow aspirate
- Renal ultrasound or abdominal computed tomography (CT)
- Chest CT
- Bone scan
- Physical exam: breasts, prostate, rectal, stool guaiac, thyroid

## EVALUATION

### IMAGING

#### *Plain Roentgenograms*

Standard anteroposterior and lateral roentgenograms of the spine still represent the most practical first study for patients with suspected spinal tumor. Good-quality studies of the symptomatic spinal segment may be sufficient to define the characteristic changes of bone destruction and tumor expansion, and they may establish a specific diagnosis in some tumor types. Plain roentgenograms will demonstrate abnormalities in 80% to 90% of patients with a spinal neoplasm (73,74). Even when the precise tumor type cannot be identified, the benign or malignant nature of the lesion can often be implied from the pattern of bone destruction (Fig. 152.1*A*, Fig. 152.1*B*).

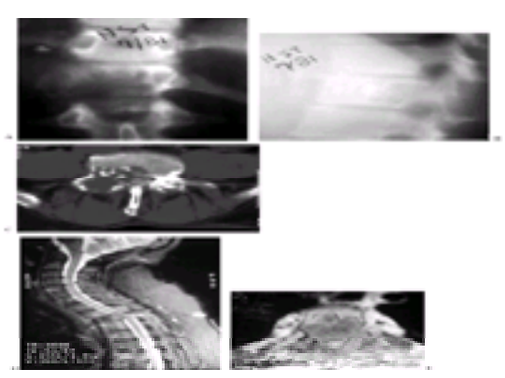

***Figure 152.1.*** The 35-year-old patient in (**A**) and (**B**) has giant cell tumor of the T-12 vertebral body. AP (**A**) radiograph shows a classic “winking owl” sign, suggesting destruction of the left pedicle by tumor. The lateral view (**B**) shows a rarified vertebral body with a geographic pattern of bony replacement. In a patient with metastatic renal carcinoma, CT demonstrates bony destruction and expansion of the anterior vertebral cortex (**C**). Sagittal (**D**) and transverse (**E**) MRIs showing vertebral destruction, collapse, and cord compression caused by a breast metastasis to the T-3 vertebral body.

#### *Nuclear Scans*

Technetium bone scans screen for bony turnover that can detect the presence of tumors before they become apparent on plain films. Because roentgenographic evidence of bony destruction is not apparent until after 30% to 50% of the trabecular bone has been demineralized or destroyed, bone scans are far more sensitive for picking up early involvement (17).

#### *Computed Tomography*

Computed tomography may provide diagnostic information on small tumor foci early in their development, before extensive bony destruction or intramedullary extension has occurred, and before cortical erosion has advanced to the point of impending fracture. CT is time consuming and not suitable for screening large segments of the spine. Once the suspected lesion is identified on plain films or bone scan, however, CT provides unsurpassed imaging of the bony architecture (Fig. 152.1*C*). It may also demonstrate characteristic features of soft-tissue calcification or trabecular remodeling, which may be pathognomonic for some types of tumors.

#### *Magnetic Resonance Imaging*

Magnetic resonance imaging (MRI) is noninvasive, safe, and readily available to most patients. It provides multiplanar images of large segments of the spine and surrounding tissues and can be used to screen for disseminated disease. MRI delineates soft-tissue extension from other processes, and newer techniques can accurately differentiate tumor from hematoma, edema, and inflammation (Fig. 152.1*D*, Fig. 152.1*E*). MRI directly images the spinal cord, cauda equina, and nerve roots without the aid of intrathecal contrast (24). It can reveal invasion of paravertebral structures better than either CT or myelography, and with gadolinium enhancement it can differentiate osteoporotic compression fractures from metastatic disease (13). Characteristics of tumors on MRI are (a) convex posterior cortex, (b) epidural mass, (c) low-intensity T1 signal, (d) high or inhomogenous T2 signal intensity, (e) high-intensity signal after gadolinium injection (13,69).

#### *Myelography*

Previously the gold standard for spinal imaging, this test has been largely replaced by MRI. When MRI cannot be done, myelography with postmyelogram CT may provide the same information.

### BIOPSY

There are three basic approaches to biopsy, each with advantages and disadvantages:

1. Percutaneous needle or trocar biopsy allows aspiration and removal of fine tissue fragments; the advantages are that needle biopsy is minimally invasive and uses local anesthetic. It is most suitable for lesions that are easily differentiated. Because samples are small, they are difficult to read, and they are frequently not diagnostic. When the differential diagnosis is limited to lesions that are easily distinguished histologically, needle biopsy is ideal (Fig. 152.2).

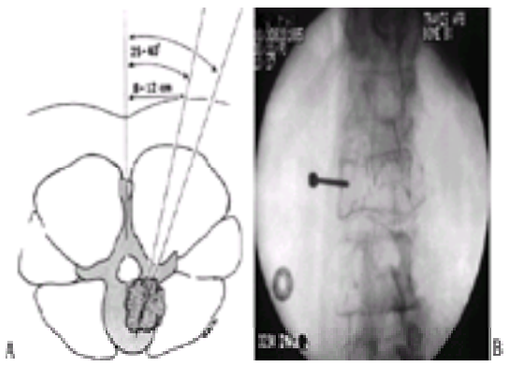

***Figure 152.2.*** **A:** Percutaneous needle biopsy of the thoracolumbar spine is performed through a posterior, percutaneous route. The needle is positioned 8–12 cm lateral of the midline at the level of the documented lesion. By advancing the needle at a 30° to 45° angle, under fluoroscopic control, the posterolateral aspect of the vertebral body is targeted. **B:** Alternatively, a small posterior exposure is made over the documented lesion, and a burr is used to take down the cortex overlying the pedicle. A Craig needle or a small curet is then passed down the pedicle to harvest bone and tumor from the vertebral body.

2. Open, incisional biopsy provides moderate-size specimens showing cellular architecture and marginal tissue. It provides diagnostic tissue and may be done just prior to formal excision when used with frozen section. Place the incision so it can be excised with the definitive procedure. Carry out the incisional biopsy as the last step in tumor staging, just before or at the time of definitive resection. The incision must be longitudinal, never transverse. Handle the tissues gently, and provide meticulous hemostasis to prevent tumor spread. Take a section of tissue large enough to allow histologic and ultrastructural analysis as well as immunologic staining from the margin of the lesion (central sections may be necrotic). Take the specimen with a sharp scalpel and be careful not to crush or distort the tissue during harvest. Avoid using electrocautery on the biopsy specimen itself.
3. Open, excisional biopsy includes removal of all tumor tissue at the time of biopsy. It provides complete treatment of local disease. Few tumors are suitable, however; the surgeon must already have a good idea of the diagnosis to plan appropriate excision.

## HINTS AND TRICKS

Because of the possibility of catastrophic hemorrhage, renal cell metastases must be approached more cautiously than most other tumors, although metastatic thyroid, melanoma, and some breast lesions may also be highly vascular (67). An abdominal ultrasound or CT will reveal the primary renal lesion before the surgeon performs a biopsy that may lead to uncontrollable bleeding. Preoperative angiography will reveal the extensive neovasculature often associated with these tumors, allowing embolization of abnormal vessels and nonessential segmental arteries.

## TUMOR TYPES

### PRIMARY TUMORS

Primary tumors make up less than 3% of all spinal lesions. Survival rates are most directly, but not entirely, related to tumor type; some low-grade lesions may permit a long survival despite their malignant nature, whereas some histologically benign lesions may prove lethal because of their location in the spine.

### BENIGN PRIMARY TUMORS

#### *Osteochondroma*

Vertebral involvement occurs in approximately 7% of osteochondromas, but symptomatic lesions are rare. Eighty percent of symptomatic osteochondromas occur in the cervicothoracic spine, above T-6 (41). MRI demonstrates the radiolucent cartilage cap, which usually causes spinal cord compression. Excision of the tumor, *en bloc* or piecemeal, provides reliable neurologic recovery with little risk of recurrence. Enchondromas rarely produce any symptoms but may prove a diagnostic dilemma when encountered incidentally. Enchondromas develop a well-defined, benign-appearing cortical margin, but calcific stippling of the lesion may suggest chondrosarcoma, prompting an excisional biopsy (46).

#### *Osteoid Osteoma and Osteoblastoma*

Osteoid osteoma and osteoblastoma are benign neoplastic lesions frequently found in the spine, originating in or from the posterior vertebral elements (35,43). Symptoms in the spine are similar to extremity lesions (see Chapter 127), except for the occasional development of a painful scoliosis.

Because osteoid osteoma is often obscured by the overlying shadows of the vertebral body, it is most readily localized by bone scan. Excision of the lesion reliably and immediately relieves the patient's pain. The key to successful treatment is accurate localization of the tumor nidus, confirmed by directed CT of the area. Osteoblastoma is considerably larger than the 2 cm osteoid osteoma; it is characterized by the expansion of the overlying cortical bone and a thin rim of reactive bone among the trabeculae. When complete excision of the osteoblastoma is not feasible, curettage and bone grafting may provide an acceptable long-term result (27,43). Scoliosis related to these lesions is often flexible and will usually improve or resolve after the lesion is removed. Instrumentation and fusion of the curve may be required if the scoliosis has been present for a long period and has become structural. Corrective surgery may be planned after the patient has recovered from the tumor surgery and has had a chance to improve spontaneously.

#### *Hemangiomas*

Magnetic resonance imaging shows that vertebral hemangiomas are common, occurring in approximately 10% of all adults. Fortunately, only a small proportion are ever symptomatic. Reports of deformity or pain associated with hemangioma are rare, and surgeons should hesitate before attributing mechanical or chronic pain symptoms to these lesions. Asymptomatic hemangiomas rarely develop into symptomatic ones, and follow-up is unnecessary (19). Plain radiographs typically show vertical striations indicative of thickened trabeculae within the involved vertebral body, and CT usually demonstrates these same trabeculae dotting the region of the lesion. These lesions often respond to radiotherapy or vascular embolization alone. If vertebral collapse or neural compression occurs, surgical decompression and reconstruction through an anterior approach are indicated.

#### *Giant Cell Tumor*

Because of the tendency of giant cell tumors to recur, these histologically benign lesions may behave in a far more malignant fashion in the spinal column, resulting in significant mortality as well as morbidity (45,70). Usually seen in the third or fourth decade of life, the tumors appear lucent on plain radiographs, with marginal sclerosis and a geographic pattern of bone destruction. These slow-growing tumors are usually anterior and may expand the surrounding cortical bone as they grow. Some authors have suggested that spinal tumors are less aggressive than extremity lesions (15,56), whereas others have acknowledged the aggressive nature of the tumor in this vulnerable region and have recommended adjuvant irradiation (55) or cryotherapy (42) for local control.

Because of the tendency of giant cell tumors to recur locally, CT and MR imaging are particularly important in planning an operation that will provide as wide a margin as possible. Complete excision is the key to eradicating these tumors (Fig. 152.3). Anterior/posterior vertebrectomy with an *en bloc* excision, followed by a combined reconstruction, limits the likelihood of recurrence and allows the most rapid return to function.

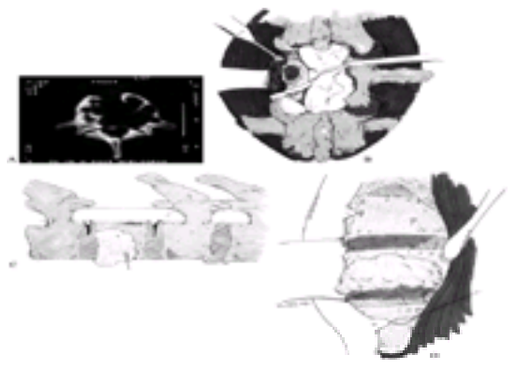

***Figure 152.3.*** Treatment of giant cell tumor. **A:** CT scan showing extensive destruction of L-1 vertebral body. **B:** An aggressive approach is taken to limit the chance of local recurrence. Wide laminectomy over the tumor level allows pedicle resection and release of the posterior annulus. **C:** After the posterior annulus is sectioned, the dorsal instrumentation is applied to stabilize the spine. **D:** An anterior approach allows *en bloc* vertebrectomy by completing the discectomies and removing the tumor with the overlying soft tissues adherent.

### *Eosinophilic Granuloma*

Eosinophilic granuloma is a benign, self-limiting lesion commonly seen in children under the age of 10 years. Vertebral involvement occurs in approximately 15% of all cases and can be associated with any of three syndromes: isolated eosinophilic granuloma, Hand-Schüller-Christian disease, and Letterer-Siwe disease. The classic radiographic presentation is caused by near-complete collapse of the vertebral body, resulting in a vertebra plana, or “coin” lesion (57). Although classic, this appearance is not pathognomonic, and a similar picture can result from either infection or Ewing's sarcoma (51). Once a definitive diagnosis is established, usually by trocar biopsy, the patient may be effectively treated by bracing and observation. Although radiotherapy has been advocated in the past, it can be avoided in most patients.

When neurologic symptoms of eosinophilic granuloma are present, either with or without vertebral collapse, the established course of biopsy followed by irradiation and immobilization remains the most widely accepted (26). Recovery of neurologic function is usually excellent, and some reconstitution of vertebral height is seen in most young patients.

### *Aneurysmal Bone Cyst*

Aneurysmal bone cysts (ABCs) rarely involve the spinal column. When they do, they usually involve the posterior elements and are most commonly seen in the lumbar spine. Radiographs demonstrate an expansile lesion with an osteolytic cavity that may extend across segmental levels to involve two or even three adjacent vertebrae. The cortex is often eggshell thin and blown out, and the cyst contains numerous strands of bone which give the “bubbly” appearance typical of ABCs. Curettage usually eradicates the lesion, and recurrences, which do not tend to invade vital structures, may be successfully treated by repeated curettage or excision (32).

## MALIGNANT PRIMARY TUMORS

### *Chordoma*

Chordoma is a relatively rare lesion arising exclusively in the axial skeleton, most often in the spine and sacrum. The tumor is derived from rests of notochordal tissue residing in the skull base, sacrococcygeal region, and the vertebral segments in between (49). The tumor is characterized by slow but relentless local progression. It metastasizes late, but it has an aggressive tendency to recur at the surgical site, which makes it highly lethal. Although uncommon in children, chordomas are more histologically variable and more clinically aggressive in this age group than in adults (11). Because of their insidious development, chordomas can reach remarkable size before they are recognized. Patients may present after months or even years of progressive pain, sitting intolerance, urinary obstruction, and constipation. Sacrococcygeal tumors are easily detected on rectal examination as firm, fixed lesions displacing the posterior rectal wall.

Surgical resection is the only curative procedure for chordomas. A wide margin is crucial to local control because these lesions are generally unresponsive to radiotherapy and chemotherapy. Whereas only 5% of patients with spinal chordoma develop metastases, nearly 70% will die of their disease, reflecting the seriousness of local tumor extension (3). Intralesional resection is associated with a high rate of local recurrence (82%) and a high mortality (71%) (7). Carry out biopsy of a suspected chordoma through a posterior approach, after all other staging studies are done. Never biopsy a sacral lesion through the rectal vault; violation of the rectal wall necessitates colectomy.

### *Osteosarcoma*

Osteosarcoma of the spine remains an ominous disease—the median survival following diagnosis has ranged from 6 to 18 months, irrespective of surgical approach (1,58,65). When effective local control can be obtained surgically, survival is comparable to that of extremity lesions; fewer than half of all spine patients achieve complete local excision, however (2).

Spinal osteosarcoma usually arises in the vertebral body. Radiographs reveal cortical destruction, soft-tissue calcification, and periosteal reaction. The paraspinal soft-tissue mass may be extensive and may encase or invest the great vessels or other contiguous structures. Intraspinal extension of the soft-tissue mass may result in either cord or cauda equina compression.

Even though cure of osteosarcoma remains elusive, more aggressive treatment protocols have improved overall survival. By combining current adjuvant therapy with extensive anterior/posterior resections, surgeons have provided patients with improved local control, neurologic function, and improved survivals (65,73).

### *Chondrosarcoma*

Approximately 10% of chondrosarcomas arise in the spinal column or sacrum. Resistant to both radiotherapy and chemotherapy, these tumors are slow growing, locally invasive, and difficult to eradicate from the spinal column. Although survival may be prolonged in spite of residual disease, the final prognosis for patients with spinal chondrosarcoma is poor.

Radiographically, chondrosarcoma is characterized by a prominent soft-tissue mass stippled with flocculent calcifications (33). CT and MR imaging are crucial to determining soft-tissue extensions and the potential for surgical resection. Although long-term survivals are occasionally associated with intralesional resection, a wide margin is the most reliable means of local control and cure (59,63).

### *Ewing's Sarcoma*

Ewing's sarcoma may arise in the spine as a primary or a metastatic lesion. Approximately 3.5% of Ewing's lesions are thought to arise in the spinal column primarily. These tumors produce a permeative destructive pattern that can be difficult to discern on plain radiographs, so that the first radiographic finding may be vertebral collapse and vertebra planum (51). Intraspinal extension may produce neurologic symptoms before bony involvement becomes apparent on plain radiographs. MRI will demonstrate the lesion and its extension, as well as showing occasional epidural metastasis that do not involve bone.

Effective therapy for Ewing's sarcoma revolves around a program of multiagent chemotherapy and high-dose radiotherapy. Surgical treatment is indicated to decompress neurologic structures and stabilize the spinal column. Thoracic and thoracolumbar laminectomies should be instrumented to prevent kyphosis (28). Although the prognosis is generally worse than for extremity lesions, encouraging disease-free survival rates have been obtained using current multimodality regimens (28,36).

### *Solitary Plasmacytoma*

Solitary plasmacytoma and multiple myeloma represent two ends to the continuum of B-cell lymphoproliferative diseases. Multiple myeloma is rapidly progressive and

highly lethal, requiring little more than supportive care for spinal involvement. Solitary plasmacytoma may remain localized for years before eventually disseminating. Prolonged survival is possible if local control can be obtained (44).

Solitary plasmacytomas make up only 3% of all plasma cell neoplasms. Whereas spinal involvement in multiple myeloma is associated with a poor 1-year survival rate, patients with solitary plasmacytoma of the spine have a 60% 5-year survival rate (44,71). Although most, if not all, of these lesions will eventually degenerate into disseminated multiple myeloma with a rapidly lethal course, survivals of 20 years or more have been reported.

Plasmacytoma and myeloma are radiosensitive tumors. Surgical treatment is indicated to stabilize the spine and reduce mechanical pain and to decompress neurologic elements in patients with rapidly progressive symptoms. Surgery is also warranted for those patients with recurrent disease or tumors that have not responded to radiotherapy (Fig. 152.4). Follow-up with MRI and serum protein electrophoresis provides the earliest indication of recurrence or dissemination.

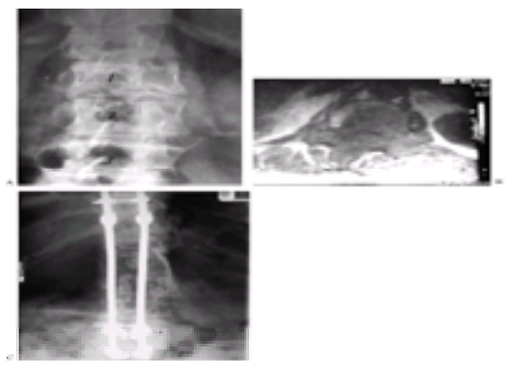

***Figure 152.4.*** **A:** AP radiograph of a 68-year-old woman with solitary plasmacytoma of the T-12 vertebra, refractory to radiotherapy. **B:** MRI shows the extent of the tumor. **C:** Complete anterior/posterior excision was followed by anterior tricortical graft and long segmental instrumentation posteriorly. She was disease free for 5 years before recurrence and dissemination occurred.

### *Lymphoma*

Lymphoma may occur as an isolated lesion or as a focal manifestation of a disseminated disease. As with plasmacytoma, surgical treatment is an adjuvant to systemic therapy and radiotherapy. Surgical decompression is indicated to decompress cord, cauda equina, or nerve root injured by tumor extension or pathologic fracture, and to stabilize damaged spinal segments.

## METASTATIC DISEASE

The vertebral column is predisposed to metastatic disease by its vascular anatomy, its architecture, and its proximity to common sources of disease. The venous drainage of the spine is contiguous with that of the thoracic and abdominal viscera. Retrograde venous flow provides a variety of tumors access to the vertebral body. There, metastatic emboli settle and implant in the capillary end-loops adjacent to the vertebral endplates. The red marrow of the vertebral body provides a physiologically favorable environment for tumor cell proliferation. The vertebral trabecular bone has a rich blood supply, with few barriers to tumor extension; once established, the tumor can grow for some time before it becomes clinically apparent.

Almost any neoplastic process can establish skeletal metastases; however, certain tumors are particularly adept at reaching and surviving in the trabecular environment (Table 152.1). Breast, lung, prostate, and lymphoreticular disease account for approximately 60% of all spinal column metastases requiring treatment. Whether a tumor requires surgical treatment is determined by the behavior of the primary lesion and the metastasis. Patients with breast, prostate, renal, thyroid, or gastrointestinal carcinoma may experience extended survivals with current adjuvant protocols, despite established metastases. Patients with multiple myeloma or pulmonary carcinoma typically deteriorate and die soon after metastasis. Breast, prostate, and renal carcinomas tend to establish spinal metastases early in the disease process, whereas gastrointestinal carcinomas typically seed the liver and lungs first. Hence, patients with breast, prostate, and renal carcinoma tend to live long enough for their spinal metastases to become a specific threat to function and quality of life, while patients with lung carcinoma and myeloma will often die before the spinal metastasis needs more than palliation, and patients with gastrointestinal carcinoma are often more directly affected by their visceral metastases than their skeletal disease.

| *Carcinoma* | *Percent (%) of All Spinal Metastases* |
|---|---|
| Breast | 21 |
| Pulmonary | 14 |
| Prostate | 7.5 |
| Renal | 5.5 |
| Gastrointestinal | 5.0 |
| Thyroid | 2.5 |

***Table 152.1. Trabecular Carcinomas***

## PEDIATRIC TUMORS

Metastatic disease is the most common malignancy of the spine in children; neuroblastoma accounts for nearly one third of all pediatric spinal tumors (20,39). Ewing's sarcoma is the most common primary malignancy, but it is still more often a metastasis than a primary lesion (73). However, 70% of primary pediatric tumors are benign.

### *Neuroblastoma*

Neuroblastoma is an aggressive malignancy that may spread to the spine either by vascular dissemination or by contiguous spread from the primary lesion. Treated with a combination of chemotherapy, radiotherapy, and surgical excision, patients with these tumors have a poor prognosis overall. Those patients that do survive are at high risk of developing a progressive spinal deformity as a result of either rib resection or hemibody irradiation (21,52).

### *Leukemia*

Leukemic infiltrates may occasionally present as the initial finding in a patient with systemic disease. Most of these patients will have back pain, and some may have vertebral collapse at the time of presentation (53). Nonspecific complaints of muscular aches and pains, lethargy, fatigue, and fever, as well as findings of anemia, should prompt a search for the underlying disease. Radiographs are not characteristic: They may show vertebral collapse, focal lytic changes, or sclerotic, geographic lesions, or they may be entirely normal. Bone scan may also be equivocal, but MRI will reliably demonstrate the infiltrate (10).

# TREATMENT

The correct treatment of any tumor depends on a number of factors unique to the individual patient:

- Is the tumor benign or malignant? Primary or metastatic?
- Is the patient systemically ill, or fit?
- Is the tumor slow growing, locally aggressive, or widely disseminated?
- Is there any neurologic compromise?
- Is there a fracture or instability?

The surgeon cannot reliably offer the patient the best treatment until these questions have been answered. See the algorithms for diagnostic workup (Fig. 152.5) and treatment and reconstruction (Fig. 152.6).

***Figure 152.5.*** Diagnostic workup algorithm for spinal tumor. *SCC*, spinal cord compression; *SPEP*, serum protein electrophoresis; *UPEP*, urine protein electrophoresis; *TX*, treatment; *Zones*, see Figure 152.7.

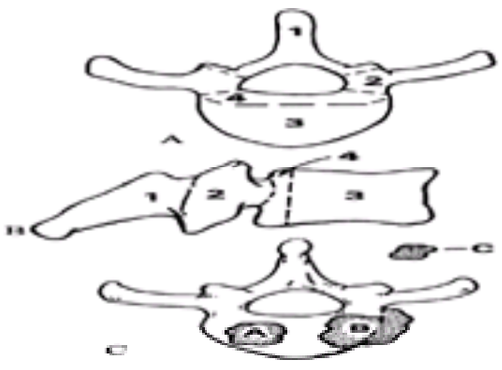

***Figure 152.7.*** Tumor staging. Axial (**A**) and lateral (**B**) views of vertebral body showing four zones of tumor involvement. **C:** Grade A represents intraosseous spread; grade B, extraosseous extension; and grade C, distant metastasis.

***Figure 152.6.*** Treatment and reconstruction algorithm for spinal tumor. *Met*, metastasis.

There is a broad spectrum of medical therapies available to treat spinal tumors, ranging from observation to total spondylectomy (Table 152.2). Both undertreatment and overtreatment can lead to trouble.

| Therapy | Indication |
|---|---|
| Observation | Indolent and slowly benign tumors—hemangioma, osteochondroma, bone island, or infarct |
| Radiotherapy | Metastatic lesions from a known radiosensitive primary, disseminated myeloma, breast carcinoma |
| Chemotherapy | Metastatic lesions from a known chemosensitive primary tumor—deposit, usually with radiotherapy |
| Intralesional excision, curettage | Benign tumors with limited potential for local recurrence—aneurysmal bone cyst, osteoblastoma; and metastatic lesions where local control will be obtained through radiotherapy |
| Marginal excision (with or without adjuvant cryotherapy or radiotherapy) | Locally aggressive benign lesions—giant cell tumor; primary and metastatic lesions sensitive to radiotherapy—solitary plasmacytoma, breast and prostate metastases; and low-grade malignancies—well-differentiated chondrosarcoma |
| Wide excision (modified) | All primary malignancies without known metastases—osteosarcoma, chondrosarcoma, chordoma, solitary metastases with likelihood of prolonged survival—breast, prostate, renal carcinoma; locally aggressive benign tumors—giant cell tumor |

***Table 152.2. Medical Therapies to Treat Spinal Tumors***

A radical margin cannot be achieved in the spinal column because any break in the vertebral ring violates the osseous “compartment.” The necessary cuts through the bony ring could expose normal tissues to contamination even in well-circumscribed tumors. Hemorrhage from the cut bone can carry tumor cells throughout the field, reducing the chance for local control. Once the tumor has extended beyond the vertebral cortex, even a marginal excision may be difficult to obtain. A tumor that adheres to or invades the dura or aorta may prove difficult or impossible to resect, and a tumor that involves the vena cava is usually unresectable. In these cases, the risks of attempting a wide resection with vascular or dural grafting must be weighed against those of following up a marginal excision with adjuvant radiation.

**INDICATIONS FOR SURGERY**

Patients with extensive metastases from a previously documented primary, or with peripheral metastases that can be easily biopsied, may not require any spinal

surgery. Unless there is neurologic impingement or mechanical instability, radiation or chemotherapy can retard tumor progression and control the spinal lesion.

Principal indications for surgical treatment include the following:

- Inability to obtain a tissue diagnosis by other methods
- Neurologic compression due to pathologic fracture or bony impingement
- Mechanical instability, with severe pain or impending neurologic injury
- Tumor progression despite, or following, radiotherapy
- Known radioresistant tumor
- Primary malignant tumor
- Resectable solitary metastasis in patient with potential long-term survival

If the tumor is resistant to radiation therapy, or if the patient suffers from neurologic compromise, spinal in-stability, or collapse, surgical treatment will be needed following biopsy. Three issues must be considered in developing a surgical plan—first, the proper margin of resection (of primary concern in locally aggressive and malignant primary tumors); second, the need for neurologic decompression; and third, the means of reconstruction.

***Resection***

Numerous studies show that the ability to completely resect the primary lesion significantly improves patient survival (4,58,63,73). Even in metastatic lesions, a complete resection can confer improved survival and quality of life (66). In locally aggressive tumors, resect the anterior and posterior longitudinal ligaments, vertebral body, adjacent discs, and the overlying dura, if necessary, to avoid leaving residual tumor behind. It is sometimes necessary to sacrifice one or more nerve roots to provide a suitable margin of excision.

Plan the surgical approach and resection margins using Weinstein's staging system (72), which divides the vertebral body into four zones and three grades of tumor extension (Fig. 152.7):

- Tumors in zones 1, 2, and 3 involve the posterior elements, pedicle and transverse process, and anterior vertebral body, respectively.
- Zone 4 lesions involve the posterior portion of the vertebral body and that portion of the cortex just anterior to the spinal cord or neural elements.
- To address any lesion involving zone 4, the surgeon must cross zone 3 and must release the vertebra from the pedicles, resecting zones 1 and 2 as well.
- Zone 4 lesions frequently require a subtotal or total vertebrectomy to obtain a clean margin. This assumes that the tumor is still intraosseous (grade A), without extraosseous spread (grade B), or distant metastases (grade C).

Computed tomography and MRI provide most of the information needed for staging, with bone scan and serologies added to determine metastatic status. Pay particular attention to the possibility of extraosseous extension—Grade B lesions may prove unresectable if vital structures are directly invested by tumor. The decision to attempt a wide resection in these lesions must be weighed against the risks of vascular or neurologic injury. In some cases, the most prudent approach may be to accept a marginal or intralesional margin, supplementing local treatment with adjuvant radiotherapy or cryotherapy.

Choose the proper surgical approach for the tumor type and location:

- Zone 1 lesions are best approached through a standard posterior incision, with the extent of the incision based on the extent of the soft-tissue mass, if any.
- Zone 2 lesions require a posterolateral approach (Fig. 152.8). The laminectomy and bone resection necessary for tumor excision generally results in some degree of segmental instability, and posterior instrumentation and fusion is usually necessary.

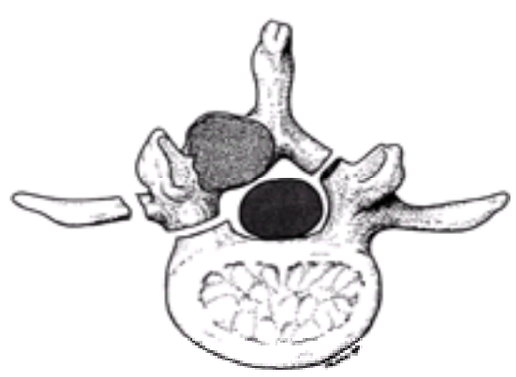

***Figure 152.8.*** Resection of zone 2 lesion. Posterolateral approach allows access to uninvolved lamina on contralateral side along with uninvolved ipsilateral pedicle. A marginal margin is obtainable if the pedicle is free of tumor.

- Zone 3 lesions can often be addressed through an anterior approach alone.
- 3A lesions can be adequately resected at any level of the spine, but 3B lesions may present different challenges at different levels. Depending on the extent of resection, a formal reconstruction may or may not be necessary.
- Zone 4 lesions require a combined surgical approach if a marginal or wide margin is to be obtained. Zones 1, 2, and/or 3 must be crossed to gain access to the zone 4 lesion, and more than one zone is usually involved with the tumor.
- Complete resection of the vertebral body requires separating the posterior structures (zones 1 and 2) from the anterior structures (zones 3 and 4), at the junction between the pedicles and the vertebral body (Fig. 152.9).

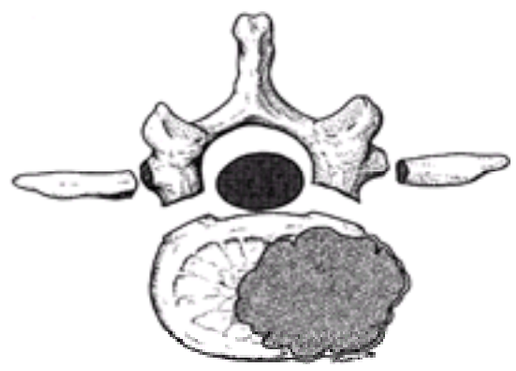

***Figure 152.9.*** A zone 4 lesion *en bloc* excision of the involved thoracolumbar vertebra.

The standard approach to vertebrectomy combines a midline posterior incision with either a retroperitoneal, a thoracoabdominal, or a transthoracic approach to the anterior vertebral body. An alternative approach is to extend the posterior dissection around the side of the vertebral body, completing the vertebrectomy through a posterolateral resection (18). If at least one pedicle is uninvolved, a wide margin is possible (6). Complete vertebrectomy requires both anterior and posterior stabilization, but experience has shown that this aggressive surgical approach does improve patient survival and neurologic function even when cure cannot be obtained (66).

For sacral lesions, a high sacral amputation is the procedure of choice (64). This combined anterior/posterior sacral approach provides improved outcome with surprisingly little long-term morbidity; as long as the S-2 nerve roots are spared bilaterally, or S-2 and S-3 are retained unilaterally, bowel and bladder function are usually unharmed (22,54). In more proximal tumors, these roots must be sacrificed to obtain local control and a reasonable likelihood of survival.

### *Decompression*

As many as 20% of all patients with disseminated carcinoma develop symptomatic spinal cord compression (12,60). To prevent permanent neurologic injury, the surgeon must recognize and treat spinal cord compression early in its development. Compression may result when an enlarging soft-tissue mass encroaches on cord or nerve roots, or when a pathologic fracture results in retropulsion of bone fragments into the canal, vertebral collapse, or kyphosis. Soft-tissue metastasis to the meninges or epidural space may directly compress neural elements (5,30).

Patients often complain of persistent and progressive back pain, radicular symptoms or “girdle” pain, lower extremity weakness, sensory loss, and bowel or bladder dysfunction. Acute spinal cord compression typically results from rapid tumor growth or pathologic fracture caused by extensive bony destruction. Early treatment is crucial:

- Patients with rapidly progressive paralysis have a poor prognosis for recovery compared to those who develop symptoms over a prolonged period.
- In ambulatory patients, 60% to 95% will retain that function after treatment.
- Only 35% to 65% of paraparetic patients will walk independently after treatment.
- Less than 30% of paraplegic patients will regain ambulation after either surgical or medical treatment (31,38).

Radiotherapy remains the most appropriate treatment for most patients with spinal column metastases. Different tumor types exhibit different levels of radiosensitivity, however, and different clones of the same primary tumor may behave differently as well:

- Prostatic and lymphoreticular neoplasms are typically radiosensitive, and satisfactory local control can be gained through postoperative radiotherapy, even after an intralesional resection (68).
- Gastrointestinal and renal neoplasms, on the other hand, are often unresponsive to irradiation.
- A number of primary tumors (e.g., chondrosarcoma, chordoma) are not radiosensitive, and, consequently, neurologic compromise resulting from these lesions is best treated by operative methods.

The best results are obtained when the surgical approach is properly matched to the compressive lesion: anterior decompression for anterior tumors and posterior decompression for posterior lesions. Using the wrong approach (e.g., laminectomy for anterior compression) provides little benefit and increases complications. For example, laminectomy has shown no added benefit relative to radiation alone in treating anterior spinal lesions, and it can compound problems by introducing or increasing segmental instability in the compromised segment (23,30). Overall, decompressive laminectomy provides neurologic improvement in only 33% of cases, and an overall satisfactory outcome (maintenance of ambulation and sphincter control) in 37% (45). By comparison, anterior decompression results in 79% improvement and 80% satisfactory outcome in similar patients (Fig. 152.10).

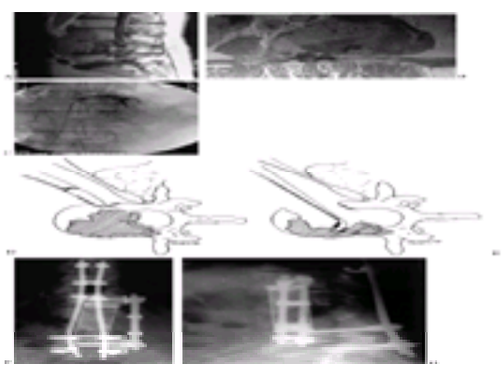

***Figure 152.10.*** Anterior vertebrectomy for metastatic disease. Sagittal (**A**) and axial (**B**) MRIs demonstrating extent of an isolated renal cell metastasis involving both L-3 and L-4 vertebral bodies. The lesion probably seeded in one vertebral body, then spread contiguously to the adjacent level. **C:** Angiography prior to surgery shows blush of neovasculature in the tumor mass just prior to embolization. **D:** Anterior decompression of radiosensitive tumors begins by resecting the normal bone exposed during the anterior approach, then excising the tumor tissue in as few pieces as can be managed, moving quickly to limit blood loss. **E:** After removal of the bulk of involved vertebra, meticulous dissection is carried out to remove retropulsed fragments and extruded tumor from in front of the thecal sac, and to curet away all gross tumor from the resection margins. AP (**F**) and lateral (**G**) radiographic views, 2 years postoperative. After resection, the anterior column is reconstructed with a strut or cage. The titanium cage selected here is packed with autograft bone because successful treatment may provide this patient with several years of life. An anterior construct stabilizes the spine until the posterior reconstruction, using segmental instrumentation, can be performed.

### *Reconstruction*

Spinal instrumentation and fusion are often needed after tumor resection to restore stability, prevent progressive deformity, and facilitate graft incorporation and fusion. The surgeon must choose an instrumentation construct that (a) can meet the mechanical demands it will face following tumor resection, (b) can compensate for loss of bony elements due to resection or laminectomy, and (c) will permit postoperative imaging with CT and MRI. Key principles to reconstruction are the following:

- Restore or augment the anterior weight-bearing column to prevent vertebral collapse and kyphosis.
- Use posterior instrumentation to provide a tension-band effect after laminectomy, to compensate for lost muscular attachments, and to prevent progressive kyphosis.
- Combine anterior and posterior constructs to restore axial, sagittal, and torsional stability after vertebrectomy.
- Anticipate disease progression—extend fixation over longer segments, maximize fixation points, and combine anterior and posterior constructs to ensure construct survival.
- Anticipate patient survival—strive for spinal fusion in patients likely to live more than 3 to 6 months.

### *Posterior Instrumentation*

Distraction instrumentation (Harrington rods) can be combined with sublaminar or Drummond wires to provide segmental fixation in the thoracic spine, but they do not contour well to the lumbar spine and they tend to flatten the normal lumbar lordosis, resulting in a painful lumbar deformity. These systems are inexpensive and are adequate to stabilize thoracic compression fractures or laminectomies. They are not the best choice for cases with extensive bone destruction, however. Rod breakage and hook pullout are common, particularly when applied to patients with combined anterior and middle column insufficiency. These systems are vulnerable to fatigue failure, particularly in tumor patients where perioperative irradiation and systemic disease increase the risk of delayed union, and nonunion.

Luque rods, used in conjunction with sublaminar wires, provide better fixation than the Harrington system in soft bone (14,16). The Luque rods–sublaminar wire system has been used successfully in treating degenerative and neoplastic disease of the cervical, thoracic, and lumbar spine. The system has good stability in torsion and flexion but cannot resist pure axial loads—the sublaminar wires are free to slide down the rod, allowing the instrumented segment to collapse considerably along the axis of the rods.

Newer segmental instrumentation systems are versatile and resilient. They allow the surgeon to neutralize the overall length of the spine while either compressing or distracting the intercalary segments involved in the reconstruction. Hook and screw fixation at multiple levels improves fixation strength, and pedicle screws allow fixation to levels where posterior elements have been removed. These systems have superior torsional and sagittal strength and are widely available in titanium, improving postoperative imaging capabilities. These versatile systems also allow the surgeon to address multiple levels of vertebral involvement, restoring normal thoracic kyphosis and lumbar lordosis in the same construct.

Pedicle screw fixation is particularly helpful in patients who have undergone previous laminectomy. They allow the surgeon to minimize the number of segments instrumented, limiting the need to extend fusions to additional levels for support. Combined with an anterior strut, screw-and-rod and screw-and-plate constructs provide sufficient axial, torsional, and sagittal rigidity to allow the surgeon to instrument only two motion segments when treating primary and metastatic lesions of the thoracolumbar spine (47). Screw failure can be expected, however, if the anterior weight-bearing column is incompetent and is not reconstructed (48).

Pedicle screws are most useful in the thoracolumbar and lumbar regions, where pedicles are relatively large and the spinal cord is not at risk. They may prove useful for lower thoracic lesions, as well, by securely anchoring the caudal end of a longer thoracolumbar construct. Use in the thoracic spine is more limited, although some authors have found that screw fixation is an important alternative in patients with extensive laminectomies. Screw-and-plate constructs can be used in the upper thoracic spine to stabilize the cervicothoracic junction, to treat laminectomized segments, and to limit the bulk of instrumentation placed under thin, irradiated soft tissues (Fig. 152.11).

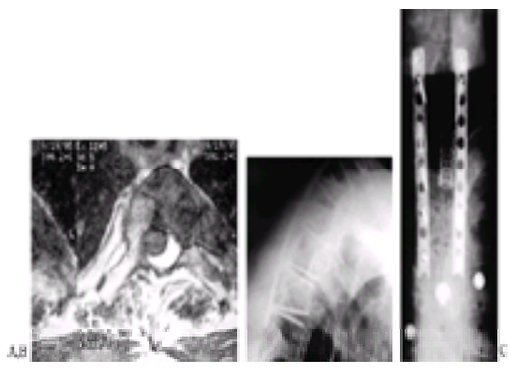

***Figure 152.11.*** **A:** MRI of $T_2$ metastasis. **B,C:** Lateral and AP views of screw and plate construct for upper thoracic spine. An alternative to rod-and-hook constructs, low-profile plates may be useful in patients with absent or incompetent posterior elements, or those with tenuous skin following irradiation.

Anterior column reconstruction may be necessary in addition to posterior procedures, or as the primary treatment in some patients. Posterior instrumentation alone cannot provide adequate stability in all cases. When posterior decompression is superimposed on anterior and middle column vertebral collapse, the resulting instability can be severe (16), and untreated anterior column deficiency leads to pedicle screw fatigue and breakage (47,48). Moreover, there is a significant incidence of wound complications associated with posterior surgery. These patients are often systemically ill. Many have undergone regional radiation therapy, have lost muscle mass and subcutaneous fat, and have impaired healing potential. Wound dehiscence, infection, and skin problems are common enough to prompt many surgeons to consider anterior reconstruction as their primary avenue of treatment.

If vertebrectomy is performed, the axial weight-bearing column must be reconstructed. Depending on the situation, the surgeon can chose from bone, methylmethacrylate, or a variety of prosthetic struts (Table 152.3).

| *Expected survival* | *Strut or spacer* | *Considerations* |
|---|---|---|
| <2 mo | Polymethylmethacrylate (PMMA) | Only for patients with very limited life expectancy; PMMA without bone graft unloaded. Functions well as spacer but has no biological fixation |
| 3–4 mo | Prosthetic cage, with PMMA, or | Provides immediate axial mobility with no risk of late collapse; subsidence can occur; can be contoured to fit any defect; no graft site morbidity |
| 3–6 mo | Allograft fibula or tricortical graft | Some potential for incorporation but typically slow in irradiated tissues; may collapse late in course due to remodeling |
| >6 mo | Prosthetic cage, with autograft, or | Provides immediate axial mobility without risk of late collapse; subsidence can occur; can be contoured to fit any defect; reduced graft site morbidity |
| >6 mo | Autograft fibula or tricortical graft, or | Maximum potential for incorporation; at risk for collapse during remodeling; graft site morbidity is considerable; may contain microtemporal disease |
| >12 mo | Strut graft or cage with anterior spinal instrumentation | Anterior instrumentation markedly increases torsional and sagittal stiffness of construct. May eliminate need for posterior procedure; technically demanding |

***Table 152.3. Choice of Struts or Spacers for Reconstruction of Anterior Spinal Tumors***

Polymethylmethacrylate (PMMA) is frequently used to reconstruct the vertebral column in metastatic disease. It is resilient in compression, but because it has no potential for biological incorporation it has a tendency to loosen and extrude over time.

- Incorporate longitudinal Steinmann pins into the PMMA mass and drive them proximally and distally into the adjacent vertebrae to anchor the spacer and improve its bending resistance (Fig. 152.12). Alternatively, insert Harrington distraction rods or Knodt rods into the vertebrectomy site to distract the defect and anchor the PMMA mass (61).

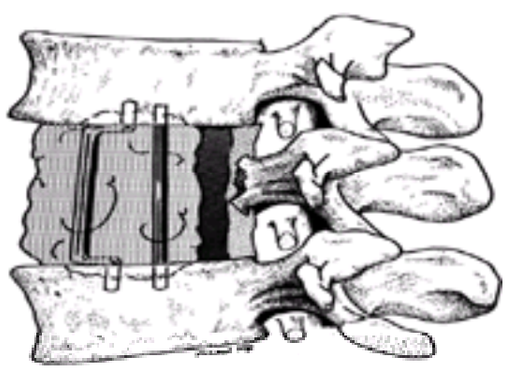

***Figure 152.12.*** Reconstruction of the anterior column with polymethylmethacrylate.

- Countersink the rod ends into the opposing endplates and distract to restore alignment.
- Apply PMMA in its dough phase to fill the defect.
- Place a Silastic or Gelfoam dam in front of the dura to protect the spinal cord from compression or thermal injury, and wash the PMMA mass constantly with cool saline during polymerization.

A tricortical strut graft or titanium cage with morcelized autograft is favored in the treatment of benign or slow-growing tumors in patients whose survival is likely to be measured in years, and similarly in malignant primaries, where successful treatment will result in prolonged survival.

- Cut tricortical struts from the anterior superior iliac crest, measuring 5–10 mm longer than the defect to be filled. Cut graft with a saw, not an osteotome.
- Key the graft into the vertebral endplates to prevent displacement when the patient is mobilized (Fig. 152.13).

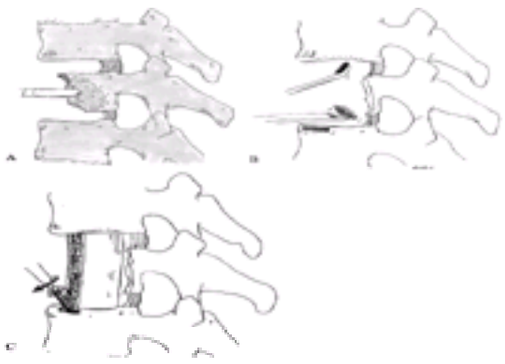

***Figure 152.13.*** Anterior reconstruction with tricortical graft. **A:** Anterior vertebrectomy provides a wide defect. Anterior superior iliac crest is harvested and contoured to fill and distract the vertebrectomy defect. **B:** Graft ends are contoured to articulate with a groove and pit fashioned in the vertebral endplates. **C:** Graft is impacted into place and locked with a single 6.5 mm cancellous screw.

- To prevent displacement, drive a single 6.5 mm cancellous interference screw into the vertebral endplate just lateral to the graft. This will keep the graft from slipping back out through the keyhole defect.

Titanium cages can be used to supplement either methylmethacrylate or autograft reconstructions.

- Impact the cage into the vertebrectomy defect.
- Sagittal compressive forces will tend to hold the cage in place until anterior or posterior instrumentation can be added.
- Do not penetrate the endplates during cage placement. Do not “key” the cage into place.
- If fusion is intended, pack the cage full of morcelized autograft bone before placing it into the defect. After inserting the cage, place more graft anteriorly to augment the fusion.
- Because the cage provides little torsional rigidity on its own, apply an anterior fixation system to stabilize the spinal construct.

**TREATMENT OF METASTATIC SPINAL TUMORS**

When conservative therapy fails to control metastatic disease, the physician must determine whether surgery is likely to improve the patient's function, quality of life, or longevity. In cases of severe pain, segmental instability, or neurologic compromise, operative intervention may be indicated.

Patients with an asymptomatic or minimally symptomatic spinal metastasis often do not require surgery. Patients who may require surgery include those with known radioresistant tumors, solitary metastasis with potential for wide resection, unknown tumor type despite systemic workup and needle biopsy, bony compression of neural elements, and mechanical instability and bone destruction.

Patients with mechanical instability and no neurologic deficit need treatment to restore stability and function.

- Treat patients with mechanical instability and neck or back pain with bracing and irradiation, unless other factors dictate surgery.
- Consider surgical reconstruction once bony destruction is advanced.
- If the tumor is radiosensitive, stabilize the spine with posterior instrumentation and control tumor growth with adjuvant radiotherapy.
- If the tumor is not radiosensitive, or if bony destruction is advanced, perform an anterior/posterior or posterolateral decompression and stabilization, and mobilize the patient early.
- If the patient presents with a solitary metastasis from a tumor with potential long-term survival (breast, colon, prostate, kidney), consider a combined procedure to obtain a wide excision of the lesion. Treat the tumor in the same way as a primary malignancy.

Once the neural elements are involved, the need for direct decompression becomes the primary indication for surgery.

- If the tumor is radiosensitive and neural progression is gradual, radiotherapy is the initial treatment of choice. If progression is rapid, unresponsive to radiotherapy, or secondary to bony as opposed to soft-tissue encroachment, decompress the cord or roots through the most direct approach.
- Use the posterior surgical approach in the cervical spine, above the level of C-3.
- Below C-3, the posterior approach should be limited to lesions of the dorsal elements. Address lesions of the vertebral body successfully through the appropriate anterior approach.
- As an alternative in lesions of the thoracic spine, use a costotransversectomy or transpedicular technique to access the vertebral body and decompress the anterior aspect of the spinal cord (37,38), (Fig. 152.14).

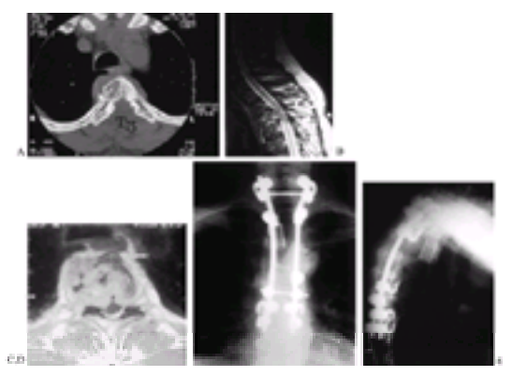

***Figure 152.14.*** Posterolateral decompression and reconstruction. CT (**A**) and MRI (**B,C**) images of a 65-year-old man with T-3 solitary plasmacytoma, cord compression, and incomplete paraplegia. **D,E:** Endoscopically assisted posterolateral approach allowed complete vertebrectomy and spinal cord decompression. Titanium cage reconstruction and posterior instrumentation through the single dorsal incision provided immediate stability as seen on AP(**D**) and lateral (**E**) radiographs. Complete neurologic recovery was facilitated by rapid mobilization and rehabilitation.

Although some authors have been dissatisfied with the decompression allowed through the posterolateral approach (8), the quality of both the decompression and the reconstruction can be improved by employing endoscopic control (Fig. 152.15).

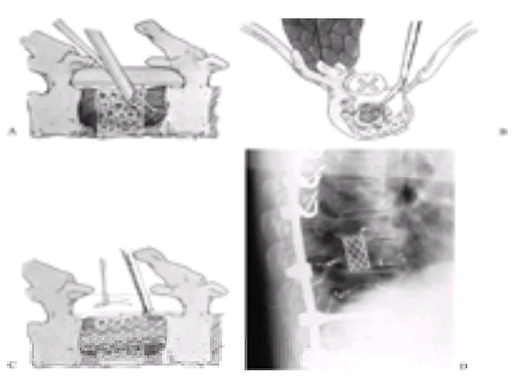

***Figure 152.15.*** Endoscopically assisted posterolateral vertebrectomy. **A:** After laminectomy and pedicle resection, the posterolateral aspect of the vertebral body and

tumor mass are cavitated with pituitaries and curets. The endoscope is then used to visualize the undersurface of the cord, the endplates, and the far pedicle. Complete decompression can be confirmed without manipulating the neural tissues. **B,C:** Once the endplates are prepared, an appropriately sized cage, packed with autograft bone or PMMA, is introduced into the defect between the ipsilateral nerve roots and impacted into place. The endoscope confirms a safe interval between the cage and thecal sack before posterior instrumentation is applied. **D:** Lateral radiograph of a patient with metastatic adenocarcinoma treated with posterolateral decompression and reconstruction.

### TREATMENT OF BENIGN TUMORS

The principal reasons for operating on benign tumors are to treat pain and to prevent local tumor expansion. Intralesional excisions are adequate in many tumor types (e.g., aneurysmal bone cyst, osteoblastoma) and should be carried out through the most direct approach with the least disruption of normal vertebral elements.

- Treat locally aggressive (aggressive benign and low-grade malignant) tumors rigorously, ensuring a clear margin wherever possible. Because recurrent tumors are more difficult to eradicate than primary lesions, these locally aggressive lesions may become unresectable if not adequately addressed in the first place.
- Resect giant cell tumors *en bloc* when possible, and check the bone margins for residual tumor.
- Repeat curetments if necessary to obtain a clean margin, and consider adjuvant cryotherapy or postoperative radiotherapy to ensure a clean tumor bed (42,55).
- As an alternative to the traditional anterior/posterior approach, consider a posterolateral dissection and vertebrectomy through a T posterior incision (18).

### TREATMENT OF PRIMARY MALIGNANT TUMORS

In primary malignancies, the principal goal of surgical treatment is local control of the disease. Plan the approach and resection to give the best chance of an adequate resection margin with the least disruption of vertebral stability.

- Approach dorsal tumors through a longitudinal posterior approach, incorporating any previous biopsy wound in the incision.
- Take care not to enter the soft-tissue mass of the tumor, either surgically or with retractors or rakes.
- Excise a cuff of normal muscle tissue with the tumor.
- Perform a laminectomy above and below the involved level and cut through uninvolved lamina or pedicle to isolate and resect the involved elements.
- Remove the tumor *en bloc* and stabilize the spine with a posterior instrumentation construct.

For anterior column tumors, combine an anterior and posterior approach to provide the widest possible margin for local control.

- Embolize the lesion preoperatively to limit blood loss during the procedure.
- Resect the posterior elements and posterior disc first to allow the vertebral body to be removed *en bloc* through an anterior approach.
- Use a transthoracic or retroperitoneal approach to reach the tumor from the front.
- Excise the adjacent discs back to the posterior longitudinal ligament, and remove all anterior soft tissues with the body, developing a plane between the great vessels and the anterior longitudinal ligament.
- Separate adherent tumor from the dura using a Freer elevator as the body is excised. Excise any involved dura and patch the defect with a fascial graft to improve local control.
- Stabilize the spine posteriorly with a segmental system at the time of posterior release.
- Restore the anterior weight-bearing column, filling the vertebrectomy defect with tricortical or fibular graft, or with a prosthetic cage.
- Use anterior plate fixation to augment overall stability.

Once extensive collapse has occurred, as in vertebra plana, a clear surgical margin is not possible, and local control is dependent on adjuvant therapy.

- Perform an intralesional resection of the vertebral body to debulk the tumor and prepare the vertebrectomy site for anterior reconstruction (40,44).
- Provide an adequate axial strut even when part of the involved vertebra can be retained, because progressive collapse can occur despite successful radiotherapy, leading to intractable pain and potential neural injury.
- In radioresistant tumors such as chondrosarcoma or chordoma, make every effort to obtain a clear surgical margin.

Lesions of the sacrum present a particular therapeutic and reconstructive dilemma. A chordoma involving the distal sacrum requires a partial sacral amputation through a combined anterior and posterior approach, sacrificing whatever nerve roots exit the involved segment. For higher sacral lesions, more roots will need to be sacrificed. If the S-2 roots can be spared bilaterally, or if S-2 and S-3 roots are spared on one side, bowel and bladder function should be retained (22). Reconstruction following sacral amputation is most challenging when one or both of the sacroiliac joints is involved (Fig. 152.16).

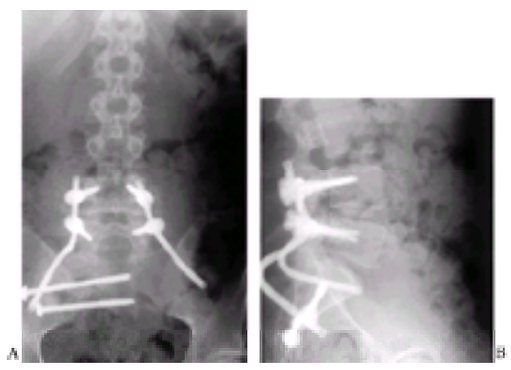

***Figure 152.16.*** AP (**A**) and lateral (**B**) radiographs after resection and reconstruction of sacral metastasis. Patient with destructive lesion of the sacral ala, presenting with pain and weakness. Posterior intralesional resection was followed by reconstruction of the ala with a bicortical iliac autograft contoured to fill the defect and transfixed with transiliac screws. Lumbosacral stability was provided with a short pedicle construct using Galveston-type fixation into the pelvis. This construct is suitable for limited resections such as this, or for more extensive tumors requiring sacrectomy and prosthetic reconstruction.

Patients presenting with a primary spinal tumor and neurologic deficit generally have one of three problems: a pathologic fracture, which may either retropulse bone fragments into the spinal canal or produce kyphosis; extraosseous extension through the posterior vertebral cortex, producing direct compression of the neural elements; or direct extension of the tumor involving one or more nerve roots.

- In every case, the resection margins are likely to be contaminated, and adjuvant therapy is the key to eventual outcome.
- Resect any nerve roots directly involved by tumor along with the primary mass.
- Adherence to or investment of the dura or great vessels is an ominous finding. Consider nonoperative or palliative modalities in these cases.

Once metastasis has occurred, the patient's survival becomes dependent on systemic therapy. Local control is still important to prevent neurologic compromise and pain, but the impetus toward more aggressive and potentially dangerous procedures is reduced. Reconstruct the involved segments carefully, however, addressing both anterior and posterior columns to ensure that late collapse, kyphosis, and pain will not occur.

### AUTHOR'S PERSPECTIVE

Improved medical and adjuvant therapies continue to enhance cancer survival in patients with both primary and metastatic disease. As patients live longer, metastatic lesions will pose a greater threat to independence and survival, and musculoskeletal lesions will require treatment that provides pain relief and protects function for years rather than months. It is no longer acceptable to assume that the patient with spinal metastasis is near death and beyond help; benign neglect is not benign, and

it is neither fiscally or ethically conscionable. Vertebrectomy, considered a radical procedure in the past, is coming to be seen as the conservative approach to tumor management in many situations. Advanced technologies have made aggressive surgery less invasive and dangerous, and improved instrumentation has all but eliminated the prolonged immobilization associated with spinal reconstruction. Appropriate surgical management can have an immediate and dramatic impact on patient function and survival, and it should never be dismissed without consideration.

## CHAPTER REFERENCES

Each reference is categorized according to the following scheme: *, classic article; #, review article; !, basic research article; and +, clinical results/outcome study.


# 1. Barwick KW, Huvos AG, Smith J. Primary Osteogenic Sarcoma of the Vertebral Column. *Cancer* 1980;46:595.

+ 2. Bielack SS, Wulff B, Delling G, et al. Osteosarcoma of the Trunk Treated by Multimodality Therapy: Experience of the Cooperative Osteosarcoma Study Group. *Med Pediatr Oncol* 1995;24:6.

+ 3. Bjornsson J, Wold LE, Ebersold MJ, Laws ER. Chordoma of the Mobile Spine. A Clinicopathological Analysis of 40 Patients. *Cancer* 1993;71:735.

# 4. Bohlman HH, Sachs BL, Carter JR, et al. Primary Neoplasms of the Cervical Spine. *J Bone Joint Surg Am* 1986;68:483.

* 5. Boland PJ, Lane JM, Sundaresan N. Metastatic Disease of the Spine. *Clin Orthop* 1982;169:95.

+ 6. Boriani S, Biagini R, De Lure F, et al. En-bloc Resections of Bone Tumors of the Thoracolumbar Spine. A Preliminary Report on 29 Patients. *Spine* 1996;21:1927.

+ 7. Boriani S, Chevalley F, Weinstein JN, et al. Chordoma of the Spine above the Sacrum: Treatment and Outcome in 21 Cases. *Spine* 1996;21:1569.

+ 8. Bridwell KH, Jenny AB, Saul T, et al. Posterior Segmental Spinal Instrumentation (PSSI) with Posterior Decompression and Debulking for Metastatic Thoracic and Lumbar Spinal Disease. *Spine* 1988;13:1383.

* 9. Clain A. Secondary Malignant Disease of Bone. *Br J Cancer* 1965;19:15.

+ 10. Clausen N, Gotze H, Pedersen A, et al. Skeletal Scintigraphy and Radiography at Onset of Acute Lymphocytic Leukemia in Children. *Med Pediatr Oncol* 1983;11:291.

+ 11. Coffin CM, Swanson PE, Wick MR, Dehner LP. Chordoma in Childhood and Adolescence. A Clinicopathological Analysis of 12 Cases. *Arch Pathol Lab Med* 1993;117:927.

* 12. Constans JP, Divitiis E, Donzelli R, et al. Spinal Metastases with Neurological Manifestations: Review of 600 Cases. *J Neurosurg* 1983;59:111.

# 13. Cuenod CA, Laredo JD, Chevret S, et al. Acute Vertebral Fracture due to Osteoporosis vs. Malignancy: Appearance on Unenhanced and Gadolinium-enhanced MR Images. *Radiology* 1996;199:541.

+ 14. Cybulski GR, Von Roenn KA, D'Angelo CM, DeWald RL. Luque Rod Stabilization for Metastatic Disease of the Spine. *Surg Neurol* 1987;28:277.

* 15. Dahlin DC. Giant-Cell Tumor of Vertebrae above the Sacrum. *Cancer* 1977;39:1350.

+ 16. DeWald RL, Bridwell KH, Prodromas C, Rodts MF. Reconstructive Spinal Surgery as Palliation for Metastatic Malignancies of the Spine. *Spine* 1985;10(1):21.

! 17. Edelstyn GA, Gillespie PJ, Grebell ES. The Radiologic Demonstration of Osseous Metastases: Experimental Observations. *Clin Radiol* 1967;18:158.

+ 18. Fidler MW. Radical Resection of Vertebral Body Tumors: A Surgical Technique Used in Ten Cases. *J Bone Joint Surg Br* 1994;76:765.

# 19. Fox MW, Onofrio BM. The Natural History and Management of Symptomatic and Asymptomatic Vertebral Hemangiomas. *J Neurosurg* 1993;78:36.

# 20. Fraser RD, Paterson DC, Simpson DA. Orthopaedic Aspects of Spinal Tumours in Children. *J Bone Joint Surg Br* 1977;59:143.

# 21. Freiberg AA, Graziano GP, Loder RT, Hensinger RN. Metastatic Vertebral Disease in Children. *J Pediatr Orthop* 1993;13:148.

+ 22. Gennari L, Azzarelli A, Quagliuolo V. A Posterior Approach for the Excision of Sacral Chordoma. *J Bone Joint Surg Br* 1987;69:565.

* 23. Gilbert RW, Kim JH, Posner JB. Epidural Spinal Cord Compression from Metastatic Tumor: Diagnosis and Treatment. *Ann Neurol* 1978;3:40.

# 24. Godersky JC, Smoker WRK, Knutzon R. Use of Magnetic Resonance Imaging in the Evaluation of Metastatic Spinal Disease. *Neurosurgery* 1987;21:676.

# 25. Graham WD. Metastatic Cancer to Bone. In: *Bone Tumours.* London: Butterworths, 1966:94.

+ 26. Green NE, Robertson WW, Kilroy AW. Eosinophilic Granuloma of the Spine with Associated Neural Deficit. *J Bone Joint Surg Am* 1980;62:1198.

+ 27. Griffin JB. Benign Osteoblastoma of the Thoracic Spine. *J Bone Joint Surg Am* 1978;60:833.

+ 28. Grubb MR, Currier BL, Pritchard DJ, Ebersold MJ. Primary Ewing's sarcoma of the Spine. *Spine* 1994;19:309.

! 29. Harada M, Shimizu A, Nakamura Y, Nemoto R. Role of the Vertebral Venous System in Metastatic Spread of Cancer Cells to the Bone. *Adv Exp Med Biol* 1992;324:83.

# 30. Harrington KD. Current Concepts Review: Metastatic Disease of the Spine. *J Bone Joint Surg Am* 1986;68:1110.

+ 31. Harrington KD. Anterior Decompression and Stabilization of the Spine as a Treatment for Vertebral Collapse and Spinal Cord Compression from Metastatic Malignancy. *Clin Orthop* 1988;233:177.

+ 32. Hay MC, Paterson D, Taylor TKF. Aneurysmal Bone Cysts of the Spine. *J Bone Joint Surg Br* 1978;60:406.

+ 33. Hermann G, Sacher M, Lanzieri CF, et al. Chondrosarcoma of the Spine: An Unusual Radiographic Presentation. *Skeletal Radiol* 1985;14:178.

# 34. Jaffe HL. *Tumors and Tumorous Conditions of the Bones and Joints.* Philadelphia: Lea and Febiger, 1958.

* 35. Keim HA, Reina EG. Osteoid-Osteoma as a Cause of Scoliosis. *J Bone Joint Surg Am* 1975;57:159.

+ 36. Kornberg M. Primary Ewing's Sarcoma of the Spine. *Spine* 1986;11:54.

* 37. Kostuik JP. Anterior Spinal Cord Decompression for Lesions of the Thoracic and Lumbar Spine, Techniques, New Methods of Internal Fixation, Results. *Spine* 1983;8:512.

+ 38. Kostuik JP, Errico TJ, Gleason TF, Errico CC. Spinal Stabilization of Vertebral Column Tumors. *Spine* 1988;13:250.

+ 39. Leeson MC, Makley JT, Carter JR. Metastatic Skeletal Disease in the Pediatric Population. *J Pediatr Orthop* 1985;5:261.

+ 40. Loftus CM, Michelsen CB, Rapoport F, Antunes JL. Management of Plasmacytomas of the Spine. *Neurosurgery* 1983;13:30.

+ 41. Malat J, Virapongse C, Levine A. Solitary Osteochondroma of the Spine. *Spine* 1986;11:625.

+ 42. Marcove RC, Sheth DS, Brien EW, et al. Conservative Surgery for Giant Cell Tumors of the Sacrum: The Role of Cryosurgery as a Supplement to Curettage and Partial Resection. *Cancer* 1994;74:1253.

* 43. Marsh BW, Bonfiglio M, Brady LP, Enneking WF. Benign Osteoblastoma: Range of Manifestations. *J Bone Joint Surg Am* 1975;57:1.

+ 44. McLain RF, Weinstein JN. Solitary Plasmacytomas of the Spine: A Review of 84 Cases. *J Spinal Disord* 1989;2:69.

* 45. McLain RF, Weinstein JN. Tumors of the Spine. *Semin Spine Surg* 1990;2:157.

+ 46. McLain RF, Weinstein JN. An Unusual Presentation of a Schmorl's Node. Report of a Case. *Spine* 1990;15: 247.

+ 47. McLain RF, Kabins M, Weinstein JN. VSP Stabilization of Lumbar Neoplasms: Technical Considerations and Complications. *J Spinal Disord* 1991;4:359.

* 48. McLain RF, Sparling E, Benson DR. Failure of Short Segment Pedicle Instrumentation in Thoracolumbar Fractures: Complications of Cotrel-Dubousset Instrumentation. *J Bone Joint Surg Am* 1993;75:162.

# 49. Mindell ER. Current Concepts Review: Chordoma. *J Bone Joint Surg Am* 1981;63:501.

* 50. Pettine KA, Klassen RA. Osteoid-Osteoma and Osteoblastoma of the Spine. *J Bone Joint Surg Am* 1986;68:354.

+ 51. Poulsen JO, Jensen JT, Tommesen P. Ewing's Sarcoma Simulating Vertebra Plana. *Acta Orthop Scand* 1975;46:211.

+ 52. Rate WR, Butler MS, Robertson WW Jr, D'Angio GJ. Late Orthopaedic Effects in Children with Wilm's Tumor Treated with Abdominal Irradiation. *Med Pediatr Oncol* 1991;19:265.

# 53. Rogalsky RJ, Black GB, Reed MH. Orthopaedic Manifestations of Leukemia in Children. *J Bone Joint Surg Am* 1986;68:494.

+ 54. Samson IR, Springfield DS, Suit HD, Mankin HJ. Operative Treatment of Sacrococcygeal Chordoma. A Review of Twenty-One Cases. *J Bone Joint Surg* 1993;75:1476.

+ 55. Sanjay BK, Sim FH, Unni KK, et al. Giant Cell Tumor of the Spine. *J Bone Joint Surg Br* 1993;75:148.

+ 56. Savini R, Gherlinzoni F, Morandi M, et al. Surgical Treatment of Giant-Cell Tumor of the Spine. *J Bone Joint Surg Am* 1983;65:1283.

* 57. Sherk HH, Nicholson JT, Nixon JE. Vertebra Plana and Eosinophilic Granuloma of the Cervical Spine in Children. *Spine* 1978;3:116.

* 58. Shives TC, Dahlin DC, Sim FH, et al. Osteosarcoma of the Spine. *J Bone Joint Surg Am* 1986;68:660.

* 59. Shives TC, McLeod RA, Unni KK, Schray MF. Chondrosarcoma of the Spine. *J Bone Joint Surg Am* 1989;71:1158.

+ 60. Siegal T, Siegal T. Current Considerations in the Management of Neoplastic Spinal Cord Compression. *Spine* 1988;14:223.

* 61. Siegal T, Tiqva P, Siegal T. Vertebral Body Resection for Epidural Compression by Malignant Tumors. *J Bone Joint Surg Am* 1985;67:375.

* 62. Sim FH, Dahlin DC, Stauffer RN, Laws ER. Primary Bone Tumors Simulating Lumbar Disc Syndrome. *Spine* 1977;2:65.

+ 63. Stener B. Total Spondylectomy in Chondrosarcoma Arising from the Seventh Thoracic Vertebra. *J Bone Joint Surg Br* 1971;53:288.

+ 64. Stener B, Gunterberg B. High Amputation of the Sacrum for Extirpation of Tumors. *Spine* 1978;3:351.

+ 65. Sundaresan N, Rosen G, Huvos AG, Krol G. Combined Treatment of Osteosarcoma of the Spine. *Neurosurgery* 1988;23:714.

+ 66. Sundaresan N, Sachdev VP, Holland JF, et al. Surgical Treatment of Spinal Cord Compression from Epidural Metastasis. *J Clin Oncol* 1995;13:2330.

+ 67. Sundaresan N, Scher H, DiGiacinto GV, et al. Surgical Treatment of Spinal Cord Compression in Kidney Cancer. *J Clin Oncol* 1986;4:1851.

+ 68. Tomita T, Galicich JH, Sundaresan N. Radiation Therapy for Spinal Epidural Metastases with Complete Block. *Acta Radiol Oncol* 1983;22:135.

+ 69. Traill Z, Richards MA, Moore NR. Magnetic Resonance Imaging of Metastatic Bone Disease. *Clin Orthop* 1995;312:76.

+ 70. Turcotte R, Sim FH, Unni KK. Giant Cell Tumor of the Sacrum. *Clin Orthop* 1993;291:215.

* 71. Valderrama JAF, Bullough PG. Solitary Myeloma of the Spine. *J Bone Joint Surg Br* 1988;50:82.

+ 72. Weinstein JN. Surgical Approach to Spine Tumors. *Orthopaedics* 1989;12:897.

* 73. Weinstein JN, McLain RF. Primary Tumors of the Spine. *Spine* 1987;12:843.

+ 74. Wong DA, Fornasier VL, MacNab I. Spinal Metastases: The Obvious, the Occult, and the Impostors. *Spine* 1990;15:1.

# CHAPTER 153

# SURGERY OF THE SPINE IN ANKYLOSING SPONDYLITIS

*Edward H. Simmons*

**E. H. Simmons:** Buffalo, New York, 14201.

Atlantoaxial Instability
Posterior Arthrodesis of C1–C2
Transoral Decompression
Atlanto-Occipital Disability
Occipitocervical Fusion
Spondylodiscitis
Flexion (Kyphotic) Deformities of the Spine
Clinical Assessment
Kyphotic Deformity of the Lumbar Spine
Kyphotic Deformity of the Thoracic Spine
Kyphotic Deformity of the Cervical Spine
Chapter References

Ankylosing spondylitis and rheumatoid arthritis, although commonly considered together, are two distinct diseases. Ankylosing spondylitis has often been described as “rheumatoid” spondylitis, but it is a different disease with a different serology. It is more common in men than in women and has a predilection for the spine and major joints; rheumatoid arthritis is more common in women and tends to affect smaller joints and the joints of the appendicular skeleton (10,15,16). Clinical manifestations of ankylosing spondylitis occur in 0.2% to 0.3% of the general population.

In ankylosing spondylitis, the major clinical problems of the spine are gross fixed deformities. In rheumatoid arthritis the spine is subject to local destruction and instability. Atlantoaxial subluxation and dislocation may occur in both diseases, however.

## ATLANTOAXIAL INSTABILITY

Recognizing atlantoaxial instability in patients with rheumatoid arthritis and ankylosing spondylitis requires careful clinical monitoring. Rheumatoid disease is discussed in greater detail in Chapter 154. In ankylosing spondylitis, a solid column of bone below may place excessive stress at the craniocervical junction. With the attritional effects of inflammation of the transverse ligament and associated hyperemia on its bony attachments, atlantoaxial subluxation and dislocation may occur. With subluxation, the joint may subsequently stabilize in the subluxated position without significant symptoms.

Consider the possibility of significant instability when planning surgery on any patient who might undergo neck manipulation, either by the anesthesiologist or during the surgery itself. Obtain routine flexion and extension lateral radiographs of the cervical spine before performing any such procedures.

### POSTERIOR ARTHRODESIS OF C1–C2

Surgical stabilization is justified when there is gross symptomatic atlantoaxial instability and the patient is at risk. Stabilization can be effectively achieved by a Gallie-type posterior atlantoaxial arthrodesis (12,19,22,23,25).

- Shape a modified **H** graft from the iliac crest and contour it to fit over the posterior arches of C-1 and C-2, astride the spinous process of C-2.
- Pass a single piece of 22-gauge stainless-steel wire inferior to the spinous process of C-2 and through the interspinous ligament of C2–C3. Carry the ends of the wire upward posteriorly to the graft around a notch in its upper border and under the arch of C-1 on each side of the graft.
- Tie the wire ends posteriorly over the graft, fixing it into position and pulling back the arch of C-1 into alignment with the arch of C-2 (Fig. 153.1). Some form of wire tightener is needed, such as that developed by Harris (8). The wire tightener grasps the wire, allowing tension to be applied, so that a knot can be tied firmly in the narrow confines of the wound with only gentle manual pressure (discussed in more detail in Chapter 154).

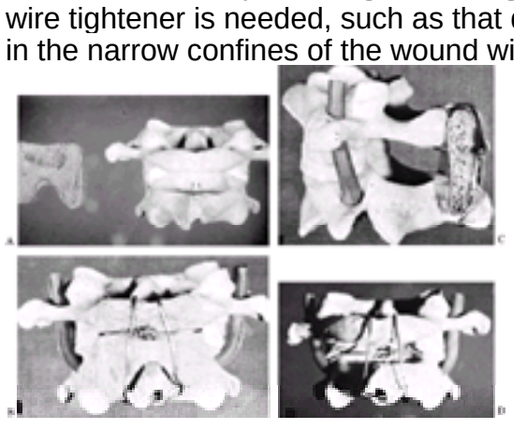

***Figure 153.1.*** **A:** Skeletal model showing deep cancellous surface of Gallie modified **H**-graft, which is contoured from the posterior iliac crest to fit over the posterior arches of C-1 and C-2, sitting astride the spinous process of C-2. **B:** Posterior view showing the graft in position with cortical surface superficially. Pass the Gallie wire through the interspinous ligament of C2–C3 below the spinous process of C-2, upward over the graft on each side. Bring it out below the arch of C-1 laterally and tie it firmly posteriorly. **C:** Lateral view showing the position of the modified H-graft, with the wire pulling back the C-1 vertebra into a normal relationship with the odontoid. The inferior portion of the wire passes below the spinous process of C-2 through the interspinous ligament of C2–C3, which should be preserved during exposure and wiring because it assists in maintaining the wire in position until it is tightened. **D:** Posterior view of model showing the configuration of the wire without the graft in position.

### TRANSORAL DECOMPRESSION

In the few instances when the odontoid is causing major anterior pressure that cannot be reduced, transoral resection of the odontoid may be required. This procedure is more hazardous than posterior decompression and stabilization; if the instability is recognized earlier, the procedure will be less frequently required. Transoral surgery is reserved for patients with significant anterior compression.

Two different types of abnormality can be differentiated: In the first, basilar invagination is present without gross instability, and in the second there is additional atlantoaxial instability and luxation. Posterior column involvement also may be evident in the second type, caused by posterior compression of the spinal cord by the posterior arch of C-1, which slides anteriorly.

Pure basilar invagination with narrowing of the anterior cerebellomedullary cistern is the primary indication for transoral decompression. Decompression may involve the removal of not only the odontoid process, but also the body of C-2 and the space-occupying portion of the clivus. In cases of pure atlantoaxial instability, a stable posterior atlantoaxial arthrodesis is preferred. Results of primary anterior decompression combined with simultaneous anterior fusion are not encouraging, and it would appear preferable to perform a posterior fusion as a secondary procedure following a primary anterior decompression.

Before surgery, identify and clear any evidence of oral infection or dental sepsis. Obtain nasal, oral, and pharyngeal swabs for bacterial culture and sensitivity, and administer the most appropriate antibiotic combination before surgery, intravenously during surgery, and in the immediate postoperative period.

***Operative Technique***

- Position the patient supine for surgery, with the neck extended. Lateral radiographic control is necessary. Some recommend routine tracheostomy and endotracheal anesthesia (6). However, the endotracheal tube is not an obstacle at surgery, and in some ways it is best to leave the airway intact.
- In patients who do not have a tracheostomy, place a gastric tube for postoperative nutrition, with normal oral nutrition beginning 7–8 days after surgery. If tracheostomy is indicated, perform it at the beginning of the operation with ventilation continued through a cuffed tracheal tube.
- After preparation of the oral cavity, introduce a Whitehead retractor and depress the tongue. Pack off the nasopharynx and hypopharynx.
- The procedure can usually be done without division of the soft palate. Fold the soft palate back on itself and suture it to the junction of the hard and soft palates to expose the lower portion of the nasopharynx. Release these sutures at the end of the procedure (Fig. 153.2).




***Figure 153.2.*** Diagram of transoral exposure. Use two stay sutures to fold the soft palate on itself and keep it in position. Incise the posterior pharyngeal wall vertically.

- If division of the soft palate is considered necessary, incise it on one side of the midline to avoid the uvula, and retract the flaps laterally (Fig. 153.3).

***Figure 153.3.*** Exposure showing incision of the soft palate on one side, avoiding the uvula.

- Palpate the posterior pharyngeal wall to locate the prominence of the anterior tubercle of the atlas. In atlantoaxial dislocation, it is quite evident.
- Make a 2-inch midline incision from the lower portion of the clivus to the lower portion of C-2.
- Center the incision one finger breadth below the anterior tubercle of the atlas.
- Carry the incision down to bone.
- Strip the soft tissues laterally to the outer margin of the lateral masses of the atlas and axis. The soft tissues may be anchored with retraction stay sutures.
- Expose the anterior arch of the atlas and the body of the axis.
- Remove the anterior arch of the atlas with sharp rongeurs and expose the odontoid (Fig. 153.4).

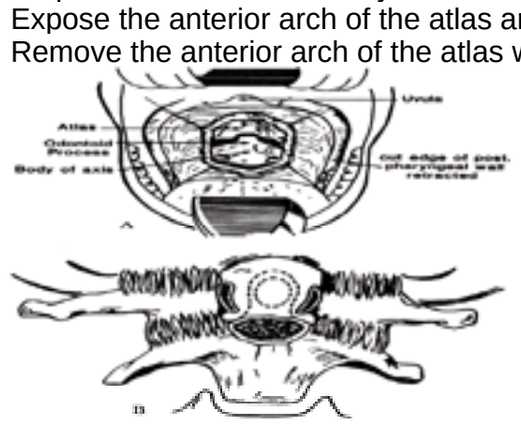


***Figure 153.4.*** **A:** Anterior exposure of the atlas and axis with the soft tissues stripped laterally. **B:** Excision of the anterior arch of the atlas allowing exposure of the odontoid.

- Remove the odontoid process with a high-speed drill and a diamond burr.

Removal of the odontoid process, which is displaced upward and projects backward, is the most complicated part of the surgery.

- Carefully and gently free the odontoid of its soft-tissue attachments, using sharp dissection as necessary.
- If resection of the odontoid is difficult because of its elevation and the angle of approach, commence the resection in the central part of the body of the axis.
- Remove the lower portion of the clivus (anterior margin of the foramen magnum) only when necessary; when it is required, I recommend a diamond burr and upward-cutting bone forceps.
- If lateral fusion of the C1–C2 joint is to be attempted, clear the articular cartilage from the joints and wedge iliac grafts between the lateral masses.
- Close the posterior pharyngeal wall.

Some authors recommend a multilayer closure involving the anterior ligament, the buccopharyngeal fascia and constrictor muscles, and the pharyngeal mucosa. Many, however, recommend a loose, single-layer closure because it allows wound secretions to drain more easily and it has technical advantages (6,7,14). Defer oral feedings 6–7 days to allow adequate healing; introduce liquids before solids. See Chapter 138 and Chapter 154.

## ATLANTO-OCCIPITAL DISABILITY

Occasionally in ankylosing spondylitis, severe disability may arise from destructive changes at the atlanto-occipital joint. Destructive changes may produce intractable pain associated with minimal persisting motion, justifying surgical stabilization. On occasion, subluxation or even rotatory deformity can occur, which may warrant gradual reduction with halo traction followed by stabilization with occipitocervical fusion.

### OCCIPITOCERVICAL FUSION

I prefer to use double-cortical and cancellous onlay iliac grafts fixed to the base of the skull and the upper cervical spine, reinforced by multiple cancellous bone grafts. The onlay grafts are contoured to fit over the posterior arches of the upper cervical vertebrae (usually down to C-4), the cancellous surface of the graft being contoured

to fit over the posterior arches.

- Apply a cranial halo preoperatively to support the head during surgery.
- Position the patient supine and prepare and drape the neck well up onto the head and to the ears.
- Hold the grafts firmly against the skull and fix them directly to the posterior arches of the cervical vertebrae using transfixing threaded Compere wires. Drive these wires percutaneously from the side of the neck, through the graft on one side of the spine, then through the base of the spinous process, and then through the graft on the opposite side. Cut the wire free on the side of its entrance in the wound lateral to the graft.
- Before the grafts are fixed to the upper cervical spine, pass a wire through drill holes in the skull to fix the grafts against the skull, which has been denuded; then pass it around the ends of the threaded Compere wires for fixation to the skull and to fix the grafts to the posterior arches of the cervical spine.
- Reinforce the main grafts with cancellous strips laterally on both sides and superiorly against the skull (Fig. 153.5).

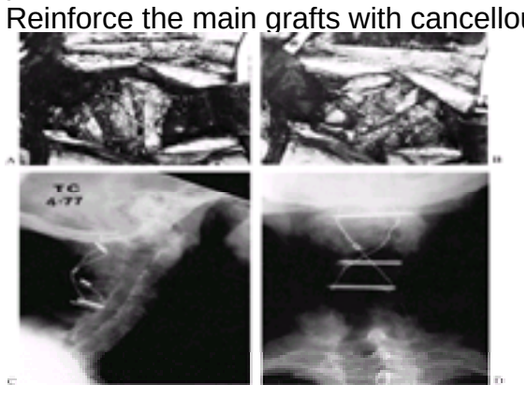

***Figure 153.5.*** Occipitocervical Fusion: **A:** Posterior operative view showing double onlay cortical and cancellous iliac grafts. **B:** Operative view showing additional onlay cancellous bone grafts, which reinforce the main grafts and extend from the cervical spine to the skull. **C:** Postoperative lateral radiograph showing a solid fusion extending from the occiput to the cervical spine. The wiring passes through the skull. Compere wires fix onlay grafts to the posterior arches of the cervical spine. **D:** Postoperative anteroposterior radiograph demonstrating the configuration of the wire loop, Compere wires, and grafts.

- Postoperative immobilization in a well-fitted halo cast is essential to protect the area of fusion from abnormal stress (5).

## SPONDYLODISCITIS

Erosion and sclerosis of bone adjacent to the sacroiliac joints is a typical radiographic feature of ankylosing spondylitis. This erosive, sclerotic process may occasionally extend into the intervertebral disc and adjacent bone, and it is then called spondylodiscitis. Such lesions were first reported by Andersson in 1937 (2).

Two opposing views exist as to the nature of these lesions. The first view is that spondylodiscitis is an inflammatory process affecting the intervertebral disc and surrounding bone. Detailed assessment and biopsy specimens support this view. The second, less commonly held view is that spondylodiscitis is secondary to trauma with excessive forces localized at one intervertebral segment, resulting in mechanical destruction and a functional pseudarthrosis.

The radiographic appearance is fairly typical (Fig. 153.6). The erosive process widens the disc space, breaking down the subchondral bony plates. The surrounding bone becomes sclerotic and radiodense. The prominence of either erosion or sclerosis varies. Spondylodiscitis has a reported incidence of 5% to 6% in ankylosing spondylitis (9,17,18). Most of the lesions develop in the lower thoracic spine. A little more than half the lesions are discovered on routine radiographic studies and are asymptomatic (9). About half the patients with spondylodiscitis present with back pain.

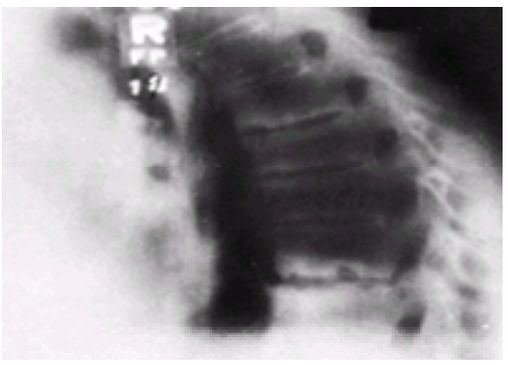

***Figure 153.6.*** Lateral radiograph showing the typical lesion of spondylodiscitis in the lower thoracic spine (the most frequent location). Erosive sclerotic changes involve the vertebral endplates adjacent to the disc space.

The lesion generally follows a benign course and usually responds to conservative management. Surgical stabilization may occasionally be required for intractable pain, particularly when there is an associated fracture or disruption of the posterior fused spine resulting from loss of bony substance anteriorly. If the lesion presents with intractable pain and no deformity, as in the mid-thoracic spine, then anterior resection and strut grafting may be indicated. The involved disc space and adjacent eroded bone are resected, and fibular or iliac strut grafts are fixed into the defect in a keystone fashion (24). Supplemental rib and iliac grafts are added as necessary.

When the lesion is painful, it is most often in the lower thoracic spine—an area subject to shear stress—with increasing deformity shifting the weight-bearing line anterior to the lesion, causing further erosion and increasing pain. In my experience, successful handling of this lesion requires correction of the overall spinal deformity. In my experience with more than 20 patients with this problem, the lesion has healed following resection–extension osteotomy of the mid-lumbar spine, shifting the weight-bearing line posteriorly, and changing the direction of the area of spondylodiscitis to horizontal, thus converting the shear force to a compression force (Fig. 153.7). This outcome is preferable to multiple anterior and posterior procedures, which have a higher failure rate when the overall deformity is not corrected, and which do not alleviate the shear stress.

***Figure 153.7.*** **A:** A 58-year-old man had severely painful spondylodiscitis at T12–L1, which resulted in an increasing flexion deformity of the thoracolumbar spine. **B:** A lateral radiograph of T12–L1 shows gross destructive spondylodiscitis at the apex of the deformity. **C:** A lateral standing 3-foot radiograph shows the weight-bearing line to be anterior to the area of spondylodiscitis, producing shear stress on the lesion. **D:** A standing lateral 3-foot radiograph after an extension osteotomy of the mid-lumbar spine shows that the weight-bearing line has been shifted posteriorly, converting shear force to compression force at the site of the spondylodiscitis. **E:** A lateral radiograph at T12–L1, 4 months after surgery, shows spontaneous healing of the area of spondylodiscitis as a result of the conversion of shear stress to compression. **F:** The patient following healing of the osteotomy and area of spondylodiscitis. The extension osteotomy of his lumbar spine corrected his deformity and allowed spontaneous healing of the spondylodiscitis.

The incidence of spondylodiscitis may be greater than previously suggested. In my review of 124 patients referred for surgical correction of spinal deformity for whom radiographs of the entire spine were available for study, 28 (23%) were found to have spondylodiscitis. When the lesion was in the area of the deformity and contributed to it, correction of the deformity resulted in fusion at the site of the spondylodiscitis (20,21).

## FLEXION (KYPHOTIC) DEFORMITIES OF THE SPINE

Severe flexion deformities of the spine may occur in patients suffering from Marie-Strümpell spondylitis or ankylosing spondylitis associated with psoriasis. Prevention of deformity by early recognition and appropriate medical care should be the aim. Despite improvements in medical care, however, patients still present with gross disability from advanced kyphotic deformity of the trunk.

The indications for surgical correction vary with the extent of deformity, the degree of functional impairment, the general condition and age of the patient, the feasibility of correction, and, perhaps most important, the willingness of the patient to accept the risks and undergo the reconstructive and rehabilitative measures required for correction.

### CLINICAL ASSESSMENT

If any major correction is to be obtained, surgery must address the area of involvement. For example, a patient with apparent spinal deformity actually may have a major deformity in the hip joints. If a hip flexion deformity is the cause of the patient's malalignment, then it should be corrected through surgery on the hip joints. Also, accurate assessment and measurement of any deformity are required to gauge the results of treatment. The most effective and reliable measure of a spine flexion deformity is the chin-brow-to-vertical angle. It is a measure of the angle formed by a line from the brow to the chin through the vertical, when the patient stands with the hips and knees fully extended, and the neck in its neutral or fixed position (Fig. 153.8).

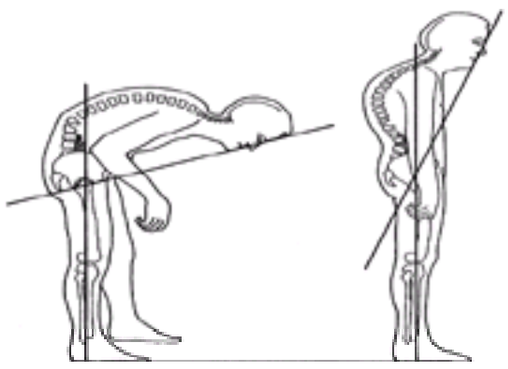

***Figure 153.8.*** Technique for measuring the degree of flexion deformity of the spine in ankylosing spondylitis. The chin-brow-to-vertical angle is measured from the brow to the chin to the vertical, with the patient standing with hips and knees extended and the neck in its fixed or neutral position.

### KYPHOTIC DEFORMITY OF THE LUMBAR SPINE

Kyphotic deformity of the lumbar spine was the first type of deformity corrected surgically in arthritic disease, as reported by Smith-Peterson et al. in 1945 (26). The initial procedure was done under general anesthesia with the patient lying prone. Difficulties with the prone position were later avoided by performing the surgery with the patient on the side, as recommended by Adams (1).

Some have recommended a two-stage or double-exposure procedure with surgical division of the longitudinal ligament anteriorly. I do not find it necessary: Correction can be achieved through the posterior approach alone.

A major complication of lumbar osteotomy is gastric dilatation and abdominal ileus. As the spine is extended, the superior mesenteric artery is stretched over the third part of the duodenum, predisposing to gastric dilatation. A nasogastric tube must be in position after surgery until intestinal motility is established.

A review of the literature until 1969 indicated a mortality rate of 8% to 10% with this procedure; some degree of neurologic deficit, including paraplegia, occurred in up to 30% of patients. Two thirds of the deaths were related to the use of general anesthesia. As a result, I used my experience in cervical osteotomy, as well as the recommendations of others, to perform surgical correction of lumbar flexion deformity with a resection–extension osteotomy under local anesthesia. From the 1970s to the early 1990s, I used this method in a series now totaling 100 patients. Generally, correction under local anesthesia has proved to be a safe, reliable, and practical procedure (19,21,23). The main advantage of local anesthesia is that it allows a critical assessment of the patient's neurologic and vital functions throughout the operation.

Over the past 10 years, there have been substantial improvements in anesthesia, including fiberoptic intubation and spinal cord monitoring. The risks of surgery under general anesthesia have decreased; therefore, today I use general anesthesia following the strict guidelines that will be discussed later.

#### *Resection–Extension Osteotomy at L3–L4*

The primary deformity of patients selected for lumbar extension osteotomy is in the lumbar spine and loss of lumbar lordosis. There may be some associated increase in thoracic kyphosis, which can be balanced by overcorrecting the lumbar deformity so that the chin-brow-to-vertical angle will be normal. This angle is measured and transposed to a lateral radiograph of the lumbar spine, placing the apex of the angle at the posterior longitudinal ligament over the L3-4 disc space. The L3–L4 level is selected for correction because it is the center of the lumbar lordosis and is below the spinal cord. The L4–L5 level is used only on rare occasions.

Do a careful preoperative evaluation, including medical assessment, pulmonary function tests, and electrocardiography. Instruct the patient in deep breathing and extremity exercises, which will be used postoperatively. Psychological preparation includes explaining to the patient the procedure and the importance of awake intubation and positioning, prior to inducing general anesthesia. Make plaster molds of the upper and lower halves of the body before surgery. The upper half extends from the waist up, supporting the chest and head; the lower half extends from the waist to the knees. These shells are used for support when the patient is turned prone after the correction is done. The molds protect the face and allow the anesthesiologist to administer oxygen by face mask through the opening in the shell (Fig. 153.9).




***Figure 153.9.*** **A:** Cephalad and caudad anterior molds. The cephalad mold supports the head and has an opening for the face. **B:** Postoperative view. After correction of deformity, the patient is supported in the prone position by the anterior molds with a jack below the upper mold. Note the restoration of lordosis with correction of the

flexion deformity.

In planning the osteotomy, it is important to know whether the patient has normal spinal canal dimensions. If the patient has a canal of normal or above-average size, then less bone may be removed posteriorly with closer approximation of the laminae. However, if the canal dimensions are fairly small (less than 20 mm on the anteroposterior diameter) or in the stenotic range, then considerably more caution must be taken to ensure that the posterior decompression is generous, particularly superiorly. In this situation, it is best to leave the central laminectomy area open significantly above and below to avoid any compression from postoperative edema, buckling of the dura, or minimal translation. Some indication of adequate canal size may be noted on a lateral view of the spine; patients with large foramina and long pedicles have a greater canal size than those in whom the foramina appear small and the pedicles short. If a narrow canal is suspected, make accurate computed tomography (CT) canal measurements.

My method is based on the original technique by Smith-Petersen et al. (26). They described a posterior wedge resection of the mid-lumbar spine in a V fashion. This resection was carried superiorly and laterally through the superior facet of the vertebra above and the inferior facet of the vertebra below in an oblique fashion. More bone was resected superiorly than inferiorly. The oblique plane of the osteotomy was designed to produce overlap of the posterior elements following correction, in an effort to prevent displacement. Since the deformity was corrected by manipulation of the spine after the posterior resection was completed, the anteriorly longitudinal ligament was fractured. This technique is the basis for the procedure described next.

- Have your neuromonitoring technician apply the spinal cord monitoring electrodes and confirm that the spinal cord monitoring is satisfactory.
- Have the anesthesiologist intubate the patient while he is awake and lying on the gurney on which he was brought into the operating room. When the endotracheal tube is in position, ask the patient to stand (with assistance) and transfer to a suitable spinal OR table with his knees and hips flexed. Adjust the supports to provide comfortable positing for his head, chest, and pelvis, avoiding any strain on his neck. Ask him to give an OK signal with his hand when he is comfortable, and then induce general anesthesia (28).
- Compared to our previous use of local anesthesia only, general anesthesia makes the posterior bony resection easier to perform. It is much easier to undercut the pedicles above and below the area of resection, and a more complete decompression of the L-3 nerve roots is possible.
- Prepare and drape the back.
- The general anesthesia can be augmented by infiltration of the skin and the paravertebral muscles with 0.5% bupivacaine with 1:200,000 epinephrine. This will reduce somewhat the level of general anesthesia required and provides some hemostasis.
- Make a midline exposure and confirm the proposed L3–L4 osteotomy site radiographically with towel clips placed on the base of the spinous processes at the level of the laminae of L-3 and L-4.
- I now routinely use pedicle screw fixation; therefore the next step is the insertion of the pedicle screws prior to the performance of the osteotomy. The number of levels of fixation required depends on bony quality, but usually I place screws in the pedicles of L-1, L-2, L-3, as well as L5 and S-1 (Fig. 153.10*A*).

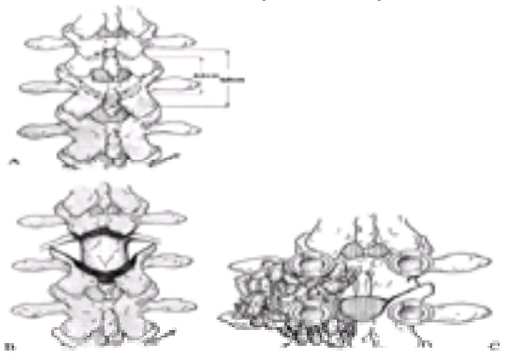

***Figure 153.10.*** Resection-Extension Osteotomy, L3–4: **A:** The osteotomy is planned to completely decompress the thecal sack in the midline, with symmetrical lateral resections extending cranially and laterally. Pedicle screw insertion sites are identified, and screws may be placed prior to osteotomy. **B:** Following decompression, the Smith-Peterson osteotomy provides two wedges of posterior bone that will lock together when the spine is placed in extension. Relieve the undersurface of the lamina to prevent impingement as the spine is extended into its reduced position. **C:** Closure of the osteotomy by extension of the spine. Pack resected bone and autograft posterolaterally over the transverse processes and dorsal cortex of the osteotomy. Place the fixation rods into the screws and compress the osteotomy site, locking the wedges together to ensure stability and reliable arthrodesis.

- Next, perform a V-shaped wedge resection osteotomy at the interlaminar space, as recommended by Smith-Petersen et al. (26), resecting the ossified ligamentum flavum and adjacent laminae.
- Extend the resection upward and laterally on each side through the fused posterior joints at L3–L4. The amount of bone to be removed posteriorly is measured from the radiograph at the level of the tips of the spinous processes, the laminae, the posterior aspect of the posterior joints, and inside the canal at the level of the pedicles. The obliquity of this resection allows locking of the vertebrae following correction.
- Remove the spinous processes in small strips to be used for grafting. Remove the bone with bone cutters and rongeurs.
- A power burr may be a useful tool for cutting slowly through the fused posterior elements toward the spinal canal, which is opened. The ossified ligamentum flavum is harder and denser than the vertebral elements.
- Protect the dura with cotton patties. In many instances, the dura is atrophic and occasionally it may adhere to the laminae, making separation difficult.
- Completely expose the dural sac laterally on each side to the level of the pedicles.
- Undercut the laminae above and below to avoid impingement on the dura following extension. Undercut the pedicles to avoid any impingement on the third lumbar nerve roots following extension.
- Remove bone from each side symmetrically, to allow symmetrical closure of the defect (Fig. 153.10*B*).
- When the osteotomy is completed, correct the kyphotic deformity by extending the hips with the adjustments of the spine table. This will produce an anterior osteoclasis and an opening wedge anteriorly with closure of the posterior osteotomy. Perform this maneuver gently and carefully, constantly watching the neuromonitoring for any evidence of compromise of neurologic function, and close the osteotomy down to obtain good posterior bone apposition (Fig. 153.10*C*).
- Full correction must be obtained with the weight-bearing line shifted posterior to the osteotomy site, so that gravity will maintain and increase the correction as it heals; it will also stimulate bone formation across the osteotomy sites of the resected posterior fusion masses (Fig. 153.11).
- Complete the stabilization by fixing the rods to the pedicle screws using TSRH instrumentation (Sofamor-Danek, Memphis, TN).

***Figure 153.11.*** **A:** Lateral view of a patient standing with hips and knees extended. This patient still had mobility of his cervical spine and was compensating with the neck hyperextended. When the neck was in the neutral or comfortable position, he had a chin-brow-to-vertical angle of 45°. **B:** Lateral radiograph of lumbar spine showing the chin-brow-to-vertical angle superimposed with the apex at the L3-4 disc space. The amount of bone to be resected is indicated at each depth posteriorly. **C:** Postoperative lateral radiograph following correction under local anesthesia showing the angle of correction obtained after closure of the resected defect posteriorly with an opening osteoclasis at L3-4 of 48°. The weight-bearing line has been shifted posterior to the osteotomy site. **D:** Postoperative standing lateral radiograph showing complete correction of the deformity after removal of a calculated wedge of bone based on preoperative assessment.

Initially, I used no internal fixation, as suggested by Smith-Petersen et al. (26), relying on the **V**-shaped configuration of the osteotomy to provide locking and reasonable stability. The patients were kept recumbent for 6 weeks, followed by ambulation in a Minerva plaster cast (19,21,23). Subsequently, I used internal wire loop fixation for additional stability and comfort in the early postoperative interval. Before the advent of pedicle screw fixation, I used a Luque rectangle with posterior

segmental instrumentation and Drummond buttons and wires. The advantage of internal fixation with segmental instrumentation was that it decreased the risk of translation and allowed earlier postoperative mobilization (Fig. 153.12). I now prefer pedicle screw and rod fixation with the decompression technique just described, as it allows easier and more liberal decompression; the rigid internal fixation decreases the risk of displacement and allows easier and quicker mobilization of the patients, who seem to have less postoperative pain. The disadvantages of pedicle screw and rod fixation are increased operating time, and increased risk of neurologic injury from improper insertion of bone screws because of the altered anatomy of the pedicles. Overall, however, I feel that the advantages outweigh the disadvantages, as illustrated by the patient in Figure 153.13.

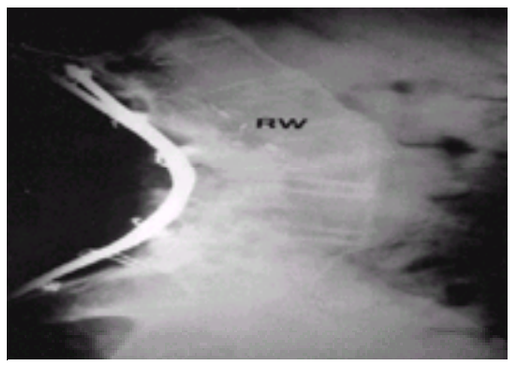


***Figure 153.12.*** Postoperative lateral radiograph showing Luque instrumentation in position using Drummond buttons and wires, which add stability to the osteotomy. A rectangle is usually used and is bent to the desired angle of correction at the time of insertion. The use of Drummond buttons avoids the necessity to invade the spinal canal, the insertion being done under local anesthesia.

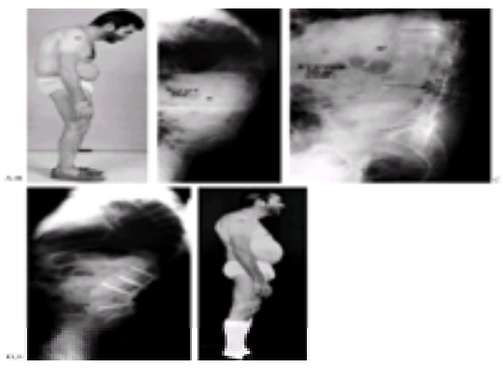

***Figure 153.13.*** **A:** This 41-year-old man with a 21-year history of ankylosing spondylitis has had a major kyphotic deformity for 10 years, with a chin-brow-to-vertical angle measuring 55°. He has been unable to work for about 6 years. **B:** Lateral standing 3-foot radiograph of the spine shows a thoracic kyphosis of 75° and a decreased lumbar lordosis of 18°. The weight-bearing line is well anterior to the mid-lumbar spine. **C:** Preoperative lateral radiograph of the lumbar spine shows the planned resection/osteotomy of 50° to 55° located at L3–L4. **D:** This lateral standing 3-foot radiograph, taken 16 months postoperatively, shows the healed lumbar osteotomy with pedicle screw fixation and rods in place. The lumbar lordosis now measures 74°; the thoracic kyphosis is approximately 70° and the spine is in balance. The weight-bearing line is posterior to the osteotomy site. **E:** The patient 16 months after surgery. He returned to a normal lifestyle. (From White AH, Schofferman JA. *Spine Care: Operative Treatment*, vol.2. Philadelphia: Mosby, 1995:1678, with permission.)

- Strip the spine further lateral to the osteotomy site, exposing the transverse processes of L-3 and L-4. Divide the autogenous bone removed during the resection into equal portions and place it posterolaterally on both sides, creating an adequate fusion mass.
- Close the wound with suction drainage.
- When the patient is still prone after wound closure, apply a well-molded posterior plastic shell, before transfer to a Roto-rest bed. The shell must be rigid and the contour of the spine must be maintained with adequate support under the pelvis, so that the rounded hump of the thoracic spine is not pushed forward in relation to the lumbar spine as the patient rests in the supine position (Fig. 153.14). The posterior shell is necessary to support the patient adequately when the Roto-rest trap door is removed for use of a bedpan.

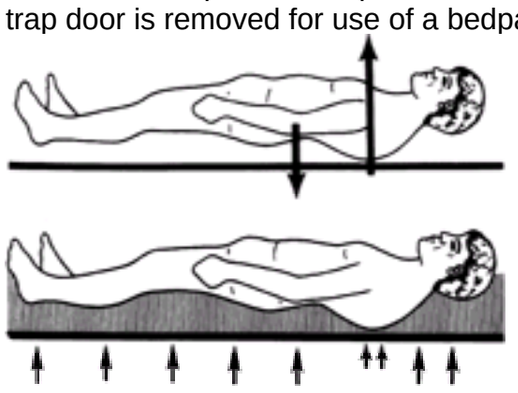

***Figure 153.14.*** **A:** Lateral diagrammatic view showing the contour of the corrected spine when lying supine unsupported. The posteriorly projecting thoracic hump bears most of the weight, with less support on the lumbar spine and the spine below the osteotomy. As a result, the rigid thoracic hump tends to be displaced forward and the lumbar spine posteriorly. **B:** With the patient supine in a well-molded, rigid shell, equal support is created throughout the spine, with elimination of any uneven contact forces that would tend toward displacement.

**Postoperative Care** Continue nasogastric suction until the patient is expelling flatus. About 7–10 days after surgery, when the patient is comfortable, he is lifted to an orthopaedic table in the posterior shell. Partly suspend the patient by the lower portion of the shell while the upper portion and sides are trimmed away, and then immobilize him in a well-molded plaster jacket. Take care in transferring and supporting him during application of the jacket, to avoid any loss of position.

**Results and Complications** This technique, with Luque instrumentation and performed under local anesthesia, was used in 100 patients between 1969 and 1993 without major intraoperative difficulty. Satisfactory correction was achieved, with restoration of normal functional alignment. There were no major respiratory complications and there was no pneumonitis in the series. Three nonunions occurred, one in a patient without internal fixation who subsequently responded to posterior instrumentation and fusion. In one patient, the fusion site appeared to be united, but a fracture of the osteotomy site was sustained in an automobile accident, requiring anterior strut-grafting. In a third patient who had severe osteopenia, union was not achieved and subsequent anterior strut-grafting with allograft and autogenous bone was performed.

One female patient who was on oral contraceptives suffered a sudden fatal pulmonary embolism 15 days after surgery, at which time she had been ambulatory in a plaster jacket. Eight patients developed L-3 root or cauda equina compression within 2 to 14 days after surgery; all except two compressions occurred in patients in whom internal fixation with segmental instrumentation was not used. In one of these, the compression was thought to be vascular in nature—he was an obese patient (about 300 pounds) who developed vena caval compression from thrombosis with neural venous stasis.

Management problems contributing to other cases of compression included patients slipping during the course of turning on a Circoelectric frame, the removal of the trap door on a Roto-rest bed with the patient not supported in a posterior shell, and in one patient, manipulation on a table for cast application. In most of these, estimates of canal dimension had not been done and in retrospect were probably on the low side. In most of these patients, the osteoclasis occurred through the body

of L-2 rather than through the disc space, and this would appear to be a risk factor.

In certain instances when the ossification at the disc is considerably greater than at the vertebral body, selected preliminary anterior L3–L4 disc division might be considered, but I have not done this. Patients who presented with these problems were promptly reexplored and further decompression was carried out (usually superiorly), with the spine stabilized by internal fixation in the form of Luque instrumentation and Drummond buttons. On the whole, this prompt treatment allowed satisfactory recovery.

In my experience, if the correction is complete and the weight-bearing line is shifted posterior to the osteotomy site, fusion will occur with a 97% success rate and the correction will be maintained. Our results using pedicle screw fixation under general anesthesia are equally good.

Resection–extension osteotomy of the lumbar spine is a reasonably safe, practical, and reliable procedure in this high-risk type of patient. This technique allows a greater degree of correction of purely lumbar spinal deformity, in that it produces more hyperextension at the osteotomy site than can be obtained with multiple anterior and posterior osteotomies using compression instrumentation (either Harrington or Zielke) of the thoracolumbar spine. The range of osteotomy correction in our patients was from 40° to 104° (average, 56°). The preoperative chin-brow-to-vertical angle varied from 35° to 134° (the latter was in a patient with associated hip deformity), with an average of 60°. The postoperative chin-brow-to-vertical angle ranged from – 5° to +15°, with an average of +15° (Fig. 153.11).

***Alternative Approach to Lumbar Osteotomy and Stabilization***

The technique presented in this section was contributed by Dr. Isadore Lieberman.

The “eggshell” closing wedge osteotomy is an alternative to the opening wedge technique just described. In this approach, carry out the dorsal osteotomy and decompression as described, but complete the anterior correction through the posterior approach by removing the vertebral pedicles, and by decancellating and collapsing the vertebral body to correct the sagittal alignment. Then stabilize corrected segments with a pedicle screw fixation construct.

- Position the patient prone as described, and use the routine midline longitudinal dorsal approach to the thoracic and thoracolumbar spine.
- Begin by removing the spinous processes and laminae over the L2–L3 interspace, cutting a wedge-shaped defect posteriorly.
- Isolate and remove the pedicles and transverse processes of L-2, carefully resecting the pedicles until they are flush with the back of the vertebral body.
- Working through the pedicles, use curets and pituitary rongeurs to break up and remove the cancellous bone from within the vertebral body.
- Use curved curets or a burr to remove cancellous bone from between the pedicles and along the dorsal cortex of the body.
- Take care not to breach the anterior cortical wall.
- Place pedicle screws at adjacent levels before attempting the final correction.
- Use a blunt impactor to fracture the posterolateral cortex of the body, then score the dorsal cortex with an osteotome and implode it into the vertebral body cavity, away from the thecal sack.
- Slowly hyperextend the operating table, or bring the patient's legs into extension to collapse the dorsal aspect of the vertebral body and close the dorsal osteotomy.
- Instrument the spine from L-4 to the thoracic spine and graft for fusion (Fig. 153.15).

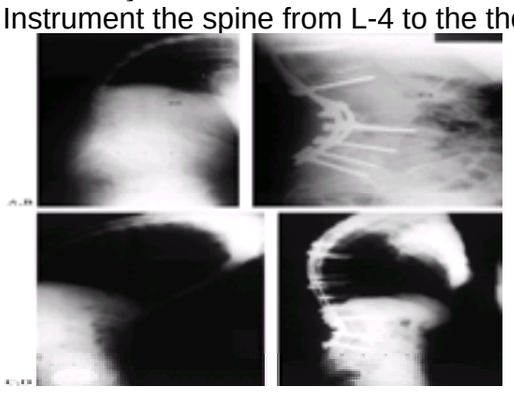

***Figure 153.15.*** **A:** Lateral view of a 50-year-old man with multilevel deformity. Severe cervical deformity was corrected prior to treating the thoracolumbar kyphosis. He also suffered from a persistent thoracolumbar pseudarthrosis. An L-2 decancellation and pedicle reduction osteotomy was carried out, fully correcting sagittal balance. **B:** Posterior segmental instrumentation and grafting provided immediate stability and a solid fusion. **C:** A 58-year-old man with severe, fixed deformity, localized primarily to the thoracolumbar junction. **D:** After “eggshell” osteotomy of L-2, posterior instrumentation was extended from the upper thoracic segments to L-5. Sagittal correction was excellent and well maintained. The patient's visual horizon was restored to normal.

- Place the patient in a molded thoracolumbosacral orthosis for 4–6 months after surgery.

**KYPHOTIC DEFORMITY OF THE THORACIC SPINE**

A degree of thoracic kyphosis is common in spinal deformity associated with ankylosing spondylitis. It is much less common for the only deformity or primary deformity to be in the thoracic region, requiring the correction to be confined to that area.

Patients with thoracic kyphosis can be classified into two groups (19,21,23). In the first group, the main or primary deformity is in the thoracic spine, but in addition there is a loss of lumbar lordosis. If the thoracic kyphosis is mild or moderate and the lumbar spine rigid and flattened, the overall deformity can be satisfactorily corrected by a compensatory osteotomy in the midlumbar spine. With sufficient extension of the lumbar spine, the thoracic kyphosis can be compensated for with restoration of spinal balance and a normal chin-brow-to-vertical angle.

Patients in the second group have thoracic kyphosis with normal or exaggerated cervical and lumbar lordosis. These patients require correction of the primary thoracic deformity. It is impossible to do this safely with a single major angular correction. Correction of purely thoracic deformity requires multiple anterior and posterior intervertebral osteotomies, instrumentation, and grafting.

Patients who have thoracic kyphosis with normal cervical and lumbar lordosis can be further subdivided into two subgroups, depending on the rigidity of the thoracic spine. In the first subgroup, with incomplete ossification of the thoracic spine or extensive areas of destructive spondylodiscitis, preliminary correction can be obtained by halo-dependent traction; this is followed by multiple posterior resection osteotomies and compression instrumentation with second-stage anterior resection of the areas of spondylodiscitis and the disc spaces, with supportive strut-grafting (Fig. 153.16).

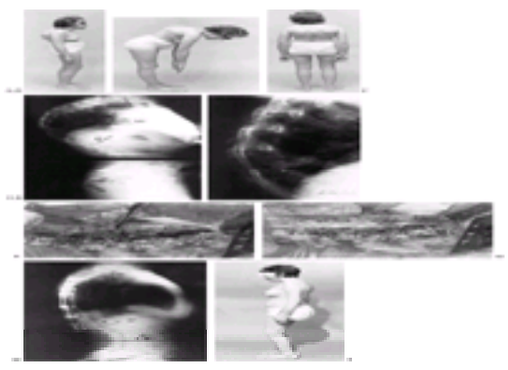

***Figure 153.16.*** **A:** Lateral view of a 32-year-old woman with severe kyphosis confined to the thoracic region, associated with ankylosing spondylitis and steroid therapy. Patient had lost 6 inches in height, and her ribs impinged against the pelvis. **B:** Lateral bending view showing angular kyphotic deformity. **C:** Posterior view showing impending skin breakdown. **D:** Standing lateral radiograph showing thoracic kyphosis of 120° with increased lumbar lordosis. **E:** Lateral radiograph showing destructive spondylodiscitis at the apex of the thoracic deformity, indicating that it is likely to be flexible. The patient was treated with halo-dependent traction to reduce the main deformity, followed by posterior joint resections with bilateral Harrington compression instrumentation and fusion. **F:** Operative view at second-stage anterior procedure (following previous posterior instrumentation) showing resection of areas of spondylodiscitis with a trough prepared from T-6 to T-11 for a fibular strut graft. **G:**

Operative view showing the fibular strut graft locked into the spine from T-6 to T-11 with onlay rib grafts. **H:** Postoperative standing lateral radiograph showing posterior Harrington compression instrumentation with fibular strut grafts supporting the spine anteriorly. **I:** Postoperative standing lateral view of the patient showing correction of the deformity. She had regained 5 inches in height.

The second and more common subgroup involves patients with rigid thoracic kyphosis and relatively complete ossification. These patients require a first-stage anterior transthoracic procedure.

***Correction of Thoracic Kyphosis***

- Approach the thoracic spine through a right-sided thoracotomy with removal of the rib at the level of the apex of the deformity in the midaxillary line.
- Reflect the pleura and resect the ossified disc spaces completely from right to left, anterior to the posterior longitudinal ligament. Thoroughly curet the disc spaces and pack them with autogenous bone, using portions of the removed rib supplemented by iliac crest bone where necessary.
- Apply halo-dependent traction after surgery.
- Perform the second-stage procedure about 7–10 days later using a posterior approach. Perform multiple V-shaped resection osteotomies at each level, resecting the ossified ligamentum flavum and adjacent portions of the laminae upward and outward on each side through the intervertebral foramen, removing enough bone to allow adequate correction following closure.
- Apply bilateral segmental compression instrumentation, gradually closing the osteotomy sites and correcting the deformity (Fig. 153.17).

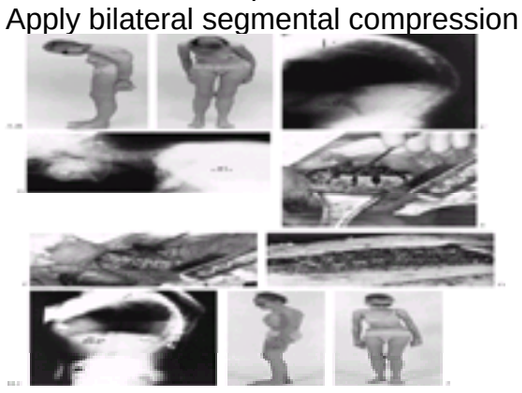

***Figure 153.17.*** **A:** Lateral view of a 34-year-old woman with rigid thoracic kyphosis and normal lordosis of the cervical and lumbar spines. The patient had lost 5 inches in height. **B:** Anterior view of the patient showing restricted field of vision with rib impingement on the pelvis. Pulmonary function was reduced to 54% of predicted normal. **C:** Preoperative standing lateral 3-foot radiograph of the spine showing thoracic kyphosis of 110° with normal lumbar lordosis. **D:** Lateral radiograph of the cervical spine showing normal or increased cervical lordosis. **E:** Operative view showing anterior transthoracic resection of the ossified disc spaces completely through, from one side to the other. **F:** Operative view showing rib grafting of resected ossified disc spaces. **G:** Operative view showing multiple posterior V-shaped osteotomies, which were followed by bilateral posterior Harrington compression instrumentation with fusion. The ossified ligamentum flavum has been resected at each level, passing upward and laterally through the fused posterior joints. The margins are undercut before the compression instrumentation was performed. **H:** Postoperative lateral standing 3-foot radiograph showing correction of major deformity with restoration of normal spinal alignment. **I:** Postoperative lateral view of patient showing correction of the thoracic kyphosis with the ribs being lifted out of the pelvis. **J:** Postoperative anterior view of the patient showing restoration of normal field of vision.

**HINTS AND TRICKS**

- Perform multiple osteotomies in the thoracic region so that correction at any one level is minimal, yet the cumulative effect allows substantial improvement.
- Anterior and posterior osteotomies with interval traction produce some of the correction while the patient is awake, reducing neurologic risk.
- Place the posterior instrumentation using spinal cord monitoring to allow reasonable correction in a critical area with greater safety.
- The technique of multiple, two-stage anterior and posterior osteotomies with posterior instrumentation is the obvious choice for primary thoracic deformity with a normal cervical and lumbar lordosis.
- Resection–extension osteotomy of the mid-lumbar spine is ideal for purely lumbar kyphosis with a normal or reduced thoracic kyphosis.

Despite the feasibility, multiple anterior and posterior osteotomies under general anesthesia in two procedures are more hazardous than a single-stage extension correction of the lumbar spine under local anesthesia. Tracheostomy, with its attendant problems, may be required in the management of patients with kyphotic deformity. However, where the primary deformity is thoracic with a normal lordosis above and below, these risks must be accepted if the deformity is to be corrected.

Although Harrington, Zielke, and Cotrel-Dubousset instrumentation systems have been used in the past, current segmental instrumentation systems offer more reliable correction and fixation. I favor the TSRH system, which provides a variety of pedicle-screw fixation options that allow the surgeon to tailor the instrumentation construct to the individual. Other systems are available that provide similar features. The surgeon should be well versed in the technical features of any selected instrumentation before undertaking this sort of reconstruction.

- In kyphosis procedures, place pedicle screws above and below the selected level before performing the osteotomy.
- Use fluoroscopy or plain radiography to confirm position and alignment during placement. I use spinal cord monitoring in all patients done under general anesthesia, and I stimulate the screws to confirm safe placement during instrumentation.
- After the osteotomy is completed, extend the patient's hips until the osteoclasis occurs, then place contoured fixation rods into the screws and fix them in place.
- Pack milled bone graft along the lateral gutters and across the osteotomy site. Place a well-molded plaster shell over the patient's back before rolling him off the operating table. This will prevent excessive pressure over the dorsal kyphosis in the immediate postoperative period, and it will be converted to a plaster cast when abdominal distension resolves.

**KYPHOTIC DEFORMITY OF THE CERVICAL SPINE**

In a few patients with ankylosing spondylitis, flexion deformity of the spine occurs primarily in the cervical region. This deformity can be severely disabling, with restriction of the field of vision, and it may progress to the point where it interferes with opening of the mouth. Surgical correction is fraught with hazard. Anecdotal reports of isolated attempts to correct this deformity under general anesthesia indicate a high rate of disastrous complications including death.

For the few severely afflicted patients with this type of deformity, it is important that the surgeon clearly understand the principles related to its possible correction and its indications. Over the past 30 years, I have routinely used a technique of correction under local anesthesia that has allowed a consistent, satisfactory, and somewhat dramatic correction with relative safety (3,4 and 5,7).

***Diagnosis of Fracture***

Not all patients with a “chin-on-chest” deformity in ankylosing spondylitis require cervical osteotomy, as the underlying problem is fracture. Those who present with a recent onset of a painful flexion deformity often do not require osteotomy, as, again, an underlying problem is fracture. In fact, any patient with ankylosing spondylitis whose spinal alignment has been relatively unchanged over time and who has had little pain, who then experiences painful, progressive flexion deformity after minor trauma, has a fracture of the cervical spine until proven otherwise. The fracture is usually at the base of the neck at the cervicothoracic junction. Unfortunately, the pain is often attributed to the patient's disease.

A fracture of the spine in ankylosing spondylitis resembles a fracture of an osteoporotic tubular bone, with a transverse shear pattern. The fracture is difficult to recognize radiographically, being obscured by the shoulders, and it may vary in its location from C-6 to T-2, although most commonly it is in the area of C-7 or T-1.

The fracture undergoes gradual erosion, causing compression and collapse anteriorly, with the chin approaching the chest. The patient is aware that the position of the head varies during the day, being more elevated on waking in the morning and dropping more toward the chest after being ambulatory during the day. The patient may

hold the head with the hands to ease the distress.

It is important to diagnose this fracture using lateral tomography at the cervicothoracic junction. Patients with this fracture do not require cervical osteotomy. Apply a cranial halo and initiate traction along the line of the deformed neck. Then slowly restore normal alignment under careful observation until the head is restored to its normal functional position. It is usually possible to obtain a fairly normal chin-brow-to-vertical angle, after which place the patient in a well-molded halo cast for 4 months. The halo cast is essential: A halo vest does not provide adequate immobilization.

The craniocervical junction is the other area of the cervical spine where lesions may occur that cause painful flexion deformities. Destructive arthritis at the atlanto-occipital joint may cause the patient to flex the neck at this joint with the chin held downward, while the lateral radiograph of the cervical spine shows a relatively normal lordosis. Correct this by graduated halo traction to restore a normal chin-brow-to-vertical angle, followed by posterior stabilization, usually with occipitocervical fusion and, where necessary, excision of the posterior fragmented arch of C-1.

***Cervical Osteotomy under Local Anesthesia***

Unrecognized and untreated fractures at the base of the cervical spine ultimately heal, at which time the pain disappears, leaving the patient with a painless, fixed flexion deformity. At this stage, osteotomy is required for correction.

Of those patients for whom I have performed cervical osteotomy, 36% have shown evidence of previous cervical fracture. In 31%, the fracture contributed significantly to the spinal deformity. In only 15% of those who presented with evidence of fracture had the fracture been diagnosed previously. This experience underscores the fact that early recognition of the fracture and adequate immobilization are essential if the risk of further deformity is to be avoided.

**Preoperative Considerations** Determine the amount of bone to be resected from preoperative radiographs. Measure the chin-brow-to-vertical angle and transpose it to a lateral radiograph of the cervical spine with the apex of the angle at the posterior margin of the C7–T1 disc space. A lateral tomogram probably will be necessary to show this clearly. Center the angle over the posterior arch of C-7. The amount of bone to be resected is determined from the radiograph with the angle superimposed over the spinous processes, the laminae, the posterior margin of the facet joints, and the posterior margin of the spinal canal at the level of the pedicles. The lines of resection are beveled upward at the superior margin and downward at the inferior margin. Following correction, the two surfaces will be parallel and in apposition.

One or two days before surgery, fit the patient with a rigid plaster or fiberglass body jacket incorporating the supports for the halo unit. The jacket must be rigid and made of a material that will not soften with body heat. It must be very skillfully contoured to the patient's trunk so that it cannot slide up or down. It must be molded under the rib cage and the sides of the chest to prevent it from going upward, and over the pelvis and iliac crests to prevent it from moving distally.

A commercial plastic halo jacket is inadequate for the postoperative immobilization required for these patients. In most instances, because the spine is completely solid above and below the area of osteotomy, a flexible jacket creates excessive forces that tend to cause movement at the osteotomy site with almost any activity. If the patient is not rigidly immobilized, he will have extreme distress when trying to get in or out of bed or to move about. Excessive mobility can even result in some neurologic compromise with irritation of the C-8 nerve root. Apply the jacket and test it carefully with the patient up and about to make certain that it is well contoured and secure; do this far enough before the surgery that there is time to make any necessary adjustments. Fit a halo to the skull preoperatively under local anesthesia in a stable position, below the maximum circumference of the skull.

**Operative Technique** As Urist (27) has recommended, perform the operation under local anesthesia with the patient in the sitting position. Use a dental-type chair, so that the patient can be placed in a recumbent position if necessary. Having the patient awake avoids any major anesthetic hazards, and allows accurate monitoring of neurologic and other vital functions. The patient can assist with anatomic localization of the level during the decompression by indicating at any time any paresthesias or discomfort along the distribution of a cervical nerve root: This ability is of real value in confirming the location of the C-8 nerve root canal and the level of the root.

Perform the excision posteriorly with subsequent fracturing and extension of the spine at the cervicothoracic junction. The preferred level for correction is between C-7 and T-1 (Fig. 153.18), because, as Mason et al. (11) and Urist (27) have indicated, this interspace is more receptive to surgical treatment than any other level of the cervical region. The advantages are many:

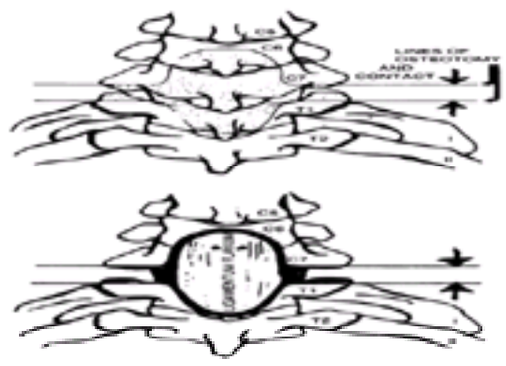

***Figure 153.18.*** Diagrammatic posterior view of the area of resection for cervical osteotomy. Bevel the margins of the resection of the lateral fused joints slightly away from each other extending posteriorly, so that after correction the two surfaces are parallel and in apposition. Undercut the pedicles significantly to avoid impingement on the C-8 nerve roots. Bevel the midline resection on its deep surface above and below to avoid impingement against the dura after extension correction. (From Simmons EH. Surgery of the Spine in Rheumatoid Arthritis and Ankylosing Spondylitis. In: Cruess RL, Mitchell NS, eds.*Surgery of Rheumatoid Arthritis.* Philadelphia: Lippincott, 1971, with permission.)

- The spinal canal is relatively wide.
- The cervical cord and C-8 nerve root have reasonable mobility in this area.
- Any weakness caused by compromise of the C-8 nerve root results in less disability than with other roots.
- The vertebral artery and veins usually pass in front of the transverse process of C-7 and enter the transverse foramen at the sixth vertebra.
- The position of these vessels above the level of T-1 protects them from injury during osteotomy at the C7–T1 level (Fig. 153.19).

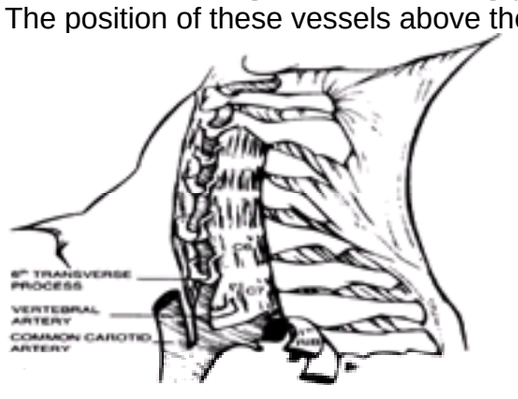


***Figure 153.19.*** Lateral anatomic diagram showing the normal passage of the vertebral arteries and veins in front of the transverse process of the seventh vertebra, entering the transverse foramen at the sixth vertebra. (Simmons EH. Surgery of the Spine in Rheumatoid Arthritis and Ankylosing Spondylitis. In: Cruess RL, Mitchell NS, eds.*Surgery of Rheumatoid Arthritis.* Philadelphia: Lippincott, 1971, with permission.)

Use diazepam for preoperative sedation, with the exposure carried out posteriorly under local infiltration (1% lidocaine and epinephrine 1:200,000). Use fentanyl for supplementary analgesia during the procedure.

- Identify the last bifid spinous process, which is usually C-6. Compare the architecture of the lower cervical spinous processes using a lateral radiograph of the cervical spine. If you encounter any difficulty in anatomic localization, obtain radiographic confirmation of the level.
- Remove the C-7 spinous process, the inferior spine of C-6, and the superior spine of T-1 in strips and preserve them for grafting. Remove the entire posterior arch of C-7 along with the inferior half of the arch of C-6 and the superior half of the arch of T-1 (Fig. 153.20).

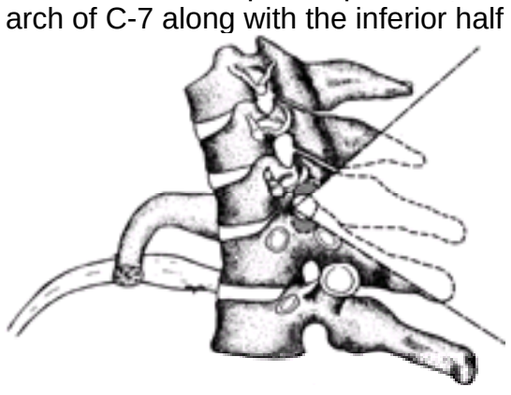

***Figure 153.20.*** Lateral diagrammatic outline of the area of posterior resection at the C7–T1 level. The *shaded areas* represent where the pedicles are undercut to avoid nerve root impingement after extension correction.

- Open the spinal canal. Protect the dura and spinal cord with cotton patties.
- Extend the decompression laterally on each side beyond the lateral margin of the spinal cord to the level of the pedicles. Undercut the laminae above and below the decompression to avoid impingement following extension correction.
- Identify the C-8 nerve root and pass a curved probe into its canal. The patient may be able to assist in confirmation of the level by indicating the distribution of any paresthesias associated with displacement of the root. Extend the resection through the fused area of the posterior joints of C7–T1, decompressing the C-8 nerve root completely.
- Expose the inferior aspect of the pedicles of C-7 and the superior aspect of the pedicles of T-1.
- Cut the pedicles through in a curved fashion away from the C-8 root, leaving a shell to protect the nerve root while the main bone is removed; the shell is removed at the completion of the nerve root decompression. This is done to undercut the pedicles above and below adequately, so that after the extension correction, there will be a bony recess for the eighth nerve root to avoid impingement or a pincer effect.
- Follow the nerve root laterally, and remove all bone that could impinge on it.
- Resect the lateral masses completely through from medial to lateral so that there is no remaining bridge of bone laterally that could interfere with extension correction (Fig. 153.21*A*).

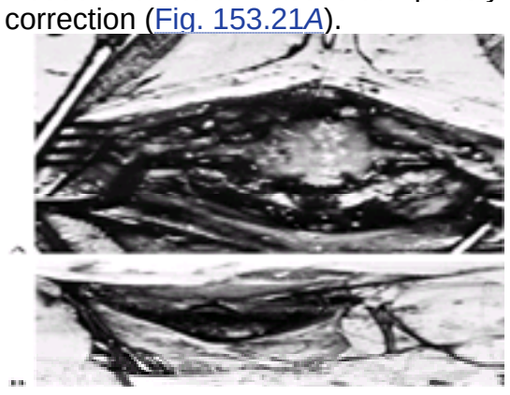

***Figure 153.21.*** **A:** Posterior operative view showing midline decompression with resection of lateral masses, decompression of C-8 nerve roots, and undercutting of pedicles. **B:** Posterior operative view of wound after anterior osteoclasis and extension correction. The lateral masses have come together posteriorly on each side. The wound has been transformed from a vertical configuration to a transverse one.

- Insert the deep closing sutures and a suction drain before the osteoclasis is done.
- Have the anesthesiologist give supplemental oxygen during the procedure, either by nasal catheter or face mask. The patient is allowed to listen to music from a radio or tape recorder. This is an important part of the anesthetic management, along with a continuing, cheerful conversation between the anesthesiologist or an attendant and the patient. When this is done well, the amount of discomfort or concern expressed by the patient can be minimized.
- Complete the decompression. The patient is given a small dose of a short-acting barbiturate, such as brevitol.
- When the anesthesiologist indicates the sedation is effective, extend the neck by grasping the halo firmly and tilting the neck backward. An audible snap may be heard and a physical sense of fracture will be appreciated.
- Extend the neck until resistance occurs. The lateral masses can be palpated as they come together posteriorly on each side (Fig. 153.21*B*).
- The patient is allowed to awaken almost instantly and can confirm normal neurologic function of the extremities.
- Hold the head firmly in the corrected position while an assistant stabilizes it by connecting the anterior supports for the halo unit to the cast.
- Avoid overcorrection, particularly in patients with a rigid cervical spine and no compensatory movement at the occipitocervical junction. The final position should effect a compromise for the patient between looking ahead for walking and being able to work at a desk (Fig. 153.22).

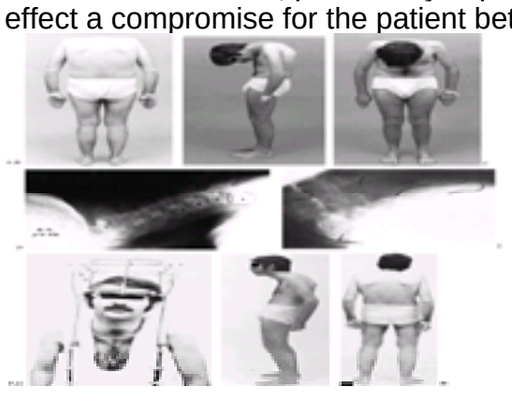

***Figure 153.22.*** **A:** Posterior view of a male patient with a severe rigid flexion deformity of the cervical spine. His head is not visible from the posterior aspect. **B:** Lateral view of the patient showing marked restriction of the field of vision. His chin is rigidly fixed against his chest, interfering with his ability to open his mouth. **C:** Anterior view showing complete restriction of his field of vision. **D:** Lateral view of the cervical spine showing ossification of posterior joints with previous subluxation of C6–C7. **E:** Postoperative lateral radiograph of the cervical spine showing extension–resection osteotomy correction. **F:** Postoperative anterior view of the patient in a halo cast, showing return of his normal field of vision. **G:** Postoperative lateral view of the patient after union of the osteotomy, demonstrating return of normal chin-brow-to-vertical angle. **H:** Postoperative posterior view of the patient demonstrating return of normal head–trunk configuration.

- Place the bone that has been removed during the course of the decompression posterolaterally on both sides over the apposed lateral masses; do not place it in the midline over the exposed dura.
- Tie the deep sutures after extension correction, and complete the wound closure.

Excessive force is not required to straighten the neck if there has been an adequate and complete decompression posteriorly. If the spine does not fracture readily, check to be sure there is not a bridge of bone remaining laterally and that the correct level has been operated on.

Although full correction is usually obtained at the initial procedure, correction of a severe deformity is sometimes limited by tightness of the anterior musculature, or by the patient's apprehension that the deformity is going to be overcorrected. In this case, most of the correction can be established at the time of surgery, with further correction added 7–10 days later by adjustment of the halo-jacket. By this time, the soft tissues will have had an opportunity to stretch and the patient will have had an opportunity to assess the amount of correction that has been achieved. With the patient supine under diazepam and fentanyl sedation, the head may be supported by

the surgeon, and the attachments for the halo released, and the neck allowed to extend to obtain full correction.

**Postoperative Care** Place the patient on a circo-electric bed during the immediate postoperative period. It allows the patient to be brought to a vertical position fairly easily, to stand and walk about and then return to the recumbent position without difficulty. When sufficiently mobile to get in and out of a regular bed, the patient is transferred to a hospital bed with or without a trapeze attachment. Immobilize the patient in a halo cast for 4 months, then remove the cast and perform careful radiographic studies, including lateral tomography centered at C7–T1. When there is radiographic evidence of union and clinical evidence of stability and no pain, remove the halo. Have the patient wear a skull-occiput-mandibular immobilizer (SOMI) brace for at least 2 more months or until it is certain that there is solid union, clinically and radiographically.

**Results and Complications** I have used this technique consistently without any major deviations over the past 20 years in a total of 130 patients. The results have been exceedingly satisfactory, with a minimum of complications, considering the nature of the deformity and the associated disease process. Nonunion occurred in four patients (3%). Three of these responded to anterior cervical fusion at the C7–T1 level with an iliac crest graft. The fourth patient required not only anterior cervical fusion, but also posterior segmental instrumentation and fusion to obtain solid union. Transient neurologic complaints occurred in 16 patients, including 13 patients with transient C-8 paresthesias, one with Horner's syndrome, one with mild central cord syndrome 2 weeks after surgery, and one with transient paresis of the ninth and tenth cranial nerves thought to be secondary to traction. All of these cleared spontaneously without treatment. Five other patients had persistent C-8 nerve root deficits; one of these underwent further decompression, with subsequent improvement. All improved with minimal residual signs and no gross functional handicap.

There has been no major permanent injury to the spinal cord. One dramatic intraoperative experience demonstrates the necessity for surgery performed under local anesthesia. A 70-year-old man had a severe flexion deformity accentuated by an unrecognized fracture that had healed in such a way that his chin rested on his chest. On posterior decompression, dense scarring was noted about the dura related to the previous fracture. As the spine was decompressed in the midline, the patient suffered increasing weakness of his lower limbs and had difficulty with speech.

The dura was exceedingly tense with dense scarring about it. In view of this tension, it was split longitudinally down to the arachnoid. As this was done, there was an immediate, dramatic return of neurologic function in the lower extremities, and the patient's speech returned to normal. The operation was continued and as the decompression was being completed on both sides, he again developed weakness of his lower extremities. The remaining exposed dura was split further distally, again with immediate recovery of neurologic function. The operation was completed without any further difficulty and the patient went on to a satisfactory result without neurologic deficit.

This observation is in keeping with McKenzie and Dewar's report (13) describing the results of laminectomy for cord compression associated with kyphoscoliosis. They related the compressive effect of the dura to the kyphosis and recommended that the dura be split both longitudinally and transversely. Surgeons undertaking this type of surgery should be familiar with this recommendation. If this problem should occur during surgery, adequate splitting of the dura should be done longitudinally and transversely. When incising the dura, take care not to violate the arachnoid; cerebrospinal fluid leakage is thus avoided. If leakage should occur, it can be stopped with a sheet of Gelfoam or a free fat graft.

No major intraoperative problems were noted immediately following the osteoclasis. However, a sudden cardiac arrest occurred in one patient toward the end of the decompression. The chair was flattened and the patient responded to resuscitation without late sequelae. The cause of this arrest remains unknown. Air embolism was considered, but aspiration of the heart showed negative for it. Air embolism is a possibility with surgery in the sitting position, and a doplar is now routinely used over the chest and care is taken to control venous bleeding.

One 79-year-old woman suffered a fatal pulmonary embolism 21 days after surgery; her lungs showed multiple previous areas of subclinical embolism. Another patient suffered a fatal pulmonary embolism before the osteotomy was done. Autopsy revealed multiple thrombi in his leg veins, with evidence of previous pulmonary infarctions. Other complications have been related to the age of the patient and associated disease processes, including one nonfatal pulmonary embolism, a perforated peptic ulcer, and myocardial infarction.

Considering the age and medical risk factors of these patients, the results and complication rates compare favorably with any other type of major reconstructive procedure in a similar group of patients with the same disease process. These patients have an increased tendency for peptic ulceration. Considering the lethal nature of any intra-abdominal catastrophe in these patients, who breathe entirely with the diaphragm, I now place all patients routinely on cimetidine.

In this series of patients the average desired angle of correction was 60°. In 15 patients, cervical osteotomy was combined with lumbar osteotomy for major deformity in both areas; the procedures were performed either on separate admissions or during the same hospitalization. When you plan to repair severe deformity in both areas during the same admission, do the cervical osteotomy first, followed by lumbar osteotomy 1–2 weeks later. Both procedures are done under local anesthesia (Fig. 153.23).

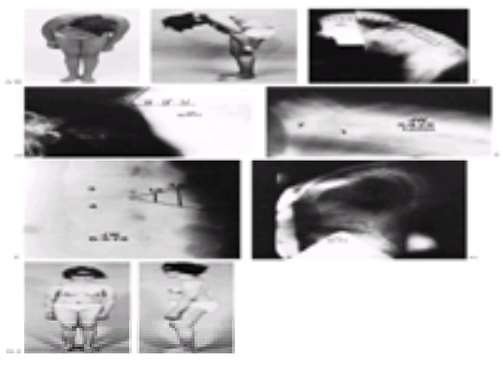

***Figure 153.23.*** **A:** Anterior view of a 43-year-old woman suffering combined neck and lumbar flexion deformities with severe restriction of field of vision. She had suffered arthritic disease since her teens. **B:** Lateral view demonstrating severe flexion deformity of the cervical spine combined with flexion deformity of the lumbar spine. Patient had undergone total hip replacement arthroplasties with some residual hip flexion deformity. **C:** Composite lateral radiograph showing combined neck and lumbar flexion deformities. **D:** Lateral radiograph of the cervicothoracic spine showing the plan of the extension osteotomy. **E:** Postoperative lateral tomogram showing resection–extension osteotomy at C7–T1. **F:** Planned resection–extension osteotomy of the flattened lumbar spine, which was performed 6 weeks after cervical osteotomy. Both procedures were performed under local anesthesia. **G:** Standing lateral 3-foot radiograph of the spine showing cervical and lumbar extension osteotomies. The weight-bearing line is shifted posterior to the lumbar osteotomy site. **H:** Postoperative anterior view demonstrating normal field of vision. **I:** Postoperative lateral view showing complete correction of spinal deformities with restoration of normal chin-brow-to-vertical angle.

## CHAPTER REFERENCES

Each reference is categorized according to the following scheme: *, classic article; #, review article; !, basic research article; and +, clinical results/outcome study.


+ 1. Adams JC. Technique, Dangers and Safeguards in Osteotomy of the Spine. *J Bone Joint Surg Br* 1952;34:226.

* 2. Andersson O. Rontgenbilden vid Spondylarthritis Ankylopoetica. *Nord Med* 1937;14:2000.

# 3. Bland JH. Rheumatoid Arthritis of the Cervical Spine. *J Rheumatol* 1974;3:319.

+ 4. Conlon PW, Isdale IC, Rose BS. Rheumatoid Arthritis in the Cervical Spine: An Analysis of 333 Cases. *Ann Rheumatol Dis* 1966;25:120.

+ 5. Davey JR, Rorabeck CH, Bailey SI, et al. A Technique of Posterior Cervical Fusion for Instability of the Cervical Spine. *Spine* 1985;10:722.

+ 6. Fang HSY, Ong GB. Direct Approach to the Upper Cervical Spine. *J Bone Joint Surg Am* 1962;44:1588.

+ 7. Gilsbach J. Transoral Operations for Craniospinal Malformations. *Neurosurg Rev* 1983;6:199.

* 8. Harris RI. New Investigations: Instrument for Tightening Knots in Steel Wire. *Lancet* 1944;1:504.

+ 9. Little H, Urowitz MB, Smythe HA, et al. Asymptomatic Spondylodiscitis: An Unusual Feature of Ankylosing Spondylitis. *Arthritis Rheum* 1974;17:487.

+ 10. Martel W, Duff IF, Preston RE, et al. The Cervical Spine and Rheumatoid Arthritis: Correlation of Radiographic Clinical Manifestations (abstr.). *Arthritis Rheum* 1964;7:326.

+ 11. Mason CC, Cozen L, Adelstein L. Surgical Correction of Flexion Deformity of the Cervical Spine. *Calif Med* 1953;7:244.

+ 12. McGraw RW, Rusch RM. Atlanto-Axial Arthrodesis. *J Bone Joint Surg Br* 1973;55:482.

+ 13. McKenzie KG, Dewar FP. Scoliosis with Paraplegia. *J Bone Joint Surg Br* 1949;31:162.

+ 14. Pasztor E. Transoral Approach for Epidural Cranio-Cervical Pathological Processes. *Adv Tech Stand Neurosurg* 1985;12:125.

+ 15. Pellicci PM, Ranawat CS, Tsarairis P, et al. Progression of Rheumatoid Arthritis of the Cervical Spine. *J Bone Joint Surg Am* 1981;63:342.

+ 16. Ranawat CS, O'Leary P, Pellicci PM, et al. Cervical Spine Fusion in Rheumatoid Arthritis. *J Bone Joint Surg Am* 1979;61:1003.

+ 17. Rosen PS, Graham DC. Ankylosing Spondylitis: A Clinical Review of 128 Cases. *Arch Int Am Rheumato*l 1962;5:158.

+ 18. Scuhlitz KP. Destruktive Veranderungen an Wirbelkorpern bei der Spondylarthritis Ankylopoetica. *Arch Orthop Unfall Chir* 1968;64:116.

# 19. Simmons EH. Surgery of Rheumatoid Arthritis. In: *Surgery of the Spine in Rheumatoid Arthritis and Ankylosing Spondylitis.* Philadelphia: Lippincott, 1971.

+ 20. Simmons EH. The Surgical Correction of Flexion Deformity of the Cervical Spine in Ankylosing Spondylitis. *Clin Orthop* 1972;86:132.

+ 21. Simmons EH. Kyphotic Deformity of the Spine in Ankylosing Spondylitis. *Clin Orthop* 1977;128:65.

# 22. Simmons EH. Alternatives in the Surgical Stabilization of the Upper Cervical Spine. In: Tator CH, ed.*Early Management of Acute Spinal Cord Injury.* New York: Raven Press, 1982.

# 23. Simmons EH. Surgery of the Spine in Rheumatoid Arthritis and Ankylosing Spondylitis. In: Evarts CM, ed. *Surgery of the Musculoskeletal System*, vol. 2. New York: Churchill-Livingstone, 1983.

+ 24. Simmons EH, Bhalla SK. Anterior Cervical Discectomy and Fusion (Keystone Technique). *J Bone Joint Surg Br* 1969;51:225.

+ 25. Simmons EH, Fielding JW. Atlanto-Axial Arthrodesis. *J Bone Joint Surg Am* 1967;49:1022.

* 26. Smith-Petersen MN, Larson CB, Aufranc OE. Osteotomy of the Spine for Correction of Flexion Deformity in Rheumatoid Arthritis. *J Bone Joint Surg* 1945;27:1.

* 27. Urist MR. Osteotomy of the Cervical Spine: Report of a Case of Ankylosing Rheumatoid Spondylitis. *J Bone Joint Surg Am* 1958;40:833.

+ 28. Wills DG. Anesthetic Management of Posterior Lumbar Osteotomy. *Can Anesth Soc J* 1985;83:248.

# CHAPTER 154

# RHEUMATOID ARTHRITIS OF THE CERVICAL SPINE

*Robert A. Hart and Charles R. Clark*

**R. A. Hart:** Department of Orthopaedic Surgery, Division of Spine Surgery, Oregon Health Sciences University, Portland, Oregon, 97201.
**C. R. Clark:** Departments of Orthopaedic Surgery and Bioengineering, University of Iowa Hospitals and Clinics, Iowa City, Iowa, 52242.

Pathophysiology
Diagnostic Evaluation
Natural History
Perioperative Management
Operative Treatment and Results
Atlantoaxial Arthrodesis
Occipitocervical Arthrodesis
Subaxial Arthrodesis
Odontoid Resection
Surgical Techniques
Pitfalls and Complications
Authors' Perspective
Chapter References

Rheumatoid involvement of the articulations of the cervical spine is extremely common among patients with rheumatoid arthritis. Estimates of frequency vary. Conlon et al. (16) documented radiographic changes in the cervical spine for 85% (283 of 333) of patients with classic rheumatoid arthritis. While the majority of such patients do not develop significant neurologic deficits, identification of those at high risk of neurologic compromise remains a difficult clinical problem.

The three primary patterns of instability due to rheumatoid involvement of the cervical spine are referred to as atlantoaxial instability, cranial settling, and subaxial instability. Clinically relevant radiographic measurements associated with the risk of neurologic compromise have been described for these instability patterns (4). In addition, advanced radiographic techniques such as magnetic resonance imaging (MRI) allow a more precise determination of spinal cord compression.

Surgical indications have historically included significant neurologic compromise, intractable pain, or both. As the concept of impending neurologic compromise has been defined, the selection of patients at risk for neurologic injury for surgical stabilization has also improved. Given the uncertainty of recovery once significant neurologic deficits are present, early stabilization of the unstable rheumatoid spine appears to improve the outcome for these patients. In addition, continued developments of surgical and anesthetic techniques have facilitated their management.

## PATHOPHYSIOLOGY

The involvement of synovial articulations by rheumatoid arthritis is well described. The response to immune complex (IgG and antibodies to IgG) deposits in the articular cartilage and synovium of involved joints includes proliferation of fibrovascular tissue, known as pannus. Examination of these tissues shows the presence of chronic and acute-phase inflammatory cells, including lymphocytes, plasma cells, and macrophages. The persistent inflammation leads to cartilage loss and bony erosion, as well as ligamentous laxity. In addition, the rheumatoid disease process per se leads to diffuse osteopenia. Chronic steroid use may contribute to these ligamentous and osseous changes as well.

The cervical spine is susceptible to involvement with rheumatoid arthritis because of the large number of articulations and their significant mobility. The subaxial facet joints and intervertebral discs as well as the ligaments and bursae of the cervical spine are all potential locations of involvement (10,25). The most common clinical involvement, however, includes the atlanto-occipital, the atlantoaxial, the periodontoidal, and the zygoapophyseal (facet) joints.

Historically, the patterns of instability described in rheumatoid patients are anterior atlantoaxial instability, cranial settling, and subaxial instability (Fig. 154.1) (16,43,54). In addition to these patterns, other observed instability types have included posterior instability of the atlas, subaxial dislocation, and rotation and lateral subluxation of the atlas (5,26,42,45 and 46,50,57,60).

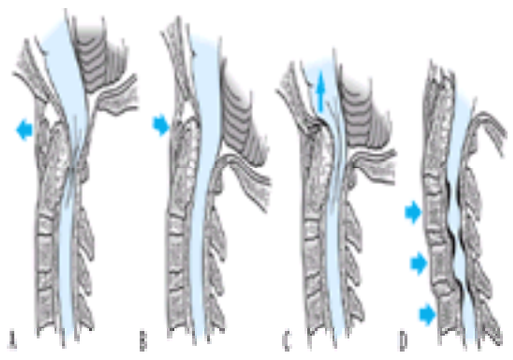

***Figure 154.1.*** Patterns of cervical spine instability due to rheumatoid arthritis. **A,B:** Atlantoaxial instability. **C:** Cranial settling. **D:** Subaxial instability.

The primary concern with all patterns of cervical involvement is the development of neurologic compromise due to compression of the spinal cord and nerve roots. This compression can arise as a dynamic phenomenon due to the instability, or it can be secondary to a mass effect caused by fixed vertebral subluxations or pannus formation. In addition, deficits can arise that are attributable to compromise of vascular supply at the level of either the anterior and posterior spinal arteries or the vertebral arteries themselves (19,21,56).

Patterns of neurologic involvement can include radiculopathy, myelopathy, and cranial nerve compromise. The most common radicular complaint is suboccipital headache due to irritation of the second cervical nerve root by atlantoaxial degeneration or instability (14,43). Radiculopathy can also produce motor weakness due to disc collapse or instability in the subaxial spine. The symptoms of myelopathy are hyperreflexia and spasticity, with or without motor weakness. The Ranawat classification of neurologic compromise has been widely used in published reports of rheumatoid patients. Normal patients are considered grade I, patients with paresthesias and hyperreflexia but without motor weakness are grade II, and patients who demonstrate motor weakness constitute grade III. Grade IIIA describes ambulatory patients, and grade IIIB is used for nonambulatory patients (43).

Motor compromise resulting from spinal cord involvement may be asymmetric, and it may show greater involvement of the upper extremities. Cruciate paralysis (of Bell) develops in some patients, with a striking lack of weakness in the lower extremities but profound involvement of the upper extremities due to medullary compression at the pyramidal decussation of upper extremity motor fibers (3,65). Cranial nerves, particularly the lower cranial nerves such as cranial nerve IX (involving the gag reflex), can also be compromised, especially in patients with cranial settling. Finally, respiratory paralysis may also occur with upper cervical involvement, sometimes with fatal results (16).

## DIAGNOSTIC EVALUATION

Neurologic examination of patients with rheumatoid arthritis can be notoriously difficult because of the effects of extremity contracture, deformity, pain, and inflammation, as well as weakness from muscle wasting and mechanical loss of function. A high index of suspicion in patients complaining of neck and occipital pain or new extremity weakness or loss of function is therefore important. Descriptions of an electric shock sensation with head and neck motion (Lhermitte's sign) should also arouse suspicion.

Begin diagnostic imaging with cervical spine plain radiographs, including an open-mouth odontoid view and lateral flexion–extension views. These films may disclose osteopenia, erosion of the atlantoaxial and subaxial facet joints, or erosion of the odontoid process itself. While plain radiographs do not directly demonstrate synovial pannus or spinal cord compression, much indirect information may be gained, such as the presence of bony instability.

Atlantoaxial instability is measured from lateral flexion–extension cervical spine radiographs. Historically, instability was measured as the change in the anterior atlantodental interval (AADI) (Fig. 154.2). Posterior displacement greater than 3 mm of the dens relative to the anterior ring of the atlas is considered abnormal. Displacement ranging from 6 to 10 mm has been considered an indication for surgery, even in patients without neurologic abnormalities (14,15,27,43,51).

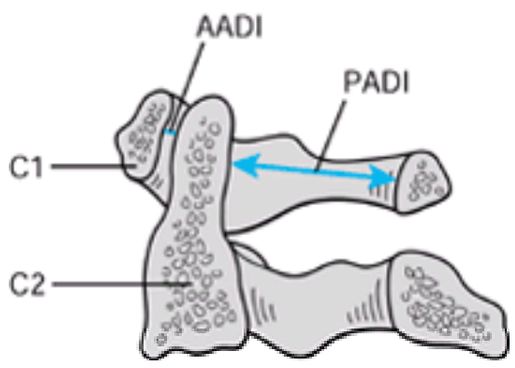


***Figure 154.2.*** Measures of atlantoaxial instability. The anterior atlantodental interval (AADI) measures mobility between the anterior ring of C-1 and the dens. The posterior atlantodental interval (PADI) also measures this mobility but also directly measures the space available to the spinal cord. The PADI has been shown to more accurately predict neurologic impairment than the AADI.

A better radiographic measurement for predicting spinal cord compromise due to atlantoaxial instability is the posterior atlantodental interval (PADI). Also referred to as the space available to the cord, the PADI is measured from the posterior aspect of the dens to the anterior edge of the posterior ring of the atlas, along the transverse axis of the ring of the atlas (Fig. 154.2). Boden et al. (4) demonstrated that a PADI of less than 14 mm correlated with a significant risk of neurologic impairment, and that the PADI was a better predictor of not only the development of neurologic compromise but also the potential for neurologic recovery.

Numerous landmarks for measurement of cranial settling have been described (Fig. 154.3*A*). Chamberlain's line runs from the posterior foramen magnum to the hard palate. Wackenheim's line is drawn tangent to the cranial surface of the clivus. McGregor's line runs from the lowest point of the occiput to the hard palate. McRae's line extends between the basion and the posterior edge of the foramen magnum. For the projection of the dens above McGregor's line, 4.5 mm is considered the upper limit of normal (12,20).

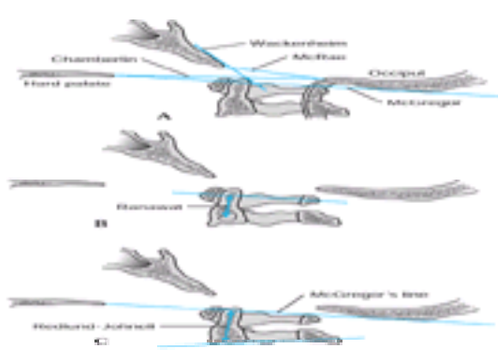

***Figure 154.3.*** Measures of cranial settling. **A:** Radiographic landmarks of the craniocervical junction. Chamberlain's line extends from the posterior foramen magnum to the hard palate. Wackenheim's line is a tangent to the cranial surface of the clivus. McGregor's line extends from the lowest point of the occiput to the hard palate. McRae's line extends between the basion and the posterior edge of the foramen magnum. **B:** Ranawat's measure of cranial settling extends from the center of the pedicle of the second cervical vertebra to the transverse plane of the ring of the atlas. **C:** The Redlund-Johnell method measures the distance from the base of the axis to McGregor's line.

Ranawat et al. (43) proposed a measurement from the center of the pedicle of the second cervical vertebra to the transverse axis of the ring of the atlas (Fig. 154.3*B*). They found normative values for this distance of 17 mm in men and 15 mm in women. This measurement has the advantage that visualization of the dens and skull base is not required.

Redlund-Johnell and Patterson (46) measured the distance from the base of the axis to McGregor's line (Fig. 154.3*C*). Less than 34 mm in men or 29 mm in women indicates cranial settling. The Sakaguchi-Kauppi method involves determination of the station of the medial aspect of the superior facet of the axis relative to the anterior ring of the atlas. These authors (29) felt that their method was easier to apply than the Redlund-Johnell method, and that it had the advantage of not relying on visualization of the skull base or odontoid tip.

Computerized tomography (CT) evaluation of the cervical spine provides excellent detail of the bony structures. Erosion of the dens and facet joints is much better demonstrated on CT images than on plain radiographs (6). In addition, fractures of the dens may be diagnosed with this modality.

Sagittal reconstructions based on CT scans are important not only diagnostically, but also in some cases for surgical planning. Posterior atlantoaxial arthrodesis using transarticular screws requires sufficient width of the cervical two-vertebral isthmus to allow passage of a 3.5 mm screw (35). In addition, sclerosis and erosion of the posterior ring of the atlas may result in insufficient bone stock for arthrodesis with conventional atlantoaxial wiring techniques and thereby require atlantoaxial screw fixation or extension of the arthrodesis to the occiput (14). There can be problems even with these techniques, however, when there is significant bone loss.

Magnetic resonance imaging has become the best imaging modality for evaluation of neurologic compression; use it to evaluate any patient who has neurologic weakness or spasticity (7,30,31). MRI provides enhanced definition of soft tissues and can demonstrate spinal cord compression from pannus at the atlantodental articulation. Recently, use of dynamic flexion–extension MRI views has been recommended for preoperative planning in patients with neurologic compromise (34). Patients for whom neurologic compression is not relieved by maximal reduction of the atlantodental articulation may be candidates for posterior decompression either by removal of the posterior rim of the foramen magnum and laminectomy of the atlas, or by anterior resection of the odontoid.

Sensory impairment in patients with rheumatoid arthritis has been demonstrated with somatosensory evoked potentials and cutaneous electric stimulation, both peripherally and in the trigeminal nerve distribution (58). While such techniques may confirm neurologic impairment, they are not widely used by orthopaedic surgeons or neurosurgeons for diagnosis or treatment planning, although they may have expanded roles in the future.

## NATURAL HISTORY

It is clear that as a direct result of cervical spinal instability, some patients with rheumatoid arthritis develop severe neurologic impairment with profound motor deficits,

occasionally leading to respiratory paralysis and death. It is also clear that once neurologic deficits develop, there is no universally successful means of regaining lost function. Unfortunately, our understanding of which factors predict neurologic progression remains incomplete (12).

Several investigations of the natural history of rheumatoid involvement of the cervical spine have been reported (16,40,43,51,52,55,62,63). Conlon et al. (16) provided an early estimate of the incidence of cervical instability among an unselected group of 333 rheumatoid patients. Plain radiographs disclosed atlantoaxial subluxation in 84 (25%) of their patients, while an additional 23 (7%) demonstrated subaxial subluxation. Although cervical instability was statistically correlated with the severity of peripheral disease, no correlation was found with duration of disease or use of steroid medications. Although 23 patients (7%) demonstrated symptoms of spasticity, the authors did not feel that these findings correlated with the presence of cervical instability.

Smith et al. (55) reviewed 130 rheumatoid arthritis patients with significant atlantoaxial instability but without neurologic compromise at the time of initial radiographs. They reevaluated 84 surviving patients an average of 7.8 years after the initial examination. Four patients (3%) had developed spinal cord compromise, while an additional six (5%) described symptoms of transient weakness. Of the 84 (74%) surviving patients, 62 had been maintained on chronic oral steroid medication, which appeared to correlate with radiographic progression of instability. No effect of cervical instability on long-term survival could be demonstrated.

Winfield et al. (62,63) followed 100 patients prospectively with annual flexion–extension radiographs. Over an average of 7 years' follow-up, they documented that 12 patients (12%) developed atlantoaxial instability, 8% developed subaxial instability, and 3% developed cranial settling. All the patients who developed instability demonstrated onset of subluxations within 2 years of diagnosis with rheumatoid arthritis. By an average of 9 years and 5 months' follow-up, one patient had developed myelopathy and two had undergone posterior cervical fusion for severe occipital headache (3%). These authors also demonstrated a significant correlation between the presence of severe peripheral erosive disease and cervical spine involvement.

Santavirta et al. (51) described the progression of symptoms in 16 patients with 8 mm or greater atlantodental instability or cranial settling. They compared disease progression in these patients with a group of 18 surgically treated patients with a comparable degree of radiographic instability but more significant neurologic symptoms. Although this was not a randomized study, they found that none of the operatively treated group had worsening of their neurologic status, and 8 of 14 (57%) who had had preoperative neurologic deficits showed improvement. Postoperative complications were relatively minor. In the nonoperatively treated group, however, 7 of 14 surviving patients (50%) suffered neurologic worsening. A further report on this patient group documented progression of cranial settling in 12 untreated patients, three of whom developed neurologic progression (52).

Pellici et al. reported prospective data on 106 rheumatoid arthritis patients with initial complaints of cervical pain over a 5-year period (40). They noted neurologic progression in 27 of 85 surviving patients (36%) and radiographic progression in 60 (80%). Seven patients had undergone surgical intervention by the end of the study secondary to severe neurologic involvement. Only two patients underwent spontaneous fusion of the atlantoaxial articulation, one of whom subsequently developed subaxial subluxations (Fig. 154.4). They also found that patients without radiographic changes at the time of their initial complaints did not develop significant instability over the 5 years of the study.

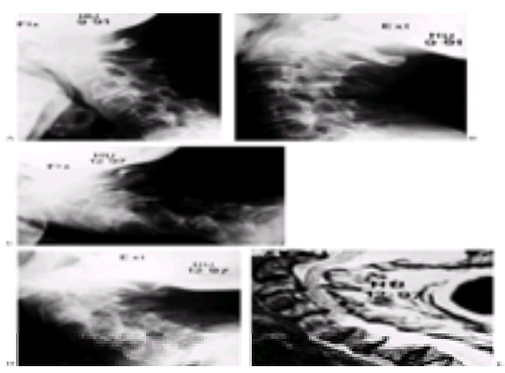

***Figure 154.4.*** An adverse natural history. **A,B:** Flexion–extension lateral radiographs obtained in 1991 demonstrate significant atlantoaxial instability, although the patient was neurologically normal. Significant erosion of the dens was already present, allowing posterior displacement of the ring of C-1 in extension. **C,D:** Six years later, a fixed posterior subluxation of C-1 has developed. Subaxial subluxation is also present. The patient at this time was quadriparetic and unable to ambulate (Ranawat IIIB). **E:** A sagittal view from an MRI scan demonstrates cord compression at both the atlantoaxial and subaxial levels. This patient would likely have benefited from an atlantoaxial arthrodesis at an earlier stage.

Boden et al. (4) described 73 patients followed for an average of 7 years, 42 of whom (58%) developed neurologic compromise. These authors demonstrated the importance of the PADI as a predictor for neurologic injury (Fig. 154.2). They noted that a reduction of the PADI below 14 mm, or a reduction of the spinal canal diameter below 14 mm in the subaxial cervical spine, was correlated with an increased prevalence of nonrecoverable neurologic deficit. They also demonstrated an increased risk of neurologic deficit in patients with atlantoaxial subluxation combined with cranial projection of the odontoid of 5 mm or greater above McGregor's line.

## PERIOPERATIVE MANAGEMENT

Medical management of rheumatoid arthritis continues to improve. Many patients are now maintained on methotrexate or other nonsteroid medical regimens, with steroid use limited to short-duration bursts for flares of the rheumatoid disease. The effect of this shift in treatment patterns on the progression of cervical instability is not known.

Patients with rheumatoid arthritis who are scheduled for other operative procedures requiring general anesthetic should undergo cervical radiographic evaluation with dynamic flexion–extension lateral views. Patients with neck pain but without significant instability can be treated with pain medication and a cervical orthosis. While orthotics may provide symptomatic relief, they neither slow the disease process nor provide significant additional stability, and these patients should be followed for possible progression of their disease (1).

Airway and pulmonary management is a significant concern in surgical patients with rheumatoid arthritis. Patients undergoing multiple-level anterior cervical spine procedures and those with severe neurologic compromise should be considered for elective tracheostomy (27). If a tracheostomy is not likely to be necessary, patients may need to remain intubated postoperatively for an additional period of time. All other rheumatoid patients should be considered for fiberoptic intubation (14). This a good practice for all neurologically vulnerable patients, and a reduction in postoperative airway complications in rheumatoid patients undergoing fiberoptic intubation has been demonstrated (59).

Preoperative skull traction has been recommended for patients with cranial settling or subluxations that do not reduce on voluntary flexion–extension lateral radiographs. Traction for 24–48 hours has proven useful, with most reductions occurring within this time (38). Extended periods of traction probably do not improve reduction and should generally be avoided because of the preexisting physical weakness of many patients with rheumatoid arthritis and the rapid physical deterioration that occurs with extended bed rest. Halo-wheelchair traction provides traction while allowing the patient to be upright.

Postoperative immobilization must be tailored to the individual patient's needs. Historically, several means of immobilization have been used ranging from skull traction or a halo cast to a cervicothoracic or hard cervical orthosis (14,16,27,43,66). Halo-bracing is generally well tolerated by rheumatoid patients, perhaps because of their lower physical demands. The advantages of reducing the risks of hardware failure and nonunion in this patient population probably outweighs the easier mobility afforded by less aggressive bracing.

Evaluate the patient's suitability for cervical spine surgery before deciding on a specific surgical plan; pay attention to the patient's activity level, expectations, and overall health status. Preoperative evaluation should include pulmonary, cardiac, and renal testing. Patients with longstanding, severe neurologic injury and patients with limited pulmonary or cardiac reserve should be considered for nonoperative management.

## OPERATIVE TREATMENT AND RESULTS

### ATLANTOAXIAL ARTHRODESIS

Indications for atlantoaxial arthrodesis include neurologic compromise demonstrated by spasticity or motor weakness (Ranawat II or III), impending neurologic

compromise as demonstrated by spinal cord compression on MRI or a PADI of 14 mm or less on plain films, and intractable occipital headache with demonstrated atlantoaxial degeneration or instability. If preoperative reduction in cranial traction is insufficient to allow spinal cord decompression, consider a laminectomy of the atlas, and enlargement of the foramen magnum as well, which usually requires extension of the arthrodesis to the occiput.

A number of methods of posterior atlantoaxial arthrodesis have been described. Historically, posterior wiring techniques have been very successful in other patient populations but have had significant nonunion rates in patients with rheumatoid arthritis. In addition, atlantoaxial wiring techniques require availability of the posterior ring of the atlas. Recently, the technique of transarticular screw fixation has improved fusion rates and can be performed with laminectomy of the posterior ring of the atlas. Risks of neurologic and vascular injury with this technique are still being evaluated, however, and it should not be used when reduction of the atlantoaxial facet joints cannot be achieved. A CT scan with sagittal reconstructions to evaluate the position of the vertebral arteries is a prerequisite for this technique.

Brooks and Jenkins (8) described their wedge compression method of bone grafting and sublaminar wiring as an alternative to Gallie's (22) midline wiring and demonstrated fusion in 12 of 13 patients (Fig. 154.5*A*, Fig. 154.5*B*). They had less success in patients with rheumatoid arthritis, however, describing one patient who developed nonunion and a second who suffered an intraoperative fracture and required extension of the arthrodesis to the occiput. Clark et al. (14) modified this technique by using a single, larger piece of corticocancellous bone graft (Fig. 154.5*C*). They reported a bony fusion rate of 75% in a series of 20 patients with rheumatoid arthritis, with an additional two patients achieving stable fibrous union (Fig. 154.6).

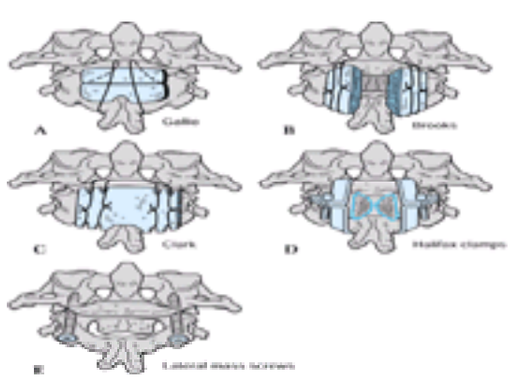

***Figure 154.5.*** Methods of C-1/C-2 fixation. **A:** Gallie wiring. **B:** Brooks wedge-compression wiring. **C:** Clark wiring. **D:** Halifax clamps. **E:** Posterior transarticular screws.

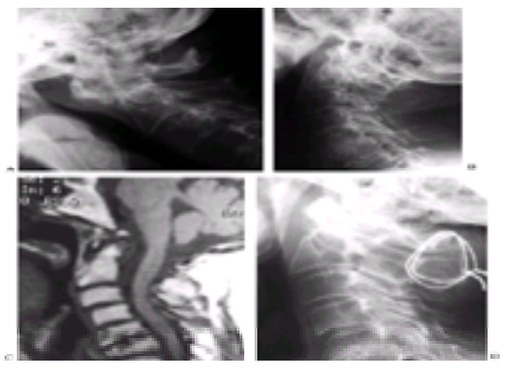

***Figure 154.6.*** This female patient had longstanding rheumatoid arthritis with new-onset long-tract signs without motor weakness (Ranawat II). **A,B:** Flexion–extension lateral radiographs demonstrate significant atlantoaxial instability with full reduction in extension. **C:** MRI in extension demonstrates resolution of neurologic compression with reduction of the atlantoaxial articulation. **D:** Following posterior wiring and fusion, solid arthrodesis occurred with resolution of myelopathic symptoms.

Bryan et al. (9) described the use of polymethylmethacrylate (PMMA) as part of a longer arthrodesis construct from the atlas to the subaxial spine in a series of five patients with either prior nonunions (two patients) or combined atlantoaxial and subaxial subluxations (three patients). Two of these patients progressed to nonunion, and a third patient developed a wound infection and fistula. Because of this higher incidence of wound problems, as well as reports of bone lysis, PMMA is no longer recommended as a supplement to cervical fixation (37).

Moskovich and Crockard (39) described results with an interlaminar clamp in a series of 25 patients (Fig. 154.5*D*). While the overall fusion rate in this series was 80% (20 of 25), the rate for rheumatoid arthritis patients was only 73% (11 of 15). This technique thus seems to offer little improvement over wiring techniques with respect to fusion rate, although it may be neurologically safer than sublaminar wires for patients with severe stenosis.

Since Magerl and Seemann (36) described posterior transarticular screw placement for atlantoaxial stabilization and arthrodesis, this technique has been given increasing attention (Fig. 154.5*E*). Grob et al. (24) described their experience with transarticular 3.5 mm screws supplemented with midline wiring in a series of 161 patients, including 51 with rheumatoid arthritis. They achieved a 99.4% fusion rate at an average of 24 months. Although no symptomatic vertebral artery injuries were reported, there were five postoperative deaths, three in patients undergoing simultaneous transoral odontoid resection.

The issue of injury to the vertebral arteries or other structures due to screw malposition continues to be evaluated. Madawi et al. (35) reported an 87% fusion rate in 61 patients (37 rheumatoid patients) using transarticular screw fixation. They reported that 14% of screws were malpositioned with an 8% (5 of 61) rate of vertebral artery injury, although only one patient was symptomatic. These authors also described anatomic measurements on 25 cadaverous C-2 vertebrae, demonstrating an insufficient diameter of the pars interarticularis to accommodate a 3.5 mm screw in 20% of individuals. Recently published survey data from 847 neurosurgeons regarding 1,318 patients treated with transarticular screws revealed a rate of vertebral artery injury of 4.1%. Most arterial injuries were asymptomatic, however, with only 0.2% of all patients suffering a neurologic deficit (64).

While surgeons have gained substantial experience with the transarticular atlantoaxial screw technique (64), the risk of vertebral artery injury in rheumatoid patients has not been fully evaluated. This risk is probably somewhat higher than in the nonrheumatoid population because of the tortuous anatomy of the vertebral artery that can develop with rheumatoid arthritis, as well as the difficulty of reducing the atlantoaxial facets in some patients, complicating appropriate screw trajectory.

While transarticular screw fixation seems to offer a higher rate of arthrodesis, further documentation of outcome in rheumatoid patients is needed. Despite a lower mechanical rigidity compared with transarticular screw fixation, wiring techniques are still appropriate in many patients because they offer a reduced risk of neurologic and vascular complications, particularly when reduction of the atlantoaxial articulation cannot be obtained, or when the isthmus is smaller than 3.5 mm in diameter (53).

## OCCIPITOCERVICAL ARTHRODESIS

Indications for including the occiput in a posterior cervical arthrodesis include cranial settling with current or impending neurologic compromise, inability to obtain fusion to the posterior ring of the atlas due either to insufficient bone stock or to the need for a laminectomy, nonunion from a prior atlantoaxial arthrodesis, and severe involvement in patients with combined atlantoaxial and subaxial instability. While inclusion of the occiput in the arthrodesis further reduces neck motion over an isolated atlantoaxial fusion, incorporating the occiput affords strong fixation, allowing a variety of constructs for stabilization.

As with atlantoaxial arthrodesis, wiring techniques have historically provided acceptable results in a large number of patients. De Groote et al. (18) described results in 14 rheumatoid arthritis patients using an **H**-graft and a wiring technique based on the method of Robinson and Southwick (47). They obtained fusion in 11 patients, and none of the three patients with nonunion required revision surgery during the follow-up period.

Wertheim and Bohlman (61) described a three-wire technique [also derived from Robinson and Southwick (47)] using a spinous process wire at C-2, a looped sublaminar wire at C-1, and a wire through the inion along with structural corticocancellous bone grafting posteriorly. In a series of 13 patients, eight of whom had rheumatoid arthritis, they achieved a 100% fusion rate with all patients with preoperative neurologic deficits showing improvement. Clark et al. (11,14) described a

six-wire technique using paired lateral sublaminar wires at the atlas and axis (Fig. 154.7*A*). This method can still be used when a laminectomy of the atlas has been performed.

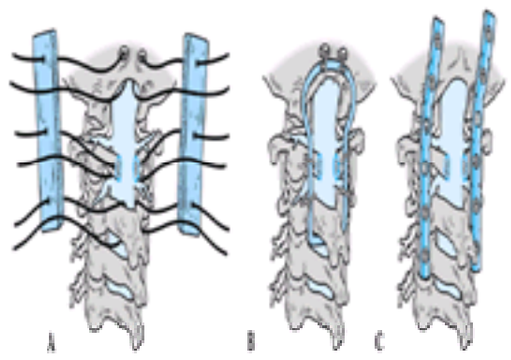

***Figure 154.7.*** Methods of occipitocervical stabilization. **A:** Clark wiring. **B:** Ransford loop. **C:** Occipitocervical plating.

McAfee et al. reported on 37 patients, 20 of whom had rheumatoid arthritis. They had an 85% fusion rate (33 of 37 patients). They noted that when reduction of cranial settling was achieved and maintained, patients had a significantly better prognosis for neurologic recovery than when reduction was not possible (93% versus 40%). Only two patients underwent a late anterior odontoid resection due to persistent compression and neurologic deficits; both eventually recovered normal neurologic function.

Ransford et al. (44) described occipitocervical fixation with a contoured, threaded Steinmann pin and sublaminar wiring along with laminectomy of the atlas and foramen magnum enlargement in a series of three patients (Fig. 154.7*B*). Although none of the patients had rheumatoid arthritis, the authors recognized the potential application to this population. Itoh et al. (28) described 13 rheumatoid patients treated with this technique, fusing an average of 5.9 cervical levels. Ten of these patients had cranial settling, and 12 had subaxial involvement. Of 8 patients with moderate or severe myelopathy, 7 (88%) had significant postoperative neurologic improvement. Twelve of 13 patients (92%) went on to solid arthrodesis. All patients had relief of occipital pain.

Apostolides et al. (2) reported results with this technique in 39 patients, 12 of whom had rheumatoid arthritis. Five of the 12 rheumatoid patients (42%) had cranial settling, while 4 (33%) had prior nonunions. Four patients (33%) underwent foramen magnum enlargement and laminectomy of the atlas, while 5 (42%) underwent transoral resection of the odontoid. Ten of these patients (83%) went on to solid arthrodesis, with 2 developing stable fibrous union. None of these patients suffered hardware failure. All 10 patients with preoperative myelopathy showed improvement, although 9 (90%) demonstrated persistent deficits to varying degrees.

Occipitocervical plating has gained popularity in recent years (Fig. 154.7*C*). Like transarticular screw fixation for atlantoaxial arthrodesis, this technique was developed in Europe but is increasingly used in the United States as well. The advantages claimed for occipitocervical plating include avoiding entry into the spinal canal and reducing the number of caudal segments required to obtain rigid fixation. An early report by Grob et al. (23) described this technique in 14 patients, seven of whom had rheumatoid arthritis. Using a **Y**-shaped plate with a single arm for cranial fixation and including transarticular atlantoaxial screws as part of their construct, they reported fusion in all patients.

Smith et al. (54) described preliminary results in 14 patients using bilateral, contoured steel pelvic 3.5 mm reconstruction plates. They used a pedicle screw at the C-2 vertebra in place of transarticular screws. Five of these patients had rheumatoid arthritis, and the arthrodesis extended an average of 4.6 cervical levels. Fusion was reportedly obtained in all patients. While these early results are promising, long-term follow-up of these patients to evaluate for instability caudal to the arthrodesis is needed.

As in instrumentation for atlantoaxial arthrodesis, these techniques require training and experience prior to routine use. The specific risks of neurologic or vertebral artery injury during lateral mass or atlas pedicle screw placement have not been documented in rheumatoid arthritis patients, where marked distortion of the anatomy can occur. A CT scan to determine the course of the vertebral arteries is advised. While these techniques offer the potential to improve fusion rates and reduce postoperative immobilization, the long-term effects of these constructs on adjacent motion segments is also unknown.

## SUBAXIAL ARTHRODESIS

Posterior arthrodesis with or without laminectomy is indicated for patients with subaxial instability or fixed subluxation with impending or actual neurologic compromise. As with atlantoaxial instability, a measurement of the space available to the cord on a lateral radiograph of 14 mm or less indicates that the spinal cord is at risk of compromise. Patients with subaxial instability who also have atlantoaxial instability or cranial settling often require treatment of these combined instability patterns by a single operation (4).

Less has been reported about treatment of isolated subaxial rheumatoid spine problems than of upper cervical spine involvement. Ranawat et al. (43) discussed posterior arthrodesis in six patients with subaxial subluxations. Three of these patients underwent arthrodesis to the occiput due either to coexisting atlantoaxial instability or cranial settling. All patients had significant pain relief and three (50%) had improvement of myelopathic symptoms.

Less-satisfactory results occurred in five patients treated with anterior surgery; no patient achieved neurologic improvement, because of graft collapse and dislodgement. These authors felt that anterior surgery was contraindicated in patients with rheumatoid arthritis because of the mechanically insufficient, osteopenic bone of the vertebral bodies (43). In addition, the anterior longitudinal ligament may be one of the last remaining stabilizers in rheumatoid patients, and this ligament is necessarily disrupted during an anterior procedure.

Conaty et al. (15) reported results in seven patients with isolated subaxial involvement treated by posterior fusion without wiring. Two patients underwent laminectomy due to severe neurologic compromise, but neither recovered significant function. Patients were managed postoperatively either in cranial traction or a halo. All six surviving patients went on to solid arthrodesis, with satisfactory results reported in 4 of 7 patients (57%).

Heywood et al. (27) treated seven patients with subaxial instability, four of whom had had preoperative myelopathy. Five patients treated with posterior subaxial bone grafting and wiring went on to solid fusion, with all neurologically compromised patients experiencing significant recovery. No laminectomies were performed in this series. Two patients treated with anterior procedures died postoperatively of pulmonary complications. These authors argued against the need for a laminectomy to obtain neurologic recovery, and they argued for posterior rather than anterior procedures.

Clark et al. (14) reported on 41 rheumatoid patients, seven of whom had posterior subaxial arthrodesis for subaxial instability. They reported no subaxial nonunions with spinous process wiring and bone grafting. Four patients (67%) had clinical improvement of pain complaints, and no patient suffered neurologic worsening. One patient who had undergone an anterior corpectomy and attempted arthrodesis had developed graft subluxation, which necessitated the posterior procedure.

Santavirta et al. (49) reported results in 16 patients with subaxial instability treated with a posterior procedure. Ten patients had myelopathy and seven had severe neck and shoulder pain. All patients underwent posterior wiring and arthrodesis, and patients with myelopathy also underwent laminectomy. Eight patients were treated in postoperative skull traction. All achieved solid fusion, and 90% (9 of 10) with myelopathy recovered. Two perioperative deaths occurred. Three patients developed adjacent segment instability during an average follow-up period of 4.4 years.

Several authors have reported disappointing results for subaxial anterior decompression procedures in patients with rheumatoid arthritis (14,27,43). The reasons for failure seem to be the tendency of the osteoporotic vertebral bodies to collapse around the bone graft, with resulting nonunion, kyphosis, and graft extrusion. In most cases, rheumatoid patients with subaxial instability and osteopenia or combined subaxial and upper cervical involvement should be treated with posterior surgery.

Patients with persistent neurologic deficits and anterior spinal cord compression following posterior fusion may be candidates for anterior decompression and structural bone grafting. In addition, there appears to be a subclass of rheumatoid patients with less severe involvement that can be effectively treated with anterior decompression and arthrodesis procedures. These patients may have fewer peripheral joint deformities, less corticosteroid exposure, greater bone density, and a shorter duration of rheumatoid disease. The radiographic appearance of these patients is similar to that of patients with cervical spondylosis, without significant

subaxial or atlantoaxial instability (Fig. 154.8).




***Figure 154.8.*** Subaxial cervical degeneration treated by anterior corpectomy and fusion. **A:** Lateral cervical spine radiograph demonstrates subaxial spondylosis in this 66-year-old man. He had a 20-year history of seropositive rheumatoid arthritis but displayed limited peripheral joint deformity. He was maintained on a combination of methotrexate and a daily dose of 5 mm prednisone. Despite the long history of rheumatoid arthritis, his clinical appearance is more consistent with cervical spondylosis without significant instability. **B:** Postmyelogram CT image through the C-5/C-6 disc level demonstrates significant spinal cord compression. Spasticity without motor weakness was present. The patient had undergone a laminoplasty with subsequent reclosure of the laminae. **C:** Sagittal MRI demonstrates spinal cord compression at the C-3/C-4, C-4/C-5, C-5/C-6, and C-6/C-7 discs. **D:** This patient underwent anterior corpectomy of C-4, C-5, and C-6 with autologous fibular strut grafting with successful fusion and resolution of his myelopathic symptoms.

### ODONTOID RESECTION

Anterior decompression at the level of the odontoid process is sometimes required because of severe cranial settling with persistent neurologic compression despite maximal reduction in skeletal traction. For many patients, decompression can be accomplished at the time of occipitocervical arthrodesis via traction reduction with foramen magnum enlargement and laminectomy of the atlas. For patients who fail to improve despite this treatment or whose compression is so severe that posterior decompression is likely to be inadequate, anterior resection of the odontoid is indicated.

Resection of the odontoid is usually performed through a transoral approach. Crockard et al. (17) performed simultaneous odontoid resection and posterior occipitocervical arthrodesis in 14 patients with rheumatoid arthritis, all of whom had myelopathy with significant weakness. One patient suffered a vertebral artery injury requiring abortion of the procedure. No patient developed a wound infection. These authors argue that this procedure results in faster neurologic recovery and avoids the need to obtain intraoperatively and hold postoperatively an anatomic reduction.

Many authors, however, report good results with only limited use of this procedure (4,14,28,37,43). Postoperative MRI imaging has documented reduction in the periodontoid pannus following solid arthrodesis. In addition, significant numbers of patients have demonstrated good neurologic recovery with solid posterior arthrodesis in a reduced position (14,37). Be aware of the fact that the physiologic stress and difficulties of airway management during combined anterior/posterior cervical spine surgery in this population are considerable. Finally, patients who do not fully recover from neurologic deficits following arthrodesis may obtain further neurologic recovery after a delayed anterior odontoid resection (37).

## SURGICAL TECHNIQUES

### ATLANTOAXIAL WIRING

- After fiberoptic intubation and placement of spinal cord monitoring leads, position the patient prone using tongs or halo traction on a head rest to control the head position. Position the head in sufficient extension to reduce the atlantoaxial articulation, and verify the reduction fluoroscopically prior to preparing and draping. Recheck neurologic status after positioning, either via spinal cord monitoring or a brief wake-up test. Alternatively, position patients while awake to allow continuous neurologic monitoring prior to the induction of general anesthesia.
- Following a midline posterior approach, expose the ring of the atlas; strip only 1.5 cm laterally on either side of the midline to avoid injuring the vertebral arteries.
- Expose the C-2 and C-3 vertebrae to the lateral edge of the C-2 and C-3 facets, avoiding injury to the joint capsules.
- Gently strip the attachments of ligamentum flavum from the cranial and caudal edges of the laminae of both the atlas and the axis vertebrae with a 4-0 curved curet. Pass a threaded 1.5-cm-diameter French-eye needle, blunt end first, sequentially under both laminae, retrieving the leading end with a small needle driver.
- Carefully follow the curvature of the needle during advancement under the laminae to avoid injuring the dura. Repeat this maneuver until a total of four sutures (usually #2 Ticron) are under the laminae of both the atlas and the axis.
- Tie a free end of one of the sutures to the looped end of a 24-gauge wire that has been doubled on itself and twisted to form a single strand. Gently pull this wire into position under the lamina and detach the suture.
- Be careful to avoid significant pressure on the dura during positioning of the wire, pulling the wire posteriorly away from the spinal cord with a small nerve hook at the C1-2 interspace.
- Position the wire laterally and repeat this maneuver with the remaining sutures to produce two pairs of sublaminar wires on either side.
- Once the paired sublaminar wires are in place, obtain a thick corticocancellous bone graft from the posterior iliac crest. It should be a plate of cortical bone with the full thickness of cancellous bone remaining underneath, measuring at least 2 by 4 cm.
- Shape the graft on its cancellous surface, removing bone to form a wedge shape, thickest at the center and diminishing toward the cranial and caudal edges.
- Notch the caudal edge of the graft centrally with a rongeur to accommodate the spinous process of the atlas.
- Lightly decorticate the posterior elements of C-1 and C-2 with a burr.
- Once the cancellous side of the graft lies flush against the laminae of the atlas and axis, tighten one wire by twisting with steady posterior tension. Tighten it until it is flush with the cortical surface of the graft throughout its length and the knot just begins to double on itself.
- Alternate sides until all four wires are tight, cutting the ends and tamping them down to the cortical surface of the bone graft.
- Following closure and dressing of the wound, place the patient in a halo brace in neutral flexion–extension to be worn for 12 weeks (Fig. 154.5*C* and Fig. 154.6).

### HINTS AND TRICKS

- Do not dissect farther than 1.5 cm lateral to midline at the ring of C-1 to avoid injury to the vertebral arteries.
- Thoroughly free the cranial and caudal attachments of the ligamentum flavum before attempting to pass the free needle. A 4-0 curved curet should pass readily along the cranial and caudal surfaces of the laminae. Do not, however, attempt to pass the curet or any other instrument underneath the laminae.
- Once sutures or wires are in place, clamp free ends with a small hemostat to prevent entanglement.
- Avoid breaking the graft during removal. Thoroughly cut all four sides of the graft with an osteotome, visualizing the end of the osteotome all the way to the end of the cut. Do not lever the graft out until the deep surface of cancellous bone has been completely separated from the deep cortex and the graft moves freely.

### POSTERIOR ATLANTOAXIAL TRANSARTICULAR SCREWS

- Place the patient in three-point tongs prior to positioning. Radiolucent tongs with a radiolucent operating table improve fluoroscopic visualization of the atlantoaxial facet joints. Position the patient prone, with the upper cervical spine in slight flexion and the lower cervical spine in extension. This position allows better access to the starting points and better trajectory for screw placement. Check fluoroscopically that the atlantoaxial articulation is reduced and that both facet joints are visible on the anteroposterior (AP) view. Reassess neurologic function after positioning, either by a brief wake-up test or by verification of maintenance of baseline somatosensory evoked potentials. Position patients with marked instability while they are awake to allow continuous neurologic monitoring prior to inducing general anesthesia.
- Use a midline posterior cervical approach. Take care not to expose the occiput, as the fusion mass can unexpectedly extend to areas of exposed bone.
- Achieve the exposure described for the atlantoaxial wiring and extend it cranially from the C-2/C-3 facets along the isthmus of C-2 to expose the C-1/C-2 facet joint. Be careful to remain subperiosteal and to perform the dissection bluntly to avoid injury to the C-2 nerve roots exiting posterior to the C-1/C-2 facets. Place a Penfield 4 elevator gently along the medial wall of the C-2 pedicle and into the C-1/C-2 facet joint to verify orientation.
- Obtaining a sufficiently steep trajectory for screw placement can be very difficult. Start the screw on the medial side of the inferior facet of the axis, aiming for the

exposed isthmus cranially.

- Under fluoroscopic or stereotactic guidance, aim for the middle of the C-1/C-2 facet joint on the AP view, and for the anterior ring of the atlas on the lateral view.
- Use a cannulated drill system to allow repositioning of the guide wire until you are satisfied with the orientation and location.
- The thoracic cage can obstruct hand position and block the appropriate trajectory. If it does, a percutaneous incision distally on the back can improve orientation. Use a flexible, cannulated 2.5 mm drill and articulated screwdriver to improve the inclination.
- Place both guide wires prior to drilling and screw placement, to stabilize the articulation during passage of the first screw.
- Tap past the facet joint to improve ease of screw insertion. After cannulated drilling and tapping, place either a solid 3.5 mm or cannulated 4.0 mm screw. Use fully threaded narrow-pitch screws for the best purchase. Screw length should come just to the inferior edge of the anterior C-1 ring on the lateral view.
- If entry into the vertebral artery is suspected, abandon the procedure on the opposite side to avoid the potential of a bilateral injury.
- Once screws have been placed, augment the construct with a corticocancellous bone graft and wiring following the previous guidelines (Fig. 154.5*E*, Fig. 154.9).

***Figure 154.9.*** This 66-year-old woman had hyperreflexia in upper and lower extremities without weakness or pathologic reflexes. **A,B:** Flexion–extension lateral radiographs demonstrate reduction of the posterior atlantodental interval to 15 mm in flexion. Full reduction occurs with extension. **C,D:** Because of the limited space available to the spinal cord, this patient underwent posterior atlantoaxial arthrodesis with transarticular screw fixation and supplementary wiring. She obtained a solid fusion with no neurologic deterioration.

See Hints and Tricks on the next page.

**OCCIPITOCERVICAL WIRING**

- Prepare and position the patient as in previous descriptions. Check atlantoaxial reduction radiographically and verify neurologic status once positioning is complete. Prepare and drape well the back of the head, approximately 5 cm cranial to the inion. Use a posterior cervical approach, extending the cranial exposure approximately 1 cm cranial to the inion. Exposure of the posterior ring of the atlas should extend no more than 1.5 cm lateral on either side.

## HINTS AND TRICKS

- Do not begin the procedure until fully satisfied with the head position, visualization of necessary anatomy on both AP and lateral fluoroscopic views, and reduction of the atlantoaxial articulation.
- Verify on preoperative CT sagittal reconstructions that the C-2 isthmus is sufficiently large to accommodate at least a 3.5 mm screw.
- Extend preparation and draping distal to the scapulae to allow percutaneous incisions for drilling and screw placement if needed.
- A looped sublaminar wire at C-1 can improve reduction and allow stabilization of the C-1 ring during passage of the guide wires and screws. An alternative procedure such as C-1 laminectomy and occipitocervical arthrodesis should be performed in patients whose C-1/C-2 articulation cannot be anatomically reduced.
- Accurate assessment of screw orientation in the coronal plane is critical. Lateral screw position can produce injury to the vertebral artery, while medial positioning threatens neurologic structures.

- If a laminectomy of C-1 and foramen magnum enlargement are necessary, do these before preparing for wiring.
- Free the ring of C-1 of ligamentous attachments cranially and caudally with a sharp 4-0 angled curet. If the ring is too thick to remove with a 1 mm Kerrison rongeur, it may be thinned with a burr.
- Start the resection at the lateral limits of the exposure of the laminae first, leaving a floating central fragment to be resected last. This technique reduces the potential pressure against the cord during the laminectomy.
- Enlarge the foramen magnum by thinning the occiput with a burr in a semicircle measuring approximately 5–7 mm. Then resect the remaining inner table piecemeal with a 2 mm Kerrison rongeur to remove the posterior lip of the foramen magnum; always do this to allow safe passage of occipital wires.
- Create two occipital burr holes with a 4 mm carbide burr approximately 1 cm lateral to the inion and approximately 7 mm cranial to the foramen magnum.
- Complete the holes through the inner table with a diamond burr. Elevate the dura off the inner table toward the burr holes and from the foramen magnum with a 4-0 curved curet.
- Pass a looped, double-twisted 24-gauge wire through the holes on both sides using the suture-passing technique previously described.
- If a laminectomy of C-1 has been performed, drill a small hole through the remnant of the lamina on either side, if there is sufficient remaining bone, and pass a single 24-gauge wire through this hole. Otherwise, pass bilateral sublaminar wires at both C-1 and C-2 using a technique similar to that described for atlantoaxial wiring.
- Alternatively, if neurologic compression is present, pass a wire through the spinous process of C-2 by drilling transversely approximately a third of the length up the spinous process from the laminae. Use a 2 mm burr to perforate the cortex on either side of the spinous process and connect those holes with a towel clip. Then pass a 20-gauge wire through the hole, loop it under the spinous process, and pass it a second time. Use a similar method if the fusion is to be extended caudally; we do not use sublaminar wires caudal to C-2.
- As in atlantoaxial arthrodesis, obtain a thick corticocancellous bone graft from the posterior iliac crest. For occipitocervical arthrodesis, harvest a graft measuring approximately 3 by 5 cm.
- Divide the graft lengthwise and place three evenly spaced drill holes in both grafts.
- Lightly decorticate the occiput, C-1 ring (if still present), and C-2 laminae using a carbide burr.
- Thread the more lateral arm of the wire at each level through the corresponding holes, and maneuver the graft down the wires until it is in apposition to the decorticated bone. Bring the second arm of each wire medially around the graft and tighten the wires sequentially as described previously.
- If fixation is secure and bone quality is good, use a skull–occiput–mandibular immobilization (SOMI) or Minerva brace postoperatively. If fixation is compromised because of osteopenic bone, maintain the patient in a halo vest for 6–12 weeks after surgery (Fig. 154.7*A*, Fig. 154.10).

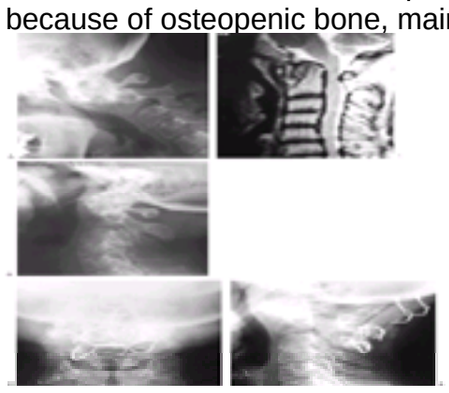

***Figure 154.10.*** This patient had hyperreflexia and bilateral Babinski and Hoffman's signs without motor weakness (Ranawat II). **A,B:** Flexion–extension lateral radiographs demonstrate atlantoaxial subluxation with incomplete reduction in extension. Posterior atlantodental interval (PADI) is 11 mm. Mild cranial settling is also present. **C:** MRI demonstrates persistence of spinal cord compression by the posterior ring of the atlas despite maximal reduction in extension. **D,E:** This patient underwent occipitocervical arthrodesis with laminectomy of the atlas and foramen magnum enlargement. Spinous process wires were used at C-2 and C-3. The patient obtained solid arthrodesis with resolution of spasticity.

### SUBAXIAL ARTHRODESIS

The subaxial arthrodesis in the patient with rheumatoid arthritis is essentially the same as that in cervical trauma and is discussed in Chapter 140.

- Approach the appropriate cervical vertebrae through a midline posterior approach. Place a Gelpy retractor longitudinally in the incision to remove skin folds. For subaxial approaches, obtain a lateral radiograph with a Kocher clamp placed on an exposed spinous process to determine the appropriate spinal level. A triple-wire fixation technique is most widely applicable. If the spinous processes are deficient, use lateral mass plates.
- Postoperatively, immobilize the patient in a Philadelphia collar for 12 weeks.

## HINTS AND TRICKS

- Pay careful attention to staying in the midline during initial dissection. If you can see muscle fibers, the dissection has strayed to one side. Maintaining a midline position will limit bleeding.
- Stabilize the C-2 vertebra with a towel clip or Kocher clamp during dissection of soft tissues to prevent gross movements of the vertebrae.
- Do not use sublaminar wires at C-1 or C-2 if neurologic compression is present. In these cases, perform a careful laminectomy of C-1 and use a spinous process wire at C-2.
- If a spinous process wire is used, gently work the towel clip from side to side until it moves readily through the hole. This technique will allow passage of the transverse wire with relative ease.

## PITFALLS AND COMPLICATIONS

Early complications from these procedures include perioperative mortality due to airway compromise, neurologic deterioration, infection and wound problems, hardware and graft failure, and surgical complications such as myocardial infarction, pulmonary embolus, and pulmonary or urinary tract infection. Late complications include nonunion and adjacent segment instability with recurrent neurologic compromise.

Airway and pulmonary complications are always a significant concern after cervical spine surgery. These concerns are magnified in the case of rheumatoid arthritis, because these patients often have decreased pulmonary reserve and difficulties with postoperative mobilization. For these reasons, consider preoperative tracheostomy for patients undergoing anterior corpectomies or dens resection and patients with severe neurologic compromise (14,27). Alternatively, maintain these patients on a ventilator for several days postoperatively to allow resolution of airway edema. All other patients with rheumatoid arthritis should undergo fiberoptic intubation to reduce postoperative airway complications (59).

Infection and wound healing problems are a significant concern in rheumatoid patients because of the atrophy of their skin and soft tissues, as well as the immunosuppressive effects of their medication regimens. Administer intravenous antibiotics preoperatively, and maintain patients on antibiotics until postoperative drains have been removed. Reduction of foreign material in the wound is also important in obtaining wound healing. While supplementary PMMA was recommended in the past, it has been associated with wound healing problems and is no longer used (9,13,14).

Intraoperative or acute postoperative neurologic deterioration should be a rare occurrence. Interoperative spinal cord monitoring should be used routinely to allow the earliest possible detection of potential spinal cord injury and immediate institution of measures with the potential to reverse neurologic compromise, such as removal of hardware or wires. Obtain a CT scan or MRI on patients in whom deficits develop or worsen postoperatively to rule out an epidural hematoma and bone graft or hardware malposition. Patients with new deficits and radiographic evidence of spinal cord compromise should undergo an emergent wound exploration, and appropriate steps should be taken to reverse the source of the neurologic compression.

The majority of patients with preoperative neurologic deficits experience improvement in function with surgical decompression and solid fusion. The long-term stability of these results, however, has been a concern because of the potential for new subluxations caudal to the original arthrodesis (41). While new subluxations may partly reflect disease progression, they also may be accelerated by the mechanical effect of the adjacent fusion.

Santavirta et al. (48) reported a minimum 10-year follow-up of a series of 38 patients treated with posterior arthrodesis. Nineteen patients died during the follow-up period. Four patients (11%) underwent further arthrodesis for subluxations caudal to the original procedure. Although 12 of 24 patients (50%) undergoing a Gallie (22) atlantoaxial arthrodesis developed nonunion, it did not appear to adversely affect their clinical outcome.

Kraus et al. (32) reported the incidence of caudal subluxations of 79 patients treated with either occipitocervical (24 patients) or atlantoaxial (55 patients) arthrodesis. They found that patients undergoing occipitocervical arthrodesis experienced a higher and more rapid rate of caudal subluxation requiring revision surgery. Of the patients with occipital arthrodesis, 36% developed subaxial subluxation in an average of 2.6 years, compared with 5.5% of the patients undergoing atlantoaxial arthrodesis in an average of 9 years postoperatively.

Krieg et al. (33) performed a minimum 7-year follow-up of the 41 patients originally studied by Clark et al. (12,14). Thirteen patients (32%) had died by the time of the later follow-up. Eighteen patients underwent clinical and radiographic evaluation, and nine were interviewed. None of these 27 patients had had clinical or radiographic deterioration over the length of the follow-up.

Nonunion has also been a significant problem for rheumatoid patients following arthrodesis. Overall rates of nonunion have ranged from 8% to 50% in various series of posterior cervical arthrodesis in patients who have rheumatoid arthritis (8,14,27,28,41,43,48,49). In series of patients with mixed diagnoses treated with uniform surgical procedures, rates of nonunion are somewhat higher for rheumatoid patients than for patients with other diagnoses (2,8,35,37,39,61). While new technology may ultimately improve patient outcomes, adherence to proven surgical techniques such as use of structural corticocancellous autograft, good apposition of graft to bony surfaces, and appropriate postoperative bracing lead to good results for the majority of patients.

## AUTHORS' PERSPECTIVE

It is worthwhile to identify patients with rheumatoid arthritis who are at risk of developing neurologic injury, as recovery of neurologic function once deficits develop is uncertain and often incomplete. New imaging modalities, as well as means of interpretation of plain radiographs, allow more accurate selection of patients at risk for neurologic injury. While new techniques of internal stabilization should improve rates of achieving solid arthrodesis, an assessment of the risks of these techniques in rheumatoid patients is needed. The long-term effect of such fixation on adjacent motion segments is not known. The primary determinants of satisfactory outcomes remain careful patient selection, appropriate choice of surgical procedures, and adherence to the principles and techniques of neurologic decompression and spinal arthrodesis.

### CHAPTER REFERENCES

Each reference is categorized according to the following scheme: *, classic article; #, review article; !, basic research article; and +, clinical results/outcome study.


+ 1. Althoff B, Goldie I. Cervical Collars in Rheumatoid atlantoaxial Subluxation: A Radiographic Comparison. *Ann Rheum Dis* 1980;39:485.

+ 2. Apostolides P, Dickman C, Golfinos J, et al. Threaded Steinmann Pin Fusion of the Craniovertebral Junction. *Spine* 1996;21:1630.

* 3. Bell H. Paralysis of Both Arms from Injury of the Upper Portion of the Pyramidal Decussation: “Cruciate Paralysis.” *J Neurosurg* 1970;33:376.

* 4. Boden S, Dodge L, Bohlman H, Rechtine G. Rheumatoid Arthritis of the Cervical Spine. *J Bone Joint Surg Am* 1993;75:1282.

+ 5. Bogduk N, Major G, Carter J. Lateral Subluxation of the Atlas in Rheumatoid Arthritis: A Case Report and Post-mortem Study. *Ann Rheum Dis* 1984;43:341.

+ 6. Braunstein E, Weissman B, Seltzer S, et al. Arthritis and Rheumatism. *Arthritis Rheum* 1984;27:26.

+ 7. Breedveld F, Algra P, Vielvoye C, Cats A. Magnetic Resonance Imaging in the Evaluation of Patients with Rheumatoid Arthritis and Subluxations of the Cervical Spine. *Arthritis Rheum* 1987;30:624.

* 8. Brooks A, Jenkins E. Atlantoaxial Arthrodesis by the Wedge Compression Method. *J Bone Joint Surg Am* 1978;60:279.

+ 9. Bryan W, Inglis A, Sculco T, Ranawat C. Methylmethacrylate Stabilization for Enhancement of Posterior Cervical Arthrodesis in Rheumatoid Arthritis. *J Bone Joint Surg* 1982;64:1045.

+ 10. Bywaters E. Rheumatoid and Other Diseases of the Cervical Interspinous Bursae, and Changes in the Spinous Processes. *Ann Rheum Dis* 1982;41:360.

# 11. Clark C. Occipitocervical Fusion for the Unstable Rheumatoid Neck. *Orthopaedics* 1989;12:469.

# 12. Clark C. Rheumatoid Involvement of the Cervical Spine: An Overview. *Spine* 1994;19:2257.

# 13. Clark C, Boden S. Rheumatoid Arthritis of the Cervical Spine. In: Clark C, ed. *The Cervical Spine.* Philadelphia: Lippincott-Raven, 1998:693.

* 14. Clark C, Goetz D, Menezes A. Arthrodesis of the Cervical Spine in Rheumatoid Arthritis. *J Bone Joint Surg Am* 1989;71:381.

+ 15. Conaty J, Mongan E, California D. Cervical Fusion in Rheumatoid Arthritis. *J Bone Joint Surg* 1981;63:1218.

* 16. Conlon P, Isdale I, Rose B. Rheumatoid Arthritis of the Cervical Spine. *Ann Rheum Dis* 1966;25:120.

+ 17. Crockard H, Poxo J, Ransford A, et al. Transoral Decompression and Posterior Fusion for Rheumatoid Atlantoaxial Subluxation. *J Bone Joint Surg Br* 1986;68:350.

+ 18. De Groote W, Vercauteren M, Uyttendaele D. Occipitocervical Fusion in Rheumatoid Arthritis. *Acta Orthop Belg* 1981;47:685.

+ 19. Delamarter R, Bohlman H. Postmortem Osseous and Neuropathologic Analysis of the Rheumatoid Cervical Spine. *Spine* 1994;19:2267.

+ 20. El-Khoury G, Wener M, Menezes A, et al. Cranial Settling in Rheumatoid Arthritis. *Diagn Radiol* 1980;137:637.

+ 21. Fedele F, Ho G Jr, Dorman B. Pseudoaneurysm of the Vertebral Artery: A Complication of Rheumatoid Cervical Spine Disease. *Arthritis Rheum* 1986;29:136.

* 22. Gallie W. Fractures and Dislocations of the Cervical Spine. *Am J Surg* 1939;46:495.

+ 23. Grob D, Dvorak J, Panjabi M, et al. Posterior Occipitocervical Fusion. *Spine* 1991;16:S17.

+ 24. Grob D, Jeanneret B, Aebi M, Markwalder T. Atlantoaxial Fusion with Transarticular Screw Fixation. *J Bone Joint Surg Br* 1991;73:972.

+ 25. Halla J, Fallahi S. Cervical Discovertebral Destruction, Subaxial Subluxation, and Myelopathy in a Patient with Rheumatoid Arthritis. *Arthritis Rheum* 1981;944.

+ 26. Halla J, Fallahi S, Hardin J. Nonreducible Rotational Head Tilt and Lateral Mass Collapse. *Arthritis Rheum* 1982;25:1316.

+ 27. Heywood A, Learmonth I, Thomas M. Cervical Spine Instability in Rheumatoid Arthritis. *J Bone Joint Surg* 1988;70:702.

+ 28. Itoh T, Tsuji H, Katoh Y, et al. Occipitocervical Fusion Reinforced by Luque's Segmental Spinal Instrumentation for Rheumatoid Diseases. *Spine* 1988;13:1234.

+ 29. Kauppi M, Sakaguchi M, Konttinen Y, Hamalainen M. A New Method of Screening for Vertical atlantoaxial Dislocation. *J Rheumatol* 1990;17:167.

+ 30. Kawaida H, Sakour T, Morizono Y, Yoshikuni N. Magnetic Resonance Imaging of Upper Cervical Disorders in Rheumatoid Arthritis. *Spine* 1989;14:1144.

+ 31. Kinnunen EKM, Ketonen L, Sepponen R, et al. Low-field MRI in the Evaluation of Rheumatoid Cervical Spine. Comparison with Neurological Findings and Routine Plain Radiography. *Clin Exp Rheumatol* 1990;8:365.

+ 32. Kraus D, Peppelman W, Agarwal A, et al. Incidence of Subaxial Subluxation in Patients with Generalized Rheumatoid Arthritis Who Have Had Previous Occipital Cervical Fusions. *Spine* 1991;16:S486.

+ 33. Krieg J, Clark C, Goetz D. Cervical Spine Arthrodesis in Rheumatoid Arthritis: A Long-Term Follow-Up. *Yale J Biol Med* 1993;66:257.

+ 34. Krodel A, Refior H, Westermann S. The Importance of Functional Magnetic Resonance Imaging (MRI) in the Planning of Stabilizing Operations on the Cervical Spine in Rheumatoid Patients. *Arch Orthop Trauma Surg* 1989;109:30.

+ 35. Madawi A, Casey A, Solanki G, et al. Radiological and Anatomical Evaluation of the atlantoaxial Transarticular Screw Fixation Technique. *J Neurosurg* 1997;86:961.

+ 36. Magerl F, Seemann P. Stable Posterior Fusion of the Atlas and Axis by Transarticular Screw Fixation. In: Kehr P, Weidner A, eds. *Cerv Spine* Wien: Springer-Verlag, 1986;322.

+ 37. McAfee P, Cassidy J, Davis R, et al. Fusion of the Occiput to the Upper Cervical Spine: A Review of 37 Cases. *Spine* 1991;16:S490.

+ 38. Meijers KAE CA, Kremer HPH, Luyendijk W, et al. Cervical Myelopathy in Rheumatoid Arthritis. *Clin Exp Rheumatol* 1984;2:239.

+ 39. Moskovich R, Crockard H. Atlantoaxial Arthrodesis Using Interlaminar Clamps: An Improved Technique. *Spine* 1992;17:261.

* 40. Pellicci P, Ranawat C, Tsairis P, Bryan W. A Prospective Study of the Progression of Rheumatoid Arthritis of the Cervical Spine. *J Bone Joint Surg Am* 1981;63:342.

+ 41. Peppelman W, Kraus D, Donaldson W, Agarwal A. Cervical Spine Surgery in Rheumatoid Arthritis: Improvement of Neurologic Deficit After Cervical Spine Fusion. *Spine* 1993;18:2375.

* 42. Rana NA, Hancock DO, Taylor AR, Hill AGS. Upward Translocation of the Dens in Rheumatoid Arthritis. *J Bone Joint Surg Am* 1973;55:471.

* 43. Ranawat C, O'Leary P, Pellicci P, et al. Cervical Spine Fusion in Rheumatoid Arthritis. *J Bone Joint Surg Am* 1979;61:1003.

+ 44. Ransford A, Crockard H, Pozo J, et al. Craniocervical Instability Treated by Contoured Loop Fixation. *J Bone Joint Surg Br* 1986;68:173.

+ 45. Redlund-Johnell I. Subaxial Caudal Dislocation of the Cervical Spine in Rheumatoid Arthritis. *Neuroradiology* 1984;26:407.

* 46. Redlund-Johnell I, Pettersson H. Vertical Dislocation of the C1 and C2 Vertebrae in Rheumatoid Arthritis. *Acta Radiol Diagn* 1983;25:133.

# 47. Robinson R, Southwick W. Surgical Approaches to the Cervical Spine. *Instr Course Lect* 1960;299.

+ 48. Santavirta S, Konttinen Y, Laasonen E, et al. Ten-year Results of Operations for Rheumatoid Cervical Spine Disorders. *J Bone Joint Surg Br* 1991;73:116.

+ 49. Santavirta S, Konttinen Y, Sandelin J, Slatis P. Operations for the Unstable Cervical Spine in Rheumatoid Arthritis. *Acta Orthop Scand* 1990;61:106.

+ 50. Santavirta S, Sandelin J, Slatis P. Posterior Atlantoaxial Subluxation in Rheumatoid Arthritis. *Acta Orthop Scand* 1985;56:298.

+ 51. Santavirta S, Slatis P, Kankaanpaa U, et al. Treatment of the Cervical Spine in Rheumatoid Arthritis. *J Bone Joint Surg Am* 1988;70A:658.

+ 52. Slatis P, Santavirta S, Sandelin J, Konttinen Y. Cranial Subluxation of the Odontoid Process in Rheumatoid Arthritis. *J Bone Joint Surg Am* 1989;71:189.

! 53. Smith M, Kotzar G, Yoo J, Bohlman H. A Biomechanical Analysis of atlantoaxial Stabilization Methods Using a Bovine Model: C1/C2 Fixation Analysis. *Clin Orthop* 1993;290:285.

+ 54. Smith M, Anderson P, Grady M. Occipitocervical Arthrodesis Using Contoured Plate Fixation. *Spine* 1993;18:1984.

+ 55. Smith P, Benn R, Sharp J. Natural History of Rheumatoid Cervical Luxations. *Ann Rheum Dis* 1972;31:431.

+ 56. Snelling J, Pickard J, Wood S, Prouse P. Case Report: Reversible Cortical Blindness as a Complication of Rheumatoid Arthritis of the Cervical Spine. *Br J Rheumatol* 1990;29:228.

+ 57. Teigland J, Magnaes B. Rheumatoid Backward Dislocation of the Atlas with Compression of the Spinal Cord. *Scand J Rheumatol* 1980;9:253.

+ 58. Toolanen G, Knibestol M, Larsson S, Landman K. Somatosensory Evoked Potentials (SSEPs) in Rheumatoid Cervical Subluxation. *Scand J Rheumatol* 1987;16:17.

+ 59. Wattenmaker I, Concepcion M, Hibberd P, Lipson S. Upper-Airway Obstruction and Perioperative Management of the Airway in Patients Managed with Posterior Operations on the Cervical Spine for Rheumatoid Arthritis. *J Bone Joint Surg Am* 1994;76:360.

+ 60. Weiner S, Bassett L, Spiegel T. Superior, Posterior, and Lateral Displacement of C1 in Rheumatoid Arthritis. *Arthritis Rheum* 1982;25:1378.

+ 61. Wertheim S, Bohlman H. Occipitocervical Fusion. *J Bone Joint Surg Am* 1987;69:833.

+ 62. Winfield J, Cooke D, Brook A, Corbett M. A Prospective Study of the Radiological Changes in the Cervical Spine in early Rheumatoid Disease. *J Rheum Dis* 1981;40: 109.

+ 63. Winfield J, Young A, Williams P, Corbett M. Prospective Study of the Radiological Changes in Hands, Feet and Cervical Spine in Adult Rheumatoid Disease. *Ann Rheum Dis* 1983;42:613.

+ 64. Wright N, Lauryssen C. Vertebral Artery Injury in C1-2 Transarticular Screw Fixation: Results of a Survey of the AANS/CNS Section on Disorders of the Spine and Peripheral Nerves. *J Neurosurg* 1998;88:634.

# 65. Zeidman S, Duckler T. Rheumatoid Arthritis. *Spine* 1994;19:2259.

+ 66. Zoma A, Sturrock R, Fisher W, et al. Surgical Stabilization of the Rheumatoid Cervical Spine. *J Bone Joint Surg Am* 1987;69:8.

# CHAPTER 155

# ANTERIOR APPROACH TO SCOLIOSIS

*Jesse Butler and Michael F. Schafer*

**J. Butler:** Department of Orthopaedic Surgery, Our Lady of Resurrection Spine Center, Chicago, Illinois, 60646.
**M. F. Schafer:** Department of Orthopaedic Surgery, Northwestern University Medical School, Chicago, Illinois, 60611.

Historical Background
Indications
Preoperative Planning
Selection of Levels to be Fused
Idiopathic Scoliosis
Paralytic Scoliosis
Myelomeningocoele
Cerebral Palsy
Congenital Hemivertebra
Adult Scoliosis
Surgical Technique
Selection of Instrumentation
Postoperative Care
Pitfalls and Complications
Instrumentation
Medical
Neurovascular
Chapter References

## HISTORICAL BACKGROUND

Scoliosis is a complex three-dimensional deformity characterized by coronal, sagittal, and horizontal plane deviation. Although posterior spinal fusion and instrumentation can be used for most patients, there are many situations in which the anterior approach is necessary. With recent advances in thoracoscopic techniques, the indications for anterior surgery may be expanded (46). The deformity surgeon must, therefore, be aware of the anterior surgical options available.

Although Compere reported the resection of a hemivertebra by the anterior approach in 1932 (4), anterior surgery for the treatment of spinal conditions started with Hodgson, who reported the results of anterior spinal decompression and fusion for tuberculosis of the spine in 1956 (13,14). Dwyer expanded the technique developed by Hodgson to approach the convex side of a scoliosis curve (9,10). During the past 30 years, spinal surgeons have become facile with the anterior or combined anterior and posterior approaches.

## INDICATIONS

Indications for an anterior approach include certain cases of idiopathic, congenital, neuromuscular, and adult scoliosis. The neuromuscular curves include those caused by cerebral palsy, myelomeningocoele (MM), muscular dystrophy, polio, trauma, Friedrich's ataxia, and syringomyelia. The combination of curve magnitude, rigidity, spasticity, and paralysis frequently necessitates combined anterior and posterior spinal fusion.

The spinal deformities associated with neuromuscular disease are often progressive and disabling. The indications for surgery are at times controversial in severely involved children, and complications are frequent. Patients with impending skin compromise due to pelvic obliquity or kyphosis, poor sitting balance with muscular fatigue and pain, loss of upper extremity function due to using their arms to support and elevate the trunk, and progressive deterioration of pulmonary function are strong indications for surgery (39). Attempts to delay surgery with bracing until adequate trunk height is obtained are a common dilemma in the preadolescents with significant deformity. Absolute Cobb angular measurements for which surgery is indicated range from 40° to 60°. Issues regarding age, medical comorbidity, and family acceptance make rigid guidelines difficult to implement.

When combined anterior and posterior fusion is indicated, same-day sequential surgery usually is performed. The anterior approach allows more correction by excising the discs and ligaments (5), increases fusion rates, prevents crankshafting in immature spines (8,20,21), decompresses the spinal cord, and provides exposure for internal thoracoplasty (40). This is followed by posterior instrumentation and fusion. Powell et al. (36) compared the results between staged and same-day surgery. They found less blood loss, shorter hospital stays, and reduced cost with same-day surgery. Ferguson et al. (11) reviewed the results of same-day surgery in patients with neuromuscular scoliosis. The overall complication rate was reduced from 124% to 88%. The number of patients without any complications in this high-risk group increased from 35% to 63%.

The indications for anterior instrumentation have changed since the second edition of this book. The Dwyer and Zielke instrumentations are no longer used in our practice. Anterior instrumentation is used now for structural support as well as for deformity correction. In select cases of idiopathic scoliosis, anterior instrumentation may be all that is necessary. Valuable motion segments may be preserved in the lumbar spine when fusing with anterior instrumentation.

## PREOPERATIVE PLANNING

The initial step in preparing the patient for an anterior procedure is a thorough history and physical examination. For all cases, obtain an appropriate medical consultation prior to surgical intervention. A complete examination of the chest, abdomen, back, and lower extremities is important. Assess spinal balance, as this aides in determining fusion level. For example, a lumbar scoliosis with an associated rigid thoracic kyphosis must be fused across both curves to prevent decompensation and progression of the thoracic deformity.

Carefully evaluate neuromuscular patients for asymmetric muscle strength, rapid curve progression, increasing motor weakness, or cavus foot deformity. Evaluate with magnetic resonance imaging (MRI) to look for an intraspinal lesion or tethered cord (37). Do a myelogram only in cases that are difficult to interpret. An assessment of pelvic obliquity and hip joint contracture is vital if the fusion is to be carried into the lumbosacral region. At times, a release of hip flexion contracture may be required to decrease excessive lumbar lordosis prior to spine surgery.

A complete radiographic assessment includes standing or sitting 14×36 films in the posteroanterior and lateral planes. Supine side bending films determine the curve flexibility and assist in determining the fusion endpoint. Image the lumbosacral junction to detect an occult spondylolisthesis. Preoperative MRI is not necessary for idiopathic adolescent (48) and adult deformity.

Pulmonary function studies are mandatory. This helps determine which group of patients will require respiratory assistance in the perioperative period. Forced vital capacity (FVC) values less than 40% of predicted values, and small children with recurrent upper respiratory infections should be evaluated closely (16). In idiopathic scoliosis, little effect on the FVC occurs until curves approach 60° to 100°. However, patients with spinal muscular atrophy or muscular dystrophy have marked reductions in FVC to less than 50% with curves of only 30° (39).

We obtain preoperative lower extremity somatosensory evoked potential exams to establish a baseline with which comparison can be made intraoperatively. Theoretically, detecting early subtle changes in evoked potential can enhance the safety of the procedure.

Congenital curves require a detailed evaluation by multiple disciplines. A careful history should elicit any urologic, cardiac, musculoskeletal, or neurologic anomalies. Approximately one third of these patients have urologic abnormalities, and 10% possess cardiac malformations (24). Evaluation of the genitourinary system with an

intravenous pyelogram or ultrasound can detect anomalies, which may need treatment prior to spinal surgery.

Perioperative nutritional assessment is important to minimize infection and wound healing problems (1). Mandelbaum's review (28) of staged anterior and posterior surgery noted that all infectious complications but one occurred in malnourished patients. A serum albumin over 3.5 g/dl and total lymphocyte count of more than 1,500/µl are acceptable. The normalization of nutritional parameters following combined spinal surgery correlates with the length of fusion according to Lenke et al. (22). Shorter fusions required approximately 6 weeks, and longer fusions about 12 weeks before nutritional parameters normalized when perioperative hyperalimentation was not used.

We use intravenous hyperalimentation in all of our patients undergoing combined anterior and posterior procedures. We place a central line at surgery and continue hyperalimentation until the postoperative ileus resolves and the patient's appetite returns. We have found a decrease in hospital stay and perioperative morbidity with this regimen.

We encourage the preoperative donation of autologous blood (6,31). Autologous donation does not compromise nutritional status, nor does it increase complication rates or the need for postoperative transfusions. The blood lost during surgery in these patients is more dilute, since their hematocrit at the time of surgery is lower. Homologous blood donation causes immunosuppression and places the patient at risk for transmission of viral diseases.

While intraoperative autologous transfusion (IAT) is used in our institution, there are recent studies that question its utility (41,42 and 43) in selected populations. There are significant costs for equipment and technicians, and the salvaged blood has a low hematocrit. There is no definitive evidence that IAT reduces the need for postoperative transfusion in select populations. However, for our combined procedures to correct scoliosis and kyphosis, IAT is used. We feel that this decreases the amount of homologous blood required for the surgery.

## SELECTION OF LEVELS TO BE FUSED

### IDIOPATHIC SCOLIOSIS

The majority of cases will be approached posteriorly, but for certain lumbar and thoracolumbar curves we use the anterior approach. Anterior instrumentation systems provide better correction of rotation, as forces are exerted directly through the vertebral body and disc spaces. When an anterior approach is selected, fewer levels are fused, which may prevent the future development of low-back pain. The Dwyer system was one of the first used this way (9,10). The lower pseudarthrosis rates and improved sagittal contour fueled the transition to solid rod systems such as Isola, the Texas Scottish Rite Hospital system (TSRH), and Kaneda.

The patients selected should have a lumbar or thoracolumbar curve of 60° or less, with a flexible thoracic deformity that reduces to less than 20° on supine bending films. The number of levels to be fused depends on whether the curve apex is at the disc or the vertebral body level. When the apex lies at the disc, two levels above and below are fused. If the apex is at the body, then one body above and below the apical vertebra is fused.

Hall et al. (12) noted similar correction of coronal deformity when comparing their results using the Dwyer, Zielke, and TSRH systems. The TSRH system produced less segmental kyphosis. There was only one pseudarthrosis in their series of 18 cases with TSRH. This was successfully salvaged with a posterior fusion.

### PARALYTIC SCOLIOSIS

While the etiologies of paralytic scoliosis are diverse, there are many common features. The curves tend to occur early, progress rapidly, involve the entire spine, and result in pelvic obliquity, and they progress in adulthood (39). A combined anterior and posterior procedure is often utilized with fusion from T2 to the pelvis.

The criteria for anterior release are based on curve flexibility and leveling of the pelvis on side-bending films. When the pelvis becomes level on side-bending films, an anterior release is not necessary. However, when lumbar rigidity precludes correction to less than 30°, the anterior discectomy and bone grafting is performed prior to the posterior procedure.

We have modified our technique from combined anterior and posterior instrumentation (Dwyer anterior and Luque-Galveston posterior) to anterior release with segmental fixation posteriorly with either Isola (DePuy Acromed, Warsaw, IN) or CD Horizon (Sofamor Danek, Memphis, TN) instrumentation. This change emphasizes the role of the anterior procedure in mobilizing a rigid deformity, establishing lumbar lordosis, and improving fusion rates and overall sagittal balance. Recently, we have utilized titanium cages anteriorly to improve sagittal contour prior to the posterior procedure. This prevents loss of lordosis from graft settling that may be seen with the use of autograft or allograft alone. Pelvic fixation varies with the patients' anatomy, but an iliac post is most commonly used. The iliac post, placed between the inner and outer tables of the ilium, increases the rigidity of the fixation.

### MYELOMENINGOCOELE

The treatment of scoliosis in the MM population is complex and complications are frequent (see Chapter 157). As the level of neurologic compromise rises, so does the incidence of spinal deformity (25,37), approaching 100% in thoracic-level patients. Nearly 60% of L4 level patients have scoliosis. The overall goal of surgery is to achieve a vertical torso centered over a level pelvis. Therefore, most patients require a fusion from T2 to the sacrum (Fig. 155.1).

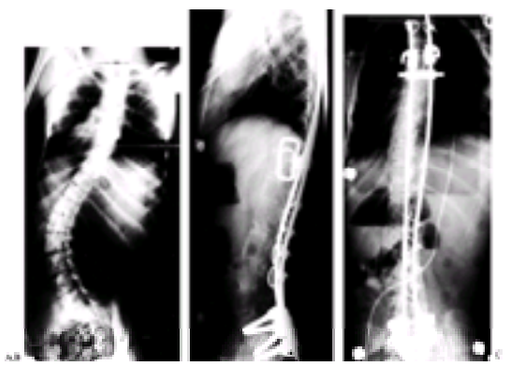

***Figure 155.1.*** **A:** Preoperative AP view of a child with myelomeningocoele and a curve of 58°. A combined anterior release and posterior fusion with Cotrel-Dubousset rods, pedicle screws, and Luque wires was utilized. Postoperative lateral (**B**) and AP (**C**) views show excellent correction of coronal and sagittal deformities. A solid fusion is evident at 1-year follow-up. (Courtesy of John Sarwark.)

From 1980 to the early 1990s, we followed all anterior instrumentation and fusions with the Dwyer technique with a supplemental posterior fusion to the sacrum with Luque instrumentation. This technique allowed excellent coronal and sagittal correction. We had only one pseudarthrosis with this technique and it was associated with persistent infection necessitating early removal of the posterior hardware.

Currently, we perform anterior discectomy and fusion followed by posterior Isola instrumentation with iliac post fixation in the pelvis. The fusion rates have remained acceptable with this modification. The real benefit has been the improved sagittal balance obtained from the anterior mobilization followed by posterior deformity correction and fusion. Segmental fixation posteriorly combines hooks, sublaminar wires, and pedicle screws.

We have not used isolated anterior instrumentation for MM patients because of reported high complication and revision rates (25,44). The kyphosis caused by some anterior instrumentation is only exacerbated in this population. Anterior instrumentation also reduces the sagittal correction obtained by posterior techniques.

### CEREBRAL PALSY

There is controversy over the treatment of scoliosis in cerebral palsy (CP) patients. As the magnitude of neurologic involvement increases, the severity of the curve increases (27,38,39). Ambulatory patients with CP have approximately half the rate of significant deformity that nonambulators have. Curve progression into adulthood

is known to occur; therefore, maintenance of ambulation through aggressive physical therapy and close follow-up is necessary.

There is often not one right answer for the CP patient. The risks and benefits of surgery should be thoroughly discussed with the parents. When there is any prospect of functional benefit to the patient, surgery is recommended. It is difficult to judge the true benefit for those with severe cognitive impairment, seizure disorder, and malnutrition.

The curves frequently are quite large and rigid. Therefore, fusion is required from the upper thoracic spine to the pelvis. The anterior procedure releases the rigid structures, which enhances posterior correction and fusion. If pelvic obliquity is not significant (i.e., it corrects on side-bending films), then fusion may be carried down to L4 or L5.

**CONGENITAL HEMIVERTEBRA**

Treatment of a congenital hemivertebra depends on whether the hemivertebra is segmented, semisegmented, or incarcerated. The fully segmented variety is the most common and produces the greatest deformity. In growing patients, use an anterior and posterior approach to perform a hemiepiphysiodesis, where obliteration of the convex endplates will halt spinal growth on the convexity and allow concave growth to correct the deformity (47). Thompson et al. (45) reported their results of convex epiphysiodesis for hemivertebra. The operative objectives were to prevent the development of severe deformity and allow growth of the remaining concave epiphysis to correct scoliosis. They found the procedure to be safe, and it yielded some correction in 76% of their patients and slowed progression in the remaining patients. The greatest correction was obtained in the lumbar spine of the youngest patients in their series.

Hemivertebral excision is an alternative treatment. The technique has been described for lumbosacral hemivertebra with severe coronal plane imbalance. Callahan et al. (3) reported the results of hemivertebral excision in 10 patients. Nine of 10 were excised in a single stage from T12 to L3. The procedure was safe and effective with a curve correction of 67% obtained. Greatest correction was obtained in the younger patients (under 4 years old).

**ADULT SCOLIOSIS**

One of the major concerns in the treatment of adult scoliosis is the high rate of complications, particularly pseudarthrosis. In a review of 62 adult cases, a 16.7% incidence of pseudarthrosis was present among patients undergoing posterior spinal fusion with Harrington rod instrumentation (34).

To minimize pseudarthrosis and improve correction, we treat all thoracolumbar or lumbar structural curves greater than 65° by combined anterior discectomy and fusion, followed by posterior spinal fusion with Cotrel-Dubousset (CD) instrumentation. This aggressive approach is indicated because these curves are stiff and there is little correction with posterior instrumentation and fusion alone. The anterior discectomy and fusion, followed by posterior instrumentation and fusion, results in a better correction of the curve and a more balanced spine, and it enhances the fusion rate (Fig. 155.2).

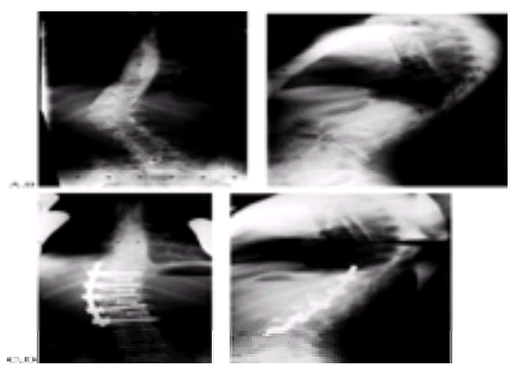

***Figure 155.2.*** **A:** A 26-year-old woman with an increasing throracolumbar curve and low back pain. **B:** A lateral x-ray reveals a junctional kyphosis from T11 to L1. **C:** The postoperative AP x-ray shows correction of the curve to 20° with titanium cages filled with autogenous bone placed between T11 and L3. **D:** The lateral x-ray demonstrates the restoration of the normal lordosis between T11 and L3.

In adult curves of less than 65° that are located in either the thoracolumbar or the lumbar area, an anterior approach using anterior CD instrumentation is performed. If a curve has an associated kyphosis of the thoracolumbar or lumbar spine, we have used titanium cages to correct sagittal alignment. The cage size is selected to restore each disc space to a more lordotic posture.

## SURGICAL TECHNIQUE

- Place the patient in the lateral decubitus position with the table in a flexed position. Move the upper arm forward to rotate the scapula away from the posterior portion of the vertebral column. Place an axillary roll between the patient and the table to minimize pressure on the brachial plexus during the procedure (Fig. 155.3).

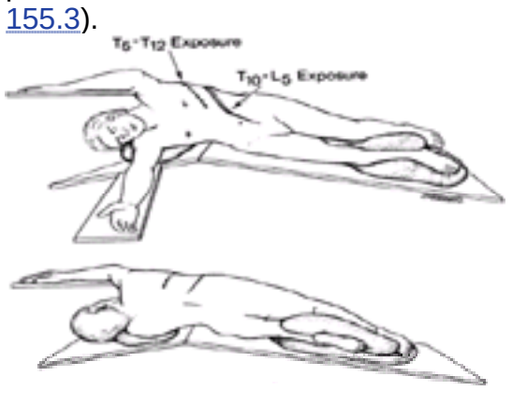


***Figure 155.3.*** **A:** Anterior view of a patient in the lateral decubitus position. A roll is placed under the axilla to minimize the compression of the axillary artery. The *dotted line* represents the skin incision for exposure of T5 to T12. For both exposures, the table is flexed to accentuate the spinal curvature. **B:** The posterior view of the patient showing the position of the arms and the posterior extent of the incisions.

- Expose the anterior spine by one of two standard approaches: Approach the thoracic spine through the bed of the convex fifth rib, which provides good visualization of T5 to T12 (Fig. 155.3); or approach the thoracolumbar spine through the bed of the tenth rib. Extend this incision anteriorly to the lateral border of the rectus sheath. The incisional length varies, depending on the number of levels exposed.

The rib to be removed by either the thoracic or thoracolumbar approach is the rib cephalad to the upper-end vertebra in the fusion. For example, if the upper vertebra to be instrumented or fused is T10, then the ninth rib is resected. Once the rib is excised, the pleura is incised to expose the vertebral column. A double lumen endotracheal tube combined with moist laparotomy sponges and a well-contoured malleable retractor allows excellent retraction of the thoracic contents.

- The thoracolumbar approach enters the retroperitoneal space on the convex side of the curve.
- After removing the appropriate rib, split the costal cartilage along the longitudinal axis. Identify the yellow fatty tissue of the retroperitoneal space immediately beneath the split costal cartilage. Enter the plane by blunt, finger dissection.
- Sweep the peritoneum off the undersurface of the diaphragm and the anterior surface of the psoas muscle to expose the spine. Incise the diaphragm along its peripheral margin from anterior to posterior (Fig. 155.4). Leave 1.5 cm of diaphragm as an edge for reattachment at the conclusion of the procedure. Place stay sutures at 3 cm intervals. If the diaphragm is cut too close to the periphery, muscular contraction may make closure difficult.

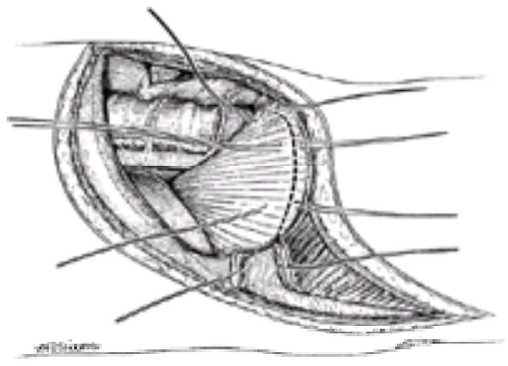

***Figure 155.4.*** The costal cartilage has been split and marking sutures are placed on both cut ends. The *dotted line* demonstrates the detachment of the peripheral portion of the diaphragm. The diaphragm is detached 0.75 inch from the periphery to facilitate closure.

- Reflect the pleura and ligate the intercostal vessels in the midportion of the vertebral body to complete the thoracic exposure (Fig. 155.5). Carefully elevate the vessels off of the vertebral body, and double-ligate with suture, then retract the vascular elements from the working field.

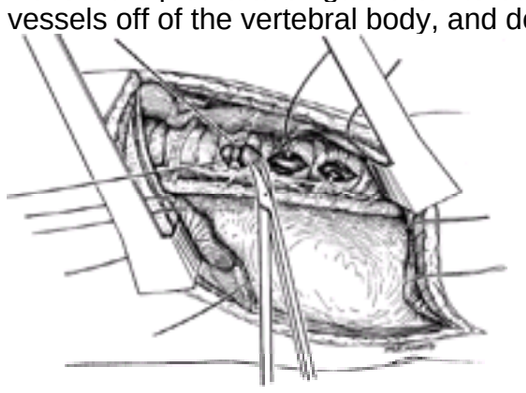

***Figure 155.5.*** The segmental vessels are ligated at the midportion of the vertebral body.

The segmental vessels usually join the anterior median longitudinal arterial trunk of the spinal cord and also the posterior lateral longitudinal arterial trunks of the cord. Spinal cord blood supply is not compromised by ligating multiple intercostal vessels as long as this anastomosis is preserved (7).

- Detach the crura of the diaphragm to expose the thoracolumbar spine at L1-2. Detach the origin of the psoas at the L1 vertebral body or reflect it anteriorly. For patients with large psoas muscles, the muscle may be split along its longitudinal axis to expose the spine.

When exposure of the L4 level is required, it is critical that the lumbar segmental vessels arising from the iliac artery and vein be ligated in the middle of the vertebral body. There is also a lumbar segmental vessel from the iliac artery and vein that passes into the pelvis. Identify this vessel carefully so that the iliac artery and vein can be mobilized away from the spine. Inadvertent transection of this vessel is difficult to manage because the vessel retracts into the pelvis. This can lead to extensive hemorrhage.

- Once the spine is completely exposed, place retractors to protect the vascular structures. Place a Chandler elevator on the opposite side of the disc space to be resected.
- Resect the disc back to the posterior longitudinal ligament with a knife and rongeurs (Fig. 155.6). Use a headlight and loupes during this phase of the procedure. Meticulous technique is needed to avoid inadvertently penetrating the ligament, which is closely adherent to the dura and spinal cord. Exposing a broader surface area improves the fusion rate.

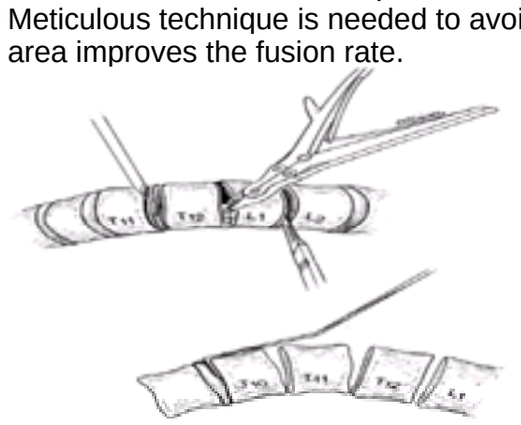

***Figure 155.6.*** **A:** After exposure of the spinal column, the intervertebral disc is removed thoroughly by means of sharp dissection with a knife and rongeur. The vertebral endplates are removed by using a fine osteotome. **B:** After the disc has been removed at all levels, the staple starter is placed on the superior border of the uppermost vertebra that is to be fused.

**HINTS AND TRICKS**

- If the posterior longitudinal ligament is inadvertently transected, brisk bleeding may be encountered from the epidural venous plexus. Obtain control by gently packing with thrombin-soaked Gelfoam pledgets. Small dural tears may be sealed in a similar fashion. It is the second-listed author's experience that this local treatment plus curve correction will cause the tear to seal off. Larger tears require closure. Facilitate exposure of the tear by removal of a portion of the vertebral body, and use 6-0 nylon sutures to repair the dural tear.
- On completion of the discectomy, excise the vertebral endplates using a fine osteotome. Take care to remove only the endplate. If too much of the body is removed, the purchase of any form of instrumentation on the vertebra will be compromised.

## SELECTION OF INSTRUMENTATION

Recent technical advances in instrumentation have given the surgeon multiple options for anterior fixation. The anterior surgical options include discectomy and fusion with autograft or threaded/solid rod systems. Personal experience, anatomy and location of the curve, number of levels, patient age, and cost will dictate the specific approach. The indications and contraindications for anterior instrumentation are outlined in Table 155.1. Additional consideration should be given for anterior instrumentation when prominent posterior hardware and crankshaft phenomena are a concern.

| *Indications* | *Contraindications* |
|---|---|
| Thoracolumbar and lumbar curves | Need to extend fusion to L5 |
| Compensatory thoracic curve is flexible. | Severe curves > 75°F |
| Lordosis across segment to be fused | Kyphosis across fusion segment |
| Strong vertebral bodies | Osteoporotic bodies |
| Minimize fusion levels | |

***Table 155.1. Indications and Contraindications for Anterior Instrumentation***

The number of levels to be instrumented anteriorly is determined the same way regardless of the instrumentation used. The apex of the curve of concern is determined from the standing radiograph. It is the most laterally displaced portion of the Cobb curve from a line joining the center of the end vertebral bodies as measured by the Cobb method. If the regional apex is a vertebra, further apparent as the single most rotated vertebra, the apex vertebra plus one vertebra above and one below are included in this instrumentation construct. As the scoliosis reaches 55° or greater, it is generally necessary to add two vertebrae above and two vertebrae below the end vertebra. If the regional apex is a disc, further apparent because of similar adjacent vertebral rotation, then two vertebrae above and two vertebrae below are added. In addition, the first caudal disc space that shows reversal of coronal plane angulation on a convex bending radiograph can usually be excluded.

The following sections describe the specific surgical techniques for insertion of a threaded rod system [Zielke (Osteotech, Inc., Eatontown, NJ)] and two solid rod systems (DePuy Motech and Isola).

**ZIELKE INSTRUMENTATION**

Zielke instrumentation utilizes a threaded rod and vertebral body screws to correct deformity (Fig. 155.7).



***Figure 155.7.*** The threaded Zielke rod with associated locking nuts. (Courtesy of Daniel Benson, M.D.)

- Insert the instrumentation after exposure of the anterior spine has been completed. Place appropriate-size screws across the vertebral bodies (Fig. 155.8) by measuring the width of the vertebral body, and selecting the appropriate-length screw to allow several threads to protrude from the opposite cortex. Place the screw as posterior as possible in the vertebral body.

***Figure 155.8.*** The slotted screw head for the insertion of the Zielke rod. (Courtesy of Daniel Benson, M.D.)

- Following appropriate placement of the screws (Fig. 155.9), place a threaded rod in the screw heads, beginning at the apex; working proximally and distally, compress the convexity (Fig. 155.10).

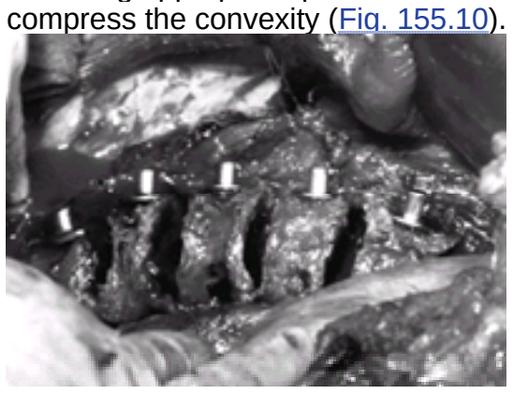

***Figure 155.9.*** The spine has been exposed and all the Zielke screws are in place. (Courtesy of Daniel Benson, M.D.)

***Figure 155.10.*** The compression force has been applied to the convex side of the curve, and resected rib for the graft is placed into the intervertebral disc space. (Courtesy of Daniel Benson, M.D.)

- Prior to any significant compression across the apex, place the derotator bar (Fig. 155.11). This consists of a metal bar that is fitted to the ends of the rod. and a tension screw that is placed between the apex of the rod and the bar. Tightening the tension screw affords some increase in lordosis of the spine, which may be further increased by rotating the bar (Fig. 155.12). This is seen intraoperatively by an opening anteriorly of the disc spaces.



***Figure 155.11.*** The derotation bar has been applied to the Zielke rod. (Courtesy of Daniel Benson, M.D.)

***Figure 155.12.*** The Zielke rod has been inserted and all hex nuts tightened. This provides the curve correction. (Courtesy of Daniel Benson, M.D.)

- Place rib graft anteriorly to facilitate fusion and maintain adequate lumbar lordosis. Then achieve compression by tightening the hex nuts.

***Results***

The Zielke procedure is an accepted treatment for coronal correction of scoliosis. The rate of curve correction varies between 60% and 80%, with adolescents achieving the higher rate of correction. In an early report that looked at the correction of this instrumentation, 19 patients were evaluated with an average success rate of 77% for the thoracolumbar curve and 92% correction in the lumbar curve (49). These results have been duplicated in many studies (15,30,35). In a report that stratified results obtained by Zielke, Dwyer, and Harrington rod instrumentation, the Zielke appeared to have the highest rate of correction (26).

The adult population does not fare as well as the adolescents. Kaneda reported a correction rate of 59%, with all developing a pseudarthrosis. The literature suggests that loss of correction occurs between surgical intervention and later follow-up. In one report, 18 patients who had an initial mean correction of 82% in the lower curve found the rate dropped to 63% at follow-up. The same trend was found in the correction rates associated with the upper curve, with a loss from 33% to 18% at follow-up. Rotational correction was also reduced from 66% to 56%. This loss of correction is likely the result of a lack of stiffness of the threaded rod.

The Zielke instrumentation tends to produce kyphosis with an average loss of lordosis of 8° to 10° over the instrumented segments. Many studies (17,23,32) have documented the occurrence of this increased kyphosis, but none have shown it to affect the surgical outcome. This, however, can be reduced with appropriate anterior column support by structural grafts such as femoral rings, and threaded or titanium cages.

**DEPUY MOTECH**

The anterior instrumentation developed by DePuy Motech uses a solid rod connected to vertebral screws.

- Place the patient in the lateral decubitus position and make a single skin incision paralleling the eighth rib. Mobilize and detach the serratus anterior muscle. Make an incision in the intercostal space at T4 or T5 for instrumentation of the T5 vertebra. Make a second incision between the intercostal space three or four ribs distally (i.e., to T8 or T9) for instrumentation of T12 (Fig. 155.13).

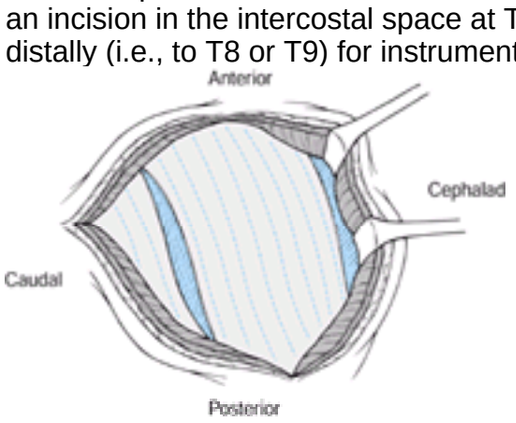


***Figure 155.13.*** Incisions made at the intercostal space at T4 or T5, and between the intercostal spaces at approximately three to four ribs distally. (Redrawn from Moss Miami 4.0 mm Anterior System Surgical Technique: Anterior Treatment of Thoracic Idiopathic Scoliosis. DePuy Motech, Warsaw, Indiana, 1997.)

- If the preoperative analysis suggests that a thoracoplasty is necessary for cosmetic reasons, perform it at this stage. A rib approximately 2 cm in length is removed as far posteriorly as possible between the two intercostal space entrances. If there is a very significant rib hump, then the entire posterior 2 cm of rib is removed from each of the vertebrae to be instrumented. Rib resections better mobilize the chest wall, making the discectomies and instrumentation less difficult to perform.
- Facilitate exposure of the disc space, especially near the proximal vertebrae, by removing the rib head covering the disc space. Insert the vertebral body staples in approximately the same anatomic position in each vertebral body. Position these as far posteriorly as possible to prevent penetration of the spinal canal with the staple prongs.
- In the most proximal vertebrae, insert the most proximal staple so that the screw can be placed eccentrically into the vertebral body. Insert the screw from posterior to anterior, as with the other screws. This superior eccentric placement adds strength by putting the screw threads against the superior endplate of the vertebral body. Place an identical staple in the most inferior vertebral body so that the screw is in the inferior aspect of that vertebral body (Fig. 155.14).

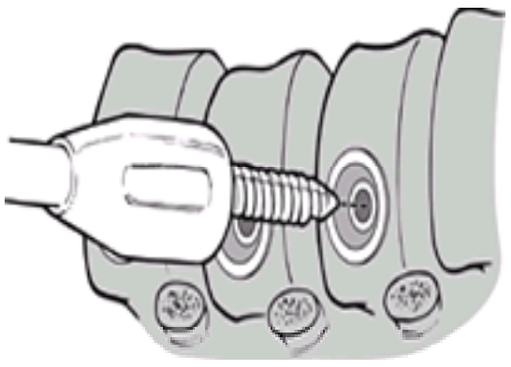

***Figure 155.14.*** Proximal screw placed in inferior aspect of vertebral body. (Redrawn from Moss Miami 4.0 mm Anterior System Surgical Technique: Anterior Treatment of Thoracic Idiopathic Scoliosis. DePuy Motech, Warsaw, Indiana, 1997.)

- Use an awl to make a hole for the insertion of the screws. When the screws are positioned, it is important that they penetrate the concave side of the vertebral body.
- Perform bone grafting before rod insertion. Begin distally, and wedge the disc space open and pack the interspaces. It is important to pack the discs between T10 and L2 firmly with bone graft. A structural type of anterior support may be needed to help ensure maintenance of the sagittal correction. When grafting the apical vertebrae, consider the original sagittal contour. If the starting sagittal profile is lordotic or hypokyphotic, only a small amount of graft can be inserted into the disc at the apex of the curve, to allow kyphosis to occur during compression with instrumentation.
- Measure the appropriate length of the rod from the proximal to the distal screw. Add ¼ inch (i.e., $^{1}/_{8}$ inch for each end), and cut the rod. Bend the rod to parallel the anatomically correct kyphosis–lordosis of the area of the spine needing instrumentation. Insert the rod so that the kyphosis is used to accommodate the scoliosis that is still present. It is important to remember to straighten out the table if it has been bent to facilitate the thoracotomy and disc exposure. When applying the nuts, it is easier to start at the top three nuts and then work toward the distal end.
- After inserting the inner setscrews and outer nuts, the rods should be loose. The spine can be corrected by rotating the rod into a normal sagittal plane (Fig. 155.15). Correction can be facilitated by the anesthesiologist pulling on the lower arm and by the surgeon pressing on the apex of the curvature. With the rod rotated into an anatomically correct position, tighten both the inner and outer apical nuts. At this point, a decision has to be made about the anticipated coronal correction that is needed. If there is a structural upper thoracic curve, only a modest correction can be obtained in the main thoracic curve equal to the correction seen on the bending films of the upper thoracic curve. If there is no residual structural curve, then near-complete reduction of the curve can be obtained.

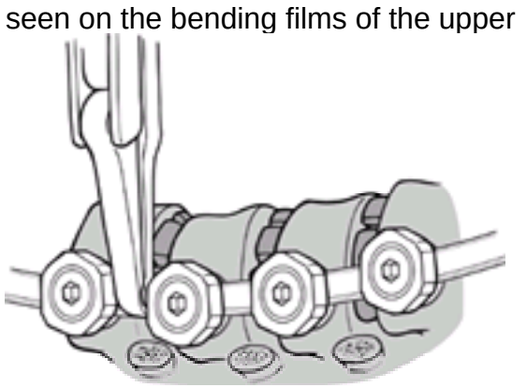

***Figure 155.15.*** Rotating the rod into a normal sagittal plane. (Redrawn from Moss Miami 4.0 mm Anterior System Surgical Technique: Anterior Treatment of Thoracic Idiopathic Scoliosis. DePuy Motech, Warsaw, Indiana, 1997.)

- Obtain correction by using a compressor on each screw. Gradually compress each screw toward the apex. This needs to be done slowly and sequentially. After it has been completed, perform the final tightening in both the inner setscrews and the outer nuts. It is important to be cautious during this final tightening, especially in the end vertebrae. Torquing the screw could translate the screw out of the vertebral body. It is recommended that you use the rod stabilizer device that goes over the rod and provides neutralizing forces while tightening the inner setscrews and outer nuts (Fig. 155.16).

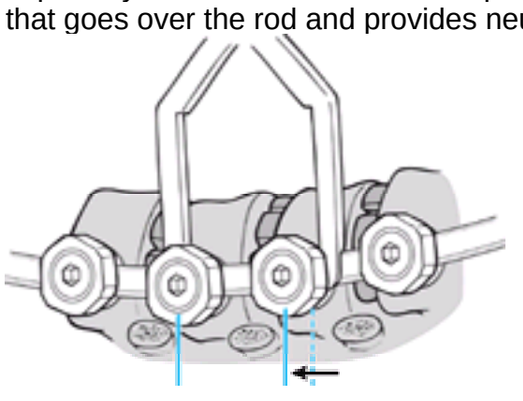

***Figure 155.16.*** Screws are gradually compressed toward the apex. (Redrawn from Moss Miami 4.0 mm Anterior System Surgical Technique: Anterior Treatment of Thoracic Idiopathic Scoliosis. DePuy Motech, Warsaw, Indiana, 1997.)

Figure 155.17 shows the results obtained with this instrumentation. Preoperative side-bending films of a thoracic curve show excellent flexibility. The postoperative anteroposterior (AP) and lateral films show near-complete correction.

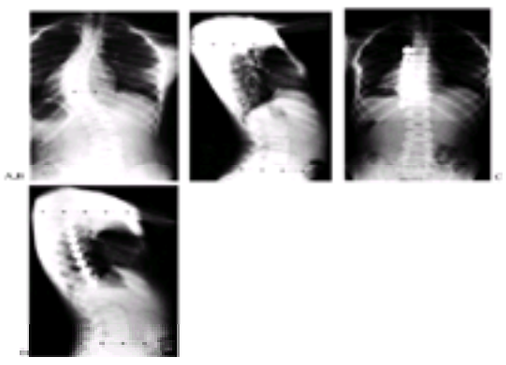

***Figure 155.17.*** The preoperative AP (**A**) and lateral (**B**) views of a child with a thoracic scoliosis. The postoperative films (**C,D**) show near complete correction of the coronal and sagittal deformities. The cage is used to prevent kyphosis at the thoracolumbar junction.

**ANTERIOR ISOLA INSTRUMENTATION**

- Expose the anterior spine as previously described.
- Place the end screws first from posterior to anterior, horizontal to the frontal plane of the vertebral body and paralleling the apex. Start the hole with an awl and continue with the 5.5 mm tap. Tap the vertebra until the tip just exits the far side of the cortex (Fig. 155.18). Insert a ballpoint probe to make sure that the far side

of the cortex has been exited. Tap the first third of the hole with a 7 mm tap and insert a 7 mm closed-top screw with washer (Fig. 155.19).

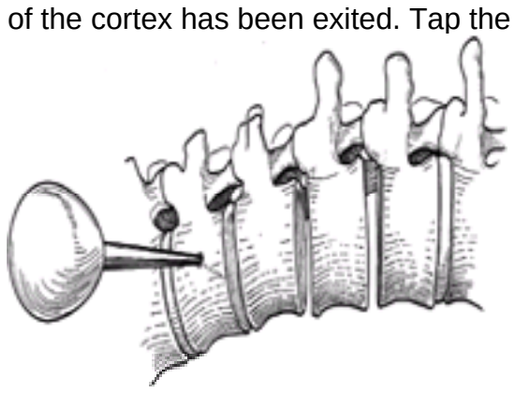

***Figure 155.18.*** ollowing a thorough 360° discectomy in which the posterior longitudinal ligament is exposed, placement of the upper vertebral screw site is begun with an awl, which is positioned at the furthest lateral waist of the vertebral body. (Redrawn from Asher MA. *Surgical Technique for Anterior Segmental Instrumentation of Thoracolumbar and Lumbar Scoliosis Using the Anterior Isola Spinal System.* AcroMed Corp., Cleveland, OH, 1996.)

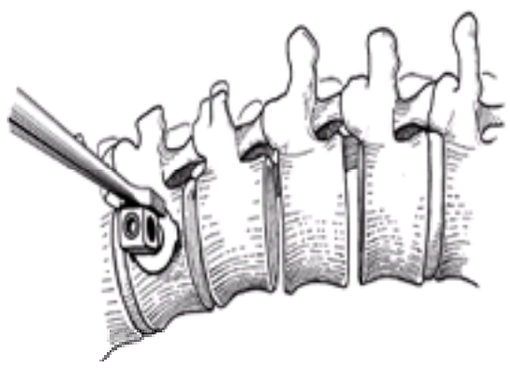

***Figure 155.19.*** Insertion of a 7 mm closed-top screw with washer. A staple may be used if desired. (Redrawn from Asher MA. *Surgical Technique for Anterior Segmental Instrumentation of Thoracolumbar and Lumbar Scoliosis Using the Anterior Isola Spinal System.* AcroMed Corp., Cleveland, OH, 1996.)

- Use a staple, and place it prior to the insertion of the screw. Insert the screw to maximum torque. The screw should protrude through the far cortex by at least one to two threads.
- Repeat the same process at the lower-end vertebra. After the superior and inferior vertebrae have been instrumented with the staple and screws, cut the rod and contour it so that it fits through both the superior and inferior screws (Fig. 155.20). Add about 1 cm to each side of the rod to ensure that the rod passes completely through the end screws. After the rod has been cut to length and contoured, it is used as a guide for placement of the intermediate screws.

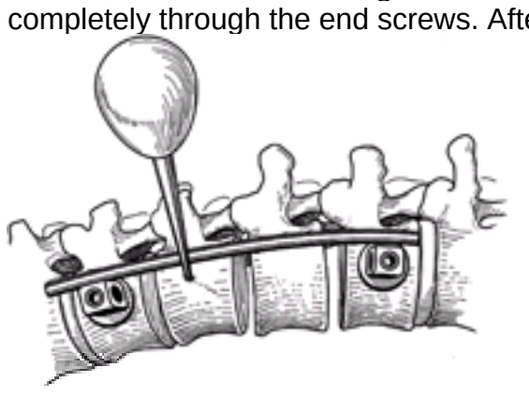

***Figure 155.20.*** Rod is cut and contoured. Intermediate screws should be placed very slightly posterior on the waist of the body. (Redrawn from Asher MA. *Surgical Technique for Anterior Segmental Instrumentation of Thoracolumbar and Lumbar Scoliosis Using the Anterior Isola Spinal System.* AcroMed Corp., Cleveland, OH, 1996.)

- Insert open-ended screws and staples at the intervening levels. Insert the rod into the superior and inferior screws and drop into the intermediate screws (Fig. 155.21). Place caps on the intermediate screws. After placing the caps, rotate the rod approximately 180° to obtain both a coronal and a sagittal correction (Fig. 155.22).

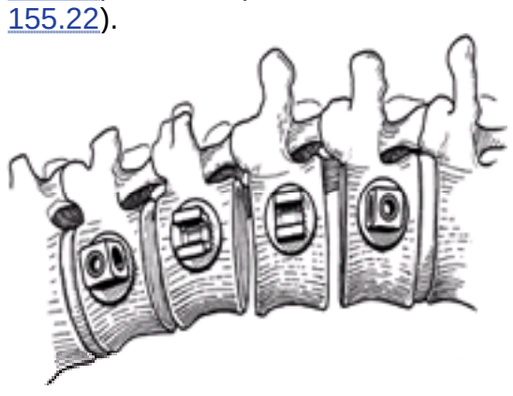

***Figure 155.21.*** The middle screws are 7.0 mm in diameter and should protrude through the far cortex of the body by one to three turns. (Redrawn from Asher MA. *Surgical Technique for Anterior Segmental Instrumentation of Thoracolumbar and Lumbar Scoliosis Using the Anterior Isola Spinal System.* AcroMed Corp., Cleveland, OH, 1996.)

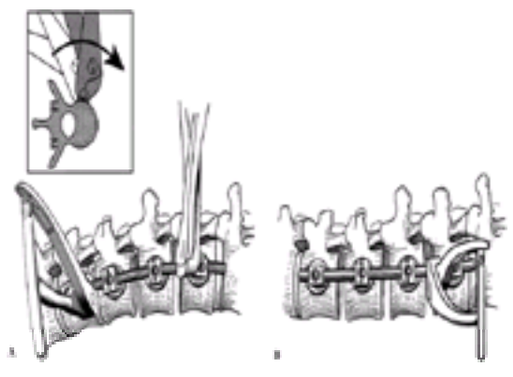

***Figure 155.22.*** **A:** The rod is rotated to place the sagittal plane contour of the rod (**B**) in the true sagittal plane. (Redrawn from Asher MA. *Surgical Technique for Anterior Segmental Instrumentation of Thoracolumbar and Lumbar Scoliosis Using the Anterior Isola Spinal System.* AcroMed Corp., Cleveland, OH, 1996.)

- Secure the rod by tightening one of the intermediate setscrews. After the rod has been rotated, a Cobb elevator can be placed into the vertebral space to pry open the previously concave side of the curve (Fig. 155.23). At this point, some distraction may actually be applied between the screw connector bodies to further open the space. Completely fill the disc spaces with bone graft.

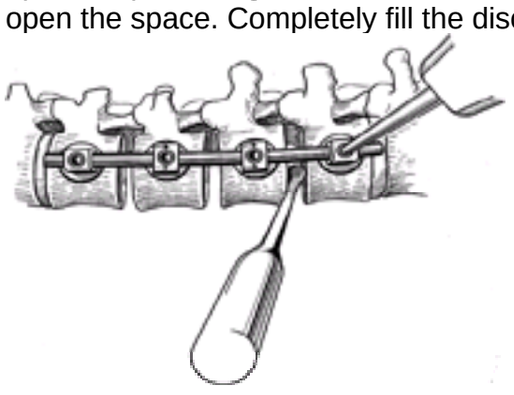

***Figure 155.23.*** Disc space is restored utilizing a Cobb elevator. (Redrawn from Asher MA. *Surgical Technique for Anterior Segmental Instrumentation of Thoracolumbar and Lumbar Scoliosis Using the Anterior Isola Spinal System.* AcroMed Corp., Cleveland, OH, 1996.)

- Compress the vertebral screws in order to compress the disc spaces. This is done sequentially, starting from the top to the second screw (Fig. 155.24). The second compression occurs between the bottom and the next upper screw. The final compression is applied across the apical vertebra.

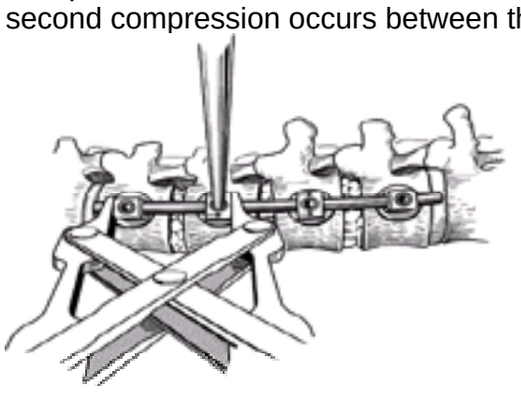

***Figure 155.24.*** Disc spaces are compressed to provide anterior column load sharing. (Redrawn from Asher MA. *Surgical Technique for Anterior Segmental Instrumentation of Thoracolumbar and Lumbar Scoliosis Using the Anterior Isola Spinal System.* AcroMed Corp., Cleveland, OH, 1996.)

- Close the wound over a chest tube as previously described. A sample case is illustrated in Fig. 155.25.

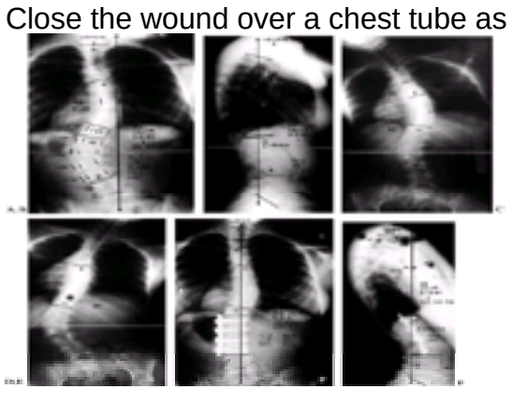

***Figure 155.25.*** This 14-year-old girl has left thoracolumbar major and right thoracic compensatory scoliosis. Standing frontal plane (**A**) and sagittal plane (**B**) radiographs show imbalance to the left in the coronal plane, and in the sagittal plane flattening of the upper lumbar spine. On the left bend x-ray, there is not a clear opening of the disc space above the lower Cobb (**C**). On the right bend (**D**), the upper scoliosis corrects from 44° to 15°. Two-year postoperative radiographs (**E,F**)show restoration of coronal balance and a well-healed fusion with normal sagittal plane alignment. The standing postoperative posteroanterior radiograph (**E**) shows instrumentation from T12 to L3, the upper end vertebra level having been left out to allow for compensation. The sagittal plane angulation has been restored (**F**).

## POSTOPERATIVE CARE

Monitor all patients in an intensive care unit postoperatively. Carefully monitor hemodynamic parameters such as hemoglobin and hematocrit, platelets, blood coagulation, electrolytes including calcium and magnesium, and urinary output. Record chest tube and drain outputs. Obtain daily chest radiographs until the chest tube is discontinued, usually by the third postoperative day. The goal of respiratory care is to prevent atelectasis and wean the patient from the ventilator safely and as soon as possible.

Mobilize the patient to a chair once extubated. The patient may ambulate when the chest tube is removed. Apply a custom-molded underarm thoracolumbar spine orthosis (TLSO) to all patients; this is worn full time for 6 months. Strongly stress walking to improve aerobic conditioning and an overall sense of well-being. Formal physical therapy is not required except for gait training.

## PITFALLS AND COMPLICATIONS

### INSTRUMENTATION

Significant compressive forces are generated by all instrumentation systems, and vertebral fracture can occur. Apply corrective force slowly over time to allow the viscoelastic characteristics of the spine to work. Patients with osteoporosis require even more care while tensioning instrumentation. Advanced osteoporosis is a contraindication to anterior instrumentation.

Hardware pullout is another potential complication. Bicortical fixation significantly improves fixation strength and should be attempted at each level. Many systems utilize screw–staple or screw–washer combinations that maximize stability. When pullout does occur, it is usually at the proximal or distal end of the instrumented levels. Augmentation with methylmethacrylate can be utilized, or the level may need to be bypassed.

### MEDICAL

Perioperative medical complications are classified as major when they significantly alter the expected course of recovery, or minor when there is no delay in expected recovery. McDonnell et al. (29) reviewed complications of anterior spine procedures. They noted that pulmonary (37%) and thoracostomy tube (14%) complications were the most common of the major complications. Genitourinary complications were present in 11.6% of all patients and made up 42% of the minor complications.

Certain diagnostic groups are at higher risk for complications. The neuromuscular, adult, and congenital scoliosis groups had overall complication rates of 52%, 41%, and 36%, respectively (29). Patient age is also a significant factor contributing to perioperative morbidity. McDonnell et al. (29) found that the complications increased with patient age and were highest in the 61- to 85-year age group.

Prolonged operative time, dilutional anemia, and hypothermia can produce a severe coagulopathy. Careful monitoring of only the hemoglobin during surgery is not adequate. The prothrombin and partial thromboplastin times and platelet counts must also be monitored in these procedures. The administration of fresh frozen plasma and platelets may at times be required. Arrangements with the hematology lab to provide a quick turnaround on coagulation profiles can be critically important.

**NEUROVASCULAR**

Vascular compromise of the spinal cord after the ligation of multiple segmental vessels is rare. Take care to avoid the foraminal region where the vascular anastomosis of the cord lies. The aorta and vena cava need to be carefully protected. Reported rates of injury in 447 cases of anterior spine procedures are low, with McDonnell et al. (29) reporting no great vessel injuries in 447 cases.

Spinal cord injury may result from overcorrection of deformity. Animal studies have confirmed that spinal cord injury can result from distraction or compression of the spine. While mechanical disruption does not typically occur, infarcts or hemorrhages can result from aggressive deformity correction. Bridwell et al. (2) reported their incidence of major neurologic deficits after adult and pediatric deformity surgery: Four cases were identified in 1,153 patients. All these cases were similar in that anterior and posterior procedures were performed on the same day for large deformity with the ligation of segmental vessels on one side, and intraoperative or perioperative hypotension placing the mean arterial pressure below 50 mm Hg for at least 15 minutes.

Mechanical damage to the cord may be the result of misdirected vertebral body screws. Taking care to place the screws parallel to the posterior longitudinal ligament can avoid canal penetration. If misdirection occurs, revise the screw or bypass the level.

Postoperative blindness is a rare but devastating complication after spine surgery. Myers et al. (33) reviewed 37 cases of postoperative visual loss. Significant risk factors were intraoperative hypotension, prone positioning, anemia, and prolonged operative time. They noted that “the lowest intraoperative blood pressure averaged 77 mm Hg, with an average of 260 minutes spent below 75% of the baseline preoperative pressure.” The cause of blindness was ischemic optic neuropathy in 19 and retinal artery occlusion in seven. Improvement was obtained in only five patients who had partial loss of vision initially. Mayfield tongs may be of benefit in reducing facial pressure when the patient is placed prone for posterior surgery.

**CHAPTER REFERENCES**

Each reference is categorized according to the following scheme: *, classic article; #, review article; !, basic research article; and +, clinical results/outcome study.


# 1. Boachie-Adjei O. Implications of Malnutrition in the Surgical Patient. In: Bridwell KH, DeWald RL, eds. *Textbook of Spinal Surgery.* Philadelphia: JB Lippincott, 1997:101.

! 2. Bridwell KH, Lenke LC, Baldus C, Blanke K. Major Intraoperative Neurologic Deficits in Pediatric and Adult Spinal Deformity Patients—Incidence and Etiology at One Institution. *Proceedings of the Scoliosis Research Society*, 1996.

! 3. Callahan BC, Georgopoulos G, Eilert RE. Hemivertebral Excision for Congenital Scoliosis. *J Pediatr Orthop* 1997;17:96.

* 4. Compere EL. Excision of Hemivertebrae for Correction of Congenital Scoliosis. *J Bone Joint Surg* 1932;14:555.

* 5. Denis F. Anterior Surgery in Scoliosis. *Clin Orthop* 1994;300:38.

! 6. Dick J, Boachie-Adjei O, Wilson M. One Stage vs. Two Stage Anterior and Posterior Spinal Reconstruction in Adults. *Spine* 1992;18(S):310.

* 7. Dommissee GF. The Blood Supply of the Spinal Cord. *J Bone Joint Surg Br* 1974;56:225.

* 8. Dubousset J, Herring JA, Shufflebarger H. The Crankshaft Phenomenon. *J Pediatr Orthop* 1989;9:541.

* 9. Dwyer AF, Newton NC, Sherwood AA. An Anterior Approach to Scoliosis: A Preliminary Report. *Clin Orthop* 1969;62:192.

! 10. Dwyer AF, Schafer MF. Anterior Approach to Scoliosis: Results of Treatment in Fifty-One Cases. *J Bone Joint Surg Br* 1974;56:218.

! 11. Ferguson RL, Hansen MM, Nicholas DA, Allen BL. Same-Day vs. Staged Anterior-Posterior Spinal Surgery in a Neuromuscular Scoliosis Population: The Evaluation of Medical Complications. *J Pediatr Orthop* 1996;16:293.

# 12. Hall JE, Millis MB, Snyder BD. Short Segment Anterior Instrumentation for Scoliosis. In: Bridwell KH, DeWald RL, eds. *Textbook of Spinal Surgery.* Philadelphia: JB Lippincott, 1997:665.

* 13. Hodgson AR, Stock FE. Anterior Spine Fusion. *Br J Surg* 1956;44:266.

* 14. Hodgson AR, Stock FE, Fang HSY, Ang GB. Anterior Spine Fusion. *Br J Surg* 1960;48:172.

* 15. Kaneda K, Fujiya N, Satoh S. Results with Zielke Instrumentation for Idiopathic Thoracolumbar and Lumbar Scoliosis. *Clin Orthop* 1986;205:195.

# 16. Kemp JS. Pulmonary Function Testing. In: Bridwell KH, DeWald RL, eds. *Textbook of Spinal Surgery.* Philadelphia: JB Lippincott, 1997:101.

* 17. Kostuik JP, Carl AL, Ferron S. Anterior Zielke Instrumentation for Spinal Deformity in Adults. *J Bone Joint Surg Am* 1989;51:898.

! 18. Kostuik JP, Maurais GR, Richardson WJ, et al. Combined Single Stage Anterior and Posterior Osteotomy for Correction of Iatrogenic Lumbar Kyphosis. *Spine* 1988;13:257.

! 19. Lagrone MO, Bradford DS, Moe JH, et al. Treatment of Symptomatic Flatback after Spinal Fusion. *J Bone Joint Surg* 1988;70:569.

! 20. Lapinsky AS, Richards BS. Preventing the Crankshaft Phenomenon by Combining Anterior Fusion with Posterior Instrumentation. *Spine* 1995;20:1392.

! 21. Lee CS, Nachemson AL. The Crankshaft Phenomenon after Posterior Harrington Fusion in Skeletally Immature Patients with Thoracic or Thoracolumbar Idiopathic Scoliosis Followed to Maturity. *Spine* 1997;22:58.

! 22. Lenke LG, Bridwell KH, Blanke K, Baldus C. Prospective Analysis of Nutritional Status Normalization Following Spinal Surgery. *Spine* 1995;20:1359.

! 23. Lowe TG, Peters JD. Anterior Spinal Fusion with Zielke Instrumentation for Idiopathic Scoliosis. *Spine* 1993;18:423.

# 24. Lubicky JP. Congenital Scoliosis. In: Bridwell KH, DeWald RL, eds. *Textbook of Spinal Surgery.* Philadelphia: JB Lippincott, 1997:345.

# 25. Lubicky JP. Spinal Deformity in Myelomeningocele. In: Bridwell KH, DeWald RL, eds. *Textbook of Spinal Surgery.* Philadelphia: JB Lippincott, 1997:903.

! 26. Luk KD, Leong JC, Reyes FL, Hsu LC. The Comparative Results of Treatment in Idiopathic Thoracolumbar and Lumbar Scoliosis Using the Harrington, Dwyer and Zielke Instrumentation. *Spine* 1989;14:275.

! 27. Madigan RR, Wallace, SL. Scoliosis in Institutionalized Cerebral Palsy Population. *Spine* 1981;6:583.

! 28. Mandelbaum BR, Tolo VT, McAfee PC, Burest P. Nutritional Deficiencies after Staged Anterior and Posterior Spinal Reconstructive Surgery. *Clin Orthop* 1988;234:5.

! 29. McDonnell MF, Glassman SD, Dimar JR, et al. Perioperative Complications of Anterior Procedures on the Spine. *J Bone Joint Surg* 1996;78:839.

! 30. Moe JH, Purcell GA, Bradford DS. Zielke Instrumentation (VDS) for the Correction of Spinal Curvature. *Clin Orthop* 1983;180:133.

! 31. Moran MM, Kroon D, Tredwell SJ, Wadsworth LD. The Role of Autologous Blood Transfusion in Adolescents Undergoing Spinal Surgery. *Spine* 1995;20:532.

! 32. Moskowitz A, Trommanhauser S. Surgical and Clinical Results of Scoliosis Surgery Using Zielke Instrumentation. *Spine* 1993;18:244.

! 33. Myers MA, Hamilton SR, Wagner TA. Postoperative Blindness after Spine Surgery: An Analysis of 37 Cases. *Proceedings of the Scoliosis Research Society*, 1996.

# 34. Nuber GW, Schafer MF. Surgical Management of Adult Scoliosis. *Clin Orthop* 1986;208:228.

* 35. Ogiela DM, Chan DP. Ventral Derotation Spondylodesis. *Spine* 1986;11:18.

! 36. Powell ET, Krengel WF, King HA, Lagrone MO. Comparison of Same-Day Sequential Anterior and Posterior Spinal Fusion with Delayed Two-Stage Anterior and Posterior Spinal Fusion. *Spine* 1994;19:1256.

! 37. Rodgers WB, Frim DM, Emans JB. Surgery of the Spine in Myelodysplasia. *Clin Orthop* 1997;338:19.

! 38. Rosenthal RK, Levine OB, McCarver CL. The Occurrence of Scoliosis in Cerebral Palsy. *Dev Med Child Neurol* 1974;16:664.

# 39. Shook, J.E, Lubicky, J.P. Paralytic Scoliosis. In: Bridwell KH, DeWald RL, eds. *Textbook of Spinal Surgery.* Philadelphia: JB Lippincott, 1997:839.

! 40. Shufflebarger HL, Smiley K, Roth HJ. Internal Thoracoplasty. *Spine* 1994;19:840.

! 41. Siller TA, Dickson JH, Erwin WE. Efficacy and Cost Considerations of Intraoperative Autologous Transfusion in Spinal Fusion for Idiopathic Scoliosis with Predeposited Blood. *Spine* 1996;21:848.

! 42. Simpson MB, Georgopoulos G, Eilert RE. Intraoperative Blood Salvage in Children and Young Adults Undergoing Spinal Surgery with Predeposited Autologous Blood: Efficacy and Cost Effectiveness. *J Pediatr Orthop* 1993;13:777.

! 43. Solomon MD, Rutledge ML, Kane LE, Yawn DH. Cost Comparison of Intraoperative Autologous versus Homologous Transfusion. *Transfusion* 1988;28:378.

! 44. Stark A, Saraste H. Anterior Fusion Insufficient for Scoliosis in Myelomeningocele. *Acta Orthop Scand* 1993;64:22.

! 45. Thompson AG, Marks DS, Sayampanathan S, Piggott H. Long-Term Results of Combined Anterior and Posterior Convex Epiphsiodesis for Congenital Scoliosis Due to Hemivertebrae. *Spine* 1995;20:1380.

* 46. Waisman M, Saute M. Thoracoscopic Spine Release before Posterior Instrumentation in Scoliosis. *Clin Orthop* 1997;336:130.

! 47. Winter RB, Lonstein JE, Denis FE, Roscoe HS. Convex Growth Arrest for Progressive Congenital Scoliosis Due to Hemivertebrae. *J Pediatr Orthop* 1988;8:633.

! 48. Winter RB, Lonstein JE, Heithoff KB, Kirkham JA. Magnetic Resonance Imaging Evaluation of the Adolescent Patient with Idiopathic Scoliosis before Spinal Instrumentation and Fusion. *Spine* 1997;22:855.

* 49. Zielke K, Stunkat R, Beaujean F. Ventrale Derotations Spondylodese. *Arch Orthop Unfallchir* 1976;85:257.

# CHAPTER 156

# POSTERIOR SURGERY FOR SCOLIOSIS

*Howard A. King*

**H. A. King:** St. Luke's Regional Medical Center, Boise, Idaho 83712.

Principles of Posterior Techniques
Indications for Surgery
Preoperative Planning
- Radiologic Evaluation
- Laboratory Studies
- Pulmonary Evaluation
- Selection of Fusion Levels

Surgical Techniques
- Posterior Spinal Fusion
- Resection of the Rib Hump
- Instrumentation System

Postoperative Management
Pitfalls and Complications
- Blood Loss
- Spinal Cord Injury
- Wound Infection
- Dural Tears
- Flatback Syndrome
- Pseudarthrosis

Author's Perspective
Chapter References

## PRINCIPLES OF POSTERIOR TECHNIQUES

The principles of achieving a solid arthrodesis and a stable, balanced spine tend to be overshadowed by the marketing of new implant systems. With the development of each new system comes the promise of “perfect results with no complications.” The belief that more hardware is better has shifted our focus away from the concepts of precise planning and selection of fusion levels, meticulous operative technique, and careful postoperative management. New implant systems can and should be added to our armamentarium of scoliosis management, but scientific study is mandatory, and the tried and proven principles must not be forgotten.

Posterior techniques are effective for managing scoliosis associated with a wide variety of disease processes (Table 156.1). Establish the exact diagnosis in each patient whenever possible. An understanding of the natural history and the type of curve pattern that might develop is necessary to determine the appropriate approach for the treatment of idiopathic scoliosis; a patient with congenital scoliosis requires still another approach during evaluation and treatment.

| | |
|---|---|
| Idiopathic scoliosis | Collagen disorders |
| Infantile | Marfan syndrome |
| Juvenile | Ehlers-Danlos syndrome |
| Adolescent | |
| Adult | Infections |
| Neuromuscular | Tumors |
| Upper motor neuron | Vertebral column |
| Cerebral palsy | Spinal cord |
| Spinocerebellar degeneration | Trauma |
| Charcot-Marie-Tooth | Fracture |
| Friedreich's ataxia | Surgical |
| Syringomyelia | Posterior osteotomy |
| Viral myelitis | Posterior spinal procedure |
| Trauma | Irradiation |
| Spinal cord tumor | Osteochondrodystrophies |
| Lower motor neuron disorders | Dwarfing syndromes |
| Poliomyelitis | Mucopolysaccharidoses |
| Spinal muscle atrophy | Spondyloepiphyseal dysplasia |
| Myopathy | Other |
| Muscular dystrophy | Metabolic disorders |
| Arthrogryposis | Rickets |
| Congenital hypotonia | Osteogenesis imperfecta |
| Congenital | Others |
| Failure of formation | Congenital heart disease |
| Failure of segmentation | Congenital limb deformity |
| Neurofibromatosis | |

***Table 156.1. Etiology of Scoliosis: Conditions for Which Posterior Techniques Are Useful***

## INDICATIONS FOR SURGERY

The indications for surgical treatment vary, depending on the underlying diagnosis, curve magnitude and progression, the patient's age and health, and the surgeon's skill and judgment. All variables must be carefully considered before rendering a surgical decision. In general, there are four indications for surgical treatment in idiopathic or congenital scoliosis: severe curves, unacceptable curve progression, pain, and unacceptable cosmesis (Table 156.2).

| |
|---|
| Unacceptable curve progression |
| Unacceptable curve magnitude |
| Greater than 50° if skeletally mature |
| Greater than 40° if skeletally immature |
| Failure of bracing to control progression if curve magnitude meets above criteria |
| Intolerable Pain |
| Unacceptable cosmesis |
| Loss of neurologic function |

***Table 156.2. Indications for Surgery for Idiopathic Scoliosis***

Curves of greater than 65° reduce total lung capacity (8,14,39,55). Therefore, large or progressive curves should be corrected and stabilized. Winter et al. (61,62) reported on the role that thoracic lordosis plays in decreasing pulmonary function and recommended screening and treatment in severe cases. In patients with thoracic lordosis, surgery may be necessary even though the coronal curve may not appear large enough to warrant it.

Collis and Ponseti (14) have shown that curves greater than 50° tend to progress even after skeletal maturity. There is a correlation between age, Risser sign, and curve magnitude as prognostic indications for progression (34,54). In young patients without evidence of menarche, a Risser sign of 1 or less, and a curve of 40° or more, orthotics management is less effective and surgery might be indicated. On the other hand, there are times when combined thoracic and lumbar curves exceed 45° to 50° in magnitude but show no loss of pulmonary function, are cosmetically acceptable, and remain stable. These curves might be best managed by observation.

All patients are different, so determine treatment on an individual basis.

Pain is rarely associated with idiopathic scoliosis in the adolescent group. If a patient complains of pain, a thorough investigation to rule out organic causes must be undertaken. Adults with untreated curves, especially large curves, may have disabling pain that can be relieved by surgical treatment (30,43,48,51,57).

An unacceptable cosmetic appearance may be an indication for surgical treatment. Severe trunk decompensation or rotation may be a reason for surgery, but that decision must be made by the patient and family. Scoliosis surgery is a major undertaking: Careful thought must be given if the only indication is cosmesis. Rib deformity may not be corrected by correcting the curve, and improving the deformity always leaves a surgical scar.

In neuromuscular conditions, the indications for surgery are similar to those for idiopathic or congenital problems (Table 156.3). In patients who are marginal ambulators or wheelchair bound, progressive spinal curvatures may compromise ambulation or sitting balance. In wheelchair-bound patients, listing to the side because of a decompensated spine necessitates increased use of the upper extremities to achieve support and balance, which severely impairs overall function. In patients with poor sensation, progressive scoliosis tends to create pelvic obliquity, with subsequent asymmetric pressure-loading on the buttocks and eventual skin breakdown.

| |
|---|
| Unacceptable curve progression |
| Unacceptable curve magnitude |
| More than 40°–50° |
| Failure of bracing to control progression of the curve |
| Intolerable pain |
| Unacceptable loss of function |
| Impaired ambulation |
| Loss of or impaired sitting balance |

***Table 156.3. Indications for Surgery for Neuromuscular Scoliosis***

## PREOPERATIVE PLANNING

Careful preoperative evaluation and planning are integral to the overall success of spinal surgery. Attention to detail at this phase is essential for a smooth perioperative course. Document a careful history and physical examination of the patient. The neurologic evaluation is especially important in patients with congenital or neurologic conditions. Any abnormal findings will necessitate further evaluation with electromyography, myelogram, computed tomography (CT), or magnetic resonance imaging (MRI). In the physical examination of the spine, note rotational prominences, the amount of decompensation of the spine, and any evidence of defects or cutaneous abnormalities along the midline. Cutaneous abnormalities such as hair patches, nevi, dermal sinuses, and lipomas are frequently associated with intraspinal pathology (19,27,61). Myelography or MRI may be indicated to rule out disease in or about the spinal cord.

### RADIOLOGIC EVALUATION

Magnetic resonance imaging is a relatively recent advance for evaluating the spinal column and its contents. This noninvasive tool has been valuable in diagnosing syringomyelia and other spinal cord anomalies. However, the three-dimensional nature of scoliosis can make clear imaging difficult. A close working relationship with the radiologist is necessary so that specific problems may be more carefully evaluated. (See Chapter 4 on imaging modalities.)

Myelography is indicated when abnormal neurologic findings are present on the physical examination, when spinal dysraphism is expected, and when MRI has proven inadequate or equivocal. Water-soluble dyes are preferred whenever, possible because they can be used in conjunction with CT and are useful in conditions in which the neurologic deficits are not consistent with the known diagnosis.

Begin preoperative radiographic evaluation with upright posteroanterior and lateral radiographs of the spine. Measure the curve by the Cobb method (12). Look for rotation and any evidence of congenital anomalies, tumors, or bony abnormalities. The Nash and Moe classification of rotation is useful in determining structural curvatures and selecting fusion levels (29). The lateral radiograph shows curvatures in the sagittal plane and the possible coexistence of lumbosacral spondylolisthesis. Supine right and left side-bending films demonstrate curve flexibility and give a good indication of the amount of correction that can be anticipated from surgery (29). In severe deformities, bending films help in deciding whether to perform anterior procedures. For patients with severe rigid curves, it may be desirable to consider anterior releases or wedge resection before the posterior procedure. (See Chapter 155 for the anterior approach to scoliosis.) This allows better mobility of the spine and may decrease the pseudarthrosis rate. When excessive kyphosis or lordosis is noted, take lateral flexion and extension views. In patients with paralytic scoliosis, a supine view in maximum traction including the pelvis is useful to determine the amount of curve flexibility and what type of correction of pelvic obliquity might be expected.

Other diagnostic modalities may be necessary, depending on the clinical setting. In adolescent patients with scoliosis and back pain, perform technetium polyphosphate bone imaging to rule out tumor or inflammatory causes. Keim and Reina (28) have reported osteoid osteoma as a cause of painful scoliosis.

### LABORATORY STUDIES

Preoperatively, obtain a complete blood count, urinalysis, and electrolyte values in patients who are otherwise healthy. Any major medical problem might necessitate further studies. In patients with neuromuscular conditions or with severe scoliosis, obtain a preoperative electrocardiogram. Electrocardiography is also indicated in adults undergoing corrective spinal surgery. In patients with known cardiomyopathy, congenital heart disease, or cor pulmonale, obtain anesthesia, pulmonary, and cardiology consultations before surgery. For patients with severe debilitating health problems, careful preoperative evaluation and management by an appropriate team of physicians, surgeons, and paraprofessionals ensures an easier and smoother postoperative course.

### PULMONARY EVALUATION

Vital capacity and total lung capacity are decreased in patients with scoliosis (8,18,38,60). The amount of decrease seems to correlate with the degree of curvature (39,60). Neuromuscular conditions tend to compound the loss of vital capacity from the scoliosis (17). For most patients, however, the decreased pulmonary function does not play a major role in the perioperative course. Therefore, routine preoperative pulmonary function studies are unnecessary.

Pulmonary function studies and arterial blood gases are indicated in patients with cor pulmonale, severe curves, thoracic lordosis, neuromuscular conditions, or a history of pulmonary problems. A 40% or greater loss of vital capacity and maximum breathing capacity increases the risk of postoperative complications (60). In patients with recurrent pneumonia and bronchitis secondary to scoliosis, a complicated postoperative course must be anticipated; pulmonary studies are helpful in these patients.

A trial of halo traction may be indicated in patients with severe lung disease or cor pulmonale. This trial of traction will establish the operability of a patient's curve. Any increase in cardiac or pulmonary compromise in halo traction is a contraindication for surgery (9).

The use of preoperative casting, traction, and other modalities to make the curve more mobile (or limber) or to obtain preliminary correction has been advocated in the past. There are now few indications for these methods because they add little if any correction to the spine. With rare exception, they have limited applicability.

### SELECTION OF FUSION LEVELS

Proper selection of fusion levels is one of the most important aspects of the preoperative planning. An inadequate length of fusion will lead to progression of the curve above or below the fusion (lengthening or “adding on” to the curve). This may eventually lead to loss of spine balance. A fusion that is too long, however, unnecessarily immobilizes the spine. A careful review of curve patterns and preoperative side-bending radiographs is valuable in defining the primary and compensatory curves. In general, the primary curve should be fused and the compensatory curves should be left unfused. For idiopathic scoliosis, fusion levels should include all vertebrae that

are measured as a part of the primary curve (9,11,16,47).

When pelvic obliquity is present in neuromuscular scoliosis, understanding the curve pattern will help avoid a common pitfall: not incorporating the sacrum into the fusion. An oblique sacrum and pelvis must be considered as part of the curvature and should be included in the instrumentation and fusion.

### *Idiopathic Scoliosis*

The selection of fusion levels is controversial in combined thoracic and lumbar idiopathic scoliosis. It is generally accepted that the fusion should include all vertebrae that are a part of the measured curve. In thoracic scoliosis, Harrington (24,25) suggests fusion from one level above the curve to two levels below, as long as the inferior level falls within the “stable zone.” Moe (44,45,47) and Goldstein (20,21 and 22) stressed the importance of extending the fusion from the neutrally rotated vertebra superiorly to the neutral vertebra inferiorly. Moe advocates thoracic fusion for combined thoracic and lumbar curves when the lumbar curve is more flexible on preoperative side-bending radiographs.

In 1983, King et al. (29) reported the long-term results of the Twin Cities Scoliosis Center's management of thoracic and combined thoracic and lumbar scoliosis. A category of curve types and criteria for selection of fusion levels were established. In addition, the results of this work support the concept of selective fusion of the thoracic spine in selected cases. These authors were able to identify five different thoracic curve patterns (Table 156.4). Type I curves are managed by fusion to L-4. In curve types II through V, a selective thoracic fusion can be performed if the lowest level of the fusion is centered over the sacrum (Fig. 156.1, Fig. 156.2, Fig. 156.3, Fig. 156.4 and Fig. 156.5). The lowest level of the fusion is established by drawing a line parallel to the iliac wings. A vertical line is then drawn perpendicular to the pelvic line centered on the sacrum. (It is important that any limb-length inequality be compensated for when the radiographs are taken.) The lowest vertebra most closely bisected by this line is called the stable vertebra (Fig. 156.6). Ending the fusion at the stable vertebra gives uniformly good results.

| |
|---|
| **Type I** |
| Combined thoracic and lumbar |
| Lumbar curve larger than the thoracic curve |
| Thoracic curve more flexible than the lumbar curve on side-bending radiographs |
| **Type II** |
| Thoracic curve larger than the lumbar curve |
| Lumbar curve more flexible than the thoracic curve on side-bending radiographs |
| **Type III** |
| Thoracic curves when the lumbar curve does not cross the midline |
| **Type IV** |
| Long thoracic curve when L-5 is centered over the sacrum but L-4 tilts into the lumbar curve |
| **Type V** |
| Double thoracic curve with T-1 tilted into the concavity of the upper curve |
| The upper curve structural on side-bending radiographs |

***Table 156.4. Thoracic Scoliosis Curve Patterns***

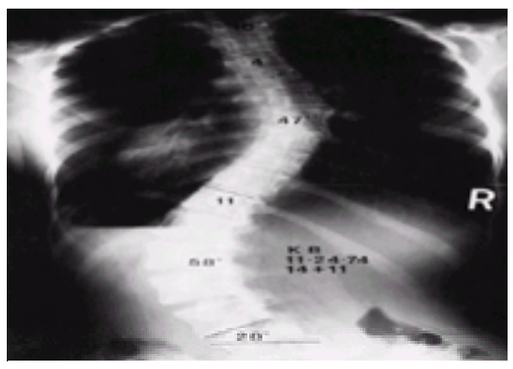


***Figure 156.1.*** Type I curve. (From King HA, Moe JH, Bradford DS, Winter RB. The Selection of Fusion Levels in Thoracic Idiopathic Scoliosis. *J Bone Joint Surg Am* 1983;65:1302, with permission.)

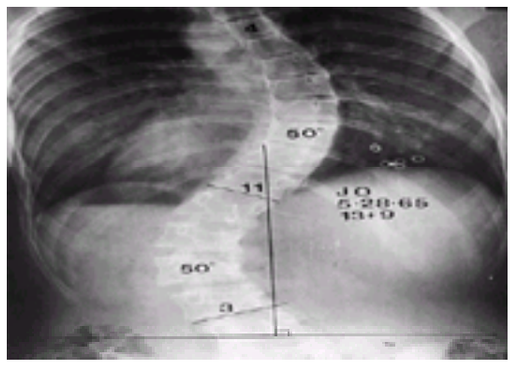

***Figure 156.2.*** Type II curve. The center sacral line has been created. The stable vertebra is T-12.

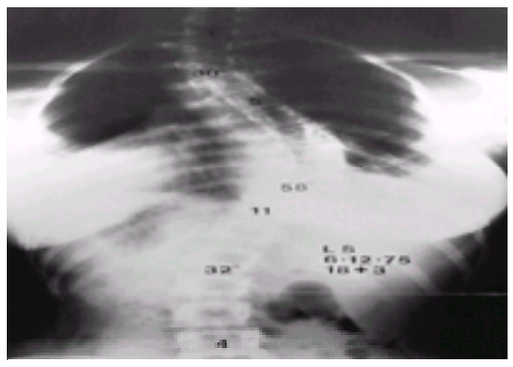

***Figure 156.3.*** Type III curve. (From King HA, Moe JH, Bradford DS, Winter RB. The Selection of Fusion Levels in Thoracic Idiopathic Scoliosis. *J Bone Joint Surg Am* 1983;65:1302, with permission.)

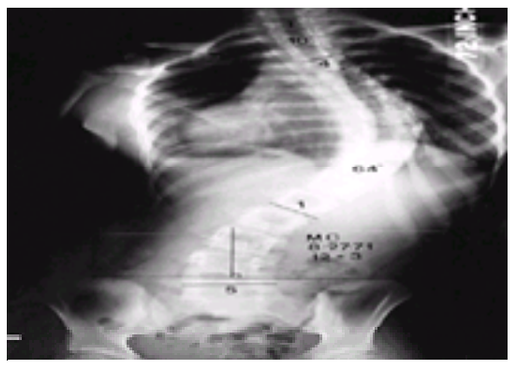

***Figure 156.4.*** Type IV curve. (From King HA, Moe JH, Bradford DS, Winter RB. The Selection of Fusion Levels in Thoracic Idiopathic Scoliosis. *J Bone Joint Surg Am* 1983;65:1302, with permission.)

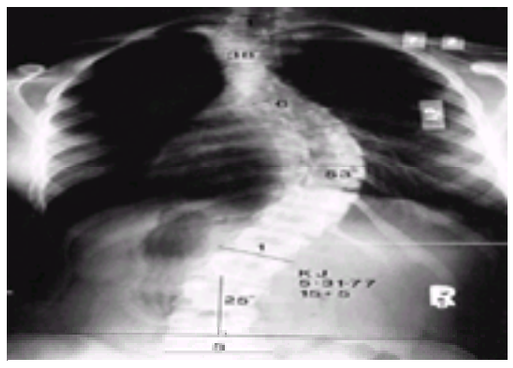

***Figure 156.5.*** Type V curve. (From King HA, Moe JH, Bradford DS, Winter RB. The Selection of Fusion Levels in Thoracic Idiopathic Scoliosis. *J Bone Joint Surg Am* 1983;65:1302, with permission.)

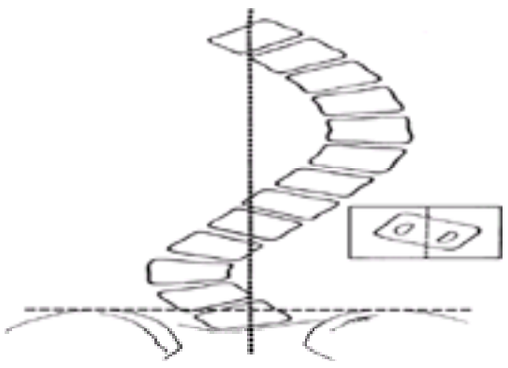

***Figure 156.6.*** The technique for creating the center sacral line to establish the stable vertebra.

In most curves, this method produces a fusion area that is substantially shorter than the standard T4–L4 fusion previously recommended. King et al. (29) concluded that selective thoracic fusion can give good long-term results with balanced stable spines. When the fusion falls short of the stable vertebra, the curves tend to progress, adding vertebrae to the measured curve, and occasionally an additional surgical procedure is needed to extend the fusion. Fusing beyond the stable vertebrae, especially in type II curves, tends to aggravate the lumbar curve and also removes additional valuable motion segments.

Aaro and Ohlen (1) and Chochran et al. (13) have clearly detailed the complications of fusion that extend into the lumbar spine. Harrington rod fusions flatten the lumbar spine, and fusions to L-4 and L-5 carry a higher incidence of back pain on long-term follow-up. In their report, 62% were fused to L-4, and 82% were fused to L-5. (1). Be aware of compensatory curves and avoid extensive fusion when possible. In idiopathic scoliosis, avoid fusion to L-4. Rarely, if ever, is fusion to L-5 indicated. Fusion to the sacrum is not indicated in adolescents. However, if symptomatic spondylolisthesis is present, lumbosacral fusion might be indicated. When an asymptomatic spondylolysis or spondylolisthesis is present, fusion using the criteria just outlined can be safely performed (9).

### *Neuromuscular Scoliosis*

In many neuromuscular conditions (e.g., Friedreich's ataxia, Charcot-Marie-Tooth disease, and ambulators with cerebral palsy), the curve patterns are similar to idiopathic scoliosis. In those instances, fusion levels may be chosen as just described for idiopathic curves. Analysis of the lateral roentgenograms is important to avoid stopping the fusion at the apex of a kyphosis.

In the more common neuromuscular curve where pelvic obliquity is noted, the sacrum and pelvis must be considered part of the scoliosis. This situation is most frequently seen in cerebral palsy, myelomeningocele, muscular dystrophy, spinal muscle atrophy, and scoliosis secondary to spinal cord injury. If the sacrum and pelvis are not included in the instrumentation and fusion, progressive pelvic obliquity and loss of sitting balance result. If there is doubt about extending the fusion to the pelvis in a neuromuscular curve, err on the side of extending the fusion. In the nonambulator with pelvic obliquity, a short fusion invariably leads to curve progression. When the sacrum is included in the fusion, lumbar lordosis must be maintained. A flat lumbar spine leads to poor sitting balance, and to skin breakdown in patients with insensate skin.

The superior level of fusion is more controversial. In patients with idiopathic patterns, the rules are similar to idiopathic curves. In wheelchair-bound patients, the superior extension of the instrumentation and fusion should be carried high into the thoracic spine, usually to T-2 or T-3. The underlying problem is poor muscle tone or muscle imbalance. Failure to extend the fusion proximally will lead to the development of deformity above the fusion. A progressive kyphosis above a short lumbar fusion inevitably leads to loss of sitting balance and risks potential skin breakdown.

### *Congenital Scoliosis*

When congenital scoliosis has progressed and surgical treatment is contemplated, carefully analyze the curves in the coronal and sagittal planes. Preoperative MRI or myelography is warranted. Use side-bending films to analyze compensatory curve flexibility. Much as in the patient with idiopathic scoliosis, the fusion must be balanced over the center of gravity, and compensatory motion must be preserved. I tend to follow guidelines similar to those given previously in the section on idiopathic scoliosis. In congenital scoliosis, curves are variable, so exact guidelines are difficult to define. Carefully analyze primary and compensatory curves and adhere to the principles of balancing the fusion mass over the center of gravity and fusing selectively, and you will generally obtain a good result. (See Chapter 158 for further details on congenital conditions of the spine.)

## SURGICAL TECHNIQUES

### POSTERIOR SPINAL FUSION

The primary goal of spinal arthrodesis is to establish an environment favorable for bone maturation and union. For the surgery, a four-poster frame (a variation of the Hall-Relton frame) allows the abdomen to fall free, thereby decreasing intra-abdominal and venous pressure.

- Position the patient prone on the frame, avoiding pressure on the brachial plexus and ulnar nerves. Pad the knees and ankles. When fusion to the lumbar spine or sacrum is planned, position the patient with the hips extended to maintain normal lumbar lordosis.
- Prepare and drape the back for an extensive surgical exposure.
- Make a straight incision and infiltrate the skin with 1:500,000 epinephrine in normal saline to help control bleeding.
- Use self-retaining retractors for exposure. The pressure from the retractors also helps reduce the capillary bleeding.
- Use electrocoagulation to control all bleeders.
- Initiate the subperiosteal exposure of the spine with a sharp Cobb elevator.

It is absolutely mandatory that the elevators, curets, gouges, and osteotomes be sharp and well maintained. Avoid excessive force at all times around the spine! Sharp instruments make gentle surgery possible.

- Use the Cobb elevator to dissect the soft tissues from the spinous processes, lamina, and facets out to the tips of the transverse processes. Control bleeding with electrocautery and sponge packs.
- Place a metallic marker on a spinous process and obtain an intraoperative radiograph to document the position on the spine. It is amazingly easy to become confused about the proper spine level without radiographic control.
- Place Adson self-retaining retractors deep into the wound and clear the facet joints of ligaments and capsules. Sharp curets facilitate adequate clearing of the soft tissues.
- Roll and pack gauze sponges along the areas that have been exposed. Gentle pressure, along with meticulous electrocoagulation, will maintain a dry field. Good-quality bone and instrument work are impossible in a bloody operative field.
- Bone bleeding can also be controlled with bone wax and Gelfoam patties soaked with topical thrombin.
- Blood loss is best reduced by meticulous operative technique and controlled hypotension by an anesthesiologist experienced in hypotensive anesthesia. (See Chapter 7 for more details.)
- When you have adequate exposure of the spine and hemostasis, obtain a bone graft from the posterior iliac crest if autologous bone is to be used for fusion. Either use a separate incision over the iliac crest or, if the primary surgical incision is to be carried down to the lumbar spine, the same surgical incision can be used. A subperiosteal exposure of the iliac crest is preferred. (For many neuromuscular conditions and for spina bifida, I have had excellent results using cadaver bone.)
- With a Capner gouge or air-driven impact osteotome, take cortical and cancellous strips of bone from the outer table and the underlying cancellous bone. Harvest a generous amount of bone and carefully store it in saline or cover it with a blood-soaked sponge. (See Chapter 9 for bone-graft harvesting techniques.)
- Control graft-site bleeding with bone wax.
- Fuse the facet joints as a standard procedure, regardless of the instrumentation system used. The long-term success of any fusion depends on a solid arthrodesis, and it is the combination of techniques and instrumentation that will accomplish this.
- In the thoracic spine, use a Capner gouge to remove a generous portion of the inferior facets on both the concave and convex sides of the curve.
- With a curet, remove the visible cartilage. Then use the gouge to decorticate the superior portion of the junction of the transverse process and the facet. Pack a generous piece of cancellous bone into the facet with the Moe bone impactor (Fig. 156.7).

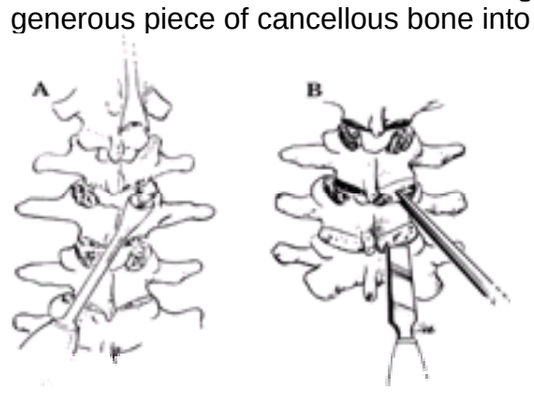


***Figure 156.7.*** The techniques used for excising the thoracic joint (**A**) and packing with cancellous bone (**B**).

- In the lumbar spine, the facet joints can be excised using a straight ¼-inch Lambotte osteotome or a Lexcel rongeur. It is important to see the joint and remove the articular cartilage completely (Fig. 156.8). Then pack a piece of cancellous bone into place with the Moe impactor.

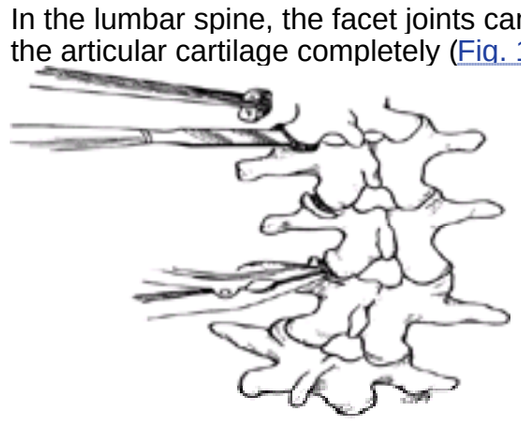

***Figure 156.8.*** The technique used for excising lumbar facets and packing with cancellous bone plugs.

- After the facets have been excised and the bone grafts placed, remove the spinous processes. Complete decortication of the spine with either a sharp, curved gouge or with an air-driven impact osteotome. Use extreme caution here, because open lamina or instrument sites are present and may be entered by the gouge. Pack the bone graft obtained by decortication of the spinous processes and iliac crest along the decorticated spine.

**RESECTION OF THE RIB HUMP**

In patients with large, unsightly rib humps, rib resections can be performed through the same surgical incision.

- Develop a skin and subcutaneous flap on the affected side to the posterior axillary line.
- Subperiosteally dissect each rib and then cut it with a rib cutter medially and as far laterally as possible. Steel (56) has reported excellent cosmetic results with this technique.
- The ribs supply abundant bone graft and make a separate iliac exposure unnecessary.
- Take care to avoid entering the pleural cavity. If the pleural cavity is entered, place a chest tube and connect it to a closed water-seal suction system.
- Close the wound using a running 0 Vicryl (Ethicon) suture for the fascia.
- Prior to closure of the wound, I routinely place a suction drainage system. Place the tubing on the fascia, not next to the cancellous bone, to avoid excessive drainage of blood and to prevent clogging of the drain by the bone.
- Close the subcutaneous tissue with a 2-0 Vicryl suture and the skin with a running subcuticular 3-0 Vicryl suture. The latter makes a good cosmetic closure and avoids the cross-hatching of interrupted sutures. Relieve skin tension with adhesive skin tapes and apply a bulky pressure dressing.

**INSTRUMENTATION SYSTEM**

Recent years have brought many new spinal instrumentation systems to the forefront, and more and better systems will undoubtedly be developed. Evaluate each system on its own merits (Table 156.5). One system will probably not solve every problem, so you must be facile and knowledgeable in the use of many systems.

| | Cobb correction | Rotation correction | Stability | Safety | Ease of use | Cost | Postoperative immobilization |
|---|---|---|---|---|---|---|---|
| Harrington | ++ | + | ++ | +++ | ++++ | ++++ | + |
| Harrington with minor wire | ++ | + | +++ | ++ | ++ | ++++ | ++ |
| Luque | ++ | + | +++ | ++ | ++ | ++++ | ++ |
| Cotrel-Dubousset | ++ | + | +++ | ++ | + | + | +++ |
| 3-D rod, wire, hook system | +++ | ++ | +++ | ++ | + | + | +++ |

+, low; ++, average; +++, above average; ++++, most.

***Table 156.5. Harrington Instrumentation System and Variations***

As implant systems have come onto the market, the most successful seem to have similar characteristics. They generally have a broad range of applicability and usually combine options for the use of hooks, screws, and wires. Most combine open and closed hooks for ease of use. It is important that the implant profile is such that it is not prominent in thin patients.

### *Harrington Instrumentation*

The Harrington instrumentation system was the gold standard in the treatment of idiopathic scoliosis for many years. New implant systems using dual rods and multiple points of fixation with hooks, wires, and screws have replaced the Harrington system. Most systems have moved away from simple distraction and have evolved into a more three-dimensional technique using translation, counter torsion, and limited distraction.

### *Instrumentation without Fusion*

When the patient's curve is difficult or impossible to manage with braces or orthoses, and spinal growth is desirable, instrumentation without fusion can be performed (15,35,36 and 37,40,46). The technique is useful in small children with infantile idiopathic scoliosis and in patients with selected neuromuscular conditions in whom curve control and spinal growth are necessary.

The surgical technique is similar to standard instrumentation technique, varying with the patient's size and bone stock.

- Use standard positioning, preparation, draping, and incision as described previously, but expose the spine only at the proximal and distal hook sites. Do not expose the remainder of the spine.
- Confirm proper levels by radiography.
- I prefer to use one of the new multi-hooks and rod systems for the implant system. I originally used the Harrington system, but it allowed for simple distraction only and could not accommodate more than one hook at the top and one at the bottom of the instrumented levels. I currently prefer the ISOLA system (DePuy Acromed, Raynham, MA) because of its low profile and adaptability for difficult problems.
- Create a claw configuration at the top of the curve and use a down-going hook at the inferior end of the curve. A claw can also be created on the inferior end of the curve, if desired. This will add extra stability (Fig. 156.9, Fig. 156.10).

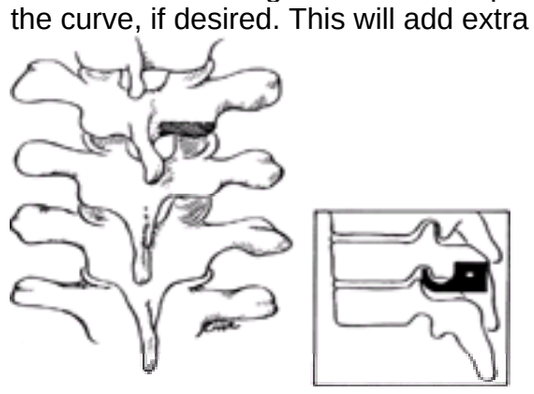

***Figure 156.9.*** Create hook sites in the thoracic spine by excising a portion of the inferior facet.

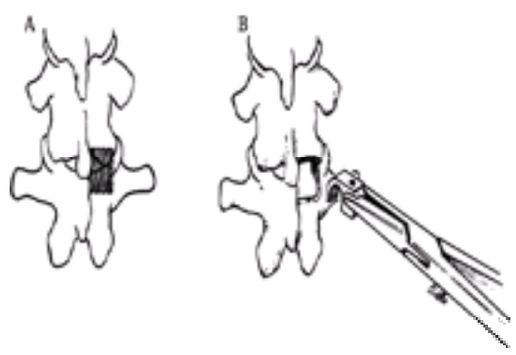


***Figure 156.10.*** **A:** Position of the laminar Harrington hook. **B:** The Cotrel-Dubousset laminar hooks are positioned with similar technique.

- It is possible to use concave and convex rods to enhance correction and control of the curve.
- Thread the rods beneath the skin and through the subcutaneous tissues in the middle of the curve, and avoid subperiosteal stripping, which risks spontaneous fusion.
- Use two rod segments connected by an axial connector (i.e., a rod sleeve into which both rods fit and are held in place with screw fixation). Axial connectors allow you to return to the site in 6–9 months and lengthen the rods without having to open the entire incision. Such lengthening can often be done as an outpatient procedure.
- It is also possible to merely leave the rods long on either end. This allows extra length for subsequent lengthenings and avoids the need of axial or side-by-side connectors.

In very young patients with very small and soft bones, expose the superior and inferior hook sites and place bone graft at these areas. This will create a localized fusion that can be used for hook placement 4–6 months later, at which time these “platforms” can be used to establish claw constructs as previously described.

**Postoperative Care** After subcutaneous rodding, keep the patients in a postoperative orthosis. Lengthening is generally necessary every 6–9 months and can be continued until adequate growth has been achieved. At that time, the definitive spinal fusion and instrumentation can be completed.

### *Luque Instrumentation*

Luque has described a procedure combining segmental instrumentation and rodding but no fusion (35 and 36,37,53,). Theoretically, this avoids the need for postoperative immobilization. Luque has clearly shown that subperiosteal dissection alone does not alter spinal growth. However, this is a procedure with many

complications. I prefer a modification of the Moe (15) and Marchetti (40) techniques of rodding without fusion.

The concept of segmental spine instrumentation was introduced by Eduardo Luque in 1975 (36,37). He originally developed the technique by augmenting standard Harrington rods with segmental sublaminar wires, then modified it to use dual smooth **L**-shaped rods with sublaminar wires and spinal fusion.

I use many of Luque's original concepts but have adapted newer approaches combined with sublaminar wire fixation. The technique is excellent for neuromuscular scoliosis, in patients with soft bone, and in patients where fusion to the sacrum may be necessary. When fusion to the sacrum is indicated, I combine the modified Luque technique with Galveston pelvic fixation as described by Allen and Ferguson (2). I also use pedicle screw fixation in the sacrum, and I may also use pelvic screws instead of the contoured smooth rod for pelvic fixation. The addition of sacral screws has been invaluable in obtaining sacral fixation. The conventional **L**-shaped rod with Galveston fixation does not obtain sacral purchase. It really bypasses the sacrum, crosses the sacroiliac joint, and obtains fixation in the iliac wings. This has some obvious disadvantages; however, the fixation to the pelvis combined with screw fixation in the sacrum seems to give the best purchase and best control of the lumbosacral junction.

The Luque technique begins with the standard positioning, preparation, and surgical exposure as described earlier in this chapter.

- Excise the facets at each level and the ligamentum flavum with a Lexcel rongeur. Kerrison rongeurs can be used to complete removal of the ligamentum flavum.
- Loop a 16-gauge wire and pass it carefully under the lamina at each level to be fused. The diameter of the curve in the wire should be about the same width of the lamina, so that as the wire passes, it will smoothly pass under the lamina and then come out over the superior edge of the next lamina (Fig. 156.11, Fig. 156.12).



***Figure 156.11.*** Luque wiring; Carefully manage sublaminar wires. A looped wire may be cut to create two wires. **A:** Carefully pass a looped wire beneath the lamina from inferior to superior, avoiding impingement on the spinal cord or roots. **B:** Centralize the wire and place a strand of wire on each side of the spinous process. **C:** Cut the loop of the wire and secure it around the rods on each side.

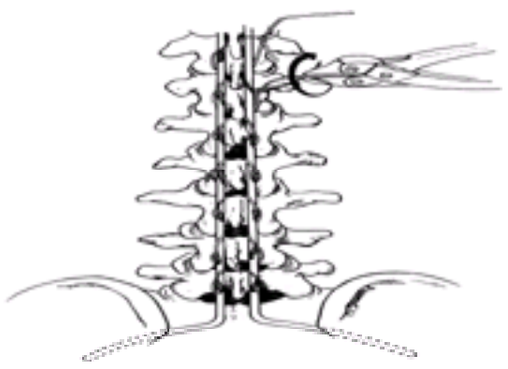

***Figure 156.12.*** Tighten the wires. The Galveston fixation is positioned between the inner and outer tables just below the posterior superior iliac spine and above the greater sciatic notch. See text for details.

- Grasp the wire with a needle holder and pull it through. Maintain constant upward force, which keeps the wire taut against the undersurface of the lamina and avoids downward movement toward the spinal cord.
- Wire management is very important to avoid deep wire penetration into the spinal canal. I prefer the technique described by Yngve et al. (65) (Fig. 156.11).
- As the wire comes up, tighten it down over the lamina.
- After positioning the rod, cut the loop on the wire, creating two separate wires at each level (Fig. 156.11*C*). The wires can then be sequentially tightened, bringing the spine to the rod. This technique decreases the amount of wire handling and tends to keep the operative field easier to manage.

I have recently changed my technique for the superior portion of the rod. Luque described using wires at all levels, including the top of the rod. However, on occasion a junctional kyphosis can develop at the superior end of the fusion because of the removal of the ligamentum flavum and posterior interspinous ligaments. I now use open hooks at the top two levels to create a claw construct.

- Place a supra-laminar hook or transverse process hook from cephalad to caudad.
- Place the up-going hook at the level of the down-going hook, or at the level below (Fig. 156.13).

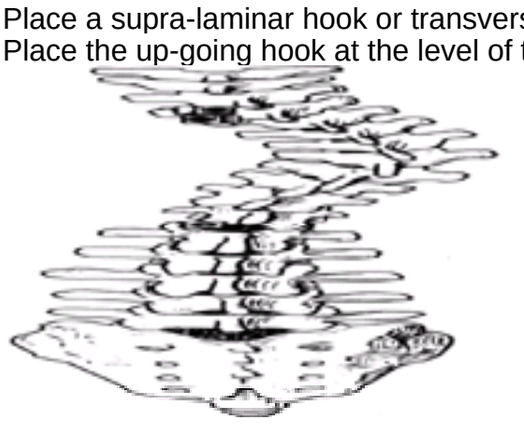

***Figure 156.13.*** Create anchor sites at the superior curve and inferiorly at the stable vertebra in thoracic types II, III, IV, and V curves. See text for details. (By permission of Dr. Marc Asher.)

- Excise the inferior facet with a ¼-inch osteotome. Remove the cartilage with a sharp curet and position an open hook.
- As the rod is brought close to the spine by wire tightening, the rod will come into the open hooks and then can be secured with hook caps (Fig. 156.14, Fig. 156.15).

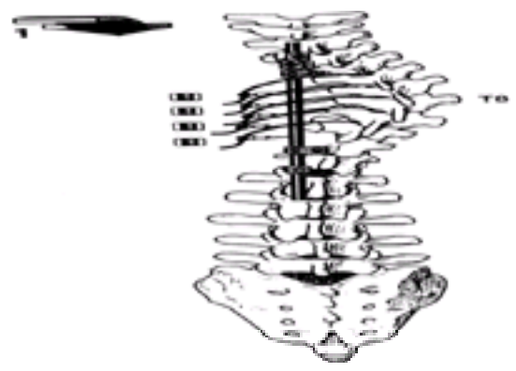

***Figure 156.14.*** Place sublaminar wires at the apex to help create translation forces. See text for details. (By permission of Dr. Marc Asher.)

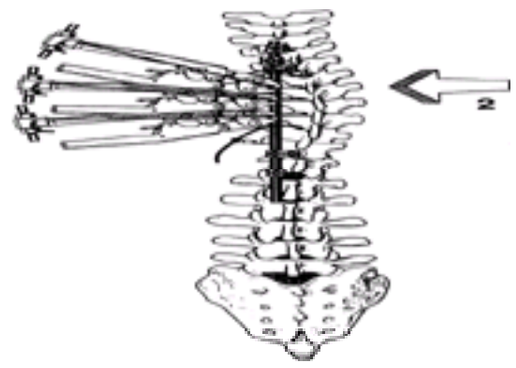

***Figure 156.15.*** Wire tightening. (By permission of Dr. Marc Asher.) See text for details.

The choice of system is generally decided by the surgeon's own personal preference. At the inferior level of the sacrum, use sacral screw fixation in addition to the Galveston or pelvic screw fixation. The sacral screws link the ilium and the sacrum and help reduce the amount of stress on the pelvis. I have noted significantly less bone absorption around the pelvic posts with the addition of sacral screw fixation, especially in patients with neuromuscular scoliosis and soft bone.

The screws are usually situated in the sacral pedicle just below and lateral to the L5–S1 facet.

- Identify the pedicle and probe it with the gear shift probe.
- Confirm the placement with a ball-tipped pedicle probe and lateral roentgenogram.
- I generally use bicortical purchase.
- Tap for the screw, and again probe, and then position a screw of the appropriate length and diameter.
- Confirm screw placement with a roentgenogram or fluoroscopic image.
- Once the screws have been placed, attach them to the rod using slotted connectors. If the angle is difficult to accommodate with rod contouring, use a variable-angle slotted connector.

When the fusion is continued to the pelvis, I tend to favor the Galveston technique or the use of an iliac bolt, which can be attached to the rod by a slotted connector. I generally expose both iliac wings through the midline incision. Adequate exposure is necessary to visualize the greater sciatic notches bilaterally. The entry point for the **L** portion of the rod is usually just below the posterior superior iliac spine (PSIS).

- Make a hole in the superior border of the posterior ileum just below the PSIS with a $^{3}/_{16}$- or ¼-inch drill, depending on the size of the rod chosen.
- Insert the rod between the tables of the ileum so that it lies 1–1.5 cm above the greater sciatic notch. The length of the rod or screw is usually 6–8 cm, depending on the size of the patient.
- Rod contour is important to correct the deformity and maintain normal sagittal balance. I generally use a malleable template to help establish the appropriate bend. The rods are then contoured using the Cotrel-Dubousset French bender and the Asher ISOLA bending irons.
- After appropriate bending, position the rods and sequentially tighten and secure the wires (Fig. 156.16, Fig. 156.17 and Fig. 156.18).

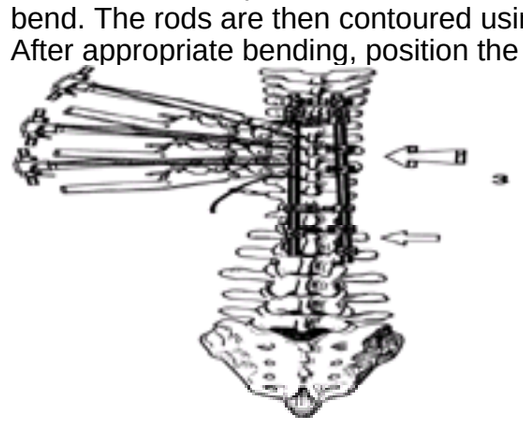

***Figure 156.16.*** Place a convex rod to create a countertorsion force. (By permission of Dr. Marc Asher.) See text for details.

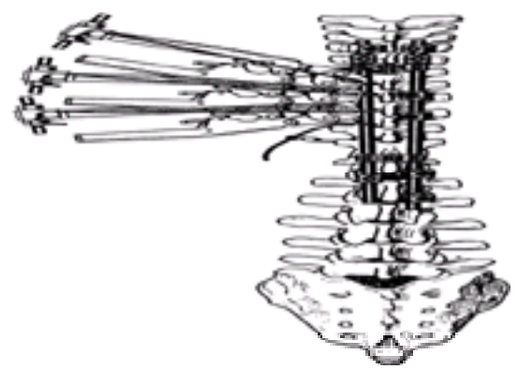

***Figure 156.17.*** Complete tightening of the wires. (By permission of Dr. Marc Asher.) See text for details.

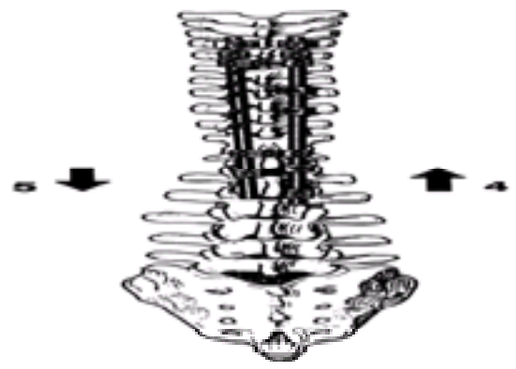

***Figure 156.18.*** Application of concave distraction and convex compression complete the instrumentation sequence. See text for details. (By permission of Dr. Marc Asher.)

- After the hardware is secured and all wires are tightened, decorticate the remaining exposed transverse processes and lamina using gouges and rongeurs. Take great care to avoid penetrating the open laminotomies.
- Carefully pack autogenous iliac bone or banked bone around the decorticated spine.
- Close the wound using a drain above the fascia as described previously.

Although some surgeons (2,35,36 and 37) feel that no postoperative immobilization is necessary, Herndon et al. (26) reported a 10% pseudarthrosis rate when no postoperative bracing was used, and a near-zero incidence with bracing. In my experience, a custom-molded, bivalved, polypropylene brace prevents loss of correction and makes most patients more comfortable and more mobile postoperatively.

***Multi-Hooks and Rod Systems***

**Historical Background** In 1981, Yves Cotrel and Jean Dubousset of France introduced a spine implant system that combined segmental fixation with distraction compression and derotation of the spine. Their system consisted of a series of open and closed hooks and a knurled rod with a diamond-patterned surface. It allowed the two rods to be connected by cross-links, increasing the overall stability of the system. Cotrel and Dubousset stressed the importance of maintaining and creating normal sagittal contours. Their system of rotation and Luque's concept of translation were the first efforts to move away from the old concept of pure distraction and move toward an attempt to obtain three-dimensional spine correction. As the popularity of the Cotrel-Dubousset system grew, others started to develop their own implant systems. Most of the new systems have been based on the concept of flexibility in use and the ability to fix to the spine with multiple points of fixation. Most use hooks, wires, and screws, in combination, as the means of spine fixation. Virtually all of the systems, when used properly, will give good spine correction and excellent results.

The new multi-hooks and rod systems are complicated, and their application is complex. When first using these systems, obtain hands-on training with surgeons who are experienced with them.

Because these new systems use multiple hooks, screws, and wires to rigidly stabilize the cross-linked dual rods, the need for bracing is diminished, which is a huge advantage for the patient. Bracing is occasionally used for patients who have soft bone or for whom compliance is questionable. I have used bracing to control an unfused lumbar curve, surgically treating the thoracic curve and using bracing to control the unfused segment. The criteria for discontinuing the use of a brace are those used in a standard brace program.

The selection of fusion levels using the new systems has been controversial. I select fusion levels based on the criteria established by King et al. (29). Early in the Cotrel-Dubousset experience, there were numerous reports of lumbar curve decompensation after selective thoracic fusion (10,33,41). These problems had not been noted in series reporting the use of Harrington instrumentation. Cotrel and Dubousset have proposed that instrumentation levels should include all sagittally abnormal zones, create rotational neutralization, and finish in the Harrington stable zone. This frequently necessitates fusion into the upper lumbar spine. Thompson et al. (58) and Wood et al. (63,64) have reported data suggesting that overrotation of the thoracic curve locks the transitional thoracolumbar rotation segments, making it impossible for the lumbar curve to balance the thoracic spine. This situation leads to a shift of the thoracic curve to the left and frequently causes progression of the lumbar curve. Richards et al. (52) and Benson et al. (7) have shown that large curves and less flexible lumbar curves are more likely to decompensate with standard Cotrel-Dubousset techniques. Richards et al. believe that in thoracic curves greater than 60°, with a lumbar component greater than 45°, lumbar decompensation may occur with selective thoracic fusion (52). They suggested fusion of both curves when the thoracic and lumbar curves are large.

In 1949, Von Lackum and Miller (59) advised caution when correcting the primary curve. They stated that the primary curve must not be corrected beyond the compensatory curve's ability to correct and balance the spine. It is important to realize that these words were written prior to the advent of internal fixation; with advanced corrective devices they are more timely than ever! Massey et al. (42) have reported on their series of fusions using Cotrel-Dubousset instrumentation and fusing to levels selected according to King's criteria. They found no problems with lumbar decompensation as long as no attempt was made to overcorrect the thoracic spine. Previous implant systems have not provided the powerful corrective forces that the newer systems offer. We may have temporarily lost sight of the importance of spinal stability and balance. Our patients are not as concerned about the number of degrees of correction as they are about the appearance of a balanced stable spine. We must remember the wisdom of Von Lackum and Miller (59).

Recent work by Asher and others has advanced our concept of scoliosis correction. Asher has done extensive three-dimensional studies to better understand and explain the findings noted in idiopathic scoliosis. In a report of his three-dimensional studies of the scoliosis deformity, Asher and Cook (5) found that in progressive curves the apex vertebra tends to displace laterally and posteriorly, and that the spine tends to collapse toward the midcoronal plane as the curve progresses. This was consistent with Pedriolle and Vidal's (50) concept of the evolution of scoliosis in the transverse plane. Asher believes that this fits well with the engineer's concept of scoliosis as a geometrical torsion or a property of a helical line. This is in distinction to a mechanical torsion in which two objects immediately adjacent to each other are rotated on each other. It is Asher's idea that scoliosis develops as a series of imperfect torsions. He notes that the apical vertebra did not always torque posteriorly in thoracolumbar curves. He believes that there are many reasons for these findings, including rib cage constraints, soft tissues, and asymmetry of motion segments (3,4,5 and 6).

It is my belief that correction of scoliosis should include translation and countertorsion if we hope to correct the true complex scoliosis deformity described by Asher. I have tended to drift away from the derotation maneuver described by Cotrel and Dubousset because of the problems seen with lumbar decompensation in type II curves and the intuitive notion that the derotation movement is done in the same counterclockwise motion that scoliosis tends to develop in.

The rules of selective fusion have changed little from the days of Harrington instrumentation. I still use the concept of selective fusion in thoracic curve patterns to avoid unnecessary fusion of the lumbar spine. The fusion should end at the stable vertebra unless that vertebra is at the apex of a kyphosis. If the stable vertebra is located at the apex of those segments, variation of standard hook-and-wire patterns may be applied in compression across the kyphotic segments to correct the abnormal segment (23).

Thorough preoperative planning is essential to ensure a smooth operation (it helps avoid confusion for the surgeons and nursing staff) and a good result. One may choose to label the hook-and-wire sites on the preoperative roentgenogram, or know in advance where sites might be most appropriate. The predetermined hook sites, however, may need to be altered in response to findings during surgery.

**Operative Technique** For the standard right thoracic curve, I use a basic hook-and-wire placement, which is useful in types II, III, IV, and V curves. The type V curve differs only in that the upper stiff thoracic curve must also be instrumented and fused to avoid an objectionable shoulder asymmetry. I generally choose the upper level of instrumentation as the upper level measured by the Cobb method, or a level that is closest to the midline (Fig. 156.6). The upper level of instrumentation is generally T-3 or T-4. I currently use the ISOLA system, which uses open and closed hooks, wire, and screw fixation.

- Prepare the upper facets on both sides of the superior vertebra by removing 4 mm of the inferior facet with a ¼-inch osteotome. Remove the cartilage with a curet.
- Position an appropriate-size hook in the up-going position (Fig. 156.9). The hook should have a nice snug fit, and the throat of the hook should allow adequate room around the facet.
- On both sides of the upper vertebra, create a “claw” by placing a closed hook on a holder, placing the foot of the hook on the superior edge of the transverse process, and allowing the hook to slide around the process (Fig. 156.19). This should give firm fixation on the vertebra.

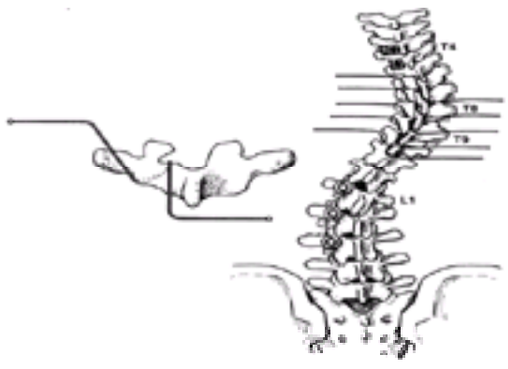

***Figure 156.19.*** Type I thoracic and lumbar curve screw foundation wire fixation on thoracic cavity. See text for details. (By permission of Dr. Marc Asher.)

- I generally use an intermediate up-going pedicle hook on the concave side of the curve, one or two levels below the upper end vertebra. This hook is positioned in a similar manner.
- On the convex side at the apical vertebra, create another claw to assist in the countertorsion movement with the second rod.
- Position the inferior hook on the concave side after a limited laminotomy is created. It is important that the laminotomy be large enough to position the hook, but small enough to prevent deep penetration of the hook into the spinal canal.
- I generally use a closed hook with an appropriate radius to just fit around the lamina (Fig. 156.10).

Some surgeons have started to use screw fixation on the inferior end vertebra for right thoracic curves. I have experience with this technique in types III and IV curves but have not used it in type II curves because the lower thoracic pedicles in adolescents tend to be quite small. The lumbar pedicles, however, can be quite large and adequate for screw placement. The advantages of screw fixation are the secure purchase and the translational control that can be achieved.

- At this point in the procedure, segmentally secure the apical three or four vertebra with sublaminar wires or cables. I use the same technique described in the Luque fixation section (Fig. 156.19).
- After the wires have been passed, excise the concave facets and graft bone.
- Fashion and contour an appropriate length of rod using French and tube benders. (A malleable template is useful to obtain rod length and contour.)
- Feed the rod up through the upper hooks and then rotate into the appropriate plane (Fig. 156.20). Then feed the rod down into the inferior hook.

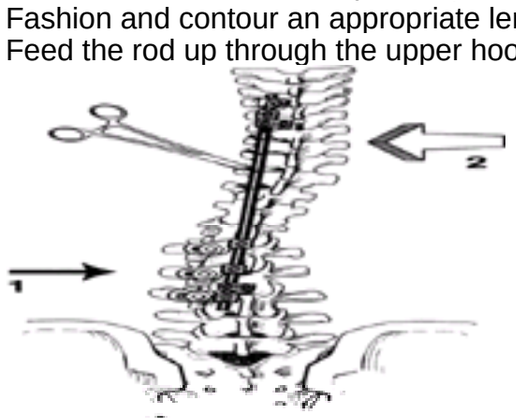

***Figure 156.20.*** Thoracic concave rod placement wire tightening. See text for details. (By permission of Dr. Marc Asher.)

- The upper claw can then be secured with the compression device and the setscrews tightened (Fig. 156.21).

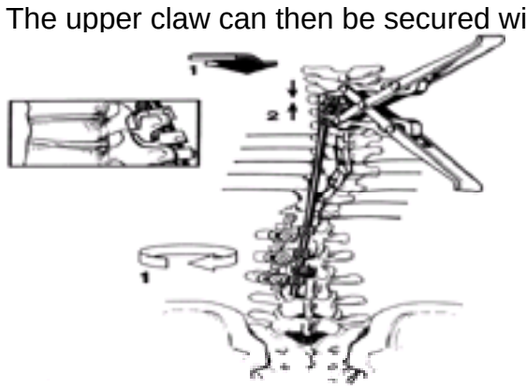

***Figure 156.21.*** Claw compression wire tightening creates translation of the thoracic spine, and rod rotation creates countertorsion in the lumbar spine. See text for details. (By permission of Dr. Marc Asher.)

- Sequentially tighten the wires or cables, translating the spine toward the rod (Fig. 156.22).

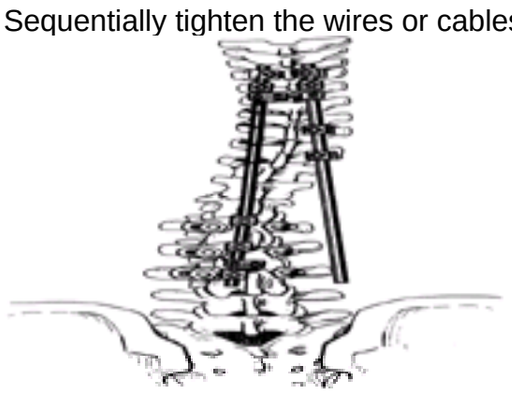

***Figure 156.22.*** The opposite rod creates countertorsion in the thoracic spine and translation in the lumbar spine. See text for details. (By permission of Dr. Marc Asher.)

- I generally favor wires because of their low cost and ease of use. Braided cables are an alternative.
- After the wires have been tightened, complete distraction and secure all setscrews.
- Position the convex rod after facets have been excised and bone grafted (Fig. 156.22).
- Pass the rod through the upper hooks, place the intermediate hooks on the rod, and bring the positioned rod down to the spine. The positioning of the rod serves as a countertorsion movement and tends to push the spine out of rotation and toward the midline (Fig. 156.23).

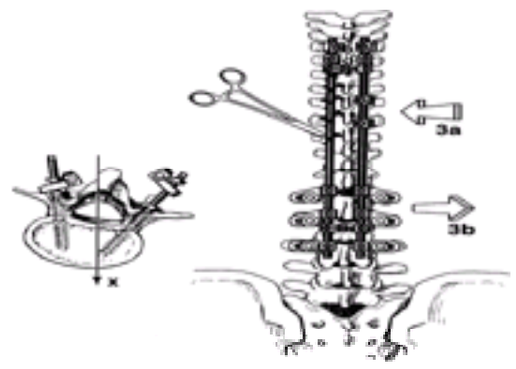


***Figure 156.23.*** Rod sequence is completed. The screws allow a solid inferior anchor and move corrective forces anteriorly into the vertebral body. See text for details. (By permission of Dr. Marc Asher.)

- Place an upward-directed hook under the inferior lamina and advance the rod to engage the hook.
- After the rod is positioned, apply compressive forces to complete the sequence. The sublaminar wires can be retightened; revisit and tighten all setscrews a final time.
- I use cross links to create a rectangle and increase the strength of the system (Fig. 156.24).

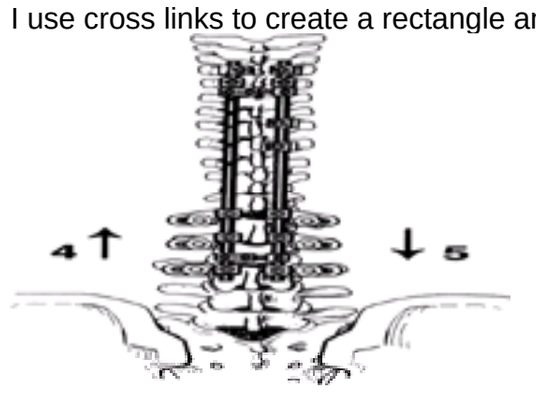


***Figure 156.24.*** Compression and distraction are completed. See text for details. (By permission of Dr. Marc Asher.)

Avoid overcorrection of the instrumented curve. The lumbar curve must be able to accommodate the corrected thoracic curve. Type II curves require particular care and caution. Overcorrection of the thoracic curve can lead to lumbar curve decompensation. I have had minimal problems with lumbar curve decompensation using the translation and countertorsion technique. It seems to cause far fewer problems than the old derotation technique that was based on the techniques of Cotrel and Dubousset. Particularly in the type II curves, we use instrumentation and fusion to treat the main thoracic curve, and then a thoracolumbosacral orthosis (TLSO) to treat the unfused lumbar curve. This has been an effective technique for young patients with a Risser sign of 0 to 2 where growth is anticipated and possible progression of the lumbar curve might be expected.

The double thoracic and lumbar type I curves can be treated with a technique different from that used for thoracic scoliosis curve types. In type I curves, fuse both thoracic and lumbar curves, choosing the upper level of fusion as for the type II to IV curve patterns. (Fig. 156.25, Fig. 156.26, Fig. 156.27, Fig. 156.28, Fig. 156.29 and Fig. 156.30 show typical cases.)



***Figure 156.25.*** Preoperative AP radiograph of the right thoracic curve.

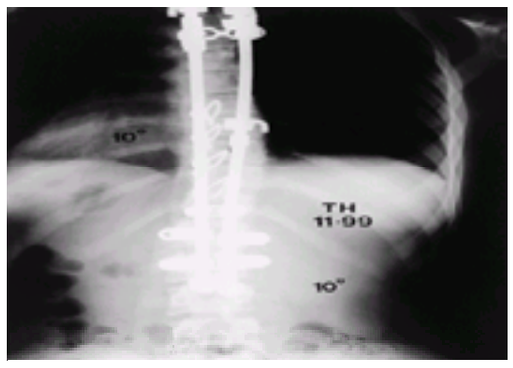


***Figure 156.26.*** Postoperative AP radiograph of the right thoracic curve.

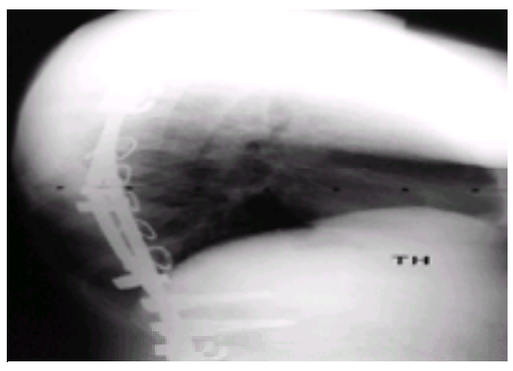


***Figure 156.27.*** Postoperative lateral radiograph of the right thoracic curve.



***Figure 156.28.*** Preoperative AP radiograph of type I thoracic and lumbar curves.



***Figure 156.29.*** Postoperative lateral radiograph of type I thoracic and lumbar curves.

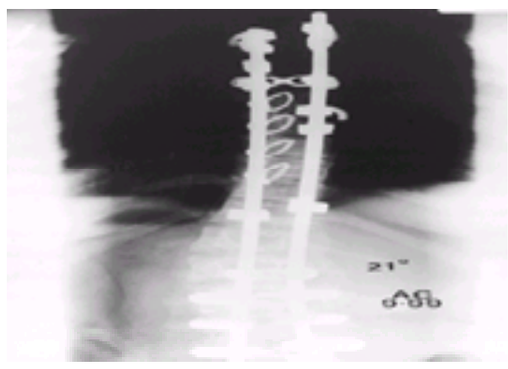

***Figure 156.30.*** Postoperative AP radiograph of type I thoracic and lumbar curves.s

- First, create bilateral claws at the upper level of the fusion, and place a claw or up-going hook at the apex of the thoracic curve.
- At the inferior level of the thoracic curve, place a down-going hook; it is usually preferred to use an open hook at this level.
- On the convex side of the lumbar curve, screw fixation is preferable to hooks, as it seems to give a better base for correction and avoids possible hardware displacement.
- The thoracic curve is generally managed with sublaminar wires.
- Place the concave thoracic and convex lumbar rod first.
- Before tightening the setscrew, rotate the rod counterclockwise. This rotation movement does not change the thoracic curve much, but it does effectively translate and countertorque the lumbar curve.
- Place the second rod and anchor it superiorly with hooks.
- Use an up-going hook at the thoracolumbar junction.
- Use sublaminar wires on the concavity of the lumbar curve, and generally use screws at the last two or three levels.
- Place the second rod with wires or screws in the lumbar curve.
- Use compression along the convexity of the thoracic curve and distraction along the concave lumbar curve.
- Apply transverse connectors and retighten all set- screws.

It is important to be aware of sagittal plane alignment. When fusions must be extended into the lumbar spine, maintain the normal lordosis to avoid the creation of flatback syndrome.

The postoperative program is similar to that of other techniques. Where poor bone or inadequate fixation has been encountered, a bivalved TLSO brace is used. For patients in whom firm fixation is achieved, no postoperative immobilization is required. Mobilize patients on the first or second postoperative day. Encourage them to start walking early, and let them return to school when comfortable. Generally, hold them out of sports for 6–9 months.

The ISOLA system has proven to be a very flexible system that can be applied to many spine problems. Evolution of implant systems is inevitable, and with each new change we are better able to manage more complex deformities.

## POSTOPERATIVE MANAGEMENT

Postoperative management is extremely important. Careful attention to detail is as necessary for this phase as it is for the preoperative planning and the surgical procedure.

After surgery, manage patients in a conventional hospital bed (rather than turning frames or other rotating beds), as patient acceptance and nursing familiarity make this an excellent choice. Use foam pad and sheepskins to facilitate skin care. In the immediate postoperative period, log-roll the patient every 1–2 hours to prevent skin sores, improve ventilation, and reduce pulmonary complications.

During the initial 48-hour postoperative period, administer intravenous fluids and limit oral intake. Avoid early oral feeding because postoperative ileus is common. An aggressive pulmonary care program with frequent coughing, deep breathing, and the use of an incentive spirometer is a standard part of the postoperative program. For patients with reduced pulmonary capacity, a respiratory therapist can be called in to use suction and a more aggressive pulmonary program.

Provide postoperative support of the spine with a plastic bivalved body jacket. It is easy to use and is equally well tolerated by patients with idiopathic scoliosis and those with a wide variety of neuromuscular conditions. If patient compliance is questionable, a more standard Risser cast can be used successfully. A cervicothoracolumbosacral orthosis (CTLSO) is helpful when instrumentation is carried into the high thoracic spine. In patients with neuromuscular curves or when instrumentation high into the thoracic spine necessitates immobilization, a sternal-occipital-mandibular immobilization (SOMI) device can be added to a bivalved jacket. Maintain postoperative immobilization for 4–6 months. The removable jackets make postoperative hygiene and skin care much easier; allow compliant patients to

shower without the brace after the first few weeks. The multi-hooks and rod systems require no postoperative immobilization.

During the early postoperative period, encourage patients to increase their aerobic activities by walking, gradually increasing to several miles per day after the first 2 weeks. Their endurance and normal physiologic functions improve more rapidly with a regular walking program.

A patient with idiopathic scoliosis may resume noncontact sports after the first month if wearing a postoperative orthosis. For a patient with a multi-hooks and rod system, noncontact sports are not allowed for 3–4 months unless the patient is wearing a body jacket.

Obtain radiographs of the spine before the patient is discharged from the hospital. This set of films establishes the amount of correction and confirms adequate positioning of the hardware. Virtually all hardware pullout occurs in the early postoperative period. Have the patient return 3–4 weeks after discharge for posteroanterior and lateral radiographs to confirm curve stability and hardware position. Take subsequent films at 3 and 6 months. Also take oblique radiographs at the 6-month visit to check the maturity and integrity of the spinal arthrodesis. If the fusion is questionable or unclear on standard radiographs, obtain tomograms. If poor incorporation of the graft is noted, additional immobilization or augmentation of the fusion with additional bone graft may be necessary.

## PITFALLS AND COMPLICATIONS

Unfortunately, major surgical procedures have the potential for complications. Many can be avoided by careful planning and surgical execution. Others, however, occur despite the best efforts.

### BLOOD LOSS

The best way to avoid complications from blood transfusion is to minimize intraoperative blood loss. Proper positioning, hypotensive anesthesia, and careful surgical technique are the cornerstones of minimizing blood loss. I have used preoperative autologous blood donations for about 5 years. Preoperative donations can begin 3–4 weeks before surgery. Iron supplementation is helpful to maintain adequate red blood cell production. With a good autologous blood program, banked blood can generally be avoided. The risks of human immunodeficiency virus (HIV) transmission from bank blood are low, but they can be eliminated with an autotransfusion plan. In cases where blood loss is expected to be high (e.g., in osteotomy or reconstructive procedures), another cost-effective and safe way to reduce the need for blood transfusion is intraoperative blood salvage with a cell-saver.

If major intraoperative blood loss is encountered, immediate hematologic workup, even during the procedure, is mandatory. Transfusion of platelets and appropriate clotting factors can be lifesaving. Fortunately, in my experience, major blood loss is rare if attention to detail is observed.

### SPINAL CORD INJURY

Spinal cord injury is one of the most feared complications in treating scoliosis. The neurologic injury may occur from direct trauma to the cord by instruments, hooks, or sublaminar wires, or by stretch of the spinal cord. Stretch of the spinal cord is presumed to cause vascular compromise that leads to neurologic loss. Certain techniques seem to carry more risks. The 1997 Morbidity and Mortality Report (available from the Scoliosis Research Society) reported an incidence of spinal cord injury during adolescent idiopathic scoliosis surgery of 0.28%. There did not seem to be a correlation based on the type of implant used. A 0.14% incidence of nerve root injury was also noted.

Excessive traction on the spinal cord can occur during correction of scoliosis. This is most frequently seen in large rigid curves but can occur with the manipulation and correction of any curve. Congenital scoliosis carries a higher risk of neurologic injury; these curves tend to be rigid and may be associated with cord tethering by bone spurs, fibrous bands, or a tight filum terminale. As discussed earlier, we recommend the use of MRI prior to the surgical treatment of congenital curves.

The advent of the wake-up test gave spine surgeons a way to assess neurologic function after instrumentation and before sending the patient to the recovery room. In this test, the patient is momentarily awakened from anesthesia and asked to move her toes. Lack of volitional movement calls for careful examination of the procedure and elimination of any potential cause of neurologic impairment. Because of the anesthetic medication, the patient usually neither recalls the wake-up test nor mentions that she felt pain during the procedure. I usually use electronic spinal cord monitoring with sensory evoked potentials (SEP) during surgery. This gives continuous readouts of cord function without waking the patient, with the risks of extubation and the increased bleeding that occur when the blood pressure rises during wake-up. I had false-positive readings during my early experience with SEP, so the wake-up test was used to confirm that no neurologic deficits were present. With added experience and the use of multiple recording sites (epidural, scalp, and cervical), the SEP has proved to be reliable, and it is most helpful during long, involved reconstruction procedures.

Electronic monitoring necessitates careful coordination with the anesthesia staff, because many of the popular anesthetic agents interfere with accurate monitoring. If a neurologic deficit is noted during or after surgery, reduce the traction force on the spine. This usually necessitates releasing distraction and may require hardware removal. If a severe neurologic deficit is noted in the recovery room or after surgery, immediately return the patient to the operating room for wound exploration and probable hardware removal. Laminectomy is not usually indicated unless an epidural hematoma is identified or bone is encroaching on the cord. If early sublaminar wire removal is indicated, the technique should be that of cutting one end of the wire close to the lamina, grasping the other end, and pulling straight up. The work of Nicastro et al. (49) shows this to be least likely to cause the wire to push down into the spinal cord.

### WOUND INFECTION

With careful technique and the use of intraoperative and postoperative antibiotics, postoperative wound infection should be 1% or less. If an early infection occurs, prompt wound debridement is indicated, and a successful spinal correction and fusion can be salvaged.

- Obtain blood cultures before surgery.
- Take the patient to the operating room, where, under anesthesia, the skin is prepared and draped, and the entire wound is opened. Do not disrupt the hardware and bone graft.
- Obtain cultures.
- Carefully debride the hematoma and nonviable tissue, followed by irrigation with antibiotic solution. Leave the bone graft intact.
- Generally, avoid large retention sutures.
- Close the wound in layers over suction irrigation tubes that are left in for 3–5 days.
- Administer appropriate intravenous antibiotics for 7–10 days; then, if antibiotic sensitivity allows, change to an oral agent for an additional 6 weeks.

### DURAL TEARS

If, during the process of passing sublaminar wires or placing hardware, a dural tear is noted by the leakage of clear cerebrospinal fluid, repair it immediately. Patients fare better with early repair than with later repairs of chronic leaks. Perform a limited laminotomy, or laminectomy if necessary, to expose the dural tear. Once the extent of the tear is identified, repair by careful suturing with a fine, nontraumatic needle and 5-0 or 6-0 nylon. If large tears are noted, it may be necessary to perform a fascial graft. the lumbodorsal fascia is a good source for a patch graft. Keep patients with this complication at bed rest for several days after repair.

### FLATBACK SYNDROME

The loss of normal lumbar lordosis is a major long-term problem (1,31,32). It creates an unsightly cosmetic deformity and leads to back pain. This flattening of the lumbar spine is associated with instrumentation of the lumbar spine and can be created by using noncontoured Harrington rods (15). The best way to prevent this iatrogenic problem is to avoid fusion of the lumbar spine when possible. As described earlier in this chapter, selective thoracic fusion is the best way to maintain lumbar motion. When fusion into the lumbar spine is necessary, position the patient on the operating table to maintain lordosis and contour the rods. When fusion to the sacrum is indicated, the Luque rods with Galveston pelvic fixation and sacral screws are the best means of creating or maintaining lumbar lordosis.

### PSEUDARTHROSIS

Successful completion of a scoliosis procedure is based on obtaining a solid fusion. After 4–6 months, perform an evaluation for a solid arthrodesis. Take oblique views and carefully review the films for lucent lines in the fusion mass. If broken hardware is noted, a pseudarthrosis is highly likely.

When there is hardware breakage or when oblique radiographs demonstrate a pseudarthrosis, open and explore the entire wound. The pseudarthrosis may be covered by a fine layer of bone. Therefore, careful evaluation is mandatory. The pseudarthrosis is generally difficult to expose and will show motion when stressed. Freshen the bone with a gouge, and instrument the pseudarthrosis with a heavy Harrington compression system. The multi-hooks and rod system can also be used to apply compression. Apply generous quantities of local and iliac bone graft to complete the procedure. I immobilize the patient for 4–6 months in a bivalved body jacket. Lumbosacral pseudarthroses that have failed repeated attempts at repair may be best managed by an additional anterior fusion. It is mandatory that solid arthrodesis be achieved if you hope to obtain a stable balanced spine.

## AUTHOR'S PERSPECTIVE

The surgical management of scoliosis requires careful preoperative evaluation and planning. Curve types and patterns must be carefully identified to select fusion levels. Spinal fusion and instrumentation techniques are demanding and should be carefully performed. The surgeon should have hands-on experience with these systems before initiating the procedure. The keys to success are attention to detail and skillful surgical execution. The new implant systems seem to offer better correction and more options in treatment, but they do not replace the need for good fusion techniques.

### CHAPTER REFERENCES

Each reference is categorized according to the following scheme: *, classic article; #, review article; !, basic research article; and +, clinical results/outcome study.


+ 1. Aaro S, Ohlen G. The Effect of Harrington Instrumentation on the Sagittal Configuration and Mobility of the Spine in Scoliosis. *Spine* 1983;8:570.

# 2. Allen BL, Ferguson RL. Basic Considerations in Pelvic Fixation Cases. In: Luque ER, ed. *Segmental Spinal Instrumentation.* Thorofare, NJ: Slack, 1984:185.

# 3. Asher MA. ISOLA Spinal Instrumentation System for Scoliosis. In: Bridwell KH, DeWald RL, eds.*The Textbook of Spinal Surgery.* Philadelphia: Lippincott, 1996:569.

+ 4. Asher MA, Cook L. Adolescent Idiopathic Scoliosis Transverse Plane Evolution. In: D'Amico M, Merrill A, Santambrogio GC, eds.*Three Dimensional Analysis of Spine Deformities.* Amsterdam: IOS Press, 1995:353.

+ 5. Asher MA, Cook L. The Transverse Plane Evolution of the Most Common Adolescent Idiopathic Scoliosis Deformities. A Cross-Sectional Study of 181 Patients. *Spine* 1995;20:1386.

# 6. Asher MA, Strippgen WE, Heinig CF, Carson WL. ISOLA Spinal Instrumentation: Emphasizing Application during the First Two Decades of Life. In: Weinstein SC, ed.*]The Pediatric Spine: Principles and Practice.* New York: Raven Press, 1999:1619.

+ 7. Benson L, Ibrahim K, Goldberg B, Harris G. Coronal Balance in Cotrel-Dubousset Instrumentation: Compensation vs. Decompensation. Presented at the Scoliosis Research Society Annual Meeting, Honolulu, September, 1990.

+ 8. Bergofsky EH, Turino GH, Fishman AP. Cardiorespiratory Failure in Kyphosciolosis. *Medicine* 1959;38: 263.

# 9. Bradford DS, Moe JH, Winter RB. Scoliosis and Kyphosis. In: Rothman RH, Simeone FA, eds. *The Spine*, 2nd ed. Philadelphia: Saunders, 1982.

+ 10. Bridwell KH, McAllister JW, Betz RR, et al. Coronal Decompensation Produced by Cotrel-Dubousset “Derotation” Maneuver for Idiopathic Right Thoracic Scoliosis. *Spine* 1991;16:769.

+ 11. Butte FL. Scoliosis Treated by the Wedging Jacket. Se- lection of the Area to be Fused. *J Bone Surg* 1983; 20:1.

* 12. Cobb JR. Outline for the Study of Scoliosis. *Instr Course Lect* 1948;5.

+ 13. Cochran T, Irstam L, Nachemson A. Long Term Anatomic and Fuctional Changes in Patients with Adolescent Idiopathic Scoliosis Treated by Harrington Rod Fusion. *Spine* 1983;8:576.

+ 14. Collis DK, Ponseti IV. Long Term Followup of Patients with Idiopathic Scoliosis Not Treated Surgically. *J Bone Joint Surg Am* 1969;51:425.

+ 15. Cummine J, Winter R, Grobler C, et al. Harrington Instrumentation without Fusion Combined with Milwaukee Brace for Difficult Scoliosis Problems in Young Children. *Orthop Trans* 1979;3:59.

* 16. Ferguson AB. The Study and Treatment of Scoliosis. *South Med J* 1930;23:116.

* 17. Flagstad AE, Kollman S. Vital Capacity and Muscle Study in One Hundred Cases of Scoliosis. *J Bone Joint Surg* 1928;10:724.

+ 18. Gazioglu K, Goldstein LH, Femi-Pearse D, Yu PN. Pulmonary Function in Idiopathic Scoliosis: Comparitive Evaluation Before and After Orthopaedic Correction. *J Bone Joint Surg Am* 1968;50:1391.

+ 19. Gillespie R, Faithfull DK, Roth A, Hall JE. Intraspinal Anomalies in Congenital Scoliosis. *Clin Orthop* 1973;93:103.

+ 20. Goldstein LA. Surgical Management of Scoliosis. *Clin Orthop* 1964;35:95.

+ 21. Goldstein LA. Surgical Management of Scoliosis. *J Bone Joint Surg Am* 1966;48:167.

+ 22. Goldstein LA. Surgical Management of Scoliosis. *Clin Orthop* 1971;77:32.

+ 23. Hammill GL, Lenke LG, Bridwell KH, et al. The Use of Pedicle Screw Fixation to Improve Correction in the Lumbar Spine of Patients with Idiopathic Scoliosis: Is It Warranted? *Spine* 1996;21:1241.

* 24. Harrington PR. Treatment of Scoliosis: Correction and Internal Fixation by Spine Instrumentation. *J Bone Joint Surg Am* 1962;44:591.

* 25. Harrington PR. Technical Details in Relation to the Successful Use of Instrumentation in Scoliosis. *Orthop Clin North Am* 1972;3:49.

+ 26. Herndon W, Sullivan JA, Gross R, et al. Segmental Spinal Instrumentation: Critical Appraisal. *Orthop Trans* 1986;10:492.

+ 27. Hood RW, Riseborough EJ, Nehme AM, et al. Diastematomyelia and Structural Spinal Deformities. *J Bone Joint Surg Am* 1980;62:520.

+ 28. Keim HA, Reina EG. Osteoid Osteoma as a Cause of scoliosis. *J Bone Joint Surg Am* 1975;57:159.

+ 29. King HA, Moe JH, Bradford DS, Winter RB. The Selection of Fusion Levels in Thoracic Idiopathic Scoliosis. *J Bone Joint Surg Am* 1983;65:1302.

+ 30. Kostuik JP, Israel J, Hall JE. Scoliosis Surgery in Adults. *Clin Orthop* 1973;93:225.

+ 31. LaGrone MO. Loss of Lumbar Lordosis. A Complication of Spinal Fusion for Scoliosis. *Orthop Clin North Am* 1988;19:383.

+ 32. LaGrone MO, Bradford DS, Moe JH, et al. Treatment of Symptomatic Flatback after Spinal Fusion. *J Bone Joint Surg Am* 1988;70:569.

+ 33. Lenke LG, Bridwell KH, Blanke K. Preventing Decompensation in King Type II Curves Treated with Cotrel-Dubousset Instrumentation. *Spine* 1992;17:5274.

+ 34. Lonstein JE, Carlson JM. The Prediction of Curve Progression in Untreated Idiopathic Scoliosis during Growth. *J Bone Joint Surg Am* 1984;66:1061.

+ 35. Luque ER. Paralytic Scoliosis in Growing Children. *Clin Orthop* 1982;163:202.

* 36. Luque ER, Cardosa AM. Segmental Correction of Scoliosis with Rigid Internal Fixation. *Orthop Trans* 1977;1:136.

* 37. Luque ER, Cardosa AM. Treatment of Scoliosis without Arthrodesis or External Support. *Orthop Trans* 1977;1:37.

+ 38. Makley JT, Herndon CH, Inkley S, et al. Pulmonary Function in Paralytic and Non-Paralytic Scoliosis Before and After Treatment. A Study of Sixty-Three Cases. *J Bone Joint Surg Am* 1968;50:1379.

+ 39. Mankin HJ, Graham JJ, Schack J. Cardiopulmonary Function in Mild and Moderate Idiopathic Scoliosis. *J Bone Joint Surg Am* 1964;46:53.

# 40. Marchetti PG. Harrington Rods. In: Bradford DS, Hensinger RH, eds. *The Pediatric Spine.* New York: Thieme, 1985;426.

+ 41. Mason DE, Carango P. Spinal Decompensation in Cotrel-Dubousset Instrumentation. *Spine* 1991;16: 5394.

+ 42. Massey TB, Winter RB, Lonstein JE, Denis F. Selection of Fusion Levels with Special Reference to Coronal and Sagittal Balance in Right Thoracic Adolescent Idiopathic Scoliosis Using Cotrel-Dubousset Instrumentation. Presented at Scoliosis Research Society Annual Meeting, Honolulu, September, 1990.

# 43. Micheli LJ, Riseborough EJ, Hall JE. Scoliosis in the Adult. *Orthop Rev* 1977;6:27.

* 44. Moe JH. A Critical Analysis of Methods of Fusion for Scoliosis. An Evaluation of Two Hundred and Sixty-Six Patients. *J Bone Joint Surg Am* 1958;40:529.

+ 45. Moe JH. Methods of Correction and Surgical Techniques in Scoliosis. *Orthop Clin North Am* 1972;3: 17.

+ 46. Moe JH, Sundberg B, Gustilo R. A Clinical Study of Spine Fusions in the Growing Child. *J Bone Joint Surg Br* 1964;46:784.

# 47. Moe JH, Winter RB, Bradford DH, Lonstein JE. Scoliosis and Other Spinal Deformities. Philadelphia: W. B. Saunders, 1978.

* 48. Nachemson A. A Long Term Followup Study of Non-Treated Scoliosis. *Acta Orthop Scand* 1968;39:466.

! 49. Nicastro JF, Hartjen CA, Traina J, Lancster JN. Intraspinal Pathways Taken by Sublaminal Wires during Removal. An Experimenatl Study. *J Bone Joint Surg Am* 1986;68:1206.

+ 50. Pedriolle R, Vidal J. Morphology of Scoliosis. Three Dimensional Evolution. *Orthopaedics* 1987;10:909.

* 51. Ponder RC, Dickson JH, Harrington PR, Erwin WE. Results of Harrington Instrumentation and Fusion in the Adult Scoliosis Patient. *J Bone Joint Surg Am* 1975;57:797.

+ 52. Richards BS, Burch JG, Herring JA, et al. Frontal Plane and Sagittal Plane Balance Following Cotrel-Dubousset Instrumentation for Idiopathic Scoliosis. *Spine* 1989;14:733.

+ 53. Rinsky LA, Gamble JG, Bleck EE. Segmentation Instrumentation without Fusion in Children with Progressive Scoliosis. *J Pediatr Orthop* 1985;5:687.

* 54. Risser JC. The Iliac Apophysis. An Invaluable Sign in the Management of Scoliosis. *Clin Orthop* 1958;11:111.

+ 55. Shannon DC, Riseborough EJ, Valeca LM, Kazemi H. The Distribution of Abnormal Lung Function in Kyphoscoliosis. *J Bone Joint Surg Am* 1970;52:131.

+ 56. Steel HH. Rib Resection and Spine Fusion in Correction of Convex Deformity in Scoliosis. *J Bone Joint Surg Am* 1983;65:920.

+ 57. Swank S, Lonstein JE, Moe JH, et al. Surgical Treatment of Adult Scoliosis. *J Bone Joint Surg Am* 1981;63: 268.

+ 58. Thompson JB, Transfeldt EE, Bradford DS, et al. Decompensation after Cotrel-Dubousset Instrumentation of Idiopathic Scoliosis. *Spine* 1990;15:927.

+ 59. Von Lackum WH, Miller JP. Critical Observation of the Results in the Operative Treatment of Scoliosis. *J Bone Joint Surg Am* 1949;31:102.

+ 60. Westgate HD. Pulmonary Function in Thoracic Scoliosis Before and After Corrective Surgery. *Minn Med* 1970;53:839.

+ 61. Winter RB, Lipscomb PR. Back Pain in Children. *Minn Med* 1978;61:141.

+ 62. Winter RB, Lovell WW, Moe JH. Excessive Thoracic Lordosis and Loss of Pulmonary Function in Patients with Idiopathic Scoliosis. *J Bone Joint Surg Am* 1975;57:972.

+ 63. Wood KB, Olesweski JM, Schendel MJ, et al. Rotational Changes of the Vertebral Pelvic Axis after Sublaminar Instrumention in Adolescent Idiopathic Scoliosis. *Spine* 1997;22:51.

+ 64. Wood KB, Transfeldt EE, Ogilvie JW, et al. Rotational Changes of the Vertebral-Pelvic Axis Following Cotrel-Dubousset Instrumentation. *Spine* 1991;16:5401.

+ 65. Yngve DA, Burke SW, Price C, Riddick MF. Sublaminar Wiring. *J Pediatr Orthop* 1986;6:605.

# CHAPTER 157

# SPINAL SURGERY FOR MYELO MENINGOCELE

*Thomas E. Kuivila*

**T. E. Kuivila:** Department of Orthopaedic Surgery, The Cleveland Clinic Foundation, Cleveland, Ohio 44195.

Pathophysiology
Principles of Treatment
Patient Assessment
Radiologic Evaluation
Principles and Indications for Surgical Treatment
Surgical Goals
Surgical Decision Making
Preoperative Planning and Management
Imaging
Surgical Principles
Scoliosis
Kyphosis
Postoperative Care and Rehabilitation
Pitfalls and Complications
Chapter References

Myelomeningocele is a serious and complex congenital abnormality associated with a host of problems that cross several disciplines of medicine and rehabilitation. Of the problems presenting to pediatric orthopaedic surgeons, none is as daunting, complex, and fraught with pitfalls as the management of the associated spinal deformities. In addition to the kyphotic, lordotic, or scoliotic deformities typically faced by spinal-deformity surgeons, patients with myelomeningocele bring the added challenge of a markedly abnormal anatomy marked by the absence of a significant portion of the posterior spinal elements. Additionally, these structures are frequently smaller, the bone is more osteopenic, the skin, muscle, and fascia available for coverage of hardware are frequently poor, and significant additional medical problems frequently coexist (13). A solid grounding in the treatment of idiopathic spinal deformities is therefore a prerequisite to embarking on the management of patients with myelomeningocele (6,34).

Orthopaedic care for patients with spina bifida should not exist in a vacuum. More than perhaps any other condition with which orthopaedists are concerned, myelomeningocele should be managed by a team of pediatric specialists. In addition to an orthopaedic surgeon, a pediatric neurosurgeon, a urologist, a neurologist, and a physiatrist must be allied with a health care team consisting of occupational and physical therapy, social workers, and nutritionists. As patient demands on each of these individuals is fairly high, most major pediatric centers employ specialty clinics, where the specialists convene on individual patients, rather than each specialist seeing patients individually. Once thought to be a chronic and stable condition, myelomeningocele is now known to be condition that changes throughout life (8). It is therefore necessary for patients to be followed well into their adult years.

While the focus of this chapter is the surgical management of spinal deformities, readers need to be ever mindful of the associated conditions and the need to manage the spine within the larger framework just discussed.

## PATHOPHYSIOLOGY

The mechanism by which myelomeningocele occurs embryologically is unknown. Two major theories exist, and both have their proponents. Von Recklinghausen, who initially described the condition, felt that the abnormality was due to a failure of closure of the neural canal. The opposing theory is that a closed neural tube ruptures, exposing the neural elements (16). This theory was initially advanced by Morgagni (33). A long discussion of the points that make both theories at least histologically plausible is beyond the scope of this chapter; suffice it to say that a certain modicum of evidence exists for both viewpoints. The abnormality resulting in the formation of a myelomeningocele occurs very early in gestation—most likely at the third to fourth week after conception. In many cases, the defect is present before a woman recognizes that she is pregnant.

While there is no agreement on the embryologic process that causes the formation of a myelomeningocele, many risk factors have been identified that markedly increase the incidence of this birth defect. Use of the the antiseizure medication valproic acid (Depakene) during pregnancy has been demonstrated to markedly increase the risk of myelomeningocele (9). As valproic acid can alter serum folate levels, this adds credence to the work of Yates et al. (45), who showed an association between the incidence of neural tube defects and depressed red cell folate levels. In their study, the diminished folate levels could not be entirely attributed to decreased dietary intake, suggesting that an inborn error of folate metabolism existed. This study was subsequently supported by Seller and Nevin (40), who noted a decreased incidence of myelomeningocele and other neural tube defects when adequate vitamin and folate supplementation began before conception. These studies led to the general dietary recommendation that all women of childbearing age consume a minimum of 1.0 µg of folic acid daily (9). Many foods are being supplemented with folic acid in direct response to this work.

The gold standard for the prenatal diagnosis of myelomeningocele remains the amniotic fluid level of alpha-fetoprotein (AFP) obtained through amniocentesis. A high concentration of AFP within the amniotic fluid, which is usually sequestered within the cerebrospinal fluid (CSF) of the fetus, is pathognomonic for an open or otherwise compromised neural canal. Most centers continue to use serum AFP levels to screen expectant mothers. While high AFP concentrations have a relatively high correlation with neural tube defects, the sensitivity and specificity of this test is only about 80% (1). Prenatal diagnosis is most useful because it is important to plan for delivery at a tertiary care facility, where neurosurgical and neurosurgical intensive care unit support is available; it is also important because it is believed that elective cesarean section may result in neural function at one to two levels higher than otherwise.

## PRINCIPLES OF TREATMENT

The management of a child born with myelomeningocele begins with closure of the defect, typically by a neurosurgeon, within the first 12–24 hours of life. Without treatment, such children will typically die. Several series of untreated children reported in the 1970s demonstrated mortality rates in the range of 90% to 100% (20,23). The cause of death in untreated infants is bacterial meningoventriculitis. Those who survive meningoventriculitis have higher levels of paralysis, more profound mental retardation, and frequently uncontrolled hydrocephalus, leading to additional problems. Therapeutic nihilism was frequently practiced in the United States 40 years ago because of the difficulty in treating many of the sequelae of myelomeningocele. However, with advances in orthopaedic, neurologic, and urologic care, myelomeningocele is very treatable. It has therefore become the standard of care in the United States to perform early sac closure and ventriculoperitoneal shunting in infants with myelomeningocele.

Positioning of the patient after sac closure is very important to protect the fragile soft tissues overlying the repair. Additionally, this period of prone recumbency is advantageous in positioning the hips to avoid subluxation or dislocation.

It is possible, though unusual, for a neurosurgeon to require the services of an orthopaedist when performing the initial shunt closure. Occasionally, the child will be born with a severe gibbous deformity that will necessitate a two- to three-level kyphectomy to facilitate closure.

## PATIENT ASSESSMENT

As with the management of any spinal deformity, take a careful history and perform a thorough physical examination. Do not immediately focus on the spinal deformity. It is important relative to surgical indications, as well as other prognostic factors, to know about the general health of the child. Inquire about the patient's mental functioning, school attendance, and level of socialization, as well as the activities of daily living that the patient is able to perform. The presence or absence of hydrocephalus or a shunt is prognostic relative to overall intellectual function (Fig. 157.1) (18). Inquire about the patient's urologic status and bowel function. Knowledge of the status of these matters is yet another reason why a multidisciplinary clinic is so valuable. Finally, it is important to have a good understanding of parents'

perceptions and patients' needs, desires, and expectations regarding eventual ambulation and the use of ambulatory aids.

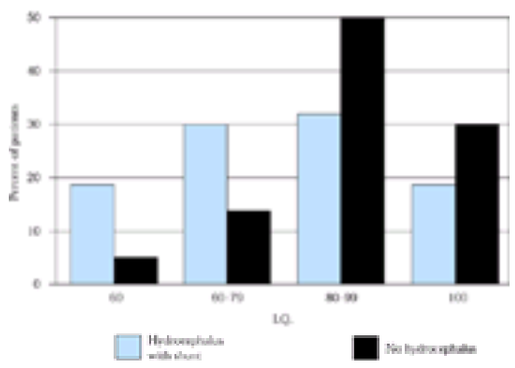


***Figure 157.1.*** Average I.Q. as a function of shunt presence in patients with myelomeningocele.

As far as the spine is concerned, determine the level of neurologic function, the perception of patients and caregivers regarding spinal curvature progression, and any symptoms or problems directly related to the curve, including pain, skin breakdown, loss of balance, difficulty with breathing, or changes in gastrointestinal (GI) or genitourinary (GU) function. It is also important to inquire about previous trials of bracing and spinal surgery.

An increasingly common finding in patients with myelomeningocele is sensitivity to latex. It is mandatory to ask a dermatologist to test patients for latex allergy in the preoperative period. Use a latex-free protocol in surgery and in the postoperative period, even with nonallergic patients. Allergic reactions to latex have become a significant health problem for patients and health care professionals over the last 5 years. It is believed that 50% of spina bifida patients in the United States have evidence of severe allergy to latex. As many as 5% to 10% of myelomeningocele patients may have a potentially life-threatening form of this allergy (3,11). The allergen causing the hypersensitivity response is a component of the latex substance itself, and therefore only strict avoidance of latex contact is effective (42). Immediate hypersensitivity reactions to latex have been reported through several different routes of exposure. Deaths have been reported after mucous membrane exposure and infusion through latex-containing intravenous lines (3,11). Intraoperative anaphylactic reactions have been reported simply after the opening of latex gloves in the operating suite. It is believed that patients with myelodysplasia are at increased risk for latex allergy due to the multiple contacts that they have had with the substance (11), although some feel that there is a yet unknown reason for their proclivity to an allergic response.

As improved non-latex-containing operative and patient care materials become available, inadvertent exposure to latex will become less and less common. The Joint Commission for the Accreditation of Hospital and Healthcare Organizations currently requires that all patients be asked specifically about a history of latex sensitivity at their initial outpatient or inpatient visit. All hospitals should have policies and procedures in place regarding bed assignment and room preparation and strict protocols for direct patient care activities in a nonlatex environment. It behooves the surgeon and operative team, however, to doubly reinforce this concept in the operating room and with the ancillary staff.

Next, perform a detailed physical examination. Examine the extremities, paying special attention to the neurologic examination. Whereas the lower extremities are typically the sites of major neurologic compromise, conditions such as hydromyelia or syringomyelia may also compromise strength and sensation in the upper extremities. Careful neurologic examination to identify the specific level of neurologic involvement is important as a predictor of both ambulatory ability and the likelihood of curve progression (Fig. 157.2). It must be kept in mind that the neurologic pattern may differ from one extremity to the other, even (in rare cases) nearly to the point of having one normal extremity and near-total paralysis of the other extremity, a condition known as hemimyelodysplasia (29).

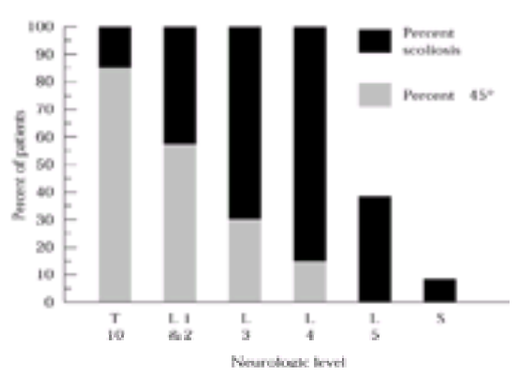


***Figure 157.2.*** The incidence and the severity of scoliosis depend on the level of neurologic compromise.

In addition to observing the general curvature of the spine (lordosis, kyphosis, scoliosis), examine the spine to assess flexibility and balance. Additionally, assess the quality and the condition of the skin throughout the torso. This is important not only for wound coverage and closure but also for any postoperative casting or bracing that may be anticipated. While radiographic studies will convey a good deal of information regarding the underlying bony structure, careful and thorough palpation of the spine for the presence or absence of bony elements can immeasurably add to one's understanding of the deformity.

## RADIOLOGIC EVALUATION

Plain radiographs, preferably standing or sitting in the posteroanterior (PA) and lateral projections and supine bending films, are essential for preoperative planning. Magnetic resonance imaging (MRI) of the spine, as well as spiral computed tomography (CT) with three-dimensional (3D) reconstruction, adds to one's ability to understand the nuances of the curve, note congenital elements and dysplastic features, and undertake rigorous preoperative planning. There is no aspect of spinal surgery where the adage “failure to plan is a plan for failure” better applies than in myelosurgery.

Ultrasound may be useful in the very immature, minimally ossified spine and in areas where there is no bone overlying the neural elements. For the most part, myelography has been replaced by MRI.

## PRINCIPLES AND INDICATIONS FOR SURGICAL TREATMENT

The orthopaedic management of myelomeningocele centers around three major goals:

To maximize patients' abilities and maintain the stability and range of motion of the spine and extremities

To provide for locomotion either by wheelchair or by ambulation with or without braces and orthotics, depending on the level of neurologic involvement

To prevent deterioration of neurologic function

As previously noted, myelomeningocele is a condition in which neurologic change can be expected. The observation of diminished extremity function frequently leads to the diagnosis of subtle neurologic deterioration.

The specific goal in the management of the myelomeningocele spinal deformity is to maintain or achieve a well balanced spine (Fig. 157.3). Spinal balance is important for compensated sitting, as well as standing. A well supported spine (12) allows free use of the upper extremities, and balanced seating pressure diminishes the

likelihood of skin breakdown in insensate areas.

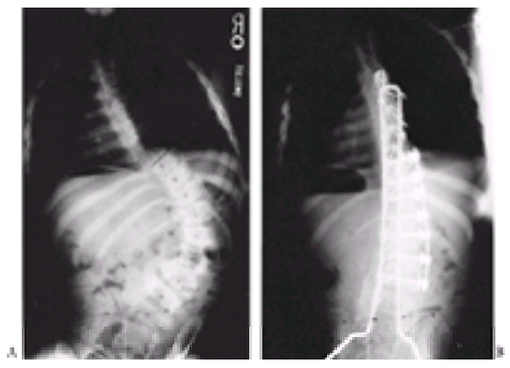

***Figure 157.3.*** **A:** A 13-year-old boy with a thoracic-level myelomeningocele. He had a severe, progressive right thoracolumbar paralytic curve of 84° and significant pelvic obliquity of 21°. Staged anterior and posterior procedures 1 week apart were necessary to correct the rigid spinal deformity and pelvic obliquity. The combination of an anterior Zielke procedure followed by posterior instrumentation and fusion with a Luque rod with Galveston pelvic fixation provided adequate correction of his deformities **(B)**.

As with any spinal deformity, the three options for management include observation, bracing, and surgery. However, unlike idiopathic adolescent spinal deformities, there is no “routine” management for the myelodysplastic spine. Patient size and age, level of curve involvement, coexisting hemivertebrae, and wildly variant anatomy make a highly individualized treatment plan mandatory. However, certain rules do apply and are useful to bear in mind.

Because of coexistent muscle paralysis, scoliosis in patients with spina bifida tends to progress faster and more relentlessly than in idiopathic scoliosis. When scoliosis is simply being observed, this option is generally chosen not so much because of the low-level magnitude of the curve but because the patient either may not be of appropriate size for definitive surgery or may have a curve that is not amenable to orthotic management.

Orthotic treatment of scoliosis should be considered a temporary measure, intended to allow further spinal growth and patient maturation before definitive operative management. Many potential problems exist with bracing the paralytic spine. First, the brace exerts pressure on insensate or sensory-impaired skin, which can result in decubitus ulcers, particularly over the bony prominences of the spine and the edges of the rib cage and pelvis. Second, the degree of compression necessary to maintain control of the curve will frequently compromise an already restricted pulmonary capacity and definitely impair an already compromised ability to be mobile. Any orthotic must be custom-made and requires very careful fitting and supervised wear. Insensate skin can break down very quickly, and children must be introduced to the orthotic slowly, beginning with 1 hour at a time. Inspect the skin carefully after removal of the orthosis. Increase the wearing time slowly over 3–4 weeks until the patient is wearing it throughout the waking hours. Remember that night- and nap-time brace wear is not as beneficial in slowing the progression in the paralytic spine as it is in the idiopathic spine.

Although spinal deformities develop in 75% of children with spina bifida (7), most are not present at birth. Deformities usually appear by age 5 years and, in most cases, are fully developed by 10 years of age (25,37). Congenital deformities (unsegmented bars and hemivertebrae, and combinations thereof) can coexist. These will be noted at birth and tend to require surgery at an earlier age than the paralytic deformity (2). Despite the high percentage of spinal deformities, one cannot be complacent regarding the exact cause of any given curve. As in any spinal deformity, investigation is necessary to determine whether there is an underlying correctable cause for the disorder, and therefore MRI and CT are useful in evaluating the spine for hydromyelia, a tethered spinal cord, or ventricular porencephaly, which can contribute to the deformity (8).

### SURGICAL GOALS

The goal of surgery is to provide a stable, well balanced spine with the head centered over a nonoblique pelvis, allowing good balance and affording patients the use of both hands. Those with collapsing deformities, who must push up with their hands to support themselves or to maintain good pulmonary or GI function, are severely hindered in their ability to perform activities of daily living (27).

### SURGICAL DECISION MAKING

As a general rule, curves that progress beyond 50° require surgery. It is assumed that most children with myelomeningocele, who will eventually require spinal surgery, will have curves greater than 50° well before skeletal maturity. Whereas it is preferable to wait until age 10–12 years for instrumented fusion, one will occasionally need to intervene at an earlier age to prevent irretrievable progression. As with surgery for other medically “delicate” patients, such as those with muscular dystrophy, optimization of general medical health at the time of surgery is important. Before surgery, any hydrocephalus should be well controlled, and shunts, if in place, should function normally. Ideally, the urinary tract should be free of any obstruction, ureteral reflux managed, and the urine sterile. In many cases, of course, obtaining sterile urine is temporary at best, and in these instances, the known colonizing bacteria should be suppressed with appropriate antibiotic prophylaxis. Failure to control bacteria in the urinary tract can lead to an inordinately high infection rate (2). Finally, the condition of the skin generally and in the operative area, in particular, must be at its best. Whenever the potential for the introduction of infection into the fusion through skin contaminants is high, it is advisable to do appropriate plastic surgical reconstruction first. This will often require tissue expansion, midline scar excision, and closure. After the new area is well healed, definitive spinal surgery can then proceed with less risk of infection.

## PREOPERATIVE PLANNING AND MANAGEMENT

### IMAGING

The explosion in technology over the past decade has greatly enhanced the ability to image the deformed spine, immeasurably improving preoperative planning. Despite these advances, however, plain radiographs (standing or sitting PA and lateral views and supine bending films) are critical for initial planning. These images will demonstrate the existing spinal alignment, head and shoulder balance, and pelvic obliquity. Bending films assess the degree of correction that may be possible. Keep in mind that the bone in the paralytic spine is likely not to be as strong as in the idiopathic spine and may not tolerate attempts to restore true anatomic alignment.

Bone scans are generally not required, although they are useful in diagnosing a preexistent underlying osteomyelitis, which would be a short-term contraindication for instrumented fusion. Patients with chronic skin breakdown over the deformity or a history of prolonged drainage may have chronic osteomyelitis. Bone infection must be eradicated before correction of the deformity.

In the evaluation of the bony anatomy, CT is most useful when 3D reconstructions are performed. Spiral CT data can be manipulated into excellent 3D images, and this minimizes the amount of radiation to which patients are exposed. 3D reconstructions allow virtual spinal visualization and can be useful when placement angles of hooks or pedicular screws are being planned.

It has been said that all patients with myelomeningocele who underwent a surgical closure after birth have by definition a degree of cord tethering (21). In some patients, the tethering is a major factor in scoliosis progression. In addition to demonstrating significant tethering, MRI will show any other cord abnormalities that may be present, including syringomyelia and hydromyelia, which may need correction before a definitive spinal fusion. MRI will also demonstrate the degree of Arnold–Chiari malformation and any change from baseline.

### SURGICAL PRINCIPLES

In no area of orthopaedic surgery is preoperative planning more important than in the paralytic spinal deformity. Be prepared for the following:

- Patients as a rule are smaller.
- The deformities are more severe and more rigid.
- Bone is osteopenic.
- Spinal elements in the involved area are altogether absent.

Patients' underlying medical condition is frequently more precarious then expected.
Arrangements may need to be made to have special instrumentation and additional bone-grafting products available.

Most patients with spina bifida require combined anterior and posterior spinal instrumentation combined with fusion that includes the sacrum.

- Start the fusion typically two levels above the end of the curve, and extend to the sacrum or pelvis (25,34).
- The most common technical error is to perform too short a fusion that necessitates later revision for progressive imbalance.
- Wait until age 10–12 years if the curve magnitude is moderate.
- It is better to accept some permanent truncal shortening than to let a curve progress beyond 70° to 80°.
- The majority of patients with myelodysplasia have a small, underdeveloped, osteopenic pelvis. Plan to use allograft bone and other bone-graft extenders for the primary grafting material.

As these typically are lengthy procedures, controlling blood loss intraoperatively is critical (17).

- Use subcutaneous epinephrine (1:400,000–500,000) and a Bovie electrocautery, a bipolar coagulator, and in some cases an argon laser to maintain a dry operative field. Employ hypotensive anesthesia judiciously to minimize uncontrolled blood loss.
- Remember that one of the most important factors related to complications and blood loss is the prevention of hypothermia (24).
- Use blood and intravenous fluid warmers, as well as warming blankets, to maintain normothermia. Simply turning the room temperature up to 85° will not have the desired effect.
- Intraoperative salvage of blood with a cell saver is useful because the volume of blood in these patients as a result of their size is frequently not enough for salvage by conventional means. Use of state-of-the-art processing units and intraoperative plasmapheresis is an exciting new concept for intraoperative cell salvage that requires markedly less volume of salvaged cells to be useful.

A surgeon managing the spinal deformity of myelomeningocele must deal with the issue of deficient bone stock on two levels. First, is a congenital deficiency of the posterior elements that provides limited sites for traditional sublaminar wires or hooks. Secure the rods to the spine at these levels with a cable or a wire encircling the pedicle through the neural foramen; otherwise do not instrument these levels. Where soft-tissue coverage is adequate, the newer, smaller pedicle screw systems appear to be an excellent means of securing these levels of the spine to the rod. Remember that the majority of pull-out strength with a pedicle screw is within the pedicle itself. The screw should be optimally sized to the pedicle and need not extend farther than 50% of the way through the vertebral body. Be fully familiar with the available instrumentation, and arrange to have a wide array of screw sizes and lengths available on the day of surgery.

The second problem with deficient bone stock is the availability of autogenous graft. Portions of both iliac crests, the ribs, and portions of the spinous processes were once the only bone available. With modern bone banking technology and the availability of graft extenders, the use of autogenous graft is now typically not advised unless a patient is unusually robust; commercially available graft extenders include Grafton (Grafton Corporation, Edison, NJ), a demineralized bone matrix; Coralene (Interpore International, Irvine, CA), and Osteoset pellets (Wright Medical Products, Arlington, TN). Additional products on the horizon will make the issue of deficient autogenous graft a moot point.

Postoperative infection is one of most serious and devastating complications that may follow instrumented spinal fusion in this patient population. At our institution, dual-coverage antibiotics (a first-generation cephalosporin and an aminoglycoside) are typically given for 48–72 hours postoperatively.

- Prolong antibiotic coverage if drains remain in place or significant drainage persists.
- A potential for later infection is present if systemic urosepsis occurs or if the soft tissue overlying the instrumentation breaks down.
- Use all available means of obtaining thick, well vascularized flaps to cover the spinal instrumentation, particularly in the lumbar region, where the overlying tissue is typically most atrophic and poorly vascularized.
- Stage procedures in instances where the scarred area has had repeated episodes of breakdown or the scar is in particularly poor repair.
- Excise nonviable scar initially, and mobilize flaps to bring new, healthy skin to the midline.
- As simple flap mobilization may not be possible, consider placing tissue-expansion bladders on either side of the midline to create new skin.
- Then resect the midline scar, bring the new expanded skin together in the midline, and allow the wound to heal for 4–6 weeks before the definitive procedure.

Much has changed in spinal instrumentation since the 1982 paper by Osebold et al. (34), for whom the best results for spinal fusion in these patients involved combined anterior and posterior instrumentation. They noted that the anterior–posterior approach gave the best degree of correction, best maintenance of correction, and best correction of pelvic obliquity. The instrumentation in this series was with Harrington rods and either the Dwyer or Zielke device anteriorly. These three systems have long since passed out of favor, but the concept of a 360° fusion still makes sense from the standpoint of maximal rigidity and stability. However, with improved posterior segmental instrumentation, a separate anterior approach is not always necessary.

Permanent wheelchair users usually require fusion to the pelvis. One problem with fusion to the pelvis is the historically high rate of pseudarthrosis (10,14,15,34). The development by Allen and Ferguson (2) of the Galveston technique, in which Luque rods are inserted into the iliac wing, was a significant advance in pelvic fixation. Their first reported series in 1979 demonstrated that the technique, although not foolproof, was a major improvement over previous attempts to fix the rod to the sacrum.

The chief problem with this technique is that the pelvis, particularly in nonambulators, tends to be osteopenic and hypoplastic. Rods can migrate within the bone and can break out through the thin cortex anteriorly or posteriorly. The other frequent problem is the difficulty in securing adequate fixation in the lower lumbar spine, where the posterior elements are absent (10). No study has yet been published in which pedicular hooks were used at the lower lumbar levels along with the Galveston technique; however, one would expect that problems with iliac wing breakage would be less common.

A modification of the Luque-Galveston technique has been described by Dunn (14,19). In this technique, the rod is contoured to fit just anterior to the sacral ala or passed through a window in the superior aspect of the ala down into the sacrum itself, paralleling the sacroiliac joint rather than going into the ilium. Our experience with the latter intraosseous modification suggests that rod pull-out by fracture of the posterior sacral cortex is a major drawback.

Another technique for securing the long spinal construct to the pelvis employs an intrailiac bolt or a long pedicle screw inserted in the same manner as the end of the rod in the Luque-Galveston technique. The rod is then appropriately contoured and attached to the screw or bolt in the same fashion as the screw would otherwise be attached to a rod. The advantage of this technique is that the rod–screw construct may be inserted in a “modular” fashion. The screw has a greater initial pull-out strength than the smooth end of a contoured rod. Studies have not shown a long-term benefit from this construct relative to improved lumbosacral fusion. It is, however, easier for surgeons to place. Be certain that the screw–rod interface is sufficiently tight, as any modular system can disengage over time.

**SCOLIOSIS**

Scoliosis is the most common spinal deformity in myelomeningocele, afflicting 80% of patients (27,38). The risk of scoliosis is higher with progressively higher levels of neurologic involvement (Fig. 157.2). As previously noted, typical management usually involves anterior and posterior fusion (32). With improved segmental fixation, a patient who is beginning to show signs of skeletal maturity or in whom the triradiate cartilage of the acetabulum has closed (39), may not require additional anterior fixation. However, when the anterior procedure is performed, it is done first and consists of anterior release or discectomy and fusion, anterior release with strut grafting, or, most commonly, anterior fusion and correction with CD Horizon, CD Hopf (Sofamor-Danek, Medtronic-Sofamor-Danek, Memphis, TN), or Kaneda (Johnson & Johnson, Depuy-Acromed, Raytham, MA) style instrumentation.

***Anterior Lumbar Fusion***

- After induction of general anesthesia, place the patient in the lateral decubitus position with the convexity of the lumbar curve placed upward. Place the apex of the curve at the break in the operating table so that the table can be gently flexed, with the head and foot portion lower than the middle. A deflatable bean bag, with or without kidney rests, maintains excellent positioning of the patient. Carefully pad all bony prominences, and ensure that the Bovie pad is not over a minimally protected bony prominence. Perform a wide field preparation of the skin. If an adhesive surgical drape is not utilized over the entire surgical field, seal the edges of the drapes.
- Enter the thorax one or two levels above the superiormost vertebrae to be instrumented. Utilizing two levels above will facilitate placing the uppermost screw in its best position, parallel to the end plates.
  - If not experienced in using the Bovie cautery for all cutting beyond the dermal level, use subcutaneous epinephrine to secure hemostasis.
  - A needle-tip Bovie unit is particularly useful for the subcutaneous dissection.
  - Start the incision proximally, approximately a hand's-breadth from the midline over the rib in question, and extend along the rib to the costochondral junction. Then curve the incision gently distally, following the lateral edge of the rectus sheath.
  - The distal extent of the incision will depend on whether the instrumentation is to be carried down to the L-3 or L-4 level. It is exceedingly difficult and perhaps

dangerous to attempt to get to the L-5 level through this approach.

- Carry the incision down proximally to the periosteum of the rib, and incise it longitudinally.
- Expose the rib subperiosteally without violating the chest cavity. When the rib is freed, disarticulate it from its chondral end, and with blunt finger dissection remove it entirely from its vertebral articulation.
- Place a ringed lap sponge into the proximalmost portion of the wound to maintain hemostasis.
- Incise the costal cartilage longitudinally with a knife, and find the extraperitoneal plane immediately beneath with blunt finger dissection. The key to this exposure is developing the correct retroperitoneal plane. Open the rib bed longitudinally to enter the chest, and use a self-retaining chest retractor to spread the ribs.
- Carry the incision distally under direct vision, taking care to not transect the external oblique, internal oblique, and transverse abdominal muscles other than through their tendinous condensations at the lateral aspect of the rectus sheath.
- Take down the diaphragm from the chest wall from the site of the chondral split, working posteriorly toward the diaphragmatic crus. The diaphragm may be taken off the chest wall nearly flush, as some surgeons prefer, or, more typically, with a 1–1.5 cm cuff left, which is useful for reapproximation at closure.
- Place marking sutures of alternating colors every 3–4 cm to facilitate a more anatomic closure.
- After the diaphragm has been taken down to the vertebral body or the crus and the distal extent of the abdominal portion is complete, use a self-retaining retractor system, such as a laparotomy retractor (Omnitract, Omnitract Surgical, Minneapolis, MN), to maintain broad exposure.
- Incise the pleura over the thoracic levels to be instrumented, and using a Kidner sponge, elevate the pleura generously toward the opposite side of the vertebral body and equally generously back over the heads of the ribs. Taking time at this point to mobilize the good pleura will facilitate covering the upper end of the hardware construct at the end of the procedure.
- If instrumentation is placed, then gently and carefully isolate, ligate, and tease the vertebral segmental vessels from the vertebral body with a Kidner-type sponge.
- Vessels may be ligated with suture or with vascular clips. Clips should be made of titanium, and use of an automatic clip loader will speed the process. The vessels are readily and easily exposed to the level of L-1, beyond which they are obscured by the psoas musculature.
- Be careful of the nearby genitofemoral and ilioinguinal nerves.
- Pay close attention to the tributaries of the thoracic duct, as well as the sympathetic chain. If a portion of the lymphatic chain is inadvertently cut, chylous spillage will be evident; the two duct ends may be ligated without complication.
- After ligating the segmental arteries, remove the intervertebral discs.
- Use a long handled #15 blade to incise the annulus as near the endplate as possible.
- Resect the annulus as fully as possible, except posteriorly, where a portion is frequently left adherent to the posterior longitudinal ligament.
- The endplates are generally thick and are easily removed with a large curet within the intervertebral space. Pay particular attention not to stray through the fairly soft subchondral bone into the vertebral body itself (Fig. 157.4).

***Figure 157.4.*** Anterior discectomy technique. **A:** Intraoperative photograph demonstrates the anterior lumbar discectomies. Note the motor-potential monitoring electrodes to the left. This patient had some distal motor sparing. **B:** A uterine curet may be useful to remove the cartilaginous endplate. Care needs to be exercised in endplate removal, as the underlying bone is frequently very soft.

- As each discectomy is performed, pack the intervertebral space with thrombin-soaked Surgicel to provide hemostasis.
- When the desired degree of release has been achieved, place the vertebral screws across the vertebral bodies. The dual-screw systems available (CD-Horizon) and the Kaneda anterior scoliosis system (KASS) demonstrate improved pull-out strength compared with single-screw systems (Fig. 157.5) (32). However, the small myelodysplastic spine may not always accommodate two screws. The choice of whether to use a one- or two-screw vertebral construct is an essential part of the preoperative planning.

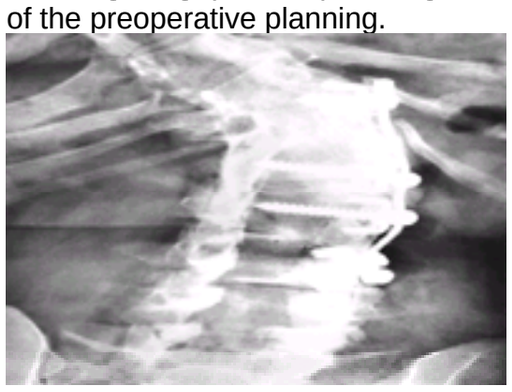

***Figure 157.5.*** PA radiograph of the lumbar spine after Dwyer instrumentation. The lumbar component is well fused despite hardware pull-out. However, note the decompensation at the thoracolumbar junction secondary to “fusing too short.”

- If possible, place screws with bicortical fixation to maximize pull-out strength.
- After placement of the screws in each vertebral body, contour a flexible template rod to the spinal deformity.
- Cut and carefully contour an appropriate-length implantable rod to match the curvature of the template rod.
- After fixing the rod to the vertebral screws, reinflate the vacuum bean bag to soften it and make the table surface flat.
- Now, slowly and gently rotate the rod anteriorly to convert the scoliotic curve into a gentle lumbar curve. When 90° of rotation has been achieved, lock the rod into position.
- Sequentially, beginning from the center, gently distract the intervertebral disc spaces, remove the thrombin-soaked Surgicel, and pack the disc space with bone graft. Use the excised rib and additional allograft cancellous bone as needed. Pack the disc space completely and tightly, and then gently compress the disc.
- Fill each vertebral level with bone graft so that at completion of the grafting, the spine appears as though arthrodesis has already occurred. Leaving large segments of unfilled disc space will increase the likelihood of fibrous union or nonunion, which can lead to hardware failure (6,15,31).
- Allow the reflected psoas musculature to overlie the distal construct, and close the pleura superiorly with a running 2-0 absorbable suture attached to a tapered needle; the use of a cutting needle will result in excessive tearing of the pleura. Reattach the diaphragm either in layers or in a single layer, depending on your preference. Alternate #1 Vicryl and Ethibond sutures for a very strong and secure diaphragmatic closure. Place an appropriate-size chest tube in the anterior axillary line, and tubularize the rib bed to facilitate regrowth of the rib. Close the remainder of the wound in layers. Typically, no drain other than the chest tube is needed. If the anterior–posterior fusion is to be staged, do the posterior procedure in 7 days. However, there is no reason why the procedure must be staged, provided it is safe to proceed with several hours of additional anesthesia. Blood loss from the anterior approach can be kept to a reasonable amount—usually less than 150 ml.

An advantage to same-day anterior–posterior surgery is that the nutritional status of any patient is usually at its best at the time of the first surgery (4,35). It is therefore advisable, whenever possible, to do anterior and posterior surgery under the same anesthetic.

### *Posterior Spinal Fusion*

Use the prone position. Depending on the patient's size, the surgeon's preference, and associated contractures and deformities, any of several positioning devices is appropriate. I believe that the four-post frame is the most useful for smaller adolescents. Once again, it is extremely important to carefully pad all bony prominences, as skin slough at the chest and anterior iliac wings is a significant potential pitfall from prolonged prone positioning.

Preoperative evaluation of the scarred, closed dural sac is mandatory. If the original scar remains in place, take meticulous care to keep the flap edges as thick as

possible. Do not use subcutaneous epinephrine in this scarred area because of the increased risk of postoperative skin slough.

- After positioning the patient in the prone position, make a straight midline incision as for any posterior spinal approach.
- As the distal anatomy is often quite difficult, approach the abnormal anatomy from areas of normal anatomy demonstrated cephalad.
- As the paraspinal musculature is stripped from the posterior elements, maintain good hemostasis and use Bovie cautery for the majority of soft-tissue cutting.
- To avoid the midline scarred area, use an inverted-**Y** incision. With this approach, one entirely avoids the midline sac area, and the midline lumbar area is not undermined at all. This allows good exposure of the transverse processes and pedicles but avoids entering the dural sac, which increases the likelihood of wound breakdown or infection. Be prepared for a small skin slough at the junction of the **Y**, and be careful that the distal limbs of the **Y** portion are far enough apart to allow adequate collateral blood flow to this “island” flap.
- When the spine has been subperiosteally exposed to the transverse processes throughout the length of the incision, facilitate further lateral exposure at the caudal end by transecting the paraspinal muscles in an **L**-type fashion.
  - Contour the appropriate-length rods to maintain the sagittal curves, especially the lumbar lordosis.
  - The degree of contouring toward the scoliosis will depend on the degree of correction that can be obtained once the rod is in place. Gentle pressure on the spine from two persons will allow fairly accurately prediction of what curvature correction will be possible.
  - Affix the upper end of the rod to the spine with a sublaminar hook or sublaminar wires or cables. Sublaminar cables have the advantage of being more flexible; however, they are clearly more expensive, and retightening a cable once crimped is generally not possible unless a second crimp device has been added first. If one desires to maintain an all-titanium construct, however, cables may be the only option (Fig. 157.6).

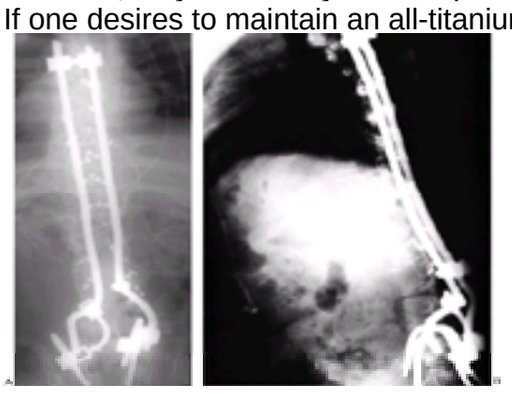

***Figure 157.6.*** PA (**A**) view of a patient who initially underwent pelvic fixation with insertion of rod ends into the sacral ala. Approximately 2 weeks postoperatively, the rod ends displaced dorsally through the bone. Revision surgery utilized a construct with a separate rod placed anterior to the ala and attached posteriorly with Texas Scottish Rite Hospital links (TSRH, Medtronic-Sofamor-Danek, Inc., Memphis, TN). The patient did well after the revision. (See Figure 157.11 for clinical photos.) Lateral (**B**) view of a patient who initially underwent pelvic fixation with insertion of rod ends into the sacral ala. Approximately 2 weeks postoperatively, the rod ends displaced dorsally through the bone. Revision surgery utilized a construct with a separate rod placed anterior to the ala and attached posteriorly with Texas Scottish Rite Hospital links (TSRH, Medtronic-Sofamor-Danek, Inc., Memphis, TN). The patient did well after the revision. (See Figure 157.11 for clinical photos.)

  - Pass the sublaminar wires or cables in the usual fashion in the normal part of the spine and around the remaining pedicle through the neural foramen in the bifid portion of the spine.
  - Pedicle screws can be used where the posterior elements are deficient, as noted previously.
- Fixation to the pelvis, also previously discussed, is based on surgeon preference and bony anatomy. The traditional one-piece Luque “unit” rod is technically demanding, but fortunately alternatives exist. The one-piece bilateral rod may be cut and then reconnected with any of several rod cross-links available on the market. The overall stability will not be compromised by this technique (Fig. 157.7). Additionally, there may even be cases in which the surgeon may wish to use two rods on each side connected by rod-to-rod connectors.

***Figure 157.7.*** PA radiograph of the thoracolumbar spine demonstrates a segmental sublaminar fixation utilizing flexible stainless steel cables. Cross-links are required to maintain rod–rod stability. Fixation to the pelvis (not seen here) is by the Galveston technique.

***Figure 157.11.*** Pre- (**A**) and postoperative (**B**) photographs show a 12-year-old girl who underwent kyphectomy and thoracolumbar instrumented fusion. Note the improved sitting balance and the better contour for seating. (The same patient is the subject as Figure 157.6.)

- After completion of the instrumentation, carefully decorticate the spine before applying the bone graft. If the soft tissue has been satisfactorily removed from the bone, this may be sufficient for the myelodysplastic spine. Meticulous decortication, as done in idiopathic scoliosis, runs the risk of further weakening already weak bone, which results in lamina fracture and wire pull-through. The experienced surgeon will need to straddle this fine line between risk of hardware failure and potential for nonunion.

Again, while the tendency in idiopathic scoliosis surgery is to allow patients to be free of bracing or an orthosis postoperatively, such is not the case in the myelodysplastic spine. There is much greater risk for hardware failure, and most surgeons place patients into a custom-made bivalved underarm body jacket 5–7 days after surgery. It should be worn for 9–15 months after surgery (34). Whereas bracing has significant pitfalls in attempting to *improve* a curve, the likelihood of skin problems with a postoperative brace that is simply *holding* position is much less. However, do advise the family that skin problems can still occur. It is important that an experienced orthotist make these braces.

Many patients with scoliosis have a congenital component to their curve. Congenital curves are best addressed early and are most frequently treated by *in situ* fusion of the congenital curve. Resection of hemivertebrae is rarely indicated, except in the lower-lumbar regions, most typically at L-5. A hemiepiphysiodesis will occasionally allow the contralateral portion of the spine to grow and actually provide some correction. However, in the majority of patients, epiphysiodesis serves to stop all growth, and significant improvement is never realized.

Many myelodysplasia clinics have patients with 100° + curves that have progressed relentlessly to this point through the desire of the family to refrain from surgery or

by fear that early surgery will result in too much truncal shortening. Surgeons must be aggressive about treating the progressive and significant curve, even in a patient with 6–8 years of growth remaining. It is better to have a short trunk than to end up with a severe curve and loss of function. The subcutaneous “growth” rod remains an excellent short-term way of slowing some curve progression. The growth rod is similar to the concept developed for juvenile idiopathic curves, but in the myelodysplastic spine, it frequently requires additional points of skeletal fixation. The Luque trolley, utilizing loose sublaminar wires and no bone graft, was introduced in an attempt to maintain position until formal fusion (36). The chief problem with it is the difficulty in getting the spine to truly “slide.” This may still be worth a try if it is the only alternative to fusing a spine prematurely, and has been shown of greater utility when combined with short-segment epiphysiodesis (36).

## KYPHOSIS

Significant structural lumbar kyphosis occurs in approximately 15% of patients with myelomeningocele (30). Operative management of collapsing kyphosis routinely requires an anterior and posterior approach, and unlike the typical anterior procedure, these frequently require some additional posterior-element resection so that the kyphotic component can be corrected toward a more anatomic configuration.

Normal lumbar lordosis rarely develops in children with a mid- to upper-level lumbar meningocele. The absence of the posterior elements and overlying musculature, combined with tight hamstrings rocking the pelvis posteriorly, creates a hypolordotic, if not kyphotic, lumbar spine. In severe cases, the kyphosis becomes profound, and in some the lumbar spine will virtually fold over on itself, creating a near 180° gibbous deformity (Fig. 157.8). Lumbar kyphosis is more disabling than scoliosis in many respects because the forward-flexed lumbar spine creates a relatively hypokyphotic thoracic spine. Such spines are not mechanically stable, and patients must prop themselves up on their hands. This creates problems with pulmonary function, as well as with GI and GU tract motility in the long-term. In addition, by constantly having to prop themselves up with their hands, patients are unable to function well in activities of daily living.

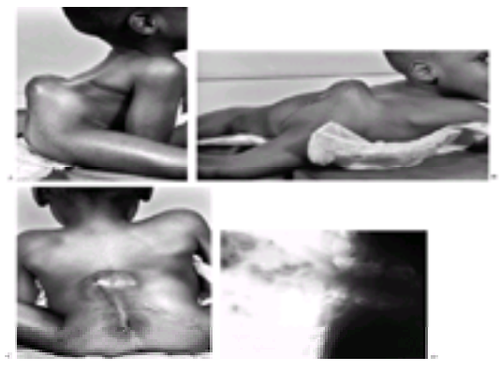

***Figure 157.8.*** A 4-year-old boy with a 180° gibbus. **A:** Lateral sitting view demonstrates the problems with a significant gibbus. There is limited upper-extremity mobility, as the elbows support much of his weight. **B:** A recumbent view demonstrates no appreciable mobility of the gibbous segment. **C:** Note the extensive scarring in the midline and the fragility of the skin overlying the gibbus. **D:** Lateral radiograph shows the hairpin bony deformity.

Lumbar kyphosis is often present at birth and may be significant very early on. Bracing is very difficult because of the very prominent bone underlying poor skin (5).

There are two broad categories of lumbar kyphosis. The more common type is a rigid kyphotic deformity, usually with the apex at the L1-2 level. This is associated with a rigid compensatory lower-thoracic lordosis. The other, less common, less severe kyphosis is typically less rigid and has no proximal lordosis (19). Indications for correcting lumbar kyphosis include recurrent skin ulcerations over the prominence, difficulty with wheelchair fitting, progressive pulmonary, GI, or GU problems, and difficulties with activities of daily living secondary to the forward-flexed posture (5). Surgical reconstruction (26,43), a major undertaking, should accomplish three goals, according to Lindseth and Slezer (22): It should (a) straighten and stabilize the spine for better sitting posture, (b) markedly diminish the prominence of the kyphos, and (c) increase the overall height of the abdominal cavity.

Sharrard (41) was the first to describe resection of vertebral bodies in the management of this condition. His 1968 study demonstrated good correction, but follow-up studies have demonstrated that simple excision of the apex leads to an unacceptable recurrence rate of the initial kyphosis (22). Lindseth and Slezer (22) showed that excision of one or two vertebrae proximal to the apex of the kyphosis both realigned the lumbar spine to the proximal thoracic portion and improved long-term results.

Kyphectomy is generally done at birth, in 2–5-year-olds, or most commonly in young adolescents. A one- to two-vertebral-level kyphectomy may be required at birth for the very rare situation in which skin closure is not possible. For the 2–5-year-old group, in whom the gibbus is a problem, a procedure has been described in which the proximal segment of the gibbus is resected and the remaining lumbar spine is brought into apposition with the thoracic spine and held with a single-level wiring of one pedicle to the other (Fig. 157.9) (22). No fusion or other instrumentation is necessary in these young, usually quite lightweight patients who then wear a pantaloon cast or brace for 6 months followed by an additional 6 months of underarm bracing. The advantage of doing this procedure earlier rather than later stems from the fact that only one level is fused and the remainder of the lumbar and thoracic vertebral bodies continue to grow. The majority of these patients will likely require additional surgery in the long term, but the benefits tend to outweigh this minor drawback. The Luque trolley, as noted previously, has also been utilized for kyphotic deformities (36). I prefer to wait until a child is 10–12 years of age before proceeding with a multisegmented instrumentation.

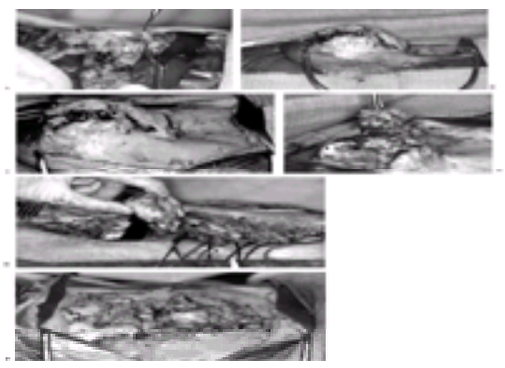

***Figure 157.9.*** Intraoperative photographs of the patient in Figure 157.8. **A:** In a patient undergoing a gibbus resection in whom significant growth remains, the spine is opposed after resection with single-level wiring of one pedicle to the other. Note the transverse incision. Here, the dural sac is being freed from the posterior aspect of the bony canal. **B,C:** Nonfunctional nerve roots are ligated. **D:** The dural sac is carefully elevated in a subperiosteal manner. **E:** While the sac is retracted cephalad, a Gigli saw is used to resect the superior portion of the gibbus. **F:** The vertebral bodies have been opposed and cabled together.

### *Lumbar Kyphectomy*

Kyphectomy in a 10–12-year-old patient typically involves the same technique in which the superior portion of the apex is resected and the lumbar and thoracic segments are joined back together with an accompanying segmental instrumentation construct extending from the pelvis to the upper-lumbar spine (Fig. 157.10 and Fig. 157.11). In contrast to the approach in 2–5-year-old patients, in whom a transverse incision works very nicely, use a traditional longitudinal incision for this procedure. Start in the midline from the more normal upper-thoracic spine and extend downward to the sacrum. The dura is typically just beneath the skin, and care must be exercised as the dissection proceeds from the midline laterally to leave the dura intact and the overlying skin as thick as possible. It is very easy to violate the dural sac. Promptly close any durotomy.

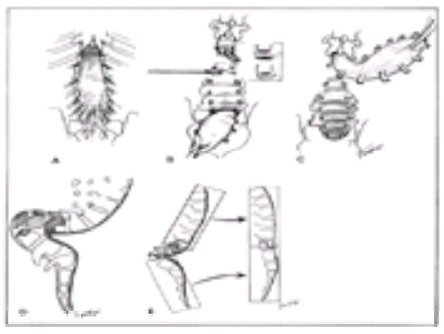

***Figure 157.10.*** **A:** A typical total spina bifida of the lumbar spine as seen in congenital lumbar kyphosis. The *dotted line* shows the level of dural transection. **B:** The nonfunctional cord is transected, and the dura is sutured distal to the cord transection. The central canal of the cord must be left open to communicate with the subdural space. The nerve roots are transected at each foramen. The discs are removed from behind. **C:** An alternative technique is distal detachment of the neural sac and progressive upward dissection with division of the nerve roots at the level of the foramina. The sac is usually not entered, and the cord does not have to be transected. The risk of acute hydrocephalus is reduced, and the sac is laid down over the instrumentation to provide better coverage. **D:** A typical rigid myelomeningocele kyphosis. The *hatched area* represents the vertebrae to be resected, usually those between the apex of the kyphosis and the apex of the lordosis. **E:** The general principle is to relate the distal segment (sacrum and lower-lumbar vertebrae) to the proximal segment (thorax) so that the two are in a stable vertical relationship. The anterior longitudinal ligament is preserved as the hinge on which the segments are aligned. (From Bradford DS, Lonstein JE, Moe JH, et al. *Moe's Textbook of Scoliosis and Other Spinal Deformities.* Philadelphia: WB Saunders, 1987:322, with permission.)

- While dissecting laterally after exposing the posterior elements, elevate the dural sac from the spinal canal to expose the posterior aspects of the vertebral bodies. This is done after distal transection of the dura. (These patients typically have a functioning level at L-1 or higher.)
  - Typically, when the dura is transected at the sacral level, the spinal cord itself, even in cases of significant tethering, is well proximal. Take extreme care when closing this dural transection not to ligate any element of the cord itself, as this can result in sudden increased CSF pressure that will cause profound intraoperative hypotension and possibly death. The central canal often functions as a major CSF conduit when there are poorly functioning ventricles (18,44).
  - Cut the nerve roots at each level, and ligate them to prevent CSF leakage. (The roots may be ligated, as there is no CSF circulation within the nerve roots themselves.)
  - After these have been ligated, elevate the sac, from distal to proximal, off the posterior aspect of the vertebral bodies (Fig. 157.9*D*).
  - Avoid significant blood loss by taking care to stop the bleeding from the numerous venous sinuses lying within the canal. Bovie electrocautery is useful for extraosseous bleeding, and bone wax packed into the interstices is useful for bone bleeding.
- After the sac has been mobilized anteriorly and the stump is closed without evidence of leakage, turn your attention to the kyphotic segment. With the nerve roots gone, gently elevate the structures on either side of the transverse processes subperiosteally, and proceed anteriorly back toward the midline. This dissection generally proceeds quite easily if one takes time and care to stay, if not subperiosteal, immediately supraperiosteal. Remember that the aorta and vena cava are in this soft-tissue mass that you are dissecting off the anterior portion of the vertebral body and these vessels could be injured by any sharp transgression into the mass.
  - After the spine is circumferentially freed (Fig. 157.9*E*), determine the segments for excision. It is always better to start with a fewer number than your preoperative template led you to believe.
  - Typically, two to three vertebral bodies must be removed to realign the spine in a reasonable configuration.
- After the appropriate vertebral segments are resected *en bloc* (Fig. 157.9*E*), the proximal and distal portions will still be prominent. Use gentle finger pressure to approximate the two ends, which can then be approximated with pedicle-to-pedicle wire or cable, following with an overlying construct of hooks, wires, cables, or pedicle screws (Fig. 157.9*F*). Pelvic fixation may be of the Galveston type in the manner described by Dunn (14) or the variation described by McCarthy et al. (28).
- After instrumentation is completed, allow the dural sac to fall back into its original position, and close the wound in routine fashion. Some authors advise against using a suction drain because it may increase the potential for CSF leak in their view.

Note that before you allow the dural sac to lay back down over the lumbar spine, several intravertebral discs will be exposed. This represents an excellent opportunity to perform a posterior lumbar interbody fusion (PLIF) and obviate a second stage of fusion to be performed later from the front. Obviously, in certain situations, a formal anterior fusion may be needed, but with several levels of PLIF in a patient who is unlikely to crankshaft, a second-stage anterior procedure is not always necessary.

Begin mobilizing patients by 1 week after surgery after fabrication of a custom bivalved underarm body jacket, which is worn for 12–18 months after surgery.

## POSTOPERATIVE CARE AND REHABILITATION

Scoliosis correction and kyphectomy are extensive operations in children with multiple medical problems. Blood loss can be high, anesthesia times are long, and a postoperative pediatric intensive care unit is therefore mandatory. Many patients will remain intubated for 24 hours, and some will require short-term ventilatory support. Aggressive blood replacement therapy is indicated, and good urinary output must be maintained. As these patients are at higher risk for postoperative infection, maintain a longer period of prophylactic antibiotic therapy (often 5–7 days after surgery), and at the very least prescribe one dose beyond the point when all drains and central lines are removed. Use an aminoglycoside together with a cephalosporin to adequately cover the gram-negative organisms associated with chronic GU tract colonization and infection.

Other authors have advocated the use of total parenteral nutrition for patients undergoing staged procedures whose nutritional status is poor. This is certainly an option if the anterior–posterior fusion cannot be accomplished under one anesthetic. While monitoring of somatosensory-evoked potentials is typically not used intraoperatively, postoperative clinical neurologic monitoring is extremely important, especially in patients who have a history of hydrocephalus and a working shunt.

After patients have been medically stabilized, it is imperative to mobilize them as quickly as possible. However, do not place a patient in a sitting or standing position until the custom orthosis is available. A good relationship with the orthotist will facilitate obtaining a brace with 24° to 48° postoperatively. Early mobilization helps prevent muscle atrophy and acute postoperative osteopenia. There is typically no reason or indication for prolonged bed rest after surgery.

Physical skills, which these patients have slowly gained, are rapidly lost after surgery, and physical therapy is exceedingly important to regaining their preoperative level of function. Whereas the surgery should improve sitting and standing balance, there is definitely a risk for marginal ambulators to become wheelchair-bound, particularly after fusion to the pelvis. This functional loss frequently occurs in patients with myelomeningocele in the early teenage years, but this possibility or eventuality should be discussed and well understood by patients and families before the surgical procedure. As socialization of these patients is of high importance as well, they should be allowed to return to their school setting as soon as they are ready—usually at about 4 weeks after surgery.

## PITFALLS AND COMPLICATIONS

The surgical management of spinal deformity in myelodysplasia is difficult because of the severity of the deformity, the abnormal anatomy, and the multiple medical problems with which patients present. The first caveat therefore regarding this sort of spine surgery is that it is not for the casual spinal surgeon. Even in the best of hands, the postoperative complication rate is high. Without an experienced surgical team and an experienced surgeon in charge, the results can be disastrous.

Whereas any spinal deformity in any patient should be approached on an individual case-by-case basis, patients with myelomeningocele, perhaps even more so, cannot be treated in assembly-line or cookbook fashion. While the newer instrumentation may make it somewhat less necessary to combine anterior with posterior fusion, one must be careful not to neglect to perform both when both are necessary. It can be difficult to achieve a good, solid fusion if the posterior elements do not lend themselves to good bone-rod fixation or the exposed areas are too sparse to achieve a good fusion mass.

As these procedures are not cookbook in their design, the surgeon must be willing and able to compromise, devise, create, and improvise intraoperatively. Routine surgery always needs a flexible plan. Surgery of this nature requires not only plans A and B but plans C, D, and E, as well.

One of the most common technical errors is to attempt to preserve distal-lumbar motion segments and to “fuse too short” (6). Whereas maintaining lumbar motion is desirable in virtually any other spinal surgery, it is a significant mistake to leave the L5-S1 junction mobile in the paralytic spine. Not only will this area degenerate and

cause pain over time in some patients, but it will almost certainly be unstable and can result in a junctional kyphosis or hyperlordosis in the paralytic spine. Similarly, stopping the fusion too short proximally can allow the upper portion of the thoracic spine to develop forward kyphosis, which will cause postural difficulties.

Never perform a unilateral fusion. The amount of bone stock present is rarely sufficient to provide significant stability by fusion of only one side of the spine.

Infection, the second most common postoperative complication, rears its ugly head in up to 25% of cases (34). As previously noted, prophylaxis with two antibiotics is considered the standard of care. It is very difficult to achieve true urine sterility in most patients, but if the organisms can be suppressed to the colonization level, postoperative sepsis secondary to GU contamination is less likely. Infection secondary to hematoma and dead-space and wound breakdown secondary to poor skin is best addressed preoperatively, as previously noted. The two best options for preventing deep infection because of skin problems include using an inverted-**Y** incision or doing a two-stage tissue expansion, as previously outlined.

Pseudarthrosis has been a common problem in the past. With the availability of bank bone graft and bone-graft extenders, the pseudarthrosis rate should decline in future studies. However, it is important to realize that bone must fuse to bone and therefore meticulous preparation of the bone graft bed is a requirement.

Instrumentation failure is also a common problem both intraoperatively and in the early postoperative period. Its cause is rarely metal breakage, but rather rod, hook, or wire pull-out from osteopenic bone. Addressing calcium balance and osteopenia preoperatively can be of use. One must be careful about being overly aggressive in tightening wires and distracting hooks. Despite adequate segmental fixation, the postoperative brace is still key in the postoperative management. Late instrumentation failure (wire or rod breakage) must be considered a pseudarthrosis until proven otherwise. Again, meticulous attention to bone grafting technique will minimize the pseudarthrosis rate.

Sometimes, even when the most extreme care has been exercised in providing postoperative hardware coverage, a sore will form over a prominent portion of the hardware. Once this covering is violated to the point where the metal is observable from the outside, securing a sterile environment is virtually impossible until all metal has been removed. If the wound becomes colonized and infected, significant long-term complications can ensue, resulting in difficult-to-treat chronic deep infections. If spinal osteomyelitis occurs, I have used debridement, long-term parenteral antibiotics, free-flap coverage to provide improved blood supply, and even hyperbaric oxygen to manage this most difficult problem.

## CHAPTER REFERENCES

Each reference is categorized according to the following scheme: *, classic article; #, review article; !, basic research article; and +, clinical results/outcome study.


+ 1. Alan LD, Donald I, Gibson AA, et al. Amniotic Fluid Alpha-fetoprotein in the Antenatal Diagnosis of Spina Bifida. *Lancet* 1973;2:522.

# 2. Allen B, Ferguson R. Operative Treatment of Myelomeningocoele Spinal Deformities. *Orthop Clin North Am* 1979;10:845.

+ 3. American Academy of Allergy and Immunology: Task Force Report on Allergic Reactions to Latex. *J Allergy Clin Immunol* 1993;92:16.

+ 4. Banta J, Park SM. Improvement in Pulmonary Function in Patients Having Combined Anterior and Posterior Spine Fusion for Myelomeningocoele Scoliosis. *Spine* 1983;8:766.

+ 5. Banta JV, Hamanda JS. Natural History of the Kyphotic Deformity in Myelomeningocele. *J Bone Joint Surg Am* 1976;58:279.

# 6. Bradford DS, Lonstein JE, Moe JH, et al. *Moe's Textbook of Scoliosis and Other Spinal Deformities,* 3rd ed. Philadelphia: WB Saunders, 1995.

# 7. Brown HP. Management of Spinal Deformity in Myelomeningocele. *Orthop Clin North Am* 1978;9:391.

+ 8. Bunch WH, Sharff TB, Dvonch VM. Progressive Neurological Loss in Myelomeningocele Patients. *Orthop Trans* 1983;7:185.

+ 9. Centers for Disease Control and Prevention. Recommendations for the Use of Folic Acid to Reduce the Number of Cases of Spina Bifida and Other Neural Tube Defects. *MMWR* 1992;41(RR-14):1.

+ 10. Dickens DVR. The Surgery of Scoliosis and Spina Bifida. *J Bone Joint Surg Br* 1979;61:386.

# 11. Dormans JP, Templeton JJ, Edmonds Cl, et al. Intraoperative Anaphylaxis Due to Exposure to Latex (Natural Rubber) in Children. *J Bone Joint Surg Am* 1994;76:1688.

! 12. Drennan JC. The Role of Muscles in the Development of Human Lumbar Kyphosis. *Dev Med Child Neurol* 1970;12:33.

+ 13. Drummond DS, Moreau M, Cruess RL. The Results and Complications of Surgery for the Paralytic Hip and Spine in Myelomeningocoele. *J Bone Joint Surg Br* 1980;62:49.

+ 14. Dunn HK. Kyphosis of Myelodysplasia: Operative Treatment Based on Physiology. *Orthop Trans* 1983;7:19.

* 15. Dwyer AF, Newton MD, Sherwood AA. An Anterior Approach to Scoliosis. *Clin Orthop* 1969;62:192.

+ 16. Gardner WJ. Myelocele: Rupture of the Neural Tube? *Clin Neurosurg* 1968;15:57.

# 17. Hack HP, Zielke K, Harms J. Spinal Instrumentation and Monitoring. In: Bradford DS, Hensinger RM, eds. *The Pediatric Spine.* New York: Thieme, 1985.

+ 18. Hall PV, Lindseth RE, Campbell RL, et al. Scoliosis and Hydrocephalus in Myelocele Patients: The Effects of Ventricular Shunting. *J Neurosurg* 1979;50:174.

+ 19. Heydemann JS, Gillespie R. Management of Myelomeningocele Kyphosis in the Older Child by Kyphectomy and Segmental Spinal Instrumentation. *Spine* 1987;12:37.

+ 20. Hide DW, Williams HP, Ellis HL. The Outlook for the Child with a Myelomeningocele for Whom Early Surgery was Considered Inadvisable. *Dev Med Child Neruol* 1972;14:304.

+ 21. Hull WJ, Moe JH, Winter RB. Spinal Deformity in Myelomeningocoele: Natural History, Evaluation, and Treatment. *J Bone Joint Surg Am* 1974;56:1767.

+ 22. Lindseth RE, Slezer L. Vertebral Excision for Kyphosis in Children with Myelomeningocele. *J Bone Joint Surg Am* 1979;61:699.

+ 23. Lorber J. Selective Treatment of Myelomeningocele: To Treat or Not to Treat? *Pediatrics* 1974;53:307.

+ 24. Matan AJ, Smith JT, Dunn HK. Risk Factors Associated with Anterior Surgery of the Thoracic Spine. Presented at the Pediatric Orthopaedic Society of North America Annual Meeting, Cleveland, Ohio, May 1998.

# 25. Mayfield JK. Spine Deformity in Myelomeningocele. In: Bradford DS, Hensinger RM, eds. *The Pediatric Spine.* New York: Thieme, 1985.

+ 26. Mayfield JK. Severe Spine Deformity in Myelodysplasia and Sacral Agenesis: An Aggressive Surgical Approach. *Spine* 1981;6:498.

+ 27. Mazur J, Menelaus MB, Dickens DR, et al. Efficacy of Surgical Management for Scoliosis in Myelomeningocele: Correction of Deformity and Alteration of Functional Status. *J Pediatr Orthop* 1986;6:568.

+ 28. McCarthy RE, Dunn J, McCullough FL. Luque Fixation to the Sacral Ala Using the Dunn-McCarthy Method. *Spine* 1989;14:281.

+ 29. McGuire CD, Winter RB, Mayfield JK, Erickson DL. Hemimyelodysplasia: A Report of Ten Cases. *J Pediatr Orthop* 1982;2:9.

+ 30. McMaster MJ. The Long-term Results of Kyphectomy and Spinal Stabilization in Children with Myelomeningocele. *Spine* 1988;13:417.

+ 31. McMaster MJ. Anterior and Posterior Instrumentation and Fusion of Thoracolumbar Scoliosis Due to Myelomeningocele. *J Bone Joint Surg Br* 1987;69:20.

+ 32. Moe JH, Purcell GA, Bradford DS. Zielke Instrumentation (VDS) for the Correction of Spinal Curvature. *Clin Orthop* 1983;180:133.

! 33. Morgagni JB. *The Seats and Causes of Diseases Investigated by Anatomy,* vol 3. London: A Millar & T Cadell, 1979.

+ 34. Osebold WR, Mayfield JK, Winter RB, Moe JH. Surgical Treatment of Paralytic Scoliosis Associated with Myelomeningocele. *J Bone Joint Surg Am* 1982;64:841.

+ 35. Powell ET, Krengel WF, King HA. Comparison of Same-day Sequential Anterior and Posterior Spinal Fusion with Delayed Two-stage Anterior and Posterior Spinal Fusion. *Spine* 1994;19:1256.

+ 36. Pratt RK, Webb JK, Burwell RB, Cummings SL. Luque Trolley and Convex Epiphysiodesis in the Management of Infantile and Juvenile Idiopathic Scoliosis. *Spine* 1999;24:1538.

# 37. Raycroft JE, Curtis BH. Spinal Curvature in Myelomeningocele: Natural History and Etiology. In: *American Academy of Orthopaedic Surgeons: Symposium on Myelomeningocele.* St. Louis, MO: Mosby, 1972.

+ 38. Samuelsson L, Eklof O. Scoliosis in Myelomeningocele. *Acta Orthop Scand* 1988;59:122.

* 39. Sanders JO, Nerring JA, Browne RH. Posterior Arthrodesis and Instrumentation in the Immature (Risser Grade-0) Spine in Idiopathic Scoliosis. *J Bone Joint Surg Am* 1995;77:39.

+ 40. Seller MD, Nevin NC. Periconceptional Vitamin Supplementation and the Prevention of Neural Tube Defects in South-east England and North Ireland. *J Med Genet* 1984;21:325.

+ 41. Sharrard WJ. Spinal Osteotomy for Congenital Kyphosis in Myelomeningocele. *J Bone Joint Surg Br* 1968;50:466.

+ 42. Tosi LL, Slater JE, Shaer C, Mostello LA. Latex Allergy in Spina Bifida Patients: Prevalence and Surgical Implications. *J Pediatr Orthop* 1993;13:709.

+ 43. Warner WC Jr, Fackler CD. Comparison of Two Instrumentation Techniques in Treatment of Lumbar Kyphosis in Myelodysplasia. *J Pediatr Orthop* 1993;13:704.

+ 44. Winston K, Hall J, Johnson D, Micheli L. Acute Elevation of Intracranial Pressure Following Transection of Non-functional Spinal Cord. *Clin Orthop* 1977;128:41.

+ 45. Yates JR, Ferguson-Smith MA, Shenkin A, et al. Is Disordered Folate Metabolism the Basis for the Genetic Predisposition to Neural Tube Defects? *Clin Genet* 1987;31:279.

# CHAPTER 158

# SPINAL SURGERY IN CONGENITAL SYNDROMES

*Paul D. Sponseller*

**P. D. Sponseller:** Department of Pediatric Orthopaedics, Johns Hopkins Hospital School of Medicine, Baltimore, Maryland, 21287.

Cervical Spine Abnormalities
- Odontoid Hypoplasia/atlantoaxial Instability
- Cervical Stenosis
- Cervical Spina Bifida
- Operative Techniques

Thoracolumbar Abnormalities
- Congenital Stenosis
- Congenital and Acquired Kyphosis
- Congenital Scoliosis

Management of Specific Syndromes
- Skeletal Dysplasias
- Osteogenesis Imperfecta
- Arthrogryposis Multiplex Congenita
- Neurofibromatosis
- Marfan Syndrome

Surgical Techniques
- Hemiepiphyseodesis for Congenital Deformity Due to Hemivertebrae
- Hemivertebra Excision
- Thoracolumbar Laminoplasty Versus Laminectomy

Chapter References

The development of the spine may be upset by abnormalities of connective tissue, muscle balance, or ossification. Although a congenital syndrome is by definition present at birth, an associated spinal deformity in most cases is not. It may develop with growth as a result of bone dysplasia, a connective tissue disorder, or miscellaneous chromosomal abnormalities. The orthopaedic surgeon must understand the natural history of these growth disturbances to determine when, as well as how, to intervene. Three factors should always be kept in mind when evaluating the patient with a congenital syndrome: (a) coexisting medical problems, (b) characteristics of bone shape and quality, and (c) the effect of the syndrome on the neural elements.

## CERVICAL SPINE ABNORMALITIES

The cervical spine in many congenital syndromes is vulnerable to deformity, stenosis, and, most important, instability. The surgical team must rule out or characterize the potentially unstable cervical spine before general anesthesia is administered or any skeletal surgery is performed. Plain film radiography with or without flexion–extension may be helpful. Table 158.1 lists characteristic cervical spine problems in most common congenital syndromes.

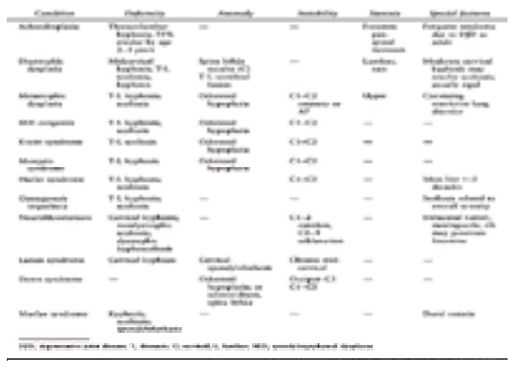

***Table 158.1. Characteristic Cervical Spine Problems in Common Congential Syndroms***

### ODONTOID HYPOPLASIA/ATLANTOAXIAL INSTABILITY

The term *hypoplastic odontoid* generally refers to an odontoid process that does not extend to the midportion of the ring of the atlas. It may be seen in numerous conditions; the most common are skeletal dysplasia and Down syndrome (21,31,35). Odontoid hypoplasia may also be an idiopathic occurrence. In extreme cases, the dens may be essentially absent (*aplasia*). The majority of these cases of odontoid hypoplasia are the result of skeletal dysplasias. Another condition that exhibits similar clinical symptoms is *transverse ligament insufficiency,* which may be caused by ligamentous laxity or damage to the ligament. Finally, a number of patients have an *os odontoideum*, a chronic condition in which the odontoid is present only as a small ossicle, not united to the body of the axis. Although os odontoideum was long presumed to be a congenital lesion, more recent evidence suggests that most cases may be the result of unrecognized fracture of the odontoid.

Patients with any of these four problems share a variety of symptoms: (a) They may show signs and symptoms of neck instability, manifested by the muscles' response to guard it: neck pain and spasm, torticollis, or headache. These symptoms appear most often after activity or a fall. (b) Neurologic symptoms involving the long cervical tracts may be present, such as developmental delay, hyporeflexia or hyperreflexia, and weakness. (c) Finally, cerebrovascular symptoms may prevail, from ischemia to stroke involving the posterior circulation. Plain radiographs are helpful in establishing the diagnosis, and computed tomography (CT) can usually demonstrate the pathology clearly, if needed.

Plain films that include lateral views in flexion and extension will help to quantify the instability. The normal space available for the cord at this level should be at least 13 mm, and the translation of the ring of the atlas should be less than 5 mm. Magnetic resonance imaging (MRI) may be helpful to demonstrate cord impingement, but this can often be deduced from plain films and clinical exam alone.

If radiography reveals signs of instability beyond a critical limit (more than 5–8 mm of translation on flexion/extension films), stenosis, or neurologic signs, surgical fusion of C-1 to C-2 is indicated (24). Reduction to a neutral position is the goal; if this cannot be accomplished, decompression may also be required.

### CERVICAL STENOSIS

When cervical stenosis is seen in children, the diagnosis is usually achondroplasia, Klippel-Feil syndrome (36), or idiopathic congenital cervical stenosis. Signs and symptoms include those of acute compression (numbness and tingling in the extremities, acute weakness) or chronic myelopathy with developmental delay, spasticity, weakness, and muscle atrophy. In the teenage athlete with idiopathic cervical stenosis, transient quadriparesis is a common presenting phenomenon, with forced hyperextension in the presence of a narrowed spinal canal (41). Fortunately, this symptom tends to resolve rapidly if there is no vertebral subluxation or dislocation. In the child with achondroplasia, the greatest degree of stenosis occurs at the foramen magnum, causing failure to meet developmental milestones and a tendency to develop sleep apnea. Clinically significant stenosis of the remainder of the cervical spine in the person with achondroplasia generally develops only in adulthood, if at

all.

Certain other skeletal dysplasias (such as spondyloepiphyseal dysplasia and mucopolysaccharidoses) may produce localized stenosis of the ring of the axis as well as atlantoaxial instability; these can cause additive damage to the cord. On lateral radiographs, cervical stenosis should be suspected if the distance from the posterior laminar line to the posterior vertebral body line is less than 80% of the width of the vertebral bodies (Pavlov's ratio) (41). Also, the distance from the posterior laminar line to the line of the facets is diminished (Fig. 158.1). In patients with Klippel-Feil syndrome, this finding may be missed because attention is drawn to the vertebral fusions. The stenosis is made more problematic if there are large blocks of fusion with just a few motion segments.

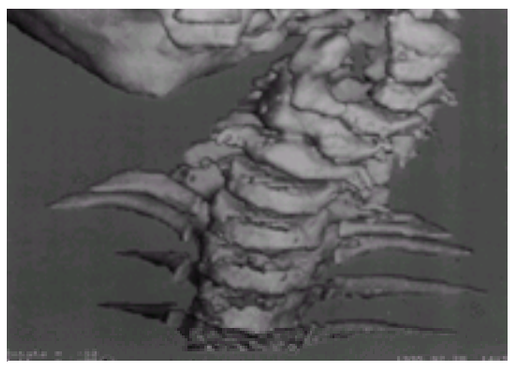

***Figure 158.1.*** Torticollis in a young child, in this case due to three consecutive hemivertebrae in the upper cervical spine. In infants, computed tomograms provide superior visualization compared with plain films, because of the baby's large head, difficulty positioning, and the complexity of the case. Treatment was by realignment with distraction of the concave side and derotation in a halo-vest, followed by fusion.

Patients with known cervical stenosis should be counseled to avoid contact sports, especially those that produce forcible flexion or extension of the cervical spine, such as wrestling and playing lineman in American football. Surgical decompression of the lower cervical spine is generally best avoided, as it could produce a region of decreased stability adjacent to further stenosis. Localized decompression and fusion may be carried out if indicated. Patients with congenital stenosis of the upper cervical spine may require decompression. If this is so, fusion should be considered if there is associated instability or if the decompression involves more than two segments, in order to prevent development of localized kyphosis.

## CERVICAL SPINA BIFIDA

Occult defects in the cervical spine occur primarily in two congenital syndromes: Larsen syndrome and diastrophic dysplasia. Larsen syndrome is characterized by multiple joint dislocations, foot deformities, and an accessory calcaneal apophysis. In one series, more than half the patients had cervical spina bifida and resultant kyphosis (22). In diastrophic dysplasia, diastrophic patients are often born with significantly short stature, rigid clubfeet, joint contractures, and a closed cervical spina bifida, although the incidence of kyphosis is not as high.

The presence of spina bifida in the cervical region indicates a deficiency of posterior ligamentous support (interspinous ligament, ligamentum flavum) as well as of posterior muscle control. This may be a reason for the development and progression of kyphosis. In addition, the vertebral bodies in the region are hypoplastic and may be rounded or wedge shaped. The kyphosis may progress as the child becomes upright. Initially, the physical features of kyphosis are not externally evident, except for a slight loss of the normal cervical lordosis. There are no external clues to the presence of bifid cervical laminae. Therefore, a high index of suspicion must be maintained for these conditions.

Patients may exhibit myelopathy, which may be difficult to detect in children with severe skeletal deformities. Signs such as muscle weakness, failure to achieve normal milestones, and hyperreflexia or clonus may be seen. Endotracheal intubation for other surgical procedures in the presence of this kyphosis may worsen the neurologic condition if not done by knowledgeable persons. In some patients with diastrophic dysplasia, a mild cervical kyphosis may improve spontaneously with time (18). Observation may be indicated if there are no established signs of neurologic compromise. Bracing, however, does not seem to be feasible or warranted. In Larsen syndrome, progression is more likely (22).

### *Posterior Fusion*

The optimal treatment is an early posterior fusion, which may function as a tether and allow spontaneous correction of the deformity.

- Perform fusion early in the patient with Larsen syndrome, before the kyphosis exceeds 50° and becomes rigid. Consider fusion in patients with diastrophic dysplasia who do not improve over the first several years of life, or whose deformity or neurologic condition worsens.
- Perform posterior fusion over the levels involved in the kyphosis, using autogenous bone graft from the iliac crest or the tibial metaphysis.
- Use a halo-vest or halo-cast to control the head and prevent the kyphosis from worsening during incorporation of the fusion. For mild deformities, a Minerva-type cast or orthosis is also an option. Order them in advance of the procedure.
- Take care in exposing the spine, because of the open laminae.
- Dissect the muscles off only the extent of the spine intended for fusion, since extension of the fusion to adjacent exposed levels is a risk. Confirm levels radiographically.
- Decorticate the spine gently and perform a bone graft.

Instrumentation of the spine is not possible for patients of a very young age. Some degree of correction in the halo-vest may be possible by a combination of three maneuvers: (a) positioning the head in slight extension and posterior translation, (b) securing the shoulder straps of the vest so that they are snug (but not too tight), to maintain the length of the cervical spine rather than allowing it to settle, and (c) placing a padded sling behind the apex of the kyphosis, which is attached to the bars of the halo-vest, to prevent the kyphosis from settling posteriorly. When this is done, the tension of the strap must be checked periodically to be certain that there is not too much pressure on the skin.

If the deformity is severe or there is significant neurologic compromise, an anterior decompression and strut graft may be needed in addition to the posterior fusion. The spine should be immobilized for a minimum of 3 months, and continuity of the fusion mass should be demonstrated radiographically at the end of this period to prevent loss of position due to a pseudarthrosis.

Congenital fusion of the cervical spine, or Klippel-Feil syndrome, may occur with congenital upper or lower thoracic or lumbar fusion, or it may be present as an isolated finding. It has been classified into three types: *Type I* involves fusion of cervical and upper thoracic vertebrae, *type II* involves isolated fusions of the cervical spine, and *type III* refers to cervical fusions associated with lower thoracic or upper lumbar fusion (36). Surgery is almost never required for the cervical anomaly itself.

The main significance of the diagnosis is to encourage a search for other anomalies both within and outside the spine, such as Sprengel deformity, hearing impairment, spina bifida, and associated scoliosis. Scoliosis is most common in types I and III. Progressive congenital cervical scoliosis is rare and usually involves the cervicothoracic junction. Monitor young children with this finding closely, since the shoulder tilt it produces may be highly deforming. Perform surgery if progression of more than 10° is seen. A posterior fusion *in situ* is the gold standard for this region.

Scoliosis of the upper cervical spine is quite rare and usually presents as torticollis, which must be differentiated from muscular torticollis, Grisel syndrome, ocular disturbance, and abnormalities of the brainstem and cord. Other causes of fusion in a young child include juvenile rheumatoid arthritis, as well as residua of infection in the region. The upper cervical spine may be very hard to image in children under age 5; it is frequently necessary to obtain a multiplanar CT or an MRI under sedation. If a vertebral anomaly is seen that is deforming, surgery may be indicated (Fig. 158.1).

## HINTS AND TRICKS

- Achieve a degree of correction of the head tilt by applying a halo-vest and gradually adjusting the head position using the uprights.
- Any malrotation may be improved by using bilateral rotation with Ilizarov turnbuckles attached to the halo (15).
- Once an acceptable head position is achieved, carry out fusion.
- If more than two levels are fused, consider an anterior epiphyseodesis as well, to prevent progressive lordosis with growth.

## OPERATIVE TECHNIQUES

Because in many congenital syndromes, age and bone quality affect halo application and upper cervical fusion, these techniques deserve special consideration (10).

### *Halo Application*

Check the halo size and shape in advance, and modify it if there is plagiocephaly or cranial disproportion (14). Also, if there is risk of positional neurologic damage in children too young to cooperate with examination, evoked potentials are useful.

- General anesthesia is preferred for halo application, although local anesthesia and sedation are possible.
- Because of the danger of hyperflexion caused in part by children's relatively large head size, elevate the torso or have an assistant hold the head off the end of the table.
- Do not place pins in the thin temporal regions (14).
- In children under 2 years of age, Mubarak et al. (28) recommend placement of six to ten pins at low torque (finger tightness through 2 inch-pounds) in the four traditional regions (Fig. 158.2).) Kopits and Steingass (25) found four pins to be sufficient in most cases, and loads up to 5 inch-pounds to be safe in older children. My experience confirms these findings. At our institution, we use 4 inch-pounds of torque for children up to age 4 years, 6 inch-pounds for those aged 5 to 10, and 8 inch-pounds for those over 10.



***Figure 158.2.*** A technique of halo application in the infant or child under age 2. The increased number of pins allows decreased torque on each. (Reproduced with permission from Mubarak SJ, Camp JF, Vuletich W, et al. Halo Application in the Infant. *J Pediatr Orthop* 1989;9:612.)

- The vest may be custom ordered from a prior cast or from tape measurements, or it may be made of plaster using a special frame. The pins may be retightened on the first or second day after halo placement using intravenous analgesia, but do not retighten after this time. If a pin becomes painful later, it is usually that it has become loose or infected. Try oral antibiotics first if there is no obvious loosening; if there is no relief, replace the pin in an alternative site.

### *Posterior Cervical Fusion*

Many congenital disorders require fusion of the upper cervical spine for deformity or instability. Techniques of fusion are well described elsewhere (in Chapter 139, Chapter 140, and Chapter 154). Two special aspects require further comment. First, anomalies of the posterior arches are common in several syndromes. Second, in very young children, the posterior elements and occipital cortex may not allow wire fixation of any substantial strength, or the lamina may be resected in cases of stenosis. Study good plain radiographs and, in most cases, CT scans in the areas of planned fusion to rule out spina bifida or anomalies of the arches. If anomalies are present, start dissection from a “normal” area, where depth can safely be established, and proceed up and down over the facets in the deficient areas.

### *Posterior Occipitocervical Fusion*

**Koop Technique** Koop et al. demonstrated a union rate of greater than 90% for upper cervical fusion in children with halo immobilization, even when grafts are not wired in place (24). This finding is relevant for infants or certain patients with skeletal dysplasia who do not have adequate bone size or quality for wire fixation.

- Apply the halo as described previously for young children.
- Turn the patient prone and affix the halo to a halo-holder. Use spinal cord monitoring during turning and throughout the entire procedure.
- Check a lateral radiograph to confirm proper alignment of the neck.
- Gently expose the spine, taking care to remain medial to the vertebral arteries at C1–C2.
- Avoid unnecessary exposure of caudal levels, which often leads to unwanted extension of the fusion distally. If a distal level is exposed unintentionally, covering it with bone wax may prevent it from incorporating into the fusion mass.
- After exposure and wide decortication, place autologous bone in the desired areas (Fig. 158.3).

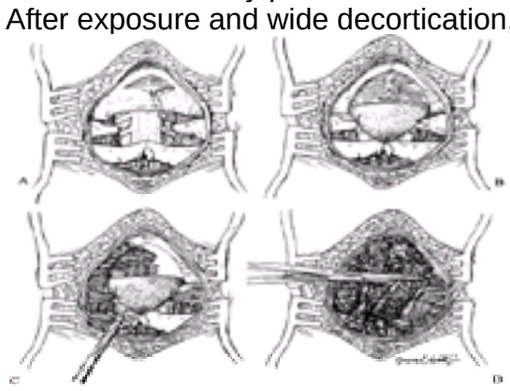

***Figure 158.3.*** Technique of occipitocervical fusion in infants. **A,B:** An occipital periosteal flap is raised and sutured distally. **C,D:** An air drill is used for decortication, and the graft is inserted. (Reproduced with permission from Koop SE, Winter RB, Lonstein JE. The Surgical Treatment of Instability of the Upper Part of the Cervical Spine in Children and Adolescents. *J Bone Joint Surg Am* 1984;66:403.)

- When fusion to the occiput is desired, use a triangular periosteal flap equal to the distance to C-2. Using a stay suture, dissect the flap, leaving it attached at its base, and suture it to C-1 and C-2. Place the bone graft on top, abutting the decorticated occiput.

The average time in halo until radiographic union is seen is 5 months.

**Dormans and Drummond Technique** An alternative technique has been described by Dormans and Drummond for children whose bone is adequate to permit wire fixation (11). Use of autogenous bicortical iliac crest in combination with occipitocervical wires forms a construct that is stable in flexion and extension.

- Perform the halo placement, with positioning and exposure as previously described.
- Fashion a trough in the outer table of the base of the occiput below the inion, at a level so that a graft can be inserted on top of the laminae (Fig. 158.4).

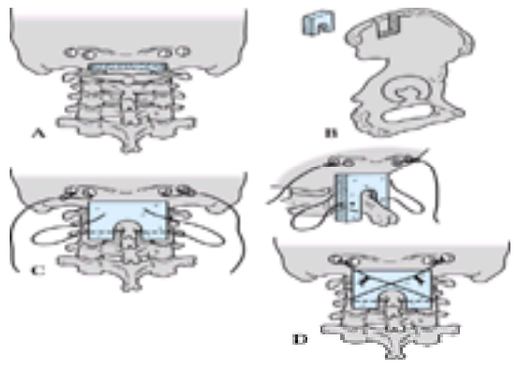

***Figure 158.4.*** Technique of occipitocervical fusion (Drummond), used for children with slightly better bone density that can support wire fixation. **A:** A trough is made in the base of the occiput, and two burr-holes are made on either side. **B:** A corticocancellous graft is taken from the ilium and shaped to fit the space between the occiput and the second or third cervical vertebra. **C:** Four strands of wire are passed to be ready to twist together: one from each side of the occiput, and one Drummond button-wire from each side of the C-2 or C-3 spinous process. **D:** The wires are twisted together to lock the graft into place. (Redrawn from Dormans JP, Drummond DS, Sutton LN. Occipitocervical Arthrodesis in Children: A New Technique and Analysis of Results. *J Bone Joint Surg Am* 1995;77:1234.)

- Make two burr holes through both cortices of the occiput just superior and lateral to the trough.
- Loop a 16- to 18-gauge wire through these holes.
- Make a hole at the base of the most caudal lamina to be fused, and pass a pair of Wisconsin (Drummond) wires through the hole in opposite directions.
- Obtain a corticocancellous autogenous iliac crest graft the width of the laminae and the height of the combined levels to be fused.
- Fashion a notch in the inferior edge to fit around the lowest spinous process, and lay it in place after the Wisconsin wires have been placed.
- Start each Wisconsin wire distally under the graft, then pass it around the graft and over it, across to the spinal wire in the opposite side of the occiput.
- Control the extension of the spine by the head position and the size and shape of the graft.
- Tighten the wires and take a lateral radiograph to confirm alignment.
- Place extra bone graft at the upper and lower edges of the main graft.
- Take flexion–extension radiographs about every 4 weeks.
- The halo may be removed after a mean of only 8 weeks with excellent results; have the patient wear a hard collar for 4–6 weeks after the halo is removed.

This technique is also applicable even if laminectomy has been performed at levels above the lowest level to be fused.

***Posterior Atlantoaxial Fusion***

For children with intact laminae and an isolated mild to moderate C1–C2 instability, Mah et al. (27) described a modified Gallie method of wiring around the base of the spinous process to preserve strength yet avoid the risks of wire passage under C-2 (Fig. 158.5). It also avoids the risks of cutout or dorsal displacement of the wires, which could otherwise occur in children with standard Gallie technique.

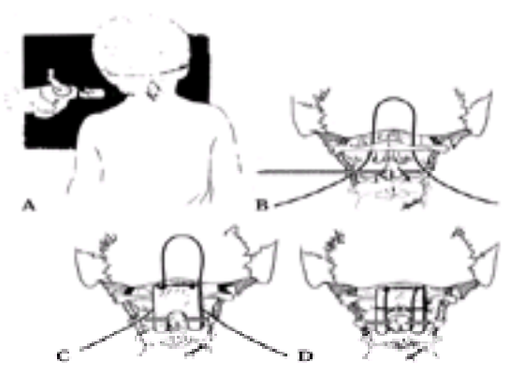

***Figure 158.5.*** Atlantoaxial fusion by the modified Dewar technique. **A:** After C-1 and C-2 are exposed, a threaded Steinmann pin is inserted percutaneously through the base of C-2. **B:** A sublaminar wire is passed under the C-1 arch. **C,D:** The wire is brought over the contoured graft and held under the Steinmann pin. (Reproduced with permission from Mah JY, Thometz J, Emans J, et al. Threaded K-Wire Spinous Process Fixation of the Axis for Modified Gallie Fusion in Children and Adolescents. *J Pediatr Orthop* 1989;9:675.)

- Position the patient in the standard fashion, with the cervical spine reduced to an optimal position, and the neck draped widely, allowing access to the lateral portion of the neck from both sides.
- Contour a rectangular unicortical iliac crest graft to fit over the C-1 arch and straddle the C-2 spinous process.
- Drill a threaded Steinmann pin percutaneously through the widest portion of the base of the spinous process of C-2 and cut it to leave 1 cm on each side.
- Pass an 18-gauge sublaminar wire under the C-1 arch.
- Place the loop of the wire deep to the Steinmann pin and draw it tightly over the graft, keeping it apposed to the lamina. This placement allows the wire to obtain good cortical purchase around C-2 and prevents dorsal migration.
- Add extra cancellous graft. Tie the free ends of the wire transversely over the graft.

Postoperatively, use a soft collar until union, if the translatory instability of the atlantoaxial segment is not too great. A halo-vest may be used at the surgeon's discretion.

***Bone Graft***

Some bone graft is almost always obtainable from the posterior ileum in children. If the amount is inadequate, such as in an infant with a small pelvis in whom long cortical and cancellous grafts are needed, the grafts may be obtained from one or both tibiae (see Chapter 9).

## THORACOLUMBAR ABNORMALITIES

### CONGENITAL STENOSIS

Congenital stenosis of the thoracic and lumbar spine is seen mainly in achondroplasia; to a lesser degree, it is seen in other skeletal dysplasias such as hypochondroplasia, diastrophic dysplasia, and spondyloepiphyseal dysplasia. Patients with isolated congenital spinal malformations such as scoliosis and kyphosis also commonly have associated narrowing of the spinal canal in the region. Take this narrowing into account when planning deformity correction and instrumentation.

A rare syndrome of focal, severe congenital stenosis, termed *segmental spinal dysgenesis*, has been described (13). It is usually present at the thoracolumbar junction and may be associated with segmental instability, scoliosis, or kyphosis. In patients with complete neurologic deficit, return has not been seen after decompression and stabilization, but these are indicated in those with preservation of at least some distal neurologic function who have progression or instability.

In addition, there are some young patients without any congenital malformation, who exhibit spinal stenosis that has been made symptomatic by disc protrusion or mild degenerative change. Symptoms include pain and tingling or numbness in the lower extremities more than pain in the back. Standing or walking worsens these symptoms, and rest usually relieves them. Plain films suggest stenosis by virtue of the narrow distance between the posterior laminar line and the posterior vertebral line, but they are less accurate in identification of stenosis in the thoracic and lumbar spine than they are in the cervical spine. MRI more clearly delineates the degree

of neurologic compression.

Conservative treatment such as activity modification or a flexion back brace may alleviate symptoms. Hip flexion contractures may need to be addressed, as they increase the obligatory lumbar lordosis. Decompressive laminectomy may be necessary if these measures fail; careful examination and judgment are necessary to determine the extent of unroofing required. Techniques of decompression may involve traditional laminectomy, laminoplasty (enlarging the canal by hinging open the lamina), or fenestration (removal of the stenotic inferior portion of each involved lamina and the medial facets). Further details are discussed in the later section on achondroplasia.

**CONGENITAL AND ACQUIRED KYPHOSIS**

Congenital kyphosis is less common but has potentially more serious neurologic consequences than congenital scoliosis. The basic types include failure of vertebral formation (type I) and failure of segmentation (type II) (see Chapter 161). If progression is seen, treatment is required. Bracing has no value in halting the increase of the curve.

Surgery is indicated at an early age if any progression at all is discovered. It should take the form of an *in situ* posterior fusion of the level above and the one below the abnormal vertebra in a type I kyphosis, unless it exceeds about 55°. If it exceeds this value, the fusion mass will be under tension and will not effectively halt growth; an anterior epiphyseodesis may be needed as well. A type II kyphosis may be fused posteriorly between the two involved vertebrae, to match the anterior bar; this may be extended one level above and one below in young children if it is desired to achieve some correction with cast and growth.

Postoperative cast immobilization for 3 months is the rule; follow-up should be performed to rule out pseudarthrosis and progression. Undertake osteotomy or vertebrectomy in treatment of congenital kyphosis only if the deformity is severe and is causing neurologic compromise or an unacceptable appearance.

Acquired kyphosis in children is seen most often after laminectomy, especially of the cervicothoracic or thoracolumbar junctions. In congenital syndromes, this situation may occur after decompression of spinal stenosis (in achondroplasia) or of intradural tumors (in neurofibromatosis) (17,19). More detail is given later in the sections on these conditions. It is important to realize that the risk of this phenomenon is greater in children than it is in adults. When there is preexisting kyphosis or vertebral wedging, it becomes even more likely.

Prevention of kyphosis is much easier than later treatment of an established deformity, if it can be anticipated. Limited posterior fusion *in situ* over the region of the junction is usually effective. Another alternative is laminoplasty, which allows many of the interlaminar ligaments to remain intact and may prevent kyphosis from developing.

**CONGENITAL SCOLIOSIS**

Congenital scoliosis may be an isolated finding, or it may be associated with various syndromes. The most common association is with the VATER syndrome (vertebral anomalies, anal atresia, tracheoesophageal fistula, renal and radial abnormalities). Some physicians include a *C* for cardiac abnormalities. The vertebral anomalies are the most common component of the VATER syndrome, so orthopaedic surgeons will see most of these children. Other syndromes that include congenital vertebral anomalies are Goldenhar (oculoauriculovertebral) syndrome, myelomeningocele, Klippel-Feil syndrome, and Jarcho-Levin syndrome (spondylothoracic dysplasia).

Although there may be a dimple, a vascular marking, or a patch of hair over the spine in the occasional case of congenital scoliosis, often patients have no external physical findings except for the deformity, which may be mild in early childhood. Early diagnosis usually comes about because of an incidental event such as a radiograph for trauma or a chest film. Vertebral anomalies are frequently seen on ultrasound of fetuses, and concerned parents as well as sonographers often consult the orthopaedist for a prognosis. Isolated hemivertebrae without neural tube defects or other sonographic anomalies typically have a good outcome. The presence of other abnormalities reduces the rate of survival.

Radiographic findings in congenital scoliosis usually include hemivertebra, wedged vertebra, or fusion of vertebrae (bar). Many times there are elements of both in a given curve. The best opportunity to understand the underlying growth abnormality is to study the films of the patient at the youngest possible age; they will show the asymmetries of ossification and allow diagnosis of hemivertebrae and fusion.

If a hemivertebra does not have a growth plate on both surfaces, or if it is “carved into” the adjacent vertebra (incarcerated), it is less likely to produce an increasing curve. Upon diagnosis of congenital scoliosis, do a thorough exam, searching for limb atrophy or other deformities. Chest auscultation should be done, but cardiac imaging is not routinely indicated. However, the genitourinary tract should be visualized at least once by ultrasound or intravenous pyelogram. Some experts recommend a routine MRI on all children with this diagnosis, since at least 25% will show some abnormality such as a Chiari malformation, syrinx, or tether. This is not a well-accepted recommendation, however, as the indications for treating these conditions in the asymptomatic stage are highly debatable. Most surgeons instead prefer to order an MRI only when corrective surgery is planned, or if unexplained progression occurs.

Treatment of congenital scoliosis is largely surgical. There is no documented efficacy of brace treatment. Some curves such as those with a segmented hemivertebra and a contralateral bar have a virtual certainty of progression and should be fused when first seen. All others should be followed during growth with serial radiographs, always comparing them to the first film, rather than to the last prior film.

If progression of more than 5° to 10° is seen, I recommend surgery. There are several surgical options, whose indications depend on the characteristics of the curve, the acceptability of the current deformity, and the likelihood of future increase in the curve. Options include the following:

- Posterior fusion *in situ*
- Anterior and posterior fusion
- Hemiepiphyseal fusion
- Hemivertebral excision
- Spinal osteotomy for correction

***Operative Techniques***

**Posterior Fusion *in Situ*** Posterior fusion *in situ* is the most widely accepted procedure. It is indicated for progressive curves if the deformity is acceptable and the likelihood of anterior crankshaft progression is not high.

- Take care in exposing the spine, since midline laminar defects are sometimes seen in congenital curves.
- Fuse all vertebrae within the curve.
- Some correction may be obtained through bracing if there is flexibility in the curve.
- Postoperatively, immobilize the patient in a cast or brace for 3 to 4 months, when consolidation of the fusion should be demonstrated.

**Anterior and Posterior Fusion** If you suspect that significant growth potential also exists anteriorly that could cause a deformity due to the crankshaft phenomenon, perform anterior and posterior fusion.

- Perform the anterior procedure in the traditional open fashion, through a thoracoscopic approach, or by a transpedicular or costotransversectomy approach. See Chapter 155.
- Consider a hemiepiphyseodesis, as a variation on this theme, for young patients' curves with some growth potential on the concave side.
- Fuse the curve anteriorly and posteriorly only on the convexity, to allow for some corrective growth on the concavity. Measurable correction is seen only in children under age 6 at surgery, and the amount of correction rarely exceeds 10° to 20°.
- Hemivertebra excision is now accepted as a safe alternative for curve correction in experienced hands (8) (see the Surgical Techniques section later). It is mostly, although not solely, applicable to anomalies at or below the thoracolumbar junction. Use this technique for curves too large to be fused *in situ*.
- Both anterior and posterior procedures may be performed in the same operative session.
- Spinal osteotomy may be needed to correct large, stiff curves composed of multiple bars, or ones that have been fused previously. It carries an element of risk and should be performed by experienced surgeons and only for curves that are significantly disabling.
- In all cases where corrective surgery is planned for congenital deformities, a preoperative MRI of the spinal canal is indicated.

## MANAGEMENT OF SPECIFIC SYNDROMES

Down syndrome (trisomy or translocation involving chromosome 21) is commonly associated with cervical abnormalities. Anterior subluxation of C-1 on C-2 of more than 5 mm in flexion is seen in 15% to 20% of patients. Over 4 mm posterior translation of the occiput on C-1 is seen in 60% (29,31). Also seen is increased frequency of os odontoideum, ossiculum terminale, and spina bifida of any upper cervical vertebra (31). Management of the instability is controversial.

Screen all Down syndrome children, and restrict from high-risk sports those with more than 5 mm C1–C2 subluxation. Perform fusion for those with more than 1 cm subluxation, neurologic deficit, or persistent neck pain. In cases to be fused, it may be necessary to extend the fusion to the occiput (42) if there is significant posterior atlanto-occipital translation in extension. Increasing quadriparesis during surgery has been reported in cases of preoperative myelopathy or longstanding displacement. It appears that in such cases there may be chronic degeneration within the cord, rendering it extremely susceptible to insult. In addition, the space available for passing wires is decreased. Reduction, if necessary, should be achieved before surgery with evoked potential monitoring or preoperative awake traction. If significant reduction cannot be achieved but the patient's neurologic condition is acceptable, only a fusion without wires is recommended. Use a CT scan to rule out spina bifida.

## SKELETAL DYSPLASIAS

Cervical spine abnormalities are common in many skeletal dysplasias. Odontoid hypoplasia and ligamentous laxity are common in spondyloepiphyseal dysplasia (congenita more than tarda), Morquio syndrome, Kniest syndrome, and metatrophic dysplasia (2,38). It may also be seen in the occasional patient with pseudoachondroplasia. Symptomatic instability frequently results. In addition, cervical stenosis may be seen with metatrophic dysplasia, Maroteaux-Lamy syndrome, or achondroplasia. Obtain neutral, flexion, and extension cervical spine films in all patients with these conditions. Diagnosis of cervical myelopathy is difficult in infants and may be aided by checking motor milestones, and spinal cord monitoring, flexion–extension MRI, and sleep studies. Metatrophic patients may also have painful torticollis due to rotatory C1–C2 instability (Fig. 158.6).

***Figure 158.6.*** **A:** A 15-month-old child with metatrophic dysplasia and painful torticollis. The head is kept in marked hyperextension. **B:** Lateral roentgenogram shows some anterior C-1 displacement with rotation and stenosis. **C:** CT-myelogram confirms rotational malalignment and stenosis. **D:** Posterior C1–C2 decompression and occiput to C-3 fusion done by the method of Koop. Wires seen are through facets (Southwick type). Tibial graft is used. Unfortunately, the patient died 3 months postoperatively due to the restrictive lung disease associated with metatrophic dysplasia.

In contrast to the upper cervical abnormalities seen in other dysplasias, diastrophic dysplasia frequently causes mild cervical kyphosis and spina bifida (19). Surprisingly, many of these kyphoses, especially those that are less than 80°, resolve over time with or without bracing. Quadriplegia has been reported with some larger kyphoses, however, so surgical treatment is indicated for those with progression or neurologic deficit.

If the curve is flexible, correction may be accomplished by postural reduction and posterior fusion. Place the patient in a halo body jacket, and gradually extend the head over several days with serial neurologic examinations. A posterior sling may be added at the apex of the curve. If satisfactory improvement is obtained, identify bifid areas on CT and perform a posterior fusion with a tibial cortical graft. If the kyphosis is rigid, anterior release and strut graft fusion, followed by posterior fusion, are indicated. Apply the halo before the fusion, to protect the strut graft in young patients. The anterior bar of the frame should be removable on the side of the anterior approach.

Larsen syndrome of multiple joint dislocations with flattened facies is occasionally associated with cervical spondylolysis and kyphosis, causing neurologic deficit (22). Screening of the cervical spine is recommended for all patients with this diagnosis. Treatment follows the guidelines given for diastrophic dwarfism. Note, however, that spontaneous resolution has not been documented in this condition, and the posterior arches may also be deficient.

### *Achondroplasia*

In achondroplasia, panspinal developmental stenosis, sagittal deformity, and arthrosis combine to produce compressive neurologic lesions in 30% to 80% of patients. Infantile kyphosis at the thoracolumbar junction, resulting from muscular hypotonia, ligamentous laxity, and a relatively large head, resolves in 75% to 85% of cases but persists or progresses in the remainder, leading to wedging of thoracolumbar vertebrae (19,26,37,40). Wedging may be focal, involving a single vertebra, or gradual, involving multiple levels. Some geneticists feel that it is important to prevent children with achondroplasia from sitting unsupported, and to use hard-backed sitting devices (30). I feel that it is impossible to prevent a child from sitting who is developmentally ready, and that the only effective support is a thoracolumbosacral orthosis. Therefore, it seems prudent to brace all achondroplastic children with significant kyphosis after 2 to 3 years of age.

Correction of kyphosis should be undertaken in the following situations:

- For any curve more than 50° to 60° with focal wedging, in patients over age 5 to 6 years
- In any patient undergoing laminectomy with a curve over 30° in the thoracolumbar region or 50° in the thoracic region
- For any curve that progresses on its own (37)

Fusion should always be both anterior and posterior because of deformity and small posterior elements, especially after laminectomy. If the kyphosis is sharp and angular, and if neurologic deficit is present, perform a corpectomy with strut graft fusion. Follow with posterior fusion. Both procedures can be done on 1 day if the patient is young, or 1–2 weeks apart in older patients or those requiring extensive laminectomy. Correction of deformity may be either by cast or instrumentation. There is a 25% or greater chance of somatosensory evoked potential or clinical neurologic deterioration when instrumentation is used, although recovery is common (37). This effect is probably caused by instrumentation impinging on a narrowed canal, downward pressure on apical laminae, or stretch of nerve roots in lordotic segments. This risk can be minimized by using cast correction only, with 4–6 months of recumbency. If instrumentation is used, it should include only pedicle screws in the lower thoracic or lumbar region (Fig. 158.7). Stabilization and fusion, rather than significant correction, should be the goals. It is best not to fuse below L-4 in most cases, because mobility is always a problem in patients with achondroplasia. Laminectomies should be done in marginally stenotic levels. Spinal stenosis in achondroplasia is caused by deficient endochondral growth in the neurocentral synchondroses, with decreased sagittal and coronal canal dimensions, increasing in severity caudally. Foramen magnum and cervical stenosis may occur in addition to the more common thoracolumbar stenosis.

***Figure 158.7.*** **A:** A 6-month-old girl with achondroplasia, never braced. **B:** The same patient at age 12 with severe 90° wedging of L-2 with early weakness. **C:** One

year after anterior decompression and posterior fusion. The patient had an initial postoperative increase in weakness, but recovered fully within 3 months.

Degenerative changes or disc bulge may make the narrowing symptomatic. True disc herniations are a distinct minority, however. Symptoms in older teenagers or adults include leg pain while standing or walking, decreased endurance, numbness, and urgency or incontinence. On examination, an upper or lower motor neuron picture may be seen, depending on the level of compression. Evaluation should include CT-myelography, cystometrogram, and postvoid residual. MRI is less helpful because it does not show the bony compressive structures as well. If stenosis symptoms or any neurologic deficit is present, decompressive laminectomy should be done, after ruling out disc herniation (43). Laminectomy should include all involved levels, most commonly T8–S1. The most frequently reported surgical error is insufficient length of laminectomy. Because of the limited canal space, dural tear or cord contusion during decompression is not infrequent.

### *Diastrophic Dysplasia*

In diastrophic dysplasia, scoliosis or kyphosis is extremely common (4,5,18), having been seen in over 70% of patients in the largest reported series. Only 30% of the curves, however, were over 30°. Two curve types are seen: benign and idiopathic-like, and severe, rigid types with kyphosis. The latter are considered by Tolo to be the result of wedged or unsegmented vertebrae like those seen in congenital scoliosis (39). These curves are apparent before age 4, often in infancy.

Try bracing early, for all curves. It is sometimes successful for the gradual idiopathic-like curves. If the curve progresses past 45° despite bracing, consider instrumentation without fusion in young children if there is not too much kyphosis. Tolo and Kopits (39) state that significant growth ceases at age 9–10 in these patients, so fusion at this age, if it is necessary, would have little effect on height. At any point where the curve progresses significantly despite subcutaneous instrumentation, perform fusion, for little of what is lost in progression can be regained.

To arrest progression effectively, add anterior release and fusion if the kyphosis or scoliosis is large or if there is much growth remaining before skeletal maturity. Although the canal is relatively stenotic in the lower lumbar region, hook placement can be done safely (38). The incidence of postoperative neurologic deficit in hook placement was more than 50% in one series (5). The deficit seems to be due to zealous attempts to correct these rigid curves, rather than to the instrumentation itself.

### *Pseudoachondroplasia*

Pseudoachondroplasia is occasionally associated with thoracolumbar kyphosis and hip flexion contractures. Treat the kyphosis by anterior and posterior fusion if severe. Neurologic injury from surgery is less common than in achondroplasia because the canal is larger. Sublaminar instrumentation may be used. If excessive lumbar lordosis is present and flexible, correction of any hip flexion contracture by femoral extension osteotomies should be the first step.

### *Metatrophic Dysplasia*

Metatrophic dysplasia is usually associated with curves that appear early and are difficult to control. The most common pattern is a double major scoliotic curve with a severe junctional kyphosis, which may equal or exceed the scoliosis in magnitude. The curves are rigid, and bracing is poorly tolerated. The kyphosis and poor bone quality contraindicate subcutaneous instrumentation. Definitive spine fusion is frequently necessary at an early age. Restrictive lung disease is common because of short ribs. Consult a pulmonary specialist if you are contemplating anterior fusion or to determine if even posterior fusion will be tolerated. Fusion with cast correction is the most common method used.

### *Kniest Syndrome*

Kniest syndrome and its resultant scoliosis are similar to metatrophic dysplasia but less severe. Rib length is normal, and restrictive lung disease is not as frequent as in metatrophic dysplasia (2).

### *Mucopolysaccharidoses*

Of the mucopolysaccharidoses, kyphosis with or without scoliosis is common in Hurler syndrome. It most often has an apex at the thoracolumbar junction, where wedging of vertebrae and translation may occur. Bracing is warranted, but its efficacy remains unproven. The limited life expectancy of these patients historically has made fusion untenable. With the increasing success of bone marrow transplantation, patients who are longer-term survivors may require treatment by a limited posterior fusion over the kyphotic segment if it is progressive.

### *Spondyloepiphyseal Dysplasia*

Spondyloepiphyseal dysplasia is manifested in the spine by marked platyspondyly and, frequently, thoracic kyphosis and scoliosis (2). Bracing is advised for scoliosis less than 45° or for any increased kyphosis in growing children. In some cases, the kyphosis has been permanently improved by bracing. Scoliosis should be fused if the curve is over 45°. Pseudarthrosis is common after posterior fusion of either kyphosis or scoliosis, resulting in significant loss of correction. Therefore, patients with severe curves may need an anterior as well as a posterior fusion if the curve is rigid, if the patient is adult, or if he has had prior laminectomy.

## OSTEOGENESIS IMPERFECTA

Spine deformity in osteogenesis imperfecta correlates with bone involvement (3,16,47) (see Chapter 180). Although many classification systems have been proposed, the radiographic system of Hanscom has been best correlated with spinal involvement (16). Type A patients, those with only bowing of the long bones, have the best bone quality and generally maintain some correction if scoliosis surgery and instrumentation are required. Type B patients, who also have biconcave vertebrae, and type C, who have a trefoil pelvis, have a greater tendency to kyphosis. Type D patients are more severely involved, having also cystic changes in the metaphyses. With these latter three types, less correction is obtainable, and there is more postoperative loss. Type E patients, with absent long-bone cortices, should not be subjected to instrumentation at all.

Brace treatment has little if any role in osteogenesis imperfecta curves except for postoperative protection because of the potential for rib deformation. Posterior fusion should be done for curves of more than 45° in type A, or 35° to 40° in types B through E. Even at a young age, delaying fusion to preserve trunk height should not be a consideration, because the trunk is so short in nonscoliotic adults of these types, let alone those with curves.

In some cases of severe deformity with poor bone stock, carefully applied halo–gravity traction after anterior release may be used to decrease the amount of force that must be applied through the rods. All patients should be evaluated preoperatively for basilar invagination and for pulmonary compromise. Segmental fixation using hooks at as many levels as possible, augmented when necessary by doubled Luque wires, is the preferred technique. The following points should be noted:

- Hooks placed on fragile laminae may be supplemented with methylmethacrylate.
- Pack the methylmethacrylate after the hook is inserted; it should extend to the lamina above and below.
- Preserve the spinous processes at these levels.
- Supplement the fusion with banked bone.
- Bone from other spinous processes is also helpful; these may be relatively large in osteogenesis imperfecta.
- Blood loss is usually greater than in other conditions.
- Use postoperative recumbency and orthoses as the quality of fixation dictates.

## ARTHROGRYPOSIS MULTIPLEX CONGENITA

Scoliosis is present in up to one third of patients with the diagnosis of arthrogryposis multiplex congenita. Usually the curve is a long, uncompensated, “paralytic” type. Increased lumbar lordosis may occur, especially with hip flexion contractures. In a sizable minority, congenital anomalies may occur; take care to distinguish these patients from those with multiple pterygium syndrome.

Congenital curves should be treated according to the usual rules. Noncongenital curves can be braced if less than 50°, but fusion should be performed for larger curves. The spine, like the joints, is stiff, and correction is not often great unless the spine is mobilized extensively anteriorly and posteriorly. Bone is osteoporotic and hypervascular. Low lumbar curves with pelvic obliquity should have fixation extended to the pelvis. Where excessive lumbar lordosis is the main problem, patients

respond poorly to posterior distraction, and anterior column shortening by multiple partial vertebrectomies is most successful.

## NEUROFIBROMATOSIS

Neurofibromatosis is estimated to make up 1% to 2% of a scoliosis clinic population, so its signs should be looked for on all initial examinations (9,44). The diagnosis can be made with the presence of two or more of the criteria from the 1987 Consensus Development Conference of the National Institutes of Health (Table 158.2). In a patient with neurofibromatosis, it is important to make the distinction between dystrophic and nondystrophic curves (44). Nondystrophic curves can be treated with brace or surgery according to guidelines for idiopathic scoliosis. They are in the minority, however, making up 25% to 35% of most series.

| |
|---|
| Diagnosis: Two or More of NIH Criteria |
| Six or more café-au-lait spots >1.5 cm |
| Subcutaneous neurofibromas |
| Elephantiasis neuromatosa |
| Positive biopsy |
| Positive family history |
| Dystrophic osseous manifestation |
| Features of Dystrophic Spinal Curve |
| Vertebral scalloping |
| Spindled ribs or transverse processes |
| Paravertebral soft-tissue mass |
| Short curve with severe apical rotation |
| Foraminal enlargement |
| Possible Abnormalities of Spinal Canal or Cord |
| Dural ectasia |
| Meningocele |
| Neurofibroma in canal |
| Stretch over sharp kyphosis |
| Ribs impinging on spinal cord through foramina |

NIH, National Institutes of Health.

***Table 158.2. Relevant Aspects of Neurofibromatosis***

Dystrophic curves require more aggressive treatment. Bracing is unsuccessful. Obtain cervical spine films and MRI or a myelogram with CT before surgery. To rule out cervical deformity, which is frequently associated with thoracolumbar deformity, obtain radiographs of the neck before general anesthesia is done or halo traction is applied (46). Abnormalities identified within the canal by MRI or myelogram, such as thinning of laminae, neurofibromas, meningoceles, and rib penetration, have obvious implications for both the technique of the dissection and the choice of fixation levels (6,12,23).

Dystrophic curves more than 35° to 45° should be fused regardless of age because progression may be rapid, and loss of height will be greater if the curve is allowed to progress than if early fusion is accomplished. If the curve is less than 50°, kyphosis less than 60°, and no obvious anterior scalloping or bony involvement is present, posterior fusion alone is indicated (9). Six months postoperatively, obtain oblique films or tomograms, or perform routine reexploration to detect and treat early pseudarthrosis.

Curves with kyphosis over 50°, anterior scalloping or deficiency, or scoliosis more than 50° should have anterior and posterior fusion. Because of potential vertebral body destruction by tumor, anterior surgery has a more important mechanical role in neurofibromatosis than in other conditions. Note the following points:

- Fuse all involved levels.
- If there is significant anterior tumor, use strut grafts of fibula or vascularized rib, and establish good bone continuity with vascularized tissue on the concavity of the curve.
- Halo traction may be used to optimize correction at the time strut grafts are inserted.
- Posteriorly, segmental hook fixation is desirable; increasing rigidity of fixation will increase success of surgery (20).
- Use postoperative bracing if the vertebrae are weakened or the severity or location of the kyphosis is causing excessive strain on end hooks, or if there are not optimum numbers of fixation points above and below the apex (three on each side).

Treatment of neurologic deficit depends on its cause. If it is due to intracanal tumor or rib penetration, decompress it posteriorly and do subsequent fusion according to previous guidelines. If it is due to kyphosis, correct it anteriorly and posteriorly with decompression if focal.

In summary, spinal curvature in neurofibromatosis patients ranks as a major threat to patient welfare. Take all possible care in preoperative planning, surgery, and postoperative follow-up.

## MARFAN SYNDROME

Improved cardiovascular management has greatly increased the life expectancy of patients with Marfan syndrome to nearly that of the general population, thereby increasing the importance of appropriate treatment of spinal disorders. Scoliosis of greater than 10° is present in approximately half of these patients. Less than 10%, however, will require a brace or surgery (33). There is no typical curve: In Marfan syndrome, the patient may have any of the curve types seen in idiopathic scoliosis. Sagittal plane deformities are equally common and vary from hyperkyphosis to hypokyphosis. There is a fairly common finding of thoracolumbar kyphosis. Use bracing for the same standard indications as in idiopathic scoliosis; although the success rate is lower, there are cases where the brace has been associated with curve stabilization.

Severe infantile or early juvenile curves are in some cases treated with subcutaneous distraction instrumentation if they are greater than 50° (34). This technique is contraindicated, however, in cases where significant kyphosis exists. The rod should be contoured to match the patient's sagittal profile—that is, not too straight. Dorsal displacement of hooks is a frequent cause of failure of this technique, and it is due in part to inadequate contouring. Postoperative bracing is mandatory. Despite all of these precautions, the rate of hook cutout or continued progression is significant. If cutout occurs, undertake posterior fusion with or without anterior fusion, depending on curve size and the patient's overall condition.

Curve patterns in adolescents and adults are similar to idiopathic patterns (33). One difference is the tendency to develop moderate thoracolumbar kyphosis and the marked rotational listhesis that sometimes occurs in lumbar curves. Evidence suggests an increased risk of pseudarthrosis in patients with Marfan syndrome, especially in regions of kyphosis at the thoracolumbar junction (7). Anterior release and fusion should be added in such cases (Fig. 158.8) or when curves are large and rigid. Spondylolisthesis of severe degree occurs in approximately 2% of Marfan patients. Check for it on lateral radiographs.

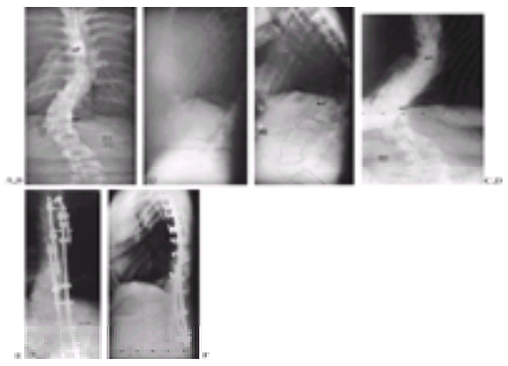

***Figure 158.8.*** Progressive kyphoscoliosis in Marfan syndrome. **A,B:** Posteroanterior and lateral films at age 25, with 53° thoracolumbar scoliosis and 22° kyphosis. **C,D:** Repeat films 8 years later (after two pregnancies) show increase of scoliosis to 64° and, especially, of kyphosis to 64°. **E,F:** One year after anterior release and fusion and posterior fusion with Cotrel-Dubousset instrumentation. Note that standard rods were not long enough in this patient; longer rods may be specially ordered.

Other features of Marfan syndrome that should be kept in mind include the following: (a) The rate of dural ectasia is high (63%) in the lower lumbar or sacral canal (32) (Fig. 158.9). The dural ectasia is probably another manifestation of the effect of gravity on abnormal connective tissues. The enlarged sac has thin dural walls and may

leak or erode laminae; take care with decortication and instrumentation in these areas. (b) Instrumentation of double curves in these already tall patients may require special ordering of long rods (Fig. 158.8). (c) The patients have implanted cardiovascular devices that must be considered when ordering prophylactic antibiotics or treating a postoperative infection.

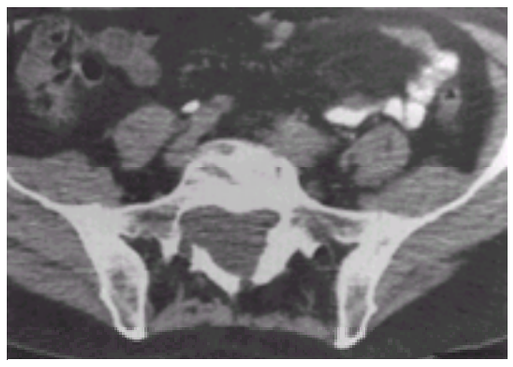

***Figure 158.9.*** CT scan without contrast shows dural ectasia with foramenal meningocele. This is common in Marfan syndrome, in the lower lumbar spine and sacrum. Exercise care if working inside the canal. Marked thinning of laminae may compromise fixation strength.

## SURGICAL TECHNIQUES

Some authors advocate subcutaneous instrumentation for young patients with considerable growth remaining. I try to avoid subcutaneous instrumentation in almost all cases, because the gains over time are minimal and not worth the time and morbidity.

### HEMIEPIPHYSEODESIS FOR CONGENITAL DEFORMITY DUE TO HEMIVERTEBRAE

Hemiepiphyseodesis (Winter technique) is intended not only to prevent progression of a congenital curve but also to allow some correction of the curve with growth (45). It is indicated for patients under about age 6 years who have some growth potential on the concavity of the curve. The advantage of the procedure is that it does not destabilize the spine and does not require internal fixation, even though it is a corrective procedure. The disadvantage is that it does not work for very large curves and is not recommended for curves over 70°. There should be no significant kyphosis or lordosis in the area to be fused. Although the anterior portion of the procedure may be performed endoscopically, the patient must be a satisfactory candidate for a thoracotomy. Take bending films to assess the flexibility of the spine preoperatively. If some correction of the curve is possible, accomplish it in the cast after surgery.

- Place the patient in the lateral position so that both anterior and posterior exposures may be performed without repositioning (Fig. 158.10*B*).

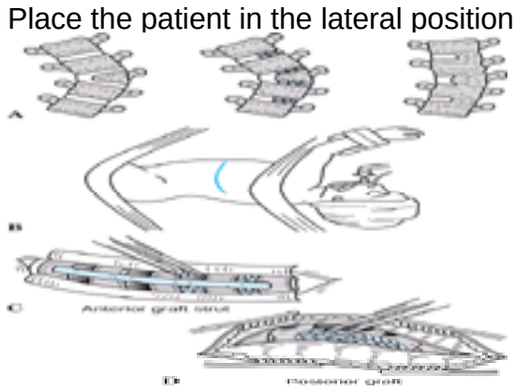

***Figure 158.10.*** Technique of hemiepiphyseodesis for congenital scoliosis. **A:** Concept: The spine is fused anteriorly and posteriorly over the convexity, allowing some correction to occur with growth. **B:** The patient is placed in the mid-lateral position so that anterior and posterior approaches may be made simultaneously. **C:** Anteriorly, 30% to 50% of the disc and endplates are removed and replaced with bone graft; a strut graft is added if available. **D:** Posteriorly, only the convex side of the curve is exposed and grafted over the involved levels. (Redrawn with permission from Winter RB, Lonstein JE, Denis F, de la Rosa HS. Convex Growth Arrest for Progressive Congenital Scoliosis due to Hemivertebrae. *J Pediatr Orthop* 1988;8:633.)

- In the open technique, expose the spine anteriorly through the rib that is one level above the most cranial to be fused.
- Confine dissection primarily to the convexity of the curve, and confirm the levels either by the characteristic shapes of the vertebrae, or by an intraoperative radiograph with markers both anteriorly and posteriorly over the levels to be fused.
- Remove the lateral one third to one half of the disc along with the corresponding portion of the endplates of the vertebrae.
- Obtain bone graft from the morcelized rib or from another source and pack into the disc spaces to promote fusion (Fig. 158.10*C*).
- Make a trough across consecutive vertebrae to allow a bone graft (such as rib) to be placed longitudinally, bridging them.
- Perform posterior exposure at the same time, to be sure that the levels fused in the front and in the back correspond exactly (Fig. 158.10*D*).
- Expose only the convexity of the posterior curve.
- Avoid elevating the muscles from the concavity of the curve, to prevent fusion from occurring on this side as well.
- Verify which levels are the end vertebrae to be fused by palpating the vertebrae from the front and the back simultaneously.
- If in doubt, pass small Kirschner wires from front to back at the tip of a transverse process to help confirm levels.
- Excise the convex facets and decorticate the spine.
- If additional correction is desired, a level above and below the curve itself may be partially fused as well, to allow further correction with growth.
- Postoperatively, place the patient in a cast to correct as much of the flexible portion of the deformity as possible. Apply the cast either in the operating room, or a few days after surgery, if there is significant edema or need to have access to the patient. The patient wears the cast, or a cast followed by a brace, for at least 6 months postoperatively. In the series of 13 patients reported by Winter et al. (45), prevention of curve progression was achieved in all but one, and in five of these, curve correction occurred with growth. The mean correction for these five patients was 10° (Fig. 158.11).

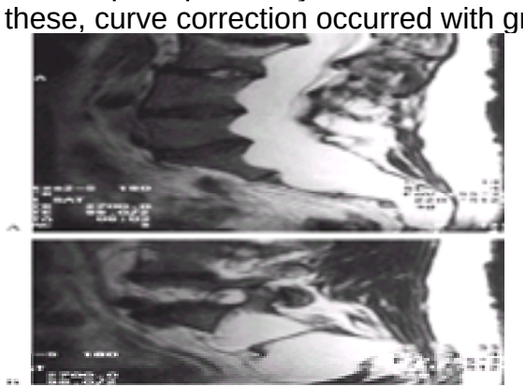

***Figure 158.11.*** Result of convex hemiepiphyseodesis at 6-year follow-up. **A:** Curve measures 27° at age 4, due to unincarcerated hemivertebra with a bar just distal to it on the opposite side. The hemiepiphyseodesis extended two levels above and one level below the hemivertebra. **B:** At age 10½, the curve has corrected itself to 10°.

### HEMIVERTEBRA EXCISION

Excision is indicated for rigid decompensation of the spine due to a hemivertebra. It entails somewhat more risk than a hemiepiphyseodesis because the spinal canal is entered both anteriorly and posteriorly, and the spine is partially destabilized to achieve the correction. A significant degree of correction is possible, however, and the risks are generally acceptable with current techniques in experienced hands (8).

Preoperative assessment may include bending films to determine whether the desired degree of correction can be obtained without vertebral resection. In addition, MRI should be performed in all patients preoperatively because there is an increased frequency of abnormalities within the spinal canal (Chiari malformation, syrinx, diastematomyelia, and fibrous tether), which may predispose the patient to neurologic complications. Hemivertebra excision in the thoracic spine generally entails more neurologic risk as well as less correction, but it is not contraindicated.

Usually, both the anterior and the posterior portions of the procedure are performed in the same surgical session, if possible. Use sensory and motor spinal cord monitoring.

- Place the patient in the straight lateral position (Fig. 158.12).

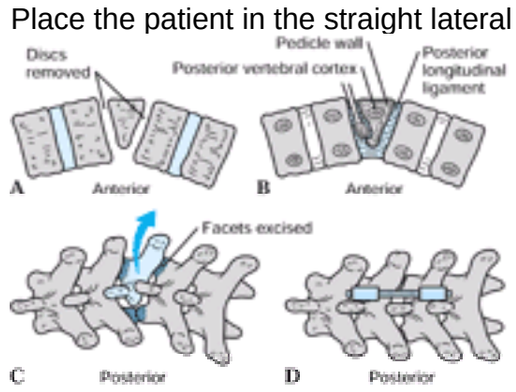


***Figure 158.12.*** Hemivertebra excision. **A:** Remove discs and endplates above and below the hemivertebra. **B:** Curet and remove the hemivertebra. **C:** Resect the corresponding posterior elements. **D:** Complete the correction with posterior compression rod or wire fixation.

- Make a transpleural, transdiaphragmatic, or retroperitoneal anterior approach as dictated by the level of the curve.
- Identification may be possible by local landmarks as well as by the shape of the vertebrae, but it should be confirmed by a radiograph if there is any question.
- If segmental arteries are to be ligated in the thoracic spine of a patient with congenital anomalies, some surgeons recommend placing a “bulldog” vascular clamp on the vessels to occlude flow for 10 minutes, using spinal cord monitoring to be sure that the intended vessels do not provide critical perfusion to the cord (1).

- Resect the discs above and below the vertebrae first, followed by the body.
- Leave the posterior portion of the vertebra and the medial cortex of the pedicle intact until last, as their resection may cause epidural bleeding.
- Place bone graft into the defect, but not so much as to limit the correction.
- Resect the posterior elements over the corresponding level.

In young patients whose correction is maintained without excessive difficulty, a pantaloon cast may be all that is necessary for correction. However, if the patient's size and bone density are adequate, use internal fixation, which may include a wire for a simple resection, or more rigid and complex fixation. It is the surgeon's judgment whether to perform these procedures in the same position, or whether to turn the patient prone for the posterior fixation. It depends on the complexity of the fixation intended.

The entire extent of the curve should generally be fused. Bone from the resected vertebra and rib usually provides adequate graft. The need for a postoperative brace depends on the security of fixation and the presence of other, noncongenital curves in the spine (Fig. 158.12, Fig. 158.13). In the largest recently reported series (21), the mean final correction was 35%, and there were 16% neurologic complications, but only 3% were permanent.



***Figure 158.13.*** Patient with congenital scoliosis due to thoracic hemivertebra, treated with anterior and posterior convex hemiepiphyseodesis. **A:** At age 4, immediately before surgery, the curve had progressed to 27°. **B:** At 6 years postoperatively, the curve has improved to 10°.

**THORACOLUMBAR LAMINOPLASTY VERSUS LAMINECTOMY**

Spinal decompression in young people is most commonly indicated for tumor or for stenosis, as in achondroplasia. In both cases, the presence of mild preexisting kyphosis when there is remaining growth increases the risk of progression postoperatively. This is greatest at the cervicothoracic and thoracolumbar junctions. Progressive kyphosis may be prevented by performing a fusion at the time of decompression, or in some cases by performing a laminoplasty.

To accomplish a safe and effective decompression in achondroplasia, Uematsu et al. recommend a technique that involves minimal use of instruments in the canal (Fig. 158.14) (43). Spinal motor and sensory monitoring is helpful.



***Figure 158.14.*** A 5-year-old girl with congenital scoliosis due to hemivertebra at <2. She has the VATER association. Her curve has progressed to 45°. Treatment by hemivertebra excision was selected because the hemivertebra is easily accessible and the patient is significantly off-balance. **A:** Preoperatively, the hemivertebra may be easily seen. **B:** Two years after excision and fusion, the patient is in much better balance.

- Position the patient prone, taking care to reverse as much of the increased lumbar lordosis as possible.
- Make bilateral laminar grooves just medial to the facets, using a high-speed burr.
- Carry these down to the deep cortex, and gently lift off the laminae.
- Preserve the facets if possible.
- Perform the amount of length and width of decompression necessary.
- A small (#10) rubber catheter should be able to pass centrally into the opening in the canal when the decompression is adequate.
- Suture paraspinous muscles over the defect.

If there is kyphosis more than 30° over the area to be decompressed, posterior (with possible anterior) fusion should be done as described previously. Even if no significant kyphosis is present preoperatively, it should be watched for postoperatively and fused if it develops. If laminoplasty is to be performed, the laminae with interspinous ligaments are elevated in one continuous strip, and reattached at the end with sutures into the adjacent facets, using bony “shims” if needed to elevate the laminae.

## CHAPTER REFERENCES

Each reference is categorized according to the following scheme: 01, classic article; #, review article; !, basic research article; and +, clinical results/outcome study.


+ 1. Apel DM, Marrero G, King J, et al. Avoiding Paraplegia during Anterior Spine Surgery: The Role of Somatosensory Evoked Potential Monitoring with Temporary Occlusion of Segmental Spinal Arteries. *Spine* 1991;16(suppl):365.

# 2. Bassett GS, Scott CI Jr. The Osteochondrodysplasias. In: Morrissy RT, Weinstein SL, eds. *Pediatric Orthopaedics*, 4th ed. Philadelphia: Lippincott-Raven, 1996:203.

+ 3. Benson DR, Newman DC. The Spine and Surgical Treatment in Osteogenesis Imperfecta. *Clin Orthop* 1981;159:147.

+ 4. Bethem D, Winter RB, Lutter L, et al. Spinal Disorders of Dwarfism. *J Bone Joint Surg Am* 1981;63:1412.

+ 5. Bethem D, Winter RB, Lutter L. Disorders of the Spine in Diastrophic Dwarfism. *J Bone Joint Surg Am* 1980;62:529.

+ 6. Betz RR, Iorio R, Lombardi AV, et al. Scoliosis Surgery and Neurofibromatosis. *Clin Orthop* 1989;245:53.

+ 7. Birch JG, Herring JA. Spinal Deformity in Marfan Syndrome. *J Pediatr Orthop* 1987;7:546.

+ 8. Bradford DS, Boachie-Adjei O. One-Stage Anterior and Posterior Hemivertebral Resection and Arthrodesis for Congenital Scoliosis. *J Bone Joint Surg Am* 1990;72:536.

+ 9. Crawford AH. Pitfalls of Spinal Deformities Associated with Neurofibromatosis in Children. *Clin Orthop* 1989;245:29.

+ 10. Dormans JP, Criscitiello AA, Drummond DS, Davidson RS. Complications in Children Managed with Immobilization in a Halo Vest. *J Bone Joint Surg Am* 1995;77:1370.

+ 11. Dormans JP, Drummond DS, Sutton LN, et al. Occipitocervical Arthrodesis in Children: A New Technique and Analysis of Results. *J Bone Joint Surg Am* 1995;77:1234.

+ 12. Flood BM, Butt WP, Dickson RA. Rib Penetration of Intervertebral Foraminae in Neurofibromatosis. *Spine* 1986;11:172.

+ 13. Flynn JM, Otsuka NY, Emans JB, e al. Segmental Spinal Dysgenesis: Early Neurologic Deterioration and Treatment. *J Pediatr Orthop* 1997;17:100–104.

+ 14. Garfin SR, Roux R, Botte MJ, et al. Skull Osteology as It Affects Pin Placement. *J Pediatr Orthop* 1986;6:434.

+ 15. Graziano G, Herzenberg JE. Halo Ilizarov Distraction Cast for Correction of Cervical Deformity. Report of Six Cases. *J Bone Joint Surg Am* 1993;75:996.

# 16. Hanscom DA, Bloom BA. The Spine in Osteogenesis Imperfecta. *Orthop Clin North Am* 1988;19:449.

+ 17. Hensinger RN. Kyphosis Secondary to Skeletal Dysplasias and Metabolic Disease. *Clin Orthop* 1987;128:113.

# 18. Herring JA. The Spinal Disorders of Diastrophic Dwarfism. *J Bone Joint Surg Am* 1978;60:177.

+ 19. Herring JA. Kyphosis in an Achondroplastic Dwarf. *J Pediatr Orthop* 1982;3:250.

+ 20. Holt RT, Johnson R. Cotrel-Dubousset Instrumentation in Neurofibromatosis Spinal Curves. *Clin Orthop* 1989;245:19.

+ 21. Holte DC, Winter RB, Lonstein JE, Denis F. Excision of Hemivertebrae and Wedge Resection in the Treatment of Congenital Scoliosis. *J Bone Joint Surg Am* 1995;77:159.

+ 22. Johnston CE III, Birch JG, Daniels JL. Cervical Kyphosis in Patients Who Have Larsen Syndrome. *J Bone Joint Surg Am* 1996;78:538.

# 23. Kim HW, Weinstein SL. Spine Update—The Management of Scoliosis in Neurofibromatosis. *Spine* 1997;22:2770.

+ 24. Koop SE, Winter RB, Lonstein JE. The Surgical Treatment of Instability of the Upper Part of the Cervical Spine in Children and Adolescents. *J Bone Joint Surg Am* 1984;66:403.

+ 25. Kopits S, Steingass MH. Experience with the Halo Cast in Small Children. *Surg Clin North Am* 1970;50:934.

# 26. Lonstein JE. Treatment of Kyphosis and Lumbar Stenosis in Achondroplasia. In: Nicoletti B, Kopits SE, Ascani E, McKusick VA, eds. *Human Achondroplasia. Basic Life Science*, 48:283. New York: Plenum Press, 1988.

+ 27. Mah JY, Thometz J, Emans J, et al. Threaded K-Wire Spinous Process Fixation of the Axis for Modified Gallie Fusion in Children and Adolescents. *J Pediatr Orthop* 1989;9:675.

+ 28. Mubarak SJ, Camp JF, Vuletich W, et al. Halo Application in the Infant. *J Pediatr Orthop* 1989;9:612.

+ 29. Nordt JC, Stauffer ES. Sequelae of Atlanto Axial Stabilization in Two Patients with Down's Syndrome. *Spine* 1981;6:437.

+ 30. Pauli RM, Breed A, Horton VK, et al. Prevention of Fixed Angular Kyphosis in Achondroplasia. *J Pediatr Orthop* 1997;17:726.

+ 31. Pueschel SM, Scola FH, Tupper TB, Pezzillo JC. Skeletal Anomalies of the Upper Cervical Spine in Children with Down Syndrome. *J Pediatr Orthop* 1990;10:667.

+ 32. Pyeritz RE, Fishman EK, Bernhardt BA, Siegelman SS. Dural Ectasia Is a Common Feature of the Marfan Syndrome. *Am J Hum Genet* 1988;43:726.

+ 33. Sponseller PD, Hobbs W, Riley LH III, Pyeritz RE. The Thoracolumbar Spine in Marfan Syndrome. *J Bone Joint Surg Am* 1995;77:867.

+ 34. Sponseller PD, Sethi N, Cameron DE, Pyeritz RE. Infantile Scoliosis in Marfan Syndrome. *Spine* 1997;22:509.

+ 35. Svensson O, Aaro S. Cervical Instability in Skeletal Dysplasia. *Acta Orthop Scand* 1988;59:66.

+ 36. Thomsen MN, Schneider U, Weber M, et al. Scoliosis and Congenital Anomalies Associated with Klippel-Feil Syndrome Types I–III. *Spine* 1997;22:396.

# 37. Tolo VT. Surgical Treatment of Kyphosis in Achondroplasia. In: Nicoletti B, Kopits SE, Ascani E, McKusick VA, eds. *Human Achondroplasia. Basic Life Science*, 48:257. New York: Plenum Press, 1988.

# 38. Tolo VT. Spinal Deformity in Short Stature Syndromes. *Instr Course Lect* 1990;39:399.

+ 39. Tolo VT, Kopits SE. Spinal Deformity in Diastrophic Dysplasia. *Orthop Trans* 1983;7:31.

+ 40. Tolo VT, Kopits SE. Surgical Treatment of Thoracolumbar Kyphosis in Achondroplasia. *Orthop Trans* 1988;12:254.

+ 41. Torg JS, Pavlov H, Genuario SE, et al. Neurapraxia of the Cervical Spinal Cord with Transient Quadriplegia. *J Bone Joint Surg Am* 1986;68:1354.

+ 42. Tredwell SJ, Newman DE, Lockitch G. Instability of the Upper Cervical Spine in Down Syndrome. *J Pediatr Orthop* 1990;10:602.

+ 43. Uematsu S, Wang H, Hurko O, Kopits SE. The Subarachnoid Space in Achondroplastic Spinal Stenosis: The Surgical Implications. In: Nicoletti B, Kopits SE, Ascani E, McKusick VA, eds. *Human Achondroplasia. Basic Life Science*, 48:275. New York: Plenum Press, 1988.

+ 44. Winter RB, Moe JH, Bradford DS, et al. Spine Deformity in Neurofibromatosis. *J Bone Joint Surg Am* 1979;61:677.

+ 45. Winter RB, Lonstein JE, Denis F, de la Rosa HS. Convex Growth Arrest for Progressive Congenital Scoliosis due to Hemivertebrae. *J Pediatr Orthop* 1988;8:633.

+ 46. Yong-Hing K, Kalamchi A, MacEwen GD. Cervical Spine Abnormalities in Neurofibromatosis. *J Bone Joint Surg Am* 1979;61:695.

+ 47. Yong-Hing K, MacEwen GP. Scoliosis Associated with Osteogenesis Imperfecta. *J Bone Joint Surg Br* 1982;64:36.

# CHAPTER 159

# SURGICAL TREATMENT OF ADULT SCOLIOSIS

*Robert F. McLain and Isador Lieberman*

**R. F. McLain:** Department of Orthopaedics, The Cleveland Clinic Foundation, Cleveland, Ohio, 44195.
**I. Lieberman:** Department of Orthopaedics, The Cleveland Clinic Foundation, Cleveland, Ohio, 44195.

Natural History
Clinical Presentation
Indications for Surgery
Preoperative Planning and Preparation
Principles of Segmental Instrumentation
Surgical Techniques
Posterior Procedures
Anterior Procedures
Postoperative Management
Pitfalls and Complications
Pseudarthrosis and Failure of Instrumentation
Flatback Syndrome
Persistent Pain
Neurologic Compromise
Authors' Preferred Technique
Authors' Perspective
Chapter References

Adult scoliosis is usually the product of an unarrested adolescent idiopathic curve. It may also develop secondary to progressive degenerative collapse or neuromuscular disease. It may, rarely, be attributable to a progressive idiopathic curve arising after skeletal maturity, in which the curves tend to be more rigid than those seen in adolescence.

Scoliosis in adults brings with it a host of associated problems (pain, neurologic signs and symptoms, progression of deformity, and cosmetic concerns). Postsurgical complications are more common, more severe, and less well tolerated than in younger patients. Even though advances in diagnostic modalities and surgical technique provide for more effective treatment options than in the past, the treatment of adult scoliosis remains one of the most complex and challenging disorders confronting the spinal surgeon.

## NATURAL HISTORY

Adolescent idiopathic scoliosis was once believed not to progress past skeletal maturity. It is now well documented that large curves continue to progress into adulthood. Curves less than 30° at the end of growth rarely progress and do not need close observation, but as Weinstein and Ponseti have shown, curves measuring greater than 50° at skeletal maturity are at significant risk for progression (28). Thoracic curves are even more likely to progress than lumbar curves.

Scoliosis arising from degenerative disc disease with asymmetric disc space collapse is distinct from adolescent and adult idiopathic scoliosis. The degenerative scoliosis is commonly a lumbar curve of moderate severity characterized by less rotation at the apex and more lateral listhesis between adjacent segments. Degenerative scoliosis is discussed more fully in Chapter 160.

## CLINICAL PRESENTATION

Pain is the most common complaint among adults with scoliosis. The pain tends to be mechanical in nature, worse in the morning and late evening, exacerbated by strenuous activity and certain bending or twisting activities, and characterized by limited sitting tolerance. Pain along the convexity of the curve can also be due to muscle fatigue or scapulothoracic incongruency. With advancing age and curve severity, the pain tends to concentrate in the concavity of the curve. Focal back pain across the concavity may be due to disc degeneration, facet arthrosis, junctional disc degeneration, or segmental instability (30).

Patients with scoliosis experience the same progression of disc degeneration as seen in normal spines, but eccentric loads may accelerate the degenerative process. Distortion of the outer annulus or posterior longitudinal ligament could generate back pain localized to the site of highest compressive load. The degenerating disc may release pain mediators that sensitize local receptors or the nerve root itself. The asymmetrically loaded facet joints could also be the source of pain in some patients.

Facet arthrosis or subluxation in both the concavity and convexity of the curve can stimulate capsular receptors capable of generating pain. Painful degeneration of the junctional disc may occur at the end of a rigid structural segment, within a flexible compensatory curve, or between opposing curves. In these areas, exaggerated bending forces tend to break down normal restraints and produce instability that may eventually result in coronal or sagittal displacements, abnormal motion, or axial and radicular pain. Radicular pain usually occurs on the concavity of lumbar or thoracolumbar curves, where nerve root compression in the lateral recess or foramen is caused by facet arthrosis and hypertrophy, disc herniation, or a combination of the two (Fig. 159.1). Radicular symptoms may also occur on the convexity when traction and kinking of the nerve root occur as it passes around the pedicle and out of the foramen.

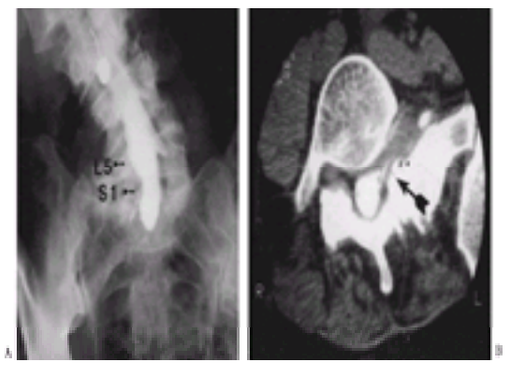


***Figure 159.1.*** A 55-year-old woman with a large lumbar curve that was not progressing. She developed radicular pain in her lower left extremity that markedly limited her walking and standing tolerance. Back pain had not changed for years. Myelogram (**A**) and postmyelographic (**B**) CT scan demonstrated nonfilling of left L-5 nerve root and displacement of left S-1 nerve root secondary to facet hypertrophy and subarticular and foraminal stenosis. Limited decompression consisting of left hemilaminotomy, partial medial facetectomy, and internal foraminotomy provided relief of lower extremity radicular pain. The curve has not progressed in over 1 year since surgery.

Curve progression is another common presenting complaint. Patients may complain of a loss of height, an increase in rib prominence, or changes in shoulder or waistline symmetry. In general, scoliosis in the adult progresses slowly, in the range of 1° per year (28). More rapid changes in posture may signal a more complex underlying disorder (i.e., metabolic bone disease, associated neurologic disorders, unrecognized congenital abnormalities) or may simply mean that the patient is losing the ability to compensate for the longstanding deformity.

When compared with progressive adolescent curves, the progressive adult scoliotic spine acts more like a leaning tower of Pisa, in that the rigid spine cannot compensate for curve progression to maintain sagittal or coronal balance. Since the primary curve (thoracic, thoracolumbar, or lumbar) becomes rigid early in the curve's development, it can no longer compensate in the sagittal or coronal plane as the compensatory curve progresses and eventually becomes structural. Frequently, the patient notices progression of coronal and sagittal imbalance as he or she falls farther and farther to one side (Fig. 159.2).

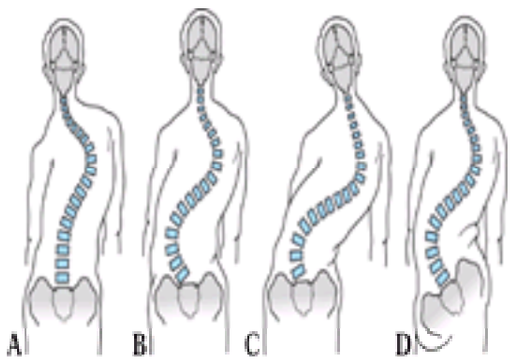


***Figure 159.2.*** Progression and decompensation. **A:** Adult patient with longstanding thoracic curve. The curve is rigid but well balanced in coronal plane. The lumbar compensatory curve is low-grade and supple. **B:** Over time, the lumbar compensatory curve progresses. The ability of the spinal column to compensate is limited by the rigid thoracic curve. Degenerative changes, superimposed on the secondary curve, accelerate the curves' progression. **C:** When the limits of spinal compensation are reached, the progressive lumbar curve begins to throw the thoracic curve out of coronal balance. The patient begins to lean or collapse to one side. Decompensation progresses rapidly because of the mechanical disadvantage, and the apparent deformity becomes dramatically worse in a short time. **D:** The final compensatory mechanism is postural; the patient stands with the left hip flexed and shoulders askew, trying to balance the head over the pelvis.

Cosmesis is often a major concern for patients seeking treatment, but many patients are reluctant to raise this issue with their doctors. Rib prominence, changes in the waistline, and lateral postural imbalance all contribute to an undesirable appearance. While the cosmetic aspects of spinal deformity are often downplayed by physicians, they are often extremely important to the patient and should be carefully considered in formulating a treatment plan.

Cardiopulmonary compromise can occur in idiopathic scoliosis but is rarely the main reason the patient seeks treatment. Large thoracic curves (greater than 100°) may cause restrictive pulmonary disease, particularly when the chest is hypokyphotic (3). Although most patients with large curves have pain as their major complaint, the presence of deteriorating pulmonary function is an additional indication for surgical intervention. Key features of cardiopulmonary involvement include

- Measurable losses in pulmonary function that are first noted in curves greater than 60°; significant impairment occurs where curves exceed 100°;
- Direct correlation between curve magnitude and loss of pulmonary capacity;
- Complaints of fatigue and shortness of breath with minor exertion;
- Neuromuscular disease that can amplify pulmonary compromise.

Pulmonary function testing is indicated for any patient with significant signs or symptoms.

Neurologic deficits are uncommon in scoliosis. Spinal cord compression with myelopathy has not been reported in idiopathic scoliosis. Occasionally, patients may have activity-related deficits due to central stenosis. These deficits usually occur in older patients, where degenerative changes have set in on top of the original deformity. Lateral or sagittal translation can cause rapid progression of stenosis symptoms.

## INDICATIONS FOR SURGERY

The major indications for surgery in adults with scoliosis are the following:

- Pain, focal or radicular
- Documented curve progression
- Curve greater than 60°
- Severe cosmetic deformity
- Flatback syndrome, sagittal or coronal imbalance
- Vertebral translation or instability due to severe lumbar curve

Once curve progression has been documented, nonsurgical modalities are ineffective in stopping it and surgical treatment should be considered. Because of the high likelihood of progression, patients with thoracic curves measuring 60° or more should generally consider surgical treatment. Patients with lumbar curves of less magnitude may sometimes require surgery because of pain and progression (4).

If pain alone is the indication for surgery, the patient must decide if the symptoms are severe and limiting enough to justify the risks of major surgery. The physician must be certain that the pain is related to a structural spinal problem, since idiopathic back pain is just as common in people with scoliosis as in the general population. Discography may be helpful in determining whether symptoms of low back pain are related to disc degeneration or junctional problems. The radiographic appearance of the discogram is not important, but the reproduction of the patient's pain pattern during injection is diagnostic (13,26).

## PREOPERATIVE PLANNING AND PREPARATION

Before embarking on surgical treatment, clearly define the goals of surgery and the treatment expectations to the patient. The treatment recommendations must be tailored to the patient's specific complaints. In most cases, they represent a combination of pain, neurologic symptoms, curve progression, and cosmesis. When pain is the major complaint, *the pain generator* must be identified and treatment targeted accordingly. The contribution of sagittal and coronal imbalance to pain must be evaluated and treatment planned to include the appropriate realignment procedure. If neurologic symptoms are the major concern, the source of root or cord compression must be identified and treated.

Neurologic symptoms may be addressed through direct posterior decompression or may be alleviated by indirect decompression through curve realignment. When curve progression is the most significant concern, its rate and extent must be documented to provide the correct treatment recommendation—fusion *in situ* or curve correction. If cosmesis is the primary indication for surgery, then the curve flexibility must be evaluated and the most appropriate realignment technique utilized. Thoracoplasty may be needed to correct the rib hump in patients with adult scoliosis.

During preoperative planning, mark radiographs to indicate the location of implants and the application of corrective forces to be used (Fig. 159.3). Side-bending radiographs are crucial to the decision process. Measure bending films to determine the best passive correction obtainable for each curve. Most adult curves can be adequately treated with posterior techniques alone, but larger, more rigid curves are better treated with a combined approach of anterior release and interbody grafting followed by posterior instrumentation and grafting. Anterior release and interbody fusion should be considered when




***Figure 159.3.*** Radiograph marked before surgery to indicate types and sites of hook placement in a 24-year-old woman with double major thoracic and lumbar curves.

- The thoracic and thoracolumbar curves do not correct to an angle of less than 50° on lateral-bending radiographs;
- The primary curve cannot be corrected on lateral-bending radiographs to match the corrected compensatory curve (to achieve two balanced curves) (5);
- The patient has a higher than usual risk of pseudarthrosis (neurofibromatosis);
- L-4 does not reach neutral on maximal side-bending radiographs and the surgeon wants to avoid fusion to L-5 or the sacrum;
- Fusion to the sacrum is necessary.

An L-5–S-1 interbody fusion minimizes the risk of pseudarthrosis in a posterior lumbosacral fusion. In painful curves, discography can ensure that the fusion is not terminated at the level of a symptomatic degenerative disc. If radicular symptoms are prominent, magnetic resonance imaging (MRI) is indicated.

When possible, plan to do anterior and posterior fusions as a single surgical procedure. Preoperative autologous blood donation is routine unless contraindicated. Perform pulmonary function tests, measure nutritional parameters, and do a full medical workup before undertaking a combined procedure. Although a single-stage operation is physically taxing, complications for it are significantly less than for two-stage procedures (19,20). If blood loss during the anterior approach is excessive or the patient is hemodynamically unstable, the posterior procedure may be postponed for 5–7 days. In the interim, maximize pulmonary function, prevent or treat urinary tract or wound infections, and maintain sound nutritional status.

If a severe rigid curve is encountered and maximal correction is the goal, consider a staged procedure incorporating 2 to 3 weeks of halo–femoral traction between the anterior and posterior surgeries. Most adults can tolerate this regimen physically and psychologically. Pin site and skin care must be meticulous. We recommend prophylaxis against deep-vein thrombosis. Initiate physical therapy to encourage deep breathing and extremity range-of-motion exercises. During traction, tilt the head of the bed up 15° to 20°. Attach the halo ring to the bed frame and apply 10–20 pounds of weight to each of the femoral traction pins. The patients may be out of traction for bathing and may be up with a walking or wheelchair traction frame as tolerated.

## PRINCIPLES OF SEGMENTAL INSTRUMENTATION

Segmental fixation is the preferred method of internal fixation in adult scoliosis. Greater curve correction and better sagittal plane balance are possible with segmental instrumentation than with traditional Harrington instrumentation. Modern segmental instrumentation systems are based on a longitudinal member to which a variety of hooks, screws, sublaminar wires, or connectors can be attached. Stronger spinal fixation is afforded by multiple fixation points along the rod and by using strategic combinations of screws, sublaminar wires, and hooks to gain firm purchase on the pedicles, laminae, and transverse processes.

Place additional fixation whenever possible to increase implant stability, as adults fuse more slowly than adolescents, and they have stiffer curves and often poorer bone stock. The rate of pseudarthrosis and rod failure with segmental instrumentation is lower than with Harrington instrumentation (18,22,24). In addition, the prolonged postoperative immobilization necessary after Harrington instrumentation is often unnecessary after segmental instrumentation.

The use of pedicle screws in the treatment of scoliosis is controversial and does carry a theoretically greater risk of screw misplacement because of the bony deformity. Pedicle screws do provide superior fixation in adult patients, however, and their use can enhance correction by harnessing the “force nucleus” (junction of pedicle lamina and transverse process), as described by Steffee et al. (23) and others (27). Pedicle screws also allow for parallel, purely axial corrective forces between adjacent segments.

Hooks, by contrast, may produce focal kyphosis or lordosis when distraction or compression forces are applied. Specifically, pure distraction in the lumbar spine can produce a painful flatback syndrome unless multiple hooks are used and rods are carefully contoured to maintain lordosis. Sublaminar wires are most valuable in lateral translation of the spine during correction. They cannot control rotation or axial collapse and as such work best in a combined construct with hooks or screws.

Traditional teaching has been that the fusion should end at the stable vertebra, which is the vertebra intersected by the central sacral line (12) (see chapter 156). With segmental instrumentation, the lower end of the fusion should be the vertebra that becomes level on maximal side-bend radiographs. Patients with a rigid lumbosacral curve who have significant residual tilt of L-4 on bending films, and those with low back pain due to disc degeneration at L-4–L-5 or L-5–S-1, require fusion to the sacrum. Avoid fusion down to L-5 alone, as the incidence of subsequent low back pain is high (6).

Segmental instrumentation systems improve correction of spinal deformity by addressing all three planes of deformity (7):

- Coronal plane deformities can be corrected by longitudinal compression and distraction forces.
- Sagittal plane contours can be restored by properly contouring the rods and avoiding strong distraction forces in the lower lumbar segment.
- Finally, there is limited potential to improve rotational deformity through proper contouring of the rods.

By correcting rotational deformity, the cosmetic results of surgery can be improved, especially with regard to the thoracic rib hump. The cosmetic correction possible in the adult is usually less than what can be achieved in the adolescent, but it can be maximized by a circumferential release of the spine including concave and convex facetectomies. Severe rib-cage deformities may be improved through thoracoplasty, but not without some additional pain and potential morbidity.

Long scoliosis fusions ending at the sacrum have a high rate of pseudarthrosis and fixation failure. For neuromuscular scoliosis, the modified Galveston technique of Allen and Ferguson achieves firm pelvic fixation and a high fusion rate (1). For ambulatory patients, instrumenting across the intact sacroiliac joints is not recommended and sacral fixation is needed. Single-level hook or screw purchase into the sacrum is often inadequate when an extended construct acts as a long lever arm above the sacrum. The two options that can be considered are (a) additional pedicle screws into S-2 and (b) an intrasacral rod technique. Any long construct terminating at the sacrum should be augmented with an L-5–S-1 interbody fusion using either an anterior or a posterolateral technique.

Anterior segmental instrumentation can correct and stabilize a curve until fusion is achieved. The Zielke instrumentation is the prototype, but many useful systems are now available. Double-rod anterior systems have recently been described (11) and appear promising. Anterior instrumentation can be more advantageous than posterior and may even preclude a posterior procedure.

By virtue of their anatomic location, anterior instrumentation systems are better suited to correct deformity in the coronal, sagittal, and axial planes (8,10,14), but they have their limitations. If screws are not properly aligned, anterior instrumentation may produce kyphosis in the thoracolumbar and lumbar spine. Also, instrumentation extending to the low lumbar spine may impinge on the vascular structures.

Placement of the screws must be meticulous to avoid penetration of the spinal canal. Protect the spinal canal by identifying landmarks and bluntly dissecting around the opposite side of the vertebral body. Place a finger at the junction of the transverse process, pedicle, and vertebral body to act as an aiming guide.

With the first-generation anterior implant systems, screw and rod breakage were common. With more modern, robust instrumentation, breakage is far less common, but screw pullout at the proximal or distal end of the construct remains a problem. To prevent this problem, use a pullout-resistant nut on the opposite side of the vertebral body (16), or extend the instrumentation to other levels to distribute the load.

## SURGICAL TECHNIQUES

### POSTERIOR PROCEDURES

- Position the patient on an appropriate spinal frame, ensuring that the abdomen hangs freely and that compression of the inferior vena cava is minimized. If pedicle screws will be needed, use a radiolucent table or frame; otherwise, use either a Wilson frame or longitudinal bolsters. Take care during positioning to make sure that the face is well padded and that there is no pressure on the eyes. Drape the back to provide access to the entire spine and to the iliac crest for graft harvest.
- Center a longitudinal midline incision over the apical vertebra. After stripping the paraspinous musculature, expose the spine subperiosteally to the tips of the transverse processes.
- Identify levels radiographically by placing a towel clip through the transverse process of the selected vertebra.
- After exposing the lamina at the levels to be fused, identify hook and screw sites and prepare them for implant placement. The technique of hook insertion is identical to that performed in adolescent patients (Fig. 159.4).

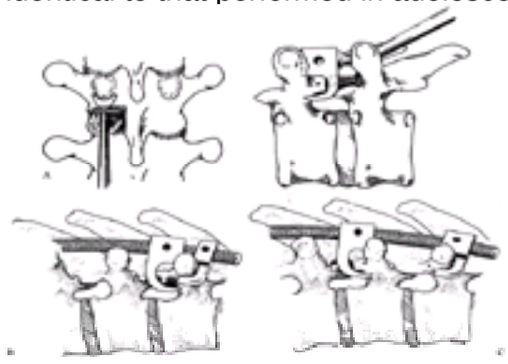

***Figure 159.4.*** **A:** Insertion of the pedicle hook. **B:** Construction of the upper claw. Two forms of transverse-pedicular claws can be used to secure the upper end of the construct. A single-level claw using a transverse process hook and standard pedicle hook is the most common combination. **C:** For longer constructs, a two-level claw may be easier to apply. Use standard closed lumbar lamina and pedicle hooks. Either of these constructs can be substituted for the other when a transverse process is fractured during instrumentation.

- After excising the inferior facet with a narrow osteotome, remove the articular surface of the underlying superior facet with a straight curet. Locate the pedicle, which lies at the level of the transverse processes, with the pedicle finder. With the finder well seated on the pedicle, the vertebral body can be moved side to side with the finder. If the two do not move as a unit, the purchase is inadequate.
- Then insert the pedicle hook, taking care not to split the lamina during placement.
- Place additional hooks, if desired, to increase the overall strength of the construct and to distribute forces over a greater number of vertebrae (Fig. 159.5). Extra hooks may be especially helpful in patients with osteoporotic bone (Fig. 159.6).



***Figure 159.5.*** Postoperative radiograph of patient in Figure 159.3, treated with Cotrel-Dubousset segmental instrumentation. This triple-rod technique distributes corrective forces over many spinal segments using multiple fixation hooks. Combined with anterior thoracic and lumbar releases, this approach provided 45% correction of the thoracic curve (101° to 55°) and 55% correction of the lumbar curve (108° to 48°).

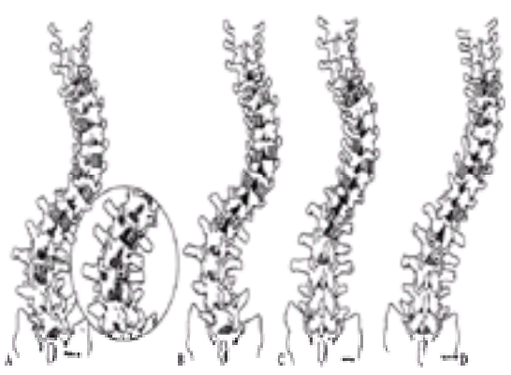

***Figure 159.6.*** Hook patterns for specific scoliotic curves. **A:** King type I curve—S-shaped curve with lumbar curve that is larger and less flexible than the thoracic. This hook pattern uses the standard thoracic pattern (see type III) but adds hooks distally to allow compression of the lumbar convexity and distraction of the lumbar concavity. (*Inset*) Pedicle screws may be used in the lumbar segment and are most easily placed on the convexity. Distal hooks or screws allow correction of any junctional kyphosis when the curve is corrected. **B:** King type II curve—S-shaped curve in which both thoracic and lumbar curves cross the midline. In this curve, the lumbar curve is more flexible and does not require full instrumentation. Correction of the thoracic curve using a standard thoracic pattern is adequate to provide a satisfactory anteroposterior (AP) contour. Add upper lumbar fixation to help prevent decompensation and to restore sagittal balance. **C:** King type III curve—typical right thoracic curve. Construct other fixation patterns around this one. Instrument the concavity with pedicle hooks at the upper end-vertebra and one level above the apex, and sublaminar hooks downgoing at the lower end-vertebra and one level below the apex. This pattern allows uniform distraction over the concave side, along with some derotation. Provide compression over the convex side with a transverse-pedicular claw at the upper end-vertebra, an open pedicle hook at the level of the apex, and a sublaminar hook under the lamina of the lower end-vertebra. Additional open hooks may be added in patients with poor bone quality. **D:** King type IV curve—long thoracic curve in which lower lumbar vertebrae also tilt into the curve. Instrumentation of this curve is similar to that of type III, with the distal hooks carried to the upper lumbar spine to correct the longer curve. Attempt to spare the lower lumbar segments and allow the patient to compensate spontaneously. If the lumbar deformity is rigid, instrumentation and fusion may have to be extended to the lower lumbar spine.

- Although rotational correction is possible in reasonably flexible curves, derotation may not be possible or safe in very stiff curves. Overzealous attempts to derotate or translate vertebral elements may result in fractures of the laminae or pedicles, and possible penetration of implants into the spinal canal (9).
- For stiffer curves, gain correction by segmental distraction, along with appropriate sagittal contouring to maintain or correct kyphotic or lordotic segments. Large, rigid thoracic curves may be partially corrected with a short apical rod placed in the concavity, before completing the construct with a long distraction rod. The long rod can then be coupled to the short apical distraction rod, and, after distraction, both can be coupled to the convex rod (Fig. 159.7).

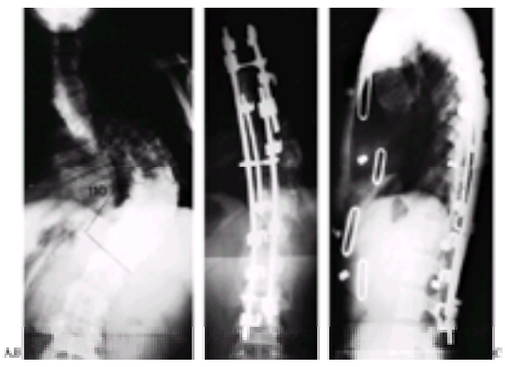

***Figure 159.7.*** A 28-year-old woman with a stiff King-type V thoracic scoliosis. **A:** Preoperative PA radiograph demonstrates double thoracic curve. Upper curve (apex T-5) measured 76°. Lower curve (apex T-10–T-11) measured 110°. **B:** Following right anterior thoracic release, a short, apical distraction rod used to correct the uppermost curve. A longer rod spanning the convexity of the lower thoracic curve was connected to the first rod in bayonet fashion with a double-barrel "domino." Both these rods combine to make the third member of a triple-rod construct using a short reduction rod at the apex of the lower thoracic curve. **C:** Lateral view shows restoration of thoracic kyphosis and neutral thoracolumbar alignment.

- Always crosslink rod constructs to increase the torsional stiffness of the construct (2).
- Before completing the instrumentation, excise all facet joints and thoroughly decorticate the exposed spine. Although segmental instrumentation offers rigid fixation, strict adherence to these principles is crucial to obtain a consistent fusion in adult patients. During decortication, preserve the integrity of the laminae and transverse processes on which hooks are to be placed.
- We advocate the use of autogenous iliac bone graft, particularly if wide laminectomy has been performed in the lumbar spine, in cases of pseudarthrosis, or with fusion to the sacrum.
- Radicular pain resulting from foraminal or lateral recess stenosis often resolves with curve correction and stabilization. Medial facetectomies and foraminotomies, however, may be carried out if there is documented foraminal or lateral recess stenosis consistent with the lower extremity symptoms. If the curve is stable, and not progressive, root compression may be treated with decompression alone. Partial medial facetectomies and foraminotomies may be carried out through a limited laminotomy, taking care to preserve the pars interarticularis and dorsal facet joints.
- Achieve posterior releases by performing an osteotomy at each of the rigid periapical segments. Beginning in the midline, open the ligamentum flavum, and then use Kerrison rongeurs to excise the ligamentum flavum. In longstanding deformities, the ligamentum flavum may be ossified and will need to be taken down with a burr and Kerrison rongeurs. Proceeding laterally on both sides, excise the facets and enter the neural foramen. These osteotomies will significantly increase the mobility of the curve.

### ANTERIOR PROCEDURES

- Treat rigid, high-degree curves by anterior release and interbody grafting before proceeding with posterior instrumentation, correction, and grafting. Carry out the traditional anterior release as described in Chapter 155, with two particular precautions: First, because vascular supply to the cord is less robust in adults, and particularly tenuous in kyphotic segments, exercise caution when approaching those segments anteriorly. It may be wise to preserve segmental vessels in these regions, or at least to temporarily occlude large segmentals with a vascular clamp and observe for changes in the somatosensory evoked potentials.
- Second, very rigid curves may require an extensive release, including excision of the posterior longitudinal ligament, before correction can be obtained. In order to shorten the vertebral column (to restore thoracic kyphosis and avoid stretching the neural elements) during correction, partial vertebrectomy may be necessary at apical levels.
- Anterior instrumentation may improve curve correction and may allow the surgeon to spare lower lumbar segments in some patients with thoracolumbar and lumbar curves. Place vertebral body screws as far posteriorly as possible on the convex side of the spine, traversing each body in an anterolateral direction, slightly away from the canal. In a badly rotated specimen, this orientation can be difficult to obtain. By placing the end-vertebral screws slightly more anterior to the periapical screws, instrumentation and correction will naturally tend to rotate the lumbar curve and restore lumbar lordosis.
- Because the vertebral cortex in the midbody is thin, create the starting hole with a hand-held awl. Bicortical purchase is desirable, particularly at end vertebrae. If posterior pedicle screw instrumentation is planned, place the anterior vertebral body screws below the midpoint of the vertebral body.
- With the advent of endoscopic techniques, thoracotomy and thoracolumbotomy may be avoided and the anterior release and interbody grafting performed in a minimally invasive fashion. Using endoscopy, the anterior and posterior procedures may even be performed simultaneously with the patient in the prone position (17).

## POSTOPERATIVE MANAGEMENT

Try to get patients out of bed to a chair the day after surgery, and walking within 3–5 days. If bone quality is good and implant purchase is thought to be secure, no brace is needed. If there is any concern about the security of internal fixation, use a thoracolumbosacral orthosis (TLSO) for 4 to 6 months. Bracing is also commonly used in patients fused to L-3 or L-4, as there is greater stress on the lower lumbar implants. Bracing to neutralize lower lumbar or lumbosacral curves should include a thigh cuff with a drop-lock hinge.

Patients are allowed to sleep and shower without the brace. Walking is recommended from the outset. A walking program, progressing to 1 mile daily, provides regular exercise during fusion consolidation.

## PITFALLS AND COMPLICATIONS

Potential complications in the surgical treatment of adult scoliosis are the following:

- Blood-loss-induced anemia
- Pulmonary compromise
- Pseudarthrosis
- Failure of instrumentation
- Flatback syndrome
- Neurologic compromise
- Continued pain
- Infection

### PSEUDARTHROSIS AND FAILURE OF INSTRUMENTATION

The complication rate in adults is significantly higher than in adolescents undergoing surgery for scoliosis (21). The most common complication, pseudarthrosis, occurs in 9% to 27% of patients (18,22,24,25). Hook dislodgement and rod fractures have been common, but primarily with Harrington instrumentation.

Although long-term complication rates of segmental instrumentation are not yet known, these will probably be lower than with older systems due to the more rigid fixation. Hook displacement and cutting-out of lumbar hooks have been reported with Cotrel-Dubousset instrumentation (9). "Claw" hook configurations on a single lamina may predispose to lamina fracture, and an inferior claw spanning two laminae is recommended to help prevent pullout. The use of pedicle screws in lower lumbar vertebrae may improve purchase in osteoporotic patients and those with stiff lumbar curves. The surgeon may use multiple pedicle screws or a pedicle–laminar claw for maximum fixation (Fig. 159.8).

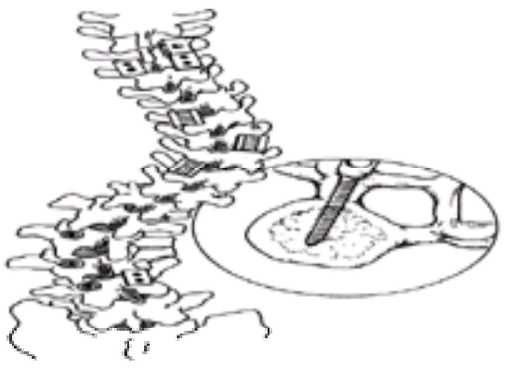

***Figure 159.8.*** Lumbar fixation can be maximized by using pedicle screws in stiff thoracolumbar and lumbar curves. The rotation of the vertebra leaves the convex pedicle oriented in the AP plane, allowing easy placement of screws. Place a sublaminar hook on the concave side to allow distraction.

### FLATBACK SYNDROME

Lumbar flatback syndrome is a known complication of distraction instrumentation, but it has been less troublesome since the introduction of segmental systems. This disabling condition causes back pain, forward tilt of the trunk, and severe sagittal imbalance (15). It can be avoided in segmental fixation systems by carefully contouring the rods to the normal lumbar lordosis and avoiding excessive distraction in the lumbar spine. Preventing this complication is critical, as surgical correction of the established condition is fraught with complications and often gives a poor result.

### PERSISTENT PAIN

Few patients become completely pain free after spinal fusion, but, if a discreet pain generator has been identified, improvement can generally be expected (18,22). Even though the curve has been stabilized, patients may continue to experience back pain.

### NEUROLOGIC COMPROMISE

Intraoperative complications, such as excessive blood loss and neurologic injury, are more common in adults than in adolescents. Neurologic complications with Harrington instrumentation have been uncommon; the risk of spinal cord injury is primarily related to overdistraction of a rigid curve. The same risks are present during distraction using segmental instrumentation and may be magnified by the increased mechanical advantage provided by segmental systems. Attempts to derotate a rigid curve in an osteoporotic spine may cause a concave pedicle hook to fracture the pedicle and penetrate the spinal canal. Gurr and McAfee reported such a case, which resulted in a Brown-Séquard syndrome (9). Rigid curves, especially in the presence of osteoporosis, should be treated with distraction and compression, avoiding derotation or strong translation forces. Remember that the primary goal of surgery in the adult with scoliosis is to stabilize the curve and halt progression; correction is a secondary objective.

Spinal cord monitoring should be used in all cases, as this allows recognition of subtle neurologic changes, permitting the surgeon to take prompt action to reverse them (29).

## AUTHORS' PREFERRED TECHNIQUE

There is no routine approach to adult patients with scoliosis; each curve has its own “personality,” and each patient presents with his own confounding variables (Fig. 159.9). The presenting complaint, level of deformity, and rigidity of the curves dictate the specifics, but a general approach can be proposed.



***Figure 159.9.*** A 46-year-old woman with severe, progressive thoracolumbar scoliosis. **A:** Preoperative PA radiograph demonstrates high-degree thoracic and lumbar curves. Bending films revealed little correction of either curve. Occiput was 4.0 cm left of the central sacral line. **B:** After anterior lumbar release and instrumentation, the lumbar curve was improved but the thoracic curve was no better and out of balance. **C:** Thoracic release and posterior instrumentation were performed 7 days later, under one anesthetic. Lateral view shows pedicle screws properly placed in the lumbar pedicles, passing above the vertebral body screws that were placed low in each vertebral body. Thoracolumbar kyphosis has been improved to mild lordosis. Custom-designed pullout nuts (*lower arrow*) improve pullout strength of the vertebral body screws. **D:** Anterior thoracic release, combined with posterior segmental instrumentation, provided 50% correction of the thoracic curve. The combined approach to the lumbar curve provided correction of almost 60%.

- Release any curve that cannot be reduced to less than 50° on bending films anteriorly prior to posterior instrumentation.
- If both thoracic and lumbar curves must be addressed, carry out the lumbar retroperitoneal approach at the initial operation. Perform an anterior release, interbody fusion, and anterior instrumentation.
- Give the patient 5–7 days to recover before performing the definitive second procedure.

At the second operation, carry out an anterior thoracic release and full-length posterior instrumentation as staged or simultaneous procedures.

- In the staged procedure, place the patient in a lateral decubitus position with the curve convexity up. Through the anterior approach, release as many levels as can be reached, removing as much of the concave soft tissues as is necessary to allow motion when pressure is applied to the vertebral body.
- Once the convex release is completed, lightly pack the morcelized rib into the intervertebral spaces, close the wound, and turn the patient prone on the spinal frame.
- Perform posterior instrumentation, incorporating all of the thoracic and lumbar curves.
- Place multiple hooks to correct both coronal and sagittal alignment. Place pedicle screws distally to obtain the most stable foundation for the rest of the construct.
- Contour the rods to impart more normal thoracic kyphosis and lumbar lordosis, and then lock them into the lumbar screws distally.
- Sequentially reduce the rods into remaining hooks, taking time to allow viscoelastic forces to dissipate.

For severe curves, the thoracic and lumbar sagittal curves may reflect the existing scoliotic curves, and rod placement may be easier if the rods are placed in an off-axis, rotated position (Fig. 159.10).

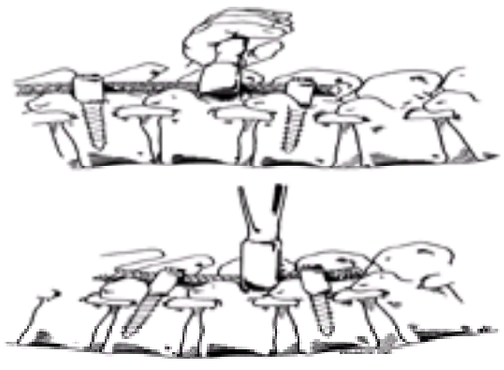

***Figure 159.10.*** Correction of junctional kyphosis is crucial to sagittal plane balance. Derotation of a contoured fixation rod using hooks or pedicle screws allows the surgeon to restore thoracolumbar lordosis and thoracic kyphosis at the time of curve correction.

- After loosely affixing the hooks and screws to the rod, apply C-rings to prevent hooks from displacing.
- Slowly rotate the rods back into normal orientation, placing the kyphotic and lordotic curves back in the sagittal plane. This “derotation” maneuver simply uses rod contours to apply translational forces to correct the coronal deformity. There is no actual derotation of the vertebrae.

In the simultaneous approach, place the patient prone, and prep anteriorly to the midaxillary line on the side of the concavity. A thoracoscopic approach can then be used to release multiple disc spaces through a few periapical portals. Carry out the posterior instrumentation without changing the patient's position.

## AUTHORS' PERSPECTIVE

Adult idiopathic scoliosis is a complex disorder requiring thorough patient evaluation and careful preoperative planning. An accurate assessment of spinal pain and curve progression, and knowledge of the natural history of scoliosis are essential components in formulating an appropriate treatment plan. With more advanced surgical techniques, patients once thought to be untreatable may now be effectively managed. Although surgery is a major undertaking, with a significant complication rate, the results of surgical treatment of adult scoliosis can be extremely gratifying.

### CHAPTER REFERENCES

Each reference is categorized according to the following scheme: *, classic article; #, review article; !, basic research article; and +, clinical results/outcome study.


* 1. Allen BL Jr, Ferguson RL. The Galveston Technique for L Rod Instrumentation of the Scoliotic Spine. *Spine* 1982;7:276.

# 2. Ashman RB, Birch JG, Bone LB, et al. Mechanical Testing of Spinal Instrumentation. *Clin Orthop* 1988;227:113.

* 3. Bjure J, Nachemson A. Nontreated Scoliosis. *Clin Orthop* 1973;93:44.

# 4. Briard JL, Jegou D, Cauchoix J. Adult Lumbar Scoliosis. *Spine* 1979;4:526.

+ 5. Byrd JA, Coles PV, Winter RB, et al. Adult Idiopathic Scoliosis Treated by Anterior and Posterior Spinal Fusion. *J Bone Joint Surg Am* 1987;69:843.

+ 6. Cochran T, Irtam L, Nachemson A. Long-Term Anatomic and Functional Changes in Patients with Adolescent Idiopathic Scoliosis Treated by Harrington Rod Fusion. *Spine* 1983;8:576.

+ 7. Cotrel Y, Dubousset J. A New Technique of Segmental Instrumentation of the Spine. *Orthop Trans* 1985;9:584.

* 8. Giehl JP, Zielke K, Hack HP. Die Ventrale Derotationsspondylodese nach Zielke. *Orthopade* 1989;18:101.

+ 9. Gurr KR, McAfee KC. Cotrel-Dubousset Instrumentation in Adults, A Preliminary Report. *Spine* 1988;13:510.

+ 10. Kaneda K, Fujiya N, Satoh S. Results of Zielke Instrumentation for Idiopathic Thoracolumbar and Lumbar Scoliosis. *Clin Orthop* 1986;205:195.

+ 11. Kaneda K, Shono Y, Satoh S, Abumi K. Anterior Correction of Thoracic Scoliosis with Kaneda Anterior Spinal System. A Preliminary Report. *Spine* 1997;22:1358.

* 12. King HA, Moe JH, Bradford DS, Winter RB. The Selection of Fusion Levels in Thoracic Idiopathic Scoliosis. *J Bone Joint Surg Am* 1983;65:1302.

# 13. Kostuik JP. Decision-Making in Adult Scoliosis. *Spine* 1979;4:521.

+ 14. Kostuik JP, Carl A, Ferron S. Anterior Zielke Instrumentation for Spinal Deformity in Adults. *J Bone Joint Surg Am* 1989;71:898.

* 15. Lagrone MO, Bradford DS, Moe JH, et al. Treatment of Symptomatic Flat Back after Spinal Fusion. *J Bone Joint Surg Am* 1988;70:569.

! 16. Lieberman IH, Khazim R, Woodside T. Anterior Vertebral Body Screw Pull-out Testing: A Comparison of Zielke, Kaneda, Universal Spine System, and Universal Spine System with Pull-out Resistant Nut. *Spine* 1998;23:908.

+ 17. Lieberman IH, Orr RD, Salo PT, Kraetschmer BG. The Results of Simultaneous Endoscopic Anterior Release and Posterior Instrumentation for Spinal Deformity. Orthopaedic Proceedings. *J Bone Joint Surg Br* 1998;80(supp 1):5.

* 18. Ponder RC, Dickson JH, Harrington PR, Erwin WD. Results of Harrington Instrumentation and Fusion in the Adult Scoliosis Patient. *J Bone Joint Surg Am* 1975;57:797.

+ 19. Schiffman DN, McLain RF, Benson DR. Luque Galveston Instrumentation in Neuromuscular Scoliosis: Surgical and Functional Outcomes. *Proceedings of the Scoliosis Research Society*, 32nd Annual Meeting, St Louis, MO, September 1997.

+ 20. Shufflebarger HL, Grimm JO, Bui V, Thomson JD. Anterior and Posterior Spinal Fusion: Staged versus Same Day Surgery. *Spine* 1991;16:930.

+ 21. Simmons EDJ, Kowalski JM, Simmons EH. The Results of Surgical Treatment for Adult Scoliosis. *Spine* 1993;18:718.

* 22. Sponseller PD, Cohen MS, Nachemson AL, et al. Results of Surgical Treatment of Adults with Idiopathic Scoliosis. *J Bone Joint Surg Am* 1987;69:667.

* 23. Steffee AD, Biscup RS, Sitkowski DJ. Segmental Spine Plates with Pedicle Screw Fixation. A New Internal Fixation Device for Disorders of the Lumbar and Thoracolumbar Spine. *Clin Orthop* 1986;203:45.

+ 24. Swank S, Lonstein JE, Moe JH, et al. Surgical Treatment of Adult Scoliosis: A Review of 222 Cases. *J Bone Joint Surg Am* 1981;63:268.

+ 25. Van Dam DE, Bradford DS, Lonstein JE, et al. Adult Idiopathic Scoliosis Treated by Posterior Spinal Fusion and Harrington Instrumentation. *Spine* 1987;12:32.

! 26. Walsh TR, Weinstein JN, Spratt KF, et al. Lumbar Discography in Normal Subjects. *J Bone Joint Surg Am* 1990;72:1081.

+ 27. Webb JK, Burwell RG, Cole AA, Lieberman I. Posterior Instrumentation in Scoliosis. *Eur Spine J* 1995;4:2.

* 28. Weinstein SL, Ponseti IV. Curve Progression in Idiopathic Scoliosis. *J Bone Joint Surg Am* 1983;65:447.

+ 29. Wilber RG, Thompson GH, Shaffer JW, et al. Postoperative Neurological Deficits in Segmental Spinal Instrumentation. A Study Using Spinal Cord Monitoring. *J Bone Joint Surg Am* 1984;66:1178.

# Winter RB, Lonstein JE, Dennis F. Pain Patterns in Adult Scoliosis. *Orthop Clin North Am* 1988;19:399.
30.

# CHAPTER 160

# SURGICAL MANAGEMENT OF DEGENERATIVE SCOLIOSIS

*Serena S. Hu and David S. Bradford*

**S. S. Hu and D. S. Bradford:** Department of Orthopaedic Surgery, University of California Medical Center, San Francisco, California, 94143.

Clinical Presentation
Natural History
Components of Deformity
Conservative Management
Indications for Surgery
Surgical Techniques
Decompression
Fusion *in Situ*
Decompression and Fusion
Combined Anterior–Posterior Techniques
Anterior Fusion with Femoral Rings
Pitfalls and Complications
Minimally Invasive Techniques
Authors' Perspectives
Chapter References

Degenerative scoliosis is a curvature that develops in the adult secondary to degenerative disc disease. It may be difficult in many cases to determine whether scoliosis is arising *de novo* or if patients had mild to moderate degrees of scoliosis that became symptomatic or progressed late in adulthood. The treatment of degenerative scoliosis follows many of the same principles as the treatment of adult idiopathic scoliosis, however, so the distinction in many cases may be moot. This chapter discusses the factors that should be considered in treating patients with this condition.

## CLINICAL PRESENTATION

### NATURAL HISTORY

Mild to moderate degrees of degenerative scoliosis may not progress, and they may not be symptomatic. With more advanced disease, axial pain and neurogenic claudication are typical symptoms. As with any degenerative spine disease, facet hypertrophy, diffuse disc bulges, disc degeneration, and narrowing and redundant ligamentum flavum can result in spinal stenosis and produce symptoms of neurogenic claudication and radiculopathy (25). The degree of compression can be aggravated in the presence of lateral listhesis or spondylolisthesis, by traction on the nerve roots.

Lateral listhesis, where slippage of one vertebra upon another occurs in the coronal plane, appears to correlate with a greater risk of curve progression (25,27). Significant lateral listhesis, particularly when it occurs at multiple adjacent levels, can result in significant truncal imbalance with resultant pain and fatigue. In many patients, these symptoms can be managed conservatively with anti-inflammatories, physical therapy, and epidural steroids. With progression of the patient's curvature, however, failure to respond to conservative measures or significant compromise of the patient's quality of life may call for consideration of surgical intervention.

Curve progress is variable, but among those who progress, it has been reported to average 3° a year (25). Risk factors for curve progression include curve magnitude greater than 30°, osteoporosis, and lateral listhesis or rotatory spondylolisthesis (9,14). Prior decompressive surgery, such as a laminectomy, can increase curve progression as well, sometimes secondary to development of a postsurgical fracture of the pars interarticularis and spondylolisthesis. Rapid progression of scoliosis in a patient with a prior laminectomy is highly suspect for a pars fracture, which should be sought in the workup of such a patient.

### COMPONENTS OF DEFORMITY

Asymmetric *disc space collapse* can result in spinal deformity, as can rotatory *spondylolisthesis* or lateral listhesis. *Compression fractures* with a lateral wedge component may aggravate or cause development of scoliosis. These patients may have a relative loss of lumbar lordosis as well. Patients with *lateral listhesis* appear to be at greater risk for curve progression (25,27), and, in addition, they are subject to traction on their nerve roots at the involved levels. Asymmetric wear on the facet joints may contribute to facet arthropathy, leading to central or foraminal stenosis. Although most patients present with pain secondary to nerve root compression, others present with weakness. Pain and weakness may be particularly intractable from severe disc space collapse, with or without listhesis, and decreasing space between the adjacent pedicles results in foraminal stenosis. Patients with stenosis secondary to degenerative scoliosis suffer a similar pathophysiology as a cause of their neurogenic claudication—namely, a vascular insufficiency to the neural elements secondary to the stenosis, which is generally worsened by lumbar extension.

Clearly, vascular claudication and neurogenic claudication occur in similar patient populations, and it is important to distinguish the true cause of the patient's leg pain. A careful history, palpation of distal pulses, examination of feet and skin, and, if indicated, referral to a vascular specialist may be needed. In general, neurogenic claudication is improved by forward flexion of the spine, including sitting, and it may be worse going downhill because hyperextension is necessary (see Chapter 147). However, at least some patients with stenosis secondary to degenerative scoliosis have reported that their extremity symptoms are not reliably relieved by forward flexion (11).

### CONSERVATIVE MANAGEMENT

Patients with degenerative scoliosis can be managed according to the conditions that cause the most symptoms. For example, the patient with more back pain secondary to the degenerative disease can be managed successfully using nonsteroidal anti-inflammatories, rest, physical therapy, cardiovascular conditioning, and, occasionally, bracing. Patients with neurogenic claudication may respond to any of these measures but may receive relief from epidural cortisone injections. Bracing can be used on occasion for the patient with mild degenerative scoliosis with back pain only. Rigid bracing has not been shown to prevent progression in adults with scoliosis. However, bracing may be a reasonable alternative for a patient who has a degenerative scoliosis with mild to moderate progression, but who is medically unable to tolerate a major reconstructive procedure.

Bracing may need to include a rigid molded thoracolumbar orthosis for more severe scoliosis or kyphosis, or it may simply be a lightweight, corset-type brace for milder curves. However, since symptom improvement is the primary goal, rather than curve control, results with a specific patient will be the final determining factor.

### INDICATIONS FOR SURGERY

As for adult idiopathic scoliosis, pain, curve, and neurologic deterioration are the main indications for surgical intervention. In general, bracing in adults is discouraged because it does not halt progression and may result in patient dependence on the brace and associated trunk deconditioning. However, in certain cases, such as an elderly patient who is too ill to tolerate a major surgical procedure, or a patient whose severely osteoporotic bone is too weak to support instrumentation, bracing may slow progression or attenuate the pain symptoms.

Determining whether a patient's back pain can be improved by stabilization and fusion of her degenerative scoliosis can be difficult. Once surgery has been deemed likely to help such a patient, however, choice of the fusion levels requires consideration of curve pattern, sagittal and coronal balance, pain locale, levels needing decompression, and the presence of degenerated or listhetic levels, as well as patient expectations and activity levels. Facet blocks, discography, and nerve root blocks may be helpful in determining symptomatic levels, although their predictive value for fusion surgery has not been proven. Grubb et al. (12) used provocative discography to help determine fusion levels in adult scoliosis patients (degenerative and idiopathic) and felt that this aided them in their surgical planning. However, in

their study, all positive discograms were at morphologically abnormal levels, and it is not clear whether they might have included such levels based on radiographic or magnetic resonance imaging (MRI)–determined degenerative levels. Fortunately, fusion for back pain secondary to scoliosis appears more predictable than fusion for back pain secondary to degenerative disc disease without deformity. We do not routinely perform discography in these patients, because it has not proven of benefit in predicting the outcome of fusion surgery.

Patients with degenerative scoliosis and neurogenic claudication should have their stenosis decompressed concurrently with stabilization of the curvature. In most patients, an MRI will give adequate information for localization of stenotic levels; in some patients, however, the lateral deformity or rotatory component precludes clear delineation of the anatomy. In these cases, computed tomography (CT) or myelography is indicated for preoperative planning.

## SURGICAL TECHNIQUES

### DECOMPRESSION

For patients with limited regions of spinal stenosis, neurogenic claudication, and only mild degrees of scoliosis, it may be reasonable to address the compressive symptoms with laminotomy, laminectomy, or foraminotomy as needed. Aggressive decompression can result in curve progression; this isolated procedure should be reserved for milder cases in which limited decompression can be expected to help the patient. Be sure the patient understands the possibility of curve progression and recurrence of symptoms.

### FUSION *IN SITU*

For patients with limited disease, a posterior fusion alone may be sufficient. The majority of patients with degenerative scoliosis will require instrumentation and grafting to achieve fusion over multiple segments that require stabilization. Because of the increased pseudarthrosis rate with multiple-level fusions, it is rare to have a patient who can be managed without instrumentation. However, certain older patients, particularly the medically fragile, may better tolerate laminectomy and limited uninstrumented fusion (i.e., at the level where there is a degenerative spondylolisthesis). In some patients, moderate to severe osteoporosis may preclude fixation, but, as with laminectomy alone, there is a risk of curve progression and recurrence of symptoms. Therefore, this approach is limited to patients who clearly understand the limitations of what surgery can accomplish for them and are willing to risk recurrent symptoms. In general, we have not found age or osteopenia to be a contraindication for fusion with instrumentation.

Selection of fusion levels should take into account several factors. The levels that should be fused should include at least the entirety of the symptomatic curve, but often additional levels must be included to address symptomatic degenerative levels and permit maintenance or restoration of coronal and sagittal balance. Generally, preoperative bending films can help predict the amount of correction that can be obtained after exposure, facetectomy, and application of appropriate corrective forces. The end vertebra, particularly distally, should be a vertebra that is level on side bending. Sagittal balance is exceedingly important to consider, particularly because many of these patients have osteoporosis. Most degenerative curves are kyphotic; if the kyphosis is not flexible, a combined anterior–posterior approach may be indicated to achieve sagittal realignment and successful arthrodesis. It is also important not to end the fusion at a kyphotic segment. Many of these patients have lumbar or thoracolumbar curvatures, and including only the major curve often can result in ending the fusion at the mid or lower thoracic spine—in the middle of the kyphosis. Such patients are at considerable risk for development of progressive junctional kyphosis, and in general it is best to include the minor compensatory thoracic curve and end the fusion at the end vertebra of the kyphosis (usually T-4 or T-5).

Only in patients with acceptable bone quality and a nonkyphotic thoracolumbar junction can the fusion safely stop at the thoracolumbar junction. Choosing the distal end vertebra can be difficult in the patient with degenerative scoliosis and low back pain. Deciding whether L-4–L-5 and/or L-5–S-1 is symptomatic is crucial because long fusions to the sacrum generally necessitate combined anterior and posterior surgery and have a higher rate of complications. Not including a symptomatic level will result in limited pain relief, however, and thus it will decrease the success of the surgery. In addition, fusions ending at L-4 or L-5 are at risk for development of symptomatic degeneration below the fusion. This development 5–10 years after the surgery may be acceptable for the older patient, but its occurrence 2 years or so after the surgery is not. Therefore, consider whether a more distal fusion is indicated. Involvement of the lumbosacral region is very common in degenerative scoliosis, and the majority of these patients require combined anterior and posterior spinal fusion to the sacrum.

#### *Considerations for Instrumentation*

Segmental instrumentation in the form of variable hook-and-rod systems are preferred for instrumentation of degenerative scoliosis. These systems allow much better correction of coronal and particularly sagittal plane deformity. However, such surgery is technically demanding, and the surgeon must have a clear understanding of the corrective forces that should be applied and how they affect the patient's curvature, coronal balance, sagittal balance, and shoulder obliquity. The following considerations are important:

- Avoid distraction in the lumbar spine to avoid flattening it. Apply compression across the curve convexity first in the lumbar spine.
- It is rare to be able to perform rod rotation in the patient who has degenerative scoliosis.
- If the patient has significant osteoporosis, and multiple-level laminectomy is not required for coexisting spinal stenosis (see below), consider using sublaminar wires supplemented by hooks and/or pedicle screws at strategic levels (generally the end vertebra of each curve and sometimes the apical vertebra as well). Such wires are quite easy to attach to rods and, for an osteoporotic patient whose trabecular bone has numerous vascular channels, their use can potentially decrease operative time and therefore decrease blood loss.
- Do not affix rods to end vertebrae with sublaminar wires, because wires do not provide axial control of the spine and can allow axial collapse and subsequent junctional kyphosis. Use pedicular fixation or hook combinations at the ends of constructs to decrease the likelihood of this problem.
- To ensure coronal balance, we prefer to obtain intraoperative long radiographs of the entire spine after the correction has been partially or completely performed. Adjustments in the corrective forces can be made at this time if desired.
- Although *in situ* bending to fine-tune the coronal balance can be performed in some adult scoliosis patients, most patients with degenerative scoliosis have osteoporotic bone, and *in situ* bending can result in loss of fixation.

### DECOMPRESSION AND FUSION

Many patients with degenerative scoliosis also have spinal stenosis as part of their degenerative process. As part of preoperative planning, evaluate with an MRI or CT/myelogram any patient with degenerative scoliosis who notes leg pain or buttock pain. As previously noted, the MRI is adequate for many patients; with greater degrees of curvature, however, CT/myelography gives better bony detail and permits better understanding of the anatomy in the presence of the curvature. It is important to identify symptomatic levels of stenosis so that decompression can be performed at the time of posterior fusion. In most cases, this can be determined anatomically according to dermatomal levels and nerve root distributions; however, occasionally, selective nerve root injections may be needed to determine which levels with mild to moderate degrees of stenosis are the symptomatic ones.

Once laminectomy has been performed for decompression, pedicle screw instrumentation may be needed to attain fixation. Generally, fusion rates are improved with instrumentation, particularly in patients with conditions such as degenerative scoliosis (13). As with deformity surgery in general, try to visualize the medial wall of the pedicle before screw placement, to correctly account for spinal rotation. This is a simple matter after laminotomy or laminectomy has already been performed. Frazier et al. (8) reported on patients who underwent decompression for spinal stenosis, including 19 who had at least 15° of scoliosis preoperatively. The majority of their patients with scoliosis did not have fusion performed at the time of decompression. They found that a greater degree of preoperative scoliosis was associated with less improvement in back pain. We have not found curve severity to correlate with outcomes of reconstructive surgery in these patients. We do take a more aggressive approach, however, preferring to fuse patients with scoliosis who are undergoing a laminectomy even if the underlying medical condition permits only limited fusion.

Selection of fusion levels and instrumentation guidelines are otherwise as noted in the prior section.

### COMBINED ANTERIOR–POSTERIOR TECHNIQUES

If they are fairly healthy, the majority of patients with degenerative scoliosis will require anterior and posterior procedures to achieve fusion, as well as coronal and sagittal balance. There are several indications for combined techniques in this complex patient population.

- Inflexible sagittal-plane imbalance is one of the most common indications for combined surgery. Relative lumbar kyphosis must be corrected to achieve sagittal plane balance. The use of structural allografts facilitates the restoration of lumbar lordosis. We favor femoral allografts, packed with autogenous cancellous graft; Harms-type mesh cages with autograft may also be used. Consideration of the scoliotic deformity is necessary; otherwise, mere placement of the structural grafts on the side of the approach—usually the curve convexity—will limit correction of the scoliosis.
- Degenerative curves of significant magnitude, especially with limited flexibility, may also require combined surgery. Coronal imbalance may also indicate the need

for combined surgery.

- Patients who require a long fusion to the sacrum should also have a combined procedure because posterior fusion alone in this setting has a high incidence of failure (4,12). Most of these patients have significant degeneration across the lumbosacral junction, and many also have thoracolumbar kyphosis (which is a contraindication for ending the fusion at the thoracolumbar junction), so combined surgery is frequently indicated.
- In patients who have had failed posterior instrumented fusions, consider combined surgery. We and others (1,10,23) have found iliac fixation in the form of Galveston rods or iliac screws to be useful for achieving distal fixation (Fig. 160.1). For patients with reasonable bone quality, anterior structural allograft at the lumbosacral junction coupled with sacral screws alone that penetrate the anterior cortex may be adequate. Others (2,7,16,17) have used iliosacral screws or intrasacral screws (Jackson technique) for distal fixation.

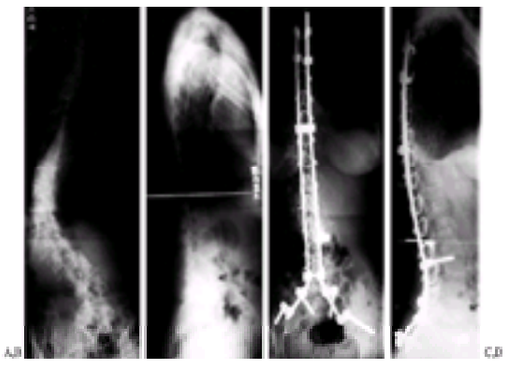

***Figure 160.1.*** This 71-year-old woman was first diagnosed with scoliosis at age 45. In the 5 years previous to presentation at this institution, she developed increasing low back pain and increasing prominence of her right hip. Anteroposterior (**A**) and lateral (**B**) standing radiographs demonstrate degenerative scoliosis with collapsing curve. The patient underwent a staged anterior and posterior spinal fusion, T-5 to the sacrum; the posterior fusion included multiple sublaminar wires and iliac screws. Her postoperative course had some brief episodes of cardiac ectopy and a urinary tract infection. Postoperative radiographs (**C,D**) demonstrate correction of the deformity, with coronal and sagittal balance achieved. At 2-year follow-up, she was doing well, with excellent improvement of her function and marked pain relief.

As with posterior instrumented fusions, segmental fixation is preferred for combined surgery in this patient population. Sublaminar wires may be used as a component of the fixation, but use fixed components (hooks in a claw construct in the mid and upper thoracic spine, pedicle screws at the thoracolumbar junction) at the proximal end of the construct to decrease the risk of junctional kyphosis.

When the patient can tolerate it, perform both procedures under a single anesthetic to lower overall incidence of complications, nutritional depletion, and blood loss (5,21,24). Older patients, particularly those with coexisting medical conditions or significant osteoporosis, may be less able to tolerate the lengthy anesthetic, however. Older patients with significantly osteoporotic bone may experience increased blood loss, which can lead to development of a coagulopathy during a prolonged procedure.

If the combined procedures in these older patients cannot be completed in 8–10 hours, then stage the procedure. The scheduled delay between stages may be 3–7 days, depending on coexisting medical conditions, the age of the patient, and scheduling issues. The occurrence of complications, however, may further delay the second-stage procedure.

Staged spinal surgery can result in nutritional depletion, which may lead to an increased incidence of infection, pneumonia, and urinary tract infection (5,21,24). We have shown that, particularly in the older patient population, use of total parenteral nutrition may decrease the rate of nutritional depletion, which may in turn decrease the risk of complications (15).

Grubb et al. (12) have found an average of 70% reduction of pain in patients fused for painful degenerative scoliosis, which is somewhat less than that seen for patients fused for painful adult idiopathic scoliosis (80% pain relief).

### ANTERIOR FUSION WITH FEMORAL RINGS

- Perform a standard thoracoabdominal or retroperitoneal approach on the convexity of the curve to be addressed. Be sure to prep down to the pubic symphysis if L-5–S-1 is to be fused, as is the case in most of these patients.
- Identify segmental vessels and ligate or clip. Sweep the psoas muscle posteriorly, using bipolar cautery to control bleeding. Use blunt but careful dissection to sweep the great vessels forward. The common iliac will need to be mobilized if L-4–L5 or L-5–S-1 is to be exposed. This generally requires ligating the recurrent lumbar vein.
- Incise the disc space with a #11 blade. Use a rongeur to remove loose disc material, and a rongeur or osteotome to remove the osteophyte so that the endplate can be visualized. Peel the disc from the endplate using a Cobb elevator—exercise care in patients with osteoporosis.
- Remove additional disc material with a curved or straight curette, supplementing with a rongeur. A Blount spreader may be used with care to keep the disc space from collapsing in the convexity. The release must extend across to the contralateral annulus. If there is significant kyphosis, divide the anterior longitudinal ligament.
- The distalmost levels generally are in the fractional curve and also are most important for maintaining lordosis. Therefore, placement of the structural allograft should not block correction. If disc spaces in the convexity are to be placed, take care to place them as far toward the concavity as possible; do not place so large a graft that correction is blocked. For disc spaces that are not to receive structural allograft, pack morcelized cancellous bone lightly within, preferably autograft, although allograft can be used.
- Measure the height of the disc space to be filled with allograft. We use femoral shaft pieces cut at the time of surgery to fit the evacuated disc space. (Other surgeons prefer mesh cages.) The graft should be snug but not overly tight; that is, the release should open the disc space, not the graft itself. After confirming the size, fill the marrow cavity of the femoral allograft with rib graft or local bone graft, or morcelized cancellous allograft, and impact gently into place. Forcing an overly large graft or inadequate release will result in graft breakage (with high risk for pseudarthrosis) or endplate fracture (with increased risk for subsidence).
- Use interference screws to prevent allograft migration. Place a 6.5 mm cancellous screw with a plastic washer lateral to the graft, into the vertebral body. Alternatively, a long enough screw can be placed lateral to the adjacent graft, skewering the graft below, to prevent migration of two allografts. It may be necessary to burr a small impression into the lateral aspect of the adjacent allograft to allow the washer to seat snugly. Although theoretically possible, we have not generally found that these screws impair our ability to place pedicle screws during the posterior instrumentation. Since instituting the use of these interference screws, we have not needed to replace anterior structural allograft.

## PITFALLS AND COMPLICATIONS

Technically, surgery in this patient population can be very challenging for the following reasons:

- Osteoporotic bone is nearly always present and its vascular channels can contribute to greater bleeding rates than seen in the patient with normal bone.
- Many of these patients may have chronic hypertension, coronary artery disease, or other vascular conditions that contraindicate or limit the use of controlled hypotension to decrease surgical blood loss.
- One must select fusion levels carefully. Ending the fusion at a kyphotic level can lead to junctional kyphosis.
- Although sublaminar wires may be preferred in many patients because their use spreads corrective forces over many levels, they should not be used at the end vertebra because they do not control the spine in the axial plane; they may also result in junctional kyphosis. Use hooks or screws at the ends of the construct.
- Overcorrection of the curve may lead to truncal imbalance, which, if significant, may require revision surgery.
- Patients who undergo fusion surgery are at risk for developing degeneration above or below the fusion. Consider including severely degenerated adjacent levels to avoid rapid development of this problem. Extending the fusion should be balanced by the consideration of how much surgery should be done on the older, less healthy patient.
- Although osteoporotic patients have not been shown to have a higher rate of pseudarthrosis, poorer fixation due to poor bone quality, combined with autogenous bone graft from a site with more fat infiltration and fewer osteoprogenitor cells, is of concern.

The risk of complications among older patients undergoing spinal surgery is about 60% (6,12,18,19,22). Although the rate is not significantly greater with increasing age (60–70 years, 70–80 years), there is no doubt that older patients are less able to tolerate complications and recover quickly from them. Keep this in mind when

planning the surgery. We have shown that older patients may be more at risk for development of complications such as pneumonia and urinary tract infections, particularly if they are undergoing staged surgery. Consider nutritional supplementation to decrease their risk of nutritional depletion (15). Thromboembolic disease leading to pulmonary embolism occurs more commonly in older patients, particularly after combined anterior and posterior surgery (3). Our current practice is to use elastic stockings and sequential compression boots for prophylaxis of deep venous thrombosis. We remain vigilant in patients who have combined surgery, but we do not routinely anticoagulate these patients.

Although the mortality rate is not known, and most published studies in this patient population include small numbers of patients, we estimate it to be 1% to 5%. Discuss fully the numerous potential risks of spinal surgery with the patient, as well as her family, if desired, when she is offered any spinal surgery.

### MINIMALLY INVASIVE TECHNIQUES

Recent advances in minimally invasive surgery have suggested that endoscopic surgery, both thoracoscopy and lumbar endoscopy, may result in lower morbidity and decreased length of hospital stay (20,26). Unfortunately, such techniques are difficult to learn and have not yet been proven to demonstrate comparable fusion rates to that achieved in open procedures. In general, for degenerative scoliosis, the indicated anterior procedure is in the lumbar or lumbosacral spine. Currently, most of the lumbar endoscopic techniques have concentrated on screw-in–type cages, which are not well suited for degenerative scoliosis because of the presence of multiplanar deformity.

## AUTHORS' PERSPECTIVES

Reconstructive surgery in the patient with degenerative scoliosis is complex and requires a thorough understanding of a multitude of factors, including pain sources, coronal and sagittal balance, fusion techniques, indications for decompression, indications for combined anterior and posterior surgery, and instrumentation choices, as well as the potential for complications. With appropriate patient selection, however, and realistic expectations of surgery on the part of both the patient and the surgeon, the majority of patients will have a satisfactory outcome.

### CHAPTER REFERENCES

Each reference is categorized according to the following scheme: *, classic article; #, review article; !, basic research article; and +, clinical results/outcome study.


+ 1. Boachie-Adjei O, Dendrinos G, Ogilvie J, et al. Management of Adult Spinal Deformity with Combined Anterior-posterior Arthrodesis and Luque-Galveston Instrumentation. *J Spinal Disorder* 1991;4:131.

! 2. Camp JF, Caudle R, Ashmun RD, Roach J. Immediate Complications of Cotrel-Dubousset Instrumentation to the Sacro-pelvis: A Clinical and Biomechanical Study. *Spine* 1990;15:932.

+ 3. Dearborn J, Hu S, Tribus C, et al. Thromboembolic Complications after Spinal Reconstructive Surgery. *Spine* 1999;24:1471.

+ 4. Devlin V, Boachie-Adjei O, Bradford D, et al. Treatment of Adult Spinal Deformity to the Sacrum Wing: CD Instrumentation. *J Spinal Disord* 1991;4:1.

* 5. Dick J, Boachie-Adjei O, Wilson M. One-stage versus Two-stage Anterior and Posterior Spinal Reconstruction in Adults. *Spine* 1992;17:S310.

# 6. Dickson J, Mirkovic S, Noble P, et al. Results of Operative Treatment of Idiopathic Scoliosis in Adults. *J Bone Joint Surg Am* 1995;77:513.

+ 7. Farcy J, Rawlins B, Glassman S. Technique and Results of Fixation to the Sacrum with Iliosacral Screws. *Spine* 1992;17:S190.

+ 8. Frazier D, Lipson S, Fossel A, et al. Associations between Spinal Deformity and Outcomes after Decompression for Spinal Stenosis. *Spine* 1997;22:2025.

+ 9. Gillespy T, Gillespy T, Revak C. Progressive Senile Scoliosis: Seven Cases of Increasing Spinal Curves in Elderly Patients. *Skeletal Radiol* 1985;13:280.

! 10. Glazer P, Colliou O, Lotz J, et al. Biomechanical Analysis of Lumbosacral Fixation. *Spine* 1996;21:1211.

+ 11. Grubb S, Lipscomb H, Coonrad R. Degenerative Adult Onset Scoliosis. *Spine* 1988;13:241.

+ 12. Grubb S, Lipscomb H, Suh P. Results of Surgical Treatment of Painful Adult Scoliosis. *Spine* 1994;19:1619.

# 13. Hanley E. The Indications for Lumbar Spinal Fusion With and Without Instrumentation. *Spine* 1995;20:S143.

+ 14. Healey J, Lane J. Structural Scoliosis in Osteoporotic Women. *Clin Orthop* 1985;195:216.

* 15. Hu S, Fontaine F, Kelley B, et al. Nutritional Depletion in Staged Spinal Reconstructive Surgery: The Effect of Total Parenteral Nutrition. *Spine* 1998;23:1401.

! 16. Jackson RP, McManus AC. The Iliac Buttress: A Computer Tomographic Study of Sacral Anatomy. *Spine* 1993;18:1318.

+ 17. Jackson RP, Ebelke DK, McManus AC. Clinical Results and Standing Radiographic Sagittal Plane Analysis in Spondylolisthesis Insrumented to the Sacrum with New Techniques. *Orthop Trans* 1995–1996;19:593.

+ 18. Jonsson B, Shromqvist B. Lumbar Spine Surgery in the Elderly: Complications and Surgical Results. *Spine* 1994;19:1431.

+ 19. Kostuik J, Hall B. Spinal Fusions to the Sacrum in Adults with Scoliosis. *Spine* 1983;8:489.

+ 20. Kuslich S, Ulstrom C, Griffith S, et al. The Bagby and Kuslich Method of Lumbar Interbody Fusion. *Spine* 1998;23:1267.

+ 21. Mandelbaum BR, Tolo VT, McAfee PC, Burest P. Nutritional Deficiencies after Staged Anterior and Posterior Spinal Reconstructive Surgery. *Clin Orthop* 1988;234:5.

# 22. Nuber G, Schafer M. Surgical Management of Adult Scoliosis. *Clin Orthop* 1986;208:228.

! 23. Pashman RS, Hu S, Schendel MJ, Bradford DS. Sacral Screw Loads in Lumbosacral Fixation for Spinal Deformity. *Spine* 1993;18:2465.

+ 24. Powell ET, Krengel WF, King HA, Lagrone MO. Comparison of Same-day Sequential Anterior and Posterior Spinal Fusion with Delayed Two-staged Anterior and Posterior Spinal Fusion. *Spine* 1994;19:1256.

+ 25. Pritchett J, Bortel D. Degenerative Symptomatic Lumbar scoliosis. *Spine* 1993;18:700.

+ 26. Regan J, Ben-Yishay A, Mack M. Video-assisted Thoracoscopic Excision of Herniated Thoracic Disc: Description of Technique and Preliminary Experience in the First 29 Cases. *J Spinal Disord* 1998;11:183.

+ 27. Velis KP, Healey JH, Schneider R. Osteoporosis in Unstable Adult Scoliosis. *Clin Orthop* 1988;237:132.

# CHAPTER 161

# SURGERY FOR KYPHOSIS DEFORMITY

*Jack K. Mayfield*

**J. K. Mayfield:** Phoenix Spine Center, St. Luke's Hospital Medical Center, Phoenix, Arizona, 85006; and Department of Materials, Chemical and Bioengineering, Arizona State University.

Principles of Treatment
Indications for Surgery
- Congenital Type I Kyphosis
- Congenital Type II Kyphosis
- Posttraumatic Kyphosis
- Spondylolisthesis Grades IV and V
- Postlaminectomy Kyphosis
- Scheuermann's Kyphosis
- Postradiation Kyphosis
- Paralytic Kyphosis
- Neurofibromatosis
- Diastrophic Dwarfism
- Achondroplasia
- Adult Idiopathic Kyphoscoliosis
- Flatback Syndrome
- Rheumatoid Spondylitis

Preoperative Planning
Surgical Techniques
- Anterior Strut Graft
- Interbody Arthrodesis
- Inlay Graft
- Vascularized Rib Graft
- Anterior Vertebral Osteotomy
- Anterior Instrumentation to Correct Rotational Kyphosis
- Intervertebral Cages and Femoral Allograft Dowels or Rings
- Segmental Spinal Instrumentation
- Posterior Spinal Osteotomy
- Eggshell Procedure

Postoperative Care and Rehabilitation
Pitfalls and Complications
Chapter References

## PRINCIPLES OF TREATMENT

Kyphosis is a posteriorly directed convex curvature of the spine in the sagittal plane. In the thoracic spine, the normal kyphosis ranges from 20° to 40° as measured from the superior endplate of the second thoracic vertebra to the inferior endplate of the twelfth thoracic vertebra. In the adult cervical and lumbar spine, both of which are normally lordotic, any posteriorly directed curvature of 5° or greater is considered abnormal kyphosis.

A distinction should be made between *sagittal kyphosis* and *rotational kyphosis.* In sagittal kyphosis, the vertebral bodies remain in the sagittal plane and the spine angulates in that plane (Fig. 161.1). In rotational kyphosis, however, the vertebral bodies are rotated out of the sagittal plane, as is commonly seen in paralytic curvatures and kyphosis secondary to neurofibromatosis (Fig. 161.2). In either situation, once the anterior vertebral column is no longer in the sagittal plane, there is reduced resistance to kyphotic bending moments and thus an increased propensity for a kyphosis to progress. Most kyphotic deformities seem to fall within the sagittal kyphosis category.

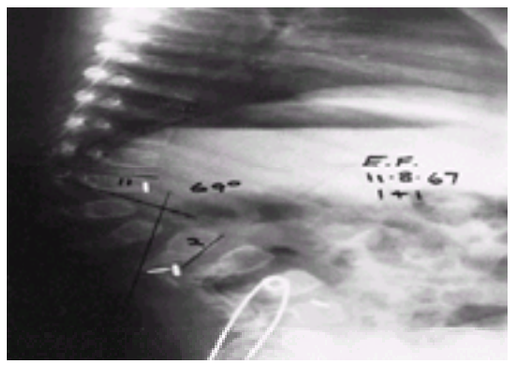

***Figure 161.1.*** This 1-year-old child has a short-radius sagittal kyphosis secondary to radiation and laminectomy for neuroblastoma.

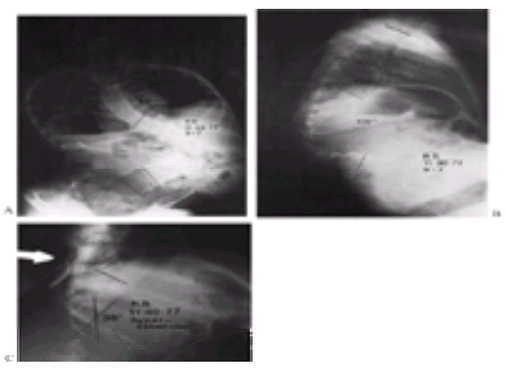

***Figure 161.2.*** **A:** A 9-year-old child has a paralytic right thoracolumbar scoliosis of 125°. **B:** In addition to the paralytic scoliosis, a rotational thoracolumbar kyphosis of 107° is present. **C:** The rotational kyphosis corrects to 36° on supine hyperextension (a flexible kyphosis).

A distinction should also be made between a short-radius and a long-radius kyphotic deformity. A shortradius curve is one that is more angular over a few vertebral

segments, and a long-radius kyphosis is a smooth curve of less acute angulation over many vertebral segments (Fig. 161.1, Fig. 161.3).

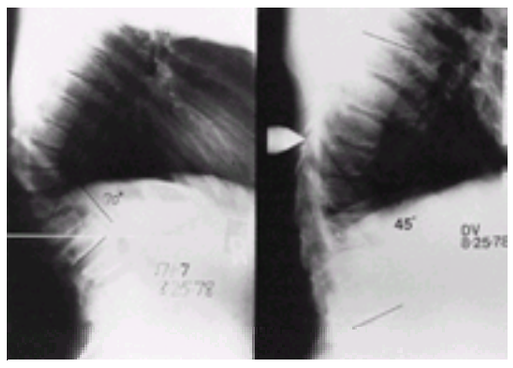


***Figure 161.3.*** At age 17 years, this patient developed a long-radius thoracolumbar kyphosis of 70° as a result of radiation. This kyphosis corrects to 45° on a supine hyperextension lateral radiograph.

All kyphotic spinal deformities have variable degrees of rigidity and flexibility. Frequently there is an element of apical rigidity with variable degrees of flexibility at the ends of the curvature. The goal in correcting the kyphosis is to mobilize the rigid apex or to correct the flexible ends of the curve to bring the apex closer to the center of gravity, thereby placing the bone graft in the area of fusion under maximum compression (Fig. 161.4).

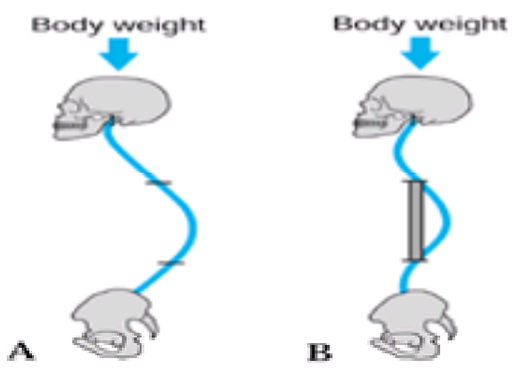


***Figure 161.4.*** **A:** Diagram of kyphosis. **B:** The apex has been corrected somewhat and the flexible ends of the kyphosis are corrected so that the anterior strut graft is now in line with the body weight (*BW*).

The degree of flexibility can be determined before surgery by a supine hyperextension lateral radiograph of the spine taken with a bolster placed under the apex of the kyphosis (Fig. 161.3) in short-radius kyphosis, and by a lateral radiograph of the spine with the patient in traction in long-radius paralytic curves.

Although traction as a means of correction has been gradually replaced by more aggressive anterior and posterior fusion and segmental instrumentation, in some situations traction can be helpful. Three traction techniques can be beneficial in the treatment of kyphosis: halo-wheelchair traction, halo-femoral traction, and halo-hyperextension traction. Halo-wheelchair traction provides longitudinal traction against gravity and allows the patient mobility. Halo-femoral traction provides stronger, steady axial forces if continuous traction is essential.

A word of caution, however, is necessary about the use of heavy axial traction. If there is apical rigidity of the curve as determined by hyperextension lateral radiographs, paraplegia can be a complication because of the spinal cord's stretching over the rigid acute kyphotic apex. Mobilizing the apex of a kyphotic deformity is essential before heavy traction is used. In large kyphotic deformities that have a short radius (neurofibromatosis), axial traction is more beneficial than three-point bending. In comparison, large kyphotic deformities with a long radius (such as Scheuermann's kyphosis) respond more effectively to three-point bending. In short-radius kyphotic deformities (such as spondylolisthesis), a combination of axial traction and three-point bending is needed (Fig. 161.5) (13).

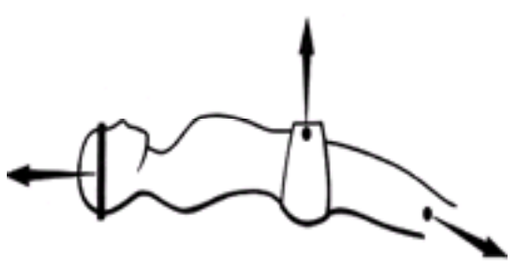

***Figure 161.5.*** Halo-femoral longitudinal and pelvic hyperextension traction for lumbosacral kyphosis from spondylolisthesis.

Many disorders manifest kyphotic spine deformities that may need treatment. Any kyphosis that is increasing in magnitude may need surgical stabilization. It is helpful to classify the disorders by the degree of rigidity and flexibility as well as the magnitude of curve radius (Table 161.1).

| *Sagittal* | *Rotational* |
|---|---|
| Short-radius rigid | Short-radius rigid |
| Long-radius rigid | Long-radius rigid |
| Short-radius flexible | Short-radius flexible |
| Long-radius flexible | Long-radius flexible |

***Table 161.1. Classification of Kyphoses***

## INDICATIONS FOR SURGERY

Indications for surgical treatment of kyphosis depend on the diagnosis, the etiology of the kyphosis, the curve progression, the location of the kyphosis, and the age of the patient. In general, the kyphotic spine deformity that is increasing in magnitude in an adult needs surgical stabilization. In the child, however, a brace may be helpful, depending on the age of the child, the etiology of the kyphosis, and the magnitude of the curve.

### CONGENITAL TYPE I KYPHOSIS

The congenital type I kyphotic spinal deformity, in which there is incomplete vertebral formation, is usually diagnosed in childhood and has an average progression of 5° yearly (26,27,29). It usually involves only two to three vertebrae, and surgical stabilization is usually recommended when progression has been documented. There is a high incidence of spinal cord compression with large degrees of kyphosis, and early stabilization in a young child when the curve is small is ideal. An *in situ* posterior fusion before the age of 3 years will prevent late deformity. *In situ* posterior fusion must include the normal vertebrae above and below the congenital kyphosis. The posterior fusion will tether the posterior growth of these normal vertebrae so that their anterior growth will correct the deformity (these normal vertebrae will become trapezoidal in shape with growth) (Fig. 161.6).

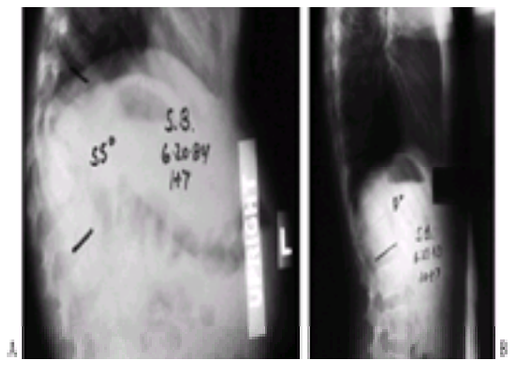

***Figure 161.6.*** **A:** This 1½-year-old girl has type II congenital kyphosis at T-12–L-1 of 55°. **B:** At age 10, after *in situ* posterior fusion that included the normal vertebra above and below the congenital kyphosis. The kyphosis has corrected to 8°.

Augment the posterior fusion at 6 months to achieve a thick posterior mass, thick enough to withstand the anterior growth forces. When an angulation of 50° or more is present, an anterior fusion is also needed. If the spinal cord is compressed anteriorly, perform an anterior decompression concomitantly with the anterior strut graft fusion. In the adult, I recommend a second-stage posterior fusion with instrumentation after the anterior correction. Osteotomies for deformity correction are not commonly used as in type II congenital kyphosis.

### CONGENITAL TYPE II KYPHOSIS

In the congenital type II kyphotic disorder, in which failure of segmentation of the spine occurs anteriorly, progression of the kyphosis usually averages 5° yearly (15). The segmentation failure can involve only two vertebrae but also may involve many contiguous vertebrae. For young patients, I recommend an *in situ* posterior fusion to include one normal vertebral segment at each end of the curve. In the young child, an augmentation posterior spinal fusion may be necessary 6 months later to generate a thick fusion (Fig. 161.6). In the adolescent patient with an unacceptable kyphosis greater than 50°, a staged correction is indicated, with anterior osteotomy and anterior fusion using an intervertebral cage structural graft, followed by posterior fusion and instrumentation (15,26,27,29). Spinal cord compression is usually not seen in type II congenital kyphosis.

### POSTTRAUMATIC KYPHOSIS

Acute kyphosis associated with spinal instability due to fracture or dislocation usually requires reduction of the kyphosis, with spinal fusion (14,19). When the kyphosis occurs late and is increasing in magnitude, surgical stabilization and fusion are indicated. Particularly if the kyphosis spans multiple vertebral segments, a two-stage anterior and posterior fusion and stabilization are frequently necessary. In late posttraumatic kyphosis, the use of intervertebral structural cages with anterior fusion maintains lumbar lordosis below the fracture more effectively than an interbody fusion alone.

### SPONDYLOLISTHESIS GRADES IV AND V

Anatomically, the grade IV and V spondylolistheses are usually lumbosacral kyphotic deformities and require reduction, stabilization, and fusion (4).

### POSTLAMINECTOMY KYPHOSIS

Any progressive postlaminectomy kyphotic deformity (usually in a child) requires stabilization and fusion (11). Posterior segmental instrumentation and fusion will be necessary along with anterior fusion. Frequently, strut graft stabilization will be needed in larger kyphotic deformities. The entire kyphotic deformity must be instrumented and fused (11).

### SCHEUERMANN'S KYPHOSIS

Scheuermann's kyphosis is seen in older adolescents and adults (19). In older adolescents with little vertebral growth remaining, a kyphosis of 70° or more usually requires surgical correction and fusion, especially if associated with back pain. In the adult, back pain associated with thoracic kyphosis greater than 75° to 80° is an indication for surgical treatment. If the kyphosis is located in the thoracolumbar spine, surgical treatment is indicated when the curve magnitude is much less than 70° because of the acute lumbar hyperlordosis below the kyphosis and associated problems with low back pain in an adult. A staged anterior interbody fusion followed by a posterior fusion with segmental instrumentation will effectively correct and stabilize this kyphosis; intervertebral cages could be used to maintain correction of the kyphosis and maintain lumbar lordosis (Fig. 161.7).

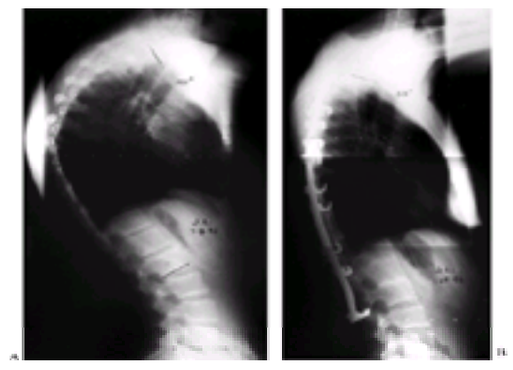

***Figure 161.7.*** **A:** An 18-year-old man with 101° thoracic kyphosis from Scheuermann's disease. **B:** Four years after staged anterior interbody fusion and posterior fusion and segmental instrumentation. The kyphosis is corrected to 38°.

### POSTRADIATION KYPHOSIS

Surgery in children is indicated when postradiation kyphosis (12) is documented to be progressive despite adequate orthotic treatment. It is also indicated when the kyphosis is too large for orthotic control, or the deformity is cosmetically unacceptable. These curves are usually rigid and the potential for correction is limited.

### PARALYTIC KYPHOSIS

Paralytic kyphoses are usually collapsing deformities that are seen in children (14,19). Surgical treatment of the kyphosis is usually planned when the child has a skeletal age of 10–12 years, when most of the axial skeletal growth has occurred. Until that age, orthotic treatment is recommended.

### NEUROFIBROMATOSIS

Kyphosis in neurofibromatosis does not respond to orthotic treatment, and surgery is indicated when the kyphosis is 50° or more in a child or is documented to be increasing in magnitude (1,28). Anterior and posterior arthrodesis and instrumentation are usually necessary. Complications are common.

### DIASTROPHIC DWARFISM

Progressive cervical kyphosis in diastrophic dwarfism should be stabilized early to prevent neurologic complications (2). Thoracic and thoracolumbar kyphoses usually appears in the juvenile years, is associated with scoliosis, and should receive early orthotic treatment. If progression occurs despite orthotic treatment, surgical treatment of the kyphosis is indicated.

### ACHONDROPLASIA

Kyphosis usually occurs in the thoracolumbar spine and may occur at an early age, but most kyphoses resolve. When apical vertebral hypoplasia is present (achondroplasia) (25), progression may occur and orthotic treatment is recommended. Surgical treatment of the kyphosis is indicated if progression occurs despite orthotic treatment or if anterior spinal cord compression occurs.

### ADULT IDIOPATHIC KYPHOSCOLIOSIS

Rotational kyphosis in the adult is usually treated surgically when the kyphoscoliosis is progressing and if the scoliosis is greater than 60° to 70° (19). Frequently, the lumbar curve in kyphoscoliosis has rotational vertebral subluxation and is relatively kyphotic. Adult scoliosis frequently requires anterior and posterior arthrodesis and instrumentation. Structural intervertebral cage grafts anteriorly are useful in creating and maintaining lumbar lordosis.

### FLATBACK SYNDROME

Flatback syndrome results from the loss of lumbar lordosis and normal sacral slope. For patients with flatback syndrome to stand, their trunks must remain bent forward. To maintain this position, they are required to flex their knees, and they complain of pain and fatigue (6,8,10). This syndrome is frequently seen after posterior distraction instrumentation in the lumbar spine, especially if the instrumentation approaches L-5 or the sacrum without supplemental anterior support (Fig. 161.8).

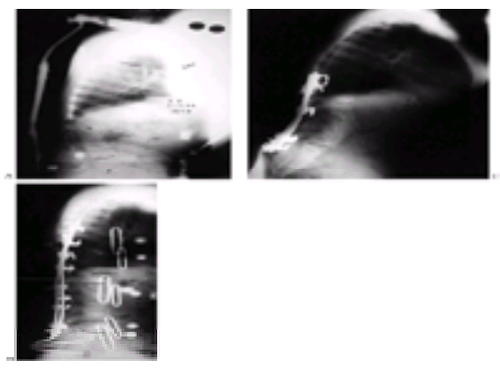

***Figure 161.8.*** **A:** This 14-year-old boy has Gauché's disease with collapse of T-12, L-2, and L-5, with kyphosis and back pain. He has been treated for several years with an orthosis. **B:** Six months after posterior fusion and instrumentation to the sacrum, the lumbar lordosis was minus 13°. He had difficulty maintaining an upright posture (flatback syndrome). **C:** After anterior/posterior osteotomies, fusion, and instrumentation, the sagittal alignment is much improved.

In young children with osteopenic bone, posterior compression instrumentation cannot maintain correct sagittal alignment. In this situation, intervertebral structural cage arthrodesis may be helpful to correct and maintain lumbar lordosis, in conjunction with posterior segmental instrumentation and arthrodesis. A flatback from a previous fusion needs posterior osteotomies along with anterior and posterior stabilization and arthrodesis.

### RHEUMATOID SPONDYLITIS

Progressive kyphosis in rheumatoid spondylitis (Marie-Strümpel Kyphosis) is common and requires surgical treatment to maintain an upright head position. Usually, anterior and posterior osteotomies with segmental instrumentation are necessary. Single-level or multiple-level osteotomies may be utilized (5,7,9,21,22,24) (see Chapter 153, Chapter 154).

## PREOPERATIVE PLANNING

In preoperative planning, distinguish between a short-radius and a long-radius kyphosis, and determine whether the curve is flexible or rigid. In short-radius curves, obtain a hyperextension cross-table lateral radiograph with a bolster under the apex of the kyphosis. Two interpretations should be made: the correctability of the apex of the kyphosis and the correctability of the ends of the kyphosis (Fig. 161.4) (13).

In Figure 161.4, the correction occurs in the more flexible ends of the kyphotic curve. When the ends of the kyphosis are flexible, a long-radius, unstable kyphosis can be converted to a short-radius stable curve. In this situation, use an anterior strut and interbody fusion as a first stage to stabilize the apical rigid component. Follow with a posterior approach to correct the flexible ends of the kyphosis, usually with segmental instrumentation. The goal at completion is to have the body weight in line with the apical strut graft, a curve configuration that is biomechanically stable (Fig. 161.4) (13).

In long-radius curves, a cross-table lateral radiograph, with the patient in longitudinal traction, is more helpful, particularly in paralytic curves. In general, rigid kyphotic deformities require strut grafting and interbody fusion of the rigid apical component in addition to posterior fusion and stabilization. Some mobilization of the rigid apex can be accomplished with disc excision and osteotomy, placing a strong strut graft in the corrected position.

### *Traction*

Preoperative traction in rigid kyphotic curves (e.g., congenital kyphosis) is generally contraindicated because of the risk of precipitating anterior spinal cord compression. Preoperative traction for relatively inflexible long-radius curves is usually not beneficial, but it can be beneficial after an anterior disc excision, interbody fusion, and anterior release. In this situation, halo-hyperextension traction for 2 weeks between an anterior spinal release and fusion and a second-stage posterior fusion and instrumentation can be useful.

In neurofibromatosis with kyphoscoliosis and early spinal cord compression, careful and judicious halo-femoral traction may provide enough correction to improve

neurologic function before surgical stabilization. Preoperative traction is useful in this situation, because the apex of the kyphosis is frequently rotated and inherently more flexible (28). A preoperative myelogram and computed tomography (CT) scan are recommended in neurofibromatosis because of the high incidence of dural ectasia and intradural and extradural tumors.

In cervical kyphosis resulting from diastrophic dwarfism and in thoracolumbar kyphosis in achondroplasia, obtain a CT scan to verify the spinal-canal size and bony architecture before surgery. Preoperative somatosensory, evoked potentials are useful for baseline measurements in preparation for intraoperative spinal cord monitoring.

In preoperative planning, determine the levels of posterior instrumentation. To be mechanically sound, the posterior instrumented end vertebrae should be close to the weight-bearing line. Include the entire length of the kyphotic curve in the fusion and instrumentation.

## SURGICAL TECHNIQUES

The anterior surgical techniques used in the surgical treatment of kyphosis are as follows:

- Strut graft (fibula or rib)
- Inlay rib graft
- Interbody fusion
- Vascularized rib or fibular graft
- Anterior vertebral osteotomy
- Interbody screw and rod instrumentation for rotational kyphosis
- Intervertebral structural cages

The posterior techniques for the surgical treatment of kyphosis are the following:

- Posterior spinal fusion with Moe facet fusion
- Posterior segmental instrumentation
- Posterior vertebral osteotomy
- Eggshell technique

### ANTERIOR STRUT GRAFT

In all nonrotational kyphosis surgery, a subperiosteal exposure of the spine is recommended for maximal bone exposure for arthrodesis.

- Note the end vertebrae of the kyphosis and perform complete discectomies at each disc space between the end vertebrae. Incise the annulus fibrosus with a knife and excise the annulus with a narrow Luxsell rongeur.
- Incise the periphery of the cartilaginous endplate down to bone with a knife and peel it off the bony vertebral endplate with a narrow Cobb elevator.
- Remove the endplates with rongeurs, and remove the remaining disc with straight and angled curets.
- Pack the disc space with thrombin-soaked Gelfoam.

Once all disc spaces are cleaned back to the posterior annulus, curet the endplates and interior of the bodies of the end vertebrae to create a seating hole for the strut.

- Correct the kyphosis by pushing on the apex of the curve and measure the length of strut required in the corrected position.
- Cut the graft (rib or fibula) longer than measured and round the ends with bone cutters.
- Insert one end of the strut in the end vertebra. Cut a trough in the lateral aspect in the other end vertebra. Correct the kyphosis by pushing on its apex, and impact the strut through the side trough and into the undercut end vertebra (Fig. 161.9). The intervening vertebra may have to be fashioned to allow the strut graft to fit.

***Figure 161.9.*** Intraoperative picture of an anterior strut graft.

- Pack the intervertebral disc spaces solidly with morselized rib graft.
- If the kyphosis is larger and angular, several parallel struts may have to be used. Use Pinto distractors to correct the kyphosis while the struts are inserted. These distractors are nonimplantable and come in three sizes. Each distractor is a turnbuckle with pronged feet at each end that anchor in the vertebral bodies. When maximum correction of the apical kyphosis is achieved, insert the struts and remove the Pinto distractors (Fig. 161.10).



***Figure 161.10.*** **A:** Pinto distractors (nonimplantable). **B:** Acute angular kyphosis with two Pinto distractors holding the deformity in a corrected position. **C:** The Pinto distractors are removed and the three strut grafts are anchored in the vertebrae.

- In large kyphotic deformities it is important to fill the dead space between the vertebral bodies and the strut graft with bone graft (Fig. 161.11) (19).

***Figure 161.11.*** Radiograph shows an anterior fibular graft with bone graft positioned back to the vertebral bodies.

In rotational kyphosis, an additional and very useful strut graft technique, originally pioneered by P. Stagnara, consists of creating an osteoperiosteal flap from the vertebral bodies that are in the kyphotic area (23).

- Use a wide osteotome to reflect the anterior portion of the vertebrae for the length of the kyphotic curve. This technique creates a good vascular bed.
- Countersink the fibular or rib strut graft, with the bony flap adjacent to the graft, usually on the concavity of the scoliotic curve.
- Pack the intervertebral disc spaces with bone graft (Fig. 161.12).



***Figure 161.12.*** **A:** A Lambotte osteotome is used to create a vertebral flap. **B:** The vertebral flap is mobilized. **C:** The fibular strut graft is placed with the intervertebral disc spaces filled with bone graft. Bone graft is then placed from the flap to the vertebral bodies.

## INTERBODY ARTHRODESIS

Perform an intervertebral disc excision as previously described. Break the bony endplates with an angled Lambotte osteotome or curet, and pack the entire disc space with rib graft (see Chapter 146, Chapter 155).

## INLAY GRAFT

The inlay graft technique is useful when the kyphosis is not acutely angulated.

- Clean all the intervening disc spaces and prepare each end vertebra of the curve as described in the strut graft technique.
- Cut a trough in the interposed vertebral bodies with large Luxsell and Adson rongeurs and curved curets. The trough should be deep enough to bury the rib or fibular graft.
- The trough may also be filled with morcelized bone graft if anterior flexibility is needed during the posterior instrumentation.
- Correct the kyphosis by pushing on the apex of the curve, countersink the premeasured graft in the trough, and lock it in the end vertebrae.

## VASCULARIZED RIB GRAFT

A vascularized rib graft has a distinct advantage in circumstances when early stabilization, earlier arthodesis, and shorter immobilization are needed.

- When the thoracotomy is performed, make the entrance to the chest cavity through the intercostal muscle of the rib that articulates with the superior end vertebra of the kyphosis.
- Determine the length of the vascular pedicle needed. Measure the length of the strut graft that is needed on the anterior portion of the rib and cut it free with a rib cutter, leaving all soft tissue attached.
- Sharply dissect the neurovascular pedicle back to the rib base to allow mobilization of the strut. Expose each end of the strut subperiosteally for approximately 2 cm and impact and countersink these graft ends in the prepared end vertebra of the kyphosis, being careful not to kink the vascular pedicle (Fig. 161.13) (3).

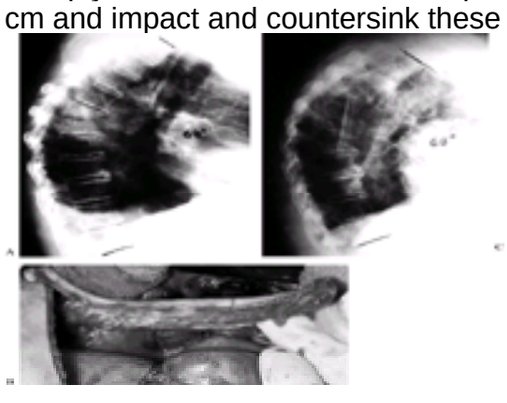

***Figure 161.13.*** **A:** A 72-year-old man with vertebral osteomyelitis T-6–T-7. **B:** The vascularized rib graft with the neurovascular pedicle is at the left. **C:** This postoperative radiograph shows the anchored vascularized rib graft. Note the supplemental inlay and interbody grafts in the area of the osteomyelitis.

## ANTERIOR VERTEBRAL OSTEOTOMY

After performing a subperiosteal exposure of the vertebra in a type II congenital kyphosis, the remnant of the posterior disc can be visualized. If the disc remnant cannot be visualized, perform the osteotomy at the level of the vertebral foramina to allow sagittal correction after the osteotomy.

- Perform multiple vertebral osteotomies at the levels of the posterior disc remnants or foramina using gouges, osteotomes, and curets. A power burr can be helpful for a portion of the osteotomy.
- Clean the disc spaces of all soft tissue back to the posterior annulus using curets and rongeurs.
- Use angled curets to complete the osteotomy on the opposite side, back to the posterior annulus.
- Check mobility of each intervertebral space with a Blount spreader, and pack each space with rib graft cut into small pieces (Fig. 161.14) (19).

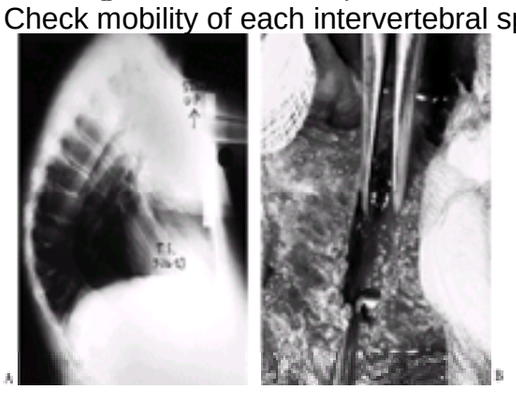

***Figure 161.14.*** **A:** Type II congenital kyphosis. Note the posterior disc remnants in the area of the anterior bar. **B:** After osteotomy is completed with angled

curets, gouges, and rongeurs. Mobility is then checked with a Blount spreader. See Figure 161.11 for the postoperative radiograph.

- Use intervertebral structural cages to correct sagittal alignment and prevent vertebral collapse at the site of the osteotomies. The longer kyphotic curves will also need strut graft support.

**ANTERIOR INSTRUMENTATION TO CORRECT ROTATIONAL KYPHOSIS**

- Expose the anterior spine extraperiosteally on the convex side.
- Using rongeurs and curets, clean the disc space of its annulus fibrosus and nucleus pulposus, along with the cartilage endplates at each vertebral level to be instrumented (the same technique as an interbody fusion).
- Measure the vertebral body size with a caliper to determine the appropriate length of screw to be used.
- Prepare a hole with a trocar in each vertebral body to be instrumented at the midlateral aspect of the rotated vertebra.
- Insert a vertebral screw and washer, aiming each screw toward the opposite pedicle or anterior to the pedicle.
- Take great care to identify the anterior longitudinal ligament at each level so that the degree of vertebral rotation is appreciated before the screw is inserted.
- Prepare the disc spaces for grafting by breaking the bony endplates with an osteotome and curets to ensure good cancellous bony exposure.
- Distract the disc spaces with a Blount spreader, and hold them open with whole-rib grafts.
- After assembling the rod-and-screw construct, correct the sagittal deformity.
- With the Zielke system, attach the derotation bar and derotate the spine as the nuts are sequentially tightened. As the spine is derotated, the scoliosis and rotational kyphosis are corrected.
- With segmental rod-and-screw systems, sequentially distract the intervertebral segments as the rod is introduced into one screw at a time.

The whole-rib intervertebral grafts prevent intervertebral collapse and the development of sagittal kyphosis after derotation has occurred. A supplementary posterior fusion and segmental instrumentation is usually done as a second-stage procedure (Fig. 161.15).



***Figure 161.15.*** **A:** Zielke instrumentation. **B:** Measuring the vertebral size with a caliper. **C:** Inserting a vertebral screw with a plate (a washer may be used instead). **D:** Rod insertion. Double nuts are used at the end of the construct and single nuts are used at other levels compressing toward the apex of the curve. **E:** Whole-rib grafts may be used to prevent collapse and sagittal kyphosis. Intervertebral cages may be useful in this situation. **F:** The derotator bar is used to pull the vertebral bodies back toward the sagittal plane, derotating the spine and correcting rotational kyphotic collapse. **G:** After derotation, the system is locked and the nuts are tightened.

**INTERVERTEBRAL CAGES AND FEMORAL ALLOGRAFT DOWELS OR RINGS**

The use of metallic intervertebral cages and femoral allograft dowels or rings as structural grafts has been useful in correcting and maintaining correction of kyphosis. They unload the posterior segmental instrumentation by participating in load sharing. This combination creates a more rigid construct for arthrodesis. They are especially useful in maintaining lumbar lordosis.

- Expose the spine extraperiosteally and create a flap of the annulus. Tag the flap with suture, then clean the disc spaces of all soft tissue as previously described.
- The most useful cages are those that allow abundant bony ingrowth through a mesh design and add sufficient structural support. The allografts are hollow in the center for autografts, for early bony ingrowth.
- Insert a wedge into the disc space and impact it. Measure the height of the disc space and select the size of the cage. Fill the cage or allograft with bone graft and insert and impact it into place.
- Remove the wedge and insert the second cage or allograft.
- Decorticate the remaining vertebral endplates and fill the remaining space with autogenous graft (20).
- Reapproximate the annular flap and suture the margins together to act as a barrier for the bone graft.

Two small cages side by side or one large cage may be used, depending on the circumstances; usually a single allograft is sufficient. Follow the anterior procedure by a posterior arthrodesis and segmental instrumentation (Fig. 161.16).

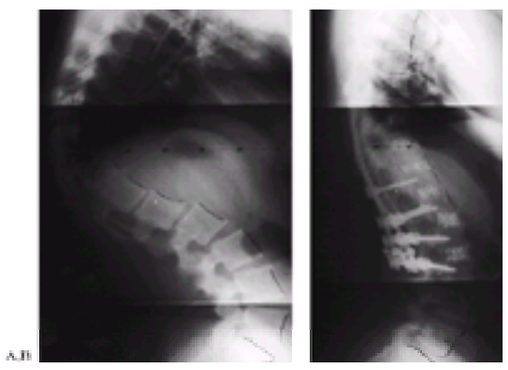

***Figure 161.16.*** **A:** Postlaminectomy sagittal thoracolumbar kyphosis from resection of an arteriovenous malformation. **B:** Postoperative radiograph with intervertebral Harm's cages used as structural intervertebral grafts and posterior segmental instrumentation [three-stage (posterior–anterior–posterior), same-day surgery]. (Images courtesy of Dr. Harry Schufflebarger, Miami, FL.)

**SEGMENTAL SPINAL INSTRUMENTATION**

The posterior surgical techniques used in correcting kyphosis are (a) segmental spinal instrumentation and Moe facet fusion and posterior arthrodesis, (b) posterior spinal osteotomy, and (c) the eggshell procedure.

Multiple segmental spinal instrumentation systems are now available, and most are strong enough to be acceptable. Which system to use is based on the experience of the surgeon. It is important to note, however, that some systems have a lower design profile than others. It is important to minimize the prominence of the instrumentation beneath the skin (see Chapter 156).

**POSTERIOR SPINAL OSTEOTOMY**

In previously fused patients, especially those with flatback syndrome, posterior osteotomies will be necessary for correction. When the spine is also fused anteriorly, combined anterior and posterior osteotomies will be necessary. The osteotomy site is selected by locating the vertebral foramina across which the osteotomy will be performed. The cranial–caudal width of the osteotomy is determined by the degree of closure that is necessary. Multiple osteotomies will spread the degree of correction across multiple levels and reduce the risk of neurologic compromise as compared with a single-level osteotomy. Single-level osteotomies can be useful, however, in ankylosing spondylitis and in patients with paralysis.

- Perform the osteotomy with osteotomes, gouges, curets, and Kerrison rongeurs (see Chapter 163). Remove the bone in sizable pieces and save them for later use as an autograft.
- A power burr can be used, although bone that can be used as an autograft is often lost. By attaching a Luken's trap to the suction system, much of the fine bone removed by the burr can be recaptured.
- Carry the osteotomy down to the inner cortical table, which is then osteotomized with Kerrison rougeurs.
- It is important to adequately decompress the spinal canal and undercut the osteotomy at the edges of the canal to prevent nerve root entrapment or central canal stenosis upon closure of the osteotomy (10,17).
- Provide adequate fixation to maintain correction and prevent displacement of the osteotomy.

In patients who have not had a previous fusion, the osteotomy should include removal of lamina, spinous processes, facets, and bilateral pars interarticularis. The amount of bone removal is determined by the degree of correction that is desired and that is judged to be safe (7,16,17,21,22,24).

**EGGSHELL PROCEDURE**

The eggshell procedure (9) is an operative technique that allows the spine surgeon to operate on the anterior thoracic or lumbar vertebral column through a posterior approach. It is most useful caudal to T-6 because of the more rigid conduit to the anterior spine (transpedicular vertebrectomy) (18). This approach can be used for a vertebral biopsy or decompression of a vertebral body abscess, but most eggshell procedures are done for chronic or acute deformity. In deformity surgery, the eggshell procedure is performed in addition to other procedures done for correction, arthrodesis, and stabilization.

- Position the patient prone on a spinal frame.
- Prepare the spine for segmental posterior instrumentation by inserting all hooks and screws in preparation for stabilization at the time of deformity correction.
- Locate the pedicle by plain radiographs or image intensification. The location of the pedicle is identified by the bifurcation of a line transecting the transverse process and a line along the lateral margin of the pars interarticularis (Fig. 161.17).

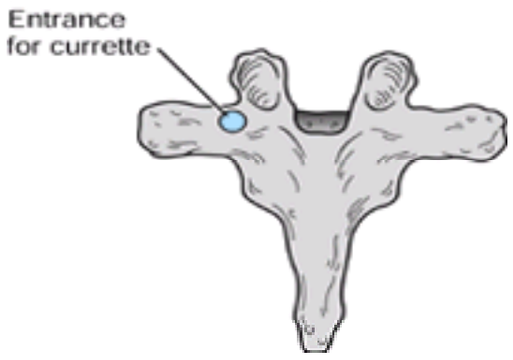


***Figure 161.17.*** Entrance to the pedicle posteriorly.

- Enter the pedicle with either a power burr or osteotomes and curets. Introduce a small curet into the pedicle and into the vertebral body.
- Enlarge the pedicle hole by progressively increasing the size of the curets.
- Leave the posterior elements intact and do not disturb the medial wall of the pedicles at this time. An extension moment promotes kyphosis correction and posterior bone removal may not be necessary.
- Use a sweeping motion to remove progressively more of the cancellous bone of the vertebral body.
- The surgeon can operate at an angle of approximately 45° from lateral to medial and decancellate an area directly anterior to the spinal canal.
- Perform the same procedure through the opposite pedicle (Fig. 161.18) and continue until the desired amount of material (e.g., bone, tumor) is removed.

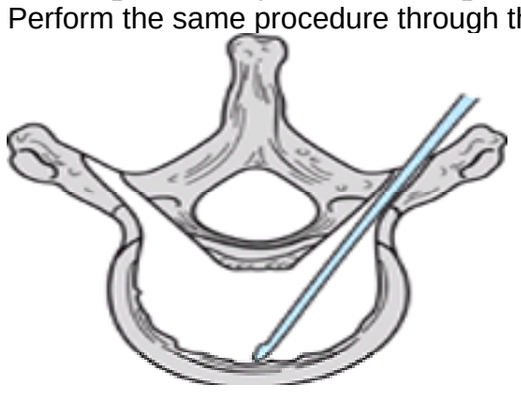

***Figure 161.18.*** The curet is in the vertebral body to perform decancellation. The vertebral body is entered from both pedicles. An eggshell is created.

- To remove additional bone from just anterior to the spinal canal, remove the lateral wall of the pedicle to allow a more oblique angle for the curet to approach this area. Once this is accomplished, an eggshell is created (Fig. 161.18).
- If correction of localized kyphosis is planned, fracture the lateral wall of the pedicles and extend the fracture into the shell of the vertebral body. An extension moment applied to the spine may assist in this technique. If additional correction is necessary, perform a sequential posterior decompression by removing the spinous process, lamina, pars interarticularis, and pedicles (Posterior Subtraction Osteotomy) (Fig. 161.19).

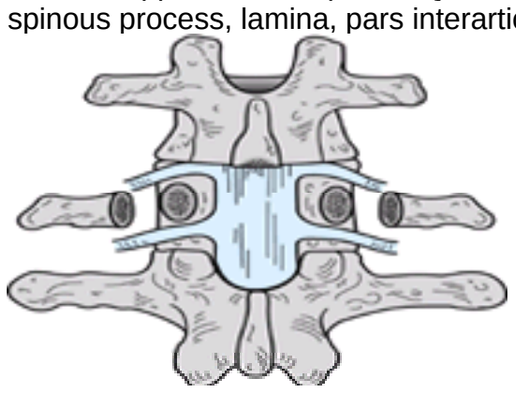

***Figure 161.19.*** Complete posterior decompression is done.

- In the thoracic spine, it is often necessary to remove the proximal ribs and rib heads for adequate correction and closure of the osteotomy.
- Pack morcelized bone graft anteriorly before closing the osteotomy for anterior arthrodesis.
- Complete this wedge osteotomy and use segmental posterior instrumentation to correct the kyphosis and stabilize the spine. When the posterior elements are removed, a slow correction of the deformity is recommended to be sure that there is no encroachment of bone on the spinal canal or malalignment of the vertebra causing dural compression. Be careful of nerve root impingement.
- The inferior and superior laminae need to be undercut to avoid impingement on the dura during closure of the osteotomy.
- The axis of the closure of the osteotomy is anterior to the spinal canal, thus shortening the neural tube.
- Stable posterior fixation is required to maintain osteotomy stability, kyphotic correction, and arthrodesis (Fig. 161.20).

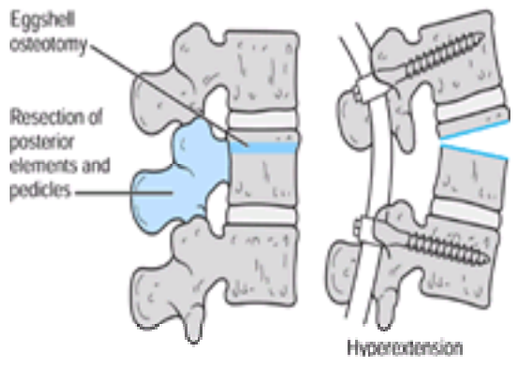


***Figure 161.20.*** Extension of the eggshell osteotomy and posterior segmental fixation.

- The ultimate stability of the spinal construct depends on whether or not facet-to-facet or bone-to-bone apposition is obtained.

## POSTOPERATIVE CARE AND REHABILITATION

Between the stages of operative correction, maintain patients on egg-crate or air mattresses, and log-roll them frequently to prevent decubiti and atelectasis. Prescribe daily bedside physical therapy for muscle strengthening, and joint range-of-motion exercises. Remove any chest tube and posterior drains on the second postoperative day or when the drainage is minimal.

At 5–7 days after the last staged procedure, place the patient in a bivalved polypropylene body jacket. If the patient is a teenager or young adult with good fixation and good-quality bone, bracing may not be needed. If there is any question about the stability of the instrumentation, bone weakness, or situations in which instrumentation cannot be used in the cervicothoracic spine (e.g., achondroplasia, diastrophic dwarfism), use a halo brace. In cervical kyphosis, apply a halo brace intraoperatively. Then allow patients to ambulate in the brace.

In patients with shorter kyphotic curves, do the anterior and posterior procedures at the same surgical setting to minimize anesthesia and recovery times. Sometimes a staged procedure may be indicated in patients who have had previously failed attempts at correction with resultant pseudarthroses and progressive curves, depending on the individual circumstances (19).

## PITFALLS AND COMPLICATIONS

Many potential pitfalls are recognized:

- Failing to fuse the entire kyphotic curve (fusion too short) may allow progression of the kyphosis. This is especially true in children due to the adding-on phenomenon, in which vertebrae cranially and caudally tilt into the curve and are added to the curve.
- Placing the strut graft too far anteriorly with no bony contact with the apex of the kyphosis will lead to graft fracture.
- Placing the anterior strut graft too far posterior to the weight-bearing axis may lead to failure and progressive deformity.
- Failure to supplement an anterior procedure with a posterior fusion and instrumentation may lead to inadequate correction or late failure.
- Inadequately countersinking the strut graft may result in graft dislodgement after surgery.
- Failure to make osteotomies wide enough and the vertebral canal edges round enough may lead to nerve root entrapment at osteotomy closure.
- Dural, spinal cord, and nerve root injuries from too aggressive disc removal can occur.
- Inadequate disc removal will lead to failed fusion or to late progression of the deformity.
- Focusing on spinal instrumentation and inattention to fusion technique may lead to pseudoarthrosis and failure.
- Inadequate placement of posterior instrumentation may result in incomplete correction or an unbalanced torso, and failure to maintain lumbar lordosis below the kyphosis will lead to unbalanced sagittal alignment.
- Too-vigorous correction of the kyphotic deformity with posterior instrumentation in osteopenic bone can lead to bony failure, with loss of fixation and correction.
- Too-vigorous derotation with the Zielke instrumentation can cause spinal root injuries.
- With any anterior instrumentation, take care to prevent flatback syndrome.
- When there is severe vertebral rotation, anterior screw placement is critical so that spinal canal penetration does not occur.
- Finally, a well-applied brace is extremely important in some patients and should not be delegated to the inexperienced surgeon, or a less-than-ideal result may occur in an otherwise masterfully performed surgical procedure.

## CHAPTER REFERENCES

Each reference is categorized according to the following scheme: *, classic article; #, review article; !, basic research article; and +, clinical results/outcome study.


# 1. Akbarnia B. Spine Deformity in Neurofibromatosis. In: Bradford DS, Hensinger RM, eds.*The Pediatric Spine.* New York: Thieme, 1985;356.

+ 2. Betham D, Winter RB, Luther L. Disorders of the Spine in Diastrophic Dwarfism. *J Bone Joint Surg Am* 1980;62:529.

* 3. Bradford DS. Anterior Vascular Pedicle Bone Grafting for the Treatment of Kyphosis. *Spine* 1980;5:318.

# 4. Bradford DS. Spondylolysis and Spondylolisthesis in Children and Adolescents: Current Concepts in Management. In: Bradford DS, Hensinger RM, eds.*The Pediatric Spine.* New York: Thieme, 1985;416.

+ 5. Bradford DS, Schumacher WL, Lonstein JE, Winter RB. Ankylosing Spondylitis: Experience in Surgical Management of 21 Patients. *Spine* 1987;12:238.

+ 6. Bradford DS, Tribus CB. Current Concepts and Management of Patients with Fixed Decompensated Spinal Deformity. *Clin Orthop* 1994;306:64.

* 7. Briggs H, Keats S, Schlesinger PT. Wedge Osteotomy of the Spine with Bilateral Intervertebral Foraminotomy. *J Bone Joint Surg* 1947;29:1075.

# 8. Canale ST, Beaty JH.*Operative Pediatric Orthopaedics.* St. Louis, MO: Mosby Year Book, 1991.

# 9. Chewning SJ, Heinig CF. Eggshell Procedure. In: Bradford DS, ed.*Master Techniques in Orthopaedic Surgery.* Philadelphia: Lippincott-Raven, 1997;199.

* 10. Lagrone MO, Bradford DS, Moe JH, et al. Treatment of Symptomatic Flatback after Spinal Fusion. *J Bone Joint Surg Am* 1988;70:569.

+ 11. Lonstein JE. Postlaminectomy Kyphosis. In: Chou SN, Seljesky ED, eds.*Spinal Deformities and Neurological Dysfunction.* New York: Raven Press, 1978;53.

# 12. Mayfield JK. Post-Radiation Spinal Deformity. *Orthop Clin North Am* 1979;10:829.

# 13. Mayfield JK. Biomechanics of Spinal Deformities in Management of Spinal Deformity. In: Dickson R, Bradford D, eds. *Butterworths Int. Med. Rev. Orthop*, vol. 2, 1984;38.

+ 14. Mayfield JK, Erkkila J, Winter RB. Spine Deformity Subsequent to Acquired Childhood Spinal Cord Injury. *J Bone Joint Surg Am* 1981;63:1401.

* 15. Mayfield JK, Winter RB, Bradford DS, Moe JH. Congenital Kyphosis Due to Defects of Anterior Segmentation. *J Bone Joint Surg Am* 1980;62:1291.

* 16. McMaster MJ, Coventry MB. Spinal Osteotomy in Ankylosing Spondylitis. *Mayo Clin Proc* 1977;128:65.

* 17. McMaster PE. Osteotomy of the Spine for Fixed Flexion Deformity. *J Bone Joint Surg Am* 1962;44:1207.

* 18. Michelle A, Krudger FJ. A Surgical Approach to the Vertebral Body. *J Bone Joint Surg Am* 1949;31:873.

# 19. Moe JH, Bradford DS, Lonstein JE, Winter RB.*Scoliosis and Other Spinal Deformities.* Philadelphia: WB Saunders, 1987.

+ 20. Shufflebarger H. Complex Revision Spinal Surgery:Posterior-Anterior-Posterior Sequence. In: *Proceedings of the Scoliosis Research Society*, St. Louis, 1997.

* 21. Simmons EH. Kyphotic Deformity of the Spine in Ankylosing Spondylitis. *Clin Orthop* 1977;128:65.

* 22. Smith-Peterson MN, Larson CB, Aufranc OE. Osteotomy of the Spine for Correction of Flexion Deformity in Rheumatoid Arthritis. *J Bone Joint Surg* 1945;27:1.

* 23. Stagnara P.*Spinal Deformity.* London: Butterworths, 1988.

* 24. Thomasen E. Vertebral Osteotomy for Correction of Kyphosis in Ankylosing Spondylitis. *Clin Orthop* 1985;194:142.

# 25. Tolo V. Spinal Deformity in Dwarfs. In: Bradford DS, Hensinger RM, eds.*The Pediatric Spine.* New York: Thieme, 1985.

# 26. Winter RB, Lonstein JE, Boachie-Adjei O. Congenital Spinal Deformity. *Instr Course Lect* 1996;45:117.

# 27. Winter RB, Lonstein JE, Leonard AS.*Congenital Deformities of the Spine.* New York: Thieme-Stratton, 1983.

* 28. Winter RB, Moe JH, Bradford DS, et al. Spine Deformity in Neurofibromatosis. *J Bone Joint Surg Am* 1979;61:1677.

* 29. Winter RB, Moe JH, Wang JF. Congenital Kyphosis. *J Bone Joint Surg Am* 1973;55:223.

# CHAPTER 162

# SPONDYLOLISTHESIS

*John D. Miles and Robert W. Gaines, Jr.*

**J. D. Miles and R. W. Gaines, Jr.:** Columbia Spine Center, Columbia Orthopaedic Group.

Pathophysiology
Classifications
Clinical Assessment
Radiographic Assessment
Natural History and Risk Factors for Progression
Nonoperative Management
Indications and Surgical Techniques
Treatment of Spondylolysis and Low-Grade (<50%) Spondylolisthesis
Primary Repair of Pars Defect
Instrumented Posterolateral Fusion *in Situ*
Decompression
Anterior Interbody Fusion
Treatment of High-Grade Spondylolisthesis (>50%)
Arthrodesis
Instrumentation and Reduction
Anterior Interbody Fusion
Decompression
Treatment of Spondyloptosis
Authors' Preferred Technique for Spondyloptosis
Pitfalls and Complications
Chapter References

The concepts of spondylolysis, spondylolisthesis, and spondyloptosis have caused considerable confusion for students of orthopaedics. This chapter conveys the essentials of what is understood about these lesions to provide a foundation for rational treatment.

*Spondylolisthesis* is derived from the Greek *spondylos* (vertebra) and *olisthanein* (to slip or fall). This most commonly describes the forward slippage of a cephalad vertebra on a caudal vertebra (Fig. 162.1*A*). The term *spondylolysis* is also derived from the Greek word *lysis* (loosening). Spondylolysis is now specifically used to describe a bony defect in the pars interarticularis, the portion of the neural arch just caudal to the confluence of the pedicle and the superior articular process and at the most cephalad part of the lamina and inferior articular process (Fig. 162.1*B*). Spondylolisthesis can be present with or without spondylolysis (Fig. 162.1*C*). *Spondyloptosis* has similar origins, with the same root appended to the Greek word *ptosis* (falling). In modern usage, this refers to the most severe form of spondylolisthesis, when the body of L-5 has slipped into the pelvis and is positioned directly anterior to the sacrum (Fig. 162.1*D*).

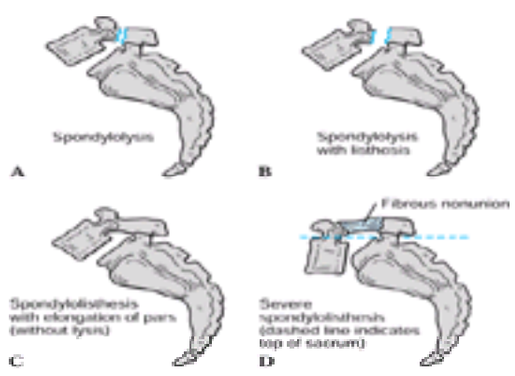


***Figure 162.1.*** **A:** Spondylolysis. **B:** Spondylolysis with listhesis. **C:** Spondylolisthesis and elongation of the pars interarticularis (without lysis). **D:** Severe spondylolisthesis (*dashed line* indicates top of sacrum).

## PATHOPHYSIOLOGY

Two processes—dysplastic and traumatic—can give rise to spondylolisthesis. These can occur simultaneously, but generally one predominates.

The first, so-called dysplastic pathway is initiated by a congenital defect in the bony hook or its catch. The hook is composed of the pedicle, pars interarticularis, and inferior articular process of the cephalad vertebra, and the catch is the superior articular process of the caudal level. Dysplasia of any of these structures sets the stage for olisthesis when the weight of the trunk is transferred through the area at the initiation of upright stance and ambulation. The olisthesis is only potential at birth. Subluxation occurs when the soft-tissue restraints (intervertebral disc, anterior and posterior longitudinal ligaments, ligamentum flavum, and posterior ligamentous complex) undergo plastic deformation due to repetitive loading unopposed by bony constraints. If pronounced subluxation occurs while significant growth still remains, the slippage will be accompanied by abnormal growth in the involved vertebral bodies or sacrum. These dysplastic changes form the basis for various classification schemes. Such changes include a trapezoidal shape of L-5, rounding of the superoanterior aspect of the sacrum, vertical orientation of the sacrum, junctional kyphosis at the involved segments, and a compensatory hyperlordosis at adjacent levels. There is evidence to support a genetic predisposition to this process, although no pattern of inheritance has been identified.

The second, so-called traumatic pathway is initiated by repetitive cyclic loading that ultimately results in a stress fracture. Impingement between the inferior articular process of the cephalad vertebra and the superior articular process of the caudal vertebra creates a bending moment that must be resisted by the pars (Fig. 162.2). Repetitive impingement causing loads in excess of the fatigue limit results in a fatigue (stress) fracture of an otherwise normal pars interarticularis. This repetitive loading is the same process that causes stress fractures in other anatomic locations, such as the femoral neck or the fifth metatarsal. The hard cortical bone of the pars predisposes it to fatigue fracture, as well as nonunion, decreasing the likelihood of spontaneous healing. If healing occurs, the pars often heals in an elongated position. Either outcome (nonunion or healing with elongation) permits vertebral subluxation. This fundamental change in bony anatomy exposes the disc to increased shear load, even though the axial load remains unchanged. The increased shear load on the disc causes premature disc degeneration. Activities involving repetitive maximal flexion and extension (e.g., interior line play in football, pole vaulting, or gymnastics) are notoriously associated with fatigue fractures of the pars.

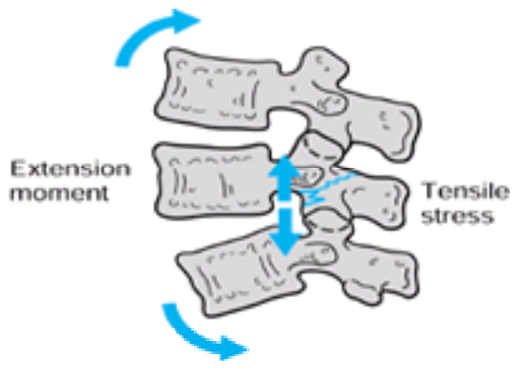


***Figure 162.2.*** Extension of the lumbar spine causes a tension load in the pars interarticularis.

Spondylolisthesis may also be caused by other processes, although these are sufficiently different as to be considered distinct entities. They are included here for completeness.

Degenerative spondylolisthesis represents segmental instability and subluxation caused solely by degenerative change in the intervertebral disc and facet joints. The degree of subluxation is necessarily mild because the intact neural arch provides a bony limit to forward translation. Relatively more sagittal orientation of the facet joints is associated with degenerative spondylolisthesis (2,22).

A local or systemic pathologic process may cause a defect in the neural arch that can then permit subluxation. This is a pathologic fracture with resultant translational deformity.

High-energy trauma can cause translational deformity. In this setting, the spine will have sustained multiple bony and soft-tissue injuries, which may include a fracture in the pars. Other skeletal and visceral injuries will typically be present. This traumatic type of spondylolisthesis is a fracture–dislocation from high-energy trauma, not from repeated low-energy injuries.

Finally, a laminectomy that removes an entire articular process or more than half of each articular process can functionally destabilize the spine and permit translational deformity. This is iatrogenic postsurgical instability. Segments adjacent to previously fused segments are also at risk for development of degenerative spondylolisthesis (45). This subluxation is likely due to resection of the capsular, interspinous, or supraspinous ligaments at the adjacent level, but the loss of motion of the fused segment may contribute by increasing the motion demands at the next open level.

## CLASSIFICATIONS

The classification scheme of Wiltse et al. (58) has gained wide acceptance (Table 162.1). It combines both anatomic and etiologic elements; however, this combination is one criticism of this system.

| Type | Name | Description |
|---|---|---|
| I | Congenital | Dysplastic abnormalities in the posterior elements or the upper sacrum cause olisthesis |
| II | Isthmic | Three types are recognized: A: lytic, presumed to be a stress fracture of the pars B: a healed version of the lytic type, resulting in an elongated but intact pars C: an acute fracture of the pars interarticularis from a high-energy injury |
| III | Degenerative (pseudospondylolisthesis) | Neural arch (including the pars) is intact and the olisthesis results from longstanding segmental instability. |
| IV | Traumatic | Fracture of the bony hook other than the pars interarticularis (i.e., articular processes) |
| V | Pathologic | Generalized or localized bone disease that predisposes to olisthesis |
| VI | Postsurgical | Iatrogenic slippage as a result of loss of the posterior elements secondary to surgery |

***Table 162.1. Wiltse–Newman–Mcnab Classification of Spondylolisthesis***

Marchetti and Bartolozzi (34) proposed a classification scheme based on etiologic criteria that has also gained wide acceptance (Table 162.2). The principal distinction in their system is between developmental and acquired forms, which correspond respectively to the dysplastic and traumatic pathways discussed previously.

I. Developmental
- A. High dysplastic
  - With lysis
  - With elongation
- B. Low dysplastic
  - With lysis
  - With elongation

II. Acquired
- A. Traumatic
  - Acute fracture
  - Stress fracture
- B. Postsurgery
  - Direct (from excessive removal of facet articulation)
  - Indirect (usually immediately above an arthrodesis)
- C. Pathologic
  - Local pathology
  - Systemic pathology
- D. Degenerative
  - Primary (intact bony arch with degeneration in disc and facet joints)
  - Secondary (adjacent to nonsurgically fused segments)

***Table 162.2. Marchetti and Bartolozzi Classification of Spondylolisthesis***

## CLINICAL ASSESSMENT

The symptoms associated with spondylolisthesis are caused by chronic muscle contraction (spasm) as the body attempts to limit motion around a painful pseudarthrosis of the pars interarticularis, by tears in the annulus fibrosus of the degenerating discs, or by compression of nerve roots. Pain may also derive directly from impingement at the fibrous pars nonunion, as nerve endings have been identified there (47). Children and younger adults who have symptomatic high-grade spondylolisthesis commonly complain of back fatigue and back pain on movement, particularly with hyperextension, as well as hamstring fatigue and pain. On examination, the paraspinal muscles are in chronic reactive contraction (spasm) to splint the painful underlying motion segment, and the hamstring muscles are in reactive contraction to stabilize the pelvis under the painful spinal motion segments. After months of continuous contraction in a growing child, fixed contractures of the hamstrings and paraspinal muscles may occur, limiting forward bending and hip flexion. These may be evident on clinical examination (Fig. 162.3*A*). Palpation elicits tenderness over the pars defect when the patient is lying prone with the spinal muscles relaxed, similar to the tenderness that exists over any other skeletal nonunion.

***Figure 162.3.*** Physical findings in spondylolisthesis. **A:** Severely limited forward bending in a patient with moderate slippage and paravertebral muscle and hamstring spasm. **B:** Sciatic scoliosis in a patient with a disc rupture at the level above a pars defect. This patient's chief complaint was sciatica with mild back pain. **C:** Accentuated lordosis in a patient with mild slippage and a low slippage angle. **D:** Severe posterior tilting of the pelvis and secondary thoracolumbar lordosis are evident in this patient with a high-grade spondylolisthesis and high slippage angle. **E:** Heart-shaped buttocks and trunk foreshortening are visible in this patient with a high-grade slip. **F:** The same patient demonstrates an abdominal crease. **G:** Standing posture of a patient during olisthetic crisis with severe deformity, canal occlusion, and multiple root compression.

As aging proceeds and disc degeneration occurs (either at the level of the slippage or at the level above it), episodes of the back “giving out” may occur. These episodes may or may not involve sciatica and vary in severity. As disc degeneration or subluxation increases, both the spinal canal and the lateral root foramina narrow, often causing symptoms related to nerve root compression (Fig. 162.3*B*). Such compression is manifested by sciatic pain radiating from the buttock into the posterior thigh and into the calf and foot. It is associated with numbness in a similar dermatomal distribution and with positive nerve stretch signs, such as straight-leg raising. Symptoms of spinal claudication indicate high-level stenosis. Compression of the central canal is confirmed by one or more of the following:

- Bowel or bladder symptoms or dysfunction
- Bilateral leg symptoms
- Positive straight-leg-raising test bilaterally
- Positive crossed straight-leg-raising test

Patients with spondylolysis or minor slips have no spinal deformity. As the amount of subluxation increases, spinal deformity becomes increasingly visible on inspection of the patient's torso. As the spine slides forward, the pelvis rotates posteriorly so that the top of S-1 becomes progressively more horizontal. This produces lumbosacral kyphosis and a relative posterior prominence of the posterior parts of the iliac crests (Fig. 162.3*C*, Fig. 162.3*D*). The gluteal muscles become less prominent. Patients with high-grade spondylolisthesis are often described as having heart-shaped buttocks (Fig. 162.3*E*). As the amount of telescoping approaches total dislocation (spondyloptosis), foreshortening of the lumbar spine becomes obvious on physical examination, and a crease appears across the abdomen (Fig. 162.3*F*). Patients in olisthetic crisis with total canal occlusion (the most severe type of spinal stenosis) relieve disc pressure and reduce nerve root tension by supporting trunk weight with hands on knees (Fig. 162.3*G*).

## RADIOGRAPHIC ASSESSMENT

Plain anteroposterior and lateral radiographs document the amount of vertebral subluxation; often, they also reveal a pars interarticularis defect if one is present (Fig. 162.4). Oblique views have also been used to highlight the Scotty-dog sign (Fig. 162.5). In young patients, flexion–extension views can be used to show excessive movement across the site of pseudarthrosis in the pars interarticularis and subluxation of the vertebral body as the patient moves from extension into flexion. This motion may be more evident if the films are taken with the patient lying in the lateral decubitus position rather than standing (60). Plain standing radiographs are also quite useful for documenting progression of deformity (Fig. 162.6).

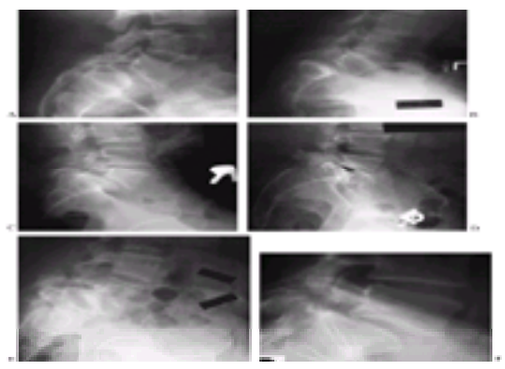

***Figure 162.4.*** Spondylolisthesis in five patients with varied combinations of slippage, slippage angle, sacral inclination, sacral rounding, and disc degeneration. **A:** Moderate dysplastic spondylolisthesis. No pars defect is seen, and the slippage angle is low. **B:** Moderate isthmic spondylolisthesis. A pars defect is seen, and the slippage angle is higher than in the previous image. **C:** Moderate isthmic slip with moderate disc degeneration. The slippage angle is low, but striking retrolisthesis is present at the level above (L4-5). **D:** Moderate isthmic slippage with severe disc degeneration and a vacuum disc. **E:** High-grade slip with a higher slippage angle, vertical sacrum, high lumbar index, and severe disc degeneration. **F:** Low-grade slip with low slippage angle and minimal disc degeneration. A pars defect is present.

***Figure 162.5.*** Varied radiographic appearance of spondylolysis without olisthesis. **A:** Oblique radiograph shows lysis at L-3. Note the collar on Scotty dog. **B:** Oblique radiograph reveals atrophic nonunion at an L-5 pars defect. Oblique (Scotty dog) radiographs reveal a pars defect (**C**) and an elongated healed pars (**D**) in the same patient with a low-grade slip. (Courtesy of Harry Griffiths, MD, University of Missouri Health Sciences Center, Columbia, MO.)

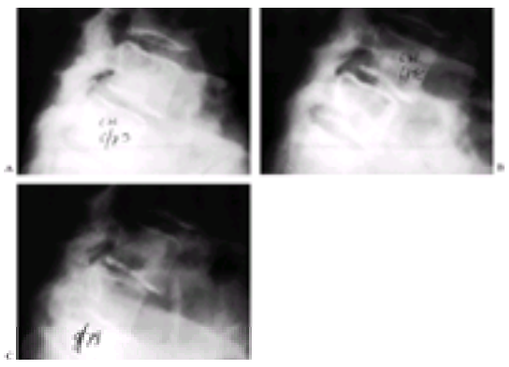

***Figure 162.6.*** Progression of degenerative spondylolisthesis at L4-5 over a 5-year period as seen on lateral radiographs. **A:** 1973. **B:** 1975. **C:** 1978. (Courtesy of Harry Griffiths, MD, University of Missouri Health Sciences Center, Columbia, MO.)

Older references grade the degree of vertebral subluxation by the Meyerding classification, which is based only on the amount of anterior (forward) subluxation of the cephalad vertebra in reference to the caudal vertebra (Fig. 162.7A). Slippage is graded as a percentage relative to the sagittal diameter of the inferior body:

| | |
|---|---|
| Grade I | 0% to 25% |
| Grade II | 25% to 50% |
| Grade III | 50% to 75% |
| Grade IV | 75% to 100% |
| Grade V | Greater than 100% |

This classification is particularly useful for low-grade (grade I or II) slips.

Boxall et al. (5) described the many adaptive changes in vertebral and disc anatomy that occur in response to chronic vertebral subluxation (Fig. 162.7*B*, Fig. 162.7*C* and Fig. 162.7*D*). In particular, they emphasized the importance of the kyphotic component of the deformity in producing canal narrowing and sagittal-plane malalignment. Correction of kyphosis is very important in treating the condition, especially with regard to achieving a solid fusion (13). The radiographic measurement techniques described by Boxall et al. (5) emphasize the importance of the slippage angle as the best way to quantify the degree of kyphosis in a patient with spondylolisthesis.

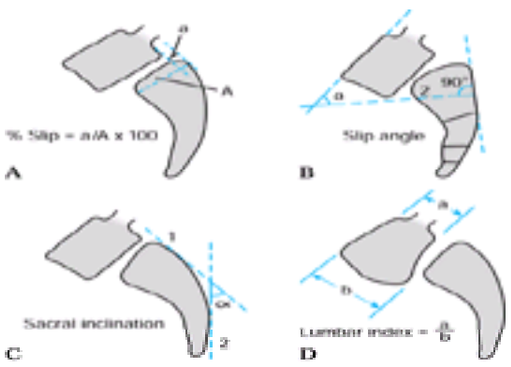


***Figure 162.7.*** **A:** Calculation of the slippage percentage for spondylolisthesis. **B:** For a domed sacrum, the slippage angle is calculated from the posterior sacral body cortex and the superior endplate of L-5. **C:** The sacral inclination is the angle between the posterior sacral body cortex at S-1 and a vertical line (standing radiograph). **D:** Calculation of the lumbar index.

Bone scintigraphy or single-photon emission computed tomography may occasionally be useful in symptomatic patients without radiographic evidence of spondylolisthesis (Fig. 162.8) (33). These studies document increased bone metabolic activity in an acutely injured pars interarticularis; however, they may revert to normal in a chronic unhealed defect or after a stress fracture heals (33).

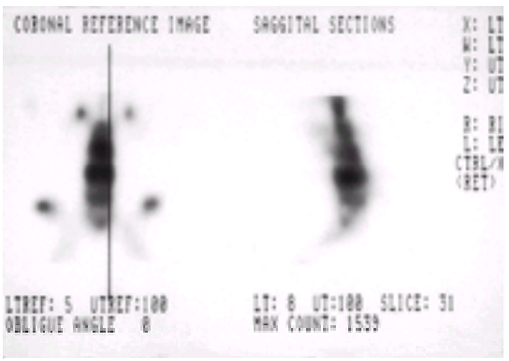


***Figure 162.8.*** Bone scan shows increased activity in a patient with bilateral pars defects. (Courtesy of Harry Griffiths, MD, University of Missouri Health Sciences Center, Columbia, MO.)

Plain radiographs are sufficient for evaluating patients with solely mechanical complaints. If root symptoms, bowel or bladder complaints, or physical evidence of cord or root compression are present, then evaluate the soft tissues of the back with magnetic resonance imaging (MRI) (Fig. 162.9), myelography (Fig. 162.10), computed tomography, or a combination of these studies. MRI findings have been well correlated with clinical evidence of radiculopathy (28). Cystometric studies are helpful in patients with bladder dysfunction, although they are often confirmatory rather than diagnostic. Somatosensory-evoked cortical or spinal potentials may be of diagnostic value but are usually only confirmatory.

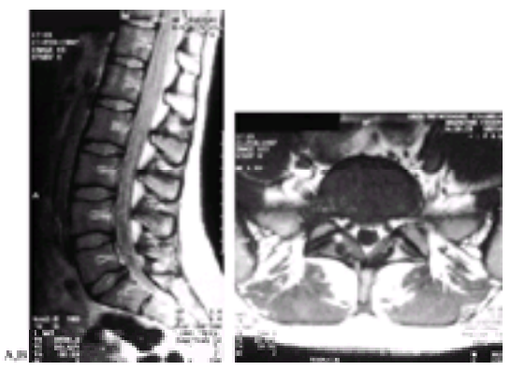

***Figure 162.9.*** Sagittal (**A**) and axial (**B**) MR images reveal a herniated nucleus pulposus in a patient with spondylolysis and complaints of sciatica.

***Figure 162.10.*** **A:** Myelogram reveals a block as the dural sac is tethered over S-1 in a high-grade slip. **B:** Lateral disc herniation is evident at L4-5 in a patient with an L-5 pars defect.

## NATURAL HISTORY AND RISK FACTORS FOR PROGRESSION

Dysplastic spondylolisthesis most commonly occurs at the lumbosacral junction, with decreasing frequency at more cephalad levels in the lumbar spine. It is seldom seen in the cervical spine and rarely in the thoracic spine. Pars defects (spondylolysis) have not been reported at birth. However, the prevalence by early childhood is between 4% and 5% (17). By adulthood, the prevalence has increased to 6% or 7% (57,31). The great majority of patients with spondylolysis (radiographic evidence of a pars defect) are asymptomatic, and substantial slippage (spondylolisthesis) never develops (11,18,49). In a long-term study of adolescents with isthmic spondylolisthesis, 90% of slips occurred at the time of the initial presentation, and the only factor predictive of progression was the magnitude of the initial slippage (50). Pronounced vertebral subluxation (>75%), if it occurs, generally arises during late childhood, at the time of the adolescent growth spurt, or during pregnancy (1,44). In patients who manifest a major deformity during adulthood, it is generally thought that the deformity developed before 20 years of age. The prevalence of spondylolisthesis is no higher in groups with chronic debilitating low back pain than in the general population (20). The association between low-back pain and spondylolisthesis is weak but is significant in women (56). The degree of dysplasia, including spina bifida occulta and small transverse processes, has been associated with progression but has not proven to be predictive. Rounding of the sacral promontory, trapezoidal wedging of L-5, vertical position of the sacrum, and segmental kyphosis all contribute to the mechanics of progression but are believed to be secondary changes. Similar to Harrington's stable zone in scoliosis, there may be a point of no return, beyond which progression is a certainty; however, documentation of this has not yet occurred.

Conversely, slippages that develop after 20 years of age (acquired) tend to be more stable, less symptomatic, and less likely to progress (38). Spondylolisthesis due to a fatigue fracture of the pars interarticularis will frequently occur in a high-level athlete. However, participation in athletics has little effect on progression of symptoms (35).

Degenerative spondylolisthesis usually occurs after 60 years of age, and progression is limited by the intact neural arch. Symptoms are generally due to stenosis, and progression to surgery is variable. A more sagittal orientation of the facet joints at L4-5 is strongly associated with the development of degenerative and postlaminectomy spondylolisthesis (22,43). Oophorectomy has also been identified as a risk factor for degenerative spondylolisthesis (26).

Both postsurgical and pathologic spondylolisthesis are relatively uncommon. Each patient must be evaluated and treated individually. Nerve root decompression and instrumented spinal fusion are the fundamentals of treatment.

Traumatic spondylolisthesis is a fracture–dislocation, and hence it is extremely unstable (24). Surgical stabilization is usually required.

## NONOPERATIVE MANAGEMENT

Most patients who have a greater proportion of back pain than leg pain can be managed nonsurgically. In the pediatric population, symptoms may be controlled by a period of bed rest, bracing, or cessation of aggravating activities. For adults with any type of spondylolisthesis, initial nonoperative treatment is the rule.

- A corset and activity modifications are usually beneficial.
- For exacerbations, prescribe periods of bed rest.
- Palliate symptoms with hot or cold therapy, and use massage to treat the muscle fatigue or spasm resulting from disproportionate effort to limit movement across a painful motion segment.
- Initiate a program of aerobic conditioning; specific back exercises have variable effectiveness.
- Obese patients should lose weight to return to their healthy physiologic range.
- Nonsteroidal antiinflammatory medications and epidural steroid injections may be of some value.

These conservative measures are usually effective because fewer than 10% of symptomatic patients eventually require operative treatment. Surgery should be contemplated only after a trial of nonoperative care. In adult patients with predominantly sciatic complaints, nonoperative treatment may be less effective.

## INDICATIONS AND SURGICAL TECHNIQUES

The surgical indications are different for children and adolescents than for adults. For children and adolescents, the indications for surgery are as follows:

- Documented progression of a slip beyond 25%
- Presentation with a high-grade slip (>50%)
- Intractable pain or neurologic symptoms
- Progressive postural deformity or gait abnormality

For adults, the usual surgical indication is persistent back pain and neurologic or radicular symptoms unresponsive to nonoperative management. As with other spine surgery, sciatica is more responsive than back pain to surgery (9). Patients with more severe symptoms will generally experience greater benefit from surgery than those with milder symptoms. Poor outcomes following surgery have been strongly associated with active workers' compensation claims and smoking (46,55).

## TREATMENT OF SPONDYLOLYSIS AND LOW-GRADE (<50%) SPONDYLOLISTHESIS

### PRIMARY REPAIR OF PARS DEFECT

In 1970, Buck (7) described a technique for direct repair of a pars defect with a screw placed through the lamina across the defect. There have since been other direct-repair techniques involving wires, hooks, and pedicle screws (30). The appropriate patient has spondylolysis but no olisthesis and a normal disc. Good results have been reported with these techniques, but because of the simplicity and predictability of fusion *in situ,* repair is not performed as often as fusion (3).

### INSTRUMENTED POSTEROLATERAL FUSION *IN SITU*

The majority of symptomatic patients with mild to moderate (<50%) slips can be successfully treated with posterolateral fusion *in situ* (typically from L-5 to S-1) (8,19,27). Even patients with radicular symptoms may get good relief with fusion *in situ* (12). Wiltse et al. (58) advocated a muscle-splitting approach with two

paramedian incisions; we favor a midline approach.

Internal fixation is rarely needed for children, although it is commonly used for adolescents and adults. The most popular systems today use pedicle screws. The biomechanical superiority of these systems for stabilizing spondylolisthesis has been demonstrated. Their effect on fusion rates and clinical outcomes is less clear, although generally beneficial (16,42,53,54,61).

- Position the patient prone on a Jackson table or blanket rolls without changing the patient's kyphosis or lordosis.
- Make a midline incision of sufficient length, and expose the posterior elements laterally to the tips of the transverse processes and sacral ala and thoroughly decorticate.
- For most adult-sized patients, we then place pedicle screws across the defect.
- We now routinely perform a laminectomy of the loose arch to provide local graft, instead of iliac crest, to reduce postoperative morbidity.
- Place morcelized autologous bone graft from the laminectomy in the prepared gutter under the plates (between the screws).
- Place rods or plates.
- Perform routine closure over a suction drain and epidural catheter.

Postoperatively, allow patients to be ambulatory, as tolerated, in a corset. Prohibit driving and sitting, except on a raised toilet seat, for 2 months.

The healing rate for a one-level fusion is approximately 95%. Most children have good or excellent results, with eventual return to full activity. As in other spine surgery, children do better than adults. The most common long-term problem is degenerative change at the level above the fusion (59).

### DECOMPRESSION

Neural decompression is seldom required for children unless there is a cauda equina syndrome. Although foraminal stenosis with associated root pain is common in adults with isthmic spondylolisthesis, the indications for decompression are unclear because the addition of decompression may increase the rate of postoperative pseudarthrosis (10). Some authors have reported excellent fusion rates and relief of sciatica with fusion *in situ* (39), whereas others advocate formal decompression (6).

Adults with degenerative spondylolisthesis and secondary stenosis commonly present with claudication. Pedicle-to-pedicle posterior decompression is generally accepted, although the addition of intertransverse fusion has been shown to produce significantly better results than decompression alone for the treatment of degenerative spondylolisthesis (23).

The Gill procedure (excision of the loose laminar arch), long considered adequate decompression, actually fails to decompress the root in the neural foramen. A thorough decompression must include a foraminotomy, especially in the patient with radicular complaints. The best use of the loose laminar arch is as bone graft. We routinely perform Gill's procedure to obtain bone graft, not for the purpose of neural decompression.

### ANTERIOR INTERBODY FUSION

Anterior interbody fusion is rarely indicated as a primary treatment for low-grade spondylolisthesis. It can be useful for failed posterior spinal fusion, however. Complications are potentially severe and include injury of the great vessels, sexual dysfunction, and retrograde ejaculation (see Chapter 146).

## TREATMENT OF HIGH-GRADE SPONDYLOLISTHESIS (>50%)

High-grade spondylolisthesis is rare but is a clinical challenge. Opinions vary widely as to optimal management.

### ARTHRODESIS

Essentially, all authors would incorporate a bilateral posterolateral fusion in the treatment plan, but the agreement would stop there. Some authors have reported good results with isolated posterior fusion *in situ* (14,27,29). However, the pseudarthrosis rates are high, and progression is common, even with a radiographically solid fusion. In addition, fusion *in situ* fails to correct the clinical deformity and sagittal imbalance that generally accompany these severe deformities (51).

### INSTRUMENTATION AND REDUCTION

The indications for instrumentation and reduction remain controversial (41). The relative indications for instrumented reduction include olisthetic crisis, cauda equina syndrome, a slip greater than 50% with a slippage angle greater than 30°, and major clinical deformity with global sagittal imbalance. Most intraoperative reduction techniques involve insertion of pedicle screws into L-4, L-5, and the sacrum. Often, a second point of pelvic fixation is added (iliac screws, intrasacral rods, or S-2 screws) to gain mechanical advantage. The forces applied are distraction, posterior translation of L-5, and sacral flexion. The terminal portion of the reduction maneuver has been shown to produce a disproportionate amount of nerve root tension, suggesting that postural reduction is a reasonable intermediate alternative (40). Many authors stress the importance of sacral flexion for restoring sagittal-plane balance (40). All series of instrumented reductions have reported nerve root injury, typically L-5, which manifests as foot drop. For the majority of affected patients, there is complete or partial recovery. These procedures are technically demanding and should be attempted only by experienced surgeons for patients who understand the potential risks. At long-term follow-up, most series have reported durable correction and clinical improvement with acceptable complication rates (15,25,37).

### ANTERIOR INTERBODY FUSION

The addition of anterior interbody fusion is controversial (36). Some series report good results with isolated posterior spinal fusion, whereas others report higher fusion rates, less progression, and fewer implant failures with circumferential fusion (4,6). The relative indications are incomplete reduction, residual kyphotic slippage angle, and revision for previous pseudarthrosis. We favor the addition of anterior interbody fusion because of the relative difficulty of obtaining arthrodesis on the tension side of the lumbosacral kyphosis. The anterior interbody fusion generally heals readily on the compression side, but the lower pseudarthrosis rate must be weighed against the increased morbidity.

### DECOMPRESSION

The need for decompression is also controversial. Decompression is commonly used in conjunction with fusion for patients with radicular or neurologic symptoms (52). However, relief of radicular symptoms has been reported with isolated posterior fusion (39). We use the presence of a positive seated straight-leg-raising test as an indication for nerve root exploration.

## TREATMENT OF SPONDYLOPTOSIS

A patient with spondyloptosis presents a difficult, and fortunately rare, clinical challenge. In spondyloptosis, the entire body of L-5 is caudal to the sacrum. Although the slippage angle varies widely, the inferior endplate of L-4 is always closer than the inferior endplate of L-5 to the S-1 endplate. This observation provides the anatomic rationale for our technique, which is the resection of L-5 and reduction of L-4 onto the sacrum. The relative paucity of cases and the variable clinical presentation have led to a plethora of suggested techniques (4,6,13,27,36,37,39,41,48,52). Treatment options include observation, reduction and casting, fusion *in situ,* reduction of L-5 onto the sacrum, and resection of L-5 with reduction of L-4 onto the sacrum. All options, including nonoperative management, have been associated with similar complications, including motor and sensory deficits or a cauda equina syndrome (48). The two-stage technique described in the following section is designed to eliminate lumbosacral kyphosis, restore sagittal-plane balance, and realign the spinal and nerve root canals while avoiding distraction and potentially devastating iatrogenic cauda equina injury.

### AUTHORS' PREFERRED TECHNIQUE FOR SPONDYLOPTOSIS

Our preferred technique for spondyloptosis involves resection, instrumentation, and reduction of L-4 onto S-1. As in other forms of spondylolisthesis, the severity of clinical symptoms in patients with spondyloptosis does not necessarily correlate with the degree of subluxation. Thus, L-5 vertebrectomy and reduction are advised only for severely disabled patients (Fig. 162.11).



***Figure 162.11.*** **A:** Preoperative lateral radiograph of a 42-year-old man with spondyloptosis and debilitating back and leg pain. **B:** Preoperative myelogram shows total blockage. **C:** Lateral radiograph after first-stage L-5 anterior vertebrectomy. **D:** Lateral radiograph after second-stage reduction of L-4 onto the sacrum and pedicle-screw fixation. Alignment and lordosis have been restored.

The procedure consists of two parts performed 1 week apart (21).

- Perform the first part through an anterior retroperitoneal approach (see Chapter 146).
- Resect the L4-5 disc, the body of L-5, and the L5–S1 disc.
- Take the resection back to the base of each pedicle, and take care to avoid injury to the L-5 root.
- Remove the inferior cartilage endplate of L-4. Retain the bony endplate.

Postoperatively, place the patient in an intensive care unit for 1 week to await the second stage. Nursing care includes use of a rotokinetic bed.

- Perform the second stage through a midline posterior approach.
- Place Harrington outriggers from L-2 onto the sacral ala to provide very gentle (1–2 cm) distraction. (This step may be omitted after the surgeon gains more experience.)
- Remove the loose posterior elements, transverse processes, and pedicles of L-5. Take special care to avoid injury to the L-5 root.
- Remove the cartilage endplate of S-1 before reduction. Preserve the bony endplate.
- Place pedicle screws into L-4 and S-1. Cortical purchase is essential.
- Accomplish reduction of L-4 onto the sacrum by removing the outriggers or by gentle distraction and translation applied to the screws in L-4. Constantly assess the L-4 and L-5 nerve roots during reduction both visually and with a nerve hook.
- Decorticate the transverse processes of L-4 and the sacral ala.
- Place autograft retained from the vertebrectomy and from the posterior elements of L-5 in the lateral gutter.
- Apply rods or plates to the screws. Two nerve roots (L-4 and L-5) will pass through the reconstructed neural foramen at L4–S1. Check to ensure that there is no impingement on the nerve roots before and after application of the rods or plates.

Postoperatively, keep patients at bed rest in a thoracolumbar spinal orthosis for 6 weeks, at which time begin mobilizing patients.

With this technique, 18 of 27 patients have experienced weakness in dorsiflexion postoperatively. This has been transient for all but two. All patients with preoperative cauda equina syndrome recovered postoperatively; no patient has had iatrogenic cauda equina injury (because the spine is not lengthened). When reviewed by an independent observer, patients reported very high satisfaction, with significant improvements in pain, function, and appearance (32).

## PITFALLS AND COMPLICATIONS

The resection described is one of the most difficult operations in spinal reconstruction. It should be only performed by surgical teams that are accustomed by experience to performing spinal osteotomies on a routine basis and are very experienced in handling the dural tube and nerve roots.

The anterior exposure requires extensive mobilization of the aorta, vena cava, and both internal and external iliac arteries and veins. Two to four assistants are regularly required to retract major vessels, roots, or vertebrae during various portions of the procedure.

Incomplete removal of the L4-5 or L5-S discs or the L-5 vertebra creates the potential for iatrogenic single- or multiple-root injury or incomplete reduction. Slow rehabilitation of patients is essential. One month of bed rest is routine before ambulation in a brace. No work or physical rehabilitation is started until convincing evidence of union is obvious.

## CHAPTER REFERENCES

Each reference is categorized according to the following scheme: *, classic article; #, review article; !, basic research article; and +, clinical results/outcome study.


# 1. Blackburne JS, Velikas EP. Spondylolisthesis in Children and Adolescents. *J Bone Joint Surg Br* 1977;59:490.

+ 2. Boden SD, Riew KD, Yamaguchi K, et al. Orientation of the Lumbar Facet Joints: Association with Degenerative Disc Disease. *J Bone Joint Surg Am* 1996;78:403.

+ 3. Bonnici AV, Koka SR, Richards DJ. Results of Buck Screw Fixation in Grade I Spondylolisthesis. *J R Soc Med* 1991;84:270.

+ 4. Boos N, Marchesi D, Zuber K, Aebi M. Treatment of Severe Spondylolisthesis by Reduction and Pedicular Fixation: A 4–6 Year Follow-up Study. *Spine* 1993;18:1655.

* 5. Boxall D, Bradford DS, Winter RB, Moe JH. Management of Severe Spondylolisthesis in Children and Adolescents. *J Bone Joint Surg Am* 1979;61:479.

+ 6. Bradford DS, Boachie-Adjei O. Treatment of Severe Spondylolisthesis by Anterior and Posterior Reduction and Stabilization: A Long-term Follow-up Study. *J Bone Joint Surg Am* 1990;72:1060.

* 7. Buck JE. Direct Repair of the Defect on Spondylolisthesis. *J Bone Joint Surg Br* 1970;52:432.

+ 8. Burkus JK, Lonstein JE, Winter RB, Denis F. Long-term Evaluation of Adolescents Treated Operatively for Spondylolisthesis: A Comparison of *in Situ* Arthrodesis Only with *in Situ* Arthrodesis and Reduction Followed by Immobilization in a Cast. *J Bone Joint Surg Am* 1992;74:693.

+ 9. Butterman GR, Garvey TA, Hunt AF, et al. Lumbar Fusion Results Related to Diagnosis *Spine* 1998;23:116.

+ 10. Carragee EJ. Single Level Posterolateral Arthrodesis, with or without Posterior Decompression, for the Treatment of Isthmic Spondylolisthesis in Adults: A Prospective, Randomized Study. *J Bone Joint Surg Am* 1997;79:1175.

+ 11. Danielson BI, Frennered AK, Irstam LK. Radiologic Progression of Isthmic Lumbar Spondylisthesis in Young Patients. *Spine* 1991;16:422.

+ 12. de Loubresse CG, Bon T, Deburge A, et al. Posterolateral Fusion for Radicular Pain in Isthmic Spondylolisthesis. *Clin Orthop* 1996;323:194.

# 13. Dubousset J. Treatment of Spondylolysis and Spondylolisthesis in Children and Adolescents. *Clin Orthop* 1997;337:77.

+ 14. Esses SI, Natout N, Kip P. Posterior Interbody Arthrodesis with a Fibular Strut Graft in Spondylolisthesis. *J Bone Joint Surg Am* 1995;77:172.

+ 15. Fabris DA, Constantini S, Nena U. Surgical Treatment of Severe L5-S1 Spondylolisthesis in Children and Adolescents: Results of Intraoperative Reduction, Posterior Interbody Fusion, and Segmental Pedicle Fixation. *Spine* 1996;21:728.

+ 16. Fischgrund JS, Mackay M, Herkowitz HN, et al. Degenerative Lumbar Spondylolisthesis with Spinal Stenosis: A Prospective, Randomized Study Comparing Decompressive Laminectomy and Arthordesis with and without Spinal Instrumentation. *Spine* 1997;22:2807.

* 17. Frederickson BE, Baker D, McHolick WJ, et al. The Natural History of Spondylolysis and Spondylolisthesis. *J Bone Joint Surg Am* 1984;66:699.

+ 18. Frennered AK, Danielson BI, Nachemson AL. Natural History of Symptomatic Isthmic Low-grade Spondylolisthesis in Children and Adolescents: A Seven-year Follow-up Study. *J Pediatr Orthop* 1991;11:209.

+ 19. Frennered AK, Danielson BI, Nachemson AL, Nordwall AB. Midterm Follow-up of Young Patients Fused *in Situ* for Spondylolisthesis. *Spine* 1991;16:409.

+ 20. Frennered K. Isthmic Spondylolisthesis among Patients Receiving Disability Pension under the Diagnosis of Chronic Low Back Pain Syndromes. *Spine* 1994;19:2766.

+ 21. Gaines RW, Nichols WK. Treatment of Spondyloptosis by Two Stage L5 Vertebrectomy and Reduction of L4 onto S1. *Spine* 1985;10:680.

! 22. Grobler LJ, Robertson PA, Novotney JE, Pope MH. Etiology of Spondylolisthesis: Assessment of the Role Played by Lumbar Facet Joint Morphology. *Spine* 1993;18:80.

+ 23. Herkowitz HN, Kurz LT. Degenerative Lumbar Spondylolisthesis with Spinal Stenosis: A Prospective Study Comparing Decompression with Decompression and Intertransverse Process Arthrodesis. *J Bone Joint Surg Am* 1991;73:802.

+ 24. Hilibrand AS, Urquhart AG, Graziano GP, Hensinger RN. Acute Spondylolytic Spondylolisthesis: Risk of Progression and Neurologic Complications. *J Bone Joint Surg Am* 1995;77:190.

+ 25. Hu SS, Bradford DS, Transfeldt EE, Cohen M. Reduction of High-grade Spondylolisthesis Using Edwards Instrumentation. *Spine* 1996;21:367.

+ 26. Imada K, Matsui H, Tsuji H. Oophorectomy Predisposes to Degenerative Spondylolisthesis. *J Bone Joint Surg Br* 1995;77:126.

+ 27. Ishikawa S, Kumar SJ, Torres BC. Surgical Treatment of Dysplastic Spondylolisthesis: Results after *in Situ* Fusion. *Spine* 1994;19:1691.

! 28. Jinkins JR, Rauch A. Magnetic Resonance Imaging of Entrapment of Lumbar Nerve Roots in Spondylolytic Spondylolisthesis. *J Bone Joint Surg Am* 1994;76:1643.

+ 29. Johnson JR, Kirwan EO. The Long-term Results of Fusion *in Situ* for Severe Spondylolisthesis. *J Bone Joint Surg Br* 1983;65:43.

+ 30. Kakiuchi M. Repair of the Defect in Spondylolysis: Durable Fixation with Pedicle Screws and Laminar Hooks. *J Bone Joint Surg Am* 1997;79:818.

+ 31. Leboeuf C, Kimber D, White K. Prevalence of Spondylolisthesis, Transitional Anomalies and Low Intercrestal Line in a Chiropractic Patient Population. *J Manipulative Physiol Ther* 1989;12:200.

+ 32. Lehmer SM, Steffee AD, Gaines RW Jr. Treatment of L5-S1 Spondyloptosis by Staged L5 Resection with Reduction and Fusion of L4 onto S1 (Gaines Procedure). *Spine* 1994;19:1916.

! 33. Lusins JO, Elting JJ, Cicoria AD, Goldsmith SJ. SPECT Evaluation of Lumbar Spondylolysis and Spondylolisthesis. *Spine* 1994;19:608.

* 34. Marchetti PG, Bartolozzi P. Classification of Spondylolisthesis as a Guideline for Treatment. In: Bridwell KH, DeWald RL, eds. *The Textbook of Spinal Surgery,* 2nd ed. Philadelphia: Lippincott–Raven Publishers, 1997:1211.

+ 35. Muschik M, Hahnel H, Robinson PN, et al. Competitive Sports and the Progression of Spondylolisthesis. *J Pediatr Orthop* 1996;16:364.

+ 36. Muschik M, Zippel H, Perka C. Surgical Management of Severe Spondylolisthesis in Children and Adolescents: Anterior Fusion *in Situ* versus Anterior Spondylodesis with Posterior Transpedicular Instrumentation and Reduction. *Spine* 1997;22:2036.

+ 37. O'Brien JP, Mehdian H, Jaffray D. Reduction of Severe Lumbosacral Spondylolisthesis: A Report of 22 Cases with a Ten-year Follow-up Period. *Clin Orthop* 1994;300:64.

+ 38. Ohmori K, Ishida Y, Takatsu T, et al. Vertebral Slip in Lumbar Spondylolysis and Spondylolisthesis: Long-term Follow-up of 22 Adult Patients. *J Bone Joint Surg Br* 1995;77:771.

+ 39. Peek RD, Wiltse LL, Reynolds JB, et al. *In Situ* Arthrodesis without Decompression for Grade III or IV Isthmic Spondylolisthesis in Adults Who Have Severe Sciatica. *J Bone Joint Surg Am* 1989;71:62.

! 40. Petraco DM, Spivak JM, Cappadona JG, et al. An Anatomic Evaluation of L-5 Nerve Stretch in Spondylolisthesis Reduction. *Spine* 1996;21:1133.

+ 41. Poussa M, Schlenzka D, Seitsalo S, et al. Surgical Treatment of Severe Isthmic Spondylolisthesis in Adolescents. *Spine* 1993;18:894.

+ 42. Ricciardi JE, Pflueger PC, Isaza JE, Whitecloud TS 3rd. Transpedicular Fixation for the Treatment of Isthmic Spondylolisthesis in Adults. *Spine* 1995;20:1917.

! 43. Robertson PA, Grobler LJ, Novotney JE, Katz JN. Postoperative Spondylolisthesis at L4-5: The Role of Facet Joint Morphology. *Spine* 1993;18:1483.

+ 44. Sanderson PL, Fraser RD. The Influence of Pregnancy on the Development of Degenerative Spondylolisthesis. *J Bone Joint Surg Br* 1996;78:951.

+ 45. Schlegel JD, Smith JA, Schleusener RL. Lumbar Motion Segment Pathology Adjacent to Thoracolumbar, Lumbar, and Lumbosacral Fusions. *Spine* 1996;21:970.

+ 46. Schnee CL, Freese A, Ansell LV. Outcome Analysis for Adults with Spondylolisthesis Treated with Posterolateral Fusion and Transpedicular Screw Fixation. *J Neurosurg* 1997;86:56.

! 47. Schneiderman GA, McLain RF, Hambly MF, Nielson SL. The Pars Defect as a Pain Source: A Histologic Study. *Spine* 1995;20:1761.

+ 48. Schoenecker PL, Dole HO, Herring HA, et al. Cauda Equina Syndrome after *in Situ* Arthrodesis for Severe Spondylolisthesis at the Lumbosacral Junction. *J Bone Joint Surg Am* 1990;72:369.

+ 49. Seitsalo S. Operative and Conservative Treatment of Moderate Spondylolisthesis in Young Patients. *J Bone Joint Surg Br* 1990;72:908.

+ 50. Seitsalo S, Osterman K, Hyvarinen H, et al. Progression of Spondylolisthesis in Children and Adolescents: A Long-term Follow-up of 272 Patients. *Spine* 1991;16:417.

+ 51. Shelokov A, Haideri N, Roach J. Residual Gait Abnormalities in Surgically Treated Spondylolisthesis. *Spine* 1993;18:2201.

+ 52. Smith MD, Bohlman HH. Spondylolisthesis Treated by a Single-stage Operation Combining Decompression with *in Situ* Posterolateral and Anterior Fusion: An Analysis of Eleven Patients Who Had Long-term Follow-up. *J Bone Joint Surg Am* 1990;72:415.

+ 53. Soini J, Laine T, Pohjolainen T, et al. Spondylodesis Augmented by Transpedicular Fixation in the Treatment of Olisthetic and Degenerative Conditions of the Lumbar Spine. *Clin Orthop* 1993;297:111.

+ 54. Thomsen K, Christensen FB, Eiskjaer SP, et al. The Effect of Pedicle Screw Instrumentation on Functional Outcome and Fusion Rates in Posterolateral Lumbar Fusion: A Prospective, Randomized Clinical Study. *Spine* 1997;22:2813.

+ 55. Vaccaro AR, Ring D, Scuderi G, et al. Predictors of Outcome in Patients with Chronic Back Pain and Low-grade Spondylolisthesis. *Spine* 1997;22:2030.

+ 56. Virta L, Ronnemaa T. The Association of Mild–Moderate Isthmic Spondylolisthesis and Low Back Pain in Middle-aged Patients is Weak and It Only Occurs in Women. *Spine* 1993;18:1496.

+ 57. Virta L, Ronnemaa T, Osterman K, et al. Prevalence of Isthmic Lumbar Spondylolisthesis in Middle-aged Subjects from Eastern and Western Finland. *J Clin Epidemiol* 1992;45:917.

* 58. Wiltse LL, Newman PH, MacNab I. Classification of Spondylolysis and Spondylolisthesis. *Clin Orthop* 1976;117:23.

+ 59. Wimmer C, Gluch H, Krismer M, et al. AP-translation in the Proximal Disc Adjacent to Lumbar Spine Fusion: A Retrospective Comparison of Mono- and Polysegmental Fusion in 120 Patients. *Acta Orthop Scand* 1997;68:269.

! 60. Wood KB, Popp CA, Transfeldt EE, Geissele AE. Radiographic Evaluation of Instability in Spondylolisthesis. *Spine* 1994;19:1697.

+ 61. Zdeblick TA. A Prospective, Randomized Study of Lumbar Fusion: Preliminary Results. *Spine* 1993;18:983.

# CHAPTER 163

# REVISION AND SALVAGE AFTER SURGERY FOR SPINAL DEFORMITY

*Robert F. McLain*

**R. F. McLain:** Department of Orthopaedics, The Cleveland Clinic Foundation, Cleveland, Ohio, 44195.

Causes of Failure
Pseudarthrosis
Fixation Failure
Inadequate Fusion Length
Crankshaft Phenomenon
Progression of the Secondary Curve
Indications for Surgery
Pain
Deformity
Imbalance
Dyspnea
Preoperative Planning
Treatment
Pseudarthrosis
Fixation Failure
Progressive Deformity
Operative Technique
Postoperative Care
Pitfalls and Complications
Chapter References

Surgical therapy for scoliosis has evolved considerably over the years, from *in situ* fusions and fusion with casting, to fusion using Harrington and Luque instrumentation, to the current generation of segmental systems that attempt to correct spinal deformity in three planes. Regardless of the treatment method, there have always been some patients who lose correction—either because of a pseudarthrosis or by progression of the curve—or who have poor results because of pain. Although acute failures can be treated by immediately reinstrumenting and augmenting the fusion, patients who have lost correction over time typically require a more aggressive approach to reconstruction. To successfully manage these patients, the surgeon must understand why the loss of correction occurred, develop a sound preoperative plan, and choose a surgical approach designed to provide a painless arthrodesis, good correction of deformity, and a well-balanced trunk.

## CAUSES OF FAILURE

The therapeutic failures of the past have led to changes in the way fusions are performed, the way fusion levels are selected, and the types of instrumentation used to stabilize the spine (2,7,9,21). Despite technical advances, the following remain the most common causes of failure:

- Pseudarthrosis
- Fixation failure
- Inadequate fusion length
- Progression of deformity due to the “crankshaft” phenomenon
- Addition of new segments to the old curve
- Progression of an untreated, secondary curve

### PSEUDARTHROSIS

In 1964, Moe and Gustilo (21) reported the results of 196 patients treated by cast correction and posterior fusion. They noted that 46 patients (23%) required reoperation for pseudarthrosis repair or a combination of pseudarthrosis repair and osteotomy. McMaster and James (20) reviewed the experience of a number of authors and concluded that pseudarthrosis rates ranged from 3.3% to 68.3% (average, 22.5%) in patients treated without internal fixation. When internal fixation was used, this rate was significantly lower (2% to 17%; average, 6.4%). With current instrumentation techniques, a pseudarthrosis rate of between 2% and 5% is typical in adolescent idiopathic scoliosis (1,5,7,10). However, other deformity groups remain at much greater risk. Adults treated for idiopathic and paralytic scoliosis have a 10% to 15% incidence of pseudarthrosis (12,23,25,26,28). Patients with myelodysplasia and paralytic scoliosis have a 20% to 45% incidence of pseudarthrosis (18,22).

Three factors have contributed to improved fusion rates. First, the fusion technique itself has improved over the years. Decortication of transverse processes, removal of facet joints, and meticulous exposure of the lumbar transverse processes have all resulted in improvements in fusion rates. Second, the use of autograft bone to augment the fusion mass has greatly improved success rates. Finally, the use of spinal instrumentation and the subsequent improvement in instrumentation constructs have further reduced pseudarthrosis rates. Still, some failures are inevitable. The surgeon has no control over the patient's age at the time of surgery, the nature of the deformity (paralytic, congenital, or those associated with neurofibromatosis or Marfan's syndrome), or the location and severity of the curve at presentation. All of these factors have an impact on fusion rates. Regardless of technique or instrumentation, pseudarthroses will continue to occur in patients with severe and recalcitrant curves.

### FIXATION FAILURE

Despite a variety of hook types, construct patterns, and the addition of pedicle screws, instrumentation failures are inevitable. Excessive distraction and rotational forces applied to large, rigid curves can result in hardware displacement if the hook fractures through the lamina. Poor purchase of the hook over a deformed or rotated lamina may result in hook displacement at either end of the curve. Transverse process fractures may compromise the transversopedicular claw even in a well-designed scoliosis construct. Patients with poor bone quality or osteomalacia are also at increased risk for hardware displacement. Rod breakage, seen in 7% to 10% of Harrington constructs, is less common with current segmental systems but can still occur as either an acute or a late complication (7). Whether fixation is lost because of failure through the bone or failure of the hardware itself, the patient is exposed to a great risk of pseudarthrosis, pain, and loss of any correction gained at the initial surgery.

### INADEQUATE FUSION LENGTH

In 1973, Kostuik et al. (12) reported that, among adult patients requiring revision surgery, the initial spinal fusion had been too short in a significant number. Cummine et al. (4) found that 40 of 59 patients requiring reconstruction for failed scoliosis fusion had curve progression due to incorrect selection of fusion levels at the initial operation. Inadequate fusion length may result in the following situations:

- The initial surgery stopped short of the appropriate end vertebra, leaving part of the primary curve unfused.
- The surgeon inadvertently selected a fusion level that did not address all the involved segments, particularly when there were a number of parallel end-vertebrae in the primary curve.
- Sagittal malalignment was not corrected, leaving an unfused kyphosis that tended to increase over time (17).
- In children fused at a young age, progression can be seen even when the initial fusion correctly addressed the entire primary curve. Over time, additional vertebrae not part of the original scoliotic curve may become involved.

### CRANKSHAFT PHENOMENON

Bending of the fusion mass may occur in children fused at an early age. These patients, through growth and remodeling, experience an increase in curve magnitude without an increase in curve length. One of the earliest descriptions of what is now considered the “crankshaft” phenomenon was provided in Ponseti and Friedman's 1950 paper on progressive deformity after fusion (24). Letts and Bobechko (16) reviewed the outcome of children undergoing spine fusion before the age of 8 years and found that 26% had significant curve progression despite successful arthrodesis. They found that progression was an even bigger problem in children fused at less than 4 years of age. Curve progression was greatest during the rapid growth phase, and the patients who had the greatest problem with this type of curve progression were those with a congenital scoliosis requiring fusion at a very early age. The progressive bending of an apparently solid fusion mass has been explained as the continued growth of the anterior vertebral elements within a spinal segment that has been fused (tethered) posteriorly (6,14). As the anterior elements elongate, the vertebral bodies are forced farther out from the midline, increasing both the sagittal and scoliotic deformities. Anterior fusion at the time of the initial posterior surgery prevents this phenomenon.

### PROGRESSION OF THE SECONDARY CURVE

A small number of patients present with progressive imbalance and deformity despite appropriate initial treatment and a successful primary fusion. In these patients, the progression occurs in the secondary curve either above or below the primary curve, resulting in significant trunk imbalance and an increase in apparent deformity. Whether this happens because of relentless progression of the secondary curve or the patient's progressive inability to compensate for the fused primary curve, the problem generally begins with a mild to moderate compensatory curve that, with age, becomes more severe and structural.

Progressive lumbar curves are a particular problem in the adult population. Curve progression in the lumbar segments results in low back pain, degenerative disc disease, translational deformities, and, in some cases, nerve root compression in the concavity of the curve. Once these curves become structural, correction may not be possible without simultaneously addressing the previously fused primary curve.

## INDICATIONS FOR SURGERY

### PAIN

Pain is the most common symptom in patients requiring reconstructive surgery of the spine (2,17). Generalized pain may involve either the convexity or the concavity of the curve. In the thoracic region, pain over the convexity of the curve usually involves paraspinous muscles overlying the ribs and bony prominence. Patients may also complain of subscapular or interscapular pain in the region of the rhomboid and levator muscle attachments. Pain on the concavity may be localized to the paraspinous muscles or may be radicular in nature. In thoracolumbar and lumbar curves, pain in the concavity is frequently associated with degenerative disease and facet arthrosis. Translational shifts, commonly seen in degenerative curves of the lumbar spine, may cause severe and debilitating pain related to both segmental instability and muscle spasm, as well as nerve root impingement and stenosis.

Conservative therapy is as appropriate for these patients as for any patient with chronic low back pain. Patients complaining primarily of pain without evidence of curve progression warrant a full course of nonoperative treatment, including physical therapy, anti-inflammatory medications, pain behavior modification, and a trial of bracing, before entertaining surgical options. All reasonable conservative measures should be explored prior to scheduling surgery.

When pain is severe and well localized to a region of previous fusion, suspect a pseudarthrosis. Pain from pseudarthrosis usually increases with activity and improves with rest. The area may be tender; however, if spinal instrumentation is in place, palpation may not produce symptoms. The patient may complain of a popping or grating sensation with movement, fatigue at the end of the day, or a sense that the deformity is progressing. Fixation failure, broken hardware, and progressive deformity strongly suggest the presence of a pseudarthrosis. Standard tomography is the most reliable method of demonstrating the defect.

Patients with pain at the end of a spinal fusion usually suffer at the levels immediately caudal to the fusion mass. This may be related either to discogenic pain or to facet arthrosis. Cochran et al. (3) demonstrated a proportionally greater incidence of degenerative disc disease as fusions are carried more distally. Their study showed that patients with fusions to L-2 had a 20% incidence of symptomatic disc degeneration; those with fusions to L-3, a 40% incidence; those with fusions to L-4, a 60% incidence; and those with fusions to L-5, an 80% incidence. Changes in spinal mechanics result in degeneration of the intervertebral disc and facet joints at the junction of the fused and mobile segments. Disc prolapse, facet hypertrophy, and translational deformities may produce spinal or foraminal stenosis. Patients with these disorders typically have radicular symptoms as well as back pain. Discography, done correctly, is frequently helpful in confirming the diagnosis of a painful disc below a previous fusion (2,11).

### DEFORMITY

A perception of increased deformity is the second most common symptom among patients presenting for revision surgery. Patients frequently sense that the curve has changed in magnitude or contour, and they complain of changes in shoulder alignment, height, or comfort when sitting or standing. They may also complain of alteration in waistline contour or discomfort in the flank caused by impingement of their ribs on the iliac crest. Patients may develop progressive deformity in either the sagittal or coronal plane, or both.

### IMBALANCE

Although progressive trunk imbalance is related directly to progression of the deformity, it is a more particular concern in patients with a previous fusion; increasing curvature below a solid fusion, which allows no compensation, can generate a disproportionate imbalance relative to the change in curvature. With age, a previously compensatory curve may become structural, compromising the patient's ability to compensate for the original, static curve. As trunk imbalance increases, the patient's function is progressively impaired, and the pain may increase dramatically.

### DYSPNEA

While only 15% of patients with idiopathic curves complain of dyspnea, pulmonary dysfunction is much more common in neuromuscular and postpoliomyelitic patients (4,17). Winter et al. (31) and Weinstein et al. (29) noted that patients with idiopathic scoliosis develop pulmonary insufficiency only when their curves become severe. However, advanced age may significantly aggravate this problem in patients undergoing revision surgery. Scoliosis surgery is more often done to *prevent* pulmonary complications in high-risk patients than to treat existing or progressive dysfunction.

## PREOPERATIVE PLANNING

Obtain upright anteroposterior (AP) and lateral scoliosis radiographs to carefully document the magnitude of deformity and establish the correct end-vertebrae. The lateral view is particularly important because sagittal imbalance is common and debilitating in these patients. Loss of normal lordosis, or marked lateral decompensation, may cause the patient to stand with one or both knees flexed; it is important that upright radiographs be taken with the knees extended to adequately represent the deformity. Other studies include supine, oblique radiographs to evaluate the fusion mass, and tomograms to confirm the presence of pseudarthrosis. Assess spinal rigidity through side-bending views in scoliotic patients, and use hyperextension views, supine over a bolster, for kyphotic deformities. Side-bending films should visualize the full extent of both upper and lower curves, assessing the cervicothoracic junction in thoracic curves and the lumbosacral junction in thoracolumbar or lumbar curves. Use magnetic resonance imaging (MRI) or myelography to evaluate any neurologic abnormality in a patient with progressive scoliosis. Diastematomyelia, tethered cord, syrinx, and cord or root compression may be ruled out by using these studies.

Careful evaluation of pulmonary reserve is always important in adults, where pulmonary complications are common and potentially life-threatening. Pulmonary function testing is indicated in any patient complaining of dyspnea and in all those with neuromuscular or chronic pulmonary disease. Patients with a severe thoracic lordosis, with a reduced AP chest diameter, may also need pulmonary function testing even if asymptomatic. A medicine consultation is often appropriate for middle-aged patients preparing to undergo a major spine reconstruction, and it is particularly important in those with underlying cardiovascular, pulmonary, or renal disease.

Autologous blood donation is beneficial and should be initiated 3–4 weeks prior to the operation. Prescribe supplemental iron for any patient donating her own blood.

## TREATMENT

The key to treating most failures of scoliosis fusion is early identification of the problem. If a pseudarthrosis or failure of fixation is identified in the early postoperative phase, reinstrumentation can be carried out easily without osteotomies or major reconstruction. Likewise, if progression of an adjacent compensatory curve is identified early, it may be corrected by simply extending the fusion while the curve is still supple. If these problems are neglected for long, however, compensatory curves may become structural and pseudarthroses may lead to progressive deformity and decompensation. In these patients, reconstruction and hardware revision can be

challenging.

**PSEUDARTHROSIS**

Pseudarthrosis may be present with or without progressive deformity. In cases with no loss of correction, the surgeon may address the pseudarthrosis directly, retaining or replacing hardware as necessary.

- After exposing the fusion mass over its full length, strip the thickened periosteum laterally with Cobb elevators. Carefully expose the cortical bone of the fusion mass throughout its length and from transverse process to transverse process.
- At the pseudarthrosis, the periosteum will be bound down to the fibrous tissue insinuated into the bony defect. At this point, it becomes difficult to strip the periosteum away, and the persistent fibrous tissue left behind reveals the defect.
- The fusion defect is usually located at the level of unfused facets. Using curets and rongeurs, remove this fibrous tissue completely from the pseudarthrosis.
- Expose the facet joints, remove any residual fibrous tissue or articular cartilage, and pack the joints with cancellous autograft bone. If the transverse processes were not previously exposed, strip away the soft tissue and decorticate the bone prior to applying the bone graft.

If pseudarthrosis is associated with progressive deformity, correct the deformity at the time of the pseudarthrosis repair. Better curve correction at the time of revision surgery correlates with a significantly better fusion rate (15). Increased age, lower lumbar pseudarthrosis, and nonsegmental instrumentation are associated with a significantly higher rate of salvage failure.

- If segmental instrumentation is in place and in good alignment, do not remove it to treat the pseudarthrosis. Revise hardware that has failed or is loose, however.
- Remove and replace nonsegmental instrumentation with segmental fixation: Pseudarthrosis repair using Harrington rods is successful in fewer than 60% of patients, while repair using segmental instrumentation has provided 100% success in some series (15,30).
- Substitute a shorter compression construct at the site of the pseudarthrosis, if possible, to avoid reinstrumenting the entire spine.
- In a mature fusion, insert compression hooks through the dorsal cortex of the fusion mass without entering the neural canal.
- Place pedicle screws in the thoracolumbar region to restore fixation where hooks have failed. Position pedicle screws under fluoroscopic or stereotactic control.
- Once the pseudarthrosis has been debrided of all soft tissue, decorticate the facets and pack the defect with cancellous bone. Then reapply the instrumentation, decorticate the fusion mass extensively with a gouge, and reapply local and autograft bone to obtain fusion.

In patients with failed pseudarthrosis repairs, and in adult patients with risk factors for delayed healing or recurrent pseudarthrosis, perform anterior interbody fusion in conjunction with the posterior repair. Particularly in pseudarthroses of the lower lumbar spine or where fusion crosses the lumbosacral junction, anterior interbody fusion increases the chances of a successful arthrodesis. Likewise, in patients with pseudarthrosis and progressive deformity, anterior release and fusion may be necessary to obtain sagittal correction and maximize the chance of a solid fusion. The debilitating sagittal imbalance associated with the lumbar flatback syndrome is most successfully corrected through a combined approach, coupling anterior osteotomy and interbody fusion with posterior osteotomy or pseudarthrosis repair and instrumentation (13).

**FIXATION FAILURE**

Failure of fixation in the early postoperative period is usually heralded by the sudden onset of severe pain. Pain is usually well localized to the region of failure, and the displaced hook or rod is sometimes palpable through the skin. There is sometimes an associated episode of trauma, and symptoms may begin several days before the instrumentation actually displaces. If the patient's curve was particularly rigid, or if poor bone quality or severe rotation made fixation particularly difficult, have a higher index of suspicion for hardware displacement.

There are three options for treatment:

1. First, if correction has not been lost and the patient's pain is tolerable, postpone surgical revision and treat the patient in a rigid orthosis until fusion occurs. Solid fusion of the operated segments will eliminate the problem of the displaced hardware, and any prominent hardware can be removed at a later date if necessary.
2. A second option is to reoperate, and either reinsert the dislodged hook or remove it, shortening the construct. This may reduce the patient's pain and eliminate the prominent hardware, but it could lead to a loss of correction.
   - If the dislodged hook is surgically replaced, take care to see that other fixation hooks are not displaced during the revision.
   - Carefully inspect the lamina under which the hook was seated to ensure that it is not fractured and that the bone is sound enough to allow rigid fixation; reinstrumenting a damaged or disrupted lamina is unwise.
   - If you choose to remove the displaced hook and shorten the instrumentation construct, you may significantly compromise construct stiffness. Only when fusion is established and curve progression is unlikely does removal of an end-hook make good sense.
3. The third option is to revise the hardware with a modified construct. This is most often necessary in patients with end-hook displacement, particularly those with rigid curves. In these cases, revising the terminal segment fixation may salvage the overall construct.
   - Where a single hook has pulled out or dislodged, a claw configuration may provide rigid fixation and salvage the construct.
   - Salvage a transverse process fracture by applying a sublaminar hook in place of the transverse process hook.
   - Use one or two pedicle screws on the convex side to salvage hook failure in lower lumbar curves (Fig. 163.1).

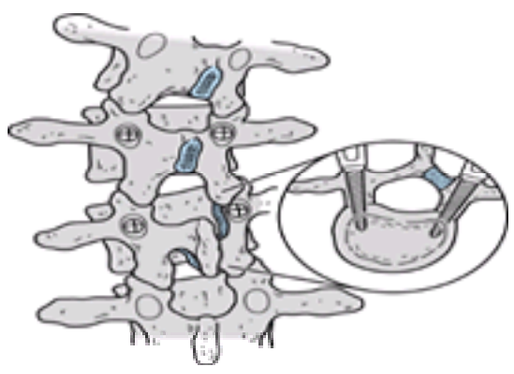

***Figure 163.1.*** Pedicle screws can be used to salvage sites where hooks have loosened or pulled through the lamina. Orientation of the pedicles is determined on preoperative computed tomography. Pedicle screw fixation allows the surgeon to reinstrument the spine without extending the fusion to adjacent segments.

When the vertebral lamina has been so disrupted by hook pullout that it is unsalvageable, you must make a critical judgment. If shortening the construct to the next intact lamina will compromise fixation of the appropriate segments of the curve, then the instrumentation must be extended over a longer segment. This may necessitate removal of the previous instrumentation.

- In some cases it may be possible to salvage and lengthen an instrumentation construct by using “domino” rod connectors, extending the construct to the next stable level. This provides a bulky construct, however, which is more acceptable in the lumbar region than in the upper thoracic segments. This technique is particularly useful if fusion must be extended to the sacrum. Short segmental rods may be fixed to the sacrum either directly, using pedicle screws, or using a Galveston technique to instrument the iliac wings. These rods are then joined to the original construct using the “domino” connectors.

If the fixation rod has broken, then the whole construct must be replaced. All hook and screw attachments should be checked in the process. Reactive bone often reinforces the hook or screw insertion site, and these implants may be left in place. If the hook or screw site has been eroded by excessive motion or has fractured, a new fixation point must be chosen, or a different implant used—exchanging a pedicle screw for a hook, for example.

**PROGRESSIVE DEFORMITY**

In patients who have progressive deformity because of multiple pseudarthroses, adding unfused segments or bending the fusion mass may require multiple osteotomies, reinstrumentation, and extensive fusion before the spine is adequately corrected, stable, and balanced over the sacrum.

- When a progressive curve develops below a previous thoracic fusion, correct the upper curve when you correct the lumbar curve to avoid causing significant coronal imbalance (19) (Fig. 163.2).

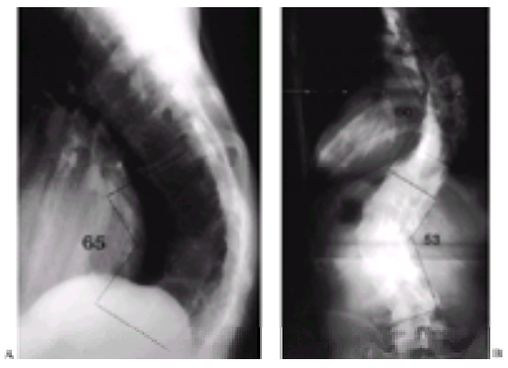

***Figure 163.2.*** AP (**A**) and lateral (**B**) views of a 36-year-old woman with Marfan syndrome who presented 20 years after an *in situ* thoracic fusion for scoliosis (T-6 to T-12). She had low-back pain, progressive shoulder asymmetry, and progressive thoracic and lumbar deformities. The lateral view shows a significant thoracolumbar kyphosis, centered at T-9, which resulted in sagittal imbalance. The thoracic fusion was substantial and solid. (From McLain RF. Revision and Salvage in Deformity Surgery. *Semin Spine Surg* 1993;5:214, with permission.)

- Use preoperative radiographic studies to determine the stiffness of the previously fused curve, as well as the potential to correct the progressive compensatory curve.
- If pseudarthrosis is contributing to curve progression, obtain tomograms to document the extent and location of the defect.
- Obtain a bone scan to confirm the level of pseudarthrosis in difficult cases. Oblique radiographs can often identify the suspicious level.

**OPERATIVE TECHNIQUE**

In cases where the deformity is severe and rigid, it is necessary to perform anterior release and interbody fusion prior to posterior reconstruction. Both procedures may be performed under one anesthetic, but the two procedures in combination are time-consuming and demanding on both surgeon and patient. If excessive blood loss occurs or the patient experiences problems, perform a two-staged procedure.

- *For the anterior procedure*, place the patient in a lateral decubitus position. Establish appropriate monitoring lines prior to positioning the patient: Arterial and central venous lines are usually indicated, and some patients may require Swan-Ganz catheterization to more carefully monitor pulmonary pressures and cardiac output.
- Position the patient with the convexity of the most rigid and severe curve upward.
- Use a transthoracic or thoracolumbar surgical approach, taking one rib, or in some cases two, to expose the anterior spinal column.
- Expose as many interspaces as can be reached and excise the discs.
- Isolate and ligate segmental vessels on one side only, and spare particularly prominent vessels.
- If the patient has a severe kyphosis, peripheral vascular disease, or any other risk factor for cord ischemia, place a “bull-dog” vascular clip across the segmental vessels to temporarily occlude segmental flow. Spinal cord monitoring may then determine whether the vessel is crucial to cord perfusion.
- Once the interspaces are exposed, remove the discs with a scalpel and rongeurs, and remove the endplates with a sharp osteotome directed away from the spinal canal. In very rigid deformities, it may be necessary to release the entire posterior longitudinal ligament and lateral annulus before correction can be obtained. This is not necessary in more supple curves.
- When the endplates have been removed, morcelize iliac crest or rib graft and gently pack it into the interspace. Do not entirely fill the interspace with bone, as this may interfere with correction during the posterior procedure.
- Correct kyphotic segments by distracting the disc space anteriorly with a large vertebral body spreader and inserting a tricortical graft or titanium cage to restore sagittal lordosis.
- At the end of the anterior procedure, pull the pleura, or the paraspinous muscles in the thoracolumbar region, gently over the spinal column to prevent graft extrusion.
- Place a chest tube and close the wound.
- *For the posterior part of the procedure*, turn the patient or dress the wound and return the patient to the intensive care unit in anticipation of a staged posterior fusion.
- Perform the posterior reconstruction through the old surgical wound. Expose the old fusion mass and the spinous processes and lamina of the secondary curve.
- Obtain a radiograph after the rigid and compensatory curves are fully exposed, to verify levels.
- Perform thoracic osteotomies at levels previously chosen in the preoperative plan (Fig. 163.3). Center the initial osteotomy over the apex of the curve, and subsequent osteotomies at every second level above and below the apex for the length of the previous fusion (8).

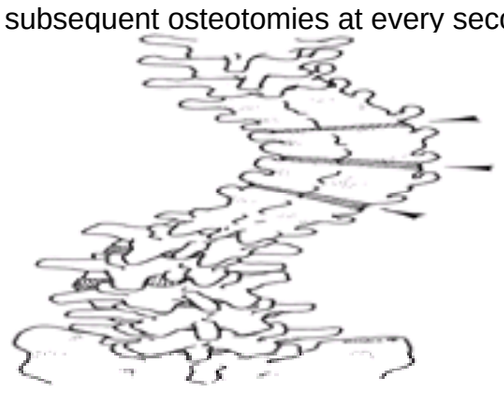

***Figure 163.3.*** The preoperative plan for the patient in Figure 163.2. To correct the progressive lumbar curvature without precipitating a marked thoracic imbalance, multiple osteotomies were planned as indicated. The initial osteotomy was centered over the curve apex; subsequent ones were located at every second level above and below the apex. (From McLain RF. Revision and Salvage in Deformity Surgery. *Semin Spine Surg* 1993;5:214, with permission.)

- Take care to complete the osteotomy across the full width of the fusion, and to take a wide enough wedge to allow correction of the scoliosis.
- Remove the outer cortex with either a burr or rongeurs, creating a defect that spans the fusion mass just below the transverse processes (Fig. 163.4*A*).

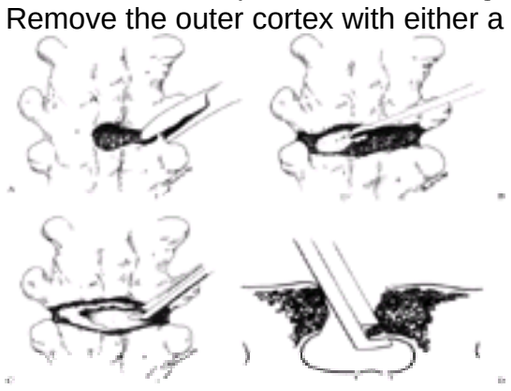

***Figure 163.4.*** Osteotomy technique. See text for details. (From McLain RF. Revision and Salvage in Deformity Surgery. *Semin Spine Surg* 1993;5:214, with permission.)

- Remove the cancellous bone down to the anterior, or volar, cortex of the fusion mass. To avoid plunging through the inner cortex, direct the forces away from the midline and in an axial direction (Fig. 163.4*B*).

- After exposing the anterior cortex, penetrate it on the convexity with a burr or curet, creating a window large enough to admit the Kerrison rongeur. Use the Kerrison punch to complete the osteotomy across the full width of the fusion mass (Fig. 163.4*C*).
- After completing the osteotomy, use the Kerrison punch to undercut the margins of the osteotomy defect. This will reduce the chances that the cut edge of the fusion mass might impinge on the thecal sac when the osteotomy is closed, a particular risk when a kyphotic deformity is being corrected. Cut the osteotomies so that they are wider posteriorly than anteriorly (again, particularly if a kyphotic deformity is being corrected) (Fig. 163.4*D*).
- Once the osteotomy is complete, the spinal segments above and below the cut should be independently mobile. Position hooks or pedicle screws proximally and distally for correction of both scoliotic curves.

Segmental instrumentation allows simultaneous correction of the scoliotic deformity with compression of the osteotomy sites.

- If the fusion mass is sufficient, place sublaminar wires or hooks through the dorsal cortex of the fusion without entering the canal.
- Carefully prepare and decorticate the area of the spine that was not previously fused, and pack the facet joints with cancellous bone graft prior to instrumentation.
- Once the segmental wires or hooks have been placed, apply the rods and correct the deformity either by tightening the segmental wires to bring the spine to the contoured rod or by gently rotating the rod, and sequentially distracting and compressing the hook combinations (Fig. 163.5).

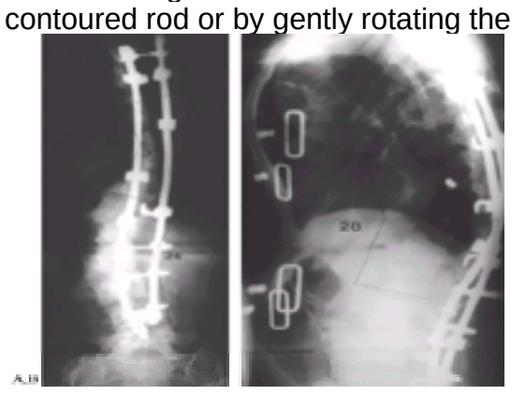

***Figure 163.5.*** Postoperative radiographs of patient in Figure 163.2. After multiple osteotomies from T-6 to T-10, segmental instrumentation was used to correct the double curve to less than 50% of the preoperative deformity. Both sagittal and coronal deformities were improved, and shoulder asymmetry was corrected. (From McLain RF. Revision and Salvage in Deformity Surgery. *Semin Spine Surg* 1993;5:214, with permission.)

- Pack local bone and iliac crest autograft around the osteotomy sites and over the previously unfused segment of spine.

At the end of the procedure, evaluate the patient for pneumothorax. If he has not undergone an anterior procedure and a chest tube was not previously placed, it is important to obtain a radiograph in the operating or recovery room to look for a pneumothorax and to place a chest tube if necessary.

**POSTOPERATIVE CARE**

In the first few postoperative days, the patient is carefully mobilized:

- Encourage the patient to sit up in bed or on a bedside chair on the first postoperative day.
- Independent ambulation is not possible until a molded thoracolumbosacral orthosis (TLSO) is available.
- The TLSO is usually molded by postoperative day 3 or 4, when the chest tube is removed.
- Begin transfers and ambulation when the brace arrives, and discharge the patient when he is independent.

The TLSO is worn full-time for 3–6 months, but it may not be needed at night after the third month. Wean the patient from the TLSO by 5–6 months, and begin physical rehabilitation for lifting and trunk strengthening at 6–8 months. Take oblique radiographs to evaluate the maturing fusion and thus ensure that the timing of brace removal and rehabilitation is appropriate.

## PITFALLS AND COMPLICATIONS

Complications are common in adults undergoing scoliosis surgery, and even more frequent when it is revision surgery. Complications in revision scoliosis surgery include the following:

- Pneumothorax, pneumonia, and/or respiratory insufficiency
- Infection
- Persistent or adjacent-level pseudarthrosis
- Instrumentation failure
- Neurologic injury
- Sagittal or coronal imbalance
- Thromboembolic disease and pulmonary embolism
- Death (a 1% to 2% mortality rate)

Swank et al. (26) demonstrated that the risks associated with scoliosis surgery appear to go up with each decade of life. The overall complication rate for primary surgery ranges from 53% to 62%, with a mortality rate of roughly 1.5% (23,25,26). The complication rates in patients undergoing revision surgery are even more daunting. Floman et al. (8) reported that 52% of revision patients had a serious complication; 10% developed pseudarthrosis, 14.5% had a significant neurologic complication, 11% had significant pulmonary complications, and 1.6% died (other complications made up the remaining 12.9%). Considering the young age of this group of patients (average, approximately 21 years), this is a high rate of complications. Kostuik (11) discussed outcomes in 31 patients undergoing revision surgery for scoliosis. The overall incidence of pseudarthrosis in this group was 23%, as opposed to a 6.5% incidence in adults undergoing primary fusion. He noted a 10% incidence of pulmonary complications, including nine pneumothoraces.

Cummine et al. (4) reviewed 59 patients undergoing reconstructive surgery for failed scoliosis fusion. The overall complication rate was 71%, with two postoperative deaths (3.4%) in the group. They noted a 17% incidence of pseudarthrosis, a 5% incidence of pulmonary complications, and an 8% incidence of deep wound infections. There was one fatal and one nonfatal pulmonary embolism in this study group.

**HINTS AND TRICKS**

- Monitor patients postoperatively to maintain an adequate blood pressure. Postoperative hypotension can lead to cord ischemia, particularly after extensive anterior dissection or multiple procedures that may have compromised collateral blood flow. Case reports have documented transient and permanent neurologic injuries associated with episodes of postoperative hypotension (27,30).

Current protocols for deep venous thrombosis prophylaxis and the routine use of prophylactic antibiotics have significantly reduced the incidence of pulmonary embolism and deep wound infections over those seen in previous studies. Likewise, the use of autograft bone and improved techniques in instrumentation and surgical fusion should reduce pseudarthrosis rates. Nonetheless, complications in revision scoliosis surgery are likely to remain high, particularly in older patients and those with neuromuscular or paralytic disorders.

Improvements in preoperative planning, patient management, surgical technique, and instrumentation technology will not eliminate the common complications associated with reconstructive surgery of the scoliotic spine. Early recognition of curve progression or pseudarthrosis remains the most reliable way to limit the complexity of these challenging reconstructions. In those patients who do develop rigid curvatures with marked loss of correction, careful preoperative planning is the key to a good surgical result.

**CHAPTER REFERENCES**

+ 1. Aurori BF, Weierman RJ, Lowell HA, et al. Pseudarthrosis after Spinal Fusion for Scoliosis. *Clin Orthop* 1985;199:153.

# 2. Bradford DS. Adult Scoliosis. *Clin Orthop* 1988;229:70.

+ 3. Cochran T, Irstram L, Nachemson A. Long-term Anatomic and Functional Changes in Patients with Adolescent Scoliosis Treated by Harrington Rod Fusions. *Spine* 1983;8:576.

+ 4. Cummine JL, Lonstein JE, Moe JH, et al. Reconstructive Surgery in the Adult for Failed Scoliosis Fusion. *J Bone Joint Surg Am* 1979;61:1151.

+ 5. Dodd CAF, Fergusson CM, Freedman L, et al. Allograft versus Autograft Bone in Scoliosis Fusion. *J Bone Joint Surg Br* 1988;70:431.

* 6. Dubousset J, Herring JA, Shufflebarger H. The Crankshaft Phenomenon. *J Pediatr Orthop* 1989;9:541.

* 7. Erwin WD, Dickson JH, Harrington PR. Clinical Review of Patients with Broken Harrington Rods. *J Bone Joint Surg Am* 1980;62:1302.

+ 8. Floman Y, Penny N, Micheli L, Riseborough EJ. Osteotomy of the Fusion Mass in Scoliosis. *J Bone Joint Surg Am* 1982;64:1307.

* 9. King HA, Joe JH, Bradford DS, Winter RB. The Selection of Fusion Levels in Thoracic Idiopathic Scoliosis. *J Bone Joint Surg Am* 1983;65:1302.

+ 10. Knapp DR, Jones ET. Use of Cortical Cancellous Allograft for Posterior Spinal Fusion. *Clin Orthop* 1988;229:99.

+ 11. Kostuik JP. Recent Advances in the Treatment of Painful Adult Scoliosis. *Clin Orthop* 1980;147:238.

+ 12. Kostuik JP, Israel J, Hall JE. Scoliosis Surgery in Adults. *Clin Orthop* 1973;93:225.

+ 13. Lagrone MO, Bradford DS, Moe JH, et al. Treatment of Symptomatic Flatback after Spinal Fusion. *J Bone Joint Surg* 1988;70:569.

+ 14. Lapinksy AS, Richards BS. Preventing the Crankshaft Phenomenon by Combining Anterior Fusion with Posterior Instrumentation. Does It Work? *Spine* 1995;20:1392.

+ 15. Lauerman WC, Bradford DS, Transfeldt EE, Ogilvie JW. Management of Pseudarthrosis after Arthrodesis of the Spine for Idiopathic Scoliosis. *J Bone Joint Surg* 1991;73:222.

+ 16. Letts RM, Bobechko WP. Fusion of the Scoliotic Spine in Young Children. *Clin Orthop* 1974;101:136.

# 17. Lonstein JE. Salvage and Reconstructive Surgery. In: Bradford DS, Moe JH, Lonstein JE, et al., eds.*Moe's Textbook of Scoliosis and Other Spinal Deformities.* Philadelphia: WB Saunders, 1987.

+ 18. Mayfield JK. Severe Spine Deformity in Myelodysplasia and Sacral Agenesis. *Spine* 1981;65:498.

+ 19. McLain RF. Revision and Salvage in Deformity Surgery. *Semin Spine Surg* 1993;5:214.

+ 20. McMaster MJ, James JIP. Pseudarthrosis after Fusion for Scoliosis. *J Bone Joint Surg Br* 1976;58:305.

* 21. Moe JH, Gustilo RB. Treatment of Scoliosis. Results in 196 Patients Treated by Cast Correction and Fusion. *J Bone Joint Surg Am* 1964;46:293.

+ 22. Osebold WR, Mayfield JK, Winter RB, et al. Surgical Treatment of Paralytic Scoliosis Associated with Myelomeningocele. *J Bone Joint Surg Am* 1982;64:841.

+ 23. Ponder C, Dickson J, Harrington P, et al. Results of Harrington Instrumentation and Fusion in the Adult Idiopathic Scoliosis Patient. *J Bone Joint Surg Am* 1975;57:797.

* 24. Ponseti IV, Friedman B. Changes in the Scoliotic Spine after Fusion. *J Bone Joint Surg Am* 1950;32:751.

* 25. Sponseller PD, Cohen MS, Nachemson AL, et al. Results of Surgical Treatment of Adults with Idiopathic Scoliosis. *J Bone Joint Surg Am* 1987;69:667.

* 26. Swank S, Lonstein JE, Moe JH, et al. Surgical Treatment of Adult Scoliosis. *J Bone Joint Surg Am* 1981;63:268.

+ 27. Taylor BA, Webb PJ, Hetreed M, et al. Delayed Postoperative Paraplegia with Hypotension in Adult Revision Scoliosis Surgery. *Spine* 1994;19:470.

+ 28. Van Dam BE, Bradford DS, Lonstein JE, et al. Adult Idiopathic Scoliosis Treated by Posterior Spinal Fusion and Harrington Instrumentation. *Spine* 1987;12:32.

* 29. Weinstein SL, Zavala DC, Ponseti IV. Idiopathic Scoliosis: Long-term Follow-up in Untreated Patients. *J Bone Joint Surg Am* 1981;63:702.

+ 30. Winter RB, Denis F, Lonstein JE, Dezen E. Salvage and Reconstructive Surgery for Spinal Deformity using Cotrel-Dubousset Instrumentation. *Spine* 1991;16:S412.

+ 31. Winter RB, Lovell WW, Moe JH. Excessive Thoracic Lordosis and Loss of Pulmonary Function in Patients with Idiopathic Scoliosis. *J Bone Joint Surg Am* 1975;57:972.

# CHAPTER 164

# OPERATIVE TREATMENT OF CHILDREN'S FRACTURES AND INJURIES OF THE PHYSES

*George T. Rab and Brian E. Grottkau*

**G. T. Rab:** Department of Orthopaedics, University of California, Davis, Sacramento, California, 95817.
**B. E. Grottkau:** Department of Orthopedics, Tufts University School of Medicine Floating Hospital for Children, Boston, Massachusetts 02111.

General Approach to Surgery
Physeal Injuries
Upper Extremity
Proximal Humeral Epiphyseal Fractures
Supracondylar Fractures of the Humerus
Lateral Condylar Fractures of the Humerus
Radial Neck Fractures
Medial Epicondylar Fractures of the Humerus
Forearm Fractures
Lower Extremity
Pelvis
Proximal Femoral Fractures
Femoral-shaft Fractures
Physeal Injuries of the Distal Femur
Tibial Tubercle Avulsion
Open Fractures of the Tibial Shaft
Distal Tibial Epiphyseal Fractures
Management of Growth-plate Injuries and Physeal Bars
Chapter References

## GENERAL APPROACH TO SURGERY

Fracture treatment in children is often simpler than in adults because of the rapid healing and remodeling of bone that occurs in children. A perceptive surgeon realizes that children differ a great deal from adults and care of their fractures can be affected by a child's preinjury status, the specific fracture mechanics of childhood injuries, the response to injury, and the unique treatment problems and complications that occur in the pediatric age group.

Although fracture management in children is usually nonoperative, there are certain instances when surgical management is required, desirable, or optional. Open surgical treatment is indicated in certain physeal fractures where there is joint incongruence and closed reduction has not led to satisfactory position, and where exact reduction improves the chances of normal physeal growth. Open reduction should be performed when anatomic reduction is required for normal function, as in a displaced, both-bone forearm fracture in an older adolescent. Surgical treatment should be considered in children with multiple trauma if stabilization of major long-bone fractures will enhance nursing care and pulmonary management. It should also be considered in children with major long-bone fractures (especially femoral shaft) in the presence of a severe head injury.

An additional relative indication for open reduction and internal fixation is to alleviate the psychological stress of either children or parents associated with prolonged hospitalization. An example is a 13-year-old boy with a closed midshaft femoral fracture that would eventually heal with skeletal traction and spica-cast treatment—a treatment that might take 8 weeks or more. A closed intramedullary nail would allow rapid mobilization, discharge from the hospital in a few days, and return to home and school within 1 week.

## PHYSEAL INJURIES

The Salter–Harris classification of injuries to the growing physis is widely accepted in North America (Fig. 164.1):

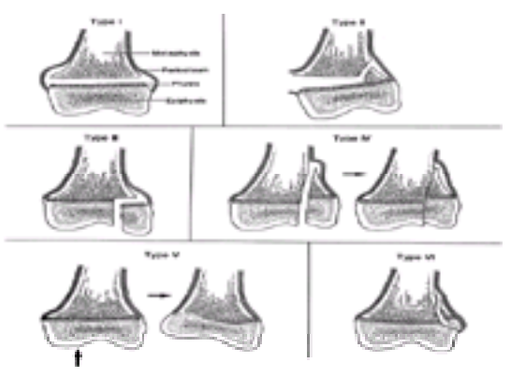

***Figure 164.1.*** Salter–Harris classification of physeal fractures. See text for description of types. (Redrawn from Salter RB, Harris WR. Injuries Involving the Epiphyseal Plate. *J Bone Joint Surg Am* 1963;45:587, with permission.)

| | |
|---|---|
| Type I | Separation of the epiphysis |
| Type II | Separation of the epiphysis with fracture through the metaphysis |
| Type III | Intra-articular fracture of part of the epiphysis that extends through the physis, causing it to separate from the metaphysis |
| Type IV | Intra-articular fracture of part of the epiphysis that extends through the physis and the metaphysis (malreduction of the physis results in bony union across the growth plate at the fracture site). |
| Type V | Crush injury to the physis resulting in premature closure of the growth plate |
| Type VI | Avulsion or crushing of the peripheral physis |

Specific injuries are covered elsewhere in this chapter, but some general principles will be reviewed here. Nondisplaced fractures through the growth plate tend to be stable and require immobilization without internal fixation. Minimally displaced growth-plate injuries do not require reduction, and the chance of growth arrest is not increased by leaving them displaced. Displaced fractures requiring reduction should be treated early (within 48 hours) because growth arrest is common after attempts at late reduction. Atraumatic fracture reduction and suitable fixation (casting or surgical) are mandatory.

The younger the patient, the more remodeling potential exists and greater degrees of displacement are acceptable. However, younger patients in whom physeal arrest develops have a greater potential for deformity. Likewise, a growth plate that requires higher energy to cause failure because of its geometry tends to have a higher rate of problems with growth arrest. For instance, the distal femoral and proximal tibial growth plates are only rarely injured but are responsible for the majority of longitudinal and angular growth abnormalities following growth-plate fracture. Salter–Harris types III and IV fractures require anatomic reduction of both the growth

plate and the articular surface; thus they frequently require open reduction with internal fixation.

An extensive discussion of operative fracture management of children's fractures is beyond the scope of this chapter. Following are descriptions of techniques that we have found useful for the surgical treatment of common pediatric injuries, as well as uncommon injuries requiring surgery. This chapter includes some generalizations and personal preferences in both indications and treatment options; readers should consult fracture textbooks and the scientific literature for more extensive descriptions.

## UPPER EXTREMITY

### PROXIMAL HUMERAL EPIPHYSEAL FRACTURES

Fractures of the proximal humerus (6,16,40,49) are most frequently seen in neonates and adolescents. Neonatal fractures are typically Salter–Harris type I injuries caused by an abduction–external rotation force imparted during the process of delivery. Orthopaedic consultation is obtained in these cases because a neonate will not actively move the involved extremity. Fracture of the clavicle, Erb's palsy, and infection are the main differential diagnoses. Radiographs may not be helpful, although ultrasonography yields a clear representation of this cartilaginous injury. Simple immobilization of the arm to the trunk with a loose elastic bandage for 1–2 weeks allows complete healing.

Adolescents are more prone to Salter–Harris type II and metaphyseal fractures of the humerus. Most of these can be managed by splinting because remodeling is rapid in this region and anatomic reduction is not required for excellent function. Fortunately, physeal growth arrest is rare and neurovascular injury uncommon. Closed reduction is generally necessary only in patients near skeletal maturity whose fracture has greater than 50° to 70° of angulation in either the sagittal or the coronal plane. After initial muscle spasms abate after treatment in a sling for 5–7 days, however, fracture alignment frequently improves enough to eliminate the need for closed reduction. If closed reduction does not yield an acceptable position, reduction under anesthesia with shoulder spica-cast immobilization usually suffices. On occasions when a spica cast may not be appropriate (e.g., when there is a chest injury), surgical fixation may be accomplished by introducing a large, smooth Steinmann pin into the reduced humeral head through a 1 cm incision over the deltoid tubercle. Bend the pin end to decrease the chance of proximal migration, and immobilize the arm with a sling and swath. Image intensification is necessary, and it is surprisingly difficult to place the pin in the head with enough purchase to fix the fracture. Remove the pin at 3–4 weeks.

### SUPRACONDYLAR FRACTURES OF THE HUMERUS

Supracondylar humeral fractures (2,24,41,54,64,68,73) have the highest rates of complications of any pediatric fracture. Volkmann's ischemic contracture due to compartment syndrome, neurologic or vascular compromise, and cubitus varus have historically complicated the treatment of these fractures. Supracondylar fracture of the humerus is often a surgical emergency, and prompt reduction and stabilization will reduce the incidence of complications. Although closed methods of immobilization may be used, percutaneous pin fixation has emerged in the last decade as the preferred method for unstable, displaced fractures. Pin fixation, properly done, is a low-risk procedure that provides excellent control of fracture fragments, nearly eliminating the risk of cubitus varus that accompanies cast immobilization. In addition, percutaneous pinning allows partial extension of the elbow without loss of reduction, which is much safer when there is swelling and vascular compromise.

Before attempting reduction, carefully evaluate the extremity for neurovascular compromise or compartment syndrome (usually in the flexor compartment of the forearm), and document the findings in the chart. An absent radial pulse is an indication for prompt reduction but is not in itself an indication for surgical exploration if the capillary refill is intact and the hand well perfused after reduction is accomplished. Neurologic deficits are common in supracondylar fractures but generally disappear spontaneously within 3 months after treatment. Exploration of the nerve is probably indicated only when closed reduction is impossible in the face of a preexisting nerve deficit (implying interposed nerve tissue in the fracture), or when nerve deficit occurs coincident with reduction.

Approximately 2% of supracondylar fractures are anteriorly displaced as a result of a flexion force applied to the elbow. The remaining supracondylar fractures are caused by hyperextension injuries of the elbow. They have been classified by Wilkins (74) as follows:

| | |
|---|---|
| Type I | Nondisplaced |
| Type II | Displaced with an intact posterior cortex |
| Type III | Completely displaced |

Posteromedial displacement is more common than posterolateral displacement. Regardless of the direction of displacement of the distal fragment in an extension-type supracondylar fracture, the posterior periosteum is generally intact and may be used to assist reduction. Most supracondylar fractures occur with the forearm in pronation; therefore, the distal fragment is internally rotated relative to the proximal fragment. Thus, most are more unstable after reduction with the arm internally rotated, a fact that has implications when radiographs are obtained (see later discussion).

#### *Closed Reduction and Percutaneous Pinning*

- Place the patient in the supine position, and administer a general anesthetic. Use an image intensifier in a vertical position next to the table. The receiver can be used as a minitable to set the arm on.
- Perform closed reduction by manually distracting the fracture with the elbow slightly hyperextended and the forearm in supination. Correct the medial or lateral displacement, and then align the varus–valgus position of the arm to match the opposite normal elbow. While still distracting, flex the supinated arm while pushing posteriorly on the distal portion of the humeral shaft (proximal fragment). Flex the elbow acutely, and temporarily hold it flexed by wrapping a gauze or tape between the wrist and shoulder (Fig. 164.2*A*); pronation of the forearm to “lock” the fracture is unnecessary if percutaneous fixation is to be used. The pulse may not be palpable at this time.

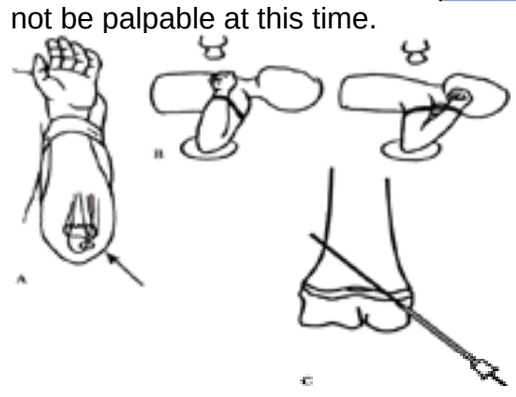

***Figure 164.2.*** Surgical technique for percutaneous pinning of supracondylar fracture of the humerus. **A:** The hand and wrist are secured to the upper arm. **B:** AP and lateral image intensifier views are obtained by rotating the arm. **C:** A 14-ga needle is useful as a pin guide. See text for explanation.

- Check an anteroposterior (AP) image, using the image intensifier. Obtain a lateral view by externally rotating the flexed arm on the image intensifier (Fig. 164.2*B*); internal rotation can destabilize the fracture at this point and cause loss of reduction. Exact anatomic reduction is unnecessary, but the carrying angle should be restored. Some translation or angulation on the lateral x-ray film is acceptable because it should correct with remodeling.
- Percutaneous pinning requires two pins, usually 0.045 Kirschner wires (K-wires), both of which may be inserted from lateral and parallel or from medial, lateral, and crossed. If crossed, they should not cross at the fracture site. Although crossed pins have been shown to be biomechanically advantageous, two parallel lateral pins are safer. An ulnar nerve palsy may result from injury to the nerve at the time of insertion of a medial pin or from chronic contact with the pin throughout the course of treatment. These neurotmeses usually resolve in 3–4 months. When a medial pin is used, massage the medial epicondyle for a few minutes to “milk out” edema to be sure that the ulnar nerve is avoided, or insert the pin through a 1 cm incision under direct visualization. If the medial epicondyle cannot be palpated, two lateral pins must be used. In either event, the pins must pass through the distal fragment and engage the opposite cortex of the proximal (shaft) fragment by passing just through the entire cortex. We always use two lateral pins, if possible.
- To make pinning easier, insert a 14-gauge needle into the periosteum of the distal fragment laterally at the desired angle of the pin (Fig. 164.2*C*). Obtain AP and lateral views (by external rotation), using the image intensifier. After adjustment of the direction of the needle, insert an 0.045 K-wire through the needle, and drill it through the opposite cortex of the proximal fragment. Place a second pin in a similar manner. Withdraw the needles, bend the pins outside the skin to avoid migration, and apply pin caps (Fig. 164.3).

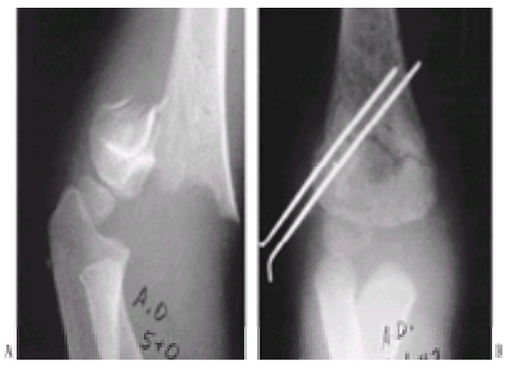

***Figure 164.3.*** Displaced supracondylar fracture of the humerus fixed by closed reduction and percutaneous pinning with two parallel lateral pins. Note the engagement of the cortex of the medial proximal fragment.

- Extend the arm fully, and check the carrying angle of the elbow; if it is not correct, repeat the preceding procedure after a second reduction. Anatomic reduction on x-ray images is not necessary, but cubitus varus will not remodel and must be avoided. Flex the elbow to 90° (or less if the pulse disappears with flexion), and immobilize with a posterior splint, sling, and swath.

Obtain radiographs 1 week postoperatively to check position. Remove the pins and splint at 4 weeks after the fracture, and begin motion as tolerated. Immobilization beyond 4 weeks is unnecessary, and physical therapy is not appropriate.

The most serious complication following supracondylar fracture is compartment syndrome (Volkman's ischemic contracture). It is more common when there has been vascular compromise or massive swelling has occurred, but it can appear in less dramatic clinical situations. The hallmark feature of compartment syndrome is pain with passive finger extension, but it is easy to misinterpret the examination in a frightened or sedated child. Measure compartment pressures if necessary; this is facilitated by the stability achieved with percutaneous pinning.

Loss of position rarely occurs if pinning is adequate and both fragments are engaged by the pins. If loss of position is detected at 1 week, it may be possible to salvage a satisfactory carrying angle by extending the arm fully, adjusting the carrying angle back into valgus, and applying a long-arm cast with the forearm in supination and the elbow extended. Do not remove the pins. Continue immobilization for a total of 4 weeks.

Complete loss of position requires re-reduction and pinning in the operating room. This is not advisable or possible after approximately 10 days, as healing is too far advanced.

### *Supracondylar Fractures with Vascular Injury*

Displaced (Salter–Harris type III) supracondylar humeral fractures may be associated with injury to the brachial artery. The brachial artery and the median nerve are juxtaposed to the fracture site and thus are subject to direct and stretch injury at the time of fracture and reduction. A well-documented neurovascular examination before closed reduction is mandatory to avoid unnecessary exploration afterward. Brachial artery compromise may be due to acute thrombi, intimal tears, laceration, transection, or entrapment within the fracture site. Absence of a radial pulse or the presence of a mottled arm and hand is an indication to proceed urgently to surgery for closed reduction. Do not delay treatment because circulation returns with fracture reduction. Because the site of vascular compromise is known, angiography is usually not necessary.

If an absent pulse does not return after reduction and extension, make a decision based on clinical examination of the hand. If the fingers are pink and well perfused, it is safe to observe, even if pulses are present. If the fingers are dusky, exploration of the artery is indicated.

If the pulse was present before reduction but absent afterward, obtain a vascular surgery consultation. The vascular surgeon may choose to obtain an angiogram with the image intensifier on the operating-room table or proceed directly to exploration. If revascularization is needed, closely monitor the patient for compartment syndrome, and give serious consideration to performing prophylactic forearm compartment releases.

### *Open Reduction*

If an adequate closed reduction cannot be attained, consider an open reduction. Remember that anterior-to-posterior translation and angulation are generally acceptable, and even the AP radiograph does not need to be anatomic as long as the carrying angle is satisfactory with the elbow extended. Open reduction usually proves to be more difficult than anticipated. Use a surgical approach on the side of the largest fracture gap. Periosteum and the brachial muscle, nerve, and artery can all block reduction and should be looked for and extricated. Open reduction has not been associated with increased stiffness in children with this complication.

## LATERAL CONDYLAR FRACTURES OF THE HUMERUS

Lateral condylar fractures (4,22,23,30,37,47,65,74) usually occur as the result of a fall on an outstretched hand and consequently are Salter–Harris type IV intra-articular fractures, with the initial failure beginning at the capitellar or trochlear surface. Errors in interpretation of the radiograph can lead to a missed diagnosis. Such fractures may be mistaken for type II fractures because of their metaphyseal component (Fig. 164.4*A*), but they are usually highly unstable injuries that require surgical treatment. Lateral condylar fractures that are truly nondisplaced may be treated nonoperatively, but they must be radiographed weekly because they have a propensity to displace late.

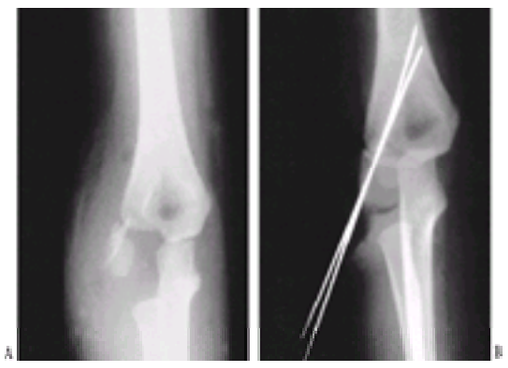

***Figure 164.4.*** Lateral condylar fracture of the humerus treated by open reduction and pinning. **A:** AP radiograph of acute fracture. **B:** Fracture is anatomical after fixation with two K-wires.

True type II fractures (transcondylar fractures) may be seen in children approximately 2 years of age. They are usually hyperextension injuries and are analogous to supracondylar fractures. They can be distinguished from lateral condylar fractures by their longer, more posterior metaphyseal fragment. Closed reduction (occasionally together with percutaneous pinning) is appropriate for these injuries.

The indication for surgical management of lateral condylar fractures is displacement, either acute or progressive, of the visible fragments by more than 2 mm. Some have advocated closed reduction and pinning for selected minimally displaced lateral condylar injuries (47) as determined by intraoperative arthrography. We generally perform open reduction because the joint surface is often remarkably displaced.

### *Open Reduction*

- Under tourniquet control, make a curved longitudinal incision over the lateral humeral condyle. There is usually a longitudinal rent in the brachioradialis muscle; develop this interval and carefully expose the lateral margin of the condyle. Take great care at this point to keep all subsequent dissection anterior to the condyle because the blood supply of the capitellum lies posteriorly and a major complication of this procedure is osteonecrosis of this fragment.
- Open the elbow joint, and retract the synovium anteriorly, using the long end of an army–navy retractor. The distal fragment is frequently rotated up to 90° and may be much larger than expected, including a sizable portion of the cartilaginous trochlea.
- Gently clean the fracture ends of hematoma and fibrous tissue, and reduce the fracture. Reduction may be unstable. Sometimes, stability is facilitated by inserting a K-wire in the fragment and using it as a "joystick" to control the fragment; however, be careful to plan its insertion point so that it may be used later to fix the fracture.
- Fix the fracture with two K-wires (Fig. 164.4*B*). If the metaphyseal fracture is large, they may pass through it, but often they must begin in the distal cartilaginous portion of the condylar fragment. Leave a space of at least 3 mm between the wires, and pass them just through the medial cortex of the proximal shaft to ensure stability. Bring the wires out through small stab wounds in the skin in the appropriate site. Bend the ends to prevent migration and place pin caps.
- Close the wound with fine, absorbable suture. Apply a splint at 90° of elbow flexion.

Remove the pins and splint at 4 weeks postoperatively, and begin motion as tolerated. Immobilization beyond 4 weeks is unnecessary.

The most common complications of lateral condylar fractures in children are missed diagnosis, nonunion, malunion, lateral growth arrest, and cubitus valgus. Tardy ulnar nerve palsy is possible late but fortunately is rare. Fractures treated by cast immobilization only that do not heal by 8 weeks after the injury should be treated with pin fixation and *in situ* bone grafting of the metaphyseal portion. If an arthrogram shows contrast agent between the capitellum and the trochlea, then do an open reduction with pin fixation. This can be done as late as 8 weeks after the injury. If contrast does not penetrate the fracture, then we pin the fracture percutaneously to add stability and facilitate healing. Leave wires in for 6 weeks, and then remove them.

Nonunions that are older than 12 weeks are difficult to treat. If the fracture is pain-free and there is no joint instability, treatment is not required. This avoids the possibility of stiffness secondary to bone grafting.

## RADIAL NECK FRACTURES

Radial neck fractures (27,38,50,57,67,72) generally occur as a consequence of a fall on an outstretched hand that cause buckling and impaction of the radial neck. They are uncommon injuries. Their treatment is highly controversial because they often have good potential for remodeling and the results of open reduction are often poor. Despite the relatively minor appearance of some of these fractures, they are significant injuries, and compartment syndrome may occur.

Unless there are other considerations, we do not reduce fractures with angulations of 45° or less, particularly in children younger than 10 years. With greater angulation, closed manipulative reduction or percutaneous reduction techniques are indicated (Fig. 164.5). Remember that open reduction can be complicated by elbow stiffness, heterotopic ossification, growth arrest, and synostosis. A percutaneous technique described by Metaizeau uses a curved K-wire inserted retrograde into the canal from the distal radius (27). We have no experience with this technique, but it has been reported to be simple and effective.

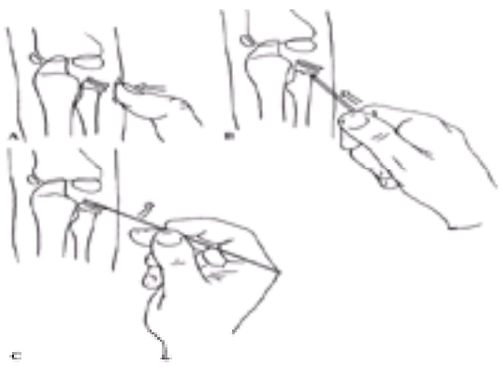

***Figure 164.5.*** Three options for management of a severely angulated radial neck fracture that may allow avoidance of open reduction. See text for description.

### *Closed or Percutaneous Reduction*

- Under general anesthesia, attempt a closed reduction first; an assistant is helpful. Supinate the forearm, apply traction and varus stress to the elbow, and place the thumb over the radial head. By pronation and supination of the forearm, the deformity may be palpable. When the radial head feels most prominent, reduce the fracture by forceful pressure with the thumb (Fig. 164.5*A*). An image intensifier may be helpful for localizing the deformity. If reduction to 45° or less is obtained, accept the reduction, and immobilize the elbow in a splint for 3 weeks.
- If reduction fails, rotate the forearm so that the tilt of the radial head is maximal, and pass a Steinmann pin percutaneously just below (distal to) the physis of the radial head, using the image intensifier. Use the Steinmann pin to push the head fragment back to an acceptable position (Fig. 164.5*B*). If this succeeds, immobilize the elbow for 3 weeks.
- If this fails in an older child with an ossified radial head, a third option is to carefully pass an 0.035 K-wire transversely into the ossified radial head (be sure not to damage the physis). Use this wire to manipulate the head fragment into an improved position (Fig. 164.5*C*).
- In both of these percutaneous techniques, if the fracture is unstable, it may be held for 2–3 weeks with a small K-wire inserted percutaneously obliquely, usually from proximal to distal, from the radial head to the shaft fragment. Be careful when using pins for manipulation or fixation near the radial head not to pass through the radius into the ulna; even one pass may cause synostosis.

## MEDIAL EPICONDYLAR FRACTURES OF THE HUMERUS

There has been much debate in the literature regarding the proper treatment of medial epicondylar fractures of the humerus (24,76), with particular concern about how much displacement of the fragment is acceptable. The true significance of this fracture, however, is that avulsion of the epicondyle is due to a subluxation or dislocation of the elbow joint. Consequently, the fracture should be thought of as similar to a medial collateral ligament injury, and the proper treatment is dictated by the instability of the elbow and not by some arbitrary degree of fracture displacement seen on radiographs.

The prognosis after medial epicondylar fractures is guarded. Periarticular injury may accompany an elbow dislocation, whether recognized or not, and can lead to permanent loss of elbow motion of a magnitude unexpected in a child. Warn parents about this early in the course of treatment. The medial epicondyle has a tendency to enlarge because of hyperemia after surgery; thus, the cosmetic result may be compromised after treatment.

Indications for operative reduction and fixation of medial epicondylar fractures include the following:

Incarceration of the medial epicondylar fragment in a dislocated, unreducible elbow

Gross valgus instability of the elbow

Displacement of 1.5–2 cm if accompanied by rotation of the fragment and marked weakness of the forearm flexors

Displacement of 1–2 cm in the dominant elbow of a child heavily involved in throwing sports

However, these indications, which we use, are arbitrary, and each child must be individually evaluated. The surgical technique is straightforward, but take care to avoid injury to the ulnar nerve during the dissection. Fixation may involve either K-wires or small-fragment screws because the amount of growth remaining in the usual patient is so small that cubitus varus will not develop.

### FOREARM FRACTURES

In children younger than 10–12 years, closed management of forearm fractures (3,17,51,56,62,77) is usually successful. Growing children exhibit excellent remodeling potential, and angular and rotational deformities up to 15° are well tolerated. In older children, treatment can be closed, as long as reduction achieves satisfactory alignment, because union is rapid and stiffness unlikely. Adolescents with both-bone forearm fractures, however, represent a transitional situation between that of young children (who tolerate imperfect reduction) and that of adults (who generally require open reduction). We treat both-bone forearm fractures in older adolescents with open distal radial or ulnar physes, regardless of age, by performing closed reduction first; if the reduction is anatomic or nearly so, we accept it and follow the child with weekly radiographs until union occurs. If the reduction is not acceptable, we proceed with open reduction, using either one-third tubular plates or 3.5 mm compression plates and the same technique employed in adults (see Chapter 16). In most cases, it is wise to use the larger, 3.5 mm plate because nonunion is not unusual in this age group. After open reduction, immobilize the forearm in a long-arm cast until union occurs.

Occasionally, in younger children, diaphyseal both-bone forearm fractures either cannot be reduced by closed means or, once reduced, are too unstable to maintain the reduction in a cast (usually when the fractures are at the same level in the bone). Unreducible fractures may require a small incision to remove soft tissues blocking the reduction. An intramedullary K-wire or flexible nail can then be introduced either proximally through the olecranon in the ulna or distally in the radial metaphysis. Flynn (22) showed that intramedullary fixation of a single bone in both-bone forearm fractures in conjunction with long-arm casting results in excellent fracture fixation. The pins are left outside the skin and the ends bent over. They can be removed in the office 4–6 weeks after insertion.

Noonan and Price (51) outlined the acceptable limits of reduction for pediatric forearm fractures. In children younger than 9 years, 15° of angulation, 45° of malrotation, and complete displacement can be accepted. In children age 9 years or older, bayonet apposition, 30° of angulation, and 10° of malrotation are acceptable. The closer the fracture is to the growth plate and the younger the child, the greater is the remodeling potential in all planes, except for rotational malalignment.

A special situation requiring open reduction arises in younger children (approximately 10 years) with distal both-bone fractures in which the ulnar fracture is a greenstick fracture and the radial fracture is displaced and translated dorsally with shortening of approximately 1 cm. The radial fragment is often buttonholed through a rent in the periosteum and cannot be reduced back to length. In such cases, make a small dorsal incision, and pry the fragment back with an elevator. Usually, no internal fixation is required after reduction is achieved.

## LOWER EXTREMITY

### PELVIS

Relevant literature on pediatric pelvic fractures spans four decades (9,26,28,33,46,55,59). Unlike adults, most children with massive pelvis injuries do not exhibit gross instability of the fragments. Pubic symphysis widening is well tolerated and tends to decrease after the child begins to walk. Proximal displacement of the iliac bone is rare, but patients with fracture patterns susceptible to displacement must be followed with serial radiographs. In rare instances, they require external or internal fixation, as in adults. For most children, bed rest followed by mobilization to a chair and progression to weight bearing as tolerated, along with pain control, is all that is required.

Acetabular fractures in children are likewise rare and can usually be treated nonoperatively. When fragment displacement is wide, assessment with computed tomography (CT) or, especially, magnetic resonance imaging (MRI) will determine whether there is involvement of the triradiate cartilage. The surgical principles for the management of acetabular fractures in adults are outlined in Chapter 18. They must be applied sparingly in children because triradiate cartilage closure can be a serious complication in younger children, and nonoperative treatment may be safer. Sometimes, cartilage joint surfaces may remain intact, even though the underlying bone is displaced, and these fractures need not be surgically treated (Fig. 164.6).

***Figure 164.6.*** An 11-year-old boy with a fracture of the pubic ramus apparently involving the acetabulum. In reality, the triradiate cartilage and acetabular articular cartilage were intact, and the acetabulum was normal 1 year later without reduction.

Avulsion fractures of an iliac or ischial apophysis, seen in adolescent athletes, are known as transitional fractures because they occur when the muscle forces approximate those in adults but the bone is still immature. Surgical reattachment of the avulsed fragment usually results in redisplacement; therefore, symptomatic treatment is best for these injuries.

### PROXIMAL FEMORAL FRACTURES

Femoral neck and intertrochanteric fractures in children (12,18,33,35,42,48,58) are dangerous injuries and do not behave similarly to their adult counterparts. Because they are so rare, few orthopaedic surgeons have extensive experience with them, and there is a natural tendency to treat them as one would in adults, which can lead to significant complications. Most proximal femoral fractures in children require operative management (Fig. 164.7). General principles and guidelines for surgical management include the following:

***Figure 164.7.*** Operative fixation used for pediatric femoral neck fracture. The patient was immobilized in a spica cast.

- Do not cross the proximal femoral physis with internal fixation devices. The exception to this occurs in older children with a very proximal femoral neck fracture (e.g., Salter–Harris type I fracture of the hip) in whom fixation into the head is necessary and leg-length discrepancy may be addressed later. Depending on the patient's age and the fracture configuration, devices may include pins, cancellous screws, cannulated screws, or specialized pediatric blade-plate or screw-plate devices.
- Use a spica cast as supplemental fixation for all proximal femoral fractures, whether or not they are surgically stabilized. For most children, we prefer a full double-spica cast because it provides more effective mobilization.

- Treat most nondisplaced fractures of the femoral neck in a spica cast. Internal fixation with a Steinmann pin or cancellous bone screw, combined with a cast, is used by some surgeons for additional protection against displacement.
- Gently reduce and internally fix displaced fractures of the femoral neck, and supplement this with a spica cast until union.
- Intertrochanteric fractures of the femur in children have a tendency to drift late into varus. If they are nondisplaced, treat in a double-spica cast. Follow with serial radiographs, and continue cast immobilization for 8–10 weeks. If they are displaced, treat with closed reduction and fixation, using a pediatric hip screw-plate device supplemented by spica-cast immobilization.
- Most subtrochanteric fractures of the femur are treated in 90°/90° traction with the use of a distal femoral traction pin. A below-knee cast with a suspension loop to support the leg makes this form of traction easy to adjust and comfortable for children. Once callus is present, bring the leg into extension, and apply a spica cast. An alternative to traction is operative reduction and fixation with a screw and plate device, but this must be supplemented with a spica cast during healing.

Avascular necrosis may follow hip fracture in children. The involvement may be epiphyseal (partial or complete), physeal (limiting growth potential or causing angulation of the femoral neck with growth), or metaphyseal. Long-term follow-up of pediatric hip fractures is therefore essential to allow prompt detection of complications and timely intervention if required.

## FEMORAL-SHAFT FRACTURES

Treatment of fractures of the femoral shaft (1,5,13,32,33,34,36,44,52,60,69,71,78,79) differs for young children and older children. Simple skin traction and early spica-cast application generally work well for younger children with fractures of the femoral shaft. Although such treatment leads to shortening, the predictable overgrowth of 1–2 cm that occurs in children 2–10 years of age allows excellent functional results. Angulation of up to 15° in the frontal plane and up to 30° in the sagittal plane will quickly remodel.

However, in children age 10 years or older, traction treatment is more difficult. Because overgrowth does not occur, prolonged traction (up to 4 weeks) may be required to ensure maintenance of length before cast application. The callus that forms in such patients may be flexible, and early angulation is common after casting; often, the angulated femur then heals rapidly with resulting malunion. The expense (both emotional and financial) of prolonged traction may be considerable, and school education can be severely disrupted. For these reasons, we often favor operative treatment of femoral-shaft fractures in children older than 10 years.

Surgical fixation may involve plate and screws (generally with a cast for additional protection) or external fixation; however, we usually favor intramedullary fixation. There are two general approaches to intramedullary fixation in children.

In highly unstable fractures, especially in older adolescents, standard intramedullary fixation with interlocking may be used. Use nails as small as 9 mm in diameter, and take great care to avoid penetrating the distal femoral physis with either the guidewire or the nail. Keep the proximal entry site as lateral as possible; using an entry guide pin is safer than using an awl to avoid inadvertently slipping posteriorly. Standard interlocking techniques, when required, can be safely applied to children (Fig. 164.8). It is wise to leave the proximal rod a little “proud” to facilitate later removal. Heterotopic bone often forms at the insertion site and may be symptomatic, but the pain resolves when the rod and heterotopic bone are removed 1 year postinjury. There have been reports of avascular necrosis of the proximal femoral epiphysis with intramedullary nailing, especially with larger nails or posterior and medial insertion sites. For this reason, we prefer flexible nails, such as the Ender nail (See Chapter 19 and Chapter 20). In stable fractures, flexible intramedullary nails can be inserted antegrade or retrograde without risk to the blood supply to the femoral head.

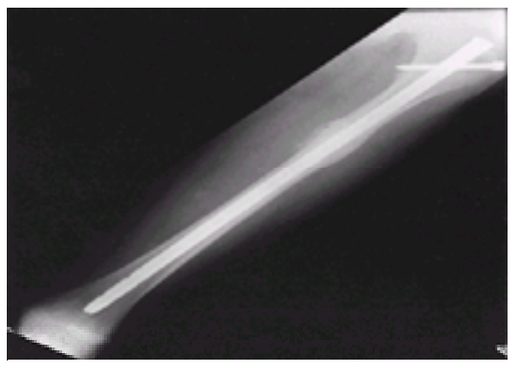

***Figure 164.8.*** Interlocked intramedullary nail used to fix femoral-shaft fractures in children with open physes.

The second option is external fixation of closed pediatric femoral fractures. Use a stable unilateral fixator along the lateral aspect. Once callus appears, apply compression across the fracture because early callus is soft and flexible and reducing distraction may help the callus mature. Do not remove the fixator too early, as malunion will occur. A main disadvantage of external fixation is the high rate of refracture; it is difficult to tell when the fracture is healed enough to discontinue the fixator. Dynamize the fixator, if possible, to minimize the risk.

Indications for operative treatment of pediatric femoral fractures include open femoral fractures and fractures in patients with multiple injuries or a serious head injury. Grade I open femoral fractures can be treated as outlined above after thorough irrigation and debridement. Fractures with more extensive wounds may require external fixation, although skeletal traction is often a viable option. If a head injury is likely to lead to spasticity and posturing, fixation of femoral fractures by one of the methods outlined previously is helpful. Even in younger head-injured children, intramedullary nailing with antegrade Ender nails, Rush rods inserted antegrade distal to the greater trochanter, flexible Nancy nails, or external fixation is usually necessary. It has been our experience that children with head injuries recover neurologic function more completely than adults; therefore, pay careful attention to the management of long-bone fractures to avoid malunion (see Chapter 14 and Chapter 20).

### *Flexible Intramedullary Nail Fixation of Femoral-shaft Fractures*

- Place the child supine on a fracture table. Skin or foot traction usually suffices for children younger than 11–12 years with recent fractures, but the fracture should be reducible under fluoroscopy before the skin incision is made. If necessary, use skeletal traction while avoiding injury to the physes (see Chapter 20).
- For antegrade nailing, size the Ender nail by holding it over the leg, with the eye at the greater trochanter. The nail should end short of the distal femoral physis. Make a longitudinal incision from the lateral prominence of the trochanter proximally for about 5–7 cm. Incise the fascia lata to expose the trochanter. The entry point is the flat lateral surface of the trochanter (Fig. 164.9*A*).

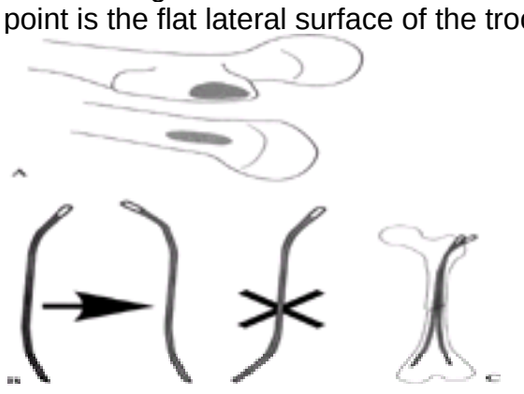

***Figure 164.9.*** Approach for flexible (Ender) nailing of the femur. **A:** The entry point is generally at the lateral trochanter (for antegrade nail) or medial distal metaphysis (for retrograde nail). **B:** If an S-shaped nail is needed, perform the bending at the eyelet end of the nail to maintain proper entry shape. **C:** Multiple pins are used to fill the canal; a transverse, minimally comminuted fracture pattern is best for flexible-nail techniques.

- Make an entry hole with a 6.5 mm drill, and introduce a curved Ender nail. Keep it aligned with the longitudinal axis of the femur. Gently tap it down the shaft, allowing the oblique blunt end to “bounce” off the medial cortex and pass down the canal. Verify its position on the image intensifier in two planes. At the fracture site, use the curve of the nail to hook the distal fragment, or make a small incision to openly reduce the fracture so that the nail can be passed. Once it is past the fracture, trap the nail distally so that it ends up in the lateral condyle, short of the physis. Leave the eye of the nail outside the cortex proximally for later removal.
- If the canal is large enough, insert a second nail. Many surgeons bend the nail into an S shape so that it will anchor in the medial condyle distally. Place the S

curve at the proximal end of the nail to maintain the proper orientation of the oblique blunt entry tip (Fig. 164.9*B*). For most pediatric patients, two nails across the fracture give sufficient longitudinal stability. Adding a third (or occasionally a fourth) nail is optional. These extra nails may be shorter, just long enough to pass the fracture site and fill the canal. This helps align transverse fractures (Fig. 164.9*C*).

- For retrograde nailing (usually for subtrochanteric or intertrochanteric fractures), place the patient on the fracture table with the legs abducted. Approach the distal medial femur from the medial side, using a longitudinal incision just proximal to the physis. Elevate the vastus medialis, and cauterize the leash of geniculate vessels that sits against the bone.
- Make a 6.5 mm drill hole proximal to this leash, and carefully insert the first Ender nail from below. There is slightly more risk of penetrating the weaker cortex as the rod passes up the canal, and adding a slight curve to the end of the nail helps pass into the canal, as well as into the femoral neck. Reduce the fracture as for antegrade nailing, and carefully rotate the nail as it is inserted up into the neck. Stop short of the proximal physis. Two-plane fluoroscopy is essential to accomplish this maneuver. Use two or more nails as described for antegrade nailing.

## PHYSEAL INJURIES OF THE DISTAL FEMUR

Most physeal injuries of the distal femur are Salter–Harris type I or II fractures. Unlike similar fractures in other anatomic locations, these have a likelihood of growth arrest as high as a 50%. This is both because high energy is required to fracture the distal femur and because the physeal mamilary processes are frequently sheared off during injury. Leg-length inequality can ensue from altered growth of this rapidly growing physis.

Distal femoral physeal fractures are occasionally accompanied by neurovascular injuries but not as frequently as are knee dislocations in adults. They are often unstable and may require internal fixation.

### *Closed Reduction and Fixation of Distal Femoral Physeal Fractures*

- Use general anesthesia and muscle relaxation for the reduction. Closed reduction may require surprising force. Occasionally, the bone end will buttonhole through the periosteum, making closed reduction impossible and necessitating open reduction. Once the fracture is reduced, test the stability of the reduction, as internal fixation is usually required. If there is a large metaphyseal component, it may be possible to stabilize the fracture by inserting a screw percutaneously across the metaphyseal fracture parallel to the physis. Otherwise, stabilize the fracture with two medium-sized, smooth Steinmann pins inserted from the medial and lateral femoral condyles at a 45° angle. Be sure that the pins pass into and just through the opposite cortex of the proximal fragment; otherwise, the fracture may remain unstable. Drive the pins slowly so as not to cause thermal damage.
- Bury the pin ends because they are intra-articular and the risk of infection is great if they are left protruding. After fixation, check the stability of the fixation. If it is stable, apply an above-knee cast; if there is any question, use a one-half hip spica cast with the knee in extension.
- Postoperatively, remove the pins under general anesthesia after 3–4 weeks. Immobilization for 4–6 weeks is sufficient for healing. Obtain follow-up radiographs every 3 months to look for evidence of growth arrest; if it occurs, it can be managed by methods outlined in Chapter 170 on leg-length discrepancy. In older children, however, an early epiphysiodesis of the contralateral distal femur may be a simple solution.

## TIBIAL TUBERCLE AVULSION

Avulsion of the tibial tubercle (15,29,33) is characteristically a jumper's injury and occurs most commonly in boys 14 years of age. It usually happens when the patient lands, and the quadriceps muscles contract to support the falling weight. The avulsion may involve only the tubercle or may extend through the condyles and the tibial articular surface of the knee. Use CT to delineate the exact fracture pattern.

Anatomically reduce and rigidly fix displaced fractures of the tibial tubercle. Because the fracture usually occurs in a physis that is in the process of closing, it is unnecessary to avoid crossing the growth plate because growth arrest that can cause hyperextension will not be significant. For this reason, use fixation that provides the optimal strength and stability.

## OPEN FRACTURES OF THE TIBIAL SHAFT

Treatment of open fractures of the tibial shaft is easier in children than in adults because children possess excellent healing potential (10,33,61,63,70). Initially, administer antibiotics, and irrigate and debride all open tibial-shaft fractures under a general anesthetic as described in Chapter 12. In younger children with Gustilo type I injuries and little periosteal injury, it is usually possible to treat the fracture with a long-leg cast. Some children may exhibit overgrowth, but this is unpredictable. In older children or children with severe soft-tissue wounds, external fixation is usually required to manage the soft-tissue injury.

Although plate fixation is possible, we prefer external fixation for the vast majority of open tibial-shaft fractures with a Gustilo type II or III wound. This allows excellent fracture control for repeated wound debridements as required. Usually, a single unilateral half-pin anterior frame is sufficient if supplemented by a posterior splint or cast. In most cases, we have achieved excellent immobilization and pain control, using a supplementary below-knee cast. This can be placed directly over the fixator if fluff gauze is packed in the recesses of the device, and the whole construct is then covered with cast padding. It can be removed and replaced by splitting the cast and opening it like a clamshell. Leave the fixator in place until callus is present, which usually requires 8 weeks or more, or until pin loosening occurs. Remove the fixator under a general anesthetic, and apply a long-leg cast with the knee straight until the fracture has united.

## DISTAL TIBIAL EPIPHYSEAL FRACTURES

The anatomy of physeal closure as maturity approaches and the susceptibility of the distal tibial physis to fracture produce a group of fractures that may require operative management (20,21,39,45,66). The physis begins to close centrally, and then over 18 months to 2 years closure progresses medially, posteriorly, and laterally, sweeping like the hand of a clock. The last portion of the physis to close is the anterolateral corner (Fig. 164.10).

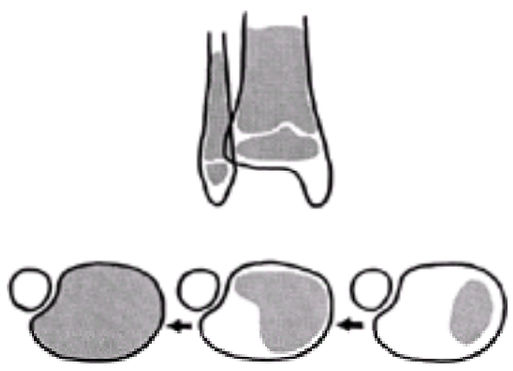

***Figure 164.10.*** The sweep of closure of the distal tibial physis is a process that takes 18 months to 2 years to complete. Fracture patterns often parallel this pattern.

Depending on the portions of physis that are closed, stresses may be directed to open physeal regions, leading to a specific group of fracture patterns (Fig. 164.11). Before physeal closure (age 11 years and younger), Salter–Harris type II fractures are common and can usually be managed by nonoperative means. When inversion is included in the mechanism, Salter–Harris type III or IV injuries can be seen, and joint incongruence and physeal alignment may necessitate open reduction if closed reduction is not anatomic. It has been our experience that Salter–Harris type III fractures are quite rare; if radiographs are taken in various degrees of rotation, a metaphyseal fragment is usually detectable (type IV). Plan surgical fixation to avoid the physis, if at all possible, because growth remains in the distal tibia and a varus deformity may be a complication of treatment.

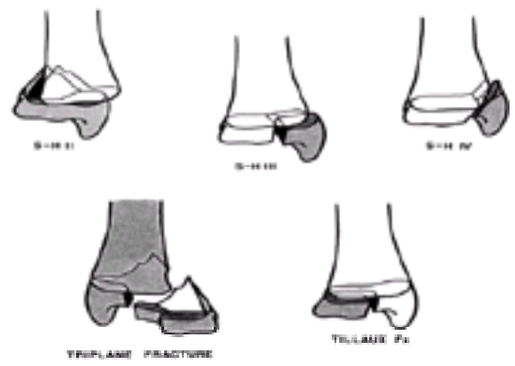

***Figure 164.11.*** Common fracture patterns seen in the region of the distal tibial physis (*S-H*, Salter–Harris; *Fx*, fracture).

When the central or centromedial physis closes (age 12–14 years), a triplane fracture, originally described by Marmor (45), becomes common. This complex fracture may consist of two, three, or occasionally more parts, and the fibula may be fractured (Fig. 164.11). Open reduction may be required for joint incongruence. Interpret standard radiographs cautiously because the fragments can be spread posteriorly while reduced anteriorly, giving a false sense of security on the AP view, or there may be out-of-plane fractures. A transverse plane CT cut is often most helpful for exact delineation of the fracture pattern and displacement. We generally recommend open reduction if displacement after closed reduction is greater than 2 mm or if there is an articular surface step-off visible on the AP view, which is rare. Because the physis is in the process of closing, angular deformity does not occur if fixation devices cross it; fixation may therefore be planned for maximum fixation effectiveness.

When the medial and posterior portions of the physis close, which occurs age 15 years or older, the remaining anterolateral component may be avulsed by the ligaments of the anterior syndesmosis during forced external rotation. This is known as a juvenile Tillaux fracture, and surgical treatment is indicated if closed reduction does not close the gap to 2–3 mm or less. Like the triplane fracture, this fracture does not lead to late angular deformity because the physis is nearly closed.

***Open Reduction of Salter–Harris Type III or IV Fractures of the Distal Tibial Physis***

- Make a medial or anteromedial incision over the malleolus. Take care not to strip more periosteum than is required, and do not further injure the physis. Carefully reduce the fracture; a fluoroscopic image intensifier may be helpful. If a Salter–Harris type IV fracture has a small metaphyseal component, carefully remove it with a rongeur to allow better visualization and alignment of the physeal plate (Fig. 164.12).

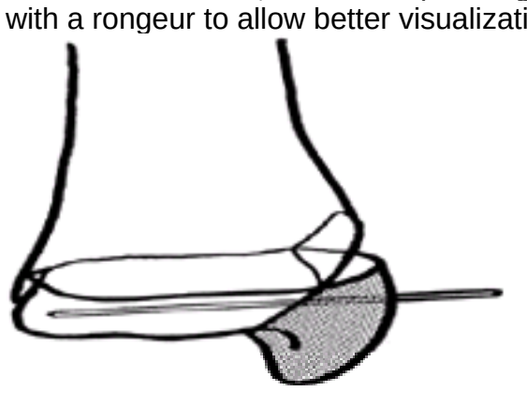

***Figure 164.12.*** A metaphyseal fragment may be removed for better physeal visualization when open reduction of a Salter–Harris type IV fracture of the distal tibial epiphysis is performed.

- Fix the fracture with a transverse screw directed entirely within the epiphysis (a small cannulated screw works well if available). Try not to cross the physis, even with a smooth K-wire, because of the risk of physeal closure.

Postoperatively, immobilize the limb in a below-knee cast for 6 weeks. Weight bearing may then be increased as tolerated.

***Open Reduction of Triplane Fractures***

- Two incisions may be required. Reduce the medial epiphyseal fragment first through a medial or anteromedial incision, and fix it by stabilizing the posterior metaphyseal fragment with small-fragment screws or K-wires. Reduce the lateral (Salter–Harris type III) component through a lateral incision, and fix it with a cancellous small-fragment screw. It is unnecessary to avoid the physis because so little growth remains in the distal tibia.
- A Tillaux fracture is treated surgically in the same fashion as the Salter–Harris type III component of a triplane fracture.

Postoperatively, immobilize the limb in a below-knee cast for 6 weeks. Weight bearing may then be increased as tolerated.

**MANAGEMENT OF GROWTH-PLATE INJURIES AND PHYSEAL BARS**

The majority of growth-plate injuries heal uneventfully and proceed with no alteration in growth of the extremity. Occasionally, complete growth arrest will result in limb-length inequality, or partial growth arrest through formation of a bony bar will result in longitudinal and angular bone deformity. These complications are less significant the closer a patient is to skeletal maturity. In the lower extremity, if the limb-length difference is projected to be greater than 2–3 cm at skeletal maturity, consider treatment.

Base the treatment of significant posttraumatic growth arrest on a patient's (and parent's) height, projected degree of longitudinal or angular deformity, extent of physeal injury (size of the bony bar), and the patient's tolerance for the proposed treatment. Partial arrests of more than 30% to 50% of the cross-sectional area of the growth plate are not amenable to treatment designed to restore growth; they can be treated by early contralateral epiphysiodesis (see Chapter 170) or bone lengthening (Chapter 171). Children who are projected to be tall may be more easily treated by epiphysiodesis of the noninjured side than very short children. Partial arrest of less than 30% of the area of the growth plate in a patient with at least 2 years of growth remaining may be considered for excision of the bony bar if it is surgically accessible. The most common sites requiring surgery are the distal femur, proximal tibia, or distal radius, where significant loss of length will have functional consequences.

When there is angular deformity, it is preferable in some instances to treat by acute opening-wedge osteotomy. This gains length and avoids complex, prolonged treatment. Such osteotomies, utilizing a tricortical wedge of iliac bone and appropriate internal fixation, heal rapidly in adolescents. If osteotomy is carried out before skeletal maturity, remember to complete the growth arrest by total epiphysiodesis to avoid recurrent deformity, with epiphysiodesis of the opposite extremity if indicated.

The feasibility of bar excision depends on its size and location within the physis. Plain x-ray films, scanogram, and bone-age determinations are important initially in determining which patients should be considered for bar excision (7,8,11,14,19,31,43,75). Standard tomography, trispiral tomography, CT, and MRI have each been advocated for physeal mapping. Plain tomography has long been utilized for characterizing physeal bars, but resolution is frequently inadequate. Images must be taken in two projections, and radiation exposure is quite high. Spiral and hypocycloidal tomography improve the resolution, but radiation exposure and scanning time remain high.

Axial CT of physeal bars requires precise placement of the extremity within the scanner and multiple thin cuts. The transverse section of these studies is inadequate, so sagittal and coronal reconstructions must be used and detail is poor. Direct and specific communication with the radiologist is frequently required to obtain clinically useful images. Helical CT has been reported to offer many advantages over other methods of growth-plate mapping. These include excellent bony detail, diminished radiation exposure, ability to manipulate the images into multiple perspectives, and significantly decreased scanning times that obviate sedation or anesthesia (Fig. 164.13). Advocates of MRI mapping cite the lack of ionizing-radiation exposure and excellent detail afforded. Scanning times are prolonged, and children frequently require sedation or general anesthesia. MRI data can be processed by either three-dimensional (3D) rendering or 3D projection to provide excellent detail to assist

preoperative planning.

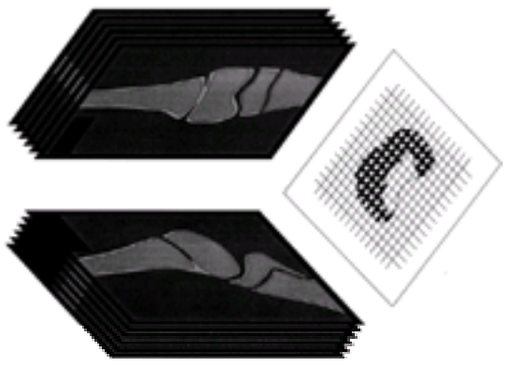

***Figure 164.13.*** Reconstruction of the position of a physeal bar by AP and lateral tomograms. Scaled graph paper is used to plot the presence of physeal bar on all radiographs in two planes; the resulting graph gives a good indication of the extent and location of the area of growth arrest.

When significant angular deformity accompanies partial physeal arrest, the surgeon must decide whether to correct the angulation and complete the epiphysiodesis, correct the angulation and resect the physeal bar, or resect the physeal bar alone and allow remodeling with growth. Even though there are no simple answers to this dilemma, the basic guidelines used for management of postfracture angular deformities may be applied. For example, a 25° flexion deformity of the distal femur in an 8-year-old child might be expected to remodel after resection of a peripheral posterior bar, but a similar degree of varus deformity with a medial bar would not remodel, necessitating concurrent osteotomy. Central bars that are readily approached from a metaphyseal osteotomy site may lead to a decision to perform full early correction of an angular deformity. In the upper extremity, completion of epiphysiodesis and closure of the physis of the other forearm bone (usually the ulna) may be technically easier and appropriate, given the functional unimportance of equal upper-limb length.

***Excision of a Physeal Bar***

Assess the extent of the bar and its anatomic location with tomography or CT or MRI reconstructions. If a bar is 30% or less of the total physeal area, resection has a fairly high likelihood of success; with bars greater than 50% of the physeal area, failure is almost certain.

Plan the best approach to the bar (Fig. 164.14). If the bar is peripheral, it can be directly approached from the surface. Approach central bars through a large metaphyseal window proximal to the physis. If osteotomy is required, it is usually easiest to perform a transverse osteotomy and position the limb to avoid neurovascular damage; the bar is then approached from above through the distal face of the osteotomy.

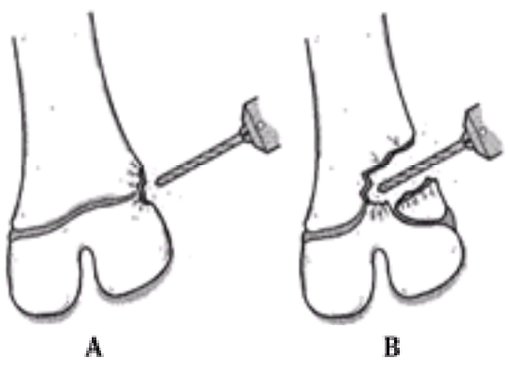


***Figure 164.14.*** Approach to a physeal bar depends on its location. **A:** Peripheral bars are approached directly. **B:** Central bars may be approached through a metaphyseal window or osteotomy. Use a burr for this procedure.

- Complete exsanguination and tourniquet control are essential for a dry field.
- When resecting a peripheral bar, directly expose the region of the bar, using an image intensifier as necessary to confirm the location. With a #15 blade, sharply incise the perichondrial ring and a small cuff of proximal periosteum at the resection site, and completely remove both structures to a point where the edge of the resection contains the visualized physis; this helps prevent peripheral recurrence.
- Use a small, high-speed burr to carefully remove the bar in layers; it will have a dense, slightly yellow appearance that will change into the normal cancellous-bone appearance as the edge of the bar is reached. Use irrigation to avoid overheating. Do not stray too far distally; if deeper visualization is required, burr more proximally. Eventually, the blue-gray cartilage of the physis will be visible, and with patience the physeal line will be exposed completely around the cavity of the resected bar (Fig. 164.15). Carefully sweep the burr up and down to smooth the edge of the physis and the contiguous bone.

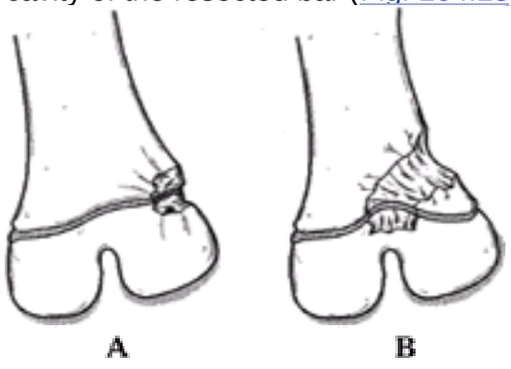


***Figure 164.15.*** A burr is used to remove the dense, yellowish bar material until the physis is visualized throughout the cavity.

- When resecting a central bar, remove a large cortical window in the metaphysis through a periosteal window, taking care not to damage the actual physis or perichondrial ring. Alternatively, perform a transverse osteotomy with a saw, and displace it by bending to allow visualization from above.
- Using the burr and generous irrigation, slowly advance until the dense, yellow bony bridge is identified, and carefully burr in layers to follow the yellowish structure down through the physeal plane. An image intensifier will help avoid burring too far. Use a dental mirror to view difficult corners, and enlarge the cortical window proximally as necessary for exposure. Eventually, identify the length of the blue-gray cartilage physis completely as it surrounds the cavity, and smooth it and the attached bone with an up-and-down motion of the burr.
- At this point, place radiographic markers such as vascular clips or small K-wire fragments in the epiphyseal and metaphyseal portions of the bone to allow later measurement of longitudinal growth (Fig. 164.16).

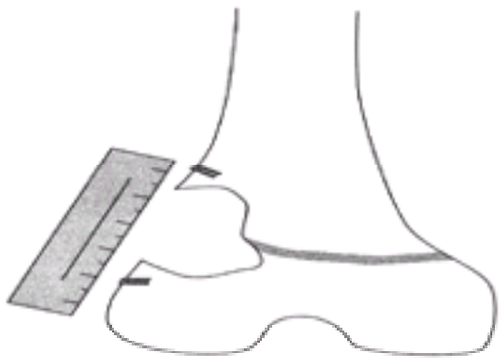

***Figure 164.16.*** Small radiolucent markers (wires, staples, or vascular clips) help in the assessment of longitudinal growth after surgery for partial physeal growth arrest.

- Before deflating the tourniquet, fill the cavity to prevent blood and eventual fibrous tissue from filling the space. We prefer Cranioplast, a slow-polymerizing polymethyl methacrylate (PMMA) that gives off very little heat as it cures. This material, familiar to orthopaedic surgeons, fully fills the cavity and leaves very little space for accumulation of organizing fibrous tissue. Alternatively, autogenous fat may be used, harvested locally or from the buttock. Fat tends to float out of the wound, and provides no structural compressive strength, so we no longer recommend it. Medical-grade Silastic has also been used; however, it is not available to surgeons for this use and offers no distinct advantages. The object of the filling is to completely obliterate the cavity without interlocking with cancellous bone above and below the physis.
- Allow the PMMA to become doughy before inserting it, and gently push (do not “pressurize”) it while it cures, irrigating with cool saline to minimize thermal damage. Once the PMMA is cured, replace the cortical window or fix the osteotomy if one has been made (see discussion above). Use iliac bone graft as needed for stability in opening-wedge osteotomies.
- Close the wound, and immobilize the limb, even if internal fixation has been used for an osteotomy.

Postoperatively, protect the patient until the bone is well healed, usually 6 weeks, and gradually begin increasing protected weight bearing. PMMA is load-sharing and allows safe weight bearing once muscle strength has recovered.

Physes that have been injured and partially closed will often exhibit premature closure after several years of normal growth after successful bar resection. Patients must be carefully monitored with periodic clinical, radiographic, and limb-length examinations until skeletal maturity. Be prepared to reassess late physeal closure and to carry out prompt treatment by epiphysiodesis, osteotomy, or other indicated procedure.

## CHAPTER REFERENCES

Each reference is categorized according to the following scheme: *, classic article; #, review article; !, basic research article; and +, clinical results/outcome study.


+ 1. Allen BJ Jr, Kant AP, Emery FE. Displaced Fractures of the Femoral Diaphysis in Children: Definitive Treatment in a Double Spica Cast. *J Trauma* 1977;17:8.

+ 2. Aronson DD, Prager BI. Supracondylar Fractures of the Humerus in Children: A Modified Technique for Closed Pinning. *Clin Orthop* 1987;219:174.

* 3. Bado J. The Monteggia Lesion. *Clin Orthop* 1967;50:71.

+ 4. Bast SC, Hoffer MM, Aval S. Nonoperative Treatment for Minimally and Nondisplaced Lateral Humeral Condyle Fractures in Children. *J Pediatr Orthop* 1998;18:448.

+ 5. Beaty JH, Austin SM, Warner WC, et al. Interlocking Intramedullary Nailing of Femoral-shaft Fractures in Adolescents: Preliminary Results and Complications. *J Pediatr Orthop* 1994;14:178.

+ 6. Beringer DC, Weiner DS, Noble JS, Bell RH. Severely Displaced Proximal Humeral Epiphyseal Fractures: A Follow-up Study. *J Pediatr Orthop* 1998;18:31.

+ 7. Birch JG. Surgical Technique of Physeal Bar Resection. *Instr Course Lect* 1992;41:445.

+ 8. Broughton NS, Dickens DR, Cole WG, Menelaus MB. Epiphyseolysis for Partial Growth Plate Arrest: Results after Four Years or at Maturity. *J Bone Joint Surg Br* 1989;71:13.

+ 9. Bryan WJ, Tullos HS. Pediatric Pelvic Fractures: Review of 52 Patients. *Trauma* 1979;19:799.

+ 10. Buckley SL, Smith G, Sponseller PD, et al. Open Fractures of the Tibia in Children. *J Bone Joint Surg* 1990;72-A:1462.

+ 11. Burke SW. Principles of physeal bridge resection. *Instr Course Lect* 1989;38:337.

+ 12. Canale ST, Bourland WL. Fracture of the Neck and Intertrochanteric Region of the Femur in Children. *J Bone Joint Surg Am* 1977;59:431.

+ 13. Carey TP, Galpin RD. Flexible Intramedullary Nail Fixation of Pediatric Femoral Fractures. *Clin Orthop* 1996;332:110.

+ 14. Carlson WO, Wenger DR. A Mapping Method to Prepare for Surgical Excision of a Partial Physeal Arrest. *J Pediatr Orthop* 1984;4:232.

+ 15. Christie MJ, Dvonch VM. Tibial Tuberosity Avulsion Fracture in Adolescents. *J Pediatr Orthop* 1981;1:391.

+ 16. Dameron TB Jr, Reibel DB. Fractures Involving the Proximal Humeral Epiphyseal Plate. *J Bone Joint Surg Am* 1969;51:289.

+ 17. Davis DR, Green DP. Forearm Fractures in Children: Pitfalls and Complications. *Clin Orthop* 1976;120:172.

+ 18. Davison BL, Weinstein SL. Hip Fractures in Children: A Long-term Follow-up Study. *J Pediatr Orthop* 1992;12:355.

+ 19. DeCampo JF, Boldt DW. Computed Tomography of Partial Growth Plate Arrest: Initial Experience. *Skeletal Radiol* 1986;15:526.

+ 20. Dias LS, Giegerich CR. Fractures of the Distal Tibial Epiphysis in Adolescence. *J Bone Joint Surg Am* 1983;65:438.

+ 21. Ertl JP, Barrack RL, Alexander AH, Van Buecken K. Triplane Fracture of the Distal Tibial Epiphysis: Long-term Follow-up. *J Bone Joint Surg Am* 1988;70:967.

+ 22. Flynn JC. Nonunion of Slightly Displaced Fractures of the Lateral Humeral Condyle in Children: An Update. *J Pediatr Orthop* 1989;9:691.

+ 23. Foster DE, Sullivan JA, Gross RH. Lateral Humeral Condylar Fractures in Children. *J Pediatr Orthop* 1985;5:16.

+ 24. Fowles JV, Kassab MT. Displaced Supracondylar Fractures of the Elbow in Children: A Report on the Fixation of Extension and Flexion Fractures by Two Lateral Percutaneous Pins. *J Bone Joint Surg Br* 1974;56:490.

+ 25. Fowles JV, Slimane N, Kassab MT. Elbow Dislocation with Avulsion of the Medial Humeral Epicondyle. *J Bone Joint Surg Br* 1990;72:102.

+ 26. Garvin KL, McCarthy RE, Barnes CL, Dodge BM. Pediatric Pelvic Ring Fractures. *J Pediatr Orthop* 1990;10:577.

+ 27. Gonzalez-Herranz P, Alvarez-Romera A, Burgos J, et al. Displaced Radial Neck Fractures in Children Treated by Closed Intramedullary Pinning (Metaizeau Technique). *J Pediatr Orthop* 1997;17:325.

+ 28. Hamsa WR. Epiphyseal Injuries about the Hip Joint. *Clin Orthop* 1957;10:119.

+ 29. Hand WL, Hand CR, Dunn AW. Avulsion Fractures of the Tibial Tubercle. *J Bone Joint Surg Am* 1971;53:1579.

+ 30. Hardacre JA, Nahigian SH, Froimson AI, Brown JE. Fractures of the Lateral Condyle of the Humerus in Children. *J Bone Joint Surg Am* 1971;53:1083.

+ 31. Havranek P, Lizler J. Magnetic Resonance Imaging in the Evaluation of Partial Growth Plate Arrest after Physeal Injuries in Children. *J Bone Joint Surg Am* 1991;73:1234.

+ 32. Heinrich SD, Drvaric D, Darr K, MacEwen GD. Stabilization of Pediatric Diaphyseal Femur Fractures with Flexible Intramedullary Nails (a Technique Paper). *J Orthop Trauma* 1992;6:452.

# 33. Hensinger RN, ed. *Operative Management of Lower Extremity Fractures in Children.* Park Ridge, IL: American Academy of Orthopaedic Surgeons, 1992:11.

+ 34. Herndon WA, Mahnken RF, Yngve DA, Sullivan JA. Management of Femoral Shaft Fractures in the Adolescent. *J Pediatr Orthop* 1989;9:29.

+ 35. Ingram AJ, Bachynski B. Fractures of the Hip in Children. *J Bone Joint Surg Am* 1953;35:867.

+ 36. Irani RN, Nicholson JT, Chung SM. Long-term Results in the Treatment of Femoral Shaft Fractures in Young Children by Immediate Spica Immobilization. *J Bone Joint Surg Am* 1976;58:945.

+ 37. Jakob R, Fowles JV, Rang M, Kassab MT. Observations Concerning Fractures of the Lateral Condyle in Children. *J Bone Joint Surg Br* 1975;57:430.

+ 38. Jones ERL, Esah M. Displaced Fractures of the Radial Neck in Children. *J Bone Joint Surg Br* 1971;53:429.

+ 39. Klieger B, Mankin HJ. Fracture of the Lateral Portion of the Distal Tibial Epiphysis. *J Bone Joint Surg Am* 1964;46:25.

+ 40. Kohler R, Trillaud JM. Fracture and Fracture Separation of the Proximal Humerus in Children: Report of 136 Cases. *J Pediatr Orthop* 1983;3:326.

+ 41. Labelle H, Bunnell WP, Duhaime M, Poitras B. Cubitus Varus Deformity Following Supracondylar Fracture of the Humerus in Children. *J Pediatr Orthop* 1982;2:539.

+ 42. Lam SF. Fractures of the Neck of the Femur in Children. *J Bone Joint Surg Am* 1971;53:1165.

+ 43. Loder RT, Swinford AE, Kuhns LR. The Use of Helical Computed Tomographic Scan to Assess Bony Physeal Bridges. *J Pediatr Orthop* 1997;17:356.

+ 44. Lombardo SJ, Harvey JP Jr. Fractures of the Distal Femoral Epiphysis: Factors Influencing Prognosis. *J Bone Joint Surg Am* 1977;59:742.

+ 45. Marmor L. An Unusual Fracture of the Tibial Epiphysis. *Clin Orthop* 1970;73:132.

+ 46. McDonald GA. Pelvic Disruptions in Children. *Clin Orthop* 1980;151:130.

+ 47. Mintzer CM, Waters PM, Brown DJ, Kasser JR. Percutaneous Pinning in the Treatment of Displaced Lateral Condyle Fractures. *J Pediatr Orthop* 1994;14:462.

# 48. Morrissey R. Hip Fractures in Children. *Clin Orthop* 1980;152:202.

+ 49. Neer CS II, Horwitz BS. Fractures of the Proximal Humeral Epiphyseal Plate. *Clin Orthop* 1965;41:24.

+ 50. Newman JH. Displaced Fractures of the Neck of the Radius in Children. *Injury* 1977;9:114.

# 51. Noonan KJ, Price CT. Forearm and Distal Radius Fractures in Children. *J Am Acad Orthop Surg* 1998;6:146.

+ 52. O'Malley DE, Mazur JM, Cummings RJ. Femoral Head Avascular Necrosis Associated with Intramedullary Nailing in an Adolescent. *J Pediatr Orthop* 1995;15:21.

+ 53. Peters CL, Scott SM. Compartment Syndrome in the Forearm Following Fractures of the Radial Head or Neck in Children. *J Bone Joint Surg Am* 1995;77:1070.

+ 54. Pirone AM, Graham HK, Krajbich JI. Management of Displaced Extension-type Supracondylar Fractures of the Humerus in Children. *J Bone Joint Surg Am* 1988;70:641.

* 55. Ponseti IV. Growth and Development of the Acetabulum in the Normal Child: Anatomical, Histological, and Roentgenographic Studies. *J Bone Joint Surg Am* 1978;60:575.

+ 56. Price CT, Scott DS, Kurzner ME, Flynn JC. Malunited Forearm Fractures in Children. *J Pediatr Orthop* 1990;10:705.

+ 57. Radomisli TE, Rosen AL. Controversies regarding Radial Neck Fractures in Children. *Clin Orthop* 1998;353:30.

# 58. Ratliff AHC. Fractures of the Neck of the Femur in Children. In: Salvati EA, ed. *The Hip: Proceedings of the Ninth Open Scientific Meeting of the Hip Society, 1981.* St. Louis, MO: Mosby, 1981:188.

+ 59. Reichard SA, Helikson MA, Shorter N, et al. Pelvic Fractures in Children: Review of 120 Patients with a New Look at General Management. *J Pediatr Surg* 1980;15:727.

+ 60. Riseborough EJ, Barrett IR, Shapiro F. Growth Disturbances Following Distal Femoral Physeal Fracture-separations. *J Bone Joint Surg Am* 1983;65:885.

+ 61. Robertson P, Karol LA, Rab GT. Open Fractures of the Tibia and Femur in Children. *J Pediatr Orthop* 1996;16:621.

+ 62. Sanders WE, Heckman JD. Traumatic Plastic Deformation of the Radius and Ulna: A Closed Method of Correction of Deformity. *Clin Orthop* 1984;188:58.

+ 63. Shannak AO. Tibial Fractures in Children: Follow-up Study. *J Pediatr Orthop* 1988;8:306.

+ 64. Shifrin PG, Gehring HW, Iglesias LJ. Open Reduction and Internal Fixation of Displaced Supracondylar Fractures of the Humerus in Children. *Orthop Clin North Am* 1976;7:573.

+ 65. Shimada K, Masada K, Tada K, Yamamoto T. Osteosynthesis for the Treatment of Non-union of the Lateral Humeral Condyle in Children. *J Bone Joint Surg Am* 1997;79:234.

+ 66. Spiegel PG, Mast JW, Cooperman DR, Laros GS. Triplane Fractures of the Distal Tibial Epiphysis. *Clin Orthop* 1984;188:74.

+ 67. Steinberg EL, Golomb D, Salama R, Weintraub S. Radial Head and Neck Fractures in Children. *J Pediatr Orthop* 1988;8:35.

+ 68. Thometz JG. Techniques for Direct Radiographic Visualization during Closed Pinning of Supracondylar Humerus Fractures in Children. *J Pediatr Orthop* 1990;10:555.

+ 69. Thompson JD, Stricker SJ, Williams MM. Fractures of the Distal Femoral Epiphyseal Plate. *J Pediatr Orthop* 1995;15:474.

+ 70. Tolo VT. External Skeletal Fixation in Children's Fractures. *J Pediatr Orthop* 1983;3:435.

+ 71. Viljanto J, Kiviluoto H, Paananen M. Remodeling after Femoral Shaft Fracture in Children. *Acta Chir Scand* 1975;141:360.

+ 72. Vocke AK, Von Laer L. Displaced Fractures of the Radial Neck in Children: Long-term Results and Prognosis of Conservative Treatment. *J Pediatr Orthop B* 1998;7:217.

+ 73. Weiland A, Meyer S, Tolo VT, et al. Surgical Treatment of Displaced Supracondylar Fractures of the Humerus in Children: Analysis of Fifty-two Cases Followed for Five to Fifteen Years. *J Bone Joint Surg Am* 1978;60:657.

# 74. Wilkins KE. Fractures and Dislocations of the Elbow Region. In: Rockwood CA Jr, Wilkins KE, King RE, eds. *Fractures in Children.* Philadelphia: JB Lippincott Co, 1984:432.

+ 75. Williamson RV, Staheli LT. Partial Physeal Growth Arrest: Treatment by Bridge Resection and Fat Interposition. *J Pediatr Orthop* 1990;10:769.

+ 76. Wilson JN. The Treatment of Fractures of the Medial Epicondyle of the Humerus. *J Bone Joint Surg Br* 1960;42:778.

+ 77. Yung SH, Lam CY, Choi KY, et al. Percutaneous Intramedullary Kirschner Wiring for Displaced Diaphyseal Forearm Fractures in Children. *J Bone Joint Surg Br* 1998;80:91.

+ 78. Ziv I, Blackburn N, Rang M. Femoral Intramedullary Nailing in the Growing Child. *J Trauma* 1984;4:432.

+ 79. Ziv I, Rang M. Treatment of Femoral Fracture in the Child with Head Injury. *J Bone Joint Surg Br* 1983;5:276.

# CHAPTER 165

# CONGENITAL SHOULDER AND ELBOW MALFORMATIONS AND DEFORMITIES

*Michelle A. James and Karen D. Heiden*

**M. A. James:** Associate Clinical Professor, Department of Orthopaedic Surgery, University of California–Davis, Shriners Hospital for Children, Northern California Sacramento, California, 95817.
**K. D. Heiden:** Department of Orthopaedic Surgery, University of California, Davis Medical Center, Sacramento, California, 95817.

Arthrogryposis
Pathophysiology and Principles of Treatment
Assessment, Indications, and Relative Results
Classifications
Preoperative Management
Operative Techniques
Complications
Conclusions
Brachial Plexus Birth Palsy
Pathophysiology and Principles of Treatment
Assessment, Indications, and Relative Results
Classifications
Preoperative Management
Preoperative Planning
Operative Techniques
Complications
Conclusions
Congenital Transverse Failure of Formation of the Upper Extremity
Pathophysiology and Principles of Treatment
Assessment, Indications, and Relative Results
Classifications
Conclusions
Congenital Dislocation of the Radial Head
Pathophysiology and Principles of Treatment
Assessment, Indications, and Relative Results
Classifications
Preoperative Planning
Operative Technique
Complications
Conclusions
Congenital Elevation of the Scapula (Sprengel's Deformity)
Pathophysiology and Principles of Treatment
Assessment, Indications, and Relative Results
Classifications and Terminology
Operative Techniques
Complications
Conclusions
Congenital Pseudarthrosis of the Clavicle
Pathophysiology and Principles of Treatment
Assessment, Indications, and Relative Results
Classifications
Operative Technique
Complications
Conclusions
Congenital Pseudarthrosis of the Ulna
Pathophysiology and Principles of Treatment
Assessment, Indications, and Relative Results
Classifications
Preoperative Planning
Operative Technique
Complications
Conclusions
Congenital Proximal Radioulnar Synostosis
Pathophysiology and Principles of Treatment
Assessment, Indications, and Relative Results
Classification
Preoperative Planning
Operative Technique
Complications
Conclusions
Elbow and Forearm Deformity Due to Multiple Hereditary Exotoses
Pathophysiology and Principles of Treatment
Assessment, Indications, and Relative Results
Classifications and Terminology
Operative Techniques
Complications
Conclusions
Acknowledgments
Chapter References

Congenital malformations of the shoulder and elbow are frequently accompanied by hand malformations or absence; in these cases, treatment of the shoulder and elbow must be integrated with treatment of the hand. Surgical reconstruction of the shoulder or elbow, or both, is not indicated if the hand is absent or nonfunctional, unless the goal of surgery is to reduce pain. See Chapter 69, Congenital Hand Malformations, for a discussion of pathophysiology and principles of treatment of congenital malformations of the upper extremity.

## ARTHROGRYPOSIS

### PATHOPHYSIOLOGY AND PRINCIPLES OF TREATMENT

Arthrogryposis multiplex congenita (sometimes termed amyoplasia) is characterized by multiple, symmetric, nonprogressive, congenital joint contractures (45) (Fig. 165.1*A*). Many etiologic factors have been associated with arthrogryposis (including fetal exposure to mutagens, toxins, hyperthermia, neuromuscular blocking agents, and mechanical immobilization) (158). The final common pathway for these etiologies is probably lack of fetal movement. Because fetal movement is necessary for joint development, immobile joints fail to develop normally and become contracted (43,108,182).

***Figure 165.1.*** **A:** Infant with arthrogryposis. **B:** Facial features of child with Freeman–Sheldon syndrome (craniocarpal-tarsal dysplasia).

Although myopathic arthrogryposis has been reported, most cases studied show evidence of a neuropathic condition, possibly a disorder of the anterior horn cells, which partially paralyzes the fetus. Even though many different fetal exposures to drugs, chemicals, and mutagens have been associated with arthrogryposis in humans, in most cases, the cause remains unknown (50,72). Arthrogryposis is not an inherited condition (121), but many other syndromes that feature multiple joint contractures are inherited (72), and most children with this condition should be seen by a geneticist. The incidence of arthrogryposis is unknown, although congenital joint contractures are seen in about 1 in 3,000 live births (72).

Treatment of arthrogryposis focuses on enhancing the child's ability to perform activities of daily living, especially eating, toileting, and dressing (30).

## ASSESSMENT, INDICATIONS, AND RELATIVE RESULTS

Arthrogryposis is a clinical diagnosis, usually made at birth. Mothers of children with this condition frequently report that fetal movement was diminished compared with their other pregnancies. Oligohydramnios is a frequent finding.

Joint contractures associated with arthrogryposis are usually more severe distally than proximally, and most patients have upper extremity involvement (58). The shoulder lacks abduction and external rotation (178), and the elbow (one of the most frequently involved joints) (108) may lack flexion or extension (161,167). The wrist is usually flexed and deviated ulnarward (176), the fingers flexed, and the thumb flexed in the palm (184) (see The Fingers: Camptodactyly and The Thumb: Clasped Thumb in Chapter 69, Congenital Hand Malformations). Severe clubfoot, knee flexion contracture, dislocated hip, and scoliosis are frequently associated with arthrogryposis (45,161). Joint contractures similar to those seen in arthrogryposis are associated with syndromes such as cranio-carpo-tarsal dysplasia (Freeman–Sheldon syndrome) (Fig. 165.1*B*) (53,161).

Shoulder contractures do not usually limit performance of activities of daily living (20) and are not usually amenable to range-of-motion exercises, splinting, or surgery. The most limiting deficit, lack of active elbow flexion, prevents the child from reaching the mouth and head, especially when accompanied by an elbow extension contracture. Children with only passive elbow flexion frequently discover “tricks” to help get their hand to their face, such as leaning the forearm on the edge of a table or on their leg. Serial casting, splinting, and range-of-motion exercises may improve elbow range of motion. If less than 90° of passive elbow flexion is gained after 6 months of supervised elbow stretching, posterior capsulotomy with triceps lengthening is indicated (167). In one study of this operation, postoperative improvement in passive elbow flexion was maintained for at least 2 years, although range of motion was occasionally limited by intra-articular incongruity (167).

Many different tendon transfers have been used to provide active elbow flexion, including pectoralis major, latissimus dorsi, triceps-to-biceps transfers, or proximal reattachment of the wrist and finger flexor muscles (Steindler flexorplasty) (12,44,167,178). Tendon transfer is indicated in children older than 4 years of age who lack active elbow flexion and have at least 90° of passive elbow motion, reasonable ipsilateral hand function, absent contralateral active elbow flexion, and an available donor muscle. Bilateral tendon transfer is not usually indicated; asymmetric function is usually desirable, especially when the triceps is the best donor available, and elbow extension is sacrificed for elbow flexion. Potential donor muscles must be carefully assessed preoperatively because they may be weak and therefore unsuitable for transfer. Triceps-to-biceps transfer gives the most reliable results (167), although this operation creates an elbow flexion contracture (31) and is contraindicated in children who need active elbow extension to ambulate or transfer because of lower extremity contractures. The pectoralis major is the best donor when the triceps is unavailable, but the scar left by this operation is large (extending from sternum to antecubital fossa) and crosses the breast, and transfer of the pectoralis may cause breast asymmetry. Latissimus dorsi and finger and wrist flexors are frequently weak in arthrogryposis, so latissimus dorsi-to-biceps transfer and Steindler flexorplasty are rarely indicated.

## CLASSIFICATIONS

Many different terms have been used to describe arthrogryposis, including arthrogryposis multiplex congenita, multiple congenital articular rigidities, amyoplasia congenita, myodystrophia foetalis deformans, and congenital arthromyodysplasia (162). No classification scheme useful to orthopaedists has been described for this disorder.

## PREOPERATIVE MANAGEMENT

Stretching, splinting, and serial casting of contracted elbows and wrists may increase passive range of motion, particularly for infants younger than 1 year of age. A creative occupational therapist may help the child improve function with the use of mechanical aids.

## OPERATIVE TECHNIQUES

### *Posterior Elbow Capsulotomy with Triceps Lengthening*

- Use loupe magnification (for the ulnar nerve dissection) and perform the operation under general anesthesia and a tourniquet. A sterile tourniquet may be necessary.
- Through a longitudinal incision on the posterior elbow, find the ulnar nerve. Open the cubital tunnel and retract the nerve with a Penrose drain, taking care not to damage branches to the flexor carpi ulnaris.
- Perform a V-Y lengthening of the triceps tendon. First, make a V incision through the tendon, with the point of the V proximal. Expose the humeroulnar joint, leaving the triangular tail of tendon attached to the olecranon.
- Using scissors, transect the posterior elbow joint capsule. If necessary to obtain flexion, transect the lateral and medial capsule, including collateral ligaments.
- Repair the triceps tendon with nonabsorbable suture while holding the elbow in maximum flexion.
- The ulnar nerve does not usually require transposition.
- Close the skin with an absorbable, running subcuticular suture. Apply a long-arm cast with the elbow in maximum flexion.

Remove the cast after 2 weeks and begin a program of frequent gentle passive elbow flexion exercises, supervised by an occupational therapist. Supplement with night splinting in maximum flexion, to be continued indefinitely.

### *Triceps-to-Biceps Transfer*

Figure 165.2 shows a typical triceps-to-biceps transfer (31).

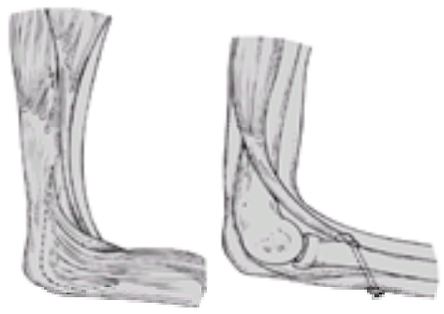

***Figure 165.2.*** Triceps-to-biceps transfer (Reprinted from ref. 44, with permission).

- Perform the operation under general anesthesia and a tourniquet. A sterile tourniquet may be required.
- Through a posterolateral longitudinal elbow incision, expose the triceps tendon and divide it at its insertion. Dissect it from the posterior aspect of the distal fourth of the humerus, and transfer it around the lateral aspect, superficial to the radial nerve.
- Through a separate anterior zigzag elbow incision, expose the biceps tendon.
- Pass the triceps tendon through a longitudinal slit in the biceps tendon, and suture it under tension with the elbow in flexion.
- Close the skin with an absorbable, running subcuticular suture. Apply a long-arm cast with the elbow in maximum flexion and neutral rotation.

Immobilize the elbow for 6 weeks, then begin a program of active elbow flexion exercises. Supplement with night splinting until active flexion strength is at least antigravity.

#### *Pectoralis Major-to-Biceps Transfer*

For the surgical technique for a pectoralis major-to-biceps transfer, see the article by Schottstaedt et al. (147).

### COMPLICATIONS

Inadequate lengthening of the triceps tendon will restrict elbow flexion following posterior elbow capsulotomy. The outcome of elbow flexion tendon transfer is frequently unsatisfactory, even when the donor muscle is normal; in arthrogryposis, donor muscles are likely to be weak and have poor excursion.

### CONCLUSIONS

Children with arthrogryposis frequently function much better than their strength and range-of-motion measurements would predict. Surgery should be directed at functional goals shared by the surgeon, child, and family.

Although triceps-to-biceps transfer provides the best elbow flexion, patients may not like the mandatory elbow flexion contracture that accompanies this operation.

## BRACHIAL PLEXUS BIRTH PALSY

### PATHOPHYSIOLOGY AND PRINCIPLES OF TREATMENT

Brachial plexus birth palsy (BPBP), also known as obstetric palsy, occurs when the brachial plexus is injured by traction during birth. The mechanism of injury is forceful separation of the head from the shoulder by lateral flexion of the cervical spine and depression of the shoulder (Fig. 165.3). This most commonly occurs during a cephalic vaginal birth, owing to shoulder dystocia. The primary cause of shoulder dystocia is fetal macrosomia, which may be associated with maternal diabetes or a multiparous mother. The brachial plexus may also be injured during a breech delivery; injury during caesarian section is very rare (7,55). Obstetrics literature indicates that injury may occur prenatally (56,130,133), although this finding is controversial (38,60).

***Figure 165.3.*** Breech (**A**) and Vertex births (**B**), showing wide separation of the head from the downside shoulder.

BPBP occurs in 0.5 to 2.6 per 1,000 live births, with the incidence unchanged or possibly increasing in the past 30 years, in spite of an increasing rate of caesarian sections (64,75,76,88,103,117,118,134,170). Although BPBP may often be attributable to poor prenatal care or obstetrician error, some cases cannot be reliably predicted or prevented. Macrosomia (fetal weight greater than 4,500 g) is difficult or impossible to detect with current prenatal diagnostic techniques (62), and shoulder dystocia, which occurs in up to 2% of deliveries, may be difficult to recognize and treat (63,74,80,118). In addition, shoulder dystocia and BPBP frequently occur in normal birth-weight fetuses (64,128). Other variables, including prolonged gestation, prolonged labor, use of oxytocin, use of forceps or vacuum suction, and previous maternal obstetric history of macrosomia are all associated with birth injuries, but even when combined, these problems fail to predict most birth injuries (134). BPBP in an older sibling is the only factor that may reliably predict BPBP (4) (Fig. 165.4).

***Figure 165.4.*** **A to C:** Three siblings with brachial plexus birth palsy. Both boys (A, B) have Horner's syndrome.

The disability caused by BPBP varies from mild, partial, and transient upper extremity weakness [approximately 80% of newborns have full or near-full recovery of function (66,76,88,122)] to complete permanent upper extremity paralysis. Most of the improvement gained from nerve recovery is seen in the first 12 months of life, and the remainder by 2 years of age (5); recovery of sensation is more complete than recovery of motor function. Residual disability depends on the severity and location of the plexus injury (78) (Fig. 165.5). Injury to the upper trunk, where the C5 and C6 nerve roots join and the suprascapular nerve leaves the plexus, is called Erb's palsy (49). This the most common type of plexus injury; the child with this type of BPBP has weakness or paralysis of shoulder external rotation and possibly abduction. The next most common type is global plexus palsy. Isolated injury to the lower trunk (C-8 and T-1 nerve roots), called Klumpke's palsy, is the least common type (6,90) and may actually represent partial recovery from global plexus palsy rather than injury to the lower trunk alone (172) (Fig. 165.6).

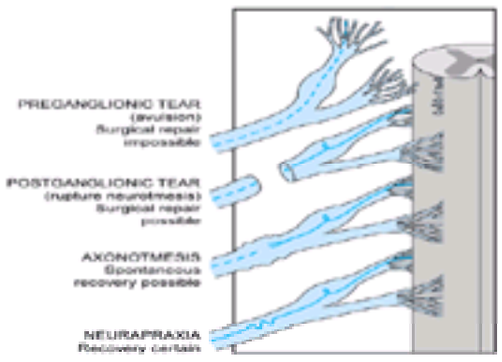


***Figure 165.5.*** Different types of brachial plexus injury (78).

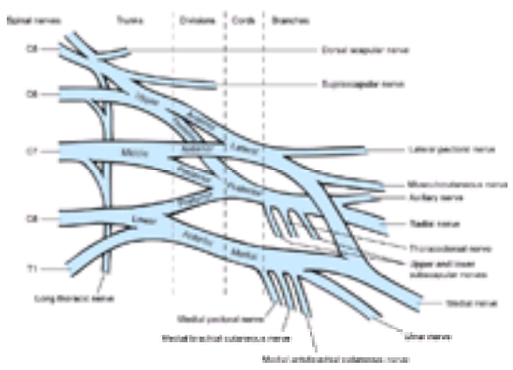

***Figure 165.6.*** The brachial plexus (172).

The muscle imbalance resulting from BPBP may cause multiple deformities at the shoulder, including internal rotation contracture and posterior subluxation or dislocation, as well as at the elbow, including flexion, supination, or pronation contracture, radial head dislocation, or complete elbow dislocation (3,13,41,83,104,110,174). The affected arm is smaller than the opposite side, in proportion to the severity of the BPBP (Fig. 165.7).

***Figure 165.7.*** Severe brachial plexus birth palsy in a teenager.

The goals of treatment are to prevent the formation of contractures while recovery is occurring, to restore neurologic function, to augment weak muscles, and to improve the appearance of deformities that occur as a result of muscle imbalance. Treatment depends on age and extent of weakness, and may include passive range-of-motion exercises (PROM), goal-directed occupational therapy, brachial plexus exploration and grafting, tendon transfers, osteotomies, and arthrodeses. Because of the complexity of their care, children with BPBP benefit from a multidisciplinary team approach (36). The BPBP team may include an orthopaedic surgeon, a surgeon with microneurosurgery expertise, a physiatrist, a pediatric neurologist, occupational and physical therapists, a social worker, and a therapeutic recreation specialist. Parents and older children appreciate team-sponsored activities, such as play groups and peer contacts (Fig. 165.8).

***Figure 165.8.*** Two children who met through a peer contact program, wearing shoulder abduction splints following shoulder external rotation tendon transfers.

**ASSESSMENT, INDICATIONS, AND RELATIVE RESULTS**

The infant with BPBP presents with asymmetric upper extremity motion. The affected side is typically held in internal rotation at the shoulder, with the elbow extended and the wrist flexed (Fig. 165.9). The differential diagnosis includes hemiparesis, a septic glenohumeral joint, and congenital elevation of the scapula (Sprengel's deformity). Clavicle fracture and proximal humeral epiphyseal separation may be either differential diagnoses or associated lesions (5,59,103). Although most infants with BPBP recover useful function, those with an ipsilateral Horner's syndrome (due to injury to the sympathetic ganglia, associated with avulsion of the C-8 and T-1

nerve roots off the spinal cord) or hemidiaphragm paralysis (injury to the phrenic nerve) have a poor prognosis for recovery (122).

***Figure 165.9.*** Infant with left brachial plexus birth palsy.

Teach parents to begin PROM exercises of the shoulder when the infant is 3 to 4 weeks of age. Examine the infant every 1 to 2 months for signs of recovery. The Infant Active Movement Scale (36) (Table 165.1) helps the examiner measure muscle recovery more accurately than do scales devised for adults because it does not require cooperation for testing muscles against resistance. Brachial plexus exploration with nerve grafting and transfer may be indicated if the infant does not recover elbow flexion strength.

| *Observation* | *Muscle grade* |
|---|---|
| Gravity eliminated | |
| No contraction | 0 |
| Contraction, no motion | 1 |
| Motion ≤1/2 range | 2 |
| Motion >1/2 range | 3 |
| Full motion | 4 |
| Against gravity | |
| Motion ≤1/2 range | 5 |
| Motion >1/2 range | 6 |
| Full motion | 7 |

From Clarke HM, Curtis CG. An Approach to Obstetrical Brachial Plexus Injuries. *Hand Clin* 1995;11:563, with permission.

***Table 165.1. Infant Active Movement Scale***

Recovery of active elbow flexion is closely monitored for three reasons: It is easy to observe; the timing of natural recovery of elbow flexion may be a prognostic sign for plexus recovery; and early nerve grafting to the lateral cord of the plexus (Fig. 165.6) may be the best way to restore elbow flexion, which is difficult to replace with tendon transfers (112). In one often-quoted but unpublished study, children with full recovery from BPBP at 5 years of age showed antigravity elbow flexion and shoulder abduction by age 3 months (59,160). Later recovery of elbow flexion (between 3 and 6 months of age) has been associated with residual shoulder weakness (160,171). In contrast, however, other investigators have reported that most children with biceps recovery after 3 months of age are likely to have a good ultimate outcome, but lack of sensation and wrist extension at 3 months are poor prognostic signs (21).

Electromyography (EMG), nerve conduction studies (NCS), contrast computerized tomography (CT) myelography, magnetic resonance imaging (MRI), and intraoperative somatosensory-evoked potentials have all been used to measure and provide images of damage to the neonatal brachial plexus, with the goal of differentiating nonrepairable preganglionic rupture from postganglionic injury, which may be repairable or may recover without surgical treatment (52,77,78,123,153). EMG and NCS may help differentiate neuropraxia from axonal degeneration. CT myelography and MRI can identify preganglionic nerve root injuries (avulsions) if they are associated with traumatic pseudomeningoceles, as they are in many avulsions; however, root avulsions may occur without creating a pseudomeningocele, and pseudomeningoceles may be visualized at the level of a root that has not been avulsed. All tests require sedation, and CT myelography is invasive. Testing should be reserved for infants who are candidates for nerve surgery, to help the surgeon plan the operation.

Thus, the indications for brachial plexus exploration with nerve grafting and transfer are unclear. Some surgeons recommend this procedure for all children without full recovery of active elbow flexion and shoulder abduction by 3 months of age (59); others prefer to allow more time for recovery (35,79,102,137). Most surgeons agree that complete avulsion of the plexus is rare, so at least one root has a repairable injury in most cases, and the results are poor for surgical plexus reconstruction for BPBP performed after 12 months of age. Most surgeons resect the scarred plexus and graft nonavulsed roots to the lateral cord, suprascapular nerve, and posterior cord (79) (see Chapter 60). Nerve transfer (neurotization) of the accessory nerve may be helpful (94), but neurolysis of a neuroma-in-continuity probably is not (35). The results of plexus surgery vary, and few patients have had long-term follow-up, but nerve grafting and transfer in infants with poor prognostic signs probably result in better function than if no surgery was performed, and complications are unusual in the hands of experienced surgeons (59,79).

Children with upper-trunk BPBP frequently have residual weakness of shoulder external rotation and abduction (Fig. 165.10). Such a child may have difficulty positioning his or her hand in space, particularly to reach the head and face, or to throw, climb, turn a jump rope, or play a musical instrument. Eventually, the child may develop a shoulder internal rotation contracture, with glenohumeral joint changes and eventual posterior dislocation of the humeral head (70,81,174). Shoulder function may be classified using Mallet's scale (109,172) (Fig. 165.11). To diminish unopposed internal rotation, Sever (150), in 1925, recommended releasing the pectoralis major and subscapularis. In 1934, L'Episcopo (101) described the results of combining Sever's anterior release with transferring the teres major to the proximal humerus in order to provide active shoulder external rotation. This operation was later modified by Hoffer and colleagues (19,84,136), who described latissimus dorsi and teres major transfer to the supraspinatus, with release of the pectoralis major only (because release of the subscapularis can cause glenohumeral instability); and Covey et al. (39), who described latissimus dorsi and teres major rerouting around the proximal humerus.

***Figure 165.10.*** Decreased shoulder abduction and external rotation due to right brachial plexus birth palsy.

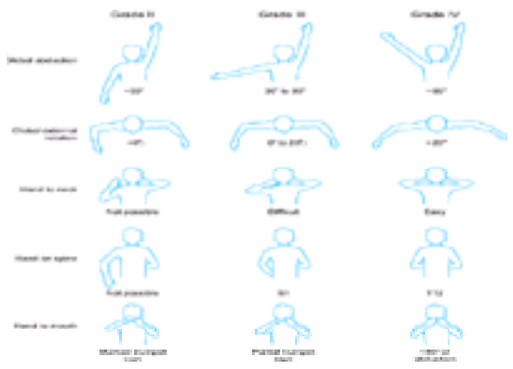

***Figure 165.11.*** Modified Mallet's classification (172). Grade I has no function.

Shoulder external rotation tendon transfer and rerouting both reliably increase abduction, as well as external rotation in abduction by an average of 20° to 40° each. Abduction is increased because the transfer helps stabilize the glenohumeral joint, allowing the deltoid to function more efficiently. The rerouting procedure is more technically demanding and requires more excursion of the teres and latissimus muscles but may provide more external rotation than the transfer procedure (92). Other patient requirements for these operations include sufficient maturity to work with a therapist postoperatively to strengthen the transfer (4 years of age or older), minimal changes in the glenohumeral joint from unopposed internal rotation (usually 12 years of age or younger), and enough deltoid strength to abduct to at least 60° against gravity. However, Hoffer and Phipps (83) have reported that when posterior shoulder dislocation occurs early (before 4 years of age) latissimus and teres transfer and pectoralis release can be combined with closed shoulder reduction with good results and maintenance of reduction (83).

Tendon transfers do not reliably restore elbow flexion (112,127) but they may restore wrist extension, finger extension and flexion, and thumb opposition if adequate donors are available (26). For forearm supination deformity, biceps rerouting and forearm osteoclasis improve forearm position (23,106,110,185). Elbow flexion contractures can be treated with serial elbow drop-out casts (long-arm casts applied in maximum elbow extension, with the posterior above-elbow aspect cut out so that the elbow can extend farther but cannot flex). Surgical release of elbow flexion contractures is not usually indicated.

For the untreated older child or teenager, glenohumeral deformity and contracture may make shoulder tendon transfers less effective. External rotation osteotomy of the humerus improves the appearance and function of a limb with a shoulder internal rotation contracture in the older child (61,174).

If the deltoid is completely paralyzed, shoulder arthrodesis may improve function by conferring stability (139) (see Chapter 101). Wrist arthrodesis can improve hand position when wrist motors are paralyzed and no muscles are available for transfer (see Chapter 72). Arm-lengthening procedures are not indicated for treating the global extremity hypoplasia associated with severe BPBP.

Throughout childhood, the child with BPBP may benefit from goal-directed occupational and physical therapy.

## CLASSIFICATIONS

There is no standard classification system for BPBP, aside from classification by level of plexus involvement, as described previously. Shoulder limitation has been classified by Mallet (60,109,172) (Fig. 165.11).

## PREOPERATIVE MANAGEMENT

PROM exercises help prevent or diminish contractures due to BPBP. PROM is especially important in the infant, because the shoulder can become fixed in internal rotation and subluxate or dislocate before the child is old enough to undergo shoulder external rotation tendon transfer or rerouting (83,164). Weekly manipulation by a therapist is not adequate; the child's shoulder should undergo PROM several times each day, so the child's caregivers must be trained to do shoulder PROM exercises.

## PREOPERATIVE PLANNING

CT myelography or MRI may be helpful for planning brachial plexus exploration and nerve grafting, although the decision to proceed with this operation is based on lack of clinical recovery, and the most helpful planning information is gained from somatosensory-evoked potentials performed intraoperatively.

Before shoulder external rotation tendon transfer or rerouting, the waist portion of the shoulder spica cast can be applied with the child standing, to improve fit, then removed and reapplied at the end of the operation. Postoperative therapy is especially important following these procedures, so arrangements for this should be made prior to surgery.

## OPERATIVE TECHNIQUES

### *Brachial Plexus Exploration and Nerve Grafting*

See Chapter 60 and Figure 165.12 for details on surgical techniques for brachial plexus exploration. Repair of BPBP differs slightly from repair of traumatic brachial plexus palsy in adults. The differences stem from the following aspects of BPBP:

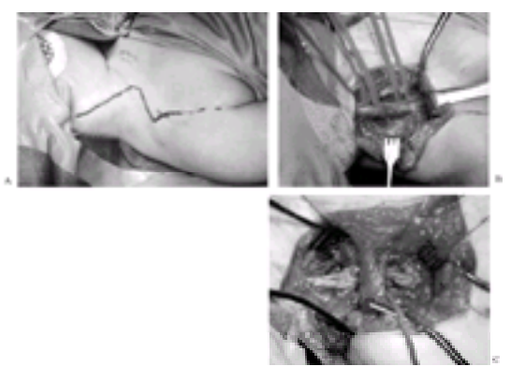

***Figure 165.12.*** **A:** Marks indicate planned incision for brachial plexus exploration (child is supine, with head to the left). **B:** Intraoperative view of scarred plexus (same child as in *A*). The head is to the left, vessel loops surround the roots; the central horizontal structure is the plexus. **C:** Intraoperative view of clavicle and sural nerve cable grafts (same child as *A* and *B;* head is to the left, central vertical structure is clavicle).

- Nerve transfer (neurotization) is not usually necessary; at least one root is usually available as a proximal source of intact neurons.
- The entire plexus is often shifted distally, so landmarks such as the clavicle crossing the plexus at the level of the divisions are not reliable.
- Clavicular osteotomy is not usually necessary.

If sural nerve grafts are obtained and the child is ambulatory, apply short-leg walking casts. Apply a custom-fabricated chest and neck splint at the end of the operation (Fig. 165.13). The ipsilateral arm can be placed in a sling or attached to the chest splint with a Velpeau wrap. Remove the chest and neck splint, sling, and short-leg walking casts and resume shoulder PROM exercises 3 weeks after surgery. Return of function may take 6 months to 2 years.

***Figure 165.13.*** Infant in custom-fabricated neck brace following brachial plexus exploration and grafting.

***Shoulder External Rotation Tendon Transfer***

Tendon transfers (84,136) (Fig. 165.14 and Fig. 165.15) are methods used to improve shoulder motion in children with BPBP. The surgical technique is as follows:

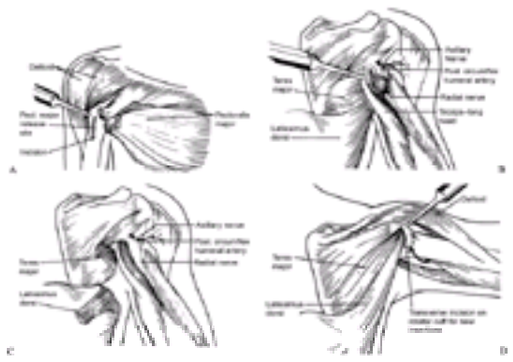

***Figure 165.14.*** Tendon transfer procedure (84). **A:** Pectoralis major release. **B:** Teres major and latissimus dorsi, before attachment from humerus. **C:** Teres major and latissimus dorsi, after detachment from humerus. **D:** Teres major and latissimus dorsi transferred to rotator cuff.

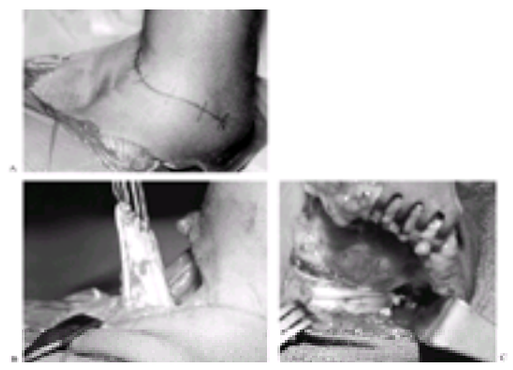

***Figure 165.15.*** Shoulder external rotation tendon transfer. **A:** Transverse axillary incision. The patient is in right lateral decubitus position, with left arm abducted to 90°. **B:** Latissimus dorsi and teres major tendons after detachment from humerus. **C:** Latissimus dorsi and teres major tendons have been sutured to supraspinatus tendon (at tip of Army-Navy retractor).

- Perform the operation under general anesthesia.
- Place the patient in a lateral decubitus position and hold with a beanbag. Isolate the affected axilla and arm with a U drape. Range the shoulder under anesthesia; if there is less than 80° passive external rotation when the arm is abducted to 90°, perform the pectoralis major lengthening as described later. If there is more than 80° rotation, pectoralis lengthening is not necessary.
- Make a transverse axillary incision after infiltrating the area with bupivacaine with epinephrine. Extend the incision posteriorly to the deltoid-triceps interval.
- In the anterior end of the incision, locate the pectoralis major muscle. The tendon is short and most prominent on the deep side of the muscle. Using Bovie cautery, transect the tendinous and fascial portions of the muscle near its insertion on the humerus. Do not transect the entire muscle. Subscapularis lengthening is rarely necessary and may destabilize the shoulder.
- In the posterior part of the incision, locate the teres major and latissimus dorsi muscles. Trace them to their humeral insertions, using blunt dissection; these tendons are frequently conjoined (19). The axillary nerve and posterior humeral circumflex artery cross from anterior to posterior deep to the latissimus and teres major tendons, just proximal to their insertions. They are easier to visualize after detaching the tendons.
- Detach the teres major and latissimus tendons from their humeral insertions. Bluntly free the muscle bellies from surrounding attachments, avoiding the circumflex scapular and thoracodorsal vessels. Tag the tendons with 0 nonabsorbable suture.
- Through the deltoid-triceps interval, locate the rotator cuff tendon. Stay proximal to avoid the axillary nerve.
- Position the arm in 90° of abduction and 60° to 80° of external rotation, bring the latissimus and teres major tendons posterior to the triceps muscle, and suture them into the rotator cuff tendon as high as possible.
- Close the skin incision in two layers. Apply the prefabricated waist portion of the spica cast, and attach a long-arm cast to the waist portion (Fig. 165.16).

***Figure 165.16.*** Shoulder spica cast used after shoulder external rotation tendon transfer or rerouting. (Drawing by Anthony Marotta, with permission).

Remove the shoulder spica cast 6 weeks after surgery. Apply an adjustable removable shoulder abduction splint (Fig. 165.8). Prescribe twice-daily occupational therapy (OT) for 2 weeks. The OT program is designed to strengthen the tendon transfer. Have the child wear the splint for the first week whenever he or she is not in therapy; in the second week, the splint can be discontinued during the day. The child should continue to wear the splint at night for 6 months. Continue OT at less frequent intervals for 6 to 12 months.

### *Shoulder External Rotation Tendon Rerouting*

The surgical technique for tendon rerouting (39) (Fig. 165.17 and Fig. 165.18) follows the same first five steps as those used for tendon transfer (preceding technique). If the teres major and latissimus tendons are conjoined, this operation cannot be performed; the tendons must be transferred instead of rerouted. The surgical technique continues as follows:

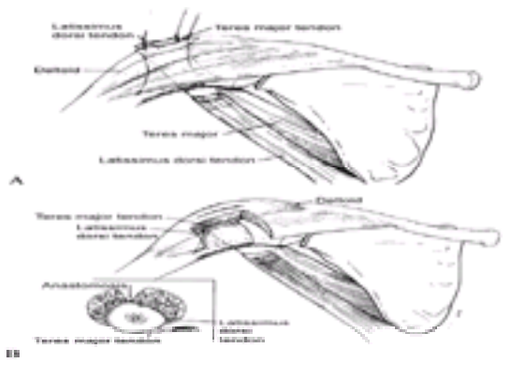

***Figure 165.17.*** Tendon rerouting procedure. **A:** Latissimus dorsi tendon and teres major tendon pulled through a split in the deltoid. **B:** Latissimus dorsi tendon and teres major tendon after anastomosis. Reprinted from ref. 39, with permission.

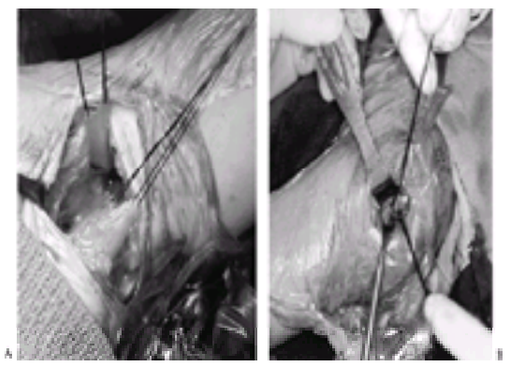

***Figure 165.18.*** Tendon rerouting procedure. **A:** Left axilla, upper sutures are in the latissimus dorsi tendon, lower sutures are in the teres major tendon. **B:** Left shoulder, head is to the right. Latissimus dorsi and teres major tendons pulled through a split in the deltoid muscle.

- Transect the latissimus at the muscle–tendon junction. Attach the latissimus muscle belly side to side to the teres major muscle belly; avoid excess tension, or mobilization of the teres will be difficult. Tag the latissimus tendon, which is still attached to the humerus at its insertion, with 0 nonabsorbable suture.
- Detach the teres major from its humeral insertion. Tag it with 0 nonabsorbable suture.
- Make a 3 cm incision starting at the acromion, at the posterior one third or anterior two thirds junction of the deltoid, after infiltrating with bupivacaine and epinephrine. Split the deltoid fibers bluntly down to the humerus. Stay proximal to the axillary nerve insertion.
- Bluntly make tunnels around the proximal humerus, starting at the humeral insertion site of the teres major. Each tunnel should reach the deltoid incision superiorly. The posterior tunnel must be large enough to accommodate the teres major muscle; the latissimus tendon will pass through the anterior tunnel.
- Pass the latissimus tendon anteriorly, and the teres major muscle posteriorly. Both should be visible through the deltoid incision.
- Attach the latissimus tendon to the teres major muscle by tying their tag sutures together through the deltoid incision, with the shoulder in 90° of abduction and 45° to 90° of external rotation.
- Close the skin incision in two layers. Apply the prefabricated waist portion of the spica cast, and attach a long-arm cast to the waist portion (Fig. 165.16).

### *External Rotation Osteotomy of Humerus*

Goddard and Fixsen (61) address the rotational osteotomy of the humerus for birth injuries of the brachial plexus. The surgical technique for osteotomy is as follows:

- Perform the operation under general anesthesia.
- Place the patient in supine position with a small beanbag under the scapula. Examine the arm carefully, estimating the amount of external rotation necessary for the patient to reach the face and head. Prepare and drape the affected arm using a U drape.
- Make a longitudinal anterolateral shoulder incision after infiltrating with bupivacaine and epinephrine. Approach the humerus through the deltopectoral and anterior deltoid–biceps intervals (between the radial and musculocutaneous nerves, neither of which are usually visualized). The radial nerve will be more anterior than usual because of the internal rotation contracture.
- Select the osteotomy site at the deltoid insertion, with enough exposure proximally and distally to apply a small six-hole AO plate. Predrill, measure, and tap two holes proximal to the osteotomy site before making the osteotomy.
- Make the osteotomy after making a longitudinal mark across the osteotomy site.
- Rotate the distal fragment the amount previously estimated to allow the patient to reach the face and head. Insert two screws proximally and one distal to the osteotomy, and carefully range the shoulder to make sure the new position is optimal. Remove the distal screw and adjust the rotation if necessary. Insert the remaining screws, check the position of the fixation on a radiograph, if necessary, and close the wound in layers.
- Apply a shoulder immobilizer with an abduction pillow.

Remove the shoulder immobilizer 6 weeks after surgery and check radiographs for bridging callus. If callus is present, discontinue immobilization. Postoperative rehabilitation is not usually necessary.

### *Biceps Rerouting and Forearm Osteoclasis for Supination Deformity*

Manske and McCarroll (110) discuss biceps rerouting (Fig. 165.19) and osteoclasis (Fig. 165.20) in treating supination deformity in obstetric palsy. The general surgical technique is as follows:

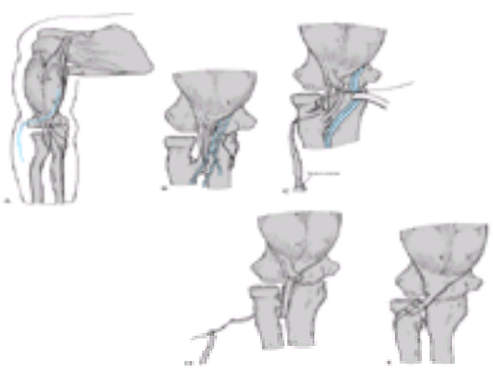

***Figure 165.19.*** Rerouting of the biceps tendon. See text for description of the surgical technique. Reprinted with permission from Manske PR, McCarroll HR Jr. Biceps

Tendon Re-routing and Percutaneous Osteoclasis in the Treatment of Supination Deformity in Obstetrical Palsy. *J Hand Surg* 1980;5:153.

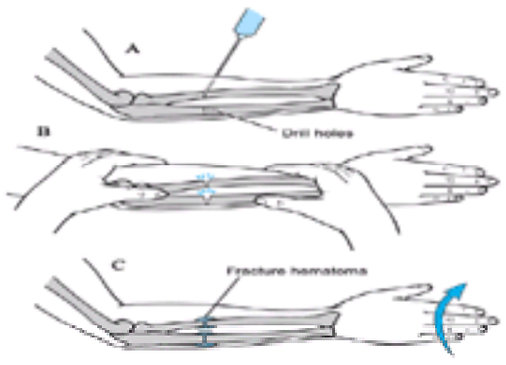


***Figure 165.20.*** Osteoclasis of the forearm. See text for a description of technique (110).

- Perform the operation under general anesthesia, and use a tourniquet. A sterile tourniquet may be necessary.
- Approach the biceps tendon through an anterior zigzag incision, placing the transverse limb of the zigzag along the elbow flexion crease (Fig. 165.19*A*).
- Incise the lacertus fibrosis, and retract the median nerve and brachial artery ulnarward (Fig. 165.19*B*).
- Expose the biceps tendon to its insertion on the bicipital tuberosity of the radius. Divide the biceps tendon by a Z lengthening (the Z should be as long as possible). Protect the radial artery, which crosses the palmar surface of the tendon near its insertion.
- Pass a folded wire suture or a curved suture carrier around the neck of the radius. Reroute the distal tendon segment so that it has a pronating torque by attaching it to the suture carrier (Fig. 165.19*C*).
- Reattach the distal tendon to the proximal tendon in a side-to-side fashion using nonabsorbable suture. The biceps tendon usually requires 1.5 cm of lengthening to be repaired after rerouting (110). Close the wound in layers and apply a long-arm cast in neutral forearm rotation, with the elbow flexed 90° (Fig. 165.19*D*, Fig. 165.19*E*).
- If biceps rerouting does not achieve adequate correction of the supination deformity, perform two-stage forearm osteoclasis any time after the rerouting has healed (Fig. 165.20).
- Perform the operation under general anesthesia, and use a tourniquet.
- Through small incisions, use a one-eighth-inch drill to make three bicortical drill holes in the middle third of the radius and ulna (Fig. 165.20*A*). Fracture the bones by manipulating the forearm (Fig. 165.20*B*). Do not rotate the distal fragment at this time, or the fragments will displace. Close the wounds.
- Place the arm in a long-arm cast, with the elbow at 90°.

After 10 to 14 days, under sedation or general anesthesia, remove the cast and manipulate the distal forearm to the desired position (0° to 40° of pronation) (Fig. 165.20*C*). Enough callus will have formed by this time that the fragments will not displace. Reapply the long-arm cast, with the elbow at 90° and the forearm in the desired position of rotation. Immobilize for 6 weeks after biceps rerouting. Focus the postoperative rehabilitation on active elbow flexion and extension, and forearm rotation. Then immobilize for 3 to 4 weeks after the second stage of forearm osteoclasis. Postoperative rehabilitation is not usually necessary.

#### *Other Surgical Techniques*

See Chapter 55 for the surgical technique for the wrist extension transfer, Chapter 56 for the opponensplasty, Chapter 101 for shoulder arthrodesis, and Chapter 72 for wrist arthrodesis.

### COMPLICATIONS

Most pitfalls related to brachial plexus exploration and nerve grafting occur in patient selection. If the surgeon underestimates the infant's potential for recovery, resection and grafting of the plexus may do more harm than good. If the surgeon waits too long to operate (after 1 year of age), the limited improvement achieved before surgery will be lost and may not be recovered.

Just as in nerve exploration and grafting, most pitfalls related to shoulder external rotation tendon transfer and rerouting occur in patient selection. If the deltoid is too weak, the tendon transfer will not improve range of motion. If the patient is unable to cooperate with postoperative therapy, the tendon transfer will probably not function as well. If the shoulder contracture is due to extensive glenohumeral changes, or if long-standing posterior shoulder dislocation is present, the tendon transfer will not improve range. The transverse axillary scar in this procedure is nearly invisible.

In a external rotation osteotomy of the humerus, if the elbow flexion contracture is severe (more than 45°), the patient will probably be unhappy with the position of the forearm after the humerus is rotated externally. With the shoulder internally rotated, the forearm can lie across the front of the body, but after an external rotation osteotomy, the forearm and hand will “stick out.” Also, the anterolateral arm scar widens and is quite noticeable.

Likewise, the anterior elbow scar from biceps rerouting and forearm osteoclasis often widens and is quite noticeable.

### CONCLUSIONS

BPBP is very distressing to parents, perhaps because of the etiology, that is, because it is an injury rather than a congenital malformation. BPBP is a common cause of malpractice claims against obstetricians. The well-documented increased risk of recurrent BPBP with subsequent pregnancies has not been featured in the obstetrics literature; we advise parents of this risk so they can pass this information along to their obstetrician.

Although most series show high rates of full recovery, these data are based on relatively short follow-up. We frequently see 3- to 4-year-old children with functional limitations from BPBP who were declared fully recovered at 3 to 6 months of age, before they could cooperate with a thorough active motion and strength examination. However, many children with slightly limited shoulder range of motion and strength can function almost normally, and even when function is limited, older children and parents may be bothered more by the decreased size of the extremity and length discrepancy than the decreased function.

## CONGENITAL TRANSVERSE FAILURE OF FORMATION OF THE UPPER EXTREMITY

### PATHOPHYSIOLOGY AND PRINCIPLES OF TREATMENT

Transverse failure of formation, often inaccurately termed “congenital amputation,” occurs when the upper limb fails to form below a certain level. Finger nubbins usually form at the distal end of the limb, regardless of level (Fig. 165.21); their presence helps differentiate this condition from congenital constriction ring syndrome, in which nubbins do not form (see Chapter 69).



***Figure 165.21.*** Nubbins at end of below elbow transverse failure of formation.

Transverse failure of formation is not inherited. The leading hypothesis for the etiology of transverse failure of formation is the subclavian artery supply disruption sequence theory: disruption of the embryonic subclavian blood supply causes transverse failure of formation, Poland anomaly, symbrachydactyly, Mobius syndrome, or other conditions, depending on the location of the blockage and the timing and duration of disruption (16,154,175). One study (86) showed evidence of fetal vascular occlusive disease in the placentas of infants with transverse failure of formation, and hypothesized that embolization from placental vascular thrombi caused this condition. Others (85,115) have found an increased incidence of transverse failure of formation and other limb defects in infants whose mothers underwent chorionic villus sampling before 10 weeks' gestation.

The most common level of transverse failure of formation is proximal forearm (below elbow), followed by transcarpal, distal forearm, and through humerus (above elbow) (181) (Fig. 165.22). This condition is almost always unilateral (148), and the left side is more commonly affected (91). Children with this condition have remarkably few functional deficits, and surgery has not been proven to improve their abilities (18). A prosthesis enhances prehension and possibly appearance but blocks sensory feedback. When indicated, goal-directed occupational therapy may help the school-aged child learn to perform activities of daily living with and without a prosthesis.

***Figure 165.22.*** **A:** Transcarpal transverse failure of formation with thumb nubbin. **B:** Long below-elbow transverse failure of formation. **C:** Short below-elbow transverse failure of formation. **D:** Through elbow amputation. **E:** Above-elbow transverse failure of formation.

**ASSESSMENT, INDICATIONS, AND RELATIVE RESULTS**

Transverse failure of formation is usually an isolated anomaly, but children with amelia (failure of formation at the shoulder level) have a high incidence of scoliosis (138) (Fig. 165.23). Cognition and developmental milestones are usually normal, except that the child with a very short arm may not crawl.

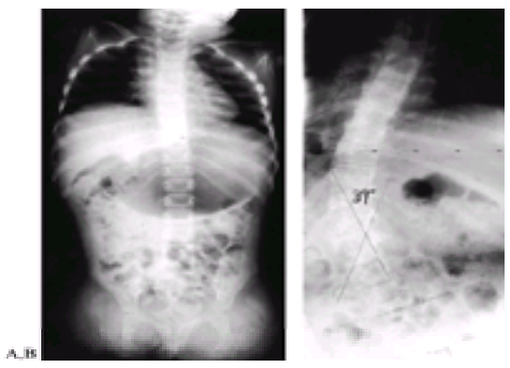

***Figure 165.23.*** Girl with transverse failure of formation of upper (and lower) extremities. **A:** Radiograph of the spine (the child was 2 years of age). **B:** Radiograph of the spine (12 years of age) with 39° scoliosis.

The child with above-elbow or below-elbow failure of formation should be assessed by a prosthetic team (which includes a physician, a prosthetist, and an occupational therapist, and may include a recreation therapist and social worker) at around 6 months of age, and fitted with a prosthesis with a passive hand or mitt when able to sit independently (91) (Fig. 165.24). Parents are encouraged to gradually increase wearing time until the child tolerates the prosthesis for the majority of the waking hours. Children with more proximal or distal failure of formation are not usually fitted with a prosthesis in infancy. If the deficiency is at shoulder level, the prosthesis is too heavy for comfortable wear; if the deficiency is at the distal forearm or through the carpus, the child functions better without a prosthesis (148).

***Figure 165.24.*** Passive below-elbow upper-extremity prosthesis.

Follow the child's condition closely (three to four times each year) to check prosthesis fit and reinforce the importance of regular wear. Children who are fitted with a prosthesis before 2 years of age are more likely to continue to use the prosthesis throughout childhood (148). To enhance acceptance and use of the prosthesis by the family and child, the prosthetic team may organize supervised play groups for children who use prostheses, and the prosthetist can fabricate dolls with prostheses (Fig. 165.25). At 2 to 3 years of age, evaluate the child for readiness for an active terminal device (TD). If the child readily bears weight on the passive prosthesis when crawling and uses it for pulling up, balance, and two-handed activities, such as throwing and catching, he or she is probably ready to learn to use an active TD.

***Figure 165.25.*** Doll with prosthesis.

At this point, the physician and parents choose between a body-powered (cable-operated) prosthesis, which works best with a hook or similar type TD, and a prosthesis powered by electrical signals from proximal forearm muscle contractions (myoelectric prosthesis), which usually has a TD that looks like a hand and uses a chuck pinch (Fig. 165.26 and Table 165.2). Each of these prostheses has advantages and disadvantages; fortunately, because the growing child needs a new prosthesis every 1 to 2 years, no choice is permanent. The body-powered hook prosthesis is more difficult to learn to use, but children who learn to use this type of prosthesis first can usually learn to use a myoelectric prosthesis easily. Children who learn to use a myoelectric prosthesis first have more difficulty learning to use a body-powered hook prosthesis. Most studies comparing performance of body-powered and myoelectric prostheses use a hand TD on both prostheses. The cosmetic glove used with this TD increases resistance to opening, which is easily overcome by the myoelectric motor but makes the body-powered prosthesis very difficult to use. In spite of this handicap, however, these studies show that children perform most tasks faster with the body-powered prosthesis (47), and consistent users of a body-powered prostheses are more likely to be pleased with prosthetic function (100). However, parents and older children are often influenced by the “high-tech” image of the myoelectric prosthesis and the fact that the TD most commonly used with this prosthesis looks like a hand.



***Figure 165.26.*** **A and B:** Body-powered hook prosthesis. **C and D:** Myoelectric hand prosthesis.

| | *Body powered* | *Myoelectric* |
|---|---|---|
| Weight | Lighter | Heavier |
| Speed | Faster | Slower |
| Strength | Weaker | Stronger |
| Noise | Quiet | Audible motor |
| Suspension | Figure 8 or 9 shoulder harness | No harness |
| Terminal device | Hook works best | Hand or hook |
| Maintenance | Infrequent, simple | Frequent, complex |
| Accommodation for growth | Growth liner can be removed when prosthesis becomes too small, extending prosthetic life | Can't use growth liners |
| Cost | $7000 | $15000 |

***Table 165.2. Comparison of Upper-Extremity Prostheses: Body vs. Myoelectric Power***

Forearm lengthening has been described for the very short below-elbow stump to improve prosthetic fitting (149); this is very rarely indicated. The Krukenberg procedure, in which the radius and ulna are separated and muscles reattached so that the radius pinches against the ulna, is most useful for blind bilateral distal forearm amputees, because it provides unilateral prehension with sensory feedback. This operation may occasionally be indicated for a sighted child with above-wrist failure of formation who does not have access to prosthetic facilities (34,69,157). However, because children with unilateral above-wrist failure of formation have very few functional deficits and the appearance of the Krukenberg forearm is strikingly abnormal, this operation is rarely indicated for the child with a unilateral deficiency.

## CLASSIFICATIONS

There is no classification system for transverse failure of formation other than level, which has been previously described.

## CONCLUSIONS

The biggest challenge in the treatment of children with transverse failure of formation is helping parents adjust their often unrealistically high expectations of prosthetic technology. The importance of good communication with the child and family cannot be overstressed. We focus on

- The remarkable abilities of the child with or without the prosthesis (most children with below-elbow failure of formation tell us that the only activity they cannot perform is traveling hand over hand on the monkey bars)
- The opportunity to try a different type of prosthesis when the child outgrows the current one.
- The need for improved prosthetic technology [well documented in a recent nationwide survey of upper-extremity prosthesis users (11)].
- The importance of maintaining the prosthesis so that the child can use it, and the responsibilities of the child, family, prosthetist, and physician in accomplishing this task.

We prefer to prescribe a body-powered hook TD prosthesis, but will prescribe a myoelectric prosthesis if the family strongly prefers it and has demonstrated that they can keep their clinic appointments and return promptly if the prosthesis breaks or if the child outgrows it. Older children who use a body-powered prosthesis may appreciate interchangeable TDs: a hook for function and a prosthetic hand when appearance is more important than function.

## CONGENITAL DISLOCATION OF THE RADIAL HEAD

### PATHOPHYSIOLOGY AND PRINCIPLES OF TREATMENT

Congenital dislocation of the radial head (CDRH) is the most common congenital anomaly of the elbow (1,9,125). Although the etiology of CDRH is unknown, it is known to be associated with dysplasia of the capitellum and proximal radius, as well as shortening of the ulna (95,125). In CDRH, the radial head may be dislocated in an anterior, posterior, or lateral direction; in one series, 47% were anterior, 43% posterior, and 10% lateral (9).

CDRH is usually bilateral (1,9,97,111,125). It may be isolated and either sporadic or familial, or it may be associated with congenital radioulnar synostosis (124), or with a syndrome, such as Klinefelter's, Cornelia de Lange, Ehlers–Danlos, and nail-patella syndrome (1,9,46,71,97,111,125,140,156). Not all cases are congenital; progressive subluxation of the radial head progressing to dislocation has also been reported (97).

### ASSESSMENT, INDICATIONS, AND RELATIVE RESULTS

CDRH may be noted in infancy but often escapes detection until the child is of school age (97). The presenting complaint is usually posterolateral elbow prominence, restricted elbow extension and forearm rotation, elbow “popping,” or pain with activity (1,95), although pain is uncommon before adolescence. Often, the limitations due to CDRH are first perceived after an unrelated elbow injury and may be erroneously attributed to that injury. When the condition is unilateral, CDRH may be difficult to distinguish from chronic traumatic dislocation (29) (Table 165.3).

| | Congenital | Traumatic |
|---|---|---|
| Anterior dislocation, radial head | | |
| Radial head | Head is dome shaped with no central depression | Head has normal shape with central depression |
| Ulna | Prime bow | Normal |
| Posterior dislocation, radial head | | |
| Radial head | Head is elongated & narrow | Head has normal shape with central depression |
| Ulna | Accentuated dorsal bow | Normal |
| Capitellum | Hypoplastic or absent | Normal |
| Bilateral | Common | Rare |
| Other anomalies | Common | Rare |
| Trauma | Possible | Necessary |

Data from Mankin-Rey, Glen T. Congenital Radial Head Dislocation. J Hand Surg 1979;4:104-110; and Kelly DW. Congenital Dislocation of the Radial Head: Spectrum and Natural History. J Pediatr Orthop 1981;1:256-258, with permission.

***Table 165.3. Congenital vs Traumatic Radial Head Dislocation***

The dislocated radial head is palpable just distal to the cubital fossa in anterior CDRH, and palpable and visible laterally in posterior CDRH (see Fig. 165.27 and Fig. 165.28). Elbow motion deficits are often minimal, usually nonprogressive, and worse in anterior than posterior CDRH. Loss of supination is the most prominent limitation in both anterior and posterior CDRH. Anterior CDRH blocks full flexion, and posterior CDRH blocks full extension, causing a flexion contracture (usually 30° or less). Wrist range of motion may also be limited (1,9,97,111). In the infant, the unossified dislocated radial head may be visualized with diagnostic ultrasound (14), but the diagnosis is most commonly made by plain radiography (Fig. 165.27 and Fig. 165.28).

***Figure 165.27.*** Anterior congenital dislocation of the radial head.

***Figure 165.28.*** AP and lateral views of a posterior dislocation of the radial head.

Surgical intervention is seldom necessary in childhood because most children are asymptomatic and have minimal functional limitations (46,125). Radial head resection before skeletal maturity has been associated with several different complications (see Complications, later). Surgical reduction of the radial head and reconstruction of the annular ligament or rotational radial and ulnar osteotomies have not been consistently successful (9,124,125). In adolescence or adulthood, the laterally or posteriorly dislocated radial head may become painful owing to degenerative changes at the contact point between the radial head and the distal humerus; radial head excision relieves pain, improves appearance, and may improve range of motion (29,97).

### CLASSIFICATIONS

CDRH is classified by the direction of the dislocation, as previously described.

### PREOPERATIVE PLANNING

Examine the wrist for distal radioulnar joint (DRUJ) instability, and obtain bilateral wrist radiographs before radial head resection. If the DRUJ is unstable and the symptomatic side is ulna positive, resection of the radial head may cause wrist pain.

### OPERATIVE TECHNIQUE

***Resection of the Radial Head (Posterior or Lateral Dislocation)***

- Perform the operation under general anesthesia, and use a tourniquet.
- Make a longitudinal incision using a Kocher approach over the dislocated radial head. Develop the interval between the extensor carpi ulnaris and anconeus muscles.
- Incise the capsule with the forearm in maximal pronation, and do not extend the capsular incision distal to the radial neck, to avoid injuring the posterior interosseous nerve. Preserve the annular ligament to enhance proximal radius stability and protect the posterior interosseous nerve. Avoid violating the periosteum of the proximal ulna to prevent radioulnar synostosis.
- Excise the radial head with an oscillating saw, osteotome, or rongeur perpendicular to the radial neck. Check elbow flexion and extension and forearm pronation and supination to make sure that the proximal radius does not contact the distal humerus; if it does, resect more until it moves freely. Remove any loose intra-articular osteochondral fragments.
- Close the capsule with nonabsorbable suture. Close the subcutaneous tissue with interrupted absorbable suture, and close the skin with running subcuticular suture.
- Immobilize the elbow at 90° of flexion in a long-arm splint.

Remove the splint after 7 to 10 days, and begin early range-of-motion exercises.

### COMPLICATIONS

If radial head resection is performed before skeletal maturity, several complications can occur, including regrowth of the proximal radius, postoperative radioulnar synostosis (29), and cubitus valgus deformity. However, radial head resection for a variety of indications, including CDRH, did not cause cubitus valgus in 27 elbows of 25 children with an average age of 14 years (range 5 to 18 years) (87). Other potential complications include injury to the posterior interosseous nerve, radioulnar synostosis, proximal migration of the radius, valgus elbow instability, cubitus valgus, and wrist pain (9,29,97,111).

### CONCLUSIONS

If the dislocated radial head rubs against the distal humerus, painful degenerative changes can occur. Radial head resection reliably relieves pain and is sometimes necessary, even when the DRUJ is unstable. When wrist pain occurs following radial head resection for CDRH, it is usually mild and activity related.

## CONGENITAL ELEVATION OF THE SCAPULA (SPRENGEL'S DEFORMITY)

### PATHOPHYSIOLOGY AND PRINCIPLES OF TREATMENT

Congenital elevation of the scapula results from a failure of the normal caudal migration of the scapula during the fetal period of development (32,48). The scapula with this malformation is usually hypoplastic with decreased vertical length and increased horizontal width-to-height ratio (27), which is 2 to 10 cm more cephalad than normal (Fig. 165.29). The inferior pole is rotated medially with the glenoid displaced inferiorly. The periscapular muscles may be hypoplastic or absent, causing scapular winging (32,33). In 20% to 30% of cases, the superomedial scapula is connected to the spinous processes, laminae, or transverse processes by a fibrous tissue, cartilage, or bone called the omovertebral connection; this connection is diagnostic of congenital elevation of the scapula (27,32,33). Right and left sides are affected with equal frequency, and bilateral involvement occurs in 10% to 30% of the cases (168).

***Figure 165.29.*** Congenital elevation of the scapula.

The majority of patients with congenital elevation of the scapula have associated anomalies, most commonly congenital scoliosis, Klippel-Feil syndrome, fused or absent ribs, spina bifida, and VATER association (17,27,32,33).

This condition is usually treated nonoperatively, except for resection of the omovertebral connection. Surgical mobilization and caudal repositioning of the scapula have been recommended, but most children with congenital elevation of the scapula do not need surgical treatment (168).

### ASSESSMENT, INDICATIONS, AND RELATIVE RESULTS

Children usually present with evaluation of scapular asymmetry, diminished shoulder motion, and fullness at the base of the neck. The affected scapula appears to be elevated and hypoplastic. Shoulder abduction is significantly limited in 40% of patients, and elevation is often limited (33,73). Basilar neck fullness is due to the prominence of the superomedial angle of the scapula (32). Congenital elevation of the scapula is usually not painful.

Differential diagnosis includes brachial plexus birth palsy and isolated scoliosis or Klippel-Feil syndrome (33). An anteroposterior (AP) radiograph of the shoulder demonstrates scapular elevation, especially when compared with the contralateral normal side. A bony omovertebral connection may be seen on the AP view (Fig. 165.30) or on lateral oblique views and CT scan. Examine the child for scoliosis and other associated anomalies.

***Figure 165.30.*** Bony omovertebral connection.

Function may be limited by decreased shoulder abduction, but many children with this condition have excellent shoulder function. Passive stretching and abduction early in infancy may improve shoulder range of motion, and removal of an omovertebral connection may also improve range of motion.

The cosmetic deformity and degree of disability are proportional to the severity of deformity; children with mild grade 1 to grade 2 elevation (see next section, on classifications and terminology) have little functional impairment.

For more severe malformations with functional impairment, surgical repositioning of the scapula may be indicated in addition to resection of the omovertebral connection, with the goal of improving appearance and range of motion. Various methods of scapular mobilization have been described. Woodward (180) recommended moving the trapezius and rhomboid muscle origins to a more caudal position along the spine. Borges et al. (27) modified Woodward's procedure to include excision of the superomedial scapular prominence, to improve appearance. Clavicular osteotomy is recommended to allow further scapular descent and prevent damage to the brachial plexus (27,33,67).

One long-term study (67) of 23 patients who underwent four different operations for congenital elevation of the scapula found that the average reduction of elevation was 2.7 cm, and average improvement in abduction was 19 degrees for repositioning procedures, with the best results in patients who underwent Woodward's procedure. Optimal age for surgery is probably between 3 and 8 years of age (32,68). Good results of scapular mobilization have been reported in older patients, but with less functional improvement (27). Normal appearance and function should not be expected at any age (33).

**CLASSIFICATIONS AND TERMINOLOGY**

Although congenital elevation of the scapula is commonly called Sprengel's deformity, it is actually a malformation instead of a deformity (see Chapter 69). The condition has been classified by severity (Table 165.4). This classification helps the surgeon determine treatment and prognosis and evaluate the postoperative result (33).

| *Grade* | *Description* |
|---|---|
| 1 | Very mild; shoulders are level; deformity is not visible when patient is dressed |
| 2 | Mild; shoulder joints are almost level; deformity visible as lump in web of neck |
| 3 | Moderate; affected shoulder elevated 2–5 cm; deformity is easily visible |
| 4 | Severe; superior angle of scapula near occiput |

From Cavendish ME. Congenital Elevation of the Scapula. *J Bone Joint Surg BR* 1972;54:395, with permission.

***Table 165.4. Classification of Congenital Elevation of the Scapula***

**OPERATIVE TECHNIQUES**

***Resection of Omovertebral Connection***

Figure 165-31 is an intraoperative photo of a resection of an omovertebral connection for the same patient whose radiograph is shown in Figure 165-30. The surgical procedure is as follows:

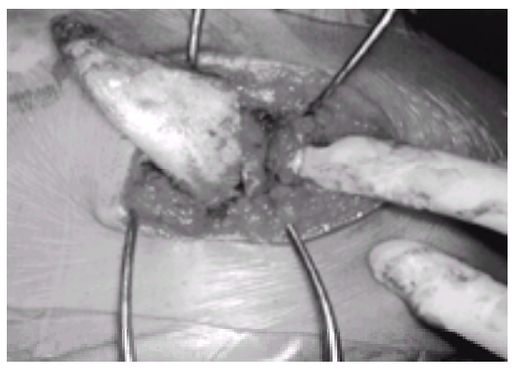

***Figure 165.31.*** Intraoperative view of resection of omovertebral connection (same patient as in Fig. 165.30).

- Place the patient in the prone or lateral decubitus position with the affected side up.
- Place the incision directly over the omovertebral connection, in a transverse direction, if possible. Inject skin and subcutaneous tissue with bupivacaine and epinephrine; this provides pre-emptive analgesia and improves hemostasis.
- Expose and transect the connection at its scapular and spinous connections, and remove it.
- Close the incision in layers, and immobilize the arm in a sling or shoulder immobilizer.

Allow normal use of the shoulder as soon as postoperative pain has diminished.

***Surgical Repositioning of the Scapula***

This operation is rarely indicated, and its description is beyond the scope if this text. For details, please see Woodward (180), Wilkinson and Campbell (177), Klisic et al. (99), and Borges et al. (27).

**COMPLICATIONS**

Complications of omovertebral resection are uncommon. Complications of surgical repositioning of the scapula include scar widening and residual scapular elevation (27,32,33,177,180). Brachial plexus and vascular injury can occur (27); clavicular osteotomy (or morcellation) may prevent neurovascular injury with scapular repositioning (142). In addition, the suprascapular nerve may be injured with resection of the superior scapula.

**CONCLUSIONS**

Resection of the omovertebral connection is simple and usually improves appearance and range of motion. Scapular repositioning, a major operation with considerable risk of neurovascular injury and a good possibility of inadequate correction, is rarely indicated.

## CONGENITAL PSEUDARTHROSIS OF THE CLAVICLE

### PATHOPHYSIOLOGY AND PRINCIPLES OF TREATMENT

Congenital pseudarthrosis of the clavicle is a rare anomaly that results from failure of normal clavicular ossification (8,82,131). The etiology is unknown; one hypothesis suggests that the subclavian artery may compress the developing right clavicle, which might explain the predominance of right-sided lesions and the occurrence of left-sided lesions in association with dextrocardia. Bilateral involvement is rare (57,107,163). Another hypothesis is that the pseudarthrosis is caused by the failure of two ossification centers to fuse (82), but the normal clavicle in the developing embryo has only one ossifcation center (146). Unlike congenital pseudarthrosis of the tibia and ulna, this condition is not associated with neurofibromatosis, although it may be inherited in an autosomal recessive fashion (8,57,146).

This condition does not usually require surgical treatment, and historically surgery for clavicular pseudarthrosis has had a high rate of serious complications (8,68,131,163). Surgical resection of the pseudarthrosis and internal fixation may be indicated if the pseudarthrosis is very prominent or painful.

### ASSESSMENT, INDICATIONS, AND RELATIVE RESULTS

Children with this rare condition are often noted to have a prominent middle third of the right clavicle at birth or soon thereafter; the prominence may increase with age (146). The pseudarthrosis is usually not painful, and shoulder range of motion is normal. Radiographs of the pseudarthrosis reveal an osseous separation with enlarged, rounded bone ends, and a distinctive absence of fracture callus (Fig. 165.32). Although case reports indicate that the natural history of pseudarthrosis of the clavicle is benign (151), no large series of cases has been reported.

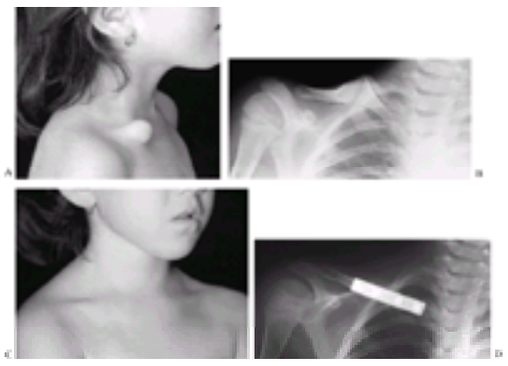

***Figure 165.32.*** Congenital pseudarthrosis of the clavicle. **A:** Preoperative photo. **B:** Preoperative radiograph (pseudarthrosis outlined). **C:** Postoperative photo. **D:** Postoperative radiograph.

Differential diagnosis includes traumatic clavicle fracture (a common birth injury, which is accompanied by pseudoparalysis of the involved limb, painful range of motion, and radiographic callus) and cleidocraniodysostosis (a bilateral inherited disorder of fetal membranous bone ossification, with clavicle, cranial, and pelvic dysplasia) (2,8,68,131,146,168).

Occasionally the pseudarthrosis is so prominent that surgical removal and repair with internal fixation is indicated (Fig. 165.32). Multiple complications of surgery have been reported, including sepsis, nonunion, and brachial plexus injury (8,163). Simple excision of the clavicular prominence without internal fixation or any attempt to obtain union is generally recommended in the postpubertal patient who wishes to improve appearance. In prepubertal children, most authors who advocate surgical treatment recommend excision of the pseudarthrosis, bone grafting, and plating (8,57,68,82,131,146).

### CLASSIFICATIONS

There are no classification systems for congenital pseudarthrosis of the clavicle.

### OPERATIVE TECHNIQUE

#### *Pseudarthrosis Resection and Bone Grafting*

- Position the patient supine, with a pad under the affected scapula.
- Incise the skin longitudinally along the inferior clavicular border, and expose the pseudarthrosis.
- Incise the periosteum longitudinally. Resect the pseudarthrosis subperiosteally. Measure the defect.
- Obtain autologous corticocancellous iliac crest bone graft to span the clavicular defect created by resection of the pseudarthrosis, if necessary.
- Internally fix the clavicle with a semitubular or small low-profile dynamic compression plate. Avoid inferior placement of the plate or graft, which could cause subclavian vessel or brachial plexus injury (the subclavian artery passes between the clavicle and first rib immediately deep to the clavicular defect) (146).
- Close the incision in layers, and immobilize the arm in a sling.

Remove the sling 6 weeks after pseudarthrosis and grafting. The osteotomy sites are difficult to see on radiographs. If the plate or screws are prominent, they should be removed after osteosynthesis has occurred.

### COMPLICATIONS

Many complications of pseudarthrosis resection, grafting, and plating have been described, including hypertrophic scar formation, infection, nonunion, neurovascular injury, and bone graft donor site morbidity (8,131). Steinmann pin fixation should never be used because it provides inadequate fixation and pins have been reported to migrate or cause neurologic injury (163). Simple excision of the pseudarthrosis without bone graft or internal fixation causes the affected shoulder to droop (68,131).

### CONCLUSIONS

Surgical treatment of this condition is indicated only when the malformation is conspicuous and bothersome to the patient or the patient's parents. As with any elective operation, the patient and the parents must fully understand the potential risks. Resection, grafting, and plating can improve the patient's appearance considerably in this condition.

## CONGENITAL PSEUDARTHOSIS OF THE ULNA

### PATHOPHYSIOLOGY AND PRINCIPLES OF TREATMENT

Congenital pseudarthrosis of the ulna is a very rare condition that is usually associated with neurofibromatosis (114). Pseudarthrosis may be present at birth, or it may develop spontaneously after a fracture or after osteotomy; it has been reported to occur in the tibia, ulna, femur, clavicle, radius, and humerus (40). The etiology of congenital pseudarthrosis is unknown; in the majority of cases, the pseudarthrosis contains fibrous tissue, not neurofibroma (40) (see Chapter 169).

Congenital pseudarthrosis of the ulna causes a progressive forearm deformity. The forearm is short and bowed, and eventually the radial head dislocates (114) (Fig. 165.33). The goal of treatment is to obtain union without sacrificing motion.

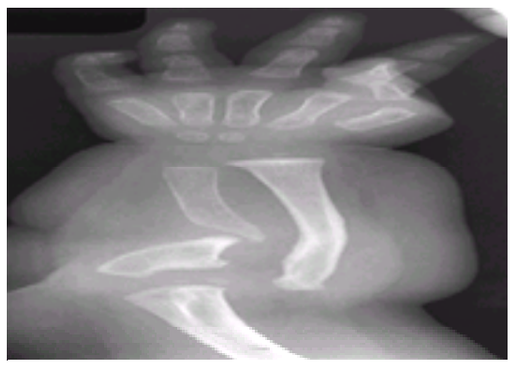

***Figure 165.33.*** Congenital pseudarthrosis of the ulna.

### ASSESSMENT, INDICATIONS, AND RELATIVE RESULTS

Pseudarthrosis of the ulna causes deformity, instability, weakness, and sometimes pain, although motion is usually not limited. Like the same condition in the tibia, union can be achieved with bone grafting and immobilization, but pseudarthrosis usually recurs. Historically, creation of a one-bone forearm was the only option available. This operation successfully restores forearm stability (169) but eliminates forearm rotation. Although the Ilizarov technique may successfully restore union in tibial pseudarthrosis (132), the use of prolonged immobilization and differential lengthening of the forearm bones is also likely to result in loss of forearm rotation.

Several authors (54,114,116,183) have reported treating ulnar pseudarthrosis with free vascularized fibular graft; in most cases, union was achieved, length was maintained, and forearm rotation was diminished but not completely lost. The indications for vascularized fibular graft, including the optimal age of the patient, have not yet been established, but this technique is promising.

### CLASSIFICATIONS

There is no classification system for congenital pseudarthrosis of the ulna.

### PREOPERATIVE PLANNING

When a free vascularized fibular graft is planned, preoperative arteriograms of the donor and recipient sites help identify possible vascular abnormalities (54).

### OPERATIVE TECHNIQUE

#### *Free Vascularized Fibular Graft to the Ulnar Pseudarthrosis*

Gerwin and Weiland (54) discuss this technique. See Chapter 36 for the surgical technique of harvesting a free fibular graft.

- Resect the pseudarthrosis and fix the graft in place using short plates at the proximal and distal ends, before performing vascular anastomoses. Avoid using intramedullary fixation or a long plate that spans both ends of the graft because these fixation methods interfere with graft vascularity.
- Use an end-to-side anastomosis in the forearm, if possible, to minimize reduction of hand perfusion.
- Use a supplemental cancellous bone graft at each end of the fibular graft to enhance union.

Allow ambulation 3 to 5 days after surgery in a short-leg walking cast, which can be removed after 3 to 4 weeks. Immobilize the arm with a long-arm cast and check radiographs out of plaster every 6 weeks. Continue immobilization until graft incorporation is seen on radiographs; the average time to graft incorporation is 3 to 6 months.

### COMPLICATIONS

Union may be difficult to achieve, and subsequent regrafting with cancellous allograft may be necessary. Even after union is achieved, pseudarthrosis may recur. If painful pseudarthrosis recurs and regrafting fails, creation of a one-bone forearm is the only remaining surgical option.

### CONCLUSIONS

Because this condition is so rare, the indications for vascularized fibula grafting are not well established, and follow-up to skeletal maturity is lacking. The best indications probably are pain and progressive deformity.

## CONGENITAL PROXIMAL RADIOULNAR SYNOSTOSIS

### PATHOPHYSIOLOGY AND PRINCIPLES OF TREATMENT

Congenital proximal radioulnar synostosis (PRUS) is a malformation caused by failure of normal prenatal separation of the radius and ulna. The persistent connection between the two bones is nearly always proximal; distal radioulnar synostosis is extremely rare (15,96,144,152,173). The connection is initially cartilaginous, but it usually eventually ossifies, forming a bony synostosis (Fig. 165.34). The forearm is usually fixed in pronation, probably because this is the normal fetal position (96,173).

***Figure 165.34.*** Proximal radioulnar synostosis.

PRUS is usually an isolated malformation, but it may be associated with other malformations or syndromes in up to one third of affected children (152). Other malformations associated with PRUS include thumb hypoplasia, carpal coalition, symphalangism, and clubfoot (124); syndromes associated with PRUS include Apert's syndrome, arthrogryposis, fetal alcohol syndrome, and Klinefelter's syndrome (98,152,165,166). Familial occurrence (37,71) with autosomal dominant inheritance (141) has also been reported.

### ASSESSMENT, INDICATIONS, AND RELATIVE RESULTS

Children with PRUS usually present between 2.5 and 6 years of age with painless limitation of forearm rotation and a slight flexion contracture (37,152), although occasionally PRUS is not noted until adolescence (71). Typically, a parent or teacher notices that the child has difficulty positioning the hand to catch a ball, drink from a cup, or accept small objects in an open palm and tends to hold objects in a backhanded, or hyperpronated, position. Bilateral involvement (60% to 80%) (129,152) and fixation in more than 60° of pronation (up to 40%) (152) are usually noted earlier because they cause more significant impairment.

On examination, children with PRUS have an elbow flexion contracture, altered carrying angle, and short forearm in addition to a fixed forearm pronation deformity (129,144,152). Children with PRUS partially compensate for lack of forearm rotation by developing rotational hypermobility at the wrist and positioning the shoulder in internal rotation, flexion, and abduction (37,65,129).

PRUS usually does not cause significant functional impairment (15). In one study of the natural history of untreated PRUS (37), 96% of patients had mild or no limitations in daily activities regardless of forearm position, and the authors concluded that treatment of PRUS is rarely indicated. Other authors (157) consider fixed pronation between 15° and 60° a relative indication, and forearm fixation in greater that 60° pronation a definite indication for surgery, if functional limitations are significant.

Surgery to regain forearm rotation has nearly always been unsuccessful (126), although recently a free vascularized fascial flap placed between the separated forearm bones has been reported to successfully block postoperative recurrence of the synostosis (93). At present, however, the generally accepted surgical treatment is derotation osteotomy through the fusion mass, using K-wires or small Steinmann pins to fix the osteotomy (65,126,129,152). Others have described gradual correction to neutral following osteotomy, using the Ilizarov method (25), and two-stage osteoclasis without internal fixation (105).

The optimal position of the forearm is controversial because the best position of rotation varies with the task. Some surgeons recommend placement of the dominant forearm in 10° to 20° of pronation, and the nondominant forearm in neutral rotation, if necessary; and for unilateral PRUS, placement in 0° to 15° of pronation (152). Others (65,126) advocate placing the nondominant forearm in 20° to 35° of supination first, and the dominant forearm in 30° to 45° only, if necessary; and for unilateral involvement, 0° to 20° supination.

### CLASSIFICATION

Radiographic classification based on radial head position and the presence of a radioulnar synostosis does not predict function (37). PRUS is part of a spectrum of malformations ranging from radial head abnormalities to complete synostosis with marked forearm shortening and absence of the radial head (124,152), although these have not been formally divided into types.

### PREOPERATIVE PLANNING

Preoperative evaluation by an occupational therapist helps determine the child's functional deficits and optimal forearm position. If possible, surgery should be performed before school age (152), but this timing precludes considering the child's future intended occupation to determine the optimal forearm position, as recommended by some surgeons (37).

### OPERATIVE TECHNIQUE

#### *Rotational Osteotomy*

Green and Mital (65) discuss surgical treatment of congenital radioulnar syntosis. The general surgical technique follows:

- Perform the operation under general anesthesia and a tourniquet.
- Make a dorsal longitudinal incision just radial to the subcutaneous border of the ulna. Incise the fascia in the interval between the anconeus and extensor carpi ulnaris muscles (Kocher approach). Expose the fusion mass subperiosteally.
- Pass a smooth K-wire from the olecranon apophysis into the intramedullary canal of the ulna under fluoroscopic guidance. This wire helps maintain longitudinal position while allowing adjustment of rotation.
- Make a mark across the osteotomy site to determine rotation. Perform the osteotomy around the wire, using multiple drill holes and an osteotome or oscillating saw. The osteotomy should be distal to the coronoid and radial head (if present).
- Rotate the forearm to the desired position and transfix the osteotomy site with a K-wire, passing obliquely from proximal ulna to distal radius. Leave the end of this wire through the skin to facilitate urgent removal for postoperative derotation if vascular compromise occurs.
- If a large change in forearm rotation is necessary, consider resecting 5 mm of bone at the osteotomy site (129), prophylactic forearm fasciotomy (152), or two-stage derotation to decrease the risk of postoperative neurovascular traction or compartment syndrome.
- Close the subcutaneous tissues and skin, and place the arm in a splint or long-arm cast with the elbow flexed to 90°.

Keep the forearm elevated and monitor the patient's neurovascular status closely for at least 48 hours postoperatively. If a long-arm splint was applied, change to a long-arm cast after 1 to 2 weeks. Remove the cast 6 weeks postoperatively to check forearm radiographs. Remove pins when the forearm bones show signs of healing. Therapy is not usually necessary.

### COMPLICATIONS

The complication rate for forearm rotational osteotomy was 36% in one series (152), and the reoperation rate was 23% in another (65). The most serious complications are vascular compromise and compartment syndrome, which occur more frequently with rotational position change of greater than 85°. If this much correction is needed, obtain it in two stages. If either of these complications occur, remove the transfixion pin and return the forearm to its original position; if forearm compartment pressures are elevated, perform fasciotomies (see Chapter 13). Rotational correction can be reachieved 5 to 10 days later (152). Other complications include nerve palsy (due to either intraoperative damage to the posterior interosseous nerve or traction from rotational change), wound infection, loss of correction, and nonunion (37,105,129,152).

### CONCLUSIONS

In our experience, children with PRUS associated with fetal alcohol syndrome have more severe pronation contractures than most other children with PRUS. Children with fetal alcohol syndrome are often mentally retarded, and they may be unable to describe symptoms of nerve traction following rotational osteotomy.

## ELBOW AND FOREARM DEFORMITY DUE TO MULTIPLE HEREDITARY EXOSTOSES

### PATHOPHYSIOLOGY AND PRINCIPLES OF TREATMENT

Multiple hereditary exostoses (MHE) is a disorder of enchondral bone growth in which cartilaginous exostoses (also called osteochondromas) grow from the physes of long bones and from the pelvis, ribs, scapula, and vertebrae (10,135). The exostoses may be sessile or pedunculated (Fig. 165.35). They grow until the patient is skeletally mature and eventually ossify. The forearm is affected in 30% to 67% of patients with this condition (22,89,145), and the proximal humerus is also commonly involved (Fig. 165.36).

***Figure 165.35.*** Multiple hereditary exostoses. **A:** Forearm, with distal ulna growth arrest and radial head dislocation. **B:** Proximal humeral exostosis.

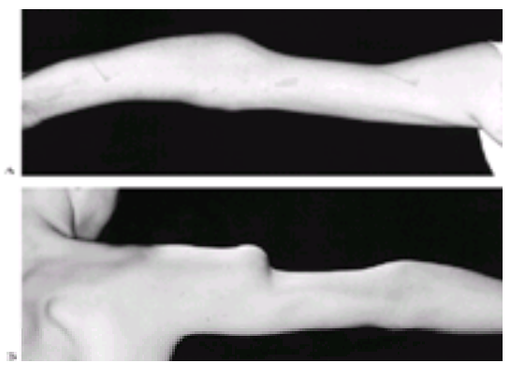

***Figure 165.36.*** Multiple hereditary exostoses. Forearm deformity associated with radial head dislocation (same patient as in Fig. 165.35*A*).

The prevalence of MHE is approximately 1 in 50,000 (145). MHE is inherited in an autosomal dominant pattern with high penetrance (145) and variable expressivity. Although MHE has an equal prevalence in both sexes, boys tend to have more severe involvement (120). Genetic studies of families with this condition have mapped the chromosomal abnormality to at least three different loci (119,120), indicating that the MHE phenotype can be subdivided into at least three different genotypes. Multiple exostoses also occur in other conditions, such as metachondromatosis and the Langer–Giedion syndrome (120).

Estimates of the risk of malignant degeneration of osteochondromas (secondary chondrosarcoma) in MHE vary from 0.5% to 50% of patients; the lower incidence is most likely correct. Malignant degeneration is quite rare in the upper extremity; the pelvis and proximal femur are the most common locations of secondary chondrosarcoma (159). Malignant degeneration in children is also very rare (120,135).

Most exostoses are asymptomatic and do not need to be surgically removed; exostoses removed before skeletal maturity may recur. However, exostoses can cause local discomfort, nerve or tendon impingement, decreased range of motion, and longitudinal and angulatory growth abnormalities (135). Growth abnormalities may also occur in MHE in the absence of radiologically visible exostoses (24).

**ASSESSMENT, INDICATIONS, AND RELATIVE RESULTS**

The patient's history of local pain, crepitance, or decreased range of motion, combined with a clinical examination for bony bumps of the upper extremity, helps the physician determine which areas to radiograph. Most exostoses have a cartilage cap and, therefore, are larger than their radiograph appearance suggests.

Local pain, often due to nerve, tendon, or vessel impingement, is a frequent indication for exostosis removal. Subscapular exostoses are common but do not usually cause pain or require removal. Proximal humeral exostoses may impinge on muscle tissue, the brachial plexus, or the axillary nerve, causing pain, paresthesias, or paresis; exostoses of the distal radius and ulna may impinge on the dorsal radial sensory, median, or ulnar nerves or the radial or ulnar arteries. These are indications for surgical removal, which effectively relieves symptoms of impingement (135). An exostosis in the interosseous space that is blocking forearm rotation should also be removed. Recurrence is unlikely if the patient is near skeletal maturity.

The forearm deformities caused by growth arrest due to MHE are complex, and their interrelationships are not well understood. Distal ulnar growth arrest is a common sequelae of MHE, even when osteochondromas of the distal ulna are not visible on radiographs. The radial articular angle may increase, and the carpus may “slip” ulnarward, but neither of these findings appears to be associated with negative ulnar variance (28). Radius bowing, radial head dislocation (179) (Fig. 165.35), and forearm shortening also occur, causing loss of forearm rotation.

Early osteochondroma removal may (113,135) or may not (51) retard these progressive growth disturbances. Hemiepiphyseal stapling of the radial side of the distal radius retards the growth of that side while allowing the ulnar side to continue to grow, which corrects the increased radial articular angle (179) (Fig. 165.37). This procedure may be performed in conjunction with ulnar lengthening (51,135). Resection of a dislocated radial head relieves pain and removes the associated prominence (10,113) but probably does not improve forearm rotation significantly. This procedure should be reserved for skeletally mature patients because removal of the radial head in the growing child may cause cubitus valgus or proximal radial overgrowth (95,97). Single-stage ulnar lengthening with or without radial osteotomy can be performed (179), or using the Ilizarov technique, the ulna and radius can be differentially lengthened, radial bowing corrected, and the dislocated radial head reduced (42) (Fig. 165.38). Differential lengthening requires several months of external fixation and may diminish forearm rotation. Finally, radioulnar fusion may be performed as a salvage procedure (143).

***Figure 165.37.*** Correction of increased radial articulation angle (radial tilt) in multiple hereditary exostoses by hemiepiphyseal stapling. **A:** Forty-two degree radial tilt, immediately following distal radial stapling. **B:** Twenty-nine degree tilt, 2 years following distal radial stapling.

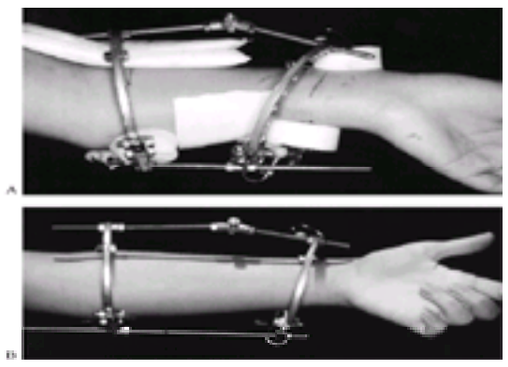

***Figure 165.38.*** Differential radius and ulna lengthening for multiple hereditary exostoses. **A:** After application of Ilizarov fixator, before initiation of lengthening. **B:** After lengthening.

Two recent studies show that skeletally mature people with untreated forearm deformities due to MHE maintain function are comfortable with their appearance (10,155). The authors of these studies recommend a less aggressive approach to surgical treatment of the forearm in MHE. They point out that relatively simple procedures, such as removal of symptomatic osteochondromas and dislocated radial heads, can improve appearance and relieve pain, but no surgical treatment has been shown to improve forearm function in MHE.

One final indication for surgery in MHE is an enlarging osteochondroma in a skeletally mature person because this condition may be a sign of malignant degeneration.

## CLASSIFICATIONS AND TERMINOLOGY

Many different names have been used to describe MHE, including multiple cartilaginous exostoses, diaphyseal aclasis, dyschondroplasia, hereditary deforming chondrodysplasia (89,179), and osteochondromatosis. The individual tumors may be called exostoses or osteochondromas. MHE is frequently confused with multiple enchondromatosis (Ollier's disease), an entirely different condition (89).

Two different classification systems have been described for forearm deformity caused by MHE. In the first, type I forearms are the most common type (24,113) (Table 165.5).

| Type | Ulna | Radius |
|---|---|---|
| I | Short, with distal osteochondromas | Bowed |
| IIa | Short, with distal osteochondromas | Radial head dislocated, with proximal osteochondroma |
| IIb | Short, with distal osteochondromas | Radial head dislocation |
| III | Relatively unaffected | Short, with distal osteochondromas |

From Bado CW, Reed MH. Forearm Deformities in Multiple Cartilaginous Exostoses. *Skeletal Radiol* 1991;20:485-488, and Masada K, Tsuyuguchi Y, Kawai H, et al. Operation for Forearm Deformity Caused by Multiple Osteochondromas. *J Bone Joint Surg* 1989;71:204-20, with permission.

***Table 165.5. Classification of the Forearm with Multiple Hereditary Exostoses***

In the second classification system (159), forearm involvement is used as an index of overall disease severity (Table 165.6). Group III, with forearm shortening, had earlier initial symptoms, more frequent lower extremity deformity, a higher number of osteochondromas, and a shorter height; the authors hypothesize, but do not prove, that group III patients may be at higher risk of malignant degeneration.

| *Group* | *Distal forearm* | *Forearm shortening* |
|---|---|---|
| I | Not involved | No |
| II | Radius or ulna involved | No |
| III | Radius or ulna involved | Yes |

From Taniguchi K. A Practical Classification System for multiple Cartilaginous Exostoses in Children. *J Pediatr Orthop* 1995;15:585, with permission.

***Table 165.6. Classification of Forearm Involvement as an Index of Overall Disease Severity in Multiple Hereditary Exostoses***

## OPERATIVE TECHNIQUES

### *Removal of Osteochondroma (Proximal Humerus or Distal Forearm)*

- Perform the operation under a tourniquet, if possible.
- Approach the osteochondroma through a longitudinal incision, centered over the tumor.
- Use the most readily available anatomic interval. Usually the osteochondroma splits the surrounding structures, and approach is not difficult. Watch for nerves or vessels wrapped around the pedicle of the tumor, or a nerve flattened over its surface.
- Remove the entire tumor, leaving a smooth contour.

Postoperatively, a soft dressing and wrist splint for 2 to 3 weeks is adequate immobilization.

### *Distal Radius Hemiepiphyseal Stapling*

- Perform the operation under a tourniquet, with fluoroscopic guidance.
- Approach the radial aspect of the distal radial physis through a longitudinal incision. Find and protect the dorsal radial sensory nerve.
- Under fluoroscopic guidance, place three extraperiosteal epiphyseal staples across the distal radial physis: one directly radial, one slightly palmar, and one slightly dorsal, all outside of the first dorsal compartment.

A soft dressing and wrist splint for 2 to 3 weeks postoperatively is adequate immobilization. Obtain radiographs of the distal radius twice a year, and remove the staples when the desired amount of radial tilt (usually 20°) is attained.

### *Radial Head Excision (Posterolateral Dislocation)*

This technique is discussed in Chapter 16.

### *Differential Forearm Lengthening*

This complex operation is rarely indicated and beyond the scope of this text. See Dahl (42) for a detailed description of planning osteotomies, designing fixation, ulnar lengthening and angular correction, and radial head reduction.

## COMPLICATIONS

If the periosteum and physis are disrupted during insertion of hemiepiphyseal staples, permanent physeal arrest and overcorrection could occur. Hemiepiphyseal staples usually require removal at the end of growth, if not sooner, because of adequate correction or local irritation.

## CONCLUSIONS

Hemiepiphyseal stapling and removal of osteochondromas and the radial head are simple operations with good results. We measure forearm rotation twice a year for children with MHE with forearm involvement, and consider progressive loss of forearm rotation an indication for osteochondroma removal.

## ACKNOWLEDGMENTS

The authors thank Deanna Simonis, medical librarian, Shriners Hospital Northern California, for her assistance with references, and Julia Serat, photographer, Shriners Hospital Northern California, for her assistance with clinical photographs and radiographic studies.

## CHAPTER REFERENCES

Each reference is categorized according to the following scheme: *, classic article; #, review article; !, basic research article; and +, clinical results/outcome study.


+ 1. Agnew DK, Davis RJ. Congenital Unilateral Dislocation of the Radial Head. *J Pediatr Orthop* 1993;13:526.

* 2. Ahmadi B. Steel HH. Congenital Pseudarthrosis of the Clavicle. *Clin Orthop* 1977;126:129.

* 3. Aitken J. Deformity of the Elbow Joint as a Sequel to Erb's Obstetrical Paralysis. *J Bone Joint Surg* 1952;34B:352.

+ 4. Al-Qattan MM, Al-Kharfy TM. Obstetric Brachial Plexus Injury in Subsequent Deliveries. *Ann Plast Surg* 1996;37:545.

+ 5. Al-Qattan MM, Clarke HM, Curtis CG. The Prognostic Value of Concurrent Clavicular Fractures in Newborns with Obstetrical Brachial Plexus Palsy. *J Hand Surg* 1994;19B:729.

+ 6. Al-Qattan MM, Clarke HM, Curtis CG. Klumpke's Birth Palsy: Does in Really Exist? *J Hand Surg* 1995;20B:19.

+ 7. Al-Qattan MM, el-Sayed AA, Al-Kharfy TM, al-Jurayyan NA. Obstetrical Brachial Plexus Injury in Newborn Babies Delivered by Caesarean Section. *J Hand Surg* 1996;21B:263.

* 8. Alldred AJ. Congenital Pseudarthrosis of the Clavicle. *J Bone Joint Surg* 1963;45B:312.

* 9. Almquist EE, Gorden LH, Blue AL. Congenital Dislocation of the Head of the Radius. *J Bone Joint Surg* 1969;51A:1118.

+ 10. Arms DM, Strecker WB, Manske PR, Schoenecker PL. Management of Forearm Deformity in Multiple Hereditary Osteochondromatosis. *J Pediatr Orthop* 1997;17:450.

+ 11. Atkins DJ, Heard DCY, Donovan WH. Epidemiologic Overview of Individuals with Upper-limb Loss and Their Reported Research Priorities. *Journal of Prosthetics and Orthotics* 1996;8:2.

+ 12. Atkins RM, Bell MJ, Sharrard WJ. Pectoralis Major Transfer for Paralysis of Elbow Flexion in Children. *J Bone Joint Surg* 1985;67B:640.

+ 13. Ballinger SG, Hoffer MM. Elbow Flexion Contracture in Erb's Palsy. *J Child Neurol* 1994;9:209.

+ 14. Bar-On E, Howard CB, Porat S. The Use of Ultrasound in the Diagnosis of Atypical Pathology in the Unossified Skeleton. *J Pediatr Orthop* 1995;15:817.

+ 15. Bauer M, Jonsson K. Congenital Radioulnar Synostosis. Radiological Characteristics and Hand Function: Case Reports. *Scand J Plast Reconstr Surg Hand Surg* 1988;22:251.

+ 16. Bavinck JN, Weaver DD. Subclavian Artery Supply Disruption Sequence: Hypothesis of a Vascular Etiology for Poland, Klippel-Feil, and Mobius anomalies. *Am J Med Genet* 1986;23:903.

# 17. Beals RK, Rolfe B. VATER Association: A Unifying Concept of Multiple Anomalies. *J Bone Joint Surg* 1989;71A:948.

# 18. Beasley RW. Hand and Finger Prostheses. *J Hand Surg* 1987;12A:144.

+ 19. Beck PA, Hoffer MM. Latissimus Dorsi and Teres Major Tendons: Separate or Conjoint Tendons? *J Pediatr Orthop* 1989;9:308.

# 20. Bennett JB, Hansen PE, Granberry WM, Cain TE. Surgical Management of Arthrogryposis in the Upper Extremity. *J Pediatr Orthop* 1985;5:281.

+ 21. Benson L, Ezaki M, Carter PR, Knetzer D. Brachial Plexus Birth Palsy: A Prospective Natural History Study. *Orthopaedic Transactions* 1996;20:311.

+ 22. Black B, Dooley J, Pyper A, Reed M. Multiple Hereditary Exostoses. An Epidemiologic Study of an Isolated Community in Manitoba. *Clin Orthop* 1993;287:212.

* 23. Blount WP. Osteoclasis for Supination Deformities in Children. *J Bone Joint Surg* 1940;22:300.

+ 24. Bock GW, Reed MH. Forearm Deformities in Multiple Cartilaginous Exostoses. *Skeletal Radiol* 1991;20:483.

+ 25. Bolano LE. Congenital Proximal Radioulnar Synostosis: Treatment with the Ilizarov Method. *J Hand Surg* 1994;19A:977.

+ 26. Bonnard C, Narakas AO. Restoration of Hand Function after Brachial Plexus Injury. *Hand Clin* 1995;11:647.

+ 27. Borges JL, Shah A, Torres BC, Bowen JR. Modified Woodward Procedure for Sprengel Deformity of the Shoulder: Long-term Results. *J Pediatr Orthop* 1996;16:508.

+ 28. Burgess RC, Cates H. Deformities of the Forearm in Patients Who Have Multiple Cartilaginous Exostosis. *J Bone Joint Surg* 1993;75A:13.

+ 29. Campbell CC, Waters PM, Emans JB. Excision of the Radial Head for Congenital Dislocation. *J Bone Joint Surg* 1992;74A:726.

+ 30. Carlson WO, Speck GJ, Vicari V, Wenger DR. Arthrogryposis Multiplex Congenita. A Long-term Follow-up Study. *Clin Orthop* 1985;194:115.

* 31. Carroll RE, Hill NA. Triceps Transfer to Restore Elbow Function. *J Bone Joint Surg* 1970;52A:239.

+ 32. Carson WG, Lovell WW, Whitesides TE. Congenital Elevation of the Scapula. *J Bone Joint Surg* 1981;63A:1199.

* 33. Cavendish ME. Congenital Elevation of the Scapula. *J Bone Joint Surg* 1972;67A:539.

+ 34. Chan KM, Ma GFY, Cheng JCY, Leung PC. The Krukenberg Procedure: A Method of Treatment for Unilateral Anomalies of the Upper Limb in Chinese Children. *J Hand Surg* 1984;9A:548.

+ 35. Clarke HM, Al-Qattan MM, Curtis CG, Zuker RM. Obstetrical Brachial Plexus Palsy: Results Following Neurolysis of Conducting Neuromas-in-Continuity. *Plast Reconstr Surg* 1996;97:974.

+ 36. Clarke HM, Curtis CG. An Approach to Obstetrical Brachial Plexus Injuries. *Hand Clin* 1995;11:563.

+ 37. Cleary JE, Omer GE Jr. Congenital Proximal Radio-ulnar Synostosis. *J Bone Joint Surg* 1985;67A:539.

+ 38. Coene LN. Mechanisms of Brachial Plexus Lesions. *Clin Neurol Neurosurg* 1993;95(Suppl):S24.

+ 39. Covey DC, Riordan D, Milstead ME, Albright JA. Modification of the L'Episcopo Procedure for Brachial Plexus Palsies. *J Bone Joint Surg* 1992;74B:897.

# 40. Crawford AH. Neurofibromatosis. In: Lovell WW, Winter RB, ed. *Pediatric Orthopaedics*. Philadelphia: J.B. Lippincott Company, 1986:1121.

+ 41. Cummings RJ, Jones ET, Reed FE, Mazur JM. Infantile Dislocation of the Elbow Complicating Obstetric Palsy. *J Pediatr Orthop* 1996;16:589.

+ 42. Dahl MT. The Gradual Correction of Forearm Deformities in Multiple Hereditary Exostoses. *Hand Clin* 1993;9:707.

+ 43. Del Torto U, Bianchi O, Pone G, Sante G. Experimental Study on the Etiology of Congenital Multiple Arthrogryposis. *Ital J Orthop Traumatol* 1983;9:91.

+ 44. Doyle JR, James PM, Larsen LJ, Ashley RK. Restoration of Elbow Flexion in Arthrogryposis Multiplex Congenita. *J Hand Surg* 1980;5A:149.

# 45. Drennan JC. Neuromuscular Disorders. In: Lovell WW, Winter RB, ed. *Pediatric Orthopaedics.* Philadelphia: J.B. Lippincott Company, 1986:259.

+ 46. Echtler B, Burckhardt A. Isolated Congenital Dislocation of the Radial Head. Good Function in 4 Untreated Patients after 14–45 Years. *Acta Orthop Scand* 1997;68:598.

+ 47. Edelstein JE, Berger N. Performance Comparison Among Children Fitted with Myoelectric and Body-powered Hands. *Arch Phys Med Rehabil* 1993;74:376.

* 48. Engel D. The Etiology of the Undescended Scapula and Related Syndromes. *J Bone Joint Surg* 1943;25A:613.

* 49. Erb W. Veber Eine Eigen Thumliche Localisation von Lahmungen in Plexus Brachialis. *Verh Dtsch* 1874;2:130.

+ 50. Fahy MJ, Hall JG. A Retrospective Study of Pregnancy Complications Among 828 Cases of Arthrogryposis. *Genet Couns* 1990;1:3.

+ 51. Fogel GR, McElfresh EC, Peterson HA, Wicklund PT. Management of Deformities of the Forearm in Multiple Hereditary Osteochondromas. *J Bone Joint Surg* 1984;66A:670.

+ 52. Francel PC, Koby M, Park TS, et al. Fast Spin-echo Magnetic Resonance Imaging for Radiological Assessment of Neonatal Brachial Plexus Injury. *J Neurosurg* 1995;83:461.

* 53. Freeman EA, Sheldon JH. Cranio-carpal-tarsal Dystrophy: An Undescribed Congenital Malformation. *Arch Dis Child* 1938;13:277.

+ 54. Gerwin M, Weiland AJ. Vascularized Bone Grafts to the Upper Extremity. Indications and Technique. *Hand Clin* 1992;8:509.

+ 55. Geutjens G, Gilbert A, Helsen K. Obstetric Brachial Plexus Palsy Associated with Breech Delivery. *J Bone Joint Surg* 1996;78B:303.

+ 56. Gherman RB, Goodwin TM, Ouzounian JG, et al. Brachial Plexus Palsy Associated with Cesarean Section: An In Utero Injury? *Am J Obstet Gynecol* 1997;177:1162.

+ 57. Gibson DA, Carroll N. Congenital Pseudarthrosis of the Clavicle. *J Bone Joint Surg* 1970;52B:629.

+ 58. Gibson DA, Urs NDK. Arthrogryposis Multiplex Congenita. *J Bone Joint Surg* 1970;52B:483.

+ 59. Gilbert A, Brockman R, Carlioz H. Surgical Treatment of Brachial Plexus Birth Palsy. *Clin Orthop* 1991;264:39.

+ 60. Gilbert A, Razaboni R, Amar-Khodja S. Indications and Results of Brachial Plexus Surgery in Obstetrical Palsy. *Orthop Clin North Am* 1988;19:91.

+ 61. Goddard NJ, Fixsen JA. Rotation Osteotomy of the Humerus for Birth Injuries of the Brachial Plexus. *J Bone Joint Surg* 1984;66B:257.

+ 62. Gonen R, Spiegel D, Abend M. Is Macrosomia Predictable, and Are Shoulder Dystocia and Birth Trauma Preventable? *Obstet Gynecol* 1996;88:526.

+ 63. Gonik B, Hollyer VL, Allen R. Shoulder Dystocia Recognition: Differences in Neonatal Risks for Injury. *Am J Perinatol* 1991;8:31.

+ 64. Graham EM, Forouzan I, Morgan MA. A Retrospective Analysis of Erb's Palsy Cases and Their Relation to Birth Weight and Trauma at Delivery. *Journal of Maternal-Fetal Medicine* 1997;6:1.

+ 65. Green WT, Mital MA. Congenital Radioulnar Synostosis: Surgical Treatment. *J Bone Joint Surg* 1979;61:738.

+ 66. Greenwald AG, Schute PC, Shiveley JL. Brachial Plexus Birth Palsy: A 10-year Report on the Incidence and Prognosis. *J Pediatr Orthop* 1984;4:689.

+ 67. Greitemann B, Rondhuis JJ, Karbowski A. Treatment of Congenital Elevation of the Scapula. 10 (2–18) Year Follow-up of 37 Cases of Sprengel's Deformity. *Acta Orthop Scand* 1993;64:365.

+ 68. Grogan DP, Love SM, Guidera KJ, Ogden JA. Operative Treatment of Congenital Pseudarthrosis of the Clavicle. *J Pediatr Orthop* 1991;11:176.

+ 69. Gu Y, Zhang L, Zheng Y. Introduction of a Modified Krukenberg Operation. *Plast Reconstr Surg* 1996;97:222.

+ 70. Gudinchet F, Maeder P, Oberson JC, Schnyder P. Magnetic Resonance Imaging of the Shoulder in Children with Brachial Plexus Birth Palsy. *Pediatr Radiol* 1995;25:S125.

+ 71. Guma M, Teitel AD. Adolescent Presentation of Congenital Radioulnar Synostosis. *Clin Pediatr* 1996;35:215.

+ 72. Hall JG. Genetic Aspects of Arthrogryposis. *Clin Orthop* 1985;44.

+ 73. Hamner DL, Hall JE. Sprengel's Deformity Associated with Multidirectional Shoulder Instability. *J Pediatr Orthop* 1995;15:641.

+ 74. Hankins GD, Clark SL. Brachial Plexus Palsy Involving the Posterior Shoulder at Spontaneous Vaginal Delivery. *Am J Perinatol* 1995;12:44.

+ 75. Hansen OH, Andersen NO. Congenital Radio-ulnar Synostosis: Report of 37 Cases. *Acta Orthop Scand* 1970;41:225.

+ 76. Hardy AE. Birth Injuries of the Brachial Plexus: Incidence and Prognosis. *J Bone Joint Surg* 1981;63B:98.

+ 77. Hashimoto T, Mitomo M, Hirabuki N, et al. Nerve Root Avulsion of Birth Palsy: Comparison of Myelography with CT Myelography and Somatosensory Evoked Potential. *Radiology* 1991;178:841.

# 78. Hentz VR. Brachial Plexus Injuries. In: Manske PR, ed. *Hand Surgery Update*. Rosemont, IL: American Academy of Orthopaedic Surgeons, 1996:243.

# 79. Hentz VR, Meyer RD. Brachial Plexus Microsurgery in Children. *Microsurgery* 1991;12:175.

+ 80. Hernandez C, Wendel GD. Shoulder Dystocia. *Clin Obstet Gynecol* 1990;33:526.

+ 81. Hernandez RJ, Dias L. CT Evaluation of the Shoulder in Children with Erb's Palsy. *Pediatr Radiol* 1988;18:333.

+ 82. Hirata S, Miya H, Mizuno K. Congenital Pseudarthrosis of the Clavicle. Histologic Examination for the Etiology of the Disease. *Clin Orthop* 1995;242.

+ 83. Hoffer MM, Phipps GJ. Closed Reduction and Tendon Transfer for Treatment of Dislocation of the Glenohumeral Joint Secondary to Brachial Plexus Birth Palsy. *J Bone Joint Surg* 1998;80A:997.

+ 84. Hoffer MM, Wickenden R, Roper B. Brachial Plexus Birth Palsies. Results of Tendon Transfers to the Rotator Cuff. *J Bone Joint Surg* 1978;60A:691.

+ 85. Holmes LB. Report of National Institute of Child Health and Human Development Workshop on Chorionic Villus Sampling and Limb and Other Defects. *Teratology* 1992;48:7.

+ 86. Hoyme HE, Jones KL, Van Allen MI, et al. Vascular Pathogenesis of Transverse Limb Reduction Defects. *J Pediatr* 1982;101:839.

+ 87. Hresko MT, Rosenberg BN, Pappas AM. Excision of the Radial Head in Patients Younger than 18 Years. *J Pediatr Orthop* 1999;19:106.

+ 88. Jackson ST, Hoffer MM, Parrish N. Brachial-plexus Palsy in the Newborn. *J Bone Joint Surg* 1988;70A:1217.

* 89. Jaffe HL. Hereditary Multiple Exostoses. *Arch Pathol* 1943;36:335.

+ 90. Jahnke AH Jr, Bovill DF, McCarroll HR Jr, et al. Persistent Brachial Plexus Birth Palsies. *J Pediatr Orthop* 1991;11:533.

+ 91. Jain S. Rehabilitation in Limb Deficiency: The Pediatric Amputee. *Arch Phys Med Rehabil* 1996;77:S-9.

+ 92. James MA, McCarroll HR Jr. Shoulder External Rotation Tendon Transfers in Brachial Plexus Birth Palsy: Results of Two Techniques. *Orthopaedic Transactions* 1996;20;311.

+ 93. Kanaya F, Ibaraki K. Mobilization of a Congenital Proximal Radioulnar Synostosis with Use of a Free Vascularized Fascio-fat Graft. *J Bone Joint Surg* 1998;80A:1186.

+ 94. Kawabata H, Kawai H, Masatomi T, Yasui N. Accessory Nerve Neurotization in Infants with Brachial Plexus Birth Palsy. *Microsurgery* 1994;15:768.

+ 95. Kelikian H. Dislocation of the Radial Head. In: Kelikian H, ed. *Congenital Deformities of the Hand and Forearm.* Philadelphia: W.B. Saunders Company, 1974:902.

+ 96. Kelikian H. Radioulnar Synostosis. In: Kelikian H, ed. *Congenital Deformities of the Hand and Forearm.* Philadelphia: W.B. Saunders Company, 1974:939.

+ 97. Kelly DW. Congenital Dislocation of the Radial Head: Spectrum and Natural History. *J Pediatr Orthop* 1981;1:295.

+ 98. Kitoh H, Nogami H, Oki T, et al. Antley-Bixler Syndrome: A Disorder Characterized by Congenital Synostosis of the Elbow Joint and the Cranial Suture. *J Pediatr Orthop* 1996;16:243.

+ 99. Klisic P, Filipovic M, Uzelac O. Relocation of Congenitally Elevated Scapula. *J Pediatr Orthop* 1981;1:43.

+ 100. Kruger LM, Fishman S. Myoelectric and Body-powered Prostheses. *J Pediatr Orthop* 1993;13:68.

* 101. L'Episcopo JB. Tendon Transplantation in Obstetrical Paralysis. *Am J Surg* 1934;25:122.

+ 102. Laurent JP, Lee RT. Birth-related Upper Brachial Plexus Injuries in Infants: Operative and Nonoperative Approaches. *J Child Neurol* 1994;9:111.

+ 103. Levine MG, Holroyde J, Woods JRJ, et al. Birth Trauma: Incidence and Predisposing Factors. *Obstet Gynecol* 1984;63:792.

+ 104. Liggio FJ, Tham S, Price A, et al. Outcome of Surgical Treatment for Forearm Pronation Deformities in Children with Obstetric Brachial Plexus Injuries. *J Hand Surg* 1999;24B:43.

+ 105. Lin HH, Strecker WB, Manske PR, et al. A Surgical Technique of Radioulnar Osteoclasis to Correct Severe Forearm Rotation Deformities. *J Pediatr Orthop* 1995;15:53.

+ 106. Lipskeir E, Weizenbluth M. Derotation Osteotomy of the Forearm in Management of Paralytic Supination Deformity. *J Hand Surg* 1993;18A:1069.

* 107. Lloyd-Roberts GC, Apley AG, Owen R. Reflections Upon the Aetology of Congenital Pseudarthrosis of the Clavicle. *J Bone Joint Surg* 1975;57B:24.

* 108. Lloyd-Roberts GC, Lettin AWF. Arthrogryposis Multiplex Congenita. *J Bone Joint Surg* 1970;52B:494.

* 109. Mallet J. Paralysie Obstetricale du Plexus Brachial Symposium: Traitement des Sepuelles: Primaute du Traitement de L'Epaule—Methode d'Expression des Resultats. *Rev Chir Orthop* 1972;58:166.

+ 110. Manske PR, McCarroll HR Jr. Biceps Tendon Re-routing and Percutaneous Osteoclasis in the Treatment of Supination Deformity in Obstetrical Palsy. *J Hand Surg* 1980;5:153.

+ 111. Mardam-Bey T, Ger E. Congenital Radial Head Dislocation. *J Hand Surg* 1979;4:316.

+ 112. Marshall RW, Williams DH, Birch R, Bonney G. Operations to Restore Elbow Flexion after Brachial Plexus Injuries. *J Bone Joint Surg* 1988;70B:577.

+ 113. Masada K, Tsuyuguchi Y, Kawai H, et al. Operations for Forearm Deformity Caused by Multiple Osteochondromas. *J Bone Joint Surg* 1989;71B:24.

+ 114. Masterson E, Earley MJ, Stephens MM. Congenital Pseudarthrosis of the Ulna Treated by Free Vascularized Fibular Graft: A Case Report and Review of Methods of Treatment. *J Hand Surg* 1993;18B:285.

+ 115. Mastroiacovo P, Tozzi AE, Agosti S, et al. Transverse Limb Reduction Defects after Chorion Villus Sampling: A Retrospective Cohort Study. GIDEF: Gruppo Italiano Diagnosi Embrio-Fetali. *Prenat Diagn* 1993;13:1051.

+ 116. Mathoulin C, Gilbert A, Azze RG. Congenital Pseudarthrosis of the Forearm: Treatment of Six Cases with Vascularized Fibular Graft and a Review of the Literature. *Microsurgery* 1993;14:252.

+ 117. McFarland LV, Raskin M, Daling JR, Benedetti TJ. Erb/Duchenne's Palsy: A Consequence of Fetal Macrosomia and Method of Delivery. *Obstet Gynecol* 1986;68:784.

+ 118. McFarland MB, Langer O, Piper JM, Berkus MD. Perinatal Outcome and the Type and Number of Maneuvers in Shoulder Dystocia. *Int J Gynaecol Obstet* 1996;55:219.

+ 119. McKusick VA. *Exostoses, Multiple, Type II;EXT2.* Online Mendelian Inheritance in Man, OMIM (TM) MIM Number:133701.1998. Baltimore, MD: Johns Hopkins University, 1998.

+ 120. McKusick VA. *Exostoses, Multiple, Type I;EXT1.* Online Mendelian Inheritance in Man, OMIM (TM) MIM Number:133700.1998. Baltimore, MD: Johns Hopkins University, 1998.

+ 121. Mennen U, Williams E. Arthrogryposis Multiplex Congenita in a Monozygotic Twin. *J Hand Surg* 1996;21B:647.

+ 122. Michelow BJ, Clarke HM, Curtis CG. The natural history of obstetrical brachial plexus palsy. *Plast Reconstr Surg* 1994;93:675.

+ 123. Miller SF, Glasier CM, Griebel ML, et al. Brachial Plexopathy in Infants after Traumatic Delivery: Evaluation with MR Imaging. *Radiology* 1993;189:481.

+ 124. Mital MA. Congenital Radioulnar Synostosis and Congenital Dislocation of the Radial Head. *Orthop Clin North Am* 1976;7:375.

+ 125. Miura T. Congenital Dislocation of the Radial Head. *J Hand Surg* 1990;15B:477.

+ 126. Miura T, Nakamura R, Suzuki M, Kanie J. Congenital Radio-ulnar Synostosis. *J Hand Surg* 1984;9B:153.

+ 127. Moneim MS, Omer GE Jr. Latissimus Dorsi Muscle Transfer for Restoration of Elbow Flexion after Brachial Plexus Disruption. *J Hand Surg* 1986;11:135.

+ 128. Morrison JC, Sanders JR, Magann EF, Wiser WL. The Diagnosis and Management of Dystocia of the Shoulder. *Surg Gynecol Obstet* 1992;175:515.

+ 129. Ogino T, Hikino K. Congenital Radioulnar Synostosis: Compensatory Rotation Around the Wrist and Rotation Osteotomy. *J Hand Surg* 1987;12B:173.

+ 130. Ouzounian JG, Korst LM, Phelan JP. Permanent Erb Palsy: A Traction-related Injury? *Obstet Gynecol* 1997;89:139.

+ 131. Owen R. Congenital Pseudarthrosis of the Clavicle. *J Bone Joint Surg* 1970;52B:644.

+ 132. Paley D, Catagni M, Argnani F, et al. Treatment of Congenital Pseudoarthrosis of the Tibia Using the Ilizarov Technique. *Clin Orthop* 1992;81.

+ 133. Paradiso G, Granana N, Maza E. Prenatal Brachial Plexus Paralysis. *Neurology* 1997;49:261.

+ 134. Perlow JH, Wigton T, Hart J, et al. Birth Trauma. A Five-year Review of Incidence and Associated Perinatal Factors. *J Reprod Med* 1996;41:754.

+ 135. Peterson HA. Multiple Hereditary Osteochondromata. *Clin Orthop* 1989;222.

+ 136. Phipps GJ, Hoffer MM. Latissimus Dorsi and Teres Major Transfer to Rotator Cuff for Erb's Palsy. *J Shoulder Elbow Surg* 1995;4:124.

+ 137. Piatt JH Jr, Hudson AR, Hoffman HJ. Preliminary Experiences with Brachial Plexus Exploration in Children: Birth Injury and Vehicular Trauma. *Neurosurgery* 1988;22:715.

+ 138. Powers TA, Haher TR, Devlin VJ, et al. Abnormalities of the Spine in Relation to Congenital Upper Limb Deficiencies. *J Pediatr Orthop* 1983;3:471.

+ 139. Pruitt DL, Hulsey RE, Fink B, Manske PR. Shoulder Arthrodesis in Pediatric Patients. *J Pediatr Orthop* 1992;12:640.

+ 140. Reichenbach H, Hormann D, Theile H. Hereditary Congenital Posterior Dislocation of Radial Heads. *Am J Med Genet* 1995;55:101.

+ 141. Rizzo R, Pavone V, Corsello G, et al. Autosomal Dominant and Sporadic Radio-ulnar Synostosis. *Am J Med Genet* 1997;68:127.

+ 142. Robinson RA, Braun RM, Mack P, Zadek R. The Surgical Importance of the Clavicular Component of Sprengel's Deformity. *J Bone Joint Surg* 1967;49A:1481.

+ 143. Rodgers WB, Hall JE. One-bone Forearm as a Salvage Procedure for Recalcitrant Forearm Deformity in Hereditary Multiple Exostoses. *J Pediatr Orthop* 1993;13:587.

+ 144. Sachar K, Akelman E, Ehrlich MG. Radioulnar Synostosis. *Hand Clin* 1994;10:399.

+ 145. Schmale GA, Conrad EU, Raskind WH. The Natural History of Hereditary Multiple Exostoses. *J Bone Joint Surg Am* 1994;76:986.

+ 146. Schnall SB, King JD, Marrero G. Congenital Pseudarthrosis of the Clavicle: A Review of the Literature and Surgical Results of Six Cases. *J Pediatr Orthop* 1988;8:316.

* 147. Schottstaedt ER, Larsen LJ, Bost FC. Complete Muscle Transposition. *J Bone Joint Surg* 1955;37A:897.

+ 148. Scotland TR, Galway HR. A Long-term Review of Children with Congenital and Acquired Upper Limb Deficiency. *J Bone Joint Surg* 1983;65B:346.

+ 149. Seitz WH. Distraction Osteogenesis of a Congenital Amputation at the Elbow. *J Hand Surg* 1989;14A:945.

* 150. Sever JW. Obstetric Paralysis: Report of Eleven Hundred Cases. *JAMA* 1925;85:1862.

+ 151. Shalom A, Khermosh O, Wientroub S. The Natural History of Congenital Pseudarthrosis of the Clavicle. *J Bone Joint Surg* 1994;76B:846.

+ 152. Simmons BP, Southmayd WW, Riseborough EJ. Congenital Radioulnar Synostosis. *J Hand Surg Am* 1983;8:829.

+ 153. Smith SJM. The Role of Neurophysiological Investigation in Traumatic Brachial Plexus Lesions in Adults and Children. *J Hand Surg* 1996;21B:145.

+ 154. St. Charles S, DiMario FJJ, Grunnet MS. Mobius Sequence: Further In Vivo Support for the Subclavian Artery Supply Disruption Sequence. *Am J Med Genet* 1993;47:289.

+ 155. Stanton RP, Hansen MO. Function of the Upper Extremities in Hereditary Multiple Exostoses. *J Bone Joint Surg* 1996;78A:568.

+ 156. Steel HH, Piston RW, Clancy M, Betz RR. A Syndrome of Dislocated Hips and Radial Heads, Carpal Coalition, and Short Stature in Puerto Rican Children. *J Bone Joint Surg* 1993;75A:259.

+ 157. Swanson AB, Swanson GC. The Krukenberg Procedure in the Juvenile Amputee. *Clin Orthop* 1980;148:55.

+ 158. Swinyard CA, Bleck EE. The Etiology of Arthrogryposis (Multiple Congenital Contracture). *Clin Orthop* 1985;194:15.

+ 159. Taniguchi K. A Practical Classification System for Multiple Cartilaginous Exostosis in Children. *J Pediatr Orthop* 1995;15:585.

+ 160. Tassin JL. Paralysies Obstetricales du Plexus Brachial. Evolution Spontanee, Resultats des Interventions Reparatrices Precoces (Thesis). Universite Paris VII 1983.

# 161. Temtamy SA, McKusick VA. Contracture Deformities of Digits. In: Bergsma D, Mudge JR, Paul NW, Greene SC, eds. *The Genetics of Hand Malformations.* New York: Alan R. Liss, Inc., 1978:441.

+ 162. Thompson GH, Bilenker RM. Comprehensive Management of Arthrogryposis Multiplex Congenita. *Clin Orthop* 1985;194:6.

+ 163. Toledo LC, MacEwen GD. Severe Complication of Surgical Treatment of Congenital Pseudarthrosis of the Clavicle. *Clin Orthop* 1979;139:64.

+ 164. Troum S, Floyd WEI, Waters PM. Posterior Dislocation of the Humeral Head in Infancy Associated with Obstetrical Paralysis. *J Bone Joint Surg* 1993;75A:1370.

+ 165. Tsukahara M, Matsuo K, Furukawa S. Radio-ulnar Synostosis, Short Stature, Microcephaly, Scoliosis, and Mental Retardation. *Am J Med Genet* 1995;58:159.

+ 166. Uthoff K, Bosch U. [Proximal Radioulnar Synostosis within the Scope of Fetal Alcohol Syndrome]. *Unfallchirurg* 1997;100:678.

+ 167. Van Heest A, Waters PM, Simmons BP. Surgical Treatment of Arthrogryposis of the Elbow. *J Hand Surg* 1998;23A:1063.

+ 168. Van Heest AE. Congenital Disorders of the Hand and Upper Extremity. *Pediatr Clin North Am* 1996;43:1113.

+ 169. Vitale CC. Reconstructive Surgery for Defects in the Shaft of the Ulna in Children. *J Bone Joint Surg* 1952;34A:804.

+ 170. Walle T, Hartikainen-Sorri AL. Obstetric Shoulder Injury. Associated Risk Factors, Prediction and Prognosis. *Acta Obstet Gynecol Scand* 1993;72:450.

+ 171. Waters PM. *When Is the Timing of Biceps Return of Function Reliable in Patients with Obstetrical Brachial Plexopathy?* San Francisco: American Society for Surgery of the Hand, 1995.

# 172. Waters PM. Obstetric Brachial Plexus Injuries: Evaluation and Management. *Journal of the American Academy of Orthopaedic Surgeons* 1997;5:205.

# 173. Waters PM, Simmons BP. Congenital Anomalies: Elbow Region. In: Peimer CA, ed. *Surgery of the Hand and Upper Extremity.* New York: McGraw-Hill, 1996:2049.

+ 174. Waters PM, Smith GR, Jaramillo D. Glenohumeral Deformity Secondary to Brachial Plexus Birth Palsy. *J Bone Joint Surg* 1998;80A:668.

# 175. Weaver DD. Vascular Etiology of Limb Defects: The Subclavian Artery Supply Disruption Sequence. In: Herring JA, Birch JG, ed. *The Child With a Limb Deficiency.* Rosemont, Ill: American Academy of Orthopaedic Surgeons, 1998;25.

+ 176. Wenner SM, Saperia BS. Proximal Row Carpectomy in Arthrogrypotic Wrist Deformity. *J Hand Surg* 1987;12A:523.

+ 177. Wilkinson JA, Campbell D. Scapular Osteotomy for Sprengel's Shoulder. *J Bone Joint Surg* 1980;62B:486.

+ 178. Williams PF. Management of Upper Limb Problems in Arthrogryposis. *Clin Orthop* 1985;194:60.

+ 179. Wood VE, Sauser D, Mudge D. The Treatment of Hereditary Multiple Exostosis of the Upper Extremity. *J Hand Surg* 1985;10A:505.

* 180. Woodward JW. Congenital Elevation of the Scapula. Correction by Release and Transplantation of Muscle Origins: A Preliminary Report. *J Bone Joint Surg* 1961;43A:219.

+ 181. Wynne-Davies R, Lamb DW. Congenital Upper Limb Anomalies: An Etiologic Grouping of Clinical, Genetic, and Epidemiologic Data from 387 Patients with “Absence” Defects, Constriction Bands, Polydactylies, and Syndactylies. *J Hand Surg* 1985;10A:958.

+ 182. Wynne-Davies R, Williams PF, O'Connor JC. The 1960s Epidemic of Arthrogryposis Multiplex Congenita: A Survey from the United Kingdom, Australia and the United States of America. *J Bone Joint Surg Br* 1981;63-B:76.

+ 183. Yajima H, Tamai S, Ono H, Kizaki K. Vascularized Bone Grafts to the Upper Extremities. *Plast Reconstr Surg* 1998;101:727.

+ 184. Yonenobu K, Tada K, Swanson AB. Arthrogryposis of the Hand. *J Pediatr Orthop* 1984;4:599.

* 185. Zancolli EA. Paralytic Supination Contracture of the Forearm. *J Bone Joint Surg* 1967;49A:1275.

# CHAPTER 166

# SURGERY FOR DEVELOPMENTAL DYSPLASIA OF THE HIP

*George T. Rab*

**George T. Rab:** Department of Orthopaedics, University of California, Davis, Sacramento, California, 95817.

Nonoperative Treatment
Open Reduction of the Hip
- Indications
- Preoperative Considerations
- Closed Reduction
- Open Reduction
- Combined Open Reduction and Femoral Shortening
- Complications

Femoral Osteotomy
- Indications
- Intertrochanteric Varus Derotation Osteotomy

Pelvic Osteotomy
- Indications
- Prerequisites and Selection of Osteotomy Site
- Salter Innominate Osteotomy
- Pemberton Pericapsular Osteotomy
- Triple Innominate Osteotomy
- Chiari Osteotomy

Chapter References

Abnormalities in newborns or in children consisting of dysplasia of the acetabulum and subluxation or dislocation of the femoral head from the acetabulum, if present at birth, have been known in the past as dysplasia or dislocation of the hip. Westin et al. (30) reported on late dislocation of the hip in children with apparently normal neonatal clinical and radiographic examinations, which they termed *developmental dysplasia of the hip* (DDH). Since then, the term *DDH* has come to be used to describe all dysplasias of the hip, reflecting the uncertainty about the exact time of onset and detection of the condition. Many mechanisms for DDH have been proposed, including the following:

Mechanical factors including breech delivery and postnatal positioning of the hips in extension and adduction

Hormone-induced joint laxity
Genetic inheritance
Primary acetabular dysplasia

Dysplasia of the hip occurs in approximately 1 in 1,000 live births. Involvement of the left hip alone or bilateral involvement is more common than involvement of the right hip alone.

Risk factors increasing the incidence of DDH have been identified; examiners should be alert to the following:

Female sex (5:1 female-to-male ratio)
Breech delivery
First-born child
Positive family history
White or Navajo Indian race

Associated disorders such as metatarsus abductus, talipes calcaneovalgus, and congenital torticollis

Early detection of DDH in newborns with early initiation of treatment is important to avoid the severe disability that results in late diagnosis, particularly after 5 years of age. Physicians and other paraprofessionals involved in delivering children must be competent in routine clinical screening with Ortolani's test and Barlow's provocative maneuver.

Use of ultrasound screening of newborns has proven useful in the hands of experienced ultrasonographers (9,15). False-positive sonography is common in the first 10 weeks of life; practitioners should take this into account when making treatment decisions.

In children between 6 and 18 months of age in whom a dislocated hip was missed at birth or who subsequently dislocate a dysplastic hip, reduction of the hip or dislocation of the hip by Ortolani's test and Barlow's maneuver becomes impossible. Important clinical findings in this age group include asymmetry in abduction of the hip because of adductor muscle contractures, asymmetric skin folds with gathering on the dislocated side, and Galeazzi's sign showing apparent shortening of the femur on the side of the dislocation. Bilateral dislocations are more difficult to detect because they are symmetrically abnormal. If affected children reach walking age, they will usually demonstrate a waddling (Trendelenburg) gait.

Radiographic findings are not reliable in newborns because the lack of ossification of the proximal femur makes detection difficult. Indications of DDH in newborns include the following:

Acetabular index of more than 30°
Decreased center–edge angle of Wiberg
Disruption of Shenton's line

Location of the metaphyseal beak of the proximal femur outside the inner lower quadrant of the grid formed by the vertical line of Perkins and the horizontal line of Hilgenreiner (Fig. 166.1)

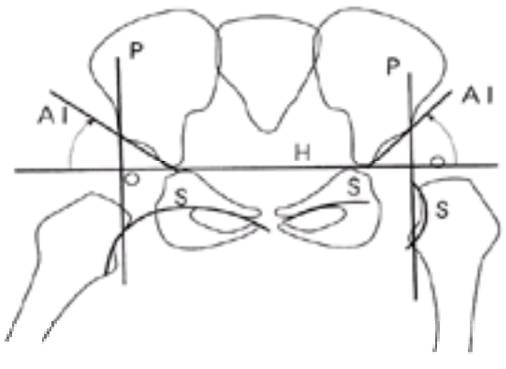

***Figure 166.1.*** Radiographic signs of subluxation and dysplasia on an AP view. The proximal femoral ossification center has been drawn but may be absent before age 6 months (*H,* Hilgenreiner's line; *P,* Perkins' line; *S,* Shenton's line (broken on left); *AI,* acetabular index). Note the subluxation in the left hip.

## NONOPERATIVE TREATMENT

Most patients with DDH or dislocation can be treated by nonoperative methods if the condition is detected in the first 6 months of life. Pavlik harness treatment in this age group has a high rate of success, and I have been able to achieve reduction of hips in some children up to 9 months of age with this harness.

Pavlik-harness adjustment is critical to success. The shoulder harness portion should be tight enough to cover the chest at the nipple line. The anterior (medial) foot straps are tensioned enough so that the hips are flexed greater than 90°. The posterior (lateral) straps are tensioned enough so that the knees cannot touch in the midline; they must not be too tight.

The Pavlik harness should be worn full-time. I reexamine a child in 1–2 weeks and readjust the device, which is often necessary because it is confusing to parents. After it is accepted by the family and properly adjusted, the harness will rapidly produce a reduction of the hip if Pavlik treatment is going to be successful. If the hip reduces, the device should be worn for 3 or more months until stable reduction is accompanied by resolution of acetabular dysplasia (e.g., normal acetabular index, appearance of proximal femoral ossific nucleus).

If the Pavlik harness fails to effect a reduction in 2 weeks of wear after the initial readjustment, it should be discontinued, as it will not be effective if utilized longer. When Pavlik-harness treatment fails to achieve congruent reduction, closed reduction and casting must be considered. Prereduction traction, long considered to reduce the incidence of avascular necrosis, is now controversial; I personally do not use it.

When closed reduction fails, open reduction is indicated. Open reduction is a delicate, specialized operation with complications that can affect a patient for a lifetime, and it should not be undertaken by an inexperienced surgeon. Surgery for the residual dysplasia that can follow closed or open treatment of DDH also requires adequate follow-up and experienced judgment in its applications and execution. The techniques described in this chapter are those that I have found most effective in surgical management of this condition, but they are not exclusive and many alternatives can be found in the literature (3,4,7,8,13,16,18).

## OPEN REDUCTION OF THE HIP

### INDICATIONS

Open reduction of a dislocated hip is indicated when closed reduction fails or when closed reduction would result in such extremes of position that avascular necrosis would be a likely consequence. It is also indicated in children older than 12–18 months, when it is frequently combined with femoral shortening to decrease the overall time of immobilization required to achieve remodeling of the hip. Open reduction is indicated in a subluxated hip when abduction fails to reposition the femoral head deeply into the true acetabulum; in this instance, osteotomy of the pelvis or proximal femur is usually performed simultaneously.

Failures of closed reduction under anesthesia that obviously do not allow the femoral head to be centered in the acetabulum or that result in extremes of position are easy to detect and should be followed with prompt open reduction, preferably as a continuation under the same anesthetic. In children younger than 12 months, closed reduction that results in a reduction that is stable but not deep and concentric may be accepted initially. Follow these reductions by arthrography in 8–12 weeks; if soft-tissue remodeling has not occurred and the reduction is not congruent and deep, proceed with open reduction.

The use of prereduction traction and femoral shortening in 1–3-year-old children is somewhat controversial (8,13,20,22,23,25). Standard open reduction can be performed with relative safety in some children, but many surgeons (including myself) elect femoral shortening in a walking child because it allows prompt open reduction without preoperative traction and with an extremely low incidence of avascular necrosis. It also permits derotation of the anteverted femur, thus stabilizing the reduction. This allows early ambulation and may speed hip remodeling; both of these goals are admirable in a child who has never had a reduced hip joint before surgery. Open reduction is occasionally useful in diseases other than congenital hip dysplasia, such as cerebral palsy or reconstruction following trauma or infection.

### PREOPERATIVE CONSIDERATIONS

The use of preoperative traction, once so universally accepted, has been widely questioned in recent years (2,10,20); I personally no longer use it. In general, open reduction and its variants should be done without the use of blood transfusions. This requires great care on the surgeon's part. The use of X or 3X loupes is valuable in the dissection, and electrocautery greatly facilitates dissection without excessive bleeding. All tissues must be handled extremely gently, and the surgeon should have a thorough knowledge of hip anatomy. For children younger than 2–3 years, attempt a closed reduction immediately before proceeding with an open procedure because occasionally a stable reduction can be achieved with good long-term prognosis for resolution of the dysplasia.

I prefer open reduction from an anterior approach because capsulorrhaphy and other reconstructive procedures can easily be accomplished. Open reduction from a medial (adductor) approach does not give sufficient exposure for these essential parts of the operation and is indicated only in very young children who will undergo prolonged casting to maintain reduction while the capsulotomy heals and remodels. The medial approach is not described here; see Chapter 3 and Ferguson's (7) description for details.

Although the standard exposure is a classic Smith–Petersen approach, I prefer a skin incision that falls in, or is parallel and superior to, the inguinal crease. Inguinal incisions can be extended medially and laterally, and they allow excellent deep longitudinal exposure with a nearly undetectable scar that is hidden beneath standard clothing. If open reduction and femoral shortening are combined, the use of an inguinal incision for the open reduction and a lateral incision for the femoral shortening yields a more cosmetic appearance and permits simple removal of internal fixation devices later through the lateral incision.

### CLOSED REDUCTION

With the patient under a deep general anesthetic, gently flex, lift, and abduct the femur with the knee flexed until reduction is felt. In older children, the reduction is usually either definite or unobtainable, but younger children may not have distinct stability. Arthrography and fluoroscopy greatly improve assessment of the reduction (Fig. 166.2). Occasionally, percutaneous adductor-longus tenotomy enhances stability. If the hip is unstable in less than 55° of abduction, strongly consider open reduction. Full double-spica casting is safest in 90° to 100° of flexion, neutral rotation, and less than 55° of abduction, which is Salter's (18,19) “human” position.

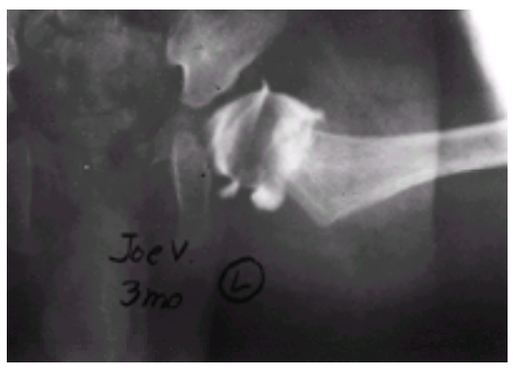


***Figure 166.2.*** Arthrography during closed reduction can delineate anatomic features and aid in assessment of stability.

Change the cast every 6–8 weeks until fluoroscopy demonstrates stability in the weight-bearing position. Usually, 12–18 weeks in a spica cast is required. Abduction

bracing may be used long-term, although there is no scientific evidence of its value in this circumstance.

**OPEN REDUCTION**

- Drape the affected limb and hip free with the pelvis elevated on a small towel.
- Make a transverse inguinal incision directly in the most prominent flexion crease of the hip (Fig. 166.3*A*). After incising the skin, use electrocautery to expose the fascial layer.

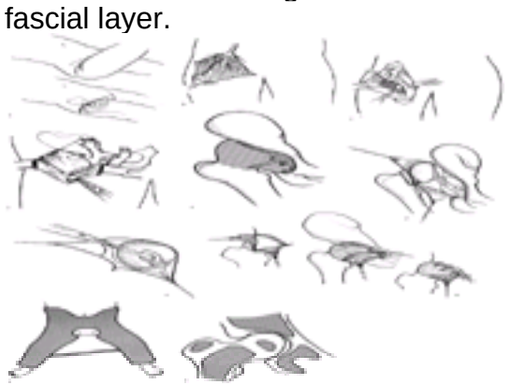

***Figure 166.3.*** Surgical technique for open reduction of the hip through an anterior approach. See the text for a full description. **A:** Skin incision. **B:** Subcutaneous dissection and lateral femoral cutaneous nerve. **C:** Deep dissection exposes the hip joint capsule. **D:** Isolation and section of the iliopsoas tendon. **E:** Capsular incisions. **F:** Intra-articular pathology. **G:** Use of the sectioned ligamentum teres to locate the true acetabulum. **H:** Repair and reefing of the joint capsule. **I:** Double-hip spica cast. **J:** The hip and its ossific nuclei as seen on an AP radiographic view after reduction.

- Dissect subcutaneously both proximally to the iliac crest and sufficiently distally to mobilize the skin and subcutaneous tissue and allow a longitudinal incision of the deeper layers of the wound.
- Identify the lateral femoral cutaneous nerve as it emerges from the sartorius. Isolate and protect it with Silastic tape (Fig. 166.3*B*).
- If an innominate osteotomy is to be done, now split the apophysis, but for standard open reduction, it is unnecessary to dissect the proximal iliac apophysis.
- Carefully develop the interval between the sartorius and the tensor fasciae latae. Retract the sartorius me-dially and the tensor laterally to expose the rectusfemoris.
- Using a Kidner dissector, identify, tag, and transversely section the tendinous attachment of the rectus femoris to expose the reflected head of the rectus femoris, which is the key to the anterior capsule (Fig. 166.3*C*).
- Expose the capsule, using gentle blunt dissection with a periosteal elevator and a Kidner dissector. Use electrocautery for any bleeders. The capsule will be found to be large, redundant, and extending superiorly and posteriorly.
- Carry the capsular exposure medially under the adherent iliopsoas muscle and distally until the lesser trochanter can be palpated with a fingertip.
- At the medial border of the capsule, identify the iliopsoas muscle, hook its tendon with a right-angle clamp, and bring it into the wound, where it is sectioned (Fig. 166.3*D*).
- Next, divide the capsule in a fashion, taking care to avoid damage to the underlying femoral head (Fig. 166.3*E*). The vertical limb of the lies parallel to the femoral neck, with the cross of the lying parallel and 0.5 cm distal to the labrum of the hip joint. Scissors may be used to extend the superior border of the cross part of the around to the upper and posterior portions of the hip capsule. At this point, place suture tags in the two corners of the capsulotomy for later use in repairing the capsule.
- Now inspect the hip joint (Fig. 166.3*F*). Unless the patient is older, the ligamentum teres will be seen as a large, hypertrophic, flattened structure. Carefully excise it sharply from its attachment on the femoral head. Leave its acetabular attachment intact, and follow the ligament into the acetabular fovea to locate the true acetabulum (Fig. 166.3*G*). With external rotation or flexion and adduction, the femoral head can be pulled out of the way to allow full exposure of the acetabulum. After the fovea has been clearly identified, cut the remaining stump of the ligamentum teres. Clean any fibro-fatty tissue from the acetabulum, using rongeurs and Kidner dissectors, being careful to avoid damage to the articular surface. Sometimes, the anterior capsule is adherent to the acetabulum and must be painstakingly dissected free to expose the entire “horseshoe” of the acetabular surface. In nearly every case, the transverse acetabular ligament (a capsular thickening that lies across the base of the horseshoe of the acetabular surface) will need to be sectioned. This ligament is hypertrophic and prevents the descent of the femoral head into the depths of the true acetabulum.

Management of the labrum is controversial. Occasionally, the labrum may actually be inverted, but more often it is rolled and hypertrophic. If an actual inversion can be demonstrated and it cannot be adequately dissected to allow placement of the femoral head, use axial (radial) incisions to allow part of the labrum to be teased out of the acetabulum. This is rarely necessary. Do not excise the labrum because it contributes to future growth of the acetabular rim.

- Now reduce the hip by traction, abduction, and internal rotation. The femoral head is often flattened on its medial border and somewhat bullet-shaped; this is usually not a problem if the hip is abducted and the apex of the femoral head can be brought inside the acetabular labrum. If any force is required to bring the femoral head into the acetabulum, perform a femoral shortening osteotomy. If the hip reduces but is stable only when the hip is flexed and abducted, consider performing an innominate osteotomy (usually Salter osteotomy), especially if the child is near 3 years of age. In addition, if severe internal rotation is required in an older child, consider a derotation osteotomy through a lateral incision.
- With the hip held in internal rotation, close the capsulotomy (Fig. 166.3*H*). Bring the superior flap corner (tagged A in Fig. 166.3*H*) into the inferomedial portion of the capsule, at the lower end of the T. The redundant lower flap can then be either excised or sewn over the superior flap (tagged B in Fig. 166.3*H*). After additional capsular repair, the hip joint should be stable. Close the wound by reattaching the tendons of the rectus femoris and by subcutaneous and subcuticular skin closure with absorbable 5-0 synthetic suture. Drainage is usually unnecessary.

Immobilize the child in a double-hip spica cast with the legs in 30° of abduction, 20° of flexion, and gentle internal rotation (Fig. 166.3*I*). The position is safe if the femur has been shortened and the iliopsoas lengthened. After open reduction in older children, this extended internally rotated position is more appropriate than the flexed “human” position used after closed reduction.

Postoperative radiographs must show a reduced femoral head, although the small ossific nucleus is often seen to be somewhat inferior to its expected position. This results from the misshapen femoral head and the hypertrophic labrum, and will remodel (Fig. 166.3*J*). Casting for 6 weeks is usually sufficient to allow healing of any osteotomy and development of satisfactory joint stability after open reduction. Ambulation with or without abduction bracing, as the clinical situation dictates, may begin immediately.

**COMBINED OPEN REDUCTION AND FEMORAL SHORTENING**

Femoral shortening is done during open reduction of the hip to minimize the compressive force across the joint (thus decreasing the risk of avascular necrosis) and to avoid preoperative traction in older children. It is also done in combination with derotation osteotomy to stabilize the reduction in the weight-bearing position (5,20,22).

I prefer a second longitudinal lateral incision for the femoral-osteotomy portion of the combined procedure (Fig. 166.4*A*). This lateral approach is more cosmetic and facilitates plate removal, if desired. However, the proximal femoral shaft can, with more difficulty, also be reached anterolaterally through the lower arm of an extended standard Smith–Petersen incision.

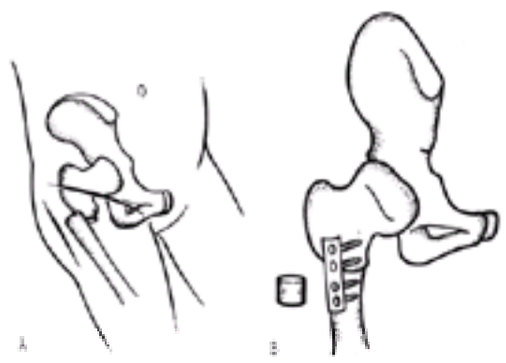

***Figure 166.4.*** Surgical technique for femoral shortening derotation osteotomy combined with open reduction of the hip. **A:** Surgical incisions and osteotomy. **B:** Resection of a femoral segment and plate fixation.

- Carry the lateral approach longitudinally through the fascia lata distal to the trochanteric apophysis.
- Free the proximal origin of the vastus lateralis from the trochanter, and dissect the muscle from its posterior attachment longitudinally along the shaft of the femur. This avoids denervation of the vastus lateralis, but take care to cauterize perforating vessels that enter the muscle posteriorly. Then reflect the entire muscle subperiosteally anteriorly to expose the proximal femoral shaft.
- Select a small plate for internal fixation; I use a four-hole $^{1}/_{3}$-tubular small-fragment plate. Place the plate along the lateral shaft of the femur just below the trochanteric flare.
- Drill, measure, and tap the two proximal screw holes (because the shaft is so small, this is more easily done before the osteotomy).
- Between the second and third holes of the plate, make a transverse osteotomy with a small, sharp oscillating saw.
- After completion of the osteotomy, the proximal femur can easily be reduced into the hip joint through the anterior incision. Gently pull the thigh, and observe the bayonet overlap of the femoral fragments; this determines the amount of shortening to be done (usually 2 cm). Remove the selected length of shaft by a second transverse osteotomy of the distal fragment (Fig. 166.4*B*).
- Secure the plate to the proximal femoral fragment, and temporarily fix the plate to the distal fragment with a small bone clamp. Adjust anteversion by putting the hip through the full range of motion while observing the joint through the anterior incision. Derotation should not be excessive; usually there should be 15° to 20° of residual anteversion after the osteotomy is fixed. I do not routinely increase varus; however, varus derotation osteotomy with shortening is an alternative at this point.
- Once the three-dimensional position of the fragments is satisfactory, fix the distal two holes of the plate to the distal shaft with screws (Fig. 166.5).

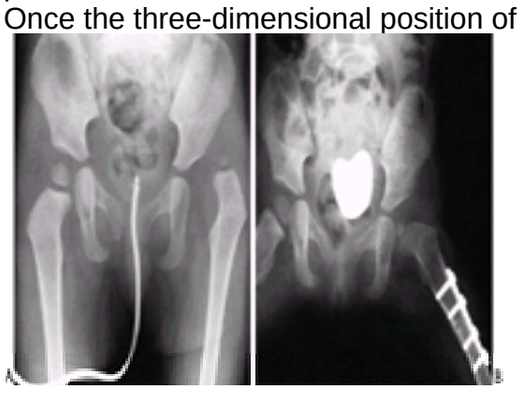

***Figure 166.5.*** **A:** Radiographic appearance of complete congenital dislocation of the hip treated with primary open reduction and femoral shortening using plate fixation of the osteotomy (**B**).

- After a final check of hip coverage by the acetabulum during motion, close the lateral wound with fine, absorbable synthetic suture.

## COMPLICATIONS

### *Infection*

Infection is rare, but if it occurs, open all wounds, including a second lateral incision (if done), down to the skeletal structures. Leave the plate in place if a femoral shortening osteotomy was done. Thoroughly irrigate and debride the wound. The hip capsule may be opened if necessary to irrigate the joint, but it must be repaired in the same fashion as the original capsulorrhaphy. The wounds may be packed open or closed over suction drains, depending on the severity of infection and the surgeon's preference. Cast immobilization is mandatory. Administer appropriate antibiotic therapy.

### *Redislocation*

Early redislocation is evidence that the capsulorrhaphy has failed. If it is detected early, simple manipulation under general anesthesia and application of a spica cast should suffice to restore reduction. Late redislocation is often associated with residual stiffness. It may occur because of insufficient immobilization, capsulorrhaphy failure, or excessive derotation. Rarely, it can be secondary to severe ligamentous laxity, even when appropriate surgery has been done, usually in an older child with a markedly dysplastic acetabulum. Management of late redislocation must be based on careful radiographic studies to determine the cause. Sometimes, fluoroscopy or arthrography is helpful. A proper diagnosis will suggest the most appropriate treatment.

### *Subluxation*

Late subluxation of the hip following open reduction can occur, particularly in older children. Assessment is almost always radiographic. If subluxation is subtle and mild, I postpone additional surgical treatment for 6 months to allow complete rehabilitation of the hip girdle musculature and joint remodeling; abduction bracing during this period may be appropriate.

If a previous femoral shortening or derotation osteotomy was performed, subluxation is usually best treated by an innominate osteotomy. Repeat open reduction may be required. Unless the surgeon is extremely experienced in all aspects of congenital hip surgery, it is safer to perform such acetabular procedures as secondary treatment, even if it is initially thought that both femoral and acetabular surgery will be necessary. If previous femoral surgery was not done, the surgeon may elect either pelvic or femoral osteotomy, especially if the child is younger than 5 years.

### *Stiffness*

A hip that has been properly reduced should not be stiff, even if open reduction was required. Stiffness is almost always a sign of subluxation or avascular necrosis. Make every attempt to accurately diagnose the problem; fluoroscopy and arthrography can be helpful.

### *Avascular Necrosis*

Avascular necrosis may be mild and subtle (e.g., delayed or irregular ossification in a clinically normal joint) and require observation only. More extensive avascular necrosis may lead to temporary subluxation, which should be managed by casting, ambulatory abduction bracing, or surgical treatment. Severe subluxation associated with avascular necrosis may require reorientation of the acetabulum by innominate osteotomy (1), although it is safe to wait and observe if the hip is reduced in an abduction brace. Arthrography to visualize cartilaginous structures is recommended before surgical treatment for avascular necrosis. Avascular necrosis is a potential complication of all additional treatment options for patients and reduces the success of reconstructive surgery. It can also lead to early osteoarthrosis of the hip.

Extensive avascular necrosis involving the growth plate will be followed by leg-length discrepancy and deformity of the proximal femur. These deformities (head deformity, coxa breva, coxa valga) may appear late. Initiate a regular program of leg-length evaluation and x-ray observation to detect these complications and plan long-term management (11,27).

### *Proximal Femoral Growth Arrest and Leg-length Discrepancy*

A leg-length discrepancy after congenital hip dysplasia usually occurs as a result of vascular damage to the proximal femoral physis (14). In most children (except very short ones), the appropriate management is properly timed epiphysiodesis of the contralateral limb, based on routine yearly leg-length measurements through childhood. Occasionally, femoral lengthening may be necessary (see Chapter 171). The slight temporary discrepancy that accompanies femoral shortening osteotomy is usually followed by slight femoral overgrowth, so treatment is unnecessary.

***Surgery for Residual Dysplasia***

After reduction has been achieved in DDH, treatment must be continued until remodeling has eliminated the secondary dysplastic features of the acetabulum and the proximal femur. Monitor dysplasia and residual subluxation both radiographically (acetabular index, center–edge angle) (21) and clinically (subtle loss of abduction, Trendelenburg gait). The use of casts, abduction braces, and surgery for residual dysplasia is somewhat arbitrary and should be based on the patient's age, the parents' wishes, and the surgeon's experience. However, failure of significant remodeling of dysplasia by 5 years of age makes additional surgery worth considering because there is good evidence that excellent remodeling can occur if correction is achieved by that age. Obvious subluxation warrants a more aggressive surgical approach because prompt treatment improves the dysplasia and the prognosis. Both femoral and pelvic osteotomies can be done for residual dysplasia.

## FEMORAL OSTEOTOMY

### INDICATIONS

Proximal femoral derotation or varus osteotomy is indicated in subluxation or dysplasia of the hip when reorientation can stabilize a reduction, resolve mild subluxation, or stimulate remodeling of the joint (4,5,12,22,25). Often, it is used to achieve a congruent joint in the weight-bearing position after closed or open reduction to allow a child of walking age to ambulate with less risk of subluxation. When acetabular dysplasia persists after reduction, femoral osteotomy can stimulate remodeling of the acetabulum, if done by 5 years of age (12). The choice of femoral or pelvic osteotomy in this situation is often a matter of the surgeon's personal preference; I prefer the pelvic procedure.

The usual deformity of the femur in congenital hip dysplasia is excessive anteversion. This contributes to anterolateral subluxation in the weight-bearing position and encourages superolateral subluxation in the sitting position. Femoral derotation alone is generally sufficient to correct the deformity. This becomes obvious when radiographs are taken with the legs internally rotated and a normal neck–shaft angle (135°) is seen. If abduction is also necessary to produce a congruent reduction, then varus can be added, as well. Take great care not to overcorrect the femoral deformity. Avoid retroversion; increased varus of greater than 20° is rarely indicated. If a varus osteotomy is done, the hip must have an adequate range of abduction to allow functional motion after surgery. In my opinion, the prerequisites for femoral osteotomy in hip dysplasia are critical and should be the same as those for innominate osteotomy: congruent reduction of the hip and a full range of motion.

Internal fixation is necessary for femoral osteotomy. Some have advocated single-screw fixation or multiple smooth pins, but I strongly prefer rigid fixation with a small plate (for derotation alone) or a pediatric blade plate (for a varus osteotomy in an older child). This allows more accurate control of position during healing.

### INTERTROCHANTERIC VARUS DEROTATION OSTEOTOMY

- Perform the operation with the hip and leg draped free, the patient on a radiolucent table, and an image intensifier available positioned anteroposteriorly. This allows testing of range of motion and reduces the chance of overcorrection, compared to the more conventional fracture table.
- Make a longitudinal lateral incision from the greater trochanter to a point distant enough to accommodate the fixation device selected. Incise the fascia lata and reflect the vastus lateralis anteriorly from its posterior femoral insertion, taking care to cauterize perforating vessels. Expose the proximal femoral shaft subperiosteally to the apophysis of the greater trochanter.
- The osteotomy site is critical. It must be intertrochanteric because internal rotation of the proximal fragment would otherwise increase iliopsoas tension (Fig. 166.6). If a subtrochanteric osteotomy is preferred, expose and release the tendinous portion of the iliopsoas insertion.

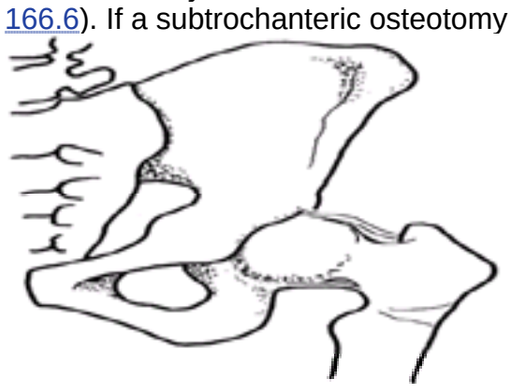

***Figure 166.6.*** Proper intertrochanteric level for femoral derotation osteotomy. This allows relaxation rather than tightening of the iliopsoas muscle.

- Position the guide pins for a blade plate, using anteroposterior (AP) and frog-lateral image intensification. Use appropriate reamers or blade chisels according to the manufacturer's directions, depending on the specific fixation system being used. Drill and tap any proximal fixation holes before cutting the femur.
- Perform the osteotomy with a saw, taking an appropriate wedge out medially if varus positioning is desired. Fix the plate to the proximal fragment, externally rotate the distal fragment, and temporarily clamp the plate to the shaft. Now put the hip through a full range of motion while studying the joint with fluoroscopy, making special note of anteversion (which should not be less than 15°). Readjust the position until you are satisfied that subluxation has been adequately treated, and fix the plate to the distal fragment. Close the wound with fine, absorbable suture, including the skin; I prefer 5-0 undyed polyglycolic acid subcuticular suture. Apply a double-spica cast. Remove the cast at 8 weeks postoperatively or after radiographic union. Allow ambulation as tolerated. Physical therapy is unnecessary. Warn the family that the perineum will appear wide until the child grows and that a limp may persist for 2–3 months but will eventually disappear.

## PELVIC OSTEOTOMY

### INDICATIONS

Pelvic osteotomy is indicated when there is primary acetabular dysplasia, residual subluxation of the hip, or failure of gradual improvement of radiographic dysplasia following reduction of a dislocated hip. In general, pelvic osteotomy should be done when severe dysplasia is accompanied by significant radiographic changes (high acetabular index, failure of lateral acetabular ossification) on the acetabular side of the hip joint, as opposed to changes on the femoral side (e.g., marked anteversion), which are best treated by femoral osteotomy (5). Surgical treatment of definite hip subluxation by either pelvic or femoral osteotomy before age 4 years will be accompanied by at least partial remodeling and resolution of anatomic abnormalities on the opposite surface of the joint (12).

Pelvic osteotomy is ideal for treatment of dysplasia when expected remodeling has ceased (as assessed by serial radiographs) and dysplasia or subluxation persists (5). Often, after the hip is reduced, pelvic osteotomy can be postponed until 4 years of age to allow adequate time for remodeling.

Pelvic osteotomy is also indicated when necessary to stabilize reduction during or after open reduction of the hip.

### PREREQUISITES AND SELECTION OF OSTEOTOMY SITE

The many osteotomies described for acetabular dysplasia may be categorized as indicated either for primary treatment of dysplasia (Salter innominate osteotomy, Pemberton osteotomy, triple innominate osteotomy) or for salvage of a poor result in the later stages of dysplasia when complete remodeling is not expected (Chiari osteotomy). The primary osteotomies are generally reorientation procedures for the acetabulum, although the Pemberton procedure allows actual diminution of acetabular volume at the expense of some acetabular congruity. The Salter and Pemberton osteotomies are the most common osteotomies performed in North America.

To be successful as a primary treatment of dysplasia, an osteotomy must be done only in the presence of a congruent reduction, satisfactory range of motion, and reasonable femoral sphericity. These prerequisites have been popularized primarily by Salter (18,19) for his innominate osteotomy, and they are appropriate preoperative goals for any primary osteotomy about the hip (acetabular or femoral).

The Salter and Pemberton osteotomies differ somewhat in concept, although both are designed to limit anterolateral subluxation by improving coverage in this area. The Salter osteotomy, because it goes completely through the pelvis, allows anterior and lateral rotation of the acetabulum through an axis formed by the sciatic notch and the pubic symphysis. There is a limit to the degree of correction that can be obtained, and the procedure does not change acetabular shape (17). Conversely, the Pemberton osteotomy is an incomplete osteotomy that hinges the anterolateral acetabular roof on the flexible triradiate cartilage for correction (16). This actually

changes the configuration of the acetabulum and introduces joint incongruence that must be corrected by remodeling during growth. For these reasons, the Pemberton procedure may be indicated when there is an elongated, dysplastic acetabulum, but it is most effectively done in children younger than 8 years, as there is still flexibility in the triradiate cartilage and growth remains for remodeling of the joint surfaces (29).

In older children with deficient, dysplastic acetabulae but a relatively congruent reduction, the Salter osteotomy does not provide sufficient angular correction to improve stability. When the triradiate cartilage is closed, the Ganz periacetabular osteotomy (see Chapter 104) can achieve the extremes of reorientation required. When the triradiate cartilage is open, the same freedom to reorient the acetabulum in space can be achieved by cutting the ischium and pubis in addition to the ilium (triple innominate osteotomy). Variations of this technique have been described by Steel (24), Tönnis et al. (28), and Tachdjian (25). All are complex operations that should not be attempted by an inexperienced surgeon.

In older children, salvage of a hip that is too deformed to remodel for the growth time remaining requires a different type of procedure. The Chiari (3) osteotomy is probably the most commonly used operation. It is a displacement osteotomy that essentially provides a shelf or buttress to limit further proximal subluxation of the femoral head. The superior hip capsule provides an interpositional surface between the cancellous bone of the shelf and the femoral head, and the capsular tissue may undergo metaplasia into fibrocartilage. Thus, the functional size of the acetabulum can be increased by the operation. If done properly, the Chiari osteotomy also moves the hip joint center medially and improves the mechanical advantage of the abductor muscles, both of which tend to decrease the intra-articular resultant force across the hip joint. The Chiari osteotomy does not require a concentric reduction; it may be done above a subluxated hip. The chief indication for Chiari osteotomy is pain associated with a subluxated, dysplastic hip in an older child. It should not be performed if degenerative changes are present or the hip is stiff. Do not do a capsulotomy at the same time as a Chiari osteotomy.

The exact indications for salvage surgery in congenital hip dysplasia are controversial. The goal of surgery most often stated is to treat chronic hip pain in an adolescent who has significant dysplasia as seen on radiographs. For many surgeons, another appropriate indication is radiographically demonstrated progressive subluxation, often associated with increasing degenerative changes of the hip. Although it may be unwise to consider surgery in an adolescent who has no pain, regardless of the radiographic appearance of the hip, there are surgeons who are exploring the use of late reconstructive procedures (e.g., the Ganz osteotomy) in asymptomatic patients who have severe radiographic dysplasia (see Chapter 104).

**SALTER INNOMINATE OSTEOTOMY**

- Prepare and drape the affected hip and leg free. Use a transverse inguinal skin incision as described earlier in this chapter (Salter describes a slightly more oblique incision), and identify the lateral femoral cutaneous nerve where it exits at the upper border of the sartorius; protect it with Silastic tape. Develop the proximal interval between the sartorius and the tensor fasciae latae muscles and between the straight head of the rectus femoris and the tensor fasciae latae muscles.
- Split the iliac apophysis with a single longitudinal scalpel cut from the anterosuperior spine to the mid crest (Fig. 166.7*A*), and carefully pull the cartilage away from the crest. Strip the inner and outer walls of the ilium subperiosteally. Strip the anteroinferior spine medially with its attached rectus femoris. Carry the subperiosteal dissection to the sciatic notch. The notch is best exposed by gently teasing the periosteum away from it both medially and laterally with right-angle clamps; the tips of the two clamps should touch when stripping is complete. Stay subperiosteal to avoid sciatic nerve injury.

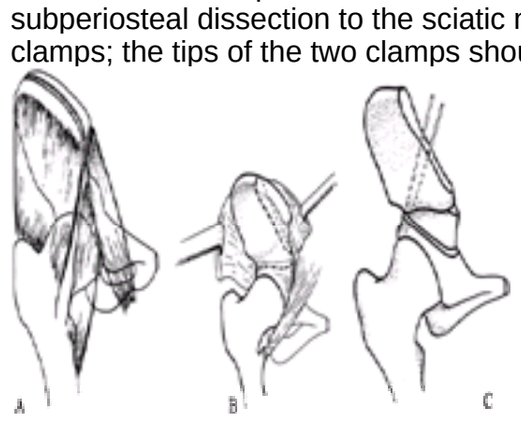


***Figure 166.7.*** Surgical technique for Salter innominate osteotomy. **A:** Split of the iliac apophysis and fascial incision. **B:** Exposure of the ilium and sites of the osteotomy. **C:** Completed osteotomy.

- In the inferior wound, identify the hip capsule and the iliopsoas muscle anterior to it. Pull the tendinous portion of the muscle into the wound with a right-angle clamp and sever it.
- Pass a Gigli saw through the notch with right-angle clamps. Saw a straight osteotomy from the notch to the anteroinferior iliac spine (Fig. 166.7*B*), keeping the hands as far apart as possible to avoid binding; protect the skin with ribbon retractors. Incline the osteotomy slightly in the frontal plane so that the lateral edge is superior to the medial edge.
- Open the osteotomy by externally rotating, abducting, and extending the hip to place the extremity into a figure-four position while holding the posterior osteotomy site closed and slightly anteriorly with a tenaculum. Do not pull the proximal ilium upward; this tends to displace the proximal ileum rather than the distal fragment containing the acetabulum. Do not use a lamina spreader because damage to the fragile ilium may result.
- With an oscillating saw (my preference) or a large rib cutter, fashion a triangular graft with one angle of 30° from the anterior portion of the proximal fragment. Place the graft into the osteotomy site, keeping the posterior osteotomy closed, and fix it with two threaded pins inserted from the proximal fragment, through the graft, and into the distal ischium posterior to the hip joint (Fig. 166.7*C*). Check the pin length carefully, and move the hip joint to feel for any crepitus, which might indicate pin protrusion into the joint. Temporarily leave the pin ends long.
- Irrigate the wound and reapproximate the apophysis over the pins with simple absorbable sutures passed directly around the cartilaginous apophysis. Cut the pins so they will be palpable beneath the skin, and close the subcutaneous tissue and skin with fine, absorbable suture.
- Apply a well-molded one-and-one-half spica cast with the hip in 25° of flexion, 25° of abduction, and slight internal rotation. Remove the cast and pins 8 weeks after surgery, when radiographic union has occurred, under a brief general anesthetic. The patient can then begin weight bearing as tolerated. Physical therapy is usually unnecessary.

**PEMBERTON PERICAPSULAR OSTEOTOMY**

- Perform the operation on a radiolucent table with image-intensifier control.
- Make a transverse skin incision in the inguinal crease, but use subcutaneous dissection to mobilize the proximal and distal flaps. Then use a standard Smith–Petersen exposure of the hip (see Chapter 3). Protect the lateral femoral cutaneous nerve.
- Develop the interval between the sartorius and tensor fasciae latae muscles, and incise the iliac apophysis longitudinally with a sharp scalpel.
- Expose the anterior two thirds of the inner and outer tables of the pelvis with a periosteal elevator. The subperiosteal stripping does not need to go behind the sciatic notch (as in the Salter osteotomy) but must proceed distally to the triradiate cartilage. This can be felt as a line of resistance to further stripping; facilitate a safe approach to the area by teasing subperiosteally with a right-angle clamp.
- Beginning on the outer wall of the pelvis, use a small, curved osteotome to make a cortical pericapsular osteotomy, starting at the anteroinferior iliac spine and continuing parallel to the joint. This osteotomy curves down to, but not into, the triradiate cartilage and must end anterior to the sciatic notch (Fig. 166.8*A*).

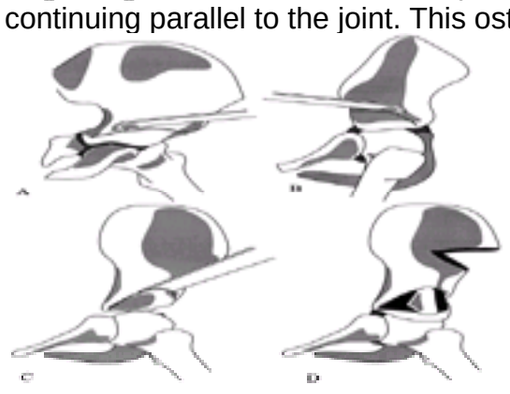


***Figure 166.8.*** Pemberton osteotomy. **A:** Make a cortical pericapsular osteotomy cut. **B,C:** Make a similar cortical osteotomy in the inner wall of the pelvis. **D:** Cut a triangular graft from the proximal ilium, and carefully wedge the graft into the osteotomy site.

- Make a similar cortical osteotomy in the inner wall of the pelvis, again ending at the triradiate cartilage but avoiding both the sciatic notch and the joint itself (Fig. 166.8*B*).
- Join the two osteotomies, using a curved or spherical osteotome and taking care to avoid penetration of the sciatic notch or the joint. Use the image intensifier at this point to confirm the safe position of the osteotome.
- Carefully pry the anterolateral acetabular fragment distally with the osteotome and a smooth, broad lamina spreader, without too much force. When this is properly done, the triradiate cartilage should be visible in the depths of the osteotomy.
- Cut a triangular graft from the proximal ilium; a saw helps to make this cut without crushing the bone (Fig. 166.8*C*). Flatten a notch in the faces of the pelvic osteotomy, as needed, to receive the graft and lock it in place. Carefully wedge the triangular graft into the osteotomy site, and remove the lamina spreader; the graft should be secure and require no fixation (Fig. 166.8*D*).
- Close the wound with absorbable sutures, and apply a spica cast as described in the technique of Salter osteotomy.

Remove the cast 8 weeks after surgery (Fig. 166.9). Allow weight bearing as tolerated. Physical therapy is unnecessary. Older children may exhibit transient stiffness of the hip joint because of changes in the acetabular surface configuration caused by the Pemberton osteotomy.

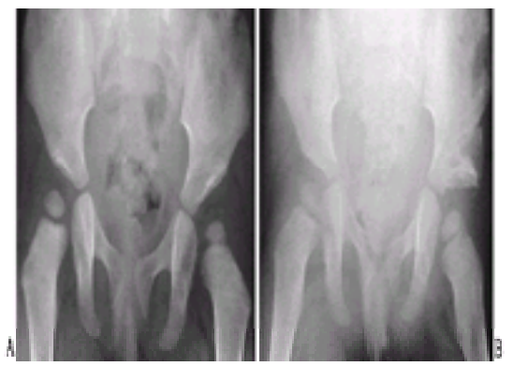

***Figure 166.9.*** Radiographs of a Pemberton osteotomy of a dysplastic left hip. **A:** Preoperative radiograph. **B:** Radiograph taken 6 weeks postoperatively.

## TRIPLE INNOMINATE OSTEOTOMY

General approaches to the variations in triple innominate osteotomy are presented here (24,26,28). These are highly specialized operations, and their powerful ability to reorient the acetabulum can lead to overcorrection (6). There is also significant potential risk of neural and vascular injury; these are not operations for the inexperienced. Of the operative approaches, I prefer Tachdjian's (26), but each has its proponents. For fully detailed descriptions, readers are referred to the originators of each approach (24,26,28).

- Drape the patient on a radiolucent table with the leg free. The iliac portion of the osteotomy (usually performed last) is performed exactly as in the Salter osteotomy.

### *Steel Variation*

Steel (24) makes the pubic cut through an inguinal incision and the ischial cut through the buttock (Fig. 166.10*A*).

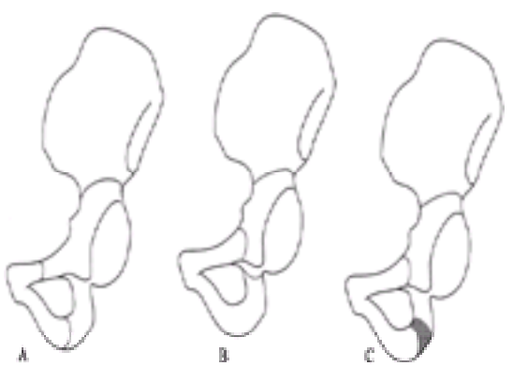

***Figure 166.10.*** Site of iliac, pubic, and ischial osteotomies in the various triple innominate osteotomy procedures. **A:** Steel osteotomy. **B:** Tönnis osteotomy. **C:** Tachdjian triple osteotomy.

- Flex the hip 90° to expose the buttock and ischial tuber-osity. Make the ischial cut first through a transverse incision positioned 1 cm proximal to the gluteal crease. Retract the gluteus maximus laterally, and sharply dissect the origin of the biceps femoris from the ischium. Identify the sciatic nerve, using a nerve stimulator if necessary, and protect it throughout the procedure.
- Separate the origins of the semimembranosus and semitendinosus muscles, and pass a very curved hemostat subperiosteally around the ischium, starting from the obturator foramen and emerging posterior to the ischial ramus. Stay carefully on the bone to avoid vascular injury. Cut the ramus, using the clamp as protection, with an osteotome as wide as the ischial ramus directed 45° posteriorly and laterally. Then close the wound. Steel recommended changing gloves, gowns, and instruments at this stage because of the risk of contamination in this area of the perineum.
- Expose the anterior pelvis as for a Salter osteotomy (see above), continuing the dissection medially to identify the pectineus muscle. Detach the pectineus from the pubic ramus, clearing the pubis to about 1 cm medial to the pectineal tubercle. Pass a significantly curved hemostat subperiosteally from above the pubis and around the bone to emerge in the obturator foramen. Again using the instrument for protection, cut the pubic ramus by directing an osteotome posteriorly and medially.
- Then make the iliac cut as described for the Salter osteotomy, and under image-intensifier control reposition the entire acetabular unit to its desired position. A towel clip or Steinmann pin (inserted as a “joystick”) can be helpful in controlling the fragment.
- Position a triangular graft in the iliac osteotomy site, and fix the ilium with threaded pins directed either as in the Salter osteotomy or from the distal fragment upward into the wing of the ilium.
- Close the wound, and immobilize the hip in a one-and-one-half hip spica cast for 8 weeks. Follow-up care is similar to that for Salter osteotomy.

### *Tönnis Variation*

Tönnis (28) uses a posterior gluteal approach for the ischial cut (Fig. 166.10*B*). He felt that redirection should emphasize more lateral and less anterior coverage of the hip than advocated by Salter or Steel.

- With the patient lying prone, expose the ischial tuberosity through an oblique incision in the direction of the fibers of the gluteus maximus, which are split bluntly and separated. Cut the obturator internus and the inferior and superior gemellus muscles to expose the ischial ramus. Protect the sciatic nerve and the gluteal vessels with a blunt retractor in the sciatic notch, and place special retractors around the ischial ramus, preserving the sacrotuberous and sacrospinalis ligaments for stability. Make the ischial cut as frontal as possible, from lateral to medial, connecting the ischial and obturator foramina. The osteotomy must be complete, without spikes remaining on the cut surfaces of the bone.
- Close the wound and reposition the patient supine. Rather than using an extended inguinal incision (see the Steel technique above), make a small incision over the pubis where it is palpable just medial to the psoas. Insert two retractors above the pubis and through the obturator foramen, and make the osteotomy cut parallel with the hip joint.
- The remaining procedure is performed similarly to the Steel osteotomy, except that in the frontal plane the iliac osteotomy is oriented from superolateral to

inferomedial, which allows easier lateral rotation of the fragment.

### *Tachdjian Variation*

Tachdjian (26) performs the ischial cut anteromedially through a subinguinal incision between the adductor magnus and obturator externus (Fig. 166.10*C*).

- With the extremity in the frog-leg position, make a transverse adductor incision over and posterior to the adductor longus. Although Tachdjian (26) released the adductors, I have found that the ischium can usually be exposed by bluntly developing the interval between adductor brevis and magnus and then carefully dissecting toward the ischial tuberosity on a line between the adductor magnus and obturator externus insertions. Expose the ischium subperiosteally, and protect the soft tissues with Chandler retractors. The ischial osteotomy is a laterally based about 1.5 cm wide wedge that allows moving the acetabulum medially.
- Expose the pubis through the same incision by retracting the iliopsoas muscle (which may be fractionally lengthened) laterally and elevating the pectineus to expose the iliopectineal eminence. Protect the pubis subperiosteally with two Chandler retractors. Make the pubic osteotomy parallel to the joint, 1.5 cm medial to the acetabulum as seen on image intensification, with the osteotome directed 15° medially.
- Using a second incision (or an extension of the medial one), perform the iliac osteotomy in a similar fashion to that in the Steel osteotomy.

## CHIARI OSTEOTOMY

Perform a Chiari (3) osteotomy on a radiolucent table with AP image-intensifier control.

- Drape the hip and leg free, with the affected side elevated on a small towel or sandbag.
- Make an extended transverse inguinal incision as previously, carrying it well lateral to the mid-lateral line. Undermine the subcutaneous tissue to expose the proximal crest of the ilium, and isolate and protect the lateral femoral cutaneous nerve.
- Detach and tag the straight head of the rectus femoris. Split the iliac apophysis longitudinally, and expose the inner and outer walls of the ilium by subperiosteal dissection down to the sciatic notch. Carefully cut the reflected head of the rectus femoris, and dissect it free to expose the edge of the capsule. Under the reflected head of the rectus femoris, identify the edge of the capsule where it attaches to the pelvis. Use an instrument and the image intensifier to confirm the position of the capsular attachment on the ilium. The correct spot will be several millimeters above the superior edge of the acetabulum as seen on the fluoroscope because of the thickness of the capsule.

The original osteotomy described by Chiari (3) was straight from the front to the back of the pelvis. Most surgeons (including myself) prefer a curved cut, which limits anteroposterior sliding of the osteotomy. However, if the cut is made as a conical rather than cylindric curve three-dimensionally, the fragments will not displace; therefore, accurate three-dimensional control is mandatory.

- Make the osteotomy just at the superior edge of the thickened hip capsule at a 15° upward angle as viewed in the AP plane with the image intensifier. Use two alternate ¾ in (1.5– 2.0 cm) straight osteotomes and frequent radiographs to make a slightly curved osteotomy from the front of the pelvis to near the notch. Both osteotomes must be kept absolutely parallel to each other (at 15° inclination); otherwise, the osteotomy will not slide properly. Although logic suggests that the entire osteotomy should follow the arc of the hip joint, there has never been any demonstrated advantage to such a cut, and it is unrealistic to expect perfect congruence with the hip capsule, except by the rapid remodeling that follows Chiari osteotomy.
- Protect the inner wall of the pelvis with malleable retractors. The cut must be smooth so there are no spikes of bone to catch during displacement.
- Complete the posterior part of the osteotomy with a Gigli saw passed behind the sciatic notch with right-angle clamps, as described above for Salter osteotomy.
- Displace the osteotomy by abducting the leg widely. The displacement should be one-half of the width of the ilium at the site of the cut; too much displacement reduces the contact area of the osteotomy surface and may lead to delayed union (Fig. 166.11). Do not pull the proximal ilium laterally in an attempt to move the fragments; if the cut will not displace, it is because the osteotomy is not complete or is irregular or conical or because spikes of medial cortex remain.

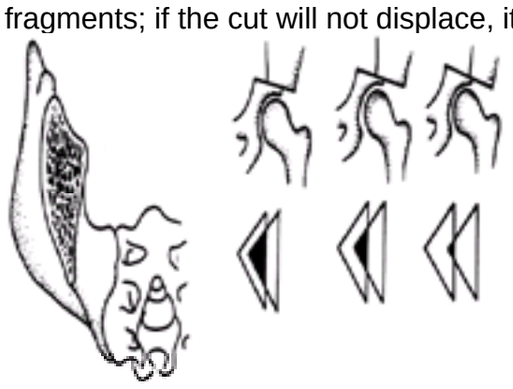

***Figure 166.11.*** The Chiari osteotomy is made through a triangular section of the ilium. Avoid excessive displacement of the distal fragment, which reduces the contact area and may result in delayed union.

- If there is a large anterior defect over the capsule after displacement, it may be filled with corticocancellous graft from the proximal ilium.
- I prefer internal fixation with a long, 4.5 mm cancellous bone screw introduced from the lateral proximal ilium into the distal fragment. Use the image intensifier to ensure that the hip joint is not penetrated. Alternatively, threaded Steinmann pins may be used. Internal fixation is not absolutely necessary, but if it is not used, the leg must be immobilized in abduction (with a spica cast or traction) to maintain displacement until the pelvis begins healing in 2–3 weeks (Fig. 166.12).

***Figure 166.12.*** An adolescent girl with a painful dysplastic hip was treated by Chiari osteotomy. **A:** Preoperative radiograph. **B:** Postoperative radiograph. Note the upward inclination of the osteotomy. Postoperative hip function was excellent, with complete relief of pain.

- Close the wound over a suction drain. If internal fixation was used and is stable, allow early touch-down crutch walking.

## CHAPTER REFERENCES

Each reference is categorized according to the following scheme: *, classic article; #, review article; !, basic research article; and +, clinical results/outcome study.


+ 1. Bar-On E, Huo MH, DeLuca PA. Early Innominate Osteotomy as a Treatment for Avascular Necrosis Complicating Developmental Hip Dysplasia. *J Pediatr Orthop B* 1997;6:138.

+ 2. Brougham DI, Broughton NS, Cole WG, Menelaus MB. Avascular Necrosis Following Closed Reduction of Congenital Dislocation of the Hip: Review of Influencing Factors and Long-term Follow-up. *J Bone Joint Surg Br* 1990;72:557.

* 3. Chiari K. Displacement Osteotomy of the Pelvis. *Clin Orthop* 1974;98:55.

* 4. Chuinard EG. Femoral Osteotomy in the Treatment of Congenital Dysplasia of the Hip. *Orthop Clin North Am* 1972;3:157.

# 5. Coleman SS. *Congenital Dysplasia and Dislocation of the Hip.* St. Louis, MO: Mosby, 1978.

+ 6. de Kleuver M, Kooijman MA, Pavlov PW, Veth RP. Triple Osteotomy of the Pelvis for Acetabular Dysplasia: Results at 8 to 15 Years. *J Bone Joint Surg Br* 1997;79:225.

* 7. Ferguson AB Jr. Primary Open Reduction of Congenital Dislocation of the Hip Using a Median Adductor Approach. *J Bone Joint Surg Am* 1973;55:871.

+ 8. Galpin RD, Roach JW, Wenger DR, et al. One-stage Treatment of Congenital Dislocation of the Hip in Older Children, Including Femoral Shortening. *J Bone Joint Surg Am* 1989;71:734.

+ 9. Gerscovich EO. A Radiologist's Guide to the Imaging in the Diagnosis and Treatment of Developmental Dysplasia of the Hip. II. *Skeletal Radiol* 1997;26:447.

+ 10. Kahle WK, Anderson MB, Alpert J, et al. The Value of Preliminary Traction in the Treatment of Congenital Dislocation of the Hip. *J Bone Joint Surg Am* 1990;72:1043.

+ 11. Kalamchi A, MacEwen GD. Avascular Necrosis Following Treatment of Congenital Dislocation of the Hip. *J Bone Joint Surg Am* 1980;82:878.

+ 12. Kasser JR, Bowen JR, MacEwen GD. Varus Derotation Osteotomy in the Treatment of Persistent Dysplasia in Congenital Dislocation of the Hip. *J Bone Joint Surg Am* 1985;67:195.

+ 13. Klisic P, Jankovic L. Combined Procedure of Open Reduction and Shortening of the Femur in Treatment of Congenital Dislocation of the Hips in Older Children. *Clin Orthop* 1976;119:60.

+ 14. O'Brien T, Millis MB, Grifffin PP. The Early Identification and Classification of Growth Disturbances of the Proximal End of the Femur. *J Bone Joint Surg Am* 1986;68:970.

+ 15. Paton RW, Srinivasan MS, Shah B, Hollis S. Ultrasound Screening for Hips at Risk in Developmental Dysplasia: Is It Worth It? *J Bone Joint Surg Br* 1999;81:255.

* 16. Pemberton PA. Pericapsular Osteotomy for Congenital Dislocation of the Hip: Indications and Techniques. *J Bone Joint Surg Am* 1965;47:437.

+ 17. Rab GT. Preoperative Roentgenographic Evaluation for Osteotomies about the Hip in Children. *J Bone Joint Surg Am* 1981;63:306.

* 18. Salter RB. Innominate Osteotomy in the Treatment of Congenital Dislocation and Subluxation of the Hip. *J Bone Joint Surg Br* 1961;43:518.

* 19. Salter RB. The First 15 Years' Personal Experience with Innominate Osteotomy in the Treatment of Congenital Dislocation and Subluxation of the Hip. *Clin Orthop* 1974;98:55.

+ 20. Schoenecker PL, Strecker WB. Congenital Dislocation of the Hip in Children: Comparison of the Effects of Femoral Shortening and of Skeletal Traction in Treatment. *J Bone Joint Surg Am* 1984;66:21.

+ 21. Scoles PV, Boyd A, Jones PK. Roentgenographic Parameters of the Normal Infant Hip. *J Pediatr Orthop* 1987;7:656.

+ 22. Simons GW. A Comparative Evaluation of the Current Methods for Open Reduction of the Congenitally Displaced Hip. *Orthop Clin North Am* 1980;11:161.

# 23. Staheli LT, Coleman SS, Hensinger RN, et al. Congenital Hip Dysplasia. *Instr Course Lect* 1984;33:350.

* 24. Steel HH. Triple Osteotomy of the Innominate Bone. *J Bone Joint Surg Am* 1973;55:343.

# 25. Tachdjian MO, ed. *Congenital Dislocation of the Hip.* New York: Churchill Livingstone, 1982.

# 26. Tachdjian MO, ed. *Pediatric Orthopedics,* 2nd ed. Philadelphia: WB Saunders, 1990:493.

+ 27. Thomas CL, Gage JR, Ogden JA. Treatment Concepts for Proximal Femoral Ischemic Necrosis Complicating Congenital Hip Disease. *J Bone Joint Surg Am* 1982;64:817.

+ 28. Tönnis D, Behrens K, Tscharani F. A Modified Technique of the Triple Pelvic Osteotomy: Early Results. *J Pediatr Orthop* 1981;1:241.

+ 29. Vedantam P, Capelli AM, Schoenecker PL. Pemberton Osteotomy for the Treatment of Developmental Dysplasia of the Hip in Older Children. *J Pediatr Orthop* 1998;18:254.

# 30. Westin GW, Ilfeld FW, Makin M, Paterson D. Developmental Hip Dislocation. *Contemp Orthop* 1988;16:17.

# CHAPTER 167

# CONGENITAL DEFORMITIES OF THE FOOT

*George T. Rab and Peter B. Salamon*

**G. T. Rab and P. B. Salamon:** Department of Orthopaedics, University of California Davis Medical Center, Sacramento, California, 95817.

Congenital Clubfoot
- Clubfoot Release
- Management of Recurrence or Undercorrection
- Lateral Column Shortening Procedures
- Double Tarsal Osteotomy
- OS Calcis Osteotomy to Correct Hindfoot Varus
- Metatarsal Osteotomies
- Anterior Tibial Tendon Transfer to the Third Cuneiform
- Split Anterior Tibial Tendon Transfer

Cavus Foot
- Dorsal Wedge Osteotomy of the Cuneiforms

Polydactyly
- Postaxial Polydactyly
- Resection of a Sixth Toe
- Preaxial Polydactyly

Juvenile Hallux Valgus
Tarsal Coalition
- Resection of Calcaneonavicular Tarsal Coalition
- Resection of Medial Subtalar Coalitions
- Triple Arthrodesis

Congenital Vertical Talus
- Dorsolateral Approach
- Single-Stage Repair

Pitfalls and Complications
Chapter References

Foot deformities in children may be either congenital or acquired during childhood. Before starting a treatment program for congenital foot deformity, search for associated deformities that may also need treatment (e.g., congenital hip dysplasia, torticollis) and associated conditions that may require further evaluation and that might affect the prognosis of the foot deformity (e.g., arthrogryposis, spinal dysraphism, bone dysplasia). Deformities that develop during childhood are often manifestations of underlying neuromuscular disease that must be evaluated before intelligent treatment of the foot can be planned.

Primary treatment for congenital deformities often begins the first day of life and generally should be concluded by the time the child begins walking. Secondary treatment and treatment of recurrence are often necessary, because mild muscular imbalance and incomplete correction of deformities are common. The foot may require long-term bracing or repeated surgery to maintain adequate function. For these reasons, experience and judgment are as important as surgical skill in the long-term management of foot deformities. The surgeon with only occasional exposure to these problems should not undertake treatment.

## CONGENITAL CLUBFOOT

Congenital clubfoot (talipes equinovarus) is a hereditary foot deformity of unproven etiology. It affects males more often than females and may be unilateral or bilateral. It is often associated with other conditions, such as myelodysplasia, arthrogryposis, and congenital hip dysplasia. Pathologic changes seen in clubfoot include bony deformity, particularly of the talus (short neck, medial deviation of the neck, abnormal articular surface of the head) and soft-tissue contracture (muscle, tendon sheath, capsule, ligament, skin) (14). Externally, the clubfoot is smaller than the normal foot. There is equinus of the ankle, varus and internal rotation of the heel, accompanied by adduction, supination, and cavus of the midfoot. The calf is atrophic and smaller in circumference than the opposite calf. The leg lengths are generally equal. Internally, the deformity is most clearly defined as a rotational subluxation of the talocalcaneonavicular joint complex, with the talus in plantar flexion and the talocalcaneonavicular (subtalar) complex in medial rotation and inversion (20). There is controversy over whether the soft tissue or bony changes are the primary cause of the disorder, although nonoperative and surgical treatment both address the soft-tissue portion of the deformity with the expectation that at least some of the bony abnormalities will remodel. Regardless of the form of treatment, the resultant foot will be smaller and less mobile, and the calf relatively atrophic, when compared with a normal limb.

Management of the congenital clubfoot is initially nonoperative and, if possible, should begin on the first day of life. Serial manipulation of clubfoot and maintenance of correction with casting is a skill that all orthopaedic surgeons dealing with children should develop (15,26). It is essential to correct the midfoot adductus and hindfoot varus in the casts before you make any attempt to address the equinus. We have concern that overly aggressive attempts at dorsiflexion may damage the talus, and we often abandon casting once progression of the correction into dorsiflexion stops.

When casting fails, surgical release is indicated. The need for and the exact timing of the surgery depends on the severity of the clubfoot. We normally make a decision to treat surgically by 3–4 months of age. Surgery, however, can be timed so that the postoperative casting is completed at about the time the child begins to bear weight on the foot. Some surgeons prefer operative treatment at a much younger age, but there is also literature support for postponing surgery up to 1 year of age or beyond, if the surgeon feels technically more able to operate on a larger foot (33). In children with syndromes, delay of surgery until a year of age or beyond is often desirable or necessary.

Stress dorsiflexion lateral radiographs of an incompletely corrected clubfoot reveal inadequate dorsiflexion of the os calcis or parallelism of the talar and calcaneal axes. Anteroposterior (AP) views show medial deviation of the first metatarsal axis relative to the talar axis, a function of subluxation of the talonavicular joint (the navicular ossification center itself does not appear for several years, and its position must be inferred); the axes of the talus and calcaneus likewise become parallel because the external rotation of the subtalar joint is lost. Most of the angles described for evaluation of clubfoot are based on radiographs of older children, and they date from an era when treatment was nonoperative and involved prolonged casting. We have not found radiographs to be helpful in determining which children should have early surgery; the decision is made more easily on clinical grounds.

The aim of surgical treatment is to release soft-tissue restraints on proper positioning of the tarsal bones. The exact surgical procedure can be tailored to the residual deformity of the foot at the completion of casting. The usual surgical release always includes posterior structures (tendo Achillis, posterior tibial tendon, calcaneofibular ligament, posterior ankle, subtalar capsulotomy, and, sometimes, long toe flexors). If significant midfoot deformity remains (medial talonavicular subluxation), release the medial talonavicular joint and the tendon sheaths of posterior tibial, flexor digitorum longus (FDL), and flexor hallucis longus (FHL) muscles. Some clubfeet have significant medial subluxation of the calcaneocuboid joint, requiring capsular release (2,21). The medial subtalar capsule can be partially or completely released to correct hindfoot varus. These releases allow the talus to be dorsiflexed into neutral position, the navicular to be abducted and rotated onto the true axial head of the talus, and the os calcis to be brought out of varus and into lateral rotation under the talus to reduce the subtalar joint. Hold the reduction with pin fixation in a cast until the soft tissues heal.

Although surgeons have recognized for years that posterior and medial releases are necessary to correct clubfoot, recent attention to the posterolateral ankle structures (fibulocalcaneal ligament and peroneal sheaths) has emphasized the importance of correction of *internal rotation* of the subtalar joint if full correction of the clubfoot is to be achieved (20,21,22,28,29,32). The exact incision used may not be important, but it must provide adequate exposure of these structures or the correction is incomplete. We prefer the Cincinnati circumferential subtalar incision (or portions of it), because it gives the fullest visualization of the entire midfoot and hindfoot, including the posterolateral region; you can use portions of this incision for more limited releases (8). Because tarsal bones are largely cartilaginous in the small child, they are inevitably deformed at the time of reorientation, and the correction must be maintained for at least 3–4 months to allow remodeling. Many children

require further bracing for a year or more to maintain position during walking.

Tailor the operative procedure to the deformity. If the releases performed are overly aggressive, the result may be an overcorrected clubfoot when the child becomes older. There are good methods that have been developed to later improve undercorrected feet or relapsed feet, but there are no good secondary procedures that adequately deal with the overcorrected clubfoot. Although our initial feeling was that complete correction of a clubfoot was necessary in most cases, the long-term follow-up of many of our earlier patients with clubfoot has led us to temper these beliefs. In the mild and moderate clubfoot, we now favor a more limited release of posterior structures, which generally leads to better foot function as the child matures.

## CLUBFOOT RELEASE

- Perform clubfoot release with the patient prone or supine, using a pneumatic tourniquet.
- Make a full Cincinnati skin incision, extending it from the navicular tuberosity under the medial malleolus, arching slightly over the os calcis posteriorly, and extending obliquely around to the calcaneocuboid joint laterally (Fig. 167.1*A*). Portions of the incision may be used for less extensive releases.



***Figure 167.1.*** **A:** The Cincinnati incision used for standard clubfoot release. **B:** Isolation of the neurovascular bundle and posterior tibial tendon. The flexor digitorum longus (in its sheath) is visible medially. **C:** Preferred Z-plasty technique for the Achilles tendon. **D:** Incision of the fibulocalcaneal ligament and peroneal tendon sheaths. **E:** External rotation of the os calcis during dorsiflexion. **F:** The interosseous ligament, seen from the posterior incision. **G:** Release of the plantar fascia in the presence of cavus. **H:** Use of two pins to fix the talonavicular joint and subtalar joint. See text for details.

- Keep the knife at a 90° angle to the skin, and carry the incision sharply through the subcutaneous tissue with minimal retraction. Use caution as the knife crosses the Achilles tendon, which is deep in the subcutaneous tissue of the posterior wound.
- Use a fine scissors for the remaining dissection.
- Identify and mobilize the neurovascular bundle in the posteromedial wound both proximally and distally (to the point where the nerve branches into the calcaneal branch and medial and lateral plantar nerves); retract it with a Silastic tape.
- Posterolaterally, identify the sural nerve running with the lesser saphenous vein; mobilize and protect these structures with a Silastic tape.

### *Posterior Release*

Perform the posterior release portion of the procedure first.

- Protecting the neurovascular bundle and the sural nerve, perform a Z-lengthening of the Achilles tendon, making the distal transverse cut in the medial half of the tendon (the lateral half is left attached to the calcaneus). Tag each end with #0 absorbable suture (Fig. 167.1*C*).
- Just posterior and lateral to the neurovascular bundle lies the FHL tendon; incise its sheath, identify it, and protect it during the next stage with a Silastic tape, because it is easy to sever inadvertently.
- Excise the entire posterior capsule of the tibiotalar and subtalar joints and identify the joint lines; the subtalar joint will still be unyielding.
- If the midfoot deformity has been corrected by casting, the dissection just described may be enough to correct the deformity; in this case, the posterior tibial tendon usually requires Z-lengthening, as may the FHL and FDL tendons.
- If you are satisfied with the correction obtained after posterior release alone, manipulate the forefoot into corrected position and blindly pin it from back (talus) to front, bringing the pin out the dorsum of the foot; bend the tip to prevent migration (Fig. 167.1*H*).
- Close the wound as will be described later.

### *Lateral Release*

Frequently, additional release may be required.

- In the posterolateral portion of the wound, identify and transect the heavy fibulocalcaneal ligament (Fig. 167.1*D*); this allows external rotation of the os calcis as it is dorsiflexed (Fig. 167.1*E*). Use a pair of scissors to cut the sheaths of the peroneal tendons circumferentially, taking care not to injure the tendons. Slide the scissors along the posterolateral subtalar joint capsule to incise it.

### *Medial Release*

- Incise the posterior tibial tendon sheath and perform a Z-lengthening of the tendon, grasping the distal tendon stump with a small Kocher clamp.
- Follow the tendon stump as it inserts into the navicular, and transversely incise the deep posterior tibial sheath and the medial, dorsal, and plantar talonavicular capsules.
- Blending with the inferior capsule are the spring ligament (connecting the navicular with the sustentaculum tali) and Henry's knot (where the flexor hallucis and flexor digitorum cross). While appearing in textbooks as discrete structures, these usually are difficult to separate and are released as the capsule is incised (Fig. 167.1*B*). One of us (GTR) separates the intact knot of Henry from the navicular, and one of us (PBS) incises it longitudinally, freeing the flexor tendons.
- Incise the anterior subtalar joint with scissors just above the sustentaculum. If the talus still does not mobilize, incise the remaining medial subtalar capsule. It is usually easiest to start from the posterior exposure of the subtalar joint at the site of the previous capsulectomy. Retract the FHL and the neurovascular bundle to cut the firm medial capsule, staying right at the joint level. It is very easy to inadvertently cut the FHL during this portion of the dissection.
- Incise the FDL tendon sheath transversely as you encounter it. Take care not to drift superiorly out of the subtalar joint, or injury to the deep deltoid ligament may occur.
- Once the subtalar capsule has been circumferentially incised to the anterior end of the os calcis, open the joint by everting the os calcis. This exposes the subtalar interosseous ligament, which can be seen through either the medial or the posterior portions of the wound as a thick, ribbonlike band (Fig. 167.1*F*). You should not divide this ligament except in the most severe cases (usually arthrogryposis), because this can lead to significant overcorrection.
- If the lateral border of the foot is still convex, or if preoperative radiographs demonstrate significant medial subluxation of the calcaneocuboid joint, release that joint. We prefer to dissect the medial wound distal to the anterior os calcis, which is now well exposed. Cut the long plantar ligament and identify the medial calcaneocuboid capsule; incise its entire medial surface and use a fine scissors to incise the superior and inferior capsule as well. If that does not free the joint sufficiently, expose the calcaneocuboid joint in the distal part of the lateral incision and release the capsule there.
- If significant cavus is present, you may release the plantar fascia through the posteromedial wound. Identify the interval between the calcaneal sensory branch and the lateral plantar branch of the posterior tibial nerve, and gently retract the lateral branch anteriorly while dissecting down the medial and inferior side of the os calcis with scissors (Fig. 167.1*G*). Stay right on the bone, taking great care not to injure the neurovascular bundle, because after a Cincinnati incision it supplies the major vascularity to the heel pad. With a blunt scissors, cut the plantar fascia where it originates from the inferior os calcis; you will feel a palpable relaxation of the cavus.
- Reduce the talonavicular joint, being careful not to overreduce it or allow it to subluxate dorsally (the most common malreduction), and hold it with an 0.035 Kirschner wire (K-wire), inserted from the posterior talus through the joint and out the skin of the dorsum of the foot (Fig. 167.1*H*). Pull the pin flush with the posterior talus, and cut and bend it superficial to the dorsal skin to prevent migration.
- If you desire, insert a second pin through the heel pad longitudinally across the subtalar joint after it has been reduced into neutral varus–valgus and slight subtalar external rotation (Fig. 167.1*H*). Move the ankle to ensure that this pin stops before entering the ankle joint. Cut and bend the pin outside the heel skin.
- Hold the ankle at 90° and use the two suture tags coming from the ends of the Achilles tendon to hold tension on the tendon so that the structure is snug at a neutral ankle position. Repair the tendon in this position. Be careful not to overlengthen the Achilles tendon, or calcaneus gait can result. Small gaps in the tendon fill in spontaneously in a child under 4–6 months of age.
- Repair the Z-lengthened posterior tibial tendon, and perform sliding Z-lengthenings of the FDL (in the medial wound) and the FHL (in the posterior wound), if they are snug and prevent correction of the deformity.

- Arrange the tendons properly in the wound, and close the skin with 4-0 absorbable sutures. We prefer deep, loose, through-and-through simple sutures, although subcutaneous and subcuticular suture may be used if there is minimal skin tension. If the wound seems too tight to close safely, allow the ankle to fall into slight plantar flexion and close the wound; the foot can easily be brought up in 3 weeks by changing the cast in the office, without risk to the skin.
- Apply a well-padded, long-leg cast extending beyond the flexed toes, with the knee bent 90°; take care to gently externally rotate the heel. (If you used two subtalar pins, you can apply a short-leg cast at this point, because the hindfoot will not rotate.)

**Postoperative Care** The cast is usually changed 6 weeks postoperatively, when the pins are removed. Apply a second cast for an additional 6 weeks. If the child is of walking age, the first 6–8 weeks of immobilization should be in a long-leg cast with a 90° bend to control subtalar rotation and prevent ambulation, but the last 6 weeks may be in a short-leg cast with a walking heel. Some surgeons use orthotic devices for the first 12–24 months following clubfoot release, but we have generally found them unnecessary. An exception may be made if a mild clubfoot has required only posterior release; in these cases, maintaining alignment with an ankle–foot orthosis (AFO) while postural muscles develop seems to lessen the flexible midfoot deformity.

## MANAGEMENT OF RECURRENCE OR UNDERCORRECTION

Recurrence, relapse, or undercorrection occurs in up to 15% of operated clubfeet. The most common residual finding is adduction and supination of the forefoot so that the first metatarsal does not touch the ground during walking, and callosities develop on the lateral border of the foot. This can be associated with hindfoot varus and internal rotation. When noted early, it may be treated with an AFO, or a Perlstein brace (straight-last shoe, medial upright, lateral T-strap, and 90° plantarflexion stop). If the deformity persists, however, the treatment is surgical.

In a child younger than 2 years, you may manage recurrence by repeating the posterior medial release. In our experience, however, this is usually not enough, especially when adequate initial surgery was performed. Lateral column shortening is often extremely helpful to accomplish secondary correction (cuboid decancellation, Evans procedure, or Lichtblau osteotomy with a medial release). We use the Lichtblau procedure because it produces predictably good results.

After the age of 5 years, the joints of the foot are sufficiently formed that it is better to accept the malposition of the joints and perform secondary bony procedures to reorient the foot. Metatarsal or midfoot osteotomies (1) can be used to correct forefoot adduction, but they are of limited use since they do nothing for the main deformity in the hindfoot and midfoot. The soft-tissue alternative, mobilization of the tarsometatarsal joint by capsulotomies (Heyman-Herndon procedure), has been abandoned because it has been found to cause pain and midtarsal stiffness in an already stiff foot. The double tarsal osteotomy (opening wedge osteotomy of the medial cuneiform, accompanied by shortening of the lateral column of the foot) and a combination of a closing lateral column shortening procedure (cuboid osteotomy or Lichtblau procedure) and an opening wedge osteotomy of the medial cuneiform are excellent alternatives (19,23). Osteotomy of the os calcis can be used to correct the hindfoot inversion and varus (11).

Recurrence may be a manifestation of muscle imbalance in a growing foot (4). Regardless of the success of treatment, the clubfoot patient has an atrophic calf and a small foot on the affected side. Weakness of the peroneals or the peroneus tertius appears to contribute to the late tendency toward hindfoot varus, forefoot supination, and adductus. This can be improved with either lateral or split transfer of the anterior tibial tendon. The posterior tibial tendon transfer and FHL transfer have been described for residual anterior tibial muscle weakness in the clubfoot, but we have no personal experience with either procedure (22,34). Skeletal deformities should be corrected before the tendon transfers.

The last-resort salvage procedure, a triple arthrodesis, is best postponed until the age of 10–12, when the foot is fully grown.

## LATERAL COLUMN SHORTENING PROCEDURES

- Perform lateral column shortening procedures (10,17) under pneumatic tourniquet control. Use the medial and lateral arms of the Cincinnati incision described for congenital clubfoot; leave the posterior portion of the skin intact.
- On the medial side, expose the posterior tibial tendon sheath and incise it, exposing the tendon.
- Perform a Z-lengthening of the tendon and tag both free ends.
- Use a fine curved scissors to dissect deep to the distal posterior tibial tendon stump, and identify the talonavicular joint; incise its capsule superiorly, medially, and inferiorly.
- In the lateral wound, expose the calcaneocuboid joint and incise its capsule sufficiently to mobilize it.
- If performing a *Lichtblau osteotomy* (Fig. 167.2*A*) (17), resect the distal portion of the os calcis to cancellous bone, using a small osteotome. This shortens the calcaneus at the same level as the talonavicular joint, allowing the midtarsal joint to translate easily to a corrected position.

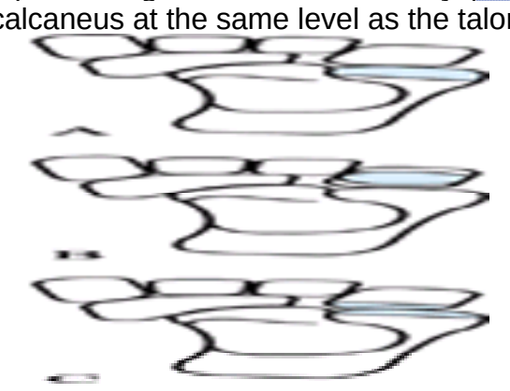

***Figure 167.2.*** Lateral column shortening options for residual adduction deformity in clubfoot. **A:** Lichtblau osteotomy (resection distal os calcis). **B:** Cuboid decancellation. **C:** Evans procedure (calcaneocuboid fusion).

- Abduct the midfoot to check correction. If the medial release has been performed fully and enough os calcis has been resected, the foot should appear corrected. If it does not, resect more of the os calcis or release the medial foot more until the correction is adequate. Although the articular surface has been removed from the calcaneus, the cuboid articular cartilage remains, and a painless synchondrosis will develop.
- If performing a *cuboid decancellation* (Fig. 167.2*B*), incise only enough of the capsule to identify the joint surface plane (10). Use either a small osteotome or a curet to remove a wedge of bone from the middle portion of the cuboid. In younger children, it is usually easiest to simply curet out the ossific nucleus, leaving a shell of the cartilaginous anlage.
- Compress the cuboid closed as the released talonavicular joint is reduced. Check correction as for the Lichtblau osteotomy, and adjust the medial release and bone resection accordingly.
- If performing a *calcaneocuboid fusion* (Evans procedure) (Fig. 167.2*C*), curet or resect with an osteotome the articular surfaces of both joints. Excessive resection is unnecessary, since the fusion reduces lateral column growth potential and the midfoot will gradually abduct (10).
- Insert an 0.062 K-wire longitudinally across the corrected calcaneocuboid articulation. For the Evans and Lichtblau procedures, this is done most easily by adducting the forefoot and placing the pin retrograde from the distal os calcis to the heel, correcting the lateral column, and advancing the pin antegrade into the forefoot, where it is withdrawn into the heel and left protruding on the dorsum of the foot.
- Carefully check forefoot pronation–supination, and reduce and pin the talonavicular joint with a second pin introduced from the dorsum of the foot. Bend the pins externally to prevent migration.
- Release the tourniquet, obtain hemostasis, and repair the posterior tibial tendon. Close the skin and subcutaneous layer loosely with a single layer of 4-0 interrupted absorbable sutures.
- Pad the pins and apply a long-leg cast with the foot in corrected position. Change the cast at 4–6 weeks, at which time you may remove the pins. Apply a second short-leg walking cast for an additional 4 weeks.

## DOUBLE TARSAL OSTEOTOMY

- Begin the double tarsal osteotomy (19,23) with an oblique or longitudinal incision over the cuboid.
- Identify the peroneal tendons, open the sheath, and retract these tendons in a plantar direction. Incise the periosteum of the cuboid bone.
- Using an oscillating saw, remove a laterally based trapezoidal fragment of bone from the cuboid. It is important to go through the medial cortex of the bone so that the osteotomy can be mobilized. Guide wires and image intensification facilitate these cuts and help prevent injury to the articular surfaces. Attempt to remove the trapezoid in a single piece.
- Make a second incision over the medial cuneiform. Protect the anterior tibial tendon and retract it dorsally and distally.
- Dissect the medial cuneiform subperiosteally and expose its plantar and dorsal aspects. Use an image intensifier at this point to identify the midportion of the bone.

- Make a single osteotomy cut transversely in the cuneiform (Fig. 167.3*A*). After you complete this osteotomy, place an instrument such as a small lamina spreader across the osteotomy and open it.

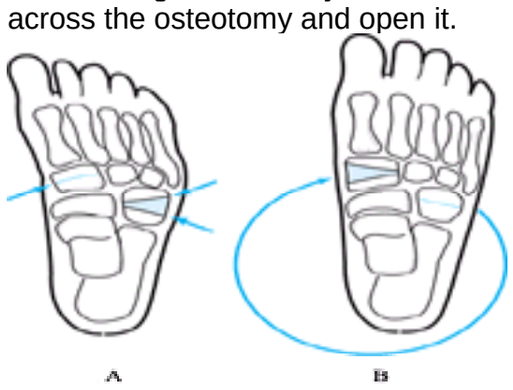


***Figure 167.3.*** Double tarsal osteotomy for residual adductus deformity. Wedge resected from cuboid (**A**) is inserted into opening osteotomy of medial cuneiform (**B**).

- Insert the bone graft that was taken from the cuboid into the osteotomy of the medial cuneiform (Fig. 167.3*B*). Usually the bone graft is quite stable, but a small K-wire can be used to secure the graft in place. Place it through the base of the first metatarsal and across the two fragments of the cuneiform, securing the bone graft.
- Close the cuboid osteotomy and hold it with K-wires. Close the wounds with 4-0 absorbable suture.
- Place the patient in a long-leg, bent-knee cast to prevent weight bearing. At 6 weeks, exchange the cast for a weight-bearing short-leg cast, to be worn for an additional 4 weeks (19,23).

**OS CALCIS OSTEOTOMY TO CORRECT HINDFOOT VARUS**

- When performing an os calcis osteotomy to correct hindfoot varus, make a curved lateral incision just inferior and parallel to the peroneal tendon sheaths, and dissect down to the os calcis (Fig. 167.4*A*).

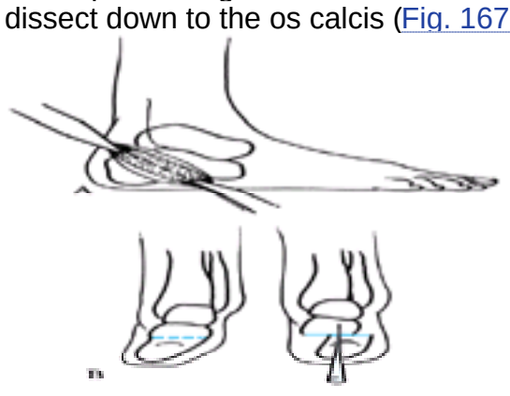

***Figure 167.4.*** **A:** The lateral approach for osteotomy of the os calcis. **B:** Fixation with a small Steinmann pin inserted at a 45° upward angle from the tip of the os calcis.

- Incise the periosteum parallel with the skin wound. Perform limited subperiosteal dissection to allow passage of a metatarsal (Hayes or Blount) retractor posteriorly between the Achilles tendon and bone, and inferiorly between the plantar structures and the calcaneus.
- After locating the site for the osteotomy, confirm the position with an image intensifier.
- With an osteotome or oscillating saw, cut an oblique osteotomy through the lateral cortex and medullary bone of the os calcis. Carefully complete the cut through the medial cortex with controlled use of an osteotome and varus manipulation of the heel (to crack the medial cortex). The neurovascular bundle lies on the medial side and must not be injured.
- Manipulate the heel to loosen the periosteum on the medial side, and slide the tuberosity of the os calcis laterally until the heel pad is positioned in the appropriate position.
- Hold the osteotomy with an oblique 0.065 K-wire or a small Steinmann pin inserted through the heel (Fig. 167.4*B*) and bent to prevent migration. Close the wound with subcuticular 4-0 synthetic absorbable suture.
- Apply a long-leg cast with the knee bent 90° to prevent weight bearing. Change the cast at 4 weeks and remove the pin. Then use a weight-bearing short-leg cast until clinical and radiographic union is achieved, usually 6 weeks after surgery. An alternative method is to do a closing wedge osteotomy in the same location. This is generally recommended in the older child.

**METATARSAL OSTEOTOMIES**

- The procedure for metatarsal osteotomies begins with three longitudinal incisions on the dorsum of the foot; the first is on the dorsomedial aspect of the proximal first metatarsal, and the remaining two are between the second and third metatarsals and the fourth and fifth metatarsals (Fig. 167.5). (An alternative is to use a curved transverse incision at the level of the tarsometatarsal joints.) Take care to protect the small dorsal veins, the superficial nerves, and the dorsalis pedis artery.




***Figure 167.5.*** **A:** Preferred longitudinal incisions for metatarsal osteotomies. **B:** Supination of the forefoot relative to the heel must be corrected with the metatarsal osteotomies.

- Expose the proximal shaft of the first metatarsal by medial longitudinal subperiosteal dissection. The periosteum is adherent proximally, where the physis of the first metatarsal is located. The physis must not be injured: Use a Keith needle or intraoperative radiograph, if necessary, to locate and protect it.
- Use a small oscillating saw to perform a transverse osteotomy 1 cm distal to the physis, starting from the medial side. If possible, do not quite complete the cut through the dorsolateral cortex, but instead create a greenstick-type fracture to act as a hinge, or leave an intact sleeve of periosteum laterally.
- Perform similar osteotomies of the remaining proximal four metatarsals using the saw; the physes of these bones are distal, so there is no risk of injury to them. Try not to injure the lateral periosteal sleeves.
- Manipulate the metatarsals into corrected position. Hold them in place with two K-wires inserted obliquely through the first and fifth metatarsal shafts into the midtarsus. Be sure to correct any forefoot supination (Fig. 167.5*B*) and cavus that are present. These must be evaluated clinically because axial deformity in particular will not be evident on radiographs. The foot should appear fully corrected externally when lying relaxed on the table, and the entire sole should be plantargrade from heel to metatarsals.
- Cut the wires outside the skin and bend them to prevent migration.
- Check the position of the wires on a radiograph. Minor displacement of the middle metatarsals remodels easily if the lateral periosteum has not been violated (Fig. 167.6). Gross displacement of lesser metatarsals can lead to nonunion, which, although not always painful, should be corrected. If the hindfoot is in rigid varus, perform an os calcis osteotomy, or perform any desired tendon transfers at this time.

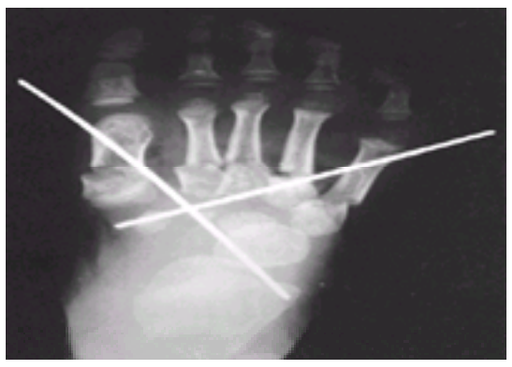

***Figure 167.6.*** Radiograph of internal fixation used for metatarsal osteotomies.

- Close the wounds with subcuticular 4-0 absorbable synthetic suture.
- Apply a well-padded short-leg cast. At 3–4 weeks, change the cast and remove the wires. Apply a new well-molded cast in the corrected position and allow weight bearing. Remove the cast 6–8 weeks after surgery.

### ANTERIOR TIBIAL TENDON TRANSFER TO THE THIRD CUNEIFORM

Although Garceau (12) originally described anterior tibial tendon transfer to the cuboid, we have found that a less lateral position, to the third cuneiform, is more appropriate, especially when correction of fixed deformity is performed prior to the tendon transfer.

- Make a small dorsal medial incision (Fig. 167.7). Detach the insertion of the anterior tibial tendon close to bone through the wound, leaving the tendon as long as possible. Place a Bunnell suture of #1 or #0 synthetic absorbable suture in the tendon.

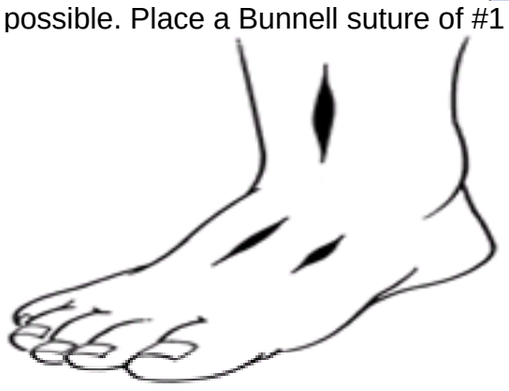

***Figure 167.7.*** Preferred incisions for anterior tibial tendon transfer to the third cuneiform.

- Make a second, longitudinal incision over the anterior tibial muscle belly above the ankle, identify the muscle by pulling on the tendon, and pull the tendon into this incision.
- Make a third incision over the third cuneiform bone. Pull on the periosteum in line with the selected transfer insertion site to dorsiflex the foot, observing inversion–eversion. Modify the insertion site to obtain balanced dorsiflexion.
- Make a drill hole through the third cuneiform to the plantar surface. Pass the tendon through the subcutaneous tissue from the proximal wound to the third cuneiform (not beneath the ankle retinaculum). Thread the suture in the tendon into two Keith needles and pull it through the hole in the cuneiform. Bring the Keith needles out the plantar surface, tying the suture over a button or dental roll on the plantar aspect of the foot.
- Close the wounds with fine absorbable synthetic subcuticular suture.
- Apply a short-leg cast, which is worn for 6 weeks. Allow weight bearing after 4 weeks.

### SPLIT ANTERIOR TIBIAL TENDON TRANSFER

- For a split anterior tibial tendon transfer (13), make a small medial incision (Fig. 167.8). Isolate the insertion of the anterior tibial tendon through the wound. There is usually a natural longitudinal division of the tendon. Split the tendon from proximal to distal. Do not attempt to split the tendon from below, because it is easy to rupture it. If rupture occurs, abandon the procedure and proceed with a standard anterior tibial transfer as described previously, using the remaining tendon stump. Free up the lateral half of the insertion into the navicular at this split, and place a suture of #1 or #0 synthetic absorbable suture in it using a crisscross Bunnell technique.

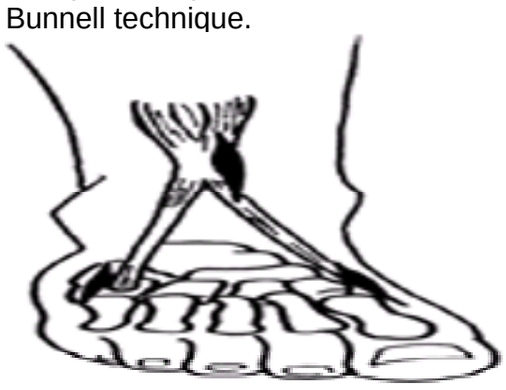

***Figure 167.8.*** The concept of split anterior tibial tendon transfer to cuboid. Incisions are shown.

- Make a second, longitudinal incision anteriorly above the ankle. Identify the anterior tibial muscle by pulling on the split tendon end, and pass a tendon passer from the proximal wound to distalward along the tendon, taking care to remain in the tendon sheath.
- Grasp the Bunnell stitch, pull it back into the second wound, and deliver the lateral half of the split tendon up into the proximal wound.
- Transfer the split portion of the tendon to the cuboid bone by the technique described previously for anterior tibial transfer. Adjust the tension so that the lateral arm of the transfer is just slightly tighter than the medial arm (observed through the superior wound). Anchor the transfer as described previously, or bring it through a hole in the cuboid and sew it back on itself.
- Closure and postoperative care are the same as for anterior tibial tendon transfer.

## CAVUS FOOT

Rarely, cavus foot is idiopathic and seen in infancy. Cavus is a common component or residuum of clubfoot. However, isolated cavus or cavovarus deformity usually develops insidiously with growth and is a sign of occult neuromuscular disease. Some of the more common associated disorders are listed in Table 167.1.

| |
|---|
| Peripheral nervous system |
| Charcot-Marie-Tooth disease |
| Other hereditary peripheral neuropathies |
| Traumatic peripheral nerve lesions |
| Spinal cord |
| Spinal cord tumor |
| Tethered cord syndrome |
| Spina bifida |
| Poliomyelitis |
| Diastematomyelia |
| Central nervous system |
| Cerebral palsy |
| Friedreich's ataxia |
| Muscle disease |
| Duchenne's muscular dystrophy |

***Table 167.1. Common Conditions Associated with Cavus or Cavovarus Feet***

Because the orthopaedic surgeon is often the first physician to recognize the deformity, it is important to do a careful neurologic examination and initiate necessary ancillary studies (e.g., electromyography, muscle enzyme studies, spine radiographs, and spine magnetic resonance imaging) and obtain appropriate consultation before attempting treatment.

Cavus is generally progressive until growth stops. Orthotic management is never successful; the deformity is either accepted or treated surgically. The mainstay of treatment is triple arthrodesis (see Chapter 115), but dorsal wedge osteotomy may be appropriate in selected cases. There is usually associated hindfoot varus. Determine whether hindfoot varus is fixed by the Coleman block test (Fig. 167.9). This test differentiates between rigid varus, which must be surgically treated by triple arthrodesis, and varus secondary to first metatarsal depression, which is flexible and corrects once the medial column cavus has been corrected using midfoot dorsal wedge osteotomy.

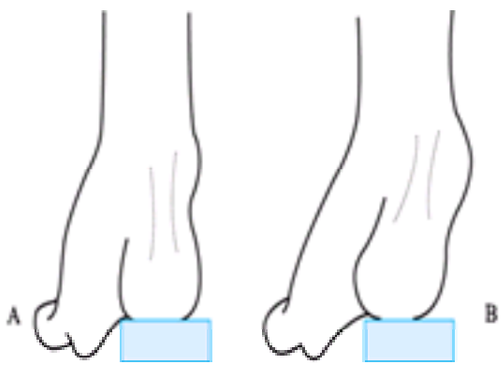


***Figure 167.9.*** Coleman block test. A block is placed beneath the heel and the fifth metatarsal head while the patient stands. **A:** The heel varus corrects, indicating hindfoot flexibility. **B:** Heel varus persists, indicating hindfoot rigidity.

If cavus is severe and disabling in a young child, plantar release and metatarsal osteotomies can successfully temporize while the foot matures. However, bony procedures at maturity (after age 11 or 12 years) almost always are required, even after earlier soft-tissue release.

**DORSAL WEDGE OSTEOTOMY OF THE CUNEIFORMS**

Dorsal wedge osteotomy of the cuneiforms is appropriate only if the hindfoot varus is flexible and fully correctable; otherwise, perform triple arthrodesis with appropriate wedge resection (see Chapter 115). Plan the osteotomy on a lateral radiographs of the foot so that the correction will bring the forefoot plantigrade when the hindfoot is in the weight-bearing position.

- Make a longitudinal midline dorsal incision from the mid talus to the base of the third metatarsal.
- Identify and protect the dorsal is pedis vessels, and incise the periosteum from the navicular to the cuneiform bones.
- Strip the periosteal and capsular structures medially and laterally to expose the cuneiforms dorsally, as far as the cuboid laterally and to the navicular medially.
- Under image intensification, insert two guide pins at the osteotomy edges, avoiding the talonavicular and cuneiform–metatarsal joints; converge the pins so that their tips meet at the plantar surface of the bones, producing a wedge large enough to correct the deformity (Fig. 167.10).

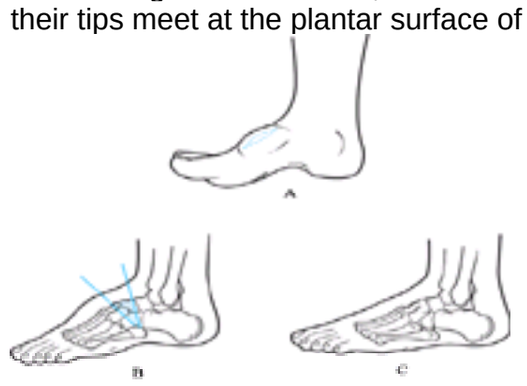

***Figure 167.10.*** Dorsal wedge osteotomy for cavus foot. **A:** Dorsal skin incision. **B:** Bone resection is guided by K-wires. Talonavicular, calcaneocuboid, and tarsometatarsal joints are preserved. **C:** Closure of osteotomy corrects cavus. Residual pronation must be corrected as the osteotomy is closed.

- Use an oscillating saw to cut the two faces of the wedge just inside the guide pins. Make the cut slowly, all in one pass, since the small bones shift and it is easy to lose the plane of the cut. Remove the wedge with an osteotome and a small rongeur.
- Close the wedge, correct for supination deformity, and carefully align the rotation of the forefoot with the hindfoot. Fix the osteotomy with dorsal staples, or crossed smooth Steinmann pins or K-wires inserted from medially and laterally through the metatarsal bases.
- Close the wound with absorbable sutures.
- Apply a padded splint or a short-leg cast in neutral dorsiflexion. It is usually necessary to split the cast.

***Aftercare***

Change to a cast in neutral position when swelling in the foot resolves. Allow, but do not force, weight bearing as tolerated. Continue casting until union occurs, which is usually 6–8 weeks.

## POLYDACTYLY

Polydactyly is a hereditary foot deformity inherited with an autosomal dominant pattern. The most common form is postaxial duplication of the fifth digit. Less common is preaxial duplication of the great toe. Rarest is middle toe duplication. Both preaxial and postaxial polydactyly may be associated with syndromes, which you should look for. The hand is often involved as well; when this is the case, the foot deformities are usually more severe than the hand deformities in that the duplications are more proximal. Generally, it is desirable to treat polydactyly of the toes because untreated patients experience difficulty with fitting shoes. In addition, extra digits, even

though asymptomatic, can subject a child to ridicule from peers (9,25,35).

### POSTAXIAL POLYDACTYLY

In most postaxial (lesser toe) deformities, it is generally easiest and most effective to remove the peripheral (lateral) toes. The metatarsal is nearly always abnormal, ranging from a widened lateral metatarsal, through Y- or T-shaped distal metatarsals, to duplication of the entire bone. You must shave a widened or prominent metatarsal to reduce the width of the foot, or a bunionette will result. Preoperative radiographs are important for planning, because occasionally there is an obvious internal (central) duplication that requires more complex reconstruction. In such a case, it is desirable to preserve the toe that is more functional and has the best axial alignment. A risk of removing the intercalary digit may be the development of an angular deformity of the lateral toe. It may therefore be necessary to create a partial syndactyly between the remaining lateral toe and the fourth toe to prevent this from occurring. If the metatarsal is duplicated, you must remove this as well (Fig. 167.11).

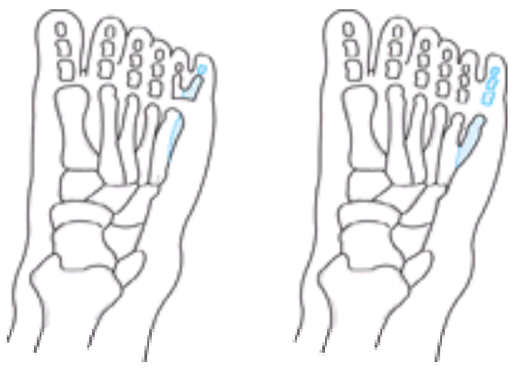

***Figure 167.11.*** Examples of resection required (*shaded area*) for postaxial toe duplication correction. Trim the metatarsal so there is no lateral prominence.

### RESECTION OF A SIXTH TOE

- To resect a sixth toe, make a dorsal curvilinear incision over the base of the toe (Fig. 167.12). Make a longitudinal dorsal cut down the middle of the digit to be excised, and fillet it out.

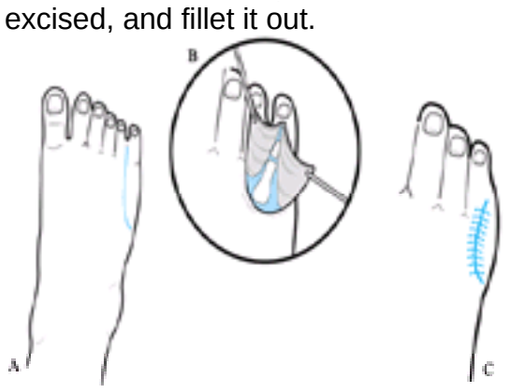


***Figure 167.12.*** Excision of sixth digit. **A:** Curved dorsal incision and longitudinal sixth toe incision. **B:** Dorsal exposure of sixth toe allows complete excision and any necessary metatarsal trimming. **C:** Filleted skin flap is pulled dorsally, shaped, and closed. The resulting scar is dorsal and does not rub against shoewear.

- If the proximal phalanges of toes five and six are joined, cut the cartilaginous portion cleanly with a scalpel. Trim the metatarsal head to the size of a normal bone, using a sharp scalpel and osteotome; growth arrest will not occur. Wrap up the plantar flap dorsally, trim it, and stitch it with fine absorbable suture.
- Resect a fifth toe as a wedge, including the digit and any rudimentary metatarsal.
- Bring the fourth and sixth digits together, closing this wedge.
- Perform syndactylization if appropriate when drifting of the remaining toes is likely.
- A short-leg cast can be used for 3 or 4 weeks to allow the wounds to heal and the toes to stabilize.

### HINTS AND TRICKS

If the postaxial digits are congenitally syndactylized, the principles of reconstruction remain the same. Preserve the most functional digits. A duplication of the nail frequently exists. It is important to carefully resect the nail and its matrix with the digit to be sacrificed to prevent recurrence of an abnormal nail. Plan skin flaps carefully.

### PREAXIAL POLYDACTYLY

Preaxial duplications present a much more complex problem in reconstruction than postaxial duplications. Each of these reconstructions must be planned individually. The first metatarsal may be shortened and have a longitudinal epiphyseal bracket epiphysis that has an L or a C shape and acts as a medial tether to the growth of the toe (Fig. 167.13) (18,24). The hallux itself may be in varus. If a longitudinal epiphyseal bracket is present, central physeal lysis has been reported to be successful. The results of reconstruction of preaxial polydactyly can be disappointing. Residual or recurrent hallux varus occurs frequently and difficulties with shoe wear are common complications. Consider syndactylization of the first and second toes in the more difficult cases, especially if there is a recurrent deformity.

***Figure 167.13.*** Duplicated first toe is frequently associated with a short, rounded first metatarsal with an epiphysis that surrounds both ends and the medial side of the bone—a longitudinal epiphyseal bracket. Excision (*shaded area*) at the time of toe removal may allow more normal longitudinal growth of the first metatarsal; failure to recognize this may lead to a very short first ray at maturity.

We recommend excising the toe that will allow the foot and remaining toes to assume the most normal contour. In most cases, this is the most medial or tibial toe in patients with duplication of the hallux. Sometimes it is appropriate to excise the tibial toe even if the second toe is more hypoplastic, since the risk of hallux varus is less. If a longitudinal epiphyseal bracket is present, excise the central portion of the bracket epiphysis. Because hallux varus has been the most common and most symptomatic long-term problem following surgery on duplicated great toes, make an effort to reinsert the adductor hallucis muscle into the proximal phalanx of the great

toe. In addition, consider a partial syndactyly of the great and second toes. Syndactylization may be necessary at a separate procedure if extensive dissection would be necessary on both sides of the toe, resulting in an endangered blood supply. This combination of reconstructive procedures leads to an acceptable result for shoe wear. The cosmetic result is often less than satisfactory.

## JUVENILE HALLUX VALGUS

Bunions, or hallux valgus deformities, are relatively common problems in children and adolescents (6,7,31). The incidence is unknown. It occurs much more commonly in girls than boys. Ill-fitting shoes have been implicated as a causative factor in adult hallux valgus, but the association of shoe wear with juvenile hallux valgus is unclear. There is often a positive family history. The deformity is usually bilateral. The age of onset may be as young as 10 years of age.

The general indications for surgical intervention are problems with shoe wear and dissatisfaction with the cosmetic appearance of the foot. Despite the fact that surgical intervention is noted to have a high failure rate, most reports on the correction of juvenile hallux valgus have presented the results of a single, specific technique of surgical reconstruction. We agree with Coughlin (6) that the operative procedure to correct juvenile hallux valgus must be customized to the specific deformities in the foot. Surgical correction prior to epiphyseal closure is controversial. Whereas there is rarely a rush to perform surgery to correct the deformities of juvenile hallux valgus, the notion that surgery performed on a patient with an open epiphysis is contraindicated has not been substantiated.

In assessing the patient with juvenile hallux valgus, obtain an AP weight-bearing radiograph of the foot. Measure the following: (a) the hallux valgus angle, (b) the first-to-second intermetatarsal angle, (c) the distal metatarsal articular angle, and (d) the first metatarsophalangeal joint congruency (the relationship of the articular surface of the base of the proximal phalanx to the articular surface of the 1st metatarsal) (Fig. 167.14, Fig. 167.15).

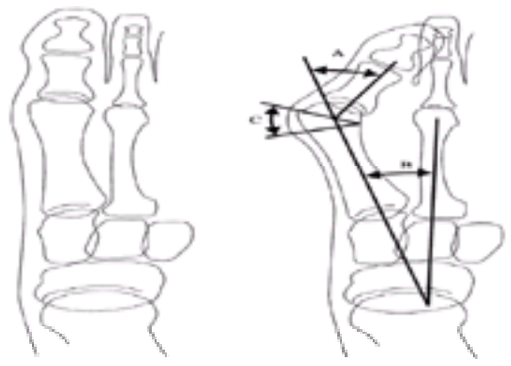

***Figure 167.14.*** Lines used for assessing patient with juvenile hallux valgus. Normal values are in *parentheses.* **A:** Hallux valgus angle (<15°). **B:** First-to-second intermetatarsal angle (<9°). **C:** Distal metatarsal articular angle (useful for assessing subluxation and congruency).

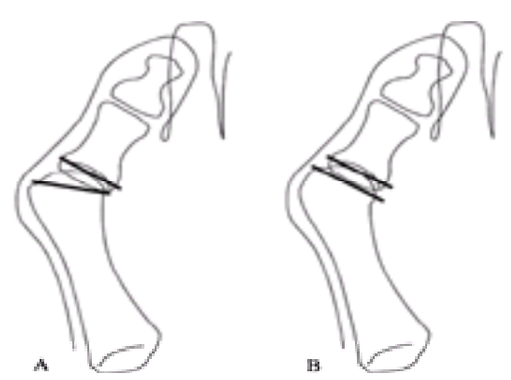


***Figure 167.15.*** The first metatarsal phalangeal joint may be incongruent (**A**) with lateral subluxation of the joint, or congruent (**B**) with a tilted distal metatarsal articular surface.

Operative procedures to correct juvenile hallux valgus can be grouped into four categories:

1. Distal soft-tissue procedures, such as the McBride operation. In most series, this has been associated with a high recurrence rate.
2. Distal metatarsal osteotomies, such as a chevron osteotomy or a Mitchell osteotomy. These procedures have a relatively high rate of patient satisfaction. They should be used for patients with less severe deformities and a relatively normal distal metatarsal articular angle. These procedures can be modified if the distal metatarsal articular angle is abnormal (see the fourth category).
3. A proximal metatarsal osteotomy with a distal soft-tissue procedure. These procedures can be used successfully in moderate hallux valgus deformities with fibular valgus subluxation of the metatarsophalangeal joint but are less successful in correcting a patient with a congruent joint and an increased distal metatarsal articular angle.
4. Double metatarsal osteotomies. We believe that this is the best method of correction in a patient with an increased first-to-second intermetatarsal angle and an increased distal metatarsal articular angle with a congruent joint. The proximal osteotomy corrects the first-to-second intermetatarsal angle (Fig. 167.16*A*), and the distal osteotomy corrects the hallux valgus and the increased distal metatarsal articular angle (Fig. 167.16*B*). The distal osteotomy can be a chevron or Mitchell type, with more bone resected on the tibial side of the osteotomy than on the fibular side.

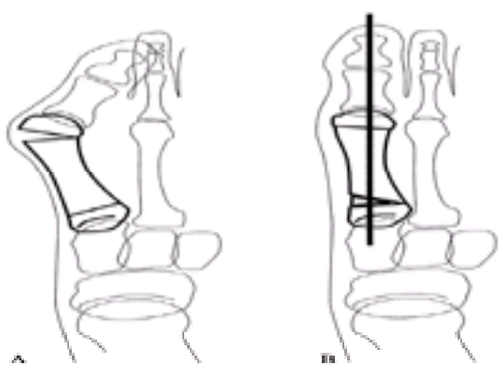

***Figure 167.16.*** Double metatarsal osteotomy is used when a patient with hallux valgus has an increase of both the first-to-second intermetatarsal angle and the distal metatarsal angle. The proximal cut can be as shown or crescentic. The distal cut may also be a chevron type, with more resection on the tibial side of the osteotomy. **A:** The osteotomies. **B:** Completion of osteotomies and fixation with a longitudinal Kirschner wire.

These procedures are covered in more detail in Chapter 112. No one standard operation is suited for all juvenile patients with hallux valgus. Versatility is the surgeon's most important asset when treating the juvenile bunion. It is important not to stretch the indications for a particular technique to correct the deformity.

## TARSAL COALITION

Tarsal coalition (9,23) is a congenital fusion between two or more of the tarsal bones. The coalition can be a true bony fusion, or a cartilaginous or fibrous connection.

The overall incidence of tarsal coalitions is unknown, but many are inherited with an autosomal dominant pattern. Many tarsal coalitions are not symptomatic and therefore go unrecognized. The most common symptomatic tarsal coalitions occur between the calcaneus and the talus, and between the calcaneus and the navicular. Complex coalitions also accompany fibular hemimelia and proximal femoral focal deficiency, but these rarely require treatment.

Pain is the principal presenting symptom, occurring when the coalition or bar begins to ossify. The usual age of onset is the second decade of life. The most common clinical finding is restriction of subtalar motion. The hindfoot is in valgus, and the patient may experience peroneal muscle spasm exhibiting in a rigid flatfoot. An attempt to invert the hindfoot, especially as a rapid maneuver, causes an increase in pain.

For radiographic evaluation, take AP, lateral, and oblique radiographs of the foot. The best radiographic view to detect a calcaneonavicular bar is the 45° oblique view (Fig. 167.17*A*). A lateral radiograph of the foot or of the ankle will usually demonstrate the so-called anteater nose sign, which is elongation of the anterosuperior aspect of the calcaneus as it is directed toward the navicular.

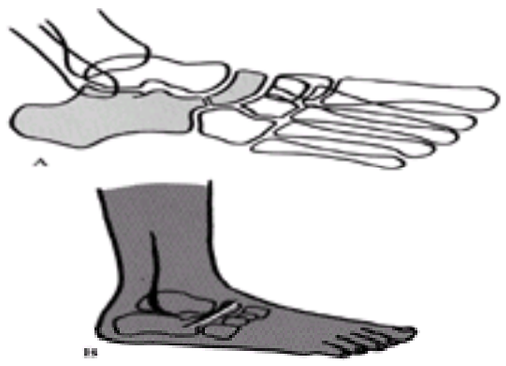

***Figure 167.17.*** Tarsal coalition. **A:** Calcaneonavicular coalition is best visualized on a 45° oblique radiograph. **B:** Incision used to resect calcaneonavicular coalition.

A talocalcaneal bar is much more difficult to demonstrate on plain radiographs. Oblique subtalar (Harris) views can be helpful, but often the best study to demonstrate a medial subtalar coalition is a computerized tomographic examination. When done in the coronal plane, this study usually successfully demonstrates talocalcaneal coalition.

The treatment of a symptomatic tarsal coalition is initially conservative. Start with 4–6 weeks of immobilization in a short-leg walking cast. If this and other conservative measures fail, consider resection of the tarsal coalition if the child is still young, particularly when some subtalar motion is present. Results are generally favorable with resection of calcaneonavicular tarsal coalitions. The results are less predictable with tarsal coalitions between the talus and calcaneus. The presence of symptoms for many years and advanced degenerative changes on midfoot radiographs are contraindications for resection of the coalition. In such cases, triple arthrodesis may be appropriate.

### RESECTION OF CALCANEONAVICULAR TARSAL COALITION

- Using a thigh tourniquet, make an oblique incision across the sinus tarsi from near the heel to the head of the talus, or use a horizontal incision (Fig. 167.17*B*). Protect the branches of the sural nerve.
- Identify the fat of the sinus tarsi and the extensor digitorum brevis muscle, and reflect them distally from their origins on the calcaneus, exposing the sinus tarsi. Leave these tissues attached distally.
- Identify the calcaneonavicular coalition. Remove the coalition as a large rectangle of bone, using an osteotome and a rongeur. The removed bone is larger than one would expect when looking at the radiograph, and it must be rectangular in shape so that there is no bony impingement in the depths of the resection.
- Demonstrate motion between the calcaneus and the navicular, and between the talus and the calcaneus after the resection is complete. Apply bone wax to the cut bony surfaces.
- Place a Bunnell suture through the origin of the extensor digitorum brevis muscle. Pass the sutures through the coalition with Keith needles, and bring them out on the medial aspect of the midfoot.
- Pull the distally based pedicle flap of fat and the extensor digitorum brevis into the space created by resection of the coalition, and tie the sutures on the medial aspect of the foot over a dental roll.
- Close the wound with absorbable sutures.
- Place the patient in a non-weight-bearing cast for 3–4 weeks until soft tissues are healed. Generally, motion is regained over the following 6 weeks.

### RESECTION OF MEDIAL SUBTALAR COALITIONS

Surgical resection of talocalcaneal tarsal coalitions is more controversial. In our opinion, it seems reasonable to attempt resection of the subtalar coalition when there are no associated degenerative changes in the joints of the foot. It has been observed that resection of even the more sizable subtalar tarsal coalitions can be successful. If the operation fails, a subtalar or triple arthrodesis can be a satisfactory salvage procedure. The technique involves a medial approach to the medial facet of the subtalar joint. Determine the exact location and size of the coalition preoperatively with coronal plane computerized tomography.

- Under pneumatic tourniquet, make a horizontal incision over the sustentaculum tali.
- Retract the muscle fibers of the abductor hallucis longus plantarward and divide the flexor retinaculum over the sustentaculum.
- Retract the FDL and neurovascular bundle plantarward.
- Identify the FHL (which is just beneath the sustentaculum tali) and retract it plantarward.
- Retract the posterior tibial tendon, above the sustentaculum, dorsally.
- Reflect the periosteum off the sustentaculum tali. Do this with care so that you can later approximate it to hold a fat graft in place.
- Identify the anterior and posterior boundaries of the coalition. We excise the coalition using a high-speed burr, gradually taking away bone until we identify the normal posterior facet of the subtalar joint. You must visualize the joint cartilage anteriorly, posteriorly, and laterally through the site of the excision. Once the excision is completed, subtalar motion should improve.
- The final step is to interpose fat between the two bony surfaces. You can obtain the fat locally, through a small incision at the ankle, or from a separate incision made in the suprapubic area, which gives a cosmetically invisible scar when the patient becomes more mature. Seal the resected bony surfaces with bone wax, and carefully push the fat graft into the defect created by the excision. Hold it in place by approximating the periosteum with sutures.
- Close the wound.
- Place the patient in a short-leg, non-weight-bearing cast for 4 weeks, and then allow progressive weight bearing as tolerated.

### TRIPLE ARTHRODESIS

If resection of the tarsal coalition fails to relieve the patient's symptoms, triple arthrodesis is a successful salvage procedure. You can use it as a secondary procedure after a failed attempt at coalition resection, or as a primary procedure when the coalition is extremely large, symptoms have extended for years, or degenerative changes are present. This procedure is generally successful in relieving the pain associated with tarsal coalition. Techniques of triple arthrodesis are described in Chapter 115.

## CONGENITAL VERTICAL TALUS

Congenital vertical talus (CVT), also know as congenital convex pes valgus, is a complex, rare, foot deformity that is resistant to conservative treatment. There is a continuum from a relatively mild, flexible form (oblique talus) to a rigid, severe deformity characterized by a plantar-flexed talus, hindfoot equinus, and dorsal dislocations of the talonavicular and calcaneocuboid joints. The heel is always in rigid valgus. There are contractures of the Achilles tendon, peroneus tertius, long-toe extensors, and tibialis anterior muscle (Fig. 167.18). Lateral roentgenographs taken in full dorsi- and plantarflexion differentiate the more flexible oblique talus from the severe variety; oblique talus exhibits severe deformity in dorsiflexion but a relatively normal relation between the talus and calcaneus in full plantar flexion (16).

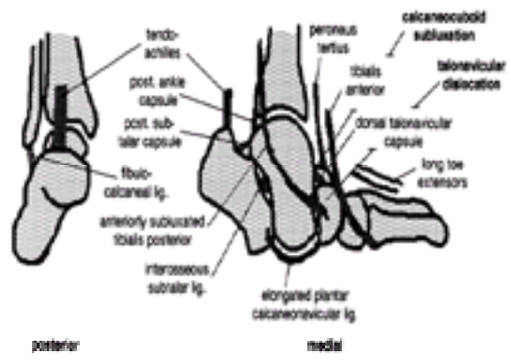


***Figure 167.18.*** Contractures involved in severe congenital vertical talus.

In more than 80% of cases, CVT is associated with other anomalies and syndromes (Marfan's syndrome, arthrogryposis, multiple pterygium syndrome), genetic abnormalities (trisomy 13–15, trisomy 18), or neuromuscular defects (myelomeningocele) (16). Unless the cause of the anomaly is clear, perform a thorough neuromuscular and genetic workup. Many children with CVT who would otherwise be candidates for surgery are wheelchair bound and can be treated by protecting the foot with a soft tennis shoe.

When indicated, treatment of rigid CVT is always surgical. Most experts recommend preliminary casting to mobilize the skin, but casting does not correct the bony deformity. Single-stage correction usually involves mobilization and reduction of all subluxed joints, internal fixation, and appropriate soft-tissue repair with transfer of the anterior tibial tendon to the neck of the talus to maintain dorsiflexion of the talus and minimize heel valgus (16,30).

The other commonly used approach is a two-stage method, with the procedures spaced 6–8 weeks apart (5). In this approach, first reduce the dorsally dislocated midfoot through an anterior incision, and lengthen contracted toe extensors and anterior tibialis muscles. Stabilize the subtalar joint in appropriate position with a subtalar bone block. Six weeks later, release the posterior ankle and subtalar joints, lengthen the heel cord, and reconstruct the anteriorly displaced posterior tibial muscle to support the talar head and neck. Whereas many surgeons attempt correction by soft-tissue means, this approach (using a subtalar fusion) can be highly effective in difficult cases.

Seimon (27) has described correction of deformities in CVT with a single dorsolateral longitudinal incision and a percutaneous posterior release. This procedure has been used with excellent success in patients under the age of 2 years.

Surgery is ideally done at 4–6 months of age, although accompanying anomalies and illnesses often require postponement to age 1 year or later. After the age of 2 to 5 years, reduction is difficult unless the foot is decompressed by navicular excision (3). Partial talectomy and decancellation of the tarsal bones may be required. Triple arthrodesis may be necessary in neglected or severe cases, and it may be necessary in maturity even when surgery early in life has corrected the gross deformity. This is especially true when tarsal bones are excised, leading to late degenerative arthritis.

**DORSOLATERAL APPROACH**

- Approach the dorsolateral aspect of the foot with either an oblique incision or a longitudinal incision over the mid-dorsum of the foot (27).
- Lengthen the extensor digitorum longus and peroneus tertius tendons. Accomplish digital extensor lengthening by dividing a portion of the tendons proximally and a portion distally, and suturing the long proximal stumps to the long distal stumps in the elongated position.
- Identify the neurovascular bundle. Retract the tibialis anterior and extensor hallucis longus tendons medially.
- Generally, the peroneal tendons are contracted and lengthening is necessary.
- Divide the dorsal and lateral talonavicular joint capsule. This allows the navicular to be readily reduced onto the head of the talus. The dorsal and lateral calcaneocuboid capsule may require release as well. You can elongate the tibialis anterior and extensor hallucis longus tendons if they are obstacles to an easy reduction.
- Transfix the talonavicular joint with a smooth K-wire. If the calcaneocuboid joint is released (or subluxated), transfix it as well. Take care to correct midfoot supination when fixing these joints.
- Lengthen the Achilles tendon percutaneously.
- You may perform posterior capsulotomies of the ankle and subtalar joint to come to equinus, but usually this is not required.
- Once the hindfoot has been corrected, pass a second K-wire from the plantar aspect of the heel through the calcaneus and talus into the tibia.
- Apply an above-knee cast to be worn for 6 weeks. After 6 weeks, remove the two K-wires and apply a below-knee cast to be worn for a further 6 weeks.

**SINGLE-STAGE REPAIR**

- Make three incisions (Fig. 167.19): The first is concave downward over the medial talonavicular joint; the second is oblique over the sinus tarsi to expose the calcaneocuboid joint and peroneal and extensor tendons; the third is along the lateral border of the Achilles tendon to allow posterior release.

***Figure 167.19.*** Preferred incisions for single-stage repair of congenital vertical talus (medial and lateral views).

- Begin laterally and make the dorsolateral approach already described. Inspect the calcaneocuboid joint, and release its capsule as necessary to correct lateral column alignment.
- In the medial wound, divide the dorsal talonavicular (deltoid) ligament and open the capsule of the dorsolateral talonavicular joint.
- Subluxate the posterior tibial tendon superiorly; divide it and tag it for later repair.
- The navicular is riding on the anterior talar neck; continue mobilizing the joint capsules dorsally through both incisions until the midfoot can be brought into plantar flexion, with reduction of the talonavicular and calcaneocuboid joints.
- Through the posterior incision, perform Z-lengthening of the Achilles tendon with the distal transverse cut directed laterally; tag the ends with #0 absorbable synthetic suture.
- Incise or excise the posterior capsules of the ankle and subtalar joints, and release the contracted fibulocalcaneal ligament and tendon sheaths of the peroneals by cutting circumferentially with small scissors. In severe cases, the interosseous subtalar ligament may require full or partial release.
- Reduce the talonavicular joint and pin it with a K-wire directed from the posterior tuberosity of the talus through the center of the joint. Bring the pin out anteriorly and bend it to prevent migration.
- Check the ankle to be sure there is adequate dorsiflexion and slight heel varus. Obtain an intraoperative lateral radiograph. The first metatarsal axis should line up exactly with the long axis of the talus; if it does not, repeat the preceding steps until it is correct.
- Repair the talonavicular joint capsule by reefing the elongated plantar calcaneonavicular ligament and remaining capsule, and repair the posterior tibial tendon, sewing it beneath the talar head and neck to assist in support.
- Release the origin of the anterior tibial tendon and transfer it to the midtalar neck, using a drill hole and sewing it to itself, to prevent abnormal plantar flexion of the talus; in the young child, make a small gutter in the medial cartilage of the talar neck and sew the tendon over this and into the soft tissues below the neck (Fig. 167.20).

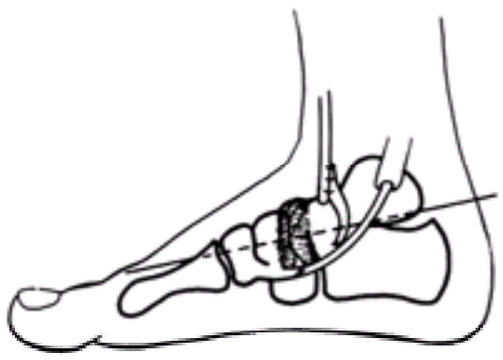

***Figure 167.20.*** A completed repair of congenital vertical talus. See text for details.

- Repair the Achilles tendon with the heel in neutral position.
- Close the skin with fine interrupted absorbable synthetic suture.
- Apply a long-leg cast, molded in the arch. Change the cast at 3-week intervals; it is worn for 4 months. Often a reverse Perlstein brace or AFO is necessary for 1–2 years.

Feet with CVT are invariably somewhat stiff after surgery; a normal foot never can be obtained. Persevere to obtain a plantigrade foot that fits easily into normal shoes and that has no pain or pressure sores. Late subtalar or triple arthrodesis may be required. The vertical talus associated with myelomeningocele or cerebral palsy may require modifications of the surgical treatment and individualized tendon transfer to achieve a balanced foot.

## PITFALLS AND COMPLICATIONS

Do not miss associated anomalies and conditions. Misdiagnosis can lead to a poor outcome or, worse, a serious complication when there is serious associated systemic disease or other disorders.

Precise, careful surgical technique is necessary to avoid neuromas from inadvertently cutting superficial sensory nerves, more serious injury to the main neurovascular bundles and tendons, and skin sloughs. In small feet, magnifying loupes are quite helpful.

Avoid incomplete correction or overcorrection, particularly the latter as it is more difficult to correct, by careful preoperative planning.

### CHAPTER REFERENCES

Each reference is categorized according to the following scheme: *, classic article; #, review article; !, basic research article; and +, clinical results/outcome study.


+ 1. Berman A, Gartland JJ. Metatarsal Osteotomy for the Correction of Adduction of the Forepart of the Foot in Children. *J Bone Joint Surg Am* 1971;53:498.

# 2. Carroll N. Pathoanatomy and Surgical Treatment of the Resistant Clubfoot. *Instr Course Lect* 1998;37:93.

+ 3. Clark MW, D'Ambrosia RD, Ferguson AB Jr. Congential Vertical Talus: Treatment by Open Reduction and Navicular Excision. *J Bone Joint Surg Am* 1977;59:816.

# 4. Coleman SS. *Complex Foot Deformities in Children.* Philadelphia: Lea & Febiger, 1983.

+ 5. Coleman SS, Stelling FH, Jarrett J. Pathomechanics and Treatment of Congenital Vertical Talus. *Clin Orthop* 1970;70:62.

+ 6. Coughlin MJ. Juvenile Hallux Valgus: Etiology and Treatment. *Foot Ankle Int* 1995;16:682.

# 7. Coughlin MJ, Mann RA. The Pathophysiology of the Juvenile Bunion. *Instr Course Lect* 1987;36:123.

+ 8. Crawford AH, Marxen JL, Osterfield DL. The Cincinnati Incision: A Comprehensive Approach for Surgical Procedures of the Foot and Ankle in Childhood. *J Bone Joint Surg Am* 1982;64:1355.

# 9. Drennan JC. *The Child's Foot and Ankle.* New York: Raven Press, 1992.

+ 10. Evans D. Relapsed Clubfoot. *J Bone Joint Surg Br* 1961;43:722.

+ 11. Fisher RL, Shaffer SR. An Evaluation of the Calcaneal Osteotomy in Congenital Clubfoot and Other Disorders. *Clin Orthop* 1970;70:141.

* 12. Garceau GJ. Anterior Tibial Tendon Transfer for Recurrent Clubfoot. *Clin Orthop* 1972;84:61.

+ 13. Hoffer MM, Reiswig JA, Garrett AM, Perry J. The Split Anterior Tibial Tendon Transfer in the Treatment of Spastic Varus Hindfoot of Childhood. *Orthop Clin North Am* 1974;5:31.

* 14. Irani RN, Sherman MS. The Pathological Anatomy of Clubfoot. *J Bone Joint Surg Am* 1972;45:45.

* 15. Kite HJ. Nonoperative Treatment of Congenital Clubfoot. *Clin Orthop* 1972;84:29.

# 16. Kumar SJ, Cowell HR, Ramsey PL. Foot Problems in Children. Part I. Vertical and Oblique Talus. *Instr Course Lect* 1982;31:235.

+ 17. Lichtblau S. A Medial and Lateral Release Operation for Clubfoot. A Preliminary Report. *J Bone Joint Surg Am* 1973;55:1377.

+ 18. Light TR, Ogden JA. The Longitudinal Epiphyseal Bracket, Implications for Surgical Correction. *J Pediatr Orthop* 1981;1:299.

+ 19. McHale KA, Lenhart MK. Treatment of Residual Clubfoot Deformity—The “Bean-Shaped” Foot—By Opening Wedge Medial Cuneiform Osteotomy and Closing Wedge Cuboid Osteotomy. *J Pediatr Orthop* 1991;11:374.

+ 20. McKay DW. New Concept of and an Approach to Clubfoot Treatment. Section I. Principles and Morbid Anatomy. *J Pediatr Orthop* 1982;2:347.

+ 21. McKay DW. New Concept of and an Approach to Clubfoot Treatment. Section II. Correction of the Clubfoot. *J Pediatr Orthop* 1983;3:10.

+ 22. McKay DW. New Concept of and an Approach to Clubfoot Treatment. Section III. Evaluation and Results. *J Pediatr Orthop* 1983;3:141.

# 23. Morrissy RT. *Atlas of Pediatric Orthopaedic Surgery.* Philadelphia: Lippincott-Raven, 1996.

+ 24. Mubarak SJ, et al. Metatarsal Epiphyseal Bracket: Treatment by Central Physiolysis. *J Pediatr Orthop* 1993;13:124.

+ 25. Phelps DA, Grogan DP. Polydactyly of the Foot. *J Pediatr Orthop* 1985;5:446.

* 26. Poseti IV, Smoley EM. Congenital Clubfoot: The Results of Treatment. *J Bone Joint Surg Am* 1963;45:261.

+ 27. Seimon LP. Surgical Correction of Congenital Vertical Talus under the Age of Two Years. *J Pediatr Orthop* 1987;7:405.

+ 28. Simons GW. Complete Subtalar Release in Clubfeet. Part I. *J Bone Joint Surg Am* 1985;67:1044.

+ 29. Simons GW. Complete Subtalar Release in Clubfeet. Part II. *J Bone Joint Surg Am* 1985;67:1056.

# 30. Tachdjian MO. Congenital Convex Pes Valgus. *Orthop Clin North Am* 1972;3:131.

# 31. Thompson GH. Bunions and Deformities of the Toes in Children and Adolescents. *Instr Course Lect* 1996;45:355.

+ 32. Turco VJ. Surgical Correction of the Resistant Clubfoot. *J Bone Joint Surg Am* 1971;53:477.

# 33. Turco VJ. *Clubfoot.* New York: Churchill-Livingstone, 1981.

+ 34. Turner JW, Cooper RR. Anterior Transfer of the Tibialis Posterior through the Interosseous Membrane. *Clin Orthop* 1972;83:241.

# 35. Venn-Watson EA. Problems in Polydactyly of the Foot. *Orthop Clin North Am* 1976;7:909.

# CHAPTER 168

# SURGICAL MANAGEMENT OF TORSIONAL DEFORMITIES OF THE LOWER EXTREMITIES

*Vincent S. Mosca and Lynn T. Staheli*

**V. S. Mosca and L. T. Staheli:** Children's Hospital and Regional Medical Center, Seattle, Washington, 98105.

Femoral Rotational Osteotomies
Operative Techniques
Complications
Tibial Rotational Osteotomies
Operative Techniques
Complications
Chapter References

The most common reason for children to seek orthopaedic evaluation, except perhaps for trauma, is for suspected torsional or angular deformities of the lower extremities. Most of these children are normal. Studies have shown that measurements of torsion and angulation in children have wide ranges of normal values and that these values change spontaneously with age until they reach the narrower adult normal ranges (3,15,17,21,22).

Values within two standard deviations of the mean are termed *physiologic variations.* Those beyond two standard deviations are called *deformities.*

It is the role of the orthopaedist to identify the few true torsional or angular deformities, as well as to identify disease entities that mimic or resemble these deformities. Do this with a careful history and clinical assessment. Perform the torsional profile examination and document it for all children who are referred for evaluation of their lower extremities or gait abnormalities (18). Clinical photographs are helpful for documentation, especially for serial evaluations. Accurate anatomic diagnosis can be made by routine radiographs for angular deformities and biplane radiographs or computed tomography (CT) scan for torsional deformities. These studies are reserved for severe deformities and for preoperative planning.

Having ruled out true deformities and other disease entities, convince the parents (and grandparents) that the apparent deformity is a normal finding, although it may not represent the average value. Point out that the apparent deformity will probably become “more normal” with time. There is no convincing evidence that orthotic management of torsional or angular variations or deformities has any beneficial effect over simple observation of the natural history alone (4,10). Therefore, the management decision is between observation with parent education, and surgery.

The parents' main concern is usually the child's appearance. Education about natural history, the uselessness and expense of orthotic devices, and the cost–benefit ratio of surgery establishes a rational basis for the observational approach. If the parents are not convinced, see their child yearly and review the torsional or angular profile with them. Clinical photographs are most helpful in this setting. Also stress that even if full spontaneous correction of torsional variations does not occur, the child may be able to volitionally change the foot-progression angle when self-appearance takes on increased meaning during adolescence.

Function is frequently the family's second concern. One study has shown that severe medial femoral torsion appears to adversely affect running, but a moderate amount of torsion does not (23). Marked genu valgum appears to adversely affect running performances as well, but this has not been documented.

Although secondary deformities have been attributed to some variations, only the concurrence of lateral tibial torsion with medial femoral torsion in late childhood has been documented (5). Likewise, genu valgum is often associated with foot pronation, but a cause-and-effect relationship has not been documented.

A final concern about torsional or angular variations or deformities is the development of arthritis (6,8,9,11,12,24,25). No documentation to date proves a cause-and-effect relationship between such variations or deformities and arthritis of the hip or patellofemoral joint.

It follows from the foregoing that indications for surgery for torsional or angular variations or deformities are extremely narrow. Because of the natural tendency for rotational deformities to remodel and improve with growth, surgical treatment is not indicated in children under 10–12 years of age. The decision hinges primarily on cosmetic concerns in the adolescent.

In most cases, variations or deformities are bilateral and often at more than one level; for example, medial femoral torsion often accompanies lateral tibial torsion. Surgical correction at one level frequently necessitates surgical correction at the other level. Staged unilateral surgery prolongs the period of temporary disability. Simultaneous bilateral surgery increases the extent of temporary disability.

The risk of complications from surgery is quite high. A 15% complication rate was found in a review of operative treatment for medial femoral torsion alone (20). In another study, a 13% incidence of peroneal nerve palsy was reported following proximal tibial rotational osteotomies if the fibula was not osteotomized (16).

Indications for surgery are subjective and must be individualized. The patient's general body habitus, the torsional and angular profile at all levels, the patient's emotional and psychologic makeup, and the torsional and angular variations of other family members must be considered. With these parameters carefully evaluated and in perspective, consider surgical correction when (a) femoral rotation values are more than three standard deviations from the mean, (b) tibial rotation values are more than four standard deviations from the mean, or (c) there is more than 25° of genu valgum in a child older than 8 years. A busy, full-time pediatric orthopaedist may find one or two torsional or angular variations or deformities per year that require surgery. The operations to be described are used much more frequently to correct the anteversion and coxa valga in cerebral palsy, the lateral tibial torsion with ankle valgus in myelodysplasia, and the angular deformities from old infection, partial physeal arrest, metabolic disorders, ischemia, ionizing irradiation, or genetic conditions.

## FEMORAL ROTATIONAL OSTEOTOMIES

Femoral rotational osteotomies can be carried out proximally, in the mid shaft, or distally. The intertrochanteric region of the femur is the preferred site for proximal osteotomies (19). Osteotomy at this level is safe, heals rapidly, and leaves an acceptable cosmetic scar. The intertrochanteric region is usually the site of the pathology and is easily accessible. The essence of the problem is torsional malalignment of the femoral neck and shaft, and it is in the intertrochanteric region that these two anatomic structures meet. If proximal femoral angulation is a problem in addition to torsion, simultaneous corrections can be made with osteotomy at this level. The technique and instrumentation for intertrochanteric osteotomy are simple and no special training or equipment is required. Early partial weight bearing is possible when rigid internal fixation is used.

Closed, mid-shaft, intramedullary rotational osteotomy of the femur is an alternative for the older adolescent in whom there is adequate intramedullary shaft diameter and little concern about iatrogenic arrest of the greater trochanter (26,27). The utility of this operation in the immature child, however, is limited both by its complexity and by the small but real risk of avascular necrosis of the femoral head related to the proximal insertion site for the nail. The scar is acceptable cosmetically and the patient may bear weight immediately. Special expertise and equipment are required, and after surgery the femur may tend to derotate around the rod unless a locked nail is used. Some angular deformities can be corrected simultaneously (see Chapter 30).

Distal femoral osteotomy in the supracondylar region gives the least acceptable scar, runs the highest risk of potential injury to growth plates, is more likely to leave residual angulation, and is farthest from the site of pathology, unless there is an associated marked patella-tracking problem (7).

## OPERATIVE TECHNIQUES

### *Proximal Femoral Rotational Osteotomy*

Use preoperative planning with radiographs and templates to determine which blade-plate angle will permit entrance of the blade just distal to the greater trochanteric apophysis, and to determine seating of the tip of the blade in the inferior proximal femoral neck.

- Place the patient supine on a radiolucent operating table extension to permit use of the image intensifier. Place folded towels under the buttocks in such a way as to allow the lateral soft tissues of the buttocks and thigh to overhang the edge of the towels. Isolate the perineum with an adherent plastic drape. Prepare both lower extremities from the iliac crests over most of the hemipelvis down to the toes.
- Make a straight lateral longitudinal incision extending distally from the greater trochanter. Incise the fascia lata longitudinally. Incise the vastus lateralis transversely just distal to the vastus ridge, and then longitudinally just anterior to the linea aspera. Bring the transverse cut in the vastus lateralis anteromedially, sufficient to see the base of the femoral neck. This creates an L-shaped flap of the muscle that can be easily reattached at the completion of the procedure.
- Expose the femur subperiosteally. Carefully incise the linea aspera with a scalpel at the proposed level of the osteotomy. Attempts at blunt elevation are difficult and may result in plunging into highly vascularized soft tissues. Using image intensification, internally rotate the extremity until the femoral neck is in the horizontal plane. Place a Steinmann pin along the anterior femoral neck in the proposed position of the blade and use the image intensifier to confirm the appropriateness of the chosen angle (Fig. 168.1).

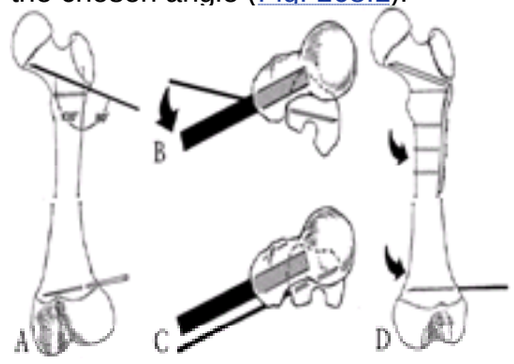


***Figure 168.1.*** Proximal femoral rotational osteotomy with blade plate. **A:** Steinmann pin confirms appropriateness of 100° blade plate. Notice placement of distal femoral alignment pin. **B:** Initial position of distal pin and chisel. Angle represents degree of desired correction. **C:** Pin and chisel (which is actually the plate holder) aligned parallel after osteotomy. Note residual average amount of torsion. **D:** Final position with blade-plate fixation after intertrochanteric osteotomy.

- Introduce the seating chisel (13), mounted on the seating chisel guide, distal to the vastus ridge and in the anterior half of the greater trochanter when viewed laterally. Hold the chisel in the horizontal plane (which is the plane of the femoral neck as positioned earlier) and angled away from the femoral shaft by 180° minus the predetermined blade-plate angle. Most importantly, rotate the chisel until the flap of the seating chisel guide is exactly in line with the long axis of the femur. Incorrect alignment of this position will result in flexion or extension at the osteotomy site when fixing the plate to the shaft. The proximal femoral shaft must be well exposed to make this alignment possible. Insert the chisel to the desired depth under image intensifier control. Check the frog-leg lateral view as well as the anteroposterior view to guide your chisel correctly.
- Insert a smooth Steinmann pin in the distal femoral metaphysis perpendicular to the long axis of the femur and rotated away from the chisel (in the direction of the rotational deformity) by the desired degree of correction. Perform the osteotomy with an oscillating saw beginning 5–10 mm distal to the entrance point of the chisel and perpendicular to the long axis of the femur.
- Use a bone-holding clamp to stabilize the proximal fragment as the chisel is removed. Carefully insert the blade plate on the plate holder. It is vital to maintain your attention and orientation during this maneuver or the blade plate could easily find a new seat in the femoral neck. Confirm the position in two planes with the image intensifier.
- Rotate the femoral shaft until the Steinmann pin and plate holder are aligned parallel. Then clamp the plate firmly on the shaft and rotate the extremity with a finger on the osteotomy site to ensure that there is no false rotation at this level. If the arc of rotation of the extremity is as desired, the side plate can be attached to the shaft with cortical screws in the usual fashion. Make sure that the side plate sits squarely on the shaft prior to making drill holes. An oblique orientation will create undesired and uncalculated additional rotation as the screws are tightened. It is better to accept a few millimeters of translation than to accept an oblique plate. Once again, check rotation and confirm final position of instrumentation by image intensification.
- Reattach the vastus lateralis with 0 Vicryl sutures. Repair the fascia lata with the same suture material. Use an absorbable subcuticular suture for the skin.
- A soft sterile dressing is all that is required. Rigid external immobilization is not needed. The child may begin touch-down weight bearing with crutches when comfortable, usually within several days of surgery. If both femurs have been osteotomized, weight bearing is not permitted. Continue this for 6–8 weeks, at which time healing should be sufficient for full weight bearing. Remove the blade plate 1 year after surgery, with 6 weeks of protected weight bearing after plate removal.

### *Closed Intramedullary Femoral Rotational Osteotomy*

Closed intramedullary femoral rotational osteotomy is described in detail in Chapter 30. A brief description follows:

- The patient can be either lateral or supine on a fracture table. Make a longitudinal incision just proximal to the greater trochanter. Incise the abductors in the direction of their fibers to expose the trochanteric recess just medial to the greater trochanter. Open the medullary canal and then pass a bulb-tipped guide down the canal. Ream the canal up to the desired diameter.
- Place a smooth Steinmann pin percutaneously in the lateral cortex of the proximal femur. Place a second pin through the lateral cortex of the distal femur rotated internally from the plane of the first pin by the desired amount of rotational correction.
- Introduce the intramedullary saw down to the mid diaphysis under image intensifier control and make the osteotomy (Fig. 168.2). Rotate the distal fragment until the two Steinmann pins are parallel; then drive the intramedullary nail. Statically lock the intramedullary nail with the osteotomy in compression. This guarantees that rotational correction will not be lost. Immediate weight bearing with assistive devices is usually possible.

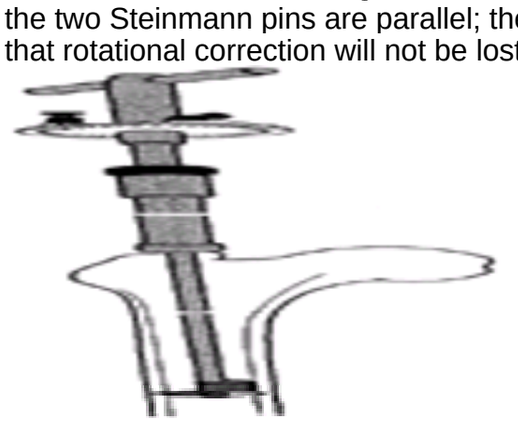

***Figure 168.2.*** Closed femoral rotational osteotomy with an intramedullary saw. (From Winquist RA. Closed Shortening of the Femur: Utilizing a New Type of Intramedullary Saw. In: Hempel D, Fischer S, eds. *Intramedullary Nailing.* New York: Thieme-Stratton, 1982;214.)

- Begin crutch-assisted weight bearing when tolerated and continued for 6 weeks. Remove the nail approximately 1 year after the operation or when healing is solid (see Chapter 30).

### *Distal Femoral Rotational Osteotomy*

- Prep the entire leg and hip area free so the limb is free to move in space. Make a longitudinal incision over the posterolateral distal femur, but do not extend distally beyond the lateral epicondyle of the femur. Lift the vastus lateralis fibers from the posterior fascia lata, and incise the muscle along its femoral insertion. Take time to carefully identify and cauterize the two or three perforating vessels before dividing or tearing them.
- Strip the periosteum and retract it using a Bennett or Hohmann retractor. As the periosteum is gently stripped distally, a point of resistance will be felt; this is the region just above the physis, and dissection should not be carried more distally. An image intensifier may be used to confirm this position.

- Place a six-hole, 3.5 mm AO plate longitudinally along the femur with the distal portion just at the end of this subperiosteal dissection. Predrill, measure, record, and tap the distal three holes. Steinmann pins may be inserted proximally and distally to mark the desired rotational correction, as described before for proximal femoral osteotomy. Do not put the pins where they will interfere with the plate after derotation.
- Using an oscillating saw, make a transverse saw cut just above the proximal hole. Fix the plate to the distal three holes and rotate the femur into its corrected position, using a Lowman clamp to fix the proximal plate into place. Check clinical rotation, and, if correct, complete the fixation by attaching the proximal screws in compression. It is unnecessary to contour the plate to the minor bend of the lateral femur, since it will elastically conform, enhancing medial compression. Check rotation again, and close using absorbable sutures and subcuticular technique.
- Place the limb in a knee immobilizer and protect from weight-bearing until callus is seen medially (usually 4–6 weeks). At this time, allow weight bearing. Knee function spontaneously returns, and the plate may be electively removed at 1 year after the surgery.

### COMPLICATIONS

There are few potential complications from proximal femoral rotational osteotomy other than those that accompany any surgical procedure—superficial and deep wound infections, anesthetic risk, and bleeding.

A potential complication with any form of fixation is malrotation. When using the blade plate, clamp the side plate on the femoral shaft and check rotation before inserting the screws. Also, recheck rotation after the screws have been inserted. The position may shift during screw insertion. Guide pins are not precisely accurate and final confirmation by intraoperative range of motion is required.

Rotational malunion should not occur if all the described steps are followed, and the final position is checked by image intensification and by range of motion on the table. Angular malunion can occur if the osteotomy is not precisely perpendicular to the femoral shaft. Should either occur, the same careful assessment used for the initial surgical decision should be made to determine if repeat osteotomy is indicated.

In adolescents, nonunion of femoral osteotomies in the intertrochanteric region is extremely rare. However, this could result from failure to achieve reasonable apposition of bone, or from distraction of the osteotomy by the hardware. In cases of delayed union, prolonged external immobilization or prolonged partial weight bearing is usually all that is necessary to achieve union.

The blade of the blade plate is extremely sharp and can easily miss the track left by the chisel. Maintain precise orientation during the switch and insert it by pushing manually. Check final position with the image intensifier.

Holes left in the bone after hardware removal are potential stress risers for fractures. If a blade plate has been used, there are multiple stress risers and temporary (6–8 weeks) partial weight bearing with crutches must be enforced after removal of the hardware.

If a fracture occurs, it should be treated as any intertrochanteric or subtrochanteric fracture—that is, by skin or skeletal traction followed by spica casting. Internal fixation may be used but is reserved for fractures that cannot be reduced or held well in a spica cast.

## TIBIAL ROTATIONAL OSTEOTOMIES

Indications for tibial rotational osteotomies are even narrower than for femoral rotational osteotomies. They are perhaps most commonly performed in conjunction with femoral osteotomies in the case of medial femoral torsion with lateral tibial torsion. Cosmesis is the prime indication.

Preoperatively, the angle of the transmalleolar axis and the thigh–foot angle must be assessed to determine that the rotational problem is in the tibia and not in the foot. Tibial rotational osteotomy is reserved for tibial torsion problems. Transverse or coronal plane deformities of the foot should be managed by appropriate surgery on the foot.

Distal tibial rotational osteotomy is preferred for its accessibility, simplicity, safety, rapid healing, and cosmetically acceptable scar. It is also versatile in cases where rotational abnormalities are accompanied by distal angular abnormalities.

Proximal tibial osteotomy has the disadvantages of potential injury to the common peroneal nerve and the popliteal artery at its trifurcation, as well as damage to the tibial apophysis. There is a greater risk of compartment syndrome. Scars at the knee are perhaps less cosmetically acceptable than scars at the ankle.

Mid-shaft osteotomies have the disadvantages of potential for compartment syndrome and delayed union or nonunion.

For pure rotational deformity in the tibia, the advantages of distal osteotomy over proximal or mid-shaft osteotomy are overwhelming. We therefore feel there are no reasonable alternatives.

### OPERATIVE TECHNIQUES

#### *Distal Tibial Rotational Osteotomy*

- Position the patient supine on a radiolucent operating table extension. Prepare both limbs from the toes to the tourniquets on the proximal thighs (Fig. 168.3). The distal thigh and knee must be exposed in the surgical field. In the skeletally immature child, identify the distal tibial physis with the image intensifier and mark its level on the skin.

***Figure 168.3.*** Distal tibial rotational osteotomy. **A:** Both limbs prepped and exposed up to tourniquets. **B:** Initial axial rotation between alignment pins checked with goniometer. **C:** Pins aligned parallel after osteotomy. Fixation pins enter malleoli and cross osteotomy. **D:** Final thigh–foot angle checked with hip and knee flexed 90° and also with joints in extension. **E:** Good early healing. Notice fibular osteotomy.

- Make a 5 cm longitudinal incision 1–2 cm lateral and parallel to the tibial crest ending at the physeal line. Retract the anterior compartment tendons laterally and protect the anterior tibial neurovascular bundle. Incise the periosteum longitudinally down to, but not across, the physis, and expose the tibial metaphysis subperiosteally.
- Through the same skin incision, make an extrafascial approach to the fibula between the lateral and anterior compartments. Expose the fibula subperiosteally at a level 1–2 cm proximal to the anticipated osteotomy of the tibia. Make a long oblique osteotomy with an osteotome.
- Drill a smooth $^{3}/_{32}$-inch Steinmann pin into the anterior proximal tibia in the sagittal plane. Drill a second smooth pin into the distal metaphysis just proximal to the physis. This pin should be perpendicular to the long axis of the tibia and axially rotated away from the first pin (in the direction of the deformity) by the amount to be corrected. The goal is a transmalleolar axis of +20° and a corresponding thigh–foot angle of + 10°.
- Perform the osteotomy 1–1.5 cm proximal to and parallel with the physis using an oscillating saw. Then rotate the distal fragment until the two Steinmann pins are aligned parallel. Fix the osteotomy with crossed smooth $^{3}/_{32}$-inch Steinmann pins that enter each malleolus, cross the osteotomy, and engage the tibial cortex of the proximal fragment. Occasionally a third Steinmann pin will be needed for fixation across the osteotomy. Check fixation and bone apposition with the image intensifier. Check the angle of the transmalleolar axis and the thigh–foot angle with the hip and knee flexed 90° and again with these joints in extension.
- Perform a blind, prophylactic, subcutaneous fasciotomy of the anterior and lateral compartments with Metzenbaum scissors. Be certain that the fascia is cut.
- Loosely reapproximate the tibial periosteal edges with 2-0 Vicryl sutures. Following irrigation and hemostasis, approximate the subcutaneous tissues with 3-0

Vicryl sutures, and approximate the skin with running subcuticular 4-0 Vicryl sutures. Bend the fixation Steinmann pins at the point they exit the skin and cut them long.

- Apply a well-padded, bent-knee, long-leg cast. A long-leg cast with 5° to 10° of knee flexion can be applied 3 weeks after surgery so partial weight bearing can begin. Remove the pins at approximately 6–8 weeks. Use radiographs to determine the need for further immobilization in a short-leg cast.

## COMPLICATIONS

Because you want to make the smallest incision possible, exposure of the fibula is necessarily limited. To avoid damage to the superficial peroneal nerve or the peroneal vascular structures, perform the fibular osteotomy with an osteotome.

Although the risk of compartment syndrome is lowest with distal tibial osteotomy, prophylactic subcutaneous anterior and lateral compartment fasciotomy is advised. Nevertheless, frequent careful postoperative assessment is mandatory to detect impending compartment syndrome early. Perform four-compartment fasciotomy if it occurs.

Malunion indicates failure to confirm correction intraoperatively, as described. The decision for repeat osteotomy should be made as carefully as the initial decision to operate.

Nonunion at this level is extremely unusual. Weight bearing in a cast with or without pins in place should effectively treat delayed union.

## CHAPTER REFERENCES

Each reference is categorized according to the following scheme: *, classic article; #, review article; !, basic research article; and +, clinical results/outcome study.


* 1. Blount WP. A Mature Look at Epiphyseal Stapling. *Clin Orthop* 1971;77:158.

+ 2. Bowen JR, Leahey JL, Zhang Z, MacEwen GD. Partial Epiphysiodesis at the Knee to Correct Angular Deformity. *Clin Orthop* 1985;198:184.

# 3. Engel GM, Staheli LT. The Natural History of Torsion and Other Factors Influencing Gait in Childhood: A Study of the Angle of Gait, Tibial Torsion, Knee Angle, Hip Rotation, and Development of the Arch in Normal Children. *Clin Orthop* 1974;99:12.

+ 4. Fabry G. Torsion of the Femur. *Acta Orthop Belg* 1977;43:454.

+ 5. Fabry G, MacEwen GD, Shands AR Jr. Torsion of the Femur: A Follow-up in Normal and Abnormal Conditions. *J Bone Joint Surg Am* 1973;55:1726.

+ 6. Halpern AA, Tanner J, Rinsky L. Does Persistent Fetal Femoral Anteversion Contribute to Osteoarthritis? A Preliminary Report. *Clin Orthop* 1979;145:213.

+ 7. Hoffer MM, Prietto C, Koffman M. Supracondylar Derotational Osteotomy of the Femur for Internal Rotation of the Thigh in the Cerebral Palsied Child. *J Bone Joint Surg Am* 1981;63:389.

+ 8. Hubbard DD, Staheli LT, Chew DE, Mosca VS. Medial Femoral Torsion and Osteoarthritis. *J Pediatr Orthop* 1988;8:540.

+ 9. Insall J, Falvo KA, Wise DW. Chondromalacia Patellae: A Prospective Study. *J Bone Joint Surg Am* 1976;58:1.

+ 10. Knittel G, Staheli LT. The Effectiveness of Shoe Modifications for Intoeing. *Orthop Clin North Am* 1976;7:1019.

# 11. MacEwen GD, Shands AR Jr. Rotation and Angulation Deformities of the Lower Extremity in Childhood. *Orthopedics* 1960;2:66.

+ 12. McSweeny A. A Study of Femoral Torsion in Children. *J Bone Joint Surg Br* 1971;53:90.

# 13. Müller ME, Allgöwer M, Schneider R, Willenegger H. *Manual of Internal Fixation: Techniques Recommended by the AO Group*, 2nd ed. New York: Springer-Verlag, 1979.

+ 14. Pistevos G, Duckworth T. The Correction of Genu Valgum by Epiphysial Stapling. *J Bone Joint Surg Br* 1977;59:72.

+ 15. Salenius P, Vankka E. The Development of the Tibiofemoral Angle in Children. *J Bone Joint Surg Am* 1975;57:259.

+ 16. Schrock RD Jr. Peroneal Nerve Palsy Following Derotation Osteotomies for Tibial Torsion. *Clin Orthop* 1969;62:172.

+ 17. Shands AR Jr, Steele MK. Torsion of the Femur: A Follow-up Report on the Use of the Dunlap Method for Its Determination. *J Bone Joint Surg Am* 1958;40:803.

# 18. Staheli LT. Torsional Deformity. *Pediatr Clin North Am* 1977;24:799.

# 19. Staheli LT. Medial Femoral Torsion. *Orthop Clin North Am* 1980;11:39.

+ 20. Staheli LT, Clawson DK, Hubbard DD. Medial Femoral Torsion: Experience with Operative Treatment. *Clin Orthop* 1980;146:222.

+ 21. Staheli LT, Corbett M, Wyss C, King H. Lower-Extremity Rotational Problems in Children: Normal Values to Guide Management. *J Bone Joint Surg Am* 1985;67:39.

+ 22. Staheli LT, Engel GM. Tibial Torsion: A Method of Assessment and a Survey of Normal Children. *Clin Orthop* 1972;86:183.

+ 23. Staheli LT, Lippert F, Denotter P. Femoral Anteversion and Physical Performance in Adolescent and Adult Life. *Clin Orthop* 1977;129:213.

+ 24. Terjesen T, Benum P, Anda S, Svenningsen S. Increased Femoral Anteversion and Osteoarthritis of the Hip Joint. *Acta Orthop Scand* 1982;53:571.

+ 25. Turner MS, Smillie IS. The Effect of Tibial Torsion on the Pathology of the Knee. *J Bone Joint Surg Br* 1981;63:396.

# 26. Winquist RA. Closed Shortening of the Femur: Utilizing a New Type of Intramedullary Saw. In: Hempel D, Fischer S, eds. *Intramedullary Nailing.* New York: Thieme-Stratton, 1982;214.

+ 27. Winquist RA, Hansen ST Jr, Pearson RE. Closed Intramedullary Shortening of the Femur. *Clin Orthop* 1978;136:54.

# CHAPTER 169

# ANGULAR DEFORMITIES OF THE LOWER EXTREMITIES IN CHILDREN

*George H. Thompson*

**G. H. Thompson:** Division of Pediatric Orthopaedics, Case Western Reserve University, Cleveland, Ohio 44106.

Normal Developmental Alignment of the Lower Extremity
Genu Varum
Physiologic Genu Varum
Pathologic Genu Varum Deformities
Genu Valgum
Physiologic Genu Valgum
Pathologic Genu Valgum Deformities
Congenital Angulation Deformities of the Tibia and Fibula
Congenital Anterolateral Bowing of the Tibia: Congenital Pseudarthrosis
Congenital Posteromedial Angulation of the Tibia and Fibula
Chapter References

Angular deformities of the lower extremities in children are common and are a frequent reason for orthopaedic referral. They predominantly occur in the tibia; the femur is much less frequently involved. Angulation may occur in the frontal plane (varus and valgus), the sagittal plane (anterior and posterior), or a combination of both (anterolateral or posteromedial). Torsion may also be involved. It is important to understand the various physiologic and pathologic causes of angular deformities, the methods of evaluation, and the natural histories of the abnormalities to determine appropriate treatment (50,115,287). The classification for the differential diagnoses of genu varum (bowleg), genu valgum (knock-knee), and congenital angular deformities of the tibia and fibula are presented in Table 169.1, Table 169.2 and Table 169.3.

*Physiologic genu varum*
*Pathologic genu varum*
Tibia vara (Blount's disease)
- Infantile
- Juvenile
- Adolescent

Focal fibrocartilaginous dysplasia
Physeal injury
- Trauma
- Infection
- Tumor

Metabolic disorders
- Vitamin D deficiency (nutritional rickets)
- Vitamin D–resistant rickets
- Hypophosphatasia

Renal osteodystrophy
Skeletal dysplasia
- Metaphyseal chondrodysplasia
- Achondroplasia
- Enchondromatosis

Osteogenesis imperfecta

***Table 169.1. Classification of Genu Varum or Bowleg Deformities of the Lower Extremities in Children***

*Physiologic genu valgum*
*Pathologic genu valgum*
Trauma
- Physeal injury
- Genu valgum following fracture of the proximal tibial metaphysis
- Malunion

Infection
- Physeal damage

Tumor
- Physeal involvement

Metabolic disorders
- Vitamin D deficiency (nutritional rickets)
- Vitamin D–resistant rickets
- Renal osteodystrophy

Skeletal dysplasia
- Multiple epiphyseal dysplasia
- Pseudoachondrodysplasia
- Kniest syndrome

Congenital abnormalities
- Congenital dislocation of the patella

Neuromuscular disorders
- Cerebral palsy
- Myelodysplasia

***Table 169.2. Classification of Genu Valgum or Knock-knee Deformities of the Lower Extremities in Children***

*Posteromedial angulation*
*Anterolateral angulation*
Congenital pseudarthrosis of the tibia
Congenital longitudinal deficiency of the tibia (paraxial tibial hemimelia)
Congenital longitudinal deficiency of the fibula (paraxial fibular hemimella)

***Table 169.3. Differential Diagnosis of Congenital Angular Deformities of the Tibia and Fibula***

## NORMAL DEVELOPMENTAL ALIGNMENT OF THE LOWER EXTREMITY

Mild to moderate bowing of the lower extremities is a common finding in infants and young children. It is the result of molding of the lower extremities *in utero.* The bowed appearance of the lower extremities is actually a combination of external or lateral rotation of the hip (tight posterior capsule) and internal or medial tibial torsion. This physiologic genu varum tends to persist during the first year of life with only minimal improvement. After a child begins to walk, the bowing corrects spontaneously. Complete correction may require up to 36 months of ambulation.

Physiologic genu valgum may appear by 3–4 years of age. This is true genu valgum, not the result of a torsional combination from *in utero* positioning. This deformity also undergoes spontaneous correction with normal adult knee alignment of mild genu valgum obtained by 5–8 years of age. Cahuzac et al. (55) demonstrated that girls have a consistent genu valgum alignment by 10 years of age that remains constant as they finish musculoskeletal growth. Boys, however, tend to have a decreasing valgus alignment until approximately 16 years of age. Thus, men have less valgus at maturity than do women.

Salenius and Vankka (242) analyzed the femoro-tibial angles clinically and radiographically in 1,279 children between birth and 16 years of age (Fig. 169.1). They found a mean varus alignment of 15° in newborns. This decreased to approximately 10° of varus alignment by age 1 year. Neutral alignment occurred between 18 and 20 months of age. The maximum valgus of approximately 12° was achieved by 3–4 years of age. The results were similar for boys and girls. By age 7 years, the children's valgus alignments had corrected to those of normal adults (8° in women, 7° in men). The researchers estimated that in approximately 95% of the children physiologic genu varum or valgum alignments resolved spontaneously with growth. In a follow-up study of 20 children between 1 and 4 years of age with pronounced physiologic varus (16° to 33°) or valgus (15° to 20°) deformities of the knees, Vankka and Salenius (279) found that even these pronounced deformities resolved during growth, although some did not completely correct until adolescence. They recommended that surgical correction be cautiously considered for children between 10 and 13 years of age, when corrective osteotomies are usually performed.

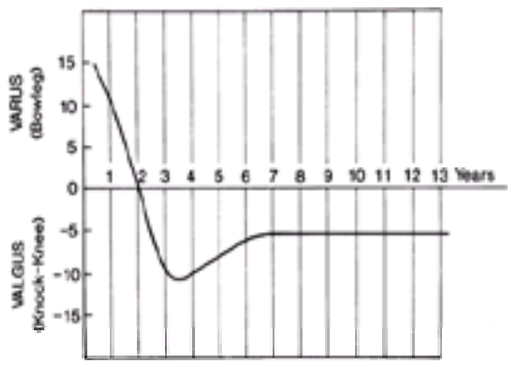


***Figure 169.1.*** Normal development of knee alignment from infancy through childhood. (Adapted from Salenius P, Vankka E. The Development of the Tibio-femoral Angle in Children. *J Bone Joint Surg Am* 1975;57:259.)

## GENU VARUM

Genu varum, or bowleg, is a common childhood deformity and one of the most common causes of parental concern. In the majority of cases, it will be physiologic in origin and will correct with normal growth and development. However, there are pathologic genu varum disorders that may progress and produce functional impairment (Table 169.1).

The evaluation of a child with genu varum consists of a careful history and physical examination. The history will frequently distinguish physiologic from pathologic genu varum. Obtain a birth history, family history, the age at which developmental milestones occurred, a nutritional history, and the previous percentiles for height and weight. A family history of short stature or varus alignment or progression of the deformity may indicate a pathologic process.

On physical examination, measure height and weight, and determine the percentile for age. Shortening of the extremities relative to the trunk may indicate a skeletal dysplasia. In ambulatory children, the appearance to the lower extremities during standing and gait can provide important information. Determine the location of the deformity, as well as whether there is a lateral knee thrust while walking. Measure the range of motion of the hips, knees, and ankles. Assess the presence of ligamentous laxity. Measure the degree of genu varum in the standing and the supine positions. Measure and record the distance between the medial femoral condyles in centimeters. In addition, measure the torsional profile as described by Mosca and Staheli (see Chapter 168). This includes the foot progression angle, hip range of motion in extension, the thigh–foot angle, and the shape of the foot. Torsional changes in the femur and tibia are common in angular deformities of the lower extremities. Obtain serial photographs, if possible, and place them in the child's chart as an aid in documentation of improvement or worsening over time.

Radiographs are not routinely necessary in genu varum. However, if the child is short, the deformity is asymmetric, there is a history of progression, or the child is older than 3 years, obtain radiographs consisting of a standing anteroposterior (AP) projection of the lower extremities, including the hips, knees, and ankles. Position the patellae pointing forward. Measure the femoro-tibial angle, the mechanical axis, and the metaphyseal–diaphyseal angles. Assess the physes of the femur and tibia, especially those about the knee. Metaphyseal and physeal widening suggest an underlying metabolic disorder.

The history, physical examination, and radiographic evaluation then provide the basis for an accurate assessment of whether the child has a physiologic or pathologic genu varum deformity. The specifics of further evaluation and treatment are based on the diagnosis.

### PHYSIOLOGIC GENU VARUM

#### *Pathophysiology*

Physiologic genu varum due to *in utero* positioning is a common finding in children between birth and 2 years of age. It is usually associated with a toe-in gait due to medial tibial torsion.

While the child is standing, the lower extremities appear bowed. However, physical examination demonstrates excessive lateral rotation of the extended hip and medial tibial torsion (Fig. 169.2). Contracture of the posterior capsule is a normal finding in children up to 1 year of age. It tends to improve during the first 3 years of life, and ultimately medial rotation slightly exceeds lateral rotation (222). Medial tibial torsion is the major component of physiologic genu varum. The knees are normal, except for possibly a slight residual knee-flexion contracture. A lateral knee thrust during gait is uncommon and indicates a pathologic genu varum deformity (161,163). The degree of varus can be measured by a goniometer (femoro-tibial angle) or the distance between the medial femoral condyles (55,65,126).

***Figure 169.2.*** **A:** Physical examination of a 9-month-old boy with physiologic genu varum. The infant may still comfortably assume the *in utero* position with the hips flexed, abducted, and laterally rotated. The knees are flexed, with the lower legs and feet medially rotated. This position results in a hip flexion contracture, a contracture of the posterior aspect of the hip capsule, knee flexion contracture, and medial tibial torsion. **B:** When the lower extremities are extended, the posterior hip capsule contracture results in increased lateral rotation (80° to 90°) and limited medial rotation (0° to 10°). When the patellae point laterally, the medial tibial torsion is not readily apparent. **C:** When the hips are maximally rotated medially and the patellae are directed anteriorly, the medial tibial torsion is more apparent. The medial tibial torsion can be measured by the thigh–foot angle or the transmalleolar axis. The medial tibial torsion may also produce in-toeing during ambulation. This can be assessed by measuring the foot progression angle.

On radiographs, the typical features of physiologic genu varum include the following (268):

Transverse planes of the knees and the ankle joints are tilted medially.
Tibia is slightly bowed laterally at the junction of its proximal and middle thirds and the femur at its distal third.

Medial cortices of the tibia and femur are thickened and sclerotic.
Epiphyses, physes, and metaphyses have normal appearances, and there is no evidence of intrinsic bone disease.
Involvement is usually symmetric.

It can be difficult to differentiate radiographically between physiologic genu varum and tibia vara (Blount's disease) in children younger than 3 years of age. Levine and Drennan (176) developed the metaphyseal–diaphyseal angle to aid in differentiating these two disorders (Fig. 169.3). An angle of 11° or less indicates physiologic genu varum, and angles greater than 11° suggest that progressive tibia vara is likely (Fig. 169.4). However, a later study by Feldman and Schoenecker (101) indicated that angles greater than 16° are predictive of tibia vara, whereas angles of 9° or less suggest physiologic genu varum and angles between 10° and 15° are indeterminate. The metaphyseal–diaphyseal angle has been shown to have good interobserver and intraobserver reproducibility (104). However, it is important that standing radiographs be obtained with the knees in a neutral position, as rotational changes can alter measurements (265).

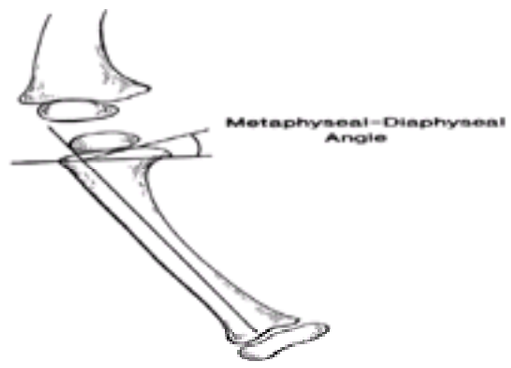


***Figure 169.3.*** Metaphyseal–diaphyseal angle. Draw a line between the radiographic corners of the medial and the lateral metaphyses of the proximal tibia, and another line parallel to the longitudinal axis of the tibial diaphysis. Then construct a line perpendicular to the diaphyseal line at the intersection of the metaphyseal and diaphyseal lines, and measure the angle between the right-angle line and the metaphyseal line. (Adapted from Levine AM, Drennan JC. Physiologic Bowing and Tibia Vara: The Metaphyseal–Diaphyseal Angle in the Measurement of Bowleg Deformities. *J Bone Joint Surg Am* 1982;64:1158.)

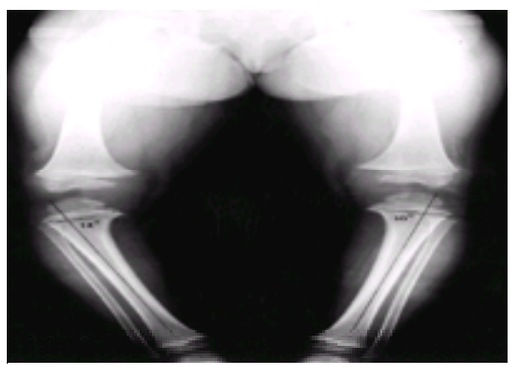

***Figure 169.4.*** Standing AP radiograph of an 18-month-old girl with asymmetric bowing of the lower extremities. The metaphyseal–diaphyseal angle is 14° on the right, indicating infantile tibia vara; it is 10° on the left, representing physiologic genu varum. There is already medial metaphyseal irregularity and beaking, as well as mild medial epiphyseal flattening on the right.

If a metabolic disorder is suspected, obtain serum calcium, phosphorus, and alkaline phosphatase levels. Obtain a pediatric endocrinology evaluation to assist in diagnosis and management.

Physiologic genu varum resolves spontaneously with normal growth and development (94,124,161,163,190,242,252,268,279). Operative treatment is rarely indicated. Orthoses or corrective shoes are not recommended because there is no evidence that they improve alignment of the extremity. Follow infants and young children with physiologic genu varum at 6-month intervals (Fig. 169.5). Recording accurate clinical measurements is useful in reassuring anxious parents that improvement is occurring.

***Figure 169.5.*** **A:** A 16-month-old girl with physiologic genu varum. Observe the lateral rotation of the thighs and knees and the medial tibial torsion. **B:** One year later, with no treatment, there has been complete resolution of the physiologic genu varum.

### *Operative Techniques*

The techniques for correction of genu varum are listed in Table 169.4. The usual procedures for physiologic genu varum include a proximal tibial valgus derotation and diaphyseal fibular osteotomies, proximal tibial hemiepiphyseal stapling, or proximal tibial hemiepiphysiodesis. The latter two procedures are based on adequate remaining growth to achieve complete correction (39). The graph developed by Bowen et al. (38) can be helpful in determining proper timing.

| |
|---|
| *Distal femur* |
| Valgus osteotomy |
| Closing wedge |
| Opening wedge |
| Callotasis |
| Lateral hemiepiphyseal stapling |
| Lateral hemiepiphysiodesis |
| *Proximal tibia* |
| Valgus osteotomy (including derotation and diaphyseal fibular osteotomy) |
| Closing wedge |
| Opening wedge |
| Dome |
| Oblique |
| Callotasis |
| Other |
| Lateral hemiepiphyseal stapling |
| Lateral hemiepiphysiodesis |

*Table 169.4. Surgical Options for Genu Varum Deformities*

**Proximal Tibial Valgus Osteotomy and Diaphyseal Fibular Osteotomy** This is the most common procedure in persistent physiologic genu varum because it addresses both the varus and the medial tibial torsion. A variety of techniques can be used, including closing-wedge, opening-wedge, oblique, or dome osteotomies. These are essentially the same procedures as for tibia vara or Blount's disease. A diaphyseal fibular osteotomy is performed concomitantly because the fibula is usually too long and may be contributing to the deformity. The technique of a closing-wedge proximal tibial and diaphyseal fibular osteotomy is discussed in the section on tibia vara (see below). Internal or external fixation to maintain alignment is necessary and usually supplemented by a long-leg cast until complete healing has occurred.

**Proximal Tibial Hemiepiphyseal Stapling** Temporary retardation of growth in the lateral aspect of the proximal tibial epiphysis with staples is an effective method for correction of persistent physiologic genu varum. If the deformity is severe or there is limited remaining growth, a combined lateral stapling of the distal femoral and the proximal tibial epiphyses may need to be performed. This procedure will not correct any coexistent medial tibial torsion.

**Proximal Tibial Hemiepiphysiodesis** Percutaneous closure of the lateral aspect of the proximal tibial epiphysis can be effective in correcting persistent physiologic genu varum in adolescents. The indications are essentially the same as for stapling. However, once complete correction has been achieved, a second procedure may be necessary on the medial side to prevent overcorrection. The proximal fibular epiphysis is usually closed concomitantly. This procedure will not correct any medial tibial torsion.

### *Rehabilitation and Postoperative Principles*

In general, children treated with a proximal tibial valgus derotation and diaphyseal fibular osteotomies are managed similar to patients undergoing the same procedure for tibia vara. In children treated with a proximal tibial hemiepiphyseal stapling or hemiepiphysiodesis, apply a knee immobilizer postoperatively for approximately 2 weeks. This allows healing of the skin incision and minimizes discomfort. Then begin active range of motion exercises, and allow return to normal activities, typically at 4–6 weeks postoperatively.

### *Pitfalls and Complications*

Complications of proximal tibial osteotomies have been well described in the orthopaedic literature (88,103,148,187,202,204,263). There is a risk for injury to the peroneal nerve as it passes around the lateral aspect of the proximal fibula, and to the anterior tibial artery as it passes into the anterior compartment through the hiatus between the proximal tibia and fibula. Compartment syndromes have been described, and a child must be carefully evaluated for the first 24–48 hours postoperatively. Perform prophylactic anterior compartment fasciotomies at the time of surgery.

Complications of hemiepiphyseal stapling or epiphysiodesis occur much less frequently. Physeal damage with asymmetric closure and complete closure secondary to prolonged compression are the most common problems but are fortunately rare.

### *Conclusion*

Physiologic genu varum rarely persists to such a degree that surgical intervention is necessary. There is a relationship between this disorder and tibia vara (Blount's disease). Persistent varus deformity may progress to the latter disorder. It has been my experience that the most common residual abnormality of physiologic genu varum is persistent medial tibial torsion. This is a more common indication for surgical treatment (see Chapter 168).

## PATHOLOGIC GENU VARUM DEFORMITIES

### *Tibia Vara*

Idiopathic tibia vara (Blount's disease) is the most common pathologic genu varum deformity. It is characterized by abnormal growth of the medial aspect of the proximal tibial epiphysis that results in progressive varus angulation beneath the knee. This disorder was first described by Erlacher (95) in 1922 and further analyzed by Blount (35) in 1937.

**Classifications** Tibia vara may occur at any age in a growing child. It was initially classified into two broad groups, depending on the age at clinical onset: infantile, with onset between 1 and 3 years of age; and adolescent, with onset inconsistently described as occurring after 6–8 years of age or just before puberty (33,35,97,110,111,157,158,260). In 1984, Thompson et al. (275) proposed a three-group classification based on the age at onset: infantile (1–3 years), juvenile (4–10 years), and adolescent (11 years or older). The juvenile and adolescent forms are commonly combined as late-onset tibia vara. However, the incidence of recurrent deformity after a corrective valgus osteotomy of the proximal tibia is much higher in the juvenile group, justifying a three-group classification. All three groups share relatively common clinical characteristics, although the radiographic changes in the late-onset groups are less pronounced. Although the exact cause of tibia vara remains unknown, it appears to be secondary to growth suppression from increased compressive forces across the medial aspect of the knee (22,29,33,35,59,60,69,111,157,168,171,172,274,275,286). Familial cases have been reported (23,111,173,250,253).

The natural history of tibia vara is one of progressive varus deformity. Infantile tibia vara can produce the greatest degree of deformity because of the greater amount of growth time remaining. In 1952, Langenskiöld (172) described six stages of progressive deformity in infantile tibia vara. Each grade advanced the degree of physeal growth inhibition (Fig. 169.6). It is possible to restore normal growth and development of the proximal tibial physes in grades I and II and probable grades III and IV. Grades V and VI represent severe damage to the medial proximal tibial physis and probable premature or asymmetric closure. The rate of deformity in grades V and VI is rapid, resulting in severe deformity and articular malformation. There is relatively good interobserver agreement with the use of this classification, especially for the early and late stages (264).

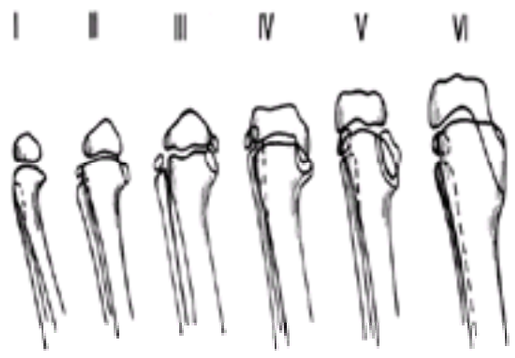


***Figure 169.6.*** Six grades of radiographic changes in infantile tibia vara as described by Langenskiöld (172). These represent a continuum of progressing deformity over time.

**Assessment, Indications, Relative Results** Comparison of the clinical characteristics of the infantile (22,23,33,35,46,90,91,95,97,103,110,111,116,151,167,168,169,172,173,180,181,223,248,260) and late-onset (juvenile and adolescent) (29,46,129,167,274,275,286) forms of tibia vara shows similarities as well as distinct differences (Table 169.5). The infantile form is the most common (Fig. 169.7). However, the late-onset forms also occur frequently (Fig. 169.8). Anterior cruciate ligament incompetence may occur in severe deformities (28).

| *Infantile* | *Late-onset (juvenile and adolescent)* |
|---|---|
| African-American race | African-American race |
| Female predominance | Male predominance |
| Marked obesity | Marked obesity |
| Bilateral involvement (80%) | Bilateral involvement (50%) |
| Medial metaphyseal beak | No medial metaphyseal beak |
| Medial tibial torsion | Minimal medial tibial torsion |
| Lower-extremity length inequality | Mild lower-extremity length inequality |
| | Pain rather than deformity |
| | Mild medial collateral ligament laxity |
| | Steadily progressive deformity |

***Table 169.5. Comparison of the Clinical Characteristics of Tibia Vara***

***Figure 169.7.*** **A:** Clinical photograph of a 5-year-old African-American girl with left infantile tibia vara. Observe the obesity, the unilateral left genu varum deformity, and the associated medial tibial torsion. **B:** Standing radiograph of the left knee demonstrates Langenskiöld grade III changes in the medial aspect of the proximal tibial epiphysis and metaphysis. Notice the metaphyseal beaking.

***Figure 169.8.*** **A:** Standing preoperative photograph of a 13-year-old African-American boy with bilateral adolescent or late-onset tibia vara. A previous proximal tibial osteotomy was performed on the right, producing only partial correction. Observe the marked obesity and the untreated left genu varum deformity and its medial tibial torsion. The patient subsequently underwent a laterally based closing-wedge proximal tibial osteotomy, including the physis, and a diaphyseal fibular osteotomy for correction of this deformity. **B:** On a standing AP radiograph of the left knee, the radiographic changes in adolescent tibia vara are less striking than in the infantile form. There is narrowing of the medial aspect of the proximal tibial epiphysis, physeal irregularity, and increased height of the lateral aspect of the epiphysis.

Radiographically, fragmentation with a protuberant step deformity and beaking of the proximal medial tibial metaphysis are the major features of infantile tibia vara (Fig. 169.7*B*) (54,116,151,260). The changes in the proximal medial tibia are less conspicuous in the late-onset forms and are characterized by wedging of the medial portion of the epiphysis, a mild posteromedial articular depression, a serpiginous cephalad-curved physis, and mild or no fragmentation or beaking of the proximal medial metaphysis (Fig. 169.8*B*) (29,46,54,77,78,254,255 and 256,274,275,286). The differences among the three tibia vara groups appear to be primarily due to the age at onset, the amount of remaining growth, and the magnitude of the medial compression forces on the involved side.

The major deformity that must be differentiated from tibia vara is physiologic genu varum deformity. It is difficult to differentiate these disorders in patients younger than 2 years. Children with tibia vara are typically African-American and obese and have a clinically apparent lateral thrust of the knee during the stance phase of gait. The deformities are progressive and may be asymmetric. Radiographic differentiation may be difficult. Standing radiographs of the lower extremities in children younger than 18 months of age with genu varum deformities are typically normal. However, normal knee radiographs do not eliminate infantile tibia vara from consideration. A metaphyseal–diaphyseal angle greater than 16° is an early prognosticator of infantile tibia vara (Fig. 169.3) (101). After 2–3 years of age, the radiographic characteristics become apparent, and the condition can be classified according to the six grades of Langenskiöld (172). The radiographic changes in late-onset forms of tibia vara are less dramatic but nevertheless diagnostic.

**Pathophysiology** Histopathologic studies indicate a similar pathologic process for all three groups. Only a few biopsies of the proximal medial tibial condyle have been obtained from patients with infantile tibia vara (35,95,111,171,173). Histopathologic abnormalities included islands of densely packed chondrocytes exhibiting a greater degree of hypertrophy than would be expected from their topographic position, areas of almost acellular cartilage, and abnormal groups of capillaries. Langenskiöld (171) and Golding and McNeil-Smith (111), in studies of nine and six biopsies, respectively, concluded that the abnormalities were localized principally to the physes and that there was no evidence of avascular necrosis.

More extensive histopathologic data are available for the late-onset forms of tibia vara (59,60,223,274,275,286). The major histologic aberrations include the following:

Disorganization and misalignment of the physeal zones
Abnormal histochemical staining and excess of hypocellular matrix
Cystic degeneration and necrosis
Multidirectional clefts and fissures
Transphyseal canals of capillaries
Intraphyseal ossification centers
Increased necrotic chondrocytes throughout the proliferative and hypertrophic zones
Abnormal collagen fibers in the cartilage matrix
Chondrocytes at the apex of the vascular invasion front, which has increased width and length
Extension of noncalcified cartilaginous bars into the proximal and distal metaphyses

These changes are found uniformly throughout the medial and lateral aspects of the physes, although they are quantitatively greater on the medial side. They are remarkably similar to the changes observed in infantile tibia vara and in slipped capital femoral epiphysis, suggesting a common cause (1,2). Lovejoy and Lovell (182) described two patients with late-onset tibia vara associated with slipped capital femoral epiphysis.

The histopathologic abnormalities indicate that asymmetric compression and shear forces acting across the proximal tibial physis result in suppression and deviation of normal endochondral ossification, producing tibia vara. This concept, which reflects the Heuter–Volkmann law, has been confirmed experimentally by Arkin and Katz (13). Golding and McNeil-Smith (111) concluded that children who had significant physiologic varus deformity, walked early and stretched their knee ligaments. This resulted in asymmetric compression with subsequent suppression of posteromedial physeal growth and ultimate formation of an osseous bridge, producing a

permanent and progressive varus deformity. This pathogenesis is consistent with Blount's (33,35) initial observations that infantile tibia vara is first recognized when there is an increase of physiologic bowing during the first 3 years of life. Langenskiöld (172,173) emphasized that necrosis of the physeal cartilage is the principal cause of growth disturbance, leading to varus deformity; he attributed the abnormal cartilage to abnormal pressure or shear in overweight children with physiologic bowleg. Others agreed that abnormal pressure is probably the primary etiologic factor in infantile tibia vara (22,35,46,111,157,162).

In predisposed older children or adolescents with minimal residual deformity after physiologic bowleg, rapid growth and weight gain repetitively injure the posteromedial portion of the proximal tibial physis, resulting in a cycle of varus-growth suppression similar to the cycle described by Golding and McNeil-Smith (111) for the infantile form (127,129,274,275,286). Progressive genu varum deformity is not due to an osseous bridge but is caused by suppression of normal endochondral growth after repetitive local injury (29,162,260,274,275,286). The concept of physeal growth suppression in tibia vara has been confirmed biomechanically by Cook et al. (69) in a finite element analysis. As varus increases, the forces in the proximal medial tibial physis increase. Obesity and mild varus (10°) in older children create enough force to suppress growth. However, Henderson and Green (127) reported a case of late-onset tibia vara in an adolescent with previously documented neutral mechanical alignment, suggesting that, at least in some cases, preexisting varus alignment is not a prerequisite.

**Preoperative Management and Planning** If radiographic findings confirm the diagnosis of infantile tibia vara, begin treatment immediately. Orthotic management may be considered for children 3 years of age or younger with Langenskiöld's grade II and possibly grade III involvement. Approximately 50% to 65% of these in children can be corrected with an orthosis (151,180,232,248). Children with suspected infantile tibia vara with metaphyseal–diaphyseal angles of 10° to 15° are more likely to benefit from orthotic management (232). Use a knee–ankle–foot orthosis with a single medial upright without a knee hinge. Place pads, straps, or elastic webbing over the distal femur and proximal tibia to apply a valgus force. The orthosis should be worn for 22–23 hours each day. Tighten the straps at 1–2-month intervals to provide progressive correction. Obtain standing radiographs at 3-month intervals to document correction of the tibia vara deformity. The metaphyseal–diaphyseal angle should decrease (122). After obtaining an absolute valgus mechanical axis, begin weaning from the orthosis. Follow the child carefully thereafter to ensure maintenance of correction.

A maximum trial of 1 year of orthotic management is currently recommended. If correction is not obtained after 1 year of bracing, corrective osteotomy is indicated. Orthotic treatment is not indicated after 3 years of age or for severe deformities. Bracing children older than 3 years risks delaying performance of a corrective osteotomy. Loder and Johnston (180) showed that delay in performing corrective osteotomy, even by a few months, beyond 4 years of age risks failure to achieve lasting reversal of the physeal inhibition of the proximal tibia. This predisposes a child to repeated operative procedures to maintain a satisfactory result.

Conservative management in the late-onset forms of tibia vara is contraindicated. The children are too large and the remaining growth is too small to allow adequate correction. Compliance with an orthosis in this age group is difficult to achieve.

The indications for surgical treatment in infantile tibia vara include age 4 years or less, failure of orthotic management, and Langenskiöld grade III or higher. The possible procedures are presented in Table 169.4. Proximal tibial valgus osteotomy with fibular diaphyseal osteotomy is usually the procedure of choice. Perform an anterior compartment fasciotomy concomitantly. Tibial osteotomy techniques include closing-wedge, opening-wedge, dome, and oblique osteotomies. The procedure selected must correct the varus deformity and any associated medial tibial torsion. Tibial length is usually not a problem in infantile tibia vara. It is important that the selected osteotomy overcorrect the mechanical axis of the knee to 5° or more of valgus. This ensures that the supine correction obtained in the operating room is adequate. Overcorrection compensates for the tendency of the knee to fall back into varus after a patient resumes weight bearing because of the depression in the posteromedial articular surface and the ligamentous relaxation laterally. The goal is to transfer the line of weight bearing to the lateral compartment of the knee. Schoenecker et al. (248) reported that correction within 5° of neutral usually proves satisfactory. However, others recommend overcorrection (168,173,180,229). Considering the physeal inhibition phenomena as proposed by Cook et al. (69), overcorrection to absolute valgus alignment is necessary to relieve the excessive compressive forces medially.

Rab (229) described an oblique osteotomy of the proximal tibia for tibia vara. It is a single-plane osteotomy that allows simultaneous correction of the varus and medial tibial torsion deformities and permits postoperative cast wedging, if necessary, to improve position. This ability to adjust the osteotomy postoperatively is important because of the difficulty in achieving satisfactory alignment intraoperatively.

In older children with infantile tibia vara, especially those with Langenskiöld grade IV lesions or higher, a single osteotomy of the proximal tibia is usually insufficient to restore normal alignment and physeal growth. Langenskiöld grades IV and V act effectively as medial physeal arrests. Possible procedures for these children include the following (25,47,65,87,103,117,130,152,158,159,166,177,195,217,229,245,246,247 and 248,255,261,274,275):

Multiple proximal tibial metaphyseal osteotomies and fibular diaphyseal osteotomies
Proximal tibial osteotomy with physeal resection
Intraepiphyseal osteotomy to elevate the medial tibial articular surface (elevation of the medial tibia plateau)
Physeal bridge resection and replacement with interposition material such as fat or Silastic
Hemiepiphysiodesis of the lateral aspect of the proximal tibial epiphysis
Oblique proximal tibial osteotomy
Ilizarov ring fixation system and callotasis technique

In the juvenile and adolescent forms of tibia vara, surgical correction is necessary to restore the mechanical axis of the knee. The same surgical options as those for older children with infantile tibia vara are applicable in these groups. Correction to physiologic genu valgum with careful preoperative biotrignometric planning for the tibial osteotomy is the goal (57). Kline et al. (160) demonstrated that distal femoral varus is a part of the deformity in late-onset tibia vara. Evaluate this possibility, and perhaps consider it in the treatment plan.

Obtain intraoperative radiographs with the knee in extension and with slight varus stress to ensure contact between the medial femoral condyle and the posteromedial articular depression of the proximal tibia. This technique can help minimize undercorrection of the deformity. Aim to achieve at least 5° of valgus at the time of osteotomy. The recurrence rate for the juvenile-onset group approaches 25% overall and is even higher in boys (274,275). Evaluate all juvenile-onset patients with tomography or magnetic resonance imaging (MRI) before surgery for evidence of premature closure or impending closure of the proximal medial tibial physis. If premature closure is not present, a simple closing-wedge metaphyseal osteotomy or oblique proximal tibial osteotomy with correction to physiologic valgus may be performed (229). Correction using the Ilizarov ring fixation system and callotasis may be applicable, especially if there is a significant lower-extremity length discrepancy (227).

If the deformity recurs, indicating significant physeal inhibition, then additional surgery is necessary; techniques include physeal bridge resection and interposition graft, intraepiphyseal osteotomy, elevation of the medial tibial plateau, and physeal excision (117,152,174,177,185,245,248,255,289). Internal or external fixation is usually necessary to maintain alignment until satisfactory healing occurs. Physeal distraction with an external fixator has also been used in Europe (86,88), but it is not widely used. The procedure selected depends on the patient's age, the amount of growth remaining, and the severity of the deformity. Proximal tibial physeal excision with proximal fibular epiphysiodesis is usually recommended for recurrent deformities with premature medial tibial physeal closure or for patients 12 years of age or older (274). Healing is rapid and the correction permanent. Measure any residual lower-extremity length discrepancy with scanograms, and manage by contralateral epiphysiodesis, when necessary.

Henderson et al. (128) reported results in nine children with late-onset tibia vara treated by hemiepiphysiodesis of the lateral aspect of the proximal tibial epiphysis. The average preoperative varus was 13° (range, 3° to 25°). They found a correction rate of 7° per year. Three patients required a proximal tibial osteotomy because of incomplete correction. The authors thought that hemiepiphysiodesis was an effective procedure with less morbidity for managing varus deformities of the extremities of obese children. Similar results can probably be anticipated with staples, although they were not used in this study.

**Operative Techniques**

*Proximal Tibial Valgus Osteotomy and Fibular Diaphyseal Osteotomy*

- Make a 5 cm horizontal or transverse skin incision below the level of the tibial tubercle (Fig. 169.9).

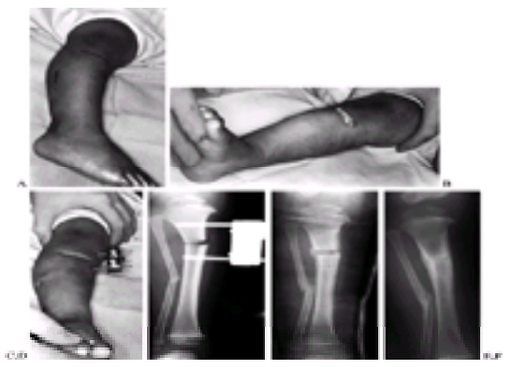

***Figure 169.9.*** **A:** Intraoperative photograph shows the location and extent of the incisions for a proximal tibial and diaphyseal fibular osteotomy. **B:** After a transverse osteotomy of the proximal tibia, derotate the leg to correct the associated medial tibial torsion. Remove an appropriate, laterally based wedge to correct the residual varus deformity. **C:** Insert a threaded Steinmann pin above and below the proximal tibial osteotomy. Take care to ensure that the proximal pin is inferior and posterior to the apophysis of the tibial tubercle. Secure the pins with an external fixation clamp. **D:** Postoperative radiograph after correction shows that there has been some distraction at the osteotomy site. This is usually not a problem. Ideally, the osteotomy should remain closed. The external fixation clamp is incorporated into the cast, providing secure fixation. **E:** AP radiograph in a long leg cast shows that there is partial healing and the external fixation system has been removed. **F:** AP radiograph obtained 3 months after surgery demonstrates satisfactory healing of the osteotomy and correction of the tibia vara deformity. The extremity is in approximately 5° to 7° of genu valgum.

- Expose the proximal tibia subperiosteally.
- Release the fascia of the anterior compartment. The fibers of the patellar tendon insertion are usually visible in the proximal portion of the incision.
- Perform a fibular diaphyseal osteotomy through a 3 cm vertical incision at the junction of the middle and proximal thirds of the fibula.
- Identify the muscles of the lateral compartment, and retract them anteriorly. Split the periosteum of the fibula longitudinally, and reflect it circumferentially.
- Make an oblique osteotomy with a small oscillating saw.
- With the fibular osteotomy completed, proceed with the proximal tibial osteotomy. This may be a closing-wedge, opening-wedge, or dome osteotomy. The procedure should allow correction of the medial tibial torsion and the varus deformity. I prefer a closing-wedge osteotomy. It is important to correct the medial tibial torsion first and then perform the laterally based, closing-wedge osteotomy. Excessive correction and unnecessary bone excision may occur if the torsion is not corrected first.
- Fix the osteotomy with crossed Steinmann pins, compression plate and screws, or an external fixation device. I prefer the latter because the pins can be removed in the outclinic without a separate operative procedure.
- Obtain intraoperative radiographs with the knee in extension to confirm that approximately 5° of valgus alignment have been obtained.
- After closure, immobilize the leg in a long-leg cast with the knee in extension and a slight valgus stress.

*Oblique Tibial Osteotomy*

- Make a transverse incision just beneath the tibial tubercle. Make a Y-shaped incision in the periosteum, and elevate it circumferentially
- Insert a small Steinmann pin at a cephalad angle of approximately 45° 1 cm distal to the tibial tubercle, and advance it under image-intensifier control until it passes through the posterior cortex distal to the proximal tibial physis. The angle of insertion determines the amount of correction for the varus and the medial tibial torsion. Have a nomogram available to assist in preoperatively determining the appropriate angle of guide-pin insertion.
- Carefully perform the osteotomy immediately beneath the Steinmann pin.
- After completion of the tibial osteotomy, perform a fibular diaphyseal osteotomy. This results in free mobility at the tibial osteotomy.
- Drill a hole in the anteroposterior direction across the osteotomy and lateral to the tibial tubercle.
- Insert a single 3.5 mm cortical or cancellous lag screw, align the osteotomy, and loosely tighten the screw to allow later adjustments, if necessary.
- After an anterior compartment fasciotomy, close the incisions. Insert a suction drain at the time of closure.
- Apply a long-leg cast. Rab (229) advised injection of contrast material into the knee to enhance the ability to check the radiographic alignment after the dressings are applied but before the long-leg cast is applied.

*Excision of the Proximal Tibial Physis* If the deformity recurs in an older child with the adolescent form of tibia vara, excision of the proximal tibial physis may be advantageous.

- This procedure is similar to the proximal tibia osteotomy previously described. Make a similar incision, although more proximally.
- Mobilize the patellar tendon on its medial and lateral sides.
- Place a smooth Steinmann pin through the epiphysis just below the articular surface.
- Excise the entire physis in a closing-wedge osteotomy. Insert a second pin distally, and apply an external fixator.

Always perform a fibular diaphyseal osteotomy. The advantage of this procedure is that it is performed at the site of the deformity and therefore allows maximal correction and physiologic realignment of the tibia. Healing is usually rapid, and there is no risk of recurrent deformity. A contralateral proximal tibia epiphysiodesis may be performed at the same time. However, in most cases, the degree of lower-extremity length discrepancy is followed scanographically, and any residual leg-length discrepancy is corrected by a contralateral distal femoral epiphysiodesis at the appropriate time.

**Other Techniques** In the late-onset form of the disease, a callotasis technique may be beneficial with either a cantilever or Ilizarov ring fixation system. The advantage of this procedure is that it allows slow, progressive correction. Because the patient is bearing weight, the precise degree of desired correction can be achieved. This procedure is being used more frequently today (see Chapter 171).

**General Rehabilitation and Postoperative Principles** The postoperative management of children is similar after any corrective osteotomy of the proximal tibia. Continue immobilization until healing is complete; then place the children on a physical therapy program at home for approximately 2 weeks. After complete rehabilitation, allow them to return to normal activities. Because of associated obesity, these children frequently benefit from a dietary consultation.

**Complications** Complications during and after a proximal tibial osteotomy are common. They include peroneal nerve palsy, injuries to the anterior tibial artery, and compartment syndromes (88,103,148,187,202,204,249,263). Occurrence of a compartment syndrome may be minimized by performing an anterior compartment fasciotomy at the time of surgery. If a compartment syndrome occurs, temporarily reduce the correction, and perform a four-compartment fasciotomy. Children with the infantile form of tibia vara require long-term follow-up to assess the results of surgery. The deformity may recur, especially in older children and those with advanced Langenskiöld grades. Deformity persisting after skeletal maturity predisposes to degenerative osteoarthritis (137,291).

**Conclusion** I prefer a proximal tibial valgus derotation and fibular diaphyseal osteotomy to correct infantile tibia vara. This allows simultaneous correction of both components of the deformity. It is important that the deformity be slightly overcorrected so that the mechanical axis passes medial to the ankle joint. It can be difficult to assess the degree of correction intraoperatively because radiographs on a long cassette cannot be obtained. A helpful hint is to visualize the iliac crest on the involved side. The cord from the electrocoagulation knife can be used to measure the mechanical axis on the fluoroscope. This can be stretched between the anterosuperior iliac spine and the middle of the patella. Its distal extension can then be judged with respect to the ankle joint. Undercorrection is a common problem that prevents adequate alignment. Radiographic contrast material in the knee joint at the time of surgery may also be helpful. Manually manipulate the knee into varus after the osteotomy is internally stabilized, as this gives a more realistic feeling for the alignment of the extremity during weight bearing.

In older children with infantile or late-onset tibia vara, especially the juvenile type, a preoperative MRI may be helpful in assessing the integrity of the physis. However, even if the physis appears open, it may still be abnormal and not respond to normalization of the compressive forces postoperatively. Correction in these children can be accomplished using an Ilizarov frame and callotasis. This allows precise correction of the deformity. Weight-bearing radiographs may be obtained during treatment.

In children with recurrent deformities in whom a physeal bridge is suspected, I would suggest excision of the physis with concomitant correction of both the residual tibia vara deformity and any medial tibial torsion. Postoperatively, patients will need to be evaluated for residual lower-extremity length discrepancy. An appropriately timed contralateral epiphysiodesis will be necessary to achieve relatively equal leg lengths at skeletal maturity.

***Tibia Vara Caused by Focal Fibrocartilaginous Dysplasia***

Tibia vara secondary to focal fibrocartilaginous dysplasia involving the medial aspect of the proximal tibial metaphysis was first reported by Bell et al. (26) in 1985.

Since then, additional cases have been reported (3,45,67,131,145,208,290). Tibia vara may also involve other areas of the body. Lincoln and Birch (178) reported upper-extremity involvement. It is an uncommon cause of pathologic genu varum but one that must be differentiated from Blount's disease because the natural histories of the two disorders are distinctly different.

**Pathophysiology** Biopsy of the lesion at the time of corrective osteotomy or for diagnostic purposes has shown consistent histopathologic features. Grossly, there is a white cartilaginous lesion with well defined margins deep to the insertion of the pes anserinus. Histopathologic findings include acellular or sparsely cellular collagenous tissue, inactive fibrocytes, plump cells resembling chondrocytes in lacunae, and dense, nondescript fibrous tissue (26,45,155,192,208). No giant cells, osteoid, or bone are found within these lesions. The lesions suggest fibrocartilage centrally and tendinous tissues peripherally. They do not involve the physis or epiphysis. Bell et al. (26) observed that the tissue resembles that normally found at the site of the insertion of tendons into cortical bone, as described by Cooper and Misol (70) in 1970. They suggested that these children had abnormal development of fibrocartilage at the insertion of the pes anserinus. The exact mechanism of this abnormal growth is unknown. The defect may be congenital.

**Assessment** All children with tibia vara caused by focal fibrocartilaginous dysplasia present with unilateral bowing. There is no apparent sex or side predilection. The onset is usually before age 1 year, and the deformity progresses until approximately age 2 years and then begins to resolve. During the time of progression, the deformity may become quite prominent, reaching 20° to 30° of varus. Medial tibial torsion and mild tibial length discrepancy (0.5–1.0 cm) are common associated findings (26, 45). The lesions are characteristically not tender to palpation, and there is no prominence of the proximal medial metaphysis, as seen in infantile tibia vara.

Radiographically, there is a cortical defect in the medial metaphyseal region of the proximal tibia with an area of surrounding sclerosis (Fig. 169.10). MRI will demonstrate dense fibroconnective tissue (192). Computed tomography shows similar findings, with an elliptical fibrous cortical defect but no soft-tissue mass (131,290). On the basis of reported cases, it appears that the metaphyseal lesion resolves spontaneously after age 2 years, followed by correction of the tibia vara deformity. Significant improvement is usually evident by 4 years of age (26,45). Use of an orthosis does not increase the rate of improvement.

***Figure 169.10.*** **A:** Standing AP radiograph of a 2-year-old Caucasian boy shows asymmetric genu varum involving the left lower extremity. **B:** Observe the typical radiographic features of focal fibrocartilaginous dysplasia of the proximal tibia. There is a cortical defect involving the medial aspect of the proximal tibial metaphysis. There is associated sclerosis, as well as the mild tibia vara deformity. **C:** The lateral radiograph is relatively normal.

**Preoperative Planning** Although data are limited, it appears that only children with no evidence of spontaneous correction by 4 years of age are candidates for corrective osteotomy (290). This typically involves a proximal tibial osteotomy distal to the apophysis of the tibial tubercle and a diaphyseal fibular osteotomy. Because of the associated medial tibial torsion, the procedure of choice is a laterally based closing derotation osteotomy or an oblique proximal tibial osteotomy as described by Rab (229).

**Operative Techniques** The procedures for focal fibrocartilaginous dysplasia are the same as those for tibia vara. There is no intrinsic osseous pathology that interferes with bone healing. Immobilization in a long-leg cast or a one-and-one-half spica cast is necessary, depending on the child's age. A spica cast is usually advised for younger children. After healing, there is usually rapid rehabilitation and return to normal activities. Prolonged follow-up is necessary to assess resolution of the lesion and subsequent growth and development of the proximal tibia. Periodic scanograms are necessary to assess the length of the extremities.

**Complications** A peroneal nerve palsy and persistent valgus deformity into adolescence were reported by Bradish et al. (45) after corrective osteotomy. This appears to have been a technical problem. No other complications have been reported for operative treatment of this lesion.

***Other Pathologic Genu Varum Deformities***

**Vitamin D–Resistant and Nutritional Rickets** Persistent or progressive genu varum deformities are common in children with metabolic disorders such as vitamin D–resistant rickets (hypophosphatemic rickets) or nutritional rickets. Vitamin D–resistant rickets is an X-linked dominant disorder due to vitamin D resistance that results in defective bone mineralization. Affected children typically have bilateral symmetric genu varum; they are relatively short, usually being in the tenth percentile. The varus deformity is due to a combination of bowing and involvement of the distal femur and the proximal tibia. Hematologic studies reveal normal serum calcium and decreased phosphate values. In nutritional rickets, the child has been receiving an unusual diet from the parents.

Radiographically, the features are widening of the metaphyses, widening of the physes, and a cup-shaped relationship between the physis and the metaphysis. The bowing is usually symmetric throughout the femur and the tibia. Marked osteopenia and thinning of the cortices are also common. Obtain serum calcium, phosphorus, and alkaline phosphatase levels, as well as a pediatric endocrinology consultation to confirm the diagnosis.

Medical treatment is important before any form of orthopaedic intervention is considered (96,239). This typically includes oral phosphate supplementation and high doses of vitamin D for vitamin D–resistant rickets, and dietary changes for nutritional rickets. Surgical measures to correct genu varum deformities are usually unsuccessful unless adequate medical control has been obtained preoperatively. If such control cannot be obtained, it is usually best to wait until skeletal maturity before attempting to realign the mechanical axes.

If metabolic control can be obtained and a child is young, observation is appropriate. Spontaneous improvement may occur in children younger than 5 years. However, in older children or those who are not improving spontaneously, surgical treatment is necessary (96,239). This may consist of osteotomies of the distal femur, proximal tibia, or both. If involvement is extensive, proximal femoral and distal tibial osteotomies may be necessary to adequately realign the lower extremities. Cast immobilization postoperatively may result in immobilization-induced hypercalcemia and may require modification of medical management. When osteotomies are done, healing time may be twice normal. It is often advantageous to postpone major alignment procedures until adolescence to minimize the recurrence that is common in younger children.

**Renal Osteodystrophy** Children who have end-stage renal disease may manifest renal osteodystrophy. The physes in these children show the same pathologic changes found in tibia vara and slipped capital femoral epiphysis. These include disorganized endochondral ossification at the physeal–metaphyseal junctions. Because end-stage renal failure occurs more commonly in older children who have achieved physiologic valgus alignment, valgus deformities are much more common. Varus is more likely when renal failure occurs at 3 years of age or younger. Renal osteodystrophy has many of the same radiographic features as vitamin D–resistant and nutritional rickets. There is physeal cupping and widening at both the distal femoral and proximal tibial physes. Marked osteopenia and thinning of the cortical bone are also present.

Treatment of genu varum deformities secondary to renal osteodystrophy is similar to that for vitamin D–resistant and nutritional rickets. Surgical treatment is usually postponed until the renal status has stabilized in response to medical treatment, hemodialysis, or kidney transplantation. There will be a rapid recurrence of the deformity if the underlying metabolic bone disease is not corrected first.

**Skeletal Dysplasias** Many skeletal dysplasias may result in a progressive genu varum deformity (Table 169.1). Metaphyseal chondrodysplasia (both Jansen and Schmid types), which results in abnormal chondroblast function and chondroid production, is a common cause. Occasionally, these may be difficult to distinguish from rickets. Although the physes are widened and cupped in the Schmid type, the epiphyses are normal, and the presence of short stature may be helpful in making the correct diagnosis.

Genu varum frequently occurs in achondroplasia. This rhizomelic dwarfing condition is due to abnormal endochondral bone formation. Affected children have short

stature and characteristic craniofacial features. The genu varum deformity is due to asymmetric growth of the proximal tibial epiphysis and overgrowth of the fibula. These children rarely have knee pain.

For some surgeons, the treatment options for genu varum deformities secondary to achondroplasia must be surgical because orthotic management historically has not been effective. Their usual procedure is a proximal tibial valgus osteotomy and proximal fibular epiphysiodesis (Fig. 169.11). The latter must be done early in childhood to prevent recurrence and progression of the genu varum deformity. Others feel that genu varum in achondroplasia is not associated with functional difficulty or increased risk of osteoarthritis, and surgery may not be recommended (see Chapter 180).

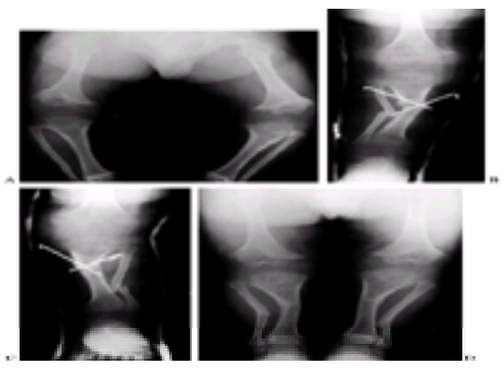

***Figure 169.11.*** **A:** Standing preoperative radiographs of a 6-year-old Caucasian boy with achondroplasia genu varum demonstrating the typical epiphyseal and metaphyseal changes, as well as overgrowth of the fibulae. **B:** Postoperative radiograph after proximal tibial and fibular diaphyseal valgus derotation osteotomies of the right leg shows that internal fixation was achieved with percutaneous smooth Steinmann pins. **C:** Postoperative radiograph of the left lower leg. **D:** Standing radiographs 6 months postoperatively demonstrates satisfactory healing and excellent correction of the genu varum deformities.

Osteogenesis imperfecta results from a defect in type I collagen and produces varying degrees of skeletal fragility. Repeated fractures often lead to bowing and torsional malalignment of the lower extremities. The distal third of the femur is a common location for these fractures, which frequently result in anterolateral angulation. Residual deformities after fractures are common, and the varus angulation often increases as a result of repeated fractures. Occasionally, in the more severe cases, osteotomies with intramedullary fixation may be beneficial (see Chapter 180).

**Other Causes** Any condition, such as infection or trauma, that damages the physis may result in asymmetric growth and deformity. The distal femur is the most common site of growth disturbance following a physeal fracture. Physeal fractures of the proximal tibia occur much less commonly. The management of genu varum deformities secondary to physeal growth disturbance is complex. If an asymmetric physeal bar is present, it may be resected and grafted with fat or Silastic. The deformity is corrected concomitantly by an osteotomy. If the physeal damage is extensive, complete physeal closure and management of the associated leg-length discrepancy may need to be considered (see Chapter 164).

## GENU VALGUM

Genu valgum, or knock-knee, is a common condition affecting the lower limbs in children and adolescents. Physiologic genu valgum is the most common form, but pathologic genu valgum disorders occur and may require treatment (Table 169.2). The most common pathologic causes of genu valgum are posttraumatic and renal osteodystrophy.

Evaluation of a child with genu valgum is similar to that for genu varum and includes a careful history and physical examination. In the majority of children with genu valgum, the femoro-tibial angles are within the physiologic range of two standard deviations above or below the mean. Only those with an angle greater than two standard deviations from the mean are considered to have a deformity. Fat thighs, ligamentous laxity, and flat feet are often the results of associated out-toeing, and this can accentuate the appearance of the knock-knee, making physiologic genu valgum appear more severe. Measurements of the femoro-tibial angle (with a goniometer) and the intermalleolar distance are methods for assessing and following genu valgum (55,65,126). However, the intermalleolar distance may be misleading. The same intermalleolar distance in an individual of short stature may be more significant than the same distance in a taller individual. Torsional malalignment is less common in genu valgum, but the combination of femoral anteversion or torsion and compensatory external tibial torsion gives the appearance of a valgus knee.

The indications for radiographs for genu valgum are similar to those for genu varum. Short stature, asymmetry, history of injury, or history of progression are indications. Standing AP radiographs of the lower extremities, including the hip, knee, and ankle, are the best method (Fig. 169.12). The majority of children with genu valgum have physiologic genu valgum or its persistence into later childhood and early adolescence. However, there are other pathologic genu valgum disorders that may progress and cause functional impairment.

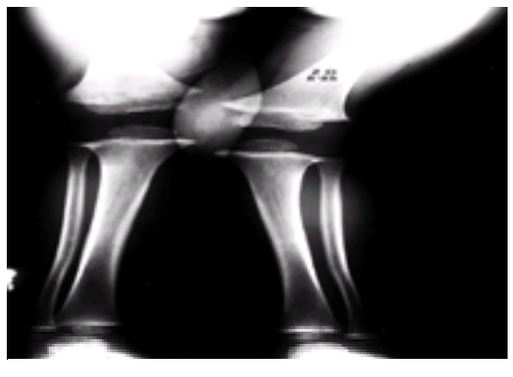

***Figure 169.12.*** Standing AP radiographs of the lower extremities of a 3-year-old boy with physiologic genu valgum show no radiographic abnormalities of the distal femoral or proximal tibial epiphyses or metaphyses.

### PHYSIOLOGIC GENU VALGUM

#### *Pathophysiology*

Physiologic genu valgum is a normal finding in children between 2 and 6 years of age (Fig. 169.13). The maximal deformity occurs between 3 and 4 years of age. It rarely causes symptoms or disability unless the deformity is severe. In these cases, the knees may rub, and the child walks and runs with a circumduction gait. With severe genu valgum deformities, the feet are pronated. In older children or adolescents, malalignment of the quadriceps mechanism may occur, resulting in patellar subluxation or dislocation. Severe genu valgum occurs more frequently in obese children. The abnormal weight may produce a medial thrust that can result in laxity of the medial collateral ligament and possibly early degenerative osteoarthritis.

***Figure 169.13.*** Typical appearance of physiologic genu valgum in a 4-year-old boy. With the knees approximated, there is a wide separation between the ankles. There is approximately 15° of genu valgum bilaterally.

### *Preoperative Management and Planning*

In 95% of cases, physiologic genu valgum resolves spontaneously with normal growth (94,161,163,190,197,207,242,268,279). Use of an orthosis is controversial and is not recommended. Even significant deformities persisting into adolescence can be expected to improve or resolve if slow, steady improvement can be documented. Persistent deformities that are not improving may benefit from surgical treatment.

The major indication for surgical intervention in physiologic genu valgum is a persistent, severe deformity (>15°) in the immediate preadolescent years (ages 11 years in girls and 12 years in boys). After this age, significant spontaneous improvement is not likely to occur (141).

The methods for surgical correction of genu valgum are presented in Table 169.6. Three methods are usually employed for physiologic genu valgum:

| |
|---|
| *Distal femur* |
| Varus osteotomy |
| Closing wedge |
| Opening wedge |
| Callotasis |
| Medial hemiepiphyseal stapling |
| Medial hemiepiphysiodesis |
| *Proximal tibia* |
| Varus osteotomy (may also include derotation and diaphyseal fibular osteotomy) |
| Closing wedge |
| Opening wedge |
| Dome |
| Oblique |
| Callotasis |
| Other |
| Medial hemiepiphyseal stapling |
| Medial hemiepiphysiodesis |

***Table 169.6. Surgical Options for Genu Valgum Deformities***

Medial physeal stapling
Medial physeal hemiepiphysiodesis
Osteotomy

These procedures are applicable in the distal femur, proximal tibia, or both, depending on the patient's age and the severity and location of the deformity.

### *Operative Techniques*

**Medial Physeal Stapling of the Distal Femur or Proximal Tibia** Retardation of growth about the medial aspect of the distal femur or proximal tibia by medial physeal stapling is a relatively easy, reliable method of correcting a genu valgum deformity if there is sufficient remaining growth to produce satisfactory alignment (Fig. 169.14) (36,105,141,193,221,282,294). If the deformity is pronounced or there is insufficient remaining skeletal growth, a combined stapling of the medial aspect of the distal femoral and the proximal tibial physes may be necessary (105,221).

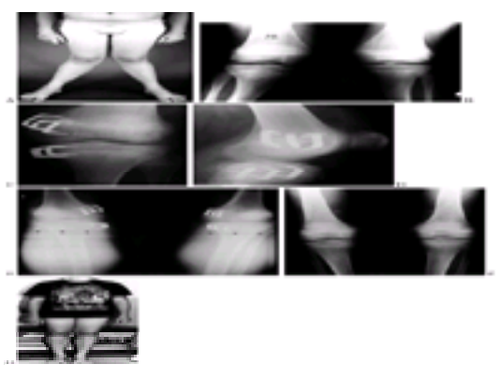

***Figure 169.14.*** **A:** A 14-year-old boy with persistent severe physiologic genu valgum. **B:** Standing AP radiograph of both lower extremities demonstrates a valgus deformity in the distal femora and proximal tibiae. Observe the physeal widening at the proximal tibial physes. A metabolic evaluation was normal. **C:** Postoperative radiograph of the left knee after stapling of the medial aspect of the distal femoral and proximal tibial epiphyses shows the three staples used to bracket each epiphysis. **D:** Lateral radiograph. **E:** Standing radiograph of both knees 9 months postoperatively shows excellent correction of the genu valgum deformities. **F:** On a standing radiograph 6 months after staple removal, physiologic alignment is being maintained. **G:** Clinical photograph.

The medial aspect of the distal femoral epiphysis is palpable at the junction of the maximal metaphyseal flare and the medial femoral condyle. Stapling of the distal femoral epiphysis proceeds as follows.

- Approach the physis through a 4–5 cm longitudinal incision between the anterior and posterior margins of the medial femoral condyle. Begin the incision approximately 1–1.5 cm distal to the physis, and extend it proximally.
- Divide the subcutaneous tissues, deep fascia, and patellar retinaculum. If necessary, retract the medial margin of the vastus medialis anteriorly. Identify the physeal plate with a straight Keith needle or by fluoroscopy. Identification of the physis and insertion of the staples occur more quickly and more accurately with fluoroscopy. If the physeal plate is identified by probing with a Keith needle, the plate is softer than the adjacent cancellous bone.
- Select Blount staples that are rectangular or oblique, depending on the shape of the medial femoral condyle and metaphysis. Vitallium staples cause less reaction, are stronger, and are less likely to be extruded than stainless steel staples.
- Avoid subperiosteal stripping to protect the perichondrial ring and the physeal plate.
- With a staple holder, partially insert three staples. Insert one directly medially and one each in the anteromedial and the posteromedial aspects of the distal femur. Before completely setting the staples, confirm their location and orientation with radiographs or fluoroscopy. The physis should be in the mid portion of each staple. Insert the ends of the staple parallel to the physis to avoid physeal injury. If position and orientation are satisfactory, drive the staples flush with the

periosteum. Do not bury the staples into the bone to avoid injury to the perichondrial ring.
- Close the patellar retinaculum and the deep fascia separately. It is important that the patellar retinaculum not be bound down by the staples because it can cause loss of knee motion, local swelling, and pain.
- Close the subcutaneous tissues and skin with absorbable sutures. A subcuticular closure of the skin gives the best cosmesis. Reinforce the incision with adhesive closure strips, and apply sterile dressings and a knee immobilizer.

If the proximal tibial physis is selected for stapling, the procedure is similar to that for the distal femur.

- Make a 4–5 cm longitudinal incision directly over the medial aspect of the knee. The incision usually begins just distal to the joint line and proceeds distally.
- Identify and retract anteriorly the medial border of the pes anserinus, if possible. Occasionally, the pes anserinus must be split. After the periosteum of the proximal tibia is visualized, identify the physeal plate with a Keith needle or by fluoroscopy.
- Insert one staple directly medially and one each in the anteromedial and the posteromedial aspects of the proximal tibia. The oblique or angulated Vitallium Blount staples are quite useful in this location because they conform to the flare of the medial aspect of the proximal tibia. Insert the staples parallel to the physis and the articular surface. Center the staples over the physeal plate. Before setting the staples, confirm the position radiographically.
- Close the wound in layers. If the pes anserinus is split, repair it with absorbable sutures. Close the subcutaneous tissues and skin in a similar manner, and apply sterile dressings.

Postoperatively, use a knee immobilizer for approximately 2 weeks. Follow up at 2–3-month intervals, and assess radiographically for correction. After the desired amount of correction has been achieved, remove the staples. However, there is frequently rebound overgrowth and slight recurrence of the deformity. Zuege et al. (294) recommended allowing 5° of rebound. Accomplish this by allowing the correction to proceed to slight overcorrection before staple removal. However, Fraser et al. (105) found that the amount of rebound overgrowth was minimal and unpredictable. They also advised against leaving the staples in place for longer than 1 year because of possible premature closure of the physis. The amount of correction can be calculated mathematically on the basis of the width of the physis and the amount of remaining growth (38).

**Medial Hemiepiphysiodesis of the Distal Femur or Proximal Tibia** Partial or hemiepiphysiodesis of the medial aspect of the distal femur or proximal tibia has been proposed as a method for gradual correction of genu valgum deformity. The table devised by Bowen et al. (38) can be used to determine the appropriate time for epiphysiodesis. However, because of the variability in the data necessary to make these determinations, a second operative procedure is often required to close the remaining lateral portion of the epiphysis.

Rotational bone blocks, as described by Phemister (218), were once popular. However, the percutaneous techniques of epiphysiodesis using curet, drills, burrs, or a combination of these are now preferred (37,39,58,207,276). These are as accurate and much more cosmetic than the open bone graft epiphysiodesis techniques. Although this technique is most commonly used for lower-extremity length discrepancies, it can also be used successfully in the correction of persistent angular deformities such as genu valgum and genu varum (39).

**Percutaneous Epiphysiodesis**

- Position the patient supine on a fluoroscopy table. Identify and mark the mid portion of the medial aspect of the distal femoral physis.
- Make a 2–3 mm incision directly over the physeal plate.
- Enter the medial aspect of the physis with a small curet or drill, and remove the medial portion of the physis. This allows the formation of a medial bone bridge. Do not extend the epiphysiodesis across the midline of the physis to avoid symmetric closure.
- Only a single subcutaneous suture is usually necessary to close the wound.

A similar procedure may be performed on the medial aspect of the proximal tibial epiphysis, if necessary.

After epiphysiodesis of the distal femur or proximal tibia, use a knee immobilizer for approximately 2 weeks. This allows skin and soft-tissue healing. The physis after epiphysiodesis is weak and must be protected for a short period to prevent complete physeal separation. At the end of 2 weeks, discontinue the knee immobilizer and allow the child active range-of-motion exercises and full weight bearing. Continue restriction of activities until 6 weeks postoperatively. Institute quadriceps and hamstring strengthening exercises at that time, with a gradual return to normal activities. After the desired correction has been achieved with medial epiphysiodesis, a lateral epiphysiodesis of the distal femur or proximal tibia is necessary to prevent overcorrection if the lateral physes remain open.

**Osteotomy of the Distal Femur or Proximal Tibia** Correction of a genu valgum deformity by distal femoral or proximal tibial and fibular diaphyseal osteotomies allows full correction of the deformity with a single operative procedure. However, both procedures are extensive and require internal or external fixation to maintain alignment until healing has occurred. In the correction of a valgus deformity, attention must be given to the peroneal nerve because neurapraxia or partial paralysis may occur if the nerve is stretched. The osteotomy may be performed in early adolescence or after skeletal maturity. Several techniques are available, including opening-wedge, closing-wedge, and dome osteotomies. The choice of technique is frequently based on the length of the lower extremity and the individual bones. An opening-wedge or dome-shaped osteotomy adds length to the extremity. DePablos et al. (87) described a progressive opening-wedge osteotomy using an external fixator; a fibular osteotomy is not required, and the osteotomy allows progressive and adjustable correction. Both lower extremities can be corrected simultaneously. Ordinarily, osteotomies are considered for boys age 14 years or older and girls age 12 years or older.

Varus osteotomy of the proximal tibia and diaphyseal osteotomy of the fibula are indicated if the valgus deformity is in the proximal tibia below the knee joint and there is no associated lateral tilt to the articular surface. The osteotomy is usually performed at the junction of the metaphysis and the diaphysis, just distal to the tibial tubercle. If there is associated lateral torsion of the tibia, derotation may also be accomplished. If a closing-wedge osteotomy is to be performed, perform the derotation initially because it frequently decreases the amount of bone requiring resection to correct the angular deformity. After satisfactory correction has been achieved, internal or external fixation is required. Compression plate and screws, crossed Steinmann wires, or an external fixator are suitable. In some cases, the Ilizarov ring fixator and the callotasis technique may be beneficial; this allows slow correction of the valgus and the derotation. Hemichondrodiastasis, or asymmetrical physeal lengthening, has been recommended by some, but it is not popular in the United States. This procedure allows simultaneous correction of limb-length inequality and correction of the genu valgum deformity. Because the physeal plate closes after this procedure, it is best performed for patients in late adolescence.

Treat a genu valgum deformity associated with a valgus alignment of the distal femur with an osteotomy of the distal femur. Deformities in this area are associated with a lateral tilt to the joint line that cannot be corrected by a proximal tibial osteotomy. The osteotomy may be performed through a medial or a lateral approach to the distal femur. The medial approach is more complex because of the proximity of the femoral artery, but it allows easier visualization of the operative site. The lateral approach is simpler, and there is less risk to the femoral artery as it passes posteriorly at the upper margin of a medial incision. Opening- or closing-wedge osteotomies are commonly performed because it is difficult to perform a dome osteotomy of the distal femur. After the osteotomy is complete, internal or external fixation is performed with a compression plate and screws, crossed threaded Steinmann pins, or an external fixation device. See Chapter 30 and Chapter 31 for additional information on osteotomies of the femur and the tibia, respectively.

***General Rehabilitation and Postoperative Principles***

After an osteotomy has been performed, postoperative management depends on the type of internal or external fixation. If rigid internal fixation has been achieved with a compression plate and screws, immobilization is usually unnecessary, other than perhaps a knee immobilizer for 1–2 weeks for comfort. Allow only toe-touch weight bearing until early callus formation; then increase weight bearing, although not to full weight bearing, until the osteotomy site is completely healed. Remove the compression plate and screws 12–18 months postoperatively.

If simple external fixation is used, supplement it with a long-leg cast. Have the patient avoid weight bearing for 3–4 weeks, until there is early radiographic callus formation. Then allow toe-touch weight bearing. Usually, at 4–6 weeks after surgery, there is sufficient healing to allow removal of the external fixation device in the clinic. Apply a cylinder cast for an additional 2 weeks to allow solid union. After this has been accomplished, institute range-of-motion exercises. Failure to obtain a full range of motion at the end of 2 weeks is an indication for a referral to physical therapy. After full motion has been regained, begin strengthening exercises of the quadriceps and hamstring muscles. Return the patient to full activities after rehabilitation of the leg is complete.

***Complications***

The problems of asymmetric growth retardation associated with physeal stapling were outlined by Tachdjian (268): unpredictability of growth after the staples have been removed, possibility of asymmetric medial physeal closure, widening or loosening of the staples with eventual extrusion requiring revision, irregular patterns of initial growth retardation after stapling, the need for a second surgical procedure to remove the staples or to perform a lateral epiphysiodesis, and long and frequently wide operative scars due to stretching with knee motion. In 49 patients with genu valgum treated with stapling by Pistevos and Duckworth (221), there were no

complications other than scarring, although six patients did not obtain complete correction. Staples may be painful; however, this resolves after removal.

Osteotomies of the distal femur or proximal tibia may result in peroneal nerve palsy, injury to the femoral or anterior tibial arteries, and anterior compartment syndrome (148,187,202,204,249,263,268). These severe complications are more common after proximal tibial osteotomies. Monitor patients closely postoperatively so that immediate intervention can be taken if a complication occurs. Postoperative wound infection, delayed union, nonunion, overcorrection, and undercorrection may occur after corrective osteotomies.

### *Conclusion*

Because physiologic genu valgum does not usually have a rotational component, medial physeal stapling is my procedure of choice. This is usually performed on the proximal tibial epiphysis. In severe deformities, however, the distal femur may be included. I have not used the chart described by Bowen et al. (38). Once slight overcorrection is achieved, I remove the staples, and I have not encountered a case of premature physeal closure. This procedure is simple and effective and requires minimal postoperative immobilization.

## PATHOLOGIC GENU VALGUM DEFORMITIES

### *Genu Valgum after Fractures of the Proximal Tibial Metaphysis*

Fractures of the proximal tibial metaphysis are relatively common and tend to occur most frequently in children between 3 and 6 years of age (range, 1–12 years) (79,146,150,205,237). Three times as many boys are affected as girls, which is typical for all tibial fractures (123). Skak et al. (258) reported an incidence of 5.6 fractures per 100,000 children per year. The fractures are usually the result of direct injury to the lateral aspect of the extended knee. The primary injury patterns are compression (i.e., torus fracture), incomplete tension–compression (i.e., greenstick fracture), or complete fractures (235). The fibula is typically intact but may be fractured or have a plastic deformation. The incomplete tension–compression or greenstick fracture is the most common pattern. The medial cortex on the tension side fractures, whereas the lateral cortex on the compression side remains intact or hinges slightly. The distal fragment may angulate into a slight valgus deformity, but there is no displacement and the apposition remains normal. However, most fractures are nondisplaced and without angulation.

The most common sequelae of the fracture of the proximal tibial metaphysis are valgus deformity and overgrowth of the tibia. In 1953, Cozen (72) reported on four patients with valgus deformities after nondisplaced or minimally angulated fractures of the proximal tibial metaphysis. Many other reports of this complication have been published (16,18,21,27,30,44,51,66,71,76,79,109,113,133,146,147,150,153,183,184,226,258,273,281,283,292,293). Similar valgus deformities were observed after other insults to the immature proximal tibial metaphysis, such as osteomyelitis, bone-graft harvest, osteochondroma excision, and osteotomy (18,243,280).

The incidence of genu valgum deformity after proximal tibial metaphyseal fractures varies. It appears to occur in approximately 50% of cases. Salter and Best (244) reported on 21 patients with proximal tibial metaphyseal fractures, observing the development of a valgus deformity of 11° to 22° in 13 (62%) of them. Robert et al. (235) reported the development of a genu valgum deformity in 12 (48%) of 25 patients. However, Skak et al. (258) reviewed 40 consecutive patients and found the development of deformity in only 4 (10%). Boyer et al. (44) reported no valgus deformity in seven children 2–5 years of age who sustained fractures while jumping on a trampoline with a heavier child or adult. Valgus deformities occur predominantly in association with greenstick or complete fractures and are uncommon after a torus fracture (235,258).

Theories about the cause of valgus deformity include injury to the lateral aspect of the proximal tibial physis, inadequate reduction, premature weight bearing, hypertrophic callus formation, dynamic muscle action, soft-tissue interposition, tethering from the intact fibula, and asymmetric physeal growth stimulation (14,16,18,21,27,30,34,51,61,66,71,72,76,80,113,133,139,140,146,147,153,183,184,191,205,206,226,230,237,243,244,257,273,281,283,292,293).

In 1990, Ogden et al. (206) measured the medial and the lateral metaphyseal–diaphyseal–metaphyseal tibial distances in 17 children with 19 proximal tibial metaphyseal fractures. They found four patients in whom the medial distance of the injured tibia was longer than the lateral distance, which was the same distance as the uninjured tibia. In 11 patients, there was overgrowth on both the medial and the lateral sides of the injured tibia. This indicates that a valgus deformity following a proximal tibial metaphyseal fracture is usually due to eccentric proximal medial overgrowth.

**Assessment, Indications, and Relative Results** Valgus deformity usually develops within 5 months of injury, reaches its maximum in 1–2 years, stabilizes, and then begins to improve by longitudinal growth through the proximal and distal physes (Fig. 169.15) (216). Unfortunately, there are no data indicating how much improvement can be anticipated. Salter and Best (244) found no improvement in 21 patients, and 13 later required proximal tibial varus osteotomies. Visser and Veldhuizen (281) reported no spontaneous improvement in the valgus deformity from the proximal tibial physis but observed some correction in alignment from the distal tibial epiphysis. Taylor (273) found improvement in some patients but not all. Of the 12 children with valgus deformity described by Jordan et al. (153), 11 had documented improvement, although four subsequently required corrective osteotomies. Two of these children had their deformities recur, and two had compartment syndromes. Six children had complete correction of their deformities.

***Figure 169.15.*** **A:** Standing AP radiograph of a 5-year-old boy after treatment for a greenstick fracture of the right proximal tibial metaphysis. At the time of cast removal, there was already 22° of genu valgum on the right but only 5° on the left. **B:** One year later, there was increased genu valgum deformity.

Jackson and Cozen (147) and later Ippolito and Pentamalli (146) observed that deformities of 15° or less usually remodeled completely, especially in young children. The more severe deformities, however, did not completely correct. Bahnson and Lovell (16) found some improvement in the valgus deformities in five children followed for a minimum of 3 years after injury. Balthazar and Pappas (18) reported that two of nine patients who were treated nonoperatively had resolution of their valgus deformity in 1–3 years. Skak et al. (258) found that valgus deformities tended to increase during the first year after injury and then remained constant for 1–2 years and finally improved. Only one of their six patients had residual deformity at final follow-up.

MacEwen and Zionts (183,293) followed seven children with posttraumatic tibial valgus deformities for a mean of 39 months after injury. These children were 11 months to 6 years of age. The valgus deformities progressed most rapidly during the first year after injury and then continued at a slower rate for as long as 17 months. Overgrowth of the tibia accompanied the valgus deformities. The mean overgrowth was 1 cm (range, 0.2–1.7 cm). Clinical correction with subsequent growth occurred in six of their seven patients. They recommended that the alignment of the lower extremities be measured by the mechanical femoro-tibial angle as described by Visser and Veldhuizen (281) rather than the metaphyseal–diaphyseal angle of Levine and Drennan (176). The latter measured only the alignment of the proximal tibia. Much of the late correction of the deformity is due to distal realignment (183,258,281). The distal epiphysis tends to realign itself perpendicular to the applied forces, resulting in asymmetric growth and an S-shaped appearance of the tibia radiographically (216).

**Preoperative Management and Planning** The treatment of proximal tibial metaphyseal fractures must consist of correction of any associated valgus angulation by manipulative reduction and immobilization in a long-leg cast with the knee in extension for 4–6 weeks or until the fracture is well healed (238). If closed reduction is required, it is best performed under general anesthesia. Radiographic evaluation of fracture alignment may be difficult unless radiographs of both lower extremities with the knee in extension are obtained on a long cassette. Greenstick fractures with slight valgus angulation may require that the intact hinged lateral cortex be manually fractured. This usually allows correction of the deformity. Slight overcorrection is desirable (205).

Displaced fractures also require correction of any residual angulation. However, normal apposition is not always necessary. There are limited indications for open reduction of these fractures. Inability to correct a significant valgus deformity by manipulation under general anesthesia rather than failure to close the medial fracture

gap is currently the major indication. Most angulated displaced fractures are amenable to reduction by nonoperative methods.

The final step in initial management is to advise the family that although anatomic alignment of the fracture has been obtained, the possibility of valgus angulation and tibial overgrowth exist as a natural consequence of this fracture. This information prepares the family for complications if they occur.

Assess fracture alignment radiographically at least weekly during the first 3 weeks after injury. Correct any loss of alignment. During this initial period, children should avoid bearing weight to minimize compression forces and the possibility of valgus angulation within the cast.

Treatment of valgus deformities after proximal tibial metaphyseal fractures is predominantly nonoperative with prolonged observation. The use of orthoses has been suggested, but there is no evidence to substantiate the efficacy of this method (89,133,146). MacEwen and Zionts (183) recommended observation until early adolescence. If spontaneous improvement fails to provide sufficient clinical correction, surgical intervention may be necessary. McCarthy et al. (188) reported no difference in the long-term results between 10 patients treated nonoperatively and five managed operatively.

The major indications for surgical intervention include severe valgus deformities (>25°) and failure to achieve satisfactory correction by the immediate preadolescent years. All children should be allowed 2–4 years of growth after injury to allow spontaneous correction to occur. Most deformities of 15° or less resolve, and those that are 25° or more may not. Deformities between 15° and 25° must be carefully followed. The development of a medial thrust during this observation period is an indication for surgical intervention to prevent laxity in the medial collateral ligament.

**Operative Techniques** The operative procedures to correct genu valgum deformities after proximal tibial metaphyseal fractures are similar to those for other valgus deformities and include the following:

Medial physeal stapling
Medial physeal epiphysiodesis
Osteotomy with internal or external fixation

Because the deformity is usually restricted to the tibia, these procedures are most commonly applicable to the proximal tibia. They are described in the section on physiologic genu valgum. If surgical intervention is contemplated, it is important to assess the degree of tibial-length inequality. Surgery must address the valgus deformity and residual tibial overgrowth. In young children with severe genu valgum deformities that are not improving with spontaneous growth and development, a corrective osteotomy may be indicated. This should include shortening of the tibia by approximately 5 mm to allow recurrent overgrowth. Similar consideration is necessary in the early adolescent years when surgical intervention is planned.

**Recurrence of Deformity** Recurrence has been attributed to the same overgrowth phenomenon that led to the initial valgus deformity. Balthazar and Pappas (18) reported that the valgus deformity recurred, although lesser in magnitude, in six children undergoing a proximal tibial varus osteotomy. Four of the six also had further longitudinal overgrowth of the tibia. DalMonte et al. (80) reported recurrent valgus deformities in 7 (44%) of 16 patients after proximal tibial osteotomies. The recurrence rate for children younger than 5 years was 60%, and for those between 5 and 10 years of age, it was 36%. The authors concluded that the osteotomy is essentially a second fracture and therefore has the same risks of deformity. If surgery is undertaken, families should be advised that the deformity can recur and that prolonged follow-up is required.

**Conclusion** With the recent demonstration that the majority of children with genu valgum following a proximal tibial metaphyseal fracture will undergo spontaneous correction during growth, I now feel that these children should be observed for as long as possible. Only a severe disabling deformity should be considered for early surgical correction. Deformities persisting into adolescence can be corrected with a proximal tibial or distal femoral medial hemiepiphyseal stapling (or both). Typically, this allows for rapid correction of any residual deformity. I try to avoid corrective osteotomy because this may induce the same genu valgum deformity that followed the initial fracture.

***Other Pathologic Genu Valgum Deformities***

**Metabolic Disorders** Metabolic causes of pathologic genu valgum include vitamin D–resistant rickets, nutritional rickets, and renal osteodystrophy. These disorders are more likely to produce genu valgum rather than genu varum. This is due to their later onset, at which time the physiologic valgus alignment of the knee has already been achieved. Renal osteodystrophy is the most common metabolic disorder producing genu valgum (12,19,32,62,75,81,132,143,210). Oppenheim et al. (210) described changes in the lateral proximal tibial epiphysis and metaphysis in children with renal osteodystrophy similar to those seen in the medial proximal tibia in Blount's disease.

Treatment is generally initiated after correction of the underlying metabolic disorder. Treatment before that time has a high incidence of recurrence. After the metabolic condition has been controlled, treatment may be by either osteotomy or physeal stapling of the distal femur or proximal tibia. The latter is a particularly effective method, provided there is sufficient remaining growth (Fig. 169.16).

***Figure 169.16.*** **A:** Preoperative standing radiograph of a 15-year-old boy 2 years after renal transplantation. His genu valgum has not been improving, although the physes now appear normal. **B:** Postoperative radiograph after insertion of staples about the medial aspect of the distal femoral epiphyses. **C:** Standing radiograph at 18 months postoperatively and 9 months after staple removal demonstrates physiologic alignment and no evidence of growth disturbance.

**Trauma** Injuries to and about the distal femoral or proximal tibial epiphyses is a common cause of genu valgum (142,233). The deformities are progressive and require surgical treatment if there is an asymmetric physeal bar or bridge. The extent of the bar can be assessed by tomography or, preferably, MRI. Treatment options consist of physeal bar excision and grafting with fat or Silastic (Langenskiöld [169] procedure), together with a corrective osteotomy. If the bar is extensive, then complete physeal closure and corrective osteotomy may be performed, with delayed management of the leg-length discrepancy (see Chapter 164).

**Neuromuscular** Ambulatory children with neuromuscular disorders, such as cerebral palsy, often have a pes valgus and excessive external tibial torsion that may produce a progressive genu valgum. This is more likely to be a torsional malalignment than a true genu valgum deformity. Treatment may involve soft-tissue releases to restore muscle balance and osteotomies to correct torsional and angular deformities (see Chapter 177).

**Infection/Osteomyelitis** Osteomyelitis may cause genu valgum directly by damaging the physis or producing a reactive hyperemia and asymmetric growth stimulation. Asymmetric physeal arrest is managed similarly to trauma (see Chapter 176).

**Skeletal Dysplasia** Genu valgum will occur in children with skeletal dysplasia, including multiple epiphyseal dysplasia, spondyloepiphyseal dysplasia, metaphyseal dysplasia, and pseudoachondroplasia. Treatment is based on the diagnosis. Orthotic management is usually ineffective in skeletal dysplasia. Surgery with either stapling or corrective osteotomies is usually necessary (Fig. 169.17) (see Chapter 180).

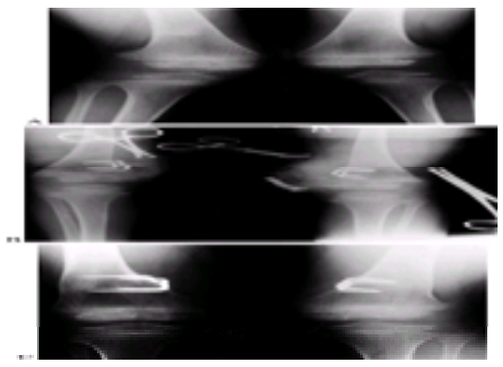

***Figure 169.17.*** **A:** Preoperative standing radiograph of a 13-year-old boy with spondyloepiphyseal dysplasia and severe genu valgum. **B:** Intraoperative radiograph after closing-wedge distal femoral osteotomies. Staples were used to maintain alignment. **C:** Standing radiograph 3 years postoperatively demonstrates that normal alignment is being maintained. Note the proximal migration of the staples with growth.

**Inflammatory Disorders** Juvenile rheumatoid arthritis may produce a progressive genu valgum deformity, but this is uncommon. Correction can be achieved by physeal stapling (240). In older children and adolescents, an osteotomy may be necessary.

## CONGENITAL ANGULATION DEFORMITIES OF THE TIBIA AND FIBULA

Congenital angular deformities of the tibia and fibula are uncommon (Table 169.3). Anterior and anterolateral angulation or bowing is the most common form and is usually associated with other congenital anomalies, such as congenital pseudarthrosis (8,11,15,120,125,135,165,200,212,231). Congenital posteromedial angulation is less common, resolves spontaneously, and is not associated with significant osseus pathology other than residual lower-extremity length inequality.

### CONGENITAL ANTEROLATERAL BOWING OF THE TIBIA: CONGENITAL PSEUDARTHROSIS

Anterolateral bowing of the tibia is usually associated with significant pathologic disorders (Table 169.3). The most common are congenital pseudarthrosis of the tibia, congenital longitudinal deficiency of the tibia (paraxial tibial hemimelia), and congenital longitudinal deficiency of the fibula (paraxial fibular hemimelia) (see Chapter 174).

Congenital pseudarthrosis of the tibia is a rare congenital malformation that includes all congenital fractures of the tibia and pseudarthrosis of the tibia arising after pathologic fracture in a tibia with congenital anterolateral angulation (4). Usually, anterior or anterolateral bowing of the tibia is recognized shortly after birth. Only occasionally are the fracture and pseudarthrosis present at birth, and the pseudarthrosis is therefore not truly congenital. Its incidence has been estimated to be 1 in 190,000 live births (149). The left side is affected slightly more often than the right (270); bilateral involvement is rare. Beals and Fraser (24,106) reported cases with bilateral and familial involvement. Congenital pseudarthrosis of the tibia is one of the most difficult and challenging deformities confronting orthopaedic surgeons (120,213,270).

#### *Pathophysiology*

The exact cause of congenital pseudarthrosis of the tibia is unknown (43,49,52). Between 40% and 80% of children with this disorder are ultimately diagnosed with neurofibromatosis (5,49,52,56,74,186,203,213,214,262). Others have fibrous dysplasia or no associated disorders. Brown et al. (52), in a study of 17 children with a congenital pseudarthrosis, found that eight had neurofibromatosis, three had fibrous dysplasia, and six had no apparent disorder. Despite the clinical association with neurofibromatosis, the cause remains obscure.

Biopsy material removed from the tibia in the area of the pseudarthrosis shows a dense, cellular, fibrous connective tissue with variable areas of cartilage formation (43,49,52,114). Electron microscopy reveals the lack of a basement membrane, and the cells resemble fibroblasts rather than Schwann cells or perineural cells, even in children with known neurofibromatosis (49). Only rarely is neurofibromatosis tissue observed in these specimens, and these samples are usually from intraosseous neurofibromas (114). In some cases, the tissue does resemble fibrous dysplasia (42). This dense, fibrous connective tissue with fibrocartilage and occasional bone trabeculae fills a poorly vascularized gap between the sclerotic bone ends to create the nonunion. This is not a true pseudarthrosis. The defective tissue occurs within the bone itself, the periosteum, the surrounding soft tissue, and possibly in the nerve and vascular supply to the involved area.

#### *Assessment, Indications, and Relative Results*

An infant predisposed to congenital pseudarthrosis of the tibia characteristically presents with anterior or anterolateral bowing of the tibia (Fig. 169.18). This rarely occurs in conjunction with an acute fracture. The bowing is rarely anteromedial. The angular deformity of the tibia is congenital. Unless there is a fracture, the area is not tender, and a bony prominence is palpable. With an acute fracture, the area is unstable and is usually painful.

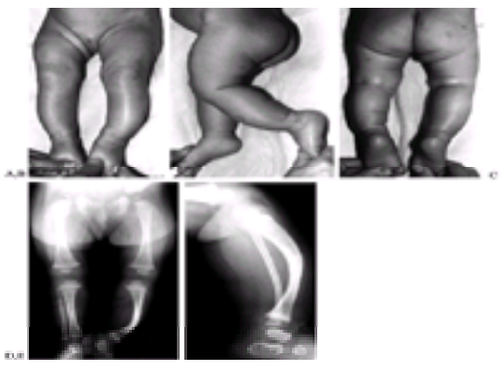

***Figure 169.18.*** **A:** Photograph of a 3-month-old girl with anterolateral bowing of the left tibia shows numerous café-au-lait spots involving the left lower extremity. **B:** Lateral view shows anterior bowing of the tibia. **C:** On the posterior view, observe the café-au-lait spots. **D:** AP radiographs of the lower extremities demonstrate anterolateral bowing of the left tibia. The central portion of the tibia is sclerotic, and there is thinning of the fibula. This indicates a congenital prepseudarthrosis. **E:** Lateral radiograph demonstrates marked anterior bowing of the tibia. The apical sclerosis is more easily visualized in this view.

Because of the high incidence of neurofibromatosis in these patients, the hallmarks of this disease must be sought. The criteria used by Crawford (73) for diagnosis required at least two of the following:

Multiple café-au-lait spots
Positive family history
Definitive biopsy

Characteristic bony lesions, such as pseudarthrosis of the tibia, hemihypertrophy, or a short, sharply angulated spinal curvature

Café-au-lait spots are typically smooth-edged. The presence of at least five spots measuring more than 0.5 cm in diameter is considered diagnostic. The number of spots increases with the patient's age. Subcutaneous nodules (i.e., fibroma molluscum) are uncommon until adolescence and are typical of chronic disease. Although other bones may be involved in neurofibromatosis, involvement of more than one bone is extremely rare. Isolated cases of congenital pseudarthrosis of the fibula with an intact tibia have been reported (79,92,170). They were usually associated with anterior bowing of the tibia and ankle valgus. Curly and overlapping toes have been

reported, as well as congenital constriction bands (201,271).

In children younger than 2 years presenting with anterior or anterolateral bowing of the tibia, there may be no clinical evidence of neurofibromatosis. The clinical features of neurofibromatosis usually become more apparent with growth and development. Radiographs of the tibia before the establishment of a pseudarthrosis may show an intact bowed tibia exhibiting sclerosis in the area of angulation without a medullary canal. After a fracture has occurred and a pseudarthrosis has been established, the proximal and the distal ends of the fracture site become tapered. Both tapered bone ends remain sclerotic.

### *Classification*

Many classifications of pseudarthrosis have been based on the prognosis for various radiographic types (6,7,15,20,40,73,125,186,270). The classification by Boyd (40) is one of the most commonly used methods of assessment (Table 169.7). Crawford (73) proposed a four-group functional classification:

| | |
|---|---|
| Type I | Occurs in patients born with anterior bowing and a defect in the tibia (rare) |
| Type II | Occurs in patients born with anterior bowing and an hourglass constriction of the tibia<br>Spontaneous fracture usually occurs before 2 years of age<br>Is often associated with neurofibromatosis |
| Type III | Develops in a bone cyst, often at the junction of the upper and lower thirds of the tibia<br>Anterior bowing may precede or follow a fracture |
| Type IV | Originates in a sclerotic segment of the tibia without any narrowing or fracture; the medullary canal is partially or completely obliterated<br>Progresses to a stress-type fracture that fails to unite |
| Type V | Occurs in patients who also have a dysplastic fibula; pseudarthrosis develops later |
| Type VI | Occurs in patients with an intraosseous neurofibroma or schwannoma (very rare) |

Adapted from Boyd HB. Pathology and Natural History of Congenital Pseudarthrosis of the Tibia. Clin Orthop 1971;84:9; with permission.

***Table 169.7. Boyd Classification of Congenital Pseudarthrosis***

Type I Anterolateral bow with a normal medullary canal
Type II Anterolateral bow with a narrow, sclerotic medullary canal (Fig. 169.19)

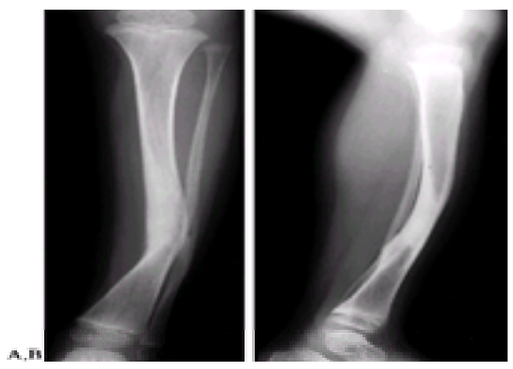

***Figure 169.19.*** **A:** AP radiograph of a 5-year-old boy with neurofibromatosis with a type II lesion of the left tibia. He has been managed in an ankle–foot orthosis since he began ambulation, and he has not had a fracture. **B:** Lateral radiograph demonstrates the apical sclerosis, which has been slowly improving.

Type III Anterior bow with a cystic lesion
Type IV Anterolateral bow with a fracture, cyst, or frank pseudarthrosis (Fig. 169.20)

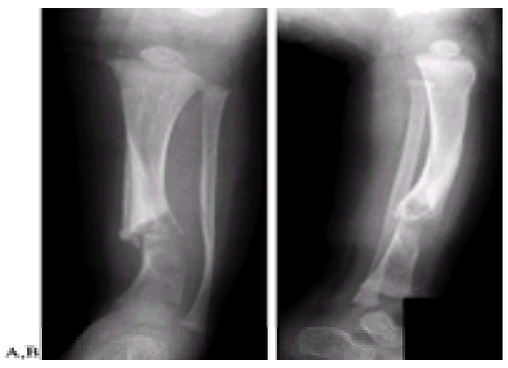

***Figure 169.20.*** **A:** AP radiograph of a 3-month-old child with a type IV congenital pseudarthrosis of the left tibia. Notice the cystic lesion and fracture. There is thinning of the distal aspect of the fibula. **B:** Lateral radiograph demonstrates anterior bowing.

The type of radiographic deformity is related to the recommended treatment. In Crawford's classification, a type I lesion has the best prognosis, and the remaining three types have progressively worse prognoses. However, the relation between the type of pseudarthrosis and the clinical result is not always predictable (4,73,183,198). The presence or absence of established neurofibromatosis makes no difference in the classification and is not a factor in determining treatment or prognosis. Cases in which bone-end resorption and sclerosis are evident radiographically and bone graft rapidly resorbs postoperatively have a poor prognosis. Those with a cystic lesion have a more favorable prognosis (198).

The natural history of anterior or anterolateral bowing of the tibia secondary to neurofibromatosis or fibrous dysplasia is a fracture with the establishment of a pseudarthrosis. The treatment of anterior and anterolateral bowing with an intact tibia is directed toward prevention of the fracture and pseudarthrosis. Congenital pseudarthrosis of the tibia is more than a mechanical problem (199); it represents a complex biologic problem because the established pseudarthrosis is extremely difficult to manage.

### *Preoperative Management and Planning*

Patients with anterior or anterolateral bowing of the tibia without pseudarthrosis are best treated initially with a total-contact plastic orthosis. This is usually an ankle–foot orthosis. Prophylactic treatment may delay or prevent a fracture and subsequent pseudarthrosis. These orthoses are worn for years. With growth and in the absence of a fracture, the tibial bowing usually improves. There is typically some residual shortening within the bone. The medullary canal develops slowly over 5–10 years. It is possible, although unlikely, that a fracture and pseudarthrosis can be avoided with the use of an orthosis alone. If the tibia has straightened sufficiently, the medullary canal has reconstituted, and there is adequate cortical thickness, the orthosis may be discontinued as skeletal maturity is approached. Vigorous physical activities should be avoided. There are no long-term reports of successful orthotic management in adolescents or adults.

After a pathologic fracture and pseudarthrosis have occurred, the treatment is usually surgical. Casting alone rarely results in healing. However, Roach et al. (234) demonstrated that a late-onset fracture in a dysplastic tibia may heal with prolonged immobilization. Six of 11 fractures healed, but four of the six had a residual anterior bow susceptible to a stress fracture.

### *Operative Techniques*

The indication for surgical management is an established pseudarthrosis. The goals of treatment include obtaining union at the pseudarthrosis site, maintaining union throughout growth and development, and obtaining an acceptable limb length at maturity (213,278). Previously, surgery was advised only for children age 4 years or older (6,125,203). Most physicians now recommend early surgical intervention and revision if the first procedure does not result in union of the pseudarthrosis (186,199,213,214). Morrissey et al. (199) reported that a good result did not occur in any child whose tibia was not united by 6 years of age. Masserman et al. (186) reported that union was more related to the pathologic process than the age at surgery. Earlier union produces more normal growth of the distal tibial epiphysis and less lower-extremity length discrepancy.

The current methods of surgical treatment include bone grafting alone, bone grafting and internal fixation, electrical stimulation, microvascular bone grafting, Ilizarov external fixation methods, and amputation.

**Bone Grafting Alone** Prophylactic bone grafting has been used for the deformed tibia before a pathologic fracture occurs (179,191,266,270). This was thought to strengthen the deformed area and decrease the risk for pathologic fracture. The technique described by McFarland (191) is the most common procedure. A long corticocancellous graft from the opposite tibia is placed posteriorly, spanning the deformity in the normal biomechanical longitudinal axis of weight bearing. Lloyd-Roberts and Shaw (179), however, reported success in only three of their seven patients, while Tachdjian (270) reported success in all five children. Recently, Strong and Wong-Chung (266) prevented fracture in six of nine children with a prepseudarthrosis secondary to neurofibromatosis. Paterson (213), however, felt that the procedure was indicated primarily for cystic prepseudoarthrosis. Tachdjian (270) suggested concomitant curettage and bone grafting of any cystic lesions.

Many possible bone-grafting procedures have been used to treat an established congenital pseudarthrosis of the tibia (41,42 and 43,98,100,191,225,228). Morrissey et al. (199) reviewed 167 operations performed in 40 patients. The Farmer procedure, using a composite bone graft from the opposite tibia, demonstrated the best result, with a success rate of 53% (100). Other procedures had lower success rates, including onlay grafts (13%), bypass grafts (7%), Sofield procedure (25%), sliding grafts (33%), bone allograft (17%), and autogenous grafts (10%).

**Bone Grafting and Internal Fixation** Surgical excision of the pseudarthrosis, correction of the angular deformity of the tibia, and rigid internal fixation in addition to bone grafting have improved the rate of primary union. Stabilization has been achieved with compression plates and intramedullary rods. The former is rarely used because of difficulties involved in achieving adequate fixation (6,213). The most common methods at this time are tibial or dual tibial and fibular intramedullary rods. These techniques usually transfix the ankle and subtalar joints to adequately stabilize the distal tibial segment (4,9,17,63,108,278). These joints are progressively freed with growth of the tibia and proximal migration of the rod. This method does not result in significant stiffness of the joints. Postoperatively, immobilize with a unilateral hip spica cast followed by a long-leg cast and then a knee–ankle–foot orthosis. Anderson et al. (9) reported that 10 of 13 pseudarthroses healed with an intramedullary rod technique. However, their mean follow-up time was short (6.9 years).

Several researchers used extending intramedullary rods and bone grafting (e.g., double cortical onlay, cancellous) (31,102). These rods extended with growth, decreasing the need for revision surgery and protecting the union until skeletal maturity. They were not inserted across the ankle or subtalar joint. Bitan et al. (31) reported satisfactory extension of the rods in four of seven patients when these rods were used in revision surgery after primary union. Fern et al. (102) recommended that the outer sleeve of an extendable rod be inserted across the pseudarthrosis site to provide more strength and decrease the risk of refracture. They reported primary union in all five patients in whom extendable rods and bone grafting were used. All rods expanded with growth up to a maximum of 6.4 cm.

The use of intramedullary rods, especially those that stabilize the hind foot, and cancellous bone grafting increases the rate of primary union. The correction of anterior or anterolateral bowing undoubtedly enhances healing by allowing compression across the pseudarthrosis. These rods are not removed until after skeletal maturity because the tibia may undergo progressive bowing or refracture.

**Electrical Stimulation** Electrical stimulation has been used in the treatment of congenital pseudarthrosis of the tibia for the past two decades (20,48,164,214,215,251,267). The various techniques include implanted direct-current bone growth stimulators and external stimulation devices with pulsating electromagnetic fields. The addition of electrical stimulation has improved success rates after bone-grafting procedures (213,214). Most reports recommend that electrical stimulation be used in conjunction with internal fixation and bone grafting. In 1982, Kort et al. (164) observed that the most important variable in healing was the radiographic morphology of the nonunion. Patients with spindled bone ends, a large gap, and gross mobility had a poor prognosis, whereas those with a cystic or sclerotic transverse fracture and a gap of less than 5 mm had better responses.

Paterson and Simonis (214) described a technique of excision of the pseudarthrosis and abnormal tissue, fibular osteotomy, intramedullary rod fixation (i.e., large Steinmann pin or Kuntscher nail), cancellous bone grafting, and an implanted direct-current electrical bone growth stimulator. The leg was protected in a long-leg plaster cast until clinical and radiographic healing was achieved. Weight bearing was allowed and encouraged. They reported primary union in 20 (74%) of 27 patients. The average time for union was 7.2 months (range, 3–18 months). During a mean follow-up period of 3.8 years (range, 6 months to 10 years), no refractures were reported. The reasons for failure in seven patients included inadequate correction of the anterior tibial bowing, poor internal fixation, incorrect placement of the cathode, and extensively diseased bone. Brighton et al. (48) reported that only one of four patients with congenital pseudarthrosis of the tibia healed with direct-current stimulation from an implanted single cathode. However, they did not excise abnormal tissue, provide internal fixation, or use bone grafting. The extremities were immobilized in a plaster cast, and weight bearing was not allowed. They thought that the results did not prove the efficacy of this technique for congenital pseudarthrosis of the tibia.

In 1981, Bassett et al. (20) reported the results in 34 patients with congenital pseudarthrosis of the tibia treated with pulsed electromagnetic fields (PEMFs) by way of external coils. They reported that 17 of 34 patients achieved complete healing with reconstitution of the medullary canal. An additional seven (21%) patients achieved union with function but required continued protection with an orthosis. Healing of the pseudarthrosis occurred in 24 (71%) of 34 patients. Analysis of the failures demonstrated that most occurred in male patients with a history of early fracture (younger than 1 year) and with an atrophic, spindled, hypermobile pseudarthrosis. The researchers did not employ any additional surgical procedures in the initial treatment. However, after early healing was demonstrated radiographically, surgical realignment, immobilization, and bone grafting were combined with the PEMFs. This did not have an adverse affect on the ultimate outcome. In 1982, Sutcliffe and Goldberg (267) reported the results of 49 patients treated for congenital pseudarthrosis of the tibia with PEMFs. The definite end point of treatment was reached in 37 patients, and in 26 (70%) of them there was a successful outcome. Fifteen pseudarthroses healed with PEMFs alone. The remaining 11 patients required subsequent surgery, usually cancellous bone grafting, and a second course of PEMFs before healing was obtained.

It appears that electrical stimulation may help induce bone formation in the area of a pseudarthrosis and abnormal tissue. Electrical stimulation alone is effective in approximately 50% of the successful cases. In the remainder, additional procedures are necessary before primary union can be achieved, including excision of the pseudarthrosis and abnormal tissue, correction of existing deformity, intramedullary fixation, and cancellous bone grafting. However, in approximately 30% of cases, electrical stimulation with or without surgical intervention results in failure. The incidence of refracture appears to be low.

**Microvascular Bone Graft** Free vascularized bone grafts represent another popular procedure for congenital pseudarthrosis of the tibia (64,68,84,85,93,108,112,121,154,175,196,219,220,259,272,277,284,285,295). Vascularized rib, iliac crest, and fibula grafts have been used, and the latter appears to be superior in congenital pseudarthrosis of the tibia (64,68,84,85,92,108,121,154,175,219,220,284,285). The graft can be ipsilateral if it is of sufficient size (68,196,259,295). The procedure consists of transferring the contralateral fibular diaphysis on its vascular pedicle with a cuff of muscle to maintain the periosteal blood supply into a defect created by resecting the pseudarthrosis and abnormal soft tissue on the involved side (Fig. 169.21). Supplemental cancellous bone grafting may be included to facilitate bone healing. The fibular graft is advantageous because it is straight, a long segment can be harvested, and it tends to hypertrophy after healing. Leung (175) reported three successful microvascularized iliac crest grafts in congenital pseudarthrosis of the tibia. He thought that it was easier to harvest the iliac crest and there was a more rapid healing because the graft was predominantly corticocancellous bone rather than cortical bone alone. Iliac crest grafts ranging from 3 to 10 cm may be obtained in children age 4 years or older. Rib grafts are less advantageous because of their curvature. Hagan and Buncke (121) reported that this curvature does not tend to correct with growth after satisfactory incorporation and the curvature may increase. Use of extensive corticocancellous grafting may prevent progressive bowing of the vascularized rib graft. Donor site problems after vascularized fibula transfers have been reported (209).

***Figure 169.21.*** **A:** AP radiograph of the right lower leg of a 6-month-old boy with neurofibromatosis and a congenital pseudarthrosis of the distal tibia. **B:** Lateral radiograph. **C:** A procedure using a vascularized fibula graft from the left leg was performed at 17 months of age. Internal fixation was not used, and the ends of the fibula graft were inserted into the medullary canal proximally and into the metaphysis distally. **D:** Lateral radiograph. **E:** Two months after vascularized-fibula grafting, there is extensive subperiosteal new bone formation and hypertrophy of the graft. **F:** Lateral radiograph. **G:** Twenty-two months later, the tibia is healed, but the leg is protected in a knee–ankle–foot orthosis. **H,I:** Thirty-three months postoperatively, the tibia has healed well, and the medullary canal is reforming in the area of the vascularized fibula.

In 1990, Weiland et al. (285) reported on the long-term results in 19 consecutive children with congenital pseudarthrosis of the tibia treated with a vascularized fibula graft. The mean age at surgery was 5.1 years (range, 1.4–11.4 years). The mean follow-up was 6.3 years (range, 2–11 years). They reported that 18 (95%) of the 19 pseudarthroses healed. The lower-extremity length discrepancy at follow-up was a mean of 1.6 cm (range, 0–4 cm). Sixteen of the children had been treated with electrical stimulation techniques, which failed, for at least 1 year before surgery. However, the fibular graft hypertrophied rapidly, and no graft fractured during follow-up. Five patients required secondary procedures for nonunion and angulation. Only one child failed and subsequently required an amputation. Four patients ultimately achieved healing, although they required nine bone-grafting procedures. Two children had fractures through normal bone distal to the vascularized bone graft; they also required bone-grafting procedures to achieve union. Morbidity of the donor site was minimal, but one patient sustained a nondisplaced fracture of the tibia through a screw hole, and a 20° valgus deformity requiring osteotomy developed in another. Thirteen tibiae had residual deformity: valgus deformity (five patients); anterior angulation (two patients), or both (six patients). The mean valgus deformity was 25° (range, 5° to 45°), and the mean anterior angulation was 24° (range, 10° to 30°). Two patients with a valgus deformity required correction with an osteotomy. Four patients had anterior bowing of more than 20°, but none required additional surgery. All children were treated with orthoses until skeletal maturity was achieved.

The five basic steps of free vascularized bone grafts are applicable whether iliac crest or fibula graft is used (220):

- Harvest of the vascularized bone with an intact vascular pedicle
- Excision of the tibial pseudarthrosis and abnormal tissue
- Fixation of the vascularized bone *in situ*
- Microvascular anastomosis
- Skin closure

The procedure is usually performed with two surgical teams. One team harvests the vascularized bone, and the second prepares the recipient site. Some form of internal fixation is usually necessary to maintain alignment of the extremity. One advantage of microvascularized bone grafts is the simultaneous correction of any residual deformity and possible tibial lengthening, depending on the mobility of the tibial segments. Prolonged immobilization is necessary until healing occurs, with protected weight bearing allowed thereafter. Weiland et al. (285) maintain their children in hip spica casts for 2–3 months to allow healing. After healing occurs, protected weight bearing with a knee–ankle–foot orthosis is allowed. The orthosis is worn until skeletal maturity (see Chapter 36).

**Ilizarov Fixation System** The Ilizarov method has been shown to be effective in achieving union at the pseudarthrosis site and in simultaneously correcting any associated angular deformity and lengthening of the tibia to restore length (85,99,119,144,211,224). The apparatus can be used in four ways: compression of the pseudarthrosis, compression with metaphyseal tibial lengthening, compression followed by distraction for hypertrophic nonunion, and distraction alone for hypertrophic nonunion. Excellent short-term results for union were reported. Whether the union is maintained in the long term remains uncertain.

**Amputation** In children with persistent congenital pseudarthrosis of the tibia after previous surgical procedures, an amputation may be advised. This should be a Boyd or Symes ankle-disarticulation amputation of the foot (82,134,149,189). See Chapter 175 on principles of pediatric amputation and Chapter 120 and Chapter 122 on lower-extremity amputations and prostheses. Amputation with appropriate prosthetic fitting allows rapid rehabilitation and return to normal function. McCarthy (189) recommended amputation for several criteria: failure to achieve bony union after three surgical attempts, a significant lower-extremity length inequality (usually 5 cm or greater), development of a deformed foot, undue functional loss from prolonged hospitalizations, and high medical costs.

The Boyd or Symes amputation is usually the procedure of choice. It preserves the heel pad and distal tibial epiphysis, which allows end bearing on the stump. The bone and skin are lengthened as a unit to avoid problems with overgrowth (82). A below-knee amputation through the pseudarthrosis produces a poor end-bearing stump for ambulation. The abnormal tissue and previous surgical scar provides poor skin coverage and predisposes to breakdown. There are also the problems of overgrowth and frequent revision. Amputation above the pseudarthrosis site provides better skin coverage, but there are problems with bony overgrowth.

Jacobsen et al. (149) reported the results of Symes amputation in eight children with pseudarthrosis of the tibia. The average age at amputation was 8.2 years, and the mean follow-up was 5.9 years. These children had a mean of 3.8 surgical procedures performed before amputation. None of the pseudarthroses healed, but with an appropriate Symes prosthesis, the children were able to engage in normal activities, including sports. The lower-extremity length inequality and some of the angular deformity were corrected within the prosthesis. Herring et al. (134) reported that 21 children (none with congenital pseudarthrosis) who had 23 Symes amputations had better psychological functioning than children undergoing multiple corrective surgical procedures. The better psychological function correlated with their better orthopaedic function. The level of family stress influenced the child's behavior, self-perception, and intelligence. The physicians thought that an early Symes amputation in a young patient was compatible with good athletic and psychological functioning, which closely approached that of a nonhandicapped child of the same age. Similar results were reported by Davidson and Bohne (82) for 23 children, including one with a congenital pseudarthrosis of the tibia that did not heal.

Because of the complexities associated with the treatment of pseudarthrosis of the tibia, it is recommended that Symes amputation be discussed as an alternative method of treatment with the parents and child from the outset. Discussion should not be delayed until later in the treatment. Tell the family of the difficulties that will be encountered in attempting to obtain primary tibial union and satisfactory function.

### *General Rehabilitation and Postoperative Principles*

Each surgical procedure has its specific postoperative regimen, but all share long-term orthotic management. The extremity needs to be protected with a plastic ankle–foot orthosis. This helps prevent recurrent refracture. Protection is required at least until skeletal maturity and perhaps even longer. This decision is based on the radiographic appearance of the tibia, the degree of residual deformity, and the presence or absence of a reconstituted medullary canal.

Rehabilitation to restore maximum strength and function after healing of a congenital pseudoarthrosis of the tibia is very important. Karol et al. (156) recently performed gait analysis on 12 patients with healed lesions and four patients treated by amputation. Gait and muscle strength were markedly disturbed. Early onset of fracture, early surgery, and transankle fixation lead to an inefficient gait compared with that of amputees.

### *Complications*

Congenital pseudarthrosis of the tibia is a difficult and challenging deformity. Refracture, tibial and lower-extremity length discrepancy, stiffness of the ankle and subtalar joints, progressive anterior angulation of the tibia, and ankle valgus are the major complications (270,285). Surgical complications are also common. Most children have had multiple surgical procedures and are at risk for infection and neurovascular injury. Because of these problems, the true outcome of a congenital pseudarthrosis cannot be fully assessed until skeletal maturity. Crossett et al. (74) found that the clinical results for their patients remained stable after skeletal maturity. Neurofibromatosis does not increase the incidence of complications or adversely affect the final clinical result (198).

### *Conclusion*

Probably, the most important aspect of the management of children with congenital pseudarthrosis of the tibia is to minimize the number of operative procedures and to maintain as normal function as possible. Prevention of fractures in children with prepseudarthrosis lesions is critically important. This can sometimes be achieved with a clamshell ankle–foot orthosis. After a pseudarthrosis is established, the best results with respect to union are achieved with a vascularized fibula graft or intramedullary rod. I feel that the initial surgical procedure should be the latter. This allows straightening of the tibia, with weight bearing providing compression across the pseudarthrosis. The results of a vascularized fibula transfer are also good, but I am concerned about a major operative procedure on the uninvolved extremity. Once it is apparent that a pseudarthrosis cannot be satisfactorily healed, Symes amputation and prosthetic replacement permit restoration of relatively normal function.

## CONGENITAL POSTEROMEDIAL ANGULATION OF THE TIBIA AND FIBULA

### *Pathophysiology*

The cause of congenital posteromedial angulation of the tibia and fibula is unknown. There is some evidence to indicate a primary chondro-osseous defect in the embryologic development of the distal tibial and fibular epiphyses (138,212). Pappas (212) demonstrated delayed development of the secondary center of ossification of the distal tibia and a relative reduction in the height of the distal epiphysis. Other possibilities include intrauterine fracture of the tibia and fibula with malunion, restriction of growth from soft-tissue contractures, or intrauterine malpositioning with the affected leg molded under the buttock (15,83,107,165).

### *Assessment, Indications, and Relative Results*

Congenital posteromedial angulation of the tibia and fibula has three associated clinical problems (120,135,136,194,212,231,236):

Angular deformity
Calcaneovalgus foot
Lower-extremity length inequality

The tibia and fibula are shortened and bowed posteriorly and medially at the junction of the middle and distal thirds of their shafts. The deformity, which is obvious at birth, is usually unilateral. The right and left sides are equally affected, and there is no sex predilection (138). Infants are typically normal, and there is no increased incidence of other congenital anomalies (288). Hofmann and Wenger (138) reported on a child who had a contralateral talipes equinovarus (clubfoot) deformity. Angulation can vary from 25° to 65°, with the magnitude of deformity in the posterior and medial directions being almost equal (241). The foot is hyperdorsiflexed and has a marked calcaneovalgus posture. It appears to fit into the anterior cavity of the lower leg. The anterior compartment muscles appear shortened and limit plantar flexion of the foot. The posterior bow of the shaft causes the distal portion of the tibia and fibula at the ankle to angulate anteriorly. This makes the limitation of plantar flexion seem even more severe. There is no true bone deformity of the ankle or foot. The calf musculature is usually slightly atrophic, and the foot is smaller than on the opposite, normal side (8,138). There may be a dimple at the apex of the posteromedial angulation (8,53,135,138,212). Occasionally, an extra skin crease is associated with the dimple (212).

Anteroposterior and lateral radiographs of the lower extremities of an affected child are necessary for complete assessment. The proximal aspects of the tibia and fibula, including their epiphyses, are normal. The degree of posteromedial angulation of the distal aspect of the tibia and fibula can be measured directly from the radiographs. The cortices in the concave aspect of the posterior and medial bows are thickened, and the distal aspects of the tibia and fibula are broader than the opposite, uninvolved side (212). The intramedullary cavities at the apex of the bowing are usually poorly developed or obliterated by sclerotic bone. The alignment of the tarsal and metatarsal bones is relatively normal, although occasionally there may be a slight valgus orientation. Radiographs of the femora and pelvis should be obtained for thorough assessment of the lower extremities. Special diagnostic studies, such as MRI, are rarely indicated.

The posteromedial angulation or bowing resolves with growth, especially during the first 3 years of life (Fig. 169.22). The posterior bowing resolves more quickly than the medial bowing, which may not resolve until 5 years of age (120,212). However, the associated shortening of the tibia and fibula, which is unrelated to the bowing, persists and progresses during growth (8,138,212,288). The fibula is frequently slightly shorter than the tibia; there is usually no shortening in the femur. The mean growth inhibition in the involved tibia and fibula averages 12% to 13% (range, 5% to 27%). This percentage of growth inhibition persists throughout growth and development. There appears to be a direct correlation between the degree of tibial shortening and the degree of posteromedial angulation: The greater the angulation, the more severe is the lower-extremity length discrepancy (135,136,138,165). The mean tibial length difference is approximately 1.2 cm in the first 2 months of life, 2.4 cm by 5 years of age, 3.3 cm at 10 years, and 4.1 cm (range, 3.3–6.9 cm) at maturity (138,212). It is possible to determine the percentage of inhibition and the ultimate leg-length inequality by annual scanographic evaluation and bone-age determination after the posteromedial angulation has resolved. During the first 6 months of life, correction of the bowing is rapid, and by 2 years of age approximately 50% of the angulation has undergone spontaneous correction. After 3 years of age, improvement in the deformity occurs at a much slower rate.

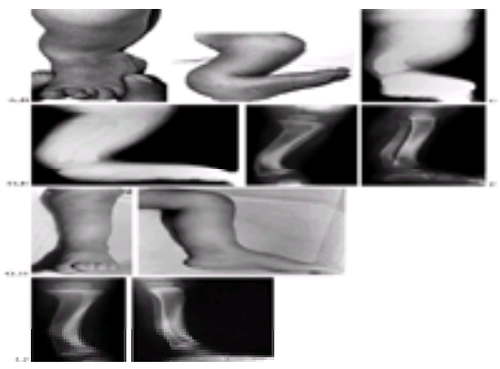

***Figure 169.22.*** **A:** Clinical photograph of a 1-month-old boy with congenital posteromedial bowing of the left tibia. Observe the medial bowing of the distal aspect of the tibia. **B:** The posterior bow of the distal tibia produces a calcaneovalgus appearance of the left foot. **C:** AP radiograph of the left leg confirms the severe medial bowing of the distal third of the tibia and fibula. **D:** Lateral radiograph demonstrates the posterior bowing and the calcaneovalgus appearance to the foot. The alignment of the foot is due to the dorsal angulation of the distal tibia and ankle. **E:** AP radiograph obtained at 1 year demonstrates decreased medial angulation of the distal tibia. **F:** Lateral radiograph shows a significant decrease in the posterior bow of the tibia and improved alignment of the ankle joint. **G:** Clinical photograph at 2 years of age shows marked improvement in the appearance of the left lower leg. **H:** There is only slight residual posterior angulation of the tibia in the sagittal plane. **I:** AP radiograph at 2 years of age shows further improvement in the medial angulation of the distal tibia. **J:** Lateral radiograph confirms further improvement in posterior angulation.

The appearance of the foot gradually improves with growth and development. As the posterior bowing decreases, the degree of plantar flexion improves. A pes planovalgus appearance of the foot may persist. Hofmann and Wenger (138) found mild loss of ankle dorsiflexion in older children. They thought that this was due to mild equinus contracture from toe-walking to compensate for the length discrepancy. It may also be due to the slightly shorter fibula.

### *Preoperative Management*

Because posteromedial angulation of the tibia and fibula in children undergoes spontaneous resolution, treatment is predominantly conservative. In newborn and young infants, passive stretching exercises of the hyperdorsiflexed foot may be performed to stretch the anterior compartment muscles and improve plantar flexion. It is important to assess maximal plantar flexion of the foot on a lateral radiograph because of the anterior angulation of the distal tibia, fibula, and ankle joint. What appears to be limited plantar flexion may only be secondary to the anterior tilt to the articular surface of the distal tibia. The talus may be in full plantar flexion in the ankle mortise, but the foot still may not appear plantigrade.

In selected cases, use serial short-leg casts to hold the foot in maximal plantar flexion and inversion (83,194,231,288). In 3–6 weeks, maximal stretching of the anterior compartment musculature and anterior ankle capsule is usually achieved. Yadav and Thomas (288) reported that six children with a unilateral posteromedial bow of the tibia did well with serial casting, although one patient underwent an anterior soft-tissue release before initiation of casting. After complete correction has been obtained, passive exercises may be continued to maintain alignment. In severe cases, Tachdjian (269) recommended the use of night splints to hold the foot in plantar flexion and inversion. After 2–3 years of age, a University of California Biomechanics Laboratory or similar foot orthosis may be worn to support the planovalgus foot deformity. However, in view of the natural history and management of posteromedial bowing, the use of casts and orthoses is probably not indicated. Heyman and Herndon (135) initially thought that an orthosis was necessary to reduce the posterior thrust at the apex of the deformity during weight bearing. However, in their later report, they stated that the use of an orthosis was unnecessary (136).

Follow children with posteromedial angulation of the tibia and fibula with annual scanograms and bone-age determinations (10,118,200) (see Chapter 170 on leg-length inequality).

### *Operative Techniques*

Typically, there are only two operative procedures utilized in this disorder:

- Osteotomy to correct severe or persistent angulation
- Equalization of lower-extremity length inequality

**Tibia and Fibula Osteotomy** Osteotomy to correct posteromedial bowing of the tibia is rarely indicated. If severe medial bowing persists after 3 or 4 years of age, corrective osteotomy may be considered. Bone healing is not a problem after a corrective osteotomy or a fracture because there is no underlying bone disorder affecting healing (8,83,165,231). Hofmann and Wenger (138) suggested corrective osteotomy in cases of severe bowing with progressive shortening during the first 5 years of life. They thought that an osteotomy would add length by correcting the deformity and realigning the physes perpendicular to the axis of weight bearing, stimulating growth. These concepts were not confirmed clinically. Osteotomy can realign the tibia, but it has a minimal effect on the ultimate lower-extremity length inequality. Krida (165) reported that all three patients treated by corrective osteotomies had significant residual leg-length discrepancies.

**Leg-length Equalization** Lower-extremity length discrepancy is the most common sequela of posteromedial angulation of the tibia and fibula. Most affected children have enough inequality (2 cm) to require equalization. The procedure performed to equalize the leg length depends on the estimated tibial length inequality at maturity and the predicted normal height of the child (see Chapter 170).

### *Conclusion*

In patients with posteromedial angulation of the tibia, I prefer prolonged observation. Casting of the foot is rarely indicated, as the limitation of dorsiflexion is due primarily to the alignment of the ankle. This will correct with growth. The associated lower-extremity length inequality is followed by scanograms at 1- or 2-year intervals. An appropriately timed contralateral percutaneous proximal tibial and fibular epiphysiodesis is the procedure of choice for most patients. Leg-lengthening techniques are usually not necessary, unless the discrepancy is severe or the patient has short stature.

## CHAPTER REFERENCES

Each reference is categorized according to the following scheme: *, classic article; #, review article; !, basic research article; and +, clinical results/outcome study.


+ 1. Agamanolis DP, Weiner DS, Lloyd JK. Slipped Capital Femoral Epiphysis: A Pathological Study. I. A Light Microscopy and Histochemical Study of 21 Cases. *J Pediatr Orthop* 1985;5:40.

+ 2. Agamanolis DP, Weiner DS, Lloyd JK. Slipped Capital Femoral Epiphysis: A Pathological Study. II. An Ultrastructural Study of 23 Cases. *J Pediatr Orthop* 1985;5:47.

+ 3. Albiñana J, Cuervo M, Certucha JA, et al. Five Additional Cases of Focal Fibrocartilaginous Dysplasia. *J Pediatr Orthop B* 1997;6:52.

+ 4. Andersen KS. Congenital Pseudarthrosis of the Leg: Late Results. *J Bone Joint Surg Am* 1976;58:657.

+ 5. Andersen KS. Congenital Pseudarthrosis of the Tibia and Neurofibromatosis. *Acta Orthop Scand* 1976;47:108.

+ 6. Andersen KS. Operative Treatment of Congenital Pseudarthrosis of the Tibia: Factors in Influencing the Primary Results. *Acta Orthop Scand* 1974;45:935.

+ 7. Andersen KS. Radiological Classification of Congential Pseudarthrosis of the Tibia. *Acta Orthop Scand* 1973;44:719.

+ 8. Andersen KS, Bohr H, Sneppen O. Congenital Angulation of the Lower Leg: Crus Curvatum Congenitum. *Acta Orthop Scand* 1968;39:387.

+ 9. Anderson DJ, Schoenecker PL, Sheridan JJ, Rich MM. Use of an Intramedullary Rod for the Treatment of Congenital Pseudarthrosis of the Tibia. *J Bone Joint Surg Am* 1992;74:161.

! 10. Anderson M, Green WT, Messner MB. Growth and Prediction of Growth in the Lower Extremities. *J Bone Joint Surg Am* 1963;45:1.

+ 11. Angle CR. Congenital Bowing and Angulation of Long Bones. *Pediatrics* 1954;13:257.

+ 12. Apel DM, Millar EA, Moell DI. Skeletal Disorders in Pediatric Renal Transplant Population. *J Pediatr Orthop* 1989;9:505.

! 13. Arkin AM, Katz JF. The Effects of Pressure on Epiphyseal Growth: The Mechanism of Plasticity of Growing. *J Bone Joint Surg Am* 1956;38:1056.

! 14. Aronson DD, Stewart DC, Crissman JD. Experimental Tibial Fractures in Rabbits Simulating Proximal Tibial Fractures in Children. *Clin Orthop* 1990;255:61.

+ 15. Badgley CE, O'Connor SJ, Kudner DF. Congenital Kyphoscoliotic Tibia. *J Bone Joint Surg Am* 1952;34:349.

+ 16. Bahnson DH, Lovell WW. Genu Valgum Following Fractures of the Proximal Tibial Metaphysis in Children. *Orthop Trans* 1980;4:306.

+ 17. Baker JK, Cain TE, Tullos HS. Intramedullary Fixation for Congenital Pseudarthrosis of the Tibia. *J Bone Joint Surg Am* 1992;74:169.

+ 18. Balthazar DA, Pappas AM. Acquired Valgus Deformity of the Tibia in Children. *J Pediatr Orthop* 1984;4:538.

+ 19. Barrett IR, Papadimitriou DG. Skeletal Disorders in Children with Renal Failure. *J Pediatr Orthop* 1996;16:264.

+ 20. Bassett CAL, Caulo N, Kort J. Congenital “Pseudarthroses” of the Tibia: Treatment with Pulsing Electromagnetic Fields. *Clin Orthop* 1981;154:136.

+ 21. Bassey LO. Valgus Deformity Following Proximal Metaphyseal Fractures in Children: Experience in the African Tropics. *J Trauma* 1990;30:102.

+ 22. Bateson EM. The Relationship between Blount's Disease and Bow Legs. *Br J Radiol* 1968;41:107.

+ 23. Bathfield CA, Beighton PH. Blount Disease: A Review of Etiological Factors in 110 Patients. *Clin Orthop* 1978;135:29.

+ 24. Beals RK, Fraser W. Familial Congenital Bowing of the Tibia with Pseudarthrosis and Pectus Excavatum: Report of a Kindred. *J Bone Joint Surg Am* 1976;58:545.

+ 25. Beck CL, Burke SW, Roberts JM, Johnston CE II. Physeal Bridge Resection in Infantile Blount Disease. *J Pediatr Orthop* 1987;7:161.

* 26. Bell SN, Campbell PE, Cole WG, Menelaus MB. Tibia Vara Caused by Focal Fibrocartilaginous Dysplasia: Three Case Reports. *J Bone Joint Surg Br* 1985;67:780.

+ 27. Ben-Itzhak I, Erken EHW, Molkin C. Progressive Valgus Deformity after Juxta-epiphyseal Fractures of the Upper Tibia in Children. *Injury* 1987;18:169.

+ 28. Berg EE. Case Report: Anterior Cruciate Ligament Incompetence in Severe Blount's Disease. *J Pediatr Orthop* 1994;3:197.

+ 29. Beskin JL, Burke SW, Johnston CE II, Roberts JM. Clinical Basis for a Mechanical Etiology in Adolescent Blount's Disease. *Orthopaedics* 1986;9:365.

+ 30. Best TN. Valgus Deformity after Fracture of the Upper Tibia in Children. *J Bone Joint Surg Br* 1973;55:222.

+ 31. Bitan F, Rigault P, Padovani JP, Touzet P. Congenital Pseudarthrosis of the Tibia in Childhood: Results of Treatment by Nailing and Bone Graft in 18 Cases. *Fr J Orthop Surg* 1987;1:331.

+ 32. Blockney NJ, Murphy AV, Mocan H. Management of Rachitic Deformities in Chldren with Chronic Renal Failure. *J Bone Joint Surg Br* 1986;68:791.

+ 33. Blount WP. Tibia Vara: Osteochondrosis Deformans Tibiae. *Curr Pract Orthop Surg* 1966;3:141.

# 34. Blount WP. *Fractures in Children.* Baltimore: Williams & Wilkins, 1955;171.

* 35. Blount WP. Tibia Vara: Osteochondrosis Deformans Tibiae. *J Bone Joint Surg* 1937;19:1.

* 36. Blount WP, Clarke GR. Control of Bone Growth by Epiphyseal Stapling: A Preliminary Report. *J Bone Joint Surg Am* 1949;31:464.

+ 37. Bowen JR, Johnson WJ. Percutaneous Epiphysiodesis. *Clin Orthop* 1984;190:170.

* 38. Bowen JR, Leahey JL, Zahang Z, MacEwen GD. Partial Epiphysiodesis at the Knee to Correct Angular Deformity. *Clin Orthop* 1985;198:184.

+ 39. Bowen JR, Torres RR, Forlin E. Partial Epiphysiodesis to Address Genu Varum or Genu Valgum. *J Pediatr Orthop* 1992;12:359.

! 40. Boyd HB. Pathology and Natural History of Congenital Pseudarthrosis of the Tibia. *Clin Orthop* 1982;166:5.

+ 41. Boyd HB. Congenital Pseudoarthrosis: Treatment by Dual Bone Grafts. *J Bone Joint Surg* 1941;23:497.

+ 42. Boyd HB, Fox KW. Congenital Pseudarthrosis: Follow-up Study after Massive Bone Grafting. *J Bone Joint Surg Am* 1948;30:274.

+ 43. Boyd HB, Sage FP. Congenital Pseudarthrosis of the Tibia. *J Bone Joint Surg Am* 1958;40:1245.

+ 44. Boyer RS, Jaffe RB, Nixon GW, Condon VR. Trampoline Fractures of the Proximal Tibia in Children. *AJR* 1986;146:83.

+ 45. Bradish CF, Davies SJM, Malone M. Tibia Vara Due to Focal Cartilaginous Dysplasia: The Natural History. *J Bone Joint Surg Br* 1988;70:106.

# 46. Bradway JK, Klassen RA, Peterson HA. Blount's Disease: A Review of the English Literature. *J Pediatr Orthop* 1987;7:472.

+ 47. Bright RW. Surgical Correction of Partial Growth Plate Closure: A Clinical Study of 24 Cases. *Orthop Trans* 1977;1:82.

+ 48. Brighton CT, Friedenberg ZB, Zemsky LM, Pollis PR. Direct-current Stimulation of Non-union and Congenital Pseudarthrosis. *J Bone Joint Surg Am* 1975;57:368.

! 49. Briner J, Yunis E. Ultrastructure of Congenital Pseudarthrosis of the Tibia. *Arch Pathol* 1973;95:97.

# 50. Brooks WC, Gross RH. Genu Varum in Children: Diagnosis and Treatment. *J Am Acad Orthop Surg* 1995;3:326.

+ 51. Brougham DI, Nicole RO. Valgus Deformity after Proximal Tibial Fractures in Children. *J Bone Joint Surg Br* 1987;69:482.

+ 52. Brown GA, Osebold WR, Ponseti IV. Congenital Pseudoarthrosis of Long Bones: A Clinical, Radiographic, Histologic and Ultrastructure Study. *Clin Orthop* 1977;128:228.

+ 53. Caffey J. Prenatal Bowing and Thickening of Tubular Bones with Multiple Cutaneous Dimples in the Arms and Legs. *Am J Dis Child* 1946;74:543.

+ 54. Caffey JP. *Pediatric X-ray Diagnosis,* 7th ed. Chicago: Year Book Medical Publishers, 1978.

+ 55. Cahuzac JPH, Vardon D, Sales de Gauzy J. Development of the Clinical Tibiofemoral Angle in Normal Adolescents: A Study of 427 Normal Subjects from 10 to 16 Years of Age. *J Bone Joint Surg Br* 1995;77:729.

+ 56. Campanacci M, Nicoll EA, Pagella P. Differential Diagnosis of Congenital Pseudarthrosis of the Tibia. *Int Orthop* 1981;4:283.

! 57. Canale ST, Harper MC. Biotrigonometric Analysis and Practical Applictions of Osteotomies of the Tibia in Children. *Instr Course Lect* 1981;30:85.

+ 58. Canale ST, Russell RA, Holcomb RL. Percutaneous Epiphysiodesis: Experimental Study and Preliminary Clinical Results. *J Pediatr Orthop* 1986;6:150.

+ 59. Carter JR, Leeson MC, Thompson GH, et al. Late-onset Tibia Vara: A Histopathologic Analysis: A Comparative Analysis with Infantile Tibia Vara and Slipped Capital Femoral Epiphysis. *J Pediatr Orthop* 1988;8:187.

+ 60. Carter JR, Thompson GH, Leeson MC, et al. Physeal Histopathology in Late-onset Tibia Vara. In: Uthoff HK, Wiley JJ, eds. *Behavior of the Growth Plate.* New York: Raven Press, 1988:285.

! 61. Carvell JE. The Relationship of the Periosteum to Angular Deformities of Long Bones: Experimental Operations in Rabbits. *Clin Ortho* p 1983;173:262.

+ 62. Cattell HS, Levin S, Kopits S, Lyne ED. Reconstructive Surgery in Children with Azotemic Osteodystrophy. *J Bone Joint Surg Am* 1971;53:216.

+ 63. Charnely J. Congenital Pseudarthrosis of the Tibia Treated by the Intramedullary Nail. *J Bone Joint Surg Am* 1956;38:283.

+ 64. Chen CW, Yu ZJ, Wang Y. A New Method of Treatment of Congenital Pseudarthrosis Using Free Vascularized Fibular Graft: A Preliminary Report. *Ann Acad Med Singapore* 1979;8:465.

+ 65. Cheng JC, Chan PS, Chiang SC, Hui PW. Angular and Rotational Profile of the Lower Limb in 2630 Chinese Children. *J Pediatr Orthop* 1991;11:154.

+ 66. Coates R. Knock-knee Deformity Following Upper Tibial “Greenstick” Fractures. *J Bone Joint Surg Br* 1977;59:516.

+ 67. Cockshott WP, Martin R, Friedman L, Yuen M. Focal Fibrocartilaginous Dysplasia and Tibia Vara: A Case Report. *Skeletal Radiol* 1994;23:333.

+ 68. Coleman SS, Coleman DA. Congenital Pseudarthrosis of the Tibia: Treatment by Transfer of the Ipsilateral Fibula with Vascular Pedicle. *J Pediatr Orthop* 1994;14:156.

! 69. Cook SD, Lavernia CJ, Burke SW, et al. A Biomechanical Analysis of the Etiology of Tibia Vara. *J Pediatr Orthop* 1983;3:449.

! 70. Cooper RR, Misol S. Tendon and Ligament Insertion: A Light and Electron Microscopy Study. *J Bone Joint Surg Am* 1970;52:1.

+ 71. Cozen L. Knock-knee Deformity after Fracture of the Proximal Tibia in Children. *Orthopaedics* 1959;1:230.

* 72. Cozen L. Fracture of the Proximal Portion of the Tibia in Children Followed by Valgus Deformity. *Surg Gynecol Obstet* 1953;97:183.

# 73. Crawford AH. Neurofibromatosis in Childhood. *Instr Course Lect* 1981;30:56.

+ 74. Crossett LS, Beaty JH, Betz RR, et al. Congenital Pseudarthrosis of the Tibia: Long-term Follow-up Study. *Clin Orthop* 1989;245:16.

+ 75. Crutchow WP, David DS, Witsell J. Multiple Skeletal Complications in a Case of Chronic Renal Failure Treated by Kidney Homotransplantation. *Am J Med* 1971;50:390.

+ 76. Currarino G, Pickney LE. Genu Valgum after Proximal Tibial Fractures in Children. *AJR* 1981;136:915.

+ 77. Curriano G, Kirks DR. Lateral Widening of Epiphyseal Plates in Knees of Children with Bowed Legs. *AJR* 1977;129:309.

+ 78. Dalinka MD, Coren G, Hensinger RN, Irani RN. Arthrography in Blount's Disease. *Radiology* 1974;113:161.

+ 79. DalMonte A, Donzelli O, Sudanese A, Baldini N. Congenital Pseudarthrosis of the Fibula. *J Pediatr Orthop* 1987;7:14.

+ 80. DalMonte A, Manes E, Cammarota V. Post-traumatic Genu Valgum in Children. *Ital J Orthop Traumatol* 1985;11:5.

+ 81. Davids JR, Fisher R, Lumbar G, Von Glinski S. Angular Deformity of the Lower Extremity in Children with Renal Osteodystrophy. *J Pediatr Orthop* 1992;12:291.

+ 82. Davidson WH, Bohne WHO. The Syme Amputation in Children. *J Bone Joint Surg Am* 1975;57:905.

+ 83. Dawson GR. Intra-uterine Fracture of the Tibia and Fibula: Report of a Case with Correction by Osteotomy and Plating. *J Bone Joint Surg Am* 1949;31:406.

+ 84. DeBoer HH, Verbout AJ, Nielsen HK, van der Eijken JW. Free Vascularized Fibular Graft for Tibial Pseudarthrosis in Neurofibromatosis. *Acta Orthop Scand* 1988;59:425.

# 85. Delgado-Martinez AD, Rodriguez-Merchan EC, Olsen B. Current Concepts: Congenital Pseudarthrosis of the Tibia. *Int Orthop* 1996;20:192.

+ 86. DePablos J, Franzreb M. Treatment of Adolescent Tibia Vara by Asymmetrical Physeal Distraction. *J Bone Joint Surg Br* 1993;75:592.

+ 87. DePablos J, Azcaráte J, Barrios C. Progressive Opening-wedge Osteotomy for Angular Long-bone Deformities in Adolescents. *J Bone Joint Surg Br* 1995;77:387.

+ 88. deSanctis N, Della Corte S, Pempinello C, et al. Infantile Type of Blount's Disease: Complications concerning Etiopathogenesis and Treatment. *J Pediatr Orthop B* 1995;4:200.

# 89. Dias LS. Fractures of the Tibia and Fibula. In: Rockwood CH Jr, Wilkens KE, King RE, eds. *Fractures in Children.* Philadelphia: JB Lippincott Co, 1984:983.

+ 90. Dietz FR, Weinstein SL. Spike Osteotomy for Angular Deformities of the Long Bones in Children. *J Bone Joint Surg* 1988;70:848.

+ 91. Dietz WH Jr, Gross WL, Kirkpatrick JA Jr. Blount Disease (Tibia Vara): Another Skeletal Disorder Associated with Childhood Obesity. *J Pediatr* 1982;101:735.

+ 92. Dooley BJ, Menelaus MB, Paterson DC. Congenital Pseudarthrosis and Bowing of the Fibula. *J Bone Joint Surg Br* 1974;56:739.

+ 93. Dormans JP, Krajbich JL, Zucker R, Demuynk M. Congenital Pseudarthrosis of the Tibia: Treatment with Free Vascularized Fibular Grafts. *J Pediatr Orthop* 1990;10:623.

+ 94. Engel GM, Staheli LT. The Natural History of Torsion and Other Factors Influencing Gait in Childhood: A Study of the Angle of Gait, Tibial Torsion, Knee Angle, Hip Rotation and Development of the Arch in Normal Children. *Clin Orthop* 1974;99:12.

+ 95. Erlacher P. Deformierende Prozesse der Epiphysengegend bei Kindern. *Arch Orthop Unfallchir* 1922;20:81.

+ 96. Evans GA, Arulanantham K, Gage JR. Primary Hypophosphatemic Rickets: Effects of Oral Phosphate and Vitamin D on Growth and Surgical Treatment. *J Bone Joint Surg Am* 1980;62:1130.

+ 97. Evensen A, Steffenson J. Tibia Vara (Osteochondrosis Deformans Tibiae). *Acta Orthop Scand* 1957;16:200.

+ 98. Eyre-Brook HL, Bailey RAJ, Price CHG. Infantile Pseudarthrosis of the Tibia: Three Cases Treated Successfully by Delayed Autogenous Bypass Graft with Some Comments on the Causative Lesion. *J Bone Joint Surg Br* 1969;51:604.

+ 99. Fabry G, Lammens J, van Melkebeek J, Stuyck J. Treatment of Congenital Pseudarthrosis with the Ilizarov Technique. *J Pediatr Orthop* 1988;8:67.

+ 100. Farmer AW. The Use of a Composite Pedicle Graft for Pseudarthrosis of the Tibia. *J Bone Joint Surg Am* 1952;34:591.

+ 101. Feldman MD, Schoenecker PL. Use of the Metaphyseal–Diaphyseal Angle in the Evaluation of Bowed Legs. *J Bone Joint Surg Am* 1995;75:1602.

+ 102. Fern ED, Stockley I, Bell MJ. Extending Intramedullary Rods in Congenital Pseudarthrosis of the Tibia. *J Bone Joint Surg Br* 1990;72:1073.

+ 103. Ferriter P, Shapiro F. Infantile Tibia Vara: Factors Affecting Outcome Following Proximal Tibial Osteotomy. *J Pediatr Orthop* 1987,7:1.

+ 104. Foreman KA, Robertson WW Jr. Radiographic Measurement of Infantile Tibia Vara. *J Pediatr Orthop* 1985;5:452.

+ 105. Fraser RK, Dickens DRV, Cole WG. Medial Physeal Stapling for Primary and Secondary Genu Valgum in Late Childhood and Adolescence. *J Bone Joint Surg Br* 1995;77:733.

+ 106. Fraser W. Congenital Pseudarthrosis of the Tibia. *J Bone Joint Surg Br* 1964;46:167.

* 107. Freund E. Congenital Defect of Femur, Fibula, and Tibia. *Arch Surg* 1936;33:349.

+ 108. Gilbert A, Brockman R. Congenital Pseudarthrosis of the Tibia: Long-term Follow-up of 29 Cases Treated by Microvascular Bone Transfer. *Clin Orthop* 1995;314:37.

# 109. Goff CW. *Surgical Treatment of Unequal Extremities.* Springfield, IL: Charles C Thomas, 1960.

+ 110. Golding JSR, Bateson EM, McNeil-Smith JDG. Infantile Tibia Vara (Blount's Disease or Osteochondrosis Deformans Tibiae) In: Rang M, ed. *The Growth Plate and its Disorders.* Edinburgh: Churchill Livingstone, 1969:10.

+ 111. Golding JSR, McNeil-Smith JDG. Observations on the Etiology of Tibia Vara. *J Bone Joint Surg Br* 1963;45:320.

+ 112. Gordon L, Weulker N, Jergensen H. Vascularized Fibular Grafting for the Treatment of Congenital Pseudarthrosis of the Tibia. *Orthopaedics* 1986;9:825.

+ 113. Green NE. Tibia Valga Caused by Asymmetrical Overgrowth Following a Nondisplaced Fracture of the Proximal Tibial Metaphysis. *J Pediatr Orthop* 1983;3:235.

+ 114. Green WT, Rudo N. Pseudarthrosis and Neurofibromatosis. *Arch Surg* 1943;46:639.

# 115. Greene WB. Genu Varum and Genu Valgum in Children. *Instr Course Lect* 1994;43:151.

# 116. Greene WB. Instructional Course Lecture: Infantile Tibia Vara. *J Bone Jont Surg Am* 1993;75:130.

+ 117. Gregosiewicz A, Wosko I, Kandzierski G, Drabik Z. Double-elevating Osteotomy of Tibiae in the Treatment of Severe Cases of Blount's Disease. *J Pediatr Orthop* 1989;9:178.

! 118. Greulich WW, Pyle SI. *Radiographic Atlas of Skeletal Development of the Hand and Wrist.* Stanford, CA: Stanford University Press, 1959.

+ 119. Grill F. Treatment of Congenital Pseudarthrosis of the Tibia with the Circular Frame Technique. *J Pediatr Orthop B* 1996;5:6.

# 120. Grogan DP, Love SM, Ogden JA. Congenital Malformations of the Lower Extremities. *Orthop Clin North Am* 1987;18:537.

+ 121. Hagan KF, Buncke HJ. Treatment of Congenital Pseudarthrosis of the Tibia with Free Vascularized Bone Graft. *Clin Orthop* 1982;166:34.

+ 122. Hägglund G, Ingvarsson T, Ramgren B, Zayer M. Metaphyseal–Diaphyseal Angle in Blount's Disease: A 30-year Follow-up of 13 Unoperated Children. *Acta Orthop Scand* 1997;68:167.

+ 123. Hansen BA, Greiff J, Bergmann F. Fractures of the Tibia in Children. *Acta Orthop Scand* 1976;47:448.

+ 124. Hanson LI, Zayer M. Physiologic Genu Varum. *Acta Orthop Scand* 1975;46:221.

+ 125. Hardinge K. Congenital Anterior Bowing of the Tibia. *Ann R Coll Surg* 1972;51:17.

+ 126. Heath CH, Staheli LT. Normal Limits of Knee Angles in White Children: Genu Varum and Genu Valgum. *J Pediatr Orthop* 1993;13:259.

+ 127. Henderson RC, Green WB. Etiology of Late-onset Tibia Vara: Is Varus Alignment a Prerequisite? *J Pediatr Orthop* 1994;14:143.

+ 128. Henderson RC, Kemp GJ Jr, Greene WB. Adolescent Tibia Vara: Alternatives for Operative Treatment. *J Bone Joint Surg Am* 1992;74:342.

+ 129. Henderson RC, Kemp GJ Jr, Hayes PRL. Prevalence of Late-onset Tibia Vara. *J Pediatr Orthop* 1993;13:255.

+ 130. Henderson RC, Lechner CT, Demasi RA, Greene WB. Variability in Radiographic Measurement of Bowleg Deformity in Children. *J Pediatr Orthop* 1990;10:491.

+ 131. Herman TE, Siegel MJ, McAlister WH. Focal Fibrocartilaginous Dysplasia Associated with Tibia Vara. *Radiology* 1990;177:767.

+ 132. Herring JA. Instructional Case: Valgus Knee Deformity—Etiology and Treatment. *J Pediatr Orthop* 1983;3:527.

+ 133. Herring JA, Moseley C. Post-traumatic Valgus Deformity of the Tibia: Instructional Case. *J Pediatr Orthop* 1981;1:435.

+ 134. Herring JA, Barnhill B, Gaffney C. Syme Amputation: An Evaluation of the Physical and Psychological Function in Young Patients. *J Bone Joint Surg Am* 1986;68:573.

+ 135. Heyman CH, Herndon CH. Congenital Posterior Angulation of the Tibia. *J Bone Joint Surg Am* 1949;31:571.

+ 136. Heyman CH, Herndon CH, Heiple KG. Congenital Posterior Angulation of the Tibia with Talipes Calcaneus: A Long-term Report of Eleven Patients. *J Bone Joint Surg Am* 1959;41:476.

+ 137. Hofmann A, Jones RE, Herring JA. Blount's Disease after Skeletal Maturity. *J Bone Joint Surg Am* 1982;64:1004.

+ 138. Hofmann A, Wenger DR. Posteromedial Bowing of the Tibia: Progression of Discrepancy in Leg Lengths. *J Bone Joint Surg Am* 1981;63:384.

! 139. Houghton GR, Dekel S. The Periosteal Control of Long Bone Growth. *Acta Orthop Scand* 1979;50:635.

! 140. Houghton GR, Rooker GD. The Role of the Periosteum in the Growth of Long Bones: An Experimental Study in the Rabbit. *J Bone Joint Surg Br* 1979;61:218.

+ 141. Howorth B. Knock Knees: With Special Reference to the Stapling Operation. *Clin Orthop* 1971;77:233.

+ 142. Hresko MT, Kasser JR. Physeal Arrest about the Knee Associated with Non-physeal Fractures in the Lower Extremity. *J Bone Joint Surg Am* 1989;71:698.

+ 143. Hsu AC, Kooh SW, Fraser D, et al. Renal Osteodystrophy in Children with Chronic Renal Failure: An Unexpectedly Common and Incapacitating Complication. *Pediatrics* 1982;70:742.

+ 144. Huang SC, Yip KM. Treatment of Congenital Pseudarthrosis of the Tibia with Ilizarov Method. *J Formos Med Assoc* 1997;96:359.

+ 145. Husien AM, Kale VR. Tibia Vara Caused by Focal Fibrocartilaginous Dysplasia. *Clin Radiol* 1989;40:104.

+ 146. Ippolito E, Pentamalli S. Post-traumatic Valgus Deformity of the Knee in Proximal Metaphyseal Fractures in Children. *Ital J Orthop Traumatol* 1984;10:103.

+ 147. Jackson DW, Cozen L. Genu Valgum as a Complication of Proximal Tibial Metaphyseal Fractures in Children. *J Bone Joint Surg Am* 1971;53:1571.

+ 148. Jackson JP, Waugh W. The Technique and Complications of Upper Tibial Osteotomy: A Review of 226 Operations. *J Bone Joint Surg Br* 1974;56:236.

+ 149. Jacobsen ST, Crawford AH, Millar EA, Steel HH. The Syme Amputation in Patients with Congenital Pseudarthrosis of the Tibia. *J Bone Joint Surg Am* 1983;65:533.

+ 150. Johnson PH. Beware: Greenstick Fractures of the Proximal Tibial Metaphysis. *J Arkansas Med Soc* 1983;80:215.

+ 151. Johnston CE II. Infantile Tibia Vara. *Clin Orthop* 1990;225:13.

+ 152. Jones GB, Poiakoff SJ, Bright RW. Surgical Correction of Severe Blount's Disease by Physeal Bridge Resection and Silastic Interposition. *J Bone Joint Surg Br* 1988;70:680.

+ 153. Jordan SE, Alonso JE, Cook FF. The Etiology of Valgus Angulation after Metaphyseal Fractures of the Tibia in Children. *J Pediatr Orthop* 1987;7:450.

+ 154. Kanaya F, Tsai TM, Harkness J. Vascularized Bone Grafts for Congenital Pseudarthrosis of the Tibia. *Microsurgery* 1996;17:459.

+ 155. Kariya Y, Taniguchi K, Yagisawa H, Ooi Y. Focal Fibrocartilaginous Dysplasia: Consolidation of Healing Process. *J Pediatr Orthop* 1991;11:545.

+ 156. Karol LA, Haideri NF, Halliday SE, et al. Gait Analysis and Muscle Strength in Children with Congenital Pseudarthrosis of the Tibia: The Effect of Treatment. *J Pediatr Orthop* 1998;18:381.

+ 157. Kessel L. Annotations on the Etiology and Treatment of Tibia Vara. *J Bone Joint Surg Br* 1970;52:93.

+ 158. Khermosh O, Weintroub S. Serrated (W/M) Osteotomy: A New Technique for Simultaneous Correction of Angular and Torsional Deformity of the Lower Limb in Children. *J Pediatr Orthop B* 1995;4:204.

+ 159. Klassen RA, Peterson HA. Resection of Epiphyseal Bars. *Orthop Trans* 1982;6:134.

+ 160. Kline SC, Bostrum M, Griffin PP. Femoral Varus: An Important Component in Late-onset Blount's Disease. *J Pediatr Orthop* 1992;12:197.

# 161. Kling TF Jr. Angular Deformities of the Lower Limbs in Children. *Orthop Clin North Am* 1987;18:513.

+ 162. Kling TF Jr. Tibia Vara: A Mechanical Problem. *Orthop Trans* 1981;5:138.

# 163. Kling TF Jr, Hensinger RN. Angular and Torsional Deformities of the Lower Limbs in Children. *Clin Orthop* 1983;176:136.

+ 164. Kort JS, Schink MM, Mitchell SN, Bassett CAL. Congenital Pseudarthrosis of the Tibia: Treatment with Pulsating Electromagnetic Fields. The International Experience. *Clin Orthop* 1982;165:124.

+ 165. Krida A. Congenital Posterior Angulation of the Tibia: A Clinical Entity Unrelated to Congenital Pseudoarthrosis. *Am J Surg* 1951;82:98.

+ 166. Kruse RN, Bowen JR, Heithoff S. Oblique Tibial Osteotomy in the Correction of Tibial Deformity in Children. *J Pediatr Orthop* 1989;9:476.

+ 167. Langenskiöld A. Tibia Vara: A Critical Review. *Clin Orthop* 1989;246:195.

+ 168. Langenskiöld A. Tibia Vara: Osteochondrosis Deformans Tibiae—Blount's Disease. *Clin Orthop* 1981;158:77.

+ 169. Langenskiöld A. An Operation for Partial Closure of an Epiphyseal Plate in Children and its Experiential Basis. *J Bone Joint Surg Br* 1975;57:325.

+ 170. Langenskiöld A. Pseudarthrosis of the Fibula with Progressive Valgus Deformity of the Ankle in Children: Treatment by Fusion of the Distal Tibial and Fibular Metaphysis: Review of 3 Cases. *J Bone Joint Surg Am* 1967;49:463.

+ 171. Langenskiöld A. Aspects of the Pathology of Tibia Vara. *Ann Chir Gynaecol* 1955;44:58.

* 172. Langenskiöld A. Tibia Vara (Osteochondrosis Deformans Tibiae): A Survery of 23 Cases. *Acta Chir Scand* 1952;103:1.

+ 173. Langenskiöld A, Riska EB. Tibia Vara (Osteochondrosis Deformans Tibiae): A Survey of Seventy-one Cases. *J Bone Joint Surg Am* 1962;46:1405.

+ 174. Laurencin CT, Ferriter PJ, Millis MB. Oblique Proximal Tibial Ostoeomty for the Correction of Tibia Vara in the Young. *Clin Orthop* 1996;327:218.

+ 175. Leung PC. Congenital Pseudarthrosis of the Tibia: Three Cases Treated by Free Vascularized Iliac Crest Graft. *Clin Orthop* 1983;175:45.

+ 176. Levine AM, Drennan JC. Physiologic Bowing and Tibia Vara: The Metaphyseal–Diaphyseal Angle in the Measurement of Bowleg Deformities. *J Bone Joint Surg Am* 1982;64:1158.

+ 177. Lichtblau PO, Waxman BA. Blount's Disease: Review of the Literature and Description of a New Surgical Procedure. *Contemp Orthop* 1981;3:526.

+ 178. Lincoln TL, Birch JG. Focal Fibrocartilaginous Dysplasia in the Upper Extremity. *J Pediatr Orthop* 1997;17:528.

+ 179. Lloyd-Roberts GC, Shaw NE. The Prevention of Pseudarthrosis in Congenital Kyphosis of the Tibia. *J Bone Joint Surg Br* 1969;51:100.

+ 180. Loder RT, Johnston CE II. Infantile Tibia Vara. *J Pediatr Orthop* 1987;7:639.

+ 181. Loder RT, Schaffer JJ, Bardenstein JA. Late-onset Tibia Vara. *J Pediatr Orthop* 1991;11:162.

+ 182. Lovejoy JF Jr, Lovell WW. Adolescent Tibia Vara Associated with Slipped Capital Femoral Epiphysis: Report of Two Cases. *J Bone Joint Surg Am* 1970;52:361.

# 183. MacEwen GD, Zionts LE. Proximal Tibial Fractures in Children. In: Uhthoff HK, Wiley JJ, eds. *Behavior of the Growth Plate.* New York: Raven Press, 1988:141.

+ 184. Mahnken RF, Yngve DA. Valgus Deformity Following Fracture of the Tibial Metaphysis. *Orthopaedics* 1988;11:1320.

+ 185. Martin SD, Moran MC, Martin TL, Burke SW. Proximal Tibial Osteotomy with Compression Plate Fixation for Tibia Vara. *J Pediatr Orthop* 1994;14:619.

+ 186. Masserman RL, Peterson HA, Bianco AJ Jr. Congenital Pseudarthrosis of the Tibia: A Review of the Literature and 52 Cases at the Mayo Clinic. *Clin Orthop* 1974;99:140.

+ 187. Matsen FA III, Steheli LT. Neurovascular Complications Following Tibial Osteotomy in Children. *Clin Orthop* 1975;110:210.

+ 188. McCarthy JJ, Kim DH, Eilert RE. Posttraumatic Genu Valgum: Operative versus Nonoperative Treatment. *J Pediatr Orthop* 1998;18:518.

+ 189. McCarthy RE. Amputation for Congenital Pseudarthrosis of the Tibia: Indications and Techniques. *Clin Orthop* 1982;166:58.

# 190. McDade W. Bow Legs and Knock Knees. *Pediatr Clin North Am* 1977;24:825.

+ 191. McFarland B. Pseudarthrosis of the Tibia in Childhood. *J Bone Joint Surg Br* 1951;33:36.

+ 192. Meyer JS, Davidson RS, Hubbard AM, Conrad KA. MRI of Focal Fibrocartilaginous Dysplasia. *J Pediatr Orthop* 1995;15:304.

+ 193. Mielke CH, Stevens PM. Hemiepiphyseal Stapling for Knee Deformities in Children Younger than 10 Years: A Preliminary Report. *J Pediatr Orthop* 1996;16:423.

+ 194. Miller BF. Congential Posterior Bowing of the Tibia with Talipes Equinovarus. *J Bone Joint Surg Br* 1951;33:50.

+ 195. Monticelli G, Spinelli R. A New Method of Treating the Advanced Stages of Tibia Vara (Blount's Disease). *Ital J Orthop Traumatol* 1984;10:295.

+ 196. Mooney JF III, Moore R, Sekiya J, Koman LA. Congenital Pseudarthrosis of the Tibia Treated with Free Vascularized Fibular Graft. *J South Orthop Assoc* 1997;6:227.

# 197. Morley AJM. Knock Knees in Children. *Br Med J* 1957;2:976.

+ 198. Morrissey RT. Congenital Pseudarthrosis of the Tibia: Factors that Affect Results. *Clin Orthop* 1982;166:21.

+ 199. Morrissey RT, Riseborough EJ, Hall JE. Congenital Pseudarthrosis of the Tibia. *J Bone Joint Surg Br* 1981;63:367.

+ 200. Moseley CF. A Straight-line Graph for Leg-length Discrepancies. *J Bone Joint Surg Am* 1977;59:174.

+ 201. Moss MC, Davies MS, Simonis RB. Curly and Overlapping Toes in Congenital Pseudarthrosis of the Tibia. *J Bone Joint Surg Br* 1994;76:983.

+ 202. Mubarak SJ, Carroll NC. Volkmann's Contracture in Children: Aetiology and Prevention. *J Bone Joint Surg Br* 1979;61:285.

+ 203. Murray HH, Lovell WW. Congenital Pseudarthrosis of the Tibia: A Long-term Follow-up Study. *Clin Orthop* 1982;166:14.

+ 204. Mycoskie PJ. Complications of Osteotomies about the Knee in Children. *Orthopaedics* 1981;4:1005.

# 205. Ogden JA. Tibia and Fibula. In Ogden JA, ed. *Skeletal Injury in the Child.* Phildelphia: Lea & Febiger, 1990:787.

+ 206. Ogden JA, Ogden DA, Pugh L, et al. Tibia Valga after Proximal Metaphyseal Fractures in Childhood: A Normal Biologic Response. *J Pediatr Orthop* 1995;15:489.

+ 207. Ogilvie JW, King K. Epiphysiodesis: Two-year Clinical Results Using a New Technique. *J Pediatr Orthop* 1990;10:809.

+ 208. Olney BW, Cole WG, Menelaus MB. Case Report: Three Additional Cases of Focal Fibrocartilaginous Dysplasia Causing Tibia Vara. *J Pediatr Orthop* 1990;10:405.

+ 209. Omokawa S, Tamai S, Takakura Y, et al. A Long-term Study of the Donor-site Ankle after Vascularized Fibula Grafts in Children. *Microsurgery* 1996;17:162.

+ 210. Oppenheim WL, Shayestehfar BS, Salusky IB. Tibial Physeal Changes in Renal Osteodystrophy: Lateral Blount's Disease. *J Pediatr Orthop* 1992;12:774.

+ 211. Paley D, Catagni M, Argnani F, et al. Treatment of Congenital Pseudarthrosis of the Tibia Using the Ilizarov Technique. *Clin Orthop* 1992;280:81.

+ 212. Pappas AM. Congenital Posteromedial Bowing of the Tibia and Fibula. *J Pediatr Orthop* 1984;4:525.

+ 213. Paterson D. Congenital Pseudarthrosis of the Tibia: An Overview. *Clin Orthop* 1989;247:44.

+ 214. Paterson DC, Simonis RB. Electrical Stimulation in the Treatment of Congenital Pseudarthrosis of the Tibia. *J Bone Joint Surg Br* 1985;67:454.

+ 215. Paterson DC, Lewis GH, Cass CA. Treatment of Congenital Pseudarthrosis of the Tibia with Direct Current Stimulation. *Clin Orthop* 1980;148:129.

+ 216. Pauwels F. Grundriss einer Biomechanik der Fraktur Heilung. *Verh Dtsch Orthop Gesell* 1940;34:62.

+ 217. Peterson HA. Partial Growth Arrest and Its Treatment. *J Pediatr Orthop* 1984;4:246.

* 218. Phemister DB. Operative Arrestment of Longitudinal Growth of Long Bones in the Treatment of Deformities. *J Bone Joint Surg* 1933;15:1.

+ 219. Pho RWH, Levack B. Preliminary Observations of Epiphyseal Growth Rate in Congenital Pseudarthrosis of the Tibia after Free Vascularized Fibular Graft. *Clin Orthop* 1986;206:148.

+ 220. Pho RWH, Levack B, Satku K, Patradul A. Free Vascularised Fibula Graft in the Treatment of Congenital Pseudarthrosis of the Tibia. *J Bone Joint Surg Br* 1985;67:64.

+ 221. Pistevos G, Duckworth T. The Correction of Genu Valgum by Epiphyseal Stapling. *J Bone Joint Surg Br* 1977;59:72.

+ 222. Pitkow RB. External Rotation Contracture of the Extended Hip: A Common Phenomenon of Infancy Obscuring Femoral Neck Anteversion and the Most Frequent Cause of Out-toeing in Children. *Clin Orthop* 1975;110:139.

+ 223. Pitzen P, Marquardt WO. Beinbildung durch Umschriebene Epiphysen Wachstumsstörung (Tibia Vara Bilbung). *Z Orthop* 1939;69:174.

+ 224. Plawecki S, Carpentier E, Lascombes P, et al. Treatment of Congenital Pseudarthrosis of the Tibia by the Ilizarov Method. *J Pediatr Orthop* 1990;10:786.

+ 225. Pompe van Meedervort HF. Infantile Pseudarthrosis of the Tibia. *J Bone Joint Surg Br* 1978;60:296.

+ 226. Potthoff H. Ein Beitrag zur Behandlung der Proximalen Metaphysaren Tibia Fraktur in Kindesalter. *Aktuel Traumatol* 1982;12:127.

+ 227. Price CT, Scott DS, Greenberg DA. Dynamic Axial External Fixation in the Surgical Treatment of Tibia Vara. *J Pediatr Orthop* 1995;15:236.

+ 228. Purvis GD, Holder JE. Dual Bone Graft for Congenital Pseudoarthrosis of the Tibia: Variations of Technic. *South Med J* 1960;53:926.

+ 229. Rab GT. Oblique Tibial Osteotomy for Blount's Diesase. *J Pediatr Orthop* 1988;8:715.

# 230. Rang M. *Children's Fractures.* Philadelphia: JB Lippincott Co, 1974;189.

+ 231. Rathgeb JM, Ramsey PL, Cowell HR. Congenital Kyphoscoliosis of the Tibia. *Clin Orthop* 1974;103:178.

+ 232. Richards BS, Katz DE, Sims JB. Effectiveness of Brace Treatment in Early Infantile Blount's Disease. *J Pediatr Orthop* 1998;18:374.

+ 233. Riseborough EJ, Barrett IR, Shapiro F. Growth Disturbance Following Distal Femoral Physeal Fracture-separations. *J Bone Joint Surg Am* 1983;65:885.

+ 234. Roach JW, Shindell R, Green NE. Late-onset Pseudarthrosis of the Dysplastic Tibia. *J Bone Joint Surg Am* 1993;75:1593.

+ 235. Robert M, Khouri N, Carlioz H, Alain JL. Fractures of the Proximal Tibial Metaphysis in Children: Review of a Series of 25 Cases. *J Pediatr Orthop* 1987;7:444.

+ 236. Rabinowitz MS. Congenital Curvature of the Tibia with Talipes Calcaneo-valgus. *Bull Hosp Joint Dis* 1951;12:63.

# 237. Rooker GD, Coates RL. Deformity after Greenstick Fractures of the Upper Tibial Metaphysis. In: Houghton GR, Thompson GH, eds. *Problematic Musculoskeletal Injuries in Children.* London: Butterworth 1983:1.

+ 238. Rooker GD, Salter R. Prevention of Valgus Deformity Following Fracture of the Proximal Metaphysis of the Tibia in Children. *J Bone Joint Surg Br* 1980;62:527.

+ 239. Rubinovitch M, Said SE, Glorieuz FH, et al. Principles and Results of Corrected Lower Limb Osteotomies for Patients with Vitamin D–Resistant Hypophosphatemic Rickets. *Clin Orthop* 1988;237:264.

+ 240. Rydholm U, Brattstrom H, Bylander B, et al. Stapling of the Knee in Juvenile Chronic Arthritis. *J Pediatr Orthop* 1987;7:63.

+ 241. Sadiq SA, Varshney GK. Congenital Posterior Angulation of the Tibia. *Int Surg* 1977;62:48.

* 242. Salenius P, Vankka E. The Development of the Tibio-femoral Angle in Children. *J Bone Joint Surg Am* 1975;57:259.

# 243. Salter RB, Best TN. Pathogenesis of Progressive Valgus Deformity Following Fractures of the Proximal Metaphyseal Region of the Tibia in Young Children. *Instr Course Lect* 1992;45:409.

+ 244. Salter RB, Best T. The Pathogenesis and Prevention of Valgus Deformity Following Fractures of the Proximal Metaphyseal Region of the Tibia in Children. *J Bone Joint Surg Am* 1973;55:1324.

+ 245. Saski T, Yagi T, Monji J, et al. Transepiphyseal Plate Osteotomy for Severe Tibia Vara in Children: A Follow-up Study of Four Cases. *J Pediatr Orthop* 1986;6:61.

+ 246. Scheffer MM, Peterson HA. Opening-wedge Osteotomy for Angular Deformities of Long Bones in Children. *J Bone Joint Surg Am* 1994;76:325.

+ 247. Schoenecker PL, Johnston R, Rich MM, Capelli AM. Elevation of the Medial Plateau of the Tibia in the Treatment of Blount Disease. *J Bone Joint Surg Am* 1992;74:351.

+ 248. Schoenecker PL, Meade WC, Pierron RL, et al. Blount's Disease: A Retrospective Review and Recommendations for Treatment. *J Pediatr Orthop* 1985;5:181.

+ 249. Schrock RD Jr. Peroneal Nerve Palsy Following Derotation Osteotomies for Tibial Torsion. *Clin Orthop* 1969;62:172.

+ 250. Sevastikoglou JA, Eriksson I. Familial Infantile Osteochondrosis Deformans Tibiae: Idiopathic Tibia Vara: A Case Report. *Acta Orthop Scand* 1967;38:81.

+ 251. Sharrard WJW. Treatment of Congenital and Infantile Pseudarthrosis of the Tibia with Pulsing Electromagnetic Fields. *Orthop Clin North Am* 1984;15:143.

+ 252. Sherman M. Physiologic Bowing of the Legs. *South Med J* 1960;53:830.

+ 253. Sibert JR, Bray PT. Probable Dominant Inheritance in Blount's Diseae. *Clin Genet* 1977;11:394.

+ 254. Siegling JA, Gillespie JB. Adolescent Tibia Vara. *Radiology* 1939;32:483.

+ 255. Siffert RS. Intraepiphyseal Osteotomy for Progressive Tibia: Case Report and Rationale for Management. *J Pediatr Orthop* 1982;2:81.

+ 256. Siffert RS, Katz JF. The Intra-articular Deformity in Osteochondrosis Deformans Tibiae. *J Bone Joint Surg Am* 1970;52:800.

+ 257. Skak SV. Valgus Deformity Following Proximal Metaphyseal Fracture in Children. *Acta Orthop Scand* 1982;53:141.

+ 258. Skak SV, Toftgard T, Torben DP. Fractures of the Proximal Metaphysis of the Tibia in Children. *Injury* 1987;18:149.

+ 259. Smit CS, Zeeman BJ, Wade WJ. Congenital Pseudarthrosis of the Tibia: Treatment with Free Vascularised Fibular Grafts. *S Afr Med J* 1993;83:750.

# 260. Smith CF. Current Concepts Review: Tibia Vara (Blount's Disease). *J Bone Joint Surg Am* 1982;64:630.

+ 261. Smith DN, Harrison MHM. The Correction of Angular Deformities of Long Bones by Osteotomy–Osteoclasis. *J Bone Joint Surg Br* 1979;61:410.

+ 262. Sofield HA. Congenital Pseudarthrosis of the Tibia. *Clin Orthop* 1971;76:33.

+ 263. Steel HH, Sandrow RE, Sullivan PD. Complications of Tibial Osteotomy in Children for Genu Varum and Valgum: Evidence That Neurologic Changes Are Due to Ischemia. *J Bone Joint Surg Am* 1971;53:1629.

+ 264. Stricker SJ, Edwards PM, Tidwell MA. Langenskiöld Classification of Tibia Vara: An Assessment of Interobserver Variability. *J Pediatr Orthop* 1994;14:152.

+ 265. Stricker SJ, Faustgen JP. Radiographic Management of Bow Leg Deformity: Variability Due to Method and Limb Rotation. *J Pediatr Orthop* 1994;14:147.

+ 266. Strong ML, Wong-Chung J. Prophylactic Bypass Grafting of the Prepseudarthrotic Tibia in Neurofibromatoses. *J Pediatr Orthop* 1991;11:757.

+ 267. Sutcliffe ML, Goldberg AAJ. The Treatment of Congenital Pseudarthrosis of the Tibia with Pulsating Electromagnetic Fields: A Survey of 52 Cases. *Clin Orthop* 1982;166:45.

# 268. Tachdjian MO. Angular Deformities of the Long Bones of the Lower Limbs. In: Tachdjian MO, ed. *Pediatric Orthopaedics.* Philadelphia: WB Saunders, 1990:2820.

# 269. Tachdjian MO. Congenital Posteromedial Angulation of the Tibia and Fibula. In: Tachdjian MO, ed. *Pediatric Orthopaedics.* Philadelphia: WB Saunders, 1990:651.

# 270. Tachdjian MO. “Congenital” Pseudarthrosis of the Tibia. In: Tachdjian MO, ed. *Pediatric Orthopaedics.* Philadelphia: WB Saunders, 1990:656.

+ 271. Tanguy AF, Dalens BJ, Boisgard S. Congenital Constricting Band with Pseudarthrosis of the Tibia and Fibula: A Case Report. *J Bone Joint Surg Am* 1995;77:1251.

+ 272. Taylor GI, Miller, GDH, Ham FJ. The Free Vascularized Bone Graft: A Clinical Extension of Microvascular Techniques. *Plast Reconstr Surg* 1975;55:533.

+ 273. Taylor SL. Tibial Overgrowth: A Cause of Genu Valgum. *J Bone Joint Surg Am* 1963;45:659.

+ 274. Thompson GH, Carter JR. Late-onset Tibia Vara (Blount's Disease): Current Concepts. *Clin Orthop* 1990;255:24.

* 275. Thompson GH, Carter JR, Smith CW. Late-onset Tibia Vara: A Comparative Analysis. *J Pediatr Orthop* 1984;4:185.

+ 276. Timperlake RW, Bowen JR, Guille JT, Choi IH. Prospective Evaluation of Fifty-three Consecutive Percutaneous Epiphysiodeses of the Distal Femur and Proximal Tibia and Fibula. *J Pediatr Orthop* 1991;11:350.

+ 277. Townsend PL. Vascularized Fibular Graft Using Reverse Peroneal Flow in the Treatment of Congenital Pseudarthrosis of the Tibia. *Br J Plast Surg* 1990;43:261.

+ 278. Umber JS, Moss SW, Coleman SS. Surgical Treatment of Congenital Pseudarthrosis of the Tibia. *Clin Orthop* 1982;166:28.

+ 279. Vankka E, Salenius P. Spontaneous Correction of Severe Tibiofemoral Deformity in Growing Children. *Acta Orthop Scand* 1982;53:567.

+ 280. Verhelst MP, Spaas FM, Fabry G. Progressive Valgus Deformity of the Knee after Resection of an Exostosis at the Proximal Medial Tibial Metaphysis: A Case Report. *Acta Orthop Belg* 1975;41:689.

+ 281. Visser JD, Veldhuizen AG. Valgus Deformity after Fracture of the Proximal Tibial Metaphysis in Childhood. *Acta Orthop Scand* 1982;53:663.

+ 282. Volpon JB. Idiopathic Genu Valgum Treated by Epiphysiodesis in Adolescence. *Int Orthop* 1997;21:228.

+ 283. Weber BG. Fibrous Interposition Causing Valgus Deformity after Fracture of the Upper Tibial Metaphysis in Children. *J Bone Joint Surg Br* 1977;59:290.

# 284. Weiland AJ. Vascularized Bone Transfers. *Instr Course Lect* 1984;33:446.

+ 285. Weiland AJ, Weis APC, Moore JR, Tolo VT. Vascularized Fibular Graft in the Treatment of Congenital Pseudarthrosis of the Tibia. *J Bone Joint Surg Am* 1990,72:654.

+ 286. Wenger DR, Mickelson M, Maynard JA. The Evolution and Histopathology of Adolescent Tibia Vara. *J Pediatr Orthop* 1984;4:78.

# 287. White GR, Mencio GA. Genu Valgum in Children: Diagnosis and Therapeutic Alternatives. *J Am Acad Orthop Surg* 1995;3:275.

+ 288. Yadav SS, Thomas S. Congenital Posteromedial Bowing of the Tibia. *Acta Orthop Scand* 1980;51:311.

+ 289. Zayer M. Hemicondylar Tibial Osteotomy in Blount's Disease: A Report of 2 Cases. *Acta Orthop Scand* 1992;63:350.

+ 290. Zayer M. Tibia Vara in Focal Fibrocartilaginous Dysplasia: A Report of 2 Cases. *Acta Orthop Scand* 1992;63:353.

+ 291. Zayer M. Osteoarthritis Following Blount's Disease. *Int Orthop* 1980;4:63.

+ 292. Zionts L, Harcke TH, Brooks KM, MacEwen GD. Post-traumatic Tibia Valga: A Case Demonstrating Asymmetric Activity of the Proximal Growth Plate on Technetium Bone Scan. *J Pediatr Orthop* 1987;7:458.

+ 293. Zionts LE, MacEwen GD. Spontaneous Improvement of Post-traumatic Tibia Valga. *J Bone Joint Surg Am* 1986;68:680.

+ 294. Zuege RC, Kempken TC, Blount WP. Epiphyseal Stapling for Angular Deformities of the Knee. *J Bone Joint Surg Am* 1979;61:320.

+ 295. Zumiotti A, Ferreira MC. Treatment of Congenital Pseudarthrosis of the Tibia by Microsurgical Fibula Transfer. *Microsurgery* 1994;15:37.

# CHAPTER 170

# LIMB-LENGTH DISCREPANCY IN CHILDREN

*Kent A. Vincent and Colin I. Moseley*

**K. A. Vincent:** Staff Surgeon, Shriners' Hospital for Children, Portland Department of Orthopaedics, Oregon Health Sciences University, Portland, Oregon, 97201.
**C. I. Moseley:** Shriners' Hospital for Children, Los Angeles, California, 90020.

Introduction
Incidence
Natural History
Spine
Hip
Knee and Foot
Gait
Growth
Longitudinal Data
Skeletal Age
Different Growth Patterns
Anatomic Sites of Length Inequality
Causes of Limb-Length Discrepancy
Inhibition of Growth
Stimulation of Growth
Evaluation
Clinical Examination
Radiographic Evaluation
Analyzing the Data
Evaluation of Efficacy
Treatment
Goals
Chapter References

## INTRODUCTION

Limb-length discrepancy problems are challenging because growth complicates the longitudinal evaluation of each patient. Therefore, the orthopaedic surgeon must have an understanding of growth and the methods by which to analyze and predict future changes; this is particularly important before considering any surgery to correct limb-length discrepancy.

Human height is the combined total of limbs, pelvis, torso, and head. The limbs constitute approximately half of this total height, and they are the most kinetic component of the body during gait. Length abnormalities of the limbs have the potential to affect both height and efficiency of gait.

## INCIDENCE

The incidence of limb-length discrepancy is relatively common. Reports have suggested some level of discrepancy in up to 70% of adult males (72). In a review of more than 100 Swedish laborers, 30% had a limb-length discrepancy of 1.0 to 1.5 cm, 4% had 2.0 to 2.5 cm, and 0.7% had more than a 2.5 cm discrepancy (35). Estimates are especially difficult in the changing pediatric population, but for individual congenital conditions, the incidence could be predicted more reliably.

## NATURAL HISTORY

### SPINE

Most important to the treating physician, as in many pediatric orthopaedic conditions, is the natural history of the condition. Parents are commonly concerned about the long-term effects of a limb-length discrepancy on the spine, but cause-and-effect relationships are unknown. Low back pain in the child is rare, even for a child with a limb-length discrepancy. Given the high rate of back pain in the normal adult population, we may assume that this rate of back pain must also exist for the same reasons in the population with limb-length discrepancies. Changes in adult spine radiographs, such as vertebral wedging and traction spurs, have been associated with limb-length differences of more than 9 mm, but these findings have not been correlated with symptoms (22,26,27,79). Reviews of adults with minor discrepancies have suggested a relatively low association with low back pain (62,77,92). Other studies confirm that adult patients presenting with low back pain associated with limb-length discrepancy appear to have symptomatic relief after equalization surgery (71,84).

An increased incidence of structural scoliosis over the general population is associated with limb-length discrepancies (66). However, the causative effects of one deformity on the other are unknown. Lumbar facet orientation does not correlate well with asymmetric changes in limb length (24). The direction of the curve is not always in the direction expected based on the limb-length difference (33). This makes it more difficult to postulate that the limb-length difference is the causative factor.

### HIP

As limb-length discrepancy increases, so does the amount of uncoverage by the acetabulum of the high-side femoral head hip (59). Theoretically, this problem should result in force concentration on the lateral edge of the acetabulum, with resultant early arthritis. Gait lab studies, however, suggest the possibility that high-side hip forces may actually decrease during stance phase (13). Little long-term clinical information exists on the subject.

### KNEE AND FOOT

Knee problems secondary to leg-length differences do not seem to be common in children. A report has been made of increased incidence of knee pain in athletes (47). The most common associated problem in the foot is equinus on the short side. When the problem is not followed closely, a contracture may result from years of compensation in this position.

## GAIT

Children tend to be better able than adults to compensate for differences in limb length. Their increased joint flexibility and higher strength-to-weight ratio may result in adjustments that produce a smooth, even gait. With greater discrepancies between the two legs, compensation becomes more difficult. Coronal plane pelvic tilt may increase the energy consumption of gait.

Data from gait lab studies of children with length discrepancies have suggested a quite variable pattern of compensation among individuals (44,51,76). Those with less than 3% discrepancy do not require compensatory strategies. Compensation for greater discrepancies results in greater work and greater vertical displacement of the center of body mass. Each child applies compensatory mechanisms differently; the most common are walking with the short-side ankle in equinus or the long-side knee in flexion. Energy consumption studies have yet to be completed to confirm the meaning of these changes to gait efficiency.

## GROWTH

## LONGITUDINAL DATA

Growth of the limbs results from the combination of physeal new bone production and actual epiphyseal size increase. Epiphyseal size increase usually accounts for only about 5% of the total growth of the limb, but for calculation purposes, this increase is usually ignored (Fig. 170.1). The growth plates at the knee contribute the most to total limb length, whereas the distal tibial and proximal femoral physes add lesser amounts.

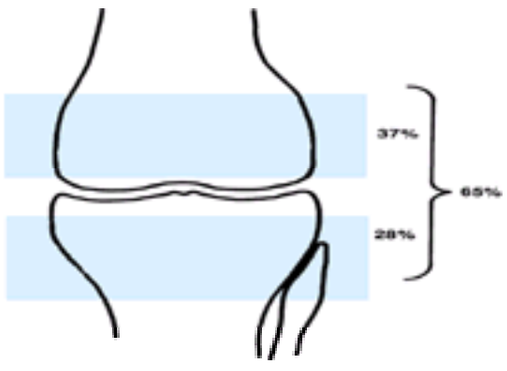


***Figure 170.1.*** The distal femoral and proximal tibial physes contribute constant proportions to the growth of the leg. (From Moseley CF. Leg-Length Discrepancy. In: Morrissy RT, Weinstein SL, eds. *Lovell & Winter's Pediatric Orthopaedics.* Philadelphia: J.B. Lippincott, 1996:855, with permission.)

Difficulty with measurement has prevented us from understanding patterns of growth in the short term. One study suggests that children have week-to-week variability in limb growth, with pulsatile patterns of miniature growth spurts every 30 to 55 days, alternating with periods of slower growth (32). In the longer term, however, the growth pattern evens out.

Data for growth calculation have come mainly from two studies by Anderson and colleagues (4,6). In one, data were collected instantaneously on children between 5 years of age and maturity. In the other, a group was followed longitudinally until maturity. Their data were reported in tabular and graphic forms as total limb length as a function of skeletal age (Fig. 170.2). These were converted into the growth-remaining charts for the distal femur and proximal tibia (Fig. 170.3).

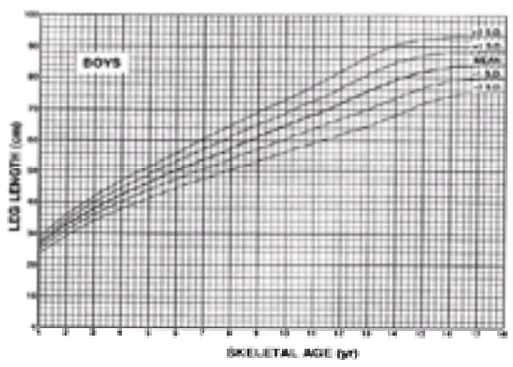


***Figure 170.2.*** Graph of total limb length (femur plus tibia only) for boys. An individual boy may be plotted instantaneously and projected into the future based on his current situation. (From Anderson M, Messner MB, Green WT. Distribution of Lengths of the Normal Femur and Tibia in Children from One to Eighteen Years of Age. *J Bone Joint Surg* 1964;46A:1197, with permission.)

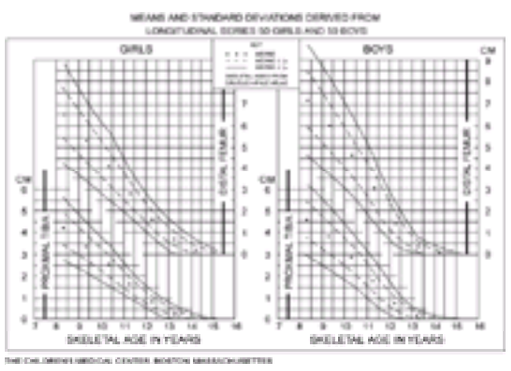


***Figure 170.3.*** Green-Anderson growth-remaining graph for girls and boys. This plots the amount of remaining growth from each of the distal femoral and proximal tibial epiphyses as functions of the skeletal age. The mean is in the center, whereas one and two standard deviations in each direction are represented by the other lines. This enables the calculation of results if an epiphysiodesis is done. (From Anderson M, Green WT, Messner MB. Growth and Predictions of Growth in the Lower Extremities. *J Bone Joint Surg* 45A:1963, with permission.)

## SKELETAL AGE

The study of limb-length discrepancy problems involves the interaction of patient age, maturity, and limb length. Growth rate is maximal at the time of birth, both in percentage gain and in absolute terms. The absolute rate of growth relative to chronologic years drops slightly between 3 years of age and the adolescent growth spurt. During the adolescent growth spurt, the absolute rate of growth increases. Cessation of growth occurs in boys at 16 to 17 years of age, and in girls at 14 to 15 years of age. When we compare different people, it becomes quickly evident that their times of maturation, as measured in chronologic years, vary considerably. One child who may appear to be tall may just be going through the process of maturation at an earlier time. In fact, this “temporarily” tall child may then end up shorter than a second child who, although shorter initially, matures at a later time as measured by chronologic age.

The best method we have to measure level of maturity appears to be radiographs of the bones. The standard radiograph has become the anteroposterior view of the left wrist, although other x-ray techniques are available (81). The skeletal age of a patient is defined as the age at which the general population, on average, reaches the same level of bony development as that patient. This skeletal age correlates more closely than chronological age with other signs of maturation, including menarche, secondary sexual characteristics, height, and limb length. Measurement of skeletal age with the anteroposterior view of the wrist, however, remains the weak point in predicting limb-length discrepancy, both because of reliability of readings and because of more variability in children with limb-length discrepancy (15,18).

For any large group of normal children at the same chronologic age, the average skeletal age should equal chronologic age. However, time of maturation varies greatly between people; thus, for any given child, the skeletal age does not necessarily equal the chronologic age. A child who matures earlier than his peers appears to go through a maturation spurt in which the skeletal age years are changing more quickly than the chronologic years. The other milestones of maturity (secondary sexual characteristics, menarche, and limb growth) are moving forward at a similar, early rate.

## DIFFERENT GROWTH PATTERNS

Based on the change in discrepancy over time, Shapiro (74) has previously divided growth patterns in children with limb-length discrepancy into five types (Fig. 170.4).

Three phases are used to describe the change over time: In the initial phase, the discrepancy develops; in the middle phase, a pattern of difference is established during further growth; and the final phase is the period of time before growth cessation. Patient age is plotted against the limb-length discrepancy on a graph. By definition, the initial phase results in an increase in discrepancy. During the middle phase, the discrepancies are variable; some continue to increase (e.g., a traumatic physeal closure), whereas others plateau (e.g., a patient being treated for juvenile rheumatoid arthritis). The final phase is also variable in that a discrepancy may increase, plateau, or decrease. Again, conditions that cause permanent physeal damage tend to cause a steady increase in discrepancy, whereas other conditions are associated with a plateau in differences (e.g., improvement in functional level in a paralytic limb, as with a brace). The most common scenario for an actual decrease in limb-length discrepancy is that of a treated juvenile rheumatoid arthritis patient (75,86).

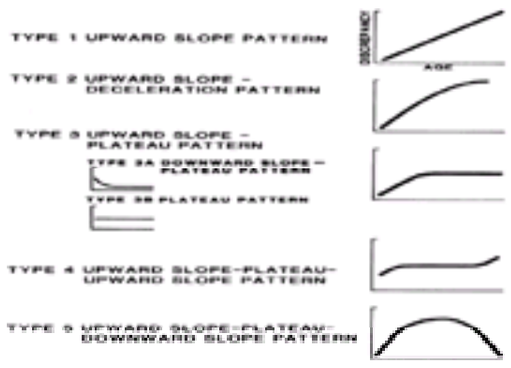


***Figure 170.4.*** Various patterns of changes in limb-length discrepancy over time. The patterns shown are based on absolute magnitude of discrepancy, and thus the graphs do not take into account the natural slowing of growth near maturity. (Shapiro F. Developmental Patterns in Lower Extremity Length Discrepancies. *J Bone Joint Surg* 1982;64-A:639.)

A discussion of patterns of change in limb-length discrepancy by Shapiro's technique are useful for large groups of patients, but it may be less useful for the individual patient. This is because patterns are plotted to age 13 rather than maturity, and the differences are related to chronologic age rather than the skeletal age. This technique also does not compare the pattern of the limb-length difference curve with the normal growth curve or take into account lengthening of either leg with growth, whether it is normal or not.

## ANATOMIC SITES OF LENGTH INEQUALITY

The femur and tibia are not the only components of the limbs that make up the leg's effective length. Variable heights of the two sides of the pelvis and pelvic obliquity to the floor result in a functional difference in limb lengths. Scoliosis and hip abduction and adduction contractures are common situations in which resultant changes in the orientation of the pelvis to the ground create apparent changes in the limb length. The other commonly overlooked source of difference between limb lengths is the foot. Some loss of height may be expected from either varus or valgus collapse of the foot, and the operated hindfoot may lose a portion of its vertical height.

## CAUSES OF LIMB-LENGTH DISCREPANCY

Limb-length discrepancy may be due to factors that change length directly or from an alteration in growth. Fractures, dislocations, and surgery are the only mechanisms by which length is changed acutely.

### INHIBITION OF GROWTH

A physis may be slowed by several mechanisms. The congenitally short limb is genetically programmed to be shorter via slower physeal growth. A growth plate injury may result in slowing or complete cessation of growth. External influences such as disuse, as may occur in polio or hemiplegia, may also cause slowing of growth. Experimental denervation of sciatic nerves in animal models suggest a slowed rate of maturation in denervated bone (20).

#### *Congenital*

Children with limbs of different lengths may be either hemihypertrophic or hemiatrophic, although distinguishing between the two may be difficult (7). Typically, the shortening involves all parts of the involved limb. It is probably best to consider each limb as being genetically programmed at a different rate of growth. Plotting sequential growth on the straight-line graph should confirm this.

Congenitally short bones may occur in conjunction with anomalies of other bones or independently. The congenital short femur is considered to be a variant of proximal focal femoral deficiency (43). The spectrum of the presentation includes anterior cruciate ligament deficiency, absence of the fibula, progressive ankle valgus deformity, absence of the lateral ray or rays of the foot, and tarsal coalitions. Congenitally short tibiae are commonly associated with both posterior and anterior bowing deformities.

#### *Trauma*

Fractures through the growth plate tend to occur through the zone of hypertrophy. Fortunately, this weak area of the physis is not responsible for the continued generation of growth cells, which occurs closer to the epiphysis. Thus in the Salter-Harris classification of epiphyseal fracture type I and II injuries (see Chapter 164) tend not to result in long-term growth disturbances, with a few exceptions. The type V crush injury, however, may permanently damage cells at all levels of the physis. Type III and IV fractures do cross the growth zone of the physis; thus, they are most prone to formation of a bridge of bone or physeal closure. Anatomic reduction of type III and IV fractures helps prevent physeal abnormalities. When physeal bars form or partial closure occurs, angular malalignment occurs because of asymmetric involvement of the growth plate. Physeal closure has also been recognized as a complication of diaphyseal fractures of the ipsilateral limb (8).

#### *Infection*

Disturbance of growth from infections tends to have more severe results because of the young age at which this occurs. Direct invasion of the physeal cells occurs in hematogenous osteomyelitis, sometimes in conjunction with a septic joint. The bridges that result tend to be broader and more central than those that result from fractures, and thus, they are more difficult to resect successfully. A so-called sick physis may develop when an infection has a global effect on a physis. The cellular effects of the infection on the physis then either slow the rate of growth or create a delayed complete or partial arrest. Meningococcemia is one of the more common infectious processes that create this delayed growth arrest.

#### *Paralysis*

The cause of limb-length differences in paralysis is not completely clear. Theories have included decreased blood flow, poor venous return, decreased neurogenic input to the physis, and disuse atrophy. Polio commonly results in significant differences in limb lengths. Hemiplegic cerebral palsy patients may have small differences in length, which seldom require surgical correction. Hemiplegic patients often appear to have more of a discrepancy because of asymmetric muscle tone and other joint contractures that result in pelvic obliquity.

#### *Tumors*

Tumors may directly invade the growth plate, having a destructive effect similar to infection. Abnormal cartilage emanating from the physeal cells may also disturb normal growth patterns. In enchondromatosis and Ollier's disease, abnormal physeal cells produce tumor cartilage rather than cartilage for longitudinal growth. Osteochondromata may have more of a mechanical effect on growth plates that may disturb growth, such as at the distal tibia. This is more commonly angular than longitudinal.

### *Avascular Necrosis*

The proximal femur is the most common location for clinical problems arising secondary to avascular necrosis. Fortunately, the proximal femur is responsible for only about 15% of limb length. Clinical presentations include the treated developmental hip dislocation, traumatic hip dislocations and fractures, slipped capital femoral epiphysis, and Legg-Calvé-Perthes disease. A common situation with avascular necrosis of the proximal femur is a severe adduction contracture secondary to femoral head collapse. This results in a large apparent length discrepancy, which is actually due to a marked coronal plane pelvic obliquity.

### STIMULATION OF GROWTH

A physis may be stimulated to increase growth by arteriovenous malformation, inflammation, fracture, and tumor. From a clinical standpoint, surgical creation of a situation that mimics these conditions has failed to provide reproducible increases in growth.

### *Tumor*

Vascular malformations such as hemangiomas may result in growth stimulation, presumably via increased blood flow. Other nonvascular growths such as neurofibromatosis, fibrous dysplasia, and Wilms' tumor may result in overgrowth, usually of focal areas of bones.

### *Fracture*

Overgrowth from fractures commonly occurs in the femur in children younger than 10 years of age (2,34). Studies of the factors most responsible for femoral overgrowth have been contradictory (45,52,54,67). The proximal tibia also has a tendency toward overgrowth following fracture (52,67). If the fibula is not also fractured, a relative increase in tibial length results in progressive valgus deformity at the knee.

### *Inflammation*

Infection may damage the growth plate, but in some cases, chronic osteomyelitis may actually result in physeal stimulation. Another common example is pauciarticular juvenile rheumatoid arthritis, in which overgrowth of the involved limb is common, particularly before 3 years of age (75,86).

## EVALUATION

### CLINICAL EXAMINATION

The physical exam remains the central tool for clinical assessment in limb-length differences. Physicians may tend to focus on radiographic findings; however, radiographic methods can have inherent artifacts from patient movement or from poor conversion of an angular deformity to two-plane measurement. In addition, many other clinical factors not measured by radiographs are important in making treatment decisions. Once the complete historical and physical evidence has been obtained, radiographs may be used to fine-tune data and to follow the condition precisely.

The most useful clinical tool is to place blocks beneath the foot of the short side of the patient in the standing position. The height can be adjusted until the pelvis is level, as judged by the anterior superior iliac spines from the front or the posterior iliac crests from the back (Fig. 170.5) This technique is generally the most reliable and provides the most comprehensive information, because it allows the clinician to take into account pelvic obliquity, contractures, angular deformities, and differences in foot height. To use the technique even more effectively, shoe lifts of variable heights may be used; this allows evaluation of gait and dynamic events, with partial to complete correction of differences (Fig. 170.17).

***Figure 170.5.*** The standing technique of limb-length measurement is done with the patient standing on blocks on the short side until the anterior superior iliac spines are at the same level. It may also be visualized from behind the patient, using the top of the iliac crests as the measure of level.

***Figure 170.17.*** Variable sizes of lifts are attached to the bottom of the shoe with hook-and-pile strips. These allow trials of differing amounts, which are particularly helpful in deciding how much to shorten a limb.

A traditional method of determining the limb length has been to measure from the anterior superior iliac spine to the medial malleolus, in the supine or standing position, using a tape measure. (Fig. 170.6). This method has some value, but reproducibility may be poor because of poorly palpable landmarks, tenting of the tape, angular deformity at the knee, and differences in the height of the pelvis (49). In addition, this measurement does not take into account angular deformity (i.e., obliquity) about the pelvis.

***Figure 170.6.*** The supine technique of limb-length measurement is done with the tape measure from the anterior superior iliac spine to the medial malleolus with the knee straight. Because of difficulties in reproducing accurate measurements, the standing technique is generally preferred.

## RADIOGRAPHIC EVALUATION

### *Scanogram*

Radiographic techniques may be inherently more accurate than clinical methods in measuring limb lengths, and thus, they may be more valuable over the long term for evaluating growth trends. All of the radiographic techniques used have variability between readings because of differences in technician techniques, changes in patient position, and differences in techniques and landmarks of people reading the films. The orthopaedic surgeon must review all of the data derived from radiographs before considering surgery, check for consistency, and correlate the data with clinical findings.

Confusion exists over the terminology used for radiographic measurement techniques. The original scanogram was done with a collimated x-ray beam directed through a transverse slit that exposed a film beneath the patient as the x-ray tube was moved from one end of the limb to the other. The teleoradiograph is a single-exposure x-ray shot from a 2 m (6 ft) distance with a radiopaque ruler placed on the film cassette. It can reveal an angular deformity but has the disadvantage of increasing distortion through parallax of the x-ray beam (Fig. 170.7) The orthoradiograph avoids the parallax problem by taking three separate exposures on the same ruled cassette. Like the teleoradiograph, the large film size can be cumbersome (Fig. 170.8). The current scanogram technique uses three exposures, but the cassette is moved beneath the patient between each image. The ruler must be fixed to the x-ray table, which is not a necessity with the single exposure techniques (Fig. 170.9). The patient must be able to remain still between exposures with the teleoradiograph and the scanogram. For children younger than 5 or 6 years of age, the teleoradiograph is more appropriate.

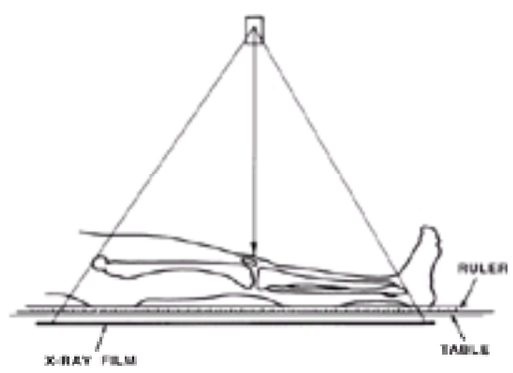


***Figure 170.7.*** The supine teleoradiogram method. Parallax effect is greater with a single exposure. (From Moseley CF. Leg-Length Discrepancy. In: Morrissy RT, Weinstein SL, eds. *Lovell & Winter's Pediatric Orthopaedics.* Philadelphia: J.B. Lippincott, 1996:865, with permission.)

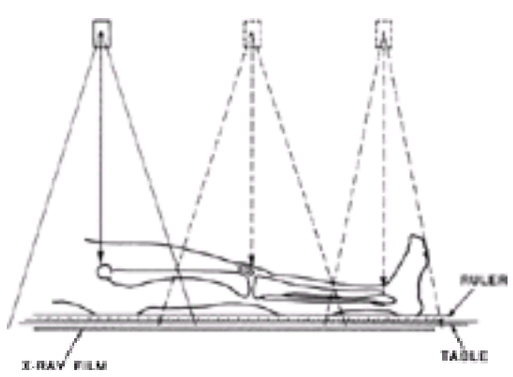

***Figure 170.8.*** The orthoradiograph. When three separate exposures are used, parallax is minimized, but the patient must be able to hold still for three images to avoid inaccuracies. (From Moseley CF. Leg-Length Discrepancy. In: Morrissy RT, Weinstein SL, eds. *Lovell & Winter's Pediatric Orthopaedics.* Philadelphia: J.B. Lippincott, 1996:865, with permission.)

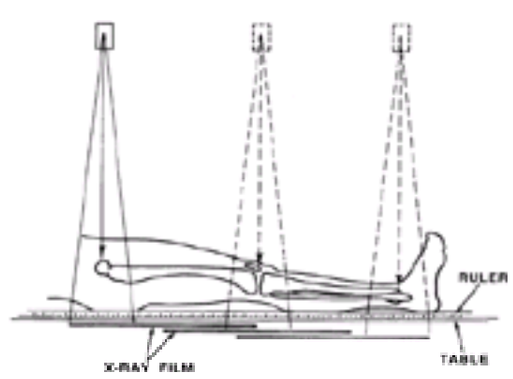


***Figure 170.9.*** The scanogram: The three exposures are taken after positioning a portion of the 14-by-17-inch cassette behind each of the hip, knee, and ankle joints. (From Moseley CF. Leg-Length Discrepancy. In Morrissy RT, Weinstein SL, eds. *Lovell & Winter's Pediatric Orthopaedics.* Philadelphia: J.B. Lippincott, 1996:866.)

The current standard of radiographic assessment for most situations is the scanogram. The images are captured on one film of relatively convenient size. As long as the patient does not move between exposures and no joint contractures are present, this provides an accurate and relatively reproducible methodology (3,29). When knee contractures are present, the bones may be measured individually by placing the patient prone for a ruled radiograph of the femur, and in the lateral position for the film of the tibia.

The scanogram is most ideally taken with the patient semierect, with the short side blocked up beneath the foot to level the pelvis. Separate images are then taken of the hips, knees, and ankles, including the plantar portion of the foot (Fig. 170.10). The semierect position has the advantage of mimicking the upright weight-bearing position, leveling the pelvis for more accurate measurement, limiting patient motion between exposures, and allowing evaluation of the contribution of the foot to the discrepancy. The only disadvantage is that a tilting x-ray table is required.

***Figure 170.10.*** The semierect scanogram method. The tilt table allows for placement of lifts for leveling the pelvis, and will give more accurate information about joint and length changes with weight bearing. The three images of the hips, knees, and ankles are taken in the same way as with the supine technique shown in Figure 170.7.

The standard landmarks used from the orthoroentgenogram are the tops of the femoral head and the middle of the “saddle” formed by the subchondral bone of the distal tibial plafond. If separation into femoral and tibial components is required, use the medial femoral condyle. Then draw a horizontal line from the chosen points to the ruled area on the film. Each of these lines should be parallel to the edge of the film. (This assumes that the edge of the cassette is close to being perpendicular to the orientation of the leg.) By subtracting these numbers, the lengths of both legs and the femoral and tibial components may be calculated (Fig. 170.11.)

***Figure 170.11.*** Sample orthoroentgenogram. Results may be analyzed on one film of convenient size, but this film does not allow accurate calculation of mechanical or anatomical axis.

***Other Methods***

The computerized axial tomogram may be used in place of the orthoroentgenogram. It offers the advantage of being more accurate and delivering less radiation, but for many centers, the technique is more cumbersome and it is expensive to obtain (1,36). A decision should be made on the basis of cost and availability because the accuracy of the two techniques appears to be comparable.

Recently, real-time ultrasonography has been reported as an effective screening tool, although slightly less accurate than radiography, for limb-length determination (42,82).

***Skeletal Age***

Determining skeletal age is done by comparing radiographic landmarks of maturity with standards. The Greulich-Pyle atlas is the most commonly used standard today (30). The left hand and wrist are imaged in the anteroposterior plane; separate standards are used for boys and girls. The standard radiograph in the atlas represents the median level of bony maturity for the chronologic age. Given a random sampling of children at the same chronologic age, half of the left hand and wrist radiographs would appear more mature and half would appear less mature than the standard. For any given child, then, the skeletal age is that which corresponds with the best radiographic match from the atlas (Fig. 170.12).

***Figure 170.12.*** Left hand and wrist anteroposterior radiograph taken for bone age estimation.

Unfortunately, the skeletal age determination is the weakest link in the process of limb-length calculations. Differences between children in the order of bone maturation around the wrist, extrapolation between ages in the atlas, and congenital anomalies of wrist bones may result in different interpretations of the radiograph for skeletal age (15,18). Other methods have been used to determine skeletal age and are probably more exacting, but they are also more cumbersome. In addition, all of the predictive growth data derived by Green and Anderson are based on the Greulich-Pyle atlas. Other methods of skeletal age determination do not necessarily correlate with the Greulich-Pyle skeletal age and, thus, should not be used with Green and Anderson's data for surgical calculations.

**ANALYZING THE DATA**

After skeletal maturity, limb-length differences do not change without surgical intervention. The growing child, on the other hand, is continuously changing. The goal of the orthopaedic surgeon must be to predict the situation at maturity. In most cases, this means analyzing the data from a young age to predict the limb-length difference at maturity. Treatment should be based on this prediction, so careful analysis of the data is crucial (10). At present, three general methods are used widely

for data analysis—the arithmetic method, the growth-remaining method, and the straight-line graph method. They all use roughly the same steps of analysis but with different techniques. The first step is evaluation of past growth, the second step is prediction of future growth, and the third step is evaluation of what the results of surgical correction would be.

### *Arithmetic Method*

The arithmetic method is based on the following assumptions of growth patterns (Fig. 170.13):

***Figure 170.13.*** Arithmetic method of limb-length discrepancy determination. In the left column, a theoretical explanation, and on the right, a sample calculation. (From Moseley CF. Leg-Length Discrepancy. In: Morrissy RT, Weinstein SL, eds. *Lovell & Winter's Pediatric Orthopaedics.* Philadelphia: J.B. Lippincott, 1996:869.)

- Girls stop growing at chronologic age 14.
- Boys stop growing at chronologic age 16.
- The distal femur grows at a rate of $^{3}/_{8}$ inch (10 mm) per year.
- The proximal tibia grows at a rate of ¼ inch (6 mm) per year.

This technique is convenient but has some inherent inaccuracies. The estimations of growth are most accurate during the last few years of growth, but are relatively inaccurate in younger children. In addition, the chronologic age is the basis for the measurements and determinations. As discussed earlier, the patient's chronologic age and bone age may vary considerably, but the bone age is a more reliable indicator of skeletal maturity for individual patients.

This technique should be used as a tool for estimation well before surgery is being considered. As the time for surgery nears, other, more precise methods should be used to minimize errors and make correction as exacting as possible.

### *Growth-Remaining Method*

The growth-remaining method is based on the data and tables of Green and Anderson (4,5). The percentage of growth inhibition of the short leg is first calculated. Using these data, the lengths of long and short legs at maturity can be predicted. The graphs of the growth remaining from the distal femoral and proximal tibial physes are used to determine appropriate times for epiphysiodesis (Fig. 170.14).




***Figure 170.14.*** Growth-remaining method of leg-length discrepancy determination. In the left column, a theoretical explanation, and on the right, a sample calculation. (From Moseley CF. Leg-Length Discrepancy. In: Morrissy RT, Weinstein SL, eds. *Lovell & Winter's Pediatric Orthopaedics.* Philadelphia: J.B. Lippincott, 1996:870.)

The growth-remaining method is based on skeletal age and uses growth percentile of the child to predict future growth. The technique does have some disadvantages: It requires two sets of graphs in making the calculations, and it relies heavily on the most recent skeletal age for predictions.

### *Straight-Line Graph Method*

The straight-line graph method was conceived as a way of graphically representing the growth of the two limbs (61). It incorporates the data of Green and Anderson (5), and is used as a method of recording, analyzing, and predicting both growth and the results of treatment. The method is based on two principles: First, the growth of each leg can be graphically represented as a straight line, and second, a nomogram can be used to determine the growth percentile, based on skeletal age and limb length (Fig. 170.15).

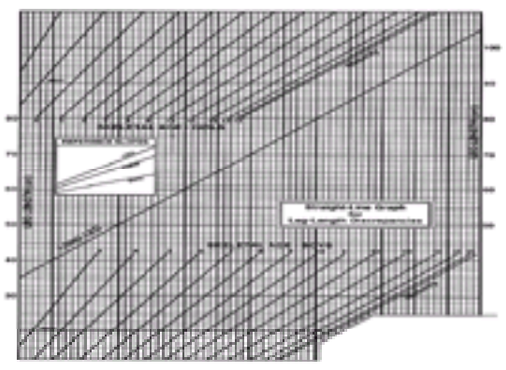

***Figure 170.15.*** Straight-line graph, composed of three sections. The central line for plotting the length of the long leg in centimeters is predefined by the graph. The sloping lines are areas for plotting bone ages, with girls above and boys below. The reference slopes allow plotting of growth lines to predict changes after epiphysiodesis. (From Moseley CF. Leg-Length Discrepancy. In: Morrissy RT, Weinstein SL, eds. *Lovell & Winter's Pediatric Orthopaedics.* Philadelphia: J.B. Lippincott, 1996:871.)

Green and Anderson's graphs have a curved pattern at each end, representing the high rate of growth during infancy and the slowing rate before skeletal maturity. By

manipulation of the scale of the x-axis at each end of the growth curve, the length of the limb can be graphically represented as a straight line. The long limb is thus assigned the graphic slope of 1.00, representing 100% of normal growth. If no variable disease process or treatment is changing the short limb, it will also follow a straight line on the graph over time. The discrepancy between the two limbs is thus represented by the vertical distance between the two growth lines, and the inhibition by the difference in the lines' slopes.

The nomogram for skeletal age has been set up on the graph to allow the long limb length to be compared with that of the Green-Anderson population. If a child grew such that the bone age and limb lengths progressed together exactly as the Green and Anderson data would suggest, the points on the nomogram would describe a perfect horizontal line. This rarely happens, both because of the inherent differences in the reading of bone ages and differences in growth of individual children. As an increasing number of estimates of bone age are obtained, these differences tend to diminish such that a more accurate best horizontal line estimate through the points can be obtained. Generally, heavier weighting is given to the most recent bone age readings when making a best horizontal line estimate.

Predictions of surgical results may be made with the graph as well. Changes in the growth rate of either leg result in a change in slope of the line representing that leg. Lengthening a limb results in simple upward vertical displacement of the line; shortening results in downward vertical displacement. When an epiphysiodesis is performed on a long limb, the slope of the line representing that leg decreases by an exact amount. This is because each epiphysis contributes a known amount to the length of the leg. Reference slopes placed on the graph include slopes of lines representing a normal (long) limb after proximal tibial epiphysiodesis, after distal femoral epiphysiodesis, and after both epiphysiodeses done simultaneously. Figure 170.16 shows a sample calculation using the straight-line graph.




***Figure 170.16.*** Straight-line graph method of leg-length discrepancy determination. The step-by-step instructions for a sample patient are shown, using the same example as in Figure 170.13. (From Moseley CF. Leg-Length Discrepancy. In: Morrissy RT, Weinstein SL. *Lovell & Winter's Pediatric Orthopaedics.* Philadelphia: J.B. Lippincott, 1996:873.)

Note that with the straight-line graph, the left edge represents the time of birth, and the long limb begins at 35 cm, not zero. If calculations depend on inhibition from the time of conception (such as congenitally short limbs), the long-limb and the short-limb lines will converge off the graph to the left, where the limb length is zero. If the growth inhibition began at a later date after birth (such as early physeal closure from infection), then convergence of lines will occur at a later date on the graph.

This technique uses skeletal age for determination, takes into account growth percentile in prediction of future growth and results of surgery, decreases the inherent error of single skeletal age measurements, eliminates the need for cumbersome arithmetic, and spots values that appear to be out of line with others in longitudinal assessment. It also allows all data to be accumulated sequentially at a single place in the medical record.

***Other Techniques***

Recently, two additional graphic techniques have been described for limb-length inequality evaluation. One is based on data from Dutch children between 1979 and 1994. It suggests that children today have longer bones than the children in the study of Green and Anderson from the 1940s and 1950s (9). The technique uses principles similar to those of the straight-line graph. In the second technique, a graphic display is made based on plotting limb-length discrepancy versus chronologic age. This is a graphic variation of the arithmetic technique (21).

### EVALUATION OF EFFICACY

In evaluating the various techniques used to assess limb-length discrepancy, studies vary with respect to interpretation of success. Theoretically, the Green and Anderson method and the straight-line graph methods should give the same prediction because they are derived from the same growth data. General success has been reported with both of these methods (19,48,61,69,78). Another recent review reported disappointing results with all three commonly used methods (50). Continued study and refinement are needed.

## TREATMENT

### GOALS

The goal in treatment of a patient with a limb-length discrepancy is based on a thorough assessment of the patient's problems, both clinically and radiographically. Each patient may have differing goals, reflecting a unique combination of associated problems. In general, it is best to consider correcting coexisting conditions before addressing the limb-length difference. Correcting a spinal deformity affects pelvic obliquity. Correcting angular deformity in the lower limb, whether it is at the level of a malunion or a contracture at a joint, usually has the effect of lengthening that limb.

Ideally, correction would result in limbs of exactly the same length, but this may not always be the best goal. In the patient with polio residuals, it is usually desirable to leave a weak extremity slightly short, which allows it to function better in the swing phase of gait. In the neuromuscularly normal child, it is best to plan for a limb-length difference of between 5 mm and 1 cm at maturity when considering epiphysiodesis. This allows for slight changes in growth patterns after the epiphysiodesis and inaccuracies in the preoperative assessment while not compromising adult height any more than necessary.

Many factors will influence the decision on the exact level in the limb at which to correct a discrepancy. The ideal situation would be to lengthen the short bone or shorten the long bone to a normal length. A general goal is to keep the legs symmetric so that knee height is equal. However, in some cases, a well-timed epiphysiodesis at one level (for instance, the distal femur) will eliminate the need for a later procedure involving two growth plates (distal femur and proximal tibia), even though it may leave the knee heights at slightly different levels. During lengthening procedures, this may be of even more concern, because differences made up are often greater than with epiphysiodeses. If lengthening is proceeding well, it may be more desirable to continue lengthening the segment past the predicted length at maturity of that segment on the opposite side so as to avoid the necessity of another segment lengthening as well. Asymmetry of knee height is generally of little functional significance but is of some cosmetic concern.

Much of the prior discussion of the workup and assessment of limb-length discrepancy has focused on the magnitude of discrepancy at maturity. This is because the predicted amount of difference at maturity helps determine the exact amount to correct and the treatment group likely to be best for equalization. These treatment groups with their suggested approaches, given a normal height range, are as follows:

- Difference of 0 to 2 cm: no treatment
- Difference of 2 to 6 cm: shoe lift, epiphysiodesis, shortening
- Difference of 4 to 15 cm: lengthening procedure
- Difference of more than 15 cm: prosthetic fitting

Discrepancies of less than 2 cm, although quite common, do not have functional significance for the majority of adults of normal stature, and therefore do not need treatment (31,72). For those patients who feel unbalanced, a shoe lift can be tried.

In the 2 to 6 cm range, shortening procedures are generally the first choice for treatment. For greater levels of discrepancy, shortening procedures are usually not considered because of disproportionate appearance in the shortened segment and loss of stature. Also, if the limb is shortened acutely, the normal-sized muscle-tendon units also have difficulty adapting to the shortened bone, and consequently they become weaker. Correction of a difference of greater than 6 cm with

epiphysiodesis may be considered when the long limb is clearly the abnormal side, because loss of stature and disproportionate appearance are not a concern.

For discrepancies of more than 4 cm, lengthening may be considered. In the 4 to 6 cm range, patient and family preference may be taken into consideration as the complications and long-term goals of lengthening versus shortening are weighed. For discrepancies greater than 6 cm, lengthening becomes the preferred treatment option. The total length possible from a lengthening procedure is variable. Generally the maximum length attainable at a single lengthening is 20% of the bone's length. Thus, if both the femur and tibia are lengthened (usually done in a staged manner), this may total more than 15 cm length gained. A complete assessment of patient needs and psychosocial situation are crucial before beginning any lengthening procedure, but the entire lengthening team must pay particularly close attention to these factors for the longer lengthenings. Consideration can be given to staged lengthenings of the same bones, spaced apart by several years for joint and soft-tissue recovery. An epiphysiodesis may also be used in combination with an opposite-side lengthening procedure as a method of limiting the amount of length required.

For discrepancies of more than 15 cm, or 20% of limb length, prosthetic fitting is the usual choice of treatment. Often, this is combined with an amputation, fusion of a joint, or rotationplasty for more functional prosthetic wear. Common clinical situations include the severe end of the spectrum of fibular hemimelia and proximal focal femoral deficiency. In many cases, discussion with the family centers on how quickly the child can return to normal function. The prosthetic option often allows a relatively fast return to a high functional level. If a lengthening device is used, much more time is required to attain the same functional level as that using a prosthetic device.

***Shoe Lift***

In a discrepancy of 2 to 5 cm, a shoe lift may be an acceptable method of treatment, particularly when the patient will not consider or is not an appropriate candidate for surgery. A lift becomes more unwieldy and thus a less viable alternative as more height is added. The weight of the lift and ankle instability are the chief problems with larger lifts. In addition, patients find them cosmetically unappealing. Lifts can be used as a trial in the preoperative period to determine the most comfortable or functional amount of lengthening or shortening (Fig. 170.17).

***Limb Shortening***

**Epiphysiodesis** Epiphysiodesis slows the rate of growth of the long limb to allow the short side to catch up. It is simple, effective, and predictable; is done in one stage; and has a low complication rate (25,28,55,78). It is the usual procedure of choice when predicted discrepancy at maturity is 2 to 6 cm (80). When the procedure is completed, the growth at that physis is assumed to be completely stopped. Loss of percentage contribution to limb length will be 38% for the distal femur, 27% for the proximal tibia, and 65% for the two combined. The distal tibia contributes 18% of leg length and occasionally is also considered for closure. The exact amount of shortening desired can be achieved only by completing the epiphysiodesis at exactly the correct time. Usually, this choice of timing comes down to three different options that correspond to the surgical site: femur only, tibia only, or both femur and tibia. Because proper timing is so important, close preoperative follow-up of patients is necessary for prediction of growth. In one review of 67 epiphysiodeses, more than half were deemed failures due solely to improper interpretation of growth data (10).

Many techniques of epiphysiodesis have been used. The goal of all of them is production of symmetric physeal closure to prevent future growth. The traditional Phemister technique uses removal of a rectangular block of bone medially and laterally at the level of the physis that is then replaced in a 18° rotated position (68) (Fig. 170.18). The rectangular window is also used to remove remaining bits of physis with a curet. White and Stubbins (90) described removal of a square block at the level of the lateral physis, which is then rotated 90° and replaced. Epiphysiodesis by stapling was originally thought to be a good technique to stop physeal growth temporarily, but problems developed with asymmetric and complete physeal closure; thus it should be considered a permanent form of growth arrest (12). Stapling has fallen out of favor but may be appropriate in less developed areas of the world without routine access to fluoroscopy (73). Screw epiphysiodesis at the knee has also been described (56).

***Figure 170.18.*** The Phemister technique of epiphysiodesis. An open exposure is done both medially and laterally. The rectangular blocks of bone are replaced in a reversed position to create a physeal bar and thus stop growth. (From Moseley CF. Leg-Length Discrepancy. In: Morrissy RT, Weinstein SL. *Lovell & Winter's Pediatric Orthopaedics.* Philadelphia: J.B. Lippincott, 1996:878.)

We recommend use of the percutaneous technique for most cases (63,83).

- Make longitudinal incisions medially and laterally. Use separate incisions for both the femur and tibia as necessary. If the tibia has been chosen, make an incision posterolaterally as well for the fibula. Incisions can be limited to approximately 1 cm in length or may be made longer if a rotated block is to be used.
- Under image control use a 2 mm wide curet to locate the medial and lateral borders of the physis. Then bore the curet into the physis both medially and laterally, using a turning motion with the curet. Sweeping from anteriorly to posteriorly with the curet scrambles the physeal cartilage.
- The lateral side of the femur and tibia can be completed through lateral incisions, and the medial side can be completed through the medial incisions. The curet tip can be crossed to the opposite side of the bone to allow more surface area to be reached. Close 50% to 75% of the area of the growth plate using this method. The remaining amount ensures that strength remains for ambulation without immobilization.
- Complete the approach to the fibula in the same manner, but with a wide enough exposure to allow direct visualization of the edge of the physis. This extra exposure allows the common peroneal nerve to be protected.
- The technique can be modified slightly in the femur and tibia by using a power drill to complete the physeal closure. A drill bit or straight Steinmann pin with a slightly bent tip damages the growth plate enough to cause closure.

Follow-up care involves the use of a compressive bandage until the wound is healed. Allow the patient to have full range of motion about the knee postoperatively and to bear weight as tolerated with the aid of crutches initially. A knee immobilizer may be added for 2 to 3 weeks for pain relief. Full activities can usually be resumed in 6 to 8 weeks. Bony fusion across the physis occurs within 8 weeks.

Epiphysiodesis is a mainstay in the treatment of limb-length discrepancies. However, it is compensatory in that a normal leg is made abnormal and usually involves decreasing the patient's stature. For these reasons, other procedures are also considered.

**Acute Shortening Procedures** Shortening procedures are considered for patients with the same amounts of discrepancy as those for epiphysiodesis but who are too old for full correction with physeal closure. In the patient who has matured, it has a distinct advantage in that the exact amount of discrepancy is known and no future growth predictions are necessary.

In general, femoral shortening is preferred to tibial shortening. The amount of shortening tolerable in the femur is approximately 5 cm. Greater shortening results in ineffective recovery of muscle-tendon units. The tibia may also be shortened but to a lesser degree (14). Maximum shortening in the tibia should be 3 cm because of shorter muscle-tendon unit lengths. Also, tibial shortening by intramedullary technique is less feasible because the bone is subcutaneous. Thus, the femur is strongly preferred.

In the past, femoral shortening used step-cut osteotomies with interfragmentary screws for fixation, but better implants have made these procedures obsolete. Current techniques include open shortening with plate fixation or proximal femoral shortening with blade plate fixation. The plating technique offers the advantage of ease of fixation but requires hardware removal and may result in scarring and stiffness of the quadriceps mechanism. Blade plate fixation offers the advantage of being

proximal to most of the quadriceps origins but has the disadvantage of a more involved operation.

More recently, closed femoral shortening has become popular (11,91). A standard closed intramedullary femoral nailing technique is used with the addition of a special eccentric cam saw. See Chapter 30 and Chapter 174 for more details. The intramedullary saw is used to make two transverse cuts in the femur. The segment of bone is then split vertically and displaced to the sides, and the femur is then shortened over an intramedullary femoral nail and locked proximally and distally. The technique is demanding technically and requires experience with closed intramedullary nailing techniques. Malrotation can be a problem; assess this before awakening the patient. In children, the nail is removed after complete healing has occurred. The procedure is cosmetic and allows secure intramedullary fixation with its inherent healing capabilities. Implant removal is less involved than plating techniques. However, this procedure causes temporary quadriceps weakness similar to that of femoral plating. Complications in the young patient have been reported, including intraoperative or postoperative fat embolus syndrome; one center reported that 4 out of 100 patients had this complication (53).

### *Growth Stimulation*

Multiple techniques for stimulation of the short extremity have been tried, including electrical stimulation, sympathectomy, surgical construction of arteriovenous fistulae, placement of foreign bodies next to the physis, and packing bone beneath the periosteum near the physis. None of these techniques have produced reproducible or clinically significant results. At present, growth stimulation through the physis is not a realistic option.

### *Limb Lengthening*

Lengthening the short limb initially appears to be the most desirable approach because it allows correction of the abnormal extremity to a normal length while not changing the normal limb. However, lengthening is generally reserved for those patients with the most severe deformities. This is because lengthening techniques are associated with multiple complications and a prolonged treatment time.

Usually, the patient who is considered for lengthening has a projected discrepancy of between 4 and 20 cm. Relatively stable joints above and below the level to be lengthened are a prerequisite. Rotational or angular malalignment usually decreases the total length attainable through lengthening procedures. The patient should be emotionally mature. The youngest child we generally consider for a lengthening is 8 to 9 years of age so that the patient can cooperate with physical therapy. Occasionally, a younger child is considered for lengthening when two different stages of lengthening are required. A decision is made preoperatively for a target goal of length.

Lengthening procedures have been widely used in the past with varying degrees of success, as described by Codivilla (17), Millis and Hall (57), Anderson and colleagues (4,5 and 6), Wagner (87,88), Ilizarov and colleagues (37,38 and 39), Wasserstein and colleagues (89), Monticelli and Spinelli (58), and Paley (64). Specific techniques are described in Chapter 32 and Chapter 171.

The use of the ring fixator with thin wires, as described by Ilizarov, has focused interest on the biology of lengthening. Lengthening success has been clearly related to the emphasis on the exact rate of small incremental lengthening of bone. Others have modified the technique of using only thin wires by adding thicker half pins for stability (16). In addition, lengthening with the uniplane frame over an intramedullary nail, which allows significantly reduced external fixator time, is gaining popularity (65). The uniplane frame alone also has a place in pure length correction when angular correction at the same time is not needed. In all of these techniques, the rate of lengthening should be the same whichever external frame is used because the recent successes have been based on a biology that is highly dependent on technique.

The biology of osteogenesis during distraction begins in the intramedullary area as multipotential cells differentiate into osteoblasts. Their bone formation resembles intramembranous growth because no cartilage matrix is laid down. Cells appear to lay down in a longitudinal direction of the retreating bone end (40). Patients are allowed to bear weight fully immediately postoperatively and participate vigorously in exercise to prevent joint contractures.

One of the most difficult decisions after bone is lengthened is when to remove the fixator. The actual length of time that the fixator is left on will vary because the amount of length gained and the bone quality laid down differs among patients.

There are several complications that result from lengthening techniques. Most series have reported more than one major complication per patient. Pin-track infection or inflammation is almost universally expected. Joint contractures are a persistent problem as well, particularly flexion or extension contracture of the knee and equinus position of the ankle. Joint subluxation or dislocation at the hip or knee are relatively common complications (41,60). In addition, nonunion, malunion, and device failures have been reported.

Growth after lengthening is completed may be variable. One review suggested normal or even accelerated growth after moderate external fixator frame lengthening, whereas longer amounts of time and length may actually diminish later growth (70).

### *Prosthetic Fitting*

Prosthetic fitting is generally the least desirable form of treatment, but it may be the best choice when a large discrepancy or severe deformity exists. When predicted discrepancy at maturity exceeds 15 to 20 cm, or 20% of the long side, this approach should be considered. A single operation can be performed during one hospitalization, so that multiple procedures and complications can be avoided.

A typical patient with fibular hemimelia, either with or without associated femoral shortening, has a large predicted discrepancy at maturity as well as progressive valgus in the foot. A Syme amputation followed by prosthetic fitting results in a functional below-knee amputation that results in a near-normal gait and activity level. This procedure is best performed when the child is younger than 1 year old. Waiting until a later age often results in a great emotional attachment of the family and the patient to saving the foot.

For the patient who has severe proximal focal femoral deficiency, Syme amputation with or without a knee fusion may be the best option. This is followed with fitting for an above-knee prosthesis. Another option is the Van Nes rotationplasty, which reverses the ankle joint to power a modified below-knee prosthesis (23,46,85). The Van Nes procedure can be performed on children at any age, but results are optimal when the procedure is completed at 3 or 4 years of age. It is particularly helpful to have parents of these patients see and talk with parents of older patients who have undergone these procedures.

## CHAPTER REFERENCES

Each reference is categorized according to the following scheme: *, classic article; #, review article; !, basic research article; and +, clinical results/outcome study.


+ 1. Aaron A, Weinstein D, Thickman D, Eilert R. Comparison of Orthoroentgenography and Computed Tomography in the Measurement of Limb-Length Discrepancy. *J Bone Joint Surg* 1992;74-A:897.

+ 2. Aitken A, Blackett C, Ciacotti J. Overgrowth of the Femoral Shaft following Fractures in Childhood. *J Bone Joint Surg* 1939;21:334.

+ 3. Altongy JF, Harcke HT, Bowen JR. Measurement of Leg Length Inequalities by Micro-dose Digital Radiographs. *J Pediatr Orthop* 1987;7:311.

* 4. Anderson M, Green W. Lengths of the Femur and Tibia: Norms Derived from Orthoroentgenograms of Children from 5 Years of Age Until Epiphyseal Closure. *Am J Dis Child* 1948;75:279.

* 5. Anderson M, Green W, Messner M. Growth and Pedictions of Growth in the Lower Extremities. *J Bone Joint Surg* 1963;45A:1.

* 6. Anderson M, Messner M, Green W. Distribution of Lengths of the Normal Femur and Tibia in Children from One to Eighteen years of age. *J Bone Joint Surg* 1964;46A:1197.

* 7. Beals RK. Hemihypertrophy and Hemiatrophy. *Clin Orthop* 1982;166:199.

+ 8. Beals RK. Premature Closure of the Physis following Diaphyseal Fractures. *J Pediatr Orthop* 1990;10:717.

+ 9. Beumer A, Lampe HI, Swierstra BA, et al. The Straight Line Graph in Limb Length Inequality. A New Design Based on 182 Dutch Childern. *Acta Orthop Scand* 1997;68:366.

+ 10. Blair V, Walker S, Sheridan J, et al. Epiphyseodesis: A Problem of Timing. *J Pediatr Orthop* 1982;2:281.

+ 11. Blair VP, Schoenecker PL, Sheridan JJ, et al. Closed Shortening of the Femur. *J Bone Joint Surg* 1989;71A:1440.

* 12. Blount W. Control of Bone Growth by Epiphyseal Stapling. A Preliminary Report. *J Bone Joint Surg* 1949;31:464.

! 13. Brand RA, Yack HJ. Effects of Leg Length Discrepancies on the Forces at the Hip Joint. *Clin Orthop* 1996;333:172.

+ 14. Broughton NS, Olney BW, Menelaus MB. Tibial Shortening for Leg Length Discrepancy. *J Bone Joint* Surg 1989;71-B:242.

+ 15. Carpenter CT, Lester EL. Skeletal Age Determination in Young Children: Analysis of Three Regions of the Hand/Wrist Film. *J Pediatr Orthop* 1993;13:76.

# 16. Catagni MA. Current Trends in the Treatment of Simple and Complex Bone Deformities Using the Ilizarov Method. *Instr Course Lect* 1992;41:423.

* 17. Codivilla A. On the Means of Lengthening in the Lower Limbs, the Muscles and Tissues which Are Shortened through Deformity. *Am J Orthop Surg* 1905;2:353.

+ 18. Cundy P, Peterson D, Morris L, Foster B. Skeletal Age Estimation in Leg Length Discrepancy. *J Pediatr Orthop* 1988;8:513.

+ 19. Dewaele J, Fabry G. The Timing of Epiphysiodesis. A Comparative Study Between the Use of the Method of Anderson and Green and the Moseley Chart. *Acta Orthop Belg* 1992;58:43.

! 20. Dietz FR. Effect of Denervation on Limb Growth. *J Orthop Res* 1989;7:292.

+ 21. Eastwood DM, Cole WG. A Graphic Method for Timing the Correction of Leg-Length Discrepancy. *J Bone Joint Surg* 1995;77-B:743.

+ 22. Friberg O. Clinical Symptoms and Biomechanics of Lumbar Spine and Hip Joint in Leg Length Inequality. *Spine* 1983;8:643.

+ 23. Friscia DA, Moseley CF, Oppenheim WL. Rotational Osteotomy for Proximal Femoral Focal Deficiency. *J Bone Joint Surg* 1989;71A:1386.

+ 24. Froh R, Yong-Hing K, Cassidy JD, Houston CS. The Relationship between Leg Length Discrepancy and Lumbar Facet Orientation. *Spine* 1988;13:325.

+ 25. Gabriel KR, Crawford AH, Roy DR, et al. Percutaneous Epiphyseodesis. *J Pediatr Orthop* 1994;14:348.

+ 26. Gibson PH, Papaioannou T, Kenwright J. The Influence on the Spine of Leg-Length Discrepancy after Femoral Fracture. *J Bone Joint Surg* 1983;65B:584.

+ 27. Giles LG, Taylor JR. Lumbar Spine Structural Changes Associated with Leg Length Inequality. *Spine* 1982;7:159.

* 28. Green WT, Wyatt GM, Anderson M. Orthoroentgenography as a Method of Measuring the Bones of the Lower Extremities. *J Bone Joint Surg* 1946;28:60.

* 29. Green W, Anderson M. Experiences with Epiphyseal Arrest in Correcting Discrepancies in Length of the Lower Extremities in Infantile Paralysis. *J Bone Joint Surg* 1947;29:659.

* 30. Greulich W, Pyle S. Radiographic Atlas of the Skeletal Development of the Hand and Wrist. Stanford, CA: Stanford University Press, 1959.

+ 31. Gross R. Leg Length Discrepancy: How Much is Too Much? *Orthopedics* 1978;1:307.

+ 32. Hermanussen M, Geiger-Benoit K, Burmeister J. Analysis of Differential Growth of the Right and the Left Leg. *Hum Biol* 1989;61:133.

+ 33. Hoikka V, Ylikoski M, Tallroth K. Leg-Length Inequality Has Poor Correlation with Lumbar Scoliosis. *Acta Orthop Trauma Surg* 1989;108:173.

+ 34. Holschneider A, Vogl D, Dietz H. Differences in Leg Length following Femoral Shaft Fractures in Childhood. *Z Kinderchir* 1985;40:341.

* 35. Hult L. The Munkfors Investigation. A Study of the Frequency and Causes of the Stiff Neck-Brachialgia and Lumbago-Sciatica Syndromes, as well as Observations on Certain Signs and Symptoms from the Dorsal Spine and the Joints of the Extremities in Industrial and Forest Workers. *Acta Orthop Scand* 1954:16(Suppl).

+ 36. Huurman WW, Jacobsen FS, Anderson JC, et al. Limb-length Discrepancy Measured with Computerized Axial Tomographic Equipment. *J Bone Joint Surg* 1987;69A:699.

* 37. Ilizarov G, Deviatov A. Surgical Lengthening of the Shin with Simultaneous Correction of Deformities. *Ortop Travmatol Protez* 1969;30:32.

+ 38. Ilizarov G, Deviatov A. Surgical Elongation of the Leg. *Ortop Travmatol Protez* 1971;32:20.

+ 39. Ilizarov G, Deviatov A, Trokhova V. Surgical Lengthening of the Shortened Lower Extremities. *Vestn Khir I I Grek* 1972;107:100.

+ 40. Ilizarov G, Palienko L, Shreiner A. Bone Marrow Hematopoietic Function and Its Relationship to Osteogenesis Activity during Reparative Regeneration in Leg Lengthening in the Dog. *Ontogenez* 1984;15:146.

+ 41. Jones D, Moseley C. Subluxation of the Knee as a Complication of Femoral Lengthening by the Wagner Technique. *J Bone Joint Surg* 1985;67-B:33.

+ 42. Junk S, Terjesen T, Rossvoll I, Braten M. Leg Length Inequality Measured by Ultrasound and Clinical Methods. *Eur J Radiol* 1992;14:185.

+ 43. Kalamchi A, Cowell H, Kim K. Congenital Deficiency of the Femur. *J Pediatr Orthop* 1985;5:129.

! 44. Kaufman KR, Miller LS, Sutherland DH. Gait Asymmetry in Patients with Limb-Length Inequality. *J Pediatr Orthop* 1996;16:144.

+ 45. Kohan L, Cumming W. Femoral Shaft Fractures in Children: The Effect of Initial Shortening on Subsequent Limb Overgrowth. *Aust NZ J Surg* 1982;52:141.

+ 46. Kostuik JP, Gillespie R, Hall JE, Hubbard S. Van Nes Rotational Osteotomy for Treatment of Proximal Femoral Focal Deficiency and Congenital Short Femur. *J Bone Joint Surg* 1975;57-A:1039.

+ 47. Kujala U, Friberg O, Aalto T, et al. Lower Limb Asymmetry and Patellofemoral Joint Incongruence in the Etiology of Knee Exertion Injuries in Athletes. *Int J Sports Med* 1987;8:214.

+ 48. Lampe HI, Swierstra BA, Diepstraten AF. Timing of Physiodesis in Limb Length Inequality. The Straight Line Graph Applied in 30 Patients. *Acta Orthop Scand* 1992;63:672.

+ 49. Lampe HI, Swierstra BA, Diepstraten AF. Measurement of Limb Length Inequality. Comparison of Clinical Methods with Orthoradiography in 190 Children. *Acta Orthop Scand* 1996;67:242.

+ 50. Little DG, Nigo L, Aiona MD. Deficiencies of Current Methods for the Timing of Epiphysiodesis. *J Pediatr Orthop* 1996;16:173.

! 51. Liu XC, Fabry G, Molenaers G, et al. Kinematic and Kinetic Asymmetry in Patients with Leg-Length Discrepancy. *J Pediatr Orthop* 1998;18:187.

+ 52. Lorenzi G, Rossi P, Quaglia F, et al. Growth Disturbances following Fractures of the Femur and Tibia in Children. *Ital J Orthop Traumatol* 1985;11:133.

+ 53. Matson P, Johnson LO. *Fat Embolism following Closed Femoral Shortening for Limb Length Inequality.* Shriners Hospitals Orthopaedic Symposium, Los Angeles, 1987.

+ 54. Meals R. Overgrowth of the Femur following Fractures in Children: Influence of Handedness. *J Bone Joint Surg* 1979;61-A:381.

* 55. Menelaus M. Correction of Leg Length Discrepancy by Epiphyseal Arrest. *J Bone Joint Surg* 1966;48-B:336.

+ 56. Metaizeau JP, Wong-chung J, Bertrand H, Pasquier P. Percutaneous Epiphysiodesis Using Transphyseal Screws (PETS). *J Pediatr Orthop* 1998;18:363.

+ 57. Millis M, Hall J. Transiliac Lengthening of the Lower Extremity. A Modified Innominate Osteotomy for the Treatment of Postural Imbalance. *J Bone Joint Surg* 1979;61-A:1182.

+ 58. Monticelli G, Spinelli R. Leg Lengthening by Closed Metaphyseal Corticotomy. *Ital J Orthop Traumatol* 1983;9:139.

+ 59. Morscher E. Etiology and Pathophysiology of Leg Length Discrepancies. *Prog Orthop Surg* 1977;1:9.

+ 60. Mosca V, Moseley CF. Results of Limb Lengthening Using the Wagner Device. *Orthop Trans* 1987;11:52.

* 61. Moseley CF. A Straight-Line Graph for Leg-Length Discrepancies. *J Bone Joint Surg* 1977;59-A:174.

+ 62. Nadler SF, Wu KD, Galski T, Feinberg JH. Low Back Pain in College Athletes. A Prospective Study Correlating Lower Extremity Overuse or Acquired Ligamentous Laxity with Low Back Pain. *Spine* 1998;23:828.

+ 63. Ogilvie JW. Epiphysiodesis: Evaluation of a New Technique. *J Pediatr Orthop* 1986;6:147.

# 64. Paley D. Current Techniques of Limb Lengthening. *J Pediatr Orthop* 1988;8:73.

+ 65. Paley D, Herzenberg JE, Paremain G, Bhave A. Femoral Lengthening Over an Intramedullary Nail. A Matched-Case Comparison with Ilizarov Femoral Lengthening. *J Bone Joint Surg* 1997;79-A:1464.

+ 66. Papaioannou T, Stokes I, Kenwright J. Scoliosis Associated with Limb-Length Inequality. *J Bone Joint Surg* 1982;64-A:59.

* 67. Parrini L, Paleari M, Biggi F. Growth Disturbances from Fractures of the Femur and Tibia in Children. *Ital J Orthop Traumatol* 1985;11:139.

* 68. Phemister P. Operative Arrestment of Longitudinal Growth of Bodies in the Treatment of Deformities. *J Bone Joint Surg* 1933;15:1.

+ 69. Porat S, Peyser A, Robin GC. Equalization of Lower Limbs by Epiphysiodesis: Results of Treatment. *J Pediatr Orthop* 1991;11:442.

+ 70. Pouliquen JC, Etienne W. [Segmentary Growth of the Lower Limb after Surgical Lengthening in the Children]. In French. *Cir Pediatr* 1978;19:179.

+ 71. Rossvoll I, Junk S, Terjesen T. The Effect on Low Back Pain of Shortening Osteotomy for Leg Length Inequality. *Int Orthop* 1992;16:388.

* 72. Rush W, Steiner H. A Study of Lower Extremity Length Inequality. *Am J Roentgenol* 1946;56:616.

+ 73. Sengupta A, Gupta P. Epiphyseal Stapling for Leg Equalization in Developing Countries. *Int Orthop* 1993;17:37.

+ 74. Shapiro F. Developmental Patterns in Lower-Extremity Length Discrepancies. *J Bone Joint Surg* 1982;64-A:639.

+ 75. Simons S, Whiffen J, Shapiro F. Leg-Length Discrepancies in Monoarticular and Pauciarticular Juvenile Rheumatoid Arthritis. J Bone Joint Surg 1981;63-A:209.

! 76. Song KM, Halliday SE, Little DG. The Effect of Limb-Length Discrepancy on Gait. *J Bone Joint Surg* 1997;79-A:1690.

+ 77. Soukka A, Alaranta H, Tallroth K, Heliovaara M. Leg-Length Inequality in People of Working Age. The Association Between Mild Inequality and Low-Back Pain is Questionable. *Spine* 1991;16:429.

+ 78. Stephens DC, Herrick W, MacEwen GD. Epiphysiodesis for Limb Length Inequality: Results and Indications. *Clin Orthop* 1978;136:41.

+ 79. Stephens MM, Hsu LCS, Leong JCY. Leg Length Discrepancy after Femoral Shaft Fractures in Children: Review after Skeletal Maturity. *J Bone Joint Surg* 1989;71-B:615.

* 80. Straub L, Thompson T, Wilson P. The Results of Epiphyseodesis and Femoral Shortening in Relation to Equalization of Leg Length. *J Bone Joint Surg* 1945;27:254.

* 81. Tanner J, Whitehouse R, Marshall W, et al. *Assessment of Skeletal Maturity and Prediction of Adult Height (TW2 method).* London: Academic Press, 1975.

+ 82. Terjesen T, Benum P, Rossvoll I, et al. Leg-Length Discrepancy Measured by Ultrasonography. *Acta Orthop Scand* 1991;62:121.

+ 83. Timperlake RW, Bowen JR, Guille JT, Choi IH. Prospective Evaluation of Fifty-three Consecutive Percutaneous Epiphysiodeses of the Distal Femur and Proximal Tibia and Fibula. *J Pediatr Orthop* 1997;11:350.

+ 84. Tjernstrom B, Rehnberg L. Back Pain and Arthralgia Before and After Lengthening. 75 Patients Questioned after 6(1–11) Years. *Acta Orthop Scand* 1994;65:328.

* 85. Van Nes CP. Rotationplasty for Congenital Defects of the Femur. *J Bone Joint Surg* 1950;32-B:12.

+ 86. Vostrejs M, Hollister J. Muscle Atrophy and Leg Length Discrepancies in Pauciarticular Juvenile Rheumatoid Arthritis. *Am J Dis Child* 1988;142:343.

* 87. Wagner H. Surgical Leg Prolongation. *Chirurg* 1971;42:260.

* 88. Wagner H. Operative Lengthening of the Femur. *Clin Orthop* 1978;136:125.

+ 89. Wasserstein I, Correll J, Niethard F. Closed Distraction Epiphyseolysis for Leg Lengthening and Axis Correction of the Leg in Children. *Z Orthop* 1986;124:743.

* 90. White J, Stubbins SJ. Growth Arrest for Equalizing Leg Lengths. *JAMA* 1944;126:1146.

* 91. Winquist RA. Closed Intramedullary Osteotomies of the Femur. *Clin Orthop* 1986;212:155.

+ 92. Yrjonen T, Hoikka V, Poussa M, Osterman K. Leg-Length Inequality and Low-Back Pain after Perthes' Disease: A 28–47-year Follow-up of 96 Patients. *J Spinal Disord* 1992;5:443.

# CHAPTER 171

# PEDIATRIC APPLICATIONS OF CIRCULAR AND UNILATERAL EXTERNAL FIXATION

*Deborah F. Stanitski*

**D. F. Stanitski:** Professor, Orthopaedic Surgery, Medical University of South Carolina, Charleston, SC, 29425.

Large Pin and Cantilever Systems
- Orthofix Unit
- Orthofix Technique for Fracture and Osteotomies

Circular External Fixation
- Osteotomy Technique

Special Applications
- The Foot
- Joint Contractures
- Upper Extremity

Trauma Applications
- Open Fractures
- Multiple Trauma
- Femoral Shaft Fractures
- Floating Knee
- Pelvic Fractures

Chapter References

Over the past decade, external fixation has gained increasing acceptance as a surgical technique in children. The most common applications include incidences of trauma, correction of limb deformity, and limb-length equalization.

The numerous fixators available fall into two general categories: circular fixators and cantilever external fixators. Biomechanical studies have demonstrated that bone formation is enhanced by cyclic axial micromotion and, perhaps, by limited-bending micromotion (23). Torsion, on the other hand, is generally deleterious to bone formation. The Ilizarov-type of circular external fixator, which is less stable to axial loading than are most cantilever systems but relatively resistant to torsion, provides an excellent biomechanical environment for bone formation (42).

Another advantage of circular external fixation is that it is applicable to patients of virtually any size from toddler to large child, obese adolescent, or adult. The system provides three-dimensional adjustability, allowing angulation, translation, rotation, and lengthening when necessary. The Taylor Spatial Frame (5) now allows these parameters to be corrected simultaneously but currently has some ring-size limitations (Fig. 171.1). The traditional Ilizarov external fixator can be constructed with hinges to correct existing limb deformity (Fig. 171.2). Circular external fixation can be used to span adjacent limb segments, to protect potentially unstable joints, or to treat joint contractures (Fig. 171.3).



***Figure 171.1.*** The Taylor Spatial frame allows simultaneous correction of angulation, rotation, length, and translation through the use of six struts and universal ball joints.



***Figure 171.2.*** Preconstructed Ilizarov tibial fixator mimics the deformity and allows gradual correction through hinges placed at the level of the deformity.

***Figure 171.3.*** **A:** Preoperative photograph of a 3-year-old patient with arthrogryposis and a nearly 90° flexion deformity of the knee. **B:** Appearance of Ilizarov fixator affixed to the femur and tibia, spanning the knee joint with corrective hinges.

The disadvantages of the traditional circular external fixator are its bulk, the fact that it is difficult to apply and adjust, and that it requires multiple sites for transfixing wires. The traditional Ilizarov external fixator uses 1.5 or 1.8 mm transfixing tensioned wires for bone fixation, with half-pin fixation in the proximal femur. Over the last 5 to 6 years, a number of surgeons have modified the originally described techniques, substituting half-pins for some of the wires. Specifically, in children, the traditional “medial face” tibial wire (parallel to the medial face of the tibia) has been eliminated in favor of an anteroposteriorly directed half-pin. Affixing half-pins to a circular fixator permits 360° adjustability at the same time it avoids some of the soft-tissue problems of transfixing wires.

Unilateral external fixators by contrast are easy to apply, require a limited number of pin sites, and are less bulky (33). They are applied to only one side of the limb and require usually no more than four to six half-pins per limb segment depending on the type of application. Cantilever systems have some disadvantages. They can be used only on limbs of a certain size, they have less stability to shear stress than circular fixators, they cannot span joints easily, and their ability to correct angulation, rotation, and translation gradually is limited. With many current systems, significant adjustments such as device and pin clamp exchange must be made under general anesthesia. Some systems, including the Heidelberg (5), Orthofix (5), and EBI (5) systems, have gradual but limited correction capabilities.

In this chapter, I provide specific application recommendations. I have had more than a decade of experience with both types of devices. The Ilizarov type of fixator remains the more versatile device, but patient acceptance and comfort clearly favor the monolateral fixator.

## LARGE PIN AND CANTILEVER SYSTEMS

A number of cantilever devices are available in North America for trauma or limb reconstruction applications, including the Orthofix device (Orthofix, Winston-Salem, NC), EBI Dynafix (EBI Corp., Parsippany, NJ), Smith and Nephew Heidelberg fixator (Smith and Nephew, Memphis, TN), the Hex-Fix (Smith and Nephew, Memphis, TN), and the Synthes External Fixator (Synthes USA, Philadelphia, PA). In each case, application requires pin clamps or pin clamp templates through which half-pins are inserted. The choice of fixator is usually determined by the problem to be addressed and size of the patient. The most commonly used limb reconstruction systems are the Orthofix and EBI, with the Heidelberg system having been recently introduced. These fixators are lightweight devices with the ability to telescope. The technique for insertion of the half-pins, and application of these types of fixators is discussed in detail in Chapter 11 and specifically for the tibia in Chapter 24.

### ORTHOFIX UNIT

The Orthofix, available in pediatric and adult sizes, has variable body lengths (Fig. 171.4). The short or standard length devices are used most often on children. Orthofix has two articulating ball joints and uses tapered predrilled half-pin fixation. The telescoping body can be unlocked once fracture or osteotomy callus formation is evident radiographically. This capacity theoretically allows axial loading or dynamization of the bone facilitating callus formation and bone healing. The standard articulated device is used for fracture management and osteotomies (16,35,40,50,53). Its ball-and-joint articulation permits approximately 30° to 35° of angulation; it can be freely rotated.

***Figure 171.4.*** Several lengths of the Orthofix pediatric (top two) and adult (bottom 3) fixators are available.

Use the straight slide-type device or LRS (5) (Limb Reconstruction System) for lengthening (Fig. 171.5). It allows placement of more than two pin clamps when necessary for situations such as bone transport. A swivel clamp can be substituted for straight clamps at one or both ends of the bone (Fig. 171.6); this technique may be useful for bifocal osteotomies with acute deformity correction or to eliminate deformity that may develop during lengthening. A variety of angulation and rotation template clamps are now available for more accurate multiplanar corrections (Fig. 171.7). Do not use the standard swivel clamps for lengthening; they are less stable than the standard pin clamps. With either the standard articulated body fixator or LRS, insert tapered predrilled half-pins through the clamp templates. Then replace the template with the standard pin clamps and tighten them. For fractures and osteotomies, generally two half-pins above and below the fracture or osteotomy are adequate. The widest pin spread in the clamp provides the best stability. For limb lengthening, use three pins proximal to the lengthening site in the femur and tibia. Two or three are adequate distally, depending on the size of the patient and amount of anticipated lengthening (Fig. 171.8) (1,22,25,46,47,48).

***Figure 171.5.*** **A:** Orthofix LRS slide lengtheners are available in various lengths, as well as pediatric and adult sizes for limb lengthening. **B:** Template clamps are placed directly on the lengthening device for parallel pin placement. **C:** LRS system with pin clamps in place and distraction device above the fixator.



***Figure 171.6.*** Swivel template clamps and swivel pin clamps are available for angular correction.



***Figure 171.7.*** **A and B:** A new rotation template clamp is now available to allow accurate planning and pin insertion for acute rotational corrections. **C:** The new angulation template clamp can be affixed to the end of the slide for planned acute angular correction 90° orthogonal to the plane of the swivel clamp.

***Figure 171.8.*** **A:** Clinical appearance of a patient with Ollier's disease after tibial lengthening with residual varus deformity of the femur and shortening. **B:** AP and lateral radiographs following application of LRS system and acute correction of femoral deformity. **C to E:** Clinical and radiographic appearance at the conclusion of lengthening and bone consolidation.

The T-Garches device (Orthofix) is useful for gradual correction of frontal plane deformity in the tibia—for example, in adolescent Blount's disease (Fig. 171.9) (59). Small lengthenings can also be achieved with this device. A new template clamp allows correction of acute sagittal plane deformity before application of the device following osteotomy (Fig. 171.10). It is not recommended for large lengthenings; the hinge may not withstand large lengthening forces, and the device, for the most part, accommodates only two proximal tibial pins (Fig. 171.11).

***Figure 171.9.*** **A and B:** The T-Garches external fixator is ideal for correction of proximal tibial frontal plane deformity. **C and D:** Clinical and radiographic appearance of a 12-year-old boy with adolescent Blount's disease and varus deformity of both the tibia and the femur. **E:** Radiographic appearance following osteotomy of the femur and tibia, and application of an Orthofix external fixator to the femur and T-Garches external fixator to the tibia. **F:** Radiograph following fixator removal with restoration of normal limb mechanical axis.



***Figure 171.10.*** The new T-Garches template clamp allows accurate pin placement for simultaneous sagittal and frontal plane deformity correction.



***Figure 171.11.*** Only two pins can be placed in the proximal T-Garches fixator. This potentially limits its use, particularly for significant lengthenings.

In applying the LRS systems, standard ball-joint fixators , and the T-Garches, it is important to note the length of the device and the pin spread for the particular application. Be certain, for example, in a limb lengthening, that the device is long enough. At least 10% extra length is needed for the tibia and 20% for the femur. The bone-to-fixator distance is relatively large, particularly in the femur. Thus, there is not always a 1:1 ratio between the amount of lengthening the device can achieve (ie, number of turns) and the actual distraction achieved in the limb. Start with some extra length in the device to avoid running out of space.

**ORTHOFIX TECHNIQUE FOR FRACTURE AND OSTEOTOMIES**

- In the case of fracture reduction or osteotomy, anticipate whether the device will need to be lengthened or shortened to achieve the correct bone position before determining pin placement. Add a supplemental pin to the fixator body if necessary for segmental fracture stabilization.
- Once pins are in place, remove the template. Obtain provisional reduction of a fracture or positioning of the bone ends following osteotomy before applying the fixator.
- Apply the fixator and tighten the pin clamps. Attach the reduction forceps to the clamps and fine-tune the bone position under image intensifier control.

***Dynafix***

The major generic difference between the Orthofix and the Dynafix (manufactured by EBI Medical Systems) is that the Dynafix itself is used as its own template. Tissue protectors and drill guides are placed directly through the pin clamps. The Dynafix articulated body fixator has mobile joints that allow angulation in the frontal and sagittal plane and rotation through the center of the fixator (Fig. 171.12). The snakelike configuration of the device and the multiple fixator body joints permit translation and rotational corrections as well as approximately 30° of angulation at each joint. As with the standard Orthofix unit, these corrections need to be completed during surgery.

***Figure 171.12.*** The EBI Dynafix external fixator allows angulation, translation, and rotation through its “snake-like” configuration.

**HINTS AND TRICKS**

- With the articulated body fixator, always secure the ball joints with methylmethacrylate to avoid slippage during weight bearing, which can lead to loss of position in fractures or after osteotomy.
- Small articulated fixators are available for specialized application in the pediatric forearm, humerus, and tibia (5).
- In general, an adult-size fixator is recommended for the femur of all except the smallest children (those weighing less than 50 to 60 lb); it can also be applied to the tibia in older children.
- Use the larger 6.0 to 5.0 mm tapered pins when possible except in the forearm or in bones smaller than 15 mm in diameter. Two pin sizes are available for small bones.

The lengthening system is similar in concept to the Orthofix LRS (Fig. 171.13 and Fig. 171.14). Both systems use pins with an external shaft diameter of 6.0 mm. The pin clamp spacing and configuration are different between the two devices; thus, it is impossible to exchange devices without changing pin locations.



***Figure 171.13.*** The EBI lengthening system is similar to the Orthofix LRS system.



***Figure 171.14.*** Swivel clamps are available for the Dynafix lengthening system.

A device similar to the Orthofix T-Garches is also available for correction of proximal tibial deformities (Fig. 171.15). Because the pin clamps are applied to the T portion of the device, more than two pins can be inserted if desired. The pins may also be applied either proximal or distal to the T allowing some longitudinal spread of the proximal metaphyseal pins.



***Figure 171.15.*** Like the T-Garches, the EBI T-fixator allows gradual angular correction in the proximal tibia and lengthening.

***Heidelberg Fixator***

Used in Europe for approximately 5 years, the Heidelberg fixator, designed by Dr. Joachin Pfeil, has recently been introduced to North America (Fig. 171.16). This device is yet another cantilever system. Its proposed benefit, however, is the ability to achieve gradual angular correction through a device called the angulator (Fig. 171.17). Pins are inserted through a drill guide template (Fig. 171-18), which can be applied to the fixator in any plane and allows correction of oblique plane deformity or correction of deformity that may arise during limb lengthening such as procurvatum and valgus in the tibia. The surgeon can also apply supplemental bone screws when necessary to enhance stability. A special clamp is also available to allow fixation to the Ilizarov ring system (Fig. 171.19). Experience thus far in North America is limited, but the device has some potentially significant advantages, particularly when gradual deformity correction is desirable. Translational correction must nonetheless be obtained intraoperatively.



***Figure 171.16.*** The Heidelberg fixator has been recently introduced to North America. Similar to other systems, it has several pin clamp types. Lengthening occurs through the body of the fixator itself.



***Figure 171.17.*** The Heidelberg “angulator” allows gradual deformity correction following lengthening.



***Figure 171.18.*** Pins are introduced through a hand-held template that matches the pin clamp.



***Figure 171.19.*** A special Heidelberg clamp allows fixator attachment to the Ilizarov ring system.

***Hex-Fix***

The Hex-Fix can be used to stabilize pediatric long-bone fractures definitively and in osteotomies in small children or children with particularly small bones, as in the skeletal dysplasias. I prefer to use it for proximal femoral fractures or fractures in very small children (those younger than 4 to 5 years of age) in whom stable fracture fixation is desired. The device can accommodate predrilled or self-drilling (eg, Schanz) half-pins of 4, 5, or 6 mm. There are several types of pin clamps available that accommodate one or two bone pins (Fig. 171.20). The single pin clamps permit flexible pin spacing. The clamps also allow some angulation and rotation, enabling multiplanar half-pin fixation on a cantilever device.



***Figure 171.20.*** The Hex-Fix is particularly useful for fracture fixation in small children. Four, five, or six millimeter pins may be introduced through the pin clamps, which act as their own template. They are available as single or double clamps as shown. Pins and pin clamps are secured using the universal tool.

Generally, insert two pins proximally and distally to the fracture or osteotomy; pin spacing is dependent on the individual situation. There is no limit to the number of pins that can be used other than the ability to put the pin clamps on the bar. The actual bar on which the pin clamps are assembled is available in several lengths, the shortest being 8 inches. Although a distractor unit is available for lengthening, I have no experience using this device for limb lengthening.

## CIRCULAR EXTERNAL FIXATION

The most commonly used circular external fixator is the Ilizarov apparatus. This device is applicable to all limb segments in both the upper and the lower extremities and can be used for deformity correction of both bone and soft tissue, and for limb lengthening (3,5,6,7,8,9,10,11 and 12,15,17,19,20 and 21,24,27,29,30 and 31,32,38 and 39,41,42,43,44 and 45,51,56,57 and 58,61,62 and 63). Acute trauma applications in the child are limited. It is used most commonly for segmental bone loss, in which it can be used for bone transport (11).

In children, the Ilizarov device is applied most commonly to the femur or the tibia. The standard tibial fixator consists of one or two rings proximally and distally depending on the size of the patient. The standard tibial wire “formula” calls for the insertion of four wires proximally and distally (Fig. 171.21) (26). These wires are either 1.5 or 1.8 mm in diameter. Use 1.5 mm wires in the tibia of smaller children, and 1.8 mm wires in the femur and the tibia of heavier children. At each end of the bone, place two “olive” wires and two smooth wires. Generally, place the olive wires transversely in the frontal plane, one olive from the medial and one from the lateral aspect of the bone. Transfix the fibula and tibia with a smooth wire, both proximally and distally. Finally, place two wires from anterolateral to posterolateral (one proximal and one distal), parallel to the medial border of the tibia. When bifocal—proximal and distal tibial osteotomies—are planned, use another ring fixed to the mid-diaphysis by two wires (Fig. 171.22). These wires are often two olive wires, or an olive wire and plain wire, depending on the direction or nature of the deformity.

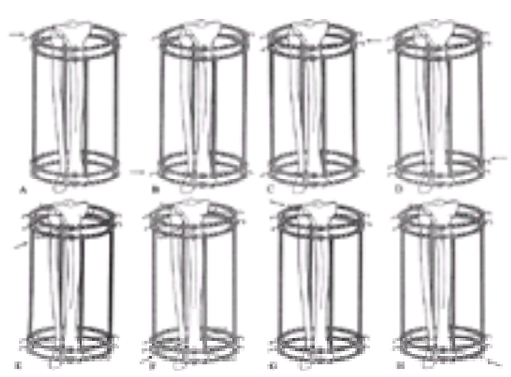

***Figure 171.21.*** **A and B:** Transverse “Olive” wires are first placed on the most proximal and distal rings. **C and D:** Two additional olive wires are placed from the opposite direction on the two middle rings. **E and F:** Smooth wires are placed from the lateral aspect of the leg, parallel to the medial face of the tibia both proximally and distally. **G and H:** Two smooth wires are placed through the proximal and distal fibula, transfixing the tibia.

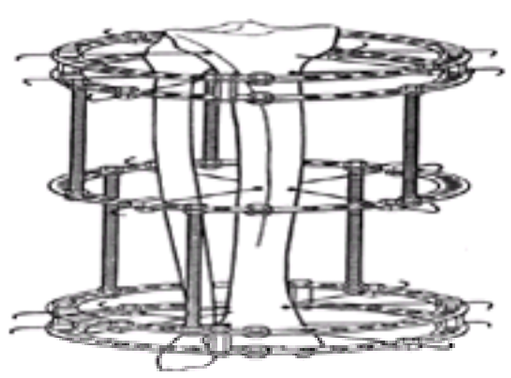

***Figure 171.22.*** Bifocal treatment for deformity or lengthening requires an additional middle ring with two-wire or wire and half-pin fixation.

Many modifications have been made to this standard wire “formula” in recent years, generally the substitution of half-pins for wires (discussed in Chapter 32).

In children, I prefer a largely “wired-based” circular fixator. Because the standard medial face tibial wire can often interfere with the pes anserinus tendons, I substitute a half-pin for this wire, leaving the remaining wires as described earlier (Fig. 171.23). In the tibia, the addition of an extra ring in the diaphysis allows bifocal treatment. It is useful for patients with deformities at more than one level (Fig. 171.24), when extensive lengthening is necessary, and in bone transport (Fig. 171.25).

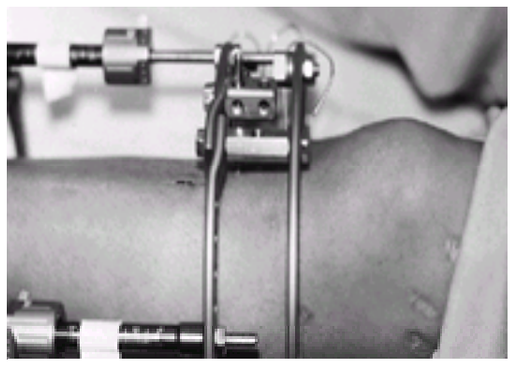

***Figure 171.23.*** A half-pin is often substituted for the traditional Ilizarov medial face wire and affixed to a Rancho cube.

***Figure 171.24.*** **A and B:** Standing and lateral teleoroentgenograms of a patient with Ollier's disease and a 13 cm limb-length inequality with bifocal tibial deformity. **C and D:** The Ilizarov external fixator with bifocal application was used for gradual correction of the proximal and distal deformities as well as 8 cm of lengthening. **E:** Radiographs at the conclusion of tibial consolidation.

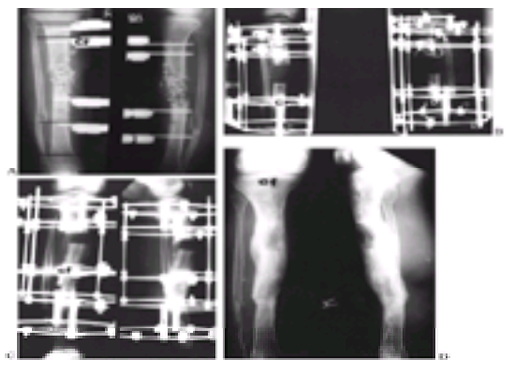

***Figure 171.25.*** Tibial radiographs of a 16-year-old boy who presented following a pedestrian motor vehicle accident with 6 cm of missing bone. Antibiotic cement beads were used as a spacer, and external fixation was applied using a Synthes external fixator. **B:** The Ilizarov apparatus was applied over the Synthes fixator, which was then removed. A proximal osteotomy was performed and bone transport was initiated to restore the defect. **C:** Radiographs at the conclusion of bone transport. **D:** Radiographs following fixator removal.

For femoral fixation I prefer an Italian modification using partial rings proximally, as compared with the original Russian technique, which uses full rings for both the proximal and distal thigh. My technique is as follows.

- Generally, I use four wires distally—two 1.8 mm olive wires and two plain wires fixed to one or two rings (Fig. 171.26).



***Figure 171.26.*** Schematic drawing of the Italian modification of standard Ilizarov fixation of the femur. Note that proximal fixation is achieved using half-pins. An empty middle ring is used to facilitate angular or rotation correction as well as lengthening. Distal fixation is traditional through four 1.8 mm transfixing wires.

- Connect these rings to an empty diaphyseal ring via lengthening rods or hinges depending on the application.
- Achieve proximal fixation by half-pin, rather than by wire fixation. Determine the diameter of the half-pin by the size of the child.
- Connect the distal rings to the proximal thigh fixation through oblique supports.
- Attach the proximal half-pins to one or two “arches,” depending on the size of the patient.
- Introduce wires or half-pins on the diaphyseal ring for bifocal application to the femur. Although bifocal lengthening is not recommended, proximal angular or rotational osteotomy can be performed acutely (Fig. 171.27), combined with distal deformity correction and lengthening.

***Figure 171.27.*** **A and B:** Preoperative photographs and teleoroentgenogram of a 6-year-old boy with congenital shortening of the femur, fibular hemimelia, and a three-ray foot. **C:** The Ilizarov technique was used for bifocal application. Acute rotational correction was performed proximally. Elimination of distal femoral valgus and subsequent lengthening was done distally. **D and E:** The photographs demonstrate symmetric internal and external rotation at the conclusion of

treatment. **F:** Radiographs demonstrate excellent healing of both femoral and tibial lengthening sites.

Circular fixation allows almost limitless modification of the fixator. During lengthening, adjacent joints are at risk for progressive contracture, subluxation, or dislocation. The risk of dislocation is particularly significant in the case of congenitally short limbs, such as the ankles associated with fibular hemimelia, knees or hips in the congenital short femur, and proximal femoral focal deficiency (PFFD). Pre-existing contracture due to trauma, burn, or infection may warrant use of circular fixation for gradual correction of deformity with combined femoral and tibial lengthening. Consider prophylactic incorporation of the foot or tibia in tibial or femoral lengthening, respectively, at the beginning or if there is any indication of subluxation or progressive contracture as lengthening proceeds. Consider extending the fixator to the pelvis when the hip is at risk for subluxation (Fig. 171.28). I recommend fixation of the foot at the initial surgery in any patient undergoing tibial lengthening who has fibular hemimelia or a pre-existing equinus contracture. Comprehensive release of the foot can be maintained with foot fixation and combined with tibial lengthening (Fig. 171.29).

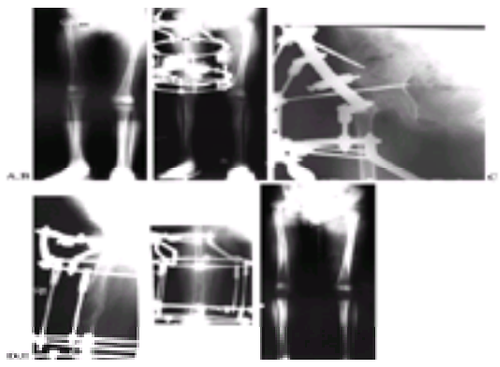

***Figure 171.28.*** **A:** Radiographs of an 11-year-old girl with a painless fibrous pseudarthrosis of her right hip and a projected limb length inequality of 9 cm. **B and C:** Radiographs demonstrate Ilizarov fixation of the femur with extension of the fixation to the pelvis to protect the potentially unstable hip. **D and E:** Radiographs at the conclusion of lengthening demonstrate excellent consolidation of the bone and no disruption of the hip joint.

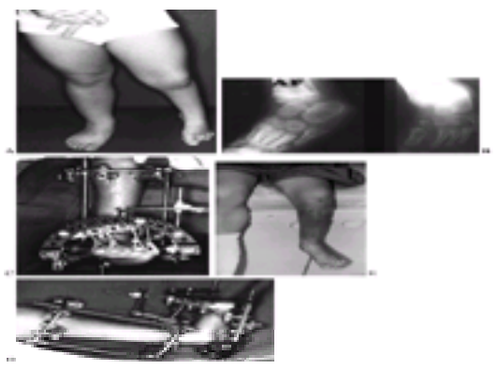

***Figure 171.29.*** **A and B:** Clinical appearance and radiographs of a 2 1/2-year-old girl with hemisacral agenesis, recurrent club foot deformity, and a leg-length inequality. **C and D:** An open soft-tissue release of the foot was combined with gradual correction of residual foot deformity and tibial lengthening using the Ilizarov technique. **E:** Clinical appearance at the end of treatment.

- Try to use two metatarsal olive wires and two calcaneal olive wires.
- In the forefoot, introduce the medially based olive wire through the first and second metatarsals and the lateral wire through the two lateral metatarsals. Fix them to an arch, tensioned no more than 50 to 80 kg. Place the wires in this fashion to avoid flattening the forefoot arch and preclude weight bearing on wires.
- Introduce one calcaneal wire from the medial side and one from the lateral side, usually diverging no more than 45° (Fig. 171.30).

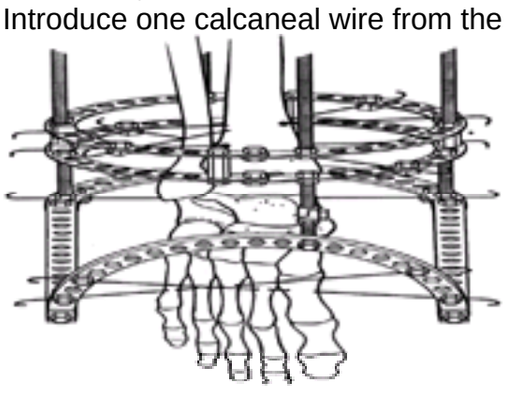

***Figure 171.30.*** A variety of options are available for foot fixation using the Ilizarov technique. I prefer hindfoot fixation through the calcaneus using opposing olive wires and forefoot fixation, with the lateral olive wire transfixing the two lateral metatarsals and the medial Olive wire transfixing the two medial metatarsals.

- Fixation of both the hindfoot and forefoot avoids midfoot deformity and forefoot equinus, which can result from tension on the long toe flexors during lengthening.
- Once the distraction phase has been completed, remove the foot fixation, allowing the ankle and foot to regain motion while the tibial lengthening site consolidates. If prophylactic circular fixation has been applied to the tibia during femoral lengthening, remove it once femoral distraction has been completed as long as there is no significant concurrent contracture of the hip.

### OSTEOTOMY TECHNIQUE

- Perform osteotomy of long bones for deformity correction or lengthening through a 1 to 1.5 cm incision, with minimal periosteal stripping generally using a sharp, thin ¼-inch osteotome.
- Predrill the bone with a 2.7 mm or 3.2 mm drill to avoid crack propagation from the osteotomy into the adjacent half-pins, which could considerably weaken fixation.
- Avoid large incisions with subperiosteal exposure of the bone and insertion of retractors to minimize scarring and promote bone healing.
- There is no need to make a true “corticotomy” as described by Ilizarov, because the periosteal blood supply is more critical than the endosteal supply. Furthermore, the endosteal blood supply usually re-establishes itself within a matter of days following osteotomy.

## SPECIAL APPLICATIONS

### THE FOOT

Circular external fixation is used to correct foot deformity (32) by one of three approaches: (1) correction by distraction alone; (2) soft-tissue release and tendon lengthening combined with distraction; and (3) osteotomy and distraction. The choice of method depends on the child's age and whether the deformity is bony alone or combined with soft-tissue contractures. Ilizarov originally described correction of all soft-tissue deformity through closed distraction or “bloodless” surgery (28,32). This situation may present itself in the child younger than 4 to 5 years old with a multiply operated club foot in poor position. In my experience, an attempt at correction by

closed distraction alone may be unacceptably painful and, owing to the scar stiffness, may result in wire cut-out thorough osteopenic bone. In this situation, perform a conventional comprehensive release first, followed by fixation of the foot and tibia with appropriate hinge placement and subsequent gradual correction (Fig. 171.31). This surgery avoids the problem of wire migration.

***Figure 171.31.*** **A and B:** Clinical and radiographic appearance of a girl with fibular hemimelia and a four-ray equinovarus foot following two previous attempts to correct her foot deformity. **C:** Comprehensive foot release was combined with gradual independent correction of the forefoot and hindfoot deformities and tibial lengthening.

Apply this technique only to stiff feet in poor position, the goal being to produce a plantigrade foot.

The distraction rate in soft-tissue corrections is limited by patient discomfort, skin tension, and the tolerance of neurovascular structures. Slight overcorrection is recommended due to soft-tissue elasticity which can cause rebound following apparatus removal. Once correction has been achieved, maintain the fixation an additional 6 to 8 weeks. Use orthotics after the removal of the fixator to maintain the correction.

Tibial fixation should span the leg with two rings. A total of four wires, or two wires and two half-pins, are adequate fixation in the tibia because there is no tibial osteotomy. The number of wires in the foot and complexity of the apparatus depends entirely on the nature of the deformity.

With bony deformity in the older child, osteotomy is usually necessary (Fig. 171.32). The nature of the deformity determines the location of the osteotomy. If the hindfoot is neutral and the problem is midfoot cavus or supination, use a midtarsal osteotomy. Hindfoot fixation can be neutral with respect to the tibial fixation. Place hinges between the hindfoot and forefoot, centered over the apex of the deformity. A hindfoot that is not in neutral may be addressed in one of two ways. If cavus exists with hindfoot deformity, use a V-shaped osteotomy to address the hindfoot and midfoot independently. Additional fulcrum wires are necessary, usually in the midfoot and talus to ensure that correction occurs through the osteotomy and not through joint distraction. If the midfoot and forefoot are relatively neutral with respect to one another and the hindfoot is the problem, use a crescent-shaped osteotomy. Perform the osteotomy from the lateral side through the calcaneus and neck of the talus. Place wires superior and inferior to the osteotomy with appropriate hinge location to avoid translation of the foot during correction.

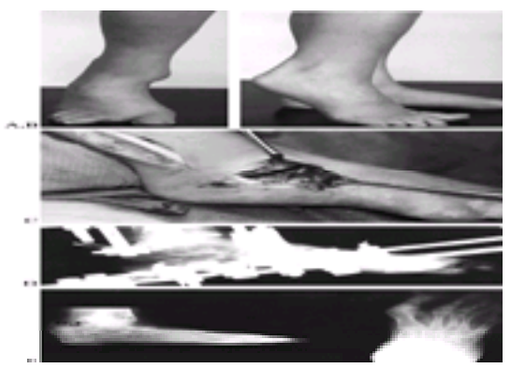

***Figure 171.32.*** **A and B:** This nearly skeletally mature boy with fibular hemimelia has a fixed deformity of his foot and limb shortening. **C:** An open crescentic osteotomy was performed through the talus and calcaneus with resection of the deforming tight fibular anlage. **D:** Lateral foot radiograph at the conclusion of correction. **E:** Radiographs following fixator removal.

**JOINT CONTRACTURES**

Circular external fixation can be used to correct joint contractures in children due to trauma (Fig. 171.33), infection, and burns. Unfortunately, to date, most surgeons' long-term experience has been disappointing. As with conventional soft-tissue and capsular release, the recurrence rate is high despite prolonged periods of posttreatment bracing. Furthermore, as with conventional surgery, depending on the duration of the deformity and the nature of the articular cartilage, the surgeon's goal may be limited to reorienting rather than increasing the arc of motion. The joints most commonly involved in the pediatric patient are the knee and ankle. The usual deformities are knee flexion and ankle equinus contractures.

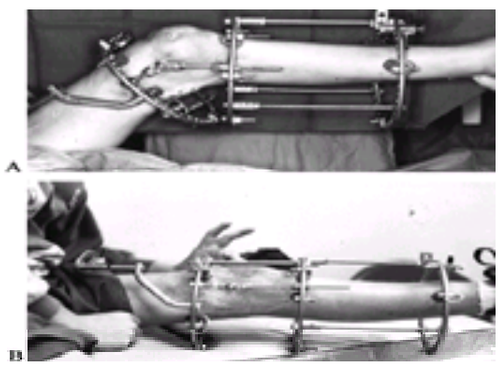

***Figure 171.33.*** **A:** A lawnmower accident resulted in a severe flexion deformity of this knee. Open posterior release achieved no improvement in knee position, and the Ilizarov external fixator was applied to the femur and tibia with hinges at the approximate center of rotation of the knee. **B:** Appearance at the conclusion of correction.

In the knee, the rate of correction is usually limited by the neurovascular bundles, in particular the sciatic nerve. Apply circular fixation to span the adjacent femur and tibia to provide an efficient lever arm. Hinges must be located as close to the center of rotation of the knee joint as possible to avoid joint compression or subluxation. After obtaining correction, depending on the preoperative range of motion, use the hinges to assist in moving the knee during physical therapy. At the ankle, center the hinge placement over the center of the talar dome to avoid anterior subluxation of the talus in the ankle mortise.

**UPPER EXTREMITY**

In general, it is easier to apply cantilever fixation than circular fixation to the upper extremity. At present, circular fixation is optimal for complex deformities that cannot

be corrected acutely (Fig. 171.34). It is also useful if the wrist needs to be spanned, for example, in lengthening of radial or ulnar club hand (12,37). Metacarpal wires can be fixed to a half-ring and attached to the forearm fixation (10,12,37,49,64).

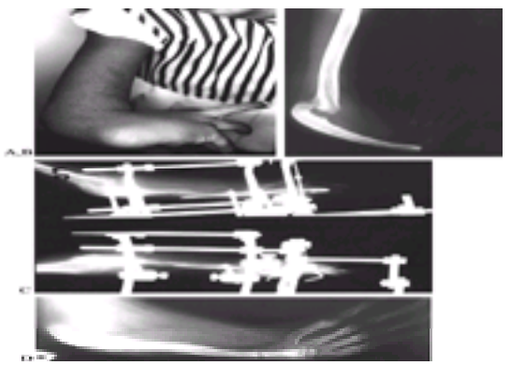

***Figure 171.34.*** **A and B:** Clinical and radiographic appearance of 6-year-old girl with a right radial club hand and no history of prior intervention. **C:** The ulna was centralized through an open procedure and the wrist stabilized with a transfixing Kirschner wire. Lengthening of forearm was then undertaken. **D:** The ulna was lengthened by more than 89%.

Cantilever fixation can be combined with circular fixation of the forearm, and the two methods can be used independently for deformities such as those associated with multiple hereditary exostosis (Fig. 171.35). In general, half-pin fixation is easier and safer to apply to the forearm than transfixing wires. The fact that the ulna is subcutaneous throughout its length makes half-pin fixation attractive. Half-pins can be attached in a multidirectional fashion to rings if desired. Two half-pins proximal and distal to the osteotomy site are enough for deformity correction or lengthening.

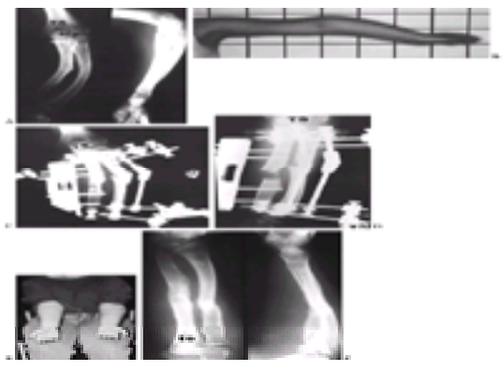

***Figure 171.35.*** **A and B:** Radiographs and clinical appearance of a 16-year-old girl with multiple hereditary exostoses with forearm shortening and deformity. **C and D:** Circular fixation was applied to the radius around a small Orthofix LRS fixator for gradual correction of radial deformity and ulnar lengthening. **E and F:** Clinical and radiographic appearance of the forearm at the conclusion of treatment.

The humerus is the most easily lengthened long bone (Fig. 171.36) (10). Perform osteotomy distal to the deltoid insertion. Two half-pins proximal and distal to the osteotomy or lengthening site are adequate in the arm. Insert the most distal pin just proximal to the olecranon fossa. The next most proximal pin must avoid the path of the radial nerve. Place it with open technique.

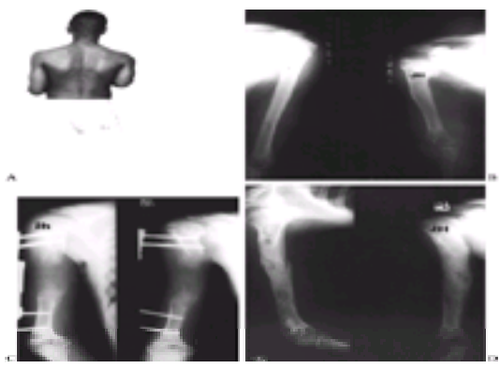

***Figure 171.36.*** **A and B:** Clinical appearance and radiographs of 13-year-old boy with 10 cm of right humeral shortening due to septic growth arrest of the proximal humerus at the age of 2 years. **C and D:** Radiographs at the conclusion of distraction and following consolidation.

## TRAUMA APPLICATIONS

### OPEN FRACTURES

At present, open fracture is the most clear-cut indication for external fixation of pediatric long-bone fractures (4,14,16,34,35,47,50,53,55,60). Depending on the size of the limb segment, apply a four-pin fixator (Hex-Fix, Orthofix, Dynafix) after irrigation and debridement of the open wound. Locate the fixator to minimize interference with subsequent wound management such as local or free flaps and skin grafts. In the case of segmental bone loss, circular fixation can be used to transport bone for definitive bone reconstruction of bone loss.

### MULTIPLE TRAUMA

Multiple trauma, particularly if combined with a concurrent severe closed head injury, is a strong indication for fixation of major long bone fractures in the pediatric patient. Those patients who require frequent computed tomography (CT) scans, magnetic resonance imaging (MRI) studies, or the operations for treatment of their associated injuries are more easily managed with stable fracture fixation. Traction or spica casts make this difficult, and spica casts may interfere with management of abdominal or chest trauma. Patients who experience spasticity or who are uncooperative following head injury are best managed with rigid stabilization of their long-bone fractures. Even in the very young child, small cantilever unilateral external fixators, such as the Hex-Fix, can be adapted to long-bone fractures, particularly of the femur and tibia.

### FEMORAL SHAFT FRACTURES

Operative management of isolated femoral diaphyseal fractures using external fixation has become accepted in patients older than 5 to 6 years of age (14,22,34,35,50,52,55). Immediate spica treatment is still preferred in small children, and older adolescents may be treated with intramedullary rodding. Current literature supports operative treatment of this intermediate age group between age 5 and 11 to 12 years, reporting excellent results with external fixation decreasing hospitalization, promoting early patient mobilization and return to school, decreasing psychosocial family stress, with an acceptable complication rate (2,4,14,16,34,50,52,53,55). A recent report (18) also demonstrated a clear cost savings when compared with traditional skeletal traction followed by spica-cast

immobilization. The major concern when using external fixation in these fractures is the risk of refracture. The incidence of refracture can be minimized by early weight bearing, early fixator dynamization, and mobilization of the knee. Anecdotal reference is made by some to suggest that the most common fracture pattern susceptible to refracture is a transverse diaphyseal fracture. In my experience, the most important factors in refracture are a stiff knee and lack of weight bearing during fracture healing.

## FLOATING KNEE

Ipsilateral concomitant fracture of both the femur and the tibia produces a floating knee. Operative stabilization of both the tibia and the femur are indicated. Depending on the skeletal maturity of the patient, intramedullary fixation of the femur, using either reamed or flexible implants, can be combined with external fixation of the tibia. In the younger child, external fixation can be applied to both the femur and the tibia. It allows rapid mobilization of the patient, motion of the knee and ankle, and normal shoe wear. Weight bearing can be initiated as soon as patient can tolerate it in most cases.

## PELVIC FRACTURES

Although they are relatively rare in children, unstable pelvic fractures, particularly open-book type fractures of the pelvis, can be treated with external fixation as in the adult (52). Posterior disruptions can be addressed by internal fixation and combined with an anterior fixator (see Chapter 17). For more details on the treatment of pediatric fractures, see Chapter 164.

## CHAPTER REFERENCES

Each reference is categorized according to the following scheme. *, classic article; #, review article; !, basic research article; and +, clinical results/outcome study.


+ 1. Aldegheri R, Renzi-Brivio L, Agostini S. Callotasis Method of Limb Lengthening. *Clin Orthop Rel Res* 1989;241:137.

+ 2. Alonso JE, Horowitz M. Use of the AO/ASIF External Fixator in Children. *J Pediatr Orthop* 1987;7:594.

+ 3. Armstrong PF, Bell DF, Rajacich N. The Ilizarov Technique. In: Malcolm Menelaus, ed. *The Management of Limb Discrepancy*. London: Churchill Livingstone, 1991:161.

+ 4. Aronson J, Tursky EA. External Fixation of Femur Fractures in Children. *Pediatr Orthop* 1992;12:157.

+ 5. Bell DF. Treatment of Adolescent Blount's Disease Using the Ilizarov Technique. In: Balderston RA, ed. *Operative Techniques in Orthopaedics*, Vol 3, No 2. Philadelphia: W.B. Saunders, 1993:149.

+ 6. Bell DF. Treatment of Post-traumatic Sequelae by the Ilizarov Technique. In. Letts M, ed: *Management of Pediatric Fractures.* London: Churchill Livingstone, 1993:711.

+ 7. Bell DF, Armstrong P, Paley D. Extensive Two-level Limb Lengthening. Early Results Utilizing the Ilizarov Technique. *J Bone Joint Surg* 1990;72-B:538.

+ 8. Bell DF, Boyer MI, Armstrong PF. The Use of the Ilizarov Technique in the Correction of Limb Deformities Associated with Skeletal Dysplasia. *J Pediatr Orthop* 1992;12:283.

+ 9. Cattaneo R, Catagni M, Johnson EE. The Treatment of Infected Nonunions and Segmental Defects of the Tibia by the Methods of Ilizarov. *Clin Orthop Rel Res* 1992;280:143.

+ 10. Cattaneo R, Villa A, Catagni MA, Bell DF. Lengthening of the Humerus Using the Ilizarov Technique. Description of the Method and Report of 43 Cases. *Clin Orthop Rel Res* 1990;250:117.

+ 11. Cattaneo R, Villa A, Catagni MA, Tentori L. Limb Lengthening in Achondroplasia by Ilizarov's Method. *Int Orthop* 1988;12:173.

+ 12. Catagni MA, Szabo RM, Cattaneo R. Preliminary Experience with Ilizarov Method in Late Reconstruction of Radial Hemimelia. *J Hand Surg* 1993;18A:316.

! 13. Chao E, Hein T. Mechanical Performance of the Standard Orthofix External Fixator. *Orthopaedics* 1988;11:1057.

+ 14. Clinkscales CM, Peterson HA. Isolated Closed Diaphyseal Fractures of the Femur in Children. Comparison of Effectiveness and Cost of Several Treatment Methods. *Orthopaedics* 1997;20:1131.

* 15. Dal Monte A, Donzelli O. Tibial Lengthening According to Ilizarov in Congenital Hypoplasia of the Leg. *J Pediatr Orthop* 1987;7:135.

* 16. DeBastiani G, Aldegheri R, Renzi-Brivio L. The Treatment of Fractures with a Dynamic Axial Fixator. *J Bone Joint Surg* 1984;66B:538.

* 17. DeBastiani G, Aldegheri R, Renzi-Brivio L, Trivella F. Limb Lengthening by Callus Distraction (Callotasis). *J Pediatr Orthop* 1987;7:129.

+ 18. Doane RM, Stanitski DF, Stanitski CL. Treatment Cost of Isolated Femoral Shaft Fractures in Children. External Fixation Versus Traction. Submitted to Journal Pediatric Orthopaedics.

+ 19. Eldridge JC, Bell DF. The Correction of Severe Growth Abnormalities Following Purpura Fulminant Using the Ilizarov Technique. *Orthop Trans* 1992–1993;16:861.

+ 20. Fabry G, Lammens J, Van Melkebeek J, Stuyck, J. Treatment of Congenital Pseudarthrosis with the Ilizarov Technique. *J Pediatr Orthop* 1988;8:67.

+ 21. Ghoneem HF, Wright JG, Cole WG, Rang M. The Ilizarov Method for Correction of Complex Deformities. *J Bone Joint Surg* 1996;78A:1480.

+ 22. Glorion C, Pouliquen JC, Langlais J, et al. Femoral Lengthening Using the Callotasis Method. Study of the Complications in a Series of 70 Cases in Children and Adolescents. *J Pediatr Orthop* 1996;16:161.

! 23. Goodship AE, Kenwright J. The influence of induced micro-movement on the healing of experimental tibia fractures. *J Bone Joint Surg* 1985;67B:650.

+ 24. Grill F. Correction of complicated extremity deformities by external fixation. *Clin Orthop Rel Res* 1989;241:166.

+ 25. Guidera KJ, Hess WF, Highhouse KP, Ogden JA. Extremity Lengthening. Results and Complications with the Orthofix System. *J Pediatr Orthop* 1991;11;90.

# 26. Hamdy RC, Stanitski DF. A Visual Presentation of Ilizarov Tibial Lengthening. *The Journal of Orthopaedic Techniques* 1995;3:55.

+ 27. Huang SC, Kuo KN. Differential Lengthening of the Radius and Ulna Using the Ilizarov Method. *J Pediatr Orthop* 1998;18;370.

# 28. Ilizarov GA. The Principles of the Ilizarov Method. *Bull Hosp Jt Dis* 1988;48:1.

# 28. Ilizarov GA. The Tension-Stress Effect on the Genesis and Growth of Tissues. Part I. *Clin Orthop* 1989;238:249.

* 30. Ilizarov GA. The Tension-Stress Effect on the Genesis and Growth of Tissues. Part II. *Clin Orthop* 1989;239:264.

* 31. Ilizarov GA. Clinical Application of Tension-Stress Effect for Limb Lengthening. *Clin Orthop* 1990;250:8.

+ 32. Ilizarov GA, Shevtsov VJ, Kuzmin NV. Method of Treating Talipes Equinocavus. *Ortop Travmatol Protez* 1983;5:46.

+ 33. Kamegaya M, Shinohara Y, Shinada Y. Limb Lengthening and Correction of Angulation Deformity. Immediate Correction by Using a Unilateral Fixator. *J Pediatr Orthop* 1996;16;477.

+ 34. Kirschenbaum D, Albert MC, Robertson WW, Davidson RS. Complex Femur Fractures in Children. Treatment with External Fixation. *J Pediatr Orthop* 1990;10:588.

+ 35. Klein W, Pennig F, Brug E. *Dynamic Axial Fixation for Femoral Fractures in Children.* Presented at the International Congress. Evolution of External Fixation. June 1990, Montpellier, France.

+ 36. Knapp DR, Price CT. Correction of Distal Femoral Deformity. *Clin Orthop Rel Res* 1990;255:75.

+ 37. Lammens J, Mukherjee A, Van Eygen P, Fabry B. Forearm Realignment with Elbow Reconstruction Using the Ilizarov Fixator. A Case Report. *J Bone Joint Surg* 1991;73B:412.

! 38. Lavini F, Renzi-Brivio L, deBastiani G. Psychologic, Vascular and Physiologic Aspects of Lower Limb Lengthening in Achondroplastics. *Clin Orthop Rel Res* 1990;250:138.

+ 39. Miller LS, Bell DF. Management of Congenital Fibular Deficiency by Ilizarov Technique. *J Pediatr Orthop* 1992;12:651.

+ 40. Noonan KJ, Price CT. The Pearls and Pitfalls of Limb Lengthening and Deformity Correction via Unilateral External Fixation. *Iowa Orthop J* 1996;16:58.

# 41. Paley D. Current Techniques of Limb Lengthening. *J Pediatr Orthop* 1988;8:73.

+ 42. Paley D, Catagni M, Argnani F, et al. Treatment of Congenital Pseudarthrosis of the Tibia Using the Ilizarov Technique. *Clin Orthop Rel Res* 1992;280:81.

! 43. Paley D, Fleming D, Catagni M, et al. Mechanical Evaluation of External Fixators Used in Limb Lengthening. *Clin Orthop Rel Res* 1990;250:50.

+ 44. Plawecki S, Carpentier E, Lascombes P, et al. Treatment of Congenital Pseudarthrosis of the Tibia by the Ilizarov Method. *J Pediatr Orthop* 1990;10:786.

+ 45. Pouliquen JC, Coelin JD, Langlais J, Pauthier F. Upper Metaphyseal Lengthening of the Tibia by Callotasis. Forty-seven Cases in Children and Adolescents. *J Pediatr Orthop* 1993;2B:49.

+ 46. Pouliquen JC, Gorodischer S, Vernevet C, Richard L. Femoral Lengthening in Children and Adolescents. A Comparative Study of a Series of 82 Cases. *Fr J Orthop Surg* 1989;3:162.

+ 47. Price CT. Limb Lengthening for Achondroplasia. Early Experience. *J Pediatr Orthop* 1989;9:512.

# 48. Price CT. Metaphyseal and Physeal Lengthening. *Instr Course Lect* 1989;38:331.

+ 49. Price CT, Cole D. Limb Lengthening by Callotasis for Children and Adolescents. Early Experience. *Clin Orthop Rel Res* 1990;250:105.

+ 50. Price CT, Levengood G, Zink W. The Treatment of Pediatric Fractures with Dynamic External Fixation. *Techn Orthop* 1989;4:74.

+ 51. Rajacich R, Bell DF, Armstrong PF. Pediatric Application of the Ilizarov Method. *Clin Orthop Rel Res* 1992;280:72.

+ 52. Reff RB. The Use of External Fixation Devices in the Management of Severe Lower Extremity Trauma and Pelvic Injuries in Children. *Clin Orthop Rel Res* 1984;188:22.

+ 53. Scavenius M, Ebskov LB, Sloth C, Torholm C. External Fixation with the Orthofix System in Dislocated Fractures of the Lower Extremities in Children. *J Pediatr Orthop* 1993;2:161.

+ 54. Schlenzka D, Poussa M, Osterman K. Metaphyseal Distraction for Lower Limb Lengthening and Correction of Axial Deformities. *J Pediatr Orthop* 1990;10:202.

+ 55. Shih HN, Chen LM, Lee ZL, Shih CH. Treatment of Femoral Shaft Fractures with the Hoffman External Fixator in Prepuberty. *J Trauma* 1989;29:498.

+ 56. Stanitski DF. Treatment of Deformity Secondary to Metabolic Bone Disease with the Ilizarov Technique. *Clin Orthop Rel Res* 1994;301:38.

+ 57. Stanitski DF, Bullard M, Armstrong P, Stanitski CL. Results of Femoral Lengthening Using the Ilizarov Technique. *J Pediatr Orthop* 1995;15:224.

+ 58. Stanitski DF, Shahcheraghi H, Nicker DA, Armstrong PF. Results of Tibial Lengthening Using the Ilizarov Technique. *J Pediatr Orthop* 1996;16:168.

+ 59. Stanitski DF, Srivastava P, Stanitski CL. Correction of Proximal Tibial Deformities in Adolescents Using the T-Garches External Fixator. *J Pediatr Orthop* 1998;18:512.

+ 60. Tolo V. External Skeletal Fixation in Children's Fractures. *J Pediatr Orthop* 1983;3:435.

+ 61. Trivella GP, Brigadoi F, Aldegheri R. Leg Lengthening in Turner Dwarfism. *J Bone Joint Surg* 1996;78B:290.

+ 62. Velazquez RJ, Bell DF, Armstrong PF, et al. Complications Using the Ilizarov Technique in the Correction of Limb Deformities in Children. *J Bone Joint Surg* 1993;75A:1148.

* 63. Vilarrubias JM, Ginebreda I, Jimeno E. Lengthening of the Lower Limbs and Correction of Lumbar Hyperlordosis in Achondroplasia. C*lin Orthop Rel Res* 1990;250:143.

+ 64. Villa A, Paley D, Catagni MA, et al. Lengthening of the Forearm by the Ilizarov Technique. *Clin Orthop Rel Res* 1990;250;125.

! 65. Young NL, Bell DF, Anthony A. Paediatric Pain Patterns During the Ilizarov Treatment of Limb Length Discrepancy and Angular Deformity. *J Pediatr Orthop* 1994;14:352.

! 66. Young NL, Davis RJ, Bell DF, Redmond DM. Electromyographic and Nerve Conduction Changes after Tibial Lengthening by the Ilizarov Method. *J Pediatr Orthop* 1993;13:473.

# CHAPTER 172

# SLIPPED CAPITAL FEMORAL EPIPHYSIS

*Randall T. Loder*

**R. T. Loder:** Chief of Staff, Shriner's Hospital for Children, Minneapolis, Minnesota, 55414.

Pathophysiology
Principles of Treatment
Assessment, Indications, and Relative Results
Classification and Assessment
Indications For Treatment
Results of Treatment
Preoperative Management
Stable SCFE
Unstable SCFE
Preoperative Planning
*In Situ* Fixation
Epiphysiodesis
Proximal Femoral Osteotomy
Surgical Techniques
Stable Slipped Capital Femoral Epiphysis
*In Situ* Fixation
Epiphysiodesis
Proximal Femoral Osteotomy
Surgical Techniques
Unstable Slipped Capital Femoral Epiphysis
Internal Fixation
Epiphysiodesis
Intertrochanteric and Basilar Neck Osteotomy
Cuneiform Osteotomy
Prophylactic Fixation of The Opposite Hip
Rehabilitation and Postoperative Principles
Stable Slipped Capital Femoral Epiphysis
Unstable Slipped Capital Femoral Epiphysis
Pitfalls and Complications
Avascular Necrosis
Chondrolysis
Other Complications
Salvage Procedures
Chapter References

## PATHOPHYSIOLOGY

Slipped capital femoral epiphysis (SCFE) is the most common adolescent hip disorder (39). It is defined as a posterior and inferior slippage of the proximal femoral epiphysis relative to the metaphysis; it occurs through the hypertrophic physeal zone. In actuality, the relationship of the epiphysis and its articular surface relative to the acetabulum does not change, and the slippage is better defined as an anterior and superior slippage of the proximal femoral metaphysis (neck) relative to the epiphysis. Familiarity with this concept makes the surgical techniques much easier to visualize.

The cause of idiopathic SCFE is unknown, and it is probably multifactorial (90). Because it occurs during the adolescent growth spurt, a subtle endocrine influence is likely. Physeal shear strength decreases during that period (17), probably reflecting the increased physeal width in response to growth hormone. However, circulating hormone levels are usually normal when standard assays are used. The majority of children with SCFE are obese, typically above the 95th percentile for body weight for age (49). In an adolescent child who is above the 95th percentile for body weight, biomechanical studies have shown that the shear stress across the proximal femoral physis from simple running is enough to create an SCFE (17,68). This stress is further increased with femoral retroversion, an associated finding in obese children and in the contralateral “normal” hips of children with SCFE (28,29). In addition, children with SCFE demonstrate a more vertical physis, further increasing the susceptibility to slip (61).

## PRINCIPLES OF TREATMENT

The goals of treatment are to (a) prevent further slipping until physeal closure; (b) avoid complications, primarily those of avascular necrosis (AVN) and chondrolysis; and (c) maintain adequate hip function. Four main treatments are described: (a) internal fixation, (b) epiphysiodesis, (c) proximal femoral osteotomy, and (d) spica cast immobilization.

## ASSESSMENT, INDICATIONS, AND RELATIVE RESULTS

### CLASSIFICATION AND ASSESSMENT

The traditional classifications of SCFE are acute, chronic, and acute-on-chronic (1,23). An acute SCFE is one with a symptom duration of less than 3 weeks; a chronic SCFE, greater than 3 weeks; and an acute-on-chronic SCFE is one with chronic symptoms for more than 3 weeks but with a sudden exacerbation of symptoms for less than 3 weeks. This classification scheme is unreliable because many children and parents cannot remember the exact duration of symptoms. It also gives no information regarding hip prognosis.

Newer classification systems account for SCFE stability, are easier to use, and impart prognostic information (37,52). A child with a stable SCFE is able to walk, with or without crutches; a child with an unstable SCFE is unable to walk, with or without crutches. The prognosis for a child with a stable SCFE is very good, with an incidence of AVN approaching zero. The prognosis for a child with an unstable SCFE is guarded because of the increased risk of AVN, which may be up to 50%. The vast majority (>95%) of SCFEs are stable.

A child with a stable SCFE has a history of intermittent limp for several weeks to months that may or may not be associated with thigh, knee, or groin pain. Hip pain is variably present, often resulting in diagnostic delay. Physical examination demonstrates loss of internal rotation and spontaneous external rotation with hip flexion. Abduction and flexion are usually decreased, especially in the more severe cases. In longstanding cases, shortening of the lower extremity with varying degrees of thigh atrophy is noted; the parents usually also describe a gradually increasing external rotation gait and limb-length discrepancy.

A child with an unstable SCFE presents with sudden, severe pain; there is often a history of a minor fall, such as tripping off a curb. The child lies perfectly still with the lower extremity in a position of flexion, abduction, and external rotation. The hip is extremely irritable, and any attempts toward active or passive hip motion are resisted. These SCFEs are analogous to an acute Salter Harris I fracture, which explains their painful nature and high AVN rate.

In a stable SCFE, the diagnosis is confirmed with anteroposterior (AP) and lateral pelvis radiographs; both views are needed because an early SCFE often is seen only on the lateral view. Always view both hips because the incidence of simultaneous bilaterally may approach 20%. Either frog-lateral or cross-table lateral radiographs may be used. Proponents of the cross-table lateral view argue that the variability with the frog positioning resulting from limitation of hip motion inaccurately represents the SCFE, and that the frog view can also theoretically convert a stable SCFE to an unstable SCFE. Proponents of the frog-lateral view argue that the lateral

epiphyseal–shaft angle, a commonly used method to assess slip magnitude, is measured on the frog-lateral view. It is also the view many of the preoperative osteotomy plans depend on. Comparisons with the literature findings are also possible with this view because of its common use.

In an unstable SCFE, only an AP pelvis radiograph can be obtained, and the diagnosis is readily made. A cross-table lateral radiograph can be attempted, but clearly a frog-lateral radiograph should not be attempted, because of both the severe discomfort for the child and the risk of further slippage. A frog-lateral view of the opposite hip should be obtained; it is easy to forget this in the excitement of assessing the unstable side.

Slip magnitude is commonly measured using two methods. The first involves the amount of epiphyseal displacement relative to the metaphysis (16) (Fig. 172.1*A*). A mild SCFE is one with less than 33% displacement; moderate, 33% to 50%; and severe, greater than 50%. This can be measured on both the AP and the lateral radiographs. In the case of a stable SCFE of many months' duration, remodeling of the femoral neck makes this measurement less reliable, underestimating the true magnitude of slip.

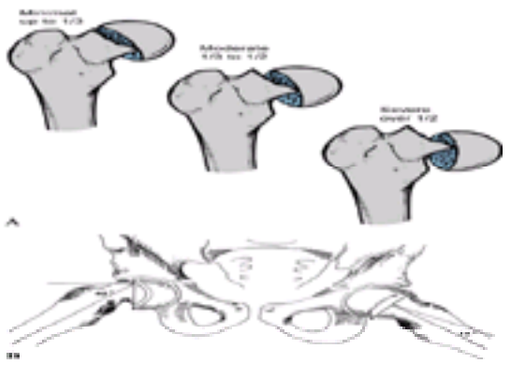

***Figure 172.1.*** Two common methods of magnitude measurement for slipped capital femoral epiphysis (SCFE). **A:** Measurement of the amount of displacement of the epiphysis relative to the metaphyseal width. The SCFE is considered mild if the measured tip is less than 33%, moderate if it is 33% to 50%, and severe if it is more than 50%. **B:** The head–shaft angle is measured on the frog-lateral pelvis radiograph of the pelvis to determine the degree of the slip, which is calculated by subtraction of the angle on the normal side from the angle of the affected hip: 49° – 12° = 37°. (From Aronson DD, Carlson WE. Slipped Capital Femoral Epiphysis: A Prospective Study of Fixation with a Single Screw. *J Bone Joint Surg Am* 1992;74:810, with permission.)

Because of these concerns with the displacement method, the epiphyseal–shaft angle, which more accurately reflects the true slip magnitude, is used (78) (Fig. 172.1*B*). This angle is measured on the frog-lateral pelvis radiograph by the following method.

- Draw a line between the anterior and posterior tips of the epiphyseal at the physeal level.
- Then draw a line perpendicular to this epiphyseal line.
- Finally, draw a line along the mid axis of the femoral shaft.
- The epiphyseal–shaft angle is the angle formed by the intersection of the perpendicular line and the femoral shaft line.
- Measure this angle for both hips; the magnitude of slip displacement is the angle of the involved hip minus the angle of the contralateral normal hip.
- By using this angle, SCFEs can be classified as mild (<30°), moderate (30° to 50°), or severe (>50°).
- In the case of bilateral SCFEs, 10° to 12° is used as the normal hip angle.

Other imaging techniques are rarely needed. Computed tomography (CT) scans are useful when doubt exists regarding the status of physeal closure or when the postoperative screw position is not adequately determined with plain radiographs. Bone scans are helpful in the rare occasion when AVN or chondrolysis is suspected but not yet visualized on plain radiographs. Magnetic resonance imaging is unnecessary in either the diagnosis or treatment of SCFE.

## INDICATIONS FOR TREATMENT

Any child with an SCFE and open physis needs treatment; without stabilization, progression is inevitable. Most authors advocate an *in situ* technique (either internal fixa- tion or epiphysiodesis) for any mild or moderate SCFE. The treatment to use for severe SCFE is more controversial. Primary osteotomy has been advocated to improve joint mechanics, motion, and hip function. However, the incidence of complications is much higher with osteotomy than *in situ* fixation, and thus most surgeons recommend *in situ* fixation as the primary treatment of a severe SCFE. *In situ* fixation allows the synovitis to subside, which will in itself result in improved motion (77). After complete physeal closure (usually 1 or 2 years later), the child's functional limitations, gait pattern, and pain can be more leisurely assessed (36,44). A decision regarding the need for osteotomy can then be made after a thorough discussion of the risks and benefits with both child and parents.

In a patient with closed physes, the only surgical treatment in the absence of severe degenerative changes is proximal femoral osteotomy. Indications are functional limitations, unacceptable gait, or cosmetic deformity. Here again, a thorough discussion of the risks and benefits is needed before performing the procedure.

## RESULTS OF TREATMENT

When selecting treatment, the results should be better than the natural history of the disease. The natural history of SCFE is one of gradual degenerative arthritis of the hip (16). The more severe the SCFE at diagnosis, the sooner the degenerative changes appear.

### *Stable SCFE*

Proximal femoral osteotomy makes the most “orthopaedic sense” for stable SCFE (Table 172.1 , Table 172.2). Although some of the literature demonstrates low complication rates with osteotomy, the majority document a higher complication rate than with *in situ* stabilization. The complications, primarily AVN (13% with cuneiform osteotomy) and chondrolysis (23% with intertrochanteric osteotomy, 16% with cuneiform osteotomy, 7% with basilar neck osteotomy), result in poor long-term outcomes. No long-term study has demonstrated an improved outcome in severe SCFEs treated by osteotomy compared to *in situ* fixation (16,72).

***Table 172.1. Results of Various Treatment Methods for Stable Slipped Capital Femoral Epiphysis (SCFE)***

| Treatment method | Avascular Necrosis (%) | Chondrolysis (%) | SCFE progression (%) |
|---|---|---|---|
| Osteotomy | | | |
| Cuneiform | 13* | 16 | 3 |
| Basilar neck | 0 | 7 | 0 |
| Intertrochanteric | 1 | 23 | 2 |
| Epiphysiodesis | 2 | 1 | 7 |
| Spica cast immobilization | 0 | 18 | 8 |
| In situ fixation with single central screw | 0 | 0 | 1 |

*The treatment method with the highest complication rate for each complication is shown in bold type.

***Table 172.2. Synopsis of Complication Rates with Different Treatments for Stable Slipped Capital Femoral Epiphysis (SCFE)***

Spica cast immobilization is difficult because of the typical body habitus of a child with SCFE, and it has an unacceptably high rate of chondrolysis (18%) and slip progression (8%) (9,59). Difficulties in mobility are encountered in these very large children in spica casts and with prolonged bed rest.

The best long-term results are with *in situ* treatment. The results of *in situ* fixation with a single central screw using today's intraoperative imaging technology are uniformly excellent (0% AVN and chondrolysis, 1% slip progression), as long as attention to technical details is maintained. The use of two screws does not double the biomechanical strength of the physeal–screw construct, and it increases the risk of complications (e.g., joint penetration) (38,41). *In situ* epiphysiodesis does not give comparable results (2% AVN, 1% chondrolysis, 7% slip progression, 1% nonunion) and is also plagued with increased morbidity [e.g., blood loss, wound problems (hematoma/seroma, infection), longer operative time, larger incisions, failure of fixation, and further slippage]. For all these reasons, most surgeons presently recommend *in situ* fixation with a single central screw for all stable SCFEs (30).

#### *Unstable SCFE*

The results in the population of unstable SCFE are much worse, primarily because of the increased risk of AVN, up to 47% (52,82). If AVN does not occur, then the outcomes and results are similar to those of the stable SCFE.

## PREOPERATIVE MANAGEMENT

### STABLE SCFE

Once the diagnosis is made, do not allow the child to bear weight on the involved limb. The ideal treatment is immediate hospital admission, enforced bed rest, and next-day surgery. There is no need or role for preoperative traction. The goal is to obtain epiphyseal fixation before the SCFE can become unstable. However, it is often difficult to convince the family, and especially insurance companies, that this is a medical urgency. If such immediate procedures cannot be done, keep the child strictly non-weight-bearing; strongly counsel regarding the concerns of walking, running, or falls that might create an unstable SCFE; and rapidly schedule stabilization in the next few days. Waiting several weeks for an opening on an elective surgical schedule is inappropriate management.

### UNSTABLE SCFE

The controversies with unstable SCFEs concern the timing of surgical stabilization and the use of preoperative traction (5,82). If an unstable SCFE resembles a displaced femoral neck fracture in a young adult in terms of concerns about AVN, then an immediate anatomic reduction should be obtained (closed, or open if necessary), and the hip joint decompressed to relieve intracapsular pressure, all in the hopes of reducing the risk of AVN. However, the present data are inadequate to either support or refute this approach. My approach is to admit the child and schedule surgery within the next 24 hours. Some advocate keeping the child at bed rest for 1 or 2 weeks; this allows the joint to quiet down, early healing to occur, and a more stable situation to develop (5). Here again, the data are lacking to either support or refute this approach.

If surgery is scheduled within the next few days, the next question concerns preoperative traction (either skin or skeletal) (21). The proponents of gentle preoperative traction argue that it allows a gradual reduction in the hopes of reducing the risk of AVN. Again, the data are inadequate to answer the question. If traction is used, the hip should be flexed. Extension decreases intracapsular volume, makes the child more uncomfortable, and theoretically increases the risk of AVN. My approach is to keep the child comfortably positioned in bed with pillows and other supports until surgery.

## PREOPERATIVE PLANNING

Take adequate AP and lateral radiographs of both hips to ensure that a contralateral SCFE is not missed. This is especially important when *in situ* fixation with a single screw is the selected treatment, because both hips should be treated under one anesthetic.

### *IN SITU* FIXATION

No further special preoperative planning is needed for *in situ* fixation. The position and length of the cannulated screw is determined intraoperatively.

### EPIPHYSIODESIS

Only adequate preoperative radiographs are needed.

### PROXIMAL FEMORAL OSTEOTOMY

Proximal femoral osteotomy can be performed at several locations: (a) physis (Fish or Dunn cuneiform osteotomy); (b) basilar neck (e.g., Abraham); and (c) intertrochanteric/subtrochanteric level (Southwick, Müller osteotomy) (Fig. 172.2.). The physeal osteotomy is at the level of pathology and allows for maximal correction (20,25,65). Its serious disadvantage is a high rate of AVN. The few studies with low AVN rates indicate that its success depends on the individual surgeon (15,25). The object of the basilar neck osteotomy is to reduce the risk of AVN by operating immediately distal to the entry site of the epiphyseal blood supply, yet close enough to the deformity for adequate correction (2,45). The intertrochanteric/subtrochanteric osteotomies are compensatory and introduce a distal reverse deformity (69,78). Their advantage is a low risk of AVN. However, they do not allow as much correction and are complicated by chondrolysis and fixation problems. Later joint replacement arthroplasty is more difficult because of the distorted proximal femoral anatomy (19).

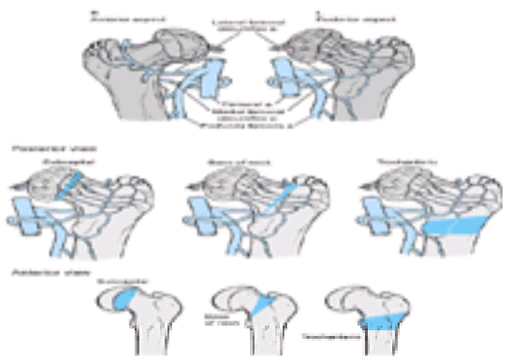

***Figure 172.2.*** The three osteotomy locations for proximal femoral osteotomy for slipped capital femoral epiphysis as shown in both anterior and posterior views. These locations are subcapital, basilar neck, and trochanteric. The wedges of bone necessary for removal are different in shape anteriorly and posteriorly. On the posterior view it is noted that the vascular supply to the proximal femoral epiphysis enters the femur just proximal to the basilar neck osteotomy, whereas with the subcapital

osteotomy the entry point of the vascularity is distal to the osteotomy which increases the risk of avascular necrosis with that osteotomy. The trochanteric osteotomy is safely distal to the entry point of the vessels into the femoral neck.

If proximal femoral osteotomy is selected as the treatment, accurate preoperative planning is mandatory. Use paper tracing cut-outs and implant templates to ensure that the osteotomy is properly performed and that the necessary internal fixation is available. In certain circumstances, the fixation device can be preoperatively bent and only fine adjustments need to be made intraoperatively.

The surgical technique for the intertrochanteric osteotomy (Southwick osteotomy) is as follows:

- Use a standard technique to obtain AP and frog-lateral radiographs of the pelvis incorporating the proximal femurs. Maintain the pelvis flat on the x-ray table and center the beam midline between the hips. For the AP film, maintain the hips in as neutral a position as possible by keeping the patellae pointing as straight up as possible. For the frog-lateral film, place the hips in maximal abduction and external rotation, with the knees flexed, the plantar surface of the feet facing each other, and their lateral surfaces resting on the table. Determine the osteotomy angles by marking the angular relationships of the femoral head to the shaft on the radiographs; use the opposite normal side for comparison (78).
- The AP measurement determines the amount of varus deformity, and the frog-lateral measurement determines the amount of posterior epiphyseal tilting (Fig. 172.3*A*, Fig. 172.3*B*). The difference in the epiphyseal–shaft angle on the AP view determines the anterior osteotomy. (If there is bilateral involvement, use 145° as the normal angle.) The difference in the epiphyseal–shaft angle on the frog-lateral view determines the lateral osteotomy. (If there is bilateral involvement, use 10° as the normal angle of retroversion.) Mark the wedges of bone to be removed on both radiographs, and fabricate templates for intraoperative use (Fig. 172.3*C*, Fig. 172.3*D*). Southwick initially used tin for the templates, but any malleable material that can be safely sterilized can be used; I have found metallic suture wrappers to be helpful (Fig. 172.3*E*). The template outlines the size and shape of the bone wedge to be removed. Typical angles are 20° to 30° anteriorly and 45° laterally. A wedge of 25° typically cuts through two thirds of the femoral shaft, and a wedge of 50° typically cuts through one half of the femoral shaft. Never exceed 45° anterior and 60° lateral.

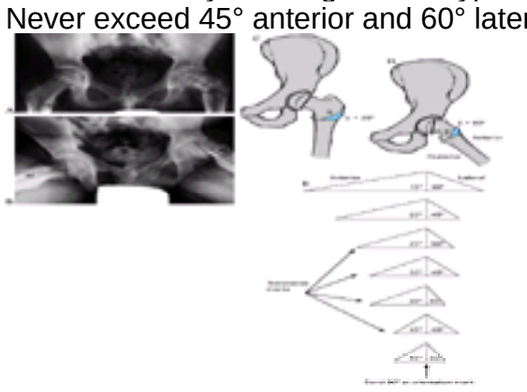

***Figure 172.3.*** Preoperative planning for the Southwick intertrochanteric osteotomy. AP and frog-pelvis radiographs of a 14-year-old boy with a left SCFE. **A:** The epiphyseal–shaft angle on the AP view is 150° on the normal side and 125° on the affected side; thus a 25° wedge is needed. **B:** The epiphyseal–shaft angle on the frog-lateral view is 20° on the normal side and 80° on the affected side; thus a 60° wedge is needed. **C:** The AP wedge is marked on the radiograph. The lateral wedge is similarly marked. **D:** The proposed osteotomy is made by using paper cut-outs from the radiographic markings. **E:** After the angles that give the desired correction have been determined, life-size paper templates are obtained from the original Southwick manuscript and traced onto a malleable, autoclavable material (e.g., tin or a metallic suture wrapper). This template is then sterilized at the time of surgery.

- Next, plan the internal fixation. After obtaining paper tracings of the proximal femurs in both AP and lateral projections, draw the intended osteotomy on paper. Use overlay templates of the selected internal fixation device(s) to plan their appropriate position and length (e.g., length and angle of side plate and lag screw if using a hip compression screw system, or the length and angle of the blade plate if using a blade-plate system). Take care to ensure that the tips of the lag screw or blade plate do not violate the posterior retinacular blood supply or penetrate the articular surface. The length of the lag screw or blade plate is often much shorter than expected; preoperative planning is imperative to ensure that the appropriate selection of devices is available at surgery. Note that some sizes of lag screws or blade plates may be special orders. After osteotomy, the femoral head should appear erect in the acetabulum in the AP view, and at a right angle to the long axis of the femoral shaft in the lateral view.

## SURGICAL TECHNIQUES

### STABLE SLIPPED CAPITAL FEMORAL EPIPHYSIS

#### *IN SITU* FIXATION

The most common stable SCFE surgical technique uses a cannulated screw system (3,48,62,87) (Fig. 172.4). In this technique, a single screw is placed into the center of the epiphysis in both AP and lateral planes.

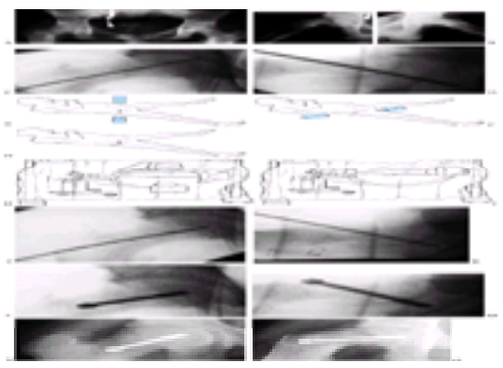

***Figure 172.4.*** Technique of *in situ* single-screw fixation for SCFE. Preoperative AP (**A**) and frog-lateral (**B**) radiographs of both hips in a 14-year-2-month-old boy. There is an SCFE of 40° on the right; the left hip is normal. A guide pin is placed onto the skin overlying the hip so that the pin is positioned in the center of the epiphysis and is perpendicular to the physis in both AP (**C**) and lateral (**D**) images. Skin lines are drawn to record the position of the guide pin on both the AP (**E**) and lateral (**F**) projections. The incision is marked at the intersection of the skin lines (**G**). After draping, multiple Kocher clamps are placed on the base of the drape to act as weights, which allows for movement of the image between AP (**H**) and lateral (**I**) images without violating surgical field sterility. The guide pin is advanced onto the anterolateral cortex of the femur so that the pin will enter the center of the epiphysis perpendicular to the physis. The guide pin is then advanced across the physis, and its tip is advanced no deeper than 5 mm from the subchondral bone [AP (**J**) and lateral (**K**) views]. The appropriate depth of the pin tip is checked using the lateral image. A cannulated screw is inserted in routine fashion after drilling and tapping the hole (**L**,**M**). Postoperative radiographs demonstrate ideal screw position in the center of the epiphysis perpendicular to the physis in both AP (**N**) and lateral (**O**) projections.

- Position the patient supine on a fracture table, moving the image intensifier rather than the lower extremity. Take care when transporting the patient onto the fracture table; no reduction maneuvers are performed and forceful traction is not applied to the lower extremity. I use the fracture table only as a positioning device, allowing the involved limb to lie comfortably in its natural position of rotation.
- Place the opposite limb into abduction with the hip extended, and move the image intensifier into position between the two lower extremities.
- Prior to surgical draping, confirm the ability to obtain adequate AP and cross-table lateral images.
- Place a guide pin onto the skin overlying the proximal femur and obtain an AP image (48). Position the pin in the center of the epiphysis and perpendicular to the

physis. Draw a line on the skin to record this guide pin position in the AP projection.
- Draw a similar skin line for the lateral image, again positioning the pin so that it is in the center of the epiphysis and perpendicular to the physis.

With an SCFE, the epiphysis is posteriorly displaced relative to the femoral neck, and the guide pin in the lateral projection angles from anterior to posterior. This is the opposite of femoral neck fractures, where it angles from posterior to anterior. Thus the two skin lines intersect on the anterolateral aspect of the thigh, and as the slip becomes more severe, the intersection point becomes more anterior. Because of the retroversion in the posteriorly displaced epiphysis in SCFE, the osseous entry point of the guide pin is on the anterior aspect of the femur. In mild SCFEs, it is often at the anterior intertrochanteric line; in severe SCFEs, it moves up onto the anterior femoral neck.

- Prepare and drape the anterolateral portion of the thigh. I prefer to use a transparent shower-curtain-type of isolation drape with multiple Kocher clamps on the base of the drape as weights; this allows movement of the image intensifier in both AP (Fig. 172.4*H*) and lateral (Fig. 172.4*I*) projections without violating surgical field sterility.
- Introduce the guide pin through the skin at the intersection of the skin lines; it may be introduced through either a stab wound or a small, 1–2 cm incision.
- Advance the guide pin onto the anterolateral cortex of the femur, keeping the drill and guide pin aligned according to the skin lines. Once the guide pin contacts the femoral cortex, its point of entry and angular direction is confirmed in both AP and lateral projections.
- When you are satisfied that the entry point and direction of the guide pin are correct, carefully advance the guide pin into the femoral neck, frequently checking the angle of entry on both AP and lateral images. Ideally, there should only be one entry point into the femoral cortex; extra holes act as stress risers and increase the risk of postoperative fracture. Do not advance the guide pin across the physis until you are certain that the pin will enter the center of the epiphysis perpendicular to the physis in both AP and lateral projections.
- After the pin has crossed the physis, advance the tip to the proper depth (no closer than 5 mm from the subchondral bone; any permanent pin position less than 5 mm from the subchondral bone increases the risk of joint penetration). This depth is determined on the lateral projection. Take care to ensure that the pin is not in the superior quadrant of the femoral head, because this position may jeopardize the epiphyseal blood supply.
- When the pin is in the appropriate position, determine screw length by placing another guide wire of identical length along the intraosseous guide wire and measuring the difference.
- Insert a cannulated screw in routine fashion after drilling and tapping. The screw should be at least 6.5 mm in diameter.
- While drilling and tapping, closely monitor the guide pin to ensure that it (a) does not break, (b) does not penetrate the joint and enter the abdominal cavity, or (c) does not withdraw from the femoral neck.
- After inserting the screw, remove the guide pin and confirm that the screw tip does not penetrate the joint. This can be done by one of several techniques: (a) move the limb in multiple directions in both AP and lateral views to confirm that it does not penetrate the joint, (b) use the approach-withdraw phenomenon, or (c) use intraoperative arthrography through the cannulated screw. My approach is a variation of the first technique. I obtain images of the hip every 10° to 15° while moving from a lateral to an AP projection, ensuring that the screw tip is no closer than 5 mm to the subchondral bone of the epiphysis. If it is closer than 5 mm, use a shorter screw.
- After confirmation of appropriate screw position and depth, close the incision.

## EPIPHYSIODESIS

### *Open Autograft Technique with an Anterolateral Approach*

The following technique is the Weiner (60) modification of the Hoyt-Heyman-Herndon procedure. The anterolateral approach (91) (Fig. 172.5) is now used instead of the older anterior iliofemoral approach (32). The advantages of this approach compared to the anterior approach are shorter operating time, less blood loss, easier instrument insertion, avoidance of lateral femoral cutaneous nerve injury, and fewer wound complications.

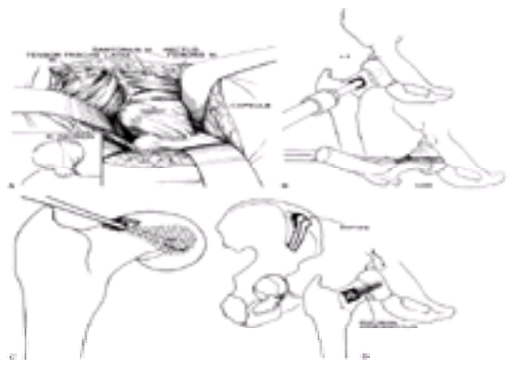

***Figure 172.5.*** Technique of open autograft epiphysiodesis. **A:** The exposure of the capsule and the H-shaped capsulotomy. **B:** The hollow mill drill used to create a tunnel across the physis. **C:** A curet is used to further enlarge the opening in the physis. **D:** Iliac crest bone graft is made into a sandwich and driven across the physis. (Parts A,C from Melby A, Hoyt WA Jr, Weiner DS. Treatment of Chronic Slipped Capital Femoral Epiphysis by Bone-Graft Epiphysiodesis. *J Bone Joint Surg Am* 1980;62:119, with permission. Parts B,D from Weiner DS, Weiner S, Melby A, Hoyt WA Jr. A 30-Year Experience with Bone Graft Epiphysiodesis in the Treatment of Slipped Capital Femoral Epiphysiodesis. *J Pediatr Orthop* 1984;4:145, with permission.)

- Position the patient supine on a radiolucent table.
- Bump up the affected hip, and be sure you can obtain adequate AP and lateral images prior to surgical draping.
- Prepare and drape free the entire lower extremity, hip, and iliac crest, as for a total hip arthroplasty.
- Make a mid-lateral incision starting 4 inches below the level of the greater trochanter in the lateral midline of the upper thigh, continue the incision proximally to the greater trochanter, and then angle it obliquely to the anterior superior iliac spine.
- Split the tensor fascia femoris proximally to the level of the anterior superior iliac spine.
- Retract the tensor anteriorly and posteriorly, exposing the underlying gluteal musculature.
- Retract the anteriormost fibers of the gluteus medius posteriorly to view the capsule.
- Perform an H capsulotomy (Fig. 172.5*A*) and use retractors (large Cobra type) to expose the femoral head and neck; the area of slipping is now directly in view.
- Make a rectangular or square window in the femoral neck and insert a large hollow mill drill through this window. Under image control, drill the hollow mill across the physis into the epiphysis (Fig. 172.5*B*).
- Remove a cylindrical core consisting of metaphyseal bone, physis, and epiphyseal bone.
- Enlarge the cylindrical tunnel further by curettage, removing more of the physis (Fig. 172.5*C*).
- Expose the outer table of the ilium, removing sections of corticocancellous bone, which are packaged together in sandwich fashion and driven into the epiphysis across the physis as a composite peg (Fig. 172.5*D*).
- Perform routine closure.
- In unstable cases, apply a bilateral hip spica cast with the epiphysis in the reduced position.

### *Percutaneous Allograft Technique*

This technique, known as the Schmidt procedure, is similar to that of *in situ* fixation using a single central screw (76).

- Position the patient supine on a fracture table with the involved hip in the neutral position and the knee extended.
- Determine stability of the SCFE radiographically before sterile draping.
- Gently mobilize the hip through internal rotation under the image intensifier. If the epiphysis moves relative to the metaphysis, the slip is considered to be unstable.
- At this point, gently position the involved hip in 10° to 15° of abduction and with internal rotation such that the femoral neck is parallel to the floor. This position allows for a true anterior and lateral view with the image intensifier. A forced reduction maneuver is never performed.
- After prepping and draping using an isolation drape, determine the guide pin entry point by the intersection of two skin lines using the same technique as *in situ* single-screw fixation.
- Introduce the guide pin through a stab incision at the intersection of the skin lines, and advance it onto the anterolateral cortex of the femur. The ideal bone entry position for the guide pin is just below the greater trochanteric physis and above the thick cortical bone of the femoral shaft to avoid creating a stress riser in the subtrochanteric region.
- Confirm the point of entry and angular direction of the guide pin in both AP and lateral views.

- Carefully advance the guide pin into the femoral neck; it should not be advanced across the physis until confirmation that it will enter the center of the epiphysis perpendicular to the physis in both AP and lateral projections. Avoid placement of the pin into the anterolateral region of the epiphysis or traversing the posterior or inferior cortex of the femoral neck; either of these may injure the vascular supply of the proximal epiphysis and result in AVN.
- After the pin has crossed the physis, advance the tip to the proper depth, stopping within 2 mm of the subchondral bone but not penetrating the joint. This depth is determined on the lateral projection.
- Now place a second guide pin parallel to the first. This second guide pin secures the femoral epiphysis during subsequent reaming. Place it in a position that does not interfere with reaming, usually inferior to the first pin. A series of movements of the lower extremity in combination with movements of the image intensifier through its full arc of motion ensures no aberrantly placed pins.
- Measure the centrally placed guide pin, and place a 10 mm cannulated reamer over it.
- Drill the femoral neck over the guide pin to a depth of about 10 mm beyond the physis, but no closer than 2 mm to the subchondral bone.
- Set the drill on reaming speed to avoid thermal necrosis. Drills more than 10 mm in diameter are not recommended; a 10 mm diameter is adequate to incite physeal closure.
- Fashion a piece of freeze-dried irradiated cortical strut allograft to the appropriate dimensions using a high-speed burr. The approximate size of prepared allograft is 10×5×85 mm. This strut graft should pass through the tissue protector apparatus of the 10 mm drill with some resistance.
- Remove the guide pin, and pass the allograft through the hole and across the physis at least 1 cm.
- Trim any allograft protruding beyond the drill hole in the femoral cortex flush with the cortex.
- Remove the second guide pin stabilizing the epiphysis, and close the wound in routine fashion.
- If the SCFE is deemed to be unstable, apply a spica cast.

## PROXIMAL FEMORAL OSTEOTOMY

### *Physeal Osteotomy*

I have had no experience with any of the physeal osteotomies, but two procedures are included here for the sake of completeness. With either the open reduction procedure of Dunn or the cuneiform osteotomy of Fish, a complete anatomic reduction can be achieved, although coxa breva will occur. Note that there is a high risk of AVN with these procedures.

**Dunn Procedure** The Dunn procedure, an open reduction of the severe SCFE, is popular in the United Kingdom and other countries with a British orthopaedic influence (13,22). An absolute prerequisite for this procedure is an open physis. The indications for this procedure in Dunn's original paper were a chronic SCFE of more than one-third the diameter of the physis, or an acute-on-chronic SCFE radiographically demonstrated by the presence of new bone along the posterior aspect of the metaphysis.

- Place the patient in the lateral decubitus position with the involved extremity up.
- Prepare and drape free the entire lower extremity, hip, and iliac crest area as for a total hip arthroplasty.
- Make an incision over the proximal part of the lateral femoral shaft, across the greater trochanter, and into the buttock.
- Incise the fascia lata and gluteus maximus in line with the skin incision.
- Define the anterior margin of the gluteus medius and drive a Jones bone spike between the glutei and the hip capsule.
- Similarly, define the posterior margin of the gluteus medius and drive a Jones bone spike between the abductors and the capsule.
- Divide the vastus lateralis 1.5 cm distal to its origin and elevate the greater trochanter through the trochanteric physis.
- Use sharp dissection to separate the muscles from the hip capsule.
- Retract the abductor muscles and attached greater trochanter proximally.
- Incise the hip capsule in the long axis of the neck and extend it around the anterior and posterior edges of the acetabulum (Fig. 172.6). The anterior capsular flap may be mobilized distally, but this must not be done with the posterior flap because the base of the posterior flap carries the blood supply to the femoral epiphysis.

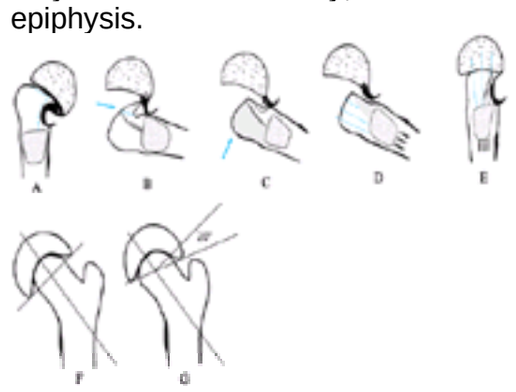

***Figure 172.6.*** Dunn procedure. See text above for a description of the technique. (From Dunn DM, Angel JC. Replacement of the Femoral Head by Open Operation in Severe Adolescent Slipping of the Upper Femoral Epiphysis. *J Bone Joint Surg Br* 1978;60:394, with permission.)

- At this point, the subluxated femoral head is seen, as is the posterior surface of the femoral neck, which has a red, velvety appearance. The anterior femoral neck is pale and avascular (Fig. 172.6*A*).
- Incise the synovial membrane on the neck just anterior to the vascular area and around the anterior margin of the head.
- Strip off the posterior covering to the margin of the head down to the base of the neck. This dissection must be done sharply and without electrocautery.
- Slip a wide gouge into the plane between the physis and the femoral metaphysis. With gentle motion it will cut the physis, making it possible to lever the epiphysis off the neck. Once the epiphysis is detached from the metaphysis, it spontaneously reduces from its subluxated position and disappears back into the acetabulum (Fig. 172.6*B*).
- Now make two osteotomies. The first is in the long axis of the neck to remove the bony beak. The second is to shorten the neck a few millimeters (Fig. 172.6*C*).
- Make the second osteotomy with a slightly curved sweep, transverse to the top of the neck. This osteotomy removes the remains of the physis from the neck (Fig. 172.6*D*).
- Draw the femoral neck to one side and use a wide gouge to curet the remains of the physis from the epiphysis.
- Make a trial fit of the metaphysis onto the epiphysis; if there is any difficulty, further shorten the metaphysis by another 1–2 mm and fashion it to fit the concave surface of the epiphysis.
- At this point, drill three threaded pins up the metaphysis, so that when the epiphysis is reduced they will engage the epiphysis in different parts (Fig. 172.6*E*).
- Now reduce the epiphysis and advance the pins into the epiphysis. After reduction, the epiphysis should sit squarely on the neck in the lateral view, and in 20° of valgus in the AP view (Fig. 172.6*F*, Fig. 172.6*G*).
- After radiographic confirmation of reduction and internal fixation, lightly suture the synovial membrane over the femoral neck and close the capsule.
- Reattach the greater trochanter with a screw and close the wound in a routine manner.

**Cuneiform Osteotomy (Fish Procedure)** The indications for this procedure according to Fish (24,25) are an SCFE greater than 30° with an open physis.

- Position the patient on a radiolucent table in the supine position with a small bump under the involved hemipelvis.
- Drape the entire limb, hip, and iliac crest area as for a total hip arthroplasty.
- Approach the hip through an anterolateral exposure. Dissect between the sartorius and tensor fascia femoris muscles, exposing the anterior capsule. The capsule must be generously exposed proximal to the acetabular rim for adequate visualization (Fig. 172.7*A*).



***Figure 172.7.*** Cuneiform osteotomy of Fish. **A:** Exposure of the femoral metaphysis. Note the minimal amount of the epiphysis that is initially seen. **B:** Location of the physis using a small curved osteotome. **B':** The osteotomy is made by removing small pieces of bone with a sharp osteotome and mallet. The fragments are wiped away while being removed to ensure continuous identification of the physis. **C:** Further removal of the physeal cartilage with a curet, and then reduction of the epiphysis on the metaphysis. The diameter of the head is larger than that of the neck after removal of the bone wedge; thus the epiphysis overlaps the neck. **D:** After reduction of the epiphysis, it is fixed with three or four threaded pins. Note how much more of the articular surface is now visible compared to the preoperative situation (**A**). (From Fish JB. Cuneiform Osteotomy of the Femoral Neck in the Treatment of Slipped Capital Femoral Epiphysis. *J Bone Joint Surg Am* 1984;66:1153, with permission.)

- Make a longitudinal incision in the anterior capsule, and extend it in an H fashion both proximally and distally. Carefully retract the capsule; no retractors should be placed around the femoral neck either medially or laterally.
- Identify the proximal femoral epiphysis; it usually is barely visible at the acetabular rim. The anterior projection of the metaphysis is quite obvious and can be mistaken for the capital femoral epiphysis. In a very severe SCFE, it may be necessary to remove a portion of the metaphysis to visualize the epiphysis.
- Next, identify the location of the physis and determine its plane by gentle probing with a Keith needle.
- Determine the size of wedge to be removed by the degree of the slip and position of the epiphysis (Fig. 172.7*B*).
- Remove enough bone to allow an effortless anatomic reduction of the epiphysis on the metaphysis. A larger wedge is needed in a more severe SCFE. The base of the wedge must be in the plane of anticipated correction of the epiphysis, and the curved contour of the physis should match the corresponding curved metaphyseal neck.
- Gently remove the wedge in small pieces with an osteotome and mallet. Maintain continuous identification of the physis.
- Use extreme caution when approaching the posterior aspect of the neck. The posterior periosteum must be protected and preserved to avoid vascular damage.
- Remove the posterior bone (a curet is usually used), and use a large curet to remove any remaining physis (Fig. 172.7*C*). Once sufficient posterior bone has been removed, the epiphysis will effortlessly reduce with flexion, abduction, and internal rotation of the limb. If inadequate posterior bone has been removed, undue tension will be placed on the posterior periosteum, potentially compromising epiphyseal vascularity.
- Once an anatomic reduction has been obtained, achieve fixation with three or four threaded pins directed toward the center of the femoral head and only deep enough to obtain firm epiphyseal fixation (Fig. 172.7*D*).
- Confirm the position of the pins and epiphysis radiographically and perform routine closure.

***Basilar Neck Osteotomy***

The basilar neck osteotomy is theoretically safer than at the physis because it is performed just distal to the entry of the posterior retinacular vessels. It may be either intracapsular (the Kramer technique) (45) or extracapsular (the Barmada/Abraham technique) (2,6). The maximum amount of correction is less than with a physeal osteotomy, usually no more than 55°.

**Intracapsular Osteotomy (Kramer Technique)** Kramer's indications are an SCFE greater than 40° on either the AP or the lateral radiographic view.

- Approach the hip laterally with an incision starting 2 cm distal and lateral to the anterosuperior iliac spine, curving distally and posteriorly over the greater trochanter and lateral femoral shaft to a point 10 cm distal to the base of the greater trochanter.
- Incise the fascia lata longitudinally and develop the interval between the gluteus medius and the tensor fascia lata. This dissection should be carried proximally to the inferior branch of the superior gluteal nerve, which innervates the tensor fascia lata.
- Open the hip capsule anteriorly along the anterosuperior surface of the femoral neck, and widely release it along the anterior intertrochanteric line.
- Reflect the vastus lateralis distally, exposing the base of the greater trochanter and the proximal femoral shaft.
- The margin between the articular cartilage of the femoral epiphysis and the callus, as well as the junction of the callus with the normal cortex of the femoral neck, can now be seen. Compare the distance between these two junctions with the amount calculated preoperatively from the radiographs. The widest part of the wedge will be in line with the widest portion of the slipped epiphysis, in the anterior and superior aspects of the neck. The most common mistake is to make the superior portion of the wedge too small, resulting in incomplete correction of the varus; if the anterior wedge is too wide, overcorrection of retroversion occurs.
- Make the distal osteotomy first, perpendicular to the femoral neck and following the anterior intertrochanteric line from proximal to distal. The cut should reach the posterior cortex but leave it intact.
- Direct the second osteotomy obliquely so that the cutting edge of the osteotome remains distal to the posterior retinacular blood supply. Anteriorly the capsule reaches the intertrochanteric line, but posteriorly the lateral third of the femoral neck is extracapsular; thus an osteotomy done at this level does not violate the posterior capsule and its retinacular supply.
- Before completing the osteotomy, drill one or two 5 mm, threaded Steinmann pins into the proximal fragment to ensure control of the osteotomy. The osteotomy is completed without penetrating the posterior cortex.
- Remove the bone wedge, and “greenstick” the posterior cortex, closing the osteotomy.
- Insert several 5-mm-diameter Steinmann pins from the outer cortex of the femoral shaft through the neck, across the osteotomy and into the epiphysis.
- Cut the pins to the appropriate length after radiographic confirmation of the osteotomy position and fixation.
- Close the wound in routine fashion.

**Extracapsular Osteotomy (Barmada/Abraham Technique)** The indication for an extracapsular osteotomy, according to Abraham, is an SCFE greater than 50°.

- Position the patient supine on the fracture table.
- Rotate the involved limb maximally internally by gently positioning the foot plate; abduct it approximately 5°.
- Widely abduct the contralateral limb, and place the image intensifier between the two lower extremities.
- Outline the patella with a marking pen and estimate the degree of fixed external rotation; most patients with a moderate or severe SCFE lack at least 15° of internal rotation.
- Prepare and drape the entire hip, thigh, and knee area.
- Make an anterolateral approach to the hip (Fig. 172.8*A*). Begin the incision at the anterosuperior iliac spine, and extend it distally and posteriorly to the anterior aspect of the greater trochanter and then distally along the proximal lateral femoral shaft.

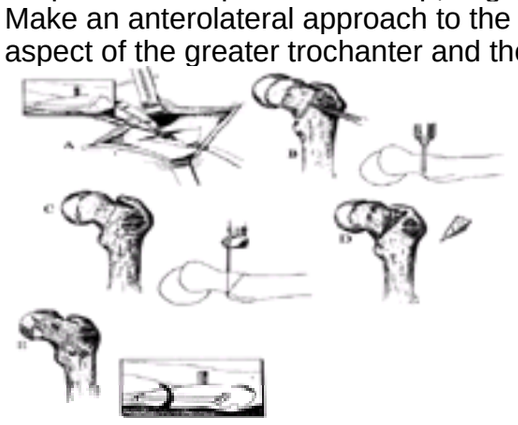

***Figure 172.8.*** Extracapsular basilar neck osteotomy of Barmada and Abraham. **A:** A periosteal elevator is used to elevate the anterior iliofemoral ligament. *Inset*: The incision of the anterolateral exposure. **B:** The proximal osteotomy cut is determined by placing a 3 cm K-wire along the base of the neck. The correct site is scored with an osteotome after fluoroscopic confirmation. A vertically placed K-wire is drilled vertical to the femoral neck at the scored line. **C:** The distal osteotomy starts at the base of the neck inferiorly and extends obliquely along the intertrochanteric line to the greater trochanter. The proximal osteotomy starts at the same position distally and extends proximally so that a proximally based triangle is formed. **D:** The bone wedge is removed. **E:** The lower extremity is internally rotated and abducted to close the osteotomy site. Fix with three to four screws. (From Abraham E, Garst J, Barmada R. Treatment of Moderate to Severe Slipped Capital Femoral Epiphysis with Extracapsular Base of Neck Osteotomy. *J Pediatr Orthop* 1993;13:294, with permission.)

- Longitudinally incise the fascia lata and develop the interval between the gluteus medius and tensor fascia lata.
- Locate the anterior joint capsule at the intertrochanteric line between the gluteus medius and the vastus lateralis.
- Using a periosteal elevator, elevate the anterior iliofemoral ligament from the anterior aspect of the femoral cortex (Fig. 172.8*A*).
- Gently place a narrow-tip Hohmann retractor around the superior aspect of the femoral neck superior and deep to the iliofemoral ligament; place another deep to the iliofemoral ligament proximal to the lesser trochanter.
- Plan the two-plane wedge osteotomy on the anterior surface by delineating a triangle based anteriorly and superiorly. The triangle base is usually 15–20 mm wide.

- Locate the proximal osteotomy by placing a 3-cm-long Kirschner wire (K-wire) on the anterior femoral surface from the lesser trochanter to the greater trochanter at the base of the neck and along the edge of the hip capsule (Fig. 172.8*B*).
- Confirm the position radiographically and mark the bone along the wire edge with an osteotome.
- After externally rotating the limb, drill a second K-wire just distal to the first wire in the AP plane, vertical to the femoral neck.
- Then internally rotate the limb and take a lateral image to confirm proper wire placement.
- The second, distal osteotomy line again starts from the lesser trochanter and goes to the physis of the greater trochanter. The angle this line makes with the first varies according to the amount of correction needed. A 15-mm-wide superiorly based wedge is usually needed.
- Make the osteotomy cuts with an oscillating saw (Fig. 172.8*C*), converging posteriorly to a single cortical cut.
- For maximal correction, remove the entire wedge of bone (Fig. 172.8*D*), especially superiorly.
- Internally rotate and abduct the lower extremity to close the osteotomy; maintain traction to prevent proximal femoral migration. Adequate correction is achieved when the patella can be internally rotated 15°. If the correction is inadequate, further bone may be removed from the metaphyseal side, but 20 mm of width anterosuperiorly is the maximum that should be removed.
- Now fix the osteotomy with three or four cannulated screws; only one screw need cross the physis to stabilize the slipped epiphysis (Fig. 172.8*E*). Avoid the superolateral quadrant of the femoral head when placing the transphyseal screw.
- Obtain permanent radiographs to confirm correction and internal fixation and then close the wound routinely.
- Reattach the iliofemoral ligament and capsule only if excessively elevated from the bone.

### *Intertrochanteric Osteotomy*

The intertrochanteric osteotomy is the safest with regard to the risk of AVN, but it has an increased risk of chondrolysis in some studies (26,35,74,78,79). It is a compensatory osteotomy because of its distance from the level of pathology. This makes future total hip arthroplasty more difficult (19). Because it is in the inter- and subtrochanteric areas, the risk of delayed union may be increased (69,74,79); internal fixation is more difficult because of the zigzag deformity that is present after osteotomy. According to Southwick (79), the maximal amount of correction that can be achieved is 70°.

**Biplane Trochanteric Osteotomy (Southwick Technique)** The indication for this procedure according to Southwick is an SCFE greater than 30°. This osteotomy corrects all three planes of deformity (varus, rotation, and flexion). The biplane osteotomy corrects the varus and adduction; rotation of the distal fragment relative to the proximal corrects the rotational deformity. Meticulous preoperative planning is essential (78,79).

- Position the patient supine on the fracture table with the affected limb draped free.
- Make a lateral incision 15–20 cm long along the posterior border of the greater trochanter.
- Incise the tensor fascia lata and vastus lateralis, and expose the femoral shaft subperiosteally.
- Identify the lesser trochanter; it can be brought into prominence by abduction and external rotation of the hip.
- Detach the psoas insertion from the lesser trochanter, taking care not to injure the nearby vessels or sciatic nerve.
- Identify the junction between the flat anterior surface and the slightly curved lateral surface of the femur; make a longitudinal mark along this junction using a sharp osteotome or oscillating saw. This mark identifies the anterolateral edge of the femur. It corresponds to the lateral (AP radiograph) and anterior edge of the femur (frog-lateral radiograph) used to make the intraoperative template.
- Next, make a transverse mark at the level of the lesser trochanter (Fig. 172.9*A*).



***Figure 172.9.*** Operative technique of the Southwick intertrochanteric osteotomy. **A:** The osteotomy site is marked as shown. **B:** The osteotomy is made and the bone wedge removed. **C:** The remainder of the medial and posterior transverse cut is made and, while controlling the proximal fragment with the pin attached to a T-handle chuck, the distal fragment is abducted and flexed, bringing the osteotomy surfaces together. The osteotomy is then internally fixed. Postoperative radiographs (D,E) of the child in Figure 172.2 demonstrate fixation with a Southwick plate. The AP radiograph (**D**) demonstrates equal epiphyseal–shaft angles of 147°; the lateral radiograph (**E**) demonstrates a residual epiphysis–shaft angle on the left of 17° (34° – 17°).Radiographs at last follow-up (**F**,**G**) (child now 16 years old) demonstrate union of the osteotomy; note the remodeling at the osteotomy seen on the lateral views. Fixation of a Southwick osteotomy with the more customary intertrochanteric lag/compression hip screw system (H–M). This 20-year-old man presented with a longstanding SCFE as shown on the AP (**H**) and lateral (**I**) views. The old SCFE deformity measured 82° using the lateral epiphysis–shaft angles (94° – 12°). Immediate postoperative radiographs [AP (**J**) and lateral (**K**) views] demonstrate fixation with a hip screw system using a 95° dynamic compression plate. Note the short lag screw: It does not penetrate into the femoral head but rather into the proximal femoral metaphysis and neck, stopping just short of the calcar. The amount of correction achieved was 34°, with a final lateral epiphysis–shaft angle of 48°. The radiographs at last follow-up, at age 22.7 years, demonstrate osteotomy union [AP (**L**) and lateral (**M**) views]; again note the remodeling of the osteotomy in the lateral view. (Parts A–C from Tachdjian MO. *Pediatric Orthopaedics*, vol. 2, 2nd ed. Philadelphia: Saunders, 1990:1057, plate 37, with permission.)

- Bend the previously made template, which consists of two right angles, at 90° and superimpose it on the femur, with the hypotenuse of each triangle based proximally; they intersect at the longitudinal orientation mark.
- Wrap the template around the anterior and lateral surfaces of the femur and the outlines marked (Fig. 172.9*B*).
- Drill a 5.6 mm Haynes pin (or Schanz screw) into the greater trochanter parallel to the hypotenuse of the anterior triangle, starting about 6 mm proximal to the hypotenuse and directed toward the lesser trochanter. This pin is attached to a T-handled chuck and used to control the proximal fragment.
- Make the osteotomy following the template outline.
- Remove the wedge of bone, which consists of the lateral and anterior femoral cortices. The proximal oblique surface is flat and angled by the amounts previously calculated in both sagittal and frontal planes (Fig. 172.9*C*).
- Make the remaining transverse cut of the osteotomy through the posterior and medial cortices at the level of the lesser trochanter.
- While stabilizing the proximal fragment with the pin, abduct the distal fragment and flex it to place the proximal oblique surface in contact with the transverse surface of the distal fragment (Fig. 172.9*D*). The orientation marks on both fragments should meet. As the osteotomy is closed, the two halves of the lesser trochanter separate, adding length to the limb. The combination of posterior tilting and external rotation are related, so that internal rotation of the shaft relative to the proximal fragments is rarely necessary except in a very severe deformity. If the posterior SCFE is greater than 60°, then the distal fragment may need some additional internal rotation.
- Now fix the osteotomy with the special side plate discussed by Southwick (79) (Fig. 172.9*E*), or with more typical intertrochanteric fixation (57,93) (either blade plate, compression hip screw, or dynamic compression plate) (Fig. 172.9*F*). Whatever method is selected, it must be appropriately templated out preoperatively using paper tracings and implant drawings. The operating room is not the place to first consider the method of fixation.
- If the Southwick plate is used, apply it first to the posterolateral aspect of the greater trochanter using cancellous bone screws at least 5 cm long. The calcar should be engaged with at least one of the screws, and another one should be placed up into the femoral neck.
- Next, attach the distal portion of the plate.
- Apply compression at the osteotomy; use of a temporary compression device with pins while attaching the plate is often necessary.
- If an AO blade plate is used, insert at least one of the screws attaching the distal fragment in compression mode using a standard AO technique.
- Take final radiographs to confirm correction and fixation, and close the wound in routine fashion.

### Biplane Trochanteric Osteotomy (Clark Modification of the Southwick Technique)

- Use the standard exposure; make the transverse mark at the level of the lesser trochanter and the longitudinal mark at the junction of the anterior and lateral femoral cortices.
- Mark the wedge to be cut using length measurements (18). Measure 15 mm proximal from the transverse mark along the longitudinal orientation mark and draw a line across the anterior shaft; this represents the anterosuperior wedge of bone to be removed (Fig. 172.10*A*). On the lateral surface of the shaft, measure 13 mm posteriorly along the transverse mark and draw a line from this point to the superior proximal line (Fig. 172.10*B*). This completed wedge is nearly the entire anterior surface and between a half to two thirds of the lateral surface of the shaft along the transverse line.

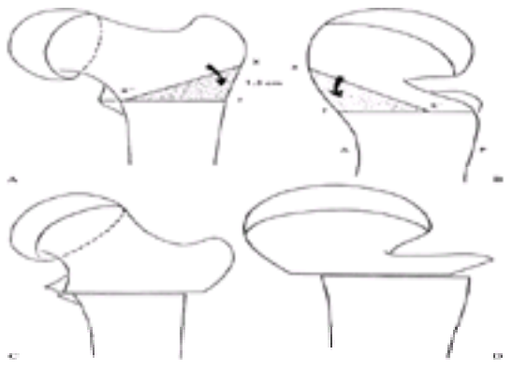

***Figure 172.10.*** Clark modification of the Southwick intertrochanteric osteotomy. **A:** The transverse line is inscribed on the anterior and lateral surfaces of the femur at the level of the lesser trochanter (line *X*" – *T*). Then a point *X* is measured 15 mm proximal from the transverse line along the longitudinal orientation mark. The line from *X*" to *X* is then drawn, and the triangle *X*"*XT* denotes the anterior wedge to be removed. **B:** Next, the point *X*' is measured 13 mm posterior to the longitudinal mark at the level of the transverse mark. The line from *X* to *X*' is drawn. The triangle *X*'*XT* denotes the posterior wedge to be removed. The osteotomy is then made in standard Southwick fashion and the osteotomy closed. **C:** AP view after osteotomy. **D:** Lateral view after osteotomy. (From Clark CR, Southwick WO, Ogden JA. Anatomic Aspects of Slipped Capital Femoral Epiphysis and Correction by Biplane Osteotomy. *Instr Course Lect* 1980;29:90, with permission.)

- Then continue with the osteotomy in standard Southwick fashion, first making the oblique osteotomy, then the transverse cut, removing the wedge of bone, and then completing the transverse cut. The bone wedge that is removed should be large enough so that the upper oblique surface squarely fits on the lower transverse surface.
- Close the osteotomy (Fig. 172.10*C*, Fig. 172.10*D*) and perform internal fixation as previously described.

## SURGICAL TECHNIQUES

## UNSTABLE SLIPPED CAPITAL FEMORAL EPIPHYSIS

### INTERNAL FIXATION

- Gently transfer the child from the bed to the fracture table after anesthesia induction. The induction of anesthesia removes the child's muscle spasm and guarding. This often results in a spontaneous, unintentional reduction of the slip with simple positioning of the child on the fracture table. I do not employ any intentional reduction maneuver unless the deformity is so severe that adequate internal fixation is not possible because of inadequate osseous contact between the epiphysis and metaphysis.
- Then proceed with cannulated screw fixation in the usual fashion. Place the first screw just as you would for a stable SCFE. The use of a second screw is controversial. Some authors advocate a second screw to control rotation and increase stability. Biomechanical studies do not show a two-fold increase in strength, and any screw off center axis has a much higher chance of joint penetration (38,41). Therefore, if a second screw is used, place it inferior to the first screw and with the final tip position at least 1 cm from the subchondral bone to reduce the risk of intraarticular penetration.

### EPIPHYSIODESIS

The surgical technique is the same as that for a stable SCFE; the only difference is the application of a spica cast.

### INTERTROCHANTERIC AND BASILAR NECK OSTEOTOMY

Intertrochanteric and basilar neck osteotomy procedures are contraindicated in the unstable SCFE.

### CUNEIFORM OSTEOTOMY

Both Fish (24,25) and Dunn (22) will undertake their procedures in an acute-on-chronic SCFE as long as the other operative indications are met. There is no difference in the operative technique from that for a stable SCFE.

## PROPHYLACTIC FIXATION OF THE OPPOSITE HIP

Prophylactic fixation of the opposite hip is controversial in North America, although it is more commonly accepted in Europe (31). In children with underlying endocrine or metabolic disorders (e.g., renal failure), prophylactic fixation of the uninvolved hip should be strongly considered (51,53). However, these types of SCFE are infrequent compared to the idiopathic SCFE.

In the idiopathic SCFE, the prevalence of bilaterality is 20% to 35% (49), with simultaneous presentation of bilaterality of 10% to 20%. Thus, if all children with unilateral SCFE have the opposite hip prophylactically fixed, 65% to 80% of these fixations will be unnecessary. This high rate of unnecessary surgery makes it difficult to recommend prophylactic fixation. There might be justification for prophylactic fixation to prevent an asymptomatic SCFE when patient follow-up is unreliable. The true incidence of asymptomatic SCFEs is unknown, as is the potential for the development of degenerative arthritis later in life. Also, it is not known if prophylactic fixation of these asymptomatic SCFEs will prevent the development of degenerative arthritis. Until this information is known, prophylactic fixation in the idiopathic situation should be approached with caution.

## REHABILITATION AND POSTOPERATIVE PRINCIPLES

### STABLE SLIPPED CAPITAL FEMORAL EPIPHYSIS

*In Situ* Fixation

Toe-touch weight bearing is allowed immediately after *in situ* fixation with stable SCFE (3,87). Discharge is often the same evening for a morning surgery, or the next day for an afternoon surgery. I recommend toe-touch weight bearing for 4–6 weeks; however, many children have no postoperative discomfort and it is not uncommon to see them return for their first postoperative visit 1–2 weeks later carrying their crutches! At the first postoperative visit, check the incision and obtain radiographs to ensure no change in fixation. The next visit is 4–6 weeks after surgery; obtain radiographs then also. Obtain both AP and frog-lateral radiographs of the pelvis so as to follow the opposite hip. After this time, allow normal activities except for running, jumping, and contact sports.

Counsel the child and parents to return immediately if there is any pain or loss of motion in either hip. Otherwise, return visits occur every 3 or 4 months, with repeat AP and frog-lateral radiographs of the pelvis, until complete physeal closure (50). After physeal closure, all physical activities are allowed. Screw removal is controversial. The morbidity and complications (incision, operative time, blood loss, fracture risk) for screw removal are much greater than for insertion.

#### *Epiphysiodesis*

Allow the child out of bed 48–96 hours after epiphysiodesis surgery and keep the child non-weight-bearing until physeal closure ensues. Full weight bearing is usually achieved by the tenth postoperative week (70,76,91).

#### *Proximal Femoral Osteotomy*

**Dunn Procedure** Dunn (22) originally recommended 4 weeks of postoperative skin traction, with active range of motion exercises starting on the first postoperative

day. Hip flexion to 90° should be achieved by 4 weeks. Then mobilize the patient with crutches; do not allow full weight bearing until radiographic union of the osteotomy, usually 2–3 months after surgery.

**Fish Cuneiform Osteotomy** Keep the child in bed until comfortable and then allow the child up with crutches, with toe-touch weight bearing (25). Permit full weight bearing when there is radiographic evidence of osteotomy union, at an average of 5 months. Fish recommends pin removal; allow full activity 2 months after pin removal.

**Basilar Neck Osteotomy** Kramer et al. (45) recommend partial weight bearing with crutches starting in the eighth postoperative week. Progression to full weight bearing varies according to the patient's weight, reliability, and generalized hip osteopenia.

Abraham et al. (2) recommend partial weight bearing with crutches for 6 to 8 weeks. Full weight bearing is allowed at 8 weeks. In the case of bilateral osteotomies, permit weight bearing as tolerated.

**Intertrochanteric Osteotomy** Southwick (78) recommends bed rest with the limb in balanced suspension for 2 to 4 weeks. Keep the hip at 30° flexion. On the second or third postoperative day, allow the patient to sit at the bedside with support. Encourage mild active flexion of the hip and knee; when this flexion is comfortable and the wound is healed, allow non-weight-bearing with crutches.

Rao et al. (69) allow the patient to get out of bed on the first postoperative day and to walk with crutches without bearing weight on the third postoperative day. Start active range of motion exercises of the hip and knee on the seventh postoperative day. Permit full weight bearing when there is radiographic evidence of osteotomy union; physeal closure is not necessary for full weight bearing.

Müller (64) keeps the patient at bed rest for the first postoperative week. The limbs are held in abduction and internal rotation with the aid of boots and bars. On the tenth postoperative day, allow crutch walking with minimal weight bearing. Allow full weight bearing after 6 months.

### UNSTABLE SLIPPED CAPITAL FEMORAL EPIPHYSIS

#### *Screw Fixation*

Allow the child to get up with crutches once she is comfortable (5,82). If there is any question regarding compliance or stability of fixation, I recommend the use of a wheelchair for the first 6 weeks. Maintain non-weight-bearing until early callus is seen at the slip. Once there is evidence of early healing, allow gradual and progressive weight bearing. This typically begins at 8–12 weeks. Progression to full weight bearing is usually achieved by 3–4 months after fixation. These children must be closely observed for the development of AVN; it will usually occur within the first 12 months after the slip. The remainder of the postoperative rehabilitation is no different from that of a stable SCFE.

#### *Epiphysiodesis*

In epiphysiodesis, a spica cast is applied, usually for 6–8 weeks. After cast removal, recommend non-weight-bearing until there is physeal closure. Full weight bearing is usually achieved 10 weeks after surgery (76,91,92).

#### *Proximal Femoral Osteotomy*

**Dunn Procedure and Fish Cuneiform Osteotomy** The postoperative protocol is the same as for the stable SCFE.

## PITFALLS AND COMPLICATIONS

Table 172.1 shows the results, including complications, of treatment methods for SCFE.

### AVASCULAR NECROSIS

Avascular necrosis usually occurs within the first year after an SCFE (52). AVN has not been reported in an untreated chronic stable SCFE. Its iatrogenic occurrence may be due to either realignment procedures (either closed reduction or proximal femoral osteotomy) or intraosseous vascular injury from internal fixation. Fixation that posteriorly exits the neck and reenters the epiphysis may damage the posterior retinacular vessels (Fig. 172.11) (71). Also, the superior weight-bearing quadrant of the femoral head is supplied by an artery that can be potentially injured by fixation devices (12). This may explain the high incidence of AVN when the fixation device is in this portion of the femoral head (Fig. 172.12). In the unstable SCFE, AVN is common and a result of the disease itself.

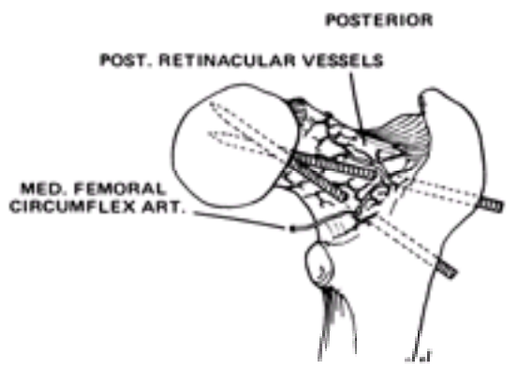


***Figure 172.11.*** Diagram illustrating the potential for vascular injury when internal fixation is placed posteriorly through the neck in an SCFE. (From Riley PM, Weiner DS, Gillespie R, Werner SD. Hazards of Internal Fixation in the Treatment of Slipped Capital Femoral Epiphysis. *J Bone Joint Surg Am* 1990;72:1500, with permission.)

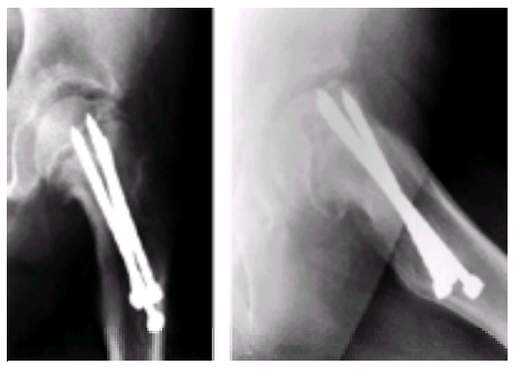

***Figure 172.12.*** The radiographs of a 12-year-old girl with avascular necrosis after pinning of a left SCFE. Note cluster of pins placed anteriorly.

The long-term prognosis for AVN from SCFE is variable; many patients do reasonably well for some time. Degenerative changes gradually develop, but reconstructive surgery can usually be delayed until adulthood (44). In one series of 24 hips with AVN after an SCFE at 31 year follow-up, reconstructive surgery was required in four

hips during adolescence and in five during adulthood. The remainder had not required reconstructive surgery but did show degenerative changes on recent radiographs. AVN from an acute unstable SCFE appears to be worse than that from a stable SCFE.

Avascular necrosis may either be segmental or complete (55). Treatment is difficult and there is no perfect solution. The first goals are to maintain joint motion and, as much as possible, to prevent further collapse. Relief from weight bearing is initially recommended. Unfortunately, healing of the necrotic areas may require a prolonged time, and most adolescents will not be compliant with prolonged non-weight-bearing.

Internal fixation may penetrate the joint and require removal if the collapse is in the area of the pin (Fig. 172.13). If the physis is still open, the epiphysis needs to be restabilized with appropriately redirected internal fixation. Further progression of a slip with concomitant AVN after hardware removal is a difficult problem that should be avoided.

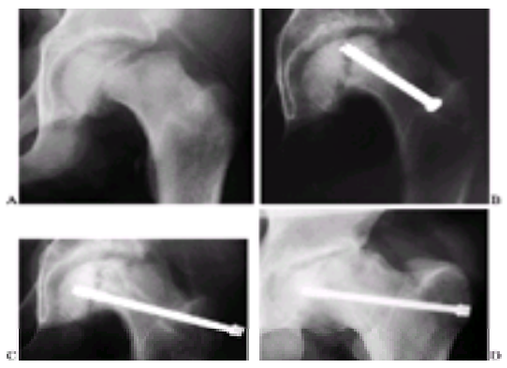

***Figure 172.13.*** **A:** AP radiograph of the pelvis of a 14-year-old boy with an unstable left SCFE. **B:** Four months after fixation, the onset of avascular necrosis is apparent, and there is a concern for intraarticular screw penetration. **C:** The screw was removed and redirected in a different position. **D:** The last follow-up, 4 years after the initial SCFE, demonstrates physeal closure, partial joint incongruity, and a healed necrotic segment.

After healing of the necrotic area, hip motion may be reasonably good if the AVN is segmental with no gross joint deformity present. With more extensive involvement, poor motion and pain may persist. In this case, there are multiple options to consider when medical therapy fails [e.g., nonsteroidal anti-inflammatory drugs (NSAIDs), range-of-motion exercises, activity modification]. If hip motion can be improved by redirecting a noninvolved area of the femoral head to a more congruent weight-bearing position, then proximal femoral osteotomy may be considered. Another alternative is bone grafting the collapsed area to improve joint congruity (42,75) and to provide further containment by femoral and/or pelvic osteotomy. Arthrodesis or total joint arthroplasty are considered if the hip is not salvageable. It must be remembered that these patients are young and heavy, which is a concern regarding the longevity of a total hip arthroplasty.

**CHONDROLYSIS**

Chondrolysis is an acute loss of articular cartilage in association with increasing joint pain and stiffness (54,58,89). Unlike AVN, chondrolysis can occur in the untreated stable SCFE. It may be aggravated by persistent intraarticular fixation or with spica casts. In the past, it was thought that black children and those of Hawaiian ancestry were more susceptible to its development (58,85); recent reports question this view (4,40,80). The exact etiology is unknown, although it may be an autoimmune process aggravated by the persistent pin penetration and secondary mechanical joint damage (63). Chondrolysis does not occur in all joints with pin penetration; however, its incidence is higher as the number of pins increases or they become closer to the subchondral bone (10). Transient intraoperative pin penetration that is corrected at surgery does not increase the risk of chondrolysis (96).

Chondrolysis usually appears within 1 year after diagnosis of the SCFE. Its clinical hallmark is severe loss of motion and pain in relation to slip magnitude. It is radiographically defined as a loss of more than 50% of the width of the weight-bearing portion of the articular space in children with unilateral SCFE (Fig. 172.14), or less than 3 mm width of the articular space in children with bilateral SCFE. When the diagnosis is suspected but there is no plain radiographic evidence, a technetium-99 methylene-diphosphonate bone scan may be helpful (57). Marked periarticular uptake and premature closure of the greater trochanteric physis are highly predictive of future chondrolysis.

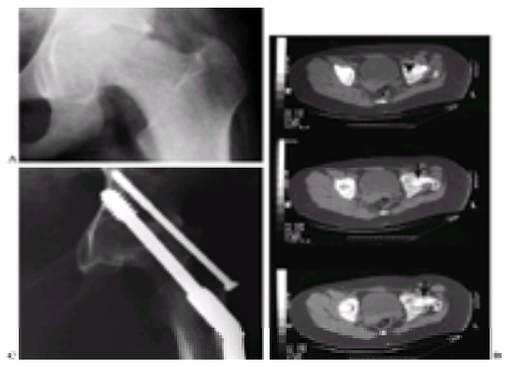

***Figure 172.14.*** **A:** AP radiograph of the pelvis of a 13-year-old girl, 13 months after *in situ* fixation of a left SCFE. The radiographs with the fixation present were not available, and the single screw had since been removed. **B:** CT scan demonstrates the old screw track (*arrow*), with the tip being extremely close to the cartilage surface (*arrowhead*). The hip was painful and in an unacceptable position due to a marked flexion contracture. Conservative therapy was not beneficial and an arthrodesis was performed at age 14 years. **C:** Last follow-up at age 16 years demonstrated no pain, excellent ambulation ability, and a solid arthrodesis.

Once chondrolysis is diagnosed, it is incumbent on the surgeon to prove that there is no intraarticular hardware penetration (Fig. 172.15). If there is, the fixation must be removed and repositioned if the physis is still open. Occult sepsis must also be ruled out. The initial treatment for chondrolysis is rest, NSAIDs, and maintenance of joint motion by physiotherapy, traction, and protected weight bearing. In the refractory case, aggressive capsulotomy has been advocated (73).

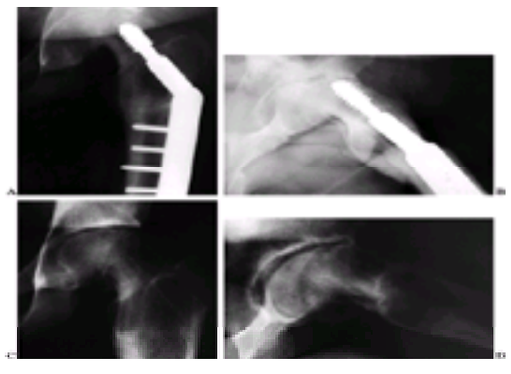

***Figure 172.15.*** The AP (**A**) and lateral (**B**) radiographs of a 15-year-old boy who had undergone an osteotomy for a left SCFE 5 months before. He presented with increasing pain and stiffness. Note the joint narrowing and proximity of the lag screw tip to the joint. A CT scan confirmed intraarticular penetration by the lag screw. The hardware was removed. At last follow-up at age 18, his pain was completely gone and joint motion had improved. Note partial reconstitution of the joint space on both AP (**C**) and lateral (**D**) radiographs.

The long-term outcome is variable. Up to 60% may do well with at least partial reconstitution of the articular cartilage and restoration of a clinically useful range of motion. In other cases, spontaneous ankylosis may occur. If spontaneous ankylosis occurs in an acceptable position, nothing further needs to be done. If spontaneous ankylosis occurs in an unacceptable position, then a femoral osteotomy below the ankylosis may be necessary to appropriately reposition the lower extremity in space. A painful, malpositioned hip often requires a formal hip arthrodesis (Fig. 172.14).

## OTHER COMPLICATIONS

Other complications include slip progression, hardware complications beside joint penetration, femoral fracture, nerve palsy/injury, and nonunion or delayed union of an osteotomy or epiphysiodesis (71).

The incidence of slip progression in the stable SCFE is approximately 1% with *in situ* single-screw fixation; the incidence after epiphysiodesis is approximately 7% (Table 172.1, Table 172.2).

If the internal fixation is left prominent from the cortical bone entry point, loosening of the screw due to a “windshield-wiper effect” can occur (56). A false aneurysm has also been reported with retained prominent hardware (33). Because of this, the screw head should not be more than 1.5 cm from the cortical surface. Sciatic nerve injury and septic arthritis are rare but described complications with internal fixation of SCFE.

Hardware breakage before removal was more common when smaller, multiple pins were used, especially when they entered the femoral neck posteriorly and reentered the epiphysis (Fig. 172.16) (71). It is less common with the single-cannulated screw and anterolateral placement. The hardware may also strip or break during removal, making complete removal impossible. This is much more common with titanium cannulated screws; in the young child with SCFE and hard bone, no titanium implants should be used (47,86).

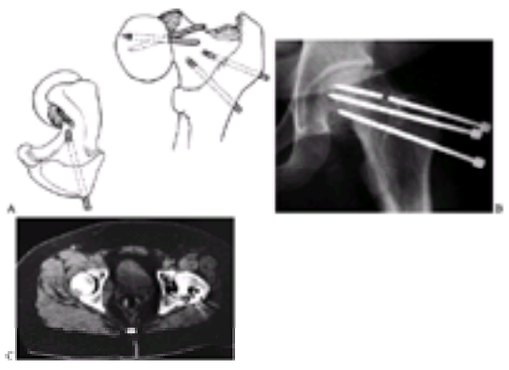

***Figure 172.16.*** Broken pins in SCFE. **A:** Diagram showing how pins can break when they exit the femoral neck and then reenter the femoral head. **B:** The AP radiograph of the pelvis of a 23-year-old man who had an SCFE treated as a teenager with multiple-threaded Steinmann pins. Note the broken pin. **C:** The CT scan demonstrates the pin exiting the femoral neck and then reentering the femoral head. (Part A from Riley PM, Weiner DS, Gillespie R, Werner SD. Hazards of Internal Fixation in the Treatment of Slipped Capital Femoral Epiphysis. *J Bone Joint Surg Am* 1990;72:1500, with permission.)

Fracture of the femur may occur at the subtrochanteric, intertrochanteric, or neck level. Holes after hardware removal act as a stress riser and may lead to an intertrochanteric or subtrochanteric fracture. Fracture may also occur immediately after internal fixation if multiple starting points are made on the femur, even in the region of the femoral neck (7).

The Southwick osteotomy has a slight risk of delayed union or nonunion (69,74,79). This is not surprising when considering the low intertrochanteric position of the osteotomy in these obese children. With bone graft epiphysiodesis, there is a low but persistent incidence of epiphysiodesis failure.

## SALVAGE PROCEDURES

Most salvage procedures are adequately discussed elsewhere [e.g., hip arthrodesis (8,11,14,67,81), total hip arthroplasty (19)]. Also see Chapter 105 and Chapter 106. For the rare case in which a trap door or other bone grafting procedure is needed for AVN, the reader is referred to the original manuscripts (42,75).

There are certain considerations regarding these procedures peculiar to children with SCFE. The most important is their young age and obesity. Union of an arthrodesis is more difficult because of obesity; a postoperative hip spica cast is recommended, even if rigid internal fixation is used. Arthrodesis after AVN is also more difficult, because of the lack of blood supply. If possible, both an intra- and an extraarticular arthrodesis should be performed.

The difficulties with arthrodesis in this patient population makes arthroplasty more appealing. However, the risk of loosening and need for revision arthroplasty is likely to be quite high in these patients. Unfortunately, there are no published series specifically addressing the outcomes of total hip arthroplasty as the treatment for associated complications of SCFE.

## CHAPTER REFERENCES

Each reference is categorized according to the following scheme: *, classic article; #, review article; !, basic research article; and +, clinical results/outcome study.


* 1. Aadelen RJ, Weiner DS, Hoyt W, Herndon CH. Acute Slipped Capital Femoral Epiphysis. *J Bone Joint Surg Am* 1974;56:1473.

\+ 2. Abraham E, Garst J, Barmada R. Treatment of Moderate to Severe Slipped Capital Femoral Epiphysis with Extracapsular Base of Neck Osteotomy. *J Pediatr Orthop* 1993;13:294.

* 3. Aronson DD, Carlson WE. Slipped Capital Femoral Epiphysis: A Prospective Study of Fixation with a Single Screw. *J Bone Joint Surg Am* 1992;74:810.

\+ 4. Aronson DD, Loder RT. Slipped Capital Femoral Epiphysis in Black Children. *J Pediatr Orthop* 1992;12:74.

\# 5. Aronson DD, Loder RT. Treatment of the Unstable (Acute) Slipped Capital Femoral Epiphysis. *Clin Orthop* 1996;322:99.

\+ 6. Barmada R, Bruch RF, Gimbel JS, Ray RD. Base of the Neck Extracapsular Osteotomy for Correction of Deformity in Slipped Capital Femoral Epiphysis. *Clin Orthop* 1978;132:98.

\+ 7. Baynham GC, Lucie RS, Cummings RJ. Femoral Neck Fracture Secondary to *in Situ* Pinning of Slipped Capital Femoral Epiphysis: A Previously Unreported Complication. *J Pediatr Orthop* 1991;11:187.

\+ 8. Benaroch TE, Richards BS, Haideri N, Smith C. Intermediate Follow-Up of a Simple Method of Hip Arthrodesis in Adolescent Patients. *J Pediatr Orthop* 1996;16:30.

\+ 9. Betz RR, Steel HH, Emper WE, et al. Treatment of Slipped Capital Femoral Epiphysis: Spica Cast Immobilization. *J Bone Joint Surg Am* 1990;72:587.

\! 10. Blanco JS, Taylor B, Johnston CE II. Comparison of Single Pin vs Multiple Pin Fixation in Treatment of Slipped Capital Femoral Epiphysis. *J Pediatr Orthop* 1992;12:384.

\! 11. Blasier RB, Holmes JR. Intraoperative Positioning for Arthrodesis of the Hip with Double Beanbag Technique. *J Bone Joint Surg Am* 1990;72:766.

\! 12. Brodetti A. The Blood Supply of the Femoral Neck and Head in Relation to the Damaging Effects of Nails and Screws. *J Bone Joint Surg Br* 1960;42:794.

\+ 13. Broughton NS, Todd RC, Dunn DM, Angel JC. Open Reduction of the Severely Slipped Capital Femoral Epiphysis. *J Bone Joint Surg Br* 1988;70:435.

* 14. Callaghan JJ, Brand RA, Pedersen DR. Hip Arthrodesis. *J Bone Joint Surg Am* 1985;67:1328.

+ 15. Carlioz H, Vogt JC, Barba L, Doursounian L. Treatment of Slipped Upper Femoral Epiphysis: 89 Cases Operated on over 10 Years. *J Pediatr Orthop* 1984;4:153.

! 16. Carney BT, Weinstein SL, Noble J. Long-Term Follow-up of Slipped Capital Femoral Epiphysis. *J Bone Joint Surg Am* 1991;73:667.

! 17. Chung SMK, Batterman SC, Brighton CT. Shear Strength of the Human Femoral Capital Epiphyseal Plate. *J Bone Joint Surg Am* 1976;58:94.

# 18. Clark CR, Southwick WO, Ogden JA. Anatomic Aspects of Slipped Capital Femoral Epiphysis and Correction by Biplane Osteotomy. *Instr Course Lect* 1980;29:90.

+ 19. DeCoster TA, Incavo S, Frymoyer JW, Howe J. Hip Arthroplasty after Biplanar Femoral Osteotomy. *J Arthroplasty* 1989;4:79.

+ 20. DeRosa GP, Mullins RC, Kling TF Jr. Cuneiform Osteotomy of the Femoral Neck in Severe Slipped Capital Femoral Epiphysis. *Clin Orthop* 1997;322:48.

+ 21. Dietz FR. Traction Reduction of Acute and Acute-on-Chronic Slipped Capital Femoral Epiphysis. *Clin Orthop* 1994;302:101.

+ 22. Dunn DM, Angel JC. Replacement of the Femoral Head by Open Operation in Severe Adolescent Slipping of the Upper Femoral Epiphysis. *J Bone Joint Surg Br* 1978;60:394.

* 23. Fahey JJ, O'Brien ET. Acute Slipped Capital Femoral Epiphysis: Review of the Literature and Report of Ten Cases. *J Bone Joint Surg Am* 1965;47:1105.

* 24. Fish JB. Cuneiform Osteotomy of the Femoral Neck in the Treatment of Slipped Capital Femoral Epiphysis. *J Bone Joint Surg Am* 1984;66:1153.

+ 25. Fish JB. Cuneiform Osteotomy of the Femoral Neck in the Treatment of Slipped Capital Femoral Epiphysis. A Follow-up Note. *J Bone Joint Surg Am* 1994;76:46.

+ 26. Frymoyer JW. Chondrolysis of the Hip Following Southwick Osteotomy for Severe Slipped Capital Femoral Epiphysis. *Clin Orthop* 1974;99:120.

+ 27. Gage JR, Sundberg AB, Nolan DR, et al. Complications after Cuneiform Osteotomy for Moderately or Severely Slipped Capital Femoral Epiphysis. *J Bone Joint Surg Am* 1978;60:157.

! 28. Galbraith RT, Gelberman RH, Hajek PC, et al. Obesity and Decreased Femoral Anteversion in Adolescence. *J Orthop Res* 1987;5:523.

! 29. Gelberman RH, Cohen MS, Shaw BA, et al. The Association of Femoral Retroversion with Slipped Capital Femoral Epiphysis. *J Bone Joint Surg Am* 1986;68:1000.

+ 30. Goodman WW, Johnson JT, Robertson WW Jr. Single Screw Fixation for Acute and Acute-on-Chronic Slipped Capital Femoral Epiphysis. *Clin Orthop* 1996;322:86.

+ 31. Hägglund G. The Contralateral Hip in Slipped Capital Femoral Epiphysis. *J Pediatr Orthop* 1996;5B:158.

* 32. Herndon CH, Heyman CH, Bell DM. Treatment of Slipped Capital Femoral Epiphysis by Epiphysiodesis and Osteoplasty of the Femoral Neck. A Report of Further Experiences. *J Bone Joint Surg Am* 1963;45:999.

+ 33. Herndon WA, Yngve DA, Janssen TP. Iatrogenic False Aneurysm in Slipped Capital Femoral Epiphysis. *J Pediatr Orthop* 1984;4:754.

+ 34. Irani RN, Rosenzweig AH, Cotler HB, Schwentker EP. Epiphysiodesis in Slipped Capital Femoral Epiphysis: A Comparison of Various Surgical Modalities. *J Pediatr Orthop* 1985;5:661.

+ 35. Ireland J, Newman PH. Triplane Osteotomy for Severely Slipped Upper Femoral Epiphysis. *J Bone Joint Surg Br* 1978;60:390.

! 36. Jones JR, Paterson DC, Hillier TM, Foster BK. Remodelling after Pinning for Slipped Capital Femoral Epiphysis. *J Bone Joint Surg Br* 1990;72:568.

* 37. Kallio PE, Paterson DC, Foster BK, Lequesne GW. Classification in Slipped Capital Femoral Epiphysis. Sonographic Assessment of Stability and Remodeling. *Clin Orthop* 1993;294:196.

! 38. Karol LA, Doane RM, Cornicelli SF, et al. Single versus Double Screw Fixation for Treatment of Slipped Capital Femoral Epiphysis: A Biomechanical Analysis. *J Pediatr Orthop* 1992;12:741.

* 39. Kelsey JL, Keggi KJ, Soutwhick WO. The Incidence and Distribution of Slipped Capital Femoral Epiphysis in Connecticut and Southwestern United States. *J Bone Joint Surg Am* 1970;52:1203.

+ 40. Kennedy JP, Weiner DS. Results of Slipped Capital Femoral Epiphysis in the Black Population. *J Pediatr Orthop* 1990;10:224.

! 41. Kibolski LJ, Doane RM, Karol LA, et al. Biomechanical Analysis of Single versus Double Screw Fixation in Slipped Capital Femoral Epiphysis at Physiological Load Levels. *J Pediatr Orthop* 1994;14:627.

+ 42. Ko J-Y, Meyers MH, Wenger DR. “Trapdoor” Procedure for Osteonecrosis with Segmental Collapse of the Femoral Head in Teenagers. *J Pediatr Orthop* 1995;15:7.

* 43. Koval KJ, Lehman WB, Rose D, et al. Treatment of Slipped Capital Femoral Epiphysis with a Cannulated Screw Technique. *J Bone Joint Surg Am* 1989;71:1370.

+ 44. Krahn TH, Canale ST, Beaty JC, et al. Long-term Follow-up of Patients with Avascular Necrosis after Treatment of Slipped Capital Femoral Epiphysis. *J Pediatr Orthop* 1993;13:154.

+ 45. Kramer WG, Craig WA, Noel S. Compensating Osteotomy at the Base of the Femoral Neck for Slipped Capital Femoral Epiphysis. *J Bone Joint Surg Am* 1976;58:796.

+ 46. Kulick RG, Denton JR. A Retrospective Study of 125 Cases of Slipped Capital Femoral Epiphysis. *Clin Orthop* 1982;162:87.

+ 47. Lee TK, Haynes RJ, Longo JA, Chu JR. Pin Removal in Slipped Capital Femoral Epiphysis: The Unsuitability of Titanium Devices. *J Pediatr Orthop* 1996;16;49.

* 48. Lindaman LM, Canale ST, Beaty JH, Warner WC. A Fluoroscopic Technique for Determining the Incision Site for Percutaneous Fixation of Slipped Capital Femoral Epiphysis. *J Pediatr Orthop* 1991;11:397.

! 49. Loder RT, and 47 Coinvestigators from 33 Orthopaedic Centers and 6 Continents. The Demographics of Slipped Capital Femoral Epiphysis. *Clin Orthop* 1996;322:8.

! 50. Loder RT, Aronson DD, Greenfield ML. The Epidemiology of Bilateral Slipped Capital Femoral Epiphysis. *J Bone Joint Surg Am* 1993;75:1141.

! 51. Loder RT, Hensinger RN. Slipped Capital Femoral Epiphysis Associated with Renal Failure Osteodystrophy. *J Pediatr Orthop* 1997;17:205.

* 52. Loder RT, Richards BS, Shapiro PS, et al. Acute Slipped Capital Femoral Epiphysis: The Importance of Physeal Stability. *J Bone Joint Surg Am* 1993;75:1134.

! 53. Loder RT, Wittenberg B, DeSilva G. Slipped Capital Femoral Epiphysis Associated with Endocrine Disorders. *J Pediatr Orthop* 1995;15:349.

+ 54. Lowe HG. Necrosis of Articular Cartilage after Slipping of the Capital Femoral Epiphysis. *J Bone Joint Surg Br* 1970;52:108.

# 55. Lubicky JP. Chondrolysis and Avascular Necrosis: Complications of Slipped Capital Femoral Epiphysis. *J Pediatr Orthop* 1996;5B:162.

+ 56. Maletis GB, Bassett GS. Windshield-Wiper Loosening: A Complication of in Situ Screw Fixation of Slipped Capital Femoral Epiphysis. *J Pediatr Orthop* 1993;13:607.

+ 57. Mandell GA, Keret D, Harcke HT, Bowen JR. Chondrolysis: Detection by Bone Scintigraphy. *J Pediatr Orthop* 1992;12:80.

+ 58. Maurer RC, Larsen IJ. Acute Necrosis of Cartilage in Slipped Capital Femoral Epiphysis. *J Bone Joint Surg Am* 1970;52:39.

+ 59. Meier MC, Meyer LC, Ferguson RL. Treatment of Slipped Capital Femoral Epiphysis with a Spica Cast. *J Bone Joint Surg Am* 1992;74:1522.

* 60. Melby A, Hoyt WA Jr, Weiner DS. Treatment of Chronic Slipped Capital Femoral Epiphysis by Bone-Graft Epiphysiodesis. *J Bone Joint Surg Am* 1980;62:119.

! 61. Mirkopulus N, Weiner DS, Askew M. The Evolving Slope of the Proximal Femoral Growth Plate Relationship to Slipped Capital Femoral Epiphysis. *J Pediatr Orthop* 1988;8:268.

* 62. Morrissy RT. Slipped Capital Femoral Epiphysis: Technique of Percutaneous in Situ Fixation. *J Pediatr Orthop* 1990;10:347.

! 63. Morrissy RT, Kalderan AE, Gerdes MH. Synovial Immunofluorescence in Patients with Slipped Capital Femoral Epiphysis. *J Pediatr Orthop* 1981;1:55.

# 64. Müller ME. Intertrochanteric Osteotomy: Indication, Pre-operative Planning, Technique. In: Schatzker J, ed. *The Intertrochanteric Osteotomy.* Berlin: Springer-Verlag, 1984;25.

+ 65. Nishiyama K, Sakamaki T, Ishii Y. Follow-up Study of the Subcapital Wedge Osteotomy for Severe Chronic Slipped Capital Femoral Epiphysis. *J Pediatr Orthop* 1989;9:412.

+ 66. Pearl AJ, Woodward B, Kelly RP. Cuneiform Osteotomy in the Treatment of Slipped Capital Femoral Epiphysis. *J Bone Joint Surg Am* 1961;43:947.

* 67. Price CT, Lovell WW. Thompson Arthrodesis of the Hip in Children. *J Bone Joint Surg Am* 1980;62:1118.

! 68. Pritchett JW, Perdue KD. Mechanical Factors in Slipped Capital Femoral Epiphysis. *J Pediatr Orthop* 1988;8:335.

+ 69. Rao JU, Francis AM, Siwek CW. The Treatment of Chronic Slipped Capital Femoral Epiphysis by Biplane Osteotomy. *J Bone Joint Surg Am* 1984;66:1169.

+ 70. Rao SB, Crawford AH, Burger RR, Roy DR. Open Bone Peg Epiphysiodesis for Slipped Capital Femoral Epiphysis. *J Pediatr Orthop* 1996;16:37.

+ 71. Riley PM, Weiner DS, Gillespie R, Werner SD. Hazards of Internal Fixation in the Treatment of Slipped Capital Femoral Epiphysis. *J Bone Joint Surg Am* 1990;72:1500.

+ 72. Ross PM, Lyne ED, Morawa LG. Slipped Capital Femoral Epiphysis Long-Term Results after 10-38 Years. *Clin Orthop* 1979;141:176.

+ 73. Roy DR, Crawford AH. Idiopathic Chondrolysis of the Hip: Management by Subtotal Capsulectomy and Aggressive Rehabilitation. *J Pediatr Orthop* 1988;8:203.

+ 74. Salvati EA, Robinson HJ Jr, O'Dowd TJ. Southwick Osteotomy for Severe Chronic Slipped Capital Femoral Epiphysis: Results and Complications. *J Bone Joint Surg Am* 1980;62:561.

+ 75. Scher MA, Jakim I. Intertrochanteric Osteotomy and Autogenous Bone-Grafting for Avascular Necrosis of the Femoral Head. *J Bone Joint Surg Am* 1993;75:1119.

+ 76. Schmidt TL, Cimino WG, Seidel FG. Allograft Epiphysiodesis for Slipped Capital Femoral Epiphysis. *Clin Orthop* 1996;322:61.

+ 77. Siegel DB, Kasser JR, Sponseller P, Gelberman RH. Slipped Capital Femoral Epiphysis: A Quantitative Analysis of Motion, Gait, and Femoral Remodeling after in Situ Fixation. *J Bone Joint Surg Am* 1991;73:659.

* 78. Southwick WO. Osteotomy through the Lesser Trochanter for Slipped Capital Femoral Epiphysis. *J Bone Joint Surg Am* 1967;49:807.

* 79. Southwick WO. Compression Fixation after Biplane Intertrochanteric Osteotomy for Slipped Capital Femoral Epiphysis. A Technical Improvement. *J Bone Joint Surg Am* 1973;55:1218.

+ 80. Spero CR, Masciale JP, Tornetta P III, et al. Slipped Capital Femoral Epiphysis in Black Children: Incidence of Chondrolysis. *J Pediatr Orthop* 1992;12:444.

+ 81. Sponseller PD, McBeath AA, Perpich M. Hip Arthrodesis in Young Patients. *J Bone Joint Surg Am* 1984;66:853.

# 82. Stanitski CL. Acute Slipped Capital Femoral Epiphysis: Treatment Alternatives. *J Am Acad Orthop Surg* 1994;2:96.

+ 83. Szypryt EP, Clement DA, Colton CL. Open Reduction or Epiphysiodesis for Slipped Upper Femoral Epiphysis. A Comparison of Dunn's Operation and the Heyman-Herndon Procedure. *J Bone Joint Surg Br* 1987;69:737.

# 84. Tachdjian MO. *Pediatric Orthopaedics*, 2nd ed. Philadelphia: Saunders, 1990.

+ 85. Tillemma DA, Golding JSR. Chondrolysis following Slipped Capital Femoral Epiphysis in Jamaica. *J Bone Joint Surg Am* 1971;53:1528.

+ 86. Vresilovic EJ, Spindler KP, Robertson WW Jr, et al. Failures of Pin Removal after *in Situ* Pinning of Slipped Capital Femoral Epiphysis: A Comparison of Different Pin Types. *J Pediatr Orthop* 1990;10:764.

* 87. Ward WT, Stefko J, Wood KB, Stanitski CL. Fixation with a Single Screw for Slipped Capital Femoral Epiphysis. *J Bone Joint Surg Am* 1992;74:799.

+ 88. Ward WT, Wood K. Open Bone Graft Epiphyseodesis for Slipped Capital Femoral Epiphysis. *J Pediatr Orthop* 1990;10:14.

+ 89. Warner WC Jr, Beaty JH, Canale ST. Chondrolysis after Slipped Capital Femoral Epiphysis. *J Pediatr Orthop* 1996;5B:168.

# 90. Weiner D. Pathogenesis of Slipped Capital Femoral Epiphysis: Current Concepts. *J Pediatr Orthop* 1996;5B:67.

* 91. Weiner DS, Weiner S, Melby A. Anterolateral Approach to the Hip for Bone Graft Epiphysiodesis in the Treatment of Slipped Capital Femoral Epiphysis. *J Pediatr Orthop* 1988;8:349.

* 92. Weiner DS, Weiner S, Melby A, Hoyt WA Jr. A 30-Year Experience with Bone Graft Epiphysiodesis in the Treatment of Slipped Capital Femoral Epiphysiodesis. *J Pediatr Orthop* 1984;4:145.

+ 93. Whiteside LA, Schoenecker PL. Combined Valgus Derotation Osteotomy and Cervical Osteoplasty for Severely Slipped Capital Femoral Epiphysis. *Clin Orthop* 1978;132:88.

! 94. Wong-Chung J, Strong ML. Physeal Remodeling after Internal Fixation of Slipped Capital Femoral Epiphysis. *J Pediatr Orthop* 1991;11:2.

+ 95. Zahrawi FB, Stephens TL, Spencer GE Jr, McClough JM. Comparative Study of Pinning *in Situ* and Open Epiphysiodesis in 105 Patients with Slipped Capital Femoral Epiphysis. *Clin Orthop* 1983;177:160.

+ 96. Zionts LE. Transient Penetration of the Hip Joint During in Situ Cannulated Screw Fixation of Slipped Capital Femoral Epiphysis. *J Bone Joint Surg Am* 1991;73:1054.

# CHAPTER 173

# LEGG-CALVÉ-PERTHES DISEASE

*John A. Herring*

**J. A. Herring:** Chief of Staff, Department of Orthopaedics, Texas Scottish Rite Hospital for Children, Dallas, Texas, 75219.

Introduction
Course of Disease and Natural History
Treatment Concepts
Indications for Containment Treatment
Restoration of Motion
Surgical Containment Treatments
Femoral Osteotomy
Salter Innominate Osteotomy
Valgus Osteotomy
Combined Femoral and Pelvic Osteotomy
Removal of Loose Body
Author's Perspective
Chapter References

## INTRODUCTION

Legg-Calvé-Perthes disease is a form of idiopathic avascular necrosis of the femoral head. Although the exact etiology of the disorder is not known, the association of Legg-Calvé-Perthes disease with delayed skeletal maturation suggests a systemic susceptibility to the problem. Some children have abnormalities of coagulation with decreases in the factors involved in thrombolysis, which may predispose them to avascular necrosis.

The clinical course is quite variable, making it difficult for the clinician to know for certain which patients need and will benefit from treatment. Current use of the lateral pillar radiographic classification has improved our ability to assess severity and prognosis in an individual case. Children younger than 6 years of age at onset usually have a benign course, and major treatment is not often necessary because they have a longer growing time to remodel abnormalities. Children between 6 and 9 years of age at onset have more symptoms and often benefit from surgical treatment. Children older than 9 years of age have a more severe course, and their response to treatment is less predictable. In the long run, 50% of patients have no disability as adults and the other half develop degenerative hip disease by the fifth or sixth decade of life.

Treatment has been based on the containment principle, which means positioning the femoral head within the acetabulum in such a way as to reduce lateralization and collapse of the softened head. In the past, this was done with braces, but at present, femoral or pelvic osteotomies are preferred.

## COURSE OF DISEASE AND NATURAL HISTORY

The initial events in the course of Legg-Calvé-Perthes disease are well established. The femoral head becomes ischemic for reasons unknown and for an unknown period of time. Several studies suggest that at least two episodes of ischemia are necessary to produce the typical changes of Legg-Calvé-Perthes disease (7,27). More recent studies have shown that a number of children have deficiencies of proteins S and C and hypofibrinolysis (8,9). The original studies suggested that the majority of children were deficient in these factors, but subsequent reports have found only a small proportion patients with Legg-Calvé with these coagulopathies (14).

Following the ischemic episode, the femoral head becomes radiodense, then appears fragmented radiographically as dead bone is resorbed, and finally reossifies with new bone formation. These sequential phases have been classified by Waldenström (30) as increased density, fragmentation, reossification, and residual stages. No treatment to date has been shown to either accelerate or delay the healing process, although it was initially thought that femoral osteotomy resulted in more rapid healing. This was disproved in studies by Clancy and Steel (4) and Kendig and Evans (15). During the fragmentation phase in more severe disease, the head loses height, enlarges, and may flatten. As the head enlarges, the anterior and lateral portions of the head extrude from the acetabulum. Over several years, the femoral head completely reossifies and may remain round in mild cases, become ovoid in moderate cases, and become flattened in severe cases. Stulberg and colleagues (29) classified these groups according to femoral head status as:

- group I normal head
- group II round head
- group III ovoid head and acetabulum
- group IV flattened head and acetabulum
- group V head collapsed and acetabulum failed to remodel

The prognosis for a child with Legg-Calvé-Perthes disease can be estimated to some degree. The most frequently reported prognostic factor is the age of the child at the onset of the disease. Most, but not all, children presenting at younger than 6 years of age have a good prognosis, whereas those between 6 and 9 years of age have a variable course. Children older than 9 years of age presenting with Legg-Calvé-Perthes disease have a worse prognosis than those with an earlier onset. Within these general guidelines, the disease is quite variable, and individual prognostication is difficult.

There are several classifications of severity of Legg-Calvé-Perthes disease. The Catterall classification delineates four groups based on areas of femoral head involvement (2):

- group I anterior head involvement
- group II central head involvement
- group III lateral and central head involvement
- group IV total head involvement

In addition, the presence of two or more risk factors (extrusion, Gage's sign, lateral calcification, and a horizontal growth plate) suggests a worse prognosis.

Because of problems with reproducibility of this classification, a newer system—the lateral pillar classification—has come into general use (Table 173.1 and Fig. 173.1, Fig. 173.2 and Fig. 173.3) (12). In this scheme, the lateral portion of the femoral head is evaluated on the anteroposterior (AP) radiograph in the early fragmentation stage of the disease.

| *Lateral pillar group* | *Classification criteria* | *Prediction of outcome* |
|---|---|---|
| Group A (Fig. 173.1) | No radiolucency<br>No loss of height | All children's hips are expected to remain round. |
| Group B (Fig. 173.2) | Some lucency in the lateral segment<br>Loss of height not greater than half the original height | Younger children's hips do very well; most have a good result.<br>One third of older children develop flattening of the femoral head. |
| Group C (Fig. 173.3) | Considerable lucency in lateral segment<br>Loss of height greater than half the original height | Half of children's hips develop a flattened femoral head. |

***Table 173.1. Lateral Pillar Classification***

***Figure 173.1.*** Lateral pillar group A classification. AP radiograph of the left hip showing well-demarcated lateral pillar. There is no loss of height in the lateral segment of the femoral head in spite of some changes in radiodensity.

***Figure 173.2.*** Lateral pillar group B classification.

***Figure 173.3.*** Lateral pillar group C classification. AP radiograph of the pelvis of a boy who has had a varus osteotomy for Legg-Calvé-Perthes disease. **A:** The lateral portion of the femoral head is lucent and collapsed relative to the central portion. **B:** AP radiograph 9 months later showing further collapse of the lateral pillar. **C:** AP radiograph several years later showing flattening of the femoral head.

The natural history of Legg-Calvé-Perthes disease has been well studied, and all reports state that the majority of individuals with the disorder do well through most of their adult lives (6,10,23). McAndrew and Weinstein (17) have shown that with follow-up studies of 48 years, about 50% of the patients will develop severe enough hip disability to require a total hip replacement by their fifth or sixth decade of life. In these studies, those with onset of disease after 9 years of age had the highest incidence of poor results. These studies demonstrate that long-term prognosis is closely related to the roundness of the femoral head and the congruity of the hip joint.

## TREATMENT CONCEPTS

The earliest treatment efforts for Legg-Calvé-Perthes disease were directed at relief from weight bearing (16). This was a natural evolution, because in those early days, the disorder had just been distinguished from tuberculosis, and weight relief was the mainstay of treatment for tuberculous hips. With time, the concept of maintaining abduction along with bed rest became the basis for containment therapy (20). Subsequent studies showed good results with weight-bearing abduction devices, and ambulatory containment was born (11,19).

Salter (24) produced avascular necrosis in pigs and found that those animals whose hips were kept in abduction had femoral heads that remained round, whereas the femoral heads of the untreated animals flattened. Based on this work, surgical containment, either with femoral or pelvic osteotomy, has been commonly performed for Legg-Calvé-Perthes disease.

## INDICATIONS FOR CONTAINMENT TREATMENT

Today there is considerable disagreement among different centers concerning indications for treatment of Legg-Calvé-Perthes disease. Our current approach is based on preliminary data from a long-term multicenter study that compared the treatment methods of range of motion, bracing, femoral osteotomy, and Salter osteotomy.

We recommend containment treatment for those children who meet the following criteria:

1. Age at onset of disease between 6 and 10 years
2. Lateral pillar group B involvement with bone age at onset of more than 6 years
3. Lateral pillar group C involvement
4. Hips with a reasonable range of motion

We recommend symptomatic treatment for the following:

1. All lateral pillar group A hips
2. Lateral pillar group B hips with a bone age at onset of 6 years or less
3. Any children younger than 6 years of age at the onset of the disease

Symptomatic treatment consists of reduction of activities when pain and limp worsen, and occasional periods of rest or traction when necessary for loss of range of motion. Anti-inflammatory medications are used when necessary. If persistent loss of motion occurs, a period of a few months of ambulatory abduction bracing may

help the patient maintain range of motion.

The treatment of children older than 10 years of age at onset is difficult. Many surgeons perform containment surgery, with the caution that all may not go well. These children often lose range of motion after surgery and may even need abduction casting or bracing postoperatively. The combination of femoral and pelvic osteotomy may be appropriate in this age group.

## RESTORATION OF MOTION

It is essential to regain range of motion before instituting containment treatment. In the child who has had recent onset of Legg-Calvé-Perthes disease and presents in the early radiographic stages, motion is usually relatively easily regained. Often a few days of bed rest are sufficient to regain enough abduction to “cover” the femoral head radiographically. If the hip is more resistant to loosening up, then a program of night traction in abduction may be helpful. After this, bracing or surgical containment may be instituted.

The child who has had symptoms for many months and who has reached the fragmentation stage may require more vigorous methods to regain motion. Try full-time traction and bed rest and, if these measures are insufficient, institute a period in Petrie plasters. The usual procedure is to evaluate the patient under anesthesia and perform an arthrogram to assess femoral head flattening. If the hip can be abducted sufficiently to cover the cartilaginous head, apply long-leg plasters with an abduction bar. If the hip will not abduct, decide whether “hinge abduction” is occurring. This is a condition in which the head levers out of the acetabulum with abduction instead of moving within the socket. If there is hinge abduction, containment surgical procedures are contraindicated because severe hip stiffness may ensue. If the head abducts but motion is limited by tight adductor muscles, an adductor tenotomy may be helpful, followed by the Petrie casts.

## SURGICAL CONTAINMENT TREATMENTS

### FEMORAL OSTEOTOMY

Some surgeons attempt to obtain sufficient range of motion to cover the hip before femoral osteotomy, but others perform the procedure even when there is reduced motion (Fig. 173.4). Because there is the occasional very stiff hip after the operation, I recommend that the surgery be performed only in children with at least 30° of hip abduction. In those patients who lack this motion, I regain range of motion by using Petrie casts for 6 weeks before performing femoral osteotomy. If the patient has had Legg-Calvé-Perthes disease for many months, there may be flattening of the femoral head, and thus I perform an arthrogram before osteotomy. If the femoral head levers out of the joint with abduction (hinge abduction), a varus osteotomy is contraindicated. Instead, a trial period of Petrie casts may be instituted with repeat arthrogram to determine if the hinge abduction has resolved, in which case the osteotomy may be performed. Otherwise, other procedures such as valgus osteotomy may be appropriate in these late cases.

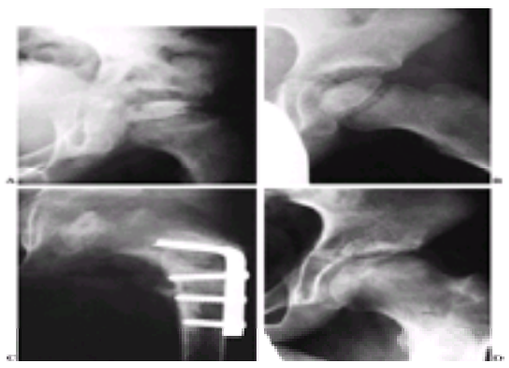

***Figure 173.4.*** A 7 1/2-year-old boy with recent onset of symptoms. **A:** An anteroposterior radiograph of the left hip showing the risk signs of lucency of the lateral portion of the femoral head, metaphyseal lucency, and lateral widening of the joint space. **B:** An abduction-internal rotation radiograph of the left hip. There is adequate coverage of the femoral head on this view. Note the subchondral lucency over two thirds of the femoral head, classifying this as a Salter-Thompson type B. There is also lateral calcification, another of Catterall's risk signs. **C:** An AP radiograph following a varus proximal femoral osteotomy fixed with a blade plate. The neck-shaft angle is 118°. **D:** An AP radiograph 4 years after osteotomy showing satisfactory roundness of the femoral head. The blade plate was removed 1 year postoperative.

The osteotomy is usually performed at the subtrochanteric level. There are a variety of opinions as to how much varus and derotation should be used. Some surgeons estimate the amount of varus based on the amount of abduction required to cover the lateral portion of the femoral head under the acetabulum. Most surgeons, however, seek a certain neck-shaft angle regardless of the estimated coverage. A commonly used angle is 115° to 120°. A greater amount of varus will result in an abductor limp that may persist. Some remodeling of the neck-shaft angle will occur in younger children with lesser involvement, but older children and those with severe disease may not have the growth capacity to remodel the neck-shaft angle. Rab (22) has published a review of preoperative radiographic evaluation for osteotomies about the hip, which is helpful in the planning stage.

Some surgeons also derotate the femur, based on the concept that this will improve anterior coverage of the femoral head. This may cause the patient to out-toe and probably should be done minimally, if at all. Other surgeons perform a proximal osteotomy, and extend or anteriorly angulate the osteotomy to improve anterior coverage.

Rigidly fix these osteotomies with one of the blade plates or screw plate devices specifically designed for children. Immobilize in a cast those patients requiring muscle releases and those who cannot cooperate with limited weight bearing. (Remember that these children tend to be extremely active.) See Chapter 166 for more details on the operative technique.

Complications often occur because of inadequate fixation with these active children. Malunion into varus is a serious problem, which will result in a poor gait. Nonunion, however, is uncommon. The more severely involved hips may become progressively stiffer following the osteotomy. When this occurs, the varus of the osteotomy results in adduction of the thigh. It may be necessary to return the patient to the operating room for adductor muscle releases and placement of Petrie casts for a period of time to restore hip range of motion. We have even had to return patients to brace wear for 6 to 8 weeks to maintain abduction postoperatively.

Remove the fixation plate a year after the osteotomy. At that time, if there is excessive varus (perhaps less than 110° neck-shaft angle), an arrest of the greater trochanter may be appropriate to keep the trochanter below the femoral head. Occasionally, when excessive varus has been introduced, it may be necessary to perform a valgus femoral osteotomy subsequently to restore a normal gait.

### SALTER INNOMINATE OSTEOTOMY

The prerequisites for an innominate osteotomy are similar to those of the femoral osteotomy but are more rigorous (Fig. 173.5). Salter has recommended that a full range of motion be obtained and that an arthrogram show no flattening of the femoral head as a prerequisite to his operation (25,26). In practice, many surgeons perform the procedure when an adequate range of motion has been obtained and the flattening of the femoral head is mild.

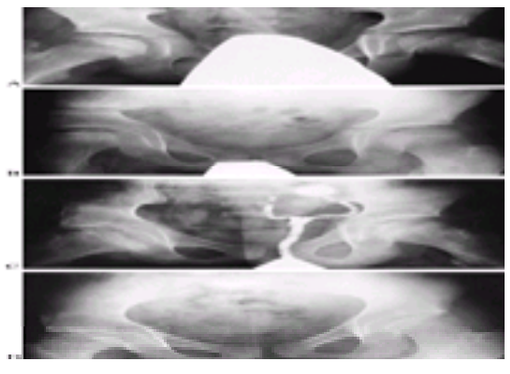

***Figure 173.5.*** An 11-year-old boy with a history of 4 months of right hip discomfort and limp. Children of this age often have the poorest results regardless of treatment. **A:** Anabduction-internal rotation radiograph showing adequate coverage of the right femoral head. The head is in the phase of increased density, and risk factors have not yet appeared. **B:** An anteroposterior radiograph 3 months after Salter innominate osteotomy. The pins have been removed, and the osteotomy is healed. The femoral head is showing signs of flattening. **C:** An AP radiograph 20 months after osteotomy. The femoral head has healed and is reasonably round. **D:** An AP radiograph 6 years after osteotomy. The femoral head has further flattened over the intervening years.

The operation is usually performed as originally described. Salter has emphasized lengthening the iliopsoas to reduce the pressure on the hip. Some surgeons prefer the Kalamchi modification of the procedure, which moves the distal fragment of the osteotomy into a notch in the posterior part of the pelvis (13). The purpose of this technique is to avoid lengthening the pelvis and increasing the pressure on the femoral head. Other surgeons add a shelf of cancellous bone over the femoral head to add to coverage. Most surgeons immobilize the hips in spica casts for 6 weeks, but some use screw fixation for the osteotomy and allow partial weight bearing until the osteotomy has healed. See Chapter 166 for details on operative technique.

An occasional complication of the procedure is hip stiffness, which at times can be severe. As with the femoral osteotomy, it may be necessary to perform muscle releases and use Petrie casts and braces postoperatively to regain range of motion. As with any osteotomy, it is important to position the osteotomy fragments properly and obtain secure internal fixation. If the fixation pins or screws are improperly placed, the osteotomy will displace posteriorly and be ineffective.

### VALGUS OSTEOTOMY

A valgus osteotomy of the femur is occasionally indicated for the patient who presents late with well-established head deformity and hinge abduction (3,21). The purpose of the osteotomy is to reduce the adduction of the thigh and allow better weight-bearing alignment. At times, the femoral head will remodel after this procedure. This should be considered a late, reconstructive operation and is not appropriate as primary treatment. See Chapter 29, Chapter 104, and Chapter 166 for details on the operation.

### COMBINED FEMORAL AND PELVIC OSTEOTOMY

The use of combined femoral varus and pelvic osteotomy (either Salter type or Chiari) has been advocated for severely involved hips, especially in children older than 9 years of age at the onset of the disease. The current reports of this approach suggest that there is an improvement in outcome, but more evaluation is necessary before this procedure should be done commonly (5,18).

## REMOVAL OF LOOSE BODY

Occasionally, a patient with Legg-Calvé-Perthes disease will develop an osteochondritic lesion, usually many years after the onset of the disorder. The symptoms of locking and popping suggest the diagnosis, which then may be confirmed with arthrography or computed tomography (CT) scanning. Arthroscopy may allow removal of either a loose body or, more commonly, a softened area in the center of the femoral head (1,28). Sometimes an anterior arthrotomy to locate the loose body is appropriate, but it may be necessary to dislocate the hip to find the loose body.

## AUTHOR'S PERSPECTIVE

My current approach to the treatment of a patient with Legg-Calvé-Perthes disease who presents when the disease is in the phase of increased density or early fragmentation follows: For a child whose bone age is six years or less, I institute conservative treatment (rest, anti-inflammatory agents) until there is enough fragmentation to determine lateral pillar classification. If the patient's hip is determined to be class A, I perform no further treatment. If the hip is determined to be class B, I continue symptomatic treatment, and if it is Class C, I prefer containment surgery, usually a Salter osteotomy.

For a child whose bone age is greater than six years, if clinical signs are minimal, I observe the patient until I am certain of a significant degree of disease beyond class A. If significant clinical signs are present, I allow the patient to regain range of motion conservatively and consider containment surgery (I prefer Salter osteotomy).

In a child older than age 10, decision making is difficult. I consider containment surgery if the disease is in the early phase. Usually a Salter osteotomy is performed, sometimes combined with a proximal femoral varus osteotomy. In children in this age group, one must recognize that the overall prognosis is poor.

### CHAPTER REFERENCES

Each reference is categorized according to the following scheme: *, classic article; #, review article; !, basic research article; and + , clinical results/outcome study.


+ 1. Bowen JR, Kumar VP, Joyce JD, Bowen JC. Osteochondritis Dissecans following Perthes' Disease. Arthroscopic-operative Treatment. *Clin Orthop Relat Res* 1986;209:49.

* 2. Catterall A. The Natural History of Perthes' Disease. *J Bone Joint Surg* 1971;53B:37.

* 3. Catterall A. *Legg-Calvé-Perthes Disease*. London: Churchill-Livingston, 1982.

! 4. Clancy M, Steel HH. The Effect of an Incomplete Intertrochanteric Osteotomy on Legg-Calvé-Perthes Disease. *J Bone Joint Surg* 1985;67A:213.

+ 5. Crutcher JP, Staheli LT. Combined Osteotomy as a Salvage Procedure for Severe Legg-Calvé-Perthes disease. *J Pediatr Orthop* 1992;12:151.

* 6. Eaton G. Long-term Results of Treatment in Coxa Plana: A Follow-up Study of Eighty-eight Patients. *J Bone Joint Surg* 1967;49A:1031.

! 7. Freeman MAR, England JPS. Experimental Infarction of the Immature Canine Femoral Head. *Proc R Soc Med* 1969;62:431.

! 8. Glueck C, Crawford A, Roy D, et al. Association of Antithrombotic Factor Deficiencies and Hypofibrinolysis with Legg-Perthes Disease. *J Bone Joint Surg* 1996;78A:3.

! 9. Glueck C, Glueck H, Greenfield D, et al. Protein C and S Deficiency, Thromphilia, and Hypofibrinolysis: Pathophysiologic Causes of Legg-Perthes Disease. *Pediatr Res* 1994;35:383.

* 10. Gower WE, Johnston RC. Legg-Perthes Disease: Long-term Follow-up of Thirty-six Patients. *J Bone Joint Surg* 1971;53A:759.

* 11. Harrison MH, Menon MP. Legg-Calvé-Perthes Disease. The Value of Roentgenographic Measurement in Clinical Practice with Special Reference to the Broomstick Plaster Method. *J Bone Joint Surg* 1966;48A:1310.

! 12. Herring JA, Neustadt JB, Williams JJ, et al. The Lateral Pillar Classification of Legg-Calvé-Perthes Disease. *J Pediatr Orthop* 1992;12:143.

+ 13. Kalamchi A. A Modified Salter Osteotomy. *J Bone Joint Surg* 1982;64A:183.

! 14. Kasser JR, Hresko T, McDougall PA, et al. Prospective Re-evaluation of the Association between Thrombotic Diathesis and Legg-Calvé-Perthes Disease. *Pediatric Orthopaedics Society of North America (POSNA) 1998 Annual Meeting.* Cleveland, 1998, p 96.

! 15. Kendig RJ, Evans GA. Biologic Osteotomy in Perthes Disease. *J Pediatr Orthop* 1986;6:278.

* 16. Legg AT. An obscure affection of the hip joint. *Boston Med Surg J* 1910;162:202.

* 17. McAndrew MP, Weinstein SL. A Long-term Follow-up of Legg-Calvé-Perthes Disease. *J Bone Joint Surg* 1984;66:860.

+ 18. Olney BW, Asher MA. Combined Innominate and Femoral Osteotomy for the Treatment of Severe Legg-Calvé-Perthes Disease. *J Pediatr Orthop* 1985;5:645.

* 19. Petrie JG, Bitenc I. The abduction weight-bearing treatment in Legg-Perthes's disease. *J Bone Joint Surg* 1971;53B:54.

* 20. Pike MM. Legg-Perthes Disease: A Method of Conservative Treatment. *J Bone Joint Surg* 1950;32A:663.

+ 21. Quain S, Catterall A. Hinge Abduction of the Hip: Diagnosis and Treatment. *J Bone Joint Surg* 1986;68B:61.

* 22. Rab G. Preoperative Roentgenographic Evaluation for Osteotomies about the Hip in Children. *J Bone Joint Surg* 1981;63A:306.

* 23. Ratliff AH. Perthes' Disease: A Study of Thirty-four Hips Observed for Thirty Years. *J Bone Joint Surg* 1967;49B:102.

! 24. Salter R. Experimental and Clinical Aspects of Perthes' Disease. *J Bone Joint Surg* 1966;48B:393.

* 25. Salter RB. Legg-Perthes Disease: The Scientific Basis for the Methods of Treatment and Their Indications. *Clin Orthop Relat Res* 1980;150:8.

* 26. Salter RB. The Present Status of Surgical Treatment for Legg-Perthes Disease. *J Bone Joint Surg* 1984;66A:961.

! 27. Sanchis M, Zahir A, Freeman MA. The Experimental Stimulation of Perthes Disease by Consecutive Interruptions of the Blood Supply to the Capital Femoral Epiphysis in the Puppy. *J Bone Joint Surg* 1973;55A:335.

+ 28. Schindler A, Lechevallier J, Rao N, Bowen J. Diagnostic and Therapeutic Arthroscopy of the Hip in Children and Adolescents: Evaluation of Results. *J Pediatr Orthop* 1995;15:317.

* 29. Stulberg SD, Cooperman DR, Wallensten R. The Natural History of Legg-Calvé-Perthes disease. *J Bone Joint Surg* 1981;63A:1095.

* 30. Waldenström H. On Coxa Plana. *Acta Chir Scand* 1923;55:557.

# CHAPTER 174

# CONGENITAL LOWER LIMB DEFICIENCY

*William L. Oppenheim, Hugh G. Watts, Robert M. Bernstein, and Yoshio Setoguchi*

**W. L. Oppenheim:** Division of Pediatric Orthopedics, University of California–Los Angeles School of Medicine; Shriners' Hospital, Los Angeles, California, 90095.
**H. G. Watts:** Shriners' Hospital; Department of Orthopedics, University of California–Los Angeles School of Medicine, Los Angeles, California, 90020.
**R. M. Bernstein:** Shriners' Hospital; Department of Orthopedics, University of California–Los Angeles School of Medicine, Los Angeles, California, 90020.
**Y. Setoguchi:** Shriners' Hospital; Department of Pediatrics, University of California–Los Angeles School of Medicine, Los Angeles, California, 90020.

Etiology
Differences Between Child and Adult Amputees
Assessment and Goal Setting
Congenital Deficiency of the Fibula
Indications for Ankle Disarticulation in Children
Technique of Syme's Amputation
Technique of Boyd Amputation
Results of Ankle Disarticulation
Complications of Ankle Disarticulation
Procedures to Stabilize the Ankle
Wiltse Osteotomy
Congenital Deficiency of the Tibia
Total Absence of the Tibia
Partial Absence of the Tibia
Congenital Dislocation of the Knee
Open Reduction
Congenital Dislocation of the Patella
Technique of Reduction
Galleazzi Procedure
Congenital Coxa Vara
Valgus Osteotomy
Congenital Deficiencies of the Femur
Congenital Short Femur
Proximal Femoral Focal Deficiency
Miscellaneous Items
Terminal Overgrowth
Conservation of Parts for Toe-To-Thumb Transfer
Lengthening of Short Amputation Stumps
A Word About Prostheses
Authors' Perspective
Chapter References

This chapter focuses on a group of diverse congenital anomalies affecting the lower extremities of children. Many involve a failure of formation of various tissues, as well as leg-length discrepancy. The general approach to these patients is to evaluate their limbs in terms of potential function, to estimate the projected leg-length discrepancy at maturity, and then to address the situation either by standard leg-length equalization techniques or through the use of a prosthesis that can be adjusted in length as the child grows. When amputation is indicated as part of the overall solution, one must identify a key joint for salvage and then convert the tissue distal to that joint into a usable weight-bearing organ. The key joint is the most distal joint with sufficient function to power a prosthesis. Complicating the technical problems are psychological feelings of helplessness, anxiety, and frustration among parents and physicians alike.

The concept of sacrificing a body part to facilitate prosthetic fitting is initially poorly accepted by most parents, particularly if the part proposed for sacrifice appears quite normal. The parents rightly question why modern technology cannot be called upon to salvage their child's limb. Physicians faced with this scenario must improvise based on their combined expertise in prosthetics and reconstructive surgery. Although some of the procedures may initially appear radical to parents, with education and counseling the child and parents can accept them as simply reconstructive. Experience has shown that it is frequently preferable to convert a limb to a logical prosthetic level rather than embark on a prolonged operative reconstruction that, even when modestly successful, frequently precludes participation in normal childhood activities (41). Treatment thus requires an understanding of the natural history of the specific defect as well as a thorough knowledge of any associated abnormalities.

Because of the complicated nature of these conditions, evaluation and treatment are best carried out at special clinics where appropriate psychological, social, and pediatric support is available. Surgical procedures are not easily undertaken and rely on the parents' informed judgment based on a balanced medical presentation and the experience gained through the consultation process. An opportunity to associate with other families in similar circumstances who have already gone through the process is a reassuring influence and should be part of the family's decision-making process.

## ETIOLOGY

The period during which a developing embryo is most susceptible to malformations being perpetuated in subsequent cell lines is between the fourth and eighth weeks postfertilization, the so-called period of organogenesis. Both the axial and appendicular skeletons form at this time. A single cell gives rise to billions of descendants, so the surprising thing is not that congenital anomalies occur, but that they do not occur even more frequently. Some conditions have a familial origin and hence a preordained genetic derivation. For example, congenital dislocation of the knee may occur sporadically or in association with Larsen's syndrome, an autosomal dominant condition in which dislocations of other joints and anomalies of the cervical spine also occur. Whatever the cause, once a defect is present, with the limb bud developing in a proximal to distal progression, areas “downstream” from the initial insult may also be affected. For example, proximal femoral focal deficiency is frequently associated with a more distal fibula deficiency, and absence of the fibula in turn may be associated with absence of lateral foot rays.

Because other organ systems also differentiate during this gestational period, limb defects frequently are seen in the presence of anomalies exclusive of the musculoskeletal system. The VACTERLS syndrome refers to the association of vertebral, anal, cardiac, tracheoesophageal, renal or radial flaws, associated with limb defects and a single umbilical artery. In the amniotic band syndrome, the insult is thought to take place after limb bud development during the fetal period of gestation. Multiple bands may be present, predisposing to autoamputations. From this brief discussion, it is clear that limb reduction defects often present as part of a more general syndrome.

## DIFFERENCES BETWEEN CHILD AND ADULT AMPUTEES

Amputation surgery in children differs from that in adults. In adults, amputation is frequently related to peripheral vascular disease or diabetes; healing is delayed and rehabilitation is difficult and prolonged. Adults are concerned about their body image, time lost from work, and their livelihood in general. Children, on the other hand, usually heal promptly and completely; conversion to an amputation at an early age is not ordinarily difficult or prolonged, and potential employability is not an immediate concern (see Chapter 175). Phantom pain and neuromas, which can significantly impact on the results in adults, do not appear as clinically significant in children and present only an occasional problem in adolescents. Gait training takes place spontaneously under the guidance of a prosthetist or physical therapist, and psychological acceptance of the limb is natural and not elaborate.

However, one problem peculiar to growing children is frequent overgrowth following transdiaphyseal amputations, particularly in the humerus, tibia, and fibula. This can result in a need for serial surgical revisions throughout growth (see section on Terminal Overgrowth at the end of this chapter). Where possible, perform amputation through an adjacent joint to avoid this problem, but this consideration must in turn be tempered by the concomitant goal of maintaining length. Through-joint amputations not only preserve length, but, by preservation of the adjacent growth plate, add to the length throughout childhood, preventing an initial adequate length

from becoming a proportionately shorter stump as adult stature is attained.

## ASSESSMENT AND GOAL SETTING

When assessing an infant with a limb deficiency, identify possible etiologic factors. Consider the influence of teratogenic agents such as thalidomide, maternal risk factors such as diabetes, and environmental factors such as radiation exposure. A genetics consultation is recommended to assess the risks for additional pregnancies and to offer counseling. Despite the gravity of the situation, the professional staff should maintain an optimistic demeanor. Nearly all children with lower extremity anomalies gain functional mobility, attend regular school, and lead quality lives, participating in sports such as swimming, skiing, tennis, and horseback riding. Schools may restrict participation in contact sports such as football and hockey because of the risk of injury to other children from prosthetic parts. The role of the parents and grandparents cannot be underestimated. Acceptance of the child as he is and the avoidance of overprotection, which can lead to an overly dependent and submissive personality, facilitates the child's development, sense of self worth, and eventual integration into the workplace.

## CONGENITAL DEFICIENCY OF THE FIBULA

Congenital malformations of the fibula usually are not associated with classic modes of genetic transmission and thus likely result from embryonic insults occurring during the development of the limb bud. The severity ranges from simple hypoplasia to total absence of the fibula. Experimental evidence suggests that the earlier the insult occurs in embryonic development, the more likely is concurrent involvement of the proximal femur. Later insults involve the fibula and foot to a greater degree (46). Fibular deficiency thus may be accompanied by proximal femoral focal deficiency, shortening and/or bowing of the tibia, general limb growth retardation, delayed epiphyseal ossification, absence of rays, tarsal coalitions, residual fibrous bands, deficiencies of various muscles, genu valgum, and loss of ankle integrity (2,18,30,31,59,68). Upper extremity anomalies are also seen in some cases. Although rare compared to diseases such as developmental dysplasia of the hip or clubfeet, the fibula is the most common congenitally absent long bone (18).

Clinically, the most important issues are the stability and function of the ankle and foot and the overall length of the limb. To better characterize the variability, Achterman and Kalamchi (2) refined a classification originally utilized by Coventry and Johnson (18) (Fig. 174.1). In type IA, the entire fibula is present but shortened, leaving the proximal fibular epiphysis distal to the upper physis of the tibia, and the distal fibular physis proximal to the dome of the talus. In type IB, there is a partial absence of the upper fibula, and the lower fibular epiphysis is likewise elevated above the talar dome and thus not buttressing the ankle. In type I deformities, the foot usually remains plantigrade but may be associated with a ball and socket ankle joint, and either equinovalgus or equinovarus may be present. In type II, by contrast, the entire fibula is absent, tibial bowing is frequent, and ankle instability is the rule. A residual lateral fibrous band may contribute to the type II deformity.

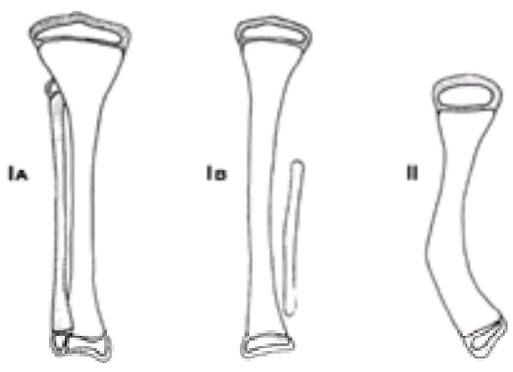


***Figure 174.1.*** Achterman-Kalamchi classification of fibula hemimelia. See text for explanation.

Some surgeons have used the absence of rays to predict ankle stability (e.g., a four-toed foot can be salvaged, but a three-toed foot should be sacrificed), but we have found that stability can be directly assessed and that a three-toed foot can often be serviceable. The degree of tibial shortening increases with advanced stages, although associated femoral shortening is maximal in type I. Children with type I feet will not require conversion to an amputation, but conversion is usually performed for the majority of children with type II deformities.

The literature abounds with ankle stabilization procedures for the treatment of type II deformities, but the test of time has not supported this approach (4,7,11,15). Stabilization by arthrodesis is complicated by delayed ossification of the epiphyses, as well as by potential inadvertent injury to the distal tibial physis. Kruger and Talbott (41) have pointed out that whereas the goal of preserving the foot might be laudable, in fact many children who undergo repetitive operations eventually undergo amputation, and that upon honest review there is good evidence that conversion should have been offered as a primary treatment rather than a secondary salvage procedure. In addition, we have found a higher incidence of complications when Syme amputation was performed as a salvage procedure in multiply operated limbs rather than as a primary procedure (6). In areas where cultural concerns do not allow amputation, or in lesser developed areas where surgery is not available, it is feasible to fit a prosthesis around the foot.

In instances where the ankle is relatively stable and the overall length can be made acceptable, leg lengthening using Ilizarov techniques, in which the ankle is stabilized during lengthening, is an acceptable approach.

### INDICATIONS FOR ANKLE DISARTICULATION IN CHILDREN

The indications for conversion to a below-knee amputation are (a) a deformity of the foot so severe that any surgery to make the foot plantigrade and functional is likely to fail (70) and (b) an estimated leg-length discrepancy at maturity of 7.5 cm or more (60). The value of 7.5 cm is arbitrary and tends to vary among physicians (46,59,60). We now base our decision more on the stability of the ankle than the leg-length discrepancy, per se, provided the overall limb-length discrepancy at maturity is not projected to exceed 12 cm.

### TECHNIQUE OF SYME'S AMPUTATION

- Begin the procedure of Syme's ankle disarticulation (Fig. 174.2) by making a fish-mouth incision with anterior and posterior skin flaps. The apex begins 1 cm distal to the medial malleolus and parallels the anterior ankle joint to a point estimated to be the level where the fibular tip would ordinarily be palpable.

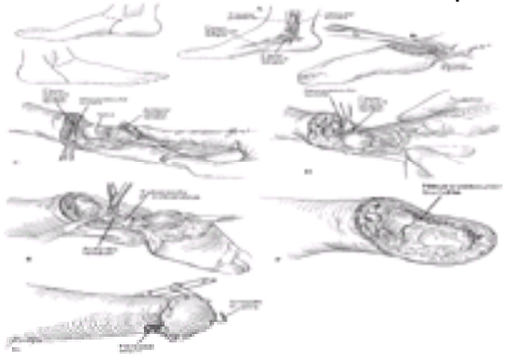

***Figure 174.2.*** Syme's ankle disarticulation as performed in children. Make skin incisions from a point 1 cm distal to the medial malleolus to the tip of what would have been the fibula malleolus, as illustrated. **A:** Schematic of the anatomy posterior to the medial malleolus. **B:** Divide the collateral ligaments to facilitate hyper plantarflexion of the ankle. **C:** Location of the flexor hallucis longus posterior to the talus. **D:** Protect the neurovascular bundle by retraction of the flexor hallucis longus muscle tendon. **E:** Divide the Achilles tendon, taking care to include excision of the apophysis of the calcaneus. **F:** Preserve the neurovascular bundle to the end of the flap; avoid injury to the bundle at the level of the ankle joint. **G:** Close the wound over a drain, and stabilize the heel pad with a stout K-wire or smooth Steinmann pin inserted into the tibia from the plantar aspect of the heel.

- Carry the dissection down through the subcutaneous tissue to the level of the medial and lateral collateral ligaments of the ankle, ligating larger vessels and

controlling smaller ones with electrocautery.

- Identify the nerves. Gently tension, sharply divide, and allow the nerves to retract away from potential subcutaneous positioning.
- Divide the collateral ligaments so that the talar dome can be pulled forward away from the distal tibia.
- In the interval between the talus and tibia, identify the flexor hallucis longus tendon. It is the key to locating and protecting the neurovascular bundle posteromedially. By protecting this tendon and drawing it medially with a retractor, the dissection can be continued with the neurovascular bundle shielded so that the actual division of the posterior tibial artery will be at the most distal portion of the posterior flap.
- Excise the calcaneus from the heel pad in a subperiosteal fashion so that the periosteum remains intact, maintaining the structural integrity of the fat pad, which has a hydraulic-like function during weight bearing. Be sure that the entire calcaneal apophysis is excised so that it will not form a persistent ossicle later (Fig. 174.3). Two centimeters of the distal Achilles tendon can be resected to ensure there will be no tendency to reattach and pull the heel pad posteriorly. Shave the distal tibia only in older children, because smoothing and remodeling occur spontaneously in younger children once the talus no longer occupies the mortise.

***Figure 174.3.*** In performing Syme's amputation, be certain to excise the entire apophysis, otherwise it will persist and complicate later prosthetic fitting. This one required removal during adolescence.

- Finally, stabilize the heel pad underneath the tibia by inserting a stout Kirschner wire (K-wire) through the pad into the tibia, and close the skin over a Penrose drain with absorbable subcutaneous sutures and interrupted nylon sutures for the skin. In approximating the heel pad to the tibia, take care to avoid crimping the posterior tibial artery.

After skin repair, apply Xeroform (Sherwood Medical, Markham, Ontario) gauze, fluffs, sterile cast padding, and a spica cast for short stumps (as when the amputation is combined with a knee fusion for proximal femoral focal deficiency). A long-leg cast can be applied when the knee can be effectively flexed to prevent the cast from sliding off. Remove the drain at 2 days and allow 6 weeks for soft-tissue healing in the cast. An elastic wrap is occasionally necessary for several additional weeks to control any residual stump edema. The stump is ready for prosthetic fitting between the tenth and twelfth weeks.

Associated tibial bowing ordinarily corrects spontaneously after a Syme's amputation, but in those cases accompanied by bowing in excess of 30°, perform a tibial osteotomy simultaneously, and extend the K-wire to act as intramedullary fixation.

**TECHNIQUE OF BOYD AMPUTATION**

Some authors have reported problems with stabilization of the heel pad in the Syme's amputation and thus prefer the Boyd amputation, in which the calcaneus is displaced anteriorly in an effort to fuse it into the distal tibia or at least to stabilize it under the tibial plafond (8,10,70). Modest additional length can also be maintained by this approach. Alternatively, the distal tibial physis can be excised at the time of calcaneal tibial fusion, so that the bulbous self-suspending stump gradually “ascends” to the level of the opposite calf. In deformities with severely displaced equinus hind feet, repositioning of the calcaneus under the tibia may not be possible, and Syme's procedure is preferred. No shaping of the malleoli is necessary in young children in either the Boyd or the Syme ankle conversion. Without the talus occupying the mortise, the malleoli remodel to a satisfactory shape. Either procedure yields a pleasing stump because the prominent malleoli atrophy after talar excision.

- Boyd amputation (8) utilizes an approach similar to the Syme procedure just described. However, excise only the talus and forefoot, leaving the calcaneus attached to the fat pad (Fig. 174.4).

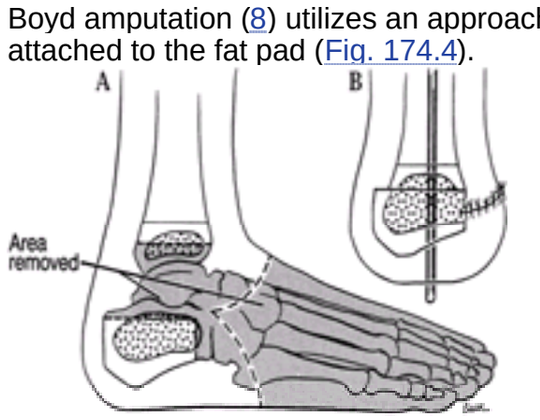


***Figure 174.4.*** Boyd's amputation. **A:** Scheme of bony resection. **B:** Final position, emphasizing anterior displacement of the calcaneus to provide a rounded stump.

- Carefully shave the articular cartilage of the distal tibia with a knife until the ossific nucleus is encountered; take care to breech neither the distal tibial physis nor its surrounding perichondrium, unless shortening of the stump is desired.
- Osteotomize the anterior portion of the calcaneus, if necessary, just distal to the peroneal tubercle; shave the superior surface flat, allowing it to sit congruously under the prepared distal tibia.
- Divide the Achilles tendon through the space left by the enucleation of the talus. When performed properly, the heel pad can be positioned in its normal weight-bearing attitude but slightly displaced anteriorly.
- Use a smooth Steinmann pin to secure the final position, extending it through the calcaneus across the distal tibial physis into the medullary canal of the tibia.
- Close the skin over a drain.

The postoperative management is similar to that described for the Syme's amputation.

**RESULTS OF ANKLE DISARTICULATION**

With the exception of one patient who died of unrelated causes, in our series of 61 patients with Syme amputations (6), all were ambulatory, and patient satisfaction was excellent. Patients participated in sports activities, including bicycling, swimming, football, soccer, and roller skating. Although some did report occasional problems, such as calluses and rashes, on closer inspection these problems seemed to be related to prosthetic fit rather than to the stump per se, and they were easily addressed with minor prosthetic accommodations in the socket. Posterior heel pad migration was commonly encountered, although it rarely required surgical intervention. Hypertrophy of the skin over the distal tibia and prosthetic adjustment were usually enough to compensate for changes in heel pad position. Of these patients, 40% felt that they had no functional restriction at all, and all of the adults reviewed were employed.

In an alternate study evaluating the physical and psychological function in young patients after Syme's amputation, the results documented a surprisingly easy adjustment process (6). The age of amputation may be important, and it seemed preferable that the procedure be performed prior to the age of 18 months to 2 years, because at this time the infant has an incompletely developed body image and adapts to the new physical status quite quickly. It seems that a missing foot compensated by a functional prosthesis is more acceptable to a child or teenager than a significantly deformed foot that compromises activities and gait.

**COMPLICATIONS OF ANKLE DISARTICULATION**

Posterior heel pad migration, wound sloughs, and damage to the distal tibial physis are seen in both the Boyd and the Syme conversions. In addition, an occult retained calcaneal apophysis and later pencilling of the distal tibia may complicate Syme's amputation. Careful attention to the indications and surgical details will limit the

problems encountered. Displacement of the heel pad, although frequent, is rarely an indication for reoperation.

### PROCEDURES TO STABILIZE THE ANKLE

In the past, many attempts have been made to create a lateral buttress to replace the fibula. The Bardenhauer procedure (7) involved inserting the talus into a sagittal split in the tibia, clearly breaching the growth plate. The Albee procedure (4) involved buttressing by autogenous bone grafted into the tibial metaphysis in an effort to replace the fibular malleolus. Lacking a growth plate, the buttress would quickly rise above the level of the ankle, mitigating its effectiveness.

More recent attempts at ankle stabilization have centered on the Gruca procedure (28,54). In a review of this technique by Thomas and Williams (60) at the Royal Children's Hospital in Melbourne, patients were considered for the procedure only if they exhibited minimal shortening of the tibia and had a foot that comfortably reached the ground with no gross deformity. Of seven attempts reported, three had been converted to an amputation, three were awaiting amputation, and the remaining patient had embarked on a program of leg-length equalization. Thus, this procedure is not definitive for most patients and can be regarded only as an interim procedure to be followed by an amputation beause of the progressive leg-length inequality that develops. With rare exception, it appears that Syme's or Boyd's amputations are the preferred primary treatment for type II (complete) fibular deficiencies.

### WILTSE OSTEOTOMY

While stabilization procedures in the absence of a fibula have not been very successful, for specific cases of partial absence resulting in a mild leg-length discrepancy and a valgus but stable ankle, Wiltse (69) proposed a supramalleolar osteotomy designed to minimize the prominence of the medial malleolus. The osteotomy is performed toward the end of growth through an anterior approach to the ankle (Fig. 174.5).

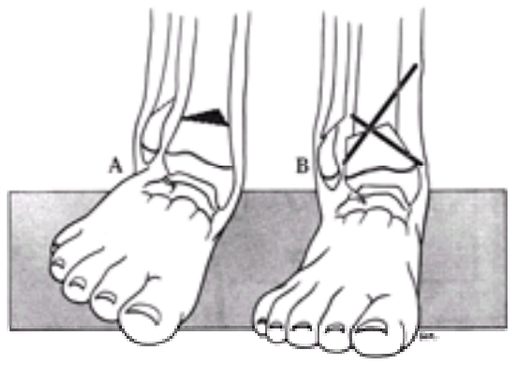


***Figure 174.5.*** The Wiltse osteotomy reduces the medial prominence of the ankle following correction of a residual valgus ankle deformity, as might accompany lesser degrees of fibula deficiency. **A:** Plan of wedge resection. **B:** After closure and fixation of the osteotomy.

## CONGENITAL DEFICIENCY OF THE TIBIA

Unlike most other longitudinal deficiencies, congenital deficiency of the tibia, the rarest form of lower extremity deficiency, may be sporadic or inherited. Both autosomal dominant and recessive patterns have been reported. The anomaly is frequently associated with other system deficits such as herniae, gonadal malformations, hypospadias, cleft palate, imperforate anus, and congenital heart disease. Associated vascular abnormalities may underlie the malformations (32). Always search for absent or duplicated rays, ipsilateral proximal femoral focal deficiency (PFFD), contralateral clubfoot, hemivertebra, hip dysplasia, coxa valga, syndactyly, and lobster claw deformities (53). In contrast to fibular deficiencies, the foot is in a varus position, and the knee may be unstable due to an associated absence of collateral or cruciate ligaments.

There are two classification systems available in the literature. The Kalamchi classification is perhaps simpler and more straightforward (Fig. 174.6), but the classification of Jones et al. (35) is the most widely accepted. It separates the deficiencies radiographically into five types: 1a, 1b, 2, 3, and 4 (Table 174.1). Both classifications are helpful in formulating treatment.

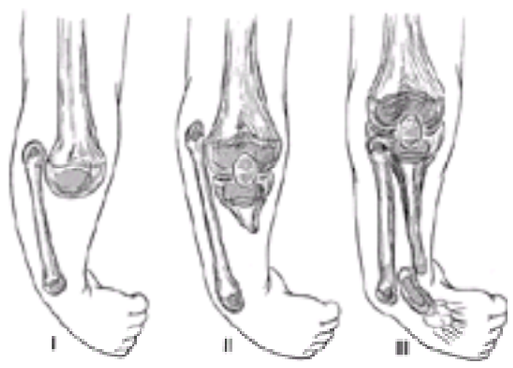


***Figure 174.6.*** The Kalamchi classification for congenital tibial deficiency. Type I, no tibial anlage. Type II, tibial anlage present. Type III, tibial fibula diastasis.

| Type | Radiologic description | Treatment possibilities |
|---|---|---|
| 1a | Tibia not seen at infancy<br>Hypoplastic lower femoral epiphysis<br>Tibia does not appear with growth | Knee disarticulation<br>Rerun fibula centralization |
| 1b | Tibia not seen at infancy<br>Normal lower femoral epiphysis<br>Proximal tibia appears later with growth | Syme's or Boyd's amputation with or without tibiofibula synostosis |
| 2 | Proximal tibial anlage seen early<br>Distal tibia absent | Syme's or Boyd's amputation |
| 3 | Distal tibia present<br>Proximal tibia not seen | Syme's amputation |
| 4 | Distal tibial diastasis | Syme's amputation versus ankle salvage and limb lengthening |

From Jones D, Barnes J, Lloyd-Roberts GC. Congenital Aplasia and Dysplasia of the Tibia with Intact Fibula. Classification and Management. J Bone Joint Surg Br 1978;60:31, with permission.

***Table 174.1. Jones Classification of Tibial Dysplasia***

The distinction is whether a proximal portion of the tibia remains, and whether this portion is meaningfully powered by a quadriceps mechanism. Usually the fragment is palpable, and active knee extension is easily discerned. However, this is not always a simple distinction in a chubby uncooperative infant, so the cartilaginous remnant may need to be sought by arthrography, ultrasonography, magnetic resonance imaging (MRI), or direct observation during surgery. Radiographically, a marked reduction in width and delayed ossification of the distal femur are also suggestive of an absent or nonfunctional proximal segment. When this tibial fragment is present and powered, surgery is warranted to fuse the fibula into the fragment and then to perform a Syme's amputation, which produces a functional below-knee amputation (Fig. 174.7). When the proximal fragment is absent (Jones type 1a), knee disarticulation is warranted, resulting in a functional above-knee amputee. Try to avoid above-knee amputation in treating congenital tibial deficiency because of problems with bony overgrowth, skin problems associated with the residual limb, not to

mention the loss of the major growth physis of the femur and resultant shortening (36).

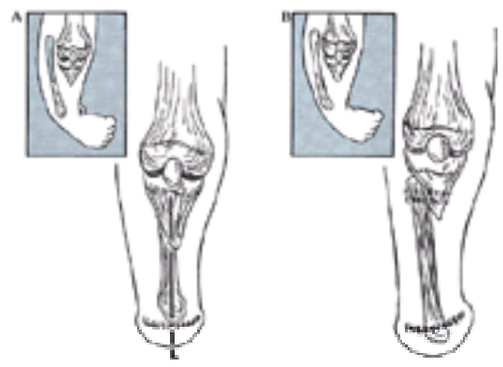

***Figure 174.7.*** **A:** Transfer of the fibular into the tibial anlage in Kalamchi type II deformities of the tibia. **B:** Side-to-side fixation of the fibula into the tibia after resection of the upper portion of the fibula.

The Brown procedure (12,13) (described in the following section), which centralizes the fibula under the femur, is an alternative that allows the child to function as a below-knee prosthetic user rather than as an above-knee amputee. Most authors report disappointing results, in part because of recurring knee flexion contractures, which result from an imbalance between the hamstrings and a weak, albeit present, quadriceps musculature (35,42,58). The Brown procedure (12) may nevertheless be offered if a functioning quadriceps mechanism of grade 3 strength or better is present, because some patients can achieve a functional below-knee stump that allows active knee flexion and extension, according to Simmons et al. (55). Residual ligamentous laxity following Brown centralization can be controlled by an appropriately designed prosthetic socket. Keep in mind that if the Brown procedure proves unsuccessful, the limb may be salvaged and a perfectly acceptable result obtained by performing a knee disarticulation, which would have been the alternative operation anyway. In some severe cases of concomitant femoral shortening, fusion of the fibula into the femur may be desirable to add length to an otherwise short above-knee stump. Unfortunately, 20% to 30% of tibial deficiencies occur bilaterally with an additional compromise of the final functional ability of the patient, regardless of the treatment approach.

When the proximal tibial anlage is present and powered (Jones types 1b and 2), surgery is warranted to fuse the fibula into the fragment when it is sufficiently ossified. Simultaneously, Syme's amputation is performed and the result is a functional below-knee amputee.

De Sanctis et al. (22) presented another strategy and reported three cases treated with Jones type 2 deformities (tibial anlage present) by correction of the foot deformity shortly after birth through a combination of casting and soft-tissue release followed by fibulotibial diaphyseal reconstruction, alignment of the axis of the leg with the foot (talofibular arthrodesis), and leg-length equalization by the Ilizarov method. In a preliminary report, two of the patients achieved satisfactory ambulation, whereas the other sustained recurrence of deformity during the lengthening process.

The Jones type 3 tibial deficiency, characterized by a deficiency of the proximal tibia with a distal, abnormally formed tibial remnant, is extremely rare. This has been adequately treated with a Syme's or Chopart's amputation. The Jones type 4 deformity, with diastasis of the distal tibia and fibula, may be treated by Syme's amputation, or an ankle reconstruction may be attempted (53).

## TOTAL ABSENCE OF THE TIBIA

### *Brown Fibula Centralization*

- Create an anterior U-shaped incision that parallels the distal femoral condyles (Fig. 174.8*A*), and develop a skin flap proximally that allows access to the quadriceps expansion.

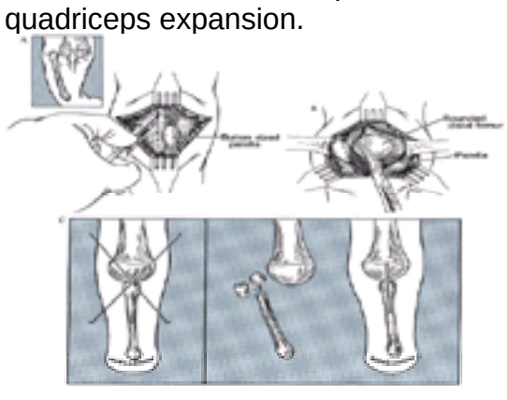

***Figure 174.8.*** The Brown procedure. **A:** Incision utilized for the Brown procedure. **B:** Release of fibular tethering; note roundness of distal femur. **C:** Cross K-wire fixation. If the fibula cannot be relocated distally under the femur, a segmental resection of the upper part of the fibula may help.

- Make a lateral parapatellar longitudinal incision through the expansion that, based on the radiograph, will allow exposure of the upper fibula, which is displaced proximally from its normal position. Now incise and excise the tissue between the upper fibula and the femoral epiphysis as necessary to allow transposition of the fibular head to a point under the midportion of the femoral epiphysis (Fig. 174.8*B*). Brown excised the upper $^{3}/_{8}$ inch of the fibula to provide a flat surface to oppose to the distal femur.
- Fix the fibula in position with cross K-wires (Fig. 174.8*C*) and leave intact the insertion of the patella ligament; reattachment to the fibula itself is not necessary. If the fibula is too high to be brought distally, remove a segment of bone from the upper third of the fibula to facilitate positioning under the femur.
- Fix the reconstituted fibula with a smooth Steinmann pin placed intramedullary. A Syme's or Boyd's ankle disarticulation can be done simultaneously or at a later time.
- Close the skin over a hemovac drain, and immobilize the limb from toe to groin in a maximal, but comfortable, degree of extension.

Change the cast at monthly intervals up to the third or fourth month, at which time remove the K-wires and immediately apply a prosthesis. We prefer to attempt the operation at the age of walking, between 1 and 2 years of age, rather than keeping the patient in a cast until the time when a prosthesis can be applied.

Complications include ligamentous instability, dislocation or subluxation of the fibula from under the femur, stiffness, and recurrent knee flexion contracture. The latter can be treated by hamstring release, but after one or two attempts at making this procedure work, consider knee disarticulation or tibial fibula fusion.

### *Knee Disarticulation*

The mainstay of treatment for Kalamchi type I tibial deformity, in which there is no meaningful tibial remnant, is a knee disarticulation with prosthetic fitting as an above-knee amputee. The distal femoral growth plate is preserved by this technique and therefore considerable growth potential is salvaged. Take care during the procedure not to inadvertently breech the growth plate or the surrounding perichondrium. The following description assumes a nonfunctional tibial anlage, so the usual structures are described. In the actual situation, modifications may be necessary depending on what is actually encountered.

- With the patient in a supine position and under tourniquet control, make an anterior transverse skin incision commencing 1–2 cm distal to the tibial tubercle (or where it should be), sloping upward medially and laterally toward the joint line to a point slightly posterior to the mid-coronal plane (Fig. 174.9). Carry the incision posteriorly 2–3 cm distal to the popliteal crease. Any extraneous flap tissue can always be trimmed later, but too short a flap may necessitate shortening the femur, potentially injuring the physis.

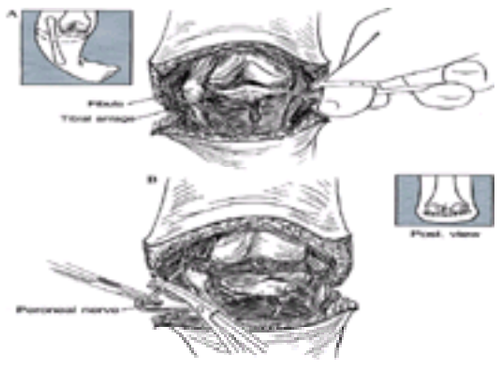

***Figure 174.9.*** Knee disarticulation for severe tibial deficiency. **A:** Expose the distal femur through a transverse incision. The patellar and tibial anlage shown here for clarity are usually absent in those cases requiring knee disarticulation. **B:** Divide the collateral ligaments, ligate the neurovascular bundle, and divide the peroneal nerve. We routinely resect the patella to prevent later chrondromalacia.

- Incise the deep fascia in line with the fish-mouth skin incision. If present, divide the patellar ligament and excise the patella to prevent later chondromalacia.
- With the knee flexed to 90°, divide the medial and lateral collateral ligaments and anterior and posterior cruciate ligaments as distally as feasible.
- Isolate and ligate the popliteal artery and accompanying veins individually.
- Gently pull the posterior tibial nerve distally and divide it proximally; if it is accompanied by large veins, ligate these before they are allowed to retract proximally. Treat the peroneal nerve similarly.
- Next, divide the sartorius, gracilis, semimembranosus, and semitendinosus tendons at their insertions into the tibia, and the biceps femoris at its fibular insertion. Section the iliotibial band transverse to its fibers, and incise the capsule of the knee at the joint line, eventually circumferentially.
- Finally, divide the gastrocnemius muscle heads at their origins on the femur, and pass the leg off the table.
- Close by approximating the hamstring tendons and the patellar ligament to the cruciate ligaments, trimming any excess skin and closing the skin flaps over a drain. It is unnecessary and meddlesome to trim the femoral condyles, as might be attempted for an adult.
- Apply a rigid plaster dressing that will remain for 4–6 weeks; in small children, a single hip spica may be necessary to keep the cast in position.

## PARTIAL ABSENCE OF THE TIBIA

### *Transfer of the Fibula into the Proximal Tibial Anlage*

The transfer of the fibula into the proximal tibial anlage can be done in an end-to-end fashion with intramedullary pins, or by side-to-side approximation with interfragmentary screw fixation. Fusion must await the development of a bony tibial diaphysis, if it is not initially present.

- Make a longitudinal anterior incision centered over the distal portion of the tibial remnant (Fig. 174.7).
- Approach the fibula through a separate lateral incision and dissect the peroneal nerve free where it crosses the fibula.
- Transect the fibula at the level of the distal tibial anlage, and excise the proximal portion. Transpose the distal fibula by incising intervening tissue as necessary. Align the distal transected fibula with the tibial anlage and secure the final alignment with the tibia with a K-wire or smooth intramedullary Steinmann pin.
- Alternatively, if the anlage is very short, a side-to-side fusion may be performed by fixation with small screws or cross K-wires. Apply a long-leg or single-hip spica cast until healing is assured (2–3 months).

Perform prosthetic fitting shortly after cast removal. At times, the union can appear tenuous, especially if considerable residual cartilage was encountered in the tibial anlage, but progressive ossification of the fibrous union does mature over time. A simultaneous Syme's amputation is usually performed, although some surgeons continue to attempt preservation of the foot by tibiofibular fusion. The Ilizarov apparatus can be used to align and fuse the foot, but the results of such an approach are thus far unreported.

## CONGENITAL DISLOCATION OF THE KNEE

Congenital dislocation of the knee (CDK) is a rare condition encompassing a continuum from mild subluxation to frank dislocation. According to Parsch (48), Koptis reported a frequency of about 1.7 per 100,000 live births. Breech presentation occurs in 30% to 40% (44). CDK is easily recognized in the neonatal period, with the knee fixed in hyperextension. The femoral condyles may be palpable in the popliteal region. The patella may not be easily located, often being displaced laterally.

Table 174.2 presents the associated anomalies and syndromes of CDK. Accompanying musculoskeletal anomalies occur in more than 50% of cases, the most common being dislocated hips and clubfeet (37). In association with Larsen's syndrome, abnormalities of the cervical spine are frequent and should be sought (9).

| |
|---|
| Talipes equinovarus |
| Talipes equinovalgus |
| Developmental dislocation of the hip |
| Larsen's syndrome |
| Multiple joint dislocations |
| Cervical or other spine abnormalities |
| Typical facies and spatulate thumbs and toes |
| Arthrogryposis |
| Multiple contractures |
| Fusiform joints |
| Extensor dimpling |

***Table 174.2. Congenital Dislocation of the Knee: Associated Anomalies and Syndromes***

Thus, CDK might better be characterized as a syndrome rather than an isolated entity. Pathologic findings at surgery include quadriceps fibrosis, ablation of the suprapatellar pouch, anterior dislocation of the hamstring tendons, femoral and tibial articular surface dysplasia, and anterior cruciate elongation and attenuation (19). Children seen in the first few months of life can be treated with biweekly casting or traction until reduction is obtained or progress toward reduction is deemed to have failed. Parsch (48) found conservative treatment to be successful in two thirds of patients.

Should conservative treatment fail, open reduction is necessary. A failure is defined by persistent subluxation of the tibia on the femur, as visualized on a lateral radiograph, or the inability to obtain 45° of flexion after a trial of closed reduction and serial casting. Obliteration of the suprapatellar pouch may be seen when arthrography is performed in nonresponsive patients. Accompanying congenital hip dislocation can be difficult to treat by conventional closed methods until the knee deformity has been controlled. This is due to a tight quadriceps becoming even tighter with knee reduction and in turn precluding reduction of the hip. The Pavlik harness in such cases, aside from being difficult to apply, may actually be counterproductive unless knee flexion has been obtained prior to application. Some authors have reported its successful use in such instances (33,45).

## OPEN REDUCTION

Given the pathologic findings in CDK, direct surgery toward lengthening the contracted quadriceps mechanism by V-Y advancement or Z-plasty, and releasing the tight medial and lateral capsular structures; after that, reduction can be accomplished (Fig. 174.10). Anterior cruciate ligament augmentation or advancement, meniscectomy, and posterior capsule reefing are rarely necessary.

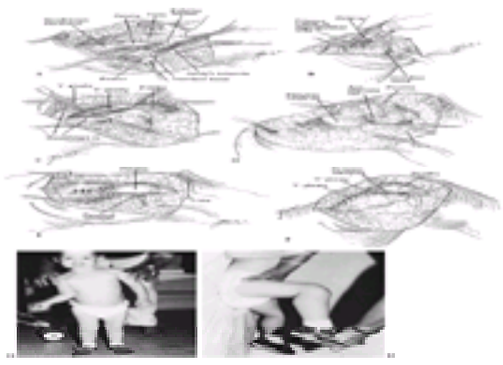

***Figure 174.10.*** Open reduction of congenital dislocation of the knee. **A:** Visualize the pathology through a lateral approach. The iliotibial band and quadriceps tendon are usually contracted, the hamstring tendons may be subluxed anterior to the femoral epicondyles, and the anterior cruciate often is attenuated, stretched, or absent. **B:** A condensation of fibrous tissue may connect the distal quadriceps expansion to the distal femur and should be released. **C:** Perform a V-Y quadriceps plasty. **D:** With the quadriceps divided, flexion of the knee promotes spontaneous reduction and the anterior cruciate can be inspected. Do not repair the cruciate, even if attenuated. **E:** Repair the quadriceps with the knee located. **F:** Position of immobilization postoperatively. **G,H:** Result at 3-year follow-up. From Johnson EJ, Audell R, Oppenheim WL. Congenital Dislocation of the Knee. *J Pediatr Orthop* 1987;7:194, with permission.

- Use an anterior midline incision curving distally and laterally. Enter the joint through a parapatellar approach. If the iliotibial band is tight anteriorly to the lateral femoral condyle, release it with a diagonal incision that can later be reapproximated in a lengthened position.
- The quadriceps tendon must be lengthened. Employ a V-Y technique (Fig. 174.10*E*). This release allows inspection of the joint prior to repair of the quadriceps, so that any remaining adhesions in the suprapatellar pouch area can be released, and reduction can then be obtained and secured by flexion of the knee.
- The collateral ligaments of the knee may need to be carefully released to facilitate knee flexion. The hamstring tendons ordinarily spontaneously retreat from an anterior position to one posterior to the femoral epicondyles.
- After quadriceps repair and closure, immobilize the knee in a long-leg cast flexed to 45° for 6–8 weeks.

Most children spontaneously move their knees following cast removal without the need for formal physical therapy. The goal is 90° of active flexion. Bilateral cases, however, do not seem to recover as much motion as unilateral cases (34).

## CONGENITAL DISLOCATION OF THE PATELLA

Congenital dislocation of the patella (CDP) presents a challenge to the orthopedist. Not only is the patella small and misshapen, but the femoral groove is often shallow, and the entire quadriceps musculature is displaced laterally and contracted. In longstanding cases, the tibia may be laterally rotated, subluxated, and in mild valgus because of the abnormal pull of the quadriceps. The tibial tubercle appears lateral to its usual position, resulting in an increased Q angle. The diagnosis can be made by direct palpation and confirmed by radiography, ultrasonography, or MRI. Keep in mind that the patella does not normally ossify until 4–6 years of age. It is thus easy to miss the diagnosis if relying on radiography alone. The keys to diagnosis are a high level of suspicion in addition to the clinical findings of a knee flexion contracture associated with an external rotation deformity of the tibia, lack of full extension, and weakness. Because of this, the diagnosis is rarely made before the age of walking.

Congenital dislocation of the patella may be familial, occur sporadically, or be associated with Down syndrome or arthrogryposis. It frequently occurs bilaterally. The natural history of untreated patellar dislocation is early degenerative arthritis, pain, and disability. Conservative therapy is futile; surgery is indicated once the diagnosis becomes clear. Most operative techniques have stressed a soft-tissue release of the quadriceps associated with a V-Y-plasty of the quadriceps tendon, with realignment of the patellar ligament insertion. The operative technique must not breach the tibial physis in skeletally immature individuals, but realignment of the patellar ligament can be performed utilizing the Roux Goldthwait procedure (split patellar tendon transfer), or alternatively, the patellar ligament, in its entirety, can be medially transposed into the periosteum over the proximal tibia. We routinely perform a Galleazzi semitendinosus tenodesis of the patella. In skeletally mature individuals, the tibial tubercle itself may be translocated medially.

### TECHNIQUE OF REDUCTION

There are several techniques to correct a congenitally dislocated patella (26,27,56). We prefer the following technique.

- Begin with a straight lateral incision at the junction of the middle and upper thirds of the thigh and extend it distally lateral to the dislocated patella across the femoral condyle, and then swing medially across but 2 cm distal to the tibial tubercle (Fig. 174.11).

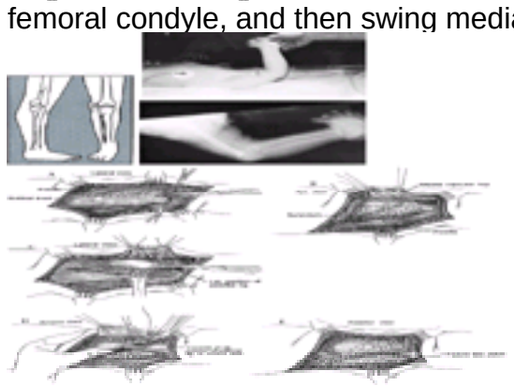

***Figure 174.11.*** Congenital dislocation of the patella. Plan of incision. **A:** Release the iliotibial tract. **B:** Raise the medial capsular flap. **C:** Develop the lateral half of the patellar ligament for transfer. **D:** Transfer the lateral patellar ligament to the medial aspect of the tibia. **E:** Repair the medial capsular flap over the patella and advance the vastus medialis insertion. The resulting lateral capsular defect may be patched with a piece of harvested fascia lata.

- Dissect down to the iliotibial band, and divide it obliquely so it may later be repaired in a lengthened position if necessary. Follow the band posteriorly to its insertion on the femur by separating it from the adherent fibers of the vastus lateralis; this portion of the band is known as the lateral intermuscular septum.
- Elevate the quadriceps extraperiosteally off the femur and up the lateral aspect of the femur to the proximal one-quarter.
- Lateral to the patella, make an incision through the capsule and connect it to the main release along the vastus lateralis.
- On the medial side of the patella, incise the large flap of attenuated capsule for later plication, and separate the vastus medialis from the quadriceps expansion distally.
- Relocate the patella in the femoral groove. If flexion cannot be accomplished to 90° with the patella in the groove, lengthen the quadriceps in a V-Y fashion and/or release any fibrotic bands.
- Now sew the semicircular flap over the patella and anchor it to the tissue along its lateral aspect. Advance the vastus medialis as necessary to produce stable tracking of the patella. Flex the knee at each stage to see if the patella is becoming more stable in the femoral groove; if not, adjust the tension of the suturing accordingly.
- The patellar ligament almost always appears to be attached too laterally on the tibia, so split the patellar ligament longitudinally and detach the lateral portion just proximal to its insertion. Then transfer this detached free stump under the medial portion of the ligament and suture it into the periosteum along the medial aspect of the tibia near the insertion of the tibial collateral ligament. Take care not to make the attachment so tight that the patella becomes rotated around its longitudinal axis. A piece of tensor fascia lata may be used to close the lateral capsular defect, if desired, although we do not routinely do this.

### GALLEAZZI PROCEDURE

As mentioned, we routinely perform the Galleazzi semitendinosus transfer procedure to keep the patella relocated.

- First, identify the semitendinosus tendon at its insertion into the pes anserinus. Through the main incision or through a separate incision, release the tendon at its musculotendinous junction and free the tendon to its distal insertion into the pes anserina, which can be partially released to allow the insertion of the tendon to

move more medially on the tibia.
- Make an oblique drill hole from inferomedially to superolaterally through the lower medial patella, parallel to the articular surface.
- Then pass the semitendinosus stump through the drill hole and suture it to itself or to the dorsal periosteum of the patella to complete the tenodesis.
- After wound closure, apply a long-leg cast for 4–6 weeks.

Commence active and passive exercises of the knee when the cast is removed if the child does not exhibit spontaneous motion and improvement. In older children, the hamstrings may occasionally need to be lengthened to correct a residual fixed flexion deformity. We have not employed prolonged bracing following cast removal.

## CONGENITAL COXA VARA

Congenital or developmental coxa vara occurs perinatally and is characterized by a decreased femoral neck shaft angle in association with a primary femoral neck defect. This defect involves both the inferior portion of the capital physis and the adjacent metaphysis. Histologically, it represents a defect in enchondral ossification (16,51). Some authors have commented on a hereditary tendency, but there is no predilection for sex or race (5,16,46,67). Radiographs confirm the decreased neck shaft angle as well as a shallow acetabulum and widened teardrop. Because of the varus, the center–edge angle may appear to be normal, which can cause the examiner to underestimate the true dysplasia of the acetabulum.

Although the etiology is unknown, studies of the natural history suggest the early onset of degenerative arthritis and increasing disability for those cases that progress (5). Because of this, the mainstay of treatment has been proximal valgus osteotomy. Most cases are diagnosed because of a limp or waddling gait in children 3–12 years of age. Only a few children present with leg or back pain. Coxa vara can also present in association with syndromes such as coxa vara with femoral shortening, coxa vara as part of PFFD, multiple epiphyseal dysplasia, cleidocranial dysostosis, achondroplasia, or hypothyroidism. In addition, coxa vara can be acquired as a sequella of Legg-Perthes disease, infection, trauma, or as a complication of treatment for developmental hip dysplasia or other diseases. For the true developmental or congenital cases with only mild shortening or femoral bowing, Weinstein et al. (67) utilized Hilgenreiner's epiphyseal angle to help define treatment indications. This is the angle formed between Hilgenreiner's line and a line drawn on the anteroposterior (AP) radiographic projection parallel to the capital physis. In the study by Weinstein et al., when the angle was in excess of 60°, progression was the rule; if it was less than 45°, the deformities spontaneously corrected. In the 46° to 59° range, the natural history was not predictable so the patients were observed for signs of progression prior to undergoing surgery. The goal of surgical correction was to restore the Hilgenreiner epiphyseal angle to less than 45° (Fig. 174.12).

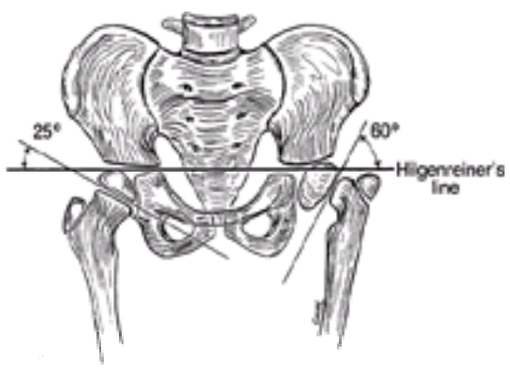


***Figure 174.12.*** The Hilgenreiner epiphyseal angle. This measurement is helpful in predicting which cases of coxa vara should be observed and which should be operated on.

In our practice, we simply utilize the neck–shaft angle on standing AP radiographs with both knees in the same position and pointing as anteriorly as possible. Deformities associated with a neck–shaft angle of 110° or better are followed with the expectation of resolution. Those less than 100° are operated early to avoid continued shear stress on the physis. The group between 100° and 110° are observed for 6 months to 1 year to see whether they will spontaneously resolve.

The goal of surgery is to restore a normal neck–shaft angle while avoiding damage to the capital physis and greater trochanteric apophysis. However, Schmidt and Kalamchi (52) have noted premature closure of the capital physis in 90% of operated case, even when direct injury was avoided. In addition, they carefully studied the acetabular development, noted it to be deficient, and concluded that unless correction to 140° or better was achieved at surgery, the acetabular dysplasia did not improve. Thus the goal is correction of the neck–shaft angle to at least 140°.

### VALGUS OSTEOTOMY

Determine the amount of correction to be obtained on the preoperative radiograph. Use an image intensifier prior to commencing the actual surgery to obtain a final check on the true neck–shaft angle. Rotate the hip until the femoral neck appears the longest, and then measure the neck–shaft angle on that particular projection. If necessary, perform a percutaneous adductor tenotomy to facilitate later closure of the bony osteotomy. Because of the incidence of premature physeal closure of the capital physis, and the possibility that this may be related to tight musculature, consider lengthening the iliopsoas as well.

- Approach the hip laterally through a longitudinal skin incision and split the iliotibial band. Elevate the vastus lateralis subperiosteally from the proximal femur. Use a pediatric osteotomy screw (or, alternatively, a pediatric blade plate and matching instrument set) (Fig. 174.13).

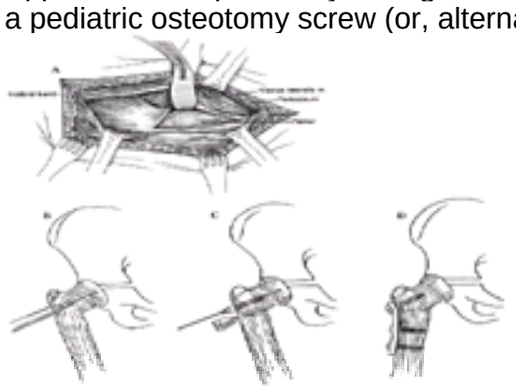

***Figure 174.13.*** Valgus osteotomy for congenital coxa vara. **A:** Make a standard lateral exposure to the upper lateral femur through the iliotibial tract, dividing the posterior portion of vastus lateralis and reflecting it anteriorly. **B:** Guide wire placement and overreaming short of the capital physis. **C:** Insertion of cannulated pretapped screw and removal of lateral wedge of bone. **D:** Application of sideplate.

- Place a guide wire along the front of the femoral neck to locate its axis, and introduce a guide pin through the lateral cortex up to but not through the capital physis.
- Ream over this wire, then tap the hole under image intensifier control, and finally introduce a screw of appropriate length. Attach the spanner to the femoral neck screw to control the proximal portion while removing with an oscillating saw a wedge of bone based laterally at the level of the lesser trochanter.
- Now close the osteotomy and apply a two-hole side plate bent with the bending irons to accommodate the new shape of the lateral cortex.
- Check the position with the image intensifier or plain radigraphs, and then secure the plate to the proximal femoral shaft using 4.5 mm screws.
- Then irrigate the wound and close it over a hemovac drain, which is removed at 48 hours.

Immobilize the child in a one-and-one-half hip spica cast for 6 weeks or until the osteotomy is radiographically united. Treat residual leg-length discrepancy by a lift and, if necessary, by an appropriately planned epiphysiodesis of the opposite femur.

Complications include continued acetabular dysplasia, premature closure of the capital physis, overgrowth of the greater trochanteric, leg-length discrepancy, recurrence of varus, malunion, nonunion, failure of fixation, avascular necrosis, and infection. These problems may be treated as necessary by techniques described in Chapter 29, Chapter 166, Chapter 170, Chapter 171, and Chapter 173. Repeat valgus osteotomy is sometimes required if the enchondral neck defect has not healed

within a year.

## CONGENITAL DEFICIENCIES OF THE FEMUR

Congenital deficiencies of the femur form a continuum from simple hypoplasia to total absence. The deficiencies may be diffuse or limited to the upper or lower portions, and they are often associated with other limb deficits and other organ anomalies. Many classification schemes have been proposed to aid in selecting proper treatment. Most focus on PFFD. Some include congenital short femur as the least affected category in the spectrum. However, a child with a congenital short femur is most frequently amenable to lengthening, whereas few with PFFD are. Hence, we prefer to think of these deformities as separate entities.

Treatment can range from observation to amputation and fitting with a prosthesis, so a general treatment protocol is not easy to describe. Subtleties of hip, knee, or ankle strength and motion, along with the wishes of the family regarding cosmesis, may play pivotal roles in the final plan, and no one treatment will ever be correct for every child.

### CONGENITAL SHORT FEMUR

For children with congenital shortness of the femur who have a stable hip and knee (including those instances in which a stable knee and hip have resulted through surgical intervention), limb lengthening may be indicated. Children whose limbs are predicted to have a discrepancy at maturity in the range of 5–15 cm can be considered for lengthening. We prefer to lengthen using Ilizarov's biology (i.e., lengthening of a healing callus) while utilizing a unilateral half-pin fixator (such as the Wagner) (64) for its safety and convenience. For less than 5 cm of predicted leg-length discrepancy, we perform percutaneous epiphysiodesis.

Leg equalization of up to 5 cm can usually be gained by epiphysiodesis. For example, a child with a predicted discrepancy of 7.5 cm would be left with a 2.5 cm discrepancy after epiphysiodesis. The parents need to decide whether the potential complications associated with lengthening are worth it to correct the remaining discrepancy.

Keep in mind that the need to equalize the length of the extremities does not have to be accomplished by a single technique. A difference of 10 cm could, for example, be made up with an acceptance of a 2 cm difference, the addition of a 1 cm lift inside the shoe, and an epiphysiodesis of 7 cm, resulting in a final lengthening of 10 cm. A lengthening of 10 cm is within reason, whereas a lengthening of 20 cm would be beyond the margin of current practice. For discrepancies predicted to be in excess of 20 cm, seriously consider amputation and prosthetic fitting.

In general, the milder forms of femoral dysplasia are associated with coxa vara, whereas the more serious forms, normally classified under the banner of PFFD, are associated with subtrochanteric bowing. Subtrochanteric bowing may be corrected prior to consideration of limb-length equalization. However, coxa vara can help stabilize the hip joint during femoral lengthening and is better corrected after the lengthening is complete.

### PROXIMAL FEMORAL FOCAL DEFICIENCY

The management of children with PFFD has been confused by an array of classification systems that have focused on the radiographic appearance of the hip. The major decisions in caring for a child with PFFD concern primarily the marked limb shortening and depend very little on the anatomy of the hip.

#### *Classification*

Clearly, children with PFFD are not all the same. Classification systems can be used to organize clinical material for presentation in the medical literature, or they can be used to help the orthopedic surgeon make clinical decisions for an individual child; sometimes they serve both functions. Aitken's (3) classification of PFFD is an example of the first use. It focuses entirely on the radiographic appearance of the bones of the upper end of the femur and the pelvis (Fig. 174.14). This classification plays a moderately small role in the overall decision making. The classifications of Pappas (47), Fixen (24), and Amstutz (5) are similarly constrained. By contrast, the classification by Torode and Gillespie (62) is concise and practical: “short” (i.e., lengthenable) or “very short” (extend with a prosthesis). This useful classification scheme focuses on the real problem—the marked limb shortening.

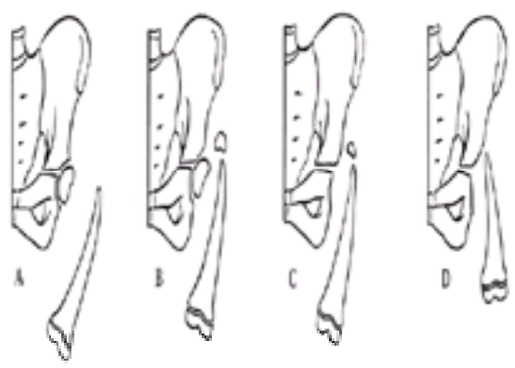


***Figure 174.14.*** The Aitken classification for proximal femoral focal deficiency. Types A and B generally have a well-developed acetabulum and by implication a femoral head anlage, even when not initially visualized. Types C and D are usually shorter and the acetabular landmarks are ill defined. Types B and C are characterized on early radiographs by a tufted appearance of the upper femur, which most likely is an ossified portion of femur above a nonossified area.

#### *Clinical Decision Issues*

Initially, help the family decide whether their child has a useful extremity that can be lengthened, or whether lengthening is unrealistic and the leg needs to be shortened and the difference to the ground made up with a prosthesis.

Amstutz (5) made a significant contribution by pointing out that the length of the short leg compared to the normal leg at infancy remains in the same proportion at maturity. This allows prediction, while the child is still an infant, of what the ultimate leg-length difference will be at the end of growth. The parents can become accustomed to the problems that need to be faced, which usually makes their decisions easier. Orthopedic surgeons have differed between stating leg-length differences as absolute numbers of centimeters versus percentages of the bone length. There is no agreement currently. An average male femur at maturity is approximately 46 cm, and an average female femur is 43 cm. A leg-length difference anticipated to be greater than 40% to 50% of the normal length at maturity will not likely leave a child with a good functioning extremity even if lengthened.

The options for making up for the marked leg-length difference are to (a) lengthen; (b) remove the foot and fit the child as a below-knee amputee, accepting the huge difference in knee heights; (c) remove the foot, fuse the knee, and shorten the limb so that the child can be fitted as an above-knee amputee; or (d) perform a Van Nes rotationplasty.

**Lengthen the Short Bone** If children with a congenitally short femur are excluded from the category of PFFD, relatively few children with a PFFD would have limbs that can be equalized by lengthening.

The hip needs to be stable before lengthening can proceed, although rarely the proximal arm of the lengthening device can be fixed to the pelvis.

Even though the diagnosis is described as a proximal femoral deficiency, most children have deformity in the distal femoral condyles and the ligaments about the knee, as well as deficiencies of the fibula and foot. Lengthening a femur that has a congenital deficiency is much more likely to result in anterior subluxation of the femur on the tibia, ultimately resulting in poor knee function. Lengthening should not be performed by surgeons who do not do it on a frequent basis.

**Fit as a Below-Knee Amputee** Remove the foot by Syme's or Boyd's amputation (discussed previously) and use an extra-long below-knee prosthesis. This is a simple solution, but it is cosmetically unappealing due to the great difference in knee heights, which is especially obvious when the child is sitting. This choice is less frequently

taken now than in years past.

**Shorten and Fit at the Above-Knee Level** If lengthening is not a realistically practical option, consider shortening the limb sufficiently that the child will be able to function well as an above-knee amputee. King (38) initially suggested the concept of a single skeletal lever, and he fused the knee joint in an effort to improve hip function and to facilitate prosthetic fitting. As a part of this procedure, the foot must be removed. This can be done either as Syme's or as Boyd's amputation. Many surgeons favor Syme's amputation because of its simplicity. However, Syme's amputation done in infancy has more of a tendency to “pencil-point thinning” of the distal tibia. The worries about heel-pad migration are probably overstated, because the skin of children will modify to the pressures applied, as witnessed in children with untreated clubfeet who are able to walk on the dorsum of their feet without skin breakdown. However, there is not good scientific evidence to enable an informed choice between these two procedures, so the choice tends to be one of personal preference of the surgeon.

Ultimately, the end of the stump on the deficient side should be sufficiently short to allow room for a standard mechanical knee joint in the prosthesis to be at the level of the opposite, normal knee. Although orthopedic surgeons have often focused on the end of the bony stump as seen on a scanogram, remember that there is soft tissue beyond that as well as room needed for the socket padding and the thickness of the socket itself—a total of almost 3 cm. An ideal to aim for is that the end of the bone of the stump be 10 cm proximal to the knee joint on the opposite side.

Most children with PFFD have a tibia on the short side that is approximately 90% or more of the normal length (i.e., in boys about 37 cm and in girls about 35 cm, or about 10 cm shorter than the average normal femur). This means that if the tibia is left intact and there is any segment of femur remaining, the probability is overwhelming that the stump will be excessively long. There should therefore be plans to either excise one or both physes around the knee if considering a knee fusion or, alternatively, be a plan for epiphysiodesis at the appropriate time.

**Knee Fusion** Most children with PFFD live with the anatomic knee held in flexion. They will often sit on the thigh section of their prosthesis. This gives decreased control and power over the prosthesis and aligns the vertical axis of the prosthesis lateral to the center of gravity, producing a lateral lurch in the stance phase of gait. Function can be greatly enhanced if the femur is fused to the tibia. When this is done, the fusion must be done with the knee in full extension. Initially, there may be enough of a hip flexion contracture that the residual extremity will not come to neutral at the hip, but this stretches out in short order (38). In the past, this procedure was not frequently performed, but it is now routine. Delay knee fusion until the proximal tibial center of ossification is easily visualized by plain radiography, usually between 18 months and 2 years of age.

- Use an anterolateral approach. Section the patellar ligament and remove the patella along with the menisci and cruciate ligaments. Perform the femoral resection just proximal to the distal physis; divide the gastrocnemius at the level of the insertions to the posterior femoral condyles. Protect the peroneal nerve and posterior neurovascular bundle throughout the resection.
- Use a knife or micro–air saw to resect the articular cartilage of the tibia, carefully exposing the ossification nucleus to its widest diameter.
- Introduce a Rush rod retrograde through the intercondylar notch of the femur, exiting along the lateral aspect of the proximal femur. Then withdraw it and drive it antegrade across the knee to fix the fusion in good alignment. The Rush rod should be centralized in the proximal tibial physis as much as possible. We have not observed growth arrest, but cross K-wire fixation above the tibial physis is an alternative method of fixation.
- Use the resected distal femur for supplemental bone graft, if needed.
- Close the wound over suction drainage.

Syme's amputation may be performed at the same time, although some surgeons delay this stage for 6 weeks.

**Van Nes Procedure** An alternative to the knee fusion just described and the fitting as an above-knee amputee is the Van Nes rotationplasty (63), in which the leg is rotated 180° so that the ankle functions as a substitute for the knee (25,29,39,40,63) (Fig. 174.15). A special prosthesis is used that uses the ankle as the knee and the foot as the leg, similar to a standard below-knee prosthesis. (The socket usually has an additional thigh support attached with outside hinges.) For this to be successful, there are three requirements:

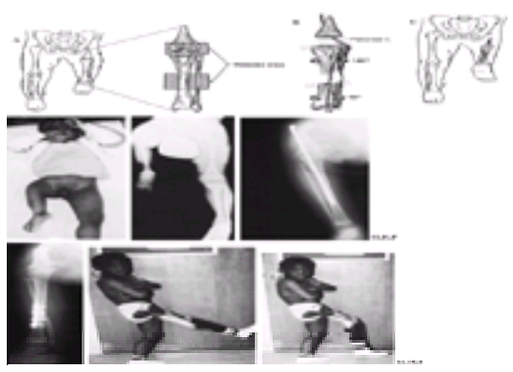

***Figure 174.15.*** The Van Nes turnaround procedure. **A:** Area of bony resection. **B:** Plan for derotation. The removal of bone leads to soft-tissue redundancy and the ability to rotate without injuring the muscle or neurovascular bundles. **C:** After derotation, the ankle is 180° from its usual orientation. **D,E:** Preoperative clinical appearance. **F:** Radiographs show the knee fusion and the tibial turnaround osteotomy. **G:** Radiographs show the knee fusion and the tibial turnaround osteotomy. **H,I:** Postoperative clinical appearance.

- The length must be appropriate. Ultimately, the reversed ankle should be at approximately the level of the opposite knee joint. Plantar flexion and dorsiflexion of the foot is a composite of the motion at the ankle and the subtalar joints. The axis of rotation for the purposes of prosthetic fitting is at the tip of the lateral malleolus. The limb can be shortened an appropriate amount at the time of rotation and/or knee fusion. It is rare to have the extremity too short, because that would be due to a considerable deformity in the tibia and would probably be associated with an inadequately functioning ankle joint.
- The ankle must be sufficiently normal to function as a substitute knee. It must have an appropriate range of motion and sufficient strength to power a prosthesis. A foot with all five rays usually has these requirements, but not invariably.
- The psychological acceptance of the procedure needs to be within the tolerable limits of the patient, the family, and the medical personnel looking after the child. Concerns may vary from age to age and culture to culture. In medical centers where the Van Nes procedure is frequently performed, there are usually other children and families who can act as models and counsel potential patients and their parents. The psychology of the medical staff cannot be ignored. If the medical personnel feel that such procedures are bizarre, it is clear that they will not be offered, or they will be presented in such a manner that no patient would accept the choice. As a consequence, some centers in the United States have moderately large numbers of children who have had the procedure and other centers have none.

Additionally, prosthetic facilities must be considered. The prosthesis that is required following a Van Nes procedure is difficult to fit. If good prosthetic facilities are not available, avoid this operation.

- Perform the knee fusion as previously described, but use the soft-tissue redundancy obtained from the femoral resection to derotate the limb.
- Secure the knee derotation with an oblique K-wire across the fusion site, supplementing the Rush rod fixation (61).
- Either extend the knee wound along the tibial crest or use an additional incision over the mid tibia. Incise the periosteum and resect and discard at least 1 inch of the tibia.
- Further rotate the limb laterally until the ankle is repositioned 180° with respect to the hip.
- Fix the tibia with a four-hole semitubular AO plate, or use a long enough intramedullary Rush rod to fix both the knee and the hip, and another oblique K-wire to secure rotation.
- Perform an anterior compartment release prior to closure, and use a spica cast until radiographic consolidation of the osteotomies, which usually requires 6–8 weeks.

*Complications* Late fractures at the end of the intramedullary fixation device occurred in two of our patients but healed uneventfully in a spica cast. Although Hall and Bochman (29) have stated that the procedure should not be performed until maturity because remodeling and derotation of the limb require further surgery, we perform the procedure at about 2 years of age. We are content with rerotating the limb as necessary. In our experience, approximately half the patients required one repeat surgery to rerotate the limb, but only one patient of 13 required a third surgery.

### *Other Issues*

**Length of the Stump** As discussed, most children who have had conversion of their PFFD extremity to an above-knee amputation end up with a stump that is too long. At the time of knee fusion, consider excision of the distal femoral and/or the proximal tibial physis. Some orthopaedic surgeons are wary of doing this for fear that the extremity will be much too short; however, proper application of growth data using the Green-Anderson-Mesner charts (see Chapter 170) can alleviate that fear. Moseley's straight line graph (see Chapter 170) does not differentiate between the femur and the tibia and does not provide the answer for this calculation.

**Before the Definitive Surgery** Regardless of what the decision is for ultimate management, there is a period when the difference in leg lengths can be considerable, yet it is too early to do anything definitive surgically. Lifts greater than 5 cm in height tend to lead to ankle sprains, but ankle–foot prostheses can be used to decrease this likelihood. However, when the difference gets to 8 or 9 cm, an extension prosthesis (sometimes called an extension orthosis or even a prosthosis) can be made that has a hole in the front of the prosthesis distally through which the forefoot extends. If tried at too young an age, when the length difference is less than 5 cm, however, there is not room enough below the socket to fit a foot on the end of such a prosthesis.

**Reconstruction of the Hip Joint** In the past, there has been a great deal of focus on the radiograph of the upper end of the femur. What is seen by the radiograph, however, is only the bone. What is going on with the cartilage, let alone the muscles, is not seen. If there is absolutely no acetabulum, the decisions regarding the management of limb length given in this chapter apply. If, on the other hand, the acetabulum is satisfactorily formed and there is some element of a femoral head in the acetabulum and some segment of upper femur that are not joined, consider surgery. Wait until there is sufficient ossification of the two fragments that they can be fused together, bone to bone. There is certainly no rush to do this, and more complications occur from proceeding too soon, before there is adequate bone stock.

**Fusion of the Distal Femur to the Pelvis** The distal femur can be fused to the pelvis in order to use the knee joint as a replacement for the hip joint (Fig. 174.16). This has the theoretical advantage of providing a stable hip. However, the knee joint does not allow reasonable rotation. Once it is fused to the pelvis, the distal femur has some capacity to grow, and the hip joint will grow to a point that is mechanically disadvantageous, depending on the orientation of the distal femur at the time of fusion to the pelvis. Although there have been a small number of reports of such cases (24,57), most surgeons feel that this is not an advantageous procedure and avoid it (23,25).

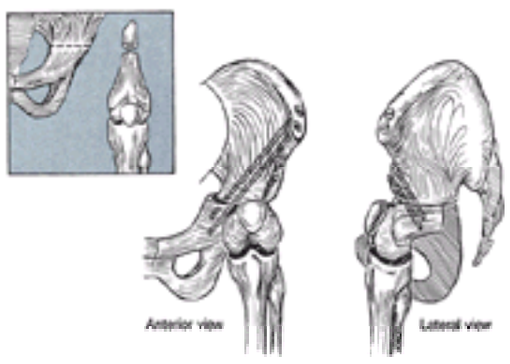


***Figure 174.16.*** In rare cases, the knee can be used as a surrogate hip in conjunction with a Chiari osteotomy combined with fusion of the femoral remnant into the pelvis.

## MISCELLANEOUS ITEMS

### TERMINAL OVERGROWTH

“Overgrowth” of amputation stumps in children has always been a problem and can occur even in congenital amputees. It is particularly a problem in the humerus, the fibula, and the tibia. Pellicore et al. (1,49) found that 15% of their juvenile patients who had amputations before 12 years of age required revision, whereas none did if the amputations were done at a later age. Yet, if children required stump revisions and they were older than 12 years, overgrowth could still occur.

This overgrowth is not a result of stimulation of the physis proximally but of the development of appositional new bone on the end of the stump (see Chapter 175). The easiest way to manage the problem is to avoid it by performing amputations through a joint, where possible, so that the end of the bone is covered by its normal cartilage. If this is not possible, a number of maneuvers have been used with varying success. Silastic end pieces (either as a stemmed plug that fits into the medullary cavity or as a cap that fits over the end of the diaphyseal bone) have been tried, but frequent breakage and dislodgement of the plug or cap have led to their abandonment. Surgical procedures that provide a smooth periosteal surface around the end of the bone appear to be successful in many cases. The Marquardt method (50) (Fig. 174.17) introduced the use of autogenons epiphyseal caps. Davids et al. (21) recently reviewed their patients. Apophyseal cartilage from the iliac crest can be used. Our preference is to use the proximal fibula and invert its diaphysis into the tibial or humeral medullary canal. This cartilage cap is not expected to grow but only to provide a smooth nonosseous surface to prevent osteoblastic reaction. This has been very effective. Keep this technique in mind for situations in which transosseous amputations are required. It may be possible to salvage an epiphysial cap from part of the discarded specimen (e.g., the first metatarsal head, the talar head, or the os calcis), which could then be attached to the end of the cut bone.

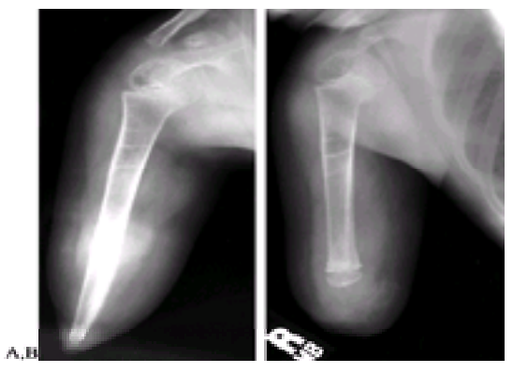


***Figure 174.17.*** Modified Marquardt method of capping bony overgrowth in a transdiaphyseal amputation in a growing child. **A:** Preoperative radiograph showing terminal overgrowth of an above-elbow amputation. **B:** Postoperative appearance after transfer of a epiphyseal cartilage graft onto the revised distal humerus.

In children who have had amputations for tumors and who receive postoperative chemotherapy, bone protrusion at the end of the stump may be caused by soft-tissue retraction rather than terminal overgrowth. In such children, the chemotherapy adversely influences the healing of the fascia, so that the muscles draw proximally, leaving the bone protruding subcutaneously. If a stump revision is done while the child is still receiving chemotherapy, the complication is likely to recur. Several revisions may lead to an unfortunately short stump. It is better to wait until 3–6 months after the cessation of the chemotherapy to do a definitive procedure.

### CONSERVATION OF PARTS FOR TOE-TO-THUMB TRANSFER

Not infrequently in treating lower extremity defects, there are concurrent hand abnormalities. Toe-to-hand transfers are now well-established procedures, so before any lower extremity parts are discarded, search for possible uses for the reconstruction of the upper extremities. We have assisted the hand surgeon with harvesting the parts prior to Syme's or Boyd's amputation, with very gratifying results.

## LENGTHENING OF SHORT AMPUTATION STUMPS

For children who have amputation stumps that are very short (acquired or congenital), the gain of even a small amount of length may provide an adequate lever to use a more functional prosthesis. The advantages are decreased energy consumption, improved prosthetic control, decreased heat retention, increased comfort from the lesser weight of the prosthesis, and fewer components requiring repairs, as well as decreased cost.

Children with loss of an upper extremity, especially if the loss is congenital, frequently choose not to wear prostheses. However, longer residual limbs may allow for grasping objects in the midline between the stumps for “bimanual” activity without a prosthesis. Additionally, a longer distal segment can permit objects to be grasped between a lengthened humeral stump and the chest, or between a lengthened forearm and the upper arm.

Watts (66) reported lengthening 32 short amputation stumps in 27 patients. All were lengthened by gradual distraction using Ilizarov techniques (see Chapter 32 and Chapter 171). The 16 children who completed lengthening of their femurs or tibias achieved sufficient length to be fitted with a prosthesis at one level more distal than previously possible (Fig. 174.18). Children who underwent lengthening of their upper extremities were more difficult to assess. Three patients were lengthened with the anticipation that a prosthesis would not be used after lengthening. All became “users,” in that they became able to grasp objects between the lengthened stump and trunk. Of the remaining patients—all with upper extremity lengthenings—all but one are “wearers” of their prostheses but not constantly.

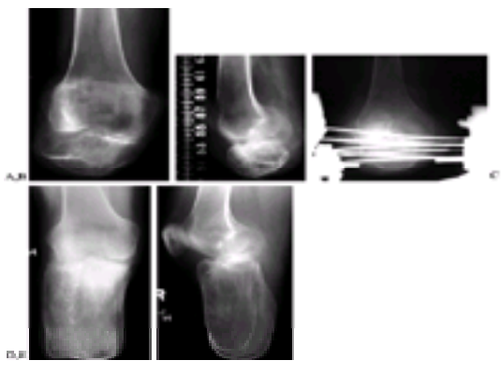

***Figure 174.18.*** AP (**A**) and lateral (**B**) radiographs of a short, below-knee stump prior to lengthening. Lengthening in progress with an Ilizarov device (**C**). AP (**D**) and lateral (**E**) radiographs showing the result of lengthening the stump. The patient was converted from a functional above-knee prosthesis to a below-knee prosthesis.

## A WORD ABOUT PROSTHESES

Modern prosthetic methods help make the surgeon look good. Of less importance today than previously is the exact placement of the surgical scar, the nature of the skin, or even such complications as a displaced fat pad. Further enhancing the activities of these amputees are recent advances in prosthetic feet utilizing newer space-age energy-storing materials that have the ability to absorb and store energy at the beginning of stance, only to redeliver the energy at toe-off (14,43,65). This results in a livelier feel to the limb, and it may enhance certain activities such as running. Amputees now compete in athletic activities previously felt to be beyond their capabilities. A cottage industry has arisen that caters to amputees who are high-grade athletes in such sports as running, swimming, and skiing. Young children growing up with such conversions have a better chance than ever to enjoy an enhanced physical and psychological environment (6,21).

## AUTHORS' PERSPECTIVE

This is a very rewarding group of patients to treat surgically. Patients with these complex problems are frequently beyond the capabilities of most community orthopaedic surgeons and hospitals and are cared for at specialized centers. The long-term physician–patient relationship that develops is gratifying. The children are otherwise healthy and their zest for living and full participation in life is admirable. Early medical intervention is important for them to develop early independence and to reach their maximal potential. It is a privilege to care for them.

## CHAPTER REFERENCES

Each reference is categorized according to the following scheme: *, classic article; #, review article; !, basic research article; and +, clinical results/outcome study.


+ 1. Abraham E, Pellicore RJ, Hamilton RC. Stump Overgrowth in Juvenile Amputees: *J Pediatr Orthop* 1986;6:66.

+ 2. Achterman C, Kalamchi A. Congenital Deficiency of the Fibula. *J Bone Joint Surgery Br* 1979;61:133.

* 3. Aitken GT. Amputation as a Treatment for Certain Lower-Extremity Congenital Anomalies. *J Bone Joint Surg Am* 1959;41:1267.

# 4. Albee F. *Orthopaedic and Reconstruction Surgery.* Philadelphia: WB Saunders, 1921:914.

# 5. Amstutz HC. The Morphology, Natural History, and Treatment of Proximal Femoral Focal Deficiencies. In: Aitken GT, ed. *Proximal Femoral Focal Deficiency. A Congenital Anomaly.* Washington, DC: National Academy of Sciences, 1969:50.

+ 6. Anderson L, Westin GW, Oppenheim WL. Syme Amputation in Children: Indications, Results, and Long-Term Follow-up. *J Pediatr Orthop* 1984;4:550.

+ 7. Bardenhauer. Reported by Rincheval. Ein Neues Operations Verfahren zur Behandlung Congenitaler Deffecte Eines Unterarm und Unterschenkelknochens. *Arch Klin Chir* 1894;48:802.

+ 8. Blum CE, Kalamchi A. Boyd Amputations in Children. *Clin Orthop* 1982;165:138.

+ 9. Bowen JR, Ortega K, Ray S, MacEwen GD. Spinal Deformities in Larsen's Syndrome. *Clin Orthop* 1985;197:159.

* 10. Boyd HB. Amputation of the Foot with Calcaneotibial Arthrodesis. *J Bone Joint Surg* 1939;21:997.

* 11. Braun H. Ueber Die Intrauterinen Frakturen der Tibia. *Arch Klin Chir* 1886;34:668.

+ 12. Brown FW. Construction of Knee Joint in Congenital Total Absence of the Tibia (Paraxial Hemimelia Tibia). *J Bone Joint Surg Am* 1965;47:695.

+ 13. Brown FW, Pohnert WH. Construction of a Knee Joint in Meromelia Tibia (Congenital Absence of the Tibia). A Fifteen Year Follow-up Study. *J Bone Joint Surg Am* 1972;54:1333.

+ 14. Burgess EM, Hittenberger DA, Forsgren SM, Lindh D. The Seattle Prosthetic Foot—A Design for Active Sports: Preliminary Studies. *Orthotic Prosthetics* 1983;37:25.

+ 15. Choi BI, Kumar SJ, Bowen RJ. Amputation or Limb Lengthening for Partial or Total Absence of the Fibula. *J Bone Joint Surg Am* 1990;72:1391.

! 16. Chung SMK, Riser WH. The Histological Characteristics of Congenital Coxa Vara. A Case Report of a Five Year Old Boy. *Clin Orthop* 1978;132:71.

* 17. Conn HR. A New Method for Operative Reduction for Congenital Luxation of the Patella. *J Bone Joint Surg Am* 1925;7:370.

+ 18. Coventry MB, Johnson EW. Congenital Absence of the Fibula. *J Bone Joint Surg Am* 1952;34:941.

+ 19. Curtis BH, Fisher RL. Congenital Hyperextension with Anterior Subluxation of the Knee. *J Bone Joint Surg Am* 1969;51:255.

+ 20. Dal Monte A, Donzelli O. Tibial Lengthening According to Ilizarov in Congenital Hypoplasia of the Leg. *J Pediatr Orthop* 1987;7:135.

+ 21. Davids JR, Meyer LC, Blackhurst DW. Operative Treatment of Bone Overgrowth in Children Who Have an Acquired or Congenital Amputation. *J Bone Joint Surg Am* 1995;77:1490.

+ 22. De Sanctis N, Razzano E, Scognamiglio R, Rega AN. Tibial Agenesis: A New Rationale in Management of Type II—Report of Three Cases with Long-Term Follow-Up. *J Pediatr Orthop* 1990;10:198.

# 23. Epps CH. Proximal Femoral Focal Deficiency. Current Concepts Review. *J Bone Joint Surg Am* 1983;65:867.

+ 24. Fixen JA, Lloyd-Roberts GC. The Natural History and Early Treatment of Proximal Femoral Dysplasia. *J Bone Joint Surg Br* 1984;56:86.

+ 25. Friscia DA, Moseley CF, Oppenheim WL. Rotational Osteotomy for Proximal Femoral Focal Deficiency. *J Bone Joint Surg Am* 1989;71:1386.

* 26. Goldthwait JR. Permanent Dislocation of the Patella. *Ann Surg* 1938;29:62.

+ 27. Green JP, Waugh W. Congenital Lateral Dislocation of the Patella. *J Bone Joint Surg Br* 1968;50:285.

+ 28. Gruca A. *Chirurgia Ortopedyczna*, PZWL. 1959;329.

# 29. Hall JE, Bochman D. The Surgical and Prosthetic Management of Proximal Femoral Focal Deficiency. In: Aiken GT, ed. *Proximal Femoral Focal Deficiency. A Congenital Abnormality*. Washington, DC: National Academy of Sciences, 1969:92.

+ 30. Herring JA, Barnhill B, Gaffney C. Syme Amputation. *J Bone Joint Surg Am* 1986;68:573.

+ 31. Hootnick D, Boyd NA, Fixsen JA, Lloyd-Roberts GC. The Natural History and Management of Congenital Short Tibia with Dysplasia or Absence of the Fibula. *J Bone Joint Surg Br* 1977;59:267.

+ 32. Hootnick DR, Packard DS, Levinsohnl EM, Cady RB. Soft Tissue Abnormalies in a Patient with Congenital Tibial Aplasia and Talo-calcaneal Synchrondrosis. *Teratology* 1987;36:153.

+ 33. Iwaya T, Sakaguchi R, Tsuyama N. The Treatment of Congenital Dislocation of the Knee with the Pavlic Harness. *Int Orthop* 1983;7:25.

+ 34. Johnson EJ, Audell R, Oppenheim WL. Congenital Dislocation of the Knee. *J Pediatr Orthop* 1987;7:194.

+ 35. Jones D, Barnes J, Lloyd-Roberts GC. Congenital Aplasia and Dysplasia of the Tibia with Intact Fibula. Classification and Management. *J Bone Joint Surg Br* 1978;60:31.

+ 36. Kalamchi A, Dawe RV. Congenital Deficiency of the Tibia. *J Bone Joint Surg Br* 1985;67:581.

+ 37. Katz MP, Grogono BJS, Soper KC. The Etiology and Treatment of Congenital Dislocation of the Knee. *J Bone Joint Surg Br* 1967;49:112.

# 38. King RE. Surgical Correction of Proximal Femoral Focal Deficiency. *Int Clin Info Bull* 1965;4:1.

+ 39. Kostuik JP, Gillespie R, Hall JE, Hubbard S. Van Nes Rotational Osteotomy for Treatment of Proximal Femoral Focal Deficiency and Congenital Short Femur. *J Bone Joint Surg Am* 1975;57:1039.

+ 40. Kritter AE. Tibial Rotation-plasty for Proximal Femoral Focal Deficiency. *J Bone Joint Surg Am* 1977;59:927.

+ 41. Kruger LM, Talbott RD. Amputation and Prosthesis as Definitive Treatment in Congenital Absence of the Fibula. *J Bone Joint Surg Am* 1961;43:625.

+ 42. Loder RT, Herring JA. Fibula Transfer for Congenital Absence of the Tibia: A Reassessment. *J Pediatr Orthop* 1987;7:8.

+ 43. Michael JW, Gailey RS, Bowker JH. New Developments in Recreational Protheses and Adaptive Devices for the Amputee. *Clin Orthop* 1990;256:64.

+ 44. Niebauer JJ, King DE. Congenital Dislocation of the Knee. *J Bone Joint Surg Am* 1960;42:207.

+ 45. Nogi J, MacEwen GD. Congential Dislocation of the Knee. *J Pediatr Orthop* 1982;2:509.

+ 46. Pappas AM. Congenital Abnormalities of the Femur and Related Lower Extremity Malformations: Classifications and Treatment. *J Pediatr Orthop* 1983;3:45.

# 47. Pappas AM, Hanawalt BJ, Anderson M. Congenital Defects of the Fibula. *Orthop Clin North Am* 1972;3: 187.

# 48. Parsch K. Congenital Dislocation of the Knee. In: de Pablos J, ed. *The Immature Knee*. Barcelona (Spain): Masson, 1998:11.

# 49. Pellicore RJ, Sciora J, Lambert CN, Hamilton RC. Incidence of Bone Overgrowth in Juvenile Amputee Population. *Int Clin Info Bull* 1974;13:1.

+ 50. Pfeil J, Marquardt E, Holtz T, et al. The Stump Capping Procedure to Prevent or Treat Terminal Osseous Overgrowth. *Prosthet Orthot Int* 1991;15:96.

+ 51. Pylkkanen PV. Coxa Vara Infantum. *Acta Orthop Scand* 1960;48:1.

+ 52. Schmidt TL, Kalamchi A. The Fate of the Capital Femoral Physis and Acetabular Development in Developmental Coxa Vara. *J Pediatr Orthop* 1982;2:534.

+ 53. Schoenecker PL, Capelli AN, Millar EA, et al. Congenital Longitudinal Deficiency of the Tibia. *J Bone Joint Surg Am* 1989;71:278.

+ 54. Serafin J. A New Operation for Congenital Absence of the Fibula. *J Bone Joint Surg Br* 1967;49:59.

+ 55. Simmons ED Jr, Ginsburg GM, Hall JE. Brown's Procedure for Congenital Absence of the Tibia Revisited. *J Pediatr Orthop* 1996;16:85.

+ 56. Stanisavljevic S, Zemenick G, Miller D. Congenital, Irreducible, Permanent Lateral Dislocation of the Patella. *Clin Orthop* 1976;116:190.

+ 57. Steel HH, Lin PS, Betz RR, et al. Iliofemoral Fusion for Proximal Femoral Focal Deficiency. *J Bone Joint Surg Am* 1987;69:837.

+ 58. Sulamaa M, Ryoppy S. Congenital Absence of the Tibia. *Acta Orthop Scand* 1964;34:337.

# 59. Tachdjian M. In: Wickland EH, ed. *Pediatric Orthopedics*, vol. 1, 2nd ed. Philadelphia: WB Saunders, 1990:626.

+ 60. Thomas IH, Williams PF. Operation for Congenital Absence of the Fibula. *J Bone Joint Surg Br* 1987;69:587.

+ 61. Torode IP, Gillespie R. Rotationplasty of the Lower Limb for Congenital Defects of the Femur. *J Bone Joint Surg Br* 1983;65:569.

+ 62. Torode IP, Gillespie R. The Classification and Treatment of Proximal Femoral Deficiencies. *Prosthet Orthot Int* 1991;15:117.

* 63. Van Nes CP. Rotationplasty for Congenital Defects of the Femur. Making Use of the Ankle of the Shortened Limb to Control the Knee Joint of a Prosthesis. *J Bone Joint Surg Br* 1950;32:12.

+ 64. Wagner H. Operative Lengthening of the Femur. *Clin Orthop* 1978;136:125.

+ 65. Wagner J, Sienko S, Supan T, Barth D. Motion Analysis of SACH vs. Flex Foot in Moderately Active Below-Knee Amputees. *Clin Prosthet Orthot* 1987;II:55.

# 66. Watts HG. Lengthening of Short Residual Limbs in Children. In: Herring JA, Birch JG, eds. *The Child with a Limb Deficiency.* Chicago: American Association of Orthopedic Surgeons, 1998:281.

+ 67. Weinstein JN, Kuo KN, Millar EA. Congenital Coxa Vara. A Retrospective Review. *J Pediatr Orthop* 1984;4:70.

+ 68. Westin GW, Sakai DN, Wood WL. Congenital Longitudinal Deficiency of the Fibula. *J Bone Joint Surg Am* 1976;58:492.

+ 69. Wiltse LL. Valgus Deformity of the Ankle: A Sequel to Acquired or Congenital Deformities of the Fibula. *J Bone Joint Surg Am* 1972;54:595.

+ 70. Wood WL, Zlotsky N, Westin GW. Congenital Absence of the Fibula: Treatment by Syme Amputation— Indications and Technique. *J Bone Joint Surgery Am* 1965;47:1159.

# CHAPTER 175

# PRINCIPLES OF AMPUTATION IN CHILDREN

*George T. Rab*

**G. T. Rab:** Department of Orthopaedics, University of California–Davis, Sacramento, California, 95817.

General Principles
Disorders Requiring Amputation in Children
Congenital Amputations
Traumatic Amputations
Burn Amputations
Amputations for Malignant Tumors
Specific Amputation Techniques for Children
Upper Extremity
Lower Extremity
Pitfalls and Complications
Chapter References

Amputations in children, while following many of the same principles as in adults, require special considerations and techniques because of continuing growth (1). This chapter reviews the general disorders requiring amputation and specific techniques useful in the skeletally immature patient.

## GENERAL PRINCIPLES

Skeletal growth and remodeling have an enormous effect on the ultimate success of a pediatric amputation, particularly in the younger child. For example, a 6-year-old child who has a successful above-knee amputation will have an extremely short stump at maturity because of loss of the distal femoral physis. In addition, stumps in children tend to become narrow and conical with growth, and this may subsequently lead to poor rotational control of a prosthesis.

A problem unique to pediatric amputations is terminal overgrowth. Overgrowth probably results from distal apposition of bone by the active periosteum, although the exact mechanism is not understood. Overgrowth is not dependent on the physis, and epiphysiodesis will not arrest it. Overgrowth never occurs after disarticulation. Terminal overgrowth is most severe before 6 years of age, and several revisions (three or more) may be required during the growing years. Overgrowth is not seen after about 12 years of age. The bones most likely to exhibit overgrowth are the humerus, fibula, and tibia. The exact incidence depends on the diagnostic categories of the reported series (congenital or traumatic). Many surgical remedies for overgrowth, such as capping, osteotomy, and surgical cross-union, have been attempted and discarded; the only effective treatment seems to be surgical revision of the pointed distal bone and its overlying bursa.

Emotional issues are generally far less troublesome for the pediatric amputee than for the adult amputee. The congenital amputee, born without the limb segment, accepts the condition as normal. Children who lose a limb traumatically generally rehabilitate quickly when a prosthesis is fitted. The main requirement of the child is function and durability, often with little concern for appearance or body image. However, parental acceptance of congenital or acquired amputations may be difficult. Feelings of guilt or inappropriate fears may require specialized counseling. Phantom limb and phantom pain, common in the adult amputee, are rare in children and generally absent in the congenital amputee.

The unique congenital disorders of children, special surgical techniques, and the special aspects of prosthetic fittings during growth have led to multidisciplinary child amputee clinics in centers throughout the country (6). The value and success of this approach has been documented, and the surgeon should consider referral to a regional center if one is available.

Standard surgical principles for amputation in the child include the following:

- Preserve the physis. Amputations through the metaphysis (such as above-knee or distal forearm level) or diaphysis are not recommended in children because of the progressive relative shortening of the residual limb. This is most critical in the femur, but it is applicable to other long bones as well.
- Disarticulate when possible. Disarticulation completely eliminates the problem of terminal overgrowth and subsequent revision surgery.
- Preserve stump shape. The pediatric amputation stump becomes conical with growth, so preservation of bony architecture such as a short segment of proximal fibula or the distal condyles of the humerus will assist in subsequent rotational control of the prosthesis.
- Be creative with soft-tissue coverage. Pediatric amputees rarely suffer from the wound-healing problems that commonly affect dysvascular adult amputees. Split-thickness skin can often be successfully used in the child to preserve an otherwise satisfactory stump without adequate skin coverage. The split-thickness skin graft can hypertrophy and become sufficiently strong to withstand the shear forces of prosthesis use.

## DISORDERS REQUIRING AMPUTATION IN CHILDREN

### CONGENITAL AMPUTATIONS

The child born with a single or multiple limb deficiency knows no other body image and has a remarkable ability to use a prosthesis to enhance function (5,8). Although the child automatically accepts the limb deficiency as normal, parents are often emotionally overwhelmed by depression and guilt. Early referral of the family to a regional child amputee clinic facilitates the counseling and acceptance by the family that is as necessary for a satisfactory outcome as orthopaedic or prosthetic management.

Many congenital amputees require no surgical conversion to a different level, but revision of stumps for terminal overgrowth is common, particularly for the humerus. Conversion of the upper extremity is rarely necessary. It is usually unnecessary to remove upper extremity nubbins, which the child may find useful for holding small objects or activating powered prostheses. Lower extremity conversion should be done to enhance prosthetic fitting if it facilitates ambulation, but durability and function, not cosmesis, are the goals. In general, useful deformities should be retained.

Prosthetic fitting of the upper extremity is done when the child is sitting independently, usually at about 6 months. Initial upper extremity terminal devices are passive, but they can be activated when grasping becomes important (1.5 to 2 years of age). Lower extremity prostheses are fitted when the child begins pulling to stand or cruising. A fixed knee with waistband suspension is used for above-knee amputees. Frequent length adjustments of the prosthesis will be required with growth. Children will discard upper-limb prostheses if they perceive them to be nonfunctional, and children with multiple limb deficiencies often reject prostheses because they interfere with the specialized movements required by daily living activities.

### TRAUMATIC AMPUTATIONS

While traumatic injuries can occur to any child, there is considerable evidence that the typical child with a traumatic amputation comes from a socially dysfunctional background. Most are boys from single-parent homes who are rebellious or running away from home. The psychological ability of these patients to undergo extensive treatment, revision of level, and rehabilitation is often very limited. Be sensitive to these psychosocial issues and obtain consultation early from appropriate professionals.

Set surgical and rehabilitation goals early. Often it is necessary to consider amputation at a more proximal level rather than subject the child to an emotionally draining series of heroic procedures to preserve length. Traumatic amputees may not tolerate multiple procedures or extensive rehabilitation efforts if they do not have the emotional base of support of a functioning family system.

Most traumatic amputations involve the lower extremity, and terminal overgrowth, particularly of the tibia, is often a problem. Many of these patients will wait until they can no longer tolerate their prosthesis before presenting for a revision of the overgrown stump, making smooth coordination of surgery and prosthetic fitting difficult.

A special problem arises when the traumatic amputee has lost soft tissue from a degloving injury proximal to the bony amputation level. Occasionally, it is appropriate to sacrifice bone length if considerations warrant it. However, other options include extensive use of split skin graft (much better tolerated in children than in adults), tissue expanders, or microvascular free tissue transfer. Skin traction (Fig. 175.1) over a 1- to 2-week period can add several centimeters of full-thickness circumferential skin and allows inspection of the open wound for appropriate care in the interim.

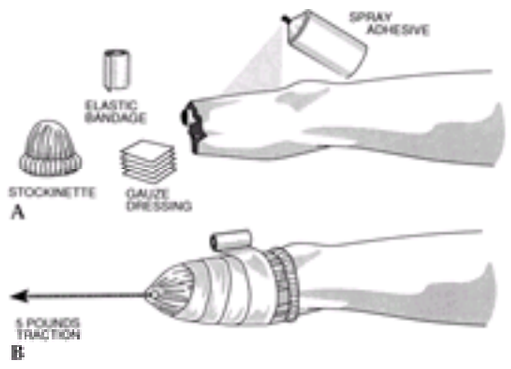


***Figure 175.1.*** Technique of application of skin traction after traumatic amputation.

If the wound allows it, a rigid plaster dressing permits rapid mobilization of the trauma patient, while minimizing pain and reducing the tendency to form contractures.

### BURN AMPUTATIONS

Burn amputations present a dilemma: how to obtain skin coverage while salvaging the most distal amputation level possible. Extensive use of split-thickness skin is often successful in the child. Stump breakdown is less of a problem in the child than in the adult. Attempt to preserve length if at all possible. Proximal joint stiffness seems to be more of a problem in burn amputees than in other amputees, and it should be addressed early and aggressively in the rehabilitation effort.

### AMPUTATIONS FOR MALIGNANT TUMORS

Limb salvage for malignant bone and soft-tissue tumors has become technically feasible in older children, but amputation is still often necessary for local control of tumors. Amputation also may be the treatment of choice for malignant tumors in children younger than 10 years because skeletal growth is disturbed by limb-sparing techniques. Amputation is usually indicated when a pathologic fracture occurs through a malignant lesion.

Amputation for a tumor requires the same technical care as any tumor procedure, with the goal being complete local control of the lesion for cure or palliation. Adjuvant chemotherapy or radiation therapy may be appropriate.

Because of the possibility of a short lifespan, and the added psychological stress to the family and child of adjuvant treatments in the addition to limb loss, these children should receive aggressive, early rehabilitation. Rigid dressings and immediate pylons can ease the immense emotional strain of the diagnosis and treatment. Use interim prostheses early, as chemotherapy and weight loss may postpone definitive fitting.

## SPECIFIC AMPUTATION TECHNIQUES FOR CHILDREN

The surgical techniques (e.g., handling of soft tissues, division of bones, and treatment of sectioned nerves) for amputations in children are generally the same as the techniques in adults (see Chapter 120, Chapter 121 and Chapter 122). However, amputations in skeletally immature patients present special considerations.

### UPPER EXTREMITY

#### *Above-Elbow Amputation*

Very short above-elbow amputations preserve the cosmetic contour of the shoulder girdle, but most children reject prosthetic fitting attempts. Mid-humerus and longer levels allow artificial limb function, but the stump will become thin and conical, so every attempt should be made to maintain its shape by preserving the distal humeral condyles if possible. Marquardt (7) has described a right-angle osteotomy 5 cm proximal to the end of the above-elbow stump to assist with prosthesis suspension and rotational control. Above-elbow amputees have a high incidence of terminal overgrowth, and parents should be warned of the likelihood of multiple revisions.

#### *Elbow Disarticulation*

Elbow disarticulation, while rarely performed, is an excellent amputation option for children. It eliminates the problem of overgrowth, and the preservation of the distal humeral condyles aids in prosthetic fitting. As puberty approaches, consider epiphysiodesis of the distal humeral epiphysis. This provides shortening of the amputated limb in comparison to the contralateral limb, allowing internal prosthetic elbow hinges.

#### *Below-Elbow Amputation*

Overgrowth is generally not a problem in the below-elbow stump. Preserve as much length as possible. Even short below-elbow stumps, distal to the biceps insertion on the radius, can aid with prosthetic stabilization and internal prosthetic control.

#### *Wrist Disarticulation*

Wrist disarticulation is an excellent amputation level in the child. It does not restrict pronation–supination, and overgrowth does not occur.

### LOWER EXTREMITY

The same techniques described for adult amputation for hemipelvectomy and hip disarticulation are applicable to children. As in adults, the prosthetic rejection rate after hemipelvectomy or hip disarticulation is high (see Chapter 120 and Chapter 122).

#### *Above-Knee Amputation*

Except in adolescents, the above-knee amputation level is a poor option for children because of loss of the distal femoral physis. The relative shortening of the leg with growth is dramatic and is worsened by the problem of terminal overgrowth.

#### *Knee Disarticulation*

The long stump, preservation of growth, muscle control, and lack of terminal overgrowth make knee disarticulation an ideal amputation level in the child. The patella may be retained. Suture the hamstrings to the cruciate stump and oversew the quadriceps tendon to them. This tenodesis preserves the strength of the muscles for walking and prevents their slippage around the distal bone end.

As maturity (bone age 10–11 years in girls and 12–13 years in boys) approaches, do a distal femoral epiphysiodesis to allow slight shortening, which facilitates prosthetic design using an internal hinge. Consult a prosthetist to determine the optimal amount of shortening for prosthetic fitting.

### *Below-Knee Amputation*

In adult amputees, preserving the knee joint enhances prosthetic ambulation potential, because above-knee amputees require more energy for prosthetic ambulation than do below-knee amputees. As most pediatric amputees will become geriatric amputees, it is desirable to salvage the knee joint in pediatric amputation surgery if possible. However, below-knee amputations have specific problems in children. Terminal overgrowth of the tibia and fibula are almost inevitable, and multiple revisions are the rule. Varus angulation in younger children occurs often and may be severe enough to require tibial osteotomy. The thin, conical stump makes rotational control difficult. Patellar-tendon-bearing prosthesis is a misnomer in the growing child, because the rapid change in length makes nearly all prostheses essentially end-bearing. For all of these reasons, ankle disarticulation is preferable to below-knee amputation if at all possible.

Surgical techniques for the below-knee amputations are the same for the child as for the adult, except that the skin flaps can be widely variable because the vascular supply in children is so rich. If possible, avoid scars directly over the end of the stump. Split-thickness skin is remarkably well tolerated in the child and may hypertrophy to give good results in maturity, even at this weight-bearing level. Preserve the fibula if at all possible, even if it is very short. The broad shape of the combined proximal tibia and fibula enhances rotational prosthetic control. Surgical cross-union and other techniques to prevent terminal overgrowth do not work and may lead to proximal migration of the fibula.

### *Ankle Disarticulation (Pediatric Syme Amputation)*

Although the classic Syme amputation is not done in children, the similar procedure of ankle disarticulation carries the same name by popular usage (Fig. 175.2). The pediatric Syme amputation, while having the benefits of a disarticulation, can be difficult to perform well because of the late problem of posterior heel-pad migration (2). Modern prosthetic technique allows fitting of bulbous stumps, which often taper with maturation. The main use of the Syme amputation is in congenital anomalies, especially fibular hemimelia and proximal femoral focal deficiency. I prefer the Boyd amputation, described in the next section, over the Syme.

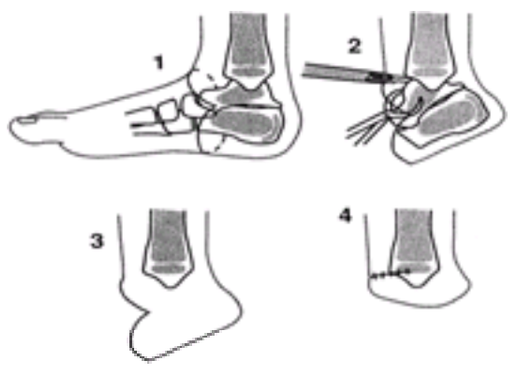


***Figure 175.2.*** Technique of pediatric Syme amputation. See text for details.

- Perform surgery with a pneumatic tourniquet. Between points just distal to the medial and lateral malleoli, connect an anterior incision dorsally and a plantar incision directly inferiorly (Fig. 175.2). Carry the incisions, without extensive subcutaneous undermining, straight down to bone, ligating vascular structures and tagging the anterior tibial and toe extensor tendons.
- Grab the talus with a towel clip and plantar-flex it to its extreme. With a scalpel directed toward the bone, carefully dissect out first the talus and then the os calcis in a similar manner. Avoiding any injury to the subcutaneous tissue is critical to the success of the operation. Ensure that the excision includes the cartilaginous apophysis of the posterior os calcis.
- Sever the Achilles tendon and allow it to retract into the leg. Trim the cartilaginous malleoli transversely to the level of the tibial plafond with a scalpel. Suture the anterior tibial and toe extensor tendons to the anterior edge of the heel pad to prevent posterior migration. Avoid the temptation to trim the dog-ears over the malleoli: They will remodel. Trimming may jeopardize the vascular supply to the heel flap.
- Close the skin and subcutaneous tissue with fine absorbable suture over a suction drain, and apply an above-knee rigid plaster dressing with molding over the femoral condyles.

### *Boyd Amputation*

The Boyd amputation, while similar to the pediatric Syme amputation, preserves the posterior os calcis and thus stabilizes the heel pad (Fig. 175.3) (3). Take care to place the heel in a plantigrade position and to divide the Achilles tendon, so that the heel does not drift into plantar flexion. If properly done, the Boyd produces an excellent end-bearing stump without the problem of terminal overgrowth. Boyd amputations produce a bulbous stump that may improve with growth.

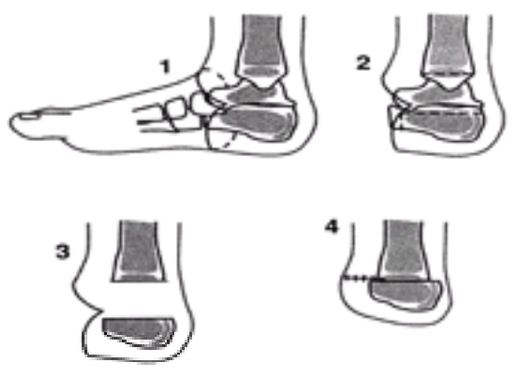


***Figure 175.3.*** Technique of Boyd amputation. See text for details.

- Make a skin incision in a fashion similar to that for the pediatric Syme amputation. Tagging the anterior tendons is unnecessary. Disarticulate the midfoot and forefoot from the talus and calcaneus. Grab the talus with a towel clip and carefully shell it out by plantar-flexing it and releasing soft-tissue attachments to the talus with a small scalpel. The subcutaneous tissue must not be damaged during this procedure.
- Shave the distal tibial articular surface transversely until the ossific nucleus of the distal tibial epiphysis is exposed, using a scalpel or fine osteotome (usually just held by hand; a mallet is unnecessary). Similarly, shave the superior surface of the os calcis down to cancellous bone, making it flat parallel to the weight-bearing surface of the heel. Shorten the anterior end of the os calcis. Sever the Achilles tendon and allow it to retract; this prevents late plantar flexion drift of the os calcis.
- Approximate the raw surfaces of the tibial epiphysis and os calcis while bringing the os calcis forward (anterior) slightly. Hold them together with one or more smooth Kirschner wires inserted through the heel pad. If the Boyd amputation is being combined with a knee fusion for proximal femoral focal deficiency, the heel can be fixed with a longitudinal Rush rod passed up the heel, tibial canal, and through the knee fusion site. Use bone graft from discarded bones if desired. Ensure that the weight-bearing surface of the heel is plantigrade; avoid even slight plantar flexion.
- Close the wound over a suction drain using fine absorbable stitches for all layers (I use 4-0 polyglycolic acid), and bend the pin(s) externally to avoid migration. Immobilize the limb in a spica cast or long-leg cast, depending on age.
- Remove the pins at 4–6 weeks and continue immobilization in a long-leg cast (molded over the femoral condyles) until radiographic union.

### *Foot Amputation*

Midfoot amputations at the Lisfranc or Chopart level are usually traumatic; this is not a desirable level for an elective amputation. In managing these injuries, sever the Achilles tendon to help prevent equinus contracture, and anchor extensor tendons, if available, to the anterior bony structures. Conversion to a higher-level (Boyd or pediatric Syme) amputation is often required (4).

Distal partial foot amputations, usually at a metatarsal level, are very well tolerated by children and require only a space-filling prosthetic shoe insert.

## PITFALLS AND COMPLICATIONS

The primary pitfalls and complications unique to the management of pediatric amputations come from the improper applications of adult amputation principles to the child. Adult principles fail to take into account the need to preserve epiphyses for normal growth, to preserve distal shape for prosthetic control, or to be creative with skin coverage so that length is not traded for simplicity of initial wound closure. The complication of terminal overgrowth following through-bone amputations in children is predictable and requires surgical revision at 2- to 4-year intervals until growth ceases. Painful neuromas and phantom pain are very rare and generally occur only when the amputation is acquired in adolescence. Management is the same as adults (see Chapter 120 and Chapter 121).

### CHAPTER REFERENCES

Each reference is categorized according to the following scheme: *, classic article; #, review article; !, basic research article; and +, clinical results/outcome study.


+ 1. Aiken GT. Surgical Amputation in Children. *J Bone Joint Surg Am* 1963;45:1735.

+ 2. Anderson L, Westin GW, Oppenheim WL. Syme Amputations in Children: Indications, Results, and Long-term Follow-up. *J Pediatr Orthop* 1984;4:550.

+ 3. Blum CE, Kalamchi A. Boyd Amputations in Children. *Clin Orthop* 1982;165:135.

+ 4. Green WB, Carey JM. Partial Foot Amputations in Children: A Comparison of the Several Types with the Syme Amputation. *J Bone Joint Surg Am* 1982;64:438.

# 5. Kaimchi A, ed. *Congenital Lower Limb Deficiencies.* New York: Springer-Verlag, 1989.

+ 6. Lambert CN, Hamilton RC, Tellicore RJ. The Juvenile Amputee Program: Its Social and Economic Value. A Follow-up Study after the Age of 21. *J Bone Joint Surg Am* 1969;51:1135.

# 7. Marquardt E. In: Bowker JH, Michael JW, eds. *Atlas of Limb Prosthetics: Surgical, Prosthetic, and Rehabilitation Principles.* St. Louis, MO: Mosby-Year Book, 1992:852.

# 8. Setoguchi Y, Posenfelder R. *The Limb-Deficient Child.* Springfield, IL: Charles C. Thomas, 1982.

# CHAPTER 176

# BONE AND JOINT INFECTIONS IN CHILDREN

*Paul P. Griffin*

**P. P. Griffin:** Department of Orthopaedic Education, Medical University of South Carolina, Greenville Memorial Hospital, Greenville, SC, 29690.

Acute Hematogenous Osteomyelitis
- Pathology
- Clinical Picture
- Radiographs
- Bone Imaging
- Diagnosis
- Treatment
- Surgical Treatment

Subacute Osteomyelitis
- Clinical Picture
- Diagnosis
- Treatment

Chronic Osteomyelitis
- Treatment

Special Conditions
- Sickle Cell Disease
- Chronic Recurrent Multifocal Osteomyelitis
- Infection in the Spine
- Osteomyelitis of the Pelvis

Septic Arthritis
- Bacteriology
- Pathophysiology
- Clinical Signs and Symptoms
- Diagnosis
- Differential Diagnosis
- Treatment

Tuberculous Arthritis
Chapter References

Septic arthritis and osteomyelitis in children are similar in their clinical presentation, diagnosis, and treatment. Both are usually secondary to bacteremia, but they may occur simultaneously, or the septic arthritis may be secondary to the osteomyelitis. When the two are present, the problems of diagnosis, treatment, and sequelae are greater than when either occurs alone. Although there are similarities between them, subtle differences occur in the physical findings, pathology, treatment, and prognosis. These differences make it important that they be viewed as separate problems.

## ACUTE HEMATOGENOUS OSTEOMYELITIS

Acute hematogenous osteomyelitis occurs in all age groups but is more common in children than in adults. The peak age for occurrence is 18 to 24 months, and the mean age about 6 years. Since the development of antibiotics, prognosis and results of treatment have dramatically improved so that acute hematogenous osteomyelitis should no longer be a life-threatening disease. Sequelae from the infection, if diagnosed early and treated appropriately, are minimal and chronic osteomyelitis is now rare. In older children, osteomyelitis is usually monostotic, but in the neonate, it is not uncommon to find multiple sites of infection.

### PATHOLOGY

Acute hematogenous osteomyelitis is a blood-borne infection that begins in the metaphysis of long bones and in the metaphyseal equivalent areas of the remainder of the skeleton. In 1911, Koch (25) demonstrated that the intravenous injection of bacteria frequently caused infection that began in the metaphyses of long bones near the physis. The metaphyseal location of infection is related to the vascular anatomy in the region, where the terminal nutrient vessels enter large sinusoidal vessels. The blood flow velocity in these vessels is slow, which encourages the bacteria to settle. In addition, the host defense mechanism is compromised because of the paucity of monocytic cells in the sinusoidal spaces.

More recently, Morrissy and Haynes (29) demonstrated in the rabbit model that the inflammatory response and bone destruction are slightly more distal to the physis than the area where the bacteria are found. It is in the area of this inflammatory response that the destruction of the bone trabeculae occurs as a response to the inflammatory process. By injuring the metaphyseal area of the rabbit's extremity just before intravenous injection of a bolus of bacteria, Morrissy found that the development of osteomyelitis was much more predictable than when there was no preceding injury. This correlates with the clinical finding that there is frequently a history of injury before the onset of osteomyelitis. Trauma may cause thrombosis of the sinusoidal vessels, and the thrombus serves as a culture medium for the bacterial growth.

The inflammatory process begins with edema and a cellular influx that will evolve into an abscess if the response is not altered by appropriate treatment. The purulent exudate spreads through the thin porous cortex of the metaphysis and elevates the periosteum, which causes subperiosteal reactive bone formation.

If the infection is untreated, the periosteum eventually is destroyed. Loss of the periosteum severely interferes with the healing of a fracture should one occur in the course of the disease. Before the development of antibiotics, the exudate, if it was not surgically released, would eventually drain through the skin, as described by Smith in 1874 (39). The elevation of the periosteum interrupts the periosteal blood supply to the cortex. Loss of the periosteal blood supply, along with vascular thrombosis caused by the pus passing through the haversian system, renders the cortex ischemic. The ischemic bone becomes a cortical sequestrum.

In children younger than 2 years of age, it is rare that a cortical sequestrum is produced. The reason for this is not clear, but it may be that the increased porosity of the metaphyseal cortex in the young child allows the exudate to exit through the metaphyseal cortex and decompresses the bone before it is forced through the haversian system of the diaphysis. Where the metaphysis of the long bone is partially intracapsular, as in the proximal femur, humerus, and ankle, secondary septic arthritis can result from the spontaneous decompression of the metaphysis.

In newborns, Trueta (42) demonstrated that metaphyseal vessels transverse the proximal femoral physis. These vessels passing from the metaphysis to the epiphysis apparently allow bacteria and the inflammatory process to cross the physis into the epiphysis. In this age group, the physis and the epiphysis can be severely damaged from the infection (Fig. 176.1). The vessels that cross the physis in the neonate progressively disappear beginning at 8 months of age (42). By 18 months, the epiphyseal and metaphyseal circulations are completely separate. Once the physis becomes a barrier to the metaphyseal vessels, inflammatory destruction of the physis and epiphysis is rare.

***Figure 176.1.*** **A:** Two-month-old infant with osteomyelitis in the right femur. Note the soft-tissue swelling. **B:** Three months later, there is widening of the metaphysis with cupping as well as resorption of the ossified epiphysis. **C:** Seven months later, the femur was already shorter than the opposite femur.

**CLINICAL PICTURE**

The presenting symptoms of osteomyelitis depend on the severity of the infection, its location, and the age of the patient. Approximately 30% of the patients with osteomyelitis are not ill and have few systemic symptoms. In patients who are not ill, the initial diagnosis is frequently in error, with the most common misdiagnosis being some type of malignancy. Except for an elevated sedimentation rate, which is almost always present, the laboratory data may be normal in this subgroup of patients.

Regardless of the severity of the infection, the most constant symptom is localized pain that causes the child to limp or not use the extremity. Swelling is usually present, and its extent reflects the severity of the infection. Local tenderness is always present. The more superficial the bone, the more easily this can be demonstrated. Why 30% of patients have a mild presentation of osteomyelitis is not clear. In some instances, it reflects the use of antibiotics to treat fever of undetermined etiology or other infections in other areas of the body. It may also reflect the prevalence of the use of antibiotics in the production of meat for consumption.

In acutely unaltered hematogenous osteomyelitis, the signs and symptoms are an elevated temperature in an anorexic, irritable child with significant pain and limitation of function of an extremity. Swelling, tenderness, and sometimes redness are common and impressive. In the infant, swelling may extend throughout the entire segment of the extremity (Fig. 176.2). Motion in the adjacent joint is limited and causes protective muscle spasm. Infants may present with pseudoparalysis, and older children will limp or refuse to walk if the lower extremity is affected. Pain with localized tenderness and swelling in the metaphysis of a long bone is sufficient to make a presumptive diagnosis of osteomyelitis in an ill child.

***Figure 176.2.*** Osteomyelitis of the humerus. Swelling extends both proximal and distal to the humerus.

The peripheral blood changes vary with the severity of the infection. The white blood cell count is usually elevated, with a shift to the left. If infection has been present for several days, the red blood cell count, hemoglobin, and hematocrit will be lower than normal. Sedimentation rate is almost always elevated. Blood cultures should always be taken when osteomyelitis is suspected; a positive culture is usually found in 60% to 65% of patients.

**RADIOGRAPHS**

Initial radiographic evidence of osteomyelitis is not in the bone but in the deep soft tissues, where swelling is the initial radiographic sign (Fig. 176.3). The swelling occurs within the first 2 days of symptoms and obliterates the lucent muscle planes progressively from the bone to the subcutaneous tissue. With this pattern of soft-tissue swelling, the diagnosis of osteomyelitis must be considered. When osteomyelitis is suspected, take radiographs with the appropriate exposure and anatomic position. It is important that both extremities have radiographs in the identical position for comparison. Ask the radiographic technician to use soft-tissue technique for the first radiograph and bone technique for a second. After 10 days of uncontrolled infection, radiolucent areas can be seen in the metaphysis. New periosteal bone is another late radiographic manifestation of osteomyelitis. This periosteal bone is a result of the elevation of the periosteum by the exudate that has passed through the cortex.

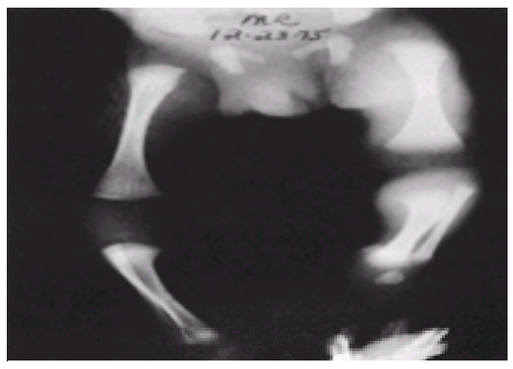

***Figure 176.3.*** Soft-tissue swelling of the left thigh in a neonate with osteomyelitis.

**BONE IMAGING**

The current standard in evaluating a patient for possible early osteomyelitis includes the option of imaging with radionuclides. An increase in uptake may be present in the area of infection as early as 24 hours after onset, but an increase in uptake is not diagnostic of osteomyelitis; it only reflects increased blood flow and osteoblastic activity, which may also occur in the presence of tumors and trauma. The value of the radionuclear studies is in localization of the area of infection and in identifying multiple sites of infection. The greatest help from a bone scan is in a patient who has been partially treated; when the clinical signs are poorly defined, as in infection of the pelvis or spine; and in managing a patient with subacute osteomyelitis. False-negative bone scans and gallium scans do occur (1). This is particularly true in osteomyelitis of the pelvis and in the neonate. It is probably related to the decreased blood flow from thrombosis. In the neonate, the bone scan is accurate in only 30% to 40% of patients (2). However, if both technetium and gallium scans are positive, the diagnosis is almost always infection. This is particularly helpful in patients with suspected osteomyelitis in the pelvis and will facilitate an early diagnosis (12). Because gallium has more radioactivity than technetium, it should not be used except in

very difficult cases (5). Computed tomography (CT) scan and magnetic resonance imaging (MRI) can be of benefit when the clinical facts are not sufficient to make the diagnosis. Mazur et al. (27) reported a sensitivity of 97% and a specificity of 92% for MRI. However, these imaging modalities are seldom needed and should be used only in difficult cases. Their routine use is not justified. A particularly valuable area for the use of CT is in osteomyelitis of the pelvis, in which early swelling can be identified as well as very early bone changes that are seldom seen on routine radiographs made early in the course of the infection.

**DIAGNOSIS**

The diagnosis of acute hematogenous osteomyelitis is made from the history, physical examination, and laboratory studies, and is confirmed by radiographs, bone scan, MRI if needed, and aspiration of the bone. Although 30% of the patients are not acutely ill, the remainder are ill and give a history of the fairly rapid onset of pain accompanied by swelling, localized tenderness, and impaired function such as a limp, refusal to walk, or pseudoparalysis. In those who are ill, the temperature is elevated, and the young child is irritable and anorexic. An exception is in the neonate who may not show an elevated temperature and who may have minimal laboratory changes. Neonates frequently present with failure to thrive. The neonate may be moribund and respond poorly to physical stimulation. Because of these differences, the diagnosis is frequently delayed until destruction of the physis and epiphysis has occurred. In the neonate who shows failure to thrive, osteomyelitis should be considered as a possible cause. The most dramatic physical finding in the neonate usually is swelling of an entire extremity (Fig. 176.2). Radiographs should show the characteristic soft-tissue swelling.

With these findings, always aspirate metaphysis in the area of maximum tenderness with a large-bore needle. Use fluoroscopic control to make certain that the needle enters the metaphysis near but not in the physis. If pus is not obtained from beneath the periosteum, push the needle through the cortex. Culture any aspirate, pus, or blood obtained. In addition to culturing the aspirate, culture the blood, nose, throat, and any skin lesions. Perform peripheral blood studies, including a white blood cell count, hematocrit, and sedimentation rate.

**TREATMENT**

Early effective treatment is the most important factor that influences the results in osteomyelitis (43). Two significant sequelae arise with osteomyelitis. One is physeal and epiphyseal destruction in the neonate and infant; the other is chronic osteomyelitis with a cortical sequestrum in the older child. Prevention of these two problems depends on early diagnosis and effective treatment. When these two sequelae are prevented, the results from treatment of osteomyelitis is uniformly good.

Conservative treatment with systemic antibiotics plus rest and protection of the involved limb is successful in most patients. Surgical treatment is indicated if pus is obtained on bone aspiration or if the response to conservative treatment is not favorable within 48 hours. A favorable response is one in which the temperature elevation rapidly diminishes, and the pain and swelling is decreased. If no abscess is present and the correct antibiotic is delivered in an adequate dose, pain, fever, and even swelling should be significantly reduced by 48 hours.

Start antibiotics immediately after the aspiration. The choice of antibiotics is made from the statistics concerning the most likely pathogen as influenced by age, presence of chronic disease, and any organisms found on the Gram stain. After culture results and sensitivities are known, change the antibiotic to a more appropriate one, if necessary.

In the neonate, *Staphylococcus aureus,* group B Streptococcus, and gram-negative bacilli are frequent pathogens. Therefore, in the neonate a semisynthetic penicillin will be effective for the staphylococcal and streptococcal infections, but an aminoglycoside should be added because of the possible presence of a gram-negative organism.

In the child between 2 months and 3 years of age who has not been vaccinated for *Haemophilus influenzae,* this organism can be the pathogen in as many as 10% of the cases. For these patients, cefuroxime may be the drug of choice because it is effective against Staphylococcus, Streptococcus, and *H. influenzae.* If *H. influenzae* is the pathogen, the possibility of secondary meningitis is always present.

After 3 years of age, Staphylococcus and Streptococcus organisms are the most common pathogens causing osteomyelitis. In this age group, a semisynthetic penicillin or a first-generation cephalosporin is the antibiotic of choice. Both give adequate bone levels and are effective. The advantage of the cephalosporins over semisynthetic penicillins is that if the treatment is changed from parenteral to oral antibiotics, the oral cephalosporins are more palatable than either cloxacillin or dicloxacillin. If the pathogen cultured is a methicillin-resistant *S. aureus,* vancomycin is the drug of choice.

Administer the initial antibiotics parenterally. After 2 or 3 days, if the response to treatment has been favorable with a decrease in the fever, pain, and swelling, oral antibiotics may be the preferred route of delivery in a selected group of patients. To use oral antibiotics, there should be a positive culture to ensure that the appropriate antibiotic is being administered. Compliance must be ensured by knowing the dependability of the patient and family. Tolerance of the oral antibiotic at the required dosage must be shown. The dose of antibiotic must be sufficient to give a bactericidal level as determined by measurement of the antibiotic level or by the dilution technique. In the dilution method, a 1 to 8 dilution at the peak and a 1 to 2 in the trough should be bactericidal. The required dose of a semisynthetic penicillin to obtain these bactericidal levels can be reduced by the addition of probenecid in children of 2 years and older (33).

Among the controversies that surround the treatment of osteomyelitis, the duration of the antibiotic treatment is the greatest. Dich et al. (10) reported data on a series of patients with staphylococcal osteomyelitis treated for less than 21 days compared with a group treated for more than 21 days. The rate of recurrence of development of chronic osteomyelitis was 19% in those treated for less than 21 days and only 2% in those treated for more than 21 days. I prefer to judge the need for extended treatment on the patient's response and on the presence of bone changes on routine radiographs. In all patients, antibiotics for 21 days should be the rule, extending this to 6 weeks or more in selected cases. In the patient who presents early and responds rapidly and in whom no abscess is demonstrated by aspiration, the shorter period of antibiotic therapy may be adequate. When pus is present or radiographic evidence of bone destruction or a sequestrum is present, give antibiotics for longer periods of time. Before antibiotics are discontinued, the sedimentation rate should be declining and near normal.

**SURGICAL TREATMENT**

There are three indications for surgical drainage: if pus is obtained on the initial aspiration, if the clinical response is not significant after 48 hours of antibiotics, or if there is radiographic evidence of bone destruction requiring removal of a metaphyseal sequestrum or granulation tissue. This latter indication is controversial, and it may be preferable to depend on conservative treatment before undertaking surgical curettage.

The surgical treatment is to remove pus, dead bone, and granulation tissue. Even though antibiotics may have been started, the material removed at surgery should always be cultured. Make the opening in the cortex small but large enough to insert a curet for removal of granulation tissue and to irrigate the metaphysis thoroughly. Place the hole near the physis in the area of maximum tenderness (Fig. 176.4), taking care to protect the physis. This is best done under fluoroscopy or by a marker placed at the level of the physis and confirmed by a radiograph.

***Figure 176.4.*** The surgical opening in this proximal humerus is too distal to the epiphysis. The patient had a recurrence of symptoms 2 months later.

Close the wound over drains. I prefer a suction drain. Controversy exists as to whether irrigation with saline is helpful. If it is done well, it should be of some benefit. Drains should be removed after 48 hours.

Protection of the extremity in a splint in a functional position is important to prevent a fracture. It usually increases the patient's comfort level as well. Unprotected weight bearing after surgical decompression or where there is extensive cortical destruction with or without a sequestrum may result in a fracture.

## SUBACUTE OSTEOMYELITIS

The host defense against pathogen virulence frequently results in a standoff, with local bone destruction that is limited compared with that of acute osteomyelitis. This results in a subacute infection. In 1969, King and Mayo (24) reported data on a series of patients diagnosed as having subacute osteomyelitis. In all of these patients, radiographic changes were seen at the time the patients were first evaluated. They described eight types of subacute osteomyelitis based on the radiographic appearance. Others have added to this clinical description (14,15).

### CLINICAL PICTURE

The onset of subacute osteomyelitis is insidious. The child is not ill, and little or no functional impairment is present. The most constant complaint is a localized pain that may have periods of exacerbation and remission. The pain frequently is exacerbated following a period of unusual activity. If the involvement is in a subcutaneous bone, local swelling is occasionally present. Like the pain, the swelling seems to increase and subside with activity. Symptoms may be present for weeks or months before the child is brought to a physician for evaluation. Laboratory studies may be normal, including the sedimentation rate, although it is elevated in some patients.

The diagnosis is made on the radiographic appearance of the lesion. The most common type of subacute osteomyelitis is a well-circumscribed lytic lesion with sclerotic borders, which is known as Brodie's abscess. Such lesions may be found in the metaphysis, epiphysis, and rarely, in the diaphysis. Metaphyseal lesions frequently extend across the physis and into the epiphysis (Fig. 176.5). Fortunately, this appears to be a response that does not injure the physis. A second type exhibits a lytic area in the cortex with little or no bone response. In others, the cortex becomes very sclerotic but without onion skin—like periosteal new bone. However, there is a subperiosteal new bone type that has an onion skin appearance. Rarely, the involvement in the metaphysis may be diffuse without a clear border.




***Figure 176.5.*** Brodie's abscess extended from the metaphysis to the epiphysis. Normal growth continued after curettage of the lesion.

### DIAGNOSIS

As many as 50% of patients with subacute osteomyelitis have an initial incorrect diagnosis. Subacute osteomyelitis should be the diagnosis until proven otherwise if there is local swelling, with local pain, and one of the classic radiographic appearances, along with an elevated sedimentation rate. Bone scans are almost always positive, although they are not diagnostic. MRI is frequently the most useful imaging and should be used in those with a destructive lesion or in any patient with radiographic changes suggestive of a malignancy.

### TREATMENT

The initial step in treatment of the lytic type is surgery. If the diagnosis is established by the pathology, both gross and microscopic, curet and culture the granulation tissue present in the lesion. Start antibiotics immediately after surgery. In most of these lesions, *S. aureus* is the pathogen; therefore, a semisynthetic penicillin or a first-generation cephalosporin is the drug of choice. If the diagnosis is made without biopsy, some lesions will respond to antibiotics without surgery (35). If the lesion is in the epiphysis and a surgical approach is potentially harmful, the initial treatment should be antibiotics for several weeks (Fig. 176.6). However, most epiphyseal lesions can be drained without harm to the articular surface or to the physis if the surgical approach is appropriately planned (15). In the subperiosteal, cortical, sclerotic, and diffuse metaphyseal types, surgical treatment has less to offer. In these patients, the clinical picture is more likely to resemble a neoplasm, and a surgical biopsy will be necessary for diagnosis. These types usually respond to adequate antibiotic therapy.

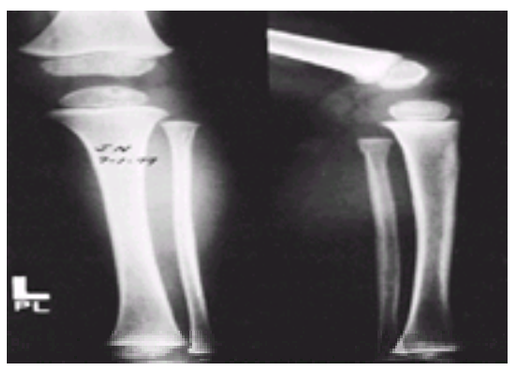

***Figure 176.6.*** Lesion in the proximal epiphysis of the tibia.

## CHRONIC OSTEOMYELITIS

Chronic osteomyelitis is seen much less frequently today than before the antibiotic era. It usually results from a delay in diagnosis or inadequate treatment. It is seen more often today in North America in immigrants from underdeveloped countries. The delay in controlling the infection results in the formation of a cortical sequestrum, which is due to ischemia from the cortical, intramedullary, and subperiosteal spread of pus. The antibiotic cannot adequately reach the bacteria located within dead bone, so surgical removal of the infected tissue must be done.

### TREATMENT

In chronic osteomyelitis, start antibiotics immediately after deep tissue cultures of the wound are made. Continue the antibiotics for an extended period of time until the sedimentation rate is normal and the wound is benign. The indication for surgical treatment in chronic osteomyelitis is the presence of local pain and swelling, with or without drainage, in a bone with an area of lysis or a sequestrum, or both. Removal of the sequestrum and granulation tissue is the goal of the surgical exploration. Care must be taken not to jeopardize the integrity of the diaphysis by excessive removal of bone. The sequestrum should be removed, preferably after the involucrum is mature. Wide saucerization of the cortex should not be done because bone regeneration in chronic osteomyelitis may be severely limited. This is particularly true when there is no involucrum.

The removal of all dead tissue is the first step in surgical treatment. If possible, the wound should be closed and drains placed in the wound. Suction drainage and irrigation should be done for several days postoperatively. An antibiotic irrigation solution may be preferable to saline. The insertion of antibiotic-impregnated

methylmethacralate beads in the defect after debridement should be considered in the patient who has had repeated surgical procedures. The absence of an involucrum indicates an inadequate periosteum. Periosteal healing is then unlikely. In such a patient, a cancellous bone graft should be placed in the defect after there is healing from the initial debridement and the infection is under control. If the bone cannot be covered by local skin, a local muscle should be transferred to cover the defect. In large uncovered areas, a myocutaneous flap may be required to cover the bone and fill the defect adequately (41). In some locations, a free microvascularized flap may be necessary. Good full-thickness and soft-tissue skin coverage will accelerate and improve the quality of healing (see Chapter 8 and Chapter 35). After surgical debridement, protect the extremity to prevent pathologic fracture.

## SPECIAL CONDITIONS

### SICKLE CELL DISEASE

In the patient with sickle cell disease, differentiation between an infarct and acute osteomyelitis can be difficult (23,26,31,32). Both produce fever, bone pain, tenderness, erythema, and swelling. An increase in the white cell count and an elevated sedimentation rate are also present. The presence of swelling and tenderness in the shaft of a long bone is more typical of osteomyelitis in a patient with sickle cell disease, whereas in a patient who does not have sickle cell disease, osteomyelitis has its onset in the metaphysis.

To distinguish an infarct from infection requires an astute evaluation of the degree of clinical signs and symptoms. The bone should be aspirated and cultured, and blood cultures should made if there is a strong possibility of infection. The pathogen in sickle cell osteomyelitis may be *S. aureus,* salmonella, or any other organism. Staphylococcus and salmonella are the two most common organisms cultured in osteomyelitis in a patient with sickle cell disease. In 15 patients with sickle cell disease with osteomyelitis, Epps et al. (11) reported that *S. aureus* was culture in eight, salmonella in six, and *Proteus mirabilis* in one.

Treatment of osteomyelitis is surgical (11) with the addition of antibiotics for 6 weeks. Chronic osteomyelitis in the patient with sickle cell disease is more common than in those who do not have sickle cell disease. Repeat surgical debridement may be needed in those patients who are not free of symptoms by 6 weeks. As in all patients with sickle cell disease, good hydration and transfusion are preoperative requirements.

### CHRONIC RECURRENT MULTIFOCAL OSTEOMYELITIS

This is a rare condition of unknown etiology. It is more common in Europe than in the United States. In some reports, many patients have pustulosis palmaris et plantaris as well as recurrent multiple osteomyelitis (3,6,22). However, Yu and associates (45) reported on seven patients, none of whom had pustulosis palmaris et plantaris. Benhamou and associates (3) found some patients who in addition to pustulosis palmaris et plantaris also had Crohn's disease and some others had polyarthritis. They suggested that this condition was linked with seronegative spondyloarthritis.

The onset of chronic recurrent multifocal osteomyelitis is gradual and usually without significant temperature elevation. Pain is commonly reported. Lesions are most common in the femur, tibia, and spine, but other bones may be involved. There may be swelling and erythema over the lesions. Pressure over the involved part is painful, and if the spine is affected, flexion and extension and pressure over the involved vertebra causes pain.

The diagnosis is one of exclusion. Radiographs may show sclerosis, hyperostosis, or lysis. The radiographic changes have the appearance of bacterial osteomyelitis or of a sarcoma. Peripheral blood changes are minimal. A technetium-99 scan may show increased uptake or may be normal. Changes of inflammation suggestive of osteomyelitis are seen on biopsy material. Cultures of the lesions are negative.

The symptoms usually last between 1 and 4 years. When the patient has polyarthritis, symptoms generally last longer. Vertebra plana may result if a vertebra is involved. The height of the vertebra is not restored with time (45). Carr et al. (6) reported one patient with progressive kyphosis that required spinal fusion. Treatment is symptomatic with a nonsteroidal anti-inflammatory drug. Carr et al. (6) found that antibiotics may be helpful, and I have used cefalexin in one patient during recurrent episodes with possible benefits; however, antibiotics are not generally recommended.

### INFECTION IN THE SPINE

The meaning of the “discitis” has been a source of confusion for many years. In 1964, Menelaus (28) gave credit to Eric Price for coining the word discitis for an infection of the disc space with little or no bone involvement. For many years, this remained a common concept of spinal infection in children. However, with the use of tomography it became apparent that osteomyelitis of the adjacent vertebrae always was present when the disc was infection. Ring et al. (34) labeled this condition pyogenic infectious spondylitis. The nomenclature for discitis from a bacterial infection should no longer be confusing. Pyogenic infectious spondylitis is not common but must be considered as a possible cause of back pain in a child and particularly in the very young child. The most frequent etiologic agent cultured is staphylococcus; however, streptococcus and, to a lesser extent, salmonella may be cultured (19,37).

The gradual onset of back pain is the most consistent symptom. Small children refuse to sit or walk. Leg pain and weakness may cause the child to not walk or to limp. The classic picture is a child sitting with the spine in extension and hands resting on the bed behind the trunk for support. Percussion over the affected vertebrae is painful even before changes on routine radiographs are present. When the clinical picture of bacterial spondylitis is present, blood cultures should be done. Hoffer et al. (19) recommended computer-guided biopsy if cultures were negative. I believe with the predominate bacteria known to cause this condition being staphylococcus and streptococcus that it is reasonable to assume that one of these organisms is present and to treat the child with the appropriate antibiotic. A response should be noted within 3 days, and if not, an additional antibiotic added or biopsy done. Patients who are not treated with antibiotics do recover when the spine is immobilized; however, this approach may prolong the time to recovery and can increase the need for surgical drainage (34). I prefer to administer an antibiotic for the infection and to provide symptomatic treatment to relieve back pain.

### OSTEOMYELITIS OF THE PELVIS

Infection of the pelvis is rare, and the diagnosis is difficult (18). The ilium is the most frequent pelvic bone affected, but the ischium and pubis may be involved. Pain about the hip and a limp or refusal to walk are commonly reported. Most patients have a fever. The white cell count is elevated, as is the sedimentation rate.

Symptoms may be localized to the hip, the abdomen, the buttocks or low back, with sciatica-like symptoms. The location of the infection determines the location of pain. The hip is the most common area for pain, and when this is the presentation, an infection has to be considered. This pain occurs when the ilium is involved near the innominate bone, and osteomyelitis near the acetabulum can decompress in the hip joint and infect the joint. Buttock pain occurs if the ilium outer table is eroded, usually near the sacroiliac joint. Decompression through the inner wall may cause sciatica-like symptoms if the pus goes into the true pelvis and irritates the sciatic nerve or the pus may ascend and cause abdominal pain.

The diagnosis of osteomyelitis is made from the laboratory changes, the physical examination, and the use of the bone scan, CT, and MRI (30,40). Initial imaging with any of these modalities may be normal early in the course of the disease, but all tests will become positive eventually. The MRI will ordinarily be the first to show the swelling and bone involvement. It can distinguish soft-tissue swelling and show whether it is from bone or has a nonosseous origin. The MRI cannot differentiate infection from a tumor or infarction (40).

Physical evaluation includes observing the gait if the patient can walk. Perform range-of-motion examination of the hip gently. Passive motion of the infected hip is usually quite painful and limited whereas in infection of the pelvis more motion is present and less painful. Pressure on the pelvis is painful. Pressure over the buttock is painful if the ilium has decompressed through the outer table.

Administer appropriate antibiotics parenterally then orally. If treatment is started before an extraosseous abscess develops, antibiotic treatment is the only treatment required. When an abscess is present, surgical drainage is appropriate. Drain gluteal abscess posterior through the gluteus maximus, and a pelvic abscess through the abdomen but stay retroperitoneally. Chronic osteomyelitis of the pelvis is very rare, and most patients recover without residual problems (30).

## SEPTIC ARTHRITIS

Septic arthritis occurs in all age groups but primarily affects the very young child. The peak incidence is between the age of 1 and 2 years of age (16). In neonates and other infants, the hip is the joint most commonly affected, but the knee is more commonly involved in older children. Infection in the hip joint is frequently secondary to osteomyelitis of the proximal femur, particularly in the infant. Septic arthritis of the shoulder and ankle may be secondary to spontaneous decompression of pus from the proximal humerus and distal fibula, respectively. Residual effects from septic arthritis are related to a delay in diagnosis and treatment, and to the presence of osteomyelitis.

## BACTERIOLOGY

Over the last 20 years, the pathogens common in septic arthritis have changed. In the 1950s and 1960s, *S. aureus* was the organism most commonly cultured from septic joints. In a 1967 study of 116 infected joints in children with a mean age of 3 years, *S. aureus* was the most frequent organism cultured and 8% had *H. influenzae* (14). In the 1970s, the incidence of *H. influenzae* increased and was the most common organism cultured in children younger than 4 years of age (17). Jackson and Nelson (20) reported *S. aureus* in 30%, group B streptococcus in 21%, and gram-negative organisms in 28% in children aged 1 month to 5 years. However, in the infant younger than 3 months of age who acquires a joint infection while in the hospital, staphylococcus is the most common organism cultured. Approximately two thirds of hospital-acquired joint infections were found by Dan (8) to have *S. aureus* and one fifth Candida species as the pathogen. Since the development of the vaccine for *H. influenzae,* this organism is rarely the pathogen in septic arthritis.

## PATHOPHYSIOLOGY

Septic arthritis in children is usually acquired by a hematogenous route. This may be either direct inoculation into the synovium or secondary to hematogenous osteomyelitis that decompresses into the joint. Osteomyelitis with secondary septic arthritis of the hip is common in the neonate but can occur in children of all ages. The ankle and shoulder, where the metaphysis may be partially intracapsular, occasionally is infected secondary to osteomyelitis. In the infant, in whom there are vessels that transverse the physis from the metaphysis to the epiphysis, the infection can spread from the metaphysis to the epiphysis and the adjacent joint. Bacteria are deposited in the synovium, and an inflammatory reaction develops. The inflamed synovium allows blood products and bacteria to enter the synovial fluid, including large numbers of leukocytes. The inflamed synovium, the white blood cells, and the bacteria contribute to the enzymatic destruction of the articular cartilage by the release of collagenase and proteases. Even the chondrocyte may contribute to cartilage destruction; Jasin (21) has shown that the chondrocyte may be stimulated to release chondrolytic enzymes by the action of either bacterial liposaccharide or interleukin 1 (IL-I). The depletion of glycoaminoglycans in the cartilage matrix begins rapidly. Within 24 hours there is a significant loss. The loss of collagen follows (38). It is because of the multiple sources of these enzymes (bacteria, white blood cells, and synovial cells) that antibiotics alone cannot prevent destruction of the cartilage. Thorough cleansing of the joint is essential to successful treatment.

## CLINICAL SIGNS AND SYMPTOMS

The onset of septic arthritis is characterized by the rapid development of joint pain and a fever of 100° to 104°F (38° to 40°C). Although the rapid onset of pain is variable, it is usually severe within 24 to 48 hours so that the child refuses to use the extremity. Irritability and malaise may precede the onset of pain. Pseudoparalysis is common in the very young. The physical examination is dramatic in the severity of the limitation of motion of the affected joint. Even with the gentlest attempt to move the extremity passively, there is extreme pain and spasm, and little motion is obtained. The joint is swollen, hot, and globally tender. The affected joint assumes a resting position that maximizes the capsular volume to reduce the tension in the joint. The hip is held flexed abducted and externally rotated. The most comfortable position for most other joints is some degree of flexion. In the neonate, minimal spontaneous movement, swelling of the joints, slight fever, and irritability may be the only changes present.

## DIAGNOSIS

The clinical features of acute septic arthritis are usually, but not always, dramatic enough to exclude other diagnoses. However, always aspirate a joint when infection is considered to be a possibility, even when the child does not have the classic severe pain of septic arthritis. Infected joint fluid is cloudy, and mucin is diminished. A drop of fluid rubbed between the thumb and a finger will feel watery and will not string as the opposed fingers are separated. The most important studies of the fluid are a culture, Gram stain, white blood cell count, and differential. If sufficient fluid is available, other valuable measurements that should be obtained are glucose and lactic acid levels. The white cell count is usually between 50,000 and 200,000. More important, the differential is greater than 90% polymorphonuclear leukocytes. A joint fluid sugar of 50 mg/dl less than the blood sugar is common. In nongonococcal arthritis, the lactic acid level is elevated. It is important that the specimen for cell count is anticoagulated; if this is not done, the fluid will quickly coagulate. This makes the cell count incorrect. Aspiration of the hip and shoulder should be done under fluoroscopic control. If no fluid is aspirated, injection of a radiopaque dye into the joint will confirm that the needle is intra-articular.

In addition to the joint aspiration, peripheral blood studies should be done to include a complete blood count and sedimentation rate. The white blood cell count is generally elevated with an increase in polymorphonuclear leukocytes, and the sedimentation rate is elevated. If the child is seriously ill and the infection present for several days, the erythrocyte count and hematocrit will be low.

Counterimmunoelectrophoresis of the synovial fluid can be helpful when the cultures are negative; it is particularly helpful when there has been partial treatment by antibiotics. This test can identify the presence of *H. influenzae, Streptococcus pneumoniae,* and meningococcus (9). A gallium scan has some use when the diagnosis is difficult. Bowman et al. (5) used gallium and reported accuracy in diagnosis of 91% in 34 patients with septic arthritis. The radiation dose from gallium is higher than from technetium, and it should be used only in difficult cases.

## DIFFERENTIAL DIAGNOSIS

In the patient with the classic onset of fever, severe joint pain, and limited motion, there is little to confuse the diagnosis. However, conditions such as toxic synovitis, monarticular rheumatoid arthritis, and osteomyelitis can at times present a diagnostic problem. The child with toxic synovitis can usually be excluded by the clinical findings. The child is not ill, pain is not severe, and motion is only slightly limited. Acute-onset monoarticular rheumatoid arthritis may have many of the features of sepsis, and in such a patient, joint fluid analysis may be the only way to differentiate between these two diseases early in the course of the disease. In rheumatoid arthritis, pain can be severe, motion very limited, and the child febrile and ill. The synovial fluid may have as many as 70,000 cells, but on the differential, there will be less than 80% polymorphonucleocytes, unlike the 90% to 100% found in septic arthritis. In rheumatoid arthritis, the joint sugar level is similar to that in the blood sugar. The mucin in rheumatoid synovial fluid is diminished, as it is in septic fluid. The leukocyte differential and the glucose levels may be the only differentiating feature between these two diseases.

Osteomyelitis can be difficult to differentiate from septic arthritis. In both conditions, the child may be febrile and have the peripheral blood changes of infection. In both conditions, the patient exhibits limited joint motion, but in osteomyelitis, the adjacent joint will generally have a moderate range of motion if the examiner is gentle and protects the extremity from sudden motion. By careful palpation, tenderness will be found over the infected metaphysis and not the joint. Swelling is also different. In osteomyelitis, the swelling begins over the metaphysis and spreads to include much of the extremity segment (Fig. 176.2). The adjacent joint may be swollen from a sympathetic effusion, but it is not particularly tender. The swelling in septic arthritis is confined to the intracapsular space. If there is swelling over the bone and also joint effusion, it is important to aspirate both the joint and the bone, with aspiration first at the most unlikely site for the infection, followed by aspiration of the suspected site. Radiographs will show the typical deep soft-tissue swelling if osteomyelitis is present. When soft-tissue swelling is present in the thigh and the hip joint space is wide on the radiograph, the patient has osteomyelitis plus a secondary septic arthritis until proven otherwise (Fig. 176.7).

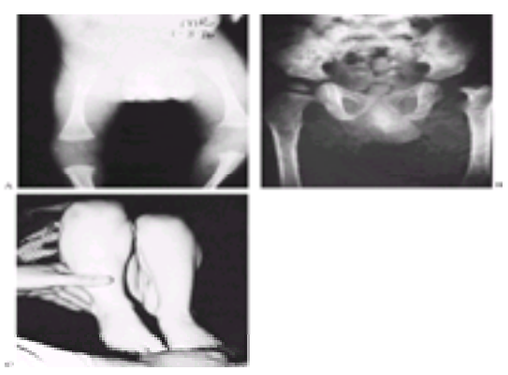

***Figure 176.7.*** **A:** Soft-tissue swelling in a neonate. Notice the hip joint space. **B:** Two years later, the metaphysis is subluxated, the acetabulum is dysplastic, and there is no ossified femoral head. **C:** This image demonstrates the shortening of the left femur.

## TREATMENT

The objectives of treatment are to sterilize the joint, evacuate the debris associated with infection, relieve pain, and prevent deformity. Since the discovery of antibiotics,

controversy has arisen as to the most effective way to cleanse the joint of the products of infection. This has centered mainly on whether or not aspiration and irrigation are as effective as arthrotomy and irrigation. There are no adequate studies to evaluate the superiority of one method over the other, and because of the many variables, it is unlikely that a comparative study will ever be done.

What we do know is that early diagnosis and treatment with the appropriate antibiotic are the most important aspects of treatment (17). There is little argument that the hip is special and needs to be decompressed to prevent dislocation as well as a tamponade of the circulation to the femoral head. Arthrotomy is necessary for the hip to be cleansed adequately of the debris and intra-articular pressure relieved. Intermittent or continuous irrigation for 48 to 72 hours through catheters has been used in the past (16). There is little proof that it affects the outcome, but it is not to be condemned. However, antibiotic solution should not be used for irrigation. Antibiotics reach the synovium and synovial fluid sufficiently to deliver the necessary bactericidal concentration of the antibiotic into the joint. If postarthrotomy intermittent irrigation is used, extreme care to maintain sterile technique is important to prevent a nosocomial infection through the irrigation system. I no longer use postarthrotomy irrigation.

The first step in treatment of septic arthritis is aspiration of the joint to confirm the diagnosis. If pus is obtained, the joint should be irrigated with saline until the irrigation fluid returns clear. The hip and shoulder should be immediately opened and irrigated after aspiration and joint fluid analysis confirms the diagnosis. In other joints, if infection has been present for 4 or 5 days, the large amount of fibrin and debris that has accumulated may be difficult to remove by needle. In these patients, arthrotomy or irrigation by arthroscopy is the preferred method of joint debridement. I do not recommend arthroscopic irrigation because I believe the motions of the arthroscope necessary to remove the debris adequately irritates the inflamed synovium. I have seen several failures when this technique is used in a joint that by all rights should have had a successful outcome.

***Decompression/Debridement of the Hip***

I prefer the anterior approach to the hip to the posterior approach. In the anterior approach the posterior superior epiphyses vessels are less likely to be damaged, and the anterior arthrotomy does not leave a posterior defect in the capsule where the hip can dislocate.

- Make an anterior approach (see Chapter 3).
- Then make a 1 cm capsulotomy through which the joint is irrigated.
- I do not drill the femoral neck. In the infant, only a small portion of the neck within the capsule is ossified, so drilling is likely to injure the physis. If the septic hip is secondary to osteomyelitis, the femoral neck has already decompressed itself.
- Although I no longer use irrigation postoperatively, I do leave a drain near the opening in the capsule and remove it at 48 hours.
- Take a synovial biopsy for culture and close the skin. Synovial tissue cultures may be positive when the aspiration is negative.

After either the aspiration, arthroscopic drainage, or arthrotomy, I place the extremity in balance suspension traction for several days in the older child. If properly applied, traction protects the joint and relieves pain, separates the joint surfaces, and allows motion. Protective use of the joint can begin shortly after the joint is no longer painful. If the hip appears unstable or it is dislocated, it should be held in the reduced position with a spica cast. Salter et al. (36) has shown that in the rabbit, continuous passive motion is beneficial to the articular cartilage. Its value in septic arthritis in children has not been established, however.

Immediately after the aspiration, the appropriate systemic parenteral antibiotic should be started. It should be one that is effective for the most likely pathogen. Age, environment, and the Gram stain determine the initial choice of antibiotic. In the neonate, multiple organisms are not uncommon. A semisynthetic penicillin for the staphylococci and streptococci plus an aminoglycoside for the gram-negative organisms should be used in the neonate. Between the age of 1 month and 5 years, *H. Influenzae* is as common as staphylococcus and streptococcus infection if the child has not been vaccinated for *H. influenzae.* In this age group, cefuroxime or ceftriaxone may be the drug of choice because they are effective against both the gram-positive cocci and *H. influenzae.* After age 5 years, a semisynthetic penicillin or a first-generation cephalosporin is the drug of choice. Both are effective against streptococcus and staphylococcus organisms. The oral cephalosporins taste better than the oral synthetic penicillin, and for that reason, a cephalosporin may be preferable.

The use of oral antibiotics after 2 to 3 days of intravenous antibiotics can be effective in selected patients. The prerequisite for the use of oral treatment is a rapid clinical response to treatment, a positive culture, an available laboratory to measure serum levels, a reliable family, and proof that the child can tolerate the oral antibiotic. A positive culture is beneficial for proving the effectiveness of the blood level of the agent being used. The dosage has to be sufficient to give a peak serum bactericidal level at a dilution of between 1 to 8 and 1 to 16, and a dilution of 1 to 2 at the trough or a bactericidal concentration present in the trough for those antibiotics that have a bactericidal level. In a patient who does not have a positive culture but who has shown a rapid response to the parenteral antibiotic, it is not unreasonable to continue treatment with an oral antibiotic. The duration for antibiotic treatment is not absolute. In uncomplicated cases without osteomyelitis, 2 to 3 weeks should be sufficient. Be sure the patient is symptomatically doing well and that the sedimentation rate is reduced before discontinuing the antibiotic.

The residual effects from septic arthritis diagnosed and treated within 2 days and in some cases even longer are minimal. In the infant, a delay in diagnosis and treatment is more likely than in older children. The hip is more commonly affected in the infant, and osteomyelitis with secondary septic arthritis is more common in the proximal femur. Until the physis becomes a barrier to the metaphyseal vessels crossing into the epiphysis, the physis and epiphysis are in jeopardy. This anatomic fact and the frequent delay in diagnosis in the infant are the reasons that the poorest results from septic arthritis are in infants and in the hip. The physis and the epiphysis may both be completely destroyed by osteomyelitis with associated septic arthritis. Spontaneous decompression of the pus into the hip joint may cause damage to the epiphyseal blood supply by tamponade, and the intracapsular pressure may cause a dislocation of the hip. In my report in 1967, 15% of infected hips had a poor result and 75% of poor results were patients with septic arthritis of the hip secondary to osteomyelitis (16).

Significant sequelae to septic arthritis are rare except in the hip, where delay in treatment of the infant has allowed the partial or complete destruction of the physis and epiphysis. If the hip is dislocated, closed reduction is superior to open reduction (44). When the residual femoral head is inadequate to be effective as a functioning hip; attempts at surgical reconstruction should be avoided. Following total destruction of the head and neck, trochanteric arthroplasty has been done in an attempt to improve function and to maintain length (7). This procedure has many problems. With time, dislocation gradually occurs. A varus osteotomy delays the subluxation, but with time, the varus gradually straightens and subluxation occurs (13). Betz et al. (4) reported that the long-term functional results in the patient in whom the head is destroyed is better if reconstruction is not attempted.

If coxa vara, coxa valga, or acetabular dysplasia is the sequela to hip infection, it can be successfully treated by the appropriate osteotomy. The prerequisite to an osteotomy about the hip is a femoral head that is stable and sufficient to function effectively. If this is not possible, reduction of the head should not be attempted.

## TUBERCULOUS ARTHRITIS

Tuberculosis of the bones and joints is uncommon in the countries of the developed world, particularly in North America. But it remains a common scourge in underdeveloped countries. Over the past decade, there has been a substantial increase in migration to developed countries from underdeveloped areas, such that tuberculosis is now more common and must always be suspected in children who present with chronic infections, particularly if their families have recently immigrated from underdeveloped countries. Tuberculosis is a chronic granulomatous infection caused by *Mycobacterium tuberculosis.* In countries where raw milk is consumed, bovine transmission can cause infection by *Mycobacterium bovi.* Tuberculosis is a localized destructive disease that spreads by the hematogenous route from a primary focus, most commonly located in the lungs and infected mediastinal lymph nodes.

As with pyogenic infections, tuberculous infections of joints can occur by direct hematogenous infection of the synovium or by invasion of the joint from an adjacent osteomyelitis involving the epiphysis or metaphysis. A tuberculous focus in bone spreads by centrifugal destruction of bone, producing increasing amounts of exudate and caseous necrotic material. Increasing pressure and bone destruction results in perforation of the bony cortex, forming a soft-tissue “cold abscess” so named because of the absence of acute inflammation. The infection spreads along tissue planes and may present as a subcutaneous abscess or fistula.

Primary joint tuberculosis or secondary spread from adjacent bone involvement results in the proliferation of tuberculous granulation tissue in the joint, which produces a pannus that rapidly covers articular cartilage, destroying the cartilage and underlying subchondral bone. Destruction is most extensive around the periphery of the joint at the attachments of the synovial membrane.

The clinical presentation of a chronically ill child with a history of easy fatigability and weight loss. The evolution of the disease is insidious, and involvement is usually monoarticular or in a single site. It is important to seek a family history of tuberculosis. With lower extremity involvement, the patients limp and the affected joint is stiff. Crying at night is typical, because the pain seems to increase because protective muscle spasm relaxes at night. Physical findings depend on the anatomic area involved. Infection is most frequent in the spine, followed in order of frequency by the hip, knee, ankle, sacroiliac joint, shoulder, and wrist. Tuberculous spondylitis in the child is characterized by a painful, stiff back and a protective gait in which the child keeps the back hyperextended. Infection in the thoracic spine and the thoracolumbar junction is common. Kyphosis develops as bone destruction progresses. In the extremities, muscular atrophy is usually marked.

Characteristic laboratory findings are a hypochromic anemia, normal or only a slight increase in the peripheral white blood cell count, a modestly elevated erythrocyte

sedimentation rate, and positive tubercular skin test. Synovial fluid analysis shows a white blood cell count averaging 20,000 cells/$mm^3$ (range 3,000 to 100,000 cells), with 40% lymphocytes and monocytes, which is much more than that seen in pyogenic infections. Cultures are usually positive, but diagnosis can be quickly confirmed by histologic examination of tissue obtained by biopsy of the synovium of infected joints or sites of bone involvement.

Plane film radiography is usually adequate to demonstrate the changes from tuberculous arthritis, although it is often indistinguishable from monoarticular rheumatoid arthritis. Characteristic findings are the triad of Phemister, which consists of periarticular osteoporosis, gradual narrowing of the joint space, and erosions of the bone peripherally at the synovial attachments. In the late stage of tuberculosis, there may be complete destruction of joints, with dense sclerotic changes in adjacent bone. The disease is typically monoarticular, as opposed to juvenile arthritis, which is usually polyarticular. In the spine, the initial presentation shows disk space narrowing and destruction of the adjacent endplates of the vertebrae. With progression of the disease, a paraspinal mass is common. Subsequent collapse of involved vertebra and extension of the infection to adjacent levels leads to kyphosis and formation of a gibbous. Infection often extends along the psoas muscle sheaths and can present as abscesses in the flanks or groin. Paraplegia can occur due to tuberculous involvement of the meninges or due to mechanical pressure from the infection and collapse of the vertebral elements. This is known as Pott's disease.

Treatment is primarily with multiple antituberculous drugs. General medicine measures to treat other focuses of the disease and to ensure good health habits and adequate nutrition are important. Orthopaedic care consists of conservative measures to preserve motion and strength, and to prevent deformity. Surgery is performed when necessary to debride necrotic bone and soft tissue, and to eliminate abscess. Today, surgery is most commonly required to correct spinal deformity and treat paraparesis. For treatment, three drugs are preferred, and because of the large percentage of drug-resistant infections in certain areas, four drugs may be advisable. Drugs include isoniazid, rifampin, streptomycin, ethambutol, and pyrazinamide, as well as others. Pyridoxine supplementation may be necessary when treating with isoniazid. Monitor patients for hepatotoxicity, impaired renal infection, eighth cranial nerve toxicity, serum sickness–like syndromes, and thrombocytopenia.

**CHAPTER REFERENCES**

Each reference is categorized according to the following scheme: *, classic article; #, review article; !, basic research article; and +, clinical results/outcome study.


+ 1. Ang JG, Gelfand MJ. Decreased Gallium Uptake in Acute Hematogenous Osteomyelitis. *Clin Nucl Med* 1983;8:301.

+ 2. Ash JM, Gilday DL. The Futility of Bone Scanning in Neonatal Osteomyelitis: Concise Communication. *J Nucl Med* 1980;21:417.

+ 3. Benhamou L, Chamot AM, Kahn MF. Synovitis-Acne-Pustulosis Hyperostosis-Osteomyelitis Syndrome (SAPHO) A new Syndrome Among the Spondyloarthritis. *Clin Exp Rheumatol* 1988;6:109.

+ 4. Betz RR, Cooperman DR, Wopperer JM, et al. Late Sequelae of Septic Arthritis of the Hip in Infancy and Childhood. *J Pediatr Orthop* 1990;10:365.

+ 5. Bowman TR, Johnson RA, Sherman FC. Gallium Scintigraphy for Diagnosis of Septic Arthritis and Osteomyelitis in Children. *J Pediatr Orthop* 1986;6:317.

+ 6. Carr AJ, Cole WG, Roberton DM, Chow CW. Chronic Multifocal Osteomyelitis. *J Bone Joint Surg* 1993;75-B:582.

+ 7. Choi IH, Pizzutillo PD, Bowen JR, et al. Sequelae and Reconstruction after Septic Arthritis of the Hip in Infants. *J Bone Joint Surg* 1900;72-A:1150.

+ 8. Dan M. Septic Arthritis in Young Infants: Clinical and Microbiologic Correlations and Therapeutic Implications. *Rev Infect Dis* 1984;6:174.

+ 9. DeLucas PA, Gutman LT, Ruderman RS. Counterimmunoelectrophoresis of Synovial Fluid in the Diagnosis of Septic Arthritis. *J Pediatr Orthop* 1985;5:167.

+ 10. Dich VQ, Nelson JD, Haltalin KC. Osteomyelitis in Infants and Children: A Review of 163 Cases. *Am J Dis Child* 1975;129:1278.

+ 11. Epps CH, Bryant DD, Coles MJM. Osteomyelitis in Patients Who Have Sickle Cell Disease. *J Bone Joint Surg* 1991;73:A:1281.

+ 12. Farley T, Conway J, Shulman ST. Hematogenous Pelvic Osteomyelitis in Children. Clinical Correlates of Newer Scanning Methods. *Am J Dis Child* 1985;139:946.

+ 13. Freeland AE, Sullivan DJ, Westin GW. Greater Trochanter Hip Arthroplasty in Children with Loss of the Femoral Head. *J Bone Joint Surg* 1980;62-A:1351.

+ 14. Gledhill RB. Subacute Osteomyelitis in Children. *Clin Orthop* 1973;96:57.

+ 15. Green NE, Beauchange RD, Griffin PP. Primary Subacute Epiphyseal Osteomyelitis. *J Bone Joint Surg* 1981;63-A:107.

# 16. Griffin PP. Bone and Joint Infections in Children. *Pediatr Clin North Am* 1967;14:533.

+ 17. Herndon WA, Knauer S, Sullivan, Gross RH. Management of Septic Arthritis in Children. *J Pediatr Orthop* 1986;6:576.

+ 18. Highland TR, LaMont RL. Osteomyelitis of the Pelvis in Children. *J Bone Joint Surg* 1983;65A:230.

+ 19. Hoffer FA, Strand RD, Gebhardt MC. Percutaneous Biopsy of Pyogenic Infection of the Spine in Children. *J Pediatr Orthop* 1988;8:442.

+ 20. Jackson MA, Nelson JD. Etiology and Medical Management of Acute Suppurative Bone and Joint Infections in Pediatric Patients. *J Pediatr Orthop* 1982;2:313.

! 21. Jasin HE. Bacterial Lipopolysaccharides Induce In Vitro Degradation of Cartilage Matrix through Chondrocyte Activation. *J Clin Invest* 1983;72:2014.

+ 22. Jurik AG, Hehnig O, Ternowitz T, Muller BN. Chronic Recurrent Multifocal Osteomyelitis: A Follow-up Study. *J Pediatr Orthop* 1988;8:49.

+ 23. Keely K, Buchanan GR. Acute Infarction of Long Bone in Children with Sickle Cell Anemia. *J Pediatr* 1982;101:170.

+ 24. King DM, Mayo KM. Subacute Hematogenous Osteomyelitis. *J Bone Joint Surg* 1969;51-B:458.

* 25. Koch J. Undersuchangen uber die Lokalisation der Bakteries das Verhalten des Knochen Markes und die Verenderungen der Knochen, inc besondere der Epiphysen bei Infekuouskrankheiten. *Z Hyg Infectionskr* 1911;69:436.

+ 26. Mallouk A, Talab Y: Bone and Joint Infections in Patients with Sickle Cell Disease. *J Pediatr Orthop* 1985;5:158.

+ 27. Mazur JH, Ross G, Cumming J, et al. Usefulness of Magnetic Resonance Imaging for the Diagnosis of Acute Musculoskeletal Infections in Children. *J Pediatr Orthop* 1995;15:144.

+ 28. Menelaus MB. Discitis: An Inflammation Affecting the Intervertebral Discs in Children. *J Bone Joint Surg* 1964;46:B:16.

! 29. Morrissy RT, Haynes DW. Acute Hematogenous Osteomyelitis: A Model with Trauma as an Etiology. *J Pediatr Orthop* 1989;9:447.

+ 30. Mustafa MM, Saez-Llorens X, McCracken GH Jr, Nelson JD. Acute Hematogenous Pelvic Osteomyelitis in Infants and Children. *Pediatr Infect Dis J* 1990;9:416.

+ 31. Piehl FC, Davis RJ, Pugh SI. Osteo in Sickle Cell Disease. *J Pediatr Orthop* 1993;13:225.

+ 32. Pugh CA, Hughes JK, Abrams BC. Osteo in Patients with Sickle Cell Disease. *J Bone Joint Surg* 1971;53-A:1.

+ 33. Prober CG, Yeager AS. Use of the Serum Bactericidal Titer to Assess the Adequacy of Oral Antibiotic Therapy in the Treatment of Acute Hematogenous Osteomyelitis. *J Pedaitr* 1979;96:131.

+ 34. Ring D, Johnston CE, Wenger DR. Pyogenic Infectious Spondylitis in Children. *J Pediatr Orthop* 1995;15(5):652.

+ 35. Roberts JM, Drummond DS, Breed AL, Chesney J. Subacute Hematogenous Osteomyelitis in Children: A Retrospective Study. *J Pediatr Orthop* 1982;2:249.

! 36. Salter RB, Bell RS, Keeley FM. The Protective Effect of Continuous Passive Motion on Living Articular Cartilage in Acute Septic Arthritis: An Experimental Investigation in the Rabbit. *Clin Orthop* 1981;159:223.

+ 37. Silverthorn KG, Gillespie WJ. Pyogenic Spinal Osteomyelitis. *N Z Med J* 1986;99:62.

! 38. Smith RL, Schurman DJ, Kajiyania G, et al. The Effect of Antibiotics on the Desctruction of Cartilage in Experimental Infectious Arthritis. *J Bone Joint Surg* 1987;69-A:1063.

* 39. Smith T. On the Acute Arthritis of Infants. *St. Bartholemew's Hospital Report* 1874;10:189.

+ 40. Stutley JE, Conway WF. Magnetic Resonance Imaging of the Pelvis and Hips. *Orthopedics* 1994;17:1053.

+ 41. Tong Y, Wei XR, Qiu GX, et al. The Treatment of Chronic Hematogenous Osteomyelitis. *Clin Orthop* 1987;215:72.

* 42. Trueta J. The Normal Vascular Anatomy of the Human Femoral Head During Growth. *J Bone Joint Surg* 1957;39-B:358.

+ 43. Vaughan PA, Newman NM, Rosman MA. Acute Hematogenous Osteomyelitis in Children. *J Pediatr Orthop* 1987;7:652.

+ 44. Wopperer JM, White JS, Gillespie R, et al. Long Term Follow-up of Infantile Hip Sepsis. *J Pediatr Orthop* 1988;8:322.

+ 45. Yu L, Kasser JR, O'Rourke E, Kozakowich H. Chronic Recurrent Multifocal Osteomyelitis Associated with Vertebra Plana. *J Bone Joint Surg* 1989;71A:105.

# CHAPTER 177

# SURGERY FOR CEREBRAL PALSY

*Lawrence A. Rinsky*

**L. A. Rinsky:** Palo Alto, California, 94304.

Goals of Treatment
Foot and Ankle Deformities
Equinus Deformity
Varus Deformity
Valgus Deformity
Excessive Tibial Torsion
Knee Deformities
Flexion Deformity
Extension Deformity
Hip Deformities
Adduction Deformity
Flexion Deformity
Internal Rotation Deformity
Subluxation and Dislocation of the Hip
Chapter References

Cerebral palsy (CP) is a disorder of movement or posture caused by a nonprogressive lesion of the brain acquired at or around the time of birth (3). Although musculoskeletal deformities and imbalances are usual, and certain clinical patterns are relatively common, the condition is extremely heterogeneous. The brain lesions tend not to be highly localized and therefore usually produce more than an isolated deficit. At least five basic movement disorders—spasticity, athetosis, ataxia, rigidity, and tremor—are described; various possibilities for distribution include monoplegia, hemiplegia, diplegia, and total body involvement.

Although spasticity is most common, many patients have more than one movement disorder. It is important to identify the primary movement disorder because, in general, operations are designed for patients with spasticity. Because the brain lesion is often diffuse, deficits in proprioception, stereognosis, and perceptual integration can result. Keeping cognizant of these other deficits will remind the orthopaedic surgeon to set reasonably modest goals for treatment.

Specific deformities and functional losses are seen repetitively in patients with CP, depending on the pattern of neurologic involvement. For example, the combination of windblown hips and scoliosis is typically seen in the total-body-involved spastic quadriplegia patient. Valgus feet and mild crouch gait are typically seen in spastic diplegia. By applying basic principles of surgical correction, the orthopaedist may improve positioning, function, and appearance of the extremities in selected patients.

## GOALS OF TREATMENT

Many CP patients will need and benefit from lower extremity surgery. The goals vary depending on the overall functional ability of the patient (i.e., nonambulator, “therapy” or nonfunctional ambulator, household ambulator, community ambulator with assistive devices, or independent community ambulator). Goals for lower extremity surgery in nonambulators are often limited to improving comfort and easing nursing care, or decreasing contractures sufficiently to allow deformed feet to be fitted with shoes. Assisted transfers of a nonambulator in and out of a wheelchair can be facilitated if the patient can be stood on plantigrade feet with fairly straight hips and knees. For household or community walkers, the goal should be to improve the efficiency of gait (i.e., decrease the energy cost) by minimizing contractures and balancing spasticity. However, the basic ability to walk is dictated by the patient's brain and is not affected by the orthopaedic surgeon. Because the prognosis for independent walking can be established by 2 or 3 years of age (depending on the equilibrium and primitive reflexes), the surgeon should have realistic goals in mind by the time surgery is undertaken (3).

A far smaller percentage of CP patients will need or truly benefit from upper extremity surgery. The goals of upper extremity reconstructive surgery usually relate to improvement in function, occasionally for ease of hygiene or personal care (such as pulling a long sleeve shirt over a wrist and hand that is locked in flexion), and rarely for improvement in cosmesis. Coexistent deficits in stereognosis and motor planning limit the goals that should be expected when trying to rebalance motor control about the wrist and hand. Additionally, any cognitive problems further minimize the ability of the CP patient to cooperate in a postoperative therapy program. In general, this will mean that most upper extremity surgery *for functional improvement* will be performed on children who are spastic hemiplegics with only mild or no cognitive deficits.

For the sake of clarity, it is important to discuss only one anatomic deformity at a time. However, it is vital always to think of the joints and muscles above and below the target deformity. Make repeated examinations before deciding on surgical intervention. Consideration must be given not only to the effects of other deformities on the index deformity, but also to the effects that any proposed surgery will have on the neighboring joints. A classic example of this is the increased lordosis that occurs after an apparently appropriate hamstring lengthening because of a lack of attention to preexisting increased hip flexor spasticity. Similarly, a mild tendency toward crouch gait will often worsen following a heel cord lengthening done in isolation.

I have found the gait analysis laboratory to be helpful in planning surgical procedures in CP, especially when several procedures must be performed simultaneously. By using combinations of dynamic gait electromyographic (EMG) analysis and video monitoring of joint range during gait, I have found that in more than half the cases the preoperative gait analysis affects my decision as to which operative procedures are necessary.

Most surgery designed for gait improvement should probably be delayed until the pattern of gait is fairly well established (usually between 4 and 8 years of age) with a goal of finishing surgical intervention (if possible) by the first or second grade of school. Similarly, surgery for upper extremity functional improvement usually is most appropriate at about the same age. It often takes a series of examinations on a young child to accurately assess the motor, sensory, and cognitive resources of a not-always-cooperative child.

The procedures described here represent my preferences for treating the most common lower-extremity deformities in spastic CP. Keep in mind that even with well-planned and carefully executed surgery, deformities occasionally recur or progress in children with CP, and salvage or reconstructive procedures may later become necessary.

## FOOT AND ANKLE DEFORMITIES

### EQUINUS DEFORMITY

#### *Indications for Surgery*

Equinus deformity is very common and is one of the few deformities that may actually exist in isolation in spastic CP, especially in hemiplegics. The indications for surgical correction are simple: fixed equinus such that the ankle cannot be dorsiflexed to neutral, with the hindfoot locked in varus in a walking or potentially ambulatory patient. In diplegics, equinus helps in transferring the weight-bearing line anteriorly, which assists in extending the knee. Thus, when crouching is present in diplegia, the surgeon should not lengthen the triceps surae in isolation; usually, hamstring or hip flexor surgery must be combined with it. Not all tiptoeing CP patients have fixed equinus. For a dynamic deformity, it is best to try an extended period of bracing with a rigid plastic ankle–foot orthosis or a series of short-leg walking casts for 2–3 weeks at a time.

An additional alternative for the patient with dynamic equinus is an injection of botulinum-A toxin (1–2 mm/kg body weight per calf), which will fairly reliably temporarily

relieve spasticity and tone for a period of up to 6 months (16).

### *Tendo-Achilles Lengthening through the Posteromedial Approach*

In an older patient with a severe, longstanding equinus contracture (e.g., a 10-year-old hemiplegic who has always walked on his toes), heel cord lengthening through a standard posteromedial longitudinal incision with a Z-type tendon lengthening is recommended, because there is likely to be a fixed capsular contracture of the ankle requiring capsulotomy as well. The amount of lengthening should be approximately enough that with the foot in neutral, half the available excursion of the tendo-Achilles is set. An additional check for the amount of lengthening is the so-called geometric method, in which the amount of lengthening is half the perpendicular distance that the first metatarsal head protrudes inferiorly to the heel during maximal passive dorsiflexion (10). Once the amount of lengthening is determined, perform the suture repair with the foot in equinus so as to minimize tension during the repair. After the repair, check the foot in the neutral position to make sure that there is still some residual tension on the muscle–tendon unit.

### *Hoke Procedure*

- In most patients, a Hoke procedure is preferred for heel cord lengthening (Fig. 177.1). This can be accomplished in a number of ways. The method involves three opposing cuts, each one halfway through the tendon. Make two medial cuts proximally and distally, with one lateral cut halfway between the two, or vice versa. Then dorsiflex the foot just to neutral, thus causing a sliding lengthening. No sutures are necessary.

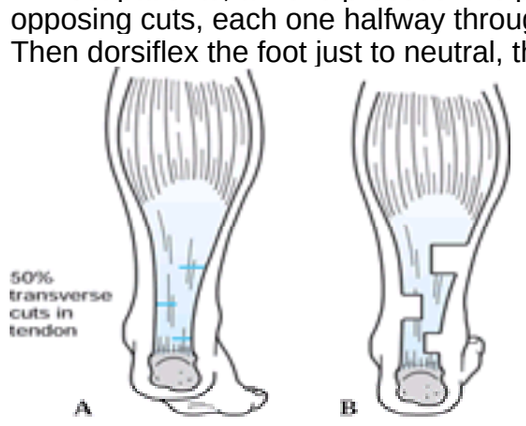


***Figure 177.1.*** Hoke technique for tendo-Achilles lengthening.

- The best visualization of the procedure is accomplished through a medial longitudinal incision 4–6 cm in length. It is rare to need a posterior capsulotomy of the ankle in CP. By placing the incision slightly further anteriorly, the posterior tibial tendon or toe flexors may also be approached, if desired. However, occasionally the longitudinal scar may be prominent. Alternatively, use two small transverse incisions, with two of the tendon cuts through one incision and one tendon cut through a second incision. With a subcuticular closure, the scar is essentially invisible.
- Finally, the entire procedure can be performed percutaneously. This is now my preferred technique if a heel cord lengthening is the only procedure needing to be done. Make the same three cuts in the tendon using a #15-C scalpel blade through three tiny percutaneous incisions. The proximal cut should be at about the level of the musculotendinous junction. It is essential to dorsiflex the foot to only 10° or 15° above neutral, with the knee slightly flexed.

### *Gastrocnemius Recession*

In the occasional ambulatory, tiptoeing child with a dramatic and consistently positive Silfverskiöd test (in which the amount of dorsiflexion is much improved with the knee flexed as compared to the degree in full knee extension), I perform a simple gastrocnemius recession (24).

- Make a longitudinal incision in the lower middle calf slightly medially over the palpable lower border of the gastrocnemius muscle belly. Separate the gastrocnemius aponeurosis from the underlying soleus; this plane is easier to find proximally.
- Divide transversely only the gastrocnemius aponeurosis and dorsiflex the foot to 5° to 10° above neutral. I will usually tack down the aponeurosis with a few absorbable stitches. Occasionally, it is also necessary to divide a few fibers of the underlying soleus aponeurosis to obtain adequate dorsiflexion. No muscle fibers, however, are divided. This has the theoretical advantage that overcorrection is very unlikely, although recurrence of equinus may be slightly more likely.

### *Postoperative Care*

The postoperative care is the same whatever type of equinus correction is chosen. Apply an above-knee cast with the knee in 5° or 10° of flexion. At 2–3 weeks, cut the cast down to a below-knee walking cast. Allow ambulation immediately after surgery if no other contraindications are present. If no other simultaneous surgery was performed requiring immobilization above the knee (e.g., hamstring or iliopsoas release), a below-knee walking cast can be used following any type of heel cord lengthening. The child will tend to flex the knees with only a below-knee cast, but within 24 hours she can be coaxed into extending her knees to near neutral. Using a below-knee cast facilitates the rehabilitation. Remove all casts at 6–8 weeks. A plastic, right angle, or articulated ankle–foot orthosis (AFO) is frequently used part-time for at least 3–6 months. Patients who have no selective control of dorsiflexion will often require the orthosis on a more or less permanent basis. Use nighttime splinting in neutral in those patients who tend to drift back into equinus.

### *Complications*

If fixed equinus recurs, lengthen the tendon by the Z technique a second time. Forewarn parents that recurrence of some equinus does occur in perhaps 10% of children who undergo tendo-Achilles lengthening (TAL); however, many children who do not make heel contact at foot strike do so more because of flexed knees than because of fixed equinus. Overlengthening is far worse than a recurrence of the original equinus. There is no universally successful management for postoperative calcaneus deformity. The first rule is to avoid overlengthening. Some tension should always remain on the tendon unit after lengthening. If calcaneus deformity does occur, tendon reconstructions have not always been satisfactory. Reshortening of the tendo-Achilles may be tried, or tenodesis of the Achilles to the posterior tibia or fibula, but these are unlikely to restore true muscle function.

A dynamic gait analysis may demonstrate which muscles are active in stance. The anterior tibial tendon can be transferred posteriorly to the heel, and theoretically the peroneus brevis and half the posterior tibial tendon can also be transferred to the os calcis. However, restoration of fully satisfactory plantar flexor strength is unlikely. Should postoperative calcaneus deformity occur, a rigid AFO with a wide proximal anterior tibial restraint (“floor reaction” AFO) will have to be used in addition to attempts at reinforcing plantar flexor strength.

## VARUS DEFORMITY

### *Indications for Surgery*

Varus deformity may be either dynamic or fixed. It appears most often in hemiplegics, compared with the more typical valgus deformity seen in diplegics. Dynamic gait EMG analysis is most helpful in determining the phasic nature of the tibialis anterior and posterior muscles and the peroneals. Generally, patients under 4 years of age have not fully established a gait pattern and can be managed with orthotics. The indications for surgery then depend on the age of the patient, whether the varus is mild or severe, and which muscles are most “at fault” on the EMG.

For the milder, flexible varus deformities, a posterior tibial myotendinous lengthening (25) is the simplest approach, but it is rarely appropriate to perform it as an isolated procedure. This is often combined with a TAL. For more significant, but still flexible, varus deformities, a split anterior tibial tendon (SPLATT) procedure (13) can be combined with the posterior tibial myotendinous lengthening, or the posterior tibial tendon can be split and transferred laterally to the peroneus brevis (15,23).

If any of these procedures are being considered, preoperative gait EMG, if available, should demonstrate excessive or even continuous phasic firing of the anterior and posterior tibial muscles throughout the gait cycle. One should not expect postoperative changes in the phasic pattern of muscle firing after transfer (11). Currently, I favor the split posterior tibial tendon transfer (usually along with TAL) in patients with dynamic varus and equinus deformity, because plantar flexor strength is not sacrificed quite as much, and only the muscle direction is changed. It is important to realize that spastic muscles, although overactive, are still weakened. In fact, I frequently split both the anterior and the posterior tibial tendons with lateral transfer of both in cases of dynamic varus. Others perform just the SPLATT transfer with TAL for the same dynamic varus deformity. The postoperative regimen in either case is the same as described for TAL.

I would caution against ever transferring the entire posterior tibial tendon anteriorly through the interosseous membrane in a patient with spastic CP. I have abandoned that technique because of the occurrence of late calcaneovalgus deformity. I would also caution against complete tenotomy of the posterior tibial tendon in the spastic foot, because late valgus is likely.

If a fixed varus deformity is present in the hindfoot, as determined by the block test, add a bony reconstruction to the soft-tissue releases or transfer. Perform the block test by having the patient stand with a 1–2 cm block under the heel and lateral border of the foot. If the heel varus resolves, then it is compensatory and results from forefoot pronation of the first ray. If heel varus persists on the block, it is fixed (see the section on cavus in Chapter 167). In the case of a younger patient, the choices are either a sliding lateral displacement osteotomy or a Dwyer-type of laterally based closing wedge of the calcaneus. In a patient older than 12 years with significant fixed varus deformity, perform a triple arthrodesis.

***Posterior Tibial Tendon Lengthening***

- Through a longitudinal supramalleolar posteromedial incision, approach the posterior tibial muscle. At least 2–4 cm proximal to the most distal muscle fibers, divide the tendinous portion of the posterior tibial muscle obliquely. Passively evert the foot under direct visualization to observe the tendon slide. This produces an aponeurotic lengthening that leaves the muscle fibers in continuity. No sutures are needed.
- Alternatively, a supramalleolar Z-lengthening of the posterior tibial tendon can be performed, but this is a more complex procedure and requires suture repair.

I prefer the first method, usually in combination with a TAL and SPLATT. Use a postoperative short-leg walking cast for 6 weeks.

***SPLATT Procedure***

- Isolate the anterior tibial tendon at its insertion as far distally as possible through a 1-inch (2.5 cm) incision over the first cuneiform bone. Split the tendon in half longitudinally and free the lateral half (see Chapter 167).
- Make a second incision over the anterior compartment of the leg 3–4 inches (7.5–10.0 cm) above the ankle. Pass the lateral half of the tendon proximally into the second incision. It is helpful to have a Bunnell-type suture through the free end of the tendon.
- Then make a third incision laterally over the cuboid bone. Pass the lateral half of the anterior tibial tendon subcutaneously, deep to the extensor retinaculum to the third incision. Suture the tendon either to the periosteum of the cuboid or, better, route it through a small bony vertical tunnel in the cuboid. I prefer using an absorbable pullout stitch over a padded plantar button or splint. On subsequent removal of the cast, the pullout suture can simply be cut flush with the skin.
- Prior to closure, tension on the tendon proximally should tend to dorsiflex the foot in a neutral position. That is, a yoke has been created and the tension in each limb both medially and laterally should be fairly similar. Use a short-leg cast for 6 weeks.

***Split Posterior Tibial Tendon Transfer***

Usually four small 1- to 1.5-inch (2.5 to 3.4 cm) incisions are used, although the entire procedure can readily be performed through the Cincinnati horizontal transverse incision commonly used for clubfoot (31) (see Chapter 167).

- Begin with a 1-inch (2.5 cm) medial longitudinal incision over the navicular tuberosity. Isolate the posterior tibial tendon at its insertion and split it distally, detaching the plantar half. Tag this with a heavy nonabsorbable suture. (Fig. 177.2).

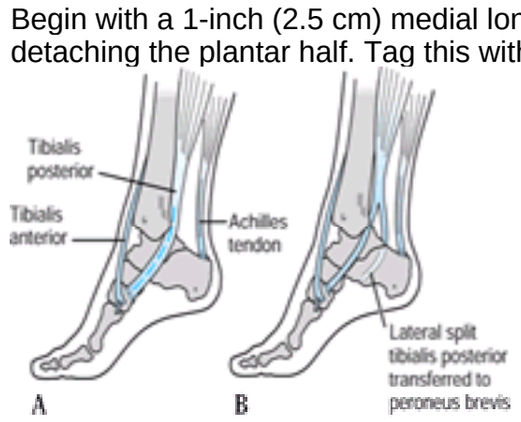


***Figure 177.2.*** Split posterior tibial tendon transfer.

- Make the second incision medial and longitudinal, 1 cm posterior to the medial border of the tibia. Using a curved tendon passer, pass the tagged suture with the plantar half of the posterior tibial tendon through the sheath directly posterior to the tibia. Tease this backward to propagate the split. Deliver the tendon into the medial proximal incision.
- Place a third incision just posterior to the distal fibula. Then pass the tagged tendon laterally just posterior to the tibia and fibula to the peroneal tendon sheath. Pass the split tendon within the sheath to the area of the fifth metatarsal–cuboid articulation, where the fourth short incision is made. Then suture the split tendon to the peroneus brevis under moderate tension with the foot in neutral. Apply a short-leg cast.

***Calcaneal Osteotomy (Lateral Displacement, or Dwyer)***

- Expose the lateral calcaneus subperiosteally through an oblique lateral incision immediately behind the peroneal tendons. Use an oscillating saw to cut through the calcaneus more or less parallel to the posterior calcaneal facet. Temporarily open the osteotomy laterally to use a curved Freer or small elevator to medially strip subperiosteally. Unless this step is done, it will be impossible to displace the tuberosity fragment. I caution against hammering an osteotome to complete the osteotomy medially because of the danger to the neurovascular bundle and flexor tendons, which are directly apposed medially (Fig. 177.3).

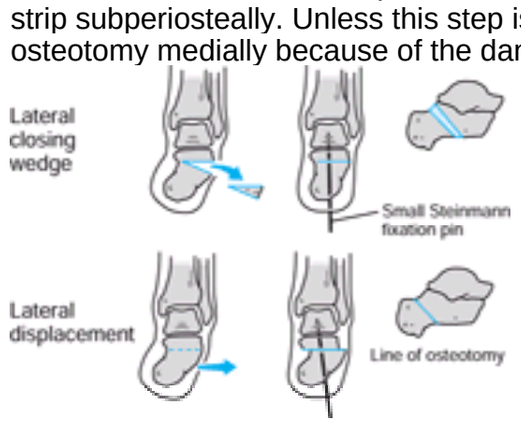


***Figure 177.3.*** Calcaneal osteotomy for fixed hindfoot varus.

- When the tuberosity has been sufficiently mobilized, displace it laterally enough (0.5–1.2 cm) to put the heel in neutral or slight valgus. Make sure that the tuberosity fragment does not slide proximally. Insert a single smooth pin from the plantar surface of the calcaneus across the osteotomy to hold the reduction. Leave it in place for 3 or 4 weeks.
- The Dwyer technique is perhaps simpler because no medial dissection is necessary; however, it mildly decreases the heel height and theoretically also decreases plantar flexor strength. Make the first bony cut as described previously, but then remove an oblique laterally based wedge (Fig. 177.3) sufficient to correct the hindfoot varus, bringing the heel directly in line with the long axis of the tibia. Close the bony surfaces and stabilize with either a smooth Steinmann pin (which is removed in 3 weeks) or a staple. I prefer pins. Allow weight bearing after 3 weeks.

***Triple Arthrodesis***

The technique for triple arthrodesis is fairly standard (see Chapter 115).

- Make an oblique incision over the sinus tarsi and expose the sinus by maintaining a distally based flap of the extensor brevis muscle and overlying fat pad. Instead of continuing distally in the subperiosteal plane toward the calcaneal–cuboid joint, I use a 2 cm osteotome to cut across the joint dorsally in the longitudinal plane. This creates a small myo-osseous flap, but more important, it nicely exposes the calcaneal–cuboid articulation.
- Depending on the degree of varus, take laterally based wedges from the subtalar and calcaneocuboid joints. I use a micro-oscillating or sagittal saw. In general, the wedges should probably be taken smaller than you initially think is necessary, so that an excessive amount of bone is not removed.
- I usually use two pins, both placed axially: one to hold the calcaneocuboid joint and the other the talonavicular joint. A third pin, vertically placed across the talocalcaneal articulation, is optional. Apply a heavily padded, above-knee cast.

Allow no weight bearing until the pins are removed at 6 weeks. Then apply a short-leg walking cast and maintain it until the fusion is solid, which usually takes an additional 6–8 weeks.

## VALGUS DEFORMITY

Valgus feet are common in CP and are especially frequent in spastic diplegia and quadriplegia. Although, at first glance, predominant spasticity of the peroneal muscles would seem to be the primary cause, the etiology usually is multifactorial and includes excessive external tibial torsion, knee flexion deformity, and calcaneal equinus. The deformity usually remains flexible until adolescence. Secondary callosities develop over the talar head and the first metatarsal head, and hallux valgus develops. Initially, manage the deformity with an AFO; however, if the deformity becomes severe, brace fitting is increasingly difficult.

### *Indications for Surgery*

Subtalar stabilization is indicated before the valgus deformity becomes fixed, usually by 6–10 years of age. Traditionally, some modification of the Grice extra-articular arthrodesis procedure was most commonly performed, using internal fixation (3,7). Depending on calcaneal position, a TAL is often necessary as well. The deformity must be passively correctable (at least with the foot in equinus) for the Grice procedure to work. More recently, one of several types of calcaneal osteotomies has become preferred because it maintains subtalar mobility while correcting the valgus (18,23,27). Although correction can be obtained by a simple opening lateral wedge osteotomy in the tuberosity using a cortical graft (bank or autogenous), I prefer either a medial calcaneal slide, or, occasionally, a lateral column lengthening. This latter technique of Evans, popularized by Mosca (18), has the advantage that it can partially correct the lateral subluxation at the midfoot. All of these also require reasonably supple feet that are passively correctable to neutral, or that can be made so with a simple heel cord lengthening.

The Grice procedure should not be performed in children less than 4 years of age because the bones are too small and cartilaginous. After age 12, a triple arthrodesis is usually more appropriate unless the valgus remains totally flexible. Occasionally, all or much of the apparent valgus is built into the tibiotalar joint with a relatively short fibula. A preoperative standing anteroposterior radiograph of the ankle should always be taken before the Grice procedure is performed. Do not attempt to correct the subtalar joint into varus to make up for ankle valgus. True ankle valgus must be corrected by a supramalleolar osteotomy or, rarely, a medial growth arrest, depending on age. Of course, the patient should be at least a household assisted ambulator (or have a reasonable prognosis for attaining that level of function) before considering foot reconstructive surgery.

### *Calcaneal Osteotomy (Medial Displacement or Lengthening)*

- Use the same lateral oblique incision (posterior and parallel to the peroneal tendons) as for a Dwyer osteotomy. Use an oscillating saw to cut the tuberosity parallel to and below the posterior facet. If only the hindfoot is in valgus, then there is a choice of either using a laterally based opening wedge (held with an allograft cortical wedge), or sliding the distal fragment medially (Fig. 177.4).

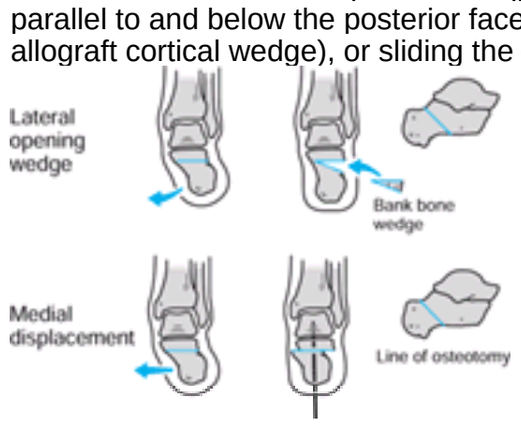


***Figure 177.4.*** Calcaneal osteotomy for fixed hindfoot valgus.

- To successfully displace medially, it is necessary to carefully subperiosteally dissect medially from the lateral approach to mobilize the distal fragment. After medial displacement sufficient to place the heel in neutral alignment, accomplish fixation with a smooth Steinmann pin placed vertically from the plantar surface.
- I do not have long-term experience with distal calcaneal lengthening, but I have used it in cases of mild to moderate, very flexible valgus, and early results have been excellent. In this technique, make a transverse vertical osteotomy in the calcaneal neck, parallel to the calcaneal–cuboid joint. After mobilizing the distal fragment, use a lamina spreader to open the osteotomy, and simultaneously reduce the lateral talonavicular subluxation. Insert a trapezoidal cortical cancellous graft (I prefer allograft). It may be wise to provisionally fix the calcaneocuboid joint with a smooth Kirschner wire before lengthening; this prevents subluxation. A longitudinally placed K-wire, from distally across the calcaneal–cuboid joint, is optional if needed to maintain stability, and once it is passed through the calcaneocuboid joint, the original wire is removed. If a TAL has not been performed prior to the osteotomy, recheck after completion of the osteotomy to make sure that there is not a fixed ankle equinus deformity.

### *Grice Procedure*

- Through an oblique incision extending from the lateral talonavicular joint to the peroneal tendons, sharply elevate the contents of the sinus tarsi from proximal to distal. Clean the lateral body and neck of the talus and the calcaneal floor of the sinus tarsi of all soft tissue. Ideally, expose no articular surfaces.
- Pack the sinus tarsi with corticocancellous graft taken from the iliac crest. Iliac graft rather than tibial or fibular is preferred because it is incorporated readily, it is abundantly available, there is enough graft from one crest to fuse both feet simultaneously, and the iliac crest graft does not carry the risks of donor site fatigue fracture after surgery (as do tibial grafts) or later valgus deformity (as with fibular grafts). Unlike “structural” grafts of tibial or fibular cortex, iliac graft is not used to correct deformity, only to obtain fusion. Because the iliac graft itself does not provide fixation, supplemental internal fixation is mandatory.
- Some surgeons insert a screw through the neck of the talus into the calcaneus, and this has the advantage of earlier weight bearing. However, I prefer to use a percutaneous Steinmann pin, inserted under direct vision from the lateral plantar aspect of the calcaneus proximally across the sinus tarsi into the talus, because there is no retained hardware that can either back out or impinge against the anterior ankle structures (Fig. 177.5).

***Figure 177.5.*** **A:** Subtalar arthrodesis with screw fixation. **B:** Temporary fixation using a Steinmann pin for subtalar arthrodesis.

- Apply a long-leg cast for 4 weeks postoperatively, and then remove the pin. Weight bearing may be allowed in a short-leg cast for the next 4–6 weeks.

### *Complications*

Failure to deal with fixed equinus of the hindfoot will make reduction of the calcaneus under the talus difficult or impossible. The heel will remain in valgus despite positioning the graft. Another potential complication is that the graft may “melt away.” This is especially likely when excessive external tibial torsion is present. Occasionally, sufficient fibrous stability may remain even with graft resorption so that further treatment is not necessary. If significant valgus recurs, triple arthrodesis may be considered as a salvage procedure.

Overcorrection into varus may appear to develop gradually, but it is usually the direct result of intraoperative overcorrection. If the extra-articular arthrodesis is solid, correction of a postoperative varus can be obtained with a closing lateral wedge osteotomy of the heel.

### *Triple Arthrodesis*

The basic technique for triple arthrodesis is described in Chapter 115; however, for spastic valgus feet, additional principles are important. It is critical to ascertain before surgery that the ankle itself is in relatively normal alignment. If there is excessive external tibial torsion, correct this before performing the triple arthrodesis. Although flexible valgus feet can be corrected by the simple removal of joint surfaces, possibly with an inlay graft, most spastic valgus feet in older patients are rigid and require extensive bony wedge resection to obtain correction. Additionally, poor correction can be caused by inadequate exposure of the talonavicular joint.

- Use an additional 1-inch (2.5 cm) medial longitudinal incision over the talonavicular joint if the medial aspect is not well visualized from the main incision. This will allow excellent visualization when a Chandler retractor is passed from the main lateral incision out through the medial incision to protect the dorsal soft-tissue structures.
- If the foot is passively correctable to neutral before surgery, only the cartilaginous joint surfaces must be removed. However, in more severe valgus feet, remove medially based wedges of bone. Pack the sinus tarsi with cancellous bone from either the wedges or the iliac crest.
- I recommend using at least two smooth Steinmann pins for fixation. Pass one distally through the center of the exposed navicular and pass a second distally through the center of the cuboid. Then drive them retrograde into the talus and calcaneus, respectively. A third vertical pin through the talocalcaneal joint is optional. Take intraoperative radiographs; it is surprising how misplaced the pins can be. I usually place a small suction drain.
- Use an above-knee (or patellar tendon bearing) non-weight-bearing cast for 6 weeks postoperatively, and then remove the pins and apply a short-leg walking cast.

## EXCESSIVE TIBIAL TORSION

### *Indications for Surgery*

Excessive external tibial torsion is commonly seen in diplegia and quadriplegia, apparently as a compensation for excessive medial femoral torsion. This malalignment will contribute to valgus foot deformities, bunions, and other problems. Tibial osteotomy is indicated when it is necessary to keep the foot pointed correctly forward, especially following femoral derotation (external) osteotomy, or as part of correction for severe valgus feet.

### *Tibial Osteotomy*

- Make a 5–10 cm longitudinal incision proximally over the lateral anterior compartment. Always perform a fasciotomy of both the anterior and the peroneal compartments.
- By following the intermuscular septum, make a limited subperiosteal exposure of the fibula somewhat more distal than the tibial site to avoid the peroneal nerve. Osteotomize the fibula with a micro power saw.
- Expose the tibia circumferentially subperiosteally just distal to the tibial tubercle. To avoid anterior growth arrest, the osteotomy site must be distal to the anterior extension of the physis. The operation can also be performed in the supramalleolar metaphysis, where the risk of compartment syndrome and peroneal palsy is less. I recommend operating distally if correction of an ankle valgus is also desired.
- Insert half-pins from medial to lateral through separate incisions prior to the osteotomy. Place one pin proximal to the incision and one distal, with both pins going through two cortices but only through the medial skin. Perform the osteotomy with an oscillating power saw, and control rotation with the pins. It is helpful to insert the pins so that the angle between them is the same as the angle of rotation you want. Then, when rotation is complete, the pins will be exactly parallel to each other.
- Immobilize the limb in a long-leg cast, incorporating the pins in plaster. If no additional tendon work has been done, an external fixator could be used, but this does not seem worth the expense. Clinical union occurs within 2 months in children. Weight bearing is usually allowed after 4 weeks, at which time the pins are pulled out through the cast.

See Chapter 168 for the alternative technique of supramalleolar tibial rotational osteotomy.

# KNEE DEFORMITIES

## FLEXION DEFORMITY

### *Indications for Surgery*

Although the most common knee deformity in spastic CP is flexion contracture, the knees may be neutral or even hyperextended during the midstance phase of gait (3,8,21,23). The knees (like every other joint in CP) cannot be evaluated in isolation. The cause of severe knee flexion—whether dynamic or fixed—is rarely as simple as excessive hamstring spasticity. Overlengthened or weak plantar flexors, fixed hip flexion contracture, and poor equilibrium all contribute to crouch. We can do little about faulty equilibrium, and we certainly recognize that a small knee flexion deformity is usually preferable to recurvatum. Therefore, not all knee flexion deformities (even fixed ones) require surgical release.

I divide spastic knee flexion deformity into two types. In the more common and familiar “crouched” type, the knee flexion is associated with feet that are flat on the floor or the heels are only slightly elevated (often in valgus). There is usually a fixed hip flexion deformity with increased iliopsoas spasticity, which must be released. The worst thing to do in these cases is a TAL, because it will increase the crouch.

In the “jumped” type of knee flexion deformity, the ankles are in marked fixed equinus. This type of patient needs a modest TAL, in addition to lengthening of the hamstrings and probably the iliopsoas.

In ambulators or potential ambulators, perform distal hamstring lengthening when the knees cannot be straightened during ambulation to less that 15° of flexion, and when other causes of crouch gait (at the hips or ankles) are absent or can be dealt with simultaneously. Knee flexor release is also indicated in older patients who are crouched and have knee pain during transfers or limited ambulation. If the degree of fixed contracture of the knee is greater than 20°, posterior knee capsulotomy is occasionally needed, but usually this is not needed in a walking CP patient with crouch.

In nonambulators, distal hamstring release is occasionally performed to decrease extreme flexor spasticity at the knee; this facilitates sitting and dressing. The hamstrings may also be released proximally through the same medial incision used for adductor and psoas release. However, the only time I use a proximal release of the hamstrings is in the patient who has not only tight hamstrings but also severe hip extension deformity. Such a patient stands with an absent or reversed lumbar lordosis. She tends to slide out of a wheelchair because the hamstring spasticity extends the hips. When proximal release is performed, the sciatic nerve must be avoided; it can be confused with the tendinous origin—a potential catastrophe.

### *Distal Hamstring Lengthening*

- Place the patient supine and make a short, midaxial, longitudinal incision on the back of the knee. This allows repeated intraoperative assessments of the degree of improvement of straight-leg raising. In a typical patient with either no fixed-knee flexion contracture or only a mild one (10° to 20°), the contracture can be stretched out by wedging casts after hamstring release.
- Perform a Z-lengthening or simple tenotomy of the semitendinosis. The gracilis may also be tenotomized at your discretion. Perform an aponeurotic lengthening of the semimembranosus and biceps tendon by oblique division of the tendon within the muscle belly. The lengthening should be sufficient to allow 70° of straight-leg raising. This is easily determined in the supine position.
- I always lengthen the biceps last because it is often not as tight as the medial hamstrings. In such cases, if adequate straight-leg raising is present after

lengthening only medially, leave the biceps intact.

After surgery, apply a cylinder or long-leg cast. Mobilize the patient immediately with a walker or crutches if equilibrium is satisfactory. Mobilize more severely equilibrium-impaired patients in a standing frame chosen by the physical therapist.

Recently, if no additional surgery has been performed simultaneously at the ankles, I have used only a knee immobilizer postoperatively, again allowing immediate mobilization. If a joint capsule contracture was present preoperatively, do not apply the cast fully straight, but only at the limits of the maximal preoperative degree of extension. Begin wedging in 2 days.

In the rare, walking CP patient who actually needs a posterior capsulotomy, a better exposure is obtained by operating with the patient prone. In such cases, I prefer short posterior medial and posterior lateral incisions to better visualize the capsule. After a simple hamstring release, 3 weeks of immobilization is usually sufficient, although a little extra time may be needed if the casts have to be progressively wedged into extension following a capsulotomy.

#### *Proximal Hamstring Lengthening*

If you elect to release the hamstrings proximally (21), perform the operation through an oblique adductor approach or through a short medial transverse incision just below the buttocks.

- Make certain that this operation is performed without the use of anesthetic paralyzing agents, so that stimulation of the sciatic nerve with the cautery can warn you if the sciatic nerve is in close proximity to the hamstring origins.
- After choosing which skin incision to use, make a longitudinal incision in the fascia. Use blunt finger dissection in the plane posterior to the adductor magnus tendon. Start with the knee in flexion to relax the sciatic nerve, which is deep in the incision, near the femoral shaft. Intermittently extend the knee while flexing the hip to aid in defining and delivering the hamstring origins. Use a nerve stimulator if there is any confusion between the nerve and tendon.
- Do not divide the proximal hamstrings until you are certain that the nerve is safe from harm; use the cautery. Gently retest the range of knee extension with the hip flexed; after satisfactory release, knee extension should markedly increase. Never forcefully extend the knee maximally while the hip is flexed.
- Base postoperative immobilization on whatever other releases are carried out. If only hamstrings are released, then knee immobilizers for 2–3 weeks is sufficient, and mobilization can begin immediately.

#### *Complications*

Failure to fully assess the cause of the knee flexion deformity before surgery may lead to a poor result. The crouch gait will persist if a hip flexion deformity is ignored or if hyperdorsiflexed ankles are not braced. If preoperative quadriceps spasticity is severe, recurvatum may occur following overly generous hamstring weakening. Myotendinous (aponeurotic) lengthening, when performed too far distal (close to the junction of the tendon with the most distal muscle fibers), may result in complete transverse separation. The key here is simply to get enough proximal exposure so that there are plenty of muscle fibers distally to allow the slide after the intramuscular release of the tendon.

The popliteal artery and sciatic nerve are limiting structures about the knee. When applying the cast, do not try to forcibly straighten the knee if the patient is under anesthesia. A sciatic stretch palsy is difficult to detect acutely in a CP patient with severe involvement but is still a very undesirable complication. If the preexisting fixed contracture is significant (i.e., more than 20°), plan to correct it gradually after surgery using wedged casts with the patient awake.

### EXTENSION DEFORMITY

#### *Indications for Surgery*

Knee hyperextension is not a fixed deformity in CP. It usually occurs dynamically at midstance and is secondary to fixed ankle equinus or excessive quadriceps spasticity, especially of the rectus femoris. The heel cord contracture, if present, must be corrected, but weakening of the quadriceps remains a problem. There is a natural reluctance to weaken the quadriceps, because it is necessary to maintain upright posture. However, many CP patients, even with mild degrees of crouch, will have excessive cospasticity of the rectus femoris. The simultaneous, excessive rectus femoris and hamstring spasms lead to a stiff-kneed, short-stride gait (8). However, I do not believe that every ambulatory patient who undergoes a hamstring lengthening needs a simultaneous rectus femoris procedure.

If knee hyperextension is associated with a hip flexion deformity, it is simple to release and recess a small section of the origin of the rectus femoris tendon at the time of the iliopsoas recession or lengthening. This produces minimal quadriceps weakening, but it is safe. Unfortunately, a tenotomized rectus may spontaneously reattach to the anterior inferior iliac spine.

Do not release the rectus origin routinely at the time of hip flexor release in CP. Release it only if there is a hyperextended knee gait, or occasionally in nonwalkers if the fixed flexion contracture is very severe.

For the patient with a rigid stiff-knee gait without much of a hip flexion deformity, the usual indication for rectus surgery is inadequate knee flexion late in the swing phase. Such extensor spasticity interferes with foot clearance. In such cases, it is reasonable to selectively transfer the rectus femoris either medially to the semitendinosis or laterally to the iliotibial band. If a laboratory analysis of the gait is available, the rectus will usually be found to fire excessively or throughout swing phase on dynamic gait EMG. The rectus femoris transfer can be performed simultaneously with hamstring lengthening without fear of increasing crouch, or it can be performed some time later if the knee tends toward recurvatum.

#### *Distal Rectus Femoris Transfer*

- Make an anterior incision transversely or longitudinally about 6 cm proximal to the patella (8). Undermining proximally allows identification and separation of the interval between the vasti and the rectus. Proximally, this can easily be done bluntly, but distally the rectus tendon blends with the common quadriceps tendon. Further separation must be done sharply, while avoiding entry into the knee joint, to a level near the superior pole of the patella.
- If a slight correction of gait into external rotation is desired (i.e., in cases where there is excessive inturning at the knee), isolate the rectus tendon and bluntly separate proximally. Then transfer the distal stump through a subcutaneous tunnel to the semitendinosis medially. If the hamstrings have been lengthened sometime previously, and the distal stump of the semitendinosis is not available, the transfer can be into the sartorius. If there is preexisting excessive external rotation at the knee, then transfer the distal stump of the rectus through a subcutaneous tunnel to the iliotibial band or the biceps femoris. There should be no tendency toward increased crouch as long as the vastus medialis, lateralis, and intermedius remain intact, because they provide the bulk of quadriceps strength.
- Postoperatively, use removable extension knee immobilizers part time for 3–4 weeks.

## HIP DEFORMITIES

Hip deformities in CP span a spectrum from mild hip dynamic flexion deformity to complete painful dislocation. The three most common components are adduction, flexion, and internal rotation. Although these components will be considered separately, usually all three coexist to some degree.

### ADDUCTION DEFORMITY

Some degree of excessive adductor spasticity is seen in most patients with CP. Primary abduction deformity is rare and usually the result of overzealous adductor release and neurectomy of both the anterior and the posterior branches of the obturator nerve.

#### *Indications for Surgery*

Adductor release is indicated in ambulators when scissoring occurs or when passive abduction (in extension) is less than 20°. It is also indicated in limited walkers or sitters as part of the surgery for early hip subluxation. Occasionally, in the patient with severe total body involvement, the adductor release is necessary to facilitate perineal care. Adductor release is nearly always a part of the treatment for more severe degrees of hip subluxation, which require sufficient release to obtain a satisfactory range of abduction (1). Patients must be assessed individually because the extent of release required and the need for adductor transfer or neurectomy varies. In general, there is a trend away from anterior branch neurectomy except in the severely involved, nonwalking patient.

As an alternative procedure, the longus and gracilis may be recessed (sutured more distally to the underlying adductor magnus or brevis) or transferred posteriorly to

the ischium (3,6,22). To accomplish a posterior transfer, the lithotomy position is best. The theoretical advantage of posterior adductor transfer is improvement in hip extensor tone. The brevis may also be transferred; however, its entire origin is a fleshy muscle belly that does not hold sutures well. In at least two of the adductor transfers I have performed, the transferred origins pulled off the bony ischium. Postoperative radiographs proved this, as I placed radiopaque markers in the origin of the longus. Others have also noted the tendency for posteriorly transferred adductors to migrate postoperatively back to their origins (17). The extra dissection necessary for adductor transfer hardly seems worthwhile in most patients, and I have abandoned it. I simply perform a release without anterior neurectomy in the majority of cases. The extent of the release depends on the degree of deformity.

Bilateral adductor release should be performed in most diplegic and quadriplegic patients when both hips are adducted or have limited passive abduction. This is the most common situation. Even when one is less adducted than the other, both hips should usually be released in these patients, because when only a unilateral soft-tissue release is performed, there is a tendency for the nonoperated hip to subsequently become unstable (4).

However, an occasional severe quadriplegic CP patient will have true windblown hips. This is especially common with severe neurogenic scoliosis and pelvic obliquity (the pelvis is “down” on the abducted side). The abducted hip will be well covered and should not have an adductor release if the abduction is fixed. Of course, the hemiplegic patient with adductor limitation will also need only a unilateral release. The posterior branch of the obturator nerve should very rarely be divided. Only following failure of a prior extensive adductor release and anterior branch obturator neurectomy with recurrence or persistence of adduction deformity would one consider a posterior branch or intrapelvic obturator neurectomy.

### *Adductor Release*

Under most circumstances, other surgery will be performed simultaneously on the hip (e.g., iliopsoas recession, open reduction). Therefore, my preferred technique is to simply extend the anterior bikini incision slightly medially. (The bikini incision is oblique, just distal and parallel to the inguinal ligament.) The skin incision also may be made longitudinally or obliquely over the adductor longus origin. Through the Ludloff-type approach (Chapter 3), the psoas tendon can be tenotomized, but it cannot easily be recessed or divided above the pelvic brim.

- Whichever skin incision is chosen, define the adductor tendons, including the longus and gracilis, by blunt dissection after longitudinally opening the fascia. Completely release the longus and gracilis at their origins as proximally as possible. Next, assess the range of passive abduction. If this is not at least 40°, further release is necessary, including the brevis and pectineus. If still it is tight, the medial hip capsule may need to be divided transversely.
- Because the anterior branches of the obturator nerve lie on the anterior surface of the adductor brevis, always identify the nerve before releasing much of the brevis. Only in the nonwalking patient with severe involvement is a segment of the nerve (usually two or three branches) removed. I often use a small suction drain for the rather considerable dead space.
- Maintain postoperative abduction for 2–3 weeks, using two long-leg casts with a bar between them. Recently, I have used just two knee immobilizers with an abduction pillow, allowing immediate weight bearing and mobilization if there was no simultaneous bony surgery requiring a cast.

### *Complications*

The most common problem with adductor release is expecting too much and doing too little. If there is a pelvic obliquity from scoliosis and the “higher” femoral head is luxating, adductor release alone will not maintain hip reduction unless the structural scoliosis and obliquity are controlled. If there is any evidence of early hip subluxation (even with a level pelvis), the iliopsoas must be lengthened.

## FLEXION DEFORMITY

A mild degree of fixed hip flexion deformity is normal in neonates. In the spastic CP patient, this flexion deformity may persist or gradually worsen, especially if the patient is a nonwalker. Spasticity of the iliopsoas is the main cause of the deformity, although every muscle that passes anterior to the transverse axis of the hip contributes to hip flexion. Clinical measurement of hip flexion deformity is best performed by the prone-lying Staheli test (28). The better-known Thomas test is affected more by spasticity of the contralateral side, which tends to roll the pelvis as the opposite limb is flexed. This makes it difficult to ascertain the neutral position of the pelvis.

Radiographic assessment of hip flexion deformity is made by measuring the lateral sacrofemoral angle on films taken with the patient prone or supine and the hips maximally extended. The sacrofemoral angle is that formed between the top of the sacrum and the axis of the extended femoral shaft. The normal angle is 40° to 60°, which decreases with hip flexion deformity. Fixed hip flexion deformity causes the patient to stand with either a lordotic spine and fairly straight knees or a flat back and crouched knees. In either case, the sacrofemoral angle is reduced (3).

### *Indications for Surgery*

Iliopsoas weakening is indicated in walkers with radiographically normal hips if fixed hip flexion is greater than 15°. Release or lengthening of the psoas is also a part of correction of any degree of hip subluxation in CP. Usually, whenever a derotation osteotomy is performed for excessive anteversion, the iliopsoas should be lengthened or recessed. In nonwalkers, a simple complete distal tenotomy (usually performed with an adductor release) can be made through either a Ludloff incision or an anterior bikini incision. In patients with bilateral flexion deformities but fixed, windblown hips, adductor release is performed only on the adducted (high) side. The iliopsoas is released bilaterally. In the rare case when there is truly limited adduction on the abducted side of the pelvis (the down hemipelvis), the origins of the tensor and the gluteus medius and minimus are also released on the abducted side.

In most cases of ambulatory CP patients, I prefer a simple oblique tenotomy of the psoas tendon as far proximally as possible, where there are still abundant investing iliacus muscle fibers. This has the net effect of markedly weakening the psoas while only moderately weakening the iliacus portion. No sutures are required, making it simpler than the formal recession, as no suture repair is necessary. This is similar to what most surgeons usually do in performing open reduction of congenitally dislocated hips in otherwise normal children.

### *Iliopsoas Recession or Lengthening*

- I perform an iliopsoas recession or lengthening through the usual bikini anterior incision by identifying the interval between the sartorius and the iliacus, assuming no acetabular procedure or open reduction is necessary (Fig. 177.6). Visualize and protect the lateral femoral cutaneous nerve deep to the enveloping fascia exiting the pelvis on the anterior surface of the sartorius just medial to the anterosuperior iliac spine. Do not detach the sartorius. On the other hand, if the psoas lengthening is a part of an open reduction or acetabular procedure, use the more extensile standard Smith-Peterson anterior interval between the sartorius and the tensor fascia muscle.

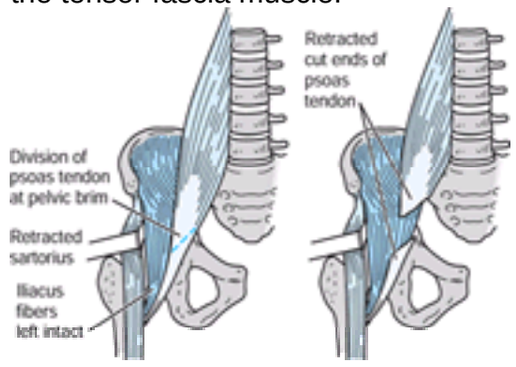


***Figure 177.6.*** Iliopsoas lengthening at the pelvic brim.

- Locate the femoral nerve on the anterior surface of the iliacus but deep to the iliacus fascia, and retract it gently medially with a blunt retractor. The psoas tendon is deep in the iliacus muscle fibers and tightly applied to the anterior medial hip capsule. Isolate the tendon proximally, separating it from the muscle fibers of the iliacus, and divide it at the pelvic brim (30).
- In performing a formal recession, flex and externally rotate the hip so that the tendon can be followed distally to the lesser trochanter where the entire tendon is detached. Free the conjoined muscle–tendon unit from the anterior hip capsule and reattach it with two heavy sutures more proximally on the anterior capsule (2). The net effect is to decrease the mechanical advantage of the iliopsoas muscle by placing the insertion closer to the axis of hip flexion.

### *Postoperative Care*

Postoperatively, avoid prolonged hip flexion for 3 weeks. This is most easily accomplished by applying two long-leg casts. If bilateral adductor release has also been done, place a broomstick bar between the casts to maintain abduction. The patient is cared for in the prone, the supine, or even a standing position as long as hip flexion is avoided, except briefly for meals, transport, and so forth. If the patient underwent an open reduction, some type of spica cast will be necessary for at least 6 weeks. If the hips were windblown before surgery, two long-leg casts with a spreader bar can be used, but instruct the parents to maintain the hips windblown to the opposite direction. If the pelvis is level and only soft-tissue procedures have been done, I now prefer to mobilize the patient immediately postoperatively, so I use just knee immobilizers and an abduction pillow at night.

### *Complications*

There should not be any confusion between the femoral nerve and the psoas tendon. Distal tenotomy of the entire psoas tendon severely weakens hip flexion and should not be done in a child who can or potentially might be an independent, crutch-free walker. One should expect that in most patients younger than 7 years without severe scoliosis or pelvic obliquity, a psoas and adductor release performed in the presence of no more than mild hip dysplasia will prevent subsequent dislocation. There is not universal agreement as to whether postoperative nighttime abduction bracing is necessary. However, I recommend at least 3–6 months of abduction bracing using a foam wedge or abduction brace if there is any radiographic evidence of dysplasia (14).

When there is severe preexisting pelvic obliquity, severe acetabular dysplasia, or another type of secondary bony change (typically in patients older than 8–10 years), correction of the scoliosis or acetabular reconstruction must be performed to maintain hip reduction; muscle release alone will be insufficient in such cases. Most commonly, for patients 6 years or older, with mild to moderate degrees of acetabular dysplasia, I will add a Dega-type pelvic osteotomy (19) or Staheli acetabular augmentation (shelf)-type procedure (32).

## INTERNAL ROTATION DEFORMITY

### *Indications for Surgery*

Excessive medial femoral torsion (increased femoral anteversion) is very common in spastic CP. It manifests as internal rotation deformity, mainly in walkers. In spastic patients who are only sitters, the excess anteversion contributes to hip dysplasia and dislocation, but the internal rotation is not so apparent with the patient in the sitting position. The cause of the increased anteversion is probably muscle imbalance of more than just the psoas; the iliopsoas is nearly always contracted in patients with excessive hip anteversion and internal rotation gait. In normal patients, the anterior fibers of the gluteus medius and minimus and the tensor are the main hip internal rotators. This fact has encouraged Steel (29) to perform anterior transfer of the trochanteric insertion of the gluteus medius and minimus for internal rotation gait, converting abductors to external retractors. In general, I do not favor this operation because it carries the risk of weakening the abductor mechanism, thus possibly trading an internal rotation deformity for a Trendelenburg limp. Furthermore, the operation is indicated only in patients with no flexion contracture (i.e., a normal iliopsoas) and spastic abductors—a situation seldom encountered.

My preferences for correction of internal rotation gait are based on patient age and ambulator status. In patients 4–8 years of age, I usually perform adductor release and iliopsoas intramuscular lengthening or recession, and I follow the patient for a number of years. In most patients, the excessive internal rotation will gradually improve as the hip flexion contracture and adduction tendency improve and the anteversion decreases. After 8–10 years of age, if the patient is still ambulating with an excessive internal rotation gait, I usually prefer subtrochanteric derotation osteotomy using the AO-ASIF (Association for the Study of Internal Fixation) technique. In many cases, little varusization is needed because the “coxa valga” seen on radiographs is more apparent than real, and it will disappear with derotation alone.

### *Subtrochanteric Derotation Osteotomy*

- Perform the operation on the image intensifier table with the patient supine and the leg draped free. Place a small folded blanket or towel under the buttocks so that the prep and exposure will be sufficiently proximal and posterior.
- Make a standard lateral approach to the proximal femur and insert three guide pins: one for the chisel alignment, one more proximal in the greater trochanter to be used as a joy stick to control the proximal fragment, and one distal to the end of the plate to control rotation. Typically, the distalmost pin will be inserted at an angle of 30° to 45°, internally rotated in relation to the proximalmost pin (Fig. 177.7).

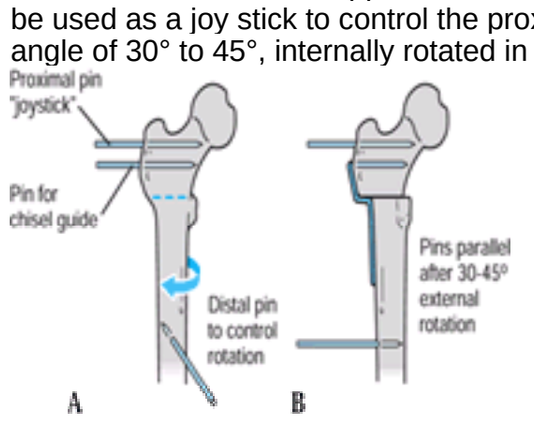


***Figure 177.7.*** Use of pins to control rotation.

- Make sure that the femur is circumferentially exposed subperiosteally in the area of the planned osteotomy. Insert the appropriate child or adolescent blade chisel into the greater trochanter along the course of the first pin so that the osteotomy can be cut through the middle of the lesser trochanter. Always use the chisel guide; otherwise, there is a tendency to angle the blade so that the shaft of the plate is placed in flexion.
- Confirm the chisel position with the image intensifier; remove the chisel halfway through, and complete the osteotomy with an oscillating saw. Rotate the distal fragment externally using the preplaced pins as a guide. If increased varus is desired, remove a small wedge medially, which is one half of the shaft diameter after derotating. Insert the blade plate using the bone-holding forceps to maintain reduction. I use the dynamic compression feature of the plate to close the osteotomy further. At least 20° to 30° of residual internal rotation should be left after the derotation (i.e., the distal fragment should not be excessively externally rotated). Varus should be added to the osteotomy only when there is a true valgus deformity of the femoral neck, and when there is an abundant range of abduction. Each added degree of varus is equivalent to adding 1° of adduction and subtracting 1° of abduction.

If hamstring lengthening is contemplated, the femur may easily be derotated through the lateral hamstring exposure incision. Use a six-hole plate, as described in Chapter 168.

If preoperatively there was no subluxation, and neither acetabular reconstruction nor capsulorrhaphy has been performed, then no cast is needed. Manage the patient in a wheelchair for 4–6 weeks, allowing gentle motion. Then allow partial weight bearing with crutches or a walker until healing of the bone is secure, usually at about 3 months. Most commonly in CP, some other acetabular work will have been done, so a spica cast will be necessary. The spica cast should usually be placed in nearly full hip extension and moderate abduction. Iliopsoas recession or release is usually performed prior to or simultaneously with the subtrochanteric osteotomy.

One potential pitfall is failure to consider concomitant excessive external tibial torsion. In such a case, following femoral derotation, the foot will point excessively laterally unless a simultaneous internal derotation is performed on the tibia (3).

## SUBLUXATION AND DISLOCATION OF THE HIP

Hip dislocation generally occurs in nonwalkers with total body involvement, whereas in those patients who walk with crutches, the deformity more often progresses only to subluxation. However, even patients who are independent ambulators may develop complete dislocations. The etiology of the dislocation is a combination of excessive femoral anteversion with persistent spastic adduction and flexion, often associated with pelvic obliquity secondary to structural scoliosis. Dislocation has been alleged to cause scoliosis, seating problems, decubiti, fractures, and difficulties with perineal care (5,12,14,19,20,26). Although hip dislocation is associated with all these problems, they are in fact caused not by the dislocation but by the muscle imbalance and the rigidity of the hip contracture. Furthermore, for CP adults, the status of hip location per se is not as important a determinant of walking ability as having reasonable cognitive function, balance, and a level pelvis with mobile hips.

### *Indications for Surgery*

Not all severely subluxated or dislocated spastic hips will cause pain, although probably at least half will be symptomatic. The ability for a severely involved patient to sit comfortably probably has as much to do with the enthusiasm and motivation of the people caring for him as it does with whether his hip is radiographically reduced. Thus, it is not always necessary to treat older patients with spastic dislocated hips (20).

On the other hand, it is always desirable to maintain range of motion and prevent subluxation by appropriate early soft-tissue release and bracing in younger patients. The following guidelines and prerequisites are suggested for decision making for surgical correction of spastically dislocated hips:

1. Prevention of hip dislocation by early soft-tissue release is easier and more effective than late reconstructions (14).
2. The degree of reconstruction is determined by the degree of dysplasia. That is, to relocate a completely dislocated hip in an 8-year-old CP patient will usually require at least a femoral osteotomy, possibly a pelvic osteotomy, as well as soft-tissue release.
3. Soft-tissue release is always necessary whenever bony reconstruction is planned.
4. Femoral varus osteotomy, although still useful in maintaining reduction, cannot be counted on to induce acetabular development in patients older than 8 years. The femoral neck–shaft angle should not be placed in excessive varus (i.e., leave at least 110°).
5. Femoral shortening is a useful adjunct to relocating a high-riding dislocation without tension. This is far preferable to any type of traction, which is generally poorly tolerated by CP patients.
6. For patients older than 8 years with hip dysplasia and dislocation, acetabular reconstruction usually will be necessary (3,9,19,32). Although nearly all types of pelvic osteotomies have been performed in the past, including Salter and Pemberton procedures, the most useful include the Dega and Chiari osteotomies and the shelf procedure (acetabular augmentation). The shelf procedure can be added to any other pelvic osteotomy should additional femoral head coverage be necessary.
7. A severely deformed femoral head with absent cartilage should not be relocated. A painful located hip is probably no better than a painful dislocated hip. This is common in patients older than 10 years with a chronically subluxated hip.
8. Always try to keep spica cast immobilization to a minimum.
9. Finally, do not attempt relocation of a unilateral hip dislocation using hip surgery alone if a severe scoliosis with fixed pelvic obliquity is present. The pelvis should probably be leveled first.

In those patients 8 years or older with a fully dislocated spastic hip, my typical correction would consist of, in one stage, a femoral shortening and Chiari osteotomy with a supplemental shelf. Very little varus would be added to the femur, and appropriate soft-tissue release (e.g., adductors, psoas) and anterior branch obturator neurectomy would also be performed (Fig. 177.8). In the more common 6- to 10-year-old spastic patient with moderate dysplasia but without frank dislocation, I do extensive soft-tissue release and a Dega osteotomy, or possibly an acetabular augmentation. I find the advantages to be no retained hardware, technical simplicity, the possibility of doing both hips simultaneously, and consistently satisfactory results (Fig. 177.9). In a patient under 6 years with a unilateral dislocation, a soft-tissue release with femoral derotation and shortening is performed, with the occasional addition of a pelvic osteotomy or shelf procedure (Fig. 177.10).

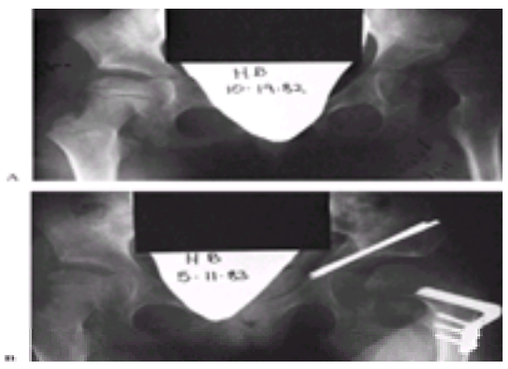

***Figure 177.8.*** **A:** A 9-year-old child with spastic cerebral palsy and severe dislocation of left hip. **B:** The same child after Chiari osteotomy and varus osteotomy.

***Figure 177.9.*** **A:** A 7-year-old with spastic cerebral palsy and a unilateral dysplastic left hip. **B:** The same child after acetabular augmentation and iliopsoas and adductor release.

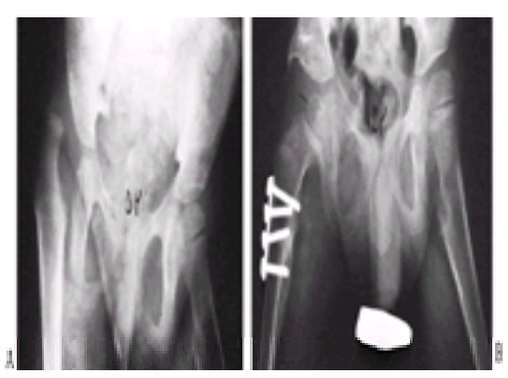

***Figure 177.10.*** **A:** A 4-year-old child with spastic cerebral palsy and complete dislocation of the right hip. **B:** Following open reduction, femoral osteotomy, Pemberton procedure, and adductor and psoas release.

The Dega procedure is similar to a Pemberton osteotomy in that both are periacetabular incomplete innominate osteotomies that bend down the superior portion of the acetabular roof. The main difference is that the hinge for acetabular roof redirection is medial with the Dega (so that the added coverage is more superolateral), whereas with Pemberton's osteotomy the hinge is more posteriomedial (so that the coverage is more anterolateral). I prefer the Dega procedure in cases of CP because it more adequately deals with the usual elongated acetabulum with superolateral deficiency.(Fig. 177.11).

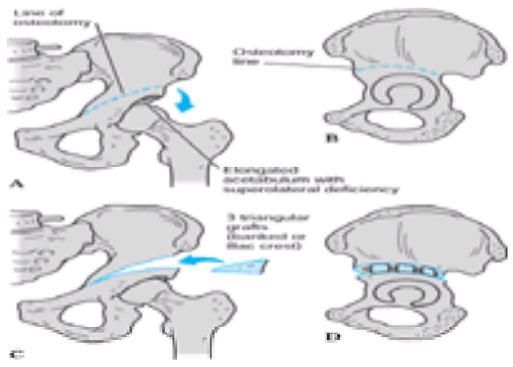


***Figure 177.11.*** Dega osteotomy.

### *Dega Osteotomy*

Usually, a medial adductor and psoas release is performed first, often with a femoral shortening and/or varus osteotomy if necessary for reduction (19). Use an image intensifier with the leg draped free.

- Perform the Dega osteotomy through the standard anterior bikini incision with the iliac apophysis split and the iliac wing exposed both medially and laterally. I usually do not separately detach the sartorius but leave it attached to the medial half of the apophysis and abdominal muscles. Release the origin of the direct head of the rectus tendon and peel off the reflected head from the superior capsule. Place blunt retractors superior and inferior to the capsule for a wide exposure.
- If there is dysplasia but no significant subluxation, the capsule does not have to be opened. However, subluxated or dislocated hips require a standard acetabular debridement and capsulorraphy.
- The Dega osteotomy itself is performed from directly lateral, on a line from the middle of the anterior inferior iliac spine to the sciatic notch. Use a series of curved osteotomes after initiating the cut with a saw or high-speed cutting tool. Aim the osteotomy cuts medially and inferiorly, extending to but not through the medial cortex near the triradiate cartilage, as monitored on the image intensifier. Both anterior and posterior corners of the osteotomy need to be completed to the medial wall. Anteriorly, this is easy to do, as it is under direct visualization. Posteriorly, place a blunt Hohmann retractor in the notch, and use a 45° Kerrison rongeur to complete the posterior corner of the osteotomy from lateral.
- Next, insert a wide, curved osteotome into the osteotomy and lever the superior portion of the acetabulum in a caudal direction until the relatively vertical lateral acetabulum has been brought to a more horizontal position. There will now be a lateral gap at the osteotomy site of 1–1.5 cm. To hold the osteotomy open, use two or three bicortical triangular grafts from the anterior crest (or occasionally from the femoral varus osteotomy, if done). No internal fixation is necessary. When performed correctly, the osteotomy will be remarkably stable because of the intact medial column.
- After routine closure, apply a hip spica cast and leave it in place for 6 weeks.

### *Shelf Procedure*

The technique for a shelf procedure is as follows (32):

- Make a standard anterior approach to the hip using a slightly extended bikini incision. Expose subperiosteally the entire outer wing of the ilium. Isolate the direct head of the rectus tendon but leave it intact; detach and tag the reflected head where it veers off the direct head just below the anterior inferior spine.
- Perform a proximal psoas lengthening or tenotomy simultaneously with any other necessary adductor release. Expose the hip capsule extensively, as for an open reduction. Tease the reflected head of the rectus femoris tendon as far posteriorly as possible, at least to a position of approximately 1 or 2 o'clock. This can be done easily more anteriorly, but it will require sharp dissection from where the origin of the reflected head blends with the capsule posteriorly.
- Thin the superior capsule near the bone of the lateral wall of the ilium using a scalpel and curet. Make a series of drill holes or use a high-speed burr to create a gently curved slot over the superior dome of the acetabulum. Either plain film radiographic control or image intensification is mandatory to confirm that the slot is created far enough inferiorly. Ideally, the slot should be just proximal to the acetabular cartilage; there is always a tendency to create the slot several millimeters too far superiorly. (*Hint*: Continue thinning the superior capsule against the lateral iliac cortex until a fine line of cartilage is just visible.) The hip joint itself is usually not entered despite the ease with which the femoral head may be palpated thorough the capsule.
- After creating the slot, harvest abundant corticocancellous strips with a gouge from the outer wall of the ilium. It is perfectly acceptable to take a full-thickness graft from the crest in the area just behind and including the anterior superior spine. This will facilitate closure, although it will diminish the normal pelvic contours. It is important, however, that the bone graft be no thicker than unicortical when placed, so that it will mold to the convexity of the femoral head.
- Pack the grafts into the slot, first in a radial direction and then perpendicularly. Bring the previously tagged reflected head of the rectus back over the entire mass of bone graft, helping to seat it, and anchor it on the superior capsule. Tie the reflected head of the rectus back to the original straight head of the rectus. The purpose of retying the reflected head is simply to hold the graft in place.
- Closure is routine. A single spica cast may be used if the patient is hemiplegic or if the opposite hip has a fixed abduction contracture. However, it is usually preferable in patients with CP to use a one-and-a-half spica or a double spica cast if both hips are done simultaneously.

### *Pitfalls*

The graft for a shelf must be placed at least part way posterior as well as superior. It is easier to pack grafts superiorly and anteriorly, but it is probably more important in a sitting patient to cover the posterosuperior femoral head. It is possible to pack too much graft over the femoral head. In this situation, abduction will be limited, although one would expect remodeling to eventually occur. An acetabular augmentation is usually not needed in a very young patient, 4 years or younger. If it is placed, one cannot expect the augmented portion of the acetabulum to enlarge because there is no growth cartilage in the shelf itself. Therefore, the femoral head as it grows may gradually “outgrow” its socket.

### *Salvage Procedures*

If the femoral head is severely deformed and the patient is skeletally mature with a high-riding dislocation, the alternatives are arthrodesis, resectional arthroplasty, or total hip arthroplasty. None of these procedures is highly desirable for the majority of patients (3,12). All are salvage procedures, and all have considerable complications. Femoral head and neck resection usually improves perineal care in the adult patient with a severe high-riding dislocation and severe contracture. However, subsequent heterotopic ossification is common, and some of the patients still have pain despite femoral head and neck resection. In such cases, it is desirable to interpose some type of soft tissue, such as by closing the hip capsule or by sewing the psoas tendon to the stump of the proximal femur. There is no agreement as to how much of the femur to resect, but it should certainly be enough to allow a full range of motion. This usually means that the resection must be down to the level above, at, or just below the lesser trochanter. This is certainly much more bone resection than would be done in any other Girdlestone-type resection. The patient should not be immobilized in a spica cast but may be placed in skeletal traction for 2 weeks. If the patient will tolerate it, an articulated external fixator is a reasonable alternative. As femoral head and neck resection is a salvage procedure, perform it only in total-care, severely involved patients to improve nursing care and comfort.

## CHAPTER REFERENCES

Each reference is categorized according to the following scheme: *, classic article; #, review article; !, basic research article; and +, clinical results/outcome study.


* 1. Banks HH, Green WT. Adductor Myotomy and Obturator Neurectomy for the Correction of Adduction Contracture of the Hip in Cerebral Palsy. *J Bone Joint Surg Am* 1960;42:11.

* 2. Bleck EE. Postural and Gait Abnormalities Caused by Hip-Flexion Deformity in Spastic Cerebral Palsy: Treatment by Iliopsoas Recession. *J Bone Joint Surg Am* 1971;53:1468.

\# 3. Bleck EE. *Orthopaedic Management in Cerebral Palsy.* London: MacKeith Press, 1987.

\+ 4. Carr C, Gage GR. The Fate of the Nonoperated Hip in Cerebral Palsy. *J Pediatr Orthop* 1987;7:262.

\+ 5. Cooperman DR, Bartucci E, Dietrick E, Millar EA. Hip Dislocation in Spastic Cerebral Palsy: Long-Term Consequences. *J Pediatr Orthop* 1987;7:268.

\+ 6. Couch WH, DeRosa GP, Throop FB. Thigh Adductor Transfer for Spastic Cerebral Palsy. *Dev Med Child Neurol* 1977;19:343.

+ 7. Dennyson WG, Fulford GE. Subtalar Arthrodesis by Cancellous Grafts and Metallic Internal Fixation. *J Bone Joint Surg Br* 1976;58:507.

# 8. Gage JR. Surgical Treatment of Knee Dysfunction in Cerebral Palsy. *Clin Orthop* 1990;253:45.

# 9. Gamble JG, Rinsky LA, Bleck EE. Established Hip Dislocations in Children with Cerebral Palsy. *Clin Orthop* 1990;253:90.

! 10. Garbarino JL, Clancy M. A Geometric Method of Calculating Tendoachilles Lengthening. *J Pediatr Orthop* 1985;5:573.

+ 11. Green NE, Griffin PP, Shiavi R. Split Posterior Tibial Tendon Transfers in Spastic Cerebral Palsy. *J Bone Joint Surg Am* 1983;65:748.

+ 12. Hoffer MM, Abram E, Nickel VL. Salvage Surgery at the Hip to Improve Sitting Posture of Mentally Retarded, Severely Disabled Children with Cerebral Palsy. *Dev Med Child Neurol* 1972;14:51.

+ 13. Hoffer MM, Barakat G, Koffman M. Ten-Year Followup of Split Anterior Tibial Tendon Transfer in Cerebral Palsied Patients with Spastis Equinovarus Deformity. *J Pediatr Orthop* 1985;5:432.

+ 14. Kalen V, Bleck EE. Prevention of Paralytic Dislocation of the Hip. *Dev Med Child Neurol* 1985;27:17.

+ 15. Kling TF, Kauffer H, Hensinger RN. Split Posterior Tibial Tendon Transfers in Children with Cerebral Spastic Paralysis and Equinovarus Deformity *J Bone Joint Surg Am* 1985;67:186.

+ 16. Koman LA, Mooney JF, Smith BP, et al. Management of Spasticity in Cerebral Palsy with Botulinum-A Toxin: Report of a Preliminary, Randomized, Double-Blind Trial. *J Pediatr Orthop* 1994;14:299.

+ 17. Loder RT, Harbuz A, Aronson DD, Lee CL. Postoperative Migration of the Adductor Tendon after Posterior Adductor Transfer in Children with Cerebral Palsy. *Dev Med Child Neurol* 1992;34:787.

+ 18. Mosca VS. Calcaneal Lengthening for Valgus Deformity of the Hindfoot: Results in Children Who Had Severe, Symptomatic Flatfoot and Skewfoot. *J Bone Joint Surg Am* 1995;77:500.

+ 19. Mubarak SJ, Valencia FG, Wenger DR. One-Stage Correction of the Spastic Dislocated Hip. *J Bone Joint Surg Am* 1992;74:1347.

+ 20. Pritchett JW. The Untreated Unstable Hip in Severe Cerebral Palsy. *Clin Orthop* 1983;173:169.

* 21. Reimers J. Contracture of the Hamstrings in Spastic Cerebral Palsy: A Study of Three Methods of Operative Correction. *J Bone Joint Surg Br* 1974;56:102.

+ 22. Reimers J, Poulsen S. Adductor Transfer versus Tenotomy for Stability of the Hip in Spastic Cerebral Palsy. *J Pediatr Orthop* 1984;4:52.

# 23. Renshaw TS, Green NE, Griffin PP, Root L. Cerebral Palsy: Orthopaedic Management. *Instr Course Lect* 1996;45:475.

# 24. Rosenthal RK, Simon SR. The Vulpius Gastrocnemius-Soleus Lengthening. In: Sussman M, ed. *The Diplegic Child.* Rosemont, IL: American Academy of Orthopaedic Surgeons, 1992:355.

* 25. Ruda R, Frost HM. Cerebral Palsy: Spastic Varus and Forefoot Adductus, Treated by Intramuscular Posterior Tibial Tendon Lengthening. *Clin Orthop* 1971;79:61.

# 26. Sherk HH, Pasquariello PD, Doherty J. Hip Dislocation in Cerebral Palsy: Selection for Treatment. *Dev Med Child Neurol* 1983;25:738.

* 27. Silver CM, Simon SD, Lichtman HM. Long-term Follow-up Observations on Calcaneal Osteotomy. *Clin Orthop* 1974;99:181.

* 28. Staheli L. The Prone Hip Extension Test. *Clin Orthop* 1977;123:1215.

+ 29. Steel HH. Gluteus Medius and Minimus Insertion Advancement for Correction of Internal Rotation Gait in Spastic Cerebral Palsy. *J Bone Joint Surg Am* 1980;62:919.

+ 30. Sutherland DH, Silberfarb JL, Kaufman KR, et al. Psoas Release at the Pelvic Brim in Ambulatory Patients with Cerebral Palsy: Operative Technique and Functional Outcome. *J Pediatr Orthop* 1997;17:563.

+ 31. Townsend DR, Wells L, Lowenberg D. The Cincinnati Incision for the Split Posterior Tibial Tendon Transfer: A Technical Note. *J Pediatr Orthop* 1990;10:667.

+ 32. Zuckerman JD, Staheli LT, McLaughlin JF. Acetabular Augmentation for Progressive Hip Subluxation in Cerebral Palsy. *J Pediatr Orthop* 1984;4:436.

# CHAPTER 178

# MUSCLE AND NERVE DISORDERS IN CHILDREN

*William G. Mackenzie and J. Richard Bowen*

**W. G. Mackenzie:** Assistant Professor, Jefferson Medical College, Wilmington, Delaware, 19899.
**J. R. Bowen:** Professor, Jefferson Medical College; Surgeon in Chief of duPont Hospital for Children, Wilmington, Delaware, 19899.

Diagnosis of Muscle and Nerve Disorders
History and Physical Examination, Laboratory Tests
Investigation
Genetic Analysis
Electromyography
Nerve Conduction Studies
Malignant Hyperthermia
Muscle Biopsy
Nerve Biopsy
Common Muscle Disorders with Orthopaedic Deformities
Benign Congenital Myopathies of Childhood
Muscular Dystrophy
Myotonic Syndromes
Common Nerve Disorders with Orthopaedic Deformities
Peripheral Neuropathies
Spinal Muscular Atrophy
Poliomyelitis
Arthrogryposis
Chapter References

The hallmark of a muscle or nerve problem is weakness, but signs such as delayed motor development, fatigability, muscle cramps during activity, muscle wasting, and orthopaedic conditions such as cavus feet, claw hands or toes, a long C-shaped scoliosis, and dynamic scapular winging are often seen (111). Most muscle and nerve disorders can be diagnosed by a careful history and physical examination, and by specific laboratory tests, electromyography, nerve conduction studies, muscle and nerve biopsies, and genetic evaluation.

## DIAGNOSIS OF MUSCLE AND NERVE DISORDERS

### HISTORY AND PHYSICAL EXAMINATION, LABORATORY TESTS

Each symptom in the patient's history must be pursued to determine its onset, duration, exacerbating or relieving factors, and response to any treatment. The history can provide important clues to help in the diagnosis. Was the weakness present at birth or of recent onset and is it progressive? Weakness present at birth but not progressive may describe a child with a congenital myopathy, whereas onset of weakness in a young boy with gradual worsening is typical of muscular dystrophy. Detecting muscle weakness, usually by observation or muscle testing, is a major component of the clinical examination. Generalized muscle weakness results in hypotonia (floppiness), ptosis, a tent shaped mouth (bouche de tapir) and delayed motor development. Localized muscle atrophy is often observed at the shoulder girdle and the quadriceps muscle.

Strength can be evaluated by observing activities such as walking, dressing or undressing, and by testing individual muscles. Grading of activity-related muscle strength is a good screening method, especially in young, uncooperative patients. The activities are considered by regions: the hips, legs, shoulders, arms, and bulbar area (ie, respiratory function). Weakness can result in delayed development of the motor milestones (e.g., head control, sitting, crawling, standing, walking, running), Meryon's sign (i.e., reduced muscle resistance of the shoulder against the examiner's hand when lifted under the arms), Gowers' sign (i.e., use of the hands to “climb up the legs” to a standing position when rising from a sitting position on the floor), and difficulty in climbing steps or rising from a chair (117,137,229). A 5-year-old boy with Duchenne muscular dystrophy may have a normal walk but when asked to run, the pelvic girdle and quadriceps weakness is quickly unmasked.

Evaluation of muscle strength is an excellent means of localizing the distribution of weakness, but it requires patient cooperation and can be difficult if there are associated fixed deformities. Agonist muscles (ie, prime movers) and antagonist muscles (ie, stabilizers) are graded for strength through the range of joint mobility. For example, the muscles controlling the foot may be tested for strength in dorsiflexion, plantar flexion, inversion, and eversion.

Although individual muscle testing is time consuming, tedious, and almost impossible in young, uncooperative children, it is essential as a baseline study for patients with suspected muscle or nerve disease. Muscle testing often is better performed in a special therapy session in which adequate time can be allotted. The Medical Research Council scale is generally accepted and grades muscle power as follows: 0, no contraction; 1, flicker or trace of contraction; 2, active motion with gravity eliminated; 3, active motion against gravity; 4, active motion against gravity and resistance; and 5, normal power (226). Myometric (dynamometric) methods are also useful in quantitating muscle strength, especially in evaluating therapeutic techniques (97).

Deep tendon reflexes of the biceps, triceps, knee, and ankle should be tested, along with the superficial reflexes of the abdomen and the great toe plantar response. The quality of reflex is judged by the briskness of muscle contracture and is best graded as absent, hypoactive, normal, or hyperactive. Children with spinal muscular atrophy and peripheral neuropathies typically have absent reflexes, whereas myopathic disorders such as muscular dystrophy have reflexes until later in the course of the disease.

The sensory examination includes the evaluation of pain, light touch, deep touch, two-point tactile, vibration, and temperature. Self-mutilation and Charcot joint changes are almost always manifestations of sensory loss. In neuropathies, multiple modalities may be affected, producing a “glove” or “stocking” distribution of loss, paresthesia, “pins and needles” sensation, and dysesthesia. Bulbar involvement is evaluated by cranial nerve testing. Cerebellar testing, particularly the Romberg sign for ataxia, is important when the differential diagnosis includes Friedreich's ataxia.

Muscle fasciculation, best seen by looking at the tongue or hands, is common in neuropathic disorders such as spinal muscular atrophy.

### INVESTIGATION

#### *Serum Enzymes*

The serum enzymes elevated in muscle disorders include the aminotransferases (transaminases), aldolase, lactate dehydrogenase, and creatine phosphokinase (CPK). The serum CPK level is a sensitive and valuable screening test to demonstrate disease of striated muscle (343). Skeletal muscle, heart muscle, and brain tissue contain CPK, which catalyzes the release of phosphate from creatine phosphate. The high CPK level seen in Duchenne's muscular dystrophy (50 to 100 times normal) and other muscle disorders represents leakage from the muscle cell during necrosis. Aldolase and serum glutamic-oxaloacetic transaminase levels also may be elevated in muscle disease but are not as sensitive as the CPK level (352) and are also elevated by hepatic dysfunction.

### GENETIC ANALYSIS

Recent advances in molecular genetics have greatly enhanced our knowledge of the gene abnormalities causing neuromuscular diseases (Table 178.1). This

information should eventually result in more effective management of these disorders.

| *Chromosomal disorder* | *Location* | *Reference* |
|---|---|---|
| Duchenne and Becker's muscular dystrophy | Xp21.2 | Cell 51:509, 1987<br>Ann Rev Genet 1988<br>Proc Jap Acad 1988<br>Neuron 2:1019, 1989<br>Nature 344:65, 1990 |
| Emery-Dreifuss dystrophy | Xq28 | Am Acad Neur Course 240 |
| Fascioscapulohumeral dystrophy | 4q35 | Lancet 336:651, 1990 |
| Myotonic dystrophy | 19q13 | Proc Natl Acad Sci 1982<br>Neurology 36:1146, 1986 |
| Charcot-Marie-Tooth | | Hum Genet 34:388, 1981 |
| Type I | 17p11.2 | Ann Neurol 14:679, 1983 |
| Type II | 8p35–p36 | Exp Neurol 104:186, 1989 |
| Spinal muscular atrophy | | |
| Bulbar type | Xq21.3-12 | Science 237:120, 1987 |
| Chronic childhood | 5q11.2–13.3 | Nature 344:768, 1990 |
| Friedreich's ataxia | 9q21 | Am Acad Neur Course 240 |
| Huntington's disease | 4 | Nature 304:234, 1983 |
| McArdle's disease | 11 | Nature 1987 |
| Wilson's disease | 13 | Am Acad Neur Course 240 |

***Table 178.1. Gene Location of Some Neuromuscular Disorders***

Molecular genetic techniques have been used to define other rare neuromuscular disorders in children. Metabolic myopathies, which are caused by abnormalities of glycogen, glucose, or lipid metabolism, have been well characterized. Mitochondrial DNA defects or mutations cause a broad spectrum of mitochondrial encephalomyopathies, which feature variable weakness with encephalopathic, cardiac, and visceral manifestations.

***Cardiac and Pulmonary Evaluation***

Cardiac and pulmonary abnormalities are very common in children with neuromuscular disease. Careful evaluation allows optimal daily management and an assessment of preoperative risks.

Electrocardiography and echocardiography are used to evaluate cardiac function (66). Patients with muscular dystrophy may develop cardiomyopathy or mitral valve prolapse secondary to papillary muscle weakness. Children with Friedreich's ataxia, Emery-Dreifuss dystrophy, and infantile myasthenia gravis may have arrhythmias (99,113,166,288,295,378).

Pulmonary compromise so commonly seen in these patients can be assessed by questions about shortness of breath, frequency of pulmonary infections, and more objectively, by pulmonary function or sleep studies.

**ELECTROMYOGRAPHY**

Electromyographic (EMG) studies can differentiate a neuropathy from a myopathy but are seldom specific. A normal muscle is silent at rest and produces an interference pattern at maximal activity. In neuropathies, fibrillations and fasciculations occur at rest and the interference pattern is reduced at maximal activity. In myopathies, the muscle is silent at rest and has polyphasic individual potentials of low amplitude and short duration during activity. Myotonia frequently presents as a classic pattern of spontaneous bursts of potentials that wax and wane and give an acoustic pattern resembling a dive bomber. Muscle evaluation should include the areas of the body involved in the weakness, and examination of four muscles is usually sufficient. The deltoid and vastus lateralis are good muscles to study in children, because they are frequently involved in neuromuscular diseases of childhood. In myopathies, there may be no correlation between the severity of the muscle weakness and the electromyography.

**NERVE CONDUCTION STUDIES**

Nerve conduction velocities depend on the degree of myelination and the diameter of the neuron. The median, ulnar, peroneal, and posterior tibial nerves most commonly are studied, and normal adult values are 45 to 65 m/sec. In infants, the velocity is about half that of the adult level, which is reached by 3 to 5 years of age (235). Motor conduction velocity typically is delayed in demyelinating neuropathies but is normal in anterior horn cell disease, root disease, or myopathies. Repetitive stimulation of the motor nerve can reveal pathologic fatigability, as in myasthenia gravis (34). Sensory conduction velocities are delayed and occasionally are helpful in diagnosing the mixed neuropathies, such as peroneal muscle atrophy or Friedreich's ataxia.

**MALIGNANT HYPERTHERMIA**

Malignant hyperthermia is characterized by muscle rigidity and necrosis associated with a rapid rise in body temperature (82,219,274). One in about 15,000 people in the general population develops malignant hyperthermia during general anesthesia. Although it has been reported to be associated with many disorders including the congenital myopathies, muscular dystrophy, osteogenesis imperfecta, myelomeningocele, and King's syndrome (ie, short stature, scoliosis, cryptorchidism, pectus carinatum, characteristic facial features) (82,174,175,189,225,328,336,360), it is mainly associated with central core myopathy, with which it is closely linked. There is an abnormality of the ryanodine receptor gene at the 19q13.1 locus (121).

These reactions of malignant hyperthermia can be triggered by the administration of depolarizing muscle relaxants (e.g., succinylcholine chloride) or inhalational anaesthetics (e.g., halothane). If possible, these medications should be avoided in patients at known risk. Patients with previous episodes or a positive family history (transmitted as an autosomal dominant trait) of malignant hyperthermia may be treated prophylactically with sodium dantrolene. Preoperative assessment of risk is difficult (315). In vitro muscle contraction tests to various triggering agents are available but require a muscle biopsy. There are presently no commercially available means of establishing the presence of the malignant hyperthermia gene.

Prompt treatment of malignant hyperthermia is imperative at the earliest signs of tachycardia, tachypnea, or a rigid masseter muscle, because survival is unlikely after significant hyperthermia. Treatment consists of termination of all anesthetic agents, ventilation with 100% oxygen, cooling (e.g., ice packs, iced intravenous fluids, gastric irrigation, cooling blankets), intravenous sodium bicarbonate for metabolic acidosis, and administration of sodium dantrolene (1 mg/kg/min, up to 10 mg/kg total dose) (187,193). Treatment is continued for as long as 6 hours after an attack. In patients at high risk for malignant hyperthermia, the recommended local anesthesia is procaine, and for general anesthesia, narcotics, barbiturates, or neuroleptic drugs, and prophylactic dantrolene sodium are used (239).

**MUSCLE BIOPSY**

A muscle biopsy is often valuable for a definitive diagnosis of muscle disorder (140). Three issues are important: selection of the muscle, technique of the biopsy, and specimen care. Muscles with mild involvement should be selected in chronic disease, but severely involved muscle should be chosen in acute disease. The histology of severely involved muscle in chronic disease may show only secondary changes and not be diagnostic. Commonly selected muscles are the vastus lateralis, rectus femoris, deltoid, gastrocnemius, and biceps brachii. Obtain an adequate specimen from the belly of the muscle. Avoid areas of musculotendinous junction, scar from previous surgery, immunization sites, and electrode insertion sites for EMG (103).

Obtain an adequate specimen, and either give it directly to the technologist or have it transported quickly to the laboratory. Traditional techniques of maintaining muscle length are not needed for routine muscle biopsy. A moderate volume (250 mg) is needed to assay for enzyme systems to characterize metabolic myopathies. Part of the specimen is sent for genetic and protein analysis, and part of the specimen is frozen rapidly in liquid nitrogen to preserve the enzymes and prevent. Histochemical evaluation includes staining with hematoxylin and eosin, Verhoeff–van Gieson, periodic acid–Schiff (PAS) stain for glycogen, Gomori trichrome, oil red O for lipids, and methylene green–pyronine for RNA. Staining for adenosine triphosphatase (ATPase) at selected pH determines fiber types. In skeletal muscle, the ratio of muscle fiber types I and II is 1 to 2. Type I fibers have low ATPase activity and glycogen and high oxidative activity, and type II fibers have the opposite relative amounts. At present, fibers are subtyped based on ATPase activity (88).

Open biopsy technique offers the advantages of a large sample and proper orientation and length of the specimen fibers, but it has the disadvantage of unsightly scars. Needle biopsy is cosmetically better but has the disadvantage of producing a small sample with disoriented fibers (63,96). Coordinate the method of specimen handling and biopsy technique with the pathologist to ensure adequate results.

### *Open Muscle Biopsy Technique*

Open muscle biopsy usually is performed with local anesthesia (1% Xylocaine without epinephrine) and sedation. The muscle must not be infiltrated with Xylocaine. Make a 2.5 cm incision, preferably following the skin lines, over the belly of the selected muscle. Expose a 2 × 0.5 cm cylinder of muscle (the long axis parallel to the muscle fibers), and excise the specimen with a scalpel. Electrocautery should not be used before removing the specimen. Sutures at either end of the specimen tied over a tongue blade or muscle biopsy forceps can be used to maintain specimen length. The procedure is usually performed on an outpatient basis, and complications are uncommon.

### *Needle Muscle Biopsy Technique*

The vastus lateralis muscle is commonly used as the site of needle biopsy. The Bergstrom needle, consisting of a cannula and sliding trocar with cutting blade, typically obtains a specimen of about 200 fibers. After administration of local anesthesia (1% Xylocaine without epinephrine), make a stab incision over the belly of the muscle. Insert the needle into the muscle, and activate the cutting blade to obtain the specimen. Suction can be applied to the needle hub to improve the biopsy size (239). Several repeat specimens may be obtained through the same skin incision by changing the direction of the needle. Close the skin by a single stitch or adhesive strip and apply pressure over the muscle for several minutes to reduce the risk of hematoma formation.

### NERVE BIOPSY

A nerve biopsy may aid in the diagnosis of a peripheral neuropathy but is rarely required. The sural nerve, which is entirely sensory, usually is selected because it innervates only a small area of the skin over the dorsolateral aspect of the foot, and the sensory loss is not usually a functional problem. Light and electron microscopy, the latter of which requires glutaraldehyde fixation are used for specimen evaluation. Preparation of the specimen needs to be coordinated with the pathologist before the biopsy (327).

To biopsy the sural nerve, make a 3-cm longitudinal incision over the posterolateral aspect of the leg parallel to the interval between the tendo Achilles and the peroneus brevis muscle. The nerve courses beside the lesser saphenous vein. Isolate 2.5 cm of the nerve in the interval and cut it sharply (not with scissors). If less than 1 cm of the nerve is taken, the ends can be reapproximated with microvascular sutures, but this repair is very time consuming for such a mild sensory loss and not usually done. If the nerve is not resutured, secure the proximal end in the deep layer of the subcutaneous fat, which helps to protect against painful neuroma formation.

## COMMON MUSCLE DISORDERS WITH ORTHOPAEDIC DEFORMITIES

Muscle diseases (myopathies) are inherited or acquired and constitute a diverse group of conditions that include structural congenital myopathies, diseases that typically present as a floppy infant, with muscle biopsy demonstrating structural abnormalities within the muscle cell; dystrophies, conditions in which the muscle initially develops and functions normally but then progressively degenerates and atrophies; myotonias, syndromes characterized by the delayed relaxation of muscle; and metabolic conditions, considered to include diseases with specific metabolic abnormalities and acquired myopathies, such as those secondary to infections, autoimmune disorders, and conditions related to toxins (62).

### BENIGN CONGENITAL MYOPATHIES OF CHILDHOOD

Congenital myopathies are a group of clinically similar illnesses that present with hypotonia and weakness from birth; muscle biopsy demonstrates structural abnormalities in the muscle cell. Most myopathies have an autosomal dominant transmission, are nonprogressive, and are characterized by symmetric proximal muscle weakness. Serum enzyme levels are normal or mildly elevated, and an EMG may show myopathic changes. The types of myopathies are differentiated by genetic studies, histochemical, or electron microscopic evaluation of the muscle biopsy specimen and include nemaline myopathy (rod body), central core disease, myotubular myopathy (central nuclear), congenital fiber-type disproportion, minicore disease, and nonspecific congenital myopathies (4,15,36,50,70,88,101,102,104,134,241,303,321). Myotubular myopathy has a gene abnormality at the xq28 locus, central core disease at 19q13.1, and nemaline myopathy at 1q21 (2-tropomyosin gene).

Orthopaedic problems include contractures, postural foot deformities, dislocation of the hip, and scoliosis (11,36,53,127,197,222,261,298,306). A potential life-threatening complication of treatment in patients with central core myopathy is malignant hyperthermia (82,101,174,175,189,238).

### *Contractures and Foot Deformities*

The contractures and foot deformities in patients with congenital myopathies are caused by hypotonia with abnormal posturing and are usually controlled with stretching therapy, periodic serial stretching casts, supportive orthoses, or occasionally, tendon lengthenings.

### *Hip Dislocation*

Dislocated hips can occur at birth or develop later in children with congenital myopathies. They are usually easily reducible in early infancy but require prolonged treatment to achieve stability. Any lax-jointed, low-toned infant or any older child who presents before walking with an easily reducible dislocated hip without contractures should be suspected of having a myopathy. The hips are treated in the early stages similar to those in infants with typical congenitally dislocated hips, except that the total time of treatment is often prolonged and stability of the hip is difficult to achieve.

The Pavlik harness is excellent for maintaining reduction in newborns and young infants. The hips reduce initially in flexion of about 110° and mild abduction of 45°. Instruct caregivers not to dislocate a hip inadvertently by positioning it in adduction. These hips tend to redislocate easily, requiring frequent (initially, almost daily) adjustment of the Pavlik harness. Prone positioning in the Pavlik harness is helpful. It is important not to allow the hip to remain persistently posteriorly dislocated in the Pavlik harness, because this creates a severe treatment complication. After the hip is stable, maintain the harness in about 90° of flexion and 45° of abduction until adequate bony and cartilaginous support develops. There is no time-honored rule for the length of treatment, but the total course should be long enough to allow joint stability and formation of a normal cartilaginous acetabulum.

Treat an older child who has developed contracture of the hip or whose hip does not easily reduce initially in skin traction until the femoral head approaches the area of the acetabulum. With the patient under general anesthesia, gently reduce the hip and apply a cast to maintain stability. Cast treatment may be necessary for as long as 6 months. Hip dysplasia after treatment for dislocation from hypotonia and joint laxity may improve with abduction bracing. Use an abduction brace and a standing frame with the legs in abduction for these children, in whom the development of walking skills is usually delayed. After ambulation is achieved, an abduction brace is helpful, but most children have difficulty walking in the brace. If dysplasia persists despite brace therapy in an ambulating child, perform a varus derotation proximal femoral osteotomy and, if needed, an acetabular redirectional osteotomy.

### *Scoliosis*

Scoliosis that presents at a young age tends to be progressive, often has a long C-shaped or double-curve pattern, and is most difficult to treat in a hypotonic patient with respiratory compromise. The orthopaedic dilemmas include poor tolerance from respiratory compromise in a thoracolumbosacral orthosis or spinal fusion with subsequent inhibition of spinal growth in a young child, resulting in a short trunk. As soon as scoliosis is recognized, institute treatment by linearly posturing the spine on pads when supine and, if respiratory capacity permits, by a thoracolumbosacral orthosis with abdominal relief. Pulmonary function studies of the patient in and out of the orthosis are necessary to determine the safety of orthotic treatment. If the orthosis cannot be used, a wheelchair can be modified with asymmetric lateral supports, a slightly reclined back, and a firm seat.

**Indications for Spinal Fusion** If the scoliosis progresses despite orthotic treatment, posterior spinal fusion is necessary, unless cardiopulmonary incapacity is life threatening, even though this fusion inhibits longitudinal growth of the spine if performed before skeletal maturity. Internal fixation is essential, preferably with segmental instrumentation. The fusion extends from the high thoracic area to the sacrum. The Luque technique has been performed without fusion to allow spinal growth in the young child, but this remains an unproven technique because of certain obvious risks, such as wire breakage, rod breakage, and growth over the upper ends of the rods, with subsequent kyphoscoliosis. We recommend a posterior spinal fusion with the unit rod, a modification of the Luque technique, from the first or second thoracic vertebra to the sacrum, and we discourage the use of anterior spinal procedures in patients with respiratory compromise. The unit rod is preferred because it prevents cephalad-caudad movement of the rods, spinal rotation, and pelvic obliquity without the use of rod interconnecting devices. In nonambulatory patients with progressive scoliosis, we recommend stabilization to the sacrum.

**Segmental Posterior Spinal Fusion with Unit Rod or Luque Rod Instrumentation**

- Place the patient in the prone position on a four-poster scoliosis operative frame so that the abdomen is free of pressure (6,25,37,77,110,213,214,218,231,247).
- Make a dorsal longitudinal skin incision over the spinous processes of the vertebrae to be fused, and forcibly retract the skin margins with Weitlander retractors to reduce the bleeding.
- Incise the subcutaneous tissue to the dorsolumbar fascia, exposing the tips of the spinous processes from T1 to the sacrum.
- Slit the cartilaginous caps of the spinous processes longitudinally, and interconnect them by splitting the supraspinous ligament.
- With a Cobb elevator, retract the cartilaginous caps laterally, perform a subperiosteal dissection down each side of the lamina, and pack gauze between the bone and paraspinous muscle to maintain hemostasis.
- Then expose each vertebra subperiosteally laterally from inferiorly to superiorly to the tips of the transverse processes in the thoracic area and to the base of the transverse processes in the lumbar area.
- Place the self-retaining Weitlander retractors progressively deeper in the wound, and spread them widely against the paraspinous muscles to minimize bleeding.
- Promptly electrocauterize soft-tissue bleeding and control bone bleeding with small quantities of bone wax.
- Expose the posterior superior iliac spines and adjacent iliac crest by elevating the erector spinae off the sacrum
- Expose the outer table of the ilium subperiosteally down to the greater sciatic notch. With the drill guide developed for the unit rod, drill holes in the ilium from the bottom of the posterior superior spines to pass 1 to 2 cm above the sciatic notch (Fig. 178.1). Be very careful to stay within the intraosseous area, and probe the hole to confirm this.

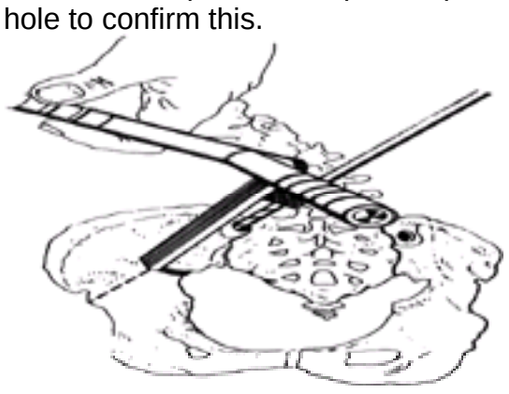

***Figure 178.1.*** The holes in the ilium are drilled by using a drill guide that hooks into the sciatic notch. The hole enters at the posterior superior iliac spine and is drilled 2 cm past the sciatic notch. (From Dias RC, Miller F, Dabney K, et al. Surgical Correction of Spinal Deformity Using a Unit Rod in Children with Cerebral Palsy. *J Pediatr Orthop* 1996;16:734, with permission.)

- Carefully remove the ligamentum flavum from the midline for sublaminar wire passage.
- Pass dual stainless steel wire strands under each lamina, except at the top of the fusion and at L5, where two dual strands are used for strength. Be extremely cautious not to cause neural damage while passing the wires.
- With a rongeur, osteotome or power burr, decorticate and perform facetectomies of the vertebrae in the area to be fused. Corticocancellous allograft is typically used in these children (150 to 250 g).
- If instrumentation with the unit rod is required, select the appropriate length of rod.
- Place a flexible measuring rod along the lamina on the concave side of the scoliosis. The unit rods are prebent to the contour of the normal spine, which corresponds to the desired postoperative spinal posture. The unit rod is available in 1/4- and 3/8-inch sizes, the smaller being used in children weighing less 30 to 40 pounds or in very osteopenic children.
- Secure the unit rod to the pelvis in a manner similar to the Galveston technique for Luque segmental spinal fusion (6,77).
- Cross the pelvic legs of the rod, and insert them into the pelvis, being careful to be in line with the drilled holes. Rod holders can be used to guide the legs during gradual alternate side impaction (Fig. 178.2).

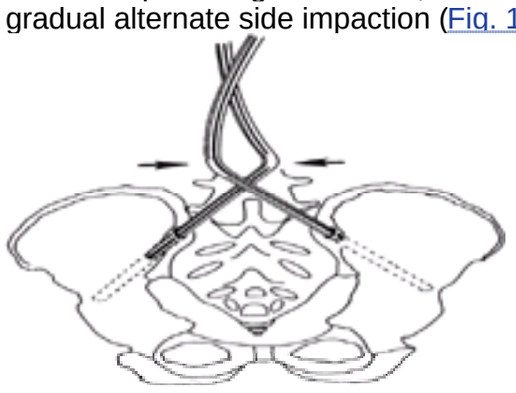

***Figure 178.2.*** The rod is inserted into the pelvis by crossing the pelvic legs, keeping them aligned with the orientation of the drilled holes. (From Dias RC, Miller F, Dabney K, et al. Surgical Correction of Spinal Deformity Using a Unit rod in Children with Cerebral Palsy. *J Pediatr Orthop* 1996;16:734, with permission.)

- Then tighten the sublaminar wires by twisting at each level starting at L5 and moving proximally. Push the rod to the spine at each level, resulting in gradual correction of the deformity.
- Close the fascia with interrupted and overlying continuous suture with no drains. Perform subcutaneous and skin closure.

If Luque rod instrumentation is desired, contour two Luque rods, one for the concave side of the scoliosis and one for the convex side. The Luque rods are available in the same sizes as the unit rods, and the suggestions for use are outlined above. Before the operative procedure, obtain lateral bending radiographs to determine the flexibility of the scoliosis, and bend the Luque rods to achieve no more than 10° additional correction beyond the preoperative bending radiographs. Bend the superior end of the convex rod and the inferior end of the concave rod into the shape of an L. Apply the rod on the concave side of the scoliosis first, and place the L portion between spinous processes or through a drill hole in the spinous process to prevent migration of the rod. If stabilization to the pelvis is required, bend the inferior end of the Luque rods as described for the Galveston technique (6). As described for the unit rod instrumentation, secure the rod to the lamina using the sublaminar wires. Apply the convex wires in similar manner, and cut and carefully tighten all wires. The two rods are connected inferiorly and superiorly to provide additional stability. We prefer to interconnect the rods securely to prevent cephalad-caudad shifting, spinal rotation and loss of pelvic obliquity correction. Rod connectors can prevent shifting of the rods. The fusion technique, bone grafting, and wound closure are identical to that described earlier for the unit rod.

**MUSCULAR DYSTROPHY**

The muscular dystrophies constitute a group of inherited muscle disorders characterized by progressive muscle weakness due to primary degeneration of muscle fibers. It has become apparent that these disorders are caused by specific gene abnormalities (301,340).

The muscular dystrophies are classified by age at onset, groups of muscles first affected, genetic transmission, and areas of body with progressive weakness (301).

***Duchenne Muscular Dystrophy***

Duchenne muscular dystrophy occurs in about 3 of 100,000 boys and usually has an early childhood onset, leading to loss of ability to walk and eventual death (128,229). It is transmitted genetically as a sex-linked recessive trait and is due to a mutation or deletion of DNA at a locus (Xp21) on the short arm of the X chromosome (106,120,163,164,200,312). About two thirds of the boys inherit the gene abnormality from the mother, and one third are thought to be due to new mutations. The onset is initially insidious, often with delayed motor milestones, with weakness clinically apparent by 3 years age (385). The weakness first involves the pelvic-girdle musculature, followed by the shoulder girdle musculature, and then distal musculature of the upper and lower extremities (2,387).

By 4 years of age, the boy stumbles, falls frequently, and has difficulty climbing steps and running. Pseudohypertrophy of the gastrocsoleus (Fig. 178.3), deltoid, and serratus anterior muscles is secondary to the dystrophic process and accumulation of fat within the muscles and fibrous tissue. The weakness results in a wide-based waddling gait associated with increased lumbar lordosis (Fig. 178.4). Gowers' sign (Fig. 178.5) is a characteristic way for a child with this type muscular dystrophy to rise from the floor to a standing position (137). This maneuver may be demonstrated by placing the boy prone on the floor. First, he crawls into the knee-elbow position;

then, with hands and feet on the floor, he raises his hands consecutively to the knees and pushes to an upright posture. The knee reflexes are diminished and sensation is normal. Progressive weakness is unremitting, and ambulation becomes more difficult, until between ages 9 and 12 years, the boy loses the ability to walk. Scoliosis and increasing contractures of the lower extremities develop. The weakness progresses until total care is required and severe cardiopulmonary compromise occurs between ages 17 and 22 years (5,14,44,49,173,201,314,319,387).

***Figure 178.3.*** Pseudohypertrophy of the calf muscles in a boy with Duchenne muscular dystrophy.

***Figure 178.4.*** A boy with Duchenne muscular dystrophy who stands with lordotic spinal posture and has pseudohypertrophy of the calf muscles.

***Figure 178.5.*** Gowers' sign is a characteristic way for a child with Duchenne muscular dystrophy to rise from the floor (**A** to **C**) by first using the hands to crawl into the knee-elbow position (**D** to **E**) and then to push on the knees to achieve an upright position. Gowers' maneuver demonstrates weakness in the shoulder and pelvic muscles.

The diagnosis can often be made on the basis of family history, clinical presentation, and an elevation of serum creatinine phosphokinase (often 100 times normal in young children). Traditionally, muscle biopsy has been used to confirm the diagnosis but modern techniques of DNA analysis using peripheral blood can provide a definitive diagnosis, help to identify carriers, and allow prenatal diagnosis for 70% to 80% of the children (298). The molecular basis of Duchenne and Becker's muscular dystrophy is the absence or abnormality of dystrophin (a subsarcolemmal protein) and dystrophin-associated glycoproteins (found in the sarcolemma or muscle cell membrane) (106,120,163,164,200,312). These proteins are found in skeletal, smooth and cardiac muscle, and brain. In the 20% of children who do not have a diagnosis by DNA analysis, muscle biopsy can be diagnostic. The biopsy typically from the vastus lateralis shows muscle fiber degeneration, regeneration, fibrosis, fatty infiltration, central nuclear migration and hypertrophic muscle cells (86). Absence of dystrophin is diagnostic. EMG, rarely required, shows myopathic changes with muscle action potentials of reduced amplitude and brief duration. The nerve conduction velocities are normal.

Orthopaedic treatment is aimed at maintenance of strength and walking ability for as long as practical and prevention of deformities (144,179,309,353,356,367,381,382). The single most important factor in maintaining strength is prevention of prolonged immobilization. If a boy with Duchenne muscular dystrophy is immobilized by any method, functional losses tend to be permanent. Therefore, make every reasonable effort to maintain strength by resistive muscle exercises. The patient should perform stretching exercises, especially of the muscles most subject to contractures (e.g., tensor fasciae latae, hip and knee flexors, and ankle plantar flexors) several times each day.

Prednisone and other steroids have been used successfully in these children from about 5 years of age to improve muscle strength (142). Complications from this treatment include weight gain, hypertension, behavior disturbances, increased appetite, cushingoid features, and osteopenia. Take into account chronic steroid useage when administering general anesthesia.

Myoblast transfer therapy to induce dystrophin production has not been successful (206). Attempts are being made to use viral vectors to transfer functional parts of the dystrophin gene to affected individuals.

### *Fractures*

Muscle weakness predisposes the patient with Duchenne muscular dystrophy to falls, and relative inactivity results in osteopenic bone (162). Fractures of long bones occur in 20% of children with Duchenne muscular dystrophy, typically occurring with falls during daily activity or physical therapy (26,162,305,320). These fractures often herald the end of the ambulatory stage. Treat nondisplaced fractures of the femur and tibia in lightweight long-leg casts or splints. Encourage weight bearing on the noninvolved leg immediately and within days on the fractured leg. Bed rest and traction are contraindicated. Displaced fractures of the lower limbs require prompt surgical stabilization. Apply a lightweight orthosis to the leg over the area of internal fixation and begin ambulation. The family should be aware that fracture complications are higher with early mobilization but that the added risk is necessary to avoid even more serious problems.

### *Contractures*

Contractures are inevitable in these patients, but controlling the severity greatly enhances the quality of life. Toe walking, caused by contractures of the tendo Achilles, can sometimes be detected in patients as young as 3 years of age, and it responds to stretching therapy or serial plaster casts. Tendon lengthening in young ambulatory patients is discouraged because of resulting weakness. For the ambulatory patient, a nighttime ankle-foot orthosis helps eliminate the typical equinus posturing of the foot during sleep, and muscle stretching therapy delays progression of contractures (320). Despite aggressive therapy, the ability to walk becomes threatened between 8 and 12 years of age from quadriceps muscle weakness (331); contractures of the hip flexors (Thomas test), hamstring muscles, and iliotibial tract

(Ober test); and equinovarus deformities of the feet. As these children lose the ability to walk independently, surgical releases of lower extremity contractures and long-leg bracing can prolong standing and ambulation for several years (9,26,29,64,73,156,265,272,279,310,316,320,354,355,367). When surgical releases are delayed until the children have almost stopped walking, the severity of weakness usually means that standing or walking is possible only with knee-ankle-foot orthoses. Earlier surgery followed by physical therapy and limited bracing (ankle-foot orthoses) can be just as effective (13,108,179,266).

Procedures used to treat contractures in Duchenne muscular dystrophy include Yount fasciotomy of the iliotibial tract, Ober release of the iliotibial band, distal hamstring lengthening, transfer of the posterior tibialis tendon to the dorsum of the foot, percutaneous lengthening of the tendo Achilles, and open lengthening of the tendo Achilles.

The iliotibial tract is released by a combination of the Yount (380) fasciotomy distally and the Ober (245) release proximally. The hamstrings are released distally, and the tendo Achilles is lengthened by a percutaneous method (Fig. 178.6). The late weakness of the posterior tibialis muscle often causes a varus deformity of the foot, which is sometimes treated by a posterior tibialis tendon transfer through the interosseous membrane of the tibia and fibula to the dorsum of the foot, which maintains a plantigrade foot. If, however, the varus is not severe and the posterior tibialis muscle is weak, a tenotomy can be performed easily just posterior to the medial malleolus (308). The tenotomy is often the treatment of choice, because the child must wear an orthosis in any case.

***Figure 178.6.*** A boy with Duchenne muscular dystrophy who has undergone operative release of the iliotibial tract, distal hamstring muscle release, and percutaneous tendo Achilles lengthening. He now ambulates with long-leg braces.

**Yount Fasciotomy of the Iliotibial Tract**

- Expose the iliotibial tract through a 2 cm lateral longitudinal incision, located proximal to the lateral femoral condyle.
- Incise the iliotibial tract, fascia lata, and intramuscular septum transversely at a level 2.5 cm proximal to the patella. Protect the biceps tendon and the common peroneal nerve posteriorly.
- A segment of the iliotibial tract and septum may be removed in patients with severe contractures to prevent recurrence.

**Ober Release of the Iliotibial Band**

- With the patient in a lateral decubitus position, make an incision from 3 cm posterosuperior to the greater trochanter of the femur obliquely to 2 cm inferior to the anterosuperior iliac spine.
- Incise the iliotibial band from the anterior portion of the gluteus maximus muscle anteriorly to the anterosuperior spine.
- Incise the fascia surrounding the tensor fasciae latae transversely.

**Transfer of the Posterior Tibialis Tendon to the Dorsum of the Foot**

- Through a 2 cm medial longitudinal incision centered over the talonavicular joint, free the posterior tibialis tendon from its distal insertions.
- Make a second 2 cm incision midlongitudinally at the musculotendinous junction of the posterior tibialis tendon just posteromedial to the tibia, and isolate the posterior tibialis tendon.
- Place a blunt, smooth elevator beneath the tendon and lift it medially, drawing the tendon into the proximal wound. Elevate the muscle origin from the tibia and interosseous membrane for several centimeters proximally.
- Make a third incision of 1 cm anterolaterally between the tibia and the fibula, 2.5 cm above the ankle joint.
- Direct a long, curved tendon passer from the second incision posterior to the tibia, through the interosseous membrane, to the third incision.
- Open the jaws of the tendon passer to create an opening in the interosseous membrane. Some surgeons fashion a 2-cm long window in the membrane using a scalpel; this reduces the chance of adhesions between the tendon and membrane (although this is not a major consideration in patients with Duchenne muscular dystrophy).
- Place a heavy, nonabsorbable suture in the distal end of the tibialis posterior tendon. Using a suture, draw the posterior tibial tendon forward through the interosseous membrane to the third incision.
- Make a fourth 2 cm incision over the dorsal surface of the third cuneiform or the third metatarsal.
- Retract the extensor tendons and incise the periosteum in a cruciate fashion.
- Drill a 0.6 cm hole plantarly through the bone.
- Direct the tendon passer subcutaneously from the fourth incision to the third incision, and deliver the tendon subcutaneously to the fourth incision. During passing, be careful to allow no twisting or kinking of the tendon. Some surgeons prefer to pass the tendon beneath the extensor retinaculum, but in our experience, this procedure is unnecessary, and it may become the site of tendon adhesion that restricts motion.
- Pass the sutures attached to the tendon end through the plantar surface of the foot with long, straight needles. The needles and sutures should exit the plantar surface of the foot in a non-weight-bearing area.
- Direct the tendon into the drill hole, hold the foot in a neutral position, and anchor the sutures snugly over a heavily padded button. The tendon can also be fixed to the midfoot using one of the available anchor systems.
- Further secure the tendon to the drill hole site by interrupted sutures to the periosteum.
- Close the incision and apply a well-padded long-leg cast with the foot in a slightly dorsiflexed position. Particular attention should be directed toward padding the proximal fibula, where the peroneal nerve is most cutaneous.

Postoperatively, remove the long-leg cast after 2 weeks, and apply a short-leg walking cast for an additional 4 weeks. After cast removal, remove the button, place the extremity in a brace, and begin active exercises.

**Percutaneous Lengthening of the Tendo Achilles**

- Perform a percutaneous tenotomy with the patient in a prone position.
- Dorsiflex the foot to maintain the tendo Achilles in a taut position.
- Palpitate the posterior tibial artery in the neurovascular bundle, and protect it during the procedure. The tendo Achilles rotates 90° on the longitudinal axis between its origin and insertion, and the medial fibers proximally are posterior at the insertion.
- Make a longitudinal 3 mm stab wound medial to the tendo Achilles and 1 cm superior to the calcaneus, and divide the anterior two thirds of the tendon fibers.
- Make a second stab wound incision dorsally 2 cm below the palpable musculotendinous junction and divide the medial two thirds of the tendon fibers.
- Dorsiflex the foot and the tendo Achilles lengthens.
- Close the stab wounds, and apply a well-padded cast at 5° dorsiflexion for 4 weeks.

**Open Lengthening of the Tendo Achilles**

- With the patient in a prone position, make a 5 cm longitudinal incision from the superomedial aspect of the calcaneus proximally along the medial border of the tendo Achilles.
- Divide the subcutaneous tissue and tendon sheath, and evacuate the rotation of the tendo Achilles.
- Incise the midposterior area of the tendon longitudinally by a stab wound. Place a clamp in the stab wound incision, and open it so that the tendon splits in the longitudinal direction of the fibers.

- Cut one part of the split tendon transversely distally and the other proximally, creating a Z-plasty tenotomy.
- Dorsiflex the foot to 5° above neutral and suture the tendon in the lengthened position. Apply a well-padded cast for 6 weeks, followed by a brace.

**Postoperative Care** Most surgery is performed bilaterally in one operative procedure, and lightweight long-leg casts are applied with the knees in extension and the feet neutral.

Standing is begun the day after surgery, and a rapid return to walking is encouraged. We incorporate a strip of polyurethane foam (7.5 × 1.5 cm) for padding dorsally under the standard long-leg cast. Ten days later, the casts are removed, long-leg orthoses are measured, and casts are reapplied until the orthoses are fabricated. The knee-ankle-foot orthosis prescription should include lightweight materials (usually plastics), contouring proximally to allow the buttocks to rest on the brace, drop-lock hinges at the knee, solid ankles in the neutral position, tarsal straps, and extension beyond the metatarsal heads (377).

### *Equinovarus Deformity*

Later in the disease process, the child becomes confined to a wheelchair. At this stage, contractures of the knees and hips are inevitable. Surgical releases usually are not required; instead, a program to maintain motion is indicated to prevent the progression of contracture that would hinder a good sitting position in the wheelchair. Occasionally, a patient, especially one who earlier refused surgery to prolong walking or refused orthotics, develops a severe, rigid equinovarus deformity of the foot that causes pain on the anterolateral aspect of the foot or the inability to wear shoes. Multiple tenotomies (tendo Achilles, tibialis posterior, and flexor digitorum longus) and postoperative casting can achieve a satisfactory foot position. Severe, stiff longstanding deformity can be corrected operatively with a tarsal medullostomy, but postoperative foot edema may persist for at least 6 months.

**Tarsal Medullostomy**

- Place the patient in the supine position, and control hemostasis during the procedure with a pneumatic tourniquet.
- Make a 3 mm stab wound skin incision obliquely over the sinus tarsi.
- Introduce a 3 mm oval curette into the sinus tarsi. Curette the talonavicular, calcaneocuboid, and subtalar joints, leaving the outer cortical margins intact. Carefully avoid injuring the neurovascular structures.
- Close the stab wound incision with a single stitch, and place the leg in a well-padded long-leg cast with the knee flexed and the foot in neutral position.

After surgery, elevate the foot to control edema. Use a long-leg cast for 1 month, and a short-leg cast for an additional 2 months (Fig. 178.7).

***Figure 178.7.*** **A:** A boy with Duchenne muscular dystrophy and a severe equinovarus foot deformity. **B:** The deformity was corrected by a tarsal medullostomy. **C:** After surgery, the foot has maintained a neutral position.

### *Spinal Deformities*

Scoliosis occurs in almost all boys with Duchenne muscular dystrophy (49,168,212,313). During the period that a boy with Duchenne muscular dystrophy is able to walk, spinal lordosis develops to compensate for weakness of the trunk and pelvic muscles. By the time the child must use a wheelchair, a functional kyphosis typically develops. Wilkins hypothesized that the kyphosis unlocks the posterior facet joints, causing an unstable spin and progressive scoliosis (269,366). For whatever reason, scoliosis typically becomes apparent during the last months of walking or soon after confinement to a wheelchair (41,78,230,307). The peak rate of progression occurs between 13 and 15 years, with up to 3° of progression per month. The scoliosis is typically a long C-shaped thoracolumbar curve that progresses steadily until a severe deformity results (Fig. 178.8*A*, Fig. 178.8*B*). The scoliosis eventually involves the pelvis, leading to severe pelvic obliquity and difficulty in sitting, back pain, skin breakdown, pulmonary compromise, and loss of hand function because of obligatory use of the hands for support of the trunk (313). A few patients do not develop the spinal kyphosis but persist with the lordotic posture after ambulation ceases. They develop a less progressive scoliosis, but by 6 to 8 years after ambulation ceases, severe scoliosis usually develops. Various spinal orthoses and wheelchair adaptations have been used to control the scoliosis, but none has been totally successful, and at best, they only delayed the progression of curvature.

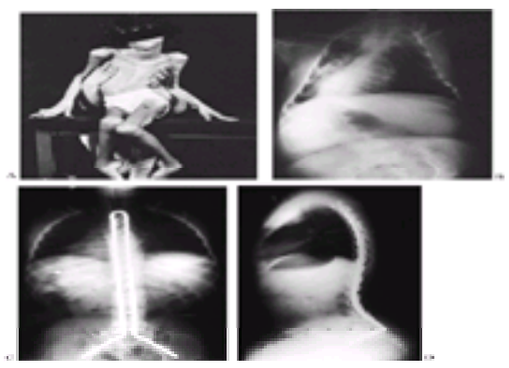

***Figure 178.8.*** **A:** After becoming nonambulatory from Duchenne muscular dystrophy, this boy developed a severe scoliosis, which led to pelvic obliquity and difficulty sitting. **B:** The radiograph demonstrates a long C-shaped pattern of scoliosis. AP (**C**) and lateral radiographs obtained after a posterior spinal fusion with Unit rod instrumentation (**D**).

Posterior spinal fusion and instrumentation is indicated for progressive scoliosis of 30° or greater. Preoperative cardiac and pulmonary evaluation must be done to determine the anesthetic risk. A vital capacity of less than 35% normal indicates that pulmonary complications are more likely (178,232,270).

We prefer segmental spinal instrumentation and posterior fusion with the unit rod or Luque instrumentation with Galveston pelvic fixation from T2 to the sacrum (37,115,284,329,330,332,362). The unit rod technique is described earlier in this chapter. The patients are ventilated for the first 24 hours in the intensive care unit and then quickly mobilized to return muscle strength and to avoid pulmonary and gastrointestinal complications. No postoperative bracing is required.

If the preoperative pelvic obliquity is 10° or less and the scoliosis is 40° or less, fusion to L5 will provide a good result (240,330) (Fig. 178.8*C*, Fig. 178.8*D*).

Vertical shifting of independent Luque rods has been reported and can be avoided by crosslinking the rods (37,126,232,240).

Intraoperative blood loss can be extensive (37,232,240,284,296,332,362). Careful intraoperative hemostasis, use of allograft, and speed will reduce blood loss. Preoperative autologous blood donation, intraoperative cell-saver techniques, and reinfusion of postoperative drainage will reduce the need for homologous

transfusion.

### *Becker's Muscular Dystrophy*

Becker's muscular dystrophy is an X-linked disorder with a clinical pattern similar to that of the Duchenne type, but it is milder and with slower progression (22,23,31). It results from a deletion in the same gene that causes the Duchenne type. Dystrophin is present but in reduced amounts, typically above 20% (164,199). Proximal girdle muscle weakness and pseudohypertrophy are apparent by 7 years of age, with maintenance of walking ability until age 16 and death occurring in middle adult life after cardiopulmonary failure (100). Clinically, the patient with Becker's muscular dystrophy resembles a “strong” patient with Duchenne muscular dystrophy in the juvenile years. The CPK level is markedly elevated, with levels similar to those seen in Duchenne muscular dystrophy, and the results of muscle biopsy resemble those in Duchenne muscular dystrophy. Orthopaedic problems include equinus, cavus, and scoliosis (186). The early major orthopaedic problem is progressive contracture of the tendo Achilles, which may be controlled by muscle-stretching therapy and by a nighttime ankle-foot orthosis to prevent the typical equinus posturing of the foot during sleep. Periodic serial stretching casts usually control the mild contractures, and tendo Achilles lengthening has occasionally been necessary.

Progressive proximal muscle weakness causes a wide-based gait and exaggerated spinal lordosis. In the teenage years, ambulation can be facilitated by canes for balance and a knee-ankle-foot orthosis. Scoliosis can occur and is managed as for the Duchenne type (186).

### *Limb Girdle Muscular Dystrophy*

The term limb girdle muscular dystrophy represents a group of patients with muscle weakness in a girdle distribution and autosomal inheritance. Leyden (209) described a type with predominantely pelvic girdle weakness, and Erb (105) described a shoulder girdle type. Typical findings include elevation of the CPK level, myopathic changes on EMG, and dystrophic changes on muscle biopsy. Recent advances in molecular genetics have established several syndromes with different gene abnormalities that had been classified as limb girdle dystrophies (87). There is a wide range of clinical severity. For example, severe autosomal recessive muscular dystrophy of childhood is characterized by absence of a sarcoglycan called adhalin (87) and can present with a clinical course similar to that of Duchenne's muscular dystrophy or with a later onset, milder type.

Orthopaedic problems are similar to those seen in other types of muscular dystrophies, and the principles of management are the same.

### *Facioscapulohumeral Dystrophy*

Facioscapulohumeral dystrophy (Landouzy-Déjérine dystrophy) is transmitted by an autosomal dominant gene, has an onset usually in adolescence, involves the facial and then the shoulder girdle muscles, and has a slow progression, with an expected average to long life span (87,148,204,349). The disease is uncommon, with a prevalence of about 1 in 20,000 (249,250). The early weakness results in a lack of facial mobility, sloping of the shoulders, and difficulty in raising the arms above the head. The upper arm and scapular muscles are involved earlier than the deltoid and forearm muscles. In longstanding, severe cases, the wrist extensor muscles are more involved than the flexors, producing a wrist drop called the praying mantis posture. The CPK level is normal to slightly elevated, and muscle biopsy shows only slight changes, such as isolated atrophic fibers and variation in fiber size. The gene abnormality has been localized to 4Q35, but no gene product has been identified (114,365).

Facioscapulohumeral dystrophy presents as four clinical variations: typical, as described; late exacerbation type, which may consist of only mild facial weakness for years and then rapid deterioration in midlife; infantile type, which has an onset before age 1 year and is severely crippling, requiring a wheelchair by age 9 years (38); and scapuloperoneal syndrome, in which the peroneal and tibialis anterior muscles are involved early in the illness (16,109).

The faciohumeral pattern of muscle weakness occurs in several diseases that must be differentiated, including myotubular myopathy, nemaline central cord disease. and mitochondrial myopathy (34).

Orthopaedic problems include a dropped wrist and foot, scapular instability, and back pain. The dropped wrist is treated by a splint and the dropped foot by an ankle-foot orthosis with a rigid ankle in neutral position. Lordosis (Fig. 178.9*A*, Fig. 178.9*B*), which is initially flexible, usually develops in the lumbar spine but may become so severe and rigid that the sacrum becomes horizontal. The lordosis produces severe back pain that may be treated by a lumbosacral orthosis. In ambulatory patients, the orthosis should support the back but not necessarily correct the lordosis, which may be necessary for walking. Surgery for back pain is almost never indicated.

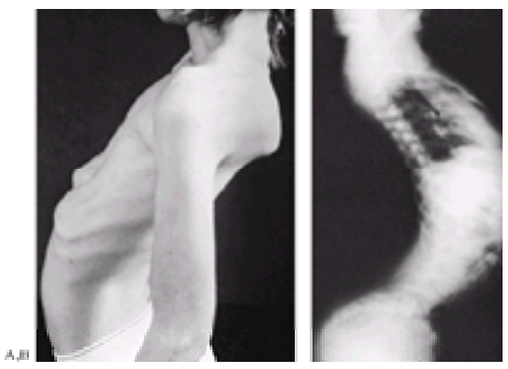

***Figure 178.9.*** Photograph (**A**) and radiograph of a boy with facioscapulohumeral dystrophy and severe spinal lordosis (**B**). The lordosis frequently results in disabling back pain.

Weakness of the serratus anterior, rhomboid, trapezium, and latissimus dorsi muscles limits elevation of the shoulder by allowing scapular winging and rotation (Fig. 178.10*A*, Fig. 178.10*B*). If the deltoid muscle is strong and scapular winging inhibits function so that the arm cannot be raised above the horizontal level, a scapulothoracic arthrodesis may be effective in improving shoulder flexion and abduction (42,43,61,177,188,207,321) (Fig. 178.10*C*). The operation initially should be performed on one side; if helpful, it can be considered for the contralateral side.

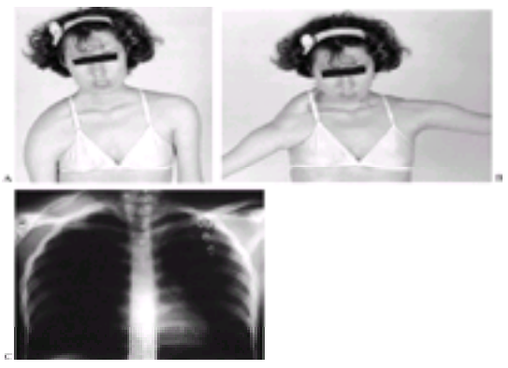

***Figure 178.10.*** Facioscapulohumeral dystrophy in a young woman with shoulders in neutral (**A**) and abduction (**B**). Note the improved abduction and appearance of left shoulder after scapulothoracic arthrodesis. Radiograph (**C**) demonstrates the wiring technique and preoperative position of the right scapula.

### *Scapulothoracic Arthrodesis*

- Place the patient prone on bolsters. Free drape the shoulder and arm to allow shoulder motion and access to the brachial and radial pulses.

- Make a 6 cm incision along the medial border of the scapula, with the scapula in a reduced position.
- Divide the insertion of the rhomboids into the vertebral border of the scapula to provide access to the thoracic surface of the scapula.
- Elevate subperiosteally the medial 2 cm of the subscapularis and the supra and infraspinatus. The medial origin of subscapularis needs to be resected to allow scapulothoracic contact.
- Position the vertebral end of the scapular spine at rib 3 or 4. Expose ribs 3,4,5, and 6 subperiosteally (avoid damaging the parietal pleura).
- Drill two sets of holes at the scapular spine and one set at the vertebral border of the scapula over each of the lower three ribs.
- Harvest a corticocancellous iliac graft, and fashion three 2 cm cortical pieces, and space two drill holes 1 cm apart in each piece.
- Place two 18-gauge stainless steel wires under rib 3 and one under the lower ribs, and thread them through the scapula and the pieces of autograft. Position the scapula so there is a 20° angle between the medial border of the scapula and the spine.
- Decorticate the ribs and undersurface of the scapula, apply cancellous autograft, and tighten the wires.
- Check for normal pulses in the arm and for desired shoulder range of motion. Use a shoulder immobilizer for postoperative immobilization.

### *Congenital Muscular Dystrophy*

The term “congenital muscular dystrophy” is used to describe an autosomal recessive group of disorders that present with muscle weakness at birth or shortly thereafter and a dystrophic pattern on muscle biopsy. Neonatal hypotonia is typical, but some children present with joint contractures (which may be an arthrogrypotic picture). The condition tends to remain static, but there can be slow progression or, alternatively, functional improvement and achievement of walking ability. Respiratory and swallowing problems depend on the severity of the weakness. The CPK may be slightly elevated, EMG reveals a myopathic pattern, and the muscle biopsy indicates severe dystrophic changes (87,224,384).

A number of syndromes of congenital muscular dystrophy in association with central nervous system involvement have been described: Fukuyama-type congenital muscular dystrophy, muscle-eye-brain disease, and the Walker-Warburg syndrome (87,124,125,190). Children with congenital muscular dystrophy have severe mental retardation and guarded prognoses. A subgroup of children with classical congenital muscular dystrophy with white matter changes in the brain lack laminin M (merosin), an extracellular protein (87,345).

Orthopaedic care includes obtaining a muscle biopsy, treating contractures, and correcting deformities (182,251,370). Mild contractures respond to therapy and splinting but tend to recur. Rigid and recurrent deformities are difficult and are treated as described in the section on arthrogryposis.

## MYOTONIC SYNDROMES

### *Pathology*

Myotonia is characterized by a sustained contraction or delayed relaxation of skeletal muscle after cessation of voluntary contracture or mechanical stimulation. It does not occur spontaneously but is initiated by voluntary contracture or stimulation and is usually accentuated by cold or periods of rest (74). Myotonia is seen in a number of illnesses, such as myotonic dystrophy, myotonia congenita, paramyotonia congenita, Schwartz-Jampel syndrome, drug-induced myotonia, and muscle contracture induced by exercise (80,227,344,372). Significant orthopaedic deformities occur in myotonic dystrophy and in Schwartz-Jampel syndrome, which is rare.

Myotonia is best demonstrated clinically by muscle contracture after a blow to the muscle belly by a reflex hammer or by a hand-grasp test, in which the patient grasps the observer's hand, tries to release, but immediate relaxation fails and an unwinding motion of the fingers must occur to unclasp the hand (34). In infants, myotonia may be manifest by delayed opening of the eyes after closure with crying. EMG demonstrates a characteristic pattern and confirms the clinical myotonia. The frequency of discharge is initially increased, followed by a gradual decrease and cessation, which produces an acoustic pattern that sounds like a dive bomber.

### *Myotonic Dystrophy*

Myotonic dystrophy (Steinert's disease) is an autosomal dominant disorder characterized by myotonia, a progressive dystrophic process of muscle leading to weakness and atrophy and various endocrine and systemic abnormalities (48,60,75,374). The molecular abnormality is an unstable expansion of DNA with a variable number of trinucleotide repeats in the myotonia protein kinase gene on chromosome 19 (12,35,45,123,151,152,157,216,291,298).

This disorder is classified into congenital and adult forms, which are very distinct.

**Congenital Myotonic Dystrophy** Congenital myotonic dystrophy occurs almost entirely in children born to mothers with myotonic dystrophy (Fig. 178.11*A*). Myotonic mothers usually have premature onset of labor, postpartum hemorrhage, and poor uterine tone, which predisposes the infant to cerebral damage and static encephalopathy (ie, cerebral palsy). The pregnancy is frequently complicated by poor fetal movements and hydramnios. In children with severe encephalopathy, an underlying myotonia can be overlooked. The child appears to have only a complex form of cerebral palsy, but evaluation of the mother demonstrates the characteristics of myotonia, and the diagnosis in the child can be suspected. In the neonatal period, the main characteristic features are hypotonia with difficulty in sucking and respiratory distress (27). The neonate frequently has facial paresis and a triangular, fish-shaped mouth, with the upper lip forming an inverted V. Mental retardation is common, and the mean IQ is approximately 66 (51). There is marked wasting of the sternocleidomastoid and trapezium muscles, and in most patients, muscle function improves in the first decade of life. Most of these children walk by age 4 or 5 years. Cataracts usually do not occur until about 14 years of age. Conduction abnormalities and myocardial dysfunction are common, and these children routinely require electrocardiograms and echocardiograms routinely (118).

***Figure 178.11.*** **A:** A mother with the adult type of myotonic dystrophy and her daughter with the congenital type of myotonic dystrophy. **B:** A foot with talipes equinovarus from congenital myotonic dystrophy. The equinus is severe, the forefoot is plantar flexed on the hindfoot, and the first toe is more flexed than the other toes.

Almost all children with congenital myotonic dystrophy have orthopaedic problems, including talipes equinovarus, congenital dislocation of the hip, severe truncal weakness, and contractures of the extremities (167). Children with congenital myotonic dystrophy should be treated aggressively orthopaedically because their conditions improve for several years after birth (24,51,153,154,246,351,386).

About half of the children with congenital myotonic dystrophy have talipes equinovarus (262) (Fig. 178.11*B*). The talipes equinovarus is not a typical clubfoot. The equinus is the most dramatic component of the deformity. The forefoot is usually plantarflexed on the hind foot, and the first toe is usually more plantarflexed than the other toes. There is usually a wide space between the first and second toes. In the newborn, the clubfoot is best treated by serial casting, gradually bringing the foot to the neutral position. There is considerable variation in the stiffness of the foot, from a rigid foot to a hypotonic positional deformity. In most patients, the foot can be casted to a neutral position. Careful attention should be given to the toe plate on the cast to maintain a neutral position; otherwise, the toes curl around the end of the cast, resulting in an increasingly severe toe deformity. The most resistant component of the clubfoot is usually the equinus deformity; therefore, attention should be directed toward molding the cast at the longitudinal arch of the foot, so that a breach of the arch will not occur. After the foot is casted to a neutral position, it must be maintained until ambulation begins. Frequently, these patients are severely hypotonic, and walking may be delayed until they are 3 to 4 years old, making prolonged maintenance a difficult orthopaedic problem. Bivalved casts are most useful, although they have a tendency to slip distally on the foot, and orthoses require frequent modifications to accommodate growth.

A few patients develop severely rigid equinovarus feet that cannot be corrected with serial casting and thus require surgical correction. We recommend that surgical

procedures not be performed before the child is 1 year of age, because the children are exceedingly hypotonic, and the risks of anesthesia and subsequent surgical complications are high. A posteromedial lateral release usually corrects the deformity (52,223,311,347,348). Overzealous correction should not be performed, because a severe valgus deformity of the foot may occur. The foot must be maintained in a neutral position after surgery, which may require an orthosis for several years.

Structural hyphoscoliosis develops slowly over the childhood years in some children (67). An orthosis typically prevents progression in the childhood years until the pubertal growth spurt, when progression occurs. Spinal fusion and instrumentation is effective, but mesenteric artery syndrome has been reported and experienced by the authors (67).

**Adult Myotonic Dystrophy** In the adult form of myotonic dystrophy, symptoms become noticeable in late adolescence or early adult life, although myotonia may be present in childhood. Muscle cramps, nasal voice character, and progressive weakness are observed first. The facial muscle atrophy of the temple, jaw, and neck muscles produces a lower lip droop called an inverted smile and a characteristic “hatchet-face” or “swan-neck” facies. The muscle weakness is more prominent distally, especially in the calf muscles and forearms, but the intrinsic muscles of the hands and feet frequently are spared until later in the disease. Smooth muscle may be involved, resulting in dysphasia, recurrent pulmonary infections, and lower gastrointestinal tract dysfunction (135). Cataracts, frontal baldness, mild mental retardation, and cardiac abnormalities are seen. The endocrine abnormalities result in abnormal glucose tolerance and insulin release, with frank diabetes mellitus, hypothyroidism, and gonadal dysfunction (171). Deep tendon reflexes are usually absent or diminished in the distal muscles, and the disease is progressive until death in the fifth to sixth decade of life from cardiorespiratory compromise.

Laboratory tests frequently show a slightly elevated CPK level, hypogammaglobulinemia with low IgA, and a glucose tolerance test of the diabetic type (143). The EMG demonstrates typical myotonia. The muscle biopsy shows changes that include internal nuclei and type I fiber atrophy.

Orthopaedic problems are associated with weakness of the neck muscles, pain, or mild subluxation that usually responds symptomatically to a soft cervical collar. Equinus deformity of the foot may be controlled by an ankle-foot orthosis. Occasionally, a pes cavovarus or pes planus deformity develops, and orthotic inserts typically resolve painful callosities. If a rigid foot deformity causes pain and instability, a triple arthrodesis to realign the hind foot and midfoot is helpful. Toe deformities consist of a flexion and a valgus deformity of the hallux, which may curl under the second toe. The second to fifth toes develop flexion contractures of the distal interphalangeal joints with dorsal callus formation. If these deformities are severe, the hallux is treated by an osteotomy of the middle phalanx with realignment and Steinmann pin fixation, and the second through fifth toes are treated by partial phalangectomy of the distal aspect of the proximal phalanx and internal fixation with Kirschner wires. These surgical techniques are described later in the section on peripheral neuropathies.

Anesthetic complications are common, and careful preoperative evaluation is important (220).

## COMMON NERVE DISORDERS WITH ORTHOPAEDIC DEFORMITIES

### PERIPHERAL NEUROPATHIES

A neuropathy is a condition of a peripheral nerve that may have motor signs manifested as weakness or decreased deep tendon reflexes; sensory abnormalities, which are usually more severe distally than proximally; or autonomic changes, resulting in impaired sweating, atrophy of the skin, or loss of hair.

The neuropathies are categorized as mononeuropathy, which is limited to a nerve, nerve root, or plexus (e.g., entrapment syndrome, brachial plexus injury, Bell's palsy); mononeuropathy multiplex, which involves multiple peripheral nerves (e.g., polyarteritis nodosa); and acquired polyneuropathies (e.g., diabetes, vitamin deficiencies, alcoholic neuropathy, drug-induced neuropathy, collagen vascular disease, genetic polyneuropathies such as Charcot-Marie-Tooth disease). Peripheral neuropathy, demyelinating polyneuropathy, myositis, encephalopathy, and recurrent infection are associated with acquired immunodeficiency syndrome (AIDS) (17,71,208). The incidence of neuromuscular disease in AIDS patients is unknown, but the diagnosis must be considered in inflammatory polyneuropathy or myopathy. Complex orthopaedic problems occur in many of the neuropathies.

The hereditary neuropathies are a group of genetically determined diseases with nerve fiber degeneration or segmental demyelinization. The pathology of nerve fiber degeneration involves a “dying-back” phenomenon that usually begins peripherally in the longest nerve fibers. Segmental demyelinating diseases involve inadequate peripheral myelinization by the Schwann cells and result in slowed nerve conduction velocities.

The hereditary neuropathies are classified as hereditary motor and sensory neuropathies (e.g., Charcot-Marie-Tooth disease), hereditary sensory neuropathy (e.g., congenital absence of pain), spinocerebellar degeneration (e.g., Friedreich's ataxia), and metabolic defects with neuropathy. The hereditary metabolic neuropathies are rare and include metachromatic leukodystrophy (ie, sulfatide lipidosis), Bassen-Kornzweig syndrome (ie, beta-lipoproteinemia), infantile and juvenile amaurotic idiocy, globoid cell leukodystrophy (ie, Krabbe's disease), angiokeratoma corporis diffusum (ie, Fabry's disease), Chédiak-Steinbrinck-Higashi syndrome, Tangier disease (ie, alpha-lipoproteinemia), and Cockayne's syndrome.

#### *Hereditary Motor and Sensory Neuropathy*

The hereditary motor and sensory neuropathies are an inherited group of diseases of peripheral nerves with sensory and motor involvement. The general clinical characteristics include distal symmetric muscle weakness, manifested by equinus feet, steppage gait, cavus feet, and loss of fine motor function in the hands; there is a mild sensory abnormality, usually causing poor balance and clumsiness and decreased deep tendon reflexes. Evaluate any patient with distal muscle weakness and cavus deformity of the feet for hereditary sensory-motor neuropathy. The disorders have been classified according to clinical manifestations, pathology, heredity, and electrophysiologic changes (72,92,94,95,98,130,141,149,185,263,264,277,278,324) (Table 178.2).

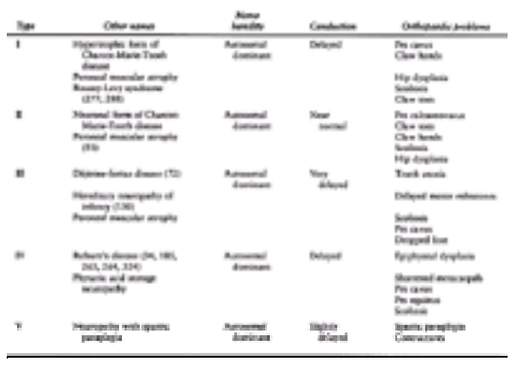

***Table 178.2. Classification of Hereditary Sensory-Motor Neuropathies***

Hereditary sensory and motor neuropathy types I and II are most common and constitute the classic forms of Charcot-Marie-Tooth disease, which is also called peroneal muscular atrophy (54,346). The hypertrophic form of Charcot-Marie-Tooth disease (type I) is associated with segmental demyelinization, reduced nerve conduction velocity, and an enlarged palpable superficial nerve with an insidious onset in the first or second decade of life. There is a broad range of clinical severity. The progression is slow, although a wheelchair is often required in middle to late adult life. Type IA is usually caused by a duplication of a gene on chromosome 17 for peripheral myelin protein 22 (PMP-22), a glycoprotein expressed in the myelin sheath. Type IB, which has a similar presentation to type IA, is caused by a mutation of the Po gene on chromosome 1n41. The neuronal form of Charcot-Marie-Tooth disease (type II) is clinically similar to the hypertrophic form, except that the pathogenesis involves axonal degeneration and not demyelination, nerve conduction velocities are near normal, the nerves are not enlarged, and leg atrophy is severe, producing a stork-leg appearance. Type II has been linked to chromosome 1p35-p36. An X-linked type has an abnormality in the connexin gene at xq13. The orthopaedic problems of Charcot-Marie-Tooth disease include pes cavus, claw toes, drop feet, hip dysplasia, and scoliosis (69,358).

Other types of hereditary motor and sensory neuropathy are type III, or Déjérine-Sottas disease, which is similar to type I but more severe; and type IV, or Refsum's disease (92). Of interest to the orthopaedic surgeon is hereditary neuropathy with a liability to pressure palsies (HNPP) (371). The onset is in adolescence, and nerve palsies can occur with minor trauma to the peripheral nerves. Extreme care must be taken during surgery to avoid traction on peripheral nerves and, if possible, to avoid the use of a tourniquet.

***Cavus Feet***

Cavus feet (Fig. 178.12*A*) are commonly seen in peripheral neuropathies, spina bifida, poliomyelitis, Friedreich's ataxia, spinal cord lesions, and several less common neurologic illnesses. The pathogenesis involves muscle imbalance, but the specific mechanism is unknown (32,33,252,283,287). A cavus foot has a pathologic elevation of the longitudinal arch of less than 150° on the lateral radiograph at the intersection of the axis of the first metatarsal and the calcaneus (169). There are three forms of pes cavus, as determined by the orientation of the os calcis during stances: pes cavovarus if the os calcis is inverted; pes calcaneocavus if the os calcis pitch (long axis of the os calcis to the floor) is greater than 30° or the long axis of the tibia to the long axis of the os calcis is greater than 130°, and pes equinocavus if the os calcis pitch is less than 20° (287).

***Figure 178.12.*** **A:** A cavus foot in a patient with Charcot-Marie-Tooth disease. **B:** A cavus foot, demonstrating heel varus during stance. The depression of the first metatarsal forces the foot into varus. **C:** The Coleman block test, demonstrating the flexibility of the hindfoot. When the depressed first metatarsal is allowed to hang off the block, the heel is no longer forced into varus during stance.

In Charcot-Marie-Tooth disease, a pes cavovarus deformity combined with decreased proprioception results in difficulty in walking, lack of balance, and painful callosities. The peripheral neuropathy initially causes weakness of the intrinsic muscles of the foot and peroneal muscles, resulting in a forefoot drop, relative shortening of the long toe extensors because of the forefoot drop, and hyperextension at the metatarsophalangeal joints. Hyperextension leads to a secondary tightening of the long toe flexor tendons and to flexion of interphalangeal joint and a claw toe deformity. The posterior tibialis muscle initially remains strong, and the first metatarsal droops more than the remainder of the forefoot. During stance, the plantarflexed first metatarsal forces the foot into supination, and contracture of the relatively strong posterior tibialis tendon holds the heel in varus (Fig. 178.12*B*). Initially, the foot is flexible, but the plantar fascia also shortens, contributing to the depression of the first metatarsal and a fixed varus deformity of the heel. The rigidity of the heel varus is determined by the Coleman lateral block test (Fig. 178.12*C*), in which a plantarflexed first metatarsal is allowed to hang over a 2.5 cm block, eliminating the forced forefoot pronation (negating the tripod effect); if the heel returns to a neutral position with this maneuver, the hindfoot deformity is not fixed (58,59,252). Therefore, attention may be directed toward the midfoot and forefoot.

The patient progressively becomes more clumsy, and as the cavovarus deformity becomes more rigid, painful calluses develop over the heel, the base of the fifth metatarsal, and the head of the first metatarsal (tripod foot). Subsequent bony adaptations result in a rigid equinocavovarus foot deformity (Fig. 178.13).

***Figure 178.13.*** **A:** A rigid cavus foot caused by Charcot-Marie-Tooth disease in a skeletally mature patient. **B:** Radiograph of a rigid cavus foot, demonstrates the elevated longitudinal arch, heel varus, hypertrophy of the fifth metatarsal, and claw toes.

Treatment of the cavus foot depends on the patient's age, flexibility of the foot, bony deformity, and muscle imbalance. In the early stages, the whole foot may be slightly supinated, the arch moderately elevated, and the great toe slightly cocked upward. As soon as the diagnosis is confirmed, begin daily manipulation of the foot to resist the depression of the first metatarsal, stretching of the plantar fascia and tendo Achilles, and extension of the toes. A nighttime ankle-foot orthosis in a neutral ankle position is recommended to prevent the foot from dangling into the equinus posture during sleep and to delay the onset of a fixed deformity. A supple foot can be treated nonoperatively by manipulation followed by serial stretching in a short walking cast, followed by an ankle-foot orthosis with a rigid ankle in neutral position and a lateral heel extension to resist varus.

If fixed soft-tissue or bony deformity develops, surgery becomes necessary to maintain a plantigrade foot. The goals of surgery are to correct deformity, restore muscle balance, and if necessary, stabilize the foot. Rigid deformities, usually consisting of a heel varus and a plantarflexed first metatarsal, must be corrected before tendon transfers are performed.

In children younger than 12 years of age, triple arthrodesis is contraindicated (364). Other procedures that can be performed include a plantar medial release to reduce the midfoot contracture; extension osteotomy of the first metatarsal to correct a rigid plantarflexed first metatarsal; transfer of the extensor hallucis longus tendon to the neck of the first metatarsal and interphalangeal fusion (Jones procedure); transfer of the extensor digitorum longus tendons to the third cuneiform (Hibbs procedure); transfer of the posterior tibialis tendon through the tibiofibular interosseous membrane to the dorsum of the foot to remove a deforming force and achieve dorsiflexion of the ankle; Dwyer or medial translation calcaneal osteotomy to correct heel varus if the heel does not correct with the Coleman block test; and a metatarsal osteotomy to correct the forefoot (90,91,161,181,273,297,302,333,359,361). In children younger than 8 to 10 years of age, the heel and first ray are usually flexible and will correct with soft-tissue releases and serial casting. Hindfoot equinus and tendo Achilles contracture are often present. Tendo Achilles lengthening should not be performed simultaneously with the plantar medial release because it is important to have a stable hindfoot to allow correction of the longitudinal arch with serial casting. In the older child with greater weakness, a rigid hindfoot, and fixed plantar flexion of the first metatarsal, the plantar medial release is combined with an extension osteotomy of the first metatarsal (and adjacent metatarsals if required), calcaneal osteotomy, and a posterior tibialis tendon transfer to the dorsum of the foot (Fig. 178.14*A*, Fig. 178.14*B*). In the skeletally immature, avoid damage to the first metatarsal physis when performing proximal osteotomies.

***Figure 178.14.*** Preoperative (**A**) and postoperative radiographs of a cavovarus foot (**B**). Surgery included a plantarmedial release; extension osteotomy of the first metatarsal, Dwyer calcaneal osteotomy, and anterior transfer of the tibialis posterior tendon (note method of fixation of tendon at arrow).

In the rigid, skeletally mature foot, definitive procedures include radical plantar fascial release (Steindler plantar flexor tenotomy) to relieve midfoot cavus; transfer of the posterior tibialis tendon through the tibiofibular interosseous membrane to the dorsum of the foot to achieve dorsiflexion of the ankle; transfer of the extensor hallucis longus tendon to the neck of the first metatarsal and interphalangeal fusion (Jones procedure); correction of claw toes by interphalangeal joint arthrodesis; and extensor tendon release or transfer, calcaneal and metatarsal osteotomies to correct a rigid cavus foot; or as a salvage procedure for severe deformity, triple arthrodesis to correct severe heel varus and severe midfoot deformity and achieve hind foot stability (7,10,57,90,91,176,181,210,281,325,361,376) (Fig. 178.15*A*, Fig. 178.15*B*). Tendon transfer is rarely indicated in the adult foot without an associated bone realignment.

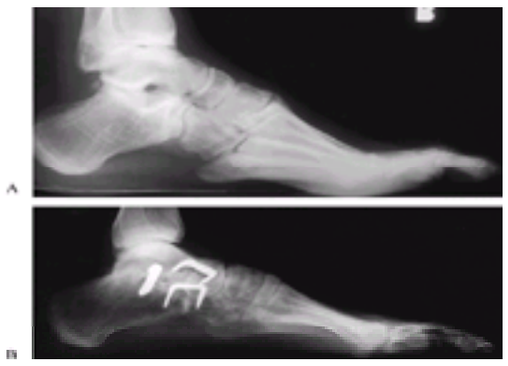

***Figure 178.15.*** Pre- (**A**) and postoperative radiographs of a cavovarus foot treated by a triple arthrodesis (**B**).

Long-term review of patients with triple arthrodesis indicates satisfactory results, but there is a high incidence of radiologic ankle and midfoot arthritis (289,364). A study of triple arthrodesis using force plate analysis demonstrates increased midfoot load bearing and load concentration under the metatarsal heads (318). The incidence of pseudarthrosis, typically in the talonavicular joint, is reported to occur up to 25% of the time. This can be symptomatic and require revision surgery (289).

**Transfer of the Common Extensor Tendon to the Third Cuneiform for Claw Toe Deformities (Hibbs Procedure)**

- Make a slightly curved, longitudinal incision on the dorsum of the common extensor tendons, centered over the third cuneiform (126).
- Incise the subcutaneous tissue by sharp dissection, and protect any neurovascular structures.
- Divide the common extensor tendons as far distally as possible.
- Drill a 6.3 mm diameter hole in the third cuneiform from dorsal to plantar.
- With a pullout suture, draw the proximal ends of the common extensor tendons into the drill hole, and secure the pullout suture on the plantar surface over a padded button.
- Close the wound, and apply a well-padded short-leg cast for 6 weeks.

**Midanterior Tarsal Wedge Osteotomy for Cavus Deformity (Cole Procedure)**

- Make a dorsolongitudinal skin incision over the extensor tendons to the third and fourth toes, beginning just proximal to the midtarsal joints and extending distally through the middle of the metatarsals (57).
- Separate the extensor tendons to the third and fourth toes, and excise the periosteum overlying the tarsal bones.
- Identify the tarsal bones radiographically.
- Perform a dorsally based wedge osteotomy centered over the navicular medially and the cuboid laterally to include the navicular cuneiform joints. The width of the wedge is determined by the severity of the deformity to be corrected.
- Remove the dorsal wedge, and elevate the forefoot to close the wedge osteotomy. Be sure to correct for rotation deformities (e.g., pronation, supination) of the forefoot at this time.
- Close the periosteum with interrupted sutures, and approximate the skin. Apply a short-leg plaster cast from the toes to the knee. Adequate healing is usually obtained within 4 weeks.

**Calcaneal Osteotomy for Pes Cavovarus Deformity (Dwyer Procedure)**

- Expose the lateral area of the calcaneus through an incision parallel, posterior, and inferior to the peroneus longus tendon (89).
- Strip the periosteum of the lateral area of the calcaneus superiorly and inferiorly.
- Remove a laterally based wedge of bone from the calcaneus just posterior, inferior, and parallel to the peroneus longus tendon. The medial edge of the wedge should not penetrate the medial cortex of the calcaneus.
- Correct the varus deformity of the calcaneus by closing the osteotomy and fracturing its medial cortex. Dorsiflex the forefoot against the pull of the tendo Achilles to stabilize the osteotomy. The varus deformity should be corrected with the heel in neutral or slight valgus position.
- Close the wound and immobilize the foot in a short-leg cast until the osteotomy is healed in about 6 weeks.

**Jones Procedure**

- A Jones procedure is transfer of the extensor hallucis longus tendon to the neck of the first metatarsal and fusion of the interphalangeal joint.
- Make a dorsolongitudinal 1.5 cm incision over the interphalangeal joint of the hallux (181).
- Expose the extensor hallucis longus tendon, and cut it transversely 1 cm proximal to the interphalangeal joint.
- Cut the dorsal capsule of the interphalangeal joint transversely, and excise the cartilaginous surfaces of the interphalangeal joint.
- Insert a Kirschner wire from distal to proximal across the interphalangeal joint; cut the wire approximately 3 mm from the cutaneous margin, and bend it to prevent migration.
- Close the skin by interrupted sutures.
- Expose the neck of the first metatarsal through a dorsomedial 2.5 cm incision, dissect the extensor hallucis longus tendon, and protect the short extensor tendon.
- Periosteally expose the neck of the first metatarsal and drill a hole transversely through the longitudinal axis of the bone approximately 1 cm proximal to the metarsophalangeal joint.
- Pass the extensor hallucis longus tendon through the hole, and suture it on itself with interrupted sutures.
- Close the wounds, and apply a well-padded short-leg cast, with a plantar extension to protect the toes.

Postoperatively, allow weight bearing after 2 weeks, and remove the cast and Kirschner wire 6 weeks after surgery.

**Plantar Medial Release (Modified Steindler Procedure)**

- Make a longitudinal 4 cm incision along the medial side of the foot from the calcaneal tuberosity distally (325). Separate the plantar aponeurosis from the plantar foot muscles, and incise the plantar fascia transversely at the plantar surface of the calcaneus.
- With a blunt periosteal elevator, lift the origins of the abductor hallucis muscle, the flexor digitorum brevis muscle, and the abductor digitiminimi muscle from the periosteum of the calcaneus. Avoid removal of cortical bone or periosteum with the fascia and muscle attachments.
- Carry the dissection to the calcaneocuboid joint, releasing the quadratus plantae and the long plantar ligament. The entire dissection should be carried out near the periosteum of the calcaneus, avoiding neurovascular structures.
- Then dorsiflex the foot to the corrected position and close the skin.
- Apply a well-padded short-leg cast with particular attention to adequate padding over the metatarsal heads and dorsum of the foot to prevent pressure necrosis of

the skin.

Postoperatively, maintain the cast for 6 weeks. Apply serial stretching casts on a weekly basis to obtain adequate correction, if desired, beginning about 1 week after surgery.

**Triple Arthrodesis**

- Make a straight 5 cm incision obliquely over the sinus tarsi, extending from the peroneus brevis tendon to the extensor tendons.
- Dissect the subcutaneous tissue sharply, and distally reflect the tendinous origin of the extensor brevis tendon.
- Incise the capsule of the calcaneocuboid joint, and remove the articular surfaces with an osteotome.
- Then incise the lateral capsule of the talonavicular joint, and remove the articular surfaces of this joint with an osteotome. A small incision over the medial aspect of the talonavicular joint allows better visualization for cartilage removal.
- Incise the capsule of the subtalar joint. With an osteotome, excise the surfaces of the anterior, medial, and posterior articular facets of the subtalar joint. Carefully remove the medial borders of the subtalar joint so that the neurovascular bundle and tendons are not damaged.
- Remove wedges of bone as necessary to correct any deformity, and position the foot in the neutral position. Maintain the foot in the neutral position, and suture the reflected flap of the extensor digitorum brevis in the sinus tarsi. Fixation can be achieved with staples, Steinman pins, or cannulated screws.
- Close the wound and overlay it with a gauze dressing. Apply a well-padded long-leg cast as the foot is maintained in neutral position.

Postoperatively, triple arthrodesis typically requires 12 weeks to heal. In patients in whom continued ambulation and standing are necessary for maintenance of function, walking may begin as soon as tolerable, but periodic radiographs are necessary to verify proper foot position.

***Claw Toes***

The claw toe deformity (Fig. 178.16) is caused by intrinsic muscle weakness that allows the long toe flexor muscles to continue to flex the interphalangeal joint and the long toe extensor muscles to extend the metatarsophalangeal joint without stability provided by the weak intrinsic muscles. Callosities develop over the heads of the proximal phalanges from contact in the shoes and under the metatarsal heads. Initially, clawing is flexible and should receive daily manipulative therapy. Fixed clawing requires operative treatment, which is usually performed simultaneously with other procedures for the cavus foot. Our choice of treatment of the second to fifth toes includes a tenotomy of the long extensor tendons, dorsal capsulotomy of the metatarsophalangeal joint, and arthrodesis of the interphalangeal joint if the toes cannot come down into 20° of passive flexion.

***Figure 178.16.*** **A:** Preoperative photograph of flexible claw toes in a patient with Charcot-Marie-Tooth disease. **B:** The toes corrected. **C:** Preoperative photograph of rigid claw toes in a patient with Charcot-Marie-tooth disease. **D:** Postoperative radiograph demonstrates straightening of the toes by an interphalangeal fusion with Kirschner wires.

- Stabilize the interphalangeal arthrodesis with intramedullary Kirschner wire fixation.
- Transfer the extensor tendons to the middorsal area of the foot to assist in active dorsiflexion of the foot, if desired (Hibbs procedure).
- For clawing of the hallux, transplant the long extensor tendon to the neck of the first metatarsal (Jones procedure), and perform interphalangeal joint fusion. Take care not to damage the extensor brevis tendon, or the hallux will droop.

**Extensor Tendon Tenotomy, Dorsal Capsulotomy of the Proximal Interphalangeal Joint, and Interphalangeal Fusion**

- Make a 1 cm dorsolongitudinal incision over the proximal interphalangeal joint of the toe.
- By sharp dissection, identify the common extensor tendon, and incise it transversely.
- Then incise the dorsal capsule of the proximal interphalangeal joint transversely, and expose the articular surface by flexing the toe.
- With an osteotome, excise the articular surfaces of the interphalangeal joint, and then close the incision.
- Extend the toe to a neutral position, and place a smooth Kirschner wire from the tip of the distal phalanx through the distal phalangeal joint and proximal interphalangeal joint to the proximal phalanx.
- Cut the Kirschner wire 0.5 cm from the tip of the phalanx and bend it at least 45° to prevent proximal migration.

After surgery, the toes are protected by a well-padded short-leg cast with the plantar surface extending well past the phalanges, or have the patient wear a hard-sole wooden shoe until interphalangeal arthrodesis has occurred in about 4 weeks.

***Scoliosis***

There is a 10% incidence of scoliosis in hereditary motor and sensory neuropathy types I and II (157). The other types of hereditary sensory-motor neuropathy also have associated scoliosis, but the incidence is unknown. Progressive curves between 20° and 40° in immature patients are treated by a thoracolumbosacral orthosis until maturity. The amount of progression after treatment is unknown. Progressive curves greater than 40° to 50° in immature patients are treated by a posterior spinal fusion and instrumentation. The patterns are similar to those seen in idiopathic scoliosis. The fusion should include the measured curve (i.e., Cobb method) and additional vertebrae as necessary to achieve adequate truncal balance because of the associated truncal weakness. No patients in our series have required fusion to the sacrum or to the cervical area. Because there is a high incidence of failure of somatosensory-evoked potential monitoring, preparation must be made for a wake-up test (195).

***Claw Hands***

Intrinsic muscle weakness (Fig. 178.17) interferes with fine motor coordination, as in writing, and wrist weakness makes sports and carrying heavy objects difficult. Most patients tolerate the weakness by adjusting their lifestyle or by using simple adaptive equipment. In some patients with type I hereditary sensory-motor neuropathy and moderate weakness, opponensplasty with intrinsic muscle reconstruction is helpful (234,375). Kling and Drennan (192) reported on a small group of patients with type II hereditary sensory-motor neuropathy who developed severe upper extremity atrophy, which leads to a functionless hand. An orthosis may help to maintain a neutral posture.

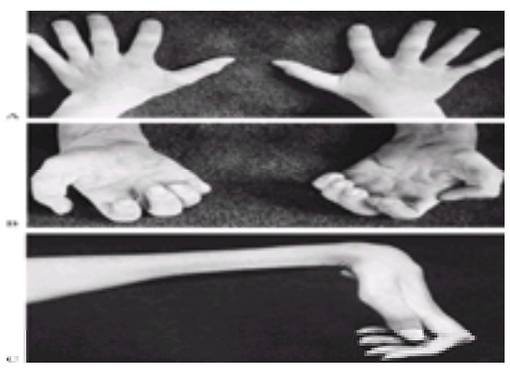

***Figure 178.17.*** **A:** Hands with intrinsic muscle weakness caused by Charcot-Marie-Tooth disease. **B:** Claw hands caused by muscle weakness and contractures from Charcot-Marie-Tooth disease. **C:** A functionless hand with severely atrophic muscles from Charcot-Marie-Tooth disease.

### *Hip Dysplasia*

Severe bilateral hip dysplasia has been reported in patients with onset of neuropathy in the first decade of life (198,357). The dysplasia can be asymptomatic or minimally symptomatic and may remain undetected until early adolescence. Children with Charcot-Marie-Tooth disease need to be evaluated radiographically to detect early dysplasia. Typically, the femur has mild coxa valga and anteversion, and the superolateral corner of the acetabulum is deficient, which allows lateral subluxation during ambulation (Fig. 178.18). The acetabular dysplasia is treated by redirection of the acetabulum by single, double, or triple innominate osteotomies or shelf arthroplasty, depending on the severity of the deformity (286,323). The Chiari procedure may be necessary if severe changes in the acetabulum prevent the femoral head from being fully reduced into the true acetabulum.

***Figure 178.18.*** Hip dysplasia in a 16-year-old boy with CMT IA.

### *Hereditary Sensory Neuropathies*

Hereditary sensory neuropathies are characterized by decreased specific sensory perceptions, painless ulcerations, and Charcot joints. There are four major hereditary sensory neuropathies: autosomal dominant hereditary sensory neuropathy, autosomal recessive hereditary sensory neuropathy, familial dysautonomia (Riley-Day syndrome), and familial sensory neuropathy with anhidrosis (248,259).

Patients with autosomal dominant hereditary sensory neuropathy have marked loss of sensation to pin prick and temperature in the lower extremities that can result in severe trophic changes. The upper extremities are less involved. A nerve biopsy shows a decreased number of myelinated sensory fibers. In autosomal recessive hereditary sensory neuropathy, the sensation of touch is more severely affected than those of pain and temperature, but the upper and lower extremities are severely affected, and nerve biopsy shows a total absence of myelinated sensory nerve fibers.

Familial dysautonomia, a disease of the peripheral nervous system secondary to a gene defect at the 9q31-33 locus, is characterized by a reduction in small and large myelinated nerve fibers. Clinical manifestations include a labile blood pressure, insensitivity to pain, abnormal gastrointestinal mobility, lack of fungiform papillae on the tongue, ataxia, areflexia and kyphoscoliosis. It occurs in Ashkenazi Jews with a prevalence of 1/3600. The children develop a progressive kyphoscoliosis, and death usually occurs in infancy or childhood from chronic pulmonary insufficiency and aspiration (267,268,379). Familial sensory neuropathy with anhidrosis is characterized by decreased temperature perception, intact touch sensation, absent axon reflex to histamine, below-normal intelligence, and anhidrosis.

Orthopaedic problems in patients with hereditary sensory neuropathy include Charcot joints, joint dislocations, fractures, chronic osteomyelitis, and severe kyphoscoliosis (215,256). Treatment of spinal deformity is difficult because of the typical high rigid kyphosis, osteopenia, labile autonomic nervous system, and insensitivity to pain. Spinal fusion and instrumentation have a high incidence of complications but is beneficial (280).

**Charcot Joints** A Charcot joint is characterized by a painless arthropathy in which the synovium is hypertrophic, ligamentous laxity causing joint instability, and eventual joint surface destruction. The lack of protective sensation allows unrestricted repetitive trauma, and large weight-bearing joints are most frequently and severely involved. Recurrent microtrauma causes synovial inflammation, hemarthrosis, periosteal elevation with subsequent cortical bone thickening, physeal widening, osteonecrosis, and osteochondritis dissecans. Minor trauma can lead to undetected dislocations and fractures (1,180,194).

Treatment initially involves protecting the joint from trauma by patient training, adaptive tools to reduce traumatic exposure, and protective orthoses. Joint instability usually can be treated by an orthosis, or if it is severe, a fusion can be attempted. Fusions are difficult to achieve and require prolonged immobilization; because delayed union and pseudarthrosis are common, augmentation with a bone graft is often required. A fusion also tends to transfer stress to adjacent joints, which can become deformed. Periodic radiographic spinal evaluation should be performed to detect early Charcot changes of vertebrae and to allow treatment by a spinal fusion to prevent neurologic damage. Osteomyelitis by hematogenous or contiguous spread occurs frequently in Charcot joints. Cutaneous ulcers should be protected to eliminate repetitive trauma and should be treated aggressively with local care to obtain healing. After a joint is infected, the prognosis is poor. Antibiotic therapy, protection of the extremity, and excision of infected or necrotic bone may contain the infection, but uncontrolled infection may require amputation (136).

**Neuropathic Ulcers** Neuropathic ulcers are caused by repetitive trauma to an anesthetized area. In children, the hands may be mutilated by repetitive biting or other trauma, causing ulceration, osteomyelitis, and autoamputation of the phalanges. In childhood, ulcerations of the feet are most common (Fig. 178.19). The only effective therapy is to teach the patient protective techniques and to use protective orthoses.

***Figure 178.19.*** Neuropathic ulcer in a patient with hereditary sensory neuropathy.

### *Friedreich's Ataxia*

Friedreich's ataxia (i.e., hereditary spinocerebellar ataxia) is the most common spinocerebellar degenerative disease. It usually is autosomal recessive, although it may be autosomal dominant or sex linked (20). The gene abnormality is on chromosome 9 (55). The onset is at the end of the first decade and is characterized by progressive ataxia of the limbs and of gait, the presence of Romberg's sign, absent knee and ankle reflexes, extensor plantar responses, dysarthria, scoliosis, pes cavus, weakness, loss of position and vibration sense in the legs, cardiomyopathy, and diabetes (30,131,202).

By the age of 15 years, most patients are severely ataxic; by 20 years of age (average, 15.8 years), most are confined to a wheelchair; and by 40 years of age (average, 36 years), death occurs from cardiopulmonary failure (47,160,338). Sural nerve biopsies show axonal degeneration; the central nervous system exhibits changes in the posterolateral columns of the spinal cord and cell loss in the deep cerebellar nuclei. Muscle biopsy reveals fiber group atrophy characteristic of denervation (88).

Although there is no known cure for Friedreich's ataxia, treatment of the orthopaedic deformities of pes cavus and scoliosis substantially enhances the quality of life, especially in the less severely involved patient.

**Foot Deformities** The foot deformities of Friedreich's ataxia are an equinus foot, pes cavovarus, tripod stance, and claw toes. As in Charcot-Marie-Tooth disease, the intrinsic muscles are weak, with the foot everters and dorsiflexors being weaker than the foot inverters and plantar flexors, unlike the usual Charcot-Marie-Tooth disease, the severe ataxia causes a markedly unstable foot.

The goals of treatment are achieving a stable plantigrade foot, balancing muscle function, and correcting deformity. In the immature foot, which is almost always flexible, an ankle-foot orthosis and stretching exercises are usually sufficient. More rigid foot deformities occur during the adolescent years. Our preference for treatment of the cavus foot and instability is a triple arthrodesis; for the muscle imbalance, a transfer of the posterior tibialis tendon through the interosseous membrane to the dorsum of the foot is indicated; and for claw toes, an interphalangeal joint arthrodesis is preferred (217). These surgical techniques were previously described under peripheral neuropathies.

**Scoliosis** Severe scoliosis occurs in more than 80% of patients presenting between ages 9 and 21 years and is relentlessly progressive, even after skeletal maturity (47,66,112,157,160,203). Scoliosis in this disorder is not a collapsing spine disorder, such as that seen in poliomyelitis. It is very similar to idiopathic scoliosis in its behavior. A thoracolumbar orthosis may be prescribed for a curve between 20° and 40°, but there is insufficient evidence to support the efficacy of this treatment, and at best, it only slows progression (47,66). The orthosis is poorly tolerated in ataxic, unstable ambulatory patients, because it eliminates trunk motion used to correct imbalance during gait. Nighttime bracing often is an acceptable compromise. For progressive scoliosis greater than 40° to 60°, extension of the fusion to the sacrum is not always required. A posterior spinal fusion from the high thoracic area is indicated. Segmental instrumentation should be used, which allows for rapid postoperative mobilization without a brace. A thorough cardiopulmonary evaluation and ongoing monitoring are mandatory because virtually all patients have cardiomyopathy.

## SPINAL MUSCULAR ATROPHY

Spinal muscular atrophy is a group of hereditary illnesses with proximal muscle weakness caused by degeneration of the anterior horn cells of the spinal cord and bulbar motor nuclei (337). The hypotonia is symmetric, the lower extremities are weaker than the upper extremities, there is no sensory loss or upper motor neuron signs, and fasciculations of the tongue and tremors of the hands are common (46,350). Cardiac function is not impaired. The prognosis for life expectancy depends on respiratory capacity. The spinal muscular atrophies are divided into several syndromes according to the severity of weakness, age at onset of symptoms, distribution of muscle weakness, and pattern of heredity (334) (Table 178.3). The clinical presentations of the syndromes vary and may overlap in the spectrum of syndromes (133). The most common forms are types I, II, and III (184,253,254).

| Form | Age at onset | Progression of disability | Inheritance |
|---|---|---|---|
| Type I | <3 mo | Rapid | Autosomal recessive |
| Type II | 6 mo–3 yr | Moderately rapid | Autosomal recessive |
| Type III | 1–15 yr | Moderate | Autosomal recessive |
| Adult (254) | 15–50 yr | Slow | Probably recessive |
| Scapular-Peroneal atrophy (154) | Variable | Slow | Autosomal dominant |
| Charcot-Marie-Tooth disease-neuronal (93) | Variable | Slow | Autosomal dominant |
| Facioscapulohumeral-neurogenic (189) | Variable | Slow | Autosomal dominant |
| Distal (216) | Variable | Slow | Autosomal recessive |

***Table 178.3. Types of Spinal Muscular Atrophy***

Type I spinal muscular atrophy (i.e., Werdnig-Hoffmann disease) is the most severe illness. The onset occurs within the first 3 months of life, and the patient presents with progressive weakness and hypotonia with spontaneous movement confined to the toes, fingers, and hands. Infants with this disease are never able to develop head control or roll over, bulbar weakness results in difficulty in sucking, tendon reflexes are absent, and death usually occurs within the first year of life, before significant orthopaedic problems develop (40,165,363). Types I, II and III are caused by abnormalities of the survival motorneuron gene (SMN) on chromosome 5.

In Type II spinal muscular atrophy (i.e., intermediate to severe spinal muscular atrophy) the infant develops normally for the first 6 months of life and learns to sit, but symmetric proximal muscle weakness ensues (155). The children never stand or walk. Fasciculations of the tongue and a fine motor tremor of the hand are helpful diagnostic signs. The weakness is moderate, with survival until late adolescence or early adult life. The patients must use a wheelchair, and they develop postural contractures of hip flexion, knee flexion, and foot equinus. Scoliosis is common, progressing rapidly and markedly reducing respiratory ability. Prognosis is related to the progressive muscle weakness and spinal deformity, which eventually lead to respiratory failure.

Type III spinal muscular atrophy (i.e., Kugelberg-Welander disease, mild spinal muscular atrophy) has an insidious onset in children from 2 to 12 years of age with episodes of weakness. Patients have a waddling gait, with difficulty in climbing steps and getting up from the floor. The prognosis is good, and there is only a minimal respiratory deficit. Patients tend to have flat feet (eversion of the foot), pelvic girdle weakness, a mild hand tremor, and scoliosis (129,196).

Evans and Drennan (107) group patients with spinal muscular atrophy according to function. Group I children are unable to sit independently and usually die in infancy of pulmonary failure. Group II children develop head control, can sit independently, and usually survive until young adult life. Group III patients pull to stand and walk, and may live into the fourth decade. Group IV patients can walk, run and climb steps, but usually require wheelchairs by the third decade and have a long life expectancy (107,383). The major orthopaedic problems are spinal deformities, contractures, and hip instability.

### *Spinal Deformities*

Spinal deformities develop in virtually all patients who are poor ambulators and in about half of those who initially learn to walk and run. The most common deformity is a long C-shaped scoliosis, and severe pelvic obliquity develops as the curve progresses. A kyphosis is usually associated with the scoliosis, and a progressive spinal deformity decreases pulmonary capacity and jeopardizes sitting posture (66,81,150,157,228,294). In a series of patients followed at the Alfred I. duPont Hospital for Children (Wilmington, DE), the average age at onset of scoliosis was 7.6 years (range, infancy to 13 years) (8). In a mild deformity, a soft thoracolumbosacral orthosis with a large abdominal relief provides trunk support and may delay progression of the curve, but the orthosis must not compress the chest and further compromise respiratory function (228). Pulmonary function evaluations before and after application of the orthosis are used to determine safe parameters, because often an orthosis decreases the tidal volume by as much as 20% (8). In severely compromised patients, the posterior half of an orthosis may be used alone, but this is less effective. Typically, scoliosis is progressive, and when the curve reaches 40° to 45°, a posterior spinal fusion from the high thoracic area to the sacrum with internal fixation is

recommended. In a child younger than 10 years old with a progressive scoliosis greater than 60°, surgery is indicated.

Before any anticipated surgical procedure, pulmonary evaluation must be performed. Severe postoperative respiratory problems are seen with a vital capacity less than 25% normal (228). An intense respiratory rehabilitation program, emphasizing inhalation strength, coughing, and maintenance of good pulmonary hygiene, can temporarily improve respiratory ability by about 15% to help during the perioperative period. After surgery, the pulmonary function usually returns to the preoperative level and gradually declines, but one study suggests an improvement (271).

We prefer segmental fixation with the Luque rods and Galveston pelvic fixation or the unit rod in this group of patients because they allow rapid postoperative mobilization, which helps in the general care and especially inpulmonary care (39,258). Patients with spinal muscular atrophy typically have severely osteopenic bone, and supplementary bone grafts are necessary to achieve an adequate fusion mass. Loss of pelvic fixation due to the rods cutting out of the ilium anteriorly requires revision because colonic perforation can occur (228). In young children with a large deformity and osteopenic bone, do not attempt an extensive correction, and use the smaller ¼ or $^{3}/_{16}$ inch rods. Rod connectors when using Luque rods prevent rod shift and increasing deformity. For 3 to 4 months postoperatively, a thoracolumbosacral orthosis can be used when the patient is sitting or standing to give additional support and to prevent the wires of the Luque rod or unit rod from pulling loose from the osteopenic bone. In patients with severe respiratory compromise with a large curve, the usual methods of internal fixation may be impossible, and halo-dependent traction followed by spinal fusion and limited instrumentation may be the only reasonable alternative. Anterior spinal fusions generally are not recommended in patients with spinal muscular atrophy because postoperative respiratory compromise is severe (8,228). Postoperative ventilation for 24 to 48 hours in an intensive care unit is often required. For all patients, the period of immobilization should be only a few days, and sitting or ambulation should be started as soon as tolerable, except for the rare problem requiring the halo-dependent technique. Even in this situation, the patient can be up in a wheelchair in overhead traction during the day.

### *Contractures*

Contractures develop in the upper and lower extremities and are more frequently seen in the severely weak children. Flexion contractures of the elbow and adduction contractures of the shoulder are common but rarely a functional problem. Bedridden infants assume a frog-leg position, and lower extremity contractures occur with the hip in flexion abduction, the knee flexed, and the foot in equinus. Wheelchair-dependent patients develop flexion contractures of the hip and knee and equinovarus deformity of the foot (107). Ambulatory patients have only mild contractures, which seldom interfere with walking. A maintenance motion-therapy program with intermittent splinting can control most contractures, and surgery is seldom required. Soft-tissue procedures are effective in reducing contractures but are indicated only if a contracture inhibits some functional ability or becomes painful. Surgical releases are used to get these children into long-leg braces or a standing frame. Hip flexion contractures require release of the fascia lata, sartorius, rectus femoris, and iliopsoas. Knee flexion contractures require tenotomy of the medial and lateral hamstrings and iliotibial band. Foot deformities seldom require surgery, but a severe equinovarus contracture occasionally causes a skin ulceration on the foot. Tenotomy of the tendo Achilles and posterior tibialis tendon with manipulation and casting for 6 weeks with lightweight plastic material are usually adequate to correct the foot posture.

Hip instability is a common problem in the more severe types of spinal muscular atrophy (107,294,341). Hip dislocation was seen in 50% of the functional group I children, 39% of group II, 37% of group III, but it did not occur in group IV, according to an unpublished series. The highest incidence of hip pain occurred in the group II children. In children who are limited ambulators or confined to a wheelchair and have a mobile painless dislocated hip, nonoperative management is recommended.

## POLIOMYELITIS

Poliomyelitis is an acute enteroviral illness that selectively involves the anterior horn cells of the spinal cord and the brain stem motor nuclei. New cases have been rare since prophylactic vaccines became available in the 1960s (282,285). The virus is transmitted by the oropharyngeal-fecal route, and humans are the reservoir. The incubation period is 6 to 20 days, and an estimated 1% to 2% of infected people develop neural symptoms. Coxsackieviruses and echoviruses produce a similar illness and should be considered in sporadic cases.

The illness is divided into three stages: acute, convalescent, and chronic. The acute stage begins with gastrointestinal symptoms (e.g., nausea, vomiting, sore throat), a febrile illness (usually less than 103°F), followed by meningeal symptoms (e.g., headache, nuchal rigidity, back pain, pain on straight-leg raising), and severe muscle pain. An asymmetric paralysis occurs within 2 days of the meningeal symptoms and usually reaches its maximum within 48 hours. The legs are usually weaker than the arms, but weakness may occur in any muscle group, including the bulbar muscles. The most commonly involved muscles are the gluteal muscles, hip flexors, quadriceps, tibialis anterior, medial hamstrings, deltoid, triceps, and pectoralis major (299). There is no sensory loss, and the cerebrospinal fluid has a high protein level in the active stage. The EMG and muscle biopsy results show denervation. During the acute phase, patients should minimize activities (usually by bed rest), apply hot packs to painful muscles, position extremities in the anatomic position to prevent contractures, and perform general passive range of motion on all joints to the limits of tolerance (293). The acute stage ends when the temperature is normal for 48 hours and there is absence of progressive muscle involvement.

The convalescent stage begins 48 hours after the temperature has returned to normal and continues for as long as 2 years, during which time muscle strength improves spontaneously. The major recovery occurs in the first month, with the exception of the triceps surae and deltoid muscles, which improve much more slowly. Sharrard (300) reports recovery of muscle strength to average two grades above the level at 1 month and one grade above the level at 6 months. Orthopaedic treatment consists of restoring a full range of motion of joints, correcting contractures, and maximizing muscle strength. Overactivity of muscles in the early convalescent stage can inhibit functional return, and contractures of antagonistic muscles must be stretched before weaker muscles are exercised. Braces and orthoses may be used at night to prevent deformities and during therapy sessions to assist function. Equinus deformity of the foot requires a short-leg brace, and quadriceps weakness of grade IV or less requires a long-leg brace with knee-hinge locks.

The chronic stage begins 2 years after the onset of weakness, and no further muscle strength recovery is anticipated. Orthopaedic treatment consists of managing the chronic consequences of paralysis, muscle imbalance, and growth. Joint imbalance is classified into two types: flaccid joints (i.e., negative, static) and active joints with muscle imbalance (i.e., dynamic). Flaccid joints deform only if allowed to be postured in an abnormal position over prolonged periods (139). Deformity can be prevented by maintaining the joint in a neutral position by an orthosis and an exercise program. Active joints with muscle imbalance develop fixed deformities that begin as soft-tissue contractures and evolve into bony deformities that worsen with growth.

Orthopaedic treatment consists of prescribing orthoses, performing muscle-balancing procedures, and performing bony procedures (Table 178.4, Table 178.5, Table 178.6, Table 178.7 and Table 178.8). Orthoses can permanently stabilize a flaccid joint or augment function in a dynamically imbalanced joint. Spring-loaded orthoses are useful to counterbalance unopposed muscle tensions. Muscle-balancing procedures consist of tendon transfers, which produce joint stability and active motor power and eliminate deforming forces (292). The principles of tendon transfer demand that muscle of normal or good strength must be used because typically one grade of strength is lost after a transfer, and loss of function of the transferred muscle must be balanced or an iatrogenic deformity will occur (158,221,236,244). The joint to be moved by the transferred tendon must be free of deformity and have an acceptable range of motion, or the transferred tendon cannot overcome the deformity. The excursion and strength of the transferred muscle must be similar to those of the muscle being replaced, and good surgical technique is essential. The tendon must be routed straight from its origin to insertion, have a smooth gliding channel, and be placed under tension. Postoperative management of a transferred tendon usually includes immobilization for 4 weeks with the joint in a slightly overcorrected position, followed by guarded motion for an additional 3 to 4 weeks. Postoperative muscle training is important to obtain optimal function of transferred tendons.

| *Deformity* | *Treatment* | *References** |
|---|---|---|
| Flexion abduction, external rotation contractures | Obe fasciotomy | JBJS 18:101,936 |
| | Tachdjian, p. 1129 | |
| | Young procedure | JBJS 8:571, 936 |
| | JBJS 20:134, 1938 | |
| | JBJS 31-A:141, 1941 | |
| Gluteus medius paralysis with hip instability | Mustard procedure | JBJS 34-A:64, 1952 |
| | JBJS 41-B:289, 1959 | |
| | External oblique transfer | JBJS 32-A:207, 1950 |
| | to greater trochanter | JBJS 45-A:999, 1963 |
| | Posterior transfer of | JAMA 80:242, 1923 |
| | tensor | |
| | fasciae latae muscle | NEJM 209:61, 1933 |
| Paralytic dislocation | Proximal femoral varus | JBJS 36-B:375, 1954 |
| | derotation osteotomy | JBJS 44-B:572, 1962 |
| | Open reduction | JBJS 41-B:279, 1959 |
| | Arthrodesis | JBJS 32-A:904, 1950 |

* JBJS, Journal of Bone and Joint Surgery, Tachdjian, M. O. Tachdjian (ed.), Congenital Dislocation of the Hip, New York, Churchill Livingstone, 1985; JAMA, Journal of the American Medical Association. NEJM, New England Journal of Medicine.

***Table 178.4. Selected Procedures for the Treatment of the Involved Hip in Poliomyelitis***

| Deformity | Treatment | References* |
|---|---|---|
| Quadriceps femoris paralysis | Biceps femoris and semitendinosus transfer | JBJS 37-A:347, 1955<br>JBJS 13:513, 1931<br>JBJS 30-A:541, 1948 |
| Flexion contracture | Soft-tissue release or femoral osteotomy | JBJS 20:819, 1938<br>JBJS 11:40, 1927 |
| Genu recurvatum | Tibial osteotomy | JAMA 120:207, 1942<br>AOS 114:40, 1957 |
| | Irwin technique | Ingram |
| | Soft-tissue tenodesis | JBJS 58-A:978, 1976 |
| Flail knee | Orthosis with drop-lock knee and arthrodesis | AS 40:90, 1940 |

* JBJS, Journal of Bone and Joint Surgery; JAMA, Journal of the American Medical Association; AOS, Acta Orthopaedica Scandinavica; Ingram, A. T. Ingram, Paralytic disorders, In A. H. Crenshaw (ed.), Campbell's Operative Orthopaedics, p. 2979, St. Louis, C.V. Mosby Co., 1963; AS, Archives of Surgery.

***Table 178.5. Selected Procedures for the Treatment of the Involved Knee in Poliomyelitis***

| Deformity | Treatment | References* |
|---|---|---|
| Partial deltoid paralysis | Anterior advancement of deltoid | Ingram |
| Extensive paralysis | Shoulder arthrodesis | |
| | Charnley | JBJS 46-B:614, 1964 |
| | Gill | JBJS 13:287, 1931 |
| | Watson-Jones | JBJS 15:862, 1933 |

* Ingram, A. T. Ingram, Paralytic disorders, In A. H. Crenshaw (ed.), Campbell's Operative Orthopaedics, p. 3002, St. Louis, C.V. Mosby Co., 1963; JBJS, Journal of Bone and Joint Surgery.

***Table 178.6. Selected Procedures for the Treatment of the Involved Shoulder in Poliomyelitis***

| Deformity | Treatment | References* |
|---|---|---|
| Paralysis of flexion | Steindler flexorplasty | AAOS 1:276, 1944<br>JBJS 45-A:513, 1963 |
| | Clark pectoralis major transfer | JBJS 34:180, 1946 |
| | Carol triceps transfer | JBJS 52-A:239, 1970 |

* AAOS, American Academy of Orthopaedic Surgeons Instructional Course Lectures; JBJS, Journal of Bone and Joint Surgery.

***Table 178.7. Selected Procedures for the Treatment of the Involved Elbow in Poliomyelitis***

| Deformity | Treatment | References* |
|---|---|---|
| Paralysis of peroneal muscle | Lateral transfer of anterior tibial tendon to base of second or third metatarsal | Ingram |
| Paralysis of anterior tibial muscle | Anterior transfer of peroneal longus | SGO 84:717, 1948 |
| Paralysis of triceps surae | Transfer of peroneus longus and tenus posterior tibial, flexor hallucis longus, tibialis anterior | [illegible] |
| Paralysis of tibialis anterior, ext extensors, and peroneal | Anterior transfer of tibialis posterior to base of third metatarsal | [illegible] |
| Instability or deformity | Triple arthrodesis | |
| | Spotnitz | [illegible] |
| | Lambrinudi | [illegible] |
| | Hoke | AJOS 3:494, 1938 |
| | Subtalar arthrodesis-Grice | [illegible] |
| | Talotalar arthrodesis | [illegible] |
| | Calcaneal osteotomy | [illegible] |
| | Dwyer | [illegible] |
| | Evans | [illegible] |
| Flexible elbow valgus | Girdlestone-Taylor transfer | [illegible] |
| | Jones procedure | [illegible] |
| Pes varus | Switcher stripping | AJOS 3:8, 1950 |
| | Cole dorsal tarsal wedge | [illegible] |

* Ingram, A. T. Ingram, Paralytic disorders, In A. H. Crenshaw (ed.), Campbell's Operative Orthopaedics, p. 3031, St. Louis, C.V. Mosby Co., 1963; AOS, Surgery, Gynecology and Obstetrics; JBJS, Journal of Bone and Joint Surgery; PRSM, Proceedings of the Royal Society of Medicine; AJOS, American Journal of Orthopaedic Surgery; BMJ, British Medical Journal.

***Table 178.8. Selected Procedures for the Treatment of the Involved Foot and Ankle in Poliomyelitis***

Bony procedures are directed toward correcting fixed deformities and stabilizing joints (56,205,242,243). Residual growth and loss of joint function must be considered before performing a bony procedure. Ideally, bony procedures are not performed until the patient reaches about 12 years of age, when adequate growth has been achieved.

## ARTHROGRYPOSIS

Arthrogryposis mutiplex congenita is a nonprogressive disorder associated with neurogenic and myopathic disease. It is characterized by rigid or dislocated joints, muscle atrophy or aplasia, fusiform or cylindrical extremities with thin subcutaneous tissue and lack of skin creases, and normal sensation and intelligence (3,19,79,119,255,275,276,326). The pathogenesis involves severe weakness during early intrauterine life that restricts fetal mobility, with subsequent loss of muscle mass and contractures of joints. All extremities are involved in 46% of patients with arthrogryposis, only lower extremities in 43%, and only upper extremities in 11% (335). Serum CPK, chromosomal analysis, EMG, and nerve conduction studies are rarely helpful in diagnosis, but a muscle biopsy may show neuropathic or myopathic changes. More than 90% of these patients have neurogenic illnesses, and 7% have myogenic disorders (18,342).

Although more than 150 conditions have been associated with congenital contractures, amyoplasia congenita or arthrogryposis multiplex congenita accounts for the classic form of arthrogryposis that is characterized by symmetric contractures; internally rotated shoulders, extended elbows, markedly flexed hands and wrists, flexed or extended knees, severe talipes equinovarus, frequently dislocated hips, and a port-wine stain over the forehead area (122,146). Even though these patients are severely disabled, many develop ambulatory potentials; 46.6% have independent ambulation, 33.3% walk with braces, and 20% use wheelchairs (322). Another infrequent form of arthrogryposis is distal arthrogryposis, which has autosomal dominant transmission with variable penetrance. The hands and feet are primarily involved, but knees and hips occasionally are affected (147).

The combination of weakness and stiffness of joints in arthrogrypotic patients produces severe disabilities, and the goals of orthopaedic treatment are to obtain the maximum range of motion of joints and maintain the extremities in a functional position. Twenty-five percent of infants with multiple congenital contractures sustain birth fractures (usually of the femoral shaft) or epiphyseal separation, which are attributed to difficult deliveries. If they are not displaced, these fractures heal rapidly with splint immobilization (76).

### *Contractures*

Initial therapy for all contractures consists of passive stretching and serial splinting to improve joint motion (132,251). Passive stretching exercises are performed at least four times daily and are guided by the patient's parents, who are trained and supervised by physical therapists. Avoid rigid cast fixation for most patients. Many

parents tend to exercise the extremity as a unit, and this should be discouraged; specific attention should be directed to passive stretching of independent joints. After each joint is passively stretched, apply thermoplastic splints between sessions to maintain position. The thermoplastic splints require frequent modifications as the patient grows and the joint mobility increases. In the knee and elbow, the contractures may be so severe that radiographs are occasionally necessary to determine the proper plane for passive flexion and extension exercises.

***Upper Extremity Deformities***

The goals of treatment of the upper extremity in children with arthrogryposis are to provide an extremity that can be brought to the mouth and stabilized for feeding and to provide for toilet care or pulling up from sitting (370).

Passive stretching exercises have been the most successful to obtain motion, but the wrist, shoulder, and fingers are the most resistant. The elbow achieves the most significant benefit from the stretching therapy, and mild changes substantially improve the ability to dress, self-feed, and care for personal hygiene. Defer most surgery until the patient is old enough to demonstrate functional achievements (211).

A derotation osteotomy of the humerus is occasionally useful if the hand is in a nonfunctional position from shoulder rotation. Perform the derotation osteotomy at the proximal third of the humerus, and immobilize the site in a shoulder spica cast until healing occurs. Tricepsplasty (i.e., lengthening of the triceps tendon and posterior capsulotomy of the elbow joint) is recommended by Williams (369) to restore motion to the extended elbow (235). Unfortunately, some motion is lost with growth. Flexor muscle power to the elbow can be facilitated by triceps tendon transfer, but this is done at the expense of active extension. In our experience, the pectoralis transfer by fascia lata extension through to the ulna has been most desirable. The maintenance of the triceps function is very helpful for the mobility of the patient. Transfer of function can be successful only if an adequate range of motion has been obtained by conservative or, if necessary, surgical methods.

The wrist flexion deformity can be managed by a proximal row carpectomy or wrist fusion toward the end of growth. Surgery of small joints of the hand has not been successful in achieving motion or improving function (21).

**Tricepsplasty and Posterior Capsulotomy of the Elbow (Williams Procedure).**

- Make a posterolongitudinal incision from the distal third of the triceps tendon to 2 cm inferior to the olecranon.
- Expose the triceps tendon, and incise it as an inverted V just below the musculotendinous junction.
- Reflect the insertion of the triceps tendon distally, and incise the capsule between the humerus and olecranon. Gently flex the elbow. Tight collateral ligaments and occasionally the radiohumeral capsule may require division to obtain adequate flexion.
- Protect the ulnar nerve by removing it from its sheath and allowing it to prolapse forward if any tension develops. The elbow should flex to at least 90°.
- Repair the triceps tendon in the lengthened position by the V-Y technique, and close the wound.
- Postoperative immobilization is necessary for 10 days, after which physical therapy is instituted to maintain the increased range of motion.

**Steindler Flexorplasty of the Elbow** A Steindler flexorplasty of the elbow to restore active elbow flexion is indicated if there are active, strong forearm pronator and flexor muscles (e.g., pronator teres, flexor carpi radialis, palmaris longus, flexor digitorum sublimis, flexor carpi ulnaris), the elbow has adequate motion, the triceps muscle extends the elbow, and the elbow flexor muscles are paralyzed.

- Make an approximately 9 cm curved longitudinal incision over the medial side of the elbow, beginning about 7 cm proximal to the medial epicondyle, extending over the posterior aspect of the medial epicondyle, and ending distally on the volar surface of the forearm along the pronator teres muscle. Identify the ulnar nerve.
- Remove the common attachment of the flexors to the medial epicondyle with an osteotome.
- Free the muscles distally for about 4 cm.
- Flex the elbow, and reattach the excised medial epicondyle with its muscles to the humerus with a screw or strong sutures 5 cm proximally at the intermuscular septum between the brachialis and triceps.
- Close the wound, and apply a cast with the elbow flexed and the forearm supinated.

Postoperatively, the cast is worn for about 6 weeks, after which begin active training.

**Transfer of the Pectoralis Major Muscle to the Ulna with Fascial Graft**

- Place the patient in a supine position, with the arm held in mild abduction and the elbow extended.
- Use two incisions. Make the first incision from the inferior half of the axillary crease distally to the level of the middle third of the humerus. Expose the insertion of the pectoralis major muscle, and free it from the humerus.
- Make a transverse incision at the anterior aspect of the elbow. Carry dissection down bluntly to the anterior surface of the ulna.
- Using the tip of the olecranon as a guide, expose the ulna anteriorly about 2 cm distal to this point.
- Incise the periosteum and drill a hole in the ulna from anterior to posterior. Leave the drill in place.
- Make an incision along the lateral aspect of the thigh from the greater trochanter to just above the knee.
- Dissect free a strip of fascia lata as long and wide as possible, and remove it.
- Close the wound in a routine manner, with no attempt to close the defect in the fascia lata.
- Sew the fascia lata into a tube with interrupted stitches. Then pass the rolled-up fascia lata subcutaneously between the wounds on the forearm.
- Crisscross a strong absorbable suture along the lower end of the fascia lata, and thread it onto two straight needles that are placed through the hole in the ulna after the drill point has been removed. Pull the end of the fascia lata down in to the ulna, and tie the free ends of the suture over a sponge and button.
- Flex the elbow 70° to 90°, and drape the other end of the fascia lata around and suture it under slight tension to the pectoralis major.
- Close the wounds, and apply a splint to hold the elbow at 90°.

At 2 to 3 weeks postoperatively, replace the cast by a dial lock brace to allow flexion and block extension just below a right angle. Gradually increase the extension over the next month, and have the patient exercize the elbow into flexion several times daily.

**Anterior Transfer of the Triceps Muscle for Restoration of Elbow Flexion (Bunnell-Williams Procedure)**

- Make a posterolongitudinal incision over the distal fourth of the triceps tendon, extending distally midway between the radius and ulna, over the proximal third of the forearm.
- Dissect the triceps tendon off the olecranon with a strip of periosteum from the upper shaft of the ulna.
- Mobilize the triceps off the humerus to the midhumeral level.
- Flex the elbow 90°, and separate the interval between the brachioradialis and pronator teres muscles.
- Roll the periosteal elongation of the triceps and tendon into a tube, pass it around the lateral side of the arm superficial to the radial nerve, and attach it to the bicipital tubercle of the radius through drill holes.
- Secure the tendon under tension with the elbow almost fully flexed.
- Close the wound.

Postoperatively, hold the arm in the flexed position for 1 month, after which general physical therapy can begin.

**Carpectomy for Severe Flexion Deformity of the Wrist (White and Stubbins Procedure)**

- Expose the carpal bones through a transverse posterior incision.
- Retract the extensor tendons medially and laterally to expose the dorsal area of the proximal row of carpal bones.
- Excise the proximal row of carpal bone, and dorsiflex the wrist to test the position. If inadequate dorsiflexion is achieved, all carpal bones except the pisiform may be excised to obtain adequate dorsiflexion. Dorsiflex the wrist to about 20°, and hold the forearm in a neutral position.

After surgery, use a long-arm cast for 3 weeks, followed by a short-arm cast for an additional 2 to 3 weeks. After removal of the cast, have the patient wear a wrist splint part time, usually at night, to prevent recurrence of the flexion deformity.

**Wrist Arthrodesis**

- Make a 6-cm incision dorsally, extending midway from the base of the second and third metacarpals, across Lister's tubercle proximally, and up the dorsal radial surface.
- Dissect the interval between the extensor pollicis longus and the extensor digitorum communis.
- Denude the dorsal surface of the radius, carpal bones, and proximal area of the second and third metacarpals of fibrous or granulation tissue to expose the distal radius, dorsal carpal bone, and proximal area of the second and third metacarpals.
- Cut a 1 cm wide bony slot in the dorsal radius across the carpal bones (i.e., lunate, scaphoid, capitate, trapezoid) into the bases of the second and third metacarpals.
- Place a corticocancellous iliac bone graft in the slot, and close the wound. A Steinman pin placed down the third metacarpal into the radius provides some fixation.

After surgery, place the wrist in neutral, and apply a long-arm cast. This cast is worn until the arthrodesis is firm, usually 10 to 12 weeks.

***Knee Deformities***

The knee deserves early aggressive attention, because most patients with arthrogryposis can walk or stand if the knee is in a suitable position (317). Motion from at least 15° to 45° of flexion is desirable but may not be obtained in rigid extremities. Rigid knees that have 35° to 40° of flexion are stable for standing and sitting; full extension makes sitting awkward, and excessive flexion makes standing impossible. Knee flexion contractures (65% of patients) are more common than extension contractures (6%). Daily passive stretching with thermoplastic maintenance splinting is the most effective treatment to increase motion in infants and young children. Forty percent of patients can be managed by nonoperative treatment programs (339).

Recurrence of a knee deformity is common, and in juvenile and adolescent patients, recalcitrant contractures, often with posterior subluxation of the tibia, respond to two-pin traction. Place the proximal pin in the proximal metaphysis of the tibia, so that the anterior traction reduces the knee subluxation, and place the distal pin in the distal metaphysis of the tibia, so that longitudinal traction can reduce the flexion contracture of the knee. The two-pin traction method requires prolonged hospitalization and may be combined with hamstring lengthening and posterior capsulotomy. Recurrence of the flexion deformities may occur in growing children because the joint capsule and rigid periarticular soft tissues do not stretch adequately during growth.

A few patients develop marked bony and cartilaginous joint deformities, making joint motion impossible. An osteotomy, usually of the distal femur, is used to reposition the knee to 35° of flexion, which allows adequate sitting and standing. The angulation of the distal femur causes a mild iatrogenic cosmetic deformity.

In the extended knee, the joint is often rigid and resistant to therapy. The patella may be dislocated laterally, and the tibia may be dislocated anteriorly. A radiograph of the knee may be necessary for orientation before initiating to stretching therapy. For the dislocated knee in the infant, apply longitudinal skin traction to the tibial area of the legs, initially at 1 lb (0.45 kg) and progressing to a maximum of 5 lb (2.25 kg). Continue traction until the tibial plateau is beneath the femoral condyle, and then initiate flexion therapy. As soon as the knee can be flexed to about 30° in the reduced position, discontinue traction and apply splints to maintain reduction. If reduction cannot be achieved by traction, open reduction, consisting of a quadriceps lengthening, release of the lateral patellar retinaculum, and occasionally, knee ligament lengthening is necessary (65). After flexion is acquired, prolonged orthotic management is necessary to maintain motion.

***Hip Deformities***

In patients with arthrogryposis, the hip joint is frequently contracted (82%) and dislocated (58%) (290). The absolute treatment goal for hip contractures is to obtain a functional position of motion in the flexion–extension plane, which is a major benefit. At birth, the hips are frequently in a nonfunctional position of abduction, flexion, and external rotation (i.e., Buddha-like position) and should be passively stretched and sprinted. In the newborn, a cloth band can be wrapped around the proximal part of the leg to reduce the abduction contracture. In patients between 1 and 3 years of age, casts are applied to the legs, with a bar incorporated between the casts to control abduction and rotation, and the hips are passively stretched, placing the patient in a prone position. A hip flexion contracture of 30° is acceptable, because the lumbar spine can provide adequate compensatory motion. If adequate correction has not been obtained in the patient by 2 years of age, a soft-tissue release is helpful, or a varus extension intertrochanteric osteotomy may allow the desired position without producing additional muscle weakness. If a rigid contracture prevents ambulation, trochanteric osteotomies can reposition the extremity at about 35° of hip flexion and bring the hip out of the abducted position to allow adequate sitting and standing (290).

Hip dislocation is typically teratogenic and can be bilateral or unilateral. Occasionally, there is a reasonably mobile, nonteratogenic dislocated hip that can be treated in a manner similar to a typical congenitally dislocated hip if treatment is initiated before 3 months of age. Bilateral hip dislocations are best left untreated and attention directed toward obtaining adequate motion (172). A teratogenic unilateral hip dislocation was formerly thought to cause severe contractures, pelvic obliquity, and secondary scoliosis, but this is not always the case in arthrogryposis (84). An ipsilateral knee flexion contracture should be corrected before reduction is attempted, because knee therapy can redislocate the hip. Skin traction (i.e., a home traction program) and passive stretching therapy are used to obtain as much hip motion as possible (183). Occasionally, the femoral head reduces to the level of the acetabulum, and a closed reduction can be performed similar to that done for a typical congenitally dislocated hip, but postoperative casting should not allow the hip to contract in a nonfunctional position.

By the time a child is 1 year old, most teratogenic unilateral dislocations of the hip require open reduction through an anterior approach, extensive soft-tissue release, and possibly femoral shortening to obtain an adequate reduction. After surgery, a maximum of 6 weeks of casting from the thorax to the toes, followed by prolonged orthotic control, is necessary for adequate joint remodeling. Inadequate reduction with subsequent redislocation or subluxation does occur. if the hip cannot be reduced adequately, the pelvic obliquity is treated by an intertrochanteric femoral osteotomy to position the leg functionally, and a shoe lift is used to accommodate the limb length discrepancy until a properly timed ipsilateral epiphysiodesis is performed (28,257). If there is any question about obtaining good motion, it is better to leave the unilateral hip dislocation unreduced. A stiff hip produces a more significant problem than the other possible related conditions.

***Foot Deformities***

The most common (84%) foot deformity in arthrogryposis is talipes equinovarus. Convex pes valgus, calcaneovalgus, and cavovarus deformities are seen occasionally. These severely deformed feet are often extremely stiff, and the goal of treatment is to obtain a pain-free plantigrade foot at maturity.

At birth, the talipes equinovarus is treated by serial taping and passive stretching therapy. The passive stretching is performed four times each day, and the taping is changed every other day to reflect changes in position. Thirty-one of the 80 patients in our series have had successful nonsurgical treatment, even though a perfect result was not obtained (251). In patients with nonplantigrade feet but reasonable motion, a posteromediolateral release was satisfactory in 15 of 20 feet. After a posteromediolateral release, prolonged orthotic care and extensive passive stretching are necessary.

Recurrence in patients older than 10 years of age is best treated by a triple arthrodesis. In the rigid foot, a talectomy performed when the child is between 1 and 2 years old gives the most satisfactory plantigrade foot (84,138,145,170,191). Recurrence after the age of 10 years is best treated by a triple arthrodesis.

**Talectomy**

- Make a skin incision from just distolateral to the head of the talus, extending obliquely inferoposteriorly to 1 inch (2.5 cm) inferior to the lateral malleolus (Ollier approach).
- Retract the peroneus longus and brevis tendons inferiorly, and incise the talocalcaneal portion of the bifurcate ligament.
- Turn the foot medially to expose the talar neck. The talus may be excised as one piece or in fragments.
- Strip the ligaments from both the medial and lateral aspects of the malleolus, and displace the foot posteriorly on the tibia so that the medial malleolus is in contact with the navicular and the lateral malleolus is at the calcaneocuboid joint.
- Align the foot to the desired rotation (i.e., long axis of the foot is perpendicular of the anterior tibia), and eshape the malleoli to fit the calcaneus in the new position. Any tight tendons or ligaments may be lengthened to allow proper orientation of the foot. The foot should align without tension.
- Close the wound, and apply a long-leg cast with the knee flexed and the foot in the corrected position. If the knee motion is inadequate to achieve cast support, place a Steinmann pin through the tibia and incorporate it into a short leg cast.

Postoperatively, change the long-leg cast at 2 weeks to a short-leg cast for an additional 10 weeks. Allow weight bearing about 1 month after surgery. After the cast is removed, use a solid ankle-foot orthosis to maintain position.

***Scoliosis***

The reported incidence of scoliosis varies from 0% to 42%, but a figure of about 20% seems acceptable (159,260). Noncongenital scoliosis may be present at birth or

may develop in early childhood; it is progressive, becomes rigid, and is associated with pelvic obliquity (83,116,304). Congenital scoliosis is far less common. A thoracolumbosacral orthosis is preferred in curves between 20° and 40°, and a posterior spinal fusion and instrumentation is preferred in progressive curves of more than about 40°. Because the scoliosis tends to be rigid, the fusion should not be delayed in progressive curves, or a severe deformity will develop. Arthrodesis is difficult to achieve, and a high incidence of pseudarthrosis is reported.

In severe curves with pelvic obliquity, an anterior release followed by a posterior spinal fusion to the sacrum with instrumentation enhances correction of the curve and pelvic obliquity (233).

## CHAPTER REFERENCES

Each reference is categorized according to the following scheme: *, classic article; #, review article; !, basic research article; and +, clinical results/outcome study.


+ 1. Abell JM Jr, Hayes JT. Charcot Knee Due to Congenital Insensitivity to Pain. *J Bone Joint Surg* 1964;46-A:1287,.

# 2. Aberion G, Alba A, Lee MH, Solomon M. Pulmonary Care of Duchenne Type Muscular Dystrophy. *NY State J Med* 1973;73:1206.

# 3. Adams RD, Denny-Brown D, Pearson CM. *Disease of Muscles.* New York: Paul B. Hoeber, 1953:229.

+ 4. Afifi AK, Smith JW, Zellweger H. Congenital Nonprogressive Myopathy. Central Core Disease and Nemaline Myopathy in One Family. *Neurology* 1965;15:371.

+ 5. Alexander MA, Johnson EW, Petty J, Stauch D. Mechanical Ventilation of Patients with Late Stage Duchenne Muscular Dystrophy: Management in the Home. *Arch Phys Med Rehabil* 1979;60:289.

* 6. Allen BL Jr, Ferguson RL. The Galveston Technique for LRod Instrumentation of the Scoliotic Spine. *Spine* 1982;7:276.

+ 7. Angus PD, Cowell HR. Triple Athrodesis—A Critical Long-Term Review. *J Bone Joint Surg* 1986;68-B:260.

+ 8. Aprin H, Bowen JR, MacEwen GD, Hall JE. Spine Fusion in Patients with Spinal Muscular Atrophy. *J Bone Joint Surg* 1982:64-A:1179.

+ 9. Archibald DC, Vignos PJ Jr. A Study of Contractures in Muscular Dystrophy. *Arch Phys Med Rehabil* 1959;40:150.

+ 10. Arendar GM, Canelo SB, Arenda T. *Long-term Follow-up of 148 Triple Arthrodesis Functional Results.* Presented at SICOT 90, XVIII, World Congress, Montreal, 1990.

+ 11. Armstro RM, Koenigsberger R, Mellinger J, Lovelace RE. Central Core Disease with Congenital Hip Dislocation: Study of Two Families. *Neurology* 1971;21:369.

! 12. Aslandis C, Jansen G, Amenmiya C, et al. Cloning of the Essential Myotonic Dystrophy Region and Mapping of the Putative Defect. *Nature* 1992;355:548.

+ 13. Bach JR, McKeon J. Orthopedic Surgery and Rehabilitation for the Prolongation of Brace-free Ambulation of Patients with Duchenne Muscular Dystrophy. *Am J Phys Med Rehabil* 1991;70:323.

# 14. Bach JR, O'Brien J, Krolenberg R, Alba AS. Muscular Dystrophy. A Management of End Stage Respiratory Failure in Duchenne Muscular Dystrophy. *Muscle Nerve* 1987;10:177.

+ 15. Badurska B, Fidziansia A, Kamieniecka Z, et al. Myotubular Myopathy. *J Neurol Sci* 1969;8:563.

+ 16. Bailey RO, Marzulo DC, Hans MB. Muscular Dystrophy. Infantile Facioscapulohumeral Muscular Dystrophy: New Observations. *Acta Neurol Scand* 1986;74:51.

# 17. Bailey RO, Turok DI, Jaufmann BP, Singh JK. AIDS. Myositis and Acquired Immunodeficiency Syndrome. *Hum Pathol* 1987;18:749.

+ 18. Banker BQ. Neuropathologic Aspects of Arthrogryposis Multiplex Congenita. *Clin Orthop* 1985;194:30.

+ 19. Banker BQ, Victor M, Adams RD. Arthrogryposis Multiplex Due to Congenital Muscular Dystrophy. *Brain* 1957;80:319.

# 20. Barbeau A. Friedreich's Ataxia 1978. An Overview. *Can J Neurol Sci* 1978;15:161.

+ 21. Bayne LG. Hand Assessment and Management of Arthrogryposis Multiplex Congenita. *Clin Orthop* 1985;194:68.

+ 22. Becker PE. Two New Families of Benign Sex-Linked Recessive Muscular Dystrophy. *Rev Can Biol Exp* 1962;21:551.

+ 23. Becker PE, Kiener F. Eline Neue X-Chromosale Muskeldystrophies *Arch Psychiatr Nervenkr* 193:427, 1955.

+ 24. Bell DB, Smith DW. Myotonic Dystrophy in the Neonate. *J Pediatr* 1972;81:83.

+ 25. Bell DF, Moseley CF, Koreska J. Unit Rod Segmental Spinal Instrumentation in the Management of Patients with Progressive Neuromuscular Spinal Deformity. *Spine* 1989;14:1301.

+ 26. Bonnet I, Burgot D, Bonnard C, Glorion B. Surgery of the Lower Limbs in Duchenne Muscular Dystrophy. *French J Orthop Surg* 1991;5:160.

+ 27. Bossen EH, Shelburne JD, Verkauf BS. Respiratory Muscle Involvement in Infantile Myotonic Dystrophy. *Arch Pathol* 1974;97:250.

+ 28. Bowen JR, Johnson WJ. Percutaneous Epiphysiodesis. *Clin Orthop* 1984;190:170.

+ 29. Bowker JH, Halpin PJ. Factors Determining Success in Reambulation of the Child with Progressive Muscular Dystrophy. *Orthop Clin North Am* 1978;9:431.

# 30. Bradley WG. *Disorders of Peripheral Nerves.* Oxford: Blackwell Scientific, 1974.

+ 31. Bradley WG, Jones MZ, Mussini JM, Fawcett PR. Becker Type Muscular Dystrophy. *Muscle Nerve* 1978;1:111.

+ 32. Brewerton DA, Sandifer PH, Sweetnam DR. “Idiopathic” Pes Cavus. *Br Med J* 1963;2:659.

+ 33. Brewster AH, Larson CB. Cavus Feet. *J Bone Joint Surg* 1940;22:361.

# 34. Brooke MH. *A Clinician's View of Neuromuscular Disease.* Baltimore: Williams & Wilkins, 1977.

! 35. Brook JD, McCurrach ME, Harley HG, et al. Molecular Basis of Myotonic Dystrophy: Expansion of a Trinucleotide (CTG) Repeat at the 3' End of a Transcript Encoding a Protein Kinase Family Member. *Cell* 1992;68:799.

# 36. Brooke MH. A Neuromuscular Disease Characterized by Fibre Type Disproportion. In: Kakulas BA, ed. *Clinical Studies in Myology.* Proceedings of the Second International Congress on Muscle Diseases. Part 2, Perth, Australia, 1971. Amsterdam: Excerpta Medica, 1973.

+ 37. Brooria MJ, Banta JV, Renshaw TS. Spinal Fusion Augmented by Luque Rod Segmental Instrumentation for Neuromuscular Scoliosis. *J Bone Joint Surg* 1989;71-A:132.

+ 38. Brouwer OF, Padberg GW, Wijmenga C, Frants RR. Facioscapulohumeral Muscular Dystrophy in Early Childhood. *Arch Neurol* 1994;51:387.

+ 39. Brown JC, Zeller JL, Swank SM, et al. Surgical and Functional Results of Spine Fusion in Spinal Muscular Atrophy. *Spine* 1989;14:763.

+ 40. Buchthal F, Olsen PZ. Electromyography and Muscle Biopsy in Infantile Spinal Muscular Atrophy. *Brain* 1970;93:15.

# 41. Bunch WH. Muscular Dystrophy. In: Hardy JH, ed. *Spinal Deformity in Neurological and Muscular Disorders.* St. Louis: C.V. Mosby, 1974.

* 42. Bunch WH. Scapulo-thoracic Fusion for Shoulder Stabilization in Muscular Dystrophy. *Minn Med* 1973;56:391.

+ 43. Bunch WH, Siegel IM. Scapulothoracic Arthrodesis in Facioscapulohumeral Muscular Dystrophy. *J Bone Joint Surg* 1993;75-A:372.

+ 44. Burke SS, Grove NM, Houser CR, Johnson, DM. Respiratory Aspects of Pseudohypertrophic Muscular Dystrophy. *Am J Dis Child* 1971;121:230.

! 45. Buxton J, Shelbourne P, Davies J, et al. Detection of an Unstable Fragment of DNA Specific to Individuals with Myotonic Dystrophy. *Nature* 1992;355:547.

+ 46. Byers RK, Banker BQ. Infantile Muscular Atrophy. *Arch Neurol* 1961;5:140.

+ 47. Cady RB, Babechko WP. Incidence, Natural History and Treatment of Scoliosis in Friedreich's Ataxia. *J Pediatr Orthop* 1984;4:673.

+ 48. Calderon R. Myotonic Dystrophy: A Neglected Cause of Mental Retardation. *J Pediatr* 1966;68:423.

+ 49. Cambridge W, Drennan JC. Scoliosis Associated with Duchenne Muscular Dystrophy. *J Pediatr Orthop* 1987;7:436.

+ 50. Campbell MJ, Rebeiz JJ, Walton JN. Myotubular Centronuclear or Pericentronuclear Myopathy. *J Neurol Sci* 1969;8:425.

+ 51. Carroll JE, Brooke MH, Kaiser K. Diagnosis of Infantile Myotonic Dystrophy. *Lancet* 1975;2:608.

# 52. Carroll NC. Pathoanatomy and Surgical Treatment of the Resistant Clubfoot. *Instr Course Lect* 1988;37:93.

+ 53. Cavanagh NPC, Lake BD, McMeniman P: Congenital Fibre Type Disproportion Myopathy. *Arch Dis Child* 1979;54:735.

* 54. Charcot J, Marie P. Sur une Forme Particuliere d'Atrophic Musculaire Progressive, Souvent Familiale, Debutant par les Pieds et les Jambes et Atteignant Plus Tard les Mains. *Rev Med* 1886;6:97.

! 55. Chamberlain S, Shaw J, Rowland A, et al: Mapping of Mutation Causing Friedreich's Ataxia to Human Chromosome 9. *Nature* 1988;334:248.

* 56. Chiari K. Medial Displacement Osteotomy of the Pelvis. *Clin Orthop* 1974;98:55.

+ 57. Cole WH. The Treatment of Claw-Foot. *J Bone Joint Surg* 1940;22:895.

# 58. Coleman SS. *Complex Foot Deformities in Children.* Philadelphia, Lea & Febiger, 1983.

* 59. Coleman SS, Chesnut WJ. A Simple Test for Hindfoot Flexibility in the Cavovarus Foot. *Clin Orthop* 1977;123:60.

+ 60. Cook AW, Bird TD, Spence AM, et al. Myotonic Dystrophy, Mitral Valve Prolapse, and Stroke. *Lancet* 1978;1:335.

+ 61. Copeland SA, Howard RC. Thoracoscapular Fusion for Facioscapulohumeral Dystrophy. *J Bone Joint Surg* 1978;60-B:547.

# 62. Cowell HR. Genetic Aspects of Orthopaedic Disease. *Clin Orthop* 1975;107:36.

+ 63. Curless RG, Nelson MB. Needle Biopsies of Muscle in infants for Diagnosis and Reserch. *Dev Med Child Neurol* 1975;17:592.

# 64. Curtis BH. Orthopaedic Management of Muscular Dystrophy and Related Disorders. *Instr Course Lect* 1970;19:78.

+ 65. Curtis BH, Fisher RL. Congenital Hyperextension and Anterior Subluxation of the Knee. *J Bone Joint Surg* 1969;51-A:255.

+ 66. Daher YH, Lonstein JE, Winter RB, Bradford DS: Spinal Deformities in Patients with Friedreich's Ataxia: A Review of 19 Patients. *J Pediatr Orthop* 1985;5:553.

+ 67. Daher Y, Lonstein J, Winter R, Bradford DS. Spinal Deformities in Patients with Muscular Dystrophy Other Than Duchenne—A Review of 11 Patients Having Surgical Treatment. *Spine* 1985;10:614.

+ 68. Daher YH, Lonstein JE, Winter RB, Bradford DS. Spinal Surgery in Spinal Muscular Atrophy. *J Pediatr Orthop* 1985;5:391.

+ 69. Daher YH, Lonstein JE, Winter RB, Bradford DS. Spinal Deformities in Patients with Charcot-Marie-Tooth Disease. A Review of 12 Patients. *Clin Orthop* 1986;202:219.

+ 70. Dahl DS, Klutzow FW. Congenital Rod Disease. Further Evidence of Innervational Abnormalities as the Basis for the Clinicopathologic Features. *J Neurol Sci* 1974;23:371.

+ 71. Dalakas MC, Pezeshkpour GH. Neuromuscular Diseases Associated with Human Immunodeficiency Virus Infection. *Ann Neurol* 1988;38:375.

* 72. Dejerine J, Sottas J. Sur la Neurite Interstitielle Hypertrophique et Progressive de l'Enfance. *Coll R Soc Biol* 1893;45:63.

+ 73. Demos J. Early Diagnosis and Treatment of Rapidly Developing Duchenne de Boulogne Type Myopathy (Type DDB1). *Am J Phys Med* 1971;50:271.

# 74. Denny-Brown D, Nevin S. The Phenomenon of Myotonia. *Brain* 1941;64:1.

+ 75. DeWind LT, Jones RJ. Cardiovascular Observations in Dystrophia Myotonica. *JAMA* 1950;144:299.

+ 76. Diamond LS, Alegado R. Perinatal Fractures in Arthrogryposis Multiplex Congenita. *J Pediatr Orthop* 1981;1:189.

+ 77. Dias CD, Miller F, Dabney K, et al. Surgical Correction of Spinal Deformity Using a Unit rod in Children with Cerebral Palsy. *J Pediatr Orthop* 1996;16:734.

+ 78. Dorando C, Newman MK. Bracing for Severe Scoliosis of Muscular Dystrophy Patients. *Phys Ther Rev* 1957;37:230.

+ 79. Drachman DB, Banker BQ. Arthrogryposis Multiplex Congenita. A Case Due to Disease of the Anterior Horn Cells. *Arch Neurol* 1961;5:77.

+ 80. Drager GA, Hammill JF, Shy GM. Paramyotonia Congenita. *Arch Neurol Psychiatry* 1958;80:1.

+ 81. Drennan JC. Skeletal Deformities in Spinal Muscular Atrophy. [Abstract.] *Clin Orthop* 1978;133:266.

# 82. Drennan JC. *Orthopedic Management of Neuromuscular Disorders.* Philadelphia: J.B. Lippincott, 1983:61.

+ 83. Drummond DS, Mackenzie DA. Scoliosis in Arthrogryposis Multiplex Congenita. *Spine* 1978;3:146.

# 84. Drummond DS, Siller TM, Cruess RL. Management of Arthrogryposis Multiplex Congenita. *Instr Course Lect* 1974;23:79.

+ 85. Dubowitz V. The Floppy Infant. *Clin Dev Med* 1969;31:41.

# 86. Dubowitz V. *Muscle Biopsy,* 2nd ed. London: Bailliere Tindall, 1985.

# 87. Dubowitz V. *Muscle Disorders in Childhood*. Philadelphia: W.B. Saunders Company, 1995.

# 88. Dubowitz V, Brooke MH. *Muscle Biopsy: A Modern Approach.* Philadelphia: W.B. Saunders, 1973.

* 89. Duchenne GB. Recherches sur le Paralysie Musculaire Pseudohypertrophique ou Paralysie Myosclerosique. *Arch Gen Med* 1868;11:5.

* 90. Dwyer FC. Osteotomy of the Calcaneum for Pes Cavus. *J Bone joint Surg* 1959;41-B:80.

# 91. Dwyer FC. The Present Status of the Problem of Pes Cavus. *Clin Orthop* 1975;106:254.

# 92. Dyck PJ. Inherited Neuronal Degeneration and Atrophy Affecting Peripheral Motor Sensory and Autonomic Neurons. In: Dyck PJ, Thomas PK, Lambert EH, eds. *Peripheral Neuropathy.* Philadelphia: W.B. Saunders, 1975:825.

# 93. Dyck PJ, Chance PF, Lebo RV, Carney JA. Hereditary Motor and Sensory Neuropathies. In: Dyck PJ, Thomas PJ, Griffin JW, et al, eds. *Peripheral Neuropathy,* 3rd ed. Philadelphia: WB Saunders, 1993:1094.

# 94. Dyck PJ, Lambert EH. Lower Motor and Primary Sensory Neuron Diseases with Peroneal Muscular Atrophy. Part 1: Neurologic, Genetic and Electrophysiologic Findings in Hereditary Polyneuropathies. *Arch Neurol* 1968;18:603.

# 95. Dyck PJ, Lambert EH. Lower Motor and Primary Sensory Neuron Diseases with Peroneal Muscular Atrophy. Part II: Neurologic, Genetic, and Electrophysiologic Findings in Various Neuronal Degenerations. *Arch Neurol* 1968;18:619.

+ 96. Edwards RHT. Percutaneous Needle-Biopsy of Skeletal Muscle in Diagnosis and Research. *Lancet* 1971;2:593.

+ 97. Edwards RHT, McDonnell M. Hand-held Dynamometer for Evaluating Voluntary Muscle Function. *Lancet* 1974;2:757.

+ 98. Eldjarn L, Try K, Stokke O, et al. Dietary Effects on Serum Phytanic-Acid Levels and on Clinical Manifestations in Heredopathia Atactica Polyneuritiformis. *Lancet* 1966;1:691.

* 99. Emery AE. X-Linked Muscular Dystrophy with Early Contractures and Cardiomyopathy (Emery-Dreifuss Type). *Clin Genet* 1987;32:360.

+ 100. Emery AEH, Skinner R. Clinical Studies in Benign (Becker Type) X-Linked Muscular Dystrophy. *Clin Genet* 1976;10:189.

+ 101. Eng GD, Epstein BS, Engel WK, et al. Malignant Hyperthermia and Central Core Disease in a Child with Congenital Dislocating Hips. *Arch Neurol* 1978;35:189.

+ 102. Engel AG. Late Onset Rod Myopathy (a New Syndrome?): Light and Electron Microscopic Observations in Two Cases. *Mayo Clin Proc* 1966;41:713.

+ 103. Engel WK. Focal Myopathic Changes Produced by Electromyographic and Hypodermic Needles. *Arch Neurol* 1967;16:509.

+ 104. Engel WK, Foster JM, Hughes BP, et al: Central Core Disease: An Investigation of a Rare Muscle Cell Abnormality. *Brain* 1961;84:167.

+ 105. Erb W. Uber die “Juvenile Form” progressiven Muskelatrophie ihre Beziehunger zur sogennanten Pseudohypertrophie der Muskeln. *Dtsch Arch Klin Med* 1884;34:467.

! 106. Ervasti JM, Ohlendieck K, Kahl SD, et al. Deficiency of a Glycoprotein Component of the Dystrophin Complex in Dystrophic Muscle. *Nature* 1990;345:315.

# 107. Evans GA, Drennan JC. Functional Classification and Orthopaedic Management of Spinal Muscular Atrophy. *J Bone Joint Surg* 1981;63-B:516.

+ 108. Eyring EJ, Johnson EW, Burnett C. Surgery in Muscular Dystrophy. *JAMA* 1972;222:1056.

+ 109. Fenichel GM, Emery ES, Hunt P. Neurogenic Atrophy Simulating Facioscapulohumeral Dystrophy: A Dominant Form. *Arch Neurol* 1967;17:257,.

# 110. Ferguson RL, Allen BL. Segmental Spinal Instrumentation for Routine Scoliotic Curve. *Contemp Orthop* 1980;2:450.

+ 111. Fiddian NJ, King RJ. The Winged Scapula. *Clin Orthop* 1984;185:228.

+ 112. Filla A, DeMichele G, Caruso G, et al. Genetic Data and Natural History of Friedreich's Disease: A Study of 80 Italian Patients. *J Neurol* 1990;237:345.

+ 113. Fiorista F, Brambilla G, Saviotti M, et al. Myocardial Infarction in a Child Aged Ten with Duchenne Muscular Dystrophy. *Z Kardiol* 1981;70:784.

! 114. Fisher J, Upadhaya M. Molecular Genetics of Faciocapulohumeral Dystrophy. *Neuromuscul Disord* 1997:7:55.

+ 115. Fisk JR, Bunch WH. Scoliosis in Neuromuscular Disease. *Orthop Clin North Am* 1979;10:863.

+ 116. Fitti RM, D'Auria TM. Arthrogryposis Multiplex Congenita. *J Pediatr* 1956;48:797.

# 117. Florence JM, Brooke MH, Carroll JE. Evaluation of the Child with Muscular Weakness. *Orthop Clin North Am* 1978;9:49.

+ 118. Fossberg H, Olofsson BO, Eriksson A, Andersson S. Cardiac Involvement in Congenital Myotonic Dystrophy. *Br Heart J* 1990;63(2):119.

+ 119. Fowler M. A Case of Arthrogryposis Multiplex Congenita with Lesions in the Nervous System. *Arch Dis Child* 1959;3:505.

! 120. Franco A, Lansman JB. Calcium Entry Through Stretch Inactivated Ion Channels in MDX Myotubes. *Nature* 1990;344:670.

+ 121. Frank J, Yadollah H, Butler I, et al. Central Core Disease and Malignant Hyperthermia Syndrome. *Arch Neurol* 1980;7:11.

+ 122. Friedlander HL, Westin GW, Wood WL Jr. Arthrogryposis Multiplex Congenita. *J Bone Joint Surg* 1968;50-A:89.

! 123. Fu Y-H, Pizzuti A, Fenwick RG Jr, et al. An Unstable Triplet Repeat in a Gene Related to Myotonic Muscular Dystrophy. *Science* 1992;255:1256.

! 124. Fukuyama Y, Osawa MA. A Genetic Study of the Fukuyama Type Congenital Muscular Dystrophy. *Brain Dev* 1983;6:373.

+ 125. Fukuyama Y, Osawa M, Suzuki H. Congenital Progressive Muscular Dystrophy of the Fukuyama Type—Clinical, Genetic, and Pathological Considerations. *Brain Dev* 1981;3:1.

+ 126. Galasko CSB, Delaney C, Morris P. Spinal Stabilization in Duchenne Muscular Dystrophy. *J Bone Joint Surg* 1992;74-B:210.

+ 127. Gamble JG, Rinsky LA, Lee JH: Orthopaedic Aspects of Central Core Disease. *J Bone Joint Surg* 1988;70-A:1061.

+ 128. Gardner-Medwin D. Mutation Rate in Duchenne Type of Muscular Dystrophy. 1. *Med Genet* 1970;7:334.

+ 129. Garvie JM, Woolf AL. Kugelberg-Welander Syndrome (Hereditary Proximal Spinal Muscular Atrophy). *Br Med J* 1966;1:1458.

* 130. Gee S. Hereditary Infantile Spastic Paraplegia. *St Bartholomew's Hosp Rep* 1889;25:81.

* 131. Geoffroy G, Barbau A, Breton G, et al. Clinical Description and Roentgenologic Evaluation of Patients with Friedreich's Ataxia. *Can J Neurol Sci* 1976;3:279.

+ 132. Gibson DA, Urs NDK. Arthrogryposis Multiplex Congenita. *J Bone Joint Surg* 1970;52-B:483.

+ 133. Gilliam TC, Brzustowicz LM, Castilla LH, et al: Genetic Homogeneity between Acute and Chronic Forms of Spinal Muscular Atrophy. *Nature* 1990;345:823.

# 134. Goebel H. Congenital Myopathies. In: Adachi M, Scher J, eds. Current Trends in Neurosciences—Neuromuscular Disease. New York: Igaku-Shoin, 1990:197.

+ 135. Goldberg HI, Sheft DJ. Esophageal and Colon Changes in Myotonia Dystrophica. *Gastroenterology* 1972;63:134.

+ 136. Goodman MA, Swartz W. Infection in a Charcot Joint. *J Bone Joint Surg* 1985;67-A:642.

* 137. Gowers WR. *Pseudohypertrophic Muscular Paralysis.* London: J & A Churchill, 1879.

+ 138. Green ADL, Fixsen JA, Lloyd-Roberts GC. Talectomy for Arthrogryposis Multiplex Congenita. *J Bone Joint Surg* 1984;66-B:697.

# 139. Green WT, Grice DS. The Management of Chronic Poliomyelitis. *Instr Course Lect* 1952;9:85.

+ 140. Greenfield JG, Cornman T, Shy GM. The Prognostic Value of the Muscle Biopsy in the “Floppy Infant.” *Brain* 1958;81:461.

! 141. Griffiths LR, Swi MB, McLeod JG, Nicholson GA. Chromosome I Linkage Studies in Charcot-Marie-Tooth Neuropathy Type 1. *Am J Hum Genet* 1988;42:756.

+ 142. Griggs RC, Moxley RT, Mendell JR, et al. Prednisone in Duchenne Muscular Dystrophy—A Randomized, Controlled Trial Defining the Time Course and Dose Response. *Arch Neurol* 1991;48:383.

+ 143. Grove DI, O'Callaghan SJ, Burston TO, Forbes IJ. Immunological Function in Dystrophia Myotonica. *Br Med J* 1973;3:81.

+ 144. Gucker T III: The Orthopaedic Management of Progressive Muscular Dystrophy. *J Am Phys Ther Assoc* 1964;44:243.

+ 145. Guidera KJ, Drennan JC. Foot and Ankle Deformities in Arthrogryposis Multiplex Congenita. *Clin Orthop* 1985;194:93.

# 146. Hall JG. Genetic Aspects of Arthrogryposis. *Clin Orthop* 1985;194:44.

# 147. Hall JG, Reed SD, Greene G. The Distal Arthrogryposis: Delineation of New Entities-Review and Nosologic Discussion. *Am J Med Genet* 1982;11:185.

+ 148. Hanson PA, Rowland LP. Mobius Syndrome and Facioscapulohumeral Muscular Dystrophy. *Arch Neurol* 1971;24:31.

# 149. Harding AE, Thomas PK. Genetically Determined Neuropathies. In: Asbury AK, Gilliatt RW, eds. *Peripheral Nerve Disorders.* London: Butterworths, 1984:347.

# 150. Hardy JH, ed. *Spinal Deformity in Neurological and Muscular Disorders.* St. Louis: C.V. Mosby, 1974.

! 151. Harley HG, Brook JD, Rundle SA, et al. Expansion of an Unstable DNA Region and Phenotypic Variation in Myotonic Dystrophy. *Nature* 1992a;35:545.

# 152. Harper P. *Myotonic Dystrophy,* 2nd ed. Philadelphia: W.B. Saunders, 1989.

+ 153. Harper PS. Congenital Myotonic Dystrophy in Britain. 1: Clinical Aspects. *Arch Dis Child* 1975;50:505.

# 154. Harper PS. *Myotonic Dystrophy,* 12th ed. Philadelphia: W.B. Saunders, 1979.

+ 155. Hausmanowa-Petrusewicz I. Infantile and Juvenile Spinal Muscular Atrophy. In: Walton JN, Conal N, Scarlatto G, eds. *Muscle Diseases: Proceedings of International Congress, Milan, 1969.* Amsterdam: Excerpta Medical, 1970:558.

+ 156. Heckmatt J, Dubowitz V, Hyde S, et al. Prolongation of Walking in Duchenne Muscular Dystrophy with Lightweight Orthoses: Review of 57 Cases. *Dev Med Child Neurol* 1985;27:149.

+ 157. Hensinger RN, MacEwen GD. Spinal Deformity Associated with Heritable Neurological Conditions: Spinal Muscular Atrophy, Friedreich's Ataxia, Familial Dysautonomia, and Charcot-Marie-Tooth Disease. *J Bone Joint Surg* 1976;58-A:13.

# 158. Herndon CH. Tendon Transplantation at the Knee and Foot. *Instr Course Lect* 1961;18:145.

+ 159. Herron LD, Westin GW, Dawson EG. Scoliosis in Arthrogryposis Multiplex Congenita. *J Bone Joint Surg* 1978;60-A:293.

+ 160. Hewer RL. A Study of Fatal Cases of Friedreich's Ataxia. *Br Med* 1968;3:649.

* 161. Hibbs RA. An Operation for “Claw-Foot.” *JAMA* 1919;73:1583.

+ 162. Hirotani H, Doko S, Fukunaga H, et al. Fractures in Patients with Myopathies. *Arch Phys Med Rehabil* 1979;60:178.

* 163. Hoffman EP, Brown RH Jr, Kunkull AN. Dystrophin: The Protein Product of the Duchenne Muscular Dystrophy Locus. *Cell* 1987;51:919.

+ 164. Hoffman EP, Kunkull AN, Angelini C, et al. Improved Diagnosis of Becker Muscular Dystrophy by Dystrophin Testing. *Neurology* 1989;39:1011.

* 165. Hoffman J. Uber chronische spinale Muskelatrophie im Kindersalter, auf familiarer Bases. *Dtsch Z Nervenheilk* 1893;3:427.

+ 166. Hopkins LC, Jackson JA, Elsas LJ. Emery-Dreifuss Humeroperoneal Muscular Dystrophy: An X-Linked Myopathy with Unusual Contractures and Bradycardia. *Ann Neurol* 1981;10:230.

* 167. Howard R. A Case of Congenital Defect of the Muscular System (Dystrophia Muscularis Congenita) and Its Association with Congenital Talipes Equinovarus. *Proc R Soc Med* 1908;1:157.

+ 168. Hsu JD. The Natural History of Spine Curvature Progression in the Nonambulatory Duchenne Muscular Dystrophy Patient. *Spine* 1983:8:771.

# 169. Hsu JD, Imbus CE. Pes Cavus. In Jahss MH, ed. *Disorders of the Foot,* Vol 1. Philadelphia: W.B. Saunders, 1982:463.

+ 170. Hsu LC, Jaffray D, Leong JCY. Talectomy for Clubfoot in Arthrogryposis. *J Bone Joint Surg* 1984;66-B:694.

+ 171. Huff TA, Horton ES, Lebovitz HE. Abnormal Insulin Secretion in Myotonic Dystrophy. *N Engl J Med* 1967;277:837.

+ 172. Huurman WW, Jacobsen ST. The Hip in Arthrogryposis Multiplex Congenita. *Clin Orthop* 1985;194:81.

+ 173. Inkley SR, Oldenburg FC, Vignos PJ. Pulmonary Function in Duchenne Muscular Dystrophy Related to Stage of Disease. *Am J Med* 1974;56:297.

+ 174. Isaacs H, Barlow MB. Malignant Hyperpyrexia during Anesthesia: Possible Association with Subclinical Myopathy. *Br Med J* 1970;1:275.

# 175. Isaacs H, Barlow MB. Malignant Hyperpyrexia. *J Neurol Neurosurg Psychiatry* 1973;36:228.

+ 176. Jacobs JE, Carr CR. Progressive Muscular Atrophy of the Peroneal Type (Charcot-Marie-Tooth Disease), Orthopaedic Management and End Result Study. *J Bone Joint Surg* 1950;32-A:27.

+ 177. Jakab E, Gledhill RB. Simplified Technique for Scapulocostal Fusion in Fascioscapulohumeral Dystrophy. *J Pediatr Orthop* 1993;13:749.

+ 178. Jenkins JG, Bohn D, Edmonds JF, et al. Evaluation of Pulmonary Function in Muscular Dystrophy Patients Requiring Spinal Surgery. *Crit Care Med* 1982;10:645.

# 179. Johnson EW, Kennedy JH. Comprehensive Management of Duchenne Muscular Dystrophy. *Arch Phys Med Rehabil* 1971;52:110.

# 180. Johnson JTH. Neuropathic Fractures and Joint Injuries. *J Bone Joint Surg* 1967;49-A:1.

* 181. Jones R. The Soldier's Foot and the Treatment of Common Deformities of the Foot. *Br Med J* 1916;1:749.

+ 182. Jones R, Khan R, Hughes S, Dubowitz V. Congenital Muscular Dystrophy, The Importance of Early Diagnosis and Orthopaedic Management in the Long-term Prognosis. *J Bone Joint Surg* 1979;61-B:13.

+ 183. Joseph K, MacEwen GD, Boos ML. Home Traction in the Management of Congenital Dislocation of the Hip. *Clin Orthop* 1982;165:83.

+ 184. Kaeser HE. Scapulo-peroneal Muscular Atrophy. *Brain* 1965;88:407.

! 185. Kahlke W, Wagener H. Conversion of H3-Phytol to Phytanic Acid and Its Incorporation into Plasma Lipid Fractions in Heredopathia Atactica Polyneuritiformis. *Metabolism* 1966;15:687.

+ 186. Kaneda RR. Becker's Muscular Dystrophy: Orthopaedic Implications. *J Am Osteopath Assoc* 1980;79:332.

# 187. Kaus S, Rockoff M: Malignant Hyperthermia. *Pediatr Clin North Am* 1994;41(1):221.

+ 188. Ketenjian AY. Scapulocostal Stabilization for Scapula Winging in Facioscapulohumeral Muscular Dystrophy. *J Bone Joint Surg* 1978;60-A:476.

+ 189. King JO, Denborough MA, Zapf PW. Inheritance of Malignant Hyperpyrexia. *Lancet* 1972;1:365.

! 190. Kinoshita M, Iwasaki Y, Wada F, Segawa M. A Case of Congenital Polymyositis—A Possible Pathogenesis of “Fukuyama Type Congenital Muscular Dystrophy.” *Rinsho Shinkeigaku* 1980;20:911.

+ 191. Kite JH. Arthrogryposis Multiplex Congenita. *South Med J* 1955;48:1141.

+ 192. Kling TF Jr, Drennan JC. *Orthopaedic Management of Hereditary Motor and Sensory Neuropathies.* Presented at the 34th Annual Meeting of the American Academy for Cerebral Palsy and Developmental Medicine, October 1980.

+ 193. Kolb ME, Hom ML, Martz R. Dantrolene in Human Malignant Hyperthermia. *Anesthesiology* 1982;56:254. (Facioscapulohumeral Dystrophy Presenting in Infancy with Facial Diplegia and Sensorineural Deafness. *Ann Neurol* 1985;17:513.)

+ 194. Krettek C, Gluer S, Thermann H, et al. Non-union of the Ulna in a 10-month-old Child Who Had Type IV Hereditary Sensory Neuropathy. *J Bone Joint Surg* 1997;79A:1232.

+ 195. Krishna M, Taylor JF, Brown MC, et al: Failure of Somatosensory-evoked Potential Monitoring in Sensoriomotor Neuropathy. *Spine* 1991;16:479.

+ 196. Kugelberg E, Welander L. Heredofamilial Juvenile Muscular Atrophy Stimulating Muscular Dystrophy. *Arch Neurot Psychiatry* 1956;75:500.

+ 197. Kumano K: Congenital Non-progressive Myopathy, Associated with Scoliosis—Clinical, Histological, Histochemical and Electron Microscopic Studies of Seven Cases. *J Jpn Orthop Assoc* 1980;54:381.

+ 198. Kumar SJ, Marks HG, Bowen JR, MacEwen GD. Hip Dysplasia Associated with Charcot-Marie-Tooth Disease in the Older Child and Adolescent. *J Pediatr Orthop* 1985;5:511.

! 199. Kunkel LM, Mejmancik JF, Caskey CT. Analysis of Deletions in DNA From Patients with Becker and Duchenne Muscular Dystrophy. *Nature* 1986;322:73.

! 200. Kunkel LM, Monaco AP, Hoffman E, et al. Molecular Studies of Progressive Muscular Dystrophy (Duchenne). *Enzyme* 1987;38:72.

+ 201. Kurz LT, Mubarak SJ, Schultz P, et al. Correlation of Scoliosis and Pulmonary Function in Duchenne Muscular Dystrophy. *J Pediatr Orthop* 1983;3:347.

# 202. Labelle H, Duhaime M, Allard P: Spinal Deformities in Friedreich's Ataxia. In: Weinstein SL, ed. *The Pediatric Spine: Principles and Practice.* New York: Raven Press, 1994:999.

+ 203. Labelle H, Tohmie S, Duhaime M, Allard P. Natural History of Scoliosis in Friedreich's Ataxia. *J Bone Joint Surg* 1986;68-A:564.

* 204. Landouzy L, Dejerine J. De la Myopathie Atrophique Progressive (Myopathic Hereditaire), Debutant, Dans I'Enfance, par le Face, sans Alteration du Systeme Nerveux. *Coll R Acad Sci Paris* 1884;98:53.

+ 205. Lau JHK, Parker JC, Hsu LCS, Leong JCY. Paralytic Hip Instability in Poliomyelitis. *J Bone Joint Surg* 1986;68-B:528.

! 206. Law PK, Bertorini TE, Goodwin TG, et al. Dystrophin Production Induced by Myoblast Transfer Therapy in Duchenne Muscular Dystrophy. [Letter.] *Lancet* 1990;14:114.

+ 207. Letournel E, Fardeau M, Lytle JO, et al. Scapulothoracic Arthrodesis for Patients Who Have Facioscapulohumeral Muscular Dystrophy. *J Bone Joint Surg* 1990;72-A:78.

# 208. Levy RM, Bredesen DE, Rosenblum ML. Neurological Manifestations of the Acquired Immunodeficiency Syndrome (AIDS): Experience at UCSF and Review of the Literature. *J Neurosurg* 1985;62:475.

* 209. Leyden E. *Klinik der Ruckenmarks-Krankheiten,* Vol 2. Berlin: Hirschwalk, 1876.

+ 210. Lipscomb PR, Sanchez JJ. Anterior Transplantation of the Posterior Tibial Tendon for Persistent Palsy of the Common Peroneal Nerve. *J Bone Joint Surg* 1961;43-A:60.

+ 211. Lloyd-Roberts GC, Lettin AWF. Arthrogryposis Multiplex Congenita. *J Bone Joint Surg* 1970;52-B:494.

+ 212. Lord J, Behrman B, Varzos N, et al. Scoliosis Associated with Duchenne Muscular Dystrophy. *Arch Phys Med Rehabil* 1990;71:13.

* 213. Luque ER. The Anatomic Basis and Development of Segmental Spinal Instrumentation. *Spine* 1982;7:256.

+ 214. Luque ED, Cardoso A. Sequential Correction of Scoliosis with Rigid Internal Fixation. [Abstract.] *Orthop Trans* 1977;1:136.

# 215. MacEwen GD, Floyd GC. Congenital Insensitivity to Pain and Its Orthopaedic Implications. *Clin Orthop* 1970;68:100.

! 216. Mahadevan M, Tsilfidis C, Saboourin L, et al. Myotonic Dystrophy Mutation: An Unstable CTG Repeat in the 3' Untranslated Region of the Gene. *Science* 1992;255:1253.

+ 217. Makin M. The Surgical Treatment of Friedreich's Ataxia. *J Bone Joint Surg* 1953;35-A:425.

+ 218. Maloney WJ, Rinsky LA, Gamble JG: Simultaneous Correction of Pelvic Obliquity, Frontal Plane and Sagittal Plane Deformities in Neuromuscular Scoliosis Using a Unit Rod with Segmental Sublaminar Wires: A Preliminary Report. *J Pediatr Orthop* 1990;10:742.

# 219. Marhidon MB. Malignant Hyperthermia: Current Concepts. *Arch Surg* 1982;117:349.

+ 220. Mathieu J, Allard P, Goberl G, et al. Anesthetic and Surgical Complications in 219 Cases of Myotonic Dystrophy. *Neurology* 1997;49(6):1646.

# 221. Mayer L. The Physiologic Method of Tendon Transplants: Review after Forty Years. *Instr Course Lect* 1956;13:116.

+ 222. McComb RD, Markesbery WR, O'Connor WN. Fatal Neonatal Nemaline Myopathy with Multiple Congenital Anomalies. *J Pediatr* 1979;94:47.

* 223. McKay DW. New Concept of and Approach to Clubfoot Treatment: Section 2—Correction of the Clubfoot. *J Pediatr Orthop* 1983;3:10.

+ 224. McManamin JB, Becker LE, Murphy EG. Congenital Muscular Dystrophy: A Clinicopathologic Report of 24 Cases. *J Pediatr Orthop* 1982;100:692.

+ 225. McPherson EW, Taylor CA Jr. The King Syndrome: Malignant Hyperthermia, Myopathy, and Multiple Anomalies. *Am J Med Genet* 1981;8:159.

# 226. Medical Research Council. *Aids to the Investigation of Peripheral Nerve Injuries.* London: Her Majesty's Stationery Office, 1943.

+ 227. Mereu TR, Porter LH, Hug G. Myotonia, Shortness of Stature and Hip Dysplasia: Schwartz-Jampel Syndrome. *Am J Dis Child* 1969;117:470.

+ 228. Merlini L, Granata C, Bonfiglioli S, et al. Scoliosis in Spinal Muscular Atrophy: Natural History and Management. *Dev Med Child Neurol* 1989;31:501.

* 229. Meryon E. On Granular or Fatty Degeneration of the Voluntary Muscles. *Trans Med Chir Sec Edinb* 1852;35:72.

+ 230. Miller F, Moseley CF, Koreska J, Levison I. Pulmonary Function and Scoliosis in Duchenne Dystrophy. *J Pediatr Orthop* 1988;8:133.

# 231. Miller F, Moseley C, Koreska J: Pelvic Anatomy Relative to Lumbosacral Instrumentation. *J Spinal Disord* 1990;3(2):169.

+ 232. Miller F, Moseley CF, Koreska J. Spinal Fusion in Duchenne Muscular Dystrophy. *Dev Med Child Neurol* 1992;34:775.

+ 233. Miller LS, Gray JM, Ashley RK, Skinner SR. *The Surgical Management of Scoliosis in Poliomyelitis.* (Shriners Hospital for Crippled Children, University of California) Presented at SICOT 90, XVIII, World Congress, Montreal, 1990.

+ 234. Miller MJ, Williams LL, Slack SL, Nappi JF. The hand in Charcot-Marie-Tooth Disease. *J Hand Surg [Br]* 1991;16(2):191.

+ 235. Moosa A, Dubowitz V. Postnatal Maturation of Peripheral Nerves in Preterm and Full-term Infants. *J Pediatr* 1971;79:915.

# 236. Mortens J, Pilcher MF. Tendon Transplantation in the Prevention of Foot Deformities after Poliomyelitis in Children. *J Bone Joint Surg* 1956;38-B:633.

# 237. Morton NE, Chung CS. Formal Genetics of Muscular Dystrophy. *Am J Hum Genet* 1959;11:360.

+ 238. Moulds RFW, Denborough MA. Procaine in Malignant Hyper-pyrexia. *Br Med J* 1972;4:526.

+ 239. Mubarak SJ, Chambers HG, Wenger DR. Percutaneus Muscle Biopsy in the Diagnosis of Neuromuscular Disease. *J Pediatr Orthop* 1992;12:191.

+ 240. Mubarak SJ, Morin WD, Leach J. Spinal fusion in Duchenne Muscular Dystrophy—Fixation and Fusion to the Sacropelvis? *J Pediatr Orthop* 1993;13:752.

+ 241. Munsat TL, Thompson LR, Coleman RF. Centronuclear (“Myotubular”) Myopathy. *Arch Neurol* 1969;20:120.

* 242. Mustard WT. Iliopsoas Transfer for Weakness of the Hip Abductors: A Preliminary Report. *J Bone Joint Surg* 1952;34-A:647.

+ 243. Mustard WT. A Follow-up Study of Iliopsoas Transfer for Hip Instability. *J Bone Joint Surg* 1959;41-B:289.

* 244. Ober FR. Tendon Transplantation in the Lower Extremity. *N Engl J Med* 1933;209:52.

+ 245. Ober FR. The Role of the Iliotibial Band and Fascia Lata as a Factor in the Causation of Lowback Disabilities and Sciatica. *J Bone Joint Surg* 1936;18:105.

+ 246. O'Brien TA, Harper PS. Course, Prognosis and Complications of Childhood-Onset Mytonic Dystrophy. *Dev Med Child Neurol* 1984;26:62.

+ 247. Oheneba B, Lonstein JE, Winter RB, et al. Management of Neuromuscular Spine Deformities with Luque Segmental Instrumentation. *J Bone Joint Surg* 1989;71-A:548.

+ 248. Okuno T, Inoue A, Izumo S. Congenital Insensitivity to Pain with Anhidrosis. *J Bone Joint Surg* 1990;72-A:279.

* 249. Padberg G. *Facioscapulohumeral Disease.* Thesis, University of Leiden, 1982.

+ 250. Padberg G, Eriksson AW, Volkers WS, et al. Linkage Studies in Autosomal Dominant Facioscapulohumeral Muscular Dystrophy. *J Neurol Sci* 1984;65:261.

+ 251. Palmer PM, MacEwen GD, Bowen JR, Matthews PA. Passive Motion Therapy for Infants with Arthrogryposis. *Clin Orthop* 1985;184:54.

+ 252. Paulos L, Coleman SS, Samuelson KM. Pes Cavovarus. *J Bone Joint Surg* 1980;62-A:942.

+ 253. Pearn J, Hudgson P. Distal Spinal Muscular Atrophy. *J Neurol Sci* 1979;43:183.

+ 254. Pearn JH, Hudgson P, Walton JN. A Clinical and Genetic Study of Spinal Muscular Atrophy of Adult Onset. *Brain* 1978;101:591.

+ 255. Pearson CM, Fowler WG. Hereditary Nonprogressive Muscular Dystrophy Inducing Arthrogryposis Syndrome. *Brain* 1963;86:75.

+ 256. Petrie JG. A Case of Progressive Joint Disorders Caused by Insensitivity to Pain. *J Bone Joint Surg* 1953;35-B:399.

* 257. Phemister DB. Operative Arrestment of Longitudinal Growth of Bones in the Treatment of Deformities. *J Bone Joint Surg* 1933;15:1.

+ 258. Piasecki JO, Mahinpour A, Levine DB: Long-term follow-up of spinal fusion in spinal muscular atrophy. *Clin Orthop* 1986;207:44.

+ 259. Pinsky L, DiGeorge AM. Congenital Familial Sensory Neuropathy with Anhidrosis. *J Pediatr* 1966;68:1.

# 260. Poznanski AK, La Rowe PC. Radiographic Manifestations of the Arthrogryposis Syndrome. *Radiology* 1970;95:353.

+ 261. Ramsey PL, Hensinger RN. Congenital Dislocation of the Hip Associated with Central Core Disease. *J Bone Joint Surg* 1975;57-A:648.

+ 262. Ray, S, Bowen JR, Marks HG. Foot Deformity in Myotonic Dystrophy. *Foot Ankle* 1984;5:125.

* 263. Refsum S. Heredopathia Atactica Polyneuritiformis: A Familial Syndrome Not Hitherto Described. *Acta Psychiatr Neurol Suppl* 1946;38:1.

* 264. Refsum S, Salmonsen L, Skatvedt M. Heredopathia Atactica Polyneuritiformis in Children. *J Pediatr* 1949;35:335.

+ 265. Rideau Y, Duport G, Delaubier A. Premieres remissions reproductibles dans l'evolution de la dystrophie musculare de Duchenne. *Bull Acad Natl Med* 1986;170:605.

+ 266. Rideau Y, Glorion B, Duport G. Prolongation of Ambulation in the Muscular Dystrophies. *Acta Neurol [Napoli]* 1983;5:390.

+ 267. Riley CM, Day RL, Greeley DM, Langford WS. Central Autonomic Dysfunction with Defective Lacrimation. *Pediatrics* 1949;3:468.

# 268. Riley CM, Moore RH. Familial Dysautonomia Differentiated from Related Disorders. *Pediatrics* 1966;37:435.

+ 269. Robin GC, Brief LP. Scoliosis in Childhood Muscular Dystrophy. *J Bone Joint Surg* 1971;53-A:466.

+ 270. Robin JC. Scoliosis in Duchenne's Muscular Dystrophy. *Isr J Med Sci* 1977;13:203.

+ 271. Robinson D, Galasko CS, Delaney C, et al. Scoliosis and Lung Function in Spinal Muscular Atrophy. *European Spine Journal* 1995;4:268.

+ 272. Rodillo EB, Fernandez-Bermejo E, Heckmatt JZ, Dubowitz V. Prevention of Rapidly Progressive Scoliosis in Duchenne Muscular Dystrophy by Prolongation of Walking with Orthoses. *J Child Neurol* 1988;3 $_0$ 9.

+ 273. Roper BA, Tibrewal SB. Soft Tissue Surgery in Charcot-Marie-Tooth Disease. *J Bone Joint Surg* 1989;71(B):17.

+ 274. Rosenberg H. Clinical Presentation of Malignant Hyperthermia. *Br J Anaesth* 1981;60:268.

* 275. Rosenkranz E. Uber kongenitale Kontrakturen der oberen Extremitaten: Im Anschluss an die Mitteilung eines einschlagigen Falles. *Z Orthop* 1905;14:905.

+ 276. Rossi E. Le Syndrome Arthromyodysplasique Congenital. *Helv Paediatr Acta* 1947;2:82.

* 277. Roussy G, Levy G. Sept Cas d'une Maladie Familiale Particulaire: Troubles de la Marche, Pieds, Bets et Areflexie Tendineuse Generalisee, avec Accessoirement, Legere Maladresse des Mains. *Rev Neurol* 1926;54:427.

* 278. Roussy G, Levy G. A Propos de la Dystasie Areflexique Hereditaire. *Rev Neurol* 1934;62:763.

+ 279. Roy L, Gibson DA. Pseudohypertrophic Muscular Dystrophy and Its Surgical Management: Review of 30 Patients. *Can J Surg* 1970;13:13.

+ 280. Rubery PT, Spielman JH, Hester P, et al. Scoliosis in Familial Dysautonomia. *J Bone Joint Surg* 1995;77A:1362.

* 281. Ryerson EW. Arthrodesing Operations on the Feet. *J Bone Joint Surg* 1923;5:453.

# 282. Sabin AB. Oral Poliovirus Vaccine: History of Its Development and Prospects. Eradication of Poliomyelitis. *JAMA* 1965;194:872.

+ 283. Sabir M, Lyttle D. Pathogenesis of Pes Cavus in Charcot-Marie-Tooth Disease. *Clin Orthop* 1984;184:223.

+ 284. Sakai DN, Hsu JD, Bonnett CA, Brown JC. Stabilization of the Collapsing Spine in Duchenne Muscular Dystrophy. *Clin Orthop* 1977;128:256.

* 285. Salk JE. Studies in Human Subjects on Active Immunization Against Poliomyelitis. *JAMA* 1953;151:1081.

+ 286. Salter RB, Dubos JP. The First Fifteen Years' Personal Experience with Innominate Osteotomy in the Treatment of Congenital Dislocation and Subluxation of the Hip. *Clin Orthop* 1974;98:72.

# 287. Samilson RL, Dillon W. Cavus, Cavovarus, and Calcaneocavus. *Clin Orthop* 1983;177:125.

+ 288. Sanjal SK, Leung RK, Tierney RC, et al. Mitral Valve Prolapse Syndrome in Children with Duchenne's Progressive Muscular Dystrophy. *Pediatrics* 1979;63:116.

+ 289. Santavirta S, Turunen V, Ylinen P, et al. Foot and Ankle Fusions in Charcot-Marie-Tooth Disease. *Arch Orthop Trauma Surg* 1993;112:175.

# 290. Sarwark JF, MacEwen GD, Scott CI Jr. Amyoplasia (A Common Form of Arthrogryposis). *J Bone Joint Surg* 1990;72-A:465.

! 291. Schonk D, Coerwrankel-Driessen M, vanDalen I, et al. Definition of Subchromosomal Intervals Around the Myotonic Dystrophy Gene Region at 19q. *Genomics* 1989;4:384.

+ 292. Schottsdaedt ER, Larsen LJ, Bost FC. Complete Muscle Transposition. *J Bone Joint Surg* 1955;37-A:897.

+ 293. Schuch CP, Farmer TW. Physical Therapy in Acute Infectious Polyneuritis. *Phys Ther Rev* 1955;35:238.

+ 294. Schwentker EP, Gibson DA. The Orthopaedic Aspects of Spinal Muscular Atrophy. *J Bone Joint Surg* 1976;58-A:32.

+ 295. Seay AR, Ziter FA, Thompson JA. Cardiac Arrest during Induction of Anesthesia in Duchenne Muscular Dystrophy. *J Pediatr Orthop* 1978;93:88.

+ 296. Shapiro F, Sethna N, Colan S, et al. Spinal Fusion in Duchenne Muscular Dystrophy: A Multidisciplinary Approach. *Muscle Nerve* 1992;15:604.

# 297. Shapiro F, Specht L. Current Concepts Review: The Diagnosis and Orthopaedic Treatment of Childhood Spinal Muscular Atrophy, Peripheral Neuropathy, Friedreich Ataxia and Arthrogryposis. *J Bone Joint Surg* 1993;75(A):1699.

# 298. Shapiro F, Specht L: Current Concepts Review. The Diagnosis and Orthopaedic Treatment of Inherited Muscular Diseases of Childhood. *J Bone Joint Surgery* 1993;75(A):439.

+ 299. Sharrard WJW. The Distribution of the Permanent Paralysis in the Lower Limb in Poliomyelitis. *J Bone Joint Surg* 1955;37-B:540.

+ 300. Sharrard WJW. Muscle Recovery in Poliomyelitis. *J Bone Joint Surg* 1955;37-B:63.

# 301. Sher JH. Neuromuscular Disease. In: Adachi M, Sher JH, eds. *Muscular Dystrophy.* New York: Igaku-Shoin, 1990:122.

+ 302. Sherman FC, Westin W. Plantar Release in the Correction of Deformities of the Foot in Children. *J Bone Joint Surg* 1981;63-A:1382.

+ 303. Shy GM, Engel WK, Somers JE, Wanko T. Nemaline Myopathy. A New Congenital Myopathy. *Brain* 1963;86:793.

+ 304. Siebold RM, Winter RB, Moe JH. The Treatment of Scoliosis in Arthrogryposis Multiplex Congenita. *Clin Orthop* 1974;103:191.

+ 305. Siegel I. Fractures of Long Bones in Duchenne Muscular Dystrophy. *J Trauma* 1977;17:219.

+ 306. Siegel I. Foot Deformity in Myotubular Myopathy: Pathology of Intrinsic Foot Musculature. *Arch Neurol* 1983;40:589.

+ 307. Siegel IM. Scoliosis in Muscular Dystrophy. *Clin Orthop* 1973;93:235.

+ 308. Siegel IM. Prolongation of Ambulation through Early Percutaneous Tenotomy and Bracing with Plastic Orthoses. *Isr J Med Sci* 1977;13:192.

# 309. Siegel IM. The Management of Muscular Dystrophy: A Clinical Review. *Muscle Nerve* 1978;1:453.

+ 310. Siegel I, Miller JE, Ray RD. Subcutaneous Lower Limb Tenotomy in the Treatment of Pseudohypertrophic Muscular Dystrophy. *J Bone Joint Surg* 1968;50(A):1437.

+ 311. Simons GW. Complete Subtalar Release in Clubfeet. Part 1. A Preliminary Report. *J Bone Joint Surg* 1985;67-A:1044.

! 312. Slater GR. The Missing Link in Duchenne Muscular Dystrophy. *Nature* 1987;330:693.

+ 313. Smith AD, Koreska J, Moseley CF. Progression of Scoliosis in Duchenne Muscular Dystrophy. *J Bone Joint Surg* 1989;71-A:1066.

+ 314. Smith PE, Claverley PM, Edwards RH. Hypoxemia during Sleep in Duchenne Muscular Dystrophy. *Am Rev Respir Dis* 1988;137:884.

# 315. Smith RJ. Malignant Hyperthermia. Preoperative Assessment of Risk Factors. *Br J Anaesth* 1988;60:317.

+ 316. Smith SE, Green NE, Cole RJ, et al. Prolongation of Ambulation in Children with Duchenne Muscular Dystrophy by Subcutaneous Lower Limb Tenotomy. *J Pediatr Orthop* 1993;13:336.

+ 317. Sodergard J, Ryoppy S. The Knee in Arthrogryposis Multiplex Congenita. *J Pediatr Orthop* 1990;10:177.

+ 318. Southwell RB, Sherman FC. Triple Athrodesis: A Long-Term Study with Force Plate Analysis. *Foot Ankle* 1981;1:15.

# 319. Spencer GE Jr. Orthopaedic Care of Progressive Muscular Dystrophy. *J Bone Joint Surg* 1967;49-A:1201.

+ 320. Spencer GE Jr, Vignos PJ Jr. Bracing for Ambulation in Childhood Progressive Muscular Dystrophy. *J Bone Joint Surg* 1962;44A:234.

+ 321. Spira E. The Treatment of Dropped Shoulder—A New Operative Technique. *J Bone Joint Surg* 1948;30(A):229.

+ 322. St Clair HS, Zimbler S. A Plan of Management and Treatment Results in the Arthrogrypotic Hip. *Clin Orthop* 1985;194:74.

* 323. Steel HH. Triple Osteotomy of the Innominate Bone. *J Bone Joint Surg* 1973;55-A:343.

+ 324. Steinberg D, Vroom FQ, Engel WK, et al.: Refsum's Disease—A Recently Characterized Lipidosis Involving the Nervous System. *Ann Intern Med* 1967;66:365.

* 325. Steindler A. Stripping of the Os Calcis. *J Orthop Surg* 1920;2:8.

+ 326. Stern WG. Arthrogryposis Multiplex Congenita. *JAMA* 1923;81:1507.

# 327. Stevens JC, Lofgren EP, Dyck PJ. Biopsy of Peripheral Nerves. In: Dyck PJ, Thomas PK, Lambert EH, eds. *Peripheral Neuropathy,* Vol 1. Philadelphia: W.B. Saunders, 1975:410.

+ 328. Stevenson AJ, Torkelson RD. King's Syndrome with Malignant Hyperthemia. Potential Outpatient Risks. *Am J Dis Child* 1987;141:271.

+ 329. Sullivan JA, Conner SB. Comparison of Harrington Instrumentation and Segmental Spinal Instrumentation in the Management of Neuromuscular Spinal Deformity. *Spine* 1982;7:299.

+ 330. Sussman MD. Advantage of Early Spinal Stabilization and Fusion in Patients with Duchenne Muscular Dystrophy. *J Pediatr Orthop* 1984;4:532.

# 331. Sutherland DH, Olshen R, Cooper L. The Pathomechanics of Gait in Duchenne Muscular Dystrophy. *Dev Med Child Neurol* 1981;23:3.

+ 332. Swank SM, Brown JC, Perry R. Spinal Fusion in Duchenne's Muscular Dystrophy. *Spine* 1982;7:484.

+ 333. Swanson AB, Brown HS, Coleman JD. The Cavus Foot Concept of Production and Treatment by Metatarsal Osteotomy. *J Bone Joint Surg* 1966;48A:1019.

# 334. Swash M, Schwartz MS. *Neuromuscular Disease.* New York: Springer-Verlag, 1981.

# 335. Swinyard CA, Mayer V. Multiple Congenital Contractures: Public Health Considerations of Arthrogryposis Multiplex Congenita. *JAMA* 1963;183:23.

+ 336. Tello CA, de Tello AM. *Malignant Hyperthermia and Congenital Lordo Scoliosis.* Poster 34, presented at EPOS and POSNA combined meeting, Montreal, CA, September 1990.

+ 337. Thieffry S, Arthuis M, Bargeton E. Werdnig-Hoffman: 40 Cases with 11 Autopsies. *Rev Neurol* 1955;93:621.

+ 338. Thilenius OG, Grossman BJ. Friedreich's Ataxia with Heart Disease in Children. *Pediatrics* 1961;27:246.

+ 339. Thomas B, Schopler S, Wood W, Oppenheim WL. The Knee in Arthrogryposis. *Clin Orthop* 1985;194:87.

! 340. Thomas NS, Williams H, Eisas LJ, et al. Localization of the Gene for Emery-Dreifuss Muscular Dystrophy to the Distal Long Arm of the X-Chromosome. *J Med Genet* 1986;23:596.

+ 341. Thompson CE, Larsen LJ: Recurrent hip dislocation in intermediate spinal atrophy. *J Pediatr Orthop* 1990;10:638.

# 342. Thompson GH, Bilenker RM. Comprehensive Management of Arthrogryposis Multiplex Congenita. *Clin Orthop* 1984;194:6.

+ 343. Thomson WH, Leyburn P, Walton JN. Serum Enzyme Activity in Muscular Dystrophy. *Br Med J* 1960;2:1276.

+ 344. Thrush DC, Morris CJ, Salmon MV. Paramyotonia Congenita: A Clinical, Histochemical and Pathological Study. *Brain* 1972;95:537.

+ 345. Tome FMS, Evangelista T, Lecleric A, et al. Congenital Muscular Dystrophy with Merosin Deficiency. *Life Sci* 1994;317:351.

* 346. Tooth HH. The Peroneal Type of Progressive Muscular Atrophy. London: H.K. Lewis, 1886.

* 347. Turco VJ. Surgical Correction of the Resistant Clubfoot: One-Stage Posteromedial Release with Internal Fixation. A Preliminary Report. *J Bone Joint Surg* 1971;53-A:466.

* 348. Turco VJ. Resistant Congenital Clubfoot—One-Stage Posteromedial Release with Internal Fixation. A Follow-up Report of a 15-Year Experience. *J Bone Joint Surg* 1979;61-A:805.

+ 349. Tyler FH, Stephens FE. Studies in Disorders of Muscle. II: Clinical Manifestations and Inheritance of Facioscapulohumeral Dystrophy in a Large Family. *Ann Intern Med* 1950;32:640.

+ 350. Van Wijngaarden GK, Bethlem J. Benign Infantile Spinal Muscular Atrophy: A Prospective Study. *Brain* 1973;96:163.

+ 351. Vanier TM. Dystrophia Myotonia in Childhood. *Br Med J* 1960;2:1284.

+ 352. Vignos PJ Jr. Diagnosis of Progressive Muscular Dystrophy. *J Bone Joint Surg* 1967;49-A:1212.

+ 353. Vignos PJ Jr, Spencer GE Jr, Archibald KC. Management of Progressive Muscular Dystrophy in Childhood. *JAMA* 1963;184:89.

+ 354. Vignos PJ Jr, Wagner MB, Kaplan JS, Spencer GE. Predicting the Success of Reambulation in Patients with Duchenne Muscular Dystrophy. *J Bone Joint Surg* 1983;65-A:719.

+ 355. Vignos PJ, Wagner MB, Karlinchak B, Katirji B. Evaluation of a Program for Long-Term Treatment of Duchenne Muscular Dystrophy. Experience at the University Hospitals of Cleveland. *J Bone Joint Surg* 1996;78A:1844.

+ 356. Vignos PJ Jr, Watkins MP. The Effect of Exercise in Muscular Dystrophy. *JAMA* 1966;197:843.

+ 357. Walker JJ, Nelson KR, Heavilon JA, et al. Hip Abnormalities in Children with Charcot-Marie-Tooth Disease. *J Pediatr Orthop* 1994;14(1):54.

+ 358. Walker JJ, Nelson KR, Stevens DB, et al. Spinal Deformity in Charcot-Marie-Tooth Disease. *Spine* 1994;19(9):1044.

+ 359. Wang GJ, Shaffer LW. Osteotomy of the Metatarsals for Pes Cavus. *South Med J* 1977;70:77.

+ 360. Wang JM, Stanley TH. Duchenne Muscular Dystrophy and Malignant Hyperthermia—Two Case Reports. *Can Anesth Sec J* 1986;33:492.

+ 361. Watanabe RS. Metatarsal Osteotomy for the Cavus Foot. *Clin Orthop* 1990;252:217.

+ 362. Weimann R, Gibson DA, Moseley CF, et al. Surgical Stabilization of the Spine in Duchenne Muscular Dystrophy. *Spine* 1983;8:776.

* 363. Werdnig G. Zwen fruhintantile hereditare Falle von progressiver Muskelatrophie unter dem Bilde der Dystrophic, aber auf Neurotischer. *Grundlage Arch Psychiatr Nervenkrankh* 1891;22:437.

+ 364. Wetmore RS, Drennan JC. Long-term Results of Triple Arthrodesis in Charcot-Marie-Tooth Disease. *J Bone Joint Surg* 1989;71-A:417.

! 365. Wijmenga C, Frants RR, Brouwer OF, et al. The Facioscapulohumeral Muscular Dystrophy Gene Maps to Chromosome 4. *Lancet* 1990;2:651.

+ 366. Wilkins KE, Gibson DA. The Patterns of Spinal Deformity in Duchenne Muscular Dystrophy. *J Bone Joint Surg* 1976;58-A:24.

+ 367. Williams EA, Read L, Ellis A, Morris P, Galasko CSB. The Management of Equinus Deformity in Duchenne Muscular Dystrophy. *J Bone Joint Surg* 1984;66-B:546.

# 368. Williams P. The Management of Arthrogryposis. *Orthop Clin North Am* 1978;9:67.

+ 369. Williams PF. The Elbow in Arthrogryposis. *J Bone Joint Surg* 1973;55B:834.

+ 370. Williams PF. Management of Upper Limb Problems in Arthrogryposis. *Clin Orthop* 1985;194:60.

# 371. Windebank AJ. Inherited Recurrent Focal Neuropathies. In: Dyck PJ, Thomas PJ, Griffin JW, et al. eds. *Peripheral Neuropathy,* 3rd ed. Philadelphia: W.B. Saunders, 1993:1137.

+ 372. Winters JL, McLaughlin LA. Myotonia Congenita. *J Bone Joint Surg* 1970;52-A:1345.

# 373. Wirth CR, Jacobs RL, Rolander SD. Neuropathic Spinal Arthropathy: A Review of the Charcot Spine. *Spine* 1980;5:558.

+ 374. Wolintz AH, Sonnenblick EH, Engel WK. Stokes-Adams Syndrome and Atrial Arrythmias as the Presenting Symptoms of Myotonic Dystrophy, with Response to Electrocardioversion. *Ann Intern Med* 1966;65:1260.

+ 375. Wood VE, Huene D, Nguyen J. Treatment of the Upper Limb in Charcot-Marie-Tooth Disease. *J Hand Surg [Br]* 1995;20(4):511.

+ 376. Wukich DK, Bowen JR. A Long-term Study of Triple Arthrodesis For Correction of Pes Cavovarus in Charcot-Marie-Tooth Disease. *J Pediatr Orthop* 1989;9:433.

# 377. Yates G. Molded Plastics in Bracing. *Clin Orthop* 1974;102:46.

+ 378. Yazawa Y. Mitral Valve Prolapse Related to Geometrical Changes of the Heart in Cases of Progressive Muscular Dystrophy. *Clin Cardiol* 1984;7:198.

+ 379. Yoslow W, Becker MH, Bartels J, Thompson WAL. Familial Dysautonomia Review of Sixty-Five Cases. *J Bone Joint Surg* 1971;53-A:1541.

* 380. Yount CC. The Role of the Tensor Fasciae Femoris in Certain Deformities of the Lower Extremities. *J Bone Joint Surg* 1926;8:171.

+ 381. Zatz M, Betti RT. Benign Duchenne Muscular Dystrophy in a Patient with Growth Hormone Deficiency: A Five-Year Follow-up. *Am J Med Genet* 1986;24:567.

+ 382. Zatz M, Betti RT, Frota-Pessoa O. Treatment of Duchenne Muscular Dystrophy with Growth Hormone Inhibitors. *Am J Med Genet* 1986;24:549.

+ 383. Zerres K, Rudnik-Schoneborn S, Forrest E, et al. A Collaborative Study on the Natural History of Childhood and Juvenile Onset Proximal Spinal Muscular Atrophy. J Neurosci 1997;146:67.

+ 384. Zetlweger H, Afifi A, McCormick WF, Mergner W. Severe Congenital Muscular Dystrophy. *Am J Dis Child* 1967;114:591.

+ 385. Zellweger H, Antonik A. Newborn Screening for Duchenne Muscular Dystrophy. *Pediatrics* 1975;5:30.

+ 386. Zellweger J, Lonasescu V. Early Onset of Myotonic Dystrophy in Infants. *Am J Dis Child* 1973;125:601.

+ 387. Ziter FA, Allsop KG, Tyler FH. Assessment of Muscle Strength in Duchenne Muscular Dystrophy. *Neurology* 1977;27:981.

# CHAPTER 179

# THE ORTHOPAEDIC MANAGEMENT OF MYELODYSPLASIA AND SPINA BIFIDA

*Nigel S. Broughton and Malcolm B. Menelaus*

**N. S. Broughton:** Consultant Orthopaedic Surgeon, Department of Orthopaedics, Frankston Hospital, Victoria, Frankston, Australia.
**M. B. Menelaus:** Chief Orthopaedic Surgeon, Emeritus, Royal Children's Hospital, Melbourne, Australia.

Assessment of Neurosegmental Level
Causes of Deformity
- Muscle Imbalance Due to Lower Motor Neuron Lesions
- Muscle Imbalance Due to Upper Motor Neuron Lesions
- Intrauterine Posture
- Habitually Assumed Posture
- Arthrogryposis-Like Deformities
- Unknown Factors

Goal of Orthopaedic Management
Surgical Correction of Deformities of the Hip
- Release of Hip Flexion Contracture
- Correction of Hip Dislocation
- Provision of Abductor and Extensor Power at the Hip

Correction of Deformities of the Knee
- Knee Flexion Contracture
- Extension Deformity
- Valgus Deformity

Correction of Torsional Deformities of the Tibia
- External Rotation of the Tibia
- Internal Rotation of the Tibia

Correction of Deformities of the Foot
- Triple Arthrodesis
- Equinovarus Deformity
- Calcaneus Deformity
- Valgus Deformity
- Cavus Deformity
- Paralytic Convex Pes Valgus (Vertical Talus)
- Flail Ankle
- Claw Toes

Chapter References

Myelodysplasia and spina bifida are congenital anomalies characterized by abnormality of the closure of the neural tube. They constitute a group of disturbances including failure of full development of structures derived from the neural tube and the meninges. These disturbances result in abnormal neural control of organs innervated by the affected part of the spinal cord. This abnormal innervation gives rise to multiple organ involvement, including effects on bladder and bowel, as well as denervation of muscles resulting in paralysis.

The orthopaedic management of spina bifida is aimed at allowing children to fulfill their maximum physical and social potential within the limitations imposed by the congenital anomaly.

## ASSESSMENT OF NEUROSEGMENTAL LEVEL

Assessment of the neurosegmental level is important because it allows us to predict the functional status of the child. Assessment should be performed as early as possible and repeated annually, using the grading indicated in Table 179.1 with accurate recording of muscle power. Neurosegmental level can be confirmed and any significant deterioration in neurologic status requiring investigation for a tethered cord or cord syrinx is easily detected (Fig. 179.1). Assessment of the level becomes more accurate after the age of 5 years, when the child is more cooperative.

| | |
|---|---|
| 0—none | No contraction felt in the muscle |
| 1—trace | Can see, or feel, muscle belly flicker but no visible movement |
| 2—poor | Movement possible with gravity eliminated |
| 3—fair | Movement possible against gravity but takes no resistance |
| 4—good | Movement possible and takes resistance to break test |
| 5—normal | Movement possible and muscle cannot be "broken" in shortened range |

***Table 179.1. Coding of Muscle Strength***

***Figure 179.1.*** In hemimyelodysplasia, there is gross asymmetry of the neurosegmental level, often resulting in leg-length discrepancy. The difference in leg lengths can usually be managed by epiphyseodesis in the long limb, but when there is gross discrepancy, leg lengthening may be more appropriate. (Reproduced with permission from Menelaus MB. *Orthopaedic Management of Spina Bifida Cystica,* 2nd ed. Edinburgh: Churchill Livingstone, 1980.).

We use a classification based on Sharrard's original description of nerve root innervation to define a precise level and code the power in the muscle as shown in Table 179.2. Assessment of quadriceps and hip abductor power provide a reasonable estimate of walking ability. Community ambulation is unlikely if the quadriceps and hip abductors have no power; community ambulation with splints and aids is likely if quadriceps are innervated but hip abductors are not; and community ambulation is probable if both quadriceps and hip abductors have power. The prediction of walking ability is important in determining the type and extent of surgical treatment required to correct deformity in childhood.

| | |
|---|---|
| Thoracic | No active movement at the hip |
| L-1 | Iliopsoas grade 2 or better |
| L-2 | Iliopsoas, sartorius, and adductors all grade 3 or better |
| L-3 | Quadriceps grade 3 or better and meet criteria for L-2 |
| L-4 | Medial hamstring or tibialis anterior grade 3 or better and meet criteria for L-3 |
| L-5 | Lateral hamstrings grade 3 or better and meet criteria for L-4 plus one of the following three: gluteus medius grade 2 or better, peroneus tertius grade 4 or better, tibialis posterior grade 3 or better. |
| S-1 | Two of the following three: gastrocnemius or soleus grade 2 or better, gluteus medius grade 3 or better, gluteus maximus grade 2 or better and meet criteria for L-5. |
| S-2 | Gastrocnemius or soleus grade 3 or better and gluteus medius and gluteus maximus grade 4 or better and meet criteria for S-1. |
| No loss | All leg muscles normal strength |

***Table 179.2. Assessment of Neurosegmental Level***

Recent work has suggested that the hip abductors are innervated at the same or higher level than the tibialis anterior and has confirmed that the medial hamstrings are innervated at a higher level than was originally described (15). However, further work is necessary to determine the significance of these findings.

## CAUSES OF DEFORMITY

### MUSCLE IMBALANCE DUE TO LOWER MOTOR NEURON LESIONS

In large part, the lowest innervated segment is determined by the developmental defect. However, further lower motor neuron lesions may be caused by postnatal drying and infection of the neural plate. If the child is expected to survive, this should be avoided by closure of the defect within 24 hours. Shurtleff has also demonstrated that trauma to the exposed neural plate at vaginal delivery can produce further lower motor neuron lesions; this problem can be prevented by electing to deliver known spina bifida fetuses by cesarean section at 36 weeks' gestation (20). Lower motor neuron lesions can also be produced in childhood when growth produces traction on a tethered cord, damaging nerve roots.

Various patterns of paralysis are seen according to the lowest innervated myotome. The resulting muscle imbalance can, in some cases, predict the likely deformity. For example, in a limb where there is innervation down to and including L-5, indicated by activity in the tibialis anterior, peroneus tertius, and the extensor digitorum longus with no activity in soleus or gastrocnemius, a calcaneus or calcaneovalgus deformity of the foot commonly occurs.

Sharrard stated that hip flexion contracture was greatest where the muscle imbalance was greatest, that is, with innervation to L-2, L-3, and L-4 (19). However, our findings have been that hip flexion contracture is most common in children with a thoracic level lesion where there is no muscle activity at the hip. There is no evidence of spasticity in patients with the most severe flexion contracture at the hip (2,21). Fixed hip deformity is not predictable from the state of muscle activity around the hip.

Dislocation of the hip in spina bifida has been considered to be due to muscle imbalance (19), but our studies have shown that about 30% of hips with no muscle imbalance dislocate, whereas 70% of hips with innervation to L-4 and presumed to have the greatest muscle imbalance neither dislocate nor require any operation. Dislocation of the hip in spina bifida is not inevitable when there is muscle imbalance across the hip (2).

Studies on the natural history of deformity at the knee also raise doubts about the role of muscle imbalance in producing fixed deformity (24).

### MUSCLE IMBALANCE DUE TO UPPER MOTOR NEURON LESIONS

Upper motor lesions resulting in spasticity of muscles are present in two thirds of children with myelomeningocele (Fig. 179.2*A*, Fig. 179.2*B*, Fig. 179.2*C*).

***Figure 179.2.*** Spasticity has resulted in deformity in the upper and lower limbs of this child. **A:** An abduction contracture has developed at the hip. This was corrected by a lateral release. **B:** Spasticity of flexor hallucis longus. **C:** Spasticity of wrist flexors and the intrinsics in the hand. (B and C reproduced with permission from Menelaus MB. *Orthopaedic Management of Spina Bifida Cystica,* 2nd ed. Edinburgh: Churchill Livingstone, 1980.)

Three patterns can be recognized. In the first pattern, flaccid paralysis is present, but in levels more distal, there is a spastic paralysis with exaggerated reflex activity. In the second pattern, there is only a narrow segment of flaccid paralysis (resembling spinal cord transection) and purely reflex activity below the level. In the third pattern, there is incomplete transection and hence myotomes can show spasticity with increased reflexes, but there is also a degree of voluntary movement.

Because muscles across a joint may be flaccid, normally innervated, or spastic, various degrees of imbalance may be produced. Although muscle imbalance between flaccid and spastic muscles can give rise to severe deformity of the foot, the argument for this is less convincing at the hip or knee, and other explanations for severe deformity should be sought.

### INTRAUTERINE POSTURE

The average hip flexion contracture, in all children with myelomeningocele at birth, is about 20°, and this angle decreases with lesions at all levels up to the age of 1 year. In children with a lesion at the thoracic level, this decrease is less than in other levels. Intrauterine pressure causes various patterns of foot deformity at birth in paralyzed feet.

### HABITUALLY ASSUMED POSTURE

Children with thoracic level lesions often develop external rotation and abduction deformities of the hips if they are allowed to lie for long periods in this position. Prolonged sitting may be a factor in the development of flexion deformity at the hips and knees in high-level lesions.

### ARTHROGRYPOSIS-LIKE DEFORMITIES

Some children with significant deformity at birth resemble patients with arthrogryposis multiplex congenita, with rigidity of joints and absence of normal creases. These deformities may be present at one or more joints, are resistant to standard management, and require radical surgery for their correction.

### UNKNOWN FACTORS

We simply do not know why most patients with thoracic level lesions develop deformity, including all possible foot deformities.

## GOAL OF ORTHOPAEDIC MANAGEMENT

The goal of orthopaedic management is to produce a stable posture for sitting or walking. Hip flexion contractures and knee flexion contractures give rise to difficulties in standing and walking, as well as increased energy expenditure. Successful treatment of these deformities ensures a stable posture.

Conservative treatment of deformity in the child with spina bifida is ineffective and gives rise to cast sores and pathologic fractures; therefore, in general, surgical intervention is preferable.

The goals of surgical management are to avoid unnecessary operations that confer no benefit on the patient, to perform multiple operations at the same time, and to use the minimum period of postoperative immobilization possible. We plan surgery with an awareness of what the child is likely to achieve in walking in the long term so that the surgical goals are realistic (11,12 and 13).

Children with thoracic neurosegmental levels are unlikely to continue effective walking into adolescence. Until then, we encourage them to walk and they enjoy standing. As their condition progresses, we use reciprocating gait orthoses or hip-knee-foot orthoses (HKFOs). They will require increasing use of a wheelchair with time. Surgery aims at a trouble-free wheelchair existence. We correct foot deformity of a degree that precludes normal footwear, generally by soft-tissue release. Extensive hip surgery is not indicated, but we aim to correct excessive flexion contracture by soft-tissue release to prevent excessive lumbar lordosis.

Children with L-1 and L-2 neurosegmental levels are rarely community ambulators as adolescents, but the time spent walking in braces may be longer than in children with thoracic level lesions, so surgery to improve brace fitting should be considered.

Children with L-3, L-4, and L-5 neurosegmental levels with strong quadriceps are usually good walkers. They usually require an ankle-foot orthosis to stabilize the ankle. The need for crutches or walking aids depends on the strength of the abductors at the hip. The surgeon should assume that the child will achieve worthwhile walking, and therefore, extensive surgery to correct deformities at the hip, knee, and foot may be justified. Furthermore, soft-tissue surgery is justified for these patients during childhood, recognizing that bony surgery, such as triple arthrodesis, may be necessary at maturity.

The child may start walking with extensive bracing, including hip control orthoses, but as confidence builds up, the extent of the bracing can be reduced to below the knee.

Most children with sacral lesions are effective community ambulators until adulthood, when some deteriorate and cease walking. Hip deformity is uncommon, but surgery is often necessary for foot and toe deformities.

## SURGICAL CORRECTION OF DEFORMITIES OF THE HIP

Hip flexion contracture and hip dislocation were previously thought to be due entirely to muscle imbalance across the hip (19). We have now shown that the hip flexion contracture is most common and most severe in children with thoracic neurosegmental level (2). Dislocation of the hip is also common in thoracic neurosegmental level, whereas in children with innervation to L-4, who presumably have maximum muscle imbalance, only a third develop hip dislocation or require hip surgery (2). Therefore, muscle imbalance is one of a number of factors implicated in the development of hip flexion contracture and hip dislocation. Prophylactic surgery to correct muscle imbalance is no longer undertaken because many children with muscle imbalance develop no deformity or dislocation at the hip.

### RELEASE OF HIP FLEXION CONTRACTURE

Hip flexion contracture is commonly seen in normal neonates and in neonates with spina bifida with all neurosegmental levels. The deformity decreases during the first year of life but improves least in thoracic neurosegmental levels (2,21), and in these patients, it has a strong tendency to increase again with advancing years.

If hip flexion deformity is interfering with the child's ability to walk (generally this occurs when the deformity is greater than 20°), we perform a soft-tissue release.

- Drape the patient so that Thomas' test can be performed throughout the procedure.
- The procedure is best performed through the incision described by Salter for innominate osteotomy (see Chapter 166).
- Sweep the muscles off both the inner and the outer surfaces of the ilium, divide the psoas tendon, release the sartorius and rectus femoris, and if necessary, divide the anterior capsule of the hip joint transversely.
- At the conclusion of this procedure, the anterior superior iliac spine and adjacent portions of the iliac crest will protrude forward and should be removed.

Our results of long-term follow-up are satisfactory (8). If the hip is also dislocated, consider reducing the hip along the lines described in the next section. In a thoracic-level nonwalker, correction of the hip flexion contracture is commonly attempted without reduction of a dislocated hip (Fig. 179.3*A*, Fig. 179.3*B*, Fig. 179.3*C*).

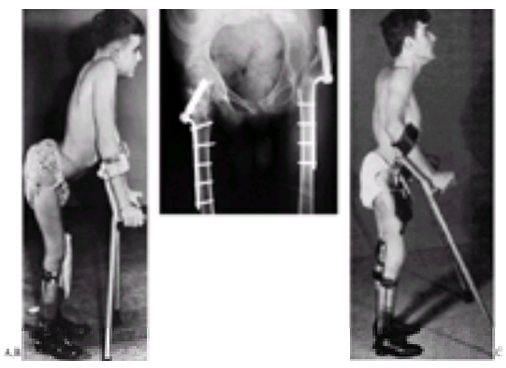

***Figure 179.3.*** **A:** Undesirable flexion posture in a boy with L-4 lesion. He has strong psoas and quadriceps muscles but gluteal weakness and has developed fixed flexion deformity of both hips. Note the gross lumbar lordosis and that his center of gravity is in front of rather than directly over his feet. **B:** We are usually able to correct the deformity with an extensive soft-tissue anterior hip release. However, on this occasion, because of the severity of the deformity, extension femoral osteotomies have been performed. No attempt was made to reduce the left hip; he remains a community ambulator. **C:** Postoperatively he has a much better extension posture, although some of his lumbar lordosis is fixed. The operation was performed 25 years ago and the patient is still walking. (Reproduced with permission from Menelaus MB. *Orthopaedic Management of Spina Bifida Cystica,* 1st ed. Edinburgh: Churchill Livingstone, 1971.)

Postoperatively, the child should be nursed alternately prone and supine, with the hips extended for 6 weeks. We also use low trolleys on casters so the child can lie prone on these and move around the house using the arms.

### CORRECTION OF HIP DISLOCATION

The presence of hip dislocation is not an indication to attempt reduction. Reduction should be attempted only when the child will derive considerable benefit from this

procedure (6,7,10). Attempts at operative reduction are not always successful, may result in stiff painful hips, are sometimes associated with heterotopic calcification, and generally reduce the child's ability to walk. An untreated dislocated hip is rarely painful, but if the dislocation is unilateral, it may give rise to limb-length discrepancy, which is troublesome for walkers and can cause seating difficulties for wheelchair users. Most specialists would agree that there is little difference in walking ability of children with high neurosegmental levels who have located or dislocated hips (Fig. 179.4*A*, Fig. 179.4*B*).

***Figure 179.4.*** **A:** This child was born with severe arthrogrypotic deformities of the lower limbs. He was treated by soft-tissue releases on one occasion, but his bilateral hip dislocations were not reduced. **B:** Same child at the age of 17 years demonstrating a satisfactory extension posture in KAFOs. He is now 32 years old and remains a household ambulator. (Reproduced with permission from Menelaus MB. *Orthopaedic Management of Spina Bifida Cystica,* 2nd ed. Edinburgh: Churchill Livingstone, 1980.)

Children with hip dislocation who would benefit from surgery to reduce the hip are those with low-level lesions at L-3 and below. They usually have strong quadriceps, do not require bracing above the knee, and will probably be good walkers. In this group, unilateral hip dislocations should generally be reduced (Fig. 179.5*A*, Fig. 179.5*B*, Fig. 179.5*C*, Fig. 179.5*D* and Fig. 179.6*A*, Fig. 179.6*B*). In general, bilateral hip dislocations in this group do not benefit from attempts at reduction, but reduction is occasionally performed if the dislocated hips are not high and surgery is necessary in any case for hip flexion contracture. In children with high-level lesions (thoracic, L-1, and L-2) and therefore weak quadriceps, bilateral hip dislocations should not be reduced. Children with unilateral hip dislocations may benefit from reduction if the dislocation is not gross, the other leg has a low lesion, and surgery is necessary anyway to correct hip flexion deformity. We have seen few problems from leaving a unilateral hip dislocation untreated in a child with a high-level lesion (Table 179.3).

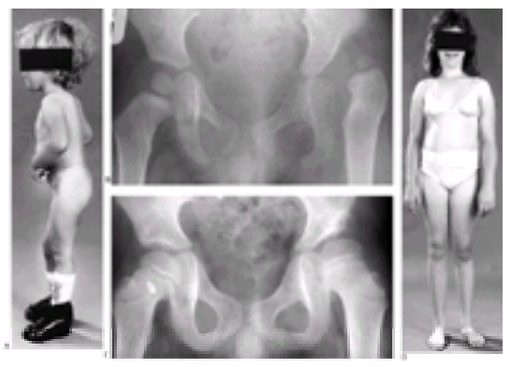

***Figure 179.5.*** **A:** This child had normal muscle power in her right leg but an L-5 lesion on the left. **B:** A radiograph demonstrates dislocation of the left hip. **C:** Same child treated by open reduction, psoas lengthening, and a Pemberton osteotomy. The follow-up radiograph shows a concentric reduction. **D:** At the age of 15 years there is little leg-length discrepancy, but note the left calf is slightly smaller. (**A** and **B** reproduced with permission from Williams PF, Cole WG. *Orthopaedic Management in Childhood.* London: Chapman and Hall, 1991)

***Figure 179.6.*** **A:** Unilateral hip dislocation in a low-level lesion. **B:** This dislocation has been treated by open reduction, Pemberton osteotomy, and a femoral osteotomy.

| | Unilateral | Bilateral |
|---|---|---|
| High-level lesion<br>Weak quadriceps<br>Require above-knee bracing<br>Probably short-term walkers | Occasionally reduce if dislocation is not gross, the other leg has a low lesion, or surgery is required in any case for flexion deformity | Never reduce |
| Low-level lesion<br>Strong quadriceps<br>Short bracing<br>Lifetime walkers | Usually reduce | Occasionally reduce if dislocation is not gross and surgery is required in any case for flexion contracture |

***Table 179.3. Indications for Reduction of Hip Dislocation in Spina Bifida***

If the hip dislocation is present at birth and is irreducible, attempts at reduction should not be made because it will lead to stiffness. If the hip is unstable but can be easily reduced by Ortolani's test and the lesion is low, it is worthwhile using abduction bracing to encourage acetabular development. However, the brace should not interfere with closure of the spinal defect and its postoperative management.

Operative reduction should aim for correction with the minimum of postoperative immobilization. The principles of the operation are

- to achieve a concentric reduction of the femoral head with capsulorrhaphy and excision of intra-articular structures (see Chapter 166).
- correction of muscle imbalance by flexor and adductor releases.

- improvement in acetabular coverage, generally by a Pemberton osteotomy. This is performed through an approach similar to that described for a soft-tissue release of the hip (see the previous section).

Plaster immobilization is necessary for only 6 weeks postoperatively.

### PROVISION OF ABDUCTOR AND EXTENSOR POWER AT THE HIP

Muscle transfers about the hip were popular for spina bifida (4) when it was thought that muscle imbalance caused hip dislocation and contractures. Because we now know that the relationship between muscle imbalance and hip deformity is less clear, we believe that there is no place for the use of prophylactic muscle transfers, because prediction of development of deformity is not possible from muscle strengths.

Some surgeons believe that muscle transfers are appropriate in selected circumstances, but there is general agreement now against the use of posterior iliopsoas transfer (19) because gait analysis has established that the energy cost following this procedure is unacceptably high.

If the surgeon believes that there is a specific patient with a low lumbar lesion who might have a better gait following muscle transfer (gait analysis may facilitate the decision-making process), then the triple transfer, described by Yngve and Lindseth (25), or external oblique transfer alone would seem to be the most logical, considering our present state of knowledge. The triple transfer consists of external oblique transfer to the greater trochanter, transfer of the adductor origin posteriorly, and posterior transfer of the origin of tensor fascia lata, often in combination with a varus derotation femoral osteotomy to improve gait and reduce the risk of dislocation. Transfer of the iliopsoas to the anterior greater trochanter, as described by Mustard (16), frequently leads to fixed flexion deformity. The indications for muscle transfers at the hip are now few.

## CORRECTION OF DEFORMITIES OF THE KNEE

### KNEE FLEXION CONTRACTURE

Flexion deformity of the knee and limitation of flexion of the knee are most common in children with thoracic neurosegmental lesions and not in children in whom there is muscle imbalance at the knee (24).

Flexion of up to 20° is common at birth and generally improves spontaneously. If there is a fixed flexion deformity of greater than 20° in the neonate, then serial casting may be necessary. If a fixed flexion deformity is found in a child older than 3 years of age who has the potential for walking, we perform a soft-tissue release. Knee flexion correction often occurs with hip flexion contracture, and both should be corrected at the same time. Knee flexion is corrected by releasing all of the hamstring tendons at the knee. Posterior capsulotomy of the knee is usually necessary to achieve full correction (14) (Fig. 179.7*A*, Fig. 179.7*B*, Fig. 179.7*C*). It is important that a full correction of the flexion deformity is obtained at operation because recurrence follows incomplete correction and further correction with serial plaster casts is usually incomplete. Transfers of the hamstrings into the patella or lower femur have generally been disappointing and are not advised. An extension supracondylar osteotomy is infrequently used for flexion deformity in the child approaching skeletal maturity.

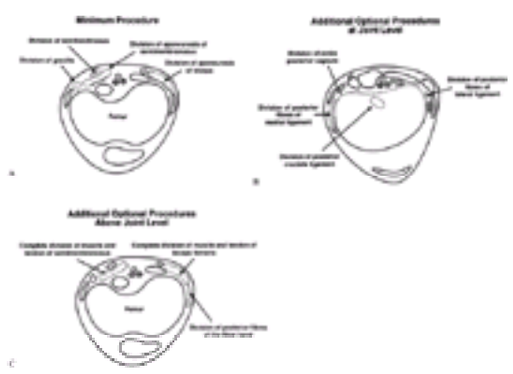

***Figure 179.7.*** **A:** Transverse section at the distal femur showing the minimum procedure for soft-tissue release. **B:** Additional procedures at the knee level that may be necessary to achieve a full correction. **C:** Additional procedures above the joint level that may be necessary to achieve a full correction. (Reproduced with permission from Marshall PD, Broughton NS, Menelaus MB, Graham HK. Surgical Release of Knee Flexion Contractures in Myelomeningocele. *J Bone Joint Surg* 1996;78B:912.)

### EXTENSION DEFORMITY

Some neonates present with a recurrent extension deformity of the knee, but this usually responds to serial casting. The knee may be held rigidly in extension and have the featureless appearance of arthrogryposis multiplex congenita. Tenotomy of the ligamentum patella (18) is best performed at about 6 years of age, when the extension deformity becomes troublesome as the legs grow. At this age the child can manage knee locks on a long-leg brace without assistance. Walking in a knee-ankle-foot orthosis can begin a few days after the operation. The child uses night splints at 90° of flexion for 2 months. Quadricepsplasty is usually not indicated because there is usually insufficient voluntary power in the muscle to make the procedure worthwhile.

### VALGUS DEFORMITY

Valgus deformity is uncommon. It can generally be managed by medial growth plate stapling, and it seldom requires lower femoral or upper tibial osteotomy.

## CORRECTION OF TORSIONAL DEFORMITIES OF THE TIBIA

### EXTERNAL ROTATION OF THE TIBIA

External rotation of the tibia is commonly associated with a valgus ankle. It should be treated after the age of 8 years by supramalleolar rotational osteotomy of the tibia, which can be combined with correction of the valgus ankle at the supramalleolar level (see later).

### INTERNAL ROTATION OF THE TIBIA

Although minor degrees of internal rotation of the tibia can be corrected by transfer of the semitendinosus to the biceps femoris, we have now largely abandoned the procedure because such an indication is seldom present. Gross degrees of the deformity are corrected in the first 3 years of life by osteoclasis of the tibia and fibula (Fig. 179.8) or at a later age by supramalleolar external rotation osteotomy.

***Figure 179.8.*** Internal tibial torsion of the left leg. This problem was treated by tibial osteoclasis.

## CORRECTION OF DEFORMITIES OF THE FOOT

Deformities of the foot in spina bifida are common at all levels of neurosegmental defect. In patients with high-level lesions, 89% of feet are deformed despite the absence of muscle imbalance (3). Of those with low-level lesions, 76% are deformed, and the incidence of various deformities are similar to those encountered in high-level lesions (9). Those with calcaneus deformity have a higher incidence of activity of the tibialis anterior with calf weakness but calcaneus is common in the absence of this muscle imbalance. Spasticity is present in a high percentage of patients with high-level lesions but in none of those with undeformed feet. Spasticity is much less common (ratio of 1:2) in patients with low-level lesions.

### TRIPLE ARTHRODESIS

The goal of the management of foot deformity is to achieve a plantargrade and mobile foot. However, there are occasions when triple arthrodesis is the most appropriate method to correct a complex deformity. The lateral inlay technique (23) has proved particularly valuable in patients with spina bifida (Fig. 179.9*A*, Fig. 179.9*B*, Fig. 179.9*C*). Long-term follow-up has confirmed this impression (17). Triple arthrodesis must be used with caution in the older ambulatory patient because of the risk of plantar pressure sores in a rigid foot that is devoid of sensation.

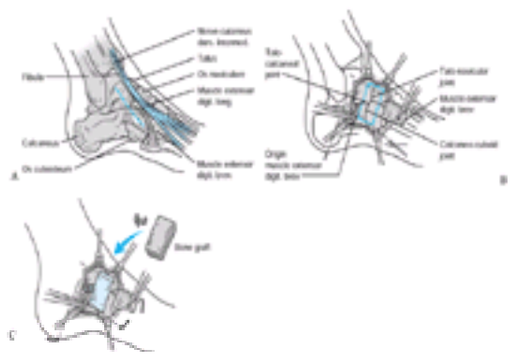

***Figure 179.9.*** Surgical technique for triple arthrodesis as originally described by Eric Price of Melbourne; the “inlay triple arthrodesis.” (Redrawn with permission from Romness MJ, Menelaus MB. Inlay Triple Arthrodesis: A Technique for the Undeformed or Valgus Foot. *Orthop Traumatol* 1995;4:114.)

- Make a straight incision centered over the junction of the four bones to be fused (Fig. 179.9*A*).
- Lift the extensor digitorum brevis distally and retract the extensors medially to allow exposure of the talonavicular, calcaneocuboid, and subtalar joints. Excise the capsules and expose the sinus.
- Hold the foot in the desired position and insert 4.5 mm wires through the talonavicular, the calcaneocuboid, and the subtalar joints (Fig. 179.9*C*). Cut a trough as shown and decorticate the sinus tarsi. Take an oblong-shaped graft from the upper third of the ipsilateral tibia and punch it into the trough to give a tight fit. Insert chips of bone graft into the subtalar joint.

### EQUINOVARUS DEFORMITY

The rigidity of the equinovarus deformity varies from that seen in the usual form of talipes equinovarus to the more commonly seen rigid, “arthrogrypotic” deformity, which has a high rate of recurrence despite apparent adequate correction initially. In general, a varus deformity requires operative correction to establish a plantigrade foot; otherwise, pressure sores due to weight bearing on a small area of the sole are inevitable.

Initially, the treatment consists of serial correction in well-padded plaster casts that are changed frequently while the baby is still hospitalized after birth, and later at 2- to 4-week intervals as circumstances demand. Although it may not be apparent at birth, the tendo Achillis is usually short, and a closed tenotomy should be performed when convenient, between 3 and 6 months of age.

If a child older than 3 months of age is thriving and does not require surgery for concomitant conditions in other systems, we perform a posteromedial release. The Cincinnati surgical approach for this technique is described in Chapter 167. Because recurrence is likely, excision of portions of the tendo Achillis, tibialis anterior, tibialis posterior, and the long toe flexors is necessary rather than lengthening. If the deformity recurs, we perform a repeat soft-tissue release.

In some patients for whom demands on the foot are high, trophic ulceration is likely, so in cases in which repeat soft-tissue release is not controlling the deformity, further procedures are necessary. Although we have used talectomy for this situation in the past, we now prefer variations of the Vereberlyi-Ogston procedure with decancellation of the talus and cuboid to allow collapse of these bones and correction of deformity (22). Tendon transfers have no part in the management of this deformity (see Chapter 167).

If deformity recurs between the ages of 7 and 14 years, it is wise to accept the deformity, provide appropriate footwear, and aim to correct the deformity by triple arthrodesis at skeletal maturity.

#### *Pure Equinus Deformity*

A pure equinus deformity can be present in patients with any neurosegmental level. It responds well to open or closed tenotomy, depending on the severity of the deformity and the age of the child.

### CALCANEUS DEFORMITY

Calcaneus deformity is common in spina bifida patients, most commonly seen in children with an L-5 neurosegmental lesion but also commonly seen in the absence of muscle imbalance. The major problem with calcaneus deformity is the development of pressure sores because large forces are transmitted through a small area of insensitive heel. This deformity is usually left untreated until muscle power can be properly assessed at the age of about 3 years.

If the deformity is progressing and the tibialis anterior is of normal strength, a transfer of the tibialis anterior through the interosseous membrane to the heel is appropriate, although some surgeons simply lengthen it. If extensor hallucis longus, extensor digitorum longus, or peroneus tertius are active, they should be divided at the same time. If the calcaneus deformity is fixed, we combine this procedure with a full anterior ankle capsulotomy to allow correction of the deformity (1).

If the anterior muscles are weak or spastic, we perform a tenodesis of the tendo Achillis to the lower fibular metaphysis. This procedure may stimulate growth at the lower end of the fibula and correct any tendency to develop ankle valgus.

In a late-presenting severe fixed calcaneus deformity with a “pistol-grip” heel, an osteotomy of the calcaneus removing a wedge based posteriorly improves the weight-bearing area. Concomitant valgus of the heel may be corrected by adding varus to the osteotomy. This can be performed in combination with tendon transfers and tenodesis as appropriate. A plantar release may be required as well in the treatment of concomitant cavus deformity.

### VALGUS DEFORMITY

In general, valgus feet create less trouble than varus feet and can usually be controlled by orthoses until adolescence. The precise site of bony deformity should be

identified; it may be at the ankle, at the subtalar joint, or at both these sites. Clinical examination and weight-bearing radiography enable the precise site of deformity to be identified.

### *Ankle Valgus*

Ankle valgus can be recognized clinically because the distal end of the fibula can be palpated proximal to the tip of the medial malleolus. On the radiograph, the distal fibular growth plate lies proximal to the dome of the talus, as opposed to the normal relationship for that age. This appearance is associated with a wedge-shaped distal tibial epiphysis.

The relative shortening of the fibula can be reduced by tendo Achillis tenodesis to the fibula if this procedure is indicated for coexisting calcaneus deformity. The valgus effect of the wedge-shaped distal tibia epiphysis can be corrected by a medial arrest of the distal tibial growth plate either by the insertion of a screw from the tip of the medial malleolus across the growth plate or by the Phemister technique. To be effective, this procedure must be performed before the child is 7 to 8 years of age. After this age, a supramalleolar osteotomy is indicated if the deformity is sufficiently severe to be producing undue pressure on the skin over the medial malleolus, where its excessive prominence rubs on ankle-foot orthoses or footwear. This is done 1 cm above the growth plate with excision of a medially based wedge, together with an oblique distal fibular osteotomy. The tibial osteotomy is fixed with two crossed K-wires. Any rotational deformity can be corrected at the same time. We have experienced a 5% incidence of wound breakdown and delayed union following this procedure.

### *Subtalar Valgus*

Subtalar valgus can usually be controlled by orthoses in children younger than the age of 10 years, but division of spastic peroneal muscles may be necessary. If an orthosis fails to control this problem, we would now avoid subtalar fusion and perform a calcaneal osteotomy by excising a medially based wedge and also shifting the distal calcaneus medially. The position is held by a Steinmann pin. If the presentation is close to skeletal maturity, it is commonly associated with a planoabductus deformity, which is best treated by a lateral inlay triple fusion (23).

### *Ankle Plus Subtalar Valgus*

Each deformity should be addressed separately and corrected as described in the previous section. If the patient is nearly mature, this may well necessitate a supramalleolar osteotomy with a lateral inlay triple fusion.

## CAVUS DEFORMITY

Management of a cavus deformity depends on the degree and rigidity of the deformity and the age of the child. Minor deformity can be observed and any pressure effects minimized with an appropriate insole. Treat progressive deformity for children up to the age of 5 years by a plantar release procedure. For children older than 5 years, soft-tissue release may have to be combined with osteotomies at the bases of all metatarsals. If there is an element of supination in the forefoot deformity and the hindfoot is mobile, the osteotomies may be limited to the first or first and second metatarsal bases to improve the weight- bearing area of the foot. Osteotomy of the calcaneus is indicated if there is an associated varus deformity of the heel. Triple arthrodesis is indicated if there is a significant varus and cavus deformity in the child close to skeletal maturity.

## PARALYTIC CONVEX PES VALGUS (VERTICAL TALUS)

Paralytic convex pes valgus (vertical talus) occurs in less than 2% of children with spina bifida. It can present at birth and is then similar to the congenital vertical talus that is not associated with spina bifida. It can also occur in a less rigid form, which develops slowly over the first years of life (5).

Surgical correction is necessary and involves reduction of the talonavicular (and sometimes the calcaneocuboid) joint and correction of the ankle equinus and heel valgus. These objectives can be achieved through a Cincinnati surgical approach (see Chapter 167). The operation is best performed in the first year of life.

- Section the tibialis anterior, extensor digitorum longus, and the peroneal muscles, and lengthen the tendo Achillis.
- Perform a lateral release of the subtalar joint and, if the valgus deformity is gross, insert a lateral bone block into the subtalar joint.
- Maintain correction with longitudinal and vertical K-wires for 4 to 6 weeks, as well as immobilization in a cast for 3 months postoperatively.
- Use a carefully molded ankle-foot orthosis to control planus, heel valgus, and the flail ankle.

## FLAIL ANKLE

We treat the flail ankle with an ankle-foot orthosis until maturity. Ankle fusion in children has a high failure rate, as does pantalar fusion.

## CLAW TOES

Claw toes are common in patients with L-5 and sacral lesions. In the second to fifth toes, open flexor tenotomy and closed extensor tenotomy generally corrects the mobile deformity sufficiently to prevent pressure effects on the tip or dorsum of the affected toe. Rigid deformity requires interphalangeal arthrodesis and extensor tenotomy, as well as dorsal release at the metatarsophalangeal joint.

Clawing of the hallux can give rise to pressure sores over the first metatarsal head and over the dorsum of the interphalangeal joint. If the deformity is correctable in the younger child, tenodesis of flexor hallucis longus to the proximal phalanx corrects the deformity but may have to be combined with a dorsal capsulotomy of the first metatarsophalangeal joint. In the older child, when the interphalangeal joint deformity is fixed, we perform a Robert Jones procedure with fusion of the interphalangeal joint and transfer of the extensor hallucis longus to the neck of the first metatarsal (Fig. 179.10).

***Figure 179.10.*** Interphalangeal valgus and pronation of the hallux. This problem was treated by interphalangeal arthrodesis. (Reproduced with permission from Menelaus MB. *Orthopaedic Management of Spina Bifida Cystica,* 2nd ed. Edinburgh: Churchill Livingstone, 1980.)

## CHAPTER REFERENCES

Each reference is categorized according to the following scheme: *, classic article; #, review article; !, basic research article; and +, clinical results/outcome study.


+ 1. Bliss DG, Menelaus MB. The Results of Transfer of the Tibialis Anterior to the Heel in Patients Who Have a Myelomeningocele. *J Bone Joint Surg* 1986;68-A:1258.

* 2. Broughton NS, Menelaus MB, Cole WG, Shurtleff DB. The Natural History of Hip Deformity in Myelomeningocele. *J Bone Joint Surg* 1993;75-B:760.

+ 3. Broughton NS, Graham G, Menelaus MB. The High Incidence of Foot Deformity in Patients with High-level Spina Bifida. *J Bone Joint Surg* 1994;76-B:548.

+ 4. Buisson JS, Hamblen DL. Eectromyographic Assessment of the Transplanted Iliopsoas Muscle in Spina Bifida Cystica. *Dev Med Child Neurol Suppl* 1972;27:29.

+ 5. Duckworth T, Smith TW. The Treatment of Paralytic Convex Pes Valgus. *J Bone Joint Surg* 1974;56-B:305.

* 6. Feiwell E, Sakai D, Blatt T. The Effect of Hip Reduction on Function in Patients with Myelomeningocele. *J Bone Joint Surg* 1978;60-A:169.

+ 7. Fraser RK, Bourke HM, Broughton NS, Menelaus MB. Unilateral Dislocation of the Hip in Spina Bifida—A Long-term Followup. *J Bone Joint Surg* 1995;77-B:615.

+ 8. Frawley PA, Broughton NS, Menelaus MB. Anterior Release for Fixed Flexion Deformity of the Hip in Spina Bifida. *J Bone Joint Surg* 1996;78-B:299.

+ 9. Frawley PA, Broughton NS, Menelaus MB. Incidence and Type of Foot Deformities in Patients with Low-level Spina Bifida. *J Pediatr Orthop* 1998;18:312.

+ 10. Heeg M, Broughton NS, Menelaus MB. Bilateral Dislocation of the Hip in Spina Bifida. A Long Term Follow-up Study. *J Pediatr Orthop* 1998;18:434.

# 11. Hoffer MM, Feiwell E, Perry J, Bonnett C. Functional Ambulation in Patients with Myelomeningocele. *J Bone Joint Surg* 1973;55A:137.

# 12. Menelaus MB. Orthopaedic Management of Children with Myelomeningocele: A Plea for Realistic Goals. Dev Med Child Neurol 1976;37(Suppl):18.

* 13. Broughton NS, Menelaus MB. *Menelaus' Orthopaedic Management of Spina Bifida Cystica,* 3rd ed. London: Saunders, 1998.

+ 14. Marshall PD, Broughton NS, Menelaus MB, Graham HK. Surgical Release of Knee Flexion Contractures in Myelomeningocele. *J Bone Joint Surg* 1996;78-B:912.

# 15. McDonald CM, Jaffe KM, Shurtleff DB. *Functional Patterns of Innervation in the Lower limb Musculature of Children with Myelomeningocele: Implications for Ambulation.* Presented at International Society for Research into Hydrocephalus and Spina Bifida, New Castle, Northern Ireland, 1987.

+ 16. Mustard WT. A Follow-up Study of Iliopsoas Transfer for Hip Instability. *J Bone Joint Surg* 1959;41-B:289.

+ 17. Olney BW, Menelaus MB. Triple Arthrodesis in Spina Bifida Patients—A Long-Term Followup. *J Bone Joint Surg* 1988;70-B:234.

+ 18. Sandhu PS, Broughton NS, Menelaus MB. Tenotomy of the Ligamentum Patellae in Spina Bifida: Management of Limited Flexion Range at the Knee. *J Bone Joint Surg* 1995;77-B:832.

* 19. Sharrard WJW. Posterior Iliopsoas Transplantation in the Treatment of Paralytic Dislocation of the Hip. *J Bone Joint Surg* 1964;46-B:426.

# 20. Shurtleff DB. Myelomeningocele: A New or a Vanishing Disease? *Z Kinderchir* 1986;1(Suppl):5.

+ 21. Shurtleff DB, Menelaus MB, Stahlei LT, et al: Natural History of Flexion Deformity of the Hip in Myelodysplasia. *J Pediatr Orthop* 1986;6:666.

+ 22. Spires TD, Gross, RH, Low W, Barringer W. Management of the Resistant Myelodysplastic or Arthrogrypotic Clubfoot with the Vereberlyi-Ogston Procedure. *J Pediatr Orthop* 1984;4:705.

+ 23. Williams PF, Menelaus MB. Triple Arthrodesis by Inlay Grafting—A Method Suitable for the Undeformed or Valgus Foot. *J Bone Joint Surg* 1977;59B:333.

+ 24. Wright JD, Menelaus MB, Broughton NS, Shurtleff DB. Natural History of Knee Contractures in Myelomeningocele. *J Pediatr Orthop* 1991;11:725.

+ 25. Yngve DA, Lindseth RE. Effectiveness of Muscle Transfers in Myelomeningocele Hips Measured by Radiographic Indices. *J Pediatr Orthop* 1982;2:121.

# CHAPTER 180

# BONE DYSPLASIAS, METABOLIC BONE DISEASES, AND GENERALIZED SYNDROMES

*Lori A. Karol*

**L. A. Karol:** Orthopaedic Department, Texas Scottish Rite Hospital for Children, Dallas, Texas, 75219.

Skeletal Dysplasias
- Achondroplasia
- Diastrophic Dysplasia
- Metaphyseal Chondrodysplasia
- Multiple Epiphyseal Dysplasia
- Osteogenesis Imperfecta
- Multiple Femoral Osteotomies and Insertion of Bailey-Dubow Rods
- Morquio's Syndrome
- Multiple Hereditary Osteochondromatosis
- Enchondromatosis
- Fibrous Dysplasia
- Neurofibromatosis

Metabolic Bone Diseases
- Nutritional Rickets
- Neonatal Rickets
- Vitamin D–Resistant Rickets
- Miscellaneous Forms of Rickets
- Renal Osteodystrophy

Generalized Syndromes
- Down Syndrome
- Arthrogryposis Multiplex Congenita
- Osteopetrosis

Chapter References

## SKELETAL DYSPLASIAS

The skeletal dysplasias are a diverse group of disorders in which the structure of the bone is inherently abnormal, thus altering the growth of affected individuals. The trunk and extremities are abnormally sized, leading to disproportionate short stature, defined as a height less than the third percentile for the individual's chronologic age. Some of the dysplasias are genetically transmitted, whereas others occur sporadically.

The diagnosis in skeletal dysplasias can most often be made clinically. Short stature should be noted when present, and body proportion and trunk and limb shortening may be helpful. The various definitions of skeletal dysplasias are shown in Table 180.1. If limb shortening is most notable in the proximal segments (i.e., humerus or femur), the term *rhizomelic* can be applied. Shortening of the midportion of the limb is termed *mesomelic*, and *acromelic* describes distal shortening. The area of the bone most disturbed by the dysplasia can help establish the diagnosis. For example, multiple epiphyseal dysplasia (MED) affects the epiphyses, whereas the metaphysis is most involved in the various forms of metaphyseal chondrodysplasia. The presence or absence of spinal involvement also is helpful in reaching a diagnosis.

| | |
|---|---|
| rhizomelic | shortening in the proximal segments of the extremity |
| mesomelic | affecting the midportions of the limb |
| acromelic | distal shortening |

***Table 180.1. Definitions***

Associated medical findings, such as precocious puberty in fibrous dysplasia, may aid in the diagnosis. In addition, identifying a specific dysplasia may lead to the identification and, therefore, treatment of associated medical conditions. For example, patients with nail-patella syndrome are at increased risk for renal failure, the onset of which is insidious and would go unnoticed if not for the proper surveillance due to the known association with the syndrome (94).

Collaboration with a geneticist can facilitate making the diagnosis in difficult cases. Genetic counseling may be of interest to the patient and family. Some dysplasias are unclassifiable and should be treated on an individual basis.

Advances in molecular genetics have furthered understanding of the mechanisms of bony abnormalities in these conditions. Although gene replacement treatment is not yet possible, research is progressing rapidly in this direction. See Dietz and Mathews (65) for an excellent review of the genetic basis of the inherited skeletal dysplasias.

### ACHONDROPLASIA

Achondroplasia is the most common form of dwarfism, with a prevalence of 1.3 per 100,000 live births (3). It is inherited in an autosomal dominant pattern, although most cases are the result of spontaneous mutations. Molecular genetic research has found that there is a point mutation in the gene that encodes fibroblast growth factor receptor 3 (19,32,229), located on the short arm of chromosome 4 (183). Achondroplasia is characterized by a rhizomelic pattern of involvement, with the humerus and femur affected more than the distal extremities. Prenatal diagnosis is possible by monitoring the growth of the femur during the second trimester (165).

Histology reveals disturbed endochondral ossification. Intramembranous bone formation is not affected. Pathologic study of the growth plate shows marked abnormalities in the zone of hypertrophy, with loss of normal columnation of chondrocytes and accumulation of excess matrix (171). Periosteal bone formation is histologically normal. Additionally, the epiphysis itself is not affected by the dysplasia; therefore, there is no predisposition toward early degenerative arthritis.

The clinical appearance of achondroplasia is recognizable at birth. The baby is short limbed and has a disproportionately large head. Trunk length is normal. Facial features include a flattened nasal bridge, prominent mandible, and enlarged forehead. The hands characteristically have a space between the long and ring fingers,

referred to as the “trident hand.” Elbow flexion contractures and radial head dislocation may be present. The lower limbs may be bowed, and the musculature appears enlarged. Thoracolumbar kyphosis may be present in infants (Fig. 180.1).

***Figure 180.1.*** Four-year-old boy with achondroplasia. Note the prominent forehead, flexion contractures of the elbow, trident hand, and thoracolumbar kyphosis.

Radiographic findings in achondroplasia include an inverted V-shaped growth plate, best seen in the distal femur (Fig. 180.2). The metaphysis is widened, and the epiphysis is relatively normal. The long bones of the leg may be bowed. The pelvis is wide but short, with small sciatic notches. The shape of the inner pelvis has been described as a “champagne glass” appearance. The radiographic hallmark of the achondroplastic spine is progressive narrowing of the transverse interpedicular distance as one measures from cephalad to caudad in the lumbar spine (Fig. 180.3). The pedicles are thickened, and there may be posterior scalloping of the vertebral bodies.

***Figure 180.2.*** One-year-old girl with achondroplasia. The physis of the distal femur appears as an inverted V.

***Figure 180.3.*** Progressive interpedicular narrowing in the lumbar spine of a 5-year-old girl with achondroplasia.

Orthopaedic concerns most frequently focus on the spine (25,237). In infancy, compression of the brain stem and cervical cord secondary to stenosis of the foramen magnum has been described (127,167,265). Symptoms include sleep apnea (more specifically, central hypoapnea), and neurologic examination may reveal hypotonia (which is common in all infants with achondroplasia) or clonus. When compression is noted, posterior surgical decompression of the foramen magnum is recommended to prevent sudden death (265,269). Other neurosurgical concerns include Chiari malformations at the craniocervical junction and hydrocephalus, which occasionally requires shunting (76). Sleep apnea can also occur because of upper airway obstruction, and sleep studies may be able to identify those children whose respiratory compromise is due to craniocervical abnormalities and those due to obstructive airway problems (254,255,272). Because the orthopaedist often is involved in the care of the infant with achondroplasia, awareness of these conditions is imperative if appropriate neurosurgical referral is to be made.

Thoracolumbar kyphosis occurs in the slightly older infant with achondroplasia (Fig. 180.4). Kyphosis occurs nearly universally in the young baby. Possible causes include ligamentous laxity, hypotonia, enlarged head size, and hip flexion contractures. In most cases, the kyphosis resolves as the child begins to walk. A recent theory, popularized by Hall (100) and Pauli et al. (168), proposes that unsupported sitting by the hypotonic infant leads to the development of thoracolumbar kyphosis. The authors advocate prohibiting unsupported sitting to prevent the kyphosis from occurring, and early brace treatment with a thoracolumbosacral orthosis (TLSO) for those babies who do develop kyphosis. Other authors have recommended using a brace if kyphosis persists beyond 2 years of age. For refractory cases, surgical treatment consisting of anterior and posterior fusion without instrumentation may be necessary. Progressive kyphosis and kyphosis measuring greater than 40° at 5 years of age are indications for surgery (237). Fusion is generally obtained without instrumentation, because the narrowed canal and kyphotic deformity predispose the patient to neurologic injury and paraplegia if hardware is introduced (see Chapter 158 and Chapter 161).

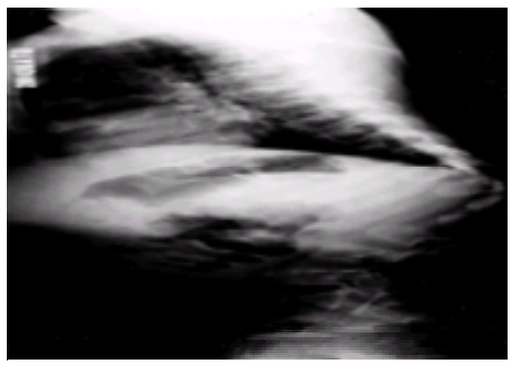

***Figure 180.4.*** Persistent thoracolumbar kyphosis in a 4-year-old boy with achondroplasia.

Spinal stenosis is the most common orthopaedic problem in achondroplasia (237) and may become symptomatic in patients in their early teen years (119). Symptoms

include leg and back pain (neurogenic claudication), lower extremity weakness, and loss of endurance during ambulation. The patient attempts to relieve pain during walking by hunching over to reduce the lumbar lordosis, which produces more space within the spinal canal. The decreased space within the spinal canal is due to narrowing and thickening of the pedicles, hypertrophy of the facets, and enlargement of the laminae (132). Magnetic resonance imaging (MRI) is useful in visualizing the extent of the stenosis. The condition is treated by posterior decompression, with wide laminectomy. The surgeon should attempt to preserve the facets, but this may not be possible if the stenosis is severe. Primary fusion usually is not necessary.

Angular deformity may occur in the lower limbs in childhood (18), and may be due in part to overgrowth of the fibula in relation to the tibia (171) (Fig. 180.5). Tibial osteotomy remains the treatment of choice for patients with symptomatic or cosmetically objectionable varus. Epiphysiodesis of the fibula has had mixed results (see Chapter 169).

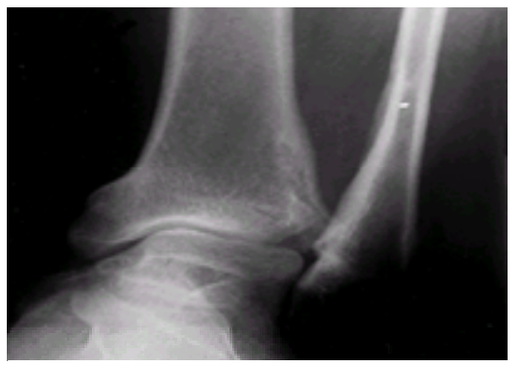

***Figure 180.5.*** Relative fibular overgrowth in a 13-year-old girl with achondroplasia.

Treatment of the patient's short stature remains controversial. There has been enthusiasm, particularly in Europe, for the application of the Ilizarov technique for lengthening the limbs in children with achondroplasia (88,267) (see Chapter 171). Treatment with recombinant growth hormone has been investigated and found to increase growth in some individuals with achondroplasia (111,156,257,266).

**DIASTROPHIC DYSPLASIA**

Diastrophic dysplasia is a severe form of short-limbed dwarfism, which is inherited in an autosomal recessive pattern. Its gene, located on chromosome 5, is responsible for the sulfation of proteoglycans, a crucial component of cartilage (230). Prenatal DNA testing can establish the diagnosis. Histologic study of the growth plate shows abnormalities in collagen (221) and decreased numbers of chondrocytes.

Clinical features are striking at birth. The child has very short limbs. There is flattening of the nasal bridge and a puffy-cheeked appearance. Cleft palate is frequently present. Severe clubfoot deformities are always present, and joint contractures are common. The thumb, which is radially deviated and short, has been described as a “hitchhiker thumb.” Within the first months of the child's life, the pinnae of the ears become swollen and ossify. The crumpled and enlarged pinnae have been termed “cauliflower ear” (249). In some affected children, tracheomalacia may be life-threatening during the neonatal period. The child's intelligence is normal.

Radiographic findings include the delayed appearance of the epiphyses. When the epiphyses do ossify, they are irregular and may be flattened (especially at the proximal femur) (244). Coxa vara is common and may result in hip dislocation. The long bones are short but appear thickened. Scoliosis is seen in older children (Fig. 180.6). The first metacarpal is short in relation to the rest of the hand and is triangular in shape, leading to the development of the hitchhiker deformity.

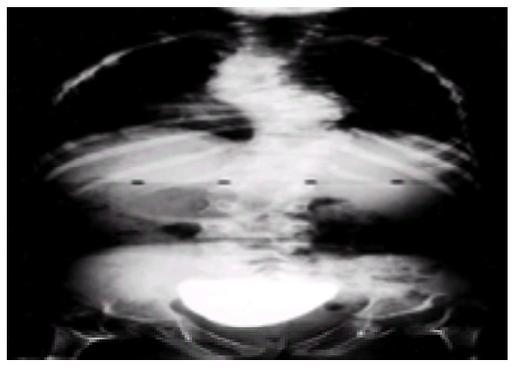

***Figure 180.6.*** Scoliosis in an 8-year-old girl with diastrophic dysplasia. Note the bilateral hip dislocations.

Orthopaedic concerns include the severe clubfeet, which are resistant to casting and are prone to early recurrence after surgical intervention. Postoperative bracing is used in these children. Repeated surgical releases of the feet are difficult but should be aggressive (see Chapter 167). Other foot deformities are also seen in patients with diastrophic dysplasia (190). Joint contractures of the hip and knee may not be treatable with soft-tissue release. Osteotomy is required for fixed deformity. Hip dislocation is common and is difficult to treat. Because of the epiphyseal abnormalities, premature degenerative arthritis does occur.

Scoliosis is common and frequently severe in children with diastrophic dysplasia (109,173,237). Surgical fusion is indicated for large curves. Cervical kyphosis may be severe and lead to neurologic compromise (80,173) (Fig. 180.7). Atlantoaxial instability has also been described with diastrophic dysplasia (180). Careful assessment of the child's neck before general anesthesia can prevent death due to neurological causes (24). Surgical atlantoaxial fusion is indicated in progressive cases.

***Figure 180.7.*** Cervical kyphosis in a 2-year-old girl with diastrophic dysplasia.

**METAPHYSEAL CHONDRODYSPLASIA**

Metaphyseal chondrodysplasia is a group of diseases of autosomal dominant and recessive inheritances. The two most common forms are the Schmid and McKusick types. The McKusick form is also known as cartilage hair hypoplasia. The primary defect is an abnormality in the physis of the zone of primary calcification, with

clusters of chondrocytes protruding into the metaphysis. The gene coding for type X collagen, which is present in hypertrophic chondrocytes located at the growth plate, is abnormal in Schmid metaphyseal chondrodysplasia (250,253).

Clinically, short stature is always present but varies in severity (182). Genu varum is common. Radiographs reveal widened physes and cupping of the epiphysis (Fig. 180.8), which may be mistaken for rickets. Serum chemistry, however, is normal in metaphyseal chondrodysplasia (77) (except for Jansen type, in which hypercalcemia may be present [197]). Coxa vara can be seen in the Schmid form, and cervical instability may be seen in the McKusick form. The long bones may be bowed, leading to angular deformities. The epiphyses are normal.

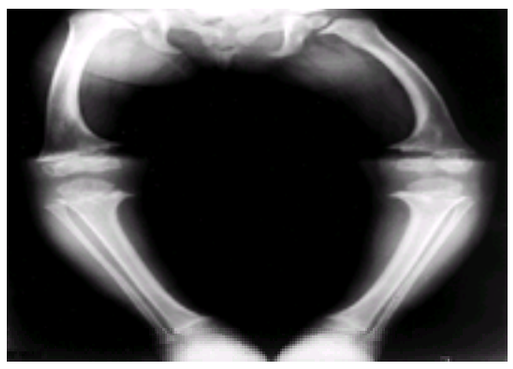

***Figure 180.8.*** Radiograph of the lower extremities of a 4-year-old girl with metaphyseal chondrodysplasia. Genu varum and widened physes are seen.

Orthopaedic treatment consists of osteotomies for symptomatic or progressive angular deformities. Patients with the McKusick form, which has been linked with immunodeficiency, have recently been treated by bone marrow transplantation (23,245).

**MULTIPLE EPIPHYSEAL DYSPLASIA**

Multiple epiphyseal dysplasia (MED) is one of the most common of the bone dysplasias. It is inherited by autosomal dominant transmission and has been found to be genetically variable among families (60).

The disorder is characterized by symmetric involvement of the epiphyses with a delay in their ossification. Radiographically, they appear mottled and irregular. The hips, knees, and ankles are most frequently involved; in the upper extremity, the shoulder is most commonly affected (113). The spine is essentially normal. In the differential diagnosis of bilateral Legg-Calvé-Perthes disease, always include MED (2) and perform radiographs of the knees and ankles. An abnormal epiphyseal height-to- metaphyseal width ratio for the distal femur has been found in most children with MED and has been proposed as helpful in early diagnosis (246). Another characteristic finding is the double-layered appearance of the patella on lateral radiographs (205). Avascular necrosis of the femoral head frequently occurs in patients with MED (133).

Adult height usually is at the lower range of normal. Joint pain may appear in the first decade or remain quiescent until early adult life. Treatment is the same as that for osteoarthritis, consisting of joint replacement for advanced cases (238).

**OSTEOGENESIS IMPERFECTA**

Osteogenesis imperfecta (OI) is a group of genetically transmitted dysplasias in which the bones are extremely fragile, predisposing the patient to multiple fractures. Several classifications of the disease exist (124). In 1906, Looser divided OI into congenita and tarda forms, with the specific type determined by whether the patient developed fractures at birth or later. The most commonly applied classification is that by Sillence (208), who categorized patients based on how the condition was inherited (i.e., autosomal dominant or recessive) and on the presence of specific clinical features (Table 180.2).

| *Type* | *Inheritance* | *Clinical features* |
|---|---|---|
| I | Autosomal dominant | Blue sclerae<br>Fractures—variable<br>Hearing loss—common<br>± Poor dentition |
| II | Autosomal recessive | Blue sclerae<br>Intrauterine or early death<br>Severe fractures |
| III | Autosomal recessive | Rare<br>Fractures—multiple<br>Extreme short stature<br>Normal sclerae |
| IV | Autosomal dominant | Fractures—variable<br>Normal sclerae<br>Hearing normal<br>± Poor dentition |

***Table 180.2. Sillence Classification of Osteogenesis Imperfecta***

The prevalence of OI is 21.8 per 100,000 live births, with Sillence type I being the most common form (3). Prenatal diagnosis of the congenital form of OI is possible with ultrasound (22), but milder forms of OI (e.g., Sillence types I and IV) do not have abnormal ultrasound findings (235). In families with known mutations, chorionic villous sampling may help establish the prenatal diagnosis (235).

The underlying genetic defect in OI is an abnormality in the gene that encodes for the alpha chain of type I collagen (45). Mutations are almost always present, involving either the COL1A1 or COL1A2 genes, which encode the procollagen. In affected individuals, the organization of type I collagen is in disarray. In type I OI, there is a quantitative abnormality in the amount of type I collagen; in the other forms of OI, there are both quantitative and qualitative anomalies in type I collagen (44). Abnormalities can be seen in dermal fibroblasts obtained from skin biopsies, in which the ratio of type I to type III collagen (which is uninvolved in patients with OI) is compared with age-matched normal specimens. Routine use of skin biopsy for diagnosis is discouraged, however, because the history and physical examination usually are sufficient to establish the diagnosis (224).

Morphologic changes are seen in growth plate cartilage (193). Histologically, there is a relative increase in woven bone that does not mature to lamellar bone. The osteocyte number is increased. Trabeculae are thin and poorly arranged, and the haversian canal system does not develop. Bone mineral density is decreased on dual energy x-ray absorptiometry (DEXA) scans, even in milder forms of the disease (271).

Clinical manifestations vary, with the spectrum ranging from that of stillborn babies with numerous fractures and intracranial bleeds to active adolescents with a history of several fractures occurring at various times during their childhood. Musculoskeletal findings include short stature, bowing of the extremities, and scoliosis. Blue sclerae are seen in Sillence type I and II patients, and in some type III patients, with the color most intense and long-lasting in type I patients (209). Dentition may be poor due to defective dentin, a condition known as *dentinogenesis imperfecta*. Hearing loss may occur secondary to middle ear involvement. The face is trefoil shaped. Clinical findings in patients with type IV OI may be quite subtle, and the differential diagnosis between OI and child abuse can be vexing.

Radiographic findings vary with disease severity as well. Fractures may be seen throughout the skeletal system. Coxa vara is a common sequela of femoral neck fracture. Protrusio acetabuli can develop. *Wormian* bones are seen on skull radiographs. The vertebrae may be biconcave, and compression fractures may be present (Fig. 180.9). The long bones are thin and osteopenic. The femur may have a “concertina” appearance, that is, a crumpled shape due to multiple fractures. There is widening of the metaphyses, and growth arrests may occur. Irregular calcifications may extend into the metaphysis, a condition referred to as “popcorn epiphysis” (Fig. 180.10).

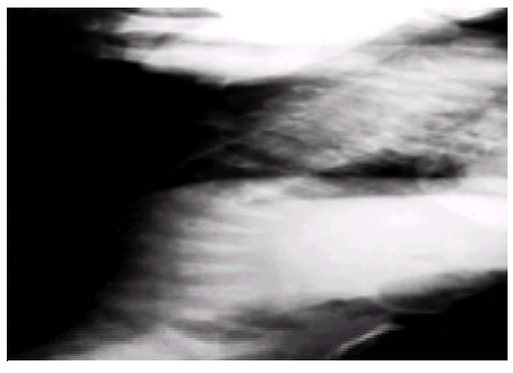

***Figure 180.9.*** Flattened vertebral bodies throughout the spine of a 1-year-old boy with severe osteogenesis imperfecta.



***Figure 180.10.*** Severe bowing, multiple healed fractures, and epiphyseal calcifications in the lower extremity of a child with severe osteogenesis imperfecta.

The motor development of children with severe OI is delayed. Physical therapy has been useful in helping the patient develop head and trunk control, and when therapy is used in combination with surgery and bracing, sitting and ambulation may be improved (27). The ability of the child to sit independently by age 10 months has been correlated with achieving walking as a primary means of mobility (55).

Orthopaedic management is required to treat fractures as well as to attempt to prevent fractures. Fractures usually heal within a normal time interval, but the tendency to refracture persists. Disuse osteopenia further weakens the bones, so immobilization should be kept to the minimum time necessary to ensure fracture healing. Orthoses may be needed on a long-term basis to assist in weight bearing and to reduce the incidence of fractures (89). Nonunions may occur (867).

Surgical intervention can help prevent fractures and maintain limb alignment. Intramedullary fixation for load sharing, in combination with multiple osteotomies, was popularized by Sofield and Miller (218). Telescoping rods are technically more challenging to insert, but because they grow with the child, the chances of refracture with growth are lessened (13,14) (Fig. 180.11). Gamble et al. (87) showed that although the Bailey-Dubow rod was difficult to insert properly, it was beneficial in providing internal support to growing bones. Other authors also have published favorable results using the Bailey-Dubow device but state that the hardware does require periodic revision during patient growth (154,270).

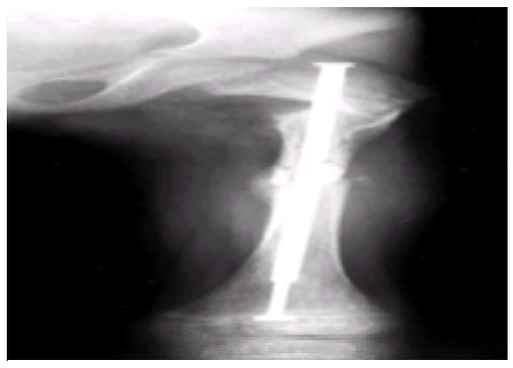

***Figure 180.11.*** Bailey-Dubow elongating rod in the femur of a 7-year-old boy with osteogenesis imperfecta.

**MULTIPLE FEMORAL OSTEOTOMIES AND INSERTION OF BAILEY-DUBOW RODS**

The insertion of a Bailey-Dubow rod in the femur proceeds as follows (Fig. 180.12):

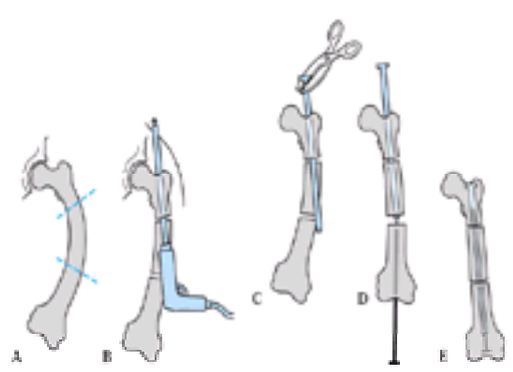

***Figure 180.12.*** Surgical technique for inserting Bailey-Dubow elongation rod. **A:** Bowed femur and planned osteotomies. **B:** Hollow rod drilled into proximal fragment and out a small incision in buttock. **C:** Exchange of drill bit for T-piece; crimp with pliers. **D:** Solid rod inserted through knee. **E:** Rods engaged, advanced fully, and buried in femoral epiphysis.

- Preoperatively, check available lengths of rods.
- Type and crossmatch blood.
- Position the patient in the lateral decubitus position on a radiolucent table and drape the lower extremity free.
- Perform a gentle subperiosteal exposure of the femur.
- Perform multiple osteotomies where needed to pass a straight rod.
- Ream the medullary canal to allow rod passage.

- Drill the female end of the rod into proximal fragment in a retrograde direction through the fracture or osteotomy, exiting just medial to the greater trochanter.
- Exchange the drill bit for a T-piece through the proximal skin incision.
- Crimp the T-piece onto the female end of the rod using pliers.
- Perform a perapatellar exposure of the femoral intercondylar notch at the knee.
- Insert the male solid rod up through the femoral notch.
- Engage the male rod into the female rod.
- Tap each rod in fully.
- Twist the male rod 90° within the femoral epiphysis to deter distal migration into the knee.
- Close and dress the incisions and apply a spica cast.

Rush and Sheffield rods also have been used to treat OI-related fractures (228). Intramedullary fixation has been recommended in the treatment of severely involved young children with type III OI (43). Motor development has been augmented in children with type III OI by performing surgery before 3.5 years of age (74).

Vertebral involvement leads to scoliosis and kyphosis in the severely affected groups of patients. Biconcave deformity of the vertebral bodies has been linked with the early onset of scoliosis (114). Chest cage deformity may result from bracing because of rib fragility (21), and curve progression is not halted by brace wear (102,268). Treatment is surgical but is fraught with technical problems. Fixation of the spine with conventional spinal hardware is difficult to achieve because of osteopenia. Methylmethacrylate augmentation and the use of mersilene tapes have been proposed as means to assist in fixation (21). Fusion *in situ* is the norm, because correction is very difficult to achieve.

Brain stem compression from basilar invagination has received recent attention (42). The condition has been found in as many as 25% of patients (210) and is often associated with macrocephaly and hydrocephalus. Clinical signs of basilar invagination include nystagmus, cranial nerve palsies, papilloedema, and facial spasm. Surgical treatment is difficult (104). In severely involved patients, basilar invagination may lead to early death due to respiratory arrest (143).

Anesthetic management of the child with OI can be complicated. There is a predisposition to hyperthermia that is biochemically different from the classic malignant hyperthermia (172). Blood loss during surgery may also be massive (219).

Medical treatment of OI is still experimental. Fluoride, vitamin therapy, and calcitonin have been tried in the past. Current research is aimed at treating OI at the molecular level (90,139).

**MORQUIO'S SYNDROME**

Morquio's syndrome, one of the mucopolysaccharidoses, is characterized by the lack of N-Ac-Gal-6 sulfate sulfatase, a lysosomal enzyme. Deficiency of this enzyme causes an increase in urinary keratan sulfate (112). The syndrome is inherited in an autosomal recessive pattern.

Clinically, affected patients appear normal when they are babies. The clinical features appear later, as glycosaminoglycans accumulate (Fig. 180.13). Signs of Morquio's syndrome include short-trunk dwarfism, ligamentous laxity, and genu valgum. Facial features are not striking. Kyphosis of the thoracic spine and pectus carinatum may be present. The patient's intelligence is normal. Hepatosplenomegaly is not associated with Morquio's syndrome.

***Figure 180.13.*** Clinical appearance of a 6-year-old boy with Morquio's syndrome.

Radiographs reveal tongue-shaped projections originating from the anterior vertebral body (Fig. 180.14). Platyspondyly is present. Odontoid hypoplasia, resulting in atlantoaxial instability, is common and the surgeon should look for it (152). The epiphyses are irregular and flattened, and may fragment in the weight-bearing joints. The bases of the metacarpals are pointed, and the bones of the hand are short and thick (196). The radiographic appearance is very similar to that seen in spondyloepiphyseal dysplasia.

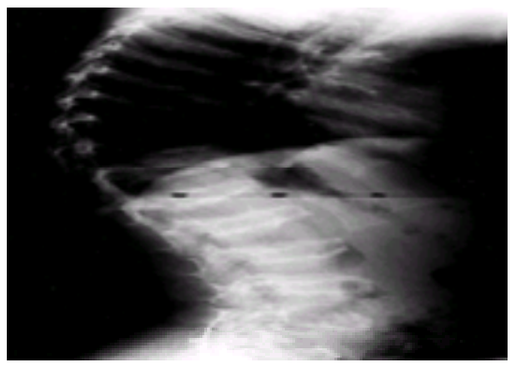

***Figure 180.14.*** Platyspondyly and vertebral irregularities in a 6-year-old boy with Morquio's syndrome.

Orthopaedic management of atlantoaxial instability often is necessary, with atlantoaxial fusion the recommended treatment (152,226) (Fig. 180.15) (see Chapter 158). Difficulty in walking is easily attributed to the genu valgum (Fig. 180.16), but the surgeon must be cautious and confirm that the cervical spine is not the cause of the changes in ambulation. Anesthesiology concerns are related to possible cervical instability. Life expectancy usually is normal.

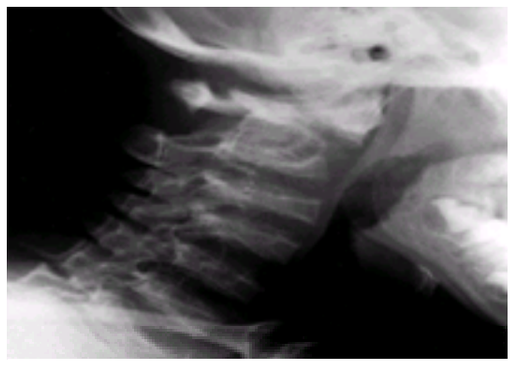

***Figure 180.15.*** Odontoid hypoplasia and atlantoaxial instability in a 6-year-old boy with Morquio's syndrome.

***Figure 180.16.*** Genu valgum in a child with Morquio's syndrome.

**MULTIPLE HEREDITARY OSTEOCHONDROMATOSIS**

Multiple hereditary osteochondromatosis is one of the more common forms of dysplasia, occurring in 9 per million people. It is genetically transmitted as an autosomal dominant trait. Severity of involvement varies among family members, but penetrance is 100% (260). Masses develop in those bones that are formed by endochondral ossification, with a predisposition for the long bones, scapula, ribs, and pelvis.

Histologic examination reveals normal bone that is in continuity with the metaphysis of the parent bone. The exostosis is covered by a cap of hyaline cartilage, usually less than 3 mm in thickness. The deep surface of the cartilaginous cap is involved in endochondral ossification, leading to growth of the lesion.

The diagnosis normally is made during the patient's first decade of life. Multiple bumps, which are usually nontender, may be palpable throughout the skeleton. The patient tends to be short in stature. The spine is rarely affected (1,9,157). Limb-length discrepancy and angular deformity are common because of disturbance of normal longitudinal growth. Scapular lesions can lead to “winging” (56).

On radiographs, lesions can be seen around the metaphysis of the long bones, along the borders of the scapula, on the ribs, or originating from the iliac apophysis. The exostoses may be sessile, with a broad base or origin, or they may be pedunculated, arising from the bone on a bony stalk. The medullary canal of the mass is in continuity with the canal of the long bone. There is a predilection for the masses to appear at the end of the bone that grows fastest (e.g., the distal rather than the proximal radius) and for greater involvement of the smaller bone of two-bone limbs (e.g., the ulna more so than the radius) (Fig. 180.17). Pedunculated lesions typically point away from the epiphysis.

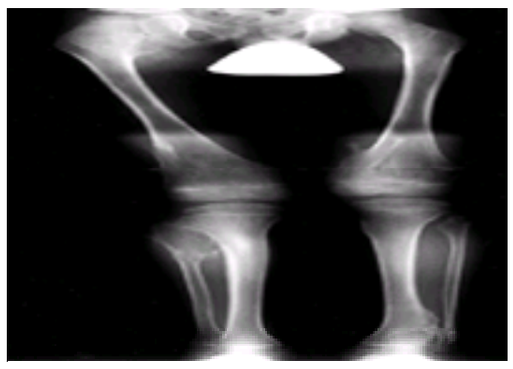

***Figure 180.17.*** Multiple osteochondromatosis of the femur, tibiae, and fibulae in a 6-year-old boy.

Orthopaedic management consists of excision of painful exostoses and observation of those that remain asymptomatic (40,264). Excision may be postponed until adolescence, when multiple symptomatic lesions can be excised under one anesthetic. Angular deformities may require correction, especially at the knee, where valgus is common (168). Genu valgum may lead to patellofemoral instability (151). Compression of surrounding structures may occur owing to the size of the osteochondromas. The peroneal nerve is particularly prone to compression from masses and is susceptible to injury during surgical excision of proximal fibular lesions (38,264). Proximal tibial lesions may irritate the pes anserinus (81). Large exostoses of the distal tibia can compress the adjacent fibula, leading to erosion and deformity (57,214).

Wrist involvement in hereditary osteochondromatosis is quite common, consisting of distal ulnar and radial osteochondromas, shortening of the ulna, tilt of the distal radial epiphysis, and ulnar translation of the carpus (Fig. 180.18). Dislocation of the radial head may occur because of the ulnar shortening (117). At present, treatment of osteochondromatosis of the forearm is controversial. Some authors advocate early excision of osteochondromas around the wrist, believing that such treatment prevents subsequent deformity and radial head dislocation (169,170). However, a recent study comprising 78 patients with forearm osteochondromas found that function was not compromised and that cosmetic concerns were rare in those patients who did not have early, aggressive treatment of their exostoses (10). Outcome studies agree that deformities of the upper extremity in patients who have hereditary multiple exostoses are well tolerated and cause little loss of function as measured both objectively and subjectively (222). When osteochondromas result in progressive discrepancy in length between the radius and the ulna, and forearm rotation becomes painful, osteotomy of the bowed radius can be performed with satisfactory but not perfect results. Acute lengthening and gradual lengthening of the ulna (via the Ilizarov technique) have both been described (54,256). Radial head excision is reserved for pain relief in skeletally mature patients.

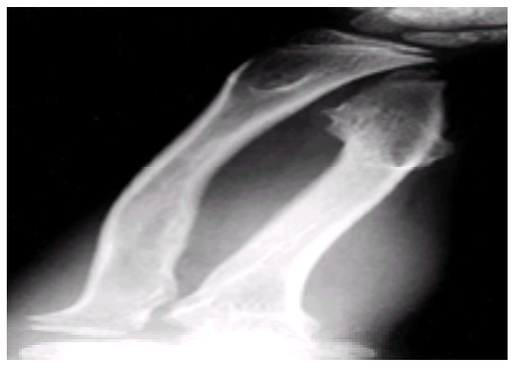

***Figure 180.18.*** Shortening of the ulna and translation of the carpus due to multiple osteochondromatosis.

Malignant transformation of benign osteochondromas into chondrosarcoma occurs in less than 1% of affected individuals. The physician should become clinically suspicious when a lesion increases in size or becomes painful after skeletal maturity. The cartilage cap of a benign osteochondroma is quite thin; a cap greater than 1

cm in thickness suggests malignant transformation. Accurate measurements of cartilage cap thickness can be made using MRI or ultrasound scans (135). Even if a chondrosarcoma occurs, such malignancies are late to metastasize; usually respond well to wide resection; and have a good prognosis, particularly in long bone lesions (see Chapter 127 and Chapter 128).

**ENCHONDROMATOSIS**

Enchondromatosis is a noninherited bone dysplasia in which masses of cartilage form within the metaphyses of tubular bones and the pelvis. Lesions may be single or multiple and involve only a single extremity, or they may affect multiple extremities. Asymmetry is a hallmark of the disease, with one side of the body markedly more involved than the other side. Multiple enchondromatosis is known as Ollier's disease; enchondromatosis with multiple hemangiomas is known as Maffucci's syndrome.

Pathology reveals clusters of chondrocytes within the lesions. Mitotic figures may be present but should be few in number. Grossly, the lesions appear as gray-white masses amid the bone and may feel gritty due to calcification.

Radiographic findings show lucent, streaky lesions within the metaphyses (134,194). Calcification can be seen within the lesion. The cortex of the bone may expand with the lesion, especially in the phalanges of the hand. The metaphysis becomes widened and trumpet shaped. Angular deformity and shortening are seen (179) (Fig. 180.19).

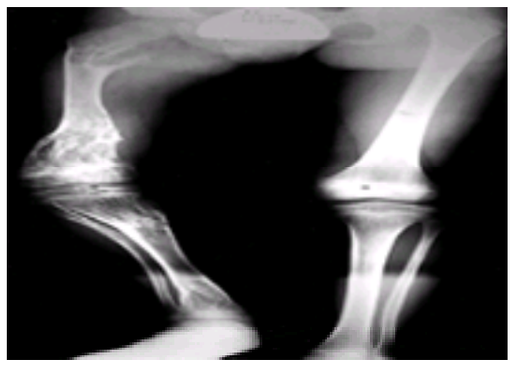

***Figure 180.19.*** Unilateral enchondromatosis in an 8-year-old boy.

Orthopaedic management involves correcting angular deformity and equalizing limb length. Osteotomy addresses angulation, and lengthening procedures are useful for shortened extremities. Regenerate formation is adequate during lengthening despite the presence of enchondromas.

Malignant degeneration of enchondromas to chondrosarcoma does occur, and newly painful lesions should trigger suspicion. Maffucci's syndrome is associated with nonskeletal malignancies at an alarming rate (199). See Chapter 127 and Chapter 128 for more detail.

**FIBROUS DYSPLASIA**

Fibrous dysplasia is a noninherited dysplasia in which bone is replaced by abnormal fibrous tissue. One bone (monostotic fibrous dysplasia) or multiple bones (polyostotic fibrous dysplasia) may be affected. In the polyostotic form, usually one side of the patient's body is involved to a greater degree than the other side. The disease can be associated with endocrine abnormalities and hyperpigmented skin lesions, known as McCune-Albright syndrome (41,126,129). Precocious puberty is the hallmark of the McCune-Albright variant.

Pathology reveals a fibrous stroma full of fibroblasts. Multiple immature fragments of woven bone are seen within the stroma, an appearance similar to that of alphabet soup. The bone has widened osteoid seams and does not mature into lamellar bone.

The clinical diagnosis usually becomes apparent within the patient's first two decades of life. Presenting signs include pain, limp, deformity, or pathologic fractures. Involvement of the skull and facial bones can occur in varying degrees. Leg-length discrepancy is common.

Radiographs reveal ill-defined, lucent lesions that have a ground-glass appearance because of the calcification of immature bone. The cortex is thinned, and the shaft of the involved bone may expand. Lesions are metaphyseal or diaphyseal in location. Coxa vara with “shepherd's crook” deformity of the proximal femur is a classic radiographic finding (Fig. 180.20). Isolated lesions may be mistaken for simple bone cysts, particularly in the humerus. Spinal involvement, usually associated with neurologic compromise, has been described (73,96,150,174). Because the diagnosis can usually be made from radiographs, biopsy is rarely necessary.

***Figure 180.20.*** Extensive fibrous dysplasia of the femur and pelvis in a 13-year-old boy. Note the “shepherd's crook” deformity of the proximal femur.

Orthopaedic treatment depends on the site of the lesions and on the biomechanical implications of the weakened bone. Pain, progressive deformity, and impending pathologic fracture are indications for surgery. Closed treatment of fractures due to fibrous dysplasia usually is sufficient for the upper extremities but is rarely successful for the lower extremities, for which the demands of weight bearing require strong bony support (225). Excision and curettage rarely work because bone graft is quickly replaced by the abnormal fibrous tissue (97). When bone grafting is necessary, cortical strut grafts (e.g., the fibula) take longer to resorb and thus provide more structural support (35,75).

Femoral neck lesions are particularly problematic. Osteotomy to correct coxa vara, combined with curettage and grafting of the femoral neck (usually with cortical bone), is performed when the calcar becomes progressively thin, leading to coxa vara and a painful limp. Internal fixation should be used, but extension of the lesion up into the femoral neck makes standard fixation tenuous (97). Osteotomies to correct deformity and intramedullary fixation, particularly using reconstruction nails, which provide fixation into the femoral head and neck, can help restore alignment and support in the femur and tibia (82). Because the medullary canal in fibrous dysplasia is less distinct and very vascular, the surgeon should anticipate difficulties when using closed techniques as well as increased blood loss during intramedullary fixation. Osteotomies tend to heal reasonably well, and nonunions are uncommon.

Leg-length discrepancy may be significant enough to require surgical equalization. For moderate discrepancies, contralateral epiphysiodesis is far simpler than lengthening procedures.

The activity of the disease usually regresses in adulthood (106). Malignant tumors have been described as having originated from both the monostotic and the polyostotic forms of fibrous dysplasia (105,189,195). A 3% rate of malignant transformation has recently been reported by the Mayo Clinic, with the majority of tumors

being osteosarcomas (189). Degeneration of fibrous dysplasia into aneurysmal bone cysts has also been described (153) (see Chapter 127).

**NEUROFIBROMATOSIS**

Neurofibromatosis (von Recklinghausen's disease) is the most prevalent skeletal dysplasia transmitted by a single gene. It is inherited in an autosomal dominant pattern with variable expression, although the disease is believed to occur due to a new mutation in half of the affected individuals (248). The estimated prevalence is 1 per 1000 live births.

The disorder has two forms. Neurofibromatosis type I (NF-I) is the more common form and is characterized by peripheral neurofibromas, skeletal involvement, and "café au lait spots." The genetic locus for NF-I has been localized to chromosome 17q11.2, an area that encodes for the protein neurofibromin (98,206). This protein is present in several organ systems and is believed to be a tumor suppressor (249). Neurofibromatosis type II (NF-II) manifests as central neurofibromas with bilateral acoustic neuromas and usually presents in the third or fourth decade of life (142). The gene for NF-II has been localized to chromosome 22 and encodes for the protein schwannomin (131).

Histologic examination of neurofibromas has shown a palisading arrangement of densely packed fibrous bundles and spindle cells. Grossly, the masses are firm and pale.

There are numerous clinical features of neurofibromatosis. The National Institutes of Health has developed specific criteria for the diagnosis of neurofibromatosis (Table 180.3). The most common skin lesion is the café au lait spot, a hyperpigmented irregular area with a smooth border that varies in size and shape (Fig. 180.21). These spots usually are not present immediately after birth but appear and increase in number throughout childhood. More subtle skin findings in patients with neurofibromatosis include axillary or inguinal freckling. Fibroma molluscum are superficial, raised nodules that represent dermal neurofibromas. They are not seen in prepubertal children. Nevi are heavily pigmented lesions that may present unilaterally. The lesions may be hypersensitive and may overlie plexiform neurofibromas. Plexiform neurofibromas are large nerve tumors that are locally invasive, feel like a "bag of worms," and have the potential for malignant transformation.

Patients must have at least two of the following findings:

- Six or more café au lait spots, measuring 0.5 cm in diameter in prepubertal children or 1.5 cm in postpubertal individuals
- Two or more neurofibromas, or one plexiform neurofibroma
- Axillary or inguinal freckling
- Optic glioma
- Two or more Lisch's nodules (tan specks in the iris that represent hamartomas)
- A distinctive bony lesion, such as cortical thinning of a long bone without pseudarthrosis or frank pseudarthrosis
- A first-degree relative with neurofibromatosis

***Table 180.3. NIH Criteria for Diagnosis of Neurofibromatosis***

***Figure 180.21.*** Multiple café au lait spots in a 3-year-old boy with neurofibromatosis and scoliosis.

Skeletal lesions vary as well. Scoliosis is most common, occurring in up to 64% of patients with neurofibromatosis (50). Three types of scoliosis exist. The first is an idiopathic-appearing curve without significant bony changes or kyphosis. A second form is the dysplastic type, a short, sharp curve in which six or fewer vertebrae are involved. The dysplastic curve occurs in up to 72% of patients with neurofibromatosis and scoliosis (212). The vertebrae may assume a wedge shape, rotation usually is severe, and penciling of the apical ribs is characteristic. The neural foramen may be expanded owing to pressure from dumbbell neurofibromata. A third form of scoliosis is a dysplastic curve with associated hyperkyphosis (Fig. 180.22*A*, Fig. 180.22*B*).

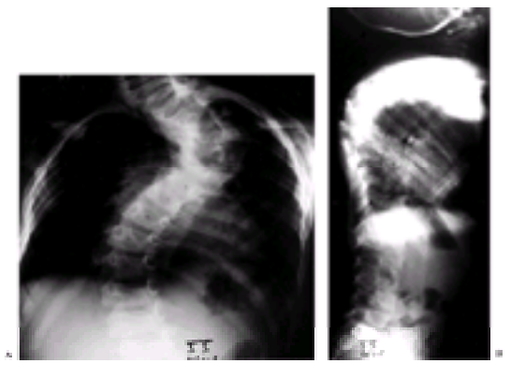

***Figure 180.22.*** PA (**A**) and lateral (**B**) radiographs of a dysplastic kyphotic curve in a 3-year-old boy with neurofibromatosis.

Hypertrophy or hemiatrophy due to neurofibromatosis can be seen, and the physician should rule out the disease whenever evaluating a child with hemihypertrophy. Congenital pseudarthrosis of the tibia and forearm may be present. Protrusio acetabuli is also seen in patients with neurofibromatosis.

Orthopaedic treatment of the skeletal involvement of neurofibromatosis most often involves the spine. Treatment of the idiopathic-type curve is similar to the treatment of adolescent idiopathic scoliosis (see Chapter 155, Chapter 156, and Chapter 158). Bracing is used for progressive curves in growing patients, with spinal fusion reserved for larger curves. Dysplastic curves have a more ominous prognosis, with rapid progression commonly seen. Those curves that are most prone to progression occur in younger patients, are greater in magnitude at presentation, are associated with kyphosis, and have vertebral and rib erosive changes (84). Spinal fusion was often complicated by pseudarthrosis (50,212), leading to the current recommendation of combined anterior and posterior spinal fusions to treat these curves (263). Surgery should not be delayed in young children with dystrophic curves (37). Even with anterior and posterior fusion, some dystrophic curves continue to progress, requiring difficult subsequent revision procedures (50,110,118,261).

Spinal surgery in patients with neurofibromatosis is technically challenging for several reasons. First, the bone itself is often soft due to erosion from neurofibromas. This compromises the purchase of hooks or screws used during instrumentation. Second, the surgical approach can be difficult owing to thoracic neurofibromas surrounding the spine (198). Last, intradural lesions and outpouchings of dura (known as *dural ectasia*) are seen in patients with neurofibromatosis, increasing the risk

of neurologic complications during surgical correction (72,108). Preoperative MRI studies of the spinal cord are imperative in patients with neurofibromatosis (50).

Cervical spine involvement in patients with neurofibromatosis has also been described (50,99). Severe cervical kyphosis has been seen in patients with plexiform neurofibromas (252) (Fig. 180.23). Neurologic compromise has been described in these patients (47,130).

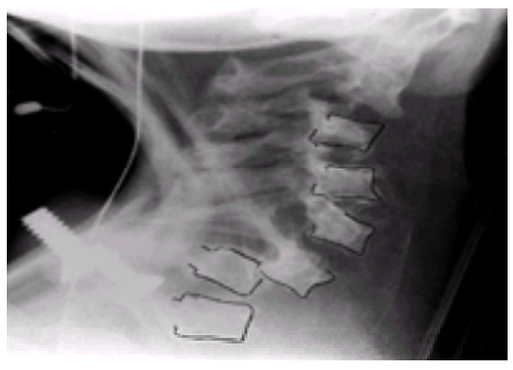

***Figure 180.23.*** Cervical kyphosis in a 3-year-old girl with neurofibromatosis.

Leg-length discrepancy may occur due to neurofibromatosis. The treatment of hemihypertrophy is individualized and ranges from epiphysiodesis for mild cases to ablative amputation for severely affected persons.

Congenital pseudarthrosis of the tibia is one of the most challenging disorders treated by pediatric orthopaedists. The condition usually, but not always, is associated with neurofibromatosis. Boyd (33) described four types of congenital pseudarthrosis of the tibia (Fig. 180.24; Table 180.4).

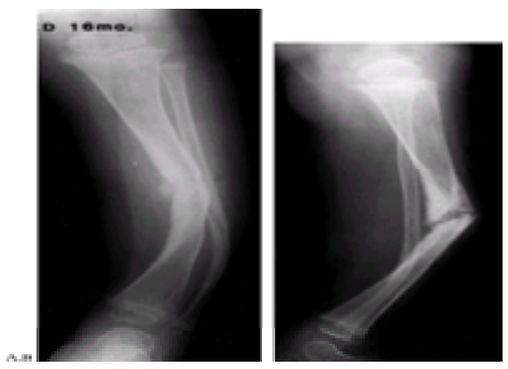

***Figure 180.24.*** AP (**A**) and lateral (**B**) views of the tibia of a 16-month-old girl with congenital pseudarthrosis of the tibia and neurofibromatosis.

| | |
|---|---|
| Type I | Increased density of the medullary canal<br>Bowing present |
| Type II | Defect in tubulation of the medullary canal<br>Bowing and constriction present |
| Type III | Cystic lesion at the apex of the bow; precursor to frank pseudoarthrosis |
| Type IV | True pseudoarthrosis, with tapering of the ends of the fracture |

***Table 180.4. Types of Pseudarthrosis of the Tibia***

A recently described variant of congenital anterolateral bowing of the tibia has been described in which the fibula is stout, and the bowing remodels without treatment and does not progress to pseudoarthrosis. This benign form does not occur in patients with neurofibromatosis (241).

Treatment of congenital pseudarthrosis of the tibia is controversial (166). Myriad methods have been employed to obtain union, but all have led to failures in some patients (15). The prepseudarthrosis should be treated with total contact clamshell orthoses. Once the tibia has fractured, closed treatment will not be successful (49). The traditional treatment for congenital pseudarthrosis of the tibia is intramedullary fixation of the tibia and fibula, with excision of the pseudarthrosis and bone grafting. The Williams rod can be inserted through the calcaneus into the tibia and usually is left protruding across the ankle joint. With growth, the rod migrates proximally into the tibia (4) (Fig. 180.25*A*, Fig. 180.25*B*).

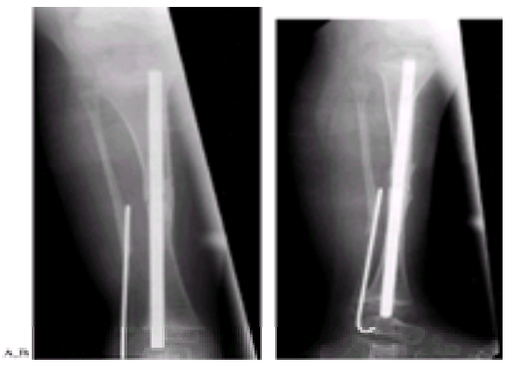

***Figure 180.25.*** **A:** Intramedullary fixation in congenital pseudarthrosis of the tibia. **B:** Note the proximal migration of the distal end of the rod.

Newer methods of treating congenital pseudarthrosis of the tibia have been recommended in response to the high rate of nonunion using intramedullary fixation. Advocates for Ilizarov fixation and bone transport as well as for vascularized fibula transfer find that union can be achieved in some, but not all, patients with congenital pseudarthrosis of the tibia (31,46,62,66,78,91,93,211,242,258) (see Chapter 36, Chapter 169, and Chapter 171). The long-term ability to maintain union in these patients remains unknown. Amputation continues to be a feasible option for the patient who has undergone several operations and still fails to achieve union (115). A long-term study by Crossett et al. (52) found that approximately half of their patients with congenital pseudarthrosis of the tibia eventually were treated by amputation. Regardless of the method used to achieve union, precaution must be taken to prevent recurrent fractures. Protection of the tibia with ankle-foot orthoses is usually

prescribed. Even when union is achieved, muscle weakness and gait disturbances are almost always present (122).

Leg-length discrepancy is nearly universal following congenital pseudarthrosis of the tibia, with the affected leg being shorter than the normal limb. Equalization surgery is often indicated.

Pseudarthrosis of the forearm is also associated with neurofibromatosis and likewise is difficult to treat (48,141). Protrusio acetabuli may also result from neurofibromatosis (118) and usually is associated with contiguous neurofibromas (136).

Patients with neurofibromatosis are prone to developing malignancies of tissues of neural crest origin as well as others (49,204).

## METABOLIC BONE DISEASES

Metabolic bone disease is caused by abnormalities in the metabolism of calcium and phosphate. Rickets and renal osteodystrophy are the most common forms of metabolic bone disease in children. A thorough understanding of calcium metabolism is required to evaluate affected patients properly (30,138).

The human body is very sensitive to calcium, particularly the cardiovascular and neurologic systems, in which irritability, conductivity, and contractility rely on the precise control of serum calcium levels. Nearly all of the body's calcium is stored in bone in the form of hydroxyapatite, with a small proportion circulating in the bloodstream. Serum calcium levels are regulated by vitamin D and parathyroid hormone (PTH) through their actions on the gut, kidneys, and bone. Calcium is absorbed in the distal duodenum and proximal jejunum by means of a transport mechanism that is activated by the active form of vitamin D (1,25-dihydroxy vitamin D) and by PTH.

Provitamin D is ingested as ergosterol or is produced by the liver as 7-dehydrocholesterol. When they are exposed to ultraviolet light, these compounds become calciferol and cholecalciferol. The first hydroxylation occurs in the liver and the second hydroxylation takes place in the kidney, with the end result being 1,25-dihydroxy vitamin D (233). Conversion to this dihydroxy form is stimulated by hypocalcemia and high levels of PTH.

PTH is produced in the parathyroid glands and is released in response to hypocalcemia. PTH allows for the absorption of calcium from the gut and renal tubules, frees calcium from hydroxyapatite in bone, and activates osteoclasts, an event that takes on importance in renal osteodystrophy.

### NUTRITIONAL RICKETS

Nutritional rickets is caused by inadequate dietary intake of vitamin D in the growing child. Although the condition is uncommon in the United States (116), it remains a problem throughout the rest of the world. Children who are fed a vegetarian diet or who are breast fed for prolonged periods of time are at increased risk for nutritional rickets (188). Malabsorption of vitamin D due to celiac or hepatic disease results in gastrointestinal rickets, which is more commonly seen in developed countries. In either form, the lack of vitamin D results in the inability to absorb calcium or phosphorus. PTH is released in response to the hypocalcemia, but hypophosphatemia persists. Laboratory studies reveal normal or mildly decreased serum calcium, decreased serum phosphate, elevated PTH, and decreased vitamin D.

Histologic changes are most notable at the growth plate, where loss of columnation occurs in the zone of hypertrophy. Because there is insufficient calcium to mineralize bone, plump chondrocytes persist into the zone of provisional calcification and down into the metaphysis. There is sparse mineralization and elongation of the growth plates. Within trabecular bone, large amounts of unmineralized osteoid surround the fragile trabeculae.

Radiographic findings show marked widening of the growth plate due to the absence of the zone of provisional calcification (Fig. 180.26). The metaphyses are flared or cupped. The long bones may be abnormally bowed because they are unable to withstand mechanical stress. The trabecular pattern of the bone is indistinct. Osteopenia is present. Looser's lines (radiolucent lines extending transversely across the axis of the bone) are associated with rickets and are present in approximately 20% of patients with all forms of rickets (223).

***Figure 180.26.*** Osteopenia and growth plate widening in the knee of a 1-year-old girl with nutritional rickets.

Most children affected with nutritional rickets are quite young (188). Clinical features include short stature, muscular weakness, and ligamentous laxity. Genu varum and periarticular enlargement of the wrists, elbows, and ankles may be noted. The term “rachitic rosary” refers to the prominence of the costochondral cartilages along the chest wall. The abdomen may be protuberant. Neurologic involvement, such as listlessness and irritability, may be present.

Treatment of nutritional rickets, which should be supervised by a pediatric endocrinologist, consists of vitamin D replacement. Osteotomies are rarely required for residual deformity following medical treatment.

### NEONATAL RICKETS

A form of rickets has been described in which premature neonates in intensive care units sustain multiple fractures without antecedent trauma (125). Risk factors include hepatobiliary disease, total parenteral nutrition, diuretic therapy, physical therapy with passive motion, and chest percussion therapy. The fractures require minimal immobilization to heal. The patients are treated by the neonatal intensivists with supplemental feedings (53).

### VITAMIN D–RESISTANT RICKETS

Vitamin D–resistant rickets, also known as familial hypophosphatemic rickets, is a group of diseases in which ordinary dietary intake of vitamin D is inadequate in maintaining normal mineral balance (251). The condition usually is inherited in an X-linked dominant pattern, although an autosomal dominant form also exists (69). The genetic locus for the disease has been identified (7,71,184,185). A renal tubular defect leads to the inability to reabsorb phosphate, resulting in phosphate diabetes and hypophosphatemia (39,71,101). Laboratory studies reveal near-normal levels of calcium, PTH, and vitamin D but low levels of serum phosphate. Urinary phosphate and serum alkaline phosphatase are elevated.

Affected children present with bowing of the lower extremities, short stature, bone pain, and dental caries (69). The disease becomes clinically apparent after 12 months of age, but it can be diagnosed earlier by laboratory testing for urine phosphate levels in suspected infants (146).

Radiographic changes and histologic findings are similar to those seen in patients with nutritional rickets (Fig. 180.27).

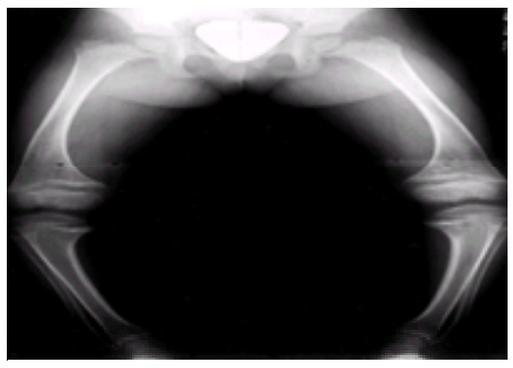

***Figure 180.27.*** Bowing and physeal widening in the lower extremities of a 4-year-old girl with hypophosphatemic rickets.

Treatment of hypophosphatemic rickets is primarily medical, typically consisting of oral replacement of phosphate and large amounts of vitamin D (247). Nephrocalcinosis is a known complication of medical treatment (227). Growth hormone therapy has been used to improve phosphate metabolism and increase stature in these patients (164,191,262).

Orthopaedic management consists of osteotomies to treat residual deformities of the lower extremities (79,187) (see Chapter 168 and Chapter 169). Careful preoperative planning is required because the deformities are multiplanar and thus may benefit from external fixation that precisely corrects angulation in each plane (121). Bone healing is delayed after osteotomy and may take approximately twice as long as expected in metabolically normal children. Calcification of ligaments and degeneration of articular cartilage may occur in affected adults (79).

**MISCELLANEOUS FORMS OF RICKETS**

On rare occasions, rickets may occur in patients with neurofibromatosis or fibrous dysplasia (137). Anticonvulsant drug therapy may also produce rickets (236). In addition, certain tumors may produce hypophosphatemic rickets. Patients with no family history of rickets should be suspect. Tumors usually are present in bone or skin (103).

**RENAL OSTEODYSTROPHY**

Renal osteodystrophy is a more common form of metabolic bone disease (29). Glomerular disease leads to retention of phosphate. The injured kidney is unable to perform the final hydroxylation of vitamin D. Hypocalcemia ensues, which stimulates secondary hyperparathyroidism. It is the secondary hyperparathyroidism that produces most of the skeletal manifestations of renal osteodystrophy.

PTH enables osteoclasts to resorb bone. In renal osteodystrophy, lysis of bone is extensive, resulting in the development of osteitis fibrosa (163). A small number of patients may develop osteosclerosis.

Laboratory studies show elevated levels of blood urea nitrogen (BUN), creatinine, alkaline phosphatase, and PTH. Serum calcium and vitamin D levels are low, whereas the serum phosphate level is high.

Children with renal osteodystrophy are short for their age. Bone pain may be present, and pathologic fractures can occur (11). Hip pain and limp, secondary to slipped capital femoral epiphysis, may be present (203). This occurs in children who are younger than those most often seen with slipped epiphyses, and the condition usually is bilateral. The previously described features of nutritional rickets may also be present. Bowing of the long bones and genu valgum are common.

Radiographic findings are striking. Resorption of bone can be seen at the terminal tufts of the distal phalanges, the symphysis pubis (Fig. 180.28), and the end of the clavicle. Metaphyseal resorption of bone leads to widened physes and slipped capital femoral epiphysis (SCFE; see Chapter 172) (Fig. 180.29). Disturbance of the proximal lateral tibial physis with associated genu valgum has been described (161). Brown tumors appear as large, lucent lesions with indistinct margins within the pelvis or long bones. These tumors can best be seen on MRI (158). “Rugger jersey” spine describes the sclerotic appearance of the vertebral endplates seen on a lateral radiograph. Periarticular soft-tissue calcification may be seen.

***Figure 180.28.*** Resorption of the pubis due to renal osteodystrophy.

***Figure 180.29.*** Physeal widening and slipped capital femoral epiphysis in a 7-year-old boy presenting with hip pain. A diagnosis of renal failure was made.

Treatment is primarily medical and is aimed at correcting the metabolic imbalance. Calcitriol, administered in high doses intravenously, orally, or by dialysis, has been found to be helpful in the treatment of pediatric renal osteodystrophy by lowering PTH levels (192). Pinning of SCFEs may be necessary (107), but osteopenia and continued metaphyseal resorption may compromise fixation (see Chapter 172). The patient's hip pain may resolve simply with medical treatment. Osteolysis of the distal femoral physis has also been described, with cast immobilization and medical treatment sufficient to promote healing and remodeling (231). When an angular deformity of the lower extremities interferes with gait, osteotomy of the femur or tibia is indicated. Best results are obtained if the patient's metabolic state is optimized before surgery (58,160).

## GENERALIZED SYNDROMES

### DOWN SYNDROME

Down syndrome is one of the most common genetically transmitted diseases, with a prevalence of 9.2 per 10,000 live births (5,159). It results from trisomy of chromosome 21 because of maternal nondisjunction, translocation, or mosaicism. One risk factor for Down syndrome is advancing maternal age. The most notable feature is mental retardation, but a variety of other congenital malformations, including heart defects, commonly occur (120). The IQs of children with Down syndrome vary considerably. About 30% of patients develop orthopaedic problems that require hospitalization (63).

Clinical features include a characteristic facies, with upslanting palpebral fissures, prominent epicanthal folds, mild microcephaly, and a protruding tongue. The child tends to be short. Ligamentous laxity is universal. Development is delayed, with the onset of ambulation usually not occurring until 2 to 3 years of age.

Radiographic findings include a characteristic appearance of the pelvis. The iliac wings are widened, the ischial rami are small and tapered, and the acetabulae are horizontal. Coxa valga is present. Hand radiographs show that all five metacarpals are equal in length, and there is clinodactyly of the small finger.

Orthopaedic concerns arise from the ligamentous laxity and its effects on the spine, hips, knees, and feet. Atlantoaxial instability, the most commonly recognized skeletal manifestation of Down syndrome, is caused by laxity in the transverse ligament. The radiographic definition of atlantoaxial instability is an increase in the atlanto-dens interval (ADI), as seen on flexion lateral cervical radiographs (Fig. 180.30). It has been reported to occur in 9% to 31% of persons with Down syndrome (177). Patients with atlantoaxial instability have a particularly high rate of associated congenital cervical spine anomalies (e.g., os odontoideum, hypoplasia of the posterior arch of C-1, and hypoplasia of the dens) that may have an impact on surgical treatment (140,176).



***Figure 180.30.*** The atlanto-dens interval is increased in flexion in this 12-year-old boy with Down syndrome.

Children with Down syndrome are usually screened for cervical instability. The American Academy of Pediatrics Committee on Sports Medicine and Fitness conducted a review of the literature and concluded that greater effort should be directed toward “identification of those patients who already have or who later have complaints or physical findings consistent with symptomatic spinal cord injury” rather than obtaining routine radiographs (6). This report pointed out that almost all children who suffered catastrophic neurologic injury because of atlantoaxial instability had pre-existing neurologic symptoms, and that children rarely develop abnormal radiographic findings following normal films (147).

Activity modification to protect patients with increased ADI from head trauma by removing them from “at-risk” athletic activities is the traditional recommendation. A few authors have proposed that because neurologic abnormalities are so rare even in affected children, activity restriction may be unnecessary (51). Others have found that an equal proportion of patients have neurologic signs with and without radiographic instability of the cervical spine, and they question the need to screen all patients (186). Once atlantoaxial instability is documented radiographically, rarely does it increase significantly over time (175). Neurologic injury following nonspinal surgery has been described; thus, preoperative radiographic evaluation of the cervical spine in patients with Down syndrome is warranted (59,148,240).

Surgical treatment of atlantoaxial instability consists of posterior spinal fusion with halo immobilization (181). A high complication rate with major complications, including nonunion, loss of reduction, neurologic deterioration, late subaxial instability, infection, and wound dehiscence, should be anticipated after posterior arthrodesis of the upper cervical spine in patients with Down syndrome. Ligamentous laxity in patients with precarious preoperative neurologic status increases the neurologic mortality risk during surgery (213). Nonsurgical management is currently recommended for patients with Down syndrome who have atlantoaxial instability but no neurologic signs or symptoms (67,200).

Recent attention has also been directed at instability between the occiput and C-1. Posterior occipitoatlantal hypermobility (POAH), defined as subluxation of the occiput posteriorly during extension of the neck, has been identified in 8% to 63% of patients with Down syndrome (85,162). The discrepancy in prevalence is probably due to the difference in techniques used to measure motion at this level. Plain radiographs may suggest instability, but precise measurement of hypermobility is fraught with error and is best evaluated with MRI (123,259). POAH may be seen in patients with atlantoaxial instability (243). Treatment is based on the child's neurologic status and on the amount of space available for the spinal cord (239). Posterior occipital-cervical fusion has been recommended (145).

The lower cervical spine may also become symptomatic in patients with Down syndrome. Spondylolysis of the cervical spine and early degenerative arthritis have been described (239).

Ligamentous laxity may predispose the patient to instability of the joints of the lower extremities, resulting in hip dislocations and patellar subluxation and dislocation. Approximately 7.9% of patients with Down syndrome have some hip abnormality, including dysplasia, dislocation, avascular necrosis, or SCFE (202). Dislocation of the hip in patients with Down syndrome is rarely painful initially but may become so over time. Treatment is difficult, because redislocation is not uncommon. Nonoperative bracing is rarely successful, but prolonged spica casting may allow the hip to stabilize in a reduced position. Open reduction, capsulorrhaphy of the attenuated capsule, and femoral and pelvic osteotomy may result in a stable hip (20) (see Chapter 166).

SCFE is also associated with Down syndrome. Hypothyroidism may be a predisposing factor, so thyroid function tests should be ordered for children with both Down syndrome and SCFE. Treatment is *in situ* fixation, but hardware failure may occur (see Chapter 172).

Patellofemoral instability is present in more than one third of patients with Down syndrome, but it rarely affects their ability to walk (68). Surgery is advised in selected cases and consists of aggressive realignment and Galleazzi transfer of the semitendinosus to the patella (see Chapter 87).

Planovalgus of the feet is nearly universal in these patients.

### ARTHROGRYPOSIS MULTIPLEX CONGENITA

Arthrogryposis multiplex congenita is a syndrome in which multiple joints are rigid at birth (100). The disorder is nonprogressive, and the cause is unclear. Abnormalities of muscles, joints, and nervous system; teratogens; infection; and environmental factors have all been implicated. Many genetic syndromes include arthrogrypotic contractures and, thus, should be considered when evaluating a child with joint rigidity. The disease can resemble spinal muscular atrophy, and genetic associations between the two diseases have been proposed (36). Arthrogryposis usually is not genetically transmitted, but genetic research is being performed on the less common inherited forms (16,28,36,83,207,217).

Myopathic and neuropathic forms of arthrogryposis exist (178). The neuropathic type is more common (17). Muscle changes include replacement of skeletal muscle by fibrofatty tissue. Neuropathic findings include a decrease in the number of anterior horn cells, with sparing of the posterior columns. Sensation is not affected.

Clinically, most children have contractures of all four extremities. There is occasional sparing of the upper extremities and rare sparing of the lower extremities. There is a distal form of the disease that consists of hand and foot contractures, including clubfeet (16). Intelligence is usually normal to above normal (217).

The affected limbs appear smooth, without transverse creases at the joints. Muscle mass is decreased, but the atrophy may be difficult to appreciate in young infants. Motion in the joints is limited but painless, and a solid block is felt at the extremes of range of motion.

In patients with extensive involvement, the hips are flexed, abducted, and externally rotated. Dislocation is common. The knees may have flexion or hyperextension contractures. Rigid clubfeet usually are present, but vertical talus may occur. The upper extremities, when involved, are adducted at the shoulder and internally rotated. The elbows may have flexion or extension contractures. The wrist may be flexed and ulnarly deviated, with flexion of the fingers and thumb-in-palm deformity. Scoliosis may be seen in young children.

Orthopaedic treatment is individualized. The goal of surgery is to improve function and enable ambulation when possible. With surgery, it has been found that up to 85% of patients with amyoplasia can walk at least on a limited basis by 5 years of age (201). The prognosis for ventilator-dependent babies is less favorable (26). Recurrence of deformities is common following surgery, and orthoses are usually prescribed.

In the neonatal period, focus on establishing a correct diagnosis. Include examination by a geneticist and a pediatric neurologist. Muscle biopsy is occasionally needed. Initiate physical therapy for range-of-motion and developmental skills. Range of motion should always be performed with great care, because pathologic fractures may occur.

Surgery to address hip dislocation has been recommended in patients with arthrogryposis. Pavlik harness treatment is unsuccessful, so open reduction is the treatment of choice. The medial approach has been specifically advocated by Staheli et al. (220) for use in arthrogryposis. Bilateral dislocations may be addressed medially during the same surgery, with good results reported in 80% of a series of 40 dislocated hips in arthrogrypotic children (232) (see Chapter 166).

Knee contractures are difficult to treat. Knee flexion contractures require surgery more often than hyperextension contractures (149,215). Surgery is indicated if physical therapy fails to attain less than 30° flexion contracture. Hamstring tenotomy and posterior capsulotomy, with or without femoral shortening osteotomy, are required (234). Sectioning of the cruciate ligaments and resection of intra-articular fibrous tissue often is necessary. Femoral extension osteotomy can increase extension at the knee, but flexion deformity of the distal femur recurs with growth of the child (61). Chronic contractures lead to bony changes, such as squaring off of the femoral condyles and joint incongruity (94). Ilizarov techniques have been used in difficult cases (34) (see Chapter 171). Many children who have undergone knee flexion contracture surgery stop walking in adolescence (149).

Surgical correction of clubfeet should be performed around the age when the child learns to walk, which is nearly always delayed in babies with arthrogryposis. Posteromedial release, with resection of tendons and capsules, and lateral column shortening, when needed, is the initial surgery of choice. Recurrence of deformity has been seen in 73% of children with arthrogryposis (155). Talectomy or tarsal medullostomy is usually reserved for recurrent severe deformity, but the procedure has been performed in primary releases by some surgeons (64,92,144,216) (see Chapter 167).

Upper extremity surgery should be delayed until a complete functional assessment can be performed. Optimally, one elbow should be extended for toileting and use of walking aids, and the contralateral elbow should be flexed to enable the child to self-feed (12). The ability of these intelligent children to adapt to their deformities can be surprising, so care should be taken not to intervene surgically when the child is functioning satisfactorily. Surgical procedures that may be useful for the upper extremities include rotational osteotomy of the humerus, triceps transfer to gain active elbow flexion, capsulotomies at the elbow, and wrist stabilization.

**OSTEOPETROSIS**

Osteopetrosis, otherwise known as Albers-Schönberg disease and “marble bone disease” is apparently a hereditary disease of bone characterized by abnormal function of osteoclasts. This results in varying degrees of bone remodeling deficiency, the skeleton being predominately composed of primary unremodeled trabecular bone and calcified cartilage. On electron microscopy, there are increased numbers of osteoclasts but their ruffled border is absent or diminished.

This is an exceedingly rare disorder. Most orthopaedic surgeons will not encounter a single case in their lifetime. Pediatric referral centers may see only a few cases at any given time. A recent review of the management of osteopetrosis by Armstrong, Newfield, and Gillespie based upon a review of the literature and a survey of the members of the Pediatric Orthopaedic Society of North America (10a), is highly recommended for readers interested in more details on this rare disorder. They provide an excellent summary of the characteristics of osteopetrosis, list 63 references, and provide clinical details on 79 patients found in their survey.

Osteopetrosis can be classified into an infantile malignant type. It is inherited by autosomal recessive transmission and a more benign adult form, which is autosomal dominant. The latter can be divided into Type I. This is characterized by marked thickening of the cranial vault, and a substantially lesser risk of fractures. Type II is characterized by vertebral end-plate thickening resulting in the classic appearance of “rugger jersey” spine and “endobones” in the pelvis. Type II has a higher incidence of fracture and delayed union as well. There is an extremely rare third form that is autosomal recessive. It is regarded as an “intermediate” form.

The underlying molecular abnormality, which results in dysfunction of the osteoclast, has not yet been established in humans. However, mutations have been found in the mouse and rat that produce an autosomal recessive type of osteopetrosis. In the *op* mouse and the *tl* rat, the production of colony-stimulating factor – 1 (CSF-1) appears to be deficient or the factor is inactive.

Patients with infantile malignant osteopetrosis are usually diagnosed during their first year of life and only 30% of patients survive past the age of 6 years, dying of complications resulting from myelophthisic anemia which is due to obliteration of their marrow spaces by unremodeled bone. Clinical characteristics include blindness, failure to thrive, seizures, repeated infections, pathologic fractures, hepatosplenomegaly, hypersplenism, hydrocephalus, mental retardation, cranial nerve palsies, and hemorrhagic diathesis.

The infants are lethargic and underdeveloped with macrocephaly, frontal bossing, hypertelorism, exophthalmos, and flattening of the nasal bridge with chronic rhinitis.

Radiographs show increased density in the bone of the entire skeleton and the complete absence of the medullary canal. There is metaphyseal widening producing club-shaped long bones, and the “bone within a bone” phenomenon is seen in the pelvis, vertebra, hands and feet. Transverse radiolucent bands can be seen in the metaphyseal regions of the long bones. The skull may progressively thicken and show a “hair-on-end” appearance. Transverse or short oblique pathologic-type diaphyseal and metaphyseal fractures are common.

The adult form is compatible with a normal lifespan although patients are prone to long-bone fractures. The age of presentation of these patients can be quite variable depending upon the severity of the disease. Up to 40% of patients may remain asymptomatic. There may be a family history of the disease or of multiple fractures. Laboratory studies show mild or moderate anemia and increased serum acid phosphatase. Bone involvement is less severe than in the infantile form but osteomyelitis of the jaw, progressive coxa vara, lateral bowing of the long-bones, spondylolysis and spondylolisthesis of L4 and L5 or both, and osteoarthritis of the hips and the knees may develop in adults. Dental malocclusion and caries can be problems. The diagnosis is usually obvious from the clinical presentation and characteristic radiographs. It can be confirmed by bone biopsy.

There is no treatment for osteopetrosis, although bone marrow transplantation (in selected patients) has been successful in reversing hematologic and skeletal defects of the disease. Variable results have been obtained with restriction of dietary calcium, splenectomy, high dose prednisone to increase bone marrow hematopoiesis, parathormone, calcitriol, and gamma-interferon.

Orthopaedic treatment is usually focused on management of their fractures (which usually respond to nonoperative closed treatment), and treatment for coxa vara. In the 79 patients reviewed by Armstrong et al. (10a) 20 were treated surgically for coxa vara, all of whom had complications. Valgus osteotomy provided the most consistent results. Fourteen subtrochanteric and 31 other fractures of the femur were treated with traction or casting, with good results in the majority. Twenty-nine tibial fractures, and upper extremity fractures healed well with closed reduction and cast immobilization. For the most part, spine problems were treated non-operatively.

The diaphyseal bone in osteopetrosis is quite hard, chalky, and brittle. It is difficult to drill. It is easily over heated causing necrosis, possibly leading to implant loosening or infection. When placing screws for pins in osteopetrotic bone, it is extremely important to use sharp, fresh drill points and pins. Clean these often and exchange them if necessary to maintain their sharpness. The drills must be cooled constantly by bathing them with sterile saline. The lack of a medullary canal makes drilling even more difficult. Intramedullary nailing is nearly always impossible and internal fixation with plates, because of the multiple screw holes required, is usually best avoided. The presence of a plate on the diaphysis often results in a stress riser, which leads to subsequent fractures at the ends of the plate. If rigid fixation is required for treatment than external fixation is probably the best choice. These patients seem to heal their fractures well in most cases of the adult form. The bone they heal with, however, is defective.

## CHAPTER REFERENCES

Each reference is categorized according to the following scheme: *, classic article; #, review article; !, basic research article; and +, clinical results/outcome study.


+ 1. Albrecht S, Crutchfield JS, Se Gall GK. On Spinal Osteochondromas. *J Neurosurg* 1992;77:247.

# 2. Andersen PE Jr, Schantz K, Bollerslev J, Justesen P. Bilateral Femoral Head Dysplasia and Osteochondritis. Multiple Epiphyseal Dysplasia Tarda, Spondylo- epiphyseal Tarda, and Bilateral Legg-Perthes Disease. *Acta Radiol* 1988;29:705.

* 3. Andersen PE Jr, Hauge M. Congenital Generalised Bone Dysplasia: A Clinical, Radiological, and Epidemiological Survey. *J Med Genet* 1989;26:37.

+ 4. Anderson DJ, Schoenecker PL, Sheridan JJ, Rich MM. Use of an Intramedullary Rod for the Treatment of Congenital Pseudarthrosis of the Tibia. *J Bone Joint Surg* 1992;74A:161.

5. Anonymous. Down Syndrome Prevalence at Birth—United States, 1983–1990. *MMWR Morb Mortal Wkly Rep* 1994;43:617.

* 6. Anonymous. Atlantoaxial Instability in Down Syndrome: Subject Review. American Academy of Pediatrics Committee on Sports Medicine and Fitness. *Pediatrics* 1995;96:151.

! 7. Anonymous. A Gene (PEX) with Homologies to Endopeptidases is Mutated in Patients with X-linked Hypophosphatemic Rickets. The HYP Consortium. *Nat Genet* 1995;11:130.

+ 8. Aprin H, Zink WP, Hall JE. Management of Dislocation of the Hip in Down Syndrome. *J Pediatr Orthop* 1985;5:428.

+ 9. Arasil E, Erdem A, Yuceer N. Osteochondroma of the Upper Cervical Spine: A Case Report. *Spine* 1996;21:516.

+ 10. Arms DM, Strecker WB, Manske PR, Schoenecker PL. Management of Forearm Deformity in Multiple Hereditary Osteochondromatosis. *J Pediatr Orthop* 1997;17:450.

10a. Armstrong DG, Newfield JT, Gillespie R. Orthopaedic Management of Osteopetrosis: Results of a Survey and Review of the Literature. *J Pediatr Orthop* 1999;122.

+ 11. Arvin M, White SJ, Braunstein EM. Growth Plate Injury of the Hand and Wrist in Renal Osteodystrophy. *Skeletal Radiol* 1990;19:515.

# 12. Axt MW, Niethard FU, Doderlein L, Weber M. Principles of Treatment of the Upper Extremity in Arthrogryposis Multiplex Congenita Type I. *J Pediatr Orthop B* 1997;6:179.

+ 13. Bailey RW. Further Clinical Experience with the Extensible Nail. *Clin Orthop* 1981;159:171.

* 14. Bailey RW, Dubow HI. Evolution of the Concept of an Extensible Nail Accommodating to Normal Longitudinal Bone Growth: Clinical Considerations and Implications. *Clin Orthop* 1981;159:157.

+ 15. Baker JK, Cain TE, Tullos HS. Intramedullary Fixation for Congenital Pseudarthrosis of the Tibia. *J Bone Joint Surg* 1992;74A:169.

# 16. Bamshad M, Jorde LB, Carey JC. A Revised and Extended Classification of the Distal Arthrogryposes. *Am J Med Genet* 1996;65:277.

# 17. Banker BQ: Neuropathologic Aspects of Arthrogryposis Multiplex Congenita. *Clin Orthop* 1985;194:30.

# 18. Bassett GS. Lower-extremity Abnormalities in Dwarfing Conditions. *Instr Course Lect* 1990;39:389.

! 19. Bellus GA, Hefferon TW, Ortiz de Luna RI, et al. Achondroplasia Is Defined by Recurrent G380R Mutations of FGFR3. *Am J Hum Genet* 1995;56:368.

+ 20. Bennet GC, Rang M, Roye DP, Aprin H. Dislocation of the Hip in Trisomy 21. *J Bone Joint Surg* 1982;64B:289.

+ 21. Benson DR, Newman DC. The Spine and Surgical Treatment in Osteogenesis Imperfecta. *Clin Orthop* 1981;159:147.

! 22. Berge LN, Marton V, Tanebjaerg L, et al. Prenatal Diagnosis of Osteogenesis Imperfecta. *Acta Obstet Gynecol Scand* 1995;74:321.

! 23. Berthet F, Siegrist CA, Ozsahin H, et al. Bone Marrow Transplantation in Cartilage-hair Hypoplasia: Correction of the Immunodeficiency but not of the Chondrodysplasia. *Eur J Pediatr* 1996;155:286.

+ 24. Bethem D, Winter RB, Lutter L. Disorders of the Spine in Diastrophic Dwarfism. *J Bone Joint Surg* 1980;62A:529.

# 25. Bethem D, Winter RB, Lutter L, et al. Spinal Disorders of Dwarfism: Review of the Literature and Report of Eighty Cases. *J Bone Joint Surg* 1981;63A:1412.

+ 26. Bianchi DW, Van Marter LJ. An Approach to Ventilator-Dependent Neonates with Arthrogryposis. *Pediatrics* 1994;94:682.

# 27. Binder H, Conway A, Hason S, et al. Comprehensive Rehabilitation of the Child with Osteogenesis Imperfecta. *Am J Med Genet* 1993;45:265.

! 28. Bingham PM, Shen N, Rennert H, et al. Arthrogryposis due to Infantile Neuronal Degeneration Associated with Deletion of the SMNT Gene. *Neurology* 1997;49:848.

# 29. Blockey NJ, Murphy AV, Mocan H. Management of Rachitic Deformities in Children with Chronic Renal Failure. *J Bone Joint Surg* 1986;68B:792.

# 30. Boden SD, Kaplan FS. Calcium Homeostasis. *Orthop Clin North Am* 1990;21:31.

+ 31. Boero S, Catagni M, Donzelli O, et al. Congenital Pseudarthrosis of the Tibia Associated with Neurofibromatosis I: Treatment with Ilizarov's Device. *J Pediatr Orthop* 1997;17:675.

! 32. Bonaventure J, Rousseau F, Legeai-Mallet L, et al. Common Mutations in the Fibroblast Growth Factor Receptor 3 (FGFR 3) Gene Account for Achondroplasia, Hypochondroplasia, and Thanatophoric Dwarfism. *Am J Med Genet* 1996;63:148.

* 33. Boyd HB. Pathology and Natural History of Congenital Pseudarthrosis of the Tibia. *Clin Orthop* 1982;166:5.

+ 34. Brunner R, Hefti F, Tgetgel JD. Arthrogrypotic Joint Contracture at the Knee and the Foot: Correction with a Circular Frame. *J Pediatr Orthop B* 1997;6:192.

+ 35. Bryant DD, Grant RE, Tang D. Fibular Strut Grafting for Fibrous Dysplasia of the Femoral Neck. *J Natl Med Assoc* 1992;84:893.

! 36. Burglen L, Amiel J, Viollet L, et al. Survival Motor Neuron Gene Deletion in the Arthrogryposis Multiplex Congenita—Spinal Muscular Atrophy Association. *J Clin Invest* 1996;98:1130.

+ 37. Calvert PT, Edgar MA, Webb PJ. Scoliosis in Neurofibromatosis: The Natural History with and without Operation. *J Bone Joint Surg* 1989;71B:246.

+ 38. Cardelia JM, Dormans JP, Drummond DS, et al. Proximal Fibular Osteochondroma with Associated Peroneal Nerve Palsy: A Review of Six Cases. *J Pediatr Orthop* 1995;15:574.

# 39. Carpenter TO. New Perspectives on the Biology and Treatment of X-linked Hypophosphatemic Rickets. *Pediatr Clin North Am* 1997;44:443.

+ 40. Cates HE, Burgess RC. Incidence of Brachydactyly and Hand Exostosis in Hereditary Multiple Exostosis. *J Hand Surg* 1991;16:127.

+ 41. Cavanah SF, Dons RF. McCune-Albright Syndrome: How Many Endocrinopathies Can One Patient Have? *South Med J* 1993;86:364.

+ 42. Charnas LR, Marini JC. Communicating Hydrocephalus, Basilar Invagination, and Other Neurologic Features in Osteogenesis Imperfecta. *Neurology* 1993;43:2603.

+ 43. Cole WG. Early Surgical Management of Severe Forms of Osteogenesis Imperfecta. *Am J Med Genet* 1993;45:270.

+ 44. Cole WG, Dalgleish R. Perinatal Lethal Osteogenesis Imperfecta. *J Med Genet* 1995;32:284.

! 45. Cole WG. The Nicholas Andry Award—1996. The Molecular Pathology of Osteogenesis Imperfecta. *Clin Orthop* 1997;343:235.

+ 46. Coleman SS, Coleman DA. Congenital Pseudarthrosis of the Tibia: Treatment by Transfer of the Ipsilateral Fibula with Vascular Pedicle. *J Pediatr Orthop* 1994;14:156.

+ 47. Craig JB, Govender S. Neurofibromatosis of the Cervical Spine: A Report of Eight Cases. *J Bone Joint Surg* 1992;74B:575.

+ 48. Craigen MA, Clarke NM. Familial Congenital Pseudarthrosis of Ulna. *J Hand Surg* 1995;20:331.

* 49. Crawford AH Jr, Bagamery N. Osseous Manifestations of Neurofibromatosis in Childhood. *J Pediatr Orthop* 1986;6:72.

* 50. Crawford AH. Pitfalls of Spinal Deformities Associated with Neurofibromatosis in Children. *Clin Orthop* 1989;245:29.

+ 51. Cremers MJ, Bol E, de Roos F, van Gijn J. Risk of Sports Activities in Children with Down's Syndrome and Atlantoaxial Instability. *Lancet* 1993;342:511.

+ 52. Crossett LS, Beaty JH, Betz RR, et al. Congenital Pseudarthrosis of the Tibia: Long-term Follow-up Study. *Clin Orthop* 1989;245:16.

+ 53. Dabezies EJ, Warren PD. Fractures in Very Low Birth Weight Infants with Rickets. *Clin Orthop* 1997;335:233.

+ 54. Dahl MT. The Gradual Correction of Forearm Deformities in Multiple Hereditary Exostoses. *Hand Clin* 1993;9:707.

+ 55. Daly K, Wisbeach A, Sanpera I Jr, Fixsen JA. The Prognosis for Walking in Osteogenesis Imperfecta. *J Bone Joint Surg* 1996;78B:7.

+ 56. Danielsson LG, el-Haddad I. Winged Scapula due to Osteochondroma: Report of 3 Children. *Acta Orthop Scand* 1989;60:728.

+ 57. Danielsson LG, el-Haddad I, Quadros O. Distal Tibial Osteochondroma Deforming the Fibula. *Acta Orthop Scand* 1990;61:469.

+ 58. Davids JR, Fisher R, Lum G, Von Glinski S. Angular Deformity of the Lower Extremity in Children with Renal Osteodystrophy. *J Pediatr Orthop* 1992;12:291.

+ 59. De Leon SY, Ilbawi MN, Egel RT, et al. Perioperative Spinal Canal Narrowing in Patients with Down's Syndrome. *Ann Thorac Surg* 1991;52:1325.

! 60. Deere M, Blanton SH, Scott CI, et al. Genetic Heterogeneity in Multiple Epiphyseal Dysplasia. *Am J Hum Genet* 1995;56:698.

+ 61. Del Bello DA, Watts HG. Distal Femoral Extension Osteotomy for Knee Flexion Contracture in Patients with Arthrogryposis. *J Pediatr Orthop* 1996;16:122.

+ 62. Delgado-Martinez AD, Rodriguez-Merchan EC, Olsen B. Congenital Pseudarthrosis of the Tibia. *Int Orthop* 1996;20:192.

# 63. Diamond LS, Lynne D, Sigman B. Orthopedic Disorders in Patients with Down's Syndrome. *Orthop Clin North Am* 1981;12:57.

+ 64. Dias LS, Stern LS. Talectomy in the Treatment of Resistant Talipes Equinovarus Deformity in Myelomeningocele and Arthrogryposis. *J Pediatr Orthop* 1987;7:39.

# 65. Dietz FR, Mathews KD. Update on the Genetic Bases of Disorders with Orthopaedic Manifestations. *J Bone Joint Surg* 1996;78A:1583.

+ 66. Dormans JP, Krajbich JI, Zuker R, Demuynk M. Congenital Pseudarthrosis of the Tibia: Treatment with Free Vascularized Fibular Grafts. *J Pediatr Orthop* 1990;10:623.

+ 67. Doyle JS, Lauerman WC, Wood KB, Krause DR. Complications and Long-term Outcome of Upper Cervical Spine Arthrodesis in Patients with Down Syndrome. *Spine* 1996;21:1223.

+ 68. Dugdale TW, Renshaw TS. Instability of the Patellofemoral Joint in Down Syndrome. *J Bone Joint Surg* 1986;68A:405.

! 69. Econs MJ, Francis F. Positional Cloning of the PEX Gene: New Insights into the Pathophysiology of X-linked Hypophosphatemic Rickets. *Am J Physiol* 1997;273:F489.

! 70. Econs MJ, McEnery PT, Lennon F, Speer MC. Autosomal Dominant Hypophosphatemic Rickets is Linked to Chromosome 12p13. *J Clin Invest* 1997;100:2653.

# 71. Econs MJ, Samsa GP, Monger M, et al. X-linked Hypophosphatemic Rickets: A Disease Often Unknown to Affected Patients. *Bone Miner* 1994;24:17.

+ 72. Egelhoff JC, Bates DJ, Ross JS, et al. Spinal MR Findings in Neurofibromatosis Types 1 and 2. *AJNR Am J Neuroradiol* 1992;13:1071.

+ 73. Ehara S, Kattapuram SV, Rosenberg AE. Fibrous Dysplasia of the Spine. *Spine* 1992;17:977.

+ 74. Engelbert RH, Helders PJ, Keessen W, et al. Intramedullary Rodding in Type III Osteogenesis Imperfecta: Effects on Neuromotor Development in 10 Children. *Acta Orthop Scand* 1995;66:361.

* 75. Enneking WF, Gearen PF. Fibrous Dysplasia of the Femoral Neck: Treatment by Cortical Bone-grafting. *J Bone Joint Surg* 1986;68A:1415.

+ 76. Erdincler P, Dashti R, Kaynar MY, et al. Hydrocephalus and Chronically Increased Intracranial Pressure in Achondroplasia. *Childs Nerv Syst* 1997;13:345.

+ 77. Evans R, Caffey J. Metaphyseal Dysostosis Resembling Vitamin D Refractory Rickets. *Am J Dis Child* 1958;95:581.

+ 78. Fabry G, Lammens J, Van Melkebeek J, Stuyck J. Treatment of Congenital Pseudarthrosis with the Ilizarov Technique. *J Pediatr Orthop* 1988;8:67.

+ 79. Ferris B, Walker C, Jackson A, Kirwan E. The Orthopaedic Management of Hypophosphataemic Rickets. *J Pediatr Orthop* 1991;11:367.

+ 80. Forese LL, Berdon WE, Harcke HT, et al. Severe Mid-cervical Kyphosis with Cord Compression in Larsen's Syndrome and Diastrophic Dysplasia: Unrelated Syndromes with Similar Radiologic Findings and Neurosurgical Implications. *Pediatr Radiol* 1995;25:136.

+ 81. Fraser RK, Nattrass GR, Chow CW, Cole WG. Pes Anserinus Syndrome due to Solitary Tibial Spurs and Osteochondromas. *J Pediatr Orthop* 1996;16:247.

+ 82. Freeman BH, d Bray EW, Meyer LC. Multiple Osteotomies with Zickel Nail Fixation for Polyostotic Fibrous Dysplasia Involving the Proximal Part of the Femur. *J Bone Joint Surg* 1987;69A:691.

+ 83. Frijns CJ, Van Deutekom J, Frants RR, Jennekens FG. Dominant Congenital Benign Spinal Muscular Atrophy. *Muscle Nerve* 1994;17:192.

+ 84. Funasaki H, Winter RB, Lonstein JB, Denis F. Pathophysiology of Spinal Deformities in Neurofibromatosis: An Analysis of Seventy-one Patients Who Had Curve Associated with Dystrophic Changes. *J Bone Joint Surg* 1994;76:692.

+ 85. Gabriel KR, Mason DE, Carango P. Occipito-atlantal Translation in Down's Syndrome. *Spine* 1990;15:997.

+ 86. Gamble JG, Rinsky LA, Strudwick J, Bleck EE. Non-union of Fractures in Children Who Have Osteogenesis Imperfecta. *J Bone Joint Surg* 1988;70A:439.

+ 87. Gamble JG, Strudwick WJ, Rinsky LA, Bleck EE. Complications of Intramedullary Rods in Osteogenous Imperfecta: Bailey-Dubow Rods Versus Nonelongating Rods. *J Pediatr Orthop* 1988;8:645.

+ 88. Ganel A, Horoszowski H. Limb Lengthening in Children with Achondroplasia: Differences Based on Gender. *Clin Orthop* 1996;332:179.

+ 89. Gerber LH, Binder H, Weintrob J, et al. Rehabilitation of Children and Infants with Osteogenesis Imperfecta: A Program for Ambulation. *Clin Orthop* 1990;251:254.

# 90. Gertner JM, Root L. Osteogenesis Imperfecta. *Orthop Clin North Am* 1990;21:151.

+ 91. Gilbert A, Brockman R. Congenital Pseudarthrosis of the Tibia: Long-term Followup of 29 Cases Treated by Microvascular Bone Transfer. *Clin Orthop* 1995;314:37.

+ 92. Greene ADL, Fixen JA, Lloyd-Roberts GC. Talectomy for Arthrogryposis Multiplex Congenita. *J Bone Joint Surg* 1984;66:697.

+ 93. Grill F. Treatment of Congenital Pseudarthrosis of Tibia with the Circular Frame Technique. *J Pediatr Orthop B* 1996;5:6.

+ 94. Guidera KJ, Kortright L, Barber V, Ogden JA. Radiographic Changes in Arthrogrypotic Knees. *Skeletal Radiol* 1991;20:193.

+ 95. Guidera KJ, Satterwhite Y, Ogden JA, et al. Nail Patella Syndrome: A Review of 44 Orthopaedic Patients. *J Pediatr Orthop* 1991;11:737.

+ 96. Guille JT, Bowen JR. Scoliosis and Fibrous Dysplasia of the Spine. *Spine* 1995;20:248.

+ 97. Guille JT, Kumar SJ, MacEwen GD. Fibrous Dysplasia of the Proximal Part of the Femur. *J Bone Joint Surg* 1998;80A:648.

! 98. Gutmann DH, Collins FS. The Neurofibromatosis Type I Gene and Its Product, Neurofibromin. *Neuron* 1993;10:335.

+ 99. Haddad FS, Williams RL, Bentley G. The Cervical Spine in Neurofibromatosis. *Br J Hosp Med* 1995;53:318.

# 100. Hall JG. Arthrogryposis Multiplex Congenita: Etiology, Genetics, Classification, Diagnostic Approach, and General Aspects. *J Pediatr Orthop B* 1997;6:159.

! 101. Hanna JD, Niimi K, Chan JC. X-linked Hypophosphatemia: Genetic and Clinical Correlates. *Am J Dis Child* 1991;145:86.

+ 102. Hanscom DA, Winter RB, Lutter L, et al. Osteogenesis Imperfecta: Radiographic Classification, Natural History, and Treatment of Spinal Deformities. *J Bone Joint Surg* 1992;74:598.

+ 103. Hanukoglu A, Chalew SA, Sun CJ, et al. Surgically Curable Hypophosphatemic Rickets: Diagnosis and Management. *Clin Pediatr* 1989;28:321.

+ 104. Harkey HL, Crockard HA, Stevens JM, et al. The Operative Management of Basilar Impression in Osteogenesis Imperfecta. *Neurosurgery* 1990;27:782.

+ 105. Harris NL, Eilert RE, Davino N, et al. Osteogenic Sarcoma Arising from Bony Regenerate Following Ilizarov Femoral Lengthening through Fibrous Dysplasia. *J Pediatr Orthop* 1994;14:123.

* 106. Harris WH, Dudley HR Jr, Barry RJ. The Natural History of Fibrous Dysplasia. *J Bone Joint Surg* 1962:44A:207.

+ 107. Hartjen CA, Koman LA. Treatment of Slipped Capital Femoral Epiphysis Resulting from Juvenile Renal Osteodystrophy. *J Pediatr Orthop* 1990;10:551.

+ 108. Helfen M, Gotzinger R, Lutke A, et al. Intrathoracic Dural Ectasia Mimicking Neurofibroma and Scoliosis: A Case Report. *Int Orthop* 1995;19:181.

* 109. Herring JA. The Spinal Disorders in Diastrophic Dwarfism. *J Bone Joint Surg* 1978;60A:177.

+ 110. Holt RT, Johnson JR. Cotrel-Dubousset Instrumentation in Neurofibromatosis Spine Curves: A Preliminary Report. *Clin Orthop* 1989;245:19.

+ 111. Horton WA, Hecht JT, Hood OJ, et al. Growth Hormone Therapy in Achondroplasia. *Am J Med Genet* 1992;42:667.

! 112. Humbel RC, Marchal C, Fall M. Diagnosis of Morquio's Disease: A Simple Chromatographic Method for the Identification of Keratosulfate in Urine. *J Pediatr* 1972;81:107.

+ 113. Ingram RR. The Shoulder in Multiple Epiphyseal Dysplasia. *J Bone Joint Surg* 1991;73B:277.

+ 114. Ishikawa S, Kumar SJ, Takahashi HE, Homma M. Vertebral Body Shape as a Predictor of Spinal Deformity in Osteogenesis Imperfecta. *J Bone Joint Surg* 1996;78A:212.

+ 115. Jacobsen ST, Crawford AH, Millar EA, Steel HH. The Syme Amputation in Patients with Congenital Pseudarthrosis of the Tibia. *J Bone Joint Surg* 1983;65A:533.

+ 116. Jacobsen ST, Hull CK, Crawford AH. Nutritional Rickets. *J Pediatr Orthop* 1986;6:713.

+ 117. Janelle C, Stanciu C. Relationship Between Osteochondromas of the Forearm in Children and Dislocation of the Radial Head. *Ann Chir* 1993;47:888.

+ 118. Joseph KN, Bowen JR, MacEwen GD. Unusual Orthopedic Manifestations of Neurofibromatosis. *Clin Orthop* 1992;278:17.

* 119. Kahanovitz N, Rimoin DL, Sillence DO. The Clinical Spectrum of Lumbar Spine Disease in Achondroplasia. *Spine* 1982;7:137.

# 120. Kallen B, Mastroiacovo P, Robert E. Major Congenital Malformations in Down Syndrome. *Am J Med Genet* 1996;65:160.

+ 121. Kanel JS, Price CT. Unilateral External Fixation for Corrective Osteotomies in Patients with Hypophosphatemic Rickets. *J Pediatr Orthop* 1995;15:232.

+ 122. Karol LA, Haideri NF, Halliday SE, et al. Gait Analysis and Muscle Strength in Children with Congenital Pseudarthrosis of the Tibia: The Effect of Treatment. *J Pediatr Orthop* 1998;18:381.

+ 123. Karol LA, Sheffield EG, Crawford K, et al. Reproducibility in the Measurement of Atlanto-occipital Instability in Children with Down Syndrome. *Spine* 1996;21:2463.

# 124. Kocher MS, Shapiro F. Osteogenesis Imperfecta. *J Am Acad Orthop Surg* 1998;6:225.

+ 125. Koo WW, Sherman R, Succop P, et al. Fractures and Rickets in Very Low Birth Weight Infants: Conservative Management and Outcome. *J Pediatr Orthop* 1993;13:577.

+ 126. Kupcha PC, Guille JT, Tassanawipas A, Bowen JR. Polyostotic Fibrous Dysplasia and Acromegaly. *J Pediatr Orthop* 1991;11:95.

# 127. Lachman RS. Neurologic Abnormalities in the Skeletal Dysplasias: A Clinical and Radiological Perspective. *Am J Med Genet* 1997;69:33.

+ 128. Li MH, Holtas S. MR Imaging of Spinal Neurofibromatosis. *Acta Radiol* 1991;32:279.

* 129. Lichenstein L, Jaffe HL. Fibrous Dysplasia of Bone: A Condition Affecting One, Several, or Many Bones, the Graver Cases of which May Present Abnormal Pigmentation of Skin, Premature Sexual Development, or Still Other Extraskeletal Abnormalities. *Arch Pathol* 1942;33:777.

+ 130. Lovell AT, Alexander R, Grundy EM. Silent, Unstable, Cervical Spine Injury in Multiple Neurofibromatosis [Letter]. *Anaesthesia* 1994;49:453.

! 131. Lutchman M, Rouleau GA. The Neurofibromatosis Type 2 Gene Product, Schwannomin, Suppresses Growth of NIH 3T3 Cells. *Cancer Res* 1995;55:2270.

! 132. Lutter LD, Longstein JE, Winter RB, Langer LO. Anatomy of the Achondroplastic Lumbar Canal. *Clin Orthop* 1977;126:139.

+ 133. Mackenzie WG, Bassett GS, Mandell GA, Scott CI Jr. Avascular Necrosis of the Hip in Multiple Epiphyseal Dysplasia. *J Pediatr Orthop* 1989;9:666.

+ 134. Mainzer F, Minagi H, Steinbach HL. The Variable Manifestations of Multiple Enchondromatosis. *Radiology* 1971;99:377.

+ 135. Malghem J, Vande Berg B, Noel H, Maldague B. Benign Osteochondromas and Exostotic Chondrosarcomas: Evaluation of Cartilage Cap Thickness by Ultrasound. *Skeletal Radiol* 1992;21:33.

+ 136. Mandell GA, Harcke HT, Scott CI, et al. Protrusio Acetabuli in Neurofibromatosis: Nondysplastic and Dysplastic Forms. *Neurosurgery* 1992;30:552.

# 137. Mankin HJ. Rickets, Osteomalacia, and Renal Osteodystrophy: An Update. *Orthop Clin North Am* 1990;21:81.

# 138. Mankin HJ. Metabolic Bone Disease. *Instr Course Lect* 1995;44:3.

# 139. Marini JC, Gerber NL. Osteogenesis Imperfecta: Rehabilitation and Prospects for Gene Therapy [Clinical Conference]. *JAMA* 1997;277:746.

+ 140. Martich V, Ben-Ami T, Yousefzadeh DK, Roizen NJ. Hypoplastic Posterior Arch of C-1 in Children with Down Syndrome: A Double Jeopardy. *Radiology* 1992;183:125.

+ 141. Mathoulin C, Gilbert A, Azze RG. Congenital Pseudarthrosis of the Forearm: Treatment of Six Cases with Vascularized Fibular Graft and a Review of the Literature. *Microsurgery* 1993;14:252.

# 142. Mautner VF, Tatagiba M, Guthoff R, et al. Neurofibromatosis 2 in the Pediatric Age Group. *Neurosurgery* 1993;33:92.

+ 143. McAllion SJ, Paterson CR. Causes of Death in Osteogenesis Imperfecta. *J Clin Pathol* 1996;49:627.

+ 144. Menelaus MB. Talectomy for Equinovarus Deformity in Arthrogryposis and Spina Bifida. *J Bone Joint Surg* 1971;53B:468.

* 145. Menezes AH, Ryken TC. Craniovertebral Abnormalities in Down's Syndrome. *Pediatr Neurosurg* 1992;18:24.

! 146. Minamitani K, Minagawa M, Yasuda T, Niimi H. Early Detection of Infants with Hypophosphatemic Vitamin D Resistant Rickets (HDRR). *Endocr J* 1996;43:339.

+ 147. Morton RE, Khan MA, Murray-Leslie C, Elliot S. Atlantoaxial Instability in Down's Syndrome: A Five Year Follow Up Study. *Arch Dis Child* 1995;72:115.

+ 148. Msall ME, Reese ME, Di Gaudio K, et al. Symptomatic Atlantoaxial Instability Associated with Medical and Rehabilitative Procedures in Children with Down Syndrome. *Pediatrics* 1990;85:447.

+ 149. Murray C, Fixsen JA. Management of Knee Deformity in Classical Arthrogryposis Multiplex Congenita (Amyoplasia Congenita). *J Pediatr Orthop B* 1997;6:186.

+ 150. Nabarro MN, Giblin PE. Monostotic Fibrous Dysplasia of the Thoracic Spine. *Spine* 1994;19:463.

+ 151. Nawata K, Teshima R, Minamizaki T, Yamamoto K. Knee Deformities in Multiple Hereditary Exostoses: A Longitudinal Radiographic Study. *Clin Orthop* 1995;313:194.

+ 152. Nelson J, Thomas PS. Clinical Findings in 12 Patients with MPS IV A (Morquio's Disease): Further Evidence for Heterogeneity. Part III: Odontoid Dysplasia. *Clin Genet* 1988;33:126.

+ 153. Nguyen BD, Lugo-Olivieri CH, McCarthy EF, et al. Fibrous Dysplasia with Secondary Aneurysmal Bone Cyst. *Skeletal Radiol* 1996;25:88.

+ 154. Nicholas RW, James P. Telescoping Intramedullary Stabilization of the Lower Extremities for Severe Osteogenesis Imperfecta. *J Pediatr Orthop* 1990;10:219.

+ 155. Niki H, Staheli LT, Mosca VS. Management of Clubfoot Deformity in Amyoplasia. *J Pediatr Orthop* 1997;17:803.

+ 156. Nishi Y, Kajiyama M, Miyagawa S, et al. Growth Hormone Therapy in Achondroplasia. *Acta Endocrinol* 1993;128:394.

+ 157. O'Brien MF, Bridwell KH, Lenke LG, Schoenecker PL. Intracanalicular Osteochondroma Producing Spinal Cord Compression in Hereditary Multiple Exostoses. *J Spinal Disord* 1994;7:236.

+ 158. Olmastroni M, Seracini D, Lavoratti G, et al. Magnetic Resonance Imaging of Renal Osteodystrophy in Children. *Pediatr Radiol* 1997;27:865.

! 159. Olsen CL, Cross PK, Gensburg LJ, Hughes JP. The Effects of Prenatal Diagnosis, Population Ageing, and Changing Fertility Rates on the Live Birth Prevalence of Down Syndrome in New York State, 1983–1992. *Prenat Diagn* 1996;16:991.

+ 160. Oppenheim WL, Fischer SR, Salusky IB. Surgical Correction of Angular Deformity of the Knee in Children with Renal Osteodystrophy. *J Pediatr Orthop* 1997;17:41.

+ 161. Oppenheim WL, Shayestehfar S, Salusky IB. Tibial Physeal Changes in Renal Osteodystrophy: Lateral Blount's Disease. *J Pediatr Orthop* 1992;12:774.

* 162. Parfenchuck TA, Bertrand SL, Powers MJ, et al. Posterior Occipitoatlantal Hypermobility in Down Syndrome: An Analysis of 199 Patients. *J Pediatr Orthop* 1994;14:304.

# 163. Parfitt AM. Renal Osteodystrophy. *Orthop Clin North Am* 1972;3:681.

+ 164. Patel L, Clayton PE, Brain C, et al. Acute Biochemical Effects of Growth Hormone Treatment Compared with Conventional Treatment in Familial Hypophosphataemic Rickets. *Clin Endocrinol* 1996;44:687.

+ 165. Patel MD, Filly RA. Homozygous Achondroplasia: US Distinction Between Homozygous, Heterozygous, and Unaffected Fetuses in the Second Trimester. *Radiology* 1995;196:541.

# 166. Paterson D. Congenital Pseudarthrosis of the Tibia: An Overview. *Clin Orthop* 1989;247:44.

+ 167. Pauli RM, Horton VK, Glinski LP, Reiser CA. Prospective Assessment of Risks for Cervicomedullary-junction Compression in Infants with Achondroplasia. *Am J Hum Genet* 1995;56:732.

+ 168. Pauli RM, Breed AM, Horton VK, et al. Prevention of Fixed Angular Kyphosis in Achondroplasia. *J Pediatr Orthop* 1997;17:726.

# 169. Peterson HA. Multiple Hereditary Osteochondromata. *Clin Orthop* 1989;239:222.

+ 170. Peterson HA. Deformities and Problems of the Forearm in Children with Multiple Hereditary Osteochondromata. *J Pediatr Orthop* 1994;14:92.

* 171. Ponseti IV. Skeletal Growth in Achondroplasia. *J Bone Joint Surg* 1970;52A:701.

+ 172. Porsborg P, Astrup G, Bendixen D, et al. Osteogenesis Imperfecta and Malignant Hyperthermia. Is There a Relationship? *Anaesthesia* 1996;51:863.

# 173. Poussa M, Merikanto J, Ryoppy S, et al. The Spine in Diastrophic Dysplasia. *Spine* 1991;16:881.

+ 174. Przybylski GJ, Pollack IF, Ward WT. Monostotic Fibrous Dysplasia of the Thoracic Spine: A Case Report. *Spine* 1996;21:860.

+ 175. Pueschel SM, Moon AC, Scola FH. Computerized Tomography in Persons with Down Syndrome and Atlantoaxial Instability. *Spine* 1992;17:735.

# 176. Pueschel SM, Scola FH, Tupper TB, Pezzullo JC. Skeletal Anomalies of the Upper Cervical Spine in Children with Down Syndrome. *J Pediatr Orthop* 1990;10:607.

+ 177. Pueschel SM, Scola FH, Pezzullo JC. A Longitudinal Study of Atlanto-dens Relationships in Asymptomatic Individuals with Down Syndrome. *Pediatrics* 1992;89:1194.

+ 178. Quinn CM, Wigglesworth JS, Heckmatt J. Lethal Arthrogryposis Multiplex Congenita: A Pathological Study of 21 Cases. *Histopathology* 1991;19:155.

+ 179. Raupp P, Kemperdick H. Neonatal Radiological Aspect of Enchondromatosis (Ollier's Disease). *Pediatr Radiol* 1990;20:337.

+ 180. Richards BS. Atlanto-axial Instability in Diastrophic Dysplasia: A Case Report. *J Bone Joint Surg* 1991;73A:614.

+ 181. Rizzolo S, Lemos MJ, Mason DE. Posterior Spinal Arthrodesis for Atlantoaxial Instability in Down Syndrome. *J Pediatr Orthop* 1995;15:543.

+ 182. Rosenbloom AL, Smith DW. The Natural History of Metaphyseal Dysostosis. *J Pediatr* 1965;66:857.

! 183. Rousseau F, Bonaventure J, Legeai-Mallet L, et al. Mutations in the Gene Encoding Fibroblast Growth Factor Receptor-3 in Achondroplasia. *Nature* 1994;371:252.

! 184. Rowe PS, Goulding J, Francis F, et al. The Gene for X-linked Hypophosphataemic Rickets Maps to a 200-300 kb Region in Xp22.1 and Is Located on a Single YAC Containing a Putative Vitamin D Response Element (VDRE). *Hum Genet* 1996;97:345.

! 185. Rowe PS, Goulding J, Read A, et al. Refining the Genetic Map for the Region Flanking the X-linked Hypophosphataemic Rickets Locus (Xp22.1-22.2). *Hum Genet* 1994;93:291.

+ 186. Roy M, Baxter M, Roy A. Atlantoaxial Instability in Down Syndrome—Guidelines for Screening and Detection. *J R Soc Med* 1990;83:433.

+ 187. Rubinovitch M, Said SE, Glorieux FH, et al. Principles and Results of Corrective Lower Limb Osteotomies for Patients with Vitamin D–Resistant Hypophosphatemic Rickets. *Clin Orthop* 1988;237:264.

+ 188. Rudolf MK, Arulanantham K, Greenstein RM. Unsuspected Nutritional Rickets. *Pediatrics* 1980;66:72.

+ 189. Ruggieri P, Sim FH, Bond JR, Unni KK. Malignancies in Fibrous Dysplasia. *Cancer* 1994;73:1411.

+ 190. Ryoppy S, Poussa M, Merikanto J, et al. Foot Deformities in Diastrophic Dysplasia: An Analysis of 102 Patients. *J Bone Joint Surg* 1992;74B:441.

! 191. Saggese G, Baroncelli GI, Bertelloni S, Perri G. Long-term Growth Hormone Treatment in Children with Renal Hypophosphatemic Rickets: Effects on Growth, Mineral Metabolism, and Bone Density. *J Pediatr* 1995;127:395.

+ 192. Sanchez CP, Salusky IB. The Renal Bone Diseases in Children Treated with Dialysis. *Adv Ren Replace Ther* 1996;3:14.

! 193. Sanguinetti C, Greco F, De Palma L, et al. Morphological Changes in Growth-plate Cartilage in Osteogenesis Imperfecta. *J Bone Joint Surg* 1990;72B:475.

# 194. Scarborough MT, Moreau G. Benign Cartilage Tumors. *Orthop Clin North Am* 1996;27:583.

+ 195. Schajowicz F, Santini-Araujo E. Adamantinoma of the Tibia Masked by Fibrous Dysplasia: Report of Three Cases. *Clin Orthop* 1989;238:294.

* 196. Schenk EA, Haggerty J. Morquio's Disease: A Radiologic and Morphologic Study. *Pediatrics* 1964;34:839.

! 197. Schipani E, Langman CB, Parfitt AM, et al. Constitutively Activated Receptors for Parathyroid Hormone and Parathyroid hormone–related Peptide in Jansen's Metaphyseal Chondrodysplasia. *N Engl J Med* 1996;335:708.

+ 198. Schorry EK, Crawford AH, Egelhoff JC, et al. Thoracic Tumors in Children with Neurofibromatosis-1. *Am J Med Genet* 1997;74:533.

* 199. Schwartz HS, Zimmerman NB, Simon MA, et al. The Malignant Potential of Enchondromatosis. *J Bone Joint Surg* 1987;69A:269.

* 200. Segal LS, Drummond DS, Zanotti RM, et al. Complications of Posterior Arthrodesis of the Cervical Spine in Patients Who Have Down Syndrome. *J Bone Joint Surg* 1991;73A:1547.

+ 201. Sells JM, Jaffe KM, Hall JG. Amyoplasia, the Most Common Type of Arthrogryposis: The Potential for Good Outcome. *Pediatrics* 1996;97:225.

+ 202. Shaw ED, Beals RK. The Hip Joint in Down's Syndrome: A Study of Its Structure and Associated Disease. *Clin Orthop* 1992;278:101.

+ 203. Shea D, Mankin HJ. Slipped Capital Femoral Epiphysis in Renal Rickets: Report of Three Cases. *J Bone Joint Surg* 1966;48A:349.

+ 204. Shearer P, Parham D, Kovnar E, et al. Neurofibromatosis Type I and Malignancy: Review of 32 Pediatric Cases Treated at a Single Institution. *Med Pediatr Oncol* 1994;22:78.

+ 205. Sheffield EG. Double-layered Patella in Multiple Epiphyseal Dysplasia: A Valuable Clue in the Diagnosis. *J Pediatr Orthop* 1998;18:123.

! 206. Shen MH, Harper PS, Upadhyaya M. Molecular Genetics of Neurofibromatosis Type 1 (NF1). *J Med Genet* 1996;33:2.

! 207. Shohat M, Lotan R, Magal N, et al. A Gene for Arthrogryposis Multiplex Congenita Neuropathic Type is Linked to D5S394 on Chromosome 5qter. *Am J Hum Genet* 1997;61:1139.

* 208. Sillence D. Osteogenesis Imperfecta: An Expanding Panorama of Variants. *Clin Orthop* 1981;159:11.

+ 209. Sillence D, Butler B, Latham M, Barlow K. Natural History of Blue Sclerae in Osteogenesis Imperfecta. *Am J Med Genet* 1993;45:183.

! 210. Sillence DO. Craniocervical Abnormalities in Osteogenous Imperfecta: Genetic and Molecular Correlation. *Pediatr Radiol* 1994;24:427.

+ 211. Simonis RB, Shirali HR, Mayou B. Free Vascularized Fibular Grafts for Congenital Pseudarthrosis of the Tibia. *J Bone Joint Surg* 1991;73B:211.

+ 212. Sirois JLD, Drennan JC. Dystrophic Spinal Deformity in Neurofibromatosis. *J Pediatr Orthop* 1990;10:522.

+ 213. Smith MD, Phillips WA, Hensinger RN. Fusion of the Upper Cervical Spine in Children and Adolescents: An Analysis of 17 Patients. *Spine* 1991;16:695.

+ 214. Snearly WN, Peterson HA. Management of Ankle Deformities in Multiple Hereditary Osteochondromata. *J Pediatr Orthop* 1989;9:427.

+ 215. Sodergard J, Ryoppy S. The Knee in Arthrogryposis Multiplex Congenita. *J Pediatr Orthop* 1990;10:177.

+ 216. Sodergard J, Ryoppy S. Foot Deformities in Arthrogryposis Multiplex Congenita. *J Pediatr Orthop* 1994;14:768.

+ 217. Sodergard J, Hakamies-Blomqvist L, Sainio K, et al. Arthrogryposis Multiplex Congenita: Perinatal and Electromyographic Findings, Disability, and Psychosocial Outcome. *J Pediatr Orthop B* 1997;6:167.

* 218. Sofield HA, Miller EA. Fragmentation, Realignment and Intramedullary Rod Fixation of Deformities of the Long Bones in Children: A Ten-year Appraisal. *J Bone Joint Surg* 1959;41A:1371.

+ 219. Sperry K. Fatal Intraoperative Hemorrhage during Spinal Fusion Surgery for Osteogenesis Imperfecta. *Am J Forensic Med Pathol* 1989;10:54.

* 220. Staheli LT, Chew De, Elliot JS, Mosca VS. Management of Hip Dislocations in Children with Arthrogryposis. *J Pediatr Orthop* 1987;7:681.

+ 221. Stanescu V, Stanescu R, Maroteaux P. Pathogenic Mechanisms in Osteochondrodysplasias. *J Bone Joint Surg* 1984;66A:817.

+ 222. Stanton RP, Hansen MO. Function of the Upper Extremities in Hereditary Multiple Exostoses. *J Bone Joint Surg* 1996;78A:568.

+ 223. Steinbach HL, Kolb FO, Gilfillan R. Mechanism of Production of Pseudofractures in Osteomalacia (Milkman's Syndrome). *Radiology* 1954;62:388.

! 224. Steiner RD, Pepin M, Byers PH. Studies of Collagen Synthesis and Structure in the Differentiation of Child Abuse from Osteogenesis Imperfecta. *J Pediatr* 1996;128:542.

+ 225. Stephenson RB, London MD, Hankin FM, Kaufer H. Fibrous Dysplasia: An Analysis of Options for Treatment. *J Bone Joint Surg* 1987;69A:400.

+ 226. Stevens JM, Kendall BE, Crockard HA, Ransford A. The Odontoid Process in Morquio-Brailsford's Disease: The Effects of Occipitocervical Fusion. *J Bone Joint Surg* 1991;73B:851.

+ 227. Stickler GB, Morgenstern BZ. Hypophosphataemic Rickets: Final Height and Clinical Symptoms in Adults. *Lancet* 1989;2:902.

+ 228. Stockley I, Bell MJ, Sharrard WJ. The Role of Expanding Intramedullary Rods in Osteogenesis Imperfecta. *J Bone Joint Surg* 1989;71B:422.

! 229. Stoilov I, Kilpatrick MW, Tsipouras P. A Common FGFR3 Gene Mutation Is Present in Achondroplasia but Not in Hypochondroplasia. *Am J Med Genet* 1995;55:127.

! 230. Superti-Furga A, Rossi A, Steinmann B, Gitzelmann R. A Chondrodysplasia Family Produced by Mutations in the Diastrophic Dysplasia Sulfate Transporter Gene: Genotype/phenotype Correlations. *Am J Med Genet* 1996;63:144.

+ 231. Swierstra BA, Diepstraten AF, vd Heyden BJ. Distal Femoral Physiolysis in Renal Osteodystrophy: Successful Nonoperative Treatment of 3 Cases Followed for 5 years. *Acta Orthop Scand* 1993;64:382.

+ 232. Szoke G, Staheli LT, Jaffe K, Hall JG. Medial-approach Open Reduction of Hip Dislocation in Amyoplasia-type Arthrogryposis. *J Pediatr Orthop* 1996;16:127.

! 233. Takeyama K, Kitanaka S, Sato T, et al. 25-Hydroxyvitamin D3 1 Alpha-hydroxylase and Vitamin D Synthesis. *Science* 1997;277:1827.

+ 234. Thomas B, Schopler S, Wood W, Oppenheim WL. The Knee in Arthrogryposis. *Clin Orthop* 1985;194:87.

+ 235. Thompson EM. Non-invasive Prenatal Diagnosis of Osteogenesis Imperfecta. *Am J Med Genet* 1993;45:201.

! 236. Timperlake RW, Cook SD, Thomas KA, et al. Effects of Anticonvulsant Drug Therapy on Bone Mineral Density in a Pediatric Population. *J Pediatr Orthop* 1988;8:467.

# 237. Tolo VT. Spinal Deformity in Short-stature Syndromes. *Instr Course Lect* 1990;39:399.

+ 238. Treble NJ, Jensen FO, Bankier A, et al. Development of the Hip in Multiple Epiphyseal Dysplasia: Natural History and Susceptibility to Premature Osteoarthritis. *J Bone Joint Surg* 1990;72B:1061.

* 239. Tredwell SJ, Newman DE, Lockitch G. Instability of the Upper Cervical Spine in Down Syndrome. *J Pediatr Orthop* 1990;10:602.

+ 240. Trumble ER. Myseros JS, Smoker WR, et al. Atlantooccipital Subluxation in a Neonate with Down's Syndrome: Case Report and Review of the Literature. *Pediatr Neurosurg* 1994;21:55.

+ 241. Tuncay IC, Johnston CE, Birch JG. Spontaneous Resolution of Congenital Anterolateral Bowing of the Tibia. *J Pediatr Orthop* 1994;14:599.

+ 242. Uchida Y, Kojima T, Sugioka Y. Vascularised Fibular Graft for Congenital Pseudarthrosis of the Tibia: Long-term Results. *J Bone Joint Surg* 1991;73B:846.

+ 243. Uno K, Kataoka O, Shiba R. Occipitoatlantal and Occipitoaxial Hypermobility in Down Syndrome. *Spine* 1996;21:1430.

+ 244. Vaara P, Peltonen J, Poussa M, et al. Development of the Hip in Diastrophic Dwarfism. *J Bone Joint Surg* 1998;80B:315.

# 245. van der Burgt I, Haraldsson A, Oosterwijk JC, et al. Cartilage Hair Hypoplasia, Metaphyseal Chondrodysplasia Type McKusick: Description of Seven Patients and Review of the Literature. *Am J Med Genet* 1991;41:371.

+ 246. van Mourik J, Weerdenburg H. Radiographic Anthropometry in Patients with Multiple Epiphyseal Dysplasia. *AJR Am J Roentgenol* 1997;169:1105.

* 247. Verge CF, Lam A, Simpson JM, et al. Effects of Therapy in X-linked Hypophosphatemic Rickets. *N Engl J Med* 1991;325:1843.

! 248. von Deimling A, Krone W, Menon AG. Neurofibromatosis Type 1: Pathology, Clinical Features and Molecular Genetics. *Brain Pathol* 1995;5:153.

# 249. Walker BA, Scott CI, Hall JG, et al. Diastrophic Dwarfism. *Medicine* 1972;51:41.

! 250. Wallis GA, Rash B, Sykes B, et al. Mutations within the Gene Encoding the Alpha 1 (X) Chain of Type X Collagen (COL10A1) Cause Metaphyseal Chondrodysplasia Type Schmid but Not Several Other Forms of Metaphyseal Chondrodysplasia. *J Med Genet* 1996;33:450.

# 251. Walton J. Familial Hypophosphatemic Rickets: A Delineation of Its Subdivisions and Pathogenesis. *Clin Pediatr* 1976;15:1007.

+ 252. Ward BA, Harkey HL, Parent AD, et al. Severe Cervical Kyphotic Deformities in Patients with Plexiform Neurofibromas: Case Report. *Neurosurgery* 1994;35:960.

! 253. Warman ML, Abbott M, Apte SS, et al. A Type X Collagen Mutation Causes Schmid Metaphyseal Chondrodysplasia. *Nat Genet* 1993;5:79.

# 254. Waters KA, Everett F, Sillence D, et al. Breathing Abnormalities in Sleep in Achondroplasia. *Arch Dis Child* 1993;69:191.

+ 255. Waters KA, Everett F, Sillence DO, et al. Treatment of Obstructive Sleep Apnea in Achondroplasia: Evaluation of Sleep, Breathing, and Somatosensory-evoked Potentials. *Am J Med Genet* 1995;59:460.

+ 256. Waters PM, Van Heest AE, Emans J. Acute Forearm Lengthenings. *J Pediatr Orthop* 1997;17:444.

+ 257. Weber G, Prinster C, Meneghel M, et al. Human Growth Hormone Treatment in Prepubertal Children with Achondroplasia. *Am J Med Genet* 1996;61:396.

+ 258. Weiland AJ, Weiss AP, Moore JR, Tolo VT. Vascularized Fibular Grafts in the Treatment of Congenital Pseudarthrosis of the Tibia. *J Bone Joint Surg* 1990;72A:654.

! 259. White KS, Ball WS, Prenger EC, et al. Evaluation of the Craniocervical Junction in Down Syndrome: Correlation of Measurements Obtained with Radiography and MR Imaging. *Radiology* 1993;186:377.

+ 260. Wicklund CL, Pauli RM, Johnston D, Hecht JT. Natural History Study of Hereditary Multiple Exostoses. *Am J Med Genet* 1995;55:43.

+ 261. Wilde PH, Upadhyay SS, Leong JC. Deterioration of Operative Correction in Dystrophic Spinal Neurofibromatosis. *Spine* 1994;19:1264.

+ 262. Wilson DM, Lee PD, Morris AH, et al. Growth Hormone Therapy in Hypophosphatemic Rickets. *Am J Dis Child* 1991;145:1165.

* 263. Winter RB, Moe JH, Bradford DS, et al. Spine Deformity in Neurofibromatosis: A Review of One Hundred and Two Patients. *J Bone Joint Surg* 1979;61A:677.

+ 264. Wirganowicz PZ, Watts HG. Surgical Risk for Elective Excision of Benign Exostoses. *J Pediatr Orthop* 1997;17:455.

+ 265. Yamada Y, Ito H, Otsubo Y, Sekido K. Surgical Management of Cervicomedullary Compression in Achondroplasia. *Childs Nerv Syst* 1996;12:737.

+ 266. Yamate T, Kanzaki S, Tanaka H, et al. Growth Hormone (GH) Treatment in Achondroplasia. *J Pediatr Endocrinol* 1993;6:45.

+ 267. Yasui N, Kawabata H, Kojimoto H, et al. Lengthening of the Lower Limbs in Patients with Achondroplasia and Hypochondroplasia. *Clin Orthop* 1997;344: 298.

+ 268. Yong-Hing K, MacEwen GD. Scoliosis Associated with Osteogenesis Imperfecta. *J Bone Joint Surg* 1982;64B:36.

+ 269. Yundt KD, Park TS, Tantuwaya VS, Kaufman BA. Posterior Fossa Decompression without Duraplasty in Infants and Young Children for Treatment of Chiari Malformation and Achondroplasia. *Pediatr Neurosurg* 1996;25:221.

+ 270. Zionts LE, Ebramzadeh E, Stott NS. Complications in the Use of the Bailey-Dubow Extensible Nail. *Clin Orthop* 1998;348:186.

! 271. Zionts LE, Nash JP, Rude R, et al. Bone Mineral Density in Children with Mild Osteogenesis Imperfecta. *J Bone Joint Surg* 1995;77B:143.

+ 272. Zucconi M, Weber G, Castronovo V, et al. Sleep and Upper Airway Obstruction in Children with Achondroplasia. *J Pediatr* 1996;129:743.